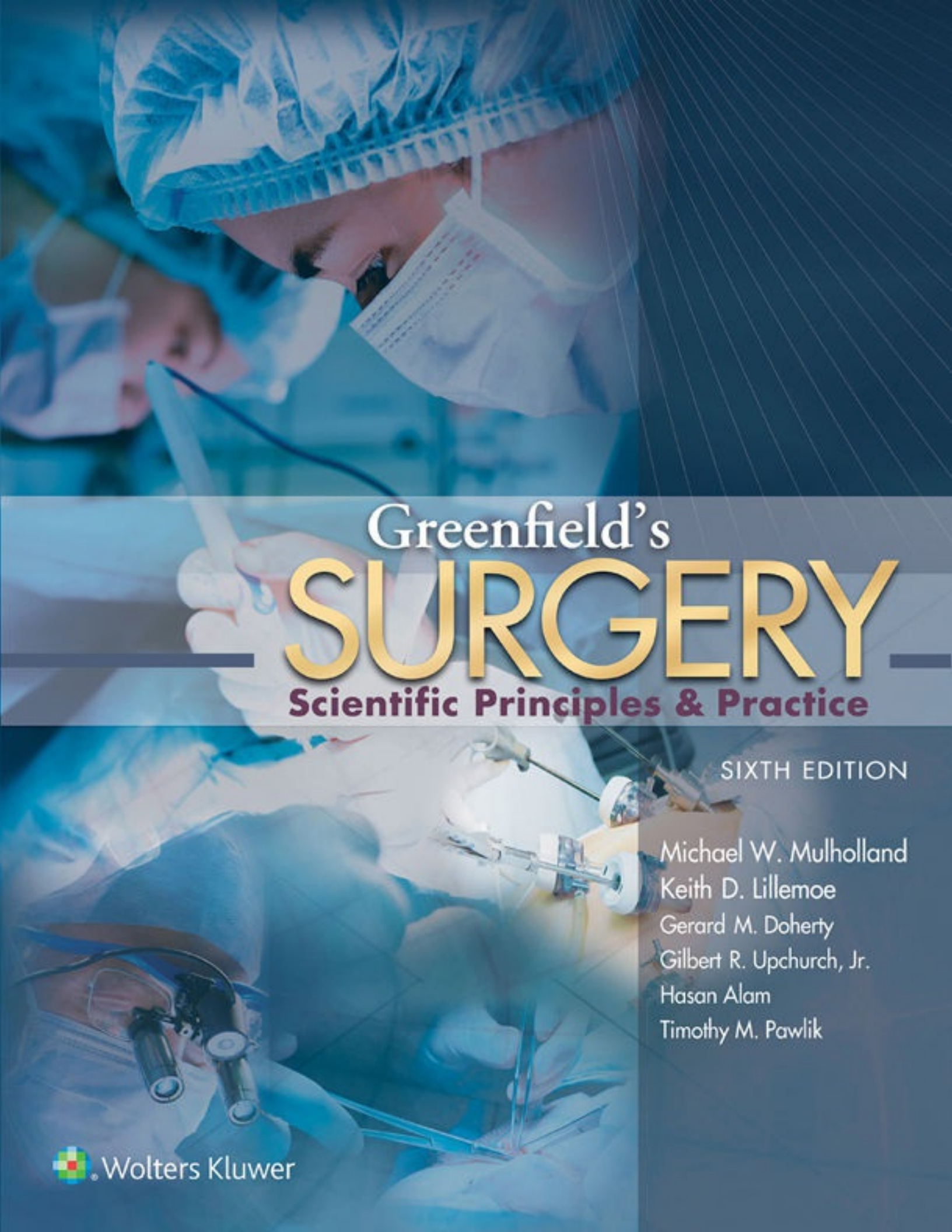

Greenfield's SURGERY

Scientific Principles & Practice

SIXTH EDITION

Michael W. Mulholland
Keith D. Lillemoe
Gerard M. Doherty
Gilbert R. Upchurch, Jr.
Hasan Alam
Timothy M. Pawlik

Wolters Kluwer

Greenfield's SURGERY

Scientific Principles & Practice

SIXTH EDITION

EDITORS

Michael W. Mulholland, MD, PhD
Frederick A. Coller Distinguished Professor of Surgery
Chair, Department of Surgery
University of Michigan
Ann Arbor, Michigan

Keith D. Lillemoe, MD
Surgeon-in-Chief
Chief, Department of Surgery
Massachusetts General Hospital
The W. Gerald Austen Professor
Harvard Medical School
Boston, Massachusetts

Gerard M. Doherty, MD
Surgeon-in-Chief
Brigham and Women's Health Care & Dana-Farber Cancer Institute
Moseley Professor of Surgery
Harvard Medical School
Boston, Massachusetts

Gilbert R. Upchurch, Jr., MD
Chief of Vascular and Endovascular Surgery
William H. Muller, Jr. Professor of Surgery
Professor of Molecular Physiology and Biological Physics
University of Virginia
Charlottesville, Virginia

Hasan B. Alam, MD
Norman W. Thompson Professor of Surgery
Head of General Surgery

Department of Surgery
University of Michigan
Ann Arbor, Michigan

Timothy M. Pawlik, MD, MPH, PhD
Professor of Surgery and Oncology
The Urban Meyer III and Shelley Meyer Chair for Cancer Research
Chair, Department of Surgery
The Ohio State University Wexner Medical Center
Columbus, Ohio

Illustrations by Holly R. Fischer, MFA



Acquisitions Editor: Keith Donnellan
Product Development Editor: Brendan Huffman
Production Project Manager: Bridgett Dougherty
Design Coordinator: Elaine Kasmer
Senior Manufacturing Coordinator: Beth Welsh
Marketing Manager: Dan Dressler
Prepress Vendor: Aptara, Inc.

Sixth Edition

Copyright © 2017 Wolters Kluwer

Fifth Edition © 2011 by LIPPINCOTT WILLIAMS & WILKINS, a WOLTERS KLUWER business
Fourth Edition © 2006 by LIPPINCOTT WILLIAMS & WILKINS
Third Edition © 2001 by LIPPINCOTT WILLIAMS & WILKINS

All rights reserved. This book is protected by copyright. No part of this book may be reproduced or transmitted in any form or by any means, including as photocopies or scanned-in or other electronic copies, or utilized by any information storage and retrieval system without written permission from the copyright owner, except for brief quotations embodied in critical articles and reviews. Materials appearing in this book prepared by individuals as part of their official duties as U.S. government employees are not covered by the above-mentioned copyright. To request permission, please contact Wolters Kluwer at Two Commerce Square, 2001 Market Street, Philadelphia, PA 19103, via email at permissions@lww.com, or via our website at lww.com (products and services).

9 8 7 6 5 4 3 2 1

Printed in China

Library of Congress Cataloging-in-Publication Data

Names: Mulholland, Michael W., editor.
Title: Greenfield's surgery : scientific principles and practice / editors,
Michael W. Mulholland, Keith D. Lillemoe, Gerard Doherty, Gilbert R.
Upchurch, Jr., Hasan B. Alam, Timothy M. Pawlik ; illustrations by Holly
R. Fischer.
Other titles: Surgery : scientific principles and practice
Description: Sixth edition. | Philadelphia : Wolters Kluwer, [2017] |
Includes bibliographical references and index.
Identifiers: LCCN 2016038680 | ISBN 9781469890012
Subjects: | MESH: General Surgery | Surgical Procedures, Operative
Classification: LCC RD31 | NLM WO 100 | DDC 617—dc23
LC record available at https://lccn.loc.gov/2016038680

This work is provided "as is," and the publisher disclaims any and all warranties, express or implied, including any warranties as to accuracy, comprehensiveness, or currency of the content of this work.

This work is no substitute for individual patient assessment based upon healthcare professionals' examination of each patient and consideration of, among other things, age, weight, gender, current or prior medical conditions, medication history, laboratory data and other factors unique to the patient. The publisher does not provide medical advice or guidance and this work is merely a reference tool. Healthcare professionals, and not the publisher, are solely responsible for the use of this work including all medical judgments and for any resulting diagnosis and treatments.

Given continuous, rapid advances in medical science and health information, independent professional verification of medical diagnoses, indications, appropriate pharmaceutical selections and dosages, and treatment options should be made and healthcare professionals should consult a variety of sources. When prescribing medication, healthcare professionals are advised to consult the product information sheet (the manufacturer's package insert) accompanying each drug to verify, among other things, conditions of use, warnings and side effects and identify any changes in dosage schedule or contraindications, particularly if the medication to be administered is new, infrequently used or has a narrow therapeutic range. To the maximum extent permitted under applicable law, no responsibility is assumed by the publisher for any injury and/or damage to persons or property, as a matter of products liability, negligence law or otherwise, or from any reference to or use by any person of this work.

LWW.com

Contributors

David B. Adams, MD
Professor of Surgery
The Department of Surgery
Medical University of South Carolina
Charleston, South Carolina

N. Scott Adzick, MD
Surgeon-in-Chief
Children's Hospital of Philadelphia
C. Everett Koop Professor of Pediatric Surgery
Perelman School of Medicine at the University of Pennsylvania
Philadelphia, Pennsylvania

Gorav Ailawadi, MD
Chief, Section of Adult Cardiac Surgery
Associate Professor, Cardiothoracic Surgery and Biomedical Engineering
Director, Minimally Invasive Cardiac Surgery
Surgical Director, Advanced Cardiac Valve Center
Chair, VCSQI Research and Writing Committee
University of Virginia
Charlottesville, Virginia

Hasan B. Alam, MD
Norman W. Thompson Professor of Surgery
Head of General Surgery
Department of Surgery
University of Michigan
Ann Arbor, Michigan

Shehab Ahmad Redha AlAnsari, MD
Resident physician
Department of Internal Medicine
Cleveland Clinic Foundation
Cleveland, Ohio

Husain T. AlQattan, MD
Department of Surgery
Miller School of Medicine
University of Miami – Jackson Health System

Miami, Florida

Marjorie J. Arca, MD
Professor of Surgery–Pediatric Surgery and Pediatrics
Surgical Director of Pediatric Critical Care
Milwaukee, Wisconsin

Ali Azizzadeh, MD
Department of Cardiothoracic and Vascular Surgery
University of Texas Medical School at Houston
Memorial Hermann Heart & Vascular Institute
Houston, Texas

Chad G. Ball, MD
Associate Professor of Surgery and Oncology
Department of Surgery
University of Calgary
Foothills Medical Center
Calgary, Canada

Thanh U. Barbie, MD
Instructor of Surgery
Harvard Medical School
Attending Surgeon
Brigham and Women's Hospital/Faulkner Hospital/Dana Farber Cancer Institute
Boston, Massachusetts

Bradley D. Beasley, DPM, CWS
Private Practice
Restoration Foot & Ankle, PLLC
Broken Arrow, Oklahoma

Adam W. Beck, MD
Assistant Professor of Surgery
Division of Vascular Surgery and Endovascular Therapy
University of Florida College of Medicine
Gainesville, Florida

Elizabeth R. Benjamin, MD, PhD
Assistant Professor of Surgery and Emergency Medicine
Division of Trauma and Surgical Critical Care
University of Southern California
Los Angeles, California

Christopher K. Bichakjian, MD
Professor of Dermatology
Department of Dermatology
University of Michigan
Ann Arbor, Michigan

Timothy R. Billiar, MD
George Vance Foster Endowed Professor
Distinguished Professor of Surgery
Chair, Department of Surgery
University of Pittsburgh
Pittsburgh, Pennsylvania

John D. Birkmeyer, MD
Executive Vice President, Integrated Delivery Systems
Chief Academic Officer
Dartmouth-Hitchcock Health
One Medical Center Drive
Lebanon, New Hampshire

C. Richard Boland, MD
Chief, Division of Gastroenterology
Baylor Scott and White
Baylor University Medical Center
Dallas, Texas

Edward L. Bove, MD
Helen and Marvin Kirsh Professor of Cardiac Surgery
Chair, Cardiac Surgery Department
Cardiovascular Center
Ann Arbor, Michigan

Darren Bowe, MD
Attending Surgeon
Wyoming Medical Center
Casper, Wyoming

Robert S. Bresalier, MD
Professor of Medicine
Birdie J. and Lydia J. Resoft Distinguished Professor in Gastrointestinal Oncology
Department of Gastroenterology, Hepatology, and Nutrition
The University of Texas MD Anderson Cancer Center
Houston, Texas

Jonathan R. Brody, PhD
Director of Surgical Research, Professor
Department of Surgery
Thomas Jefferson University
Philadelphia, Pennsylvania

Carlos V.R. Brown, MD
Associate Professor
Dell Medical School
University of Texas at Austin
Trauma Medical Director
University Medical Center Brackenridge
Austin, Texas

David L. Brown, MD
Associate Professor of Surgery
Section of Plastic Surgery
University of Michigan
Ann Arbor, Michigan

Brandon R. Bruns, MD
Associate Professor
Department of Surgery
University of Maryland School of Medicine
R Adams Cowley Shock Trauma Center
Baltimore, Maryland

Steven R. Buchman, MD
M. Haskell Newman Professor in Plastic Surgery
Professor of Neurosurgery
Program Director, Craniofacial Surgery Fellowship
University of Michigan Medical School
Chief, Pediatric Plastic Surgery
CS Mott Children's Hospital
Director, Craniofacial Anomalies Program
University of Michigan Medical Center
Ann Arbor, Michigan

J. Kenneth Byrd, MD
Assistant Professor
Department of Otolaryngology – Head and Neck Surgery
Medical College of Georgia
Augusta, Georgia

Andrew M. Cameron, MD, PhD
Associate Professor of Surgery
Director of Liver Transplantation
The Johns Hopkins University School of Medicine
Baltimore, Maryland

E. Ramsay Camp, MD
Associate Professor of Surgery
Division of Oncologic and Endocrine Surgery
Medical University of South Carolina
Charleston, South Carolina

Darrell A. Campbell, Jr., MD
Professor of Surgery
University of Michigan
Ann Arbor, Michigan

Robert M. Cannon, MD
Instructor/Fellow
Department of Surgery
Division of Transplantation
University of Alabama at Birmingham
Birmingham, Alabama

Kenneth Cardona, MD
Assistant Professor of Surgery
Division of Surgical Oncology
Emory University Hospital Midtown
Emory Winship Cancer Institute
Atlanta, Georgia

Darrell L. Cass, MD
Associate Professor
Departments of Surgery, Pediatrics, and Obstetrics and Gynecology
Baylor College of Medicine
Co-Director, Texas Children's Fetal Center
Texas Children's Hospital
Houston, Texas

Paul S. Cederna, MD
Chief, Section of Plastic Surgery
Robert Oneal Professor of Plastic Surgery
Professor, Department of Biomedical Engineering
University of Michigan

Ann Arbor, Michigan

Rajiv Chandawarkar, MD
Director, Plastic Surgery, OSU East Hospital
Associate Professor of Plastic Surgery
Adjunct Associate Professor of Orthopedics
The Ohio State University Wexner Medical Center
Columbus, Ohio

Andrew C. Chang, MD
Associate Professor of Surgery
John Alexander Distinguished Professor
Head, Section of Thoracic Surgery
Department of Surgery
University of Michigan
Ann Arbor, Michigan

Kristofer M. Charlton-Ouw, MD
Department of Cardiothoracic and Vascular Surgery
University of Texas Medical School at Houston
Memorial Hermann Heart & Vascular Institute
Houston, Texas

Randall M. Chesnut, MD
Professor
Neurological Surgery, Orthopaedics and Sports Medicine
University of Washington
Seattle, Washington

Jayer Chung, MD, MSc
Assistant Professor
Michael E. DeBakey Department of Surgery
Division of Vascular Surgery and Endovascular Therapy
Baylor College of Medicine
Houston, Texas

Kevin C. Chung, MD, MS
Chief of Hand Surgery
University of Michigan
Charles B. G. de Nancrede Professor of Surgery
Section of Plastic Surgery
Department of Surgery
Professor of Orthopaedic Surgery
Assistant Dean for Faculty Affairs

University of Michigan Medical School
Ann Arbor, Michigan

Robert E. Cilley, MD
Professor of Surgery and Pediatrics
Penn State College of Medicine
Penn State Children's Hospital
State College, Pennsylvania

Damon Clark, MD
Assistant Professor of Surgery
Department of Surgery
Acute Care Surgery
University of Southern California
Los Angeles, California

Dawn M. Coleman, MD
Assistant Professor – Vascular Surgery
University of Michigan
Cardiovascular Center
Ann Arbor, Michigan

Dorin T. Colibaseanu, MD
Assistant Professor of Surgery
Section of Colon and Rectal Surgery
Department of Surgery
Mayo Clinic
Jacksonville, Florida

Zara Cooper, MD
Assistant Professor of Surgery
Harvard Medical School
Division of Trauma, Burns, and Surgical Critical Care
Department of Surgery
Brigham and Women's Hospital
Boston, Massachusetts

Bryan A. Cotton, MD, MPH
Professor of Surgery
University of Texas Health Science Center
Houston, Texas

Joseph Cuschieri, MD
Professor of Surgery

Director of Surgical Critical Care, Harborview Medical Center
Associate Program Director, Surgical Critical Care Fellowship
University of Washington
Seattle, Washington

Michael C. Dalsing, MD
Chief
Department of Surgery
Division of Vascular Surgery
Indiana University School of Medicine
Indianapolis, Indiana

Kimberly A. Davis, MD, MBA
Professor of Surgery
Vice Chairman of Clinical Affairs
Chief of the Section of General Surgery, Trauma, and Surgical Critical Care
Yale School of Medicine
Trauma Medical Director
Surgical Director, Quality and Performance Improvement
New Haven, Connecticut

Jonathan D'Cunha, MD, PhD
Associate Professor of Surgery
Vice Chairman, Academic Affairs
Surgical Director, Lung Transplantation
Surgical Director, ECMO
Associate Program Director, Thoracic Surgery Program Director, Advanced Lung/Heart Failure Fellowship
Department of Cardiothoracic Surgery at UPMC
Pittsburgh, Pennsylvania

M. George DeBusk, MD, MSc, FACS, FCCP
Assistant Professor
Division of Trauma, Surgical Critical Care and Acute Care Surgery
UMass Memorial Medical Center
Worcester, MA

Steven R. DeMeester, MD
Thoracic, Foregut and Minimally Invasive Surgery
The Oregon Clinic
Portland, Oregon

Demetrios Demetriades, MD, PhD
Professor of Surgery

Director of Trauma, Emergency Surgery, Surgical Critical Care
University of Southern California
Los Angeles, California

Justin B. Dimick, MD, MPH
George D. Zuidema Professor of Surgery
Director, Center for Healthcare Outcomes & Policy
Chief, Division of Minimally Invasive Surgery
Department of Surgery
University of Michigan
Ann Arbor, Michigan

Gerard M. Doherty, MD
Surgeon-in-Chief
Brigham and Women's Health Care & Dana-Farber Cancer Institute
Moseley Professor of Surgery
Harvard Medical School
Boston, Massachusetts

Christine Durand, MD
Assistant Professor of Medicine and Oncology Division of Infectious Diseases
The Johns Hopkins University School of Medicine
Baltimore, Maryland

Jean C. Emond, MD
Thomas S. Zimmer Professor of Surgery
Director of Transplantation
Columbia University and The New York Presbyterian Hospital
New York, New York

Michael J. Englesbe, MD
Associate Professor of Surgery
Division of Transplantation
University of Michigan
Ann Arbor, Michigan

Anthony L. Estrera, MD
Department of Cardiothoracic and Vascular Surgery
University of Texas Medical School at Houston
Memorial Hermann Heart & Vascular Institute
Houston, Texas

Sandy H. Fang, MD
Assistant Professor

Department of Surgery
Ravitch Division, Colon and Rectal Surgery
Johns Hopkins Hospital
Baltimore, Maryland

Robert L. Ferris, MD, PhD
Professor
Vice-Chair for Clinical Operations
Chief, Division of Head and Neck Surgery
Associate Director for Translational Research
Co-Leader, Cancer Immunology Program
University of Pittsburgh Cancer Institute
Pittsburgh, Pennsylvania

Robert J. Fitzgibbons, Jr., MD
Harry E. Stuckenhoff Professor and Chairman
Department of Surgery
Creighton University School of Medicine
Medical Director of Surgical Services and Anesthesia
Alegent Creighton Clinic
Co-editor-in-Chief, Hernia
Omaha, Nebraska

James W. Fleshman, MD
Helen Buchanan and Stanley Joseph Seeger Professor and Chairman
Department of Surgery
Baylor University Medical Center
Professor of Surgery
Texas A&M Health Science Center
Dallas, Texas

Yuman Fong, MD
Professor and Chairman
Department of Surgery
City of Hope Medical Center
Duarte, California

Douglas L. Fraker, MD
Jonathan E. Rhoads Associate Professor of Surgery
Chief, Division of Surgical Oncology
University of Pennsylvania
Philadelphia, Pennsylvania

Heidi Frankel, MD

Department of Surgery
University of Southern California
Los Angeles, California

Chris E. Freise, MD
Professor of Surgery
Transplant Division
University of California
San Francisco, California

Samir K. Gadepalli, MD
Clinical Lecturer
Co-Director of Pediatric Surgical Critical Care
University of Michigan
Ann Arbor, Michigan

Julio Garcia-Aguilar, MD, PhD
Chief, Colorectal Service
Benno C. Schmidt Chair in Surgical Oncology
Memorial Sloan Kettering Cancer Center
New York, New York

Paul G. Gauger, MD
William J. Fry Professor of Surgery
Professor of Learning Health Sciences
Program Director – General Surgery
Division Head – Endocrine Surgery
Department of Surgery
University of Michigan
Ann Arbor, Michigan

Ravi K. Ghanta, MD
Assistant Professor of Surgery
Division of Cardiothoracic Surgery
University of Virginia
Charlottesville, Virginia

Kristina A. Giles, MD
Assistant Professor of Surgery
Division of Vascular Surgery and Endovascular Therapy
University of Florida College of Medicine
Gainesville, Florida

William E. Gillanders, MD

Professor of Surgery
Washington University School of Medicine
Attending Surgeon
Barnes-Jewish Hospital
St. Louis, Missouri

A. Marc Gillinov, MD
Staff Surgeon
The Judith Dion Pyle Chair in Heart Valve Research
Department of Thoracic and Cardiovascular Surgery
Cleveland Clinic
Cleveland, Ohio

Jason S. Gold, MD
Department of Surgery
Brigham and Women's Hospital
Harvard Medical School
Boston, Massachusetts
Chief of Surgical Oncology
Surgical Service
VA Boston Healthcare System
West Roxbury, Massachusetts

Batya R. Goldwaser, DMD, MD
Oral and Maxillofacial Surgeon
Former Fellow and Resident
Department of Oral and Maxillofacial Surgery
Massachusetts General Hospital
Boston, Massachusetts

Niraj J. Gusani, MD, MS
Associate Professor of Surgery, Medicine, & Public Health Sciences
Section of Surgical Oncology
Penn State College of Medicine
Director, Program for Liver, Pancreas, & Foregut Tumors
Co-Medical Director, Outpatient Services
Penn State Cancer Institute
Hershey, Pennsylvania

Jonathan W. Haft, MD
Associate Professor, Cardiac Surgery
University of Michigan
Ann Arbor, Michigan

Mark R. Hemmila, MD
Professor of Surgery
Division of Acute Care Surgery
University of Michigan
Ann Arbor, Michigan

Peter K. Henke, MD
Leland Ira Doan Professor of Surgery
Chief, Vascular Surgery AAVA
University of Michigan
Ann Arbor, Michigan

Jennifer C. Hirsch-Romano, MD
Assistant Professor of Cardiac Surgery & Pediatrics
Associate Director, Pediatric Cardiothoracic Intensive Care Unit
C.S. Mott Children's Hospital
Ann Arbor, Michigan

John B. Holcomb, MD
Professor of Surgery
University of Texas Health Science Center
Houston, Texas

Michael G. House, MD
Associate Professor of Surgery
Indiana University School of Medicine
Indianapolis, Indiana

Thomas S. Huber, MD, PhD
Professor of Surgery
Chief, Division of Vascular Surgery and Endovascular Therapy
University of Florida College of Medicine
Gainesville, Florida

David T. Hughes, MD
Assistant Professor of Surgery
Department of Surgery
Division of Endocrine Surgery
University of Michigan
Ann Arbor, Michigan

Kenji Inaba, MD
Associate Professor of Surgery, Emergency Medicine, and Anesthesia
Division of Trauma and Surgical Critical Care

University of Southern California
Los Angeles, California

Craig M. Jarrett, MD, MBA
Fellow in Cardiothoracic Surgery
Division of Cardiac Surgery
Brigham and Women's Hospital
Boston, Massachusetts

Eric K. Johnson, MD
MultiCare Colon and Rectal Surgery
Tacoma, Washington
Associate Professor of Surgery
Uniformed Services University of the Health Sciences
Bethesda, Maryland

Timothy M. Johnson, MD
Lewis and Lillian Becker Professor
Department of Dermatology
University of Michigan
Ann Arbor, Michigan

Bellal Joseph, MD,
Associate Professor of Surgery
University of Arizona
Tucson, Arizona

Gregory J. Jurkovich, MD
Professor and Vice-Chairman
Department of Surgery
UC Davis Health System
Sacramento, California

Leonard B. Kaban, MD, DMD
Chief, Oral and Maxillofacial Surgery
Massachusetts General Hospital
Boston, Massachusetts

Loay S. Kabbani, MD
Senior Staff Surgeon
Department of Vascular Surgery
Henry Ford Hospital
Detroit, Michigan

Jussuf T. Kaifi, MD, PhD
Assistant Professor of Surgery
Chief, Thoracic Surgery
Department of Surgery
University of Missouri
Columbia, Missouri

Giorgos C. Karakousis, MD
Assistant Professor of Surgery
Division of Endocrine and Oncologic Surgery
University of Pennsylvania
Philadelphia, Pennsylvania

George Kasotakis, MD, MPH
Assistant Professor of Surgery
Boston University Medical School
Division of Trauma, Acute Care Surgery & Surgical Critical Care
Department of Surgery
Boston Medical Center
Boston, Massachusetts

Kaitlyn J. Kelly, MD
Assistant Professor of Surgery
Division of Surgical Oncology
Moores Cancer Center
University of California, San Diego
La Jolla, California

Sachin Kheterpal, MD
Associate Professor of Anesthesiology
University of Michigan
Ann Arbor, Michigan

Eric T. Kimchi, MD, MBA
Associate Professor of Surgery
Chief, Surgical Oncology
Medical Director, Ellis Fischel Cancer Center
University of Missouri
Columbia, Missouri

Martyn Knowles, MD
Assistant Professor
Division of Vascular and Endovascular Surgery
University of Texas Southwestern

Dallas, Texas

David A. Kooby, MD
Professor of Surgery
Director of Surgical Oncology
Emory/Saint Joseph's Hospital
Director of Minimally Invasive GI Surgical Oncology
Emory University School of Medicine
Winship Cancer Institute
Atlanta, Georgia

Marijan Koprivanac, MD, MS
Resident
Department of General Surgery Research Fellow
Department of Cardiothoracic Surgery
Cleveland Clinic
Clinical Instructor
Case Western University
Cleveland, Ohio

Lauren A. Kosinski, MD
Welkin Group, Inc.
Chestertown, Maryland

Jeffrey H. Kozlow, MD, MS
Clinical Assistant Professor
Section of plastic Surgery
University of Michigan
Ann Arbor, Michigan

Devi Mukkai Krishnamurty, MD
Clinical Fellow
Colon and Rectal Surgery
Washington University School of Medicine-Barnes Jewish Hospital
St. Louis, Missouri

William M. Kuzon, Jr., MD, PhD
Reed O. Dingman Professor of Surgery
Section of Plastic Surgery
University of Michigan
Chief of Surgery
Ann Arbor VA Healthcare
Ann Arbor, Michigan

David W. Larson, MD, MBA
Professor of Surgery and Chair
Division of Colon and Rectal Surgery
Mayo Clinic
Rochester, Minnesota

Adriana Laser, MD
University of Maryland Medical Center
Baltimore, Maryland

Harish Lavu, MD
Section Chief HPB Surgery
Associate Professor
Thomas Jefferson University
Philadelphia, Pennsylvania

Steven G. Leeds, MD
Assistant Clinical Professor of Surgery
Texas A&M College of Medicine
Medical Director of MIS Research and Surgical Simulation
Division of Minimally Invasive Surgery
Baylor University Medical Center at Dallas
Dallas, Texas

Benjamin Levi, MD
Director, Burn/Wound and Regenerative Medicine Laboratory
Director, Burn Reconstruction and Scar Rehabilitation Program
Assistant Professor in Surgery
Divisions of Plastic and Reconstructive Surgery and Burn Surgery
University of Michigan
Ann Arbor, Michigan

Edward A. Levine, MD
Professor of Surgery
Chief, Surgical Oncology
Wake Forest University
Winston-Salem, North Carolina

Keith D. Lillemoe, MD
W. Gerald Austen Professor of Surgery, Harvard Medical School
Chief of Surgery and Surgeon-in-Chief
The Massachusetts General Hospital
Boston, Massachusetts

Jules Lin, MD
Surgical Director, Lung Transplant
Associate Professor
Section of Thoracic Surgery
University of Michigan
Ann Arbor, Michigan

Kirk Ludwig, MD
The Vernon O. Underwood Professor
Professor of Surgery
Chief, Division of Colorectal Surgery
Department of Surgery
Medical College of Wisconsin
Milwaukee, Wisconsin

Felix Y. Lui, MD
Associate Professor of Surgery
Section of General Surgery, Trauma, and Surgical Critical Care
Yale School of Medicine
New Haven, Connecticut

James D. Luketich, MD
Chairman, Department of Cardiothoracic Surgery
University of Pittsburgh Medical Center
University of Pittsburgh
Henry T. Bahson Professor of Cardiothoracic Surgery
Chairman, Department of Cardiothoracic Surgery
University of Pittsburgh School of Medicine
Pittsburgh, Pennsylvania

Geoffrey T. Manley, MD, PhD
Professor and Vice Chairman of Neurological Surgery
University of California, San Francisco
Chief of Neurosurgery, San Francisco General Hospital
Co-Director, Brain and Spinal Injury Center
San Francisco, California

John C. Mansour, MD
Surgical Oncologist
Associate Professor Surgery
Chief, Division of Surgical Oncology
Department of Surgery
University of Texas Southwestern Medical Center
Dallas, Texas

David J. Maron, MD, MBA
Vice Chair
Department of Colorectal Surgery
Cleveland Clinic Florida
Weston, Florida

Juan L. Martinez-Poyer, MD
Clinical Assistant Professor of Obstetrics and Gynecology
Perelman School of Medicine
University of Pennsylvania
Attending Physician, The Center for Fetal Diagnosis and Treatment
The Children's Hospital of Philadelphia
Philadelphia, Pennsylvania

Michael R. Marvin, MD
Chief, Division of Transplantation
Director of Liver Transplantation
Associate Professor of Surgery
University of Louisville
Jewish Hospital
Louisville, Kentucky

Peter T. Masiakos, MS, MD
Associate Professor of Surgery, Harvard Medical School
Associate Visiting Pediatric Surgeon
Director, Pediatric Trauma Service
Massachusetts General Hospital
Boston, Massachusetts

Michael R. Mathis, MD
Clinical Lecturer, Anesthesiology
University of Michigan
Ann Arbor, Michigan

Amit K. Mathur, MD, MS
Assistant Professor of Surgery
Mayo Medical School
Senior Associate Consultant
Transplant Surgery
Mayo Clinic Arizona
Phoenix, Arizona

Tomislav Mihaljevic, MD
Professor of Surgery

Cleveland Clinic Lerner College of Medicine
Chief Executive Officer, Cleveland Clinic Abu Dhabi
Abu Dhabi, UAE

Dianna Milewicz, MD, PhD
Department of Cardiothoracic and Vascular Surgery
University of Texas Medical School at Houston
Memorial Hermann Heart & Vascular Institute
Houston, Texas

Michael J. Miller, MD
Chairman
Department of Plastic Surgery
The Ohio State University Wexner Medical Center
Columbus, Ohio

Charles C. Miller III, PhD
Department of Cardiothoracic and Vascular Surgery
University of Texas Medical School at Houston
Memorial Hermann Heart & Vascular Institute
Houston, Texas

Rebecca M. Minter, MD
Professor of Surgery
Alvin Baldwin, Jr. Chair in Surgery
University of Texas Southwestern Medical Center
Dallas, Texas

Jason S. Mizell, MD
Assistant Professor of Surgery
Division of Colon and Rectal Surgery
Director of Surgery Clerkship
University of Arkansas for Medical Sciences
Little Rock, Arkansas

J. Gregory Modrall, MD
Professor of Surgery
Division of Vascular and Endovascular Surgery
University of Texas Southwestern Medical Center
Dallas, Texas

Adeyiza O. Momoh, MD
Assistant Professor of Surgery
Section of Plastic Surgery

Department of Surgery
University of Michigan
Ann Arbor, Michigan

Gregory L. Moneta, MD
Professor of Surgery, Chief of Vascular Surgery
Knight Cardiovascular Institute
Oregon Health & Science University
Portland, Oregon

Katherine A. Morgan, MD
Professor of Surgery
Division of Gastrointestinal and Laparoscopic Surgery
Medical University of South Carolina
Charleston, South Carolina

Nathan Mowery, MD
Associate Professor of Surgery
Wake Forest University
Winston-Salem, North Carolina

Marc de Moya, MD
Associate Professor of Surgery
Acute Care Surgery Program Director
Division of Trauma, Acute Care Surgery
Department of Surgery
Massachusetts General Hospital
Harvard Medical School
Boston, Massachusetts

Michael W. Mulholland, MD, PhD
Frederick A. Coller Distinguished Professor of Surgery
Chair, Department of Surgery
University of Michigan
Ann Arbor, Michigan

George B. Mychaliska, MD
Robert Bartlett, M.D. Collegiate Professor of Pediatric Surgery
Associate Professor of Surgery and Obstetrics and Gynecology
Director, Fetal Diagnosis and Treatment Center
Associate Chair for Faculty Development
Co-Director, ECMO Program
University of Michigan Medical School
Section of Pediatric Surgery

Department of Surgery
Ann Arbor, Michigan

Satish N. Nadig, MD, PhD
Assistant Professor Surgery, Microbiology, & Immunology
Transplant Surgery
Medical University of South Carolina
Charleston, South Carolina

Jeffry Nahmias, MD
Assistant Professor, Surgery
Tufts University School of Medicine
Director of Trauma Summer Undergraduate Research Program (T-SURP)
Baystate Medical Center
Springfield, Massachusetts

Attila Nakeeb, MD
Professor of Surgery
Indiana University School of Medicine
Indianapolis, Indiana

Lena M. Napolitano, MD
Professor of Surgery
Division Chief, Acute Care Surgery
Director, Trauma and Surgical Critical Care
Department of Surgery
University of Michigan
Ann Arbor, Michigan

Hari Nathan, MD, PhD
Assistant Professor
Department of Surgery
University of Michigan
Ann Arbor, Michigan

Laura L. Neff, MD
Attending Otolaryngologist
Pediatric Otolaryngology
The Children's Mercy Hospital
Kansas City, Missouri

Erika Adams Newman, MD
Assistant Professor in Pediatric Surgery
Associate Program Director, General Surgery

Surgical Director, Mott Solid Tumor Oncology Program (MSTOP)
Translational Oncology Program
CS Mott Children's Hospital
The University of Michigan
Ann Arbor, Michigan

Trevor L. Nydam, MD
Assistant Professor and Transplant Surgeon
University of Colorado Hospital (UCH)
Aurora, Colorado

Robert W. O'Rourke, MD
Associate Professor
Department of Surgery
University of Michigan and Ann Arbor Veteran's Administration Hospital
Ann Arbor, Michigan

Daniel S. Oh, MD
Assistant Professor of Surgery
Division of Thoracic Surgery
Keck School of Medicine
University of Southern California
Los Angeles, California

Richard G. Ohye, MD
Professor of Cardiac Surgery
Head, Section of Pediatric Cardiovascular Surgery
Surgical Director, Pediatric Cardiovascular Transplant Program
Program Director, Congenital Cardiac Surgery Residency
Co-Director, Michigan Congenital Heart Center
Ann Arbor, Michigan

John A. Olson, Jr., MD, PhD
Campbell and Jeanette Plugge Professor of Surgery
Vice Chair, Department of Surgery
Chief, Division of General and Oncologic Surgery
The University of Maryland School of Medicine
Baltimore, Maryland

Mary F. Otterson, MD, MS
Professor of Surgery and Physiology
Medical College of Wisconsin
Zablocki Veteran Affairs Medical Center
Milwaukee, Wisconsin

Francis D. Pagani, MD, PhD
Otto Gago, MD Professor in Cardiac Surgery
Department of Cardiac Surgery
University of Michigan
Ann Arbor, Michigan

John M. Park, MD
Cheng-Yang Chang Professor of Pediatric Urology
Department of Urology
University of Michigan
Ann Arbor, Michigan

Pauline Park, MD
Department of Surgery
University of Michigan
Ann Arbor, Michigan

Richard N. Pierson III, MD
Professor of Surgery
Cardiac Surgery
University of Maryland School of Medicine
College Park, Maryland

Thomas H. Quinn, MS, PhD
Professor of Anatomy and Surgery
Assistant Dean for Medical Admissions
Past President, American Association of Clinical Anatomists
Creighton University School of Medicine
Omaha, Nebraska

Reza Rahbar, DMD, MD
Associate Otolaryngologist-in-Chief
McGill Chair in Pediatric Otolaryngology
Department of Otolaryngology
Boston Children's Hospital/Harvard Medical School
Boston, Massachusetts

Steven E. Raper, MD, JD
Associate Professor of Surgery
Department of Surgery
Perelman School of Medicine, University of Pennsylvania
Philadelphia, Pennsylvania

Todd E. Rasmussen, MD

Harris B Shumacker Professor of Surgery
The Uniformed Services University of the Health Sciences
Bethesda, Maryland

John E. Rectenwald, MD, MS
Associate Professor of Surgery & Radiology
Program Director, Vascular Surgery
Section of Vascular Surgery
University of Michigan
Ann Arbor, Michigan

Rishindra M. Reddy, MD
Assistant Professor of Thoracic Surgery
University of Michigan
Ann Arbor, Michigan

Amy B. Reed, MD
Chief and Program Director, Vascular Surgery
Heart and Vascular Institute
Penn State Hershey Medical Center
Hershey, Pennsylvania

Peter Rhee, MD, MPH
Senior Vice President
Chief of Acute Care Surgery and Trauma Medical Director
Grady Memorial Hospital
Atlanta, Georgia

Taylor S. Riall, MD, PhD
Professor, Chief of General Surgery and Surgical Oncology
Banner-University Medical Center
University of Arizona
Tucson, Arizona

Haris Riaz, MD
Resident physician
Department of Internal Medicine
Cleveland Clinic Foundation
Cleveland, Ohio

William P. Robinson III, MD
Associate Professor
Division of Vascular and Endovascular Surgery
University of Virginia

Charlottesville, Virginia

Heron E. Rodriguez, MD
Associate Professor of Vascular Surgery
Northwestern University Feinberg School of Medicine
Chicago, Illinois

Matthew R. Rosengart, MD, MPH
Associate Professor of Surgery, Critical Care Medicine
Director, University of Pittsburgh Surgical Critical Care Fellowship Program
Co-Director, University of Pittsburgh Department of Surgery, Surgical Outcomes Research Center
University of Pittsburgh
Pittsburgh, Pennsylvania

Michael S. Sabel, MD
Chief, Division of Surgical Oncology
Associate Professor of Surgery
University of Michigan Health System
Ann Arbor, Michigan

Hazim J. Safi, MD
Department of Cardiothoracic and Vascular Surgery
University of Texas Medical School at Houston
Memorial Hermann Heart & Vascular Institute
Houston, Texas

Ali Salim, MD
Professor
Harvard Medical School
Division Chief, Trauma, Burns, and Surgical Critical Care
Brigham and Women's Hospital
Boston, Massachusetts

Gordan Samoukovic, MD
Department of Cardiothoracic Surgery
McGill University
Montreal, Quebec
Canada

Gurjit Sandhu, PhD
Assistant Professor
Departments of Surgery and Learning Health Sciences
Department of Surgery
University of Michigan

Ann Arbor, Michigan

Ariel P. Santos, MD, MPH
Assistant Professor
Associate Program Director of Emergency General Surgery
Department of Surgery
Division of Trauma, Acute Care and Critical Care Surgery
Penn State Milton S. Hershey Medical Center
Hershey, Pennsylvania

Mary C. Santos, MD
Associate Professor of Surgery and Pediatrics
Penn State College of Medicine
Penn State Children's Hospital
State College, Pennsylvania

Thomas T. Sato, MD
Professor of Surgery
Division of Pediatric Surgery
CEO, Children's Specialty Group
Senior Associate Dean of Clinical Affairs
Children's Hospital of Wisconsin and The Medical College of Wisconsin
Milwaukee, Wisconsin

Thomas M. Scalea, MD
Physician-in-Chief, Shock Trauma Center
System Chief for Critical Care Services
University of Maryland Medical System
The Honorable Francis X. Kelly Distinguished Professor in Trauma
Director, Program in Trauma
University of Maryland School of Medicine
Baltimore, Maryland

Richard D. Schulick, MD, MBA
The Aragón/Gonzalez-Gíustí Chair
Professor and Chair
Department of Surgery
University of Colorado Anschutz Medical Campus
Aurora, Colorado

Alexander D. Shepard, MD
Head, Division of Vascular Surgery
Szilagyi Chair in Vascular Surgery
Henry Ford Hospital

Professor of Surgery
Wayne State University School of Medicine
Detroit, Michigan

Junichi Shindoh, MD, PhD
Assistant Professor
Hepatobiliary-pancreatic Surgery Division
Department of Surgery
Graduate School of Medicine
The University of Tokyo
Tokyo, Japan

Matthew J. Sideman, MD
Associate Professor
Department of Surgery
Vascular Surgery Division
University of Texas Health Science Center at San Antonio
San Antonio, Texas

Raymond Malcolm Smith, MB CHB, MD
Chief, Orthopaedic Trauma Service
Massachusetts General Hospital
Associate Professor of Orthopaedics
Harvard Medical School
Boston, Massachusetts

Elizabeth S. Soukup, MD, MMSc
Pediatric Surgeon, Elliot Health System
Assistant Professor of Surgery
Geisel School of Medicine
Dartmouth Hitchcock Medical Center
Hanover, New Hampshire

David I. Soybel, MD
David L. Nahrwold Professor of Surgery
Division Chief, General Surgery Specialties & Surgical Oncology
Penn State Hershey Medical Center
Hershey, Pennsylvania

Kevin F. Staveley-O'Carroll, MD, PhD
Hugh E. Stephenson, Jr., MD, Chair of Surgery
Director, Ellis Fischel Cancer Center
Professor of Surgery
University of Missouri

Columbia, Missouri

Scott R. Steele, MD
Vice Chairman for Clinical Affairs, Department of Surgery
Chief, Division of Colorectal Surgery
University Hospitals Case Medical Center
Professor of Surgery
Case Western Reserve University
Cleveland, Ohio

Peter G. Stock, MD, PhD
Professor of Surgery
University of California, San Francisco
San Francisco, California

Randall S. Sung, MD
Assistant Professor of Surgery
Surgical Director, Kidney and Pancreas Transplantation
University of Michigan
Ann Arbor, Michigan

Brooke Swearingen, MD
Professor of Neurosurgery
Neurosurgical Service, Massachusetts General Hospital
Harvard Medical School
Boston, Massachusetts

Phiroz E. Tarapore, MD
Assistant Professor of Clinical Neurosurgery
Department of Neurological Surgery
University of California San Francisco
San Francisco, California

Kevin E. Taubman, MD
Assistant Professor of Surgery and Program Director Vascular Surgery Fellowship
Section of Vascular and Endovascular Surgery
Department of Surgery
University of Oklahoma College of Medicine, Tulsa
Tulsa, Oklahoma

John R. Taylor III, MD
Clinical Instructor in Surgery
University of Texas Health Science Center
Houston, Texas

Carlos H. Timaran, MD
Chief, Endovascular Surgery
G. Patrick Clagett Professorship in Surgery
Associate Professor, Division of Vascular and Endovascular Surgery
University of Texas Southwestern
Dallas, Texas

Shahab Toursavadkohi, MD
Assistant Professor of Surgery
Division of Vascular Surgery
University of Maryland Medical Center
Baltimore, Maryland

Nicholas A. Tritos, MD, DSc
Neuroendocrine Unit
Department of Medicine
Massachusetts General Hospital
Assistant Professor of Medicine
Harvard Medical School
Boston, Massachusetts

Maria J. Troulis, DDS, MSc
Chief, Oral Maxillofacial Surgery
Massachusetts General Hospital
Walter Guralnick Professor and Chair, Oral Maxillofacial Surgery
Harvard Dental School
Boston, Massachusetts

Richard H. Turnage, MD
Professor and Chairman
Department of Surgery
University of Arkansas for Medical Sciences
Little Rock, Arkansas

Douglas J. Turner, MD
Associate Professor of Surgery
University of Maryland School of Medicine
Chief of Surgery
Baltimore VA Medical Center
Baltimore, Maryland

Gilbert R. Upchurch, Jr., MD
Chief of Vascular and Endovascular Surgery
William H. Muller, Jr. Professor of Surgery

Professor of Molecular Physiology and Biological Physics
University of Virginia
Charlottesville, Virginia

Jean-Nicolas Vauthey, MD
Professor
Department of Surgical Oncology
The University of Texas MD Anderson Cancer Center
Houston, Texas

George Velmahos, MD, PhD, MSEd
John F. Burke Professor of Surgery
Harvard Medical School
Chief, Division of Trauma, Emergency Surgery, and Surgical Critical Care
Massachusetts General Hospital
Boston, Massachusetts

Christian J. Vercler, MD, MA
Assistant Professor
Section of Plastic Surgery
Department of Surgery
University of Michigan
Ann Arbor, Michigan

Richard B. Wait, MD, PhD
Professor Emeritus of Surgery
Tufts University School of Medicine
Boston, Massachusetts
Chairman of Surgery (retired)
Baystate Medical Center
Springfield, Massachusetts

Thomas W. Wakefield, MD
Stanley Professor of Vascular Surgery
Section Head, Section of Vascular Surgery, Department of Surgery
Director, Samuel and Jean Frankel Cardiovascular Center
University of Michigan
Ann Arbor, Michigan

J. Patrick Walker, MD
Chief of Surgery
Houston County Medical Center
Crockett, Texas
Vice-Chair of Education

Department of Surgery
University of Texas Medical Branch
Galveston, Texas

Julian Wan, MD
Reed Nesbit Professor of Urology
Department of Urology
University of Michigan
Ann Arbor, Michigan

Stewart C. Wang, MD, PhD
First Endowed Professor of Burn Surgery
Director, Burn Center
Director, State of Michigan Burn Coordinating Center
Director, Morphomic Analysis Group
Director, International Center for Automotive Medicine
University of Michigan
Ann Arbor, Michigan

Mitchell R. Weaver, MD
Assistant Clinical Professor
Division of Vascular Surgery
Henry Ford Hospital
Wayne State University School of Medicine
Detroit, Michigan

Sharon Weber, MD
Tim and MaryAnn McKenzie Chair of Surgery
Director for Surgical Oncology, UW Carbone Cancer Center
Vice Chair of Academic Affairs, General Surgery
Professor of Surgery, Department of Surgery
University of Wisconsin School of Medicine and Public Health
Madison, Wisconsin

Theodore H. Welling, MD
Assistant Professor of Surgery
Co-Director, Multidisciplinary Liver Tumor Program
Section of Transplantation
University of Michigan
Ann Arbor, Michigan

Hunter Wessells, MD
Professor and Nelson Chair
Department of Urology

University of Washington
Seattle, Washington

Steven D. Wexner, MD, PHD (Hon)
Director, Digestive Disease Center
Chair, Department of Colorectal Surgery
Cleveland Clinic Florida
Affiliate Professor, Florida Atlantic University College of Medicine
Clinical Professor, Florida International University College of Medicine
Miami, Florida

Edward E. Whang, MD
Department of Surgery
Brigham and Women's Hospital
Boston, Massachusetts

Elizabeth C. Wick, MD
Associate Professor of Surgery
University of California San Francisco
San Francisco, California

Edwin G. Wilkins, MD, MS
Professor of Surgery
Section of Plastic Surgery
University of Michigan
Ann Arbor, Michigan

Joshua H. Winer, MD
Assistant Professor of Surgery
Division of Surgical Oncology
Emory University/Saint Joseph's Hospital
Winship Cancer Institute
Atlanta VA Medical Center
Atlanta, Georgia

Sandra L. Wong, MD, MS
Professor and Chair
Department of Surgery
Dartmouth-Hitchcock Medical Center
Geisel School of Medicine at Dartmouth
Hanover, New Hampshire

Charles J. Yeo, MD
Samuel D. Gross Professor and Chairman

Department of Surgery
Jefferson Medical College
Thomas Jefferson University
Philadelphia, Pennsylvania

Adam C. Yopp, MD
Assistant Professor of Surgery
Department of Surgery
Division of Surgical Oncology
University of Texas Southwestern Medical Center
Dallas, Texas

Preface

The editors are pleased to present the sixth edition of *Greenfield's Surgery: Scientific Principles & Practice*. The field of surgery has changed fundamentally in the years since the first edition of this text. Growth in the knowledge base of clinical surgery continues exponentially. Surgical practice has been transformed through advancements in physiologic and cellular investigation, integration of new techniques derived from imaging and robotics, from the concept of patient-centered care, and from the emerging field of biocomputation. The accelerating pace of scientific progress demands rapid adoption of new ideas into surgical therapy and a commitment to lifelong learning. Accordingly, the new edition of *Greenfield's Surgery* seeks to integrate new scientific knowledge with evolving changes in surgical care.

The sixth edition has been enhanced in every way, with changes to the book's editorial board, authorship, content, organization, and visual presentation. It reflects the founding principles and guidance of Lazar J. Greenfield, MD, whose perceptive wisdom helped to create a truly unique book that balances scientific advance with clinical practice. With this new edition, we welcome new editors—Hasan Alam, MD and Timothy Pawlik, MD. Their expertise, energy, and vision have invigorated this edition.

We have solicited contributions from well over 200 authors, all chosen because of their scientific and clinical sophistication. Each contributor is currently an active practitioner in the field of surgery. Moreover, many have presented seminal articles and developed the new concepts in their disciplines that are featured in the text. Advances ranging from patient safety to fetal surgery mark the book as truly unique.

Organizationally, the book begins with topics of broad relevance to the practice of surgery, followed with chapters arranged by organ system. Trauma and transplantation are presented in the form of separate sections rather than subdivided chapters. The content within each has been presented as individual chapters in appreciation of the significance of each topic.

The book has been designed to create a text that not only looks better but also works better. The text is produced in a full range of colors, creating both visual impact and more opportunity to convey information quickly and with greater meaning. We continue our commitment to superb medical art in the form of line drawings. These illustrations have been enhanced to ensure a presentation that maximizes teaching effectiveness and clinical utility. Each chapter begins with a series of highlighted key teaching points, which are referenced within the text that follows. Individually numbered decision-making algorithms are featured throughout the book to provide diagnostic and management information in a simplified format. Tables carry classification bars, such as diagnosis or results, useful both when scanning the text for information and when accessing the book's contents digitally. The most important articles and chapters on the topic are highlighted in the reference list.

The sixth edition continues to be highly integrated with electronic elements to provide supplemental educational material, including Morbidity and Mortality Case Discussions and an interactive question bank.

Today, *Greenfield's Surgery: Scientific Principles & Practice* has become the gold standard text in the field of surgery. The editors continue their commitment to the education of contemporary surgeons, and to improved care of the patients that they serve. We believe that with the many improvements implemented in this sixth edition, it will continue be the text by which all other surgery texts are judged.

Michael W. Mulholland, MD, PhD

Contents

Contributors
Preface

Part One **Scientific Principles**

1 Lifelong Learning
Gurjit Sandhu and Rebecca M. Minter

2 Principles of Intermediary Metabolism
Steven E. Raper

3 Surgical Nutrition and Metabolism
George Kasotakis

4 Obesity and Metabolic Disease
Robert W. O'Rourke and Michael W. Mulholland

5 Wound Healing
Rajiv Chandawarkar and Michael J. Miller

6 Hemostasis
Peter K. Henke and Thomas W. Wakefield

7 Inflammation
Matthew R. Rosengart and Timothy R. Billiar

8 Surgical Infections
Lena M. Napolitano

9 Shock
Joseph Cuschieri and Darren Bowe

10 Critical Care
Damon Clark and Heidi Frankel

11 Fluids, Electrolytes, and Acid–Base Balance
Richard B. Wait, M. George DeBusk, and Jeffry Nahmias

12 Burns
Benjamin Levi, Mark R. Hemmila, and Stewart C. Wang

13 Anesthesiology and Pain Management
Sachin Kheterpal and Michael R. Mathis

14 Oncology
Adam C. Yopp and John C. Mansour

15 Preoperative Risk Assessment

Pauline Park

16 Measuring the Quality of Surgical Care
Justin B. Dimick and John D. Birkmeyer

17 Policy Approaches to Improving Surgical Quality
John D. Birkmeyer and Justin B. Dimick

18 Patient Safety
Darrell A. Campbell, Jr.

Part Two **Surgical Practice**

SECTION A: TRAUMA

19 Trauma and Trauma Care: General Considerations
Hasan B. Alam

20 Prehospital and New Advances in Resuscitation
John R. Taylor III, John B. Holcomb, and Bryan A. Cotton

21 Head Trauma
Phiroz E. Tarapore, Geoffrey T. Manley, and Randall M. Chesnut

22 Maxillofacial Injuries
Batya R. Goldwaser, Leonard B. Kaban, and Maria J. Troulis

23 Neck Injuries
Brandon R. Bruns and Thomas M. Scalea

24 Thoracic Trauma
Marc de Moya and George Velmahos

25 Abdominal Trauma
Kenji Inaba, Elizabeth R. Benjamin, and Demetrios Demetriades

26 Genitourinary Trauma
Hunter Wessells

27 Vascular Trauma
Adriana Laser, Shahab Toursavadkohi, and Todd E. Rasmussen

28 The Principles of Orthopedic Surgery for Trauma
Raymond Malcolm Smith

29 Pediatric Trauma
Elizabeth S. Soukup and Peter T. Masiakos

30 Geriatric Trauma
Carlos V.R. Brown, Zara Cooper, and Ali Salim

31 Trauma in Pregnancy
Felix Y. Lui and Kimberly A. Davis

32 Postinjury Management
Bellal Joseph and Peter Rhee

33 Environmental Injuries
J. Patrick Walker and Gregory J. Jurkovich

SECTION B: TRANSPLANTATION

34 Clinical Transplant Immunology
Amit K. Mathur and Satish N. Nadig

35 Organ Procurement and Preservation
Michael J. Englesbe

36 Renal Transplantation
Chris E. Freise and Peter G. Stock

37 Hepatic Transplantation
Theodore H. Welling

38 Cardiac Transplantation
Richard N. Pierson III

39 Pulmonary Transplantation
Jules Lin and Andrew C. Chang

40 Pancreas and Islet Transplantation
Randall S. Sung

SECTION C: HEAD AND NECK

41 Head and Neck
J. Kenneth Byrd and Robert L. Ferris

SECTION D: ESOPHAGUS

42 Esophageal Anatomy and Physiology and Gastroesophageal Reflux Disease
Daniel S. Oh and Steven R. DeMeester

43 Esophageal Tumors and Injury
Jonathan D'Cunha and James D. Luketich

SECTION E: STOMACH AND DUODENUM

44 Gastric Anatomy and Physiology
Michael W. Mulholland

45 Gastroduodenal Ulceration
Michael W. Mulholland

46 Management of Obesity
Robert W. O'Rourke

47 Gastric Neoplasms
Hari Nathan and Rebecca M. Minter

SECTION F: SMALL INTESTINE

48 Anatomy and Physiology of the Small Intestine
E. Ramsay Camp, Kevin F. Staveley-O'Carroll, Niraj J. Gusani, Jussuf T. Kaifi, and Eric T. Kimchi

49 Ileus and Bowel Obstruction
David I. Soybel and Ariel P. Santos

50 Crohn Disease
Scott R. Steele and Eric K. Johnson

51 Small Bowel Tumors
Steven G. Leeds and James W. Fleshman

SECTION G: PANCREAS

52 Pancreas Anatomy and Physiology
Taylor S. Riall

53 Acute Pancreatitis
Jason S. Gold and Edward E. Whang

54 Chronic Pancreatitis
Katherine A. Morgan and David B. Adams

55 Neoplasms of Exocrine Pancreas
Attila Nakeeb, Michael G. House, and Keith D. Lillemoe

56 Neoplasms of the Endocrine Pancreas
Harish Lavu, Jonathan R. Brody, and Charles J. Yeo

SECTION H: HEPATOBILIARY AND PORTAL VENOUS SYSTEM

57 Hepatobiliary Anatomy
Trevor L. Nydam and Richard D. Schulick

58 Hepatic Infection and Acute Liver Failure
Andrew M. Cameron and Christine Durand

59 Cirrhosis and Portal Hypertension
Michael R. Marvin, Robert M. Cannon, and Jean C. Emond

60 Hepatic Neoplasms
Junichi Shindoh and Jean-Nicolas Vauthey

61 Calculous Biliary Disease
David A. Kooby, Joshua H. Winer, and Kenneth Cardona

62 Biliary Injuries and Strictures and Sclerosing Cholangitis
Chad G. Ball and Keith D. Lillemoe

63 Biliary Neoplasms
Kaitlyn J. Kelly, Yuman Fong, and Sharon Weber

SECTION I: COLON AND RECTUM

64 Colon and Rectal Anatomy and Physiology
Sandy H. Fang and Elizabeth C. Wick

65 Acute Gastrointestinal Hemorrhage
Jason S. Mizell and Richard H. Turnage

66 Ulcerative Colitis
Dorin T. Colibaseanu and David W. Larson

67 Colonic Polyps and Polyposis Syndromes
Robert S. Bresalier and C. Richard Boland

68 Colorectal Cancer
Julio Garcia-Aguilar

69 Diverticular Disease
Lauren A. Kosinski, Kirk Ludwig, and Mary F. Otterson

70 Anorectal Disorders
David J. Maron and Steven D. Wexner

71 Diseases of Appendix
Edward A. Levine and Nathan Mowery

SECTION J: HERNIA AND SPLEEN

72 Abdominal Wall Hernias
Robert J. Fitzgibbons, Jr., Thomas H. Quinn, and Devi Mukkai Krishnamurty

73 The Spleen
Giorgos C. Karakousis and Douglas L. Fraker

SECTION K: SURGICAL ENDOCRINOLOGY

74 Breast Disease
Thanh U. Barbie and William E. Gillanders

75 Thyroid Gland
David T. Hughes and Paul G. Gauger

76 Parathyroid Glands
Gerard M. Doherty

77 Adrenal Gland
John A. Olson, Jr. and Douglas J. Turner

78 Pituitary Surgery
Brooke Swearingen and Nicholas A. Tritos

SECTION L: LUNG

79 Lung Neoplasms

Andrew C. Chang and Jules Lin

80 Non-Neoplastic Thoracic Disease

Rishindra M. Reddy

SECTION M: VASCULAR DISEASE

81 Congenital Heart Disease

Jennifer C. Hirsch-Romano, Richard G. Ohye, and Edward L. Bove

82 Valvular Heart Disease and Cardiac Tumors

Tomislav Mihaljevic, Craig M. Jarrett, Husain T. AlQattan, Shehab Ahmad Redha AlAnsari, Haris Riaz, Marijan Koprivanac, and A. Marc Gillinov

83 Ischemic Heart Disease

Jonathan W. Haft

84 Mechanical Circulatory Support for Cardiac Failure

Gordan Samoukovic and Francis D. Pagani

85 Thoracic Aortic Aneurysms and Aortic Dissection

Ravi K. Ghanta and Gorav Ailawadi

86 Pericardium

Jules Lin

87 Vascular Diagnostics: The Noninvasive Vascular Laboratory

Gregory L. Moneta

88 Vascular Infection

Jayer Chung and J. Gregory Modrall

89 Cerebrovascular Disease

Martyn Knowles and Carlos H. Timaran

90 Upper Extremity Arterial Disease

Heron E. Rodriguez

91 Renal and Splanchnic Vascular Disease

Dawn M. Coleman, John E. Rectenwald, and Gilbert R. Upchurch, Jr.

92 Aortoiliac Disease

Loay S. Kabbani, Mitchell R. Weaver, and Alexander D. Shepard

93 Peripheral Arterial Disease

William P. Robinson III

94 Lower Extremity Amputation

Matthew J. Sideman, Kevin E. Taubman, and Bradley D. Beasley

95 Thoracoabdominal Aortic Aneurysms

Hazim J. Safi, Anthony L. Estrera, Charles C. Miller III, Kristofer M. Charlton-Ouw, Dianna Milewicz, and Ali

Azizzadeh

96 Abdominal Aortic Aneurysms
Adam W. Beck, Kristina A. Giles, and Thomas S. Huber

97 Lower Extremity Aneurysms
Amy B. Reed

98 Venous Disease
Thomas W. Wakefield and Michael C. Dalsing

SECTION N: PEDIATRIC SURGERY

99 Fetal, Neonatal, and Pediatric Physiology
Samir K. Gadepalli and George B. Mychaliska

100 Fetal Intervention
George B. Mychaliska and Darrell L. Cass

101 Pediatric Head and Neck
Laura L. Neff and Reza Rahbar

102 The Pediatric Chest
Mary C. Santos and Robert E. Cilley

103 Pediatric Abdomen
Thomas T. Sato and Marjorie J. Arca

104 Pediatric Genitourinary System
John M. Park and Julian Wan

105 Childhood Tumors
Erika Adams Newman

106 The Pregnant Patient
Juan L. Martinez-Poyer and N. Scott Adzick

SECTION O: SKIN AND SOFT TISSUE

107 Cutaneous Neoplasms
Michael S. Sabel, Timothy M. Johnson, and Christopher K. Bichakjian

108 Sarcomas of Soft Tissue and Bone
Sandra L. Wong

109 Plastic and Reconstructive Surgery
Christian J. Vercler, David L. Brown, Steven R. Buchman, Paul S. Cederna, Kevin C. Chung, Jeffrey H. Kozlow, William M. Kuzon, Jr., Adeyiza O. Momoh, and Edwin G. Wilkins

Index

List of Algorithms

Algorithm 8-1.	Empiric antimicrobial treatment of extrabiliary cIAIs, community acquired versus healthcare associated
Algorithm 8-2.	Biliary infections and algorithm for diagnosis and management
Algorithm 8-3.	Step-up approach to management of necrotizing infected pancreatitis
Algorithm 9-1.	Neurohormonal response to hypovolemia
Algorithm 9-2.	Shock resuscitation algorithm
Algorithm 11-1.	Hyponatremia
Algorithm 11-2.	Acute hyperkalemia
Algorithm 11-3.	Guidelines for the treatment of diabetic ketoacidosis
Algorithm 12-1.	Protocol for frostbite injury
Algorithm 13-1.	Decision aid for preoperative cardiac evaluation prior to noncardiac surgery. This decision tree for preoperative evaluation takes into account not only the patient's physical status but also the severity of the surgical procedure
Algorithm 13-2a-b.	Algorithm for managing a patient on chronic buprenorphine therapy
Algorithm 15-1.	Stepwise Approach to Perioperative Cardiac Assessment for CAD
Algorithm 15-2.	Proposed algorithm for antiplatelet management in patients with PCI and noncardiac surgery
Algorithm 15-3.	Preoperative evaluation of patients with lung cancer for resection
Algorithm 15-4.	Proposed algorithm for preoperative evaluation of patients with liver disease
Algorithm 19-1.	2011 Guidelines for the Field Triage of the Injured Patients
Algorithm 21-1.	Glasgow Coma Scale (GCS) triage guide for initial evaluation of head injury. For the motor scale, the best response for any limb is recorded
Algorithm 21-2.	Prehospital evaluation and treatment of a patient with severe traumatic brain injury. "Signs of increased ICP" is the decision point for determining the necessity of intracranial pressure (ICP)-lowering therapy. These signs include pupillary abnormalities, motor posturing, or neurologic deterioration not related to medications. The order of steps is determined by the risk–benefit ratio for individual treatment maneuvers. This

	algorithm should be viewed as “expert opinion” and used as a framework, which may be useful in guiding an approach to field management of such patients
Algorithm 21-3.	Evaluation and treatment of the patient with severe traumatic brain injury on arrival at the trauma center. The order of steps is determined by the risk–benefit ratio for individual treatment maneuvers. This algorithm should be viewed as “expert opinion” and used as a framework, which may be useful in guiding an approach to initial hospital management of such patients prior to the initiation of ICP monitoring
Algorithm 26-1.	Algorithm for the evaluation and management of renal injury
Algorithm 26-2.	Algorithm for the evaluation and management of ureteral injury
Algorithm 26-3.	Algorithm for the evaluation and management of urethral injury
Algorithm 28-1.	The Denver Protocol for management of major pelvic fractures
Algorithm 29-1.	PECARN rules to identify children at very low risk of clinically important TBI. CT algorithm for children younger than 2 years (A) and for those aged 2 years and older (B) with GCS scores of 14–15 after head trauma
Algorithm 29-2a-b.	Algorithm generated by the Brain Trauma Foundation Committee for the first edition of the *Guidelines for the Medical Management of Severe Traumatic Brain Injury in Infants, Children, and Adolescents* for first-tier therapies (A) and second-tier therapies (B)
Algorithm 29-3.	New ATOMAC guidelines for management of pediatric solid organ injury
Algorithm 36-1.	Stepwise approach to the management of decreased low urine output posttransplant
Algorithm 39-1.	The donor management algorithm used at the University of Michigan in coordination with the organ procurement organization, Gift of Life. Optimal PEEP is determined by increasing PEEP 2 cm of H_2O every 3 to 5 minutes until compliance decreases. Recruitment maneuvers include CPAP at 30 cm of H_2O for 30 seconds every 20 minutes $\times$ 3
Algorithm 41-1.	Workup of a Neck Mass in an Adult Patient
Algorithm 42-1.	24-Hour Esophageal pH Monitoring
Algorithm 43-1.	Evaluation and treatment of esophageal perforation
Algorithm 43-2.	Proposed algorithm for evaluation and management of acute caustic ingestion
Algorithm 43-3.	Evaluation and treatment of esophageal leiomyoma
Algorithm 45-1.	Treatment of bleeding duodenal ulceration
Algorithm 46-1.	Algorithm for management of abdominal pain months or years

after Roux-en-Y reconstruction
Algorithm 47-1. Treatment of gastric adenocarcinoma
Algorithm 49-1. Algorithm for the management of adhesive small bowel obstruction
Algorithm 49-2. Approach to the management of malignant bowel obstruction
Algorithm 50-1. Crohn disease with anal complaints
Algorithm 50-2. Anal skin tags in Crohn disease
Algorithm 50-3. Hemorrhoids in Crohn disease
Algorithm 50-4. Anal abscess/fistula in Crohn disease
Algorithm 50-5. Anal fissure in Crohn disease
Algorithm 50-6. Anal stenosis/stricture and Crohn disease
Algorithm 51-1. Management algorithm for patients with advanced neuroendocrine tumors (NETs) of the gastrointestinal tract
Algorithm 51-2. Algorithm showing the management of patients with small bowel adenocarcinomas. The treatment strategy depends on disease stage and involves en bloc resection for locoregional disease and systemic chemotherapy for metastatic disease. All current recommendations are based on case series, retrospective reviews or nonrandomized prospective trials because of an absence of any randomized data
Algorithm 51-3. Treatment algorithms for patients with (A) advanced/metastatic GIST and (B) resectable GIST. GIST indicates gastrointestinal stromal tumor
Algorithm 53-1. Algorithm for the management of acute pancreatitis
Algorithm 54-1. Algorithm for operative decision-making in chronic pancreatitis
Algorithm 55-1. International consensus guidelines for the management of IPMNs
Algorithm 55-2. Management strategy based on CT criteria for resectability of pancreatic cancer
Algorithm 56-1. Diagnosis and management of pancreatic endocrine neoplasms
Algorithm 59-1. Suggested treatment options, in order of preference, for patients who fail medical management for variceal bleeding
Algorithm 60-1. BCLC algorithm for treatment selection in patients with HCC
Algorithm 60-2. Treatment algorithm of patients with hepatocellular carcinoma (HCC) based on serum bilirubin level and indocyanine green retention rate at 15 minutes
Algorithm 60-3. Multidisciplinary treatment approach for colorectal liver metastasis
Algorithm 61-1. Algorithm for the management of common bile duct stones
Algorithm 61-2. Management of acute cholangitis
Algorithm 62-1. Algorithm for diagnosis and management of bile duct injury

associated with laparoscopic cholecystectomy
Algorithm 65-1. Diagnostic steps in the evaluation of gastrointestinal hemorrhage
Algorithm 68-1. Approach to rectal cancer according to clinical staging
Algorithm 68-2. Approach to locally advanced rectal cancer based on a three-tier risk stratification system (“the good, the bad, and the ugly”)
Algorithm 68-3. Stage IV rectal cancer treatment algorithm
Algorithm 69-1. Diverticulitis Treatment based on Modified Hinchey Score (0–IV)
Algorithm 72-1. Management of initial inguinal hernia
Algorithm 72-2. Management of recurrent inguinal hernia
Algorithm 72-3. Management of groin pain after herniorraphy
Algorithm 72-4. Management of incisional hernia
Algorithm 74-1. Diagnosis and management of the patient with a clinically benign breast mass. The use of imaging studies varies according to age because breast carcinoma is infrequent in women younger than 35 years old
Algorithm 74-2. Diagnosis and management of the patient with a clinically indeterminate or suspicious solid breast mass. In this circumstance, imaging studies are insufficient to exclude malignancy, and tissue sampling is required
Algorithm 74-3. Diagnosis and management of the patient with a cystic lesion. Bloody fluid on aspiration, failure of the mass to resolve completely, and prompt refilling of the same cyst are indications for surgical biopsy
Algorithm 74-4. Management of the patient with an abnormal screening mammogram. When pathology is benign, concordance or discordance with imaging findings dictates whether surgical excisional biopsy is indicated
Algorithm 75-1. Management algorithm for thyroid mass
Algorithm 77-1. Diagnosis of hypercortisolism
Algorithm 77-2. Diagnosis and management of hyperaldosteronism
Algorithm 77-3. Diagnosis and management of the incidental adrenal mass
Algorithm 78-1. Treatment algorithm for acromegaly
Algorithm 78-2. Treatment algorithm for Cushing disease
Algorithm 79-1. Management of the incidental solitary pulmonary nodule
Algorithm 79-2. Evaluation of the patient who presents with a pulmonary mass
Algorithm 79-3. This algorithm illustrates the preoperative functional evaluation prior to lung cancer resection
Algorithm 80-1. Algorithm for management of lung abscess
Algorithm 80-2. Hemoptysis management

Algorithm 80-3. LVRS candidate workup
Algorithm 80-4. Algorithm to treat pneumothorax.
Algorithm 80-5. Algorithm for management of tracheal masses
Algorithm 84-1. Current algorithm for assessing patients with advanced heart failure for heart transplantation and mechanical circulatory support. Transplant status is initially assessed to determine appropriate indication for MCS use; BTT vs. DT
Algorithm 86-1. This algorithm outlines the initial approach to a patient with a large pericardial effusion
Algorithm 92-1. Patient with symptomatic aortoiliac occlusive disease
Algorithm 97-1. Management of femoral pseudoaneurysm
Algorithm 98-1. Treatment of chronic venous insufficiency

Part One **Scientific Principles**

Chapter 1

Lifelong Learning

Gurjit Sandhu and Rebecca M. Minter

Key Points

1. Self-regulated learning is a skill that can be taught to trainees.
2. The Dreyfus model of skill development is helpful for understanding the growth and depth of self-regulated learning from novice to expert level.
3. As self-regulated learning solidifies and becomes habitual for the trainee, it enhances transitions into effective lifelong learning.
4. Lifelong learning is an essential component of safe patient care with up-to-date knowledge and skills.
5. Surgeons who are lifelong learners are better prepared to deal with the complexities of future practice.

LIFELONG LEARNING FOR PERSONAL, PROFESSIONAL, AND SOCIAL RESPONSIBILITY

The Accreditation Council for Graduate Medical Education (ACGME) Task Force on Quality Care and Professionalism has drawn a clear and explicit connection among professionalism, safe patient care, and lifelong learning.[1] This is a direct reference to ensuring that graduate medical education programs are graduating fully trained physicians who are prepared to practice independently.[1,2] In order to achieve this goal, *exposure* to the curriculum is insufficient. Surgeons in training must demonstrate that they are able to perform the activities of a specialist in that field. This becomes a complex feat of curriculum development and learner assessment when one considers that even as learners are graduating from their training programs, their specialties are evolving. With a patient population that is older, has higher acuity, greater number of chronic diseases and comorbidities, accompanied with unprecedented growth in medical knowledge, it is naive to assume that trainees will graduate with mastery of every facet of their discipline.[3,4] Hence, graduating physicians who are primed for lifelong learning becomes a salient professional and social responsibility of graduate medical education programs.

Ultimately, lifelong learning is about bringing together individual responsibility with safe patient care. The commitment to ongoing reflective learning lends itself to a practice where research, education, and experience come together to best serve the needs of the patient. ACGME emphasis on lifelong learning is evidenced in two concrete ways: (1) by the continuum with which milestones are developed – beginning with the pretrained novice and extending throughout the physician's career – reinforcing learning and growth beyond graduation; and (2) an explicit ACGME Common Program Requirement stating "residents must demonstrate the ability to investigate and evaluate their care of patients, to appraise and assimilate scientific evidence, and to continuously improve patient care based on constant self-evaluation and lifelong learning."[5,6] Several surgical specialties have gone on to include lifelong learning as a milestone within the practice-based learning and improvement competency.[7–10]

If lifelong learning is an outcome that is sought among high performing, safe, up-to-date surgeons, it is imperative that surgeons in training develop appropriate knowledge, skills, and attitudes during training that will foster this habitual behavior for when they are in professional practice. Just as management of complex problems or knowledge about postoperative complications of most essential operations are milestones that are met in a progressive manner, the same is true about lifelong learning as a milestone that is met in a progressive manner. As a trainee works toward honing and demonstrating expertise for lifelong learning, progressive development toward this goal while still in a residency program would be called self-regulated learning. In other words, the goal over time is for a resident/fellow to fully and intuitively adopt self-regulated learning and graduate from training entrusted to embrace lifelong learning. Before considering the development of self-regulated learning in a graduated manner across the continuum of graduate medical education, it is important to define and establish the relationship

between self-regulated and lifelong learning.

SELF-REGULATED LEARNING

1 Self-regulated learning has been used to describe students who are "metacognitively, motivationally, and behaviorally active participants in their own learning process."[11] This includes the ability to plan and organize self-instruction, monitor and assess self, and seek out optimal learning opportunities. White et al.[12] argue that these are not merely innate attributes, but skills that can be taught during medical training. Self-regulated learning is framed as a cycle of four phases[12]:

1. Planning
2. Learning
3. Assessment
4. Adjustment

Planning is about setting personal goals, establishing desired outcomes, and having the belief in one's ability to achieve those goals. In this phase, intrinsic motivation and extrinsic motivation are important considerations in the setting and reaching of learning goals. While extrinsic motivation is embedded in graduate medical education (e.g., passing certifying oral examinations), it is intrinsic motivation that is "key to the development of autonomy" and "autonomy is key to lifelong learning."[12] Therefore, during the planning phase, learners develop a sense of urgency for their own learning and an ability to plan and act on goals.

During the *Learning* phase, learners need clarity about how they learn most effectively. This includes developing awareness about one's personal beliefs toward acquiring knowledge, preferred ways of learning (e.g., visual, auditory), learning strategies (e.g., where and when studying happens), and finally aligning learning expectations with those of the educator.

Assessment requires timely, specific, and regular formative feedback (e.g., from supervisors, colleagues, medical students) as well as internal monitoring that compares one's progress against the goal that was set. Together these sources of feedback guide the learner's next steps toward reaching the goal.

Finally, *Adjustment* is where the learner synthesizes what has been gained through the planning, learning, and assessment phases and makes adjustments either in the nature of the goal or in the strategies needed to reach the goal. How learners integrate information about successes or failures could be seen as a matter of attribution – how performance is accounted for ranging from ability to effort. Examining the performance feedback that has been gathered to date, considering the validity of the information, and then determining how to make sense of it in relation to what they already know is a complex process of reflection.[13]

Through explicit teaching and practice at each phase, learners are guided toward sustaining strategies for ongoing, more effective self-regulated learning. Sustainable strategies form the basis for lifelong learning. White et al.[12] underscore sustainable strategies as a key to continuing medical education (CME) for the practicing surgeon and point to the link between CME and quality health care.

LIFELONG LEARNING

If the phases of self-regulated learning solidify for the trainee, they become **habitual** characteristics of effective lifelong learning. In the broadest sense, lifelong learning is about ongoing learning from cradle to grave. However, in the context of entering the workplace after graduate medical education, we look at physicians and lifelong learning more closely as the "ability to guide their own learning throughout their lives and in the wide variety of situations they will encounter after leaving formal education."[14]

This ongoing reflexive process of lifelong learning includes five characteristics[14]:

1. set goals
2. apply appropriate knowledge and skills
3. engage in self-direction and self-evaluation
4. locate required information
5. adapt their learning strategies to different conditions

These characteristics are meant to extend the physician's concept of ongoing learning from "lifelong schooling" to "life-wide learning" so that personal inquiry can happen, for example, at the bedside or in the community and is not constrained to formal educational opportunities.[14]

As a trainee transitions through different levels in residency, the nature of self-regulated learning will also change depending on the learner's needs. As learners meet increasingly more complex patient care milestones, the practice of self-regulated learning transforms accordingly. Solidifying the phases of self-regulated learning during graduate medical education feeds into establishing effective characteristics for lifelong learning that become a critical part of a physician's everyday practice (Table 1-1). As such, medical education programs have a social and professional obligation to further develop and deepen characteristics of self-regulated learning among learners so that graduating surgeons pursue professional learning throughout their careers.[5] It is critically important that a robust curriculum be established within graduate medical education for teaching, engaging with, and assessing practices for lifelong learning.

Table 1-1 Relationship Between Self-Regulated Learning and Lifelong Learning

Self-Regulated Learning Phases	Lifelong Learning Characteristics
Planning	Set goals
Learning	Apply appropriate knowledge and skills
Assessment	Engage in self-direction and self-evaluation Locate required information
Adjustment	Adapt their learning strategies to different conditions

Self-regulated learning evolving and deepening into lifelong learning is best understood using the Dreyfus model for skill development.[15] This is in keeping with the foundational framework from which the milestone frameworks have been structured to assess residents/fellows in surgical disciplines.[1]

DREYFUS MODEL FOR SKILL DEVELOPMENT

The Dreyfus model for skill development identifies five levels of skill development[15–17]:

1. Novice
2. Advanced Beginner
3. Competent
4. Proficient
5. Expert

On this continuum, learners pass from one level to the next as skills are acquired. At each level, there are "recognizable, qualitatively different ways of acting and performing in the process of learning a given skill. Individuals at a given level do better than individuals at the previous level."[18] Table 1-2 presents the five levels of the Dreyfus model with the addition of delineating each level along four characteristics of skill development: knowledge; decision-making; perception of context; and autonomy.[19–23] Increasing understanding, confidence, and independence associated with these characteristics is in keeping with higher levels of competency with the skill being measured. This delineated view demonstrates in a granular way how a learner progresses and performs differently at each level. Based on criteria, it is clear why not every learner reaches the highest level. The criterion-based foundation of the Dreyfus model makes it a widely adapted process for assessment.[23,24]

2 At the novice level, learners largely have textbook familiarity with a skill. After having advanced to the expert level, learners have extensive experiential knowledge with a skill and are seen to be highly intuitive. We understand self-regulated learning to be a skill that can be learned, will progressively grow and deepen over time, is carried out differently at each successive level, and ought to be carried out in the workplace. As the skill is honed and becomes habitual, self-regulated learning transitions into lifelong learning. This progression in skill development makes the Dreyfus model highly appropriate for understanding, teaching, and assessing self-regulated learning.

Table 1-2 Dreyfus Model of Skill Development: Novice to Expert Levels for Self-Regulated Learning

Level	Characteristics			
	Knowledge	Decision-Making	Perception of Context	Autonomy
1. Novice	Primarily textbook knowledge with few previous experiences Context free following of taught rules Unconscious incompetence	Considers everything and makes tentative judgments with no flexibility Unable to deal with complexity when something unexpected happens Rational	Understand each action as a separate entity Analytic	Close supervision and instruction Observes procedure being performed
2. Advanced Beginner	Gaining practical experiences and knowledge Beginning to apply rules based on context Conscious incompetence	Perception improving, but judgments continue to be largely limited Realizes complexity of situation, but still has difficulty with troubleshooting Rational	Understands actions as related steps Analytic	Requires supervision for overall procedure Assists with performing a procedure and receives opportunities to try some tasks on own
3. Competent	Well-developed background of understanding, conceptual models, and working knowledge in a specialty Led by guidelines that are specific to each situation, yet sees the larger context Conscious competence	Handles complex situations through deliberate planning and own judgment Able to troubleshoot on own, but seeks out expert consult for confirmation Rational	Relates actions to long-term goals Analytic	Direct supervision Able to perform an entire procedure under direct supervision
4. Proficient	Depth of knowledge in field of practice Increasingly working from intuition with less dependence on rules; using analytic approaches primarily to address unusual problems in context Unconscious competence	Merges intuitive and analytic approaches in complex situations Uses pattern recognition to determine essential elements in a situation and what is a deviation Rational	Considers context holistically and how individuals contribute to it Holistic	With indirect supervision, takes full responsibility for performing a procedure Reflects on personal performance and experiences of others for continuous self-improvement
5. Expert	Influential authority in the field Intuitive understanding outweighs reliance on rules, yet uses analytic approaches in novel circumstances Deep understanding	Manages complex conditions with confident decision-making Uses pattern recognition in context and for forward planning Intuitive	Sees larger context and alternative approaches to what may be possible Holistic	Independently performs the procedure without any supervision Takes full responsibility for going beyond maxims

DREYFUS MODEL OF SKILL DEVELOPMENT APPLIED TO SELF-REGULATED LEARNING IN SURGERY

The attributes and practice of self-regulated learning change as learners transition from one level to the next. In other words, as learners attain greater levels of responsibility, the goals they set for themselves, insights adopted about learning, feedback they require, and adjustments they make based on successes and failures will be different from one level to the next. This is in line with gradually more mature forms of reflection and insightful learning plans learners develop for themselves. Self-regulated learning will be described at each level in terms of the learner's skills, but also includes suggestions for educators on how to teach at the level of the learner and establish scaffolds to support the learner advancing to the next level.[23,24]

Novice

The novice learner is focused on figuring out how textbook knowledge applies to the current experience. The goals learners set for themselves are about making sense of uncertain or unfamiliar content by connecting it to existing familiar sets of knowledge. At this point, the learner adheres to step-by-step rules, regardless of context. Working through a methodical line of reasoning without situational awareness or discretion makes it difficult for the trainee to deal with exceptions and complexity.[24] The learner searches for absolute answers. Tendencies toward binary sets of knowledge reveal that learners at this level often do not know what they do not know (unconscious incompetence), suggesting they have an incomplete development of self-assessment.[25] After routine-guided observations of procedures being performed, novice learners are incrementally moved to close supervision with explicit instruction in order to complete tasks. Reflecting on their behavior during experiential opportunities along with the feedback received from faculty or more senior residents and fellows causes learners to revisit the knowledge they believed to be universally true and adjust their goals and views on learning.

Educators must be deliberate and specific in the feedback that is provided, even being explicit about the phases of effective self-regulated learning that should be developed. Educators become a resource as trainees learn to develop appropriate goals and establish a plan forward. Determining the existing level of the learner and learning preferences of the trainee is essential for educators so that they can guide the learner toward suitable challenges that will scaffold him/her to the next level.

Advanced Beginner

For the advanced beginner, emphasis is on gaining practical experiences and knowledge. The balance tilts from taking textbook knowledge and applying it to the context, to better understanding the context, patient indicators, and beginning to discern and apply rules. Although perception is improving, judgments are still quite limited. The advanced beginner continues to be rational and analytic, but now sees actions as related rather than a series of independent steps.[24] Developing an understanding of connectedness helps learners realize the complexity of situations and with that comes an appreciation for how much they do not know (conscious incompetence).[25]

Faculty provide trainees with structured opportunities and directly observe their skills. Under this closely guided practical experience, trainees assist with performing a procedure and receive some opportunities to try simpler tasks on their own. There is a high likelihood these trainees will be able to accomplish these simpler tasks successfully. With the learner starting to see steps as related, this is an opportunity for the educator to give feedback that will push the learner to be aware of more complex connections. Learners still require supervision for the procedure largely because they continue to have difficulty with troubleshooting. Educators should provide challenges just at the edge of the learners comfort level. The trainee's performance will help the educator identify where emphasis needs to be placed in the next educational encounter. It is important to debrief this experience with the learner so s/he can reflect back on emotions, thinking, and skills and establish subsequent goals. Educators simultaneously assess how much scaffolding learners require to extend them to the next level while also removing scaffolds as the learner demonstrates task competence.

Competent

At the competent level, the learner has well-developed conceptual models and fund of knowledge in a specialty. Although still primarily rational and analytic in decision-making, the learner is largely led by guidelines that are specific to the given context. In other words, through deliberate planning and judgment, the trainee can see the larger context and handle complex situations.[24] Trainees recognize what they know, for example, the limits of what they are able to troubleshoot on their own, and also know when to ask for guidance or help (conscious competence).[25] Safely progressing in a high-stakes environment while knowing when to slow down or stop is indicative of being able to reflect while in the moment. A competent level learner will reflect on actions and develop long-term goals.

Educators recognize that learners are able to complete an entire procedure independently to an optimal level. Nevertheless, educators still provide direct supervision to guide refinement, efficiencies, and standardization of procedures. With increasingly complex skills, educators will model specific methods. Learners at the competent stage ask for feedback and the response of the educator becomes less about general principles and more about fostering specific opportunities for individualized growth. While still under direct supervision, individualized instruction allows faculty to release greater degrees of responsibility for the full spectrum of patient care to residents/fellows so they can begin to take ownership and think ahead in developing a care plan.

Proficient

The proficient level represents a learner who sees context, actions, and interactions holistically. Physician core competencies (e.g., Patient Care and Professionalism), as outlined by the ACGME, are understood and enacted in an integrated way into the roles and responsibilities of the learner.[6] It is in seeing the bigger picture that the trainee is able to filter out extraneous materials and focus on essential information that results in less labored decision-making and consistently high levels of performance.[24] Residents/fellows are able to apply the depth of knowledge they have acquired in their specialty and increasingly become more intuitive with less dependence on rules (unconscious competence).[25] Trainees continue to be guided by maxims and rationale approaches to address unusual problems or deviations from expected patterns. The trainee reflects on personal performance with the goal of being able to efficiently merge intuitive and rationale approaches in complex situations.

Proficient residents/fellows have demonstrated that they reliably perform at an acceptable standard; therefore, there is a greater degree of indirect supervision. The role of faculty is to provide opportunities for learners to take full responsibility for performing a procedure, as well as work through uncommon cases. The feedback provided to learners is specific and formative (i.e., not scored) in helping them reach self-identified goals, as well as extend their critical thinking to unique problems and situations.

Expert

At the expert level, individuals have deep holistic understanding in their specialty. Depth of knowledge has provided them with intuitive understanding, confidence in decision-making, and ability to successfully manage complex situations with ease.[24] When faced with novel situations, they are able to seamlessly proceed with alternative approaches, consciously draw on guidelines and maxims, and consider innovative possibilities. Internal creative inquiry challenges these individuals to raise questions to themselves, put the mental brakes on what is familiar, and set goals that extend the field in new directions.[26] Experts are thought to be authorities in their specialties.

Individuals at this level rarely receive feedback unless they ask for it.[27] They adjust and adapt their learning with regular review of current literature, participating in CME, and pursuing and publishing research. As surgeons who independently perform procedures without any supervision, experts also rely on patient outcomes – by reflecting *in* action (e.g., adapting to unexpected conditions) and reflecting *on* action (e.g., follow-up care with patient) – as forms of feedback to inform practice.[13,28] The expert level does not represent completion in learning, rather it signifies that a learner has the skills to continue to stay informed through workplace-based learning. This transition into habitual, ongoing, life-wide learning illustrates that a learner has solidified skills for lifelong learning.

SELF-REGULATED LEARNING AND LIFELONG LEARNING IN SURGERY EDUCATION

3 4 The purpose of this discussion is to show that skills for self-regulated learning can be learned, developed, and transformed into lifelong learning. The Dreyfus model provides an accessible model for visualizing the development and progression of skills from self-regulated learning into lifelong learning. The implications for overlooking development of lifelong learning skills are less obvious while under the observation and guidance of a Surgery Education program. However, if the goal of Surgery Education programs is to produce surgeons who are able to practice independently, actively pursue safe patient care with up-to-date knowledge and skills, then the development of skills for lifelong learning cannot be easily overlooked while still in training. As such, the role of faculty educators to model and explicitly teach about self-regulated learning and lifelong learning is essential.

Educators of residents/fellows at early levels of skill development must be explicit and concrete when explaining how to set independent goals for advancing abilities, as well as provide specific instructions on how to pursue inquiry on their own. As trainees deepen their skills and apply those more routinely, the responsibility for stimulating habitual inquiry begins to shift from the faculty to the trainee. The faculty now looks for the ways in which surgeons in training seek, receive, and provide feedback as indicators of the awareness learners have about where they need to focus their attention for growth.[29] With still further development of self-regulated learning, learners will likely transition into lifelong learners.

5 When advancing in training and moving into careers as experts, there is a great deal of familiarity with procedures, processes, and knowledge. When there is unconscious competence or deep understanding, automaticity sets in. Individuals at this level have ingrained skills and habits that routinely incite internal creative inquiry causing them to challenge these familiar patterns. The lifelong learner purposefully "makes unconventional linkages (…) in order to reveal unseen aspects."[26] The lifelong learner also seeks, applies, and makes new meaning. These are the surgeons who are prepared to deal with the problems of today, but even better prepared to deal with complexities that are yet to be encountered.

References

1. ACGME. The ACGME 2011 Duty hour standard: enhancing quality of care, supervision and resident professionalism development. 2011. Available from: http://www.acgme.org/acgmeweb/Portals/0/PDFs/jgme-monograph%5b1%5d.pdf. Accessed May 27, 2016.
2. Nasca TJ, Heard JK, Commentary: trust, accountability, and other common denominators in modernizing medical training. *Acad Med* 2010;85(6):932–934.
3. Are American Patients Getting Sicker? 2012. Available from: http://www.aha.org/research/reports/tw/12dec-tw-ptacuity.pdf.
4. Arora S, Thornton K, Komaromy M, et al. Demonopolizing medical knowledge. *Acad Med* 2014;89(1):30–32.
5. ACGME. ACGME common program requirements. 2013. Available from: https://www.acgme.org/acgmeweb/Portals/0/PFAssets/ProgramRequirements/CPRs Accessed May 27, 2016.
6. ACGME. Milestones. 2011. Available from: https://www.acgme.org/acgmeweb/tabid/430/ProgramandInstitutionalAccreditation Accessed May 27, 2016.
7. ACGME. Thoracic surgery milestones. 2012. Available from: https://www.acgme.org/acgmeweb/Portals/0/PDFs/Milestones/ThoracicSurgeryMile Accessed May 27, 2016.
8. ACGME. The plastic surgery milestone project. 2013. Available from: https://www.acgme.org/acgmeweb/Portals/0/PDFs/Milestones/PlasticSurgeryMilest Accessed May 27, 2016.
9. ACGME. The pediatric surgery milestone project. 2014. Available from: https://www.acgme.org/acgmeweb/Portals/0/PDFs/Milestones/PediatricSurgeryMil Accessed May 27, 2016.
10. ACGME. The hand surgery milestone project. 2013. Available from: https://www.acgme.org/acgmeweb/Portals/0/PDFs/Milestones/HandSurgeryMilesto Accessed May 27, 2016.
11. Zimmerman BJ. Becoming a self-regulated learner: which are the key subprocesses? *Contemp Educ Psychol* 1986;11(4):307–313.
12. White CB, Gruppen LD, Fantone JC. Self-regulated learning in medical education. In: Swanwick T, ed. *Understanding Medical Education: Evidence, Theory and Practice.* 2nd ed. Oxford: John Wiley & Sons, Ltd; 2013:201–211.
13. Embo MP, Driessen E, Valcke M, et al. Scaffolding reflective learning in clinical practice: a comparison of two types of reflective activities. *Med Teach* 2014;36(7):602–607.
14. Kirby JR, Knapper C, Lamon P, et al. Development of a scale to measure lifelong learning. *Int J Lifelong Educ* 2010;29(3):291–302.
15. Dreyfus SE. The five-stage model of adult skill acquisition. *Bull Sci Technol Soc*

2004;24(3):177.
16. Dreyfus S, Dreyfus H. A five stage model of the mental activities involved in directed skill acquisition. Operations Research Center University of California, Berkeley [monograph on the Internet]; 1980. Available from: http://www.dtic.mil/docs/citations/ADA084551.
17. Batalden P, Leach D, Swing S, et al. General competencies and accreditation in graduate medical education. *Health Aff (Millwood)* 2002;21(5):103–111.
18. Flyvbjerg, B. Making social science matter: why social inquiry fails and how it can succeed again. Cambridge: Cambridge University Press; 2001 (trans. Steven Sampson).
19. Dreyfus SE. Formal models vs. human situational understanding: inherent limitations on the modeling of business expertise. *Office Technology People* 1982;1(2/3):133–165.
20. Dreyfus H, Dreyfus S. Putting computers in their proper place: analysis versus intuition in the classroom. *Teach Coll Rec* 1984;85(4):578–601.
21. Institute of Conservation. PACR Professional Standards. 2008. Available from: http://www.collectionstrust.org.uk/events/item/882-pacr-professional-standards. Accessed May 27, 2016.
22. Stan Lester Developments. Novice to expert: the dreyfus model of skill development. 2005. Available from: http://devmts.org.uk/dreyfus.pdf. Accessed May 27, 2016.
23. Honken N. Dreyfus five-stage model of adult skills acquisition applied to engineering lifelong learning. 120th American Society for Engineering Education. 2013. Available from: http://www.google.com/url?url=http://www.asee.org/public/conferences/20/papers/6110/download&rct=j&frr Accessed May 27, 2016.
24. Carraccio CL, Benson BJ, Nixon LJ, et al. From the educational bench to the clinical bedside: translating the Dreyfus developmental model to the learning of clinical skills. *Acad Med* 2008;83(8):761–767.
25. Robinson WL. Conscious competency - the mark of a competent instructor. *Pers J* 1974;53(7):538.
26. Wagoner B. Commentary: making the familiar unfamiliar. *Cult Psychol* 2008;14(4):467–474.
27. Finkelstein SR, Fishbach A. Tell me what I did wrong: experts seek and respond to negative feedback. *J Cons Res* 2012;39(1):22.
28. Schon D. Educating the reflective practitioner. 1987. Available from: http://resources.educ.queensu.ca/ar/schon87.htm.
29. Delva D, Sargeant J, Miller S, et al. Encouraging residents to seek feedback. *Med Teach* 2013;35(12):e1625–e1631.

Chapter 2

Principles of Intermediary Metabolism

Steven E. Raper

Key Points

1 Intermediary metabolic pathways – the metabolic manipulation and balancing of ingested carbohydrate, fat, and protein – can process essentially all nutrients to acetyl coenzyme A (CoA) for energy production predominantly through aerobic glycolysis, the citric acid cycle, and oxidative phosphorylation.

2 Glucose must always be available for brain function; if not available directly from the diet, it can be mobilized for a brief period from glycogen stores and then derived from proteins in the liver and kidneys.

3 Free fatty acids are a direct source of energy for cardiac and skeletal muscles.

4 Hepatic protein synthesis, when excess amino acids are available, includes albumin, fibrinogen, and apolipoproteins and can reach 50 g/day.

5 The citric acid cycle includes a series of mitochondrial enzymes that transform acetyl CoA – itself derived from pyruvate or fatty acyl CoA – into water, carbon dioxide, and hydrogen-reducing equivalents. Each molecule of acetyl CoA that enters the citric acid cycle yields 12 molecules of adenosine triphosphate (ATP).

6 Oxidative phosphorylation converts the energy from NADH and $FADH_2$ into ATP by the electron transport chain and ATP synthase with a process called the proton motive force.

7 Biotransformation of potentially toxic, often hydrophobic, compounds into hydrophilic, excretable compounds occurs mainly in the liver by the cytochromes P-450, the uridine diphosphate-glucuronyl (UDP-glucuronyl) transferases, the glutathione (GSH) S-transferases, and the sulfotransferases.

INTERMEDIARY METABOLISM: AN OVERVIEW

Introduction

Intermediary *metabolism* – derived from the Greek word for change – is predominantly the fate of dietary carbohydrate, fat, and protein in a series of life-sustaining cellular chemical transformations. Although admittedly intricate, all surgeons should be familiar with the basics of the biochemistry by which nutrients are converted to energy. Understanding the major biochemical pathways is a prerequisite to making use of the rapid – and exciting – expansion of medical knowledge directed at managing human metabolic derangement and improving health by beginning at the cellular level.

1 Intermediary metabolic pathways – the metabolic manipulation and balancing of ingested carbohydrate, fat, and protein – can process essentially all nutrients to acetyl coenzyme A (CoA) for energy production predominantly through aerobic glycolysis, the citric acid cycle, and oxidative phosphorylation. The major intermediary metabolites are glucose, fatty acids, glycerol, and amino acids. Glucose is metabolized to pyruvate and lactate by glycolysis. Aerobic metabolism allows conversion of pyruvate to acetyl CoA. Acetyl CoA enters the citric acid cycle resulting in carbon dioxide, water, and hydrogen-reducing equivalents (a major source of adenosine triphosphate [ATP]). In the absence of oxygen, glycolysis ends in lactate. Glucose can be stored as or created from glycogen. Glucose can also enter the phosphogluconate pathway, where it is converted to reducing equivalents for fatty acid synthesis and ribose five-carbon sugars important in nucleotide formation. Glucose can be converted into glycerol for fat formation and pyruvate for amino acid synthesis. Gluconeogenesis allows synthesis of glucose from lactate, amino acids, and glycerol.

With regard to lipid metabolism, long-chain fatty acids arise from dietary fat or synthesized from acetyl CoA. Fatty acids can be oxidized to acetyl CoA by the process of beta-oxidation or converted to acylglycerols (fat) for storage as the main energy reserve. In addition to the fats noted previously, acetyl CoA can be used as a precursor to cholesterol and other steroids and in the liver can form the ketone bodies, acetoacetate and 3-hydroxybutyrate, which are critical sources of energy during periods of starvation.

Proteins are degraded in two major ways: an energy independent path, usually in lysosomes, and an energy requiring path, usually through the ubiquitin pathway. About three-fourths of the amino acids generated in protein catabolism are reutilized for protein synthesis and one-fourth is deaminated to form ammonia and subsequently urea. Amino acids may be divided into nutritionally essential and nonessential. Nonessential amino acids require fewer enzymatic reactions from amphibolic intermediates or essential amino acids. Each day, humans turn over 1% to 2% of total body protein.

CARBOHYDRATE METABOLISM

The products of intestinal carbohydrate digestion are glucose (80%) and fructose and galactose (20%). Fructose and galactose are rapidly converted to glucose, and the body uses glucose as the primary molecule for transport and uptake of carbohydrates by cells throughout the body. Despite wide fluctuations in dietary intake, blood glucose levels are tightly regulated by the liver. About 90% of portal venous glucose is removed from the blood by liver cells through carrier-facilitated diffusion. Large numbers of carrier molecules on the sinusoidal surface of the hepatocyte are capable of binding glucose and transferring it to the cytoplasm. The rate of glucose transport is enhanced (up to 10-fold) by insulin. Given the critical role of glucose in survival, complex metabolic pathways have evolved for the storage of glucose in the fed state, the release of glucose from glycogen, and the synthesis of new glucose.

Blood glucose is stored, primarily in liver and muscle, as glycogen. Glycogen is a complex polymer of glucose with an average molecular weight of 5 million. The liver can convert up to 100 g of glucose into glycogen per day by glycogenesis. The liver can also release glucose into the blood by glycogenolysis, (breakdown of glycogen), or gluconeogenesis, (formation of new glucose from substrates such as alanine, lactate, or glycerol). Hormones play a key role in the hepatic regulation of glycogen balance. Insulin, for example, stimulates glycogenesis and glycolysis; glucagon stimulates glycogenolysis and gluconeogenesis through cyclic adenosine monophosphate (AMP) and protein kinase A.[1]

Glycogenesis and Glycogenolysis

2 Glucose must always be available for brain function; if not available directly from the diet, it can be mobilized for a brief period from glycogen stores and then derived from proteins in the liver and kidneys. The first step in glycogen storage is the transport of glucose through the plasma membrane. Once in the hepatocyte, glucose and ATP are converted by the enzyme glucokinase to glucose-6-phosphate (G6P), the first intermediate in the synthesis of glycogen (Fig. 2-1). Because complete oxidation of one molecule of G6P generates 37 molecules of ATP, and storage uses only one molecule of ATP, the overall efficiency of glucose storage as glycogen is a remarkable 97%.

Glycogenolysis does not occur by simple reversal of glycogenesis. Each glucose molecule on a glycogen chain is released by glycogen phosphorylase (Fig. 2-2). Eventually, G6P is reformed. G6P cannot exit from cells and must first be converted back to glucose. The conversion of G6P to glucose is catalyzed by glucose-6-phosphatase, which exists only in hepatocytes, kidney, and intestinal epithelial cells. Brain and muscle both use glucose as a primary fuel source and do not contain the phosphatase enzyme. This lack of glucose-6-phosphatase ensures a ready supply of glucose for the energy needs of brain and muscle. Liver uses glucose primarily as a precursor for other molecules and not for fuel.

Glycolysis

Glycolysis is the mammalian cellular pathway by which glucose is converted to pyruvate or lactate (Fig. 2-3). The glycolytic pathway is interesting in that glucose can be metabolized in the presence (aerobic) or absence (anaerobic) of oxygen. Aerobic glycolysis is one of four stages in the oxidation of glucose and the only stage that occurs in the cytosol. As will be discussed below, stages II to IV occur in mitochondria; the citric acid cycle, electron transport generation of the proton motive force, and ATP synthase leading to generation of ATP.

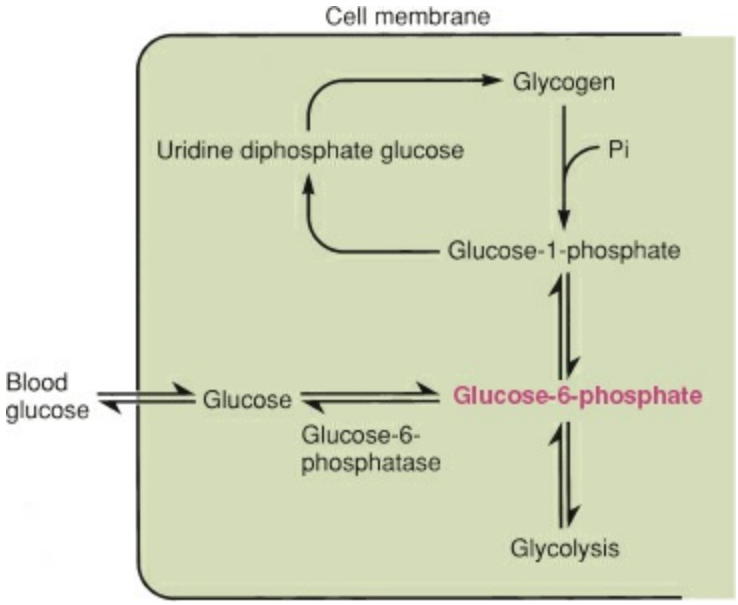

Figure 2-1. The chemical reactions of glycogenesis and glycogenolysis. Glucose-6-phosphatase allows hepatic glucose to be transported out of the hepatocyte for use in other tissues. Glucose-6-phosphate, in *red,* plays a central role in carbohydrate metabolism.

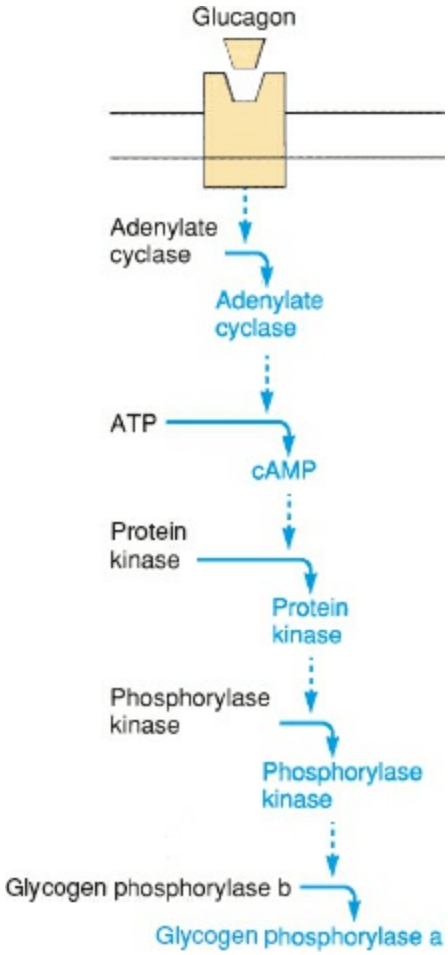

Figure 2-2. Glucagon-stimulated enzyme cascade, responsible for the control of glycogen metabolism. Inactive forms are shown in *black,* active forms in *blue.*

The aerobic conversion of glucose to pyruvate has three effects: (a) a net gain of two ATP molecules, (b) generation of two reducing equivalents of the nicotinamide adenine nucleotide (NADH + H^+), and usually, (c) conversion of pyruvate to acetyl CoA with subsequent conversion of acetyl CoA in the mitochondria to ATP. The conversion of glucose to pyruvate is regulated by three enzymes: hexokinase (glucokinase), phosphofructokinase, and pyruvate kinase, which are nonequilibrium reactions and as such, functionally irreversible.

Under anaerobic conditions, NADH cannot be reoxidized by transfer of reducing equivalents through the electron transport chain to oxygen. Instead, pyruvate is reduced by NADH to lactate. Glycolysis takes place in the cytoplasm, in contrast to the citric acid cycle and oxidative phosphorylation which are mitochondrial processes. During times of glucose excess, as in the fed state, hepatic glycolysis can generate energy in the form of ATP, but the oxidation of ketoacids is a preferred energy source in liver.

The conversion of lactate (through pyruvate) to glucose – a process possible only in the presence of oxygen – is an important means of preventing severe lactic acidosis. Active skeletal muscles and erythrocytes form large quantities of lactate. In patients with large wounds, lactate also accumulates. The liver is exceptionally efficient at converting lactate to pyruvate through the Cori cycle (Fig. 2-4). As a result, one would expect that only significant liver dysfunction would affect the Cori cycle and lead to hyperlactatemia. However, lactate levels are now widely used to assess shock – septic and otherwise.[2] The

hypothesis is that circulatory hypoperfusion impairs tissue oxygen delivery with resultant mitochondrial hypoxia. In the absence of adequate oxygen, mitochondria switch to anaerobic glycolysis and oxidative phosphorylation stops. As a result, serum lactate concentrations appear proportional to ongoing tissue oxygenation deficits; thus improved lactate clearance can be used as a surrogate for success of sepsis therapy.[3] Serum lactate can also be used to assess prognosis and triage patients to ICU level care.[4]

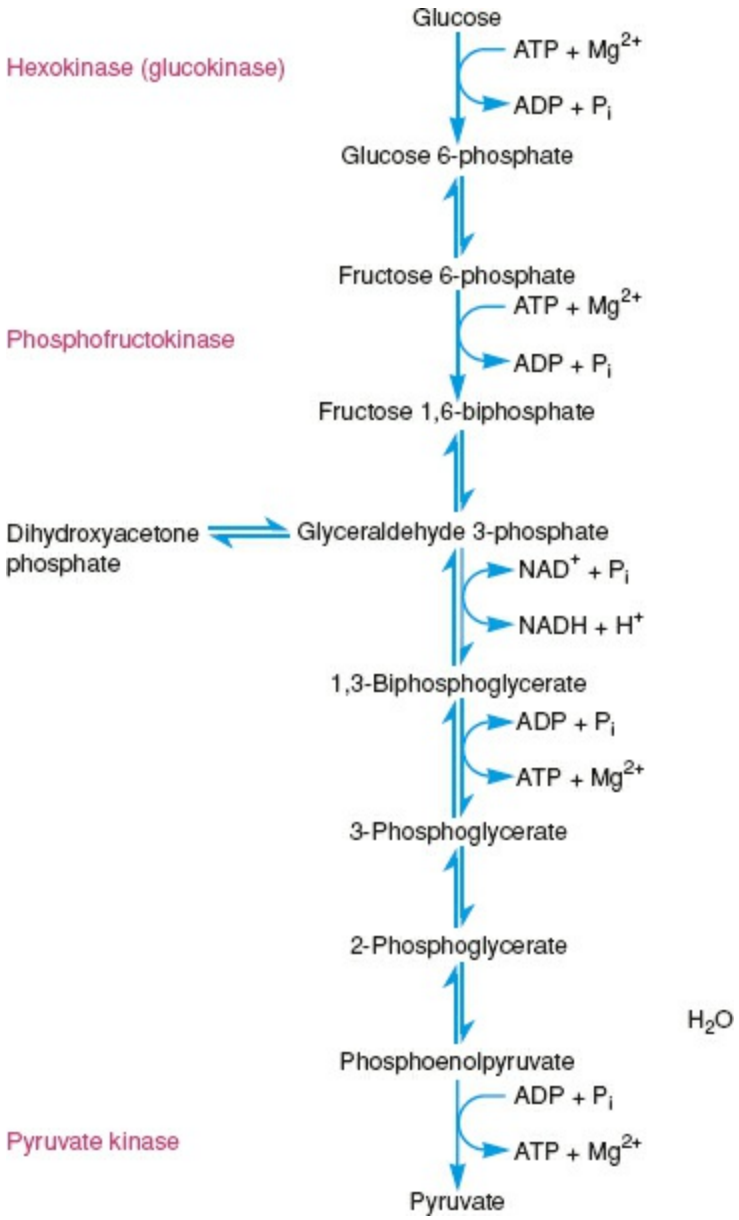

Figure 2-3. The glycolytic pathway. There is a net gain of two ATP molecules per glucose molecule. Phosphofructokinase is the key regulatory enzyme in this pathway; however, all the enzymes in *red* catalyze irreversible reactions. The pathway shown here is active only in the presence of aerobic conditions.

In erythrocytes, a unique variant of glycolysis enhances oxyhemoglobin dissociation. The first site in glycolysis for generation of ATP is bypassed, leading to the formation of 2,3-bisphosphoglycerate by an additional enzyme called bisphosphoglycerate mutase. Kinetics of the mutase present in erythrocytes allow the presence of high concentrations of 2,3-bisphosphoglycerate to build up. The 2,3-bisphosphoglycerate displaces oxygen from hemoglobin, allowing a shift of the oxyhemoglobin dissociation curve to the right.

Gluconeogenesis

There is an absolute minimum requirement for glucose in humans. Below a certain blood glucose concentration, brain dysfunction causes coma and death. When glucose becomes scarce, as in the fasting state, glycogenolysis occurs. Once glycogen stores have been depleted, the liver and kidneys are capable of synthesizing new glucose by the process of gluconeogenesis. Glucagon is produced in response to low blood sugar levels and stimulates gluconeogenesis.

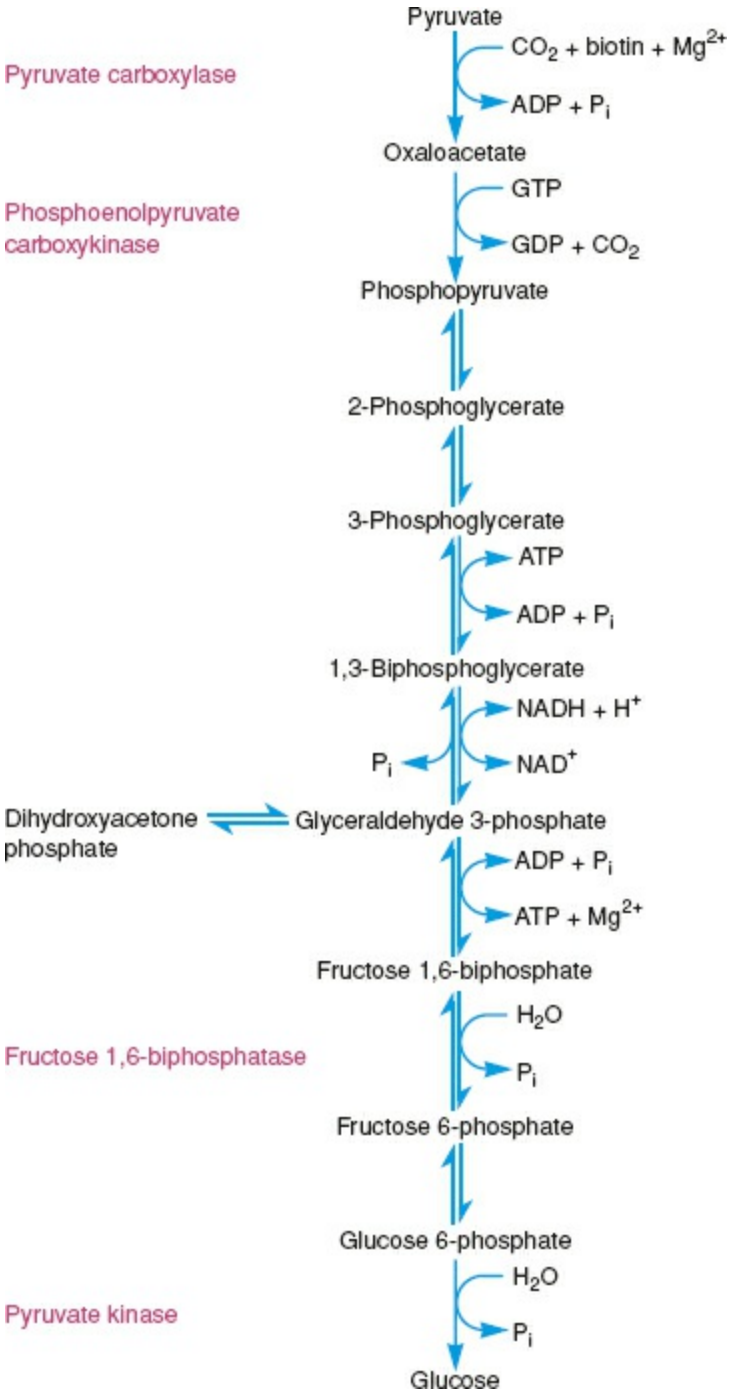

Figure 2-4. The gluconeogenesis pathway. The irreversible nature of the glycolytic pathway means that a different sequence of biosyntheses is required for glucose production. The enzymes in *red* catalyze irreversible reactions that are different from those in glycolysis. In mammals, glucose cannot be synthesized from acetyl coenzyme A, only from cytosolic pyruvate.

Gluconeogenesis is not a simple reversal of the glycolytic pathway. In glycolysis, as noted previously, the conversion of glucose to pyruvate is a one-way reaction. As a result, four separate, functionally irreversible enzyme reactions are required to convert pyruvate into glucose (Fig. 2-5). These enzymes are pyruvate carboxylase, phosphoenolpyruvate carboxykinase, fructose-1,6-bisphosphatase, and glucose-6-phosphatase. Other enzymes are shared with the glycolytic pathway.

About 60% of the naturally occurring amino acids, glycerol, or lactate can also be used as substrates for glucose production. Alanine is the amino acid most easily converted into glucose. Simple deamination allows conversion to pyruvate, which is subsequently converted to glucose. Other amino acids can be converted into three-, four-, or five-carbon sugars and then enter the phosphogluconate pathway (next section). Gluconeogenesis is enhanced by fasting, critical illness, and periods of anaerobic metabolism.

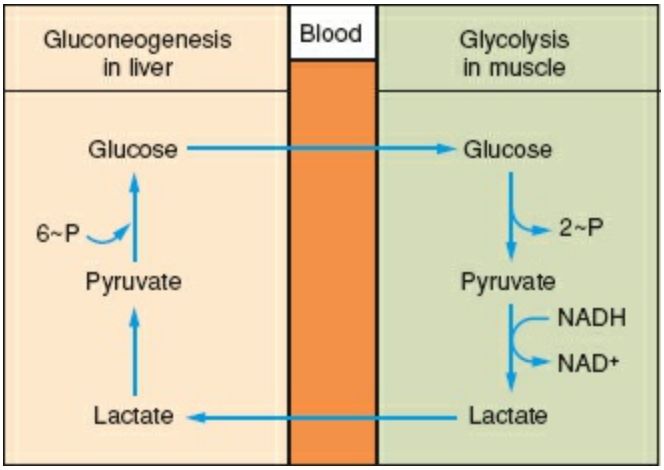

Figure 2-5. The Cori cycle, an elegant mechanism for the hepatic conversion of muscle lactate into new glucose. Pyruvate plays a key role in this process.

Phosphogluconate Pathway

When glucose enters the liver, glycogen is formed until the hepatic glycogen capacity is reached (about 100 g). If excess glucose is still available, the liver converts it to fat by the phosphogluconate pathway (also known as the pentose phosphate pathway) (Fig. 2-6). The cytosolic phosphogluconate pathway can completely oxidize glucose, generating CO_2 and nicotinamide adenine dinucleotide phosphate (NADPH) through what is known as the oxidative phase. Hydrogen atoms released in the phosphogluconate pathway combine with oxidized nicotinamide adenine dinucleotide phosphate ($NADP^+$) to form reduced nicotinamide adenine dinucleotide phosphate ($NADPH - H^+$).[5] The oxidative phase is present only in tissues, such as the adrenal glands and gonads, that require reductive biosyntheses such as steroidogenesis or other forms of lipid synthesis. Essentially, all tissues contain the nonoxidative phase, which is reversible and produces ribose precursors for nucleotide synthesis. In erythrocytes, the phosphogluconate pathway provides reducing equivalents for the production of reduced glutathione by glutathione reductase. Reduced glutathione can remove hydrogen peroxide, which increases the conversion of oxyhemoglobin to methemoglobin and subsequent hemolysis.

LIPID METABOLISM

Lipid Transport

Lipid transport throughout the body is made complicated by the fact that lipids are insoluble in water. To overcome this physicochemical incompatibility, dietary triglycerides are first split into monoglycerides and fatty acids by the action of intestinal lipases. After absorption into small intestinal cells, triacylglycerols are reformed and aggregate into chylomicrons, which then enter the bloodstream by way of lymph. Chylomicrons are removed from the blood by the liver and adipose tissue. The capillary surface of the liver contains large amounts of lipoprotein lipase, which hydrolyzes triglycerides into fatty acids and glycerol. The fatty acids freely diffuse into hepatocytes for further metabolism. Similar to chylomicrons, very low-density lipoproteins (VLDLs) are synthesized by the liver and are the main vehicle for transport of triacylglycerols to extrahepatic tissues. The intestines and liver are the only two tissues capable of secreting lipid particles. In addition to chylomicrons and VLDLs, there are two other major groups of plasma lipoproteins: low-density lipoproteins (LDLs) and high-density lipoproteins (HDLs). LDLs and HDLs contain predominantly cholesterol and phospholipid.

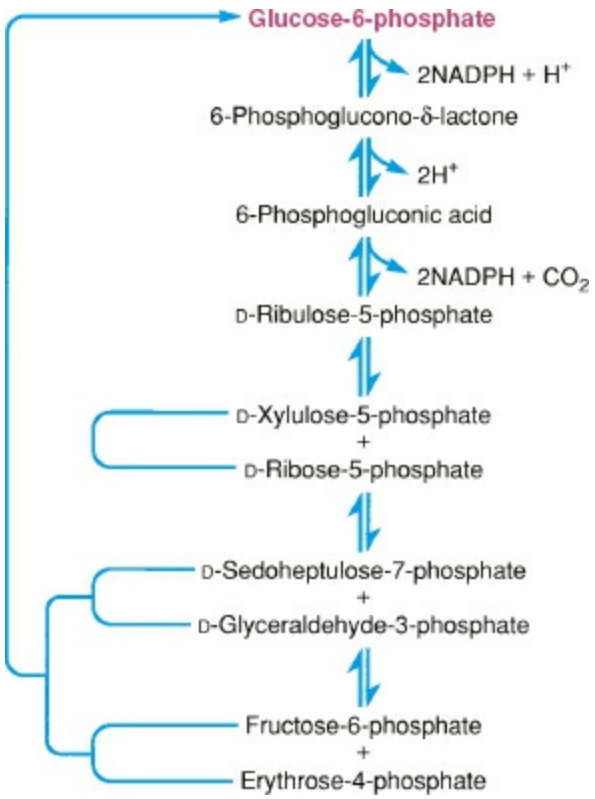

Figure 2-6. The phosphogluconate pathway. One of the major purposes of this pathway is to generate reduced nicotinamide adenine dinucleotide, which can serve as an electron donor and allow the liver to perform reductive biosynthesis. Glucose-6-phosphate, in *red*, plays a central role in carbohydrate metabolism.

The structure of all classes of lipoproteins is similar. There is a core of nonpolar lipids, either triacylglycerols or cholesteryl esters, depending on the particular lipoprotein. This nonpolar core is coated with a surface layer of amphipathic phospholipid or cholesterol

oriented so that the polar ends are in contact with the plasma. A protein component is also present. The A apolipoproteins occur in chylomicrons and HDLs. The B apolipoproteins come in two forms: B-100 is the predominant apolipoprotein of LDLs, whereas the shorter B-48 is located in chylomicrons. The C apolipoproteins can transfer between VLDLs, LDLs, and HDLs. Apolipoproteins D and E also exist. Apolipoproteins have several functions in lipid transport and storage. Some, such as the B apolipoproteins, are an integral part of the lipoprotein structure. Other apolipoproteins are enzyme cofactors, such as C-II for lipoprotein lipase. Lastly, the apolipoproteins act as ligands for cell surface receptors. As an example, both B-100 and E serve as ligands for the LDL receptor.[6]

Plasma variations in LDL cholesterol, HDL cholesterol, and triglycerides affect risk for atherosclerotic cardiovascular disease. As dyslipidemias are being identified and studied, new therapeutic approaches are needed. A convergence of human genetics and functional biology has led to recent advances in the study of lipoprotein metabolism. Genome-wide association studies have identified about 100 genes associated with plasma lipid phenotypes – many of which were not previously known to be associated with lipids. These genes are now being functionally validated through human genetic analysis such as deep targeted resequencing of kindreds with Mendelian lipid abnormalities or gene manipulation (over- or underexpression) in cultured cells and animal models.[7]

FATTY ACID METABOLISM

Most human fatty acids in plasma are long-chain acids (C-16 to C-20). Because long-chain fatty acids are not readily absorbed by the intestinal mucosa, they must first be incorporated into chylomicrons. In contrast, short-chain and medium-chain fatty acids are absorbed directly into the portal circulation and are avidly taken up by the liver. Free fatty acids in the circulation are noncovalently bound to albumin and are transferred to the hepatocyte cytosol by way of fatty acid–binding proteins. Fatty acid-CoA esters are synthesized in the cytosol after hepatic uptake of fatty acids. These fatty acid-CoA esters can be converted into triglyceride, transported into mitochondria for the production of acetyl CoA and reducing equivalents, or stored in the liver as triglycerides. The rate-limiting step in the synthesis of triglyceride is the conversion of acetyl CoA to malonyl CoA. Malonyl CoA, in turn, inhibits the mitochondrial uptake of fatty acid-CoA ester, favoring triglyceride synthesis. The liver also contains dehydrogenases that can unsaturate essential dietary fatty acids. Structural elements of all tissues contain significant amounts of unsaturated fats, and the liver is responsible for the production of these unsaturated fatty acids. As another example, dietary linoleic acid is elongated and dehydrogenated to the prostaglandin precursor arachidonic acid.

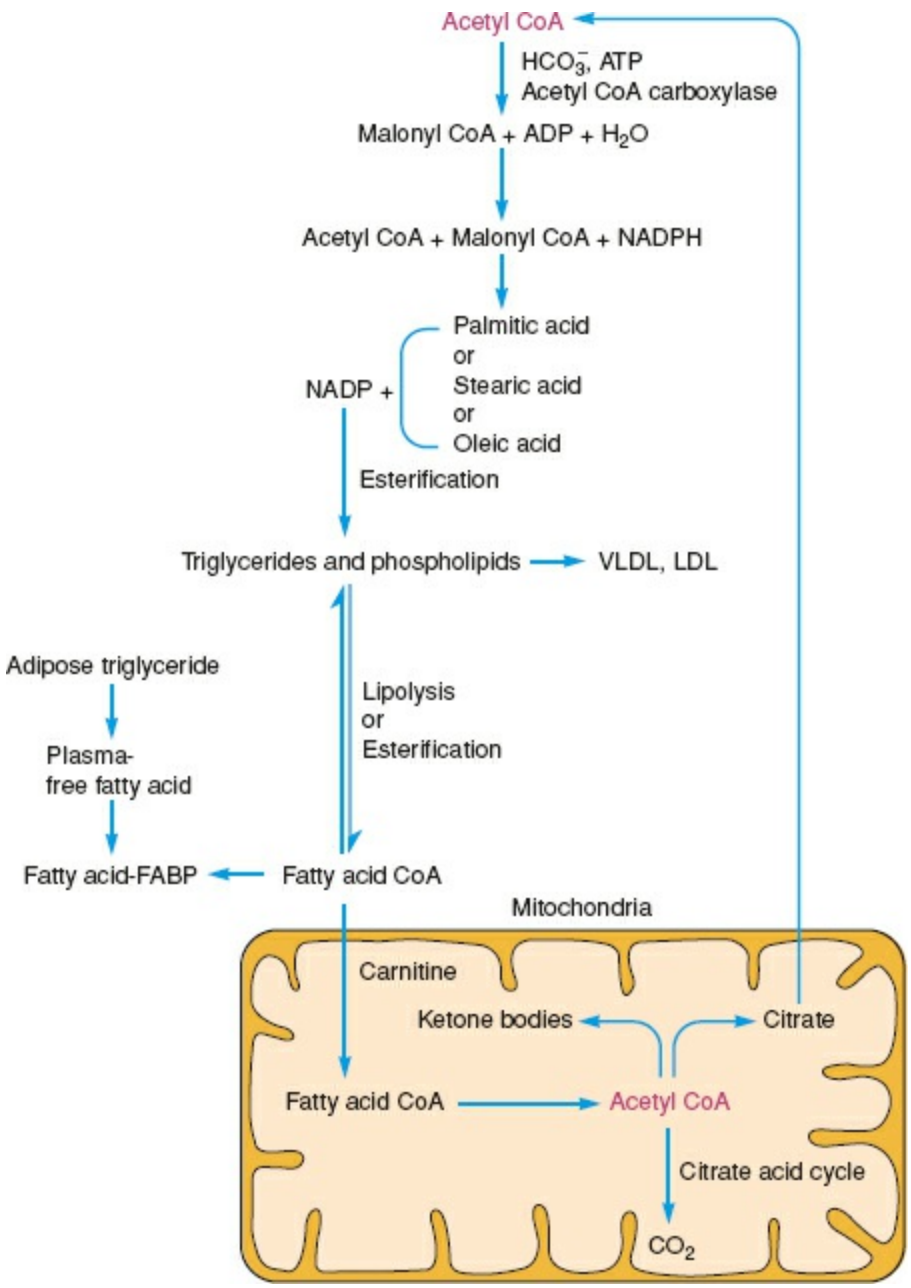

Figure 2-7. Diagram of hepatic fatty acid metabolism. Both dietary and newly synthesized fatty acids are esterified and subsequently degraded in the mitochondria for energy, first as reducing equivalents, then adenosine triphosphate via the electron transport chain. Acetyl CoA, in *red*, plays a central role in lipid metabolism.

3 Free fatty acids are a direct source of energy for cardiac and skeletal muscles and under basal conditions, most free fatty acids are catabolized for energy. Under conditions of adipocyte lipolysis, the liver can take up and metabolize fatty acids. Although fatty acid synthesis occurs in the cytosol, fatty acid oxidation occurs in the mitochondria. Fatty acid-CoA esters bind carnitine, a carrier molecule, and in the absence of cytosolic malonyl CoA, they enter the mitochondria, where they undergo beta-oxidation to acetyl CoA and reducing equivalents (Fig. 2-7). Acetyl CoA can then take one of the following routes: (a) enter the tricarboxylic acid cycle and be degraded to carbon dioxide, (b) be converted to citrate for fatty acid synthesis, or (c) be converted into 3-hydroxy-3-methylglutaryl CoA (HMG-CoA), a precursor of cholesterol and ketone bodies. The mitochondrial hydrolysis of fatty acids is a source of large quantities of ATP. The conversion of stearic acid to carbon dioxide and water, for instance, generates 136 molecules of ATP and demonstrates

the highly efficient storage of energy as fat. By a process called beta-oxidation, acetyl-CoA molecules are cleaved from fatty acids. The acetyl CoA is then metabolized through the citric acid cycle under normal circumstances.

In times of significant lipolysis – starvation, uncontrolled diabetes, or other conditions of triglyceride mobilization from adipocyte stores – the predominant ketone bodies 3-hydroxybutyrate and acetoacetate are formed in hepatic mitochondria from free fatty acids and are a source of energy for extrahepatic tissues. Ketogenesis is regulated primarily by the rate of mobilization of free fatty acids. Once in the liver mitochondria, the relative proportion of acyl CoA destined to undergo beta-oxidation is limited by the activity of an enzyme, carnitine palmitoyltransferase-1. Lastly, there are mechanisms that keep the levels of acetyl CoA entering the citric acid cycle constant, so that only at high mitochondrial levels will acetyl CoA be converted to ketone bodies. Even the brain, in times of starvation, can use ketone bodies for half of its energy requirements. At some point, however, the ability of liver to perform beta-oxidation may be inadequate. Under such circumstances, hepatic storage of triglyceride or fatty infiltration of the liver can be significant, leading to the development of nonalcoholic steatohepatitis. Triglyceride storage by itself does not appear to be a cause of hepatic fibrosis, but fatty infiltration may be a marker for the derangement of normal processes by alcohol or drug toxicity, diabetes, or long-term total parenteral nutrition. A specific type of microvesicular fatty accumulation is also seen in a variety of diseases, such as Reye syndrome, morbid obesity, and acute fatty liver of pregnancy.

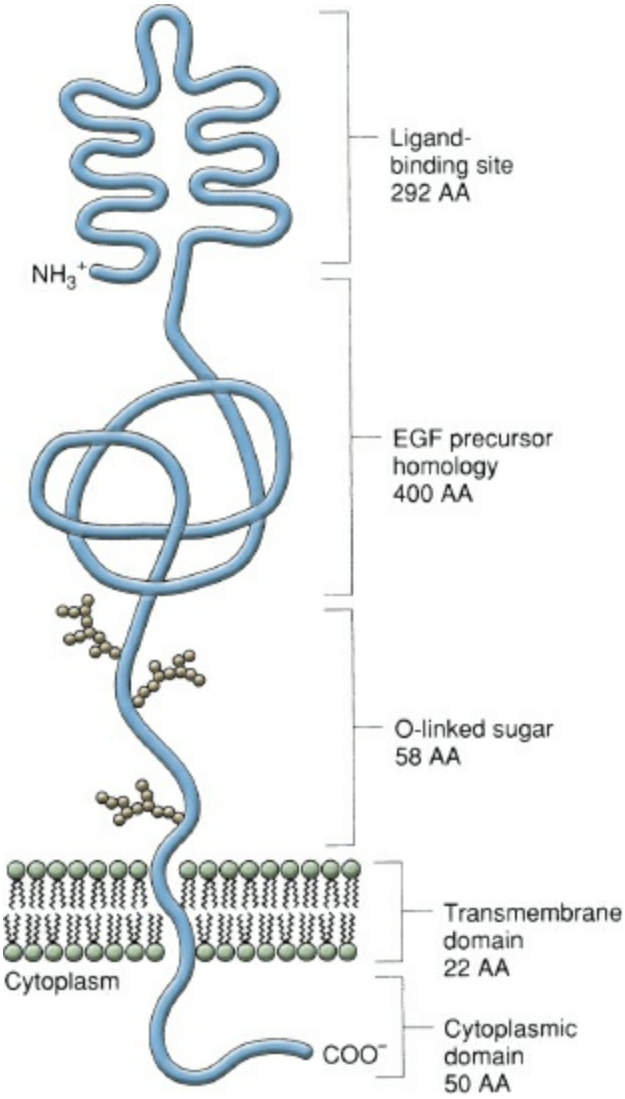

Figure 2-8. The LDL receptor, an example of a transmembrane receptor that participates in receptor-mediated endocytosis. The LDL receptor specifically binds lipoproteins that contain apolipoprotein B-100 or E. Once internalized, the lipoproteins are degraded. AA, amino acids; EGF, epidermal growth factor.

As noted above, fatty acids are critical elements of all mammalian cells; as energy substrate, in cellular structure, and for intracellular signaling. Evolutionarily, storage of excess fat in adipose tissue mitigated starvation. But in most modern societies the ready availability of calorie-dense foods has led to an epidemic of obesity as is discussed in detail in other chapters. In terms of intermediary metabolism, excess dietary fatty acids are now known to cause insulin resistance in muscle through intramyocellular triglyceride content leading to type II diabetes. This effect is likely due to intracellular perturbations in active lipid metabolites such as diacylglycerols or ceramides. Other studies have documented mitochondrial abnormalities possibly through interference with serine kinases.[8]

CHOLESTEROL METABOLISM

Cholesterol is an important regulator of membrane fluidity and is a substrate for bile acid and steroid hormone synthesis. Cholesterol may be available by dietary intake or by de novo synthesis. In mammals, mostly new cholesterol is synthesized in the liver from its precursor, acetyl CoA. Dietary cholesterol intake can suppress endogenous synthesis by inhibiting the rate-limiting enzyme in the cholesterol biosynthetic pathway, HMG-CoA reductase. A competitive antagonist, lovastatin, can also block HMG-CoA reductase and effectively lower plasma cholesterol by blocking cholesterol synthesis, stimulating LDL receptor synthesis, and allowing an increased hepatic uptake and metabolism of cholesterol-rich LDL lipoproteins. The structure of the LDL receptor is known and serves as a model for the structure and function of other cell membrane receptors (Fig. 2-8).

Cholesterol is lipophilic and hydrophobic, and most plasma cholesterol is in lipoproteins esterified with oleic or palmitic acid. The liver can process cholesterol esters from all classes of lipoproteins. Hepatocytes can also take up chylomicron remnants containing dietary cholesterol esters. Abnormally elevated levels of cholesterol in VLDLs or LDLs are associated with atherosclerosis, whereas high HDL levels are protective. Newly synthesized hepatic cholesterol is also used to synthesize bile acids for further intestinal absorption of dietary fats. A large proportion of the bile acids secreted by the liver into bile are returned to the liver via the enterohepatic circulation (Fig. 2-9).

Phospholipids

The three major classes of phospholipids synthesized by the liver are lecithins, cephalins, and sphingomyelins. Although most cells in the body are capable of some phospholipid synthesis, the liver produces 90%. Phospholipid formation is controlled by the overall rate of fat metabolism and by the availability of choline and inositol. The main role of phospholipids of all types is to form plasma and organelle membranes. The amphiphilic nature of phospholipids makes them essential for reducing surface tension between membranes and surrounding fluids. Phosphatidylcholine, one of the lecithins, is the major biliary phospholipid and is important in promoting the secretion of free cholesterol into bile. Thromboplastin, one of the cephalins, is needed to initiate the clotting cascade. The sphingomyelins are necessary for the formation of the myelin nerve sheath.

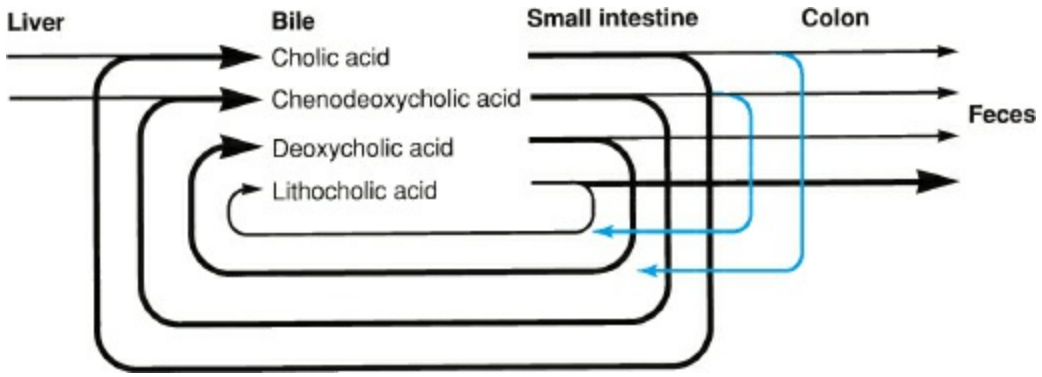

Figure 2-9. The enterohepatic circulation of bile acids. The primary bile acids, cholic acid, and chenodeoxycholic acid, are synthesized in the liver from cholesterol. Deoxycholic acid and lithocholic acid are formed in the colon (*blue lines*) during bacterial degradation of the primary bile acids. All four bile acids are conjugated with glycine or taurine in the liver. Most of the lithocholic acid is also sulfated, which decreases reabsorption and increases fecal excretion. Bile acids are absorbed passively in the epithelium of the small and large intestine and actively in the distal ileum.

PROTEIN METABOLISM

Formation and Catabolism of Plasma Proteins

4 Hepatic protein synthesis, when excess amino acids are available, includes albumin, fibrinogen, and apolipoproteins and can reach 50 g/day. Of the total hepatic protein synthesized, 75% is destined for export in plasma. Most newly synthesized proteins are not stored in the liver, and the rate of protein synthesis is primarily determined by the intracellular levels of amino acids. The tertiary structure of many proteins undergoes posttranslational modification after they have been synthesized in the liver's rough endoplasmic reticulum (ER). Glycosylation, or the addition of carbohydrate moieties, occurs in the smooth ER. Sialation, or the addition of sialic acid, occurs in the Golgi. Glycosylation is important in allowing some proteins to bind with specific receptors for subsequent hepatic uptake and processing. Removal of sialic acid residues, or desialation, from the terminal galactose molecules of glycoproteins allows them to bind to the asialoglycoprotein (ASGP) receptor in the liver and undergo degradation. Desialation, therefore, is important in the clearance of senescent proteins from the plasma.

Intracellular proteases hydrolyze proteins into peptides, and the peptides are in turn hydrolyzed by peptidases. Ultimately, free amino acids are generated. Unlike carbohydrate and lipids, excess amino acids are degraded if they are not immediately reincorporated into new proteins. Protein degradation occurs primarily by one of two routes. ASGPs are internalized into lysosomes via receptor-mediated endocytosis. The lysosomal enzymes do not require ATP and are nonselective in their activities; more than 20 known hydrolytic enzymes are present in lysosomes. A second pathway involves the covalent attachment of ubiquitin, named for the fact that it exists in all mammalian cells, targeting proteins for destruction. This pathway is ATP dependent and generally is used for proteins with shorter half-lives.[9]

Amino Acid Synthesis

Essentially, all the end products of dietary protein digestion are amino acids, which are absorbed by the enterocytes into the portal circulation in an ionized state. Liver amino acid uptake occurs by one of several active transport mechanisms. Amino acids are not stored in the liver but are rapidly used in the production of plasma proteins, purines, heme proteins, and hormones. Under certain conditions, the amine group is removed from amino acids, and the carbon chain is used for carbohydrate, lipid, or nonessential amino acid synthesis.[10]

Ten nutritionally essential amino acids must be obtained from dietary intake (Table 2-2). However, human tissues contain transferases, which convert the α-keto acids of leucine, valine, and isoleucine so that the corresponding α-keto acids can be used as dietary supplements. The remaining nutritionally nonessential amino acids can be synthesized in one to three enzyme-catalyzed reactions. Hydroxyproline and hydroxylysine do not have a corresponding tRNA and arise by posttranslational modification of proline or lysine by mixed function oxidases. Glutamate, glutamine, and proline are derived from the citric acid cycle intermediate α-ketoglutarate. Aspartate and asparagine are synthesized from oxaloacetate. Serine and glycine are synthesized from the glycolysis intermediate 3-phosphoglycerate. Cysteine and tyrosine are formed from essential amino acids (methionine and phenylalanine, respectively).[11]

Table 2-1 Amino Acids Required by Adult Humans

Nutritionally Essential	Nutritionally Nonessential	
	Amino Acid	Precursor
Arginine	Alanine	Pyruvate
Histidine	Asparagine	Oxaloacetate
Isoleucine	Aspartate	Oxaloacetate
Leucine	Cysteine	Methionine
Lysine	Glutamate	α-Ketoglutarate
Methionine	Glutamine	α-Ketoglutarate
Phenylalanine	Glycine	3-Phosphoglycerate
Threonine	Hydroxyproline	α-Ketoglutarate
Tryptophan	Hydroxylysine	Lysine
Valine	Proline	α-Ketoglutarate
	Serine	3-Phosphoglycerate
	Tyrosine	Phenylalanine

Catabolism of Amino Acid Nitrogen

Ammonia, derived largely from the deamination of amino acids, is toxic to all mammalian cells. The ammonia formed as a result of the deamination of amino acids is detoxified by one of two routes.[12] The most important pathway involves the conversion of ammonia to urea by enzymes of the Krebs–Henseleit, or urea cycle, which occurs only in the liver (Fig. 2-10). A second route of ammonia metabolism involves synthesis of L-glutamine from ammonia and glutamate by renal glutamine synthetase.

CELLULAR ENERGY GENERATION

Overview and Stage I

5 The citric acid cycle includes a series of mitochondrial enzymes that transform acetyl CoA – itself derived from pyruvate or fatty acyl CoA – into water, carbon dioxide, and hydrogen-reducing equivalents. Each molecule of acetyl CoA that enters the citric acid cycle yields 12 molecules of ATP. The fundamental mechanism by which mammalian cells generate energy is the aerobic conversion of sugars and fatty acids into ATP. There are four stages with stage I – glycolysis – (see glycolysis above) beginning in the cytosol, converting glucose into two molecules of pyruvate. Also, cytosolic fatty acids are converted to fatty acyl CoA. Pyruvate and fatty acyl CoA are transported to the mitochondrial matrix and converted to acetyl CoA; generating the electron carriers NADH or $FADH_2$ as well as CO_2. In stage II, mitochondrial acetyl CoA enters the citric acid cycle further generating NADH, $FADH_2$, additional CO_2, and GTP. In stage III, oxygen is reduced to water via the electron transport chain using previously generated molecules of NADH and $FADH_2$ as electron donors. The electron transport chain causes hydrogen ions to move from the mitochondrial matrix to the intermembrane space generating a proton motive force. Lastly, in stage IV, ATP synthase uses energy generated by the proton motive force to generate large amounts of ATP.[13]

Stage II: The Citric Acid Cycle: Integration of Metabolic Pathways and Oxidation of Acetyl CoA

One major function of the citric acid cycle (also known as the Krebs cycle or the tricarboxylic acid cycle) is to act as a common pathway for the oxidation of carbohydrate, lipid, and protein and generate energy in the form of ATP. Conversely, the citric acid cycle is important in gluconeogenesis, lipogenesis, and amino acid metabolism. In the fed state, a large proportion of ingested energy from foodstuffs is converted to glycogen or fat. The metabolism of sugars, fats, and proteins, then, allows adequate fuels for all tissue types under conditions from fed to fasting to starvation. The body accomplishes production of fuel substrates for organs and regulates intestinally absorbed nutrients for tissue consumption or storage by integrating three key metabolites: G6P, pyruvate, and acetyl CoA (Fig. 2-11). Each of these three simple chemical molecules can be extensively modified to allow a large number of metabolites.

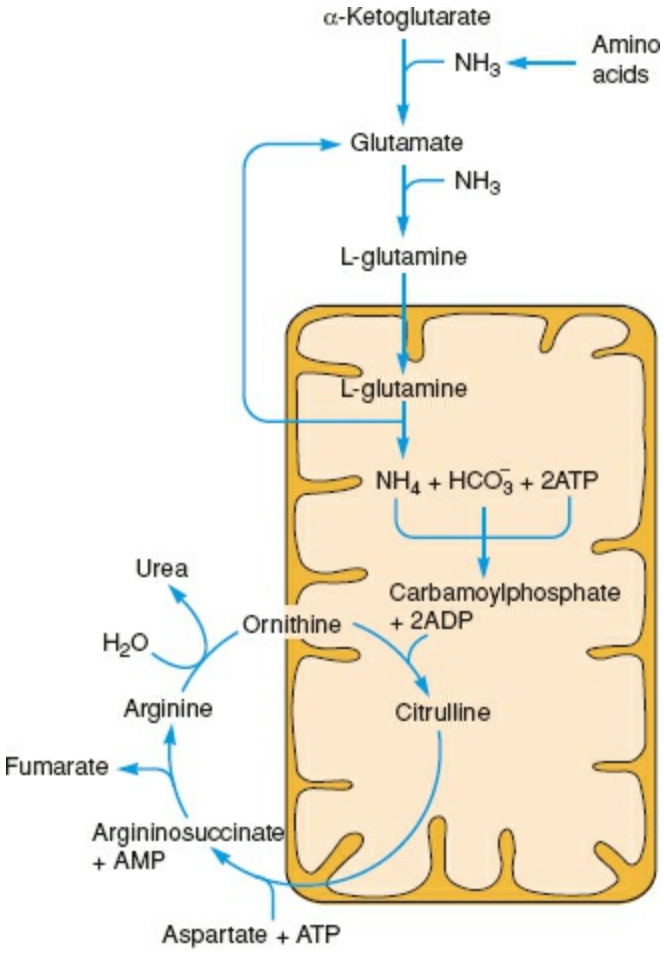

Figure 2-10. The urea cycle. Ammonia entering the urea cycle is derived from protein and amino acid degradation in tissues (endogenous) and the colonic lumen (exogenous).

G6P can be stored as glycogen or converted into glucose, pyruvate, or ribose-5-phosphate (a nucleotide precursor). Pyruvate can be converted into lactate, alanine (and other amino acids), and acetyl CoA, or it can enter the tricarboxylic acid cycle by conversion to oxaloacetate. Acetyl CoA is converted to HMG-CoA (a cholesterol and ketone body precursor) or citrate (for fatty acid and triglyceride synthesis), or it is

degraded to carbon dioxide and water for energy. In humans, acetyl CoA cannot be converted into pyruvate due to the irreversible reaction of pyruvate dehydrogenase. Thus, lipids cannot be converted into either carbohydrates or glucogenic amino acids.

Probably the most important citric acid cycle function is to oxidize acetyl CoA into CO_2. The citric acid cycle is composed of a series of enzyme reactions that occur in the mitochondrial matrix and inner membrane. Here, acetyl CoA combines with oxaloacetate to form citrate. Through a series of subsequent enzymatic reactions involving both dehydrogenases and decarboxylases, citrate is catabolized to result in the generation of hydrogen-reducing equivalents and carbon dioxide (Fig. 2-12). With each revolution of the citric acid cycle, a molecule of acetyl CoA generates three molecules of the reduced coenzyme NADH, one molecule of the reduced coenzyme $FADH_2$, and one molecule of GTP. The reduced coenzymes NADH and $FADH_2$ are charged with high-energy electrons that subsequently drive the electron transport chain of stage III to generate a hydrogen ion gradient. These reducing equivalents are transported to the inner mitochondrial membrane and the electron transport chain to generate more ATP. Each molecule of NADH is oxidized to yield three molecules of ATP, and each molecule of $FADH_2$ is oxidized to yield two molecules of ATP. One molecule of ATP is generated at the substrate level in the conversion of succinyl CoA to succinate; thus, the total molecule of ATP generated per molecule of acetyl CoA is 12.

Stages III and IV: Oxidative Phosphorylation

6 Oxidative phosphorylation converts the energy from NADH and $FADH_2$ into ATP by the electron transport chain and ATP synthase with a process called the proton motive force. The covalent bond energy in glucose and fatty acids is transferred into high-energy electrons in stages I (glycolysis) and II (citric acid cycle). Flow of these high-energy electrons from NADH and $FADH_2$ to oxygen, creating water, is coupled to transport of protons across the mitochondrial inner membrane from the matrix to the intermembrane space. Originally called Mitchell's chemiosmotic hypothesis, many researchers now refer to this process as the proton motive force. The voltage gradient caused by the transport of these protons, and the ATP subsequently generated is the process known as oxidative phosphorylation. Below is an admittedly simplified explication of a complex process, and the stoichiometry of the reactions has been modified for clarity. Anyone interested in the precise biochemistry should consult the relevant sources (Fig. 2-13).

Two high-energy electrons carried by NADH or $FADH_2$ pass through three of four major multiprotein complexes: I – NADH-CoQ reductase; II – succinate-CoQ reductase; III – $CoQH_2$-cytochrome *c* reductase; and, IV – cytochrome *c* oxidase. The paths of NADH and $FADH_2$ are different initially. NADH electrons are transferred through complex I – NADH-CoQ reductase – to flavin mononucleotide (FMN), seven iron–sulfur clusters (Fe-S), and then coenzyme Q (CoQ) to create $CoQH_2$. Four protons are transported from the mitochondrial matrix as a result of the actions of complex I. Unlike NADH, $FADH_2$ is oxidized by complex II – succinate-CoQ reductase. The two $FADH_2$ electrons are transferred to succinate dehydrogenase-bound FAD when succinate is oxidized to fumarate, then an iron–sulfur cluster, and finally to CoQ creating $CoQH_2$.

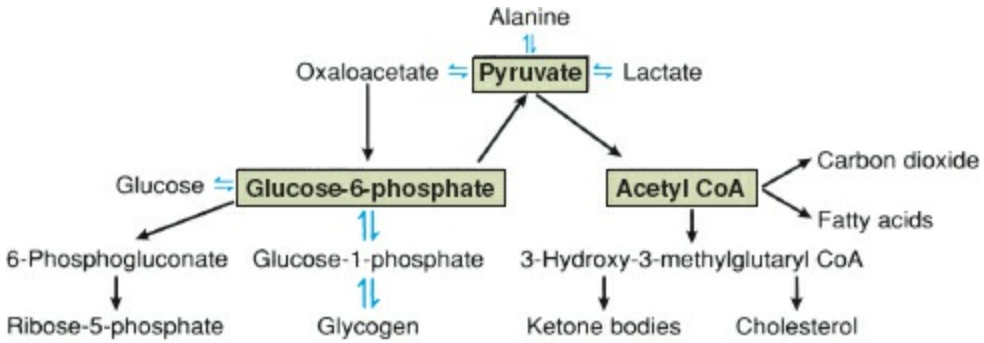

Figure 2-11. Summation of the key regulatory molecules used by the liver during diverse metabolic functions. Essentially, any compound found in the body can be synthesized in the liver from glucose-6-phosphate, acetyl coenzyme A, or pyruvate. As a consequence of the inability of mammalian liver to convert acetyl coenzyme A to pyruvate, fats cannot be converted to carbohydrates.

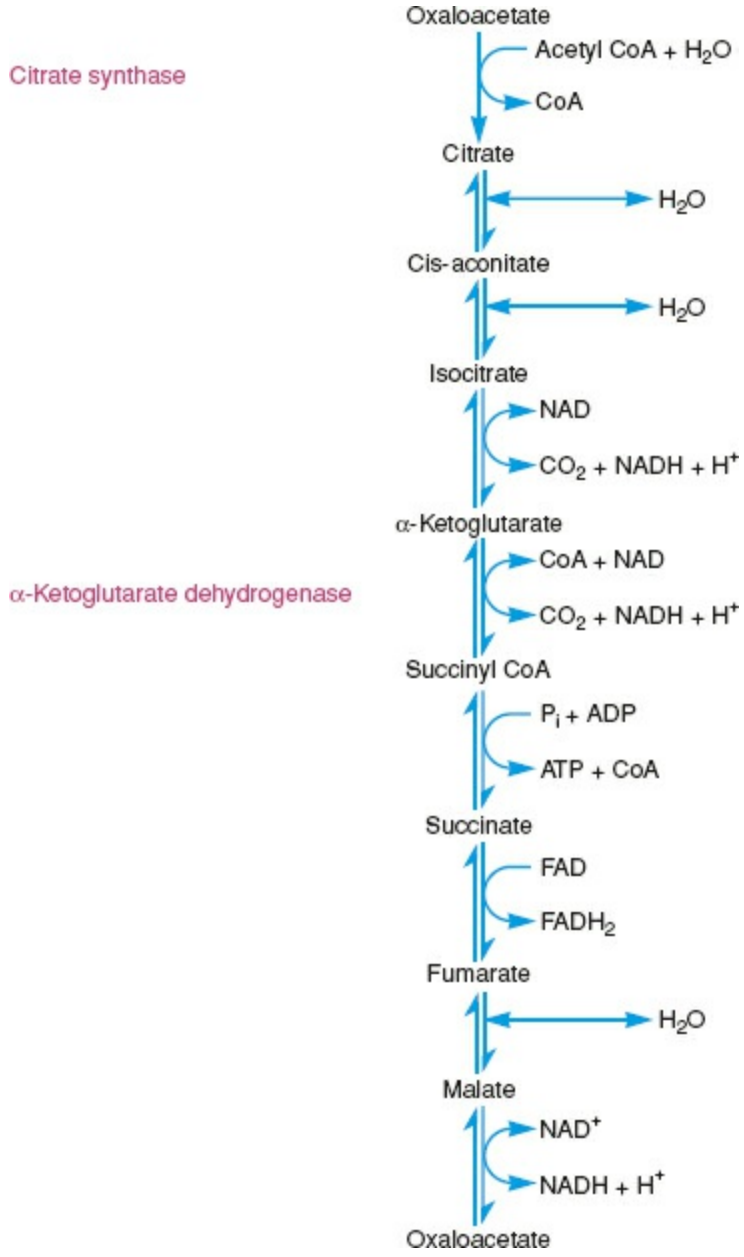

Figure 2-12. The citric acid cycle. Reduced nicotinamide adenine dinucleotide and reduced flavin adenine dinucleotide, formed in the citric acid cycle, are subsequently oxidized in mitochondria by means of the electron transport chain to generate ATP. Acetyl CoA plays a key role.

$CoQH_2$ from NADH or $FADH_2$ is shuttled to complex III – $CoQH_2$-cytochrome *c* reductase – within the inner membrane. The two electrons are further transferred to cytochromes b_L and b_H, resulting in pumping of two additional hydrogen ions into the intermembranous space. Electrons are further transferred to another iron–sulfur cluster, cytochrome c_1, and ultimately the intermembranous space protein cytochrome *c,* pumping two additional hydrogen ions. Complex II catalyzes the conversion of fatty acyl CoA to acetyl CoA for further metabolism through the citric acid cycle. Cytochrome *c* shuttles the two electrons through the intermembranous space to complex IV – cytochrome *c* oxidase – reoxidizing the cytochrome *c* molecule, transferring the electrons to copper containing Cu_a, the heme moiety of cytochrome a_3, Cu_b, cytochrome a_3, and ultimately to oxygen, yielding water.

The net result of the electron transport chain is the pumping of ten H^+ ions into the

intermembranous space for two electrons flowing from NADH to O_2, and six H^+ ions for each two electrons from $FADH_2$ to O_2. This generates the proton motive force; a voltage gradient across the inner mitochondrial membrane that directly provides energy for ATP generation in stage IV. ATP synthase harnesses the voltage gradient of protons across the inner membrane by interconverting the chemical potential energy into phosphoanhydride bonds of ATP. ATP synthase is composed of two main complexes: $F_{0,}$, consisting of three types of membrane proteins, and F_1, a five-polypeptide complex protruding into the matrix.

Alternative Fuels

Regardless of the fed state of the human body, there is a requirement for glucose utilization. The nervous system and erythrocytes have an absolute requirement for glucose. Glucose is a source of glycerol-3-phosphate for adipose tissue, and most other tissues for integrity of the citric acid cycle. To maintain adequate glucose for survival, other fuels can be used depending on environmental conditions. Under conditions of carbohydrate shortage, ketone bodies and free fatty acids are utilized to spare oxidation of glucose in muscle. These alternate fuels increase intracellular citrate, which inhibits both phosphofructokinase and pyruvate dehydrogenase. In starvation, fatty acid oxidation results in the production of glycerol, which, along with gluconeogenesis from amino acids, is the only source of the required glucose. Ultimately, even the brain can substitute ketone bodies for about half of its energy requirements.

The preferred energy substrates for liver are ketoacids derived from amino acid degradation even in well-fed states. This is designed to allow the consumption of glucose by obligate tissues. Glucose produced by the dephosphorylation of G6P rapidly diffuses out of the cell and is taken up by the brain, muscles, and other organs. Hepatic glycolysis is used primarily for the production of intermediates of metabolism and not for energy. Hepatic fatty acid degradation for energy is also inhibited under most circumstances and occurs only during adipocyte lipolysis. By way of clinical relevance, alterations in liver mitochondrial function are now known to be important in two common diseases. Patients with type 2 diabetes have reduced ATP synthesis and abnormal ATP repletion in response to substrate-induced ATP depletion. Nonalcoholic fatty liver disease is also associated with lowered ATP repletion in response to oxidative stress.[14]

Most short-, medium-, and long-chain fatty acids (C8 to C20) are metabolized by mitochondria to generate ATP. Mitochondria cannot metabolize fatty acids with acyl chains greater than 20, and these very long-chain fatty acids are metabolized in peroxisomes, predominantly in the liver. Peroxisomes do not contain elements of the citric acid cycle or electron transport chain and thus do not generate ATP. Most of the energy is released as heat.[15]

Adipocyte Phenotype, Thermogenesis, and Obesity

Epidemic obesity has created a surge of interest in the adipocyte, or fat cell. There are three basic types of adipocytes; white, brown, and beige. White adipocytes differentiate for the storage of fat and contain few mitochondria. The traditional view is that adult human fat is comprised predominantly of white adipocytes. These adipocytes accumulate lipid in times of over feeding leading to obesity and insulin resistance.[8]

Brown adipocytes are so named because of the brown color created by a high density of cellular mitochondria. Unlike the mitochondria of other organs, the mitochondria of brown adipocytes contain uncoupling protein-1 which can catalyze a protein leak across the inner membrane uncoupling electron transport from ATP synthesis. This results in the dissipation of energy as heat, or thermogenesis. Brown adipocytes were thought to be present only in human infants, and rare circumstances such as cold-climate outdoor workers or pheochromocytoma patients. Recently, the identification of “beige” adipocytes has led to the realization that the adipocyte may be a target for therapy of obesity. Beige adipocytes appear capable of switching from a white phenotype to brown, and the hope that adipocytes could be switched to utilize excess calories for thermogenesis rather than storage as fat.[16]

A

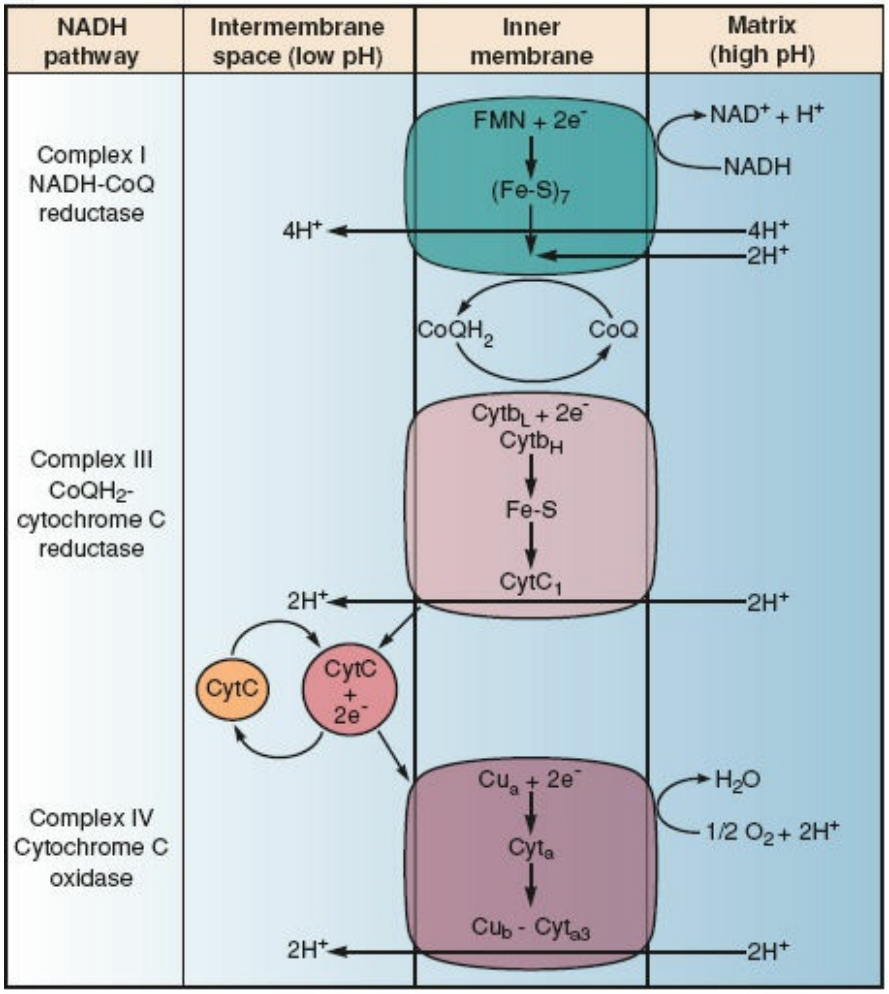
NADH pathway
Intermembrane space (low pH)
Inner membrane
Matrix (high pH)
Complex I NADH-CoQ reductase
FMN + 2e⁻
(Fe-S)7
NAD⁺ + H⁺
NADH
4H⁺
4H⁺
2H⁺
CoQH2
CoQ
Complex III CoQH2-cytochrome C reductase
Cytb_L + 2e⁻
Cytb_H
Fe-S
CytC1
2H⁺
2H⁺
CytC
CytC + 2e⁻
Complex IV Cytochrome C oxidase
Cu_a + 2e⁻
Cyt_a
Cu_b - Cyt_a3
H2O
1/2 O2 + 2H⁺
2H⁺
2H⁺

B

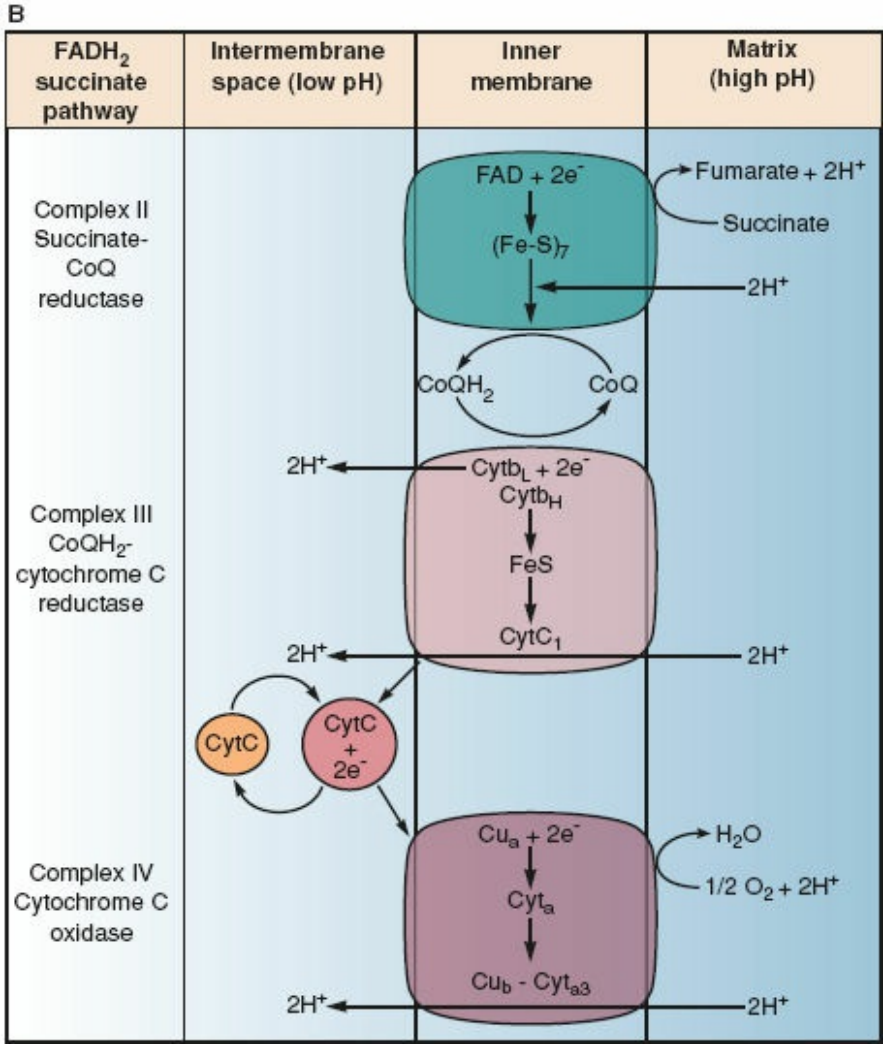
FADH2 succinate pathway
Intermembrane space (low pH)
Inner membrane
Matrix (high pH)
Complex II Succinate-CoQ reductase
FAD + 2e⁻
(Fe-S)7
Fumarate + 2H⁺
Succinate
2H⁺
CoQH2
CoQ
Complex III CoQH2-cytochrome C reductase
2H⁺
Cytb_L + 2e⁻
Cytb_H
FeS
CytC1
2H⁺
2H⁺
CytC
CytC + 2e⁻
Complex IV Cytochrome C oxidase
Cu_a + 2e⁻
Cyt_a
Cu_b - Cyt_a3
H2O
1/2 O2 + 2H⁺
2H⁺
2H⁺

Figure 2-13. The electron transport chain. **A:** NADH pathway. Electrons flow through complex I to complex III via the lipid soluble molecule CoQ. From complex III, the electrons are transported through the intermembrane space by cytochrome *c* to complex IV. For every two electrons that flow from NADH to O_2, 10 protons are pumped to the intermembranous space. **B:** $FADH_2$-succinate pathway. Electrons flow through complex II to complex III via the lipid soluble molecule Coenzyme Q (CoQ). From complex III, the electrons are transported through the intermembranous space by cytochrome *c* to complex IV. For every two electrons that flow from $FADH_2$ and succinate to O_2, six protons are pumped to the intermembranous space.

BIOTRANSFORMATION

Biotransformation is defined as the intracellular metabolism of endogenous organic compounds (e.g., heme proteins and steroid hormones) and exogenous compounds (e.g., drugs and environmental compounds). Most biotransformation occurs chiefly in the liver, which contains enzyme systems that can expose functional groups, such as hydroxyl ions (phase I reactions), or alter the size and solubility of a wide variety of organic and inorganic compounds by conjugation with small polar molecules (phase II reactions). A general strategy is to convert hydrophobic, potentially toxic compounds into hydrophilic conjugates that can then be excreted into bile or urine.

7 Biotransformation of potentially toxic, often hydrophobic, compounds into hydrophilic, excretable compounds occurs mainly in the liver by the cytochromes P-450, the uridine diphosphate-glucuronyl (UDP-glucuronyl) transferases, the GSH S-transferases, and the sulfotransferases. Biotransforming enzymes are not distributed uniformly within the cells of the hepatic lobule. This heterogeneity may account for the ability of some drugs to cause damage preferentially in zone 3 hepatocytes (those nearest the central venule).

Cytochromes P-450

The cytochromes P-450 are named for their ability to absorb light maximally at 450 nm in the presence of carbon monoxide. These enzymes are bound to the ER and collectively catalyze reactions by using NADPH and oxygen. The P-450 isozymes present in mammalian liver catalyze reactions such as oxidation, hydroxylation, sulfoxide formation, oxidative deamination, dealkylation, and dehalogenation. Such reactions allow further phase II conjugation with polar groups such as glucuronate, GSH, and sulfate. The cytochromes P-450 can also create potentially toxic metabolites. Drugs such as acetaminophen, isoniazid, halothane, and the phenothiazines can be converted into reactive forms that cause cellular injury and death. The cytochromes also are responsible for the formation of organic free radicals, reactive metabolites that can directly attack and injure cellular components or act as haptens in the generation of an autoimmune response. Several of the most potent known carcinogens are aromatic hydrocarbons, which are modified by cytochromes P-450.

Uridine Diphosphate-glucuronyl Transferases

Glucuronidation is the conjugation of UDP-glucuronic acid to a wide variety of xenobiotics by either ester (acyl) or ether linkages. The transferases catalyzing these reactions reside in the ER. Many common compounds are metabolized in this way, including bilirubin, testosterone, aspirin, indomethacin, acetaminophen, chloramphenicol, and oxazepam. Clinically significant loss of activity can occur with acute ethanol exposure or acetaminophen overdose, when formation of UDP-glucuronic acid from UDP-glucose is outstripped by use. Some acyl linkages lead to the generation of electrophilic centers that can react with other proteins. The covalent linkage of conjugated bilirubin to albumin is believed to occur by this mechanism.

Glutathione S-transferases

The GSH transferases are more selective in the biotransformations they perform. GSH conjugation occurs only with compounds that have electrophilic and potentially reactive centers. The role of GSH conjugation catalyzed by the GSH S-transferases is demonstrated by acetaminophen. In metabolism of this drug, cytochromes P-450 create an electrophilic center that reacts with protein thiol groups or GSH.[17] The presence of GSH S-transferase allows the preferential detoxification of acetaminophen rather than its potentially injurious binding to thiol groups. A class of GSH S-transferases, known as *ligandins,* appears to facilitate the uptake and intracellular transport of bilirubin, heme, and bile acids from plasma to liver. In addition to the detoxification of potential toxins, GSH is a substrate for GSH peroxidase, an enzyme important in the metabolism of hydrogen peroxide.

Sulfotransferases

The sulfotransferases catalyze the transfer of sulfate groups from 3'-phosphoadenosine-5'-phosphosulfate (PAPS) to compounds such as thyroxine, bile acids, isoproterenol, α-methyldopa, and acetaminophen. They are located primarily in the cytosol. Although many P-450 derivatives can be further conjugated by either the sulfotransferases or the glucuronyl transferases, a limited ability of the liver to synthesize PAPS makes glucuronidation the predominant mechanism.

HEME AND PORPHYRIN METABOLISM

Heme is formed from glycine and succinate and is the functional iron-containing center of hemoglobin, myoglobin, cytochromes, catalases, and peroxidases. From glycine and succinate precursors, δ-aminolevulinic acid (δ-ALA) is synthesized by the rate-limiting enzyme ALA synthase. The porphyrinogens are intermediates in the pathway from δ-ALA to heme, and porphyrins are oxidized forms of porphyrinogen (Fig. 2-14). Inherited enzyme defects in the heme synthetic pathway cause the overproduction of various porphyrinogens, which can in turn cause clinical manifestations known as the *porphyrias*.[18] Acquired porphyria can be caused by heavy metal intoxication, estrogens, alcohol, or environmental exposure to chlorinated hydrocarbons.

Bilirubin IXa is the predominant heme degradation product in humans and is derived mostly from hemoglobin. The enzyme heme oxygenase, located in cells of the reticuloendothelial system, is primarily responsible for this conversion. Heme oxygenase resides in the ER and requires NADPH as a cofactor. Hepatic processing of bilirubin is further detailed in the section on bile formation.

METAL METABOLISM

Iron uptake appears to occur by two distinct processes: (a) receptor-mediated endocytosis of iron–transferrin complexes and (b) facilitated diffusion across the plasma membrane. More iron is taken up and stored by the liver than by any other organ, with the exception of the bone marrow. Transferrin is synthesized in the liver and has specific plasma membrane receptors on a number of different tissues. After endocytosis, the transferrin and iron dissociate and the transferrin and transferrin receptors return to the cell surface for recycling. A pathway appears to involve the dissociation of iron and transferrin at the plasma membrane and subsequent internalization by carrier-mediated diffusion. Once internalized, iron is stored and forms a complex with apoferritin. Each apoferritin molecule is capable of storing several thousand iron molecules. The iron–apoferritin complex, called *ferritin,* is responsible for iron storage under physiologic conditions. Iron storage in a protein-bound form is essential because free iron can catalyze free radical formation, leading to cell injury.[19]

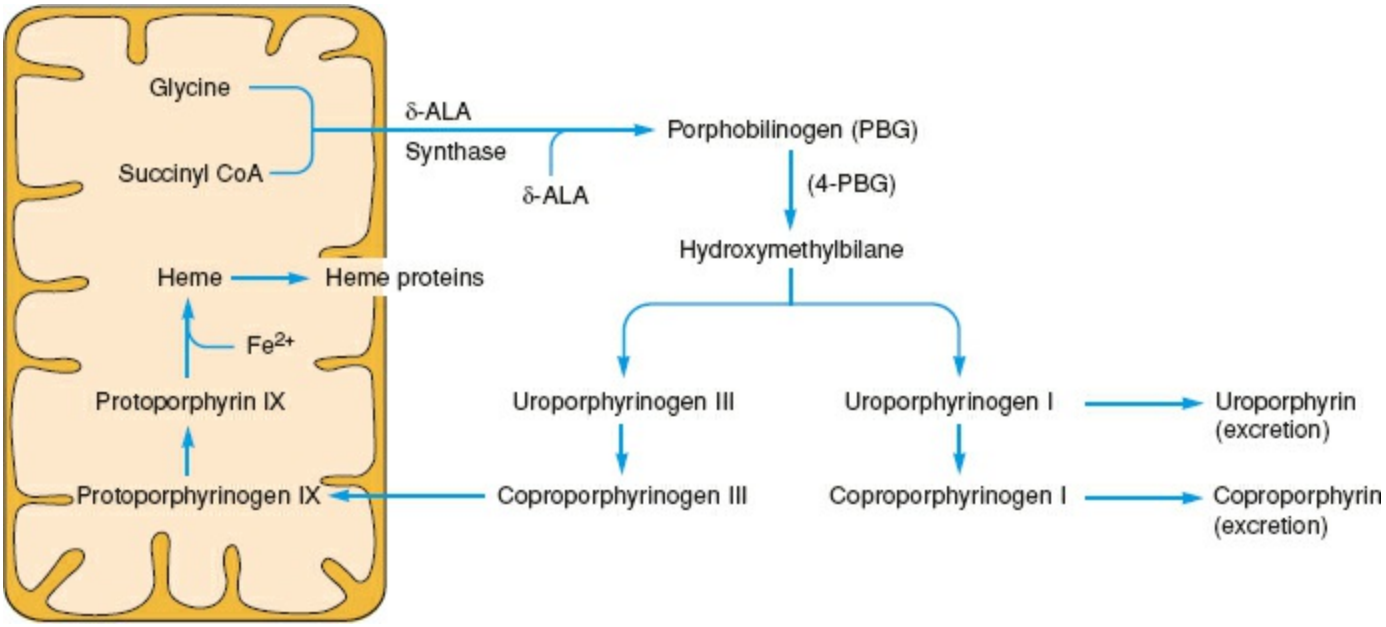

Figure 2-14. The heme biosynthetic pathway. Inherited defects of each of the heme biosynthetic enzymes except δ-aminolevulinic acid synthase have been described and lead to the clinical disorders known as the porphyrias.

Copper is transported to the liver bound to albumin or histidine and enters the hepatocytes by a process of facilitated diffusion. Once inside the cell, copper can bind to several intracellular proteins for storage or as a necessary enzyme cofactor. Copper-binding proteins include metallothionein, monoamine oxidase, cytochrome *c* oxidase, and superoxide dismutase. *Ceruloplasmin* is a liver-derived protein that binds hepatic copper for transport to other tissues. The low levels of ceruloplasmin seen in patients with Wilson disease suggest a pathogenetic defect.

Zinc is taken up by and competes for the same binding sites as copper. In hepatocytes, zinc binds predominantly to metallothionein and is excreted into bile, in which it enters the enterohepatic circulation. Other metals, usually found in trace amounts, are lead, cadmium, selenium, mercury, and nickel. These metals are usually bound to

metallothionein or GSH, and intoxication is associated with free radical formation and liver injury.

SUMMARY

The broad brush-stroke fundamentals of intermediary metabolism have been known for years, however, knowledge on the details expands at an ever-increasing rate. A working understanding of the fundamental biochemical reactions by which substrates are metabolized is important for all surgical disciplines. Advanced knowledge of the genetics, cellular biology, bioenergetics, and molecular biology is being exploited to support and perhaps enhance general and specialized cellular function, combat disease, and improve health.

References

1. Lodish H, Berk A, Kaiser CA, et al., eds. *Molecular Cell Biology*. 7th ed. New York, NY: WH Freeman; 2013:699–704.
2. The ProCESS Investigators; Yealy DM, Kellum JA, Huang DT, et al. A randomized trial of protocol-based care for early septic shock. *N Engl J Med* 2014;370:1683–1693.
3. Jones AE, Shapiro NI, Trzeciak S, et al. Lactate clearance vs central venous oxygen saturation as goals of early sepsis therapy. *JAMA* 2010;303(8):739–746.
4. Whittaker SA, Fuchs BD, Gaieski DF, et al. Epidemiology and outcomes in patient with severe sepsis admitted to the hospital wards. *J Crit Care* 2015;30(1):78–84. Available from: http://dx.doi.org/10.1016/j.jcrc.2014.07.012. Accessed May 27, 2016.
5. Berg JM, Tymoczko JL, Stryer L, et al., eds. *Biochemistry*. 7th ed. New York, NY: WH Freeman; 2012:601–605.
6. Botham KM, Mayes PA. Lipid transport and storage. In: Murray RK, Bender DA, Botham KM, et al., eds. *Harper's Illustrated Biochemistry*. 29th ed. New York, NY: McGraw-Hill; 2012:237–249.
7. Bauer RC, Stylianou IM, Rader DJ. Functional validation of new pathways in lipoprotein metabolism identified by human genetics. *Curr Opin Lipidol* 2011;22:123–128.
8. Turner N, Cooney GJ, Kraegen EW, et al. Fatty acid metabolism, energy expenditure and insulin resistance in muscle. *J Endo* 2014;220:T61–T79.
9. Römisch K. Endoplasmic reticulum-associated degradation. *Annu Rev Cell Dev Biol* 2005;21:435–456.
10. Brosnan JT. Interorgan amino acid transport and its regulation. *J Nutr* 2003;133(6 suppl 1):2068S–2072S.
11. Berg JM, Tymoczko JL, Stryer L, et al., eds. *Biochemistry*. 7th ed. New York, NY: WH Freeman; 2012:711–722.
12. Ah Mew N, Lanpher BC, Gropman A, et al. Urea Cycle Disorders Overview. In: Pagon RA, Adam MP, Ardinger HH, et al., eds. GeneReviews® [Internet]. Seattle, WA: University of Washington; 2003:1993–2014. Available from: http://www.ncbi.nlm.nih.gov/books/NBK1217/. Accessed May 27, 2016.
13. Lodish H, Berk A, Kaiser CA, et al., eds. *Molecular Cell Biology*. 7th ed. New York, NY: WH Freeman; 2013:517–552.
14. Koliaki C, Roden M. Hepatic energy metabolism in human diabetes mellitus, obesity, and non-alcoholic fatty liver disease. *Mol Cell Endo* 2013;379:35–42.
15. Chapter 12: cellular energetics. In: Lodish H, Berk A, Kaiser CA, et al., eds. *Molecular Cell Biology*. 7th ed. New York, NY: WH Freeman; 2013:531–532.
16. Rosen ED, Spiegelman BM. What we talk about when we talk about fat. *Cell* 2014;156:20–44.

17. Riddick DS. Drug biotransformation. In: Kalant H, Grant DM, Mitchell J, eds. *Principles of Medical Pharmacology*. 7th ed. Toronto: Saunders-Elsevier; 2007.
18. Bonkovsky HL, Guo JT, Hou W, et al. Porphyrin and heme metabolism and the porphyrias. *Compr Physiol* 2013;3(1):365–401.
19. Winter WE, Bazydlo LA, Harris NS. The molecular biology of human iron metabolism. *Lab Med* 2014;45(2):92–102.

Chapter 3

Surgical Nutrition and Metabolism

George Kasotakis

Key Points

1. Starvation and systemic inflammatory response result in erosion of the fat-free mass and body weight (malnutrition) and are indicators for nutrition support if present.
2. Inflammation increases energy utilization and alters the metabolism of glucose, protein, fat, and trace minerals.
3. Hypermetabolism is seen in numerous disease states, and not merely in trauma and sepsis.
4. Numerous methods exist to aid assessment of patients' nutritional status, each with its own advantages and disadvantages.
5. A strong relation between protein depletion and postoperative complications has been demonstrated in nonseptic, nonimmunocompromised patients undergoing elective major gastrointestinal surgery.
6. The main goal of perioperative or posttraumatic nutritional support is repletion or maintenance of protein, energy stores, and other nutrients to allow rapid and full recovery from illness.
7. Whenever providing nutritional support, supply caloric intake in the form of carbohydrate and fat in a 2:1 ratio, if no contraindications exist.
8. Enteral nutritional support is always preferable than parenteral nutrition, in the presence of a functioning gastrointestinal tract.
9. The maintenance of an intact brush border and intercellular tight junctions prevents the movement of toxic substances into the intestinal circulation and minimizes bacterial translocation. These functions may be affected in critical illness. Enteral nutrition helps restore them.
10. Allow hypocaloric enteral feedings in the acute phase of critical illness for up to 5 to 7 days in previously well-nourished patients. Start as early as feasible.
11. Routine glutamine supplementation is not supported during critical illness.
12. Supply micronutrients to prevent refeeding syndrome, and monitor electrolytes, liver function tests, and triglyceride levels as needed.
13. The adequacy of nutritional support should be reassessed frequently and adjustments made as needed until full convalescence.

INTRODUCTION

Patients undergoing gastrointestinal procedures with evidence of malnutrition at baseline are more likely to suffer postoperative morbidity, mortality, and require longer hospital stays compared to their well-nourished counterparts.[1,2] The problem is greater than most realize, with up to 14% of patients scheduled for elective gastrointestinal tract procedures found to be malnourished and up to 40% of those with gastrointestinal disease found to be at risk for malnutrition.[3] It has been shown that poor nutritional status can detrimentally affect postoperative outcomes,[4] and in a consensus review of Enhanced Recovery After Surgery, it was recommended that patients receive carbohydrate loading 24 hours preoperatively and nutritional supplements, from the day of surgery, until oral intake is achieved.[5]

In addition to patients undergoing elective surgery, severe injury and critical illness are associated with a hypermetabolic state that can increase energy expenditure dramatically and complicate the resuscitation and recovery of the critically ill or severe injury victim. Over the last few years, aggressive nutritional support has been underlined as an integral part of the caring of the critically ill surgical patient, and the Society for Critical Care Medicine (SCCM) and the American Society for Parenteral and Enteral Nutrition (ASPEN) have made recommendations toward providing early, aggressive nutritional support that enables patients to preserve their immune function, maintain lean body mass, and minimize metabolic complications.[6,7] This chapter addresses the areas of nutritional assessment and management of the surgical patient, reviewing key metabolic principles and providing an overview of pertinent literature.

BASIC METABOLIC PRINCIPLES

Body Composition

Total body mass is composed of aqueous and nonaqueous components, with the former constituting approximately 55% to 60% of total body mass (total body water, TBW). Mineralized bone and adipose tissue make up the majority of the nonaqueous component. The relationship between total body mass and TBW is relatively constant for an individual and typically reflects the amount of body fat. Solid organs and muscle contain a higher proportion of water than bone and fat, therefore young lean males have a higher proportion of their total body mass as water, compared to obese or elderly individuals. Obesity, older age, and female gender shift the body composition to a greater fat mass (Fig. 3-1).[8]

The aqueous portion is divided into three functional fluid compartments: plasma (5% of body weight), interstitial or extracellular fluid (ECF; 15% of body weight), and intracellular fluid (ICF; 40% of body weight) (Fig. 3-2). In a typical 70-kg male, there are approximately 3.5 L of plasma, 10.5 L of interstitial fluid, and 28 L of intracellular volume, while the remainder 28 kg represent the nonaqueous portion. Of the above, the body cell mass constitutes the metabolic engine of the body, while the extracellular component forms the supporting "scaffolding" for the body cell mass.

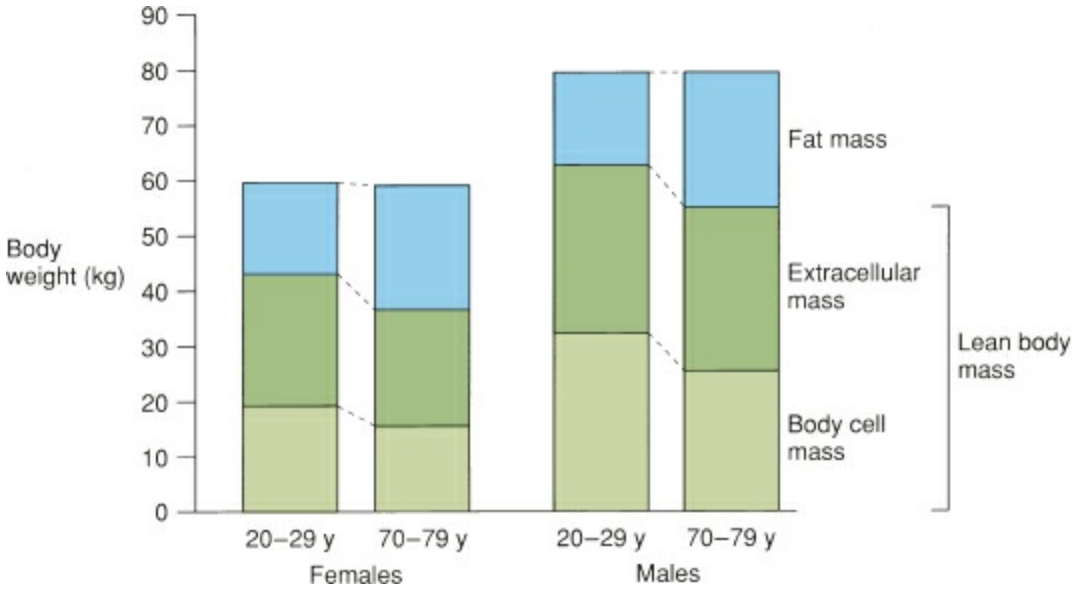

Figure 3-1. Body composition as a function of gender and age. (Data from Cohn SH, Vaartsky D, Yasumura S, et al. Compartmental body composition based on total-body nitrogen, potassium, and calcium. *Am J Physiol* 1980; 239:E524–E530.)

In clinical practice, body composition is inferred indirectly using the body mass index (BMI; kg/m^2), which reflects the fatty proportion of the total body weight. According to the Centers for Disease Control and Prevention, a BMI between 25 and 29.9 kg/m^2 is indicative of being overweight, whereas an individual with a BMI of $\geq$30 kg/m^2 is considered obese.

Body composition may change acutely after trauma or major surgery.[9] These changes

are characterized by a rapid loss of lean body mass and expansion of the ECF compartment, the latter manifesting clinically as edema. The underlying changes in body cell mass and fat mass are difficult to recognize until much later in the process, when they manifest as temporal or extremity wasting. Tools to assess changes in body composition during critical illness have been described (arm circumference and tissue bioelectrical impedance), but their use and utility in daily clinical practice are limited.[10–12]

Energy and Substrate Metabolism

Energy Production and Measurement

The human body functions much like an engine, in that it uses oxygen to burn fuel (carbohydrate, fat, and protein) and generate energy, excreting the byproducts of this combustion (carbon dioxide, water, urea, and heat) to the environment (Fig. 3-3). This energy, which is necessary for numerous functions of the human body, both on micro- (molecular synthesis and transport) and macroscopic (breathing and mobility) levels, is derived from the energy present in the chemical bonds of the nutrients consumed. When no nutrition is provided, such as during periods of starvation or immediately after surgery or trauma, the body oxidizes stored fuel to generate energy.

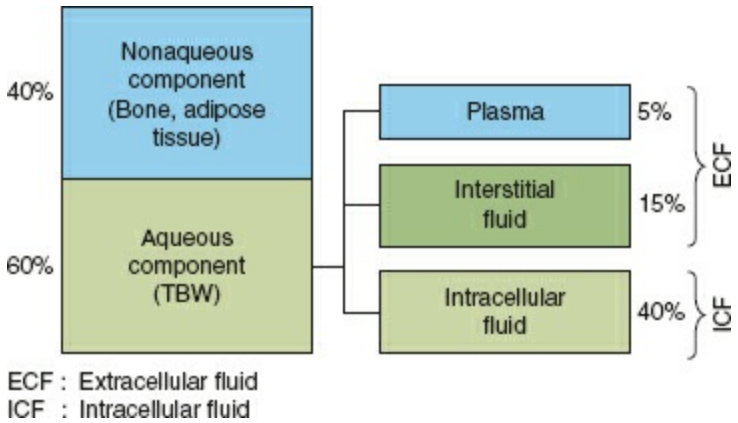

Figure 3-2. Aqueous and nonaqueous body composition.

The energy production process is relatively inefficient, as approximately half of the nutrient-containing energy is eventually converted to heat, instead of all of it being utilized for work. Some of this heat is used to help maintain body temperature (via meticulously regulated hypothalamic mechanisms), while the remainder is released to the environment – mostly through the skin. During illness, or following surgery or trauma, the central temperature regulating mechanisms become reset, leading to the development of fever, usually an appropriate response to a physiologic stressor. This increase in body temperature typically intensifies the rate of enzymatic-facilitated chemical reactions that are essential to the inflammatory response.

All energy produced by the human body comes from oxidation of fuel via a series of decarboxylation/dehydrogenation reactions. The fuel undergoing oxidation is derived from food or mobilization of fuel stores. The energy released by these reactions is captured in adenosine triphosphate (ATP), the human body's energy "coin," via a series of redox reactions. In the final step of energy production from carbohydrates or fat, hydrogen is combined with oxygen to form water. The oxygen required and the carbon dioxide produced in this process are transported by the circulatory system and exchanged with the environment by the lungs. Protein oxidation is a special case, in which nitrogen is a byproduct, in addition to carbon dioxide and water. This nitrogen is removed by the kidneys, after conversion to urea by the liver.

Energy is measured in joules or calories. The joule is the SI unit of energy and is

defined as the energy required to exert a force of 1 N for a distance of 1 m (unit of measure is $kg/m^2/s^2$). In the United States, energy is most commonly measured in g-calories (gram-calories) or kg-calories (kilo-calories or kcal). A g-calorie is the amount of heat required to raise the temperature of 1 g of water from 14.5°C to 15.5°C at the pressure of one standard atmosphere, whereas the kg-calorie is the amount of heat needed to increase the temperature of 1 kg of water under the same circumstances. Joules and g-calories are very small units of energy (1 J is expended by a resting person every hundredth of a second), therefore megajoules (MJ) and kilocalories are far more commonly used to describe energy produced from human nutrition. A megajoule is equivalent to 10^6 J, while a kilocalorie is equivalent to 10^3 calories. One megajoule corresponds to 239 kcal.

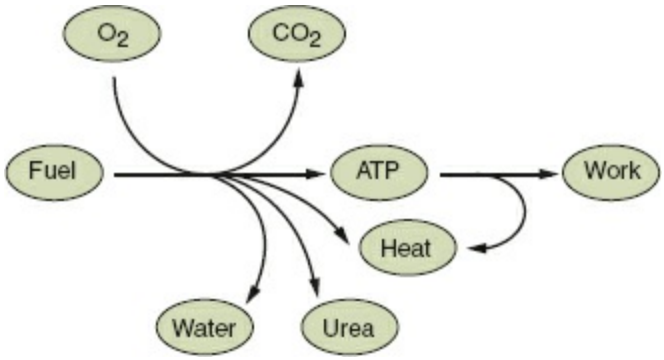

Figure 3-3. Fuel utilization in human metabolism.

Table 3-1 Fuel Reserves of a Healthy, 70-kg Adult Male

Energy Source	kg	kcal Value
Fat	14	125,000
Protein		
Skeletal muscle	6	24,000
Other	6	24,000
Glycogen		
Muscle	0.15	600
Liver	0.075	300
Free glucose	0.02	80

Body Fuels

Human metabolism is organized in such a way, so that fuel consumption occurs in a hierarchical way when more than one energy source is present, with excess stored for the postprandial or fasting period. In the postprandial state, the body contains fuel reserves that it can also mobilize in an orderly fashion, as fasting is prolonged. The same fuel reserves are accessed during stress metabolism, although in a less orderly fashion (Table 3-1).

Calorically dense fat is by far the largest energy repository, providing 9 kcal/g when

mobilized and oxidized. The ability of the body to store fat is essentially limitless. Protein comprises the next largest energy store in the human body, yet amino acids when oxidized yield 4 kcal/g. And unlike fat, protein plays both a structural and functional role in the body, thus, in severe protein loss, major functional consequences can be expected. In malnutrition, proteolysis frees up amino acids to be used for gluconeogenesis to produce glucose, which in turn can be used as fuel. Carbohydrate reserves are minimal and exist in the form of glucose or glycogen in the liver. These can be depleted quickly, typically within 12 hours, unless replenished through nutrition. Carbohydrates, like protein, also yield approximately 4 kcal/g when mobilized for energy production (Table 3-2).

Carbohydrates. Carbohydrates are the most commonly used fuel by the human body, providing frequently over 45% to 60% of daily energy requirements. Each gram of carbohydrate that is administered enterally yields approximately 4 kcal when broken down, whereas intravenously administered carbohydrates (such as dextrose-containing solutions) provide slightly less (approximately 3.4 kcal/g).

Table 3-2 Energy Value of Various Energy Sources

Energy Source	Energy Value
Fat	9 kcal/g
Carbohydrates (enteral)	4 kcal/g
Carbohydrates (intravenous)	3.4 kcal/g
Protein	4 kcal/g

The basic unit of carbohydrate metabolism in humans is glucose, and nearly all dietary carbohydrates are converted to glucose for energy production. Digestion of carbohydrates begins as proximally as the oral cavity with food ingestion, where salivary amylase breaks down polysaccharides into smaller oligo- and disaccharides. This process continues in the duodenum and proximal jejunum with the pancreatic amylase. Oligosaccharidases that are present in the brush border of the proximal small bowel further hydrolyze oligosaccharides into di- or monosaccharides, most commonly glucose, to be absorbed by the gut mucosa. Once glucose reaches the bloodstream, it stimulates secretion of insulin from the endocrine pancreas (beta cells), which has major anabolic effects and stimulates protein synthesis, inhibits lipolysis, and upregulates glycogen production. Conversely, during stress, pancreatic glucagon exerts opposite effects: it promotes breakdown of glycogen, but also fat and protein, to be used as additional energy sources during a time when energy requirements are maximal. Deficiencies in carbohydrate digestion are rare in surgical patients, even in patients in whom the pancreatic exocrine function is significantly decreased. Patients with pre-existing celiac or Whipple disease may, however, have limited capacity to absorb carbohydrates.

The human central nervous system and circulating blood cells require glucose constantly for their energy requirements. In periods of extended fasting, after the liver

has used up its stores of glycogen, the human body breaks down protein and uses the resulting amino acids to generate glucose, and even converts fat into ketones that can partly substitute glucose as an energy source. When glucose is reinstated through nutrition, these metabolic adaptations are completely reversed. During stress, gluconeogenesis and glycogen breakdown is accelerated and ketone production minimized, leading to an abundance of glucose for use as the human body mounts an inflammatory response.

Lipids. Lipids are the second most commonly used fuel for energy by the human body, accounting for 35% to 45% of daily caloric intake. Each gram of fat yields approximately 9 kcal of energy when oxidized. When lipids enter the proximal small bowel, cholecystokinin and secretin are released, which make the gallbladder contract and release bile into the duodenum. Bile salts contained in bile are necessary for lipid absorption, especially the long-chain fatty acids that are found in a typical western diet, which occurs mostly in the distal ileum. Surgical resection of the distal ileum may lead to depletion of the bile salt pool and fat malabsorption.

Lipids are most commonly classified by the length of their contained hydrocarbon chains. Short-chain fatty acids typically refer to lipids containing 2 to 5 carbon length chains and are a product of dietary fiber fermentation in the colon by the intestinal flora. They are absorbed by and are the preferred fuel for the colonocytes. Medium-chain fatty acids (6 to 9 carbon length chains) are also not typically found in the human diet, but are commonly used in numerous enteral nutrition formulas, as they are easier to digest, compared to longer chain triglycerides. They are water soluble, and hence require no emulsification or micelle formation for transport. Lipase is not required. The medium-chain triglycerides are absorbed directly into the portal circulation. Unlike the short- and medium-chain fatty acids which can be produced from other dietary substrates, two long-chain fatty acids (>9 carbon length chains), linoleic and linolenic acids, are essential for human nutrition. These are not water soluble and require bile salts for emulsification as stated above, lipase for digestion, and micelle/chylomicron formation for transport. They gain access to the bloodstream via the lymphatic system (thoracic duct). Insufficient intake of these essential fats can lead to fatty acid deficiency, which can be prevented with provision of at least 3% to 4% of the daily calories as linoleic and linolenic acids. These two fatty acids are also a precursor of eicosanoids, significant mediators of the inflammatory response. On a cellular level, lipoprotein lipase is necessary for intake, and carnitine for transport from the cytosol into the mitochondria for oxidation. Long-chain triglycerides are the main form of energy storage in the human body, given the numerous high-energy bonds they contain.

Protein. Protein is different from carbohydrate and lipids in that it contains nitrogen that neither fatty acids nor glucose do. It is also a key structural component, and there are no inactive protein stores. Essentially all proteins are either functional or structural in the human body.

Proteins are polypeptides, containing numerous amino acids as their building blocks,

and yield 4 kcal/g when used for energy production. Dietary protein is broken down into amino acids and smaller peptides by gastric pepsin and pancreatic proteases, the latter activated by enterokinase in the duodenum. These amino acids and oligopeptides get absorbed mostly in the proximal gastrointestinal tract and travel to the liver, where they are recycled to synthesize new protein. In a healthy, 70-kg weighing adult male over 300 g of protein are recycled daily. The branched-chain amino acids (BCAAs; leucine, isoleucine, and valine) are transported to muscle unaltered, while other amino acids are distributed to the intra- and extracellular pool for protein synthesis as needed. Excess amino acids are usually converted to glycogen or free fatty acids.

In addition to the dietary protein, intracellular proteins are continuously recycled, and the resulting free nitrogen is excreted, mostly through urine. Most of the urine nitrogen is in the form of urea (85%), with smaller amounts excreted as creatinine and ammonia. Urinary nitrogen decreases significantly with protein-free diets (decreased intake), but increases during stress (greater turnover).

Amino acid metabolism generates ammonia, a highly toxic compound, which is converted into urea (nontoxic) in the liver. Glutamine and alanine serve as ammonia-transporting vehicles in a nontoxic form from the metabolically active peripheral tissues to the viscera. There, ammonia is resynthesized and either excreted (by the kidneys, where it also acts as a buffering system) or detoxified to urea (liver). Diseases that affect the functional capacity of either the kidneys or the liver can lead to significant ammonia build up in the body, with potentially toxic consequences to the central nervous system.

Other Nutrients

To maintain health, in addition to energy, numerous other nutrients are required for the numerous metabolic functions of the human body. These include nucleotides, vitamins, and trace elements. The former are increasingly identified as important for the nutrition of the critically ill patient, whereas vitamins and trace elements are important for numerous anabolic functions.

Nucleotides. Nucleic acids are the building blocks for DNA and RNA, and are not typically considered essential for a balanced nutrition in healthy adults. However, dietary requirements become significant during severe stress and critical illness, as nucleic acids are necessary for rapidly proliferating cells, such as the cells participating in the immune function. Diets augmented with RNA or the nucleotide uracil have been shown to restore delayed hypersensitivity and improve the lymphoproliferative response. As such, they have been included in enteral nutrition formulas, where they may aid recovery from severe infections.[13]

Vitamins. Vitamins A, D, E, and K are fat soluble and are absorbed in the small bowel in association with long-chain fatty acids. From there, they are transported to the liver (vitamins A and K) or the skin and subcutaneous tissue (vitamins D and E) for storage. Fat-soluble vitamins are required for normal immune function and play a significant role in wound healing. Daily vitamin A intake in patients on chronic corticosteroid regimens

may counteract most of steroid-mediated adverse effects of wound healing.

Unlike vitamins A, D, E, and K, vitamins B1, B2, B6, and B12, along with vitamin C, niacin, folate, biotin, and pantothenic acid are water soluble and are absorbed in the proximal small bowel. From there, they are transferred to the liver with the portal circulation for use or storage. Water-soluble vitamins are required for normal amino and nucleic acid metabolism.

Electrolytes and Trace Elements. Electrolytes are important components of both the intra- and extracellular compartment, where they play a major role in maintaining electrical and osmotic balance across the body's plasma membranes. Such electrolytes include sodium (Na^+), potassium (K^+), calcium (Ca^{2+}), magnesium (Mg^{2+}), chloride (Cl^-), and are cations (with a positive charge) or anions (with a negative charge), due to uneven distribution of electrons. Sodium is the main extracellular electrolyte and is important in maintaining volume homeostasis and blood pressure control. Conversely, potassium is one of the key intracellular cations. The role of electrolytes is diverse, and includes functions as varied as the conduction of electric signals, cotransport of larger molecules against their concentration gradient, muscular contraction, and participation in numerous essential biochemical reactions.

Trace elements play an important role in numerous metabolic, immunologic, and healing functions and eight minerals have been identified as "essential." These include iron, iodine, zinc, chromium, copper, selenium, manganese, and molybdenum.

Iron is an integral component of the heme core in hemoglobin and of the mitochondrial cytochrome complex. Subtle impairments in central nervous, musculoskeletal, and immune system function can be identified in patients with iron deficiency, before microcytic anemia becomes clinically evident. Impaired cerebral, muscular, and immunologic function can occur in patients with iron deficiency before anemia becomes clinically evident. Particular attention has to be paid to pregnant and lactating females, in whom iron requirements are even greater than the rest of the population.

Iodine is a key component of the thyroidal hormonal system. Deficiencies are rare in the western world, due to widespread use of iodinated salt. However, chronically malnourished patients can develop significant iodine deficiency, which can typically manifest clinically as diffuse goiter and hypothyroidism.

Zinc deficiency can manifest with skin discoloration and perioral rash, neuritis, hair loss, and alterations in taste and smell. Chromium deficiency presents as impaired glucose tolerance during prolonged fasting and is fairly common with total parenteral nutrition (TPN). Copper deficiency presents with microcytic anemia, typically unresponsive to iron, abnormal skin keratinization, and, in its most severe cases, pancytopenia. Selenium deficiency, which can similarly be identified in cases of prolonged TPN administration, manifests as neuromuscular dysfunction or cardiac conduction defects, which in the most severe cases can lead to heart failure. Manganese deficiency can be identified as the underlying cause in a syndrome presenting as unintentional weight loss, hair color changes, and hypolipidemia. Molybdenum deficiency is associated with hypomethioninemia and hypouricemia, resulting in nausea and vomiting, tachycardia, and

nonfocal central nervous system dysfunction (Table 3-3).

Nutritional Assessment

Metabolism is altered to varying degrees by stress, namely surgical injury, critical illness, infection, and physical trauma. In most cases, these alterations are short lived and reversible in a previously well-nourished individual, even if fasting is superimposed during acute illness. However, pre-existing malnutrition, even if mild, and prolonged post-stressor fasting, intentional or not, can adversely affect healing, recovery, and overall outcomes after injury or surgery.[14–20] In addition, the nutritional needs of a patient recovering from severe infection, injury, or a major operation are different than those of nonstressed individuals and aggressive postoperative or postinjury nutritional regimens are associated with improved outcomes.[21] This recognition has led nutrition science to become an integral part of modern medicine and critical care, and nutritional support to continue to gain ground as primary therapy in the care of the surgical and critically ill patient.

Table 3-3 Summary of the Daily Requirements of Vitamins, Electrolytes, and Trace Elements in a per os Diet by Healthy Adults

Vitamins	
Retinol (vitamin A)	1,000 mcg
Thiamine (vitamin B1)	1.4 mg
Riboflavin (vitamin B2)	1.7 mg
Pyridoxine (vitamin B6)	2.2 mg
Ascorbic acid (vitamin C)	60 mg
Niacin	20 mg
Folate	200 mcg
Biotin	150 mcg
Pantothenic acid	4–7 mg
Retinol (vitamin A)	1 mg
Vitamin D	5 mcg
Vitamin E	10 mg
Vitamin K	75–150 mg
Electrolytes	
Sodium	90–150 mEq
Potassium	60–90 mEq
Calcium	1,300 mg
Magnesium	350 mg
Phosphorus	800 mg
Trace Elements	
Iron	10 mg
Iodine	150 mcg
Zinc	15 mg
Chromium	5–200 mcg
Copper	2–3 mg
Selenium	100 mcg
Manganese	2.5–5 mg
Molybdenum	100–500 mcg

Subjective Global Assessment

12 Subjective global assessment of a patient's nutritional status is commonly utilized to assess the presence and degree of malnutrition in surgical patients. It is one of the few clinical methods that has been validated as a reproducible method assessing a patient's nutritional status and has been consistently associated with clinical outcomes. This global assessment utilizes numerous variables, including physical examination and anthropometric measurements such as weight, height, and weight loss history; dietary questionnaires and portion size analyses; along with pertinent past medical history to classify patients in three distinct categories: *class A* is assigned to individuals with no evidence of malnutrition; *class B* to patients with moderate or indeterminate malnutrition; and *class C* to patients with definitive malnutrition. Patients in this last category typically present with recent history of unintentional weight loss and signs of tissue wasting (temporal and/or extremity most commonly). While the subjective global assessment can provide coarse information about the severity of malnutrition, it rarely yields clues pertaining to the underlying etiology (starvation vs. inflammation).

Similar methods of assessing overall nutritional status encompassing dietary history, baseline health, anthropometric and laboratory measurements have been described and used in certain patient subpopulations. These include the mini-nutritional assessment, the malnutrition universal screening tool, the instant nutritional assessment, the geriatric nutritional risk index, among others.

Anthropometric Measurements and Nutritional Indices

Anthropometric measurements have been used extensively to provide information regarding lean body mass, total fat stores, and overall nutritional health. Body composition studies aid in determining TBW, fat, and nitrogen. These anthropometric measurements can be easily performed at the bedside or an ambulatory setting, and may include an individual's height and weight (which allow calculation of the BMI), triceps skinfold, midhumeral circumference, and other body part summations. The BMI is widely used as a measure of overnutrition (a BMI of 25 to 29.9 suggests overweight status, whereas a BMI >30 defines obesity). The BMI is calculated from an individual's height and weight using the formula:

$$\text{BMI} = \text{weight (kg)/height (m)}^2 = 703 * \text{weight (lb)/height (in)}^2$$

More advanced techniques and measurements include x-ray absorptiometry that allows a more accurate assessment of total fat and lean body mass. With the exception of the BMI, most anthropometric measurements are operator dependent, and skill and experience are important in order to obtain accurate studies.

Nutritional indices provide a means of risk-stratifying and objectively comparing individuals, as well as to guide nutritional support. The BMI is one of the most commonly utilized nutritional indices. It provides information on normal, overweight, or obese status. It also provides information on degree of protein–calorie malnutrition in underweight individuals. Other commonly used indices include the prognostic nutritional index (PNI), the nutritional risk index (NRI), and the creatinine height index (CHI).

These are calculated with the following formulas respectively:

$$\text{PNI} = 158 - (16.6*\text{Alb}) - (0.78 * \text{Tricep skinfold}) - (0.2*\text{transferrin}) - (5.8 * \text{Delayed cutaneous hypersensitivity})$$

$$\text{NRI} = (15.9*\text{Alb}) + 41.7*(\text{actual weight [kg]/ideal weight [kg]})$$

$$\text{CHI} = (\text{24-hour urine creatine excretion})/(\text{predicted creatine excretion based on height})$$

Serum Protein Levels. An ideal biochemical marker of malnutrition would be one that is highly sensitive and specific to nutrition intake. Although a single laboratory biomarker that could effectively describe a patient's nutritional status is lacking, numerous freely circulating serum transport proteins have been used. The most commonly utilized ones are albumin, prealbumin, transferrin, and retinol-binding protein (RBP), each with its own advantages and disadvantages. Many nutrition-unrelated parameters, most

commonly inflammation, dilution secondary to large volume resuscitation, and chronic liver failure, affect the levels of these serum markers. Although it is customary for markers of inflammation, usually the C-reactive protein, to be measured with the aforementioned biomarkers (most commonly prealbumin), little data exist to support this practice.[22,23]

Albumin. Albumin is a serum protein synthesized in the liver with a long half-life (approximately 20 days) and a relatively large total pool size. Only 5% of total body albumin is produced daily. Its main function is to carry molecules in the bloodstream and to help maintain intravascular oncotic pressure. Due to its large pool, long half-life, and relative slow turnover, it has been used as an indirect marker of protein intake, hepatic synthetic ability, and chronic nutritional status. Unfortunately, it is a negative acute–phase reactant, decreasing during the acute-phase response, and numerous nutrition-unrelated factors may affect its levels in either direction (Table 3-4). Albumin is neither a sensitive nor specific marker for malnutrition, as patients with even severe starvation can have normal levels.[24–26] In critical care, hypoalbuminemia more commonly reflects illness acuity, especially during the acute phase, due to its function as a negative acute–phase reactant, its redistribution to the interstitial space, and dilution secondary to large volume resuscitation.[27]

Prealbumin. Prealbumin, also known as transthyretin or transthyretin-bound prealbumin, similar to albumin, is a visceral protein synthesized in its majority by the liver, and to a smaller extent by the choroid plexus in the central nervous system. Its name prealbumin was originally given because it ran faster than albumin on electrophoretic gels. Its main function is to transport thyroxine (T4) and retinol (vitamin A) in the bloodstream. As a visceral protein, it is a small part of the total body protein pool, which includes serum and intracellular proteins. Consequently, it is similarly affected by many of the same factors that affect serum albumin concentrations. The main advantage of prealbumin over albumin is its shorter half-life (2 to 3 days) which makes it more sensitive and rapidly adaptable to acute, short-lived changes in nutrient intake. Like albumin, prealbumin is also a negative-phase reactant, with values decreasing during the acute inflammatory response. Therefore, rising prealbumin levels may reflect improvement in nutritional status or resolution of the inflammatory condition. Prealbumin is commonly measured along C-reactive protein, and low levels of the former accompanied by high levels of the latter are commonly seen in inflammatory conditions, as opposed to malnutrition. While this practice is not well validated, a better use for prealbumin as a marker of overall nutritional status is to monitor trends.[28,29]

Retinol-Binding Protein. The majority of retinol-binding protein (RBP) is present in the bloodstream in the form of retinol-circulating complex that includes prealbumin, retinol (vitamin A), and RBP. It is catabolized in the kidneys and its levels may be elevated in end-stage renal failure. RBP is dependent on vitamin A and zinc, as low levels of these conutrients inhibit mobilization of RBP in the liver.[30] Due to its extremely short half-life

(approximately 12 hours) and typically expensive laboratory level assessment, it is rarely used as a malnutrition marker.

Transferrin. Transferrin has also been identified and used as a nutrition biomarker. It has a half-life between that of albumin and prealbumin (8 to 10 days) and fairly small total body pool size. However, because it plays a key role in iron transport, its levels are affected by iron status. Iron deficiency may lead to increased levels secondary to greater iron absorption. Under these circumstances, it may be a better marker of total iron-binding capacity, rather than malnutrition.

Nitrogen Balance

Nitrogen balance is another marker for overall nutritional status. It is an indicator of whether protein intake and catabolism are in balance, and along with trends in prealbumin levels, it is a commonly employed method to assess progress in patients on nutritional support. Nitrogen balance is calculated from the amount of nitrogen entering minus the amount leaving the human body over a 24-hour period. Nitrogen intake is estimated from total protein intake divided by 6.25 (the average nitrogen content of human protein is approximately 16%). The main route of nitrogen excretion is the urine (90% or more). Nitrogen is also lost through the skin and stool, but this loss is usually small (<2 g/day), difficult to measure, and therefore typically accounted for with a constant of 2 in the nitrogen balance equation. Total urinary nitrogen (TUN) is ideally measured, but is frequently substituted by urine urea nitrogen (UUN), because it is easier to estimate. In the latter case, an additional 2 to 3 g are typically added to the output side of the nitrogen balance equation to account for the unmeasured losses. The nitrogen balance equations are as follows:

Table 3-4 Serum Proteins Used in Nutritional Status Assessment

Marker	Reference Range	Half-Life	Elevated In	Decreased In
Albumin	3–5 g/dL	14–20 days	Dehydration, marasmus, blood transfusions, and exogenous albumin administration	Aggressive resuscitation, ascites, eclampsia, liver failure, inflammatory states, nephrotic syndrome, protein-losing states, burns, trauma/postoperative states, kwashiorkor, cancer, collagen diseases, corticosteroid use, chronic bed rest, zinc deficiency, and pregnancy
Prealbumin	18–45 mg/dL	2–3 days	End-stage renal failure, corticosteroid use, and oral contraceptives	Postoperative states, hepatitis, liver failure, inflammatory states, dialysis, hyperthyroidism, pregnancy, and severe hyperglycemia
Retinol-binding protein	4–6 mg/dL	12 hours	End-stage renal failure, diabetes, obesity, vitamin A overdose, corticosteroid use, and oral contraceptives	Postoperative states, hepatitis, liver failure, inflammatory states, and vitamin A deficiency
Transferrin	200–250 mg/dL	8–10 days	Iron deficiency, dehydration, pregnancy (third trimester), oral contraceptives, estrogens, chronic anemia, hepatitis, liver failure, hypoxia, and end-stage renal failure	Pernicious anemia, anemia of chronic disease, folate deficiency anemia, aggressive resuscitation, chronic infectious states, iron overload, acute catabolic states, uremia, nephrotic syndrome, liver failure, kwashiorkor, old age, zinc deficiency, corticosteroids, and cancer

Adapted from Parrish CR. Serum proteins as markers of nutrition: what are we treating? *Nutr Issues Gastroenterol* 2006;43(10):48–64.

Nitrogen balance (g/day) = Protein intake/6.25 - (TUN + 2)
Nitrogen balance (g/day) = Protein intake/6.25 - (UUN + 2 + 3)

A nitrogen balance of –2 to +2 g/day indicates nitrogen equilibrium, and typically represents the goal in medically indicated nutritional support. More negative balances are managed with increases in protein intake, while more positive values typically reflect anabolism in recovering patients, or simply errors in measurement in the acutely ill (a positive nitrogen balance implies anabolism, but bedridden patients with active inflammation are not anabolic). Achievement of a positive balance has been associated with improved outcomes in certain critically ill patients.[31] Limitations of the nitrogen balance assessment include false-negative results in overfed patients; long time for the equation to re-equilibriate after adjustments in nutritional support; and renal insufficiency and upper gastrointestinal bleeding may invalidate results (due to incomplete excretion of urea nitrogen and due to excess urea nitrogen production respectively).

Indirect Calorimetry

Resting energy expenditure can be measured at the bedside with indirect calorimetry. This method, based on thermodynamic principles, calculates heat produced through the measurement of oxygen consumed and carbon dioxide exhaled. Patients must be either sedated or able to tolerate a respiration chamber placed over their heads that allows collection of exhaled air. (A less commonly utilized method is *direct calorimetry,* in which the patient is placed inside the calorimeter for measurement.) Intubated patients must have a fraction of inspired oxygen of <60%, while spontaneously breathing patients must be on room air. No air leaks (that would allow heat to escape the collection chamber) can be present. Numerous protocols have been developed to measure resting energy

expenditure with as little as 5-minute testing sessions.[32]

Metabolic Energy Expenditure

In most cases, energy expenditure is not measured, but estimated, on the basis that all metabolic activity occurs within the fat-free body mass. Fat-free mass is a function of body weight, height, age, and gender, and therefore, resting energy expenditure can be predicted quite reliably from these variables. In obesity, where adipose tissue becomes hypertrophic and hyperplastic, most of these relationships are preserved, but carry a weaker predictive ability. Several equations that predict basal energy expenditure, and hence daily caloric requirements, have been developed from the aforementioned variables, with the Harris–Benedict one being among the most widely used (Table 3-5).[33]

Once the basal metabolic rate has been calculated, minor adjustments based on exercise frequency and intensity can be made for estimation of the daily caloric requirement for an adult to maintain current weight.[33]

Table 3-5 The Harris–Benedict Equation and Adjustment Using the Harris–Benedict Principle

Men	BMR = 88.362 + (13.397 × weight in kg) + (4.799 × height in cm) – (5.677 × age in years)
Women	BMR = 447.593 + (9.247 × weight in kg) + (3.098 × height in cm) – (4.330 × age in years)
Little to no exercise	Daily kilocalories needed = BMR × 1.2
Light exercise (1–3 days/week)	Daily kilocalories needed = BMR × 1.375
Moderate exercise (3–5 days/week)	Daily kilocalories needed = BMR × 1.55
Heavy exercise (6–7 days/week)	Daily kilocalories needed = BMR × 1.725
Very heavy exercise (twice per day, extra heavy workouts)	Daily kilocalories needed = BMR × 1.9

Adapted from Roza AM, Shizgal HM. The Harris Benedict equation reevaluated. *Am J Clin Nutr* 1984;40(1):168–182.

The Mifflin–St. Jeor equation appears to be even more accurate in estimating basal metabolic rate in healthy individuals[34]:

Men	BMR = (10 × weight in kg) + (6.25 × height in cm) – (5 × age in years) + 5
Women	BMR = (10 × weight in kg) + (6.25 × height in cm) – (5 × age in years) – 161

For critically ill, or patients with highly inflammatory conditions, the estimated basal metabolic rate is adjusted upward. Not surprisingly, basal energy requirements increase significantly with an active inflammatory response, but minimally after elective surgery.

The largest increases in energy expenditure are seen in patients with severe polytrauma or major burns.[35]

Other Parameters for Nutritional Assessment

In addition to the aforementioned methods of assessment of nutritional status, many more anthropomorphic, clinical and laboratory parameters have been described. These include total lymphocyte count (<2,000/mm3), CHI (<80%), ideal body weight (<90%), weight loss over time (>10%/6 months), and skin antigen testing (<3/4 reactive sites over number placed). The numbers in the parentheses are suggestive of malnutrition.

OVERFEEDING AND MALNUTRITION

Overfeeding

While adequate caloric intake is necessary to maintain weight and promote health, overprovision of calories can lead to overfeeding and obesity. Excess calories, especially as carbohydrates, can lead to increased carbon dioxide production (which may prolong ventilatory weaning), hyperglycemia (which can contribute to immunosuppression and increase the risk for infectious complications), lipogenesis (indicated by a respiratory quotient >1), and hepatic steatosis (which can interfere with normal liver function). Additionally, excessive nutritional support, may lead to mineral or vitamin poisoning, and severe electrolyte imbalances, with hypophosphatemia being the most common. To avoid overfeeding, specifically in critically ill patients with numerous active medical conditions, indirect calorimetry may be indicated to accurately estimate energy expenditure during the various stages of disease.

Malnutrition

Starvation

3 During short periods of fasting, insulin levels drop and glucagon levels rise in the plasma, while glycogen is being broken down in the liver to release glucose. Liver glycogen stores are typically depleted within 24 hours of fasting. After carbohydrate stores are used up, caloric needs are met by protein and fat degradation. During starvation, down-regulated insulin results in net muscle wasting, as protein is broken down to release amino acids. These amino acids – most commonly alanine and glutamine – are used for gluconeogenesis in the liver. The resulting glucose is used primarily by the central nervous system and the hemopoietic system that rely heavily on glucose metabolism for their energy requirements. Hepatic gluconeogenesis itself also requires energy, which is typically supplied by the free fatty acid oxidation. The drop in circulating insulin levels, along with the concomitant rise in plasma glucagon, activates hormone-sensitive lipase in fatty tissue that hydrolyzes triglycerides to release free fatty acids, which in turn help generate energy for the aforementioned gluconeogenesis. Both gluconeogenesis and fatty acid oxidation require the permissive effect of cortisol and thyroxine.

During starvation, the human body attempts to recycle energy sources to the greatest extent possible. Lactate produced by the white blood cells or the muscles during anaerobic metabolism is recycled back to glucose in the liver, through the Cori cycle. BCAAs, unlike glutamine and alanine, which are taken up by the liver, are secreted by the gland, in order to provide skeletal and cardiac muscles an energy substrate. Once BCAAs are oxidized for energy, their residual amino groups are utilized to recycle alanine and glutamine, which in turn return to the liver to allow further gluconeogenesis. However efficient this conservation of energy and substrates may seem, gluconeogenesis from amino acids in the liver results in a significant loss of lean body mass, which may reach fatal levels after approximately 4 weeks. The brain adapts to prolonged starvation after about 7 to 10 days (*chronic starvation*) to use ketones derived from fat, as its primary energy source. At this stage, the basal metabolic rate decreases by as much as 30%, and all functions requiring significant amounts of energy expenditure slow down, including voluntary muscle activity and cardiac function.

Starvation versus Inflammation as the Cause of Malnutrition

Both starvation and the systemic inflammatory response result in lean body mass loss, which should indicate nutritional support.[1–4] However, the two processes have key dissimilarities that differentiate one from the other. On one hand, starvation leads to progressive loss of both lean mass and body fat, preservation of serum protein levels, and reversal of the metabolic response with feeding. The most common causes of starvation in the surgical patient are functional, and include nausea and emesis, ileus, dysphagia, and malabsorption. On the other hand, during a significant inflammatory response, the basal metabolic rate increases significantly (both anabolism and catabolism) and becomes relatively insensitive to feeding, and levels of acute-phase proteins change. Inflammation

may additionally worsen malnutrition by interfering with caloric intake acutely (anorexia of acute illness) or in the chronic state (cancer cachexia). The key differences between the metabolic response to simple starvation and injury are summarized on Table 3-6.

Table 3-6 Metabolic Differences Between the Response to Simple Starvation and Stress

	Simple Starvation	Stress/ Inflammation
Basal metabolic rate	–	++
Presence of mediators	–	+++
Major fuel oxidized	Fat	Mixed
Ketone body production	+++	±
Hepatic ureagenesis	+	+++
Negative nitrogen balance	+	+++
Gluconeogenesis	+	+++
Muscle proteolysis	+	+++
Hepatic protein synthesis	+	+++

METABOLIC RESPONSE TO STRESS

Neuroendocrine and Cytokine-Mediated Response to Stress

4 After injury, two distinct phases of a neurohumoral response that affect metabolism can be identified. A shorter, early "ebb" or shock phase, which typically lasts 12 to 24 hours, occurs immediately following injury. During this early phase, cardiac output, body temperature, oxygen consumption, and therefore overall metabolism are reduced. These events are often associated with blood loss and commonly lead to anaerobic metabolism and lactic acid synthesis. With restoration of the blood volume, metabolism accelerates, and is associated with increased cardiac output, altered glucose metabolism, faster tissue catabolism, and greater urinary nitrogen losses. During the "flow" phase, the basal metabolism increases to greater rates than what would be predicted on the basis of age, gender, and body size in a healthy individual. The degree of hypermetabolism is generally related to the severity of the original insult, and hence the intensity of the inflammatory response. This delayed "flow" phase response to injury is not dissimilar to what occurs following elective surgery. The response to injury, however, is usually much more intense and extends over longer periods of time.

The response to accidental injury or elective surgery, with both its phases, comprises two components: a neuroendocrine response and an inflammatory response. Catecholamines, corticosteroids, and glucagon play a principal role in the neuroendocrine response. Cytokines, complement, eicosanoids, and platelet-activating factor are key mediators of the inflammatory response. During elective surgery, the inflammatory response is typically local and confined to the surgical wound. Following a major accidental injury, extensive uncontrolled tissue damage triggers an inflammatory response and release of mediators that commonly spills over into the systemic circulation.

The hormonal response to stress appears to be the result of extensive neuroendocrine stimulation. Glucagon along with insulin resistance has potent glycogenolytic and gluconeogenic effects on the liver, which signal the hepatocytes to produce glucose from hepatic glycogen stores and gluconeogenic precursors. These gluconeogenic precursors are typically amino acids (alanine and glutamine) released from muscle. This action is facilitated by thyroid hormone. Catecholamines also stimulate hepatic glycolysis and gluconeogenesis and increase lactate production from peripheral tissues (skeletal muscle). Catecholamines additionally increase metabolic rate and stimulate lipolysis (Fig. 3-4).

The inflammatory portion of the response is arbitrated by a host of mediators, including cyto- and chemokines, complement, and eicosanoids. The initial trigger stimulates local mast cells to release numerous mediators, with pro- or anti-inflammatory properties.[36] The intermediaries that promote inflammation usually predominate early (tumor necrosis factor [TNF], interleukin [IL]-1, IL-6, prostaglandin-E2 [PGE2], leukotriene-4 [LT4]), whereas anti-inflammatory effectors are released later, as the body is trying to control the inflammatory response. The TNF and IL-1 stimulate IL-6 release. One of the effects of IL-6 is to reduce the level of insulin-like growth factor 1 (IGF-1), which promotes proteolysis and amino acid release from muscle. Cytokines act in concert

with catecholamines, cortisol, and thyroid hormone to mobilize amino acids from skeletal muscle. As the inflammatory stimulus is controlled and eliminated, the anti-inflammatory cytokines (IL-4, IL-10, and IL-13) and eicosanoids (PGE3 and LT5) begin to predominate, and bring the inflammatory response to a conclusion. This is not to say that only pro- or anti-inflammatory mediators are being expressed, a balance between the two sets of factors favors a pro- or anti-inflammatory state at any given time, depending on the presence of ongoing stimulation.

This combined neuroendocrine- and cytokine-based response provides key nutrients to support cellular metabolism at a time when enteral nutrition typically cannot be acquired. The primary metabolic component of the acute-phase response affected by IL-6 is a qualitative alteration in hepatic protein synthesis with a resulting alteration in plasma protein composition. Characteristically, proteins acting as serum transport and binding molecules (albumin and transferrin) are reduced, and acute-phase proteins (fibrinogen and C-reactive protein) are increased. While the role of many acute-phase proteins remains unclear, many act as opsonins, antiproteases, or coagulation and wound-healing factors, with the greater aim to minimize tissue destruction associated with inflammation. For example, fibrinogen promotes thrombus formation to control bleeding, while antiproteases lessen tissue damage caused by proteases released by dying cells. C-reactive protein has scavenger function and its serum levels have been identified to be a measure of the inflammatory response.

This inflammatory response occurs at various levels. Small-scale localized inflammatory changes can be identified frequently in minor illness with no major systemic consequences, and the neuroendocrine component is only minimally, if at all, activated. In fact, these responses may be an important mechanism through which the body allows controlled exposure of the immune system to antigen. Moderate inflammation is still localized, but its effects are more obvious. Severe accidental injury or major surgery triggers a hyperactive inflammatory reaction, along with the full neuroendocrine response, the systemic effects of which are more readily identifiable (hypermetabolism, body protein catabolism, insulin resistance, fever, and acute-phase protein response). Occasionally, such an exuberant response leads to multiorgan failure, in which widespread endothelial damage, metabolic derangements, immune function collapse, and, finally, end-organ dysfunction occur.[37] This type of inflammation-driven illness is a major cause of death in the intensive care unit (ICU). Significant lean body mass loss is seen in survivors, however, when convalescence is under way, the inflammatory-driven metabolic changes abate, and the body can be repleted with appropriate nutritional support and exercise.

Inflammation, for reasons not fully understood, can occasionally become a chronic condition in survivors, in which impairments in metabolism typically seen in the acute phase endure, and cachexia sets in.[38,39] This form of chronic inflammation is maladaptive and a common feature in many chronic disease states, inflammatory or not (renal, hepatic, or cardiac failure, many autoimmune diseases, cancer), and is increasingly identified in ICU survivors after prolonged and complicated ICU stays.[38,39]

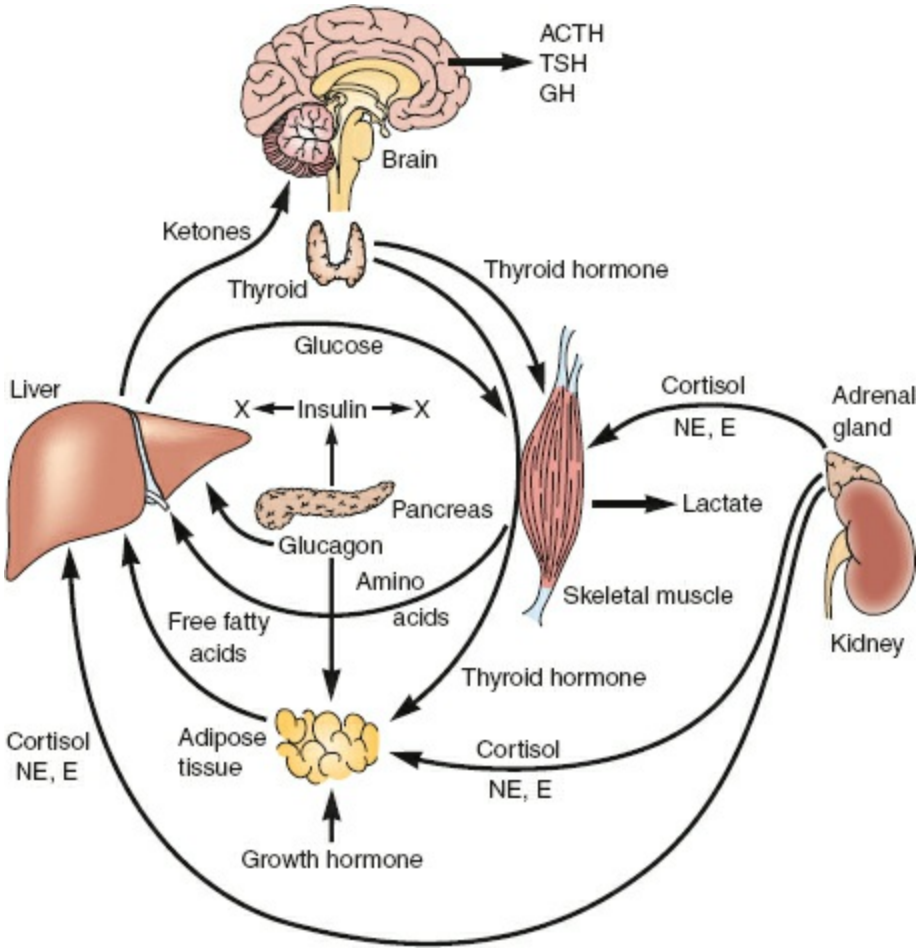

Figure 3-4. The neuroendocrine response to stress stimulates proteolysis and lipolysis, promotes gluconeogenesis and leads to glucose intolerance.

Substrate Metabolism Changes during Stress

5 During the neuroendocrine response to stress, metabolism of commonly used nutritional substrates undergoes significant changes.

Altered Carbohydrate Metabolism

Hyperglycemia occurs commonly after injury, and its intensity generally reflects the severity of the stressor. During the ebb phase, insulin levels are low and glucose production is only minimally elevated. During the flow phase, hepatic gluconeogenesis occurs at a faster pace from peripheral tissue-released precursors and hyperglycemia persists, while insulin levels are normal or elevated. This phenomenon suggests relative insulin resistance.

Altered Protein Metabolism

After major injury, nitrogen losses increase. These correlate to the extent of trauma and the injury victim's pre-existing nutritional status. In patients not receiving nutrition, protein breakdown exceeds synthesis, and negative balance results. Providing exogenous calories is important to maintain a neutral nitrogen balance.[23] Skeletal muscle is the chief source of the nitrogen lost in urine following extensive injury and it appears that amino acid release from muscle is heavily skewed toward glucogenetic precursors (alanine and glutamine), even though these comprise less than 5% of muscle total protein.

In addition to skeletal muscle, the kidneys and the gastrointestinal tract also release alanine, which may be used for glucogenetic purposes, even though the majority enters metabolic pathways that favor the production of urea and ammonia, to be excreted from the body.

Altered Lipid Metabolism

To support the increased metabolic rates after injury or elective surgery, triglycerides are released from adipose tissue for energy production. Glucose administration minimally affects this lipolysis, which appears to be a result of continuous neuroendocrine stimulation. Although mobilization and oxidation of free fatty acids are accelerated in injured subjects, ketone synthesis is minimal and occurs independently of protein catabolism. When severely injured patients remain unfed, their fat and protein stores become depleted rapidly, and the resultant malnutrition increases their susceptibility to infectious complications, multiple organ system failure, sepsis, and ultimately death.

Stressor-Dependent Adjustments to the Metabolic Response

Response to Elective Surgery and Accidental Injury

One of the earliest consequences of major surgery is the rise in levels of circulating cortisol in response to a sudden release of adrenocorticotropic hormone (ACTH) from the anterior pituitary gland. This cortisol remains elevated for 24 to 48 hours after operation. Cortisol has generalized effects on tissue catabolism and mobilizes amino acids from skeletal muscle that provide substrates for wound healing and serve as precursors for the hepatic synthesis of acute-phase proteins or new glucose, as delineated earlier (Fig. 3-5). Associated with the activation of the adrenal cortex is stimulation of the adrenal medulla through the sympathetic nervous system, with release of epinephrine and norepinephrine. These circulating neurotransmitters play an important role not only in increasing vascular tone, which may be lessened from circulating cytokines, but also in promoting amino acid release from skeletal muscle, lipolysis in adipose tissue, and gluconeogenesis in the liver.

The neuroendocrine response to surgical trauma can also modify the various mechanisms that regulate salt and water excretion. Alterations in serum osmolarity and body fluid tonicity due to anesthesia, operative stress, and fluid resuscitation, stimulate antidiuretic hormone (ADH) and aldosterone secretion. ADH and aldosterone promote water and sodium reabsorption in the renal tubules respectively. Thus weight gain from salt and water retention is not uncommon after major surgery. Edema occurs to a varying extent in all surgical wounds secondary to local cytokine release that increases vascular permeability, and this local water accumulation is proportional to tissue trauma. This extravasated fluid eventually returns to the circulation as the postoperative inflammatory response subsides and diuresis commences, typically 2 to 3 days after surgery.

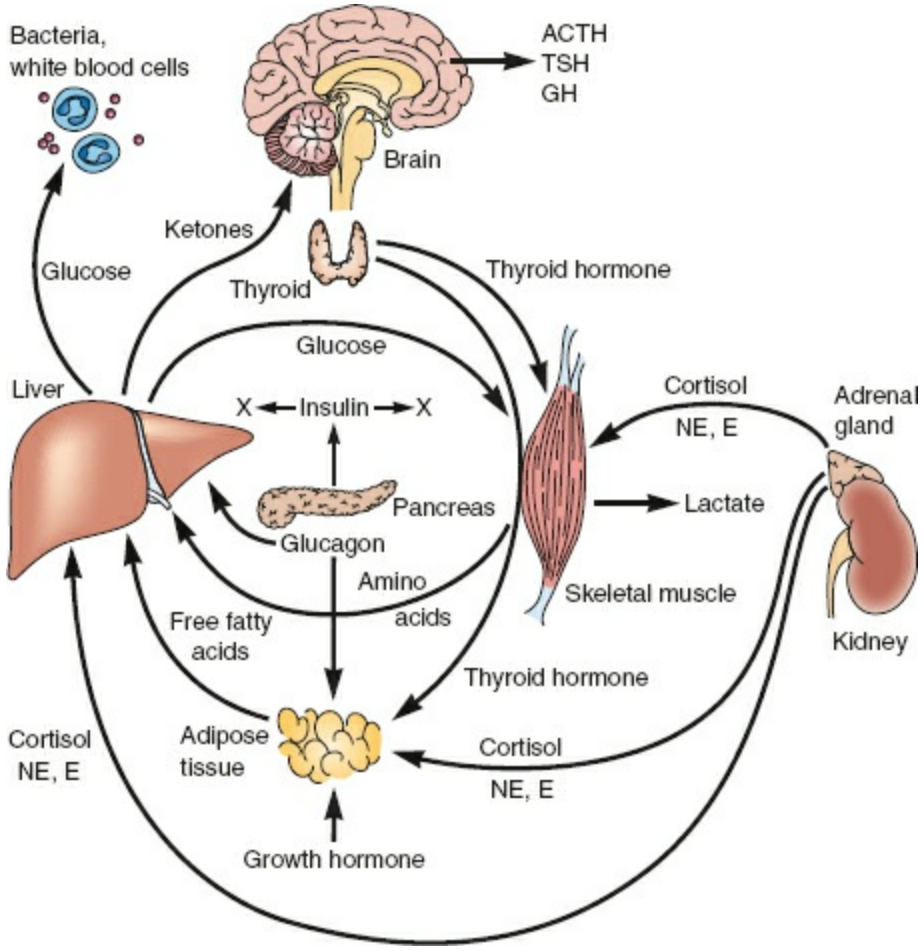

Figure 3-5. During sepsis, metabolism shifts to greater glucose synthesis and utilization, likely mirroring the greater metabolic needs of the pathogens and the mobilized host white blood cells.

Table 3-7 Differences Between Elective Surgery and Accidental Injury

Insult	Elective Surgery	Accidental Injury
Tissue damage	Minimal and controlled, usually occurring in a clean environment; tissues are dissected with care along anatomical planes and reapproximated	Can be substantial; tissues torn in contaminated field. Debridement often necessary
Hypotension	Uncommon. Pre- and intraoperative hydration employed and volume status carefully monitored intraoperatively	May occur with significant blood loss and lead to shock. Fluid resuscitation often delayed
Pain, fear, and anxiety	Typically attenuated with perioperative analgesics and anxiolytics	Generally present in the first hours after trauma
Infectious complications	Relatively rare. Procedures take place in sterile field and preoperative administration of antibiotics is commonplace	More common due to contamination and tissue devitalization
Overall stress response	Controlled and of lesser magnitude. Starvation better tolerated	Controlled and proportional to the magnitude of the injury. Malnutrition poorly tolerated

Glucagon from the endocrine pancreas is also released at greater rates postoperatively, while insulin levels decrease. This response appears to be associated with the increased sympathetic activity that typically follows surgical trauma. The rise in glucagon and the

corresponding fall in insulin act as potent signals accelerating hepatic glucose synthesis.

This postoperative catabolic period, which may be worsened by inadequate caloric intake, has been termed the "adrenergic–corticoid phase," which generally lasts 1 to 3 days and is followed by the "adrenergic–corticoid withdrawal phase," which may last an additional 1 to 3 days. An anabolic phase ensues, which can occur at a variable time during a surgical patient's convalescence. In general, in the absence of significant postoperative complications, this stage starts 3 to 6 days after major abdominal surgery, usually when the bowel function returns and an oral diet is initiated. This phase is characterized by positive nitrogen balance and weight gain. Protein is synthesized at an increased rate, and return of lean body mass and muscular strength ensues.

Whether the body is injured within the carefully monitored confines of the operating room or accidentally, the response to tissue trauma is similar, although key differences exist. In accidental injury, tissue damage is uncontrolled and happens in a contaminated environment. The associated volume loss can be substantial and life-threatening. Pain and the sympathetic nervous system overexcitation are heightened and uncontrolled. As a consequence, the magnitude of the physiologic response to major accidental injury is considerable. In contrast, the elective tissue trauma inflicted occurs in a planned and monitored setting, and the team caring after the surgical patient perioperatively ensures appropriate resuscitation designed to attenuate such changes. Hydration during and after surgery is common, and the latter typically happens in a clean field. At the same time, the anesthesiologist provides medications to minimize anxiety and fear, to minimize the sympathetic nervous system response. Appropriately selected pharmacologic agents are used to minimize undesirable cardiovascular responses, and analgesic techniques are employed to minimize postoperative pain. As a result, the physiologic responses to elective surgery are generally of lesser magnitude than those following major accidental injury and are typically tolerated better (Table 3-7).

Metabolic Adaptations to Sepsis

The metabolic changes following invasive infection are not dissimilar to those seen after elective surgery and accidental trauma, although they are typically less predictable. Severe infection is characterized by fever, hypermetabolism, diminished protein economy, altered glucose dynamics, and accelerated lipolysis, much like the injured patient. Anorexia that commonly follows systemic infection is an added factor contributing to the loss of lean body mass.

Hypermetabolism and increased oxygen consumption are additional traits, with the latter reaching peak levels that may be 50% to 60% higher compared to baseline in severe sepsis. A portion of this metabolic acceleration can be attributed to the escalation in enzymatic reaction rates associated with fever. It is estimated that the base metabolic rate rises by 10% to 13% for every 1°C rise in central temperature. Glucose metabolism is increased to much greater levels in systemically infected subjects, compared to trauma victims. As an example, burn patients synthesize glucose at a rate approximately 50% above normal. If superinfection ensues, hepatic glucose production doubles, and it appears that the additional glucose requirements correlate with the bacterial burden and

white blood cell activation (Fig. 3-5).

Increased proteolysis and nitrogen excretion leading to negative nitrogen balance typically occur following invasive infection, in a pattern that is similar to that described for injury. Visceral amino acid uptake is accelerated during sepsis, and this is matched by faster amino acid efflux from skeletal muscle. In infected burn patients, splanchnic amino acid uptake is amplified over 50% above rates in uninfected burn victims with comparable injuries. These amino acids serve either as glucose precursors, or building blocks for acute-phase protein synthesis.

Fat is another major fuel utilized for energy in infected patients. Increased fat catabolism is particularly profound in patients during periods of inadequate nutritional support or relative starvation. Lipolysis is accelerated among other reasons by a heightened sympathetic activity, and serum triglyceride levels reflect the balance between synthesis in the liver and storage in the peripheral adipose tissue. Marked hypertriglyceridemia has been associated with certain gram-negative infections, but frequently triglyceride concentrations are normal or low, indicating enhanced utilization and clearance by other organs. Infected patients cannot convert fatty acids to ketones as efficiently in the liver, and do not adapt to starvation as well as their fasted, unstressed counterparts. It is postulated that the low ketone state of infection is a consequence of the hyperinsulinemia, which in turn follows insulin resistance in high-degree catabolic states.

Trace elements and electrolytes (zinc, iron, potassium, magnesium, and inorganic phosphate) typically follow alterations in nitrogen balance. Although the iron-binding capacity of transferrin typically remains unchanged in early infection, free iron cannot be found in the plasma of patients with severe pyrogenic infections. Similar changes are seen in zinc levels. These decreases cannot be totally accounted for by total body losses, rather an accumulation of these elements appears to occur in the liver, through not yet elucidated mechanisms. Unlike iron and zinc, serum copper levels generally rise, seemingly due to greater ceruloplasmin synthesis in the liver.

Metabolic Response to Cancer and Acquired Immunodeficiency Syndrome

Patients with cancer and acquired immunodeficiency syndrome (AIDS) have similar metabolic states, characterized by chronic malnutrition, typically a result of anorexia and treatment side effects, and prolonged low-grade inflammatory changes. Cancers of the aerodigestive tract interfere with taste, swallowing and/or digestion, precluding adequate caloric and/or protein intake. Supplementation with zinc and B vitamins may help taste-related symptoms, and soft mechanical diets may allow greater caloric intake in patients with swallowing difficulties or proximal gastrointestinal tract malignancies. The aggressive management of nausea and vomiting, may also afford greater interest in food.

Cancer- and AIDS-related cachexia is seen in the later stages of disseminated disease and represents a chronic catabolic state due to unrelenting inflammation that is difficult to reverse, even with adequate caloric and protein supplementation. Proinflammatory cytokines (TNF, IL-1, and IL-6) are constantly released in response to the tumor or an infectious source in AIDS, respectively, and lead to a chronic state of muscle wasting and

fat loss. The cachexia of cancer and AIDS is difficult to manage, as removing the inflammatory stimulus can prove elusive. However, mitigation of the chronic, low-grade inflammatory response may be useful, and so can aggressive nutritional supplementation and appetite stimulants.[40]

Another practice that is becoming increasingly popular is the repurposing of the dietary balance of n-6 to n-3 fatty acids. Thirty eight fatty acids from the diet eventually become incorporated into cells' plasma membranes, influencing their function and characteristics, and act as precursors for eicosanoid synthesis.39 The eicosanoids produced depend on the type of fatty acids found in plasma membranes. The n-6 fatty acid linoleic acid is converted to arachidonic acid, which in turn gives rise to proinflammatory eicosanoids PG2 and LT4. The n-3 fatty acid linolenic, eicosapentaenoic, and docosahexaenoic acids yield more anti-inflammatory PG3 and LT5. These eicosanoids interrupt the release of IL-6, thus potentially allowing IGF-1 levels to normalize in cachectic patients.40 While a typical Western diet is high in n-6 to n-3 fatty acids ratio (~15:1), more therapeutic ratios of 2:1 to 4:1 can be targeted, in addition to maximizing protein and caloric intake. Such efforts have been met with improving clinical outcomes in patients with pancreatic cancer[41] or generalized malignancies.[42]

Stimulants of the Stress Response

Hypovolemia and End-Organ Hypoperfusion

Following hemorrhage, pressure receptors in the aortic arch and carotid, and volume (stretch) receptors in the left atrial wall detect the acute drop in circulating blood volume and pressure and respond by signaling the central nervous system. Activation of the sympathoadrenergic axis leads to a rise in stroke volume to maintain a perfusing pressure, at the expense of tachycardia. ADH and aldosterone are also released, in an attempt to restore circulating plasma volume. ADH is released by the posterior pituitary in response to hypotonicity and increases water reabsorption in the renal tubular apparatus. Aldosterone is produced through activation of the renin–angiotensin system, when the renal juxtaglomerular apparatus senses a drop in the renal perfusion pressure, and also increases reabsorption of sodium and water. These mechanisms are only partly effective and, if bleeding is not controlled surgically and resuscitation inadequate, peripheral tissue oxygenation does not suffice to meet metabolic demands and metabolism switches to anaerobic metabolism, leading to lactate production and lactic acidosis.

Tissue Damage

Tissue damage appears to be one of the principal factors that can set the stress response into motion. Hypovolemia itself is rarely an adequate stimulus to trigger a hypermetabolic response, unless associated with extensive tissue damage or infection. However, if hypoperfusion is prolonged, cellular death may ensue, which in turn will lead to release of toxic products that can initiate the “stress” response.

Pain

Pain can be an important activator of the sympathoadrenergic response and lead to a catecholamine surge with the metabolic effects described earlier. Local tissue destruction is sensed as pain centrally, which triggers numerous efferent pathways preparing the body for what is termed the “fight or flight” response.

Determinants of the Host Response to Stress

Each individual, depending on their genetic traits and certain environmental parameters may respond differently to similar tissue injury patterns. The idiosyncratic nature, intensity, and duration of the stress response may vary extensively in numerous ways in individuals with certain similar genetic and body composition characteristics.

Body Composition

Body composition is a major determinant of the metabolic response seen in the acute phase after surgical or accidental trauma. Posttraumatic nitrogen excretion is directly proportional to the size of the lean body mass. The balance between nitrogen intake and output is a useful marker of protein metabolism. A greater muscle mass due to greater long-term physical activity may also confer an advantage during acute surgical illness and

starvation, as the ability of the lean body mass to provide amino acids for gluconeogenesis during acute illness when it is needed the most, is optimal. Conversely, excessive adiposity may affect outcomes after intense stress, and this is likely due to an abundance of proinflammatory precursors.[43]

Baseline Nutritional Status

A strong relationship exists between preoperative protein depletion and postoperative complications.[4] Protein-depleted patients have lower pulmonary muscle strength and reserve, and are more susceptible to infectious complications, including of the respiratory tract, as well as of the surgical site. Patients with poorer baseline nutrition also experience impaired wound healing and are subject to longer postoperative hospital stays.

Age and Gender

Certain patterns in the metabolic response to surgical pathology that occur with aging can be attributed to alterations in body composition. Although weight remains roughly stable, fat mass tends to increase with age, while lean body mass tends to decline. The loss of strength that accompanies immobility, starvation, and acute surgical illness may have significant consequences. Although the increased energy requirements after elective surgery occur essentially independent of age, the capacity of muscle to serve as a source of amino acids may be limited during acute surgical illness in the elderly, and muscle strength may rapidly become inadequate for respiratory function.

In addition to a smaller muscle mass, older age is commonly associated with a greater prevalence of cardiovascular and pulmonary disease. Relatively decreased arterial compliance, lower baroreceptor sensitivity, and a blunted response to the catecholamine surge may impair the cardiovascular homeostatic response during acute surgical illness. Thus, tissue oxygenation may not be able to meet the heightened demand.

Gender, in addition to age, may affect the body's ability to adapt to surgical stress. Observed differences in the metabolic response between men and women in general reflect differences in body composition. Lean body mass, as a proportion of total body weight, is lower in women than in men. This difference is thought to account for the lower net loss of nitrogen after major elective abdominal surgery in women. Women in general, have approximately half the skeletal muscle mass of men of the same age. Therefore, young muscular men experience the greatest nitrogen losses during acute surgical illness, as opposed to elderly, sedentary women.[8]

NUTRITIONAL SUPPORT

Nutritional Support in Elective Surgery

Most patients undergoing elective operations are adequately nourished, and are typically only fasted the evening before surgery. Unless the patient has suffered significant preoperative malnutrition (subjective global assessment class C) or has a major intraoperative or postoperative complication, intravenous solutions containing 5% dextrose may be administered for up to 5 to 7 days with no detrimental effect on clinical outcomes. In patients who present with the evidence of starvation-related malnutrition, preoperative addition of balanced macronutrient, and high-protein supplementation could be useful. This preoperative support should be initiated as far in advance as possible, even though it is estimated that the minimum time required to derive any benefit from this support is in the range of 2 to 4 weeks.[44] During this period, electrolyte abnormalities should be addressed, and early involvement of a nutritionist would be advisable.

Bowel function typically returns within the first 5 to 7 postoperative days in the majority of surgical patients, and an oral diet or enteral feedings can be resumed. The increased cost of feedings and the potential complications associated with parenteral nutrition cannot be justified. Conversely, in patients who are malnourished preoperatively or prolonged postoperative ileus has rendered them unable to be fed enterally for more than 5 to 7 days, nutritional support should be considered. The nutritional status should be assessed early, so this piece of information can be integrated into decision-making and nutrition care planning. Enteral feedings are superior and always preferred to parenteral nutrition in patients who can tolerate an enteral diet. Standard high-protein feeding formulas are adequate. The choice of product and volume of feeding are based on the results of the nutrition assessment. The majority of tube feeding formulas today are rich in water-soluble dietary fiber, which is considered standard in the nutritional care of the surgical patient. Specific adjustments can be undertaken, if special considerations (e.g., cardiac failure, renal failure, diabetes, etc.) have to be made. Preoperative addition of a balanced macronutrient high-protein supplement is useful to initiate as far in advance of surgery as possible, although in this severely malnourished population, the time needed to see benefit from supplementation is unknown (estimated minimum of 2 to 4 weeks).

6 One of the best studies to date evaluating the efficacy of preoperative TPN was published by the Veterans Affairs Total Parenteral Nutrition Cooperative Study Group.[4] Over 3,000 patients requiring mostly elective gastrointestinal procedures were randomized to receive parenteral nutritional support for at least 7 days preoperatively versus none, if they were deemed to be malnourished preoperatively. Patients with severe malnutrition (>15% weight loss and serum albumin <2.9 mg/dL) preoperatively had fewer noninfectious complications (impaired wound healing), if they were provided TPN before surgery, however, infectious complications (pneumonia, surgical site infections, and line infections) were more common in the TPN group. This study strongly suggests that preoperative TPN should be considered only to severely malnourished

patients who cannot be fed via the enteral route.

Numerous studies that have followed have reached similar conclusions, and have led the SCCM and ASPEN to recommend targeted preoperative nutritional support for those deemed malnourished. This support should ideally be oral, enteral, or in rare circumstances parenteral and with therapeutic intent.[6] In fact, while initial guidelines advocated the use of artificial nutrition if preoperative weight loss $>10\%$ has occurred or oral intake is not deemed achievable for more than 7 days postoperatively, interest in supporting all surgical patients perioperatively has been on the rise, regardless of baseline nutritional status.[45]

7 While resuscitation, bleeding control and preservation of the vital body functions, such as maintenance of gas exchange and supporting of adequate cardiac output, remain immediate priorities for survival in any critically ill surgical patient, it is increasingly recognized that nutritional support is an integral part of the metabolic care of the critically ill, and aggressive pursuit of target energy requirements is associated with optimal wound healing, recovery, and rehabilitation. Critically ill patients commonly have anorexia that can be adaptive or maladaptive and may be unable to be fed by mouth volitionally for periods, which can range from days to months, and severe malnutrition can complicate their course and adversely affect outcomes, unless they are provided with enteral or parenteral nutrition.[46] Several studies have underlined the association between energy deficit in critical illness and longer ICU stays, greater incidence of infectious complications, and even mortality.[47–50] The finding that enteral nutrients exert a trophic effect on the cellular integrity and function of the gut mucosa has provided the rationale for initiating enteral feedings early in the course of critical illness. In fact, evidence from observational studies appears to support that critically ill patients who were fed earlier had better overall outcomes compared to those that did not,[51] and these improved outcomes have led critical care nutrition to be at the forefront of ongoing research worldwide. Therefore, regardless of baseline nutritional status, any critically ill patient who is not expected to resume an oral diet within 3 to 4 days should have nutritional support instituted as soon as technically and logistically feasible, ideally within 24 to 48 hours after admission, and have their blood glucose levels maintained <140 mg/dL.[52] Patients on enteral nutrition, should have their head of bed elevated at 45 degrees, or be in steep reverse Trendelenburg position if spinal precautions preclude this measure, to minimize aspiration risk.[18,20]

The optimal method of estimating daily energy requirements in the critically ill remains a subject of debate. It would be ideal if energy requirements were calculated precisely on a daily basis using indirect calorimetry, as this method appears to lead to greater energy provision than less precisely calculated energy targets, even though this practice was associated with a greater incidence of infectious complications and a longer overall ICU length of stay.[53] Indirect calorimetry, however precise, can be impractical, if not even impossible to apply in certain critically ill individuals.[54] Additional challenges facing critical care nutrition include the frequent interruptions in nutrition delivery for a variety of reasons, including delayed gastric emptying and transfers outside the ICU for diagnostic or therapeutic procedures. When protocols to aggressively advance nutrition are in place, it appears that critically ill patients are able to achieve their caloric goals earlier, even though these practices may not necessarily translate to better overall outcomes.[55–57] With regard to delayed gastric emptying, which is commonly cited as a reason for slow advancement of enteral feedings, it appears that advancing tube feedings without measuring or accepting residual volumes as high as 500 cc/4 hours results in quicker attainment of the caloric goals, with no concomitant rise in the incidence of nutrition-related adverse events.[58] The use of prokinetic agents (erythromycin may be

more effective than metoclopramide), as well as postpyloric feeding delivery has also been advocated to minimize the issue of delayed gastric emptying, however, other than achievement of nutritional goals being slightly earlier in the course of critical illness, no definitive improvement in outcomes has been demonstrated.[59–62] There is some divergence on whether immune- or inflammation-modulating feeding formulas are indicated in some critically ill patients. There is at least one quality study that has been published since the guidelines that support the use of such feedings in patients with sepsis and risk for acute respiratory distress syndrome or acute lung injury.[63]

Access Routes for Nutrition

Enteral or Parenteral

8 An issue with reliance solely on enteral nutrition is that attaining caloric targets may prove elusive, due to a partly functional gastrointestinal tract or side effects associated with enteral feedings. While enteral feedings are always preferable to parenteral nutrition in general, the timing of initiation of TPN in patients unable to tolerate or with contraindications for enteral feedings remains controversial. European guidelines recommend early initiation of TPN to minimize nutritional deficits, while North American guidelines favor hypocaloric enteral nutrition for up to 1 week in patients with good nutritional baseline before considering TPN.[48,49] The rationale on the delay in TPN administration is based on complications associated with the use of TPN, such as infections, hyperglycemia, hypertriglyceridemia, and liver function abnormalities.[64–67] The latter seems to be supported by more recent high-quality data that demonstrate that patients receiving partial enteral nutrition demonstrate a lower incidence of ICU-acquired weakness, spend less time in the ICU and the hospital, and require shorter length of vital-organ support, and incur less costs, compared to their counterparts in whom partial enteral nutrition was supplemented with TPN.[68–71] However, conflicting data exist on the effect of nutritional supplementation with TPN on infectious outcomes in patients receiving hypocaloric enteral feedings from more recent trials.[68,69,72] In critically ill patients with a relative contraindication (e.g., gastric residual volumes >500 mL or postoperative ileus) for early enteral nutrition, it appears that early TPN helps decrease total length of stay on mechanical ventilation.[73] Whether early parenteral nutrition is beneficial in patients with an absolute or prolonged contraindication for enterally administered nutrition remains a topic of debate, even though it is fairly well established that the greater incidence of infectious complications may outweigh the benefits of early achievement of nutritional goals in patients in their first 5 to 7 days in the ICU.[68,74]

Total Parenteral Nutrition Considerations

As the term implies, and due to the high osmolarity of its content, TPN must be delivered centrally to minimize the risk of venous sclerosis. Patients on TPN therapy should be monitored regularly by measuring blood sugar, serum electrolytes, and liver function tests, as abnormalities in these laboratories are common. TPN-related complications can be broadly categorized into those that are access related, metabolic, and infectious. A list of these is summarized on Table 3-8.

Table 3-8 TPN-Related Complications

Complication	Etiology
Access Related	
Pneumothorax	Air accumulation between the pleural leaflets from puncture/laceration
Carotid/subclavian arterial injury	Accidental puncture of the adjacent arterial structure
Catheter malposition and arrhythmias	Tip of catheter may find its way into an unintended venous structure or the right atrium causing arrhythmogenesis
Venous thrombosis	Thrombus formation in a major vein, due to alterations in blood flow and presence of a foreign body
Metabolic	
Hyperglycemia	Excessive carbohydrate administration, glucose intolerance, or combination of the two
Hypoglycemia	Sudden cessation of TPN, while insulin stimulation has not subsided
CO_2 retention	Carbohydrate calories in excess of energy requirements
Azotemia	Excessive protein administration with inadequate calories
Essential fatty acid deficiency	Inadequate essential fatty acid administration
Hypertriglyceridemia	Rapid fat infusion or decreased fat clearance
Hypophosphatemia and hypokalemia	Sudden full-strength nutritional restitution in a starved patient (refeeding syndrome)
Any electrolyte abnormality	Excess or inadequate electrolyte supplementation
Hemorrhagic diathesis	Vitamin K deficiency
Infectious	
Septicemia	Catheter tip becomes colonized with bacteria and continuously seeds bloodstream
Skin site cellulitis	Skin flora enters the subdermal/subcutaneous space
Pneumonia, other systemic infectious	High n-6 fatty acid content adversely affects immune function

9 Hyperglycemia is common in surgical patients, especially during high-stress periods, or they were relatively glucose intolerant or frankly diabetic at baseline. This side effect of TPN can generally be controlled with subcutaneous or intravenous insulin administration if mild or moderate–severe respectively, and eventually by adding insulin to the TPN formulation, once the daily insulin requirements have been calculated. It has been shown that stressed individuals can maximally oxidize up to 4 to 5 mg of glucose/kg/min. For a 70-kg man, this is equal to approximately 400 to 500 g/day (1,600 to 2,000 kcal/day). Therefore it is common for patients to receive up to two-thirds of their daily caloric needs in carbohydrate form through TPN. Excess glucose can result in hyperglycemia and glycosuria, can be converted to fat, and deposited in the liver. Glycosuria with its osmotic load can lead to osmotic diuresis, which can be misinterpreted as a sign of adequate resuscitation status or transition to recovery phase, while the patient may actually be clinically worsening.

Fat is an important fuel for the critically ill, as stressed patients preferentially utilize endogenous fat as an energy source. Fat oxidation is only minimally affected by carbohydrate administration during stress, unlike traditional starvation, and glucose infusion above certain levels may lead to hepatic steatosis. Lipids are commonly added to TPN formulations to help meet the caloric requirements, as well as to provide the essential fatty acids and to minimize complications associated with the infusion of large amounts of carbohydrate-containing fluids. Lipid emulsions for TPN solutions are mostly vegetable fat based, and contain primarily long-chain fatty acids. Inclusion of lipids in the TPN provides the essential linoleic acid, inhibits lipogenesis from carbohydrates, and

helps lower the respiratory quotient (RQ), which may benefit patients with carbon dioxide retention. However, formulations with a high n-6 polyunsaturated fatty acid content (linoleic acid in particular) may attenuate acute lung injury,[75] and by affecting plasma membrane fluidity, the ability to phagocytose bacteria may be impaired. Newer nutritional methods of modifying the catabolic response to injury and infection propose the use of n-3 fatty acids, which may decrease eicosanoid synthesis and thereby diminishing the vasoconstriction, platelet aggregation, and immunosuppression that may occur when n-6 derivatives are given. Studies suggest that n-3 fatty acids may be of benefit to the critically ill patient.[76]

The amounts of the various electrolytes provided to patients receiving TPN vary, depending on previous volume status and preexisting electrolyte abnormalities. Careful monitoring of serum electrolyte levels is critical, especially during the acute phase of disease or in severely malnourished individuals, because as metabolism switches to the anabolic phase, potassium and phosphate can move rapidly into the intracellular compartment, leading to potentially fatal hypokalemia or hypophosphatemia, in what is known as the refeeding syndrome.[77] Vitamin and trace mineral levels, although not as life-threatening, should also be occasionally monitored. The composition of a standard TPN solution is shown in Table 3-9.

A significant downside of TPN is that the gastrointestinal tract goes into misuse, and evidence suggests that this may exacerbate intestinal microflora translocation from the gut lumen to the mesenteric lymph circulation, worsening total bacterial load and stress during an already compounded clinical situation. Clinical evidence suggests that TPN, under certain circumstances, may accentuate stress, and predispose to gut-derived infectious complications, and even multiple organ failure,[78,79] while compared to enteral nutrition, it may minimize episodes of hypoglycemia and vomiting.[80]

Enteral Nutrition Considerations

10 11 Enteral nutrition is safer and less expensive than parenteral nutrition, and numerous studies have demonstrated the superiority of enteral nutrition compared to parenteral, in decreasing postoperative infectious complications and increasing collagen deposition at anastomotic sites, improving wound tensile strength.[81] The gastrointestinal tract can be used for administration of complex nutrients that cannot be provided as readily intravenously, such as polypeptides and fiber. Gut processing of many of these nutrients stimulates hepatic protein synthesis, while intravenous administration bypasses the portal circulation altogether. In addition to the systemic benefits of enteral nutrition, enteral feedings afford significant local benefits on the gut mucosa itself. Enterocytes are being fed directly, and the absorptive surface of the mucosa is stimulated and maintained. Luminal nutrients, such as glutamine and short-chain fatty acids, are used as fuel by small bowel enterocytes and colonocytes respectively.[82] The trophic effects of luminal nutrition are well documented, even if small amounts of enteral feedings are provided, and a growing body of evidence suggests that earlier enteral nutrition is preferable.[83–85] An additional immunologic benefit of enteral nutrition is that complex polypeptides and long-chain fatty acids stimulate the production of gut-derived immunoglobulin A, which is

important in reducing bacterial translocation. Luminal nutrients also help maintain a normal pH and flora, thus diminishing the risk of opportunistic bacterial overgrowth in the bowel. In addition to the physiologic, metabolic, and immunologic benefits of enteral nutrition, safety and cost benefits also exist. Enteral feedings are considered safer than parenteral nutrition. The latter places patients at a greater risk for hyperglycemic events, which may partly inhibit neutrophil-mediated immune function, and may be the reason why TPN-nourished patients may be at a greater risk for infectious complications, even though this risk may be eliminated with tight glucose control.[80] Finally, there are obvious cost benefits, as tube feedings are in general cheaper than parenteral nutrition formulations.

Table 3-9 Composition of a Standard Total Parenteral Nutrition Formulation

Volume	10% Amino acid solution	500 mL
	50% Dextrose solution	500 mL
	Fat emulsion	—
	Electrolytes + vitamins + minerals	~50 mL
	Total volume	~1,050 mL
Composition	Amino acids	50 g
	Dextrose	250 g
	Total N	50/6.25 = 8 g
	Dextrose kcal	250 g × 3.4 kcal/g = 840 kcal
	mOsms/L	~2,000
Electrolytes to Total Parenteral Nutrition Solutions		
	Usual Concentration	**Range of Concentrations**
Sodium (mEq/L)	60	0–150
Potassium (mEq/L)	40	0–80
Acetate (mEq/L)	50	50–150
Chloride (mEq/L)	50	0–150
Phosphate (mEq/L)	15	0–30
Calcium (mEq/L)[a]	4.5	0–20
Magnesium (mEq/L)	5	5–15

[a]Generally added as calcium gluconate or calcium chloride: one ampule of calcium gluconate = 1 g of calcium = 4.5 mEq.

Although enteral nutrition is the preferred method for nutritional support in malnourished patients, or subjects at risk for developing malnutrition and have an intact gastrointestinal tract, a problem surgical patients are commonly facing is intestinal inactivity, especially after gastrointestinal procedures. Postoperative ileus is frequent, reflects functional immobility of the gastrointestinal tract, and is typically proportional to the amount of manipulation the bowel sustained during the surgical intervention. Patients who are either unable to meet their daily caloric and nutrient needs are candidates for enteral support. Factors that can help determine the timing of initiation of enteral nutrition include preexisting malnutrition, current illness acuity and duration, estimated catabolic activity, and anticipated return to per os intake. Contraindications to enteral feedings are usually relative or temporary, and include short, obstructed, or perforated

bowel, a gastrointestinal tract in discontinuity, protracted vomiting, fistulas, or active gastrointestinal ischemia. While gastrointestinal bleeding or worsening hemodynamic instability has been traditionally quoted as additional contraindications, it appears that enteral nutrition can be safely administered during these.[86–88]

Despite the numerous benefits of enteral nutrition, it is not completely free of complications. These can be categorized in access related, functional, and metabolic, and are summarized in Table 3-10. In general, these can be avoided with meticulous care while inserting and maintaining feeding tubes, considering using nasal bridles,[89] ensuring head of bed elevation to minimize risk of aspiration, using motility agents when gastric motility is suboptimal, closely monitoring patients' metabolic profile and adjusting content, or adding bulking agents if osmotic diarrhea develops.

Enteral feedings are generally categorized into *intact or polymeric* (protein, carbohydrate, and lipid molecules exist in an unaltered form – usually given to patients without absorption or digestion difficulties), *hydrolyzed or monomeric* (contain predigested proteins, simple sugars, and medium-chain triglycerides – are a good option for patients with impaired digestive capacity), and *modular* (typically contain one type of fuel, carbohydrate, lipids or fat, and can be combined to address each patient's specific needs). Some of the most commonly used enteric feeding formulas and their metabolic characteristics are shown on Table 3-11.

Table 3-10 Enteral Nutrition-Related Complications

Complication	Etiology
Access Related	
Feeding tube malposition, clogging, and accidental removal	The feeding tube can be misplaced in the tracheobronchial tree, it can become clogged with dense tube feedings or inadequately crushed medications, or be accidentally removed
Oro/naso-, gastric or -enteral tube perforation of the proximal gastrointestinal tract or tracheobronchial tree	Accidental puncture of the wall of the structure the feeding tube in placed into
Pressure ulcers at skin entry site and sinusitis	A foreign body is continuously pressing against healthy skin, and increases risk of bacterial colonization of the nasal passages
Functional	
Nausea, vomiting, and abdominal distention	Usually due to delayed gastric emptying
Diarrhea	Usually polyfactorial, but high-protein content and high osmolarity of enteral feedings are the most common culprits
Metabolic	
Electrolyte abnormalities	When enteral nutrition content is inadequate to cover daily needs. Hyperosmolarity may be a consequence when calorically dense enteral feedings are administered
Volume overload	From excess sodium and water loading, typically in patients with preexisting heart failure
Hyperglycemia	Less common than in patients receiving TPN, but may manifest in patients with diabetes or impaired glucose tolerance, or can herald sepsis

Table 3-11 Commonly Used Enteral Nutrition Formulations

Product Name	Calories (per mL)	Protein (g/L)	Carbohydrates (g/L)	Fat (g/L)	Fiber (g/L)	Osmolality (mOsm/L)	Special Features
Tube Feeding Formulations							
Osmolite 1 Cal	1.06	44	144	35	0	300	Isotonic
Jevity 1.2 Cal	1.2	56	169	39	18	450	High protein with fiber
Jevity 1.5 Cal	1.5	64	50	50	22	525	Concentrated calories with fiber
Promote with Fiber	1	63	138	28	14	380	Very high protein with fiber
Nepro with Carb Steady	1.8	81	161	96	13	745	Renal formula
TwoCal HN	2	84	219	91	5	725	Calorie and protein dense
Vital AF 1.2 Cal	1.2	75	111	54	5	425	Peptide-based elemental with high protein
Vital high protein	1	88	112	23	0	353	Peptide-based elemental with high protein
Pivot 1.5 Cal	1.5	94	172	51	7.5	595	Immune support
Vivonex RTF	1	50	176	12	0	630	Elemental (amino acids)
Oral Supplements[a]							
Product Name	**Calories**	**Protein (g)**	**Carbohydrates (g)**	**Fat (g)**	**Fiber (g)**	**% Water**	**Special Features**
Ensure Plus (per 8 fl)	350	13	51	11	3	76	High calorie and high protein
Glucerna Shake (per 8 fl)	220	10	26	9	3	84	Diabetic formula
Ensure Clear (per 6.8 fl)	200	7	43	0	0	84	Clear liquid
Juven (per 24 g)	80	14 (amino acids)	8	0	0	n/a	Helps build lean body mass to support healing
Pro-Stat Sugar free (per 30 mL)	100	15	10	0	0	n/a	Protein
Nutrisource fiber (per 4 g)	15	0	4	0	3	n/a	Fiber

[a]Per amount noted in product name column.
Adapted from Boston University Medical Center's Nutrition Formulary, 2014.

Macro- and Micronutrient Selection

An additional topic of debate is whether selection of specific macro- and micronutrients to be included in nutritional formulas, be it enteral or parenteral, can afford specific benefits to patients receiving them, depending on the underlying pathology. Gluconeogenesis from amino acids (glutamine and alanine) released from muscle protein breakdown cannot be fully suppressed with exogenous glucose and insulin administration, due to the complex hormonal stress response the human body elicits during critical illness, which results in relative insulin resistance. It was postulated, therefore, that exogenous amino acid and oligopeptide infusion would help minimize lean body mass erosion. However, even though the total nitrogen equilibrium appears to be shifted toward a more positive

balance when this practice is employed, it does not translate to better outcomes.[90] Therefore, the optimal protein to total energy ratio in critical illness remains largely unknown.

12 Glutamine is the most abundant nonessential amino acid and in humans it is predominantly released with skeletal muscle proteolysis. It is one of the key precursors for hepatic gluconeogenesis at times of stress, and low glutamine levels have been associated with poor outcomes in critical illness, as it is an important nutrient necessary for the function of immune cells, enterocytes, and hepatocytes. It has been postulated that low glutamine levels are a consequence of muscle wasting, and a meta-analysis of early randomized controlled trials suggested that glutamine supplementation may help decrease infectious complications, hospital length of stay, and even mortality.[91] However, this finding has not been replicated in newer, higher-quality studies, and in fact, it appears that aggressive glutamine supplementation may increase risk of death in patients with organ failure.[92–94] These findings do not support glutamine supplementation routinely. Its supplementation may be beneficial when depletion is severe or when the intestinal mucosa is damaged by chemo- and/or radiation therapy.[95] Similarly, arginine supplementation may be associated with a lower infectious risk and shorter hospital length of stay, however, no currently available evidence support its use during critical illness.[96]

The n-3 fatty acids (present in fish oil preparations) have been shown to have anti-inflammatory effects, while n-9 fatty acids (present in olive oil) have a neutral effect on inflammation, and n-6 fatty acids (in soybean oil) appear to be proinflammatory.[97] On the basis of low levels of n-3 fatty acids in acute lung injury patients and the proinflammatory properties of n-6 fatty acids, the lipid profile of such patients was hypothesized to contribute to worsening acute lung injury, and some initial studies suggested that administration of high n-3 to n-6 fatty acid ratio formulas may benefit critically ill patients.[98,99] However, more recent, higher-quality studies have failed to show a beneficial effect of rich in n-3 fatty acid preparations in either enteral or parenteral nutrition formulations.[100,101] Currently, the lack of high-quality evidence precludes any recommendation on the use of specific lipids in critically ill patients.

13 Micronutrients, as electrolytes, vitamins and trace elements are generally termed, are administered in critical illness to prevent deficiencies and associated complications. With repletion of micronutrient stores after starvation, refeeding syndrome can occur, which typically unmasks severe deficiencies in potassium, phosphate, and thiamine. This can be life-threatening and present with lactic acidosis, cardiac arrhythmias, worsening respiratory failure, and even heart failure. Therefore, routine administration of micronutrients during critical illness is commonly warranted. Provision of therapeutic doses of trace elements (selenium, copper, zinc, and iron) and vitamins (E, C, and beta-carotene) with antioxidant activity has also been proposed,[102] however, recent randomized controlled data failed to demonstrate a benefit.[93] Selenium supplementation may also be beneficial in subjects with selenium deficiency, and the potential benefit is supported by a recent meta-analysis.[103]

Current recommendations for nutritional support during critical illness are summarized

on Table 3-12.

Access Routes

TPN solutions are administered through a central venous catheter, generally inserted in the subclavian or internal jugular vein, or through peripherally inserted central catheters (PICCs) that are typically inserted in veins of the antecubital fossa and have their ends reach the atriocaval junction. Administration of TPN through femoral venous catheters is avoided as possible, due to the greater incidence of infectious complications this access site entails. Central lines are preferred when short-term central venous access is indicated, and are commonly inserted by surgeons, intensivists, or interventional radiologists. In contrast, PICC lines are placed by specially trained nursing staff or interventional radiologists, and the logistics of insertion (scheduling, availability, and workload of the practitioners placing them) must be considered. The major benefit of PICCs is that patients can be discharged from the hospital with them, if prolonged access is required, and their safer insertion profile, while the major advantage of traditional central venous catheters is that they allow infusion of vasoactive medications, and can be used for resuscitative purposes (administration of large volume of crystalloids rapidly) and advanced hemodynamic monitoring (measurement of central venous pressure). Both carry multiple ports, and it is a common practice to save one of these for nutrition access alone, as the high-carbohydrate concentration of nutrition solutions can act as a nidus for infection, if the same port is used both for TPN administration and is frequently accessed for blood draws. Both devices can also be used for administration of medications toxic to the peripheral venous system (e.g., hypertonic saline, vancomycin, and other hyperosmolar solutions), and allow an easy access route for repeat venous sampling, which can be convenient in patients requiring frequent laboratory draws. Routine exchange of uncomplicated central or PICC lines is not advocated, and both types of catheters should be removed when the indication for their placement ceases to exist, to minimize infectious and thrombotic complications.

Table 3-12 Recommendations for Clinical Nutritional Practice in the ICU

Recommendations for Clinical Nutritional Practice during Critical Illness
Enteral nutrition is always preferable to parenteral nutrition
Allow hypocaloric enteral feedings in the acute phase of critical illness for up to 5–7 days in previously well-nourished patients. Start as early as feasible
Routine glutamine supplementation is not supported during critical illness
Supply micronutrients to prevent refeeding syndrome, and monitor electrolytes, liver function tests, and triglyceride levels as needed

Adapted from Casaer MP, Van den Berghe G. Nutrition in the acute phase of critical illness. *N Engl J Med* 2014;370(13):1227–1236.

Peripheral parenteral nutrition (PPN) can be infused through peripheral venous cannulas. Peripheral intravenous feedings may be used for infusion of protein, lipid, and lower concentration dextrose solutions. PPN is limited in caloric delivery, due to the large

volumes it would require to meet daily demands, but it avoids central venous cannulation, which has considerable complications. It can be considered for short-term parenteral nutrition, for example, in the case of postoperative patients with ileus expected to resolve in a few days.

Enteral feedings are typically administered through oro/naso-, -gastric or -enteric feeding tubes in the acute phase of disease. The stomach is easily accessed with a soft flexible feeding tube. Intragastric feedings provide several advantages compared to more distal gastrointestinal tract feedings, as the stomach has the capacity and reservoir for bolus feedings. Feeding into the stomach stimulates the biliary and pancreatic axis, with trophic benefits for the entire small bowel. Finally, gastric secretions exert a dilutional effect on tube feeding osmolarity, reducing the risk of diarrhea. An important risk of intragastric feedings is regurgitation of gastric contents with possible aspiration into the tracheobronchial tree. This risk is highest in patients with altered mental status or who are paralyzed. Placement of the feeding tube through the pylorus further down into the small bowel reduces the risk of regurgitation. Nasoduodenal/nasojejunal tubes are smaller in caliber and therefore more comfortable for patients, however, they are more prone to clogging. Patients who repeatedly remove their catheters may be candidates for feeding tube bridles. Placement of nasogastric or nasoduodenal tubes should always be confirmed radiographically prior to initiation of feedings.

Patients with chronically impaired mental status (such as those with severe traumatic brain injury), an inadequate swallowing mechanism or dysphagia, and those with oropharyngeal or proximal gastrointestinal tract pathology or recent/anticipated surgical procedure may be candidates for longer term transabdominal gastrointestinal access. This access is typically provided through temporary Stamm gastrostomies, in which a small laparotomy incision is made, and the gastric lumen in the midportion of the gastric body is accessed, while a transabdominal large-bore feeding tube is secured in place with concentric purse string sutures. Percutaneous endoscopic gastrostomy (PEG) tubes can be inserted and provide access for gastric feedings, without the need for laparotomy, general anesthesia, and even a trip to the operating room, as they can be performed at the bedside under endoscopic guidance. Using monitored anesthesia care, a gastroscope is advanced transorally into the stomach and helps transilluminate the anterior gastric wall through the abdominal wall. A small abdominal incision is made over the area of maximal transillumination, ideally over the midportion of the gastric body, and through an angiocath, a wire is advanced into the gastric lumen, which is snared and pulled back out of the mouth with the gastroscope. The wire is looped around the PEG tube and pulled through the abdominal wall in an antegrade fashion, until only the head of the feeding tube remains in the stomach, with the rest of it being extracorporeal. The inner part of the PEG tube is confirmed to be in correct position and the feeding tube is secured in place. This technique may be difficult in obese patients, whose abdominal walls can be hard to transilluminate. Modified laparoscopy-assisted techniques have also been described.

Feeding jejunostomies can be considered following any major abdominal procedure, if the need for prolonged enteral nutrition is anticipated. A loop of proximal small bowel,

typically 20 to 40 cm distal to the ligament of Treitz is elevated and secured against the abdominal wall fascia of the left upper or lower quadrant and is accessed transabdominally with a feeding tube. The tube can be covered for a short distance with bowel serosa (Witzel jejunostomy). Laparoscopic feeding jejunostomies have also been described, as well as the passage of jejunostomy tubes through percutaneously placed gastrostomy tubes.

ADDITIONAL NUTRITIONAL CONSIDERATIONS

Infectious Processes and Fever

As mentioned earlier, with core temperature elevations, such as those that occur with fever during infectious or other inflammatory processes, the base metabolic rate increases. Total energy requirements can be calculated using the aforementioned equations, multiplying by appropriate factors: mild to moderate infections increase energy requirements by 20% to 30%, and severe infection with fever increases caloric needs by over ~50% above basal levels. Even though weight gain and anabolism are difficult to achieve during the septic response, the astute clinician should be mindful of these associations and adjust nutritional support accordingly in persistently febrile patients.

Respiratory Failure

A condition commonly complicating surgical patients is respiratory failure with the need for prolonged mechanical ventilation. The main concern in mechanically ventilated patients is adequate gas exchange, which includes oxygen and carbon dioxide transport across the capillary–alveolar membrane. Not uncommonly the indication for ventilatory support is pulmonary infection, which along with a postoperative status, contributes to the overall hypermetabolism. Hypermetabolism is accompanied by increased oxygen consumption, which drives carbon dioxide production, as more substrate must be oxidized to support the greater energy requirements. While nutrition commonly takes lower priority in ventilated patients, in whom all efforts are directed toward managing the underlying etiology for the respiratory insufficiency, consideration should be given to the content of the nutritional support, as they may facilitate or prolong weaning, especially in those with chronic CO_2 retention. The RQ of a specific nutrient denotes the carbon dioxide produced over oxygen consumed, and adjustments in feedings from high RQ (e.g., carbohydrates, RQ = 1) to lower RQ (e.g., fat, RQ = 0.7), and avoidance of overfeeding should be considered in patients difficult to wean due to CO_2 retention. These adjustments have to be considered carefully, as increased fat intake, especially mixtures high in n-6 fatty acids, may exacerbate lung injury.

Renal Failure

Renal failure affects the body's ability to clear the byproducts of protein metabolism, but does not change the catabolic rate or the protein requirements. Therefore, a careful balance needs to be achieved between the need for protein and to limit uremia. When acute surgical stress is superimposed, consideration for potentially earlier or more aggressive renal support should be given, so that the body is not restricted of protein, which is critical during the hypermetabolic phase of acute disease. TPN with amino acids of high biologic value may improve survival in patients with acute renal failure.[104] The use of solutions containing high-quality amino acids can improve nitrogen balance and minimize urea production. This translates into a decreased frequency of dialysis.

Liver Failure

Patients with liver disease may be malnourished secondary to excessive alcohol intake, diminished food intake, or persistent inflammatory state from viral infection. These individuals are protein depleted, yet tolerate protein poorly, due to their likelihood to become encephalopathic with high-nitrogen intake. Due to liver damage and portosystemic shunting, these patients develop derangements in circulating levels of amino acids. The plasma aromatic-to-branched chain amino acid ratio is increased, favoring the transport of aromatic amino acids across the blood–brain barrier. These amino acids are precursors of neurotransmitters that can worsen encephalopathy and lethargy. Using solutions enriched in BCAAs and deficient in aromatic amino acids in liver failure patients enhances protein tolerance and potentially improves in clinical encephalopathy.

Heart Failure

Myocardial dysfunction can be seen as part of the critical illness cardiomyopathy (circulating cytokines TNF and IL-1 appear to have a direct myocardial depressant activity) in patients with sepsis or those with preexisting congestive cardiac failure who undergo surgery. Patients with surgical emergencies commonly third space and require significant amounts of crystalloid resuscitation, which may exacerbate their pre-existing volume overload. When considering nutritional support of these patients, efforts should be made to minimize the total fluid volume, and nutrition formulas should be concentrated if possible.

Bariatric Surgery

Bariatric patients pose a special challenge, given their chronically overnourished status and their altered gastrointestinal tract, if they have undergone weight loss surgery. The latter are at increased risk for several macro- (usually protein) and micronutrient deficiencies (most commonly vitamins D and B_{12}, calcium, iron, folic acid, zinc, and selenium),[105–107] and the clinician should be mindful of these potential complications. Nutritional support of the obese or postweight loss surgery patient is particularly complex because of the balance needed between minimizing overfeeding and avoiding the hypercatabolic state. Despite the excessive fat stores, critically ill obese patients should receive early and timely nutrition, as protein–calorie malnutrition does occur, and consideration for indirect calorimetry, which allows accurate estimation of the caloric requirements, and early involvement of a nutritionist should be considered. Hyperglycemia is an additional concern in obese patients, as glucose intolerance or frank diabetes may first manifest in acute illness, and should be addressed whenever identified.[108]

Geriatric Patients

Attention to appropriate nutritional support of the geriatric patient is of paramount importance, both in the perioperative stage, as well as in the ICU, given the multiple physiologic alterations seen in older age, including greater ratio of fat-to-muscle mass, decreased cardiac and pulmonary reserves, poor dentition, polypharmacy, and high incidence of malnutrition, which may be as high as 85% in nursing home residents.[109,110] In relation to preoperative preparation, elderly patients are more likely to have numerous disease processes affecting their general nutritional status, including diabetes, cancers, cardiac, pulmonary, and renal insufficiency. Given a certain degree of lean body mass loss is to be expected in this demographic, a higher-protein intake (>1.5 g/kg/day) should be the goal preoperatively in the elderly undergoing elective surgery, or early in the recovery phase after emergency procedure or acute surgical illness.[46] Toward that goal, numerous protein-rich supplements that are commercially available to patients who can tolerate enteral feedings, or parenteral nutrition with high-protein concentrations can be prescribed.[44]

Enterocutaneous Fistulas

Gastrointestinal cutaneous or gastrointestinal atmospheric fistulas with high output (commonly defined as having output greater than 400 cc/24 hours) represent a classic indication for long-term TPN. Oral intake in patients with such fistulas typically results in greater output, especially in fistulas involving the proximal gastrointestinal tract, which can lead to dehydration, significant metabolic disturbances, and adversely affect the ability of the fistula to heal. TPN has been shown to increase spontaneous rate of closure of enterocutaneous fistulas by improving overall nutritional status in the host, or improving perioperative outcomes in those requiring surgical therapy. Somatostatin and analogs have been used to aid with fistulous output and spontaneous closure with varying results.

Short Bowel Syndrome

Patients with history of extensive small bowel resection lose a large part of the absorptive ability of the bowel, and frequently have to rely on prolonged TPN to meet their nutritional goals. In select patients with residual small intestine of at least 18 inches, postresection hyperplasia that can allow enteral nutrition has been demonstrated in subjects treated with supplemental glutamine, growth hormone, and a high-carbohydrate, low-fat TPN.[111]

Major Thermal Injury

Burn victims often suffer from prolonged ileus, which encumbers enteral nutritional support. Even if the bowel is usable and patients not on mechanical ventilation, they are frequently unable to consume adequate calories, due to anorexia of severe injury and frequent npo status for repeated trips to the operating room. Currently available data suggest that aggressive nutritional support with high-protein intake in patients with major burns is associated with improved survival.[112]

Prolonged Postoperative Ileus

Patients undergoing major gastrointestinal procedures may develop prolonged ileus in the postoperative period, which precludes the use of the intestinal tract as a feeding route. If the patient is unable to eat by postoperative days 5 to 7, TPN should be considered. Although provision of TPN does not influence the disease process per se, it is beneficial because it prevents further erosion of lean body mass. When postoperative ileus of shorter duration is anticipated, patients can be bridged with PPN.

Acute Radiation and Chemotherapy Enteritis

Malnourished patients who receive abdominopelvic radiation or chemotherapy may develop mucositis and enterocolitis that precludes using the intestinal tract for nutrition for variable periods of time. In such individuals, parenteral nutrition should be provided, until the enteritis resolves and oral feedings can be resumed.

References

1. Correia MI, Waitzberg DL. The impact of malnutrition on morbidity, mortality, length of hospital stay and costs evaluated through a multivariate model analysis. *Clin Nutr* 2003;22:235–239.
2. Schiesser M, Muller S, Kirchhoff P, et al. Assessment of a novel screening score for nutritional risk in predicting complications in gastro-intestinal surgery. *Clin Nutr* 2008;27:565–570.
3. Elia M, Russell CA, Stratton RJ. Malnutrition in the UK: policies to address the problem. *Proc Nutr Soc* 2010;69:470–476.
4. The Veterans Affairs Total Parenteral Nutrition Cooperative Study Group. Perioperative total parenteral nutrition in surgical patients. *N Eng J Med* 1991;325:525–532.
5. Lassen K, Soop M, Nygren J, et al. Consensus review of optimal perioperative care in colorectal surgery: Enhanced Recovery After Surgery (ERAS) Group recommendations. *Arch Surg* 2009;144:961–969.
6. McClave SA, Martindale RG, Vanek VW, et al. Guidelines for the provision and assessment of nutrition support therapy in the adult critically ill patient: Society of Critical Care Medicine (SCCM) and American Society for Parenteral and Enteral Nutrition (A.S.P.E.N.). *JPEN J Parenter Enter Nutr* 2009;33:277–316.
7. Mueller C, Compher C, Ellen DM; American Society for Parenteral Enteral Nutrition (A.S.P.E.N.) Board of Directors. A.S.P.E.N. clinical guidelines: nutrition screening, assessment, and intervention in adults. *JPEN J Parenter Enter Nutr* 2011;35:16–24.
8. Cohn SH, Vartsky D, Yasumura S, et al. Compartmental body composition based on total-body nitrogen, potassium, and calcium. *Am J Physiol* 1980;239:E524–E530.
9. Frankenfield D, Cooney RN, Smith JS, et al. Age-related differences in the metabolic response to injury. *J Trauma* 2000;48:49–56; discussion 56–57.
10. Lamb MJ, Byrne CD, Wilson JF, et al. Evaluation of bioelectrical impedance analysis for identifying overweight individuals at increased cardiometabolic risk: a cross-sectional study. *PloS One* 2014;9:e106134.
11. Mathew S, Abraham G, Viayan M, et al. Body composition monitoring and nutrition in maintenance hemodialysis and CAPD patients–a multicenter longitudinal study. *Ren Fail* 2015;37(1):66–72.
12. Reid CL, Campbell IT, Little RA. Muscle wasting and energy balance in critical illness. *Clin Nutr* 2004;23:273–280.
13. Kemen M, Senkal M, Homann HH, et al. Early postoperative enteral nutrition with arginine-omega-3 fatty acids and ribonucleic acid-supplemented diet versus placebo in cancer patients: an immunologic evaluation of impact. *Crit Care Med* 1995;23:652–659.
14. Tan CS, Read JA, Phan VH, et al. The relationship between nutritional status, inflammatory markers and survival in patients with advanced cancer: a prospective

cohort study. *Support Care Cancer* 2015;23(2):385–391.
15. de Luis DA, Terroba MC, Cuellar L, et al. Association of anthropometric and biochemical markers with length of stay and mortality in the hospital. *Eur Rev Med Pharmacol Sci* 2013;17:1321–1325.
16. Ignjatovic AM, Cvetkovic TP, Pavlovic RM, et al. Endothelial dysfunction, inflammation and malnutrition markers as predictors of mortality in dialysis patients: multimarker approach. *Int Urol Nephrol* 2013;45:1715–1724.
17. Kattelmann KK, Hise M, Russell M, et al. Preliminary evidence for a medical nutrition therapy protocol: enteral feedings for critically ill patients. *J Am Diet Assoc* 2006;106:1226–1241.
18. Kreymann KG, Berger MM, Deutz NE, et al. ESPEN guidelines on enteral nutrition: intensive care. *Clin Nutr* 2006;25:210–223.
19. Heyland DK, Dhaliwal R, Drover JW, et al.; Canadian Critical Care Clinical Practice Guidelines Committee. Canadian clinical practice guidelines for nutrition support in mechanically ventilated, critically ill adult patients. *JPEN J Parenter Enteral Nutr* 2003;27:355–373.
20. ASPEN Board of Directors and the Clinical Guidelines Task Force. Guidelines for the use of parenteral and enteral nutrition in adult and pediatric patients. *JPEN J Parenter Enteral Nutr* 2002;26:1SA–138SA.
21. Latifi R. Nutritional therapy in critically ill and injured patients. *Surg Clin North Am* 2011;91:579–593.
22. Racca V, Castiglioni P, Ripamonti V, et al. Nutrition markers in patients after heart surgery. *JPEN J Parenter Enteral Nutr* 2010;34:143–150.
23. Goulet O. Assessment of nutritional status in clinical practice. *Baillieres Clin Gastroenterol* 1998;12:647–669.
24. Haluzík M, Kábrt J, Nedvídková J, et al. Relationship of serum leptin levels and selected nutritional parameters in patients with protein-caloric malnutrition. *Nutrition* 1999;15:829–833.
25. Nova E, Lopez-Vidriero I, Varela P, et al. Indicators of nutritional status in restricting-type anorexia nervosa patients: a 1-year follow-up study. *Clin Nutr* 2004;23:1353–1359.
26. Hooker C, Hall RC. Nutritional assessment of patients with anorexia and bulimia; clinical and laboratory findings. *Psychiatr Med* 1989;7:27–36.
27. Friedman AN, Fadem SZ. Reassessment of albumin as a nutritional marker in kidney disease. *J Am Soc Nephrol* 2010;21:223–230.
28. Brose L. Prealbumin as a marker of nutritional status. *J Burn Care Rehabil* 1990;11:372–375.
29. Parrish CR. Serum proteins as markers of nutrition: what are we treating? *Nutr Issues Gastroenterol* 2006;43:48–64.
30. Raguso CA, Dupertuis YM, Pichard C. The role of visceral proteins in the nutritional

assessment of intensive care unit patients. *Curr Opin Clin Nutr Metab Care* 2003;6:211–216.

31. Frankenfield DC, Smith JS, Cooney RN. Accelerated nitrogen loss after traumatic injury is not attenuated by achievement of energy balance. *JPEN J Parenter Enteral Nutr* 1997;21:324–329.
32. Compher C, Frankenfield D, Keim N, et al.; Evidence Analysis Working Group. Best practice methods to apply to measurement of resting metabolic rate in adults: a systematic review. *J Am Diet Assoc* 2006;106:881–903.
33. Roza AM, Shizgal HM. The Harris Benedict equation reevaluated: resting energy requirements and the body cell mass. *Am J Clin Nutr* 1984;40:168–182.
34. Mifflin MD, St Jeor ST, Hill LA, et al. A new predictive equation for resting energy expenditure in healthy individuals. *Am J Clin Nutr* 1990;51:241–247.
35. Frankenfield DC, Smith JS Jr, Cooney RN, et al. Relative association of fever and injury with hypermetabolism in critically ill patients. *Injury* 1997;28:617–621.
36. Bessey PQ, Watters JM, Aoki TT, et al. Combined hormonal infusion simulates the metabolic response to injury. *Ann Surg* 1984;200:264–281.
37. Anker SD, Coats AJ. Cardiac cachexia: a syndrome with impaired survival and immune and neuroendocrine activation. *Chest* 1999;115:836–847.
38. Gentile LF, Cuenca AG, Efron PA, et al. Persistent inflammation and immunosuppression: a common syndrome and new horizon for surgical intensive care. *J Trauma Acute Care Surg* 2012;72:1491–1501.
39. Vanzant EL, Lopez CM, Ozrazgat-Baslanti T, et al. Persistent inflammation, immunosuppression, and catabolism syndrome after severe blunt trauma. *J Trauma Acute Care Surg* 2014;76:21–29; discussion 9–30.
40. Ruiz Garcia V, López-Briz E, Carbonell Sanchis R, et al. Megestrol acetate for treatment of anorexia-cachexia syndrome. *Cochrane Database Syst Rev* 2013;3:CD004310.
41. Barber MD, Ross JA, Voss AC, et al. The effect of an oral nutritional supplement enriched with fish oil on weight-loss in patients with pancreatic cancer. *Br J Cancer* 1999;81:80–86.
42. Gogos CA, Ginopoulos P, Salsa B, et al. Dietary omega-3 polyunsaturated fatty acids plus vitamin E restore immunodeficiency and prolong survival for severely ill patients with generalized malignancy: a randomized control trial. *Cancer* 1998;82:395–402.
43. Neville AL, Brown CV, Weng J, et al. Obesity is an independent risk factor of mortality in severely injured blunt trauma patients. *Arch Surg* 2004;139:983–987.
44. Enomoto TM, Larson D, Martindale RG. Patients requiring perioperative nutritional support. *Med Clin North Am* 2013;97:1181–1200.
45. Smedley F, Bowling T, James M, et al. Randomized clinical trial of the effects of preoperative and postoperative oral nutritional supplements on clinical course and

cost of care. *Br J Surg* 2004;91:983–990.
46. Wolfe RR. Perspective: optimal protein intake in the elderly. *J Am Med Dir Assoc* 2013;14:65–66.
47. Alberda C, Gramlich L, Jones N, et al. The relationship between nutritional intake and clinical outcomes in critically ill patients: results of an international multicenter observational study. *Intensive Care Med* 2009;35:1728–1737.
48. Martindale RG, McClave SA, Vanek VW, et al. Guidelines for the provision and assessment of nutrition support therapy in the adult critically ill patient: Society of Critical Care Medicine and American Society for Parenteral and Enteral Nutrition: Executive Summary. *Crit Care Med* 2009;37:1757–1761.
49. Singer P, Berger MM, Van den Berghe G, et al. ESPEN guidelines on parenteral nutrition: intensive care. *Clin Nutr* 2009;28:387–400.
50. Casaer MP, Van den Berghe G. Nutrition in the acute phase of critical illness. *N Eng J Med* 2014;370:1227–1236.
51. Artinian V, Krayem H, DiGiovine B. Effects of early enteral feeding on the outcome of critically ill mechanically ventilated medical patients. *Chest* 2006;129:960–967.
52. Meyfroidt G, Ingels C, Van den Berghe G. Glycemic control in the ICU. *N Eng J Med* 2011;364:1280; author reply 1281.
53. Singer P, Anbar R, Cohen J, et al. The tight calorie control study (TICACOS): a prospective, randomized, controlled pilot study of nutritional support in critically ill patients. *Intensive Care Med* 2011;37:601–609.
54. Frankenfield DC, Ashcraft CM. Estimating energy needs in nutrition support patients. *JPEN J Parenter Enteral Nutr* 2011;35:563–570.
55. Martin CM, Doig GS, Heyland DK, et al.; Southwestern Ontario Critical Care Research Network. Multicentre, cluster-randomized clinical trial of algorithms for critical-care enteral and parenteral therapy (ACCEPT). *CMAJ* 2004;170:197–204.
56. Doig GS, Simpson F, Finfer S, et al. Effect of evidence-based feeding guidelines on mortality of critically ill adults: a cluster randomized controlled trial. *JAMA* 2008;300:2731–2741.
57. Rice TW, Wheeler AP, Thompson BT, et al.; National Heart Lung and Blood Institute Acute Respiratory Distress Syndrome Clinical Trials Network. Initial trophic vs full enteral feeding in patients with acute lung injury: the EDEN randomized trial. *JAMA* 2012;307:795–803.
58. Montejo JC, Minambres E, Bordeje L, et al. Gastric residual volume during enteral nutrition in ICU patients: the REGANE study. *Int Care Med* 2010;36:1386–1393.
59. Davies AR, Morrison SS, Bailey MJ, et al. A multicenter, randomized controlled trial comparing early nasojejunal with nasogastric nutrition in critical illness. *Crit Care Med* 2012;40:2342–2348.
60. Acosta-Escribano J, Fernandez-Vivas M, Grau Carmona T, et al. Gastric versus transpyloric feeding in severe traumatic brain injury: a prospective, randomized trial.

Intensive Care Med 2010;36:1532–1539.

61. Nguyen NQ, Chapman MJ, Fraser RJ, et al. Erythromycin is more effective than metoclopramide in the treatment of feed intolerance in critical illness. *Crit Care Med* 2007;35:483–489.
62. MacLaren R, Kiser TH, Fish DN, et al. Erythromycin vs metoclopramide for facilitating gastric emptying and tolerance to intragastric nutrition in critically ill patients. *JPEN J Parenter Enteral Nutr* 2008;32:412–419.
63. Pontes-Arruda A, Aragao AM, Albuquerque JD. Effects of enteral feeding with eicosapentaenoic acid, gamma-linolenic acid, and antioxidants in mechanically ventilated patients with severe sepsis and septic shock. *Crit Care Med* 2006;34:2325–2333.
64. Peter JV, Moran JL, Phillips-Hughes J. A metaanalysis of treatment outcomes of early enteral versus early parenteral nutrition in hospitalized patients. *Crit Care Med* 2005;33:213–220; discussion 60–61.
65. van den Berghe G, Wouters P, Weekers F, et al. Intensive insulin therapy in critically ill patients. *N Eng J Med* 2001;345:1359–1367.
66. Dissanaike S, Shelton M, Warner K, et al. The risk for bloodstream infections is associated with increased parenteral caloric intake in patients receiving parenteral nutrition. *Crit Care* 2007;11:R114.
67. Grau T, Bonet A, Rubio M, et al. Liver dysfunction associated with artificial nutrition in critically ill patients. *Crit Care* 2007;11:R10.
68. Casaer MP, Mesotten D, Hermans G, et al. Early versus late parenteral nutrition in critically ill adults. *N Eng J Med* 2011;365:506–517.
69. Hermans G, Casaer MP, Clerckx B, et al. Effect of tolerating macronutrient deficit on the development of intensive-care unit acquired weakness: a subanalysis of the EPaNIC trial. *Lancet Respir Med* 2013;1:621–629.
70. Vanderheyden S, Casaer MP, Kesteloot K, et al. Early versus late parenteral nutrition in ICU patients: cost analysis of the EPaNIC trial. *Crit Care* 2012;16:R96.
71. Casaer MP, Wilmer A, Hermans G, et al. Role of disease and macronutrient dose in the randomized controlled EPaNIC trial: a post hoc analysis. *Am J Respir Crit Care Med* 2013;187:247–255.
72. Heidegger CP, Berger MM, Graf S, et al. Optimisation of energy provision with supplemental parenteral nutrition in critically ill patients: a randomised controlled clinical trial. *Lancet* 2013;381:385–393.
73. Doig GS, Simpson F, Sweetman EA, et al. Early parenteral nutrition in critically ill patients with short-term relative contraindications to early enteral nutrition: a randomized controlled trial. *JAMA* 2013;309:2130–2138.
74. Braunschweig CL, Levy P, Sheean PM, et al. Enteral compared with parenteral nutrition: a meta-analysis. *Am J Clin Nutr* 2001;74:534–542.
75. Battistella FD, Widergren JT, Anderson JT, et al. A prospective, randomized trial of

intravenous fat emulsion administration in trauma victims requiring total parenteral nutrition. *J Trauma* 1997;43:52–58; discussion 58–60.

76. Stapleton RD, Martin JM, Mayer K. Fish oil in critical illness: mechanisms and clinical applications. *Crit Care Clin* 2010;26:501–514, ix.
77. Mehanna HM, Moledina J, Travis J. Refeeding syndrome: what it is, and how to prevent and treat it. *BMJ* 2008;336:1495–1498.
78. Bagga D, Wang L, Farias-Eisner R, et al. Differential effects of prostaglandin derived from omega-6 and omega-3 polyunsaturated fatty acids on COX-2 expression and IL-6 secretion. *Proc Natl Acad Sci U S A* 2003;100:1751–1756.
79. Fong YM, Marano MA, Barber A, et al. Total parenteral nutrition and bowel rest modify the metabolic response to endotoxin in humans. *Ann Surg* 1989;210:449–456; discussion 56–57.
80. Harvey SE, Parrott F, Harrison DA, et al. Trial of the route of early nutritional support in critically ill adults. *N Eng J Med* 2014;371(18):1673–1684.
81. Kiyama T, Onda M, Tokunaga A, et al. Effect of early postoperative feeding on the healing of colonic anastomoses in the presence of intra-abdominal sepsis in rats. *Dis Colon Rectum* 2000;43:S54–S58.
82. Chin KF, Townsend S, Wong W, et al. A prospective cohort study of feeding needle catheter jejunostomy in an upper gastrointestinal surgical unit. *Clin Nutr* 2004;23:691–696.
83. Taylor SJ, Fettes SB, Jewkes C, et al. Prospective, randomized, controlled trial to determine the effect of early enhanced enteral nutrition on clinical outcome in mechanically ventilated patients suffering head injury. *Crit Care Med* 1999;27:2525–2531.
84. Cook D, Arabi Y. The route of early nutrition in critical illness. *N Eng J Med* 2014;371(18):1748–1749.
85. McClave SA, Heyland DK. The physiologic response and associated clinical benefits from provision of early enteral nutrition. *Nutr Clin Pract* 2009;24:305–315.
86. Flordelis Lasierra JL, Perez-Vela JL, Montejo Gonzalez JC. Enteral nutrition in the hemodynamically unstable critically ill patient. *Med Intensiva* 2014;39(1):40–48.
87. Guillaume A, Seres DS. Safety of enteral feeding in patients with open abdomen, upper gastrointestinal bleed, and perforation peritonitis. *Nutr Clin Pract* 2012;27:513–520.
88. Patel JJ, Kozeniecki M, Biesboer A, et al. Early trophic enteral nutrition is associated with improved outcomes in mechanically ventilated patients with septic shock: a retrospective review. *J Intensive Care Med* 2014. (PMID 25315218).
89. Seder CW, Janczyk R. The routine bridling of nasojejunal tubes is a safe and effective method of reducing dislodgement in the intensive care unit. *Nutr Clin Pract* 2008;23:651–654.
90. Scheinkestel CD, Kar L, Marshall K, et al. Prospective randomized trial to assess

caloric and protein needs of critically ill, anuric, ventilated patients requiring continuous renal replacement therapy. *Nutrition* 2003;19:909–916.

91. Novak F, Heyland DK, Avenell A, et al. Glutamine supplementation in serious illness: a systematic review of the evidence. *Crit Care Med* 2002;30:2022–2029.
92. Andrews PJ, Avenell A, Noble DW, et al. Randomised trial of glutamine, selenium, or both, to supplement parenteral nutrition for critically ill patients. *BMJ* 2011;342:d1542.
93. Heyland D, Muscedere J, Wischmeyer PE, et al. A randomized trial of glutamine and antioxidants in critically ill patients. *N Eng J Med* 2013;368:1489–1497.
94. Wernerman J, Kirketeig T, Andersson B, et al. Scandinavian glutamine trial: a pragmatic multi-centre randomised clinical trial of intensive care unit patients. *Acta Anaesthesiol Scand* 2011;55:812–818.
95. Bollhalder L, Pfeil AM, Tomonaga Y, et al. A systematic literature review and meta-analysis of randomized clinical trials of parenteral glutamine supplementation. *Clin Nutr* 2013;32:213–223.
96. Marik PE, Zaloga GP. Immunonutrition in critically ill patients: a systematic review and analysis of the literature. *Intensive Care Med* 2008;34:1980–1990.
97. Wanten GJ, Calder PC. Immune modulation by parenteral lipid emulsions. *Am J Clin Nutr* 2007;85:1171–1184.
98. Ferrie S. Re: The use of an inflammation-modulating diet in patients with acute lung injury or acute respiratory distress syndrome: a meta-analysis of outcome data. *JPEN J Parenter Enteral Nutr* 2010;34:452; author reply 453–454.
99. Pontes-Arruda A, Martins LF, de Lima SM, et al. Enteral nutrition with eicosapentaenoic acid, gamma-linolenic acid and antioxidants in the early treatment of sepsis: results from a multicenter, prospective, randomized, double-blinded, controlled study: the INTERSEPT study. *Crit Care* 2011;15:R144.
100. Umpierrez GE, Spiegelman R, Zhao V, et al. A double-blind, randomized clinical trial comparing soybean oil-based versus olive oil-based lipid emulsions in adult medical-surgical intensive care unit patients requiring parenteral nutrition. *Crit Care Med* 2012;40:1792–1798.
101. Manzanares W, Dhaliwal R, Jurewitsch B, et al. Parenteral fish oil lipid emulsions in the critically ill: a systematic review and meta-analysis. *JPEN J Parenter Enteral Nutr* 2014;38:20–28.
102. Manzanares W, Dhaliwal R, Jiang X, et al. Antioxidant micronutrients in the critically ill: a systematic review and meta-analysis. *Crit Care* 2012;16:R66.
103. Alhazzani W, Jacobi J, Sindi A, et al. The effect of selenium therapy on mortality in patients with sepsis syndrome: a systematic review and meta-analysis of randomized controlled trials. *Crit Care Med* 2013;41:1555–1564.
104. Abel RM, Beck CH Jr, Abbott WM, et al. Improved survival from acute renal failure after treatment with intravenous essential L-amino acids and glucose. Results of a

prospective, double-blind study. *N Eng J Med* 1973;288:695–699.

105. Bal BS, Finelli FC, Shope TR, et al. Nutritional deficiencies after bariatric surgery. *Nat Rev Endocrinol* 2012;8:544–556.
106. Gletsu-Miller N, Wright BN. Mineral malnutrition following bariatric surgery. *Adv Nutr* 2013;4:506–517.
107. Isom KA, Andromalos L, Ariagno M, et al. Nutrition and metabolic support recommendations for the bariatric patient. *Nutr Clin Pract* 2014;29(6):718–739.
108. Kaafarani HM, Shikora SA. Nutritional support of the obese and critically ill obese patient. *Surg Clin North Am* 2011;91:837–855, viii–ix.
109. Morley JE. Anorexia of aging: a true geriatric syndrome. *J Nutr Health Aging* 2012;16:422–425.
110. Morley JE. Pathophysiology of the anorexia of aging. *Curr Opin Clin Nutr Metab Care* 2013;16:27–32.
111. Wilmore DW. The effect of glutamine supplementation in patients following elective surgery and accidental injury. *J Nutr* 2001;131:2543S–2549S; discussion 2550S–2551S.
112. Alexander JW, MacMillan BG, Stinnett JD, et al. Beneficial effects of aggressive protein feeding in severely burned children. *Ann Surg* 1980;192:505–517.

Chapter 4

Obesity and Metabolic Disease

Robert W. O'Rourke and Michael W. Mulholland

Key Points

1 Obesity is a polygenic phenomenon, and up to 70% of the propensity to a specific body habitus is due to genetic influences.

2 Epigenetics and environment interact with genetics to produce the obesity phenotype.

3 The hypothalamic feeding center is a dominant central site of control of energy homeostasis and receives multiple afferent inputs and delivers diverse efferent outputs to all organ systems.

4 Control of food intake via satiety and hunger is a dominant mechanism of regulation of body weight, but other processes contribute, including but not limited to metabolic rate, adipocyte physiology, and the microbiome; alterations in the set-points and regulation of these processes have been linked to the development of obesity.

5 Nutrient excess is a key early trigger in the development of cell stress that underlies the pathogenesis of metabolic disease.

6 Adipose tissue acts as a critical nutrient "buffer" to protect other tissues from nutrient excess; as adipose buffering capacity is overwhelmed, nutrient excess overflows to all tissues, inducing metabolic disease.

7 Hepatic steatosis and peripheral and central insulin resistance are dominant features of metabolic disease, but metabolic disease encompasses all organ systems with pleiotropic pathology.

GENETICS OF OBESITY

Metabolic thrift: Obesity is encoded within the human genome. The *thrifty gene hypothesis,* proposed by geneticist James Neel, posits that humans are predisposed to a *thrifty metabolism* by genes selected over eons of evolution in environments characterized by food scarcity.[1] These genes were adaptive in our ancient past but in our modern environment lead to a blossoming of obesity. In the past 50 years, the very genes which drive us to seek out calorie-dense food have led us to create, for the first time in human history, an *obesogenic environment* in which food is plentiful. While competing theories exist, such as predation release and genetic drift, Neel's thrifty gene hypothesis remains the basis of a modern understanding of obesity as a genetic phenomenon.

Metabolic thrift is a feature of all life, which exists in a perpetual struggle for energy resources. Strategies of metabolic thrift include high caloric intake, body temperature regulation, torpor, and hibernation. Humans practice thrift by storing energy in the form of adipose tissue. Lipid is not only energy dense, but also water insoluble, and thus can be stored in large quantities in cells without disrupting osmotic gradients. Because of these unique characteristics, virtually all life-forms use lipid as an energy storage molecule. Lipid droplets are found in yeast, Drosophila stores lipid in a specialized "fat body," and migratory geese store lipid in hepatocytes. Humans, along with many other vertebrates, store large amounts of lipid in adipose tissue, which can provide energy for months; monitored fasts of over a year have been documented in obese humans.[2] Adipose tissue accumulation is not the only mechanism of human metabolic thrift. Insulin resistance is thought to have evolved in humans to protect against hypoglycemia during periods of fasting and famine. The *carnivore hypothesis* posits that insulin resistance appeared in primates with the onset of the ice age when food became scarce and primates shifted away from a carbohydrate-rich diet toward a protein-rich diet, an evolutionary heritage that explains the link between obesity and diabetes.

1 *Modern genetics and human obesity:* Compelling data support the contention that obesity is rooted in genetics. *Quantitative analysis of twin studies,* in which phenotypic traits of thousands of twin pairs are analyzed using statistical methods based on Mendelian principles, is a well-accepted method for quantifying the contribution of genetics to a given phenotype or disease. Multiple twin studies have consistently demonstrated that approximately 70% of the tendency toward obesity is due to genetics, with the remainder presumably due to environmental influences.[3] *Genome-wide association studies* extend these data and permit study of human genetics at the nucleotide level. These studies involve sequencing the genomes of thousands of patients and correlating single-nucleotide polymorphisms (SNPs) with phenotypic traits and disease states. Association studies have begun to identify the thrifty genes that Neel postulated decades earlier. Many SNPs that correlate with obesity lie within genes that are directly associated with body weight regulation. Others lie in genes that are not as clearly related to energy balance, including genes that regulate neural and limb development, DNA repair, and many other cellular functions, testament to the fact that the processes that regulate energy homeostasis overlap with all aspects of physiology. As SNP data emerge,

it has become clear that the effect size of each individual SNP's contribution to the obesity phenotype is small, on the order of $<1\%$ to 3%, and that potentially hundreds of SNPs contribute to obesity. Obesity, like many chronic diseases, is a complex polygenic phenomenon. Genetic studies have so far identified over 50 SNPs that correlate with human obesity, and the list continues to grow.[4]

2 Epigenetic mechanisms contribute to obesity. The *thrifty phenotype hypothesis* was proposed by Hales and Barker in 1992 to explain the observation that infants born to malnourished mothers are at increased risk of adult obesity and metabolic disease compared to offspring born of the same mothers during well-nourished pregnancies.[5] The fetus was presumed to be responding to instability in environmental food resources by adjusting its phenotype toward a thrifty metabolism, a phenomenon termed *fetal programming*. A similar response was subsequently observed in fetuses born of obese and diabetic mothers.[6] Excess or scarcity of nutrients may be interpreted similarly by the fetus as signs of unstable food resources, which may explain the similar effect of maternal under- and overnutrition on offspring metabolic phenotype. Subsequent research has demonstrated that these effects are mediated by epigenetic mechanisms which involve covalent modification of DNA independent of changes in Watson–Crick base-pair sequence, including DNA methylation and glycosylation and histone modification. These changes may persist for one or more generations. Research over the past two decades has revealed that epigenetic modification of the genome is widespread, occurs primarily during fetal development but may extend into adulthood, and regulates normal developmental and homeostatic processes as well as pathologic responses. Epigenetics allows the fetus to respond in utero to environmental cues delivered by changes in maternal homeostasis, the so-called "weather forecast" model.[7] Epigenetic modifications in response to fetal under- and overnutrition have been demonstrated in animals and humans, play an important role in disease pathogenesis, and speak to the fact that intervention must occur early, prior to birth, to prevent adult obesity and metabolic disease. The metabolic dice are cast *in utero*.

Human metabolic diversity and the role of environment: The multiple thrifty SNPs in the human genome impart marked genetic heterogeneity that underlies the intrinsic variability of the human body habitus, with a wide range of body types from lean to obese. This heterogeneity extends to all aspect of metabolism, with individual differences in satiety and hunger thresholds, metabolic rates, metabolic handling of lipid and glucose, variability in adipocyte proliferation and hypertrophy capacities, and differing propensities to insulin resistance and hyperlipidemia. This heterogeneity explains the diversity of the obesity phenotype with its different sites of accumulation, including visceral and subcutaneous, and its variable ages of onset, triggers, severity, and responses to diet- and surgery-induced weight loss. The human species is highly metabolically diverse, a trait that had been critical to our success, allowing us to adapt to a wide range of habitats as we colonized the globe. Multiple examples exist of human subpopulations whose genetic heritages are adaptive in their native environments, but maladaptive in a modern obesogenic environment. Polynesians provide an example of a human subpopulation with a marked genetic propensity to obesity and insulin resistance, traits

that provided a selective advantage in the ancient South Pacific environment, which was characterized by labile food supplies and transoceanic voyages that entailed a high risk of starvation. This genetic heritage, in our modern environment, places Polynesians at exceptionally high risk for obesity and metabolic disease. Similar human subpopulations metabolically adapted to specific niche environments but at high risk for metabolic disease in industrialized society include Inuit Eskimos, Aboriginal Australians, and Pima Indians (Fig. 4-1).

Environment plays a critical role in the pathogenesis of obesity. Dominant modern environmental contributors are an excess of processed food and a structured *built environment* that discourages physical activity. Modern processed food is not only calorie dense but also highly palatable, and stimulates central nervous system (CNS) reward centers and hunger/satiety circuits not designed for chronic stimulation, thus reinforcing overeating. Physical activity is markedly decreased in our modern environment relative to our distant past. Paleolithic humans were estimated to have consumed 30% more calories than modern humans but engaged in significantly higher levels of physical activity.[8] Other factors also contribute to a lesser extent, including disruption in Circadian rhythms, stability in home temperatures, and assortative mating patterns. An evolving field of environmental engineering has arisen to address these issues.

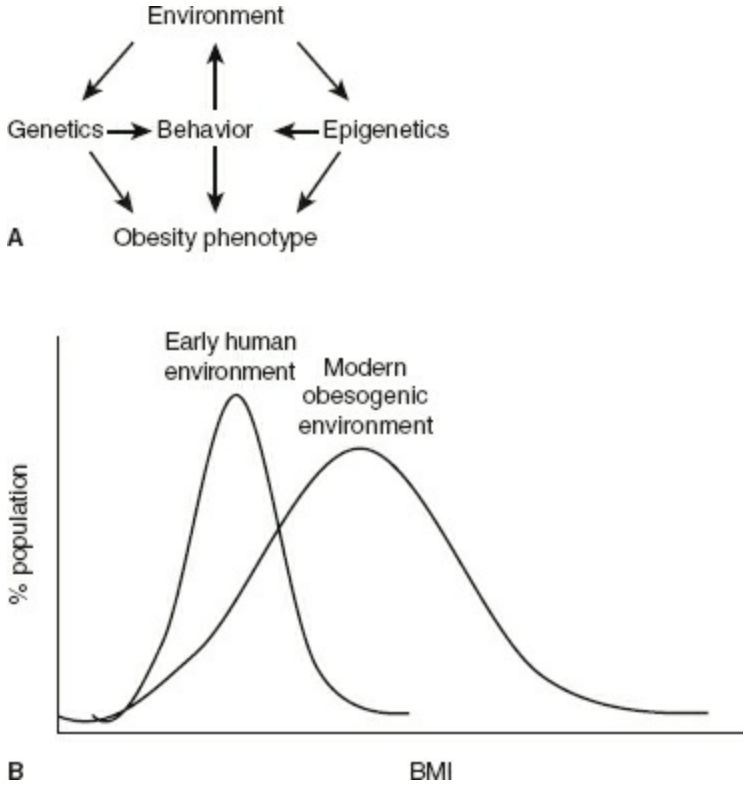

Figure 4-1. Interactions between environment and genetics dictate phenotype. **A:** Environment alters genetics over millennia, while the effects of environment on epigenetics take place over generations. In the case of humans, genetics dictates our behavior which in turn has led us to create an obesogenic environment, creating a vicious cycle that exacerbates the obesity epidemic. **B:** The obesity phenotype blossoms in a modern obesogenic environment, with the population body mass index (BMI) curve broadening and shifting rightward, with an increase in median BMI. The increase in median BMI is relatively modest, but a substantially larger percentage of people populate overweight and obese BMI ranges. Of note, the schematic graphs shown are similar to those that describe the shift in US population BMI National Health and Nutrition Examination Survey data from the late 1970s to the early 2000s.

3 *The adipostat:* A dominant determinant of systemic metabolic homeostasis is the quantity of existent adipose tissue stores, the adequacy of which is determined by the hypothalamic feeding center (HFC). The HFC receives multiple afferent neural and hormonal inputs from all organ systems, including adipose tissue, and orchestrates a range of responses via efferent outputs that regulate all aspects of metabolism. These multiple HFC-regulated systems monitor and maintain adipose tissue stores, and together comprise the *adipostat,* the sum total of all processes that defend body weight. The amount of adipose tissue deemed adequate by the HFC varies among individuals and is dictated by multiple poorly understood thrifty genes. Collectively, these genes and the proteins they regulate define the *adipostat set-point,* which determines the degree of metabolic thrift of an individual. The hypothalamus of a lean person "considers" a lower amount of adipose tissue to be adequate, while the hypothalamus of an obese person requires higher levels of baseline adipose tissue stores. Weight loss alerts the HFC to deviation from the adipostat set-point and triggers robust compensatory metabolic responses that act to restore adipose tissue mass to baseline levels, including but not limited to increased hunger, decreased satiety, and decreased metabolic rate. The HFC resides deep in the midbrain, far removed from the frontal cortex, the seat of conscious thought and what we refer to as "willpower." HFC-mediated metabolic responses are characterized by tight regulation; deviation outside the range of these responses for more than limited periods of time is not possible based on conscious choice, explaining the near-universal failure of conscious dietary efforts to lose weight. Obese patients are able to control their weight only to a point, and only for brief periods, after which compensatory responses are activated. These mechanisms also explain the lack of efficacy of liposuction as a tool for weight loss. Regardless of the method, whether diet-induced or liposuction, reduction in adipose tissue mass activates compensatory mechanisms that act to restore adipose tissue mass to set-point levels. Bariatric surgery-induced weight loss is the only exception to this rule, inducing poorly understood paradoxical responses that bypass the adipostat, including decreased satiety and increased metabolic rate.

Multiple physiologic mechanisms comprise the adipostat and regulate body weight. Most important in humans are the collective satiety and hunger systems that regulate food intake. Less powerful but nonetheless important are mechanisms that control metabolic rate, adipocyte physiology, and the microbiome.

4 *Satiety and hunger:* Regulation of food intake is the dominant mechanism by which humans control body weight. This is not true for all species. While food intake is an important mechanism of energy homeostasis in mice, regulation of metabolic rate plays a greater role in mice than in humans. Food intake in humans is controlled by a family of proteins that regulate satiety and hunger primarily by acting on receptors within the hypothalamus. These diverse proteins are secreted by multiple organ systems, including but not limited to adipose tissue, the gut, the liver, and the skeletal muscle.

The Ob mouse, a genetic mutant strain described in 1950, manifests an obese phenotype, along with a range of other abnormalities related to immune, endocrine, and

reproductive functions. The Ob mouse harbors an inactivating point mutation in the *leptin* gene (Gr. *leptos,* thin). Leptin is a 16-kD satiety hormone secreted by adipose tissue in response to a meal that in turn acts on receptors within the HFC to induce satiety. Leptin establishes communication between adipose tissue, the gut, and the brain that signals the status of adipose tissue stores to the brain, which in turn dictates food intake. As such, leptin represents a paradigmatic mediator of the adipostat, and an example of the complex interorgan communication that underlies its function (Fig. 4-2). Soon after the cloning of the leptin gene in 1994,[9] rare humans with leptin mutations were identified with an Ob phenotype that was reversed with administration of exogenous recombinant leptin. Unfortunately, similar therapy was ineffective in common human obesity, which is not due to a single-leptin mutation, but rather is polygenic and characterized by hypothalamic resistance to leptin satiety effects. Nonetheless, the discovery of leptin led to an explosion of satiety and hunger research, and over the ensuing decade multiple satiety and hunger proteins were described.

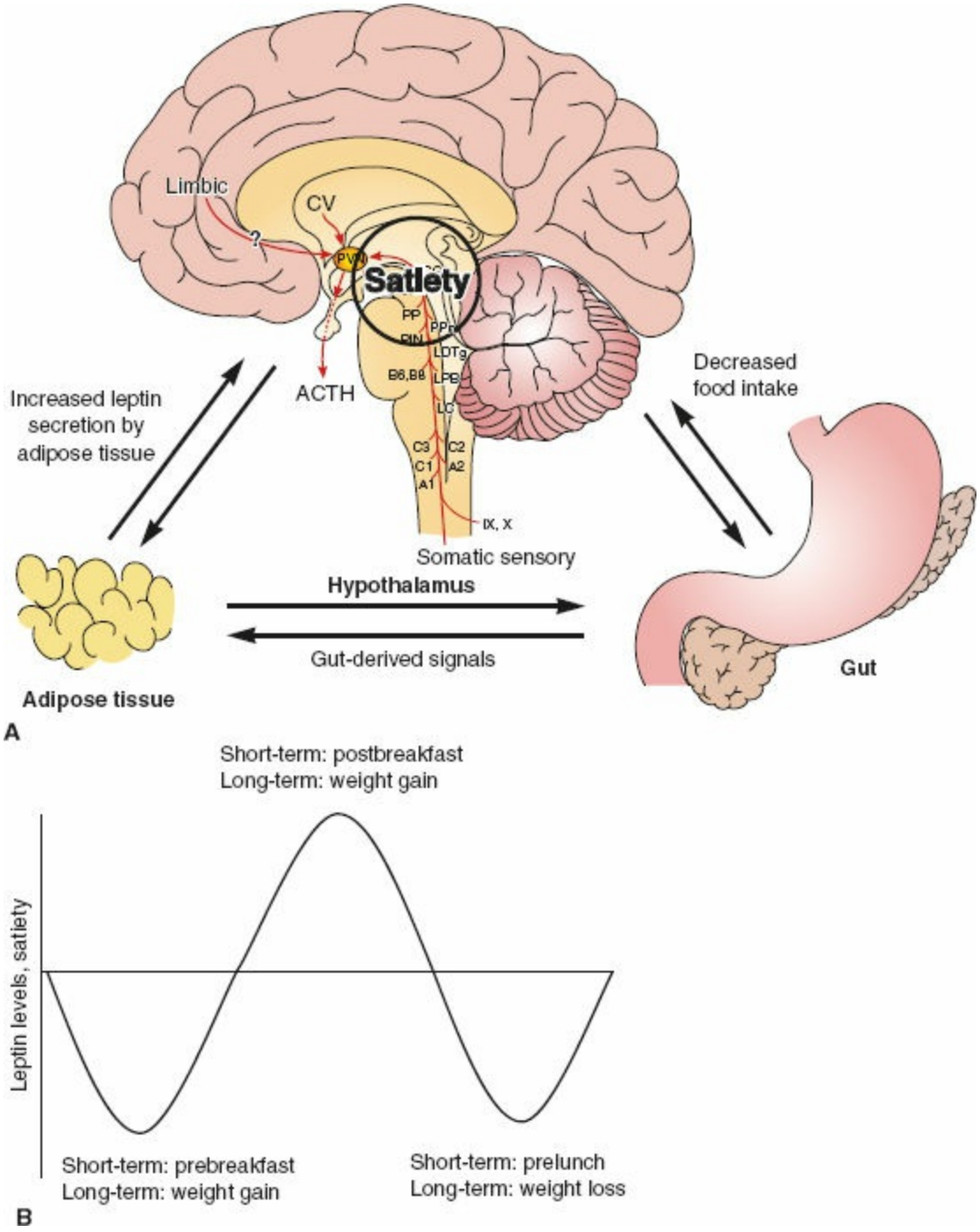

Figure 4-2. Leptin mediates communication between adipose tissue, gut, and brain. **A:** Signals from the gastrointestinal tract triggered by a meal circulate to adipose tissue and induce adipocyte leptin secretion. Leptin circulates to the hypothalamus, where it binds receptors in the arcuate nucleus to induce satiety, leading to decreased food intake. Leptin is one of many signals that mediates bidirectional communication between gut, adipose tissue, and brain. Other organ systems are also involved, including immune and reproductive systems and the liver. **B:** Leptin regulates allostatic control of short-term and long-term food intake. Postprandial leptin secretion induces satiety for a period of hours, after which leptin levels and satiety wane, prompting food intake. Similarly, leptin, along with other mediators of food intake, controls long-term weight regulation: diet-induced weight loss leads to decreased adipose tissue mass, reducing peak postprandial leptin levels, leading to decreased postprandial satiety and increased food intake at each subsequent meal until adipose tissue mass is restored to set-point levels. In this manner, leptin functions as a component of the adipostat. This allostatic control provides an explanation for rebound weight gain after diet-induced weight loss.

The control of feeding behavior and nutrient intake is a highly regulated process

centered in the hypothalamus, which integrates information regarding nutritional status, environment, and energy expenditure via central and peripheral orexigenic and anorexigenic signals. Peripheral messengers include signals from adipose tissue (*adipokines*), including leptin and adiponectin, *cytokines,* such as TNF-α and interleukin (IL-6), and *gut peptides.* Among this diverse latter class of mediators, ghrelin is a dominant stimulant of feeding. Ghrelin is expressed primarily by oxyntic glands in the fundus of the stomach. Gastric ghrelin–producing cells represent about one-fourth of endocrine cells within the gastric mucosa. Ghrelin is also produced in the hypothalamus.

Encoded by five exons, preproghrelin undergoes endoproteolytic processing and posttranslational modification to yield des-acyl ghrelin and acyl ghrelin. Both hormones share the same amino acid sequence, and both are detectable in blood, but acyl ghrelin, which undergoes acylation of the Ser3 residue, is the active form. Acyl ghrelin regulates feeding, metabolic activity, and insulin secretion. The enzyme-mediating acylation is the membrane-bound ghrelin O-acyltransferase (GOAT). Genetic disruption of the GOAT gene in mice leads to complete absence of acyl ghrelin. GOAT inhibition improves glucose tolerance and reduces weight gain in mice. Plasma acyl-ghrelin levels increase with fasting and decrease after feeding, a pattern indicating that ghrelin is involved in meal initiation. The ghrelin receptor is a member of the family of G protein–coupled receptors and contains seven transmembrane domains. Ghrelin receptors are widely distributed among both central and peripheral tissues, including the pituitary gland, hypothalamus, pancreas, stomach, and intestine. Ghrelin causes growth hormone secretion following peripheral or central administration, and release of growth hormone from cultured pituitary cells.

Ghrelin is the only orexigenic hormone identified to date. The relative scarcity of orexigenic proteins relative to anorexigenic proteins underscores an important fundamental characteristic of the global regulation of food intake, which is biased toward chronic basal hunger regulated by multiple satiety factors (rather than chronic basal satiety regulated by multiple hunger factors). This central feature of food intake control systems predisposes to excess food intake and thus provides a selective advantage in environments of food scarcity during our evolution, but leads to obesity in our modern environment. In humans, the intravenous administration of ghrelin at physiologic concentrations induces the sensation of hunger and stimulates oral intake. Circulating ghrelin levels peak just prior to meal initiation and decline rapidly postprandially. Ghrelin secretion is increased by weight loss and by restriction of caloric intake. Serum ghrelin levels are increased in anorexic individuals and depressed in obese subjects. In animals, ghrelin administration has been found to stimulate food intake, to induce growth of adipose tissues, and to increase body weight. The administration of ghrelin antibody or ghrelin receptor antagonists blunts ghrelin-induced weight gain and positive energy balance. Similar molecules are under active study as potential therapeutic agents.

Ghrelin is a circulating hormone with CNS effects. The arcuate nucleus of the hypothalamus is a crucial site for the integration of fasting and feeding signals. Two types of neurons, with opposing actions on feeding behavior, have been identified in the arcuate nucleus. Neurons that express proopiomelanocortin and cocaine- and

amphetamine-regulated transcript (CART) suppress food intake, reduce body weight, and increase energy expenditure. In contrast, neurons producing neuropeptide Y and agouti gene–related transcript (AgRP) are orexigenic. These cells act to stimulate food intake and reduce energy expenditure. Ghrelin, as well as leptin and multiple other gut peptides, adipokines, and cytokines, directly mediate the activities of these two types of neurons (Fig. 4-3). Direct peripheral effects of ghrelin on peripheral tissues also contribute to the regulation of body weight and energy homeostasis.

Leptin and ghrelin are paradigmatic adipokine and gut peptide mediators of food intake respectively, but multiple other proteins contribute. Adipokines that regulate satiety include adiponectin, visfatin, apelin, and lipocalin; gut peptides include glucose-dependent insulinotropic peptide (GIP), glucagon-like peptide-1 (GLP-1), nesfatin-1, oxyntomodulin, pancreatic polypeptide, cholecystokinin, amylin, glucagon, somatostatin, cholecystokinin, and insulin. Finally, cytokines, including TNF-α and IL-6, in addition to immunoregulatory functions, also play important roles in the control of food intake. TNF-α, for example, mediates anorexigenic responses in the context of cachexia and inflammatory states. Virtually all adipokines, gut hormones, and cytokines have multiple overlapping functions that include regulation of satiety and hunger, immune function, glucose homeostasis, lipid metabolism, and endocrine and reproductive function (Fig. 4-4). This functional diversity speaks to the intimate association of energy homeostasis with all aspects of physiology.

Genetic polymorphisms in the melanocortin 4 receptor gene, which regulates satiety and hunger responses and the HFC set-point, are implicated in 5% of cases of human obesity. Similar polymorphisms associated with obesity exist with the genes encoding leptin and its receptor, ghrelin, neuropeptide Y, adiponectin, GLP-1, and other genes associated with the control of satiety and hunger. These observations demonstrate that variability in the genes that regulate food intake, with corresponding variability in the functional control of satiety and hunger, contribute to the development of human obesity.

Metabolic rate: While less important than control of food intake, variability in metabolic rate contributes to the pathogenesis of obesity. In obese subjects who lose weight with diet, total energy expenditure is decreased up to 20% beyond that expected by loss of fat and fat-free mass alone, and is accompanied by a corresponding decrease in voluntary physical activity.[10] In contrast to diet-induced weight loss, bariatric surgery-induced weight loss paradoxically induces increased energy expenditure, which may explain the efficacy of surgery. In the absence of surgery however, compensatory decreases in energy expenditure counteract caloric restriction and contribute to adipostat responses that resist declines in adipose tissue mass. Studies of overfeeding and weight gain in obese subjects demonstrate converse changes with a compensatory increase in total energy expenditure. Importantly, overfeeding studies in twin cohorts demonstrate a significant genetic component to variability in energy expenditure responses to overfeeding, suggesting that variability in metabolic rate responses to weight loss contributes to the development of obesity in those at risk.[3]

Differences in sympathetic nervous system activity are observed in humans and represent a potential mechanism underlying variability in metabolic rate. Obese humans

demonstrate decreased sympathetic nervous system activity compared to lean humans, and higher levels of sympathetic nervous system activity predict successful diet-induced weight loss. Differences in endocrine responses also contribute, with obese humans manifesting differences in thyroid hormone and catecholamine balance associated with decreased metabolic rates. At the cellular level, differences in energy utilization and thermogenesis play an important role. Skeletal muscle energy utilization efficiency is increased in humans who achieve successful weight loss and decreased in those who gain weight. Furthermore, decreased levels of skeletal muscle nonexercise-induced thermogenesis and diet-induced thermogenesis have been demonstrated in obese humans.[11] These observations suggest that fundamental differences in cellular energy homeostasis contribute to obesity. The mechanisms underlying these variable cellular responses are not fully defined, but differences in uncoupling protein (UCP) function are implicated. UCPs uncouple oxidative phosphorylation from electron transport in mitochondria, creating a proton leak that generates heat rather than ATP. The role of UCPs in the pathogenesis of obesity is an important area of active research. UCP function is highly variable and genetically determined in mice, and polymorphisms in UCP genes correlate with obesity and metabolic disease in humans, supporting a role for genetic variability in UCP function in obesity pathogenesis. Transgenic mice overexpressing UCP-1 under control of the adipose tissue-specific AP2 promoter are resistant to obesity, suggesting the potential therapy for obesity based on manipulation of cellular thermogenesis and metabolic rate.

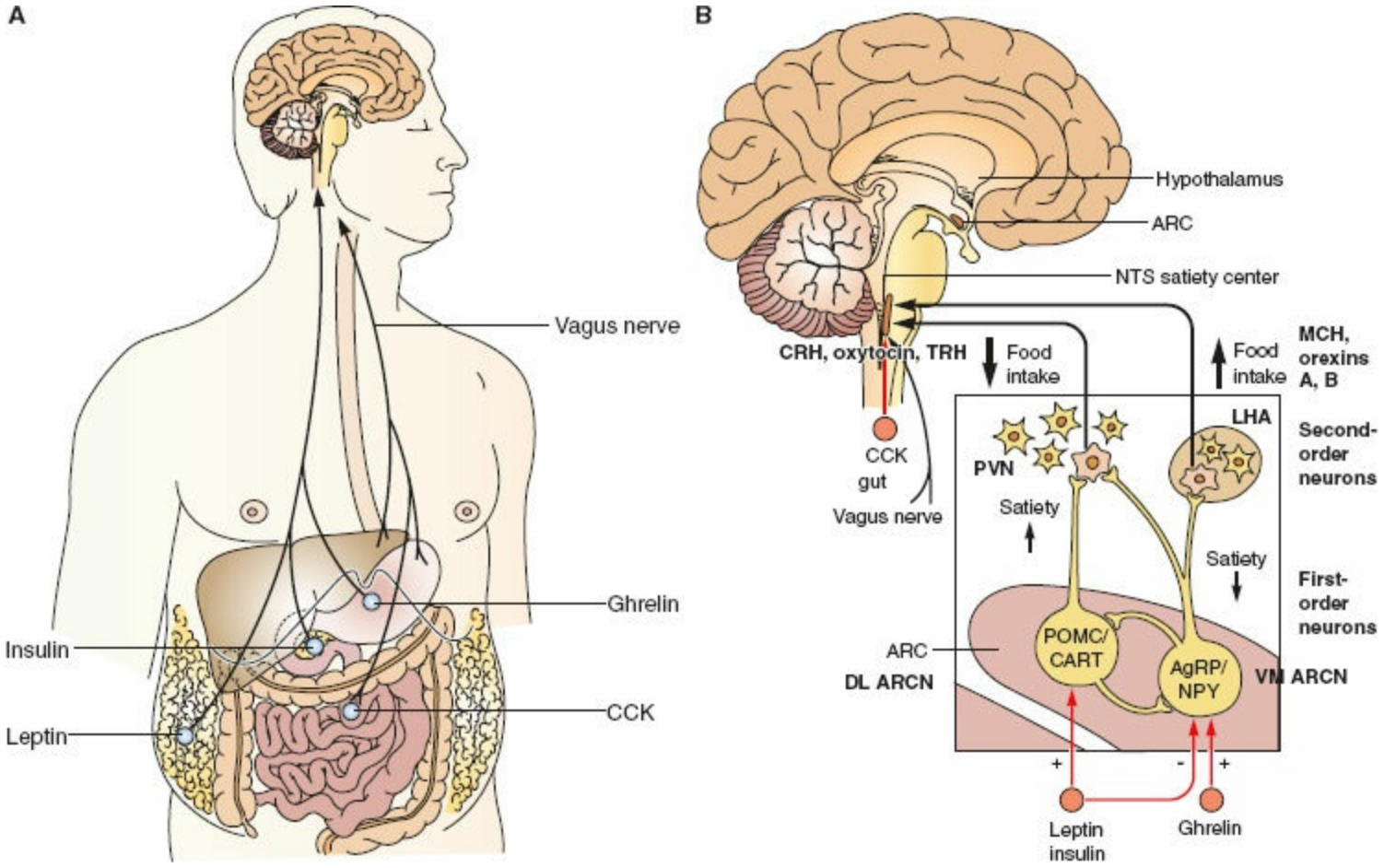

Figure 4-3. A simplified schematic of the hypothalamic feeding center and its primary afferent signals. **A.** Multiple hormones secreted by the gastrointestinal tract and adipose tissue act as afferent signals that impact on the arcuate nucleus (ArcN) within the hypothalamic feeding center to regulate feeding behavior. **B.** Peripheral afferent signals impact on first-order ArcN neurons, which in turn communicate with second-order paraventricular nucleus (PVN) and lateral hypothalamic area (LHA) neurons to coordinate behavioral and metabolic output. PVN signaling is primarily anorexigenic and catabolic, and is enhanced by leptin and insulin, while LHA signaling is primarily orexigenic and anabolic and inhibited by leptin and insulin. Higher-order anorexigenic PVN outputs include corticotropin-releasing hormone (CRH), oxytocin, and thyrotropin-releasing hormone (TRH); higher-order orexigenic LHA outputs include melanin-concentrating hormone (MCH) and orexins A and B. Both pathways negatively regulate the other. Other peripheral and central mediators stimulate first- and second-order neurons as well, including ghrelin, CCK, GLP-1, serotonin, endogenous cannabinoids, and norepinephrine.

Adipocyte physiology: Adipocytes arise from mesenchyme-derived adipocyte stem cells within adipose tissue. Nomenclature is evolving and includes the terms *preadipocyte* or *adipocyte/adipose tissue stem cell.* Adipocyte stem cells are pluripotent, and depending on the stage of differentiation, may give rise to adipocytes, fibroblast, myocytes, and other cell types. Multiple adipocyte stem cell subpopulations give rise to adipocytes of variable phenotypes, including white, brown, and beige. Evidence suggests that hematopoietic precursor cells may also give rise to adipocytes.

Until recently it was thought that adipocyte stem cell proliferation, that is, hyperplasia, did not occur in postnatal humans, and that adipocyte hypertrophy was the primary mechanism of increased adipose tissue mass in obesity. Recent data suggest that both hyperplasia and hypertrophy contribute to evolving obesity, with hyperplasia

predominating during childhood and hypertrophy predominating during adulthood. These data derive in part from ingenious methods studying incorporation of C14 into adipocyte DNA in individuals born before and after mid-20th century nuclear bomb testing, which raised environmental C14 levels.[12] Data over the last decade have demonstrated that adipocyte hyperplasia and proliferation are highly regulated and that aberrations in these processes contribute to obesity. Adipocyte necrosis and apoptosis as a result of hypoxia and nutrient excess (described below) are matched by increased adipocyte stem cell proliferation and differentiation. Furthermore, adipocytes from obese humans demonstrate increased hyperplastic and hypertrophic capacities, contributing to increased adipose tissue mass with progressive obesity.[13] The epigenetic programming of adipocyte stem cells during fetal development may underlie some of these differences in adipocyte behavior observed between obese and lean subjects. Defining regulatory mechanisms of adipocyte growth is an active area of research and will lead to methods to manipulate adipocyte biology and treat obesity at its source.

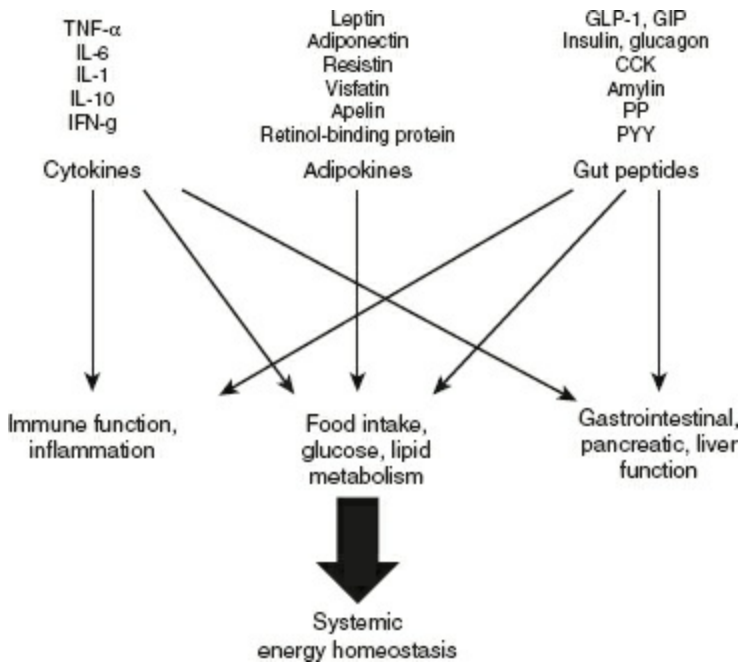

Figure 4-4. Primary peptide mediators of energy homeostasis. Cytokines, adipokines, and gut peptides regulate diverse aspects of metabolism to control global energy homeostasis. Each of these proteins has dominant functions within its primary family, but also demonstrates cross-regulatory functions in other domains. In addition, mediators participate in crosstalk at the level of cellular receptors and downstream intracellular signaling mediators. Shown are only partial lists of peptides and the physiologic functions they control.

The microbiome: In a very real sense, the microbiome may be considered a distinct organ system much like cardiopulmonary, gastrointestinal, or renal systems, and like any organ system, aberrations in the microbiome contribute to the pathophysiology of disease. The microbiome plays an important role in energy homeostasis. Animals raised in germ-free environments manifest increased food intake but decreased body weight and do not develop obesity and insulin resistance when fed a high-fat diet, demonstrating that gut microbiota contribute to nutrient digestion. Gut microbiota ferment nonhost-digestible polysaccharides into absorbable monosaccharides and short-chain fatty acids

that are absorbed by host enterocytes and colonocytes. Products of microbiota fermentation act not only as nutrients, but also regulate host metabolism: short-chain fatty acids induce host satiety, mediated in part by increased secretion of GLP-1 and peptide YY and decreased secretion of ghrelin. Separate data demonstrate interactions between microbiota and adipose tissue, liver, skeletal muscle, and CNS. These effects are mediated by short-chain fatty acids, activation of Toll-like receptors on host cells via lipopolysaccharide and other bacterial products, regulation of host systemic and cellular metabolism, and other diverse mechanisms, all of which affect diverse aspects of host energy homeostasis.

Alterations in microbiome–host interactions contribute to the pathogenesis of obesity and metabolic disease. Germ-free mice, when colonized with stool from obese mice, gain more weight than mice colonized with stool from lean mice, demonstrating an obesity-specific microbiome. The ratio of gut Firmicutes/Bacteroidetes species is increased in obese mice and humans. Ongoing research has begun to identify specific subspecies within these broad categories of bacteria that are altered in obesity and metabolic disease to provide a higher-resolution picture of the microbiome in obesity. For example, obesity in mice and humans is associated with an increase in gram-negative gut bacteria, with a concomitant increase in lipopolysaccharide absorption from the gut, which has been postulated to contribute to obesity-associated inflammation and insulin resistance. The tools used to evaluate the microbiome are rapidly evolving. Sequencing of the microbial genome using ribosomal 16S is well established, while evolving technologies include shotgun sequencing of the entire metagenome and functional assays involving transfer of human microbiota in the form of stool into germ-free animals to study in vivo effects. Manipulation of the microbiome holds significant promise. Prebiotic (nondigestible bacterial nutrients) and probiotic (specific bacterial subspecies thought to confer systemic benefits) therapies are areas of active research, while antibiotic therapy directed against gram-negative bacteria reduces steatosis and systemic inflammation in obese rodents.

Summary: Satiety and hunger, metabolic rate, adipocyte physiology, and the microbiome are but a few of the many processes that regulate metabolism and are dysregulated in obesity. Differences in lipid and glucose metabolism, immune function, central and peripheral nervous system function, and multiple other processes that impact upon energy metabolism contribute to the wide variability of the obesity phenotype in humans. This variability is the result of genetic polymorphisms that contribute to metabolic diversity among humans and the wide range in human body habitus. The question is often posed as to whether obesity should be considered a disease. Rather, obesity is better thought of as a maladaptive compensatory response to an environment that is radically different than that in which our species evolved. The obesity phenotype remained relatively underexpressed in environments of food scarcity in which we evolved, in which obesogenic genes acted to defend adipose tissue stores and enhance survival, but blossoms in our modern environment. An understanding of this intimate interplay between phenotype and environment will lead to novel therapy for obesity based on manipulation of environment and genetics.

PATHOPHYSIOLOGY OF METABOLIC DISEASE

Obesity and metabolic disease: Obesity is associated with a range of pathology involving every organ system collectively referred to as metabolic disease. While underlying mechanisms are multiple, the root cause of all metabolic disease is a failure of adipose tissue nutrient buffering capacity, leading to overflow of nutrients, metabolites, cytokines, and adipokines from adipose tissue to other tissues. The clinical effects of overflow differ depending on the target tissue, but the fundamental cellular responses to nutrient excess common to all tissues, adipose included, involve mechanisms by which cells control nutrient flux and respond to nutrient excess. These cellular responses underlie the pathophysiology of metabolic disease.

5 *Metabolism, nutrient excess, and the root cause of metabolic disease:* Energy homeostasis is the dominant and overriding goal of all biologic systems. Metabolism (Gr. *metabole,* change) may be defined as the sum total of all chemical reactions and physiologic processes that regulate cellular and systemic energy homeostasis. At the cellular level, metabolic processes are fundamental to all metazoan life and are highly conserved across phyla; examples include the citric acid cycle and mitochondrial respiration, which utilize multiple enzymes, the structure and function of which are conserved from yeast to humans. At the systemic level, metabolic processes are central to maintaining homeostasis and interface with virtually with every organ system and every physiologic process. The basic substrates of metabolism are the macro- and micronutrients that comprise the stuff of cells and tissues, the fatty acids, amino acids, and carbohydrates and their derivatives that are the constituents of complex macromolecules, and the micronutrients that contribute to the catalysis of reactions that synthesize and degrade macronutrients and higher-order macromolecules. In one sense, all cells are simply clearinghouses for nutrients. Cellular nutrient flux provides substrate for synthesis of macromolecules via anabolic metabolic processes, which are in turn degraded via catabolic metabolic processes. Maintaining the balance between anabolism and catabolism at cellular and systemic levels is of critical importance. Cancer, for example, may be viewed as a metabolic imbalance that favors cellular anabolism over catabolism. Cachexia, in contrast, may be considered as a metabolic disorder that favors systemic catabolism over anabolism.

The nutrient flux with which cells are constantly faced determines the balance between anabolism and catabolism and dictates organism-wide energy homeostasis. Nutrients are, by their very nature, high-energy capacity molecules, much like oxygen, and like oxygen, are capable of participating in energy-intensive and potentially damaging reactions. Fatty acid metabolites such as ceramides and diacylglycerols, and glucose metabolites including advanced glycation end products and glucosamines, trigger inflammation, oxidative stress, and insulin resistance at the cellular level.

Excess nutrients are therefore potentially damaging to cells, and cellular physiology has evolved processes designed to control exposure, flux, and sequestering of these high-energy molecules. These cellular processes were selected by evolution to manage *transient* nutrient excess, but are not well adapted to manage *chronic* nutrient excess, a situation

that cells only rarely encountered during evolution. Maladaptive cellular responses to chronic nutrient excess underlie the pathogenesis of all obesity-related disease and occur in all cells, explaining the involvement of virtually every organ system in metabolic disease. These processes consist of a triumvirate of fundamental cellular stress responses: *endoplasmic reticulum (ER) stress, oxidative stress,* and *inflammation.*

Cellular responses to excess nutrient flux: The ER is a complex organelle present in virtually all eukaryotic cells that orchestrates synthesis, folding, and intracellular transport of macromolecules. The rough ER, studded with ribosomes, is predominantly responsible for protein synthesis, while the smooth ER is predominantly responsible for lipid and carbohydrate synthesis. The ER receives a constant influx of nutrient substrates, which it sequesters and directs toward macromolecule synthesis or degradation, thus carefully metering cellular nutrient exposure. In this capacity, the ER acts as a nutrient sensor, responding to changes in cellular nutrient flux by directing cellular anabolism and catabolism accordingly. The ER also responds to other cell stressors, including hypoxia, toxins, disturbances in electrolyte or micronutrient balance, and a host of other stimuli that alter cell homeostasis. Excess cellular nutrient flux, like other forms of stress, leads to a series of stepwise ER responses that are collectively referred to as the ER stress response.

The initial ER stress response to modest increases in nutrient flux involves increased expression of *chaperone proteins* involved in macromolecule synthesis to accommodate increased anabolism of excess nutrients. If nutrient excess persists to exceed the capacity of cellular macromolecule synthesis and nutrient sequestration, the ER stress response progresses to activate the *unfolded protein response.* The unfolded protein response downregulates global protein expression while upregulating expression of chaperone proteins in an adaptive response designed to maintain synthesis of essential cellular proteins. If nutrient excess persists beyond the capacity of the ER to maintain proper protein synthesis, then the unfolded protein response progresses to induce cell apoptosis. The unfolded protein response thus protects cells from modest increases in nutrient flux and induces cell death in the face of extreme nutrient excess.

The ER stress response is not the only cellular response to nutrient excess. Macromolecule synthesis generates reactive oxygen species (e.g., superoxides, oxygen/hydroxyl-free radicals, hydrogen peroxide) which, like nutrients, are highly energetic molecules capable of damaging cells. Cells have evolved multiple mechanisms to sequester reactive oxygen species and manage oxidative stress, including antioxidant enzymes such as superoxide dismutase, glutathione peroxidase, and catalase, scavenging molecules such as ascorbic acid, urate, and divalent ions, and the thioredoxin and glutaredoxin systems. The ER and mitochondria are primary cellular sites of control of oxidative stress. When nutrient flux, macromolecule synthesis, and reactive oxygen species production exceed cellular antioxidant capacity, cells activate diverse oxidative stress responses, which increase expression of antioxidant proteins, sequester reactive oxygen species, and increase mitochondrial uncoupling, which transiently reduces cellular reactive oxygen species production. Oxidative stress responses overlap with ER stress responses, and if oxidative stress persists, the unfolded protein response is activated and

leads to apoptosis.

The third arm of the cellular stress response is inflammation. Increased nutrient flux generates an inflammatory response designed to scavenge debris and byproducts from increased cell turnover and macromolecule synthesis that result from ER and oxidative stress responses. Testament to the close relationship between metabolism and inflammation, central inflammatory and metabolic mediators demonstrate marked functional overlap. For example, TNF-α and leptin, in addition to their dominant functions in regulating inflammation and satiety respectively, each plays important reciprocal roles in regulating body weight and inflammation.[14,15] TNF-α and leptin are but two examples of many satiety and hunger factors and inflammatory cytokines that manifest dual immunoregulatory and energy homeostasis functions. In addition, molecular byproducts of metabolism trigger inflammation. Free fatty acids are ligands for Toll-like receptors, while advanced glycation end products trigger receptors of advanced glycation end-products pathways which directly activate innate immune effector cells, establishing a direct molecular link between metabolism and inflammation. Obesity is associated with a state of chronic systemic inflammation that plays a central role in the pathogenesis of multiple comorbid diseases. Serum cytokine levels are increased in obese animals and humans, and adipose tissue manifests a pan-leukocyte infiltrate, findings that directly correlate with the magnitude of obesity and severity of metabolic disease.

Increased ER stress, oxidative stress, and inflammation have been demonstrated in obese rodents and humans. An important aspect of cellular stress responses is that each potentiates the others via overlap in fundamental cell signaling pathways including PI3-Akt, MAPK, AMPK, mTOR, JAK-STAT, and NFκB. These signaling pathways are triggered by multiple stimuli that are dysregulated in obesity, including adipokines, cytokines, growth factors, and nutrients and metabolites. Furthermore these signaling pathways participate in robust crosstalk at multiple levels, establishing a vicious cycle that perpetuates cell stress in the face of chronic nutrient excess (Fig. 4-5). These processes are common to all cells and affect all tissues in late-stage obesity, explaining the diverse manifestations of systemic metabolic disease. But where do these processes begin, and what initiates them? To answer this question, we must explore the early events in adipose tissue in evolving overweight and obesity – it is within adipose tissue that metabolic disease originates.

Adipocyte hypertrophy, hypoxia, inflammation, and fibrosis: Adipocytes are exquisitely well designed to manage high levels of nutrients. One of the first responses of adipocytes to chronic elevations in nutrient flux in early overweight and obesity is hypertrophy. Free fatty acids are absorbed by adipocytes through pinocytosis mediated by fatty acid-binding proteins, as well as being synthesized from glucose and glutamine via de novo lipogenesis, and stored in lipid droplets via a highly regulated process mediated by perilipin proteins. Virtually all cells are capable of storing lipid to some degree, but adipocytes have an extremely high capacity for lipid storage and hypertrophy. Adipocytes are one of only a few cell types that can enlarge to diameters greater than 100 microns, the diffusion distance of oxygen. Adipocyte diameter in humans correlates directly with the magnitude of obesity and the severity of metabolic disease; adipocytes in lean

subjects are virtually all less than 100 microns in diameter, while those in obese subjects are greater than 100 microns, in some cases exceeding 200 microns.[16] Progressive adipocyte hypertrophy establishes a state of cellular hypoxia within adipose tissue that has been verified in obese mice and humans. Decreased adipose tissue capillary density and blood flow in obesity exacerbate hypoxia. This hypoxic state has broad effects on adipocyte metabolism, inducing insulin resistance, ER stress, oxidative stress, and inflammation, and inhibiting lipogenesis. Manipulation of hypoxic responses in adipocytes holds therapeutic promise. For example, targeting hypoxia-inducible factor-1α, a dominant cellular hypoxia-response protein, in murine obesity ameliorates metabolic disease.[17]

Hypoxia induces adipocyte apoptosis and necrosis which in turn recruits an inflammatory response designed to scavenge dead and dying adipocytes. This inflammatory state is a dominant aspect of adipose tissue dysfunction in obesity, and is directly linked to insulin resistance and dysregulation of lipid metabolism at local (adipose tissue) and systemic levels. Central to adipose tissue inflammation is a marked accumulation of adipose tissue macrophages (ATMs), the number of which directly correlates with the degree of obesity in mice and humans. ATMs are important mediators of metabolic disease, and are altered in phenotype, shifting from a scavenging M2 phenotype to an inflammatory diabetogenic M1 phenotype.[18] ATMs are a dominant source of inflammatory cytokines, including TNF-α, IL-6, and IL-1, all of which induce insulin resistance and aberrations in glucose and lipid metabolism in adipocytes via multiple mechanisms. In support of a central role for ATMs in the pathogenesis of metabolic disease, mice transgenically engineered to lack macrophage homing molecules in adipose tissue do not develop obesity-related ATM infiltrates and are protected from diabetes. Preliminary trials of pharmacologic agents that interfere with macrophage homing to adipose tissue in humans show promise as treatment for diabetes. Finally, adipose tissue inflammation in obesity involves more than macrophages, and is associated with a pan-leukocyte infiltrate that includes T-cells, B-cells, NK cells, NKT cells, and eosinophils. Therapy for metabolic disease based on nonmacrophage cellular immune mediators is an area of active research.

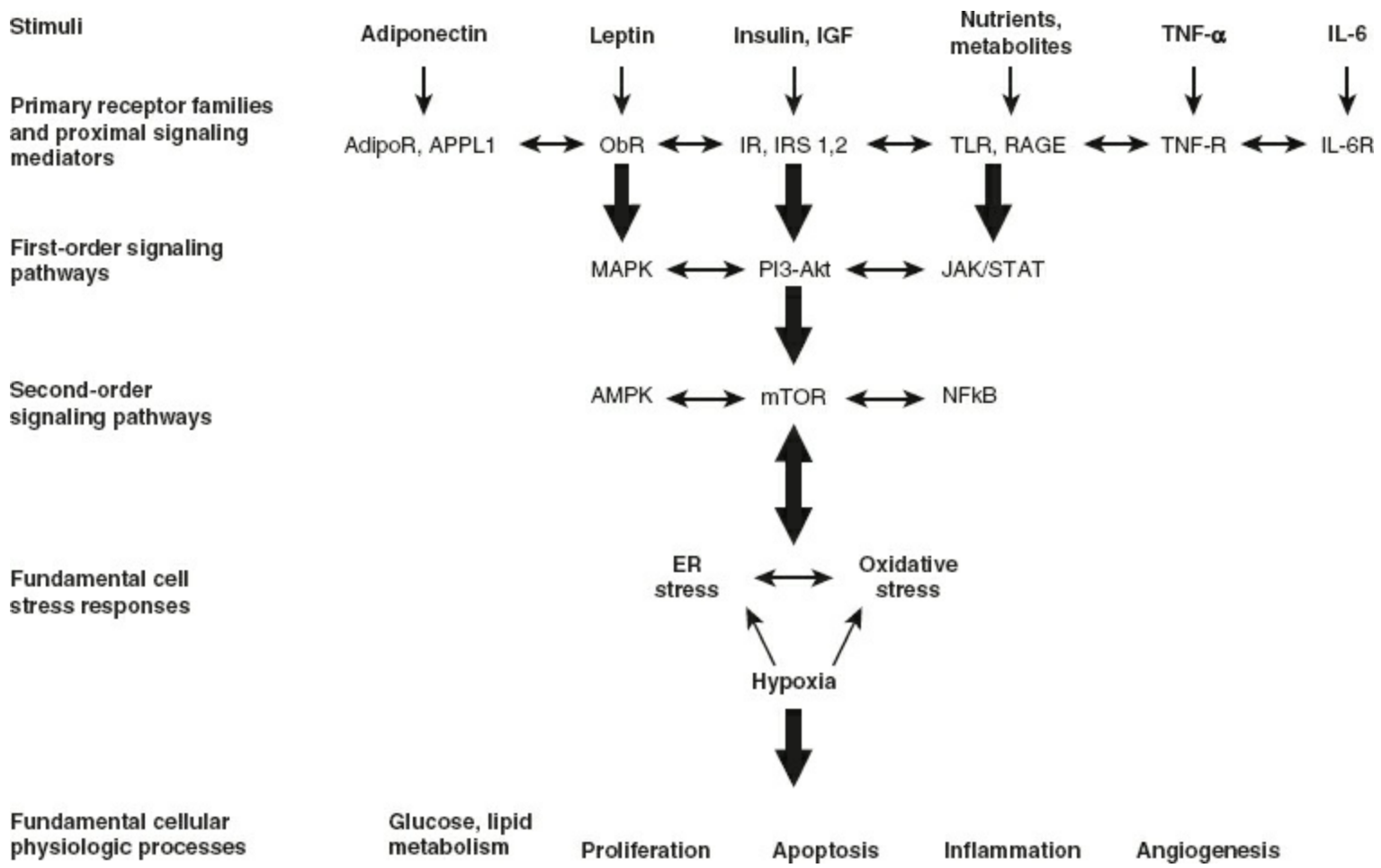

Figure 4-5. Highly simplified schematic of major cell signaling pathways that regulate energy homeostasis and cell stress responses. Primary stimuli for all cells include adipokines, insulin, IGF-1, nutrients and metabolites including free fatty acids, and their derivatives such as ceramide (which activate Toll-like receptors, TLR), glucose, fructose, and advanced glycation end products (which activate receptors for advanced glycation end products, RAGE), and cytokines. Primary intracellular signaling nexi include mitogen-activated protein kinases (MAPK), PI3-Akt, JAK/STAT signaling mediators, AMP-activated protein kinase (AMPK), mammalian target of rapamycin (mTOR), and NFκB, all of which are linked to ER stress and oxidative stress responses. These pathways engage in highly redundant crosstalk via cross-reactivity of intracellular signaling mediators and induction of gene transcription, and conspire to integrate multiple stimuli to regulate fundamental aspects of cell metabolism, survival, and death in response to nutrient availability and cell stressors such as hypoxia.

6 As inflammation persists, adipose tissue undergoes fibrotic remodeling, with increased expression of matrix metalloproteases and collagens and increased extracellular matrix turnover. Adipose tissue fibrosis limits adipocyte hypertrophic and lipid storage capacity, accelerating adipocyte stress. Obese collagen VI knockout mice demonstrate increased adipocyte hypertrophic capacity due to decreased fibrosis and are protected from systemic metabolic disease.[19] These observations speak to a critically important role for adipose tissue as a buffer for excess nutrients, metabolites, and metabolic toxins. As obesity progresses, adipose tissue buffering capacity is overwhelmed and cell stress responses, initially confined to adipose tissue, overflow into circulation and cause systemic metabolic disease (Fig. 4-6).

Adipose tissue anatomy, adipose tissue overflow, and the pathogenesis of systemic metabolic disease: Patients with rare congenital and acquired lipodystrophy syndromes characterized

by a paucity of adipose tissue suffer from metabolic disease just as in obesity, including insulin resistance, hyperlipidemia, and hepatic steatosis, demonstrating that the absence of adipose tissue is as detrimental as its excess. In lipodystrophy and obesity, adipose tissue nutrient buffering capacity is overwhelmed, and nutrients overflow to other tissues not as well adapted as adipose tissue to manage nutrient excess, inducing systemic metabolic disease.

Adipocytes are present throughout the mammalian body in discrete anatomic depots as well as within every organ and every tissue. Adipose tissue is more than simply a storage depot for lipid; only half the cells in adipose tissue are adipocytes, the remainder comprising the so-called stromovascular cell fraction, which consists of immune leukocytes, fibroblasts, endothelial cells, adipocyte stem cells, and other cell types. Adipose tissue is highly innervated with sympathetic and parasympathetic afferent and efferent fibers, and has important immunoregulatory and endocrine functions. Adipose tissue participates in robust communication with the CNS and all peripheral organs, orchestrating responses to alterations in nutrient availability, systemic health and metabolism, ambient temperature, and a host of other stimuli. Adipose tissue is a central regulator of systemic energy homeostasis.

Hibernating bears accumulate large amounts of adipose tissue without developing inflammation or other cellular stress responses, while in some humans, excess subcutaneous adipose tissue appears to protect against metabolic disease. These examples demonstrate that adipose tissue phenotype is as important as quantity with respect to systemic metabolic state. Adipose tissue may be broadly divided into white and brown phenotypes. White adipose tissue comprises the majority of adipose tissue in humans, is strongly associated with metabolic disease, increases with increasing obesity, and is a primary storage site for lipid. Brown adipose tissue, in contrast, comprises a minority of total adipose tissue in humans, has beneficial effects on metabolism, decreases with increasing obesity and with age, and manifests lower lipid storage capacity. Brown adipocytes engage in higher levels of fatty acid oxidation and thermogenesis via expression of mitochondrial UCPs. White adipose tissue derives from mesodermal stem cells that migrate to sites of canonical depots in humans in early embryonic development and proliferate to form defined depots in late fetal and early neonatal periods. White adipose tissue depots include visceral and subcutaneous, which may be further subdivided into omental, retroperitoneal, and mesenteric visceral adipose tissue (VAT) compartments, and deep and superficial subcutaneous adipose tissue compartments, each with distinct functional characteristics. Brown adipose tissue develops in rodents during gestation from precursor cells that also give rise to myocytes and form defined brown adipose tissue depots prior to birth. Brown adipose tissue in humans is less well understood; while most voluminous in the neonatal period, positron emission tomography scanning demonstrates cervical, supraclavicular, mediastinal, paraspinous, and perirenal brown adipose tissue depots in adult humans as well.[20]

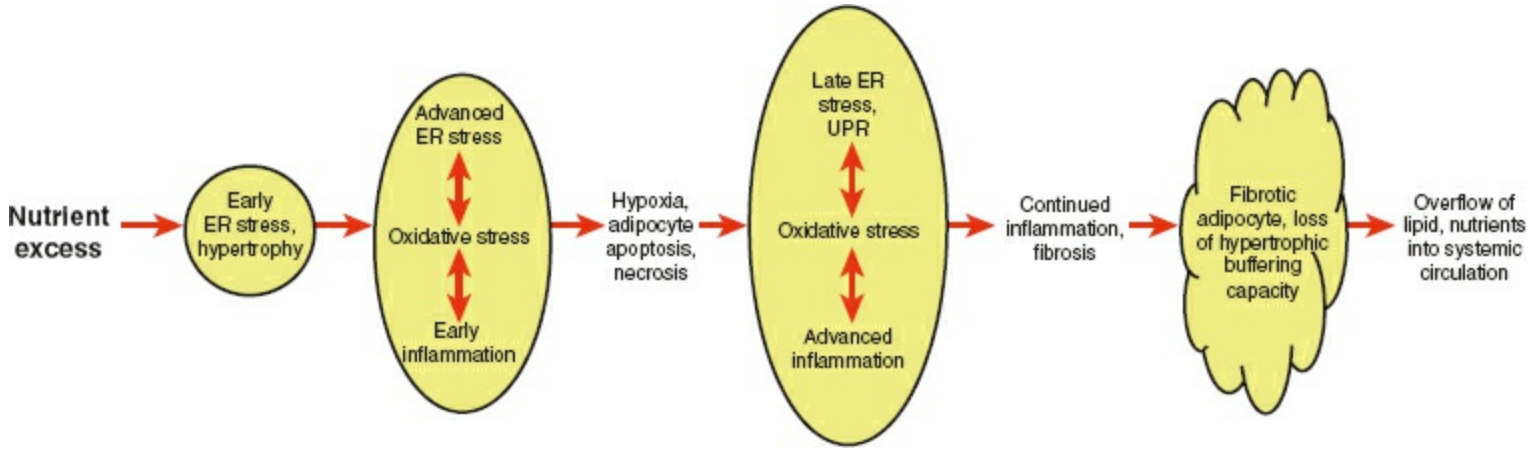

Figure 4-6. Nutrient excess and cell stress in adipocytes. Nutrient excess is an early signal that induces ER stress and hypertrophy in adipocytes. ER stress is tightly linked to oxidative stress and inflammation, and each of these processes induces and potentiates the others. As hypertrophy progresses, adipocyte diameter expands beyond the diffusion distance of oxygen, leading to cellular hypoxia, which exacerbates cell stress responses, leading to adipocyte apoptosis and necrosis via the unfolded protein response and other advanced cell stress responses. Adipocyte apoptosis and necrosis trigger recruitment of an advanced inflammatory response designed to scavenge dead and dying adipocytes. This inflammatory response is associated with fibrotic tissue remodeling which limits adipocyte hypertrophic and lipid buffering capacity of surviving adipocytes, leading to overflow of lipids, nutrients, metabolites, and inflammatory products from adipose tissue into the systemic circulation.

Recent data suggest that the dichotomy between white adipose tissue and brown adipose tissue is overly simplistic, and that adipocyte phenotype spans a spectrum. An intermediate phenotype, termed *"brite"* (brown-in-white) or "*beige adipocytes,*" is found in white adipose tissue depots in rodents and humans. These cells manifest brown adipocyte functions, and are induced to proliferate by cold stress and β-adrenergic stimuli, suggesting phenotypic plasticity. An important area of research is directed toward understanding the mechanisms that regulate adipocyte phenotype. The recently described protein *irisin* is secreted by skeletal muscle in response to exercise, induces a brown phenotype in adipocytes and improves systemic metabolism when overexpressed in mice.[21] This finding underscores the importance of interorgan communication in controlling adipose tissue biology and suggests the potential for pharmacologic mediators to manipulate adipocyte phenotype with beneficial effects on systemic metabolism, the so-called "browning" of adipose tissue.

Human adipose tissue accumulation is anatomically heterogeneous. Human obesity may be broadly classified into android and gynecoid phenotypes, defined by excess VAT and subcutaneous adipose tissue, respectively. Excess VAT is strongly associated with metabolic disease; excess subcutaneous adipose tissue, in contrast, is less strongly associated with metabolic disease, and in some studies has been shown to be protective, suggesting a greater lipid buffering capacity. Surgical lipectomy of VAT but not subcutaneous adipose tissue ameliorates murine diabetes.[22] In contrast to mice, similar studies of visceral omentectomy in humans demonstrate conflicting results, likely due to more complex human adipose tissue depot anatomy, but excess VAT as measured by waist circumference and imaging techniques nonetheless correlates strongly with metabolic

disease. The reasons for the disproportionate effect of VAT on metabolic disease are unclear. While the abdominal location of VAT plays a role, intrinsic differences between visceral and subcutaneous adipose tissues also exist, evidenced by experiments in which transplantation of subcutaneous adipose tissue into a visceral location ameliorates metabolic disease in mice.[23] VAT manifests higher levels of inflammation, lipolysis, β-adrenergic receptor expression, steroid sensitivity, insulin resistance, and adipocyte proliferation and differentiation relative to subcutaneous adipose tissue.

SYSTEMIC METABOLIC DISEASE

Mediators of systemic metabolic disease: In addition to its distinct functional phenotype, VAT also contributes to metabolic disease via its direct anatomic communication with the liver via the portal venous system. *Portal overflow* of free fatty acids, excess nutrients and metabolites, and hormones and cytokines from VAT to the liver is an early step in the progression to systemic metabolic disease. As it progresses, *peripheral overflow* extends beyond the liver to involve all tissues. Adipose tissue overflow affects not only skeletal muscle, vasculature, kidneys, and lungs, but also the CNS; inflammation and ER stress have been documented in the hypothalamus in obesity, and mediate reciprocal effects on adipose tissue and other organ systems via aberrations in CNS efferent outputs that exacerbate obesity and metabolic disease. In essence, adipose tissue dysfunction "metastasizes" as its buffering capacity is overwhelmed, inducing cell stress responses in all tissues that underlie the pathogenesis of metabolic disease (Fig. 4-7).

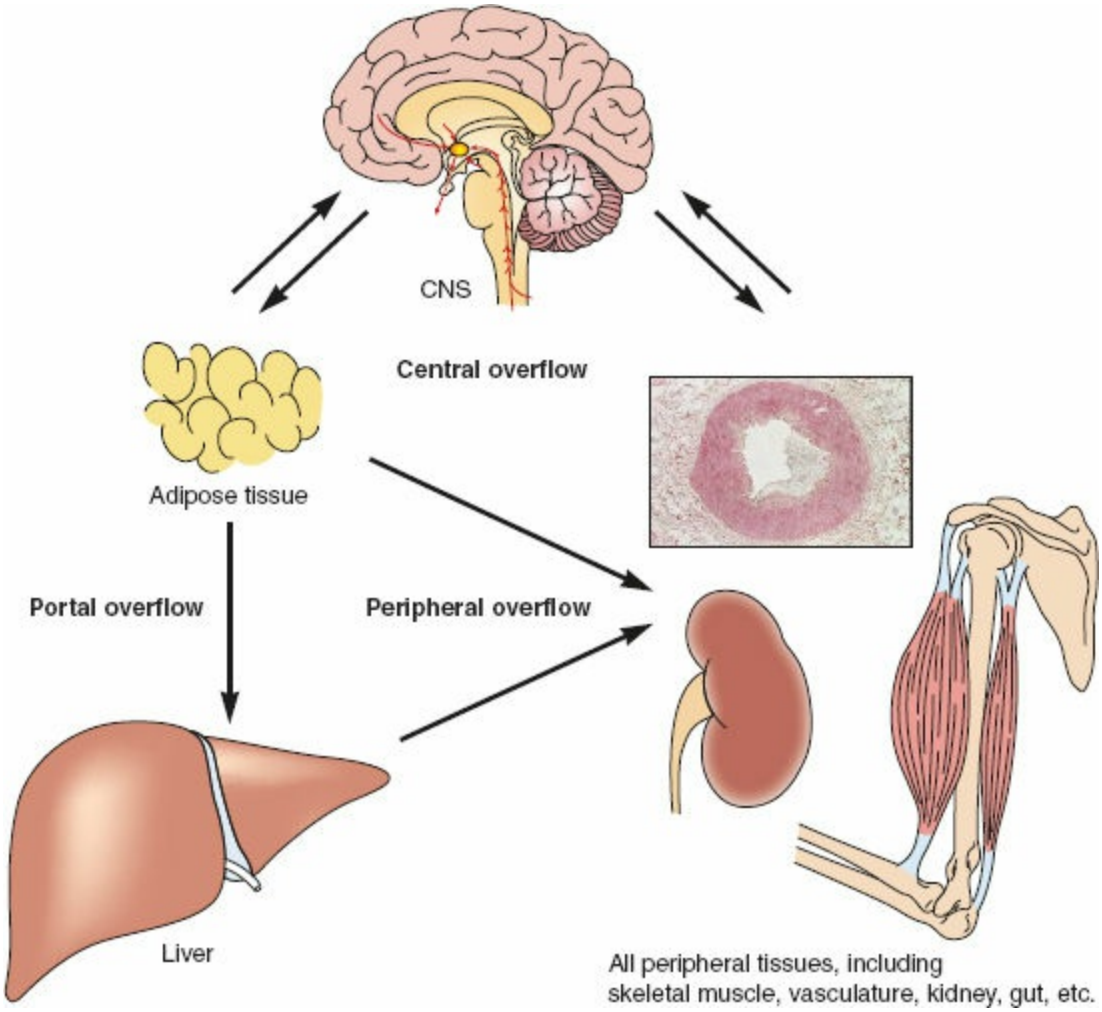

Figure 4-7. Adipose tissue overflow, interorgan communication, and systemic metabolic disease. As adipose tissue buffering capacity is overwhelmed, lipids, nutrients, cytokines, and adipokines overflow into the systemic circulation and cause systemic metabolic disease via the same cellular effects that initially unfold in adipocytes. Early overflow occurs via the portal system, which drains visceral adipose tissue venous effluent into the liver, which becomes the first site of systemic metabolic disease and an important secondary site of nutrient buffering via the development of hepatic steatosis. Overflow progresses to involve all peripheral tissues, inducing cell stress and disease in all organ systems. Overflow involves the central nervous system as well, as inflammation and cell stress have been documented in the hypothalamus in obesity, which in turn is thought to disturb peripheral metabolic function via alterations in CNS efferent signaling.

Nutrients and metabolites are central mediators of the systemic effects of adipose tissue overflow. Free fatty acids mediate systemic *lipotoxicity,* a central mechanism of metabolic disease. Free fatty acids trigger inflammation via binding to Toll-like receptors, and also act as ligands for multiple other immunostimulatory and cell stress-inducing receptor families. Lipid metabolites induce cellular insulin resistance, ER stress, and apoptosis. Metabolic products of glucose and fructose, including advanced glycation end products and glucosamines, mediate similar effects. Cytokines and adipokines overflow from adipose tissue as well. TNF-α, a dominant inflammatory cytokine expressed by ATM in obesity, exerts proinflammatory and diabetogenic effects on tissues via diverse mechanisms. Leptin also promotes inflammation and regulates cellular glucose homeostasis. Expression of adiponectin, which attenuates inflammation and has beneficial

effects of cellular metabolism, is decreased in obesity, as adipose tissue's cytokine and adipokine balance shifts toward a proinflammatory milieu. Metabolites, adipokines, and cytokines establish in multiple tissues the same cellular stress responses that initially unfold in adipose tissue, including ER stress, oxidative stress, and inflammation. Within target tissues, as in adipose tissue, these processes potentiate one another and exacerbate cell stress, forming the basis for systemic metabolic disease.

7 *Portal overflow and liver disease:* The liver is one of the first organs to be affected by failure of adipose tissue buffering, as portal overflow induces hepatic steatosis. Hepatic steatosis is the result of an imbalance in the delivery and export of hepatocyte lipid. Sources of hepatic lipid include fats absorbed from the diet and delivered from the gut as chylomicrons, lipids synthesized by hepatocytes via de novo lipogenesis, and free fatty acids delivered from VAT via the portal venous system and from subcutaneous adipose tissue via the systemic venous system. Free fatty acids from adipose tissue are a dominant source of hepatic lipid in obesity, constituting over 60% of lipid delivery to the liver.[24] Lipids are exported from the liver primarily in the form of very low-density lipoproteins (VLDL). Abnormalities in each of these aspects of hepatic lipid delivery and efflux that contribute to steatosis have been identified in obese animals and humans, including increased free fatty acid delivery to the liver from increased adipose tissue stores, increased hepatocyte de novo lipogenesis, and decreased VLDL secretion.

As lipid storage capacity is reached, hepatocytes experience ER stress, oxidative stress, and inflammatory responses via similar mechanisms as in adipose tissue, causing steatohepatitis, a histologic entity characterized by Mallory bodies, hepatocyte ballooning, and an inflammatory infiltrate consisting of macrophages (Kupffer cells) and other leukocytes. As in adipose tissue, TNF-α plays a central role in the hepatic inflammatory state, and neutralization of TNF-α ameliorates steatohepatitis in mice and is under study as therapy in humans with promising results.[25,26] IL-6 and other inflammatory cytokines have also been implicated as mediators of steatohepatitis.

Steatosis is strongly associated with obesity and is present in over 90% of patients with a BMI >40. Up to 30% of these patients will develop steatohepatitis and 10% to 30% of patients with steatohepatitis will develop cirrhosis. Genetics contributes to these risks: ethnic predispositions to steatosis and steatohepatitis exist, with Asians and Hispanics at higher risk than Caucasians or Blacks. Weight loss secondary to diet or bariatric surgery reverses steatosis and halts progression of steatohepatitis in most patients. Few pharmacologic options exist that specifically treat obesity-associated liver disease.

Diabetes: Insulin resistance is a central metabolic response of all cells to stress. ER stress, oxidative stress, and inflammation each induce insulin resistance. Insulin resistance begins in adipose tissue. Free fatty acids are central mediators of cellular insulin resistance. Insulin regulates not only glucose homeostasis in adipocytes, but also lipid metabolism, inhibiting lipolysis and free fatty acid release. Early nutrient excess, with resultant ER stress and oxidative stress, induces insulin resistance in adipocytes, not only impairing adipocyte glucose uptake, but also attenuating insulin's inhibitory effects on lipolysis and thus increasing free fatty acid release by adipocytes. Free fatty acids in turn trigger inflammation via activation of Toll-like receptors on resident adipose tissue

inflammatory cells, inducing expression of inflammatory cytokines, including TNF-α. TNF-α plays a central role in the evolution of insulin resistance, regulating the expression and phosphorylation of multiple genes involved in glucose homeostasis, including insulin receptor, insulin receptor substrates, the cell signaling nexus protein Akt, and glucose transporter molecules. TNF-α also promotes lipolysis, further exacerbating insulin resistance and free fatty acid release by adipocytes. While multiple other mediators contribute, these interactions between free fatty acids and TNF provide a cogent example of the vicious cycle established in adipose tissue that contributes to worsening insulin resistance.

As adipose tissue lipid buffering capacity is overwhelmed, free fatty acids overflow into the systemic circulation, resulting in lipotoxicity, which underlies the pathogenesis of insulin resistance in all peripheral tissues. Skeletal muscle, responsible for 60% to 80% of systemic glucose disposal, is a dominant site of systemic insulin resistance. Similar to adipocytes and hepatocytes, skeletal muscle myocytes accumulate lipid and exhibit ER stress, oxidative stress, and inflammation which contribute to insulin resistance via mechanisms described above. Skeletal muscle, like adipose tissue, becomes inflamed, with increased levels of macrophages and diabetogenic inflammatory cytokines. Increased circulating free fatty acids also have important metabolic effects on the liver and skeletal muscle. As lipid delivery to skeletal muscle and liver increases, energy production shifts from glucose utilization to fatty acid oxidation. Increased free fatty acid beta-oxidation is associated with increased gluconeogenesis in the liver and a reduction in glucose utilization in skeletal muscle, exacerbating hyperglycemia. The initial response of pancreatic beta cells to the resultant peripheral insulin resistance is a compensatory increase in insulin secretion, leading to hyperinsulinemia. As disease progresses, lipotoxicity and cell stress responses affect pancreatic beta cells. Beta cell exhaustion ensues, insulin secretion decreases, and insulin resistance progresses to frank diabetes.

Type 2 diabetes is strongly associated with obesity, with risk ratios increasing dramatically with increasing BMI. Like obesity itself, genetics plays an important role: Asian, Black, and Hispanic ethnicities are associated with increased risk and multiple SNPs that correlate with diabetes have been identified. The specific mechanisms by which genetics contribute to increased susceptibility to cellular insulin resistance and lipotoxicity are not yet well understood. Worldwide incidence is rapidly increasing and diabetes represents a dominant emerging health crisis.

The obesity–cancer connection: Obesity is a strong risk factor for cancer. The incidences of almost all types of cancer increase in a dose-dependent manner with increasing BMI, and at elevated BMI >40, risk ratios range from 2 to greater than 6 depending on the type of cancer.[27] The mechanisms underlying the association between obesity and cancer are not well defined. At the cellular level, energy homeostasis involves fundamental processes central to carcinogenesis, and signaling pathways activated by chronic overnutrition promote cell proliferation. Suggesting the potential for cancer therapy based on manipulation of metabolism, epidemiologic data suggest that long-term metformin use is associated with decreased cancer incidence. Chronic inflammation, characteristic of obesity and a well-established risk factor for cancer, activates NFκB and

other signaling pathways that potentiate cell proliferation, increase production of reactive oxygen species that may contribute to oncogenic mutation, and induce expression of inflammatory cytokines that act as cell mitogens. Overnutrition in obesity predisposes to a state of chronic anabolism and is associated with increased expression of multiple growth factors that may promote cancer, including insulin, insulin-like growth factor-1, and leptin. Chronic inflammation on a background of chronic anabolism creates an ideal milieu for carcinogenesis. Steroids represent another putative molecular link between obesity and cancer. Steroid metabolism is aberrant in obesity and adipose tissue is a source of estrogen which may promote estrogen-responsive cancers. Finally, adipocytes have been implicated in carcinogenesis, with data demonstrating that peritumor adipose tissue contributes to tumor progression. In addition, adipocyte precursors home from adipose tissue depots to tumors and provide growth factors and metabolic energy substrates that promote tumor growth. The mechanisms by which obesity causes cancer are multiple, and as details are elucidated, metabolism-based therapy for cancer will emerge.

CONCLUSION

Obesity is associated with an increased risk of cardiovascular disease, including hypertension, atherosclerosis, and hyperlipidemia, the result of cell stress responses that afflict vascular tissue. Immune diseases including allergy, atopy, and autoimmune diseases, are increased in the obese, due in part to the above described alterations in immune and inflammatory functions. While mechanical stress due to excess weight is a contributing factor to sleep apnea, osteoarthritis, and gastroesophageal reflux disease, fundamental cell stress mechanisms also contribute, as inflammation has been implicated in these diseases as well. The pan-systemic nature of metabolic disease provides substantial opportunity for developing therapy that will simultaneously treat multiple obesity-related pathologies.

References

1. Neel JV. Diabetes mellitus: a “thrifty” genotype rendered detrimental by “progress”? *Am J Hum Genet* 1962;14(4):353–362.
2. Stewart WK, Fleming LW. Features of a successful therapeutic fast of 382 days’ duration. *Postgrad Med J* 1973;49(569):203–209.
3. Bouchard C, Tremblay A, Despres JP, et al. The response to long-term overfeeding in identical twins. *N Engl J Med* 1990;322:1477–1482.
4. Rosmond R. Association studies of genetic polymorphisms in central obesity: a critical review. *Int J Obes* 2003;27:1141–1151.
5. Hales CN, Barker DJ. Type 2 (non-insulin-dependent) diabetes mellitus: the thrifty phenotype hypothesis. *Diabetologia* 1992;35(7):595–601.
6. Dabelea D, Hanson RL, Lindsay RS, et al. Intrauterine exposure to diabetes conveys risks for type 2 diabetes and obesity: a study of discordant sibships. *Diabetes* 2000;49(12):2208–2211.
7. Bateson P, Barker D, Clutton-Brock T, et al. Developmental plasticity and human health. *Nature* 2004;430:419–421.
8. Hayes M, Chustek M, Heshka S, et al. Low physical activity levels of modern Homo sapiens among free-ranging mammals. *Int J Obes (Lond)* 2005;29(1):151–156.
9. Zhang Y, Proenca R, Maffei M, et al. Positional cloning of the mouse obese gene and its human homologue. *Nature* 1994;372(6505):425–432.
10. Leibel RL, Rosenbaum M, Hirsch J. Changes in energy expenditure resulting from altered body weight. *N Engl J Med* 1995;332:621–628.
11. Levine JA, Eberhardt NL, Jensen MD. Role of nonexercise activity thermogenesis in resistance to fat gain in humans. *Science* 1999;283(5399):212–214.
12. Spalding KL, Arner E, Westermark PO, et al. Dynamics of fat cell turnover in humans. *Nature* 2008;453(7196):783–787.
13. Knittle JL, Timmers K, Ginsberg-Fellner F, et al. The growth of adipose tissue in children and adolescents. Cross-sectional and longitudinal studies of adipose cell number and size. *J Clin Invest* 1979;63:239–246.
14. Hotamisligil GS, Shargill NS, Spiegelman BM. Adipose expression of tumor necrosis factor-alpha: direct role in obesity-linked insulin resistance. *Science* 1993;259(5091):87–91.
15. Lord G, Matarese G, Howard J, et al. Leptin modulates T-cell immune response and reverses starvation-induced immunosuppression. *Nature* 1998;394:897–901.
16. O’Rourke RW, White AE, Metcalf MD, et al. Hypoxia-induced inflammatory cytokine secretion in human adipose tissue stromovascular cells. *Diabetologia* 2011;54(6):1480–1490.
17. Shin MK, Drager LF, Yao Q, et al. Metabolic consequences of high-fat diet are attenuated by suppression of HIF-1α. *PLoS One* 2012;7(10):e46562.

18. Lumeng CN, Bodzin JL, Saltiel AR. Obesity induces a phenotypic switch in adipose tissue macrophage polarization. *J Clin Invest* 2007;117:89–93.
19. Khan T, Muise ES, Iyengar P, et al. Metabolic dysregulation and adipose tissue fibrosis: role of collagen VI. *Mol Cell Biol* 2009;29(6):1575–1591.
20. Virtanen KA, Lidell ME, Orava J, et al. Functional brown adipose tissue in healthy adults. *N Engl J Med* 2009;360:1518–1525.
21. Boström P, Wu J, Jedrychowski MP, et al. A PGC1-α-dependent myokine that drives brown-fat-like development of white fat and thermogenesis. *Nature* 2012;481:463–468.
22. Shi H, Strader AD, Woods SC, et al. The effect of fat removal on glucose tolerance is depot specific in male and female mice. *Am J Physiol Endocrinol Metab* 2007;293(4):E1012–E1020.
23. Tran TT, Kahn CR. Transplantation of adipose tissue and stem cells: role in metabolism and disease. *Nat Rev Endocrinol* 2010;6:195–213.
24. Donnelly KL, Smith CI, Schwarzenberg SJ, et al. Sources of fatty acids stored in liver and secreted via lipoproteins in patients with nonalcoholic fatty liver disease. *J Clin Invest* 2005;115(5):1343–1351.
25. Barbuio R, Milanski M, Bertolo MB, et al. Infliximab reverses steatosis and improves insulin signal transduction in liver of rats fed a high-fat diet. *J Endocrinol* 2007;194:539–550.
26. Tilg H, Jalan R, Kaser A, et al. Anti-tumor necrosis factor-alpha monoclonal antibody therapy in severe alcoholic hepatitis. *J Hepatol* 2003;38:419–425.
27. Calle EE, Rodriguez C, Walker-Thurmond K, et al. Overweight, obesity, and mortality from cancer in a prospectively studied cohort of U.S. adults. *N Engl J Med* 2003;348(17):1625–1638.

Chapter 5

Wound Healing

Rajiv Chandawarkar and Michael J. Miller

Key Points

1 Nonhealing wounds affect about 3 to 6 million people in the United States, with persons 65 years and older accounting for 85% of these events. The annual cost of this problem in the United States is estimated to be as high as $25 billion for hospital admissions, antibiotics, and local wound care. The development of new data regarding the normal and pathologic wound healing responses both at the cellular levels and the biological markers associated with them will help us develop new strategies to treat these difficult expensive clinical problems.

2 Normal wound healing is achieved through four highly integrated and overlapping biophysiological phases: *hemostasis, inflammation, proliferation, and tissue remodeling or resolution.* Each phase initiates a cascading set of processes critical to the final aim of a healed wound.

3 Wound healing is a complex biological process that consists of hemostasis, inflammation, proliferation, and remodeling. Large numbers of cell types – including neutrophils, macrophages, lymphocytes, keratinocytes, fibroblasts, and endothelial cells – are involved in this process. Multiple factors can cause impaired wound healing by affecting one or more phases of the process and are categorized into local and systemic factors.

4 Clinically the process of wound healing is important to understand from several perspectives. These include: development of precise, least-traumatic surgical technique; the clear understanding of how newer developments in the field of biofilm and anti-infective therapies affect wound management; factors that lead to the formation of chronic versus acute wounds, and importantly, the comorbid conditions that affect wound healing. The role of age, gender, nutrition, obesity, and diabetes are critical factors to incorporate into the therapeutic repertoire.

The role of disease states including diabetes, and cancer-related treatments including radiation, chemotherapy and ways to mitigate these factors are as important to assimilate.

1 A fundamental understanding of wound healing is essential to surgical practice. Years of research have yielded extraordinary details of the wound healing process. The complexity can lead the practicing clinician to the conclusion that this topic is perhaps

best reserved for the wound specialist. It is critical, however, for the practicing surgeon to have a fundamental understanding of wound healing. Besides the controlled injury that occurs in elective surgery, all invasive surgical procedures cause soft tissue trauma regardless of the circumstances. All aspects of surgical care from patient selection, surgical instruments and technique, and postoperative management are intended to optimize tissue healing and avoid complications. Highly specialized neurosurgical or cardiac procedures can be fraught with complications if sound principles of soft tissue wound healing are overlooked. In addition to surgical procedures, there is the growing problem of people suffering from chronic wounds. Nonhealing wounds affect about 3 to 6 million people in the United States, with persons 65 years and older accounting for 85% of these events. The annual cost of this problem in the United States is estimated to be as high a $25 billion for hospital admissions, antibiotics, and local wound care.[1] Minimizing wound complications is essential in the current health care environment with an emphasis on quality and safety with publicly reported outcomes such as surgical site infection and readmission rates. For the benefit of the patient and to meet increasingly stringent scrutiny of surgical outcomes by the public, it is incumbent on the surgeon to be more than a technician. Specifically, the surgeon needs to understand how surgery alters tissues and the physiology of healing in order to obtain the best outcomes for their patients. This understanding is essential to allow the surgeon to constantly improve personal technique and quality outcomes. The development of new data regarding the normal and pathologic wound healing responses both at the cellular levels and the biological markers associated with them will help develop new strategies.

NORMAL WOUND HEALING

The series of events associated with wound healing begins at the moment of injury. Although different kinds of tissue (i.e., skin, fat, muscle, bone, nerve, parenchymal organs) have unique responses to injury, each follows a similar process that involves four sequential overlapping periods known as the hemostasis, inflammatory, proliferative, and remodeling phases of wound healing. The process is best understood by considering a full-thickness injury of the skin, dermis, and subcutaneous tissue associated with a simple surgical incision common to every surgical specialty.

2 Normal wound healing is achieved through **four** highly integrated and overlapping biophysiological phases: *hemostasis, inflammation, proliferation, and tissue remodeling or resolution.*[2] For a wound to heal successfully, as shown in Figure 5-1, all four phases must occur in the proper sequence and time frame (that takes almost 1 year to complete) and continue for a specific duration at an optimal intensity[3] (Table 5-1).

Cellular components, the dominant processes as well as biochemical environments that elicit each of the phases are markedly different in their functionality and work in concert to result in a normal healed wound (Fig. 5-2). As shown in Figure 5-3, each phase initiates a cascading set of processes critical to the final aim of a healed wound. In addition, the dominant cytokines for each phase are shown in Figure 5-4.

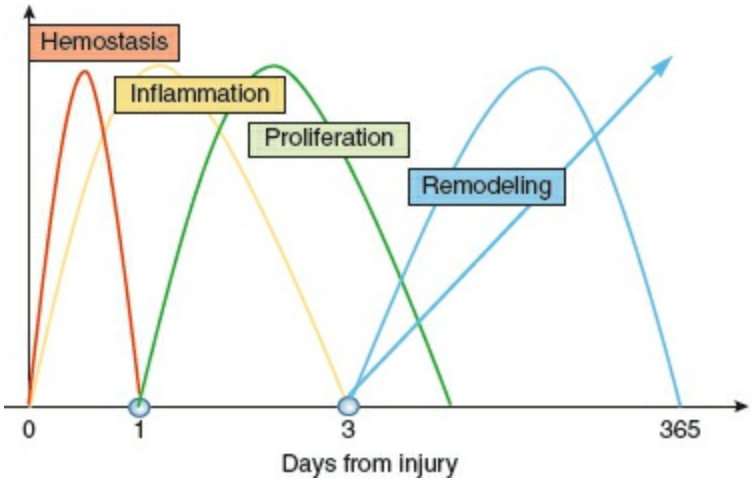

Figure 5-1. Four phases of wound healing: plotted against "Time" on the X axis, the four phases shown in different colors occur sequentially, and overlap. Overall the total time period for completion is 1 year.

Hemostasis

The first phase of hemostasis begins almost instantaneously after wounding. A scalpel drawn across intact skin injures cells in the epidermis and dermis and separates components of the extracellular matrix (ECM) that support the normal three-dimensional framework of the tissue and preserves the barrier function. The zone of injury is limited to the dimensions of the blade when using a conventional metal scalpel. With electrosurgery, the injury extends some distance into the surrounding tissues depending on the power settings on the device. As the surgeon deepens the incision, the blood vessels in the sub-dermal plexus and deeper in the subcutaneous planes, are cut, and bleeding occurs. The tissue response is mediated by factors from three sources: (1) blood leaking into the wound, (2) proteins stored in the ECM, and (3) locally resident surviving cells.

Table 5-1 Cellular and Biological Events that Frame the Normal Wound Healing Process

Phase	Cellular and Biophysiologic Events
Hemostasis	Vascular constriction Platelet aggregation, degranulation, and fibrin formation (thrombus)
Inflammation	Neutrophil infiltration Monocyte infiltration and differentiation to macrophage Lymphocyte infiltration
Proliferation	1. Re-epithelialization 2. Angiogenesis 3. Collagen synthesis 4. ECM formation
Remodeling	1. Collagen remodeling 2. Vascular maturation and regression

ECM, extracellular matrix.

Circulating factors that initiate the inflammatory phase of healing are platelets, plasma proteins, and leukocytes. Platelets are unnucleated formed elements in the blood produced in the bone marrow by megakaryocytes. The plasma membrane of each platelet contains specific receptors for collagen known as the glycoprotein Ia/IIa complex. The platelet cytoplasm contains granules holding an array of factors important for hemostasis and inflammation. When plasma membrane receptors come into contact with collagen of the ECM (type I) and the basement membrane of the vascular endothelium (Type IV), platelets bind and anchor to the site. Simultaneously, platelet activation occurs and the platelet changes from a rounded amorphous shape to a flattened configuration and discharges the contents of stored cytoplasmic granules in an event known as the platelet release reaction. These bioactive factors serve a dual purpose in hemostasis and wound healing. Hemostasis is promoted by factors that cause strengthened force of platelet binding, accelerated platelet aggregation, vasoconstriction, and activation of the clotting

cascade. Platelet anchoring is strengthened by von Willebrand factor (vWF) released by damaged endothelium and activated platelets. Platelet binding is also characterized by rapid vascular constriction and the formation of a stable fibrin clot. Platelets are the main cellular players of the first phase (Fig. 5-5A and Fig. 5-5B). By their collective function, they prevent hemorrhage. Platelet-derived functions that achieve this goal include: adhesion, aggregation, and formation of a procoagulant surface that facilitates the generation of thrombin and results in a fibrin plug. In addition, platelets express and release substances that promote tissue repair and influence processes such as angiogenesis, inflammation, and the immune response. They contain large secretable pools of biologically active proteins, including platelet-derived growth factor (PDGF), transforming growth factor-β (TGF-B), and vascular endothelial growth factor (VEGF) as well as cytokines while newly synthesized active metabolites including proteins such as PF4 and CD40L are also released. Although anucleate, activated platelets possess a spliceosome and can synthesize tissue factor and interleukin-1β. The binding of secreted proteins within a developing fibrin mesh or to the ECM can create chemotactic gradients favoring the recruitment of stem cells, stimulating cell migration and differentiation, and promoting repair.[4] The therapeutic use of platelets in a fibrin clot has a positive influence in clinical situations requiring rapid healing. Dental implant surgery, orthopedic surgery, muscle and tendon repair, skin ulcers, hole repair in eye surgery and cardiac surgery are situations where the use of autologous platelets accelerates healing.

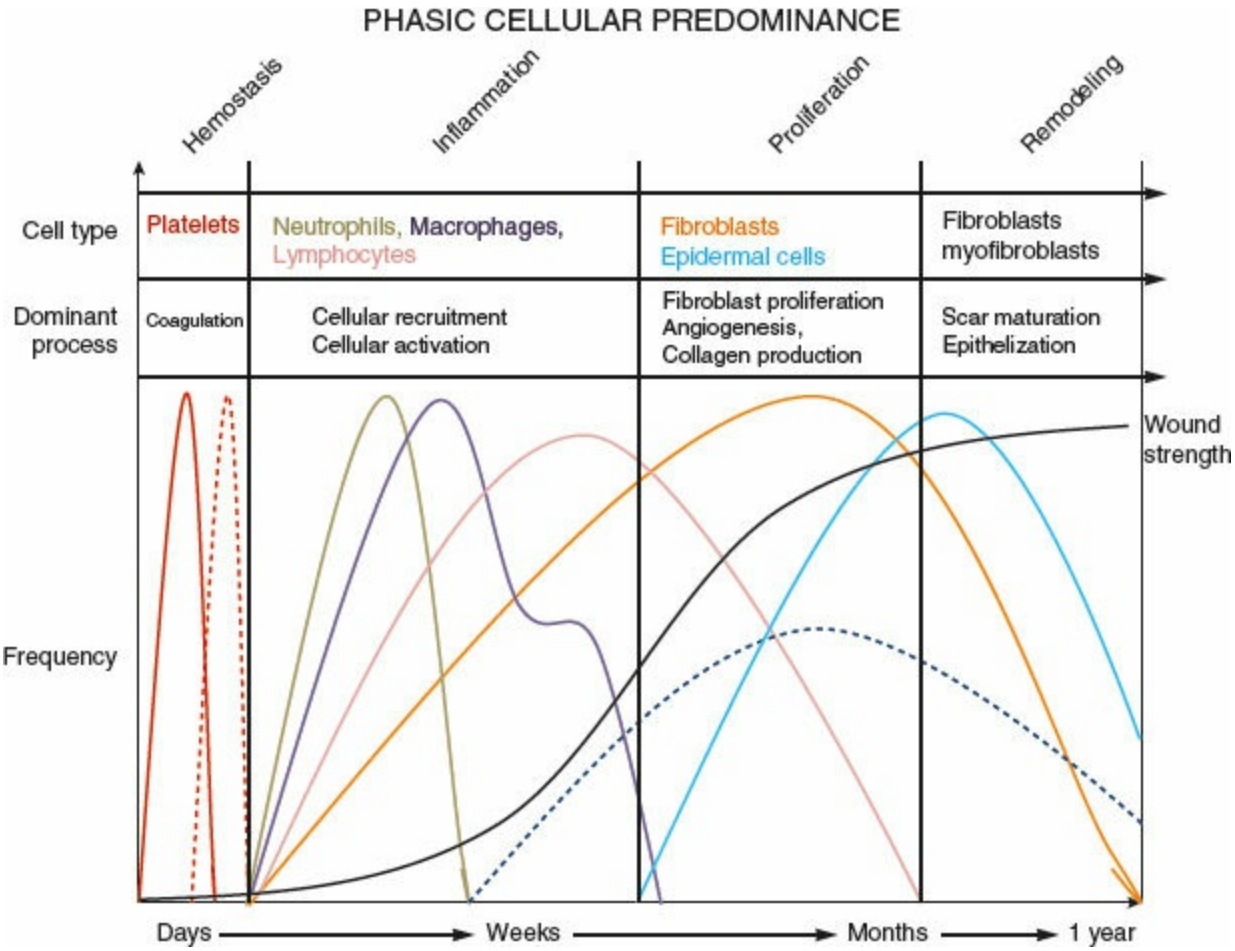

Figure 5-2. The dominant cells, physiologic process as well as the temporal distribution of the four phases of wound healing.

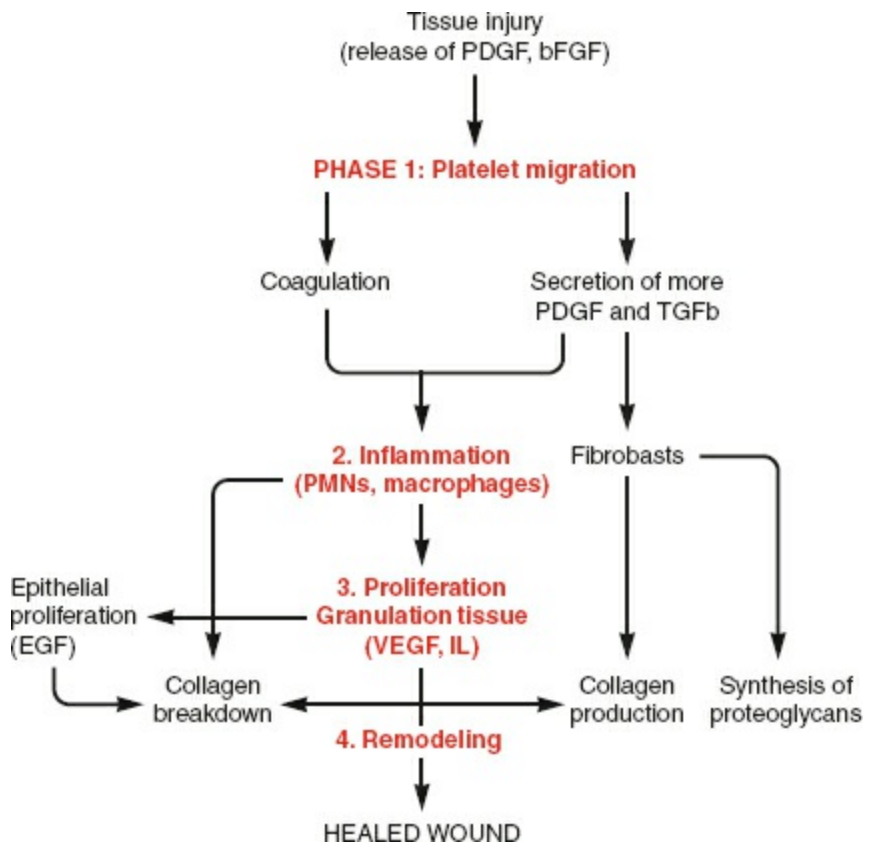

Figure 5-3. Flow chart of the phases and the cascading steps that result from each phase.

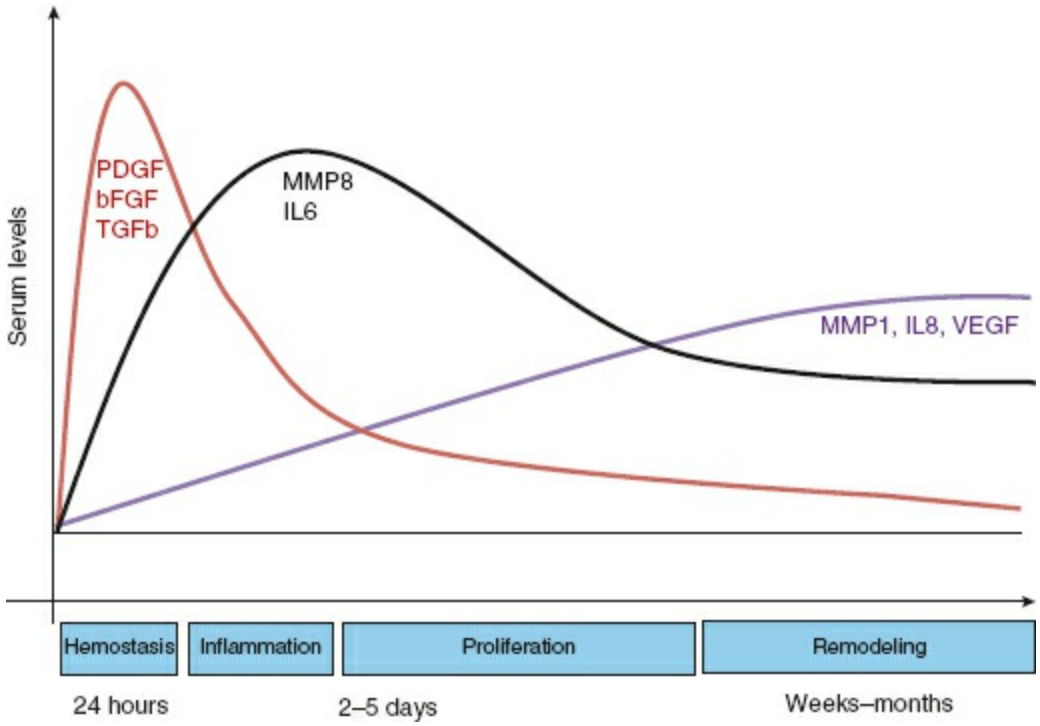

Figure 5-4. The patterns of cytokines and growth factors within each phase of wound healing.

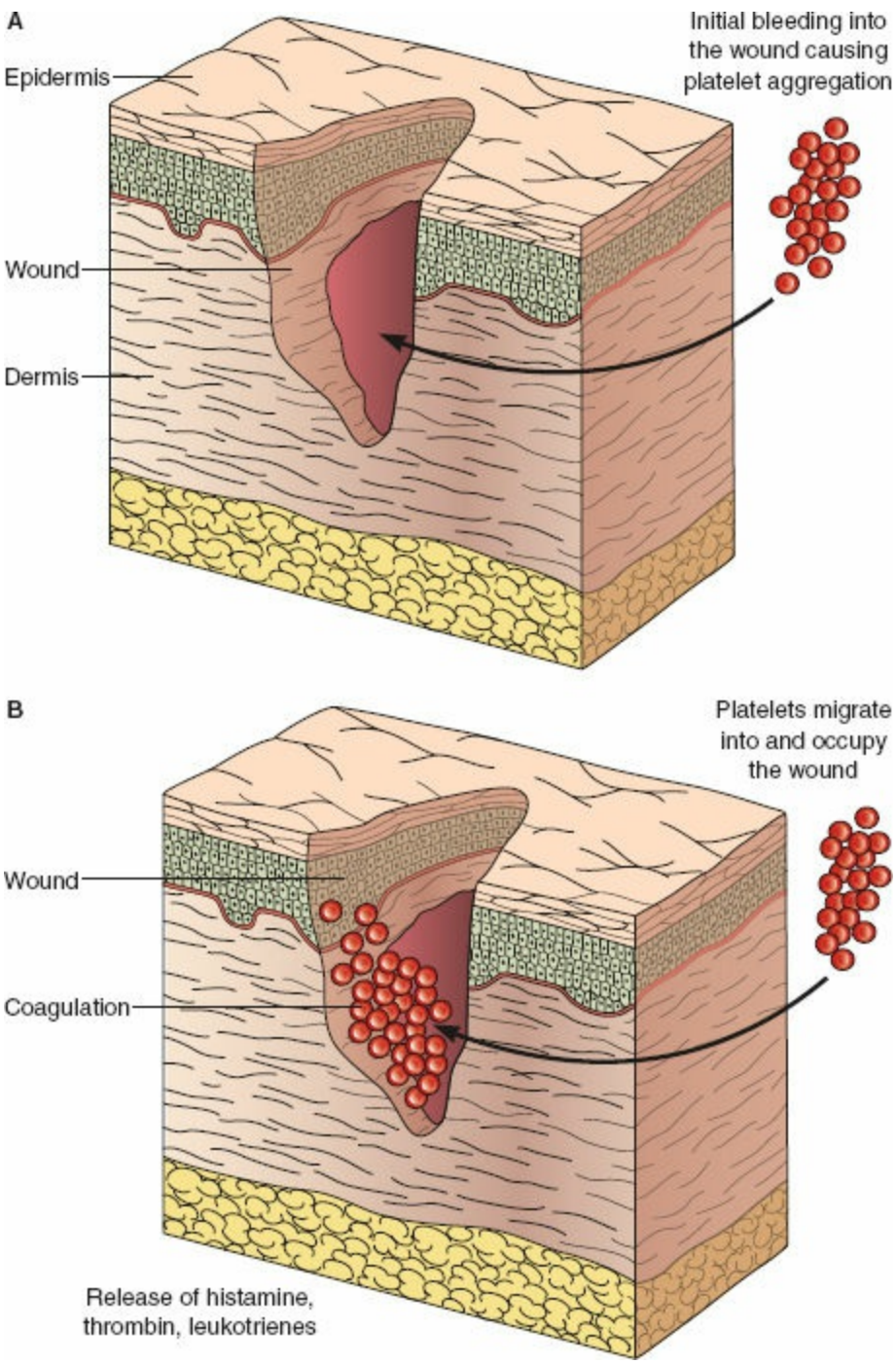

Figure 5-5. **A:** Diagrammatic wound healing model. Platelets, the first cells to arrive at the wound are critical to create a clot and establish hemostasis **B:** Phase 1 – Hemostasis.

The growing platelet plug inside the vessel is stabilized by fibrin polymerized from circulating fibrinogen. The vascular response is mediated by local factors modulated by the systemic control of the sympathetic nervous system. Vasoconstriction, mediated by catecholamines and prostaglandins (thromboxane and PGF_{2a}), normally is limited to the time required to achieve hemostasis. Vasodilation and alteration in capillary permeability soon follow mediated by histamine, prostaglandins (PGE_2 and PGI_2), and VEGF released from resident interstitial mast cells and damaged endothelium. This causes increased blood flow and controlled delivery of fluid, leukocytes, macrophages, and relevant plasma proteins to the wound environment. Platelets release two factors with particular importance for wound healing: PDGF and TGF-β. Which in turn stimulate chemotaxis and

proliferation of inflammatory cells.

Inflammatory Phase

The second phase of healing involves acute inflammation that begins at the moment of tissue disruption. Inflammatory cells appearing during this phase of healing are polymorphonuclear leukocytes (PMNs) and macrophages. PMNs are first to appear (Fig. 5-6). Their primary role is to clear devitalized tissue, blood clot, foreign material, and bacteria from the wound. PMNs are part of natural host defenses that destroy bacteria by phagocytosis and secreting oxygen free radicals. Migration of PMNs from the intravascular compartment (the lumen) to the ECM and to the wound site is controlled by several biochemical agents including selectins, cytokines, and integrins that act in series to activate, tether, and facilitate extravascular escape (Fig. 5-7). PMNs work in concert with the immune system antibodies. Their numbers and persistence depend on the initial wound conditions. A clean surgical wound performed with atraumatic tissue handing will have low PMN activity, whereas a poorly performed surgical incision or a traumatic wound may be characterized by a large amount of debris and require prolonged participation of PMNs to set the stage for appearance of macrophages, the most important cellular mediator of the inflammatory phase of wound healing.

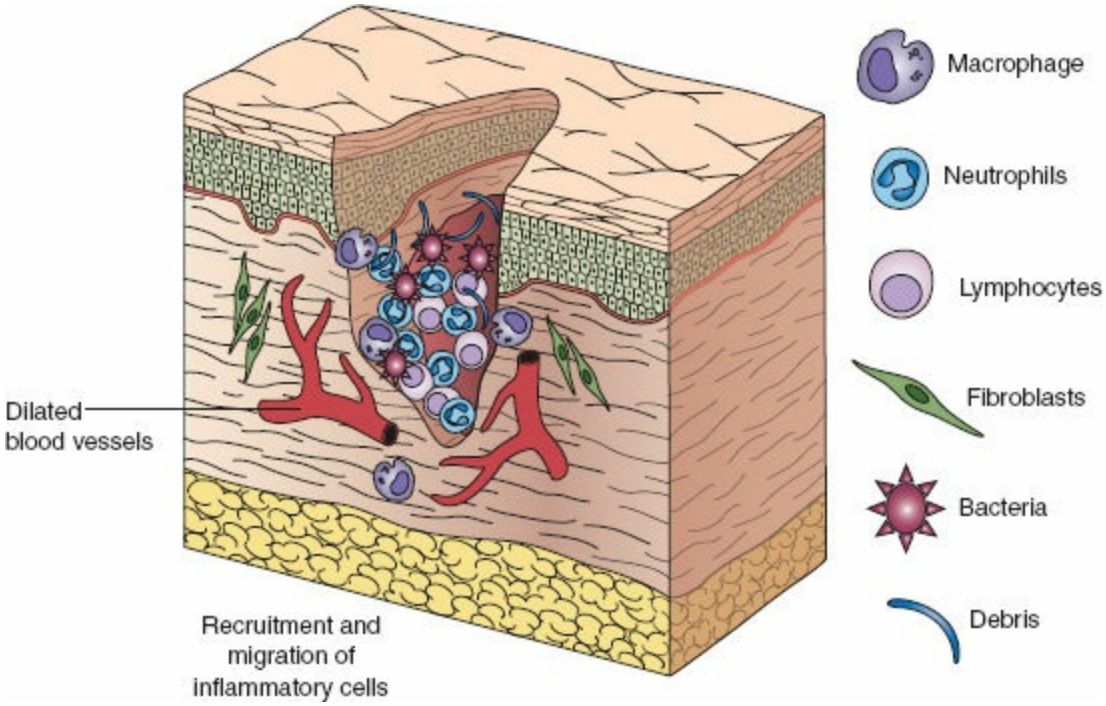

Figure 5-6. Phase 2 – Inflammation.

Macrophages appear in large numbers within 48 hours of wounding and play a central role in the inflammatory phase. They are derived from circulating monocytes or resident interstitial cells that migrate into the wound from adjacent tissues. Macrophages are multifunctional (Fig. 5-8) and complete the cleanup activities initiated by the PMNs by phagocytizing remaining wound debris. Most importantly, they secrete a vast array of cytokines and growth factors, which function in a rapidly amplifying process that affects all aspects of healing during the inflammatory phase. These factors induce recruitment and activation of additional macrophages, angiogenesis, proliferation of fibroblasts, and

ECM production. Matrix production is accelerated as the inflammatory phase of healing transitions into the next phase of healing, the proliferative phase.

Proliferative Phase

The defining characteristic of the proliferative phase of healing is ECM production (Fig. 5-9). The phases of wound healing are not discreet. While the inflammatory phase is still most active, the proliferative phase begins with formation of a provisional ECM composed of fibrin and fibronectin precipitated from blood extravasated into the wound at the time of the initial injury. The provisional matrix is a protein scaffold that stabilizes the wound edges and provides a framework for migration of PMNs, macrophages, fibroblasts, and other cells into the wound from surrounding tissues. As the inflammatory phase slows the proliferative phase begins and becomes dominant. Fibroblasts replace macrophages as the most numerous cell type. Like macrophages, fibroblasts are multifunctional. They are responsible for new tissue formation, collagen production, and the laying down of the ECM (Fig. 5-9). Angiogenesis occurs simultaneously as new capillaries form and blood vessels penetrate the provisional matrix sprouting from vessels of the surrounding uninjured tissues. The processes that actually coordinate formation of ECM and new tissue with angiogenesis are not well defined. Signaling pathways that stimulate new tissue formation involve the role of low oxygen tension that increases the expression of "hypoxia-inducible factor" (HIF) by vascular endothelial cells. HIF in turn binds to specific sequences of DNA that regulate the expression of VEGF thus stimulating angiogenesis. This also has a negative feedback loop – increased formation of new blood vessels normalizes the oxygen tension. In response, oxygen binds to HIF and blocks its activity resulting in decreased synthesis of VEGF. Epidermal growth factor and TGFa produced by activated wound macrophages, platelets, and keratinocytes play an important role at the creation of a robust scaffold.

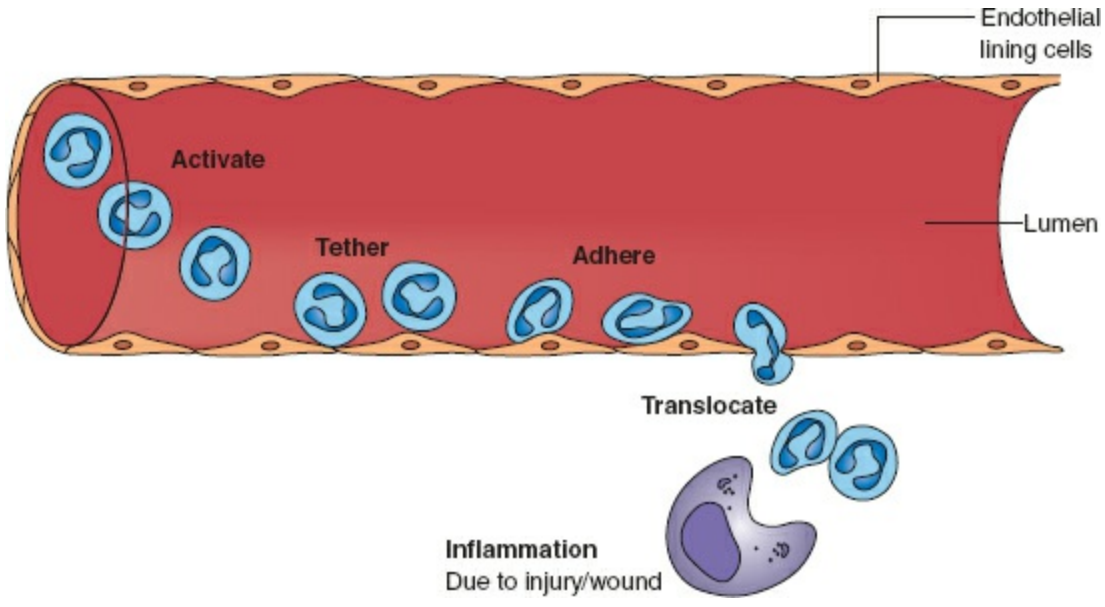

Figure 5-7. The biochemical factors that elicit migration of cells from intravascular compartment into the wound site.

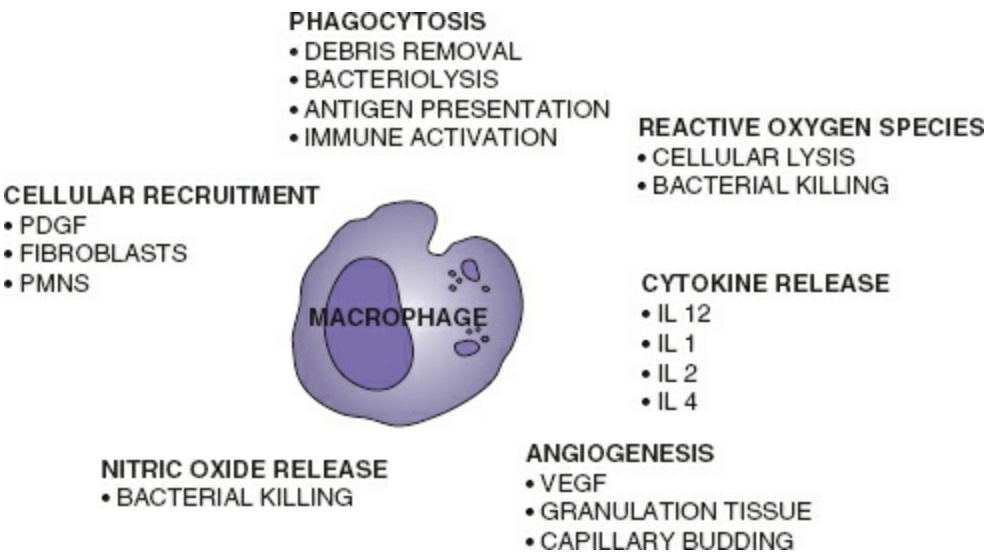

Figure 5-8. Macrophage functions.

Epidermal cells migrate over the scaffold and only after the epithelial bridge is completed, enzymes are released to dissolve the attachment at the base of the overlying scab that falls off. In response to the growing need for oxygen and nutrients at the site of healing, the wound microenvironment stimulates the release of factors needed to bring in a new blood supply (low pH, reduced oxygen tension, and increased lactate). This process – angiogenesis or neovascularization is stimulated by VEGF, basic fibroblast growth factor (bFGF), and TGFb. These factors are secreted by several cell types including vascular endothelial cells, epidermal cells, fibroblasts, and macrophages.

As the proliferative phase progresses the predominant cell in the wound site is the fibroblast. This multifunctional cell of mesenchymal origin mainly produces and deposits the new matrix for structural integrity at the level of the wound bed (Fig. 5-9B). ECM production is the defining feature of the proliferative phase. The ECM is primarily collagen. At least 23 individual types of collagen have been identified – type I is present mostly in scar tissues.[5] Fibroblasts produce collagen via their attachment to the cables of the provisional fibrin matrix.[6] After transcription and processing of the collagen messenger ribonucleic acid, it is attached to polyribosomes on the endoplasmic reticulum where the new collagen chains are produced. During this process, there is an important step involving hydroxylation of proline and lysine residues.[7] The collagen molecule transforms itself into the classical triple helical structure and thereafter its nascent chains are modified through glycosylation[8]; this procollagen molecule is released into the extracellular space.[9] The hydroxyproline in collagen gives the molecule its stable helical conformation.[10] Whereas fully hydroxylated collagen has a higher stability, unhydroxylated forms are fragile, similar to collagen produced under anaerobic disease conditions or vitamin C-deficient states (scurvy), wherein the collagen undergoes denaturation easily and can break.

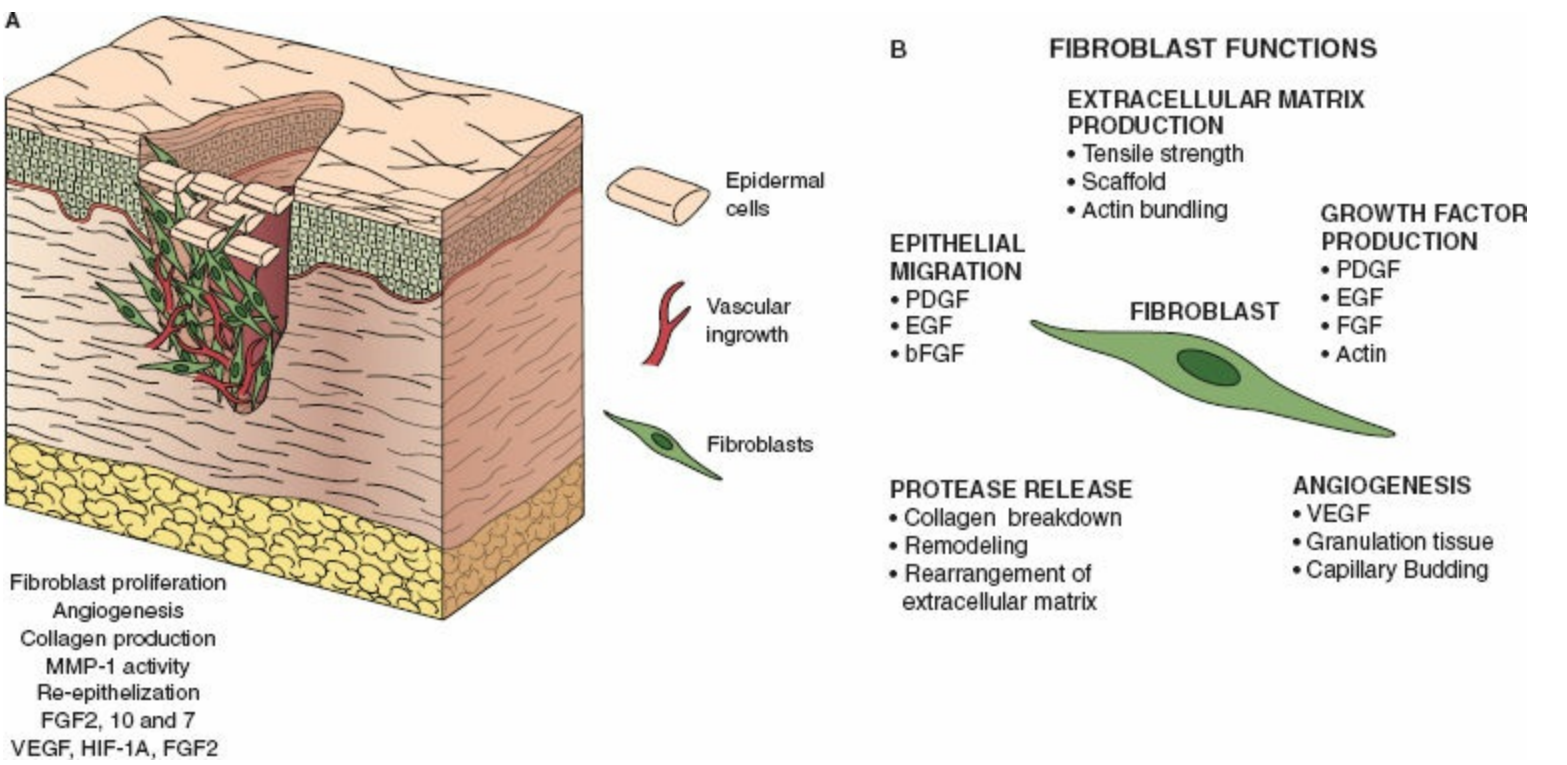

Figure 5-9. **A:** Phase 3 – Proliferation. Vast array of cells are recruited into the wound bed and carry out diverse functions including proliferation and deposition of ECM. **B:** Fibroblast functions.

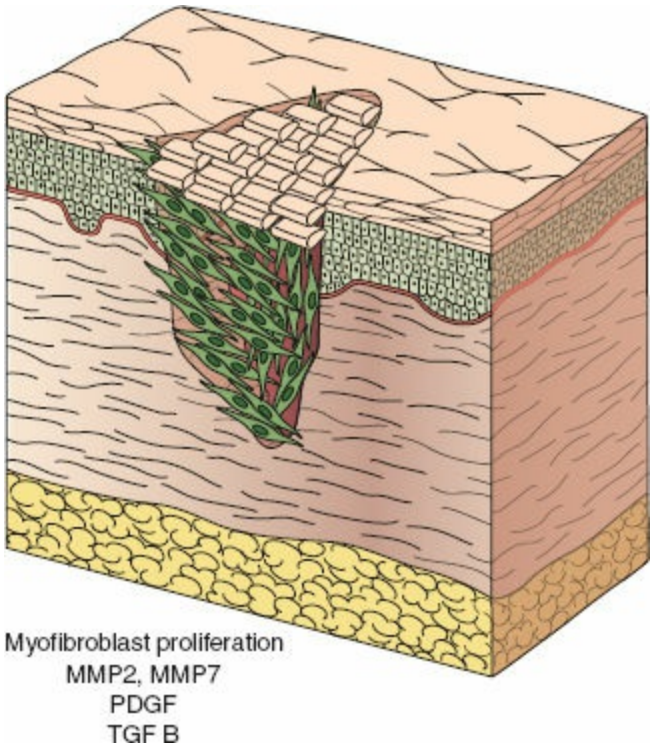

Figure 5-10. Phase 4 – Remodeling and Maturation.

Finally, collagen released into the extracellular space undergoes further processing by cleavage of the procollagen N- and C-terminal peptides. In the extracellular spaces, an important enzyme, lysyl oxidase, acts on the collagen to form stable cross-links. As the collagen matures and becomes older, more and more of these intramolecular and intermolecular cross-links are placed in the molecules. This important cross-linking step gives collagen its strength and stability over time.[11]

Remodeling Phase

The remodeling phase is characterized by continued synthesis and degradation of the ECM components trying to establish a new equilibrium – and the formation of an organized scar (Fig. 5-10). Collagen degradation occurs[12] via the action of specific collagenases that are secreted by various cells: fibroblasts, neutrophils, and macrophages each of which can cleave the collagen molecule at differing but specific locations on all three chains, and break it down to characteristic three-quarter and one-quarter pieces. These collagen fragments undergo further denaturation and digestion by other proteases. Several molecules including TGF play a major role in the remodeling phase. TGF-β-induced intracellular signaling acts via a set of proteins called the SMAD proteins, which act as direct links between the cell surface and the nucleus. The recent development of several SMAD pathway specific knockout mice and transgenic animals has confirmed the pivotal nature of the SMAD pathway in fibrogenesis and tumorigenesis. Still, several difficulties remain before the TGF-β/SMAD pathway can be efficiently targeted in situations such as tissue fibrosis or impaired wound healing. In particular, the precise spatiotemporal role of each TGF-β/SMAD pathway component during the development of excessive ECM deposition leading to tissue fibrosis remains to be ascertained.

As the scar matures, late remodeling occurs (that takes up to 1 year); the scar contracts and thins out (Fig. 5-11).

CLINICAL APPLICATIONS

Surgical Technique

The surgeon equipped with the knowledge of the fundamentals of wound healing is prepared to insightfully minimize risks of wound healing complications while performing a surgical procedure from start to finish. The stage is set for healing from the moment the incision is made. The skin and dermis should be incised perpendicularly to the plane of the surface. Attention to this principle is particularly important when making an incision on a curved surface. Electrosurgical currents should be used set on the lowest power settings that accomplish hemostasis. The deep tissues should be handled as atraumatically as possible. The incision is carried down through deeper layers ensuring that each new incision is accurately placed in the same line as the previous one. This avoids a saw tooth surface with devitalized sections. Proper tissue handling techniques in the subcutaneous fat and adjacent soft tissue are based on well-established wound healing principles, which minimize the risk of infection, seroma, delayed healing, unnecessary scarring, and other postoperative wound complications. For traumatic wounds, the first step in treatment is to convert them into controlled surgical wounds by thoughtful debridement and tissue repair. Treating traumatic wounds minimizing the risk of postoperative wound complications requires mindfulness of wound healing principles in all of these clinical circumstances. This is true regardless whether performing repair of a simple laceration or the most complex specialized procedure. Controlling the degree of injury leads to improved outcomes with fewer complications related to a failure in the wound healing process. An awareness of the wound healing process informs proper surgical technique. A clear understanding of wound healing allows the surgeon to advance in technical skill and achieve continuously improving outcomes throughout a professional career.

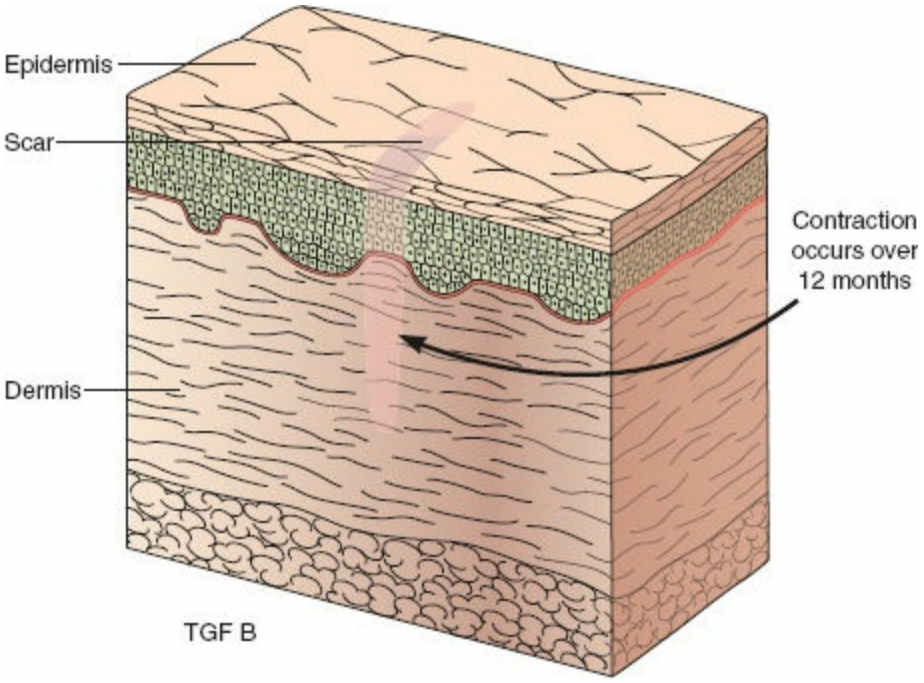

Figure 5-11. Contraction of scar – This process occurs over the course of 1 year.

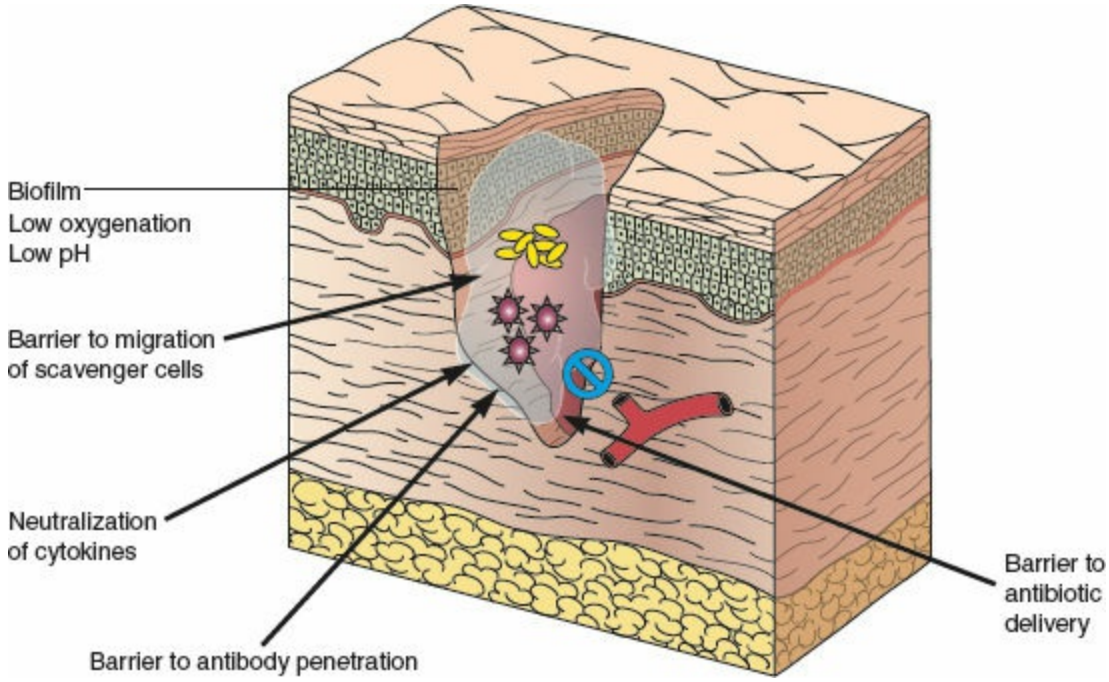

Figure 5-12. Effects of biofilm on wound healing.

Elective surgery creates controlled tissue injury. Minimizing tissue injury forms the basis of proper surgical technique. Trauma inures tissues in an uncontrolled fashion. Wounds can occur under special conditions such as pressure, physiologic impairment (e.g., diabetes) that create traumatic tissue damage in an uncontrolled injury. Finally, there are wounds that occur under specialized circumstances such as radiotherapy in cancer treatment.

Biofilm

Biofilm comprises a colony of microorganisms enveloped with a matrix of extracellular polymers. Estimated biofilm-associated infections costs >$1 billion annually. Both chronic and acute dermal wounds are susceptible to the formation and propagation of biofilm. Covered in other chapters of this book, biofilm is relevant to wound healing due to the several inhibitory effects on healing processes (Fig. 5-12).

Table 5-2 Comparison of Acute and Chronic Wounds

	Acute	Chronic
Present for	4–6 weeks	6 weeks, usually months/years
Management	Minimal needs ■ Debride ■ Dressings ■ Drugs (antimicrobials usually suffice)	Complex coordinated wound care ■ Treat ROOT CAUSE ■ Wound care ■ Surgery ■ Adjunctive care
Types	Surgical trauma Trauma Bites Uncomplicated burns	Neuropathic Diabetic Vascular Pressure sores

Chronic Versus Acute wounds

Wounds heal within a reasonable time of 4 to 6 week. Those that do not are termed chronic. As shown in Table 5-2, a variety of factors and disease conditions impair wound healing and result in chronic nonhealing wounds. Reasons that lead to chronicity instead of normal healing, are complex – but the salient points are defined in Figure 5-13. The most important concept is a persistent proinflammatory condition that paradoxically leads to increased degradation of matrix proteins, and an unstable wound that is recalcitrant to healing.

Comorbid Conditions that Influence Wound Healing

3 Wound healing is a complex biological process that consists of hemostasis, inflammation, proliferation, and remodeling. Large numbers of cell types – including neutrophils, macrophages, lymphocytes, keratinocytes, fibroblasts, and endothelial cells – are involved in this process. Multiple factors can cause impaired wound healing by affecting one or more phases of the process and are categorized into local and systemic factors (Table 5-3). The influences of these factors are not mutually exclusive.[13] Single or multiple factors may play a role in any one or more individual phases, contributing to the overall outcome of the healing process (Fig. 5-14).

Advanced Age and Gender

The elderly population (people over 60 years of age) is growing faster than any other age group (World Health Organization [WHO, www.who.int/topics/ageing]), and increased age is a major risk factor for impaired wound healing. Many clinical and animal studies at the cellular and molecular level have examined age-related changes and delays in wound healing. It is commonly recognized that, in healthy older adults, the effect of aging causes a temporal delay in wound healing, but not an actual impairment in terms of the quality of healing.[13] Delayed wound healing in the aged is associated with an altered inflammatory response, such as delayed T-cell infiltration into the wound area with alterations in chemokine production and reduced macrophage phagocytic capacity.[14] Overall, there are global differences in wound healing between young and aged individuals. A review of the age-related changes in healing capacity demonstrates that every phase of healing undergoes characteristic age-related changes, including enhanced platelet aggregation, increased secretion of inflammatory mediators, delayed infiltration of macrophages and lymphocytes, impaired macrophage function, decreased secretion of growth factors, delayed re-epithelialization, delayed angiogenesis and collagen deposition, reduced collagen turnover and remodeling, and decreased wound strength.

Table 5-3 Factors that Affect Wound Healing

Local Factors	Systemic Factors
■ Tissue hypoxia	■ Senescence
■ Pressure	■ Smoking
■ Tissue edema	■ Stress
■ Necrotic material	■ Comorbidity
■ Infection	■ Immune compromise
■ Contamination from incontinence	■ Malnourishment
■ Dessication	■ Obesity
■ Maceration	■ Diabetes, anemia

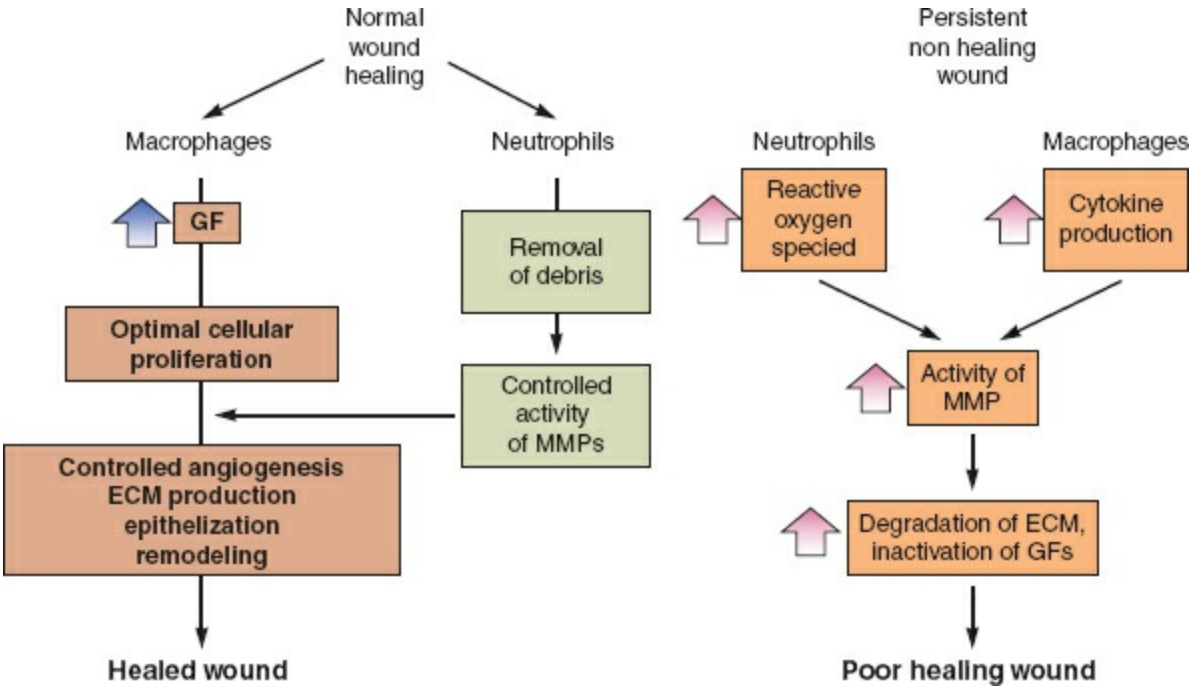

Figure 5-13. Comparison of cellular mechanisms in normal and poor wound healing.

Sex hormones play a role in age-related wound healing deficits. Compared with aged females, aged males have been shown to have delayed healing of acute wounds. A partial explanation for this is that the female estrogens (estrone and 17β-estradiol), male androgens (testosterone and 5α-dihydrotestosterone, DHT), and their steroid precursor dehydroepiandrosterone (DHEA) appear to have significant effects on the wound healing process.[15] It was recently found that the differences in gene expression between elderly male and young human wounds are almost exclusively estrogen regulated.[16] Estrogen affects wound healing by regulating a variety of genes associated with regeneration, matrix production, protease inhibition, epidermal function, and genes primarily associated with inflammation.[17] Studies indicate that estrogen can improve the age-related impairment in healing in both men and women, while androgens regulate cutaneous wound healing negatively.

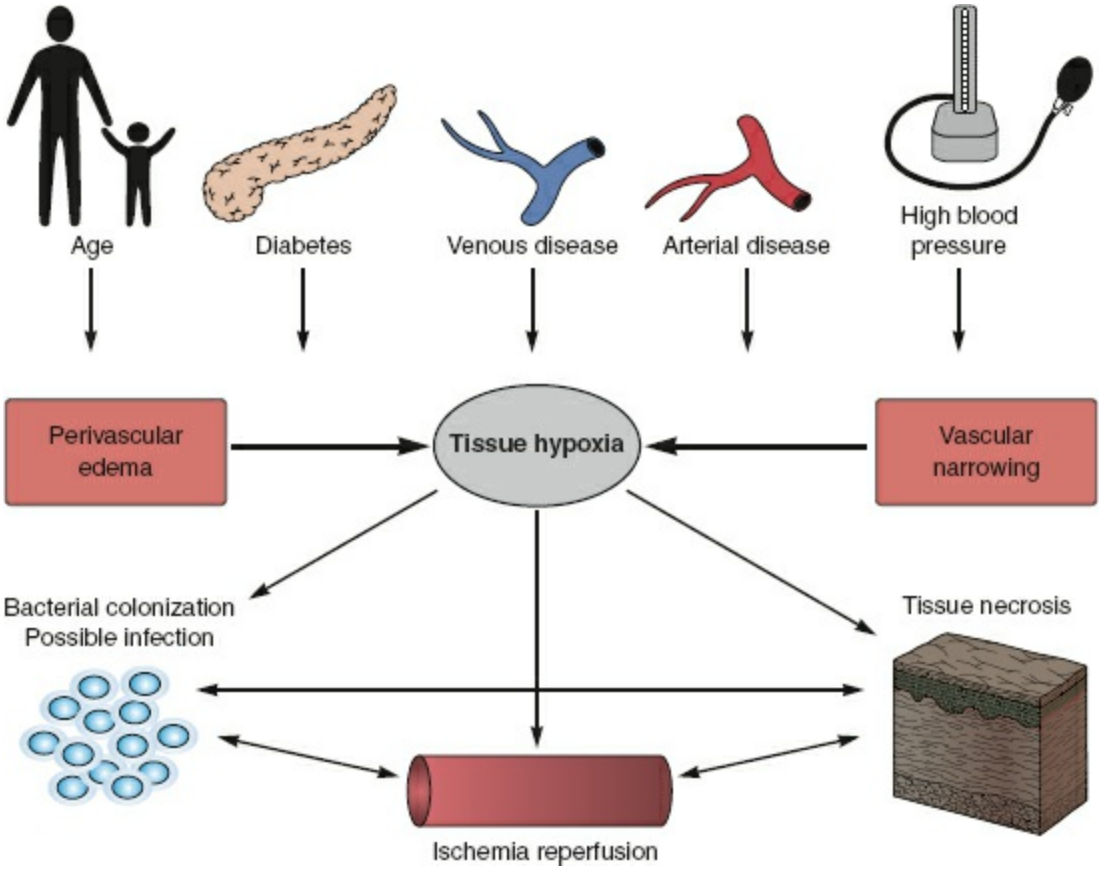

Figure 5-14. Mechanisms that elicit the effects of comorbid conditions on wound healing.

Several treatments to reduce the age-related impairment of healing have been studied. Interestingly, exercise has been reported to improve cutaneous wound healing in older adults as well as aged mice, and the improvement is associated with decreased levels of proinflammatory cytokines in the wound tissue. Improved healing response may also be due to an exercise-induced anti-inflammatory response in the wound.[18]

Nutrition

Malnutrition or specific nutrient deficiencies can have a profound impact on wound healing after trauma and surgery. Patients with chronic or nonhealing wounds and experiencing nutrition deficiency often require special nutrients. Energy, carbohydrates, proteins, fat, vitamins, and mineral metabolism all can affect the healing process.[19]

Carbohydrates, Proteins, and Amino Acids. Together with fats, carbohydrates are the primary source of energy in the wound healing process. Glucose is the major source of fuel used to create the cellular ATP that provides energy for angiogenesis and deposition of the new tissues.[20] The use of glucose as a source for ATP synthesis is essential in preventing the depletion of other amino acid and protein substrates.

Protein is one of the most important nutrient factors affecting wound healing. A deficiency of protein can impair capillary formation, fibroblast proliferation, proteoglycan synthesis, collagen synthesis, and wound remodeling. A deficiency of protein also affects the immune system, with resultant decreased leukocyte phagocytosis and increased susceptibility to infection. Collagen is the major protein component of connective tissue and is composed primarily of glycine, proline, and hydroxyproline.

Collagen synthesis requires hydroxylation of lysine and proline, and cofactors such as ferrous iron and vitamin C. Impaired wound healing results from deficiencies in any of these cofactors.[21]

Arginine is a semiessential amino acid that is required during periods of maximal growth, severe stress, and injury. Arginine has many effects in the body, including modulation of immune function, wound healing, hormone secretion, vascular tone, and endothelial function. Arginine is also a precursor to proline, and, as such, sufficient arginine levels are needed to support collagen deposition, angiogenesis, and wound contraction. Arginine improves immune function, and stimulates wound healing in healthy and ill individuals.[22] Under psychological stress situations, the metabolic demand for arginine increases, and its supplementation has been shown to be an effective adjuvant therapy in wound healing.

Glutamine is the most abundant amino acid in plasma and is a major source of metabolic energy for rapidly proliferating cells such as fibroblasts, lymphocytes, epithelial cells, and macrophages. Glutamine improves nitrogen balance and diminishes immunosuppression and plays a crucial role in stimulating the early inflammatory phase of wound healing. Major surgery, trauma, and sepsis require supplementation of glutamine. Oral glutamine supplementation has been shown to improve wound breaking strength and to increase levels of mature collagen.[23]

Fatty Acids

Lipids are used as nutritional support for surgical or critically ill patients to help meet energy demands and provide essential building blocks for wound healing and tissue repair. Polyunsaturated fatty acids (PUFAs), consist mainly of two families, n-6 (omega-6, found in soybean oil) and n-3 (omega-3, found in fish oil). Although fish oil has been widely touted, effects of omega-3 fatty acids on wound healing are not conclusive. They have been reported to affect proinflammatory cytokine production, cell metabolism, gene expression, and angiogenesis in wound sites.[24]

Vitamins, Micronutrients, and Trace Elements

Vitamins C (L-ascorbic acid), A (retinol), and E (tocopherol) show potent antioxidant and anti-inflammatory effects. Vitamin C has many roles in wound healing, and a deficiency in this vitamin has multiple effects on tissue repair. Vitamin C deficiencies result in impaired healing, and have been linked to decreased collagen synthesis and fibroblast proliferation, decreased angiogenesis, and increased capillary fragility. Also, vitamin C deficiency leads to an impaired immune response and increased susceptibility to wound infection. Similarly, vitamin A deficiency leads to impaired wound healing. The biological properties of vitamin A include antioxidant activity, increased fibroblast proliferation, modulation of cellular differentiation and proliferation, increased collagen and hyaluronate synthesis, and decreased MMP-mediated ECM degradation.[25]

Vitamin E, an antioxidant, maintains and stabilizes cellular membrane integrity by providing protection against destruction by oxidation. Vitamin E also has anti-inflammatory properties and has been suggested to have a role in decreasing excess scar

formation in chronic wounds. Animal experiments have indicated that vitamin E supplementation is beneficial to wound healing, and topical vitamin E has been widely promoted as an antiscarring agent. However, clinical studies have not yet proved a role for topical vitamin E treatment in improving healing outcomes.[26]

Several micronutrients have been shown to be important for optimal repair. Magnesium functions as a cofactor for many enzymes involved in protein and collagen synthesis, while copper is a required cofactor for cytochrome oxidase, for cytosolic antioxidant superoxide dismutase, and for the optimal cross-linking of collagen. Zinc is a cofactor for both RNA and DNA polymerase, and a zinc deficiency causes a significant impairment in wound healing. Iron is required for the hydroxylation of proline and lysine, and, as a result, severe iron deficiency can result in impaired collagen production.[27] As indicated above, the nutritional needs of the wound are complex, suggesting that composite nutrition support would benefit both acute and chronic wound healing. A recent clinical research study examined the effects of a high-energy, protein-enriched supplement containing arginine, vitamin C, vitamin E, and zinc on chronic pressure ulcers and indicated that this high-energy and nutrition-enriched supplement improved overall healing of the pressure ulcer.[28] In summary, proteins, carbohydrates, arginine, glutamine, PUFAs, vitamin A, vitamin C, vitamin E, magnesium, copper, zinc, and iron play a significant role in wound healing, and their deficiencies affect wound healing. Additional studies will be needed to fully understand how nutrition affects the healing response.

Obesity

The prevalence of obesity continues to increase among adults, children, and adolescents in the United States, with more than 30% of adults and 15% of children and adolescents classified as obese in a recent survey.[29] Obesity is well known to increase the risk of many diseases and health conditions, which include coronary heart disease, type 2 diabetes, cancer, hypertension, dyslipidemia, stroke, sleep apnea, respiratory problems, and impaired wound healing. Obese individuals frequently face wound complications, including skin wound infection, dehiscence, hematoma and seroma formation, pressure ulcers, and venous ulcers.[30] An increased frequency of wound complications has been reported for obese individuals undergoing both bariatric and nonbariatric operations.[31] In particular, a higher rate of surgical site infection occurs in obese patients. Many of these complications may be the result of a relative hypoperfusion and ischemia that occurs in subcutaneous adipose tissue. This situation may be caused by a decreased delivery of antibiotics as well. In surgical wounds, the increased tension on the wound edges that is frequently seen in obese patients also contributes to wound dehiscence. Wound tension increases tissue pressure, reducing microperfusion and the availability of oxygen to the wound.[32]

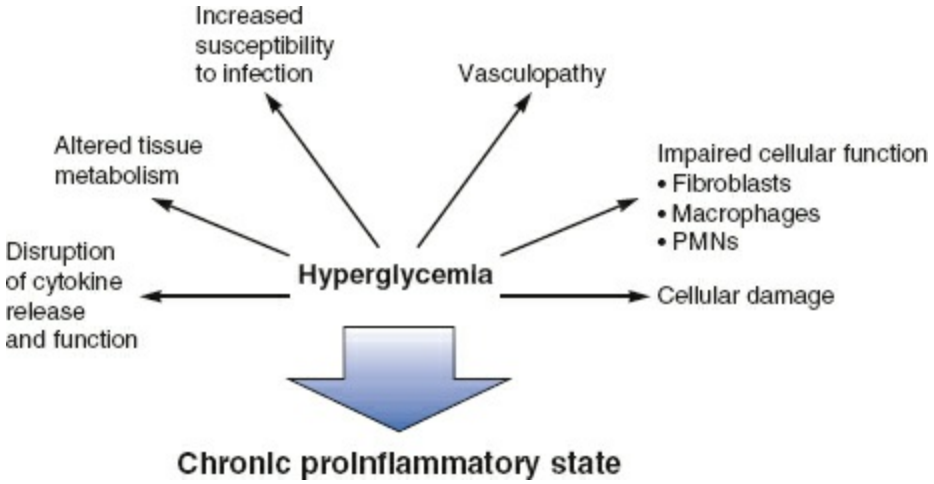

Figure 5-15. Cellular mechanisms that impair healing of the diabetic wound.

The increase in pressure ulcers or pressure-related injuries in obese individuals is also influenced by hypovascularity, since poor perfusion makes tissue more susceptible to this type of injury. In addition, the difficulty or inability of obese individuals to reposition themselves further increases the risk of pressure-related injuries. Moreover, skin folds harbor microorganisms that thrive in moist areas and contribute to infection and tissue breakdown. The friction caused by skin-on-skin contact invites ulceration. Together, these factors predispose obese individuals to the development of impaired wound healing.

In addition to local conditions, systemic factors also play an important role in impaired wound healing and wound complications in obese patients. Obesity can be connected to stress, anxiety, and depression, all situations that can cause an impaired immune response.

The function of adipose tissue used to be considered as primarily caloric storage. However, more recent findings have documented that adipose tissue secretes a large variety of bioactive substances that are collectively named adipokines. Both adipocytes as well as resident macrophages in adipose tissue are known to produce bioactive molecules including cytokines, chemokines, and hormone-like factors such as leptin, adiponectin, and resistin. Adipokines have a profound impact on the immune and inflammatory response.[33] The negative influence of adipokines on the systemic immune response seems likely to influence the healing process, although direct proof for this is lacking. Impaired peripheral blood mononuclear cell function, decreased lymphocyte proliferation, and altered peripheral cytokine levels have been reported in obesity. Importantly, many of the obesity-related changes in peripheral immune function are improved by weight loss.[34]

Diabetes Mellitus

Diabetes affects hundreds of millions of people worldwide. Diabetic individuals exhibit a documented impairment in the healing of acute wounds. Moreover, this population is prone to develop chronic nonhealing diabetic foot ulcers (DFUs), which are estimated to occur in 15% of all persons with diabetes. DFUs are a serious complication of diabetes, and precede 84% of all diabetes-related lower leg amputations.[35] The impaired healing of both DFUs and acute cutaneous wounds in persons with diabetes involves multiple

complex pathophysiological mechanisms (Fig. 5-15). DFUs, like venous stasis disease and pressure-related chronic nonhealing wounds, are always accompanied by hypoxia.[36] A situation of prolonged hypoxia, which may be derived from both insufficient perfusion and insufficient angiogenesis, is detrimental for wound healing. Hypoxia can amplify the early inflammatory response, thereby prolonging injury by increasing the levels of oxygen radicals.[37] Hyperglycemia can also add to the oxidative stress when the production of reactive oxygen species exceeds the antioxidant capacity.[38] The formation of advanced glycation end products under hyperglycemia and the interaction with their receptors are associated with impaired wound healing in diabetic mice as well.[39] High levels of metalloproteases (MMP) are a feature of DFUs, and the MMP levels in chronic wound fluid are almost 60 times higher than those in acute wounds. This increased protease activity supports tissue destruction and inhibits normal repair processes.[40]

Several dysregulated cellular functions are involved in diabetic wounds, such as defective T-cell immunity, defects in leukocyte chemotaxis, phagocytosis, and bactericidal capacity, and dysfunction of fibroblasts and epidermal cells. These defects are responsible for inadequate bacterial clearance and delayed or impaired repair in individuals with diabetes.[41]

As mentioned above, hypoxia contributes to the compromised healing of DFUs, and diabetic wounds exhibit inadequate angiogenesis. Several studies that have investigated the mechanisms behind the decreased restoration of vasculature in diabetic wounds have implied that endothelial progenitor cell mobilization and homing are impaired, and that the level of VEGF, the primary proangiogenic factor in wounds, is decreased in the diabetic state.[42] Stem-cell–based therapies aimed at inducing endothelial progenitor cells or bone marrow–derived multipotent stem cells have shown a promising outcome in diabetic nonhealing wounds, both in animals and in clinical trials.[43] In animal studies, therapeutic restoration of VEGF has been shown to improve repair outcomes significantly.[44]

The neuropathy that occurs in diabetic individuals probably also contributes to impaired wound healing. Neuropeptides such as nerve growth factor, substance P, and calcitonin gene-related peptide are relevant to wound healing, because they promote cell chemotaxis, induce growth factor production, and stimulate the proliferation of cells. A decrease in neuropeptides has been associated with DFU formation. In addition, sensory nerves play a role in modulating immune defense mechanisms, with denervated skin exhibiting reduced leukocyte infiltration.[45]

In summary, the impaired healing that occurs in individuals with diabetes involves hypoxia, dysfunction in fibroblasts and epidermal cells, impaired angiogenesis and neovascularization, high levels of MMP, damage from reactive oxygen species and advanced glycation end products, decreased host immune resistance, and neuropathy.

Medications and Dietary Supplements

Glucocorticoid Steroids. Systemic glucocorticoids, which are frequently used as anti-inflammatory agents, are well known to inhibit wound repair via global anti-inflammatory effects and suppression of cellular wound responses, including fibroblast

proliferation and collagen synthesis. Systemic steroids cause wounds to heal with incomplete granulation tissue and reduced wound contraction.[46] Glucocorticoids also inhibit production of HIF-1, a key transcriptional factor in healing wounds.[47] Beyond effects on repair itself, systemic corticosteroids may increase the risk of wound infection. While systemic corticosteroids inhibit wound repair, topical application produces quite different effects. Topical low-dosage corticosteroid treatment of chronic wounds has been found to accelerate wound healing, reduce pain and exudate, and suppress hypergranulation tissue formation in 79% of cases. While these positive effects are striking, careful monitoring is necessary to avoid a potential increased risk of infection with prolonged use.[48]

Nonsteroidal Anti-Inflammatory Drugs. Nonsteroidal anti-inflammatory drugs (NSAIDs) such as ibuprofen are widely used for the treatment of inflammation and rheumatoid arthritis and for pain management. Low-dosage aspirin, due to its antiplatelet function, is commonly used as a preventive therapeutic for cardiovascular disease, but not as an anti-inflammatory drug.[49] There are few data to suggest that short-term NSAIDs have a negative impact on healing. However, the question of whether long-term NSAIDs interfere with wound healing remains open. In animal models, systemic use of ibuprofen has demonstrated an antiproliferative effect on wound healing, resulting in decreased numbers of fibroblasts, weakened breaking strength, reduced wound contraction, delayed epithelialization,[50] and impaired angiogenesis. The effects of low-dose aspirin on healing are not completely clear. Clinical recommendations suggest that, to avoid antiplatelet effects, individuals should discontinue NSAIDs for a time period equal to 4 to 5 times the half-life of drugs before surgery. Thus, the majority of surgical patients do not have significant NSAID activity at the time of wound repair. The exception may be those cardiac patients who must be maintained on low-dose aspirin due to severe risk of cardiovascular events. In terms of the topical application of NSAIDs on the surfaces of chronic wounds, the local use of ibuprofen foam provides moist wound healing, reduces persistent and temporary wound pain, and benefits chronic venous leg ulcer healing.

Peripheral Vascular Disease

Total disease prevalence based on objective testing has been evaluated in several epidemiologic studies and is in the range of 3% to 10%, increasing to 15% to 20% in persons over 70 years.[51] Peripheral vascular disease (PVD) is an independent risk factor for subsequent ulceration and limb loss in diabetes. It is present in 50% of patients with diabetic foot ulcer (DFU), a proportion that may be increasing. Those with DFU and peripheral arterial disease (PAD) are less likely to heal and more likely to require amputation compared to patients without PAD. It is therefore essential that PVD is identified in all patients with diabetes.

Patients with PVD commonly suffer from chronic toe and foot sores, cramping leg muscles when walking or numbness, weakness or heaviness in the muscles. Other PVD symptoms include:

- Numbness in the extremities

- Weakness and atrophy of calf muscles
- A feeling of coldness in legs or feet
- Changes in the color of the feet: feet will turn pale when elevated and turn dusky red when in the dependent position
- Hair loss over the dorsum of the feet, thickening toenails
- Painful ulcers and/or gangrene in tissue, typically in the toes

Pathophysiology: The etiology of ulceration in diabetic patients with PVD is multifactorial distal polyneuropathy (motor, sensory, and autonomic), abnormal foot anatomy, functional changes in the microcirculation in the presence of PVD, lead to abnormal loading or trauma of the poorly perfused painless neuropathic foot. Infection in the foot exponentially increases the demand for oxygen, which in PVD is unmet. Healing is impaired also due to impaired humoral immunity and abnormal inflammatory responses.[52]

Traditional wound care algorithms include aggressive detection of PAD and treatment with revascularization for all patients with PVD and lower extremity wounds – in order to prevent limb amputation. The Transatlantic Inter-Society Consensus (TASCII) criteria for critical limb ischemia is a commonly used method for revascularization. When the TcPO2 is >30 mm Hg, the ankle-brachial index (ABI) and the TASC II definition of critical limb ischemia predict wound healing and should be key factors in considering conservative therapy. New strategies are being developed to diagnose PVD in patients with diabetes, referring those presenting with a new foot ulcer to a multidisciplinary team, so that appropriate interventions help preserve the limb.

Stress

Stress has a great impact on human health and social behavior. Many diseases – such as cardiovascular disease, cancer, compromised wound healing, and diabetes – are associated with stress. Numerous studies have confirmed that stress-induced disruption of neuroendocrine immune equilibrium is consequential to health.[53] The pathophysiology of stress results in the deregulation of the immune system, mediated primarily through the hypothalamic–pituitary–adrenal and sympathetic–adrenal medullary axes or sympathetic nervous system.[54]

Studies in both humans and animals have demonstrated that psychological stress causes a substantial delay in wound healing.[55] Caregivers of persons with Alzheimer's and students undergoing academic stress during examinations demonstrated delayed wound healing.[56] The hypothalamic – pituitary–adrenal and the sympathetic–adrenal medullary axes regulate the release of pituitary and adrenal hormones. These hormones include the adrenocorticotrophic hormones, cortisol and prolactin, and catecholamines (epinephrine and norepinephrine). Stress upregulates glucocorticoids and reduces the levels of the pro-inflammatory cytokines IL-1β, IL-6, and TNF-α at the wound site. Stress also reduces the expression of IL-1α and IL-8 at wound sites – both chemoattractants that are necessary for the initial inflammatory phase of wound healing.[57] Furthermore, glucocorticoids influence immune cells by suppressing differentiation and proliferation, regulating gene

transcription, and reducing expression of cell adhesion molecules that are involved in immune cell trafficking.[58] Cortisol functions as an anti-inflammatory agent and modulates the Th1-mediated immune responses that are essential for the initial phase of healing. Thus, psychological stress impairs normal cell-mediated immunity at the wound site, causing a significant delay in the healing process.[59]

Stressors can lead to negative emotional states, such as anxiety and depression, which may in turn have an impact on physiologic processes and/or behavioral patterns that influence health outcomes. In addition to the direct influences of anxiety and depression on endocrine and immune function, stressed individuals are more likely to have unhealthy habits, which include poor sleep patterns, inadequate nutrition, less exercise, and a greater propensity for abuse of alcohol, cigarettes, and other drugs. All of these factors may come into play in negatively modulating the healing response.

Cigarette Smoking

It is well known that smoking increases the risk of heart and vascular disease, stroke, chronic lung disease, and many kinds of cancers. Similarly, the negative effects of smoking on wound healing outcomes have been known for a long time.[60] Postoperatively, patients who smoke show a delay in wound healing and an increase in a variety of complications such as infection, wound rupture, anastomotic leakage, wound and flap necrosis, epidermolysis, and a decrease in the tensile strength of wounds.[61] In the realm of oral surgery, impaired healing in smokers has been noticed both in routine oral surgery and in the placement of dental implants.[62] Cosmetic outcomes also appear to be worse in smokers, and plastic and reconstructive surgeons are often reluctant to perform cosmetic surgeries on individuals who refuse to quit smoking.[63] Approximately 4000 substances in tobacco smoke have been identified, and some have been shown to have a negative impact on healing.[64] Most studies have focused on the effects of nicotine, carbon monoxide, and hydrogen cyanide from smoke. Nicotine interferes with oxygen supply by inducing tissue ischemia, since nicotine can cause decreased tissue blood flow via vasoconstrictive effects.[65] Nicotine stimulates sympathetic nervous activity, resulting in the release of epinephrine, which causes peripheral vasoconstriction and decreased tissue blood perfusion. Nicotine also increases blood viscosity caused by decreasing fibrinolytic activity and augmentation of platelet adhesiveness. In addition to the effects of nicotine, carbon monoxide in cigarette smoke also causes tissue hypoxia. Carbon monoxide binds to hemoglobin with an affinity 200 times greater than that of oxygen, resulting in a decreased fraction of oxygenated hemoglobin in the bloodstream. Hydrogen cyanide, another well-studied component of cigarette smoke, impairs cellular oxygen metabolism, leading to compromised oxygen consumption in the tissues. Beyond these direct tissue effects, smoking increases the individual's risk for atherosclerosis and chronic obstructive pulmonary disease, two conditions that might also lower tissue oxygen tension.[66]

Several cell types and processes that are important to healing have been shown to be adversely affected by tobacco smoke. In the inflammatory phase, smoking causes impaired white blood cell migration, resulting in lower numbers of monocytes and

macrophages in the wound site, and reduces neutrophil bactericidal activity. Lymphocyte function, cytotoxicity of natural killer cells, and production of IL-1 are all depressed, and macrophage sensing of gram-negative bacteria is inhibited.[67] These effects result in poor wound healing and an increased risk of opportunistic wound infection.

During the proliferative phase of wound healing, exposure to smoke yields decreased fibroblast migration and proliferation, reduced wound contraction, hindered epithelial regeneration, decreased ECM production, and upset in the balance of proteases.[68]

Pharmacologically, the influence of smoking on wound healing is complicated, and neither nicotine alone nor any other single component can explain all of the effects of smoking on wounds. What is certain is that smoking cessation leads to improved repair and reduces wound infection.[69] For surgery patients who find it difficult to forego smoking, the use of a transdermal patch during the preoperative period might be beneficial. A study has shown that the use of a transdermal nicotine patch as a nicotine replacement for smoking cessation therapy can increase type I collagen synthesis in wounds.[70] Despite the overall negative effects of smoking, some recent studies have suggested that low doses of nicotine enhance angiogenesis and actually improve healing.[71]

Alcohol and Substance Abuse

Clinical evidence and animal experiments have shown that exposure to alcohol impairs wound healing and increases the incidence of infection.[72] The effect of alcohol on repair is quite clinically relevant, since over half of all emergency room trauma cases involve either acute or chronic alcohol exposure. Alcohol exposure diminishes host resistance, and ethanol intoxication at the time of injury is a risk factor for increased susceptibility to infection in the wound.[73] Studies have demonstrated profound effects of alcohol on host-defense mechanisms, although the precise effects are dependent upon the pattern of alcohol exposure (i.e., chronic vs. acute alcohol exposure, amount consumed, duration of consumption, time from alcohol exposure, and alcohol withdrawal). A recent review on alcohol-induced alterations on host defense after traumatic injury suggested that, in general, short-term acute alcohol exposure results in suppressed pro-inflammatory cytokine release in response to an inflammatory challenge. The higher rate of postinjury infection correlates with decreased neutrophil recruitment and phagocytic function in acute alcohol exposure.[74]

Beyond the increased incidence of infection, exposure to ethanol also seems to influence the proliferative phase of healing. In murine models, exposure to a single dose of alcohol that caused a blood alcohol level of 100 mg/dL (just above the legal limit in most states in the United States) perturbed re-epithelialization, angiogenesis, collagen production, and wound closure.[75] The most significant impairment seems to be in wound angiogenesis, which is reduced by up to 61% following a single ethanol exposure. This decrease in angiogenic capacity involves both decreased expression of VEGF receptors and reduced nuclear expression of HIF-1alpha in endothelial cells.[76] The ethanol-mediated decrease in wound vascularity causes increased wound hypoxia and oxidative stress.[77] Connective tissue restoration is also influenced by acute ethanol exposure, and results in

decreased collagen production and alterations in the protease balance at the wound site. In summary, acute ethanol exposure can lead to impaired wound healing by impairing the early inflammatory response, inhibiting wound closure, angiogenesis, and collagen production, and altering the protease balance at the wound site.

As mentioned previously, the host response to chronic alcohol exposure appears to be different from that of acute alcohol exposure. Analysis of clinical data indicates that chronic alcohol exposure causes impaired wound healing and enhanced host susceptibility to infections, but the detailed mechanisms that explain this effect need more investigation.

Cancer, Chemotherapy, and Radiation

Chemotherapeutic Drugs. Most chemotherapeutic drugs are designed to inhibit cellular metabolism, rapid cell division, and angiogenesis and thus inhibit many of the pathways that are critical to appropriate wound repair. These medications inhibit DNA, RNA, or protein synthesis, resulting in decreased fibroplasia and neovascularization of wounds.[78] Chemotherapeutic drugs delay cell migration into the wound, decrease early wound matrix formation, lower collagen production, impair proliferation of fibroblasts, and inhibit contraction of wounds.[79] In addition, these agents weaken the immune functions of the patients, and thereby impede the inflammatory phase of healing and increase the risk of wound infection. Chemotherapy induces neutropenia, anemia, and thrombocytopenia, thus leaving wounds vulnerable to infection, causing less oxygen delivery to the wound, and also making patients vulnerable to excessive bleeding at the wound site.

Impaired wound healing due to chemotherapeutic drugs such as Adriamycin is most common when the drugs are administered preoperatively or within 3 weeks postoperatively.[80] Additionally, low postoperative albumin levels, low postoperative hemoglobin, advanced stage of disease, and electrosurgery use have all been reported as risk factors for the development of wound complications.[81]

A newer generation of tumor chemotherapeutics include angiogenesis inhibitors, such as bevacizumab, which is an antibody fragment that neutralizes VEGF. These therapies work in conjunction with traditional chemotherapeutics to limit the blood supply to tumors, reducing their ability to grow. Wound healing complications, including an increase in wound dehiscence, have been described in patients on angiogenesis inhibitors.[82] A caveat is that most patients on angiogenesis inhibitors are also on traditional chemotherapeutics, making it difficult to sort out whether angiogenesis inhibitors alone would perturb repair.[83] Nevertheless, current recommendations include discontinuation of angiogenesis inhibitors well in advance of any surgical procedures.

Radiation

Radiation is one of the most commonly used therapies for the treatment of multiple types of human cancer. It results in a wide range of acute and chronic toxicities, with poor health outcomes, and often become dose-limiting for patients and impairing their quality of life (QoL) and recovery in both the short and the long term.

4 Injury resulting from radiation and chemotherapy is initiated through two major paths: radiolytic hydrolysis and stimulation of the innate immune response. Of the two, oxidative stress is the best studied with respect to cancer treatment-associated tissue injury. After an initial exposure to radiation, there is immediate damage to the keratinocyte cells of the skin, which is accompanied by a simultaneous increase in free radicals, DNA damage, and inflammation. Radiation- or chemotherapy-induced oxidative stress leads to the production of oxygen free radicals; specifically the reactive oxygen species superoxides, hydrogen peroxides, and hydroxyl radicals that cause oxidative damage to the tissue. Inflammatory cells are recruited to the injured area, a process orchestrated by vasodilation and vascular permeability. On the cellular level, fibrosis involves the coordination of a variety of cell types largely mediated through the fibroblast. The infiltrating immune cells secrete cytokines that drive the differentiation of fibroblasts and other self-renewing cells into myofibroblasts which deposit collagens and other ECM proteins at and around the site of tissue damage.[84]

References

1. Staylor A. Wound care devices: growth amid uncertainty. *Med Tech Insight* 2009;11(1):32–47.
2. Gosain A, DiPietro LA. Aging and wound healing. *World J Surg* 2004;28(3): 321–326.
3. Niinikoski J, Bakker D, Cronjé F, et al. ECHM-ETRS joint conference on oxygen and tissue repair, Ravenna, Italy, October 27–28, 2006: recommendations by the international jury. *Int J Low Extrem Wounds* 2007;6(3):139–142.
4. Nurden AT, Nurden P, Sanchez M, et al. Platelets and wound healing. *Front Biosci* 2008;13:3532–3548.
5. Prockop DJ, Kivirikko KI. Collagens: molecular biology, diseases, and potentials for therapy. *Annu Rev Biochem* 1995;64:403–434.
6. Clark RA. Fibrin and wound healing. *Ann N Y Acad Sci* 2001;936:355–367.
7. Peterkofsky B. Ascorbate requirement for hydroxylation and secretion of procollagen: relationship to inhibition of collagen synthesis in scurvy. *Am J Clin Nutr* 1991;54:1135S–1140S.
8. Blumenkrantz N, Assad R, Peterkofsky B. Characterization of collagen hydroxylysyl glycosyltransferases as mainly intramembranous microsomal enzymes. *J Biol Chem* 1984;259:854–859.
9. Prockop DJ, Sieron AL, Li SW. Procollagen N-proteinase and procollagen C-proteinase. Two unusual metalloproteinases that are essential for procollagen processing probably have important roles in development and cell signaling. *Matrix Biol* 1998;16:399–408.
10. Zanaboni G, Rossi A, Onana AM, et al. Stability and networks of hydrogen bonds of the collagen triple helical structure: influence of pH and chaotropic nature of three anions. *Matrix Biol* 2000;19:511–520.
11. Hornstra IK, Birge S, Starcher B, et al. Lysyl oxidase is required for vascular and diaphragmatic development in mice. *J Biol Chem* 2003;278:14387–14393.
12. Parks WC. Matrix metalloproteinases in repair. *Wound Repair Regen* 1999; 7:423–432.
13. Keylock KT, Vieira VJ, Wallig MA, et al. Exercise accelerates cutaneous wound healing and decreases wound inflammation in aged mice. *Am J Physiol Regul Integr Comp Physiol* 2008;294(1):R179–R184.
14. Swift ME, Burns AL, Gray KL, et al. Age-related alterations in the inflammatory response to dermal injury. *J Invest Dermatol* 2001;117(5):1027–1035.
15. Gilliver SC, Ashworth JJ, Ashcroft GS. The hormonal regulation of cutaneous wound healing. *Clin Dermatol* 2007;25(1):56–62.
16. Hardman MJ, Ashcroft GS. Estrogen, not intrinsic aging, is the major regulator of delayed human wound healing in the elderly. *Genome Biol* 2008;9(5):R80.
17. Hardman MJ, Emmerson E, Campbell L, et al. Selective estrogen receptor modulators

accelerate cutaneous wound healing in ovariectomized female mice. *Endocrinology* 2008;149(2):551–557.

18. Emery CF, Kiecolt-Glaser JK, Glaser R, et al. Exercise accelerates wound healing among healthy older adults: a preliminary investigation. *J Gerontol A Biol Sci Med Sci* 2005;60(11):1432–1436.
19. Arnold M, Barbul A. Nutrition and wound healing. *Plast Reconstr Surg* 2006; 117(7 Suppl):42S–58S.
20. Shepherd AA. Nutrition for optimum wound healing. *Nurs Stand* 2003; 18(6):55–58.
21. Campos AC, Groth AK, Branco AB. Assessment and nutritional aspects of wound healing. *Curr Opin Clin Nutr Metab Care* 2008;11(3):281–288.
22. Tong BC, Barbul A. Cellular and physiological effects of arginine. *Mini Rev Med Chem* 2004;4(8):823–832.
23. da Costa MA, Campos AC, Coelho JC, et al. Oral glutamine and the healing of colonic anastomoses in rats. *JPEN J Parenter Enteral Nutr* 2003;27(3):182–185; discussion 185–186.
24. McDaniel JC, Belury M, Ahijevych K, et al. Omega-3 fatty acids effect on wound healing. *Wound Repair Regen* 2008;16(3):337–345.
25. Burgess C. Topical vitamins. *J Drugs Dermatol* 2008;7(7 Suppl):s2–s6.
26. Khoosal D, Goldman RD. Vitamin E for treating children's scars. Does it help reduce scarring? *Can Fam Physician* 2006;52:855–856.
27. Arnold M, Barbul A. Nutrition and wound healing. *Plast Reconstr Surg* 2006;117(7Suppl):42S–58S.
28. Heyman H, Van De Looverbosch DE, Meijer EP, et al. Benefits of an oral nutritional supplement on pressure ulcer healing in long-term care residents. *J Wound Care* 2008;17(11):476–478, 480.
29. Centers for Disease Control and Prevention, CDC. Available from: http://www.cdc.gov/obesity/data/index.html. Accessed April 21, 2016.
30. Wilson JA, Clark JJ. Obesity: impediment to postsurgical wound healing. *Adv Skin Wound Care* 2004;17(8):426–435.
31. Momeni M, Hafezi F, Rahbar H, et al. Effects of silicone gel on burn scars. *Burns* 2009;35(1):70–74.
32. Anaya DA, Dellinger EP. The obese surgical patient: a susceptible host for infection. *Surg Infect (Larchmt)* 2006;7(5):473–480.
33. Calabro P, Yeh ET. Obesity, inflammation, and vascular disease: the role of the adipose tissue as an endocrine organ. *Subcell Biochem* 2007;42:63–91.
34. de Mello VD, Kolehmainen M, Schwab U. Effect of weight loss on cytokine messenger RNA expression in peripheral blood mononuclear cells of obese subjects with the metabolic syndrome. *Metabolism* 2008;57(2):192–199.
35. Brem H, Tomic-Canic M. Cellular and molecular basis of wound healing in diabetes. *J Clin Invest* 2007;117(5):1219–1222.

36. Tandara AA, Mustoe TA. Oxygen in wound healing–more than a nutrient. *World J Surg* 2004;28(3):294–300.
37. Woo K, Ayello EA, Sibbald RG. The edge effect: current therapeutic options to advance the wound edge. *Adv Skin Wound Care* 2007;20(2):99–117; quiz 118–119.
38. Vincent MA, Clerk LH, Lindner JR, et al. Microvascular recruitment is an early insulin effect that regulates skeletal muscle glucose uptake in vivo. *Diabetes* 2004;53(6):1418–1423.
39. Prompers L, Schaper N, Apelqvist J, et al. Prediction of outcome in individuals with diabetic foot ulcers: focus on the differences between individuals with and without peripheral arterial disease. The EURODIALE Study. *Diabetologia* 2008;51(5):747–755.
40. Woo K, Sibbald G, Fogh K, et al. Assessment and management of persistent (chronic) and total wound pain. *Int Wound J* 2008;5(2):205–215.
41. Loots MA, Lamme EN, Zeegelaar J, et al. Differences in cellular infiltrate and extracellular matrix of chronic diabetic and venous ulcers versus acute wounds. *J Invest Dermatol* 1998;111(5):850–857.
42. Quattrini C, Jeziorska M, Boulton AJ, et al. Reduced vascular endothelial growth factor expression and intra-epidermal nerve fiber loss in human diabetic neuropathy. *Diabetes Care* 2008;31(1):140–145.
43. Liu ZJ, Velazquez OC. Hyperoxia, endothelial progenitor cell mobilization, and diabetic wound healing. *Antioxid Redox Signal* 2008;10(11):1869–1882.
44. Galiano RD, Tepper OM, Pelo CR, et al. Topical vascular endothelial growth factor accelerates diabetic wound healing through increased angiogenesis and by mobilizing and recruiting bone marrow-derived cells. *Am J Pathol* 2004;164(6):1935–1947.
45. Galkowska H, Wojewodzka U, Olszewski WL. Chemokines, cytokines, and growth factors in keratinocytes and dermal endothelial cells in the margin of chronic diabetic foot ulcers. *Wound Repair Regen* 2006;14(5):558–565.
46. Franz MG, Steed DL, Robson MC. Optimizing healing of the acute wound by minimizing complications. *Curr Probl Surg* 2007;44(11):691–763.
47. Wagner AE, Huck G, Stiehl DP, et al. Dexamethasone impairs hypoxia-inducible factor-1 function. *Biochem Biophys Res Commun* 2008;372(2):336–340.
48. Hofman D, Moore K, Cooper R, et al. Use of topical corticosteroids on chronic leg ulcers. *J Wound Care* 2007;16(5):227–230.
49. Biesenbach G, Biesenbach P, Bodlaj G, et al. Impact of smoking on progression of vascular diseases and patient survival in type-1 diabetic patients after simultaneous kidney-pancreas transplantation in a single centre. *Transpl Int* 2008;21(4):357–363.
50. Krischak GD, Augat P, Claes L, et al. The effects of non-steroidal anti-inflammatory drug application on incisional wound healing in rats. *J Wound Care* 2007;16(2):76–78.
51. Selvin E, Erlinger TP. Prevalence of and risk factors for peripheral arterial disease in the United States: results from the National Health and Nutrition Examination

Survey, 1999–2000. *Circulation* 2004;110(6):738–743.
52. Martin JM, Zenilman JM, Lazarus GS. Molecular microbiology: new dimensions for cutaneous biology and wound healing. *J Invest Dermatol* 2010; 130:38–48.
53. Kiecolt-Glaser JK, Page GG, Marucha PT, et al. Psychological influences on surgical recovery. Perspectives from psychoneuroimmunology. *Am Psychol* 1998;53(11):1209–1218.
54. Boyapati L, Wang HL. The role of stress in periodontal disease and wound healing. *Periodontol 2000* 2007;44:195–210.
55. Holmes CJ, Plichta JK, Gamelli RL, et al. Dynamic Role of Host Stress Responses in Modulating the Cutaneous Microbiome: Implications for Wound Healing and Infection. *Adv Wound Care (New Rochelle)* 2015; 4(1):24–37.
56. Glaser R, Kiecolt-Glaser JK. Stress-induced immune dysfunction: implications for health. *Nat Rev Immunol* 2005;5(3):243–251.
57. Godbout JP, Glaser R. Stress-induced immune dysregulation: implications for wound healing, infectious disease and cancer. *J Neuroimmune Pharmacol* 2006;1(4):421–427.
58. Peyroux J, Sternberg M. Advanced glycation endproducts (AGEs): pharmacological inhibition in diabetes. *Pathol Biol (Paris)* 2006;54(7):405–419.
59. Godbout JP, Glaser R. Stress-induced immune dysregulation: implications for wound healing, infectious disease and cancer. *J Neuroimmune Pharmacol* 2006;1(4):421–427.
60. Siana JE, Rex S, Gottrup F. The effect of cigarette smoking on wound healing. *Scand J Plast Reconstr Surg Hand Surg* 1989;23(3):207–209.
61. Ahn C, Mulligan P, Salcido RS. Smoking-the bane of wound healing: biomedical interventions and social influences. *Adv Skin Wound Care* 2008; 21(5):227-236; quiz 237–238.
62. Levin L, Schwartz-Arad D. The effect of cigarette smoking on dental implants and related surgery. *Implant Dent* 2005;14(4):357–361.
63. Siana JE, Rex S, Gottrup F. The effect of cigarette smoking on wound healing. *Scand J Plast Reconstr Surg Hand Surg* 1989;23(3):207–209.
64. Scolaro JA, Schenker ML, Yannascoli S, et al. Cigarette smoking increases complications following fracture: a systematic review. *J Bone Joint Surg Am* 2014;96(8):674–681.
65. S⊘rensen LT, J⊘rgensen S, Petersen LJ, et al. Acute effects of nicotine and smoking on blood flow, tissue oxygen, and aerobe metabolism of the skin and subcutis. *J Surg Res* 2009;152(2):224–230.
66. Siasos G, Tsigkou V, Kokkou E, et al. Smoking and atherosclerosis: mechanisms of disease and new therapeutic approaches. *Curr Med Chem* 2014;21(34):3936–3948.
67. McMaster SK, Paul-Clark MJ, Walters M, et al. Cigarette smoke inhibits macrophage sensing of Gram-negative bacteria and lipopolysaccharide: relative roles of nicotine and oxidant stress. *Br J Pharmacol* 2008;153(3):536–443.
68. S⊘rensen LT, Zillmer R, Agren M, et al. Effect of smoking, abstention, and nicotine

patch on epidermal healing and collagenase in skin transudate. *Wound Repair Regen* 2009;17(3):347–353.

69. S⊘rensen LT. Wound healing and infection in surgery: the pathophysiological impact of smoking, smoking cessation, and nicotine replacement therapy: a systematic review. *Ann Surg* 2012;255(6):1069–1079.
70. S⊘rensen LT, Jorgensen LN, Zillmer R, et al. Transdermal nicotine patch enhances type I collagen synthesis in abstinent smokers. *Wound Repair Regen* 2006;14(3):247–251.
71. Morimoto N, Takemoto S, Kawazoe T, et al. Nicotine at a low concentration promotes wound healing. *J Surg Res* 2008;145(2):199–204.
72. Jung MK, Callaci JJ, Lauing KL, et al. Alcohol exposure and mechanisms of tissue injury and repair. *Alcohol Clin Exp Res* 2011;35(3):392–399.
73. Choudhry MA, Li X, Chaudry IH. A role for corticosterone in impaired intestinal immunity and barrier function in a rodent model of acute alcohol intoxication and burn injury. *J Neuroimmune Pharmacol* 2006;1(4):428–434.
74. Curtis BJ, Hlavin S, Brubaker AL, et al. Episodic binge ethanol exposure impairs murine macrophage infiltration and delays wound closure by promoting defects in early innate immune responses. *Alcohol Clin Exp Res* 2014;38(5):1347–1355.
75. Aberg KM, Radek KA, Choi EH, et al. Psychological stress downregulates epidermal antimicrobial peptide expression and increases severity of cutaneous infections in mice. *J Clin Invest* 2007;117(11):3339–3349.
76. Fitzgerald DJ, Radek KA, Chaar M, et al. Effects of acute ethanol exposure on the early inflammatory response after excisional injury. *Alcohol Clin Exp Res* 2007;31(2):317–323.
77. Radek KA, Kovacs EJ, Gallo RL, et al. Acute ethanol exposure disrupts VEGF receptor cell signaling in endothelial cells. *Am J Physiol Heart Circ Physiol* 2008;295(1):H174–H184.
78. Zimmerman-Pope N, Waldron DR, Barber DL, et al. Effect of fenoldopam on renal function after nephrotomy in normal dogs. *Vet Surg* 2003;32(6):566–573.
79. Franz MG, Steed DL, Robson MC. Optimizing healing of the acute wound by minimizing complications. *Curr Probl Surg* 2007;44(11):691–763.
80. Lawrence WT, Talbot TL, Norton JA. Preoperative or postoperative doxorubicin hydrochloride (adriamycin): which is better for wound healing? *Surgery* 1986;100(1):9–13.
81. Kolb BA, Buller RE, Connor JP, et al. Effects of early postoperative chemotherapy on wound healing. *Obstet Gynecol* 1992;79(6):988–992.
82. Bessissow T, Lemmens B, Ferrante M, et al. Prognostic value of serologic and histologic markers on clinical relapse in ulcerative colitis patients with mucosal healing. *Am J Gastroenterol* 2012;107(11):1684–1692.
83. Scappaticci FA, Fehrenbacher L, Cartwright T, et al. Surgical wound healing

complications in metastatic colorectal cancer patients treated with bevacizumab. *J Surg Oncol* 2005;91(3):173–180.

84. Mancini, M, Sonis ST. Mechanisms of cellular fibrosis associated with cancer regimen-related toxicities. *Front Pharmacol* 2014;5:51.

Chapter 6

Hemostasis

Peter K. Henke and Thomas W. Wakefield

Key Points

1 At the same time that thrombin forms, natural anticoagulant mechanisms oppose further thrombin formation and help to localize thrombin activity to areas of vascular injury. Just as thrombin generation is key to coagulation, antithrombin is the central anticoagulant protein.

2 The endothelial cell acts as a nonthrombogenic surface, and inflammation tips the balance to procoagulant state.

3 Thrombosis and inflammation are closely linked, and may perpetuate each other. Leukocytes and chemokines are involved with normal DVT resolution. These essential inflammatory mechanisms may drive vein wall injury.

4 Both acquired and inherited factors contribute to pathologic thrombosis; often occurring together.

5 Heparin-induced thrombocytopenia (HIT) occurs in 0.6% to 30% of patients in whom heparin is given; severe thrombocytopenia associated with thrombosis (HITTS) is much less frequent. Cessation of heparin is critical.

6 Factor VIII and IX deficiency states are involved in hemophilia A and B and von Willebrand disease.

BASIC CONSIDERATIONS

Coagulation is an essential homeostatic mechanism for survival, and involves tightly controlled processes to maintain vascular integrity including thrombosis localization, amplification, and neutralization. These coordinated steps occur at the vessel, cellular and subcellular levels. Thrombosis, directly or indirectly, is the underlying leading cause of death in the world, and is an essential part of surgery.

Platelets form the initial hemostatic plug after vascular injury, and are locally activated and aggregation induced (Fig. 6-1). Platelet aggregation is mediated by receptors that are part of the mammalian integrin family. This family includes the β_1 family, mediating platelet interaction with cells, collagen, fibronectin, and laminin; the β_2 family (LeuCAM), present on leukocytes mediating interactions between leukocytes and other cells important in inflammation; and the β_3 family (cytoadhesion), including the megakaryocyte-specific glycoprotein (Gp) IIb/IIIa receptor and the vitronectin (Vn) receptor present on platelets and other cells.[1] Platelet aggregation is mediated by GpIIb/IIIa, which binds fibrinogen, von Willebrand factor (vWF), fibronectin, Vn, and thrombospondin to activated platelets. These high-density receptors are hidden on inactivated platelets and become exposed on the surface of activated platelets.

Two platelet activation routes are thought to occur physiologically.[2] Without direct vessel damage, platelet activation may occur via tissue factor (TF) de-encryption and activation by protein disulfide isomerase (PDI), with factor VIIa generation and activation of platelets. Alternatively, subendothelial collagen may directly bind to GpVI and vWF, leading to platelet capture and activation. Of note, PDI inhibition can directly block experimental thrombus formation.[3]

Once stimulated, activated platelets contract, with externalization of negatively charged procoagulant phospholipids, including phosphatidylserine and phosphatidylinositol (termed platelet factor 3). This allows the coagulation proteins to assemble on the surface membrane of platelets, accelerating the coagulation reaction.[4] During platelet activation, granules release their contents of calcium, serotonin, and membranes are exposed that are rich in receptors for factors Va and VIIIa,[5,6] as well as fibrinogen, vWF, and ADP, a potent activator of other platelets. vWF is responsible for platelet adhesion through binding to GpIb,[7] whereas fibrinogen forms bridges between activated platelets by binding to GpIIb/IIIa on adjacent stimulated platelets.[8] Platelets also release polyphosphates that activate factor XII and the intrinsic pathway.[9]

While long thought to be a bystander in venous thrombosis (VT) as compared to the arterial system, the role of the platelet is now thought to play a critical role, as well as directing later inflammatory cell actions.[10,11] First, recent clinical trials suggest antiplatelet therapy may reduce recurrent VTE.[12] Second, in stasis and nonstasis experimental murine VT, genetic deletion of vWF was associated with significantly reduced VT size and not restored with recombinant factor rVIII.[13] Intravital microscopy also showed direct association of leukocytes and platelets in a growing acute thrombus. Consistently, platelets via $GpIb_2$, may promote VT by colocalizing leukocytes and

coagulation factors at the site of injury or stasis in the vein.[14]

Once the platelet plug has formed, the stage is set for coagulation protein assembly (Fig. 6-2). Initiating agents for coagulation include subendothelial collagen and TF, usually from vascular injury.[2] There is also growing evidence that blood-borne TF associated with leukocytes, or circulating in soluble form, is also involved with venous thrombogenesis.[15,16] Leukocyte adhesion to platelets may trigger leukocyte activation, causing recruitment of blood-borne TF onto the surface of leukocytes associated with thrombus, or recruitment of TF-positive leukocytes onto the growing thrombus.[17] TF, both blood borne and local, activates the extrinsic pathway of coagulation by complexing with activated factor VII (VIIa), activating factors IX and X to factors IXa and Xa.[16,18] Factor Xa, activated factor V (Va), ionized calcium, and factor II (prothrombin) form on the platelet phospholipid surface to initiate the prothrombinase complex, which catalyzes the formation of thrombin faster than can be achieved with factor Xa alone.

Thrombin is central to coagulation and acts to cleave fibrinopeptide A (FPA) from the α chain of fibrinogen and fibrinopeptide B (FPB) from the β chain. This leads to the release of fibrinopeptides and the formation of new fibrin monomers, which then cross-link, resulting in fibrin polymerization. Thrombin also activates factor XIII, which catalyzes the cross-linking of fibrin to make the clot firm, activates platelets, and activates factors V and VIII, two nonenzymatic cofactors, to Va and VIIIa. This is important because only activated factors Va and VIIIa are involved in coagulation. Factor XIIIa also cross-links other plasma proteins, such as fibronectin and α_2-antitrypsin, resulting in their incorporation into clot.

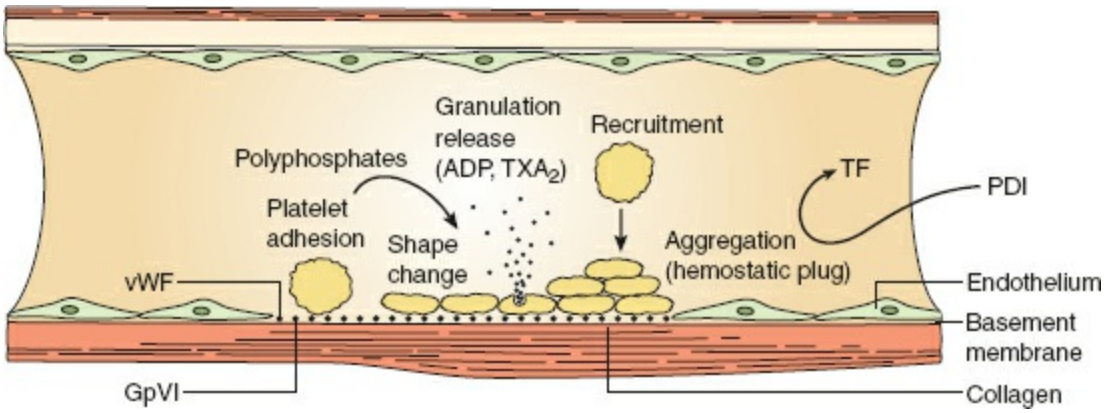

Figure 6-1. Primary hemostasis is achieved initially with a platelet aggregation as illustrated. Note that platelet adhesion, shape change, granule release, followed by recruitment and the hemostatic plug at the area of subendothelial collagen (binds to GpVI) exposure are the initial events for thrombus formation. Platelets can also be activated by PDI with de-encryption of TF.

The intrinsic pathway of blood coagulation requires activation of factor XI to XIa. This may occur by both the contact activation system through activation of factor XII, plasma prekallikrein, and high–molecular-weight kininogen and, more important, through thrombin with negatively charged surfaces.[19] Factor XIa activates factor XI autocatalytically and also catalyzes the conversion of factor IX to IXa. After activation, factor VIIIa dissociates from vWF and assembles with factors IXa and X. Factor IXa, factor

X, ionized calcium, and thrombin-activated factor VIII (VIIIa) then assemble on the platelet surface in a complex called the *Xase complex* to catalyze the activation of factor X to Xa. Factor Xa then shunts into the prothrombinase complex for further amplification of thrombin formation.

The importance of a mechanism of factor XI activation independent of the contact activation system is apparent because patients deficient in those factors of the contact activation system, including factor XI, bleed, whereas patients deficient in factor XII, prekallikrein, and high–molecular-weight kininogen do not usually bleed.[20] The contact activation system is the most important coagulation process involved in extracorporeal bypass circuits, including cardiopulmonary bypass and extracorporeal membrane oxygenation.

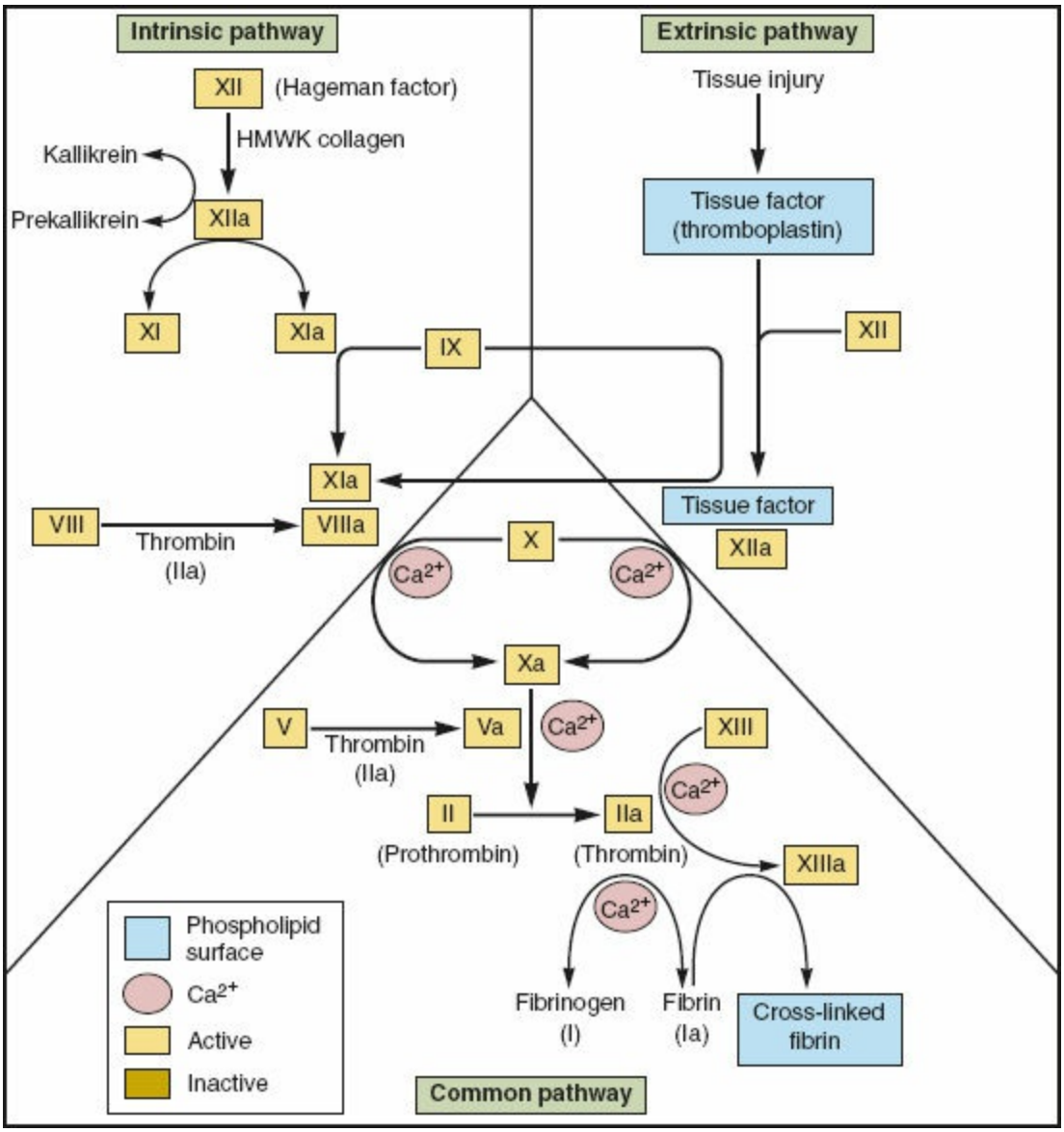

Figure 6-2. The classical pathway showing the interface between the intrinsic pathway, extrinsic pathway, and the common pathway is illustrated with the ultimate production of thrombin. This catalyzes fibrin from fibrinogen, and then cross-linking the fibrin to form a stable clot.

NATURAL ANTICOAGULANT MECHANISMS

1 At the same time that thrombin forms, natural anticoagulant mechanisms oppose further thrombin formation and help to localize thrombin activity to areas of vascular injury. Just as thrombin generation is key to coagulation, antithrombin (AT) is the central anticoagulant protein (Fig. 6-3). This glycoprotein of 70-kD molecular weight binds to thrombin, preventing the removal of FPA and FPB from fibrinogen, prevents the activation of factors V and VIII, and inhibits the activation and aggregation of platelets. In addition, AT directly inhibits factors IXa, Xa, and XIa.

A second natural anticoagulant is activated protein C (APC), which inactivates factors Va[21,22] and VIIIa, thus reducing the Xase and prothrombinase complex acceleration of the rate of thrombin formation. In the circulation, protein C is activated on endothelial cell surfaces by thrombin complexed with one of its receptors, thrombomodulin (TM).[23–25] The formation of this thrombin–TM complex accelerates the activation of protein C compared with thrombin alone. Thrombin, at the same time, by binding to TM, loses its platelet-activating activity as well as its enzymatic activity for fibrinogen and factor V. Protein S is a cofactor for APC.

Another innate anticoagulant is tissue factor pathway inhibitor (TFPI). The protein binds to TF–VIIa complex, inhibiting the activation of factor X to Xa and the formation of the prothrombinase complex.[26] A fourth natural anticoagulant is heparin cofactor II.[27] Its concentration in plasma is estimated to be significantly less than that of AT, and its action is implicated primarily in the regulation of thrombin formation in extravascular tissues. Finally, thrombin is inactivated when it becomes incorporated into the clot.

FIBRINOLYSIS

In addition to natural anticoagulants such as protein C and S, physiologic clot formation is balanced by a contained process of clot lysis, which prevents thrombus formation from proceeding outside of the injured area (Fig. 6-4). The central fibrinolytic enzyme is plasmin, a serine protease generated by the proteolytic cleavage of the proenzyme, plasminogen. Its main substrates include fibrin, fibrinogen, and other coagulation factors. Plasminogen, tissue plasminogen activator (tPA), and α_2-antiplasmin (α_2-AP) become incorporated into the fibrin clot as it forms. Plasminogen activators are serine proteases that activate plasminogen, by cleavage of a single arginine–valine peptide bond, to the enzyme plasmin. Plasminogen activation provides localized proteolytic activity.[28–30] In fact, thrombin promotes tPA release from endothelial cells as well as the production of plasminogen activator inhibitor (PAI-1) from endothelial cells.[31,32]

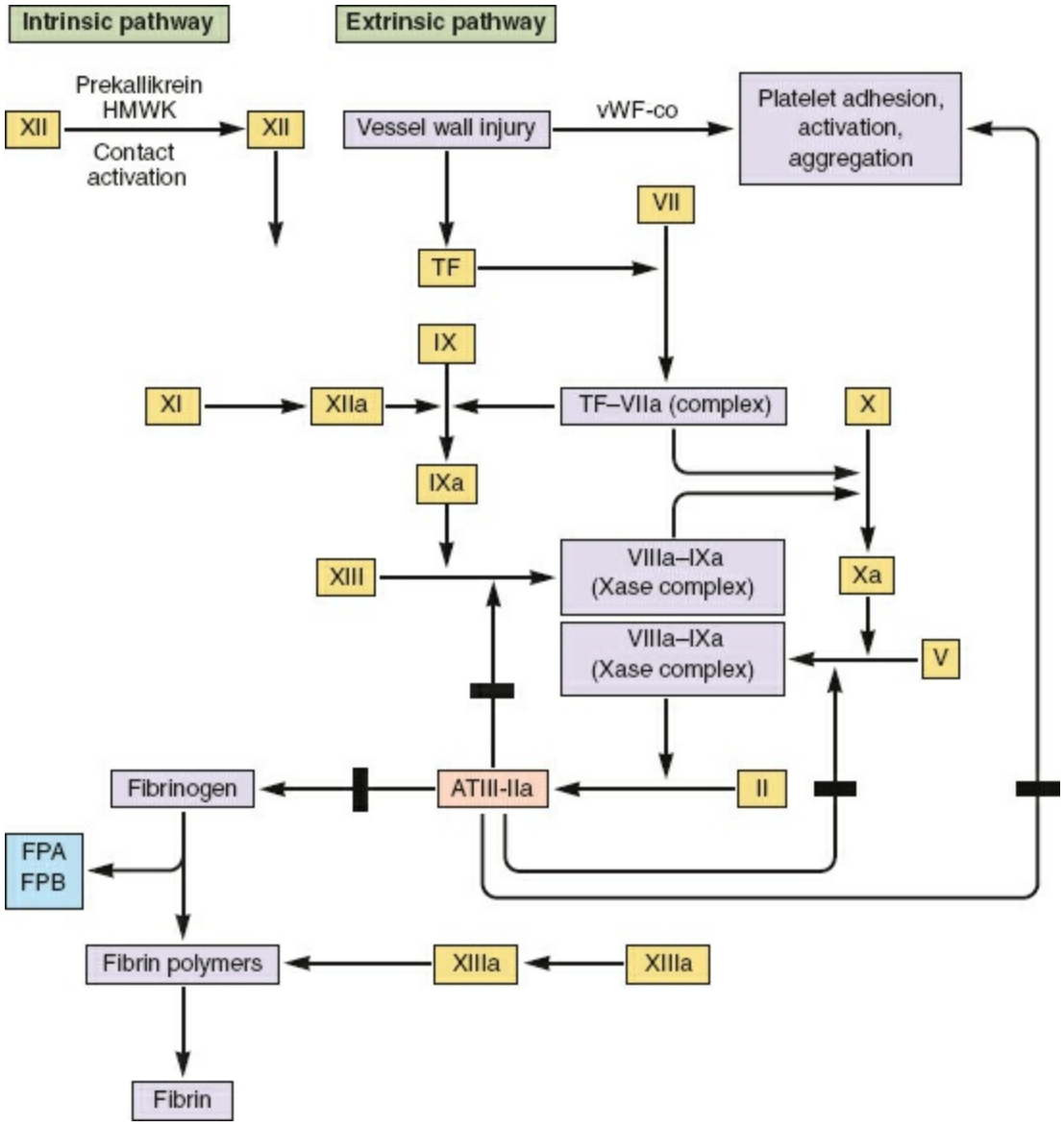

Figure 6-3. Antithrombin is a primary anticoagulant. Note antithrombin complexes with IIa to inhibit fibrin polymerization, as well as factor Xa, and an inactivating factor Va and VIIIa.

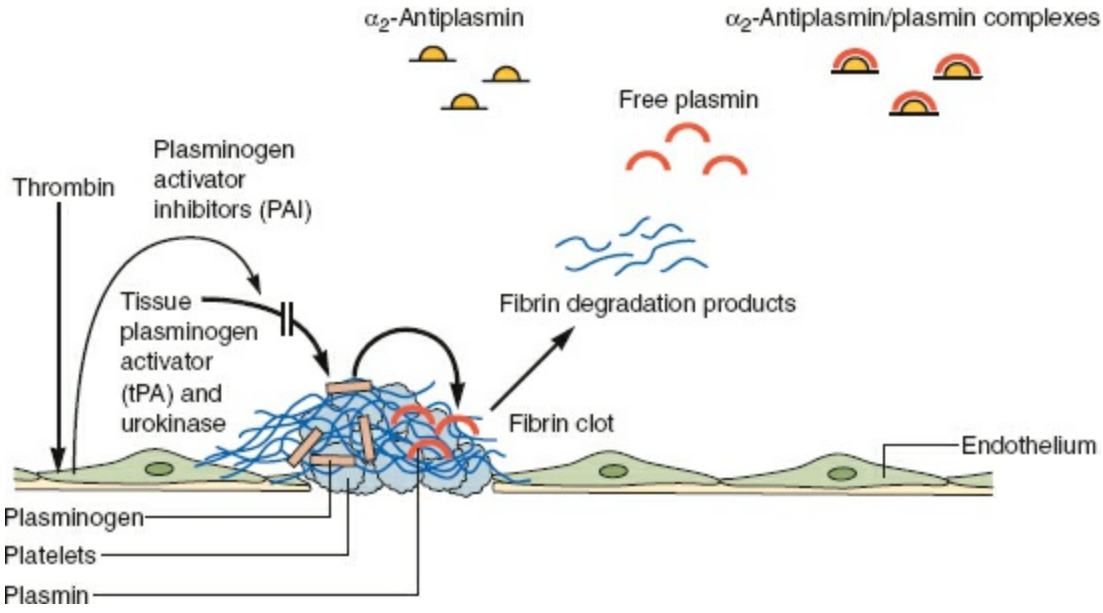

Figure 6-4. Hemostasis with thrombus production is a tight and intricate process that is locally confined. Balancing thrombus production is tissue plasmin activator and urokinase plasminogen activator which activates plasmin and causes thrombolysis. These are balanced by plasminogen activator inhibitor-1 and alpha-2-antiplasmin. Free plasmin is complexed rapidly. Fibrin degradation products, such as D-dimer are produced.

The major endogenous plasminogen activators include tPA and urokinase, and intrinsic factors, such as factor XII, prekallikrein, and high–molecular-weight kininogen. These later factors of the contact system are more important in clot lysis than thrombus formation. These enzymes may also liberate bradykinin from high–molecular-weight kininogen, resulting in an increase in vascular permeability, prostacyclin (PGI_2) liberation, and tPA secretion. Finally, APC has been found to proteolytically inactivate the inhibitor to tPA, thus promoting tPA activity and fibrinolysis.[33]

Fibrin, when digested by plasmin, yields one molecule of fragment E and two molecules of fragment D. In physiologic clot formation, fragment D is released in dimeric form (D-dimer),[20,34] and is a marker for fibrinolysis of formed clot. An elevated D-dimer level after treatment of DVT is one biomarker that has been found to accurately predict an ongoing risk of recurrent VTE.[35]

Two primary inhibitors of plasmin are important. First, α_2-AP is released by endothelial cells and complexes with plasmin. In physiologic fibrinolysis, α_2-AP is bound to fibrin and excess plasmin is readily inactivated. In plasma, PAI-1 is the primary inhibitor of plasminogen activators. It is secreted in an active form from liver and endothelial cells and stabilized by binding to Vn. PAI-1 levels are elevated by hyperlipidemia, and PAI-1 elevation appears to synergize with factor V Leiden genetic abnormalities.[36]

In summary, coagulation is an ongoing process of thrombus formation, inhibition of thrombus formation, and thrombus dissolution. The central mediators are TF, platelets, thrombin, and plasmin. Abnormalities in coagulation occur when one process – thrombus formation, thrombus inhibition, or fibrinolysis – overcomes the others and dominates the delicate balance.

ENDOTHELIUM AND HEMOSTASIS

2 Through its ability to express procoagulants and anticoagulant factors, vasoconstrictors and vasodilators, as well as key cell adhesion molecules and cytokines, the endothelial cell is a key regulator of hemostasis (Fig. 6-5).[37] Vascular endothelium maintains a vasodilatory and local fibrinolytic state in which coagulation, platelet adhesion and activation, and leukocyte activation are suppressed.

Vasodilatory endothelial products include adenosine, nitric oxide (NO), and PGI_2. A nonthrombogenic endothelial surface is maintained by four main mechanisms including; endothelial production of TM and subsequent activation of protein C, endothelial expression of surface heparan- and dermatan sulfate, constitutive expression of TFPI by endothelium (which is markedly accelerated in response to heparin), and local production of tPA and urokinase plasminogen activator (uPA).[37,38] Finally, the elaboration of NO and interleukin (IL)-10 by endothelium inhibits leukocyte adhesion and activation.

During states of endothelial disturbances such as injury, a prothrombotic and proinflammatory state of vasoconstriction is driven by the endothelial surface. Endothelial release of platelet-activating factor (PAF) and endothelin-1 promotes vasoconstriction.[38] Endothelial cells increase production of vWF, TF, PAI-1, and factor V to augment thrombosis with exposure to prothrombotic stimuli. Finally, in response to endothelial injury, endothelial cells are activated, resulting in increased surface expression of cell adhesion molecules, promoting leukocyte adhesion and activation.

THROMBOSIS, INFLAMMATION, AND RESOLUTION

3 After VT, an acute to chronic inflammatory response occurs in the vein wall and thrombus progressing from thrombus amplification, to organization, and vein recanalization (often at the expense of vein wall fibrosis and vein valvular damage). Initially, there is an increase in neutrophils (PMN) in the vein wall followed by monocytes/macrophages. Cytokines, chemokines, and inflammatory factors (e.g., tumor necrosis factor [TNF]) facilitate inflammation. The ultimate response of the vein wall depends on proinflammatory and anti-inflammatory mediator balance at the interface between the leukocyte, activated platelet, and endothelium.[39]

Selectins (P- and E-selectin) have been found to be intimately involved in this process (Fig. 6-6).[40] Selectins are the first upregulated glycoproteins on activated platelets (alpha granules) and endothelial cells (Weibel–Palade bodies). They mediate the adhesion of leukocytes, platelets, and even cancer cells in inflammation and thrombosis. The P-selectin receptor is P-selectin glycoprotein ligand-1 (PSGL-1). P-selectin:PSGL-1 interactions trigger the release of procoagulant microparticles (MPs), that support fibrin formation, thrombus growth, and increase monocyte TF expression.

MPs <1 micron fragments may be central for P-selectin's effect. It is believed that with initial thrombosis, P-selectin upregulation leads to MP formation. These procoagulant MPs, which may express TF, are then recruited into the area of developing thrombosis, amplifying the process. Consistently, P-selectin gene deficiency, results in less MP formation, and less thrombosis.[41] In an experimental study, the generation of procoagulant activity was shown to be dependent on P-selectin:PSGL-1 interactions related to MP formation.[42] The procoagulant nature of these MP was demonstrated by their ability to normalize bleeding in factor VIII–deficient mice.

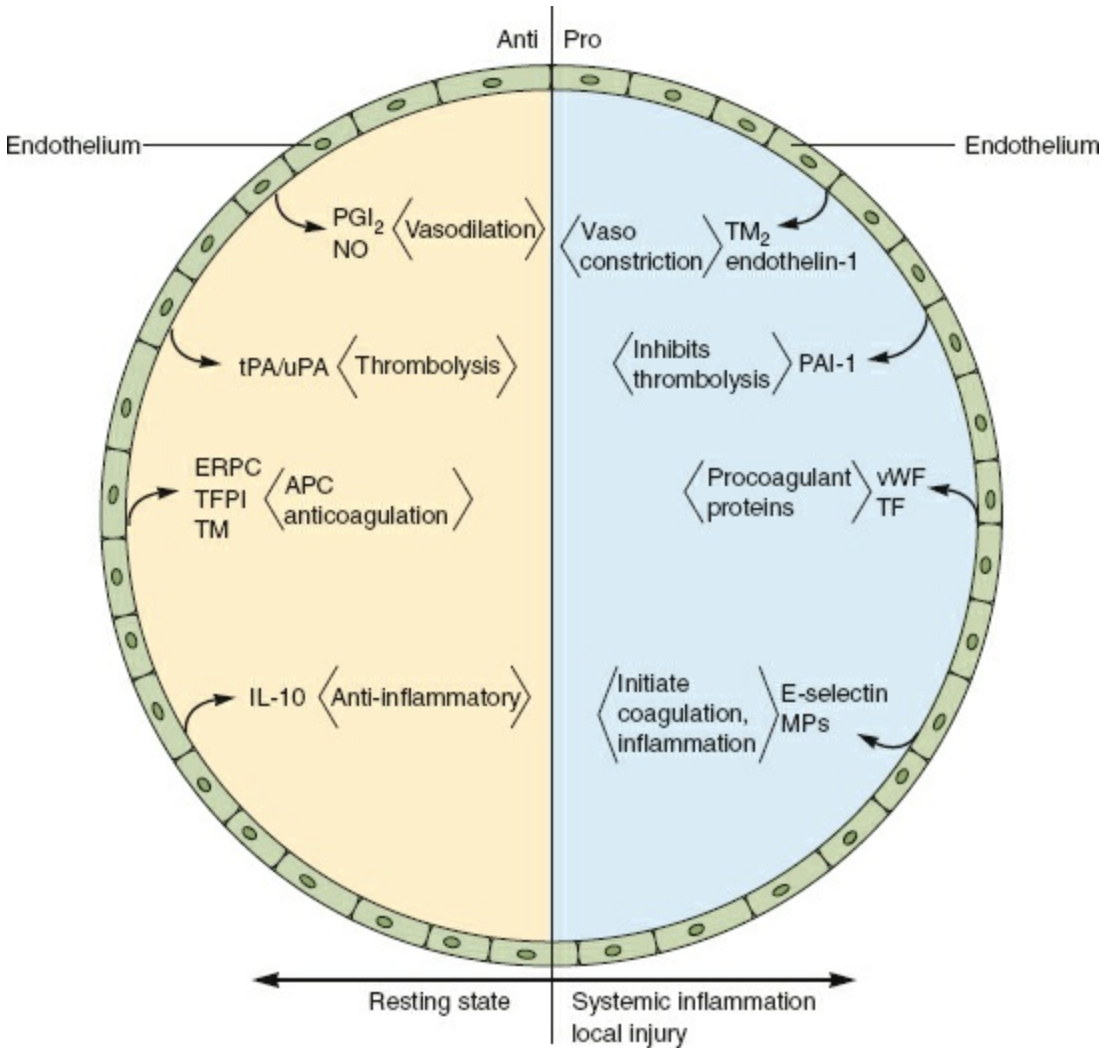

Figure 6-5. The endothelium is a primary interface allowing both anticoagulant functions in the resting state, with prostacyclin, NO, plasminogen activators, and thrombomodulin. Procoagulant proteins are expressed on activated endothelium including selectins, procoagulant proteins, such as the von Willebrand factor, TF, as well as PAI-1.

E-selectin, upregulated after P-selectin, is an important regulator of thrombus formation and fibrin content in a mouse VT model.[43,44] Endotoxin-induced TF-mediated coagulation is enhanced in humans carrying the *S128R* E-selectin allele,[45] and patients homozygous for the *S128R* E-selectin allele have an increased risk for VTE recurrence, highlighting the importance of E-selectin in DVT.[46] E-selectin has been shown to be efficient at raising the affinity and avidity of 2 (CD18) integrins which support neutrophil trafficking to sites of acute inflammation and recruit platelets and red blood cells.[47]

PSGL-1 has greatest affinity for P-selectin, and lesser affinity for E-selectin and L-selectin. The role of P-selectin in VT has been suggested by the study of a mouse with high fourfold higher circulating levels of P-selectin than wild type.[48] These mice are hypercoagulable based on clotting tests, and a receptor antagonist against the P-selectin receptor (rPSGL-Ig) reverses the hypercoagulability. Consistently, wild-type mice administered soluble P-selectin (sP-sel) become hypercoagulable. In models of VT, P-selectin inhibition given prophylactically decreases thrombosis in a dose-dependent fashion, and can treat established VT as effectively as heparin without anticoagulation.[49,50]

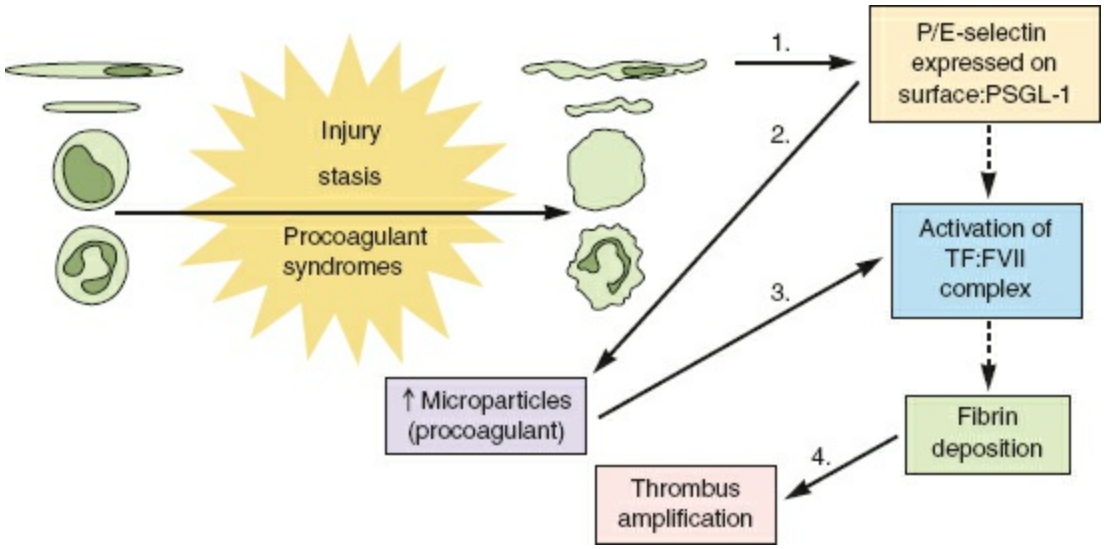

Figure 6-6. The interaction between stasis injury and procoagulant syndromes are represented by Virchow triad. Endothelial and vascular injuries cause leukocytes and platelets to express P- and E-selectin and the PSGL-1 receptor. Microparticles are released which express TF. This stimulates the coagulation pathway, fibrin production, and thrombus amplification.

sP-sel is released from activated platelets and endothelial cells and levels rise significantly during pathologic conditions.[51–53] sP-sel has been studied as a biomarker for DVT,[51,54–56] combining Sp-sel with Wells score (clinical pretest probability of DVT) establishes the diagnosis of DVT. A sP-sel (≥90 ng/mL) combined with Wells score (≥2), showed a better PPV (91%) than D-dimer (≥500 ng/mL) combined with Wells score (≥2), which was 69%.[57]

Other factors of importance to venous thrombogenesis include vWF, a factor that stabilizes procoagulant factor VIII to promote the initiation and formation of stable thrombus at the site of vascular inflammation and TF. Using a ferric chloride model of

vein wall injury, it has been shown that occlusive thrombus formation is dependent on vWF.[58] Regarding TF, mouse models using gene-targeting and bone marrow transplantation technologies found that TF in the vessel wall is more imporant than TF from leukocytes for thrombus formation when there is no flow in the experimental model.[59] TF has been linked to circulating procoagulant MPs, particularly in cancer patients, cancer is associated with high levels of DVT, and TF activity is increased in cells treated with chemotherapeutic agents.[60] In addition, cancer patients with VTE were found to have elevated levels of microparticle TF compared to cancer patients without VTE.[61,62]

Leukocytes and Thrombosis

Inflammatory cells are important to the process of thrombus recanalization and organization (Fig. 6-7).[40,63] Thrombus resolution resembles wound healing, and involves both profibrotic growth factors, collagen deposition, matrix metalloproteinase (MMP) expression, and activation.[64,65] As the thrombus resolves, a number of proinflammatory factors are released into the local environment, including interleukin-1 beta (IL-1β) and tumor necrosis factor-alpha (TNF-α).[66] The cellular sources of these different mediators are probably leukocytes and smooth muscle–like cells within the resolving thrombus and adjacent vein wall. The fact that leukocytes invade the thrombus in a specific sequence suggests their importance in the normal thrombus resolution.[66]

The first cell type in the thrombus is the PMN. Although PMNs may cause vein wall injury, they are essential for early thrombus resolution by promoting both fibrinolysis as well as collagenolysis.[67,68] In a rat model of stasis VT, neutropenia was associated with larger thrombi at 2 and 7 days, and was correlated with increased thrombus fibrosis and significantly lower thrombus levels of both uPA and MMP-9.[69] Conversely, in a nonstasis VT model, PMNs may promote thrombosis.[14] It is likely the timing of PMN influx and the amount of perithrombus blood flow that determines prothrombotic or prothrombolytic activities. Through processes that also involve the initial activation of leukocytes and platelets, PMNs form neutrophil endothelial traps (NETs), which are extracellular fragments of DNA containing histones and antimicrobial proteins.[14,70] NETs provide a scaffold for thrombus formation and are prothrombotic.[71]

In order to investigate if plasma DNA is a surrogate for NETs in patients with DVT, and to determine correlations with other biomarkers of DVT studied in our laboratory, patients presenting to our diagnostic vascular laboratory were investigated.[72] Patients were divided into positive for DVT by ultrasound, leg pain but negative for DVT by ultrasound, and control volunteers. Circulating DNA was significantly elevated in DVT patients, compared with controls. Of interest was a significant positive correlation of circulating DNA with C-reactive protein, D-dimer, vWF, and the Wells score (all $p < 0.01$).

The monocyte/macrophage is likely the most important cell for later DVT resolution.[73] Monocyte influx into the thrombus peaks at day 8 after thrombogenesis, and correlates with elevated MCP-1 levels, which has been associated with DVT resolution.[74] Targeted deletion of CC receptor-2 (CCR-2 KO) in the mouse model of stasis thrombosis was associated with late impairment of thrombus resolution, probably via impaired MMP-2 and MMP-9 activities.[75] Indeed, precedent exists in humans that the monocytic activation state may predict long-term DVT resolution.[76]

Thrombi have been found to contain increasing amounts of both tPA and uPA activities as they resolve, and this activity is expressed by invading monocytes.[77,78] In a recent study, mice genetically deleted for uPA had impaired thrombus resolution with reduced monocyte infiltration at the margins of the thrombus, with few neovascular channels present.[79] Mice gene deleted for tPA, however, were not similarly affected, suggesting that uPA, not tPA, is responsible for this activity.

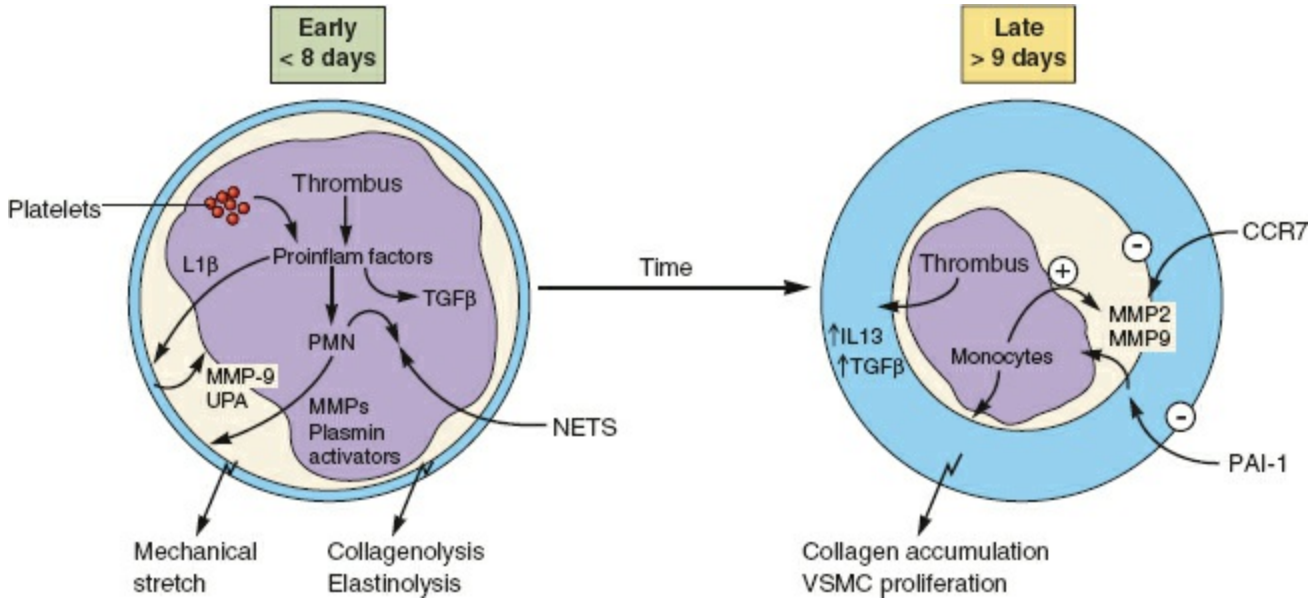

Figure 6-7. The proposed resolution mechanism involves both early thrombolysis with a large distending clot and then, over time, a fibrotic thrombus that resembles scar tissue as produced. Note proinflammatory factors, as well as neutrophils (releasing NETs), platelets, and MMP are present early with subsequent vein wall injury related to collagenolysis and elastinolysis. Later, vascular smooth muscle cell proliferation appears to occur, with thrombus resolution with increased profibrotic growth factor such as IL-13 and TGF-β. This promotes collagen accumulation. Both PAI-1 and CCR7 are protective against fibrosis.

The local venous environment is by definition hypoxic, hypoxia-inducible factor-1 alpha (HIF-1α). A major angiogenic growth factor is HIF-1α. Experimental data in a stasis model of VT suggest that thrombosis stimulates increased vein wall HIF-1α, and that by exogenous stimulation of HIF-1α expression, thrombus recanalization was increased and associated with accelerated VT resolution.[80] Thus, thrombus resolution is in part dependent on neovascularization. The effect of mechanical stretch, such as by a VT, may also stimulate HIF-1α as well as MMP-2 and MMP-9, both leading to reduced vein contractility.[81]

Recent data linking inflammation to fibrosis demonstrate that inhibition of the inflammatory response can decrease vein wall fibrosis. In a rat model of stasis DVT, treated with either low–molecular-weight heparin (LMWH) or an oral inhibitor to P-selectin 2 days after establishment of thrombosis, inhibition of P-selectin significantly decreased vein wall injury (independent of thrombus size).[82] The mechanism accounting for this protective effect is not yet known, but probably does not involve leukocyte blockade, because no differences in influx of monocytes into the vein wall were observed.

Loss of venous endothelium likely also contributes to the vein wall fibrosis, as well as the predisposition to recurrent thrombosis. An experimental model of DVT showed lower expression of homeostatic endothelial genes such as NO and TM than in controls, which correlated with loss of vWF positive cell luminal staining.[83] Other investigators have found that prolonged venous stasis is associated with decreased plasminogen activators, probably related to loss of endothelium.[84]

Associated with the early biomechanical injury from DVT is an elevation of profibrotic mediators, including transforming growth factor-beta (TGF-b), interleukin-13 (IL-13), IL-

6, and monocyte chemotactic protein-1 (MCP-1).[82,85,86] These mediators are present within the vein wall and thrombus and may drive the fibrotic response. Although exogenous MCP-1 may hasten DVT resolution, it promotes organ fibrosis in vivo. The profibrotic growth factor TGF-b is also present in the thrombus and is activated with normal thrombolysis.[87] TGF-b may be a key mechanism promoting vein wall fibrosis.

Late fibrosis has been observed in our mouse model of DVT, which demonstrated a significant increase in vein wall collagen after stasis thrombogenesis.[88–90] Based on experimental studies, elastinolysis and collagenolysis seem to occur early, as measured by an increase in vein wall stiffness, persisting through 14 days, and are accompanied by elevated MMP-2 and MMP-9 activities.[85,89] Correlating with this increase in fibrosis is altered procollagen I and III gene expression, as well as an increase in MMP-2 and MMP-9 gene expression and activity. Genetic deletion of MMP-2 or MMP-2/9 is associated with decreased midterm vein wall fibrosis, possibly by modulating vein wall elastin/collagen metabolism as well as monocyte influx.[64,65] It has been demonstrated that decreasing inflammation with a selectin inhibitor or with neutralizing IL-6 can also decrease vein wall fibrosis.[43,91,92] Moreover, the thrombus size itself does not drive the vein wall injury response; rather the mechanism of thrombosis seems more important.[85,93] Lastly, PAI-1 overexpression is associated with decreased vein wall fibrosis, in part by decreased MMP-2/9 activity.[90]

ARTERIAL VERSUS VENOUS THROMBOSIS

Thrombosis in the arterial system occurs somewhat differently than in the venous system (Fig. 6-8). The elements required for the initiation of DVT were described by Virchow as stasis, endothelial injury, and hypercoagulability of the blood. In the arterial circulation, endothelial vascular injury (whether acute or chronic) is key to thrombosis. This is most clearly demonstrated by the typical atherosclerotic plaque. In advanced lesions, the lipid core of the plaque is rich in inflammatory cells, cholesterol crystals, and TF (generated by activated macrophages within the plaque).[94] Plaque ulceration exposes highly thrombogenic lipid to the bloodstream, activating coagulation, platelet aggregation, and leading to the deposition of clot.[95] Platelet deposition occurs at the apex of stenosis, the point of maximal shear force. The blood flow velocity itself regulates how quickly both thrombi form and dissolve.[96]

A platelet-rich thrombus is observed in arterial thrombus while in contrast, venous blood stasis and changes in its composition (leading to hypercoagulability) incite the formation of thrombus from local procoagulant events, including small endothelial disruptions at venous confluences, saccules, and valve pockets.[11] Hypercoagulable states have classically been highly associated with VTE, but do play a role in cardiovascular disease as well.[97,98] Moreover, HMG-CoA reductase inhibitors (statin) not only decrease atherothrombotic events, but also incident VTE,[99] suggesting some common pathogenic pathways.

PROCOAGULANT STATES

Acquired Procoagulant States

4 Most thrombotic clinical episodes have an identifiable cause, although environment risks and genetic predispositions to thrombosis may account for many of the VTE that manifest clinically.[11] Risk factors for arterial thrombosis are primarily related to atherosclerosis, and are detailed elsewhere.

The most common risk factors for VTE are prior DVT, malignancy, immobility, intravenous catheters, increased age, major surgery, trauma, infections such as pneumonia and urinary tract infection, and certain chemotherapies (Table 6-1).[100–102] Certain medications such as oral contraceptives and hormonal replacement therapies also increase the risk of VTE.

Of primary importance to surgeons is how best to estimate perioperative VTE risk, and apply appropriate prophylaxis. This can be done with a screening form, such as that devised by Caprini et al.[103] and Pannucci et al.[104] Essentially, this is a focused assessment of VTE risks related to current illnesses and history that may not be fully covered in the routine history and physical. The recommendations are also well detailed in the routinely updated American College of Chest Physicians VTE evidence-based guidelines.[105] The higher the risk, the more intensive the prophylaxis, is the paradigm. For example, an outpatient hernia patient may require no prophylaxis outside of early ambulation where as a hip replacement in an obese patient would be best treated with anticoagulation as well as sequential compression devices for the lower extremities. However, all patients should be assessed for VTE risk.

Malignancy

Cancer represents an independent risk factor for the development of VTE, with a sixfold increased risk in cancer patients. Importantly, cancer patients undergoing surgical procedures have twice the risk of development of postoperative DVT.[106] Highest rates of VTE are seen in pancreas, stomach, and lung cancer. The malignancy itself activates a procoagulant phenotype by expression of TF by malignant cells, release of TF-bearing MPs, and increased activation of neutrophil extracellular traps – the downstream effects of which have been outlined above.[107]

Despite considerable evidence supporting the use of prophylactic anticoagulation in cancer patients, many do not receive optimal pharmacoprophylaxis for DVT while inpatient.[108] An extended duration of therapy – 28 days – was found to be associated with a decreased incidence of DVT at the end of the study period; consequently, current guidelines recommend extended thromboprophylaxis in cancer patients after an operative intervention.[108]

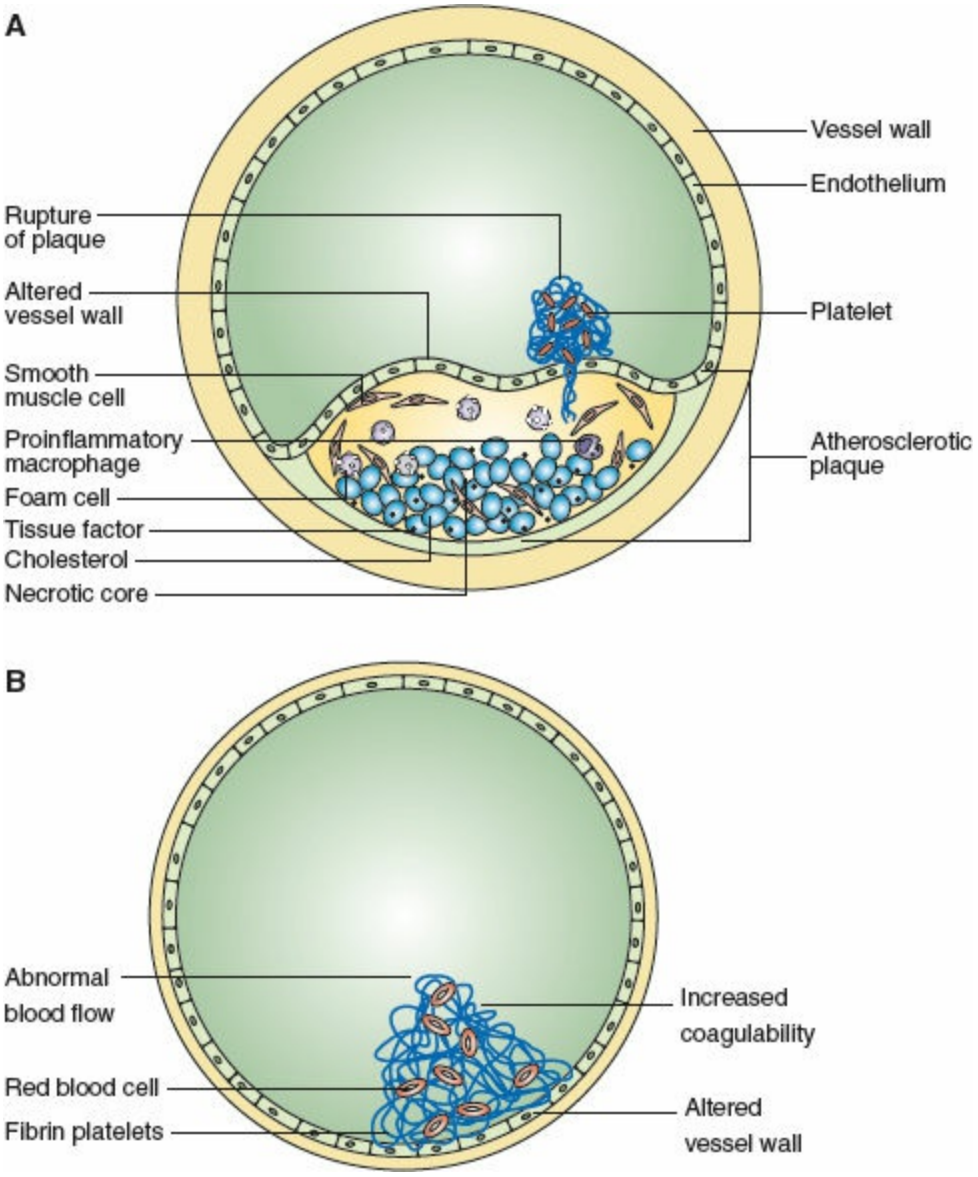

Figure 6-8. Depicted in **A** is the typical atherosclerotic thrombotic nidus, which includes rupture of a plaque, composed of smooth muscle, foam cells, and leukocytes. Platelets are the primary intermediary in arterial thrombosis, as well as TF. In figure **B,** increased coagulability, as well as vessel wall changes with procoagulant TF expression promotes thrombosis.

Inflammatory Bowel Disease

Since the first half of the last century, a link between inflammatory bowel disease (IBD) and VTE has been recognized. While there does appear some correlation between thrombosis and the inflammatory nature of the disease, the link between the inflammatory and coagulation cascades does not tell the whole story. There are several possible mechanisms for this increased tendency toward thromboembolic events under active investigation, including spontaneous platelet activation through the CD40–CD40L pathway.[109]

A recent retrospective cohort study of the National Surgical Quality Improvement Program database demonstrated that the presence of IBD is an independent risk factor for postoperative VTE with an odds ratio of 2.[110] Interestingly, there appears to be an increased tendency to form clot in unusual locations, such as cerebral and hepatic veins. Currently, guidelines recommend only standard pharmacologic thromboprophylaxis for

patients with IBD.

Trauma

As with other acquired prothrombotic states, the systemic inflammatory milieu is associated with VTE in trauma patients. Activation of inflammatory pathways through TNF-α with increased circulating TF and procoagulant MP induces a prothrombotic state.[111] Incidence of VTE in trauma patients is around 2%, and this may be higher in patients with other risk factors, such as old age, obesity, and prolonged immobility after bone fractures.[112,113] LMWH with application of pneumatic compression devices has been shown to be the preferred thromboprophylaxis in trauma patients, and this is reflected in anticoagulation guidelines.[105] However, optimal dosing regiments are not well defined.

Table 6-1 Acquired Hypercoagulable States

Risk	Relative Risk of VTE
Malignancy	++++
Trauma	++
Indwelling catheters	+
Surgery	++++
Pregnancy	+
HRT/OC	+
Lupus Anticoagulant	+++
Obesity	+
Postoperative infection	++++
IBD	+++
Prolonged immobility	++

HRT, hormone replacement therapy; IBD, inflammatory bowel disease; OC, oral contraceptive.
+, low risk; ++, moderate risk; +++, high risk; ++++, very high risk.

Lupus Anticoagulant/Antiphospholipid Syndrome (Antiphospholipid Antibody)

Antiphospholipid antibody syndrome is a particularly virulent hypercoagulable state that results in both arterial thrombosis and VT and consists of an elevated antiphospholipid antibody titer in association with thrombosis, recurrent fetal loss, thrombocytopenia, and livedo reticularis. Strokes, myocardial infarction, visceral infarction, and extremity gangrene may also occur. Although the lupus anticoagulant has been noted often in patients with systemic lupus erythematosus (SLE), it does occur in patients without SLE. It may also be induced in patients by medications, cancer, and certain infections.[114]

A number of possible thrombotic mechanisms have been suggested, including inhibition of PGI_2 synthesis or release from endothelial cells,[115] inhibition of APC by thrombin/TM,[116] elevated PAI-1 levels,[117] platelet activation,[118] endothelial cell activation,[119] and interference with the endothelial cell–associated annexin V anticoagulant activity.[120] Increased TF expression on monocytes and low free protein S plasma levels have also been found with the antiphospholipid syndrome and a history of

thrombosis.[121,122]

At least one-third of patients with lupus anticoagulants have a history of one or more thrombotic events, 70% or more being VTE.[123] Graft thrombosis has been observed in 27% to 50% of patients positive for antiphospholipid antibody.[124,125]

For the diagnosis of antiphospholipid syndrome, both clinical and laboratory criteria are necessary.

For the clinical criteria, ≥1 must be present:

1. ≥1 clinical episode of, objectively confirmed, arterial, venous, or small vessel thrombosis.
2. Pregnancy morbidity: ≥1 unexplained fetal death @ ≥10 weeks EGA; ≥1 premature birth (≤34th week of gestation) due to eclampsia, severe preeclampsia, or placental insufficiency; ≥3 unexplained consecutive spontaneous abortions @ <10 weeks EGA.[126]

For the laboratory criteria, ≥1 must be present:

1. LA (+) ≥2 occasions, at least 12 weeks apart, according to ISTH guidelines (prolonged PL-based clotting assay, lack of correction with 1:1 mix, and correction with excess PL).
2. ACLA and/or anti-β2 glycoprotein-I antibody (medium or high immunoglobulin G (IgG) and/or IgM isotype titer ≥2 occasions, at least 12 weeks apart using standardized ELISA assays).

The prolongation in the aPTT is strictly a laboratory phenomenon. The dilute Russell viper venom time confirms the presence of a lupus anticoagulant.

There is imperfect agreement between diagnostic tests for this abnormality. Approximately 80% of patients with a prolonged aPTT will have a positive antiphospholipid antibody, but only 10% to 50% of patients with a positive antiphospholipid antibody will have a prolonged aPTT.[127]

Heparin followed by warfarin has been recommended for the treatment of the antiphospholipid syndrome.[114,123] For recurrent fetal loss, heparin or LMWH use through pregnancy is recommended. In patients with lupus anticoagulants, heparin is monitored by antifactor Xa levels.

Heparin-Induced Thrombocytopenia and Thrombosis Syndrome

5 Heparin-induced thrombocytopenia (HIT) occurs in 0.6% to 30% of patients in whom heparin is given, although severe thrombocytopenia associated with thrombosis (HITTS) is seen much less frequently.[128,129] Approximately one half of HIT patients have thrombosis that is noted clinically or by duplex imaging. In an analysis of 11 prospective studies, the incidence was reported to be 3%, with thrombosis in 0.9%.[130] Although earlier morbidity and mortality rates of 61% and 23% had been reported,[116] with early diagnosis and appropriate treatment, these rates have declined to 6% and 0%, respectively.[131] HIT is caused by a heparin-dependent IgG antibody that, when bound to

platelet factor 4 (PF4), induces platelet aggregation in part by inducing MP formation.[132,133] The antibody may not be heparin specific, as the degree of sulfonation of the heparin-like compound has been suggested to be critical for this aggregation.[134]

Both porcine and bovine UFH as well as LMWH have been associated with HIT.[135] The syndrome usually begins 3 to 14 days after heparin is begun. Both arterial and venous thromboses have been reported, and even small exposures to heparin (heparin coating on catheters) can cause the syndrome.[128,136] VTE associated with HIT is <1% for LMWH, while it is approximately 12% to 13% for UFH with a higher risk for mortality.[137]

The diagnosis should be suspected when a patient experiences a 50% or greater decline in platelet count, when there is a fall in platelet count below 100,000/mL during heparin therapy, or in any patient who experiences thrombosis during heparin administration.[138] The syndrome may be difficult to diagnose as many hospitalized patients have multiple reasons for low platelet counts, and vigilance is important. A platelet count should be checked about every 2 days when on heparin therapy.

The laboratory diagnosis of HIT/HITTS is made by a number of assays. The serotonin release assay was the "gold standard" in the past. An ELISA test detecting the antiheparin antibody in the patient's plasma directed against the heparin–PF4 complex is now commonly used.[128] This assay is less specific but more sensitive and is easier to perform and interpret than the serotonin assay. However, inappropriate testing is common when HIT is suspected. The 4Ts score is a validated measure of pretest probability with a high negative predictive value that, used appropriately, can limit expensive over-testing and unnecessarily subjecting patients to cessation of heparin and alternative anticoagulation.[139,140]

When the diagnosis is made (clinically), cessation of heparin is mandatory. This includes removing heparin from intravenous catheters and flushes.[136] Warfarin should not be administered until an adequate alternative anticoagulant has been started to prevent thrombotic complications. A number of anticoagulants are now available to substitute for patients with this diagnosis. The direct thrombin inhibitor, argatroban, is FDA approved for this indication and shows no cross-reactivity to heparin antibodies.[138,141] When using argatroban, it is important to keep in mind that the INR is artificially elevated with this agent. Fondaparinux has also been used for this indication.[142]

Hypercoagulability Testing: Clinical signs of possible thrombophilia include thrombosis at a young age (<40), unprovoked thrombosis, recurrent thrombosis, thrombosis at unusual locations such as the mesentery, CNS venous sinus, and portal vein, a family history of thrombosis, particularly unprovoked, severe, and in those <50 years of age.[143] Testing for hereditary defects in patients with thrombosis with no family history has pros and cons. On the pro side, testing may: improve understanding of pathogenesis of thrombosis, identify and counsel affected family members, and obviate expensive diagnostic testing (e.g., CT scans) looking for a malignancy. On the con side, testing may identify patients with defects whose management would change, with the potential for overaggressive management, insurance implications for the patient arise, and the testing is rather costly.

In order to determine the efficacy of hypercoagulable testing, a multicenter

international observational registry on clinical characteristics, treatment patterns, and outcome in consecutive patients with symptomatic, objectively confirmed acute VTE, was done. In this study, 22,847 patients were enrolled and 4,503 tested for thrombophilia. Of the total patient population, 8.4% had with factor V Leiden, 6.8% had PTG20210A, and 3% had activated protein C resistance (APC-R). The authors concluded that for the low incidence and in accordance with the recommendations made by other authors and international bodies, "the undertaking of thrombophilia testing on patients with a first episode of VTE is not advisable."[144]

A hypercoagulable screen should include routine coagulation tests such as the aPTT and platelet count, AT activity and antigen assay, protein C antigen and activity levels, protein S antigen level, and mixing studies to identify a lupus anticoagulant (if indicated); APC-R assay and factor V Leiden gene analysis; prothrombin G20210A genetic analysis; homocysteine level; an antiphospholipid antibody screen that includes anticardiolipin antibody; fibrinogen level; FVIII, FIX, and FXI levels and a functional plasminogen assay.

Inherited Procoagulant States

Defects with High Risk for Thrombosis

Antithrombin Deficiency. AT is a serine protease inhibitor (SERPIN) of thrombin, kallikrein, and factors Xa, IXa, VIIa, XIIa, and XIa (Table 6-2). It is synthesized in the liver and has a half-life of 2.8 days. AT deficiency, accounts for approximately 0.5% to 3% of episodes of VTE, the prevalence in the population is 0.2%, and it carries a 20× increased risk for VTE when heterozygous[145–147] and may occur at unusual sites such as mesenteric or cerebral veins. Arterial and graft thromboses have also been described in AT deficiency.[148,149] It is inherited in an autosomal dominant fashion most cases become apparent by 50 years of age.[150] Homozygous patients usually die in utero, whereas heterozygous patients usually demonstrate AT levels <70% of normal. Acquired AT deficiency results from liver disease, malignancy, sepsis, disseminated intravascular coagulation (DIC), malnutrition, and renal disease.[148] AT deficiency is divided into type I deficiency (quantitative) and type II deficiency (qualitative).

Table 6-2 Severity and Frequency of VTE due to Hypercoagulable States

	Frequency (%)	Site
High Risk for Thrombosis		
■ AT deficiency	0.5–3	Venous >> arterial
■ Protein C deficiency	3	Venous >> arterial
■ Protein S deficiency	3–6	Venous >> arterial
■ Antiphospholipid antibody syndrome	3–5	Venous > arterial
Lower Risk for Thrombosis		
■ Factor V Leiden	20–60	Venous >> arterial
■ Hyperhomocysteinemia	10	Arterial ~ venous
■ PT G20210A	4–6	Venous >> arterial
■ Dysfibrinogenemia	1–3	Venous > arterial
■ Dysplasminogenemia	<1	Arterial ~ venous
■ Elevated factors VIII, IX, and XI	1	Venous > arterial

AT, antithrombin; HITTS, heparin-induced thrombocytopenia and thrombosis syndrome; PAI-1, plasminogen activator inhibitor; VTE, venous thromboembolism.

The diagnosis of AT deficiency is suspected in a patient who cannot be adequately anticoagulated with heparin or who develops thrombosis while on heparin and is made by measuring AT antigen and activity levels. However, patients should not have been exposed to heparin or related compounds for at least 2 weeks as heparin decreases AT levels 30%.[151] Conversely, warfarin increases AT levels.

For a patient with AT deficiency, anticoagulation with heparin requires the administration of fresh frozen plasma (FFP) to provide AT, 2 units every 8 hours, decreasing to 1 unit every 12 hours, followed by oral anticoagulation. A reasonable

alternative includes anticoagulation with direct thrombin inhibitors such as argatroban or bivalirudin.[105] Aggressive prophylaxis against VTE is recommended during the perioperative period, and usually lifelong anticoagulation therapy is required after a first episode of significant VTE.

Protein C and S Deficiencies. Protein C and its cofactor protein S are both vitamin K–dependent factors synthesized in the liver with half-lives of 4 to 6 hours and 12 to 14 hours, respectively. The majority of cases of protein C or protein S deficiency are inherited as autosomal dominant. Patients present with VTE, often between the ages of 15 and 30 years.[152,153] Heterozygous protein C deficiency is present in 1 in 200 to 500 individuals in the general population and in approximately 3% of individuals with VTE.[146] In a study of 10,000 healthy blood donors, protein C deficiency was noted in 1.45 per 1,000.[154] Protein deficiency is divided into a type I deficiency (quantitative) and a type II deficiency (qualitative).

Levels of protein C in those heterozygous deficient may overlap with lower limit normal levels. In addition to VTE, cases of arterial thrombosis have also been reported.[155] If present as a homozygous state at birth, infants usually die from unrestricted clotting and fibrinolysis, a condition of extreme DIC termed *purpura fulminans*. Patients heterozygous for protein C deficiency usually have antigenic protein C levels less than 60% of normal.[156,157] Acquired protein C deficiency occurs with liver failure, DIC, and nephrotic syndrome.

Protein S is a cofactor to protein C in inactivating FVa and FVIIIa, and is regulated by complement C4b-binding protein. Inheritance of protein S deficiency is in an autosomal dominant pattern.[157,158] Approximately 40% of protein S circulates in a free active form, with the remainder bound to C4b-binding protein. Free protein S is functionally active as an anticoagulant. Protein S levels increase with age, and females have lower levels than males. The deficiency of protein S results in a clinical state identical to protein C deficiency with a VTE rate 5% to 7%, an estimated 8.5× higher risk for the development of VTE.[159] The frequency of protein S deficiency ranges from 3% to 6% for those with VTE. Levels of protein S are reduced in liver disease, nephrotic syndrome, inflammation, OCP use, in pregnancy, and during breastfeeding. Nephrotic syndrome leads to a reduction in free protein S,[160] whereas inflammatory states such as SLE can result in an elevation of C4b-binding protein, reducing free protein S.

The diagnosis of protein C or S deficiency is made by measuring plasma protein C and S levels.[34,161] For protein C, both antigen and activity are measured, whereas for protein S, only antigen is measured. A condition also exists in which there is an abnormality in the function of protein C itself, resulting in a decrease in protein C activity without a decline in antigenic protein C.[153]

Treatment consists of anticoagulation, initially with heparin, usually followed by lifelong oral anticoagulation after a first thrombotic event. However, not all patients with low levels develop VTE. Many heterozygous family members of homozygous protein C–deficient infants also are unaffected.[33] Thus, the institution of anticoagulation therapy in patients should occur only following an episode of thrombosis. However, aggressive

anticoagulant prophylaxis during perioperative periods or high-risk environmental situations is necessary for asymptomatic heterozygote carriers.

With the initiation of oral anticoagulation, blood may become transiently hypercoagulable as the vitamin K–dependent factors with short half-lives are inhibited (factor VII, protein C) before the other vitamin K–dependent factors (factors II, IX, and X).[162] In someone already partially deficient in protein C or S, the levels of these anticoagulant factors will diminish even further with the initiation of warfarin. This results in temporary hypercoagulability, resulting in thrombosis in the microcirculation and warfarin-induced skin necrosis.[163] This leads to full-thickness skin loss, especially over fatty areas such as the breasts, buttocks, and abdomen. This complication can be prevented by initiating warfarin therapy under the protection of systemic heparin anticoagulation or a direct thrombin inhibitor.

Defects with Lower Risk for Thrombosis

Resistance to APC (Factor V Leiden). Resistance to APC has been reported to be present in 20% to 60% of cases of idiopathic VTE and is the most common underlying abnormality associated with VTE. This disorder is present in 1% to 2% of the general population.[164–166] In a study of 4,047 Americans, the carrier frequency of this mutation was 5.3% for Whites, 2.2% for Hispanic Americans, 1.25% for Native Americans, 1.2% for African Americans, and 0.45% for Asian Americans, with no gender differences.[164] It confers a relatively low risk for thrombosis, however, and is more common in whites than in nonwhite Americans.[164]

As a result of the substitution of a single amino acid, glutamine for arginine, at position 506 in the protein for factor V, caused by a nucleotide substitution of guanine for adenine at 1,691 in factor V gene, hypercoagulability is conferred by resistance to inactivation of factor Va by APC.[167–169] Additionally, less VIIIa is interfered with, compounding the hypercoagulability. Factor V Leiden accounts for 90% of APC-R.

Thrombotic manifestations are noted in those individuals both homozygous and heterozygous for this mutation. The relative risk for VTE in patients heterozygous for factor V Leiden is 7-fold, whereas the relative risk is 80-fold for those homozygous for factor V Leiden.[165,168] In contrast to factor deficiency states, persons homozygous for this mutation usually do not die in infancy. Additionally, thrombosis is potentiated in the presence of additional acquired risk factors.[168,170]

Combined defects with other hypercoagulable states, such as protein C and S deficiency or prothrombin G20210A, are not uncommon and increase the thrombotic risk.[171,172] In addition to cases of VTE, recurrent VTE is also more common in patients with this entity, with a relative risk 1.4-fold.[166,173] Although VTE predominates in patients with this syndrome, arterial thrombosis has also been reported.[174]

The diagnosis of APC-R is made by a clot-based functional assay with the addition of APC (modified aPTT). Additionally, genetic analysis should be performed to confirm heterozygosity versus homozygosity, as treatment decisions may be different between the two states.

Treatment options for APC-R after VTE include anticoagulation, initially heparin or

LMWH, followed by oral anticoagulation. The long-term use of warfarin is controversial. No data exist to suggest that long-term warfarin should be given after a first episode of VTE in a patient heterozygous for the mutation. The fact that APC-R is a relatively low risk for recurrent thrombosis (1.4-fold) suggests that not all patients after their first episode of VTE need long-term anticoagulant treatment. Patients must be evaluated in light of their overall risk for bleeding versus thrombosis.[152]

Prothrombin G20210A Polymorphism. Prothrombin (factor II), a vitamin K–dependent factor synthesized in the liver, becomes thrombin when activated. A genetic polymorphism in the distal 3′ untranslated region of the gene for prothrombin, a transition from guanine to adenine at the 20210 nucleotide of the prothrombin gene, has been described in patients with VTE.[175] This results in a normal prothrombin but at increased levels.[153,170,176] This polymorphism, confers an increased risk for VTE by 2.8-fold, and is associated with 4% to 6% of patients with VTE.[152,177–180] Of patients with spontaneous DVT, the incidence is 7% to 16%.[181,182] This is the second most common cause for hypercoagulability in Caucasians and its prevalence is 1% to 2% of Caucasians. The thrombosis risk is increased in pregnant women,[183] in women with early myocardial infarctions,[179] and in synergy with factor V Leiden.[170] Most patients are heterozygous for this mutation, and whites are more often affected than those of Asian or African descent.[179] Genetic analysis is the marker for this abnormality.[184]

Patients who present with VTE should be treated according to current standards and akin to the treatment for heterozygous factor V Leiden. Individuals with prothrombin G20210A who have recurrent episodes of VTE should undergo lifelong anticoagulation, as should those patients with both prothrombin G20210A and factor V Leiden.[170]

Hyperhomocysteinemia. Hyperhomocysteinemia has been a known risk factor for atherosclerosis and vascular disease for more than 25 years, though a direct cause and effect relationship has not been established.[185–187] However, a recent meta-analysis suggests the risk of VTE to be 2.5-fold with elevated homocysteine levels.[187–192]

Two enzyme deficiencies, N^5, N^{10}, methylenetetrahydrofolate reductase (MTHFR) or cystathionine beta synthase, are responsible for elevated homocysteine levels.[193] Although mutations in these enzymes are not infrequent, the common polymorphism in MTHFR alone is not a factor in either the elevation of plasma homocysteine or thrombosis.[194] Acquired causes include advanced age, smoking, coffee consumption, low dietary folate, and low vitamin B_6 and B_{12} intake. Higher levels are also associated with diabetes mellitus, cancer, hypothyroidism, lupus IBD, and medications such as metformin, methotrexate, anticonvulsants, theophylline, and levodopa.[195,196]

Hyperhomocysteinemia has a frequency of 10% in patients with a first episode of VTE, and is a risk factor for VTE in those younger than 40 years,[189] in women,[185] and for recurrent VTE in patients between 20 and 70 years of age.[186] The combination of hyperhomocysteinemia and factor V Leiden results in an increased risk of venous and arterial thromboses.[197] Elevated plasma homocysteine results in abnormal endothelial function.[198–202] Fasting homocysteine levels are determined from serum, usually on two

occasions. The test may also be performed after a methionine oral loading regimen.[203,204]

Homocysteine elevation is treated with folate supplements. Although the association between hyperhomocysteinemia and VTE has been established, treatment to lower homocysteine levels and the long-term effects of such treatment on procoagulant activity have yet to be validated.[185]

Other Disorders Associated with Thrombosis

Defective Fibrinolysis/Dysfibrinogenemia/Lipoprotein(a). Abnormal plasminogens (dysplasminogenemias), although rare (<1%), have been described in cases of spontaneous arterial or VTE.[205] Both type I quantitative and type II qualitative deficiency states have been described. Other defects in fibrinolysis may affect up to 10% of the normal population.[206] Abnormal fibrinogens may account for 1% to 3% of patients with VT and those presenting with digital ischemia.[207] Numerous molecular defects have been classified. Defective thrombin binding or resistance to plasmin-mediated breakdown has been described.[208] Although not clearly documented, defects in plasminogen activators, tPA, or uPA may incite thrombotic events.[209] Moreover, elevated PAI-1 has been associated with DVT and myocardial infarction.[205] Although the relationship between VTE and abnormal fibrinolysis is debated, it is clear that in the postoperative period there is a connection between fibrinolysis and VTE.[205,210,211] Additionally, PAI-1 is upregulated by thrombin, endotoxin, and IL-1, explaining the elevated circulating levels of PAI-1 during infections.[212]

Lipoprotein(a), associated with LDL, has both atherogenic and prothrombotic properties.[213–215] It prevents plasminogen from binding to cells or fibrin and inhibits fibrinolysis.[216] Elevated levels of lipoprotein(a) have been associated with VTE in childhood; it is a weak thrombotic risk factor in adults.[217–219] When an individual with thrombosis presents with one of the previously mentioned abnormalities, standard anticoagulation is necessary.[220,221]

Abnormal Platelet Aggregation. It has been recognized for some time that there are patients who have thrombosis and may have hyperactive/hyperresponsive platelets but this entity is poorly defined. Diabetes mellitus, which is known to be associated with hyperactive platelets and hyperlipidemic states, may be a contributing factor. Hyperactive platelets have been noted during graft thrombosis in peripheral vascular reconstructions.[117] Although platelet aggregation assays may be helpful in making the diagnosis, these assays are not commonly performed or standardized and, thus, the incidence and importance of platelets to thrombosis are not well known. Bleeding time measurements are not specific, and not recommended for making this diagnosis. This condition has been called “sticky platelet syndrome” and both arterial and venous events have been reported.[151]

Standard anticoagulant treatment is recommended for this condition. Aspirin and the thienopyridine derivatives such as clopidogrel may be useful, but their utility is unknown.[222]

Elevated Procoagulant Factors: VIII, IX, and XI

Elevated prothrombotic factors have only recently been associated with primary and recurrent VTE.[152,223] A dose–response effect has been observed; and elevated factor VIII has been best studied.[223–225] Factor VIII:C above the 90th percentile is associated with a 5-fold increased risk of VTE.[225,226] Factor VIII:C elevation is also affected by blood type and race. The risk is 6.7× after adjusting for age, sex, factor V Leiden, prothrombin G20210A, and duration of Coumadin therapy.[227] In African American women, a statistically higher level of factor VIII has been found than in the white and Asian populations.[228] Elevation of factor XI above the 90th percentile is associated with a 2-fold increase in VTE, independent of other hypercoagulability factors.[229] Similar increases in VTE risk have been observed with elevated factor IX.[230] Acquired and environmental factors precipitate VTE in patients with elevation of these factors, as opposed to inherited deficiencies of AT, protein C, and protein S that confer higher VTE risk.[231]

The diagnosis is made by the direct measurement of these factors with activity assays. However, since the carrier protein for factor VIII is vWF which is an acute-phase reactant, measurement of factor VIII levels should be combined with an acute-phase reactant such as CRP or ESR. If VTE occurs with one of these factor elevated, standard anticoagulant management should be undertaken.[221]

Disseminated Intravascular Coagulation

DIC is a primary form of acute thrombosis. Causes of DIC include sepsis, trauma, pancreatitis, obstetric complications such as abruptio placentae or amniotic embolism, transplant rejection, malignant tumors, certain snake bites, hematologic malignancies, and hepatic failure. Coagulation in DIC is activated by the release of TF into the circulation causing unregulated activation of the coagulation cascade, leading to massive thrombin production and fibrin generation. Fibrinolysis then becomes activated as well, leading to bleeding in the later, hemorrhagic stages of the syndrome because of the consumption of clotting factors, depletion of fibrinogen, and unchecked plasmin activity. The diagnosis of DIC is a clinical one, which requires consideration of the gestalt of the patient. Laboratory values in DIC reveal a downtrend in platelet count – even within the normal range, decreased fibrinogen level, prolonged PT, and concomitant elevation in fibrin split products and the presence of a positive D-dimer test. The treatment of DIC requires treatment of the underlying condition. The need for platelet or plasma transfusion is based on the presence of hemorrhage, rather than on particular laboratory values.[232]

BLEEDING DISORDERS

Although the surgeon deals more often with procoagulant states than bleeding disorders, it is important to recognize these disorders when they occur.

Coagulation Factor Deficiency

Coagulation factor deficiency states are important causes of bleeding and the most common are factor VIII and IX deficiency states, termed hemophilia A and B, and type I von Willebrand disease (vWD).

6 Hemophilia A is inherited as a sex-linked recessive deficiency of factor VIII, with fewer cases secondary to spontaneous mutation. The incidence of this abnormality is approximately 1 in 5,000 births.[233] Clinical findings range from bleeding into joints and muscles, epistaxis, hematuria, and bleeding after minor trauma, to prolonged postoperative bleeding, retroperitoneal bleeding, and intramural bowel hemorrhage. Laboratory screening tests usually reveal a prolongation of the aPTT along with decreased factor VIII levels; other test results are normal. The minimum level of factor VIII required for hemostasis is 30%, and spontaneous bleeding is uncommon with factor VIII levels greater than 5% to 10% of normal. Levels less than 2% constitute severe, 2% to 5% moderate, and greater than 5% mild deficiency.[234] Although the half-life of factor VIII is 2.9 days in normal subjects, the half-life of factor VIII concentrates is only 9 to 18 hours.[233] Levels between 80% and 100% of normal should be attained for surgical bleeding or life-threatening hemorrhage. Acquired deficiency has been reported to occur with the development of antibodies to factor VIII after therapy. Inhibitor antibodies develop in approximately 10% to 15% of patients with hemophilia A, although the incidence of antibody formation may be much higher in previously untreated patients and in those with severe hemophilia A.

Recombinant factor VIII preparation has been developed and tested in children and infants. Despite the development of low levels of inhibitors in 20% of children at a mean 9 days after first administration, these inhibitors either disappeared or remained at low levels.[235]

Factor IX deficiency (Christmas factor), known as hemophilia B, is transmitted as an X-linked recessive trait. It may also be acquired because of enhanced factor IX clearance in states such as the nephrotic syndrome, abnormal protein production in vitamin-K deficiency, and acquired specific inhibitors to factor IX in various autoimmune diseases, such as SLE. It is clinically indistinguishable from hemophilia A, and laboratory screening tests reveal a prolonged aPTT, with other test results normal, although a greater proportion of patients have only mild or moderate deficiency.[236] Severe deficiency (approximately 30% of cases) is defined as a level of activity less than 4% of normal, whereas moderate deficiency is reported with activity levels between 20% and 40%.[234] Treatment consists of plasma or factor IX concentrates and vitamin-K. It has been recommended that levels greater than 30% be achieved for hemostasis.

vWF causes platelet adhesion to collagen, initiating platelet plug formation. It also forms a complex with factor VIII in the blood. Produced in endothelial cells and megakaryocytes (compared with the liver for factor VIII), it has a circulating half-life of 6 to 20 hours. vWD, a deficiency of vWF, is the most common of the inherited coagulation disorder. A number of different subtypes have been identified for its deficiency state, and the syndrome is transmitted as both autosomal dominant (heterozygous) and autosomal

recessive (homozygous) forms. Variants include types I and III (quantitative decreases in normal-appearing vWF) and type II (qualitative abnormalities in structure and function of vWF).[237] vWF deficiency is probably as common as hemophilia A, although the true incidence may surpass what is generally appreciated because many mild cases probably remain undiagnosed.

The classic syndrome is caused by a reduction of factor VIII activity (although not as great as in hemophilia A) and vWF (vWF–factor VIII complex). Clinical manifestations include easy bruisability, mild to moderate epistaxis, gingival bleeding, menorrhagia, rare joint or muscle bleeding, prolonged bleeding following surgery, and subcutaneous bleeding. Spontaneous bleeding is not as common as in hemophilia A.

Abnormal laboratory tests include a prolonged bleeding time; a decreased level of factor VIII activity; decreased immunoreactive levels of the vWF; and abnormal platelet aggregation response to ristocetin. The most reliable source of vWF is cryoprecipitate, although many concentrates of factor VIII have vWF present and show promise. Desmopressin acetate (DDAVP) is available for the treatment of mild cases of type I vWD and type 2a and 2b, serum levels of 25% to 50% are needed for hemostasis. In other type II states and type III vWD, factor VIII concentrates are necessary. Recombinant factor VIII/vWF concentrates that avoid the infectious risks of transfusion are available.

Rare Factor Deficiencies

Other specific factor deficiencies are much less common and receive only a brief mention here. These include factors II, XI, V, VII, and X. These can be measured by serum assays, although this is not routinely available in many hospitals. The treatments are primarily FFP concentrates to give back the clotting factors.

Deficiencies of fibrinogen can also lead to bleeding disorders. This is the only factor deficiency state in which the TCT is prolonged. It is generally believed that a fibrinogen level of 100 mg/mL should be achieved to stop bleeding related to fibrinogen abnormalities. Fibrinogen deficiency may also occur from consumption during DIC and from primary fibrinolytic states.

Platelet Disorders

Platelet disorders are another important cause of bleeding. Inherited defects of platelet receptors include defects of GpIIb/IIIa (Glanzmann's thrombasthenia), characterized by impaired platelet binding to vWF, fibrinogen, and fibronectin. In patients with defects in GpIb (Bernard–Soulier syndrome), the absolute number of platelets is decreased, the platelets are larger, and platelet aggregation and adhesion are abnormal. Acquired deficits occur in uremia, both GpIb and GpIIb/IIIa receptors are defective, resulting in impaired adhesion and aggregation. Acquired deficits also occur in patients who previously received platelet transfusions and then acquire immune-mediated antiplatelet antibodies.

Abnormalities in Fibrinolysis

Abnormalities in fibrinolysis may play a role in abnormal bleeding disorders. Genetic or acquired deficiencies in α_2-AP may be associated with bleeding, whereas deficiencies in factor XIII (fibrin stabilizing factor) may lead to highly lysable clot. α_2-AP deficiency is treated with ε-aminocaproic acid or tranexamic acid. Homozygous patients with factor XIII deficiency and less than 1% of normal plasma activity often show bleeding from the umbilical cord at birth, bleeding after trauma or surgery, and delayed bleeding 24 to 36 hours later. Screening test results include a shortened euglobulin lysis time. A specific assay for factor XIII activity exists. Treatment consists of FFP, cryoprecipitate, and factor XIII concentrates.

References

1. Coller BS. Platelets and thrombolytic therapy. *N Eng J Med* 1990;322:33–42.
2. Furie B, Furie BC. Mechanisms of thrombus formation. *N Eng J Med* 2008;359:938–949.
3. Jasuja R, Passam FH, Kennedy DR, et al. Protein disulfide isomerase inhibitors constitute a new class of antithrombotic agents. *J Clin Invest* 2012;122:2104–2113.
4. Monroe DM, Hoffman M. What does it take to make the perfect clot? *Arterioscler Thromb Vasc Biol* 2006;26:41–48.
5. Sims PJ, Faioni EM, Wiedmer T, et al. Complement proteins c5b-9 cause release of membrane vesicles from the platelet surface that are enriched in the membrane receptor for coagulation factor Va and express prothrombinase activity. *J Biol Chem* 1988;263:18205–18212.
6. Gilbert GE, Sims PJ, Wiedmer T, et al. Platelet-derived microparticles express high affinity receptors for factor VIII. *J Biol Chem* 1991;266:17261–17268.
7. Hickey MJ, Williams SA, Roth GJ. Human platelet glycoprotein IX: an adhesive prototype of leucine-rich glycoproteins with flank-center-flank structures. *Proc Nat Acad Sci U S A* 1989;86:6773–6777.
8. Bennett JS, Vilaire G, Cines DB. Identification of the fibrinogen receptor on human platelets by photoaffinity labeling. *J Biol Chem* 1982;257:8049–8054.
9. Muller F, Mutch NJ, Schenk WA, et al. Platelet polyphosphates are proinflammatory and procoagulant mediators in vivo. *Cell* 2009;139:1143–1156.
10. Morrell CN, Aggrey AA, Chapman LM, et al. Emerging roles for platelets as immune and inflammatory cells. *Blood* 2014;123:2759–2767.
11. Reitsma PH, Versteeg HH, Middeldorp S. Mechanistic view of risk factors for venous thromboembolism. *Arterioscler Thromb Vasc Biol* 2012;32:563–568.
12. Brighton TA, Eikelboom JW, Mann K, et al. Low-dose aspirin for preventing recurrent venous thromboembolism. *N Eng J Med* 2012;367:1979–1987.
13. Brill A, Fuchs TA, Chauhan AK, et al. von willebrand factor-mediated platelet adhesion is critical for deep vein thrombosis in mouse models. *Blood* 2011;117:1400–1407.
14. von Bruhl ML, Stark K, Steinhart A, et al. Monocytes, neutrophils, and platelets cooperate to initiate and propagate venous thrombosis in mice in vivo. *J Exp Med* 2012;209:819–835.
15. Mackman N. New insights into the mechanisms of venous thrombosis. *J Clin Invest* 2012;122:2331–2336.
16. Mackman N, Tilley RE, Key NS. Role of the extrinsic pathway of blood coagulation in hemostasis and thrombosis. *Arterioscler Thromb Vasc Biol* 2007;27:1687–1693.
17. Himber J, Wohlgensinger C, Roux S, et al. Inhibition of tissue factor limits the growth of venous thrombus in the rabbit. *J Thromb Haemost* 2003;1:889–895.

18. Jesty J, Beltrami E. Positive feedbacks of coagulation: their role in threshold regulation. *Arterioscler Thromb Vasc Biol* 2005;25:2463–2469.
19. Naito K, Fujikawa K. Activation of human blood coagulation factor XI independent of factor XII. Factor XI is activated by thrombin and factor XIa in the presence of negatively charged surfaces. *J Biol Chem* 1991;266:7353–7358.
20. Davie EW, Fujikawa K, Kisiel W. The coagulation cascade: initiation, maintenance, and regulation. *Biochemistry* 1991;30:10363–10370.
21. Kisiel W, Canfield WM, Ericsson LH, et al. Anticoagulant properties of bovine plasma protein C following activation by thrombin. *Biochemistry* 1977;16:5824–5831.
22. Marlar RA, Kleiss AJ, Griffin JH. Mechanism of action of human activated protein C, a thrombin-dependent anticoagulant enzyme. *Blood* 1982;59:1067–1072.
23. Esmon CT, Owen WG. Identification of an endothelial cell cofactor for thrombin-catalyzed activation of protein C. *Proc Natl Acad Sci U S A* 1981;78:2249–2252.
24. Owen WG, Esmon CT. Functional properties of an endothelial cell cofactor for thrombin-catalyzed activation of protein C. *J Biol Chem* 1981;256:5532–5535.
25. Esmon NL, Owen WG, Esmon CT. Isolation of a membrane-bound cofactor for thrombin-catalyzed activation of protein C. *J Biol Chem* 1982;257:859–864.
26. Wood JP, Ellery PE, Maroney SA, et al. Biology of tissue factor pathway inhibitor. *Blood* 2014;123:2934–2943.
27. Tollefsen DM. Heparin cofactor II modulates the response to vascular injury. *Arterioscler Thromb Vasc Biol* 2007;27:454–460.
28. Dano K, Andreasen PA, Grondahl-Hansen J, et al. Plasminogen activators, tissue degradation, and cancer. *Adv Cancer Res* 1985;44:139–266.
29. Vassalli JD, Sappino AP, Belin D. The plasminogen activator/plasmin system. *J Clin Invest* 1991;88:1067–1072.
30. Kohler HP, Grant PJ. Plasminogen-activator inhibitor type 1 and coronary artery disease. *N Eng J Med* 2000;342:1792–1801.
31. Gelehrter TD, Sznycer-Laszuk R. Thrombin induction of plasminogen activator-inhibitor in cultured human endothelial cells. *J Clin Invest* 1986;77:165–169.
32. Dichek D, Quertermous T. Thrombin regulation of mRNA levels of tissue plasminogen activator and plasminogen activator inhibitor-1 in cultured human umbilical vein endothelial cells. *Blood* 1989;74:222–228.
33. Esmon CT. The regulation of natural anticoagulant pathways. *Science* 1987; 235:1348–1352.
34. Hassouna HI. Laboratory evaluation of hemostatic disorders. *Hematol Oncol Clin North Am* 1993;7:1161–1249.
35. Palareti G, Cosmi B, Legnani C, et al. D-dimer testing to determine the duration of anticoagulation therapy. *N Eng J Med* 2006;355:1780–1789.
36. Schulman S, Wiman B. The significance of hypofibrinolysis for the risk of recurrence of venous thromboembolism. Duration of anticoagulation (DURAC) trial study group.

Thromb Haemost 1996;75:607–611.
37. Aird WC. Phenotypic heterogeneity of the endothelium: I. Structure, function, and mechanisms. *Circ Res* 2007;100:158–173.
38. Gross PL, Aird WC. The endothelium and thrombosis. *Semin Thromb Hemost* 2000;26:463–478.
39. Wagner DD, Frenette PS. The vessel wall and its interactions. *Blood* 2008; 111:5271–5281.
40. Wakefield TW, Myers DD, Henke PK. Mechanisms of venous thrombosis and resolution. *Arterioscler Thromb Vasc Biol* 2008;28:387–391.
41. Myers DD, Hawley AE, Farris DM, et al. P-selectin and leukocyte microparticles are associated with venous thrombogenesis. *J Vasc Surg* 2003;38:1075–1089.
42. Hrachovinova I, Cambien B, Hafezi-Moghadam A, et al. Interaction of P-selectin and PSGL-1 generates microparticles that correct hemostasis in a mouse model of hemophilia A. *Nat Med* 2003;9:1020–1025.
43. Myers D Jr, Farris D, Hawley A, et al. Selectins influence thrombosis in a mouse model of experimental deep venous thrombosis. *J Surg Res* 2002;108:212–221.
44. Sullivan VV, Hawley AE, Farris DM, et al. Decrease in fibrin content of venous thrombi in selectin-deficient mice. *J Surg Res* 2003;109:1–7.
45. Jilma B, Marsik C, Kovar F, et al. The single nucleotide polymorphism Ser128Arg in the E-selectin gene is associated with enhanced coagulation during human endotoxemia. *Blood* 2005;105:2380–2383.
46. Jilma B, Kovar FM, Hron G, et al. Homozygosity in the single nucleotide polymorphism Ser128Arg in the E-selectin gene associated with recurrent venous thromboembolism. *Arch Intern Med* 2006;166:1655–1659.
47. Chase S, Magnani J, Simon S. E-selectin ligands as mechanosensitive receptors on neutrophils in health and disease. *Ann Biomed Eng* 2012;40:849–859.
48. Andre P, Hartwell D, Hrachovinova I, et al. Pro-coagulant state resulting from high levels of soluble P-selectin in blood. *Proc Natl Acad Sci U S A* 2000; 97:13835–13840.
49. Myers DD Jr, Schaub R, Wrobleski SK, et al. P-selectin antagonism causes dose-dependent venous thrombosis inhibition. *Thromb Haemost* 2001;85:423–429.
50. Myers D, Wrobleski S, Londy F, et al. New and effective treatment of experimentally induced venous thrombosis with anti-inflammatory rPSGL-Ig. *Thromb Haemost* 2002;87:374–382.
51. Rectenwald JE, Myers DD Jr, Hawley AE, et al. D-dimer, P-selectin, and microparticles: novel markers to predict deep venous thrombosis. A pilot study. *Thromb Haemost* 2005;94:1312–1317.
52. Wagner DD, Burger PC. Platelets in inflammation and thrombosis. *Arterioscler Thromb Vasc Biol* 2003;23:2131–2137.
53. Ridker PM, Buring JE, Rifai N. Soluble P-selectin and the risk of future cardiovascular events. *Circulation* 2001;103:491–495.

54. Smith A, Quarmby JW, Collins M, et al. Changes in the levels of soluble adhesion molecules and coagulation factors in patients with deep vein thrombosis. *Thromb Haemost* 1999;82:1593–1599.
55. Ay C, Jungbauer LV, Sailer T, et al. High concentrations of soluble P-selectin are associated with risk of venous thromboembolism and the P-selectin Thr715 variant. *Clin Chem* 2007;53:1235–1243.
56. Ramacciotti E, Blackburn S, Hawley AE, et al. Evaluation of soluble P-selectin as a marker for the diagnosis of deep venous thrombosis. *Clin Appl Thromb Hemost* 2011;17(4):425–431.
57. Vandy FC, Stabler C, Eliassen AM, et al. Soluble P-selectin for the diagnosis of lower extremity deep venous thrombosis. *J Vasc Surg Venous Lymphat Disord* 2013;1:117–125.
58. Chauhan AK, Kisucka J, Lamb CB, et al. von Willebrand factor and factor VIII are independently required to form stable occlusive thrombi in injured veins. *Blood* 2007;109:2424–2429.
59. Day SM, Reeve JL, Pedersen B, et al. Macrovascular thrombosis is driven by tissue factor derived primarily from the blood vessel wall. *Blood* 2005;105:192–198.
60. Swystun LL, Shin LY, Beaudin S, et al. Chemotherapeutic agents doxorubicin and epirubicin induce a procoagulant phenotype on endothelial cells and blood monocytes. *J Thromb Haemost* 2009;7:619–626.
61. Tesselaar ME, Romijn FP, van der Linden IK, et al. Microparticle-associated tissue factor activity in cancer patients with and without thrombosis. *J Thromb Haemost* 2009;7:1421–1423.
62. Manly DA, Wang J, Glover SL, et al. Increased microparticle tissue factor activity in cancer patients with venous thromboembolism. *Thromb Res* 2010;125:511–512.
63. Ripplinger CM, Kessinger CW, Li C, et al. Inflammation modulates murine venous thrombosis resolution in vivo: assessment by multimodal fluorescence molecular imaging. *Arterioscler Thromb Vasc Biol* 2012;32:2616–2624.
64. Deatrick KB, Luke CE, Elfline MA, et al. The effect of matrix metalloproteinase 2 and matrix metalloproteinase 2/9 deletion in experimental post-thrombotic vein wall remodeling. *J Vasc Surg* 2013;58:1375–1384.e2.
65. Deatrick KB, Obi A, Luke CE, et al. Matrix metalloproteinase-9 deletion is associated with decreased mid-term vein wall fibrosis in experimental stasis DVT. *Thromb Res* 2013;132:360–366.
66. Wakefield TW, Strieter RM, Wilke CA, et al. Venous thrombosis-associated inflammation and attenuation with neutralizing antibodies to cytokines and adhesion molecules. *Arterioscler Thromb Vasc Biol* 1995;15:258–268.
67. Varma MR, Varga AJ, Knipp BS, et al. Neutropenia impairs venous thrombosis resolution in the rat. *J Vasc Surg* 2003;38:1090–1098.
68. Stewart GJ. Neutrophils and deep venous thrombosis. *Haemostasis* 1993; 23(suppl

1):127–140.
69. Varma MR, Moaveni DM, Dewyer NA, et al. Deep vein thrombosis resolution is not accelerated with increased neovascularization. *J Vasc Surg* 2004;40:536–542.
70. Fuchs TA, Brill A, Duerschmied D, et al. Extracellular DNA traps promote thrombosis. *Proc Natl Acad Sci* 2010;107:15880–15885.
71. Massberg S, Grahl L, von Bruehl ML, et al. Reciprocal coupling of coagulation and innate immunity via neutrophil serine proteases. *Nat Med* 2010;16:887–896.
72. Diaz JA, Fuchs TA, Jackson TO, et al.; for the Michigan Research Venous Group. Plasma DNA is elevated in patients with deep vein thrombosis. Journal of vascular surgery. *J Vasc Surg Venous Lymphat Disord* 2013;1(4). doi: 10.1016/j.jvsv.2012.12.002.
73. Saha P, Humphries J, Modarai B, et al. Leukocytes and the natural history of deep vein thrombosis: current concepts and future directions. *Arterioscler Thromb Vasc Biol* 2011;31:506–512.
74. Humphries J, McGuinness CL, Smith A, et al. Monocyte chemotactic protein-1 (MCP-1) accelerates the organization and resolution of venous thrombi. *J Vasc Surg* 1999;30:894–899.
75. Henke PK, Pearce CG, Moaveni DM, et al. Targeted deletion of CCR2 impairs deep vein thrombosis resolution in a mouse model. *J Immunol* 2006;177:3388–3397.
76. Deatrick KB, Wakefield TW, Henke PK. Chronic venous insufficiency: current management of varicose vein disease. *Am Surg* 2010;76:125–132.
77. Northeast AD, Soo KS, Bobrow LG, et al. The tissue plasminogen activator and urokinase response in vivo during natural resolution of venous thrombus. *J Vasc Surg* 1995;22:573–579.
78. Soo KS, Northeast AD, Happerfield LC, et al. Tissue plasminogen activator production by monocytes in venous thrombolysis. *J Pathol* 1996;178:190–194.
79. Singh I, Burnand KG, Collins M, et al. Failure of thrombus to resolve in urokinase-type plasminogen activator gene-knockout mice: rescue by normal bone marrow-derived cells. *Circulation* 2003;107:869–875.
80. Evans CE, Humphries J, Waltham M, et al. Upregulation of hypoxia-inducible factor 1 alpha in local vein wall is associated with enhanced venous thrombus resolution. *Thromb Res* 2011;128:346–351.
81. Lim CS, Qiao X, Reslan OM, et al. Prolonged mechanical stretch is associated with upregulation of hypoxia-inducible factors and reduced contraction in rat inferior vena cava. *J Vasc Surg* 2011;53:764–773.
82. Myers DD Jr, Henke PK, Bedard PW, et al. Treatment with an oral small molecule inhibitor of P selectin (PSI-697) decreases vein wall injury in a rat stenosis model of venous thrombosis. *J Vasc Surg* 2006;44:625–632.
83. Moaveni DK, Lynch EM, Luke C, et al. Vein wall re-endothelialization after deep vein thrombosis is improved with low-molecular-weight heparin. *J Vasc Surg*

2008;47:616–624.
84. Stenberg B, Bylock A, Risberg B. Effect of venous stasis on vessel wall fibrinolysis. *Thromb Haemost* 1984;51:240–242.
85. Henke PK, Varma MR, Moaveni DK, et al. Fibrotic injury after experimental deep vein thrombosis is determined by the mechanism of thrombogenesis. *Thromb Haemost* 2007;98:1045–1055.
86. Wojcik BM, Wrobleski SK, Hawley AE, et al. Interleukin-6: a potential target for post-thrombotic syndrome. *Ann Vasc Surg* 2011;25:229–239.
87. Grainger DJ, Wakefield L, Bethell HW, et al. Release and activation of platelet latent TGF-beta in blood clots during dissolution with plasmin. *Nat Med* 1995;1:932–937.
88. Diaz JA, Ballard-Lipka NE, Farris DM, et al. Impaired fibrinolytic system in ApoE gene-deleted mice with hyperlipidemia augments deep vein thrombosis. *J Vasc Surg* 2012;55(3):815–822.
89. Deatrick KB, Eliason JL, Lynch EM, et al. Vein wall remodeling after deep vein thrombosis involves matrix metalloproteinases and late fibrosis in a mouse model. *J Vasc Surg* 2005;42:140–148.
90. Obi AT, Diaz JA, Ballard-Lipka NL, et al. Plasminogen activator-1 overexpression decreases experimental postthrombotic vein wall fibrosis by a non-vitronectin-dependent mechanism. *J Thromb Haemost* 2014;12:1353–1363.
91. Myers DD Jr, Henke PK, Bedard PW, et al. Treatment with an oral small molecule inhibitor of P selectin (PSI-697) decreases vein wall injury in a rat stenosis model of venous thrombosis. *J Vasc Surg* 2006;44:625–632.
92. Wojcik BM, Wrobleski SK, Hawley AE, et al. Interleukin-6: a potential target for post-thrombotic syndrome. *Ann Vasc Surg* 2011;25:229–239.
93. Baldwin JF, Sood V, Elfline MA, et al. The role of urokinase plasminogen activator and plasmin activator inhibitor-1 on vein wall remodeling in experimental deep vein thrombosis. *J Vasc Surg* 2012;56:1089–1097.
94. Mackman N. Triggers, targets and treatments for thrombosis. *Nature* 2008;451:914–918.
95. Ross R. Atherosclerosis–an inflammatory disease. *N Eng J Med* 1999;340:115–126.
96. Hathcock JJ. Flow effects on coagulation and thrombosis. *Arterioscler Thromb Vasc Biol* 2006;26:1729–1737.
97. Dentali F, Squizzato A, Ageno W. The metabolic syndrome as a risk factor for venous and arterial thrombosis. *Semin Thromb Hemost* 2009;35:451–457.
98. Chan MY, Andreotti F, Becker RC. Hypercoagulable states in cardiovascular disease. *Circulation* 2008;118:2286–2297.
99. Glynn RJ, Danielson E, Fonseca FA, et al. A randomized trial of rosuvastatin in the prevention of venous thromboembolism. *N Eng J Med* 2009;360(18):1851–1861.
100. Gangireddy C, Rectenwald JR, Upchurch GR, et al. Risk factors and clinical impact of postoperative symptomatic venous thromboembolism. *J Vasc Surg* 2007;45:335–341;

discussion 341–332.
101. Heit JA. The epidemiology of venous thromboembolism in the community. *Arterioscler Thromb Vasc Biol* 2008;28:370–372.
102. Heit JA, Silverstein MD, Mohr DN, et al. The epidemiology of venous thromboembolism in the community. *Thromb Haemost* 2001;86:452–463.
103. Caprini JA, Arcelus JI, Reyna JJ. Effective risk stratification of surgical and nonsurgical patients for venous thromboembolic disease. *Semin Hematol* 2001;38:12–19.
104. Pannucci CJ, Laird S, Dimick JB, et al. A validated risk model to predict 90-day VTE events in post-surgical patients. *Chest* 2013;145(3):567–573.
105. Gould MK, Garcia DA, Wren SM, et al.; American College of Chest Physicians. Prevention of VTE in nonorthopedic surgical patients: antithrombotic therapy and prevention of thrombosis, 9th ed: American College of Chest Physicians Evidence-Based Clinical Practice Guidelines. *Chest* 2012;141:e227S–e277S.
106. van den Berg YW, Osanto S, Reitsma PH, et al. The relationship between tissue factor and cancer progression: insights from bench and bedside. *Blood* 2012;119:924–932.
107. Kasthuri RS, Taubman MB, Mackman N. Role of tissue factor in cancer. *J Clin Oncol.* 2009;27:4834–4838.
108. Khorana AA. The NCCN clinical practice guidelines on venous thromboembolic disease: strategies for improving VTE prophylaxis in hospitalized cancer patients. *Oncologist* 2007;12:1361–1370.
109. Twig G, Zandman-Goddard G, Szyper-Kravitz M, et al. Systemic thromboembolism in inflammatory bowel disease: mechanisms and clinical applications. *Ann N Y Acad Sci* 2005;1051:166–173.
110. Merrill A, Millham F. Increased risk of postoperative deep vein thrombosis and pulmonary embolism in patients with inflammatory bowel disease: a study of national surgical quality improvement program patients. *Arch Surg* 2012;147:120–124.
111. Selby R, Geerts W, Ofosu FA, et al. Hypercoagulability after trauma: hemostatic changes and relationship to venous thromboembolism. *Thromb Res* 2009;124:281–287.
112. Shackford SR, Davis JW, Hollingsworth-Fridlund P, et al. Venous thromboembolism in patients with major trauma. *Am J Surg* 1990;159:365–369.
113. Paffrath T, Wafaisade A, Lefering R, et al.; Trauma Registry of DGU. Venous thromboembolism after severe trauma: incidence, risk factors and outcome. *Injury* 2010;41:97–101.
114. Khamashta MA, Cuadrado MJ, Mujic F, et al. The management of thrombosis in the antiphospholipid-antibody syndrome. *N Eng J Med* 1995;332:993–997.
115. Carreras LO, Defreyn G, Machin SJ, et al. Arterial thrombosis, intrauterine death and

"lupus" antiocoagulant: detection of immunoglobulin interfering with prostacyclin formation. *Lancet* 1981;1:244–246.

116. Comp PC, DeBault LE, Esmon NL, et al. Human thrombomodulin is inhibited by IgG from two patients with non-specific anticoagulants (abstract). *Blood* 1983;62:244–246.
117. Eldrup-Jorgensen J, Flanigan DP, Brace L, et al. Hypercoagulable states and lower limb ischemia in young adults. *J Vasc Surg* 1989;9:334–341.
118. Vermylen J, Blockmans D, Spitz B, et al. Thrombosis and immune disorders. *Clin Haematol* 1986;15:393–412.
119. Ferro D, Pittoni V, Quintarelli C, et al. Coexistence of anti-phospholipid antibodies and endothelial perturbation in systemic lupus erythematosus patients with ongoing prothrombotic state. *Circulation* 1997;95:1425–1432.
120. Rand JH, Wu XX, Andree HA, et al. Pregnancy loss in the antiphospholipid-antibody syndrome–a possible thrombogenic mechanism. *N Eng J Med* 1997;337:154–160.
121. Reverter JC, Tassies D, Font J, et al. Hypercoagulable state in patients with antiphospholipid syndrome is related to high induced tissue factor expression on monocytes and to low free protein S. *Arterioscler Thromb Vasc Biol* 1996;16:1319–1326.
122. Giannakopoulos B, Krilis SA. The pathogenesis of the antiphospholipid syndrome. *Eng J Med* 2013;368:1033–1044.
123. Greenfield LJ. Lupus-like anticoagulants and thrombosis. *J Vasc Surg* 1988; 7:818–819.
124. Ahn SS, Kalunian K, Rosove M, et al. Postoperative thrombotic complications in patients with lupus anticoagulant: increased risk after vascular procedures. *J Vasc Surg* 1988;7:749–756.
125. Nielsen TG, Nordestgaard BG, von Jessen F, et al. Antibodies to cardiolipin may increase the risk of failure of peripheral vein bypasses. *Eur J Vasc Endovasc Surg* 1997;14:177–184.
126. Miyakis S, Lockshin M, Atsumi T, et al. International consensus statement on an update of the classification criteria for definite antiphospholipid syndrome (APS). *J Thromb Haemost* 2006;4:295–306.
127. Lynch A, Marlar R, Murphy J, et al. Antiphospholipid antibodies in predicting adverse pregnancy outcome. A prospective study. *Ann Intern Med* 1994;120:470–475.
128. Alving BM. How I treat heparin-induced thrombocytopenia and thrombosis. *Blood* 2003;101:31–37.
129. Ansell JE, Price JM, Shah S, et al. Heparin-induced thrombocytopenia. What is its real frequency? *Chest* 1985;88:878–882.
130. Cancio LC, Cohen DJ. Heparin-induced thrombocytopenia and thrombosis. *J Am Coll Surg* 1998;186:76–91.
131. Almeida JI, Coats R, Liem TK, et al. Reduced morbidity and mortality rates of the

heparin-induced thrombocytopenia syndrome. *J Vasc Surg* 1998; 27:309–314; discussion 315–316.

132. Kelton JG, Smith JW, Warkentin TE, et al. Immunoglobulin G from patients with heparin-induced thrombocytopenia binds to a complex of heparin and platelet factor 4. *Blood* 1994;83:3232–3239.
133. Walenga JM, Jeske WP, Messmore HL. Mechanisms of venous and arterial thrombosis in heparin-induced thrombocytopenia. *J Thromb Thrombolysis* 2000;10(suppl 1):13–20.
134. Greinacher A, Michels I, Mueller-Eckhardt C. Heparin-associated thrombocytopenia: the antibody is not heparin specific. *Thromb Haemost* 1992; 67:545–549.
135. Warkentin TE, Levine MN, Hirsh J, et al. Heparin-induced thrombocytopenia in patients treated with low-molecular-weight heparin or unfractionated heparin. *N Eng J Med* 1995;332:1330–1335.
136. Laster J, Silver D. Heparin-coated catheters and heparin-induced thrombocytopenia. *J Vasc Surg* 1988;7:667–672.
137. Levine RL, McCollum D, Hursting MJ. How frequently is venous thromboembolism in heparin-treated patients associated with heparin-induced thrombocytopenia? *Chest J* 2006;130:681–687.
138. Warkentin TE. Heparin-induced thrombocytopenia. *Dis Mon* 2005;51:141–149.
139. Cuker A, Gimotty PA, Crowther MA, et al. Predictive value of the 4Ts scoring system for heparin-induced thrombocytopenia: a systematic review and meta-analysis. *Blood* 2012;120:4160–4167.
140. Pouplard C, Gueret P, Fouassier M, et al. Prospective evaluation of the '4Ts' score and particle gel immunoassay specific to heparin/PF4 for the diagnosis of heparin-induced thrombocytopenia. *J Thromb Haemost* 2007;5:1373–1379.
141. Warkentin TE. Heparin-induced thrombocytopenia: a clinicopathologic syndrome. *Thromb Haemost* 1999;82:439–447.
142. Anderson JA, Weitz JI. Hypercoagulable states. *Crit Care Clin* 2011;27:933–952; vii.
143. Nakashima MO, Rogers HJ. Hypercoagulable states: an algorithmic approach to laboratory testing and update on monitoring of direct oral anticoagulants. *Blood Res* 2014;49:85–94.
144. Gabriel F, Portolés O, Labiós M, et al.; RIETE Investigators. Usefulness of thrombophilia testing in venous thromboembolic disease: findings from the RIETE registry. *Clin Appl Thromb Hemost* 2013;19:42–47.
145. Schafer AI, Levine MN, Konkle BA, et al. Thrombotic disorders: diagnosis and treatment. *Hematology Am Soc Hematol Educ Program* 2003:520–539.
146. Mateo J, Oliver A, Borrell M, et al. Laboratory evaluation and clinical characteristics of 2,132 consecutive unselected patients with venous thromboembolism–results of the Spanish Multicentric Study on Thrombophilia (EMET-study). *Thromb Haemost* 1997;77:444–451.

147. Rosendaal FR. Risk factors for venous thrombotic disease. *Thromb Haemost* 1999;82:610–619.
148. Flinn WR, McDaniel MD, Yao JS, et al. Antithrombin III deficiency as a reflection of dynamic protein metabolism in patients undergoing vascular reconstruction. *J Vasc Surg* 1984;1:888–895.
149. Towne JB, Bernhard VM, Hussey C, et al. Antithrombin deficiency–a cause of unexplained thrombosis in vascular surgery. *Surgery* 1981;89:735–742.
150. Pabinger I, Schneider B. Thrombotic risk of women with hereditary antithrombin III-, protein C- and protein S-deficiency taking oral contraceptive medication. The GTH Study Group on Natural Inhibitors. *Thromb Haemost* 1994;71:548–552.
151. Thomas RH. Hypercoagulability syndromes. *Arch Intern Med* 2001;161:2433–2439.
152. Seligsohn U, Lubetsky A. Genetic susceptibility to venous thrombosis. *N Eng J Med* 2001;344:1222–1231.
153. Bick RL. Prothrombin G20210A mutation, antithrombin, heparin cofactor II, protein C, and protein S defects. *Hematol Oncol Clin North Am* 2003; 17:9–36.
154. Tait RC, Walker ID, Reitsma PH, et al. Prevalence of protein C deficiency in the healthy population. *Thromb Haemost* 1995;73:87–93.
155. Donaldson MC, Belkin M, Whittemore AD, et al. Impact of activated protein C resistance on general vascular surgical patients. *J Vasc Surg* 1997;25:1054–1060.
156. de Moerloose P, Bounameaux HR, Mannucci PM. Screening test for thrombophilic patients: which tests, for which patient, by whom, when, and why? *Semin Thromb Hemost* 1998;24:321–327.
157. Franco RF, Reitsma PH. Genetic risk factors of venous thrombosis. *Hum Genet* 2001;109:369–384.
158. Gladson CL, Scharrer I, Hach V, et al. The frequency of type I heterozygous protein S and protein C deficiency in 141 unrelated young patients with venous thrombosis. *Thromb Haemost* 1988;59:18–22.
159. Martinelli I, Mannucci PM, De Stefano V, et al. Different risks of thrombosis in four coagulation defects associated with inherited thrombophilia: a study of 150 families. *Blood* 1998;92:2353–2358.
160. Siddiqi FA, Tepler J, Fantini GA. Acquired protein S and antithrombin III deficiency caused by nephrotic syndrome: an unusual cause of graft thrombosis. *J Vasc Surg* 1997;25:576–580.
161. Jennings I, Cooper P. Screening for thrombophilia: a laboratory perspective. *Br J Biomed Sci* 2003;60:39–51.
162. Dahlback B. Blood coagulation. *Lancet* 2000;355:1627–1632.
163. Cole MS, Minifee PK, Wolma FJ. Coumarin necrosis–a review of the literature. *Surgery* 1988;103:271–277.
164. Ridker PM, Miletich JP, Hennekens CH, et al. Ethnic distribution of factor V Leiden in 4047 men and women. Implications for venous thromboembolism screening. *JAMA*

1997;277:1305–1307.

165. Rosendaal FR, Koster T, Vandenbroucke JP, et al. High risk of thrombosis in patients homozygous for factor V Leiden (activated protein C resistance). *Blood* 1995;85:1504–1508.

166. Svensson PJ, Dahlback B. Resistance to activated protein C as a basis for venous thrombosis. *N Eng J Med* 1994;330:517–522.

167. Kalafatis M, Mann KG. Factor VLeiden and thrombophilia. *Arterioscler Thromb Vasc Biol* 1997;17:620–627.

168. Mann KG, Kalafatis M. Factor V: a combination of Dr Jekyll and Mr Hyde. *Blood* 2003;101:20–30.

169. Simioni P, Prandoni P, Lensing AW, et al. The risk of recurrent venous thromboembolism in patients with an Arg506–>Gln mutation in the gene for factor V (factor V Leiden). *N Eng J Med* 1997;336:399–403.

170. De Stefano V, Martinelli I, Mannucci PM, et al. The risk of recurrent deep venous thrombosis among heterozygous carriers of both factor V Leiden and the G20210A prothrombin mutation. *N Eng J Med* 1999;341:801–806.

171. Koeleman BP, Reitsma PH, Allaart CF, et al. Activated protein C resistance as an additional risk factor for thrombosis in protein C-deficient families. *Blood* 1994;84:1031–1035.

172. Koeleman BP, van Rumpt D, Hamulyák K, et al. Factor V Leiden: an additional risk factor for thrombosis in protein S deficient families? *Thromb Haemost* 1995;74:580–583.

173. Ridker PM, Goldhaber SZ, Danielson E, et al. Long-term, low-intensity warfarin therapy for the prevention of recurrent venous thromboembolism. *N Eng J Med* 2003;348:1425–1434.

174. Ouriel K, Green RM, DeWeese JA, et al. Activated protein C resistance: prevalence and implications in peripheral vascular disease. *J Vasc Surg* 1996;23:46–51; discussion 51–52.

175. Poort SR, Rosendaal FR, Reitsma PH, et al. A common genetic variation in the 3′-untranslated region of the prothrombin gene is associated with elevated plasma prothrombin levels and an increase in venous thrombosis. *Blood* 1996;88:3698–3703.

176. Vicente V, González-Conejero R, Rivera J, et al. The prothrombin gene variant 20210A in venous and arterial thromboembolism. *Haematologica* 1999;84:356–362.

177. Cumming AM, Keeney S, Salden A, et al. The prothrombin gene G20210A variant: prevalence in a U.K. anticoagulant clinic population. *Br J Haematol* 1997;98:353–355.

178. Martinelli I, Sacchi E, Landi G, et al. High risk of cerebral-vein thrombosis in carriers of a prothrombin-gene mutation and in users of oral contraceptives. *N Eng J Med* 1998;338:1793–1797.

179. Ridker PM, Hennekens CH, Miletich JP. G20210A mutation in prothrombin gene and risk of myocardial infarction, stroke, and venous thrombosis in a large cohort of US

men. *Circulation* 1999;99:999–1004.

180. Martinelli I, Taioli E, Bucciarelli P, et al. Interaction between the G20210A mutation of the prothrombin gene and oral contraceptive use in deep vein thrombosis. *Arterioscler Thromb Vasc Biol* 1999;19:700–703.
181. Hillarp A, Zöller B, Svensson P, et al. The 20210 A allele of the prothrombin gene is a common risk factor among Swedish outpatients with verified deep venous thrombosis. *Thromb Haemost* 1997;78:990–992.
182. Ferraresi P, Marchetti G, Legnani C, et al. The heterozygous 20210 G/A prothrombin genotype is associated with early venous thrombosis in inherited thrombophilias and is not increased in frequency in artery disease. *Arterioscler Thromb Vasc Biol* 1997;17:2418–2422.
183. Gerhardt A, Scharf RE, Beckmann MW, et al. Prothrombin and factor V mutations in women with a history of thrombosis during pregnancy and the puerperium. *N Eng J Med* 2000;342:374–380.
184. McGlennen RC, Key NS. Clinical and laboratory management of the prothrombin G20210A mutation. *Arch Pathol Lab Med* 2002;126:1319–1325.
185. De Stefano V, Casorelli I, Rossi E, et al. Interaction between hyperhomocysteinemia and inherited thrombophilic factors in venous thromboembolism. *Semin Thromb Hemost* 2000;26:305–311.
186. den Heijer M, Blom HJ, Gerrits WB, et al. Is hyperhomocysteinaemia a risk factor for recurrent venous thrombosis? *Lancet* 1995;345:882–885.
187. den Heijer M, Koster T, Blom HJ, et al. Hyperhomocysteinemia as a risk factor for deep-vein thrombosis. *N Eng J Med* 1996;334:759–762.
188. den Heijer M, Keijzer MB. Hyperhomocysteinemia as a risk factor for venous thrombosis. *Clin Chem Lab Med* 2001;39:710–713.
189. Falcon CR, Cattaneo M, Panzeri D, et al. High prevalence of hyperhomocyst(e)inemia in patients with juvenile venous thrombosis. *Arterioscler Thromb* 1994;14:1080–1083.
190. Fermo I, Vigano'D'Angelo S, Paroni R, et al. Prevalence of moderate hyperhomocysteinemia in patients with early-onset venous and arterial occlusive disease. *Ann Intern Med* 1995;123:747–753.
191. Simioni P, Prandoni P, Burlina A, et al. Hyperhomocysteinemia and deep-vein thrombosis. A case-control study. *Thromb Haemost* 1996;76:883–886.
192. Den Heijer M, Rosendaal FR, Blom HJ, et al. Hyperhomocysteinemia and venous thrombosis: a meta-analysis. *Thromb Haemost* 1998;80:874–877.
193. Legnani C, Palareti G, Grauso F, et al. Hyperhomocyst(e)inemia and a common methylenetetrahydrofolate reductase mutation (Ala223Val MTHFR) in patients with inherited thrombophilic coagulation defects. *Arterioscler Thromb Vasc Biol* 1997;17:2924–2929.
194. Kottke-Marchant K. Genetic polymorphisms associated with venous and arterial

thrombosis: an overview. *Arch Pathol Lab Med* 2002;126:295–304.

195. Inherited causes of thrombosis. Indiana Hemophilia & Thrombosis Center. Available from: http://www.ihtc.org/medical-professionals/blood-disorders/clotting-disorders/inherited-causes-of-thrombosis/. Accessed May 27, 2016.
196. Schlesselman L. Novel risk factors for atherosclerotic disease. *MedScape CME.* 2001. Available from: http://www.medscape.org/viewarticle/418378. Accessed May 27, 2016.
197. Mandel H, Brenner B, Berant M, et al. Coexistence of hereditary homocystinuria and factor V Leiden–effect on thrombosis. *N Eng J Med* 1996; 334:763–768.
198. Hayashi T, Honda G, Suzuki K. An atherogenic stimulus homocysteine inhibits cofactor activity of thrombomodulin and enhances thrombomodulin expression in human umbilical vein endothelial cells. *Blood* 1992;79:2930–2936.
199. Loscalzo J. The oxidant stress of hyperhomocyst(e)inemia. *J Clin Invest* 1996;98:5–7.
200. Rodgers GM, Conn MT. Homocysteine, an atherogenic stimulus, reduces protein C activation by arterial and venous endothelial cells. *Blood* 1990; 75:895–901.
201. Tawakol A, Omland T, Gerhard M, et al. Hyperhomocyst(e)inemia is associated with impaired endothelium-dependent vasodilation in humans. *Circulation* 1997;95:1119–1121.
202. Upchurch GR, Welch GN, Randev V, et al. The effect of homocysteine on endothelial nitric oxide production. *FASEB J* 1995;9:A876.
203. George J, Alving BM, Ballem P. Platelets. In: McArthur JR, Benz EJ, eds. *Hemotology - 1994.* Washington, DC: American Society of Hematologists 1994.
204. Ueland PM, Refsum H, Brattstrom L. *Plasma homocysteine and cardiovascular disease.* New York, NY: Marcel Dekker; 1993.
205. Reiner AP, Siscovick DS, Rosendaal FR. Hemostatic risk factors and arterial thrombotic disease. *Thromb Haemost* 2001;85:584–595.
206. Towne JB, Bandyk DF, Hussey CV, et al. Abnormal plasminogen: a genetically determined cause of hypercoagulability. *J Vasc Surg* 1984;1:896–902.
207. Kwaan HC, Levin M, Sakurai S, et al. Digital ischemia and gangrene due to red blood cell aggregation induced by acquired dysfibrinogenemia. *J Vasc Surg* 1997;26:1061–1068.
208. Roberts HR, Stinchcombe TE, Gabriel DA. The dysfibrinogenaemias. *Br J Haematol* 2001;114:249–257.
209. Nilsson IM, Ljungner H, Tengborn L. Two different mechanisms in patients with venous thrombosis and defective fibrinolysis: low concentration of plasminogen activator or increased concentration of plasminogen activator inhibitor. *Br Med J (Clin Res Ed)* 1985;290:1453–1456.
210. Prins MH, Hirsh J. A critical review of the evidence supporting a relationship between impaired fibrinolytic activity and venous thromboembolism. *Arch Intern Med* 1991;151:1721–1731.

211. van Tilburg NH, Rosendaal FR, Bertina RM. Thrombin activatable fibrinolysis inhibitor and the risk for deep vein thrombosis. *Blood* 2000;95:2855–2859.
212. Paramo JA, Perez JL, Serrano M, et al. Types 1 and 2 plasminogen activator inhibitor and tumor necrosis factor alpha in patients with sepsis. *Thromb Haemost* 1990;64:3–6.
213. Ishibashi S. Lipoprotein(a) and atherosclerosis. *Arterioscler Thromb Vasc Biol* 2001;21:1–2.
214. Liao JK, Shin WS, Lee WY, et al. Oxidized low-density lipoprotein decreases the expression of endothelial nitric oxide synthase. *J Biol Chem* 1995;270:319–324.
215. Valentine RJ, Kaplan HS, Green R, et al. Lipoprotein (a), homocysteine, and hypercoagulable states in young men with premature peripheral atherosclerosis: a prospective, controlled analysis. *J Vasc Surg* 1996;23:53–61; discussion 61–63.
216. Griffin JH, Fernandez JA, Deguchi H. Plasma lipoproteins, hemostasis and thrombosis. *Thromb Haemost* 2001;86:386–394.
217. Nowak-Gottl U, Junker R, Hartmeier M, et al. Increased lipoprotein(a) is an important risk factor for venous thromboembolism in childhood. *Circulation* 1999;100:743–748.
218. Marcucci R, Liotta AA, Cellai AP, et al. Increased plasma levels of lipoprotein(a) and the risk of idiopathic and recurrent venous thromboembolism. *Am J Med* 2003;115:601–605.
219. Ignatescu M, Kostner K, Zorn G, et al. Plasma Lp(a) levels are increased in patients with chronic thromboembolic pulmonary hypertension. *Thromb Haemost* 1998;80:231–232.
220. Mosesson MW. Dysfibrinogenemia and thrombosis. *Semin Thromb Hemost* 1999;25:311–319.
221. Rosendaal FR. Venous thrombosis: a multicausal disease. *Lancet* 1999;353:1167–1173.
222. Harker LA. Platelets in thrombotic disorders: quantitative and qualitative platelet disorders predisposing to arterial thrombosis. *Semin Hematol* 1998;35:241–252.
223. Kamphuisen PW, Lensen R, Houwing-Duistermaat JJ, et al. Heritability of elevated factor VIII antigen levels in factor V Leiden families with thrombophilia. *Br J Haematol* 2000;109:519–522.
224. Koster T, Blann AD, Briët E, et al. Role of clotting factor VIII in effect of von Willebrand factor on occurrence of deep-vein thrombosis. *Lancet* 1995;345:152–155.
225. O'Donnell J, Mumford AD, Manning RA, et al. Elevation of FVIII: C in venous thromboembolism is persistent and independent of the acute phase response. *Thromb Haemost* 2000;83:10–13.
226. Mansvelt EP, Laffan M, McVey JH, et al. Analysis of the F8 gene in individuals with high plasma factor VIII: C levels and associated venous thrombosis. *Thromb Haemost* 1998;80:561–565.
227. Kyrle PA, Minar E, Hirschl M, et al. High plasma levels of factor VIII and the risk of

recurrent venous thromboembolism. *N Eng J Med* 2000; 343:457–462.

228. Miller CH, Dilley A, Richardson L, et al. Population differences in von Willebrand factor levels affect the diagnosis of von Willebrand disease in African-American women. *Am J Hematol* 2001;67:125–129.
229. Meijers JC, Tekelenburg WL, Bouma BN, et al. High levels of coagulation factor XI as a risk factor for venous thrombosis. *N Eng J Med* 2000; 342:696–701.
230. van Hylckama Vlieg A, van der Linden IK, Bertina RM, et al. High levels of factor IX increase the risk of venous thrombosis. *Blood* 2000;95:3678–3682.
231. Lane DA, Grant PJ. Role of hemostatic gene polymorphisms in venous and arterial thrombotic disease. *Blood* 2000;95:1517–1532.
232. Levi M, Toh CH, Thachil J, et al. Guidelines for the diagnosis and management of disseminated intravascular coagulation. British committee for standards in haematology. *Br J Haematol* 2009;145:24–33.
233. Coppola A, Di Capua M, Di Minno MN, et al. Treatment of hemophilia: a review of current advances and ongoing issues. *J Blood Med* 2010;1:183–195.
234. Fijnvandraat K, Cnossen MH, Leebeek FW, et al. Diagnosis and management of haemophilia. *BMJ* 2012;344:e2707.
235. Lusher JM, Arkin S, Abildgaard CF, et al. Recombinant factor VIII for the treatment of previously untreated patients with hemophilia A. Safety, efficacy, and development of inhibitors. Kogenate previously untreated patient study group. *N Eng J Med* 1993;328:453–459.
236. Larson PJ, High KA. Biology of inherited coagulopathies: factor IX. *Hematol Oncol Clin North Am* 1992;6:999–1009.
237. Ginsburg D. Biology of inherited coagulopathies: von Willebrand factor. *Hematol Oncol Clin North Am* 1992;6:1011–1020.

Chapter 7

Inflammation

Matthew R. Rosengart and Timothy R. Billiar

Key Points

1 Innate immunity, a system already poised to respond prior to any stimulus, provides the initial defense against microbes. Subsequent reinforcement is provided by the more specific adaptive immune system, which possesses exquisite specificity for subsequent exposure to individual microbes and the capacity to learn and modify subsequent responses to repeated exposures. Both are composed of cellular and humoral components.

2 Implicit with the capacity for pathogen elimination is the potential for destruction of host tissues. Numerous regulatory mechanisms provide temporal and spatial control of the inflammatory processes, including programmed cell death (i.e., apoptosis).

3 Over 30 randomized controlled clinical trials have been conducted to assess the efficacy of modulating inflammation, in particular systemic cytokine concentrations, in reducing mortality.

4 The T_H1 inflammatory response (i.e., cell-mediated immunity or delayed-type hypersensitivity) is induced by interleukin-12 (IL-12) derived from phagocytes and provides one major arm of the adaptive immune response; it is mediated by $CD4^+$ and $CD8^+$ lymphocytes and macrophages, which regulate production of opsonizing and complement fixing antibodies and are effectors of phagocyte-dependent responses.

5 The principal stimulus for T_H2 differentiation is IL-4, which is derived from T cells, mast cells, and basophils. As the cellular effectors of humoral immunity, they provide the other major arm of the adaptive immune response, which is mediated by T_H2 $CD4+$ cells, B cells, plasma cells, and antibodies.

6 The complement system is integral to both innate and adaptive immunity and has the capacity to independently eliminate organisms and facilitate host defense by marking foreign particles for phagocytosis through opsonization.

7 Additional systems, including the vascular (i.e., vasodilatation, adhesion receptors, kinin cascade) and neuroendocrine (i.e., adrenocorticotropic hormone [ACTH], arginine vasopressin [AVP], corticotropin-releasing hormone [CRH]), integrate with the immune system, sharing similar mediators and their receptors, to orchestrate an intense, coordinated response to any injurious/septic insult.

8 Danger-associated molecular patterns (DAMP) are the endogenous equivalent of

PAMPS, represent danger signals or “alarmins,” and share many characteristics similar to cytokines. They may be released following nonprogrammed cell death, such as necrosis, or secreted as mediators by immune cells, under which circumstance they may facilitate the inflammatory response.

9 Our immune system differentiates pathogens and damaged cells from self using evolutionarily ancient sets of recognition molecules called pattern recognition receptors (PRR), which bind conserved molecular structures found in large groups of pathogens, termed pathogen-associated molecular patterns (PAMPs), an example being the toll-like receptors (TLR).

Our appreciation for the complexity and our understanding of the integrated mechanisms collectively called “inflammation” has undergone considerable revision since the initial description of the four cardinal signs and symptoms by Celsus in first century AD: “rubor et tumor cum calore et dolore,” redness and swelling with heat and pain.[1] Centuries lapsed before John Hunter postulated that inflammation provides a survival mechanism to preserve the host. Ironically, he commented that an exuberant inflammatory response could be deleterious. These are all too true, as the pathologic sequelae of excessive inflammation (i.e., acute respiratory distress syndrome [ARDS], multiple organ dysfunction syndrome [MODS]) are encountered ever more frequently as technology affords survival of the initial insult.[1] The 19th century witnessed milestone contributions to our understanding of this process as Rudolph Virchow detailed the cellular pathology of inflammation, Julius Cohnheim provided microscopic details of the acute phases of inflammation (vasodilatation, edema formation, and leukocyte emigration), and Elie Metchnikoff described the events of phagocytosis.[1–3] The integration of these new data created a novel new paradigm of cellular and humoral concepts of inflammation, both of which were deemed critical in host defense against foreign pathogens.

In the 20th century, technological advancements in molecular biology and biochemistry facilitated more detailed investigation and enabled the rapid expansion of knowledge of the many interwoven facets of the inflammation process. Evidence began to accumulate that the ramifications of these processes extended beyond the confines of the insult. Many humoral mediators, in addition to local effects, influenced distant targets as well, such as the liver and neurohormonal centers. Recently it has become clear that the immune system, endocrine system, and nervous system comprise an integrated network sharing similar mediators and their receptors. Such an integrative view, introduced by J. Edwin Blalock, when combined with Hans Selye’s concept of stress, led to the contemporary understanding of sickness behavior, defined by Robert Dantzer as a highly organized strategy of the organism to fight infections and to respond to other environmental stressors. Hence, what originated nearly two millennia ago as a simple concept founded upon a constellation of signs and symptoms is now considered an intense, coordinated interplay of the nervous, vascular, endocrine, and immune systems to any injurious insult. It is the culmination of millions of years of evolution. Without it, life would be an arduous, painful, and brief existence, at best.

This chapter attempts to summarize this enormous quantity of information. An initial description of the elements involved in inflammation will provide the foundation upon which to discuss the sequence of events and interactions that comprise the inflammatory cascade.

INNATE VERSUS ADAPTIVE IMMUNITY

1 Innate immunity, a system composed of both cellular and humoral components, already poised to respond prior to any stimulus, provides our initial security against invading microbes.[4] Phylogenetically it is ancient and conserved, notably providing the primary mechanism of invertebrate host defense. The response it provides is uniform and consistent with each successive infection. Subsequent reinforcement is provided by the more specific and targeted efforts of the adaptive immune system. In contrast to innate immunity, and as the name would suggest, it "adapts" and subsequent exposure to the inciting elicits responses of increased magnitude and defensive capabilities during.[4] This exquisite specificity for individual microbes, the capacity to "learn," "remember," and modify subsequent responses to repeated exposures, has provided the impetus for the name.

Both arms of immunity are composed of cellular and serum components. In the adaptive immune response this has been divided into humoral immunity, which is mediated primarily by antibodies, and cell-mediated immunity. These are not distinct systems and form an integrated system of host defense.

CELLULAR COMPONENTS

Neutrophils

Neutrophils are integral to both innate and humoral immunity, providing the initial defense against invading viral, bacterial, and parasitic pathogens. This importance is underscored by the fact that 55% to 60% of the hematopoietic output of bone marrow is dedicated to the production of neutrophils.[5] On exiting the marrow they circulate for 7 to 10 hours before taking up residence in the tissues for 1 to 2 days (Table 7-1).[6,7] They are uniquely sensitive to minute concentration gradients of microbial products and inflammatory mediators and rapidly accumulate at sites of infection, where they ingest and dispose of a wide array of pathogens with their vast microbicidal armamentarium. This pathogenicity, however, carries with it an implicit capacity for host injury and accordingly, neutrophil function must be tightly regulated.

Recruitment

Neutrophil recruitment, conceptually, is a sequence of events progressing from (1) initial adhesion to activated endothelium, to (2) subsequent extravasation and emigration toward inflammatory foci, to (3) the ultimate elimination of foreign microorganisms through phagocytosis, the generation of reactive oxygen species (ROS), and the release of microbial substances.[4]

After injury, local and regional vasodilation induces hyperemia which facilitates the leukocyte delivery to the focus of injury. Extravasation of plasma creates edema, and in combination with the release of vasoactive substances leads to hemoconcentration, which promotes the peripheral margination of leukocytes.[8,9] Circulating neutrophils transiently interact with the endothelial cell surface molecules during “rolling,” a process that involves a series of loose and reversible attachments between the neutrophil and endothelium. (Fig. 7-1). These interactions, prerequisite for subsequent tighter cell–cell interactions, are mediated by the family of selectin receptors which bind with their counterligands, the sialyl Lewis family and other fucosylated and sulfated structures. E-selectin and P-selectin are present on endothelium and L-selectin is found on leukocytes.[4]

After stimulation by inflammatory mediators (thrombin, histamine, complement fragments, oxygen species, lipopolysaccharide [LPS], and cytokines such as IL-1, TNFα, and IFNγ), the vascular endothelium expresses P- and E-selectin, which engage neutrophil surface glycoprotein P-selectin glycoprotein ligand 1 (PSGL-1) or sialyl Lewis. P-selectin is stored intracellularly and can be rapidly mobilized for expression within minutes of cellular activation. Endothelial cells also translocate ligands for neutrophil L-selectin and release mediators like platelet-activating factor (PAF) and IL-8. Cytokines such as TNFα, granulocyte-macrophage colony stimulating factor (GM-CSF), and granulocyte colony stimulating factor (G-CSF) increase the affinity of leukocyte L-selectin for its counterreceptor. In addition to mechanical anchorage, these selectins induce signal transduction pathways that influence cellular function. P-selectin facilitates neutrophil degranulation and superoxide production, and cross-linking L-selectin primes the

neutrophil for increased superoxide production.[10–12]

After rolling, L-selectin is rapidly shed in preparation for leukocyte diapedesis and emigration into the interstitium. Subsequent exposure to chemoattractant gradients results in conversion of the neutrophil to a state of tight stationary adhesion (Fig. 7-1). The receptors mediating this interaction are members of the β_2 integrin family, most importantly leukocyte function antigen-1 (LFA-1, CD11a/CD18) and Mac-1 (CD11b/CD18). Their expression is enhanced in response to selectin binding, and thus explains the prerequisite nature of the early cell–cell interactions to neutrophil recruitment. Both integrin receptors engage the intercellular adhesion molecules ICAM-1 and ICAM-2 in mediating adhesion; yet, each provides additional important functions. Leukocyte emigration is primarily an LFA-1–dependent process, as mice deficient in this receptor exhibit reduced neutrophil attachment to ICAM-1 and endothelial cells. By contrast, mice lacking Mac-1 demonstrate impaired degranulation, superoxide production, and phagocytosis. Mac-1 also binds fibrinogen, heparin, and factor X and is implicated in neutrophil phagocytosis-induced apoptosis, a process essential for resolution of the inflammatory process (see below). The very late antigen 4 (VLA-4) binds vascular cellular adhesion molecule 1 (VCAM-1) and may provide an additional mechanism for tight adhesion. In addition to providing mechanical anchorage, these receptors interact with the cytoskeleton and other structural proteins and signaling cascades and are thought to represent a *biochemical* link between the external environment and intracellular signal transduction cascades that induce a cellular phenotype more appropriate for the inflammatory environment (Fig. 7-2).[13–15]

Table 7-1 Leukocyte Subsets

Cell	Neutrophil	Monocyte	Lymphocyte	Eosinophil	Basophil
Size (μm)	13	16–20	9–16	12–16	15
Differential (%)	40–75	2–6	20–45	1–6	<1
Life span	6 h to 7 d	1 d to years	Months to years	8 to 12 d	1 year
Activators	G-CSF, IL-8	M-CSF, GM-CSF, IFN-γ, TNFα	IL-2, IL-12 (T_H1),IL-4 (T_H2)	G-CSF, IL-5	G-CSF, IL-3

G-CSF, granulocyte colony-stimulating factor; IL, interleukin, M-CSF, macrophage colony-stimulating factor; TH, helper T cell; TNF, tumor necrosis factor. Modified from Burkitt G, Young B, Heath JW, eds. *Wheater's Functional Histology: A Text and Colour Atlas*. 3rd ed. Edinburgh, New York: Churchill Livingstone; 1993.

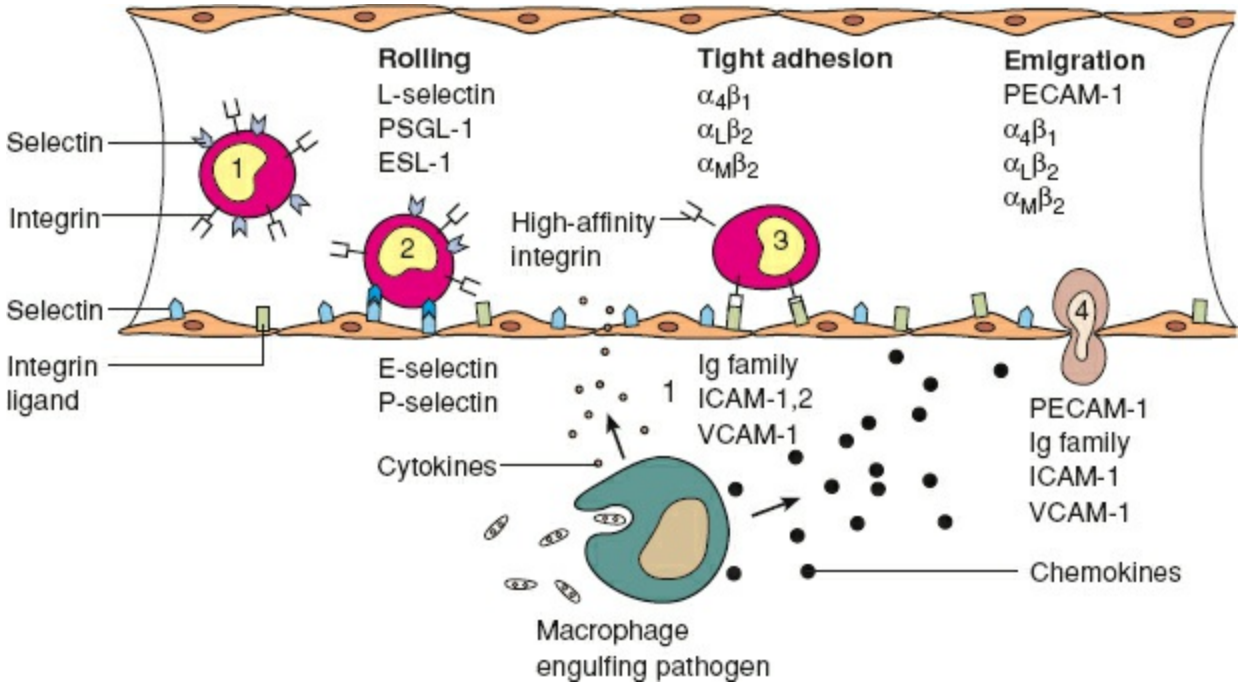

Figure 7-1. Leukocyte recruitment. 1. Circulating leukocytes express integrins in a low-affinity conformation. 2. Exposure to activated endothelium leads to rolling, which is mediated by L-selectin and P-selectin on the neutrophil and E-selectin on endothelium. 3. Leukocyte exposure to cytokines released by macrophages phagocytosing pathogens induces a high-affinity integrin conformation integrins. Tight leukocyte–endothelial adhesion involves integrin engagement with counterligand expressed on the endothelium. 4. Subsequent exposure to chemokines leads to diapedesis, which is further mediated by the family of β_1 and β_2 integrins. (Adapted from Abbas AK, Lichtman AH. *Cellular and Molecular Immunology*. 5th ed. Philadelphia, PA: Saunders; 2003.)

Once tightly adhered, neutrophils must diapedese between endothelial cells and across the basement membrane to arrive at the focus of inflammation. Platelet/endothelial cell adhesion molecule 1 (PECAM-1) and integrin-associated protein are integral to transmigration (Fig. 7-1).[13,14,16,17] PECAM-1 is concentrated along the intercellular junctions of endothelial cells, and both leukocyte and endothelial PECAM-1 appear to be essential for neutrophil and monocyte diapedesis. Other candidate receptors include the β_1 integrins, or very late antigens (VLA), which possess affinity for many constituents of the extracellular matrix, including laminin, fibronectin, and collagens, the β_3 family of integrins including the glycoprotein (gp) IIβIIIα and the vitronectin receptor.[4] Further "directions" for migration to the focus of inflammation are delivered by the concentration gradients of chemotactic factors, including complement C5a, IL-8, LTB_4, and the bacterial product N-formylmethionyl-leucyl-phenylalanine (fMLP).[18–20]

The clinical significance of even minor derangements in any aspect of this process is evident in the disease leukocyte adhesion deficiency, characterized by complete absence of CD18, and therefore all β_2 integrins. Patients usually succumb to recurrent skin and mucosal infections within the initial 10 years of life.[4]

Phagocytosis

Microbial elimination commences upon first encounter with a foreign pathogen. It is facilitated by opsonization, a process in which microbes are coated by immune globulins

and/or complement, which subsequently bind to their respective cell surface receptors, FcγRs and Mac-1.[21–23] Neutrophils constitutively express low-affinity immune globulin receptors FcγRII and FcγRIII and can be induced to express high-affinity FcγRI by incubation with IFNγ or cross-linking β_2 integrins.[5,24] Complement-dependent phagocytosis is mediated by interactions between the leukocyte Mac-1 receptor and the complement opsonin iC3b.

Once engaged, FcγRs are phosphorylated on tyrosine residues within an immunoreceptor tyrosine activation motif (ITAM) by the Src family kinases.[24] These phosphorylated sites serve as docking regions for a variety of proteins, in particular Syk. The importance of Syk is underscored by the observation that mice deficient in Syk are incapable of ingesting IgG-opsonized particles. A series of enzymes are subsequently activated including phosphoinositol 3-kinase, phospholipase C (PLC), and protein kinase C. Ultimately, the actin cytoskeleton undergoes rearrangement and the local plasmalemma is remodeled in the formation and sealing of the phagosome.[4,24]

This immature phagosome undergoes a series of maturation steps, whereby it acquires the machinery necessary for the killing and disposal of internalized microorganisms. Alterations in cytosolic calcium concentration induce the fusion of secretory vesicles and granules containing the microbicidal armamentarium with the immature phagosome.[24] Proteins effected by calcium concentration and that may govern phagosomal maturation include synaptotagmins, actin, calmodulin, and the Src family of kinases.[24] The soluble N-ethylmaleimide-sensitive-fusion-protein attachment protein receptor (SNARE) proteins are thought to assist in fusion by engaging cognate receptors on the target membrane and approximating the two membranes. Antibodies to the SNARE 5, syntaxin 6, and SNAP-23, inhibited exocytosis of azurophilic and specific granules, respectively.[24]

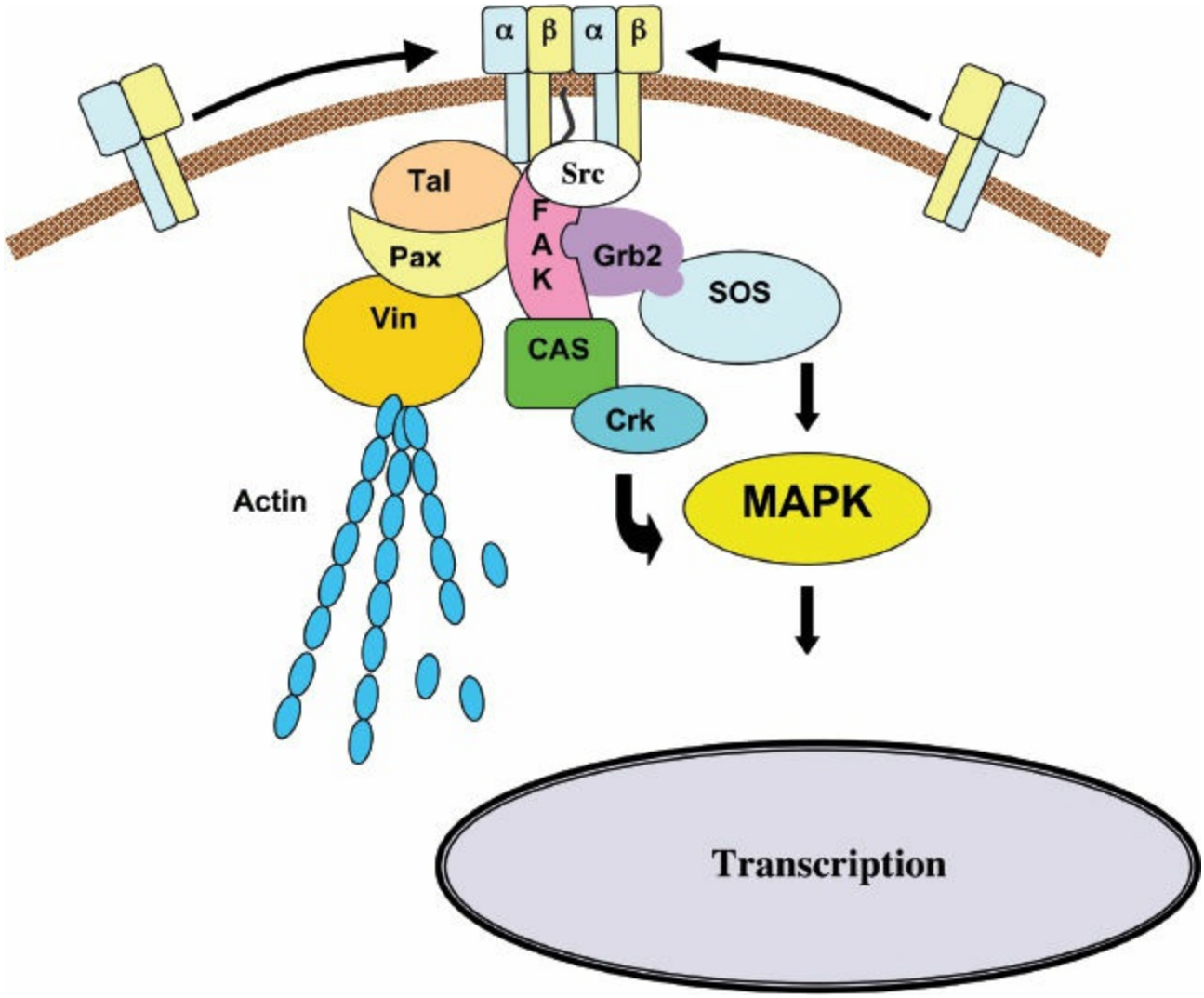

Figure 7-2. Integrin Signaling. Integrins comprise a large family of cell surface receptors that are composed of 2 subunits, a and b, and are activated by dimerization. The cytoplasmic tails are devoid of enzymatic activity, and hence, signal transduction is effected by adapter proteins that connect the receptor to the cytoskeleton, cytoplasmic kinases, and transmembrane growth factor receptors. As integrins bind the extracellular matrix they become clustered and associated with the cytoskeletal proteins talin, paxilin, and vinculin and signaling complexes. Actin stress fibers form, which increase integrin clustering. Ultimately, focal adhesion kinase (FAK) is recruited via interactions with talin and paxillin or with the b integrin subunit. Subsequent autophosphorlyation on tyrosine 397 provides a binding site for the Src homology 2 (SH2) domain of Src. The Src kinase phosphorylates a number of focal adhesion components including paxillin and tensin and pl30CAS, a docking protein that recruits Crk, which can subsequently activate proximal elements in the JNK cascade of the MAPK family. FAK may also be phosphorylated by Src on tyrosine 925, creating a binding site for the complex of the adapter Grb2 and Ras guanosine 5'-triphosphate exchange factor mSOS. These interactions also lead to activation of MAPK cascades, and ultimately the induction of a variety of genes. *(Adapted from Giancotti F & Ruoslahti E. Integrin Signaling. Science 1999:1028-1032)*

Neutrophil Granules and Secretory Vesicles

Neutrophils exhibit an oxygen-dependent "respiratory burst" pathway that generates toxic oxygen derivatives and an oxygen-independent pathway that utilizes toxic proteinases.[25] These two microbicidal arms are compartmentalized into four distinct granules or vesicles (Table 7-2).[26] They are mobilized in a hierarchical fashion in response to gradual elevations in the intracellular calcium level, which parallels the current needs of the

cell.[27] They also contain adhesion molecules and important inflammatory mediators that help further orchestrate the involvement of other cells.

Primary, or azurophil (affinity for the dye azure A), granules target the destruction of phagocytosed organisms (Table 7-2). The myeloperoxidase (MPO) within these granules generates hypochlorous acid (HOCl) from products generated by nicotinamide adenine dinucleotide phosphate (NADPH) oxidase and also imparts the characteristic greenish color of pus.[9,27] Other major constituents include (1) α-defensins, cytotoxic proteins that scaffold into transmembrane pores within the microbial cell wall and perturb the maintenance of vital transmembrane gradients, and (2) bactericidal/permeability-increasing (BPI) protein, which binds to gram-negative organisms and induces rearrangement of membrane lipids and inhibits growth.[27–30] Elastase cleaves constituents of the extracellular matrix, including proteoglycans, collagen (types I, III, IV), and fibronectin and, of course, elastin.[31] Azurocidin is chemotactic for monocytes and stimulates LPS-induced release of IL-6 and TNFα from monocytes.[4,27]

Table 7-2 Neutrophil Granules and Secretory Vesicles

Azurophil Granules	Specific Granules	Gelatinase Granules	Secretory Vesicles
Membrane			
Myeloperoxidase (MPO)	Lysozyme	Gelatinase	Plasma proteins
Lysozyme	Phospholipase A_2	Lysozyme	
Cathepsins	Gelatinase	β_2-Microglobulin	
Elastase	Collagenase	Acetyltransferase	
Proteinase 3	Lactoferrin		
Azurocidin	TNF		
BPI	β_2-Microglobulin		
Defensins	Histaminase		
iNOS	Heparinase		
α1-Antitrypsin	uPA		
α-Mannosidase			
Sialidase			
Acid mucopolysaccharide			
β-Glycerophosphatase			
Elastase			
Cytosol			
CD63	Mac-1	Mac-1	Mac-1
CD68	SNAP proteins	SNAP proteins	SNAP proteins
	CD15	Cytochrome b558	Cytochrome b558
	CD66	fMLP R	CR1
	CD67	DAG-deacylating	CD14
	Cytochrome b558	enzyme	CD45
	Fibronectin R	uPA R	fMLP R
	Laminin R		uPA R
	Vitronectin R		C1q R
	Thrombospondin R		
	fMLP R		
	uPA R		

BPI, bactericidal/permeability-increasing protein; CD, cluster of differentiation; CR1, complement component C3b; DAG, diacylglycerol; fMLP, N-formylmethionyl-leucyl-phenylalanine; iNOS, inducible nitric oxide synthase; R, receptor; TNF, tumor necrosis factor; uPA, urokinase-type plasminogen activator.
Modified from Faurschou M, Borregaard N. Neutrophil granules and secretory vesicles in inflammation. *Microbes Infect* 2003;5(14):1317–1327.

Specific granules are rich in antimicrobial substances that are released extracellularly (Table 7-2).[26] Lactoferrin, by sequestering iron, retards bacterial growth and can bind bacterial cell membranes and induce irreversible membrane damage and lysis.[27] Phospholipase A_2 (PLA_2) participates in the degradation of bacterial membrane phospholipids. Lysozyme, present in all granules, is a cationic antimicrobial peptide that cleaves peptidoglycan polymers of bacterial cell walls. Gelatinase and collagenase are other extracellular matrix degrading enzymes.[27] These granules also possess receptors for a variety of extracellular matrix proteins and cell surface ligands (i.e., β_2 integrin Mac-1) that mediates firm adhesion to the endothelium. In addition to the mechanical function of cellular anchorage, engagement of these receptors with their respective counterligands induces phenotypic alterations such as degranulation and enhanced ROS production.[4,27]

Gelatinase granules contain matrix metalloproteases, zymogens that upon proteolytic activation degrade the interstitial matrix including collagens, fibronectin, proteoglycans, and laminin; this may facilitate neutrophil extravasation and migration (Table 7-2). They too are a source of cell surface adhesion molecules.[4,27,30]

Secretory vesicles contain many of the cell surface adhesion molecules essential for leukocyte recruitment. Their membranes are dense with the β_2 integrins LFA and Mac-1, the complement receptor CR1, the LPS receptor CD14, and the FcγRIII. Through fusion with the plasmalemma, the cell surface is enriched with these receptors, which facilitates firm neutrophil-endothelial engagement and the capacity to respond to a variety of stimuli.[4,27] Not surprisingly, because of the essential nature of leukocyte recruitment, secretory vesicles possess the lowest threshold for release and thus released earliest, followed by gelatinase, specific, and azurophil granules (Table 7-2).[27]

Table 7-3 Major ROS and Their Metabolism

Ros Molecule	Main Sources	Enzymatic Defense Systems	Products
Superoxide ($O_2^{\bullet -}$)	Leakage from electron transport chain Activated phagocytes Xanthine oxidase Flavoenzymes	Superoxide dismutase Superoxide reductase	$H_2O_2 + O_2$ H_2O_2
Hydrogen peroxide (H_2O_2)	From $O_2^{\bullet -}$ via superoxide dismutase NADPH oxidase Glucose oxidase Xanthine oxidase	Glutathione peroxidase Catalase Peroxiredoxins	H_2O + GSSG $H_2O + O_2$ H_2O
Hydroxyl radical ($O_2^{\bullet -}$)	From $O_2^{\bullet -}$ and H_2O_2 via transition metals		
Nitric oxide (NO)	Nitric oxide synthases	Glutathione/TrxR	GSNO

NADPH, nicotinamide adenine dinucleotide phosphate; ROS, reactive oxygen species; TrxR, thioredoxin.
Modified from Nordberg J, Arner E. Reactive oxygen species, antioxidants, and the mammalian thioredoxin system. *Free Radic Biol Med* 2001;31 (11):1287–1312.

Oxidative Burst and Oxidant Metabolites

The generation of toxic oxygen metabolites and ROS is the cardinal characteristic of the neutrophil, though is also a defensive quality of the monocyte/macrophage. Their essential antimicrobial properties are equally destructive to host tissues and implicated in the pathophysiology of many inflammatory disorders (Table 7-3). Thus, a delicate balance must be maintained between ensuring elimination of the offending pathogen and minimizing host damage.

A free radical is any species possessing one or more unpaired electrons. They are categorized under the broader term ROS, which encompasses all molecules capable of radical formation. Despite a very brief existence (10^{-11} to 10^{-6} seconds) extensive damage may occur through the induction of free radical chain reactions. Species underlying both physiologic and pathophysiologic inflammation include the following: the superoxide anion ($O_2^{\bullet -}$), the hydroxyl radical (•OH), hydrogen peroxide (H_2O_2), the singlet oxygen, and the reactive nitrogen intermediates nitric oxide (NO) and peroxynitrite ($ONOO^-$) (Table 7-3). Counterintuitive to their role in cell destruction, recent evidence also supports a role of ROS in intracellular signal transduction.[32] Thus, in

addition to their antimicrobial properties, ROS can modulate the immune response by activating inflammatory cells and inducing proinflammatory cytokine secretion.[33,34]

2 Implicit with the capacity for pathogen elimination is the potential for destruction of host tissues. Hence, numerous regulatory mechanisms provide temporal and spatial control of the ROS production. The NADPH oxidase complex itself exists in a disassembled state, and only upon cell activation and the need for ROS production are the subunits approximated and enzymatic function enabled.[35] In addition, high plasma and tissue concentrations of proteinase inhibitors provide continuous surveillance and systemic control. However, such regulation is incomplete as evidenced by diseases such as rheumatoid arthritis, chronic obstructive pulmonary disease, and autoimmune vasculitis, which are the consequence of damage due to neutrophil-derived products.[35]

NADPH oxidase is a heteromeric complex composed of six subunits: flavocytochrome b558, the electron transporting apparatus comprises gp91(phox) and p22(phox); the cytosolic complex p40(phox), p47(phox) and p67(phox); and the oxidase factor rac-2 (Fig. 7-3).[35] Microorganisms or high concentrations of chemoattractants bind to cell surface receptors and initiate oxidase activation, heralded by phosphorylation of p47(phox). Cytochrome b558 (gp91 and p22), which exists within the plasmalemma and the membranes of specific granules and secretory vesicles, is recruited by phagocytosis and granule fusion. Phosphorylation of p47(phox) induces a conformation change that enables its incorporation within the membrane, wherein it facilitates the translocation of rac2 and p67(phox), and stabilizes the association of this cytosolic complex with cytochrome b558, thereby rendering the complex functional.[35]

At the redox center of the oxidase an electron is transferred from NADPH to oxygen, thereby generating superoxide.[36]

$$O^2 + e^- = O^-_2$$

Other mechanisms of superoxide production include uncoupling of xanthine dehydrogenase system, uncoupling of mitochondrial and endoplasmic reticulum (ER) electron transport chains, and nonenzymatic reactions such as autoxidation of hemoglobin.[37,38]

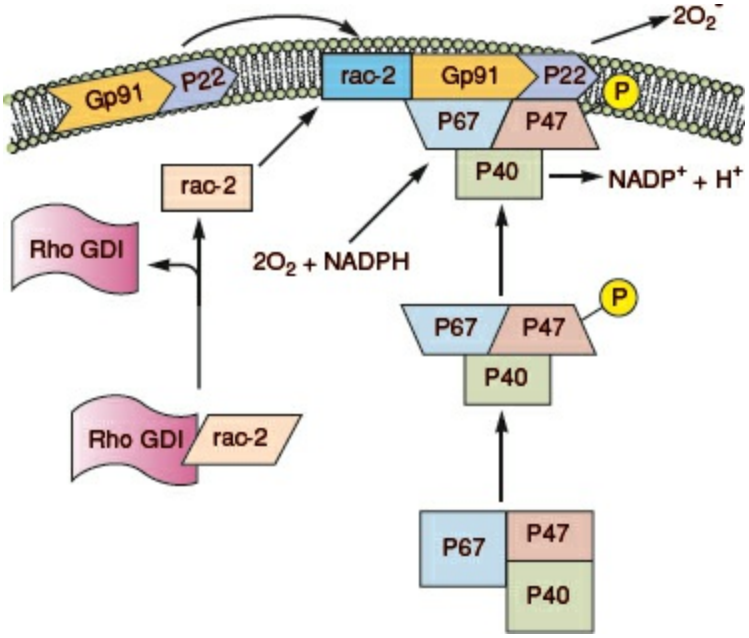

Figure 7-3. NADPH oxidase assembly. In the resting neutrophil, the cytochrome subunits gp91 and p22 are tightly bound in the membrane. P47(phox), p67(phox) and rac-s complex are in the cytosol. On activation, GDI releases rac-2, and p47(phox) becomes phosphorylated. This causes translocation of rac-2, p47(phox), and p67(phox) to the membrane and complex formation with the cytochrome components, thereby completing the assembly of the active oxidase. (Redrawn from Burg ND, Pillinger MH. The neutrophil: function and regulation in innate and humoral immunity. *Clin Immunol* 2001;99(1):7–17.)

Superoxide is relatively weak and of low bactericidal potency. However, its membrane permeability and role as a reactant in reactions yielding highly toxic products confers upon it a high potential for cellular and tissue damage.[36]

Superoxide can spontaneously or enzymatically (superoxide dismutase) dismutate into hydrogen peroxide.[35,36]

$$2H^+ + O^{\bullet}{}_2^- \Leftrightarrow H_2O_2 + O_2$$

It can also be converted to the more potent hydroxyl radical through the metal-catalyzed Haber–Weiss reaction.[35,36]

$$H_2O_2 + O_2^- + Fe^{3+} \Leftrightarrow O_2 + OH^- + OH + Fe^{2+}$$

or through the Fenton equation[35,36]

$$H_2O_2 + Fe^{2+} \Leftrightarrow Fe^{3+} + OH^- + OH + Hb\text{-}Fe^{2+} + H_2O_2$$
$$\Leftrightarrow Hb\text{-}Fe^{3+} + OH^- + OH$$

Under physiologic conditions, lactoferrin found in neutrophil specific granules provides the iron catalyst for the Haber–Weiss reaction. In the Fenton reaction, superoxide or other biologic reducing agents such as lactate or ascorbate donate electrons to generate the ferrous ions required to react with hydrogen peroxide to produce the hydroxyl radical.[35,36,39]

The hydroxyl anion is highly reactive and induces DNA strand breaks and base hydroxylations leading to adenosine triphosphate (ATP) depletion and gene mutations. It can attack lipid side chains of membrane phospholipids to form hydrogen peroxide and

lipid hydroperoxides in a process called lipid peroxidation. These products can disrupt membrane function, serve as substrates for the production of cytotoxic aldehydes, or uncouple calcium-ATPase and increase cytosolic calcium concentration. Recent data also support a mechanism by which oxidation of critical sulfhydryl residues on the ryanodine receptors induces an "open" configuration and a leak of intracellular ER calcium into the cytosol.[40] This elevation of cytosolic calcium activates calcium-dependent proteases and phospholipases that propagate cellular damage.[39]

Superoxide can react with nitric oxide to produce peroxynitrite ($ONOO^-$) and hydroxyl radical.[36,41]

$$NO^{\bullet} + O_2^{\bullet -} \Leftrightarrow ONOO^- + H^+ \Leftrightarrow ONOOH \Leftrightarrow OH + NO_2^{\bullet}$$

The hemoprotein MPO yields the potently bactericidal HOCl from the reactants chloride and H_2O_2. HOCl oxidizes amino acids, nucleotides, and hemoproteins, can activate neutrophil collagenases and permit unabated elastase injury by inhibiting α1-antitrypsin, and contribute to hydroxyl radical and singlet oxygen production.[33,39,42] Though short-lived, subsequent reactions with secondary amines generate secondary chloramines, which are equally toxic but much more stable. These metabolites can oxidize similar cellular components. They can combine with halide anions to generate toxic free halides or with taurine chloramines that induces membrane attack complex (MAC) complement formation.[33,39,42]

In light of the pivotal role of MPO during inflammation and pathogen elimination, it is surprising that MPO deficiency is common and relatively benign. Though MPO-deficient neutrophils show early depressed bacterial killing, bactericidal function normalizes within 60 minutes.[43] It is hypothesized that though bacterial killing is impaired, post-phagocytosis-oxidase–dependent neutrophil apoptosis is normal, resulting in appropriate regulation of the inflammatory response.[43]

Singlet oxygen, a highly reactive and extremely short-lived species, is formed by an input of energy to O_2 that reverses the spin direction of one of the outermost unpaired electrons away from a parallel spin. It is produced during reactions of the MPO–H_2O_2–halide system and is a potential product of superoxide dismutation and the Haber–Weiss reaction. It is highly electrophilic, reacting with compounds containing electron-rich double bonds and may react with membrane lipids to produce peroxides.[39]

The destructive potential of these ROS for both host and pathogen necessitates a mechanism of continuous tight spatial and temporal regulation. The oxidase complex itself exists spatially disaggregated; only upon cellular activation are its constituents assembled and enzymatic function restored (Fig. 7-3).[35,43] As elegant is the mechanism by which to control ROS production, so too are the measures employed to eliminate these products when no longer needed. Superoxide, the proximal reactant necessary for many of the ROS generating reactions, is removed by both spontaneous and enzymatic (superoxide dismutase) dismutation to H_2O_2 (Fig. 7-4). H_2O_2 is subsequently reduced to oxygen and water by catalase.[36,39] In the extracellular environment, this function is performed by GSH peroxidase, a selenium-dependent enzyme that reduces H_2O while

oxidizing reduced GSH to its oxidized form. The utilization of N-acetylcysteine, a reducing agent that restores GSH, reduces hepatocellular injury in an animal model of warm liver ischemia/reperfusion.[32] It has also been shown to reduce contrast-induced nephropathy in patients undergoing imaging procedures requiring the use of iodinated contrast.[44] Mechanisms for preventing hydroxyl radical-induced tissue damage include the binding of transition metal ions by albumin, ceruloplasmin, haptoglobin, lactoferrin, and transferrin.[33,36,39] Taurine is a scavenger for HOCl. Other antioxidants that may assist in controlling the reaction include vitamins E (tocopherol) and C. Vitamin C has many antioxidant properties, including the ability to regenerate α-tocopherol. It can prevent activation of neutrophil-derived collagenase and is a powerful scavenger of HOCl, superoxide, singlet oxygen, and hydroxyl radicals. Carotenoids have long double bonds to attract and sequester free radicals. Uric acid is a powerful scavenger of water-soluble radicals such as HOCl and singlet oxygen. It can also bind copper and iron ions to suppress hydroxyl radical formation. Stress proteins or heat-shock proteins (HSPs) are induced by oxygen radicals and ischemia and may play a role in defense. Furthermore, heme oxygenase-1 (HO-1) catalyzes the cleavage of heme to biliverdin, which is subsequently converted to bilirubin, an efficient free radical scavenger.[33,36,39]

All of the aforementioned participants of the NADPH oxidase are vital for health, as evidenced by those who suffer from chronic granulomatous disease (CGD).[35,43] These patients have deficient superoxide production and experience ineffective inflammatory reactions to infection. They commonly suffer from repeated bacterial infections (pneumonia, cutaneous abscesses and hepatic and perihepatic abscess, and osteomyelitis) by organisms that are catalase positive (*Staphylococcus aureus*). Organisms that produce large amounts of peroxide are less of a threat as the neutrophils can utilize bacterial peroxide to produce toxic metabolites. The use of prophylactic antibiotics and IFNγ has reduced the frequency of serious infections in this patient population.[35,43]

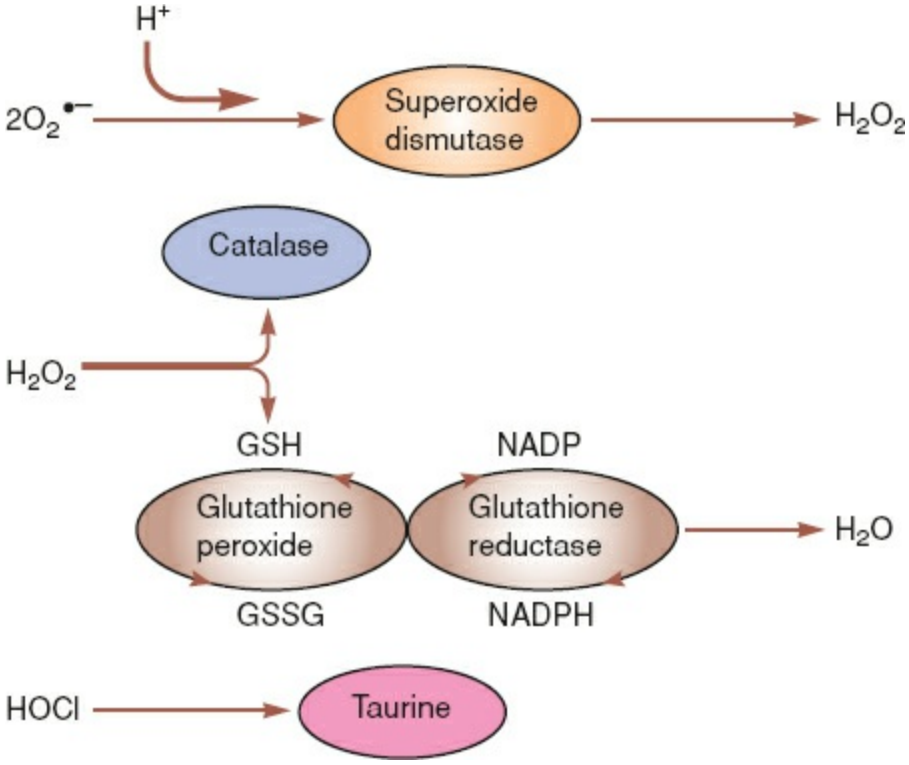

Figure 7-4. Scavengers of ROS. (Redrawn from Klebanoff SJ. In: Gallin JI, Snyderman R, eds. *Inflammation: Basic Principles and Clinical Correlates*. 3rd ed. Philadelphia, PA: Lippincott Williams & Wilkins; 1999:723.)

Neutrophil Extracellular Traps and NETosis

The arsenal of antimicrobial products and mediators possessed by neutrophils to fulfill the tasks of killing and eliminating pathogens is vast and impressive. However, another distinct antimicrobial "weapon" was recently described, in which neutrophils extrude a lattice of chromatin and histones to entrap and then kill invading pathogens. The characteristic feature is the presence of neutrophil nuclear DNA in the extracellular space. These structures were entitled neutrophil extracellular traps (NETs), and the process of NET formation called NETosis. Attached to this DNA backbone is an array of microbicidal agents that are typically compartmentalized inside the azurophilic, specific and gelatinase granules: neutrophil elastase (NE), cathepsin G, and MPO. Distinct from apoptosis, the process does lead to cell death, though clearly contributes to pathogen control. It is conserved in various vertebrates, insects, and even plants, and several microorganisms exhibit mechanisms of resistance to NETs, both of which may highlight the importance of this process. Recent data suggest that excessive NETosis or ineffective NET clearance may underly diseases or syndrome characterized by excessive inflammation, including autoimmunity.[45–47]

Pathogens (i.e., bacteria, fungi, viruses, and protozoa) and their subcellular components, such as LPS, M1 protein, and fMLP induce NET formation. Similarly, sterile insults, inflammatory stimuli (e.g., PAF, IL-8, TNFα, NO), and chemical compounds (PMA, ionomycin) all can stimulate NETosis. The process begins with engagement of the aforementioned stimuli with TLRs, Fc receptors, cytokine, and complement receptors located on the neutrophil cell surface. Subsequent calcium release stimulates PKC activity and assembly of functional NADPH oxidase, leading to ROS and NO production. ROS

is/are requisite for NET formation, as antioxidant scavengers (e.g., N-acetylcysteine) attenuate the process. Interestingly, individuals with CGD, a disease characterized by insufficient ROS production, inefficiently produce NETs. The chromatin undergoes decondensation followed by mixing of nuclear and cytoplasmic components with granulate antimicrobial contents. Plasma membrane rupture ensues with the release of chromatin decorated with granular proteins into the extracellular space.[45–47]

NETs are able to trap almost all pathogens, including those too large to be phagocytosed. Indeed, it is proposed that trapping by NETs is one of the most important functions that limits microbial spread. The antimicrobial functions of NETs are mediated by the microbicidal compounds accompanying the chromatin: NE, MPO, histones, cathepsin G, proteinase 3, lactoferrin, calprotectin, and antimicrobial peptides such as defensive or the cationic LL37. However, the histones H1, H2A, H2B, H3 and H4 themselves also possess powerful antimicrobial effects.

As fundamental as NETosis is for microbial defense, excessive formation or ineffective clearance of NETs is proposed to lead to several pathologic conditions. During acute lung injury a high concentration of stimulating factors promotes NETosis and the release of NE, LL-37, and ROS, which may exacerbate injury. In cystic fibrosis, the high concentrations of DNA due to NETosis are thought to underlie the high mucus viscosity.[45–47] Several autoimmune diseases are also characterized by perturbed NETosis, and more than 70% of NET components are potent autoantigens. Small vessel vasculitis is characterized by antineutrophil cytoplasmic antibodies reactive against PR3 and MPO. Externalization of IL-17 in the extracellular traps of neutrophils and mast cells is now thought to be central to the pathogenesis of psoriasis. In systemic lupus erythematosus (SLE), an imbalance between NET formation and clearance may underlie the systemic tissue damage that occurs. In fact, decreased NET degradation correlates with renal disease. NETs may also activate complement, thereby amplifying the disease. Furthermore, the neutrophils from patients with various autoimmune diseases appear more prone to NETose.[45–47]

NETs may also serve as a link between inflammation and thrombosis. They can provide a stimulus and scaffold for thrombus formation by promoting platelet and RBC adhesion and by concentrating effector proteins and coagulation factors. Activated endothelium produces compounds that, upon contact with neutrophils, stimulate NETosis, which in turn, promotes endothelial damage.[45–47]

Regulation of Neutrophil Activity

In addition to the previously described mechanisms for controlling the inflammatory response of neutrophils, there is substantial evidence supporting the role of apoptosis in halting and resolving the neutrophil-derived inflammation (Box A).[48] Within 90 minutes of phagocytosis, over 250 genes are induced, of which more than 30 encode proteins integral to at least three distinct apoptotic pathways.[48] These observations suggest that the mechanism inducing apoptosis is initiated quite proximal in the inflammatory cascade, in fact, just subsequent to phagocytosis. The timely execution of a controlled cell death program in human PMNs is essential for preventing damage to healthy tissues and for the

resolution of infection. Furthermore, evidence suggests that the phenotype of other immune cells, including monocytes and macrophages, is altered after encountering and phagocytosing apoptotic neutrophils. Thus, apoptotic neutrophil particles may function to downregulate the inflammatory function of neighboring cells. In some circumstances of infection or trauma, neutrophil apoptosis may be delayed, which might contribute to prolonged or a failure to resolve inflammation.

The inflammatory capacity of neutrophils is also transcriptionally regulated. Genes encoding proinflammatory mediators or signal transduction molecules such as receptors for IL-8, IL-10, IL-13 are downregulated early after activation and decrease rapidly after the initiation of apoptosis.[48] In addition, regulating oxidative stress and ROS achieve high priority as the genes involved in glutathione and thioredoxin metabolism and heme catabolism are upregulated as is the production of reduced glutathione.[48] Hence, activation-induced apoptosis in neutrophils stimulates self-directed regulation, an event that likely facilitates removal of neutrophils by macrophages. As aforementioned, removal of apoptotic neutrophils by activated macrophages also appears to serve a role in modifying their function and halting the inflammatory response.

Mononuclear Phagocytes

Monocytes circulate for about 1 to 2 days, whereafter, they constitutively hone to a particular tissue (i.e., lung, peritoneum) to differentiate into macrophages possessing a phenotype specific to the resident tissue (dendritic cells [DCs] of the skin, kupffer cells of the liver) (Table 7-1).[4,49,50] Resident macrophages are typically found at interfaces with blood (liver and spleen) and with lymph, where they can readily detect, ingest, and destroy invading organisms.[39] Mononuclear cells function as antigen-presenting cells (APC) in T cell–mediated adaptive immune responses, presenting antigen in the appropriate context to effector T cells. They provide service integral to both innate and adaptive immune responses. Evidence also supports their role in providing an "alarm" both locally and systemically through the release of intracellular proteins (i.e., high-mobility group box 1 [HMGB1]) expressing DAMP that can function as a danger signal (see below).

Recruitment

Monocytes are recruited and emigrate to foci of inflammation utilizing similar mechanisms of adhesion and diapedesis as described for neutrophils (Fig. 7-1). PAF, C5a, the CC chemokines, regulated on activation, normal T cell–expressed and secreted (RANTES), MIP-1α, and chemokines of the membrane cofactor protein (MCP) family are potent monocyte-macrophage chemotaxins.[51,52] The selectin family of adhesion receptors mediates the initial tethering of monocytes to endothelial cells.[18] Firm adhesion to the endothelium involves the interactions of β_1 and β_2 integrins on monocytes with the endothelial adhesion molecules ICAM-1 and VCAM-1.[18]

Phagocytosis

Phagocytosis involves the IgG receptor (FcγR) and the receptor for the complement factor C3b. Terminal sugar patterns on microbial surfaces also allow recognition by macrophages for nonspecific phagocytosis through the mannose lectin pathway.[22] However, phagosomal maturation differs from that which occurs in the neutrophil. Monocytes and macrophages have an endocytic pathway targeting the phagosome to a lysosome.[24] After endocytosis of a receptor–ligand complex, the contents of a vesicle are targeted to an early endosome; the ligand and receptor dissociate, and the receptor is then recycled to the cell surface.[24] This early endosome undergoes a series of maturation steps in which it is acidified (pH 5.5 to 6.0). This acidification is requisite for optimal protease and hydrolase activity involved in pathogen killing. It may also be integral for phagosome maturation as titrating the acidity inhibits phagosome–lysosome fusion.[24] Ultimately, the endosome fuses with a lysosome, which is characterized by its extreme acidity (pH <5.0) and elevated concentration of proteases.[24] Lysosomes are the terminal destination of phagocytosed material targeted for degradation.

After fusion, MPO released into phagosomes can react with hydrogen and halides to yield toxic hypohalous acids, superoxide anion, hydrogen peroxide, and hydroxyl radical (Table 7-3). Macrophages may also use peroxidase generated by adjacent neutrophils,

eosinophils, and monocytes and acquired through endocytosis to generate these ROS. In addition to supporting the inflammatory response, macrophages also play an important immunoregulatory role in inflammation by scavenging apoptotic neutrophils at sites of inflammation.[39]

Activation

IFNγ derived primarily from T cells is the primary activator of macrophages.[4,50,53] Optimal macrophage activation requires both interferon IFNγ and a sensitizing agent, both of which can be provided by activated T lymphocytes. CD40 ligand on T cells can bind CD40 on macrophages to sensitize the cell. Alternatively, membrane-associated TNFα or lymphotoxin from lymphocytes can activate macrophage TNFα synthesis and thereby sensitize the macrophage to IFNγ.[39] IL-10 promotes monocyte maturation and macrophage differentiation.[54] Other activators include GM-CSF, TNFα, IL-1, and LPS.

Activated monocytes and macrophages can produce approximately 100 different products, including GM-CSF, M-CSF, G-CSF, IL-1, TNFα, G-CSF, and NO.[39,55] Mononuclear phagocytes are important sources of chemoattractants such as IL-8, PAF, and leukotriene B_4 (LTB_4) that recruit neutrophils and other leukocytes. Their release of HMGB1 and other DAMP molecules serves as an endogenous "danger" signals to other immune cells in the local environment. These bind to various PRR to alter cell function. However, systemic release of HMGB1 may also be causally related to mortality in such inflammatory states as sepsis and trauma.[56,57] The respiratory burst and subsequent production of toxic ROS mirrors that of neutrophils.

Antigen Presentation

T cells recognize only those antigens associated with surface major histocompatibility complex (MHC) molecules. MHC class I molecules are expressed on all nucleated cells, whereas MHC class II molecules are restricted to APC. After phagocytosing pathogen, mononuclear cells process and display antigen to T cells, and in doing so, initiate the development of the adaptive response (i.e., antibody formation). There is evidence that the HSP receptor CD91 may also participate in this process (see below). This processed antigen is presented on the APC cell surface in the context of MHC molecules that are specifically recognized by T-cell receptors (TCRs) and essential for T-cell activation. $CD4^+$ T cells, or helper T cells (T_H), recognize antigen coexpressed with MCH class II molecules and induce B-cell differentiation into either memory or antigen-specific antibody-producing plasma cells. These T_H cells can also induce macrophage production of NO, ROS, and other inflammatory mediators. $CD8^+$ cytotoxic T lymphocytes (CTL) recognize antigen in the context of MHC class I molecules and induce target cell lysis; they destroy host cells infected with intracellular pathogens or cells of malignant potential.[58] Activated mononuclear phagocytes release IL-12, a potent stimulus for T_H cells and the production of inflammatory cytokines, and elaborate IL-15, the function of which mirrors that of IL-2.[59,60]

The three professional APC are DCs, macrophages, and B cells. DCs are a specialized

APC, which process and present antigen to naïve T cells. Monocytes stimulated with GM-CSF, IL-4, or IL-13 differentiate toward DC. Maturation of the DC requires TNFα or LPS stimulation.[39] Epidermal Langerhans cells, after encountering antigen, migrate through the lymphoid organs and differentiate into mature DC. DC cells are particularly effective at presenting viral antigen. They present antigen in the context of both MHC I and MHC II, and thereby induce both a T_H1 and a T_H2 response, respectively. DC can also present antigens derived from apoptotic cells in the context of MHC I.[61–63]

Macrophages present antigenic peptides from ingested pathogens that persist in the phagosomes. These peptides, usually of bacterial origin, are expressed in conjunction with MHC II molecules. B cells, by contrast, bind specific soluble molecules (insect toxins, venom, and allergens) via immunoglobulin. This is endocytosed, processed, and presented on surface MHC II.[39,63–65]

Lymphocytes

B, T, and NK cells comprise this lineage of inflammatory cells (Table 7-1). B and T cells are central to the adaptive immune response, whereas NK cells lack antigen specificity and primarily function during innate immune response. NK cells are the first line of defense against many viral infections. The loss of surface expression of MHC class I molecules as occurs with virus-infected cells serves as a target for NK cells.[39,66] Alternatively, NK cells bind cell-bound antibody and participate in antibody-dependent cell cytotoxicity. Cells targeted by either mechanism are induced to undergo cell death.

B Lymphocytes

B cells, though of bone marrow origin, attain full maturation within extramedullary sites such as lymph nodes, the spleen, and the mucosal lymph nodules of tonsils and Peyer patches. With activation, B cells differentiate into antibody-producing plasma cells, which through the elaboration of antibody, aid the neutralization of viruses and bacterial toxins, and facilitate opsonization for phagocytosis and complement activation.[4] Activation requires antigen binding to cell surface receptors and stimulation by T_H cell–derived cytokines; they do not need the assistance of APCs. Polyclonal B-cell activation can occur in a T-cell–independent mechanism if the antigen has a large repeating polymeric sequence.[39,67]

T Lymphocytes

Development of T lymphocytes begins within the marrow and is completed in the thymus. The final population profile is determined by apoptotic processes of both positive and negative selection.[68] Any protein or antigen of *host* origin is presented by APCs, and thymocytes reactive to these self-proteins are deleted.[69] Alternatively, expansion of cell lines recognizing foreign, or rather nonself antigen, occurs through positive selection. IL-7 provides the stimulation for proliferation and differentiation of developing T cells. Ultimately, two lines of mature cells, $CD4^+$ and $CD8^+$, will develop.[69]

Lymphocytes, the smallest of the leukocytes, constitute approximately 20% of circulating leukocytes.[4] Most circulating lymphocytes are T cells, and 60% of those are $CD4^+$, a marker of a T_H phenotype. The other 40% are $CD8^+$, called cytotoxic T cells, T_C. The normal ratio of $CD4^+/CD8^+$ is 2:1.[4] Lymphocytes continuously recirculate through lymph nodes, spleen, lymphatics, lymph nodules, and blood, providing continuous surveillance. Encounter with a particular antigen initiates activation toward an effector T cell. Activation of a T cell requires bind to its specific antigen plus a costimulatory signal provided by the interaction between costimulatory molecules on the APC and their cognate receptors on the T cell.[39]

Naïve T cells circulate continuously between blood and lymphoid organs, making contact with many APCs and the epitopes of the antigens they express.[70] Initially, lymphocytes enter the cortical region of lymph nodes by migrating across the high endothelial venules, a process mediated by the selectin family of receptors. L-selectin, which is found constitutively on all lymphocytes, binds sialyl Lewis carbohydrate on the

endothelium.[39] For example, L-selectin on lymphocytes binds GlyCAM-1 on the high endothelial venules in lymph nodes. In mucosal tissues, L-selectin and endothelial MAdCAM-1 guide emigration. Migration across the endothelium requires integrins, in particular LFA-1 and its interaction with ICAM-1 and ICAM-2 on endothelial cells.[71] Most lymphocytes are carried back to the blood by the efferent lymphatics. If a T lymphocyte recognizes its specific antigen on the surface of an APC, it remains for several days, then returns to the blood as an armed effector T cell.[39]

Adhesion molecules mediate many of the transient interactions between T cells and APCs that are required for the T cell to sample each antigen it encounters. Lymphocyte LFA-1 can bind the APC in a loose, reversible fashion by any of the ICAM molecules on APCs. If a match between T cell and antigen is found, conformational changes in LFA-1 greatly increase its affinity for ICAM-1 and ICAM-2 to stabilize the interaction. The T cell can then proliferate and differentiate into an effector cell. Effector T cells lose surface expression of L-selectin and no longer circulate through lymphoid tissue. Instead they express VLA-4, an integrin, which binds vascular endothelium at sites of infection, and the cell is retained at the focus. Effector T cells have increased LFA-1 and CD2 adhesion molecule expression that facilitate tight binding to target cell.[72,73]

Antigen binding in the appropriate context provides the signal for clonal expansion and differentiation of T cells into effector and memory lymphocytes. The appropriate contact is composed of antigen complexed with MHC class II molecules on APCs, costimulators, and cytokines produced by the APCs and by the T cells themselves. This first encounter of naïve T cells with antigen is the primary immune response, which serves to induce the formation of effector and memory T cells. These activated T cells hone to peripheral tissues where, upon reexposure to their specific antigen, they activate macrophages to eliminate phagocytosed microbes and induce B-cell differentiation and antigen-specific antibody secretion. The $CD8^+$ CTLs kill infected host cells and tumor cells that display class I MHC-associated antigen. Naïve T cells require activation by DCs, whereas effector T cells can respond to antigens presented by a wider variety of APCs, such as macrophages and B lymphocytes. Not surprisingly, differentiated effector and memory T cells possess lower thresholds for costimulation and require lower antigen concentration for activation than naïve T cells.

In general, antigen presented on MHC II molecules is the prototypical stimulus for $CD4^+$ T-cell activation and the subsequent production of a variety of cytokine mediators, including IL-2, which stimulate further expansion and activation. However, the circumstances under which this activation occurs may dictate disparate paths of differentiation, producing T-cell subsets with distinct cytokine profiles and effector functions. These differing phenotypes have been utilized to characterize two distinct subsets: T_H1 and T_H2.[59,60,74] IL-12 derived from phagocytes infected with intracellular pathogen provides the necessary signal for T_H1 differentiation.[39] IL-12 also stimulates production of IFNγ, the principle macrophage activator, by NK cells and CD4+ lymphocytes. Interferons stimulate T_H1 development by augmenting phagocytic IL-12 production and by maintaining IL-12 receptor expression on $CD4^+$ T cells. The principal

effector action of T_H1 cells is the activation of macrophages through the production of IFNγ, GM-CSF, TNFα, CD40L, and FasL.[39,59,60,74] They regulate production of opsonizing and complement fixing antibodies and are effectors of phagocyte-dependent responses. This inflammatory response, also referred to as cell-mediated immunity or delayed-type hypersensitivity, provides one major arm of the adaptive immune response; it is mediated by $CD4^+$ and $CD8^+$ lymphocytes and macrophages.

The principal stimulus for T_H2 differentiation is IL-4, which is derived from T cells, mast cells, and basophils.[59,60,74] These cells are the cellular effectors of humoral immunity and provide the other major arm of the adaptive immune response, which is mediated by T_H2 $CD4^+$ cells, B cells, plasma cells, and antibodies. They produce IL-4, IL-5 and CD40L, thereby inducing B-cell activation and antibody production, and a host of other proinflammatory and anti-inflammatory cytokines.[39] Activation of mast cells and eosinophils by extracellular pathogens is associated with activation of T_H2 cells. T_H2 cells quell the inflammatory response by inhibiting macrophage functions and T_H1 responses. They are considered the anti-inflammatory arm of cell-mediated inflammation. Helper T cells that express both T_H1 and T_H2 patterns of cytokine expression have been called T_H0 cells, and further studies will certainly discern other subsets of T cells.[4,74]

T-cell activation, differentiation, and expansion are orchestrated by the T cell itself. The responding T cell, in an autocrine fashion, serves as both source and target of a variety of mediators stimulating growth. The principal autocrine growth factor is IL-2, which is induced by signaling regulated by the phosphatase calcineurin (see below).[75] IL-15 stimulates the proliferation of $CD8^+$ T cells, especially memory cells of the $CD8^+$ subset. After antigen exposure, the numbers of T cells specific for that antigen may increase to about 1 in 10 for $CD8^+$ and 1 in 1000 to 10000 for $CD4^+$ cells.[4]

After activation, some proliferating T cells will differentiate into effector cells that eliminate antigens and activate other immune cells. Mature $CD4^+$ cells induce the activation of mononuclear phagocytes and B cells. $CD8^+$ cells differentiate into CTL that recognize viral and other intracellular pathogen antigens that are presented in the context of MHC class I molecules and induce target cell death by releasing the cytotoxins perforin and granzymes from cytoplasmic granules. Granzymes are serine proteases that trigger DNA fragmentation and apoptosis. Perforin stimulates cell membrane pore formation that facilitates granzyme entrance into cells. Apoptosis can also be induced by the binding of Fas ligand on CTL to Fas on the target cell. CTLs also release the cytokines IFNγ, TNFα, and CC chemokines. IFNγ and certain CC chemokines have antiviral properties, and both are potent activators of macrophage function. IL-2 produced by CTL and local helper $CD4^+$ lymphocytes expands the CTL, and IL-12 released by APC stimulates CTL activity. As with $CD4^+$ cells, early evidence suggests that the population $CD8^+$ may be divided into T_C1 and T_C2 cells based on their cytokine profiles and effector functions.[39,58–60]

Other T cells will mature into long-lived functionally quiescent memory cells. Upon antigen reexposure, a cell surface rich in adhesion molecules (i.e., integrins, CD44) facilitates rapid and efficient migration to peripheral sites of infection.[4] These cells accumulate over time and in the adult human comprise more than half of the circulating T

cells.

Mere antigen exposure is insufficient for activation of naïve T cells. Proliferation and differentiation require costimulatory signals provided by molecules on APCs. The best characterized costimulator pathway involves the T-cell surface molecule CD28 and its counterligands B7-1 and B7-2 expressed on activated APCs.[4,39] CD28 delivers signals that enhance T-cell survival, by increasing expression of the antiapoptotic protein Bcl-X, the production of cytokines such as IL-2 and the IL-2 receptor, and the differentiation of immature T cells. In vitro, purified populations of $CD4^+$ cells challenged with antigen by APCs that express B7, proliferate and secrete cytokines. This does not occur if B7 is absent. The costimulatory signal must come from the same APC that provides the initial signal. DCs are the most potent APC because they express both classes of MHC molecules and the B7 molecules, whereas macrophages and B cells must be activated to express the costimulatory molecules. This expression of costimulators is regulated so as to ensure that T-cell activation is temporally and spatially appropriate. For instance, during T-cell activation, engagement of CD40 ligand with CD40 induces upregulation of B7 costimulators on the APCs. In addition, it increases the secretion of cytokines such as IL-12 that promote T-cell differentiation, and cytokines are secreted that promote T-cell differentiation and activation. A protein CTLA-4, expressed on activated T cells, is homologous to CD28 and binds B7-1 and B7-2. Unlike CD28, CTLA-4 functions to terminate T-cell responses and plays a role in self-tolerance. On the basis of many experimental studies of costimulators, antagonists against B7 molecules and CD40L are in clinical trials to prevent the rejection of organ allografts.[4,39]

The differentiation of naïve $CD8^+$ T cells to CTL requires a stronger costimulatory signal. This can be provided by either DC, as they have the greatest intrinsic costimulatory activity, or by a $CD4^+$ helper T lymphocyte. Naïve helper T cells attached to the same APC as the $CD8^+$ T cell can be activated to elaborate IL-2. Attached effector T helper cells can stimulate the APC to express more costimulatory molecules. In the case of virulent viruses, cytotoxicity can substitute for CD28 costimulation, and so the typical costimulatory signal is not required for activation. For less virulent viruses, costimulation is necessary for CTL induction.[39,76] The absence of costimulation results in an unresponsive, or anergic T cell. Recently this has been shown to be mediated by the serine/threonine kinase calcium/calmodulin-dependent protein kinase (CaMK) II (see below).[77] Anergic T cells do not produce IL-2 and therefore cannot proliferate and differentiate into effector cells even when presented with antigen at a later time.[39]

The affinity of most TCRs for peptide–MHC complexes is low, with dissociation constants of the order of 10^{-5} to 10^{-7} and an estimated TCR–antigen interaction of less than 10 seconds. Furthermore, on any APC fewer than 1000 of the 10^5 available MHC molecules are likely to be displaying any one peptide at any particular time. Therefore, one APC can engage a small fraction of the 10^4 to 10^5 antigen receptors on a single T cell.[4] Activation of an individual T cell may require multiple sequential engagements of that cell's antigen receptors by peptide–MHC complexes on APCs. With engagement, there is clustering of membrane receptors, tyrosine phosphorylation of several proteins, and recruitment and activation of adaptor proteins.

TCRs are devoid of enzymatic activity and must utilize other signal-transducing proteins.[4] After TCR–MHC engagement, several membrane surface proteins and intracellular signaling proteins are rapidly recruited: TCR complex, CD4 or CD8, receptors for costimulators such as CD28, and enzymes and adaptor proteins.[4] After TCR clustering, activated tyrosine kinases associated with and phosphorylate tyrosine residues on CD3 and TCR (Fig. 7-5). These phosphorylation sites provide docking sites for other tyrosine and protein kinases, such as Lck, an Src family tyrosine kinase, and ZAP-70, a tyrosine kinase. These kinases become activated with phosphorylation. Activated ZAP-70 phosphorylates several adaptor proteins that subsequently induce a variety of signal transduction cascades. Adaptor proteins contain structural domains that bind other proteins and thereby facilitate the correct spatial orientation that is required for signal transduction. The ras pathway is also activated, which is an early step in the activation of the mitogen-activated protein kinases (MAPK) that can activate a variety of transcription factors. Ras is a member of a family of guanine nucleotide-binding proteins (GDP/GTP) that are involved in diverse activation responses in different cell types. This pathway is an amplification process by which few upstream kinases lead to the activation of several downstream kinases. Ultimately activation of the terminal extracellular regulated kinase (ERK 1/2) leads to the phosphorylation of the protein ELK, which stimulates the transcription of fos, a component of the activation protein 1 (AP-1) transcription factor (Table 7-4). Concomitantly, c-Jun N-terminal kinase (JNK) is activated, which phosphorylates c-Jun, the second component of AP-1. The third member of the MAPK family, p38, is also activated. The activities of the MAPKs are terminated by specific protein tyrosine/threonine phosphatases that are regulated by the MAPKs themselves. Hence, the entire system is self-regulated by a negative feedback system.[4]

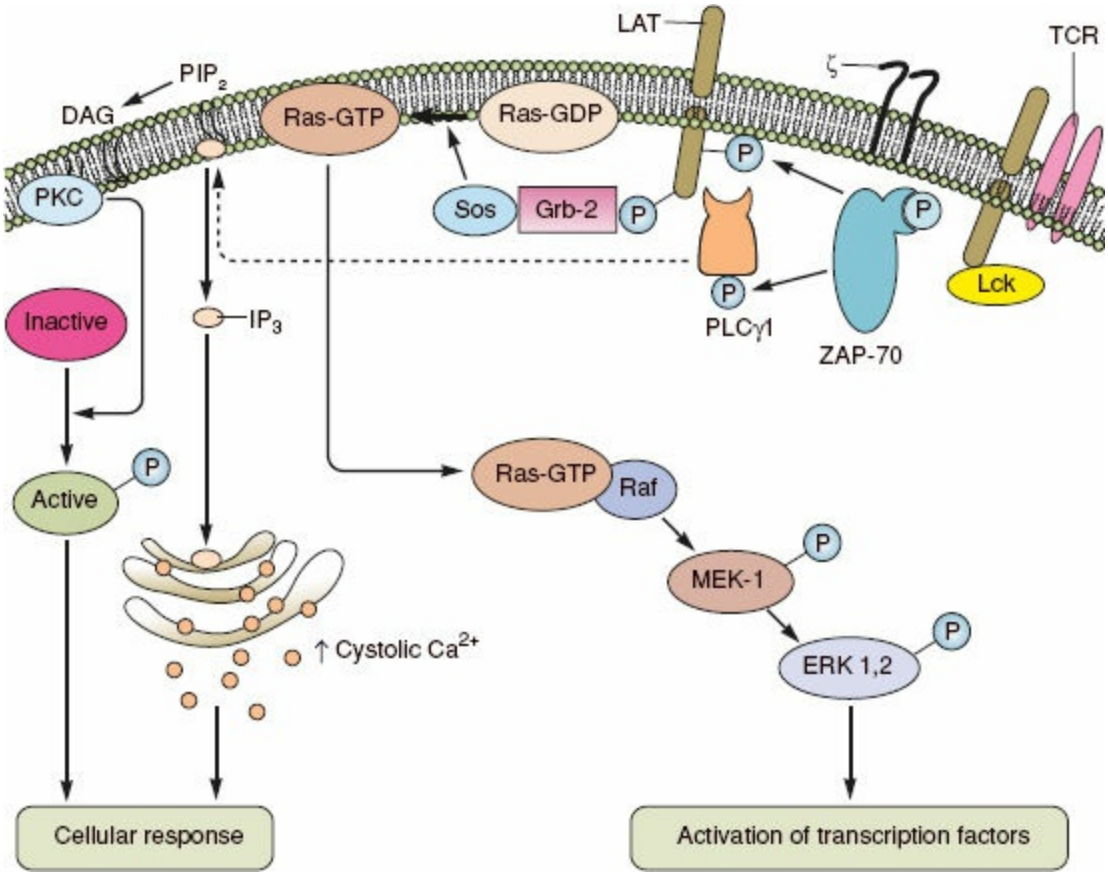

Figure 7-5. T-cell signaling and activation. (Redrawn from Abbas AK, Lichtman AH. *Cellular and Molecular Immunology*. 5th ed. Philadelphia, PA: Saunders; 2003.)

Table 7-4 Transcription Factors

Transcription Factor	Stimuli	Effector Genes
AP-1	TNF, IL-1,UV light, H_2O_2, LPS, stress, ROS, hypoxia	TNF, IL-1, IL-2, IL-5, IFN-γ, ICAM-1, E-selectin, GM-CSF, MMPs, COX-2
NFκB	TNF-IL-1, UV light, H_2O_2, LPS, ROS	IL-1, IL-2, IL-6, IL-8, IL-12, TNF, E-selecting, VCAM-1, ICAM-1, MIP-1, MCP-1, RANTES, iNOS, cotaxin, PLA_2, G-CSF, GM-CSF, IFN-β
STAT	IFNs, CSFs, GFs, IL-l to IL-15	FOS, E-selectin, Myc, ICAM-1, FcγRI
NFAT	TCR, BCR, FcεR, FcγR, histamine and thrombin receptors	IL-2, IL-3, IL-4, IL-5, IL-8, IL-13, TNF, GM-CSF, IFN-γ, CD40L, FASL

AP, activator protein; CSF, colony-stimulating factor; COX, cyclooxygenase; GF, growth factor; ICAM, intercellular adhesion molecule; IFN, interferon; IL, interleukin; iNOS, inducible nitric oxide synthase; LPS, lipopolysaccharide; MMP, matrix metalloproteinase; MPO, myeloperoxidase; NFAT, nuclear factor of activated T cells; NFκB, nuclear factor kappa-B; PLA_2, phospholipase A_2; ROS, reactive oxygen species; STAT, signal transducer and activator or transcription; TNF, tumor necrosis factor; UV, ultraviolet; VCAM, vascular cell adhesion molecule.
Modified from Gallin JI, Snyderman R, eds. *Inflammation: Basic Principles and Clinical Correlates*, 3rd ed. Philadelphia, PA: Lippincott Williams & Wilkins, 1999.

Activation of TCR also leads to the induction of PLC, in particular PLCγ1 (Fig. 7-5). Phosphorylated PLCγ1 catalyzes the hydrolysis of phosphatidylinositol 4,5-bisphosphate (PIP_2) into inositol 1,4,5-triphosphate (IP_3) and diacylglycerol (DAG), and activates enzymes that generate additional active transcription factors. IP_3 increases cytosolic calcium that leads to a large influx of both intracellular and extracellular calcium with subsequent activation of calcium- and calmodulin-dependent proteins. Calcineurin, a calcium/calmodulin-dependent phosphatase is integral to T-cell activation via modulation of the activation of the transcription factors nuclear factor of activated T cells (NFAT) and

NFκB (Table 7-4).[4,75] These transcription factors are essential for the induction of cytokine transcription, in particular IL-2 production. However, in the absence of costimulation, activation of the CaMK II opposes the actions of calcineurin as described above and produces an anergic cell.[77] DAG activates protein kinase C, which activates additional transcription factors. The role of PKC and calcium in T-cell function is made evident by studies in which pharmacologic activation of PKC and/or elevation of intracellular calcium concentration stimulates T-cell cytokine secretion and proliferation.[4] Regulation of those kinases operant in T-cell signaling involves protein tyrosine phosphatases. Through dephosphorylation they modulate TCR signaling. Two phosphatases induced with TCR clustering are SHP-1 and SHP-2.

The ultimate goal of all these signaling transduction pathways is to activate transcription factors that bind to promoter regions and enhance transcription. Three transcription factors that are activated in T cells and appear critical for most T-cell responses are NFAT, AP-1, and NFκB (Table 7-4).

A third mechanism of T-cell activation involves lipid antigens, such as cell wall protein from intracellular bacteria. These antigens bind CD1, a MHC-related cell surface molecule that presents these antigens to certain subtypes of T cells. A superantigen is an unprocessed bacterial or retroviral product that binds the MHC molecule and the TCR outside the usual antigen-binding sites. This engagement leads to a polyclonal and nonspecific stimulation of a large proportion of the T-cell population. An overwhelming activation of all arms of the immune system ensues and underlies much of the pathophysiology of toxic shock syndrome (TSS). Intravenous immunoglobulin (IVIG), by binding this antigen, is thought to be of therapeutic benefit.

Eosinophils

Eosinophils are marrow-derived granulocytes that share some properties of neutrophils, act in conjunction with basophils and mast cells as primary effectors in allergen inflammation and are involved in the eradication of helminthic infections (Table 7-1). Upon exiting the marrow, their intravascular half-life is but a few hours, whereafter they enter the mucosa of the lung, gastrointestinal, and genitourinary tracts.[39,78] IL-3, GM-CSF, and IL-5 promote eosinophil differentiation, the induction of effector functions, and survival, the last by inhibiting apoptosis.[78] Emigrating through inflamed endothelium they release inflammatory mediators and toxic agents from cytoplasmic granules. They generate superoxide anion and hydrogen peroxide, though less efficiently than neutrophils. They express IgE receptors and stimulate histamine release from basophils and mast cells through major basic protein (MBP). They can also regulate basophil and mast cell function by releasing enzymes that inactivate histamine and slow-reacting substance of anaphylaxis (SRS-A).

Recruitment and Activation

Eosinophils are recruited primarily to sites of parasitic infection and allergen challenge. Mast cells and macrophages responding to either secrete mediators (IL-5, PAF, LTB-4) that upregulate expression of endothelial adhesion molecules. Eosinophils themselves are more responsive to CC chemokines (MIP-1 α, RANTES, and MCP-3) and the cytokines produced with T_H2 activation. Engagement of eosinophil β_1 integrin VLA_4 with VCAM-1 and fibronectin on the endothelium initiates the process of emigration. IL-4 can activate both the binding and the upregulation of endothelial cell VCAM-1. Diapedesis and tissue infiltration also involves members of the β_2 integrin family (Mac-1 and LFA) similar to that which mediates neutrophil recruitment.[39,79]

Eosinophils are activated by IL-3, GM-CSF, IL-5, PAF, CC chemokines, and C3a and C5a of complement. IL-5 is a potent activating agent and enhances the ability of eosinophils to release granule contents on FcR cross-linking. A positive feedback cycle ultimately is established, in which recruited eosinophils produce cytokines and chemokines that recruit more eosinophils and other leukocytes.

Granules

Eosinophils possess a compartmentalized armamentarium of toxic substances that assist in the elimination of organisms, in particular helminths. Their specific granules contain GM-CSF and MBP, the latter of which is cytotoxic to parasites and normal cells. Further, it functions as a stimulus for histamine release from mast cells and basophils.[80] The granule matrix contains eosinophil peroxidase (EPO), eosinophil-derived neurotoxin, lysosomal enzymes, catalase, TNFα, TGFβ, and eosinophilic cationic proteins that stimulate formation of transmembrane pores to increase target cellular permeability.[81] EPO is released extracellularly on target cell surfaces where it generates hydrogen peroxide and hydrogen halides. Approximately 30% of oxygen consumed by stimulated eosinophils is utilized in the formation of halogenating species. Thiocyanate may be the major halide

for the EPO–H_2O_2 system.[82] If ingested by a neighboring phagocyte, EPO can combine with H_2O_2 and halides to form hypohalous acids. EPO also stimulates neutrophil aggregation and adhesion to endothelial cells. Although they express Fc receptors for IgG, IgA, and IgE, they are relatively insensitive to activation by antigen-mediated cross-linking of these receptors. However, they can kill microorganisms by antibody-dependent cell-mediated cytotoxicity.[4,39]

The primary targets of eosinophils are extracellular parasites. The size of these pathogens prohibits phagocytosis, and their integument is relatively resistant to the microbicidal products of neutrophils and macrophages; however they can be killed by MBP, which is released after cross-linking of Fc-bound IgE coating the parasite. The T_H2 response to parasitic invasion produces IL-4, IL-5, and IL-13. IL-4 stimulates the production of specific IgE antibodies, which opsonize helminths. IL-5 activates eosinophils, which bind to the IgE-coated helminthes via Fc receptors. Activated eosinophils then release their granule contents and generate ROS and hypohalous acids. EPO also stimulates neutrophil aggregation and adhesion to endothelial cells. The sparse uncompartmental granules contain Charcot–Leyden crystals and have lysophospholipase activity. Finally, eosinophils produce and release lipid mediators such as PAF, prostaglandins, and LTs, which probably contribute to the process of allergic diseases.[4,83,84]

Basophils and Mast Cells

Basophils and mast cells are central to the development of allergic inflammation and produce cytokines, lipid mediators, vasoactive amines, and proteases that can also participate in nonallergic inflammatory responses (Table 7-1). Both cells share a common progenitor cell, which diverges early during differentiation. The primary growth factors for basophil development are IL-3 and GM-CSF, whereas stem cell factor is the primary stimulus for mast cell maturation.[85] Although basophils and mast cells are distinct cell types, they are often grouped together because of the similarity of their granule content, the stimuli inducing activation, and their effector functions.[39]

Mature basophils constitute only 0.5% to 1% of the circulating leukocytes. Mast cells are primarily tissue-fixed residents of connective tissue. Engagement of IgE-bound antigen with the high-affinity IgE antibody receptor, FceR, provides the primary stimulus for basophil and mast cell activation and degranulation. In addition, diverse agents such as contrast media, opiates, anaphylatoxins, chemokines, and neuropeptides may serve as activators. Basophils and mast cells elaborate both preformed, as well as, newly synthesized inflammatory mediators. The main basophil proteoglycan is chondroitin sulfate A, whereas mast cells contain heparin, chondroitin sulfate, and chondroitin sulfate E and also store neutral proteases.[86] The lipid mediators LTB_4, LTC_4, and PGD_2 are synthesized de novo in response to stimulation. The LTs are powerful vasoconstrictors, bronchoconstrictors, and chemoattractants for neutrophils and eosinophils. PGD_2 inhibits platelet aggregation and is chemotactic for neutrophils. Both basophils and mast cells synthesize and secrete histamine. Histamine, or 2-(4-imidazolyl)-ethylamine, is formed by the carboxylation of histidine. It is stored in preformed granules at acid pH as a complex with proteins and proteoglycans. Mast cells carry greater quantities of histamine than do basophils. The classic vasoactive properties of arteriolar dilatation, increased vascular permeability, and bronchoconstriction are mediated by the H_1 receptors. H_2 receptors are involved in modulation of the immune response and stimulating gastric output and mucus secretion. H_3 receptors participate in neuroconduction.[39,86,87]

Platelets

Though classically considered in the context of hemostasis, studies confirm that platelets are also integral to normal and pathologic inflammation and link the processes of hemostasis, inflammation, and tissue repair. They are activated in a variety of inflammatory conditions, such as rheumatoid arthritis and inflammatory bowel disease, a testimony to their role in inflammation.[88] Upon activation, they release factors that enhance vascular permeability, chemokines, microbicidal proteins, and mitogens for endothelial cells, smooth muscle cells, and fibroblasts. They assist leukocytes in promoting the inflammatory reaction and killing microbes by providing an adhesive surface to facilitate emigration, by stimulating adhered leukocytes, and by further modulating chemokine synthesis (Table 7-5).[88,89]

Humans possess about 150 to 400 $\times$ 10^9 platelets per liter of blood.[88] Thrombopoiesis is regulated by thrombopoietin as well as a variety of other mediators (IL-3, IL-4, IL-6, IL-7, and IL-11). In fact, human IL-11 is in clinical use to stimulate thrombopoiesis in patients undergoing chemotherapy.[90] After release from the marrow, platelets circulate with a half-life of approximately 12 days. Interferon α is inhibitory for megakaryocyte growth, and the elevated levels induced with some viral and inflammatory conditions may explain the relative thrombocytopenia observed in these conditions.[88,91]

Recruitment and Activation

Platelets are activated by and aggregate in response to thrombin or activated endothelium. Clot formation triggers the release of vasoactive agents (PGE_2, PGI_2, $PGF_2\alpha$, and platelet-derived growth factor [PDGF]) and inflammatory mediators. Serotonin, PGE_2, and PAF increase vascular permeability. The adhesion molecule PECAM-1 and the β_3 integrins mediate platelet plug formation, endothelial cell adhesion, and leukocyte emigration. The integrin IIb/IIIa and P-selectin facilitate platelet interactions with other inflammatory cells. The α granules are rich in membrane-bound P-selectin; upon fusion with the cell surface membrane they enhance the cell surface density of this receptor. On stimulation, both receptors are expressed on the platelet surface in an activated state. IIb/IIIa binds various adhesive proteins containing the RGD sequence (i.e., fibrinogen), which serve as a mechanical link to other platelets, leukocytes, and the endothelium. Possibly, the immobilization of activated P-selectin–expressing platelets on the vessel wall may biochemically and functionally promote the adhesion of neutrophils to endothelial cells.[88,91]

Table 7-5 Platelet-Derived Mediators

Chemoattractants
C5a
12-HETE
PAF
α-Granule proteins
PDGF
PF-4
RANTES
Growth factors
Transforming growth factors-α and -β
Fibroblast growth factor
PDGF
Antimicrobial activity
Cationic bactericidal protein
IgE-mediated oxidant production by platelets directed at schistosomes
Vascular Reactions
Prostaglandin E_2
Prostaglandin I_2
Prostaglandin $F_2\alpha$
Serotonin
PDGF
Serotonin
PAF
Cationic proteins
Vascular endothelial growth factor

HETE, hydroxyeicosatetraenoic acid; IgE, immunoglobulin E; PAF, platelet-activating factor; PDGF, platelet-derived growth factor; PF-4, platelet factor 4; RANTES, regulated on activation, normally T-cell expressed and secreted.
Adapted from Klinger MHF, Jelkmann W. Role of blood platelet in infection and inflammation. *J Interferon Cytokine Res* 2002;22:913–922.

Platelets are a primary source of chemoattractants for neutrophils. Neutral proteinases released from stimulated platelets cleave complement factor C5, liberating the chemoattractant C5a. PDGF binds strongly to the extracellular matrix, providing a long-acting source of chemoattractant. Platelet factor 4 (PF4) is a cationic protein that penetrates the vascular wall and is a chemoattractant. Activated platelets also bind monocytes via P-selectin and PSGL-1 and induce the expression and secretion of monocyte chemotactic protein-1 (MCP-1) and IL-8. Thrombospondin released from activated platelets mediates monocyte binding to platelets. Together these substances promote leukocyte margination, activation, and recruitment to the sites of injury.[39]

Granules

The vasoactive substances and inflammatory mediators of platelets are either stored in cytoplasmic granules or synthesized de novo. A platelet contains about 35 α *granules* and 5 *dense bodies*. The dense granules contain adenosine diphosphate (ADP), ATP, serotonin, and calcium that are required during the earlier stages of inflammation. ADP is the principal platelet agonist during platelet aggregation and augments the oxidative burst of

neutrophils. Serotonin increases vascular permeability and enhances the superoxide production by macrophages.[88]

The more abundant α granules contain fibrinogen, RANTES, MIP-1α, thrombospondin, P-selectin, PF4, PDGF, TGFβ, β-thromboglobulin, high–molecular-weight kininogen (HMWK), and many other biologically active proteins. PF4 and β-thromboglobulin initiate leukocyte recruitment and activation. PF4 induces neutrophil adherence to unstimulated endothelium and the release of secondary granules. It inhibits monocyte apoptosis and promotes macrophage differentiation. PF4 can also stimulate histamine release from basophils. RANTES is deposited on the endothelium and recruits monocytes from the circulation. PAF induces platelet aggregation, increases vascular permeability, enhances phagocyte free radical formation, and the adhesion of platelets to neutrophils. Platelet activation appears to occur in allergic asthma and may precede the delayed accumulation of eosinophils in the lung after allergen exposure. The α granules also carry several important growth factors, including vascular endothelial growth factor (VEGF), PDGF, and TGFβ. VEGF promotes extravasation and aids recruitment of leukocytes. PDGF is chemotactic for neutrophils and monocytes. TGFβ is chemotactic for and activates neutrophils and monocytes early during inflammation, but displays immunosuppressive effects during later stages of inflammation.[88]

Platelets are an important source of eicosanoids, including thromboxane, prostaglandins $F_2\alpha$ and E_2. Thromboxane synthetase in platelets is responsible for the production of TXA_2, a potent vasoconstrictor that also increases vascular permeability and stimulates platelet aggregation. Aspirin and other nonsteroidal anti-inflammatory drugs (NSAIDS) inhibit platelet function by inhibiting TXA_2 production. As this effect is irreversible, new platelets must be produced (7 to 10 days) to restore normal clot formation. In emergent circumstances (management of intracranial hemorrhage) platelet administration is required. Recently, an aspirin response test has been developed that assists in guiding therapy and targeting transfusion to those with functional evidence of platelet inhibition. It has also assisted in monitoring the response to transfusion. $PGF_2\alpha$ causes vasoconstriction, whereas PGE_2 vasodilates and modulates pain.[92,93]

Platelets participate in transcellular lipoxygenase (LO) metabolism, which refers to the production of eicosanoids through interactions with neighboring inflammatory cells. Endothelial cells utilize platelet-derived endoperoxides to synthesize PGI_2. Platelets interact with neutrophils in several pathways, providing a direct link between thrombosis and inflammation. 12-hydroxyeicosatetraenoic acid (12-HETE) released from activated platelets can be used by unstimulated neutrophils to produce the chemoattractant 12,20-HETE. 12-HETE and 5-HETE from activated platelets and neutrophils, respectively, can combine in either cell type to form 5,12 diHETE, an anti-inflammatory compound, which diverts production away from the proinflammatory LTs. 12-LO from platelets and LTA_4 formed by neutrophils can produce the intermediate 5(6)-epoxytetraene. This intermediate produces lipoxins A_4 and B_4 that have primarily counterinflammatory functions.[39,89,92,94]

In addition to modulating inflammation platelets possess some direct microbicidal

activity. Platelets are activated and degranulate when exposed to certain bacteria. Electron microscopic studies have shown that activated platelets internalize bacteria and viruses. The α granules contain antibacterial proteins called thrombocidins (TC) in humans that support the killing of adherent bacteria. The two antibacterial proteins isolated from human platelets (TC-1, TC-2) are bactericidal for *Escherichia coli* and *S. aureus*.[88]

NONCELLULAR COMPONENTS

Cytokines

Cytokines are soluble protein mediators secreted by the cells of the innate and adaptive immunity in response to microbes and other antigens, including intra- and extracellular proteins, and mediate many of the functions of these cells (Table 7-6). They regulate and influence the host response to both PAMPs on bacterial, viruses, fungi, and parasites and DAMPs released during trauma, burns, allograft rejection, ischemia/reperfusion injury, and autoimmune disease. They govern lymphocyte differentiation during adaptive immunity and activate effector cells of both arms of inflammation to eliminate microbes. Cytokines play important roles in tumor biology and angiogenesis. Though essential for a normal immune response, excessive cytokine release underlies a variety of pathophysiological inflammatory states such as ARDS and MODS.[95–98]

Table 7-6 Cytokines

Cytokine	Receptor	Signal Transduction	Cellular Source	Targets	Effects
TNFα	TNF R	TRAFS Death domains	Mo/Mφ, MC, Ba, Eo, NK, B, T, F, Ep	Endothelium PMN Many cells	↑ inflammation, coagulation, adhesion molecules ↑ activation ↑ apoptosis ↑ fever, APP, catabolism
IL-1	Ig family	IRAK	Mo/Mφ, B, EC, Ep, F	Endothelium PMN Mo	↑ inflammation, coagulation, adhesion molecules ↑ activation and emigration ↑ activation and emigration ↑ shock, fever, APP production
Chemokines/ IL-8	7 transmembrane	G protein	Mo/Mφ, T, PMN, F, EC, Ep	PMN T Mo/MΦ EC Ba	↑ activation, adherence, and migration ↑ emigration ↑ emigration ↑ adhesion molecules ↑ histamine release
IL-12	Type I	JAK/STAT	Mφ	T NK	T_H1 differentiation, interferon-γ synthesis, ↑ cytolytic activity
Interferons (type I)	Type II	JAK/STAT	All	All	Antiviral, antitumor, increases MHC I activates T, Mφ, NK cells
IL-10	Type II	JAK/STAT	Mo/Mφ, T, B, MC	Mo/MΦ T B, NK, MC	↓ IL-12, costimulators, MHC II ↓ T_H1 differentiation
IL-6	Type I	JAK/STAT	Mo/Mφ, B, F, EC, Ep	T B Mo/MΦ	Differentiation ↑ antibody-producing cells APP synthesis
IL-15	Type I	JAK/STAT	Mφ	E NK T	Proliferation Proliferation
IL-18	Ig family	IRAK	Mφ	T, NK	↑ interferon-γ
IL-2	Type I	JAK/STAT	T	T B NK	T activation and proliferation, Fas apoptosis ↑ proliferation, antibody synthesis ↑ proliferation and activation Mo/Mφ activation
IL-4	Type I	JAK/STAT	T, Ba, MC	T B Mo/MΦ	T_H2 differentiation and proliferation, ↓ T_H1 Isotype switching to IgE ↓ interferon-γ-mediated function
IL-5	Type I	JAK/STAT			
Interferon-γ	Type II	JAK/STAT	T,NK	MΦ T B T	M φ activation T_H1 differentiation IgG secretion ↑ MHC I and II ↑ antiviral ↑ fever, anorexia, shock, capillary leak ↑ APP synthesis, inflammatory cytokine induction ↓ T proliferation and effector functions

TGF-β				BΦ B	↓ Mφ function ↓ proliferation ↑ matrix protein synthesis
Lymphotoxin	TNF R	TRAFs Death domains		PMN	Recruitment and activation
IL-13	Type I	JAK/STAT		Mo/Mφ B EC	↓ Mφ function switching to isotype IgE ↑ adhesion molecules and CC chemokines

APP, acute-phase protein; B, B cell; Ba, basophil; EC, endothelial cell; Ep, epithelial cell; F, fibroblast; IL, interleukin; IRAK, IL-lR-associated kinase; JAK/STAT, Janus kinase/signal transducer and activator of transcription; MC, mast cell; MHC, major histocompatibility complex; Mo, monocyte; Mφ, macrophage; NK, natural killer; PMN, polymorphonuclear leukocyte; T, T cell; TNF, tumor necrosis factor; TRAF, tumor necrosis factor receptor-associated factor.
Modified from Abbas AK, Lichtman AH. *Cellular and Molecular Immunology*. 5th ed. Philadelphia, PA: Saunders 2003:179; 181–182.

Cytokine secretion is brief, and as cytokines typically are not stored preformed, they must be transcribed and synthesize de novo synthesis, which is also transient as the messenger RNA is unstable. Their functions are pleiotropic and redundant, which has been interpreted to represent a teleological safety mechanism. However, such protective characteristics greatly limit the therapeutic utility of either cytokine administration or blockade. In fact, over 30 randomized controlled clinical trials have been conducted to assess the efficacy of modulating inflammation, on reducing mortality in a variety of contexts: trauma, sepsis. The majority have involved manipulating systemic cytokine concentrations. Only one, activated protein C, was briefly FDA approved for use; it was recently removed from the market due to lack of benefit.[99]

Cytokines often influence the synthesis and actions of other cytokines, such as IL-1–induced T-cell IL-2 production; this interaction may be synergistic (additive or multiplicative) or antagonistic. They may function in an autocrine, paracrine, or even endocrine function, although the inability to correlate plasma cytokine concentrations with the extent of tissue damage suggests that they are designed for local rather than systemic inflammation.[4,39,95]

Cytokine actions are mediated by specific membrane receptors on target cells to which they bind with high affinity (kD α 10^{-10} to 10^{-12}). Hence, only minute quantities are necessary to elicit a response. Such efficiency is accompanied by a narrow therapeutic index and potential for unwanton global effects (i.e., MODS) with even small systemic concentrations. The receptors and the cells expressing them are regulated by external stimuli, which provide some degree of specificity to the response, even though the cytokines themselves are not antigen specific. Receptor binding alters cellular gene transcription (induction or suppression) that may result in proliferation, differentiation, and the acquisition of new or suppression/enhancement of pre-existing functions.[4]

All cytokine receptors consist of at least one transmembrane protein with an extracellular portion for ligand binding and an intracellular domain mediating signal transduction. Current receptor classification is based on structural homologies among the extracellular cytokine binding domains. Type I cytokine receptors contain a domain with two conserved pairs of cysteine residues and a membrane proximal sequence of tryptophan-serine-X-tryptophan-serine, where X is any amino acid (WSXWS). Type II

resemble type I receptors, however the WSXWS motif is absent. The Ig superfamily consists of receptors with extracellular Ig domains. TNF receptors belong to a family of receptors with conserved cysteine-rich extracellular domains. Finally seven-transmembrane α-helical receptors mediate the functions of cytokines called chemokines through GTP-binding (G) proteins.[4]

Translating ligand engagement to the signaling events that alter cellular phenotype involves a variety of signaling cascades dependent upon the structure of the cytoplasmic tail of the particular receptor (Table 7-6). This is another method by which to classify cytokine receptors. These individual signaling cascades will be discussed in the context of the various cytokines and respective receptors employing them.

Early Cytokines/Innate Immunity

TNF-α

TNFα is the principal initiating mediator of the inflammatory response to gram-negative bacteria and other infectious pathogens. It is an important early mediator of inflammation and is essential for the normal initiation, maintenance, and repair of tissue injury. However, aberrant production may underlie the pathologic sequelae of many inflammatory and infectious states (i.e., MODS, rheumatoid arthritis, Crohn's disease). Mononuclear phagocytes are the principle source of TNFα, usually in response to the potent prototypical stimulus lipopolysaccharide of gram-negative organisms.[100,101] TNFα production may be augmented by concomitant stimulation with IFNγ, IL-4 and IL-10, whereas, corticosteroids are suppressive.[102] Secondary sources include mast cells, NK cells, and T and B lymphocytes. Other stimuli inducing production and release include complement C5a, GM-CSF, hypoxia, IL-1, NO, ROS, and TNFα itself.[39]

TNFα is expressed on the cell membrane as a bioactive protein and is cleaved into its soluble form by a specific TNFα converting enzyme. There are 2 distinct TNF receptors present on virtually all cell types (Fig. 7-6).[103] Ligand binding to TNF-RII leads to recruitment of TNF receptor-associated factors (TRAFs) that ultimately activate the transcription factors NFκB and AP-1, and thereby influence gene expression and cellular phenotype.[4] Alternatively, binding to TNF-RI activates caspases and triggers apoptosis, in addition to signaling transcription factors. The manner by which either a proinflammatory or apoptotic path is chosen is unknown, although the net effect of TNFα binding is probably the culmination of differential adaptor protein expression and downstream signal transduction cascades. TNF-RI appears to be more important in host defense as knockout TNF-RI mice show a greater degree of impairment in host defense than mice lacking TNF-RII.[4]

Shedding of extracellular domains of the two TNFα receptors by metalloproteinases can further alter the biologic activity of TNFα by decreasing the number of cell signaling sites on target tissues and increasing the amount of circulating inhibitors. Unlike other members of the TNF family that are primarily involved in regulation of cell proliferation, TNFα has both proinflammatory and apoptosis-inducing properties.[95,104]

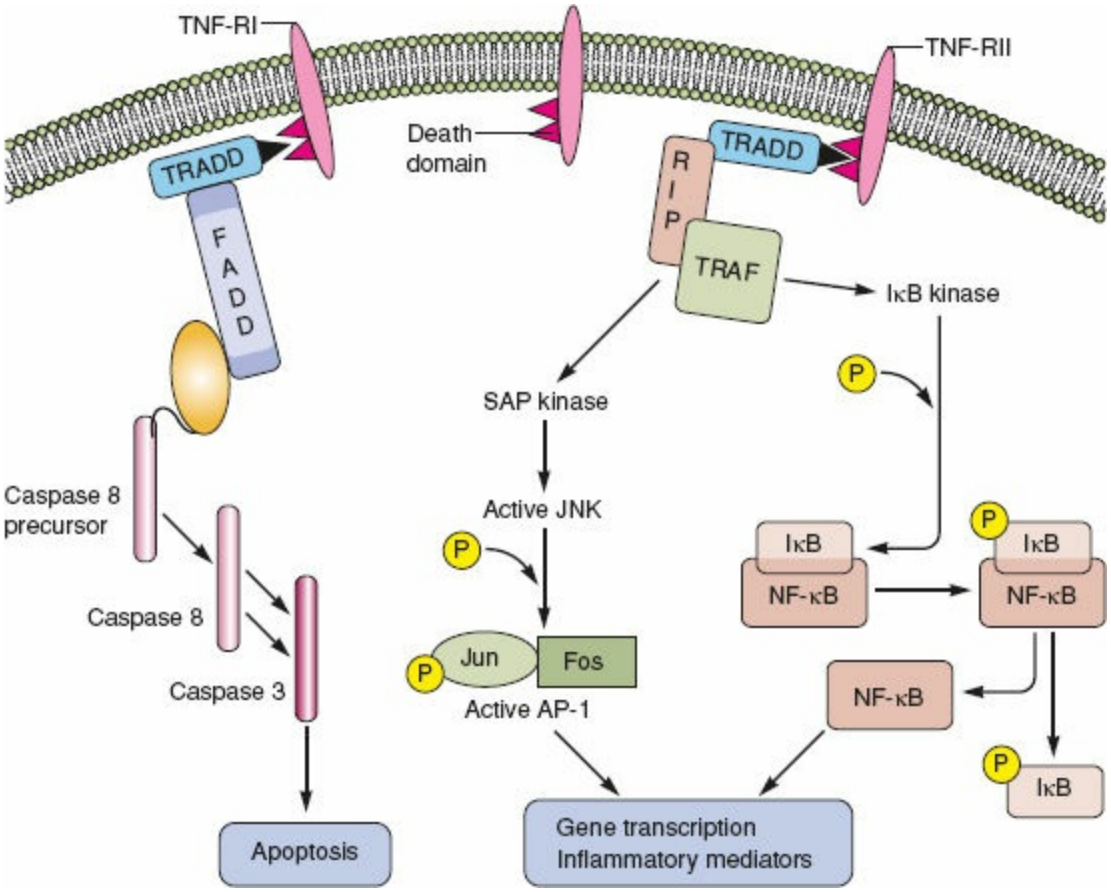

Figure 7-6. TNF receptor signaling pathway. (Redrawn from Abbas AK, Lichtman AH. *Cellular and Molecular Immunology*. 5th ed. Philadelphia, PA: Saunders; 2003.)

The principal function of TNFα is to recruit neutrophils and monocytes to foci of infections and to activate these cells to eradicate microbes. TNFα activates the endothelium to upregulate the expression of the adhesion molecules E- and P-selectin, ICAM-1, PECAM-1, and VCAM-1. It potently stimulates these cells and macrophages to secret chemokines (IL-8, MIP-1α, and Gro-α) that enhance the affinity of leukocyte integrins for their ligands and induce leukocyte chemotaxis and recruitment.[105] TNFα also can induce HMGB1 release by activated macrophages, which generates a forward feedback mechanism, as HMGB1, by signaling through RAGE (see below), also induces TNFα release.[106,107] TNFα by stimulating the release of tissue factor, PAF, von Willebrand factor, and thromboplastin generates a state of hypercoagulability. By inhibiting tissue-type plasminogen activator and thrombomodulin, it suppresses fibrinolysis, decreases protein C and S activation, and increases thrombin formation. However, TNFα also induces the release of a variety of anticoagulants (prostacyclin), fibrinolytics (urokinase-type plasminogen activator), and vasodilators (NO, PGE_2), which may offset or balance the tendency toward procoagulation. Most likely, the ultimate effect of TNFα depends on the location and quantity in which it is produced and the vascular bed with which it interacts.[4,95]

3 Though clearly vital for host defense and microbial elimination, in severe infections, exuberant production and aberrant release of TNFα wherein it possess endocrine function and can cause a plethora of pathological sequelae. These systemic effects include fever by stimulating the production of PGE_2 by the hypothalamus (hence the name endogenous

pyrogen), acute-phase protein production by the liver, cachexia, inhibition of myocardial contractility and vascular tonus, and intravascular thrombosis due to loss of normal anticoagulant properties of the endothelium and the production of tissue factor. TNFα is central to the pathogenesis of systemic inflammatory response syndrome (SIRS) and septic shock, and either state can be reproduced by the exogenous administration of TNFα.[108,109] The organ dysfunction characteristic of these states may result from the hypercoagulability and subsequent tissue ischemia induced by this cytokine. Antagonists of TNFα can prevent mortality in experimental models, but clinical trials with anti-TNFα antibodies or with soluble TNFα receptors have been to no avail.[4,108] That being said, anti-TNFα therapy has been pivotal in treating the more chronic diseases of rheumatoid arthritis, psoriasis, and Crohn's disease.

Soluble TNF receptors formed by proteolytic processing of both types of receptors bind and neutralize TNFα and serve as an endogenous regulator of cytokine activity.[39] TNFα also directly induces the expression and release of TNFα inhibitors, including IL-10, corticosteroids, and prostanoids, which in a negative feedback loop suppress TNFα production and processing.[95] Hence, TNFα serves as its own regulator.

Interleukin-1

IL-1 posseses similar functions to TNFα in mediating a proinflammatory host response to insult; it is frequently released concomitantly with TNFα (Table 7-6).[110] The major source of IL-1 is the mononuclear phagocyte. Synthesis and release are induced by LPS, cytokines such (TNFα, IL-2, TGF-β, all the interferons), antigen–antibody complexes, C5, and hypoxia.[95] IL-1 is also produced by neutrophils, B cells, helper T cells, epithelial cells, fibroblast, renal mesangial cells, and endothelial cells. There are two forms of IL-1; IL-1α and IL-1β. Both forms are active, bind to the same receptors and mediate the same effects. Most IL-1 found in circulation is IL-1β.[4]

The two IL-1 receptors (IL-1R) are members of the Ig superfamily. IL-1RI is universally expressed and transduces the majority of IL-1 responses.[111,112] IL-1RII expression is restricted to B cells, but may be induced on other cells. There is little evidence that this latter receptor serves any function, and in fact, may serve as a decoy.[113] The cytoplasmic portion of IL-1RI is homologous to a domain of TLR, which mediate the cellular responses to endotoxin (Fig. 7-7). Engagement of IL-1 with IL-1RI induces the activation of the IL-1 receptor-associated kinase (IRAK) and the subsequent induction of the transcription factors NFκB and AP-1.[4,112]

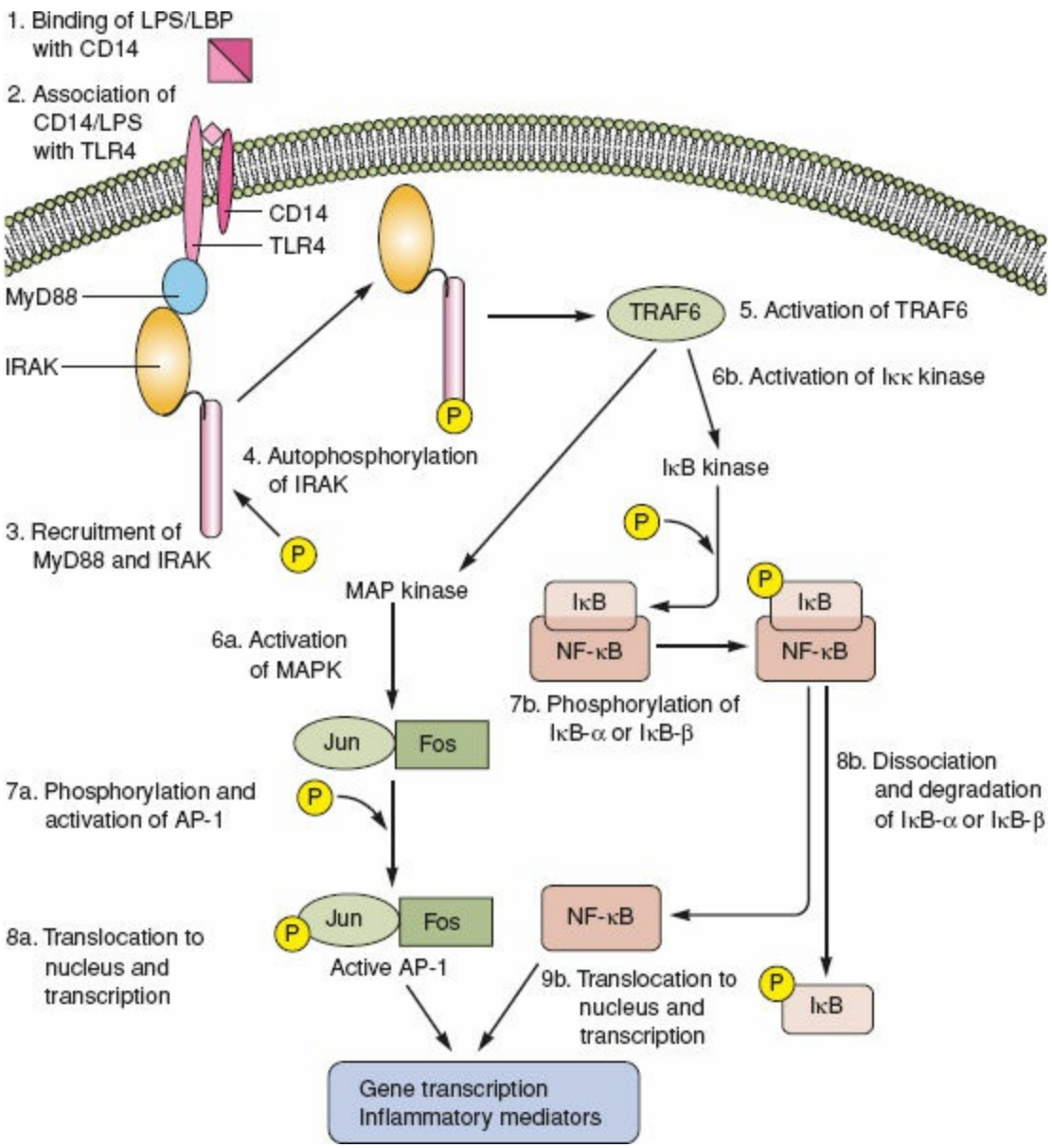

Figure 7-7. Toll-like receptor (TLR) signaling pathway. (Redrawn from Abbas AK, Lichtman AH. *Cellular and Molecular Immunology*. 5th ed. Philadelphia, PA: Saunders; 2003.)

The functions of IL-1 mirror those of TNFα, and synergy between the two cytokines is evident.[110] IL-1 activates endothelial cells to increase cell surface expression of adhesion molecules and the production of prostaglandins, PAF, and a variety of CSFs. In doing so, it facilitates the recruitment and activation of appropriate leukocyte populations for specific localized immune responses. IL-1 also induces a procoagulant state by suppressing fibrinolysis through enhanced plasminogen activator inhibitor-1 and decreased tissue-type plasminogen activator activity. It increases thrombosis by stimulating tissue factor–like procoagulant and thromboplastin production and suppressing thrombomodulin release. It induces the synthesis of PAF, a potent vasoconstrictor and stimulus for platelet and leukocyte activation. However, similar to TNFα, it also stimulates the production of prostacyclin and urokinase-type plasminogen activator, which promotes an antithrombotic state.[114] At larger concentrations, its effects become systemic causing fever, the synthesis of acute-phase proteins, cachexia, myalgia, somnolence, and hypotension. It stimulates arachidonic acid and prostaglandin metabolism, and the release

of pituitary stress hormones. It stimulates collagenase release and is a potent mitogen for neutrophils. Though similar in effect to TNFα, probably by activating similar signaling cascades and transcription factors, IL-1 does not induce apoptosis. Even at high concentrations IL-1 does not cause the physiologic derangements of septic shock.[39,110]

Mononuclear cells produce the natural inhibitor of IL-1, IL-1ra. This IL-1 structural homologue is an inactive competitive inhibitor and may function as an endogenous regulator of IL-1. As with TNFα, attempts to inhibit IL-1 have not been of clinical benefit in human trials of sepsis.[39]

Chemokines

This is a large family of cytokines that primarily govern leukocyte chemotaxis, hence the name[115–119] (Table 7-6). Those bound on the endothelial surface induce leukocyte integrins to express a high-affinity state for their ligands, which is critical for tight leukocyte adherence and subsequent migration into the extravascular space. However, they also assist in orchestrating the migration of immune cells into lymphoid organs. Unlike other chemoattractants, members of this family possess a degree of specificity, influencing the recruitment of discrete subsets of leukocytes. They mediate their effects both directly and indirectly through the induction of other mediators such as histamine and ROS. Though some chemokines, in particular those regulating cell traffic through tissues, are constitutively produced (MIP-3β and RANTES), most necessitate cellular stimulation for synthesis and release, in particular, those involved in inflammatory reactions. They are typically produced by macrophages, leukocytes, endothelial cells, fibroblasts, and many other cell types stimulated by LPS, phagocytosis, and inflammatory cytokines such as IL-1, TNFα, IL-6, and IFNγ.[39]

Chemokines can be classified into four families based on the number and location of N-terminal cysteine residues. The two major families are the CC chemokines, in which the cysteine residues are adjacent, and the CXC chemokines, in which one amino acid is interposed between these cysteine residues. This amino acid sequence appears to account for the disparate influence, either promotion or inhibition, on neutrophil chemotaxis. The three amino acids that immediately precede the first cysteine are critical in defining receptor binding and neutrophil activation.[120,121] This area has been designated the ELR motif. The other two chemokine families are represented by lymphotactin (C chemokine) and fractalkine (CX3C chemokine).[39]

Chemokine receptors are seven transmembrane receptors that signal by G proteins and the formation of the second messengers, IP_3 and DAG (Fig. 7-5). Currently 6 CXC chemokine receptors, 11 CC, and 1 receptor each for the last two subfamilies have been identified and defined. The pattern of cellular expression of the receptors determines the specificity of the cellular response to binding.[4,121]

CXC chemokines primarily govern the chemoattraction and activation of neutrophils, and to a lesser degree lymphocytes, in particular T cells. At least 12 different chemokines have been identified. They are clustered on chromosome 4 and demonstrate 20% to 50% homology at the amino acid level. IL-8 is the prototypical CXC chemokine.[98] It is produced by an array of immune and nonimmune cells including monocytes, alveolar

macrophages, neutrophils, keratinocytes, mesangial cells, epithelial cells, fibroblasts, and endothelial cells. TNFα and IL-1 are key molecules for inducing IL-8. It is chemotactic for all granulocytes and influences nearly every aspect of neutrophil function. It stimulates neutrophil degranulation, phagocytosis, transendothelial migration and shedding of L-selectin, upregulation of β_2 integrins, and augments superoxide production. It is also a potent angiogenic factor. It binds to both the CXCR1 and CXCR2, receptors that also engage the chemokines GCP-2, GRO-α, and ENA-78. ENA-78 is a potent neutrophil chemotaxin produced by the endothelium in response to TNFα or IL-1, neutrophils, or monocytes. Studies have demonstrated that ELR-containing CXC chemokines are angiogenic, whereas those lacking this motif are angiostatic.[39,95,120–122]

The interferon-influenced chemokines, IP-10 and Mig do not target neutrophils, and the ELR motif is absent. They induce IFNγ production and may play a more prominent role in mediating the inflammatory response to viral infections and autoimmune disorders. Mig is chemotactic for tumor infiltrating lymphocytes, activated T cells, and monocytes and promotes CTL activity. IP-10 is chemotactic for monocytes, T cells, and NK cells and augments T-cell adhesion. Both chemokines bind the CXCR3 receptor found on IL-2–activated T cells. IFNγ attenuates the expression of both IL-8 and ENA-78, and hence may serve as an important mechanism to the control and regulate inflammation.[39,95] Stromal cell–derived factor-1 (SDF-1) is the only known ligand for the CXCR4 receptor and in the presence of IL-7 stimulates proliferation of pre–B-cell clones and growth of bone marrow B progenitor cells. The receptor has gained much interest since it was identified as a coreceptor for HIV-1. PF4 and neutrophil-activating protein-2 are CXC chemokines of platelet origin. PL-4 has angiostatic properties and inhibits the growth of various cancer cell lines in a manner that appears to be related to its angiostatic properties. It binds heparin with high affinity to stimulate coagulation.[39]

The *CC* chemokines recruit monocytes, granulocytes, T cells, NK cells and DCs. RANTES is produced by stimulated T cells, platelets, and endothelial cells and is constitutively produced in resting T cells, which implies a homeostatic function. MIP-1α and β are produced by activated T cells and are chemotactic for neutrophils, monocytes, eosinophils, basophils, and T lymphocytes. They are also mitogenic for hematopoietic progenitor cells and upregulate TNFα, IL-1, and IL-6. The MCP family of chemokines influences the recruitment of monocytes and T cells. Their influence upon the function of these target cells is dictated by the cell's specific profile of receptor expression. MCP-1 is produced by nonlymphocytic cells (endothelial cells, epithelial cells, fibroblasts, smooth muscle cells, macrophages and mast cells). Binding to CCR1 enhances chemotaxis, whereas activation of CCR2 increases the release of intracellular substances such as histamine and LTs from basophils.[39]

Lymphotactin is the only member of the *C* chemokine family and is produced by $CD8^+$ lymphocytes, thymocytes, and NK cells, and, to a lesser degree, by DC and activated mast cells. It selectively recruits lymphoid cells.[39]

Fractalkine is the sole *CX3C* chemokine and is produced by the endothelium. In its membrane-bound form it may act as a solid-phase adhesion molecule, but upon cleavage serves as a soluble chemoattractant for lymphoid cells and monocytes.[39]

Interleukin-12 (NK Cell Stimulatory Factor, Cytotoxic Lymphocyte Maturation Factor)

IL-12 is integral in the innate immune response (Table 7-6). It is produced early during innate immune reactions and is critical for initiating a sequence of responses involving macrophages, NK cells, and T lymphocytes that results in the eradication of intracellular microbes. It stimulates subsequent adaptive responses that confer further host protection against these pathogens. Hence, it is an important link between innate and adaptive immune responses. IL-12 is primarily derived from activated mononuclear phagocytes and DCs, and most importantly stimulates IFNγ from T cells and NK cells. There are two pathways leading to IL-12 production: a T-cell dependent and an independent pathway. During innate immunity, LPS, infection by intracellular bacteria, and viral infections may induce IL-12 production. In addition, interactions between CD40 ligand and CD40 on activated lymphocytes and APC, respectively, induce the release of APC IL-12.[123,124] Thus, IL-12 is produced during the induction of and the effector phases of cell-mediated immune response when APCs present antigens to T cells.[4,39]

The IL-12 receptor is a heterodimer composed of β1 and β2 subunits, the latter of which is involved in signaling, although both are required for engaging ligand. The receptor signals through the JAK/STAT pathway (Fig. 7-8).[4] This signal transduction pathway is employed by numerous cytokines including interferons, IL-6, IL-12, IL-2, IL-7, IL-9, IL-4, and IL-10. A characteristic of this cytokine is the generation of a positive amplification loop, which heightens the inflammatory response. Expression of the IL-12 receptor is induced by IFNγ. Activated NK cells and T_H1 cells produce IFNγ that potentiates macrophage IL-12 production. IL-12 stimulates further production of IFNγ by NK cells and T lymphocytes, which continues to fuel the reaction in a positive feedback mechanism. Ultimately, IFNγ activates macrophages to kill and degrade phagocytosed microbes. IL-12 potentiates bacterial LPS-induced macrophage TNFα production. IL-12 antagonists reduce mortality in experimental models of LPS-induced septic shock; however, there is no evidence of their efficacy in human clinical trials.[4]

4 5 $CD4^+$ helper T lymphocytes, under the influence of IL-12, differentiate into T_H1 cells, which subsequently activate phagocytes in cell-mediated immunity. It enhances the cytolytic functions of activated NK cells and $CD8^+$ CTLs, and suppresses T_H2 cell differentiation and effector activity. The inhibition of T_H2 and IL-4 activity confers antiallergic properties to IL-12. IL-12 knockout mice demonstrate diminished IFNγ production and defective T_H1 cell development and cell-mediated immunity against intracellular organisms.[4,39]

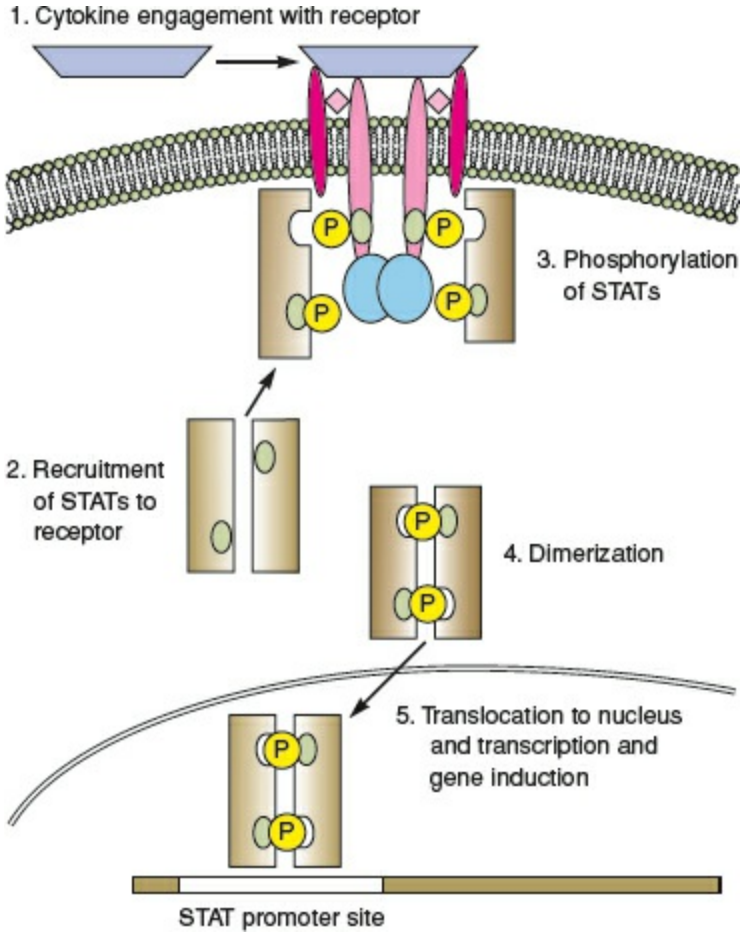

Figure 7-8. JAK/STAT signaling pathway. JAK (Janus Kinase) components are associated in an inactive form with the cytoplasmic portion of cytokine receptors. Cytokine binding leads to receptor aggregation. Adjacent JAK proteins become activated and phosphorylate each other and tyrosine residues. Through the Src homology domain, STAT proteins bind phosphotyrosine residues on the cytoplasmic portion of cytokine receptors. Bound STAT proteins are phosphorylated by bound JAK proteins and subsequently dissociate. Phosphorylated STAT proteins dimerize and then move to the nucleus where they induce transcription by binding to STAT binding regions within the promoter. (Redrawn from Abbas AK, Lichtman AH. *Cellular and Molecular Immunology*. 5th ed. Philadelphia, PA: Saunders; 2003.)

Interleukin-6

IL-6 regulates the acute-phase response to inflammation, characterized by altered thermoregulation (i.e., fever), perturbation in nitrogen balance (i.e., cachexia and catabolism), and the generation of the acute-phase reactants of innate immunity by the liver (Tables 7-6 and 7-7).[95,125] It functions in both innate and adaptive immunity to enable the host to recover. Despite in vitro data demonstrating that a variety of cells can produce IL-6, the most prominent in vivo sources of IL-6 are monocytes and macrophages stimulated with LPS or IL-1 or fibroblasts and endothelial cells stimulated with TNFα.[126] Steroids inhibit the induction of IL-6. The receptor for IL-6 consists of cytokine-binding protein and a signal-transducing subunit, which belong to the type I cytokine receptor family. It signals through the JAK-STAT pathway (Fig. 7-8).[4]

In conjunction with IL-1 and TNFα, IL-6 regulates the systemic manifestations of the acute-phase response.[125] It potentiates the immune response by inducing B-cell differentiation and activating T cells. It interacts with TNFα to enhance T-cell proliferation and promotes neutrophil activation and accumulation. In adaptive immunity,

IL-6 stimulates the growth of B lymphocytes that have differentiated into antibody-producing plasma cells. IL-6 antagonizes LPS-induced TNFα production and TNFα-induced IL-1 production.[127,128]

Table 7-7 Acute-Phase Proteins

Acute-Phase Protein	Function
Increase	
C-reactive protein	Opsonin
Serum amyloid A	Apolipoprotein
α_1-Acid glycoprotein	Platelet inhibitor
Fibrinogen	Coagulation, tissue repair
α_2-Macroglobulin	Antiprotease
α_1-Protease inhibitor	Antiprotease
α_1-Antichymotrypsin	Antiprotease
Haptoglobulin	Antioxidant
Hemopexin	Antioxidant
Ceruloplasmin	Antioxidant
C3	Complement
Factor b	Complement
Cl inhibitor	Complement
C4b-binding protein	Complement
Mannose-binding lectin	Complement
Decrease	
Albumin	Transport
Prealbumin	Transport
Transferrin	Transport

High Mobility Group Box 1 Protein

HMGB1 was initially identified as an architectural chromatin-binding factor that bends DNA and directs protein assembly on specific DNA targets. It is abundant, ubiquitous, and evolutionarily conserved, as evident by the 99% amino acid homology between rat and human proteins.[56] Thirty years after its original discovery, Tracey at al. demonstrated that HMGB1 acts as a late mediator of mortality in murine endotoxemia and sepsis. HMGB1 appeared 8 hours poststimulation and plateaued at 16 to 32 hours, very distinct from the acute rise and fall of early mediators (TNFα, IL-1β) of severe sepsis and septic shock.[56] Recent studies show that systemic concentrations are elevated in those patients who die of sepsis.[129]

HMGB1 is the prototypical DAMP. When cells die by necrosis (i.e., nonprogrammed cell death), HMGB1 is released into the extracellular medium. In contrast, apoptotic cells modify their chromatin so that HMGB1 irreversibly binds, and thus is not released.[130,131] However, HMGB1 may also be released by activated macrophages and NK cells, via an active process that necessitates shuttling the protein from nucleus to cytoplasm; this event does not require further synthesis.[130–132] Acetylation of HMGB1 appears essential for

release, however acetylation of histones as occurs during apoptosis, strengthens its interaction with chromatin and inhibits release.[130,131] Interestingly, though apoptotic cells do not release HMGB1, macrophages engulfing apoptotic cells do. Recent studies have shown that nucleocytoplasmic shuttling of HMGB1 involves serine phosphorylation by CaMKIV that enables it to be translocated to the cytoplasm by 14-3-3 and CRM1 chaperones.[133,134] Subsequent release of cytoplasmic HMGB1 appears to involve active secretion through a secretory lysosomal pathway.[130,132]

HMGB1 has many of the intercellular signaling activities characteristic of cytokines and therefore is often classified as a proinflammatory cytokine and potent regulator of the inflammatory response. In light of the fact that it is released by macrophages responding to bacterial challenge or by injured cells, it may mediate inflammation consequent to sepsis or trauma. After release, signaling is thought to occur by binding to RAGE with subsequent activation of p21ras, MEK, the MAPK kinases, and NFκB.[106,135] This receptor is expressed on mononuclear phagocytes, vascular smooth muscle cells, and neurons. Blocking antibodies to RAGE fails to completely prevent cellular activation suggesting the presence of an alternate receptor. Recent studies suggest that both TLR2 and TLR4 may mediate HMGB1-induced activation of NFκB in macrophages and neutrophils. This observation is very important as it demonstrates that a receptor classically considered specific for microbial danger signals, may interact with an endogenous molecule.[56,106,135]

HMGB1-RAGE interactions induce numerous proinflammatory events. Endothelial cells increase the expression of adhesion molecules and secrete TNFα and IL-8.[136] In neutrophils, HMGB1 activates MAPKs and enhances the expression of proinflammatory cytokines in a NFκB-dependent manner. In addition, it is chemotactic for neutrophils, monocytes, macrophages, and DCs.[106] Intratracheal administration of HMGB1 to LPS-resistant mice stimulated lung neutrophil accumulation and the local production of proinflammatory cytokines.[106] HMGB1 has potent immunostimulatory actions and promotes the maturation of both myeloid and plasmacytoid DCs. Systemic levels are markedly elevated in patients who die of sepsis, and animal studies suggest that this association is causal.[129] Recombinant HMGB1 mimics the lethality of high-dose LPS and induces the release of TNFα by macrophages. However, intravenous administration of HMGB1 does not cause shock like TNFα. More recent data call into question whether HMGB1 itself can directly promote the secretion of proinflammatory cytokines (TNFα, IL-1α/β, IL-6, IL-8) and chemokines (MIP1α/β) as initially reported. A direct proinflammatory activity of HMGB1 has not been reproduced consistently, raising some concern that this might be based on the formation of specific complexes with other molecules such as LPS. Recent studies show that highly purified recombinant HMGB1 has very weak direct proinflammatory activity.[137]

In a series of elegant studies, anti-HMGB1 antibodies conferred a dose-dependent protection in animal models of endotoxemia, even when the first dose of anti-HMGB1 antibodies was delayed for 2 hours.[57] This occurred without changes in TNFα, IL-1β, or MIP-2 concentrations. Even more striking are the in vivo CLP models, in which anti-HMGB1 administration up to 24 hours after CLP significantly increased survival, 72% versus 28%.[57] This wider therapeutic window may enable the development of inhibitors

of HMGB1 for treat of sepsis.[106,138–140] These observations have stimulated the search for other inhibitors of HMGB1. Ethyl pyruvate a nontoxic food additive, dose dependently inhibits HMGB1 release, and confers significant protection against the lethality of sepsis, even when the first dose is administered 24 hours after the onset of sepsis. In addition, it inhibits the translocation of NFκB and p38 MAPK signaling.[106,138,141,142]

HMGB1 may also serve as a danger signal for other perturbations in homeostasis, as it can also be released passively by necrotic or injured cells but not apoptotic cells.[131,140,143,144] Hypoacetylation of chromatin on the induction of apoptosis enhances HMGB1 binding, thereby preventing release during apoptotic processes. Thus, HMGB1 binding to chromatic depends on the viability of the cell and clearly distinguishes necrotic from apoptotic cells. This enables the innate immune response to respond to injury and further induce inflammation.[131,140,143,144]

HMGB1 is also elevated during hemorrhage shock.[145] In a clinical case, serum HMGB1 levels increased significantly within 24 hours of hemorrhagic shock and returned toward basal levels as the clinical condition improved.[146] HMGB1 also appears to mediate cell damage and death in other noninfectious insults. In a model of warm liver ischemia reperfusion, HMGB1 inhibition attenuates hepatocellular injury.[32] Interestingly, this protection, as well as reduced systemic concentrations of HMGB1, was also afforded by inhibiting CaMK.[32]

High levels of HMGB1 have also been found in other conditions of sterile inflammation such as rheumatoid arthritis.[147–149] In human arthritis, overexpression of HMGB1 at the site of joint inflammation may be detected in the synovial fluid of rheumatoid arthritis patients.[148,149] HMGB1 may in fact amplify the effect of local cytokines as suggested by its ability to stimulate macrophages derived from synovial fluid of rheumatoid arthritis patients to release TNFα, IL-1β, and IL-6.[147,150] Hence, HMGB1 may serve as a signal of danger from endogenous threats or perturbations.

Interleukin-15

IL-15 is produced by various cells in response to LPS and other stimuli, though the principal cellular source is mononuclear phagocytes. (Table 7-6). It is structurally homologous to IL-2, as is its receptor and the IL-2R. IL-15 stimulates the proliferation of NK cells similar to the manner by which IL-2 functions later in the adaptive immune response. It also acts as a T-cell growth and survival factor especially for long-lived memory $CD8^+$ T cells.[4]

Interleukin-18

IL-18 is structurally homologous to IL-1 and utilizes a similar IRAK signaling pathway (Table 7-6). Macrophages responding to microbial challenge or exposure to LPS are the principal source. Its primary function is to stimulate the production of IFNγ by NK cells and T cells, and in synergizing with IL-12, augments cell-mediated immunity. Knockout mice lacking IL-18 are deficient in IFNγ production, and concomitant IL-12 deficiency eliminates all IFNγ production and any T_H1 response.[4]

Interferons (Type I)

Type I interferons possess potent antiviral and antitumor properties (Table 7-6). It is from this ability to "interfere" with viral infection that the name is derived. They are subcategorized into α and β interferons. Mononuclear phagocytes are the major source of interferon α, whereas many cell types produce interferon β. The most potent stimulus inducing the synthesis and release of either is viral infection, particularly double-stranded RNA produced during viral replication. Other inducers include IL-1, TNFα, LPS, and antigen-activated T cells. Both groups bind to the same cell surface receptor and induce similar responses by signaling through the JAK/STAT pathway (Fig. 7-8).

These cytokines provide the first line of defense against viral infection and promote cell-mediated immunity against intracellular pathogen. They are secreted from virally infected cells to protect neighboring uninfected ones by inducing the synthesis of a number of enzymes that interfere with viral RNA or DNA transcription and viral replication. Through enhanced expression of class I MHC molecules, the type 1 interferons facilitate recognition of class I–associated viral antigens on infected cells by CTLs and increase the efficiency of CTL-mediated killing. Type I interferon stimulates the development of T_H1 cells by promoting these cells to express IL-12 receptor. They can also stimulate B-cell development, proliferation, and immunoglobulin heavy chain switching from IgM to IgG.[151–153] Knockout mice lacking the receptor for these cytokines are susceptible to viral infections. Interferons are currently in clinical use for hepatitis B and C infection, multiple sclerosis, CML, and Kaposi's sarcoma.[151–153]

Interleukin-10 (Cytokine Synthesis Inhibiting Factor)

IL-10 inhibits activated macrophages and APC and functions in a counterregulatory mechanism to suppress innate immune reactions (Table 7-6). It is produced mainly by macrophages, and hence functions by negative feedback. T lymphocytes, particularly the T_H2 subset, B cells, and some other nonlymphoid cells produce IL-10, in response to a variety of stimuli including LPS, TNFα, IL-2, IL-4, and IL-13.

IL-10 binds to a type II (interferon) receptor. Though the manner by which it effects curtailment of the inflammatory response is unknown, its presence inhibits NKκB activation and the generation of inflammatory mediators. Thus, it may inhibit, in some manner, the activation of signal transduction cascades and gene activation in proinflammatory pathways.[4,154]

IL-10 terminates many of the functions of activated macrophages and participates in reestablishing homeostasis as the infection resolves. It downregulates proinflammatory cytokine (TNFα, IL-1, IL-6, and IL-8) production, suppresses the production of IL-12, and inhibits IFNγ production and the innate and cell-mediated immune responses.[4,59,95] It represses the expression of costimulators and class II MHC molecules on APC, thereby terminating T-cell activation and inhibiting cell-mediated immunity.[4] In neutrophils it inhibits cytokine release, superoxide generation, migration, and even survival.[155] In combination with IL-4 it inhibits IFNγ release and IL-12 production to limit differentiation and function of T_H1 cells, favoring a T_H2 profile.[59]

IL-10 knockout mice develop inflammatory bowel disease, which is hypothesized to result from unregulated macrophage reaction to enteric microbes.[156] In observational studies of ARDS or MODS, serum IL-10 levels were often elevated, and those patients with the highest systemic concentrations died.[154] It is unclear whether this is actually a pathologic response, or merely a marker of disease severity. Contemporary belief is that IL-10 is not a mediator of immunosuppression, but rather, important for immunoregulation.

Late Cytokines/Adaptive Immunity

Interleukin-2 (T-Cell Growth Factor)

IL-2 stimulates the growth and proliferation of T lymphocytes and is responsible for T-cell clonal expansion after antigen recognition (Table 7-6).[157] IL-2 is produced by $CD4^+$, and to a lesser extent $CD8^+$ T cells. The receptor is heterotrimeric, consisting of three noncovalently associated proteins α, β, and γ. The α and β chains are involved in cytokine binding, and the β and γ chains mediate signal transduction.[4] Antigen recognition enhances the expression of functional IL-2 receptors, which confers a degree of specificity, as those T cells recognizing antigen are preferentially induced to proliferate in response to IL-2. Though, the α chain appears on T cell activation and binds IL-2, signal generation necessitates the β and γ chains. Cells expressing the complete α, β, and γ complex bind IL-2 with higher affinity (kD of 10^{-11} M), and growth stimulation of such cells occurs at a low IL-2 concentration.[4] Upon antigen receptor–mediated T-cell activation, IL-2R α is rapidly upregulated, which reduces the concentration of IL-2 needed to stimulate growth. Therefore, antigen-stimulated T cells are more responsive to IL-2 than naïve T cells. This receptor signals through numerous signal transduction pathways including the JAK/STAT and MAP kinase pathways (Figs. 7-5 and 7-8).

IL-2 functions in an autocrine and paracrine fashion to induce the proliferation of the antigen-specific cells. After exposure to IL-1, there is a rise in cyclins and activation of cyclin-dependent kinases that stimulates the progression of the cell cycle from the G1 to the S phase. A reduction in p27, an inhibitor of cyclin–kinase complexes, facilitates this progression, and the induction of Bcl-2, an antiapoptotic protein, facilitates survival. It also stimulates the production of other cytokines such as IFNγ and IL-4.[4]

IL-2 promotes the proliferation and differentiation of many immune cells. NK cells are stimulated to grow and transform into lymphocyte-activated killer cells. In combination with IFNγ and IL-12, IL-2 can trigger a positive feedback cycle of NK activation. IL-2 stimulates B-cell growth and antibody synthesis. Repeated activation of $CD4^+$ T cells in the presence of IL-2 sensitizes these cells to apoptosis by fas-fas-ligand. IL-2 may also stimulate the development of regulatory T cells, and IL-2 knockout mice develop autoimmunity. Knockout mice lacking the γ chain develop X-linked severe combined immunodeficiency syndrome. This is probably due to an inability of immature T cells to respond to IL-7. IL-2 has been used in the management of cancer, in particular renal cell carcinoma.[158]

Interleukin-4

IL-4 is the major stimulus for the production of IgE antibodies and for the development of T_H2 cells from naïve $CD4^+$ T cells (Table 7-6). The principle cellular sources are $CD4^+$ T cells, mast cells, and basophils. The IL-4 receptor belongs to the type I cytokine receptor family and signals through the JAK/STAT pathway.[159] (Fig. 7-8). IgE is integral in orchestrating the defense against parasitic infections. It stimulates IgE production and mast cell/eosinophil-mediated reactions, and induces B cell Ig heavy chain class switching to the IgE isotype. However, IL-4 also serves a counterregulatory role by inducing T_H2

cell differentiation and growth. IL-4 antagonizes the macrophage-activating effects of IFNγ and thus inhibits cell-mediated immunity.

Interleukin-5

IL-5 is produced by T_H2 cells and activated mast cells and activates eosinophils, (Table 7-6). It signals through the type I cytokine receptor and the JAK/STAT pathway (Fig. 7-8). IL-5 is an inducer of eosinophil growth, differentiation, and activation, and also participates in the eradication of helminthic infection. IL-5 also stimulates the proliferation of B cells and the production of IgA antibodies.[4]

Interleukin-13

IL-13 is produced by T_H2 cells and some epithelial cells and is structurally homologous and functionally similar to IL-4 (Table 7-6). The receptor is found mainly on nonlymphoid cells and can be activated by either IL-13 or IL-4. IL-13 downregulates the expression of Fcγ on monocytes and macrophages, thereby decreasing antibody-dependent cellular cytotoxicity. It increases 15S-HETE and lipoxin A_4, both of which antagonize proinflammatory LTs. However, they can increase the expression of MHC class II and costimulatory molecules on monocytes, and thereby serve an immunostimulatory function. The major action is to inhibit the activation of macrophages and to antagonize IFNγ.[160]

Interferon γ

IFNγ is produced by NK cells, T_H1 cells, and $CD8^+$ cells, and as the principal stimulus for macrophage activation, provides necessary functions during both innate and adaptive immune responses (Table 7-6). It modulates cellular differentiation, cytotoxicity, cytokine production, cellular adhesion, and oxidative metabolism. During innate immunity, NK cells secrete IFNγ upon exposure to pathogen or stimulation by IL-12. $CD8^+$ T cells and the T_H1 subset of $CD4^+$ T cells produce it in response to MHC-bound peptide antigen with a costimulatory signal. The IFNγ receptor is composed of two homologous proteins belonging to the type II cytokine receptor family and functions through the JAK/STAT pathway (Fig. 7-8).[4]

The antiviral and antitumor properties of IFNγ are redundant with those of type I interferons. In concert with TNFα and IL-12 it forms one arm of a positive feedback loop fueling the activation of both NK cells and macrophages. Stimulated macrophages activate NK cells by releasing TNFα and IL-12. These NK cells produce IFNγ, which further stimulates macrophages to secrete more TNFα and IL-12.[161,162]

IFNγ induces the genes encoding the enzymatic machinery required for generating ROS generation and provides the principle stimulus for macrophages to kill phagocytosed microbes. It regulates the expression of MHC class I and class II molecules and costimulators of APC, and induces the transcription of enzymes regulating antigen processing.[161,162]

IFNγ synergizes with TNFα to activate the endothelium and upregulate adhesion

molecule expression; in doing so it facilitates lymphocyte recruitment and leukocyte recruitment. Interferon promotes the differentiation of naïve $CD4^+$ cells into T_H1 cells and inhibits the proliferation of T_H2 cells, in part, by inducing IL-12, the major T_H1-inducing cytokine, from activated mononuclear phagocytes. It promotes B-cell switching to certain IgG subclasses, notably IgG2a, and inhibits the switching to IL-4–dependent isotypes such as IgE and IgG1. These IgG subclasses bind the Fcγ receptors on phagocytes and activate complement, thereby promoting phagocytosis of opsonized microbes. It activates PMNs and stimulates the cytolytic activity of NK cells. The net effect is to promote macrophage-rich inflammatory reactions while inhibiting IgE-dependent eosinophil-rich reactions. IL-10, by suppressing macrophage release of TNFα and IL-12, negatively regulates IFNγ production.

IFNγ also demonstrates counterregulatory properties. It selectively inhibits LPS-induced expression of CXC chemokines. It upregulates macrophage production of IP-10, MIG, and ELR-negative chemokines that inhibit neutrophil chemotaxis and activation and decreases macrophage release of ELR-positive CXC chemokines (e.g., IL-8), which are chemotactic for neutrophils.[4]

Transforming Growth Factor β

Transforming growth factor β (TGFβ) is a homodimer synthesized and secreted by activated T cells, macrophages, and many other cells (Table 7-6). It is primarily immunosuppressive and inhibits the proliferation and activation of lymphocytes and other leukocytes. It promotes wound healing by increasing extracellular matrix protein synthesis and stimulating mononuclear cell and fibroblast influx.[163–165] Though the family consists of three closely related isoforms, most cells utilize TGFβ. Its effects are mediated through two high-affinity TGF receptors (type I and II) that signal through a serine/threonine kinase domain that phosphorylates transcription factors called SMADS.[4]

TGFβ inhibits the proliferation and differentiation of T cells and the activation of macrophages. It favors differentiation of $CD4^+$ cells to the T_H2 subset, and inhibits MHC class II surface expression. By suppressing the expression of MHC class II antigen, it abrogates the adaptive immune response. Macrophages demonstrate diminished ROS production and TNFα and NO release. It directly counteracts the influence of proinflammatory cytokines on PMNs and endothelial cells, and in combination with IL-4, IL-13, and IL-10 can antagonize the production or effects of these proinflammatory mediators. Knockout mice, deficient in TGFβ develop uncontrolled inflammatory lesions.[4,39]

Cytokines that Stimulate Hematopoiesis

Cytokines are necessary for normal hematopoiesis. Several of the cytokines stimulated during both innate and adaptive immune responses are mitogenic for and induce differentiation of bone marrow progenitor cells. CSFs are cytokines made by activated T cells, macrophages, endothelial cells, and bone marrow stromal cells that stimulate increased production of inflammatory leukocytes by bone marrow progenitors. Receptors for GM-CSF and G-CSF are of the class I family of cytokine receptors. GM-CSF is expressed by T and B cells, macrophages, mast cells, fibroblasts, and endothelium in response to stimuli such as IL-1, IL-2, LPS, and TNFα. It stimulates neutrophils, monocytes, macrophages, and DC and is a powerful inducer of hematopoiesis. It enhances cytokine release, degranulation, and phagocytosis of opsonized particles in neutrophils. In monocytes and macrophages it enhances cytotoxicity and cytokine release. It promotes the activity of APCs and the maturation of bone marrow cells into DCs and monocytes.[166] G-CSF is produced by macrophages, endothelial cells, fibroblasts, and bone marrow stromal cells. It functions as an endocrine hormone to mobilize neutrophils and induces subsequent leukocyte proliferation and maturation. In 1991, the FDA approved the use of G-CSF for use in patients with neutropenia.[167,168]

Stem cell factor or c-Kit ligand is synthesized by marrow stromal cells and binds to a cell surface tyrosine kinase receptor on pluripotent stem cells that is the protein product of the cellular proto-oncogene c-kit. Its effects appear to be permissive, as it is corequisite for stem cell responsiveness to other CSFs, yet in isolation does not stimulate colony formation. It may also play a role in sustaining the viability and proliferative capacity of immature T cells in the thymus.[4]

IL-3 is a product of $CD4^+$ T cells that promotes the differentiation of immature marrow progenitors into all known mature cell types. It also promotes the growth and development of mast cells. Surprisingly, despite these important functions, murine knockouts do not manifest noticeable impairment of hematopoiesis.[4]

IL-7 is secreted by bone marrow stromal cells and promotes the growth and survival of immature precursors committed to the B and T lymphocyte lineages. Knockout mice, deficient in IL-7 or its receptor, are lymphopenic and possess diminished populations of B and T cells.[4]

The Complement System

6 The complement system is integral to both innate and adaptive immunity. It has the capacity to independently eliminate organisms and to facilitate host defense by marking foreign particles for phagocytosis through opsonization. Many pathophysiologic inflammatory diseases, immune complex diseases, ischemia/reperfusion injury, and ARDS are considered consequences of excessive or unregulated induction of this system.[169–172]

The system consists of three pathways comprised of approximately 30 serum and cell surface proteins that interact with one another and with other molecules of the immune system in a highly coordinated fashion. These cascades involve the sequential proteolytic activation of zymogens to generate enzymes with proteolytic activity. This mechanism for activation amplifies the response because each individual enzyme activated can cleave numerous zymogens in the next step and generate multiple activated enzyme molecules. Ultimately, the products of complement activation adhere to microbial cell surfaces or to antibody-bound microbes and other antigens to directly or indirectly eliminate these pathogens. Temporal and spatial regulation to the focus of infection is ensured both by the transience of activation of these enzymes in the absence of microbes or antigens and by several circulating proteins that provide surveillance.[169,171]

The complement cascade is divided into three distinct pathways: (1) the classical pathway (humoral immunity), which is activated by antibody bound to antigen, (2) the alternative pathway (innate immunity) in which complement is activated by components of microbial cell surfaces, and (3) the mannose/lectin pathway (innate immunity), which is activated by a plasma lectin that binds to mannose residues on microbes. Despite differences in which the cascade is activated, all three complement pathways ultimately result in the cleavage of C3 and share the same late cascade.[169,171]

The alternative pathway functions in the absence of antibody and is phylogenetically the oldest pathway (Fig. 7-9). Bacteria, viruses, fungi, and parasites all function as stimuli. Initial activation begins with the cleavage of C3 and the stable attachment of its product C3b to the microbial surface. Bound C3b finds factor B, which is subsequently cleaved by a plasma serine protease called factor D to generate Bb. The C3bBb complex is called the alternative pathway C3 convertase and functions to cleave more C3. In doing so the convertase serves as an amplification step in both the classical and alternative pathways. Properdin prolongs the half-life of C3 convertase by delaying the release of Bb from C3bBb. C3b is the recognition component of the alternate pathway and is responsible for the opsonization of bacteria. C3a in conjunction with C5a and C4a induces acute inflammation by activating mast cells and neutrophils. These inflammatory mediators play a significant role in increasing blood vessel permeability, vasodilatation, edema formation, neutrophil adhesion and activation, chemotaxis, and the release of toxic oxygen species and lysosomal enzymes from phagocytic cells. The binding of another C3b to this complex generates the alternative pathway C5 convertase, C3bBb3b.[4,169,171]

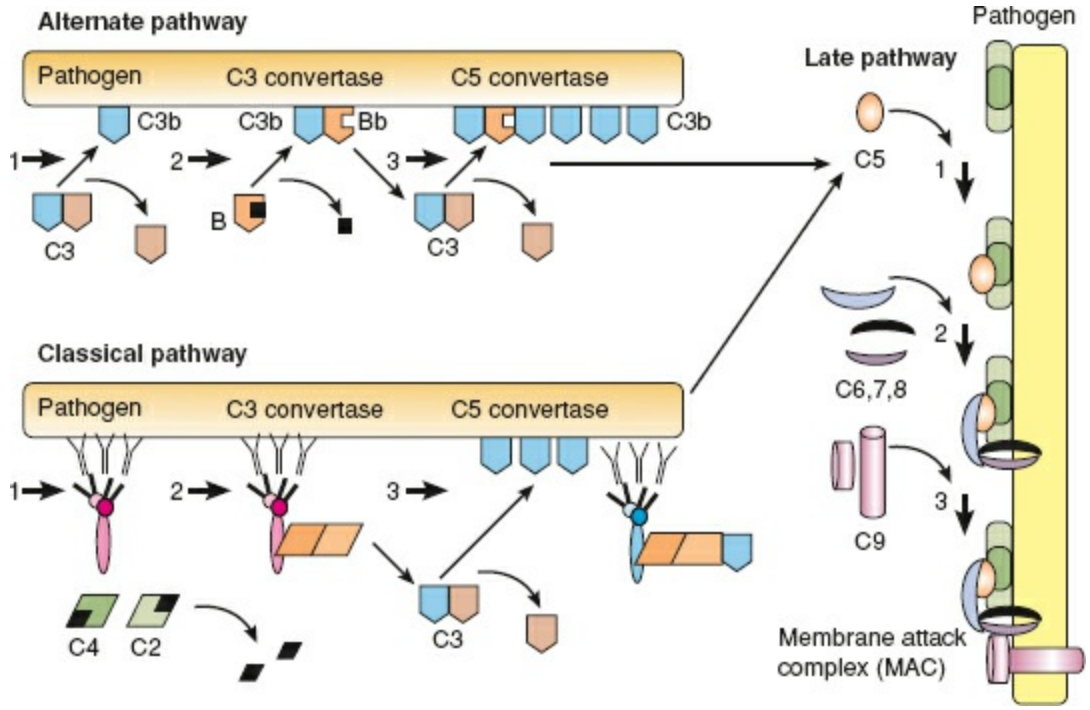

Figure 7-9. Complement pathways. Alternate Pathway: 1. C3 is cleaved to C3b. 2. C3b binds and cleaves B to Bb to form C3 convertase (C3bBb). 3. Another C3b binds C3 convertase to form C5 convertase (C3bBbC3b). Classical Pathway: 1. C1 binds immunoglobulin. 2. C1 binds and cleaves C4 and C2 to C4b and C2a to form C3 convertase (C4b2a). 3. C4b2a binds another C3b to generate C5 convertase (C4b2aC3b). Late Pathway: 1. C5 convertase cleaves C5 to form C5b, which integrates into the plasmalemma. 2. C6–8 are recruited, forming the C5b-8 complex. 3. C5b-8 recruits numerous C9 subunits, which form a pore in the pathogen cell wall. (Redrawn from Abbas AK, Lichtman AH. *Cellular and Molecular Immunology*. 5th ed. Philadelphia, PA: Saunders; 2003.)

Activation of the alternative pathway is restricted to the cell surface of microbes, as mammalian cells possess several regulatory proteins to rapidly degrade any C3bBb. Excessive amplification is regulated by factor H and factor I. H accelerates the decay and delays the formation of C3bBb. It also acts as a cofactor for I to degrade C3 into iC3b, which is unable to bind B to generate C3 convertase. Decay acceleration factor hinders C3 convertase assembly and mediates its dissociation in all three pathways. Also, the protein properdin, which stabilizes this alternative pathway C3 convertase, has a higher affinity for microbial than mammalian cell surfaces.[4,169,171]

The classical pathway is the primary mediator of adaptive humoral immunity and is initiated by binding of the complement protein C1 to IgG or IgM molecules engaged with antigen (Fig. 7-9). Other substances such as lipid A in endotoxin and mitochondrial membranes may activate this pathway independent of antigen–antibody complexes in vitro.[169,173]

C1 is a calcium-dependent trimeric protein consisting of C1q, which recognizes and binds the Fc region of the immunoglobulin, and C1r and C1s, which are proteases. C1q engages the Fc portion of the immunoglobulin μ and γ heavy chains. Each Fc region has a single C1q binding site, yet for activation, each C1q molecule must bind to two Ig heavy chains. Hence, multiple antibodies must be approximated for activation, which restricts activation to foci of immunoglobulin engagement. IgM exists as a pentamer enabling it to bind to two C1q molecules, and hence it is more efficient at complement

activation.[4,169,173]

Interaction between C1q and the immunoglobin Fc region induces a conformational change in C1q that activates C1r, which subsequently cleaves and activates C1s. C1s cleaves C4 to generate C4b and C4a. The C4a anaphylatoxin possesses properties similar to those described for C3a. C4b localizes to immune complexes on the cell surface. C2, after complexing with C4b, is cleaved by C1s, thereby generating the classical C3 convertase C4b2a complex, which has the ability to cleave C3. The C3b generated can bind Bb, producing more C3 convertase and amplifying the signal. The key early steps of the alternative and classical pathways are analogous: C3 and factor B of the alternative pathway are homologous to C4 and C2 in the classical pathway. C3b can also combine with the classical C3 convertase to generate C4b2a3b, the classical C5 convertase.[4]

Numerous regulatory mechanisms exist to restrict activation to sites of inflammation. Excessive classical C3 convertase activity is prevented by the rapid decay of C2a from the complex, which renders the complex unstable. C1 inhibitor covalently binds C1s, reducing the half-life of activated C1 to only 13 seconds. C4-binding protein enhances spontaneous dissociation of C4b2a and also acts as a cofactor for C3b/C4b inactivator, which degrades C4b.[39]

The mannose-binding lectin (MBL) pathway is activated by microbial polysaccharides bound to circulating lectins; MBL serves as the recognition unit of the MBL pathway. This pathway recognizes polysaccharides with high mannose content and other oligosaccharides with characteristic linkages found exclusively on pathogens and not on normal host components. Binding is calcium dependent and results in the activation of mannose-binding lectin-associated serine proteases (MASP-1 and MASP-2). Activated MASP-2 cleaves and activates C4 and C2 in the same fashion as the classical complement pathway. Subsequent steps of complement activation of the MBL pathway mirror those of the classical complement pathway.[169,174,175]

The C5 convertases generated during either the classical or alternative pathway initiate a cascade of events that culminates in the formation of the cytocidal MAC. Specifically, C5 convertase cleaves C5, yielding C5a and C5b. C6 and C7 bind to generate the C5b67 complex. This hydrophobic moiety penetrates deeply into the lipid bilayer as a high-affinity receptor for C8. Binding of C8 forms the complex C5b-8 that recruits numerous C9 subunits, which polymerize to form pores in the plasma membrane of bacteria. The pores structurally resemble the membrane pores formed by perforin, the cytolytic granule protein found in CTLs and NK cells. Their diameter may span 100 Å, which prevents the maintenance of vital ionic gradients, induces osmotic lysis, and ultimately the death of target cells or pathogens. Patients with deficiencies in the terminal components of C5, C6, C7, and C8 are susceptible to meningococcal and gonococcal infections.[4,176] By contrast, recent studies suggest that aberrant induction of the complement system, specifically C5a, plays an integral role in inducing paralysis of the innate immunity and the development of ARDS and MODS.

The effects of complement are in part mediated through several complement receptors. Opsonization and phagocytosis are important mechanisms for pathogen destruction, and phagocytic cells express receptors for complement factor C3 components. Complement

receptor type I (CR1), the C3b receptor for C3b and C4b, mediates engagement of and facilitates phagocytosis of complement-bound microbes and the clearance of immune complexes from the circulation. It is expressed on a variety of cells including RBC, neutrophils, monocytes, eosinophils, and T and B cells. RBCs facilitate elimination by transporting these opsonized particles to the liver and spleen where the immune complexes are removed by phagocytes. CR2 stimulates humoral immune response by enhancing B cell activation by antigen and by promoting the trapping of antigen–antibody complexes in germinal centers. In humans, this receptor is the receptor for EBV. CR3 and CR4 are β_2 integrins that bind the iC3b-processed fragment of C3 and promote macrophage and neutrophil phagocytosis of iC3b-opsonized antigen.[4,39]

This entire cascade is under strict regulation to ensure that activation is restricted to sites of inflammation and infection. This regulation is needed as low-level activation is always occurring, and if not quelled, would certainly damage normal tissues. Even when locally activated, byproducts may damage nearby cells and tissues. Several circulating proteins function to do this. C1r and C1s are inhibited by C1 inhibitor, a serine protease inhibitor that mimics C1r and C1s. C1 inhibitor targets activated C1qrs, and after attachment, C1r-C1s dissociates and activation of classical complement ceases. This inhibition prevents the accumulation of active C1r-C1s, thereby limiting the duration during which active C1r-C1s can initiate the cascade.[4] C1 inhibitor also inhibits other circulating inflammatory serine proteases including kallikrein and factor XII, both of which can activate the formation of bradykinin.[4] Hereditary angioneurotic edema is an inherited deficiency of C1 inhibitor and manifests as acute intermittent edema of the skin and mucosa causing abdominal pain, vomiting, diarrhea, and airway obstruction.

MCP, type 1 complement receptor (CR1) and DAF are regulatory proteins that bind to C3b and C4b deposited on cell surfaces and competitively inhibit the binding of other components of the C3 and C5 convertases, such as Bb and C2a, and thereby block further progression of the cascade. These proteins are only produced by mammalian cells. Deficiency of an enzyme required to form the linkages necessary to express DAF underlies paroxysmal nocturnal hemoglobinuria, a disease characterized by recurrent intravascular hemolysis due to unregulated complement activation on the surface of erythrocytes. Cell-associated C3b is proteolytically degraded by a plasma serine protease called factor I which is active only in the presence of regulatory proteins such as MCP, factor H, C4BP and CR1. MAC formation is inhibited by CD59, a membrane protein that incorporates itself into growing MACS and inhibits the incorporation of C9. It is not present in microbes. The function of these regulatory proteins may be overcome by increasing amounts of complement activation.[4]

Lipid Mediators

Eicosanoids

7 Eicosanoids are 20-carbon lipid inflammatory mediators that are derived from membrane arachidonic acid and are involved in numerous homeostatic processes and inflammation. These lipid mediators are not stored in tissues, but are synthesized de novo within seconds in response to a variety of stimuli, including mechanical trauma, specific cytokines, growth factors, and other mediators (Fig. 7-10). Although most cells are capable of producing eicosanoids, neutrophils and macrophages are the predominant sources. They are rapidly degraded in the circulation, which limits their role primarily to that of autocrine and paracrine mediators of local inflammatory changes.[177–179]

The liberation of the precursor molecule, arachidonic acid, is the major rate-limiting step. The family of PLA_2, in particular type IV cytosolic PLA_2, is responsible for eicosanoid production; cells lacking type IV PLA_2 are devoid of eicosanoid synthesis.[180] Many PLA_2 are transcriptionally regulated by IL-1 and TNFα, whereas others are regulated by the MAP kinase pathway and by calcium-dependent translocation to membranes. Once formed, arachidonic acid metabolism proceeds along one of the two pathways.[177–179]

Cyclooxygenase Pathway (Prostaglandins)

Cyclooxygenase catalyzes the initial step of a series of reactions that converts arachidonic acid to prostanoids (Fig. 7-10). There are two isoforms, COX1 and COX2; the former is constitutively expressed, whereas COX2 is inducible. COX2 is considered more important during inflammatory processes such as fever, hyperalgesia, and edema formation. Either enzyme catalyzes the conversion of arachidonic acid to the endoperoxidase PGG_2, which is subsequently converted to PGH_2. PGH_2 serves as the precursor to numerous specific prostaglandins. All of these products possess very short half-lives and are rapidly inactivated.[180,181]

Prostaglandins mediate their effects through G protein signaling (Table 7-8). Prostacyclin (PGI_2) is produced by the endothelium as a potent vasodilator and inhibitor of platelet aggregation and adhesion; these characteristics enhance tissue perfusion. PGI_2 inhibits neutrophil chemotaxis and activation and interacts synergistically with PGE_2 to increase vascular permeability through the bradykinin pathway. PGE_2 is the predominant anti-inflammatory prostaglandin and is produced by nearly all inflammatory cells. It is produced in response to IL-1 and mediates the hypothalamic fever response and synergizes with bradykinin and histamine to mediate pain. It is a bronchodilator, inhibits both IL-1 production and T-cell responsiveness to IL-1, and at low concentrations suppresses TNFα production. It also inhibits neutrophil chemotaxis and activation and T_H1 lymphocyte proliferation.[180,181] There is some suggestion from animal studies that PGE_2, PGE_1, and PGI_2 may be beneficial in response to sepsis through their endogenous counterregulatory properties. Administration of each of these has been shown to improve

survival in several animal models of hypovolemic and traumatic shock, though clinical trials have failed to identify benefit.[181] PGD_2 is a potent bronchoconstrictor that inhibits neutrophil chemotaxis and activation. TXA_2, PGG_2, and PGH_2 oppose the actions of prostacyclin by promoting platelet aggregation and inducing bronchoconstriction. TXA2 produced by platelets and macrophages is a powerful vasoconstrictor that induces neutrophil accumulation and increases vascular permeability.[177–179,182] There is substantial evidence that TXA_2 plays a significant role in early acute-phase organ injury.[181]

Lipoxygenase Pathway (Leukotrienes and Lipoxins)

LTs and lipoxins are leukocyte-derived molecules synthesized by the oxidation of arachidonic acid by three LO enzymes: 5-LO, 12-LO, and 15-LO (Fig. 7-10). 5-LO associates with the perinuclear membrane protein 5-LO-activating protein (FLAP) to catalyze the formation of 5-hydroperoxyeicosatetraenoic acid (5-HPETE). 5-HPETE is subsequently converted to LTA_4 by the combined efforts of a dehydrase and 5-LO. LTA_4 serves as the precursor for either LTB_4 or LTC_4. LTC_4 can in turn be successively hydrolyzed to the dipeptide derivative LTD_4 and the LTE_4. Additional LO activity results in the production of 12-HPETE, 12-HETE, and 15-HPETE. These compounds exhibit biological activity, although they are not as potent as the LTs or prostaglandins. The LTs are inactivated by oxidation followed by dehydration.[178–180,182,183]

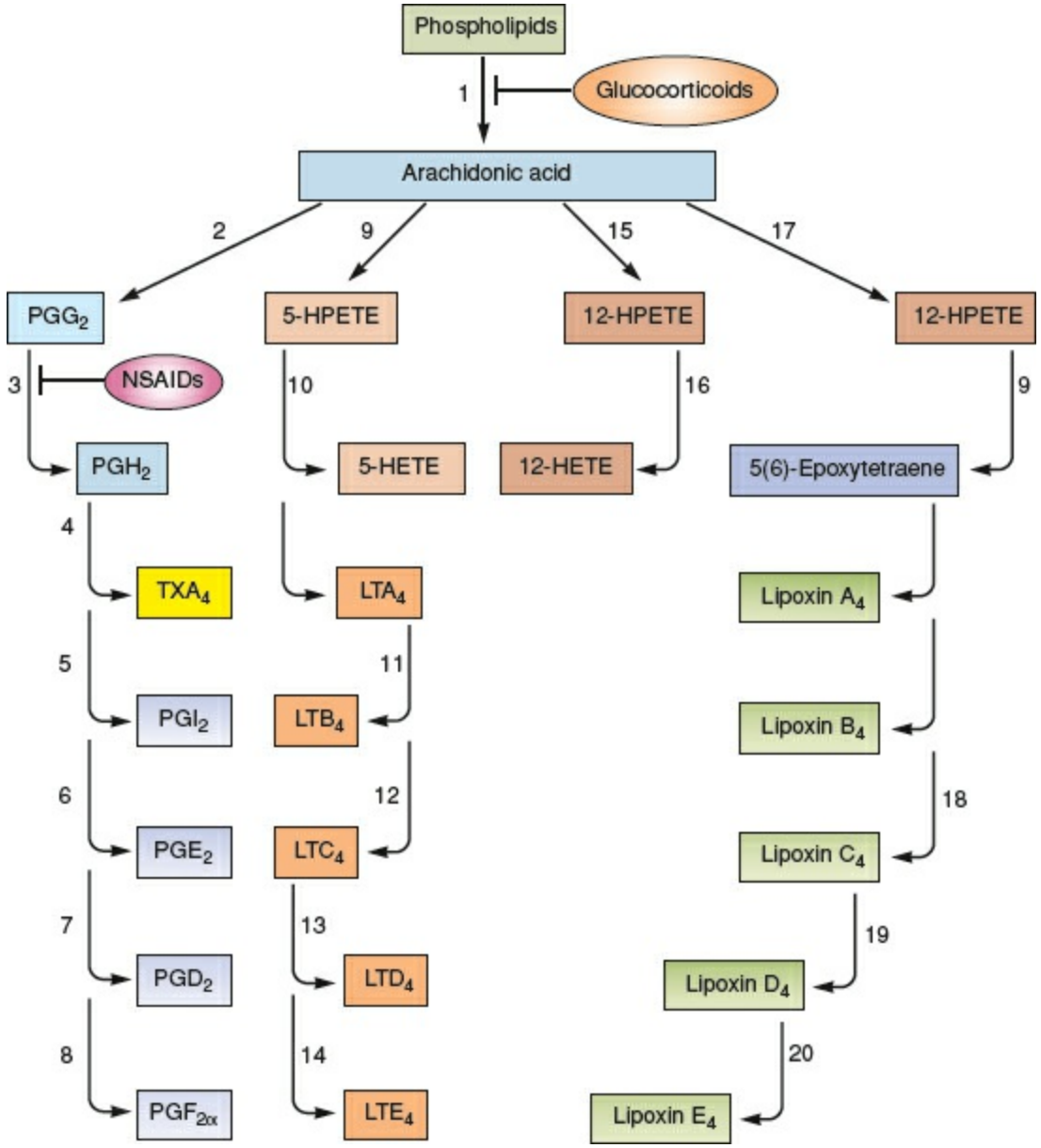

Figure 7-10. Eicosanoid production. 1. Phospholipases; 2. Cyclooxygenase; 3. Hydroperoxidase; 4. Thromboxane synthetase; 5. Prostacyclin synthetase; 6. E-isomerase; 7. D-isomerase; 8. F-reductase; 9. 5-Lipoxygenase; 10. Glutathione peroxidase; 11. Hydrolase; 12. Glutathione S-transferase; 13. γ-Glutamyl transpeptidase; 14. Cysteinyl glycinase; 15. 12-Lipoxygenase; 16. Peroxidase; 17. 15-Lipoxygenase; 18. GSH-cis-11-trans lipoxin A_4; 19. α-Glutamyl transferase; 20. Dipeptidase.

The major LO product of neutrophils is LTB_4, though macrophages may also synthesize this compound. This compound is potently chemotactic for both neutrophils and eosinophils. By upregulating endothelial cell surface adhesion molecules it promotes leukocyte recruitment. It increases vascular permeability, either directly or through interaction with neutrophils and endothelial cells. LTB_4 has also been shown to induce hyperalgesia.[94,180]

LTC_4, LTD_4, and LTE_4 comprise the family of slow-reacting substances of anaphylaxis (SRSA), compounds synthesized by mast cells during anaphylactic reactions. LTC_4 is the major eicosanoid product of eosinophils and the only mast cell–derived product of LO. These three LTs are potent vasoconstrictors and the most powerful bronchoconstrictors in humans, being three orders of magnitude more potent than histamine. They also increase

vascular permeability and are vasodilatory in skin.[43,180]

Lipoxins are biosynthesized by several routes in a tissue-specific manner. Current evidence implicates the eosinophil. A 5(6)-epoxytetraene intermediate can be formed by 5-LO activity on 15-HPETE. This reaction, when carried out in blood vessels, requires the interaction of platelets and neutrophils. On mucosal surfaces, 12-LO and 5-LO activity on LTA_4 can result in the formation of this lipoxin intermediate through leukocyte–epithelial interactions. The 5(6)-epoxytetraene intermediate is then converted to lipoxin A_4, lipoxin B_4, or lipoxin C_4, the last of which serves as the precursor for lipoxins D_4 and E_4.[92,184,185]

Table 7-8 Prostanoid Effects

	PGG_2	PGH_2	PGI_2	PGE_2	TXA_2
Chemotaxis	↑	↑	↓	↓	↑
Bronchial resistance	↑	↑	↓	↓	↑
Platelet aggregation	↑	↑	↓	↓	↑
Systemic vascular resistance		↓	↓	↑	
Pulmonary vascular resistance	↑	↑	↓	↓	↑

PG, prostaglandin; TXA_2, thromboxane A_2.

Though many of the functions of lipoxins have yet to be elucidated, they appear to counterregulate the actions of LTs. They inhibit LT production by downregulating 5-LO as 15-LO is upregulated. The anti-inflammatory cytokines IL-4 and IL-13 further contribute to suppression of inflammatory responses by enhancing 15-LO activity. In addition to inhibiting synthesis, lipoxins inhibit the actions of LTB_4 and LTD_4. Lipoxins A_4 and B_4 are potent vasoactive compounds. Lipoxins influence smooth muscle and vascular tonus by increasing NO and prostacyclin production, increasing arachidonate release, and reversing endothelin-induced vasoconstriction. Counterinflammatory functions of lipoxin A_4 include inhibition of LTs, fMLP, and other chemoattractants. Lipoxin A_4 also downregulates LTB_4-mediated delayed type hypersensitivity reactions.[92,184–186]

A large number of anti-inflammatory drugs, many of which are in clinical use, act by interfering with eicosanoid synthesis. The anti-inflammatory properties of corticosteroids are mediated at least in part by the inhibition of PLA_2 through the induction of lipocortin. They have been shown to selectively inhibit COX2 activation without affecting COX1. NSAIDS block the synthesis of both prostaglandins and thromboxanes by inhibiting COX activity. In contrast to the other NSAIDS, aspirin inhibits COX in an irreversible manner, and restoration of platelet function necessitates the administration of platelets. Aspirin, by either acetylating COX2 or by inducing the oxidation of arachidonic acid by cytochrome p450 or 5-LO, has been shown to stimulate the formation of 15R-HETE in endothelial or epithelial cells. These 15-epilipoxins exhibit higher potency in suppressing inflammation because of their prolonged half-lives. A potential complication of NSAID use and COX inhibition is the shunting of arachidonate through the 5-LO pathway and subsequent greater production of proinflammatory LTs (asthma). Such consequences minimize any benefit achieved from reducing other eicosanoid levels. In addition, NSAIDs

act systematically in a nonselective manner, so that inhibition of prostaglandin synthesis can result in dangerous side effects in locations where prostaglandins normally exert cytoprotective effects (stomach).[181,185,187]

PLATELET-ACTIVATING FACTOR

PAF is a heterogeneous mixture of 1-0-alkyl-2-acetyl-sn-glycero-3-phosphocholines that plays a prominent role in both physiologic and pathologic inflammatory states. It does not exist preformed, but is rapidly produced by activated cells. Synthesis involves either the remodeling of membrane phospholipids by PLA_2, usually more important under inflammatory conditions, or by de novo synthesis as occurs in resting cells. De novo synthesis is regulated by substrate availability and involves a constitutively active enzyme that produces PAF in small basal amounts.[188] The membrane phospholipid precursor is present in high amounts in neutrophils. Other cells that can synthesize PAF include platelets, basophils, monocytes, eosinophils, mast cells, and vascular endothelial cells. Similar to eicosanoid production, the synthesis of PAF is initiated by calcium-dependent activation of PLA_2, which yields 1-0-alkyl-sn-glycerophosphocholine (lyso-PAF); subsequent acetylation generates PAF. PAF may be released from the cell, or it may be converted back to lyso-PAF by an acetylhydrolase and to the precursor ether-phosphatidylcholine.[188]

The actions of PAF are mediated by G-protein activation. As the name implies, PAF induces platelet aggregation and degranulation; yet also possesses many other critical functions for inflammation. Its vasoactive properties include vasodilation and increased permeability, and it is an equally potent bronchoconstrictor. PAF enhances arachidonic acid metabolism, leading to increased leukocyte motility, degranulation, and free radical formation. PAF plays an integral role in promoting activation and adherence of inflammatory cells to the endothelium.[189] During the early inflammatory response, activated endothelial cells synthesize and express PAF on the cell surface. Leukocytes tethered by selectins to the endothelium are activated by endothelial PAF, which results in the induction of tight integrin-dependent adhesion and subsequent emigration and chemotaxis toward the inflammatory focus. Acyl-PAF, the major acetylated lipid from mast cells, basophils, and endothelial cells, is a less potent derivative of PAF that likely plays a similar role in the regulation of neutrophil recruitment. PAF also promotes platelet and neutrophil aggregation, thereby contributing to the prothrombotic state of acute inflammation. In circumstances of persistent pathologic stimuli, PAF may be liberated systemically, thereby causing the sequelae of an excessive inflammatory response. As a mediator of sepsis, PAF augments endotoxin-induced hypotension and neutrophil and platelet accumulation in the lungs. There is evidence that the NO-induced hypotension in experimental models of endotoxemia is mediated by PAF.[190] PAF infusion leads to a shock state that is similar to septic shock in that there is tissue hypoperfusion despite adequate fluid resuscitation. In animal studies, PAF has been shown to contribute many manifestations of sepsis including coronary vasoconstriction, reduced cardiac contractility, reduced preload, peripheral vasodilation, pulmonary vasoconstriction, increased microvascular permeability, gastrointestinal hemorrhage, and thrombocytopenia.[181] Two prospective randomized, placebo-controlled trials of PAF inhibition in sepsis have suggested a benefit.[181]

PAF acetylhydrolase, an enzyme regulated by dexamethasone, estrogen, and PAF itself,

is the enzyme responsible for degradation of PAF.

Kinins

Kinins (i.e., bradykinin and lysyl bradykinin) are small vasoactive peptides generated during the inflammatory response (Fig. 7-11). Three sources and mechanisms of kinin formation occur during inflammation: (1) plasma proteins; (2) tissue proteins; (3) cellular proteinases.[191–194]

Production of Bradykinin

Biosynthesis commences with the activation of Hageman factor (HF), or factor XII of the coagulation cascade (Fig. 7-11). HF is activated by exposure to anionic surfaces such as the basement membrane of injured endothelium, heparin, or lipid A of endotoxin. It can also be proteolytically cleaved and activated by kallikrein. Prekallikrein circulates complexed with HMWK, a nonenzymatic protein. Kininogen enhances the binding of prekallikrein to negatively charged surfaces. Activated HF converts prekallikrein to kallikrein, which in turn activates more HF in a positive feedback cycle. HFf, a cleavage product of activated HF, is also capable of activating prekallikrein. Kallikrein in plasma, tissues, and secretions specifically cleaves HMWK to release the nonapeptide bradykinin. In addition to bradykinin production, kallikrein participates in the activation of plasminogen and C1q of the complement system; yet another link between inflammation and the coagulation system. The only major plasma inhibitor of activated HF is C1 inhibitor. The primary inhibitors of kallikrein in plasma are C1 inhibitor and α_1 macroglobulin.[39,191]

Kinin Production in Tissue

Lysyl-bradykinin (kallidin) is the cleavage product of either HMWK or LMWK by tissue kallikreins, which are proteins distinct from their plasma counterparts. LMWK is present in higher concentrations intracellularly compared with HMWK. Whereas both HMWK and LMWK can be converted to lysyl-bradykinin by tissue kallikrein, only HMWK is cleaved by plasma kallikrein. Kallidin itself can be converted to bradykinin by a plasma aminopeptidase. Both kallidin and bradykinin use the same receptors and perform similar functions, but kallidin is approximately 85% as potent as bradykinin. Tissue kallikrein is synthesized from a preproenzyme and is converted intracellularly to tissue Prekallikrein by enzymes that are not yet well-characterized. The secreted Prekallikrein is then converted to tissue kallikrein extracellularly by plasmin or plasma kallikrein. The only significant inhibitor of tissue kallikreins is α_1-proteinase inhibitor.[39,191]

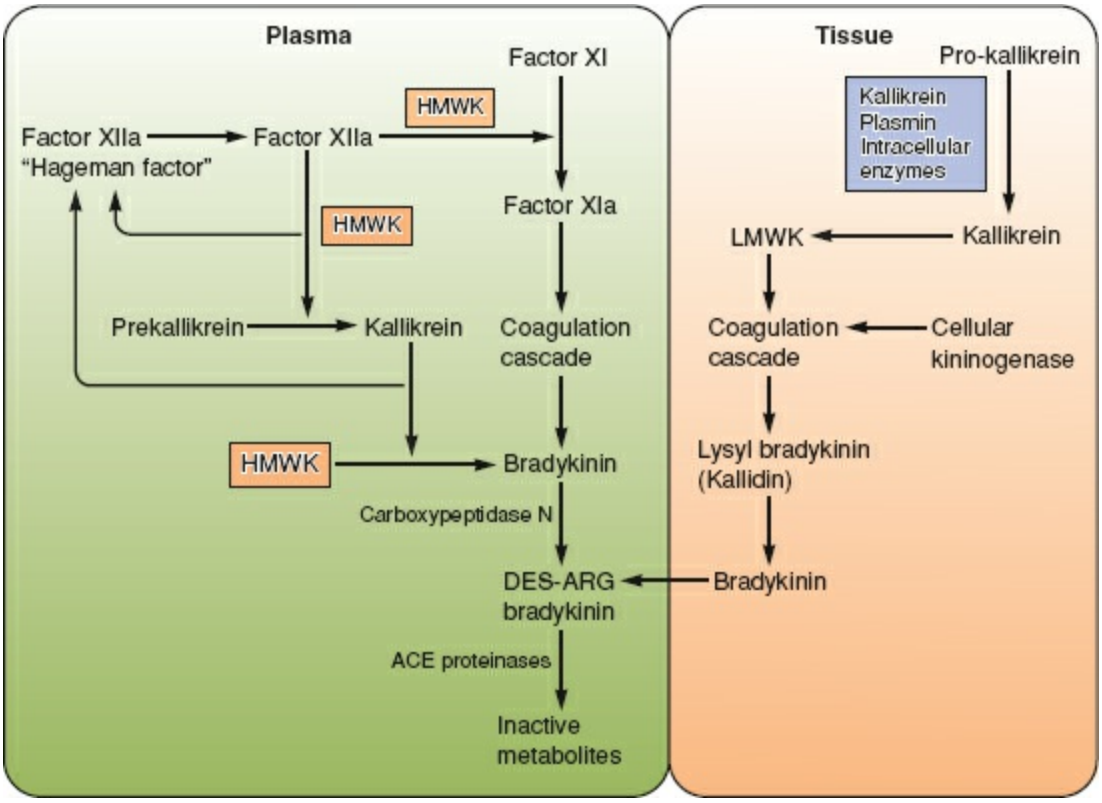

Figure 7-11. Kinin pathway. (Modified from Proud D, Kaplan AP. Kinin formation: mechanisms and role in inflammatory disorders. *Annu Rev Immun* 1988;6:49.)

Cellular Kininogenase Activity

Neutrophils, mast cells, and basophils are sources of kininogenase activity. Neutrophils produce leukokinins by way of cathepsin D. Their role in inflammation is unclear. Bradykinin is metabolized sequentially to the partially active eight amino acid peptide, des-Arg-bradykinin, by carboxypeptidase N, and then to inactive five-amino acid and three-amino acid fragments by the angiotensin-converting enzyme (ACE). ACE is the predominant enzyme to inactivate bradykinin in the pulmonary vasculature. Arginine released as a byproduct of the carboxypeptidase N reaction may contribute further to the modulation of inflammation by acting as a substrate for the formation of NO.[39,191,195]

There are three kinin receptors, of which two are well-characterized.[191,193] B1 receptors are expressed primarily on the vasculature under pathologic conditions such as tissue injury. They bind des-Arg-bradykinin and des-Arg-kallidin and mediate the hypotension characteristic of sepsis and pain.[191,196] Both B1 and the more widely distributed B2 receptors are G protein–coupled receptors. Activation of B2 receptors stimulates IP and PLC, resulting in the accumulation of the second messengers IP_3, DAG, and calcium. The B2 receptors are more important in mediating the effects of inflammatory kinins, such as bradykinin and lysyl-bradykinin. These kinins induce arteriolar dilatation and mediate pain. Similar to histamine, bradykinin increases the gaps between postcapillary venule endothelial cells leading to increase in vascular permeability. It is a potent constrictor of bronchial, uterine, and gastrointestinal smooth muscle, and the coronary and pulmonary vasculature.[193] Activation of endothelial B2 receptors stimulates production of NO to further enhance vasodilatation. Kinins have been implicated in mediating the

antihypertensive and cardioprotective effects of ACE inhibitors.[197] ACE, in addition to catalyzing the formation of angiotensin II from angiotensin I, promotes the hydrolysis of bradykinin to inactive metabolites. In addition, bradykinin can modulate platelet function by stimulating endothelial cell secretion of PGI_2 and thromboxane through activation of PLA_2.[191]

Neuropeptides

Neuropeptides may provide a neuroendocrine link between psychological stress and inflammatory diseases such as psoriasis and inflammatory bowel disease. Like cytokines, their actions are pleiotropic and redundant. Neuropeptides execute their inflammatory and immunomodulatory effect by binding to specific G protein–coupled receptors on the surfaces of target cells, and the resultant effect may be proinflammatory, anti-inflammatory, or both. For example, substance P mediates the hypothalamic fever response to PGE_2 induced by IL-1 and TNFα, whereas ACTH, AVP, and α-melanocyte stimulating hormone (α-MSH) suppress it. The pituitary peptides prolactin, CRH, and AVP have been shown to augment immune responses by enhancing T_H1 activity.[39,198,199]

Tachykinins are important proinflammatory neuropeptides that mediate pain and vasodilatation and promote the classic inflammatory signs of erythema and edema. Substance P stimulates monocyte and neutrophil influx and neutrophil phagocytosis. Its inflammatory effects appear to be mediated by the proinflammatory cytokines TNFα and IL-1 from mast cells, monocytes, macrophages, bone marrow, and endothelial cells. During allergic inflammation, substance P stimulates histamine release from mast cells. As an effector of immune function, substance P promotes T-cell proliferation and antibody production. Substance P released locally by nerve terminals is important in mediating the perception of pain.[39,191]

CRH induces the release of IL-1, IL-6, and superoxide anion from macrophages and negatively regulates its own proinflammatory effects through cortisol release. Cortisol downregulates production of proinflammatory cytokines such as IL-1, TNFα, and IL-2, metalloproteinases, and iNOS, and through this negative feedback loop, inhibits the production of CRH, ACTH, and AVP. AVP, growth hormone, and prolactin are other important proinflammatory neuropeptides.[39,198,199]

Vasoactive intestinal peptide (VIP) and its homologues display both proinflammatory and anti-inflammatory effects. VIP is widely distributed throughout the central and peripheral nervous systems and serves as a chemoattractant for macrophages, neutrophils, and T cells, and may play an important role in granulomatous reactions. VIP stimulates the release of histamine and IL-5 and is a potent vasodilator. It inhibits IL-6, TNFα, and IL-12 release and iNOS expression in activated macrophages. VIP has also been shown to stimulate the production of the anti-inflammatory cytokine IL-10 by macrophages and to inhibit T lymphocyte proliferation and the production IL-2 and IFN-γ.[200]

Somatostatin and α-MSH are primarily anti-inflammatory in action. Somatostatin, which colocalizes with substance P in sensory nerves, inhibits IgE formation and NK cell activity, whereas α-MSH inhibits leukocyte chemotaxis, IFN-γ production, and downregulates T_H1 activity. ACTH, calcitonin, and β endorphin are other neuropeptides with predominantly anti-inflammatory properties.[39]

Calcitonin gene-related peptide (CGRP) is an immunomodulator that inhibits the activity of T cells and macrophages, in part through the induction of IL-10. It also is an inhibitor of antigen presentation. CGRP promotes vasodilatation and neutrophil influx, and synergizes with bradykinin and histamine to promote edema formation.

Nitric Oxide

Endogenous NO was first discovered in 1987, and NO was the first gaseous molecule shown to be synthesized for the purpose of cell signaling.[201] NO is a weakly reactive radical that diffuses short distances from cell to cell independent of membrane channels or receptors. Its half-life is short because of its rapid inactivation by hemoglobin and other endogenous substances; thus, it functions primarily in a paracrine and autocrine fashion. The enzyme NO synthase (NOS) catalyzes the formation of NO and citrulline from the substrates L-arginine and oxygen.[53,202–204] NOS contains prosthetic groups for flavin-adenine dinucleotide, flavin mononucleotide, tetrahydrobiopterin, iron protoporphyrin IX, and zinc. Three isoforms of NOS have been identified. The calcium-dependent constitutive isoforms, neuronal NOS (nNOS) and endothelial NOS (eNOS), generate the small amounts of NO necessary for those processes maintaining physiologic homeostasis, such as neurotransmission and endothelial regulation of vascular tone. The expression of inducible NOS (iNOS), however, requires stimulation and produces larger, sustained amounts of NO that possess both cytoprotective and cytotoxic properties. This distinction is not absolute, as certain cell populations express low basal levels of iNOS, and constitutive NOS transcripts can be enhanced by certain stimuli such as shear stress and hypoxia.[53,202–204]

Many of the physiologic effects of NO are mediated by the activation of soluble guanylate cyclase. Increased levels of intracellular cyclic guanosine monophosphate trigger a reduction in calcium concentration and promote vascular smooth muscle relaxation and the inhibition of platelet aggregation and adhesion. The cellular response to NO also likely involves multiple signal transduction mechanisms, including the MAPK pathway.

Inflammation secondary to endotoxemia, hemorrhagic shock, and ischemia/reperfusion are associated with increased NO production by iNOS. First described in macrophages, iNOS can be expressed in essentially any cell type in response to immunologic stimuli. Unlike nNOS and eNOS, iNOS does not depend on elevations in intracellular calcium levels for its activity.[53,202–204] Important inducers of iNOS upregulation include LPS, IL-1, TNFα, and IFN-γ. Expression is primarily transcriptionally regulated, although stabilization of iNOS mRNA also appears to play a role. IFN-γ stabilizes iNOS mRNA, whereas TGFβ can destabilize it. Transcription of the iNOS gene is controlled by NFκB, IFNγ-responsive element, and TNF-responsive element. Induction of iNOS can be inhibited by glucocorticoids, thrombin, macrophage deactivation factor, PDGF, IL-4, IL-8, IL-10, and IL-13.[53,202–204] Dexamethasone may inhibit iNOS induction by impairing the DNA binding capacity of NFκB and by increasing levels of IκB.[205,206]

The endothelial dysfunction and vascular hyporeactivity that characterizes septic shock is consequential, in part, to iNOS production of NO.[207] NO has been shown to be the effective mediator of the negative myocardial inotropy of TNFα, IL-6, and IL-2 and the TNFα-induced vasodilatation in the systemic and microcirculations.[208] NO may indirectly increase prostaglandin production by increasing the catalytic activity of cyclooxygenase and decrease LT production by inhibiting 5-LO.[209] NO plays an autoregulatory role in the

T_H1 subset of T_H cells by limiting their own proliferation.[210]

NO can mediate tissue injury in inflammation by modulating organ perfusion, mediating interactions with neutrophils, contributing to proinflammatory signaling, and by regulating apoptosis.[211] Whereas eNOS primarily regulates perfusion during homeostasis, both eNOS and iNOS modulate organ flow in pathophysiologic states. Basal NO production from eNOS prevents the adherence of neutrophils to the endothelium and inhibits chemotaxis under physiologic conditions. Animal studies have demonstrated that pharmacologic inhibition of iNOS or genetic deletion of iNOS attenuates neutrophil accumulation in organs after ischemia/reperfusion injury.[212] Conversely, similar experiments in endotoxemia implicate an antiadhesive role for iNOS, suggesting that the effect of induced NO on neutrophil accumulation is insult specific.[211] Activated neutrophils can be stimulated by fMLP, PAF, LTB_4 to produce NO. NO produced by neutrophils at sites of inflammation can combine with superoxide to form peroxynitrite as another means of effecting toxicity.[39,213]

The reaction of NO with superoxide is the only reaction that outcompetes the reaction of superoxide with superoxide dismutase. Small amounts of peroxynitrite are produced under basal conditions from constitutively produced NO and superoxide from mitochondria and other cellular sources. However, endogenous antioxidants such as GSH, vitamins E and C, and superoxide dismutase likely limit its toxicity. A low concentration of peroxynitrite has been shown to inhibit neutrophil adhesion. Higher concentrations of peroxynitrite can initiate a wide range of toxic oxidative reactions through a peroxynitrous acid intermediate. These include the initiation of tyrosine nitration, lipid peroxidation, and direct inhibition of mitochondrial respiratory enzymes. The balance between superoxide and NO determines the reactivity of peroxynitrite; excess NO reduces the oxidation elicited by peroxynitrite. In addition, peroxynitrite may contribute to cytotoxicity by a more indirect pathway. Peroxynitrite-induced single strand breaks in DNA activate the nuclear enzyme poly (ADP-ribose) synthetase, leading eventually to irreversible energy depletion of the cells and necrotic-type cell death.[39,41]

Inducible NOS plays a key role in host defense, with NO or peroxynitrite exhibiting potent antimicrobial activity against a number of pathogens including viruses, fungi, and bacteria. Although microbicidal susceptibility to NO-mediated killing can vary considerably between species, essential roles have been identified in tuberculosis and bacterial peritonitis.[214] Induced NO has been shown to be essential for the upregulation of the inflammatory response in hemorrhage shock and other inflammatory processes. NO produced by iNOS leads to the activation of NFκB.[215] This is followed by the induction of proinflammatory cytokines and increased leukocyte recruitment and activation.

NO possesses both proapoptotic and antiapoptotic effects depending upon the circumstances. NO derived from eNOS may inhibit apoptosis.[216] Proapoptotic effects appear to be associated with pathophysiologic conditions in which iNOS is upregulated. Low concentrations of peroxynitrite have also been shown to induce apoptosis, whereas higher concentrations promote cell necrosis in vitro. The role of NO-mediated apoptosis in the regulation of the inflammatory response is yet to be more clearly defined.

In summary, NO mediates tissue injury both directly through the formation of peroxynitrite, as well as, indirectly through the amplification of the inflammatory process. Like many mediators, NO has dual regulatory functions, and it is therefore difficult to characterize NO as distinctly proinflammatory or anti-inflammatory. In general, basal levels of NO produced by constitutive NOS may confer anti-inflammatory effects, whereas induced NO may tend to promote the upregulation of the inflammatory response. It is likely that an optimal level of NO is necessary in host defense; too little NO may be as harmful as too much.

Heme Oxygenase

HO catalyzes the breakdown of heme to iron, biliverdin, and carbon monoxide.[217] Three isoforms of HO have been identified. HO-2 is constitutively expressed in many tissues, whereas HO-3 expression appears to be limited to the brain. HO-1 is not expressed constitutively in most tissues, but is rapidly upregulated by both heme and nonheme cellular stresses, including hypoxia, redox stress, and inflammation. Additionally, NO is a potent inducer of HO-1. HO-1 has profound antiapoptotic and anti-inflammatory effects. These cytoprotective effects have been attributed to the individual catalytic products of heme metabolism. Biliverdin is converted to bilirubin by biliverdin reductase, and bilirubin has been demonstrated to act as a potent intracellular antioxidant. Carbon monoxide alone can mimic many of the actions of HO-1 and has been shown to protect in models of sepsis, hemorrhagic shock, and ischemia/reperfusion when administered as an inhaled gas. The mechanisms of action of carbon monoxide have both similarities and dissimilarities with NO, and is an area of active investigation.[217]

Hydrogen Sulfide

Hydrogen sulfide is a colorless, flammable gas, with the typically malodor of putrid eggs. It is highly lipophilic and freely penetrates the cell wall, which greatly facilitates its biological activity.[218] Recent evidence highlights the widespread distribution of H_2S in the plasma, brain, and other tissues. H_2S is formed in mammalian cells largely by the activity of two pyridoxal phosphate–dependent enzymes, cystathione γ lyase (CSE), and cystathionine β synthetase (CBS) that utilize cysteine and homocysteine to form H_2S.[219] Large amounts of these enzymes occur in the brain (CBS), liver (CSE), kidney (CSE) and blood vessels (CSE). Interestingly, lipopolysaccharide exposure induces the expression of CSE, suggesting that H_2S may regulate inflammation.[218] Both pro- and anti-inflammatory actions have been described. H_2S levels and CSE expression are increased in animal models of endotoxemia, sepsis, and hemorrhagic shock.[218,220,221] It has been shown to increase leukocyte attachment and rolling in jejunal blood vessels and to increase ICAM-1 expression.[222] In human monocytes, H_2S donors induce the formation of proinflammatory cytokines and chemokines via an NFκB mechanism.[223] Inhibitors of CSE reduce the inflammation in these animal models of sepsis and hemorrhage. By contrast, H_2S decreases LPS-induced upregulation of NFκB in RAW 264.7 macrophages, and H_2S-releasing derivatives of diclofenac exhibit greater anti-inflammatory activity in endotoxic shock.[218,219,224]

RECOGNITION AND ACTIVATION PROCESSES

Exogenous and Endogenous Danger Recognition

Multicellular organisms have evolved an essential mechanism of surveillance, defense, and repair of injured cells. Implicit with this system is the ability to differentiate pathogens and damaged cells from self. The initial response is orchestrated by the evolutionarily ancient and more universal innate immune system, which employs monoclonal sets of recognition molecules called PRR.[225,226] PRRs bind conserved molecular structures found in large groups of pathogens, termed PAMPs. PAMPs are a diverse set of microbial molecules, which share a number of different recognizable biochemical features that alert the organism to intruding pathogens.[225–227] These PAMPs are recognized by cells of innate and acquired immunity, primarily through the Toll-like PRRs. Activation induces several signaling pathways, most notably NFκB.[225,227] Consequent to this activation, an immune response is triggered to destroy the pathogen and/or pathogen-infected cells, and an adaptive response is initiated to select pathogen-specific T cells and antibodies for future occasions.

However, pathogens are not the only causative agents of tissue and cell damage. Cells, and thus tissues, can be injured by various noxious insults: heat, cold, chemicals, radiation, ischemia, or direct mechanical injuries. Evolution has enabled us to deal with these damages, which though not caused by pathogens, still necessitate repair. It is becoming apparent that specific receptors exist by which to recognize extrinsic threats (i.e., pathogen) and intrinsic altered self (cytokines, oxidized mitochondrial DNA, HSPs, and uric acid).[227]

Danger-Associated Molecular Patterns

8 DAMPs, the endogenous equivalent of PAMPS, represent danger signals or "alarmins" and share many characteristics similar to cytokines.[227] DAMPs may be released following nonprogrammed cell death, such as necrosis, and under such circumstances tend to elicit inflammation. By contrast, programmed cell death (i.e., apoptosis) incorporates mechanisms such as acetylation, to minimize the release of these mediators and any subsequent inflammatory response. Cells of the immune system also can be induced to secrete these mediators.[227] This secretion may occur by specialized secretion systems or by the classical ER–Golgi secretion pathway.[227] Under these circumstances, DAMPs may facilitate the inflammatory response by aiding the recruitment of innate immune cells, most notably DCs. In doing so, they indirectly orchestrate the subsequent adaptive immune response and facilitate tissue repair.[227] The prototypical alarmin, HMGB1, has already been discussed.

S100 Proteins

The family of S100 proteins incorporates over 20 related calcium-binding proteins.[227] S100A8 and S100A9 form heterocomplexes in the cytosol of granulocytes, monocytes, and macrophages, whereas S100A12 exists as homodimers in the cytoplasm of granulocytes. S100 proteins are actively secreted at sites of inflammation via a nonclassical pathway. The receptors mediating their effects are still being defined, though it appears that S100A12 and S100B interact with RAGE, whereas S100A8/9 may interact with TLR receptors. S100 proteins have been shown to induce increased vascular permeability and a prothrombotic effect. Recent studies implicate S100 proteins in the pathogenesis of autoimmune arthritis and psoriasis.[227]

Uric Acid

Uric acid is released after cellular injury, and upon exposure to the extracellular environment, precipitates to form monosodium urate (MSU).[227] Uric acid stimulates dendritic maturation and, when coinjected with antigen in vivo, significantly enhances the generation of responses from CD8+ T cells.[227] It has significant proinflammatory properties that are best evidenced in the disease gout, in which uric acid accumulates in tissues and induces inflammation-dependent arthritis. MSU crystals engage the inflammasome, resulting in the production of IL-1β and IL-18.[227] Macrophages from mice deficient in IL-1R or in various components of the inflammasome, such as caspase-1, ASC, and NALP3 are defective in MSU-induced cytokine secretion and have reduced inflammation.[227] Extracellular uric acid is eliminated by uricase.[227]

Receptors for Danger Recognition

9 Innate immunity is not antigen specific, but rather programmed to respond to groups of evolutionarily conserved macromolecules that represent "patterns of danger" and signal a potential threat to the host. PRRs identify these PAMPS and include the TLR and NOD-like receptors. Recent studies highlight the promiscuity of these PRRs in also recognizing and mediating DAMP-dependent signaling. In fact, multiple positive feedback loops between DAMPS and PAMPs and their overlapping receptors may represent the molecular basis for the observation that infections, as well as nonspecific stress factors, can trigger flares of autoimmune diseases (i.e., rheumatic).[148] Additional novel receptors have subsequently been identified and designated PRRs, including RAGE.[226,227]

CD14

The prototypical receptor identifying external infectious threat (i.e., gram-negative infection) is CD14. CD14 was identified as the LPS receptor when transfection of CD14-negative CHO cells with CD14 conferred responsiveness to LPS.[228] Its critical role in LPS recognition is underscored by the LPS-hyporesponsive phenotype of CD14–deficient mice. It has been identified on cells of the myeloid lineage, B cells, liver parenchymal cells, and fibroblasts. Differential expression is observed; ranging from high levels on peritoneal and pleural macrophages to lower levels on Kupffer cells, alveolar macrophages, monocytes and PMN. Expression may be modified; human PMN express low levels of CD14 that is upregulated by TNFα, G-CSF, GM-CSF, and fMLP. Prototypically, CD14 binds LPS bound to LPS-binding protein (LBP) in combination with MD-2 and presents it to TLR4.[228] MD-2 is required for cellular responsiveness to LPS, as demonstrated by both transfection studies and an analysis of a CHO cell line with mutated MD-2 gene. Most of the available evidence indicates that a complex of TLR4/MD-2/CD14 directly binds LPS.[228] CD14 is also important in TLR2 signaling, whereby it presents bacterial products other than LPS.

Toll-Like Receptors

CD14 is a glycosylphosphatidylinositol-linked receptor devoid of any transmembrane domain. This, in combination with the identification of a soluble form of CD14, necessitated identifying the manner by which LPS induced activation.[229] In 1996 the Toll protein in Drosophila was shown to be necessary for an effective immune response to the fungus *Aspergillus fumigatus*.[225] In 1998, Poltorak et al.[230] discovered that the *lps* gene in LPS-hyporesponsive C3H/HEJ mice encoded a murine member of the TLR family. These data provided the initial evidence that mammalian TLRs function as PRRs. Subsequent studies have confirmed that TLR4 is the "LPS receptor" and that it is essential for the defense against gram-negative microorganisms.[228]

Thirteen mammalian TLR receptors have been characterized. Each recognizes a specific set of conserved microbial molecules, and as a family, they can detect most microbes.[228] Interestingly, the subcellular localization of different TLRs correlates to some extent with the molecular patterns of their ligands and their function.[231] TLR1, TLR2, and TLR4 are

located on the cell surface and are recruited to phagosomes after activation by their respective ligands. They are the receptors mediating the response to exogenous insults including bacterial infection and trauma. By contrast, TLR3, TLR7, and TLR9, all of which are involved in the recognition of nucleic-acid–like structures (i.e., viral DNA), are expressed intracellularly.[225,232]

TLR4 is required for the innate response to gram-negative organisms and LPS, though other TLR, such as TLR2, can also recognize and mediate this response.[226] TLR4 has been shown to trigger the response to additional ligands, including lipoteichoic acid (LTA) and peptidoglycans from gram-positive bacteria and the fusion protein of the respiratory syncytial virus.[233] Polymorphisms in the receptor confer variability in function. Individuals with the D299G polymorphism in TLR4 demonstrate increased risk of gram-negative infections, and other studies have linked this with an increased incidence of SIRS.[234] In addition, this polymorphism has been associated with alterations in the susceptibility to other inflammatory and potentially infectious processes (carotid artery atherosclerosis, coronary artery disease).[234] HSP60 of Chlamydial origin has been found in atherosclerotic plaques and can bind TLR4. Perhaps recognition of HSP60 by human TLR4 might exacerbate the inflammatory component of atherosclerosis, whereas people with D299G polymorphism might be at least partly protected from this exacerbation.[234] TLR4 has been well-characterized as a PRR for DAMPS, including HSPs (HSP60, HSP70, gp96), hyaluronate, heparan sulfate, and other matrix proteins. Because of its ability to recognize endogenous proteins, TLR4 is implicated in a variety of diseases, including arthritis and atherosclerosis.[148,232]

TLR2 recognizes lipoproteins derived from the cell wall of bacteria such as *Treponema pallidum* and *Mycoplasma fermentans,* LTA from gram-positive bacteria (i.e., Streptococcal species), lipopeptides, LPS, and lipid A.[226,232,233] It also can recognize a host of DAMPs, including the HSPs, fibronectin, fibrinogen, heparan sulfate and hyaluronate. Recent data suggest that TLR2 forms heterodimers with other TLR, including TLR1 or TLR6 to recognize these DAMPs. A likely consequence of this cooperation is an increased repertoire of ligand specificities. The R753Q polymorphism in the TLR2 is associated with decreased response to these bacteria and may increase susceptibility to staphylococcal infections or tuberculosis.[232,234]

Additional TLRs involved in inflammation include TLR9, which recognizes unmethylated CpG motifs present in bacterial DNA. By contrast, most of the host mammalian genome is methylated. TLR9-ligand engagement occurs intracellularly, in either endosomes or lysosomes, presumably following bacterial lysis. Recent evidence suggests that TLR9 can identify host DNA released by dead or dying cells, and hence, may be involved in the autoimmune diseases such as SLE.[225] TLR5 recognizes flagellin of bacterial flagella.[235] TLR3 recognizes double-stranded RNA of both viral and endogenous sources. Because of the later characteristic, TLR3 has been implicated in autoimmune arthritis.

TLRs induce signal transduction via their cytoplasmic Toll-interleukin-1 receptor (TIR) domains that promotes the subsequent expression of a variety of host defense genes. These include inflammatory cytokines and chemokines, antimicrobial peptides,

costimulatory molecules, MHC molecules, and other effectors. A considerable portion of the functional response is mediated by activating intracellular signaling pathways that culminate in the induction of the transcription factor NFκB. Specifically, the CD14/MD-2/TLR4 complex, upon engagement with LPS-LBP recruits the adapter protein MyD88, which engages the serine/threonine kinase IRAK. IRAK undergoes autophosphorylation and recruits TRAF6. Ultimately, activated IκK phosphorylates and targets for degradation the NFκB inhibitor IκB, which enables the nuclear translocation of NFκB and transcription of inflammatory genes. AP-1 and members of the MAPK transduction cascade are also activated by this mechanism. This pathway is critical to the production of IL-12, TNFα, and IL-6. All TLRs signal through this conserved signaling cascade, and for some MyD88 (TLRs 2, 6, 9) is their sole receptor-proximal adaptor. For instance, MyD88 is essential for clearance of *S. aureus,* a gram-positive bacteria, which signals through TLRs 2, 6, 9.[225,226,233]

Subsequent studies utilizing MyD88-deficient mice suggested that alternate TLR pathways existed. These mice, in response to many TLR ligands, including peptidoglycan and unmethylated CpG motifs, did not activate NFκB or MAPK. Surprisingly, however, LPS could still activate NFκB and MAPK, though in a delayed fashion. Subsequently, a MyD88-independent pathway has been characterized that is utilized by TLR4 and utilizes a distinct adaptor protein called TIR domain–containing adapter protein TIRAP or Mal. A dominant negative mutant of TIRAP specifically impairs TLR4- and TLR2- but not IL-1R or TLR9-induced NFκB, indicating a specificity of TIRAP for the TLR4 pathway. A third TIR-containing adaptor molecule, TIR-domain containing adaptor inducing IFN-β (TRIF) also appears to mediate a MyD88-independent pathway.[225,226,233]

Most of this research has occurred in the realm of sepsis and provided insight into the manner by which organisms identify infectious threats and activate the inflammatory pathway to preserve the host. However, several circumstances of sterile inflammation suggest a role of the TLRs in mediating inflammation in response to endogenous danger signals (uric acid, mitochondrial DNA, HMGB1).[228] Hepatocellular injury consequent to ischemia/reperfusion has been shown to be dependent on TLR4.[32]

RAGE

RAGE is an immunoglobulin superfamily molecule that belongs to the multiligand receptors that recognize families of ligands rather than a single polypeptide.[97,227,236,237] It has a single transmembrane spanning domain and a highly charged cytoplasmic tail that though lacking known signaling motifs, is critical for cellular activation. Though RAGE knockout mice are viable and fertile, they display a wide range of defects. Most of these defects are subtler than expected, leading to the suggestion that other receptors with overlapping function might exist. Signaling appears to necessitate clustering into a particular orientation, which facilitates binding of cytosolic signaling complexes.[97,236] Its ligands include products of nonenzymatic glycosidation (e.g., advanced glycation endproducts or AGEs), the amyloid-β precursor protein, the S100/calgranulin family of proinflammatory cytokine-like mediators, and the high mobility group 1 DNA binding proteins (HMGB-1). Its expression is upregulated at sites of diverse pathologies including

atherosclerosis and Alzheimer's disease. In fact RAGE-mediated cellular stimulation is thought to increase expression of the receptor itself, thereby generating a positive feedback mechanism and perpetuating the proinflammatory state.[97,236,237]

Recent studies demonstrate the activation of multiple signal transduction cascades subsequent to ligand binding, including the family of MAPKs (p38, ERK 1/2, and JNK) and the rho gtpases (cdc42 and rac).[237] Like TLRs and IL-1R, RAGE engagement leads to NFκB activation, suggesting that both receptor usage and signaling pathways evoke similar responses when cells are activated by PAMPs and DAMPs. It is currently hypothesized that RAGE–ligand interaction induces a new heightened basal state of activation. With a superimposed stimulus, cellular perturbation is magnified. Rather than returning to homeostasis, cellular signal transduction mechanisms favor augmented dysfunction.[97,236]

Studies have implicated RAGE to be an important receptor during various acute and chronic inflammatory processes, including tumor biology. RAGE expression and function directly correlated with tumor growth in RAGE-transfected C6 glioma cells. In a murine tumor model, mice treated with soluble RAGE, which functions as a decoy, exhibited a reduction in lung metastases, cellular invasion, and expression of matrix metalloproteinases.[237]

RAGE has also been identified as a receptor for S100A12, a member of the S100/calgranulin family of proinflammatory mediators. Endothelial cells cultured with S100A12 displayed RAGE-dependent expression of VCAM-1 and tissue factor. Mononuclear phagocytes displayed S100A12-RAGE chemotaxis, expression of tissue factor, and elaborated IL-1 and TNFα. In vivo studies of delayed-type hypersensitivity demonstrated reduced inflammatory response when mice were treated with anti-RAGE F(ab′)2, anti-S100 F(ab′)2, or soluble RAGE. Treated animals also displayed reduced NFκB activation and IL-1 and TNFα expression.[237]

The angiopathy of diabetes is thought to be consequent to inflammatory processes generated by elevated glucose concentrations. Hyperglycemia has been demonstrated to activate numerous signaling cascades. One process that might mediate these effects is through the nonenzymatic formation of AGEs.[97,236,237] AGE-RAGE interactions on endothelium lead to the expression of procoagulant tissue factor and VCAM-1 and macrophages-released tissue factor. Animals treated with soluble RAGE showed decreases in atherosclerotic lesion area and number and a marked reduction in lesion complexity. Also, treated animals had reduced expression of adhesion molecules, tissue factor, MCP-1, and matrix metalloproteinases.[97,236,237]

CD91

The immunological properties of HSPs were discovered by their ability to elicit antitumor immunity. It was later discovered that this antigenic specificity was determined by the peptides they chaperoned. APCs can bind and internalize HSP–peptide complexes derived from virus-infected cells or tumors and represent them on major histocompatibility MHC class I molecules. In addition, APC engagement of HSP–peptide complexes induces maturation, the expression of costimulatory molecules, and the induction and release of

cytokines (TNFα, IL-1, IL-12, IL-6, GM-CSF, MIP-1, RANTES, and NO).[238,239]

CD91 had been identified as a receptor for the serum protein α_2 macroglobulin, a natural protease inhibitor that like HSPs is found across many species. In fact α_2 macroglobulin is the evolutionary precursor of the C3 complement component. By binding pathogen proteases utilized during invasion and shuttling them for endocytosis, α_2 macroglobulin hinders pathogen invasion.[238,240]

However, such a method of host defense would be ineffective for intracellular pathogens that gain access by alternative means, such as mimicking host proteins and developing ligands for host receptors. Hence, another method for signaling danger is necessary. It is currently thought that upon cell death, HSPs contained within the cell transfer information regarding the infected intracellular environment to CD91. This large cell surface receptor, complexed with the HSPs, is internalized and delivers antigen to the classical MHC class I pathway. The MHCs bind and present them to $CD8^+$ T cells. On recognizing nonself, T cells are induced to proliferate and mediate killing. This mechanism could be generalized to implicate CD91 and HSP interactions in the recognition of all cellular stress that culminates in injury and death.[240]

CD91 was first identified by Binder et al. as the receptor for gp96 and then by Basu et al. as a common receptor for other HSPs (HSP70, HSP90, and calreticulin).[241,242] This large multidomain 600-kD protein possesses multiple binding sites for at least 32 ligands. The binding of this receptor to many members of the HSP family has been corroborated by several independent functional and structural studies.[240]

Several in vivo studies suggest a physiological relevance for HSP-CD91 interaction. Mice immunized with tumor-derived gp96–peptide complexes reject a subsequent tumor challenge. If CD91 antiserum is mixed with the HSP–peptide inoculum, the mice fail to reject the tumors. Srivastava et al. noted that blocking of CD91 completely inhibits the phenomenon of representation of peptides that are carried or chaperoned by HSPs, suggesting that not only is CD91 a receptor for HSPs, but it may also be the sole receptor involved in antigen representing.[239,242]

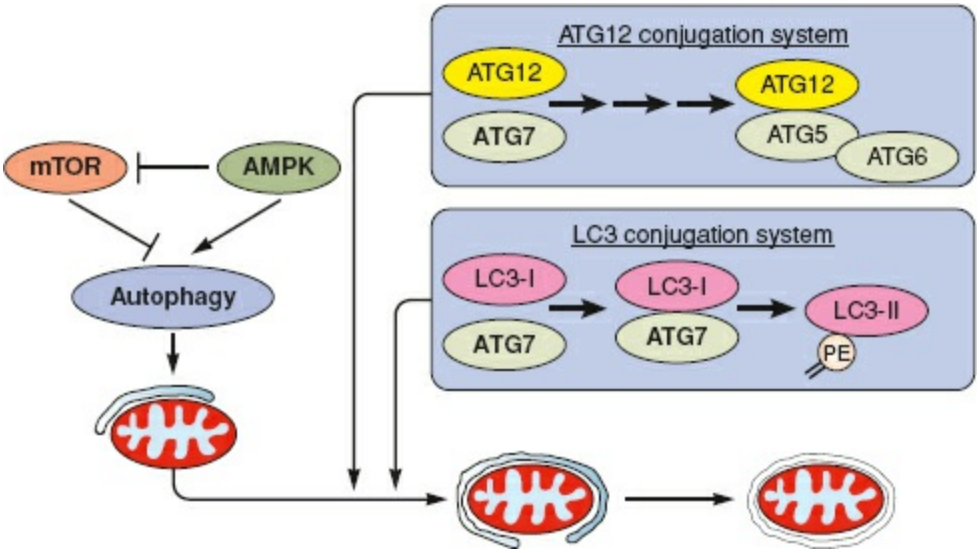

Figure 7-12. Autophagy/mitophagy. Autophagy is inhibited by the metabolic growth rheostat mTOR that inhibits autophagy when ATP and nutrients are plentiful. Sepsis and metabolic stress lead to inhibition of mTOR and initiation of the isolation membrane. Atg12-ATG5-Atg16L and LC3-II localize to the phagophore to capture selected targets for degradation. Upon completion of autophagosome formation, the Atg12-Atg5-Atg16L complex dissociates while LC3-II remains on it. The autophagosome ultimately fuses with the lysosome to form an autolysosome, where its contents are degraded.

HSPs have been shown to chaperone antigenic peptides (tumor, viral, minor histocompatibility antigens) from all cellular compartments. The family of HSPs thus appear to be a universal mechanism for antigen capture, and they permit a high-efficiency antigen uptake through a receptor-mediated mechanism.

Evidence that HSP–peptide–CD91 interactions serve to signal cellular stress is beginning to culminate. Basu et al. demonstrate that Hsp70, Hsp90, gp96, and calreticulin are released from cells as a result of necrotic cell death, but not apoptotic cell death.[241] Similarly, Melcher reported that tumor cells undergoing necrotic death are highly immunogenic as compared to those undergoing apoptotic death.[243] Actual necrosis may be unnecessary as stressed cells and cancer cells have been reported to express cell surface HSP molecules, which may activate APCs. Li et al. observed that physical contact of tumor cells artificially engineered to express cell surface HSPs with immature DCs elicits a powerful maturation of DCs.[244]

Other HSP Receptors

CD40 was reported as a receptor for Hsp70 when anti-CD40 antibodies were observed to inhibit macrophage chemokine secretion in response to mycobacterial Hsp70. Subsequently, Becker noted the association of recombinant GST-tagged CD40 with murine Hsp70.[245,246] They further demonstrated enhanced binding after the APCs were stimulated with LPS. As LPS induces expression of a number of cell surface molecules, the authors concluded that CD40 mediates recognition and binding of Hsp70.[247]

CD36 has been implicated as a receptor for gp96. Transfection of CD36 into CD36-negative cells has been shown to enhance gp96 binding. In addition, $CD36^{-/-}$ macrophages have a 52% reduction in gp96 binding compared with wild-type controls,

suggesting that some role for CD36 as an Hsp receptor.[247]

LOX-1, a member of the same scavenger superfamily as CD91 and CD36 has been postulated to be an additional receptor for endocytic uptake of Hsp70 and chaperoned peptides by human DCs. Anti-LOX-1 antibodies and LOX-1 ligand-acetylated albumin competed with Hsp70 for binding to DCs.[114]

Both TLRs and CD14 have been implicated as receptors for HSPs, such as Hsp70.[248] Hsp70 stimulates macrophage IL-12p40 production that is partially abrogated by inhibiting downstream TlR signaling cascades. In addition, human Hsp60 activated NFκB and TNFα production by 293T cells transfected with either TLR-2 or TLR-4 and MD-2.[249] Hsp60 also activated JNK kinase and IKK kinase signaling and TNFα production by macrophages, an effect that was partially eliminated by knocking out MyD88 or TRAF6. Similar functional studies have proposed that CD14 might serve as an Hsp70 receptor in APCs. All of these studies heavily suggest a role of TLRs or CD14 in HSP binding, although several investigators call into question the potential for contamination with LPS to be mediating much of these effects.[247]

AUTOPHAGY

Autophagy is an ancient cytoplasmic homeostatic process governing cellular biomass quantity, quality, and distribution through the recycling of cytoplasmic proteins and organelles to support vital functions during periods of stress (i.e., starvation).[250,251] It literally originates from the Greek words *auto* meaning "self" and *phagein* meaning "to eat." Fundamental for embryological development and survival, it integrates extensively with apoptosis and may itself function as a form of programmed (type II) cell death.[251–253] Hence, it is not surprising that it is preserved in all eukaryotic organisms, from yeast to humans.

Macroautophagy is coordinated by specialized autophagy-related proteins (ATGs) that sequester large protein aggregates, dysfunctional organelles, and even microorganisms and target them for lysosomal degradation. In the setting of nutrient deprivation, the mechanisms orchestrating this dynamic process involve the main growth rheostat mammalian target of rapamycin (mTOR) and adenosine monophosphate (AMP) kinase, a sensor of cellular energy status.[251,252,254–258] Prototypically, AMP kinase, sensing reduced cellular energy (i.e., elevated AMP) inhibits mTOR, a negative regulator of autophagy, thereby inducing autophagy.[252,254,259,260]

Autophagy is initiated by complex formation of ULK1 and ULK2, the class III phosphatidylinositol-3-phosphate kinase VPS34, and ATG14-like protein, ATG14L. This initiates the ATG conjugation cascade in which ATG5 and ATG12 complex with ATG16L1 to form an isolation membrane around the target (Fig. 7-12). The complex facilitates the addition of a phosphatidylethanolamine group to LC3-1 to form LC3-II. LC3-II together with other factors leads to elongation and closure of the autophagosome, which is then targeted for fusion with the lysosome, forming the autolysosome (Fig. 7-12).

Though the quintessential function of autophagy is to digest and recycle portions of the cytoplasm during starvation, it has recently been described as an important effector arm of immune cells responding to exogenous (i.e., PAMP: LPS)[261,262] and endogenous (DAMP: HMGB1) stimuli.[250,259,262–266] It is proposed that competition with microorganisms for nutrients, and thus nutrient deprivation, may have served as a sign of invading organisms and thereby supported the emergence of eukaryotic autophagic mechanisms of pathogen elimination. However, a host of other PAMPs and DAMPS and mediators may induce autophagy. In Mφ, LPS induces autophagy through mechanisms dependent on TLR4, TRIF, RIP1, and p38 MAPK.[261,267] Cytosolic pathogens, such as viruses, can induce autophagy, or rather xenophagy. DAMPS, such as DNA, ATP, and HMGB1 may also induce autophagy, the later through RAGE. The induction of autophagy by the inflammatory cytokine IL-1β is critical for control of *Mycobacterium tuberculosis*. Similarly, TNFα stimulates autophagy in restricting intracellular bacteria. By contrast, T_H2 cytokines such as IL-4 and IL-13 and NO inhibit autophagy.

During innate immunity, autophagy has been shown to be important in the elimination of intracellular microbes, through LC3-associated phagocytosis and xenophagy. This latter process of selectively degrading intracellular pathogens involves sequestosome 1–like receptors (SLRs) that recognize molecular motifs on invading pathogens. These SLRs help

to clear microorganisms that gain entry to the cytoplasm if they escape the defenses that are controlled by conventional PRRs. Microbial polymers, such as DNA, that are present in the cytoplasm might function as autophagy-inducing PAMPS, as in the case of *M. tuberculosis* infections. The critical importance of autophagy to cell survival is perhaps best made evident by the defenses several microbes (Listeria, Shigella, Legionella) exhibit to combat autophagy machinery.

Autophagy can assist PRR by delivering cytosolic PAMPs to endosomal TLR (i.e., TLR7) and stimulate their activity.[268–270] Nucleic acid receptors called RIG (retinoic acid inducible gene)-I-like receptors (RLRs) recognize viral RNA, and induce the production of type I IFN to thwart viral invasion. The interaction between TLRs and autophagy may also serve to augment antigen presentation by DCs.

Autophagy limits the activation of the inflammasome, a cytoplasmic complex that responds to PAMPs and DAMPs by inducing the proteolytic processing and secretion of IL-1β and IL-18. It does so by clearing the cytoplasm of debris, such as damaged or depolarized mitochondria that can function as endogenous agonists. Inhibition of autophagy leads to the release of the products, such as mitochondrial DNA and ROS.[268–270] Autophagy also affects the secretion of pro- and anti-inflammatory mediators. In senescent cells, it regulates the secretion of IL-6 and IL-8. It reduces immunoglobulin secretion from plasma cells, and thus, may be important in negatively regulating antibody production.

During adaptive immunity, autophagy contributes to MHC class II presentation. Classically this is described in the context of presenting cytoplasmic antigen (e.g., virus or self antigen) to endosomal receptors, such as TLR7 (see above). Thus, autophagy is implicated in autoimmune disorders such as autoimmune colitis and Crohn's disease. The link between autophagy and inflammatory diseases has also been reported. Polymorphisms in ATG16L1 and IRGM are linked to Crohn's disease. IRGM polymorphisms may be a risk factor for SLEs, and rheumatoid arthritis has been associated with variations in the ATG5 gene. In summary, autophagy influences adaptive immune responses through its effects of antigen presentation, naïve T cell–repertoire selection, T-cell homeostasis and T_H-cell polarization.[268–270]

Interestingly, nonimmune cells, such as hepatocytes and renal tubular cells also exhibit TLR signaling and respond to the stress of sepsis or lipopolysaccharide by inducing autophagy.[32,264,271–274] Studies suggest that these mechanisms are similarly induced in vivo in the early response to sepsis, and regulate bronchoalveolar cytokine/chemokine production and neutrophil accumulation. Others have shown that sepsis induces similar AMPK- and mTOR-dependent mechanisms of autophagy in the Mϕ, kidney, and liver.[267,271,275–277] This mechanism may be critically important for cell survival, as it has been shown that augmenting mTOR- or AMPK-dependent autophagy during CLP sepsis attenuates mitochondrial injury and reduces acute kidney injury (AKI) (Fig. 7-6).[274] In summary, recent data support a fundamental role of autophagy in nearly every arm of immunity as an antimicrobial effector of TLR.[253,264,265,267,268]

Mitophagy, autophagy directed at the removal of damaged mitochondria, is considered to of particular importance in protecting against organ injury, such as AKI.[278] At least two

mechanisms are involved in the sequestration and elimination of defective mitochondria: Atg7 and PINK1/Parkin. Atg7 is an autophagy protein that is required for the initiation of ubiquitin-like conjugation pathways of autophagy. During erythroid maturation, Atg7 serves a nonredundant role in mitochondrial clearance through canonical autophagosomal pathways.[279,280] Alternatively, PINK1 accumulation at the outer mitochondrial membrane of dysfunctional mitochondria selectively recruits Parkin, which in turn promotes their selective degradation by mitophagy.[281–284] Conditions that induce mitochondrial dysfunction and depolarization strongly induce this pathway, which is important for cell survival.[285] Indeed, endogenous Parkin production and exogenous Parkin overexpression have been found cytoprotective in different conditions of stress, including sepsis. Not surprising, due to the potential for release of cytochrome C and ROS, it is vital that a cell possess a programmatic mechanism for the elimination of defective mitochondria.

THE STRESS RESPONSE

The stress response is the cellular reaction to any perturbation or disruption in equilibrium and serves to restore homeostasis. Inducers of the stress response include physical stresses (burns, radiation, trauma), chemical agents and mediators (toxin, heavy metals, cytokines, ROS), infectious agents (bacteria, viruses, parasites), and allergens. It is often referred to as the heat-shock response after the identification in the 1960s of the HSPs, a group of genes expressed after exposure to heat.[286] However, subsequent investigations delineated additional cellular proteins that are expressed in response to a wide variety of insults. Clinically, expression of HSP has been observed under conditions in which oxygen delivery is compromised, as in hemorrhage or ischemia.[287]

Activation of the stress response is characterized by both morphologic and metabolic cellular alterations. Morphologic alterations include the accumulation of unprocessed forms of mRNA in the nucleolus, and increased numbers of actin microfilaments in the cytoplasm. Changes in cellular metabolism include a rapid reduction in intracellular ATP levels, most likely correlated with alterations in the integrity of mitochondria. The stress response is characterized by transient downregulation of most cellular products and by the upregulation of stress proteins.[288] It is the induction of stress proteins that confers the primary adaptive and protective effects of the stress response.

After expression of stress genes, cells become resistant to subsequent stresses. Members of the stress protein family include HO (see above); the multiple-drug resistance gene product P-glycoprotein; ubiquitin, involved in targeting proteins for degradation; scavengers such as superoxide dismutase, ferritin, and metallothioneins; and the glycolytic enzymes enolase and glyceraldehyde 3-phosphate dehydrogenase. The most extensively characterized are the HSPs.[39]

HSPs are molecular chaperones that may either be constitutively expressed or induced upon cellular stress.[289] Classification is based upon their molecular mass and degree of homology. The most extensively studied is the Hsp70 family, members of which possess a mean molecular mass of 70 kD and greater than 70% homology. Members of the Hsp70 family bind ATP, and are induced under conditions of energy depletion and stress. Hsp70 is integral in cellular adaptation to and survival during environmental stresses. Both Hsp72 and Hsp73 are present in the cytosol and nucleus. The former is constitutively expressed, whereas, expression of Hsp72 is exclusively induced. In most studies Hsp72 is used as a marker of HSP induction.[39,287,290,291]

The Hsp60 family members are also referred to as chaperones. The glucose-regulated protein group of HSP is induced with glucose starvation, inhibitors of N-glycosylation, and calcium ionophores. The decrease in glucose content may affect the pool of sugar donors during protein glycosylation. The low–molecular-weight HSP (molecular masses of 20 to 30 kD) may be important regulatory components of the actin-based cytoskeleton.[287]

HSP regulation of transcription occurs through the activation of heat-shock elements in the gene promoters. Two heat-shock transcriptional factors (HSF) have been identified, HSF1 and HSF2. HSF1 activates transcription of the Hsp72 gene in response to heat, heavy metals, and other inducers of the stress response. With stimulation, unbound HSF1

oligomerizes, translocates to the nucleus, and binds to the HSP promoter to activate the transcription of the gene. HSF2 is not activated by the classic inducers of heat-shock genes, but may be important in controlling the activities of HSP gene expression in the normal or unstressed cell.[39,287,290,291]

HSP can play multiple roles in modulating the inflammatory response. A number of conditions such as rheumatoid arthritis, ARDs, and asthma have been shown to benefit experimentally from increased HSP expression.[286–288,291] Functions of HSP include enhancement of immune responses, thermotolerance, regulation of apoptosis, hemostasis, and cytoprotection against ROS and other inflammatory mediators. HSP-CD91 interaction is integral to the processing and representation of antigen by APCs. HSP may shift the balance between T_H1 and T_H2 toward an increase in more anti-inflammatory T_H2 cells. ROS, including H_2O_2, hydroxyl radical, and peroxynitrite, activate HSP synthesis. In the presence of iron, ROS also induce the oxidation-specific stress proteins HO and ferritin, which afford protection against oxidative stress by binding iron and preventing it from participating in the Fenton reaction. Mechanisms of HSP-mediated cytoprotection from the toxic effects of ROS include the maintenance of cellular GSH levels (Hsp27) and mitochondrial protection (Hsp70). Hence, ROS induce a cytoprotective response that counteracts their own toxicity. Other inflammatory mediators such as NO have also been shown to induce expression of HSP.[39]

HSP may participate in intracellular signaling pathways that modulate the production or function of inflammatory mediators. For example, Hsp90 has been shown to facilitate signaling that leads to NO formation by eNOS.[292] Hsp70 has been reported to prevent apoptosis, which may promote propagation rather than resolution of inflammation. In addition, the body's immune response to bacterial and parasitic stress proteins likely protects the host from infection. The bacterial homologue of Hsp60, GroEL, is a major target of the mammalian humoral response to bacterial infections. Many activators of HSF1 are potent inhibitors of the proinflammatory transcription factor NFκB. Aspirin and other NSAIDs activate HSF while inhibiting NFκB. Therefore, the anti-inflammatory effects associated with the stress response might be related more to the inhibition of NFκB activation.[287,293]

The Acute-Phase Response

The acute-phase response consequent to trauma or cellular injury is characterized by alterations in hepatic metabolism; activation of the central nervous system, leading to fever and adaptive behaviors; altered hematopoiesis; activation of complement and the fibrinolytic and coagulation cascades; and the release of neuropeptides, kinins, and hormones. It is a rapid, nonspecific response that accompanies both acute and chronic inflammatory disorders. Many of the processes induced during the acute-phase response are mediated by cytokines. IL-6, IL-1, and TNFα play particularly central roles.[294,295] Though considered a defense mechanism promoting host survival, aberrant or unregulated production of many of these inflammatory mediators can be lethal.

Acute-Phase Proteins

An acute-phase protein is defined as a protein whose concentration increases by at least 25% during inflammation (Table 7-7).[295,296] These changes are primarily due to altered hepatic synthesis and typically occur within approximately 6 hours of the inciting stimulus. The function is to restore homeostasis: hemostatic functions (fibrinogen), microbicidal and phagocytic functions (complement components, C-reactive protein [CRP]), antithrombotic properties (plasminogen, protein S), antioxidant properties (haptoglobin), and antiproteolytic actions (α_2 macroglobulin, α_1 protease, α_1 chymotrypsin). The negative acute-phase proteins albumin, prealbumin, transferrin, and retinol-binding protein decrease by at least 25%. Levels of the negative acute-phase proteins, albumin and transferrin, drop almost immediately after operation and remain depressed for several days. The rapid initial loss of these proteins is likely due to increased vascular permeability and loss to the extravascular space. The magnitude of the response is proportional to the severity of the stress. Whereas trauma and burns lead to significant increases in acute-phase reactants, exercise and psychiatric illness induce more moderate responses.

The two major acute-phase proteins in humans are CRP and serum amyloid A (SAA). CRP, named because of its reaction with pneumococcal C-polysaccharide, displays both proinflammatory and anti-inflammatory effects. It has been shown to activate complement, recognize foreign pathogens, bind phagocytic cells, and enhance activation of tissue factor, the main initiator of coagulation. CRP can also inhibit superoxide production by neutrophils and inhibit neutrophil adhesion by decreasing surface expression of L-selectin. Changes in plasma or serum CRP, although nonspecific, may reflect the magnitude of an inflammatory process and may aid the differentiation of inflammatory from noninflammatory conditions. Measurement of CRP is more precise than the erythrocyte sedimentation rate; the latter largely depends on plasma fibrinogen levels and is influenced by a variety of other, unrelated factors in the circulation. SAA may promote chemotaxis and adhesion of phagocytes during inflammation.[39]

C1 inhibitor is of special interest as an acute-phase protein because of its effects outside of the complement cascade. This antiprotease inhibits the activity of HF, limiting kinin

production and factor XI production. Thus, enhanced expression of a complement inhibitor protein during acute inflammation may also influence coagulation, fibrinolysis, and kinin pathways.

Systemic Manifestations of the Acute-Phase Response

Systemic manifestations include neuroendocrine changes, shifts in the hematologic profile, and metabolic and chemical alterations. The classic neuroendocrine manifestation is fever. IL-1, IL-6, and TNFα mediate the fever response by resetting the hypothalamic temperature setpoint through the synthesis of PGE_2. The secretion of neuropeptides, such as CRH and AVP, and of hormones, such as glucagon, insulin, thyroxin, and aldosterone, is also characteristic of the acute-phase response. CRH and AVP are released by the hypothalamus and increase ACTH and cortisol levels. The rise in plasma cortisol levels occurs rapidly and may function to inhibit the fever response and cytokine gene expression, thereby serving a potential negative regulatory function in the acute-phase response. Glucocorticoids also stimulate macrocortin synthesis, which by inhibiting synthesis of PLA_2, limits the availability of arachidonic acid for prostaglandin synthesis. Glucocorticoids increase the rate of synthesis of certain acute-phase proteins involved in connective tissue repair and clotting, as well as antioxidants and antiproteinases. They also may function to counteract the hypoglycemic response to insulin overproduction during infection or stress.

Other alterations include a prominent leukocytosis, thrombocytosis, and the "anemia of chronic disease." Metabolic changes include altered lipid metabolism and negative nitrogen balance. Changes in the chemical and enzymatic profile include increased hepatic production of metallothionein, iNOS, HO, manganese superoxide dismutase, and glutathione (GSH). Plasma levels of zinc and iron are noted to drop, whereas copper levels increase slightly. This persists for the duration of inflammation and is likely due to sequestration induced by IL-6, glucocorticoids, and catecholamines. Low levels of iron and zinc may confer protective antimicrobial effects because they are essential micronutrients for microbial growth.[39]

Mediators of the Acute-Phase Response

Bacterial products such as LPS are probably the most potent activators of tissue macrophages, the initiators of the acute-phase response. LPS, through its interactions with LBP, CD14, and TLR, induces macrophage synthesis of ROS, including NO; lipid derivatives (e.g., PGE_2, thromboxane A_2, and PAF); and acute-phase cytokines (e.g., TNFα, IL-6). Additional mediators inducing the synthesis of acute-phase cytokines in the absence of bacterial infection include free radicals, prostaglandins, and the release of DAMPs from injured tissues.[39] Indeed the response to the sterile insult of trauma mirrors much of what is observed during severe sepsis, a similarity that may be the consequence of substantial overlap in signaling mechanisms, such as TLR4.

Acute-phase cytokines can be proinflammatory (IL-1, TNFα, IFNγ, IL-8) or anti-inflammatory (IL-10, IL-4, IL-13, TNFβ). However, it is IL-6 and IL-6-type cytokines that

are most critical in the acute-phase response. IL-6 is the major inducer of acute-phase proteins synthesis and, together with IL-1 and TNFα, is responsible for the systemic features classically associated with the acute-phase response (fever, anorexia, leukocytosis, and hormonal changes).[39]

In addition to the aforementioned cytokines, IFNγ is a potent inducer of complement components. The anti-inflammatory cytokine TGFβ stimulates synthesis of antiproteases, urokinase, and negative acute-phase proteins. IL-4 is inhibitory to some acute-phase proteins. Growth factors, including hepatocyte growth factor and TGFβ are also able to modulate the synthesis of acute-phase proteins. Glucocorticoids augment the response to cytokines, and insulin attenuates the cytokine-induced rise in acute-phase proteins.[39]

Effects of the cytokines are influenced by cytokine receptors, receptor antagonists, and hormones. IL-1RA competes with IL-1 and attenuates the acute-phase response in vivo. Soluble receptors for IL-1 and TNFα act as antagonists. In contrast, soluble receptors for IL-6 act as agonists.

Regulation of Acute-Phase Cytokines and Proteins

Several major families of transcription factors participate in the upregulation of acute-phase cytokines and proteins, the most important being NF-IL-6, AP-1, and NFκB.[297] NF-IL6 participates in the expression of the cytokines IL-1, TNFα, IL-6, and IL-8. Activation through the NFκB is probably the predominant pathway. The triggering of IL-6 in monocytes in vitro by IFNγ involves a change in the amount of the phosphorylated transcription factor Sp1, together with the induction and activation of IFN-regulatory factor.

All known acute-phase proteins are regulated primarily at the transcriptional level. Activation of TNFα and IL-1 receptors triggers signaling pathways that activate transcription factors AP-1 and NFκB. Many type I acute-phase proteins genes contain response elements for NFκB, NF-IL6, and AP-1. Acute-phase protein responses to IL-6 are mediated through the JAK-STAT signal transduction pathway. In addition, both IL-1 and IL-6 signal transduction mechanisms activate the MAPK pathway that activates transcription factors NF-IL6, linking the IL-1 and IL-6 pathways.

Reperfusion Injury

Prolonged tissue ischemia produces irreversible injury and cell death. Timely restoration of perfusion may salvage some tissue, though paradoxically can induce injury as well. Reperfusion injury is the damage caused by the restoration of blood flow in previously ischemic tissue (i.e., myocardial ischemia, transplantation, vascular surgery). Injury is the direct consequence of activation of the inflammatory response, especially complement activation and neutrophil recruitment. Components of the complement cascade promote tissue damage through the generation of anaphylatoxins and by the formation of the MAC. Invading neutrophils injure tissue through the generation of ROS and the release of proteolytic enzymes. Recent evidence points to TLR4 as a sensor of tissue stress, the signal of which is probably through release of DAMPs from ischemic cells.[32]

Alterations in the microvascular endothelium are central to the pathophysiologic process of reperfusion injury. Early loss of constitutive NO production facilitates neutrophil adherence, the upregulation of cell adhesion molecules such as P-selectin, and inhibits vasorelaxation and perfusion.[298] Low oxygen tension induces the conversion of xanthine dehydrogenase to xanthine oxidase. Reperfusion and reoxygenation yield the formation of superoxide anion and H_2O_2 and induce oxidant injury. Neutrophils and other cellular effectors are progressively recruited and activated, releasing ROS, cytokines, and NO, further contributing to increased vascular permeability and tissue injury. PAF released by neutrophils activates circulating platelets and promotes vascular plugging. Platelets also release factors that enhance platelet–neutrophil adhesion. Both cell types also release vasoconstricting agents that can further exacerbate no-reflow. Capillary plugging by neutrophils and platelets can impair local blood flow and cause the "no-reflow phenomenon."[39]

Neutrophils mediate direct toxicity to the surrounding tissue through the elaboration of ROS and granule contents. Peroxynitrite formed by the reaction of NO and superoxide can contribute directly to tissue injury during reperfusion. Neutrophil granule proteases such as elastase, collagenase, and gelatinase alter the vascular permeability and are highly destructive to local tissue. The significance of the neutrophil in mediating these effects are apparent in neutrophil depletion studies demonstrating attenuated tissue injury when compared to subjects with normal numbers of neutrophils.[299] Animal studies using blocking monoclonal antibodies to selectins and β_2 integrins show improved organ function ischemia/reperfusion.[300]

The mechanism by which complement is activated with reperfusion is not completely understood. Ischemia may alter the cell's plasma membrane or through the exposure of basement membrane or subcellular organelle components, creating a complement-activating surface. Alternatively, binding of natural antibody may lead to induction of these cascades.[172] Complement activation has been shown to occur in the setting of therapeutic thrombolysis. The generation of plasmin-dependent fibrinolytic agents and plasmin after tissue plasminogen activator administration has been associated with complement activation.[301]

Anaphylatoxins are important effectors of complement-mediated injury. They alter

vascular permeability, induce smooth muscle cell contraction, and stimulate the release of histamine from mast cells and basophils. C3a and C5a are potent chemoattractants especially for neutrophils. C5 can be activated by an abundance of oxygen free radicals. The subsequent generation of the MAC perturbs the maintenance of vital ion gradients, induces cell lysis, and facilitates neutrophil recruitment. In addition it can induce the expression of numerous inflammatory mediators, including cytokines (TNFα, IL-1, IL-8), ROS, prostaglandins, LTs, and cell surface adhesion molecules.[302]

Systemic Inflammatory Response Syndrome

The inability of host defenses to control a localized inflammatory process or an unchecked inflammatory response can result in SIRS. A recent consensus conference defined SIRS as the presence of any two of the following physiologic parameters: (1) a temperature greater than 38°C or less than 36°C; (2) leukocytosis (>12,000), leukopenia (<4,000), of more than 10% bands; (3) pulse greater than 90 beats per minute; (4) tachypnea (respiratory rate greater than 20 or $PaCO_2$ < 32 mm Hg).[303] Infection underlies a significant minority of cases as only a third of patients with SIRS will have a documented infection and meet the criteria for sepsis. There is a continuum from the development of SIRS to sepsis, to severe sepsis, septic shock, and MODS.[304] The outcome depends on the balance between SIRS and host compensatory mechanisms. In one prospective study, 26% of patients with SIRS developed sepsis and 7% died.[305]

SIRS may be initiated by infectious or noninfectious causes, such as trauma, autoimmune reactions, or pancreatitis. Gram-negative organisms, rich in LPS, induce a potent inflammatory response mediated through the CD14/TLR4/MyD88 pathway previously described and account for the majority of infectious SIRS cases. Gram-positive organisms can generate a similarly impressive degree of inflammation either through TLR2 or alternative mechanisms. Streptococcal superantigen may induce a global and nonspecific activation of T cells that culminates in massive systemic elaboration of cytokines and cardiovascular collapse termed TSS. Trauma, either through tissue injury (HMGB1-RAGE, HSP-CD91) or the ischemia/reperfusion consequent to hemorrhage can culminate in inflammatory pathophysiology indistinguishable from that accompanying these other inflammatory states. As the growing evidence continues to support the promiscuity of TLR and other signaling pathways, we are replacing the former concept distinct receptor-signaling mechanisms for each stimulus with one that emphasizes the similarities, overlap and integration. Though there are clearly mechanisms by which host distinguishes normal self from endogenous (trauma) and exogenous (infection) dangers, there is considerable overlap, and all stimuli appear to converge upon similar signaling mechanisms in attaining the goal of preserving the host.

The development of SIRS has been described as progressing through three stages: Stage I – local cytokine production recruits inflammatory cells to the injured site; Stage II – an acute-phase response is initiated and small quantities of cytokines are released into the circulation to enhance the local response; and Stage III – homeostasis cannot be reestablished.[306] Enhanced levels of CRP, the major acute-phase protein in humans, occur in SIRS/sepsis, and clinical resolution is preceded by a drop in CRP levels.

The elaboration of proinflammatory cytokines (IL-1, TNFα, and IL-6) is central to the pathogenesis of SIRS regardless of the initiating stimulus. Their release triggers increased expression of adhesion molecules, leukocyte recruitment, and the production of secondary proinflammatory mediators, such as chemokines. Endotoxin is one of the most powerful triggers of SIRS. LPS activates the complement and coagulation cascades, induces endothelial cell activation, and increases TNFα and IL-1 synthesis, and the late release of HMGB1. However, noninfectious tissue injury induces a similar inflammatory response.

LPS, TNFα, and IL-1 also induce increased production of NO by iNOS. PGI_2 and arachidonic acid, together with NO contribute to decreased systemic vascular resistance and hypotension. Autocrine and paracrine NO production also results in myocardial depression. Increased vascular permeability promotes extravasation of fluid and edema formation. Activated endothelial cells express tissue factor, PECAM, and TXA_2, which promote a procoagulant local environment that predisposes to microthrombi formation. Adherent leukocytes further exacerbate organ injury by mechanically impeding microvascular blood flow and by damaging the endothelial cells and surrounding connective tissue. The results are end-organ hypoperfusion, inadequate oxygen delivery, initiation of anaerobic metabolism, and organ failure. The metabolic and nutritional sequelae of this activated cytokine milieu includes fever, catabolism, cachexia, and altered fat, glucose, and trace mineral metabolism.

SIRS is counteracted by the concomitant induction of an anti-inflammatory response termed the compensatory anti-inflammatory response syndrome (CARS).[306] Many of the proinflammatory mediators that participate in SIRS modulate the immune function of lymphocytes and mononuclear cells. Proinflammatory mediators can inhibit their own synthesis or enhance the synthesis of natural antagonists by negative feedback mechanisms. Thus, at any given time, the clinical manifestation is SIRS, CARS, or an intermediate, mixed inflammatory response syndrome. The spectrum of features that characterizes these syndromes has been termed CHAOS (cardiovascular shock, homeostasis, apoptosis, organ dysfunction, and immune suppression). Studies employing a variety of specific anticytokine agents have failed to observe an improvement in the outcome of patients with SIRS or sepsis.

Chronic Inflammation

There are no clear boundaries between an acute and a chronic inflammatory response. In general, if the source of an acute inflammatory process is incompletely eliminated, a state of chronic inflammation eventually ensues. Chronicity is usually not characterized by the signs classically associated with acute responses, such as swelling, heat, or redness. Pain is minimal if not absent. Microscopically, a mononuclear cell infiltrate predominates (lymphocytes, monocytes, plasma cells) with proliferation of fibroblasts and vascular elements.

Many agents can create a state of chronic inflammation, including persistent infectious agents, remnants of dead organisms, foreign bodies, and metabolic byproducts. Ultimately, chronicity of inflammation is a result of the immune response to a persistent antigen. Furthermore, a chronic inflammatory response can develop in the absence of a preceding acute response, such as infections with agents of low toxicity such as mycobacterium and treponema. $CD4^+$ T cells and macrophages are the primary cellular orchestrators of chronic inflammatory response.[307] T_H1 cell–mediated immune responses are protective against most microbes and usually result in the elimination of the pathogen. If the microbe persists, the ongoing T_H1 response results in inflammatory tissue injury. Cytokines and growth factors released by T lymphocytes and macrophages stimulate proliferative responses. Neutrophils and eosinophils contribute to the release of proteolytic enzymes and oxygen derivatives. Eosinophilia occurs with chronic parasitic infections and hypersensitivity conditions. Fibroblasts are actively recruited by chemoattractants such as fibrin, collagens, and cytokines. Local IL-1 stimulates fibroblast proliferation and collagen production. Irreversible tissue damage can occur through the replacement of normal parenchyma with fibrous connective tissue. Fibroblasts can release metalloproteinases that degrade normal tissue, further contributing to tissue destruction. Mast cells are elevated in chronic conditions and may play a part in cell-mediated immune responses. Inflammatory cyst formation may occur as a result of epithelial hyperplasia.

References

1. Cotran RS. Inflammation: basic principles and clinical correlates. In: Gallin J, S R. *Inflammation: Historical Perspectives.* 3rd ed. Philadelphia, PA: Lippincott Williams & Wilkins; 1999.
2. Heifets L. Centennial of Metchnikoff's discovery. *J Reticuloendothel Soc.* 1982;31(5):381–391.
3. Cotran RS, Kumar V, Robbins T, eds. *Robbins Pathologic Basis of Disease.* 6th ed. C RS, K V, R T. Philadelphia, PA: WB Sanders; 1999.
4. Abbas AK, Lichtman AH. *Cellular and Molecular Immunology.* 5th ed. Philadelphia, PA: Saunders; 2003.
5. Wheeler JG, Abramson JS. *The Neutrophil.* Oxford: IRL Press at Oxford University Press; 1993.
6. Bainton D. The cells of inflammation: a general view. In: Weissmann G, ed. *The Cell Biology of Inflammation,* Vol 2. 1980, New York: Elsevier/North-Holland; 1980.
7. Dancey JT, Deubelbeiss KA, Harker LA, et al. Neutrophil kinetics in man. *J Clin Invest* 1976;58(3):705–715.
8. Omann GM, Hinshaw DB. Inflammation. In: Greenfield LJ, et al. eds. *Surgery: Scientific Principles and Practice,* 2nd ed. Philadelphia, PA: Lippincott-Raven; 1997:130–159.
9. Trowbridge HO, Emling RC, eds. *Inflammation: A Review of the Process.* Chicago, IL: Quintessence; 1997.
10. Dustin ML, Springer TA. Role of lymphocyte adhesion receptors in transient interactions and cell locomotion. *Annu Rev Immunol* 1991;9:27–66.
11. Kansas GS. Selectins and their ligands: current concepts and controversies. *Blood* 1996;88(9):3259–3287.
12. Tedder TF, Steeber DA, Chen A, et al. The selectins: vascular adhesion molecules. *FASEB J* 1995;9(10):866–873.
13. Frenette PS, Wagner DD. Adhesion molecules–part II: blood vessels and blood cells. *N Engl J Med* 1996;335(1):43–45.
14. Frenette PS, Wagner DD. Adhesion molecules–part 1. *N Engl J Med* 1996;334(23):1526–1529.
15. Hynes RO. Integrins: versatility, modulation, and signaling in cell adhesion. *Cell* 1992;69(1):11–25.
16. Muller WA. Leukocyte-endothelial-cell interactions in leukocyte transmigration and the inflammatory response. *Trends Immunol* 2003;24(6):327–334.
17. Vaporciyan AA, DeLisser HM, Yan HC, et al. Involvement of platelet-endothelial cell adhesion molecule-1 in neutrophil recruitment in vivo. *Science* 1993;262(5139):1580–1582.
18. Thornhill M, Haskard D. Leukocyte adhesion to endothelium. Blood cell

biochemistry. In: Horton M, ed. *Macrophages and Related Cells.* Vol 5. New York: Plenum Press; 1993.

19. Rot A. The role of leukocyte chemotaxis in inflammation. In: Whicker J, Evans S, eds. *Biochemistry and Inflammation.* Boston, MA: Kluwer Academic; 1992.
20. Wagner JG, Roth RA. Neutrophil migration during endotoxemia. *J Leukoc Biol* 1999;66(1):10–24.
21. Indik ZK, Park JG, Hunter S, et al. Structure/function relationships of Fc gamma receptors in phagocytosis. *Semin Immunol* 1995;7(1):45–54.
22. Ezekowitz R. The mannose receptor and phagocytosis. In: Furth RV, ed. *Mononuclear Phagocytes: Biology of Monocytes and Macrophages.* Boston, MA: Kluwer Academic; 1992.
23. Ezekowitz RA, Sim RB, Hill M, et al. Local opsonization by secreted macrophage complement components. Role of receptors for complement in uptake of zymosan. *J Exp Med* 1984;159(1):244–260.
24. Lee WL, Harrison RE, Grinstein S. Phagocytosis by neutrophils. *Microbes Infect* 2003;5(14):1299–1306.
25. Zychlinsky A, Weinrauch Y, Weiss J. Introduction: forum in immunology on neutrophils. *Microbes Infect* 2003;5(14):1289–1291.
26. Borregaard N, Cowland JB Granules of the human neutrophilic polymorphonuclear leukocyte. *Blood* 1997;89(10):3503–3521.
27. Faurschou M, Borregaard N. Neutrophil granules and secretory vesicles in inflammation. *Microbes Infect* 2003;5(14):1317–1327.
28. Lehrer RI, Ganz T, Selsted ME. Defensins: endogenous antibiotic peptides of animal cells. *Cell* 1991;64(2):229–230.
29. Elsbach P. The bactericidal/permeability-increasing protein (BPI) in antibacterial host defense. *J Leukoc Biol* 1998;64(1):14–18.
30. Beamer LJ, Carroll SF, Eisenberg D. The BPI/LBP family of proteins: a structural analysis of conserved regions. *Protein Sci* 1998;7(4):906–914.
31. Gabay JE, Scott RW, Campanelli D, et al. Antibiotic proteins of human polymorphonuclear leukocytes. *Proc Natl Acad Sci U S A* 1989;86(14):5610–5614.
32. Tsung A, Klune JR, Zhang X, et al. HMGB1 release induced by liver ischemia involves Toll-like receptor 4 dependent reactive oxygen species production and calcium-mediated signaling. *J Exp Med* 2007;204(12):2913–2923.
33. Chapple IL. Reactive oxygen species and antioxidants in inflammatory diseases. *J Clin Periodontol* 1997;24(5):287–296.
34. Kasahara Y, Iwai K, Yachie A, et al. Involvement of reactive oxygen intermediates in spontaneous and CD95 (Fas/APO-1)-mediated apoptosis of neutrophils. *Blood* 1997;89(5):1748–1753.
35. Roos D, van Bruggen R, Meischl C. Oxidative killing of microbes by neutrophils. *Microbes Infect* 2003;5(14):1307–1315.

36. Nordberg J, Arner ES. Reactive oxygen species, antioxidants, and the mammalian thioredoxin system. *Free Radic Biol Med* 2001;31(11):1287–1312.
37. Winyard PG, Perret D, Harris G, et al. The role of toxic oxygen species in inflammation with special reference to DNA damage. In: Whicker JT, Evans SW, eds. *Biochemistry of Inflammation.* Boston, MA: Kluwer Academic; 1992.
38. Nohl H. Generation of superoxide radicals as byproduct of cellular respiration. *Ann Biol Clin (Paris)* 1994;52(3):199–204.
39. Schuchert RD, Billiar TR. Inflammation. In: Greenfield LJ, ed. *Surgery: Scientific Principles and Practice.* 3rd ed. Philadelphia, PA: Lippincott Williams & Wilkins; 2001.
40. Menshikova EV, Salama G. Cardiac ischemia oxidizes regulatory thiols on ryanodine receptors: captopril acts as a reducing agent to improve Ca2 +uptake by ischemic sarcoplasmic reticulum. *J Cardiovasc Pharmacol* 2000;36(5):656–668.
41. Szabo C. The pathophysiological role of peroxynitrite in shock, inflammation, and ischemia-reperfusion injury. *Shock* 1996;6(2):79–88.
42. Warren J, Ward P, Johnson K. Oxygen radicals as mediators of inflammation. In: Hensen PM, Murphy RC, eds. *Handbook of Inflammation.* Vol 6. New York: Elsevier Science Publishers BV; 1989.
43. Burg ND, Pillinger MH. The neutrophil: function and regulation in innate and humoral immunity. *Clin Immunol* 2001;99(1):7–17.
44. Marenzi G, Assanelli E, Marana I, et al. N-acetylcysteine and contrast-induced nephropathy in primary angioplasty. *N Engl J Med* 2006;354(26):2773–2782.
45. Kaplan MJ, Radic M. Neutrophil extracellular traps: double-edged swords of innate immunity. *J Immunol* 2012;189(6):2689–2695.
46. Zawrotniak M, Rapala-Kozik M. Neutrophil extracellular traps (NETs) - formation and implications. *Acta biochimica Polonica* 2013;60(3):277–284.
47. Ma AC, Kubes P. Platelets, neutrophils, and neutrophil extracellular traps (NETs) in sepsis. *J Thromb Haemost* 2008;6(3):415–420.
48. Kobayashi SD, Voyich JM, DeLeo FR. Regulation of the neutrophil-mediated inflammatory response to infection. *Microbes Infect* 2003;5(14):1337–1344.
49. Burkitt HG, Young B, Heath JW. *Wheater's Functional Histology: A Text and Colour Atlas.* 3rd ed. Edinburgh, UK; Churchill Livingstone; 1993.
50. Ma J, Chen T, Mandelin J, et al. Regulation of macrophage activation. *Cell Mol Life Sci* 2003;60(11):2334–2346.
51. Ben-Baruch A, Michiel DF, Oppenheim JJ. Signals and receptors involved in recruitment of inflammatory cells. *J Biol Chem* 1995;270(20):11703–11706.
52. Kuijpers T, Hakkert B, Knol E, et al. Membrane surface antigen expression on human monocytes: changes during purification, in vitro activation and transmigration across monolayers of endothelial cells. In: Furtin RV, ed. *Mononuclear Phagocytes: Biology of Monocytes and Macrophages.* Boston, MA: Kluwer Academic; 1992.
53. Nathan C, Xie QW. Nitric oxide synthases: roles, tolls, and controls. *Cell*

1994;78(6):915–918.
54. de Waal Malefyt R, Yssel H, Roncarolo MG, et al. Interleukin-10. *Curr Opin Immunol* 1992;4(3):314–320.
55. MacMicking J, Xie QW, Nathan C. Nitric oxide and macrophage function. *Annu Rev Immunol* 1997;15:323–350.
56. Wang H, Yang H, Tracey KJ. Extracellular role of HMGB1 in inflammation and sepsis. *J Intern Med* 2004;255(3):320–331.
57. Wang H, Bloom O, Zhang M, et al. HMG-1 as a late mediator of endotoxin lethality in mice. *Science* 1999;285(5425):248–251.
58. Griffiths GM, The cell biology of CTL killing. *Curr Opin Immunol* 1995;7(3):343–348.
59. Romagnani S. Understanding the role of Th1/Th2 cells in infection. *Trends Microbiol* 1996;4(12):470–473.
60. Mosmann TR, Coffman RL. TH1 and TH2 cells: different patterns of lymphokine secretion lead to different functional properties. *Annu Rev Immunol* 1989;7:145–173.
61. Lane PJ, Brocker T. Developmental regulation of dendritic cell function. *Curr Opin Immunol* 1999;11(3):308–313.
62. Banchereau J, Steinman RM. Dendritic cells and the control of immunity. *Nature* 1998;392(6673):245–252.
63. Braciale TJ, Morrison LA, Sweetser MT, et al. Antigen presentation pathways to class I and class II MHC-restricted T lymphocytes. *Immunol Rev* 1987;98:95–114.
64. Razi-Wolf Z, Freeman GJ, Galvin F, et al. Expression and function of the murine B7 antigen, the major costimulatory molecule expressed by peritoneal exudate cells. *Proc Natl Acad Sci U S A* 1992;89(9):4210–4214.
65. Lanzavecchia A. Receptor-mediated antigen uptake and its effect on antigen presentation to class II-restricted T lymphocytes. *Annu Rev Immunol* 1990;8:773–793.
66. Gumperz JE, Parham P. The enigma of the natural killer cell. *Nature* 1995;378(6554):245–248.
67. Janeway C, Travers P. Immunobiology: the immune system in health and disease. In: Janeway C, Travers P, eds. *Immunobiology: The Immune System in Health and Disease.* 3rd ed. 1997.
68. Surh CD, Sprent J. T-cell apoptosis detected in situ during positive and negative selection in the thymus. *Nature* 1994;372(6501):100–103.
69. Zal T, Volkmann A, Stockinger B. Mechanisms of tolerance induction in major histocompatibility complex class II-restricted T cells specific for a blood-borne self-antigen. *J Exp Med* 1994;180(6):2089–2099.
70. Picker LJ. Control of lymphocyte homing. *Curr Opin Immunol* 1994;6(3):394–406.
71. Dustin ML, Springer TA. T-cell receptor cross-linking transiently stimulates adhesiveness through LFA-1. *Nature* 1989;341(6243):619–624.
72. Springer TA. Traffic signals for lymphocyte recirculation and leukocyte emigration:

the multistep paradigm. *Cell* 1994;76(2):301–314.
73. Janeway CA Jr, Bottomly K. Signals and signs for lymphocyte responses. *Cell* 1994;76(2):275–285.
74. Mosmann TR, Sad S. The expanding universe of T-cell subsets: Th1, Th2 and more. *Immunol Today* 1996;17(3):138–146.
75. Jain J, McCaffrey PG, Miner Z, et al. The T-cell transcription factor NFATp is a substrate for calcineurin and interacts with Fos and Jun. *Nature* 1993;365(6444):352–355.
76. Lee KP, Harlan DM, June CH. Role of co-stimulation in the host response to infection. In: Gallin JI, Snyderman R, eds. *Inflammation: Basic Principles and Clinical Correlates.* 3rd ed. Philadelphia, PA: Lippincott Williams & Wilkins; 1999.
77. Lin MY, Zal T, Ch'en IL, et al. A pivotal role for the multifunctional calcium/calmodulin-dependent protein kinase II in T cells: from activation to unresponsiveness. *J Immunol* 2005;174(9):5583–5592.
78. Broide DH, Hoffman H, Sriramarao P. Genes that regulate eosinophilic inflammation. *Am J Hum Genet* 1999;65(2):302–307.
79. Elsner J, Kapp A. Regulation and modulation of eosinophil effector functions. *Allergy* 1999;54(1):15–26.
80. Weller PF, Bach DS, Austen KF. Biochemical characterization of human eosinophil Charcot-Leyden crystal protein (lysophospholipase). *J Biol Chem* 1984;259(24):15100–15105.
81. Giembycz MA, Lindsay MA. Pharmacology of the eosinophil. *Pharmacol Rev* 1999;51(2):213–340.
82. Slungaard A, Mahoney JR Jr, Thiocyanate is the major substrate for eosinophil peroxidase in physiologic fluids. Implications for cytotoxicity. *J Biol Chem* 1991;266(8):4903–4910.
83. Wardlaw AJ, Moqbel R, Kay AB. Eosinophils: biology and role in disease. *Adv Immunol* 1995;60:151–266.
84. Wedi B, Raap U, Lewrick H, et al. Delayed eosinophil programmed cell death in vitro: a common feature of inhalant allergy and extrinsic and intrinsic atopic dermatitis. *J Allergy Clin Immunol* 1997;100(4):536–543.
85. Valent P, Schmidt G, Besemer J, et al. Interleukin-3 is a differentiation factor for human basophils. *Blood* 1989;73(7):1763–1769.
86. Nilsson G, Cost J, Metcalfke D. Mast cells and basophils. In: Gallin JI, Snyderman R, eds. *Inflammation: Basic Principles and Clinical Correlates.* 3rd ed. Philadelphia, PA: Lippincott Williams & Wilkins; 1999.
87. Metcalfe DD, Baram D, Mekori YA. Mast cells. *Physiol Rev* 1997;77(4):1033–1079.
88. Klinger MH, Jelkmann W. Role of blood platelets in infection and inflammation. *J Interferon Cytokine Res* 2002;22(9):913–922.
89. Marcus A. Platelets: their role in hemostasis, thrombosis, and inflammation. In :

Gallin J, Snyderman R, eds. *Inflammation: Basic Principles and Clinical Correlates.* 3rd ed. Philadelphia, PA: Lippincott Williams & Wilkins; 1999.

90. Du X, Williams DA. Interleukin-11: review of molecular, cell biology, and clinical use. *Blood* 1997;89(11):3897–3908.
91. Weyrich AS, Lindemann S, Zimmerman GA. The evolving role of platelets in inflammation. *J Thromb Haemost* 2003;1(9):1897–1905.
92. Serhan CN. Lipoxins and novel aspirin-triggered 15-epi-lipoxins (ATL): a jungle of cell-cell interactions or a therapeutic opportunity? *Prostaglandins* 1997;53(2): 107–137.
93. Marcus AJ, Safier LB, Ullman HL, et al. Platelet-neutrophil interactions. (12S)-hydroxyeicosatetraen-1,20-dioic acid: a new eicosanoid synthesized by unstimulated neutrophils from (12S)-20-dihydroxyeicosatetraenoic acid. *J Biol Chem* 1988;263(5):2223–2229.
94. Serhan CN, Haeggstrom JZ, Leslie CC. Lipid mediator networks in cell signaling: update and impact of cytokines. *FASEB J* 1996;10(10):1147–1158.
95. Colletti LM. Cytokines. In: Greenfield LJ, ed. *Surgery: Scientific Principles and Practice.* 3rd ed. Philadelphia, PA: Lippincott Williams & Wilkins; 2001.
96. Thomson A. *The Cytokine Handbook.* 3rd ed. New York: Academic Press; 1998.
97. Schmidt AM, Yan SD, Yan SF, et al. The biology of the receptor for advanced glycation end products and its ligands. *Biochim Biophys Acta* 2000;1498(2–3):99–111.
98. Strieter RM, Lynch JP III, Basha MA, et al. Host responses in mediating sepsis and adult respiratory distress syndrome. *Semin Respir Infect* 1990;5(3):233–247.
99. Opal SM, Patrozou E. Translational research in the development of novel sepsis therapeutics: logical deductive reasoning or mission impossible? *Crit Care Med* 2009;37(1 suppl):S10–S15.
100. Cerami A. Inflammatory cytokines. *Clin Immunol Immunopathol* 1992;62(1 Pt 2):S3–S10.
101. Bauss F, Droge W, Mannel DN. Tumor necrosis factor mediates endotoxic effects in mice. *Infect Immun* 1987;55(7):1622–1625.
102. Philip R, Epstein LB. Tumour necrosis factor as immunomodulator and mediator of monocyte cytotoxicity induced by itself, gamma-interferon and interleukin-1. *Nature* 1986;323(6083):86–89.
103. Adam-Klages S, Schwandner R, Adam D, et al. Distinct adapter proteins mediate acid versus neutral sphingomyelinase activation through the p55 receptor for tumor necrosis factor. *J Leukoc Biol* 1998;63(6):678–682.
104. Tartaglia LA, Ayres TM, Wong GH, et al. A novel domain within the 55 kd TNF receptor signals cell death. *Cell* 1993;74(5):845–853.
105. Meager A. Cytokine regulation of cellular adhesion molecule expression in inflammation. *Cytokine Growth Factor Rev* 1999;10(1):27–39.
106. Chen G, Ward MF, Sama AE, et al. Extracellular HMGB1 as a proinflammatory

cytokine. *J Interferon Cytokine Res* 2004;24(6):329–333.

107. Kokkola R, Andersson A, Mullins G, et al. RAGE is the major receptor for the proinflammatory activity of HMGB1 in rodent macrophages. *Scand J Immunol* 2005;61(1):1–9.
108. Tracey KJ, Fong Y, Hesse DG, et al. Anti-cachectin/TNF monoclonal antibodies prevent septic shock during lethal bacteraemia. *Nature* 1987;330(6149):662–664.
109. Tracey KJ, Lowry SF, Cerami A. Cachectin/TNF mediates the pathophysiological effects of bacterial endotoxin/lipopolysaccharide (LPS). *Prog Clin Biol Res* 1988;272:77–88.
110. Le J, Vilcek J. Tumor necrosis factor and interleukin 1: cytokines with multiple overlapping biological activities. *Lab Invest* 1987;56(3):234–248.
111. Sims JE, March CJ, Cosman D, et al. cDNA expression cloning of the IL-1 receptor, a member of the immunoglobulin superfamily. *Science* 1988;241(4865):585–589.
112. Kuno K, Matsushima K. The IL-1 receptor signaling pathway. *J Leukoc Biol* 1994;56(5):542–547.
113. Colotta F, Dower SK, Sims JE, et al. The type II 'decoy' receptor: a novel regulatory pathway for interleukin 1. *Immunol Today* 1994;15(12):562–566.
114. Bevilacqua MP, Schleef RR, Gimbrone MA Jr, et al. Regulation of the fibrinolytic system of cultured human vascular endothelium by interleukin 1. *J Clin Invest* 1986;78(2):587–591.
115. Baggiolini M, Dewald B, Moser B. Human chemokines: an update. *Annu Rev Immunol* 1997;15:675–705.
116. Bacon K, Baggiolini M, Broxmeyer H, et al. Chemokine/chemokine receptor nomenclature. *J Interferon Cytokine Res* 2002;22(10):1067–1068.
117. Bacon KB, Greaves DR, Dairaghi DJ, et al. The expanding universe of C, CX3C, and CC chemokines. In: Thomson A, ed. *The Cytokine Handbook.* 3rd ed. New York: Academic Press; 1998.
118. Rollins BJ, Chemokines. *Blood* 1997;90(3):909–928.
119. Schall TJ, Bacon KB. Chemokines, leukocyte trafficking, and inflammation. *Curr Opin Immunol* 1994;6(6):865–873.
120. Hebert CA, Vitangcol RV, Baker JB. Scanning mutagenesis of interleukin-8 identifies a cluster of residues required for receptor binding. *J Biol Chem* 1991;266(28):18989–18994.
121. Clark-Lewis I, Dewald B, Geiser T, et al. Platelet factor 4 binds to interleukin 8 receptors and activates neutrophils when its N terminus is modified with Glu-Leu-Arg. *Proc Natl Acad Sci U S A* 1993;90(8):3574–3577.
122. Clark-Lewis I, Kim KS, Rajarathnam K, et al. Structure-activity relationships of chemokines. *J Leukoc Biol* 1995;57(5):703–711.
123. D'Andrea A, Rengaraju M, Valiante NM, et al. Production of natural killer cell stimulatory factor (interleukin 12) by peripheral blood mononuclear cells. *J Exp Med*

1992;176(5):1387–1398.
124. Shu U, Kiniwa M, Wu CY, et al. Activated T cells induce interleukin-12 production by monocytes via CD40-CD40 ligand interaction. *Eur J Immunol* 1995;25(4):1125–1128.
125. Gauldie J, Richards C, Harnish D, et al. Interferon beta 2/B-cell stimulatory factor type 2 shares identity with monocyte-derived hepatocyte-stimulating factor and regulates the major acute phase protein response in liver cells. *Proc Natl Acad Sci U S A* 1987;84(20):7251–7255.
126. Van Snick J. Interleukin-6: an overview. *Annu Rev Immunol* 1990;8:253–278.
127. LeMay LG, Otterness IG, Vander AJ, et al. In vivo evidence that the rise in plasma IL 6 following injection of a fever-inducing dose of LPS is mediated by IL 1 beta. *Cytokine* 1990;2(3):199–204.
128. Tilg H, Trehu E, Atkins MB, et al. Interleukin-6 (IL-6) as an anti-inflammatory cytokine: induction of circulating IL-1 receptor antagonist and soluble tumor necrosis factor receptor p55. *Blood* 1994;83(1):113–118.
129. Sunden-Cullberg J, Norrby-Teglund A, Rouhiainen A, et al. Persistent elevation of high mobility group box-1 protein (HMGB1) in patients with severe sepsis and septic shock. *Crit Care Med* 2005;33(3):564–573.
130. Bonaldi T, Talamo F, Scaffidi P, et al. Monocytic cells hyperacetylate chromatin protein HMGB1 to redirect it towards secretion. *EMBO J* 2003;22(20):5551–5560.
131. Scaffidi P, Misteli T, Bianchi ME. Release of chromatin protein HMGB1 by necrotic cells triggers inflammation. *Nature* 2002;418(6894):191–195.
132. Gardella S, Andrei C, Ferrera D, et al. The nuclear protein HMGB1 is secreted by monocytes via a non-classical, vesicle-mediated secretory pathway. *EMBO Rep* 2002;3(10):995–1001.
133. Tang D, Shi Y, Kang R, et al. Hydrogen peroxide stimulates macrophages and monocytes to actively release HMGB1. *J Leukoc Biol* 2007;81(3):741–747.
134. Zhang X, Wheeler D, Tang Y, et al. Calcium/calmodulin-dependent protein kinase (CaMK) IV mediates nucleocytoplasmic shuttling and release of HMGB1 during lipopolysaccharide stimulation of macrophages. *J Immunol* 2008;181(7):5015–5023.
135. Chen G, Li J, Ochani M, et al. Bacterial endotoxin stimulates macrophages to release HMGB1 partly through CD14- and TNF-dependent mechanisms. *J Leukoc Biol* 2004;76(5):994–1001.
136. Fiuza C, Bustin M, Talwar S, et al. Inflammation-promoting activity of HMGB1 on human microvascular endothelial cells. *Blood* 2003;101(7):2652–2660.
137. Rouhiainen A, Tumova S, Valmu L, et al. Pivotal advance: analysis of proinflammatory activity of highly purified eukaryotic recombinant HMGB1 (amphoterin). *J Leukoc Biol* 2007;81(1):49–58.
138. Andersson U, Tracey KJ. HMGB1 in sepsis. *Scand J Infect Dis* 2003;35(9):577–584.
139. Andersson U, Wang H, Palmblad K, et al. High mobility group 1 protein (HMG-1) stimulates proinflammatory cytokine synthesis in human monocytes. *J Exp Med*

2000;192(4):565–570.
140. Andersson UG, Tracey KJ. HMGB1, a pro-inflammatory cytokine of clinical interest: introduction. *J Intern Med* 2004;255(3):318–319.
141. Riedemann NC, Guo RF, Ward PA. Novel strategies for the treatment of sepsis. *Nat Med* 2003;9(5):517–524.
142. Sama AE, D'Amore J, Ward MF, et al. Bench to bedside: HMGB1-a novel proinflammatory cytokine and potential therapeutic target for septic patients in the emergency department. *Acad Emerg Med* 2004;11(8):867–873.
143. Erlandsson Harris H, Andersson U. Mini-review: the nuclear protein HMGB1 as a proinflammatory mediator. *Eur J Immunol* 2004;34(6):1503–1512.
144. Rovere-Querini P. Capobianco A, Scaffidi P, et al. HMGB1 is an endogenous immune adjuvant released by necrotic cells. *EMBO Rep* 2004;5(8):825–830.
145. Peltz ED, Moore EE, Eckels PC, et al. Hmgb1 is markedly elevated within 6 hours of mechanical trauma in humans. *Shock* 2009;32(1):17–22.
146. Ombrellino M, Wang H, Ajemian MS, et al. Increased serum concentrations of high-mobility-group protein 1 in haemorrhagic shock. *Lancet* 1999;354(9188):1446–1447.
147. Jiang W, Pisetsky DS. Mechanisms of Disease: the role of high-mobility group protein 1 in the pathogenesis of inflammatory arthritis. *Nat Clin Pract Rheumatol* 2007;3(1):52–58.
148. Rifkin IR, Leadbetter EA, Busconi L, et al. Toll-like receptors, endogenous ligands, and systemic autoimmune disease. *Immunol Rev* 2005;204:27–42.
149. Foell D, Wittkowski H, Roth J. Mechanisms of disease: a 'DAMP' view of inflammatory arthritis. *Nat Clin Pract Rheumatol* 2007;3(7):382–390.
150. Taniguchi N, Kawahara K, Yone K, et al. High mobility group box chromosomal protein 1 plays a role in the pathogenesis of rheumatoid arthritis as a novel cytokine. *Arthritis Rheum* 2003;48(4):971–981.
151. Bogdan C. The function of type I interferons in antimicrobial immunity. *Curr Opin Immunol* 2000;12(4):419–424.
152. De Maeyer E, De Maeyer-Guignard J. Type I interferons. *Int Rev Immunol* 1998;17(1–4):53–73.
153. Uze G, Lutfalla G, Mogensen KE. Alpha and beta interferons and their receptor and their friends and relations. *J Interferon Cytokine Res* 1995;15(1):3–26.
154. Selzman CH, Shames BD, Miller SA, et al. Therapeutic implications of interleukin-10 in surgical disease. *Shock* 1998;10(5):309–318.
155. Cassatella MA, Meda L, Bonora S, et al. Interleukin 10 (IL-10) inhibits the release of proinflammatory cytokines from human polymorphonuclear leukocytes. Evidence for an autocrine role of tumor necrosis factor and IL-1 beta in mediating the production of IL-8 triggered by lipopolysaccharide. *J Exp Med* 1993;178(6):2207–2211.
156. Neurath MF, Meyer zum Buschenfelde KH. Protective and pathogenic roles of cytokines in inflammatory bowel diseases. *J Investig Med* 1996;44(9):516–521.

157. Smith KA. Interleukin-2: inception, impact, and implications. *Science* 1988;240(4856):1169–1176.
158. Smith KA. Lowest dose interleukin-2 immunotherapy. *Blood* 1993;81(6):1414–1423.
159. Zurawski SM, Vega F Jr, Huyghe B, et al. Receptors for interleukin-13 and interleukin-4 are complex and share a novel component that functions in signal transduction. *EMBO J* 1993;12(7):2663–2670.
160. de Waal Malefyt R, Figdor CG, Huijbens R, et al. Effects of IL-13 on phenotype, cytokine production, and cytotoxic function of human monocytes. Comparison with IL-4 and modulation by IFN-gamma or IL-10. *J Immunol* 1993;151(11):6370–6381.
161. Billiau A, Heremans H, Vermeire K, et al. Immunomodulatory properties of interferon-gamma. An update. *Ann N Y Acad Sci* 1998;856:22–32.
162. Boehm U, Klamp T, Groot M, et al. Cellular responses to interferon-gamma. *Annu Rev Immunol* 1997;15:749–795.
163. Lawrence DA. Transforming growth factor-beta: an overview. *Kidney Int Suppl* 1995;49:S19–S23.
164. Lawrence DA. Transforming growth factor-beta: a general review. *Eur Cytokine Netw* 1996;7(3):363–374.
165. Wahl SM. Hunt DA, Wakefield LM, et al. Transforming growth factor type beta induces monocyte chemotaxis and growth factor production. *Proc Natl Acad Sci U S A* 1987;84(16):5788–5792.
166. Romani N, Gruner S, Brang D, et al. Proliferating dendritic cell progenitors in human blood. *J Exp Med* 1994;180(1):83–93.
167. Crawford J, Ozer H, Stoller R, et al. Reduction by granulocyte colony-stimulating factor of fever and neutropenia induced by chemotherapy in patients with small-cell lung cancer. *N Engl J Med* 1991;325(3):164–170.
168. Metcalf D, Nicola NA. Proliferative effects of purified granulocyte colony-stimulating factor (G-CSF) on normal mouse hemopoietic cells. *J Cell Physiol* 1983;116(2):198–206.
169. Cooper NR. Biology of the complement system. In: Gallin JI, Snyderman R, eds. *Inflammation: Basic Principles and Clinical Correlates.* 3rd ed. Philadelphia, PA: Lippincott Williams & Wilkins; 1999.
170. Frank MM, Fries LF. The role of complement in inflammation and phagocytosis. *Immunol Today* 1991;12(9):322–326.
171. Roitt I, Brostoff J, Male D, eds. Complement. In: Roitt I, Brostoff J, Male D, eds. *Immunobiology.* 3rd ed. St. Louis, MO: Mosby; 1993.
172. Weiser MR, Williams JP, Moore FD Jr, et al. Reperfusion injury of ischemic skeletal muscle is mediated by natural antibody and complement. *J Exp Med* 1996;183(5):2343–2348.
173. Cooper NR. The classical complement pathway: activation and regulation of the first complement component. *Adv Immunol* 1985;37:151–216.

174. Matsushita M, Fujita T. Activation of the classical complement pathway by mannose-binding protein in association with a novel C1s-like serine protease. *J Exp Med* 1992;176(6):1497–1502.

175. Sim RB, Malhotra R. Interactions of carbohydrates and lectins with complement. *Biochem Soc Trans* 1994;22(1):106–111.

176. Muller-Eberhard HJ. The membrane attack complex of complement. *Annu Rev Immunol* 1986;4:503–528.

177. Marnett LJ, Rowlinson SW, Goodwin DC, et al. Arachidonic acid oxygenation by COX-1 and COX-2. Mechanisms of catalysis and inhibition. *J Biol Chem* 1999;274(33):22903–22906.

178. Seeds MC, Bass DA. Regulation and metabolism of arachidonic acid. *Clin Rev Allergy Immunol* 1999;17(1–2):5–26.

179. Smith WL, Garavito RM, DeWitt DL. Prostaglandin endoperoxide H synthases (cyclooxygenases)-1 and -2. *J Biol Chem* 1996;271(52):33157–33160.

180. Funk CD. Prostaglandins and leukotrienes: advances in eicosanoid biology. *Science* 2001;294(5548):1871–1875.

181. Bulger EM, Maier RV. Lipid mediators in the pathophysiology of critical illness. *Crit Care Med* 2000;28(4 suppl):N27–N36.

182. Gerritsen ME. Physiological and pathophysiological roles of eicosanoids in the microcirculation. *Cardiovasc Res* 1996;32(4):720–732.

183. Serhan CN. Inflammation. Signalling the fat controller. *Nature* 1996;384(6604):23–24.

184. Leff JA. Leukotriene modifiers as novel therapeutics in asthma. *Clin Exp Allergy* 1998;28(suppl 5):147–153; discussion 171–173.

185. McMahon B, Godson C. Lipoxins: endogenous regulators of inflammation. *Am J Physiol Renal Physiol* 2004;286(2):F189–F201.

186. Marcus AJ. Transcellular metabolism of eicosanoids. *Prog Hemost Thromb* 1986;8:127–142.

187. De Caterina R, Sicari R, Giannessi D, et al. Macrophage-specific eicosanoid synthesis inhibition and lipocortin-1 induction by glucocorticoids. *J Appl Physiol* 1993;75(6):2368–2375.

188. Snyder F, Fitzgerald V, Blank ML. Biosynthesis of platelet-activating factor and enzyme inhibitors. *Adv Exp Med Biol* 1996;416:5–10.

189. Snyder F. Metabolic processing of PAF. *Clin Rev Allergy* 1994;12(4):309–327.

190. Noguchi K, Matsuzaki T, Shiroma N, et al. Involvement of nitric oxide and eicosanoids in platelet-activating factor-induced haemodynamic and haematological effects in dogs. *Br J Pharmacol* 1996;118(4):941–950.

191. Blais C Jr, Marceau F, Rouleau JL, et al. The kallikrein-kininogen-kinin system: lessons from the quantification of endogenous kinins. *Peptides* 2000;21(12):1903–1940.

192. Erdos EG. Kinins, the long march–a personal view. *Cardiovasc Res* 2002;54(3):485–491.
193. Hall JM. Bradykinin receptors: pharmacological properties and biological roles. *Pharmacol Ther* 1992;56(2):131–190.
194. Schreiber AD. Plasma inhibitors of the Hageman factor dependent pathways. *Semin Thromb Hemost* 1976;3(1):32–51.
195. Volpe AR. Giardina B, Preziosi P, et al. Biosynthesis of endothelium-derived nitric oxide by bradykinin as endogenous precursor. *Immunopharmacology* 1996;33(1–3):287–290.
196. Dell'Italia LJ, Oparil S. Bradykinin in the heart: friend or foe? *Circulation* 1999;100(23):2305–2307.
197. Tschope C. Gohlke P, Zhu YZ, et al. Antihypertensive and cardioprotective effects after angiotensin-converting enzyme inhibition: role of kinins. *J Card Fail* 1997;3(2):133–148.
198. Chikanza IC, Grossman AB. Neuroendocrine immune responses to inflammation: the concept of the neuroendocrine immune loop. *Baillieres Clin Rheumatol* 1996;10(2):199–225.
199. Whicker JT, Evans SW. A role for neuropeptides in inflammation. In: Whicker JT, Evans SW, eds. *Biochemistry of Inflammation.* Boston, MA: Kluwer Academic; 1992.
200. Delgado M, Munoz-Elias EJ, Gomariz RP, et al. Vasoactive intestinal peptide and pituitary adenylate cyclase-activating polypeptide enhance IL-10 production by murine macrophages: in vitro and in vivo studies. *J Immunol* 1999;162(3):1707–1716.
201. Palmer RM, Ferrige AG, Moncada S. Nitric oxide release accounts for the biological activity of endothelium-derived relaxing factor. *Nature* 1987;327(6122):524–526.
202. Moncada S, Palmer RM, Higgs EA. Nitric oxide: physiology, pathophysiology, and pharmacology. *Pharmacol Rev* 1991;43(2):109–142.
203. Alderton WK, Cooper CE, Knowles RG. Nitric oxide synthases: structure, function and inhibition. *Biochem J* 2001;357(Pt 3):593–615.
204. Geller DA, Billiar TR. Molecular biology of nitric oxide synthases. *Cancer Metastasis Rev* 1998;17(1):7–23.
205. De Vera ME, Taylor BS, Wang Q, et al. Dexamethasone suppresses iNOS gene expression by upregulating I-kappa B alpha and inhibiting NF-kappa B. *Am J Physiol* 1997;273(6 Pt 1):G1290–G1296.
206. Kleinert H, Euchenhofer C, Ihrig-Biedert I, et al. Glucocorticoids inhibit the induction of nitric oxide synthase II by down-regulating cytokine-induced activity of transcription factor nuclear factor-kappa B. *Mol Pharmacol* 1996;49(1):15–21.
207. Titheradge MA. Nitric oxide in septic shock. *Biochim Biophys Acta* 1999;1411(2–3):437–455.
208. Finkel MS, Oddis CV, Jacob TD, et al. Negative inotropic effects of cytokines on the

heart mediated by nitric oxide. *Science* 1992;257(5068):387–389.

209. Goodwin DC, Landino LM, Marnett LJ. Effects of nitric oxide and nitric oxide-derived species on prostaglandin endoperoxide synthase and prostaglandin biosynthesis. *FASEB J* 1999;13(10):1121–1136.
210. Allione A, Bernabei P, Bosticardo M, et al. Nitric oxide suppresses human T lymphocyte proliferation through IFN-gamma-dependent and IFN-gamma-independent induction of apoptosis. *J Immunol* 1999;163(8):4182–4191.
211. Ou J, Carlos TM, Watkins SC, et al. Differential effects of nonselective nitric oxide synthase (NOS) and selective inducible NOS inhibition on hepatic necrosis, apoptosis, ICAM-1 expression, and neutrophil accumulation during endotoxemia. *Nitric Oxide* 1997;1(5):404–416.
212. Isobe M, Katsuramaki T, Hirata K, et al., Beneficial effects of inducible nitric oxide synthase inhibitor on reperfusion injury in the pig liver. *Transplantation* 1999;68(6):803–813.
213. Xia Y, Zweier JL. Superoxide and peroxynitrite generation from inducible nitric oxide synthase in macrophages. *Proc Natl Acad Sci U S A* 1997;94(13):6954–6958.
214. Szabo C, Billiar TR. Novel roles of nitric oxide in hemorrhagic shock. *Shock* 1999;12(1):1–9.
215. Hierholzer C, Harbrecht B, Menezes JM, et al. Essential role of induced nitric oxide in the initiation of the inflammatory response after hemorrhagic shock. *J Exp Med* 1998;187(6):917–928.
216. Tzeng E, Kim YM, Pitt BR, et al. Adenoviral transfer of the inducible nitric oxide synthase gene blocks endothelial cell apoptosis. *Surgery* 1997;122(2):255–263.
217. Nakahira K, Kim HP, Geng XH, et al. Carbon monoxide differentially inhibits TLR signaling pathways by regulating ROS-induced trafficking of TLRs to lipid rafts. *J Exp Med* 2006;203(10):2377–2389.
218. Li T, Zhao B, Wang C, et al. Regulatory effects of hydrogen sulfide on IL-6, IL-8 and IL-10 levels in the plasma and pulmonary tissue of rats with acute lung injury. *Exp Biol Med (Maywood)* 2008;233(9):1081–1087.
219. Li J, Zhang G, Cai S, et al. Effect of inhaled hydrogen sulfide on metabolic responses in anesthetized, paralyzed, and mechanically ventilated piglets. *Pediatr Crit Care Med* 2008;9(1):110–112.
220. Mok YY, Atan MS, Ping CY, et al. Role of hydrogen sulphide in haemorrhagic shock in the rat: protective effect of inhibitors of hydrogen sulphide biosynthesis. *Br J Pharmacol* 2004;143(7):881–889.
221. Collin M, Thiemermann C. Hydrogen sulfide and sulfite: novel mediators in the pathophysiology of shock and inflammation. *Shock* 2005;24(6):595–596.
222. Zhang H, Zhi L, Moochhala SM, et al. Endogenous hydrogen sulfide regulates leukocyte trafficking in cecal ligation and puncture-induced sepsis. *J Leukoc Biol* 2007;82(4):894–905.

223. Zhi L, Ang AD, Zhang H, et al. Hydrogen sulfide induces the synthesis of proinflammatory cytokines in human monocyte cell line U937 via the ERK-NF-kappaB pathway. *J Leukoc Biol* 2007;81(5):1322–1332.
224. Oh GS, Pae HO, Lee BS, et al. Hydrogen sulfide inhibits nitric oxide production and nuclear factor-kappaB via heme oxygenase-1 expression in RAW264.7 macrophages stimulated with lipopolysaccharide. *Free Radic Biol Med* 2006;41(1):106–119.
225. Kimbrell DA, Beutler B. The evolution and genetics of innate immunity. *Nat Rev Genet* 2001;2(4):256–267.
226. Medzhitov R, Janeway C Jr. Innate immune recognition: mechanisms and pathways. *Immunol Rev* 2000;173:89–97.
227. Bianchi ME. DAMPs, PAMPs and alarmins: all we need to know about danger. *J Leukoc Biol* 2007;81(1):1–5.
228. Beutler B. Inferences, questions and possibilities in Toll-like receptor signalling. *Nature* 2004;430(6996):257–263.
229. Triantafilou M, Triantafilou K. Lipopolysaccharide recognition: CD14, TLRs and the LPS-activation cluster. *Trends Immunol* 2002;23(6):301–304.
230. Poltorak A, He X, Smirnova I, et al. Defective LPS signaling in C3H/HeJ and C57BL/10ScCr mice: mutations in Tlr4 gene. *Science* 1998;282(5396):2085–2088.
231. Akira S, Takeda K. Toll-like receptor signalling. *Nat Rev Immunol* 2004;4(7):499–511.
232. Roach JC, Glusman G, Rowen L, et al. The evolution of vertebrate Toll-like receptors. *Proc Natl Acad Sci U S A* 2005;102(27):9577–9582.
233. Kopp E, Medzhitov R. Recognition of microbial infection by Toll-like receptors. *Curr Opin Immunol* 2003;15(4):396–401.
234. Cook DN, Pisetsky DS, Schwartz DA. Toll-like receptors in the pathogenesis of human disease. *Nat Immunol* 2004;5(10):975–979.
235. Mack KD, Von Goetz M, Lin M, et al. Functional identification of kinases essential for T-cell activation through a genetic suppression screen. *Immunol Lett* 2005;96(1):129–145.
236. Schmidt AM, Yan SD, Yan SF, et al. The multiligand receptor RAGE as a progression factor amplifying immune and inflammatory responses. *J Clin Invest* 2001;108(7):949–955.
237. Stern D, Yan SD, Yan SF, et al. Receptor for advanced glycation endproducts: a multiligand receptor magnifying cell stress in diverse pathologic settings. *Adv Drug Deliv Rev* 2002;54(12):1615–1625.
238. Stebbing J, Bower M, Gazzard B, et al. The common heat shock protein receptor CD91 is up-regulated on monocytes of advanced melanoma slow progressors. *Clin Exp Immunol* 2004;138(2):312–316.
239. Binder RJ, Han DK, Srivastava PK. CD91: a receptor for heat shock protein gp96. *Nat Immunol* 2000;1(2):151–155.
240. Srivastava P. Interaction of heat shock proteins with peptides and antigen presenting

cells: chaperoning of the innate and adaptive immune responses. *Annu Rev Immunol* 2002;20:395–425.

241. Basu S. Binder RJ, Suto R, et al. Necrotic but not apoptotic cell death releases heat shock proteins, which deliver a partial maturation signal to dendritic cells and activate the NF-kappa B pathway. *Int Immunol* 2000;12(11):1539–1546.
242. Binder RJ, Srivastava PK. Essential role of CD91 in re-presentation of gp96-chaperoned peptides. *Proc Natl Acad Sci U S A* 2004;101(16):6128–6133.
243. Melcher A, Todryk S, Hardwick N, et al. Tumor immunogenicity is determined by the mechanism of cell death via induction of heat shock protein expression. *Nat Med* 1998;4(5):581–587.
244. Zheng H, Dai J, Stoilova D, et al. Cell surface targeting of heat shock protein gp96 induces dendritic cell maturation and antitumor immunity. *J Immunol* 2001;167(12):6731–6735.
245. Heilmann HP, Doppelfeld E, Fernholz HJ, et al. [Results of radiotherapy of bronchial carcinoma (author's transl)]. *Dtsch Med Wochenschr* 1976;101(43):1557–1562.
246. Becker T, Hartl FU, Wieland F. CD40, an extracellular receptor for binding and uptake of Hsp70-peptide complexes. *J Cell Biol* 2002;158(7):1277–1285.
247. Binder RJ, Vatner R, Srivastava P. The heat-shock protein receptors: some answers and more questions. *Tissue Antigens* 2004;64(4):442–451.
248. Asea A, Kraeft SK, Kurt-Jones EA, et al. HSP70 stimulates cytokine production through a CD14-dependant pathway, demonstrating its dual role as a chaperone and cytokine. *Nat Med* 2000;6(4):435–442.
249. Vabulas RM, Ahmad-Nejad P, da Costa C, et al. Endocytosed HSP60s use toll-like receptor 2 (TLR2) and TLR4 to activate the toll/interleukin-1 receptor signaling pathway in innate immune cells. *J Biol Chem* 2001;276(33):31332–31339.
250. Klionsky DJ. Autophagy. *Curr Biol* 2005;15(8):R282–R283.
251. Klionsky DJ, Emr SD. Autophagy as a regulated pathway of cellular degradation. *Science* 2000;290(5497):1717–1721.
252. Yang Z, Klionsky DJ. Mammalian autophagy: core molecular machinery and signaling regulation. *Curr Opin Cell Biol* 2009;22(2):124–131.
253. Swanson MS, Molofsky. Autophagy and inflammatory cell death, partners of innate immunity. *Autophagy* 2005;1(3):174–176.
254. Kim J, Kundu M, Viollet B, et al. AMPK and mTOR regulate autophagy through direct phosphorylation of Ulk1. *Nat Cell Biol* 2011;13(2):132–141.
255. Hoyer-Hansen M, Jaattela M. AMP-activated protein kinase: a universal regulator of autophagy? *Autophagy* 2007;3(4):381–383.
256. He C, Klionsky DJ. Regulation mechanisms and signaling pathways of autophagy. *Annu Rev Genet* 2009;43:67–93.
257. Yorimitsu T, Klionsky DJ. Autophagy: molecular machinery for self-eating. *Cell Death Differ* 2005;12(suppl 2):1542–1552.

258. Wang CW, Klionsky DJ. The molecular mechanism of autophagy. *Mol Med* 2003;9(3–4):65–76.

259. Diaz-Troya S, Pérez-Pérez ME, Florencio FJ, et al. The role of TOR in autophagy regulation from yeast to plants and mammals. *Autophagy* 2008;4(7):851–865.

260. Meley D, Bauvy C, Houben-Weerts JH, et al. AMP-activated protein kinase and the regulation of autophagic proteolysis. *J Biol Chem* 2006;281(46):34870–34879.

261. Xu Y, Jagannath C, Liu XD, et al. Toll-like receptor 4 is a sensor for autophagy associated with innate immunity. *Immunity* 2007;27(1):135–144.

262. Xu Y, Liu XD, Gong X, et al. Signaling pathway of autophagy associated with innate immunity. *Autophagy* 2008;4(1):110–112.

263. Hoyer-Hansen M, Bastholm L, Szyniarowski P, et al. Control of macroautophagy by calcium, calmodulin-dependent kinase kinase-beta, and Bcl-2. *Mol Cell* 2007;25(2):193–205.

264. Delgado M, Singh S, De Haro S, et al. Autophagy and pattern recognition receptors in innate immunity. *Immunol Rev* 2009;227(1):189–202.

265. Delgado MA, Deretic V. Toll-like receptors in control of immunological autophagy. *Cell Death Differ* 2009;16(7):976–983.

266. Xu Y, Eissa NT. Autophagy in innate and adaptive immunity. *Proc Am Thorac Soc* 2010;7(1):22–28.

267. Waltz P, Carchman EH, Young AC, et al. Lipopolysaccaride induces autophagic signaling in macrophages via a TLR4, heme oxygenase-1 dependent pathway. *Autophagy* 2011;7(3):315–320.

268. Deretic V. Autophagy in innate and adaptive immunity. *Trends Immunol* 2005;26(10):523–528.

269. Nakagawa I, Amano A, Mizushima N, et al. Autophagy defends cells against invading group A Streptococcus. *Science* 2004;306(5698):1037–1040.

270. Paludan C, Schmid D, Landthaler M, et al. Endogenous MHC class II processing of a viral nuclear antigen after autophagy. *Science* 2005;307(5709):593–596.

271. Carchman EH, Rao J, Loughran PA, et al. Heme oxygenase-1 mediated autophagy protects against hepatocyte cell death and hepatic injury from infection/sepsis. *Hepatology* 2011;53(6):2053–2062.

272. Wu H, Chen G, Wyburn KR, et al. TLR4 activation mediates kidney ischemia/reperfusion injury. *J Clin Invest* 2007;117(10):2847–2859.

273. Carchman EH, Whelan S, Loughran P, et al. Experimental sepsis-induced mitochondrial biogenesis is dependent on autophagy, TLR4, and TLR9 signaling in liver. *FASEB J* 2013;27(12):4703–4711.

274. Howell GM, Gomez H, Collage RD, et al. Augmenting autophagy to treat acute kidney injury during endotoxemia in mice. *PloS One* 2013;8(7):e69520.

275. Guo L, Stripay JL, Zhang X, et al. CaMKIα regulates AMP kinase-dependent, TORC-1-independent autophagy during lipopolysaccharide-induced acute lung neutrophilic

inflammation. *J Immunol* 2013;190(7):3620–3628.

276. Evankovich J, Zhang R, Cardinal JS, et al. Calcium/calmodulin-dependent protein kinase IV limits organ damage in hepatic ischemia/reperfusion injury through induction of autophagy. *Am J Physiol Gastrointest Liver Physiol* 2012;303(2):G189–G198.
277. Zhang X, Howell GM, Guo L, et al. CaMKIV-dependent preservation of mTOR expression is required for autophagy during LPS-induced inflammation and acute kidney injury. *J Immunol* 2014;193(5):2405–2415.
278. Kimura T, Takabatake Y, Takahashi A, et al. Autophagy protects the proximal tubule from degeneration and acute ischemic injury. *J Am Soc Nephrol* 2011;22(5):902–913.
279. Zhang J, Randall MS, Loyd MR, et al. Mitochondrial clearance is regulated by Atg7-dependent and -independent mechanisms during reticulocyte maturation. *Blood* 2009;114(1):157–164.
280. Mortensen M, Ferguson DJ, Edelmann M, et al. Loss of autophagy in erythroid cells leads to defective removal of mitochondria and severe anemia in vivo. *Proc Natl Acad Sci U S A* 2010;107(2):832–837.
281. Cali T, Ottolini D, Negro A, et al. Enhanced parkin levels favor ER-mitochondria crosstalk and guarantee Ca(2+) transfer to sustain cell bioenergetics. *Biochim Biophys Acta* 2013;1832(4):495–508.
282. Amadoro G, Corsetti V, Florenzano F, et al. Morphological and bioenergetic demands underlying the mitophagy in post-mitotic neurons: the pink-parkin pathway. *Front Aging Neurosci* 2014;6:18.
283. Ashrafi G, Schwarz TL. The pathways of mitophagy for quality control and clearance of mitochondria. *Cell Death Differ* 2013;20(1):31–42.
284. Springer W, Kahle PJ. Regulation of PINK1-Parkin-mediated mitophagy. *Autophagy* 2011;7(3):266–278.
285. Wang Y, Nartiss Y, Steipe B, et al. ROS-induced mitochondrial depolarization initiates PARK2/PARKIN-dependent mitochondrial degradation by autophagy. *Autophagy* 2012;8(10):1462–1476.
286. Polla BS, Bachelet M, Dall'ava J, et al. Heat shock proteins in inflammation and asthma: Dr Jekyll or Mr Hyde? *Clin Exp Allergy* 1998;28(5):527–529.
287. Polla BS, Bachelet M, Elia G, et al. Stress proteins in inflammation. *Ann N Y Acad Sci* 1998;851:75–85.
288. Multhoff G, Botzler C. Heat-shock proteins and the immune response. *Ann N Y Acad Sci* 1998;851:86–93.
289. Perdrizet GA. Heat shock and tissue protection. *New Horiz* 1995;3(2):312–320.
290. Mathew A, Morimoto RI. Role of the heat-shock response in the life and death of proteins. *Ann N Y Acad Sci* 1998;851:99–111.
291. Ribeiro SP, Villar J, Slutsky AS. Induction of the stress response to prevent organ injury. *New Horiz* 1995;3(2):301–311.

292. Garcia-Cardena G, Fan R, Shah V, et al. Dynamic activation of endothelial nitric oxide synthase by Hsp90. *Nature* 1998;392(6678):821–824.

293. Wong HR, Ryan M, Wispe JR. Stress response decreases NF-kappaB nuclear translocation and increases I-kappaBalpha expression in A549 cells. *J Clin Invest* 1997;99(10):2423–2428.

294. Moshage H. Cytokines and the hepatic acute phase response. *J Pathol* 1997;181(3):257–266.

295. Pepys MB, ed. *Acute Phase Proteins in the Acute Phase Response.* New York: Springer-Verlag; 1989.

296. Gabay C, Kushner I. Acute-phase proteins and other systemic responses to inflammation. *N Engl J Med* 1999;340(6):448–454.

297. Koj A. Initiation of acute phase response and synthesis of cytokines. *Biochim Biophys Acta* 1996;1317(2):84–94.

298. Giraldez RR, Panda A, Xia Y, et al. Decreased nitric-oxide synthase activity causes impaired endothelium-dependent relaxation in the postischemic heart. *J Biol Chem* 1997;272(34):21420–21426.

299. Romson JL, Hook BG, Kunkel SL, et al. Reduction of the extent of ischemic myocardial injury by neutrophil depletion in the dog. *Circulation* 1983;67(5):1016–1023.

300. Vedder NB, Winn RK, Rice CL, et al. A monoclonal antibody to the adherence-promoting leukocyte glycoprotein, CD18, reduces organ injury and improves survival from hemorrhagic shock and resuscitation in rabbits. *J Clin Invest* 1988;81(3):939–944.

301. Agostoni A, Gardinali M, Frangi D, et al. Activation of complement and kinin systems after thrombolytic therapy in patients with acute myocardial infarction. A comparison between streptokinase and recombinant tissue-type plasminogen activator. *Circulation* 1994;90(6):2666–2670.

302. Morgan BP. Complement membrane attack on nucleated cells: resistance, recovery and non-lethal effects. *Biochem J* 1989;264(1):1–14.

303. Muckart DJ, Bhagwanjee S. American College of Chest Physicians/Society of Critical Care Medicine Consensus Conference definitions of the systemic inflammatory response syndrome and allied disorders in relation to critically injured patients. *Crit Care Med* 1997;25(11):1789–1795.

304. Bone RC. Sepsis, sepsis syndrome, and the systemic inflammatory response syndrome (SIRS). Gulliver in Laputa. *JAMA* 1995;273(2):155–156.

305. Rangel-Frausto MS, Pittet D, Costigan M, et al. The natural history of the systemic inflammatory response syndrome (SIRS). A prospective study. *JAMA* 1995;273(2):117–123.

306. Davies MG, Hagen PO. Systemic inflammatory response syndrome. *Br J Surg* 1997;84(7):920–935.

307. Dvorak HF, Galli SJ, Dvorak AM. Cellular and vascular manifestations of cell-mediated immunity. *Hum Pathol* 1986;17(2):122–137.

Chapter 8

Surgical Infections

Lena M. Napolitano

Key Points

1 Surgical infections include intra-abdominal infections (appendicitis, cholecystitis/cholangitis, diverticulitis, colitis including C. difficile colitis, pancreatitis, and peritonitis), soft tissue infections (necrotizing and nonnecrotizing), surgical site infections, and hospital-acquired infections that occur in surgical patients (pneumonia, central line–associated bloodstream infections [CLABSI], and catheter-associated urinary tract infections [CAUTI]).

2 Early empiric appropriate broad-spectrum antimicrobial therapy, to cover all potential causative pathogens, is an important adjunct to source control in the treatment of surgical infections. Inappropriate antimicrobial therapy is associated with increased mortality.

3 Any of these surgical infections can result in severe sepsis or septic shock.

4 A key concept in surgical infections is "*source control,*" defined as any physical intervention to remove or eliminate a focus of invasive infection (drainage, debridement, and device removal) and to restore optimal anatomic function.

5 Pathogen identification and appropriate deescalation of antimicrobial therapy are of paramount importance in treatment of surgical infections, as increasing prevalence of multidrug-resistant pathogens has been identified in both abdominal and skin surgical infections.

6 Complicated intra-abdominal infection (cIAI) extends beyond the hollow viscus of origin into the peritoneal space and is associated with either abscess formation or peritonitis.

7 Recommendations for specific antimicrobial therapy for cIAI are based on whether the infection is "community-acquired" or "healthcare-associated."

8 In patients with intra-abdominal infections who have undergone an adequate source control procedure, fixed-duration antibiotic therapy for 4 days is noninferior to longer duration antimicrobial therapy until resolution of physiologic abnormalities, with no difference in surgical site infection, recurrent intra-abdominal infection, or death.

9 The two surgical procedures indicated for C. difficile colitis treatment include (1) total abdominal colectomy (for peritonitis, colonic perforation, ischemia, necrosis, toxic megacolon with impending perforation, septic shock with organ failure) and (2) diverting loop ileostomy and intraoperative colonic lavage for toxin reduction. The

second option is associated with colonic preservation.

10 The initial treatment of infected pancreatic necrosis is percutaneous catheter or endoscopic (transgastric/transduodenal) drainage with additional drain placement as required.

11 Lack of clinical improvement of necrotizing infected pancreatitis with initial percutaneous drainage warrants consideration of minimally invasive techniques for pancreatic necrosectomy including video-assisted retroperitoneal debridement, minimally invasive retroperitoneal pancreatectomy, or transluminal direct endoscopic necrosectomy.

12 Acute bacterial skin and skin structure infections are defined as bacterial infection of the skin with a lesion size area of at least 75 cm^2 (lesion size measured by the area of redness, edema, or induration), including cellulitis, wound infection, and abscess.

13 Early operative debridement is the major determinant of outcome in necrotizing soft tissue infections. Delayed definitive debridement remains the single most important risk factor for death.

INTRODUCTION

1 Surgical infections include intra-abdominal infections (appendicitis, cholecystitis, diverticulitis, colitis, and pancreatitis), soft tissue infections (necrotizing and nonnecrotizing), surgical site infections (SSIs), and hospital-acquired infections that occur in surgical patients (pneumonia, central line–associated bloodstream infections [CLABSI], and catheter-associated urinary tract infections [CAUTI]).[1] Appropriate therapy of surgical infections to optimize patient outcomes includes four steps: (1) early diagnosis, (2) early initiation of appropriate empiric broad-spectrum antimicrobial therapy, (3) adequate source control (surgical or interventional radiologic), and (4) pathogen identification and appropriate deescalation of antimicrobial therapy (Table 8-1).

The initial management of all surgical infections should include the initiation of early empiric antimicrobial therapy to cover all potential possible pathogens, since early and appropriate empiric antibiotic therapy improves patient outcomes (Table 8-2).[2] The choice of early empiric antimicrobial therapy is guided by the specific site of infection, the common pathogens associated with that infection, and by local and regional antibiograms. The goal of antimicrobial therapy is to achieve antibiotic levels at the site of the infection that exceed the minimum inhibitory concentration of the microbial pathogens present.

Early Use of Appropriate Broad-Spectrum Antimicrobial Therapy

2, 3 Early use of appropriate broad-spectrum antimicrobial therapy is an important adjunct to appropriate surgical management of surgical infections. Numerous studies have confirmed that inappropriate empiric antibiotics (i.e., antibiotics that do not cover the causative pathogens) are associated with increased mortality.[3] In patients who manifest severe sepsis or septic shock, every hour delay of antimicrobial therapy is associated with increased mortality.[4] The Surviving Sepsis Guidelines recommendations are listed in Table 8-3.

Table 8-1 Appropriate Therapy of Surgical Infections

1. Early diagnosis of surgical infection
2. Early initiation of appropriate empiric broad-spectrum antimicrobial therapy
3. Adequate source control
4. Pathogen identification and appropriate deescalation of antimicrobial therapy

Source Control

4 Source control is defined as any physical intervention to remove or eliminate a focus of invasive infection (drainage, debridement, and device removal) and to restore optimal anatomic function.[5] In surgical infections, antimicrobial agents are used in conjunction with adequate source control of the initial infection. Adequate source control can be accomplished by either surgical or percutaneous interventional radiologic techniques. A number of factors have been identified that predict failure of source control for intra-abdominal infections (Table 8-4).

Pathogen Identification

5 Pathogen identification is extremely important, in part related to increased prevalence of multidrug-resistant pathogens that are associated with surgical infections. Whenever possible, high-quality specimens should be obtained from source control procedures for Gram stain and culture in order to identify causative pathogens and determine antimicrobial susceptibility of the bacterial isolates identified. This will enable appropriate deescalation of antimicrobial therapy from broad-spectrum therapy to directed potential single antimicrobial agent therapy.

INTRA-ABDOMINAL INFECTIONS

Classification

6 Complicated intra-abdominal infection (cIAI) extends beyond the hollow viscus of origin into the peritoneal space and is associated with either abscess formation or peritonitis. "Uncomplicated" intra-abdominal infection involves intramural inflammation of the gastrointestinal tract and has a substantial probability of progressing to cIAI if not adequately treated.

Table 8-2 Spectrum of Activity of Specific Antimicrobials for Specific Pathogens

Antibiotic	Gram-Negative	Gram-Positive	Resistant Gram-Negative	Resistant Gram-Positive	Anaerobe	Pseudomonas
Beta-lactam/beta-lactamase inhibitor	+	+	#	0	+	#
First-generation cephalosporins	0	+	0	0	0	0
Second-generation cephalosporins	#	#	0	0	0	0
Third-generation cephalosporins	+	+	#	0	0	#
Fourth-generation cephalosporins	+	+	#	0	0	#
Fifth-generation cephalosporins	0	+	0	+	0	0
Tigecycline	+	+	+	+	+	0
Glycopeptides	0	+	0	+	0	0
Carbapenems	+	+	#	0	+	#
Quinolones	+	+	0	0	#	#

0, no activity; +, activity; #, activity, but varies by product within class.

Table 8-3 Antimicrobial Therapy, Surviving Sepsis Guidelines 2012

1. Administration of effective intravenous antimicrobials within the first hour of recognition of septic shock (grade 1B) and severe sepsis without septic shock (grade 1C) as the goal of therapy.
2a. Initial empiric anti-infective therapy of one or more thugs that have activity against all likely pathogens (bacterial and/or fungal or viral) and that penetrate in adequate concentrations into tissues presumed to be the source of sepsis (grade 1B).
2b. Antimicrobial regimen should be reassessed daily for potential deescalation (grade 1B).
3. Use of low procalcitonin levels or similar biomarkers to assist the clinician in the discontinuation of empiric antibiotics in patients who initially appeared septic, but have no subsequent evidence of infection (grade 2C).

Diagnosis

Patients with cIAI present with abdominal pain and gastrointestinal symptoms. A comprehensive abdominal physical examination must be performed in these patients. If peritonitis is present, evaluation for emergent laparotomy without diagnostic studies is considered. If peritonitis is not present, recent evidence-based guidelines recommend that computed tomography (CT) scan of the abdomen and pelvis is the diagnostic imaging modality of choice to evaluate for cIAI and its source.[6,7]

Treatment

7 Early empiric appropriate systemic antimicrobial therapy to cover all potential causative pathogens and early source control are the mainstays of treatment of cIAIs. In order to select appropriate empiric antimicrobial agents for use, cIAIs are further classified as "community-acquired" or "healthcare-associated."

Community-Acquired Complicated Intra-Abdominal Infection

For patients who have "community-acquired" cIAI, determination of whether the disease is "mild/moderate (appendicitis, mild diverticulitis)" or "severe (fecal peritonitis, perforated diverticulitis)" facilitates appropriate antimicrobial treatment (Table 8-5). Patients with "severe" community-acquired cIAI should have antibiotics that cover *Pseudomonas* and *Enterococcus* pathogens, and both single-agent and combination-agent regimens are available for use. A number of antimicrobials are no longer recommended for use in community-acquired cIAI:

Table 8-4 Clinical Factors Predicting Failure of "Source Control" for Intra-Abdominal Infection

Delay in the initial intervention (>24 h)
High severity of illness (APACHE [Acute Physiology and Chronic Health Evaluation] II score ≥15)
Advanced age
Comorbidity and degree of organ dysfunction
Low albumin level
Poor nutritional status
Degree of peritoneal involvement or diffuse peritonitis
Inability to achieve adequate drainage or debridement
Presence of malignancy

- Ampicillin/sulbactam is not recommended because of high resistance of Escherichia coli to this agent (B-II)
- Cefotetan and clindamycin are not recommended for use because of increasing resistance of the Bacteroides fragilis group to these agents (B-II)
- Because of the availability of less toxic agents demonstrated to be of at least equal efficacy, aminoglycosides are not recommended for routine use in community-acquired IAI in adults (B-II).

Healthcare-Associated Complicated Intra-Abdominal Infection

For patients with "healthcare-associated" cIAI, separate evidence-based guideline recommendations for empiric antimicrobial treatment are provided (Algorithm 8-1). Specific antimicrobials are recommended based on whether the patient and/or institution have high risk for infection with multidrug-resistant pathogens. Quinolone-resistant E. coli have become common in many communities, and quinolones should not be used unless hospital antibiograms confirm greater than 90% susceptibility of E. coli to

quinolones. In patients with healthcare-associated cIAI, carbapenems are an excellent single-agent regimen for empiric treatment.

Table 8-5 Empiric Antimicrobial Treatment of Extrabiliary cIAIs, Community Acquired

	Community-Acquired Infections in Adults	
	Mild to Moderate	**Severe**
Single agent	■ Cefoxitin ■ Ertapenem ■ Moxifloxacin ■ Tigecycline ■ Ticarcillin/clavulanic acid	■ Imipenem/cilastatin ■ Meropenem ■ Doripenem ■ Piperacillin/tazobactam
Combination regimen	■ Cefazolin,[a] cefuroxime, ceftriaxone, cefotaxime, ciprofloxacin, or levofloxacin, each in combination with metronidazole	■ Cefepime, ceftazidime, ciprofloxacin, or levofloxacin, each in combination with metronidazole

- Ampicillin/sulbactam is not recommended because of high resistance of Escherichia coli to this agent (B-II).
- Cefotetan and clindamycin are not recommended for use because of increasing resistance of the Bacteroides fragilis group to these agents (B-II).
- Because of the availability of less toxic agents demonstrated to be of at least equal efficacy, aminoglycosides are not recommended for routine use in community-acquired IAI in adults (B-II).

[a]Caution – local antibiograms should direct use of this agent.
Adapted from Solomkin JS, Mazuski JE, Bradley JS, et al. Diagnosis and management of complicated intra-abdominal infection in adults and children: guidelines by the Surgical Infection Society and the Infectious Diseases Society of America. *Surg Infect (Larchmt)* 2010;11(1):79–109.

Duration of Antibiotics for Complicated Intra-Abdominal Infection

8 Duration of antibiotics for treatment of cIAI has long been controversial. A recent important randomized controlled trial examined the efficacy of short-course (4 days) antimicrobial therapy in patients with intra-abdominal infections who had undergone an adequate source control procedure. Fixed-duration antibiotic therapy for 4 days was noninferior to longer duration antmicrobial therapy until resolution of physiologic abnormalities, with no difference in the composite endpoints of SSI, recurrent intra-abdominal infection, or death.[8]

SPECIFIC INTRA-ABDOMINAL INFECTIONS

Appendicitis

Appendicitis is common with over 300,000 hospital discharges in the United States per year. Although appendectomy provides definitive source control for the treatment of acute nonperforated appendicitis, intravenous (IV) antibiotics should be administered preoperatively with a dose repeated intraoperatively if the surgery is prolonged, a number of controversies in diagnosis and management of appendicitis persist.[9]

Antibiotics versus Appendectomy

In patients with uncomplicated appendicitis (nonperforated, no abscess, or phlegmon), appendectomy is definitive source control. But a number of recent randomized trials have confirmed that acute nonperforated appendicitis can be treated successfully with antibiotics alone. A meta-analysis of 6 studies with 1,201 patients reported that in patients treated with antibiotics alone, 7 ± 4% failed to respond and required appendectomy, and acute appendicitis recurred in 14 ± 11%. A normal appendix was found in 7.3 ± 5.1% of patients at appendectomy. Complications were considerably less likely to occur with antibiotic treatment than with appendectomy. Major surgical complications included enterocutaneous fistula and reoperation.[10]

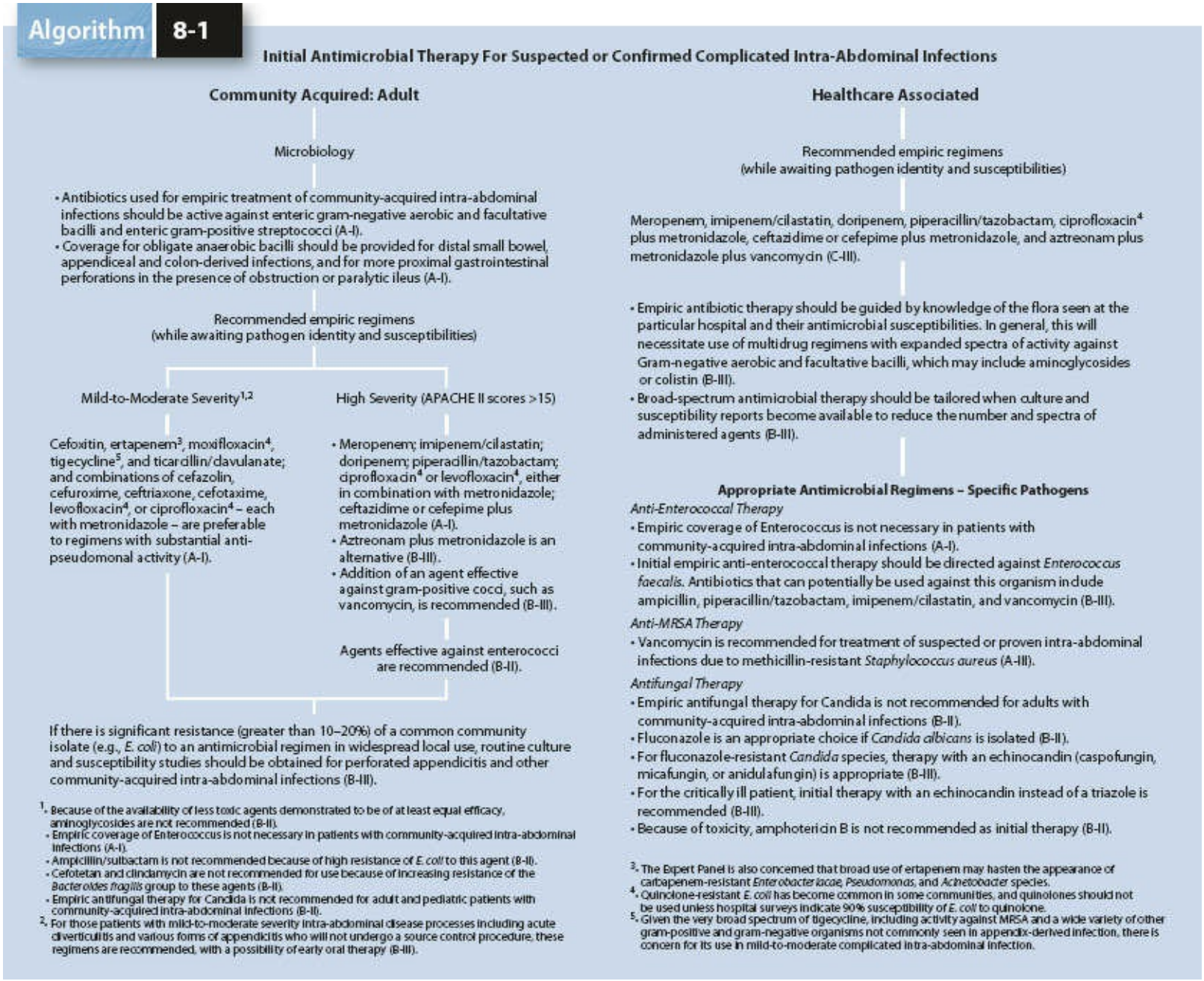

Algorithm 8-1. Empiric antimicrobial treatment of extrabiliary cIAIs, community acquired versus healthcare associated. (Adapted from Solomkin JS, Mazuski JE, Bradley JS, et al. Diagnosis and management of complicated intra-abdominal infection in adults and children: guidelines by the Surgical Infection Society and the Infectious Diseases Society of America. *Surg Infect (Larchmt)* 2010;11(1):79–109.)

A Cochrane meta-analysis of 5 trials with 901 patients reported that 73.4% of patients who were treated with antibiotics and 97.4% patients underwent appendectomy were cured within 2 weeks without major complications (including recurrence) within 1 year.[11] Another meta-analysis included only four trials and reported that efficacy was significantly higher for surgery but rates of perforated appendicitis were not different, and complication rates were significantly higher for surgery.[12]

The most recent trial (APPAC) enrolled 530 patients in Finland with uncomplicated appendicitis confirmed by CT scan and randomized to early appendectomy or antibiotic treatment (ertapenem for 3 days, then oral levofloxacin and metronidazole for 7 days) with 1-year follow-up. In the antibiotic group, 70 patients (27.3%) underwent

appendectomy within 1 year of initial presentation for appendicitis. Antibiotic treatment did not meet the prespecified criterion for noninferiority compared with appendectomy. But it was notable that 72.7% of patients with uncomplicated appendicitis treated with antibiotics alone did not require subsequent appendectomy.[13,14]

The trials published to date were primarily from European countries, used antibiotics not available in the United States and had minimal use of laparoscopic appendectomy or CT scan for diagnostic imaging.[15] Further high-quality randomized trials are therefore needed to determine which patients are most likely to benefit from antibiotic therapy alone. Although appendectomy remains the standard treatment for acute appendicitis, antibiotic treatment alone may be used as an alternative treatment in patients with contraindication to surgery (or where surgery is high risk).

Laparoscopic versus Open Appendectomy

Appendectomy can be performed by laparoscopic or open approach. A large retrospective review (2005–2008) of laparoscopic versus open appendectomy using the American College of Surgeons National Surgical Quality Improvement Program (NSQIP) reported that 76.4% were performed laparoscopically and 23.6% performed open. Open appendectomy was associated with increased morbidity, SSI, and mortality.[16]

A Cochrane review of 67 trials was updated in 2010 and reported that laparoscopic appendectomy was associated with lower SSI rates but higher intra-abdominal abscess rate. Laparoscopic approach was associated with shorter hospital length of stay, faster return to normal activity, and decreased postoperative pain. This review concluded that laparoscopic appendectomy should be considered the preferred approach where surgical expertise and equipment are available.[17]

Time to Appendectomy and Perforation Risk

It has long been thought that appendiceal luminal obstruction leads to appendiceal perforation without timely surgical intervention. This belief led to attempts to decrease time from presentation and diagnosis of acute appendicitis to operating room start time. With the advent of early appropriate empiric systemic antimicrobial therapy, this fundamental concept is no longer true. As discussed previously, in patients with uncomplicated appendicitis, antibiotic treatment alone does not lead to appendiceal perforation. Furthermore, using data from the Washington State Surgical Care and Outcomes Assessment Program (SCOAP) with 9,048 adult patients who underwent appendectomy, there was no association between appendiceal perforation and in-hospital time prior to surgery. This study confirmed that appendiceal perforation is most commonly a prehospital occurrence, and timing of surgery should be determined based on all factors relevant to the surgeon and patient.[18]

Abscess or Phlegmon Management

In patients with periappendiceal abscess or phlegmon, current evidence (mainly retrospective studies) supports nonoperative management with IV transitioned to oral antibiotics and percutaneous drainage if possible. A meta-analysis of 19 retrospective

studies from 1969 to 2005 reported that nonsurgical treatment failed in only 7.6% of patients and immediate appendectomy was associated with higher morbidity. Similar findings were confirmed in a more recent review.[19] Routine interval appendectomy is not recommended since the risk of recurrence is low (7.4%). But either colonoscopy or repeat CT imaging is recommended due to the risk of a malignant disease (1.2%) or important benign disease (0.7%) identified during follow-up.[20]

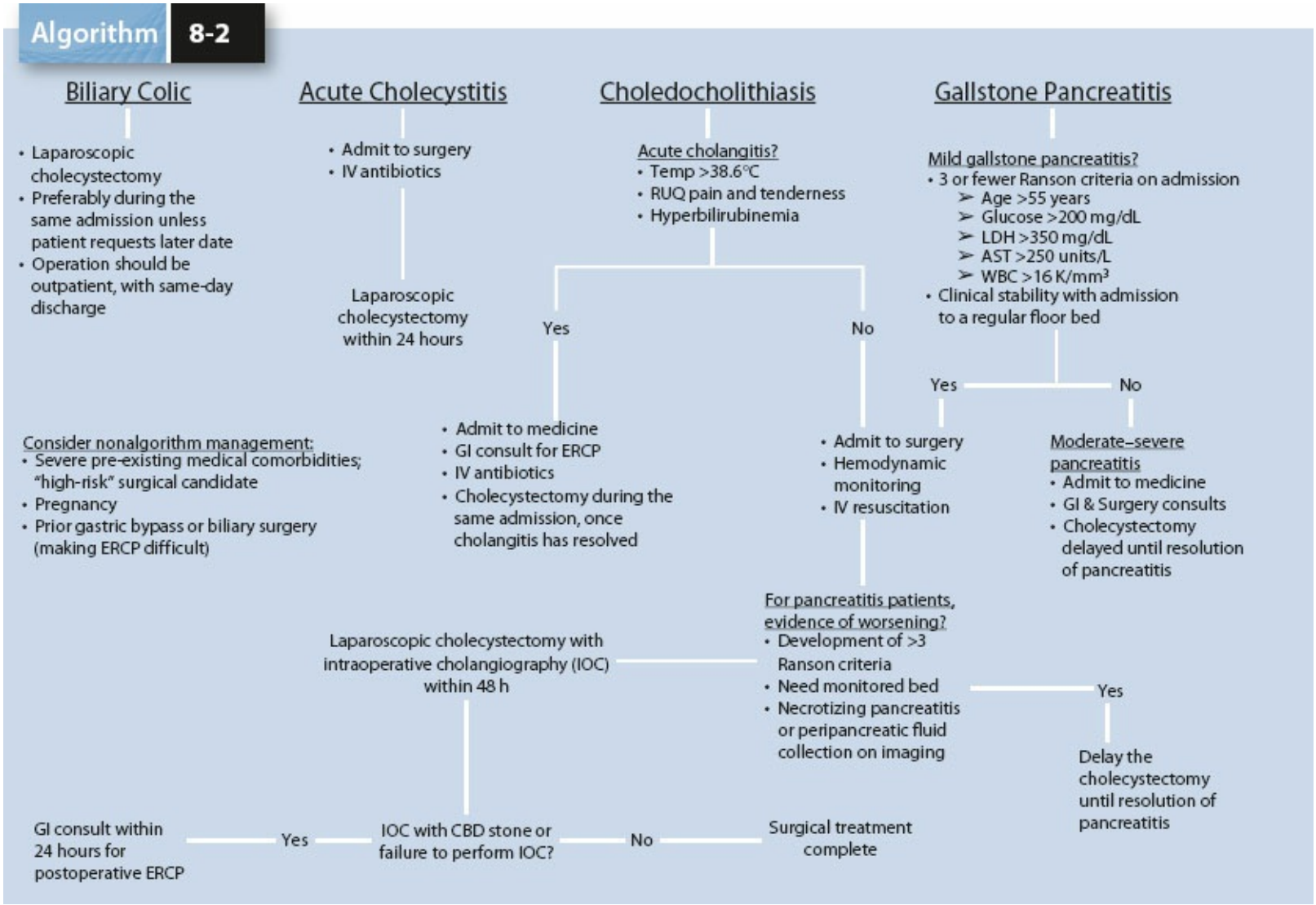

Algorithm 8-2. Biliary infections and algorithm for diagnosis and management. (From Demehri FR, Alam HB. Evidence-based management of common gallstone-related emergencies. *J Intensive Care Med* 2016;31(1):3–13.)

Interval Appendectomy after Initial Nonoperative Management

A large retrospective cohort study reported that 3% of patients were initially treated with nonoperative management. Of these, 15% had an interval appendectomy and the remaining 85% did not. Of the 864 patients that did not undergo interval appendectomy only 39 patients (5%) had recurrence of appendicitis after a median follow-up of 4 years.[21] Routine interval appendectomy after initial successful nonoperative treatment is therefore not justified and should be abandoned. In a meta-analysis including 2,771 patients initially treated nonoperatively for appendiceal phlegmon or abscess, 31 patients were found to have a malignant diagnosis and a lower rate of inflammatory bowel

disease. These data highlight the need for follow-up with either CT scan or colonoscopy after successful nonoperative management.[20] Although a retrospective study in pediatric appendicitis reported a 2.8-fold higher rate of recurrent appendicitis in patients with an appendicolith, this study is limited by small sample size ($n = 96$) and a higher overall rate of recurrent appendicitis than all other published studies.[22] See also chapter on Appendiceal Diseases.

Biliary Infections

Biliary infections include acute cholecystitis which may be calculous or acalculous, may include choledocholithiasis or not, and cholangitis.[23] Acute cholecystitis and ascending cholangitis are primary inflammations of the gallbladder and bile ducts, respectively, which are caused by infection and possible biliary obstruction.

Acute Cholecystitis

Acute cholecystitis is inflammation of the gallbladder resulting from obstruction of the cystic duct and subsequent bacterial invasion and overgrowth. Cholelithiasis is the cause of cystic duct obstruction in more than 90% of cases of acute cholecystitis in the United States. Acalculous cholecystitis is more common in critically ill patients and the pathophysiology is transmural ischemia. Acalculous cholecystitis carries higher morbidity and mortality rates than calculous cholecystitis.

The diagnosis of acute cholecystitis is made based on the common constellation of right upper quadrant tenderness, leukocytosis, and fever. Initial diagnostic imaging is right upper quadrant ultrasound to evaluate for gallstones, gallbladder wall thickening, and pericholecystic inflammation (sensitivity 88% to 94%, specificity 78% to 80%). If ultrasound is inconclusive or is discordant with the clinical evaluation, then cholescintigraphy (99mTc-hepatobiliary iminodiacetic acid, HIDA scan) is recommended and nonvisualization of the gallbladder confirms acute cholecystitis with sensitivity of 96% and specificity of 90% (Algorithm 8-2).[24]

Early systemic antimicrobial treatment is indicated for acute cholecystitis to cover the causative pathogens, including aerobic, enteric, gram-negative bacilli (i.e., E. coli, Klebsiella, Enterobacter, and Proteus), and aerobic gram-positive organisms (i.e., Enterococcus and Streptococcus). Anaerobes are uncommon, identified in approximately 15% of isolates. Clostridial organisms can be identified in cases of emphysematous cholecystitis confirmed by identification of gas in the gallbladder wall.

Cholangitis

Cholangitis signs/symptoms include jaundice, fever, right upper quadrant tenderness, hyperbilirubinemia, and leukocytosis. Ultrasound confirms common bile duct dilation (>7 mm).

Appropriate evidence-based recommendations for diagnosis and treatment from the Tokyo Guidelines are provided in Tables 8-6 and 8-7. For treatment recommendations, urgent biliary drainage (<24 hours) is indicated when (1) obstructive biliary stones are associated with severe or moderate acute cholangitis OR (2) mild acute cholangitis is not responding to IV antibiotics and fluid resuscitation.

For patients with biliary infections, specific evidence-based guideline recommendations for antimicrobial treatment are classified into four patient populations (Table 8-8). For patients undergoing cholecystectomy for acute cholecystitis with complete source control (i.e., complete cholecystectomy), antimicrobial therapy should be discontinued within 24 hours of the operation unless there is evidence of infection outside the wall of the

gallbladder. See also chapter on Calculous Biliary Disease.

Table 8-6 Diagnosis of Cholangitis: Tokyo Guidelines 2013

Systemic inflammation	■ Fever and/or shaking chills laboratory data: evidence of inflammatory response (WBC, CRP, etc.)
Cholestasis	■ Jaundice (total bilirubin ≥2 mg/dL) ■ Laboratory data: abnormal liver function tests (ALP, GGT, AST, and ALT)
Imaging	■ Biliary dilatation ■ Evidence of the etiology on imaging (stricture, stone, stent, etc.) ■ Clinical gallstone pancreatitis
Diagnosis of cholangitis	Suspected: presence of 1 item in A + 1 item in either B or C Definite: presence of 1 item in A, 1 item in B, and 1 item in C

ALP, alkaline phosphatase; ALT, alanine transaminase; AST, aspartate aminotransferase/aspartate transaminase; CRP, C-reactive protein; GGT, γ-glutamyl transferase; WBC, white blood cell.
Adapted from Kiriyama S, Takada T, Strasberg SM, et al. TG13 guidelines for diagnosis and severity grading of acute cholangitis (with videos). *J Hepatobiliary Pancreat Sci* 2013;20(1):24–34.

Table 8-7 Treatment of Acute Cholangitis by Severity Classification: Tokyo Guidelines 2013 Criteria

Severity of Acute Cholangitis	
Mild (grade I)	Does not meet the criteria of "severe" or "moderate" acute cholangitis at time of initial diagnosis
Moderate (grade II)	Acute cholangitis associated with any two of the following conditions: ■ Abnormal WBC (>12,000, <4,000/mm^3) ■ High fever (≥39°C) ■ Age ≥75 years old ■ Hyperbilirubinemia (total bilirubin ≥5 mg/dL) ■ Hypoalbuminemia (<lower limit of normal × 0.7)
Severe (grade III)	Acute cholangitis associated with the onset of dysfunction in at least one of the following organs/systems: ■ Cardiovascular dysfunction (hypotension requiring pressors) ■ Neurologic dysfunction (disturbance of consciousness) ■ Respiratory dysfunction (PaO_2/FiO_2 ratio <300) ■ Renal dysfunction (oliguria, serum creatinine >2 mg/dL) ■ Hepatic dysfunction (elevated PT/INR >1.5) ■ Hematologic dysfunction (platelet count <100,000/mm^3)

Assessment of Urgency of Draining
Urgent biliary drainage (<24 h) is indicated when a. Obstructive biliary stones are associated with severe or moderate acute cholangitis OR b. Mild acute cholangitis is not responding to IV antibiotics and fluid resuscitation
Early (but not urgent) ERCP (<72 h) is recommended for patients with mild acute cholangitis who respond to medical therapy

ERCP, endoscopic retrograde cholangiopancreatography; PT/INR, prothrombin time and international normalized ratio.
Adapted from Kiriyama S, Takada T, Strasberg SM, et al. TG13 guidelines for diagnosis and severity grading of acute cholangitis (with videos). *J Hepatobiliary Pancreat Sci* 2013;20(1):24–34.

Diverticulitis

Diverticulitis is a common intra-abdominal infection. Its pathophysiology is associated with altered gut motility, increased luminal pressure, and an altered colonic microenvironment.

Uncomplicated diverticulitis is treated with systemic antibiotics and usually resolves. Antimicrobial treatment of diverticulitis is the same as for cIAI which is reviewed above. In a cohort study of 2,366 patients hospitalized in the Kaiser Permanente system and followed for 8.9 years, only 13.3% had a first recurrence and 3.9% had a second recurrence.[25]

Surgery for acute diverticulitis is indicated for patients who present with peritonitis and/or sepsis or who do not improve with medical management and/or percutaneous drainage of associated abscess/infection. Although less than 25% of patients will develop generalized peritonitis after colonic perforation, it is severe with high mortality. Surgical options include simple colostomy formation in the setting of profound inflammation (rarely performed), traditional sigmoid resection with colostomy (Hartmann procedure), and sigmoid resection with a primary colocolonic or colorectal anastomosis with or without a diverting loop ileostomy. Laparoscopic surgery is preferred to open surgery when possible.[26]

Table 8-8 Antimicrobials for Treatment of Biliary Infections

Community-acquired acute cholecystitis of mild to moderate severity ■ Cefazolin ■ Cefuroxime ■ Ceftriaxone
Community-acquired acute cholecystitis of severe physiologic disturbance, advanced age, or immunocompromised state ■ Imipenem/cilastatin ■ Meropenem ■ Doripenem ■ Piperacillin/tazobactam ■ Ciprofloxacin, levofloxacin, or cefepime, each in combination with metronidazole
Acute cholangitis following bilioenteric anastomosis of any severity ■ Imipenem/cilastatin ■ Meropenem ■ Doripenem ■ Piperacillin/tazobactam ■ Ciprofloxacin, levofloxacin, or cefepime each in combination with metronidazole
Healthcare-associated biliary infection of any severity ■ Imipenem/cilastatin ■ Meropenem ■ Doripenem ■ Piperacillin/tazobactam ■ Ciprofloxacin, levofloxacin, or cefepime, each in combination with metronidazole ■ Vancomycin added to each regimen

Adapted from Solomkin JS, Mazuski JE, Bradley JS, et al. Diagnosis and management of complicated intra-abdominal infection in adults and children: guidelines by the Surgical Infection Society and the Infectious Diseases Society of America. *Surg Infect (Larchmt)* 2010;11(1):79–109.

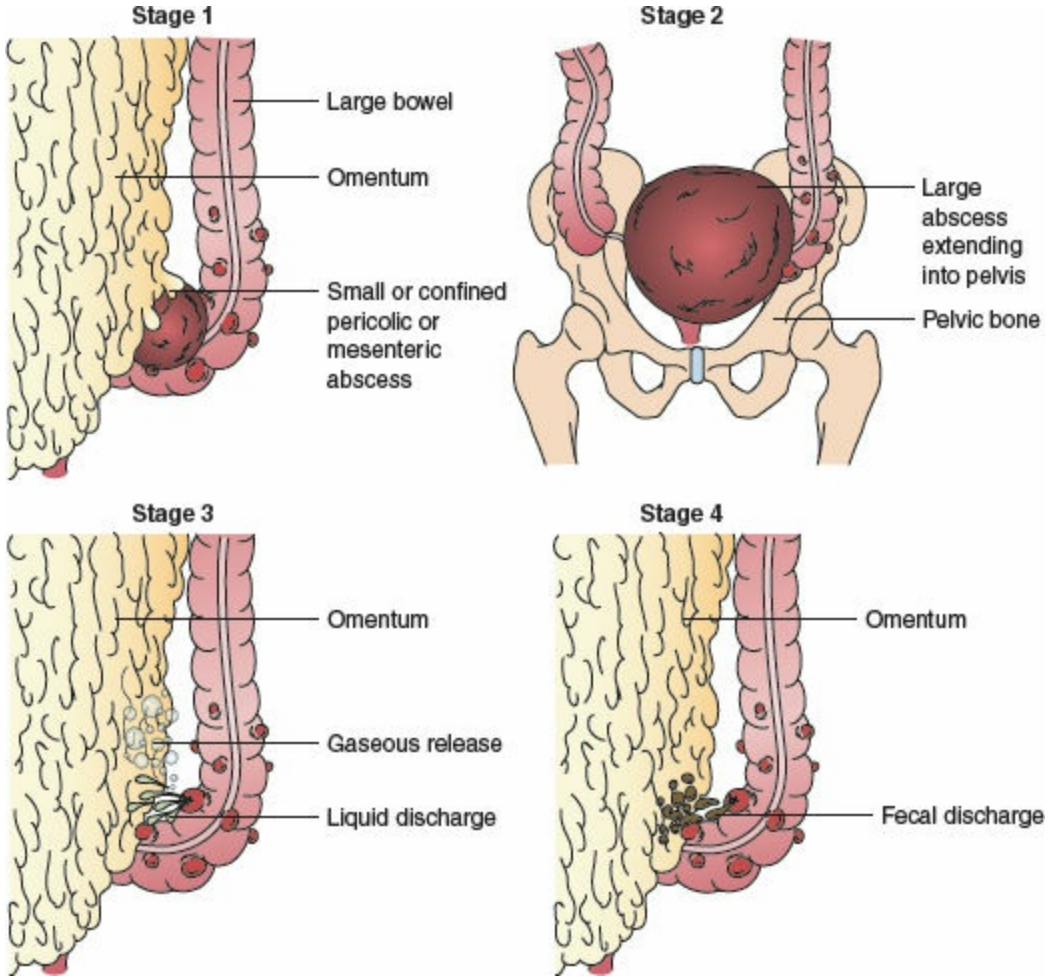

Figure 8-1. Hinchey classification scheme. Patients with stage 1 disease have small, confined, pericolic, or mesenteric abscesses, whereas those with stage 2 disease have larger abscesses, often confined to the pelvis. Stage 3 disease, or perforated diverticulitis, is present when a peridiverticular abscess has ruptured and caused purulent peritonitis. Rupture of an uninflamed and unobstructed diverticulum into the free peritoneal cavity with fetal contamination, the so-called free rupture, signifies stage 4 disease and carries the highest risk of an adverse outcome.

Since recurrence after recovery from an uncomplicated episodes of diverticulitis is rare and two or more recurrences are not associated with increased risk of complications, elective colectomy following two episodes of diverticulitis is no longer recommended. Decisions regarding surgical intervention and colectomy must therefore be based on individual potential risks and benefits of colon resection.[27]

For patients who require surgical intervention, the specific treatment that is associated with the best outcome is controversial. Hinchey proposed a practical clinical classification of diverticulitis based on the severity of peritoneal contamination (Fig. 8-1) identified at operation.[28] The modified Hinchey classification includes Hinchey Ia (confined pericolic inflammation–phlegmon) and Ib (confined pericolic abscess) and considers classification based on radiologic imaging with CT scan as well. Increasing Hinchey classification is associated with increased mortality. The mortality for patients with Hinchey III is reported as 6% but increases greatly to 35% for fecal peritonitis (Hinchey IV). A systematic review comparing surgical treatments for Hinchey III or IV colonic diverticulitis confirmed that primary resection with anastomosis has a significant advantage with lower mortality compared to Hartmann procedure. Furthermore,

laparoscopic peritoneal lavage with subsequent surgical resection if indicated had lower surgical morbidity and hospital length of stay compared to the primary resection and anastomosis group.[29] See also chapter on Diverticular Disease.

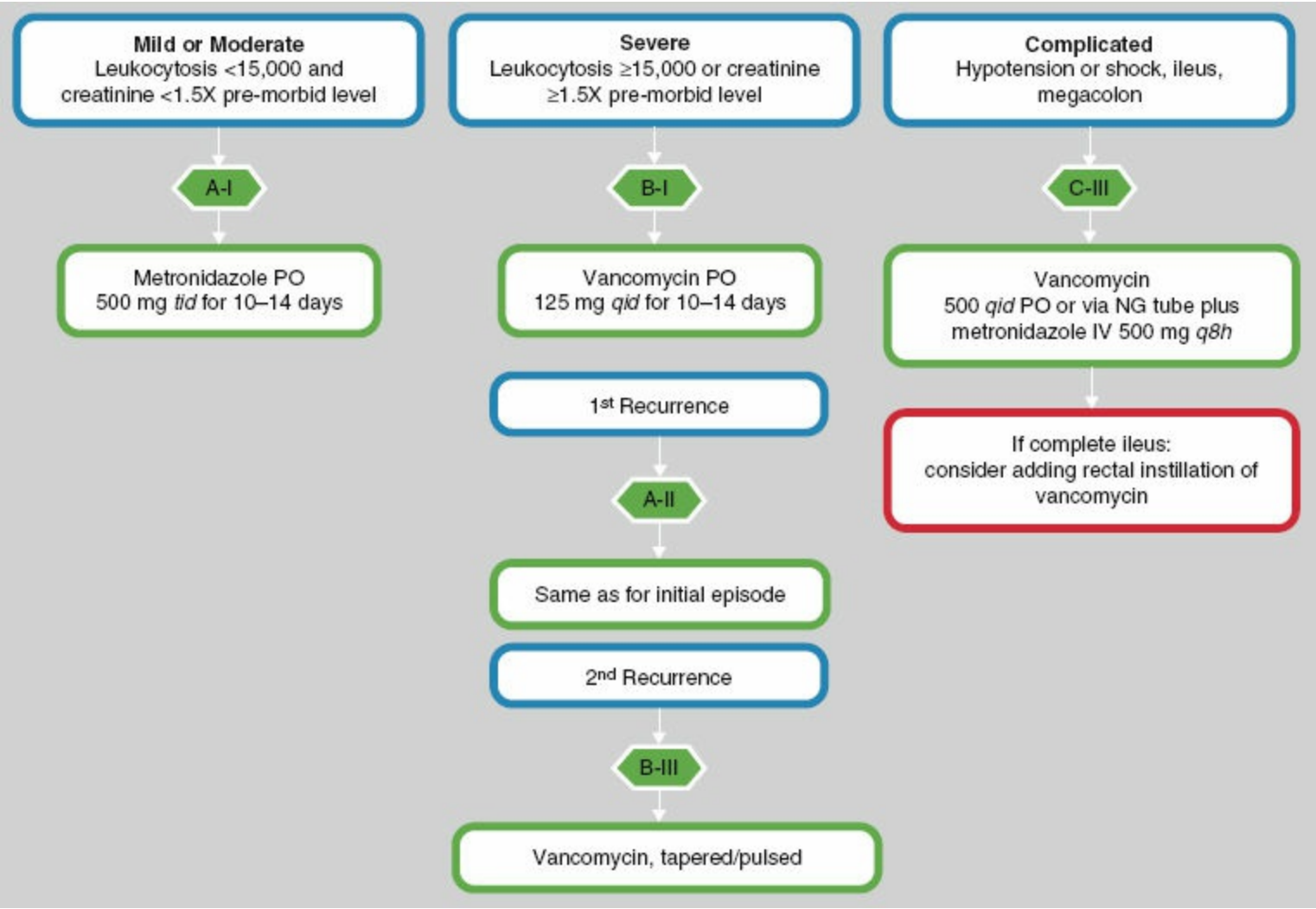

Figure 8-2. Treatment of initial episode of Clostridium difficile infection.

Clostridium Difficile Colitis

The incidence and severity of Clostridium difficile infection (CDI) has increased, particularly in surgical patients who have been exposed to prior antimicrobial therapy. There has been a substantial change in the management of CDI related to the emergence of the NAP1/BI/027 strain which is associated with higher toxin production and more severe forms of disease. CDI may be associated with mild to moderate diarrhea or colonic ileus and obstipation to severe colitis.[30]

Early diagnosis of CDI is imperative. Recommended testing includes two steps, using a glutamine dehydrogenase assay for the Clostridium difficile antigen, followed by enzyme immunoassay toxin testing. Polymerase chain reaction (PCR) confirmatory testing is used if the antigen is positive and toxin is negative.[31] Radiologic testing is helpful, and CT may show colonic mucosal edema (thumbprinting or target sign), ascites, inflammation, and fat stranding and the "accordion sign" which indicates alternating edematous colonic haustra separated by transverse mucosal ridges filled with enteral contrast.

Initial management of CDI is cessation of all antibiotics if possible. The 2010 SHEA/IDSA guidelines have evidence-based recommendations for CDI based on severity of disease (Fig. 8-2).[32] Vancomycin and metronidazole are first-line therapy. Vancomycin is preferred for severe or complicated disease. Fidaxomicin (a macrocyclic antibiotic with a narrow antimicrobial spectrum against C. difficile, staphylococci, and enterococci) may be considered for recurrent CDI or where risk of recurrence is high. A multicenter multinational randomized trial confirmed decreased recurrence rates compared to oral vancomycin and it is the U.S. Food and Drug Administration (FDA) approved with a recommended treatment dose of 100 mg po bid.[33] Fecal microbiota transplantation is associated with symptom resolution and may be effective in recurrent CDI, but has no role in primary CDI treatment.

9 CDI may warrant surgical intervention. Surgical consultation should occur very early in the course of disease in patients with severe and complicated CDI. The indications for surgical management of CDI patients are not clearly defined, but severe disease, worsening clinical condition despite appropriate treatment, and peritonitis or shock states are all potential indications. The two surgical procedures indicated for CDI treatment include (1) total abdominal colectomy (for peritonitis, colonic perforation, ischemia, necrosis, toxic megacolon with impending perforation, septic shock with organ failure) and (2) diverting loop ileostomy and intraoperative colonic lavage for toxin reduction while preserving the colon (Fig. 8-3). This new treatment strategy resulted in reduced mortality compared with the historical population who had undergone total abdominal colectomy (19% vs. 50%), and preservation of the colon was achieved in 93% of patients.[34] No randomized studies have been published to date comparing these two options.

Pancreatitis

A new classification of acute pancreatitis has been implemented and is based on local disease (whether pancreatic necrosis is present or not, whether it is sterile or infected) and systemic determinants (whether organ failure is present or not, whether it is transient or persistent) of severity (Table 8-9). Early management requires goal-directed fluid resuscitation (with avoidance of over-resuscitation and abdominal compartment syndrome), assessment of severity of pancreatitis, diagnostic CT imaging to assess for necrotizing pancreatitis, consideration of endoscopic retrograde cholangiopancreatography (ERCP) for biliary pancreatitis, and early enteral nutrition support. Antibiotic prophylaxis for severe acute or necrotizing pancreatitis is not recommended.[35]

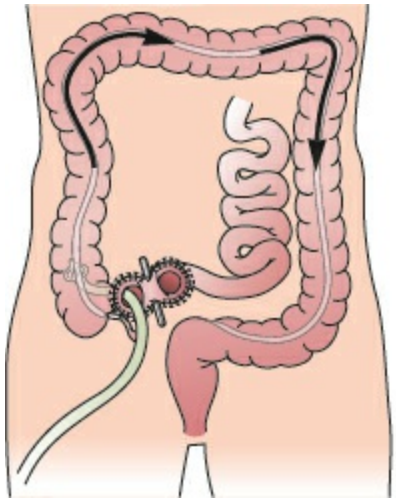

1. Creation of diverting loop ileostomy.
2. Intraoperative antegrade colonic lavage with 8 L of warmed PEG3350/electrolyte solution via ileostomy.
3. Postoperative antegrade colonic enemas with vancomycin (500 mg in 500 mL x 10 days) via ileostomy.

Figure 8-3. Diverting loop ileostomy with antegrade colonic irrigation for CDI. Before surgery is started:

1. Place the patient in lithotomy position with easy access to rectum
2. Place a fluid collection bag (commonly used by urology) under the patient's rectum for drainage collection
3. Place a rectal drainage tube (large Malecot catheter, large foley catheter, #9 or #10 endotracheal tube, or other large catheter)
4. Have 8 L of warmed polyethylene glycol 3350/electrolyte solution (GoLytely; Braintree Laboratories) available in OR for intraoperative colonic irrigation, and dulcolax suppository

Intraoperatively:

1. Ensure that the colon is viable and without perforation
2. Create a loop ileostomy (laparoscopic or open)
3. Place a 24-French Malecot catheter into the efferent limb of the ileostomy and advance into the right colon through the ileocecal valve. Secure to skin with sutures.
4. Infuse 8 L of warmed polyethylene glycol 3350/electrolyte solution (GoLytely; Braintree Laboratories) into the 24-French Malecot catheter via the efferent limb of the ileostomy
5. Once colonic lavage completed, perform rectal examination to empty rectum, place dulcolax suppository in rectum to encourage colonic emptying
6. Instill antegrade colonic enema with vancomycin (500 mg in 500 mL) via ileostomy efferent limb, continue postoperatively

(Adapted from Neal MD, Alverdy JC, Hall DE, et al. Diverting loop ileostomy and colonic lavage. An alternative to total abdominal colectomy for the treatment of severe, complicated clostridium difficile-associated disease. *Ann Surg* 2011;254(3):423–429.)

Table 8-9 New International Classification of Acute Pancreatitis: Determinants of Severity of Acute Pancreatitis by the 2011 World Congress of the International Association of Pancreatology

Mild AP	No evidence of necrosis or organ failure		
Moderate AP	Evidence of sterile necrosis or transient organ failure		
Severe AP	Evidence of infected necrosis or persistent organ failure		
Critical AP	Evidence of infected necrosis and persistent organ failure		
Local Determinant: Peri/Pancreatic Necrosis	**Systemic Determinant: Organ Failure**		
Nonviable tissue located in the pancreas alone, or in the pancreas and peripancreatic tissues, or in peripancreatic tissues alone. It can be solid or semisolid (partially liquefied) and is without a radiologically defined wall	Defined for three organ systems on the basis of the worst measurement over a 24-h period. In patients without pre-existing organ dysfunction, defined as either SOFA score of 2 or more in the assessed organ system are: ■ Cardiovascular: need for inotropic agent ■ Renal: ≥171 μmol/L (≥2 mg/dL) ■ Respiratory: PaO_2 ≤30 mm Hg (≤40 kPa)		
Sterile necrosis	No proven infection in necrosis	Transient organ failure	Evidence of organ failure in the same organ system for less than 48 h.
Infected necrosis	At least one is present: 1. Gas bubbles within peri/pancreatic necrosis on CT 2. Positive culture by image-guided fine-needle aspiration 3. Positive culture obtained during the first drainage and/or necrosectomy	Persistent organ failure	Evidence of organ failure in the same organ system for 48 h or more.

SOFA, sepsis-related organ failure assessment score; CT, computed tomography.
Adapted from Dellinger EP, Forsmark CE, Layer P, et al.; Pancreatitis Across Nations Clinical Research and Education Alliance (PANCREA). Determinant-based classification of acute pancreatitis severity: an international multidisciplinary consultation. *Ann Surg* 2012;256:875–880.

Necrotizing pancreatitis is high risk for progression to necrotizing *infected* pancreatitis. Therapeutic antibiotics are required for treatment of documented infected pancreatic necrosis. Causative pathogens include gram-negative microbes and an increase in gram-positive organisms has been reported.[36] Therefore broad-spectrum IV antimicrobials are recommended.

10 The initial treatment of infected pancreatic necrosis is percutaneous catheter or endoscopic (transgastric/transduodenal) drainage with a second drain placement as required. The "step-up" approach consisted of percutaneous drainage followed, if necessary, by minimally invasive retroperitoneal necrosectomy. The minimally invasive step-up approach, as compared with open necrosectomy, reduced the rate of the primary composite endpoint (12% vs. 50%, including major complications [new-onset multiple organ failure or multiple systemic complications, perforation of a visceral organ or enterocutaneous fistula, or bleeding] or death), but the mortality rate did not differ significantly between groups (19% vs. 16%).[37,38]

11 Lack of clinical improvement after these initial procedures warrants consideration of minimally invasive techniques for pancreatic necrosectomy including video-assisted retroperitoneal debridement (VARD), minimally invasive retroperitoneal pancreatectomy (MIRP), or transluminal direct endoscopic necrosectomy (DEN).[39] VARD and MIRP use the tract created by percutaneous drainage catheters as a guide for placement of a laparoscope into the retroperitoneum so that debridement and lavage can be performed under direct visualization. Open necrosectomy is associated with substantial morbidity, but to date no randomized trial has documented superiority of either minimally invasive or open surgical technique. Additional trials are underway to address this (Algorithm 8-

3). See also chapter on Acute Pancreatitis.

SKIN AND SOFT TISSUE INFECTIONS

Skin and soft tissue infections (SSTIs) span a broad spectrum of clinical entities from limited cellulitis to rapidly progressive necrotizing fasciitis, which may be associated with septic shock or toxic shock syndrome and associated organ failure.[40,41] These SSTIs may result in critical illness and require management in the intensive care unit (ICU).[42,43] Methicillin-resistant *Staphylococcus aureus* (MRSA) has emerged as the most common identifiable cause of severe SSTIs, therefore initiation of empiric anti-MRSA antimicrobials is warranted in all cases of severe SSTIs. In addition, appropriate critical care management, including fluid resuscitation, organ support, and nutritional support are necessary components of treatment of severe SSTIs.

The complex interplay of environment, host, and pathogen is important to consider when evaluating SSTIs and planning therapy. The key to a successful outcome in caring for patients with severe SSTIs is (1) early diagnosis and differentiation of necrotizing versus nonnecrotizing SSTI, (2) early initiation of appropriate empiric broad-spectrum antimicrobial therapy with consideration of risk factors for specific pathogens, (3) “source control,” that is, early aggressive surgical intervention for drainage of abscesses and debridement of necrotizing soft tissue infections (NSTIs), and (4) pathogen identification and appropriate deescalation of antimicrobial therapy.

Algorithm 8-3

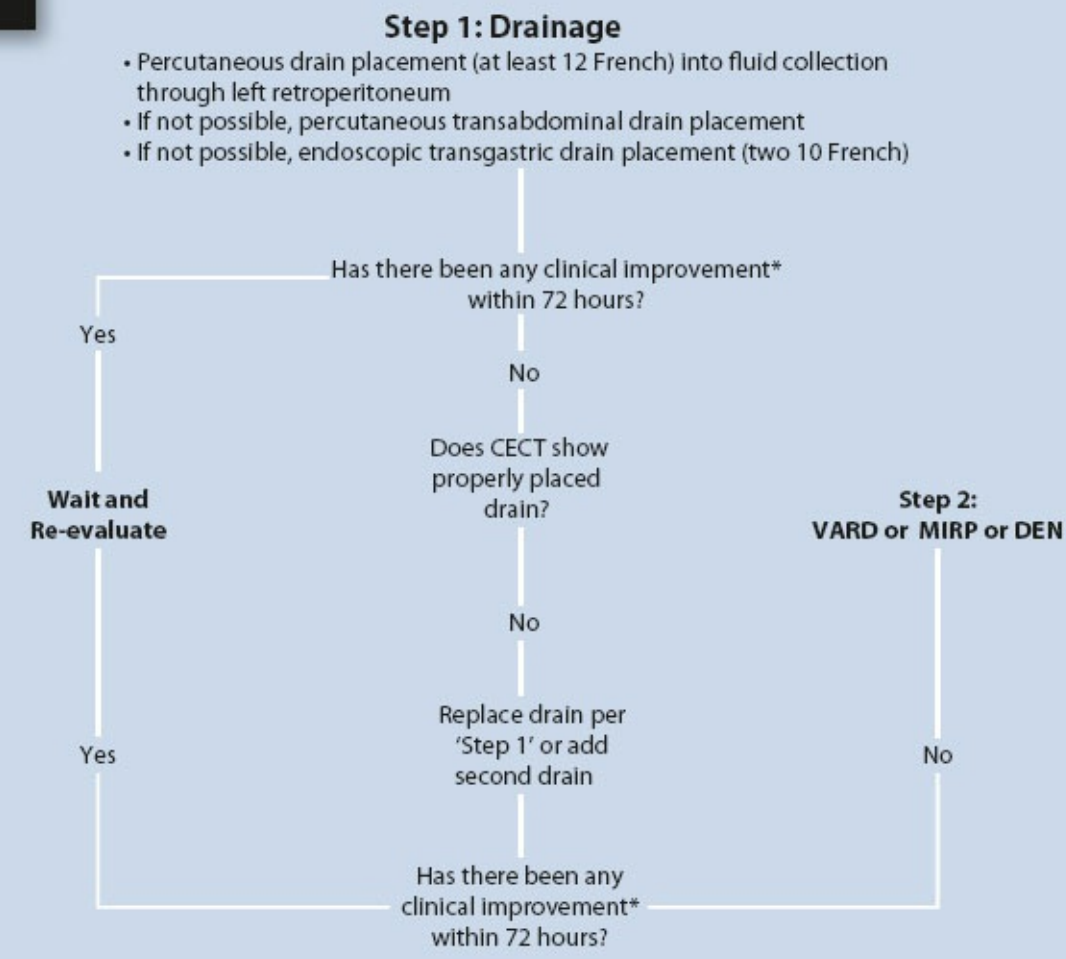

*Clinical Improvement is defined in the ICU as follows: Improved function in at least two of the following organ systems: renal, respiratory, cardiovascular, or in the ward as at least 10% improvement in two of following parameters: leukocyte count, temperature, C-reactive protein.

Algorithm 8-3. Step-up approach to management of necrotizing infected pancreatitis. (Adapted from Besselink MG, van Santvoort HC, Nieuwenhuijs, et al.; Dutch Acute Pancreatitis Study Group. Minimally invasive 'step-up approach' versus maximal necrosectomy in patients with acute necrotizing pancreatitis (PANTER trial): design and rationale of a randomized controlled multicenter trial [ISRCTN13975868]. *BMC Surg* 2006;6:6.)

Table 8-10 Comparison of Old and New Classification of SSTIs by FDA

- Uncomplicated
  - Superficial infections, such as:
    - simple abscesses
    - impetiginous lesions
    - furuncles
    - cellulitis
  - Can be treated by antibiotics or surgical incision alone
- Complicated
  - Deep soft tissue, such as:
    - infected ulcers
    - infected burns
    - major abscesses
  - Significant underlying disease state which complicates response to treatment
  - Requires significant surgical intervention and antimicrobials

New FDA Definition (October 2013):

ABSSSI defined as bacterial infection of the skin with a lesion size area of at least 75 cm^2 (lesion size measured by the area of redness, edema, or induration), including the following:

- Cellulitis/erysipelas: A diffuse skin infection characterized by spreading areas of redness, edema, and/or induration
- Wound infection: An infection characterized by purulent drainage from a wound with surrounding redness, edema, and/or induration
- Major cutaneous abscess: An infection characterized by a collection of pus within the dermis or deeper that is accompanied by redness, edema, and/or induration

From http://www.fda.gov/ohrms/dockets/98fr/2566dft.pdf. Accessed January 19, 2016.

Classification of Skin and Soft Tissue Infections

The FDA previously classified SSTIs into two broad categories for the purpose of clinical trials evaluating new antimicrobials for the treatment of SSTIs: **uncomplicated** and **complicated** (Table 8-10). **Uncomplicated** SSTIs include superficial infections such as cellulitis, simple abscesses, impetigo, and furuncles. These infections can be treated by antibiotics and/or surgical incision for drainage of abscess alone. In contrast, **complicated** SSTIs include deep soft tissue infections that require significant surgical intervention, such as infected ulcers, infected burns, and major abscesses, and these patients also have significant underlying comorbidities, that is, disease states which complicate (and usually delay) response to treatment. Complicated SSTIs are a significant clinical problem, in part related to the increasing resistance of infecting bacteria to current antibiotic therapies.

Uncomplicated Skin and Soft Tissue Infections

Uncomplicated SSTIs are associated with ***low*** risk for life- or limb-threatening infection. These patients can be treated with empiric antibiotic therapy according to likely pathogen and local resistance patterns.

Complicated Skin and Soft Tissue Infections

Complicated SSTIs are associated with ***high*** risk for life- or limb-threatening infection. In these patients, it is of paramount importance to initiate appropriate and adequate broad-spectrum initial empiric antimicrobial therapy with coverage for MRSA and to consider the need for surgical intervention for abscess drainage or debridement.

Patients with complicated SSTIs require hospitalization for treatment. Specific circumstances that warrant hospitalization include the presence of tissue necrosis, sepsis, severe pain, altered mental status, immunocompromised state, and organ failure (respiratory, renal, hepatic). SSTIs can lead to serious potentially life-threatening local and systemic complications. The infections can progress rapidly and early recognition and proper medical and surgical management is cornerstone of therapy.

12 In October 2013, the FDA changed the SSTI terminology and issued final guidance for the treatment of acute bacterial skin and skin structure infections (ABSSSI).[44] This guidance defined ABSSSI as cellulitis, erysipelas, wound infection, and major cutaneous abscess. An ABSSSI is defined as a bacterial infection of the skin with a lesion size area of at least 75 cm^2 (lesion size measured by the area of redness, edema, or induration). The minimum area of involvement of 75 cm^2 is chosen to select patients with acute bacterial skin infections for which a reliable control drug treatment effect can be estimated for the conduct of new antimicrobial treatment trials. While the FDA generally requires two phase III trials to support approval of drugs to treat ABSSSI, this guidance stated that a single phase III study that is supported by additional independent evidence may suffice.

Patients with the following infection types can be enrolled in ABSSSI clinical trials:

- **Cellulitis/erysipelas:** A diffuse skin infection characterized by spreading areas of redness, edema, and/or induration

- **Wound infection:** An infection characterized by purulent drainage from a wound with surrounding redness, edema, and/or induration
- **Major cutaneous abscess:** An infection characterized by a collection of pus within the dermis or deeper that is accompanied by redness, edema, and/or induration

Unfortunately, this new guidance does not address less serious skin infections, such as impetigo and minor cutaneous abscess, or more serious infections needing more complex treatment regimens, such as infections resulting from animal or human bites, NSTIs, diabetic foot infection, decubitus ulcer infection, myonecrosis, osteomyelitis, and ecthyma gangrenosum.

Early Diagnosis and Differentiation of Necrotizing versus Nonnecrotizing SSTI

Another classification for SSTIs that is commonly used is the differentiation of **NSTIs** from **nonnecrotizing infections**. This differentiation is critical since necrotizing infections warrant prompt aggressive surgical debridement. Clinical clues to the diagnosis of NSTIs are listed in Table 8-3. The differentiation of necrotizing infections from nonnecrotizing infections is critical to achieving adequate surgical therapy.[45] A clear approach to these infections must allow rapid identification and treatment of NSTIs because they are limb threatening and life threatening.

When clinical "hard clinical signs" (bullae, crepitus, gas on x-ray, hypotension with SBP <90 mm Hg, or skin necrosis) of NSTI are present, establishing the diagnosis of NSTI is not difficult. However, hard signs of NSTIs are often absent on presentation, thus potentially delaying diagnosis and surgical intervention. Studies have documented that less than 50% of patients with a definitive diagnosis of NSTI presented with "hard clinical signs" of NSTI.[46] Admission of white blood cell count $>15{,}400 \times 10^9$/L and/or serum sodium <135 mEq/L was documented to help differentiate NSTI from non-NSTI and aided in early diagnosis.[47,48] The Laboratory Risk Indicator for Necrotizing Fasciitis (LRINEC) score is also helpful as a laboratory aid in distinguishing necrotizing from nonnecrotizing SSTIs (see NSTI section below). In retrospective studies CT scan has been shown to have a negative predictive value of 100% and a positive predictive value of 76% in diagnosing NSTI.[49]

If there is any question regarding the possible diagnosis of an NSTI, it is imperative to proceed with surgical intervention and to be certain that the surgical incision is continued down to the fascial and muscle level to make a definitive diagnosis.

Early Initiation of Appropriate Empiric Broad-Spectrum Antimicrobial Therapy with Anti-MRSA Coverage and Consideration of Risk Factors for Specific Pathogens

Antimicrobial therapy is an essential element in the management of severe SSTIs. As in all serious life-threatening infections, it is important to initiate **early** and **appropriate** empiric antimicrobial therapy. It is well established that prompt appropriate treatment of hospitalized infections reduces mortality.[2] Similar findings were reported in studies of patients with ventilator-associated pneumonia [50] and sepsis.[51] A study of ICU patients found that the higher mortality rate associated with inappropriate initial therapy is still observed when antibiotics are switched from an inappropriate to an appropriate treatment.[52]

Furthermore, appropriate and timely antibiotic therapy improves treatment outcomes for SSTIs caused by MRSA.[53] In a study of 492 patients with community-onset MRSA SSTIs, 95% of episodes treated with an active antibiotic within 48 hours were treated successfully, compared with an 87% rate of successful treatment in patients who did not receive an active antibiotic. In logistic regression analysis, failure to initiate active antimicrobial therapy within 48 hours of presentation was the only independent predictor of treatment failure. Similarly, in a study of patients admitted to the hospital with MRSA sterile-site infection, multivariate analysis found inappropriate antimicrobial treatment to be an independent risk factor for hospital mortality.[54]

An empiric treatment algorithm for SSTI directed against community-associated MRSA (CA-MRSA) in the emergency department that promotes both the use of antibiotics likely active against CA-MRSA and early incision and drainage of abscesses was examined. Clinical failure occurred in only 3% of cases treated according to the algorithm, compared with 62% of those not treated according to the algorithm. Furthermore, among cases that underwent immediate incision and drainage, initial treatment with antibiotics active in vitro against the MRSA isolate was associated with a decreased clinical failure rate when compared to those treated with inactive antibiotics (0% vs. 67%).[55]

Empiric antibiotic therapy should be initiated in **all** patients with SSTIs. IV broad-spectrum antimicrobial therapy should be initiated when an infection is severe or progresses rapidly, when there are signs of systemic illness, when the patient has comorbidities or is immunosuppressed, for very old or young patients, when an abscess cannot be completely drained, and when the infection does not respond to incision and drainage.[56]

Timely initiation of antimicrobial therapy is also important in the treatment of severe SSTIs, particularly if associated with septic shock. In a study of 2,731 adult patients with septic shock, a strong relationship between the delay in effective antimicrobial initiation and in-hospital mortality was noted.[4] Administration of an antimicrobial effective for isolated or suspected pathogens within the first hour of documented hypotension was associated with a survival rate of 79.9%. Each hour of delay in antimicrobial administration over the ensuing 6 hours was associated with an average decrease in survival of 7.6%. By the second hour after onset of persistent/recurrent hypotension, in-

hospital mortality rate was significantly increased relative to receiving therapy within the first hour. In multivariate analysis (including Acute Physiology and Chronic Health Evaluation II score and therapeutic variables), time to initiation of effective antimicrobial therapy was the single strongest predictor of outcome. Interestingly, only 50% of septic shock patients received effective antimicrobial therapy within 6 hours of documented hypotension.

Necrotizing Soft Tissue Infections

NSTIs are aggressive soft tissue infections that cause widespread necrosis, and can include necrotizing cellulitis, fasciitis, and myositis/myonecrosis.[57,58] Establishing the diagnosis of NSTI can be the main challenge in treating patients with NSTI, and knowledge of all available tools is key for early and accurate diagnosis.[59] There have been a number of recent advances in the definition, pathogenesis, diagnostic criteria, and treatment of NSTIs.[60,61]

Patients with NSTIs require prompt aggressive surgical debridement, appropriate IV antibiotics, and intensive support. Despite aggressive treatment, their mortality and morbidity rates remain high, with some series reporting mortality rates of 25% to 35%.[62] A high index of suspicion should be used in conjunction with laboratory and imaging studies to establish the diagnosis as rapidly as possible. Successful treatment requires early, aggressive surgical debridement of all necrotic tissue, appropriate broad-spectrum systemic antibiotic therapy, and supportive care (fluid resuscitation, organ and critical care support) to maintain oxygenation and tissue perfusion. Delayed definitive debridement remains the single most important risk factor for death. Early operative debridement is the major determinant of outcome in NSTIs.

A recent single-institution series of 166 patients documented that the overall mortality rate was 17% and limb loss occurred in 26% of patients with extremity involvement.[63] Independent predictors of mortality included white blood cell count greater than 30,000 $\times$ 10^3/μL, creatinine level greater than 2 mg/dL, and heart disease at hospital admission. Independent predictors of limb loss included heart disease and shock (systolic blood pressure $<$90 mm Hg) at hospital admission. Clostridial infection was an independent predictor for both limb loss and mortality and was highly associated with IV drug use and a high rate of leukocytosis on hospital admission.

A 30-day postoperative mortality risk calculator for NSTI was developed using the NSQIP which identified seven independent variables that correlated with mortality: age older than 60 years, functional status, requiring dialysis, American Society of Anesthesiologists (ASA) class 4 or higher, emergent surgery, septic shock, and low platelet count. The receiver operating characteristic area was 0.85, which indicated a strong predictive model that can aid physicians in the decision-making process.[64]

13 Early operative debridement is the major determinant of outcome in NSTIs. However, early recognition of NSTIs is difficult clinically. A novel diagnostic scoring system for distinguishing NSTIs from other severe soft tissue infections based on laboratory tests routinely performed for the evaluation of severe SSTIs is called the LRINEC score (Table 8-11).[65] The LRINEC score was initially developed in a retrospective observational study including 145 patients with necrotizing fasciitis and 309 patients with severe cellulitis or abscesses admitted to the 2 tertiary care hospitals. The cutoff value for the LRINEC score was 6 points with a positive predictive value of 92% and negative predictive value of 96%. The LRINEC score is a robust score capable of detecting clinically early cases of necrotizing fasciitis. The variables used are routinely measured to assess severe soft tissue infections. Patients with a LRINEC score of $\geq$6 should be

carefully evaluated for the presence of necrotizing fasciitis.

Table 8-11 The Laboratory Risk Indicator for Necrotizing Fasciitis (LRINEC) Score

Variable, Units	Score
C-reactive protein, mg/L	
<150	0
≥150	4
Total white cell count, per mm^3	
<15	0
15–25	1
>25	2
Hemoglobin, g/dL	
>13.5	0
11–13.5	1
<11	2
Sodium, mmol/L	
≥135	0
≤135	2
Creatinine, µmol/L	
≤141	0
>141	2
Glucose, mmol/L	
≤10	0
>10	1

The maximum score is 13; a score ≥6 should raise the suspicion of necrotizing fasciitis and a score of ≥8 is strongly predictive of this disease.

Since the initial development of the LRINEC score, a number of other cohort studies have validated its utility in the diagnosis of NSTIs. A multicenter study in 229 patients with NSTIs from 2002 to 2005 reported an overall mortality rate of 16% and amputation rate of 26%. This study also documented that a LRINEC score ≥6 was associated with a higher rate of both mortality and amputation.[66]

Diagnostic Imaging in Necrotizing Soft Tissue Infections

NSTIs necessitate prompt aggressive surgical debridement for satisfactory treatment in addition to antimicrobial therapy. Because of the rapidly progressive and potentially fatal outcome of this condition, if imaging cannot be performed expeditiously, delaying treatment is not justified. Plain film findings may reveal extensive soft tissue gas. CT examination can reveal asymmetric thickening of deep fascia in association with gas, and associated abscesses may also be present. MR imaging can also assist in the diagnosis of NSTIs.[67] MR imaging has been documented to effectively differentiate between necrotizing and nonnecrotizing infections of the lower extremity and other areas of the body, but should not delay prompt surgical intervention in NSTIs management.[68–70]

Microbiology of Necrotizing Soft Tissue Infections

Necrotizing fasciitis and myonecrosis are typically caused by infection with group A streptococcus (GAS), Clostridium perfringens, or, most commonly, aerobic and anaerobic

organisms as part of a polymicrobial infection that may include *S. aureus.* In case series, CA-MRSA has recently been described as a predominantly monomicrobial cause of necrotizing fasciitis.[71,72] A retrospective review of patients presenting with necrotizing fasciitis indicated that MRSA was the most common pathogen, accounting for one-third of the organisms isolated.[73]

NSTIs have been classified into two types, either polymicrobial (**type I**) or monomicrobial (**type II**). Polymicrobial infections are more common, due to both aerobic and anaerobic organisms, and commonly occur in the trunk and perineum. NSTIs that are monomicrobial in origin commonly occur in the limbs and are typically caused by infection with GAS, *C. perfringens,* or *S. aureus.* NSTIs are categorized into these two specific types based on the microbiologic etiology of the infection, and this classification does impact on the specific antimicrobial agents required for treatment of these NSTIs. Increasingly, MRSA has been identified as the causative microbe in NSTIs, but a separate category for this NSTI does not currently exist.[74–78] Given this finding, anti-MRSA empiric antimicrobial therapy should be initiated in all patients with NSTIs and pathogen-directed antimicrobial therapy considered once tissue culture results are available.

Uncommon microbiologic causes of NSTIs and primary sepsis include Vibrio and Aeromonas species, virulent gram-negative bacteria, and members of the Vibrionaceae family that thrive in aquatic environments.[79] These NSTIs are likely to occur in patients with hepatic disease, diabetes, and immunocompromised conditions.[80] These organisms are found in warm sea waters and are often present in raw oysters, shellfish, and other seafood. The diagnosis of vibrio NSTIs should be suspected when a patient has the appropriate clinical findings and a history of contact with seawater or raw seafood.[81] Early fasciotomy and culture-directed antimicrobial therapy should be aggressively performed in those patients with hypotensive shock, leukopenia, severe hypoalbuminemia, and underlying chronic illness, especially a combination of hepatic dysfunction and diabetes mellitus. The rates of amputation and mortality are very high in these patients, and early definitive management is of paramount importance.[82–84] A study of 125 patients identified that a LRINEC score of 2 or greater and the presence of hemorrhagic bullous/blistering lesions in patients with Vibrio vulnificus SSTI are associated with an 12-fold increased risk for the presence of NSTI and necrotizing fasciitis.[85]

Pyomyositis

Myositis is a rare infection that may lead to serious and potentially life-threatening local and systemic complications.[86] The infection can progress rapidly, and early recognition and proper medical and surgical management is therefore the cornerstone of therapy. With the increasing prevalence of community-associated MRSA as a pathogen in severe SSTIs, pyomyositis is more common than in past years.[87,88] Myositis often occurs in muscle sites that have been compromised by injury, ischemia, malignancy, or surgery. The predominant pathogens are *S. aureus,* GAS, gram-negative aerobic and facultative bacilli, and the indigenous aerobic and anaerobic cutaneous and mucous membranes local microflora.

CT scan imaging is a rapid and sensitive diagnostic test and commonly demonstrates diffuse enlargement of the involved muscle and may demonstrate the presence of fluid or gas collections within the muscle suggesting the presence of abscesses. MRI is more sensitive in showing early inflammatory changes prior to development of abscesses in myositis.[89] Emergency surgical exploration is warranted in order to define the nature of the infective process which is accomplished by direct examination of the involved muscles. Surgical intervention is required to perform appropriate abscess drainage and debridement and also to evaluate for necrotizing myositis. Fasciotomies and extremity amputation are sometimes necessary.

SURGICAL SITE INFECTIONS

Epidemiology

SSI is the leading nosocomial infection among surgical patients and the second most common nosocomial infection overall. In the United States, greater than 40 million inpatient and outpatient surgical procedures are performed each year and 2% to 5% are complicated by SSIs. SSIs result in increased length of stay (7 days) and additional cost ($400 to $2,600 per infection; total $130 to $845 million per year).[90–93] Among the four healthcare-associated infections (pneumonia, SSI, urinary tract infection, and bloodstream infection), SSIs are the second most common healthcare-associated infection, accounting for 17% of all healthcare-associated infections among hospitalized patients. A similar rate was obtained from the National Healthcare Safety Network (NHSN) hospitals reporting data in 2006–2008 (15,862 SSI following 830,748 operative procedures, with an overall rate of nearly 2%).[94]

Definitions

SSIs are defined in three specific categories by the Centers for Disease Control and Prevention (CDC), including superficial incisional SSI, deep incisional SSI, and organ/space SSI (Fig. 8-4, Table 8-12), dependent on the depth of the infection at the surgical incision site. In addition, the SSI must occur within 30 days after the operative procedure if no implant is left in place or within 1 year if implant is in place and the infection appears to be related to the operative procedure. More specific criteria regarding these definitions are available in the CDC Guideline for Prevention of Surgical Site Infection.[95]

Risk Factors for Surgical Site Infection

SSI risk is strongly associated with wound classification, with low risk for SSI in *clean* and *clean-contaminated* wound classes, and high risk for SSI in *contaminated* and *dirty–infected* wound classes. Three independent variables have been shown to be associated with SSI risk, initially developed by the National Nosocomial Infections Surveillance System (NNIS). The NHSN was established in 2005 to integrate and supersede three legacy surveillance systems at the CDC: the NNIS system, the Dialysis Surveillance network (DSN), and the National Surveillance System for Healthcare Workers (NaSH). Similar to the NNIS system, NHSN facilities voluntarily report their healthcare-associated infection surveillance data for aggregation into a single national database.

The NHSN SSI Risk Index includes an ASA score greater than 2, classification of wound as contaminated or dirty, and prolonged duration of operation.[96,97] Although the risk of infection increases within the wound classification, it has been shown to be also dependent within each wound class on the NNIS classification.

Table 8-12 CDC/NHSN Classification of Surgical Site Infections (SSIs)

Type of SSI	Definition
Superficial incisional	Infection occurs within 30 d after the operative procedure and involves only skin and subcutaneous tissue of the incision and patient has at least one of the following: a. purulent drainage from the superficial incision b. organisms isolated from an aseptically obtained culture of fluid or tissue from the superficial incision c. at least one of the following signs or symptoms of infection: pain or tenderness, localized swelling, redness, or heat, and superficial incision is deliberately opened by surgeon and is culture positive or not cultured. A culture-negative finding does not meet this criterion d. diagnosis of superficial incisional SSI by the surgeon or attending physician
Deep incisional	Infection occurs within 30 d after the operative procedure if no implant[a] is left in place or within 1 yr if implant is in place and the infection appears to be related to the operative procedure and involves deep soft tissues (e.g., fascial and muscle layers) of the incision and patient has at least one of the following: a. purulent drainage from the deep incision but not from the organ/space component of the surgical site b. a deep incision spontaneously dehisces or is deliberately opened by a surgeon and is culture positive or not cultured when the patient has at least one of the following signs or symptoms: fever (38°C), or localized pain or tenderness. A culture-negative finding does not meet this criterion. c. an abscess or other evidence of infection involving the deep incision is found on direct examination, during reoperation, or by histopathologic or radiologic examination d. diagnosis of a deep incisional SSI by a surgeon or attending physician

[a]Implant: A nonhuman-derived object, material, or tissue (e.g., prosthetic heart valve, nonhuman vascular graft, mechanical heart, or hip prosthesis) that is permanently placed in a patient during an operative procedure and is not routinely manipulated for diagnostic or therapeutic purposes.
From Horan TC, Andrus M, Dudeck MA. CDC/NHSN surveillance definition of healthcare-associated infection and criteria for specific types of infections in the acute care setting. *Am J Infect Control* 2008;36:309–332.

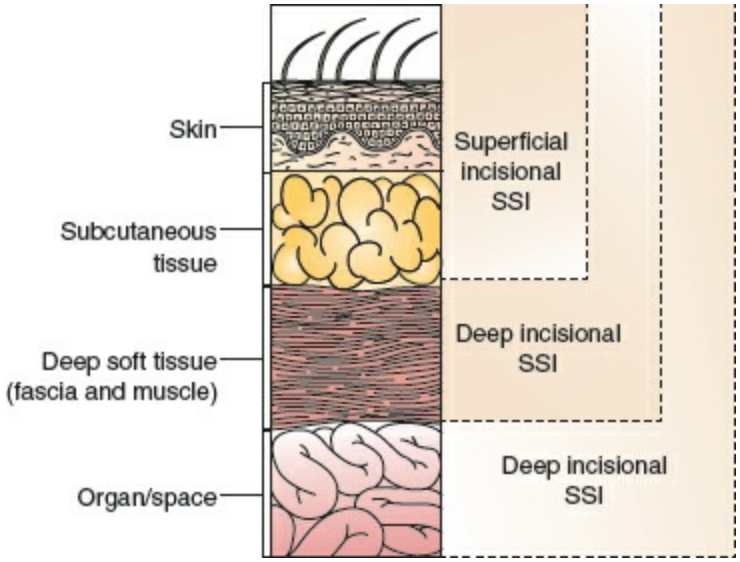

Figure 8-4. Surgical site infection (SSI) definitions by CDC.

Cross-section of the abdominal depicted.

Superficial incisional SSI involves only the skin and subcutaneous tissue layer of the incision

Deep incisional SSI involves deep soft tissues (e.g., fascia and muscle layers) of the incision

Organ/space SSI involves any part of the body, excluding the skin incision, fascia or muscle layers, that is opened or manipulated during the operative procedure (e.g., intra-abdominal abscess or thoracic empyema)

Basic SSI Risk Index

The index used in NHSN assigns surgical patients into categories based on the presence of three major risk factors:

1. Operation lasting more than the duration cut point hours, where the duration cut point is the approximate 75th percentile of the duration of surgery in minutes for the operative procedure.
2. Contaminated (class 3) or dirty/infected (class 4) wound class.
3. ASA classification of 3, 4, or 5.

The patient's SSI risk category is simply the number of these factors present at the time of the operation.

The laparoscopic surgical approach is associated with decreased SSI incidence, and a modified risk index (category 1 when procedure was performed with a laparoscope) has been created to address this approach.

Additional patient-specific risk factors for SSI have also been identified that are not included in this risk index, including the presence of anemia, blood transfusion intraoperatively, and colonization with resistant pathogens.[97,98] This SSI Risk Index warrants reevaluation for the future, particularly with regard to resistant pathogens and other patient-specific risk factors that are not modifiable prior to surgical intervention. It is of paramount importance to include an SSI risk assessment in all future clinical trials where SSI is a primary outcome measure.

Surgical Site Infection Prevention

Preventive measures for SSI include antimicrobial prophylaxis, sterilization methods, proper ventilation of operating rooms, use of barriers, no shaving, clipping if hair removal is required, proper surgical skin preparation and surgical techniques, maintenance of normothermia, glycemic control, and the provision of supplemental oxygen.[93] The National Surgical Infection Prevention (SIP) project was initiated as the first component of the Surgical Care Improvement Project (SCIP). Initiated in 2003, the SCIP partnership sought to substantially reduce surgical mortality and morbidity through collaborative efforts.

Despite evidence of effectiveness of preoperative antimicrobials for SSI prevention and the publication of guidelines for antimicrobial prophylaxis, it was recognized that use was often suboptimal. As part of the SIP initiative, three SIP performance measures were developed:

- SIP-1: Antibiotic timing: Proportion of patients in whom IV antimicrobial prophylaxis is initiated within 1 hour before incision
- SIP-2: Antibiotic selection: Proportion of patients are given prophylactic antimicrobials consistent with published guidelines
- SIP-3: Antibiotic discontinuation within 24 hours: Proportion of patients whose antimicrobial prophylaxis is discontinued within 24 hours after surgery

Numerous studies document that antimicrobial prophylaxis for SSI is most effective when provided 30 to 60 minutes prior to the initial surgical incision, allowing adequate blood and tissue concentrations at the time of skin incision. Risk of SSI increases when antimicrobial prophylaxis is given too early (more than 2 hours prior to skin incision) or too late (after skin incision). In a recent study of 4,472 patients, SSI risk increased incrementally as the interval of time between antibiotic infusion and the surgical incision increased. These data from a large multicenter collaborative study confirmed lower SSI risk when surgical antimicrobial prophylaxis with cephalosporins and other antibiotics with short infusion times were given within 30 minutes prior to surgical incision.[99]

In addition, the correct antimicrobial must be administered to cover the potential causative pathogens, dependent on the surgical procedure performed. The SCIP pocket card (Table 8-13) provides a list of the recommended preoperative antimicrobials for specific surgical procedures. The recent publication of the “Clinical practice guidelines for antimicrobial prophylaxis in surgery” by the American Society of Health-System Pharmacists, Infectious Diseases Society of America, Surgical Infection Society, and Society for Healthcare Epidemiology of America provide evidence-based national recommendations.[100]

The first report of the National SIP Project baseline results from a systematic random sample of 34,133 medicare inpatients undergoing surgery in US hospitals in 2001 documented that only 55.7% of patients received a dose of parenteral antimicrobial prophylaxis within 1 hour before surgical incision. Antimicrobial agents consistent with published guidelines were administered to 92.6% of patients and antimicrobial

prophylaxis was discontinued within 24 hours of surgery end time for only 40.7% of patients. Interestingly, only 28% of these surgical patients had compliance with all three of these performance measures.[101]

Table 8-13 Recommended Preoperative Antimicrobials for Specific Surgical Procedures

Prophylactic Antibiotic Regimen Selection for Surgery	Prophylactic Antibiotic Regimen Selection for Surgery
Surgical procedure: CABG, other cardiac or vascular	Surgical procedure: hip/knee arthroplasty
Approved antibiotics Cefazolin, cefuroxime, or vancomycin[b] If β-lactam allergy: vancomycin[a] or clindamycin[a]	Approved antibiotics Cefazolin or cefuroxime or vancomycin[b] If β-lactam allergy: vancomycin[a] or clindamycin[a]
Surgical procedure: hysterectomy	Surgical procedure: colon
Approved antibiotics Cefotetan, cefazolin, cefoxitin, cefuroxime, or ampicillin/sulbactam If β-lactam allergy: clindamycin + aminoglycoside, or clindamycin + quinolone, or clindamycin + aztreonam OR metronidazole + aminoglycoside, or metronidazole + quinolone	Approved antibiotics Cefotetan, cefoxitin, ampicillin/sulbactam, or [c]ertapenem OR cefazolin or cefuroxime + metronidazole If β-lactam allergy: clindamycin + aminoglycoside, or clindamycin + quinolone, or clindamycin + aztreonam OR metronidazole with aminoglycoside, or metronidazole + quinolone
Surgical procedure: special considerations	Surgical procedure: special considerations

[a]For cardiac, orthopedic, and vascular surgery, if the patient is allergic to β-lactam antibiotics, vancomycin or clindamycin is acceptable substitute.
[b]Vancomycin is acceptable with a physician/APN/PA/pharmacist documented justification for its use (see data element *Vancomycin*).
[c]A single dose of ertapenem is recommended for colon procedures.

We have truly made remarkable progress in the United States with appropriate perioperative antimicrobial prophylaxis since that initial published report. Compliance with SIP-1 measure (antibiotics within 60 minutes prior to incision) increased from 55.7% to 91.6%; compliance with SIP-2 measure (guideline antibiotics) increased from 92.6% to 95.8%; and compliance with SIP-3 (antibiotics discontinued) increased from 40.7% to 87.7%.

Additional Strategies for Surgical Site Infection Prevention

Surgical Hand Antisepsis

Surgical hand antisepsis, to destroy bacteria, is routinely carried out before undertaking invasive procedures. A recent review of 10 trials confirmed that alcohol rubs used in preparation for surgery by the surgical team are as effective as aqueous scrubbing in SSI prevention. There is no evidence to suggest that any particular alcohol rub is better than another. Evidence from four studies suggests that chlorhexidine gluconate–based aqueous scrubs are more effective than povidone iodine–based aqueous scrubs in terms of the numbers of bacterial colony–forming units on the hands.[102]

Chlorhexidine as Skin Surgical Site Preparation

Preoperative skin antisepsis of the surgical site is performed to reduce the risk of SSI by removal of skin microorganisms. A review of six randomized controlled trials identified significant heterogeneity and the trial results could not be pooled. There was no evidence of a benefit in four trials associated with the use of iodophor-impregnated drapes.[103] More recent studies have documented that chlorhexidine provided superior skin decontamination compared to povidone-iodine.[104–107] The most recent Cochrane systematic review found evidence that preoperative skin preparation with 0.5% chlorhexidine in alcohol was associated with lower SSI rates following clean surgery than alcohol-based povidone-iodine paint.[108]

Appropriate Hair Removal

The preparation of the surgical site has traditionally included the routine removal of body hair, however, some studies have suggested that this is deleterious. A Cochrane systematic review of 11 randomized clinical trials, and 3 trials (n = 3,193) comparing shaving with clipping, found that there were statistically more SSIs with shaving than clipping. If it is necessary to remove hair, clipping results in fewer SSIs than shaving using a razor.[109]

Normothermia Maintenance During Surgery

Perioperative hypothermia is common and adversely affects clinical outcomes. The primary beneficial effects of warming are mediated through increased blood flow and oxygen tension at the tissue level. Hypothermia may facilitate SSI in two ways. First, sufficient intraoperative hypothermia triggers thermoregulatory vasoconstriction. Second, considerable evidence indicates that mild core hypothermia directly impairs immune function including T-cell–mediated antibody production and nonspecific oxidative bacterial killing by neutrophils. Randomized controlled trials have documented that perioperative warming is associated with a significant reduction in SSI and this simple SSI preventive strategy should be implemented in all surgical patients.[110–112]

Normoglycemia Maintenance During Surgery

Perioperative hyperglycemia has been associated with increased SSIs and previous

recommendations have been to treat glucose levels above 200 mg/dL. Recent studies have questioned the optimal glycemic control regimen to prevent SSIs. A recent Cochrane Database systematic review included five randomized controlled clinical trials with a total of 773 patients randomized. Due to heterogeneity in patient populations, perioperative period, glycemic target, route of insulin administration, and definitions of outcome measures, combination of the results of the five trials into a meta-analysis was not appropriate. The authors concluded that there is insufficient evidence to support strict glycemic control in the intra- and postoperative period among surgical patients for the prevention of SSIs.[113] A Cochrane review of 12 trials that randomized diabetic patients to intensive or conventional glycemic control perioperatively concluded that no significant differences were identified in patients with diabetes mellitus. However, posthoc analysis indicated that intensive glycemic control was associated with greater incidence of hypoglycemia episodes.[114]

There are no randomized trials evaluating immediate preoperative glycemic control in any setting or intra/postoperative glycemic control in non-ICU patients. High-quality evidence for strict glycemic control in the intra- and/or postoperative period among surgical ICU patients, cardiac and noncardiac, to reduce SSIs, independent of other potential benefits, is also lacking. Further large, adequately powered, well-designed randomized trials are necessary to identify the ideal target for perioperative glycemic control in patients at high risk for SSIs. Future trials should report all nosocomial infections as well as SSIs. Given the heterogeneity seen in the included trials, it would appear that trials should be targeted at very specific populations and attempts to draw broader conclusions should not be made. At present, we should strive at least to maintain blood glucose <200 mg/dL in the perioperative period in our surgical patients.

Supplemental Oxygen in Perioperative Period

Several randomized controlled trials have been conducted to assess the benefit of perioperative supplemental oxygen in SSI reduction, yet meta-analyses have arrived at different conclusions.[115–117] On careful review, a number of problems with the conduct of these trials are noted: (1) SSI definition was not consistent with CDC definitions; (2) the interval for assessment of SSI was variable, ranging from 15 to 30 days; (3) SSI was captured retrospectively in some studies and was not always a primary outcome measure; (4) no assessment of the patient's individual risk factors for SSI was performed; (5) no control of perioperative antibiotic prophylaxis timing or selection was performed; and (6) there was variable provision of high FiO_2 supplemental oxygen in each of the studies.[118]

The first institutional priority should be to universally implement all the evidence-based practices that reduce SSIs. The "SSI Bundle" from the Institute for Healthcare Improvement includes (1) appropriate use of antibiotics, (2) appropriate hair removal, (3) perioperative glucose control, and (4) perioperative normothermia.[119] The additional provision of increased inspired oxygen concentrations should be considered as an additional quality improvement measure, particularly in institutions with high SSI rates. A collaborative of 44 hospitals implemented the SSI preventive strategies discussed above and documented a significant reduction in the SSI rate, from 2.3% to 1.7%, representing a

27% reduction from the first to the last 3 months of the 1-year project.[120] Finally, prospective SSI surveillance, including postdischarge surveillance, should be instituted to obtain accurate information regarding institutional SSI rates.[121]

Surgical Site Infection and Colorectal Surgery

Surgical care bundles have been documented to be effective in reducing SSIs in patients undergoing colorectal surgery and therefore should be implemented.[122] Surgeons have held a long-standing belief that mechanical bowel preparation is an efficient strategy to reduce SSI and anastomotic leak rates following elective colorectal surgery. Recent systematic reviews have found that there is no statistically significant evidence that patients benefit from mechanical bowel preparation either in SSI or anastomotic leak rates.[123] In contrast, the use of nonabsorbable enteral antimicrobials covering aerobic and anaerobic colonic bacteria, in addition to IV preoperative antibiotics, is associated with a significant reduction in SSI by at least 75%.[124–126]

Treatment of Surgical Site Infection

Once superficial or deep incisional SSI is diagnosed, "pathogen identification" is of paramount importance. In years past, the surgical incision was opened and dressing changes were initiated with no culture of the surgical site obtained. In today's era of multidrug-resistant pathogens, a Gram stain and culture of the surgical site should always be obtained in order to determine the optimal antimicrobial therapy that is required for SSI treatment.

SSI treatment includes four strategies for successful treatment: (1) early empiric antimicrobial therapy; (2) decision-making regarding whether the surgical site should be opened; (3) pathogen identification; and (4) deescalation of antimicrobial therapy once culture results are available.

For organ/space SSI, "source control" and "pathogen identification" are both high priorities in order to achieve successful treatment. In the case of intra-abdominal abscess, source control can be provided by either interventional radiology percutaneous drainage or open surgical drainage of the abscess. Abscess fluid should be sent for Gram stain and culture, and empiric antimicrobial treatment should be deescalated once culture results are available.

Current Challenges in Surgical Site Infection

There are a number of growing challenges in SSI, including resistant pathogens, our increasingly elderly population, more patients with chronic diseases or immunocompromised states undergoing surgery, and increasing patients undergoing surgery for solid organ transplantation and placement of prosthetic devices. MRSA was reported to be the most common cause of SSI in vascular surgery patients (n = 772 over a 2-year period) in 2004.[127,128] MRSA has emerged as the leading cause of postoperative infection in vascular surgery patients, and is associated with substantial morbidity, increased hospital length of stay, and higher incidences of amputation and graft removal.

Comparison of the causative pathogens for SSI in US hospitals documents that *S. aureus* increased from 22.5% (1986–2003) to 30% (2006–2007), with MRSA now the leading causative pathogen, comprising 49.2% of all isolates.[128,129] In a study of 8,302 patients readmitted to US hospitals with culture-confirmed SSI from 2003 to 2007, it was noted that the proportion of infections due to MRSA significantly increased from 16.1% to 20.6% and was associated with higher mortality rates, longer length of stay, and higher hospital costs.[130] Based on this important finding, some have strongly advocated for active screening for nasal carriage of MRSA prior to elective surgery with modification of antimicrobials for SSI prevention based on those results.[131–133] Eradication of MRSA before surgery appears to lower SSI rates due to MRSA and is recommended.[134,135] In contrast, a prospective interventional cohort study that employed a universal rapid MRSA admission screening strategy among 21,754 surgical patients at a Swiss teaching hospital reported that nosocomial MRSA infection, including SSI, did not decrease, but relatively low rates of MRSA infection were present at the start of this study.[136]

An "MRSA bundle" has been developed including five components:

1. MRSA nasal screening of patients upon admission, transfer, and discharge using PCR;
2. contact isolation of positive patients;
3. standardized hand hygiene;
4. cultural transformation campaign with staff and leadership engagement through positive deviance; and
5. ongoing monitoring of process and outcome measures.

Implementation of the MRSA bundle was associated with a significant decrease in MRSA transmission from 5.8 to 3.0 per 1,000 bed-days, significant reduction in MRSA nosocomial infections (2.0 to 1.0 per 1,000 bed-days), and a significant decrease in overall SSIs, with a 65% reduction in orthopedic MRSA SSIs and a 1% decrease in cardiac MRSA SSIs.[137]

The advent of CA-MRSA[138,139] has also significantly impacted SSI. Recent studies document that CA-MRSA is replacing traditional healthcare-associated or nosocomial MRSA strains in SSI among inpatients.[140] A report from a large community hospital in St. Louis, MO, examined the rates of SSI due to *S. aureus* in a total of 122,040 surgical procedures in an earlier period (2003–2006) versus later period (2006–2007). MRSA was identified as the SSI pathogen in 40% of all inpatients in both time periods. Interestingly,

the percentage of clindamycin-susceptible MRSA (distinguishing CA-MRSA) as an SSI causative pathogen for inpatients rose from 9% in the early period to 19% in the later period. This increase in the rate of CA-MRSA SSI was observed only among inpatients, not among ambulatory patients. Similarly, CA-MRSA has emerged as a leading cause of healthcare-associated infections among patients with prosthetic joint SSIs.[141]

The use of perioperative intranasal mupirocin for SSI prevention, particularly in patients with MRSA nasal colonization, remains controversial. Reviews of multiple clinical trials documented that no reduction in SSI was seen in general surgery or cardiac surgery patients; however, in nongeneral surgery patients the use of mupirocin was associated with a reduction in SSI.[134,135,142]

References

1. Napolitano LM. Perspectives in surgical infections: what does the future hold? *Surg Infect (Larchmt)* 2010;11(2):111–123.
2. Kollef MH, Sherman G, Ward S, et al. Inadequate antimicrobial treatment of infections: a risk factor for hospital mortality among critically ill patients. *Chest* 1999;115:462–474.
3. Marquet K, Liesenborgs A, Bergs J, et al. Incidence and outcome of inappropriate in-hospital empiric antibiotics for severe infection: a systematic review and meta-analysis. *Crit Care* 2015;19:63.
4. Kumar A, Roberts D, Wood KE, et al. Duration of hypotension before initiation of effective antimicrobial therapy is the critical determinant of survival in human septic shock. *Crit Care Med* 2006;34:1589–1596.
5. Marshall JC. Principles of source control in the early management of sepsis. *Curr Infect Dis Rep* 2010;12(5):345–353.
6. Solomkin JS, Mazuski JE, Bradley JS, et al. Diagnosis and management of complicated intra-abdominal infection in adults and children: guidelines by the Surgical Infection Society and the Infectious Diseases Society of America. *Surg Infect (Larchmt)* 2010;11(1):79–109.
7. Solomkin JS, Mazuski JE, Bradley JS, et al. Diagnosis and management of complicated intra-abdominal infection in adults and children: guidelines by the Surgical Infection Society and the Infectious Diseases Society of America. *Clin Infect Dis* 2010;50(2):133–164.
8. Sawyer RG, Claridge JA, Nathens AB, et al. Trial of short-course antimicrobial therapy for intraabdominal infection. *N Engl J Med* 2015; 372(21):1996–2005.
9. Wray CJ, Kao LS, Millas SG, et al. Acute appendicitis: controversies in diagnosis and management. *Curr Probl Surg* 2013;50(2):54–86.
10. Liu K, Fogg L. Use of antibiotics alone for treatment of uncomplicated acute appendicitis: a systematic review and meta-analysis. *Surgery* 2011; 150(4):673–683.
11. Wilms IM, de Hoog DE, de Visser DC, et al. Appendectomy versus antibiotic treatment for acute appendicitis. *Cochrane Database Syst Rev* 2011;(11):CD008359.
12. Ansaloni L, Catena F, Coccolini F, et al. Surgery versus conservative antibiotic treatment in acute appendicitis: a systematic review and meta-analysis of randomized controlled trials. *Dig Surg* 2011;28(3):210–221.
13. Salminen P, Paajanen H, Rautio T, et al. Antibiotic therapy vs appendectomy for treatment of uncomplicated acute appendicitis: the APPAC randomized clinical trial. *JAMA* 2015;313(23):2340–2348.
14. Livingston E, Vons C. Treating appendicitis without surgery. *JAMA* 2015;313(23):2327–2328.
15. Kao LS, Boone D, Mason RJ; Evidence-Based Reviews in Surgery Group. Antibiotics vs appendectomy for uncomplicated acute appendicitis. *J Am Coll Surg*

2013;216(3):501–505.
16. Ingraham AM, Cohen ME, Bilimoria KY, et al. Comparison of outcomes after laparoscopic versus open appendectomy for acute appendicitis at 222 ACS NSQIP hospitals. *Surgery* 2010;148:625–635; discussion 635–637.
17. Sauerland S, Jaschinski T, Neugebauer EA. Laparoscopic versus open surgery for suspected appendicitis. *Cochrane Database Syst Rev* 2010;10:CD001546.
18. Drake FT, Mottey NE, Farrokhi ET, et al. Time to appendectomy and risk of perforation in acute appendicitis. *JAMA Surg* 2014;149(8):837–844.
19. Simillis C, Symeonides P, Shorthouse AJ, et al. A meta-analysis comparing conservative treatment versus acute appendectomy for complicated appendicitis (abscess or phlegmon). *Surgery* 2010;147:818–829.
20. Andersson RE, Petzold MG. Nonsurgical treatment of appendiceal abscess or phlegmon: a systematic review and meta-analysis. *Ann Surg* 2007;246(5):741–748.
21. Kaminski A, Liu IL, Applebaum H, et al. Routine interval appendectomy is not justified after initial nonoperative treatment of acute appendicitis. *Arch Surg* 2005;140:897–901.
22. Ein SH, Langer JC, Daneman A. Nonoperative management of pediatric ruptured appendix with inflammatory mass or abscess: presence of an appendicolith predicts recurrent appendicitis. *J PediatrSurg* 2005;40:1612–1615.
23. Demehri FR, Alam HB. Evidence-based management of common gallstone-related emergencies. *J Intensive Care Med* 2016;31(1):3–13.
24. Kiewiet JJ, Leeuwenburgh MM, Bipat S, et al. A systematic review and meta-analysis of diagnostic performance of imaging in acute cholecystitis. *Radiology* 2012;264(3):708–720.
25. Broderick-Villa G, Burchette RJ, Collins JC, et al. Hospitalization for acute diverticulitis does not mandate routine elective colectomy. *Arch Surg* 2005;140(6):576–581.
26. Morris AM, Regenbogen SE, Hardiman KM, et al. Sigmoid diverticulitis: a systematic review. *JAMA* 2014;311(3):287–297.
27. Regenbogen SE, Hardiman KM, Hendren S, et al. Surgery for diverticulitis in the 21st century: a systematic review. *JAMA Surg* 2014;149(3):292–303.
28. Hinchey EJ, Schaal PG, Richards GK. Treatment of perforated diverticular disease of the colon. *Adv Surg* 1978;12:85–109.
29. Cirocchi R, Trastulli S, Desiderio J, et al. Treatment of Hinchey stage III–IV diverticulitis: a systematic review and meta-analysis. *Int J Colorectal Dis* 2013;28(4):447–457.
30. To KB, Napolitano LM. Clostridium difficile infection: update on diagnosis, epidemiology, and treatment strategies. *Surg Infect (Larchmt)* 2014;15(5):490–502.
31. Bagdasarian N, Rao K, Malani PN. Diagnosis and treatment of Clostridium difficile in adults: a systematic review. *JAMA* 2015;313(4):398–408.

32. Cohen SH, Gerding DN, Johnson S, et al.; Society for Healthcare Epidemiology of America; Infectious Diseases Society of America. Clinical practice guidelines for Clostridium difficile infection in adults: 2010 update by the society for healthcare epidemiology of America (SHEA) and the infectious diseases society of America (IDSA). *Infect Control Hosp Epidemiol* 2010;31:431–455.
33. Cornely OA, Crook DW, Esposito R, et al. Fidaxomicin versus vancomycin for infection with Clostridium difficile in Europe, Canada, and the USA: a double-blind, noninferiority, randomised controlled trial. *Lancet Infect Dis* 2012;12:281–289.
34. Neal MD, Alverdy JC, Hall DE, et al. Diverting loop ileostomy and colonic lavage: an alternative to total abdominal colectomy for the treatment of severe, complicated Clostridium difficile associated disease. *Ann Surg* 2011;254:423–427; discussion 423–429.
35. Rosenberg A, Steensma EA, Napolitano LM. Necrotizing pancreatitis: new definitions and a new era in surgical management. *Surg Infect (Larchmt)* 2015;16(1):1–13.
36. De Waele JJ, Rello J, Anzueto A, et al. Infections and use of antibiotics in patients admitted for severe acute pancreatitis: data from the EPIC II study. *Surg Infect* 2014;15:394–398.
37. van Santvoort HC, Besselink MG, Bakker OJ, et al. A stepup approach or open necrosectomy for necrotizing pancreatitis. *N Engl J Med* 2010;362:1491–1502.
38. Warshaw AL. Improving the treatment of necrotizing pancreatitis—a step up. *N Engl J Med* 2010;362:1535–1537.
39. van Brunschot S, Fockens P, Bakker OJ, et al. Endoscopic transluminal necrosectomy in necrotising pancreatitis: a systematic review. *Surg Endosc* 2014;28:1425–1438.
40. Napolitano LM. Introduction: the diagnosis and treatment of skin and soft tissue infections (SSTIs). *Surg Infect (Larchmt)* 2008;9(suppl 1):s1.
41. DiNubile MJ, Lipsky BA. Complicated infections of skin and skin structures: when the infection is more than skin deep. *J Antimicrob Chemother* 2004;53(suppl 2):ii37–ii50.
42. Vinh DC, Embil JM. Severe skin and soft tissue infections and associated critical illness. *Curr Infect Dis Rep* 2007;9(5):415–421.
43. Napolitano LM. Severe soft tissue infections. *Infect Dis Clin North Am* 2009;23(3):571–591.
44. http://www.fda.gov/downloads/Drugs/GuidanceComplianceRegulatoryInformation/
45. May AK. Skin and soft tissue infections. *Surg Clin North Am* 2009;89(2):403–420.
46. Chan T, Yaghoubian A, Rosing D, et al. Low sensitivity of physical examination findings in necrotizing soft tissue infection is improved with laboratory values: a prospective study. *Am J Surg* 2008;196(6):926–930; discussion 930.
47. Wall DB, deVirgilio C, Black S, et al. Objective criteria may assist in distinguishing necrotizing fasciitis from non-necrotizing soft tissue infection. *Am J Surg* 2000;179(11):17–21.

48. Wall DB, Klein SR, Black S, et al. A simple model to help distinguish necrotizing fasciitis from non-necrotizing soft tissue infections. *J Am Coll Surg* 2000;191(3):227–231.
49. Zacharias N, Velmahos GC, Salama A, et al. Diagnosis of necrotizing soft tissue infections by computed tomography. *Arch Surg* 2010;145(5):452–455.
50. Iregui M, Ward S, Sherman G, et al. Clinical importance of delays in the initiation of appropriate antibiotic treatment for ventilator-associated pneumonia. *Chest* 2002;122:262–268.
51. Garnacho-Montero J. Impact of adequate empirical antibiotic therapy on the outcome of patients admitted to the intensive care unit with sepsis. *Crit Care Med* 2003;31:2742–2751.
52. Alvarez-Lerma F; the ICU-Acquired Pneumonia Study Group. Modification of empiric antibiotic treatment in patients with pneumonia acquired in the intensive care unit. *Intensive Care Med* 1996;22:387–394.
53. Ruhe JJ, Smith N, Bradsher RW, et al. Community-onset methicillin-resistant Staphylococcus aureus skin and soft-tissue infections: impact of antimicrobial therapy on outcome. *Clin Infect Dis* 2007;44:777–784.
54. Schramm GE, Johnson JA, Doherty JA, et al. Methicillin-resistant Staphylococcus aureus sterile-site infection: the importance of appropriate initial antimicrobial treatment. *Crit Care Med* 2006;34(8):2069–2074.
55. Chuck EA, Frazee BW, Lambert L, et al. The benefit of empiric treatment for MRSA. *J Emerg Med* 2010;38(5):567–571.
56. Gorwitz RJ, Jernigan DB, Powers JH, et al. Participants in the CDC-Convened Experts' Meeting on Management of MRSA in the Community. Strategies for clinical management of MRSA in the community: summary of an experts' meeting convened by the Centers for Disease Control and Prevention. 2006. Available at: http://www.cdc.gov/mrsa/pdf/mrsa-strategies-expmtgsummary-2006.pdf
57. Sarkar B, Napolitano LM. Necrotizing soft tissue infections. *Minerva Chir* 2010;65(3):347–362.
58. Sarani B, Strong M, Pascual J, et al. Necrotizing fasciitis: current concepts and review of the literature. *J Am Coll Surg* 2009;208(2):279–288.
59. Anaya DA, Dellinger EP. Necrotizing soft-tissue infection: diagnosis and management. *Clin Infect Dis* 2007;44(5):705–710.
60. Cainzos M, Gonzalez-Rodriguez FJ. Necrotizing soft tissue infections. *Curr Opin Crit Care* 2007;13(4):433–439.
61. Yilmazlar T, Ozturk E, Alsoy A, et al. Necrotizing soft tissue infections: APACHE II score, dissemination, and survival. *World J Surg* 2007;31(9):1858–1862.
62. Cuschieri J. Necrotizing soft tissue infection. *Surg Infect (Larchmt)* 2008; 9(6):559–562.
63. Anaya DA, McMahon K, Nathens AB, et al. Predictors of mortality and limb loss in

necrotizing soft tissue infections. *Arch Surg* 2005;140:151–157.
64. Faraklas I, Stoddard GJ, Neumayer LA, et al. Development and validation of a necrotizing soft-tissue infection mortality risk calculator using NSQIP. *J Am Coll Surg* 2013;217(1):153–160.e3; discussion 160–161.
65. Wong CH, Khin LW, Heng KS, et al. The LRINEC (Laboratory Risk Indicator for Necrotizing Fasciitis) score: a tool for distinguishing necrotizing fasciitis from other soft tissue infections. *Crit Care Med* 2004;32(7):1535–1541.
66. Su YC, Chen HW, Hong YC, et al. Laboratory risk indicator for necrotizing fasciitis score and the outcomes. *ANZ J Surg* 2008;78(11):968–972.
67. Struk DW, Munk PL, Lee MJ, et al. Imaging of soft tissue infections. *Radiol Clin North Am* 2001;39(2):277–303.
68. Brothers TE, Tagge DU, Stutley JE, et al. Magnetic resonance imaging differentiates between necrotizing and non-necrotizing fasciitis of the lower extremity. *J Am Coll Surg* 1998;187:416–421.
69. Malghem J, Lecouvet FE, Omoumi P, et al. Necrotizing fasciitis: contribution and limitations of diagnostic imaging. *Joint Bone Spine* 2013;80(2):146–154.
70. Kim KT, Kim YJ, Won Lee J, et al. Can necrotizing infectious fasciitis be differentiated from nonnecrotizing infectious fasciitis with MR imaging? *Radiology* 2011;259(3):816–824.
71. Wong CH, Chang HC, Pasupathy S, et al. Necrotizing fasciitis: clinical presentation, microbiology, and determinants of mortality. *J Bone Joint Surg Am* 2003;85(8):1454–1460.
72. McHenry CR, Piotrowski JJ, Petrinic D, et al. Determinants of mortality for necrotizing soft-tissue infections. *Ann Surg* 1995;221(5):558–565.
73. Elhabash S, Lee L, Farrow B, et al. Characteristics and microbiology of patients presenting with necrotizing fasciitis. *Presented at the Association of VA Surgeons 31st Annual Meeting*. Little Rock: Arkansas; May 10–12, 2007.
74. Lee TC, Carrick MM, Scott BG, et al. Incidence and clinical characteristics of MRSA necrotizing fasciitis in a large urban hospital. *Am J Surg* 2007; 194(6):809–812.
75. Miller LG, Perdreau-Remington F, Rieg G, et al. Necrotizing fasciitis caused by community-associated MRSA in Los Angeles. *N Engl J Med* 2005;352(14):1445–1453.
76. Young LM, Price CS. Community-acquired MRSA emerging as an important cause of necrotizing fasciitis. *Surg Infect (Larchmt)* 2008;9(4):469–474.
77. Olsen RJ, Burns KM, Chen L, et al. Severe necrotizing fasciitis in a human immunodeficiency virus-positive patient caused by MRSA. *J Clin Microbiol* 2008;46(3):1144–1147.
78. Dehority W, Wang E, Vernon PS, et al. Community-associated MRSA necrotizing fasciitis in a neonate. *Pediatr Infect Dis J* 2006;25(11):1080–1081.
79. Tsai YH, Hsu RW, Huang TJ, et al. Necrotizing soft tissue infections and sepsis caused by Vibrio vulnificus compared with those caused by Aeromonas species. *J*

Bone Joint Surg Am 2007;89(3):631–636.

80. Tsai YH, Hsu RW, Huang KC, et al. Systemic Vibrio infection presenting as necrotizing fasciitis and sepsis. A series of 13 cases. *J Bone Joint Surg Am* 2004;86(11):2497–2502.
81. Minnaganti VR, Patel PJ, Iancu D, et al. Necrotizing fasciitis caused by Aeromonas hydrophila. *Heart Lung* 2000;29(4):306–368.
82. Vibrio vulnificus infection: diagnosis and treatment. *Am Fam Physician* 2007;76(4):539–544.
83. Tsai YH, Huang TJ, Hsu RW, et al. Necrotizing soft tissue infections and primary sepsis caused by Vibrio vulnificus and Vibrio cholerae non-O1. *J Trauma* 2009;66(3):899–905.
84. Kuo YL, Shieh SJ, Chiu HY, et al. Necrotizing fasciitis caused by Vibrio vulnificus: epidemiology, clinical findings, treatment and prevention. *Eur J Clin Microbiol Infect Dis* 2007;26(11):785–792.
85. Chao WN, Tsai SJ, Tsai CF, et al. The Laboratory Risk Indicator for Necrotizing Fasciitis score for discernment of necrotizing fasciitis originated from Vibrio vulnificus infections. *J Trauma Acute Care Surg* 2012; 73(6):1576–1582.
86. Brook I. Microbiology and management of myositis. *Int Orthop* 2004;28(5):257–260.
87. Ruiz ME, Yohannes S, Wladyka CG. Pyomyositis caused by methicillin-resistant Staphylococcus aureus. *N Engl J Med* 2005;352(14):1488–1489.
88. Woodward JF, Sengupta DJ, Cookson BT, et al. Disseminated community-acquired USA300 methicillin-resistant Staphylococcus aureus pyomyositis and septic pulmonary emboli in an immunocompetent adult. *Surg Infect (Larchmt)* 2010;11(1):59–63.
89. Garcia J. MRI in inflammatory myopathies. *Skeletal Radiol* 2000;29:425–438.
90. Napolitano LM. Severe soft tissue infections. *Infect Dis Clin North Am* 2009;23(3):571–591.
91. Wilson MA. Skin and soft tissue infections: impact of resistant gram-positive bacteria. *Am J Surg* 2003;186(5A):35S–41S.
92. Barie PS, Eachempati SR. Surgical site infections. *Surg Clin North Am* 2005;1115–1135.
93. Mangram AJ, Horan TC, Pearson ML, et al. Guideline for prevention of surgical site infection, 1999. Hospital Infection Control Practices Advisory Committee. *Infect Control Hosp Epidemiol* 1999;20:250–278.
94. Klevens RM, Edward JR, Richards CL Jr, et al. Estimating health care-associated infections and deaths in U.S. hospitals, 2002. *Public Health Rep* 2007;122:160–166.
95. http://www.cdc.gov/ncidod/dhqp/pdf/guidelines/SSI.pdf
96. National Nosocomial Infections Surveillance (NNIS) system report, data summary from January 1992–June 2001, issued August 2001. *Am J Infect Control* 2001;29:404–421.

97. Campbell DA Jr, Henderson WG, Englesbe MJ, et al. Surgical site infection prevention: the importance of operative duration and blood transfusion, results of the first American College of Surgeons National Surgical Quality Improvement Program Best Practices Initiative. *J Am Coll Surg* 2008; 207:810–820.
98. Malone DL, Genuit T, Tracy JK, et al. Surgical site infections: reanalysis of risk factors. *J Surg Res* 2002;103(1):89–95.
99. Steinberg JP, Braun BI, Hellinger WC, et al. Trial to Reduce Antimicrobial Prophylaxis Errors (TRAPE) Study Group. Timing of antimicrobial prophylaxis and the risk of surgical site infections: results from the Trial to Reduce Antimicrobial Prophylaxis Errors. *Ann Surg* 2009;250(1):10–16.
100. Bratzler DW, Dellinger EP, Olsen KM, et al. American Society of Health-System Pharmacists (ASHP); Infectious Diseases Society of America (IDSA); Surgical Infection Society (SIS); Society for Healthcare Epidemiology of America (SHEA). Clinical practice guidelines for antimicrobial prophylaxis in surgery. *Surg Infect (Larchmt)* 2013;14(1):73–156.
101. Bratzler DW, Houck PM, Richards C, et al. Use of antimicrobial prophylaxis for major surgery: baseline results from the National Surgical Infection Prevention Project. *Arch Surg* 2005;140:174–182.
102. Tanner J, Swarbrook S, Stuart J. Surgical hand antisepsis to reduce surgical site infection. *Cochrane Database Syst Rev* 2008;(1):CD004288.
103. Edwards PS, Lipp A, Holmes A. Preoperative skin antiseptics for preventing surgical wound infections after clean surgery. *Cochrane Database Syst Rev* 2004;(3):CD003949.
104. Darouiche RO, Wall MJ Jr, Itani KM, et al. Chlorhexidine-alcohol versus povidone-iodine for surgical-site antisepsis. *N Engl J Med* 2010;362(1):18–26.
105. Bibbo C, Patel DV, Gehrmann RM, et al. Chlorhexidine provides superior skin decontamination in foot and ankle surgery: a prospective randomized study. *Clin Orthop Related Res* 2005;438:204–208.
106. Saltzman MD, Nuber GW, Gryzlo SM, et al. Efficacy of surgical preparation solutions in shoulder surgery. *J Bone Joint Surg Am* 2009;91(8):1949–1953.
107. Sidhwa F, Itani KM. Skin preparation before surgery: options and evidence. *Surg Infect (Larchmt)* 2015;16(1):14–23.
108. Dumville JC, McFarlane E, Edwards P, et al. Preoperative skin antiseptics for preventing surgical wound infections after clean surgery. *Cochrane Database Syst Rev.* 2015;4:CD003949.
109. Tanner J, Woodings D, Moncaster K. Preoperative hair removal to reduce surgical site infection. *Cochrane Database Syst Rev* 2006;(2):CD004122.
110. Kurz A, Sessler DI, Lenhardt R. Perioperative normothermia to reduce the incidence of surgical-wound infection and shorten hospitalization. Study of Wound Infection and Temperature Group. *N Engl J Med* 1996; 334:1209–1215.
111. Melling AC, Ali B, Scott EM, et al. Effects of preoperative warming on the incidence

of wound infection after clean surgery: a randomized controlled trial. *Lancet* 2001;358(9285):976–980.

112. Wong PF, Kumar S, Bohra A, et al. Randomized clinical trial of perioperative systemic warming in major elective abdominal surgery. *Br J Surg* 2007;94(4):421–426.
113. Kao LS, Meeks D, Moyer VA, et al. Peri-operative glycaemic control regimens for preventing surgical site infections in adults. *Cochrane Database Syst Rev* 2009;(3):CD006806.
114. Buchleitner AM, Martínez-Alonso M, Hernández M, et al. Perioperative glycaemic control for diabetic patients undergoing surgery. *Cochrane Database Syst Rev* 2012;9:CD007315.
115. Qadan M, Akça O, Mahid SS, et al. Perioperative supplemental oxygen therapy and surgical site infection: a meta-analysis of randomized controlled trials. *Arch Surg* 2009;144(4):359–366.
116. Brar MS, Brar SS, Dixon E. Perioperative supplemental oxygen in colorectal patients: a meta-analysis. *J Surg Res* 2011;166(2):227–235.
117. Al-Niaimi A, Safdar N. Supplemental perioperative oxygen for reducing surgical site infection: a meta-analysis. *J Eval Clin Pract* 2009;15(2):360–365.
118. Napolitano LM. Invited critique. *Arch Surg* 2009;144(4):366–367. For: Qadan M, Akca O, Mahid SS, et al. Perioperative supplemental oxygen therapy and surgical site infection: a meta-analysis of randomized controlled trials. *Arch Surg* 2009;144(4):359–366.
119. Prevent surgical site infections. *Institute for Healthcare Improvement Web site.* Available at: http://www.ihi.org/IHI/Programs/Campaign/SSI.htm
120. Dellinger EP, Hausmann SM, Bratzler DW, et al. Hospitals collaborate to decrease surgical site infections. *Am J Surg* 2005;190:9–15.
121. Manniën J, Wille JC, Snoeren RL, et al. Impact of postdischarge surveillance on surgical site infection rates for several surgical procedures: results from the nosocomial surveillance network in the Netherlands. *Infect Control Hosp Epidemiol* 2006;27(8):809–816.
122. Tanner J, Padley W, Assadian O, et al. Do surgical care bundles reduce the risk of surgical site infections in patients undergoing colorectal surgery? A systematic review and cohort meta-analysis of 8,515 patients. *Surgery* 2015;158(1):66–77.
123. Guenga KK, Matos D, Wille-Jorgensen P. Mechanical bowel preparation for elective colorectal surgery. *Cochrane Database Syst Rev* 2009;(1):CD001544.
124. Nelson RL, Glenny AM, Song F. Antimicrobial prophylaxis for colorectal surgery. *Cochrane Database Syst Rev* 2009;(1):CD001181.
125. Morris MS, Graham LA, Chu DI, et al. Oral antibiotic bowel preparation significantly reduces surgical site infection rates and readmission rates in elective colorectal surgery. *Ann Surg* 2015;261(6):1034–1040.

126. Cannon JA, Altom LK, Deierhoi RJ, et al. Preoperative oral antibiotics reduce surgical site infection following elective colorectal resections. *Dis Colon Rectum* 2012;55(11):1160–1166.
127. Taylor M, Napolitano L. Methicillin-resistant Staphylococcus aureus infections in vascular surgery: increasing prevalence. *Surg Infect* 2004;5:180–187.
128. Gaynes R, Edwards JR; National Nosocomial Infections Surveillance System. Overview of nosocomial infections caused by gram-negative bacilli. *Clin Infect Dis* 2005;41(6):848–854.
129. Hidron AI, Edwards JR, Patel J, et al.; National Healthcare Safety Network Team; Participating National Healthcare Safety Network Facilities. NHSN annual update: antimicrobial-resistant pathogens associated with healthcare-associated infections: annual summary of data reported to the National Healthcare Safety Network at the Centers for Disease Control and Prevention, 2006–2007. *Infect Control Hosp Epidemiol* 2008;29:996–1011.
130. Weigelt JA, Lipsky BA, Tabak YP, et al. Surgical site infections: causative pathogens and associated outcomes. *Am J Infect Control* 2010;38(2):112–120.
131. Morange-Saussier V, Giraudeau B, van der Mee N, et al. Nasal carriage of MRSA in vascular surgery. *Ann Vasc Surg* 2006;20(6):767–772.
132. Schelenz S, Tucker D, Georgeu C, et al. Significant reduction of endemic MRSA acquisition and infection in cardiothoracic patients by means of an enhanced targeted infection control programme. *J Hosp Infect* 2005;60(2):104–110.
133. Jog S, Cunningham R, Cooper S, et al. Impact of preoperative screening for MRSA by real-time PCR in patients undergoing cardiac surgery. *J Hosp Infect* 2008;69(2):124–130.
134. Trautmann M, Stecher J, Hemmer W, et al. Intranasal mupirocin prophylaxis in elective surgery: a review of published studies. *Chemotherapy* 2008;54(1):9–16.
135. Van Rijen M, Bonten M, Wenzel R, et al. Mupirocin ointment for preventing Staphylococcus aureus infections in nasal carriers. *Cochrane Database Syst Rev* 2008; (4):CD006216.
136. Harbath S, Fankhauser C, Schrenzel J, et al. Universal screening for MRSA at hospital admission and nosocomial infection in surgical patients. *JAMA* 2008;299(10):1149–1157.
137. Awad SS, Palacio CH, Subramanian A, et al. Implementation of a methicillin-resistant Staphylococcus aureus (MRSA) prevention bundle results in decreased MRSA surgical site infections. *Am J Surg* 2009;198:607–610.
138. Popovich KF, Weinstein RA, Hota B. Are community-associated MRSA strains replacing traditional nosocomial MRSA strains? *Clin Infect Dis* 2008;46(6):787–794.
139. Klevens RM, Morrison MA, Nadle J, et al. Active Bacterial Core Surveillance (ABCs) MRSA Investigators. Invasive MRSA infections in the United States. *JAMA* 2007;298(15):1763–1771.

140. Manian FA, Griesnauer S. Community-associated MRSA is replacing traditional healthcare-associated strains in surgical site infections among inpatients. *Clin Infect Dis* 2008;47(3):434–435.
141. Kourbatova EV, Halvosa JS, King MD, et al. Emergence of community-associated MRSA USA 300 clone as a cause of healthcare-associated infections among patients with prosthetic joint infections. *Am J Infect Control* 2005;33(7):385–391.
142. Kallen AJ, Wilson CT, Larson RJ. Perioperative intranasal mupirocin for the prevention of surgical site infections: systematic review of the literature and meta-analysis. *Infect Control Hosp Epidemiol* 2005;26(12):916–922.

Chapter 9

Shock

Joseph Cuschieri and Darren Bowe

Key Points

1 Shock is the clinical syndrome that results from inadequate tissue perfusion from numerous causes: hypovolemic, cardiogenic, extracardiac obstructive, and distributive.

2 Hypovolemic shock due to ongoing blood and/or plasma loss leads to progressive cardiovascular deterioration, ultimate hypotension, oliguria, confusion, irreversible cell injury, and death.

3 Cardiogenic shock results in decreased tissue perfusion due to intrinsic pump failure.

4 Extracardiac obstructive shock attenuates cardiac pump function due to external compression of inflow and outflow (tamponade, tension pneumothorax, etc.).

5 Septic and traumatic shock, forms of distributive shock, are systemic inflammatory responses to infection or tissue injury with cellular breakdown, producing severe hypotension requiring massive volume resuscitation and high risk of multiple organ failure and death.

6 Complications of an episode of shock include ischemia–reperfusion injury from oxidant stress; potential secondary immunosuppression with enhanced nosocomial infection risk; hypothermia and coagulopathy; and multiple organ failure syndrome, including abdominal compartment syndrome (ACS).

7 Treatment of shock requires goal-directed volume resuscitation with treatment of the underlying etiology and careful monitoring of adequacy of end-organ perfusion to avoid under- and overresuscitation.

1 The current accepted concept of shock was first described in 1929 by Walter B. Cannon[1] as inadequate blood flow that results in cellular hypoxia. Persistence of cellular hypoxia results in dysfunction at both cellular and organ levels. Although shock can result from a number of etiologies, it was Blalock who first described the four major causes we still refer to today, which are hematogenic, neurogenic, cardiogenic, and vasogenic.[2]

Prior to this, the concept of shock was not understood since the nature and purpose of the heart and circulatory system were either unknown or misunderstood. Galen was the first to explore the purpose of the heart and circulatory system. He proposed that the arteries carried blood, not air, as previously thought, away from the heart. However, he incorrectly believed that arterial blood within the circulatory system subsequently

dissolved in the body to release nutrients. Blood returning to the heart was not due to recirculation, but rather was rapidly remanufactured by the liver. Additionally, since much of his dissection work was carried out in frogs, he concluded falsely that the heart had only two chambers and blood passed from the right to left chamber through invisible pores in the septum.[3]

These conclusions remained unchallenged for nearly 1,500 years until Vesalius, in the 17th century. Through a series of dissections, he demonstrated that blood did not flow directly from the right to left ventricle. Although he provided elaborate drawings of the body's network of blood vessels, he did not anticipate that blood circulated through the body and was unable to discern the heart's purpose. Shortly thereafter, Harvey moved beyond anatomy and studied physiology; he discovered the closed nature of the circulation and concluded that the heart was the main pumping mechanism. Although the microscope had not yet been invented, he proposed the existence of capillaries that connect the arterial and venous system.[3]

Due to this improved understanding of the circulatory system, the condition of shock due to blood loss and other etiologies were carefully being observed and explored. During the 18th century, military surgeons such as Henri le Dran (1740) noted that injured soldiers left unattended for several hours suddenly deteriorated as if there had been a *secousse* (jolt) to the system, which probably led to use of the word "shock."[1] Surgeons began to notice that even when a wounded extremity was amputated, the physiologic effects of the injury often continued, and shock was increasingly recognized as a distinct systemic syndrome from the wound itself.[3]

Eventually, Cannon and then Blalock described our current concept of shock and its attributed systemic effects. In fact, Blalock was the first to recognize the third-space fluid loss that follows shock resuscitation that is greater than the quantity of initial blood loss.[4] As a result, therapy began to focus not only on restoring intravascular volume but also on replacing fluid lost to the interstitium with a balanced salt solution. Investigators then became increasingly intrigued by the fact that, at some point, shock becomes irreversible and is no longer responsive to further volume resuscitation. As stated more than 60 years ago by Wiggers, "at a certain stage adequate circulation cannot be restored by merely filling the system, as one does an automobile radiator."[5] At some point, as had been observed multiple times previously, the initiating event (e.g., wound, infection, cardiac dysfunction) is no longer the primary threat. Other "unknown" factors sustain the shock state, blood pressure cannot be restored, improvements are only transient, and death occurs shortly thereafter due to progressive organ dysfunction.

The current concept of shock has led to a reclassification into four distinct groups – hypovolemic, cardiogenic, extracardiac obstructive, and distributive – that may occur independent of each other, or more characteristically synergistic with each other.[6] Early recognition and prompt treatment are essential to modern treatment. If delayed, uncorrected hypovolemia and critical oxygen delivery deficits occur that lead to irreversible shock. However, it is believed that future therapies will move beyond simple recognition and fluid resuscitation. Thus, investigators are increasingly looking to gain an understanding of the chain of events that occur, which lead to organ damage and

irreversibility. This chapter describes these events, discusses the therapeutic approaches utilized in current management, and offers a brief perspective on what may lie ahead in the future.

EVALUATION OF SHOCK

Shock is easily recognized by even the most inexperienced caregiver after the compensatory mechanisms have been overcome (Table 9-1). However, it is more difficult to recognize the patient in compensated shock, who presents with vital signs that are almost normal. It is critically important to the patient's ultimate outcome that recognition and treatment of shock occur before decompensation. The clinical assessment must be guided by the knowledge that the severity of symptoms and signs of shock vary between patients and the type of shock present. The patient is evaluated based on clinical appearance, hemodynamic measurements, physiologic responses, and biochemical analyses.

Early during various shock states, vasoconstriction frequently causes the skin to be cool leading to poor capillary refill. However, this must be contrasted to shock states induced by either neurogenic or septic states in which vasodilation is present causing the skin to be warm, with good capillary refill. Common to the various shock states is the presence of hyperventilation, a compensatory response due to progressive metabolic acidosis. As shock progresses, mental status changes occur, and decreased cerebral blood flow and increased catecholamine stimulation may lead to anxiety and restlessness. With continued shock, lethargy may result. True coma, however, seldom results due to shock alone, unless coincident complete cardiovascular collapse occurs, and is usually associated with other conditions such as direct brain injury or severe hypoxia.[7] This includes evaluation of the rate and character of the pulse; the blood pressure; and, in some cases, the central venous pressure (CVP), pulmonary artery pressure, pulse pressure variation (PPV), and echocardiography.[8]

The hemodynamic assessment should include evaluation of the rate and character of the pulse; the blood pressure; and, in some cases, the CVP, pulmonary artery pressure, and PPV.[8] Tachycardia is a normal response to volume loss but also to pain, anxiety, and fear, all of which are commonly present. Assessment of the pulse may be helpful in determining the proper diagnosis. Because of the body's ability to compensate for hypovolemia, changes in blood pressure do not occur reliably until nearly 30% of blood volume has been lost. However, the pulse pressure usually narrows, even in compensated shock, because of the effects of vasoconstriction on the diastolic blood pressure. Importantly, the CVP reflects the adequacy of and not the true blood volume, and the state of the venous tone. Changes in CVP in response to treatment or from continuing hemorrhage are more revealing than a solitary measurement. However, this concept remains debatable. Because of the misuse or overuse of pulmonary artery catheters (PACs), routine placement no longer occurs and has been associated with increased morbidity.[9] As a result, invasive monitoring using PPV, and noninvasive measures such as echocardiography have become more commonly used.[10]

An indirect but extremely valuable measure of perfusion and volume status is urine output. A urinary catheter should be inserted in every patient being evaluated for shock. Hourly urine output should be 0.5 to 1 mL/kg for adult patients, at least 1 mL/kg for most pediatric patients, and 1 to 2 mL/kg for patients younger than 2 years of age. Lack

of adequate urine output in the setting of previous normal kidney function should cause the caregiver to be highly concerned about the continued presence of inadequate perfusion and cellular hypoxia.

Although each of the physical examination components are important in the identification of shock, used alone these factors can fail to diagnose compensated shock. As a result, biochemical markers are used as a means to identify shock in its early stages. Biochemical analysis of shock is based on the shift from aerobic to anaerobic metabolism in underperfused tissues. This shift is marked by the production of lactate that can, in turn, be measured serially. Resuscitation of shock results in a decrease in serum lactate levels, and the time required to normalize serum lactate levels appears to be an important prognostic factor for survival.[11–15]

Another biochemical marker useful in the resuscitation of shock is the base deficit. This is defined as the amount of a fixed base (or acid) that must be added to an aliquot of blood to restore the pH to 7.40. Base deficit values have been categorized as normal (2 to –2), mild (–3 to –5), moderate (–6 to –9), and severe (>–10). Changes in base deficit toward normal with volume infusion can be used to judge the efficacy of resuscitation.[16–18] Base deficit has been shown to be superior to pH values in assessing the normalization of acidosis after shock resuscitation, and the time required for normalization of base deficit has perhaps even greater prognostic significance than that of lactate.[16,19]

Table 9-1 Shock Recognition

Organ System	Sign/Symptom	Cause
CNS	Mental status changes (agitation/anxiety to coma)	Decreased cerebral perfusion
Circulatory		
Cardiac	Tachycardia	Adrenergic stimulation
	Atrial/ventricular dysrhythmias	Coronary ischemia
	Hypotension	Coronary ischemia, right heart failure
Systemic	Hypotension	Decreased SVR, decreased venous return
	Decreased CVP	Hypovolemia
	Increased CVP	Right heart failure
Respiratory	Tachypnea	Pulmonary edema, sepsis, compensation for metabolic acidosis
	Cyanosis	Hypoxia
Renal	Oliguria	Decreased perfusion, afferent arteriolar vasoconstriction
Skin	Cool, clammy	Vasoconstriction
	Warm, dry	Vasodilation

CNS, central nervous system; CVP, central venous pressure; SVR, systemic vascular resistance.

The biochemical changes associated with the hypoperfusion of shock occur even with compensation. Because of the potential difficulties in diagnosing compensated shock, an arterial and/or venous blood gas analysis including base deficit and lactate should be

obtained for every patient suspected of being in shock. Additionally, any patient with a lactate of ≥ 4 mmol/L or base deficit of ≥ 6 mEq/L should be considered to be in shock until proven otherwise.[17,20,21]

Future Measures: Although each of these factors can be used to characterize shock, no single measurement has been determined to be optimal or when used singly to be always accurate for identification and treatment of shock. Currently, other measurements are being investigated that demonstrate promise. These markers include measurements of central and mixed venous oxygen saturations, end-diastolic cardiac volume indices, and specific noninvasive end-organ tissue oxygen saturations.[22–28]

TYPES OF SHOCK

Although several different classifications for shock have been described, the most widely accepted classification of shock was proposed by Weil and Shubin in 1971.[6] This classification divides the shock syndrome into four distinct categories (Table 9-2). Despite this separation, however, there is considerable overlap between the categories, with some patients presenting with more than one factor at the same time. Given this overlap, it is helpful to evaluate the hemodynamic pattern in order to elucidate the etiology and manage the patient (Table 9-3).

Hypovolemic Shock

2 Hypovolemic shock is the form of shock most commonly encountered in surgical practice (Table 9-2). The essential feature is a reduction in intravascular volume to a level that prevents the heart from being able to pump sufficient blood to vital organ systems. Substantial blood (>20% circulating volume) or plasma (via soft tissue, enteric sequestration, gastrointestinal, urinary, or other insensible losses) losses are required to produce this syndrome.

The signs and symptoms of shock vary with both the severity and duration of fluid loss. A review of the Advanced Trauma Life Support classification system of the American College of Surgeons is useful to comprehend the manifestations and physiologic changes associated with hemorrhagic shock in adults.[29] Blood volume is estimated at 7% of ideal body weight, or approximately 4,900 mL in a 70-kg patient (Table 9-4).

Class I: Mild hemorrhage, up to 15% of total blood volume. This condition is exemplified by voluntary blood donation. In the supine position, there are no measurable changes in heart or respiratory rates, blood pressure, or pulse pressure. Capillary refill is normal. This degree of hemorrhage requires little or no treatment, and blood volume is restored within 24 hours by transcapillary refill and the other compensatory methods.

Class II: Loss of 15% to 30% of blood volume (800 to 1,500 mL). Clinical symptoms include tachycardia and tachypnea. The systolic blood pressure may be only slightly decreased, especially in the supine position, but the pulse pressure is narrowed (because of the diastolic increase from adrenergic discharge). Urine output is reduced only slightly (20 to 30 mL/hr). Mental status changes (e.g., anxiety) are frequently present. Capillary refill is usually delayed. Patients with class II hemorrhage usually can be resuscitated with crystalloid solutions, but some may require blood transfusion.

Class III: Loss of 30% to 40% of blood volume (up to 2,000 mL). Patients with class III hemorrhage present with inadequate perfusion that is obvious; marked tachycardia and tachypnea; cool, clammy extremities with significantly delayed capillary refill; hypotension; and significant changes in mental status (e.g., confusion, combativeness). Class III hemorrhage represents the smallest volume of blood loss that consistently produces a decrease in systolic blood pressure. The resuscitation of these patients frequently requires blood transfusion in addition to administration of crystalloids.

Class IV: Loss of more than 40% of blood volume (more than 2,000 mL), representing life-threatening hemorrhage. Symptoms include marked tachycardia, a significantly depressed systolic blood pressure, and narrowed pulse pressure or unobtainable diastolic pressure. The mental status is depressed and the skin is cold and pale. Urine output is negligible. These patients require immediate transfusion for resuscitation and frequently require immediate surgical or other (e.g., angiographic embolization) intervention.

In practice, individual susceptibility to blood loss varies greatly and is affected by age, pregnancy, pre-existing disease, prescription and nonprescription medications (e.g., beta blockers), adequacy of compensatory mechanisms, and other factors that are poorly characterized. Presence of these factors should lead the caregiver to consider early use of invasive monitoring as an adjunct to appropriate fluid resuscitation.

Hypovolemia due to plasma losses may also lead to hypovolemic shock. The clinical findings of hemorrhagic shock are typically present, but significant differences do exist. Hemoconcentration, elevated blood urea nitrogen (BUN) and creatinine, and hypernatremia are typical of acute plasma and/or free water losses and are not necessarily present in other forms of shock. Appropriate evaluation of preload and urine output should be followed, with specific considerations for unique electrolyte abnormalities associated with specific plasma and fluid losses (e.g., gastric vs. colonic losses).

Cardiogenic Shock

3 The clinical definition of cardiogenic shock is decreased cardiac output with tissue hypoperfusion, despite presence of adequate intravascular volume. It is caused by a primary problem with the cardiac muscle, electrical conduction system, or valves. The most common cause is anterior wall myocardial infarction, although in surgical patients it is often precipitated by pulmonary embolus, myocardial contusion, or pulmonary hypertension.

Distinguishing cardiogenic shock from other shock etiologies is occasionally difficult. It is not uncommon to see combined cardiogenic and traumatic shock in the elderly patient, with one often being the precipitating event for the other. The hallmarks of the hemodynamic and neuroendocrine response to systemic hypoperfusion from other causes are also typical of cardiogenic shock. Eliciting a history of pre-existing cardiac disease, and physical findings such as pulmonary rales, cardiac murmurs, an S3 gallop, and jugular venous distention may be helpful. An electrocardiogram may detect significant ischemia or other pathology. A chest radiograph may reveal bilateral pulmonary infiltrates typical of cardiogenic edema, and cardio-specific serum tests (troponin I and creatine phosphokinase [CPK]) may indicate myocardial damage.

Manifestations of cardiogenic shock develop as a consequence of failure of peripheral perfusion, the associated adrenergic response, and the inability of the heart to accommodate blood returning from the lungs and the periphery. In the absence of sepsis or tissue injury, however, there is not usually an associated increase in the metabolic needs of the peripheral tissues. Sympathetic-mediated constriction of the peripheral vasculature attempts to maintain central blood pressure and perfusion of cerebral and coronary circulations. The clinical findings of cardiogenic shock may thus be similar to those of hypovolemic shock because both involve induction of the adrenosympathetic response.

Table 9-2 Classification System and Causes of Shock

Classification	Etiology	Cause
Hypovolemic	Hemorrhagic	Trauma
		Gastrointestinal
	Nonhemorrhagic	Absolute fluid loss (renal, gastrointestinal)
		Redistributive or "third spacing"
Cardiogenic	Myocardial	Ischemia
		Infarction
		Contusion
		Cardiomyopathy
		Myocarditis
		Pharmacologic/toxic (beta blockers, calcium channel blockers, tricyclic antidepressants, anthracycline)
		Metabolic (hypophosphatemia, hypocalcemia, acidosis)
	Valve failure	Infection
		Injury
		Ruptured papillary muscle
		Stenosis
	Arrhythmias	Ischemia
		Pharmacologic/toxic
		Metabolic
Extracardiac obstructive	Extrinsic compression	Mediastinal tumors
	Increased intrathoracic pressure	Tension pneumothorax
		Positive-pressure ventilation
	Intrinsic vascular flow obstruction	Pulmonary embolism
		Air embolism
		Tumors (myxoma)
		Proximal aortic dissection
		Aortic coarctation
		Acute pulmonary hypertension
		Tamponade
		Pericarditis
Distributive	SIRS related	Trauma
		Sepsis
		Pancreatitis
		Burns
	Anaphylactic/ anaphylactoid	Drugs
		Venoms
	Neurogenic	Spinal cord injury
	Toxic/pharmacologic	Vasodilators
		Benzodiazepines
	Endocrine	Adrenal insufficiency
		Thyroid
		Myxedema

SIRS, systemic inflammatory response syndrome.

Diminished or ineffective contractile activity of the right or left side of the heart allows blood to accumulate in the respective venous circulations. Shock from an acute left ventricular myocardial infarct occurs when more than 40% of the left ventricle is involved and may be present in approximately 20% of Q-wave infarcts.[30] Shock from an

acute right ventricular myocardial infarct, on the other hand, is rare and only occurs in approximately 10% of all inferior wall infarcts.[31] Not only does the diagnosis of each infarct vary, but also the treatment and support vary significantly.

Table 9-3 Hemodynamic Patterns in Shock

Type	CO	SVR	PAOP	CVP	SvO_2
Hypovolemic	↓	↑	↓	↓	↓
Cardiogenic					
Left ventricular MI	↓	↑	↑	N, ↑	↓
Right ventricular MI	↓	↑	N, ↓	↑	↓
Extracardiac obstructive					
Pericardial tamponade	↓	↑	↑	↑	↓
Pulmonary embolism	↓	↑	↑	↑	↓
Distributive					
Early	↑, N, ↓	↑, N, ↓	N	N, ↑	N, ↑
Early after fluid administration	↑	↓	N, ↑	N, ↑	↑, N, ↓
Late	↓	↑	N	N	↓

CO, cardiac output; CVP, central venous pressure; MI, myocardial infarction; N, normal; PAOP, pulmonary artery occlusion pressure; SvO_2, mixed venous oxygen saturation; SVR, systemic vascular resistance.

In any patient in shock, especially in those with compromised cardiac function, consideration should be given to the institution of mechanical ventilation. The work of breathing can be considerable, especially for the patient in a state of agitation or distress. Oxygen needs are decreased through intubation and mechanical ventilation. In this manner, the patient can be comfortably sedated with a secure airway; the work of breathing is undertaken by the ventilator, and gas exchange can be optimized. If there is a tenuous balance between myocardial oxygen needs and availability, the balance can thus be shifted in the patient's favor.

Like other forms of shock, cardiogenic shock tends to be self-perpetuating. Myocardial perfusion depends on the pressure gradient between the coronary artery and the left ventricle and the duration of diastole. Both are compromised by the hypotension and tachycardia that characterizes this condition. High-volume fluid resuscitation, sometimes necessary for treatment of other forms of shock, is poorly tolerated and likely to be detrimental to an individual with the compromised myocardial function of cardiogenic shock.

Extracardiac Obstructive Shock

4 A subset of patients with cardiogenic shock do not have intrinsic cardiac disease but have pump failure due to extrinsic compression that limits diastolic filling and cardiac output. Cardiac tamponade, tension pneumothorax, diaphragmatic herniation of abdominal viscera, mediastinal hematoma, and, occasionally, positive-pressure mechanical ventilation may all precipitate cardiogenic shock by exerting constricting pressure on the myocardium. The key to diagnosis and appropriate therapy is the physical examination, supplemented by use of appropriate diagnostic modalities.

The classic physical findings of cardiac tamponade, Beck triad, are hypotension, muffled heart sounds, and jugular venous distention. Unfortunately, these nonspecific clinical findings are seldom present together. Elevated jugular venous pressure, noted by either physical examination or measurement of CVP, although not specific for cardiac compression, is usually present. Pulsus paradoxus can be useful for the diagnosis of cardiac tamponade. Although it may be caused by other conditions, it is virtually always present in patients with tamponade.

Given the difficulty in evaluation of these patients, especially in combination with other shock states, early diagnostic evaluation, both invasive and noninvasive, of cardiac function is warranted. Recent guidelines suggest that any patient with concern for primary or secondary cardiac dysfunction should undergo early ultrasound evaluation. This early evaluation not only evaluates the primary cardiac function but also can lead to the early diagnosis and management of secondary causes of cardiac dysfunction including cardiac tamponade and pulmonary embolism.

Table 9-4 Classification of Hemorrhagic Shock

	Class I	Class II	Class III	Class IV
Blood loss (mL)	Up to 750	750–1,500	1,500–2,000	>2,000
Blood loss (%)	Up to 15	15–30	30–40	40
Heart rate	<100	>100	>120	>140
Blood pressure	Normal	Normal	Decreased	Decreased
Pulse pressure	Normal	Decreased	Decreased	Decreased
Respiratory rate	14–20	20–30	30–40	>35
Urine output (mL/hr)	>30	20–30	5–15	Minimal
Mental status	Normal	Mildly anxious	Anxious and confused	Confused and lethargic
Fluid replacement	Crystalloid	Crystalloid	Crystalloid and blood	Crystalloid and blood

Table 9-5 Systemic Inflammatory Response Syndrome

Systemic inflammatory response syndrome: The systemic inflammatory response to a variety of severe clinical inflammatory factors is manifested by two or more of the following conditions:

- Temperature >38°C or <36°C
- Heart rate >90 bpm
- Respiratory rate >20 breaths/min or $PaCO_2$ <32 mm Hg
- WBC count >12,000 cells/mm^3, <4,000 cells/mm^3, or >10% immature (band) forms

bpm, beats per minute; $PaCO_2$, partial pressure of arterial carbon dioxide; WBC, white blood cell count.

Distributive Shock

Distributive shock occurs in a state of inappropriate oxygen utilization associated with the systemic inflammatory response syndrome (SIRS). Classically, SIRS is triggered by sepsis, but SIRS is associated with other immune processes including trauma, pancreatitis, and other types of tissue injuries. However, other types of distributive disturbances can occur unrelated to inflammation that may be directly due to loss of vascular tone from spinal cord injury, endocrine dysfunction, or anaphylaxis.

Septic Shock

5 Septic shock is defined as a SIRS response to infection in conjunction with arterial hypotension, despite adequate fluid resuscitation.[32] It occurs when bacterial products interact with cells of the immune system, leading to elaboration of mediators that cause circulatory disturbances and direct and indirect cell damage leading to the clinical manifestations of SIRS (Table 9-5).[33] Hemodynamic changes are defined as early (warm or hyperdynamic) or late (cold or hypodynamic). These stages are primarily characterized by the degree of ventricular contractility and peripheral vasomotor impairment present, but can be misclassified if not appropriately evaluated. Early septic shock is distinguished by peripheral vasodilation, flushed and warm extremities, and a compensatory elevation in cardiac output. Although an increase in venous capacitance diminishes venous return to the heart, cardiac output is maintained via tachycardia and the decrease in afterload due to systemic vasodilation.

Late septic shock is characterized by impaired myocardial contractility due to local and systemic release of cardiac depressants, worsening peripheral perfusion, vasoconstriction, extremity mottling, oliguria, and hypotension. Peripheral oxygen utilization may be severely impaired by bacterial toxins, such as lipopolysaccharide (LPS) and the inflammatory products of the host's own immune response, resulting in metabolic dysfunction and acidosis despite a high systemic oxygen delivery. This inappropriate oxygen utilization and systemic shunting lead not only to confusion regarding the adequacy of resuscitation but also to progressive cell death. Together, both systemic hypoperfusion and the altered tissue metabolism create a vicious cycle that propagates the inflammatory response initiated in reaction to the initial infectious challenge leading to progressive cellular injury.

Due to both volume deficits and cardiovascular dysfunction, persistent perfusion deficits are common and contribute significantly to multiple organ failure and mortality. In fact, the fluid volume required for treatment may exceed that required for treatment of other forms of shock due to persistent microvascular endothelial capillary leak. As a result of this profound leak, interstitial and total-body fluid balances become extreme, leading to the potential development of marked hypoxia and the abdominal compartment syndrome (ACS).

Although appropriate early resuscitation and cardiovascular support are essential to the treatment of septic shock, as important are early infection source control and appropriate administration of antimicrobials. In fact, numerous investigators have demonstrated that even a few hours delay in initiation of antimicrobial therapy is associated with a significant increase in mortality.[34]

Traumatic Shock

The major contributor to shock after injury is hypovolemia due to hemorrhage. Even when hemorrhage ceases or is controlled, patients can continue to suffer loss of plasma volume into the interstitium of injured tissues and develop progressive hypovolemic shock. In addition, tissue injury evokes a broader pathophysiologic immunoinflammatory response and a potentially more devastating degree of shock than that produced by hypovolemia alone.

The degree to which direct tissue injury and an inflammatory response participate in the development and progression of traumatic shock distinguishes it from purely hypovolemic shock. Thus, traumatic shock results from direct tissue or bony injury, resulting in not only hypovolemia caused by fluid and blood loss but also an immunologic and neuroendocrine response to tissue destruction and devitalization. This combined insult complicates what might otherwise be straightforward hemorrhagic shock by inducing a systemic response that utilizes many of the inflammatory mediators present in septic shock.[35] These mediators propagate and intensify the effects of the initial hypovolemia and make subsequent multiple organ failure far more likely than occurs with hypovolemic shock alone.

Although this condition can lead to increased fluid requirements, common problems associated with this condition such as rhabdomyolysis should be aggressively evaluated and treated with optimal resuscitation.[36] In addition, common patient characteristics are known to alter traumatic shock resuscitation, in particular, morbid obesity that can result in delayed correction of metabolic acidosis and increased risk for organ dysfunction.[37]

Thus, initial management of the seriously injured requires the assurance of an airway, breathing, and circulation; later management requires appropriate volume resuscitation and control of ongoing losses. Control of hemorrhage is a major concern and demands priority over attention to other injuries. After resuscitation and control of volume losses, efforts become necessary to minimize the potentially lethal postshock sequelae, including acute respiratory distress syndrome (ARDS) and multiple organ dysfunction syndrome (MODS).

Neurogenic Shock

Neurogenic shock is defined as failure of the nervous system to provide effective peripheral vascular resistance, resulting in inadequate end-organ perfusion. Warm, flushed, flaccid extremities; paraplegia; confusion; oliguria; and hypotension are the classic clinical findings. Injury to the proximal spinal cord, with interruption of the autonomic sympathetic vasomotor pathways, disrupts basal vasoconstrictor tone to peripheral veins and arterioles. Profound vasodilation of all microvascular beds below the level of cord injury diminishes venous return to the heart, reduces cardiac output, and precipitates hypotension. Injuries at or above the fourth thoracic vertebrae may disrupt sympathetic enervation to the heart, resulting in significant bradycardia and severe decompensation.

Similar to the initial therapy for shock resulting from hypovolemia, treatment of the relative hypovolemia due to vasodilation of neurogenic shock requires intravenous volume resuscitation. Restoration of the pathologically expanded intravascular space improves preload and cardiac output and may reverse hypotension. However, maintenance of adequate hemodynamics often requires vasopressor support in an effort to avoid the administration of excessive fluids. CVP monitoring to assess cardiac preload should be considered as a means of determining adequate and nonexcessive filling pressures, as loss of vasomotor capacity within the pulmonary circulation predisposes these patients to pulmonary edema. As spinal cord injury is often associated with other traumatic injuries, the diagnosis of isolated neurogenic shock must be a process of exclusion.

This condition should not be confused with spinal shock. Spinal shock is defined as a loss of sensation accompanied by motor paralysis with initial loss but gradual recovery of spinal reflexes following spinal cord injury. The reflexes caudal to the spinal cord injury are hyporeflexic or absent, while those rostral are unaffected. No circulatory compromise is associated with this condition; thus, it should not be considered a shock state.

Hypoadrenal Shock

The role of adrenocortical hormones in providing resistance to shock is well recognized. The reduction in effective blood volume and changes in blood chemistry that occur after adrenalectomy are similar to those of shock and hemorrhage. Adrenalectomized animals have markedly diminished tolerance to both trauma and hypovolemia. Adrenal cortical hormones also play a key role in maintaining normal capillary tone and permeability. In recent years, the concept of functional or relative adrenal insufficiency has received increasing attention as a cause of unrecognized shock and hypoperfusion. Most critically ill patients have elevated cortisol levels, but some have low concentrations in relation to the degree of stress imposed by their disease. Administration of physiologic doses of steroids to correct this insufficiency may result in stabilization of hemodynamics and possible survival benefits.[38] However, the concept of routine administration of physiologic doses of steroids has been questioned; thus, routine and indiscriminate use is not recommended.[39]

Diagnosis of hypoadrenal shock is difficult, as classic signs of Addison disease are absent. The only clinical clues may be unexplained hypotension and refractory response to high-dose vasopressors. An isolated serum cortisol level is difficult to interpret because the range of values observed in critically ill patients varies considerably. A cortisol level below 15 μg/dL suggests a high likelihood of adrenal insufficiency, whereas a value above 35 μg/dL suggests adequate adrenal function.[40] The adrenocorticotropic hormone (ACTH) stimulation test may be used to identify hypoadrenal patients when the diagnosis is unclear, but the utility of this test, particularly with an elevated baseline value, is of questionable utility.

The utility of the ACTH stimulation test is especially questionable in patients with persistent evidence of shock and elevated baseline levels of cortisol above 35 μg/dL. These patients actually demonstrate evidence of inadequate systemic cortisol utilization with a significant risk of morality, and thus may actually benefit from systemic administration of physiologic concentrations of corticosteroids.[41]

Although hypoadrenal shock may complicate various types of shock, there is conflicting evidence to support the use of supplemental corticosteroids in patients with septic shock if there is biochemical evidence of hypoadrenalism. Thus, supplemental corticosteroids should be used with extreme caution until further evidence is available.[32,41]

Physiologic Response to Hypovolemia

Common to each shock state is usually an initial decrease in circulating intravascular volume. This reduction is due directly to fluid loss or secondarily to fluid redistribution. This reduction in circulating fluid volume initiates both a rapid and sustained compensatory response. Within minutes, a rapid compensatory response occurs primarily due to adrenergic output. Sustained responses, in contrast, occur slower and result in intravascular fluid reabsorption and renal conservation of water and electrolytes (Algorithm 9-1).

Rapid Response

Hypovolemia results in the initial secretion of epinephrine and norepinephrine from the adrenal gland due to decreased afferent impulses from arterial baroreceptors. Catecholamine release is acute and limited to the first 24 hours following the onset of hypovolemia. This results in vasoconstriction, tachycardia, and increased myocardial contractility. Adrenergic-induced vasoconstriction of the systemic capacitance of small veins and venules shifts blood back to the central venous circulation, thus increasing right-sided filling pressures. Left-sided filling and pressure are augmented by pulmonary vasoconstriction. Concomitantly, vasoconstriction occurs in the skin, kidneys, and viscera, effectively shunting blood to the heart and brain. Adrenergic-induced vasoconstriction increases cardiac filling and causes increased contractility and reflex tachycardia, all of which combine to increase stroke volume and cardiac output.

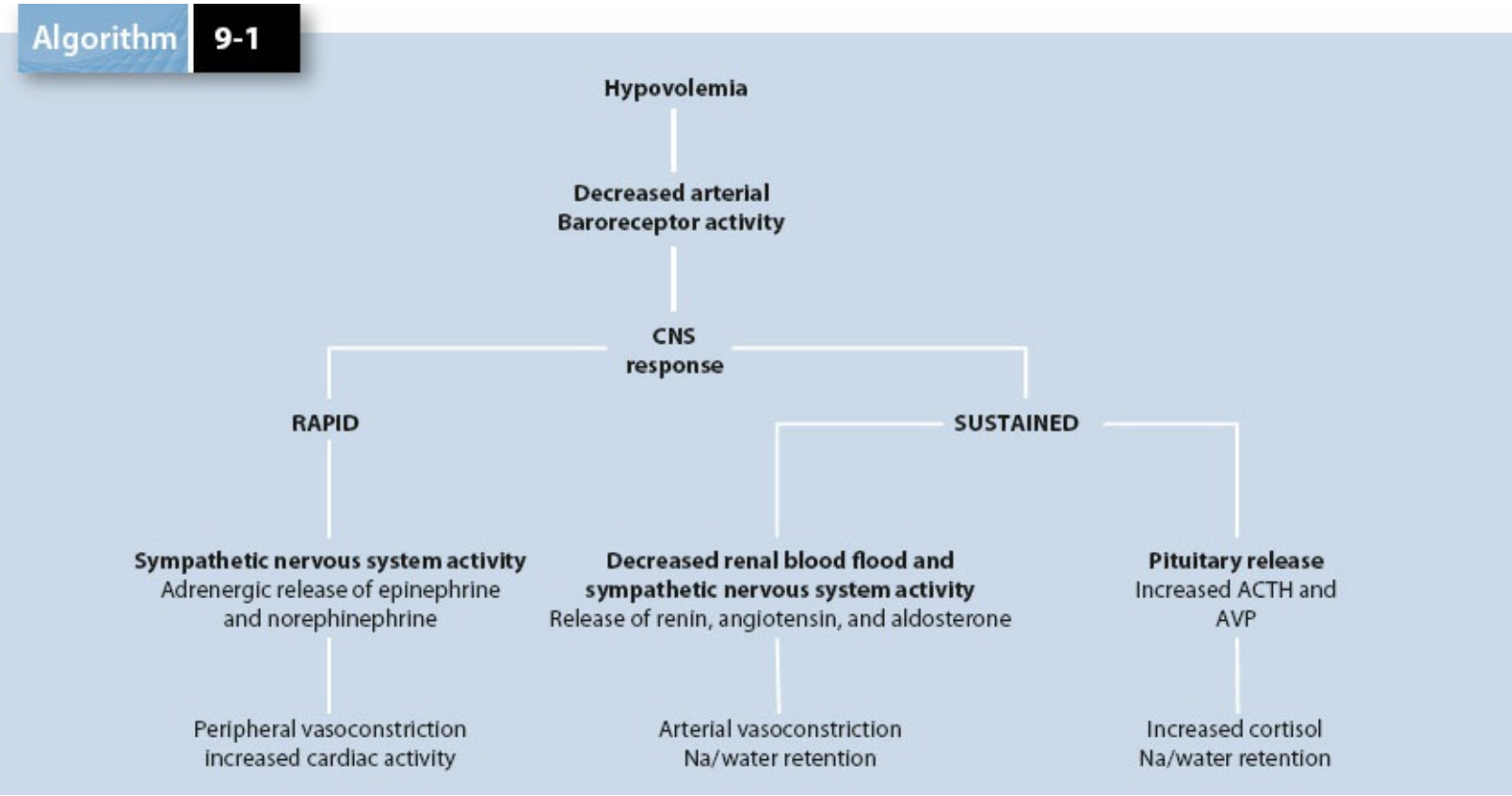

Algorithm 9-1. Neurohormonal response to hypovolemia. CNS, central nervous system; ACTH, adrenocorticotropic hormone; AVP, arginine vasopressin.

Adrenergic-mediated vasoconstriction affects arterioles, pre- and postcapillary sphincters, and small veins and venules. Due to this specific vasoconstriction, decreased hydrostatic pressure distal to the precapillary sphincter occurs that leads to reabsorption of interstitial fluid (water, sodium [Na^+], and chloride [Cl^-]) into the vascular space. This functions to restore circulating blood volume and is known as transcapillary refill.[42]

Sustained Response

Sustained compensatory responses include the release of vasoactive hormones and fluid shifts from the interstitium and the intracellular space to the intravascular compartment. Decreased renal blood flow, increased adrenergic activity, and compositional changes in tubular fluid lead to the secretion of renin from the juxtaglomerular complex. Renin results in increased formation and release of angiotensin I by the liver. Circulating angiotensin I is rapidly converted to angiotensin II by the lungs and is the most potent known arterial and arteriolar vasoconstrictor. Angiotensin II also stimulates the release of pituitary ACTH. Increased circulating levels of both angiotensin II and ACTH result in increased secretion of aldosterone. As a result, reabsorption of Na^+ in the distal renal tubules in exchange for potassium (K^+) and hydrogen ions occurs.

Additionally, due to hypovolemia and increased serum osmolarity, reduced stimulation of arterial baroreceptors occurs, leading to the release of arginine vasopressin (AVP), also known as antidiuretic hormone (ADH). This hormone not only functions as a potent vasoconstrictor but also causes increased reabsorption of water by increasing water permeability and passive Na^+ transport in the distal renal tubule. The overall net effect of aldosterone and AVP is to decrease glomerular filtration and increase salt and water tubular reabsorption in an effort to replace circulating intravascular volume deficits.

Finally, the increased release of the stress hormones (epinephrine, ACTH, cortisol, and glucagon) leads to glycogenolysis, lipolysis, and protein catabolism, causing a negative nitrogen balance and high extracellular concentration of glucose due to decreased insulin release and resistance. This leads to increased glucose utilization by insulin-independent tissues such as the brain and heart. In addition to glucose, products of anaerobic metabolism from hypoperfused cells accumulate in the extracellular compartment, inducing hyperosmolarity. This extracellular hyperosmolarity draws water from the intracellular space, increasing interstitial osmotic pressure, which in turn drives water, Na^+, and Cl^- across the capillary endothelium into the vascular space.

ORGAN-SPECIFIC COMPENSATORY RESPONSES TO SHOCK

Cardiac and Microvascular Response

Cardiovascular physiology is profoundly affected by shock (Table 9-3). Reduced stroke volume is caused by an absolute or relative loss of preload. Intrinsic neuroendocrine and renal compensatory responses, along with additional intravenous fluid, are needed to increase ventricular end-diastolic volume. Restoration of adequate preload alone is often sufficient to return cardiac output to levels required to overcome peripheral perfusion deficits. However, some cases are complicated by acquired myocardial contractility derangements. Contractile function under these conditions is less a function of preload and more related to intrinsic myocardial dysfunction.

A defining characteristic of shock is compromise of microvascular perfusion. Far from being a passive conduit, the microvasculature actively participates in the response to shock. Arteriolar vessels are innervated by sympathetic nerves, as are small veins and venules. The vasoconstriction of hypovolemic shock and the vasodilation of septic and neurogenic shock are a result of these autonomic responses. The majority of the circulating blood volume resides in the venous system, and normal physiologic compensation mechanisms rely on this venous blood pool as an autotransfusion reservoir. Collapse of underperfused veins passively propels blood toward the heart, while α-adrenergic venoconstriction actively mobilizes the venous pool. Profound peripheral vasoconstriction via α-adrenergic, vasopressin, angiotensin II, and endothelin-1 stimulation of arteriolar and precapillary smooth muscle sphincters selectively diminishes perfusion to dermal, renal, muscle, and, significantly, splanchnic vascular beds to preserve perfusion of critical central organs, primarily the central nervous system (CNS) and myocardium.[43]

The capillary endothelial monolayer maintains a semipermeable barrier between the intra- and extraluminal spaces and is compromised by shock.[44] Circulating inflammatory mediators and byproducts of infection (LPS, thrombin, tumor necrosis factor alpha [TNF-α], interleukin [IL]-1, nitric oxide, and endothelin-1) generated in response to traumatic or septic shock have been shown to induce and sustain endothelial capillary leak. Although the exact mechanisms of endothelial monolayer dysfunction are unclear, the only available therapies to reverse microvascular decompensation are timely restoration of peripheral perfusion, rapid elimination of infectious and necrotic tissue, and pharmacologic and mechanical support of cardiopulmonary function.[45–46]

Neuroendocrine Response

The neuroendocrine reaction to shock consists of involuntary responses by the hypothalamus, autonomic nervous system, and secretory endocrine glands and is directed toward restoration of tissue perfusion and a redirected utilization of metabolic substrates. The autonomic response is initially triggered by hypoxia, hypotension, or hypovolemia detected by aortic and carotid baroreceptors and chemoreceptors (Algorithm 9-2). Subsequently, sympathetic vasoconstriction of specific vascular beds, induced by direct synaptic release of norepinephrine, results in redistribution of circulating blood volume from tissue of low metabolic activity to more metabolically demanding organs. Cardiac output, diminished by loss of preload, is augmented by inhibition of cardiac vagal activity and a resulting reflex tachycardia.

Circulating epinephrine and norepinephrine alter several aspects of glucose utilization, availability, and metabolism. The hyperglycemia of stress results from catecholamine-induced glycogenolysis, gluconeogenesis, and decreased pancreatic insulin release. Simultaneously, hypothalamic stimulation of the anterior pituitary induces release of ACTH, which in turn prompts cortisol and aldosterone release by the adrenal cortex. Elevated serum cortisol contributes to postinjury hyperglycemia by increasing gluconeogenesis, enhancing lipolysis, and diminishing peripheral utilization of glucose and amino acids. The pancreatic response is characterized by a decrease in insulin release and an increase in glucagon secretion, which further stimulates hepatic gluconeogenesis. The combined actions of catecholamines, cortisol, and glucagon are synergistic and create a shock-related hyperglycemia that is often refractory to insulin treatment.

Renal juxtaglomerular secretion of renin in response toadrenergic stimulation and renal hypoperfusion triggers the formation of angiotensin I in the liver, which is subsequently converted to angiotensin II by the lungs. Angiotensin II, a potent vasoconstrictor, augments shock-induced catecholamine-mediated peripheral and splanchnic vasoconstriction and stimulates aldosterone release from the adrenal cortex. Renal tubular reabsorption of sodium in response to elevated circulating aldosterone creates highly concentrated, low-volume urine. Vasopressin secretion by the posterior pituitary similarly contributes to compensatory restoration and maintenance of intravascular volume by promoting water reabsorption by the renal distal tubules and by causing peripheral and splanchnic vasoconstriction. A major result is a prolonged severe hypoperfusion of the splanchnic vascular bed, further augmenting the deleterious host response.

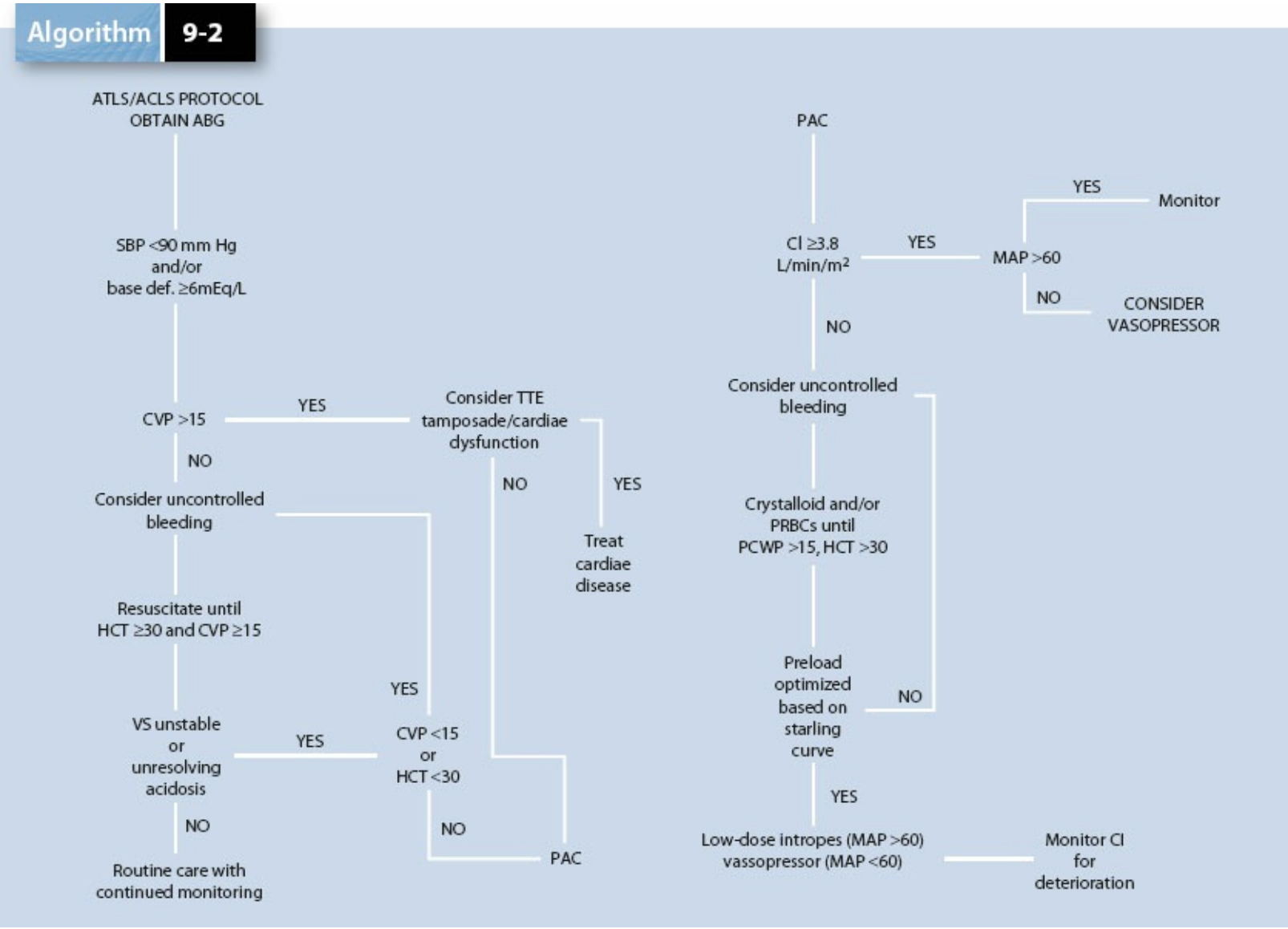

Algorithm 9-2. Shock resuscitation algorithm. ATLS, advanced trauma life support; ACLS, advanced cardiac life support; SBP, systolic blood pressure; CVP, central venous pressure; HCT, hematocrit; VS, vital signs; TTE, transthoracic echocardiography; PAC, pulmonary artery catheter; CI, cardiac index; MAP, mean arterial pressure.

Immunoinflammatory Response

Many shock-inducing events, particularly those associated with septic or traumatic shock, simultaneously trigger a massive systemic inflammatory response. Although inflammatory mediators (TNF-α, ILs, chemokines, etc.) play an integral role in the recovery of local tissue to trauma and infection, an uncontrolled systemic inflammatory response contributes to organ failure. Immunologically active cells involved in the systemic inflammatory response include nucleated blood cells (monocytes, polymorphonuclear leukocytes [PMNs]) and platelets, microvascular endothelial cells, and tissue macrophages. These cells generate and secrete scores of signal-amplifying inflammatory mediators ranging in complexity from individual molecules (nitric oxide) to large multisubunit, extensively modified proteins (TNF-α, IL-1, etc.). Even transient systemic elevation of any of these mediators has profound physiologic consequences.

Local tissue destruction, microbial contamination, and infection similarly activate the coagulation cascade and induce platelet aggregation and release of numerous platelet-, endothelial-, and clot-derived vasoactive mediators. Persistent, profound, and recurring microvascular hypoperfusion of the splanchnic and other organs likewise causes local tissue ischemia, parenchymal cell injury, microvascular coagulation, activation of inflammatory cells, and release of inflammatory mediators. Circulating monocyte, lymphocyte, and PMN adherence to activated endothelium results in extraluminal transmigration of these inflammatory cells into tissues remote from the area of injury. This hyperdynamic immunologic response, with continued generation of proinflammatory mediators, is responsible for the progression of SIRS toward MODS.[47–50]

Regulation of the systemic inflammatory response has been an active area of shock research for several decades. Elimination of particular inflammatory mediators from the systemic circulation, or inhibition of particular cell–cell interactions in experimental animal systems, has been shown to improve outcomes after shock resuscitation.[51–55] However, to date, all efforts to regulate the SIRS response with therapeutic elimination or supplementation of specific proinflammatory and anti-inflammatory mediators have proven ineffective or even harmful in humans. This lack of efficacy may relate to inadequacy of current animal models of shock, sepsis, and organ failure or to inadequate understanding of the full spectrum and interactive nature of key elements that regulate this syndrome. Unfortunately, the network of inflammatory mediators and affected cells is so complex and redundant that no single agent is likely to be effective at interrupting this response. As a result, there is probably no single common pathway likely to respond to a “silver bullet” approach.

Pulmonary Response

The lung is the organ system most sensitive to systemic insult and injury and is frequently the first organ to fail in the progression to MODS. ARDS represents a high-mortality form of pulmonary insufficiency that is often precipitated by sepsis or traumatic shock. It is triggered and perpetuated by the numerous inflammatory mediators created in the hypoperfused microvasculature elsewhere in the body.[51–56]

Interstitial edema and subsequent reduced compliance result in diminished tidal volume and tachypnea, compromising gas exchange. Surfactant abnormalities contribute to alveolar collapse, resulting in loss of functional residual capacity (FRC) and the onset of pulmonary insufficiency. The pulmonary microvascular response mirrors the systemic response, with angiotensin and α-adrenergic–induced vasoconstriction creating significant elevations of pulmonary vascular resistance, further straining the heart. Pulmonary parenchymal injury may be propagated by excessive positive-pressure ventilation generated by alveolar overdistention in particular, further contributing to alveolar damage.

No specific measures are available to reverse the ARDS process; therefore, aggressive management of predisposing conditions is most appropriate. Once ARDS has become fully developed, treatment involves intensive supportive care while minimizing iatrogenic insults. As a result, early utilization of lung-protective strategies may diminish progressive ventilator-induced lung injury and improve outcome.[57]

Renal Response

Direct sympathetic-induced renal vasoconstriction increases afferent arteriole resistance in response to shock. This effect is reinforced by elevated circulating angiotensin II and catecholamines. The resulting decrease in renal blood flow and glomerular filtration rate (GFR), along with elevated circulating aldosterone and vasopressin (ADH), produce oliguria and prerenal azotemia. Acute tubular necrosis (ATN) may result from prolonged decreases in renal cortical blood flow, as well as from toxins generated during sepsis. Oliguric renal failure, like the pulmonary insufficiency of ARDS, is a common component of MODS.

Distinguishing low urine output due to oliguric renal failure from the oliguria of decreased renal perfusion pressure can be aided by analyzing urine sodium and osmolality. Renal hypoperfusion usually results in urine sodium of less than 20 mEq/L with an osmolality of greater than 400 mOsm/kg, whereas acute tubular injury impairs sodium reabsorption and is associated with a low urinary osmolality. A fractional excretion of sodium of less than 1% may also help determine whether the cause is renal or prerenal.

Early detection of abnormal kidney function is critical to prevent progression to renal injury. Abnormal renal function can be detected as a decline in creatinine clearance. The correlation between a creatinine clearance based on a 24-hour collection and a sample collected over a shorter interval is poor. However, the 24-hour value represents an average value over that time. A sample obtained over a shorter period may reflect the time in question and allow timely recognition and treatment of renal dysfunction.

Hepatic Response

Ischemic injury to liver is not apparent early during shock. However, the liver plays an important role in the regulation of shock and subsequent tissue injury through both the release of acute-phase reactants and lack of clearance of potential toxic agents. As shock continues, hepatic necrosis occurs, leading to the release of aspartate aminotransferase and alanine aminotransferase. Continued shock results in attenuated synthesis of coagulation factors, albumin and prealbumin. Although progressive ischemia can occur, leading to complete loss of glycogen stores and marked hypoglycemia, this condition is rare without pre-existing liver disease, significant direct liver injury, or hepatic artery occlusion.

Genetic Regulation of the Response to Shock

Individuals vary considerably in their susceptibility to shock and in their ability to recover from its consequences. Recently, unique host-specific responses have been identified as important determinants of the outcome of sepsis and septic shock. Genetic predispositions in an individual's immunoinflammatory response may dictate whether infection is adequately or inadequately countered. These differences in response may be partially explained by single nucleotide polymorphisms (SNPs) in the genetic sequences for various inflammatory mediators. These subtle nucleotide variations may affect the transcription or translation of associated genes or the secretion or function of the corresponding proteins.

The recognition that genetic background may regulate the response to severe sepsis and septic shock has led to the identification of an array of genetic markers associated with enhanced risk of septic mortality. These SNPs are in genes encoding proteins involved in pathogen recognition (toll-like receptors 2, 4, and 5; CD14; and mannose-binding lectin), cytokine expression (TNF-α, IL-1, IL-6, and IL-10), and several other genes involved in mediating and controlling the innate immune response and the inflammatory cascade.[58,59]

Investigation into genetic polymorphisms should provide important insights into the pathophysiology of shock. SNP identification leading to early diagnosis of individuals at risk of developing or dying from the complications of shock may allow therapies to become more preemptive and effectively targeted.

LOSS OF COMPENSATORY RESPONSES TO SHOCK

If shock is prolonged, the arteriolar and precapillary sphincters become refractory and relax, while the postcapillary sphincter remains in spasm. Therefore, the capillary hydrostatic pressure increases, and Na^+, Cl^-, and water are moved into the interstitium, leading to depletion of intravascular volume.

Cellular membrane function is also impaired with prolonged shock. The normal negative membrane potential approaches neutrality, leading to increased permeability and interstitial flooding by K^+. This is caused, at least in part, by a decrease in the normal function of the adenosine triphosphate–dependent Na^+-K^+ membrane pump that is a result of cellular hypoxia. The loss of the membrane potential difference leads to cellular swelling due to an intracellular influx of Na^+ and fluid.

In addition to these cellular effects, severe and prolonged shock results in the development of progressive organ dysfunction. Although the mechanisms responsible are incompletely understood, it appears that the vital organs, in particular the lung early on, are limited in their ability to protect themselves during shock. As a result, direct endothelial injury occurs, resulting in leakage of various inflammatory mediators, which in turn results in accumulation of interstitial fluid and subsequent reduction in nutrient and gaseous diffusion. This condition, along with progressive microcirculatory thrombosis, is responsible for the late organ dysfunction characteristic of uncompensated shock.

COMPLICATIONS OF SHOCK

Ischemia–Reperfusion Injury

Inadequate microvasculature flow results in activation of leukocytes and converts local endothelial cells to a proinflammatory, prothrombotic phenotype. On reperfusion, the reintroduction of oxygen prompts these cells to generate superoxide anion, hydroxyl radicals, and hydrogen peroxide, further injuring local tissue. Microvascular endothelial adherence, monolayer transmigration, and local oxidative burst by activated neutrophils, along with the profound loss of endothelial monolayer integrity (i.e., microvascular capillary leak), contribute to massive interstitial edema after reperfusion. Although all tissues are sensitive to varying degrees, ischemia–reperfusion injury appears to be most detrimental to the pulmonary vasculature and the splanchnic circulations. Pulmonary interstitial edema and alveolar fluid accumulation are associated with the development of ARDS, whereas extensive visceral edema may contribute to development of ACS and mesenteric ischemia.

Second-hit Phenomena

Patients who have been successfully resuscitated from shock are at risk for what is referred to as the second-hit phenomenon. A single episode of severe or prolonged shock may precipitate organ failure, but, in addition, the initial insult may "prime" the inflammatory response, resulting in an augmented or prolonged response to a subsequent insult such as an infection, a second episode of blood loss, or major surgery.[60] For example, after the primary event, circulating neutrophils demonstrate enhanced superoxide anion production, increased endothelial cell adherence, augmented cytokine response, and increased cytotoxicity. Not only do circulating innate immune cells demonstrate this priming effect, but tissue-fixed cells, in particular the macrophage, demonstrate altered phagocytosis and augmented cytokine release.[61] This dysfunctional response leads to not only diminished microbial clearance and enhanced risk of nosocomial infection but also increased host tissue injury and subsequent development of MODS.

6 MODS rarely develops as a result of isolated cardiogenic or neurogenic shock but is most often precipitated by septic and traumatic shock complicated by second-hit events such as repeated episodes of hypovolemia, subsequent infection, or repeated blood transfusions. Similarly, the presence of an unresolved inflammatory focus (such as devitalized necrotic tissue), undrained bodily fluids, or unresolved regional perfusion deficits can be the primary causes for the persistence of SIRS and the transition to MODS.

The effects of shock, resuscitation, and reperfusion and the subsequent development of MODS appear to depend on changes in the splanchnic and pulmonary microcirculations. These vascular beds appear to be major sites of the activation and subsequent immunoinflammatory mediator production that is responsible for the SIRS response. As splanchnic microcirculatory flow decreases in response to homeostatic vasoconstrictive responses during hypovolemia, excessive and prolonged hypoperfusion of the gut results in extensive microvascular injury and subsequent activation of endothelium, neutrophils, and macrophages. In addition, mucosal barrier disruption permits translocation of bacteria and bacterial toxins to circulate and reach the large tissue-fixed macrophage population in the liver. Extensive activation of the Kupffer cells in the liver results in the release of inflammatory mediators that cause distant organ injury through the systemic activation of other immune cells.

Not only is a proinflammatory phase of SIRS present, but there is also a compensatory anti-inflammatory phase of the SIRS response that is evolutionarily designed to counter the locally generated hyperimmune response and check systemic spread of proinflammatory mediators. If the compensatory anti-inflammatory response syndrome (CARS) results in excessive immunosuppression, it may contribute to susceptibility to primary and secondary infections that can then lead to organ failure.[62]

Numerous clinical trials utilizing proinflammatory and anti-inflammatory mediators as therapeutic interventions have been conducted. Unfortunately, few therapeutic agents designed to counter immune dysfunction have had significant impact on the prevention and treatment of MODS. Although studies are planned and undergoing, no study has demonstrated a sustained impact to date. Several potential targets, including interferon, have been suggested but this theoretical benefit may prove incorrect as so many other targets have in the past.[63]

Abdominal Compartment Syndrome

ACS is a highly morbid complication of reperfusion injury to the splanchnic viscera. This syndrome appears to be increasingly prominent due to aggressive resuscitation techniques that enable salvage of profoundly hypotensive and hypovolemic patients. Splanchnic ischemia and reperfusion result in extensive visceral capillary leak and interstitial edema of the bowel. Excessive volume resuscitation during this phase leads to grossly edematous viscera within the closed space of the abdomen, which dramatically increases intra-abdominal pressure, and compromises intra-abdominal organ function, increases renovascular resistance, limits diaphragmatic excursion, and may decrease cardiac output and elevate intracranial pressure. The clinical hallmarks of ACS are a distended and tense abdomen, diminished tidal volume, pulmonary edema, decreased cardiac output, oliguria, and elevated urinary bladder pressure. Presence of all or a major part of this syndrome should prompt consideration of an urgent operative laparotomy to decompress the abdomen and treat by leaving the abdomen open.

Hypothermia

Hypothermia (core temperature <35°C) is common during shock. In addition to immobilization, both prehospital and postadmission exposure can lead to conductive, convective, and evaporative heat loss, which should all be minimized. In addition, the administration of room temperature intravenous fluids and of cold-stored blood also contributes to hypothermia.[64] Hypothermia increases fluid requirements and independently increases acute mortality rates.[65]

As the core temperature decreases, the rate of oxygen consumption also decreases, to approximately 50% of normal at 28°C. The decrease in oxygen consumption is accompanied by increased production of acid metabolites. A leftward shift in the oxyhemoglobin dissociation curve also occurs with hypothermia but is partially compensated by the acidosis. CNS effects progress from confusion and loss of manual dexterity to obtundation and frank coma as the core temperature decreases from 35°C to 26.5°C. The heart rate decreases to approximately half of baseline at 28°C, with a concomitant decrease in cardiac output. All cardiac electrical conduction intervals are prolonged, consistent with the changes in heart rate, and both atrioventricular dissociation and refractory ventricular fibrillation occur at 28°C. Other potential physiologic effects include ileus and pancreatitis (from cold enzyme activation) at temperatures lower than 35°C.

Compensatory responses to hypothermia include increased excretion of catecholamines, resulting in doubling of the basal metabolic rate, and increased production of thyroid hormones, further increasing the basal metabolic rate to five times baseline. Shivering can increase heat production as well, but it represents a significant energy expenditure and has been shown to be inhibited during episodes of hypotension or hypoxemia.[66] Compensatory responses to hypothermia are lost at temperatures below 30°C or 31°C, and a state of complete poikilothermy is reached.

The treatment for hypothermia is rewarming. The core temperature should be obtained on admission of the trauma patient. Patients whose core temperatures are 33°C to 35°C can be treated with passive rewarming, warm blankets, and hot packs. Patients with core temperatures lower than 33°C require active rewarming. If the patient is unconscious, airway control should first be obtained. Because severe hypothermia causes vasoconstriction, noninvasive blood pressure measurements may not be feasible or accurate, and an arterial line should be placed for monitoring and blood gas sampling. The inspired gas through the ventilator should be heated to 41°C and fully saturated with water vapor to increase heat conductance in the lung. The intravenous fluids should also be warmed. Commercially available rapid infusion systems with countercurrent heating elements should be used. For extreme hypothermia, continuous mechanical arteriovenous rewarming can be performed for both circulatory support and rewarming. Recently developed microtechnology permits core rewarming by percutaneous placement of countercurrent warming coils directly in the inferior vena cava (IVC). Finally, other warming methods include lavage of heated saline through nasogastric and thoracostomy tubes as well as peritoneal lavage, but are not as effective.

Coagulopathy

Coagulopathy is a frequent problem complicating shock, especially in those patients who have received large volumes of crystalloid solution and blood for resuscitation. Although this problem is incompletely understood, it is clear that coagulation defects during shock are multifactorial. The presence of shock, the fluid volume required for resuscitation, the presence of hypothermia, and pre-existing diseases all influence the likelihood and severity of coagulopathy.[67]

A major factor in coagulopathy is usually due to the dilutional thrombocytopenia that occurs after massive volume resuscitation. Although bleeding times can be prolonged with platelet counts less than 100,000 cells/mL, platelet counts of 50,000 cells/mL or greater are usually adequate for surgical hemostasis. Dilutional thrombocytopenia becomes more likely with infusions of more than one blood volume. Each unit of platelets administered increases the platelet count by 10,000 to 15,000 cells/mL. Control of surgically remediable hemorrhage is prudent before platelet transfusion to prevent the loss of the transfused platelets.

Dilution of other coagulation factors also plays a role in development of coagulopathy. Factors V and VIII are the most labile in banked blood, but levels of less than 10% of normal for factors VII, X, XI, XII, and XIII are all associated with abnormalities in hemostasis, as demonstrated by prolonged partial thromboplastin time and prothrombin time. Fresh-frozen plasma can be administered as a source of all the soluble coagulation factors. The administration of cryoprecipitate may be necessary as a concentrated source of factor VIII and fibrinogen, particularly if adequate hemostasis is not obtained with the use of fresh-frozen plasma. Recent support has emerged for the use of recombinant activated factor VIIa. Although developed initially for use in hemophiliacs who developed inhibitors to factor VIII, anecdotal evidence has suggested that recombinant activated factor VIIa may serve to quickly reverse hemorrhage-induced coagulopathy.[68] However, the use of factor VIIa is associated with significant complications including pulmonary embolism, myocardial infarction, and stroke and thus is no longer considered an optimal way to reverse hemorrhage-induced coagulopathy.[69] Other agents have demonstrated promise in rapidly reversing coagulopathy, such as tranexamic acid for massive hemorrhage-induced coagulopathy and prothrombin concentrates for rapid reversal of anticoagulants.[70–71]

Finally, evidence has suggested that coagulopathy and hemorrhage can be minimized following massive blood loss if early aggressive use of fresh-frozen plasma is administered. Military data demonstrate that significant early coagulopathy is present after massive injury, even before blood component therapy is begun. Both civilian and military experience with a 1:1 ratio of packed red blood cells to fresh-frozen plasma has been associated with reduced mortality.[72–74] However, this practice has been associated with an increase in the development of ARDS and organ dysfunction due to poorly defined mechanisms.[75] Thus, generalization of this data to all patients with hemorrhage other than the massively injured should be performed with caution as demonstrated in the PROPRR study.[76]

TREATMENT

Fluid Therapy

Early investigators of hemorrhagic shock noted that decreased CVP and a reduction in total-body oxygen delivery (DO_2) were key early findings. If the decrease in oxygen delivery was severe or prolonged, a reduction in total-body oxygen consumption ensued. After adequate fluid resuscitation, oxygen delivery and consumption increased above the baseline value for several hours, as if the body was paying back an "oxygen debt." Failure of the patient to achieve this hyperdynamic response to resuscitation was almost always fatal. Because early death from shock appeared to be explained by the dynamics of oxygen delivery and utilization, therapy focused on restoring hemodynamics and oxygen transport with fluid and inotropes.

The provision of additional fluid beyond the amount of blood loss was associated with improved survival in both clinical and experimental studies of hemorrhagic shock, leading to widespread acceptance of aggressive fluid infusion. However, some researchers have recently described a significant increase in mortality associated with crystalloid overresuscitation and have postulated that excessive fluid administration increases the clinical risk of ARDS, MODS, increased intracranial pressure, and ACS.[77–79] Because massive volumes of fluid are only provided to patients with severe shock, it is unclear if it is the excessive fluid or the associated underlying shock that increases the risk of ARDS, organ failure, or death after massive fluid resuscitation.

A minimum of two large-bore (14- to 16-gauge) intravenous catheters should be established in adults. Isotonic fluid is then infused at the same time as blood is obtained for arterial blood gas analysis, screening, and typing. Fluid can be infused up to 200 mL/min through a 14-gauge catheter and up to 220 mL/min through a 7-French catheter. A fluid challenge of 10 to 25 mL/kg is administered to the hypotensive patient and the response is assessed (i.e., 2,000 mL or 40% of blood volume of a 70-kg man). This therapeutic challenge is an effective trial in determining the amount of pre-existing or continuing volume loss. If the blood pressure returns to normal and is stabilized, the volume loss was relatively small, and the only treatment required may be infusion of isotonic fluid.

If the increase in blood pressure is transient after fluid bolus, then hemorrhage or continued fluid losses are severe and ongoing. Additional crystalloid is administered, and the need for blood transfusion is assessed. Patients who continue to require large amounts of fluid and blood to support perfusion usually have ongoing hemorrhage and require surgical intervention. No response or a minimal response to apparently adequate infusions of crystalloid solution and blood indicates exsanguinating hemorrhage and the need for urgent surgery.

Crystalloids

Balanced salt solutions are the most commonly used resuscitative fluids, and their use to restore extracellular volume significantly decreases the transfusion requirement after

hemorrhagic shock. Lactated Ringer solution is isotonic, readily available, and inexpensive. It rapidly replaces the depleted interstitial fluid compartment and does not aggravate any pre-existing electrolyte abnormalities. Previous investigations have shown that administration of lactated Ringer solution does not lead to aggravation of the lactic acidosis that is present in shock.[80] In fact, animal models have demonstrated that the use of blood plus lactated Ringer solution results in a more rapid return to normal lactate and pH than dose-shed blood alone. As volume and perfusion are restored, lactate is mobilized and metabolized to bicarbonate in a single pass through the liver. In fact, mild metabolic alkalosis may occur 1 or 2 days after large-volume resuscitations with lactated Ringer solution. Normal saline solution is also effective for resuscitation of hypovolemic patients. Concerns about inducing hypernatremic, hyperchloremic metabolic acidosis with massive resuscitation volumes remain but appear of less relevance by further investigation with normal saline and the hypertonic saline solutions.

Recently several investigations have raised concerns about the proinflammatory effects of resuscitation with lactated Ringer solution. Some commercially available lactated Ringer solutions contain racemic lactate that is made of equal concentrations of D(−)- and L(−)-isomers of lactate. The D(−)-isomer has been demonstrated in vitro to result in enhanced production of reactive oxygen species by neutrophils and inflammatory gene expression by leukocytes.[81–82] In addition, increased apoptosis in both the small intestine and the liver was seen after resuscitation from hemorrhage with lactated Ringer solution but not with hypertonic solutions or blood resuscitation.[83] These findings, however, are not consistent and do not appear dissimilar from saline resuscitation in other animal models.[84] Thus, further investigations are required to determine the overall inflammatory effect of crystalloid resuscitation and extent of D(−)-isomer use in current commercial fluids.

Colloids

Colloids have the theoretic advantages of increasing the colloid oncotic pressure and requiring smaller volumes for resuscitation than crystalloids.[85] Colloids commonly used for volume expansion in hypovolemia include albumin, dextran 70, dextran 40, and hydroxyethyl starch. Although each has unique individual characteristics, currently there is little justification for the routine addition of colloids to balanced salt solutions for volume replacement during shock. In fact routine use of colloid such as hydroxyethyl starch may be associated with increased risk of mortality without any benefit.[86]

Albumin solutions have been used during resuscitation to increase colloid oncotic pressure and, hypothetically, to protect the lung from interstitial edema; however, there is a relatively rapid flux of albumin across the pulmonary capillary membranes and relatively rapid clearance through the pulmonary lymphatics. In fact, colloid albumin infusion has been demonstrated to prolong the resuscitation phase and delay postresuscitation diuresis. Additionally, albumin may serve to depress circulating immunoglobulin levels and suppress albumin synthesis.

Dextran 40 and dextran 70 are polysaccharides with molecular weights of 40 and 70 kD, respectively. Dextran 40 (10%) is hyperoncotic and initially exerts a volume-

expanding effect. However, because of its lower molecular weight, it is more rapidly excreted. Thus, dextran 40 is commonly used in cases of peripheral vascular disease and hyperviscosity syndromes. Dextran 70, conversely, is provided as a 6% solution and does not exert a hyperoncotic effect. The volume expansion is somewhat greater than the amount infused, and because of its large molecular size the effect is maintained for up to 48 hours. The dextran preparations, however, cause decreased platelet adhesiveness and decreased factor VIII activity. They also carry an incidence of allergic reaction of up to 5% and anaphylaxis of 0.6%.[85,87]

Hydroxyethyl starch is an amylopectin with volume-expanding effects for approximately 36 hours. It has side effects similar to those of dextran, but with less frequency. The incidence of anaphylaxis is 0.006%. A new hydroxyethyl starch, pentastarch, has a lower molecular weight and fewer hydroxyethyl groups than hydroxyethyl starch. Pentastarch has a shorter duration of action (2.5 hours) and has been reported to have even fewer side effects.[87–88]

The controversy regarding use of crystalloids versus colloids in resuscitation has not been resolved. Both types of solutions can restore circulating volume. The effects of the solutions on pulmonary function are at issue and are summarized as follows: (a) the use of crystalloid solutions decreases plasma oncotic pressure, thereby leading to lung edema at lower microvascular pressures; and (b) colloids given in the face of pulmonary injury can extravasate, promoting edema because of the reduced plasma interstitial oncotic gradient. In fact, a previous meta-analysis of colloid versus crystalloid resuscitation after hemorrhagic shock demonstrated a higher mortality rate among the colloid-resuscitated patients, partly because of pulmonary complications.[89] Therefore, since colloid infusion has not demonstrated a significant benefit over crystalloid resuscitation alone, it is not currently recommended in the management of hypovolemic shock.[90–91]

Resuscitative Strategy

7 Aggressive fluid resuscitation is clearly a lifesaving modality and a key strategy in the treatment of shock and prevention of secondary consequences (Algorithm 9-2). However, indiscriminate fluid loading causes problematic edema in the lungs, gut, brain, and other organs. The amount of fluid used for resuscitation should be titrated to carefully selected hemodynamic and oxygen transport endpoints. Solutions currently in development ("artificial blood") with oxygen transport capabilities may hold the potential of restoring oxygen transport while minimizing the need for large volumes.

Permissive Hypotension

Elevation of systemic arterial pressure in patients with disruption of the arterial system or major solid organ injury, especially after penetrating trauma, may cause acceleration of hemorrhage, disrupt natural clotting mechanisms, and cause dilution of clotting factors. Laboratory and clinical evidence support judicious use of intravenous fluids until hemorrhage is controlled by surgery, angiography, or direct pressure for penetrating trauma.[92] Fluid resuscitation for patients with multisystem blunt trauma, especially with concomitant traumatic brain injury, represents a more complicated decision process, as maintaining cerebral perfusion pressure is a competing priority. Avoidance of both excessive fluid administration and prolonged hypoperfusion is best achieved in all patients not by maintenance of a marginal blood pressure, but by rapid surgical or angiographic intervention to control bleeding.

Transfusion

Anemia prompts clinical concerns because it may signify blood loss or hematologic disease, but it rarely causes tissue ischemia. The hemoglobin level that causes concern should depend on the adequacy of other mechanisms involved in oxygen delivery such as arterial oxygen saturation and cardiac output, the specific clinical situation, and the organ systems most at risk, balanced against the risk of transfusion. Clinical evidence suggests that hemoglobin values above 7 mg/dL are adequate in most patients, including the critically ill, but this has not been explored during shock. In one prospective randomized trial in critically ill patients, it was clearly demonstrated that a reduction in complications and improvement in survival were noted when lower hemoglobin values were accepted.[93] However, this study excluded patients with hypovolemia, acute coronary syndrome, and sepsis. Although the role of transfusion during shock remains problematic, it appears in patients without shock these thresholds of transfusion are even acceptable for elderly patients with significant cardiac disease.[94]

Table 9-6 Comparison of Blood Availability

Blood	Typing	Antibody Screen	Cross Match	Time
Type O	No	No	No	Immediate
Type specific	Yes	No	No	<10 min
Type and screen	Yes	Yes	Yes	20–30 min
Type and cross match	Yes	Yes	Yes	45–60 min

Given this limitation, currently it is held that most patients with class I or II shock can be resuscitated with balanced salt solutions alone. Patients who lose more than 25% to 30% of total blood volume require blood for resuscitation, as do patients with persistent evidence of inadequate end-organ perfusion.[20] The decision about the extent of blood cross match prior to being transfused is determined in part by the urgency of the situation. Blood that has been fully typed and cross matched carries the least risk of transfusion reactions, but it also takes the most time to obtain. Other transfusion options include the use of type O or type-specific blood (Table 9-6).

Type O Blood

Type O (universal donor) blood is immediately available without a cross match. Because type O blood contains no AB cellular antigens, administration of packed red blood cells is relatively safe in patients with any blood type. Males should be transfused type O Rh-positive blood, while prepubescent females and females of childbearing age should be given type O Rh-negative blood to avoid sensitization that would complicate future pregnancies. The administration of more than 4 units of type O blood to a non–O-blood-type patient, however, theoretically can result in an admixture of blood type. A pretransfusion blood specimen should be sent to the blood bank when the patient is admitted, and type-specific blood should be transfused as soon as it is available.

Type-Specific Blood

Type-specific blood is available from most blood banks within 5 to 10 minutes of receipt of the blood specimen, while the patient is being resuscitated with balanced salt solutions. Although not cross matched, this blood can be administered safely, as demonstrated in both military and civilian experiences.[95]

Autotransfusion

Autotransfusion involves collection of the shed blood and its reinfusion through a filter back into the patient. Autotransfusion can be as simple as aspiration of the blood into a citrate-containing collection chamber, followed by reinfusion through a 40-mm filter. A more elaborate system, the Haemonetics autotransfuser (Haemonetics Corp., Braintree, MA), centrifuges the collected blood and delivers washed, packed red blood cells for reinfusion. The advantages of autotransfusion include transfusion with warm, compatible blood without delays and with no risk of transmission of hepatitis, human immunodeficiency virus, or other bloodborne pathogens.

Autotransfused blood can produce disseminated intravascular coagulation and activation of fibrinolysis. In addition, collection of blood from the peritoneal cavity after hollow viscus injury, even with cell washing, may lead to bacterial contamination of the autotransfused blood.[96] Successful autotransfusion of contaminated blood has been demonstrated, but blood obtained from enteric-contaminated cavities probably should not be used, except perhaps in extreme circumstances.[97] Despite the potential benefits, investigators have found that the autotransfuser was used in only 26% of the trauma patients for whom it was prepared.[98] Currently, no evidence exists that autotransfusion improves outcome compared to exclusive homologous blood transfusions in trauma patients.

Endpoints of Resuscitation

Endpoints of resuscitation can be categorized as either global or regional indicators of perfusion. Blood pressure and pulse are global measures and are relatively poor determinants of the adequacy of tissue oxygenation. They must also be interpreted in the context of patient age and pre-existing medical conditions. Tachycardia is a component of SIRS and does not always resolve with increased preload. Arterial pressure is maintained by myriad compensatory mechanisms, even in the face of a significant volume deficit, and interpretation is complicated by highly variable baseline pressures, age, and pre-existing medical conditions.

Base deficit and serum lactate are also global indicators of perfusion and may help in the detection of patients who are in otherwise compensated shock. Acidosis arising from regional tissues may not be apparent in peripheral blood samples, as is frequently the case in patients with intestinal ischemia, in whom systemic acidosis is a late finding. An elevated base deficit and lactate can be caused by electrolyte abnormalities, accelerated glycolysis or pyruvate production, and/or decreased clearance by the liver. They may also reflect dysfunction caused by a period of hypoperfusion that has already resolved and that does not need further treatment. A positive response toward correction, however, is indicative of appropriate resuscitation.

A PAC has obvious appeal as a monitor because ensuring adequate oxygen delivery is paramount in the treatment of shock (Algorithm 9-2). A progressive decline in systemic oxygen delivery (DO_2) results in an increase in the oxygen extraction ratio, evident as a reduction in pulmonary mixed venous oxygen saturation. When DO_2 is reduced below the level needed to maintain normal tissue metabolic activity, anaerobic metabolism occurs. This is evident as a decrease in total-body oxygen consumption (VO_2). Adequate resuscitation requires eliminating any pathologic decrease in VO_2 by restoring oxygen delivery to an adequate level. In clinical practice, however, there is no precise level of VO_2 that can be used as an endpoint, as tissue oxygen needs vary according to the patient's condition, level of sedation, body temperature, and other factors, and are affected by endogenous and exogenously administered catecholamines.

Oxygen consumption may be especially difficult to interpret in patients with late-stage sepsis because acquired defects in mitochondrial respiration may prevent utilization of oxygen, resulting in decreased consumption and progressive acidosis despite normal or high DO_2.

The adequacy of resuscitation can also be assessed by measurement of end-organ function and perfusion, in addition to global measures. Blood flow to the most vital organs (brain and heart) is preserved during shock at the expense of flow to the skin, muscles, gut, and, ultimately, kidneys. Detection of ischemia in less vital organs could theoretically identify patients in compensated shock who have otherwise normal global indicators.

Low urine output (<0.5 to 1.0 mL/kg/hr) is an indicator of inadequate end-organ perfusion, but inappropriate urine output may initially be maintained by peripheral

venoconstriction and maintenance of cardiac output due to tachycardia. The use of gastric tonometry to measure intramucosal pH has highlighted the uneven recovery from shock by visceral organs. Persistent visceral hypoperfusion, as demonstrated by intramucosal acidosis despite correction to normal hemodynamics, is associated with organ failure and poor outcomes. Unfortunately, direct measurement of visceral hypoperfusion, as well as hypoperfusion in other regional vascular beds, requires use of technically challenging, labor-intensive devices that often produce variable unreliable results and has not yet had widespread application. Presently, the goal of therapy is to restore tissue perfusion, both global and regional as measured by organ function, and to normalize cellular metabolism while avoiding excessive use of fluids and inotropes.

Recently, several biomarkers, in addition to base deficit and lactate, have demonstrated potential promise. Among the most promising is procalcitonin for the early recognition of sepsis. However, in addition to being significantly elevated during sepsis, procalcitonin has recently been demonstrated, similar to lactate and base deficit, to be prognostic of outcome from hypovolemia based on rate of clearance.[99] Thus, this biomarker along with potential others may lead to early recognition and treatment of shock.

MONITORS

Central Venous Pressure

CVP has been used as a surrogate for venous return to the right heart and extended to represent preload. Preload is often diminished in the setting of shock and must be optimized in order to maintain adequate oxygen delivery. The venous system serves a capacitance function containing roughly two-thirds of our circulating blood volume. It is a compliant system that, in a healthy state, functions to maintain adequate venous return to the heart over a variable total blood volume. In states of shock, this capacitance function may be overcome by too low a circulating volume – as in the setting of hypovolemic or hemorrhagic shock – or by dysregulation – as in the setting of neurogenic or septic shock. CVP may be measured directly via an appropriately positioned central venous catheter. The catheter tip should ideally be positioned at the cavoatral junction – roughly 2 cm caudal to the carina on chest x-ray.[100] Intravenous fluids are administered to achieve adequate preload. Despite challenges for the ability for CVP to determine preload, CVP still remains used clinically.[101] In the surviving sepsis campaign, CVP is pushed to a goal of 8 to 12 mm Hg, which is thought to optimize preload.[20] This however, has been called into question in recent years with several investigators suggesting that there is no survival benefit to achieving such high CVPs.[20] It has certainly been demonstrated that CVP is not a perfect measure of venous return to the right heart or cardiac preload as there are several intrinsic cardiopulmonary factors that influence both CVP and cardiac output. The role of CVP may be most useful at its extremes and when used within the context of the patients' clinical situations. A CVP <5 mm Hg in the setting of a young, otherwise healthy trauma patient with ongoing hemorrhage is likely consistent with hypovolemic shock and warrants volume resuscitation. Alternatively, a CVP of 15 mm Hg in an elderly patient with known congestive heart failure does not alone provide adequate information as to a patient's volume status nor should it guide resuscitation. As such, CVP is one measure that can help to guide shock resuscitation when evaluated in the proper context.

Pulmonary Artery Catheter

Hemodynamic monitoring utilizing a flow-directed PAC has been a standard in the treatment of shock for decades and has been considered to be essential for optimal management of certain forms of shock. However, as a result of a multicenter study that reported that use of a PAC was associated with increased mortality, the indications for PAC use have recently been questioned.[102] PAC patients were retrospectively compared to matched control patients who were selected using a scoring system. This scoring system has not been validated, which raises the possibility that physicians inserted a PAC in the more critically ill patients.

Intensive care unit (ICU) staffing practices may have also been a factor explaining these surprising results. The study was conducted in "open" ICUs, where any physician on the medical staff could admit a patient to the unit and insert a PAC. Clinicians may not always interpret PAC data appropriately. In a multicenter study of physicians' knowledge and interpretation of PAC data, nearly half (47%) were unable to appropriately determine the wedge pressure from a clear tracing, and a similar percentage (44%) could not identify the determinants of oxygen delivery.[103] Studies have demonstrated improved outcome when patients are managed in ICUs staffed by specialists in critical care, despite their more frequent use of PACs.[104]

An additional consideration regarding the controversy over the utility of PACs is that currently used endpoints for PAC-guided resuscitation may be inappropriate. For example, efforts to augment systemic oxygen delivery have not demonstrated any benefits and, in fact, harm may be caused by this approach, whereas treatments used to alter the variables ascertained with the catheter may themselves cause harm (fluid overload, excessive inotropes, blood transfusions). Finally, PACs are associated with specific complications, including the risk of central venous catheter insertion, endocarditis, and pulmonary artery injury, which may outweigh any potential benefits. As the safety and utility of the PAC have not yet been evaluated with prospective clinical trials in specific shock states, its usefulness in the management of shock remains to be determined.

Newer versions of the PAC have been developed that provide additional hemodynamic information, including continuous determination of cardiac output, ejection fraction, and calculated right ventricular end-diastolic volume. The pulmonary artery wedge pressure is a proxy for preload. However, the amount of precontractile stretch achieved with any given wedge or chamber pressure is modulated by the compliance of the ventricle. Therefore, cardiac chamber pressure may not be an accurate indicator of ventricular end-diastolic volume, just as end-diastolic volume may not be an accurate indicator of pulmonary wedge pressure and/or risk of pulmonary edema. The combination of both wedge pressure and end-diastolic volume may be optimal to maximize preload while avoiding excessive pulmonary capillary pressure. The use, however, has been mainly supplanted with the use arterial wave contour analysis and echocardiography.

A comparison of the pH and partial pressure of carbon dioxide (PCO_2) of mixed venous blood with a matched arterial blood sample can provide evidence of shock with tissue

hypoxia. Hypoxic cells generate a hydrogen ion that is buffered by bicarbonate, resulting in increased production of H_2O and CO_2. An increase in venous PCO_2 results in an abnormal gap between mixed venous and arterial PCO_2 and pH and is a sign of anaerobic metabolism. With cessation of hydrogen ion production, this abnormal gap is quickly eliminated, whereas base deficit and hyperlactatemia may persist for several hours.

Arterial Wave Contour Analysis

Analysis of the arterial wave contour in a mechanically ventilated patient has been shown to be a marker of fluid responsiveness. This is a dynamic measurement, and as such, provides more information than static measures such as CVP or PCWP. Inspiration during positive pressure ventilation increases intrathoracic pressure and decreases venous return to the right heart. This, in turn, leads to a decrease in left ventricular preload, a lower stroke volume, and a decreased cardiac output. This effect is more pronounced in the hypovolemic patient, and calculation of PPV has been consistently shown to predict fluid responsiveness in critically ill patients. PPV is a measure of percent-change in the pulse pressure over the respiratory cycle, with a PPV greater than 12.5% being consistent with fluid responsiveness.[101] Arterial wave contour analysis relies on patients having a sinus rhythm, no spontaneous respiratory function, and a tidal volume of at least 8 mL/kg. Interpretation of PPV and other arterial wave contour measurements should be cautioned outside of these parameters.

Bedside Ultrasound and Echocardiography

Improved ultrasound technology – better image quality and improved portability – over the past several years has led to its frequent use in the emergency department and intensive care settings. Ultrasound offers the benefits of being noninvasive, real-time, accurate, and reproducible. A focused cardiac ultrasound can provide information on both left and right ventricular function as well as volume status. Additionally, a pericardial effusion is easily identified and may be leading to tamponade physiology. Valvular disease is much more difficult to identify and may require a formal transthoracic or transesophageal echo.[105]

In addition to assessment of cardiac function, ultrasound has demonstrated use in assessment of volume status and fluid responsiveness in shock states. Measurement of the superior vena cava (SVC), IVC, and left ventricular stroke area (LVSA) have proved helpful in guiding resuscitation. Measurement of the SVC and LVSA are performed via transesophageal echocardiography, which limits their routine use in patient management. However, SVC and LVSA variation over the respiratory cycle has been demonstrated to be predictive of fluid responsiveness.[106–107] Measurement of the IVC is performed using bedside ultrasound. The IVC is identified just caudal to the diaphragm, and an anterior–posterior dimension is recorded at the end of expiration. In the setting of trauma and shock, an IVC diameter of <1 cm is consistent with a transient responder and correlates with fluid responsiveness.[108,109] The use of ultrasound in critical care settings is growing and will continue to do so as technology and provider experience improves.

PHARMACEUTICAL SUPPORT

Therapeutic adjustments of preload and afterload form the basis of treatment strategies in all forms of shock. Optimal volume resuscitation should always precede measures to augment the contractile function of the heart. Inotropic augmentation of cardiac output may, therefore, be required when restoration of venous preload fails to provide sufficient cardiac output to satisfy tissue oxygen demands. The effect of inotropic agents depends on the specific adrenergic receptor affinity, chronotropic effects, and demands placed on myocardial oxygen consumption of the individual agents (Table 9-7). Vasodilators reduce demands on the myocardium and augment cardiac function via reduction in systemic vascular resistance (SVR) or afterload or by dilating the venous system and reducing cardiac preload. Afterload reduction may preserve stroke volume in the face of a failing myocardium, whereas venodilation reduces pulmonary capillary wedge pressure and pressure-driven pulmonary edema. Agents that increase afterload may be needed when blood pressure falls below the autoregulatory range of the coronary, cerebral, and renal vascular beds.

Dopamine

Dopamine is an endogenous sympathetic amine that is a biosynthetic precursor of epinephrine and functions as a central and peripheral neurotransmitter. The effects of dopamine vary from individual to individual, and are altered with increasing doses. The highest-affinity receptors are occupied at low-serum concentrations (infusions <2 to 3 μg/kg/min) and consist of dopaminergic receptors in the renal and splanchnic beds that serve to augment regional blood flow, increase urine output, and cause natriuresis. However, multiple studies, including prospective randomized trials, have failed to demonstrate that low-dose dopamine prevents acute renal failure or decreases the need for dialysis in critically ill patients. At modest concentrations (3 to 5 μg/kg/min), dopamine occupies cardiac β_1-adrenergic receptors and increases myocardial contractility and heart rate. Higher doses (>5 μg/kg/min) cause an increase in heart rate and blood pressure. α-Adrenergic receptors are stimulated at higher-dose ranges (>10 μg/kg/min), resulting in elevation of blood pressure and peripheral vascular resistance. Dopamine is, therefore, an effective agent for increasing blood pressure in hypotensive patients after appropriate fluid resuscitation. Because the relationship among a specific dose, receptor affinity, and clinical effect is unique to each patient, individual titration is required to achieve the desired effect.

Table 9-7 Pharmacodynamics of Inotropic/Vasoconstrictor Agents

Drug	Metabolism	Sites of Action				Hemodynamic Response			
		Heart β_1	Heart β_2	Vessels α	Vessels β_2	Renal Perfusion	CO	SVR	BP
Isoproterenol 1 mg/250 mL 1–2 μg/min initially	Renal	+++	+++	0	+++	+/–		–	+/–
Dobutamine 250 mg/250 mL 3 μg/kg/min initially	Hepatic	+++	0/+	0/+	0/+			–	0/+
Dopamine 200 mg/250 mL 2–5 μg/kg/min low dose 20–50 μg/kg/min high dose	Hepatic	+++	+	0	Low dose High dose		Low dose High dose	0/+	
Epinephrine 2 mg/250 mL 2 μg/min initially	Renal	+++	+++	+++	++	–		–	
Norepinephrine 4 mg/250 mL 4 μg/min initially	Renal	++	++	+++	0	–	+/–		
Phenylephrine	Renal	0	0	+++	0	–	–		

α (alpha), vasoconstrict peripheral arterioles; β_1 (beta-1) myocardial inotropy, chronotropy, enhance atrioventricular conduction; β_2 (beta-2) chronotropy, vasodilate mesenteric/skeletal bed, bronchodilation; dopaminergic, vasodilate mesenteric/renal bed. BP, blood pressure; CO, cardiac output; SVR, systemic vascular resistance.

Dobutamine

Dobutamine, a synthetic catecholamine, has a predominant affinity for β-adrenergic receptors. At clinically relevant doses (5 to 20 μg/kg/min), dobutamine enhances myocardial contractility with mild to moderate changes in heart rate. It also induces peripheral vasodilation, which limits its utility in patients with hypotension. It is an appropriate agent when cardiac output augmentation, not blood pressure support, is required and when a drop in peripheral resistance and preload is clinically tolerable or beneficial. Treatment of cardiogenic shock following myocardial infarction or cardiac dysfunction following shock and reperfusion typically requires support of myocardial contractility and reduction of peripheral resistance, which makes dobutamine an excellent choice in this setting.

Epinephrine

Epinephrine, the endogenous adrenal catecholamine, is released physiologically in response to stress. It has a broad spectrum of systemic actions, including significant cardiovascular effects. When epinephrine is administered as a pharmacologic agent (0.01 to 0.05 μg/kg/min), β_1-adrenergic effects predominate, causing increased stroke volume, heart rate, and contractility, along with modest β_2-receptor stimulation. At higher infusion rates, α-adrenergic receptors are stimulated, which overcome β_2-mediated peripheral vasodilation, resulting in an increase in blood pressure and SVR. Renal and splanchnic vasoconstriction, cardiac dysrhythmias, and increased myocardial oxygen demands limit the prolonged use of high-dose epinephrine. Transient increases in serum lactate have also been noted, possibly due to impaired regional blood flow. Epinephrine should be considered as a potential short-term agent for use in patients with impaired cardiac function not responsive to other agents such as dobutamine.

Norepinephrine

Norepinephrine, the sympathetic neurotransmitter, also has concentration-dependent cardiovascular effects. It should be considered as a drug with predominantly α-constrictor effects and less pronounced β-stimulation and is, therefore appropriate for use in patients who remain hypotensive despite dopamine administration or as a dopamine alternative. Combined α- and β-stimulation typically results in an increase in afterload and renal glomerular perfusion pressure, with preservation of cardiac output. Despite the potential for renal vasoconstriction, as a result of its effects on mean arterial pressure, norepinephrine is associated with an increase in urine output and creatinine clearance in hypotensive, and particularly septic, patients. A primary concern is to ensure adequate volume resuscitation prior to utilization due to risk of severe tissue damage from excessive vasoconstriction on the hypovolemic patient.

Isoproterenol

Isoproterenol is a synthetic catecholamine with potent β-adrenergic effects. From a cardiovascular standpoint, both cardiac and peripheral effects are significant. Stimulation

of cardiac β1-receptors prompts an increase in contractility, heart rate, and conduction velocity. The chronotropic response, however, may predominate. These activities, in conjunction with peripheral vasodilation, generate significant increases in cardiac output and pulse pressure. Isoproterenol greatly increases myocardial oxygen demand and limits coronary filling due to tachycardia. As a result, indications for isoproterenol are limited to patients with hemodynamically significant bradyarrhythmias while preparations are made for electrical pacing.

Phenylephrine

Phenylephrine is a pure α-agonist and is an effective agent for increasing peripheral vascular resistance and arterial blood pressure. Although it has no direct effect on the myocardium, the increase in afterload increases left ventricular work and oxygen demand and may cause a decrease in stroke volume and cardiac output. It is often used as a first-line agent in patients with neurogenic shock, but its use is otherwise generally restricted to patients who remain hypotensive when the dosage of agents such as dopamine or norepinephrine cannot be increased due to excessive tachycardia.

Vasopressin

Vasopressin acts directly on V_1 receptors in vascular smooth muscle to cause vasoconstriction and increases the reactivity of vascular smooth muscle to catecholamines. Release of endogenous vasopressin is a normal physiologic response to shock. After septic or prolonged hemorrhagic shock, circulating vasopressin levels are decreased, possibly due to depletion of hypophyseal secretory stores. This relative deficiency may play a role in causing refractory hypotension. Vasopressin has minimal effects on normotensive patients, but in patients with septic shock, it is effective in increasing SVR and mean arterial pressure. Vasopressin does not have inotropic properties but has potent splanchnic and coronary vasoconstrictors. It has been associated with decreased cardiac output due to myocardial ischemia and increased afterload and may worsen metabolic acidosis in patients in shock by causing splanchnic ischemia. As a result, early use of vasopressin at only physiologic concentrations to minimize associated other pressor use may be indicated in the event that other pressor agents are unable to achieve optimal perfusion.[110]

Amrinone and Milrinone

Amrinone and milrinone are noncatecholamine inotropes with cardiovascular effects similar to dobutamine, but with minimal chronotropic activity. As steroidlike phosphodiesterase antagonists, they increase smooth muscle cyclic adenosine monophosphate (cAMP) and alter calcium metabolism. Cardiac contractility, stroke volume, heart rate, and cardiac output are increased, while a concomitant reduction in afterload offsets cardiac workload. The increase in cardiac performance with minimal demands on myocardial oxygen consumption offers some utility in the treatment of cardiogenic shock or as a potential alternative to dobutamine infusion. Both agents have a relatively long half-life of nearly 3 hours and should therefore be used with caution in

patients at risk of developing hypotension, a major risk in the critically ill patient.

Vasodilators

Vasodilators are used as a means to augment cardiac function through optimization of preload and afterload, both of which reduce demands on the myocardium. The failing ventricle responds to afterload reduction with significant increases in stroke volume. The reason for this is that the compromised myocardium is working past the plateau and on the down slope of the Starling curve. As a result, afterload reduction with vasodilator agents may allow cardiac output to increase, resulting in improved oxygen delivery.

Nitroprusside

Nitroprusside is a balanced but potent arterial and venous smooth muscle vasodilator. It causes a reduction in afterload that increases cardiac output and has a less prominent venodilatory effect that reduces pulmonary venous pressure and preload. Hypotension may limit its use, particularly in the presence of contractility deficits or inadequate preload. Infusions (>3 μg/kg/min) continued for greater than 48 hours require monitoring of serum thiocyanate levels and arterial pH to detect complications of cyanide toxicity.

Nitroglycerin

Nitroglycerin is primarily a venous smooth muscle vasodilator, with less significant arterial vasodilation effects than nitroprusside. Thus, although nitroprusside predominantly decreases afterload, nitroglycerin predominantly increases venous capacitance. It is an effective treatment for acute myocardial ischemia because it reduces excessive preload and ventricular end-diastolic pressure, thereby diminishing myocardial oxygen demand.

Miscellaneous Therapeutics

Corticosteroids

In septic shock, ACTH resistance may diminish the normal cortisol response. Also, peripheral tissue resistance to corticosteroids may develop through proinflammatory-induced downregulation of normal corticosteroid receptors. Initial clinical trials showed no reduction in mortality when short courses of high-dose corticosteroids were used as adjuncts in the treatment of septic shock. However, recent studies utilizing low or physiologic doses (<300 mg/day) of hydrocortisone for a longer duration (>5 days) of treatment have demonstrated a beneficial impact on mortality, particularly in septic patients.[38] Currently, routine use of ACTH stimulation tests is not advocated since they provide little more than prognostic information.[40] Given that hypoadrenal shock complicates various shock states, routine use by some experts is considered appropriate. However, this should only be based on patients who have achieved adequate intravascular volume but remain in shock despite high vasopressor administration. Thus use of corticosteroids at only physiologic doses with immediate tapering once hemodynamics have improved should be used with caution.[39]

Metabolites and Electrolytes

Severe shock is frequently associated with hypocalcemia. Severe hypocalcemia that causes cardiac dysfunction or electrical instability should be rapidly treated. Calcium chloride rapidly corrects calcium deficits, whereas calcium gluconate must be degraded in the liver to release calcium ion, resulting in slower correction of deficits but less risk of tissue reaction. In the absence of evidence of cardiac dysfunction, attempts to restore plasma calcium to normal during shock are not warranted. Ischemia results in decreased cell membrane ATP and failure of the membrane calcium pump. Thus, reduced serum calcium levels during severe shock are probably due to movement of ionized calcium into the cells. Increased cytosolic calcium causes release of lysosomal enzymes and activation of phospholipases, protein kinases, and proteases that cause membrane damage and cytoskeletal destruction. Administration of exogenous calcium may merely worsen this uncontrolled intracellular calcium influx, whereas effective resuscitation will usually restore circulating calcium levels to normal.

Many shock resuscitation protocols emphasize correction of metabolic acidosis with fluids and inotropes until the pH begins to normalize. When interpreting an acid–base disorder, the presence of an anion gap is supportive evidence of lactic acidosis. However, a non–anion gap acidosis with worsening base deficit frequently occurs when normal saline is administered in large volumes. Efforts to correct a non–anion gap acidosis with additional fluids that may no longer be needed will only increase the risk of fluid overload.

Future Therapies

When initiating therapy for shock, the clinician does not know whether therapy has been started early, when salvage is still possible, or late, after irreversible changes have occurred within the cell and death is inevitable. Failure to respond to fluids, inotropes, and vasopressors with restoration of normal oxygen consumption and aerobic metabolism probably represents a defect in cellular and subcellular function in critical organ systems. There are many active areas of investigation that reflect the progression of our understanding of shock that have been outlined in this chapter and that have begun to move the field beyond the basics of fluid resuscitation and hemodynamic monitoring.

Efforts to control ischemia–reperfusion injury include controlled reperfusion with carbon monoxide or other compounds to reduce oxidative stress. Induced hypothermia may interrupt generation of harmful byproducts of ischemia and enable restoration of circulation and repair of structural injuries in a cellular environment where hypoxia is no longer critical. Additional biomarkers, such as procalcitonin, may allow earlier diagnosis and treatment of sepsis and shock.[99] New biosensors using near-infrared light may enable transcutaneous identification of critical limitations of blood flow and enable clinicians to more accurately target areas of regional hypoperfusion.[111] A search for agents that optimize circulation in the microvascular system by preventing activation of the endothelium may enable resuscitative efforts to restore oxygen to cells as needed to maintain normal respiration and provide critical nutrients. Ultimately, further understanding of functional genomics may enable clinicians to target transcription and translational events triggered by shock and thus alter outcome.

References

1. Cannon WB. Pharmacological injections and physiological inferences. *Science* 1929;70(1821):500–501.
2. Blalock A. Reminiscence: shock after thirty-four years. *Rev Surg* 1964;21:231–234.
3. Bogolioubov A, Keefe DL, Groeger JS. Circulatory shock. *Crit Care Clin* 2001;17(3):697–719.
4. Blalock A, Mason MF. Blood and blood substitutes in the treatment and prevention of shock: with particular reference to their uses in warfare. *Ann Surg* 1941;113(5):657–676.
5. Wiggers HC, Ingraham RC. Hemorrhagic shock: definition and criteria for its diagnosis. *J Clin Invest* 1946;25(1):30–36.
6. Weil MH, Shubin H. Proposed reclassification of shock states with special reference to distributive defects. *Adv Exp Med Biol* 1971;23(0):13–23.
7. Whittington LK, Roscelli JD, Parry WH. Hemorrhagic shock and encephalopathy: further description of a new syndrome. *J Pediatr* 1985;106(4):599–602.
8. Moore FA, McKinley BA, Moore EE, et al. Inflammation and the Host Response to Injury, a large-scale collaborative project: patient-oriented research core–standard operating procedures for clinical care. III. Guidelines for shock resuscitation. *J Trauma* 2006;61(1):82–89.
9. Chaterjee K. The Swan-Ganz Catheter: past, present, and future: a viewpoint. Circulation 2009;147–152.
10. Alhashemi JA, Cecconi M, Hofer CK. Cardia output monitoring: an integrative perspective. Critical Care 2011;214–220.
11. Vitek V, Cowley RA. Blood lactate in the prognosis of various forms of shock. *Ann Surg* 1971;173(2):308–313.
12. Abramson D, Scalea TM, Hitchcock R, et al. Lactate clearance and survival following injury. *J Trauma* 1993;35(4):584–588; discussion 588–589.
13. Nguyen HB, Rivers EP, Knoblich BP, et al. Early lactate clearance is associated with improved outcome in severe sepsis and septic shock. *Crit Care Med* 2004;32(8):1637–1642.
14. Brown JB, Cohen MJ, Minei JP, et al; Inflammation and the Host Response to Injury Investigators. Goal-directed resuscitation in the prehospital setting: a propensity-adjusted analysis. *J Trauma Acute Care Surg* 2013; 74(5):1207–1212.
15. Cuschieri J, Johnson JL, Sperry J, et al; Inflammation and Host Response to Injury, Large Scale Collaborative Research Program. Benchmarking outcomes in the critically injured trauma patient and the effect of implementing standard operating procedures. *Ann Surg* 2012;255(5):993–999.
16. Davis JW, Kaups KL, Parks SN. Base deficit is superior to pH in evaluating clearance of acidosis after traumatic shock. *J Trauma* 1998;44(1):114–118.

17. Davis JW, Shackford SR, Holbrook TL. Base deficit as a sensitive indicator of compensated shock and tissue oxygen utilization. *Surg Gynecol Obstet* 1991;173(6):473–476.
18. Davis JW, Shackford SR, Mackersie RC, et al. Base deficit as a guide to volume resuscitation. *J Trauma* 1988;28(10):1464–1467.
19. Davis JW, Parks SN, Kaups KL, et al. Admission base deficit predicts transfusion requirements and risk of complications. *J Trauma* 1996;41(5):769–774.
20. Rivers E, Nguyen B, Havstad S, et al. Early goal-directed therapy in the treatment of severe sepsis and septic shock. *N Engl J Med* 2001;345(19):1368–1377.
21. Rivers EP, Kruse JA, Jacobsen G, et al. The influence of early hemodynamic optimization on biomarker patterns of severe sepsis and septic shock. *Crit Care Med* 2007;35(9):2016–2024.
22. Bouman CS, Oudemans-van Straaten HM, Schultz MJ, et al. Hemofiltration in sepsis and systemic inflammatory response syndrome: the role of dosing and timing. *J Crit Care* 2007;22(1):1–12.
23. Cui ZG, Kondo T, Matsumoto H. Enhancement of apoptosis by nitric oxide released from alpha-phenyl-tert-butyl nitrone under hyperthermic conditions. *J Cell Physiol* 2006;206(2):468–476.
24. Englehart MS, Schreiber MA. Measurement of acid-base resuscitation endpoints: lactate, base deficit, bicarbonate or what? *Curr Opin Crit Care* 2006;12(6):569–574.
25. Goodrich C. Endpoints of resuscitation: what should we be monitoring? *AACN Adv Crit Care* 2006;17(3):306–316.
26. Jones AE, Shapiro NI, Kilgannon JH, et al. Goal-directed hemodynamic optimization in the post-cardiac arrest syndrome: a systematic review. *Resuscitation* 2008;77(1):26–29.
27. Alawade ZM, LeFebvre E, Fox EE, et al. Alternative end points for trauma studies: A survey of academic trauma surgeons. *Sugery* 2015:158(5):1291–1296.
28. Connelly CR, Schreiber MA. Endpoints in resuscitation. *Curr Opin Crit Care* 2015:21(6):512–519.
29. American College of Surgeons. *Advanced Trauma Life Support for Doctors: Student Course Manual.* 8th ed. Chicago, IL: American College of Surgeons; 2008.
30. Goldberg RJ, Gore JM, Alpert JS, et al. Cardiogenic shock after acute myocardial infarction. Incidence and mortality from a community-wide perspective, 1975–1988. *N Engl J Med* 1991;325(16):1117–1122.
31. Roberts N, Harrison DG, Reimer KA, et al. Right ventricular infarction with shock but without significant left ventricular infarction: a new clinical syndrome. *Am Heart J* 1985;110(5):1047–1053.
32. Russel JA. The current management of septic shock. *Minerva Med* 2008; 99(5):431–458.
33. Darville T, Giroir B, Jacobs R. The systemic inflammatory response syndrome (SIRS):

immunology and potential immunotherapy. *Infection* 1993; 21(5):279–290.
34. Kollef MH. Broad-spectrum antimicrobials and the treatment of serious bacterial infections: getting it right up front. *Clin Infect Dis* 2008;47(suppl 1):S3–S13.
35. Goris RJ. Pathophysiology of shock in trauma. *Eur J Surg* 2000;166(2):100–111.
36. Nespoli A, Corso V, Mattarel D, et al. The management of shock and local injury in traumatic rhabdomyolysis. *Minerva Anestesiol* 1999;65(5):256–262.
37. Mansfield ND, Forni LG. Recently published papers: treating sepsis, measuring troponin and managing the obese. *Crit Care* 2005;9(6):535–537.
38. Annane D, Sebille V, Charpentier C, et al. Effect of treatment with low doses of hydrocortisone and fludrocortisone on mortality in patients with septic shock. *JAMA* 2002;288(7):862–871.
39. Sprung CL, Annane D, Keh D, et al. Hydrocortisone therapy for patients with septic shock. *N Engl J Med* 2008;358(2):111–124.
40. Lipiner-Friedman D, Sprung CL, Laterre PF, et al. Adrenal function in sepsis: the retrospective Corticus cohort study. *Crit Care Med* 2007;35(4):1012–1018.
41. Groeneveld AB, Molenaar N, Beishuizen B. Should we abandon corticosteroids during septic shock? No. *Curr Opin Crit Care* 2008;14(4):384–389.
42. Gann DS, Carlson DE, Byrnes GJ, et al. Impaired restitution of blood volume after large hemorrhage. *J Trauma* 1981;21(8):598–603.
43. Parker MM. Pathophysiology of cardiovascular dysfunction in septic shock. *New Horiz* 1998;6(2):130–138.
44. Peters J, Mack GW, Lister G. The importance of the peripheral circulation in critical illnesses. *Intensive Care Med* 2001;27(9):1446–1458.
45. Cuschieri J, Gourlay D, Garcia I, et al. Modulation of endotoxin-induced endothelial function by calcium/calmodulin-dependent protein kinase. *Shock* 2003;20(2):176–182.
46. Cuschieri J, Gourlay D, Garcia I, et al. Modulation of endotoxin-induced endothelial activity by microtubule depolymerization. *J Trauma* 2003;54(1):104–112; discussion 112–113.
47. Barie PS, Hydo LJ. Epidemiology of multiple organ dysfunction syndrome in critical surgical illness. *Surg Infect (Larchmt)* 2000;1(3):173–185; discussion 185–186.
48. Baue AE. MOF, MODS, and SIRS: what is in a name or an acronym? *Shock* 2006;26(5):438–449.
49. Bhatia M, Moochhala S. Role of inflammatory mediators in the pathophysiology of acute respiratory distress syndrome. *J Pathol* 2004;202(2):145–156.
50. Matsuda N, Hattori Y. Systemic inflammatory response syndrome (SIRS): molecular pathophysiology and gene therapy. *J Pharmacol Sci* 2006;101(3):189–198.
51. Winn RK, Ramamoorthy C, Vedder NB, et al. Leukocyte-endothelial cell interactions in ischemia-reperfusion injury. *Ann N Y Acad Sci* 1997; 832:311–321.

52. Winn RK, Sharar SR, Vedder NB, et al. Leukocyte and endothelial adhesion molecules in ischaemia/reperfusion injuries. *Ciba Found Symp* 1995;189:63–71; discussion 72–76, 77–78.
53. Winn RK, Vedder NB, Mihelcic D, et al. The role of adhesion molecules in reperfusion injury. *Agents Actions Suppl* 1993;41:113–126.
54. Costa EL, Schettino IA, Schettino GP. The lung in sepsis: guilty or innocent? *Endocr Metab Immune Disord Drug Targets* 2006;6(2):213–216.
55. Goodman ER, Kleinstein E, Fusco AM, et al. Role of interleukin 8 in the genesis of acute respiratory distress syndrome through an effect on neutrophil apoptosis. *Arch Surg* 1998;133(11):1234–1239.
56. Papadakos PJ. Cytokines, genes, and ARDS. *Chest* 2002;121(5):1391–1392.
57. Ventilation with lower tidal volumes as compared with traditional tidal volumes for acute lung injury and the acute respiratory distress syndrome. The Acute Respiratory Distress Syndrome Network. *N Engl J Med* 2000;342(18):1301–1308.
58. Imahara SD, O'Keefe GE. Genetic determinants of the inflammatory response. *Curr Opin Crit Care* 2004;10(5):318–324.
59. O'Keefe GE, Hybki DL, Munford RS. The G–>A single nucleotide polymorphism at the -308 position in the tumor necrosis factor-alpha promoter increases the risk for severe sepsis after trauma. *J Trauma* 2002;52(5):817–825; discussion 825–826.
60. Rotstein OD. Modeling the two-hit hypothesis for evaluating strategies to prevent organ injury after shock/resuscitation. *J Trauma* 2003;54(suppl 5):S203–S206.
61. Cuschieri J, Maier RV. Oxidative stress, lipid rafts, and macrophage reprogramming. *Antioxid Redox Signal* 2007;9(9):1485–1497.
62. Sharma S, Kumar A. Septic shock, multiple organ failure, and acute respiratory distress syndrome. *Curr Opin Pulm Med* 2003;9(3):199–209.
63. Xio W, Mindrinos M, Seok J, et al. A genomic storm in critical injured humans. *J Exp Med* 2011;208(13):2581–2590.
64. Gentilello LM. Advances in the management of hypothermia. *Surg Clin North Am* 1995;75(2):243–256.
65. Gentilello LM, Jurkovich GJ, Stark MS, et al. Is hypothermia in the victim of major trauma protective or harmful? A randomized, prospective study. *Ann Surg* 1997;226(4):439–447; discussion 447–449.
66. Stoner HB. Studies on the mechanism of shock. The impairment of thermoregulation by trauma. *Br J Exp Pathol* 1969;50(2):125–138.
67. Gubler KD, Gentilello LM, Hassantash SA, et al. The impact of hypothermia on dilutional coagulopathy. *J Trauma* 1994;36(6):847–851.
68. Dutton RP, McCunn M, Hyder M, et al. Factor VIIa for correction of traumatic coagulopathy. *J Trauma* 2004;57(4):709–719.
69. Dutton RP, Parr M, Tortella BJ, et al; CONTROL Study Group. Recombinant activated factor VII safety in trauma patients: results from the CONTROL trial. *J*

Trauma 2011:71(1):12–19.

70. Roberts I, Shakur H, Ker K, et al; CRASH-2 Trial collaborators. Anitfibrinolytic drugs for acute traumatic injury. *Cochrane Database Syst Rev* 2011;19(1):CD004896.
71. Hassanein O, Smith A, Coimbra R, et al. Activated prothrombin complex and the treatment of hypocoagulable trauma patients. *Am Surg* 2015:81(6);651–652.
72. Gunter OL Jr, Au BK, Isbell JM, et al. Optimizing outcomes in damage control resuscitation: identifying blood product ratios associated with improved survival. *J Trauma* 2008;65(3):527–534.
73. Kashuk JL, Moore EE, Johnson JL, et al. Postinjury life threatening coagulopathy: is 1:1 fresh frozen plasma: packed red blood cells the answer? *J Trauma* 2008;65(2):261–270; discussion 270–271.
74. Spinella PC, Perkins JG, Grathwohl KW, et al. Effect of plasma and red blood cell transfusions on survival in patients with combat related traumatic injuries. *J Trauma* 2008;64(suppl 2):S69–S77; discussion S77–S78.
75. Sperry JL, Ochoa JB, Gunn SR, et al. An FFP:PRBC transfusion ratio >/= 1:1 5 is associated with a lower risk of mortality after massive transfusion. *J Trauma* 2008;65(5):986–993.
76. Holcomb JB, Tilley BC, Baraniuk S, et al; PROPPR Study Group. Transfusion of plasma, platelets, and red blood cells in a 1:1:1 vs a 1:1:2 ratio and mortality in patients with severe trauma: the PROPPR randomized clinical trial. *JAMA* 2015 313(5):471–482.
77. Ball CG, Kirkpatrick AW, McBeth P. The secondary abdominal compartment syndrome: not just another post-traumatic complication. *Can J Surg* 2008;51(5):399–405.
78. Bream-Rouwenhorst HR, Beltz EA, Ross MB, et al. Recent developments in the management of acute respiratory distress syndrome in adults. *Am J Health Syst Pharm* 2008;65(1):29–36.
79. Vidal MG, Ruiz Weisser J, Gonzalez F, et al. Incidence and clinical effects of intra-abdominal hypertension in critically ill patients. *Crit Care Med* 2008;36(6):1823–1831.
80. Canizaro PC, Prager MD, Shires GT. The infusion of Ringer's lactate solution during shock. changes in lactate, excess lactate, and pH. *Am J Surg* 1971; 122(4):494–501.
81. Alam HB, Stanton K, Koustova E, et al. Effect of different resuscitation strategies on neutrophil activation in a swine model of hemorrhagic shock. *Resuscitation* 2004;60(1):91–99.
82. Koustova E, Stanton K, Gushchin V, et al. Effects of lactated Ringer's solutions on human leukocytes. *J Trauma* 2002;52(5):872–878.
83. Deb S, Martin B, Sun L, et al. Resuscitation with lactated Ringer's solution in rats with hemorrhagic shock induces immediate apoptosis. *J Trauma* 1999;46(4):582–588; discussion 588–589.

84. Corso CO, Okamoto S, Ruttinger D, et al. Hypertonic saline dextran attenuates leukocyte accumulation in the liver after hemorrhagic shock and resuscitation. *J Trauma* 1999;46(3):417–423.
85. Ross AD, Angaran DM. Colloids vs. crystalloids – a continuing controversy. *Drug Intell Clin Pharm* 1984;18(3):202–212.
86. Perner A, Haase N, Guttomsen AB, et al; 6S Trial Group:Scandinavian Critical Care Trials Group. Hydroxethyl startch 130/0.42 versus Ringer's acetate in severe sepsis. *N Engl J Med* 2012;367(2)124–134.
87. Waxman K, Holness R, Tominaga G, et al. Hemodynamic and oxygen transport effects of pentastarch in burn resuscitation. *Ann Surg* 1989;209(3):341–345.
88. London MJ, Ho JS, Triedman JK, et al. A randomized clinical trial of 10% pentastarch (low molecular weight hydroxyethyl starch) versus 5% albumin for plasma volume expansion after cardiac operations. *J Thorac Cardiovasc Surg* 1989;97(5):785–797.
89. Velanovich V. Crystalloid versus colloid fluid resuscitation: a meta-analysis of mortality. *Surgery* 1989;105(1):65–71.
90. Finfer S, Bellomo R, Boyce N, et al; The SAFE Study Investigators. A comparison of albumin and saline for fluid resuscitation in the intensive care unit. *N Engl J Med* 2004;350(22):2247–2254.
91. Caironi P, Tognoni G, Masson S, et al; ALBIOS Study investigators. Albumin replacement in patients with severe sepsis or septic shock. *N Engl J Med* 2014;370;1412–1421.
92. Bickell WH, Wall MJ Jr, Pepe PE, et al. Immediate versus delayed fluid resuscitation for hypotensive patients with penetrating torso injuries. *N Engl J Med* 1994;331(17):1105–1109.
93. Hebert PC. Transfusion requirements in critical care (TRICC): a multicentre, randomized, controlled clinical study. Transfusion requirements in critical care investigators and the Canadian Critical Care Trials Group. *Br J Anaesth* 1998;81(suppl 1):25–33.
94. Hajjar LA, Vincent JL, Filomena RB, et al. Transfusion requirements after cardiac surgery: The TRACS randomized controlled trial. *JAMA* 2010; 304(14):1159–1168.
95. Gervin AS, Fischer RP. Resuscitation of trauma patients with type-specific uncrossmatched blood. *J Trauma* 1984;24(4):327–331.
96. Boudreaux JP, Bornside GH, Cohn I Jr. Emergency autotransfusion: partial cleansing of bacteria-laden blood by cell washing. *J Trauma* 1983;23(1):31–35.
97. Glover JL, Smith R, Yaw PB, et al. Autotransfusion of blood contaminated by intestinal contents. *JACEP* 1978;7(4):142–144.
98. Jurkovich GJ, Moore EE, Medina G. Autotransfusion in trauma. A pragmatic analysis. *Am J Surg* 1984;148(6):782–785.
99. Seligman R, Meisner M, Lisboa TC, et al. Decreases in procalcitonin and C-reactive

protein are strong predictors of survival in ventilator-associated pneumonia. *Crit Care* 2006;10(5):R125.

100. Stonelake PA, Bodenham AR. The carina as a radiologic landmark for central venous catheter tip position. *Br J Anesth* 2006;96(3):335–340.
101. Marik PE, Baram M, Vahid B. Does central venous pressure predict fluid responsiveness? A systematic review of the literature and the tale of seven mares. *Chest* 2008;134:172–178.
102. Boyd JH, Forbes J, Russell JA, et al. Fluid resuscitation in septic shock: A positive fluid balance and elevated central venous pressure are associated with increased mortality. *Crit Care Med* 2011;39:259–265.
103. Connors AF Jr, Speroff T, Dawson NV, et al. The effectiveness of right heart catheterization in the initial care of critically ill patients. SUPPORT Investigators. *JAMA* 1996;276(11):889–897.
104. Iberti TJ, Fischer EP, Leibowitz AB, et al. A multicenter study of physicians' knowledge of the pulmonary artery catheter. Pulmonary Artery Catheter Study Group. *JAMA* 1990;264(22):2928–2932.
105. Reynolds HN, Haupt MT, Thill-Baharozian MC, et al. Impact of critical care physician staffing on patients with septic shock in a university hospital medical intensive care unit. *JAMA* 1988;260(23):3446–3450.
106. Via G. International evidence-based recommendations for focused cardiac ultrasound. *J Am Soc Echocardiogra* 2014;27(7):683e1–683e33.
107. Vieillard-Baron A, Chergui K, Rabiller A, et al. Superior vena caval collapsibility as a gauge of volume status in ventilated septic patients. *Intensive Care Med* 2004;30(9):1734–1739.
108. Cannesson M, Slieker J, Lehot JJ, et al. Prediction of fluid responsiveness using respiratory variations in left ventricular stroke area by transesophageal echocardiographic automated border detection in mechanically ventilated patients. *Crit Care* 2006;10(6):R171.
109. Yanagawa Y, Sakamoto T, Okada Y. Hypovolemic shock evaluated by sonographic measurement of the inferior vena cava during resuscitation in trauma patients. *J Trauma* 2007;63(6):1245–1248.
110. Russell J, Walley K, Singer J, et al; the VASST investigators. Vasopressin versus norepinephrine infusion in patients with septic shock. *N Engl J Med* 2008:358:877–887.
111. Hopf HW. Molecular diagnostics of injury and repair responses in critical illness: what is the future of "monitoring" in the intensive care unit? *Crit Care Med* 2003;31(suppl 8):S518–S523.

Chapter 10

Critical Care

Damon Clark and Heidi Frankel

Key Points

1 Intensive care unit (ICU) utilization is expected to increase as “baby boomers” come of age.

2 Surgical patients benefit from receiving critical care delivered by multidisciplinary teams led by an intensivist. Around the clock intensivist presence (24 × 7) may not affect mortality in ICUs with high-intensity staffing, but is thought to be most useful in those with less-intense staffing models.

3 Delivery of evidence-based medicine in surgical ICU patients results in improved mortality and morbidity. Streamlining comprehensively written guidelines into “bundles” and use of checklists may improve compliance and outcome.

4 Scoring systems have been developed and refined to address population outcome (mortality) and to quantify organ dysfunction in the ICU.

5 Oxygen delivery and extraction can be monitored using pulmonary artery catheters (PAC). There is no benefit to supranormalization of values in ICU patients and likely of PAC monitoring in most instances. Fluid resuscitation using functional dynamic monitoring may be more efficacious than that targeted to static values. Focused echocardiography may provide advantages to interpretation of cardiac function over more traditional methods to afford therapies that can improve outcome. Patients in cardiac arrest or impending cardiac arrest should be managed with principles outlined in current Advanced Cardiac Life Support Guidelines. One of the three rhythms that can produce pulselessness can be treated electrically, the other two require pharmacologic therapy. Dysrhythmias are treated by considering their duration and association with hemodynamic instability and heart failure.

6 Hypoxemia may result from mismatch of ventilation and perfusion (V/Q), anatomic or physiologic shunting, hypoventilation, or less so due to impaired diffusion. Carbon dioxide, a readily diffusible gas, is addressed by altering alveolar ventilation. Acute lung injury (ALI) and adult respiratory distress syndrome (ARDS) fall along a spectrum of pulmonary disease. Conventional ventilatory strategies incorporate a low-stretch philosophy. Evidence-based rescue strategies include prone positioning and early chemical paralysis for those with severe ARDS. Most other ventilated patients should be lightly sedated, screened for delirium, and kept moving with daily assessment for the ability to extubate. The role for airway pressure release ventilation,

extracorporeal support, and inhaled prostacyclins is evolving.

7 Venous thromboembolism (VTE) is a significant problem in surgical ICU patients and chemical prophylaxis alone has been demonstrated to beneficially impact outcome. Low–molecular-weight heparins are more efficacious than unfractionated heparin in those at the highest risk in this population, if the risk of bleeding can be mitigated. New oral inhibitors of factors Xa and thrombin (II) have not been trialed specifically for VTE prophylaxis in general surgery ICU patients, but these agents will, undoubtedly, play a more important role in the future as more effective strategies to reverse them are developed.

8 A conservative transfusion trigger (7 g/dL hemoglobin) may be appropriate in most surgical ICU patients, including those with gastrointestinal bleeding, neurotrauma, cardiac disease, and sepsis.

9 ICU patients should undergo routine assessment and adequate support of their nutritional status to preserve lean body mass, maintain immune function, and avert metabolic complications. Enteral nutrition, delivered either gastrically or more distally, is invariably possible and preferred in most states. Earlier evidence supporting administration of immunonutrition (including components such as glutamine and omega-three fatty acids) has been refuted, although a hypocaloric, high-protein diet may be beneficial in all. Patients who are not being enterally fed, particularly those who will require mechanical ventilation for more than 48 hours or have a coagulopathy are candidates for pharmacologic prophylaxis of stress gastrointestinal bleeding. Proton pump inhibitors may be superior to histamine-2 antagonists.

10 Acute kidney injury is a common complication in the surgical ICU and portends poor outcome. Few preventative measures have been proven successful short of rapid attention to diagnosis and treatment of sepsis and adequate volume resuscitation. Both continuous and intermittent dialysis may be equally effective in treating patients and may be possible even in those with hemodynamic instability.

11 To balance the risks of hyperglycemia and iatrogenic hypoglycemia, glucose control in ICU patients should target levels between 140 and 180 mg/dL. Relative adrenal insufficiency is common in septic ICU patients. Hypotension unresponsive to volume loading and pressors should prompt consideration of glucocorticoid administration in this setting. Low levels of thyroid hormone may not be indicative of hypothyroidism in ICU patients and should only be treated if accompanied by clinical indications.

12 Successful resuscitation of sepsis requires rapid identification of acutely ill affected patients and administration of broad-spectrum antibiotics. CVP-targeted resuscitation may be no more effective than the use of clinical endpoints. Procalcitonin assays may be beneficial to appropriately shorten the course of antibiotic therapy for bacterial infections without negatively impacting outcome. Catheter-associated infections are often preventable; their prevention requires coordinated care and various strategies, the most important of which is prompt catheter removal when no longer required. Decontamination strategies aimed at reducing ventilator associated pneumonia and

methicillin-resistant *Staphylococcus aureus* infection may be efficacious.

Surgical patients requiring intensive care are unique in that they include those who have undergone elective procedures as well as those who have been injured or require emergent or urgent operations. As such, outcome, expectations and processes of care can be vastly different in surgical than in medical ICU patients, the majority of whom are admitted emergently. It is, thus important, to consider whether or not certain medical ICU literature is applicable to surgical patients. Most germane, mortality rates in surgical ICUs are roughly 5% to 10%, as opposed to greater than 20% in most medical ICUs.[1]

1 Nonetheless, surgical ICUs and their patients share many features with those in medical ICUs. Patients admitted to the critical care unit make up a large proportion of hospital cost and resources, estimated to be roughly 1% of gross domestic product. More importantly, both surgical and medical ICUs continue to find themselves understaffed. Both the supply of critical care practitioners is inadequate and the demand is extensive, largely from aging patients with complex comorbidities undergoing complicated procedures and multitrauma. There are approximately 3,000 boarded surgical intensivists with less than 200 completing training annually, most of whom do not practice critical care exclusively. In the United States, these surgical intensivists serve largely in surgical and surgical specialty units of academic medical centers that account for approximately 10% to 15% of the nearly 6,500 ICUs with roughly 100,000 beds and 5 million admissions annually. The largest growing demographic in hospitals overall and ICUs in particular, is the group over 65 years of age, now accounting for over half of all admissions, resulting in ICUs practicing at over two-thirds of capacity.

ORGANIZATIONAL STRUCTURE OF CRITICAL CARE

The intensive care unit provides an environment that allows close monitoring and care by experienced physicians, nurses, and other ancillary staff. Current ICUs have the following common features: (1) a designated geographical space, (2) specialized monitoring and therapeutic capabilities, (3) resources to provide continuous care, (4) appropriate nurse to patient ratio, and (5) specialized personnel. There is controversy, particularly in surgical ICUs, as to how superspecialized they need be (visceral transplant vs. cardiac surgery vs. noncardiac thoracic surgery). Practically, this is an issue of institutional volume and expertise as there is little data to support superspecialization in surgical units (neurosurgical patients, a notable exception). Diagnostic and therapeutic capabilities include invasive and minimally invasive cardiac monitoring, basic and rescue modes of ventilation and adjuncts, extracorporeal support, dialysis and hepatic support, and neurologic monitoring, as described below. ICU nurse to patient ratios vary from 1:3 to 2:1 depending on patient acuity and therapeutic needs that may be addressed with a scoring system such as the therapeutic intervention severity score (TISS).[3] Finally, dedicated pharmacists, dieticians, physical therapists, and advanced level practitioners such as acute care nurse practitioners have all been demonstrated to improve process compliance and patient outcomes.[4–7]

Traditionally there are two types of ICU organizational structures: open and closed formats. In an open ICU, the patients are admitted under the supervision and care of the primary physician/surgeon. The primary physician or surgeon is responsible for providing patient care including order entry and communication with the family, with ultimate decision making power over clinical decisions. The primary physician/surgeon also continues to care for patients in other areas of the hospital, providing both continuity, but also deflecting focus from the moment to moment care of the most acutely ill and injured in the ICU. In the open format, the primary physician has the opportunity for consultation of an intensivist. Within a closed format ICU, the patient's care is transferred to an intensivist whose only responsibility is to take care of patients within the ICU. Of course, hybrid models exist regarding division of labor with respect to order entry and family communication. A multidisciplinary team led by an intensivist can function in either closed or open structures (utilizing the intensivist in the consultant role in the open format); however, the ability to provide immediate and continuous care may be compromised in fully open surgical ICUs. In fact, the benefit of a high-intensity staffing model (with an intensivist-led team or mandatory intensivist consultation) is more apparent in surgical than in medical ICUs (perhaps due to the difficulty of an operative surgeon to simultaneously manage an ICU patient), with a 15% decrease in ICU mortality.[8,9] There is other work that specifically points to the benefit of a closed ICU structure in decreasing morbidity and mortality.[10,11,12] Nonetheless, despite the care model employed, exquisite communication between members of the primary surgical team, ICU team, patient (if possible), and family is mandatory to ensure best outcome and satisfaction by all. In recognition of this, in the United States, The Joint Commission for Accreditation of Hospital Organizations (TJC) requires a handoff between members of

the surgical and ICU teams when a patient is admitted to the ICU from the operating suites.[13]

2 The natural progression of work on the success of a high-intensity ICU staffing model on outcome would be to promote around the clock availability of such services.[14] However, these 24/7 intensivist models did not improve SICU mortality in several studies and reviews, although they reduced morbidity and resource utilization in others.[15–17] This may be a consequence of the fact that studies examining the effect of around the clock care have largely been carried out at academic medical centers with robust nighttime fellow coverage.[18] A noctensivist can improve morbidity and mortality in ICUs with low-intensity staffing.

Finally, a taskforce rendered recommendations on the appropriate intensivist/patient ratio in teaching institutions. A ratio of one intensivist to 14 patients should be maintained to ensure timely completion of rounds, staff satisfaction, and provision of high quality patient care and education of trainees.[19]

Evidence-Based Care

Numerous extensively researched evidence-based guidelines have been developed covering many aspects of critical care, including the management of sepsis, ventilator management, and administration of nutrition among others, the most important of which will be discussed below.[20]

3 The most robust evidence lends itself to the multidisciplinary, multiprofessional development of institutional protocols and clinical practice guidelines. Unfortunately, without electronic prompts or other mechanisms in place, compliance by even well-intentioned practitioners may be less than ideal. Thus, ICU care providers have developed memory aids in the form of checklists and bundles. Further, this simplification of ICU processes, which, in turn, may improve outcome, lends itself to regulatory scrutiny.

Checklists do not necessarily reinforce evidence-based care (although they certainly can). They are meant to embody crew resource management strategies. The use of a daily goals checklist in the ICU enables practitioners to ensure that important components of care are addressed. Vincent described the acronym "FAST HUG" as a simple checklist mnemonic for ICU use (Table 10-1).[21]

In our ICU, we have added a component to each of the letters. Use of these checklists improves the knowledge of the game plan by the entire care team. Pronovost and colleagues demonstrated that use of a daily goals sheet improved understanding of the daily plan from 10% to 95% and effected a decreased ICU length of stay.[22]

Table 10-1A FAST HUG

F	Feeding	Can the patient tolerate oral and/or enteral feeds?
A	Analgesia	Patient should not be in pain nor receive excessive analgesia
S	Sedation	Patient should not experience discomfort but should be arousable
T	Thromboembolic prevention	With chemical or mechanical adjuncts
H	HOB elevated	Optimal 30–45 degrees
U	Stress ulcers	H2 antagonists or PPI
G	Glucose control	Blood sugar levels and treatment

H2: histamine 2, PPI: proton pump inhibitor, HOB: head of bed.
From Vincent JL. Give your patient a fast hug (at least) once a day. *Crit Care Med* 2005.33(6);1225–1230, with permission.

Bundles

The process of bundling evidence-based care practices allows ICUs to keep up with regulatory changes and practice the most up to date critical care practices. Unlike checklists, ICU care bundles are always evidence based. Bundles are comprised of interrelated processes and have a limited number of elements (typically three to seven) whose key processes must be carried out in the same space and time. Bundles exist addressing ventilator-associated pneumonia, central line infection, catheter-associated urinary tract infection and pressure ulcer prevention, diagnosis and treatment of sepsis, and promotion of palliative care. Large collaborative groups in the United States, including the Voluntary Hospital Association, The Institute for Healthcare Improvement and the Michigan Health and Hospital Association-Keystone Project, have shown improved patient outcomes after implementation of various bundles.[23] Continuing education is required to maintain appropriate use and compliance with these management bundles. The implementation and use of sepsis resuscitation bundle and management bundle were significantly improved after 2 month nationwide education effort to improve compliance with the care for patients with severe sepsis.[24] These evidence-based guidelines and bundles have been shown to improve mortality and decrease morbidity and ICU related complications. Severe sepsis and septic shock bundles are associated with reduced in-hospital mortality (Table 10-2). Mortality rates in these centers using severe sepsis and septic shock bundles decreased by 16.7%.[25] It has also been shown that the implementation of central venous catheter care bundles led to decreased central line associated blood stream infections (Table 10-3).[26] Awakening, breathing, coordination, delirium, and early mobility (ABCDE) bundles show some improvement in ICU average length of stay and average days on mechanical ventilation.[27] Finally, some have "bundled" a variety of these disparate bundles together to drive global evidence-based care. The Surgical Care Improvement Project (SCIP) guidelines are perhaps the most relevant and robust example.

Table 10-1B Extended FAST HUG – as Modified by the Authors from above

F	Family and fluids	Family updated. Volume status assessment and fluid balance goals.
A	Analgesia and antibiotics	Pain control goals. Cultures and appropriate antibiotics.
S	Sedation and swallow	Sedation goals. Nutrition goals and metrics
T	Thromboprophylaxis and tube/lines	DVT prophylaxis. Need for central lines, urinary catheters, and other devices.
H	HOB/PT/OT	Ambulation, OOB, and physical and occupational therapy
U	Ulcers	Peptic and pressure ulcer prevention and skin assessment and care
G	Glucose and gas exchange	Blood sugar levels and treatment. Ventilator and pulmonary needs.

HOB: head of bed, PT: physical therapy, OT: occupational therapy, OOB: out of bed

Table 10-2 Surviving Sepsis Care Bundle

Complete Within 3 hrs	Complete Within 6 hrs
Measure lactate level	Administer vasopressors for persistent hypotension or lactate elevation after volume resuscitation
Obtain blood cultures prior to antibiotics	Measure CVP and $ScvO_2$ for persistent hypotension after volume resuscitation
Administer broad spectrum antibiotics	Repeat lactate if initial was high
Administer 30 mL/kg crystalloid for hypotension and lactate >4 mmol/L	

CVP: central venous pressure, $ScvO_2$: central venous oxygen saturation. From Dellinger RP, Levy MM, Rhodes A, et al. Surviving sepsis campaign: international guidelines for management of severe sepsis and septic shock: 2012. *Crit Care Med* 2013;41:580, with permission.

The application of evidence-based guidelines into clinical practice, even facilitated by use of bundles, is often difficult. Educational and quality improvement programs, described above, can improve the implementation of and compliance with these evidence-based guidelines. Further, it is important to realize that bundles and any evidence-based guidelines must be continuously updated as new information comes to the fore, particularly if the level of evidence or strength of recommendation was weak. Examples in the care of the septic patient will be discussed below. Finally, although use of bundles can promote team-building by providing objective feedback of performance, competent and individualized clinical decision-making should not be sacrificed.

Table 10-3 Central Line Associated Bloodstream Infection (CLABSI) Bundle

Hand hygiene – antisepsis before and after procedure
Chlorhexidine – antiseptic skin preparation before catheter insertion
Sterile precautions – hat, mask with sterile gown, gloves, and full length drapes
Catheter site – subclavian vein preferred
Daily review of line need and removal of unnecessary lines.

Table 10-4 Comparison of ICU Scoring Systems

Scoring System	Required Variables	Time of Data Collection	Estimated Parameters
APACHE IV	Physiologic data, ICU admission diagnosis, co-morbidities, age, LOS before ICU admission, emergency surgery, thrombolytic therapy, mechanical ventilation	First ICU day	APACHE IV score, predicted hospital mortality and ICU LOS
MPMO-III	Physiologic data, ICU admission diagnosis, comorbidities, age, LOS before ICU admission, vasopressors, type of admission, infections	At ICU admission	Predicted hospital mortality and ICU LOS
SAPS 3	Physiologic data, acute diagnosis and anatomical site of surgeries, comorbidities, age, LOS before ICU admission, vasopressors, type of admission, infections	At ICU admission	SAPS 3 score and predicted hospital mortality. Customized equations for seven different geographic regions

ICU: Intensive care unit, LOS: length of stay, APACHE: Acute Physiology and Chronic Health Evaluation, SAPS: Simplified Acute Physiology Score.
From Salluh JIF, Soares M. ICU severity of illness scores: APACHE, SAPS and MPM. *Curr Opin Crit Care* 2014;20:557–565, with permission.

4 ICU scoring systems have been used to provide a framework to describe patients' severity of illness for the routine evaluation of ICU performance, quality improvement initiatives and to prognosticate outcome.[28] The most robust prognostication systems compare observed and risk-adjusted hospital mortality for critically ill patient groups derived from analysis of large data sets. They operate on the premise that early physiologic derangements prior to resuscitation and therapy present early in the ICU admission will influence hospital mortality. Other systems have been developed to quantify organ dysfunction and therapeutic interventions predicted.

The ideal scoring system should be valid, reliable, calibrated, discriminating, and simple. The Glasgow coma scale score is an apt example. However, since ICU patients are heterogeneous, documentation is often incomplete and practices are not standardized, such a system is not available in the ICU. The most frequently used severity of illness scores in an adult ICU used to prognosticate hospital mortality are Acute Physiology and Chronic Health Evaluation (APACHE), the Mortality Probability Model (MPM), and the Simplified Acute Physiology Score (SAPS) with higher scores portending increased hospital mortality. APACHE and MPM were developed using data predominantly from the United States; SAPS was more global (Table 10-4). To stay relevant and useful, these scoring systems require and have undergone regular updates and regional customizations. These scoring systems are currently in their third and fourth generations. It is vital to remember that these scoring systems provide prognostication for the outcome of an ICU population more accurately than for an isolated patient.

APACHE was developed several decades ago by William Knaus and colleagues at George Washington University. The inaugural version ranked 34 acute variables from one to four and weighted chronic health conditions A to D to render a score with higher numbers suggesting more acutely ill patients. Versions two and three decreased the acute variable to 12 and 17, respectively, and created a simpler way to weight the chronic health evaluation. The proprietary (and expensive) version, APACHE III, never had large market penetration and was much more complex than earlier versions. APACHE IV[29] which included more variables has many components in the public domain; however, without a regulatory requirement to provide risk-adjusted ICU metrics and the need to employ personnel to verify and interpret data, it is also not widely used. Further, since the data is collected at the time of ICU admission, the possibility of lead-time bias exists. APACHE provides an algorithm for prediction of ICU length of stay. Several studies have indicated that the current version of APACHE, although labor intensive, is more accurate in prognosticating outcome due to better calibration and discrimination with fewer excluded patients. This is particularly true for surgical patients.

SAPS shared many variables and weightings common with APACHE but provided separate prognostication for medical, scheduled and unscheduled surgical patients; cardiac and burn patients are excluded.[30] Further, it provides customizable equations to predict outcome according to seven distinct geographic locations.

The MPM uses dichotomous physiologic (not laboratory) variables for the most part

(simplifying data collection), collecting data both upon admission and at 24 hours to measure mortality risk at 24 and 48 hours. However, it excludes more patients than does APACHE. MPM-III has been further modified with additional variables and different patient exclusions and is known as the ICU Outcomes Model (ICOM) that has been endorsed by the National Quality Forum of the United States for public reporting of risk-adjusted hospital mortality of ICU patients.[31]

The future of ICU prognostication may well involve interpretation of "big data" that relies less on traditional data acquisition and storage and more on linear or logistic regression modeling. Much work must be done in this realm before practical applications are available.[32]

Several organ failure scores exist as well, designed to link homogeneous patients for the purpose of clinical trials and quality assessment. They can be used to provide initial as well as serial assessments. The SOFA and Marshall scores consider variables in six categories (respiratory, cardiovascular, hematologic, central nervous system, renal, and hepatic). The Denver score excludes the hematologic and neurologic components. A Marshall or Denver score greater than or equal to 4 implies multiorgan dysfunction (Table 10-5).[33,34]

TISS provides a sum of all interventions in physiologic categories to assist with resource utilization.

HEMODYNAMIC MONITORING AND TREATMENT

Oxygen Delivery and Consumption

Oxygen delivery (DO_2), the rate at which oxygen is transported to the microcirculation from the lungs, is the product of cardiac output and arterial oxygen content (CaO_2) and is normally about 1,000 mL/min. CaO_2, in turn, is the product of hemoglobin and oxygen saturation (SaO_2) multiplied by 1.34 (g oxygen per 100 mL hemoglobin) added to the partial pressure of oxygen (PaO_2) multiplied by 0.003. Thus, delivery falls in instances of cardiac failure, hypovolemia, anemia, or less so due to poor oxygenation. Oxygen consumption (VO_2), the rate at which oxygen is removed from the blood by the microcirculation, is the product of cardiac output and the arteriovenous O_2 difference ($CaO_2 - CvO_2$) and is normally 250 mL/min in an average adult. Thus, oxygen extraction (OE) ratio or the ratio of VO_2 to DO_2 is normally about 25%. (The myocardium has the body's highest extraction ratio at approximately 75%.) Consumption remains constant over a wide range of DO_2 by changes in OE. For example, in situations of decreased delivery such as hemorrhagic or cardiogenic shock, consumption can be maintained by increasing the extraction ratio. This mechanism may be altered in critically ill patients who show marked increases in consumption under the influence of stress hormones and catecholamines. However, there is little evidence that artificially augmenting DO_2 to so-called supranormal levels by means of inotropes or red cell transfusion results in improvement in morbidity or mortality.

Table 10-5 Marshall Multiple Organ Dysfunction Syndrome (MODS) Versus Denver Multiple Organ Failure (MOF) Organ Failure Scores

Marshall MODS	Grade 0	Grade 1	Grade 2	Grade 3	Grade 4
Pulmonary PaO_2/FiO_2 ratio	>300	226–300	151–225	76–150	<75
Renal Cr, µmol/L	<100	101–200	201–350	351–500	>500
Hepatic total bili, µmol/L	<20	21–60	61–120	121–240	>240
Cardiovascular (PAR)	<10	10.1–15	15.1–20	20.1–30	>30
GCS	15	13–14	10–12	7–9	<6
Platelet count × 10^3	>120	81–120	51–80	21–50	<20
Denver MOF	**Grade 0**	**Grade 1**	**Grade 2**	**Grade 3**	
Pulmonary PaO_2/FiO_2 ratio	>250	250–200	200–100	<100	
Renal Cr, µmol/L	<159	160–210	211–420	>420	
Hepatic total bili µmol/L	<34	34–68	68–137	>137	
Cardiac Inotropes	None	One low dose	>1 agent at low dose or 1 at moderate dose	>2 agents at moderated dose or any at large dose	

PaO_2: partial pressure of oxygen in arterial blood, FiO_2: fraction of inspired oxygen, Cr: creatinine.
From Marshall JC, Baue AE, Berlot G, et al. Multiple Organ Dysfunction (MOD) score. In: *Sepsis and Organ Dysfunction*. Springer-Verlag; 1998;45–51 and Moore FA, Sauaia A, Moore EE, et al. Postinjury multiple organ failure: a bimodal phenomenon. *J Trauma* 1996;40:501–502.

Mixed venous oxygen saturation (SvO_2) is expressed as 1-VO_2/DO_2, with normal values of 60% to 80% that can be continuously displayed with an oximetric pulmonary artery catheter or measured from the distal port. Reductions in SvO2 reflect a mismatch between DO_2 and VO_2 (Table 10-6).

Hemodynamic Monitoring

Assessment of volume status and cardiac function of the critically ill patient is evolving. Traditional static measures of volume assessment using central and pulmonary artery catheters (PACs) are being replaced in many settings by dynamic or functional measures afforded by technologies such as pulse waveform analysis and focused cardiac ultrasound (ECHO). Similarly, indirect measurement of cardiac function by PACs is being subsumed by pulse waveform analysis and systolic and diastolic evaluation of left and right global and regional function using ECHO.

Assessment of Fluid Responsiveness

The concept of volume status using static measures has evolved to "volume responsiveness" using dynamic or functional measures to assess whether a fluid bolus will improve the stroke volume (SV) and cardiac performance of a critically ill patient, the principal goal of resuscitation. Static measures such as central venous pressure (CVP) and pulmonary artery occlusion pressure (PAOP) can give inferential data of cardiac filling pressures at a single time-point, which then extrapolates to cardiac preload (end diastolic volume) and volume status of the patient. However, these pressures can be altered depending on cardiopulmonary physiology, do not always correlate with Frank–Starling principles, and give no indication of whether the patient will respond to a bolus of infused fluid, which is ultimately what those tasked with resuscitation want to know.

Static measures of volume status include assay of CVP and PAOP. These measures are made at end expiration when the pleural pressure is closest to atmospheric pressure. Normal venous waveform components include the "a" wave (corresponding to atrial contraction), the "c" wave (tricuspid valve closure and isovolumic right ventricular contraction), and the "v" wave (ventricular ejection driving venous filling of the atrium) (Fig. 10-1). Clinically, the high point of the "a" wave is the atrial pressure at maximum contraction, where atrial pressure is greater than ventricular diastolic pressure. Here, the atrium is contracted and the tricuspid valve is open, which is synonymous with right ventricular end diastolic pressure, making the ventricle, atrium, and vena cava interconnected. Optimally, this is the point at which the CVP is measured. Unfortunately, many intracardiac and extracardiac interactions can alter these pressure relationships in the vena cava and diseased heart, and, thus, affect the CVP waveform. For example, atrial fibrillation fails to produce an "a" wave, and AV-dissociation produces irregular augmented (cannon) "a" waves with absent "c" and "v" waves, making calculation of mean CVP difficult. Tricuspid regurgitation and tamponade may produce augmentation of the v wave and falsely imply adequate or increased intravascular volume in a patient who may be hypovolemic. Thus, the CVP waveform may fail to provide an adequate reflection of volume responsiveness in diseased states.

Table 10-6 Oxygen Delivery and Consumption Equations

$DO_2 = CO \times CaO_2$	
Oxygen delivery in mL/min	
$CaO_2 = SaO_2 \times 1.36 \times Hgb + 0.003 \times PaO_2$	
Arterial oxygen content	
$VO_2 = CO \times (CaO_2 - CvO_2)$	
Oxygen consumption in mL/min	
$OE = VO_2/DO_2$	
Oxygen extraction ratio	
$SvO_2 = 1 - VO_2/DO_2$	
Mixed venous oxygen saturation	

DO_2: oxygen delivery, CO: cardiac output, CaO_2: arterial oxygen content, SaO_2: oxygen saturation, PaO_2: partial pressure of oxygen in arterial blood, VO_2: oxygen consumption, CvO_2: central venous oxygen content, OE: oxygen extraction, SvO_2: mixed venous oxygen saturation.

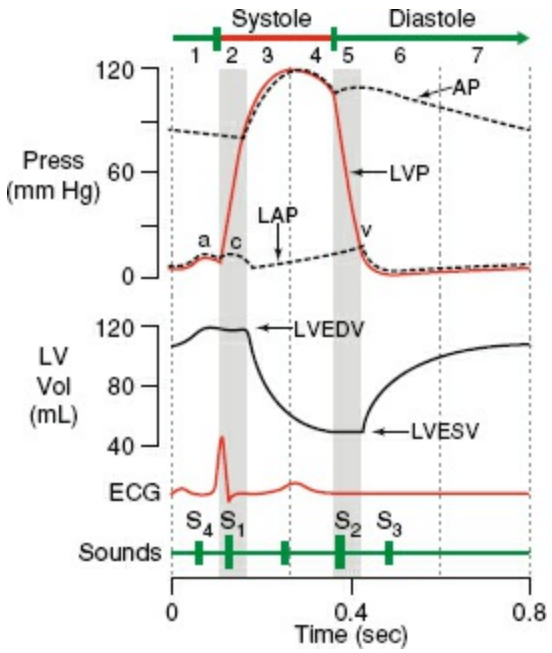

Figure 10-1. Normal venous waveform with ECG.

5 Further, the use of CVP to guide resuscitation has not been demonstrated to be beneficial in many large clinical series. A large meta-analysis revealed a very poor relationship between CVP and blood volume.[35] Additionally, several large recent trials of sepsis resuscitation demonstrated that resuscitation targeted to CVP endpoints did not improve outcome.[36,37]

Pulmonary artery catheter-based volume assessment employs the principle that a single column of fluid forms from the pulmonary artery to the left ventricle during diastole. For a given left ventricular end-diastolic pressure (LVEDP) and compliance, left ventricular end-diastolic volume (LVEDV) can be estimated. Based on the Frank–Starling principle, the force of ventricular contraction is proportional to muscle stretch and LVEDV, thus as PAOP estimates LVEDV for a given cardiac output, preload may be determined. Numerous physiologic changes may alter the relationship between PAOP and LVEDV, including veno-occlusive disease, pulmonary hypertension, ARDS, increased intrathoracic pressure, valvular disease, and altered cardiac compliance. Finally, large clinical trials have failed to demonstrate a benefit to outcome for those resuscitated to a PAOP

endpoint.[38]

Dynamic or functional measures of volume responsiveness include those on both the arterial side and venous side of the heart. Normally, the inspiratory increase in pleural pressure during positive pressure breathing reduces right ventricular preload and stroke volume, manifested on the arterial side within two to three beats in most. Left ventricular stroke volume diminution is maximal during expiration. These normal physiologic changes during the mechanically supported respiratory cycle are augmented with hypovolemia that is volume responsive. Pulse waveform analysis uses analysis of the arterial pressure waveform. The area under the curve corresponding to systole (i.e., before the dicrotic notch) is used to calculate stroke volume (Fig. 10-2). Computer calculation is made of the maximal and minimal amplitude of the curve. In general, a variation in stroke volume (SVV) of greater than 13% to 15% reflects volume responsiveness, whereas values below this threshold imply that the patient is beyond the upper inflection point of the Frank–Starling curve, and will not benefit from further volume loading. There are instances where it is possible to misinterpret these values. For example, high vasopressor burden or lack of arterial compliance (such as in diffuse atherosclerosis) may alter blood flow and arterial wave morphology, respectively. However, clinical applications of SVV as a volume assessment tool have been promising.[39]

Venous assessment of volume responsiveness is performed by ECHO, which can also perform arterial side estimation. ECHO can provide volume assessment with both static and dynamic values. Further, many static measures can be rendered functional by performing measurements both before and after a passive leg raise, a maneuver that replicates volume loading. Passive leg raising measurements may be the only accurate methodology to approximate fluid responsiveness in spontaneously breathing patients. In these patients, a breath results in an increase in SV and systolic pressure. Static values include measurement of the inferior vena cava (IVC) on the long axis view, or in some series by the superior vena cava (SVC) or internal jugular vein (IJV) on the venous side or calculation of the velocity time integral (VTI) on the arterial side. Collapsibility of the IVC (or SVC/IJV) of at least 15% and as much as 50% during respiration predicts fluid responsiveness.[40] Right-sided heart failure may alter the size relationships of the central veins, thus providing an underestimate of fluid responsiveness using venous measurements (lack of respiratory variation due to pressure overload and diminished venous return to the heart). Arterial assessments are typically done of aortic blood velocity approximated from the VTI.

Assessment of Cardiac Function is best understood by recollection of the cardiac pressure–volume curve depicting the cardiac cycle (Fig. 10-3). Starting at the top right at "A," the aortic valve opens and blood is ejected into the outflow tract. At "B" systole ends as the aortic valve closes. A period of isovolumic relaxation occurs and ventricular pressure falls until the mitral valve opens at "C," the start of diastole. Diastole ends as the mitral valve closes at "D" and then there is a period of isovolumic contraction with both valves closed until the cycle repeats. Note that the distance across the box represents SV. SV is the amount of blood ejected per beat and is expressed in mL and determined by preload, afterload, and contractility. The product of SV and heart rate is CO. Ejection

fraction (EF), a more valid estimate of cardiac function, is the proportion of preload or EDV ejected per beat or SV/EDV.

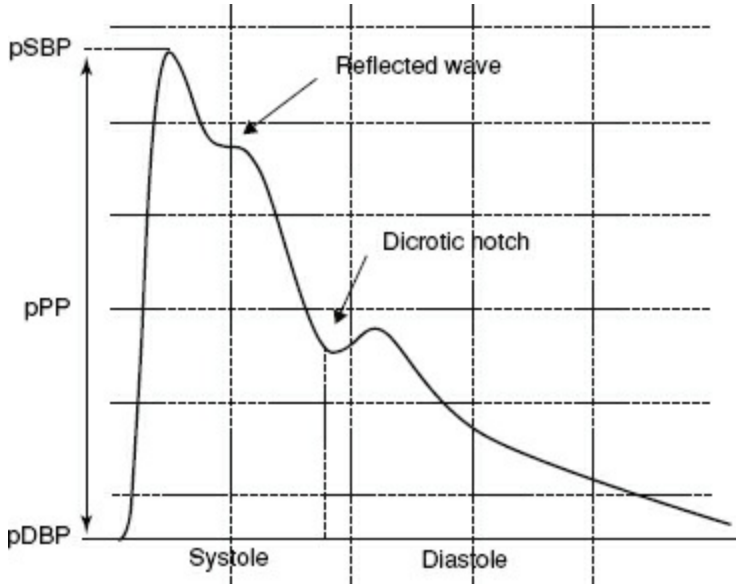

Figure 10-2. Arterial pressure waveform. Area under systole curve is used to calculate stroke volume. pSBP, peripheral systolic blood pressure; pPP, peripheral pulse pressure; pDBP, peripheral diastolic blood pressure.

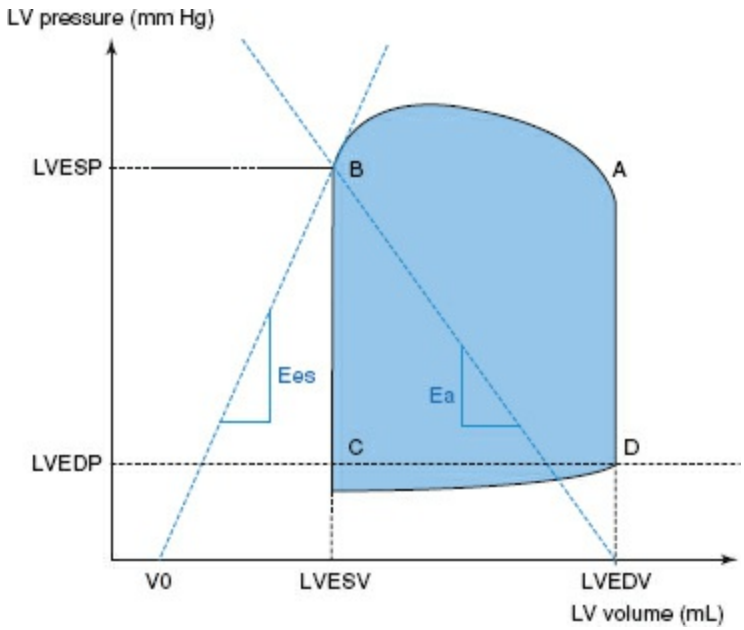

Figure 10-3. Left ventricular pressure–volume curve. Ees, LV elastance; Ea, arterial elastance; ESV, end-systolic volume; EDV, end-diastolic volume; ESP, end-systolic pressure; EDP, end-diastolic pressure; LV, left ventricle. **A:** aortic valve opens; **B:** aortic valve closes; **C:** mitral valve opens; **D:** mitral valve closes.

PA catheters determine cardiac output by thermodilution. The thermodilution technique measures temperature changes sensed by a balloon at the distal end of the catheter after a cold saline injection is performed through the proximal port. Based on the modified Stewart–Hamilton equation, which constructs a plot of temperature change against time, measurements of cardiac output can be obtained. Thermodilution technique assumes that complete mixing of the blood occurs, that there is constant blood flow in the heart, and that there is no loss in concentration of the indicator between the point of injection and

the distal balloon tip. Slow injections, incorrect volumes of injectate, incorrect temperature of injectate, either isolated or in combination with anatomic and physiologic cardiac derangements can alter the accuracy of cardiac output determination.

Pulse contour analysis can also be used to measure stroke volume (and hence cardiac output). Using PAC thermodilution as the gold standard, accuracy is acceptable.

ECHO does not suffer from many of the shortcomings of CVP, PAC, or arterial line assessment with regard to the assessment of cardiac function. ECHO can determine left ventricular function (systolic and diastolic), right ventricular function, and assess wall motion abnormalities, valve defects, pericardial fluid, and provide real-time information on effectiveness of inotropic and vasopressor therapy. ECHO can provide information about heart function in a qualitative or quantitative fashion – it can be used to assess left and right heart morphology, dynamics, and size, and can determine the difference in EF and stroke volume, and perform quantitative estimates of pulmonary artery and right ventricular pressure. ECHO is unique in that it is the only tool available that can provide EF data in addition to SV (CO). Shock states may be due to impaired EF or contractility (requiring inotropy) or due to diminished volume status and stroke volume (requiring fluid), which is not discernable with a PAC. Various ECHO methodologies are available to determine and measure EF, including a purely qualitative one that is reasonably accurate compared to quantitative means.

ECHO can also discern right heart dysfunction, very common in surgical ICU patients by examining size, morphology and function of the right ventricle. Underfilling of the left heart, typically treated by volume loading, requires attention to inotropic support in the case of right heart failure. Finally, unique to ECHO is the ability to assess for diastolic dysfunction as occurs with sepsis, tamponade, and increased pleural pressure (as with pneumothorax, abdominal compartment syndrome, and massive pleural effusions).

TREATMENT OF CARDIAC ARREST AND DYSRHYTHMIAS

Dysrhythmias are extraordinarily common in both cardiac and noncardiac surgical ICU patients. Those most life-threatening can be treated by following current American Heart Association Advanced Cardiac Life Support (ACLS) guidelines.[41] For patients who become pulseless in the ICU, rapid restoration of the circulation employing basic life support strategies (BLS) is vital. The most important features of the current BLS guidelines include the recognition that cardiopulmonary resuscitation (CPR), when indicated, be delivered by pushing hard and fast with complete recoil at a rate of at least 100 compressions/min to a depth of 2 in in adults. CPR providers should deliver no more than 2 minutes of therapy each (or five cycles of compressions) until a personnel switch is made. In adults, the ratio of 30 compressions to 2 breaths is maintained until ventilation can be controlled by intubation and controlled ventilation. Cricoid pressure is not recommended in current ACLS guidelines. Further, the rapid use of a defibrillator is key to improving postarrest survival. Of course, in ICU patients, cardiac arrest is often witnessed and the underlying rhythm known and may not respond to defibrillation. Sadly, cardiac arrest from a rhythm other than ventricular fibrillation, such as from bradycardia progressing to asystole or pulseless electrical activity (PEA), portends a poor prognosis, often as the result of acidosis or profound hypoxia incidental to sepsis and multiple organ failure. Another important feature of the current BLS and ACLS guidelines that may impact surgical ICU patients is the recognition of the need for postcardiac arrest care. This certainly includes fluid resuscitation and administration of pressors and inotropes as needed. However, there may also be a need to interrogate via coronary angiography and treat for acute coronary syndrome if anticoagulation can be tolerated and for consideration of postarrest hypothermia to preserve neurologic function. Although hypothermia protocols were established to address out of hospital cardiac arrest with coma, there has been increasing use of the modality for hospitalized patients as well. Current guidelines also address new technology with biphasic electrical sources that deliver shocks for dysrhythmias with a pulse and defibrillation in those with ventricular fibrillation. Another important component of the recommendations is the use of end-tidal CO_2 monitoring to ensure adequacy of CPR quality.

Three dysrhythmias produce pulselessness: ventricular fibrillation, asystole, and PEA. Only ventricular fibrillation is responsive to defibrillation which is with 120 to 200 J using a biphasic device as per manufacturer's recommendations. PEA and asystole are treated by administration of epinephrine (1 mg every 3 to 5 minutes) and/or vasopressin (40 U one-time dose). Pulseless ventricular tachycardia is treated like ventricular fibrillation with additional shocks given after five cycles of CPR (2 minutes). In addition, epinephrine and vasopressin are administered as CPR continues. Continued pulseless ventricular tachycardia and fibrillation can be treated with amiodarone (300 mg with a second dose of 150 mg if refractory) or lidocaine (1.0 to 1.5 mg/kg).

For the remainder of dysrhythmias, several key features should be noted. Is the patient, hemodynamically stable or unstable? Is the EF normal or altered? Is the dysrhythmia acute or long standing? Hemodynamic instability in association with a rhythm

disturbance often renders electrical therapy more desirable, if possible. In those with a low EF, antiarrhythmics that are also negative inotropes should be avoided. Finally, even duration of as little as 48 hours can increase the risk of thrombotic complications of some dysrhythmias (e.g., atrial fibrillation) and can alter therapeutic decisions.

PULMONARY GAS EXCHANGE

Consists of the intake of oxygen by pulmonary capillaries from the alveoli and the excretion of carbon dioxide in expired breaths.

Oxygenation

Normal lung function and gas exchange require patent and dry alveoli with a narrow interface with the pulmonary capillaries. Once red blood cells become saturated with oxygen, the rest dissolves into the plasma and the measured partial pressure of oxygen (PO_2) is 100 mm Hg with an oxygen saturation (SaO_2) of 100%. Since a small portion of blood is diverted away from the pulmonary circulation (via bronchial vessels), a normal PaO_2 is 90 mm Hg with 98% saturation. Insufficient blood oxygenation is termed hypoxemia. This is to be differentiated from hypoxia, which is abnormally low oxygen content in a tissue or organ. The alveolar to arterial (A-a) oxygen gradient is a common measure of oxygenation ("A" denotes alveolar and "a" denotes arterial oxygenation). PaO_2 is measured by arterial blood gas, while PAO_2 is calculated using the alveolar gas equation: $PAO_2 = (FiO_2 \times [Patm - PH_2O]) - (PaCO_2 \div R)$ where FiO_2 is the fraction of inspired oxygen (0.21 at room air), Patm is the atmospheric pressure (760 mm Hg at sea level), PH_2O is the partial pressure of water (47 mm Hg at 37°C), $PaCO_2$ is the arterial carbon dioxide tension, and R is the respiratory quotient. The normal gradient is about 10 mm Hg. Dividing the PaO_2 by the FiO_2 estimates the A-a gradient, which normally approximates 500.

Perturbations causing hypoxia and hypoxemia may be the result of hypoventilation relative to perfusion (V/Q mismatch), impaired diffusion, or shunt. Hypoventilation, a result of neuromuscular dysfunction (or more typically iatrogenic due to medications) and impaired diffusion (occurring with pulmonary edema or interstitial lung disease) can be treated effectively by exogenous administration of oxygen. The A-a gradient is normal in hypoxemia due to pure hypoventilation and increased in V/Q mismatch. V/Q mismatch, the cause of most hypoxemia in the ICU, occurs with decreased airflow to the alveoli in relation to the amount of pulmonary capillary blood flow. In the normal lung, there is V/Q mismatch because perfusion and ventilation are heterogeneous. Both ventilation and perfusion are greater in the bases than in the apices. However, the difference between apical and basilar ventilation is less than the difference between apical and basilar perfusion. Therefore, the V/Q ratio is higher in the apices than in the bases. In the diseased lung, V/Q mismatch increases because heterogeneity of both ventilation and perfusion worsen resulting in hypoxemia. Common causes of hypoxemia due to V/Q mismatch include obstructive lung diseases, pulmonary vascular diseases, and interstitial diseases. Shunting occurs when there is adequate ventilation of the alveoli but decreased pulmonary capillary blood flow. Shunting may be anatomic as with intracardiac shunts and hepatopulmonary syndrome or physiologic as when nonventilated alveoli are perfused as with pneumonia. Hypoxia due to shunting with venous admixture as with severely depressed cardiac output or anemia cannot be overcome by administration of oxygen (Fig. 10-4).

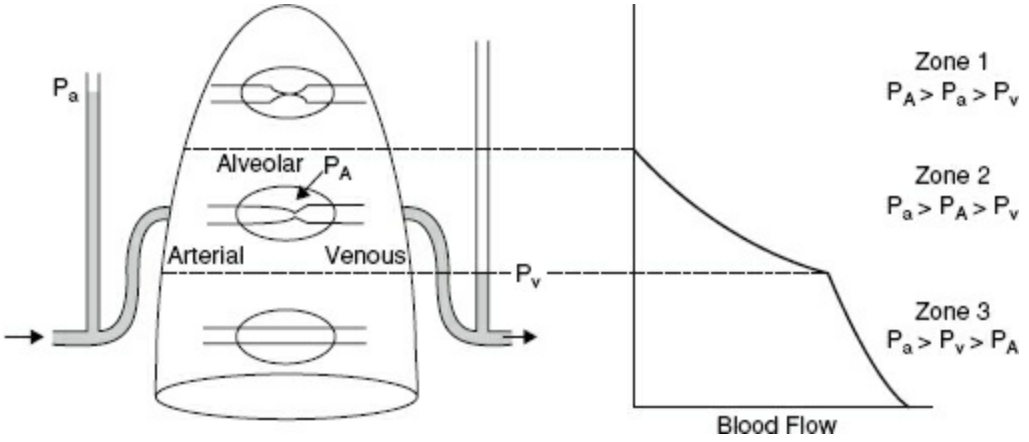

Figure 10-4. West lung zones. Zone 1: Not observed in healthy lung. Alveolar pressure exceeds pulmonary blood vessel pressure leading to alveolar dead space. Zone 2: Located approximately 3 cm above heart. Pulmonary vessel pressure exceeds alveolar pressure in a pulsatile fashion and allows pulmonary blood flow and alveolar distention. Zone 3: Majority of healthy lungs with continuous blood flow and oxygenation. P_A, Alveolar Pressure; P_a, arterial pressure; P_V, venous pressure.

Ventilation and CO_2 Removal

Ventilation refers to the exchange of air from the atmosphere to the lungs and alveoli. The rate at which alveolar ventilation occurs determines the amount of carbon dioxide (CO_2) excretion, a readily diffusible substance. The amount of CO_2 produced and requiring elimination is related to the respiratory quotient (RQ). RQ is the ratio of CO_2 produced to O_2 consumed and is normally 0.8, depending on the diet. Chemoreceptors in the medulla are responsive to pH changes and when patients become acidotic they hyperventilate to decrease $PaCO_2$ to maintain homeostasis at 40 mm Hg. End tidal CO_2 may be lower than $PaCO_2$ if substantial lung is ventilated but not perfused (dead space).

Pulmonary Mechanics

The relationship between ventilatory volumes and pressures is referred to as pulmonary mechanics and depends on compliance. The functional lung in acute lung injury is smaller with heterogeneous disease, necessitating a protective lung strategy of ventilation that will be described below.

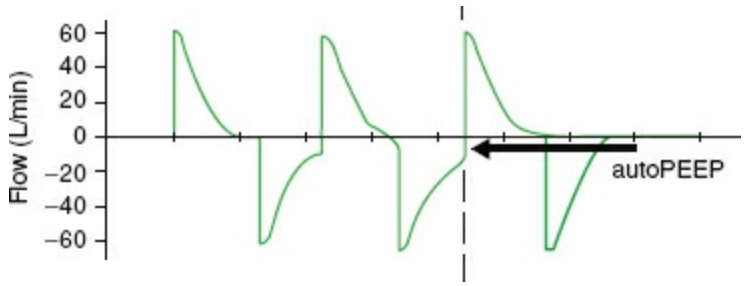

Figure 10-5. Flow–time scalar showing autoPEEP.

VENTILATOR MODES AND GRAPHICS

One of the initial steps in evaluating a patient with respiratory failure is to establish a patent and protected airway. The ICU team must determine if the patient has an acute issue causing the respiratory failure that can be treated without mechanical ventilation. Through the use of physical examination, bedside ultrasound and radiography, the ICU team may diagnose a pneumothorax or acute pulmonary edema that can be treated without intubation. If the patient has acute respiratory failure without an easily treatable process, intubation and mechanical ventilation may be safest. When setting up the mechanical ventilator there are several options and modalities from which to select.

Mechanical ventilation improves oxygenation and ventilation by attempting to improve V/Q mismatch by decreasing the amount of shunt. Current recommendations are for low tidal volume (Vt) settings of 6 to 8 mL/kg for the prevention of barotrauma in surgical ICU patients.[42] Respiratory Rate (RR) is typically set at 12 to 16 breaths/min. RR is altered to achieve an optimal $PaCO_2$. Positive end expiratory pressure (PEEP) is applied to prevent significant alveolar collapse during expiration and is particularly important in low lung volume ventilation strategies. PEEP is typically started at 5 cm H_2O but can be titrated up to improve oxygenation. The initial setting for patients with respiratory failure is an FiO_2 of 1.0. After initial check of ABG the FiO_2 is weaned down to maintain a minimal PaO_2 of 60 mm Hg and O_2 saturation of $>90\%$ with goals of FiO_2 <0.4 to prevent O_2 toxicity.

Ventilatory mechanics can be displayed graphically and include scalars and loops. Scalars are plots against time – either flow, pressure, or volume. Several loops are helpful clinically and include the pressure–volume and flow–volume loops. Each graphic can be important in demonstrating a physiologic anomaly and displays a certain pattern depending on the ventilator mode. The flow versus time scalar is helpful for identifying air trapping or auto-PEEP that can accompany certain ventilator modes (Fig. 10-5). This can result in barotrauma or hemodynamic instability. Measures to decrease auto-PEEP include decreasing tidal volume, respiratory rate, or inspiratory time (depending on ventilator mode) or increasing flow rate. The pressure time scalar allows the practitioner to view and calculate compliance (Fig. 10-6). Further, one can observe elevations in peak airway pressure that may occur as a result of a large pneumothorax or kinked endotracheal tube or a sharp decrease that may represent an airway leak or disconnection. The volume versus time scalar allows one to identify an airway leak as well (Fig. 10-7). Ventilators often display all three scalars simultaneously. A spontaneously breathing patient is identified by the negative deflection in the pressure–time scalar at breath initiation (Fig. 10-8). Distinct ventilator modes have unique methods of cycling, triggering, and limitations of breaths. In controlled mandatory ventilation, breaths are volume-cycled, time-triggered, and flow-limited (Fig. 10-9). In pressure-controlled ventilation, breaths are time-cycled, time–triggered, and pressure-limited. Note the distinct difference in the flow and pressure versus time scalars compared to CMV (Fig. 10-10). Pressure supported breaths are flow-cycled, patient-triggered, and pressure-

limited (Fig. 10-11). Pressure and volume controlled ventilation can be set in an assist control (AC) mode or intermittent mandatory ventilation (IMV) mode. With the AC mode the patient receives a set number of breaths delivered per minute whether with pressure or volume. Patients who initiate breaths on IMV will have tidal volumes determined by their own respiratory effort and not the ventilator. Patients who are critically ill may require AC for full support but these patients should be weaned to an IMV or PSV mode quickly to prevent respiratory muscle atrophy.[43]

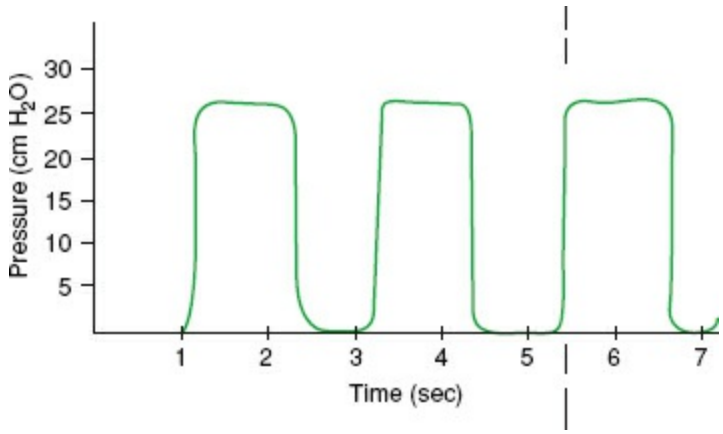

Figure 10-6. Pressure–time scalar.

Diagnosis

6 Past consensus definitions of adult respiratory distress syndrome (ARDS) and acute lung injury (ALI) categorized them by acute onset hypoxemia, bilateral infiltrates on chest radiography, and absence of left atrial hypertension (i.e., noncardiac in etiology).[44] ALI and ARDS were differentiated by the degree of hypoxia, with ALI typified by a ratio of PaO_2/FiO_2 of less than 300 and ARDS 200. Newer definitions make an attempt at describing timing relative to a known insult and acknowledge that cardiac failure is now often diagnosed without the aid of a pulmonary artery catheter. Most importantly, ALI is now part of ARDS spectrum that is classified as mild, moderate, or severe if the PaO_2/FiO_2 ratio is between 200 and 300, between 100 and 200, and less than 100, respectively.[45] Further, this gradation of disease is consistent with therapy, wherein less acute patients might be successfully treated with noninvasive ventilation, moderately ill patients with higher PEEP and possibly neuromuscular blockade, and severely ill patients possibly requiring prone positioning therapy and extracorporeal support.

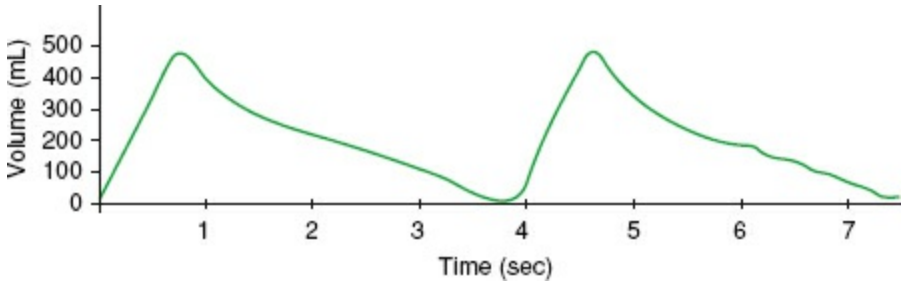

Figure 10-7. Volume–time scalar.

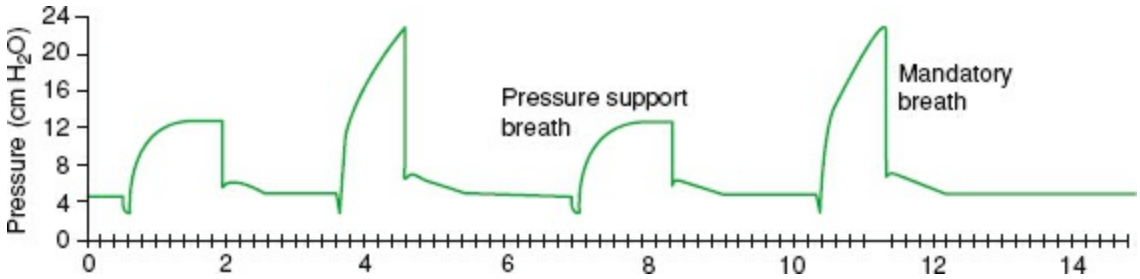

Figure 10-8. Pressure–time scalar with alternating ventilator-assisted breaths and spontaneous breaths.

Ventilator Management

Conventional Modes

The ventilatory standard of care was set forth as a result of an early study from the NIH ARDS Network. By all metrics, the patients ventilated at 6 mL/kg had better outcome than those who received 12 mL/kg. Thus, as a result, the standard of care for ventilating ARDS patients became the use of low tidal volumes, or low stretch therapy to diminish the incidence of ventilator-associated barotrauma.[46]

Rescue Therapies

Involving different ventilator modes share the fact that they achieve their end by raising mean airway pressure while preventing elevation of peak airway pressure. How the disparate modes of ventilation achieve this varies.

High PEEP. Ideally, to prevent atelectasis and avoid overdistension, PEEP is titrated to the safe window between the lower and upper inflection points of the respiratory pressure–volume curve (Fig. 10-12). The precise PEEP level to optimize outcome from ARDS, particularly in the face of low stretch ventilation, has been the subject of several trials. The Assessment of Low Tidal Volume and Elevated End-Expiratory Pressure to Obviate Lung Injury (ALVEOLI) trial did not demonstrate a benefit to adding high PEEP to those ventilated with lower tidal volumes.[47] Two other trials (LOVS and EXPRESS) reached similar conclusions.[48,49] A systematic review and meta-analysis showed no statistically significant difference in hospital mortality overall but worse in those with severe established ARDS treated with high PEEP.[50]

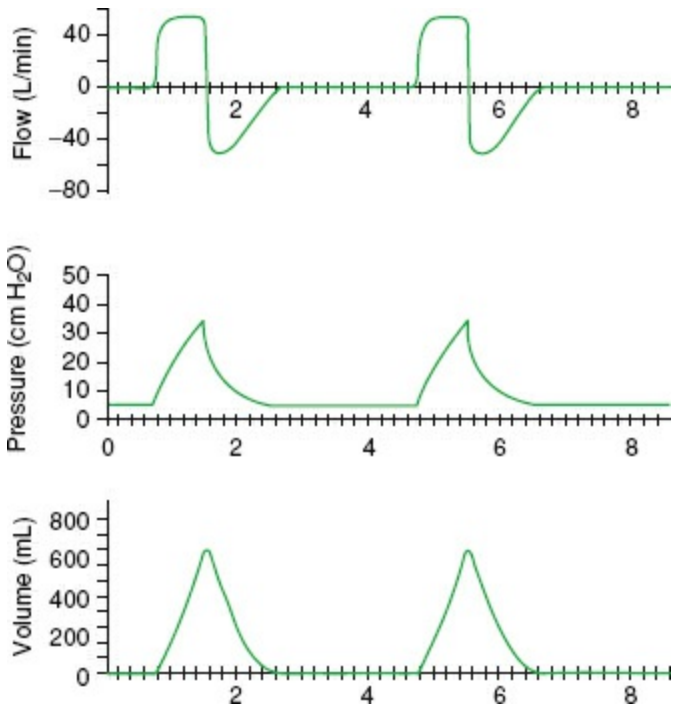

Figure 10-9. Controlled mandatory ventilation. Breaths are volume-cycled, time-triggered, and flow-limited.

Perhaps the more valuable variable to consider preventing barotrauma and atelectasis

is not the PEEP level, but rather the transpulmonary pressure. Transpulmonary pressure is the difference between airway pressure and pleural pressure. As airway pressure is normally slightly positive and pleural pressure slightly negative, transpulmonary pressure is typically zero. If transpulmonary pressure were negative, it would favor atelectasis, whereas a positive value would promote barotrauma and hemodynamic compromise. In ICU patients, there are many forces extrinsic to the lung that can raise pleural pressure and promote atelectasis. These include obesity, intra-abdominal hypertension, and anasarca. Thus, in these circumstances, it might be beneficial to utilize higher PEEP levels. Although it is not possible to measure pleural pressure directly, esophageal pressure is a reasonable surrogate. Although titrating PEEP to esophageal pressure has not yet been proven clinically efficacious, it may in the future.

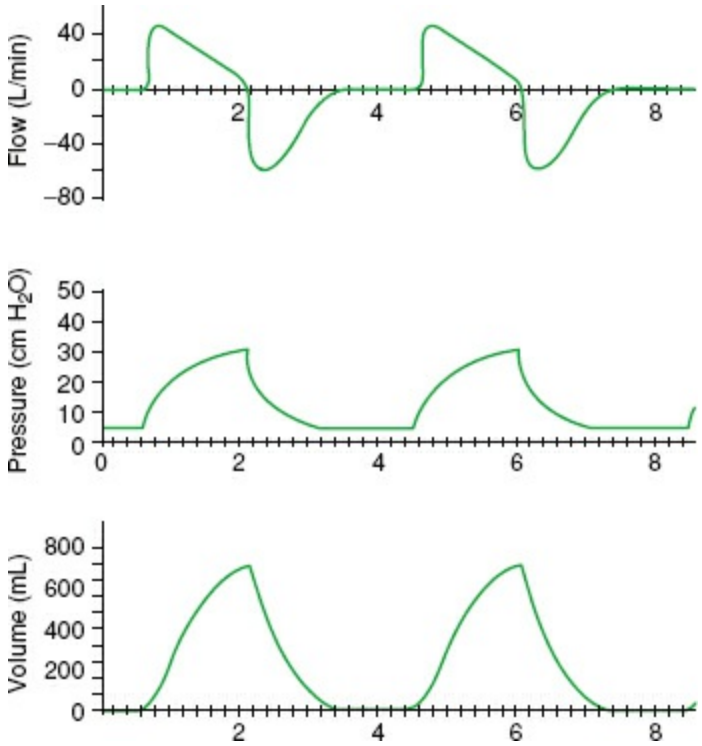

Figure 10-10. Pressure controlled ventilation: Breaths are time-cycled, time–triggered, and pressure-limited.

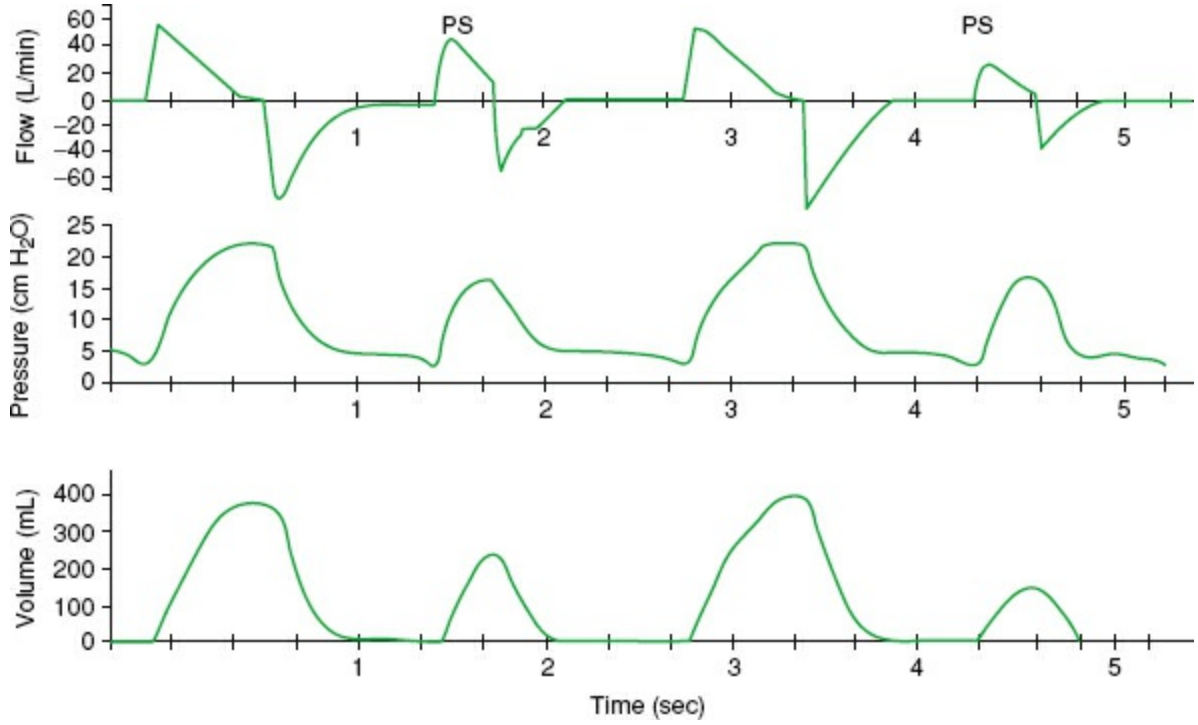

Figure 10-11. Pressure support (PS). Breaths are flow-cycled, patient–triggered, and pressure-limited. Pressure support breaths are second and fourth breaths.

High-Frequency. Modes include high-frequency jet and oscillatory ventilation. Both utilize ultrafast subtidal ventilation and can be employed for rescue or treatment of bronchopleural fistulae. In general, heavy sedation and/or paralysis are required. The ventilator decouples oxygenation ventilation such that unique settings are used to manipulate either one. The ventilatory circuit is heavy and cumbersome in this mode and secretion clearance is problematic. Importantly, two large trials failed to show improvement in ARDS patients, with one demonstrating an increased mortality in the high-frequency group.[51,52]

Airway Pressure Release Ventilation (APRV). takes advan-tage of spontaneous breathing (and hence the ability to keep patients more awake) with CPAP and a brief pressure release, generating a very high inspiratory to expiratory (I:E ratio). The extremely short phase time of pressure release builds up intrinsic PEEP to prevent atelectasis. There are increasing studies in the literature that demonstrate that APRV is at least equivalent to low stretch ventilation in terms of safety and outcome.[53,54] As APRV may be better tolerated than low tidal volume ventilation, some would say this provides an advantage. There is also some suggestion that routine use of APRV may decrease the incidence of and mortality from ARDS.[55]

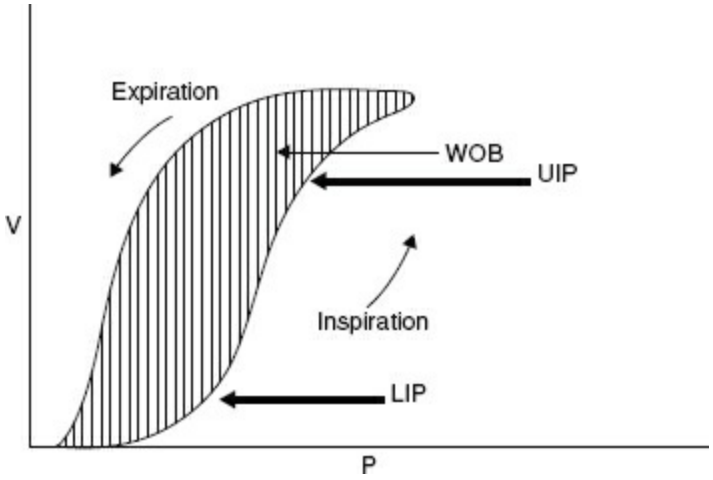

Figure 10-12. Pressure–volume curve with added PEEP. V, volume; P, pressure; LIP, lower inflection point; UIP, upper inflection point. Ideal PEEP is set between LIP and UIP.

Volumetric Diffusive Respiration (VDR). Is a hybrid mode that combines convective gas delivery similar to CPAP, diffusive gas delivery similar to oscillatory modes and a unique percussive mode to promote secretion removal. As such, it has been used extensively in the burn patient population. However, the technology is not widely available and large trials of use in rescue therapy of ARDS patients have not been completed.

Extracorporeal Support. via extracorporeal membrane oxygenation (ECMO) was thought to provide a beneficial effect to those patients in the European Conventional Ventilation or ECMO for Severe Adult Respiratory Failure (CESAR) trial.[56] However, it was apparent on further analysis that patients with severe ARDS benefit most from transfer to a center that had ECMO capabilities, whether or not the therapy was actually used. Data from recent viral pneumonia epidemics are similarly confusing. Regardless of the effect on mortality, it is apparent that ECMO may be thought of as a last ditch effort to improve oxygenation, but should not be employed after lung fibrosis and irreversible organ failure have transpired. For sure, current technology involving smaller access catheters, more portable oxygenators and venovenous deployment has made ECMO far less morbid than initial experience with it decades ago with prior mortality rates in excess of 50%. The definitive trial without crossover treatment to validate the use of ECMO for severe ARDS has not been performed.

Ventilator Associated Events

Ventilator-associated pneumonia (VAP) is the most common life-threatening healthcare associated infection, although there is some evidence that it is less morbid in surgical than in medical patients.[57] VAP is associated with increased ICU and hospital length of stay and costs, and may often be preventable. Nonetheless, it can be extraordinarily difficult to define, particularly in injured patients who may be febrile and have pulmonary infiltrates for reasons other than pneumonia. Further, if attempts are made to diagnose the entity predominantly by microbiologic criteria (using bronchoalveolar lavage to culture $>10^5$ organisms), then the incidence of VAP may be overstated. Thus, the CDC has worked with various critical care societies to define the surveillance definition of ventilator-associated events (VAE) which are publically reportable and include probable and possible VAP, which are not reportable. Briefly, VAE require patients to have a baseline period of more than 2 calendar days on the ventilator followed by a sustained decrement in oxygenation. Note there are no longer radiographic criteria for VAE or VAP. An infection-related VAE requires a change in temperature or white blood cell count and the initiation of a new antibiotic that is continued for 4 days. The differentiation between possible and probable VAP involves positive cultures as previously prescribed.[58]

Liberation from Ventilation

Automated, computerized liberation protocols significantly shorten time on ventilator and success rate compared to those directed by physicians. As opposed to the concept of "weaning" patients from support, it is now apparent that the need for ventilation can be approached in a more binomial, on–off approach. Thus, current practice is to complete daily spontaneous breathing trials (SBTs) of no longer than 30 minutes to assess patients' readiness for liberation from ventilation. Of course, these trials should not be conducted in patients with hypoxia, hemodynamic instability or neurologic disease. SBTs may be accomplished using a T-piece trial or CPAP with or without low PSV (<10 mm Hg), the latter to enable ventilatory monitoring of work of breathing and respiratory effort. If patients develop tachypnea, tachycardia, hypoxia, hypercapnia, and/or use accessory muscles during the SBT they are not ready to be extubated. Typically, the parameter that predicts extubation success most accurately is the rapid shallow breathing index or the tidal volume divided by the respiratory rate with a level of less than 105 most predictive of success.[59] Further, the requirement for airway support, as might be expected in those with burns, head injury, or anasarca must be considered separately from the requirement for ventilatory support. Checking for a cuff leak, although conceptually of benefit in identifying patients with airway edema, may not be an accurate metric of those with a stable airway. Trials in the medical literature suggest that a short course of steroids may benefit some to diminish airway edema; these have not been replicated in surgical patients.[60] Finally, some patients, such as those with COPD, may benefit from extubation to noninvasive modes of ventilation such as bilevel positive airway pressure (BiPaP) or CPAP. Additionally, the use of high-flow nasal cannula oxygen, typically delivered at 40 L/min or greater may prevent reintubation.

Adjunctive Therapies

Inhaled Nitric Oxide and Prostaglandins. Inhaled Nitric Oxide (iNO) affords selective vasodilation of the pulmonary vasculature without systemic effect. It improves oxygenation and lowers pulmonary artery pressures. If used, methemoglobinemia can result, thus, monitoring should be conducted. Five early meta-analyses showed improved oxygenation without a mortality benefit, with three demonstrating increased renal failure.[61] A more recent meta-analysis failed to show a mortality advantage for iNO use for mild, moderate, or severe ARDS.[62] Inhaled and/or intravenous prostacyclins such as epoprostenol can also lower pulmonary artery pressures and improve oxygenation. A 2010 Cochrane review demonstrated no safety or outcome differences between iNO and epoprostenol; however, at present, the latter is substantially cheaper. Although neither agent improves mortality, it seems reasonable to employ prostaglandins in ARDS patients with concomitant pulmonary hypertension.[63]

Positional Therapy. Prone positioning therapy can be done in conjunction with many other therapies previously described. It can be accomplished on a conventional ICU bed or one specially equipped to provide this therapy. Either way, extreme caution must be taken to avoid tube and line dislodgement and development of pressure-related skin

complications. The ideal amount of time to keep a patient in the prone position is of debate. Often, a patient is turned every shift or if a procedure is required. A recent large study in French ICU patients demonstrated a significant improvement in mortality in ARDS patients treating with prone positioning therapy.[64] Similarly, a systematic review and meta-analysis reinforced the mortality benefit of nearly 25% by prone positioning therapy for ARDS.[65]

Fluid Management. Another large trial conducted by the ARDSnet group Fluid and Catheter Treatment Trial (FACTT) demonstrated that ARDS patients have better outcome if managed with conservative fluid strategy that need not be guided by a PAC.[38] Of course, these findings must be reconciled with extensive data supporting improved outcome in septic patients who received more robust fluid resuscitation.[66,67]

Steroids. Trials regarding the use of steroids in ARDS are old and heterogeneous. At present, the use of steroids cannot be recommended, but future trials controlling for other factors may indicate otherwise.

Sedation and Paralysis. Recently released pain, agitation, and delirium guidelines underscore several features regarding the sedation of ICU patients. First, most ventilated ICU patients benefit from light sedation and continued emphasis on mobility (even if ventilated) and screening for delirium. If sedative agents are required, a strategy that employs narcotic analgesics first is preferred. If additional agents are necessary, there is substantial evidence that a strategy that relies heavily on use of benzodiazepines will result in a higher incidence of delirium, time on ventilator, and greater costs.[68] Ideal sedatives should be easy to titrate, short acting with rapid onset, and without accumulation with prolonged use. These sedatives should also have minimal adverse effects, minimal metabolism, and no active metabolites. Traditionally used sedatives and analgesics morphine, propofol, and benzodiazepines have well-known adverse effects, active metabolites and tend to accumulate with prolonged use. Fentanyl is widely used in ventilated surgical ICU patients due to its excellent pain control, rapid onset, short duration of action, and lack of active metabolites. Dexmedetomidine is a sedative with alpha 2-adrenoreceptor agonist properties that is used as an alternative for analgesia and sedation in the surgical ICU. Dexmedetomidine has been shown to decrease the incidence of delirium and decreased duration of mechanical ventilation versus benzodiazepines while not being inferior to benzodiazepines and propofol in maintaining comfort and sedation.[69] Using sedation scales in the ICU such as the Richmond Agitation-Sedation Scale (RASS) provide a universal numerical scale to communicate between ICU team members the target and actual sedation. Although we should not use long-term neuromuscular blockade (NMB) in those with mild ARDS, a recent French study demonstrated a significant benefit to short-term use in terms of mortality.[70] A much larger propensity-matched retrospective study documented a 4.3% absolute reduction in mortality with short-term use of NMB in severe ARDS.[71]

VENOUS THROMBOEMBOLISM PROPHYLAXIS IN THE ICU

Much attention has been focused on the prevention of venous thromboembolism (VTE) in hospitalized patients, particularly in the United States, Canada, and the United Kingdom where national initiatives are present. VTE prophylaxis is a quality metric promoted by such endeavors as the SCIP discussed elsewhere in this text. The surgical ICU patient is a particular target for VTE and has unique features rendering prophylaxis more challenging than it may be in a ward patient. VTE is a common cause of preventable morbidity and mortality in critical care patients. A large amount of VTE complications occur following surgery and injury.[12,72] Further, the risk of bleeding in the multitraumatized, immobile, and/or freshly postoperative patient may be heightened in the ICU patient. Finally, safe administration of a chemoprophylactic agent as described below must take into account drug metabolism that may be altered with renal or hepatic failure seen in ICU patients and desire to rapidly reverse the medication if frequent procedures are needed.

Table 10-7A Caprini Risk Assessment for Venous Thromboembolism (VTE) in Surgical Patients

1 Point	2 Points	3 Points	5 Points
41–60 yrs old	61–74 yrs old	>75 yrs old	Hip, pelvis, or leg fracture
BMI >25 kg/m^2	Arthroscopic surgery	PMH of VTE	Elective arthroplasty
Minor surgery	Major open surgery	FH of VTE	Stroke (<1 mo)
Swollen legs	Laparoscopic surgery	Factor V Leiden	Spinal cord injury (<1 mo)
Varicose veins	Malignancy	Prothrombin 20210 A	
Pregnancy/Postpartum	Bed rest >72 hrs	Lupus anticoagulant	
PMH of spontaneous abortion	Immobilizing cast	Anticardiolipin antibodies	
Oral contraceptives/hormone therapy	Central venous access	Elevated serum homocysteine	
Pneumonia (<1 mo)		HIT	
Sepsis (<1 mo)		Other thrombophilia	
Abnormal pulmonary function			
Acute MI			
CHF (<1 mo)			
PMH of inflammatory bowel disease			
Medicine patient on bed rest			

BMI: body mass index, PMH: past medical history, MI: myocardial infarction, CHF: congestive heart failure, FH: family history, HIT: heparin induced thrombocytopenia.

Incidence

The risk for developing asymptomatic lower extremity deep venous thrombosis (DVT) depends on the assessment of general risk factors described below and the type of surgical patient. The incidence can vary from less than 10% (in mobile, thin patients undergoing brief, minor surgery) to over 80% (in those with spinal cord injury or elderly, obese hip fracture patients) in the absence of prophylaxis. However, the true incidence may be unknown. It has become clear that upper extremity DVT (which is not routinely screened) is more common than previously appreciated and may result in pulmonary embolism at a higher rate than thought in the past,[73] thus dramatically affecting VTE rates. The incidence of fatal pulmonary embolism in surgical patients ranges from less than 1% in most undergoing elective general surgery to as high as 5% to 8% in those receiving operations for hip fractures.[74] The projected VTE incidence of the surgical ICU would, thus, depend on the composition and the use of screening for asymptomatic patients.

Risk Factor Scoring

Surgical critical care patients are at increased risk of VTE via Virchow triad of stasis, vessel wall injury, and hypercoagulability. Acquired risk factors in the surgical critical care patients are a consequence of surgery, trauma, immobilization, obesity, malignancy, advanced age, and invasive monitoring devices. The American College of Chest Physicians (ACCP) 2012 guidelines[75] stratify surgical patients into four risk categories: very low, low, moderate, and high. The most widely used tool to assist in classification is the Caprini score (Table 10-7).[76] A quick glance at the assessment would reveal that the vast majority of surgical ICU patients over the age of 40 would fall into at least the moderate risk category; if a central venous catheter were present, then they would be considered high risk.

Approaches to Prevention of VTE

Screening – Secondary Prevention

This strategy involves the early detection of subclinical venous thrombosis by regular screening tests. These tests include Duplex ultrasonography and laboratory assays such as evaluation of d-dimer, discussed in further detail elsewhere in this textbook. As most ICU patients will fall into moderate and high risk categories for VTE (in whom d-dimer assays are universally elevated), there is virtually no role for utilizing d-dimer acquisition for diagnostic purposes. Further, although many groups feel differently and perform routine screening lower extremity Duplex ultrasonography, the authors believe that there is little role for this strategy if screening upper extremity studies are not performed concomitantly. Further, as will be discussed below, the safety of early administration of chemoprophylactics is now being proven in even the highest-risk patients (e.g., neurotrauma).[77]

Table 10-7B Caprini VTE Percentage Risk Based on Score

Risk	Score	Estimated VTE Percentage Risk without Prophylaxis
Very Low	0	<0.5%
Low	1–2	1.5%
Moderate	3–4	3%
High	>5	6%

From Caprini JA. Risk assessment as a guide to thrombosis prophylaxis. *Curr Opin Pulm Med* 2010;16:448–452, with permission.

Treatment – Primary Prophylaxis

Interventions for the prevention of VTE include elastic stockings, intermittent pneumatic compression devices, low-dose unfractionated heparin (UFH), low–molecular-weight heparin (LMWH), indirect factor Xa inhibitors such as fondaparinux, direct thrombin and Xa inhibitors, aspirin, and inferior vena cava (IVC) filters.

Mechanical Devices

Alone are utilized for surgical ICU patients at the lowest risk for VTE. Intermittent compression devices may afford additional protection from VTE in those in high-risk groups if used in concert with chemical agents.[78]

Chemical

7 UFH and LMWH. Few studies have performed a head-to-head analysis of these agents for VTE prophylaxis in surgical ICU patients. A study of injured patients completed by Geerts and published in 1996[79] demonstrated that use of LMWH resulted in a significantly lower incidence of VTE (31% vs. 44%). This likely drove the 2009 ACCP recommendation that moderate and high risk ICU patients should preferentially receive LMWH for prophylaxis (with a IA strength and level of recommendation), However, in the interim, Dr. Geerts and colleagues performed a multicenter, RCT (PROTECT) that did not demonstrate a difference in the development of DVT or proximal DVT in those who received LMWH in the form of dalteparin compared to those administered twice-daily UFH.[80] There was no difference in bleeding rate, but a higher incidence of PE was noted in the UFH patients (and a nonsignificant increase in heparin induced thrombocytopenia). This study, undoubtedly, drove the 2012 ACCP recommendation that UFH or LMWH can be used interchangeably (2C recommendation).[75] However, it is vital to mention that the authors excluded injured, orthopedic and neurosurgical patients from this study. eerts himself provides guidelines suggesting that ICU patients at high risk for VTE including injured and major surgery patients should receive LMWH preferentially. UFH should be reserved for moderate-risk ICU patients. High-risk patients at risk for bleeding should receive mechanical prophylaxis until the risk for bleeding is abrogated, and then LMWH should be initiated.[81] Literature suggests that this may be substantially earlier than we might have thought in the past.[82] Finally, in those with renal dysfunction, consideration must be given to avoiding LMWH, or at least monitoring Xa levels, although there is little literature to offer guidance in this regard.

Indirect Xa inhibitors include fondaparinux and have been studied extensively in the orthopedic (non-ICU) and general surgery population. In both these populations, it may be more efficacious than LMWH without an increase in bleeding risk.[75] How this extrapolates to the ICU population is unknown; however, it may be helpful in those with HIT.

There is even less experience using oral Xa (rivaroxaban and apixaban) and thrombin II (dabigatran) inhibitors in the ICU. These agents may be less than helpful because of a long half-life and inability to reverse (particularly dabigatran that may be best removed by hemodialysis). Nonetheless, we should appreciate that all three agents had a lower

rate of significant bleeding such as intracranial hemorrhage in outpatients who were being treated for atrial fibrillation. Rivaroxaban is metabolized renally and apixaban both hepatically and renally. Due to similar concerns of time and ability to reverse, the use of aspirin and warfarin may be limited in the ICU.

IVC Filter. At present, the current ACCP guidelines do not recommend insertion of prophylactic IVCF in those who cannot be anticoagulated. They recommend initiating chemoprophylaxis as soon as is practical.[75]

TRANSFUSION OF THE ICU PATIENT

8 Transfusion of packed red blood cells, ostensibly to promote oxygen delivery, is extraordinarily common in surgical ICU patients. Nearly 85% of those who remain in the SICU after a week and over 40% overall will be transfused, many of whom are not actively bleeding.[83] It was reflexive practice a decade or so ago to prescribe a transfusion for ICU patients whose hemoglobin levels fell below 10 g/dL with at least two units being administered. However, packed cell transfusion may not dramatically improve oxygen delivery, particularly in situations where the oxygen dissociation curve has been shifted to the left, as with decreased 2,3-diphosphoglycerate concentrations (Table 10-8). In addition, in many patient populations, transfusion of packed cells has been associated with increased infections and organ failure. The Transfusion requirements in Critical Care (TRICC) trial published in 1999[84] provided data to question the universal practice of red cell transfusion. This multi-institutional trial of patients in Canadian ICUs was designed as a noninferiority trial comparing a restrictive transfusion strategy, aimed at maintaining a hemoglobin level greater than 7 to 9 g/dL, to a liberal one, targeting a level of 10 to 12. Hebert and colleagues demonstrated no difference in mortality between the groups, the primary outcome measured. Although patients with significant cardiac history were excluded a priori, nearly 300 were studied, and there was no outcome difference in this group either.[85]

Nonetheless, despite widespread dissemination of this landmark article, transfusion practice did not widely change in many surgical ICU patients since and there is still a sense that older, cardiac, actively bleeding, neurosurgical, and septic patients should be excluded from restrictive transfusion practices. However, subsequent studies have further questioned this dogma. A large propensity matched study analyzed the effect of transfusion on ICU patients who were not actively bleeding. It revealed that nontransfused patients (including those with a significant cardiac history) had a lower hospital mortality and incidence of infection and acute kidney injury.[86] The RELIEVE trial was a multicenter randomized controlled trial of ventilated ICU patients over the age of 55, including one-third with ischemic cardiac disease. Those in the restrictive group received almost a quarter fewer transfusions and had over a 30% lower mortality rate.[87] A meta-analysis of the effect of blood transfusion during myocardial infarction noted that the therapy was associated with a relative risk of 2.91 for mortality and 2.04 for a subsequent MI with a number to treat of 8.[88] Further, a British propensity-matched study of cardiac surgery patients revealed odds ratios of 3.8 and 3.5, respectively, for infection and ischemia after transfusion and ratios of 6.69 and 1.32, respectively, for 30-day and 1-year mortality in transfused patients.[89] This risk of transfusion in cardiac surgery patients is apparent even with administration of small-volume (i.e., one or two units of packed cells) transfusions.[90] A large, randomized controlled trial of cardiac surgery patients over the age of 18 undergoing a bypass or valve replacement revealed no change in 30-day all-cause mortality or morbidity utilizing a transfusion trigger of 8 versus 10 g/dL of hemoglobin.[91] Further, a large single center study randomized those with severe acute upper gastrointestinal bleeding – almost 75% variceal – to a transfusion target of 7 versus

9 g/dL of hemoglobin. Nearly half of those in the restrictive group did not receive a transfusion and the mean time to endoscopy was 6 hours. The restrictive group had a 45% relative reduction in mortality and all adverse events, mostly confined to those in Child's groups A and B (there was no difference in those in Child's C classification group). This study reinforced the findings of a previous observation study that a liberal transfusion target in active upper gastrointestinal bleeding doubled the risk of rebleeding and increased mortality by 28%,[92] presumably by promoting "popping the clot." In a randomized clinical trial of patients with traumatic brain injury, a hemoglobin target of 10 compared to 7 g/dL was associated with no improvement in neurologic outcome at 6 months but a higher incidence of adverse events including thromboembolism.[93] Finally, in a multicenter, RCT of septic patients, a hemoglobin target of 7 g/dL with transfusion of leukoreduced cells was not associated with difference in 90-day hospital mortality of adverse events compared to 1 of 9 g/dL.[94]

Table 10-8 Factors Altering the Oxygen Dissociation Curve

Left Shift	Right Shift
Decreased temperature	Increased temperature
Decreased 2,3-DPG	Increased 2,3-DPG
Increased pH	Decreased pH
High altitude, Carbon monoxide	

Oxygen dissociation curve describes how our blood carries and releases oxygen. Right shift represents a decreased affinity for oxygen by hemoglobin favoring to the ability to release oxygen to tissues in need. Left shift represents increased affinity by hemoglobin for oxygen 2,3-DPG: 2,3-diphosphoglycerate.

Although administration of both erythropoietin[95] and intravenous iron[96] would seem sound practice to mitigate against transfusion and the harmful effects thereof, in clinical practice in the SICU, neither has been effective in dramatically impacting transfusions or outcomes. It may be most prudent to "ride out" the anemia seen in ICU patients, minimize unnecessary blood draws, and improve oxygen delivery by other means (although they, too, have not afforded improved outcomes).

METABOLISM AND NUTRITION

Classic texts on surgical nutrition emphasize the metabolic and hormonal differences between the states of starvation, one of decreased metabolic rate, and that of stress, one of increased metabolism driven by so-called stress hormones. In reality, many surgical and trauma patients experience stress after a fast, although the use of early nutrition in almost all has largely prevented this.

In starvation, fat oxidation is the principle energy source after glycogen stores are exhausted within 24 hours. Patients turn to gluconeogenesis (particularly in cells that are obligate glucose users such as neurons and red blood cells) for fuel, resulting in increased free fatty acids, ketones, and glycerol. This amplified gluconeogenesis results in exhaustion of amino acid levels and protein wasting. Eventually, glucose levels drop as does insulin. Stress hormones, including cortisol and catecholamines, promote protein catabolism. As glucose is used up, a switch is made to fat metabolism with the inability to keep up via gluconeogenesis.

Critically ill patients are in a catabolic stress state with a systemic inflammatory response. Malnutrition in critically ill patients leads to worse outcomes; inability to wean from the ventilator, pressure ulcers, and increased risk of infectious complications. For these reasons, it is critical that ICU patients undergo assessment and adequate support of their nutritional status. Goals of nutrition support are to preserve lean body mass, maintain immune function, and avert metabolic complications.[1,97]

Metabolic Requirements and Assessment

Metabolic requirements for ICU patients for both calories and protein needs are based on ideal body weight. Equations, such as the Harris–Benedict calculation, can assist in determination of caloric administration and are based on the patient's baseline energy expenditure, referred to as the basal metabolic rate (BMR) and/or basal energy expenditure (BEE). BMR is the estimated rate of energy used by the body at rest and is only sufficient for the functioning of vital organs. The BEE varies with age, lean body mass, and sex. In most circumstances, ICU patients should receive 25 to 30 kcal/kg/day and 1.2 to 2.5 g/kg/day of protein (highest in stressed burn patients). In fact, hypocaloric, high-protein diets may be best for many, if not most, ICU patients. Starting critically ill patients at 8 to 10 kcal/kg/day and attempting to achieve goal nutrition of 25 to 30 kcal/kg/day within a week is optimal.[98]

The most important nutritional assessment of our ICU patients is the least high tech – that is, a careful history and physical examination documenting diet status, weight loss, and the nature of the operation or trauma. We often supplement this with quantitative assessment of protein and caloric adequacy. These include simple laboratory tests and more complicated evaluations. A variety of visceral proteins with relatively short half-lives have been assayed for their relation to protein status. These include prealbumin, transferrin, and retinol-binding protein (with half-lives of 2, 8, and 10 days, respectively) as opposed to albumin whose half-life is 21 days. However, even prealbumin levels may respond to factors other than nutritional status, including ongoing inflammation. The most accurate assessment is via indirect calorimetry. This allows for the direct measurement of oxygen consumption (VO_2). It is best determined in those on stable ventilator settings with an inspired oxygen fraction of less than 65% and no airway leaks. However, use of indirect calorimetry to guide nutritional support has not been demonstrated to result in improved outcomes to justify its expense.

Energy Sources

Carbohydrates, fat, and protein each contain a unique amount of calories per gram and respiratory quotients (RQ), a ratio of CO_2 consumption (VCO_2) over oxygen consumption (VO_2). Ratios that exceed one will result in the body's need to eliminate additional CO_2, which can be of consequence in those on ventilator support with lung disease. The goal of ICU nutrition is to provide energy from carbohydrate and fat sources, so that exogenous proteins can be used for anabolism and not catabolism. This principle is the protein sparing effect of carbohydrate and fat administration. Less than 500 kcal/day are protein sparing, although in most instances, we provide many more calories with traditional ICU nutrition.

Carbohydrates provide 3.4 kcal/g and have the highest RQ of 1.0. Thus, excess carbohydrate calories can result in prolonged ventilator needs. An RQ of greater than one is seen with glycogen storage. The ICU patient should be provided with 5 to 6 g/kg/day of carbohydrates.

Fat provides 9.0 kcal/g with an RQ of 0.7. ICU patients should receive 1 g/kg/day or less of fat. Fat deficiency used to be fairly common in ICU patients before early and adequate nutrition. Deficiency can result in anemia, thrombocytopenia, respiratory distress, and rash. Excess fat can promote cholestasis and fatty liver resulting in coagulopathy. In fact, it is possible to administer nearly all of one's nonprotein calories as carbohydrates, providing essential fatty acids are administered. However, this would result in an increased RQ (with ventilatory consequences) and issues of glycemic control. Fatty acids exist in two varieties, omega-three and omega-six. Omega-three fatty acids are derived from linolenic acid, found in fatty fish such as salmon, and are less pathogenic than omega-six fatty acids derived from linoleic acid. In stress, after the body exhausts its supply of carbohydrates, it relies on lipolysis which lowers the RQ (until the supply of fatty acids is also consumed and proteolysis occurs).

Protein delivers 4.0 kcal/g with an RQ of 0.8. Essential amino acids cannot be synthesized endogenously and must be provided in the diet and include: methionine, threonine, tryptophan, valine, phenylalanine, isoleucine, leucine, lysine, and histidine. Diets specialized for those with renal failure deliver their protein in the form of essential amino acids. Semiessential amino acids such as arginine and glutamine are difficult for the body to manufacture in times of stress and are obligately utilized by certain cell types. Protein is the important component of nutrition due to the body's obligate synthetic needs. We are able to measure the efficacy of protein nutrition by assaying nitrogen balance – a balance sheet between protein in and nitrogen out measured in the urine. This, of course, requires that we remember that a gram of protein contains 6.25 g of nitrogen. Severely burned patients can lose 25 g N (125 g pro) daily. In certain conditions, such as sepsis, we may not be able to provide enough protein to avoid negative nitrogen balance.

Vitamins and minerals. Contemporary supplemental nutrition contains sufficient trace elements and vitamins to make deficiency in ICU patients a thing of the past in most instances. A resurgence in this has occurred with the care of bariatric patients and the

deficiencies they experience post bypass, most notably of thiamine. Interesting to note, virtually all enteral formulae contain vitamin K – some in rather large amounts – so anticoagulation may be difficult (Table 10-9).

The nutritional support of the malnourished and nourished patient employs different strategies to optimize outcome. Malnourished patients may benefit from preoperative nutritional support for at least 7 days that can be delivered enterally, if possible. Well-nourished patients should have nutrition resumed within 48 hours; however, it is safe, if not wise to delay parenteral nutrition for 5 to 7 days if the enteral route is not possible. There is much controversy and regional variability regarding this issue with the Europeans preferring earlier initiation of parenteral nutrition, as will be discussed below.

Enteral Nutrition

9 In general, enteral nutrition should be used early and often in ICU patients. Standard enteral formulas include fatty acids, carbohydrates, protein, vitamins, minerals, and micronutrients. A standard formula is isotonic to serum and has a calorie density of 1 kcal/mL. A concentrated formula is used in patients who may benefit from low volume nutrition. Concentrated formula is hyperosmolar with a calorie density of 1.2 to 2.0 kcal/mL. There are specific formulations that address types of organ dysfunction. So-called pulmonary formulations are low in carbohydrates; renal formulas are concentrated with essential amino acids and hepatic formulas contain branched chain amino acids. Further, enteral feeds are either polymeric or elemental – that is, broken down to the basic building blocks of the energy substrates – proteins as free amino acids, fats as medium chain triglycerides, and carbohydrates as oligosaccharides at a calorie concentrations of 1 to 1.5 kcal/mL. Elemental feeds may be useful in the stressed patient as they require minimal intraluminal digestion. Elemental formulas should be considered in patients with nutrition absorption disorders and those that fail to tolerate standard enteral nutrition.

Table 10-9 Vitamin Deficiencies

Vitamin	Deficiency
A	Blindness and conjunctival spots (Bitot's)
D	Rickets and osteomalacia
E	Newborn anemia, neuropathy, and hemolysis
K	Bleeding
B1	Beriberi: weakness, CHF, lactic acidosis
B2	Tongue changes, photophobia
B6	Neuropathy, seizures, anemia, and glossitis
B12	Anemia, weakness, optic/MS changes
B3	Pellagra: dementia, diarrhea, and dermatitis
Folate	Diarrhea and anemia
C	Bleeding, petechiae, scurvy, and wound healing abnormalities

There are several complications related to enteral nutrition in the ICU, the most significant of which is aspiration. To decrease the aspiration risk, the ICU staff should maintain head-of-bed elevation at 45 degrees or greater and consider promotility agents. Regular assay of gastric residuals may not decrease aspiration risk.[99]

Parenteral nutrition requires the insertion of a central catheter or a centrally directed peripheral one. As such, the complications of parenteral nutrition include the risks of catheter insertion and infection in addition to the metabolic consequences of feeding (such as hyperglycemia) that can also be seen with enteral nutrition. Parenteral nutrition can be prepared in standard or concentrated formulations depending upon the glucose with added amino acids and fat. There may be evidence that hypocaloric formulas with limitation of fat early on are beneficial.[97]

Immunonutrition

In addition to use of omega-three fatty acids, there are other ingredients that may be helpful to use in the stressed patient. In small, early nonrandomized trials, semiessential amino acids arginine and glutamine have been shown to be beneficial and the use of high-protein/low-calorie strategies may be most optimal, particularly using branched chain amino acids. There was thought to be a notable exception to this strategy – arginine, in particular, was not advised in the patient who is already infected.[100] Arginine is metabolized to nitric oxide which may increase permeability, hemodynamic instability, and translocation in septic patients. However, this may be mitigated by increased production of arginase in septic patients. Increasing literature actually supports increased perfusion by giving arginine in sepsis.[101,102] Thus, arginine administration is likely safe in sepsis, but the preferred dose is still of debate. Glutamine is rapidly depleted from muscle stores and thought to be important in minimizing translocation as it assists in maintaining gut barrier function as an enterocyte fuel. A hypocaloric, high-protein strategy appears to be most beneficial with a calorie to nitrogen ratio of 100–150:1 compare to the more traditional 300:1. However, large randomized trials discussed below question the clinical efficacy of immunonutrition.

Controversial Issues in ICU Nutrition

Delivery of Early Enteral Nutrition

Most critically ill patients are unable to ingest enteral nutrition and have a need for access to the enteric track. There is no compelling evidence that enteral feeds need be delivered in a specific location – that is, there is little data to suggest that postpyloric feeding results in lower aspiration rates or in better food tolerance with higher caloric provision.[103] Gastric tube feeding is the most common method to deliver enteric nutrition. Via an orogastric or nasogastric route, sump tubes or smaller-caliber feeding tubes are placed into the stomach with confirmation by abdominal x-ray. Surgically placed gastric feeding tubes, whether placed percutaneous or via an open procedure, can also be used for a more long-term enteral nutrition access. Postpyloric tube feeding should be considered in patients who cannot tolerate gastric enteral nutrition or patients who have undergone surgical procedures that have altered anatomy. Placement of a postpyloric tube can be done with blind placement via the nasal or oral route. These tubes may also be placed via open surgical procedures with a single tube inserted directly in the intestine distal to the pylorus or with a tube with a port to drain the stomach and a distal port to deliver enteral nutrition into the duodenum. Postpyloric placement of enteral nutrition access has no benefit over gastric feeding access in terms of energy delivered or rate of aspiration pneumonia, and so it is recommended to proceed with enteral nutrition via the gastric route.[103]

Perioperative delivery of enteral nutrition may be challenging in certain circumstances. However, lessons learned in burn patients reinforce the notion that continuous feeding for nonabdominal procedures is safe.[104] Similarly, presence of an open abdomen is not a contraindication to provision of enteral nutrition.[105]

Compared to intravenous dextrose or no nutrition, early enteral nutrition results in lower morbidity (largely infectious), mortality, and cost in ICU patients.[106–108] Bowel rest is not beneficial in ICU patients. Just as asystole does not rest the heart, starvation does not inhibit bowel function, rather it decreases splanchnic flow and results in bacterial overgrowth and translocation. Enteral nutrition promotes blood flow, arguing against the routine practice of discontinuing it in those on pressors.[109,110]

There is some sense that if full feeding is not possible for whatever reason, that partial or trophic nutrition be employed. This strategy aims to prevent the overgrowth of bacteria in a static gastrointestinal tract that could result in translocation into the portal circulation causing sepsis and fueling multiple organ failure. However, the EDEN study comparing the use of trophic versus full feeding in ARDS patients did not demonstrate a benefit to the former in terms of infection rate, ventilator days, ICU length of stay, or mortality. Of course, this study does not address what one should do if full feeds are not possible – maintain trophic only enteral feeds, add partial or full parenteral feeds, or employ another strategy.[110] Earlier enteral versus parenteral nutrition studies were fraught with issues of overfeeding, imprecise glucose control, and the potential for substandard intravenous catheter care, all of which would raise the risk of infection in those parenterally fed.

Strategies When Unable to Feed Enterally/Role of Supplemental Parenteral Nutrition

Several recent studies have addressed the role of supplemental parenteral nutrition to be used in instances when enteral nutrition might not be possible. In the large EPaNIC study from Europe of over 4,000 patients randomized to "early" or "late" parenteral nutrition if caloric goals were not met by day 2, early patients did worse. Those randomized to receiving late parenteral nutrition (by day 7) had shorter ICU and hospital length of stay, fewer infections, less ventilator and dialysis days, and lower cost. The more parenteral nutrition patients received, the worse the outcome.[111] In a large Australian randomized trial, the only parameter that was improved by supplemental parenteral nutrition was a clinically insignificant, but statistically significant, difference in ventilator days (less than one half day).[112] The Swiss SPN study of supplemental parenteral nutrition demonstrated no difference in mortality, infections to day 28, length or stay or ventilator days between groups.[113] In injured patients, the use of parenteral nutrition has largely been abandoned, used in fewer than 5% of patients in one study. Supplemental parenteral nutrition in a cohort of severely blunt injured patients doubled both the rate of infections and mortality.[112] Finally, a recent randomized controlled multicenter trial – CALORIES – compares the use of early enteral and parenteral nutrition. Interestingly, the authors found no difference in the infection rate, adverse events, or mortality.[114] While some can interpret this study as one that supports the safety of early parenteral nutrition, an alternate view would be that less expensive early enteral nutrition is, in fact, able to be administered in most ICU patients.

Delivery of Immunitrition

Glutamine and omega-three fatty acids (fish oils). Previous retrospective studies of immune modulating nutrients such as glutamine, selenium, and omega-three fatty acids indicated an outcome benefit in terms of diminished infections and improved survival using high-protein enteral formulas. However, newer studies are not as conclusive. In the REDOXS trial examining the effect of supplemental intravenous or oral glutamine in septic patients with multiple organ failure, glutamine administration resulted in an increased mortality rate of over 5%.[115]

There is not convincing evidence that utilizing an omega-three-rich lipid composition in parenteral nutrition affects mortality or ICU length of stay,[116,117] but this may be a function of route delivered and baseline nutritional status. It's not clear that there is a benefit for enteral administration either, with some showing great benefit while others do not. Finally, the recent MetaPlus study described a multicenter, randomized, double-blind trial of 301 mechanically ventilated adult patients using comprehensive immunonutrition. There was no difference reported in infection rate, ventilator days, and ICU and hospital length of stay between groups. Further, although not seen in trauma and surgical patients, in this study, immunonutrition was associated with substantially higher 6-month mortality (54 vs. 35%) in medical ICU patients.[118]

Nutrition for Specific Indications

Acute Pancreatitis

Enteral nutrition, if possible, is preferable in acute pancreatitis as it decreases length of stay, improves resolution of SIRS, decreases infection rate, and does not stimulate exocrine pancreatic secretion to a great extent. A recent Cochrane review of eight trials revealed a relative risk of death of 0.18 and 0.46 for multiple organ failure for those with severe acute pancreatitis who received enteral nutrition.[119]

Obesity

Goals in management of the obese patient are to reduce fat mass, improve insulin sensitivity, and preserve lean body mass. A high-protein, hypocaloric strategy is favored with 22 to 25 kcal/kg/day based on ideal body weight and 2.0 to 2.5 g/kg/day of protein.

Stress Gastrointestinal Bleeding Prophylaxis

Endoscopic evidence of upper gastrointestinal bleeding is extraordinarily common in ICU patients. It is present shortly after admission in high-acuity ICU patients and thought due to impaired mucosal protection and less so due to acid hypersecretion and *Helicobacter pylori* infection. The latter two are features typical of more distal ulcers that can also result in upper gastrointestinal bleeding. Overt bleeding, manifested by coffee ground upper intestinal aspirates or hemoccult positive stool, is appreciated in up to 25% of patients in the ICU. Clinically significant bleeding resulting in the need for a blood transfusion and/or hemodynamic instability is much less common, noted in less than 5% of ICU patients, with or without pharmacologic prophylaxis. The strongest risk factor for stress gastrointestinal bleeding in the ICU is the need for more than 48 hours of mechanical ventilation, although epidemiologic studies pointing to this observation are dated.[120] The next most common risk factor is the presence of coagulopathy. It seems prudent that pharmacologic prophylaxis of stress gastrointestinal bleeding in ICU patients be limited to those with these two risk factors. There may, however, be a role to avoid pharmacologic agents even in the highest-risk patients, particularly if they are being enterally fed.[121] If pharmacologic prophylaxis is prescribed, proton pump inhibitors (PPI's) appear to be superior to histamine-2 receptor antagonists in diminishing gastrointestinal bleeding; however, there is no change in mortality, length of stay, or pneumonia incidence in ICU patients.[122] However, PPI's increase the risk for infection with *Clostridium difficile,* although this association has not been appreciated in ICU patients to date.

ACUTE KIDNEY INSUFFICIENCY (AKI)

Acute renal failure complicates at least 5% and as many as 30% of all surgical ICU admissions with a mortality of over 50%, as the most prognostic component of multiple organ failure. In analysis of a cohort of hypotensive, severely blunt injured patients enrolled in the "Inflammation and the Host Response to Injury" (Glue Grant) database, AKI occurred in one-quarter of patients with a threefold adjusted risk for hospital death.[123] AKI can be graded along a spectrum as described by the RIFLE classification (from risk to injury to failure to loss to end-stage kidney disease) as defined by the Acute Dialysis Quality Initiative (ADQI), and may be oliguric or nonoliguric (urine output $<$ or $>$400 mL/day in adults). Oliguric renal failure and higher grades of injury portend a higher mortality. An additional classification system has been developed by the Acute Kidney Injury Network (AKIN) and is also composed of urine output and serum creatinine criteria as described in Table 10-10. AKIN has the advantage of considering minor variations in serum creatinine better than does RIFLE and it avoids interpretation errors in the absence of a baseline creatinine value. Neither classification system, however, is favored in terms of predicating incidence of and outcome from AKI. However, to simplify matters, the Kidney Disease Improving Global Outcomes (KDIGO) work group recently proposed a hybrid definition.[124–126]

Etiology

Acute kidney injury and ultimately failure is the result of forces extrinsic to the kidney or inherently parenchymal (about 90%). Prerenal versus postrenal causes can be distinguished with serum and urine osmolality and basic metabolic panel measurements (Table 10-11). Radiographic diagnostic studies (i.e., ultrasound and CT scan) can diagnose hydronephrosis or a distended bladder as causes of postrenal AKI. Prerenal azotemia, in which the kidney perceives a lack of perfusion, may occur with both hypovolemia and hypervolemia, the latter with congestive heart failure and impaired cardiac function. Initially, the kidney is able to maintain perfusion by selectively dilating the afferent arteriole and vasoconstricting the efferent arteriole of the juxtaglomerular apparatus. As hypotension persists and the renin–angiotensin system is activated, systemic vasoconstriction occurs and cortical hypoperfusion occurs. It is important to note that laboratory markers are able to distinguish between prerenal and renal causes of AKI, but not between hypovolemic and hypervolemic/cardiogenic states that may be the proximal cause.

Table 10-10 RIFLE AKIN and KDIGO Classification of Renal Failure

RIFLE Classification of Renal Failure		
Stage	**GFR**	**Urine Output**
R – Risk renal injury	Baseline Cr × 1.5 Decrease GFR >25%	UO <0.5 mL/kg/hr × 6 hrs
I – Injury to kidney	Baseline Cr × 2 Decease GFR >50%	UO <0.5 mL/kg/hr × 12 hrs
F – Renal Failure	Baseline Cr × 3 Cr >4 mg/dL with increase of 0.0 mg/dL Decrease GFR >75%	UO <0.3 mL/kg/hr × 24 hrs anuria × 12 hr
L – Loss of renal function	Persistent renal failure Loss of renal function >4 wks	
E – ESRD	Renal failure >3 mo	
Acute Kidney Injury Network (AKIN) Classification of Acute Kidney Injury		
Stage	**GFR**	**Urine Output**
1	Baseline Cr × 1.5–2 Increase >0.3 mg/dL in 48 hrs	UO <0.5 mL/kg/hr × 6 hrs
2	Baseline Cr × 2–3	UO <0.5 mL/kg/hr × 12 hrs
3	Baseline Cr × 3 Cr >4 mg/dL with acute increase 0.5 mg/dL Renal replacement therapy	UO <0.3 mL/kg/hr × 24 hrs Anuria × 12 hrs
Kidney Disease Improving Global Outcomes (KDIGO) Staging of AKI		
Stage	**Serum Creatinine**	**Urine Output**
1	Baseline × 1.5–1.9 Increase >0.3 mg/dL	<0.5 mL/kg/hr for 6–12 hrs
2	Baseline × 2–2.9	<0.5 mL/kg/hr for >12 hrs
3	Baseline × 3 Increase >4 mg/dL Initiation of renal replacement therapy <18-yr-old decreased GFR <35 mL/min per 1.73 m^2	<0.3 mL/kg/hr for 24 hrs Anuria >12 hrs

ESRD: end stage renal disease, GFR: glomerular filtration rate, Cr: creatinine, UO: urine output.

Table 10-11 Prerenal Versus Acute Tubular Necrosis as the Cause for Acute Kidney Injury

Diagnostic Study	Prerenal	Acute Tubular Necrosis
Urinalysis	Normal	Casts and epithelial cells
Serum BUN:Cr	20:1	Normal
Urine osmolality	>500 mOsm/kg	<350–450 mOsm/kg
FENa	<1%	>2%

BUN: blood urea nitrogen, Cr: creatinine, FENa: fractional excretion of sodium; mOsm: milliosmole.

Acute tubular necrosis (ATN) results as a consequence of ischemia (most) or nephrotoxic agents. The former may occur in the face of sepsis, hypovolemia, or cardiogenic shock. The latter includes common ICU medications, radiocontrast media, or pigments (myoglobin and hemoglobin). Medications that may cause ATN include aminoglycosides, cephalosporins, amphotericin, and cisplatin. Contrast nephropathy

occurs in about 5% of those exposed; particularly at high risk are elderly diabetics with pre-existing kidney disease. Rarely will patients with contrast nephropathy progress to requiring dialysis. Only administration of intravenous saline precontrast administration has been demonstrated to lessen the incidence of contrast nephropathy.[127] The use of n-acetyl cysteine or bicarbonate has not been beneficial. In those with pre-existing renal insufficiency who nonetheless require administration of contrast media, there may be a role for prophylactic continuous dialysis. Hemoglobin pigment rarely causes ATN in surgical ICU patients. A rare but morbid cause would be the administration of incorrectly crossmatched blood products. Myoglobinuria as a consequence of rhabdomyolysis is far more common in the ICU and occurs after severe trauma, compartment syndrome, electrical burns, seizures, or coma with prolonged immobilization. Myoglobinuria should be suspected in patients with dark urine and a positive urine dipstick without red cells on microscopy. Patients with a serum myoglobin level exceeding 10,000 ng/mL or a creatinine phosophokinase (CPK) greater than 20,000 IU/L are a risk for pigment nephropathy. Myoglobin is both a potent vasoconstrictor (FeNa is $<1\%$) and a direct tubular toxin when converted to ferrihemate in an acid environment. However, alkalinization of the urine (with administration of sodium bicarbonate) has not been proven to be more effective than volume administration and forced dieresis to achieve a urine output of 2 mL/kg/hr.[128]

Postobstructive uropathy is rare in the ICU and leads to AKI as the result of a mechanical obstruction to urinary flow. An obstructed urinary catheter is the most common cause and should prompt ICU personnel caring for a patient with an abrupt cessation of urinary output to interrogate the patency of the catheter.

10 Prevention of acute renal failure is most effectively achieved by controlled fluid resuscitation of volume repletion. There is little evidence to benefit of colloid over crystalloids. Higher–molecular-weight hydroethyl starch preparations should be avoided, however, as they are nephrotoxic through tubular obstruction. If a mean arterial pressure (MAP) of greater than 65 mm Hg cannot be maintained solely with fluid administration, it is reasonable to initiate norepinephrine therapy. There is no role for the use of low-dose dopamine for protection against AKI or improvement of diuresis, as noted by several meta-analyses.[129,130]

Treatment of Acute Renal Failure

General Care

Attention must be directed toward management of electrolyte disturbances and hypervolemia in those with renal failure or impending failure. Hyperkalemia, hyperphosphatemia, metabolic acidosis, uremia, and congestive heart failure may all be of consequence. It is important to remember that treatment for hyperkalemia can either be temporizing or definitive. Temporizing treatment such as the administration of calcium or insulin will stabilize cell membranes and lessen cardiac irritability by forcing potassium intracellularly. However, only removal of potassium through the gastrointestinal tract, the urine or dialysis offers definitive therapy. Thus, if a surgical ICU patient is oliguric and not a candidate for enteral or rectal administration of a potassium binder, then dialysis must be promptly administered to those with markedly elevated potassium levels or ECG changes. Similarly, uremia causing a significant pericardial effusion or encephalopathy may be temporized or treated definitively with dialysis. Platelet dysfunction is also associated with AKI, particularly in face of a BUN in excess of 100 mg/dL. The administration of desmopressin (DDAVP) or analogues may be of benefit. Finally, as the strategy for renal replacement therapy is developed, attention must be directed toward optimizing nutritional status without worsening electrolyte disturbances or hypervolemia. Prior to initiation of dialysis, it may be necessary to limit protein administration so as to avoid exacerbating uremia. However, as renal failure typically occurs in the catabolic milieu of multiple organ failure, it is vital to administer an adequate protein substrate as well as calories to prevent excessive gluconeogenesis and protein breakdown. This, in turn, leads to worsening uremia.

Diuretics

There may be a theoretical attraction to using diuretics to ameliorate AKI. However, in practice diuretics have not been successful in either preventing or ameliorating AKI. Rather, prophylactic diuretics often raise serum creatinine levels. Systematic reviews and meta-analyses[131,132] have demonstrated that diuretic use does not alter outcome from AKI, but has a significant risk of morbidity (such as hearing loss) and even mortality in some. Finally, if diuretics are used, there is no evidence in systematic review and meta-analysis that continuous dosing is superior to bolus administration.[133,134]

Renal replacement therapy (RRT) is indicated for intractable fluid overload, hyperkalemia (potassium concentration greater than 6.5 mmol/L or 5.5 with ECG changes), severe metabolic acidosis (pH <7.1), uremic encephalopathy or pericarditis and overdose with a dialyzable agent. Hemodialysis is typically performed in ICU patients and may be continuous or intermittent. Both the Randomized Evaluation of Normal versus Augmented Level Renal Replacement (RENAL) study and the Veterans Administration/National Institutes of Health Acute Renal Failure Trial Network (ATN) failed to demonstrate a benefit from increasing the intensity of RRT beyond 20 to 25 mL/kg/hr of effluent flow, the former trial utilizing continuous modes, the latter intermittent.[135,136]

Continuous renal replacement therapy (CRRT) includes slow continuous ultrafiltration (SCUF) and continuous venovenous and arteriovenous modes. Patients who are placed on CRRT must have a temporary double lumen dialysis catheter placed in the internal jugular, femoral, or subclavian vein (in order of preference). Once the dialysis catheter is inserted, the blood flow through the filter is moved by a peristaltic pump. SCUF is utilized exclusively for volume removal which can be achieved at up to 2 L/hr. No replacement fluid is used, thus, there is minimal clearance of toxins. Arteriovenous circuits, employing the patient's own perfusion pressure to drive the system, are rarely used currently. Rather a pump is used to drive a continuous venovenous circuit that can provide hemofiltration, hemodialysis, or, most often, both. Continuous venovenous hemofiltration (CVVH) uses replacement fluid in the same direction as the blood flow to dilute toxins in plasma as the toxins are removed with the ultrafiltrate. Clearance of toxins is through the process of convection based on particle size where small, medium, and large molecules are sieved out across a pressure gradient. Thus, electrolytes are leeched out and replacement fluid is warranted. Continuous venovenous hemodialysis (CVVHD) uses a dialysate that flows through the filter in the opposite direction of blood flow (and no replacement fluid) to remove toxic waste and fluid of small molecules (such as urea) through the process of diffusion across a concentration gradient. Finally, continuous venovenous hemodiafiltration (CVVHDF) combines both convection and diffusion through a high-permeability membrane, using both dialysate and replacement fluids. In those at a high risk of bleeding, it is reasonable to consider citrate anticoagulation (in the absence of liver failure) or no anticoagulation with predilution administration of replacement fluids. In those with moderate bleeding risk and/or frequent filter clotting, low-dose unfractionated heparin or LMWH should be administered or argatroban in those with heparin-induced thrombocytopenia. The use of CRRT may be preferred in those with brain edema, persistent metabolic acidosis, large fluid removal requirements, and severe hemodynamic instability although hybrid modes, described below, may play a role. Most patients have optimal clearance and treatment with running CRRT at 30 mL/kg/hr.[137] There has been some discussion about using high flow CRRT (70 mL/kg/hr) for the treatment of sepsis. In patients with severe sepsis or septic shock without renal failure, there is no role for high volume hemofiltration as reinforced in a recent multicenter study, the high volume in intensive care (IVOIRE) trial.[138]

Intermittent hemodialysis (IHD) is performed at high flow rates (>300 mL/min) in a short session relying on diffusion to clear toxins. Although it is thought that IHD is contraindicated in the face of hemodynamic instability, it is possible to utilize this mode. Sufficient data do not exist to determine which dialysis mode is optimal in promoting eventual renal recovery. Analysis suggesting a lower rate of recovery with IHD relies heavily on data from older observational trials.[139,140]

Hybrid modes include sustained low efficiency dialysis (SLED). This can be thought of as stretching out an intermittent dialysis session to promote improved hemodynamic stability and take advantage of the cost benefits of IHD. SLED uses a conventional hemodialysis machine over 8 to 12 hours with lower blood and dialysate flow rates.

Various strategies exist to improve hemodynamic tolerance.

ENDOCRINE ISSUES IN THE ICU

Glucose Control

11 Hyperglycemia is common in critically ill patients and associated with poor clinical outcomes. Critically ill patients are hypermetabolic due to elevated cortisol, growth hormone and catecholamine levels, leading to increased hepatic gluconeogenesis, insulin resistance and hyperglycemia. Since critically ill patients with hyperglycemia have increased mortality and complications including infection and worse neurologic outcomes, assiduous glucose control has been practiced in critically ill hyperglycemic patients.[141,142] However, the optimal blood glucose range is controversial. Intensive insulin therapy (IIT) typically employs continuous insulin infusions to maintain glucose levels of 80 to 110 mg/dL. Conventional blood glucose therapy could utilize either bolus or continuous insulin to maintain glucose levels at a higher range. The Leuven surgical trial of mostly cardiac surgery patients provided the groundwork for the use of IIT. One thousand five hundred and forty-eight patients were randomized to IIT with infusion insulin versus conventional glucose management of 180 to 200 mg/dL. IIT resulted in lower ICU and hospital mortality (4.6% and 7.2% vs. 8% and 10.9%, respectively), renal failure, transfusion requirement, blood stream infections, and critical illness neuropathy, with more frequent hypoglycemia.[143] Other trials that included surgical patients reached opposite conclusions. The Volume Substitution and Insulin Therapy in Severe Sepsis (VISEP) trial was a multicenter trial that was stopped early because of the increased rate of hypoglycemia and serious adverse events in the IIT group without a difference in mortality.[144] Similarly, the multicenter Glucontrol trial was terminated early because of the high rate of hypoglycemia in the IIT group.[145] The largest trial, Normoglycemic in Intensive Care Evaluation Survival Using Glucose Algorithm Regulation (NICE – SUGAR) included over 6,000 medical and surgical ICU patients randomized to IIT with blood glucose targets of 81 to 108 mg/dL and conventional blood glucose targets of <180 mg/dL. The IIT group had decreased mean blood glucose levels, significantly higher mortality and more incidence of severe hypoglycemia.[146] Current guidelines recommend moderate blood glucose control of 144 to 180 mg/dL for critically ill patients to avoid both marked hyperglycemia and iatrogenic hypoglycemia.[147] This can be achieved predominantly by avoiding the use of glucose-containing intravenous fluids to avoid the need for insulin administration. If insulin is needed, continuous infusions and intermittent short-acting agents may be safer in ICU patients.

Adrenal Insufficiency

Absolute **adrenal insufficiency** is rare in critically ill patients, with an incidence estimated at less than 5%.[148] Relative adrenal insufficiency, manifested by hypotension and fever (and rarely with electrolyte abnormalities), is common in ICU patients and associated with worse outcomes. In general, most (absolute) adrenal insufficiency is secondary to abrupt withdrawal of therapeutic steroids. In the ICU, however, although total levels of cortisol may be normal, they may not respond appropriately to stress situations. Further, the typical diurnal variation of cortisol appreciated in normal volunteers is not seen in ICU patients, as stressors are not eliminated at night, making cortisol assay an easier task. In the past, relative adrenal insufficiency was defined by a cortisol level of less than 11 to 25 mcg/dL and/or failure to raise the level by more than 9 mcg/dL after stimulation by high-dose (250 mcg) ACTH.[149] However, there is much debate as to what cortisol level is appropriate in septic shock, what constitutes an adequate response to ACTH stimulation and what dose of ACTH should be used. After careful study, it appears that ACTH, or its synthetic analogue, cosyntropin, stimulation is not helpful in distinguishing those with relative adrenal insufficiency who would derive benefit from steroid administration. Prior work in the 1980 s and 90 s did not show benefit to high-dose steroid administration in septic shock. The more recent Annane French trial demonstrated a benefit to administration of low-dose steroid administration with concomitant mineralocorticoids in septic shock in terms of mortality.[150] However, the Corticosteroid Therapy of Septic Shock (CORTICUS) trial, a large multicenter study, did not demonstrate a mortality benefit to administration of steroids in septic shock.[151] However, patients received therapy later than in the French trial and were not also administered mineralocorticoids. Subsequent meta-analyses of the role of steroids in septic shock reveal no difference in mortality but improved shock reversal.[152,153] Current recommendations advise administration of low-dose, “replacement” steroids (glucocorticoids) to septic patients who remain hypotensive despite adequate volume resuscitation, particularly those whose serum cortisol levels are below 20 mcg/dL.[20] Still controversial is whether or not to administer a mineralocorticoid concomitantly to those felt adrenally insufficient. If fludrocortisone is not administered, then it is important to remember that glucocorticoids have varied mineralocorticoid potency – none seen with dexamethasone and half seen with methylprednisolone compared to hydrocortisone. Typically 200 to 300 mg hydrocortisone daily is administered in intermittent doses, every 8 hours, for 5 to 7 days and then tapered as guided by clinical response. A parallel to the relative insufficiency of cortisol seen in ICU patients with septic shock is that of arginine vasopressin. Therapy with low, replacement doses of vasopressin might be considered analogous to that with glucocorticoids and may, in fact, be complimentary to this therapy.[154] A final point to mention is that the induction agent etomidate is associated with relative adrenal insufficiency. Etomidate is laudatory because it is not associated with hemodynamic instability and, thus, had been favored in shock. However, etomidate is a reversible inhibitor of 11-beta-hydroxylase, and thus may cause transient adrenal insufficiency which theoretically can worsen outcome in sepsis. Studies have not

definitively demonstrated worse outcome between patients intubated using etomidate versus other induction agents such as ketamine. Practitioners should balance the risks and benefits of etomidate administration and consider the transient administration of steroids to blunt adverse effects in the airway management of those with sepsis.[155]

Thyroid Abnormalities

Thyroid abnormalities occur infrequently in ICU patients. Although the half-life of commonly administered thyroid medications is long, it is possible that chronically ill patients who eventually present to the ICU could develop severe hypothyroidism. The typical patient with myxedema coma has a long-standing need for replacement thyroid medications and is ill after infection or trauma. Patients are hypothermic, bradycardic, and obtunded with low serum sodium and glucose levels. The treatment includes securing an airway, hydration, warming, and administration of thryoxine and hydrocortisone. The treatment of thyroid storm is discussed elsewhere in more detail. It occurs in patients with Graves disease or toxic nodular goiters who become infected, pregnant, traumatized, or undergo surgery. Supportive treatment includes ICU admission to monitor hemodynamic status and arrhythmias, cooling, hydration, and beta blockade. Propylthiouracil (PTU) or methimazole is administered both to inhibit the release of T4 and to block the conversion of T4 to T3. Thereafter, iodine as SSKI or Lugol solution is given, once hemodynamics have been stabilized to inhibit T4 release. Glucocorticoids may also be indicated. Finally, there is an entity of pseudohypothyroidism, the so-called sick syndrome, that occurs in ICU patients who have normal thyroid function but low levels of T3, freeT4, and T4 as T3 is converted to its isomer reverse T3. Several mechanisms can contribute to the inhibition of 5′-monodeiodination and therefore to the low serum T3 concentrations in patients with nonthyroidal illness. These include elevated cortisol levels with glucocorticoid therapy, free fatty acids that inhibit deiodinase, cytokines, and treatment with drugs that inhibit 5′-monodeiodinase activity such as amiodarone. No treatment is required. If there is additional evidence to suggest a diagnosis of hypothyroidism, critically ill patients, should receive cautious thyroid hormone replacement beginning with approximately half the expected full replacement dose of levothyroxine.

INFECTIOUS DISEASE ISSUES IN THE ICU

Sepsis Guidelines

Evidence-based sepsis resuscitation and global care guidelines are set forth in the Surviving Sepsis Campaign, now in its third version.[20] These guidelines prioritize care for those with the most acute forms of sepsis – that is, severe sepsis and septic shock. Severe sepsis refers to those infected patients with hypotension and/or hypoperfusion with organ dysfunction (manifested by oliguria, acute mental status change, new coagulopathy or thrombocytopenia, or acute lung injury). Septic shock refers to those who require administration of pressors despite initial volume resuscitation. Care of the septic patient with severe sepsis and septic shock is suggested to adhere to bundles that optimally should be completed within 3 and 6 hours (Table 10-2). Resuscitation targets a MAP of >65 mm Hg, a central venous pressure (CVP) of >8 mm Hg, and a central venous oxygen saturation ($ScvO_2$) of >70%. Pressors are administered if the initial fluid bolus does not achieve the targets above and inotropes and/or blood transfusion are given to maintain a hemoglobin >10 g/dL if the $ScvO_2$ goal is not met. The principal evidence underlying the resuscitation strategy is derived from Emanuel Rivers' early goal-directed therapy study (EGDT) published in 2001.[156] This single center trial allocated patients to usual care or CVP-directed intravenous fluid administration with MAP and $ScvO_2$ goals achieved by administration of dopamine, dobutamine, and packed red blood cells. In this study, Rivers and colleagues demonstrated a significant difference in mortality between the groups – 30.5% in the study patients versus 46.5% in the controls. Further, the current surviving sepsis guidelines render several specific recommendations regarding fluid administration. They advocate for the use of crystalloids as the initial fluid therapy of choice and against the use of hydroethyl starches and suggest that albumin may be beneficial if large volume crystalloid resuscitation is required.

12 In the interim, three trials have been conducted that call into question Rivers' resuscitation paradigm. The ProCESS trial, a large, multicenter controlled trial randomized patients into three groups with excellent protocol compliance (90%) and equivalent usage of early antibiotics. The three groups were the EGDT group (439 patients) exactly as described by Rivers with CVP and $ScvO_2$ monitoring and administration of dobutamine and packed cells. The second (protocol-based standard care) group (446 patients) was resuscitated to clinical euvolemia within 6 hours. Insertion of a CVC or and $ScvO_2$ catheter was not mandatory. Finally, a third (usual care) group (456 patients) was resuscitated according to the clinical judgment of the provider. Approximately half of the protocol and usual group patients received CVCs. Fluid administration was not clinically different between the protocol- and goal-directed therapy groups (2.3 L vs. 3.3 L, respectively). However, dobutamine use and packed cell transfusion was roughly eight times higher and double, respectively, in the EGDT group. Most importantly, there was no difference in 60-day, 90-day, or 1-year mortality, length of stay, or organ failure.[36] The second, the ARISE trial, randomized patients with early septic shock to receive EGDT (796 patients) or usual care (804 patients) and corroborated

the results of the ProCESS trial. There was no difference in 90-day mortality, but the EGDT group was twice as likely to receive red blood cell transfusion and was six times as likely to receive dobutamine.[37] The third trial – ProMISe from the United Kingdom, still awaits publication. It is apparent that these studies will result in a de-emphasis on CVP and $ScvO_2$-guided resuscitation in future iterations. Finally, the guidelines provide an in-depth evidence-based review of the components of global sepsis care, the evidence for which is described throughout this chapter.

Use of Procalcitonin to Guide Antibiotic Therapy

Procalcitonin, a precursor of calcitonin with a half-life of about 24 hours, is released in response to bacterial toxins and interleukin-1b and has been identified as a marker of sepsis and bacterial infection for nearly a decade. Procalcitonin increases within 4 to 6 hours or bacterial infection, is attenuated in the presence of viral infection and not affected in the presence of fungal infections. Far more important clinically is the observation that procalcitonin levels halve once bacterial infection is controlled by antibacterials. Protocols have been developed to stop empiric or therapeutic antibiotics once procalcitonin levels decrease by 80% or to an absolute level of 0 to 0.5 ng/mL. Seven randomized trials in ICU patients were subjected to a systematic review and meta-analysis suggesting that procalcitonin assay reduces antibiotic use by an average of two days per patient without otherwise affecting outcome.[157] An in-depth economic analysis suggests that use of procalcitonin is effective in the ICU setting.[158] More recent studies support the notion that use of procalcitonin is useful in determining when to stop antibiotics in ICU patients and that these shorter therapeutic courses are not associated with a difference in outcome.[159,160]

Central Line Associated Blood Stream Infections

Central line associated blood stream infections (CLABSI) can be an important cause of morbidity, resource utilization, and even attributable mortality in ICU patients. Infection control measures have been successful in dramatically lowering the incidence of this infection, defined as 15 colony forming units (cfu)/mL by semiquantitative or 10^3 by quantitative means. Perhaps the most successful intervention to preventing CLABSI is to remove (or not insert) central catheters if they are not needed; this is the cornerstone of care bundles or checklists (Table 10-3).[161] Antiseptic or antibiotic-coated catheters should be considered in ICUs with a high baseline rate of infection after employing less costly measures. Chlorhexidine-impregnated dressings lower CLABSI rates as well.[162] Routine wire changing of catheters does not decrease CLABSI rate. In the past the subclavian site was felt to be the least prone to infection; however, recent studies indicate that internal jugular (and perhaps even femoral) catheters are not much worse. Further, no randomized controlled trial compares subclavian versus internal jugular versus femoral insertion in a single study.

Catheter Associated Urinary Tract Infections

Infection control measures have also been undertaken to prevent catheter associated urinary tract infections (CAUTI), a common cause of morbidity, but rarely of mortality, in surgical ICU patients. CAUTI are the leading cause of secondary healthcare-associated bacteremia and may be associated with symptomatic or asymptomatic bacteriuria of >10 cfu/mL.[5] Most strategies focus on prompt removal of indwelling catheters. There may be some role for use of antiseptic- (silver preparations) or antibiotic-coated catheters (minocycline-rifampin) in high-risk patients, although clinical trials have not been definitive.[164,165]

The Use of Selective Oral and Selective Digestive Decontamination (SOD and SDD) and Other Strategies to Address Resistant Organisms in the ICU

Antibiotic-resistant bacteria are discussed more in detail in this text. Those relevant to ICU patients include methicillin-resistant *Staphylococcus aureus* (MRSA), vancomycin-resistant enterococcus, and multi-drug resistant gram negative pathogens, including carbapenem-resistant enterobacteriaceae. Various infection control strategies have been promulgated in ICU patients to address these virulent organisms. We will discuss the use of selective decontamination and MRSA decontamination strategies here. The practice of selective decontamination was developed many decades ago and is used extensively in surgical and trauma patients in Europe. Its goal is to minimize ventilator-associated pneumonia to lessen multiple organ dysfunction and improve outcome in high-risk populations. The cornerstone of the therapy is the administration of a short course (4 day) of parenteral antibiotics to address respiratory gram negative pathogens, typically a second generation cephalosporin. SOD strategies add use of a chlorhexidine mouthwash. SDD employs a nonabsorbable enteral antibiotic (such as colistin) instead. Although there is a more robust experience with selective digestive rather than oral decontamination, both strategies are associated with a reduction in ventilator-associated pneumonia without a concomitant change in mortality.[165] Another systematic review demonstrated a reduction in multiorgan failure rates, but not of mortality.[166] A large crossover cluster trial of nearly 6,000 ICU patients in Denmark demonstrated that SOD and SDD both decreased mortality by roughly 15%, although SOD was markedly less expensive. For whatever reason, perhaps the concern for antibiotic resistance, the practice of decontamination by either route has not garnered interest in the United States. The Danish group has noted, however, that antibiotic resistance was actually lower after institution of decontamination.[167] However, another large Danish trial demonstrated that SDD patients did experience higher rates of aminoglycoside resistance by gram negative organisms.[168] Specific strategies to provide MRSA decontamination are focused on certain principles: that MRSA colonization can be rapidly identified by aggressive screening protocols using polymerase chain reaction (PCR) technology, that MRSA colonization ultimately leads to bacteremia and that therapies exist to successfully decolonize patients. The clinical data are confusing and various society guidelines have reached different conclusions regarding universal screening. Nonetheless, in the United States, 35% or more of all precaution days are due to MRSA and screening increases these contact days by 15%. A large Veterans Affairs initiative involving both ward and ICU patients demonstrated that MRSA screening decreased infection rates.[169] Two other large studies, one of surgical patients[170] and another of mixed ICU patients[171] did not show benefit of MRSA screening in lowering infection rate. Several studies have investigated the role of MRSA-directed decontamination, using such agents as topical chlorhexidine on washcloths and intranasal mupirocin with or without oral rifampin and doxycycline. This strategy has been successful in liver transplant patients[172] and in mixed ICU patients[173] in terms of decreasing colonization, infection, and bacteremia. A multicenter US study randomized

ICUs to MRSA screening and isolation, targeted decolonization, or universal decolonization with topical chlorhexidine and nasal mupirocin. Interestingly, the latter strategy was associated with reduced MRSA colonization and all-cause infections (but not MRSA), suggesting that chlorhexidine is the most efficacious component of the strategy.[173] Chlorhexidine can also decrease colonization, and perhaps infection, with VRE, but its effect of gram negative organisms is less certain.[174]

References

1. Health Forum LLC, an American Hospital Association Company. *AHA Hospital Statistics 2011*. ed. Chicago, IL: health Forum LLC, an American Hospital Association Company; 2010.
2. Halpern NA, Pastores SM, Oropello JM, et al. Critical care medicine in the United States: addressing the intensivist shortage and image of the specialty. *Crit Care Med* 2013;41(12):2754–2761.
3. Malstam J, Lind L. Therapeutic intervention scoring system (TISS)—a method for measuring workload and calculating costs in the ICU. *Acta Anethesiol Scan* 1992;36:758–763.
4. Leape LL, Cullen DJ, Clapp MD, et al. Pharmacist participation on physician and adverse drug events in the intensive care unit. *JAMA* 1999;282:267–270.
5. Braga JM, Hunt A, Pope J, et al. Implementation of dietitian recommendations for enteral nutrition results improved outcomes. *J Am Diet Assoc* 2006;106:281–284.
6. Schweickert WD, Pohlman MC, Pohlman AS, et al. Early physical and occupational therapy in mechanically ventilated, critically ill patients: a randomized controlled trial. *Lancet* 2009;373:1874–1882.
7. Kleinpell, RM, Ely EW, Grabenkort R. Nurse practitioners and physician assistants in the intensive care unit: an evidence-based review. *Critical Care Med* 2008;36:2888–2897.
8. Yoo EJ, Edwards JD, Dean ML, et al. Multidisciplinary critical care and intensivist staffing: results of a statewide survey and association with mortality. *J Inten Care Med* 2014;1–8.
9. Wilcox, ME, Chong CA, Niven DJ, et al. Do intensivist staffing patterns influence hospital mortality following ICU admission? A systematic review and meta-analyses. *Crit Care Med* 2013;41:2253–2274.
10. Sluis FJ, Slagt C, Liebman B, et al. The impact of open versus closed format ICU admission practices on the outcome of high risk surgical patients: a cohort analysis. *BMC Surg* 2011;11:18.
11. Gutsche JT, Kohl BA. Who should care for intensive care unit patients? *Crit Care Med* 2007;35(2 Suppl):S18–S23.
12. Iyegha UP, Asghar JI, Habermann EB, et al. Intensivists improve outcomes and compliance with process measures in critically ill patients. *J Am Coll Surg* 2013;216:363–372.
13. The Joint Commission. *The 2015 Accreditation Manual for Hospitals: The Official Handbook*. Oakbrook Terrace, IL: Joint Commission Resources; 2014.
14. Burnhan EL, Moss M, Geraci MW. The case for 24/7 in-house intensivist coverage. *Am J Respir Crit Care Med* 2010;181:1159–1160.
15. Wilden GM, Schmidt U, Chang Y, et al. Implementation of 24/7 intensivist presence in the SICU: effect on processes of care. *J Trauma Acute Care Surg* 2013;74:563-567.

16. Kumar K, Singal R, Manji R, et al. The benefits of 24/7 in-house intensivist coverage for prolonged-stay cardiac surgery patients. *J Thoracic and Cardiovascular Surg* 2014;148(1):290–297.
17. Kerlin MP, Small DS, Cooney E, et al. A randomized trial of nighttime physician staffing in an intensive care unit. *N Engl J Med* 2013;368:2201–2209.
18. Wallace DJ, Angus DC, Barnato AE, et al. Nighttime intensivist staffing and mortality among critically ill patients. *N Engl J Med* 2012;366:2093–2101.
19. Ward NS, Afessa B, Kleinpell R, et al. Intensivist/patient ratios in closed ICUs: a statement from the society of critical care medicine taskforce on ICU staffing. *Crit Care Med* 2013;41:638–645.
20. Dellinger RP, Levy MM, Rhodes A, et al. Surviving sepsis campaign: international guidelines for management of severe sepsis and septic shock: 2012. *Crit Care Med* 2013;41:580.
21. Vincent JL. Give your patient a fast hug (at least) once a day. *Crit Care Med* 2005;33(6);1225–1230.
22. Pronovost P, Berenholtz S, Dorman T, et al. Improving communication in the ICU using daily goals. *J Crit Care* 2003;18(2):71–75.
23. Pronovost P, Needham D, Berenholtz S, et al. An intervention to decrease catheter-related bloodstream infections in the ICU. *N Engl J Med* 2006; 355:2725–2732.
24. Ferrer R, Artigas A, Levy MM, et al. Improvement in process of care and outcome after a multicenter severe sepsis educational program in Spain. *JAMA* 2008;299:2294–2303.
25. van Zanten AR, Brinkman S, Arbous MS, et al. Guidelines bundles adherence and mortality in severe sepsis and septic shock. *Crit Care Med* 2014;42(8):1890–1898.
26. Blot, K, Bergs J, Vogelaers D, et al. Prevention of central line-associated bloodstream infections through quality improvement interventions: a systemic review and meta-analysis. *Clin Infect Disease* 2014;59(1):96–105.
27. Carrothers KM, Barr J, Spurlock B, et al. Contextual issues influencing implementation and outcomes associated with an integrated approach to managing pain, agitation and delirium in adult ICUs. *Crit Care Med* 2013;41:S128–S135.
28. Salluh JI, Soares M. ICU severity of illness scores: APACHE, SAPS and MPM. *Curr Opin Crit Care* 2014;20:557–565.
29. Zimmerman JE, Kramer AA, McNair DS, et al. Acute physiology and chronic health evaluation (APACHE) IV: hospital mortality assessment for today's critically ill patients. *Crit Care Med* 2006;34:1297–1310.
30. Moreno RP, Metnitz PG, Almeida E, et al. SAPS 3 – From evaluation of the patient to evaluation of the intensive care unit. *Inte Care Med* 2005;31:1345–1355.
31. Higgins TL, Teres D, Copes WS, et al. Assessing contemporary intensive care unit outcome: an updated Mortality Probability Admission Model (MPM0-III). *Crit Care Med* 2007;35:1853–1862.

32. Wysham NG, Abernethy AP, Cox CE. Setting the vision: applied patient-reported outcomes and smart, connected digital healthcare systems to improve patient-centered outcomes prediction in critical illness. *Curr Opin in Crit Care* 2014;20:566–572.
33. Marshall JC, Cook DJ, Christon NV, et al. Multiple organ dysfunction score: a reliable descriptor of a complex clinical outcome. *Crit Care Med* 1995;23(10);1635–1652.
34. Moore FA, Sauaia A, Moore EE, et al. Postinjury multiple organ failure: a bimodal phenomenon. *J Trauma* 1996;40:501–502.
35. Marik PE, Cavallazzi R. Does the central venous pressure predict fluid responsiveness? An updated meta-analysis and a plea for some common sense. *Crit Care Med* 2013;41:1774–1781.
36. The ProCESS Investigators. A randomized trial of protocol-based care for early septic shock. *N Engl J Med* 2014;370(18):1685–1693.
37. The ARISE Investigators and the ANZICS Clinical Trials Group. Goal-directed resuscitation for patients with early septic shock. *N Engl J Med* 2014;371:1496–1506.
38. National Heart, Lung and Blood Institute Acute Respiratory Distress Syndrome (ARDS) Clinical Trials Network, Wiedmann HP, Wheeler AP, et al. Comparison of two fluid-management strategies in acute lung injury. *N Engl J Med* 2006;354:2564–2575.
39. Lavrentieva A, Kontakiotis T, Kaimakamis E, et al. Evaluation of arterial waveform derived variables for an assessment of volume resuscitation in mechanically ventilated burn patients. *Burns* 2013;39(2):249–254.
40. Barbier C, Loubieres Y, Scmit C, et al. Respiratory changes in inferior vena cava diameter are helpful in predicting fluid responsiveness in ventilated septic patients. *Intens Care Med* 2004;30:1740–1746.
41. Anantharaman V, Gunasegaran K. Advance Cardiac Life Support guidelines 2011. *Singapore Med J* 2011;52(8):548–555.
42. Futier E, Constantin JM, Paugam-Burtz C, et al. A trial of intraoperative low-tidal-volume ventilation in abdominal surgery. *N Engl J Med* 2013; 369(5):428–437.
43. Levine S, Nguyen T, Taylor N, et al. Rapid disuse atrophy of diaphragm fibers in mechanically ventilated humans. *N Engl J Med* 2008;358(13):1327–1335.
44. Bernard GR, Artigas A, Brigham KL, et al. The American-European consensus conference on ARDS. Definitions, mechanisms, relevant outcomes and clinical trial coordination. *Am J Respir Crit Care Med* 1994;149:818–824.
45. ARDS Definition Task Force, Ranieri VM, Rubenfeld GD, et al. Acute respiratory distress syndrome: the Berlin Definition. *JAMA* 2012;307:2526–2533.
46. The Acute Respiratory Distress Syndrome Network. Ventilation with lower tidal volumes as compared with traditional tidal volumes for acute lung injury and the acute respiratory distress syndrome. *N Engl J Med* 2000;342(18):1301–1308.

47. Brower RG, Lanken PN, MacIntyre N, et al. Higher versus lower positive end-expiratory pressures in patients with the acute respiratory distress syndrome. *N Engl J Med* 2004;351(4):327–336.
48. Meade MO, Cook DJ, Guyatt GH, et al. Ventilation strategy using low tidal volumes, recruitment maneuvers and high positive end-expiratory pressure for acute lung injury and acute respiratory distress syndrome: a randomized controlled trial. *JAMA* 2008;299:637–645.
49. Mercat A, Richard JM, Vielle B, et al. Positive end-expiratory pressure setting in adults with acute lung injury and acute respiratory distress syndrome (EXPRESS). *JAMA* 2008;299:646–655.
50. Santa Cruz R, Rojas JI, Nervi R, et al. High versus low positive end-expiratory pressure (PEEP) levels for mechanically ventilated adult patients with acute lung injury and acute respiratory distress syndrome. *Cochrane Database Syst Rev* 2013;6:CD009098.
51. Young D, Lamb SE, Shah S, et al. High-frequency oscillation for acute respiratory distress syndrome. *N Engl J Med* 2013;368(9):806–813.
52. Ferguson ND, Cook DJ, Guyatt GH, et al. High-frequency oscillation in early acute respiratory distress syndrome. *N Engl J Med* 2013;368(9):795–805.
53. Dart BW, Maxwell RA, Richart CM, et al. Preliminary experience with airway pressure release ventilation in a trauma/surgical intensive care unit. *J Trauma* 2005;59(1):71–76.
54. Kaplan LJ, Bailey H, Formosa V. Airway pressure release ventilation increases cardiac performance in patients with acute lung injury/adult respiratory distress syndrome. *Crit Care* 2001;5(4):221–226.
55. Putensen C, Zech S, Wrigge H, et al. Long-term effects of spontaneous breathing during ventilator support in patients with acute lung injury. *Am J Respir Crit Care Med* 2001;164(1):43–49.
56. Peek GJ, Mugford M, Tiruvoipati R, et al. Efficacy and economic assessment of conventional support versus extracorporeal membrane oxygenation for severe adult respiratory failure (CESAR): a multicenter randomized controlled trial. *Lancet* 2009;374(9698):1351–1363.
57. Melsen WG, Rovers MM, Koeman M, et al. Estimating the attributable mortality of ventilator-associated pneumonia from randomized prevention studies. *Crit Care Med* 2011;39(12):2736–2742.
58. Boyer AF, Schoenberg N, Babcock H, et al. A prospective evaluation of ventilator-associated conditions and infection-related ventilator-associated conditions. *Chest* 2014;147(1):68–81.
59. Yang KL, Tobin MJ. A prospective study of indexes predicting outcome of trials of weaning from mechanical ventilation. *N Engl J Med* 1991;324(21):1445–1450.
60. McCaffrey J, Farrell C, Whiting P, et al. Corticosteroids to prevent extubation

failure: a systemic review and meta-analysis. *Intensive Care Med* 2009;35(6):977–986.

61. Afshari A, Brok J, Moller AM, et al. Inhaled nitric oxide for acute respiratory distress syndrome (ARDS) and acute lung injury in children and adults. *Cochrane Database Syst Rev* 2010;(7):CD002787.
62. Adhikari NK, Dellinger RP, Lundin S, et al. Inhaled nitric oxide does not reduce mortality in patients with acute respiratory distress syndrome regardless of severity: systemic review and meta-analysis. *Crit Care Med* 2014;42(2):404–412.
63. Domenighetti G, Stricker H, Waldispuehl B. Nebulized prostacyclin (PGI2) in acute respiratory distress syndrome: impact of primary (pulmonary injury) and secondary (extrapulmonary injury) disease on gas exchange response. *Crit Care Med* 2001;29(1):57–62.
64. Guerin C, Reignier J, Richard JC, et al. PROSEVA study group. Prone positioning in severe acute respiratory distress syndrome. *N Engl J Med* 2013;368:2159–2168.
65. Sud S, Freidrich JO, Adhikari NK, et al. Effect of prone positioning during mechanical ventilation on mortality among patients with acute respiratory distress syndrome: a systemic review and meta-analysis. *CMAJ* 2014;186(10):E381–E390.
66. Lee, SJ, Ramar K, Park JG, et al. Increased fluid administration in the first three hours of sepsis resuscitation is associated with reduced mortality: a retrospective cohort study. *Chest* 2014;146:908–915.
67. Sweet D, Marsden J, Ho K, et al. Emergency management of sepsis: the simple stuff saves lives. *BCMJ* 2012;54(4):176–182.
68. Bioc JJ, Magee C, Cucchi J, et al. Cost effectiveness of benzodiazepine vs. nonbenzodiazepine – based sedation regimen for mechanically ventilated, critically ill adults. *J Crit Care* 2014;29(5):753–757.
69. Jakob SM, Ruokonen E, Grounds RM, et al. Dexmedetomidine vs. midazolam or propofol for sedation during prolonged mechanical ventilation. *JAMA* 2012;307(11):1151–1160.
70. Papazian L, Forel JM, Gacouin A, et al. Neuromuscular blockers in early acute respiratory distress syndrome. *N Engl J Med* 2010;363(12):1107–1116.
71. Needham CJ, Brindley PG. Best evidence in critical care medicine: the role of neuromuscular blocking drugs in early severe acute respiratory distress syndrome. *Can J Anaesth* 2012;59(1):105–108.
72. Horlander KT, Mannino DM, Leeper KV. Pulmonary embolism mortality in the United States, 1979 – 1998. *Arch Intern Med* 2003;163:1711–1717.
73. Munoz FJ, Mismetti P, Poggio R, et al. Clinical outcome of patients with upper-extremity deep vein thrombosis: results from the RIETE registry. *Chest* 2008;133(1):143–148.
74. Geerts WH, Pineo GF, Heit JA, et al. Prevention of venous thromboembolism: the Seventh ACCP Conference on Antithrombotic and Thrombolytic Therapy. *Chest* 2004;126(3 Suppl):338S–400S.

75. Douketis JD, Spyropoulos AC, Spencer FA, et al. Perioperative management of antithrombotic therapy: antithrombotic Therapy and Prevention of Thrombosis, 9th ed: American College of Chest Physicians Evidence-Based Clinical Practice Guidelines. *Chest* 2012;141(2 Suppl):e326S–e 350S.
76. Caprini JA. Risk assessment as a guide to thrombosis prophylaxis. *Curr Opin Pulm Med* 2010;16:448–452.
77. Christie S, Thibault-Halman G, Casha S. Acute pharmacologic DVT prophylaxis after spinal cord injury. *J Neurotrauma* 2011;28(8):1509–1514.
78. Ho KM, Tan JA. Stratified meta-analysis of intermittent pneumatic compression of the lower limbs to prevent venous thromboembolism in hospitalized patients. *Circulation* 2013;128(9):1003–1020.
79. Geerts WH, Jay RM, Code KI, et al. A comparison of low-dose heparin with low-molecular-weight heparin as prophylaxis against venous thromboembolism after major trauma. *N Engl J Med* 1996;335:701–707.
80. PROTECT investigators for the Canadian critical care trials group and the Australian and New Zealand intensive care society clinical trials group, Cook D, Meade M, et al. Dalteparin versus unfractionated heparin in critically ill patients. *N Engl J Med* 2011;364(14):1305–1314.
81. Dudley RR, Aziz I, Bonnici A, et al. Early venous thromboembolic event prophylaxis in traumatic brain injury with low-molecular-weight heparin: risks and benefits. *J Neurotrauma* 2010;27:2165–2172.
82. Jamjoom AA, Jamjoom AB. Safety and efficacy of early pharmacological thromboprophylaxis in traumatic brain injury: systematic review and meta-analysis. *J Neurotrauma* 2013;30(7):503–511.
83. Corwin HL, Gettinger A, Pearl RG, et al. The CRIT Study: Anemia and blood transfusion in the critically ill – current clinical practice in the United States. *Crit Care Med* 2004;32(1):39–52.
84. Hebert PC, Wells G, Blajchman MA, et al. A multicenter, randomized, controlled clinical trial to transfusion requirements in critical care. Transfusion requirement in critical care investigators, Canadian critical care trials group. *N Engl J Med* 1999;340:409–417.
85. Hebert PC, Yetisir E, Martin C, et al. Is a low transfusion threshold safe in critically ill patients with cardiovascular disease? *Crit Care Med* 2001;29(2):227–234.
86. Leal-Noval SR, Munoz-Gomez M, Jimenez-Sanchez M, et al. Red cell transfusion in non-bleeding critically ill patients with moderate anemia: is there a benefit?*Int Care Med* 2013;39:445–453.
87. RELIEVE Investigators, Walsh TS, Boyd JA, et al. Restrictive versus liberal transfusion strategies for older mechanically ventilated critically ill patients: a randomized pilot trial. *Crit Care Med* 2013;41(10):2354–2363.
88. Chatterjee S, Wetterslev J, Sharma A, et al. Association of blood transfusion with

increased mortality in myocardial infarction: a meta-analysis and diversity-adjusted study sequential analysis. *JAMA Intern Med* 2013;173(2):132–139.

89. Murphy GJ, Reeves BC, Rogers CA, et al. Increased mortality, postoperative morbidity and cost after red blood cell transfusion in patients having cardiac surgery. *Circulation* 2007;116:2544–2552.
90. Paone G, Likosky DS, Brewer R, et al. Transfusion of 1 and 2 units of red blood cells is associated with increased morbidity and mortality. *Ann Thorac Surg* 2014;97(1):87–93; discussion 93–94.
91. Hajjar LA, Vincent JL, Galas FR, et al. Transfusion requirements after cardiac surgery: the TRACS randomized controlled trial. *JAMA* 2010;304(14):1559–1567.
92. Villanueva C, Colomo A, Bosch A, et al. Transfusion strategies for acute upper gastrointestinal bleeding. *N Engl J Med* 2013;368(1):11–21.
93. Robertson CS, Hannay HJ, Yamal JM, et al. Effect of erythropoietin and transfusion threshold on neurological recovery after traumatic brain injury: a randomized clinical trial. *JAMA* 2014;312(1):36–47.
94. Holst LB, Haase N, Wetterslev J, et al. Lower versus higher hemoglobin threshold for transfusion in septic shock. *N Eng J Med* 2014;371(15):1381–1391.
95. Corwin HL. Erythropoietin use in critically ill patients: forest and trees. *CMAJ* 2007;177(7):747–749.
96. Munoz M, Breymann C, Garcia-Erce JA, et al. Efficacy and safety of intravenous iron therapy as an alternative/adjunct to allogenic blood transfusion. *Vox Sanguinis* 2008;94:172–183.
97. McClave SA, Martindale RG, Vanek VW, et al. Guidelines for the provision and assessment of nutrition support therapy in the adult critically ill patient: society of critical care medicine (SCCM) and American society for parenteral and enteral nutrition (ASPEN). *JPEN J Parenter Enteral Nutr* 2009;33:277–316.
98. National Heart, Lung and Blood Institute Acute Respiratory Distress Syndrome (ARDS) Clinical Trials Network, Rice TW, Wheeler AP, et al. Initial trophic vs. full enteral feeding in patients with acute lung injury: the EDEN randomized trial. *JAMA.* 2012; 307:795.
99. McClave SA, Lukan JK, Stefater JA, et al. Poor validity of residual volumes as a marker for risk of aspiration in critically ill patients. *Crit Care Med* 2005;33(2):324–330.
100. Heyland DK, Novak F. Immunonutrition in the critically ill patients: more harm than good? *JPEN J Parenter Enteral Nutr* 2001;25(2 Suppl):S51–S55; discussion S55–S56.
101. Luiking YC, Engelen MP, Deutz NE. Regulation of nitric oxide production in health and disease. *Curr Opin Clin Nutr Metab Care* 2010;13:97–104.
102. Ho KM, Dobb GJ, Webb SA. A comparison of early gastric and post-pyloric feeding in critically ill patients: a meta-analysis. *Intens Care Med* 2006;32:639–649.
103. Prelack K, Dylewski M, Sheridan RL. Practical guidelines for nutritional management

of burn injury and recovery. *Burns* 2007;33(1):14–24.

104. Burlew CC, Moore EE, Cuschieri J, et al. Who should we feed? Western Trauma Association multi-institutional study of enteral nutrition in the open abdomen after injury. *J Trauma Acute Care Surg* 2012;73(6):1380–1387.
105. Heyland DK, Dhaliwal R, Drover JW, et al. Canadian clinical practice guidelines for nutrition support in mechanically ventilated, critically ill adult patients. *JPEN J Parenter Enteral Nutr* 2003;27(5):355–373.
106. Desai SV, McClave SA, Rice TD. Nutrition in the ICU: an evidence-based approach. *Chest* 2014;145(5):1148–1157.
107. Dhaliwal R, Heyland DK. Nutrition and infection in the intensive care unit: what does the evidence show? *Curr Opin Crit Care* 2005;11(5):461–467.
108. Khalid I, Doshi P, DiGiovine B. Early enteral nutrition and outcomes of critically ill patients treated with vasopressors and mechanical ventilation. *Am J Crit Care* 2010;19(3):261–268.
109. Yang S, Wu X, Yu W, et al. Early enteral nutrition in critically ill patients with hemodynamic instability: an evidence-based review and practical advice. *Nutr Clin Pract* 2014;20(1):90–96.
110. National Heart, Lung and Blood Institute Acute Respiratory Distress Syndrome (ARDS) Clinical Trials Network, Rice TW, Wheeler AP, et al. Initial trophic vs. full enteral feeding in patients with acute lung injury: the EDEN randomized trial. *JAMA* 2012;307(8):795–803.
111. Casaer MP, Mesotten D, Hermas G, et al. Early versus late parenteral nutrition in critically ill adults. *NEJM* 2011;365:506–517.
112. Sena MJ, Utter GH, Cuschieri J, et al. Early supplemental parenteral nutrition is associated with increased infectious complications in critically ill trauma patients. *J Am Coll Surg* 2008;207(4):459–467.
113. Heidegger CP, Berger MM, Graf S, et al. Optimization of energy provision with supplemental nutrition in critically ill patients: a randomized controlled clinical trial. *Lancet* 2013;381(9864):385–393.
114. CALORIES Trial Investigators, Harvey SE, Parrott F, et al. Trial of the route of early nutritional support in critically ill adults. *N Engl J Med* 2014; 371(18):1673–1684.
115. Heyland D, Muscedere J, Wischmeyer PE, et al. A randomized trial of glutamine and antioxidants in critically ill patients. *N Engl J Med* 2013; 368(16):1489–1497.
116. Palmer AJ, Ho CK, Ajibola O, et al. The role of omega 3 fatty acid supplemented parenteral nutrition in critical illness in adults: a systemic review and meta-analysis. *Crit Care Med* 2013;41(1):307–316.
117. Manzanares W, Dhaliwal R, Juresitsch B, et al. Parenteral fish oil lipid emulsions in the critically ill: a systemic review and meta-analysis. *JPEN J Parenter Enteral Nutr* 2014;38(1):20–28.
118. Van Zanten AR, Sztark F, Kaisers UX, et al. High-protein enteral nutrition with

immune-modulating nutrients vs. standard high-protein enteral nutrition and nosocomial infections in the ICU: a randomized clinical trial. *JAMA* 2014;312(5):514–524.

119. Al-Omran M, Albalawi ZH, Tashkandi MF, et al. Enteral versus parenteral nutrition for acute pancreatitis. *Cochrane Database Syst Rev* 2010;(1):CD002837.
120. Cook DJ, Fuller HD, Guyatt GH, et al. Risk factors for gastrointestinal bleeding in critically ill patients. Canadian Critical Care Trials Group. *N Engl J Med* 1994;330(6):377.
121. Marik PE, Vasu T, Hirani A, et al. Stress ulcer prophylaxis in the new millennium: a systematic review and meta-analysis. *Crit Care Med* 2010;38(11):2222–2228.
122. Leontiadis GI, Sharma VK, Howden CW. Systemic review and meta-analysis of proton pump inhibitor therapy in peptic ulcer bleeding. *BMJ* 2005;330(7941):568.
123. Kasotakis G, Sideris A, Yang Y, et al. Aggressive early crystalloid resuscitation adversely affects outcomes in adult blunt trauma patients: an analysis of the Glue Grant database. *J Trauma Acute Care Surg* 2013;74(5):1215–1221.
124. Bellomo R, Ronco C, Kellum JA, et al. Acute Renal Failure – definition, outcome measures, animal models, fluid therapy and information technology needs: the Second International Consensus Conference of the Acute Dialysis Quality Initiative (ADQI) Group. *Crit Care* 2004;8(4):R204–R212.
125. Mehta RL, Kellum JA, Shah SV, et al. Acute Kidney Injury Network: report of an initiative to improve outcomes in acute kidney injury. *Crit Care* 2007;11(2):R31.
126. KDIGO clinical practice guidelines for acute kidney injury. *Kidney Int Suppl* 2012;2:8.
127. Au TH, Bruckner A, Mohiuddin SM, et al. The prevention of contrast-induced nephropathy. *Ann Pharmacother* 2014;48(10):1332–1342.
128. Scharman EJ, Troutman WG. Prevention of kidney injury following rhabdomyolysis: a systemic review. *Ann Pharmacotherapy* 2013;47(1):90–105.
129. Chen HH, Anstrom KJ, Givertz MM, et al. Low-dose dopamine or low-dose nesiritide in acute heart failure with renal dysfunction. The ROSE acute heart failure randomized trial. *JAMA* 2013;310(23):2533–2543.
130. Joannidis M, Drumli W, Forni LG. Prevention of acute kidney inury and protection of renal function in the intensive care unit. *Int Care Med* 2010;36:392–411.
131. Wu MY, Chang NC, Su CL, et al. Loop diuretic strategies in patients with acute decompensated heart failure: a meta-analysis of randomized controlled trials. *J Crit Care* 2014;29:2–9.
132. Ejaz AA, Mohandas R. Are diuretics harmful in the management of acute kidney injury? *Curr Opin Nephrol Hypertens* 2014;23(2):155–160.
133. Algahtani F, Koulouridis I, Susantitaphong P, Dahal K, et al. A meta-analysis of continuous vs. intermittent infusion of loop diuretics in hospitalized patients. *J Crit Care* 2014;29(1):10–17.
134. Palazzuoli A, Pellegrini M, Ruocco G, et al. Continuous versus bolus intermittent

loop diuretic infusion in acutely decompensated heart failure: a prospective randomized trial. *Crit Care* 2014;18(3):R134.

135. Finfer S, Cass A, Gallagher M, et al. The RENAL (Randomised Evaluation of Normal vs. Augmented Level of Replacement Therapy) study: statistical analysis plan. *Crit Care Resus;*11(1):58–66.
136. VA/NIH Acute Renal Failure Trial Network, Palevsky PM, Zhang JH, et al. Intensity of renal support in critically ill patients with acute kidney injury. *N Engl J Med* 2008;359(1):7–20.
137. Ricci Z, Ronco C. Timing, dose and mode of dialysis in acute kidney injury. *Curr Opin Crit Care* 2011;17:556–561.
138. Joannes-Boyau O, Honore PM, Perez P, et al. High-volume versus standard-volume hemofiltration for septic shock patients with acute kidney injury (IVOIRE study): a multicenter randomized controlled trial. *Int Care Med* 2013;39:1535–1546.
139. Schneider AG, Bellomo R, Bagshaw SM, et al. Choice of renal replacement therapy modality and dialysis dependence after acute kidney injury: a systemic review and meta-analysis. *Intensive Care Med* 2013;39:987–997.
140. Rauf AA, Long KH, Gajic O, et al. Intermittent hemodialysis versus continuous renal replacement therapy for acute renal failure in the intensive care unit: an observational outcomes analysis. *J Intensive Care Med* 2008;23(3):195–203.
141. Bochicchio GV, Sung J, Joshi M, et al. Persistent hyperglycemia is predictive of outcome in critically ill trauma patients. *J Trauma* 2005;58:921–924.
142. Jeremitsky E, Omert LA, Dunham CM, et al. The impact of hyperglycemia on patients with severe brain injury. *J Trauma* 2005;58:47–50.
143. Krinsley JS. Association between hyperglycemia and increased hospital mortality in a heterogeneous population of critically ill patients. *Mayo Clin Proc* 2003;78:1471–1478.
144. Van den Berghe G, Wouters P, Weekers F, et al. Intensive insulin therapy in critically ill patients. *N Engl J Med* 2001;345:1359.
145. Preiser JC, Devos P, Ruiz-Santana S, et al. A prospective randomized multi-centre controlled trial on tight glucose control by intensive insulin therapy in adult intensive care units: the Glucontrol study. *Intensive Care Med* 2009;35(10):1738–1748.
146. NICE-SUGAR Study Investigators, Finfer S, Chittock DR, et al. Intensive versus conventional glucose control in critically ill patients. *N Engl J Med* 2009;360(13):1283–1297.
147. Egi M, Finfer S, Bellomo R. Glycemic control in the ICU. *Chest* 2011;140(1):212–220.
148. Burry LD, Wax RS. Role of corticosteroids in septic shock. *Ann Pharmacother* 2004;38(3):464–472.
149. Annane D, Sebille V, Troche G, et al. A 3-level prognostic classification in septic shock based on cortisol levels and cortisol response to corticotropin. *JAMA* 2000;283:1038–1045.

150. Annane D, Sebille V, Charpentier C, et al. Effect of treatment with low doses of hydrocortisone and fludrocortisone on mortality in patients with septic shock. *JAMA* 2002;288:862–871.
151. The CORTICUS Study Group, Sprung CL, Annane D, et al. Hydrocortisone therapy for patients with septic shock. *N Engl J Med* 2008;358:111–124.
152. Annane D, Bellissant E, Bollaert PE, et al. Corticosteroids in the treatment of severe sepsis and septic shock in adults: a systemic review. *JAMA* 2009;301(22):2362–2375.
153. Minneci PC, Deans KJ, Eichacker PQ, et al. The effects of steroids during sepsis depend on dose and severity of illness: an updated meta-analysis. *Clin Microbiol Infect* 2009;15(4):308–318.
154. Gordon AC, Mason AJ, Perkins GD, et al. The interaction of vasopressin and corticosteroids in septic shock: a pilot randomized controlled trial. *Crit Care Med* 2014;42(6):1325–1333.
155. Malerba G, Romano-Girard F, Cravoisy A, et al. Risk factors of relative adrenocortical deficiency in intensive care patients needing mechanical ventilation. *Intensive Care Med* 2005;31(3):388–392.
156. Rivers E, Nguyen B, Havsted S, et al. Early goal-directed therapy in the treatment of severe sepsis and septic shock. *N Engl J Med* 2001;345:1368–1377.
157. Kopterides P, Siempos II, Tsangaris I, et al. Procalcitonin-guided algorithms of antibiotic therapy in the intensive care unit: a systematic review and meta-analysis of randomized controlled trials. *Crit Care Med* 2010;38(11):2229–2241.
158. Heyland DK, Johnson AP, Reynolds SC, et al. Procalcitonin for reduced antibiotic exposure in the critical care setting: a systemic review and an economic evaluation. *Crit Care Med* 2011;39(7):1792–1799.
159. Stolz D, Smyrnios N, Eggimann P, et al. Procalcitonin for reduced antibiotic exposure in ventilator-associated pneumonia: a randomized study. *Eur Respir J* 2009;34(6):1364–1375.
160. Bouadma L, Luyt CE, Tubach F, et al. Use of procalcitonin to reduce patients' exposure to antibiotics in intensive care units (PRORATA trial): a multicenter randomized controlled trial. *Lancet* 2010;375(9713):463–474.
161. Tang HJ, Lin HL, Lin YH, et al. The impact of central line insertion bundle on central line-associated bloodstream infection. *BMC Infectious Diseases* 2014;14:356.
162. Safdar N, O'Horo JC, Ghufran A, et al. Chlorhexidine-impregnated dressing for prevention of catheter-related bloodstream infection: a meta-analysis. *Crit Care Med* 2014;42(7):1703–1713.
163. Lam TB, Omar MI, Fisher E, et al. Types of indwelling urethral catheters for short term catherisation in hospitalized adults. *Cochrane Database Syst Rev* 2014;9:CD004013.
164. Srinivasan A, Karchmer T, Richards A, et al. A prospective trial of a novel, silicone-based, silver ion-impregnated urinary catheters in the prevention of nosocomial

urinary tract infections (NUTIs). *Infect Control Hosp Epidemiol* 2006;27(1):38–43.

165. Liberati A, D'Amico R, Pifferi S, et al. Antibiotic prophylaxis to reduce respiratory tract infections and mortality in adults receiving intensive care. *Cochrane Database Syst Rev* 2009;(4):CD000022.
166. Silvestri L, Weir I, Gregori D, et al. Effectiveness of oral chlorhexidine on nosocomial pneumonia, causative micro-organisms and mortality in critically ill patients: a systemic review and meta-analysis. *Minerva Anestesiol* 2014;80(7):805–820.
167. De Smet AM, Kluytmans JA, Cooper BS, et al. Decontamination of the digestive tract and oropharynx in ICU patients. *N Engl J Med* 2009;360:20–31.
168. Oostdijk EA, Kesecioglu J, Schultz MJ, et al. Effects of decontamination of the oropharynx and intestinal tract on antibiotic resistance in ICUs: a randomized clinical trial. *JAMA* 2014;312(14):1429–1437.
169. Jain R, Kralovic SM, Evans ME, et al. Veterans' affairs initiative to prevent methicillin-resistant staphylococcus aureus infections. *N Engl J Med* 2011;364(15):1419–1430.
170. Harbath S, Fankhauser C, Schrenzel J, et al. Universal screening for methicillin-resistant staphylococcus aureus at hospital admission and nosocomial infection in surgical patients. *JAMA* 2008;299(10):1149–1157.
171. Huskins WC, Huckabee CM, O'Grady NP, et al. Intervention to reduce transmission of resistant bacteria in intensive care. *N Engl J Med* 2011;364(15):1407–1418.
172. Singh N, Squier C, Wannstedt C, et al. Impact of an aggressive infection control strategy on endemic staphylococcus aureus infection in liver transplant recipients. *Infect Control Hosp Epidemiol* 2006;27(2):122–126.
173. Sandri AM, Dalarosa MG, Ruschel de AL, et al. Reduction in incidence of nosocomial methicillin-resistant staphylococcus aureus (MRSA) infection in an intensive care unit: role of treatment with mupirocin ointment and chlorhexidine baths for nasal carriers of MRSA. *Infect Control Hosp Epidemiol* 2006;27(2):185–187.
174. Haung SS, Septimus E, Kleinman K, et al. Targeted versus universal decolonization to prevent ICU infection. *N Engl J Med* 2013;368(24):2255–2265.

Chapter 11

Fluids, Electrolytes, and Acid–Base Balance

Richard B. Wait, M. George DeBusk, and Jeffry Nahmias

Key Points

1 The human body is conceptualized as being composed of two primary fluid compartments: extracellular fluid (ECF) and intracellular fluid (ICF). The two compartments are separated by cellular membranes.

2 The ECF can be further divided into smaller compartments: transcellular fluid, plasma, interstitial fluid, and bone/connective tissue fluid. Blood is a composite compartment containing both ECF (plasma) and ICF (red cell volume).

3 Sodium and potassium are the dominant cations of the ECF and ICF, respectively.

4 Extracellular tonicity is under tight regulation by osmoreceptors found in the hypothalamus. As sodium accounts for the majority of ECF tonicity, these receptors function essentially as ECF monitors.

5 Effective circulating volume is sensed by volume receptors (capacitance vessels, atria, hepatic, and central nervous system [CNS]) and pressure receptors (aortic arch, carotid, and intrarenal) that alter sodium and water balance mediated by renin–angiotensin, aldosterone, atrial natriuretic peptide (ANP), dopamine, and renal prostaglandins.

6 Water losses are composed of both sensible (i.e., measurable) losses via urine, stool, and sweat and insensible (i.e., immeasurable) via evaporative loss from the skin, respiratory tract, or open abdomen.

7 Goals of fluid therapy are to normalize body fluid compartment volumes and electrolyte concentrations. This can be achieved with crystalloid (preferable) or colloid infusion to correct deficits and/or match ongoing and expected losses.

8 The major electrolytes (Na^+, K^+, Ca^{2+}, Mg^{2+}, Cl^-, HCO_3^-, and HPO_4^{2-}) should be monitored and replaced, when possible, with respect to the pathophysiology of various disease states.

9 Acid–base balance is carefully buffered within very narrow limits. Acid–base disturbances are frequently mixed, involving combined respiratory and metabolic derangements.

In this chapter, the normal physiologic mechanisms of fluid and electrolyte homeostasis, inclusive of acid–base physiology, are reviewed. This will be the starting point for a discussion of fluid and electrolyte pathophysiology and the management of specific clinical situations. With a thorough understanding of disease- and injury-related alterations from normal fluid volume and electrolyte physiology, one can effectively care for all surgical and critically ill patients.

BODY FLUIDS

Total Body Water and Body Fluid Compartments

Total body water (TBW) is defined as the total amount of water contained within the body. The relationship between TBW and body weight varies according to the percentage of body fat.[1] The average TBW in adult men is 60% of total body weight and 55% in adult women. In infants, water makes up approximately 75% to 80% of body weight. This figure decreases to approximately 65% by 1 year of age and continues to decrease slowly throughout life, primarily related to decreases in lean body mass. Estimates of TBW can be empirically adjusted for the obese and thin body habitus. In obesity, estimates of TBW can be decreased by 10% to 20%. In very thin individuals, estimates can be increased by up to 10%.[1]

1 TBW is principally distributed into the intracellular and extracellular compartments which are in dynamic equilibrium (Table 11-1). ICF makes up approximately two-thirds of the TBW, and the remaining one-third is composed of ECF. Using these techniques, ECF volume estimates range from 30% to 33% of TBW, or approximately 20% of body weight.[2]

2 The ECF compartment is subdivided into the interstitial and intravascular spaces. The interstitial space extends from the blood vessels to the cells. It includes the complex ground substance making up the acellular tissue matrix. The water in this space exists in free and bound phases. The free phase contains water that is freely exchangeable with intravascular, lymphatic, and intracellular water. It is in a constant state of flux. The bound phase is much less freely exchangeable. It is composed of water that hydrates matrix materials such as glycosaminoglycans and mucopolysaccharides. Interstitial water volume can be calculated as ECF–intravascular space volume and constitutes approximately 25% of TBW, or 15% of body weight. The intravascular space accounts for 25% of the ECF and contains the plasma volume, which is approximately 8% of the TBW or 5% of body weight.

The transcellular space, a third and smaller component of ECF, consists of water that is separated from other compartments by endothelial and epithelial barriers, including cerebrospinal, ocular, and synovial fluids, as well as fluid in the gastrointestinal (GI) tract. Under normal circumstances, fluid in the transcellular space is not easily exchangeable with that in other compartments.[3]

Composition of Body Fluids

3 Sodium and potassium are the dominant cations in the body. As mentioned above, sodium is restricted primarily to the ECF. Sodium content in an average adult is approximately 60 mEq/kg. Approximately 25% is confined to bone and is nonexchangeable. Of the exchangeable fraction, approximately 85% is in the ECF. Potassium, calcium, and magnesium make up the remainder, smaller fraction, of the cations present in the ECF (Table 11-2).

Table 11-1 Body Fluid Compartments

	Body Weight (%)	Total Body Water (%)
Total	60	100
Intracellular	40	67
Extracellular	20	33
Intravascular	5	8
Interstitial	15	25
Transcellular	2	4

In the ICF, potassium is the dominant cation. Total body potassium is normally approximately 42 mEq/kg, and most of this potassium is intracellular and freely exchangeable. Magnesium and sodium ions also contribute to a lesser extent to the cationic component of the ICF. Phosphate, sulfate anions, bicarbonate, and intracellular proteins balance these cations.

The Gibbs–Donnan equilibrium describes the relationship between charged particles in a solution that are unevenly distributed across a semipermeable membrane.[4] This special type of equilibrium exists between the ICF and ECF because of the high concentration of protein and nondiffusible phosphates in the cell. ECF cations are in electrochemical balance with chloride, bicarbonate, phosphate, and sulfate anions, although chloride is the major contributor to this balance. In addition, anionic proteins contribute to ion balance in plasma but not in interstitial fluid, which is essentially an ultrafiltrate of plasma that normally contains little protein. As a result, the content of both cations and anions in interstitial fluid is slightly higher than in plasma (Table 11-2).

Interstitial fluid, in comparison, contains little protein. These impermeable intracellular negative charges tend to favor diffusion of permeable anions into the ECF. The Gibbs–Donnan equilibrium also exists across the capillary endothelial membrane because the concentration of protein is higher on the blood side of the capillary than on the interstitial fluid side. Thus, the concentrations of diffusible ions are not necessarily equal across these membranes because of the presence of these complex anions.

Table 11-2 Electrolyte Concentrations of Intracellular and Extracellular Fluid Compartments

	Extracellular Fluid (mEq/L)		
	Plasma	Interstitial	Intracellular Fluid (mEq/L)
Cations			
Na^+	140	146	12
K^+	4	4	150
Ca^{2+}	5	3	10^{-7}
Mg^{2+}	2	1	7
Anions			
Cl^-	103	114	3
HCO_3^-	24	27	10
SO_4^{2-}	1	1	—
HPO_4^{3-}	2	2	116
Protein	16	5	40
Organic anions	5	5	—

Osmotic Activity of Body Fluids

The concentration of solutes in the fluid compartments depends on the osmotic activity generated by the ion species contained in each compartment. When two solutions are separated by a semipermeable membrane, water moves across the membrane to equalize the concentration of osmotically active particles to which the membrane is impermeable. The maintenance of osmotic equilibrium across a semipermeable membrane is based primarily on the number of solute particles rather than on the molar concentration of the solution on each side of the membrane due to the flow of water.

The unit of measurement of osmotically active particles is the osmole (Osm) or milliosmole (mOsm) rather than the conventional units of solute concentration such as milliequivalents per liter (mEq/L). In solution, osmolarity (mOsm/L) and osmolality (mOsm/kg water) define the osmotic activity of particles. When 1 mol of NaCl dissociates in water to Na^+ and Cl^-, it produces 2 Osm. The same relationship holds true of dissociating salts of multivalent ions such as calcium and magnesium. One mol of a nondissociating molecule, such as glucose, produces 1 Osm (1,000 mOsm). The measured osmolality of a solution may not equal the calculated osmolality if the ions do not totally dissociate.

Body fluids are aqueous solutions composed of water and various solutes within the different body fluid compartments. Because cells are bounded by a semipermeable membrane, adding free water to the fluid surrounding a cell causes water to move across the cell membrane to equalize the osmolality differential between the intracellular and extracellular compartments. On a larger scale, adding free water to the ECF of the body causes an immediate expansion of the extracellular space, followed by a redistribution of water into the intracellular compartment (Fig. 11-1A). Conversely, loss of free water from the extracellular space ultimately leads to a shift of water from the intracellular to the extracellular space (Fig. 11-1B). An osmotic gradient of just 1 mOsm generates a pressure gradient of 19.3 mm Hg.

Colloid Oncotic Pressure (Colloid Osmotic Pressure)

Plasma proteins are confined primarily to the intravascular space and contribute to the osmotic pressure developed between the plasma and the interstitial fluid. Normal plasma protein levels of 7 g/dL contribute approximately 0.8 mOsm/L.

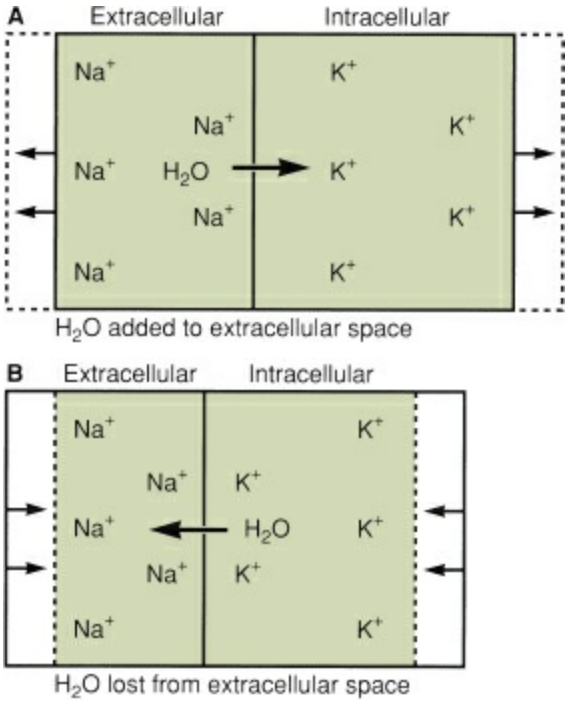

Figure 11-1. **A:** The equilibration of water from the extracellular to the intracellular space after the addition of free water to the extracellular fluid compartment. Osmolality transiently decreases in the extracellular compartment, causing water to move across the cell membranes into the intracellular space. **B:** Similar shifts after free water loss from the extracellular compartment. Water moves from the intracellular space to the extracellular space in response to the osmolal gradient that is established.

Osmoregulation

4 Osmolality of body fluids stays fairly constant at approximately 285 to 295 mOsm/L as the result of tightly regulated water balance. Osmoreceptor cells in the paraventricular and supraoptic nuclei of the hypothalamus exert central control over the thirst mechanism and antidiuretic hormone (ADH) secretion from the posterior pituitary.[5] In the presence of excess free water, ECF osmolality falls toward 280 mOsm/kg H_2O, thirst is inhibited, and ADH levels decline. In the absence of ADH, the permeability of renal collecting tubules to water is decreased, causing free water reabsorption to decrease and excretion to increase. Urine osmolality (U_{osm}) can decline to 50 mOsm/kg H_2O (Fig. 11-2). As excess free water is eliminated, P_{osm} begins to rise. Conversely, free water depletion causes an increase in P_{osm}. As P_{osm} approaches 295 mOsm/kg H_2O, thirst is stimulated as is ADH secretion. As ADH levels rise to approximately 5 pg/mL, the renal collecting tubules become maximally permeable to water. Water is reabsorbed from the collecting ducts in response to the concentration gradient developed in the renal medullary interstitium. Thus, the final concentration of urine depends on both the permeability of the collecting ducts (controlled by ADH secretion) and the concentration of the medullary interstitium.[5] Maximal U_{osm} may approach 1,200 mOsm/kg H_2O. The net effect of these mechanisms is to promptly return high or low P_{osm} to normal. The high sensitivity of the osmoreceptors and the responsiveness of the ADH feedback system ensure that even small changes in P_{osm} result in marked alterations in urine concentration. This relation can be expressed as follows:

$$\text{Urine osmolality} = 95 \times \text{Plasma osmolality}$$

Thus, a 1-mOsm change in P_{osm} results in a 95-fold change in U_{osm}.

Angiotensin II and neural input from medullary baroreceptors can also influence ADH secretion and thirst, thus tying water balance to hemodynamic alterations. Relatively small changes in pressure have little effect on ADH secretion, but large decreases in pressure can cause tremendous increases in ADH release. Therefore, ADH release as a response to changes in serum osmolality is regulated by a very sensitive system (only small changes in serum osmolality outside its normal range lead to dramatic changes in ADH release), while the nonosmotic release of ADH occurs in the setting of profound hypotension for the purposes of preserving volume homeostasis with the subsequent effect of water retention regardless of serum osmolality (Fig. 11-3).

Tonicity of Body Fluids

Tonicity refers to the effect of the particles on cell volume. (NB: O*smolality* defines the concentration of osmotically active particles in solution.) Permeable solutes can freely cross cell membranes, whereas impermeable solutes cannot. Although permeable solutes contribute to the osmolality of a solution, they have no effect on tonicity because they contribute neither to oncotic gradients across cell membranes nor to alterations in cell volume. Sodium is an example of an impermeable solute that affects both osmolality and tonicity. Urea and ethanol are permeable solutes that contribute to osmolality but have little effect on tonicity because they distribute equally across membranes.

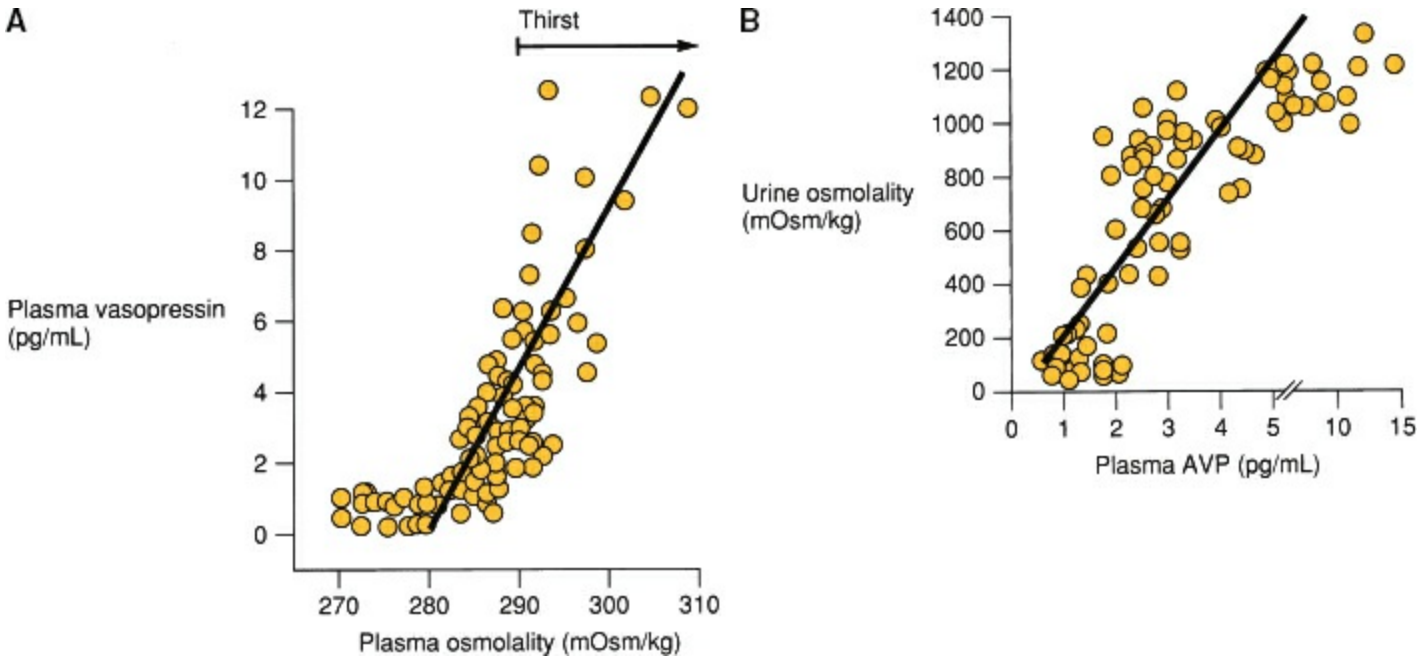

Figure 11-2. The relation of plasma antidiuretic hormone (arginine vasopressin [AVP]) secretion to plasma (**A**) and urine (**B**) osmolality in healthy adults in varying states of water balance. (Reproduced with permission from Robertson GL, Berl T. Water metabolism. In: Brenner BM, Rector FC Jr, eds. *The Kidney*. Philadelphia, PA: WB Saunders; 1986:392.)

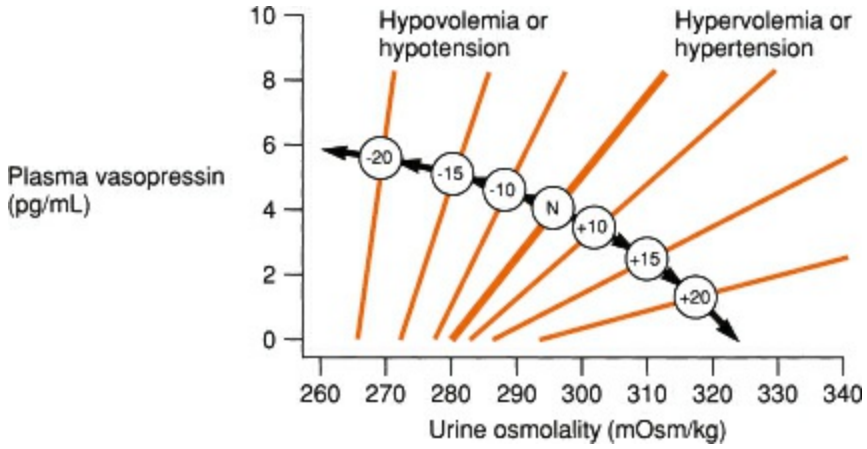

Figure 11-3. Effect of acute changes in blood volume or pressure on the osmoregulation of antidiuretic hormone (ADH; vasopressin). The heavy oblique line in the center represents the relation between plasma ADH and osmolality under normovolemic, normotensive conditions. The lines to the left and right show the shift in the relation when blood volume or blood pressure is acutely decreased or increased by the percentage indicated in the circles. (Reproduced with permission from Robertson GL. Physiology of ADH secretion. *Kidney Int* 1987;32(Suppl 21):520.)

Both impermeable and permeable solutes can contribute to *hyperosmolar* and *hypoosmolar* states. However, hypoosmolar states are always accompanied by hypotonicity, whereas hyperosmolar states are not always associated with hypertonicity. There may be marked hyperosmolality without hypertonicity with elevation of blood urea nitrogen (BUN) levels because urea is a freely permeable molecule. In contrast, elevated levels of plasma glucose in diabetic patients are associated with hyperosmolarity and associated hypertonicity. Insulin increases the transport of glucose across cell membranes, rendering these osmoles *ineffective* and reducing hypertonicity. Plasma hyperglycemia is associated with the movement of intracellular water to the extracellular space. This causes expansion of ECF and plasma volume and a consequent decrease in the concentration of plasma sodium. For every 100 mg/dL elevation in blood glucose, measured serum sodium is calculated to fall 1.5 mEq/L, without an actual alteration of body sodium content. The osmotic diuresis caused by the elevated glucose level tends to normalize the serum sodium if adequate hydration is maintained. Some patients with uncontrolled diabetes also have marked hyperlipidemia. Because of this, the concentration of measured sodium falls. This condition is termed *pseudohyponatremia,* an artifactual hyponatremia most commonly caused by severe hypertriglyceridemia, or by severe hyperproteinemia.

Plasma osmolality (P_{osm}) is an excellent measure of total body osmolality. Osmolality differentials between fluid compartments are only transient because fluid shifts maintain isosmotic conditions. Sodium is the predominant extracellular cation; thus, estimates of P_{osm} can be made by simply doubling the serum sodium concentration (serum $[Na^+]$):

$$P_{osm}\ (mOsm/L) = 2 \times \text{serum } [Na^+]$$

Because glucose and BUN may make significant contributions to P_{osm} in certain disease states, this formula is modified for glucose and for BUN:

$$P_{osm}\ (mOsm/L) = 2 \times \text{Serum } [Na^+] - \text{Glucose}/18 - \text{BUN}/2.8$$

Discrepancies of greater than 15 mOsm/L between calculated P_{osm} and P_{osm} measured in the clinical laboratory may be the result of the presence of other osmotically active particles, such as mannitol, ethanol, or ethylene glycol, or of a reduced fraction of plasma water secondary to high levels of myeloma proteins or hypertriglyceridemia.

FLUID BALANCE

Sodium Concentration and Water Balance

Abnormalities in serum sodium are usually indicative of abnormal TBW content. This is due to sodium being the primary extracellular cation. As potassium is the predominant intracellular cation, the serum $[Na^+]$ approximates the sum of the exchangeable total body sodium (Na^+_e) and total body exchangeable potassium (K^+_e) divided by TBW:

$$\text{Serum } [Na^+] = (Na^+_e - K^+_e)/\text{TBW}$$

Because the sum of total body solute content ($Na^+_e - K^+_e$) remains relatively stable over time, changes in TBW content is, therefore, inversely proportional to changes in the serum $[Na^+]$ (Fig. 11-4).

Volume Control

5 Changes in volume (i.e., hypovolemic/nonosmotic stimuli) are detected by both osmoreceptors and baroreceptors.[3] The osmoreceptors are responsible for the day-to-day fine-tuning of volume by responding to changes in tonicity, whereas the baroreceptors contribute relatively little to the control of fluid balance under normal conditions. As mentioned previously, large changes in circulating volume (10% to 20% blood volume loss) can modify the osmoregulation of ADH secretion. Cardiac atrial baroreceptors control volume by means of sympathetic and parasympathetic neural mechanisms, whereas ANP released by atrial myocytes in response to atrial wall distention may influence sodium-linked volume control by inhibition of renal sodium reabsorption.[6–8]

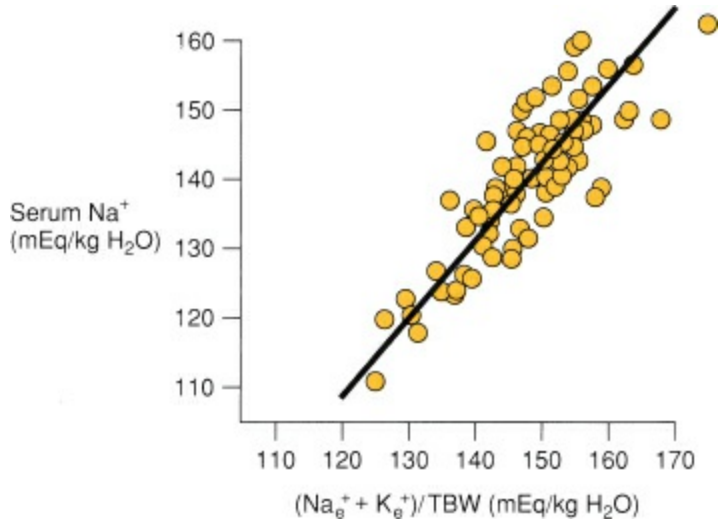

Figure 11-4. Relation between serum [Na^+] and the ratio of (Na^+_e + K^+_e) to total body water (TBW). (Reproduced with permission from Edelman IS, Liebman J, O'Meara MP, et al. Interrelationships between serum sodium concentration, serum osmolarity and total exchangeable sodium, total exchangeable potassium and total body water. *J Clin Invest* 1958;37:1236.)

Osmoreceptors

Specialized cells in the hypothalamus that respond to changes in extracellular tonicity are known as *osmoreceptors*. It is believed that the activity of ion channels in the cell membrane, aquaporins, and changes in cell volume contribute to the function of these receptors. As the majority of the ECF tonicity is contributed by sodium, under normal physiologic conditions, these receptors function as "osmo-sodium" receptors. Osmoreceptors can respond to changes in tonicity as small as a few percent. In effect, these receptors monitor water balance by monitoring the tonic effect of changes in water volume. Therefore, ECF [Na^+] is an effective monitor of TBW.

Baroreceptor Modulation of Volume Control

Effective circulating volume describes that portion of the extracellular volume that perfuses the organs of the body and affects the baroreceptors. The effective circulating volume normally corresponds to the intravascular volume.

Changes in the effective circulating volume are sensed by volume receptors in the

intrathoracic capacitance vessels and atria, pressure receptors of the aortic arch and carotid arteries, intrarenal baroreceptors, and hepatic and cerebrospinal volume receptors.[8,9] These stretch receptors respond to changes in pressure and circulating volume and, through a complex system of neural and hormonal actions, alter sodium and water balance in the kidneys. Hormonal effects are mediated by the renin–angiotensin system, aldosterone, ANP, dopamine, and renal prostaglandins.

Baroreceptor Function

The low-pressure baroreceptors of the intrathoracic vena cava and atria are located in vessels that are distensible and not affected by sympathetic stimulation; thus, they are ideally situated to detect changes in venous volume.[8] These receptors send continuous signals through vagal afferent nerves to the cardiovascular control centers of the medulla and hypothalamus, which, in turn, send signals through parasympathetic and sympathetic fibers to the heart and kidneys. Changes in stretch of these vessels result in changes in the frequency of signal output from these receptors. Increases in atrial distention cause decreased nerve signal traffic, which ultimately causes increased sympathetic tone to the heart, which results in tachycardia and inhibition of sympathetic tone to the kidney. This leads to increased renal blood flow and decreased tubular sodium reabsorption. Conversely, low volume in the intrathoracic vessels results in increased sympathetic tone to the kidneys, decreased renal blood flow, and increased sodium reabsorption.

The effects of sympathetic activity on renal sodium reabsorption are probably mediated both by direct tubular innervation and by β-adrenergic stimulation of renin production. Whether this effect is crucial to fine regulation of sodium balance under normal physiologic conditions is unclear. Renal denervation in conscious, unstressed animals results in minimal alteration of either blood flow or sodium reabsorption. The effects of renal denervation become much more marked with anesthesia administration or hypotension, suggesting that sympathetic effects on renal function may be important during periods of physiologic stress.

Arterial baroreceptors are located in the aortic arch and carotid arteries. They respond to changes in heart rate, arterial pressure, and the rate of rise in the arterial pressure. Arterial baroreceptors are important during periods in which there are extremes in the changes in arterial pressure characteristics, as occur during hemorrhage. They are probably not involved in controlling subtle volume or pressure changes. In addition to large-vessel baroreceptors, there are arterial baroreceptors in the afferent arterioles of the kidneys. These baroreceptors modulate renin secretion. Increases in transmural pressure cause suppression of renin release, and decreases in transmural pressure stimulate renin release.

Hormonal Mediators of Volume Control

Renin–Angiotensin System. Renin is a proteolytic enzyme that is released from the juxtaglomerular cells of afferent arterioles in the kidney in response to several stimuli. These include changes in arterial pressure, changes in sodium chloride delivery to the macula densa of the distal convoluted tubule, increases in β-adrenergic activity, and

increases in cellular cyclic adenosine monophosphate.

Renin cleaves angiotensin I from circulating angiotensinogen, produced by the liver. Angiotensin I is cleaved to the octapeptide angiotensin II by angiotensin-converting enzyme (ACE), which is produced by vascular endothelial cells. One pass through the pulmonary microvasculature converts most angiotensin I to angiotensin II. Angiotensin II acts both locally and systemically to increase vascular tone. It also stimulates catecholamine release from the adrenal medulla, increases sympathetic tone through central effects, and stimulates catecholamine release from sympathetic nerve terminals. Angiotensin II affects sodium reabsorption by decreasing renal blood flow and glomerular filtration. This results in altered tubuloglomerular feedback, the mechanism by which changes in distal tubular NaCl delivery alter glomerular blood flow. Finally, angiotensin II increases sodium reabsorption by direct tubular action as well as by stimulation of aldosterone release from the adrenal cortex. The multiplicity of actions of angiotensin is depicted in Figure 11-5.

Aldosterone. Aldosterone is a mineralocorticoid produced in the *zona glomerulosa* of the adrenal cortex. Aldosterone increases renal tubular reabsorption of sodium. Aldosterone acts directly on the distal tubule cells by modifying gene expression and stabilizing the epithelial Na^+ channel in the open state and by increasing the number of channels in the apical membrane of these cells.[5] By increasing protein production in these tubular cells, aldosterone induces an influx of sodium, which causes an increase in cellular Na^+-K^+-adenosine triphosphatase activity. The net result is increased sodium reabsorption and the obligate loss of potassium via the renal outer medullary potassium (ROMK) channel. Although the primary regulator of aldosterone secretion is angiotensin II, aldosterone release is also stimulated by increased potassium levels, adrenocorticotropic hormone, endothelins, and prostaglandins.[10]

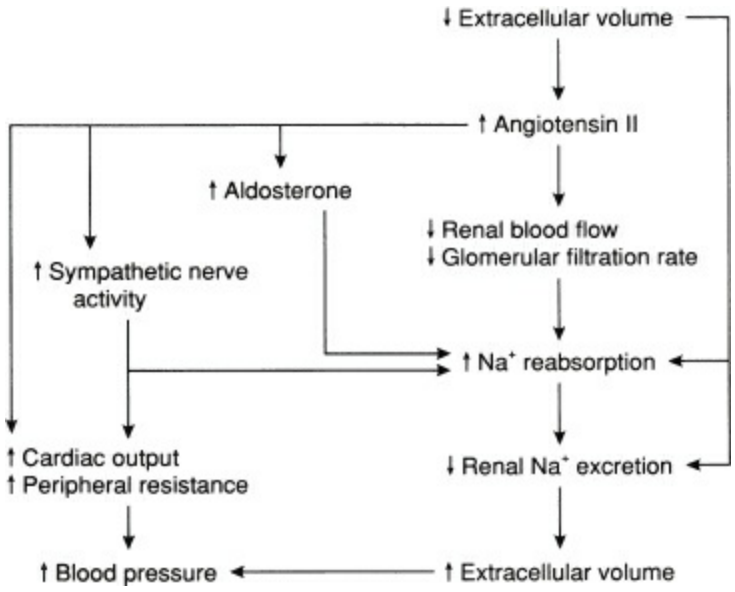

Figure 11-5. Multiple effects of increased angiotensin II release in response to the stimulus of decreased extracellular volume.

Atrial and Renal Natriuretic Peptides. ANP is synthesized and released by atrial myocytes in response to atrial wall distention. As mentioned previously, small changes in right atrial pressure produce large increases in plasma levels of ANP.[7,8] There is evidence that ANP has a direct inhibitory effect on renal sodium reabsorption, which is probably maximal at the level of the medullary collecting tubules. Although pharmacologic doses of ANP can cause changes in both renal blood flow and glomerular filtration rate (GFR), physiologic levels do not appear to have any major effect on these parameters. Other active fragments of the ANP prohormone have been found to have natriuretic activity. The best described is urodilatin, also known as *renal natriuretic* peptide. Urodilatin is a peptide with ANP-like activity that was first isolated from human urine. It is synthesized and luminally secreted by cortical collecting tubule cells. Like ANP, it is released in the kidney tubules in response to atrial distention and saline loading. It is at least twice as potent as ANP, acting in the distal nephron to cause a rise in intracellular cyclic guanosine monophosphate, leading to sodium, chloride, and water diuresis. ANP and other peptides may play an important role in controlling intravascular volume and water and electrolyte secretion.

Renal Prostaglandins. Renal prostaglandins appear to play a role in volume control, although under normal physiologic conditions, this role may be minimal. Disease states such as sepsis and jaundice, or the induction of anesthesia, may make the contribution of the prostaglandins more pronounced.[9]

Prostaglandin E_2 (PGE_2) and prostaglandin I_2 (PGI_2) appear to be the predominant prostaglandins produced in the kidney. PGE_2 is produced primarily by the interstitial cells of the renal medulla. The release of PGE_2 has been shown to depend on increases in interstitial pressure, which can be induced by changes in renal perfusion, ureteral obstruction, or alterations in oncotic pressure. Under these conditions, PGE_2 increases sodium excretion in the absence of changes in GFR. PGE_2 antagonizes the action of vasopressin (ADH) and inhibits ADH-induced sodium reabsorption along the medullary collecting duct and thick ascending limb. PGI_2 is produced by the glomeruli and endothelial cells of the kidney and is present in the greatest concentrations in the renal cortex. PGI_2 is a vasodilator, and its effects on renal vascular resistance increase both renal blood flow and GFR. PGI_2 production is augmented by increases in angiotensin, catecholamines, and sympathetic tone and may act to counterbalance their vasoconstricting effects. Although under normal physiologic conditions inhibition of prostaglandin production has little effect on renal function, administration of nonsteroidal anti-inflammatory agents, which inhibit cyclooxygenase, to patients with conditions known to cause renal dysfunction (e.g., cirrhosis) can precipitate renal failure, presumably because of loss of the protective effects of the renal prostaglandins.

Endothelins. Endothelins are peptide vasoconstrictors that are involved in volume and pressure regulation.[10] Endothelin is produced and released by endothelial and other cells to act on adjacent smooth muscle cells. In addition to increasing peripheral resistance,

endothelin infusion has a direct inotropic effect on the myocardium. In contrast to its vasoconstrictive effects, endothelin stimulates the release of other vasoactive mediators, particularly endogenous vasodilators like nitric oxide, which act to limit its intense vasoconstrictor effect.

Endothelin exerts a complex influence on sodium and water exchange through varied interactions with many other hormones that govern fluid and electrolyte balance. One net effect of endothelin is a decrease in the filtered load of sodium in the kidney. This results in inhibition of water reabsorption and decreased sodium excretion. Endothelin increases ANP secretion, activates ACE, and inhibits renin release by the juxtaglomerular apparatus. At low doses, endothelin-1 produces natriuresis and diuresis. Endothelin also modulates the biosynthesis of aldosterone, thereby inhibiting water reabsorption through aldosterone-controlled mechanisms. Vasopressin-mediated water reabsorption is also inhibited. Endothelin appears to have complex interactions with other regulators of renal perfusion and handling of water and electrolytes, which has stimulated research to evaluate the contribution of endothelin to the pathophysiology of various renal diseases.[11]

Nitric Oxide. Nitric oxide is a short-lived free radical produced from L-arginine by nitric oxide synthases.[11] This substance has numerous biologic functions, including regulation of vascular tone and tissue blood flow. Nitric oxide is produced in renal smooth muscle cells, mesangial cells, tubules, and endothelial cells and participates in the regulation of renal hemodynamics and renal handling of water and electrolytes. Nitric oxide and PGI_2 each independently cause renal vasodilation in response to a variety of stimuli. Nitric oxide contributes to tubuloglomerular feedback, which modulates the delivery and reabsorption of sodium and chloride in the renal tubules. Nitric oxide also regulates renin release by the juxtaglomerular apparatus. Nitric oxide produced in the proximal tubule may mediate the effects of angiotensin on tubular reabsorption.[11]

Normal Water and Electrolyte Exchange

Surgical patients are prone to fluid and electrolyte abnormalities. It is important to recognize that disease states, trauma, and stress-related abnormalities – especially those caused by a surgical procedure – alter many of the body's fundamental homeostatic mechanisms. It is therefore important to understand normal fluid and electrolyte balance to avoid additional iatrogenic perturbations of these mechanisms.

Normal Water Exchange

6 Water losses are both sensible (measurable) and insensible (unmeasurable). Measurable losses include urinary and intestinal. Table 11-3 summarizes the normal sensible and insensible losses encountered in a 24-hour period. The volumes of these losses may vary considerably especially in disease states. Under normal conditions, the minimal amount of water needed to excrete normal metabolic waste products is approximately 300 to 500 mL/day.

The GI tract has a net secretory action down to the level of the jejunum. After that, the resorptive capacity of the remainder of the small and large bowel acts to keep further water loss to a minimum. Fecal water loss is usually trivial: ~150 mL/day. In disease conditions like bowel obstruction, severe diarrhea, and enterocutaneous fistulas, GI losses of water and electrolytes can be significant causing secondary pathophysiologic conditions.

Table 11-3 Body Fluid Compartments

	Average Daily Volume (mL)	Minimal Daily Volume (mL)
Sensible losses		
Urinary	800–1,500	300
Intestinal	0–250	0
Sweat	0	0
Insensible losses		
Lungs and skin	600–900	600–900

Adapted from Shires GT, Canizaro PC. Fluid and electrolyte management of the surgical patient. In: Sabiston DC, ed. *Textbook of Surgery*. Philadelphia, PA: WB Saunders; 1986:77, with permission.

Sweating and diaphoresis are active processes involving the secretion of a hypotonic mixture of electrolytes and water. Sweating functions to allow the convective dissipation of heat. Diaphoresis is a similar effect, but is a pathophysiologic state stemming from a disease process.

These aforementioned conditions are distinct from the immeasurable, evaporative loss of water from the skin under normal conditions (Table 11-3). Evaporative skin losses are increased with an increase in body surface area (especially infants and small children), patient temperature, and the relative humidity of the environment. Evaporation through the skin functions through convective heat loss and is proportional to calories expended. Approximately 30 mL of water is lost for every 100 kcal expended. Respiratory exchange

depends on ambient temperature, relative humidity, and on the amount of air flow. Overall, normal insensible water losses average approximately 8 to 12 mL/kg/day. Insensible water loss increases 10% for each degree of body temperature above 37.2°C (99°F). In addition, patients who breathe unhumidified air lose additional free water. Conversely, patients who are on respirators or who breathe air that is 100% humidified have no respiratory losses and may gain free water.

FLUID AND ELECTROLYTE THERAPY

Parenteral Solutions

Crystalloids

7 The most widely used parenteral solutions are composed most commonly of sodium and chloride. They are collectively referred to as *crystalloids* (based on the solid, room temperature form of the primary ingredient sodium chloride). Crystalloids are inexpensive and highly effective for fluid maintenance and rapid volume replacement. They also have excellent safety profiles. Although crystalloid-induced hypercoagulability has been reported, its causes are multifactorial and poorly understood.[12–15] Clinically, this does not represent a significant problem.

The most commonly used crystalloid solutions available for parenteral administration are found in Table 11-4. Selection of the appropriate fluid requires assessment of the patient's maintenance fluid needs, existing fluid deficits and anticipated ongoing fluid losses. When a single solution does not accurately replace the required electrolyte components, bolus administration of specific replacement solutions is commonly performed. It is commonplace to use more than one type of crystalloid solution. This is commonly seen with parenteral medication formulations that may have specific carrier-fluid requirements. Ions such as potassium, magnesium, or calcium may be necessary and can be added to parenteral solutions to suit the patient's requirements.

Table 11-4 Electrolyte Content of Commonly Used Intravenous Crystalloid Solutions

	Electrolyte (mEq/L)					
Solution	Na^+	K^+	Ca^{2+}	Mg^{2+}	Cl^-	...
0.9% NaCl	154	—	—	—	154	—
0.45% NaCl	77	—	—	—	77	—
0.33% NaCl	56	—	—	—	56	—
0.2% NaCl	34	—	—	—	34	—
Lactated Ringer	130	4	4	—	109	28
3.0% NaCl	513	—	—	—	513	—
5.0% NaCl	855	—	—	—	855	—

Isotonic saline (0.9% sodium chloride or *normal saline*) contains 154 mEq of both sodium and chloride. Although this solution can be useful in patients with hyponatremia or hypochloremia, the excess of both sodium and chloride can lead to acid–base disturbances. For example, infusion of large volumes of 0.9% saline can lead to a hyperchloremic metabolic acidosis. In addition, the pH of normal saline and of the related solutions (0.45%, 0.33%, and 0.2% saline) is 4.0 to 5.0 further decreasing the blood pH.

Lactated Ringer solution is a buffered solution composed of the conjugate-base lactate.

It was created in the 1930s by an American pediatrician, Alexis Hartmann, as a treatment for metabolic acidosis. The solution has a lower sodium and chloride content (130 mEq/L) and adds a very small amount of potassium and calcium (4 mEq/L each). It is ideal for the replacement of acute fluid losses where serum electrolyte concentrations are initially normal. Normal renal function usually ensures that any extra free water from this solution is excreted. Hyponatremia can occur with extended use of lactated Ringer solution. Furthermore, the presence of potassium in lactated Ringer solution has been a concern when used in patients with acute kidney injury, although more recent data has suggested that normal saline (with no potassium in solution) may actually be more likely to cause hyperkalemia in this population due to metabolic acidosis-induced cellular shifts of potassium from the cell. Although the lactate anion in lactated Ringer solution is metabolized to bicarbonate in the liver, this does not appear to contribute to acidosis in normal hepatic function. Work comparing the D,L-racemic mixture of lactate has implicated the D-isomer in leukocyte activation.[16] There are no compelling data to suggest that resuscitation with this solution increases the inflammatory response. Utilization of only the L-isomer is presumed to eliminate this concern.[16] Ringer solution is not used as a diluent in blood transfusions given the concern of calcium being chelated by citrate (an anticoagulant in blood products), which may promote clotting in donor blood.

For maintenance fluid therapy especially prior to an operation with *nil per os* status or following correction of any existing deficits, less concentrated saline solutions are more appropriate to replace ongoing fluid losses (e.g., nasogastric tube losses). The specific crystalloid selected is best determined by calculated requirements. These fluids are hypoosmotic and hypotonic with respect to plasma. In theory, rapid infusion of very hypotonic solutions can result in red blood cell lysis. For this reason, 5% dextrose (50 g of dextrose per liter) has traditionally been added to these solutions to increase tonicity. The addition of dextrose is beneficial in pediatric patients who are unable to adequately control glucose homeostasis due to immature livers. A 5% dextrose solution represents 200 kcal per liter of solution.

Hypertonic saline solutions (HTSs) (3% NaCl and 5% NaCl) are generally used to replace sodium deficits in patients with symptomatic hyponatremia. These and even more concentrated (7.5% and 23% NaCl) solutions have also been used for resuscitation of hemorrhagic shock, head trauma, and burn patients.[17–19] Hypertonic saline appears to increase intravascular volume in these patients more quickly than isotonic solutions. It is believed that the osmotic gradient produced redistributes fluids from the perivascular and intracellular spaces to the intravascular space with consequent plasma volume expansion (up to fourfold). This, in turn, may decrease the total resuscitation volume requirement. When HTS is used for resuscitation of patients with severe sepsis, it has been shown to result in improvements in oxygen transport, cardiac output, and pulmonary capillary wedge pressure.[17] The systemic and mesenteric oxygen extraction coefficient improves without worsening of other markers of perfusion. This is achieved by rapid mobilization of fluids from the intracellular compartment to the extracellular compartment. These cardiovascular and hemodynamic effects are short-lived, in general lasting from 60 to 120

minutes.

The osmotic effect of hypertonic saline may benefit patients with acute severe brain injury.[19] By reducing the water content of the brain, HTS can help to control intracerebral pressure after injury. In addition, HTS has immunomodulatory effects, which are well documented.[20] HTS reduces the systemic inflammatory response syndrome and may attenuate multiple organ dysfunction syndrome. HTSs are not without adverse effects, however. Patients are at risk for electrolyte abnormalities such as hypernatremia, hyperchloremia, and consequent metabolic acidosis. Extravasation into the soft tissues can produce significant soft tissue edema and even necrosis.

Colloids

Colloids are composed of large molecules (e.g., albumin) that have a greater tendency to stay in the intravascular space. They appear to be more effective at enhancing the plasma volume than do crystalloid fluids. Colloid solutions offer the potential benefits of promoting fluid retention in the intravascular space and reducing excess interstitial fluid (edema). Worldwide, albumin and artificial colloids are relied on to a varying degree in fluid management of the surgical patient. In the United States, concerns regarding the effectiveness, cost, and potential complications of colloid administration have limited their use to specific clinical situations.

Albumin

Albumin (69 kD) is the primary protein in plasma responsible for oncotic pressure. Exogenous human albumin is derived from human plasma and heat-treated to reduce the risk of infection. It is available in a 5% (50 g/L) and a 25% solution (250 g/L) in isotonic saline. These act by increasing plasma oncotic pressures and theoretically slowing or even reversing movement of water into the interstitial space. Albumin has an approximate intravascular half-life of 4 hours in conditions of normal physiological capillary permeability. However, many of the conditions associated with edema are also associated with abnormalities in microvascular permeability (e.g., systemic inflammatory disease). For example, the pulmonary circulation in the adult respiratory distress syndrome, regional circulatory beds in postoperative patients, burns or infections, and the systemic circulation in sepsis all lead to conditions resulting in increased microvascular permeability. It is, therefore, believed that exogenously administered protein in colloid solutions quickly extravasate into the interstitial space and paradoxically intensify – rather than decrease – interstitial edema. The SAFE trial (Saline vs. Albumin Fluid Evaluation) found no overall difference in organ dysfunction or survival when comparing saline administration to albumin infusion.[21] However, the SOAP trial (Sepsis Occurrence in Acutely Ill Patients) demonstrated increased mortality in intensive care unit patients treated with colloids.[22,23] As mentioned above, albumin solutions are heat-treated to negate viral and bacterial contamination. Allergic reactions are rare. The primary concern with albumin administration is cost; the infection risk is negligible.

Hetastarch

Hydroxyethyl starches (HES) are synthetic colloids derived from hydrolyzed amylopectin. In the United States, it is available as a 6% solution of high–molecular-weight (150 to 450 kD), highly hydroxyethyl substituted HES in normal, isotonic saline. The average molecular weight of the starch molecules is equivalent to that of albumin. However, HES is slightly more effective than 5% albumin as a colloid – it has a higher colloid oncotic pressure than 5% albumin. The main advantage of hetastarch is its lower cost compared to albumin.

Hetastarch has been used as a resuscitative solution in a variety of clinical settings with variable results. Coagulopathy and bleeding complications have been widely reported after administration of highly substituted, high–molecular-weight HES.[24,25] This appears to be associated with reduced factor VIII and von Willebrand factor levels, a prolonged partial thromboplastin time, and impaired platelet function.[26] It also has a long elimination half-life (17 days). Because of its long half-life, the coagulopathy does not rapidly reverse after cessation of HES administration. Also, serum amylase enzymes continually degrade HES molecules before renal clearance. It is common for serum amylase levels to be elevated for the first few days after HES infusion. In order to differentiate this from pancreatitis, serum lipase levels should be checked and are usually normal.

The above observations and reports of renal insufficiency after HES administration prompted a prospective study, with results published in 2012.[27,28] The results of these trials were so significant that the FDA and the Pharmacovigilance Risk Assessment Committee, the European equivalent of the FDA, recommended suspending marketing authorization of all HES products and issued warnings to its use.[29,30] The Surviving Sepsis Campaign recommends against HES administration in septic patients.[31]

Dextrans

First introduced in the 1940s, dextrans are glucose polymers synthesized by *Leuconostoc mesenteroides* bacteria. These are available as synthetic plasma expanders in both 40 kD (dextran 40) and 70 kD (dextran 70) solutions. Although neither is used frequently for volume expansion, dextran 70 has been preferred because of its significantly longer half-life and better retention in plasma. It is degraded to glucose and water by cells. The use of dextrans involves risks of anaphylaxis, hyperglycemia, renal dysfunction and failure, coagulopathy (e.g., erythrocyte and platelet dysfunction), and increased thrombosis rates. The use of dextran solutions is no longer favored given a higher relative risk of mortality compared to HESs.[32]

Gelatins

Gelatin solutions produced from bovine collagen are effective as plasma volume expanders. These are currently only available outside the United States in urea-linked (Gelofusin) and succinate-linked (Haemaccel) formulations. Gelofusin has been used in similar clinical settings to HES, with similar clinical results.[33] Uniquely, coagulopathy does not appear to be an issue with gelatins. Renal impairment has been reported with these colloids as having allergic reactions ranging in severity from pruritus to anaphylaxis

with both gelatin formulations.[34]

Artificial Oxygen Carriers

Recent clinical trials and subgroup analyses using temporary hemoglobin-based oxygen-carrying solutions (e.g., PolyHeme, Northfield Laboratories, Inc.) have been encouraging albeit with some controversy.[35] PolyHeme is made from polymerized human hemoglobin. It originally began as a military project following the Vietnam war. PolyHeme's primary use is in trauma situations with massive blood loss when fresh, whole blood is not readily available for transfusion. On May 9, 2009, Northfield Laboratories, Inc. shut down operations after it failed to secure a biologic license application for PolyHeme from the FDA. However, with further studies, solutions like PolyHeme may prove beneficial in the future when volume expansion in conjunction with increased oxygen-carrying capacity is required.

GOALS OF FLUID AND ELECTROLYTE THERAPY

Maintaining homeostasis – body fluid and electrolyte concentrations – and normal hemodynamic parameters are the goals of fluid and electrolyte therapy. This is accomplished by first understanding the general maintenance fluid required by an idealized 70-kg male patient to account for normal daily losses. Thereafter, it is imperative to correct existing volume and electrolyte abnormalities and any ongoing losses associated with disease states and surgical treatments.

Table 11-5 Calculation of Maintenance Fluid Requirements

Body Weight	Fluid Requirement[a]	
For 0–10 kg	Give 100 mL/kg/day	A
For the next 10–20 kg	Give an additional 50 mL/kg/day	B
For weight >20 kg[b]	Give 20 mL/kg/day	C

[a]Maintenance fluid requirements = A + B + C.
[b]For elderly patients or patients with cardiac disease, this amount should be reduced to 15 mL/kg/day.

Maintenance Fluid Therapy

Maintenance fluid volume requirements can be calculated based on body weight taking into account a larger per kilogram volume requirement of smaller body weight individuals (Table 11-5). A 10-kg child requires 100 mL/kg/day or 1,000 mL/day. A 70-kg man requires 1,000 mL/day for the first 10 kg (100 mL/kg × 10 kg), plus 500 mL/day for the second 10 kg (50 mL/kg × 10 kg), plus 1,000 mL/day for the last 50 kg (20 mL/kg × 50 kg), for a total daily water requirement of 2,500 mL/day. In patients who may be intolerant of hypervolemia (i.e., cardiac disease, elderly patients), the requirement per kilogram over 20 kg is decreased to 15 mL/kg/day.

Maintenance Electrolyte Therapy

One to 2 mEq/kg/day of sodium is required, with any administered excess managed by urinary sodium excretion. Potassium requirements are approximately 0.5 to 1 mEq/kg/day. If sodium is replaced at 2 mEq/kg/day and potassium is replaced at 1 mEq/kg/day, a 70-kg patient requires 2,500 mL of water containing 140 mEq of sodium and 70 mEq of potassium. Each liter of parenteral solution would contain 56 mEq of sodium and 28 mEq of potassium. The solution that best fits this patient's daily maintenance requirements is 0.33% saline solution (56 mEq/L Na^+). Potassium chloride can be added to each liter of solution (20 to 30 mEq/L), with appropriate adjustments for the patient's electrolyte and renal functional status.

Additional Electrolyte Therapy

Short-term maintenance therapy generally does not require addition of calcium, phosphate, or magnesium. In patients with acute and/or chronic disorders, patients who experience significant volume shifts, or patients who require long-term parenteral fluid therapy, these electrolytes should be measured and corrected by the most practical, physiologically natural route. In general, the enteral route is preferred given normal physiology. If the enteral route is unavailable, these additional electrolytes are administered in parenteral nutrition solutions along with trace elements, vitamins, and appropriate caloric sources. Corrections and allotment must be made for disease states that may alter the need or absence of electrolytes (e.g., potassium in renal failure patients) in replacement solutions.

CORRECTION OF VOLUME ABNORMALITIES

Volume Deficits

States of subphysiologic volume (i.e., hypovolemia) are common among surgical and trauma patients. This may be related to direct blood loss or other fluids. Large volumes of fluid can be sequestered in extravascular spaces (third-space losses) as a consequence of inflammation, sepsis, or shock-related endothelial injury and increased endothelial permeability.[36] This situation is characterized by a movement of proteins and fluid from the intravascular to the interstitial compartment. Examples of disorders that cause third-space losses include bowel obstruction with edema of the bowel wall and transudation of fluid into the bowel lumen, pancreatitis (especially with retroperitoneal fluid extravasation) and extensive tissue destruction in trauma. While the disease state exists, normal homeostasis is altered and cannot be maintained. With the resolution of the pathologic condition and normalization of microvascular permeability, these fluid losses abate. Sequestered extravascular fluid returns – albeit at variable rates – to the intravascular space.

Volume deficits can manifest either acutely or over time. Chronic volume deficits may manifest with decreased skin turgor, sunken eyes, oliguria, weight loss, hypothermia, tachycardia, and orthostatic hypotension. In addition, serum BUN and creatinine values may be elevated, with a high BUN/creatinine ratio (above 15:1). The absolute hematocrit level has been shown to be a poor predictor of intravascular volume status. The hematocrit may be measured during dialysis as a way to indirectly measure volume status.[37] Optical measurements of absolute red cell mass and oxygen saturation are measured as blood passes through the dialysis tubing while a patient is undergoing dialysis treatment. The hematocrit is then determined by both the absorption properties of hemoglobin and the scattering properties of red blood cells passing through the blood chamber.[37]

Acute volume losses usually manifest by changes in vital signs. In an attempt to provide sufficient cardiac output for end-organ perfusion, the heart rate may increase. At the extreme, blood pressure will drop resulting in hypotension. Urine output is usually low by this point.

Fluid resuscitation for hypovolemia is initiated with an isotonic solution such as normal saline or lactated Ringer solution. Once routine laboratory values (e.g., chemistries) are measured, tailoring the type of solution can be done. Urine flow in critically ill patients is monitored with an indwelling Foley catheter with a goal of at least 0.5 mL/kg/hr output. In addition, a thorough history and physical examination will help determine the origins of the volume deficits, specifically addressing underlying causes and resultant losses.

Volume Excess

Volume excess may occur with significant resuscitative fluid, blood product administration, or excessive parenteral volume administration. Volume overload will occur if adjustments to fluid therapy are not made as the clinical status of the patient changes. Possible manifestations of volume overload are weight gain, truncal and peripheral edema and pulmonary congestion (identified by rales on pulmonary auscultation and/or radiographic chest imaging). Intravascular volume excess is treated by a combination of volume restriction and diuresis. At the extreme, volume overload may be treated by ultrafiltration of the blood (often done concurrently during hemodialysis).

REPLACEMENT OF ONGOING FLUID LOSSES

Ongoing losses from stomas, fistulae, open body compartments (e.g., abdomen, chest) and all tubes (e.g., nasogastric) and drains – are recorded during the course of care. Once the net "ins and outs" have been calculated, any existing volume deficits should be replaced with fluid replacement. The electrolyte content of these fluids can be estimated or measured and used to guide the choice of replacement fluid type (Table 11-6). As the disease state changes, the overall fluid balance of the patient can be estimated and replaced beyond what is considered to be maintenance.

Table 11-6 Electrolyte Concentrations in Gastrointestinal Secretions

	Electrolyte (mEq/L)					
Secretion	Na^+	K^+	Cl^-	...	H^+	Rate (mL/day)
Salivary	50	20	40	30	—	100–1,000
Gastric						
Basal	100	10	140	—	30	1,000
Stimulated	30	10	140	—	100	4,200
Bile	140	5	100	—	—	500–1,000
Pancreatic	140	5	75	—	—	1,000
Duodenum	140	5	80	—	—	100–2,000
Ileum	140	5	70	—	—	100–2,000
Colon	60	70	15	—	—	—

Intraoperative Fluid Therapy

Fluid losses during operative procedures result from evaporative losses in open wounds, blood loss, and extravascular, third-space sequestration. Relative operative blood loss can frequently be measured. Evaporative losses as well as shifts of intravascular fluid to the extravascular space are difficult to measure, but should be anticipated. Intraoperative replacement with crystalloid solutions is usually accomplished at rates of 500 to 1,000 mL/hr as this is roughly equivalent to the hourly insensible loss rate during open celiotomy cases. The choice of intraoperative fluid is dependent on many factors. Administration of buffered solutions (e.g., Ringer lactate solution) is as efficacious and safe as nonbuffered, saline-based fluids and may prevent postoperative hyperchloremia and metabolic acidosis. Close monitoring of blood pressure, blood loss, urine output, and invasive monitoring techniques aids the surgeon and anesthesiologist in gauging fluid shifts and potential problems associated with intraoperative volume depletion.

Postoperative Fluid Therapy and Monitoring

Routine monitoring of intraoperative and postoperative fluid status consists of serial vital signs (e.g., blood pressure and heart rate), measurements of all tubes, lines, and drains (e.g., urine output) and inclusive of all intravenous and enteral drips. These are recorded in the patient's medical record and used to plan ongoing fluid management. The net gains (all inputs) minus the losses allow daily and length-of-stay volume assessments to be made. Daily weight should also be recorded and compared to the patient's starting or "dry" weight prior to their surgery, if possible. In the postsurgical patient, rapid fluctuations in weight are generally related to changes in TBW. In the absence of any extenuating circumstances (e.g., renal dialysis, kidney transplantation), adequate fluid is usually given to maintain a urine output of greater than 0.5 mL/kg/hr in adult patients.

Urine specific gravity can also be measured and serves as an indicator of both volume status and renal ability to concentrate and dilute the urine. A urine specific gravity of greater than 1.010 to 1.012 indicates that the urine is being concentrated (relative to plasma), and a urine specific gravity of less than 1.010 indicates that dilute urine is being produced.

Renal failure in the postoperative period may be accompanied by low urine volume (oliguric renal failure, <0.5 mL/kg/hr, or <500 mL/day). Additionally, normal or high urine volumes (nonoliguric or high-output renal failure) may also indicate renal dysfunction. Measuring the fractional excretion of sodium compared to creatinine (i.e., FeNa) can help delineate the potential etiology of renal dysfunction by discerning prerenal states (FeNa usually $<1\%$) from acute tubular necrosis (FeNa usually $>2\%$).

$$\text{FeNa} = (\text{Urine}_{\text{Na}})(\text{Serum}_{\text{Creat}})/(\text{Urine}_{\text{Creat}})(\text{Serum}_{\text{Na}})$$

Central venous pressures (CVPs) have also been extensively used to gauge fluid status and responsiveness. Normal CVP may range from 5 to 12 mm Hg. Higher pressures usually indicate volume overload or cardiac failure, whereas pressures below this range indicate intravascular volume depletion. However, the use of CVP measurements alone has been shown to be highly variable and inaccurate in assessing intravascular volume and venous return. This is especially true in critically ill patients where abnormalities of cardiac performance and vascular tone may confound interpretation of CVP measurements.

More recently, assessments of fluid status, responsiveness, and overall tissue perfusion are being accomplished by the use of (1) bedside echocardiography (e.g., transthoracic) to measure function through ventricular filling and ejection, (2) ultrasound of the vena caval diameter, and (3) peripheral arterial pulse-volume variability calculations. The latter measures the stroke volume variability (SVV) during the ventilatory cycle via a peripherally placed arterial line. SVV is the calculated percentage of the difference between the maximal and minimal stroke volumes (SVs) divided by the mean SV. This is usually calculated over a time period between 20 to 30 seconds.[38] Use of the SVV has been shown to be a reliable indicator of fluid responsiveness.

It is important to note that the efficacy of these techniques may be altered in abnormal

right and/or left ventricular compliance, increased intrathoracic pressure (via elevated levels of positive end expiratory pressure and intra-abdominal pressure), valvular heart disease (e.g., mitral stenosis) and cardiac dysrhythmias (e.g., atrial fibrillation). In order to solve any serious questions of volume status, the gold standard technique remains pulmonary artery catheterization in the critically ill patient.

ELECTROLYTES

8 An electrolyte is defined as a substance that ionizes when dissolved in an appropriate solvent, the most common example being water. Some of the most common physiologic electrolytes include: sodium (Na^+), potassium (K^+), calcium (Ca^{2+}), magnesium (Mg^{2+}), chloride (Cl^-), and hydrogen phosphate (HPO_4^{2-}). The + or – designates the charge of the ion.

In order to maintain homeostasis, the human body has a complex yet stable arrangement of electrolytes in different concentrations in the intracellular and extracellular environments (Table 11-7). In clinical practice, only measurements of serum values (extracellular space excluding the interstitial space) are performed and used to infer disruptions of homeostasis, which cause organ damage. For instance, with hyperkalemia, the serum concentration itself does not directly cause injury. It initiates depolarization leading to impairment of cardiac conduction resulting in an end pathway of ventricular fibrillation or asystole.

Given that serum derangements can only be discovered if lab evaluation or symptoms are present, it is important to try to anticipate potentially life-threatening electrolyte abnormalities. This is especially important in surgical patients in whom the loss of electrolyte-rich GI fluids occurs and can cause predictable serum derangements (Table 11-8). For example, an infant with hypertrophic pyloric stenosis who vomits nonbilious gastric secretions will develop a predictable hypochloremic metabolic alkalosis due to the loss of hydrochloric acid. It is therefore of the utmost importance to recognize circumstances that cause predictable electrolyte derangements in order to decrease the risk of morbidity and mortality.

Table 11-7 Electrolyte Concentrations in Plasma and Intracellular Compartments

	Normal Ranges	
Solute (mEq/L)	Plasma	Intracellular
Na^+	135–145	10–15
K^+	3.5–5.0	120–150
Ca^{++}	2.5 (8.5–10.5 mg/dL)	$0.0001–10^{-7}$
Mg^{++}	1.3–1.9	7
Cl^-	98–110	3–20
HCO_3	22–28	10–15
pH	7.37–7.43	7.0–7.2
Osmolarity	280–290	280–290

Where Sodium Goes, Water Follows

Although the relationship between sodium and water is far more complex than the above adage, there is a distinct correlation between sodium and fluid status. This relationship can help establish both the etiology and treatment of various derangements. For example, when thinking about hyponatremia, it is clinically important to assess the patient's volume status as well as check laboratory studies. These include serum sodium, serum osmolality, and urine electrolytes. Other values such as serum glucose, serum protein, and serum lipids may also help to differentiate hyponatremia from pseudohyponatremia.[40]

Pseudohyponatremia

Marked elevations in serum lipid or protein result in a reduction in the fraction of serum that is water/sodium and thus causes a "dilutional" hyponatremia. Examples include hyperlipidemia, hyperproteinemia (e.g., multiple myeloma), hyperglycemia, and mannitol administration. In the case of hyperglycemia, the serum sodium concentration should fall 1.6 mEq/L for every 100 mg/dL rise in serum glucose concentration.

Hyponatremia

The most common pathophysiology is retention of water, which most commonly stems from oral intake or iatrogenic use of intravenous hypotonic fluid. The body has an innate ability to produce up to 10 L/day of urine, providing an enormous range of protection against the development of hyponatremia. However, in most surgical/trauma patients who experience hyponatremia, there is an inability to suppress ADH, as it is normally elevated during a stress response. In this case the sodium rarely falls below 130 mEq/L because the hyponatremia itself, as well as volume expansion, decreases the effects of ADH on the renal collecting tubules.

Table 11-8 Electrolyte Concentrations in Gastrointestinal Secretions

Secretion	Na^+	K^+	Cl^-	H^+	Rate (mL/day)
Salivary	50	20	40	—	100–1,000
Gastric					
Basal	100	10	140	30	1,000
Stimulated	30	10	140	100	4,200
Bile	140	5	100	—	500–1,000
Pancreatic	140	5	75	—	1,000
Duodenum	140	5	80	—	100–2,000
Ileum	140	5	70	—	100–2,000
Colon	60	70	15	—	—

In significant cases (i.e., serum sodium <130 mEq/L) it is helpful to take a more systematic approach. This entails assessing serum and urine osmolality as well as urine sodium (Algorithm 11-1).

Symptoms of hyponatremia occur in multiple organ systems including the CNS, GI, and

musculoskeletal (Table 11-9). In acute hyponatremia, symptoms often start when serum sodium is less than 130 mEq/L; whereas in chronic hyponatremia symptoms typically do not occur until serum sodium is less than 120 mEq/L.

Treatment. Treatment depends on the patient's volume status. Hypovolemic patients are treated by rehydration with isotonic saline, with caution not to correct serum sodium faster than 0.5 mEq/L/hr and less than 10 mEq/L over 24 hours. If correction is faster than this rate the patient may develop *central pontine myelinolysis*. This can lead to "locked in" syndrome, which consists of quadriplegia, dysarthria, and dysphagia. In order to best prevent this rare, yet highly morbid complication, use of the following calculation is recommended:

$$Na^+ \text{ required (in mEq)} = (\text{Desired } Na^+ - \text{Actual } Na^+) \times \text{TBW}$$

$$\text{TBW} = 0.6 \times \text{Weight (kg)}$$

Rapid correction with 3% or higher-concentration solutions should be avoided unless significant CNS symptoms such as coma or seizures are present and should be done using the calculation above to prevent overcorrection. A reasonable initial dose in an emergent situation would be 100 mL of 3% saline given as a bolus; this can be repeated in 10 minute intervals with definite need for follow-up laboratory evaluation to prevent overly rapid correction.

Cerebral Salt Wasting and Syndrome of Inappropriate Antidiuretic Hormone

Cerebral salt wasting (CSW) and syndrome of inappropriate antidiuretic hormone (SiADH) are both seen in the setting of CNS disease, which is especially pertinent to trauma patients. CSW is much rarer and typically occurs within the first 10 days of CNS insult/injury. The pathophysiology is likely related to impaired sodium reabsorption leading to volume depletion, followed by increased ADH release causing hyponatremia from water retention. Laboratory findings are nearly identical amongst CSW and SiADH. Both have elevated urine osmolality compared to serum. However, CSW is associated with ECF depletion and thus hypotension and/or elevated hematocrit, whereas SiADH patients are often net positive in fluid balance. Given the volume status associated with CSW the treatment is usually isotonic fluids which will suppress the release of ADH. On the contrary if isotonic fluid is given for SiADH it can actually worsen the hyponatremia. Other options to treat CSW include salt tablets and if needed fludrocortisone.

The initial treatment for SiADH is often fluid restriction of <800 mL/day. For more significant cases the use of oral salt tablets or 3% hypertonic saline is recommended. Finally, vasopressin receptor antagonists such as Conivaptan (IV) and Tolvaptan (PO) can be used; however these do carry risks such as hepatotoxicity and can rapidly overcorrect serum sodium levels. Furthermore, they are fairly expensive in the United States and hence should only be used in select cases.[39–41]

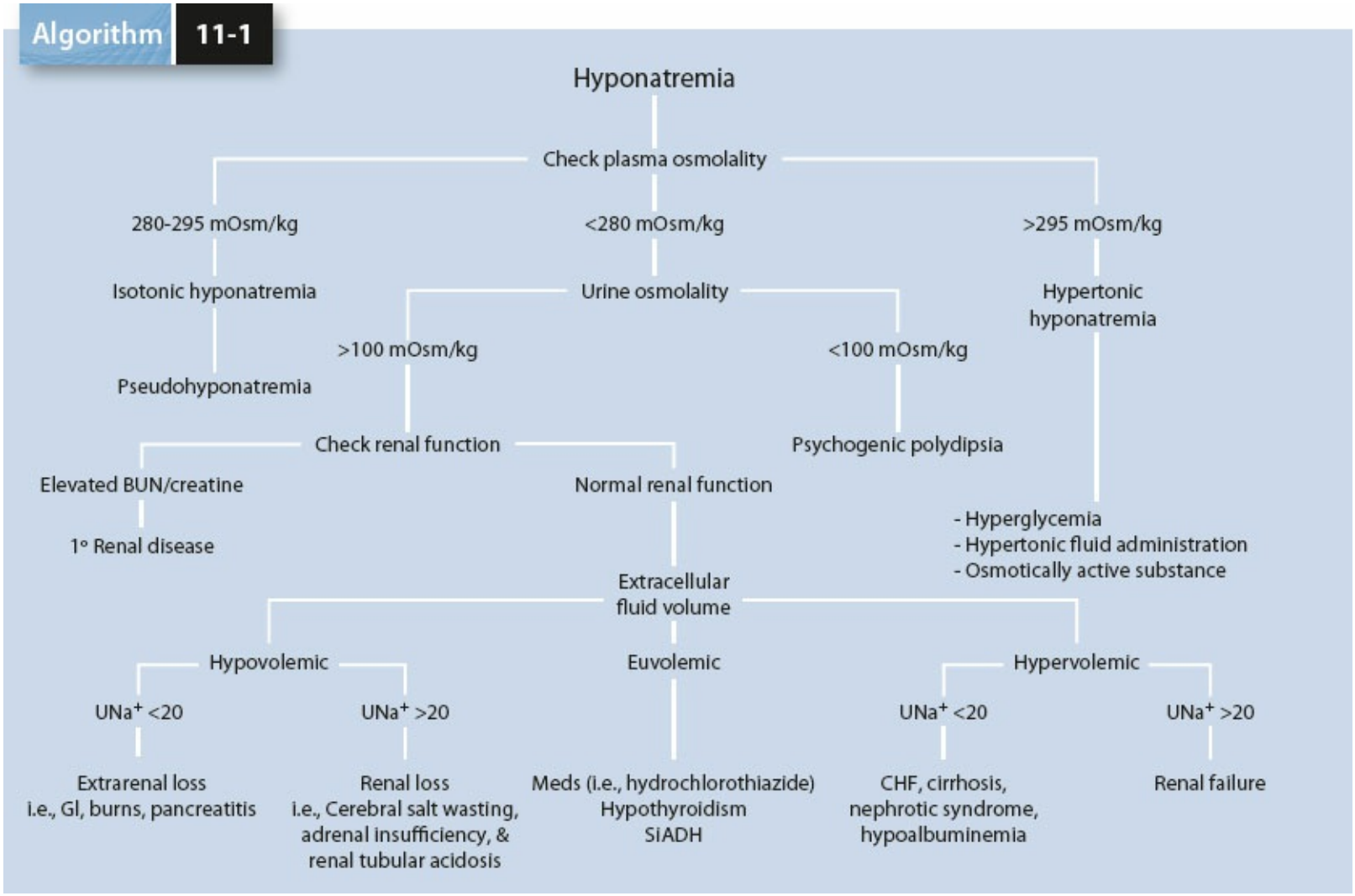

Algorithm 11-1. Hyponatremia.

Hypernatremia

Although a less common problem in surgical patients, hypernatremia has a variety of etiologies which, like hyponatremia can be categorized based on the patient's volume status (Table 11-10). The most common scenario is excessive free water loss associated with hypovolemia.

Symptoms of hypernatremia typically do not develop until serum sodium exceeds 160 mEq/L or serum osmolality is higher than 320 to 330 mOsm/kg. Also, akin to hyponatremia the degree of acuity is a factor. Acute hypernatremia can cause symptoms at lower levels than chronic hypernatremia. The majority of symptoms experienced are CNS related with early signs being irritability, restlessness, and spasms. Later symptoms include ataxia and seizures.

The treatment of hypernatremia, like hyponatremia should not occur too rapidly, otherwise complications can ensue. A rate >0.7 mEq/L is considered dangerous as it can lead to cerebral edema and brainstem herniation. The most judicious way to correct hypernatremia involves calculating the free water deficit to obtain a desired sodium level.

Table 11-9 Symptoms of Hyponatremia

Central nervous system	Headaches Confusion Delirium Coma Seizures
Gastrointestinal	Anorexia Nausea Vomiting
Musculoskeletal	Weakness Fatigue Muscle cramps

$$\text{Water requirement} = (\text{Desired change in } Na^+ \times \text{TBW})/\text{Desired } Na^+$$

$$\text{TBW} = 0.6 \times \text{Weight (kg)}$$

A caveat to this equation is that it does not take into account ongoing free water losses such as urinary or GI loss. Further calculations can be done to quantify urine losses if this is a major concern.

Table 11-10 Causes of Hypernatremia

Volume Status	Cause
Low	Free water loss Insensible—skin, respiratory Gastrointestinal loss Excessive hyperosmotic peritoneal dialysis Renal: diuretics, diabetes insipidus, nonoliguric renal failure
Normal	Same as "Low" volume status but with improper correction
High	Free water loss Increased mineralocorticoids—hyperaldosteronism, hypercortisolism Iatrogenic Excessive sodium administration

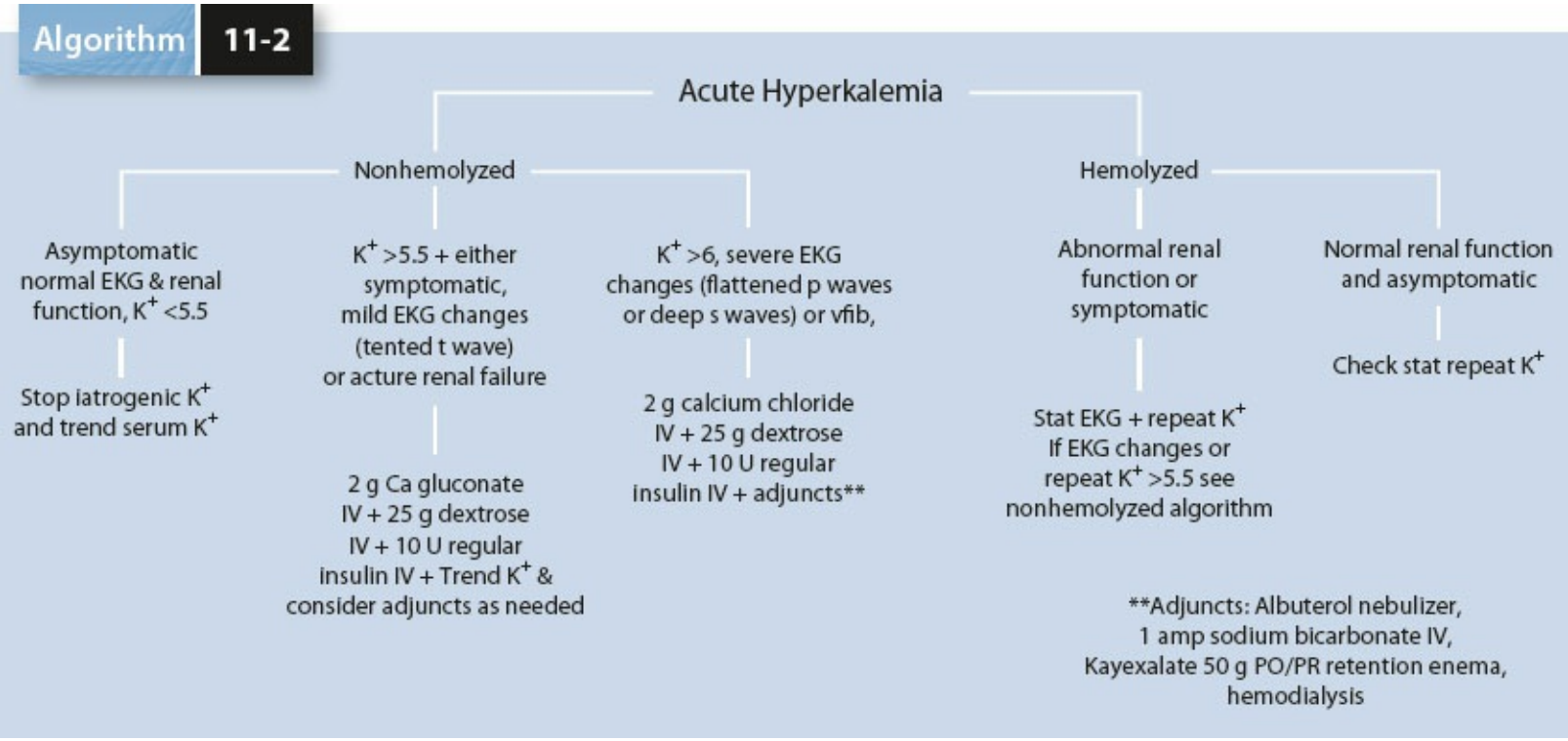

Algorithm 11-2. Acute hyperkalemia.

Potassium

Potassium is the most abundant intracellular cation with a normal intracellular concentration of 150 mEq/L as opposed to an extracellular level ranging from 3.5 to 5 mEq/L. This large gradient produces a strong membrane potential especially in cardiac, skeletal, and smooth muscles. The overall potassium balance is determined by potassium intake and renal/extrarenal excretion. Renal excretion accounts for 90% of excreted potassium. Thus, renal failure leads to hyperkalemia. Humoral factors such as aldosterone, vasopressin, and β-agonists stimulate renal excretion of potassium. Intracellular shifting is another strong causative agent for extracellular potassium change. For instance, insulin and alkalosis both cause K^+ to shift intracellular, one for glycolysis, the other in exchange for H^+ as a buffer. Conversely, acidosis causes K^+ to shift extracellular in exchange for H^+, again to buffer serum pH.

Hyperkalemia

Renal insufficiency is the leading cause of hyperkalemia in surgical patients. Hyperkalemia can occur even in the setting of nonoliguric renal failure. Potassium-rich intravenous fluids, especially blood transfusions can also lead to hyperkalemia. Disease processes associated with cellular injury such as crush injuries, reperfusion syndrome, tumor lysis syndrome, and burns are all potential causes of hyperkalemia. Additionally, medications such as succinylcholine and ACE inhibitors can worsen existing hyperkalemia.

Regardless of the etiology, the common pathway for clinical manifestations is dysfunctional membrane depolarization, the most lethal scenario effecting cardiac membrane depolarization. On an electrocardiogram (EKG) this can be seen in the mildest form with peaked T waves, in a more severe state with flattened P waves, prolongation of the QRS, or deep S waves. The final pathway can yield ventricular fibrillation with or without cardiac arrest.

The initial medication of choice for hyperkalemia is intravenous calcium for membrane stabilization, which lasts approximately 30 to 60 minutes. Subsequent therapy can include insulin coadministered with dextrose, β2 agonist, and sodium bicarbonate, which are designed to shift extracellular potassium into the intracellular space. Resin-binding agents such as Kayexalate act to decrease potassium absorption and thus are more important in the management of chronic hyperkalemia.[42,43] Loop diuretics can assist by promoting renal potassium excretion, but should only be used if the patient is not hypovolemic. A last resort in situations of complete renal failure or critical levels of potassium is hemodialysis. The treatment utilized depends upon the laboratory value, but more importantly the clinical scenario and EKG findings (Algorithm 11-2).

Hypokalemia

Similar to hyperkalemia, manifestations of hypokalemia result from the disturbance in the gradient between intracellular and extracellular potassium. The reference level of 3.5 mEq/L is often cited as the lowermost level of normal serum potassium. Below this level minor disturbances including intestinal ileus, premature ventricular complexes, and

nonfatal arrhythmias can occur. Severe cardiac and muscle manifestations often do not occur until levels fall below 2.5 mEq/L. Findings at this dangerous level include significant muscle weakness and major EKG changes. Possible changes include prolonged QT, flattened T waves, ST depression, prominent U waves, and most dangerously ventricular arrhythmias.

Initial treatment consideration must include elucidation of possible etiologies (Table 11-11); certain etiologies are especially important, as without correction of the underlying cause, the hypokalemia itself may not be correctable. Examples of this include hypomagnesemia, acute alkalosis, hyperaldosteronism, and mucus secreting villous adenoma. The mainstay of initial treatment for hypokalemia is enteral or intravenous potassium replacement. If the patient is symptomatic, then the replacement or at least a portion of it should be given intravenously to achieve a more rapid effect. Limiting the rate of intravenous potassium infusion is necessary to prevent caustic injury to veins. Maximal recommended rates include 10 to 20 mEq/hr via a peripheral IV or up to 40 mEq/hr via central access.

Table 11-11 Causes of Hypokalemia

Major Causes of Hypokalemia
Vomiting/diarrhea
Diuretics (i.e., loop diuretic)
Catecholamines (endogenous or exogenous)
Renal tubular acidosis
Refeeding syndrome
Insulin
Hypomagnesemia
Acute alkalosis

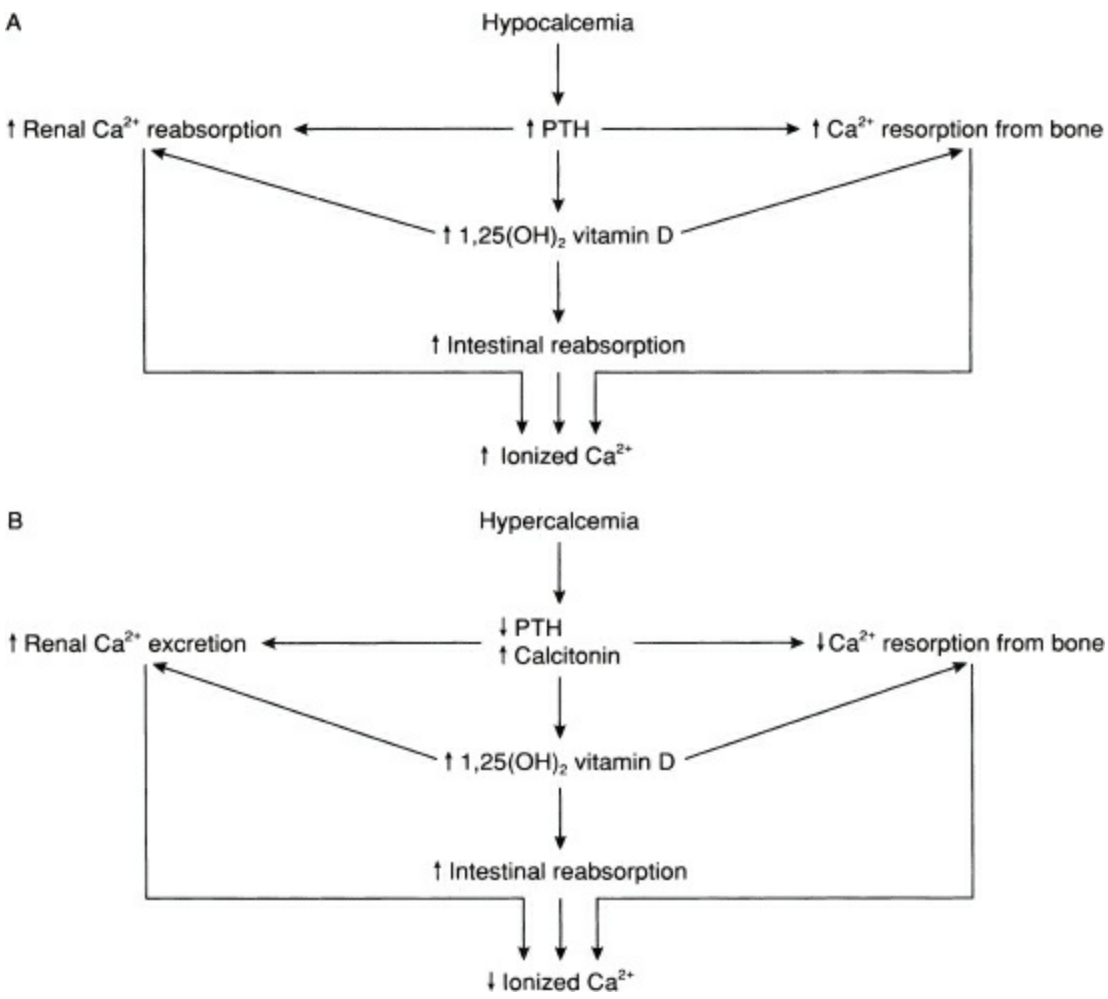

Figure 11-6. Effects of hypocalcemia (**A**) and hypercalcemia (**B**) on the mediators of calcium homeostasis. PTH, parathyroid hormone.

Calcium

Calcium (Ca^{2+}) is essential for human life. Calcium participates in numerous processes including cardiac membrane depolarization, muscle contraction, enzymatic reactions, coagulation, and formation of bone/teeth. Approximately 99% of total body calcium is located in bone. Ionized calcium, which makes up approximately 45% of total calcium, is responsible for most of the physiologic actions of calcium in the body. Normal serum concentration of ionized calcium is approximately 4.5 mg/dL and this level is tightly regulated. Both pH and plasma protein level can affect the proportion of calcium in the ionized state. A change in albumin concentration of 1 g/dL changes protein-bound calcium by 0.8 mg/dL in the same direction. The fundamentals of the regulation of calcium homeostasis are depicted in Figures 11-6 and 11-7. The effect of pH on calcium will be discussed later in this chapter.

Hypercalcemia

The most common causes of hypercalcemia are hyperparathyroidism and malignancy (Table 11-12).[44,45]

Primary hyperparathyroidism occurs when one or more parathyroid glands inappropriately produce increased amounts of PTH. Parathyroid adenomas are responsible for ~85% of cases. Chief cell hyperplasia accounts for an additional 15% of cases, while parathyroid cancer is the cause in less than 1% of cases of primary hyperparathyroidism.

Secondary hyperparathyroidism occurs when there is elevated PTH due to another organ system, namely renal failure. This occurs because of poor renal excretion of phosphate and decreased intestinal absorption of calcium secondary to impaired renal hydroxylation of vitamin D.

Tertiary hyperparathyroidism is parathyroid hyperplasia with autonomous PTH production. Most commonly, patients who had renal failure with secondary hyperplasia then undergo renal transplant and still have hypercalcemia. This occurs in up to 30% of patients with prerenal transplantation hyperparathyroidism (Table 11-13).

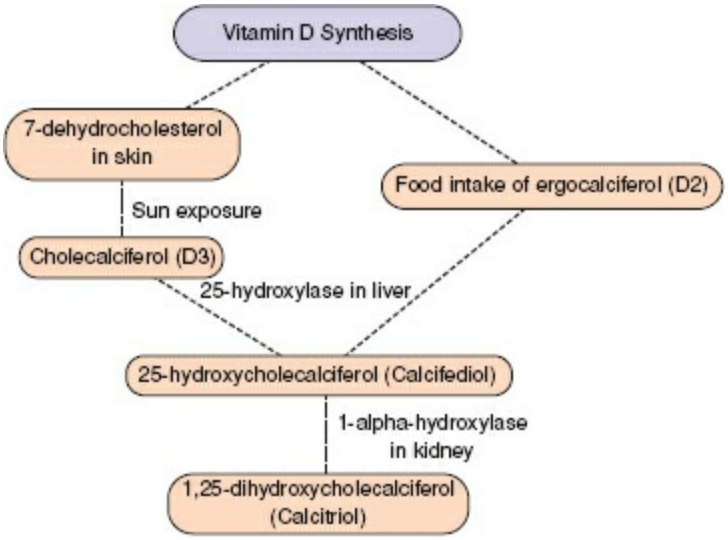

Figure 11-7. Vitamin D synthesis.

Table 11-12 Other causes of Hypercalcemia

PTH mediated	Lithium Familial hypocalciuric hypercalcemia (FHH)
Cancer	PTHrp-mediated breast, lung, renal cancer Bone metastases Multiple myeloma
Calcitriol mediated	End-stage renal disease Sarcoid/granulomatous Lymphoma (ectopic 1,25 vit D) Milk alkali syndrome Exogenous vitamin D
Other causes	Vitamin A toxicity Thyrotoxicosis Paget disease Adrenal insufficiency Medications (i.e., Thiazide)

Regardless of cause, hypercalcemia has characteristic clinical manifestations that affect various organ systems. Classically taught as "stones, moans, and psychiatric undertones," meaning renal, abdominal/GI, and neuropsychiatric manifestations (Table 11-14). The earliest symptoms are usually neuromuscular and mild GI symptoms. Cardiac and renal complications typically occur later in disease progression.

Treatment. Serum calcium concentration >14 mg/dL requires prompt treatment. If combined with hyperphosphatemia, this situation is even more concerning due to the potential for metastatic calcification. Initial treatment should include aggressive hydration with 0.9% normal saline with 20 mEq/L potassium with a goal of hydration to promote a urine output greater than 200 mL/hr. Once the patient is adequately hydrated a trial of furosemide can be performed as long as a positive fluid balance is maintained and potassium and magnesium are adequately replaced. Other adjuncts include calcitonin (especially for inhibition of bone resorption), bisphosphonates (especially to treat malignancy), and in patients with renal failure the use of low-calcium dialysate. Patients with hematologic malignancies and granulomatous disease can be considered for treatment with steroids. Lastly, for those with hyperparathyroidism, parathyroidectomy of some form is clearly indicated, with operation type dependent upon whether the etiology is adenoma or hyperplasia. In medically refractory secondary or tertiary hyperparathyroidism, total parathyroidectomy with parathyroid autotransplantation or sub-total parathyroidectomy should be considered.[46]

Hypocalcemia

There are many causes of hypocalcemia (Table 11-15). Other factors can affect the serum calcium level as mentioned previously, namely pH and albumin. In critically ill patients the incidence of hypocalcemia can be up to 85%. From a surgical perspective the most common causes are postsurgical, including hungry bone syndrome and loss of calcium from circulation.

Table 11-14 Signs and Symptoms of Hypercalcemia

Constitution symptoms	Weakness, fatigue, anorexia
CNS	Drowsiness, lethargy, altered mental status, stupor, coma
Cardiac	Short QT interval
Renal	Nephrolithiasis, polyuria, renal failure, nephrogenic diabetes insipidus, nephrocalcinosis
GI	Constipation, abdominal pain, pancreatitis
Ophthalmologic	Calcium deposits in cornea

Postsurgical hypocalcemia can occur in any neck surgery, although the incidence is higher with parathyroidectomy. In non-neck surgery hypocalcemia can occur because of hypoalbuminemia; this does not affect ionized calcium levels. Other postsurgical causes of hypocalcemia include atrophy of the remaining parathyroid glands (i.e., after removal of a large parathyroid adenoma), venous congestion, devascularization or *hungry bone syndrome*. Transient hypoparathyroidism is seen in up to 20% of thyroid cancer surgery; this is permanent in 1% or less of cases.

Other surgery-related etiologies include pancreatitis, small bowel fistula, renal failure, massive transfusion of blood, and severe hypomagnesemia. Pancreatitis-induced hypocalcemia occurs due to calcium precipitation in peripancreatic tissue. Small bowel fistula can lead to hypocalcemia by loss of calcium-rich effluent and vitamin D deficiency from malnutrition. Renal failure hypocalcemia is due to deficiency in 1,25-dihydroxyvitamin D and hyperphosphatemia. Massive transfusion hypocalcemia does not affect total calcium but decreases ionized calcium as a result of citrate binding to ionized calcium.

Symptoms typically do not occur until calcium levels are below 8 mg/dL. Chronic symptoms include cataracts, dental changes, and extrapyramidal disorders. Symptoms of acute hypocalcemia are tetany, papilledema, and seizures. Tetany is defined as repetitive discharges after a single stimulus. Tetany usually does not occur until ionized calcium is less than 4.3 mg/dL or serum total calcium is less than 7.0 mg/dL. Alkalosis also plays a strong role in the development of tetany, even beyond its association with hypocalcemia, as tetany is rarely seen in renal failure patients despite low calcium levels. This is likely due to the protective effect of concurrent metabolic acidosis. The earliest symptoms of hypocalcemia are perioral and acral paresthesias. Motor symptoms such as *Trousseau sign* (induction of carpopedal spasm by inflation of sphygmomanometer above systolic pressure for 3 minutes) and *Chvostek sign* (tap facial nerve and ipsilateral facial muscles twitch) occur later. Of note, Chvostek sign is seen in up to 10% of normal patients. The last findings to occur are cardiac, in the form of ST segment prolongation (Table 11-16).[44]

Table 11-13 Differential Diagnosis of Hypercalcemia

Cause	Ca^+	Phos	PTH	24 hr UCa
Primary PTH	Increased	Decreased	Elevated/normal	Elevated
Secondary PTH	Low or normal (can be high w/ prolonged disease)	High	Elevated	N/A
FHH	Increased	Normal	Elevated/normal	Decreased
PTHrp mediated	Increased	Decreased	Decreased	Elevated
Tertiary PTH	Increased	Decreased	Very Elevated	Elevated

PTHrp, parathyroid hormone-related peptide; UCa, urine Ca^+.

Table 11-15 Causes of Hypocalcemia

Low PTH (hypoparathyroidism)	Postsurgical (thyroidectomy, parathyroidectomy, radical neck dissection, hungry bone syndrome) Autoimmune Infiltration of the parathyroid gland (granulomatous, iron overload, metastases) Radiation-induced destruction parathyroid glands HIV infection
High PTH (secondary hyperparathyroidism in response to hypocalcemia)	Vitamin D deficiency Pseudohypoparathyroidism Hypomagnesemia Renal disease Loss of calcium in circulation (i.e., hyperphosphatemia, tumor lysis, acute pancreatitis, osteoblastic metastases, acute respiratory alkalosis, sepsis)
Drugs	Bisphosphonate, calcitonin, phenytoin, foscarnet, calcium chelators

Asymptomatic hypocalcemia needs no treatment as it is most commonly attributed to hypoalbuminemia with normal ionized calcium. Symptomatic hypocalcemia is best treated with intravenous infusion of calcium gluconate or calcium chloride. Calcium chloride is faster acting as it does not require hepatic metabolism to dissociate into an active form, hence is usually the drug of choice if severely symptomatic. A study during the anhepatic stage of liver transplantation found equally rapid increase in calcium after administration of calcium chloride and gluconate.[47] Calcium chloride carries a higher risk of irritation of veins and tissue damage should extravasation occur; hence calcium gluconate should be the drug of choice except in emergent situations. In order to minimize caustic damage to veins, any form of calcium should be administered at a rate not to exceed 1.5 mEq/min. If prolonged calcium replacement is needed it is recommended to check vitamin D levels and replace any deficiency with calcitriol, in addition to giving an oral form of calcium such as calcium carbonate, calcium citrate, or calcium lactate.

Table 11-16 Clinical Manifestations of Hypocalcemia

Acute	Neuromuscular Paresthesia (initially perioral) Seizures Tetany (i.e., Trousseau/Chvostek sign) Pulmonary Laryngospasm, bronchospasm Cardiac Prolonged QT, hypotension, heart failure, arrhythmias Ocular Papilledema
Chronic	Abnormal dentition Extrapyramidal signs Ectopic calcification Subcapsular cataracts

Magnesium

Half of the total body magnesium is confined to bone. Most of the remaining magnesium is intracellular, with less than 1% of total body magnesium found extracellular. Magnesium is primarily absorbed in the small intestine and is influenced by 1,25-dihydroxyvitamin D3. The other source of magnesium is bone.

Hypermagnesemia

Outside of renal failure, hypermagnesemia is rare, as the kidneys have a strong ability to excrete large amounts of magnesium. Instances do occur with severe burns, crush injuries, or other causes of rhabdomyolysis but usually in the setting of renal insufficiency. Symptoms of hypermagnesemia include loss of deep tendon reflexes at levels greater than 8 mg/dL. Once levels are greater than 12 mg/dL paralysis can occur. Cardiac arrest can occur if levels exceed 18 mg/dL. The mainstay of treatment is intravenous calcium to antagonize the effect of magnesium, volume expansion or loop diuretic depending on volume status, correction of acid–base disturbances and if needed, hemodialysis.

Hypomagnesemia

Kidneys are also able to conserve magnesium quite well with about 40% reabsorption in the proximal tubule. Most instances of hypomagnesemia occur with chronic malnutrition, prolonged intravenous fluid replacement without magnesium, and loop diuretics. Other causes include pancreatitis and diabetic ketoacidosis (DKA). Magnesium functions as a cofactor for many neuromuscular functions, thus deficiency can lead to muscle fasciculation or tetany. The treatment depends on the severity, which includes taking into account symptoms and magnesium level. For instance, if serum magnesium level is less than 1 mEq/L or if the patient is hemodynamically unstable or is in a torsade de pointes arrhythmia then immediate infusion of intravenous magnesium sulfate is indicated. The maximum recommended rate would be 150 mg/min excluding the above emergent situations where it can be given as IV push or over 5 minutes for torsade de pointes. If the patient has chronic or mild hypomagnesemia, oral doses of magnesium should be used, with options including magnesium oxide, magnesium chloride, and magnesium hydroxide (milk of magnesia) depending on side-effect profiles. It should be noted that doses greater than 80 mEq/day can become cathartic.

ACID–BASE

An acid is defined as a chemical that can donate a hydrogen ion (H^+), for example, HCl and H_2CO_3. A base is a chemical that can accept an H^+, for example, OH^- and HCO_3^-. Ampholytes are both acids and bases; an example is $H_2PO_4^-$, which can donate an H^+ to become HPO_4^{2-} but can also accept H^+ to become H_3PO_4. Bases are commonly anions, but neutral substances can also function as bases (e.g., ammonia and creatinine). Some chemicals do not fit the classic definition of an acid, although they retain acidic properties when dissociated in water. For example, when $CaCl_2$ is dissolved in water, the Ca^{2+} accepts OH^- to form $Ca(OH)_2$.

The concentration of hydrogen ions [H^+] determines the acidity of a solution. The pH is the negative logarithm of [H^+] expressed in moles per liter (mol/L). The concentration of H^+ in biologic systems is in the range of nanomoles (10^{-9} mol) per liter (nmol/L). The degree to which an acid dissociates determines its strength.

Table 11-17 HCO_3^- and PCO_2 Derangements in Primary and Secondary Acid–Base Disturbances

		Primary		Secondary	
Disorder	pH	HCO_3^-	PCO_2	HCO_3^-	PCO_2
Metabolic acidosis	↓	↓			↓
Metabolic alkalosis	↑	↑			↑
Respiratory acidosis	↓		↑	↑	
Respiratory alkalosis	↑		↓	↓	

The *Henderson–Hasselbalch* equation describes pH as a measure of acidity in a biologic system.

$$pH = pK_a + \log_{10}([A^-]/[HA])$$

pK_a = Negative log of the acid dissociation constant

A^- = Conjugate base

HA = Acid–base pair

Buffer Systems

Buffers are chemicals in solution that tend to minimize changes in pH that would otherwise occur after the addition of acid or alkali. For instance, if a strong base is added to a weak acid, the base is neutralized:

$$NaOH - H_2CO_3 \rightarrow NaHCO_3 + H_2O$$

One type of buffer is a mixture of a weak acid and its salt. The presence of such buffer systems in the body is crucial in minimizing changes in pH, which can be deleterious to cell function.

The principal intracellular buffers are organic phosphates, bicarbonate, and peptides. In addition, hemoglobin functions as a significant buffer in red blood cells. The major extracellular buffer is bicarbonate. An approximation of the total body buffer capacity is 15 mEq/kg. More than half of the total body alkaline buffer content is located outside the ECF and may in large part reside in bone.[50] The buffer pair carbonic acid/bicarbonate (H_2CO_3/HCO_3^-) is the primary buffer system of the body.

From a chemical point of view, the ideal buffer should have a pKa that allows normal physiologic pH. The H_2CO_3/HCO_3^- buffer system has a pKa of only 6.1, which is not the normal body pH. That said, this buffer system is efficient because of the presence of large amounts of bicarbonate, the conversion of its acid H_2CO_3 to CO_2 that is rapidly excreted through the lungs, and an inexhaustible supply of CO_2 from metabolism.

Acid–Base Disturbances

9 There are four primary acid–base disturbances, each of which are related to changes in either $[HCO_3^-]$ or PCO_2. These are categorized as metabolic and/or respiratory (Table 11-17). A metabolic acidosis is a decrease in pH as a result of a relative decrease in $[HCO_3^-]$, whereas a metabolic alkalosis is an increase in pH caused by a relative increase in $[HCO_3^-]$. A respiratory acidosis is a decrease in pH secondary to a relative increase in PCO_2, and a respiratory alkalosis is an increase in pH caused by a relative decrease in PCO_2. In each of these disorders, compensatory changes occur to minimize changes in the relative ratio of $[HCO_3^-]$ to PCO_2 and thereby blunt the effect of the primary disturbance on pH.[48,49]

Metabolic Acidosis

Anion Gap

The difference in the measured serum cations and anions yields the anion gap. This can be utilized to identify the etiology of a metabolic acidosis. The most common equation used in practice is as follows:

$$\text{Anion gap} = [Na^+] - ([Cl^-] + [HCO_3])$$

The normal value of serum anion gap is approximately 3 to 10; however, each laboratory should establish its own normal. If one includes potassium in the equation then the normal value should be increased by about 4 mEq/L. The differential for an elevated anion gap acidosis includes: lactic acidosis, salicylate poisoning, acute or chronic kidney disease, chronic acetaminophen ingestion, ketoacidosis (i.e., diabetic), and acute or chronic kidney disease. A common mnemonic used to address etiologies is the acronym: MUDPILES: methanol, uremia, diabetic ketoacidosis, propylene glycol, isoniazid, lactic acidosis, ethylene glycol, and salicylates.

Mechanisms of Metabolic Acidosis

Four mechanisms result in a decrease in extracellular bicarbonate concentration and metabolic acidosis:

1. Dilutional acidosis. Rapid infusion of an alkali-free solution results in dilution of the bicarbonate concentration.
2. Increased acid generation (e.g., lactic acidosis, ketoacidosis, salicylate poisoning).
3. Diminished renal acid excretion (e.g., renal failure or type I renal tubular acidosis [RTA]).
4. Decreased body bicarbonate content (e.g., severe diarrhea, fistula, type II RTA).

Table 11-18 Compensatory Mechanisms

Disorder	Compensation	Time
Metabolic acidosis	PCO_2 = serum HCO_3^- + 15 PCO_2 = 1.5 × serum HCO_3^- + 8 ± 2	12–24 hr
Metabolic alkalosis	0.7 mm Hg PCO_2 per 1 mEq/L HCO_3^-	12–24 hr
Acute respiratory alkalosis	2 mEq/L HCO_3^- per 10 mm Hg PCO_2	<3 days
Chronic respiratory alkalosis	4–5 mEq/L HCO_3^- per 10 mm Hg PCO_2	3–5 days
Acute respiratory acidosis	1 mEq/L HCO_3^- per 10 mm Hg PCO_2	<3 days
Chronic respiratory acidosis	–4 mEq/L HCO_3^- per 10 mm Hg PCO_2	3–5 days

The most common example of a dilutional acidosis is large resuscitation with normal saline, which causes a hyperchloremic acidosis. Clinically significant metabolic acidosis in surgical patients is most commonly related to net loss of bicarbonate. One means of classification would be renal acidosis versus extrarenal acidosis. Renal acidosis is not as readily compensated because by definition the kidney's ability to regulate acid/base is

compromised. Extrarenal acidosis can be further subdivided into increased acid production (e.g., lactic acidosis in shock) or increase bicarbonate loss (e.g., fistula).

Increased Production of Organic Acids

Increased protein intake and tissue catabolism resulting in greater metabolism of sulfur-containing amino acids can lead to generation of increased amounts of sulfuric acid. With normal kidney function, any decline in serum bicarbonate concentration stimulates renal acid excretion, which can compensate almost completely for the increase in acid production.

Nonrenal Loss of Bicarbonate

Diarrhea, intestinal or pancreatic fistulas, and burns can cause metabolic acidosis secondary to loss of bicarbonate. Urinary diversion with segments of GI tract (ureterosigmoidostomy and ureteroileostomy) can result in loss of bicarbonate with reabsorption of NH_4Cl from the urine. The potential for fistulas to result in metabolic acidosis depends on the concentration of bicarbonate in the fluid and the rate of external drainage. For instance, metabolic acidosis is less common with biliary fistulas than pancreatic fistulas. Biliary fistulas typically have only modest volumes with a bicarbonate concentration of approximately 50 to 60 mEq/L, whereas pancreatic fistulas can have profuse output with a concentration of 150 mEq/L.

Ketoacidosis

Normally, free fatty acids generated from breakdown of triglycerides in adipose tissue are either used as an energy source by tissues such as muscle or carried to the liver, where they are reesterified to triglycerides. Ketoacids are produced by mitochondrial metabolism of free fatty acids to acetyl CoA, with subsequent formation of acetoacetate and β-hydroxybutyrate (redox forms of the same compound). Under normal conditions, a small amount of ketoacid is produced. During prolonged starvation, production of ketoacid increases to modest levels, providing an important source of energy to nonhepatic tissues, particularly the brain. In DKA, the ketoacid production is excessive because of insulin deficiency, which drives ketoacid production by increasing free fatty acid release from adipose tissue, increasing transport of free fatty acids into hepatic mitochondria, promoting conversion of acetyl CoA to ketoacids, and impairing extrahepatic use of ketoacids. Insulin deficiency also contributes to hyperglycemia by decreasing the metabolism of glucose by extrahepatic tissues and increasing hepatic production of glucose. The resulting osmotic glucose diuresis causes increased renal excretion of sodium and water. Additional losses of sodium and potassium occur as a result of renal excretion of the excess ketoacid anions. Potassium excretion is further enhanced by hyperaldosteronism due to increased delivery of sodium to the distal tubule that occurs in association with the osmotic diuresis. Despite total body potassium depletion, serum potassium concentration is often increased in DKA secondary to metabolic acidosis, renal insufficiency, insulin deficiency, and hyperosmolality. These

pathophysiologic changes result in the typical clinical presentation, which includes dehydration, polyuria, polydipsia, hyperglycemia, hyperventilation, and metabolic acidosis with an increased anion gap.

Lactic Acidosis

Lactic acidosis can be characterized as type A (caused by tissue hypoxia) or type B (other causes). The generation of lactic acid is the final step of anaerobic glycolysis. Lactic acid is normally produced by muscle, blood elements, intestine, and skin and is used by the liver and kidney. Normal serum lactate concentration is below 2 mEq/L. Lactic acidosis secondary to hypoxia is usually due to increased production of lactate as well as decreased use, and exists when serum lactate concentration is greater than 6 mEq/L.

The most common cause of type B lactic acidosis is ethanol intoxication. Lactic acidosis is caused by increased generation of NADH by the metabolism of alcohol, which interferes with hepatic gluconeogenesis and, therefore, lactate use.

In lactic acidosis, the L-isomer is usually elevated because of the specificity of mammalian lactate dehydrogenase. Various bacteria found in colonic flora are capable of generating large amounts of D-lactic acid. D-lactic acidosis has been reported in humans only in the presence of short-gut syndrome because the small bowel normally absorbs the dietary substrate for bacterial D-lactic acid production. In addition, the colon must be selectively colonized by bacteria that possess D-lactate dehydrogenase. Typically, the patient has short-gut syndrome, and the acidosis is preceded by food ingestion and is accompanied by characteristic neurologic findings, including mental confusion, slurred speech, staggering gait, and nystagmus. These neurologic manifestations are secondary to bacterial neurotoxins. The acidosis is accompanied by an increased anion gap, but L-lactate and ketone levels are normal. Treatment includes oral antibiotics, recolonization of the colon with non–D-lactate dehydrogenase–forming bacteria, and a low-carbohydrate diet.

Renal Acidosis

The most common renal-associated acidosis in surgical patients is that of acute or chronic renal failure. One of the kidney's many important functions is to excrete acid. When GFR decreases so does the ability to excrete acid, thus causing a metabolic acidosis.

The impaired ability of the kidney to excrete acid may be secondary to a decrease in the number of functioning nephrons and is termed RTA. Type I (distal) RTA is most commonly caused by autoimmune diseases (e.g., Sjogren disease or rheumatoid arthritis) and hypercalciuria in adults. Distal RTA leads to impaired distal acidification.

Type II (proximal) RTA is caused by a reduction in proximal bicarbonate reabsorption – the most common cause in adults being monoclonal gammopathies or medications such as carbonic anhydrase inhibitors.

Clinical Features of Acute Metabolic Acidosis

The major cardiovascular effects of acute metabolic acidosis are peripheral arteriolar

dilatation, decreased cardiac contractility, and central venous constriction. These can lead to cardiovascular collapse and pulmonary edema. Catecholamine secretion is stimulated by metabolic acidosis, and in mild cases (pH >7.1), heart rate may be increased. In more severe metabolic acidosis (pH <7.1), the direct effects of acidosis override the catecholamine effects and result in bradycardia and decreased contractility. These depressive effects are magnified by β-blockers. In addition to these cardiovascular effects, metabolic acidosis can increase oxygen delivery by shifting the oxygen–hemoglobin dissociation curve to the right. In more prolonged metabolic acidosis, this may be partially offset by decreased production of 2,3-diphosphoglycerate in red blood cells because of a slower rate of glycolysis. Metabolic acidosis can also cause gastric distention, abdominal pain, nausea, and vomiting.

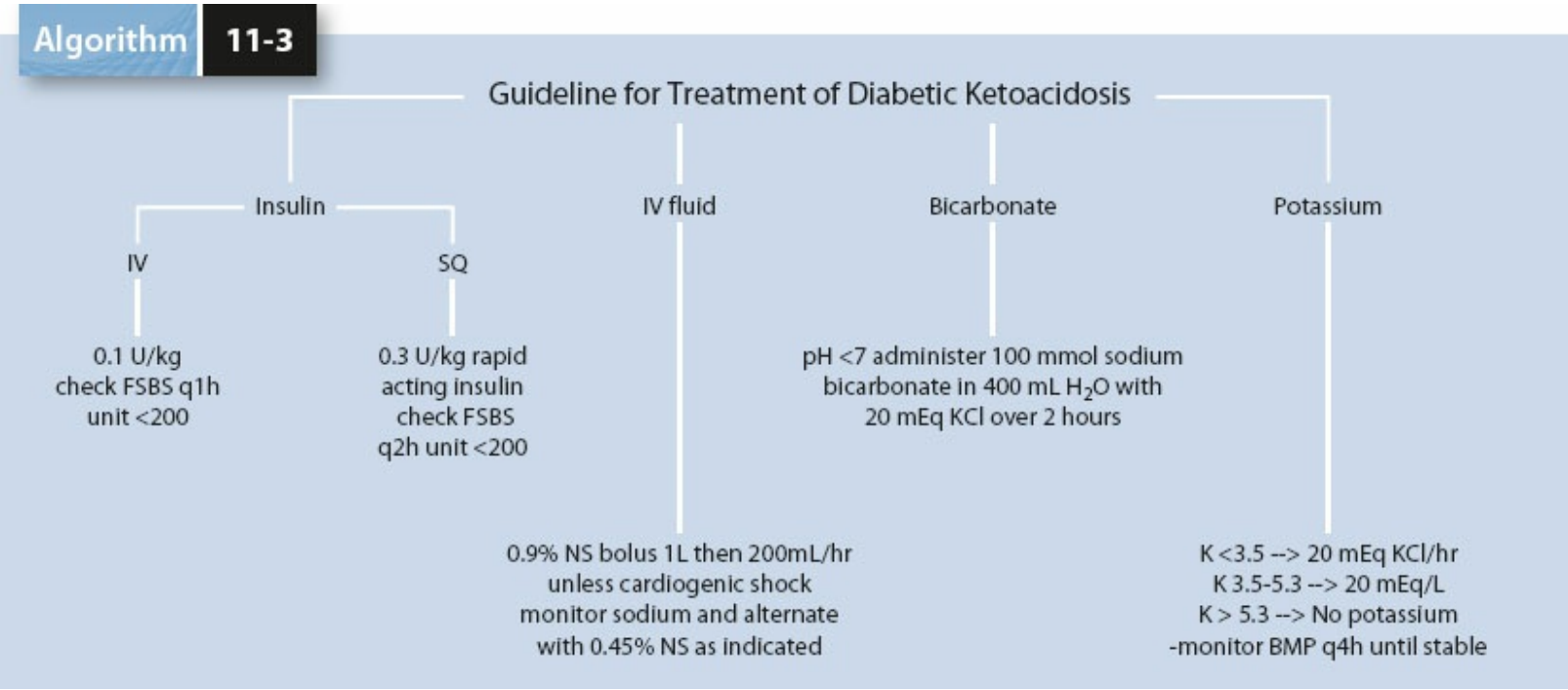

Algorithm 11-3. Guidelines for the treatment of diabetic ketoacidosis.

Renal Compensation

The kidney is extremely sensitive to changes in serum bicarbonate concentration and responds by increasing net acid excretion primarily in the form of ammonia excretion. Maximal renal compensation requires 2 to 4 days. In addition, the maximal amount of ammonia excreted during acidosis depends on factors such as glutamine delivery, GFR, and the type of anion that accompanies the acid, because renal acid secretion is stimulated to varying degrees by different anions. Although renal compensation is effective in achieving normal net acid excretion with extrarenal causes of metabolic acidosis, variable results are seen with renal acidosis, especially distal RTA.

Respiratory Compensation

A decrease in blood pH causes an immediate stimulus to hyperventilate. Although effective in promptly raising blood pH, early ventilatory compensation is only partial.

Full respiratory compensation can occur in 12 to 24 hours. The magnitude of the decrease in PCO_2 in response to a given degree of metabolic acidosis can be used to determine whether the metabolic acidosis is complicated by coexisting respiratory acidosis or respiratory alkalosis. There are multiple equations that can describe this relationship; whichever is easiest remembered can be utilized:

$$\text{Arterial } PCO_2 = \text{Serum } HCO_3^- + 15$$

$$\text{Arterial } PCO_2 = 1.5 \times \text{Serum } HCO_3^- + 8 \pm 2 \text{ (Winter equation)}$$

The PCO_2 can fall no lower than 8 to 12 mm Hg in response to a severe metabolic acidosis and this compensation can only be maintained for a limited period of time due to respiratory muscle fatigue.

Treatment of Acute Metabolic Acidosis

In surgical and trauma patients, metabolic acidosis is often the result of inadequate tissue perfusion and consequent lactic acidosis. Volume resuscitation alone may be enough to correct this acidosis. Attempts to correct acidosis with exogenous bicarbonate without addressing inadequate tissue perfusion will be unsuccessful. Furthermore, exogenous administration of bicarbonate may cause a superimposed respiratory alkalosis and a deleterious left shift of the oxygen–hemoglobin dissociation curve, by not allowing reversal of 2,3-diphosphoglycerate depletion, hence resulting in tissue hypoxia.

Diabetic Ketoacidosis

Initial therapy must include four components: intravenous fluid, insulin, potassium, and the need for bicarbonate. Intravenous fluid should be given in the form of normal saline. On average 4 to 5 L of fluid are required within the first 24 hours. While doing this, serum sodium levels should be monitored. The initial dose of insulin is typically 0.1 unit/kg intravenous or 0.3 unit/kg subcutaneously administered. Insulin should be redosed every 1 hour intravenously or every 2 hours subcutaneously until serum glucose reaches 200 mg/dL. In terms of potassium replacement, it is paramount to ensure adequate renal function (i.e., urine output of at least 0.5 mL/kg/hr). Once adequate urine output is assured, potassium repletion is dosed. If the serum potassium is >5.3 then no further potassium should be given, whereas if serum potassium is 3.5 to 5.3, 20 mEq is added to each liter of fluid. If the serum potassium is <3.5 then 20 mEq/hr of potassium can be administered until serum potassium is in the ideal 3.5 to 5.3 range. Determination for bicarbonate therapy is largely based on pH. If the pH is <7 then it is reasonable to dilute sodium bicarbonate (100 mmol) in 400 mL water and infuse over 2 hours, then rechecking the pH (Algorithm 11-3).[51,52]

Metabolic Alkalosis

Sustained metabolic alkalosis occurs only if extracellular bicarbonate concentration is increased and renal excretion of excess bicarbonate is inhibited. Extracellular bicarbonate concentration increases can occur through several mechanisms. In surgical patients, loss of HCl is a frequent cause of metabolic alkalosis, most commonly due to vomiting or nasogastric drainage in the presence of gastric outlet obstruction. External loss of gastric acid results in a net gain in bicarbonate (generated by equimolar gastric secretion of HCl), which causes alkalosis. Although the kidney can excrete excess bicarbonate, this must be accompanied by excretion of sodium. Renal excretion of sodium is limited in the presence of the volume depletion that occurs with external losses of gastric secretion. As volume depletion progresses, sodium is conserved in exchange for hydrogen, and urine will become acidic, even in the presence of severe metabolic alkalosis. This phenomenon is referred to as *paradoxical aciduria.*

Increased extracellular bicarbonate concentration can occur with administration of either bicarbonate or precursors of bicarbonate, such as lactate, citrate, or calcium carbonate, or as a result of increased renal production of bicarbonate. Conditions in which acid excretion exceeds endogenous acid production and in which the renal threshold for bicarbonate reabsorption is increased can result in metabolic alkalosis. Such conditions include moderate potassium depletion, excess mineralocorticoids, and high PCO_2.

Hypokalemia and cellular exchange of potassium for hydrogen can also lead to metabolic alkalosis. Hypokalemia results in enhanced proximal tubular bicarbonate reabsorption and distal tubular acid excretion. When potassium leaves the cell, it is exchanged for either sodium or hydrogen to maintain electrical neutrality. Loss of potassium from the body then results in a net gain in bicarbonate in the ECF.

Maintenance of elevated extracellular bicarbonate concentration can occur by a number of mechanisms. Volume contraction leads to decrease in renal blood flow and GFR thus reducing the filtered load of bicarbonate. This, in addition to increased proximal tubular reabsorption of bicarbonate, maintains high extracellular concentrations of bicarbonate. High PCO_2 causes an increase in renal threshold for bicarbonate secondary to decreased intracellular pH of the renal tubular cell. The net result is increased bicarbonate reabsorption.

Diuretics can cause or exacerbate metabolic alkalosis by both causing rapid contraction of intravascular volume and increasing renal excretion of acid. Chloride deficiency is another common factor that maintains an alkalotic state. In some instances of metabolic alkalosis, urinary excretion of chloride is markedly reduced. Reversal of metabolic alkalosis in these cases can be readily achieved by administration of chloride-containing solutions. Metabolic alkalosis can be categorically divided into chloride-responsive and chloride-resistant types.

Clinical Features

Clinical signs of metabolic alkalosis may not be prominent because the condition usually develops slowly. If acute, CNS manifestations of confusion, obtundation, stupor, and

coma may be present as well as tetany or neuromuscular irritability.

Respiratory Compensation

Respiratory compensation for metabolic alkalosis should raise the PCO_2 by 0.7 mm Hg for every 1 mEq/L elevation in serum HCO_3^-. Typically the arterial PCO_2 does not go above 55 mm Hg. Among the four major acid–base disorders, this compensatory mechanism is the least effective.[60]

Treatment

Correction of the underlying cause is the mainstay of treatment in this disorder. In general, correction of potassium depletion and volume depletion corrects the metabolic alkalosis. Renal excretion of bicarbonate cannot occur in the face of persistent volume depletion. Volume depletion should be corrected with chloride-containing solutions. In patients without intravascular volume deficits, renal excretion of bicarbonate can be enhanced by administration of the diuretic, carbonic anhydrase inhibitor acetazolamide. In extremely rare circumstances where renal excretion of bicarbonate cannot be increased because of underlying renal insufficiency or if the metabolic alkalosis is severe, acid may be administered to titrate in opposition the excess extracellular bicarbonate. Acids that can be used include ammonium chloride, arginine hydrochloride, lysine hydrochloride, or dilute hydrochloric acid (0.1N). Partial correction of the alkalosis is the initial goal and a specialist should be involved prior to instituting this care. In the face of frank renal failure, dialysis may be necessary to remove excess bicarbonate.

Respiratory Alkalosis

Respiratory alkalosis is defined as increased extracellular pH secondary to decreased PCO_2 with hyperventilation. Hyperventilation and the ensuing fall in PCO_2 may be secondary to hypoxia, reflex stimulation from decreased pulmonary compliance, drugs, mechanical ventilation, or other causes.

Hypoxia stimulates ventilation through peripheral chemoreceptors in the carotid and aortic bodies. Decrease in arterial partial pressure of oxygen (pO_2), rather than in oxygen content, is the main stimulus. Acute drops in arterial pO_2 result in sustained hyperventilation only when the PCO_2 decreases below 60 mm Hg. Although hyperventilation occurs with even slight degrees of hypoxia, the resulting increase in brain pH suppresses the stimulus for hyperventilation unless severe hypoxia is present. In contrast, chronic hypoxia results in hyperventilation even with mildly decreased PCO_2 because brain pH is lowered by metabolic compensation. The two most common causes of hypoxia resulting in respiratory alkalosis are pulmonary disease and exposure to high altitudes.

Clinical Features

Chronic respiratory alkalosis is usually asymptomatic because compensatory mechanisms are successful in maintaining pH close to normal. Acute respiratory alkalosis may cause sensations of breathlessness, dizziness, and nervousness and can result in circumoral and extremity paresthesias, altered levels of consciousness, and tetany. These signs are related to decreased cerebral blood flow secondary to the decreased PCO_2 and decreased ionized calcium concentration secondary to the increased blood pH.

Compensatory Mechanisms

Tissue buffering is the initial response to a decrease in PCO_2. Red blood cells provide one-third of the buffering. Consumption of bicarbonate results from cellular liberation of H^+. The magnitude of tissue buffering is weak compared with renal compensation. This is accomplished not by increasing bicarbonate excretion but by decreasing net acid excretion, namely ammonia. Acute compensation is not as strong as chronic compensation, which takes at least 3 days to occur.

Acute compensation: Decrease serum HCO_3^- by 2 mEq/L per 10 mm Hg reduction in PCO_2

Chronic compensation: Decrease serum HCO_3^- by 4 to 5 mEq/L per 10 mm Hg reduction in PCO_2

Treatment

The underlying stimulus for the hyperventilation should be addressed. The cause of hypoxemia should be determined and corrected. In acute symptomatic respiratory alkalosis, rebreathing or breathing 5% CO_2 temporarily relieves symptoms. If the condition is secondary to mechanical ventilation, decreasing tidal volume or respiratory

rate should result in resolution of respiratory alkalosis.

Respiratory Acidosis

Respiratory acidosis is defined by a decrease in extracellular pH from a primary increase in PCO_2, due to inadequate ventilation. Causes of hypoventilation include CNS depression, impaired pulmonary mechanics, airway obstruction, and chronic obstructive pulmonary disease (COPD). In addition, inappropriate ventilator settings may result in respiratory acidosis in patients on mechanical ventilation.

Clinical Features

The magnitude of clinical manifestations depends on the chronicity and rate of development of respiratory acidosis. Acute increases result in cerebral acidosis, manifested by drowsiness, restlessness, and tremor, as well as stupor or coma in more severe cases. Cerebral vasodilation occurs in response to acidosis, resulting in increased cerebral blood flow. This may, in turn, result in increased intracranial blood pressure, headache, and papilledema. Systemic acidosis results in peripheral vasodilatation, depressed cardiac contractility, and insensitivity to catecholamines.

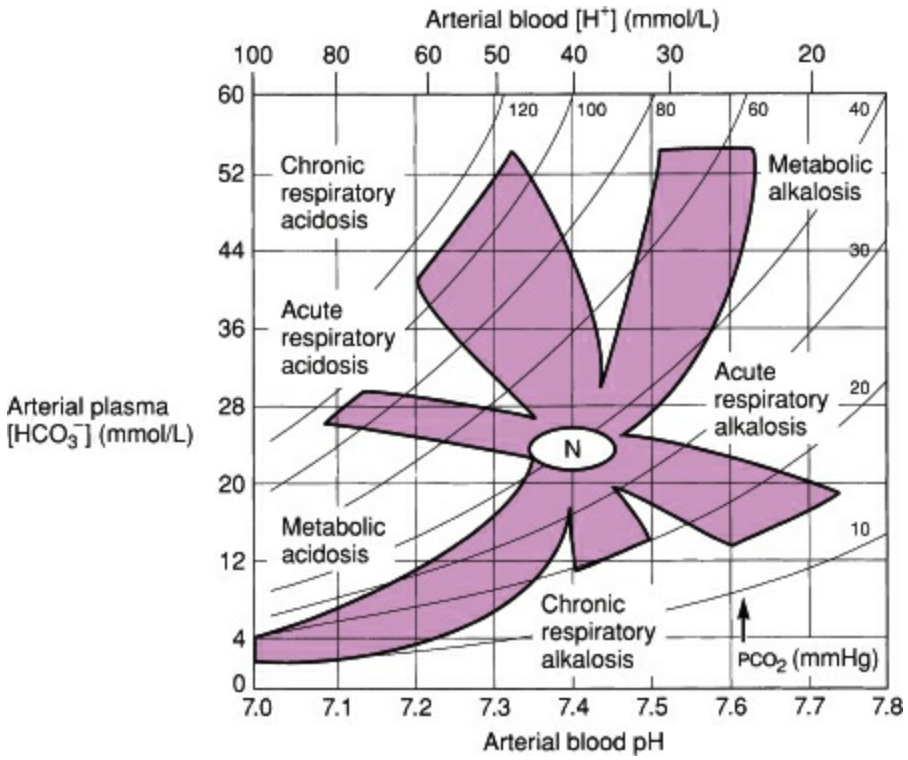

Figure 11-8. Acid–base nomogram. Shown are the 95% confidence limits of the normal respiratory and metabolic compensations for primary acid–base disturbances. (Reproduced with permission from Cogan MG, Rector FC Jr. Acid–base disturbances. In: Brenner BM, Rector FC Jr, eds. *The Kidney*. Philadelphia, PA: WB Saunders; 1986:473.)

Compensatory Mechanisms

Increased pCO_2 results in increased H_2CO_3, which dissociates into H^+ and HCO_3^-. Cellular exchange of Na^+ and K^+ for H^+ allows the reaction to continue in this direction with increased extracellular bicarbonate. This tissue buffering is accomplished within minutes. Persistently elevated PCO_2 also stimulates increased renal acid excretion, primarily the

chloride salt of ammonia, and results in increased renal generation of HCO_3^-. Full renal compensation occurs over 3 to 5 days.

Acute compensation: 1 mEq/L HCO_3^- per 10 mm Hg PCO_2

Chronic compensation ~4 mEq/L for every 10 mm Hg PCO_2

Treatment

Treatment should be directed to the underlying cause of hypoventilation. Endotracheal intubation to achieve adequate ventilation is paramount to the treatment of acute respiratory acidosis of any cause. In select cases of respiratory acidosis, namely patients with COPD, noninvasive positive pressure ventilation (i.e., CPAP/BiPAP) has proven effective. However, patients must be able to protect their airway and have no major concern for aspiration (i.e., not appropriate in the setting of a bowel obstruction). Furthermore, there must be close follow-up to ensure the acidosis is resolving.

The treatment of chronic, compensated respiratory acidosis may be complicated by the accompanying hypoxemia. In chronic hypercapnia, the central chemoreceptors may be insensitive, and the accompanying hypoxemia may supply the main respiratory drive through stimulation of peripheral chemoreceptors. In such patients, complete correction of the hypoxemia may further suppress respiration and worsen the respiratory acidosis. In addition, PCO_2 should not be normalized rapidly. Equilibration of cerebral bicarbonate concentration lags behind systemic changes. Thus, even if PCO_2 is normal, cellular and cerebral metabolic alkalosis may develop.

Mixed Acid–Base Disorders

Combinations of two or more of the four primary acid–base disorders may occur and should be suspected when blood pH approaches normal despite abnormal PCO_2 and $[HCO_3^-]$, or when compensatory changes appear to be either excessive or inadequate (Fig. 11-8). Familiarity with the acid–base disorders associated with various clinical situations and the expectation of mixed abnormalities allows appropriate interpretation of arterial blood gases and serum electrolyte determinations.

References

1. Forbes G. Body composition: overview. *J Nutr* 1999;129(1):270S–272S.
2. Briggs JP, Sawaya BE, Schnerman J. Disorders of salt balance. In: Kokko JP, Tannen RL, eds. *Fluid and Electrolytes.* Philadelphia, PA: WB Saunders; 1990:70.
3. Thompson CA, Tatro DL, Ludwig DA, et al. Baroreflex responses to acute changes in blood volume in humans. *Am J Physiol* 1990;259:R792–R798.
4. Le Fevre P. Gibbs-Donnan Effect: A Computer Simulation. http://www.philippelefevre.com/icu_medicine/gibbs_donnan. Accessed January 5, 2015.
5. Stockand JD. New ideas about aldosterone signaling in epithelia. *Am J Physiol Renal Physiol* 2002;51:F559–F576.
6. Boland DG, Abraham WT. Natriuretic peptides in heart failure. *Congest Heart Fail* 1998;4:23–33.
7. Falcao LM, Fausto P, Luciano R, et al. BNP and ANP as diagnostic and predictive markers in heart failure with left ventricular systolic dysfunction. *J Renin Angiotensin Aldosterone Sys* 2004;5:121–129.
8. Schrier R, Abraham W. Mechanisms of disease: hormones and hemodynamics in heart failure. *N Engl J Med* 1999;341:577–585.
9. Wait RB, Kahng KU. Renal failure complicating obstructive jaundice. *Am J Surg* 1989;157:256–263.
10. Naicker S, Bhoola KD. Endothelins: vasoactive modulators of renal function in health and disease. *Pharmacol Ther* 2001;90(1):61–68.
11. Roland CB, Aihua D, Mark L, et al. The complex role of nitric oxide in the regulation of glomerular filtration. *Kidney Int* 2002;61:782–785.
12. Ruttmann TG, James MF, Lombard EM. Haemodilution induced enhancement of coagulation is attenuated in vitro by restoring antithrombin III to predilution concentrations. *Anaesth Intensive Care* 2001;29:489–493.
13. Ng KF, Lam CC, Chan LC. In vivo effect of haemodilution with saline on coagulation: a randomized controlled trial. *Br J Anaesth* 2002;88:475–480.
14. Ruttmann TG, James MF, Finlayson J. Effects on coagulation of intravenous crystalloid or colloid in patients undergoing peripheral vascular surgery. *Br J Anaesth.* 2002;89:226–230.
15. De Lorenzo C, Calatzis A, Welsch U, et al. Fibrinogen concentrate reverses dilutional coagulopathy induced in vitro by saline but not by hydroxyethyl starch 6%. *Anesth Analg* 2006;102:1194–2000.
16. Koustova E, Standon K, Gushchin V, et al. Effects of lactated Ringer's solution on human leukocytes. *J Trauma* 2002;53:872–878.
17. Hanneman L, Reinhart K, Korrel R, et al. Hypertonic saline in stabilized hyperdynamic sepsis. *Shock* 1996;5:130–134.

18. Wade CE, Kramer GC, Grady JJ, et al. Efficacy of 7.5% saline and 6% dextran-70 in treating trauma. A meta-analysis of controlled clinical studies. *Surgery* 1997;122:609–616.
19. Doyle J, Davis D, Hoyt D. The use of hypertonic saline in the treatment of traumatic brain injury. *J Trauma* 2001;50:367–383.
20. Rizoli SB, Rhind SG, Shek PN, et al. The immunomodulatory effects of hypertonic saline resuscitation in patients sustaining traumatic hemorrhagic shock. *Ann Surg* 2006;243:47–57.
21. Finfer S, Bellomo R, Boyce N, et al. The SAFE Study Investigators. A comparison of albumin and saline for fluid resuscitation in the intensive care unit. *N Engl J Med* 2004;350:2247–2256.
22. Vincent JL, Sakr Y, Reinhart K, et al. Is albumin administration in the acutely ill associated with increased mortality? Results of the SOAP study. *Crit Care* 2005;9:R745–R754.
23. Greg M. Conflicting clinical trial data: a lesson from albumin. *Crit Care* 2005; 9:649–650.
24. Alexey AS, Raili S, Anne HK, et al. Rapidly degradable hydroxyethyl starch solutions impair blood coagulation after cardiac surgery: a prospective randomized trial. *Anesth Analg* 2009;108:30–36.
25. Martin G, Bennett-Guerrero E, Wakeling H, et al. A prospective, randomized comparison of thrombelastographic coagulation profile in patients receiving lactated Ringer's solution, 6% hetastarch in a balanced-saline vehicle, or 6% hydroxyethyl starch in saline during major surgery. *J Cardiothorac Vasc Anesth* 2002;16:441–446.
26. Omar MN, Shouk TA, Khaleq MA. Activity of blood coagulation and fibrinolysis during and after hydroxyethyl starch (HES) colloidal volume replacement. *Clin Biochem* 1999;32:269–274.
27. Perner A, Haase N, Guttormsen AB, et al.; 6S Trial Group; Scandinavian Critical Care Trials, Group. Hydroxyethyl starch 130/0.42 versus Ringer's acetate in severe sepsis. *N Engl J Med* 2012;367:124–134.
28. Myburgh JA, Finfer S, Bellomo R, et al. Hydroxyethyl starch or saline for fluid resuscitation in intensive care. *N Engl J Med* 2012;367:1901–1911.
29. Public Workshop: Risks and Benefits of Hydroxyethyl Starch Solutions. Vaccines, Blood & Biologics (U.S. Food and Drug Administration), September, 2012.
30. Solutions for infusion containing hydroxyethyl starch: Hydroxyethyl-starch solutions (HES) should no longer be used in patients with sepsis or burn injuries or in critically ill patients. PRAC recommendations, European Medicines Agency, October 10, 2013.
31. Dellinger R, Phillip L, Mitchell M, et al. The Surviving Sepsis Campaign Guidelines Committee including the Pediatric Subgroup (February 2013). Surviving Sepsis Campaign: International Guidelines for Management of Severe Sepsis and Septic Shock: 2012. *Crit Care Med* 2012;41(2):580–637.

32. Perel P, Roberts I. Colloids versus crystalloids for fluid resuscitation in critically ill patients. *Cochrane Database Syst Rev* 2012;6:CD000567.
33. Allison KP, Gosling P, Jones S, et al. Randomized trial of hydroxyethyl starch versus gelatine for trauma resuscitation. *J Trauma* 1999;47:1114–1121.
34. Russell WJ, Fenwick DG. Anaphylaxis to Haemaccel and cross reactivity to Gelofusin. *Anaesth Intensive Care* 2002;30:481–483.
35. Bernard AC, Moore EE, et al.; PolyHeme Study Group. Postinjury resuscitation with human polymerized hemoglobin prolongs early survival: a post hoc analysis. *J Trauma* 2011;70(5 Suppl):S34–S37.
36. Fleck A, Raines G, Hawker F, et al. Increased vascular permeability: a major cause of hypoalbuminaemia in disease and injury. *Lancet* 1985;1:781–784.
37. Rodriguez HJ, Domenici R, Diroll A, et al. Assessment of dry weight by monitoring changes in blood volume during hemodialysis using Crit-Line. *Kidney Int* 2005;68(2):854–861.
38. McGee WT. A simple physiologic algorithm for managing hemodynamics using stroke volume and stroke volume variation: physiologic optimization program. *J Intensive Care Med* 2009;24(6):352–360.
39. Androgue HJ, Madias NE. Hyponatremia. *N Engl J Med* 2000;342:1581–1589.
40. Katz MA. Hyperglycemia-induced hyponatremia—calculation of expected serum sodium depression. *N Engl J Med* 1973;289:843–844.
41. Ellison DH, Berl T. Clinical practice. The syndrome of inappropriate antidiuresis. *N Engl J Med* 2007;356:2064–2072.
42. Scherr L, Ogden DA, Mead AW, et al. Management of hyperkalemia with a cation-exchange resin. *N Engl J Med* 1961;264:115–119.
43. Magnus Nzerue C, Jackson E. Intractable life-threatening hyperkalaemia in a diabetic patient. *Nephrol Dial Transplant* 2000;15:113–114.
44. Cooper MS, Gittoes NJ. Diagnosis and management of hypocalcaemia. *BMJ* 2008;336:1298–1302.
45. Hannan FM, Thakker RV. Investigating hypocalcaemia. *BMJ* 2013;346:f2213.
46. Tohme JF, Bilezikian JP. Hypocalcemic emergencies. *Endocrinol Metab Clin North Am* 1993;22:363–375.
47. Martin TJ, Kang Y, Robertson KM, et al. Ionization and hemodynamic effects of calcium chloride and calcium gluconate in the absence of hepatic function. *Anesthesiology* 1990;73(1):62–65.
48. Javaheri S, Shore NS, Rose B, et al. Compensatory hypoventilation in metabolic alkalosis. *Chest* 1982;81:296–301.
49. Polak A, Haynie GD, Hays RM, et al. Effects of chronic hypercapnia on electrolyte and acid-base equilibrium. Adaptation. *J Clin Invest* 1961;40:1223–1237.
50. Lemann J Jr, Lennon EJ. Role of diet, gastrointestinal tract, and bone in acid-base homeostasis. *Kidney Int* 1972;1(5):275–279.

51. American Diabetes Association. www.diabetes.org. Accessed November 3, 2014.
52. Kitabchi AE, Wall BM. Management of diabetic ketoacidosis. *Am Fam Physician* 1999;60(2):455–464.

Chapter 12

Burns

Benjamin Levi, Mark R. Hemmila, and Stewart C. Wang

Key Points

1 Burn reconstruction remains a challenge given the increased survival of burn patients.
2 Most chemical injuries should be treated with dilution of the chemical rather than neutralization.
3 Frostbite outcomes are improved if patients with threatened extremities are treated with tPA within 24 hours of injury.
4 Resuscitation is of crucial importance for burn patient outcome and physicians must be aware when to begin resuscitation (>20% TBSA) and to monitor the patient's response to avoid overresuscitation.
5 Early excision and grafting within 72 hours of the injury remains a pillar of burn care.
6 Order of burn coverage can affect patient outcome and can help prevent the patient from needing a tracheostomy.
7 In addition to surgical treatment of hypertrophic scars, new laser technologies allow for scar rehabilitation improving the quality and pain associated with these scars.

INTRODUCTION

Burn injuries represent a major source of trauma, subsequent scarring and debility throughout the world. Improved worker safety programs, fire prevention efforts, and fire detection systems have significantly decreased the prevalence of major burn injuries. Burn patients have also benefited from recent improvements in surgical critical care in areas such as lung protective ventilation, blood glucose control, and antibiotic stewardship. Overall, survival after burn injuries remains high, leading to a large need for improved reconstructive treatment options for burn scar rehabilitation.

EPIDEMIOLOGY

1 Based on the American Burn Association (ABA) National Burn Repository, 450,000 people receive medical treatment for burns annually. There are 40,000 hospital admissions and 3,400 deaths per year from fire and smoke inhalation.[1] Of these patients, 69% are male, 59% are Caucasian, 20% are African American, and 15% are Hispanic. The cause of these burn injuries varies with 43% from fire or flame burns, 34% from scald burns, 9% from contact burns, and 7% are electrical and chemical burns. With increased safety emphasis in the workplace, only 9% of these injuries occur at work. The majority of chemical, electrical, and molten burns occur at home and 72% of all burn injuries happen at home. As in other trauma populations, children are affected to a greater degree. Children under 8 years of age typically suffer from scald burns caused by spilling of hot liquids. With improved surgical critical care and understanding of burn injury physiology, over 96% of burn patients survive. Thus, with improved treatments and survival, there has also been an increased focus on burn reconstruction and scar management.

Children

Infants and children up to 4 years old comprise almost one-third of burns. Burns are the fifth leading cause of unintentional nonfatal injury in infants and the third leading cause of fatal injury for newborns to children 9 years of age. Scald burns caused by hot liquids are the most common cause of pediatric burns and occur most often in the home.[2–5] The number of burns decreases from age 9 until adolescence and increases again after the age of 15, presumably due to greater exposure to hazards, experimentation, risk-taking, and employment.[6] Intentional burns account for around 10% of all cases of child abuse.[7] Scalds from hot bath immersion are the most frequent cause of these cases. Other common etiologies of intentional burns include contact with heated objects including cigarettes, irons, and heated kitchen utensils.

Adults

In contrast to the pediatric population, flame burns are the most common cause of burns in adults and the elderly. Flame burns account for 35% to 42% of hospital admissions in adults, while scald burns account for 15% to 18% of hospital admissions related to burn injuries.[3] Cigarette ignition of upholstered furniture or bedding accounts for 47% of fires and alcohol appears to be a significant contributor.[8]

Elderly

The elderly (defined by age greater than 65 years) suffer a disproportionately higher percentage of hospitalizations due to burns in comparison to the general adult population. A 10-year analysis from 1995 to 2005 using data from the National Burn Repository showed that individuals over the age of 65 comprised 12% of all burn unit admissions and that the average age of those admitted was 76 ± 7 years.[9] The most frequent cause of burns that led to death in elderly women was a result of clothing ignition during cooking.[10] Elderly burn patients treated for scald burns had relatively small burns (<13% of total body surface area [TBSA]) but high mortality rates (30%).[11–13] Overall, burns are the fourth leading cause of mortality in the elderly population. Together, these results suggest that the medical, economic, and social burdens of burn will likely increase as the general population continues to age.

Race and Ethnicity

Differences also exist in the susceptibility to burns by race and ethnicity. Burns are the leading cause of injury-related death in Black children between the ages of 1 and 9 and the rates are 2.7 times higher than in White, Hispanic, and Asian/Pacific Islander children.[14] Likewise, in adults, the rate of nonfatal burns in Black Americans aged 35 to 39 years was 221 per 100,000 Blacks, which is remarkably higher than the 135 per 100,000 Whites with burns in the same age group.[3] The emergency room visit rate for burns from 1993 to 2004 in the United States was 62% greater among Black Americans (340 per 100,000 Black Americans) than White Americans (210 per 100,000 White Americans).[15] The age-adjusted death rate from burns of all causes in the United States in 2006 was highest in Blacks (2.4 per 100,000) and lowest in Asians (0.4 per 100,000), with Native Americans (1.5 per 100,000), White non-Hispanics (1.1 per 100,000), and Hispanics (0.8 per 100,000) falling in between this range.[3] These trends can be translated to the elderly population, as the mortality rate for burn-related injuries in the elderly was 4.6 times greater in Black Americans than in White Americans.[16]

There are also significant differences in the gender distribution of burns between age groups. Adult men more frequently seek care in the emergency department (69%). This may be due to the increased severity of their burns caused by industrial accidents, compared to women (31%).[6] Elderly are also more highly represented among older burn victims than in younger populations.[17,18] The greater preponderance of older women with burn injuries reflects the decrease in workplace-related injuries among the geriatric population.

Socioeconomic Status

Socioeconomic status (SES) factors such as low household income, crowded household living conditions, and unemployment also increase the risk of burns. In the metropolitan Oklahoma City, Oklahoma, the overall fire-related hospitalization and death rate was 3.6 per 100,000.[19] Stratification of the data based on household income, property values, and quality of housing demonstrated that the injury rate in lower SES was 15.3 per 100,000.[20] The proportion of children in the lowest SES groups requiring hospitalization for treatment in US burn centers is twice the proportion of all children in the general population.[3] Furthermore, the incidence of house fires was eight times greater in low income families compared to high incomes.[21] The higher incidence of house fires has been attributed to the frequent absence of functioning smoke detectors.[21] Together, these results highlight the increased need for education and prevention campaigns for lower SES groups to reduce household fires and burn injuries.

ETIOLOGY

Numerous modalities, including fire or flame, scalds, contact, electrical conduction, and chemicals can produce burns. Between 2002 and 2011, 44% of burns were produced by fire or flame, 33% by scald, 9% by contact, 4% by electricity, 3% by chemical, and 7% defined as other.

Burns are caused by contact of heat, cold, or chemicals with the cutaneous surface of the skin. The depth of the burn injury is proportional to the temperature and duration of exposure. Burn depth is also dependent on the body region due to differences in skin thickness and blood flow.

Scald burns are most commonly caused by water in the community. Once the water temperature exceeds 156°F, only 1 second is needed for a full-thickness burn injury. The difference in contact time underlines the importance of making sure hot water heaters are set at a low enough temperature to minimize childhood bath and shower scald injuries (120°F). It takes 3 minutes for a burn to occur from 120°F whereas it takes only 1 second for a burn to occur from 156°F water.

Though water scalds do not always cause full-thickness injury due to the variation in temperature, grease burns almost uniformly cause a deep partial- or full-thickness burn. Grease is usually 400°F and thus even minimal exposure will cause significant thermal injury. Tar and asphalt also exceed 400°F to 500°F making them a high burn injury risk for industrial workers. Water and grease injury sites should be cleansed with aqueous solutions. Tar, however, requires a petroleum-based solution to remove it from the burn wound.

Flame Burns

Thermal injuries, caused by fire or flames, are the most common burn etiology reported over the past decade.[22] These injuries usually occur as a result of flammable liquids, motor vehicle crashes, cooking fires, or if bedding/clothes ignite. Despite improved fire safety at home with smoke detectors as well as improved safety at industrial sites, flame injuries are still relatively common and frequently cause partial- and full-thickness burn injuries. Flame injuries are associated with the highest risk of death and complications compared to all other burn etiologies. Flame burns most commonly occur at home (64%), while work fires and recreational fire burns account for 12% and 6% of flame burns, respectively. When evaluating thermal injuries, it is important to consider the possibility of smoke inhalation as its presence significantly impacts the morbidity and mortality of patients with flame burns. Inhalation injury occurs in 17% of patients with flame burns. The presence of smoke inhalation in burn patients is associated with an overall mortality rate of 24%, compared to the mortality rate of 4% in patients without smoke inhalation.

Contact Injuries

Contact burns occur as the result of direct contact with hot surfaces and material, most frequently glass, metal, or plastic. The depth of the injury will depend on the heat of the material and the length of contact. Frequent sites of injury include the palms of the hands as people, especially toddlers, often fall with outstretched hands. Other commonly seen contact injuries are due to hot metal devices such as space heaters, curling irons, or motorcycle exhaust systems.

Electrical Burns

Electrical injuries occur more frequently in adults than children since most result from occupational exposure. As one of the most devastating and debilitating injuries cared for in burn centers, electrical injuries comprise 4% of all reported etiologies. Patients who have high-voltage electrical injuries, defined as greater than 1,000 V, are at elevated risk of spine fracture injury due to tetany and require complete immobilization until vertebral injury is excluded. Providers must also evaluate patients with high-voltage injuries for cardiac damage. Direct muscle injury from current flow may cause gross myoglobinuria, requiring more aggressive fluid resuscitation.[23] Patients with gross myoglobinuria often require fasciotomy of affected limbs and a severe electrical injury often requires monitoring in the ICU. Bone has the highest conductance and electricity flows along the skeleton cause significant muscle necrosis adjacent to the bone. TBSA involved is not necessarily associated with prognosis and it does not quantify damage to deep tissues in electrical injuries.

Thermal injuries occur as electricity can generate temperatures over 100°C. Electroporation occurs as electrical force drives water into lipid membrane causing cell rupture. Tissue resistance in decreasing order includes bone, fat, tendon, skin, muscle, vessel, and nerve. Bone heats to a high temperature and burns surrounding structures such as muscle which is the reason why muscle swelling and compartment syndrome are common in high-voltage electrical injuries.

Alternating current causes tetanic muscle contraction and the “no let-go” phenomenon. This occurs due to simultaneous contraction of (stronger) forearm flexors and (weaker) forearm extensors. Current flow through tissue can cause burns at entrance/exit wounds and hidden injury to deep tissues. Current will preferentially travel along low-resistance pathways. Current will pass through soft tissue, contact high-resistance bone, and travel along bone until it exits to the ground. Vascular injury to nutrient arteries and damage to intima and media can result in thrombosis.

Electrical exposure can cause significant injuries to other organ systems besides the skin and musculoskeletal system. From a cardiac standpoint, arrhythmias are common at the scene (any voltage) or in the hospital (high voltage $\geq$1,000). Heart rhythm should be monitored continuously for at least 24 hours if cardiac injury is suspected at the scene or if a high-voltage injury has occurred. Ventricular fibrillation and asystole are the most common and Advanced Cardiac Life Support should be instituted immediately. Coronary artery spasm and myocardial injury and infarction have also been described. A normal cardiac rhythm on admission, however, means dysrhythmia is unlikely and thus 24-hour monitoring is not needed.[24] Additionally, injury to solid organs, acute bowel perforation, and gallstones after myoglobinuria have been described. Myoglobinuria occurs due to the disruption of muscle cells. Myoglobinuria from other causes requires increased fluid administration, however, burn resuscitation usually provides adequate fluid. Cataracts are also a long-term adverse effect of electrical injury necessitating ophthalmology evaluation and follow-up.

When taking the patient to the operating room for debridement and grafting of

electrical injuries, the physician should perform serial debridements and allow the tissue to completely declare itself. These injuries will often evolve with progressive muscle necrosis over time, thus early grafting (within the first week) often fails to fully close the burn wound. These injuries have similarities to crush injuries and thus multiple trips to the operating room for debridement should not be viewed as failure.

Chemical Burns

General Approach to Chemical Burn Treatment

2 Healthcare providers should use personal protective equipment – always considering that the chemicals are still present and must be neutralized or temporized. With few exceptions (see below), all chemical burns should be copiously irrigated with water. Water dilutes but does not neutralize the chemical and cools the injured area. Neutralization of the chemical is generally contraindicated because neutralization may induce a hyperthermic reaction leading to further thermal injuries. Water irrigation, however, is contraindicated or ineffective following exposure to elemental sodium, potassium, and lithium (precipitates an explosion). Dry lime should be brushed off, not irrigated. Phenol is water insoluble and should be wiped from the skin with polyethylene glycol-soaked sponges.

Types of Chemical Burns

Alkali causes liquefaction necrosis and protein denaturation and is found in oven and drain cleaning products, fertilizers, and industrial cleaners. Alkali injuries extend deeper into tissues following exposure and are especially disruptive to the eye. **Acids** cause damage tissue via coagulation necrosis and protein precipitation. Acid burns tend to be self-limited secondary to pain as the patient will quickly react to the offending agent. **Organic compounds (**phenol and petroleum**)** cause damage due to fat solvent action (cell membrane solvent action) and systematic absorption with toxic effects on the liver and kidneys. These agents can also cause significant erythema in the surrounding areas that can be mistaken for cellulitis.

Specific Types of Chemical Burns

Hydrofluoric acid is a potent and corrosive acid used for rust removal, glass etching, and to clean semiconductors. It is a weak acid but the fluoride ion is toxic as it leaches calcium from cells. Hydrofluoric acid causes severe pain and local necrosis and should be treated with copious water irrigation. The fluoride ion is neutralized with topical calcium gel (one ampule of calcium gluconate in 100-g lubricating jelly). If symptoms persist intra-arterial calcium infusion (10-mL calcium gluconate diluted in 80 mL of saline, infused over 4 hours) and/or subeschar injection of dilute (10%) calcium gluconate solution should be administered. Fluoride ion binds free serum calcium and thus it is crucial to make sure to check the serum calcium and replace with intravenous (IV) calcium as needed.

Phenol is commonly used in disinfectants and chemical solvents, it is an acidic alcohol with poor water solubility. Phenol causes protein disruption and denaturation resulting in coagulation necrosis. Systemically, phenol can cause cardiac arrhythmias and liver toxicity. Thus patients should have cardiac and liver functions monitored. Additional adverse effects include renal injury and demyelination. Given phenol's anesthetic effect, pain is not a reliable indicator of injury. Treatment is copious water irrigation and cleansing with 30% polyethylene glycol or ethyl alcohol.

Tar is used in the paving and roofing industry and can be heated to 260°C (~500°F) prior to application. Tar causes thermal injury and then solidifies as it cools, often becoming enmeshed with hair and skin. Patients with tar injuries should be cooled with copious water irrigation to stop the burning process. Tar removers promote micelle formation to break the tar – skin bond. Sterile surfactant mixture (De-Solv-it or Shur-Clens) allows tar to be wiped away quickly. Wet dressings using polysorbate (Tween 80) or Neomycin cream for 6 hours prior to tar removal can also be effective.

White phosphorus is used to manufacture military explosives, fireworks, and methamphetamine. Obvious particles should be brushed off. Skin should be irrigated with 1% to 3% copper sulfate solution. Copper sulfate stains the particles black for identification. Copper sulfate will also prevent ignition when particles are submerged in water. After copper sulfate irrigation, the exposed area should be placed in a water bath and the white phosphorous removed.

Anhydrous ammonia is an alkali used in fertilizer. Skin exposure is treated with irrigation and local wound care. Exposure is associated with rapid airway edema, pulmonary edema, and pneumonia. It is important to consider early intubation for airway protection in these cases.

Methamphetamine injuries have been on the rise. In addition to these compounds being highly flammable, exposure to methamphetamines causes tachycardia (greater than expected with a similar size burn), hyperthermia, agitation, and paranoia. Any suspicion of chemical injury to the globe should be treated with prolonged irrigation with Morgan lenses. Eyelids may need to be forced open due to edema or spasm. Utilize topical ophthalmic analgesic and consult an ophthalmologist.

Frostbite

Frostbite injuries frequently result in severe ischemic damage of distal extremities. Frostbite classification is similar to that of burn injury with first degree demonstrating hyperemia and no blisters with no tissue loss expected; second degree having blisters and edema but still no tissue loss; third degree with hemorrhagic blisters, throbbing pain, and likely tissue loss; and fourth degree with mottled or cyanotic skin, hemorrhagic blisters, and frozen deeper tissues.

3 Historically, these patients have been managed expectantly with long periods of observation followed by amputation of devitalized tissue. Recent advances with interventional radiology, thrombolytic therapy, and nuclear medicine have changed the treatment paradigm and protocol for these patients (Algorithm 12-1). Current treatment paradigms for patients with frostbite include rapid rewarming of affected area in 104°F to 108°F water bath, not radiant heat as well as ibuprofen 400 mg, elevation of the limb, tetanus prophylaxis, and appropriate referral. If the patient has severe frostbite within the last 24 hours, the patient should be transferred to a center with interventional radiology expertise. Once they arrive, these patients should receive an arterial line (usually brachial or femoral) and intra-arterial tPA which treat the microvascular thrombosis.[25] Additionally, patients might benefit from nitroglycerin to treat vasospasm. Patients should return to the interventional radiology suite after 12 hours to evaluate progress and potentially treat again. In general, tPA is stopped after 48 hours. After 5 to 7 days, a nuclear bone scan can help assess the extent of deeper tissue necrosis as the more superficial tissue will often appear worse than the actual extent of the injury.

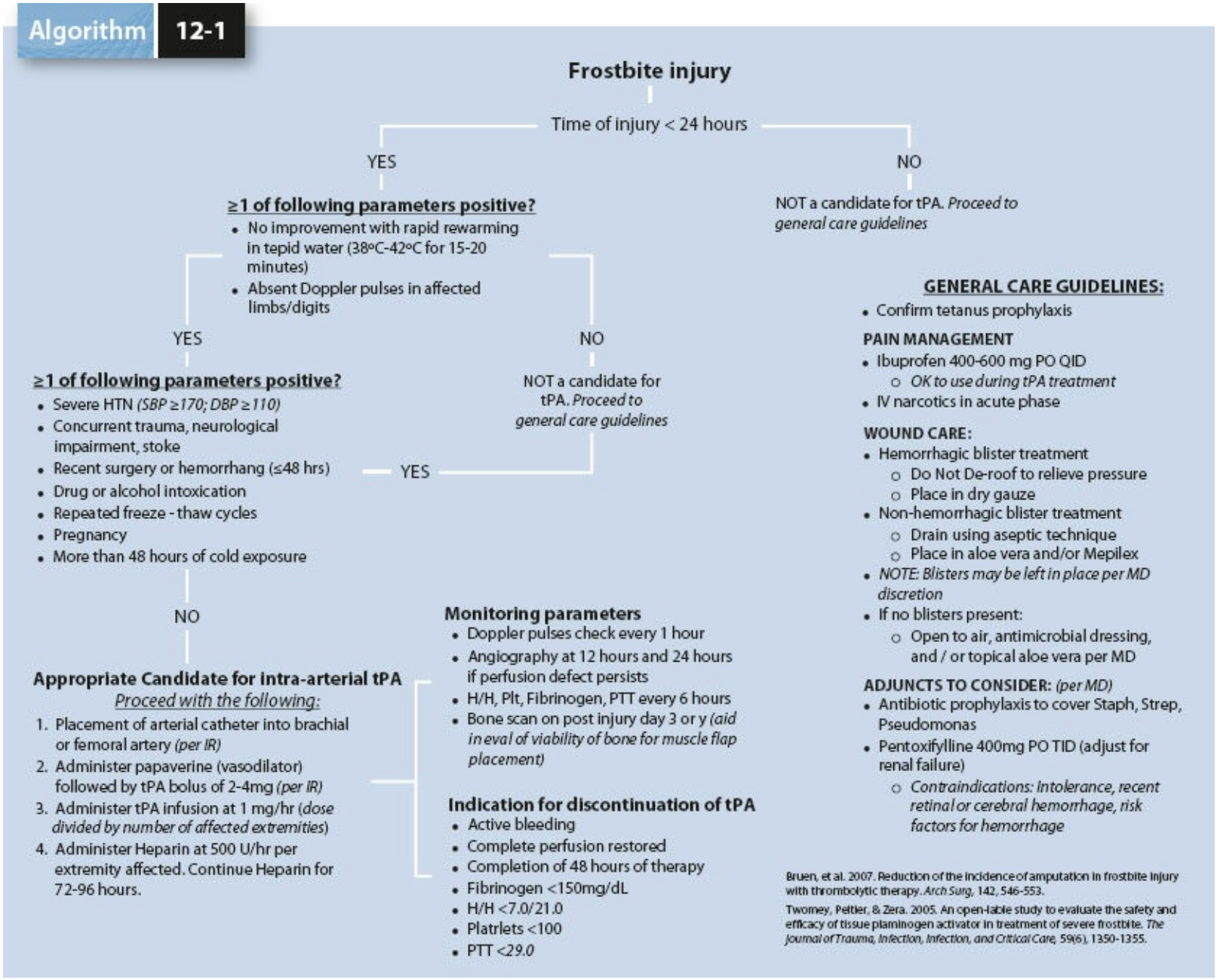

Algorithm 12-1. Protocol for frostbite injury.

PHYSIOLOGY OF BURNS

Burn Shock

Most patients with large burn or inhalation injuries will meet criteria for systemic inflammatory response syndrome (SIRS) (body temperature less than 36°C [96.8°F] or greater than 38°C [100.4°F], heart rate greater than 90 beats per minute, tachypnea greater than 20 breaths per minute, arterial partial pressure of carbon dioxide less than 4.3 kPa [32 mm Hg], blood leukocyte count less than 4,000 cells/mm3, or greater than 12,000 cells/mm3); or the presence of greater than 10% immature neutrophils (band forms). SIRS with infection is defined as sepsis and sepsis in addition to hypoperfusion is defined as "septic shock." Burn shock does not equate to septic shock in the acute setting as true sepsis from a burn injury with subsequent infection usually does not occur until after the first 48 to 72 hours.

Burn shock is unique in the degree of vascular permeability coupled with increased hydrostatic pressure.[26] This increased permeability is thought to result from the release of histamine from mast cells in burned skin following burn injury.[27] Histamine interferes with the venous tight junctions and thereby allows efflux of fluid and proteins causing intravascular hypovolemia despite total volume hypervolemia.

Platelet activation products such as eicosanoids and serotonin also act to increase pulmonary vascular resistance and amplification of the vasoconstrictive effects of norepinephrine and angiotensin II.[28] In addition to the increased vascular leak, platelet-activating factor and clotting factor dysregulation creates a hypercoagulable state with bleeding that resembles disseminated intravascular coagulation. This coagulation disorder is further amplified if patients become hypothermic during their resuscitation.[29] Thus, patient temperature monitoring and maintenance is crucial during resuscitation.

Arachidonic acid metabolism products such as eicosanoids also play a role in burn edema. Eicosanoids increase prostaglandins such as PGE2 and prostacyclin which cause arterial dilation and increased blood flow and hydrostatic pressure in regions of injury resulting in increased edema.

Changes in cardiac output are also seen acutely in burn patients as these patients often have an increase in heart rate, and systemic vascular resistance but hypovolemia. Though not defined as "cardiogenic shock," cardiac function is altered due to inflammatory mediators.[30–33] With appropriate burn resuscitation, cardiac output should return to normal levels within 24 to 72 hours.

Metabolic Response to Burn Injury

Hypermetabolism is a physiologic response unique to burn injury. Hypermetabolism is characterized by increased body temperature, glycolysis, gluconeogenesis, proteolysis, lipolysis, and prolonged substrate cycling.[34,35] The degree of the hypermetabolic response is proportional to the size of burn injury and appears to plateau at 70% TBSA. Overall the basal level of glucose is elevated despite a high insulin state which can complicate outcomes and exacerbate muscle catabolism.

Lipolysis also occurs at a rate that is higher than normal due to abnormal substrate cycling. This results in hepatic accumulation of triglycerides causing steatosis. Recent work to combat peripheral lipolysis has had some success using propranolol.[36]

Proteolysis is also increased in burn patients compared to nonburn patients. This is due to a combination of increased muscle breakdown and increased plasma protein production by the liver. Wound healing requires an increase in protein synthesis leading to the recommendation of enteral nutrition with elevated protein levels.

There are three ways to influence hypermetabolism: nutrition, medication, and surgery. Current protocols preferentially recommend continuous enteral nutrition with a high-carbohydrate diet consisting of 82% carbohydrate, 3% fat, and 15% protein. This diet is thought to stimulate protein synthesis, increase endogenous insulin production, and improve overall lean body mass when compared to standard formulas.[35]

Catecholamines are significantly elevated following a burn injury and are thought to play a role in the hypermetabolic response. This elevation is one reason why propranolol administration is thought to be helpful. Interestingly, growth hormone levels have been shown to be decreased in burn shock leading clinicians to supplement patients with the anabolic steroid oxandrolone in large burn injuries. Positive results to avoid or reduce the loss of muscle mass with oxandrolone have made its use standard in most burn units for large TBSA burn patients.[37–44] With regard to thyroid hormone, total thyronine and thyroxin (T3 and T4) are reduced whereas reverse T3 is elevated. Burn injuries also cause alterations in diurnal glucocorticoid levels leading to persistent hypercortisolemia.

Surgery represents the last way to combat hypermetabolism as early debridement and grafting is the mainstay to mitigate the hypermetabolic syndrome.

Immunologic Response to Burn Injury

The immune system in burn patients demonstrates significant dysregulation that may explain increased risk of infection. Serum levels of IgA, IgG, and IgM are decreased indicating decreased B-cell function. T-cell function or cell-mediated immunity is also impaired which is why prolonged homograft and xenograft take is seen. Interleukin 2 (IL-2) production is also decreased whereas IL-10 is increased. Similar to other types of nonthermal trauma, burn patients also have elevated tumor necrosis factor alpha and IL-6. Polymorphonuclear neutrophils have impaired chemotaxis as well as decreased oxygen consumption and impaired bactericidal capabilities.

EMERGENCY CARE

Initial care in the field and emergency room is similar to that of any trauma patient. The airway should be stabilized, IV access should be obtained, concomitant life-threatening injuries should be excluded, and escharotomies should be performed if there are any circumferential areas of full-thickness injury. Escharotomies should be placed on the lateral aspects of the extremities avoiding the sites of potential nerve and large vessel injury (Fig. 12-1). Escharotomies should be extended across the chest if there is full-thickness injuries and if difficult ventilation arises. Abdominal escharotomies can also help with ventilation.

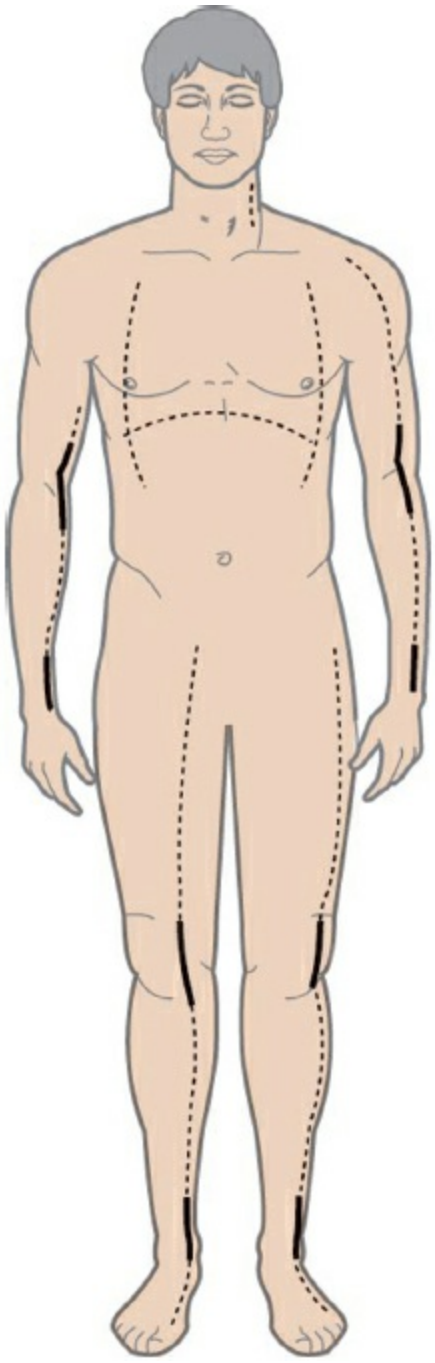

Figure 12-1. Incision lines for escharotomies. In general incisions should be kept on the lateral aspect of extremities to avoid damage to neurovascular structures. (From Holzman RS, Mancuso TJ, Polaner DM, eds. *A Practical Approach to Pediatric Anesthesia, 2e*. Philadelphia, PA: Wolters Kluwer; 2016.)

Table 12-1 Burn Center Referral Criteria[45]

Though patients often present to the nearest emergency room or urgent care center, certain patients have been shown to benefit from transfer to a designated burn center. The American Burn Association has put out a list of criteria for those patients who should be transferred. This includes:

1. Over 10% total body surface area (TBSA) partial- or full-thickness burns
2. Burns that involve difficult anatomic sites such as the face, hands, feet, genitalia, perineum, or major joints
3. Full-thickness burns in any age group
4. Electrical burns, including lightning injury
5. Chemical burns
6. Inhalation injury
7. Burn injury in patients with pre-existing medical conditions that could complicate management, prolong recovery, or affect mortality
8. Any patient with burns and concomitant trauma. If, however, the coincident trauma is of greater risk to mortality, the patient should be stabilized prior to transfer. Physician judgment will be necessary and should be in concert with the regional medical control plan and triage protocols
9. Burned children in hospitals without qualified personnel or equipment for the care of children
10. Burn injury in patients who will require special social, emotional, or rehabilitative intervention

Guidelines from the American College of Surgeons Advanced Trauma Life Support and the ABA Advanced Burn Life Support programs have standardized the care of trauma patients and have improved overall patient outcomes. A complete history and physical should be performed with specific focus placed on the cause and timing of the injury, risk of smoke inhalation injury, concomitant injuries, and treatments including IV fluids received prior to patient arrival. The primary goal is to stabilize the patient, ensure standard injury assessment, and transfer to a burn center as necessary. The ABA has published criteria to follow regarding when to transfer a patient to a verified burn center (Table 12-1).

Airway Assessment

Primary survey assessment should begin with evaluation of the airway. Inhalation injuries occur in approximately 10% of all burn patients, but are present in 70% of those who eventually die of their burn injury.[46] Thus, it is important to specifically note such findings as soon as the patient presents. Risk for inhalation injury can be first assessed by the history. In general, patients burned outside (not in an enclosed space) very rarely suffer inhalational injuries. If, however, the patient was in a burning home or a burning building, one's suspicions should be raised. Close physical examination should note facial burns, changes in voice, shortness of breath, singed nasal vibrissae, carbonaceous sputum, and intraoral swelling. If these findings are present and the patient appears to be in distress, oral intubation should be performed immediately by an experienced airway physician. In addition to a laryngoscope, the trauma team should have a video laryngoscope available and a surgeon present in case a surgical airway is required. If the patient is not in extremis and the level of inhalation injury is unknown, nasoendoscopy or bronchoscopy should be performed to directly visualize the airway and vocal cords. If significant swelling exists and the patient is expected to receive large volume IV fluid resuscitation, the airway should be immediately secured. If a patient is transferred with an endotracheal tube that the accepting physician feels is no longer needed, a spontaneous breathing trial should be performed followed by direct laryngoscopy to assess for cord swelling and assessment for a cuff leak should be performed before removing the endotracheal tube.

Oxygenation in a burned patient may be altered by carbon monoxide (CO) poisoning. Physical examination findings include red lips and altered mental status. Formal diagnosis should be based on history and evidence of CO levels in the blood. CO binding is assessed by measuring the level of carboxyhemoglobin in a peripheral arterial blood gas sample. Symptoms of CO poisoning typically begin with headaches at levels around 10%, while CO in the blood becomes lethal at around 50% to 70%. The half-life of CO is normally 4 hours when breathing room air, however, half-life is shortened considerably with administration of supplemental oxygen. Treatment with 100% oxygen (FiO_2 100%) reduces the half-life of CO to 30 to 90 minutes. Hyperbaric oxygen treatment can reduce the half-life of CO to 15 to 23 minutes. However, if the patient has additional burn injuries or is unstable, the patient should not be placed in a hyperbaric chamber. Also, the time needed to transfer patients to hyperbaric facilities and the subsequent difficulty of resuscitating a critically ill patient in a closed chamber make hyperbaric oxygen an impractical option. Prompt and aggressive evaluation and maintenance of the airway is the most important initial step in management of a burn patient.

Fluid Resuscitation

It is important to have large bore IV access with 16- or 18G peripheral IVs. IV access catheters should preferentially be placed in nonburned areas of skin although this is not always possible. If the patient will require invasive hemodynamic monitoring, a central line should be placed under sterile conditions. Peripherally inserted central catheter (PICC) lines can be used in burn patients, however, their infection rate remains high. If a central line is used, this does not need to be changed out at a certain timepoint but rather should be monitored daily for signs of infection. Ideally, burn and critical care surgeons would have access to a minimally invasive monitor of cardiac output. Though several technologies exist including esophageal Dopplers, arterial waveform monitors, and thermodilution modalities, the trend of these values is more useful than the absolute values. If a PiCCO device (Pulsion Medical Systems AG, Munich, Germany) is used to monitor the patient, it is best to have the central venous line located in the internal jugular vein and the arterial line in the femoral artery. This technology uses thermodilution to determine cardiac performance. Studies have demonstrated efficacy of this technology when compared to use of a pulmonary artery catheter.[47] Burn injury and soft tissue edema make noninvasive blood pressure measurement difficult and inaccurate, hence arterial line placement is frequently necessary.

The Parkland or Consensus formula is most commonly used to estimate fluid requirements for the first 24 hours and should be used to guide initial fluid infusion rates. This is a start point and should not be construed as a dogmatic prescription of the total fluid volume to be given during the first day after injury.[48] It is extremely important to note that the original time of the injury is used in the calculation, not the time of initial presentation to care providers. Partial- and full-thickness burns are totaled to calculate burned TBSA.

Consensus formula: First 24-hour requirement = 2–4 cc × %TBSA × weight (kg)

Half of this fluid volume is planned to be administered in the first 8 hours after burn injury and the second half is administered over the next 16 hours. For example, if a 70-kg patient with 20% TBSA burn sustained at 10 AM presents 2 hours later, the crystalloid fluid to be administered in the first 8 hours is calculated using the following formula: ([4 cc × 20% × 70 kg]/2)/6 hours. Lactated Ringers crystalloid solution is recommended as the first choice fluid to avoid complications associated with metabolic acidosis.[48] Currently data do not support hypertonic saline, dextran, or albumin during the first 24 hours of resuscitation in standard clinical situations.[49,50] Studies have suggested that limited albumin usage may play a role in reducing the rate of abdominal compartment syndrome when the patient requires substantially more fluid administration than estimated by the Parkland formula (>1.5 times).[51] Additionally, D5/LR is commonly used for maintenance of fluid in children under 1 year of age to avoid hypoglycemia. Once the Parkland formula is begun, the patient's vital signs and urine output should be closely monitored and laboratory studies should be drawn frequently. Although such formulas exist, it is important to note that proper fluid resuscitation should be guided by

overall clinical response and the trend of vital signs and laboratory values. IV fluid infusion rate should be increased or decreased based on the response of the patient on an hourly basis with fluid administration titrated to maintain urine output goals of 0.5 to 1 mL/kg/hr in adults and 1 to 1.5 mL/kg/hr in children. Blood pressure and heart rate should be monitored; burn patients are often tachycardic regardless of the degree of resuscitation. Though urine output is considered a "gold standard," it often lags the fluid status and thus clinicians must be cautious not to reflexively increase fluids with low urine output but rather consider the entire clinical picture. In addition, close monitoring of the patient's laboratories is necessary to determine the trend in organ perfusion. Laboratory values that help assess organ perfusion include lactate, base deficit, central venous O_2, and/or pH. Although any one of these values alone does not provide a sensitive marker of the patient status, trending these values during resuscitation can help direct resuscitation adjustments if the current fluid rate is causing a positive trend. If the end organs are adequately perfused, decrease in lactate and base deficit as well as increase in central venous O_2 and normalization of pH should be observed.

In the second 24 hours, all patients should receive crystalloid sufficient to maintain urine output and to maintain parameters of perfusion including lactate, pulse volume variation, and cardiac output. Infusion rate will often be at a maintenance rate plus adjustment for losses of fluid into the burn wound. Nutritional support should be started enterally within 24 hours. After 24 to 36 hours, providers can cut fluids by 1/3 if the patient continues to make adequate urine. One may decrease fluids again by 1/3 for hours 36 to 48 (assuming urine output does not drop off). Colloid can be given after initial crystalloid resuscitation (5% albumin at 0.3 to 0.5 mL/kg per %TBSA over 24 hours).

After 48 hours, fluid infusion rate should maintain urine output at 0.5 to 1 mL/kg body weight per hour. Insensible losses and hyperthermia are associated with hyperdynamic states and increase fluid requirements. Daily patient weights can be helpful to determine insensible fluid loss or retention.

Pediatric fluid resuscitation does have some differences with regard to fluid management. Due to the limited reserve in children under 20 kg, a glucose-based maintenance fluid is recommended. Additionally, fluid requirements may be as high as 6 mL/kg per TBSA and their urine output should be 1.0 to 1.5 mL/kg/hr.[52] Since burn resuscitation should be considered in the setting of a 10% TBSA in children, transfer to a burn center is recommended.

Pulmonary status is also an indicator of fluid status but in a delayed fashion. Complications such as pulmonary edema result from fluid overload and necessitate daily evaluation of oxygen requirements and ventilator settings.

Difficult to Resuscitate Patients

If the fluid resuscitation required during the first 24 hours is 1.5 times greater than initially estimated, the physician should reassess the clinical picture. Giving excessive crystalloid fluids and failure to use appropriate early resuscitation adjuncts are associated with significantly worse outcomes. Physicians often will give additional fluid due to low urine output not realizing that the kidney, like other organs during burn shock, often lags behind the clinical picture. Specific complications associated with excessive resuscitation include compartment syndrome of both the extremities and the abdomen. Signs of abdominal compartment syndrome include abdominal distention, decreased urine output, elevated ventilator pressures, and desaturation. Surgeons should have a low threshold to assess for this devastating complication in any patient requiring resuscitation above the Parkland formula. Diagnosis can be made both by observing clinical signs as well as by assessment of bladder pressure transduced through a Foley catheter. Pressures over 20 mm Hg are considered abnormal and pressures greater than 25 mm Hg with evidence of organ failure indicate the urgent need for intervention. Strategies to intervene should begin with decreasing the rate of fluid administration. If the patient has full-thickness burns on the abdomen or torso, escharotomies should be performed. The bed should be reclined and a chemical paralytic can be given to relax the musculature. If elevated bladder pressures remain despite these maneuvers, a decompressive laparotomy is often required. Some surgeons will attempt decompression with a suprapubic peritoneal drainage catheter; however, the morbidity of these procedures is significant in burn patients. Therefore, attempts should be made to minimize fluid overload with early vigilant monitoring of fluid administration.

When patients are difficult to resuscitate, additional monitoring devices can be used including monitors of cardiac output and cardiac index. Examples include esophageal Doppler, bedside echo as well as transthoracic echo. Serial echo examinations after providing a fluid bolus allow monitoring of cardiac filling, IVC variation, and wall motion changes.[53,54]

Tetanus Prophylaxis

Burns are considered tetanus-prone wounds and therefore tetanus status should be obtained upon presentation. Previous immunization within 5 years requires no treatment whereas immunization within 10 years requires a tetanus toxoid booster and unknown immunization requires both.

Escharotomies

Thoracic escharotomy is rarely required, however, if a patient has early respiratory distress, this may be due to compromised ventilation caused by chest wall inelasticity. If chest wall compliance is limited due to eschar, thoracic escharotomies should be performed bilaterally in the anterior axillary lines with additional release under the costal margin. Extremity eschartomy can be limb or digit saving. Edema of the underlying tissue under the thick, stiff eschar can produce vascular compromise. Though Doppler and pulse oximeters can be used to follow perfusion, once perfusion is lost, it is often too late to intervene. Thus, patients with circumferential full thickness extremity burns should have an escharotomy as soon as their airway is stable and vascular access has been obtained. Extremity eschartomy should be carried out medially and laterally and should extend the entire area of the full thickness burns. Additional compartments to assess include the orbital compartment. Opthomology should be consulted in large volume fluid resuscitation to assess intra-ocular pressure. If abnormally elevated, a lateral canthotomy should be performed.

BURN SEVERITY

For full-thickness burns and partial-thickness burns, identifying the extent of the burn injury is crucial. TBSA is useful to guide fluid resuscitation administration and defines the overall prognosis of patients. Only partial- and full-thickness burns are totaled to calculate TBSA.

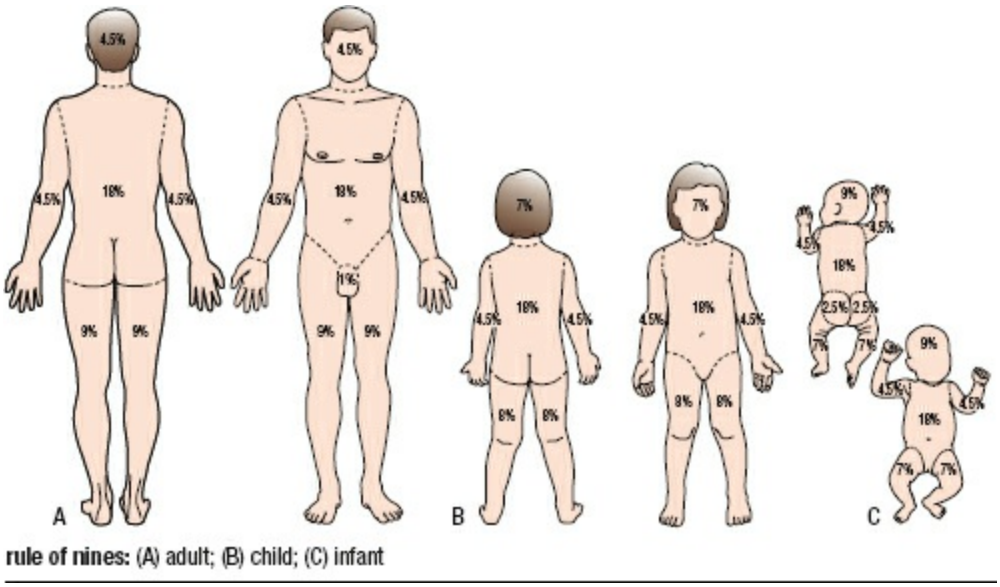

Figure 12-2. Rule of 9s used to estimate percent burns in adults (**A**), children (**B**), and infants (**C**). (From *Stedman's Medical Dictionary for the Health Professions and Nursing, Illustrated, 6e*. Philadelphia, PA: Lippincott Williams & Wilkins; 2008.)

If small areas in various distributions are affected, it may be easier to use the patient as a ruler with one palm size (patient's) representing 1% TBSA. Another useful guide is the rule of 9s, where the adult body is partitioned into several areas that each constitutes 9% of the TBSA (Fig. 12-2). Regions on the adult that constitutes 9% of the TBSA include the head and arms, while the legs, anterior trunk, and posterior trunk account for 18% of TBSA each. In children and infants, the body surface area of the lower extremities constitutes a lower percentage while the head is higher. Careful estimation of TBSA is essential for proper early management of burn patients, as patients who have burns of more than 20% TBSA commonly require IV fluid resuscitation.

Acute burn injuries require prompt intervention and serial examinations. On initial evaluation, it is important to recognize and treat constrictive circumferential burns that can lead to tissue ischemia and subsequent necrosis by limiting perfusion to the distal tissues.[46] The overarching concept, however, in acute burn care is early debridement and grafting. All blisters and nonviable tissue must be debrided upon presentation. After the initial debridement, dressing changes are initiated while the patient is stabilized from a systemic standpoint. If patients suffer from full-thickness or deep partial-thickness injuries, debridement and grafting within 72 hours should be the standard of care.

First degree or epidermal burns. These burns only involve the epidermis and therefore do not blister. They do, however, have erythema and can cause pain. These burns will

often desquamate by days 4 to 5.

Superficial partial thickness (second degree). Superficial partial thickness burns include the upper layers of the dermis and usually form blisters at the interface of the epidermis and dermis. When the blisters are removed, the wound is pink and wet and often is the site if significant pain. The wound should blanch with pressure and the hair follicles should be visible. Assuming no infection sets in, these burns should heal on their own in 3 to 4 weeks. They can be treated with xenograft to decrease pain.

Deep partial thickness (second degree). Deep partial thickness burns extend into the deep or reticular dermis. These will also blister, but appear a “lobster” red. The patient often has some pain and there is slow to absent capillary refill with applied pressure. The wound is often dry and if hair is present, it is usually easily depilated. These burns usually require debridement and grafting.

Full thickness (third degree). Full thickness burns involve all layers of the dermis. These burns appear white, insensate, and without capillary refill. The skin may appear depressed and leathery compared to surrounding tissues. These burns require debridement and grafting as nondebrided eschar forms a nidus for infection and inflammation.

Fourth degree. Fourth degree is used to describe burn into the deeper subcutaneous structures such as muscle, fat, fascia, and bone. These are common in electrical burns and patients who were either unconscious or insensate.

CRITICAL CARE OF THE BURN PATIENT

Hemodynamic Monitoring

Ideally, a critical care physician would be able to assess real time responses to fluid administration through accurate cardiac output readings. Unfortunately, no such noninvasive devices to directly assess cardiac output exist and those invasive devices that estimate cardiac output lack definitive studies supporting their use. Some centers use a PiCCO device which provides cardiac output based on temperature changes and use of the Fick equation, however, this requires a femoral arterial line and a large bore IJ or SVC catheter which introduce potential for complications. Some surgeons use pulse volume variation (>25% being abnormal), however, this too lacks accuracy. Though goal-directed therapies with a pulmonary artery catheter, esophageal Doppler, transesophageal echo, or CVP monitor have demonstrated promising results in some critical care populations, their use in burn patients has been mixed.[55,56] Frequently, the output of monitors such as pulmonary artery catheters or CVP monitors fails to reflect the actual resuscitation of the patient.[57,58]

Ventilator Strategies

Treatment for Inhalational Injury

Manifestations of inhalation injury include wheezing and air hunger. Within a few hours, the tracheobronchial epilthelium slughs and hemorrhagic tracheobronchitis develops. In cases with thermal injury interstitial edema can cause acute respiratory distress syndrome (ARDS) and oxygenation difficulty. If inhalation injury is suspected, the patient should undergo urgent airway assessment and be placed on supplemental oxygen. Inhalation injury has three components that must be considered: (1) upper airway thermal injury which can cause swelling and obstruction, (2) CO poisoning, and (3) lower airway chemical injury from toxic agents found in smoke. Upper airway thermal injury is treated by intubation of the airway and CO poisoning is treated by 100% oxygen administration. Lower airway injury is diagnosed by evidence of soot or mucosal irritation on bronchoscopy. Airway mucosal injury from chemical pneumonitis leads to increased secretions while compromising the patient's ability to clear those secretions. This leads to increased risk of mucous plugging. Airway mucosal sloughing can also result in bleeding and clot formation that further obstruct airways. The use of aerosolized heparin, albuterol, and Mucomyst (HAM) following smoke inhalation to promote airway clearance is advocated in some centers, however, larger studies are needed to validate these treatments.[53,54,59–61]

Early endotracheal intubation and mechanical ventilator support are important in patients with inhalation injury or in large TBSA burns expected to receive large volume resuscitation. Ventilator management should follow ARDSnet protocol recommendations.[62,63] Low volume protective lung ventilation is used to avoid barotrauma: 4 to 6 mL/kg tidal volume, peak airway pressures should not exceed 30 cm H_2O. Assess best positive end expiratory pressure (PEEP) to determine an optimal setting, but a PEEP of at least 5 should be used to avoid lung derecruitment. Consider esophageal monitor to aid in settings if the patient is obese. Recruitment maneuvers may be needed to improve oxygenation and/or ventilation. Permissive hypercapnia is preferred over large tidal volumes to avoid lung barotrauma. Limited studies have shown a potential role for high-frequency percussive ventilation in burn patients.[64] Elevating the head of bed to 45 degrees helps decrease airway swelling, prevents aspiration and ventilator-associated pneumonia (VAP) for ventilated patients. Daily mouth care with chlorhexidine should be used for ventilated patients.

Pulmonary infection occurs in 30% to 50% of patients. Patients with three of the following five clinical criteria should be assessed for pneumonia with culture samples and placed on empiric antibiotic therapy; purulent sputum production, fever, elevated white blood cell count, infiltrate on chest radiograph, and increasing supplemental oxygen requirements. If the patient has pneumonia and been in the hospital for over 48 hours, he should be treated for hospital-acquired pneumonia. Sputum or a bronchoalveolar lavage samples should be sent for aerobic, anaerobic, and quantitative cultures. Empiric antibiotics including coverage of Pseudomonas sp. should be started until culture results become available. Empiric treatment should also cover methicillin resistant

staphylococcus aureus and thus vancomycin or linezolid is preferred. If vancomycin is used, drug levels should be followed to adjust dosage and avoid renal toxicity.

Ventilator-Associated Pneumonia

Staphylococcus aureus and Streptococcus are common causes of early VAP. Pseudomonas aeruginosa is the most common cause of late VAP. The usual signs of pneumonia (fever, purulent sputum, or leukocytosis) are not helpful in burn patients since almost all patients are febrile, tachypneic, and have elevated white blood cell counts. The best diagnostic test is bronchoscopy-obtained bronchial alveolar lavage sample with quantification of bacteria. Bacterial counts of $>10^3$ colony forming units (CFU) are considered positive. ABA recommendations for length of VAP treatment are 8 days of antibiotic therapy for antibiotic-sensitive organisms and 15 days of therapy for multidrug-resistant organisms.[65] Consideration should be given to antifungal therapy (Diflucan) if the patient does not respond to prolonged broad-spectrum antibiotics.

Electrolyte Abnormalities and Acute Renal Failure

The immediate effects of burn injury on kidney function are secondary to hypovolemia and circulating inflammatory mediators. The diuresis phase occurs at 48 to 72 hours after "third space" fluid is reabsorbed. Hyponatremia is often seen due to large volume resuscitation with hypotonic IV fluids and will usually self-correct. Open burn wounds or the use of topical silver nitrate can also cause hyponatremia. Renal hypoperfusion exacerbates hyponatremia by decreasing glomerular filtration. Hypernatremia may also occur due to insensible and evaporative water losses. Hypophosphatemia can result from dilution or refeeding syndrome. Hypocalcemia can result from use of silver nitrate.

Acute Kidney Injury

4 Risk factors include sepsis, large TBSA burns, organ failure, and antibiotic administration. Renal function is compromised by hypoperfusion, pharmacologic nephrotoxic insult, and sepsis which are all common following major burn injury. Physiologically there is a decrease in renal perfusion, glomerular filtration rate, and renal blood flow. The renal medulla is the most sensitive to hypoxia with damage to renal tubular cells. Patients present with oliguria and decreased creatinine clearance. Early renal failure often results from hypovolemia-induced ischemic injury. However, overresuscitation can also compromise renal perfusion by causing abdominal compartment syndrome. Late renal failure occurs after the fifth postburn day and is frequently caused by sepsis or nephrotoxic antibiotics. Continuous renal replacement therapy and pharmacologic treatments such as dopamine have not definitively been shown to improve outcomes.

The initial care of acute renal failure patients should focus on reversing underlying causes and correcting any fluid and electrolyte imbalances. The physician should ensure adequate volume status, avoid nephrotoxins, and dose medications appropriately.

Metabolic Response and Nutrition

Early nutrition is now the cornerstone of burn care. Tube feeding should begin soon after admission. Attempts to feed postpyloric should be done, however, gastric feeding is also acceptable. Tube feeds are often needed even in patients who are able to feed themselves due to the need to enable wound healing and keep up with the hypermetabolic response to burn injuries. Feedings can be continued during surgery as long as prone positioning is not planned.

The metabolic rate is significantly greater in burn patients than in other critically ill patients and leads to accelerated lean body mass wasting. Positive nitrogen balance is key to prevent skeletal muscle breakdown and highlights the importance of early nutritional support. The general composition of enteral feeding should include at least 60% calories from carbohydrates not exceeding 1,600 kcal/day, 12% to 15% from lipids and essential fatty acids, and 20% to 25% from protein. Failure to meet large energy and protein requirements can impair wound healing and alter end-organ function. Even though adequate nutrition is crucial, overfeeding must be avoided. A randomized, double-blind, prospective study demonstrated that aggressive high-calorie feeding with enteral and parenteral nutrition was associated with increased mortality.[66] The daily caloric requirements can be calculated using the Curreri formula: ([25 kcal] [body wt kg]) + ([40] [% TBSA area burn]) 1 to 2 g/kg/day of protein for synthetic needs of the patient. Burn patients should receive a small proportion of calorie requirements from fat than other ICU patients. The liver in a burn patient produces less very low density lipoprotein causing hepatic triglyceride elevation. Increased fat leads to increased complications including fatty liver, infection, hyperlipidemia, hypoxia, and mortality. Decreased gastrointestinal absorption and increased urinary losses can also lead to deficiencies in vitamin C, E, zinc, iron and selenium. Burn patients, like a subset of trauma and gastrointestinal surgery patients have been shown to benefit from glutamine supplementation.

5 Acute response to thermal injury is biphasic with the hypodynamic shock state at 24 to 72 hours and hyperdynamic catabolic state beginning on the fifth postburn day. Patients have supraphysiologic cardiac output, elevated body temperature, supranormal oxygen consumption, supranormal glucose consumption and altered glucose metabolism, increased CO_2 production, and accelerated tissue catabolism. This response is thought to be caused by excessive release of catabolic hormones including catecholamines, glucagon, and cortisol. There is a shift from anabolic–catabolic homeostasis to hypercatabolic state requiring increased substrates for energy. The resting metabolic rate is directly related to the severity of burn injury and a persistent hypermetabolic state is unsustainable. This hypermetabolism can be reduced by promptly treating sepsis as well as performing early excision and grafting of burn wounds. Recent studies have shown efficacy of a nonselective beta-blocker such as propranolol which inhibits the effect of catecholamines and slows muscle catabolism. Herndon et al[67] demonstrated that propranolol in acute burns in the pediatric population improved net muscle synthesis and increased lean body mass. Additionally, current standard of care includes providing pharmacologic agents such

as oxandrolone (testosterone analog given 0.1 mg/kg q12h). Oxandrolone improves muscle synthetic activity, increases expression of muscle anabolic genes, and increases net muscle protein synthesis improving lean body mass composition and has been shown to reduce weight loss, improve donor site wound healing, and decrease hospital stay. Patients with burn injuries greater than 30% should receive oxandrolone for 6 months as the hypermetabolic state has been shown to persist following major burn injury. Despite being well tolerated, patients on oxandrolone should have liver function tests monitored weekly. Human growth hormone and insulin-like growth factor have also been investigated but results have been indeterminate.

Glucose Control

Burn injury results in an increase in hepatic gluconeogenesis and impaired insulin-mediated glucose transport into skeletal and cardiac muscles and adipose tissue. Hypermetabolism seen in burn injury also leads to hyperglycemia and insulin resistance and thus glucose should be monitored in large burn injury patients. Currently, data do not support strict glucose control (<110 mg/dL) but moderate blood glucose control is recommended (<180 mg/dL) and may decrease infectious complications.[68]

WOUND MANAGEMENT

There are a variety of burn wound dressing materials. Patient factors such as burn wound depth, condition, location of the burn, and comfort during dressing changes dictate the choice utilized.[47] Although the indications for systemic antibiotic therapy have not been clearly defined, use of antimicrobial dressings is recommended. Silvadene (silver sulfadiazine) is a silver-containing cream that has broad-spectrum coverage against both gram-negative and positive bacteria. Silvadene is commonly used on the skin of both partial- and full-thickness burn injuries. Its use is contraindicated in patients with sulfa allergies and over wounds near the eyes.[69] A self-limited leukopenia is commonly seen during the initial days of Silvadene treatment, but its use can be continued as leukocyte counts recover quickly without intervention. Sulfamylon (mafenide acetate) is an analogous agent that is used over cartilaginous areas such as the nose or ear due to increased tissue penetration compared to other dressing materials. Since topical Sulfamylon cream can be used without secondary dressing, it can be used for open burn wound therapy and regular examination of the burn wound surface. Both the cream and a 5% solution of Sulfamylon are equally effective.[70] Sulfamylon cream is useful for ear burns when there is risk of cartilage exposure. Sulfamylon may cause increased pain in the burn wound. In addition to the cream, Sulfamylon soaks can also be used for burn and postoperative dressings. Patients receiving large surface area Sulfamylon dressings should be monitored for complications such as hyperchloremic metabolic acidosis that can occur due to its mechanism of action as a carbonic anhydrase inhibitor.

Silver nitrate can also be used by soaking dressings in a 0.5% to 1.0% concentration solution and applied 3 to 4 times a day. These dressings offer several advantages over Sulfamylon soaks as they cover fungus in addition to bacteria and are more cost effective. If not careful, however, silver nitrate does cause significant staining of anything it contacts. If grafts are placed in an area with surrounding cellulitis, silver soaks can be used during the first few days when the compressive dressing is still needed.

Bacitracin and Xeroform are additional examples of antimicrobial-type dressing regimens and can be used after the first dressing takedown. While both can be used anywhere on the body, bacitracin is commonly used for facial burns.

For patients who are at lower risk of infection based on the appearance of burn wounds, dressings may be changed with less frequency to achieve a balance between pain control and the need for wound coverage. Acticoat is one such option that is mainly used in partial-thickness burn injuries. This dressing consists of silver-impregnated sheets that have antimicrobial properties and can be changed less frequently, reducing pain and cost.[71] The nanocrystalline particles in Acticoat are able to reduce wound infection and promote wound healing compared to older silver products, including silver nitrate.[72] When using Acticoat, it is important to remember to moisten it with water and not normal saline as sodium can inactivate the silver. There are other commercial products in addition to Acticoat that utilize the principle of nanocrystalline dressings. These dressings can be attached with mild adhesive (Mepilex), wrapped or placed on like a glove (Silveron).

While dressing changes are sometimes used to optimize a wound before and after operative interventions, dressings also have the potential to completely heal a wound without the need for surgical intervention depending on the overall appearance of the burn and patient as a whole. Thus, a proper wound care team must not only include a critical care physician and surgeon, but it must also include a specialized wound care nurse to appropriately address this central modality of care for any burn patient.

Donor sites can be the most painful area for the patient and thus consistent donor site care should be provided. Like other wounds, these wounds heal in a moist environment and though dry Xeroform can be used, this can be extremely painful for the patient. We prefer a non-adherent dressing like mepilex that maintains wound moisture in addition to having an antimicrobial silver.

OPERATIVE INTERVENTIONS

Excision and Grafting

After initial stabilization of the patient, which generally takes 24 to 48 hours, surgical intervention should occur as soon as possible since there are no benefits to delaying surgery when it is clear that a burn wound is of sufficient depth that it will not heal on its own.[73,74] Early excision of devitalized tissue appears to reduce the local and system effects of mediators released from burned tissue, thus reducing the progressive pathophysiologic derangements. Excision also removes dead skin which can serve as a nidus for wound infection. Tangential excision with a sharp blade on a guarded device removes necrotic tissue while preserving as much of the underlying viable tissue as possible. For large burn wounds, debridement should occur within 2 to 4 days of the initial injury. If there are insufficient donor sites to autograft all of the burn wounds, the debrided wound should be covered temporarily with allograft.[75] Alternatively, the burn can be completely excised within the first several days after injury, and a temporary skin substitute can be used to close the wound remaining after available autologous skin has been harvested and grafted (Fig. 12-3). Sequential debridement and grafting is the backbone of burn care in those suffering from large TBSA burns. The use of allograft also allows the surgeon to assess the depth of the injury and the adequacy of excision. If the homograft has good take, then it is likely an autograft will also take.



Figure 12-3. Full-thickness friction burn staged with integra to allow for full declaration of the wound prior to grafting. Top row shows initial injury. Middle row shows integra placement and bottom row shows after final debridement and graft.

During tangential excision, tissue is debrided until healthy, bleeding tissue is reached. Hemodynamic stability and correction of hematologic and metabolic derangements are helpful for such operative cases given the large amount of blood that may be lost during debridement. A discussion in the preoperative time out should take place between the surgeon and anesthetist about the amount of blood loss expected, the blood products available, and the transfusion triggers for the case. Arterial lines as well as large bore IVs and often a central line should be in place prior to beginning the operation. In general, hemoglobin fluids are not an accurate during acute blood loss anemia caused by intraoperative bleeding after a large debridement. In any burn over 20%, a preoperative blood type and crossmatch should be performed and packed red blood cells should be placed in the operating room to avoid intraoperative acute blood loss anemia. Several measures can be used to decrease intraoperative blood loss, but the need to debride to

bleeding tissue makes bloodless surgery impossible. Techniques to decrease blood loss include the use of tourniquets on the extremities as well as the use of topical spray thrombin and epinephrine-soaked Telfa pads placed immediately after excision followed by wrapping this area with epinephrine-soaked Kerlix gauze. We use 1:1,000,000 epinephrine in a saline solution as a hemostatic dressing after excision. In regions where circumferential wrapping cannot be performed, epinephrine solution can be used as an injectable solution to perform dermatoclysis. An 18G spinal needle on the end of a 60-cc syringe or tumescent device can be used to deliver this solution under the skin in areas of bleeding. Similarly, we use epinephrine injection solution as a preharvest tumescent solution for donor sites. This helps create a flat surface on which to run the dermatome and decreases postharvest blood loss. If working on an extremity, a good strategy is to start proximally and perform the excision followed by inflation of the tourniquet. Subsequently, the distal excision can be performed under tourniquet control.

In addition to achieving a healthy and well-vascularized wound bed after debridement, it is also essential to classify and examine the wounds further during this process. At this time, the distinction between superficial and deep partial-thickness burns must be made. While superficial partial-thickness injuries can heal on their own with dressing changes and without grafting, deeper burns must be treated with skin grafting. Given the association between early debridement and grafting with improved functional- and scar-related outcomes, the earlier this distinction is made the faster a treatment plan can be formulated.



Figure 12-4. Grafting back of donor site with 4:1 split-thickness skin graft. (**Top**) Intraop placement of graft back. (**Bottom**) 4 weeks postop from graft back.

Grafting exists in many forms and decisions on coverage material and thickness of graft must be made in a strategic fashion to optimize functional and aesthetic outcomes. The gold standard is to use the patient's own tissue or autograft for reconstruction. These grafts can be excised in thicknesses ranging from 0.008 to 0.018 in, with 0.012 in as a

standard. Thinner grafts are helpful if the surgeon is planning to reharvest donor sites or if the patient has thin skin due to increased age or chronic immunosuppression, as thin grafts lead to faster donor site healing. Thinner grafts increase the likelihood of skin graft take and decrease the risk of superficial epidermolysis of the graft, however, thin grafts also lead to greater secondary contracture. In patients where delayed donor site wound healing is expected such as elderly patients and patients on chronic immunosuppressives, grafting back the donor site with 4:1 meshed grafts can accelerate healing (Fig. 12-4).

After a decision regarding the use of allograft versus autograft has been made, attention is turned to the size and thickness of the skin graft. Commonly, split-thickness skin grafts (STFG) composed of the epidermis and a thin layer of dermis are utilized to minimize donor site morbidity and optimize graft take. Thin grafts are more likely to succeed than thick grafts as it is easier to adhere and for neovascularization to occur. There are certain areas, however, where split-thickness grafts should not be used since they cause greater secondary contracture and less color match over time as compared to full-thickness grafts. Areas of function, such as the hands and feet, lose a remarkable amount of utility if afflicted by scar contracture and may benefit from full-thickness grafts.[76] If split-thickness skin is used on the feet and hands, the grafts should be harvested on the thick side and meshing should be avoided if possible (Fig. 12-5). Similarly, aesthetically important areas, such as the face, are also more amenable to full-thickness skin grafting (FTSG) to optimize color match and minimize contracture.[77] If the cheeks or periorbital regions are involved, (FTSG) should be placed prior to the development of ectropion which can be extremely difficult to treat. The abdomen can offer a site for large full-thickness harvest using an abdominoplasty incision (Fig. 12-6). Full-thickness grafts, nonetheless, are limited by increased donor site morbidity due to the need to obtain both the epidermis and dermis and also require closing the tissues primarily to avoid additional wounds. There is also more difficulty with successful and complete healing of the graft given that a more robust blood supply within the wound bed is necessary to optimize take of this thicker piece of tissue. Both full- and split-thickness grafts can be meshed to increase the surface area that may be covered. Commonly performed in a 1:1 or 1:1.5 ratio, meshing also allows for fluid egress, which minimizes the risk of fluid accumulation beneath the graft, a common cause of skin graft failure. Meshing should not be performed over cosmetically sensitive areas given that the meshed pattern will be quite apparent even after complete healing has been achieved. Both types of skin grafts should be bolstered once placed to minimize shear, improve contact, and allow for imbibition and inosculation.



Figure 12-5. Sheet grafting of full-thickness hand burns. In general meshed grafts should be avoided on the hands and across important joints to avoid scar contracture. (**Left**) Preop photo. (**Middle**) Intraop photo. (**Right**) 1-month postop photo.



Figure 12-6. Use of full-thickness skin graft to prevent facial ectropion. Full-thickness graft harvested from the abdomen. (**Left column**) Intraop photos. (**Middle figures**) Intraop donor site photos. (**Right column**) Postop 2-week photo.

When burn injuries lead to large regions of exposed tendons, especially in the distal 1/3 of the lower extremity, free tissue transfer is often required (Fig. 12-7). It is necessary to ensure all dead tissue is debrided prior to coverage with a free flap to mitigate infection and flap failure. Additionally, if the patient is elderly or has vascular insufficiency, a preoperative computed tomography angiogram should be obtained.

In larger burn wounds, patients may not have an adequate surface area available for donor sites. In such cases, allograft can be used for initial coverage. This homograft will serve as a temporary coverage and its take will ensure that the initial excision was performed at the correct depth. Allografts will eventually be rejected as the body recognizes the newly engrafted skin as foreign material after 10 to 13 days. The process is initiated by the placement of the allografts, which is associated with an inflammatory process, leading to the activation of the innate immune response. Donor dendritic cells migrate from the graft to the recipient's secondary lymphoid organs where they present donor antigens and elicit an adaptive immune response. This response results in activated effector T cells from the donor leaving the secondary lymphoid organs and infiltrating the graft where they mediate the rejection of the allograft.[78]

If insufficient autograft exists even after temporary allograft, the surgeon should

consider use of cultured epidermal autografts. Cultured epidermal autografts utilize the ability to grow keratinocytes in vitro to generate cohesive sheets of stratified epithelium, which maintain the characteristics of authentic epidermis. This technique was developed by Rheinwald and Green in 1975.[79] A 3- to 4-cm^2 sample is taken usually from the axilla or pubic area at the time of initial debridement, and epidermal cells are isolated from the small skin biopsy and plated onto a layer of feeder cells that act as a supporting "feeder layer."[80] The feeder layer supports optimal clonal expansion of proliferative epithelial cells and promotes keratinocyte growth. Under optimal growth conditions, keratinocytes initiate growing colonies and after 3 to 4 weeks, the cultured epidermal autograft sheets are 8 to 10 cells thick.[81,82] These constructs require advanced planning as it takes at least 3 to 4 weeks to develop. Additionally, risks and benefits should be discussed with the family and patient as there is a high percentage of graft loss due to fragility. Furthermore, case reports of squamous cell cancer developing from cultured epidermal autograft sites exist.

Order of Coverage

6 The first operations performed in large burn patients set the stage for how quickly a patient will recover. The first priority should be to excise all eschar and achieve coverage, with autograft if available or with allograft if not available. In patients with large TBSA burns, it is crucial to get the back excised and covered first as delay of this step will make it difficult to have a patient stable enough to tolerate a prone position. Additional strategies to improve coverage of the back include the use of autograft meshed 3:1 covered with allograft meshed 2:1 and a secure bolster placed over top. This minimizes sheer and loss of the autograft. Early coverage of the back and avoidance of prone positioning may also mitigate the need to perform an early tracheostomy. Once the posterior areas of the patient are excised and covered, then attention can be turned to the anterior regions and the extremities.



Figure 12-7. Use of free anterolateral thigh flap for reconstruction of lateral full-thickness ankle burn with exposed tendon. Top left shows initial injury. Middle left shows ALT flap inset. Bottom left shows final ALT placement. Top right shows ALT donor site intra op. Middle left shows donor site 1 week postop. Bottom right shows ALT 1 week postop.

Extremity Treatment

Burns of the hands and feet often require a multidisciplinary approach with involvement of therapists, hand and plastic surgeons. Early evaluation must verify adequate perfusion. Extremity elevation benefits hand burns by limiting edema and active range of motion is necessary to maintain function. Splinting should put the axilla at 90 degrees, elbow in extension and hand in intrinsic plus with the metacarpophalangeal joints at 70 to 90 degrees and the interphalangeal joint and the wrist in 20- to 30-degree extension.

Palmar hand or plantar foot burns occur on specialized skin and are composed of a thicker dermal layer and thus should be managed conservatively. If after 3 to 4 weeks no healing has occurred, full thickness burns should be considered. Small palmar digit burns can be treated with a full thickness hyperthenar graft.

Though the hands and feet are important to excise and cover early, these areas require the use of sheet or 1:1 meshed grafts. These areas should not delay the coverage of large areas such as the back which can use widely meshed grafts. More important, for the digits, is the use of early K-wire fixation in the intrinsic plus position in deep burns to the fingers. K-wires should be placed in the fingers to keep them in the intrinsic plus position: MC flexed at 70 to 90 degrees, wrist 20 to 30 degrees, IP joints in full extension, and thumb kept abducted and slightly opposed. This will help prevent severe joint flexion contractures which can lead to the loss of digits if straightened in a delayed fashion.

Genital Burns

Genital burns should be investigated for abuse in children. Burned foreskin must be reduced to a normal position to avoid paraphimosis. Penile and scrotal burns will often heal without excision and grafting. Bladder catheterization and urethral stenting is not required for genital burns and increase the risk of infection.

Skin Alternatives

Integra is a newer alternative for temporary coverage and creation of a neodermis in a wound after debridement. Composed of bovine collagen and silicone film, this construct is designed to mimic the epidermis and dermis of the missing tissue.[75,83] Its structure allows for the growth of healthy granulation tissue into a wound bed to optimize the wound niche to promote greater and healthier take of the skin graft that will eventually be placed over the site of injury. This is especially important over areas of function, such as the hand, which has the potential for significant debility if scar or graft contracture occurs over the traumatized site. Integra is also important for areas that do not have enough viable or vascularized tissue to support a skin graft (Fig. 12-3). Integra, however, often fails in burn patients due to infection and requires constant soaks with Sulfamylon. Additionally, clinicians should examine the Integra frequently and remove any areas of silicone under which there is concern for infection.



Figure 12-8. Xenograft treatment of superficial partial-thickness burn to avoid use of STSG and to improve pain. (**Top, left**) Intraop photos of superficial partial-thickness burn. (**Top, right** and **bottom, left**) Placement of xenograft over burn using interrupted absorbably sutures. (**Bottom, right**) 1-month postop from xenograft placement.

Porcine xenografts are an alternative to dressing changes alone in superficial partial-thickness burn wounds. In wounds that are likely to heal by themselves taking the patient to the operating room, performing a good debridement under anesthetic, and placement

of xenograft to the burn wound can be beneficial (Fig. 12-8). The xenograft can minimize pain, improve wound healing, and de-escalate the complexity of dressing changes. This benefit is greatest in children or patients with tolerance to narcotic pain medications due to excessive pharmacologic supplementation prior to becoming injured.

PAIN CONTROL

Acute Pain

Burn injuries are among the most painful traumatic injuries sustained given their extensive nature. Thermal injury to the overlying epidermis leads to exposed nerve endings which are sensitive to stimulation. Thus, superficial partial-thickness burn injuries often cause the most pain to the patient. Deeper partial-thickness and full-thickness injuries may not cause as much pain to palpation; however, these regions are still painful due to the inflammatory response. Given the multifactorial nature of burn pain, elimination of pain in burn patients is not possible. Outcomes are often improved if a dedicated physician with expertise in pain management is part of the burn team. When establishing a pain regimen, the physician should focus on treating acute as well as chronic pain. A successful regimen often includes the use of short- to intermediate-acting narcotics to treat acute pain as well as a long-acting narcotic such as methadone for chronic pain. Procedural pain during dressing changes can be treated with short-acting narcotics. Some patients will also benefit from Neurontin to alleviate neurologic pain. Additional studies are underway to investigate the use of Seroquel for patients with a large anxiety component associated with their pain. Balancing of narcotic dosing over time is essential to preserve their acute pain relief effect and to avoid situations in which tolerance renders all available agents and doses ineffective.

Chronic Pain and Substance Abuse

The burn patient population that is admitted with underlying substance abuse and alcohol dependency is a particular challenge for the burn team to successfully treat with regard to pain relief. In such circumstances, the team should have high vigilance for symptoms of drug or alcohol withdrawal. New studies are investigating prophylactic treatment with barbiturates to prevent alcohol withdrawal rather than currently used strategies which are largely reactionary and treat withdrawal after symptoms occur. Involvement of psychiatrist or pain specialist in the prescription of these drugs is beneficial. Methadone can also serve as a helpful adjunct for patients with chronic pain given its decreased addictive potential relative to other narcotics.

INFECTIONS

Wound Infections

Burn wound sepsis is a severe sequelae of burn injuries caused by colonization of the damaged skin and soft tissues with infectious bacteria or fungi. The most common organisms are *Staphylococcus aureus, Streptococcus pneumoniae,* and *Pseudomonas aeruginosa.* Despite the morbidity of this complication, its incidence has decreased dramatically with the use of early excision and grafting and appropriate topical antibiotics therapy. If burn wound infection is suspected, wound dressings should be taken down and a quantitative culture should be obtained. A bacterial count of greater than or equal to 10^5 colony-forming units bacteria/gram of tissue is considered significant infection, though the data from which this number was derived date back to the 1960s. General critical care infection protocols should be followed with burn wound debridement if the patient does not yet have skin grafts placed. If adequate excision has been performed and the patient already has skin grafts placed, then antibiotic soaks or cream dressing changes and IV antibiotics will often help combat infection. Quantitative cultures should be obtained every 3 to 4 days when treating burn wound infection to gauge progress and allow for escalation or de-escalation of treatment.

Vascular Catheter–Related Infections

Central venous access should be obtained using sterile technique and antibiotic-impregnated catheters as these have proven efficacious in the general critical care population[84] (ref is Pronovost/Keystone). Additionally, central venous catheters should be placed in nonburned areas if possible. Routine changing of catheter after a specific time period has not been shown to improve outcomes. However, close attention should be paid to catheters in place for over 7 days, especially in burn areas if the patient is febrile and has signs of systemic infection. If a catheter-related infection is suspected, two peripheral blood cultures should be drawn. A culture specifically from the catheter does not improve diagnosis or outcomes. Despite the increased use of PICC lines, these catheters have equal if not increased risk of infection relative to central venous catheters.

Pneumonia

Along with increased survival of burn patients comes increased time burn patients are on the mechanical ventilator. Increased incidence of pneumonia is seen with inhalation injuries and prolonged intubation and mechanical ventilation. As in other critical care populations, an emphasis should be placed on daily awakening and extubation/spontaneous breathing trials. Additionally, all patients on the ventilator should have their head of bed elevated greater than 30 degrees and daily chlorhexidine mouthwashes may be beneficial. If a pulmonary infection is suspected, a CXR should be performed and a quantitative culture specimen should be obtained from the bronchial tree. A quantitative result greater than 10^3 is considered positive and should be treated.

Deep Vein Thrombosis

The dangers and need for prophylaxis in general surgical and burn patients have been highlighted in recent studies. Burn patients have increased risk with increased number of operations, pneumonia, and central venous access. All inpatients should receive prophylaxis with heparin 5,000 U three times a day or weight-based enoxaparin daily (PMID: 21979849).

BURN RECONSTRUCTION

Optimizing Acute Treatment to Minimize the Need for Reconstruction

As in any plastic and reconstructive surgery case, meticulous planning and foresight is imperative. During the acute burn injury stages, emphasis should be placed on general coverage of burn wounds and large flaps and local tissue rearrangements should be delayed. If there is a high likelihood that the patient might need a flap or local tissue rearrangement in the future, the region of graft harvest should be carefully planned. For example, if a patient has a large neck burn or exposed lower extremity tendons or bone and if an anterolateral thigh flap would help, then the thigh should be avoided as a donor site. Surgeons should consider the fact that a meshed skin graft will have an abnormal appearance once it heals as well as causing increased hypertrophic scarring. Donor sites should be harvested from inconspicuous locations in case a hypertrophic scar results. Other examples requiring acute reconstructive surgery include eyelid contracture with exposure keratitis and cervical contractures causing airway issues. Once acute grafts and donor sites have healed patients and physicians should focus on maximizing normal scar healing. Normal wound healing requires a balance in the hydration of the wound and water-based moisturizers should be encouraged. Silicone sheeting or other occlusive dressings can help in early hydration of the wound.[85–87] Additionally, attempts should be made to minimize tension off of the scar with potential applications of new devices. Compression garments are also commonly used to decrease formation of hypertrophic scarring, though their efficacy is still debated.[88,89]

Hypertrophic Scarring

Thermal burn injuries can cause tremendous morbidity, leaving the patient with not only cosmetic but also functional impairments. Hypertrophic scarring is a major complication after burn injury with a prevalence of 32% to 72%. Several risk factors have been identified that contribute to its development including the localization of the burn injury, burn depth, time to heal, and skin color.[90,91] While the precise mechanism by which hypertrophic scarring occurs by remain unclear, strong and persistent expression of transforming growth factor beta (TGF-β), focal adhesion kinase-1 (FAK1) and its receptors have been associated with postburn hypertrophic scarring. Furthermore, a critical step in the healing process that is altered is the transition from granulation tissue into normal scarring. During this remodeling process, wound epithelization and scar collagen are formed but accompanied by a gradual decrease in cellularity due to apoptosis. However, early immature hypertrophic scars caused by burns are hypercellular and during the process of remodeling and maturing, fibroblast density does not resemble that of normal healing.[92] Apoptosis of myofibroblasts occurs 12 days after injury in normal wound healing, but in hypertrophic scar tissue, the maximum apoptosis occurs much later at 19 to 30 months.[93] These events result in a significantly higher percentage of myofibroblast and hypertrophy of the scar tissue following severe burn injuries.

One of the key pathologic factors that must be addressed in any hypertrophic scar is tension. A new concept of “scar rehabilitation” has emerged with the key idea being to improve the environment of the scar without actually excising the scar. The most important step in rehabilitating the scar is release of tension. Rather than excising the scar, this involves just releasing the area of greatest tension. Despite not removing any tissue, a large defect is often created once the tension is released. This defect can then be treated by adding new tissue such as a FTSG or a thick STFG. Additional ways to relieve tension involve the use of tissue rearrangements such as a Z-plasty. A Z-plasty lengthens the scar at the expense of width alleviating tension along the central axis of the hypertrophic scar. In general Z-plasty rearrangements are made with 60-degree angles to maximize tissue gain without causing excess tension on the donor site closure. Alternative V-Y advancements are useful if there is healthy tissue surrounds the scar and can be advanced into the area of the contracture release. Both Z-plasties and V-Y advancements relieve tension on the scar that help create the hypertrophic environment. By relieving this tension, the scars can heal in a more normal environment and often will do so without the raised erythematous characteristics initially present. The physiology of the Z-plasty is thought to result from improved collagen remodeling after relief of tension.[94,95] Z-plasties can be used to flatten a hypertrophic scar or elevate a depressed scar as long as the lateral limbs extend into normal tissue. The classic design of a Z-plasty has a central segment with limbs oriented at 60 degrees (although can be 30 to 90 degrees) with all 3 lines of equal length (Fig. 12-9). Widening the angle of the limbs increases percent gain in length along the central limb. Multiple Z-plasties can be designed in series to improve contracture release in large hypertrophic scars.

Although less well studied, postburn pruritus is another significant problem affecting

almost 100% of pediatric and 87% adult patients and may persist for many years, resulting in a scratching/inflammation cycle leading to hypertrophic scarring. Treatment options are limited for postburn pruritus, commonly involving antihistamines and moisturization of the skin with only incomplete resolution of symptoms and thus significant deterioration in quality of life.[96]

Current treatment strategies for hypertrophic scars include surgical manipulation, intralesional corticosteroid injection, cryotherapy, and laser therapy. Surgical manipulation to remove the excess skin remains the traditional treatment for hypertrophic scar. Recent studies investigating the role of fat grafting into scars have shown promise to further improve function and appearance.[97] Patients who have undergone fat transfer reported satisfactory results 6 months after the procedure, indicating considerable improvement in the features of the skin, skin texture, and thickness. Histologic examination demonstrates new collagen deposition, neovascularization, and dermal hyperplasia in regions treated with fat grafting, which mimics surrounding undamaged skin. Intralesional corticosteroid suppresses the inflammatory process in wounds, diminishes collagen synthesis, and enhances collagen degradation.[98] Conversely, cryotherapy induces vascular damage that leads to anoxia and ultimately tissue necrosis and has yielded marked improvement of hypertrophic scars.[99] Efficacy is limited to the management of small scars.

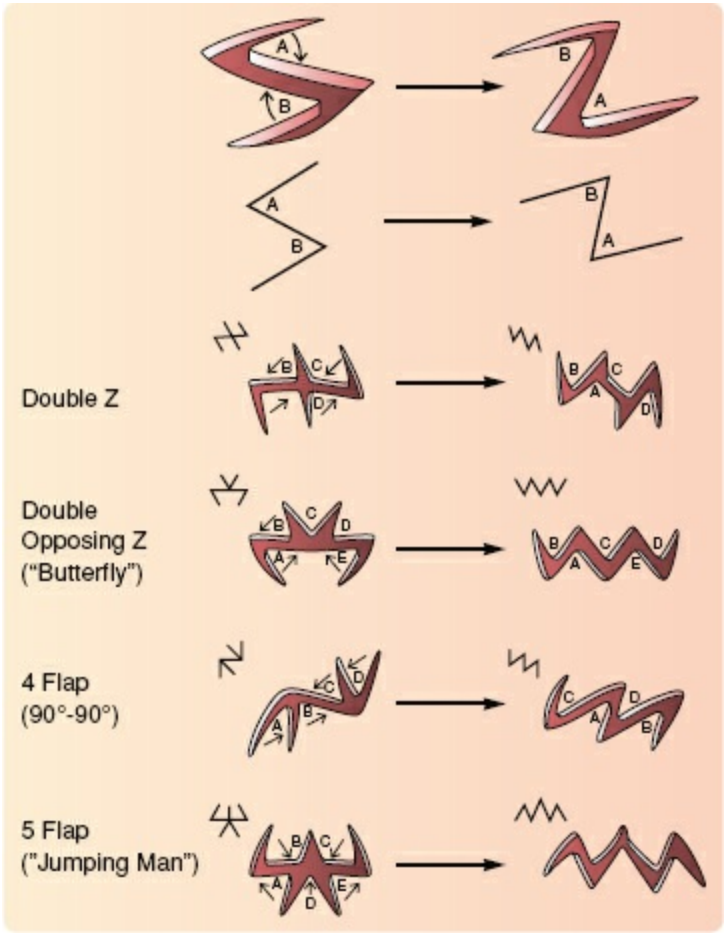

Figure 12-9. Z-plasty diagrams demonstrated tissue rearrangement used for hypertrophic burn scars.

LASER SCAR REHABILITATION

7 Since the introduction of laser treatment in the mid-1980s, additional lasers with different wavelengths have been employed. Encouraging results have been obtained with the 585-nm wavelength pulsed dye laser (PDL), which has been recognized as an excellent therapeutic option for the treatment of younger hypertrophic scars.[100] PDL induces the dissociation of disulfide bonds in collagen fibers and leads to collagen fiber realignment, decreased fibroblast proliferation, and neocollagenesis. Repeated treatments, generally between 2 and 6 are required for the optimal resolution. Shorter-pulse durations are generally more effective for scar improvement.[101] Unlike vascular malformations and hemangiomas, scars also tend to respond better to low or medium PDL fluences, about 4 to 7 J/cm^2, than to higher fluences.[102] Low-, short-pulse duration PDL fluences induce local damage to the vascular endothelium followed by mural platelet thrombi, while high PDL fluences at longer-pulse durations tend to cause immediate intravascular coagulation with cessation of blood flow.[103] Side effects include erythema/purpura for 7 to 14 days, hyperpigmentation, and hypopigmentation. Though these lasers are effective in improving scar erythema, they do not have a substantial effect on the thickness or contour of hypertrophic scars. Controversy still exists about how much of this redness would subside if given adequate time compared to laser treatments (Fig. 12-10).

Recently, research studies have demonstrated the benefit of fractional photothermolysis in the treatment of hypertrophic scarring. Though the exact mechanism is unknown, this concept uses a CO_2 laser (10,600 nm), which is an ablative laser that targets water in underlying tissues. The laser creates columns of tissue destruction, which stimulates collagen production in adjacent uninjured columns of tissue. Only a portion of the epidermis and dermis is treated with columns of energy in order to create targeted areas of thermal damage (microthermal treatment zones). The untreated areas are a reservoir of collagen and promote tissue regrowth. Fractional lasers, as opposed to nonfractional lasers allow for greater penetration with decreased risk of scarring. This healing will take place outside of the acute inflammation period and thus allow for a more normal wound healing cascade than existed at the time of the initial excision and graft. The adjacent uninjured tissue allows for more rapid tissue regeneration from follicles and sweat glands. Ablative lasers have a greater potential depth of treatment compared to nonablative lasers (4 mm compared to 1.8 mm). Ablative lasers appear to be more effective for thicker scars and those associated with restriction. Overall, this creates a more smooth appearance and allows meshed grafts to appear less obvious. Patients have described less tightness as well as decreased pruritus and improved overall appearance (Fig. 12-11).[104]

Recent studies also have demonstrated the benefit of fractional CO_2 laser for pruritis. Often multi-modality treatment with PDL for erythematous scars, fractional CO_2 laser for thick and pruritic scars and local tissue rearrangement to relieve tension lead to improved outcomes (Fig. 12-12).



Figure 12-10. Pulsed dye laser scar rehabilitation.

Tissue Expansion

A tissue expander (TE) is an artificial filling device that is used to grow and expand local tissue to reconstruct an adjacent soft tissue defect. A silicone elastomer reservoir is placed beneath the donor tissue and slowly filled over time with saline, causing the overlying soft tissue envelope to stretch with a net increase in surface area per unit volume. Advantages to TE are that it allows the surgeon to reconstruct "like with like" using donor and recipient tissues that share similarities in color, thickness, texture, and hair-bearing patterns. Larger soft tissue defects that would usually require a local flap for reconstruction can be closed primarily using expanded local tissue, limiting donor site morbidity. A robust angiogenic response is achieved histologically within the expanded local tissue resembling an incisional delay phenomenon. Predictable amounts of donor tissue can be gained through the expansion process. As a reconstructive technique, it is versatile, reliable, and repeatable, and can be applied to many regions of the body.

On should use the largest expander possible with a base diameter approximately two to three times that of the diameter of the soft tissue defect to be reconstructed. If the expander contains a base plate or rigid backing, this side should be placed along the floor of the pocket to guide the direction of expansion outward. Multiple expanders are sometimes needed to reconstruct a single defect, depending on the availability of donor tissue. Rectangular expanders are useful on the trunk and extremities, and result in the greatest amount of actual tissue gain, however, these should be avoided on the scalp (approximately 40% of theoretical tissue gain). Round expanders are most commonly used in breast reconstruction, and result in the least amount of actual tissue gain (approximately 25% of theoretical tissue gain). Crescent expanders are useful in scalp reconstruction, and gain more tissue centrally than peripherally. Custom expanders are helpful for irregular defects, but may be more expensive.

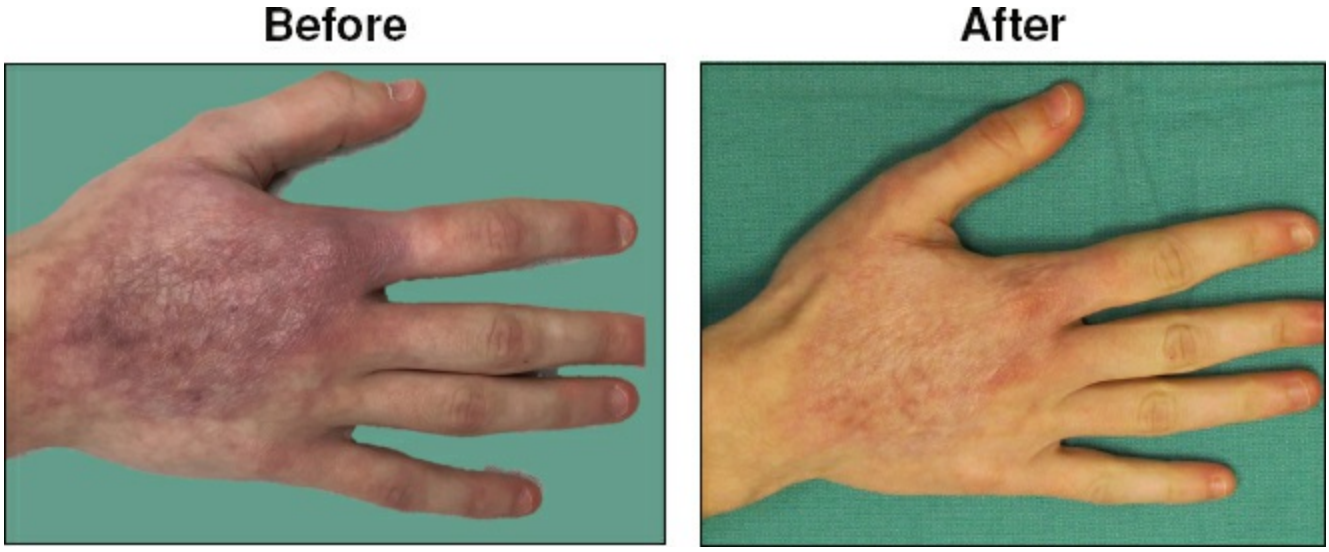

Figure 12-11. Ablative laser rehabilitation.

Remote filling ports are connected to the TE via silastic tubing, and can either be placed subcutaneously (most common) for percutaneous access or externalized for direct access. It is crucial not to make the tunnel too wide or the filling port will fall and be

difficult to fill. Integrated filling ports are located within the expander, although this design may increase the risk of inadvertent puncture of the outer shell. The expander is usually placed adjacent and parallel to the long axis of the soft tissue defect. If placed in the extremities, the expander should not cross any joints or impinge on joint motion. Donor tissue must be well vascularized, free of unstable scar. Expanders should be used cautiously in irradiated tissue or patients with poorly controlled diabetes mellitus, vascular disease, or connective tissue disorders. The expander pocket can be developed in the subcutaneous, submuscular, or subgaleal planes depending on the location of the soft tissue defect. The size of the expander pocket should be individually tailored to allow the expander to lie completely flat with minimal wrinkling.

Excessive dissection should be limited to prevent expander migration postoperatively, and meticulous hemostasis is important to minimize hematoma formation. Incisions are placed radial to the expander pocket to minimize tension on the incision during the expansion process. Undue tension placed on the incision during expansion can cause dehiscence and exposure of the expander. One should consider future reconstructive options when planning incision placement such that the incisions can easily be incorporated into planned flaps or the tissue to be resected. Endoscopic-assisted expander placement utilizes smaller incisions and allows more direct visualization of the expander pocket, but at the expense of a steep learning curve and altered depth perception.

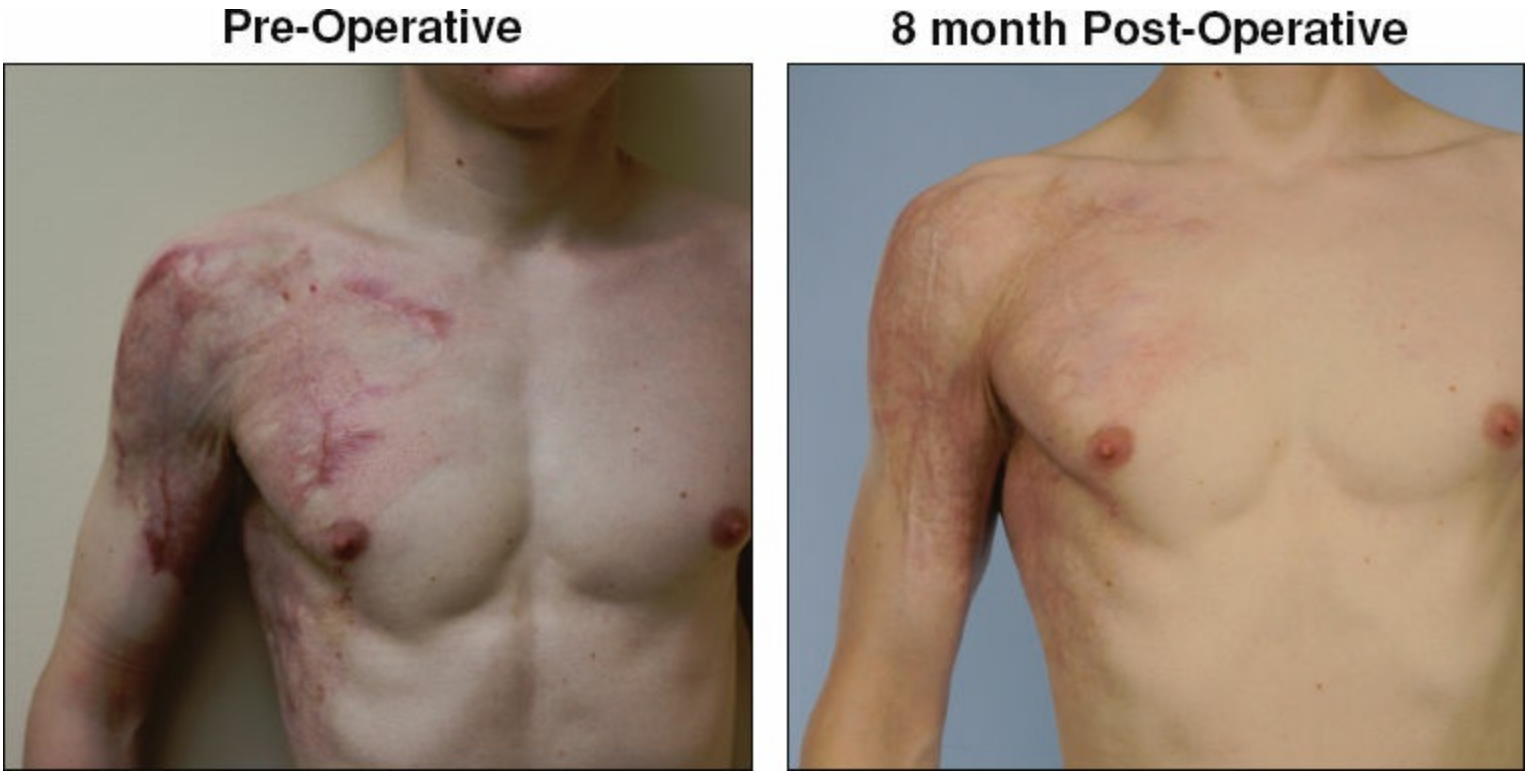

Figure 12-12. Multi-modality treatment can result in improved outcomes.

The tissue expansion process usually begins 2 weeks postoperatively and continues on a weekly basis thereafter. The expander is filled until the patient expresses discomfort or the overlying skin blanches. The expansion process is complete based on surgeon preference when he/she deems there is enough donor tissue available to reconstruct the

soft tissue defect. Additional “over” expansion is often recommended to ensure adequate soft tissue coverage.

Disadvantages of tissue expansion include the need for multiple operations (at least two for placement and removal of the expander) and outpatient visits. Definitive reconstruction is delayed secondary to the expansion process. Specific complications related to the presence of foreign material can be as high as 30% (e.g., infection, exposure, or extrusion). This complication risk is higher in the extremities and scalp.

Specific Anatomic Concerns

Neck contractures are the most common wound healing complication of burn injury. Functionally this can limit range of motion and oral competence. Surgical release of the scar contracture down to platysma or subplatysmal layer followed by coverage with large FTSG or thick STSG followed by aggressive range of motion 5 days after having patient in neck brace is an option for correction. If the contraction is severe, a free tissue transfer may be required after neck release. Postoperatively it is crucial to use compression garments for 6 to 18 months and neck bracing to keep the neck extended to prevent contracture recurrence.

Ectropion is a common complication after periorbital burns. This deformity is caused by inadequate tissue. If the ectropion is caused by an extrinsic contracture, scar release and provision of additional tissue are needed to prevent recurrence.

Early ectropion requires early opthalmologic and surgical attention as it can lead to corneal abrasions. Surgically, the contracted lid should be released and a large full thickness graft should be placed (Fig. 12-11). If excess tension, a midface lift and lateral canthoplasty can provide additional support. Additionally, temporary or permanent tarsorrhaphies should be placed to protect the globe.

The axilla also represents a common area of contracture because it is difficult to maintain adequate positioning in the acute phase of burn wound healing. Anatomically the axilla can be divided into the anterior axillary fold, midaxillary line, and posterior axillary line. The Shoulder should be kept 90 to 120 degrees abduction, 15 to 20 degrees flexion (60 to 80 degrees arm elevation). There are three grades of axillary contractures:

1A: involves anterior axillary fold
1B: involves posterior axillary fold
2: involves both axillary folds
3: involves both folds and axillary dome

Type 1 and 2 contractures can be treated with sequential release and thick STSGs or FTSGs. Type 3 contractures require local and distant flaps including parascapular and latissimus flaps. It is important to pay attention to where hair-bearing regions are transposed. Postoperative occupational therapy and splinting are necessary to prevent recurrence.

Nailbed Reconstruction

Eponychial fold and decreasing range of motion of the distal interphalangeal joint (DIP). To improve the DIP range of motion and proximal to the DIPJ releasing the skin proximally and distally taking care not to injure the underlying extensor tendon. A full thickness graft is then placed (Fig. 12-12).

ASSOCIATED COMPLICATIONS OF BURN INJURIES

Muscle Catabolism and Wasting

Burn injury involving large areas of the body is associated with significant pathophysiologic sequelae, which can persist up to several years after the acute injury. There are significant changes in essential metabolic processes, which shift physiologic homeostasis to a catabolic state, resulting in loss of lean body mass. The TBSA affected by the burn injury plays an important role, since reestablishing a functional skin barrier initially takes priority and requires a protein substrate, which is often provided by skeletal muscle.[105]

Muscle catabolism after burn injury is mediated by several factors including increased energy requirement[106] and heightened inflammatory state involving the systemic release of stress hormones, catecholamines, and glucocorticoids, which mediate the underlying metabolic derangements. Other factors include prolonged immobilization and the loss of a functional skin barrier, which lead to disturbed thermoregulation requiring increased energy expenditure to maintain body temperature. The consequences can have devastating effects on the convalescence of pediatric burn patients, where an increased catabolic state can lead to delayed linear growth for up to 2 years after the injury.[107] The physiologic response of skeletal muscle to anabolic stimuli is altered in pediatric patients with amino acid infusion therapy failing to stimulate a net protein deposition in skeletal muscle even 6 to 12 months post injury.[108,109]

Studies investigating the effect of burn injury on physiologic changes in skeletal muscle have uncovered a critical role for mitochondrial function showing that processes involving carbohydrate metabolism, lipid metabolism, and oxidative phosphorylation are significantly altered.[110] Righi et al.[111] demonstrated that treatment with a mitochondria-targeted antioxidant in a mouse burn model significantly increases mitochondrial ATP secretion and ameliorates oxidative stress, suggesting that reactive oxygen species play a significant role in burn pathogenesis. Improvements in skeletal muscle mitochondrial function have also been attributed to the effect of fenofibrate, a peroxisome proliferator-activated receptor-α agonist used to treat impaired glucose metabolism commonly observed after burn injury. In pediatric burn patients, fenofibrate treatment improved glucose levels and insulin sensitivity.[112] Other therapeutic approaches, which have shown significant benefit in clinical trials include the blockage of beta-adrenergic receptors, resulting in attenuated catecholamine effect and improved net muscle protein balance.[67] Anabolic steroids such as oxandrolone, and physical exercise have been shown to increase lean body mass in children who suffered from >40% TBSA burn injury.[113]

When the body is in a prolonged catabolic state due to the increase in caloric requirements, patients must consume at least 2.5 to 3 g/kg/day of protein.[75] Nutritional shakes and high-calorie foods are a necessity to optimize the conditions for wound healing. It is important to start nutrition as soon as possible, preferentially using the enteric route. Nasogastric or nasoduodenal/jejunal feeding tubes should be inserted early in the care of this patient population. Dieticians are crucial members of the burn care

team in creating individualized feeding plans and ensuring that nutrition is at the forefront of daily care. Albumin and prealbumin levels can be trended over time to ensure that adequate nourishment is achieved.

Patients should also be referred to physical and occupational therapy. A therapeutic exercise program should be implemented to maintain normal range of motion, strength, and endurance. In order to counteract the catabolic effects of burn injuries, a program of active and active-assisted exercise is necessary. Depending on the severity of the burn and the patient's willingness to tolerate the associated pain with exercise, passive range of motion exercises should be prescribed. In the event that full range of motion is not achievable, a program of stretching can be prescribed in its place. Anesthesia can be used to assist these exercises when patients cannot tolerate pain.

Range of motion exercises can also minimize skin contractures, as skin is a tissue that requires sustained mechanical stretch to facilitate lengthening of the underlying collagen and extracellular matrix compartments. Initial skin exercises should attempt to elongate the skin with repetitive low loads with differences in length. Following this initial precondition, a prolonged stretch is applied to maximize skin laxity. Blanching is a clinical sign that capillary blood flow is impeded and is a good sign that the tissue has reached its maximum yield point. Strength exercise should follow as soon as the patient can tolerate it. Strength programs best suited for burn patients should include progressive resistive exercises. Fatigue and loss of endurance are major issues as a patient recovers. It is important to include endurance training and monitor cardiopulmonary response. Concurrently, patients should be encouraged to walk as ambulating patients have fewer lower extremity contractures, endurance problems, and venous thrombosis.

Heterotopic Ossification

Heterotopic ossification (HO) is the pathologic formation of bone in extraskeletal regions of soft tissue including muscle, joint spaces, and often encasing major nerves (Fig. 12-13). This complication of burn injury causes significant pain, joint restriction, and contractures.[113] The incidence of HO is proportional to the severity of the injury with an increased incidence in severely burned patients. HO may affect all areas of the body but is most frequently encountered in the elbow joint (Fig. 12-13).[114,115] While the etiology of HO remains elusive, common risk factors that have been identified include upper extremity burns, large TBSA burns, young age, prolonged immobilization[116] and a delay in time to wound closure.[117]

Early detection and diagnosis of heterotopic bone formation is critical in the clinical management of this complication, which oftentimes involves surgical resection. The success rates of surgical intervention are not well established and are associated with a high recurrence rate. Perioperative radiotherapy has been suggested as an adjunct to surgical resection and has been shown to reduce the recurrence rate to some extent.[118] While the pathophysiologic processes underlying the development of heterotopic bone formation are poorly understood, several studies have implicated increased inflammatory signaling and the involvement of progenitor cells as crucial contributing elements.

Pharmacologic interventions have been shown to have some efficacy in limiting the severity of HO. Bisphosphonates and non-steroidal anti inflammatory have been used for prophylaxis and treatment of HO with some success.[119,120] However, there is no consensus on which drug should be prescribed and when treatment should begin. It has been proposed that bisphosphonates should be prescribed as soon as elevated alkaline phosphatase is noted or imaging studies establish the presence of HO. NSAIDs limit the severity of HO when delivered as a preventative therapy. The primary pathway thought to play a role is the bone morphogenetic protein (BMP) receptor 1 pathway; specifically the ALK2 kinase domain which stimulates canonical smad signaling. Though diagnosis is often not made until after 3 to 4 weeks after the burn injury, pathologic changes occur much sooner and thus treatments should target this early osteogenic signaling if prophylaxis is to be achieved. The effect of early active and passive range of motion on HO is unknown. Though the elbow is the most common site, the reason for this high incidence is unknown.



Figure 12-13. Heterotopic ossification.

Marjolin's Ulcer

Similar to chronic wounds from other etiologies, chronic untreated burn scars can lead to malignant degeneration. Squamous cell carcinoma is the most common type of malignancy observed. Malignancies are rare in an era of early excision and grafting. Malignancy requires wide excision with at least a 2 cm margin as well as sentinel lymph node biopsy. If the sentinel node is positive, a compete lymph node excision should be performed.

Clinical Research

Clinical research determines the safety and efficacy of medications, devices, diagnostic tools, and treatment regimens and has provided new insights to effectively care for burn patients. Within the last decade, critical care, wound care treatment, and burn reconstruction research have advanced in both diagnosis and identification of efficacious therapies to improve the overall recovery process for burn victims.

Critical care research has focused on the delivery of adequate care during the initial phase following the traumatic burn injury. Immediately following the trauma, burn patients experience severe shock due to concomitant inflammation leading to severe edema. While rigorous fluid resuscitation has been shown to increase overall survival for patients with high TBSA involvement, novel resuscitation methods have recently been investigated. In a prospective randomized study, clinicians investigated the use of colloids within the first 24 hours of resuscitation.[121] Patients with a TBSA burn injury greater than 15% were either provided with crystalloid resuscitation or a mixture of crystalloid and hydroxyethyl starch. Patients given colloids required less fluid, experienced less edema, and had a lower C-reactive protein indicative of less inflammation. Additional studies have investigated the use of therapeutic plasma exchange for refractory burn resuscitation and discovered that patients had reduced lactate levels, increased mean arterial pressure, and improved urine output after treatment.[122] Our recommendation and common practice use crystalloid rather than colloid as outcomes in burn patients have not been conclusively shown to be improved. These studies highlight the complexity of burn shock resuscitation and the need for ongoing research in the field.

Studies have investigated the role of regulating glucose levels in burn patients during the critical phase. Stress hyperglycemia after severe burn injury has long been established as a physiologic response to trauma. Recent studies have demonstrated the need for early glycemic control, as burn patients who did not have optimal glucose levels experienced increased mortality. Intensive insulin therapy in critically ill burn patients limited the number of infections and sepsis and improved overall organ function.[123] In general moderate glycemic control as demonstrated by the NICE-SUGAR trial appears efficacious.[124] Delivery of insulin also decreased inflammatory responses, as noted by decrease levels of systemic IL-6 and C-reactive protein, and also improved body density, body fat, and lean body mass. Insulin therapy also reduced resting energy expenditure in the first week following the burn injury, improved mitochondrial function, and hepatic glucose metabolism.[125] Furthermore, the glucose variability experienced by a burn patient during the critical period is also associated with increased mortality rates, suggesting that consistent and tight glucose control may provide a significant survival benefit.[126] Taken together, these studies build an argument that in burn patients, glucose control with insulin therapy may reduce inflammation, improve energy utilization, and improve overall prognosis.

Another important area of research is the development of new technology to aid in wound assessment and treatment. Punch biopsy, laser Doppler imaging, and near-infrared spectroscopy have been employed to diagnosis the burn depth and severity of the primary

wound site. Additional studies advocate for the use of confocal laser scanning microscopy (CLSM) due to its greater contrast and sensitivity. This technology images wounds in vivo without any physical dissection using a laser source. CLSM was able to determine wound depth by assessing the number of perfused dermal papillae and was able to accurately classify burns based on the amount of perfusion.[127] Recent development of extracorporeal shock wave treatment (ESWT) has shown promise as it promotes angiogenesis, increases perfusion, and accelerates wound healing. In a pilot study, patients treated with ESWT demonstrated increase blood flow to the burn wound within 3 weeks.[128] This therapy shows great promise, as it is a noninvasive measure to improve wound healing.

Advances in burn reconstruction have also been noted in the last decade. While TEs have been a mainstay of burn reconstruction, several studies have surveyed the use of endoscopic-assisted placement of expanders and the use of osmotic TEs.[129,130] Both endoscope-assisted placement of expanders and osmotic TEs offer advantages over the traditional methods, as they are more cosmetically acceptable and require fewer injections, respectively. As TE technology continues to improve with new expansion techniques and devices, discovering the best technique and devices will be an important component of burn reconstruction. Cultured epithelial autografts, as discussed in previous sections, have gained interest as an alternative for cutaneous coverage for patients with large burn wounds and small potential donor sites. With final engraftment percentages as high as 73% and 90% patient survival rate, it is an attractive alterative for patients with severe and extensive burns.

BASIC SCIENCE AND TRANSLATIONAL SCIENCE RESEARCH

Basic science and translational science research in burn injuries have significantly advanced in the last 50 years and have focused on both understanding and treating the primary wound site as well as complications that arise from these traumatic burn injuries.

Wound healing can be described in three different stages: inflammation, proliferation, and remodeling phase. Hypertrophic scarring is an aberrant form of the normal wound healing process that does not extend beyond the original wound margins. Hypertrophic scar formation involves the constitutively active proliferative phase of wound healing, resulting in high vascularity and dense extracellular matrix deposition.[131] Histologic studies suggest that a robust inflammatory response, involving mast cells, macrophages, fibrocytes, and lymphocytes, may underlie the excessive fibrosis seen in hypertrophic scar formation.[132] The secretion of TGF-beta1, platelet-derived growth factors (PDGFs), and epidermal growth factor contributes to the inflammatory response and results in excessive inflammatory cell stimulation, fibroblast proliferation, adhesion, neovascularization, matrix production, and ultimately contraction.[133] As such, translational science research from the bench to the bedside focuses on new therapies targeted at quenching the inflammatory response, limiting fibrosis, and inhibiting angiogenesis by targeting the mediators of this scaring process.[134,135] Additional basic science research aimed at understanding the wound healing process and translational science research investigating new treatment options will continue to advance our understanding and treatment of burn-related injuries.

Additional studies into the precise cause of secondary complications such has HO has gained significant interest due to the increase in presence of HO in veterans who have sustained combat injuries. While the precise pathophysiology behind HO is still unclear, it is thought to be related to local and systemic factors, causing osteoblastic differentiation of local cells. Previous studies have attempted to elucidate the local and systemic wound inflammatory response leading to HO, through the identification of cytokine and chemokines secreted from the wound.[136] Serum analysis demonstrated a profound systemic inflammatory response in burn patients, as burn patients maintained increased levels of IL-6 and macrophage chemoattractant protein (MCP)-1 over time. Both IL-6 and MCP-1 are inflammatory agents that function in recruiting monocytes and macrophages to the site of injury, indicating sustained inflammation throughout the wound healing process. Furthermore, MCP-1 has also been implicated in bone remodeling and may be an earlier indicator of HO development. Locally, proinflammatory cytokine MIP-1 alpha has been shown to be upregulated, indicating robust inflammation locally. This inflammatory response is believed to enhance bone regeneration; however, the precise cells and cytokines involved for this enhanced osteogenesis remain unknown. Studies have shed some light into what might contribute to this enhanced osteogenesis. RUNX2 has been shown to increase in the presence of macrophages and inflammatory cytokines and this increased expression results in an increase in bone mineralization.[137] Other studies have

demonstrated an increase in the tumor necrosis factor family and ILs, including IL-1, IL6, IL-8, IL-10, IL12, and IL-18.[139]

The most recent work in this field has focused on BMP signaling as a central mechanism that leads to ectopic bone formation. Early studies demonstrated that inhibition of transcriptional activity of BMP type I receptors with antagonists such as noggin and chordin has been shown to disrupt the osteoblast differentiation signaling pathways.[139,140] Mice lacking noggin showed overactivity of BMP and displayed HO. The role of BMP signaling as an important regulator of ectopic bone formation, along with other mediators such as PDGF, insulin-like growth factor 1 (IGF-1), and TGF-beta1, continues to be the focus of research. Identifying pharmacologic therapies that inhibit the overactive inflammatory response may inhibit the development of HO.[141]

Additional studies have focused on the identification of progenitor cells responsible for HO. Nesti et al.[140] identified and isolated a population of multilineage mesenchymal stem cells with osteogenic potential that were localized primarily in traumatized tissue. Mesenchymal stem cells are multipotent, adult progenitor cells of great interest because of their unique immunologic properties and regenerative potential.[142] These progenitor cells have been shown to promote wound healing and regeneration of surround tissues by migrating to the site of injury, promoting repair and regeneration of damaged tissue, modulate the immune and inflammatory response, and secrete trophic factors that are important in wound healing and tissue remodeling.[142–146] Tissue resident progenitor cells are known to be highly sensitive to the surrounding inflammatory milieu.[147,148] Interestingly, a study by Wu et al.[149] indicates that exposure of skeletal muscle satellite cells to the serum of burned rats is sufficient to promote their osteogenic differentiation, suggesting that both systemic and local inflammations may play a role in driving stem cell differentiation. In addition, studies have recently shown that burn injury promotes HO of adipose-derived stem cells in a murine model of scald injury. Microcomputed tomography and histologic analysis demonstrated increased endochondral ossification in the burn group compared to the sham control, a process which was most likely mediated through increased vascularization.[150] While resident mesenchymal stem cells seem to be implicated in the pathogenesis of HO, there is reason to believe that the immunomodulatory properties of these cells may be activated to suppress the proinflammatory microenvironment when applied externally.[151] Further studies are necessary to fully elucidate the therapeutic utility of these cells.

Other groups have shown that these mesenchymal progenitor cells can be isolated from both health and traumatized muscles. Both health and traumatized muscles have osteoprogenitor cells that have the potential to form ectopic bone after injury.[140] Laboratories have suggested that cells responsible for HO are from the endothelium of the local vasculature.[152] These studies suggest that in a setting of chronically stimulated BMP activity, muscle injury and associated inflammation sufficiently trigger heterotopic bone formation and that cells of vascular origin are essential to the development of ectopic bone. This cell lineage, along with stimulating factors such as BMP that create the correct environment for bone formation, could be target for the development of therapeutic interventions to treat HO.[153] Further understanding the signaling pathways

and the involvement of MSC differentiation is essential for the development of early diagnostic and prognostic tests and the development of novel prophylactic therapies.

REHABILITATION

In addition to an increased need for reconstructive surgery secondary to increased survival, there is also an increased need to focus on functional, social, and psychological rehabilitation. The National Institute of Disability and Rehabilitation Research (NIDRR) has continued to fund multi-institutional research to better understand long-term rehabilitative outcomes and needs. Therapists must play an integral role of inpatient and follow-up care. Inpatient care should include aggressive splinting and range of motion. As patients transition to discharge, therapists should work on strengthening, performing activities of daily living, and occupational guidance.

NONBURN CONDITIONS COMMONLY CARED FOR IN BURN CENTERS

Stevens–Johnson syndrome (SJS) and toxic epidermal necrolysis syndrome (TENS) have widespread necrosis of the superficial portion of the epidermis (Fig. 12-14). SJS/TEN is commonly associated with sulfonamides, trimethoprim-sulfamethoxazole, oxican NSAIDs, chlormezanone, and carbamazepine. However, a single offending drug is identified in less than 50% of cases. Antibiotic-associated SJS/TEN presents ~7 days after drug is first taken whereas anticonvulsant-associated SJS/TES can present up to 2 months after drug is first taken. TEN can also be caused by staphylococcal infections in immunocompromised patients. In general SJS total involvement is defined as less than 10% TBSA with widespread erythematous or purpuric macules or flat atypical targets are present. TEN has total cutaneous involvement of greater than 30% TBSA and SJS-TENS overlap involves 10% to 30%. Given the difficulty distinguishing these from drug eruptions we recommend a biopsy be sent. This biopsy is also crucial for treatment as steroids are often recommended for drug eruptions but they have not been shown to improve outcomes in patients with SJS and TENS. It is crucial in these patients to assess the oral, opthalmologic, and urogenital mucosa. Oral mucosal involvement can create a difficult airway as the difficult airway team should be present if intubation is necessary. We recommend aggressive lubrication of the periorbita and an ophthalmology consult if the eyes are involved and OB/Gyn should be consulted for vaginal mucosal involvement. Treatment of the skin sloughing should include a nonstick silver impregnated gauze. If large skin involvement we typically use acticoat. Some centers, however, have demonstrated success with xenograft treatment of large open areas. Currently the data do not support steroid or intravenous immunoglobulin (IVIG) treatment.



Figure 12-14. Stevens–Johnson syndrome and toxic epidermal necrolysis syndrome.



Figure 12-15. Ischemia of the extremities leading to amputation.

Staph scalded skin syndrome has a similar skin appearance to TENS except that it also has positive blood cultures. These wounds are usually more superficial than TEN and the mucosa and conjunctiva are typically not involved. Patients should receive empiric and subsequently culture-based antistaphylococcal antibiotics.

Purpura fulminans often presents after streptococcal or meningococcal sepsis. These patients often have multisystem organ failure secondary to septic shock and vasopressive treatments for cardiovascular support. Patients often suffer from ischemia of the extremities. Treatment of the wounds should be supportive until the patient is stable enough for a definitive operation. Given that tissue death occurs from ischemia, these patients often require amputations (Fig. 12-15).

CONCLUSION

Burns are responsible for significant morbidity and mortality and are among the most complex and devastating of all traumatic injuries. Early proper diagnosis of burn depth and extent allows for the delivery of appropriate treatment ensures the best prognosis for burn patients. Early tangential excision and autografting remain the foundation of burn treatment. New technologies have advanced the method of diagnosis from punch biopsies to less invasive imaging studies. Diagnosis of secondary burn complications, such as joint contracture and HO, has also advanced with new imaging tools, such as the Raman spectroscopy, that may allow for earlier detection and treatment of ectopic bone formation. The management of burn patients requires a team of physicians, nurses, critical care specialists, physical therapists, and counselor to provide optimal care to patients and lessen the burden of the initial burn injury. Novel clinical, basic science, and translational science researches continue to improve our understanding of the pathophysiology of burn injuries. By elucidating the pathophysiology of both the primary wound and secondary complications will assist in the treatment during the critical period and following the initial trauma and prevent secondary burn complications.

APPENDIX

Burn Resuscitation Flowsheet

	First 8 Hours				Next 16 Hours				Post Burn Day 2			
Time since Injury												
pH												
Bicarb												
CO_2												
BD												
Lactate												
CVP												
U/O												
Central Venous Sat.												
PICCO #s												
SVV												
SVRi												
ELWi												
GEDi												

References

1. American Burn Association National Burn Repository. In. 2013.
2. Association AB. National Burn Repository. In. 2009.
3. Repository NB. Report of data from 1999–2008. In. 2009.
4. Shields B, Comstock R, Fernandez S, et al. Healthcare resource utilization and epidemiology of pediatric burn-associated hospitalizations, United States, 2000. *J Burn Care Res* 2007;28:811–826.
5. Conner K, Williams L, McKenzie L, et al. Pediatric pedestrian injuries associated hospital resource utilization in the United States, 2003. *J Trauma* 2010;68:1406–1412.
6. CDC. Web-based injury and statistics query and reporting sytem (WISQARS). In: Control CfD, ed. Center for Disease Control; 2009.
7. Pressel D. Evaluation of physical abuse in children. *Am Fam Physician* 2000;61:3057–3064.
8. Birky M, Halpin B, Caplan Y, et al. Fire fatality study. *Fire Mater* 2004;3:211–217.
9. Davidge K, Fish J. Older Adults and Burns. *Geriatr Aging* 2008;11:270–275.
10. Ryan C, Thorpe W, Mullin P, et al. A persistent fire hazard for older adults: cooking-related clothing ignition. *J Am Geriatr Soc* 1997;45:1283–1285.
11. Ryan C, Schoenfeld D, Thorpe W, et al. Objective estimates for the probability of death from burn injuries. *N Engl J Med* 1998;338:362–366.
12. Muller M, Pegg S, Rule M. Determinants of death following burn injury. *Br J Surg* 2001;88:583–587.
13. Webbenmeyer L, Amelon M, Morgan L, et al. Predicting survival in an elderly burn patient population. *Burns* 2001;27:583–590.
14. Bernard S, Paulozzi L, Wallace D; Centers for Disease Control and Prevention (CDC). Fatal injuries among children by race and ethnicity – United States, 1999–2002. *MMWR Surveill Summ* 2007;56:1–20.
15. Fagenholz P, Sheridan R, Harris N, et al. National study of emergency department visits for burn injuries. *J Burn Care Res* 2007;28:681–690.
16. Gulaid J, Sacks J, Sattin R. Deaths from residential fires among older people, United States, 1984. *J Am Geriatr Soc* 1989;37:331–334.
17. Hunt J, Purdue G. The elderly burn patient. *Am J Surg* 1992;164:472–476.
18. McGill V, Kowal-Vern A, Gamelli R. Outcome for older burn patients. *Arch Surg* 2000;135:320–325.
19. Barillo D, Goode R. Fire fatality study: demographics of fire victims. *Burns* 1996;22:85–88.
20. Mallonee S, Istre G, Rosenberg M, et al. Surveillance and prevention of residential-fire injuries. *N Engl J Med* 1996;335:27–31.
21. Istre G, McCoy M, Carlin D, et al. Residential fire related deaths and injuries among

children: fireplay, smoke alarms, and prevention. *Inj Prev* 2002;8:128–132.
22. Repository ABA-NB. 2012 Report. In. 2013.
23. DiVincenti F, Moncrief J, Pruitt BJ. Electrical injuries: a review of 65 cases. *J Trauma* 1969;9:497–507.
24. Purdue GF, Hunt JL. Electrocardiographic monitoring after electrical injury: necessity or luxury. *J Trauma* 1986;26:166–167.
25. Bruen KJ, Ballard JR, Morris SE, et al. Reduction of the incidence of amputation in frostbite injury with thrombolytic therapy. *Arch Surg* 2007;142:546–551; discussion 551–553.
26. Gibran NS, Heimbach DM. Mediators in thermal injury. *Semin Nephrol* 1993;13:344–358.
27. Santos FX, Arroyo C, Garcia I, et al. Role of mast cells in the pathogenesis of postburn inflammatory response: reactive oxygen species as mast cell stimulators. *Burns* 2000;26:145–147.
28. Zhang XJ, Irtun O, Zheng Y, et al. Methysergide reduces nonnutritive blood flow in normal and scalded skin. *Am J Physiol Endocrinol Metab* 2000;278:E452–E461.
29. Garcia-Avello A, Lorente JA, Cesar-Perez J, et al. Degree of hypercoagulability and hyperfibrinolysis is related to organ failure and prognosis after burn trauma. *Thromb Res* 1998;89:59–64.
30. Maass DL, White J, Horton JW. IL-1beta and IL-6 act synergistically with TNF-alpha to alter cardiac contractile function after burn trauma. *Shock* 2002;18:360–366.
31. Carlson DL, Lightfoot E Jr, Bryant DD, et al. Burn plasma mediates cardiac myocyte apoptosis via endotoxin. *Am J Physiol Heart Circ Physiol* 2002;282:H1907–H1914.
32. Maass DL, Hybki DP, White J, et al. The time course of cardiac NF-kappaB activation and TNF-alpha secretion by cardiac myocytes after burn injury: contribution to burn-related cardiac contractile dysfunction. *Shock* 2002;17:293–299.
33. White DJ, Maass DL, Sanders B, et al. Cardiomyocyte intracellular calcium and cardiac dysfunction after burn trauma. *Crit Care Med* 2002;30:14–22.
34. Herndon DN, Tompkins RG. Support of the metabolic response to burn injury. *Lancet* 2004;363:1895–1902.
35. Fagan SP, Bilodeau ML, Goverman J. Burn intensive care. *Surg Clin North Am* 2014;94:765–779.
36. Morio B, Irtun O, Herndon DN, et al. Propranolol decreases splanchnic triacylglycerol storage in burn patients receiving a high-carbohydrate diet. *Ann Surg* 2002;236:218–225.
37. Jeschke MG, Finnerty CC, Kulp GA, et al. Combination of recombinant human growth hormone and propranolol decreases hypermetabolism and inflammation in severely burned children. *Pediatr Crit Care Med* 2008;9:209–216.
38. Wilkins JP, Suman OE, Benjamin DA, et al. Comparison of self-reported and monitored compliance of daily injection of human growth hormone in burned

children. *Burns* 2003;29:697–701.
39. Ramirez RJ, Wolf SE, Herndon DN. Is there a role for growth hormone in the clinical management of burn injuries? *Growth Horm IGF Res* 1998;8(suppl B):99–105.
40. Jeschke MG, Wolf SE, DebRoy MA, et al. The combination of growth hormone with hepatocyte growth factor alters the acute phase response. *Shock* 1999;12:181–187.
41. Klein GL, Wolf SE, Langman CB, et al. Effects of therapy with recombinant human growth hormone on insulin-like growth factor system components and serum levels of biochemical markers of bone formation in children after severe burn injury. *J Clin Endocrinol Metab* 1998;83:21–24.
42. Herndon DN, Pierre EJ, Stokes KN, et al. Growth hormone treatment for burned children. *Horm Res* 1996;45(suppl 1):29–31.
43. Herndon DN, Hawkins HK, Nguyen TT, et al. Characterization of growth hormone enhanced donor site healing in patients with large cutaneous burns. *Ann Surg* 1995;221:649–656; discussion 656–659.
44. Herndon DN, Barrow RE, Kunkel KR, et al. Effects of recombinant human growth hormone on donor-site healing in severely burned children. *Ann Surg* 1990;212:424–429; discussion 430–431.
45. Committee on Trauma. *Excerpted from Guidelines for the Operation of Burn Centers* (pp. 79–86), Resources for Optimal Care of the Injured Patient 2006, American College of Surgeons. http://www.ameriburn.org/BurnCenterReferralCriteria.pdf
46. Bezuhly M, Fish JS. Acute burn care. *Plast Reconstr Surg* 2012;130:349e–358e.
47. Branski LK, Herndon DN, Byrd JF, et al. Transpulmonary thermodilution for hemodynamic measurements in severely burned children. *Crit Care*. 2011;15(2): R118. doi:10.1186/cc10147.
48. Thorne C. *Grabb and Smith's Plastic Surgery*. Philadelphia, PA: Lippincott Williams & Wilkins; 2007.
49. Cartotto R, Callum J. A review of the use of human albumin in burn patients. *J Burn Care Res* 2012;33:702–717.
50. Melinyshyn A, Callum J, Jeschke MC, et al. Albumin supplementation for hypoalbuminemia following burns: unnecessary and costly! *J Burn Care Res* 2013;34:8–17.
51. Park SH, Hemmila MR, Wahl WL. Early albumin use improves mortality in difficult to resuscitate burn patients. *J Trauma Acute Care Surg* 2012;73:1294–1297.
52. Graves TA, Cioffi WG, McManus WF, et al. Fluid resuscitation of infants and children with massive thermal injury. *J Trauma* 1988;28:1656–1659.
53. Stawicki SP, Hoff WS, Cipolla J, et al. Use of non-invasive esophageal echo-Doppler system in the ICU: a practical experience. *J Trauma* 2005;59:506–507.
54. Wang GY, Ma B, Tang HT, et al. Esophageal echo-Doppler monitoring in burn shock resuscitation: are hemodynamic variables the critical standard guiding fluid therapy? *J Trauma* 2008;65:1396–1401.

55. Dai NT, Chen TM, Cheng TY, et al. The comparison of early fluid therapy in extensive flame burns between inhalation and noninhalation injuries. *Burns* 1998;24:671–675.
56. Schiller WR, Bay RC. Hemodynamic and oxygen transport monitoring in management of burns. *New Horiz* 1996;4:475–482.
57. Lorente JA, Ezpeleta A, Esteban A, et al. Systemic hemodynamics, gastric intramucosal PCO2 changes, and outcome in critically ill burn patients. *Crit Care Med* 2000;28:1728–1735.
58. Holm C, Melcer B, Horbrand F, et al. Haemodynamic and oxygen transport responses in survivors and non-survivors following thermal injury. *Burns* 2000;26:25–33.
59. Kashefi NS, Nathan JI, Dissanaike S. Does a nebulized heparin/N-acetylcysteine protocol improve outcomes in adult smoke inhalation? *Plast Reconstr Surg Glob Open* 2014;2:e165.
60. Miller AC, Rivero A, Ziad S, et al. Influence of nebulized unfractionated heparin and N-acetylcysteine in acute lung injury after smoke inhalation injury. *J Burn Care Res* 2009;30:249–256.
61. Palmieri TL, Enkhbaatar P, Bayliss R, et al. Continuous nebulized albuterol attenuates acute lung injury in an ovine model of combined burn and smoke inhalation. *Crit Care Med* 2006;34:1719–1724.
62. Salman D, Finney SJ, Griffiths MJ. Strategies to reduce ventilator-associated lung injury (VALI). *Burns* 2013;39:200–211.
63. Peck MD, Koppelman T. Low-tidal-volume ventilation as a strategy to reduce ventilator-associated injury in ALI and ARDS. *J Burn Care Res* 2009;30:172–175.
64. Chung KK, Wolf SE, Renz EM, et al. High-frequency percussive ventilation and low tidal volume ventilation in burns: a randomized controlled trial. *Crit Care Med* 2010;38:1970–1977.
65. Mosier MJ, Pham TN. American Burn Association Practice guidelines for prevention, diagnosis, and treatment of ventilator-associated pneumonia (VAP) in burn patients. *J Burn Care Res* 2009;30:910–928.
66. Herndon DN, Barrow RE, Stein M, et al. Increased mortality with intravenous supplemental feeding in severely burned patients. *J Burn Care Rehabil* 1989;10:309–313.
67. Herndon DN, Hart DW, Wolf SE, et al. Reversal of catabolism by beta-blockade after severe burns. *N Engl J Med* 2001;345:1223–1229.
68. Hemmila MR, Taddonio MA, Arbabi S, et al. Intensive insulin therapy is associated with reduced infectious complications in burn patients. *Surgery* 2008;144(4):629–635.
69. Atiyeh BS, Costagliola M, Hayek SN, et al. Review effect of silver on burn wound infection control and healing: review of the literature. *Burns* 2007;33:139–148.
70. Falcone PA, Harrison HN, Sowemimo GO, et al. Mafenide acetate concentrations and bacteriostasis in experimental burn wounds treated with a three-layered laminated

mafenide-saline dressing. *Ann Plast Surg* 1980;5:226–229.
71. Fong J, Wood F. Nanocrystalline silver dressings in wound management: a review. *Nanomedicine* 2006;1:441–449.
72. Gravante G, Caruso R, Sorge R, et al. Nanocrystalline silver: a systematic review of randomized trials conducted on burned patients and an evidence-based assessment of potential advantages over older silver formulations. *Ann Plast Surg* 2009;63:201–205.
73. Engav L, Hiembach D, Reus J, et al. Early excision and grafting vs. nonoperative treatment of burns of indeterminant depth: a randomized prospective study. *J Trauma* 1983;23:510–517.
74. Gray D, Pine R, Harnar T, et al. Early surgical excision versus conventional therapy in patients with 20 to 40 percent burns. A comparative study. *Am J Surg* 1982;144:76–80.
75. Mulholland MW. *Greenfield's Surgery*. Philadelphia, PA: Lippincott Williams & Wilkins; 2010.
76. Sterling J, Gibran NS, Klein MB. Acute management of hand burns. *Hand Clin* 2009;25:453–459.
77. Klein MB, Moore ML, Costa B, et al. Primer on the management of face burns at the University of Washington. *J Burn Care Res* 2005;26:2–6.
78. Benichou G, Yamada Y, Yun SH, et al. Immune recognition and rejection of allogeneic skin grafts. *Immunotherapy* 2011;3:757–770.
79. Ronfard V, Rives JM, Neveux Y, et al. Long-term regeneration of human epidermis on third degree burns transplanted with autologous cultured epithelium grown on a fibrin matrix. *Transplantation* 2000;70:1588–1598.
80. Atiyeh BS. Cultured epithelial autograft (CEA) in burn treatment: three decades later. *Burns* 2007;33:405–413.
81. Elliott M, Vandervord J. Initial experience with cultured epithelial autografts in massively burnt patients. *ANZ J Surg* 2002;72:893–895.
82. Paddle-Ledinek JE, Cruickshank DG, Masterton JP. Skin replacement by cultured keratinocyte grafts: an Australia experience. *Burns* 1997;23:204–211.
83. Brown D, Borschel GH. *Michigan Manual of Plastic Surgery*. Philadelphia, PA: Lippincott Williams & Wilkins; 2004.
84. O'Grady NP, Alexander M, Burns LA, et al. Guidelines for the prevention of intravascular catheter-related infections. Healthcare Infection Control Practices Advisory Committee. *Am J Infect Control* 2011;39(4 suppl 1):S1–34. doi:10.1016/j.ajic.2011.01.003
85. Tandara AA, Mustoe TA. The role of the epidermis in the control of scarring: evidence for mechanism of action for silicone gel. *J Plast Reconstr Aesthet Surg* 2008;61:1219–1225.
86. Mustoe TA. Evolution of silicone therapy and mechanism of action in scar management. *Aesthetic Plast Surg* 2008;32:82–92.

87. Saulis AS, Chao JD, Telser A, et al. Silicone occlusive treatment of hypertrophic scar in the rabbit model. *Aesthet Surg J* 2002;22:147–153.
88. Steinstraesser L, Flak E, Witte B, et al. Pressure garment therapy alone and in combination with silicone for the prevention of hypertrophic scarring: randomized controlled trial with intraindividual comparison. *Plast Reconstr Surg* 2011;128:306e–313e.
89. Van den Kerckhove E, Stappaerts K, Fieuws S, et al. The assessment of erythema and thickness on burn related scars during pressure garment therapy as a preventive measure for hypertrophic scarring. *Burns* 2005;31:696–702.
90. Lawrence JW, Mason ST, Schomer K, et al. Epidemiology and impact of scarring after burn injury: a systematic review of the literature. *J Burn Care Res* 2012;33:136–146.
91. Gangemi EN, Gregori D, Berchialla P, et al. Epidemiology and risk factors for pathologic scarring after burn wounds. *Arch Facial Plast Surg* 2008;10:93–102.
92. Nedelec B, Shankowsky H, Scott PG, et al. Myofibroblasts and apoptosis in human hypertrophic scars: the effect of interferon-alpha2b. *Surgery* 2001; 130:798–808.
93. Armour A, Scott PG, Tredget EE. Cellular and molecular pathology of HTS: basis for treatment. *Wound Repair Regen* 2007;15:S6–S17.
94. Longacre JJ, Berry HK, Basom CR, et al. The effects of Z plasty on hypertrophic scars. *Scand J Plast Reconstr Surg* 1976;10:113–128.
95. Davis JS. The relaxation of scar contractures by means of the Z-, or reversed Z-type incision: stressing the use of scar infiltrated tissues. *Ann Surg* 1931;94:871–884.
96. Parnell LK, Nedelec B, Rachelska G, et al. Assessment of pruritus characteristics and impact on burn survivors. *J Burn Care Res* 2012;33:407–418.
97. Klinger M, Marazzi M, Vigo D. Fat injection for cases of severe burn outcomes: a new perspective of scar remodeling and reduction. *Aesthetic Plast Surg* 2008;32:465–469.
98. Reish RG, Eriksson E. Scar treatments: preclinical and clinical studies. *J Am Coll Surg* 2008;206:719–730.
99. Zouboulis CC, Blume U, Buttner P, et al. Outcomes of cryosurgery in keloids and hypertrophic scars. A prospective consecutive trial of case series. *Arch Dermatol* 1993;129:1146–1151.
100. Alster TS, Handrick C. Laser treatment of hypertrophic scars, keloids, and striae. *Semin Cutan Med Surg* 2000;19:287–292.
101. Manuskiatti W, Wanitphakdeedecha R, Fitzpatrick RE. Effect of pulse width of a 595-nm flashlamp-pumped pulsed dye laser on the treatment response of keloidal and hypertrophic sternotomy scars. *Dermatol Surg* 2007;33:152–161.
102. Manuskiatti W, Fitzpatrick RE, Goldman MP. Energy density and numbers of treatment affect response of keloidal and hypertrophic sternotomy scars to the 585-nm flashlamp-pumped pulsed-dye laser. *J Am Acad Dermatol* 2001;45:557–565.
103. Garden JM, Tan OT, Kerschmann R, et al. Effect of dye laser pulse duration on

selective cutaneous vascular injury. *J Invest Dermatol* 1986;87:653–657.
104. Manstein D, Herron GS, Sink RK, et al. Fractional photothermolysis: a new concept for cutaneous remodeling using microscopic patterns of thermal injury. *Laser Surg Med* 2004;34:426–438.
105. Gore DC, Chinkes DL, Wolf SE, et al. Quantification of protein metabolism in vivo for skin, wound, and muscle in severe burn patients. *JPEN J Parenter Enteral Nutr* 2006;30:331–338.
106. Jeschke MG, Gauglitz GG, Kulp GA, et al. Long-term persistance of the pathophysiologic response to severe burn injury. *PLoS One* 2011;6:e21245.
107. Rutan RL, Herndon DN. Growth delay in postburn pediatric patients. *Arch Surg* 1990;125:392–395.
108. Tuvdendorj D, Chinkes DL, Zhang XJ, et al. Skeletal muscle is anabolically unresponsive to an amino acid infusion in pediatric burn patients 6 months postinjury. *Ann Surg* 2011;253:592–597.
109. Porter C, Cotter M, Diaz EC, et al. Amino acid infusion fails to stimulate skeletal muscle protein synthesis up to 1 year after injury in children with severe burns. *J Trauma Acute Care Surg* 2013;74:1480–1485.
110. Padfield KE, Astrakas LG, Zhang Q, et al. Burn injury causes mitochondrial dysfunction in skeletal muscle. *Proc Natl Acad Sci U S A* 2005;102:5368–5373.
111. Righi V, Constantinou C, Mintzopoulos D, et al. Mitochondria-targeted antioxidant promotes recovery of skeletal muscle mitochondrial function after burn trauma assessed by in vivo 31P nuclear magnetic resonance and electron paramagnetic resonance spectroscopy. *FASEB J* 2013;27:2521–2530.
112. Cree MG, Zwetsloot JJ, Herndon DN, et al. Insulin sensitivity and mitochondrial function are improved in children with burn injury during a randomized controlled trial of fenofibrate. *Ann Surg* 2007;245:214–221.
113. Przkora R, Herndon DN, Suman OE. The effects of oxandrolone and exercise on muscle mass and function in children with severe burns. *Pediatrics* 2007;119:e109–e116.
114. Elledge ES, Smith AA, McManus WF, et al. Heterotopic bone formation in burned patients. *J Trauma* 1988;28:684–687.
115. Esselman PC, Thombs BD, Magyar-Russell G, et al. Burn rehabilitation: state of the science. *Am J Phys Med Rehabil* 2006;85:383–413.
116. Evans EB. Orthopaedic measures in the treatment of severe burns. *J Bone Joint Surg Am* 1966;48:643–669.
117. Klein MB, Logsetty S, Costa B, et al. Extended time to wound closure is associated with increased risk of heterotopic ossification of the elbow. *J Burn Care Res* 2007;28:447–450.
118. Maender C, Sahajpal D, Wright TW. Treatment of heterotopic ossification of the elbow following burn injury: recommendations for surgical excision and

perioperative prophylaxis using radiation therapy. *J Shoulder Elbow Surg* 2010;19:1269–1275.

119. Orzel J, Rudd T. Heterotopic bone formation: clinical, laboratory, and imaging correlation. *J Nucl Med* 1985;26:125–132.
120. Neal B, Rogers A, Clark T, et al. A systematic survey of 13 randomized trials of non-steroidal anti-inflammatory drugs for the prevention of heterotopic bone formation after major hip surgery. *Acta Orthop Scand* 2000;71:122–128.
121. Fearonce G, Faraklas I, Saffle J, et al. Peripherally inserted central venous catheters and central venous catheters in burn patients: a comparative review. *J Burn Care Res* 2010;31:31–35.
122. Neff L, Allman J, Holmes H. The use of therapeutic plasma exchange (TPE) in the setting of refractory burn shock. *Burns* 2010;36:372–378.
123. Cartotto R, Zhou A. Fluid creep: the pendulum hasn't swung back yet! *J Burn Care Res* 2010;31:551–558.
124. Finfer S, Chittock DR, Su SY, et al. Intensive versus conventional glucose control in critically ill patients. *N Engl J Med* 2009;360:1283–1297.
125. Webbenmeyer L, Sevier A, Liao J, et al. The impact of opioid administration on resuscitation volumes in thermally injured patients. *J Burn Care Res* 2010;31:40–47.
126. Pidcoke H, Wanek S, Rohleder L, et al. Glucose variability is associated with high mortality after severe burn. *J Trauma* 2009;67:990–995.
127. Altintas MA, Altintas AA, Knobloch K, et al. Differentiation of superficial-partial vs. deep-partial thickness burn injuries in vivo by confocal-laser-scanning microscopy. *Burns* 2009;35:80–86.
128. Arno A, Garcia O, Hernan I, et al. Extracorporeal shock waves, a new non-surgical method to treat severe burns. *Burns* 2010;36:477–482.
129. Sood R, Roggy D, Zieger M, et al. Cultured epithelial autografts for coverage of large burn wounds in eighty-eight patients: the Indiana University experience. *J Burn Care Res* 2010;31:559–568.
130. Sood R, Balledux J, Koumanis D, et al. Coverage of large pediatric wounds with cultured epithelial autografts in congenital nevi and burns: results and technique. *J Burn Care Res* 2009;30:576–586.
131. Ehrlich H, Desmoulière A, Diegelmann R, et al. Morphological and immunochemical differences between keloid and hypertrophic scar. *Am J Pathol* 1994;145:105–113.
132. Wulff B, Parent A, Meleski M, et al. Mast cells contribute to scar formation during fetal wound healing. *J Invest Dermatol* 2012;132:458–465.
133. Wilgus T, Bergdall V, Tober K, et al. The impact of cyclooxygenase-2 mediated inflammation on scarless fetal wound healing. *Am J Pathol* 2004;165:753–761.
134. Peranteau W, Zhang L, Muvarak N, et al. IL-10 overexpression decreases inflammatory mediators and promotes regenerative healing in an adult model of scar formation. *J Invest Dermatol* 2008;128:1852–1860.

135. Gordon A, Kozin E, Keswani S, et al. Permissive environment in postnatal wounds induced by adenoviral-mediated overexpression of the anti-inflammatory cytokine interleukin-10 prevents scar formation. *Wound Repair Regen* 2008;16:70–79.
136. Potter B, Fosberg J, Davis T, et al. Heterotopic ossification following combat-related trauma. *J Bone Joint Surg Am* 2010;92:74–89.
137. Guihard P, Danger Y, Brounais B, et al. Induction of osteogenesis in mesenchymal stem cells by activated monocytes/macrophages depends on oncostatin M signaling. *Stem Cells* 2012;30:762–772.
138. Pignolo R, Xu M, Russell E, et al. Heterozygous inactivation of Gnas in adipose-derived mesenchymal progenitor cells enhances osteoblast differentiation and promotes heterotopic ossification. *J Bone Miner Res* 2011;26:2647–2655.
139. Hannallah D, Peng H, Young B, et al. Retroviral delivery of Noggin inhibits the formation of heterotopic ossification induced by BMP-4, demineralized bone matrix, and trauma in an animal model. *J Bone Joint Surg Am* 2004;86-A:80–91.
140. Nesti L, Jackson W, Shanti R, et al. Differentiation potential of multipotent progenitor cells derived from war-traumatized muscle tissue. *J Bone Joint Surg Am* 2008;90:2390–2398.
141. Zhang K, Wang L, Zhang S, et al. Celecoxib inhibits the heterotopic ossification in the rat model with Achilles tenotomy. *Eur J Orthop Surg Traumatol* 2013;23:145–148.
142. Uccelli A, Moretta L, Pistoia V. Mesenchymal stem cells in health and disease. *Nat Rev Immunol* 2008;8:726–736.
143. Caplan A. Adult mesenchymal stem cells for tissue engineering versus regenerative medicine. *J Cell Physiol* 2007;213:341–347.
144. Chamberlain G, Fox J, Ashton B, et al. Concise review: mesenchymal stem cells: their phenotype, differentiation capacity, immunological features, and potential for homing. *Stem Cells* 2007;25:2739–2749.
145. Phinney D, Prockop D. Concise review: mesenchymal stem/multipotent stromal cells: the state of transdifferentiation and modes of tissue repair–current views. *Stem Cells* 2007;25:2896–2902.
146. Gimble J, Katz A, Bunnell B. Adipose-derived stem cells for regenerative medicine. *Circ Res* 2007;100:1249–1260.
147. Mountziaris PM, Spicer PP, Kasper FK, et al. Harnessing and modulating inflammation in strategies for bone regeneration. *Tissue Eng Part B Rev* 2011;17:393–402.
148. Nelson ER, Wong VW, Krebsbach PH, et al. Heterotopic ossification following burn injury: the role of stem cells. *J Burn Care Res* 2012;33:463–470.
149. Wu X, Rathbone CR. Satellite cell functional alterations following cutaneous burn in rats include an increase in their osteogenic potential. *J Surg Res* 2013;184(2):e9–16.
150. Peterson JR, De La Rosa S, Sun H, et al. Burn injury enhances bone formation in heterotopic ossification model. *Ann Surg* 2014;259(5):993–998.

151. Djouad F, Bouffi C, Ghannam S, et al. Mesenchymal stem cells: innovative therapeutic tools for rheumatic diseases. Nature reviews. *Rheumatology* 2009;5:392–399.

152. Lounev V, Ramachandran R, Wosczyna M, et al. Identification of progenitor cells that contribute to heterotopic skeletogenesis. *J Bone Joint Surg Am* 2009;91:652–663.

153. Hsu J, Keenan M. Current review of heterotopic ossification. *J Orthopaedics* 2010;20:126–130.

Chapter 13

Anesthesiology and Pain Management

Sachin Kheterpal and Michael R. Mathis

Key Points

1 Anesthetics are generalized depressants of consciousness, pain, cardiopulmonary function, motor function, and recall.

2 To prevent movement and to facilitate the surgical exposure, neuromuscular blocking agents are generally used. These drugs are competitive or noncompetitive inhibitors of the neurotransmitter acetylcholine at the neuromuscular junction.

3 Residual neuromuscular blockade is a common and underappreciated phenomenon that impacts postoperative adverse events such as hypoxemia, pneumonia, reintubation, and prolonged recovery room stay. Suggamadex, a novel medication capable of reversing deep neuromuscular blockade, may revolutionize perioperative care for high-risk patients.

4 Opioids produce profound analgesia and respiratory depression. They have no amnesic properties, minimal direct myocardial depressive effects, and no muscle-relaxant properties.

5 Propofol is unique because it is rapidly cleared through hepatic metabolism to inactive metabolites in a way that the patient becomes alert soon after cessation of the infusion. However, as the duration and dose of the maintenance infusion is increased, the time to return of consciousness is also significantly increased.

6 Although neuraxial techniques may decrease pulmonary complications, they are associated with hemodynamic instability and are contraindicated in patients with severe flow-dependent cardiovascular diseases.

7 Peripheral nerve blockade can be used in lieu of general anesthesia as a primary anesthetic for surgery, or in conjunction with general anesthesia to serve as a postoperative pain management technique. Use of long-acting local anesthetics or placement of an indwelling continuous catheter provides long-term (16 hours to several days) pain relief.

8 The concept of airway management should be focused on not just endotracheal intubation, but also mask ventilation. Until the airway can be secured via intubation, the patient must be supported through mask ventilation. The key elements of an airway examination are an assessment of obesity, mouth opening, neck flexion and extension, Mallampati oropharyngeal classification, presence of beard, and mandibular protrusion ability.

9 Laryngeal mask airways offer an alternative to endotracheal intubation for general anesthesia airway management in selected patients and procedures.

10 More than 8% of patients undergoing major noncardiac surgery will experience postoperative myocardial ischemia, elevating their risk of 30-day mortality. Benefits must be weighed against risk of initiating preoperative beta-blockers, alpha-blockers, and aspirin.

11 The appropriate duration to defer elective surgery after coronary stenting remains controversial, but recent guidelines from the American College of Cardiology/American Heart Association recommend 365 days for drug-eluting stents and 30 days for bare-metal stents. The role for antiplatelet therapy remains a major question, but data suggest that cessation of recommended antiplatelet therapy in the perioperative period may have significant coronary thrombotic risks without major improvement in bleeding adverse events.

12 The three goals of the preoperative evaluation are (a) to develop an anesthetic plan that considers the patient's medical condition, the requirements of the surgical procedure, and the patient's preferences; (b) to ensure that the patient's chronic disease is under appropriate medical therapy before an elective procedure; and (c) to gain rapport with and the confidence of the patient, answer any questions, and allay fears.

13 Patients receiving chronic pain or opioid addiction therapy with buprenorphine (Subutex, Suboxone) can be particularly challenging to manage in the postoperative period and should be immediately referred to their primary care physician and an anesthesiologist to create a pain management plan prior to the day of surgery. Buprenorphine is mixed opioid agonist/antagonist that tightly binds at the μ-receptor and has a long and varied half-life (24 to 60 hours). It can inhibit the analgesic benefits of traditional opioids in the postoperative period, resulting in uncontrolled pain, decreased patient satisfaction, and the potential for adverse events due to the need for very high doses of opioids.

14 As positive-pressure ventilation impedes venous return within a closed thorax, decreases in systolic pressure associated with a respiratory pattern can be detected. In patients with sinus rhythm with stable cardiac contractility, the degree of systolic pressure variation (SPV) is inversely related to the intravascular volume status of the patient. The normal range of SPV is 5 to 10 mm Hg. Other measures such as pulse pressure variation (PPV) use similar physiologic assumptions to assess volume status.

15 Enhanced recovery programs incorporating preoperative optimization, standardized surgical and anesthesia protocols, and goal directed therapy may improve patient outcomes and reduce costs.

16 Postoperative acute pain management may require a multimodal approach that incorporates opioids, peripheral nerve blockade, and nonopioid analgesics. Chronic pain patients can be particularly difficult to manage and may require preoperative optimization by an anesthesiologist.

The goal of intraoperative anesthesiology interventions is to enable the safe conduct of otherwise painful interventional procedures with maintenance of patient cardiopulmonary, renal, and neurologic homeostasis while optimizing procedural conditions. The state of general anesthesia is a combination of hypnosis, amnesia, analgesia, and muscle relaxation. This state can be achieved by administration of single or multiple anesthetic agents via inhalational or intravenous routes. Historically, anesthesia was achieved by inhaling volatile anesthetic vapors that produced each of these conditions in proportion to the concentration achieved in the central nervous system. Anesthesia can also be achieved by using a balance of multiple pharmacologic agents, each targeted to produce a specific effect. These are the hypnotic/sedatives, analgesics, and neuromuscular blocking agents. As the concentration of hypnotic/sedative and analgesic agents increases, cardiovascular and respiratory functions may be progressively blunted. For this reason, modern anesthetics usually require titration of these agents to optimize conditions for the surgery while maintaining cardiovascular stability.

Surgical anesthesia is administered with a high degree of safety 30 to 40 million times a year in the United States, despite the serious potential complications of technical or judgment errors. The high degree of success of both surgical and anesthetic outcomes is due to the efforts of thousands of surgeons and anesthesiologists who have advanced the art and science of their field.[1] Although modern surgical techniques, regional or neuraxial blockade procedures, and systemic analgesics have made it possible to ameliorate perioperative pain, significant challenges in postoperative pain management remain. Pain not only is unpleasant, but also can provoke a stress response within the body, leading to significant adverse physiologic effects.

ANESTHETIC AGENTS AND THEIR PHYSIOLOGIC EFFECTS

Inhalation Agents

1 Anesthetics are generalized depressants of consciousness, pain, cardiopulmonary function, motor function, and recall. The potent inhalation agents (e.g., isoflurane, sevoflurane, desflurane) produce these effects in a dose-dependent fashion. The measurement used to compare the potency of inhalation agents is the minimum alveolar concentration (MAC), an empirically derived number defined as the expired percent concentration required to prevent movement on painful stimulation (incision) in half of experimental subjects. There is significant patient-to-patient variability independent of underlying comorbidities. Compounding this variability are the effects of age, weight, pre-existing heart disease, liver disease, and medications other than the inhalational anesthetic. Table 13-1 lists the modern commonly used inhalation agents and their MACs and side effects. In general, all agents depress blood pressure by myocardial depression and vasodilation, resulting in systemic hypotension. There is a generalized depression of cerebral function and cerebral metabolic rate of oxygen consumption, although cerebral blood flow may increase because of cerebrovascular dilatation and a loss of flow-metabolism coupling. Renal blood flow and glomerular filtration rate are reduced by 20% to 50%. The body's normally tight regulation of core body temperature is lost, resulting in a redistribution of heat from the core to the periphery. The combination of these effects, the cold environment of the operating room, and open body cavities make the patient extremely vulnerable to hypothermia (core body temperature $<36^{\circ}C$).

Intravenous Sedatives/Hypnotics

Several commonly used intravenous sedative/hypnotic medications can also be used in lieu of an inhalational anesthetic to achieve the hypnotic component of the state of anesthesia. A constant intravenous infusion of these medications is used to achieve and maintain a blood concentration that results in the loss of consciousness and prevents recall. Unlike the inhalational agents, currently, there is no ability to measure the patient's expired or blood concentration of these intravenous agents. As a result, the infusion rate is titrated to effect by observing patient movement (if muscle relaxants are not used concurrently) and hemodynamic responses to procedural stimuli. Of note, the sedative/hypnotic intravenous agents do not possess clinically useful muscle relaxant or analgesic properties and must be combined with other agents to deliver a "balanced" anesthetic. The most commonly used intravenous agent for maintenance of anesthesia is propofol, a lipid-soluble substituted isopropyl phenol, that produces hypnosis and sedation through interactions with Γ-aminobutyric acid (GABA), the primary inhibitory neurotransmitter of the central nervous system. When administered as a continuous infusion, propofol can achieve minimal levels of sedation, deep sedation, or general anesthesia. Additional details regarding the use and side effects of propofol are discussed later. Other classic agents such as benzodiazepines can also be used as maintenance infusions, but do not enable the rapid return to consciousness that propofol offers. A novel, highly specific α_2-receptor agonist, dexmedetomidine, has recently demonstrated an exciting role as an intravenous sedative/hypnotic that also has analgesic effects and a lack of respiratory depression. In the perioperative setting, it is currently limited to use as an adjunct to propofol and inhalational anesthetics for general anesthesia or as a sole agent during procedural sedation.

Table 13-1 Common Inhalation Agents: Minimum Alveolar Concentrations and Effects

Agent	Minimum Alveolar Concentration (%)	Strengths	Weaknesses
Nitrous oxide	105	Analgesia Rapid uptake and elimination Less cardiac or respiratory depression	Sympathetic stimulation Expansion of closed air spaces Interference with vitamin B_{12} metabolism Limitation of inspired oxygen fraction
Isoflurane	1.15	Good muscle relaxation Stable cardiac rate and rhythm Usability in neurosurgery	Airway irritant, may cause coughing
Desflurane	6	Rapid induction and emergence	Airway irritant, may cause coughing High vapor pressure (Boiling point 23.5°C) requiring special pressurized vaporizer High cost
Sevoflurane	1.71	Rapid induction and emergence Less pungent, does not cause airway irritation	Moderate cost

2 To prevent movement and to facilitate the surgical exposure, neuromuscular blocking agents are generally used. These drugs are competitive or noncompetitive inhibitors of the neurotransmitter acetylcholine at the neuromuscular junction. The only noncompetitive inhibitor used clinically is succinylcholine. This drug rapidly binds to the nicotinic receptors and produces depolarization at the neuromuscular junction, clinically manifesting as fine-muscle fasciculations occurring about 30 to 60 seconds after injection. Succinylcholine cannot be reversed, but has a short duration of action (<10 minutes) because it is quickly hydrolyzed in the plasma by cholinesterase. Because of rapid onset and short duration of action, succinylcholine is frequently used to facilitate endotracheal intubation when it must be accomplished quickly, or when quickly regaining neuromuscular function is beneficial.

All other clinically useful muscle relaxants are termed *competitive inhibitors* and do not cause depolarization when they attach at the neuromuscular junction (nondepolarizing). Because these agents compete with endogenous acetylcholine, the block produced is in direct proportion to the concentration of the agent relative to the concentration of acetylcholine. If the concentration ratio is low enough, competitive relaxants can be reversed if the concentration of acetylcholine is artificially elevated. Acetylcholine concentration can be increased by giving a drug that blocks its metabolism, an anticholinesterase (e.g., neostigmine). The neuromuscular blocking agent is still present, but motor function returns if the acetylcholine concentration is high enough to overwhelm the blocking agent. There is a ceiling to which anticholinesterase drugs can safely elevate circulating acetylcholine; above this threshold, a novel selective relaxant binding agent, suggamadex, may be used to reverse the effects of specific nondepolarizing neuromuscular blocking drugs (rocuronium and vecuronium). Using anticholinesterases to reverse neuromuscular relaxants is not analogous to using naloxone to reverse the effects of opioids. The reversal agent neostigmine does not compete or combine with the relaxant.

Unfortunately, there are systemic consequences to increasing the plasma concentration of acetylcholine. Acetylcholine is the predominant neurotransmitter in the preganglionic sympathetic and parasympathetic nervous systems and in the postganglionic parasympathetic nervous system. For this reason, an anticholinergic drug (atropine or glycopyrrolate) must be given with the anticholinesterase to prevent the undesirable effects of a generalized acetylcholine overdose. Given these side effect profiles of anticholinesterase drugs, the selective relaxant binding agent suggamadex – recently approved for use in the US – offers new promise for reversing high levels neuromuscular blockade. The common neuromuscular blocking drugs and their doses, durations, and side effects are listed in Table 13-2; common regimens of reversal agents are shown in Table 13-3.

3 Postoperative residual neuromuscular blockade is now recognized as a common problem after routine administration of nondepolarizing muscle relaxants. The evaluation of depth of muscle relaxation is a subjective process based upon empirical

pharmacokinetics or visual inspection of a patient's peripheral nerve response to an artificial electrical stimulation. During peripheral nerve stimulator monitoring, two electrode patches are placed on the patient's skin along the course of a peripheral nerve which innervates a distinct and observable muscle group. Commonly used monitoring locations include the ulnar nerve, ophthalmic branch of the facial nerve, or the posterior tibial nerve. Next, the electrodes are connected to a hand-held device which delivers four short transcutaneous bursts of electricity, ranging from 10 to 100 mA every 0.5 seconds, hence the term "train-of-four monitoring." A clinician visually inspects the response to each electrical stimulation. In a patient without any pharmacologic neuromuscular blockade, the strength of the fourth muscle response (or "twitch") matches that of the first. In the face of complete pharmacologic competitive inhibition of neuromuscular transmission, no muscular twitches are observed at all. At varying levels of neuromuscular blockade in between, the fourth, third, or second twitch may be absent. Due to competitive blocking of the neuromuscular junction nicotinic receptor, each incremental stimulation results in a weaker response because of increasingly limited receptors available for stimulation. The ratio between the strength of the fourth twitch and the first twitch is known as the train-of-four ratio. During normal neuromuscular transmission, the ratio is 1. Historically, a ratio of 0.7 was considered adequate muscular strength for extubation. However, more recent literature suggests that a ratio between 0.7 and 0.9 still exposes the patient to significant risks of atelectasis, hypoxemia, aspiration, pneumonia, and possibly reintubation. In routine practice, a clinician is incapable of assessing a concept as precise or nuanced as train-of-four ratio. As a result, the number of twitches observed is typically reported, that is, 0/4, 1/4, 2/4, 3/4, 4/4. A patient with 3/4 or 4/4 twitches is capable of responding to cholinesterase inhibitors and return to normal function. A patient with 0/4, 1/4, or 2/4 is unlikely to respond to cholinesterase inhibitors with full return of muscular strength. Data from multiple centers have demonstrated that a significant proportion of patients demonstrated residual neuromuscular blockade of <0.9 in the recovery room despite reversal.

Table 13-2 Common Neuromuscular Blocking Drugs and Reversal Agents

Muscle Relaxant	Intubating Dose (mg/kg)	Infusion Dose (mg/kg/min)	Strengths	Weaknesses
Depolarizing				
Succinylcholine	1.0	100[a]	Fastest onset (30–60 s) Short duration[b] (5–10 min)	Associated with malignant hyperthermia, dysrhythmias, bradycardia, and hyperkalemia, especially in patients with burns or neurologic injury
Nondepolarizing				
Cisatracurium	0.2	0.1	Spontaneous degradation, not affected by renal or liver disease	Moderate cost
Vecuronium	0.1	1	No cardiovascular effects	
Rocuronium	0.8	10	Fast onset, no cardiovascular effects	

[a]This should not be used for longer than 1 h.
[b]Duration is dramatically increased in patients with abnormal plasma pseudocholinesterase.

Table 13-3 Drugs for Antagonizing Nondepolarizing Neuromuscular Blockade[a]

Dose	Time to Peak Effect (min)	Dose	Use With	Comments
Anticholinesterases				
Edrophonium	1–2	0.5–1.0 mg/kg	Atropine	Very fast onset, not commonly used
Neostigmine	3–5	0.04–0.07 mg/kg	Glycopyrrolate	Most commonly used
Pyridostigmine	10–12	0.2–0.3 mg/kg	—	Not used clinically for neuromuscular reversal
Selective Relaxant Binding Agents				
Suggamadex	2–3	4.0 mg/kg	—	Primarily used for reversal of rocuronium and vecuronium

CNS, central nervous system.
[a]For reliable results in reversing the effects of nondepolarizing muscle relaxants, administration of anticholinesterases is delayed until spontaneous recovery permits three of four responses to a train-of-four stimulus. For patients with more profound blockade, larger amounts of anticholinesterases may be required, but doses of neostigmine higher than 0.14 mg/kg are unlikely to produce additional improvement.
Adapted from Watling SM, Dasta JF. Prolonged paralysis in intensive care unit patients after the use of neuromuscular blocking agents: a review of the literature. *Crit Care Med* 1994;22:884.

The use of subjective train-of-four monitor is inferior to objective acceleromyography, a calibrated device used to accurately establish the train-of-four ratio. It requires careful calibration and setup, and access to the patient's arm and hand. Although clinically effective at eliminating the limitations of subjective train-of-four monitoring, its use remains limited because of the time spent in set up, and an underappreciation of the frequency of residual neuromuscular blockade. It has been promoted by patient safety experts, and is beginning to demonstrate increased penetration in Europe.

In addition to the limitations intrinsic to nerve monitoring devices themselves, nerve monitoring must be performed with caution, as muscles in the body are not equally sensitive to muscle relaxants. The diaphragm is most resistant to neuromuscular blockade, whereas the neck and pharyngeal muscles that support the airway are most sensitive. It is possible for an intubated patient to spontaneously ventilate and even to produce a large negative inspiratory effort and yet develop complete airway obstruction when extubated

because of the effects of residual muscle relaxant on the upper airway muscles.

As described earlier, a novel class of compounds known as *selective relaxant binding agents,* – currently comprised of only one FDA-approved drug, suggamadex – may serve to revolutionize the practice of neuromuscular blockade and its reversal. Such compounds are able to rapidly reverse the effects of profound levels of muscle relaxation (0/4 twitches) created by steroidal nondepolarizing muscle relaxant agents such as rocuronium, vecuronium, or pancuronium. Rather than attempting to increase the concentration of acetylcholine, these agents physically bind free muscle relaxant molecules within a cyclodextrin ring structure. This decreases the concentration of free muscle relaxant and allows acetylcholine to function normally at the neuromuscular junction. The cyclodextrin–muscle relaxant combination is then eliminated via the kidney. This offers the ability to rapidly (<3 minutes) reverse profound muscle relaxation as surgical conditions warrant.[2] This will enable profound relaxation during wound closure, and then immediate reversal of blockade just prior to extubation. Its significant expense, approximately $US 200 for a single dose of reversal of deep blockade, has limited its use.

Opioids (Narcotics) and Other Intravenous Analgesics

4 Narcotics and synthetic analogues belong to the class of drugs called *opioids*. The most commonly used drugs in this family are morphine, fentanyl, and hydromorphone. Since the mid-1980s, a series of synthetic opioids have been developed with fentanyl as the prototype. More recently developed synthetics (sufentanil, alfentanil, and remifentanil) are more potent and of varying duration (Table 13-4). Opioids produce profound analgesia and respiratory depression. They have no amnesic properties, minimal direct myocardial depressive effects, and no muscle-relaxant properties. Opioids can produce significant hemodynamic effects indirectly by releasing histamine or blunting the patient's sympathetic vascular tone because of analgesic properties. The latter effect depends on the degree of sympathetic tone that is present at baseline. Acutely injured patients may be hypovolemic and in pain, with high sympathetic tone and peripheral vascular resistance. Patients in this condition can experience dramatic drops in systemic blood pressure with minimal doses of opioids. For this reason, it is important to titrate narcotics in small incremental doses. Because of the lack of direct myocardial depression and the absence of histamine release with the synthetic opioids, they are frequently used as the primary anesthetic in combination with an amnesic agent and a muscle relaxant in patients with significant myocardial dysfunction.

When opioids are titrated intravenously, patients first become apneic because of the respiratory depressive effect (shifting the CO_2 response curve), but they still breathe on command. As the dose increases, patients become apneic and unresponsive.

Opioids are primarily analgesic and not amnesic. Patients can be totally aware and have substantial recall of conversations despite appearing completely anesthetized. All opioids can be reversed with naloxone. The duration of action of naloxone can be shorter than that of the opioid, and patients must be observed carefully for renarcotization after they have been treated with naloxone. Naloxone reversal of opioids can be dangerous because the agent acutely reverses not only the analgesic effects of the opioid but also the analgesic effects of native endorphins. Naloxone treatment has been associated with acute pulmonary edema and myocardial ischemia and should not be used electively to reverse the effects of a narcotic. It is appropriately used in an emergency situation when the airway is poorly controlled and the patient is not ventilating because of an opioid overdose.

Table 13-4 Analgesics

	Potency	Sedation Dose	Duration	Infusion Dose
Opioids				
Morphine	1	0.02–0.1 mg/kg IV	2–7 h	—
Fentanyl	100	0.5–1 mcg/kg IV	30–60 min	—
Sufentanil	1,000	Not recommended	—	—
Alfentanil	25	10–20 mg/kg IV	10–15 min	—
Remifentanil[a]	—	Not recommended	10 min	0.1–0.2 mg/kg/min
Other Analgesics and Anesthetics				
Propofol		0.1–0.5 mg/kg IV[b,c]		100–200 mcg/kg/min[b]
Ketamine		0.1–0.5 mg/kg IV[b] 1.0–2.0 mg/kg IM		1–2 mg/min (anesthetic dose) 500 mcg/kg (analgesic dose)
Dexmedetomidine		Not recommended		0.2–1.0 μg/kg/h

IM, intramuscular; IV, intravenous.
[a]Will produce apnea.
[b]May produce apnea.
[c]Produces pain on injection that can be reduced by treatment with 20 mg of lidocaine IV.

Propofol

5 Propofol is a lipid-soluble substituted isopropyl phenol that produces a rapid induction of anesthesia in 30 seconds followed by awakening in 4 to 8 minutes after a single bolus. Intravenous propofol can effectively produce total anesthesia (for less stimulating procedures), including amnesia, some analgesia, and some degree of muscle relaxation. Propofol is unique because it is rapidly cleared through hepatic metabolism to inactive metabolites in a way that the patient becomes alert soon after cessation of the infusion. However, as the duration and dose of the maintenance infusion is increased, the time to return to consciousness is also significantly increased. This context-sensitive half-life of propofol must be incorporated into expectations of a "quick wake-up." Propofol has direct antiemetic properties and is a valid alternative to inhalational anesthetics in patients who have demonstrated a history of prolonged, refractory postoperative nausea and vomiting. It has an important role in intensive care units when used as a continuous infusion sedative at dosages of 25 to 50 μg/kg/min. However, prolonged infusions have been associated with a lethal metabolic derangement known as propofol infusion syndrome, characterized by a profound metabolic acidosis and cardiovascular compromise.[3] Due to dose-dependent direct myocardial depression and peripheral vasodilation, propofol can produce significant hypotension when IV induction doses are administered. It also produces significant pain on injection in peripheral veins. Pain can be diminished or eliminated by pretreatment with IV lidocaine via the vein to be used for propofol administration. Propofol is insoluble in aqueous solution and therefore comes dissolved in a lipid emulsion that has the associated risk of bacterial contamination. Once a vial of propofol is opened, it is not recommended that it be used after 12 hours.

Ketamine

Ketamine is a phencyclidine derivative that produces anesthesia characterized by dissociation between the thalamus and limbic systems. Induction of anesthesia is achieved within 60 seconds after IV injection of 1 to 2 mg/kg or within 2 to 4 minutes of intramuscular (IM) injection of 5 to 10 mg/kg. Patients appear to be in a cataleptic state in which their eyes remain open with a slow nystagmic gaze. The drug produces intense amnesia and analgesia but has been associated with unpleasant visual and auditory hallucinations that can progress to delirium. The incidence of these problems can be significantly reduced if benzodiazepines are also administered with the drug. At low doses (0.1 to 0.2 mg/kg IV or 2 mg/kg IM), patients continue to spontaneously ventilate, but cannot be expected to protect the airway should vomiting occur. At higher doses, ketamine acts as a respiratory depressant and produces complete apnea. Ketamine also has direct and indirect sympathetic nervous system stimulatory effects, which can be useful in hypovolemic patients. These effects are diminished or absent in patients who are catecholamine depleted. The sympathetic stimulatory effect increases myocardial oxygen consumption and intracranial pressure, and ketamine is relatively contraindicated in patients with ischemic heart disease or space-occupying intracerebral lesions. Owing to its analgesic properties and relatively preserved respiration, ketamine is frequently used as an IV analgesic during debridement procedures, at doses listed in Table 13-4. IM ketamine (1 to 2 mg/kg) is also very useful for sedating patients who are difficult to manage (e.g., combative or cognitively disabled patient), so IV access can be obtained. Ketamine's most frequent use is in subanesthetic doses as part of multimodal analgesic regimens hoping to minimize the use of opioids. For procedures requiring general anesthesia that may have significant postoperative opioid requirements, a preincision ketamine bolus dose with a low-dose intraoperative infusion may be associated with improved acute and chronic pain outcomes.[4]

Amnesics and Anxiolytics

Benzodiazepines are the primary class of agents used as amnesics and anxiolytics. The prototype drug, diazepam, has been more recently replaced by its water-soluble analog of shorter duration, midazolam. Lorazepam also belongs in this family of agents, but because it has a very long duration of action, it is not routinely used intraoperatively. Lorazepam has intensive care unit applications (Table 13-5). Benzodiazepines produce anxiolysis and some degree of amnesia, but have no analgesic properties. Intraoperatively, midazolam is always used in conjunction with an opioid or inhalation agent. Midazolam can be used in combination with the short-acting opioid fentanyl to produce conscious sedation for minor procedures. Benzodiazepines can produce apnea and have synergistic adverse effects with narcotics. Very small doses of midazolam and fentanyl can quickly produce an unconscious apneic patient. As with all anesthetics, benzodiazepines used as IV agents for sedation should be given in small incremental doses to achieve the desired effect. A reversal agent is also available for benzodiazepines (flumazenil). The recommended dosages of these drugs and the reversal agents appear in Table 13-5.

Table 13-5 Anxiolytics and Amnesics (Benzodiazepines)

Name	Dose (mg/kg)	Duration (h)	Strengths	Weaknesses
Midazolam (Versed)	0.05 (infusion dose 0.25 mg/kg/min)	0.5	Water soluble Short duration Good for sedation for short procedures	Acute respiratory depression
Diazepam (Valium)	0.1	1	Intermediate duration	Irritation on IV injection Phlebitis Acute respiratory depression after IV overdose
Lorazepam (Ativan)	0.02–0.08	6–8	Long duration	—
Benzodiazepine Reversal				
Flumazenil (Romazicon)	4–20 (0.2 mg repeated every 2 to 10 min until reversal is achieved) Maximum dose 1 mg	45–90 min	—	May produce seizures, panic, arrhythmias

IV, intravenous.

Local Anesthetics

Local anesthetics constitute a class of drugs that temporarily block nerve conduction by binding to neuronal sodium channels. As the concentration of the local anesthetic increases around the nerve, autonomic transmission will be blocked first, followed by sensory transmission, and then motor nerve transmission. These drugs can be injected locally into tissue to produce a field block, around peripheral nerves to produce a specific dermatomal block, around nerve plexuses to produce a major conductive block, or into the subarachnoid or epidural space to produce extensive neuraxial blockade. All the methods have been used to assist in the provision of an alternative form of balanced anesthesia by supplementing analgesia and muscle relaxation.

Adverse consequences associated with the use of local anesthetics fall into three categories: acute central nervous system toxicity due to excessive plasma concentration, hemodynamic and respiratory consequences due to excessive conduction block of the sympathetic or motor nerves, and allergic reactions. Whenever a local anesthetic is injected, there can be inadvertent intravascular injection or an overdose of the drug because of rapid uptake from the tissues. Overdose can produce seizures, as well as cardiovascular collapse from ensuing arrhythmias. Complications can be minimized by withdrawing before injection to avoid an intravascular injection and limiting dosages to the safe range (Table 13-6).

Table 13-6 Local Anesthetics

	Maximum Single Dose (mg)	Duration (h)	Comments
Amides			
Lidocaine	500	1[a]	Fast onset
Ropivacaine	200	4–12[a]	Less cardiac toxicity than bupivacaine
Bupivacaine	200	4–12[a]	Exaggerated cardiotoxicity with IV injection Slow onset Long duration
Esters[b]			
2-Chloroprocaine	1,000	0.5–1[a]	Fast onset Lowest toxicity, rapid metabolism
Tetracaine	80	0.5–1	Slow onset

IV, intravenous.
[a]Addition of 100 μg of epinephrine (0.1 mL of 1:1,000) lowers the toxicity and increases the duration of the local anesthetic.
[b]Metabolism to para-aminobenzoic acid may cause allergic reactions.

6 When local anesthetics are administered for a spinal or epidural block, they produce a progressive blockade of the sympathetic nervous system, which produces systemic vasodilation. Sympathetic nerves travel along the thoracolumbar region with the first four thoracic branches, including the cardiac sympathetic accelerators. A sympathetic blockade of this entire region produces a characteristic profound systemic vasodilatation

and bradycardia. This condition is referred to as *total sympathectomy,* and the hypotension that ensues is usually below the minimal cerebral perfusion pressure required to maintain consciousness. Affected patients are bradycardic, hypotensive, unconscious, and usually apneic. This disastrous situation is easily remedied if treated quickly with a vasopressor (phenylephrine or ephedrine) and atropine or small doses of epinephrine (increments of 10 μg for an adult). If not treated promptly, the situation proceeds to cardiac arrest. In this emergency situation, the treatment of high doses of epinephrine is 10 to 40 μg/kg, or 1 to 4 mg for an adult. The doses of epinephrine are higher than in a usual cardiac arrest because of the total sympathectomy.[5] Because the level of sympathetic block is two to six dermatomal levels higher than the sensory block, it is often difficult to obtain a high spinal sensory level without approaching a total sympathectomy. For this reason, spinal or epidural techniques can present a prohibitively high risk in patients with severe flow-dependent cardiovascular disease.

Local anesthetics are chemically divided into two groups: esters and amides. The esters (2-chloroprocaine and tetracaine) produce metabolites that are related to *p*-aminobenzoic acid and have been associated with allergic reactions. Amides (lidocaine and bupivacaine) are rarely associated with allergic reactions. If an allergic reaction does occur, it is most likely due to the preservative (methylparaben) used in multidose vials of lidocaine.

NEURAXIAL BLOCKADE

Although general anesthesia is employed for millions of surgical procedures each year in the United States, many operations can be performed safely using neuraxial blockade. The two primary neuraxial techniques, a “single-shot” spinal and continuous epidural catheter, can be used for lower extremity and lower abdominal procedures. In both techniques, a small dose of local anesthetic is administered near spinal nerve roots in order to temporarily ablate sensory input from the peripheral somatic and visceral structures. In the case of a spinal anesthetic – also known as a subarachnoid block – the intrathecal sac surrounding the cauda equina at vertebral interspace L2-L3 or below is located using a sterile, small-caliber needle (25 gauge typically). Once cerebrospinal fluid is observed in the hub of a needle, 1 to 2 mL of preservative-free local anesthetic (typically bupivacaine or lidocaine) is injected into the intrathecal space. The needle is then completely withdrawn. This local anesthetic serves to directly inactivate efferent and afferent transmission at the nerve roots it comes in contact with. Because local anesthetics are not specific to specific nerve fiber types, blockade of sensory, motor, and sympathetic nerves occurs. The spread of local anesthetic within the subarachnoid space is primarily determined by three factors: (a) the vertebral interspace accessed, (b) the density of the local anesthetic in relation to the density of cerebrospinal fluid (a concept known as *baricity*), and (c) the position of the patient during injection and immediately thereafter. In order to eliminate the risk of needle puncture of the spinal cord, subarachnoid blocks are only performed below L2-L3 in adults and L3-L4 in children. The local anesthetic solution may be combined with vasoconstrictors such as epinephrine or opioids such as fentanyl or morphine in order to increase the density or duration of the sensory blockade. Surgical anesthesia ranging from 1 to 2 hours can be achieved using a subarachnoid block. Because of concerns regarding permanent nerve damage, intrathecal catheters are typically not used.[6,7] As a result, most subarachnoid blocks are “single-shot” techniques that cannot be redosed.

In the case of epidural techniques, the nerve roots are blocked outside the thecal sac in potential space between the ligamentum flavum and dura mater. This space is accessed sterilely using a 19-gauge introducer needle and a loss of resistance technique. Once the space is identified, a 21-gauge catheter is inserted into the space via the introducer needle and the needle is removed. After testing to reduce the likelihood of inadvertent intravascular or intrathecal placement of the catheter, the epidural catheter can be taped in place. Because the epidural catheter can be left in place for several days, redosing is possible. Dilute local anesthetics combined with vasoconstrictors or opioids are the mainstay of epidural therapy. Epidural neuraxial techniques can be used for surgical anesthesia, as an adjunct to general anesthesia, or for postoperative pain relief. Epidural catheters can be placed in the thoracic or lumbar regions because the intrathecal sac is not being accessed; associated dermatomal spread and analgesia is observed. Epidural techniques often fail to result in a dense sacral nerve root blockade, so this may be a poor choice for surgical anesthesia at or below the knee.

PERIPHERAL NERVE BLOCKADE

7 Peripheral nerve blockade (PNB) has been used for surgical anesthesia of the extremities since the days of intravenous regional anesthesia described by Bier in 1908. PNB differs from neuraxial techniques in that it targets peripheral nerves after they have formed from the combinations of nerve roots. Upper extremity, lower extremity, and visceral peripheral nerves are targets of these peripheral nerve blocks. Much like neuraxial blockade, PNB can be used to achieve intraoperative surgical anesthesia, intraoperative analgesia as an adjunct to general anesthesia, or for postoperative analgesia. Use of long-acting local anesthetics or placement of an indwelling continuous catheter provides long-term (16 hours to several days) pain relief. The effective use of PNB requires excellent communication between the anesthesiologist and surgeon to ensure that the planned surgical procedure site(s) and any other sources of procedural stimulation (e.g., tourniquet) are adequately addressed by the block. A specific preoperative planning discussion to match the planned surgical procedure to a feasible dermatomal distribution of blockade is essential. Even when blockade of a dermatomal distribution specific to a surgical procedure is feasible, a PNB may be contraindicated if a neurologic examination performed at or near the surgical site in the early postoperative period is necessary.

Because of the limited distribution of sympathetic blockade, PNB has a much smaller hemodynamic effect than general or neuraxial anesthesia. In addition, if general or neuraxial anesthesia can be supplanted by a PNB, the residual unwanted side effects of these anesthetics can be avoided, resulting in improved patient satisfaction, improved quality and speed of recovery, and expedited hospital/procedural center discharge. However, PNB is not without side effects; the impact of phrenic nerve motor blockade associated with specific upper extremity blocks (common with interscalene and rare with supraclavicular) may have significant consequences for patients with underlying pulmonary disease.

Historically, anatomic landmark-based identification of peripheral nerves was complemented by use of electrical stimulator needles with the hope of eliciting specific motor responses confirming correct needle placement. The technical challenges of establishing precise anatomic location percutaneously by assessing patient symptoms in response to electric stimulation of specific muscle groups are significant. Concerns regarding possible intraneural injection or vascular injury persisted for many years. However, modern anesthesia techniques now employ real-time ultrasound guidance of a PNB needle under direct visualization. Vascular structures and nerves are visualized in relation to a PNB needle in order to decrease the likelihood of intravascular or intraneural injection, increase the likelihood of an efficacious block, and minimize the dose of local anesthetic required to achieve an efficacious block. Despite direct visualization using ultrasound, PNB in adults are typically performed in the awake state to minimize the risk of intraneural injection, which may be detected via patient complaint of significant pain upon injection. PNB can be extremely difficult or contraindicated in patients with challenging body habitus, local superficial infection at the site of needle entry, significant

coagulopathy, or implants near the area to be visualized or injected.

While PNB targets named major peripheral nerves resulting in both motor and sensory blockade sufficient for surgical anesthesia, field blocks target small cutaneous sensory nerve fibers, used more commonly to achieve moderate sensory blockade for postoperative analgesia. These blocks typically do not achieve sensory blockade sufficient for surgical anesthesia and must be augmented by general anesthesia or deep sedation. Procedures such as transversus abdominis plane (TAP), adductor canal, intercostal nerve, and local infiltration enable postoperative analgesia.

SEDATION ANALGESIA FOR MINOR SURGICAL PROCEDURES

There are a variety of minor surgical procedures that can be accomplished safely and comfortably with anesthesia provided by infiltration of local anesthetics (most commonly 1% lidocaine or 0.25% bupivacaine) and mild sedation/anxiolysis provided by IV agents. All IV benzodiazepines, narcotics, and other IV anesthetics produce apnea if given in a high enough dose. Because there is a substantial patient-to-patient variability in response to a given dose, IV anxiolytics must be given in small incremental doses slowly to achieve a safe sedated state. When attempting to provide appropriate sedation analgesia for a procedure, it is worth noting that inadequate infiltration of local anesthetic cannot be compensated by increased doses of IV sedatives. Such doses of sedatives as well as narcotics cannot overcome the pain associated with a surgical incision; furthermore, if large doses of narcotics are given for this purpose, a patient may quickly become apneic once the surgical stimulus ends. This is due to the fact that duration of the respiratory depression for even short-acting narcotics is much longer than the painful stimulus of the incision. Because of the potentially serious consequences of an apneic episode, the Joint Commission has required that all patients receiving sedation for minor surgical or medical procedures undergo the following[8]:

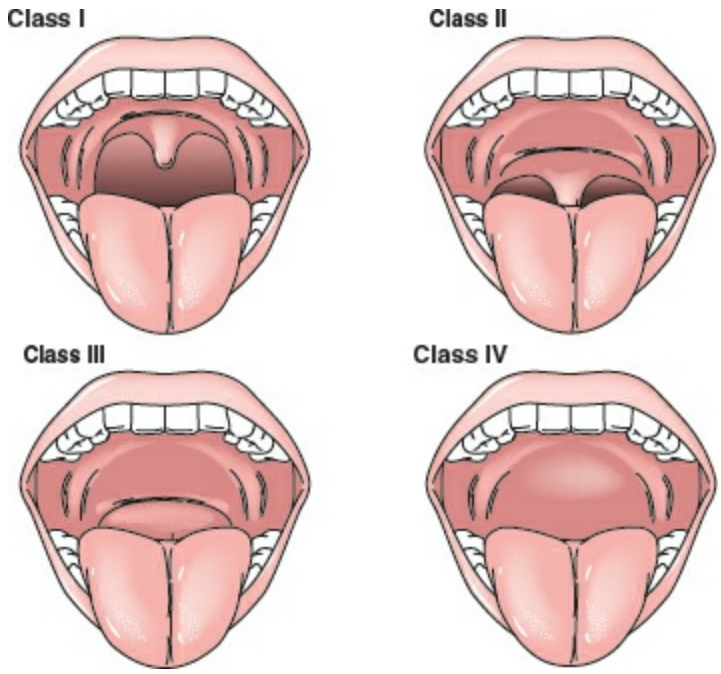

Figure 13-1. Classification of the patient's upper airway based on the size of the tongue and the pharyngeal structures visible on mouth opening. Class I, soft palate and anterior/posterior tonsillar pillars, and uvula visible; Class II, tonsillar pillars and part of uvula hidden by base of tongue; Class III, soft and hard palate visible; Class IV, soft palate not visible, only hard palate visible. (Redrawn from Stoelting RK, Miller RD. *Basics of Anesthesia*, 5th ed. New York: Churchill Livingston; 2007:146.)

Table 13-7 Sedation Scale

Sedation Scale	Description
1	Awake and alert
2	Awake and sedated
3	Asleep but arousable to touch or verbal stimuli
4	Asleep but arousable to painful stimulus
5	Asleep and not arousable to painful stimulus

1. A preprocedure evaluation including an airway examination (Fig. 13-1)
2. Appropriate monitoring: pulse oximetry as a minimum
3. Documentation of the patient's vital signs and arterial saturation as well as the dose and timing of sedatives provided during the procedure
4. Documentation of a recovery period and a return to a safe recovered state

The preprocedure evaluation should include current medications, coexisting disease, and a brief physical examination including an evaluation of the airway. The most common drug used to provide sedation is midazolam. This is a fast-onset, relatively short-acting benzodiazepine that can be easily titrated to produce a sedated yet cooperative arousable state. It is usually given to adults in incremental doses of 1 mg (0.01 mg/kg in children). Narcotics such as fentanyl even in small doses act synergistically with benzodiazepines to cause a more sedated state with a much higher incidence of apnea. To assess the effect of the drug, a validated sedation scale can be of value. The scale used at the University of Michigan is presented in Table 13-7.[9]

AIRWAY EVALUATION FOR THE NONANESTHESIOLOGIST

8 9 An essential skill for all clinicians is the assessment of a patient's airway. It is important to determine how difficult it may be to obtain control of the airway if a patient requires ventilatory support. The concept of airway management should be focused on not just endotracheal intubation, but also mask ventilation. Until the airway can be secured via intubation, the patient must be supported through mask ventilation.[10] Supraglottic airway devices (laryngeal mask airways) are of additional consideration, used for both definitive airway management as well as a rescue technique for failed mask ventilation or failed intubation. Limitations to supraglottic airway devices, however, include a relative lack of protection from aspiration, as well as a limited ability to provide adequate positive pressure ventilation in patients prone to airway obstruction (e.g. morbidly obese, sleep apnea). The key elements of an airway examination are an assessment of obesity, mouth opening, neck flexion and extension, Mallampati oropharyngeal classification, presence of beard, and mandibular protrusion ability (Table 13-8).[11] Despite decades of research, there is no perfect combination of clinical tests to predict difficult intubation. However, the presence of abnormalities in three or more of the aforementioned elements increases the likelihood of a difficult mask ventilation and/or difficult intubation by more than eight-fold.[11] In patients with multiple (three or more) airway abnormalities, the presence of a beard is an easily corrected characteristic: the patient should be asked to shave the beard in order to improve the ability to manage the airway. Assessment of oropharyngeal classification is performed by having patients open their mouth and maximally protrude the tongue without phonation. This Mallampati oropharyngeal assessment can be classified depending on whether the uvula can be completely seen (class 1), only partly seen (class 2), or not seen, with the hard and soft palate visible (class 3), or only the hard palate visible (class 4) (Fig. 13-1).[12]

Table 13-8 Standard Airway Examination for Nonanesthesiologists

Exam Element	Concerning Findings
Body mass index (kg/m^2)	Body mass index ≥31
Mouth opening	Interincisor or intergingival distance >3 cm
Mallampati classification	Class III or IV (see Fig. 13-1)
Mandibular protrusion	Inability to protrude lower incisors to meet or extend past upper incisors
Neck anatomy	Radiation changes, or thick obese neck
Cervical spine mobility	Limited extension or possibly unstable cervical spine
Beard	Presence of full beard

RISKS ASSOCIATED WITH ANESTHESIA

Because the entire purpose of surgical anesthesia is to obtund or completely block physiologic protective mechanisms, there is an underlying baseline anesthetic risk even without a surgical procedure. Fortunately, with the advent of newer agents and monitoring techniques, it is estimated that the mortality rate directly attributable to anesthesia alone has decreased from about 1 in 10,000 patients in the 1950s to as low as 1 in 200,000 or less for healthy patients today.[13] Although a 1 in 200,000 risk of death or serious neurologic impairment may appear small, when dire consequences occur in a young patient undergoing a purely elective procedure, the consequences are devastating for everyone involved. When patients are placed in a condition in which they cannot breathe, there is always the possibility of a technical or judgmental error resulting in hypoxia and brain damage or death. It has been estimated that between 50% and 75% of anesthetic-caused deaths are due to human error and are preventable. Because the consequences of an anesthetic mishap are usually severe, the emotional and financial costs are high.

Historically, the most common problems associated with adverse outcomes were related to the airway and included inadequate ventilation, unrecognized esophageal intubation, unrecognized extubation, and unrecognized disconnection from the ventilator. The incidence of these problems has been significantly reduced by including capnometry and pulse oximetry in addition to other noninvasive monitors, although a cause-and-effect relation has been difficult to prove. Efforts to improve outcome can be approached at three levels: (a) reduction of the incidence of rare but catastrophic anesthetic-related problems, (b) improvement of the care and experience of every patient undergoing anesthesia and surgery, and (c) improvement of the preparation and management of patients with pre-existing medical conditions who have higher morbidity and mortality rates. The first goal has been addressed in part with improved monitoring techniques, standardized anesthesia machine checklists, and anesthesiology training. Others have been advanced by the addition of comprehensive pain management, as discussed later in this chapter. Issues of pre-existing medical disease and how they affect the anesthetic plan are also briefly discussed later in this chapter.

Cardiovascular Diseases

Hypertension

Hypertension is the most common pre-existing medical disease in patients presenting for surgery and is a major risk factor for renal, cerebrovascular, peripheral vascular, and coronary artery diseases, as well as congestive heart failure (CHF). It is particularly associated with lipid disorders, diabetes, and obesity. It is these associated comorbidities that are most likely to lead to morbidity and mortality in the perioperative period, and therefore, the presence of hypertension should prompt the surgeon to review the history and physical examination for them. Hypertensive patients should be treated medically to render them normotensive before elective surgery. For elective surgical procedures, a sufficient period of time preoperatively should be allocated for antihypertensive management, as rapid correction of hypertension immediately prior to surgery is not without risk of comorbidities, including stroke and other end-organ malperfusion. In general, antihypertension medications should be continued throughout the perioperative period. However, patients treated with angiotensin receptor blockers (ARBs), such as valsartan, candesartan, losartan, or angiotensin-converting enzyme inhibitors (ACE-Is), such as lisinopril, captopril, or ramipril, who are exposed to general anesthesia, are at risk for developing profound, refractory intraoperative hypotension. This ACE-I/ARB hypotension has been treated successfully with terlipressin, vasopressin, and methylene blue.[14–16] As a result, most medical centers now recommend withholding ACE-Is/ARBs the morning of surgery.[17,18] Patients on concomitant diuretic therapy are at greatest risk for intraoperative hypotension requiring treatment.[19,20]

The incidence of hypotension and myocardial ischemia intraoperatively is higher in untreated hypertensive patients than in adequately treated hypertensive patients if the preoperative diastolic pressure is 110 mm Hg or higher.[21] Inadequately treated hypertensive patients undergoing carotid endarterectomies have an increased incidence of neurologic deficits, and those with a history of prior myocardial infarctions have an increased incidence of reinfarction. Patients commonly have an elevated blood pressure on admission to the hospital. Hypertensive patients can have exaggerated responses to painful stimuli and have a higher incidence of perioperative ischemia.

Coronary Artery Disease

Much of the anesthetic preoperative evaluation has historically been focused on the detection and treatment of coronary artery disease. Coronary artery disease or its risk factors are present in about 30% of patients who undergo major surgery each year.[22] It is the leading cause of death in the United States and continues to be a major cause of postoperative morbidity and mortality.[23] The goal of the preoperative cardiac evaluation is to identify patients who are at increased risk of perioperative cardiac morbidity and ensure that their chronic conditions are optimized. Although perioperative cardiac events are the leading cause of death following anesthesia and surgery, it has been difficult to define patient characteristics that accurately predict a high risk of adverse outcome.[24] It has been even more difficult to modify that risk effectively.[25] Preoperative CHF is clearly

a significant risk factor, as is recent myocardial infarction or unstable angina (Table 13-9). Diabetes mellitus (DM), atherosclerotic vascular disease, and hypertension also appear to confer risk, although less than with CHF or unstable angina. Perioperative risk in patients with valvular heart disease varies with the severity of the disease as represented by CHF, pulmonary hypertension, and dysrhythmias. Dysrhythmias are also a concern in the presence of coronary artery disease. Age and stable angina remain controversial as predictors of perioperative risk, with equal numbers of supporting and refuting studies. The value of revascularization remains controversial as well. In patients without significant pulmonary disease, the ability to climb two flights of stairs without stopping or experiencing symptoms of angina or shortness of breath is considered a good practical test of cardiac reserve. Unfortunately, many patients with ischemic heart disease have concomitant pulmonary disease or other medical problems that limit their activity. A history of myocardial infarction is important information. Large retrospective studies have found that the incidence of reinfarction is related to the time elapsed since the previous myocardial infarction.[26–28] The incidence of reinfarction appears to stabilize at about 6% (50-fold higher than patient without myocardial infarction) after 6 months. The highest rate of reinfarction occurs in the 0- to 3-month period. Mortality from reinfarction, for patients undergoing noncardiac surgery (Table 13-10), has been reported to be between 20% and 50% and usually occurs within the first 48 hours after surgery.

Table 13-9 Clinical Predictors of Increased Perioperative Cardiovascular Risk (Myocardial Infarction, Heart Failure, Death)

Major
Unstable coronary syndromes
Acute or recent MI[a] with evidence of important ischemic risk by clinical symptoms or noninvasive study
Unstable or severe[b] angina (Canadian class III or IV)[c]
Decompensated heart failure
Significant arrhythmias
High-grade atrioventricular block
Symptomatic ventricular arrhythmias in the presence of underlying heart disease
Supraventricular arrhythmias with uncontrolled ventricular rate
Severe valvular disease
Intermediate
Mild angina pectoris (Canadian class I or II)
Previous MI by history or pathologic Q waves
Compensated or prior heart failure
Diabetes mellitus (particularly insulin dependent)
Renal insufficiency
Minor
Advanced age
Abnormal ECG (left ventricular hypertrophy, left bundle-branch block, ST-T abnormalities)
Rhythm other than sinus (e.g., atrial fibrillation)
Low functional capacity (e.g., inability to climb one flight of stairs with a bag of groceries)
History of stroke
Uncontrolled systemic hypertension

ECG, electrocardiogram; MI, myocardial infarction.
[a]The American College of Cardiology National Database Library defines recent MI as >7 d but ≤1 mo (30 d); acute MI is within 7 d.
[b]May include "stable" angina in patients who are unusually sedentary.
[c]From Campeau L. Grading of angina pectoris. *Circulation* 1976;54:522.

Table 13-10 Cardiac Risk Stratification for Noncardiac Surgical Procedures

High (reported cardiac risk often >5%)[a]
Emergent major operations, particularly in the elderly
Aortic and other major vascular surgery
Peripheral vascular surgery
Anticipated prolonged surgical procedures associated with large fluid shifts and/or blood loss
Intermediate (reported cardiac risk generally <5%)
Carotid endarterectomy
Head and neck surgery
Intraperitoneal and intrathoracic surgery
Orthopedic surgery
Prostate surgery
Low[b] (reported cardiac risk generally <1%)
1. Endoscopic procedures
2. Superficial procedures
3. Cataract surgery
4. Breast surgery

[a]Combined incidence of cardiac death and nonfatal myocardial infarction.
[b]Do not generally require further preoperative cardiac testing.

10 Perioperative cardiac adverse event risk reduction has undergone significant changes over the past decade. Despite these efforts, a large, international prospective study across 15,000 patients demonstrated that more than 8% of patients undergoing major inpatient surgery still experience postoperative myocardial ischemia.[29] These patients have significantly increased 30-day mortality, even though only 15% of perioperative ischemic episodes included typical cardiac symptoms. Previous retrospective studies demonstrating value to coronary revascularization spurred aggressive preoperative coronary artery disease identification and management. However, recent data have questioned the value of coronary revascularization among asymptomatic patients in not only the perioperative period, but also in the general medical population.[30,31] The most recent American College of Cardiology (ACC)/American Heart Association (AHA) guidelines reserve preoperative coronary revascularization for patients demonstrating asymptomatic left main coronary artery disease, three-vessel disease, reduced ejection fraction, unstable angina, or acute myocardial infarction.[32] Furthermore, large retrospective and prospective studies have demonstrated that the institution of perioperative beta-blockade also bears significant risks that must be weighed against possible benefits.[33,34] As a result, the most recent ACC/AHA guidelines reserve the institution of beta-blocker therapy for only high-risk patients that would warrant blockade independent of the surgical procedure.[32] Patients already on beta-blocker therapy should be continued on the therapy throughout the perioperative period.[32] The widespread use of 3-hydroxy-3-methylglutaryl coenzyme A (HMG-CoA) reductase inhibitors, commonly known as statins, for cardiovascular disease and hyperlipidemia has introduced another medication into the surgical preoperative evaluation. Although prospective data establishing the value of instituting preoperative statin therapy are limited, there is general consensus that these medications should not be withdrawn during the perioperative period.[35] A large randomized controlled trial evaluating the benefit of other promising agents – clonidine and aspirin – as perioperative optimization standards failed to demonstrate benefit.[36,37]

All patients in high-risk groups or with a history of ischemic heart disease must be evaluated and properly treated before elective surgery. All elective surgery should be delayed for 6 months after myocardial infarction. If this is not feasible, invasive monitoring should be considered in the perioperative period and intensive postoperative observation should continue for at least 48 hours. The intrusiveness of the surgical procedure also plays a part in the overall risk and need for preoperative workup of heart disease. The AHA has produced and updated an algorithm for the recommended preoperative workup (Algorithm 13-1).[32]

Percutaneous Coronary Intervention With Stenting

11 The widespread use of percutaneous intervention for coronary artery disease via stenting (with or without drug-eluting coating) has introduced a new level of clinical complexity. In-stent thrombosis is a feared complication with profound morbidity and mortality. Given the known proinflammatory and prothrombotic physiologic state induced by acute illness, surgery, and anesthesia, coronary stents may be at elevated risk

for thrombosis during the perioperative period. Large retrospective studies have demonstrated that the risk of perioperative in-stent thrombosis is increased if noncardiac surgery is performed soon after percutaneous coronary intervention.[38,39] The appropriate duration to defer elective surgery after coronary stenting remains controversial, but recent ACC/AHA guidelines recommend 365 days for drug-eluting stents and 30 days for bare-metal stents.[32] The role for antiplatelet therapy remains a major question, but data suggest that cessation of recommended antiplatelet therapy in the perioperative period may have significant coronary thrombotic risks without major improvement in bleeding adverse events.[38,39] The decision to stop antiplatelet therapy prior to recommended guidelines should be limited to specific procedures that demand a nearly bloodless surgical field or in procedures involving closed spaces incapable of tolerating minor theoretical increases in bleeding (intracranial, minimally invasive spine surgery). Recent data and recommendations in the surgical literature demonstrate that continuation of aspirin therapy throughout the perioperative period in patients with coronary artery stents should be the standard of care.[32]

Congestive Heart Failure

CHF has been described as the single most important factor predicting postoperative cardiac morbidity.[40] All elective surgical procedures should be deferred until heart failure is medically optimized. If surgery cannot be deferred, aggressive perioperative management is warranted with a goal of optimizing cardiac output. In contrast to isolated ischemic heart disease, CHF is more easily diagnosed by history, physical examination, and basic preoperative laboratory workup, including electrocardiography (ECG) and chest radiography. Because patients with left, right, or both left and right ventricular dysfunction are less tolerant of the fluid shifts associated with surgery and the myocardial depression associated with the anesthetic, they constitute the highest-risk group for postoperative complications. Recent data demonstrate that although cardiac complications have historically been the focus of surveillance and prevention, pulmonary and infectious complications may warrant similar attention.[41]

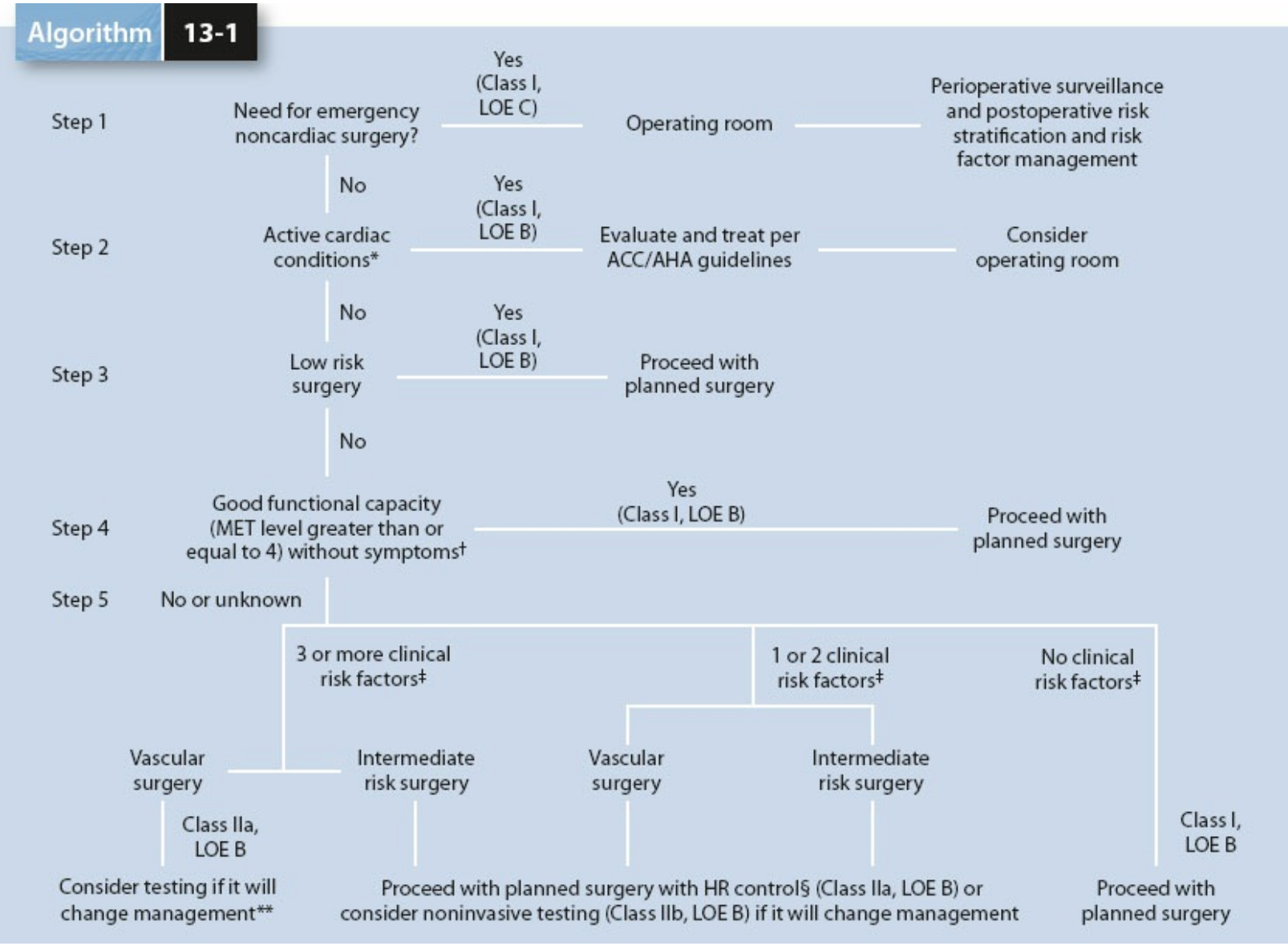

Algorithm 13-1. Decision aid for preoperative cardiac evaluation prior to noncardiac surgery. This decision tree for preoperative evaluation takes into account not only the patient's physical status but also the severity of the surgical procedure. ACC, American College of Cardiology; AHA, American Heart Association; LOE, level of evidence.

Pulmonary Disease

Pulmonary disease is classically divided into acute and chronic restrictive and obstructive disease. Restrictive disease is defined by processes that reduce lung volumes, and obstructive disease is characterized by reduced flow rates on pulmonary function tests.

Obstructive diseases are present in patients with forced expiratory volume in 1 second (FEV_1)/forced vital capacity (FVC) ratios of less than 50%. Obstructive pulmonary disease can be either chronic or acute (asthma). In either case, the reversible component of obstruction should be reversed before elective surgery. Patients are maintained on bronchodilator medications, and those with chronic secretions are appropriately hydrated and receive therapy to mobilize secretions. In patients with reactive airway disease, the endotracheal tube can induce severe bronchospasm. Even in patients who are treated well preoperatively, reactive bronchospasm can complicate anesthetic induction and the emergence from anesthesia. Severe bronchospasm is a life-threatening emergency that can be challenging to diagnose and treat. Administration of potent local (albuterol) and systemic (epinephrine) bronchodilators in a timely fashion is essential.

Regional or neuraxial anesthetics can be useful in these patients for peripheral surgery or for procedures that require an anesthetic sensory level below T6. As the sensory and motor levels rise to T6 and above, patients lose significant accessory motor function that can decrease expiratory reserve volume and the ability to cough and clear secretions. Because of tenuous pulmonary status and the high incidence of postoperative pulmonary complications, these high-risk patients should be extubated with caution only when they meet adequate extubation criteria relative to preoperative test data. Changes in pulmonary mechanics and frequency of postoperative pulmonary complications are greatest after upper abdominal surgery. Both vital capacity and functional residual capacity are reduced, reaching lowest levels in the first 24 hours postoperatively. In the high-risk groups, therapy should be directed toward restoring functional residual capacity to preoperative levels. Such therapy improves compliance and gas exchange. Because of the potential adverse effects of systemic narcotics on respiratory drive, the use of epidural narcotics and local anesthetics for postoperative pain control is very popular. These techniques allow the patients to be extubated earlier and, in patients with intrathoracic and upper abdominal surgery, help restore pulmonary function toward preoperative values.[42]

Obesity

Obesity causes a host of problems on both sides of the surgical drapes. Obesity is defined as a body mass index (BMI) greater than or equal to 30 kg/m^2. BMI can be easily calculated by dividing the patient's weight in kilograms by the square of his or her height in meters. The pathophysiologic changes associated with morbid obesity (BMI $\geq$40 kg/m^2) affect the respiratory, cardiovascular, and gastrointestinal systems. Patients have an external restrictive lung disease that reduces functional residual capacity and worsens with the supine position. Breathing effort increases and ventilation becomes diaphragmatic and position dependent. Increased airway pressures required to maintain adequate ventilation in obese patients predispose this patient group to barotrauma, furthering their risk of pulmonary complications. Obese patients frequently desaturate at night and have a high incidence of sleep apnea. Because of increased blood volume and frequent desaturations, obese patients can develop pulmonary hypertension and right-sided heart failure. Obese individuals have a high incidence of coronary artery disease. Because of size alone, they have increased cardiovascular demands with limited cardiac reserve and exercise tolerance. Obese patients have a high incidence of hiatal hernia and gastroesophageal reflux, increasing the risk for aspiration on induction and emergence from anesthesia. Issues as mundane as venous access can cause significant problems in this patient group.

A significant concern of the anesthesiologist is gaining adequate control of the airway. The combined problems of aspiration risk, rapid desaturation caused by reduced functional residual capacity and increased oxygen demand, and technical difficulties associated with intubation due to anatomic fat deposits make intubation a high-risk procedure. If problems occur, there can be significant technical difficulties in obtaining a rapid cricothyrotomy. For these reasons, a nasal or oral awake intubation can be useful or even imperative. Patients should receive prophylactic administration of H_2-receptor antagonists and a nonparticulate antacid to improve the pH of gastric contents. If intubations are to be done after induction of anesthesia, they should be performed in a rapid sequence using cricoid pressure. To prevent aspiration on emergence, obese patients should be extubated when fully awake, preferably in the sitting position. Regional anesthetics can be very useful when peripheral procedures are planned. Unfortunately, morbidly obese patients can develop pulmonary failure just by lying flat, making it difficult to use epidural or spinal anesthetics for abdominal procedures. Epidural analgesics for postoperative pain management allow earlier extubation and ambulation of these patients.[43]

Diabetes Mellitus

The incidence of DM is rising, particularly, type 2 DM in the elderly. This is a systemic disorder that has particular relevance for the anesthesiologist and surgeon because of its effect on the vascular, renal, nervous, and immune systems. Patients with DM should be investigated for the presence of concomitant coronary artery disease, peripheral vascular occlusive disease, renal failure, and autonomic and peripheral neuropathy. Problems with cardiovascular instability, fluid balance, and aspiration due to gastroparesis should be expected. In addition, these patients are more prone to infection and have problems with temperature control. The management of the diabetic state in these patients is important and complicated. Hypoglycemia during the anesthetic state is a feared complication because of challenges in prompt diagnosis. Oral hypoglycemic agents such as glipizide should be stopped prior to surgery and hyperglycemic situations treated with short-acting intravenous or subcutaneous insulin during the perioperative period. Insulin-dependent diabetics for same-day admission or outpatient surgery should take one-half of their usual morning dose of long-acting insulin. After the establishment of an IV line, laboratory blood samples are drawn and treatment of hyper- or hypoglycemia is started. Additional insulin is then given according to the results of frequent (every 1 to 2 hours) blood sugar monitoring. Although there are compelling data associating perioperative hyperglycemia with adverse postoperative events, there are no randomized controlled trials demonstrating improved outcomes with aggressive intraoperative hyperglycemia management.[44] Furthermore, complications from hypoglycemia are arguably greater than those from hyperglycemia, and are more likely as insulin therapy becomes more aggressive during the perioperative period.

Renal Insufficiency and Failure

Because the kidneys play a vital role in metabolic, synthetic, and fluid management homeostasis, renal failure is associated with many effects on the cardiovascular, pulmonary, hematologic, gastrointestinal, and immune system. Pre-existing renal insufficiency is a known risk factor for postoperative myocardial infarction and renal failure.[45,46] Optimizing the fluid and metabolic status of a patient in end-stage renal disease is of vital importance. Elective surgery should be delayed until such optimization is performed. In emergent situations, the urgent need for hemodialysis should be considered intraoperatively or postoperatively to avoid life-threatening electrolyte and fluid derangements. Although postoperative renal failure has historically been the focus of cardiac surgery researchers, national data suggest that nearly 15% of patients undergoing general surgery procedures will also experience postoperative acute kidney injury, as defined by a 0.3 mg/dL increase in serum creatinine within seven postoperative days.[47] Risk factors for postoperative acute kidney injury in patients undergoing general surgery are listed in Table 13-11. These data should be considered during the patient consent process.

Table 13-11 Predictors of Postoperative Acute Kidney Injury After General Surgery Procedures

Age ≥56 y
Male sex
Emergency surgery
Intraperitoneal procedures
Preoperative renal insufficiency (serum creatinine >1.2 mg/dL)
Ascites
Active congestive heart failure
Diabetes mellitus requiring oral hypoglycemic or insulin therapy
Hypertension requiring chronic medication

From Kheterpal S, Tremper K, Heung M, et al. Development and validation of an acute kidney injury risk index for patients undergoing general surgery. *Anesthesiology* 2009;110:505–515.

Obstructive Sleep Apnea

With the rise in obesity prevalence, obstructive sleep apnea (OSA) is emerging as a major comorbidity that has an impact on postoperative outcomes and costs.[48] The physiologic changes on the upper airway, lungs, pulmonary circulation, heart, and brain are extensive and challenge not only the immediate perioperative period, but also postoperative management.[49] These patients are prone to airway collapse at induction and emergence, hypoxemia, delayed emergence, respiratory depression, and cardiovascular collapse.[50] Preliminary data demonstrate increased sensitivity to the effects of opiates as well.[51] Observational data demonstrate a relationship between OSA treatment and a reduction in postoperative complications, but prospective interventional trials have yet to be conducted.[52,53] Nevertheless, the standard protocol for all preoperative evaluations should be the use of a locally accepted OSA screening tool (STOP-BANG questionnaire, Perioperative Sleep Apnea Prediction score, etc.) and ensuring postoperative access to continuous positive airway pressure therapy for patients currently prescribed such therapy as outpatients. Some undiagnosed or noncompliant patients may require initiation of therapy in the immediate postoperative period and the perioperative resources to fulfill clinical urgency are essential.

RISKS ASSOCIATED WITH REGIONAL TECHNIQUES IN PATIENTS BEING TREATED WITH ANTICOAGULANTS

As the indications for anticoagulant therapy have increased, ranging from drug-eluting stents to atrial fibrillation and venous thromboembolism prophylaxis, the number of patients and types of anticoagulant therapy has continued to increase. In particular, low–molecular-weight heparin (LMWH) and oral direct factor Xa inhibitors are often part of a patient's pre- or postoperative therapy plan. The use of neuraxial or PNB anesthesia in patients with preoperative anticoagulation requires careful planning and assessment of the risks and benefits of specific anesthetic techniques and withdrawal of anticoagulant therapy. LMWH raises specific concerns of crippling epidural hematoma formation when neuraxial techniques are used. For that reason, the American Society of Regional Anesthesia has published specific guidelines for central conduction block (spinal and epidural anesthesia) to try to minimize the incidence of this devastating complication[54]: In general, LMWH therapy requires coordination of neuraxial administration at least 12 hours after the last dose. Coumadin, clopidogrel, and ticlopidine should be held for at least 5, 7, and 14 days prior to neuraxial techniques, respectively. The absence of any reversal agents or reliable diagnostic testing for oral direct Xa inhibitors requires a conservative approach of withdrawal of therapy and no data currently exist to establish a specific threshold. Data regarding risks for PNB are even more scarce and local protocols should be established and followed. Unlike neuraxial techniques, the PNB techniques involve more compliant fascial planes that may allow for increased bleeding without compressive injury to nerve structures.

PREOPERATIVE EVALUATION

12 The three goals of the preoperative evaluation are (a) to develop an anesthetic plan that considers the patient's medical condition, the requirements of the surgical procedure, and the patient's preferences; (b) to ensure that the patient's chronic disease is under appropriate medical therapy before an elective procedure; and (c) to gain rapport with and the confidence of the patient, answer any questions, and allay fears.

Optimally, to complete this task, an anesthesiologist would meet every patient before the planned surgical procedure to review the medical history, complete a physical examination, discuss the options and associated anesthetic risks, and develop an anesthetic plan. In the past, this was accomplished when the anesthesiologist visited the patient in the hospital the night before surgery. Currently, it is rare to have patients admitted the night before surgery even before the most comprehensive and complex surgical procedures. The evaluation must still be accomplished, but it must be done on an ambulatory basis, which creates associated logistical problems.

A patient's medical conditions should be optimized before an elective surgical procedure. This optimization is best performed by the primary care physician, with medical specialty consultation, if necessary. The following questions must be answered when evaluating a patient undergoing an elective surgical procedure (Table 13-12). What must be included in the preoperative evaluation? Second, who is involved in this process? When and where are all the steps in this process to be conducted? How should all the information be coordinated so that it is available to the appropriate personnel at the appropriate time? If the procedure is deemed a surgical emergency, the anesthesiologist is responsible for assessing the patient quickly, developing the appropriate anesthetic plan, and proceeding to the operating room as soon as possible. In an emergency situation, the anesthesiologist is not obligated to seek medical consultation to evaluate chronic medical problems because time is essential.

The following steps must be completed before moving the patient into the operating room:

1. A comorbidity-focused history and physical examination
2. Appropriate laboratory studies and medical consultations
3. An anesthesiologist's preoperative evaluation with assignment of an American Society of Anesthesiologists (ASA) physical status
4. Discussion with the patient the options and risks
5. Development and communication of the anesthetic plan to the patient and surgeon
6. Acute optimization of any pertinent medical conditions

Table 13-12 Results Hospital Mortality Rates in Relation to Age, Preoperative Disease, and Surgery

Preoperative Disease and Surgery	Age (y) <50[a]	Age (y) 50–69[a]	Age (y) >70[a]
Chronic heart failure	0.1%/0.5%	0.4%/2%	0.8%/4%
Renal failure	0.2%/1%	0.9%/2%	2%/9%
Abdominal surgery	0.3%/2%	1%/6%	3%/12%
Chronic heart failure and renal failure	0.7%/3%	3%/13%	6%/24%
Chronic heart failure and abdominal surgery	0.9%/4%	4%/17%	7%/30%
Renal failure and abdominal surgery	2%/8%	2%/32%	16%/50%
Chronic heart failure, renal failure, and abdominal surgery	6%/26%	22%/60%	37%/76%

From Pedersen T, Eliasen K, Henriksen E. A prospective study of mortality associated with anesthesia and surgery: risk indicators of mortality in hospitals. *Acta Anaesthesiol Scand* 1990;34:176, with permission.
[a]Figures are for elective surgery (first number) and emergency surgery (second number).

The history and physical examination have repeatedly been shown to be the most valuable parts of the preoperative assessment. To enable ideal operative planning and postoperative care, it is the surgeon's responsibility to obtain a basic history that includes current medical conditions, current medication, and previous surgical history. In addition, the anesthesiologist must review previous anesthetic problems experienced by the patient or blood relatives, the patient's exercise tolerance, and additional details regarding general medical conditions. This evaluation not only determines the laboratory tests that may be required but also allows for the assignment of ASA physical status (PS) (Table 13-13). The classification serves as a general measure of the patient's state of well-being, taking into account all problems the patient brings to the operating room, including systemic disturbances caused by the surgical illness. Although studies of anesthetic mortality show a correlation with the PS classification, this categorization does not describe the risk directly. The risk of any operation is determined not only by patient-related factors but also by procedure-specific ones. For patients with complex medical problems, it is frequently helpful to supplement the surgical history and physical examination with a recent assessment by the patient's primary physician in order to assess the patient's long-term health trajectory. There are no data demonstrating the value of routine preoperative medical consultation.[55]

The value of preoperative laboratory studies has undergone substantial reevaluation since the mid-1980s. In the past, a surgical procedure was an opportunity to obtain a battery of baseline laboratory tests, even for ASA PS-1 patients. The current thinking is that a laboratory test should not be ordered unless a change in the surgical or anesthetic plan is anticipated. The only preoperative screening test required at the University of Michigan, for instance, is an ECG within a year of the planned surgical procedure for men older than 50 years and women older than 60 years of age. For procedures with significant anticipated blood loss, a type and cross match is ordered, and a preoperative hematocrit is also required. All other tests should have an indication based on history and physical examination. A current strategy for selecting tests indicated by patient history is presented in Table 13-14. Electronic patient questionnaires have also been developed, allowing the appropriate laboratories to be selected based on the patient's response to questions.[56]

Table 13-13 Physical Status Classification of the American Society of Anesthesiologists

Physical Status Classification	Description
PS-1	A normal, healthy patient
PS-2	A patient with mild systemic disease that results in no functional limitation *Examples:* Hypertension, diabetes mellitus, chronic bronchitis, morbid obesity, extremes of age
PS-3	A patient with severe systemic disease that results in functional limitation *Examples:* Poorly controlled hypertension, diabetes mellitus with vascular complications, angina pectoris, prior myocardial infarction, pulmonary disease that limits activity
PS-4	A patient with severe systemic disease that is a constant threat to life *Examples:* Congestive heart failure, unstable angina pectoris, advanced pulmonary, renal, or hepatic dysfunction
PS-5	A moribund patient who is not expected to survive without the operation *Examples:* Ruptured abdominal aneurysm, pulmonary embolus, head injury with increased intracranial pressure
PS-6	A declared brain-dead patient whose organs are being removed for donor purposes
Emergency operation (E)	Any patient in whom an emergency operation is required *Example:* An otherwise healthy 30-year-old woman who requires dilation and curettage for moderate but persistent vaginal bleeding (PS-1E)

Table 13-14 Simplified Strategy for Preoperative Testing

Estimated Energy Requirements for Various Activities			
1 MET ↓ 4 METs	Can you take care of yourself? Eat, dress, or use the toilet? Walk indoors around the house? Walk a block or two on level ground at 2 to 3 mph or 3.2 to 4.8 km/h? Do light work around the house like dusting or washing dishes?	4 METs ↓> 10 METs	Climb a flight of stairs or walk up a hill? Walk on level ground at 4 mph or 6.4 km/h? Run a short distance? Do heavy work around the house like scrubbing floors or lifting or moving heavy furniture? Participate in moderate recreational activities like golf, bowling, dancing, doubles tennis, or throwing a baseball or football? Participate in strenuous sports like swimming, singles tennis, football, basketball, or skiing?

MET, metabolic equivalent; mph, miles per hour.

Discussions of the options of anesthetic techniques and anesthetic risks are best performed by the anesthesiologist who will provide the anesthetic. If the surgeon prefers a specific anesthetic technique, this is best communicated directly to the anesthesiologist rather than recommended to the patient. The development of the anesthetic plan must be determined by the anesthesiologist.

The history, physical examination, and laboratory studies should be performed by the surgeon as soon as the surgical procedure is scheduled. The results of the laboratory studies must be evaluated well in advance of the day of surgery so that positive findings can be attended to in a timely manner. For healthy patients (ASA PS-1 and PS-2), the preoperative anesthetic assessment can be conducted by the anesthesiologist on the day of the procedure. If the patients have complex medical problems (ASA PS-3 or greater) or have significant concerns they want to discuss with an anesthesiologist, they should be evaluated before the day of surgery. Because of the logistical problems of scheduling,

most institutions have developed preoperative anesthesia clinics where this process can take place.

13 In addition, the patient's medication regimen should be reviewed to ensure that appropriate medications are continued or discontinued in the days and hours leading up to an elective procedure. In general, diuretics and ACE-I/ARB medications should not be taken the day of surgery. Several important classes of medications should be continued as per the patient's normal regimen: chronic pain therapy (including opioids), beta-blockers, statins, and proton pump inhibitors. The decision regarding anticoagulant therapy is a complex one that must take into account the indication for therapy, the likelihood and impact of surgical bleeding, and the risk of perioperative thrombosis. Insulin and oral hypoglycemic agents should be continued at a reduced dose given the fasting state of the surgical patient. Patients receiving chronic pain or opioid addiction therapy with buprenorphine (Subutex, Suboxone) can be particularly challenging to manage in the postoperative period and should be immediately referred to their primary care physician and an anesthesiologist to create a pain management plan prior to the day of surgery. Buprenorphine is mixed opioid agonist/antagonist that tightly binds at the μ receptor and has a long and varied half-life (24 to 60 hours). It can inhibit the analgesic benefits of traditional opioids in the postoperative period, resulting in uncontrolled pain, decreased patient satisfaction, and the potential for adverse events due to the need for very high doses of opioids.[57] A management protocol used at the University of Michigan is demonstrated in Algorithm 13-2.

An obvious problem that concerns anesthesiologists is the potential of a difficult intubation. This can be assessed as discussed earlier (Fig. 13-1 and Table 13-18). Even if a patient has no medical problem, the possibility of a difficult airway warrants that the patient be seen preoperatively and evaluated. These patients can always be approached by an awake fiberoptic technique, but this takes planning and can cause a significant delay if there is no prior warning.

MONITORING THE SURGICAL PATIENT

One of the more obvious changes in anesthesia care has been the routine use of an array of electronic monitoring devices to provide continuous surveillance of physiologic status. Because the art and science of anesthesiology involves titrating pharmacologic agents to produce desired physiologic effects, there must be a measured parameter to which drug dosages are titrated. Depending on the severity of pre-existing disease and the extent and duration of the surgical procedure, invasive techniques can be used to provide comprehensive continuous data to guide the titration of fluid therapy and cardiovascular agents.

Monitors of Oxygenation

Pulse oximetry has been called the most significant advance in patient monitoring to date. This device continuously, noninvasively, and inexpensively provides arterial hemoglobin saturation (SaO_2) and peripheral pulse by measuring light absorption in a manner similar to that of a laboratory co-oximeter. A laboratory co-oximeter shines light through a cuvette filled with a blood sample. Each hemoglobin species absorbs light in direct proportion to its concentration (Beer–Lambert law). A cooximeter requires one wavelength of light for each hemoglobin species to be measured, that is, one wavelength for oxyhemoglobin and one for reduced hemoglobin. To measure other hemoglobins, such as carboxyhemoglobin or methemoglobin, the device requires four wavelengths of light.

The traditional pulse oximeter uses two wavelengths of light, one red and one infrared, that shine through a tissue bed, usually a finger. Opposite the light sources is a photodiode that measures the transmitted light intensity. A large proportion of the light absorbed as it passes through the tissues is not associated with arterial blood but with other components of the tissue, such as skin, muscle, bone, and venous blood. Therefore, the device analyzes only the pulsatile component of absorption and assumes that anything that pulses within the tissue bed is arterial blood, hence the name *pulse oximeter*. Actually, the pulse oximeter measures the ratio of the pulsatile component of red light absorbed to the pulsatile component of the infrared light absorbed. This ratio changes with SaO_2. The exact relation between this ratio and SaO_2 has been empirically determined from volunteer studies and is programmed into the electronics of the oximeter. If any artifacts occur in a pulsatile nature, they may be erroneously integrated into the equation, causing erroneous SaO_2 estimates.

Several things should be remembered when interpreting a pulse oximeter's output. First, the device measures SaO_2 and not arterial oxygen tension (PaO_2). The PaO_2 must drop below 80 mm Hg before any significant change in SaO_2 occurs. As the PaO_2 drops below 60 mm Hg, the SaO_2 rapidly falls as the inflection point of the sigmoidal oxyhemoglobin dissociation curve is approached. As a rough rule of thumb, as SaO_2 drops below 90%, the PaO_2 can be estimated by subtracting 30 points from the SaO_2. For example, a SaO_2 of 85% corresponds to a PaO_2 of 55 mm Hg. Second, the pulse oximeter measures saturation (milliliters of oxygen per deciliters of blood) and not arterial content or oxygen delivery to tissues.

Because a traditional pulse oximeter uses only two wavelengths of light, it cannot detect the presence of carboxyhemoglobin (carbon monoxide poisoning) or methemoglobin. Recently introduced pulse oximeters incorporate additional wavelengths of light and are capable of detecting carboxyhemoglobin and methemoglobin ratios as well.[58] In addition, continuous measurement of hemoglobin (mg/dL) via certain pulse oximeters allows the trending of intraoperative hemoglobin during procedures involving moderate to large blood loss, guiding transfusion therapy. Although the margin of measurement error is as large as 1 mg/dL when compared to central laboratory complete blood counts, the data do offer a trend and may reduce unnecessary transfusions in

clinical settings without access to point of care blood gas machines.

Ventilation Monitors

By definition, a patient is appropriately ventilated when arterial carbon dioxide tension ($PaCO_2$) is 40 mm Hg. Measuring the respiratory rate can document only the presence of ventilation, not its adequacy. Capnography, or end-tidal CO_2 monitoring, is the visual display of the CO_2 concentration at the airway. To understand the utility of capnography, one must understand dead-space (DS) components and how they affect CO_2 removal from the body.[59] DS is defined as the portion of the tidal volume (V_T) that does not participate in gas exchange.

$$V_T = DS - V_A$$

The alveolar volume (V_A) is the volume of the inspired gas that reaches well-perfused alveoli. The remainder of the V_T, which equals the DS, can be divided into three subcomponents: apparatus dead space (DS_{ap}), anatomic dead space (DS_{an}), and alveolar dead space (DS_{al}). At the end of inspiration, the respiratory apparatus (e.g., endotracheal tube) is filled with inspired gas that should not contain CO_2. Similarly, all the anatomic airways (trachea, bronchi, and all conducting airways down to the alveoli) should be filled with inspired gas and should therefore contain no CO_2. In this model, there are two types of alveoli: those that are well perfused and those that are not perfused. The alveolar gas should completely equilibrate with the arterial blood and contain CO_2 at the same tension as the arterial blood; ideally, $PaCO_2$ should equal 40 mm Hg. As the patient expires, the CO_2 detected at the patient's mouth first reflects the DS_{ap} gas having no CO_2; followed by the DS_{an} gas, again with no CO_2; and finally the alveolar gases, containing both DS and well-perfused alveolar gas. When mixed alveolar gas reaches the airway, it produces a rapid rise in the CO_2 concentration to a level somewhere between the concentration in the alveolar gas (40 mm Hg) and the DS_{al} (0 mm Hg), depending on each component's proportion of volume. For example, if half of the alveoli are DS_{al} and $PaCO_2$ equals 40 mm Hg, then the plateau value of the capnogram should be 20 mm Hg, implying that half of the alveoli are not being perfused. With inspiration, the CO_2 value again drops to 0 until another expiration, and a square wave appears again as the alveolar gas is detected at the mouth. With each breath, there should be a square wave, whose height approaches the $PaCO_2$ value as the amount of the DS_{al} gas approaches 0.

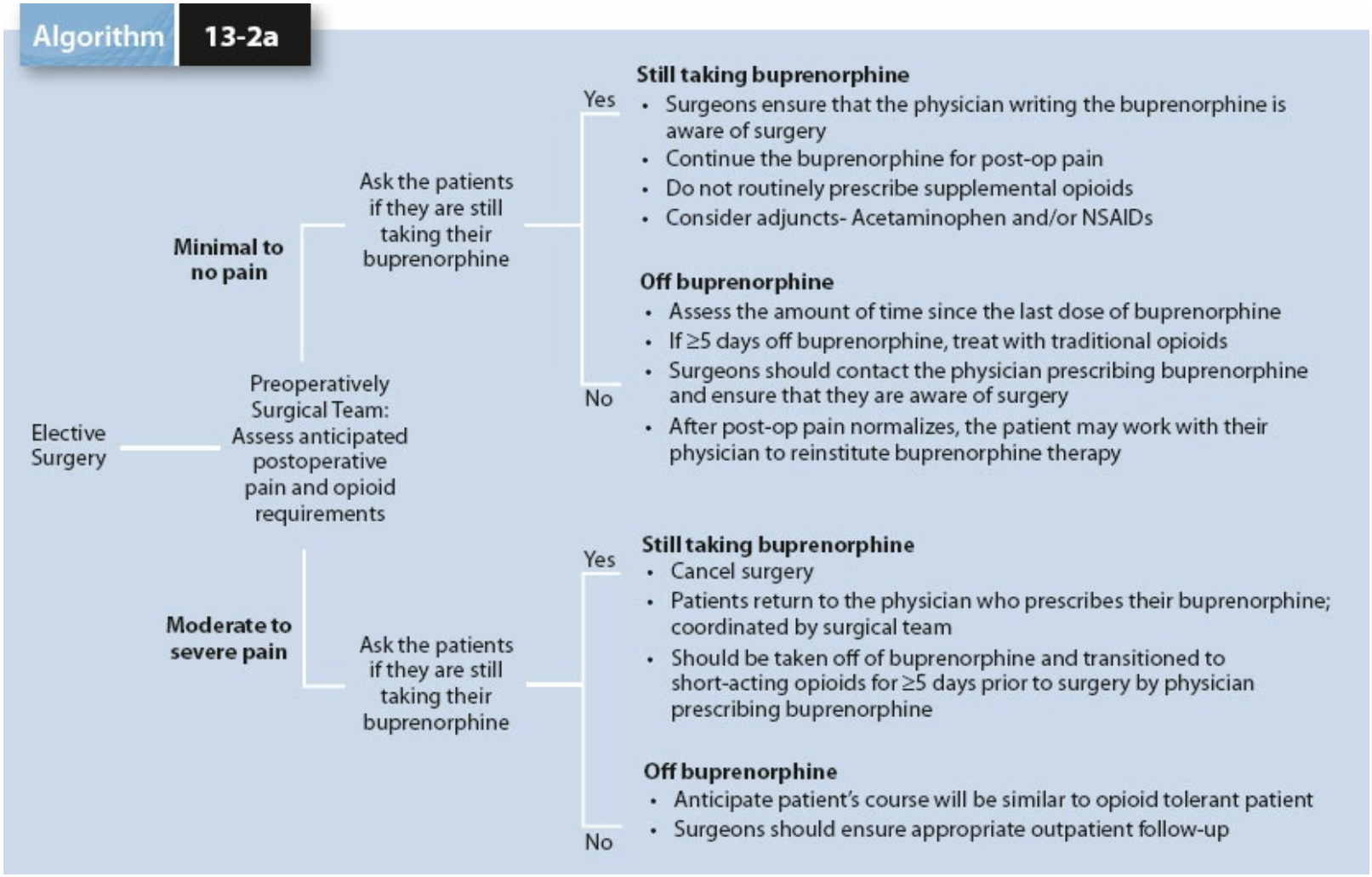

Algorithm 13-2a. Algorithm for managing a patient on chronic buprenorphine therapy. APS, acute pain service; ICU, intensive care unit; PCA, patient-controlled anesthesia; NSAIDs, nonsteroidal anti-inflammatory drugs.

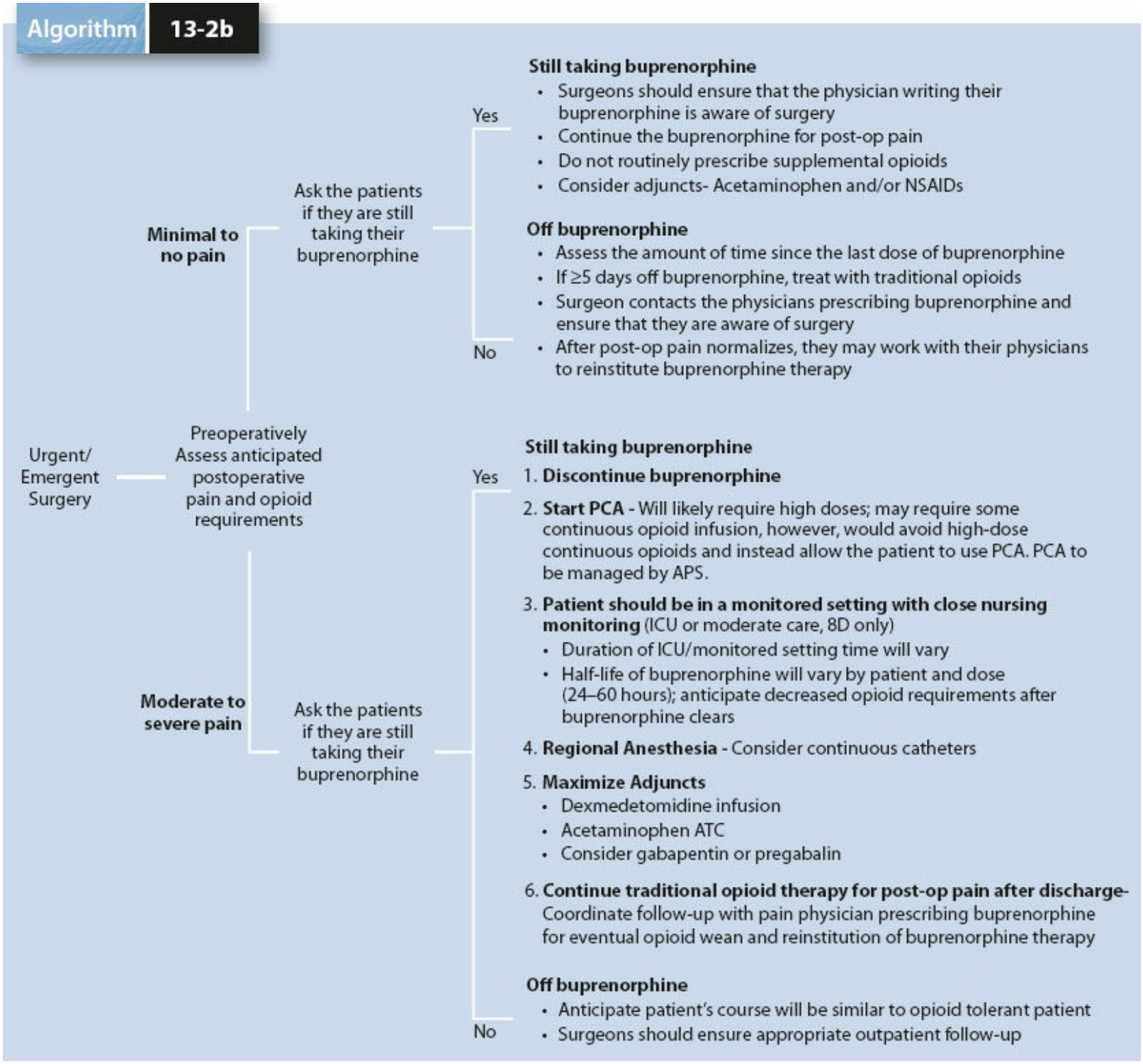

Algorithm 13-2b.

In a healthy young adult, there is no significant DS_{al} gas, and the end-tidal CO_2 value equals the $PaCO_2$. Therefore, the difference between these values indicates the proportion of DS_{al} in the patient. The presence of a capnogram itself implies that there is metabolism (the production of CO_2), circulation (blood flow to the lungs), and ventilation (respiratory rate and an intact ventilator circuit).

Providing this information on a breath-to-breath basis, the continuous capnogram is extremely useful in many critical situations. It can be used as a surveillance monitor of both the respiratory circuit and the cardiovascular system. Any acute decrease in cardiac output will decrease blood flow to the lungs and increase the DS_{al}, causing an acute drop

in end-tidal CO_2. For this reason, the device was originally used during neurosurgical procedures in the sitting position to detect the presence of air emboli. This principle also allows the detection of pulmonary emboli or any acute drop in cardiac output. In fact, the only acute catastrophic cardiopulmonary problem that will not be detected by the capnometer is arterial desaturation. Therefore, the combination of the capnometer and the pulse oximeter creates a dynamic duo for beat-to-beat and breath-to-breath surveillance of metabolism, circulation, ventilation, and oxygenation.

Circulation Monitors

14 Hemodynamic stability can be monitored by a variety of methods, the most basic of which is systemic arterial blood pressure. Intermittent, noninvasive measurement of systemic blood pressure with an oscillometric blood pressure cuff is the standard in the operating room, and its accuracy equals that of clinical measurements by auscultation. Blood pressure cuffs can be cycled as quickly as once per minute, but when used for an extended duration, they should be cycled no more than once every 3 to 5 minutes. When tighter control or observation is required in patients with significant comorbidities or large swings in hemodynamics due to surgical circumstances, invasive arterial monitoring is used. Although pressure measurements provided by invasive techniques are different from those of noninvasive techniques, they usually coincide closely. A continuous invasive arterial tracing can also be used to assess the adequacy of fluid resuscitation by following the systolic pressure variation (SPV) with positive-pressure ventilation. As positive-pressure ventilation impedes venous return within a closed thorax, decreases in systolic pressure associated with a respiratory pattern can be detected. In patients with sinus rhythm with stable cardiac contractility, the degree of SPV is inversely related to the intravascular volume status of the patient. The normal range of SPV is 5 to 10 mm Hg. A systolic pressure decrease of greater than 10 mm Hg during positive-pressure ventilation implies inadequate preload and the need for more aggressive fluid resuscitation.

In this context, central venous access may be reserved for patients and procedures with the potential for large, rapid volume resuscitation requirements or expected need for potent vasoconstrictors, inotropes, or vasodilators not amenable to peripheral administration. Transesophageal echocardiography (TEE) is now commonly used to assess cardiac function. This technique is easily used in the anesthetized, intubated patient and can quickly assess systolic and diastolic function as well as valvular dysfunction. Increasing familiarity in the use of TEE by noncardiac anesthesiologists may result in the pulmonary artery catheter being reserved for very specific patients demonstrating the need for pulmonary artery pressure monitoring or continuous cardiac output trending.

Finally, a wave of noninvasive continuous cardiac output monitors has gained the attention of surgeons and anesthesiologists alike. These monitors, promising the realization of goal-directed therapy, use indirect means to assess the missing aspect of blood pressure-focused hemodynamic management – stroke volume. Thoracic electrical bioimpedance, pulse wave transit time, peripheral pulse contour analysis, volume clamp, and other methods of estimating stroke volume have been in existence for decades, but have seen a recent rise in interest as variation in intraoperative fluid management may impact surgical outcomes. However, conflicting studies in real-world critically ill patients have failed to establish that these monitors are capable of replacing traditional invasive monitoring routes or are worth establishing as standards of care for all patients undergoing major surgery.[60] Despite the absence of compelling clinical data, many enhanced recovery protocols have begun including some type of noninvasive cardiac output monitoring to guide fluid therapy.[61] It is unclear whether these monitoring devices

offer superior guidance to sound clinical judgment administered by a vigilant anesthesiologist.

“Awareness” and Level of Consciousness Monitors

When delivering a general anesthetic, one of the major imperatives is to achieve and maintain a loss of consciousness. Normally, this is achieved through careful observation of vital signs (heart rate, blood pressure), physical examination signs (movement in a patient without neuromuscular blockade), and delivery of inhalational or intravenous agents at doses consistent with a loss of consciousness. However, this “science” is inexact and must account for patient age, comorbidities, chronic medications, surgical stimulus, and patient-to-patient variability. As a result, patients may rarely experience “awareness under anesthesia” – a state characterized not only by consciousness but also by recall of intraoperative events. The laypress and public have increased their scrutiny of this perioperative event.

First, appropriate expectations and effective communication of the anesthetic are required. Recent literature has demonstrated that patients undergoing regional anesthesia are as likely to report unpleasant “awareness” as patients undergoing a general anesthetic.[62] This is despite the reality that loss of consciousness is only a goal of general anesthesia. Clearly, anesthesiologists must communicate the anesthetic plan and expectations more accurately.

Second, several level of consciousness monitors have been developed in hopes of providing the anesthesiologist with additional objective data to guide their assessment and actions. The current generation of monitors generally uses electroencephalographic (EEG) analysis to provide the clinician with an assessment of the relative “depth” of anesthesia achieved. Several commercially available monitors such as the bispectral index (BIS) from Aspect Medical Systems and Entropy from General Electric Healthcare are in common clinical use. Data evaluating the value of these EEG-based monitors in reducing awareness are conflicting, with several large trials producing varying results.[63,64] As a result, the ASA has not adopted awareness monitors as a standard of care and leaves the decision to use such monitoring technology to each provider, patient, and situation.[65] The largest, most recent trials have failed to demonstrate a measurable reduction in awareness.[66,67]

COMMON PROBLEMS IN THE POSTOPERATIVE PERIOD

Postanesthesia care units are required in any setting where surgical procedures are conducted. The increased scope of surgery and the invasive technology used to monitor sicker patients has increased the service at and training required to operate these facilities. In 2014, the ASA revised the Standards for Postanesthesia Care (Table 13-15).

The scoring systems used to assess the postoperative patient direct attention to the primary areas of concern. The postanesthesia recovery score is an attempt to evaluate postanesthesia patient status (Table 13-16).[68] This basic information should be incorporated in a record that provides clear documentation of postoperative events. Documentation should also include details of postoperative outpatient care, with a note indicating postoperative telephone contact made to elucidate problems. Problems should receive appropriate follow-up, and written postoperative discharge instructions should be provided for the patient.

Investigators have reported that 24% of patients experience a postanesthesia care unit complication. Nausea, vomiting, and the need for airway support constitute 70% of these complications (Fig. 13-2).[69] The need to maintain airway support was by far the most common respiratory complication. The duration of the procedure as well as ASA classification and type of procedure had a significant bearing on the incidence of complications in this study. Hypothermia was also a common problem that prolonged postoperative postanesthesia care unit stay (Fig. 13-3). Hypothermia has the deleterious effects of altering drug metabolism and delaying recovery. Furthermore, it causes shivering, which increases the metabolic demand for oxygen.

Among cardiovascular complications in the postoperative period, none is more important or more difficult to diagnose than myocardial ischemia. The association of perioperative myocardial ischemia with cardiac morbidity has been clearly documented.[26] In a series of high-risk patients undergoing noncardiac surgery, researchers noted that "early postoperative myocardial ischemia is an important correlate of adverse cardiac outcomes."[26] Diagnosis is complicated by the fact that only 10% to 30% of patients suffering documented myocardial infarction have pain and that postoperative ECG T-wave changes are often nonspecific.[70] Instead, one must seek secondary indications of ongoing ischemia or "angina equivalents," such as hypotension, arrhythmias, elevated filling pressures, or postoperative oliguria. Arrhythmias are common and are significant primarily because of the association with myocardial ischemia or hypoxemia.

Table 13-15 Standards for Postanesthesia Care

Standards		Criteria to be Fulfilled
Standard I[a]	All patients who have received general, regional, or monitored anesthesia care shall receive appropriate postanesthesia management.	1. A PACU or an area that provides equivalent postanesthesia care shall be available to receive patients after anesthesia care. All patients who receive anesthesia care shall be admitted to the PACU or its equivalent *except* by specific order of the anesthesiologist responsible for the patient's care. 2. The medical aspects of care in the PACU shall be governed by policies and procedures that have been reviewed and approved by the department of anesthesiology. 3. The design, equipment, and staffing of the PACU shall meet requirements of the facility's accrediting and licensing bodies.
Standard II	A patient transported to the PACU shall be accompanied by a member of the anesthesia care team who is knowledgeable about the patient's condition. The patient shall be continually evaluated and treated during transport with monitoring and support appropriate to the patient's condition.	
Standard III	On arrival in the PACU, the patient shall be re-evaluated and a verbal report provided to the responsible PACU nurse by the member of the anesthesia care team who accompanies the patient.	1. The patient's status on arrival in the PACU shall be documented. 2. Information concerning the preoperative condition and the surgical/anesthetic course shall be transmitted to the PACU nurse. 3. The member of the anesthesia care team shall remain in the PACU until the PACU nurse accepts responsibility for the nursing care of the patient.
Standard IV	The patient's condition shall be evaluated continually in the PACU.	1. The patient shall be observed and monitored by the methods appropriate to the patient's medical condition. Particular attention shall be given to monitoring oxygenation, ventilation, circulation, and temperature. During recovery from all anesthetics, a quantitative method of assessing oxygenation such as pulse oximetry shall be employed in the initial phase of recovery. This is not intended for application during the recovery of the obstetric patient in whom regional anesthesia was used for labor and vaginal delivery. 2. An accurate written report of the PACU period shall be maintained. Use of an appropriate PACU scoring system is encouraged for each patient on admission, at appropriate intervals prior to discharge, and at the time of discharge. 3. General medical supervision and coordination of patient care in the PACU should be the responsibility of an anesthesiologist. 4. There shall be a policy to ensure the availability in the facility of a physician capable of managing complications and providing cardiopulmonary resuscitation for patients in the PACU.
Standard V	A physician is responsible for discharging the patient from the PACU.	1. When discharge criteria are used, they must be approved by the department of anesthesiology and the medical staff. They may vary depending on whether the patient is discharged to a hospital room, to the ICU, to a short stay unit, or home. 2. In the absence of the physician responsible for the discharge, the PACU nurse shall determine that the patient meets the discharge criteria. The name of the physician accepting responsibility for discharge shall be noted on the record.

ICU, intensive care unit; PACU, postanesthesia care unit.
[a]For nursing care issues, refer to Standards of Postanesthesia Nursing Practice, published by the American Society of Postanesthesia Nurses.
Based on the American Society of Anesthesiologists (ASA)'s Standards for Postanesthesia Care. A copy of the full text can be obtained from ASA, 520 N. Northwest Highway, Park Ridge, IL 60068–2573.

Nausea and vomiting are rarely unifactorial and cause considerable discomfort to patients. Opioids are responsible for stimulating the emesis center in a significant cohort of patients. These patients may provide a clear history of opioid sensitivity and anesthetic and analgesic regimens may be tailored to limit the exposure of these patients to these

drugs. In general, however, there is little evidence to favor one anesthetic or anesthetic technique over another, although propofol appears to have an antiemetic effect. Nitrous oxide, often considered causative, does not appear to increase the incidence of nausea according to well-documented studies. It is not unusual for an antiemetic agent to be included preoperatively or as part of the anesthetic technique, especially in patients with a positive history or those deemed to be at risk, such as menstruating young women undergoing laparoscopy. Standard usage includes phenothiazines, butyrophenones, $5HT_3$ antagonists, and steroids. A multimodal approach that avoids redosing of a given medication class has been demonstrated to be most beneficial.[71] Despite decades of research, classic medications such as droperidol remain a mainstay of therapy. The FDA recently added a black-box warning to droperidol due to concerns of QT prolongation, but such concerns have not been validated when compared to other perioperative medications; as a result, many institutions continue to use droperidol for postoperative nausea and vomiting prophylaxis.[72,73]

Table 13-16 Postanesthesia Recovery Score

Parameter	Score
Activity	
Voluntary movement of all limbs to command[a]	2
Voluntary movement of two extremities to command	1
Unable to move	0
Respiration	
Breathes deeply and coughs	2
Dyspnea, hypoventilation	1
Apneic	0
Circulation	
Blood pressure equals 80% of preanesthetic level	2
Blood pressure equals 50–80% of preanesthetic level	1
Blood pressure equals <50% of preanesthetic level	0
Consciousness	
Fully awake	2
Arousable	1
Unresponsive	0
Color	
Pink	2
Pale, blotchy	1
Cyanotic	0

[a]Patients should score at least 7 before discharge from the postanesthesia care unit.

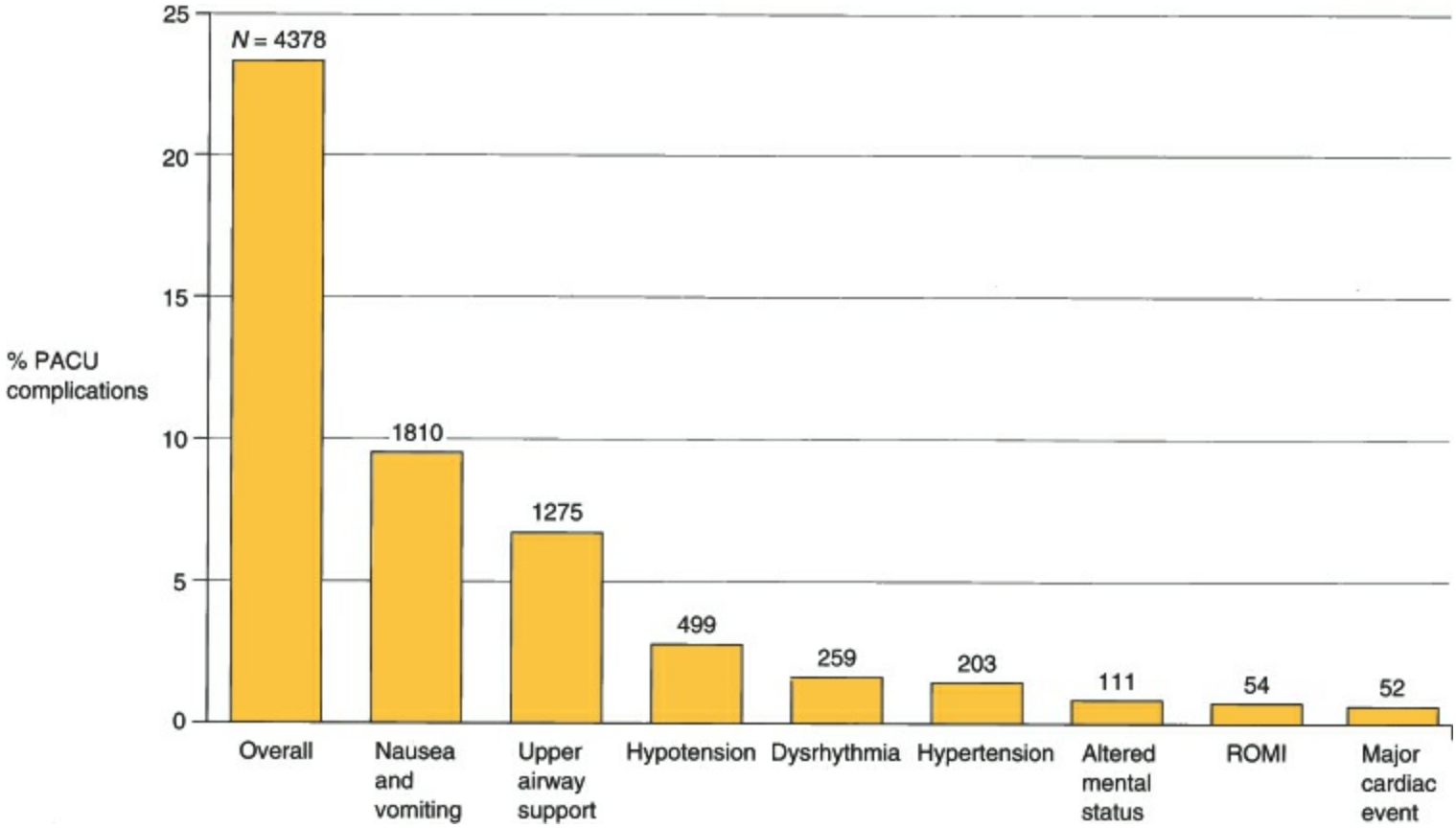

Figure 13-2. Major postanesthesia care unit complications by percentage of occurrence and number of patients experiencing each complication. Nausea and vomiting were the most frequently observed complications. ROMI, rule out myocardial infarction. (Reproduced with permission from Hines R, Barash PG, Watrous G, et al. Complications occurring in the postanesthesia care unit: a survey. *Anesth Analg* 1992;74:505.)

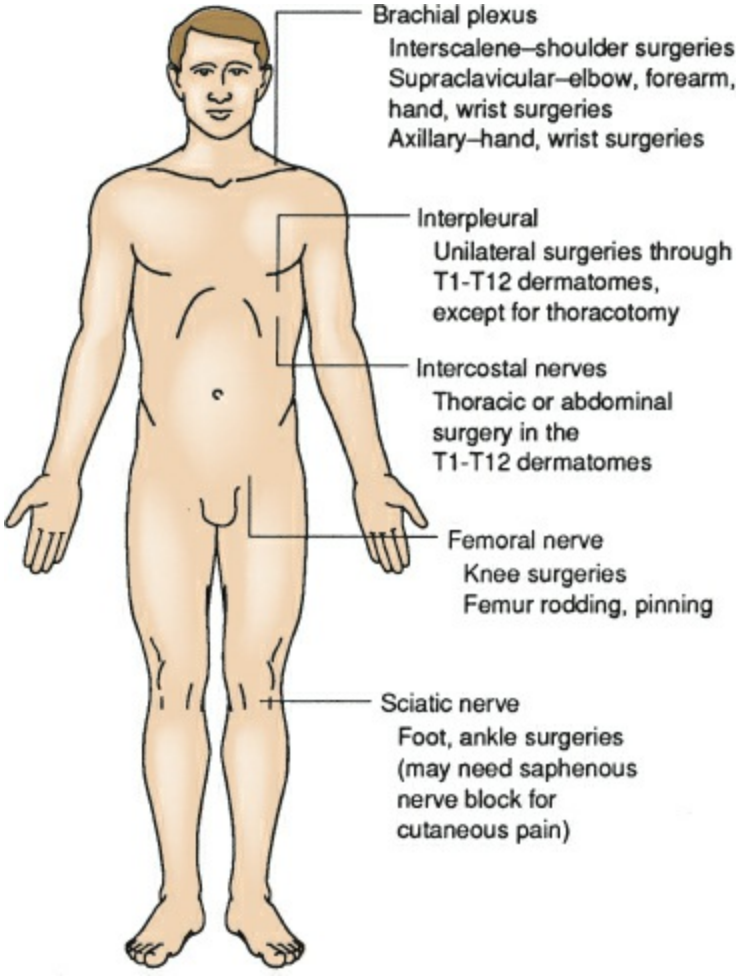

Figure 13-3. Surgical procedures in which peripheral nerve blockade can provide postoperative pain relief.

Table 13-17 Differential Diagnosis of Delayed Emergence

Metabolic Abnormalities
Hypoxia
Hypercarbia
Hypoglycemia
Hypotension
Hypothermia
Hyponatremia
Drug Effects
Muscle relaxants
Opioids
Barbiturates
Benzodiazepines
Ketamine
Anticholinergics
Inhalational anesthetics
Neurologic Injury
Ischemia
Mass lesions
Seizure disorders

The most common cause of delayed emergence is the residual effects of anesthesia. The

differential diagnosis of delayed emergence is best approached by ruling out physiologic, pharmacologic, and neurologic cases, in this order (Table 13-17). There should be little confusion about the implication of muscle relaxants because physical indications of ventilatory distress, combined with the readings of the blockade monitor, should clearly indicate the role of these drugs. Where appropriate, opioids can be reversed using titrated doses of naloxone. Flumazenil can be used for reversal of benzodiazepines.

ENHANCED RECOVERY PROTOCOLS

15 With the increasing adoption of minimally invasive surgical techniques and a realization that postoperative complications may impact intraoperative management, nearly every surgical subspecialty has begun efforts to establish enhanced recovery protocols. These comprehensive care management plans dictate the preoperative preparation, intraoperative management, surgical technique, and postoperative management choices made by all clinicians involved in the patient's care: nurses, anesthesiologists, surgeons, physical therapists, and consultants. While a consistent decrease in length of stay, complications, and costs has been observed across the many trials assessed in many surgical specialties, there are very few consistent protocols.[74,75] It appears that the process of collaboration and standardization involved in creating a multidisciplinary and multispecialty protocol may be the most causal attribute in the success of enhanced recovery protocols. While some recommend use of controversial anesthesiology management techniques such as goal-directed colloid fluid therapy, others do not make such recommendations. The evolution of enhanced recovery protocols and implementation science is an active area in all perioperative specialties.

POSTOPERATIVE ACUTE PAIN MANAGEMENT

Postoperative pain is an inevitable consequence of surgery. Its severity is site dependent (Table 13-18), but the magnitude of the pain experienced by individual patients after similar surgical procedures is influenced by a multitude of factors. Variation in patient experience has been clearly demonstrated by several authors and is reflected in deficiencies in postoperative pain control.[76] The recognition of this clinical problem has prompted interest in underlying pain mechanisms and in innovative ways to alleviate postoperative suffering.

In 1965, the crucial role of nociceptive C fiber feedback behavior and its modulation by cells in the substantia gelatinosa of the dorsal horn was recognized.[77] Repetitive stimulation of these fibers by cellular mediators, such as kinins and catecholamines, promotes neural excitation, prolongs repetitive firing, and lowers the threshold to further excitation. As a result, C fibers do not show fatigue, and the stage is set for continuous pain. Counterirritation of large afferent activity has been shown empirically to have beneficial effects. The gate-control theory provides an explanation for the inhibition of C fiber–mediated pain. Serotonergic and enkephalinergic descending inhibitory pathways modulate activity in the dorsal horn before information is relayed to the somatosensory cortex through the spinothalamic tract. The common observation that pain is worse at night, when less sensory information is processed, and that it decreases with daytime activity is an example of how this complex neural system functions.

Superficial somatic pain is well localized and has a protective function. Superficial somatic pain is readily treated by common analgesic techniques. Deep somatic pain may not be well localized; may have some protective function, as in joint immobilization; and is fairly responsive to a variety of analgesics. Visceral pain, served almost entirely by C fiber activity, is poorly localized, often referred, and difficult to treat. In major operations, all modes can be activated, compounding the clinical challenge of providing adequate pain management. These clinical observations direct the focus of postoperative pain management to the treatment of somatic pain by attacking the nociceptor and the subsequent transmission of the painful impulse by the nerve fiber. The use of nonsteroidal anti-inflammatory drugs with or without the injection of local anesthetics into the wound is very effective. If done pre-emptively at the time of surgery, this approach can significantly benefit the patient's postoperative experience.Examples of nerve blocks for various procedures are shown in Figure 13-4.

Table 13-18 Percentage of Patients Who Require Analgesic Injections

Operation	No Analgesic Needed (%)	Three or More Analgesic Injections (%)
Minor chest wall	82	0
Inguinal hernia	52	0
Appendectomy	25	10
Lower abdominal surgery	18	40
Upper abdominal surgery	10	45–65

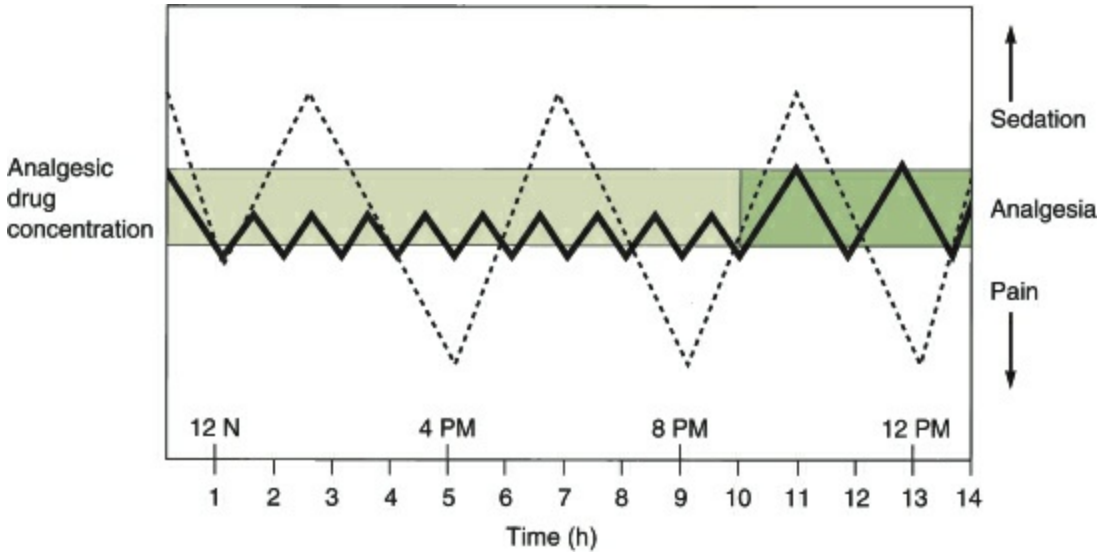

Figure 13-4. Theoretical relation among dosing interval, analgesic drug concentration, and clinical effects when comparing a patient-controlled analgesia system (*solid line*) to conventional intramuscular therapy (*dashed line*). (Reproduced with permission from White PF. Patient-controlled analgesia: A new approach to the management of postoperative pain. *Semin Anesth* 1985;4:261.)

Table 13-19 Problems That Can Occur During Patient-Controlled Analgesia (PCA) Therapy

Operator Errors
1. Misprogramming PCA device
2. Failure to clamp or unclamp tubing
3. Improperly loading syringe or cartridge
4. Inability to respond to safety alarms
5. Misplacing PCA pump key
Patient Errors
1. Failure to understand PCA therapy
2. Misunderstanding PCA pump device
3. Intentional analgesic abuse
Mechanical Errors
1. Failure to deliver on demand
2. Defective one-way valve at Y-connector
3. Faulty alarm system
4. Device malfunctions

Including potent opioids in the treatment of deep pain, both somatic and visceral, has

been routine. However, the responses to standard regimens have been notoriously unreliable, from inadequate pain relief to narcosis, with complications at both ends of the scale. It was not until the 1980s that variations in response were linked to variable serum concentrations of analgesic drugs. Interpatient variation in serum levels to any standard dose can be fivefold, and interpatient therapeutic concentrations can vary on a similar scale. When factored together, there is the potential for a 25-fold variation in patient response to a standard drug prescription. Each patient has an individual therapeutic window. The clinical implications are enormous.

In 1968, investigators demonstrated the virtue of small IV doses given on demand. As a result, the patient experienced greater pain relief, yet used the same or less total narcotic. Although there was significant patient variation, the demand from any individual patient, though cyclic, was constant. Patient-controlled analgesia (PCA) and the technologic and administrative systems to provide it have developed to a point of some sophistication, requiring servicing and a support structure with its own set of problems (Table 13-19). PCA administration requires a receptive environment, education of all personnel, and adequate patient instruction. PCA has received widespread acceptance by patients, nursing staff, and physicians because it provides more prompt and painless analgesia that more closely matches the patient's need over time. PCA is as safe as conventional IM medication. Morphine and meperidine are commonly used drugs, and an example of orders is shown in Table 13-20.

Transdermal narcotic delivery is receiving attention and may become available for postoperative pain. The method is both practical and inexpensive and aims to maintain continuous delivery and constant blood levels. Fentanyl has been the drug of choice and has been well received by patients. The method appears to be safe, but there is a significant lag time between application and the attainment of therapeutic blood levels.

The discovery of endorphins in the 1970s and recognition of their importance in modulating pain at spinal sites led to the supposition that it would be possible to selectively apply opioids directly to receptors. This led to the development of epidural opiate analgesia, in which opioids are applied directly to the receptors at spinal sites. The goal of epidural analgesia is to obtain maximal analgesia while minimizing systemic side effects. For severe acute postoperative pain caused by major surgery, epidural analgesia has proved to be a superior modality for pain control. In high-risk cases, there is evidence that it has an overall beneficial effect on morbidity.[43]

Table 13-20 Example of Orders for Patient-Controlled Analgesia (PCA)

1. Patient is to be initiated on PCA with standard monitoring protocol.		
2. Drug selection	Morphine 1 mg/mL	Hydromorphone 0.2 mg/mL
3. Loading initial dose (start PRN for pain) Maximum total loading dose	2–5 mg 10 mg	0.2–0.5 mg 1 mg
4. Pump setting PCA dose Lockout interval 4-h limit	1–2 mg 6–10 min 30–45 mg	0.1–0.2 mg 6–10 min 4–5 mg

University of Michigan Hospitals online order form Acute Pain Service, Patient Controlled Analgesia Standard Orders.

Table 13-21 Opioid Protocols in Epidural Opiate Analgesia

	Morphine[a]	Fentanyl[b]
Length of onset	Longer (30–60 min)	Shorter (15–30 min)
Duration	Longer (6–24 h for single bolus)	Shorter (1–2 h for single bolus)
Cephalad spread and side effects	More prone	Less prone
Indication	Favored for lumbar administration after abdominal surgery	Favored for thoracic administration after chest surgery
Dose	Typically 3–5 mg, q6–8h	Typically 50–75 mg/h (±dilute bupivacaine)

[a]Hydrophilic: slow in, slow out.
[b]Lipophilic: fast in, fast out.

The effective use of this sophisticated modality requires education and the establishment of protocols with rigorous attention to detail. The potential for respiratory depression demands adherence to monitoring standards. Morphine and fentanyl, often in combination with a dilute local anesthetic solution, are most often prescribed. A typical order form with monitored parameters is shown in Table 13-21.

A comprehensive postoperative pain management service demands resources and must use the physical and pharmacologic modalities available while recognizing the significant subjective component of any individual's pain problem. The ability to recognize the impact of acute pain or an underlying chronic pain disorder requires that experience be brought to bear on difficult problems. The active involvement of nursing staff and surgeons is essential for the patient to achieve maximal benefit. It is incumbent on the pain-management service to render efficient, continuous, and cost-effective care.

16 Postoperative acute pain management may require a multimodal approach that incorporates opioids, PNB, and nonopioid analgesics. Chronic pain patients can be particularly difficult to manage and may require preoperative optimization by an anesthesiologist. These patients require very large doses of IV analgesics and need to be maintained orally. The best way to evaluate an appropriate starting dose is to convert the preoperative opioid regimen to an IV morphine equivalent, then add what would be required to treat the acute surgical pain (Table 13-4). The use of nonopioid and nonpharmacologic treatments is essential in the management of acute postoperative pain in this patient population. PNB, aggressive use of acetaminophen and nonsteroidal anti-

inflammatory agents, and novel agents such as dexmedetomidine may be necessary to minimize the adverse effects associated with uncontrolled postoperative pain. As mentioned earlier, these patients may need to be evaluated by an anesthesiologist prior to the day of surgery. This should be an institutional requirement for patients on chronic buprenorphine therapy, as demonstrated in Algorithm 13-2.

Acknowledgements: The authors would like to thank Kevin K. Tremper and Timothy W. Rutter for their contributions to earlier editions of this chapter.

References

1. Calverly R. Anesthesia as a specialty: Past, present and future. In: Barash P, Cullen B, Stoelting R, eds. *Clinical Anesthesia.* Philadelphia, PA: JB Lippincott; 1992.
2. Brueckmann B, Sasaki N, Grobara P, et al. Effects of sugammadex on incidence of postoperative residual neuromuscular blockade: A randomized, controlled study. *Br J Anaesth* 2015;115(5):743–751.
3. Kam PC, Cardone D. Propofol infusion syndrome. *Anaesthesia* 2007;62:690–701.
4. Himmelseher S, Durieux ME. Ketamine for perioperative pain management. *Anesthesiology* 2005;102:211–220.
5. Rosenberg JM, Wahr JA, Sung CH, et al. Coronary perfusion pressure during cardiopulmonary resuscitation after spinal anesthesia in dogs. *Anesth Analg* 1996;82:84–87.
6. Drasner K, Smiley R. Continuous spinal analgesia for labor and delivery: A born-again technique? *Anesthesiology* 2008;108:184–186.
7. Standl TG. Catheter tip position and baricity of the local anesthetic have an impact on maldistribution in microcatheter CSA. *Anesthesiology* 1999;90:1227–1229.
8. JCAHO. Comprehensive accreditation manual for hospitals: The official handbook: Conscious sedations. Oakbrook Terrace, IL: 1999.
9. Malviya S, Naughton N, Tremper K, eds. Sedation analgesia for diagnostic and therapeutic procedures. New Jersey: Human Press; 2003.
10. American Society of Anesthesiologists Task Force on Management of the Difficult Airway. Practice guidelines for management of the difficult airway: An updated report by the American Society of Anesthesiologists Task Force on Management of the Difficult Airway. *Anesthesiology* 2003;98:1269–1277.
11. Kheterpal S, Han R, Tremper KK, et al. Incidence and predictors of difficult and impossible mask ventilation. *Anesthesiology* 2006;105:885–891.
12. Mallampati SR, Gatt SP, Gugino LD, et al. A clinical sign to predict difficult tracheal intubation: A prospective study. *Can Anaesth Soc J* 1985;32:429–434.
13. Lienhart A, Auroy Y, Pequignot F, et al. Survey of anesthesia-related mortality in France. *Anesthesiology* 2006;105:1087–1097.
14. Sparicio D, Landoni G, Zangrillo A. Angiotensin-converting enzyme inhibitors predispose to hypotension refractory to norepinephrine but responsive to methylene blue. *J Thorac Cardiovasc Surg* 2004;127:608.
15. Medel J, Boccara G, Van de Steen E, et al. Terlipressin for treating intraoperative hypotension: Can it unmask myocardial ischemia? *Anesth Analg* 2001;93:53–55, TOC.
16. Talbot MP, Tremblay I, Denault AY, et al. Vasopressin for refractory hypotension during cardiopulmonary bypass. *J Thorac Cardiovasc Surg* 2000;120:401–402.
17. Bertrand M, Godet G, Meersschaert K, et al. Should the angiotensin II antagonists be discontinued before surgery? *Anesth Analg* 2001;92:26–30.

18. Comfere T, Sprung J, Kumar MM, et al. Angiotensin system inhibitors in a general surgical population. *Anesth Analg* 2005;100:636–644, table of contents.
19. Augoustides JG. Angiotensin blockade and general anesthesia: So little known, so far to go. *J Cardiothorac Vasc Anesth* 2008;22:177–179.
20. Kheterpal S, Khodaparast O, Shanks A, et al. Chronic angiotensin-converting enzyme inhibitor or angiotensin receptor blocker therapy combined with diuretic therapy is associated with increased episodes of hypotension in noncardiac surgery. *J Cardiothorac Vasc Anesth* 2008;22:180–186.
21. Stoelting R. *Anesthesia and Co-Existing Disease.* 3rd ed. New York, NY: Churchhill Livingstone; 1993.
22. Padma S, Sundaram PS. Current practice and recommendation for presurgical cardiac evaluation in patients undergoing noncardiac surgeries. *World J Nucl Med* 2014;13:6–15.
23. Davenport DL, Ferraris VA, Hosokawa P, et al. Multivariable predictors of postoperative cardiac adverse events after general and vascular surgery: Results from the patient safety in surgery study. *J Am Coll Surg* 2007;204:1199–1210.
24. Mangano DT. Perioperative cardiac morbidity. *Anesthesiology* 1990;72:153–184.
25. Fleisher LA, Poldermans D. Perioperative beta blockade: Where do we go from here? *Lancet* 2008;371:1813–1814.
26. Mangano DT, Browner WS, Hollenberg M, et al. Association of perioperative myocardial ischemia with cardiac morbidity and mortality in men undergoing noncardiac surgery. The Study of Perioperative Ischemia Research Group. *N Eng J Med* 1990;323:1781–1788.
27. Rao TL, Jacobs KH, El-Etr AA. Reinfarction following anesthesia in patients with myocardial infarction. *Anesthesiology* 1983;59:499–505.
28. Tarhan S, Moffitt EA, Taylor WF, et al. Myocardial infarction after general anesthesia. *JAMA* 1972;220:1451–1454.
29. Botto F, Alonso-Coello P, Chan MT, et al. Myocardial injury after noncardiac surgery: A large, international, prospective cohort study establishing diagnostic criteria, characteristics, predictors, and 30-day outcomes. *Anesthesiology* 2014;120:564–578.
30. Boden WE, O'Rourke RA, Teo KK, et al. Optimal medical therapy with or without PCI for stable coronary disease. *N Eng J Med* 2007;356:1503–1516.
31. McFalls EO, Ward HB, Moritz TE, et al. Coronary-artery revascularization before elective major vascular surgery. *N Eng J Med* 2004;351:2795–2804.
32. Fleisher LA, Fleischmann KE, Auerbach AD, et al. 2014 ACC/AHA guideline on perioperative cardiovascular evaluation and management of patients undergoing noncardiac surgery: A report of the American College of Cardiology/American Heart Association Task Force on practice guidelines. *J Am Coll Cardiol* 2014;64:e77–e137.
33. Group PS, Devereaux PJ, Yang H, et al. Effects of extended-release metoprolol succinate in patients undergoing non-cardiac surgery (POISE trial): A randomised

controlled trial. *Lancet* 2008;371:1839–1847.
34. Lindenauer PK, Pekow P, Wang K, et al. Perioperative beta-blocker therapy and mortality after major noncardiac surgery. *N Eng J Med* 2005;353: 349–361.
35. Le Manach Y, Coriat P, Collard CD, et al. Statin therapy within the perioperative period. *Anesthesiology* 2008;108:1141–1146.
36. Devereaux PJ, Mrkobrada M, Sessler DI, et al. Aspirin in patients undergoing noncardiac surgery. *N Eng J Med* 2014;370:1494–1503.
37. Devereaux PJ, Sessler DI, Leslie K, et al. Clonidine in patients undergoing noncardiac surgery. *N Eng J Med* 2014;370:1504–1513.
38. Rabbitts JA, Nuttall GA, Brown MJ, et al. Cardiac risk of noncardiac surgery after percutaneous coronary intervention with drug-eluting stents. *Anesthesiology* 2008;109:596–604.
39. Nuttall GA, Brown MJ, Stombaugh JW, et al. Time and cardiac risk of surgery after bare-metal stent percutaneous coronary intervention. *Anesthesiology* 2008;109:588–595.
40. Goldman L, Caldera DL, Nussbaum SR, et al. Multifactorial index of cardiac risk in noncardiac surgical procedures. *N Eng J Med* 1977;297:845–850.
41. Maile MD, Engoren MC, Tremper KK, et al. Worsening preoperative heart failure is associated with mortality and noncardiac complications, but not myocardial infarction after noncardiac surgery: A retrospective cohort study. *Anesth Analg* 2014;119:522–532.
42. Popping DM, Elia N, Marret E, et al. Protective effects of epidural analgesia on pulmonary complications after abdominal and thoracic surgery: A meta-analysis. *Arch Surg* 2008;143:990–999; discussion 1000.
43. Yeager MP, Glass DD, Neff RK, et al. Epidural anesthesia and analgesia in high-risk surgical patients. *Anesthesiology* 1987;66:729–736.
44. Abdelmalak BB, Bonilla A, Mascha EJ, et al. Dexamethasone, light anaesthesia, and tight glucose control (DeLiT) randomized controlled trial. *Br J Anaesth* 2013;111:209–221.
45. Kheterpal S, O'Reilly M, Englesbe MJ, et al. Preoperative and intraoperative predictors of cardiac adverse events after general, vascular, and urological surgery. *Anesthesiology* 2009;110:58–66.
46. Lee TH, Marcantonio ER, Mangione CM, et al. Derivation and prospective validation of a simple index for prediction of cardiac risk of major noncardiac surgery. *Circulation* 1999;100:1043–1049.
47. Garg AX, Kurz A, Sessler DI, et al. Perioperative aspirin and clonidine and risk of acute kidney injury: A randomized clinical trial. *JAMA* 2014;312:2254–2264.
48. Memtsoudis SG, Stundner O, Rasul R, et al. The impact of sleep apnea on postoperative utilization of resources and adverse outcomes. *Anesth Analg* 2014;118:407–418.

49. Memtsoudis SG, Besculides MC, Mazumdar M. A rude awakening–the perioperative sleep apnea epidemic. *N Eng J Med* 2013;368:2352–2353.
50. Tagaito Y, Isono S, Tanaka A, et al. Sitting posture decreases collapsibility of the passive pharynx in anesthetized paralyzed patients with obstructive sleep apnea. *Anesthesiology* 2010;113:812–818.
51. Brown KA, Laferriere A, Lakheeram I, et al. Recurrent hypoxemia in children is associated with increased analgesic sensitivity to opiates. *Anesthesiology* 2006;105:665–669.
52. Mutter TC, Chateau D, Moffatt M, et al. A matched cohort study of postoperative outcomes in obstructive sleep apnea: Could preoperative diagnosis and treatment prevent complications? *Anesthesiology* 2014;121:707–718.
53. Abdelsattar ZM, Hendren S, Wong SL, et al. The Impact of Untreated Obstructive Sleep Apnea on Cardiopulmonary Complications in General and Vascular Surgery: A Cohort Study. *Sleep* 2015;38:1205–1210.
54. Horlocker TT, Wedel DJ, Rowlingson JC, et al. Regional anesthesia in the patient receiving antithrombotic or thrombolytic therapy: American Society of Regional Anesthesia and Pain Medicine Evidence-Based Guidelines (Third Edition). *Reg Anesth Pain Med* 2010;35:64–101.
55. Wijeysundera DN, Duncan D, Nkonde-Price C, et al. Perioperative beta blockade in noncardiac surgery: A systematic review for the 2014 ACC/AHA guideline on perioperative cardiovascular evaluation and management of patients undergoing noncardiac surgery: A report of the American College of Cardiology/American Heart Association Task Force on practice guidelines. *J Am Coll Cardiol* 2014;64:2406–2425.
56. Roberts DM, Meyer-Witting M. High-dose buprenorphine: Perioperative precautions and management strategies. *Anaesth Intensive Care* 2005; 33:17–25.
57. Barker SJ, Badal JJ. The measurement of dyshemoglobins and total hemoglobin by pulse oximetry. *Curr Opin Anaesthesiol* 2008;21:805–810.
58. Wahr J, Parks R, Boisvert D. Pulse oximetry. In: Blitt H, ed. *Monitoring in Anesthesia and Critical Care Medicine.* 3rd ed. New York, NY: Churchill Livingstone; 1994:385.
59. Coriat P, Vrillon M, Perel A, et al. A comparison of systolic blood pressure variations and echocardiographic estimates of end-diastolic left ventricular size in patients after aortic surgery. *Anesth Analg* 1994;78:46–53.
60. Minto G, Scott MJ, Miller TE. Monitoring needs and goal-directed fluid therapy within an enhanced recovery program. *Anesthesiol Clin* 2015; 33:35–49.
61. Wuethrich PY, Burkhard FC, Thalmann GN, et al. Restrictive deferred hydration combined with preemptive norepinephrine infusion during radical cystectomy reduces postoperative complications and hospitalization time: A randomized clinical trial. *Anesthesiology* 2014;120:365–377.
62. Avidan MS, Zhang L, Burnside BA, et al. Anesthesia awareness and the bispectral index. *N Eng J Med* 2008;358:1097–1108.

63. Myles PS, Leslie K, McNeil J, et al. Bispectral index monitoring to prevent awareness during anaesthesia: The B-Aware randomised controlled trial. *Lancet* 2004;363:1757–1763.
64. American Society of Anesthesiologists Task Force on Intraoperative Awareness. Practice advisory for intraoperative awareness and brain function monitoring: A report by the American society of anesthesiologists task force on intraoperative awareness. *Anesthesiology* 2006;104:847–864.
65. Bonner S. Admission and discharge criteria. Post anesthesia care. Connecticut: Prentice Hall International; 1990.
66. Avidan MS, Jacobsohn E, Glick D, et al. Prevention of intraoperative awareness in a high-risk surgical population. *N Eng J Med* 2011;365:591–600.
67. Mashour GA, Shanks A, Tremper KK, et al. Prevention of intraoperative awareness with explicit recall in an unselected surgical population: A randomized comparative effectiveness trial. *Anesthesiology* 2012;117:717–725.
68. Hines R, Barash PG, Watrous G, et al. Complications occurring in the postanesthesia care unit: A survey. *Anesth Analg* 1992;74:503–509.
69. Breslow MJ, Miller CF, Parker SD, et al. Changes in T-wave morphology following anesthesia and surgery: A common recovery-room phenomenon. *Anesthesiology* 1986;64:398–402.
70. Apfel CC, Korttila K, Abdalla M, et al. A factorial trial of six interventions for the prevention of postoperative nausea and vomiting. *N Eng J Med* 2004;350:2441–2451.
71. Charbit B, Funck-Brentano C. Droperidol-induced proarrhythmia: The beginning of an answer? *Anesthesiology* 2007;107:524–526.
72. Nuttall GA, Eckerman KM, Jacob KA, et al. Does low-dose droperidol administration increase the risk of drug-induced QT prolongation and torsade de pointes in the general surgical population? *Anesthesiology* 2007;107:531–536.
73. Marks RM, Sachar EJ. Undertreatment of medical inpatients with narcotic analgesics. *Ann Intern Med* 1973;78:173–181.
74. Hubner M, Blanc C, Roulin D, et al. Randomized clinical trial on epidural versus patient-controlled analgesia for laparoscopic colorectal surgery within an enhanced recovery pathway. *Ann Surg* 2015;261:648–653.
75. ERAS Compliance Group. The Impact of Enhanced Recovery Protocol Compliance on Elective Colorectal Cancer Resection: Results From an International Registry. *Ann Surg* 2015;261:1153–1159.
76. Melzack R, Wall PD. Pain mechanisms: A new theory. *Science* 1965;150: 971–979.
77. Tverskoy M, Cozacov C, Ayache M, et al. Postoperative pain after inguinal herniorrhaphy with different types of anesthesia. *Anesth Analg* 1990;70:29–35.

Chapter 14

Oncology

Adam C. Yopp and John C. Mansour

Key Points

1. Cancer is responsible for nearly 1 in 4 deaths within the United States and is the second leading all-age cause of death, regardless of gender.
2. Five percent to 10% of reported cancers are secondary to familial cancer syndromes.
3. Tobacco use and dietary factors are the two most common environmental risk factors associated with cancer.
4. Population-based screening tests are available for the following cancers: cervical, colon, breast, and prostate.

The earliest known description of cancer is documented in a series of Egyptian papyri, the Edwin Smith and George Ebers papyri, written circa 1500 BC. These scrolls detail events approximately 1,000 years earlier, documenting surgical, pharmacologic, mechanical, and magical treatments of cancer. Although illustrated in the papyri, the word “cancer” is first attributed to Hippocrates (460 to 370 BC) nearly a thousand years later. Cancer, the Greek term for crab (“karkinoma”) describes the finger-like spreading projections of an ulcer-forming tumor. Later the Roman physician, Celsus (28 to 50 BC), translated karkinoma into the Latin term cancer, the term most commonly used today. The study of cancer or oncology is attributed to another Greek physician, Galen (130 to 200 AD), who used the Greek word for swelling, oncos, to describe tumors.

EPIDEMIOLOGY

1 Cancer is responsible for nearly 1 in 4 deaths within the United States and is the second leading all-age cause of death, regardless of gender. In 2015, an estimated 1.6 million new cases will be diagnosed and over a half million patients will die of cancer within the United States. In men, the most common forms of cancer are from prostate, lung and bronchus, and colorectal origins. In women, the most common forms are breast, lung and bronchus, and colorectal. Cancers of the lung and bronchus, prostate, and colorectum in men and cancers of the lung and bronchus, breast, and colorectum in women are, in order, the most common cause of cancer-related deaths (Table 14-1).[1]

Although, the overall incidence rate of cancer has been 23% lower among women compared with men since 1992, the rate in men has also declined by −0.6% over the period from 2006 to 2011, largely due to decreases in colorectal, prostate, and lung cancers. During the same time period there was no change in incidence of cancer among women, largely due to the stable rate of breast cancer (Fig. 14-1).[1]

The decline in incidence for the most common cancer types is secondary to improvements in both cancer control and prevention. The long-term decline in colorectal cancer incidence rates since 1985 can be attributed to both changes in associated risk factors and the introduction of effective screening programs. For example, increased rates of diagnostic and therapeutic polypectomies during screening colonoscopies have contributed to declining colorectal cancer incidence rates by interrupting the adenoma to carcinoma sequence.[2–4] Similarly, lung cancer incidence rates declined in the mid-1980s in men and in the late 1990s in women as a direct result of changed smoking habits.[1,5,6] In contrast to stable or declining incidence rates in the leading cancer subtypes, increased incidence rates for skin melanoma, esophageal adenocarcinoma, thyroid carcinoma, primary liver carcinoma, kidney carcinoma, pancreas carcinoma, and human papillomavirus (HPV)-related oropharyngeal cancers were observed over the past two decades. Among both men and women the largest increase in annual incidence rates over the last decade was in thyroid cancer and primary liver cancer (Fig. 14-2).[1,7]

Throughout most of the 20th century overall mortality rate associated with cancer rose secondary to smoking-related lung cancer deaths, especially in men, peaking at 215.1 deaths per 100,000 persons in 1991.[1] However, over the past two decades the mortality rate has steadily declined as a direct result of advances in prevention, early detection, and treatment.[1] The most current, 2010 cancer mortality rate estimate is 171.8 deaths per 100,000 persons.[1] Mortality rates for the most common cancers: breast, prostate, and colorectal cancers are down from peak rates by 34%, 45%, and 46%, respectively.[3,8,9] In contrast, mortality rates are rising for cancers of the oropharynx, anus, liver, pancreas, skin melanoma, and soft tissue. Although thyroid cancer is increasing in incidence the observed mortality rate is stable over time, likely a result of indolent underlying tumor biology and a lead time screening bias (Figs. 14-1, 14-2).[1]

RISK FACTORS

Genetic Risk Factors

In 1971, Alfred Knudson described his "two-hit hypothesis" model for retinoblastoma, a rare form of childhood retinal cancer affecting 11.8 patients per one million live births in the United States.[10,11] In his hypothesis, Knudson postulated that familial retinoblastoma required a first "hit" in the form of an inherited germline mutation and a second "hit" through an acquired mutation for development of retinal tumors.[10] This hypothesis was validated more than two decades later following cloning of *RB1* as the tumor suppressor gene implicated in familial retinoblastoma, thereby ushering in a new frontier of study: cancer susceptibility or familial cancer syndromes.[12]

Table 14-1 Ten Leading Cancer Types for Men and Women by Incidence and Mortality, United States, 2015

Estimated New Cancer Cases			
Males		**Females**	
Cancer Type	**Incidence (%)**	**Cancer Type**	**Incidence (%)**
Prostate	26	Breast	29
Lung and bronchus	14	Lung and bronchus	13
Colon and rectum	8	Colon and rectum	8
Urinary bladder	7	Uterine corpus	7
Melanoma of skin	5	Thyroid	6
Non-Hodgkin lymphoma	5	Non-Hodgkin lymphoma	4
Kidney and renal pelvis	5	Melanoma of skin	4
Oral cavity and pharynx	4	Pancreas	3
Leukemia	4	Leukemia	3
Liver and intrahepatic bile duct	3	Kidney and renal pelvis	3
Other sites	19	Other sites	20
Estimated Cancer Deaths			
Males		**Females**	
Cancer Type	**Incidence (%)**	**Cancer Type**	**Incidence (%)**
Lung and bronchus	28	Lung and bronchus	26
Prostate	9	Breast	15
Colon and rectum	8	Colon and rectum	9
Pancreas	7	Pancreas	7
Liver and intrahepatic bile duct	5	Ovary	5
Leukemia	5	Leukemia	4
Esophagus	4	Uterine corpus	4
Non-Hodgkin lymphoma	4	Non-Hodgkin lymphoma	3
Urinary bladder	4	Liver and intrahepatic bile duct	3
Kidney and renal pelvis	3	Brain and other nervous system	2
Other sites	23	Other sites	22

Adapted from Siegel RL, Miller KD, Jemal A. Cancer statistics, 2015. *Ca Cancer J Clin* 2015;65:5–29.

Familial Cancer Syndromes

2 The discovery of inherited mutations of genes associated with an increased risk of cancer provides important opportunities for early detection and prevention of common and rare forms of human malignancies. Genetically related cancer is a spectrum, ranging from common variants with low penetrance to rare variants with either moderate or high penetrance (Fig. 14-3). Linkage studies have successfully identified the majority of familial cancer syndromes through DNA analysis of large families with affected individuals, linking disease phenotypes or cancer subtypes to regions of the genome, with candidate genes subsequently sequenced for a causative mutation. These linkage studies have identified the rare, highly penetrant cancers of hereditary cancer syndromes that account for about 5% to 10% of reported cancers (Table 14-2).[12] The more common, but lower-penetrant variants of genetic-, nonsyndrome-related cancers are typically found

through large, genome-wide analysis of unrelated persons with common cancers. In genome-wide association studies (GWAS) the entire genome is sequenced and single alterations, or single-nucleotide polymorphisms (SNPs), are used to delineate increased risks of cancer related to genetic risks.[13]

In both high and low penetrant genetically related cancers a high clinical suspicion is necessary for diagnosis and to formulate appropriate screening and treatment plans. To aid the clinician, tools have been developed to obtain an accurate family history, thereby assessing the risk of genetically related cancers (Table 14-3).[14] If the clinician has a reasonable suspicion that a patient may be either at risk for or has a genetically related cancer, further follow-up with a dedicated genetic counselor is recommend.[15] We herein summarize the five most prevalent familial cancer syndromes with regard to genetic mechanism and diagnosis.

Hereditary Nonpolyposis Colon Cancer

Hereditary nonpolyposis colon cancer (HNPCC), previously known as Lynch syndrome, is the most prevalent familial cancer syndrome and is responsible for 2% to 5% of all colorectal cancer.[16] An autosomal dominant syndrome, HNPCC is caused by a germline mutation in one of six genes: *MLH1, MSH2, MSH3, MSH6, PMS1,* or *PMS2.*[17–21] All six of the genes function in DNA mismatch repair and between 45% and 70% of HNPCC families have mutations in the most common gene variants: *MLH1, MSH2,* or *MSH6.* Patients with mutations in mismatch repair genes exhibit microsatellite instability, with errors in replication of highly repetitive sequences unable to be repaired, resulting in alterations of the length of the total repeat sequence.

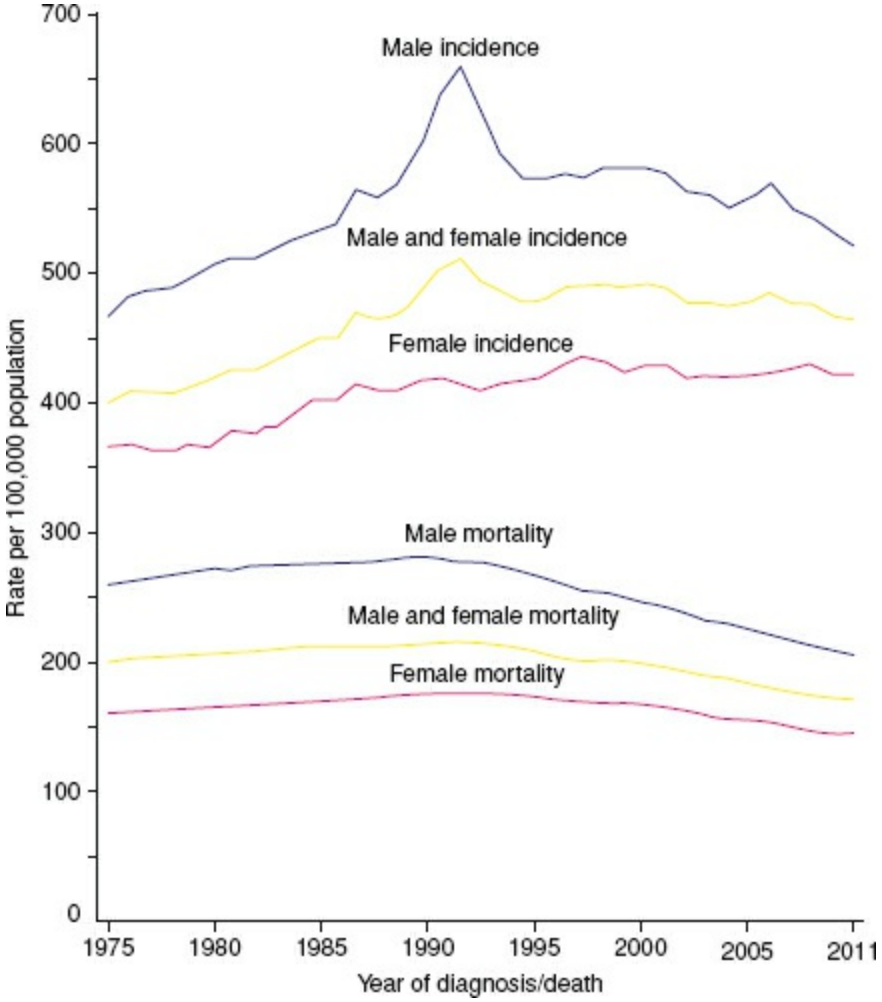

Figure 14-1. Trends in age-adjusted cancer incidence and death by gender, United States, 1975 to 2011. (From Siegel RL, Miller KD, Jemal A. Cancer statistics, 2015. *Ca Cancer J Clin* 2015;65:5–29.)

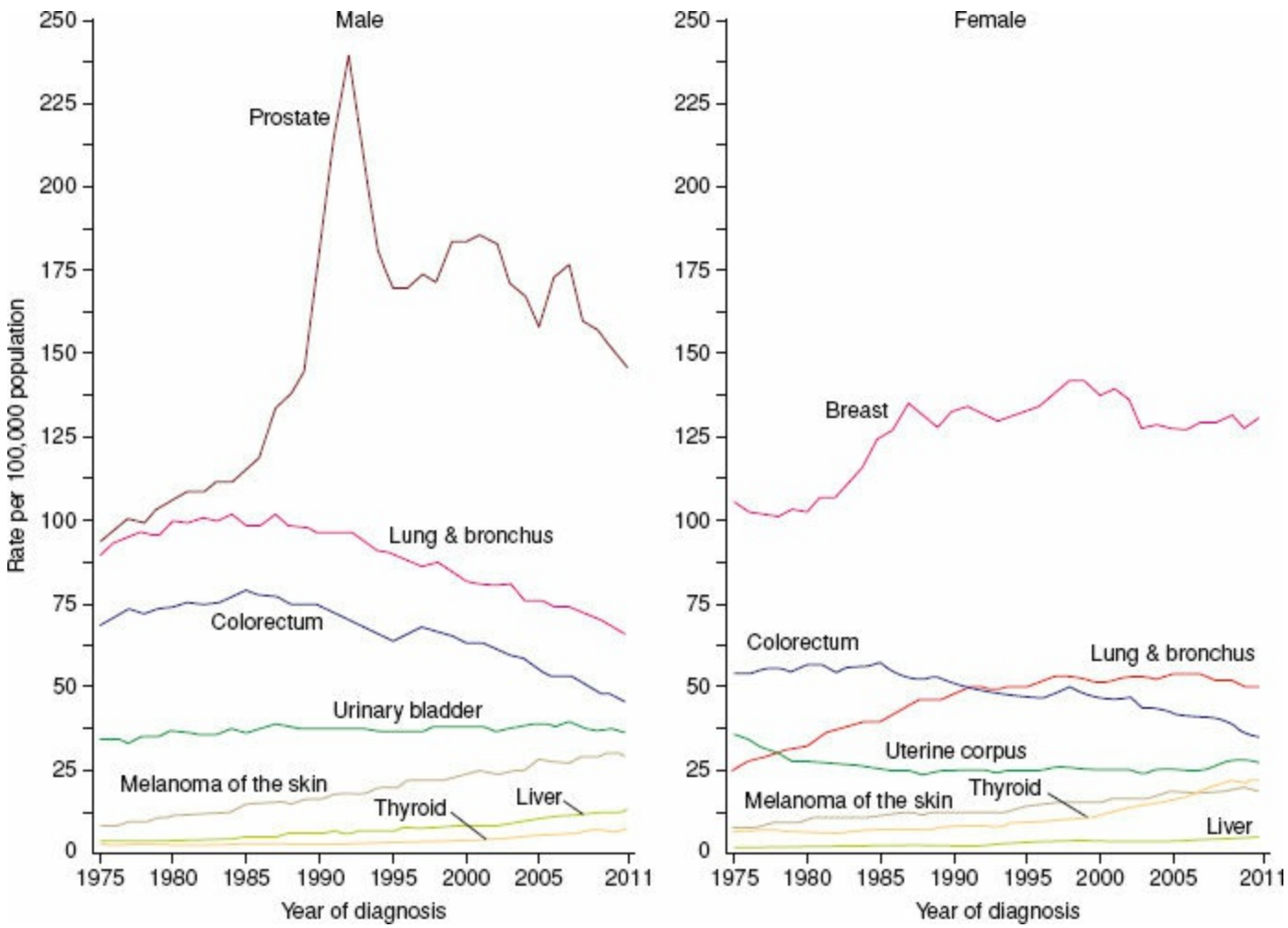

Figure 14-2. Trends in age-adjusted cancer incidence by gender and site, United States, 1975 to 2011. (From Siegel RL, Miller KD, Jemal A. Cancer statistics, 2015. *Ca Cancer J Clin* 2015;65:5–29.)

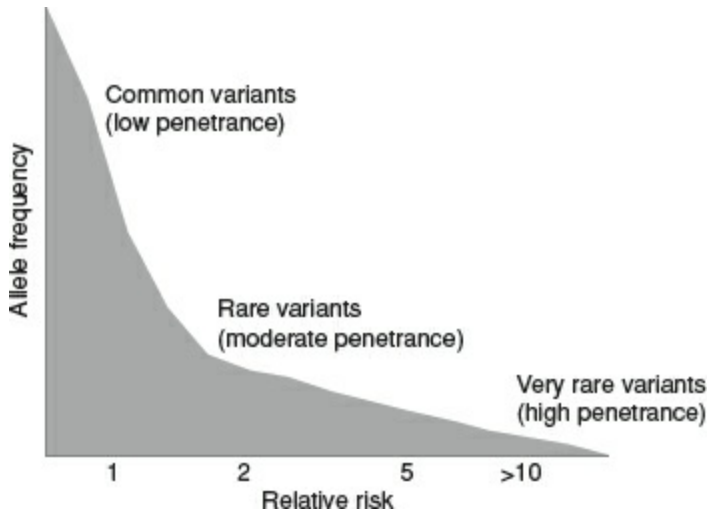

Figure 14-3. Genetic architecture by cancer risk.

Clinically, HNPCC is associated with right-sided colonic tumors with histopathology demonstrating poorly differentiated adenocarcinoma and signet ring features. Patients with HNPCC have a 50% to 80% lifetime risk of colorectal cancer, with a median age of diagnosis in the mid-40s. An increased risk of endometrial cancer, ovarian cancer, stomach cancer, small intestine cancer, ureteral cancer, and kidney cancer is also seen in HNPCC kindreds.[22–24]

Currently, testing for HNPCC is recommended for all newly diagnosed cases of colorectal cancer that fulfill the revised Bethesda guidelines, in families that meet the Amsterdam II criteria, in patients with endometrial cancer diagnosed before age 50, or in families with known HNPCC (Table 14-4).[25,26]

Table 14-2 Familial Cancer Syndromes

Autosomal Dominant Disorders
Basal cell nevus syndrome (Gorlin syndrome)
Carney syndrome
Chordoma
Cowden syndrome
Esophageal cancer with tylosis
Familial adenomatous polyposis
Familial melanoma
Hereditary diffuse gastric cancer
Hereditary breast and ovarian cancer
Hereditary nonpolyposis colon cancer
Li–Fraumeni syndrome
Multiple endocrine neoplasia, type 1 and type 2
Neurofibromatosis, type 1 and type 2
Paraganglioma
Peutz–Jeghers syndrome
Prostate cancer
Renal cancer
Retinoblastoma
Tuberous sclerosis
von Hippel–lindau disease
Wilms tumor
Autosomal Recessive Disorders
Ataxia-telegiectasia
Bloom syndrome
Fanconi anemia
Werner syndrome
Xeroderma pigmentosum

Table 14-3 Clinical Aid Suggesting the Presence of a Hereditary Cancer Disposition

Individual Patient	Patient's Family
Multiple primary tumors in same organ	One first-degree relative with same or related tumor
Multiple primary tumors in different organs	≥2 first-degree relatives with tumor types belonging to known familial cancer syndrome
Bilateral primary tumors in paired organ	≥2 first-degree relatives with same tumor
Multifocality within same organ	≥2 first-degree relative with rare tumors
Younger than usual age at diagnosis	≥2 relative in two generations with tumor of the same site
Rare histology	
In gender not usually affected	
Associated with congenital defects or other genetic traits	
Associated with an inherited precursor lesion	
Associated with another rare disease	
Associated with cutaneous lesions known to be related to cancer susceptibility disorders	

Adapted from Lindor NM, McMaster ML, Lindor CJ, et al. Concise handbook of familial cancer susceptibility syndromes - second edition. *J Natl Cancer Inst Monogr* 2008;38:1–93.

Table 14-4 Amsterdam II and Revised Bethesda Guidelines for the Testing of Hereditary Nonpolyposis Colorectal Cancer

Amsterdam II criteria

There should be at least three relatives with a hereditary nonpolyposis colorectal cancer (HNPCC)-associated cancer (cancer of the colorectum, endometrium, small bowel, ureter, or renal pelvis) and the following:

- One should be a first-degree relative to the other two
- At least two successive generations should be affected
- At least one should be diagnosed before age 50
- Familial adenomatous polyposis should be excluded
- Tumors should be verified by pathologic examination

Revised Bethesda guidelines

Tumors from patients should be tested for microsatellite instability (MSI) in the following situations:

- Colorectal cancer diagnosed in a patient who is less than 50 years of age
- Presence of synchronous, metachronous colorectal, or other HNPCC-associated cancers, regardless of age
- Colorectal cancer with MSI histology diagnosed in a patient less than 60 years of age
- Colorectal cancer diagnosed in one or more first-degree relative with an HNPCC-associated cancer, with one of the cancers diagnosed under age 50
- Colorectal cancer diagnosed in two or more first- or second-degree relative with HNPCC-associated cancers, regardless of age

Familial Adenomatous Polyposis

Familial adenomatous polyposis (FAP) is a highly penetrant, autosomal dominant syndrome with an incidence between 1 in 5,000 and 1 in 10,000 and is responsible for approximately 1% of all colon cancer cases.[27] Arising from a mutation in the antigen-presenting cell (*APC*) gene on chromosome 5q, nearly 75% of cases are due to familial germline mutations with the remainder secondary to first-generation de novo mutations.[28]

Clinically, FAP manifests with hundreds to thousands of adenomatous polyps at a young age with a resultant risk of colon cancer of 90% by age 45.[29] In addition to colonic

manifestations, duodenal and gastric polyps are also prevalent with a lifetime risk of duodenal cancer ranging from 5% to 12%, typically periampullary in location. Benign, extraintestinal manifestation of FAP includes desmoid tumors, mesenteric fibrosis, epidermoid cysts, osteomas, congenital retinal pigment epithelium, and dental anomalies and typically accompanying adenomatous polyp formation.[29]

Hereditary Breast and Ovarian Syndrome

Hereditary breast and ovarian syndrome (HBOC) occurs at an incidence rate of 1 in 500 or 1,000 and is inherited in an autosomal dominant fashion with a penetrance of nearly 85%.[30,31] Germline mutations in *BRCA1* (chromosome 17q) or *BRCA2* (chromosome 13q) are responsible for approximately 60% of HBOC, with mutations in *ATM, NBM, BRIP1, CHEK2, TP53, PTEN,* and *RAD51C* responsible for the remaining cases.[32,33] *BRCA1* and *BRCA2* are DNA damage repair genes and more than 1,000 variants have been identified with founder *BRCA* mutations documented in genetically isolated populations.[34] In the United States, the most common founder mutations occur in Ashkenazi Jewish lineage with nearly 1 in 40 carrying the common *BRCA1* or *BRCA2* mutations.[34] Genetic linkage studies of families with HBOC syndrome demonstrate that the lifetime risk of developing breast and ovarian cancers by age 70 is 56% and 17%, respectively.[30,32]

Familial Gastric Cancer

Hereditary diffuse gastric cancer (HDGC) is autosomal dominant in nature and is characterized by diffuse gastric cancer and lobular breast cancer with a nearly uniform penetrance and an 80% lifetime risk of gastric cancer.[35] The average age of developing hereditary gastric cancer is 38 years. Thirty to 40% of families with HDGC have germline mutations in *CDH1* at chromosome 16q, a gene producing the E-cadherin protein necessary for cell proliferation and adhesion within the stomach mucosa.[36] Currently, the diagnosis of HDGC is suspected if a person or family meets any of the below criteria[37]:

- At least two cases of stomach cancer in a family, with at least one being diffuse gastric cancer diagnosed before age 50
- At least three cases of stomach cancer at any age
- Diagnosis of diffuse gastric cancer before the age of 45
- Diagnosis with both diffuse gastric cancer and lobular breast cancer

von Hippel–Lindau Disease

von Hippel–Lindau Disease (VHL) is an autosomal dominant syndrome characterized by the formation of hemangioblastomas of the brain, spinal cord, and retina.[38] In addition, individuals with VHL disease may develop renal or pancreatic cysts and are at an increased risk for clear cell renal cell carcinoma, pheochromocytomas, and pancreatic neuroendocrine tumors. Arising from a germline mutation of the *VHL* gene on chromosome 3p, the protein product degrading hydroxylated hypoxia inducible factor-1α, nearly 80% of cases are familial.[39] Unlike most autosomal dominant disorders, VHL disease subscribes to the Knudson “two-hit hypothesis” with mutation of both *VHL* alleles

necessary for tumor or cyst formation.[38]

Environmental Risk Factors

Although the cause of most human cancers remains unidentified, the causal association between carcinogenesis and exposure to environmental risk factors is significant. The first known documented link between cancer and exposure to a carcinogen was documented in the treatises of the English surgeon Percivall Pott.[40] In 1775, Pott documented the high incidence of scrotal cancer among chimney sweeps secondary to soot lodging in scrotal skin. Subsequent preventive measures aimed at increasing bathing and use of protective clothing led to a dramatic decline in the incidence of scrotal cancer. It was not until the 20th century that the active carcinogens in soot were shown to be polycyclic aromatic hydrocarbons.[41] Table 14-5 lists the most common carcinogens associated with human cancers.

Table 14-5 Preventable Exposures Associated with Human Solid Organ Cancers

Cancer Site	Carcinogenic Agents with Sufficient Evidence
Oral pharynx and tonsil	Alcoholic beverages, betel quid, HPV type 16, tobacco (smoking and smokeless)
Nasopharynx	Epstein–Barr virus, formaldehyde, tobacco (smoking)
Esophagus	Alcoholic beverages, betel quid, tobacco (smoking and smokeless), gamma radiation
Stomach	H. pylori, tobacco (smoking), gamma radiation
Colon and rectum	Alcoholic beverages, tobacco (smoking), gamma radiation
Anus	HIV type 1, HPV type 16
Liver and bile duct	Aflatoxins, alcoholic beverages, *Clonorchis sinensis*, HBV, HCV, *Opisthorchis viverrini*, plutonium, thorium-232, tobacco (smoking), vinyl chloride
Pancreas	Tobacco (smoking and smokeless)
Lung	Arsenic, asbestos, beryllium, cadmium, chromium, coal, nickel, outdoor air pollution, painting, plutonium, radon-222, silica, soot, sulfur, tobacco (smoking and second hand), gamma radiation
Skin (melanoma)	Solar radiation, ultraviolet-emitting tanning, polychlorinated biphenyls
Pleura (mesothelium)	Asbestos, painting
Breast	Alcoholic beverages, diethylstilbestrol, estrogen–progestogen contraceptives and menopausal therapies, gamma radiation
Cervical	Diethylstilbestrol, estrogen–progestogen contraceptives, HIV, HPV types 16,18,31,33,35,39,45,51,52,56,58,59, tobacco (smoking)
Ovary	Asbestos, estrogen menopausal therapy, tobacco (smoking)
Kidney	Tobacco (smoking), gamma radiation, trichloroethylene
Thyroid	Radioiodines, gamma radiation

Adapted from Cogliano VJ, Baan R, Straif K, et al. Preventable exposures associated with human cancers. *JNCI* 2011;103:1–13.

Tobacco and Cancer

Tobacco use is associated with more cancer-related deaths worldwide than any other environmental risk factor. There are now 19 cancers for which causal evidence exists between cancer formation and cigarette smoking: lung, oral cavity, nasopharynx, nasal

cavity, larynx, esophagus, liver, stomach, colorectum, pancreas, kidney, ureter, urinary bladder, cervix, ovary, and bone marrow. Three cancers have known causality with smokeless tobacco use: oral cavity, esophagus, and pancreas.[42] Table 14-6 details the relative risks by cancer site of tobacco smoking.

The causative carcinogens in tobacco products are broad and heterogeneous. In fact, the International Agency for Research on Cancer (IARC) working group has identified 72 carcinogens contained in cigarette smoke linked to cancer development.[43] The underlying pathophysiology for smoking-related cancer is organ specific but likely dependent on the oxidative damage caused by the carcinogens producing free oxygen radicals and redox cycling.[44]

Viral Risk Factors

Nearly 15% of cancers or 1.3 million cancer cases worldwide can be attributed to viral infection.[45] The search for human tumor viruses is accentuated by a long appreciation of viral-linked cancers in birds and rodents. Peyton Rous in 1911 demonstrated spindle cell sarcomas could be readily transmitted from diseased to healthy chickens using tumor cell infiltrates.[46] This observation led to the identification of the Rous sarcoma virus (RSV), a member of the *Retroviridae* family, as causative agent responsible for Rous' original observation decades earlier.[46]

The lack of convincing animal models confirming epidemiologic studies coupled with the lack of oncogene expression by human tumor–associated viruses has delayed recognition of virus-induced human cancers. Using both epidemiology and molecular biology analysis, six viruses are established as causative agents of cancer (Table 14-7). Hepatitis B and C viruses (HBV and HCV), HPV, and the human herpes virus 8 (HHV-8) (Kaposi sarcoma-associated herpes virus) will be discussed in further detail.

Table 14-6 Cancer Sites Associated with Tobacco Smoking by Relative Risk According to the International Agency for Research on Cancer Working Groups

Cancer Site	Average Relative Risk
Lung	15–30
Larynx	10
Oro- and hypopharynx	4–5
Urinary tract	3
Esophagus (squamous)	2–5
Pancreas	2–4
Esophagus (adenocarcinoma)	1.5–2.5
Stomach	1.5–2.5
Liver	1.5–2.5
Uterine cervix	1.5–2.5

Adapted from Sasco AJ, Secretan MB, Straif K. Tobacco smoking and cancer: a brief review of recent epidemiological evidence. *Lung Cancer* 2004:S3–S9.

Table 14-7 Human Tumor–Associated Viruses

Virus	Family	Cancer Type	Oncogene
Hepatitis B	Hepadnaviridae	Hepatocellular carcinoma	X protein
Hepatitis C	Flaviviridae	Hepatocellular carcinoma	None
Epstein–Barr	Herpesviridae	Burkitt lymphoma, Hodgkin lymphoma, nasopharyngeal carcinoma	*LMP-1*
Human papillomavirus	Papillomaviridae	Cervical, anal, penile, and head and neck cancers	*E6/E7*
Human T -lymphotropic virus type 1	Retroviridae	Adult T-cell leukemia	*Tax*
Kaposi sarcoma	Herpesviridae	Kaposi sarcoma, pleural effusion lymphoma, multicentric, Castleman disease	vGPCR,vIL-6, vBcl2, vMIPs, vFlip, vCyclin, LANA

Hepatitis B and Hepatitis C Viruses

HBV and HCV are hepatotropic viruses causing both acute and chronic viral hepatitis and are responsible for nearly 90% of hepatocellular carcinoma (HCC) cases diagnosed worldwide.[47] HBV, a member of the *Hepadnaviridae* family, is a circular double-stranded DNA that incorporates into the cellular DNA of hepatocytes at random sites. Although the exact mechanism for induction of HBV-related HCC remains unknown due to the long latency period between viral infection and cancer appearance it is postulated to occur through either (1) induction of chronic liver cell injury leading to random chromosomal and genetic injury or (2) expression of X protein from the incorporated HBV activating the mitogen-activated protein kinase, c-jun N-terminal kinase, protein kinase C, phosphatidylinositol 3-kinase, protein kinase B, and JAK/STAT pathways.[48–51]

HCV is a single-stranded RNA virus from the *Flaviviridae* family, unique as the only human tumor virus utilizing RNA as genetic material. Responsible for the vast majority of HCC cases within the United States, HCV has six known genotypes and has a latency period from infection to HCC formation typically more than two decades. The actual pathophysiologic mechanism for HCV-related HCC development is unknown but like HBV-related HCC is thought to occur secondary to creating a state of chronic inflammation and regeneration within the liver parenchyma at the hepatocyte level.[52,53]

With the development of a HBV vaccine in the late 1970s the incidence of HBV-related HCC has decreased worldwide. Although there is no commercially available HCV vaccines, since 2010 there are orally bioavailable drugs that dramatically decrease the HCV viral load. However, it is unclear whether HCV treatment will impact HCC incidence rates as many patients have already progressed to cirrhosis prior to actual HCV diagnosis.

Human Papilloma Virus

HPV is a nonenveloped double-stranded DNA tumor virus that is responsible for a variety of epithelial disorders ranging from benign to malignant. Although consisting of over 100 known variants, HPV-16 and HPV-18 are designated high risk for tumor induction and are responsible for over 70% of known cervical and anal cancers.[54,55] The molecular pathogenesis of HPV-related cancers is better understood than other viral-associated cancers and occurs following HPV infection of keratinocytes at the basal epithelial layer of the stratified squamous epithelium. Upon HPV integration into host DNA, two viral genes, E6 and E7, are expressed and their products bind to a *p53* tumor suppressor gene (E6) and/or retinoblastoma suppressor protein (E7) to deregulate cell growth and inhibit apoptosis leading to the accumulation of mutations and the development of cancers following a length latency period.[56,57] The recent development of quadrivalent and bivalent HPV vaccines is expected to have a significant impact on the development of HPV and subsequent cervical and anal cancer incidence.[58]

Human Herpes Virus 8

HHV-8, also known as Kaposi sarcoma-associated herpes virus, is a double-stranded DNA virus from the *Herpesviridae* family associated with the development of Kaposi sarcoma, primary effusion lymphoma, and multicentric Castleman disease. HHV-8 has a latent and

lytic phase persisting in B-lymphocytes. During the latent phase HHV-8 evades the host immune system and has only minimal expression of gene products. However, in the lytic phase innumerable viral proteins are produced including viral G protein–coupled receptor, K1, v-cyclin, and v-Bcl-2 that modulates cell growth, induces vascular endothelial growth factor (VEGF) expression, and inhibits apoptosis, respectively, leading to induction of cancer.[59,60]

Dietary Risk Factors and Obesity

3 Dietary factors are thought to account for nearly 30% of cancer cases in developed countries, making dietary factors second only to tobacco use as the most preventable cause of cancer.[61] The contribution of diet to cancer risk in developing countries is considerably lower, most estimates indicate a 20% causal rate.[62] Attaining definitive evidence to confirm or refute effects of specific dietary factors on cancer incidence is oftentimes difficult with causal associations relying on migration patterns of immigrants. Migration studies have demonstrated that the incidence of many cancers change as much as 5- to 10-fold among immigrants over time, approaching that of the host country. The age at migration appears linked to cancer development among first-generation immigrants, suggesting that the susceptibility to environmental carcinogenic influences varies with age by cancer type.[63–65] Table 14-10 lists cancer sites with causal associations with dietary factors.

Obesity

The most important impact of diet on the risk of cancer is mediated through body weight. The IARC working group on weight control and physical activity estimates in developed countries a body mass index over 25 kg/m^2 accounts for approximately 39% of endometrial, 25% of kidney, 11% of colon, 9% of postmenopausal breast cancer, and 5% of total cancer incidence.[66]

The mechanisms linking obesity and cancer development are largely unknown but likely multifactorial. An example of a causal association between cancer and obesity is in postmenopausal breast cancer. A weight gain of 10 kg or more is associated with a significant increase in breast cancer incidence among women who have never used hormone replacement therapy.[67] This is likely secondary to large increases in endogenous estrogen levels, also leading to increased incidence of endometrial cancer.[68] The mechanism for obesity-related nonbreast or nonendometrial cancers remains unclear and is under clinical investigation.

Table 14-8 Human Cancers Associated with Dietary Factors and Nutrition

Dietary Factor Associated with Increased Cancer Risk	Cancer Site
Overweight and obesity	Esophagus, colorectum, breast, endometrium, kidney
Alcoholic beverages	Oral cavity, pharynx, larynx, esophagus, liver, breast
Aflatoxin	Liver
Chinese-style salted fish	Nasopharynx

Cell Cycle

Control of the cell division cycle is central for governing when the cell should progress to DNA synthesis and proliferation versus growth arrest, DNA repair, or apoptosis. Cell division proceeds through a well-defined series of stages with tightly regulated and balanced processes dependent on oncogene and tumor suppressor gene expression (Fig. 14-4). When cells leave quiescence (G_0), they enter a first gap phase (G_1) where an explosion of growth factors and macromolecules is transcribed and translated allowing cells to divide but not lose overall size. Toward the end of G_1, cells reach a restriction point governed by cell cycle checkpoint genes where thereafter they are now committed to division. It is at this restriction point where DNA repair or programmed cell death (apoptosis) occurs and where phosphorylation of the tumor suppressor product, RB protein, allows entry into the S phase. During the S phase, DNA is synthesized and progression to second gap phase (G_2) follows. Within the middle of the G_2 phase yet another restriction point or cell cycle checkpoint occurs prior to cell entry into mitosis (M), the actual cell division phase.[69]

Proto-oncogenes code for proteins that send signals to the cell nucleus promoting cell division, especially at the G_1–S and G_2–M transition points. Oncogenes are altered versions of proto-oncogenes also coding for signaling proteins but in a continuous fashion leading to incontrollable cell division and thus, tumor development. The conversion of proto-oncogenes into oncogenes occurs through three basic methods: (1) a mutation within a proto-oncogene producing an increase in protein activity (seen in the conversion of the *Ras* proto-oncogene), (2) an increase in the amount of protein within the cell resulting in amplified expression (i.e., *c-MYC* proto-oncogene), and (3) a chromosomal translocation where fusion proteins are produced or protein expression is altered (i.e., Philadelphia chromosome, *BCR/ABL*).[70]

Tumor suppressor genes also play a crucial role in the cell division cycle serving as a brake for division in response to DNA damage. The tumor suppressor genes, *p53* and *RB,* play a critical role in maintaining the checkpoint at the G_1–S transition point.[71,72] Homozygous loss of *p53* is found in 65% of colon cancers, 30% to 50% of breast cancers, and 50% of lung cancers. In addition, p53 germline mutations are associated with Li–Fraumeni syndrome, an autosomal dominant disorder associated with sarcomas, breast cancer, leukemia, and adrenal gland cancers.[73]

Cancer Immunology

The fundamental tenet of the immune surveillance hypothesis, postulated by Thomas and Burnet nearly five decades ago, is that the underlying function of the immune system is to survey the human body, recognize and then eliminate tumors based on tumor antigen expression.[74,75] Well documented in nonhuman animal models, the role of the immune system as a surveillance and treatment response in human malignancies is debatable and is best supported by tangential clinical evidence. In humans, cancer incidence rates correlate to advancing age presumably due to increased cell division and error rates in chromosomal replication over time that the immune system simply cannot overcome.

A corollary to the immune surveillance hypothesis is that immunodeficient individuals have an increased rate of cancer development.[76] Epidemiologic studies of patients with heritable immunodeficiencies demonstrate mixed results for this hypothesis. Incidence rates of traditional noncommon cancers including Kaposi sarcoma and lymphoblastic lymphoma have demonstrated increased frequency in heritable immunodeficiencies.[77] However, common epithelial-based cancers, including lung, colorectal, and breast, have similar incidence rates as the general population.[77] The initial epidemiologic studies were conducted at a time when patients with heritable immunodeficient disorders rarely lived past 30 years of age, so it is difficult to ascertain whether subtle changes in incidence seen in the more common epithelial cancers are more obvious as patients age. A similar phenomenon is seen in acquired immunodeficiencies, including acquired immunodeficient syndrome (AIDS), where uncommon cancers such as Kaposi sarcoma and non-Hodgkin lymphoma and not epithelial-based tumors remain the most common AIDS-related cancers.[78] As HIV-positive individuals are living longer due to more efficacious antiretroviral treatments, common epithelial cancers as well as cancers secondary to viral coinfectivity, with hepatitis viruses and/or HPV have increased in incidence.[79,80]

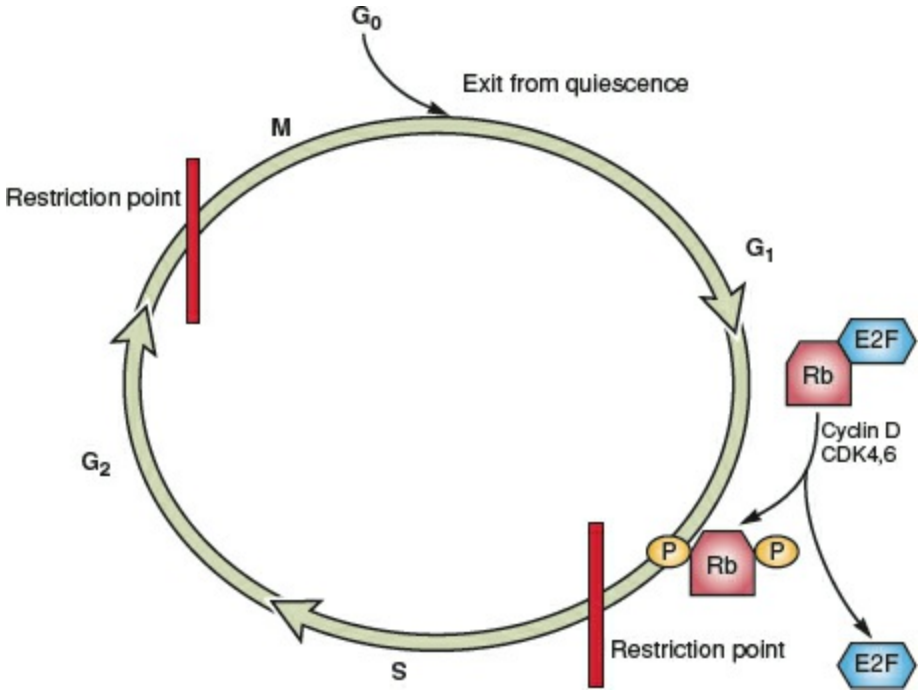

Figure 14-4. Mammalian cell cycle. Rb, a tumor suppressor gene, is complexed to E2F and is thereby unable to enter from G_1 to S phases. Upon signaling from the checkpoint genes, CDK4, 6, and cyclin D, Rb is phosphorylated allowing passage into S phase.

Another cohort, with an acquired immunodeficiency, demonstrating increased incidence rates of common and noncommon cancers are patients receiving immunosuppressive drugs following transplantation. A recent study examining cancer incidence in patients following heart and/or lung transplantation receiving immunosuppression therapy demonstrated a sevenfold increased incidence of cancer compared to the general population, with leukemia and lymphoma being the most prevalent.[81] Additionally, nearly a 200-fold increase in basal and squamous cell carcinomas is demonstrated following renal transplantation, secondary to immunosuppression and UV radiation damage.[82]

Tumors differ fundamentally from their normal cell counterparts through the production of tumor antigens, thereby allowing the immune system to differentiate self versus nonself. Tumor antigens are generated by the tumor cell and have historically been broken into two groups, tumor-specific antigens and tumor-associated antigens.[76] Tumor-specific antigens are molecules, typically proteins produced by the tumor secondary to a mutation of a proto-oncogene or tumor suppressor gene. Tumor-associated antigens are proteins produced following gene mutations unrelated to tumor formation. Due to lack of specificity between the two historical terms, tumor antigens are more accurately classified according to mutation of normal self-proteins, overexpression or aberrant expression of normal self-proteins, glycoproteins, or glycolipids, and formation of protein products of oncogenes or oncoviruses.[76]

The innate immune system response to tumors can be divided into two general compartments: a set of barriers and cell activity.[83] The barriers are comprised of mechanical factors including the skin and mucous membrane, chemical factors including high gastric acidity, and biologic barriers including commensal microbes. Natural killer

cells, macrophages, and dendritic cells comprise the cellular component of the innate immune system response.

Natural killer cells constitute the primary innate immune cell type responsible for killing nonmajor histocompatibility complex (MHC) expressing cancer cells. Many tumors lose MHC class I molecules during malignant transformation while continuing to express ligands such as MICA and MICB that constitutively bind NK receptors, including NKG2D, inducing tumor cell apoptosis through perforin and granzyme release.[84] Macrophages can efficiently eliminate apoptotic tumor cells through the release of lysosomal enzymes, reactive oxygen intermediaries, and nitric oxide. Dendritic cells link the innate immune system to the adaptive immune system. Residing in specific tissues according to dendritic cell lineage, dendritic cells phagocytize tumor antigens and carry the proteins to draining lymph tissue presenting to tumor-specific T cells. Depending on the state of dendritic cell maturity caused by costimulatory molecule signaling, either a state of anergy/tolerization (immature) or activation (mature) of tumor-specific T cells and the adaptive immune system response occur.[76]

Evidence supporting activation of the adaptive immune system response in mouse tumor cell models is well documented. However, its role in human malignancies is not as clearly defined due to the heterogeneity of the tumor microenvironment and the obvious lack of immunodeficient human models. Nevertheless, compelling clinical data supports the hypothesis that an adaptive immune system response serves as a mechanism for tumor cell death in humans. Tumor infiltrating lymphocytes (TILs) including $CD8^+$ T cells, natural killer cells, or natural killer T cells have been associated with improved prognosis for a number of different tumor types.[85–88] The initial association between favorable prognosis and TILs was first observed in melanoma patients where it was reported that patients with higher levels of $CD8^+$ T cell tumor infiltration survived longer than patients with tumors containing lower numbers.[85] The mechanism of TILs and especially $CD8^+$ T-cell–mediated tumor elimination requires tumor antigen presentation by APCs, typically dendritic cells. Activation of $CD8^+$ T cells occurs following binding of MHC class I molecules expressed by APCs and costimulatory molecule expression. The most widely studied costimulatory molecule pathway is the B7-CD28 interaction with B7 expressed on APCs and CD28 on $CD8^+$ T cells. Following $CD8^+$ T-cell activation, intracellular signaling activation of the NF-AT, NF-kb, and AP1 pathways leads to further $CD8^+$ T-cell activation and promotion of tumor cell death.[76]

Although the original immune surveillance hypothesis is critical to understanding cancer cell eradication it is likely that tumor cell tolerance and evasion play a much more important role in tumor cell growth, thus offering opportunities for development of novel immunotherapies. The most successful molecules to be targeted in clinical cancer immunotherapy are the immune checkpoint receptors, cytotoxic T-lymphocyte–associated antigen 4 (CTLA4), and programmed cell death protein 1 (PD1). Both PD1 and CTLA4 are inhibitory receptors that regulate immune responses at different levels and via different mechanisms (Fig. 14-5).[89]

CTLA4, the first immune checkpoint receptor to be clinically targeted, is expressed exclusively on T cells, where it primarily regulates the amplitude of the early stages of T-

cell activation. Although expressed on activated $CD8^+$ T cells, the major physiologic role of CTLA4 appears to be through effects on $CD4^+$ regulatory (T_{reg}) and helper cells. Thus, blockade of CTLA4 appears to switch the tumor microenvironment from immunosuppressive to immunoreactive.[90,91] An antihuman CTLA4 antibody, ipilimumab, was shown in a cohort of patients with advanced melanoma to induce an objective response rate in tumors previously treated with IL-2. Although there is significant immune-related toxicity involving skin, liver, or colon, ipilimumab has gained FDA approval for the treatment of advanced melanoma.[92]

In contrast to CTLA4, the major role of PD1 is to limit the activity of T cells in peripheral tissues at the time of T-cell activation to tumor antigen presentation. Similar to CTLA4, PD1 is highly expressed on T_{reg} cells acting as a suppressor mechanism to effector T cells ($CD8^+$ T cells).[93] Currently, two anti-PD1 inhibitors, pembrolizumab and nivolumab, have demonstrated efficacy in advanced melanoma patients with disease progression following ipilimumab treatment.[94,95]

The Role of the Surgeon in Cancer Management

For many patients, surgeons are the entry point into the healthcare system when managing cancer and cancer-related illness. For many surgeons, palliative or supportive care for patients with incurable malignancy comprises a significant portion of their practice. Surgeons are involved in every phase of cancer care from diagnosis to palliation. Many of the concepts covered in this chapter are covered on a disease-specific basis elsewhere in the textbook. Understanding the concepts underpinning many of the treatment approaches can help surgeons understand the rationale for current practice, and can also potentiate the development of new therapeutic strategies.

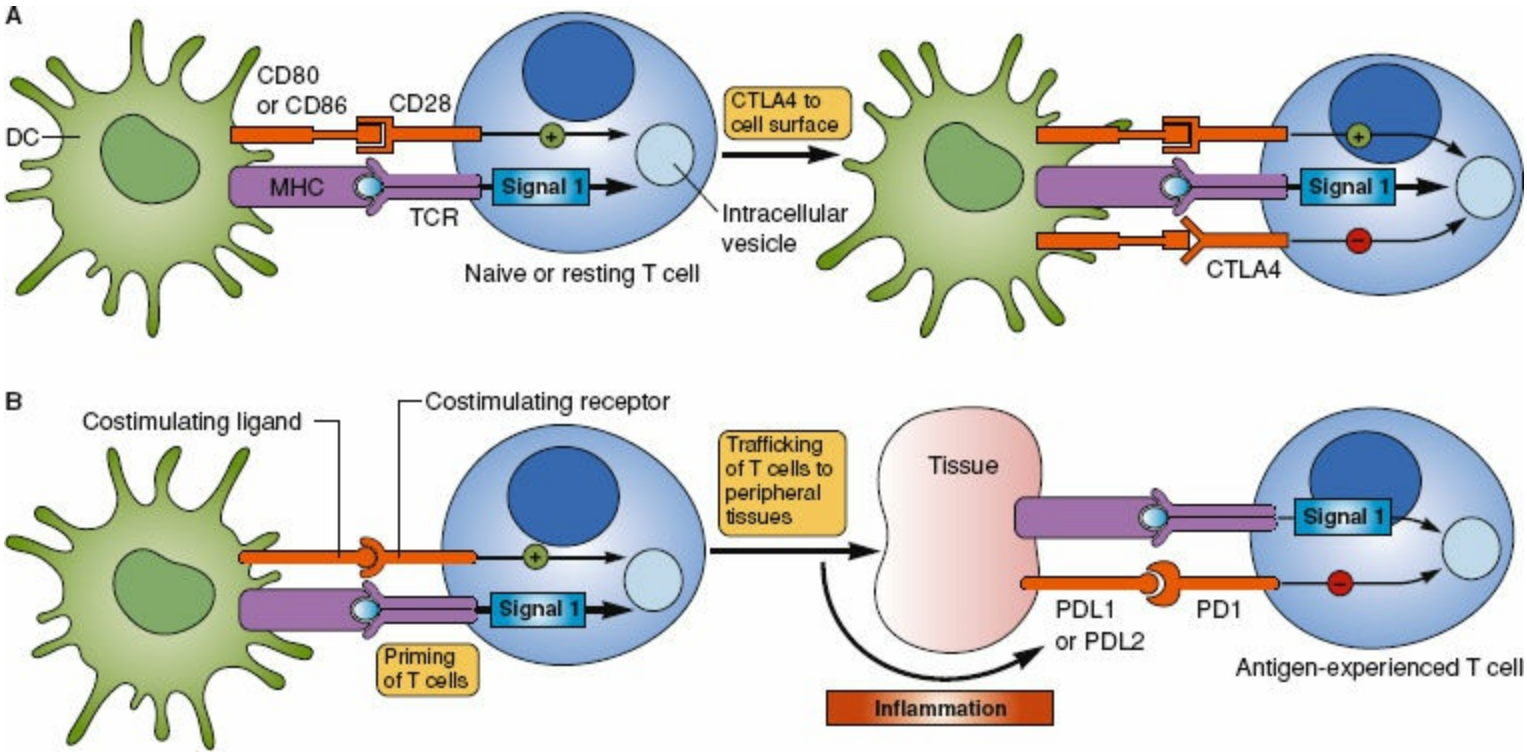

Figure 14-5. **A:** Upon antigen expression to the T cell receptor on memory or naïve T cells and subsequent stimulation, CTLA4 is transported to the T cell surface dampening further T cell activation. **B:** The activity of PD1 is further downstream in the inflammation process. PD1 is induced by activated T cells within peripheral tissues and signals to dampen further effector T-cell activation-limiting inflammatory cascade. (Adapted from Pardoll DM. The blockade of immune checkpoints in cancer immunotherapy. *Nat Rev Cancer* 2012;22:252–264.)

Surgical Intent

Although a significant portion of oncologic surgery practice focuses on curative resection of disease, the intent for many surgical situations does not include cure. Recognizing the goals of therapy prior to initiating a treatment course can help surgeons maintain a patient-centered approach with appropriate patient preoperative counseling and consent.

Diagnosis and Staging

The role of surgical biopsy to confirm the diagnosis of cancer prior to definitive therapy has been diminished recently by the advances of image-guided and endoscopic biopsy techniques. These techniques allow high levels of diagnostic accuracy with reduced

patient discomfort, expense, and use of hospital resources. Procedures such as punch biopsy for suspicious cutaneous lesions or excisional lymph node biopsy for characterization of lymphoma still remain a common diagnostic procedure for many surgeons.

A key aspect of these biopsies is a clear communication with the responsible pathologist regarding specialized tissue handling or preservation prior to initiation of the procedure. Specimen marking and orientation are critical for subsequent resection needs. Incorrect preservation of the biopsy specimen may obviate the possibility for flow cytometry when attempting to characterize lymph node suspicious for lymphoma. Intraoperatively, surgeons need to plan for a subsequent definitive resection when appropriate. Forethought in the selection of an incision or the extent of tissue plane dissection and disruption can make a subsequent definitive resection less morbid and less complex for the patient and surgeon. For instance, on occasion, extremity soft tissue tumors may require excisional biopsy. A longitudinal incision in the orientation of the affected limb can minimize the size of the incision during the subsequent definitive resection.

Surgeons may also play a key role in the staging of cancers. As entry points into the healthcare system for patients dealing with cancer, surgeons are often responsible for distilling the physical examination, radiologic, endoscopic, and surgical findings into a clinical stage assignation. For cancers, such as pancreatic adenocarcinoma, gastric adenocarcinoma, and ovarian cancer, the operative assessment of the peritoneum may identify radiographical occult carcinomatosis 10% to 25% of the time.[96–99] When performed laparoscopically in well-selected patients, this minor procedure can avoid the patient impact of a nontherapeutic laparotomy in the setting of metastatic, incurable cancer. In addition, lymphadenectomy, which will be discussed more fully elsewhere, serves an important prognostic role by allowing for complete staging of the nodal basins. The status of the nodal basins not only has important prognostic impact, but also defines the role of adjuvant therapy for many different cancer types.

Curative Resection

The ability to completely resect all viable tumors requires consideration of technical, oncologic, and functional resectability. A small number of tumor types are associated with surgical survival benefit in the setting of incomplete resection. Patients with cancers such as ovarian cancer and mucinous appendiceal cancer may benefit from cytoreduction with the possible addition of intraperitoneal chemotherapy.[100–104] Patients with life-limiting hormonal symptoms related to metastatic neuroendocrine tumors may gain survival benefit from cytoreduction and the resulting decrease in circulating hormones, such as insulin and somatostatin.[105,106] However, for the vast majority of cancers, survival benefit of resection is only associated with complete resection.[107–110] For that reason, a plan for resection should include extirpation of all viable tumor for patients with a treatment goal of cure.

The goals for curative resection should include not only complete removal of tumor, but also preservation of adequate patient function and the possibility of prolonged disease-free survival (DFS). These functional and oncologic aspects of resectability are the

metrics by which any planned resection can be judged successful. For instance, the role of resection of hepatic colorectal metastases or hepatocellular cancer is defined to a great degree by the amount of healthy residual liver and not necessarily the volume of liver tumors.[111–113] Conversely, even small-volume hepatic metastasis in the setting of pancreas adenocarcinoma precludes resection for curative intent.[114] Resectability for patients with colorectal hepatic metastases relies on functional preservation; resection for patients with pancreas cancer metastases is limited by oncologic outcomes.

Palliative Surgery

Symptoms related to the progression of malignant disease are a common problem faced by surgeons. A significant proportion of a surgeon's oncologic practice can be dedicated to providing palliation for patients with incurable conditions. This need is not limited to patients with malignancy; however, the principles associated with surgical palliation of cancer-related symptoms are a sound model for discussion regarding surgical palliation in general.

The primary concept driving decision-making for patients with palliative needs is the critical starting point of goal assessment. In order to deliver the most individualized, risk-appropriate, effective palliation to any given patient, surgeons need to ascertain the goals of therapy for each individual patient at that given time. This assessment transcends diagnosis-based treatment algorithms or pathways. Patients with gastric outlet obstruction related to metastatic gastric cancer may seem like a homogeneous group; however, the primary therapeutic goals of individual patients may vary dramatically. Treatment goals in that setting may include resolution of nausea, eating independently, long-term maintenance of nutrition, or improving performance status sufficiently to enter home hospice. These variable treatment goals can lead to variable treatment strategies, such as placement of a nasogastric decompression tube, a percutaneous gastrostomy tube, gastrojejunostomy, and/or antiemetic medications.

A second factor particularly relevant to palliative surgery for patients with cancer is the increased risk for many procedures in a population with incurable malignancy. Many patients eligible for palliative operations or procedures have been debilitated by malnutrition, physical deconditioning, prolonged hospitalization, or cytotoxic chemotherapy.[115,116] These factors, as well as the presence of metastatic disease, have all been associated with poor short-term outcomes following operations. Understanding the increased risks of even simple operations for this patient population can help the surgeon guide the patient and family conversations regarding the risks and benefits of a procedure. Making a decision with a patient and family regarding strategies for surgical palliation requires both an individualized assessment of the needs of those involved as well as a generalized awareness of the risks for that procedure based on associated risk factors.

Extent of Resection

For malignancies such as melanoma, breast cancer, or sarcoma, the requirement for radical resection has decreased significantly over the past several decades.[117–121] Conversely, for diseases such as pancreas cancer and liver tumors, the frequency and safety of radical resections have increased dramatically over that same time period.[122] A key point of judgment for surgeons involved in cancer operations is not only deciding when to operate, but also how extensive that operation should be.

Pathologic Margins

An important distinction must be made between surgical and pathologic margins. Surgical margins are the planned lines or planes of resection around a grossly visible tumor. The aim of this strategy is not to ensure a wide swath of healthy tissue around the tumor specimen, but to ensure a final negative pathologic margin. Pathologic margins are the histologically assessed borders of uninvolved tissue around the microscopic tumor. Tumors with infiltrative behavior may extend up to the pathologically assessed margin even though the grossly assessed surgical margin appears to be uninvolved. An example of this discrepancy occurs in the management of melanoma. Resection with a 1-cm surgical margin is generally considered adequate for a nonmetastatic extremity lesion with a tumor thickness of 1 to 2 mm. If the final pathologic margin is only 0.3 mm, this is considered a negative, and adequate, pathologic margin.

Table 14-9 Terms Typically Used to Describe Pathologic Margins for Cancer Resections

Margin Category	Microscopically Negative Pathologic Margin	Grossly Negative Surgical Margin
R0	x	x
R1		x
R2		x

The terms typically used to describe pathologic margins for cancer resections are defined below (Table 14-9). An R0 margin is typically considered negative and an R2 margin is considered grossly positive. For many, but not all, types of cancer, the presence of an R1 margin is associated with increased risk of recurrence. Management of a positive pathologic margin is dependent on technical and oncologic factors associated with that particular tumor. For instance, some early-stage cutaneous malignancies such as dermatofibrosarcoma protuberans or basal cell cancer are characterized by limited risk of distant disease dissemination and a high risk of local recurrence in the setting of positive pathologic resection margins. In a location where additional local excision may not be limited by adjacent structures, an effort for reexcision of a positive margin may be reasonable. Alternatively, the presence of cancer at the superior mesenteric artery (SMA) resection margin at the time of pancreaticoduodenectomy does not lead to an additional

operative attempt to achieve a negative final margin for patients with pancreas adenocarcinoma. The hesitation to attempt reresection is driven not only by the technical challenges of attempting to achieve a broader margin along the SMA, but also by the very high risk of distant recurrence for those patients and the relatively lower impact of local recurrence in this setting.[123–125]

Lymphadenectomy

The removal of regional lymph nodes at the time of resection of the primary tumor has been the focus of significant investigation and controversy throughout the contemporary history of surgical management of cancer. The surgical principles attributed to William Halsted regarding the surgeon's role in interrupting the progression of cancer from the primary tumor through lymphatic channels to regional lymph nodes and then to distant sites form the traditional rationale for regional lymphadenectomy.[126,127] However, more contemporary studies such as MSLT-1, the Dutch Gastric Cancer Lymphadenectomy, and ACOSOG Z0011 clinical studies have raised questions regarding the survival benefit of lymphadenectomy for patients with melanoma, gastric cancer, and breast cancer, respectively.[128–131]

The potential prognostic benefits of lymphadenectomy undoubtedly are more germane than therapeutic advantages. For almost all types of malignancy, the presence of cancer within regional lymph nodes portends a worse prognosis for patients, as a harbinger of systemic cancer spread. The accuracy of the assessment of the regional lymph node basin can be increased with either focused evaluation of the most at-risk lymph nodes (i.e., sentinel lymph node biopsy) or thorough sampling of a large number of nodes (i.e., lymphadenectomy). Accuracy of cancer staging, for example in colorectal cancer, is oftentimes increased through the sampling of a sufficient number of lymph nodes. The threshold for quality assurance through adequate lymph node sampling has been established for surgeons who perform colorectal cancer resections, however, that well-defined performance metric is not common to all types of resection and all types of cancer.[132–135]

For patients with bulky involved regional lymph nodes, the benefits of node removal are not likely prognostic. In selected patients, removal of these lymph nodes may provide some palliation from local symptoms. The role of "prophylactic palliation" or removal of lymph nodes, which may develop and cause local problems is less clear. For example, in melanoma or rectal cancer, eliminating all of the regional lymph nodes in the setting of positive microscopic nodal burden decreases the potential of future development of bulky, symptomatic nodes.[128,136–138] The therapeutic benefit of avoiding local recurrence in a subset of the operative population needs to be balanced against the potential adverse effects of lymphadenectomy. For many nodal basin sites, the adverse impact of interrupting lymphatic flow can have significant deleterious effects on patients following lymphadenectomy, including lymphedema, paresthesias, and even development of secondary malignancies, such as angiosarcoma (Stewart–Treves syndrome).[139–142]

In general, lymphadenectomy is an important aspect of surgical cancer care when any of the following criteria are met: (1) removal of regional lymph nodes will provide

important information to either guide adjuvant therapy decisions or provide prognostic clarity (e.g., colon cancer, gastric cancer); (2) lymphadenectomy can eliminate a predictably involved site of disease involvement which can lead to local regional complications in the setting of nodal recurrence (e.g., rectal cancer, esophageal cancer); (3) removal of at-risk lymph nodes is a minor adjunct of the procedure for primary tumor removal (e.g., pancreatectomy). The extent of our operative management for cancer is likely to change as we learn more about the therapeutic benefit of regional nodal removal. Perhaps more strikingly, the prognostic information gained by evaluating a nodal basin is likely to diminish as our ability to profile tumors and their behavior becomes more dependent on genomic, proteomic, and other expression profiling.

Resection of Metastatic Disease

Outside the palliative setting, the indications for resection of metastatic disease are relatively narrow. Despite the growing awareness and increased frequency of resection for metastatic colon cancer, endocrine tumors, and gastrointestinal stromal tumors, the vast majority of patients with metastatic disease are not eligible for metastasectomy. Although it is important to recognize the diverse spectrum of presentations for malignant disease and to be wary of absolute contraindications against surgical management of metastases, several general principles do apply to the overwhelming majority of patients with metastatic disease.

Complete elimination of all sites of disease is generally associated with dramatically improved survival compared to incomplete resection. In addition, the outcomes for patients with incompletely resected disease are frequently comparable to outcomes for patients who underwent no resection at all.[108–110,143–145] For these reasons, resection or ablation of all sites of disease is a common requirement when making a decision to proceed with resection of metastatic disease. This principle applies to patients with primary tumors in place as well; therefore, patients with unresectable primary tumors are generally not eligible for curative intent resection of their metastatic sites.

The behavior or biology of an individual's cancer may suggest a less aggressive phenotype and warrant consideration of metastasectomy. Oftentimes characteristics of favorable cancer biology are associated with improved survival outcomes following resection. A prolonged period of progression-free survival (PFS) or DFS is commonly associated with improved outcomes following resection of metastatic disease.[143–145] Progression of metastatic sites while receiving first-line systemic chemotherapy is often a harbinger of early systemic failure among patients undergoing resection of metastatic disease.[146,147] As systemic chemotherapy has grown more effective over the last decades, the impact on tumor progression and control of systemic disease has led to increased opportunities for resection of metastatic sites. This concept has been most plainly demonstrated in the context of hepatic colorectal metastases. The frequency of hepatectomy in that setting has increased in harmony with the increased effectiveness and availability of both cytotoxic and targeted chemotherapy agents.[122] Surgical management of metastatic disease may increase in frequency for other diseases as we develop more effective systemic therapy options.

Cancer-Related Surgical Outcomes

The short-term outcomes for surgical patients commonly include metrics, such as complication rates, length of stay, mortality rate, and overall survival (OS). These metrics are certainly important measures of quality and efficacy for patients undergoing operations for cancer. Similar to other surgical specialties, cancer-related surgery also carries specific outcome measures, which are particularly relevant to these clinical scenarios. Understanding these metrics is critical to balancing risk and benefit for individual patients as well as for evaluating the role of new therapeutic strategies and approaches.

Disease Recurrence

Many surgical specialties are directed at the eradication of a tangible, anatomically identifiable lesion. Peripheral and coronary vascular bypass, gastroesophageal fundoplication, and parathyroidectomy are all measured by how effectively the treatment eliminates the arterial plaque, gastroesophageal reflux, or hyperparathyroidism. Early recurrence of the condition suggests a failure of therapy or poor patient selection for the procedure. Disease recurrence is also a critical measure of the effectiveness of surgical therapy for cancer patients.

A prerequisite for disease recurrence as a measure of outcome is the initial eradication of all visible cancer. Recurrence can be measured by development of symptoms, physical examination, radiographic evaluation, biochemical evaluation, or operative exploration. Unique to the practice of surgery for cancer patients is the distinction between locoregional and distant disease recurrence. Locoregional recurrence is typically defined as recurrence in the resection bed or region of the draining regional lymph nodes. Distant recurrence is typically defined as occurrence of malignant cells outside of the initial primary tumor and lymphadenectomy resection field.

Although resection is traditionally considered a means to achieve locoregional control, and adjuvant systemic therapy is employed to control distant disease recurrence, a decision to proceed with an operation should consider how the operation impacts both locoregional and distant recurrence. A well-performed, radical, margin-negative operation can only lead to prolonged DFS if it is performed with appropriate patient selection. This distinction is the underpinning behind the approach for patients with small-volume metastatic disease in the setting of pancreatic adenocarcinoma, gastric cancer, or biliary tract cancers. Many patients, when faced with this scenario, will ask their surgeon, “Why can’t you just take out all of it?” Patients with easily resectable, distant disease are poor candidates for resection not because they cannot be rendered free of all visible disease but rather because the findings of metastases are highly predictive of early distant disease recurrence even if local control can be achieved. The trade-off for a short period of DFS after a radical operation is the chance at a more prolonged PFS or OS with the immediate initiation of effective systemic chemotherapy.

Progression-Free Survival

For patients who cannot have all visible tumor resected due to locally advanced disease or metastases, PFS is an important measure for subsequent therapy. The propensity for a treatment to control, but perhaps not eliminate, a measurable volume of tumor is the critical measure for defining the effectiveness of that therapy. For many types of cancer, PFS is a reliable surrogate for OS.[148,149] Typically, when patients experience disease progression while receiving a particular regimen of systemic therapy, the treating physician will consider initiating the next line of systemic treatment.

Radiographic progression of measurable lesions is measured by a well-defined set of criteria referred to as RECIST or modified RECIST criteria. Response Evaluation Criteria in Solid Tumors (RECIST) was developed in 2000 and subsequently modified in 2009 as a system for measuring tumor response or progression.[150] These criteria are commonly employed in clinical trials as a standardized way to determine when a tumor has progressed on therapy. A simplified description of the criteria is included in Table 14-10. This strategy requires the upfront identification of index lesions, which are measurable radiographically. RECIST has proven to be a useful measure of potential treatment benefit in phase II clinical trials. Although useful in clinical trials, stringent application of RECIST measures of progression is not as readily used outside trial settings. Even small changes in the one-dimensional measurements or characteristics of measurable lesions may be considered evidence for clinical progression and justification for a change in treatment course.

Return to Intended Oncologic Treatment

A novel measure for the quality of surgical management of cancer patients is return to intended oncologic treatment (RIOT).[151] This metric considers the place that resection holds in the multidisciplinary care of a cancer patient. Although surgical resection is required for a curative intent pathway for the majority of solid tumors, important oncologic adjuncts such as adjuvant chemotherapy, radiotherapy, and maintenance hormonal therapy can reduce the chances of recurrence and prolong survival for many patients. Delays or disqualifications due to operative adverse events may negatively impact the overall outcomes of patients. An important element in the assessment of the quality of cancer care is the ability for a health system to deliver all of the treatment modalities demonstrating benefit for a particular malignant condition. Recognizing that the definitive resection of a cancer is part of a larger treatment strategy is one of the important considerations for assessing surgical outcomes for patients with cancer.

Table 14-10 Common Criteria Used to Determine Therapy-Related Progression

Recist Category	Abbreviation	Definition
Complete response	CR	Disappearance of all target lesions
Partial response	PR	30% decrease in the sum of the longest diameter of target lesions
Progressive disease	PD	20% increase in the sum of the longest diameter of target lesions
Stable disease	SD	Small changes not meeting above criteria

The Role of Radiation Therapy in Cancer Management

Surgery is complemented by the modality of radiation therapy as part of a multimodal approach for many types of cancer. Like surgery, radiotherapy is typically focused on locoregional disease control. For that reason, many of the same principles apply to surgery and radiation oncology, such as patient selection, recognition of the behavior or tumor biology for a particular patient and cancer, and assessment of both short-term and long-term toxicities of therapy.

Mechanisms of Radiation Delivery

Energy emitted from a source travelling through space is termed "radiation." As the energy passes through materials it interacts with those substances in one of two forms: photons or freely propagating particles. Photons are packets of electromagnetic fields travelling through space at the speed of light. The shorter the wavelength of the photon the greater the frequency of the oscillation and the higher the energy contained within the photon packet. Lower-energy photons make up the energy in visible light and only interact with the surfaces of objects. Higher-energy photons are used in diagnostic and therapeutic radiology and can pass through tissues to interact with deeper material and either reveal or impact underlying structures. Freely propagating particles carrying kinetic energy can be protons, electrons, or alpha-particles. These charged particles interact with other charged particles as they travel along their path. As photons or charged particles interact with biologic materials within the target area in the setting of therapeutic radiation, the interactions lead to ionization and subsequent biologic damage.

Linear accelerators (linacs) are the most common means for generating radiation in a manner allowing focused delivery of energy to a target tissue. Linacs can be used to generate either photon radiation or electron particles to be used as the ionizing agent. The linac uses oscillating electric fields to accelerate electrons toward a metal target converting the electron beam into a spray of photons. The photons are focused through filters and shaping elements to sharpen the beam of energy being delivered. A higher energy level of the photons travelling through the shaping process will lead to a higher level of energy delivered to the surface of the treatment target. As the photon beam travels across distance through a material, the dose will attenuate as the depth of penetration increases. Photons with higher energy penetrate more deeply into any given material and maintain the energy level for a greater distance. As this ionizing radiation travels through tissues, the photons deposit energy into the materials through which it passes. The total amount of energy delivered to a biologic system is measured in terms of joules per kilogram. The dose corresponding to the amount of energy delivered is expressed in terms of Gray (units of dose).

Tissue Response to Radiation

The therapeutic effects of radiation are contingent on the damage caused to the cells through which the ionizing radiation beam passes. The mechanism of action of cellular damage can be categorized into direct and indirect effects of radiation (Fig. 14-6). Both

effects lead to the damage of DNA molecules. The direct effect of ionizing radiation is ionization of DNA molecules and the downstream effects of the damage to this critical cellular molecule. The indirect effect of ionizing radiation is best exemplified by the radiolysis of water molecules leading to the generation of free radicals. Free reactive species interact with DNA molecules causing indirect damage. The majority of total DNA damage is from this second, indirect effect. The proportional relationship between oxygen tension within tissues and the resultant damage caused by ionizing radiation is termed the *oxygen effect*.[152] The phenomenon is explained by the capacity to generate a greater concentration of free radicals in oxygen-rich tissues than in hypoxic environments.

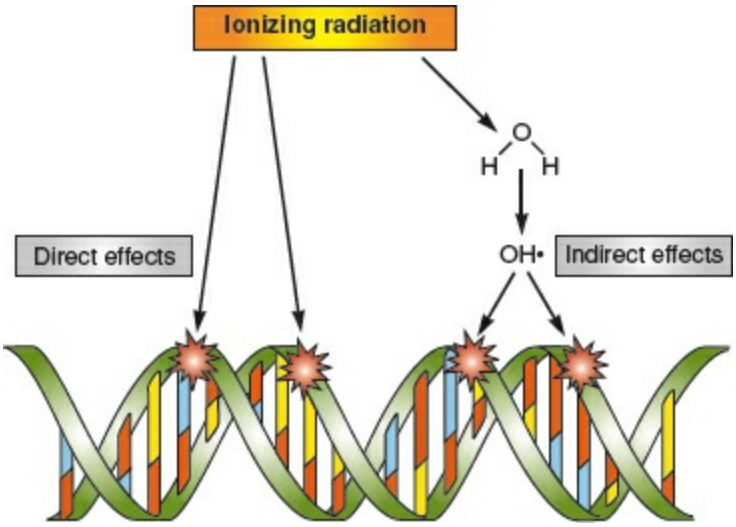

Figure 14-6. The mechanism of action of cellular damage can be categorized into direct and indirect effects of radiation.

Ionizing radiation can lead to multiple types of DNA damage: cross-linking of two DNA strands, loss of a DNA base or entire nucleotide, and breakage of the sugar-phosphate backbone.[153] Many of these types of damage are actually a failed attempt to eliminate unpaired electrons resulting from free radical generation. The mammalian cell has multiple DNA repair mechanisms operating with remarkable fidelity under typical conditions. In the setting of therapeutic radiation delivery, the DNA disruption is either too complex or too widespread to allow for normal mechanisms of repair. The generation of flawed versions of the original DNA molecule can lead to ineffective mitosis and failed cell division. Many cancer types are characterized by deficits in the DNA repair mechanism process.[154,155] When these processes function suboptimally, the impact of radiation-induced damage can be more potent on the mutated cancer cells than on the DNA-repair intact nonneoplastic cells. Disruption of DNA synthesis by fluoropyrimidines such as 5-fluorouracil and capecitabine likely contributes to the therapeutic benefit of combining these agents to radiation. Fluoropyrimidines interfere with the capacity of cellular DNA repair mechanisms to correct DNA lesions induced by ionizing radiation.

Of course, ionizing radiation is relatively nonselective in terms of its deposition of energy packets into the tissues it traverses. Both normal and neoplastic cells are targets for the effects of radiation if the tissues lie in the beam of delivery. Different types of normal tissues demonstrate different levels of sensitivity to radiation. Breast tissue,

intestinal mucosa, stem cells, lymphocytes, and bone marrow cells are considered radiosensitive based on their response to a given dose of radiation. Conversely, muscle cells, large arteries and veins, the heart, and neurons are considered more radioresistant based on the relatively low degree of cell death induced by radiation. Given a high enough radiation dose, nearly any malignancy can be destroyed. One of the key challenges of radiation therapy treatment planning is balancing the cytotoxic dose delivered to a given tumor with the impact that treatment will have on surrounding tissues. The therapeutic ratio is relationship between tumor killing and normal tissue complication rates.

Strategies to broaden the therapeutic ratio have focused on both increasing effective tumor killing and limiting the toxicity to normal tissues associated with a given dose of radiation. Approaches for increasing effective tumor killing include the use of radiosensitizers, preoperative radiation in a high oxygen tension environment, and fractionation. Fractionation is the division of a total therapeutic dose of radiation into multiple radiation treatments generally given daily. The biologic impact of dividing the total treatment dose is related to several cellular behaviors within the treatment field (Table 14-11). Fractionation increases the effectiveness of a radiation dose by allowing for *reoxygenation* and cell cycle *redistribution* within the tumor. Alternatively, approaches for reducing normal tissue toxicity include rotating gantry delivery systems using multiple beams reaching a single point via different routes through normal tissue, collimation allowing delivery of a narrow beam of energy, and fractionation. Fractionation decreases normal tissue toxicity by allowing initiation of DNA *repair* mechanisms and by a compensatory increase in cell proliferation in tissues such as stem cells in response to injury. The injury-induced increase in cell proliferation is termed *repopulation*. Since repopulation does not typically start until 4 weeks of radiation injury, most treatment plans are kept short to avoid tumor repopulation.

Understanding the deleterious effects of ionizing radiation on normal tissues is critical to understanding the therapeutic ratio for any radiation treatment plan. Desired cytotoxic effects on tumors are accompanied by undesirable cytotoxic effects on normal cells. Typically, treatment plans are developed to allow for the maximum tolerated dose (MTD) to be delivered to the structures within the treatment field. The MTD is based on the radiation tolerance of each structure or tissue type within that field. Plans incorporating shielding or avoidance of radiosensitive normal tissues can lead to safer and more effective therapy. Although radiosensitive cells generally have a lower tolerance dose than radioresistant cells, this principle does not always hold true. The early and late effects of ionizing radiation may not be wholly determined by the degree of cell killing. Downstream effects, such as compensatory proliferation, cytokine-mediated responses, and radiation-induced gene expression can lead to undesirable tissue effects within the treatment field.[156]

An important, although relatively uncommon, normal tissue effect of therapeutic radiation is the development of a second cancer. Approximately 20% of these second malignancies are leukemias. The majority of radiation-associated tumors are solid malignancies arising in the treatment field. These cancers typically develop many years

after the original treatment. The increasing number of patients surviving disease free after an initial radiation treatment course may lead to an increasing number of these late second cancer events. Children and immunocompromised adults are more likely to develop second cancers.[157] Importantly, the risk of developing a second cancer within the radiation field is relatively low. In clinical scenarios where the benefit of therapeutic radiation is clearly demonstrated, the incidence of second malignancies does not generally skew the risk/benefit assessment against therapeutic radiation. However, an awareness of the potential for the development of a second cancer is critical for those who care for long-term cancer survivors.

Table 14-11 The Biologic Impact of Dividing the Total Treatment Dose is Related to Several Cellular Behaviors Within the Treatment Field

Biologic Principle	Therapeutic Effect	Tissue Response During Treatment Interval
Reoxygenation	Increase tumor killing	Remodels tissue to increase oxygen tension within tumor leading to reduced radiation resistance
Redistribution	Increase tumor killing	Greater fraction of cells in the radiosensitive S-phase of the cell cycle
Repair	Reduce normal tissue effects	DNA repair mechanisms of normal cells activated
Repopulation	Reduce normal tissue effects	Increased cell proliferation in response to radiation-induced injury

Radiation Therapy Delivery Modalities

Ionizing radiation can be delivered to an intended treatment area in a number of ways. The choice regarding the proper treatment modality includes decisions regarding the timing of radiation, the use of concurrent chemotherapy, and the delivery system for the radiation energy. Just as with surgical therapy, the primary determinant for all of these decisions is the intent of any radiation treatment plan. Therapeutic radiation can be employed as a part of a nonsurgical definitive treatment plan, as a palliative therapy, or as a means to complement the locoregional control of a surgical resection.

Radiation Treatment Approaches

Perioperative radiation therapy with or without chemotherapy sensitizers is commonly employed for tumors, such as rectal cancers, gastroesophageal cancers, and soft tissue sarcomas.[158–160] When surgical therapy is combined with radiation and chemotherapy, this is often referred to as *trimodality* therapy. In these scenarios, radiation provides an additional element of local control by treating potential postsurgical residual disease in the tumor bed and lymphatic system. Preoperative radiation is generally preferred over postoperative radiation for several reasons. The normal tissue toxicity associated with any radiation treatment is largely within a planned field of resection when radiation is delivered preoperatively. Radiation delivered postoperatively is delivered entirely to a healing surgical bed. Additionally, treatment of a target field with an intact vascular supply and associated increased oxygen tension, theoretically enhances the indirect effects of the radiation energy. In clinical settings where the tumor is large or abuts major

structures, such as major blood vessels, nerves, or bony structures, the reduction in size of a tumor may allow for preservation of critical structures and their function.

Chemotherapy is often combined with radiation as a definitive therapy for cancers that are either unresectable or exquisitely radiosensitive. Patients with anal cancer can avoid an abdominoperineal resection the majority of time due to the extremely high complete response rates of combined chemoradiotherapy.[161] Locally advanced cancers such as pancreas adenocarcinoma or esophageal cancer may be treated with *concurrent chemoradiation* in order to alleviate local symptoms and limit the impact of local progression.

Definitive radiation therapy is not commonly employed for these locally advanced cancers. A more typical application of radiation alone is in the setting of certain small, radiosensitive cancers such as prostate cancer or nonmelanoma skin cancers.[162] Cutaneous tumors in sensitive areas such as the face or head are good candidates for this approach in order to avoid the need for significant soft tissue reconstruction. Patients with multiple high-risk comorbid factors or frailty may be good candidates for definitive radiation in order to avoid general anesthesia or prolonged inpatient recovery.

Radiation Therapy Delivery

The systems and technology used to generate and focus photons and electrons toward a target field can vary based on the requirements of each clinical scenario. Over the past several decades, techniques have advanced to generate a more focused beam of photons with increased delivery to target tissues and reduced collateral injury to normal tissue.

External beam radiation therapy is the most commonly employed therapeutic radiation strategy. Multiple angles of approach are used to deliver multiple beams of radiation to a target region. Modifiable factors with this approach include the angles of beam delivery, the shape of the beam, and the intensity of each beam. The radiation oncologist can adjust these factors to maximize the radiation dose focused on the target tissue while minimizing the effect on nearby, associated radiosensitive tissues. Patients undergo *simulation* as an early step in treatment planning. Contemporary simulation is typically performed with CT scan guidance. During this process, a patient undergoes a CT scan during which the radiation oncologist identifies the intended isocenter within target area. Using an integrated laser system to align the isocenter with sites on the patient surface, the radiation oncologist places tattoos to ensure reproducible, accurate beam alignment for future treatments. Patients typically undergo radiation treatment for 5 days a week for up to 6 weeks. *Intensity modulated radiation therapy* (IMRT) is an enhanced version of external beam therapy. IMRT uses mechanical devices or multiple beam integration to adjust the intensity within each beam in order to account for irregular patient surfaces or sensitive structures near the treatment region. By modifying the intensity within the beam, a more homogeneous dose distribution can be achieved within the target area.

Stereotactic body radiation therapy (SBRT) is a more specialized delivery system used for patients with brain tumors, lung cancer, and liver tumors. The applications of this technique are rapidly evolving as the expertise within the radiation oncology community grows. SBRT relies on precise motion control, high degrees of quality insurance,

hypofractionation (commonly 1 to 5 treatments), and a relatively high dose per fraction to deliver a potentially ablative dose to the target area. Whereas conventional external beam radiotherapy may deliver a dose of 45 to 60 Gy over a course of 25 fractions (approximately 2 Gy per fraction), SBRT delivers 7 to 15 Gy per fraction with a lower number of total fractions. This technique has the potential to be a more definitive therapeutic option than conventional radiotherapy in light of the ablative intent of the treatment.

The use of radioactive implants, or *brachytherapy,* is common in the treatment of prostate and gynecologic cancers. Radioactive seeds can be placed either directly into the tumor (interstitial therapy) or within catheter-containing applicators placed in the vicinity of the tumor bed (intracavitary therapy). Intracavitary therapy has been developed as a potential adjuvant therapy for patients following resection of soft tissue sarcoma or partial mastectomy in the setting of breast conservation therapy.[163] The use of intracavitary therapy in these clinical settings is being explored but has certainly not achieved widespread acceptance.

In addition to intraoperative placement of radiation delivery applicators following resection, surgeons have assisted with radiation delivery through the use of *intraoperative radiation therapy*. In select environments where a specialized intraoperative irradiator is available, radiation is given directly to the tumor bed where incomplete marginal resection has been performed. The radiation is delivered in a single fraction of 10 to 15 Gy in combination with more traditional perioperative external beam radiation. The most common clinical applications for this technique have been in the treatment of pelvic and retroperitoneal tumors such as recurrent rectal cancer and retroperitoneal sarcoma.

The Role of Chemotherapy in Cancer Management

The use of chemotherapy as a modality in the treatment of cancer is almost universal and its efficacy is based on systemic treatment of primary and metastatic cancer. Unlike surgical resection or radiation therapy, the goal of chemotherapy is not necessarily localized or locoregional but systemic cancer treatment.

The setting in which chemotherapy is given can be defined as neoadjuvant, conversion, adjuvant, or palliative, dependent on the goals of the planned treatment course. Neoadjuvant chemotherapy is administered prior to a planned curative surgical resection. The primary or metastatic tumor is considered technically resectable at baseline but due to oncologic concerns of aggressive tumor biology a period of chemotherapy is used. An example of neoadjuvant chemotherapy is in the treatment of advanced gastric cancer. The MAGIC trial for resectable gastroesophageal cancer included a treatment arm where patients with either node positive or locally advanced (by T tumor stage) gastric cancer were treated with a short course of chemotherapy prior to curative gastrectomy.[164] The potential benefits of neoadjuvant chemotherapy is to treat micrometastatic disease not seen on preoperative imaging, improve tumor-related symptoms, to allow for a period of time where metastatic disease can present precluding unwarranted surgical resection, and an in vivo method of determining tumor chemosensitivity. Conversion chemotherapy is also administered prior to surgical resection but the baseline tumor is considered unresectable, typically due to technical reasons, unlike in the neoadjuvant setting. An example of conversion chemotherapy is the administration of systemic chemotherapy to patients with metastatic colorectal liver metastases where upfront surgical resection is precluding by a sufficient future liver remnant.[165,166] The goal of conversion chemotherapy is to downsize the baseline tumor allowing a safe curative resection. Adjuvant chemotherapy is administered in the postoperative setting after the primary or metastatic tumor is surgically resected. This is perhaps the most common setting of chemotherapy administration. Palliative chemotherapy is the setting defined as unresectable primary or metastatic cancer where the goal of chemotherapy is prolongation of life and not necessarily conversion to a curative resection.

The choice of systemic chemotherapy regimens is oftentimes tumor specific and is based on demonstrated efficacy in large phase III randomized controlled clinical trials. Table 14-12 lists the most commonly administered chemotherapy regimens, the presumed mechanism of action, and the applicable cancers treated.

The increasing knowledge of cancer genetics and biology has generated potential new targets for systemic therapeutic regimens ushering in potential individualized cancer treatments. The best example of a genetic abnormality with a systemic therapy specific for a molecular target is the BCR-ABL chromosomal translocation seen in patients with chronic myelogenous leukemia (CML).[167] The BCR-ABL fusion protein is a dysregulated tyrosine kinase that has a causal role in the development of CML and serves as the target for a new class of molecular inhibitors, tyrosine kinase inhibitors. The use of imatinib mesylate in CML has served as a prototype for the development of molecular target agents in other cancers, including gastrointestinal stromal tumor.[168] Unfortunately, most

tumors, including the most common types, are genetically complex and do not offer a single target that serves as the critical inhibition point for cancer cell death.

Lack of single, molecular targets has led to the development of molecular targeted agents aimed at inhibition of pathways. An example of such a druggable pathway is the VEGF and its receptor (VEGFR). The VEGF pathway is an important regulator of physiologic and pathologic angiogenesis and is thought to promote tumor cell growth through increased vascular permeability, migration, differentiation of endothelial cells, and mobilization of bone marrow–derived endothelial cell precursors.[169] Overexpression of VEGF and/or VEGFR occurs in most common types of cancers and is associated with worse tumor presentation and outcome measures.[170–172] In 2004, the Federal Drug Administration approved bevacizumab, a humanized murine monoclonal antibody directed against VEGF, for the treatment of metastatic colorectal carcinoma.[173] Subsequent approval of sunitinib, sorafenib, and axitinib, three molecular targeted agents with activity against tyrosine kinase in addition to VEGF for renal cell carcinoma and HCC has established targeting pathways as a viable target for cancer therapeutics.[174–177]

Table 14-12 Common Systemic Therapeutic Agents for the Treatment of Cancer

Drug Name	Mechanism of Action	Relevant Cancers
Ziv-aflibercept (Zaltrap)	Fusion protein binding VEGF-related ligands	Colorectal cancer
Anastrazole (Arimidex)	Nonsteroidal aromatase inhibitor selectively blocks estrogen production	Breast cancer
Bacillus Calmette–Guérin (TICE BCG, TheraCys), BCG	Immunostimulant/vaccine; induces localized cellular immune response	Bladder cancer
Bevacizumab (Avastin)	Recombinant humanized monoclonal antibody binds VEGF	Colorectal cancer, NSCLC, RCC
Bleomycin (Blenoxane), Bleo	DNA strand breaks	Germ cell tumors, Hodgkin disease, squamous cell cancers, melanoma, ovarian cancer, Kaposi sarcoma
Capecitabine (Xeloda)	Oral antimetabolite prodrug	Breast cancer, colorectal cancer, head and neck squamous cell cancer
Carboplatin (Paraplatin), Carbo, CBDCA	DNA intrastrand and interstrand cross-links	Ovarian cancer, testicular cancer, squamous cell cancers – head, neck, cervix, lung cancer
Carmustine (BiCNU), BCNU, bis-chloronitrosourea	Alkylating agent	Melanoma, stomach cancer, colon cancer, liver cancer, brain tumors, multiple myeloma, Hodgkin disease, lymphoma, breast cancer
Cetuximab (Erbitux)	Recombinant humanized monoclonal antibody targeting EGFR	Colorectal cancer, head and neck cancer
Cisplatin (Platinol) – cDDP, DDP, cisplatinum, cis-diamminedichloro-platinum (II)	DNA intrastrand and interstrand cross-links	Lymphoma, testicular, ovarian, gastric cancer
Docetaxel (Taxotere), RP- 56976	Inhibits depolymerization of tubulin in the spindle apparatus	Metastatic breast cancer, NSCLC
Doxorubicin (Adriamycin, Rubex), Adria, hydroxydaunorubicin	Anthracycline induces free radical formation, altered mitochondrial function, and topoisomerase II inhibition	Breast carcinoma, sarcomas, pediatric solid tumors, Hodgkin disease, non-Hodgkin lymphomas, ovarian cancer

Epirubicin (Ellence)	Anthracycline induces free radical formation, altered mitochondrial function, and topoisomerase II inhibition	Breast cancer
Erlotinib (Tarceva)	Targets EGFR	NSCLC, pancreatic cancer
Etoposide (Vespid), VP-16, epipodophyllotoxin; also available as etoposide phosphate (Etopophos)	Plant alkaloid; topoisomerase II inhibitor	Germ cell tumors, SCLC, lymphomas, AML, brain tumors, non-SCLC, breast cancer, ovarian cancer, lymphomas
Everolimus (Afinitor)	mTOR inhibitor	Breast cancer, PNET, RCC, renal angiomyolipoma, TSC
Exemestane (Aromasin)	Steroidal aromatase inhibitor	Breast cancer
Floxuridine (FUDR), FdUR, fluorodeoxyuridine	Pyrimidine antimetabolite nucleotide analog	GI adenocarcinomas metastatic to the liver
5-Fluorouracil (Adrucil, Efudex), 5-FU	Pyrimidine antimetabolite inhibitor of thymidylate synthase	Colon, rectum, gastric, pancreas, breast carcinomas, liver metastases from GI tumors, cutaneous neoplasms, disorders
Fulvestrant (Faslodex) estrogen receptor antagonist	Estrogen receptor degradation	Breast cancer
Gemcitabine (Gemzar)	Antimetabolite nucleoside analog	Pancreatic adenocarcinoma, NSCLC, breast cancer, bladder cancer
Hydroxyurea (Hydrea) – hydroxycarbamide	Antimetabolite inhibitor of ribonucleotide reductase	CML, myeloproliferative disorders, melanoma, refractory ovarian carcinoma, squamous cell carcinoma – cervix, head, neck
Ifosfamide (Ifex)	Alkylating agent	Germ cell tumors, sarcomas, lymphoma, Hodgkin disease, breast cancer, ovarian cancer
Interferon-alpha (IntronA, Roferon)	Biologic response modifier	Melanoma, multiple leukemias and lymphomas
Interleukin-2 (Proleukin) – aldesleukin, IL-2	Cytokine stimulates lymphocytes and an inflammatory cytokine cascade	Renal cell cancer, metastatic melanoma, acute myeloid leukemia
Peginterferon alfa-2b (Sylatron)	Pleiotropic cytokine	Melanoma
Ipilimumab (Yervoy)	Human CTLA-4–blocking antibody	Melanoma
Irinotecan (Camptosar) – CPT-11	Topoisomerase I inhibitor	Colon cancer, lung cancer, ovarian cancer, lymphoma
Lapatinib (Tykerb)	EGRF and HER2 tyrosine kinase inhibitor	Breast cancer
Letrozole (Femara)	Nonsteroidal aromatase inhibitor	Breast cancer
Leuprolide acetate (Lupron) – leuprorelin acetate	Gonadotropin-releasing hormone agonist chronically inhibits pituitary gonadotropin release	Prostate cancer, breast cancer, endometriosis
Melphalan (Alkeran), l-PAM, l-phenylalanine mustard, l-sarcolysin	Alkylating agent	Myeloma, ovarian carcinoma
Methotrexate (Mexate, Folex, others) – MTX, amethopterin	Antifolate antimetabolite inhibits dihydrofolate reductase	Breast and bladder cancer, squamous cell cancers, sarcomas
Mitomycin C (Mutamycin)	Inhibits DNA and RNA synthesis	Stomach, pancreas, breast, lung adenocarcinoma
Mitotane (Lysodren), o,p'-DDD	Adrenocortical cytotoxin	Adrenal cortical carcinoma
Octreotide, octreotide long acting (Sandostatin, Sandostatin LA), l-cysteinamide	Synthetic peptide analog of somatostatin; hormonal inhibition of serotonin, insulin, glucagon, and gastrin	Carcinoid tumors
Oxaliplatin (Eloxatin)	DNA intrastrand and interstrand cross-links	Colorectal adenocarcinoma
Paclitaxel (Taxol, Onxol)	Inhibits depolymerization of tubulin in the spindle apparatus	Ovarian cancer, breast cancer, lung cancer, head and neck cancer, bladder cancer
Paclitaxel, protein bound (Abraxane)	Inhibits depolymerization of tubulin in the spindle apparatus	Breast cancer
Panitumumab (Vectibix)	Recombinant, fully humanized monoclonal antibody competitively binds to EGFR	Colorectal cancer

Pemetrexed (Alimta)	Antimetabolite; inhibits folate-dependent enzymes thymidylate synthetase, dihydrofolate reductase, and glycinamide ribonucleotide formyltransferase	Mesothelioma, NSCLC
Pertuzumab (Perjeta)	HER2/neu receptor antagonist antibody	Breast cancer
Regorafenib (Stivarga)	Small molecule inhibitor of membrane-bound and cellular kinases	Colorectal cancer
Sorafenib (Nexavar)	Inhibits VEGFR and PDGFR kinases as well as RAF/MEK/ERK kinases	Hepatocellular cancer, renal cell carcinoma
Streptozocin (Zanosar)	Alkylating agent	Neuroendocrine tumors, pancreatic carcinoma, Hodgkin disease
Sunitinib malate (Sutent)	Inhibits PDGFR and VEGFR	Renal cell carcinoma, GIST, pancreatic neuroendocrine tumors
Tamoxifen (Nolvadex)	Nonsteroidal antiestrogen	Breast cancer, melanoma, pancreatic cancer
Temozolomide (Temodar)	Atypical alkylator	Astrocytomas, gliomas, metastatic melanoma
Temsirolimus (Torisel)	mTOR inhibitor	Renal cell carcinoma
Thalidomide (Thalomid)	Antiangiogenic and immunomodulating agent	Renal cell carcinoma, metastatic melanoma, malignant gliomas
Topotecan (Hycamtin), hycamptamine	Inhibitor of topoisomerase I	Ovarian carcinoma, lung cancer, myeloid leukemias
Trastuzumab (Herceptin)	Genetically engineered humanized mouse monoclonal antibody against HER2/neu growth factor receptor	Breast cancer, gastric cancer
Vandetanib (Caprelsa)	kinase inhibitor	Thyroid cancer
Vemurafenib (Zelboraf)	Inhibits V600E serine–threonine and other kinases	BRAF+ melanoma
Vinblastine (Velban, Velsar, others), VLB, vincaleukoblastine	Vinca alkaloid; inhibitor of tubulin polymerization and mitosis; G2-phase specific	Hodgkin disease, non-Hodgkin lymphoma, germ cell tumors, breast cancer
Vincristine (Oncovin, Vincasar), leurocristine, VCR	Vinca alkaloid; inhibitor of tubulin polymerization and mitosis; G2-phase specific	Hodgkin disease, lymphomas, acute leukemias, rhabdomyosarcoma, neuroblastoma, Wilms tumor
Vinorelbine (Navelbine), 5'-noranhydrovinblastine, NVB	Semisynthetic vinca alkaloid; inhibitor of tubulin polymerization and mitosis; G2-phase specific	Breast cancer, NSCLC

Staging (Traditional and Genetic)

Cancer staging is the process of determining the cancer burden within the body and the location. Staging describes the severity of an individual's cancer based on the magnitude of the original or primary tumor as well as on the extent of cancer spread via metastases. Understanding and properly staging cancer is important as it provides a common language for communication among providers and patients, is a prognostic marker of outcome, allows appropriate treatment decisions, and stratifies patients for clinical trials.

There are four different types of staging: (1) clinical staging: based on physical examination, imaging tests, and appropriate biopsies, (2) pathologic stage: determined following surgical excision of cancer; both clinical and pathologic characteristics contribute to the pathologic stage, (3) neoadjuvant or posttherapy staging: following treatment with systemic chemotherapy or radiation therapy, relying on clinical and/or pathologic staging guidelines, and (4) restaging: the extent of recurrent disease following definitive therapy. The formal stage of a cancer does not change over time, even if the cancer progresses. A cancer that returns or demonstrates progression is still referred to by the stage it was given at first diagnosis. Restaged cancer is noted with a lower case "r" indicating a restaging designation.

Table 14-13 TNM Staging Based on AJCC and UICC Classification

T category describes the primary tumor	
Tx	Primary tumor cannot be evaluated
T0	No evidence of primary tumor
Tis	Carcinoma in situ
T1–T4	Size and/or extent of tumor
N category describes regional lymph node status	
Nx	Regional lymph nodes cannot be evaluated
N0	No regional lymph node involvement
N1–N3	Number and/or extent of lymph node involvement
M category describes distant metastatic disease	
M0	Absence of distant metastatic disease
M1	Distant metastasis

Tumor staging in most solid tumors is based on four main factors: (1) location of the primary or original tumor, (2) tumor size and/or extent of tumors, (3) lymph node involvement or spread, and (4) presence or absence of distant metastases. The TNM staging system developed by the American Joint Committee on Cancer (AJCC) and Union for International Cancer Control (UICC) is the most widely used system and is based on the extent of primary tumor (T), the extent of spread to lymph nodes (N), and the presence of metastases (M). Table 14-13 demonstrates the general AJCC/UICC TNM staging system; specific staging systems have been developed for each individual malignancy. Once the T, N, and M individual stages are determined, they are combined, and an overall stage of 0, I, II, III, or IV is assigned.

In addition to utilizing the traditional AJCC/UICC TNM staging systems, genomic data have been recently incorporated to further fine tune and guide treatment decisions. The best-studied example is the use of genomic tests for breast cancer staging. In four externally validated, commercially available tests, genomic information is coupled with pathologic staging helping providers to determine the risk of recurrence of early-stage, estrogen-receptor–positive breast cancers, and the benefit of adjuvant chemotherapy. In addition, these genomic tests also have been validated in breast ductal carcinoma in situ to determine the risk of recurrence following resection, the risk of a de novo cancer developing in the same breast, and the benefits of adjuvant radiation therapy.[178] Unfortunately, similar genomic tests with proven clinical validation are lacking in other cancer subtypes and remain exploratory and useful only in a research setting at this time.

Screening

The development of the periodic health examination in the late 19th century by medical providers was the impetus linking cancer mortality to delay in diagnosis. In 1907, Dr. Charles Childe published the first book, *The Control of a Scourge, Or How Cancer is Curable,* detailing cancer as a linear carcinogenesis pathway that could be interrupted by identification of early warning signs and symptoms, thus eradicating cancer.[179] Although too simple, this publication and others led to the upsurge of a large-scale health campaign in the 1940s within the United States aimed at advocating early cancer detection programs, or cancer screening.

Technologic advances in screening and early detection are essential for progress in both the prevention and treatment of cancer, but incorporation of such advances to useful clinical practice is often challenging and requires careful consideration of all potential risks and benefits. For any screening test to be useful, three tenets of screening should be met: (1) a test must exist that will detect the disease earlier than routine methods, (2) evidence must exist that earlier treatment leads to improved outcomes, and (3) benefits of screening must outweigh the risks associated with any subsequent diagnostic and therapeutic treatments.

The Canadian Task Force on the Periodic Health Examination and the United States Preventive Services Task Force (USPSTF) in Figure 14-7 provide the basic analytical framework necessary to delineate the steps for evaluating the worth of a screening test.[180] The framework demands a clear identification of the population at risk that is to be screened. The importance of this starting point is due to the potential changing nature of the screened population and extrapolation of findings from a subset of patients to a general population. More importantly, the framework details the adverse effects of both screening and treatment of early-stage cancers. Because screening tests are performed on healthy individuals there is significant potential harm associated with a false-positive test. A recent meta-analysis determined that after 3 years of screening tests, a man's and woman's risk of obtaining at least one false-positive test was 60% and 50%, respectively.[181,182] False-positive tests are a concern for three reasons. First, they have the potential to generate negative psychological consequences. Second, they can trigger a cascade of more invasive follow-up testing, which since the patient does not have cancer and can obtain no benefit, represents pure harm to the individual. Third, false-positive tests and the cascade of follow-up tests represent a significant burden to already strained healthcare resources.[183]

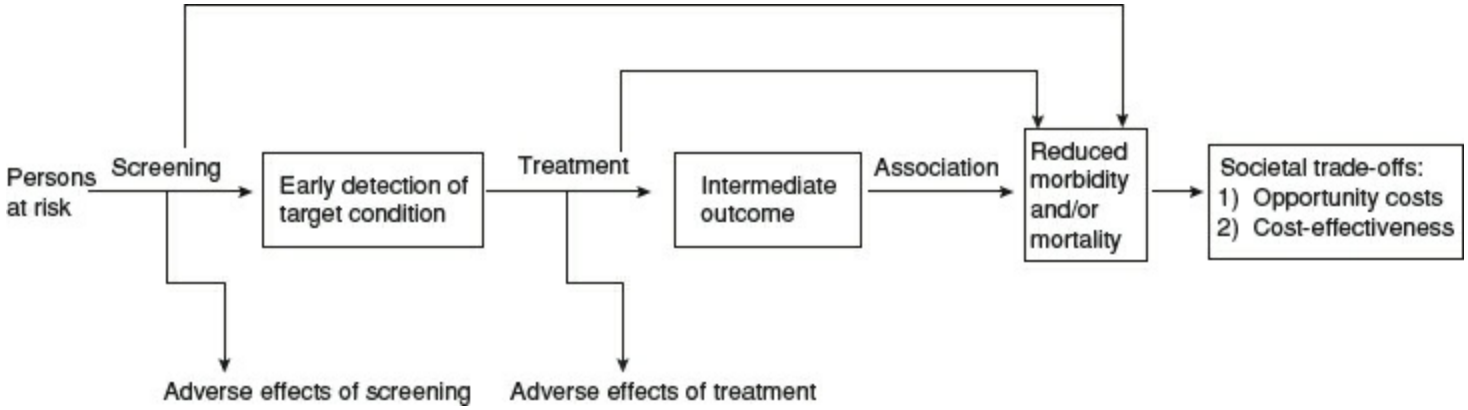

Figure 14-7. Analytic framework for evaluating a screening test. (Adapted from Harris RP, Helfand M, Woolf SH, et al. Current methods of the US Preventative Task Force: a review of the process. *Am J Prev Med* 2001;20:21–35.)

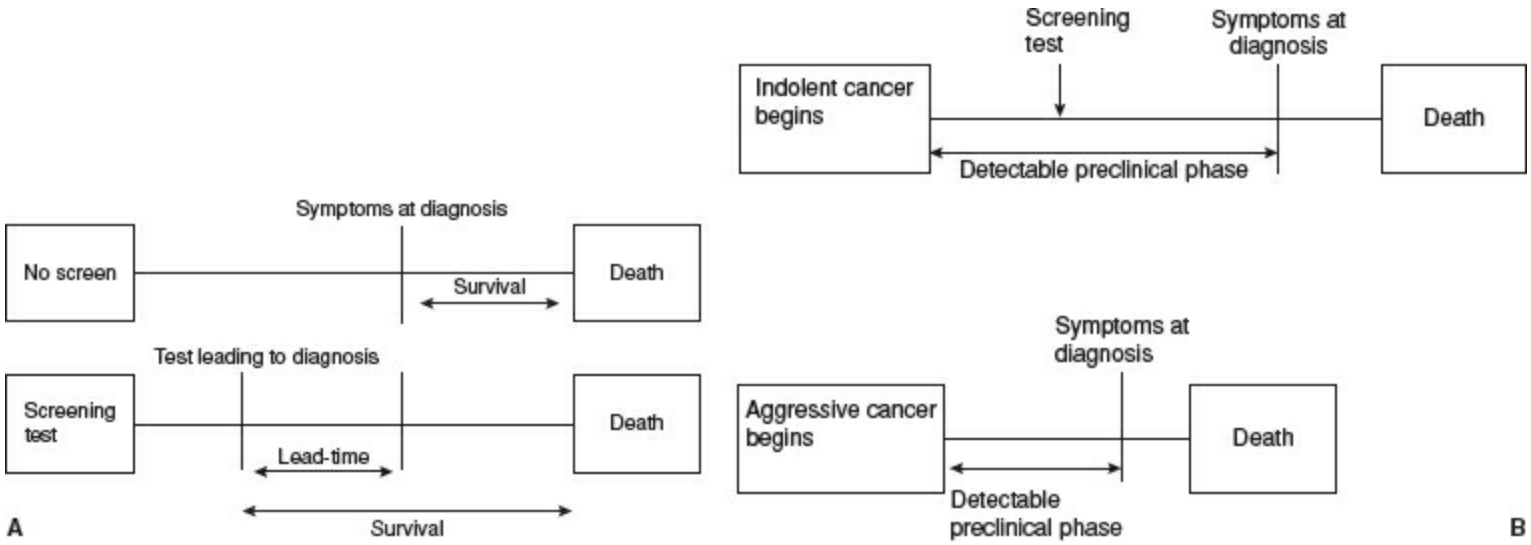

Figure 14-8. **A:** With screening, the lead time in diagnosis prolongs survival even if death is not delayed. **B:** Screening is more likely to detect indolent or slow-growing cancers therefore giving a length bias where survival appears improved with screening but is secondary to the less aggressive tumor biology.

In addition to potential harms, at least two important biases, lead-time and length, need to be accounted for prior to advocating for a screening test. The intent of screening is to advance the date of diagnosis to an earlier point in time than it would otherwise been made. Therefore, lead-time refers to the amount of time between screen-detected and symptom-detected diagnosis (Fig. 14-8A). This lead-time in diagnosis appears to prolong survival in screened individuals, although mortality in this group may not actually be delayed, creating a lead-time bias. The use of 5-year survival rates to judge the efficacy of a cancer screening test must be used with caution. For example, the Mayo Lung Project used chest x-ray and sputum cytology as screening modalities in a randomized controlled trial and demonstrated that 5-year survival rates increased from 19% to 36% in the screened population. However, lung cancer mortality rates were not significantly different between the two groups indicating that although lung cancer was diagnosed sooner in the screened group no overall benefit was noted.[184]

Length-time bias refers to the tendency of screening to detect cancers that are indolent and slower growing because of a longer detectable preclinical phase compared with

faster-growing, more aggressive forms of cancer (Fig. 14-8B). Consequently, in a group of screened individuals this phenomenon creates the appearance that screening is extending survival, when in fact extended survival is due to the more indolent nature of the cancers found in this group and not necessarily to the screening itself. Over diagnosis is one extreme form of length-time bias and can occur in two situations: (1) cancers that are so benign that they have virtually no growth potential and (2) cancers that grow so slowly that the person would die of another competing cause of death before the tumor generated symptoms. The classic indication of an over diagnosis bias is a rise in early-stage cancers coupled with a minor or even nonexistent decline in incidence of late-stage disease. An example of over diagnosis is seen in prostate cancer where although there is a decrease in the rate of late-stage disease, the absolute rate of decline makes up only a tiny fraction of the associated increase in early-stage disease. Thereby, there are more early cases being identified than late-stage cases being prevented.

4 Currently, population-based screening tests are available for the following cancers: cervical (Papanicolaou test), colon (colonoscopy, fecal occult blood test, flexible sigmoidoscopy, and double-contrast barium enema), breast (mammogram), and prostate (PSA test). The current recommendations for screening by the USPSTF and/or American Cancer Society are listed in Table 14-14.[185]

Surveillance

Improving cancer survival rates have generated an increased focus on survivorship programs, or the care of the cancer patient following treatment. One of the goals of these follow-up care programs is the early detection of tumor recurrence and new primary cancers at a point where curative treatment is still possible. Unfortunately, due to the heterogeneity of cancer treatment and outcome measures there is a paucity of evidenced-based data concerning follow-up care, surveillance protocols, and secondary prevention measures for survivors of cancer. Currently, there are recommended guidelines for only two cancers, colorectal and breast, detailing survivorship programs.[186,187]

Surveillance following curative resection of colorectal cancer is guided by the presumed risk of recurrence and functional status of the patient and is generally heightened in the first 4 years following surgery.[187] Current ASCO guidelines recommend the following: (1) a medical history, physical examination, and carcinoembryonic antigen (CEA) testing every 3 to 6 months for 5 years, (2) annual abdominal and chest imaging using computed tomography for 3 years, PET imaging is not recommend, and (3) surveillance colonoscopy approximately 1 year following surgery with repeat procedures every 5 years if no abnormal findings.

Table 14-14 Current Population-Based Screening Recommendations

Site	Recommendation
Cervical	Women, 21–65 years of age (Pap smear, every 3 years) or 30–65 years of age (in combo with HPV testing, every 5 years)
Colon	50–75 years of age (fecal occult blood testing-every year, flexible sigmoidoscopy-every 5 years, or colonoscopy-every 10 years)[a]
Breast	Women, age 50–74 years of age (biennial screening mammography)[b] or age 40 years and greater (biennial screening mammography)[c]
Prostate	Men, age 50 years and greater at average risk of prostate cancer once discussion of benefits and harms of test (PSA level)[c] USPSTF does not recommend routine prostate cancer screening

[a]USPSTF does not specify surveillance period.
[b]USPSTF recommendations.
[c]American Cancer Society recommendations.

The length of surveillance following breast cancer treatment corresponds to the risk of recurrence. As breast cancer recurrences can occur decades following curative treatment, current continual surveillance is recommended for at least 15 years.[186] Current ASCO guidelines also recommend the following: (1) history and physical examination every 3 to 6 months for the first 3 years, then every 6 to 12 months for the next 2 years, and then annually, (2) referral to genetic counseling for women at high risk for familial breast cancer syndromes, (3) mammography beginning 6 months after definitive radiation therapy, then annual mammograms following stability of mammographic findings, and

(4) regular gynecologic follow-up.

Cancer Biostatistics

The driving force behind the maturation of an epidemiologic approach to oncology has been the incorporation of statistical analysis in modern medical research. This is no more evident than when discussing survival rates following diagnosis with cancer. The most common survival statistic is OS, which is typically defined as the time from diagnosis or treatment to death from any cause and is measured either as a median (months) or as a percentage over 5 years (5-year OS). Disease-specific survival (DSS) is similar to OS and is measured in months or in a 5-year percentage but where the end measure is death due to cancer, which is oftentimes difficult to ascertain retrospectively. PFS and time to progression (TTP) are commonly used to assess efficacy in cancer drug development. PFS is defined as time of treatment start (or randomization in randomized clinical trials) to the time of disease progression or death from any cause. Similarly, TTP measures the interval from time to treatment start but concludes at time of disease progression. Unlike PFS, deaths are censored from analysis in TTP calculations. Although, used interchangeably, PFS is likely more suitable to situations where a therapy or intervention can produce an adverse event directly leading to death. Whereas, TTP is more commonly used in clinical trials with high underlying patient comorbidity, where early patient death from nontreatment-related events could negatively skew the studied treatment effects. Other commonly used survival rates include DFS and recurrence-free survival (RFS). DFS is defined as the time from treatment to recurrence of disease either from the treated cancer or a new primary. RFS is defined as the time from treatment to recurrence of disease only related to the treated cancer and not a new primary. Again, both RFS and DFS can be measured in months or time interval percentage, commonly 3- or 5-year increments.

In a typical clinical trial or study, survival outcome data are represented as a Kaplan–Meier plot (Fig. 14-9). In constructing a Kaplan–Meier survival curve, the probability of surviving in a given length of time is calculated. For each time interval, survival probability is calculated as the number of subjects surviving divided by the number of patients at risk. Subjects who have died or dropped out are no longer considered part of the at-risk population and are removed from the denominator. Within the graphical representation of the plot, if a patient is removed or no longer participating in the study before the final outcome is observed, death in OS analysis, the patient is censored and a small vertical tick mark is seen. The most common statistical method comparing Kaplan–Meier estimates is the log rank test, which calculates the chi-square for each event time for each group and sums the results giving a *p*-value. In addition to the log rank test, median values of an outcome measure can be calculated from a Kaplan–Meier plot.[188]

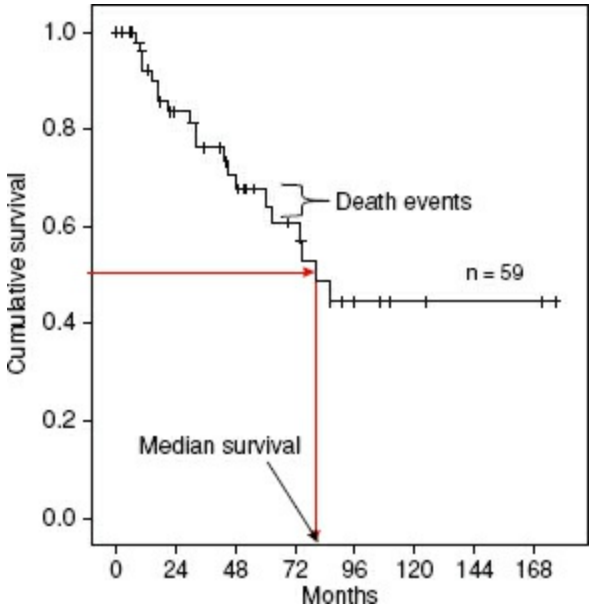

Figure 14-9. Kaplan–Meier survival curve of a hypothetical cancer. Median overall survival is plotted by the time in months of the median or 50% patient (*red line*). Deaths represent the step down lines in the curve. Censored events including lost to follow-up are represented by the vertical tick marks.

Clinical Trials

Clinical trials, in their purest form, are designed to observe outcomes of human subjects under "experimental" conditions controlled by the researcher. Prior to initiation of human clinical trials, preclinical investigations include the following animal studies: studying the treatment or drugs safety in animals at doses equivalent to human exposure, pharmacodynamics, and pharmacokinetics need to be completed. Pharmacodynamics is the study of what a drug or treatment does to the body, whereas pharmacokinetics is the study of the body's effect on the drug.

The first studies done in human are phase I trials. These are usually open-labeled studies performed in a small number of "healthy" or "diseased" individuals with the intent on obtaining the MTD useful for further trials. The MTD is determined by dose escalation of the study drug or treatment and closely following patients for predetermined, dose-limiting toxicities or adverse events. Typically, there are no therapeutic end points including survival or progression included in phase I trials.

Phase II trials, also referred to as "therapeutic exploratory" trials, are usually larger than phase I trials, and are conducted in patients with the disease in question. They are designed to test safety, pharmacokinetics, and pharmacodynamics as well as providing preliminary data on optimal doses and frequencies for future phase III trials. Trial design can include a single arm with comparison to historical controls or a randomized design comparing the study drug or treatment directly with either placebo or a known drug or treatment. Usually the narrow scope of phase II trials prevents full approval for a study drug or treatment and requires validation in a phase III trial.

Phase III trials, are typically large-scale studies performed in a more diverse target population in order to confirm efficacy of earlier trials and to identify and estimate the incidence of common adverse events. The most common type of phase III trial is comparing the intervention of interest with either a standard therapy or placebo with a balance in treatment allocation typically through randomization. Another feature of phase III trial design is stratification, which balances study arms by ensuring that specific prognostic factors of presumed clinical importance are properly balanced in the arms of a clinical trial. Following drug or treatment approval, a phase IV trial may be completed. These trials also referred to as "postmarketing" studies are observational in nature and are aimed at identifying less common adverse reactions and evaluating cost and/or drug effectiveness in diseases, populations, doses similar to or markedly different from the original population. The results of phase IV studies can lead to new black box warnings and even withdrawal of the drug or treatment for safety reasons.[189]

References

1. Siegel R, Ma J, Zou Z, et al. Cancer statistics, 2014. *CA Cancer J Clin* 2014; 64:9–29.
2. Siegel R, Desantis C, Jemal A. Colorectal cancer statistics, 2014. *CA Cancer J Clin* 2014;64:104–117.
3. Edwards BK, Ward E, Kohler BA, et al. Annual report to the nation on the status of cancer, 1975–2006, featuring colorectal cancer trends and impact of interventions (risk factors, screening, and treatment) to reduce future rates. *Cancer* 2010;116:544–573.
4. Cress RD, Morris C, Ellison GL, et al. Secular changes in colorectal cancer incidence by subsite, stage at diagnosis, and race/ethnicity, 1992–2001. *Cancer* 2006;107:1142–1152.
5. Weiss W. Cigarette smoking and lung cancer trends. A light at the end of the tunnel? *Chest* 1997;111:1414–1416.
6. Jemal A, Thun MJ, Ries LA, et al. Annual report to the nation on the status of cancer, 1975–2005, featuring trends in lung cancer, tobacco use, and tobacco control. *J Natl Cancer Inst* 2008;100:1672–1694.
7. Simard EP, Ward EM, Siegel R, et al. Cancers with increasing incidence trends in the United States: 1999 through 2008. *CA Cancer J Clin* 2012; 62:118–128.
8. Berry DA, Cronin KA, Plevritis SK, et al. Effect of screening and adjuvant therapy on mortality from breast cancer. *N Engl J Med* 2005;353:1784–1792.
9. Etzioni R, Tsodikov A, Mariotto A, et al. Quantifying the role of PSA screening in the US prostate cancer mortality decline. *Cancer Causes Control* 2008;19:175–181.
10. Knudson AG Jr. Mutation and cancer: statistical study of retinoblastoma. *Proc Natl Acad Sci U S A* 1971;68:820–823.
11. Friend SH, Bernards R, Rogelj S, et al. A human DNA segment with properties of the gene that predisposes to retinoblastoma and osteosarcoma. *Nature* 1986;323:643–646.
12. Lohmann DR, Gallie BL. Retinoblastoma: revisiting the model prototype of inherited cancer. *Am J Med Genet C Semin Med Genet* 2004;129C:23–28.
13. Stadler ZK, Thom P, Robson ME, et al. Genome-wide association studies of cancer. *J Clin Oncol* 2010;28:4255–4267.
14. Lindor NM, McMaster ML, Lindor CJ, et al. Concise handbook of familial cancer susceptibility syndromes - second edition. *J Natl Cancer Inst Monogr* 2008;(38):1–93.
15. Guillem JG, Wood WC, Moley JF, et al. ASCO/SSO review of current role of risk-reducing surgery in common hereditary cancer syndromes. *J Clin Oncol* 2006;24:4642–4660.
16. Lynch HT, de la Chapelle A. Hereditary colorectal cancer. *N Engl J Med* 2003;348:919–932.
17. Leach FS, Nicolaides NC, Papadopoulos N, et al. Mutations of a mutS homolog in

hereditary nonpolyposis colorectal cancer. *Cell* 1993;75:1215–1225.
18. Fishel R, Lescoe MK, Rao MR, et al. The human mutator gene homolog MSH2 and its association with hereditary nonpolyposis colon cancer. *Cell* 1993;75:1027–1038.
19. Bronner CE, Baker SM, Morrison PT, et al. Mutation in the DNA mismatch repair gene homologue hMLH1 is associated with hereditary non-polyposis colon cancer. *Nature* 1994;368:258–261.
20. Liu B, Parsons R, Papadopoulos N, et al. Analysis of mismatch repair genes in hereditary non-polyposis colorectal cancer patients. *Nat Med* 1996;2:169–174.
21. Wijnen JT, Vasen HF, Khan PM, et al. Clinical findings with implications for genetic testing in families with clustering of colorectal cancer. *N Engl J Med* 1998;339:511–518.
22. Bailey-Wilson JE, Elston RC, Schuelke GS, et al. Segregation analysis of hereditary nonpolyposis colorectal cancer. *Genet Epidemiol* 1986;3:27–38.
23. Vasen HF, Taal BG, Griffioen G, et al. Clinical heterogeneity of familial colorectal cancer and its influence on screening protocols. *Gut* 1994; 35:1262–1266.
24. Aarnio M, Sankila R, Pukkala E, et al. Cancer risk in mutation carriers of DNA-mismatch-repair genes. *Int J Cancer* 1999;81:214–248.
25. Vasen HF, Watson P, Mecklin JP, et al. New clinical criteria for hereditary nonpolyposis colorectal cancer (HNPCC, Lynch syndrome) proposed by the International Collaborative group on HNPCC. *Gastroenterology* 1999; 116:1453–1456.
26. Umar A, Boland CR, Terdiman JP, et al. Revised Bethesda Guidelines for hereditary nonpolyposis colorectal cancer (Lynch syndrome) and microsatellite instability. *J Natl Cancer Inst* 2004;96:261–268.
27. Burt RW, Leppert MF, Slattery ML, et al. Genetic testing and phenotype in a large kindred with attenuated familial adenomatous polyposis. *Gastroenterology* 2004;127:444–451.
28. Kinzler KW, Nilbert MC, Su LK, et al. Identification of FAP locus genes from chromosome 5q21. *Science* 1991;253:661–665.
29. Campbell WJ, Spence RA, Parks TG. Familial adenomatous polyposis. *Br J Surg* 1994;81:1722–1733.
30. Antoniou A, Pharoah PD, Narod S, et al. Average risks of breast and ovarian cancer associated with BRCA1 or BRCA2 mutations detected in case series unselected for family history: a combined analysis of 22 studies. *Am J Hum Genet* 2003;72:1117–1130.
31. Pharoah PD, Antoniou A, Bobrow M, et al. Polygenic susceptibility to breast cancer and implications for prevention. *Nat Genet* 2002;31:33–36.
32. Futreal PA, Liu Q, Shattuck-Eidens D, et al. BRCA1 mutations in primary breast and ovarian carcinomas. *Science* 1994;266:120–122.
33. Wooster R, Bignell G, Lancaster J, et al. Identification of the breast cancer susceptibility gene BRCA2. *Nature* 1995;378:789–792.

34. Kauff ND, Perez-Segura P, Robson ME, et al. Incidence of non-founder BRCA1 and BRCA2 mutations in high risk Ashkenazi breast and ovarian cancer families. *J Med Genet* 2002;39:611–614.
35. Guilford PJ, Hopkins JB, Grady WM, et al. E-cadherin germline mutations define an inherited cancer syndrome dominated by diffuse gastric cancer. *Hum Mutat* 1999;14:249–255.
36. Brooks-Wilson AR, Kaurah P, Suriano G, et al. Germline E-cadherin mutations in hereditary diffuse gastric cancer: assessment of 42 new families and review of genetic screening criteria. *J Med Genet* 2004;41:508–517.
37. Fitzgerald RC, Hardwick R, Huntsman D, et al. Hereditary diffuse gastric cancer: updated consensus guidelines for clinical management and directions for future research. *J Med Genet* 2010;47:436–444.
38. Lonser RR, Glenn GM, Walther M, et al. von Hippel-Lindau disease. *Lancet* 2003;361:2059–2067.
39. Isaacs JS, Jung YJ, Mole DR, et al. HIF overexpression correlates with biallelic loss of fumarate hydratase in renal cancer: novel role of fumarate in regulation of HIF stability. *Cancer Cell* 2005;8:143–153.
40. Waldron HA. On the history of scrotal cancer. *Ann R Coll Surg Engl* 1983; 65:420–422.
41. Dipple A, Pigott MA, Bigger CA, et al. 7,12-dimethylbenz[a] anthracene–DNA binding in mouse skin: response of different mouse strains and effects of various modifiers of carcinogenesis. *Carcinogenesis* 1984;5:1087–1090.
42. Sasco AJ, Secretan MB, Straif K. Tobacco smoking and cancer: a brief review of recent epidemiological evidence. *Lung Cancer* 2004;45(suppl 2):S3–S9.
43. IARC. IARC Monographs on the evaluation of teh carcinogenic risk of chemicals to humans, in IARC (ed): IARC press. Lyon, France, IARC, 2004.
44. Cerutti PA. Oxy-radicals and cancer. *Lancet* 1994;344:862–863.
45. Parkin DM. The global health burden of infection-associated cancers in the year 2002. *Int J Cancer* 2006;118:3030–3044.
46. Weiss RA, Vogt PK. 100 years of Rous sarcoma virus. *J Exp Med* 2011; 208:2351–2355.
47. El-Serag HB. Epidemiology of viral hepatitis and hepatocellular carcinoma. *Gastroenterology* 2012;142:1264–1273.e1.
48. Natoli G, Avantaggiati ML, Chirillo P, et al. Modulation of intracellular signal transduction pathways by the hepatitis B virus transactivator pX. *J Hepatol* 1995;22:14–20.
49. Lee YH, Yun Y. HBx protein of hepatitis B virus activates Jak1-STAT signaling. *J Biol Chem* 1998;273:25510–25515.
50. Diao J, Khine AA, Sarangi F, et al. X protein of hepatitis B virus inhibits Fas-mediated apoptosis and is associated with up-regulation of the SAPK/JNK pathway. *J Biol Chem*

2001;276:8328–8340.
51. Lee YI, Kang-Park S, Do SI, et al. The hepatitis B virus-X protein activates a phosphatidylinositol 3-kinase-dependent survival signaling cascade. *J Biol Chem* 2001;276:16969–16977.
52. Forns X, Purcell RH, Bukh J. Quasispecies in viral persistence and pathogenesis of hepatitis C virus. *Trends Microbiol* 1999;7:402–410.
53. Alter MJ, Kruszon-Moran D, Nainan OV, et al. The prevalence of hepatitis C virus infection in the United States, 1988 through 1994. *N Engl J Med* 1999;341:556–562.
54. Munoz N, Bosch FX, de Sanjose S, et al. Epidemiologic classification of human papillomavirus types associated with cervical cancer. *N Engl J Med* 2003;348:518–527.
55. Clifford GM, Smith JS, Plummer M, et al. Human papillomavirus types in invasive cervical cancer worldwide: a meta-analysis. *Br J Cancer* 2003; 88:63–73.
56. Fehrmann F, Laimins LA. Human papillomaviruses: targeting differentiating epithelial cells for malignant transformation. *Oncogene* 2003;22:5201–5207.
57. Francis DA, Schmid SI, Howley PM. Repression of the integrated papillomavirus E6/E7 promoter is required for growth suppression of cervical cancer cells. *J Virol* 2000;74:2679–2686.
58. Lehtinen M, Dillner J. Clinical trials of human papillomavirus vaccines and beyond. *Nat Rev Clin Oncol* 2013;10:400–410.
59. Dupin N, Fisher C, Kellam P, et al. Distribution of human herpesvirus-8 latently infected cells in Kaposi's sarcoma, multicentric Castleman's disease, and primary effusion lymphoma. *Proc Natl Acad Sci U S A* 1999;96:4546–4551.
60. Antman K, Chang Y. Kaposi's sarcoma. *N Engl J Med* 2000;342:1027–1038.
61. Doll R, Peto R. The causes of cancer: quantitative estimates of avoidable risks of cancer in the United States today. *J Natl Cancer Inst* 1981;66:1191–1308.
62. Key TJ, Schatzkin A, Willett WC, et al. Diet, nutrition and the prevention of cancer. *Public Health Nutr* 2004;7:187–200.
63. Kolonel LN, Hankin JH, Lee J, et al. Nutrient intakes in relation to cancer incidence in Hawaii. *Br J Cancer* 1981;44:332–339.
64. Kolonel LN, Hankin JH, Nomura AM, et al. Dietary fat intake and cancer incidence among five ethnic groups in Hawaii. *Cancer Res* 1981;41:3727–3728.
65. Ziegler RG, Hoover RN, Pike MC, et al. Migration patterns and breast cancer risk in Asian-American women. *J Natl Cancer Inst* 1993;85:1819–1827.
66. Arnold M, Pandeya N, Byrnes G, et al. Global burden of cancer attributable to high body-mass index in 2012: a population-based study. *Lancet Oncol* 2015;16:36–46.
67. Anderson GL, Neuhouser ML. Obesity and the risk for premenopausal and postmenopausal breast cancer. *Cancer Prev Res (Phila)* 2012;5:515–521.
68. Setiawan VW, Yang HP, Pike MC, et al. Type I and II endometrial cancers: have they different risk factors? *J Clin Oncol* 2013;31:2607–2618.

69. Hartwell LH, Weinert TA. Checkpoints: controls that ensure the order of cell cycle events. *Science* 1989;246:629–634.
70. Vogelstein B, Kinzler KW. Cancer genes and the pathways they control. *Nat Med* 2004;10:789–799.
71. Burkhart DL, Sage J. Cellular mechanisms of tumour suppression by the retinoblastoma gene. *Nat Rev Cancer* 2008;8:671–682.
72. Vousden KH, Lu X. Live or let die: the cell's response to p53. *Nat Rev Cancer* 2002;2:594–604.
73. McBride KA, Ballinger ML, Killick E, et al. Li-Fraumeni syndrome: cancer risk assessment and clinical management. *Nat Rev Clin Oncol* 2014; 11:260–271.
74. Burnet F. Cancer-a biological approach. *Br Med J* 1957;1:841–847.
75. Thomas L. *Cellular and Humoral Aspects of the Hypersensitive States* in Hoeber-Harpe (ed). New York, NY; 1959.
76. Pardoll D. Does the immune system see tumors as foreign or self? *Annu Rev Immunol* 2003;21:807–839.
77. Penn I. Tumors of the immunocompromised patient. *Annu Rev Med* 1988;39:63–73.
78. Carbone A, Vaccher E, Gloghini A, et al. Diagnosis and management of lymphomas and other cancers in HIV-infected patients. *Nat Rev Clin Oncol* 2014;11:223–238.
79. Yopp AC, Subramanian M, Jain MK, et al. Presentation, treatment, and clinical outcomes of patients with hepatocellular carcinoma, with and without human immunodeficiency virus infection. *Clin Gastroenterol Hepatol* 2012;10:1284–1290.
80. Rubinstein PG, Aboulafia DM, Zloza A. Malignancies in HIV/AIDS: from epidemiology to therapeutic challenges. *AIDS* 2014;28:453–465.
81. Roithmaier S, Haydon AM, Loi S, et al. Incidence of malignancies in heart and/or lung transplant recipients: a single-institution experience. *J Heart Lung Transplant* 2007;26:845–849.
82. Knoll GA, Kokolo MB, Mallick R, et al. Effect of sirolimus on malignancy and survival after kidney transplantation: systematic review and meta-analysis of individual patient data. *BMJ* 2014;349:g6679.
83. Melvold RW, Sticca RP. Basic and tumor immunology: a review. *Surg Oncol Clin North Am* 2007;16:711–735, vii.
84. Waldhauer I, Steinle A. NK cells and cancer immunosurveillance. *Oncogene* 2008;27:5932–5943.
85. Clemente CG, Mihm MC Jr, Bufalino R, et al. Prognostic value of tumor infiltrating lymphocytes in the vertical growth phase of primary cutaneous melanoma. *Cancer* 1996;77:1303–1310.
86. Lee WS, Kang M, Baek JH, et al. Clinical impact of tumor-infiltrating lymphocytes for survival in curatively resected stage IV colon cancer with isolated liver or lung metastasis. *Ann Surg Oncol* 2013;20:697–702.
87. Salama P, Phillips M, Grieu F, et al. Tumor-infiltrating FOXP3+ T regulatory cells

show strong prognostic significance in colorectal cancer. *J Clin Oncol* 2009;27:186–192.

88. Tsoutsou PG, Bourhis J, Coukos G. Tumor-infiltrating lymphocytes in triple-negative breast cancer: a biomarker for use beyond prognosis? *J Clin Oncol* 2015;33(11):1297–1298.
89. Pardoll DM. The blockade of immune checkpoints in cancer immunotherapy. *Nat Rev Cancer* 2012;12:252–264.
90. Rudd CE, Taylor A, Schneider H. CD28 and CTLA-4 coreceptor expression and signal transduction. *Immunol Rev* 2009;229:12–26.
91. Lenschow DJ, Walunas TL, Bluestone JA. CD28/B7 system of T cell costimulation. *Annu Rev Immunol* 1996;14:233–258.
92. Hodi FS, O'Day SJ, McDermott DF, et al. Improved survival with ipilimumab in patients with metastatic melanoma. *N Engl J Med* 2010;363:711–723.
93. Keir ME, Butte MJ, Freeman GJ, et al. PD-1 and its ligands in tolerance and immunity. *Annu Rev Immunol* 2008;26:677–704.
94. Robert C, Ribas A, Wolchok JD, et al. Anti-programmed-death-receptor-1 treatment with pembrolizumab in ipilimumab-refractory advanced melanoma: a randomised dose-comparison cohort of a phase 1 trial. *Lancet* 2014; 384:1109–1117.
95. Wolchok JD, Kluger H, Callahan MK, et al. Nivolumab plus ipilimumab in advanced melanoma. *N Engl J Med* 2013;369:122–133.
96. De Andrade JP, Mezhir JJ. The critical role of peritoneal cytology in the staging of gastric cancer: an evidence-based review. *J Surg Oncol* 2014;110(3):291–297.
97. Hur H, Lee HH, Jung H, et al. Predicting factors of unexpected peritoneal seeding in locally advanced gastric cancer: indications for staging laparoscopy. *J Surg Oncol* 2010;102(7):753–757.
98. Childers JM, Lang J, Surwit EA, et al. Laparoscopic surgical staging of ovarian cancer. *Gynecol Oncol* 1995;59(1):25–33.
99. Arnold JC, Neubauer HJ, Zöpf T, et al. Improved tumor staging by diagnostic laparoscopy. *Z Gastroenterol* 1999;37(6):483–488.
100. Austin F, Mavanur A, Sathaiah M, et al. Aggressive management of peritoneal carcinomatosis from mucinous appendiceal neoplasms. *Ann Surg Oncol* 2012;19(5):1386–1393.
101. Liu Y, Ishibashi H, Hirano M, et al. Cytoreductive surgery plus hyperthermic intraperitoneal chemotherapy for pseudomyxoma peritonei arising from urachus. *Ann Surg Oncol* 2015;22(8):2799–2805.
102. Sugarbaker PH. Cytoreductive surgery and peri-operative intraperitoneal chemotherapy as a curative approach to pseudomyxoma peritonei syndrome. *Eur J Surg Oncol* 2001;27(3):239–243.
103. Martinek IE, Kehoe S. When should surgical cytoreduction in advanced ovarian cancer take place? *J Oncol* 2010;2010:852028.

104. van der Burg ME, van Lent M, Buyse M, et al. The effect of debulking surgery after induction chemotherapy on the prognosis in advanced epithelial ovarian cancer. Gynecological Cancer Cooperative Group of the European Organization for Research and Treatment of Cancer. *N Engl J Med* 1995;332(10):629–634.

105. Chambers AJ, Pasieka JL, Dixon E, et al. The palliative benefit of aggressive surgical intervention for both hepatic and mesenteric metastases from neuroendocrine tumors. *Surgery* 2008;144(4):645–651; discussion 651–653.

106. Gomez D, Malik HZ, Al-Mukthar A, et al. Hepatic resection for metastatic gastrointestinal and pancreatic neuroendocrine tumours: outcome and prognostic predictors. *HPB (Oxford)* 2007;9(5):345–351.

107. Tachezy M, Bockhorn M, Gebauer F, et al. Bypass surgery versus intentionally incomplete resection in palliation of pancreatic cancer: is resection the lesser evil? *J Gastrointest Surg* 2011;15(5):829–835.

108. Uzan C, Vincens E, Balleyguier C, et al. Outcome of patients with incomplete resection after surgery for stage IB2/II cervical carcinoma with chemoradiation therapy. *Int J Gynecol Cancer* 2010;20(3):379–384.

109. Laramore GE, Scott CB, Schuller DE, et al. Is a surgical resection leaving positive margins of benefit to the patient with locally advanced squamous cell carcinoma of the head and neck: a comparative study using the intergroup study 0034 and the Radiation Therapy Oncology Group head and neck database. *Int J Radiat Oncol Biol Phys* 1993;27(5):1011–1016.

110. Ratto GB, Fabiano F, Rovida S, et al. Survival after incomplete resection or exploratory thoracotomy in patients with advanced non small cell lung cancer. *Ital J Surg Sci* 1988;18(4):377–383.

111. Donadon M, Costa G, Cimino M, et al. Safe hepatectomy selection criteria for hepatocellular carcinoma patients: a validation of 336 consecutive hepatectomies. The BILCHE score. *World J Surg* 2015;39(1):237–243.

112. Pulitano C, Crawford M, Joseph D, et al. Preoperative assessment of postoperative liver function: the importance of residual liver volume. *J Surg Oncol* 2014;110(4):445–450.

113. Guglielmi A, Ruzzenente A, Conci S, et al. How much remnant is enough in liver resection? *Dig Surg* 2012;29(1):6–17.

114. Takada T, Yasuda H, Amano H, et al. Simultaneous hepatic resection with pancreatoduodenectomy for metastatic pancreatic head carcinoma: does it improve survival? *Hepatogastroenterology* 1997;44(14):567–573.

115. Morrogh M, Miner TJ, Park A, et al. A prospective evaluation of the durability of palliative interventions for patients with metastatic breast cancer. *Cancer* 2010;116(14):3338–3347.

116. Miner TJ, Jaques DP, Karpeh MS, et al. Defining palliative surgery in patients receiving noncurative resections for gastric cancer. *J Am Coll Surg* 2004;198(6):1013–1021.

117. Balch CM, Soong SJ, Smith T, et al.; Investigators from the Intergroup Melanoma Surgical Trial. Long-term results of a prospective surgical trial comparing 2 cm vs. 4 cm excision margins for 740 patients with 1–4 mm melanomas. *Ann Surg Oncol* 2001;8(2):101–108.

118. Humphrey KL, Saksena MA, Freer PE, et al. To do or not to do: axillary nodal evaluation after ACOSOG Z0011 Trial. *Radiographics* 2014;34(7):1807–1816.

119. Ogiya A, Kimura K, Nakashima E, et al. Long-term prognoses and outcomes of axillary lymph node recurrence in 2,578 sentinel lymph node-negative patients for whom axillary lymph node dissection was omitted: results from one Japanese hospital. *Breast Cancer* 2014.

120. Rosenberg SA, Kent H, Costa J, et al. Prospective randomized evaluation of the role of limb-sparing surgery, radiation therapy, and adjuvant chemoimmunotherapy in the treatment of adult soft-tissue sarcomas. *Surgery* 1978;84(1):62–69.

121. Martin R, Paty P, Fong Y, et al. Simultaneous liver and colorectal resections are safe for synchronous colorectal liver metastasis. *J Am Coll Surg* 2003;197(2):233–241; discussion 241–242.

122. House MG, Ito H, Gönen M, et al. Survival after hepatic resection for metastatic colorectal cancer: trends in outcomes for 1,600 patients during two decades at a single institution. *J Am Coll Surg* 2010;210(5):744–752, 752–755.

123. Papavasiliou P, Hoffman JP, Cohen SJ, et al. Impact of preoperative therapy on patterns of recurrence in pancreatic cancer. *HPB (Oxford)* 2014; 16(1):34–39.

124. Paulino AC. Resected pancreatic cancer treated with adjuvant radiotherapy with or without 5-fluorouracil: treatment results and patterns of failure. *Am J Clin Oncol* 1999;22(5):489–494.

125. Sperti C, Pasquali C, Piccoli A, et al. Recurrence after resection for ductal adenocarcinoma of the pancreas. *World J Surg* 1997;21(2):195–200.

126. Halsted WS. I. A clinical and histological study of certain adenocarcinomata of the breast: and a brief consideration of the supraclavicular operation and of the results of operations for cancer of the breast from 1889 to 1898 at the Johns Hopkins Hospital. *Ann Surg* 1898;28(5):557–576.

127. Halsted WS. I. The results of operations for the cure of cancer of the breast performed at the Johns Hopkins Hospital from June, 1889, to January, 1894. *Ann Surg* 1894;20(5):497–555.

128. Durham AB, Wong SL. Sentinel lymph node biopsy in melanoma: final results of MSLT-I. *Future Oncol* 2014;10(7):1121–1123.

129. Songun I, Putter H, Kranenbarg EM, et al. Surgical treatment of gastric cancer: 15-year follow-up results of the randomised nationwide Dutch D1D2 trial. *Lancet Oncol* 2010;11(5):439–449.

130. Roder JD, Bonenkamp JJ, Craven J, et al. Lymphadenectomy for gastric cancer in clinical trials: update. *World J Surg* 1995;19(4):546–553.

131. Giuliano AE, McCall L, Beitsch P, et al. Locoregional recurrence after sentinel lymph node dissection with or without axillary dissection in patients with sentinel lymph node metastases: the American College of Surgeons Oncology Group Z0011 randomized trial. *Ann Surg* 2010;252(3):426–432; discussion 432–433.
132. Rhoads KF, Ackerson LK, Ngo JV, et al. Adequacy of lymph node examination in colorectal surgery: contribution of the hospital versus the surgeon. *Med Care* 2013;51(12):1055–1062.
133. Kidner TB, Ozao-Choy JJ, Yoon J, et al. Should quality measures for lymph node dissection in colon cancer be extrapolated to rectal cancer? *Am J Surg* 2012;204(6):843–847; discussion 847–848.
134. Mathoulin-Pelissier S, Bécouarn Y, Belleannée G, et al. Quality indicators for colorectal cancer surgery and care according to patient-, tumor-, and hospital-related factors. *BMC Cancer* 2012;12:297.
135. Parsons HM, Tuttle TM, Kuntz KM, et al. Quality of care along the cancer continuum: does receiving adequate lymph node evaluation for colon cancer lead to comprehensive postsurgical care? *J Am Coll Surg* 2012;215(3):400–411.
136. Bikhchandani J, Ong GK, Dozois EJ, et al. Outcomes of salvage surgery for cure in patients with locally recurrent disease after local excision of rectal cancer. *Dis Colon Rectum* 2015;58(3):283–287.
137. Guerrieri M, Gesuita R, Ghiselli R, et al. Treatment of rectal cancer by transanal endoscopic microsurgery: experience with 425 patients. *World J Gastroenterol* 2014;20(28):9556–9563.
138. Ueno H, Mochizuki H, Shinto E, et al. Histologic indices in biopsy specimens for estimating the probability of extended local spread in patients with rectal carcinoma. *Cancer* 2002;94(11):2882–2891.
139. Beesley VL, Rowlands IJ, Hayes SC, et al. Incidence, risk factors and estimates of a woman's risk of developing secondary lower limb lymphedema and lymphedema-specific supportive care needs in women treated for endometrial cancer. *Gynecol Oncol* 2015;136(1):87–93.
140. Farrell R, Gebski V, Hacker NF. Quality of life after complete lymphadenectomy for vulvar cancer: do women prefer sentinel lymph node biopsy? *Int J Gynecol Cancer* 2014;24(4):813–819.
141. Angioli R, Plotti F, Cafà EV, et al. Quality of life in patients with endometrial cancer treated with or without systematic lymphadenectomy. *Eur J Obstet Gynecol Reprod Biol* 2013;170(2):539–543.
142. Faries MB, Thompson JF, Cochran A, et al. The impact on morbidity and length of stay of early versus delayed complete lymphadenectomy in melanoma: results of the multicenter selective lymphadenectomy trial (I). *Ann Surg Oncol* 2010;17(12):3324–3329.
143. Fong Y, Fortner J, Sun RL, et al. Clinical score for predicting recurrence after hepatic resection for metastatic colorectal cancer: analysis of 1001 consecutive cases. *Ann*

Surg 1999;230(3):309–318; discussion 318–321.

144. Kavolius JP, Mastorakos DP, Pavlovich C, et al. Resection of metastatic renal cell carcinoma. *J Clin Oncol* 1998;16(6):2261–2266.
145. Kim S, Ott HC, Wright CD, et al. Pulmonary resection of metastatic sarcoma: prognostic factors associated with improved outcomes. *Ann Thorac Surg* 2011;92(5):1780–1786; discussion 1786–1787.
146. Blazer DG 3rd, Kishi Y, Maru DM, et al. Pathologic response to preoperative chemotherapy: a new outcome end point after resection of hepatic colorectal metastases. *J Clin Oncol* 2008;26(33):5344–5351.
147. Yoshita H, Hosokawa A, Ueda A, et al. Predictive value of optimal morphologic response to first-line chemotherapy in patients with colorectal liver metastases. *Digestion* 2014;89(1):43–48.
148. Negrier S, Bushmakin AG, Cappelleri JC, et al. Assessment of progression-free survival as a surrogate end-point for overall survival in patients with metastatic renal cell carcinoma. *Eur J Cancer* 2014;50(10):1766–1771.
149. Saad ED, Katz A, Hoff PM, et al. Progression-free survival as surrogate and as true end point: insights from the breast and colorectal cancer literature. *Ann Oncol* 2010;21(1):7–12.
150. Eisenhauer EA, Therasse P, Bogaerts J, et al. New response evaluation criteria in solid tumours: revised RECIST guideline (version 1.1). *Eur J Cancer* 2009;45(2):228–247.
151. Aloia TA, Zimmitti G, Conrad C, et al. Return to intended oncologic treatment (RIOT): a novel metric for evaluating the quality of oncosurgical therapy for malignancy. *J Surg Oncol* 2014;110(2):107–114.
152. Jalal N, Haq S, Anwar N, et al. Radiation induced bystander effect and DNA damage. *J Cancer Res Ther* 2014;10(4):819–833.
153. Murray D, McBride WH, Schwartz JL. Radiation biology in the context of changing patterns of radiotherapy. *Radiat Res* 2014;182(3):259–272.
154. Dizdaroglu M. Oxidatively induced DNA damage and its repair in cancer. *Mutat Res Rev Mutat Res* 2015;763:212–245.
155. Bak ST, Sakellariou D, Pena-Diaz J. The dual nature of mismatch repair as antimutator and mutator: for better or for worse. *Front Genet* 2014;5:287.
156. Hei TK, Zhou H, Chai Y, et al. Radiation induced non-targeted response: mechanism and potential clinical implications. *Curr Mol Pharmacol* 2011;4(2):96–105.
157. Choi DK, Helenowski I, Hijiya N. Secondary malignancies in pediatric cancer survivors: perspectives and review of the literature. *Int J Cancer* 2014;135(8):1764–1773.
158. Lee J, Lim do H, Kim S, et al. Phase III trial comparing capecitabine plus cisplatin versus capecitabine plus cisplatin with concurrent capecitabine radiotherapy in completely resected gastric cancer with D2 lymph node dissection: the ARTIST trial. *J*

Clin Oncol 2012;30(3):268–273.

159. Naing KW, Monjazeb AM, Li CS, et al. Perioperative radiotherapy is associated with improved survival among patients with synovial sarcoma: a SEER analysis. *J Surg Oncol* 2015;111(2):158–164.
160. Siegel R, Burock S, Wernecke KD, et al. Preoperative short-course radiotherapy versus combined radiochemotherapy in locally advanced rectal cancer: a multi-centre prospectively randomised study of the Berlin Cancer Society. *BMC Cancer* 2009;9:50.
161. Glynne-Jones R, Nilsson PJ, Aschele C, et al. Anal cancer: ESMO-ESSO-ESTRO clinical practice guidelines for diagnosis, treatment and follow-up. *Eur J Surg Oncol* 2014;40(10):1165–1176.
162. Nguyen NP, Ries T, Vock J, et al. Effectiveness of radiotherapy for elderly patients with non-melanoma skin cancer of the head. *Geriatr Gerontol Int* 2014;15(5):601–605.
163. Holloway CL, Delaney TF, Alektiar KM, et al. American Brachytherapy Society (ABS) consensus statement for sarcoma brachytherapy. *Brachytherapy* 2013;12(3):179–190.
164. Cunningham D, Allum WH, Stenning SP, et al. Perioperative chemotherapy versus surgery alone for resectable gastroesophageal cancer. *N Engl J Med* 2006;355:11–20.
165. Lam VW, Spiro C, Laurence JM, et al. A systematic review of clinical response and survival outcomes of downsizing systemic chemotherapy and rescue liver surgery in patients with initially unresectable colorectal liver metastases. *Ann Surg Oncol* 2012;19:1292–1301.
166. Adam R, Wicherts DA, de Haas RJ, et al. Patients with initially unresectable colorectal liver metastases: is there a possibility of cure? *J Clin Oncol* 2009;27:1829–1835.
167. Ben-Neriah Y, Daley GQ, Mes-Masson AM, et al. The chronic myelogenous leukemia-specific P210 protein is the product of the bcr/abl hybrid gene. *Science* 1986;233:212–214.
168. Joensuu H, Roberts PJ, Sarlomo-Rikala M, et al. Effect of the tyrosine kinase inhibitor STI571 in a patient with a metastatic gastrointestinal stromal tumor. *N Engl J Med* 2001;344:1052–1056.
169. Folkman J. Antiangiogenesis in cancer therapy–endostatin and its mechanisms of action. *Exp Cell Res* 2006;312:594–607.
170. Chao C, Al-Saleem T, Brooks JJ, et al. Vascular endothelial growth factor and soft tissue sarcomas: tumor expression correlates with grade. *Ann Surg Oncol* 2001;8:260–267.
171. Tokunaga T, Oshika Y, Abe Y, et al. Vascular endothelial growth factor (VEGF) mRNA isoform expression pattern is correlated with liver metastasis and poor prognosis in colon cancer. *Br J Cancer* 1998;77:998–1002.
172. Heer K, Kumar H, Read JR, et al. Serum vascular endothelial growth factor in breast cancer: its relation with cancer type and estrogen receptor status. *Clin Cancer Res* 2001;7:3491–3494.

173. Saltz LB, Clarke S, Diaz-Rubio E, et al. Bevacizumab in combination with oxaliplatin-based chemotherapy as first-line therapy in metastatic colorectal cancer: a randomized phase III study. *J Clin Oncol* 2008;26:2013–2019.
174. Llovet JM, Ricci S, Mazzaferro V, et al. Sorafenib in advanced hepatocellular carcinoma. *N Engl J Med* 2008;359:378–390.
175. Escudier B, Eisen T, Stadler WM, et al. Sorafenib for treatment of renal cell carcinoma: final efficacy and safety results of the phase III treatment approaches in renal cancer global evaluation trial. *J Clin Oncol* 2009;27:3312–3318.
176. Motzer RJ, Hutson TE, Tomczak P, et al. Sunitinib versus interferon alfa in metastatic renal-cell carcinoma. *N Engl J Med* 2007;356:115–124.
177. Rixe O, Bukowski RM, Michaelson MD, et al. Axitinib treatment in patients with cytokine-refractory metastatic renal-cell cancer: a phase II study. *Lancet Oncol* 2007;8:975–984.
178. Ellis M. Genomic analysis of breast cancer heralds a changing treatment paradigm. *J Natl Compr Canc Netw* 2014;12:750–752.
179. Childe C. *The Control of a Scourge, or How Cancer is Curable.* New York, NY: E.P. Dutton; 1907.
180. Harris RP, Helfand M, Woolf SH, et al. Current methods of the US Preventive Services Task Force: a review of the process. *Am J Prev Med* 2001;20:21–35.
181. Elmore JG, Barton MB, Moceri VM, et al. Ten-year risk of false positive screening mammograms and clinical breast examinations. *N Engl J Med* 1998;338:1089–1096.
182. Croswell JM, Kramer BS, Kreimer AR, et al. Cumulative incidence of false-positive results in repeated, multimodal cancer screening. *Ann Fam Med* 2009;7:212–222.
183. Croswell JM, Ransohoff DF, Kramer BS. Principles of cancer screening: lessons from history and study design issues. *Semin Oncol* 2010;37:202–215.
184. Fontana RS, Sanderson DR, Woolner LB, et al. Screening for lung cancer. A critique of the Mayo Lung Project. *Cancer* 1991;67:1155–1164.
185. Smith RA, Manassaram-Baptiste D, Brooks D, et al. Cancer screening in the United States, 2015: a review of current American cancer society guidelines and current issues in cancer screening. *CA Cancer J Clin* 2015;65:30–54.
186. Burstein HJ, Temin S, Anderson H, et al. Adjuvant endocrine therapy for women with hormone receptor-positive breast cancer: american society of clinical oncology clinical practice guideline focused update. *J Clin Oncol* 2014;32:2255–2269.
187. Desch CE, Benson AB 3rd, Smith TJ, et al. Recommended colorectal cancer surveillance guidelines by the American Society of Clinical Oncology. *J Clin Oncol* 1999;17:1312.
188. Guller U, DeLong ER. Interpreting statistics in medical literature: a vade mecum for surgeons. *J Am Coll Surg* 2004;198:441–458.
189. Umscheid CA, Margolis DJ, Grossman CE. Key concepts of clinical trials: a narrative review. *Postgrad Med* 2011;123:194–204.

Chapter 15

Preoperative Risk Assessment

Pauline Park

Key Points

1. Preoperative risk assessment is critical to informing patients of the risk and benefits of surgical interventions.
2. The development of postoperative complications drives patient mortality and higher health care costs. Interventions aimed at prevention and early recognition of complications may lower surgical risk.
3. Consideration of patient-centered outcomes may appropriately determine that noncurative surgical intervention may be counter to the patient's true desires.
4. National Surgical Quality Improvement Programs from the Veterans' Administration and the American College of Surgeons have examined large data sets in a data-driven approach to more finely characterize risk for mortality and complications.
5. Specific comorbidities affect both the conduct of surgery and the outcome in ways that can be anticipated and addressed.
6. Identification of patients at risk permits quality assurance monitoring and offers the opportunity to improve care with individual- and system-level interventions.

INTRODUCTION

1 The goal of preoperative assessment is to evaluate an individual's risk for postoperative adverse events and to deliberately incorporate that assessment into plans for surgical intervention. It forms the basis of the contract between the patient and the surgeon; both wish to predict future outcomes and to balance the risks and benefits of surgery. By synthesizing clinically available data, we can attempt to stratify and modify risk so that the equation will favor benefit, all the while prioritizing patient-centered goals of care.

Early landmark work in cardiac preoperative evaluation by Goldman et al.[1] clearly demonstrated that high-risk surgical patients could be identified through careful assessment of clinical history, physical examination, and laboratory data. This has been extended by further observations in specific types of surgery and in subgroups of patients with particular disease states. Granular, patient-level analyses using "big data" approaches have led to the development of targeted interventions aimed at reducing the risk of a given procedure for a given patient. Thus, preoperative evaluation has evolved to include not only prediction of risk but also consideration of potential proactive interventions at both the individual patient and system levels. Inclusion of patient values and desired outcomes completes the course of informed decision-making.

This chapter reviews the relevance of risk determination, examples of data-driven approaches to individualize risk prediction, clinical aspects of preoperative evaluation, guidelines for specific disease-related conditions, and future directions for prevention of complications and intervention should they occur. All of these should be considered in the context of selecting the best approach for each patient.

SURGICAL MORTALITY, COMPLICATIONS, AND PATIENT-CENTERED OUTCOMES

Mortality rates following surgery have continued to improve with innovations in surgical technique and advances in overall quality of medical care. Since the 1950s, large reductions in intraoperative mortality have been accomplished through anesthesiology-led initiatives championing safer operating room protocols, continuous monitoring, and error reduction. By incorporating high-reliability processes into operating room routines, the overall mortality risk attributable to a general anesthetic has been reduced from 25 per million to 50 per million in the 1970s and 1980s to 1 per million to 5 per million.[2]

From the surgical standpoint, population-based mortality rate varies sharply with the extent of the procedure and patient age.[3] Overall surgical mortality in the Nationwide Impatient Sample decreased from 1.68% in 1996 to 1.32% in 2006.[4] Substantial interhospital variation exists and underscores the possibility for additional opportunities for improvement. The Safety in Surgery Study evaluated a large cohort of general and vascular surgical patients at 128 VA and 14 academic hospitals between 2001 and 2004.[5] The overall 30-day postoperative mortality ranged between 2.19% and 2.87% over the 3 years, with adjusted odds ratios varying between individual institutions (Fig. 15-1). Similarly, in a 7-day cohort study of noncardiac surgery in Europe, adjusted in-hospital mortality after surgery varied widely between countries (odds ratio = 0.44 to 6.22) when compared with the United Kingdom.[6]

In 2000, the Institute of Medicine suggested that preventable adverse events accounted for as many as 98,000 in-hospital deaths.[7] The search for further improvement in surgical mortality has focused on reducing the incidence of postoperative complications. Surgical complications are strongly related to mortality,[8–10] with the ability to rescue from postoperative complications an important factor in determining eventual outcome.[11] The 10 most common perioperative complications seen in the Patient Safety in Surgery Study hospitals included infectious, pulmonary, cardiac, renal, and venous thrombotic events (Table 15-1).

2 Postoperative complications are associated with increased health care costs and resource utilization. Average hospital costs may double following occurrence of a complication,[12] with variation in reimbursement exerting significant effects on both hospital profit and contribution margins.[13,14] Postoperative complications are also strongly linked to hospital readmissions (Table 15-2),[15] with a substantial number of complications identified only after initial discharge.[16] As an example, approximately a quarter of colon resection patients are readmitted within 90 days, at an estimated cost of $300 million annually.[17]

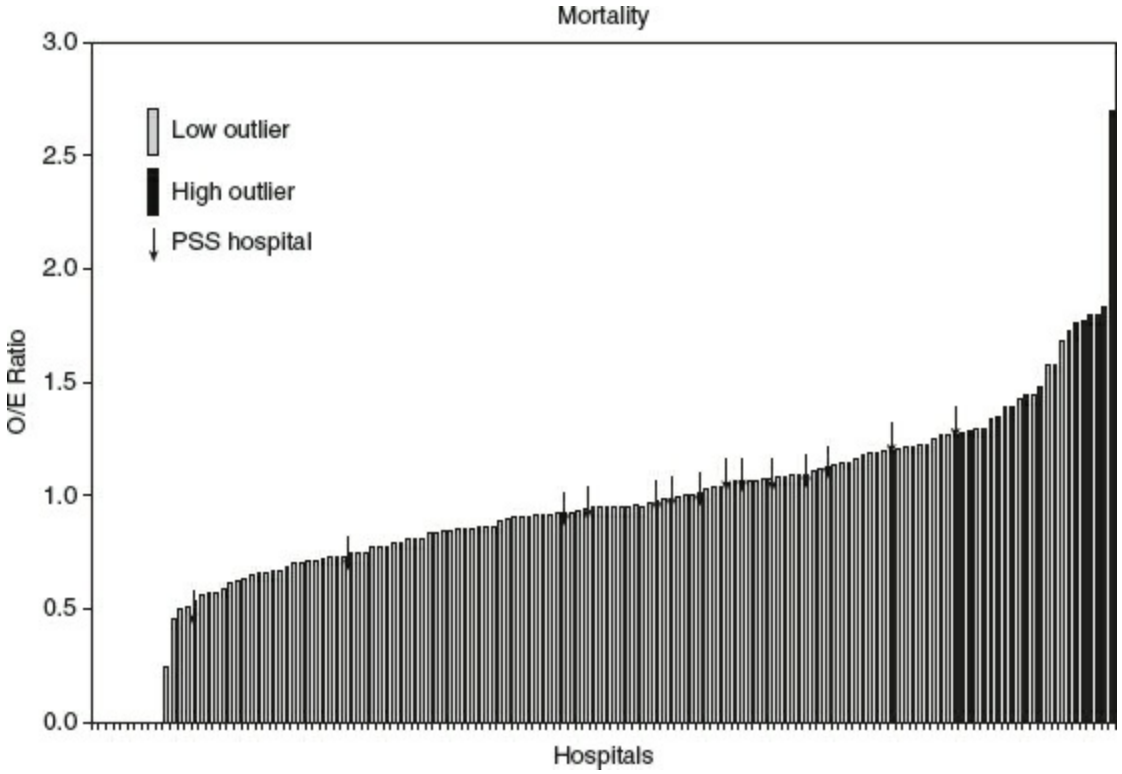

Figure 15-1. Variation in surgical mortality.

These circumstances influence both institutional and overall health care delivery. The overwhelming health care spending burden adds pressure to provide efficient, high-quality care. Hospital performances on quality measures are widely available on the Internet and mandated public reporting can easily affect market share and policy making. These system-level considerations only heighten the push toward population-based management of surgical care.

Nevertheless, the direct impact of postoperative complications on an *individual* patient's quality of life is critical. The consequences are often unrecognized by standard hospital-based review. In 2004, Clavien and Dindo proposed a complication grading scale based on the severity of intervention required to address a given complication, including the presence of associated disability (Table 15-3).[18] This classification has been validated in a cohort of more than 6,000 patients, with subsequent evaluation showing 89% interrater agreement and correlation between perceptions by patients, nurses, and physicians.[19] It is hoped that encouraging standardized complication grading will increase meaningful, patient-centered outcomes reporting.

Table 15-1 Surgical Complications: Comparison of the 10 Most Frequent Perioperative Complications Between Private Sector and VA Hospitals

14 Private Sector Hospitals ($n = 54,585$)		128 VA Hospitals ($n = 130,258$)	
Perioperative Complication	**%**	**Perioperative Complication**	**%**
1. Superficial wound infection	3.6	1. Superficial wound infection	3.1
2. Failure to wean from ventilator for >48 hrs	2.9	2. Pneumonia	2.5
3. Urinary tract infection	2.8	3. Failure to wean from ventilator for >48 hrs	2.5
4. Pneumonia	2.2	4. Reintubation	2.0
5. Systemic sepsis	2.1	5. Urinary tract infection	2.0
6. Reintubation	1.8	6. Deep wound infection	1.6
7. Deep wound infection	1.2	7. Systemic sepsis	1.6
8. Wound dehiscence	1.1	8. Wound dehiscence	1.2
9. Acute renal failure	0.7	9. Cardiac arrest	0.9
10. Deep vein thrombophlebitis	0.7	10. Myocardial infarction	0.6

Adapted from Khuri SF, Henderson WG, Daley J, et al. Successful implementation of the Department of Veterans Affairs' National Surgical Quality Improvement Program in the private sector: the Patient Safety in Surgery study. *Ann Surg* 2008;248(2):329–336.

Table 15-2 Number of Surgical Readmissions by Readmission Reason

Reason for Readmission	Number of Readmissions	%
Gastrointestinal complication	45	28.6
Surgical infection	36	22.1
Failure to thrive/malnutrition	17	10.4
Wound complication	13	8.0
Genitourinary complication	8	4.9
Vascular complication	6	3.7
Pulmonary problem	6	3.7
Cardiac problem	5	3.1
Fever	4	2.5
Pain	3	1.8
Transplant complication	3	1.8
Neurologic problem	2	1.2
Other	15	9.2

Adapted from Kassin MT, Owen RM, Perez SD, et al. Risk factors for 30-day hospital readmission among general surgery patients. *J Am Coll Surg* 2012;215(3):322–330.

Table 15-3 Grading of Surgical Complications: Clavien–Dindo Classification

Grade	Definition
Grade I	Any deviation from the normal postoperative course without the need for pharmacologic treatment or surgical, endoscopic, and radiologic interventions Allowed therapeutic regimens are drugs as antiemetics, antipyretics, analgetics, diuretics, electrolytes, and physiotherapy. This grade also includes wound infections opened at the bedside
Grade II	Requiring pharmacologic treatment with drugs other than such allowed for grade I complications. Blood transfusions and total parenteral nutrition are also included
Grade III	Requiring surgical, endoscopic, or radiologic intervention
Grade IIIa	Intervention not under general anesthesia
Grade IIIb	Intervention under general anesthesia
Grade IV	Life-threatening complication (including CNS complications)[a] requiring IC/ICU management
Grade IVa	Single organ dysfunction (including dialysis)
Grade IVb	Multiorgan dysfunction
Grade V	Death of a patient
Suffix "d"	If the patient suffers from a complication at the time of discharge (see examples in Table 15-2), the suffix "d" (for "disability") is added to the respective grade of complication. This label indicates the need for a follow-up to fully evaluate the complication

[a]Brain hemorrhage, ischemic stroke, subarachnoid bleeding, but excluding transient ischemic attacks.
CNS, central nervous system; IC, intermediate care; ICU, intensive care unit.
From Dindo D, Demartines N, Clavien PA. Classification of surgical complications: a new proposal with evaluation in a cohort of 6336 patients and results of a survey. *Ann Surg* 2004;240(2):205–213.

3 Finally, the recognition that a surgical admission may represent a turning point in the overall trajectory of a patient's life refocuses the preoperative evaluation to look beyond the index hospitalization. In 2008, one-third of Medicare decedents underwent a surgical procedure during their last 12 months of life.[20] The preoperative discussion should address the patient's understanding of the potential impact of surgical care and include expected quality-of-life outcomes. It is important to integr ate patient-centered goals of care into treatment recommendations; an operation that does not prolong meaningful quality of life may be counter to the patient's expectations of surgical care.

RISK STRATIFICATION

4 The goal of risk stratification is to identify patients at risk for adverse outcomes and to target high-risk groups for potential intervention to reduce that risk. To date, the largest organized surgical efforts have evolved through the National Surgical Quality Improvement Program (NSQIP) and the American College of Surgeons (ACS-NSQIP). In 1991, the Department of Veterans Affairs (VA) system responded to criticisms of high mortality rates by initiating a program of mandatory data collection and evaluation. The NSQIP paradigm employs local trained nurse reviewers at each site to extract individual, patient-level data. Variables collected include demographic information, baseline physiologic status, medical comorbidities, laboratory values, and surgical operative characteristics. Regression models are constructed to predict the risk of postoperative morbidity and mortality based on the collected preoperative variables (Table 15-15A,B). Ongoing system-level analysis evaluates and benchmarks performance between institutions using observed/expected (O/E) ratios for specified outcomes and allows for linkage of outcomes to process and structure of care.[5] Success in data-driven VA process improvement initiatives has led to validation and adoption in academic and community centers.[5]

Table 15-4A Logistic Regression Models for Prediction of 30-Day Operative Mortality Using Preoperative Variables

Variable	Odds Ratio
ASA class 4/5 vs. 1/2	8.1
ASA 3 vs. 1/2	3.5
Serum albumin (per gram)	0.62
Emergency operation	2.6
Age (per year)	1
Platelet count <150,000	1.9
Disseminated cancer	2.9
Dyspnea at rest vs. none	1.6
Dyspnea with minimal exertion vs. none	1.3
DNR	3.9
BUN >40 mg/dL	1.3
Work RVU (per unit)	1.02

Derived from private sector hospitals, $n = 54{,}450$ patients.
ASA, American Society of Anesthesiologist's Patient Severity Score; BUN, blood urea nitrogen; COPD, chronic obstructive pulmonary disease; DNR, do not resuscitate; RVU, relative value unit; WBC, white blood cell count K/uL.
From Khuri SF, Henderson WG, Daley J, et al. Successful implementation of the Department of Veterans Affairs' National Surgical Quality Improvement Program in the private sector: the Patient Safety in Surgery study. *Ann Surg* 2008;248(2):329–336.

Table 15-4B Logistic Regression Models for Prediction of 30-Day Operative Morbidity Using Preoperative Variables

Variable	Odds Ratio
ASA 4/5 vs. 1/2	2.1
ASA 3 vs. 1/2	1.6
Albumin (per gram)	0.73
Work RVU (per unit)	1.05
Emergency operation	1.7
Dyspnea at rest vs. none	1.7
Dyspnea with minimal exertion vs. none	1.2
Wound infection	1.6
Patient on ventilator prior to surgery	1.9
Bleeding disorder	1.5
WBC >11,000/mL^3	1.2
Age (per year)	1.01

Derived from private sector hospitals, $n = 54{,}450$ patients.
ASA, American Society of Anesthesiologist's Patient Severity Score; BUN, blood urea nitrogen; COPD, chronic obstructive pulmonary disease; DNR, do not resuscitate; RVU, relative value unit; WBC, white blood cell count K/uL.
From Khuri SF, Henderson WG, Daley J, et al. Successful implementation of the Department of Veterans Affairs' National Surgical Quality Improvement Program in the private sector: the Patient Safety in Surgery study. *Ann Surg* 2008;248(2):329–336.

Continued development has been sponsored by the American College of Surgeons (ACS) under the ACS-NSQIP® program, combining data collection, centralized benchmarking, and regular reporting. Reports have been utilized as catalysts for institutional-level change, with substantial improvements seen following targeted quality improvement efforts.[21] Following implementation, 66% of ACS-NSQIP hospitals saw reduced mortality rate and 82% saw reduction in complications. The annual benefit for a hospital enrolling in ACS-NSQIP has been estimated at 250 to 500 fewer complications and 12 to 36 fewer deaths.[22] Observed improvements in outcomes appear to be sustained, with the magnitude of quality improvement increasing over time.[23] Of note, improvements in risk-adjusted outcomes at ACS-NSQIP hospitals were not found to differ significantly from those concurrently seen in matched non-NSQIP hospitals, suggesting that while feedback and reporting may be critical to implementing process change, they are not by themselves required to drive improvement.[24,25]

Risk Calculators

Algorithm-based risk stratification based on large data sets is now available throuh the Internet or on mobile devices. In 2011, a cardiac risk calculator based on NSQIP variables compared favorably to performance of the Revised Cardiac Risk Index.[26] In 2013, the ACS released an online decision support tool including a perioperative risk calculator built on the NSQIP database of 1.3 million operations (www.riskcalculator.facs.org, last accessed March 30, 2016). The calculator incorporates 21 variables from the original VA NSQIP data collection and has excellent predictive performance for mortality, morbidity, and six specific complications.[27] Potential criticisms of the model include dependence on American Society of Anesthesiology (ASA) Physical Status grading, imprecise definition of functional outcomes, and lack of validation outside of a NSQIP cohort[28]; however, the ability to rapidly provide individualized patient risk estimation is an important advance. Figure 15-2A,B demonstrate an example of risk determination for a patient undergoing elective colon surgery, entering specific clinical variables and reporting specific complications in an individualized fashion. The use of mobile device decision support tools will also likely continue to increase; as an example, the Michigan Surgical Optimization Program's mobile app provides risk stratification for procedures derived from the Michigan Surgical Quality Collaborative data.

GENERAL CONCEPTS OF PREOPERATIVE EVALUATION

The setting for preoperative evaluation varies with the surgical procedure and with patient circumstances. Coordination of preoperative care at a dedicated facility has led to improved efficiency for outpatient elective surgery[29]; however, this advantage may lessen as intensity of routine testing decreases.

Patient education remains a key aspect of the initial preoperative visit. Preoperative teaching has been shown to improve patient satisfaction and increase cooperation with postoperative recommendations.[30] The wealth of information available on the Internet has enabled patients to be better educated, stronger consumers and has empowered many to participate more actively in their care. Prior to the first office visit, many will have researched their disease process, surgical procedure, as well as the scorecards of the hospital and surgeon. Forward-thinking surgeons can leverage this engagement and increase the value of the face-to-face appointment by providing online teaching materials ahead of the actual office visit.

Initial evaluation includes a standard medical history and complete physical examination. The presence of allergies, current medications, chronic illnesses related and unrelated to the surgical condition, prior procedures, as well as staging and acuity of disease all contribute to the risk and benefit determinations.

Routine preoperative laboratory testing is no longer recommended. The majority of preoperative laboratory tests are rarely indicated and are of limited value.[31] It has been demonstrated that, even when abnormal, preoperative testing often does not lead to change in perioperative management or adverse postoperative outcomes.[32] Despite this, preoperative testing continues to be overused in both low risk[33] and hospital settings.[34]

Selective laboratory testing has potential value in certain elective cases, as well as in remote telemedicine evaluations[35] and as part of risk assessment in elderly patients.[36] In all cases, testing should be based on clinical likelihood of finding and acting on abnormal results. Baseline hemoglobin should be assessed in elderly patients, patients undergoing procedures with expected major blood loss, and patients with underlying hematologic disorders. Renal function can be assessed in older patients, in younger patients with suspicion of renal disease or with associated diabetes, cardiac, vascular, or pulmonary disease, and in patients undergoing major surgery. Electrolytes, glucose, coagulation studies, and liver function tests should be performed selectively. Adjunctive cardiopulmonary evaluation should also be performed selectively.

Routine electrocardiogram (ECG) is not recommended before low-risk surgery. Patients with known coronary disease or elevated risk should be evaluated, unless the procedure itself is low risk. More invasive testing, including exercise testing, echocardiography, and cardiac catheterization should be based on the presence of symptoms, overall functional level, procedural factors, and calculated coronary risk (see Cardiac section). Routine chest x-ray, pulmonary function tests, and arterial blood gases are not indicated unless specific pulmonary symptoms are identified (see Pulmonary section).

Anesthesia

For otherwise healthy patients, selective, rather than routine, evaluation by an anesthesiologist is recommended. Use of a screening questionnaire may facilitate appropriate referral for a formal anesthesia consultation.[37] A nursing instrument identifying high-risk conditions (history of prior or familial anesthetic difficulty, difficult airway/limited neck motion, decreased exercise tolerance, stroke, thyroid, cardiac, asthma, and liver and renal disease) has been validated as a trigger for formal anesthesia consult.[38]

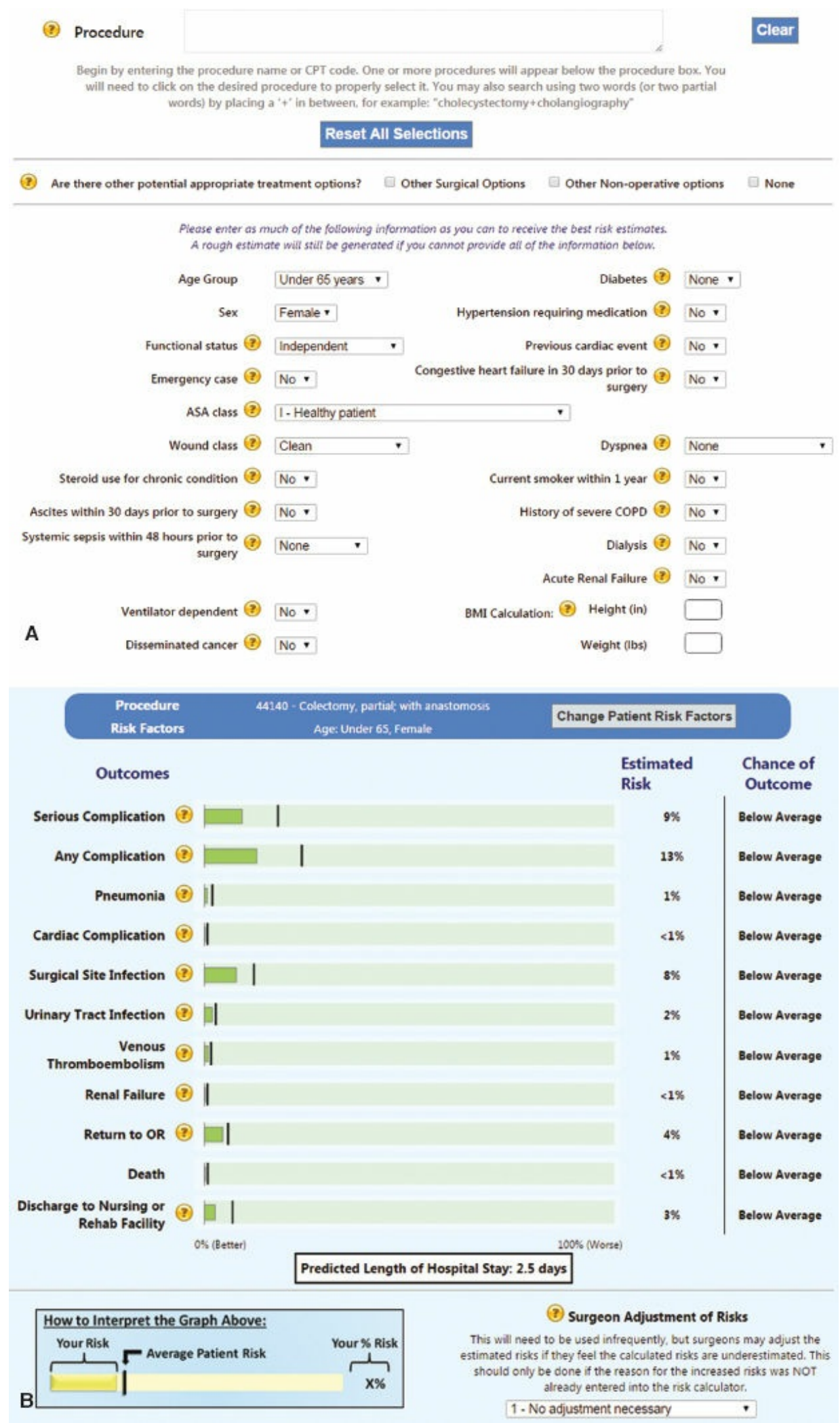

Procedure

Clear

Begin by entering the procedure name or CPT code. One or more procedures will appear below the procedure box. You will need to click on the desired procedure to properly select it. You may also search using two words (or two partial words) by placing a '+' in between, for example: "cholecystectomy+cholangiography"

Reset All Selections

Are there other potential appropriate treatment options? Other Surgical Options Other Non-operative options None

Please enter as much of the following information as you can to receive the best risk estimates.
A rough estimate will still be generated if you cannot provide all of the information below.

Age Group	Under 65 years	Diabetes	None
Sex	Female	Hypertension requiring medication	No
Functional status	Independent	Previous cardiac event	No
Emergency case	No	Congestive heart failure in 30 days prior to surgery	No
ASA class	I - Healthy patient		
Wound class	Clean	Dyspnea	None
Steroid use for chronic condition	No	Current smoker within 1 year	No
Ascites within 30 days prior to surgery	No	History of severe COPD	No
Systemic sepsis within 48 hours prior to surgery	None	Dialysis	No
		Acute Renal Failure	No
Ventilator dependent	No	BMI Calculation: Height (in)	
Disseminated cancer	No	Weight (lbs)	

A

Procedure	44140 - Colectomy, partial; with anastomosis	Change Patient Risk Factors
Risk Factors	Age: Under 65, Female	

Outcomes	Estimated Risk	Chance of Outcome
Serious Complication	9%	Below Average
Any Complication	13%	Below Average
Pneumonia	1%	Below Average
Cardiac Complication	<1%	Below Average
Surgical Site Infection	8%	Below Average
Urinary Tract Infection	2%	Below Average
Venous Thromboembolism	1%	Below Average
Renal Failure	<1%	Below Average
Return to OR	4%	Below Average
Death	<1%	Below Average
Discharge to Nursing or Rehab Facility	3%	Below Average

0% (Better) 100% (Worse)

Predicted Length of Hospital Stay: 2.5 days

How to Interpret the Graph Above:

Your Risk | Average Patient Risk | Your % Risk

X%

B

Surgeon Adjustment of Risks

This will need to be used infrequently, but surgeons may adjust the estimated risks if they feel the calculated risks are underestimated. This should only be done if the reason for the increased risks was NOT already entered into the risk calculator.

1 - No adjustment necessary

Figure 15-2. A,B: Risk stratification: ACS-NSQIP risk calculator. (Source: www.riskcalculator.facs.org, American College of Surgeons.)

The ASA Physical Status classification (Table 15-15) addresses the overall physical status of the patient, exclusive of specific surgical considerations. Despite its relative imprecision and inconsistent application, ASA class remains strongly associated with other predictors of surgical outcomes[39] and continues as a standard adjunct during preoperative evaluation. The choice of anesthetic approach (local, monitored anesthesia care/sedation, neuraxial, and general) varies on the basis of the indicated procedure as well as patient considerations, with general anesthesia carrying a higher risk for pulmonary complications.[40] Systematic review suggests that the use of neuraxial blockade in surgery is associated with overall mortality reduction and decreased complications; however, it is not possible to ascertain whether these findings were due to salutary effects of regional blockade or reduction in the use of general anesthesia.[41] The use of epidural anesthesia may decrease perioperative cardiac events in patients with hip fracture and abdominal aortic aneurysm surgery,[28] but it is not clear that intraoperative neuraxial anesthesia universally reduces perioperative cardiac events.

Table 15-5 ASA Physical Status Classification

ASA PS Classification	Definition	Examples, Including, but Not Limited to:
ASA I	A normal healthy patient	Healthy, nonsmoking, no or minimal alcohol use
ASA II	A patient with mild systemic disease	Mild diseases only without substantive functional limitations. Examples include (but not limited to) current smoker, social alcohol drinker, pregnancy, obesity (30 < BM < 40), well-controlled DM/HTN, mild lung disease
ASA III	A patient with severe systemic disease	Substantive functional limitations; one or more moderate to severe diseases. Examples include (but not limited to) poorly controlled DM or HTN, COPD, morbid obesity (BMI ≥40), active hepatitis, alcohol dependence or abuse, implanted pacemaker, moderate reduction of ejection fraction, ESRD undergoing regularly scheduled dialysis, premature infant PCA <60 wks, history (>3 mo) of MI, CVA, TIA, or CAD/stents.
ASA IV	A patient with severe systemic disease that is a constant threat to life	Examples include (but not limited to) recent (<3 mo) MI, CVA, TIA, or CAD/stents, ongoing cardiac ischemia or severe valve dysfunction, severe reduction of ejection fraction, sepsis, DIC, ARD, or ESRD not undergoing regularly scheduled dialysis
ASA V	A moribund patient who is not expected to survive without the operation	Examples include (but not limited to) ruptured abdominal/thoracic aneurysm, massive trauma, intracranial bleed with mass effect, ischemic bowel in the face of significant cardiac pathology or multiple organ/system dysfunction
ASA VI	A declared brain-dead patient whose organs are being removed for donor purposes	

Reprinted with permission of the American Society of Anesthesiologists.

Surgical Procedure

Each surgical procedure carries its own set of specific risks. The overall physiologic impact varies between procedures. Procedures involving the thoracic or abdominal cavity, neurosurgery, head and neck, or vascular system carry higher risk[42] than those limited to the extremities or subcutaneous tissue. Procedural duration, often associated with complexity and extent of resection, is also associated with increased risk.[40] The extent of surgical exposure has also been correlated with physiologic impact. Minimally invasive approaches have, in general, been associated with lower hospital length of stay, earlier return to function, reduced postoperative pain, and patient satisfaction, but in many cases encumber the risk of increased procedural duration and costs without clear mortality benefit. The urgency of the procedure affects risk assessment (Table 15-16).[28] Emergency surgery carries the additional challenges of life- or limb-threatening condition without the opportunity for medical optimization. The underlying processes are often catastrophic, with increased risk of infection, hemorrhage, and uncorrected physiologic derangement adding to the risk of postoperative complications[43] and mortality.[42]

Disparities

Disparities in surgical outcomes based on racial and socioeconomic considerations still persist. The relative rates of postoperative complications, including respiratory failure, physiologic and metabolic derangements, are generally increased for minority patients over Caucasian patients.[44] The causes are multifactorial and, likely, patient-related factors, as well as chronic and acute health care resource availability, play a role. In a survey of the US Nationwide Inpatient Sample involving more than 3 million oncologic procedures performed between 1999 and 2009, African American, but not Hispanic patients had higher rates of vascular, wound, gastrointestinal (GI), and infectious complications when compared to white patients.[45] These variations in patterns of use suggest that unexploited opportunities may exist to reduce disparities. Cultural and economic barriers to surgical care may not be readily visible to the surgeon and should be actively considered.

Age

Patients are living longer and with more substantial comorbidities. The world's population of people aged 60 years and older has doubled since 1980 and is forecast to reach 2 billion by 2050.[46] Demand for surgical services continues to increase faster than the rate of population growth; in 2006, surgery on elderly patients accounted for 35% of inpatient and 32% of outpatient surgical procedures.[47]

Table 15-6 Procedural Urgency

Category	Characteristics	Time Frame	Example
Emergency	Immediate threat to life or limb	Typically in <6 hrs	Acute traumatic hemorrhagic shock
Urgent	Threat to life or limb	6–24 hrs	Small bowel obstruction
Time sensitive	Sufficient time for evaluation and management changes that may significantly alter outcome	1–6 wks	Oncologic surgery
Elective	Condition permits delay	Up to 1 yr	Aesthetic surgery

Adapted from Fleisher LA, Fleischmann KE, Auerbach AD, et al. 2014 ACC/AHA Guideline on Perioperative Cardiovascular Evaluation and Management of Patients Undergoing Noncardiac Surgery: Executive Summary: A Report of the American College of Cardiology/American Heart Association Task Force on Practice Guidelines. *Circulation* 2014;130(24):2215–2245.

Normal aging reduces the ability to maintain homeostatic responses in the face of acute physiologic stress[48] such as surgery. In a series of over a million Medicare patients, operative mortality for patients aged 80 years and older was observed to be more than twice that for patients aged 65 to 69 years.[3] Compared with patients younger than 60 years, the risk of postoperative pulmonary complication was doubled for patients between the ages of 60 and 69 years and tripled for patients aged 70 to 79 years.[49] Optimization of surgery in the elderly requires recognition of their decreased tolerance for complications. An initial infectious or pulmonary complication is associated with significantly higher risk-adjusted failure-to-rescue rates in elderly patients when compared with younger patients.[50] Attending to prevention and early recognition of complications potentially will have great impact on these outcomes in the elderly population.

While surgical risk increases with advancing age, chronologic age alone should not be considered a contraindication to surgery in otherwise healthy patients. The association of age with other factors such as decreased functional status, an increased number of comorbidities, and more complex pharmacologic history[51] renders simple conclusions unfeasible. For example, in the Revised Cardiac Risk Index model for cardiac mortality, other risk factors become more significant than age alone,[52] while in cases of advanced age, adding age to the revised cardiac risk index (RCRI) model improves its utility for prediction.[53]

The ACS and American Geriatric Society have published best practice Guidelines for the Optimal Preoperative Assessment of the Geriatric Patient.[47] The guidelines highlight 13 geriatric-specific domains to identify and address during the preoperative period (Table 15-7). Areas of focus include traditional preoperative evaluation (cardiopulmonary risk assessment, directed preoperative testing) and added evaluations of cognition (baseline

cognition, decision-making ability, depression, risk for postoperative delirium), functional status (mobility, fall risk, and frailty), nutrition, medication (polypharmacy, alcohol/substance abuse screening), support systems (family and social), as well as discussion of goals and expectations of care.

Table 15-7 Perioperative Evaluation of the Geriatric Patient

Domain	Evaluation	Potential Intervention
Cognitive impairment and dementia	Cognitive screen: Mini-Cog, family interview	If screens positive, further evaluation by PCP, geriatrician, or mental health specialist
Decision-making capacity	The patient can: ■ clearly indicate treatment choice ■ understand relevant information ■ acknowledge condition, treatment options, and likely outcomes ■ engage in rational discussion about treatment options	If altered, discuss surrogacy for medical decision-making
Depression	Depression Screen: PHQ2	If screens positive, further evaluation by PCP, geriatrician, or mental health specialist
Risk for postoperative delirium	Risk assessment	If at risk, patients avoid benzodiazepines and antihistamines when appropriate
Alcohol and substance abuse	Modified CAGE questionnaire	■ If procedure can be delayed, consider referral to substance abuse specialist ■ Perioperative daily MVI and thiamine
Cardiac evaluation	ACC/AHA algorithm (Algorithm 1)	If positive, consider strategies to reduce risk
Risk for pulmonary complications	NSQIP predictors (Table 15-12)	If positive, consider strategies to reduce risk
Functional status, mobility, and fall risk	Timed Up and Go Test	If abnormal
Frailty scoring	Frailty Score	If abnormal
Nutritional status	■ BMI <18.5 kg/m^2 ■ Serum albumin 3.0 g/dL without renal or hepatic dysfunction ■ Unintentional weight lost >10%–15% in past 12 mo	If feasible, full nutritional assessment by dietician with perioperative nutritional planning
Medication management	Review medication list	Avoid polypharmacy
Counseling regarding: ■ advance directive and surrogate decision-making ■ the patient's treatment goals ■ the patient's expectations of surgery ■ the patient's family and social support system		
Appropriate preoperative diagnostic testing	Selective preoperative testing	Normal laboratory values obtained up to 4 mo preoperatively can be used safely as long as nonsubstantial interval change in clinical status has occurred

Adapted from Fleisher LA, Fleischmann KE, Auerbach AD, et al. 2014 ACC/AHA Guideline on Perioperative Cardiovascular Evaluation and Management of Patients Undergoing Noncardiac Surgery: Executive Summary: A Report of the American College of Cardiology/American Heart Association Task Force on Practice Guidelines. *Circulation* 2014;130(24):2215–2245.

Few of these domains are covered in detail during traditional preoperative surgical evaluation and further integration into routine practice is needed. Additional recommendations for geriatric patients include screening for cognitive deficits, with referral for support if screening is positive; recognition of risks for postoperative delirium

(inadequate pain control, sleep deprivation), avoidance of polypharmacy (specifically avoiding drugs that contribute to delirium); encouraging early return to function with mobilization and physical therapy; and dedicating adequate time for counseling with patient, family, and surrogate decision makers.

Medical Comorbidity

5 Hypertension, coronary artery disease, diabetes, and chronic obstructive pulmonary disease (COPD) are the most frequently seen comorbidities in patients older than 70 years.[51] More than 50% of these patients suffer from at least one infirmity and 30% suffer from two or more.[51] As a result, polypharmacy is common. Adaptation to multiple chronic illnesses and treatments may combine to create altered physiologic responses to surgery. For example, a patient with hypertension that is well-controlled with diuretics and β-blockade may be chronically volume depleted and unable to mount cardiovascular response to further blood loss in surgery.

Obesity/Obstructive Sleep Apnea

The prevalence of adult obesity is increasing in the United States, with one-third of adults in 2009–2010 considered to be obese (body mass index [BMI] >30 kg/m^2).[54] Paradoxically, in nonbariatric general surgery, a J-shaped relationship of lower mortality has been reported in overweight and moderately obese patients.[55] Nevertheless, an increased risk of postoperative complications and the need for additional operative planning is present for the bariatric patient. For this chapter, discussion centers on risk of airway difficulty and ventilation in the high BMI patient with sleep apnea.

The American Society of Anesthesiologists updated guidelines for perioperative management of patients with obstructive sleep apnea in 2014.[56] In this report, the prevalence of sleep-disordered breathing was 9% in women and 24% in men. Patients often present without formal confirmation of the diagnosis by polysomnography. Increases in perioperative risk are noted to occur in proportion to the severity of sleep apnea.[57] Sleep apnea should be suspected in patients with history of apparent airway obstruction during sleep, BMI >35 kg/m^2, large neck circumference, craniofacial abnormalities, snoring, frequent arousals from sleep, and unexplained daytime somnolence or fatigue. A trial of preoperative continuous positive airway pressure may be attempted to improve nighttime airway obstruction, particularly if obstructive sleep apnea is severe. Other potential interventions include the use of mandibular advancement devices, oral appliances, and preoperative weight loss; however, evidence was judged to be insufficient to make formal recommendations.

Intraoperative considerations include choice of anesthetic technique, airway management, and patient monitoring. For appropriate procedures, regional anesthesia may be preferred over general anesthesia and continuous monitoring should be employed because of the potential for airway obstruction. Patients at risk for obstructive sleep apnea may have associated difficult airway and require special attention during induction and emergence from anesthesia. Sedation and neuromuscular blockade should be carefully monitored and fully reversed prior to extubation.

Table 15-8 METs Equivalents

METs Level	Example
>10 METs	Strenuous sports (swimming, skiing, singles tennis)
>4 METs	Climbing flight of stairs Walking up a hill Walking 4 mph on level ground
<4 METs	Slow ballroom dancing Golfing with a cart Playing a musical instrument Walking at 2–3 mph
1 MET	Eating, dressing, toileting

Adapted from Fleisher LA, Fleischmann KE, Auerbach AD, et al. 2014 ACC/AHA Guideline on Perioperative Cardiovascular Evaluation and Management of Patients Undergoing Noncardiac Surgery: Executive Summary: A Report of the American College of Cardiology/American Heart Association Task Force on Practice Guidelines. *Circulation* 2014;130(24):2215–2245.

Anemia

Anemia is independently associated with mortality in noncardiac surgery,[58] yet it is not clear that correction of anemia will alter mortality. Several randomized trials examining transfusion strategies in relatively stable patients failed to demonstrate mortality benefit with higher transfusion triggers in the ICU,[59] cardiac[60] and orthopedic surgery[61] settings. At present, recommendations for perioperative transfusion are general, with consideration for higher thresholds given to patients who are symptomatic with chest pain, hypotension, or fatigue, those with known cardiac ischemia or those receiving massive transfusion for hemorrhagic shock. The use of erythropoietin stimulating agents and intravenous iron supplementation to facilitate perioperative transfusion management remains controversial,[62] secondary to increased risk in oncologic and nonanemic patients. Current evidence does not support aggressive preoperative transfusion in patients with sickle cell disease.[63] Conflicting evidence has been published regarding the relationship between age of transfused cells and mortality.[64,65]

Preoperative Functional Status

The impact of preoperative functional status has been recognized for years. Self-reported exercise intolerance (to walking four blocks or two flights of steps) is independently associated with higher risk of perioperative cardiovascular, myocardial ischemia, and neurologic events after elective major noncardiac surgery.[66] The relationship is inversely related to the total number of blocks that could be walked or flights of stairs that could be climbed. Functional ability can be quantified in terms of metabolic equivalents (METs), with 1 MET defined as the amount of oxygen consumed while sitting at rest and equal to 3.5 mL O_2 uptake/kg/min.[67] Functional status can be categorized as excellent, >10 METs; good, 7 to 10 METs; moderate, 4 to 6 METs; and poor, <4 METs. Risk is increased if unable to perform at a level of 4 METs (Table 15-8).[28] The ACS recommends a four-question survey of activities of daily living (ADLs) as a screen to identify unsuspected functional compromise in geriatric patients (Table 15-9A).[68]

Frailty

Separate from comorbidity, elderly patients may suffer from frailty and sarcopenia.[69] In the Medicare population, additional mortality has been related to frailty[70] and the relationship has been documented in a broad population, including patients undergoing gastric surgery,[71] gynecologic oncology,[72] and cardiac surgery.[73] CT-based morphomic quantitation of trunk muscle volume is associated with decreases in functional performance on ADLs and independent activities as measured by the Vulnerable Elder Survey[74] as well as poorer outcomes in liver transplantation[75] and aortic surgery.[76] An operational frailty score (Table 15-9B) has been validated in elderly surgical patients and is associated with higher incidence of postoperative adverse events, increased length of hospital stay, and higher likelihood of discharge to a skilled or assisted-living facility.[77]

Table 15-9A Short Simple Screen for Functional Assessment

Ask the patient the following questions: 1. Can you get out of bed or chair yourself? 2. Can you dress and bathe yourself? 3. Can you make your own meals? 4. Can you do your own shopping?
If NO to any of these questions, more in-depth evaluation should be performed, including full screening of activities of daily living and instrumental activities of daily living.
Deficits should be documented and may prompt perioperative interventions (i.e., referral to occupational therapy and/or physical therapy) and proactive discharge planning.

Adapted from Chow WB, Rosenthal RA, Merkow RP, et al. Optimal preoperative assessment of the geriatric surgical patient: a best practices guideline from the American College of Surgeons National Surgical Quality Improvement Program and the American Geriatrics Society. *J Am Coll Surg* 2012;215(4):453–466.

Direction of Care

One of the most important discussions between a surgeon and the patient is the understanding of the patient's desires regarding direction of care. There is little question of aggressive interventions for a healthy patient expecting rapid return to their preoperative level of function after elective surgery. Nevertheless, patients with severe underlying comorbidity or limited life expectancy should have the opportunity to direct overall goals of their care. One approach that incorporates principles of geriatric and palliative care is to frame surgical care for these patients in the context of time-limited trials.[78,79] Overall prognosis, patient priorities, and specific milestones defining improvement or deterioration are discussed with the patient and family. A mutual decision for surgical care is crafted, outlining a specific time-limited trial of care and potential actions that could be undertaken at the end of the trial or in the event that complications arise. In this fashion, treatment decisions can be matched to the individual patient's overall priorities and goals.

Table 15-9B Frailty Scoring (Operational Definition)

Criteria	Definition
Shrinkage	Unintentional weight loss ≥10 lb past year
Weakness	Decreased grip strength
Exhaustion	Self-reported poor energy and endurance
Low physical activity	Low weekly energy expenditure
Slowness	Slow walking
The patient receives 1 point for each criterion met:	
0 to 1	Not frail
2 to 3	Intermediate frail (pre-frail)
4 to 5	Frail

Adapted from Chow WB, Rosenthal RA, Merkow RP, et al. Optimal preoperative assessment of the geriatric surgical patient: a best practices guideline from the American College of Surgeons National Surgical Quality Improvement Program and the American Geriatrics Society. *J Am Coll Surg* 2012;215(4):453–466.

MEDICATION MANAGEMENT

Medication management in the perioperative period is subject to general guidelines of practice. The pharmacokinetics of drug administration, distribution, metabolism, and excretion may all be affected by surgery. Major GI procedures limit oral intake and may require alternate routes of administration. Patients receiving volume resuscitation may have increased drug volume of distribution. Fluctuations in hepatic and renal function and addition of multiple new medications may alter drug metabolism and excretion. New drug interactions may lead to increased toxicity; appropriate monitoring by drug levels may improve drug management.

A careful medication history includes prescription and nonprescription medications and nutritional and herbal supplements. Patients may be taking over-the-counter herbal supplements with substantial physiologic effects[80] but may not perceive these as being relevant to the conduct of their surgery. In one series, more than 70% of patients failed to disclose herbal medicine use during routine preoperative assessment.[81] Herbal supplements are presently not subject to FDA regulation; contents may vary substantially from manufacturer to manufacturer and frank adulteration has been documented.[82] Recommendations for commonly taken herbal supplements are summarized in Table 15-10, keeping in mind that variations in supplement content may make a 7-day holding period prudent.[83]

In the absence of clear evidence-based guidelines for perioperative medication management, a general approach is to continue drugs that would cause withdrawal within the perioperative period, and to discontinue unnecessary drugs or those with potential for adverse events, restarting them as soon as the patient condition permits.[83] Medications that are generally continued include β-blockers, clonidine, statins, and selective serotonin reuptake inhibitors (SSRIs). Medications that can be discontinued include diuretics, metformin, and, possibly, angiotensin-converting enzyme (ACE) inhibitors and angiotensin receptor blockers (ARBs) (Table 15-11).

Chronic β-blocker therapy should not be held perioperatively, as abrupt discontinuation may lead to rebound tachycardia and hypertension. Patients not previously receiving β-blockers should not have them initiated in anticipation of planned surgery, as this practice has been associated with an increase in cardiovascular events and is no longer recommended. Statins should be continued in the perioperative period when feasible. Other than β-blockers, antihypertensive medications are generally held perioperatively and should be considered individually. ACE inhibitors and ARBs are associated with perioperative hypotension[84] and renal risk. Diuretics are associated with chronic volume depletion and electrolyte abnormalities and should be held perioperatively.

Management of anticoagulation is of critical importance to surgeons and the indication for anticoagulation should be weighed against the risk of procedural bleeding. Agents should be held for the minimum interval felt safe after invasive procedure. Patients on chronic long-acting anticoagulation who are undergoing elective operation can use preoperative bridging with unfractionated or low-molecular-weight heparin prior to surgery.[85] In the emergent setting, the American College of Chest Physicians (ACCP) has

published guidelines covering reversal of vitamin K competitors based on urgency of procedure and risk of life-threatening hemorrhage.[86] Reversal of newer direct thrombin inhibitors may not be possible other than waiting for drug clearance; dabigatran may be removed with dialysis; however, rivaroxaban and apixaban are highly protein bound and unlikely to be removed with this modality. In a large series, perioperative aspirin administration was associated with an increased risk of postoperative hemorrhage[87]; however, a recent meta-analysis concluded that aspirin should not be stopped in the perioperative period unless bleeding risk outweighed thrombotic risk of holding the drug.[88] Dual antiplatelet therapy in the setting of coronary stent placement is specifically addressed in current American College of Cardiology/the American Heart Association (ACC/AHA) guidelines[28] and is discussed separately in the Cardiac section.

Table 15-10 Potential Interactions for Some Common Herbal Medicines

Common Name of Herb	Potential Interactions	Preoperative Recommendations
Echinacea	Allergic reactions; decreased effectiveness of immunosuppressants; potential for immunosuppression with long-term use, potential hepatotoxicity	No data
Ephedra	Risk for myocardial ischemia and stroke from tachycardia and hypertension; ventricular arrhythmias with halothane; long-term use depletes endogenous catecholamines and may cause intraoperative hemodynamic instability; life-threatening interaction with monoamine oxidase inhibitors	Discontinue at least 24 hrs before surgery
Dong Quai Vitamin E Evening Primrose Oil Fish Oil Feverfew Garlic Ginkgo Ginger Ginseng Guarana Goldenseal	Potential to increase risk for bleeding, especially when combined with other medications that inhibit platelet aggregation	Consider discontinuation 7 days before surgery (36 hrs for ginkgo)
Ginseng	Hypoglycemia; potential to increase risk for bleeding; potential to decrease anticoagulative effect of warfarin	Discontinue at least 7 days before surgery
Kava	Potential to increase sedative effect of anesthetics; potential for addiction, tolerance, and withdrawal after abstinence unstudied	Discontinue at least 24 hrs before surgery
St. John's Wort	Induction of cytochrome P-450 enzymes, with effect on cyclosporine, warfarin, steroids, protease inhibitors, and possibly benzodiazepines, calcium channel blockers, and many other drugs; decreased serum digoxin levels	Discontinue at least 5 days before surgery
Valerian	Potential to increase sedative effect of anesthetics; benzodiazepine-like acute withdrawal; potential to increase anesthetic requirements with long-term use	No data

Adapted from Ang-Lee MK, Moss J, Yuan CS. Herbal medicines and perioperative care. *JAMA* 2001;286(2):208–216; Halaszynski TM, Juda R, Silverman DG. Optimizing postoperative outcomes with efficient preoperative assessment and management. *Crit Care Med* 2004;32(4) (suppl):S76–S86.

Perioperative glucose control reduces mortality rate, hospital length of stay, and deep wound infections in cardiac surgery.[89] An adjusted dose of short-acting insulin is administered perioperatively, with intravenous insulin infusion intraoperatively if

needed. The oral hypoglycemic, metformin, is associated with lactic acidosis and should be held prior to surgery.

Psychiatric medications should be managed on the basis of concern for withdrawal. Abrupt withdrawal of SSRIs may lead to nausea, vomiting, and lethargy, with symptoms seen more quickly in drugs with shorter half-life.[90] The use of SSRIs may increase the risk of bleeding, particularly when used in conjunction with nonsteroidal anti-inflammatory drugs (NSAIDs).[83] Benzodiazepines may be continued perioperatively. Older agents, including tricyclic antidepressants and monoamine oxidase inhibitors, may precipitate hypertensive crisis in conjunction with indirect sympathomimetics.

Patients receiving daily maintenance buprenorphine will not have sufficient surgical analgesia from usual postoperative opioid dosing regimens. Preoperative consultation with their prescriber and with the anesthesiology pain service is recommended prior to surgery. Alternative strategies, including the use of regional anesthesia and nonsteroidal and nonnarcotic regimens, may facilitate postoperative management.

Immunosuppressant mediations may be reduced or discontinued prior to surgery, depending on the extent and the presence of associated infection, although a systematic review of immunomodulators in patients with inflammatory bowel disease has suggested no clear increased risk of total or infectious complications with azathioprine, cyclosporine, or infliximab.[91] Steroid use carries a dose-dependent relationship with an increased risk of postoperative complications, both infectious and overall.[92] Meta-analysis of randomized controlled trials suggests that perioperative stress dose steroids are not required unless there is dysfunction of the hypothalamic-pituitary-adrenal axis.[93] Anti-VEGF inhibitors are associated with an increased risk of GI perforation and delayed wound healing and their use is not recommended for 28 days before or after surgery or until surgical wounds are healed.

SPECIFIC ORGAN SYSTEM GUIDELINES

Cardiovascular

Prediction of cardiac adverse events following noncardiac surgery was pioneered in the 1970s[1] and risk stratification is most refined in this area.

Table 15-11 Common Prescription Medications That May Require Special Perioperative Management

Anticoagulants	May require reversal in acute situations May bridge therapy with unfractionated or LMW heparin
Aspirin, or dipyridamole (persantine)	In setting of PCI and prior drug eluting stent Withhold 7 days prior to surgery with increased bleeding risk May continue in select procedures
Thienopyridines (clopidogrel, ticlid)	In setting of PCI and prior drug eluting stent Withhold 7 days prior to surgery with increased bleeding risk
Glycoprotein IIb/IIIa inhibitors	In setting of PCI and prior drug eluting stent. Withhold at least 12 hrs prior to surgery, although antiplatelet effect may persist for longer
NSAIDs	Withhold prior to surgery with risk of renal complications
β-Blockers	Continue in patients already receiving drug, including day of surgery Do not begin new therapy in preoperative setting
Statins	Continue in patients already receiving drug, including day of surgery Consider initiating in patients undergoing vascular surgery
Calcium channel blockers, nitrates, most antiarrhythmics	Continue in patients already receiving drug, including day of surgery
Angiotensin-converting enzyme inhibitors, angiotensin receptor blockers	Risk of intraoperative hypotension and renal risk, hold day of surgery
Diuretics	Renal risk, potential for hyperkalemia with potassium sparing diuretics, hold day of surgery
Metformin	Risk of lactic acidosis, withhold at least 2 days prior to surgery
Insulin	Adjust dose prior to surgery
Lithium	Potential prolongation of neuromuscular blockade, sedative action, cardiac arrhythmia withhold at least 1 day prior to surgery
Monoamine oxidase inhibitors	Potential anesthetic interactions Proceed with MAO safe anesthetic or hold for 2 wks
Selective seratonin release inhibitors	Potential bleeding complications Discontinue for 3 wks preoperatively in conjunction with psychiatry evaluation
Buprenorphine/naloxone	Preoperative weaning in conjunction with the prescribing physician Postoperative pain management may require pain/addiction specialist consultation
HIV drugs	Minimize interruptions in antiretroviral therapy Prophylaxis may vary on the basis of immune status
Steroids, immunosuppressives	Stress dose steroids indicated only if evidence of abnormal hypothalamic–pituitary–adrenal axis May be advisable to discontinue or reduce dose in presence of active infection
Oral contraceptives, conjugated estrogen	Increase hypercoagulable state Consider holding 4 wks prior to surgery; if not feasible, ensure adequate DVT prophylaxis

Risk Stratification

The current Revised Cardiac Risk Index (Table 15-12)[52] is based on risk of surgery,

history of ischemic heart disease, history of congestive heart failure, history of cerebrovascular disease, preoperative insulin-requiring diabetes mellitus, and preoperative renal insufficiency and can be used to identify patients at higher risk for major cardiac complications (myocardial infarction [MI], pulmonary edema, ventricular fibrillation, primary cardiac arrest, complete heart block). The RCRI has been validated as a predictor of increased risk, although, disappointingly, targeted interventions in high-risk groups have not yet conclusively shown benefit. In 2007, evaluation of ACS NSQIP data in 211,410 patients demonstrated a 0.65% rate of perioperative myocardial infarction or cardiac arrest. Five predictors were identified: type of surgery, dependent functional status, abnormal creatinine, ASA class, and increasing age.[26] Active angina and signs of left ventricular dysfunction, such as dyspnea or worsening heart failure; syncope; significant arrhythmias; severe valvular disease; and surgery should prompt further preoperative evaluation.

The ACC and the AHA issued joint recommendations for perioperative cardiovascular evaluation and management for noncardiac surgery in 2014.[28] The guideline covers preoperative evaluation, risk assessment, perioperative management, and post–percutaneous coronary intervention (PCI) recommendations. Outcomes are defined in terms of a composite Major Adverse Cardiac Event (MACE), which includes death or MI. Low-risk procedures are defined as carrying a predicted MACE risk of $<1\%$ and elevated-risk procedures carrying a MACE risk of $\geq 1\%$.

Stable patients undergoing low-risk surgery and those with good exercise tolerance rarely need further cardiac evaluation. For those at higher risk, cardiology evaluation is recommended. In urgent or emergent situations where surgical intervention must proceed prior to any meaningful management changes, delay for cardiac evaluation will not be of benefit and care is focused on prompt recognition and treatment of any perioperative events. In this paradigm, decision-making for higher-risk patients can be simplified to (1) initial determination if the procedure can be delayed to permit additional evaluation and management which could significantly alter the outcome and (2) further risk stratification and intervention if the patient condition permits. The overall ACC/AHA algorithm is reproduced in Algorithm 15-1 and specific recommendations are summarized later.

Table 15-12 Revised Cardiac Risk Index

Revised Cardiac Risk Index Criteria	
High-risk surgery	
Intraperitoneal	
Intrathoracic	
Suprainguinal vascular	
History of ischemic heart disease	
History of myocardial infarction	
History of current angina	
Use of sublingual nitrate therapy	
History of positive exercise test	
Pathologic Q waves on electrocardiogram	
History of congestive heart failure	
Pulmonary edema, bilateral rales or S3 gallop	
Paroxysmal nocturnal dyspnea	
CXR showing pulmonary vascular redistribution	
History of cerebrovascular disease	
History of transient ischemic attack	
History of cerebrovascular accident	
Diabetes mellitus requiring insulin therapy	
Chronic renal insufficiency, defined as a baseline creatinine level of at least 2.0 mg/dL (177 umol/L)	
Patient Receives 1 Point for Any Finding Within the 6 Major Categories	
Points	**Risk of Major Cardiac Event (%)**
0	0.4
1	0.9
2	6.6
3–6	11

Adapted from Lee TH, Marcantonio ER, Mangione CM, et al. Derivation and prospective validation of a simple index for prediction of cardiac risk of major noncardiac surgery. *Circulation* 1999;100(10):1043–1049.

Preexisting Cardiac Disease

The presence of underlying coronary artery disease is associated with postoperative MACE following noncardiac surgery. Following an acute MI, the rate of subsequent postoperative ischemia and MI decreases as the time interval to surgery increases. The risk of perioperative stroke was also increased with surgery occurring within 6 months of MI.[94] In the absence of myocardial revascularization, noncardiac surgery should be delayed for 60 days or more after acute MI. Coronary artery bypass grafting (CABG) solely to reduce perioperative risk is not recommended and should be performed only if the procedure would otherwise be indicated.

The presence of heart failure is a strong predictor of perioperative cardiac morbidity and mortality. The stability of heart failure is likely to affect outcomes, with decompensated, symptomatic heart failure identified on physical examination carrying higher risk. Preservation of left ventricular ejection fraction is an independent predictor for patients undergoing elevated-risk surgery[95] and patients with an LVEF $\leq 29\%$ were identified as having higher risk in vascular surgery.[96]

Patients with clinically suspected valvular heart disease should have review of echocardiography evaluation performed within 1 year prior to surgery or have repeat study if there has been a significant change in status or physical evaluation. Concomitant evaluation for ischemic disease should be considered. If valvular intervention is clinically indicated, intervention prior to noncardiac surgery may reduce perioperative risk.[97]

Postoperative arrhythmias are common and are often triggered by the stress of surgery. Patients with heart block, implanted pacemakers, or automatic implantable cardioverter defibrillators are best served by effective communication between surgery, anesthesiology, and cardiology to optimize perioperative device management.

Although not included in most cardiac risk scoring, pulmonary hypertension is associated with increased complications[98] and patients may benefit from referral to a center with expertise for further evaluation. In a single-institution study evaluating adult patients with pulmonary hypertension undergoing anesthesia, specific risk factors were identified as associated with short-term morbidity (history of pulmonary embolism, NYHA functional class ≥ 2, elevated-risk surgery, anesthesia >3 hours) and postoperative mortality (pulmonary embolism, right axis deviation on ECG, right ventricular hypertrophy or right ventricular systolic pressure:systolic blood pressure >0.66, intraoperative vasopressor and anesthesia when nitrous oxide was not used).[99]

Adult patients with congenital heart disease, when possible, should undergo preoperative evaluation in a regional center specializing in congenital cardiology.[100]

Preoperative Testing

ECG should be considered for patients undergoing elevated risk surgery. It should also be considered in patients with a history of CHD, significant arrhythmia, peripheral arterial disease cerebrovascular disease, or significant structural heart disease, unless they are undergoing low-risk surgery.

More extensive evaluation, including exercise stress testing, assessment of left ventricular function, or coronary angiography, is performed selectively after initial risk stratification and determination of exercise tolerance. Exercise stress testing is not recommended for patients undergoing low-risk surgery or patients able to tolerate >10 METs; patients with elevated RCRI risk, but able to tolerate >4 METs, and patients with elevated RCRI risk, and unable to tolerate <4 METs, but for whom cardiac evaluation will not change management. In patients with elevated RCRI risk or unable to tolerate <4 METs in whom the opportunity exists to improve cardiac management, stress exercise testing can be useful.[28]

Management of Antiplatelet Therapy Following Percutaneous Coronary Intervention

Recommendations following percutaneous coronary interventions are evolving and center on not just the cardiac risk, but also the risk of discontinuing dual antiplatelet therapy. Premature discontinuation of antiplatelet agents increases the risk for early and late stent thrombosis and this must be weighed against the relative risk of surgical bleeding. Dual antiplatelet therapy should not be interrupted for the initial 4 to 6 weeks after PCI.

Elective surgery should be delayed at least 14 days after balloon angioplasty, 30 days after bare-metal stent implantation if antiplatelet agents are to be discontinued and 365 days after drug-eluting stent (DES) implantation, if feasible. Elective surgery may be considered earlier (180 days) following DES implantation if risk of surgical delay outweighs risk of stent thrombosis.

Management in all other situations should be determined by consensus of the surgeon, anesthesiologist, cardiologist, and patient. In patients undergoing emergent surgical procedures that mandate discontinuation of P2Y12 platelet receptor inhibitors, aspirin should be continued if possible and the P2Y12 platelet receptor inhibitor resumed as soon as possible following surgery (Algorithm 15-2).[28]

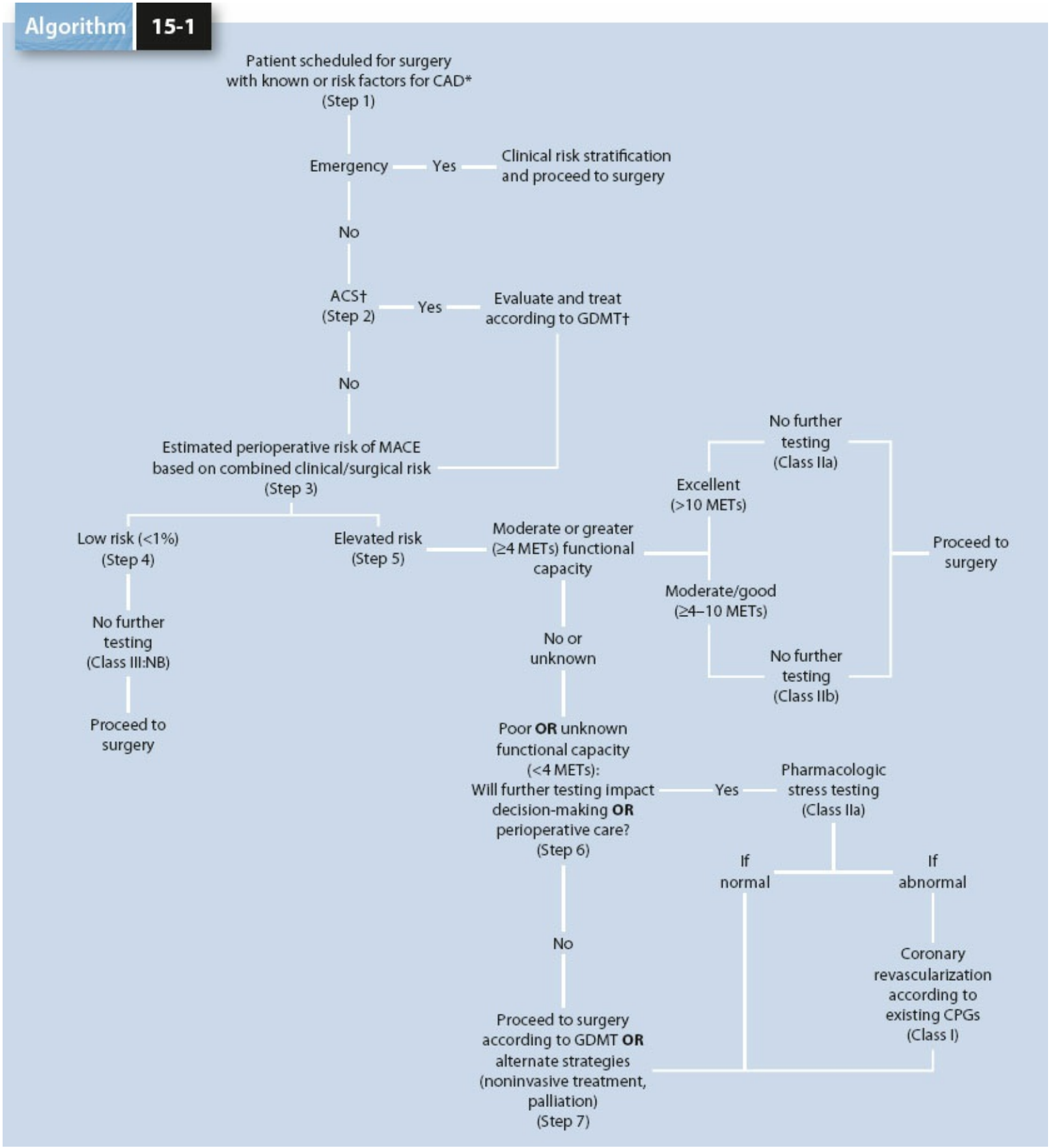

Algorithm 15-1. Stepwise Approach to Perioperative Cardiac Assessment for CAD. (From Fleisher LA, Fleischmann KE, Auerbach AD, et al. 2014 ACC/AHA Guideline on Perioperative Cardiovascular Evaluation and Management of Patients Undergoing Noncardiac Surgery: Executive Summary: A Report of the American College of Cardiology/American Heart Association Task Force on Practice Guidelines. *Circulation* 2014;130(24):2215–2245.)

Other Cardiac Medication Management

Patients on chronic β-blockade should continue treatment during the perioperative period. Prior recommendations for initiating β-blockade in patients without cardiac risk factors have been removed after meta-analysis indicated increased mortality.[101] In patients with intermediate or high risk for myocardial ischemia, that is, three or more risk factors on RCRI, new initiation of β-blockers can be considered preoperatively but enough time should be allowed to ensure stability before surgery. Statin therapy should be continued perioperatively and new initiation can be considered for vascular[102] or elevated-risk patients clinical indications. Alpha-2 blockade with clonidine should not be administered for prevention of cardiac events.[103] Aspirin, while it has a role in acute coronary syndrome and following PCI, is not indicated solely for prevention of perioperative cardiac events.[87] No benefit has been identified for perioperative nitroglycerine and routine use is not recommended.

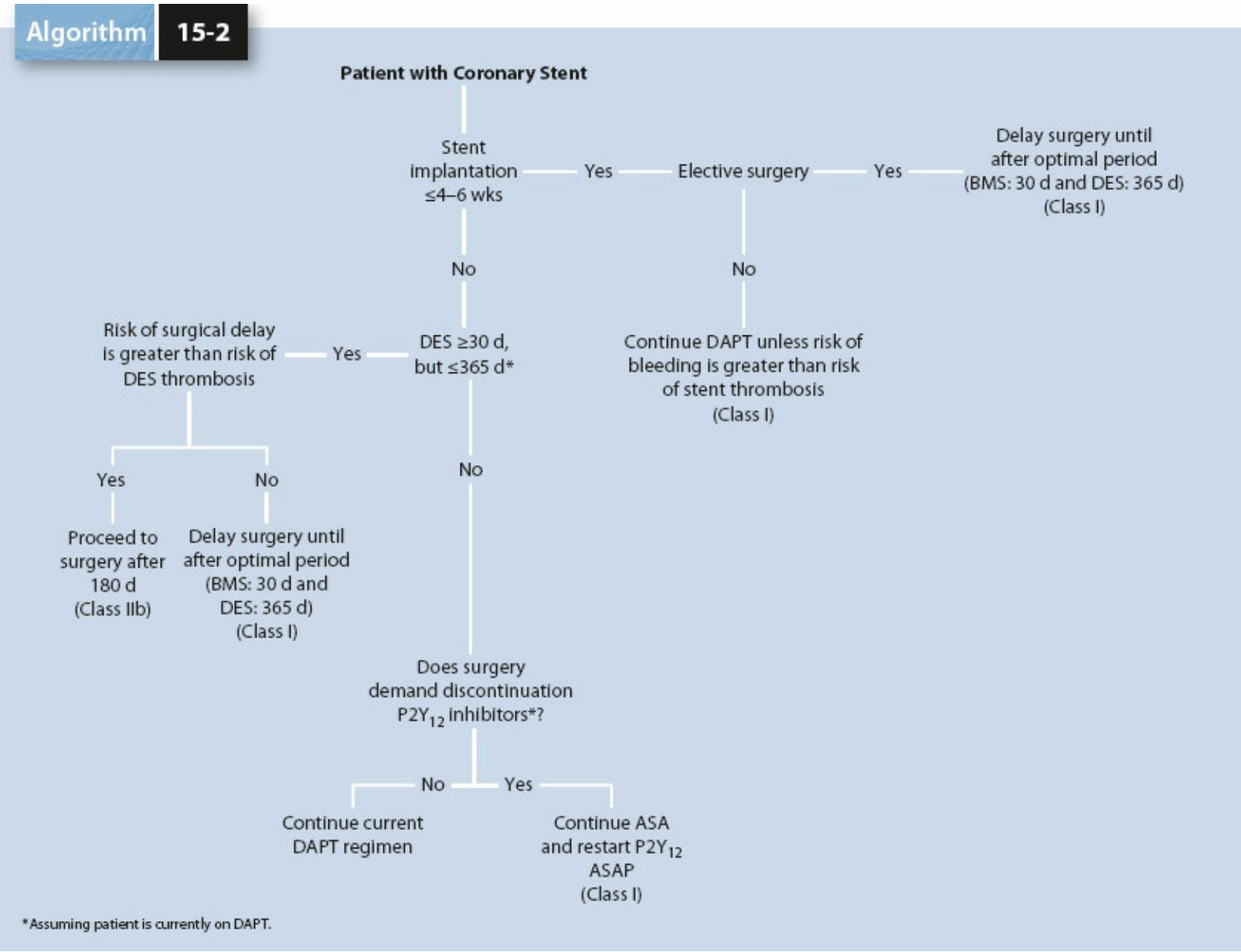

Algorithm 15-2. Proposed algorithm for antiplatelet management in patients with PCI and noncardiac surgery. (From Fleisher LA, Fleischmann KE, Auerbach AD, et al. 2014 ACC/AHA Guideline on Perioperative Cardiovascular Evaluation and Management of Patients Undergoing Noncardiac Surgery: Executive Summary: A Report of the American College of Cardiology/American Heart Association Task Force on Practice Guidelines. *Circulation* 2014;130(24):2215–2245.)

Surgical Considerations

The extent and invasiveness of the surgery must be considered, including anticipated blood loss, fluid shifts, and hemodynamic instability. In general, procedures involving extremity or noncavitary surgery pose less risk than thoracic, abdominal, or neurosurgical procedures. As hypotension and tachycardia may decrease coronary perfusion, intraoperative hemodynamic monitoring and ICU stay may be advisable for high-risk patients. Routine pulmonary artery catheter monitoring is not recommended but may be of benefit in valvular disease. Transfusion triggers for patients at risk for or experiencing active cardiac ischemia remain undefined but are generally higher than usual thresholds.

Pulmonary

Pulmonary complications following surgery are among the most frequent and costly postoperative events and lead to similar increases in morbidity, mortality, and length of stay as cardiac complications.[40] In particular, the development of pulmonary complications in the elderly may predict long-term mortality after surgery.[104] Age-related diminution of pulmonary function is associated with postoperative complications[40] and increasing age is an independent risk factor for postoperative pulmonary complications.[49] Other factors associated with increased risk of postoperative pulmonary complications are summarized in Table 15-13.

Risk Stratification

The 2006 American College of Physicians guideline for preoperative pulmonary evaluation includes evaluation of patient-related, operative, and laboratory risk factors associated with increased risk of postoperative pulmonary complications.[49] Chronic lung disease was the most frequently identified risk factor; other patient-related factors include ASA class greater than II, increasing age, congestive heart failure, functional dependence, restrictive lung disease, and uncontrolled reactive airway disease. Operative risk factors include surgical site, duration, choice of anesthetic, emergency procedures, and low serum albumin. Other pulmonary risk stratification scales also identified elevated blood urea nitrogen (BUN), dyspnea at rest or low levels of activity[105]; low preoperative arterial oxygen saturation, acute respiratory infection during the previous month, age, preoperative anemia, upper abdominal or intrathoracic surgery, surgical duration of at least 2 hours, emergency surgery[106]; and age, smoking status, airflow limitation, ASA class, hypoalbuminemia, emergency, surgery and nonlaparoscopic abdominal/cardiac and AAA repair[107] as risk factors for pulmonary complications.

Table 15-13 Pulmonary Complications in Noncardiac Surgery

Risk Assessment for Pulmonary Complications in Noncardiothoracic Surgery
Patient-related factors
Age > 60 yrs
ASA class II or greater
Chronic obstructive pulmonary disease
Functional dependence
Congestive heart failure
Dyspnea at rest or minimal exertion
Operative factors
Prolonged surgery (>3 hrs)
Abdominal surgery
Thoracic surgery
Neurosurgery
Head and neck surgery
Vascular surgery
Emergency surgery
Use of general anesthesia
Laboratory values
Serum albumin <3.5
Blood urea nitrogen >40

Modified from Qaseem A, Snow V, Fitterman N, et al. Risk assessment for and strategies to reduce perioperative pulmonary complications for patients undergoing noncardiothoracic surgery: a guideline from the American College of Physicians. *Ann Intern Med* 2006;144(8):575–580; Khuri SF, Henderson WG, Daley J, et al. Successful implementation of the Department of Veterans Affairs' National Surgical Quality Improvement Program in the private sector: the Patient Safety in Surgery study. *Ann Surg* 2008;248(2):329–336.

Preoperative Evaluation

History and physical examination can be used to screen for patients requiring further assessment. Symptomatic dyspnea is a strong predictor of pulmonary complications and should be investigated further as it may signal underlying cardiopulmonary or neuromuscular dysfunction. Chronic cough or sputum production, particularly in the setting of chronic obstructive lung disease, cigarette smoking, or occupational exposures, should trigger consideration of possible associated infection. Systemic diseases may have associated pulmonary compromise. A history of restrictive chest wall disease or neuromuscular disorders may signal impaired ventilatory reserve and may impart additional risk. Physical examination findings of abnormal auscultation, scoliosis, chest wall deformity, and accessory muscle use may denote decreased functional capacity. While a history of asthma has not been confirmed to be independently associated with postoperative pulmonary complications, patients with poor control are at increased risk.[108]

6 Routine chest radiography, pulmonary function tests, and arterial blood gases are not indicated for extrathoracic surgery[49] but may be considered in evaluation for resectional and nonresectional thoracic surgery and in patients with symptoms and undiagnosed chronic lung disease. Dyspnea on exertion should be evaluated with pulmonary function

tests and chest radiography. If a cardiac etiology is suspected by history or physical examination, echocardiography can be considered. Abnormal chest radiography suggesting diffuse parenchymal disease should be investigated further. Preoperative albumin and BUN are associated with increased complications and should be obtained as part of evaluation in patients with at least one other identified risk factor.[49] Identification of patient and operative or laboratory risks should prompt further investigation.

Cigarette smoking is directly toxic to respiratory epithelium and is associated with chronic lung disease. A large systematic review concluded that cigarette smoking led to delayed healing and complications through prolonged effect on inflammatory and reparative cell functions.[109] A history of cigarette smoking is associated with increased chance of major morbidity (surgical site infection, pneumonia, shock, unplanned intubation) and mortality.[110]

Benefits of smoking cessation likely increase with increased interval between stopping and surgery. Meta-analyses suggest that the effects of cigarette smoking on the tissue microenvironment and inflammatory cellular functions may be reversed within 4 weeks[109] and that smokers who quit more than 4 weeks before surgery have lowered risk of perioperative respiratory and wound complications.[111] Reports of increased airway reactivity during these initial weeks following smoking cessation raise concerns regarding proceeding with surgery during this period,[112,113] although more recent studies suggest no increase in complications for shorter intervals.[111,114] A general recommendation is that for maximum benefit, smoking should be discontinued 6 to 8 weeks preoperatively, but that stopping for any duration before surgery is beneficial.

In addition, surgery may represent an opportunity for a teachable moment for the patient's health. In a longitudinal study, patients undergoing major surgery doubled the chances of quitting.[115] A recent Cochrane review suggested that brief and intensive interventions reduced perioperative smoking, and that more intensive structured smoking cessation interventions, including weekly preoperative counseling and nicotine replacement therapy, may be used to extend perioperative smoking cessation to long-term success.[116]

Preoperative Evaluation Prior to Lung Cancer Resection

Considerations for patients undergoing surgical treatment of lung cancer balance the intent for curative resection with concern for residual function and long-term disability following surgery. As conditions promoting the development of lung cancer, that is, cigarette smoking and occupational exposures, are also associated with intrinsic reductions in pulmonary function, the guidelines rely on physiologic testing to estimate perioperative risk as well as the effect on postoperative lung function.

In 2007, the ACCP published recommendations for evaluation of patients with lung cancer being considered for resection (Algorithm 15-3).[117] Multidisciplinary evaluation was stressed as essential for counseling, particularly in patients with borderline function. Age alone was felt to be insufficient grounds to deny lung resection surgery. Cardiology evaluation was recommended for patients with major factors for increased perioperative

cardiac risk. Initial pulmonary function testing is recommended for patients undergoing lung resection surgery and is to be performed with the patient on optimal bronchodilator therapy. Significant hypoxemia (SaO_2 <90%) but not hypercarbia ($PaCO_2$ >45 mm Hg) was an independent risk factor for increased perioperative complications and, in its presence, physiologic testing is recommended. Additional pulmonary function testing should be prompted if forced expiratory volume in the first second of expiration (FEV_1) is <80%, if absolute values on spirometry are lower than generally accepted threshold for safe resection (1.5 L for lobectomy, 2.0 L for pneumonectomy) or if dyspnea on exertion or interstitial lung disease is suspected. Further risk stratification is based on measurement of D_{LCO}, estimation of cardiopulmonary exercise tolerance and calculation of the postoperative expected FEV_1. In patients with borderline assessments, counseling regarding nonstandard surgery and nonoperative treatment options was recommended.

Postoperative atrial fibrillation occurs in up to 19% of patients following lung cancer resection with incidence peaking on the second postoperative day.[118] Greater risk is present for men >55 years of age and in the presence of a resting heart rate >72 beats per minute and close attention should be paid to volume and electrolyte status.

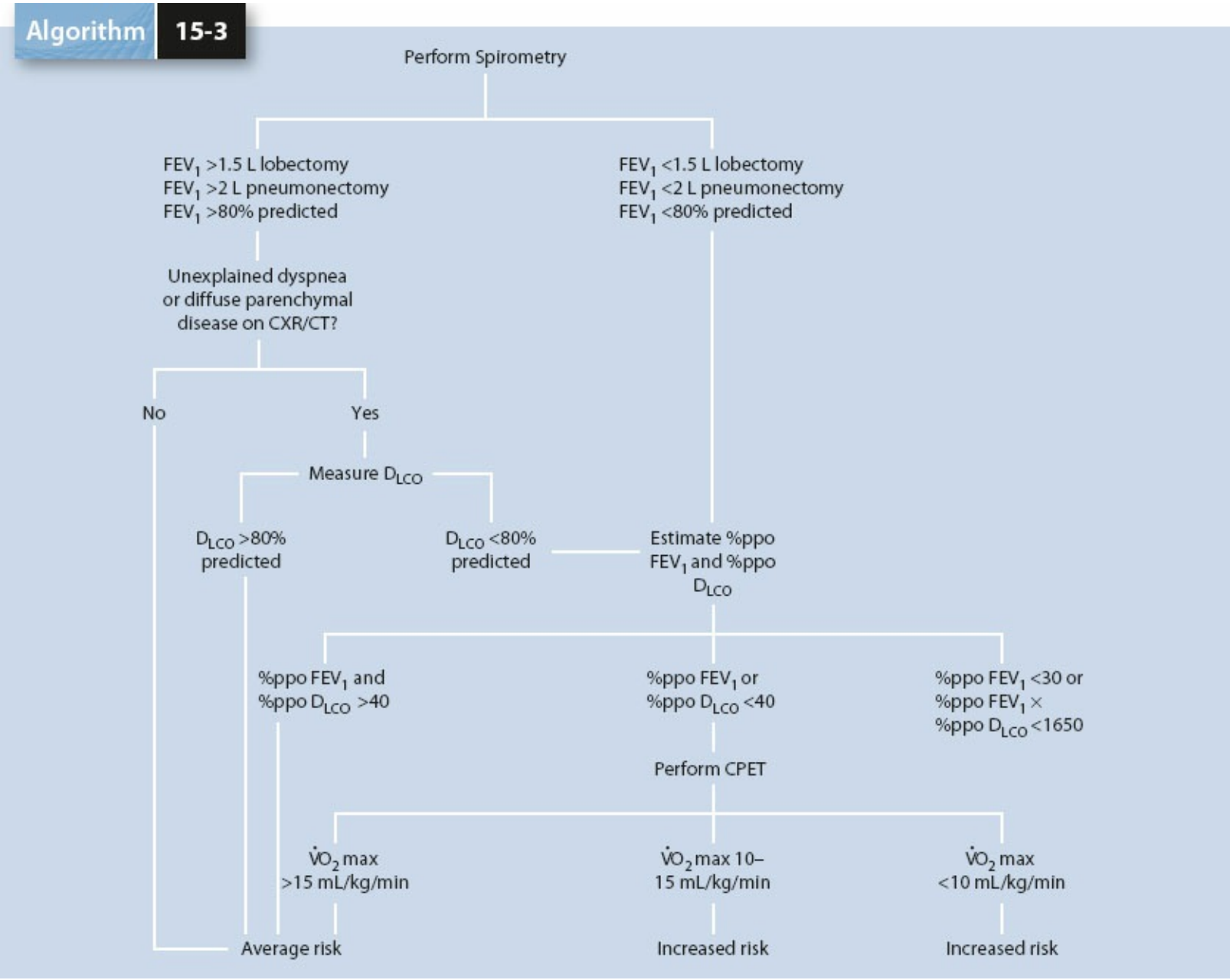

Algorithm 15-3. Preoperative evaluation of patients with lung cancer for resection. (Adapted from Colice GL, Shafazand S, Griffin JP, et al. Physiologic evaluation of the patient with lung cancer being considered for resectional surgery: ACCP evidenced-based clinical practice guidelines. 2nd ed. *Chest* 2007;132(3) (suppl):161S–177S.)

Surgical Considerations

Operative considerations include timing, site, duration, and choice of anesthetic. Emergency and extended (duration greater than 3 to 4 hours) procedures are associated with increased risk of pulmonary complications. In NSQIP, thoracic surgery, upper abdominal surgery, vascular surgery, and head and neck surgery have also been associated with additional risk of pulmonary complications, with thoracotomy and upper abdominal incisions associated with most marked changes in postoperative functional residual capacity. Minimally invasive and robotic approaches balance potential advantages in postoperative pain and early mobilization with the physiologic consequences of intracavitary insufflation and any additional operative time and are not always accompanied by reductions in pulmonary complications.[119] Improving

postoperative mobilization with minimally invasive approaches or intraoperative epidural anesthesia may have benefit in patients with underlying chronic lung disease.[120] For vascular surgery, endovascular approaches reduce risk of pulmonary complications compared with open surgery.[121]

General anesthesia-related reduction in functional residual capacity (FRC) may persist for up to 2 weeks postoperatively, with endotracheal intubation, inhalational anesthetic, and neuromuscular blockade, all potentially contributing to pulmonary dysfunction. Shorter-acting neuromuscular blocking agents may minimize periprocedural weakness and promote better recovery from general anesthesia. Meta-analysis of 141 randomized controlled trials suggested that the incidence of postoperative pneumonia and respiratory failure was decreased with the use of spinal or regional anesthesia.[41] Epidural anesthesia combined with general anesthesia can reduce intraoperative shunting and preemptively address postoperative pain.[122]

Intraoperative management is directed at minimizing overzealous volume administration. Use of lung-protective tidal volume ventilation may reduce postoperative complications and intraoperative PEEP strategies are being explored in high-risk populations. Selective use of nasogastric tubes may reduce complications after abdominal surgery.[123] Although low serum albumin is associated with increased risk, studies demonstrating pulmonary benefits of nutritional support and specific immunonutrition regimens are lacking.

Table 15-14 Modified Childs–Pugh–Turcotte Score

	Score		
	1 Point	2 Points	3 Points
Total serum bilirubin (umol/dL)	<3.4	3.4–5.0	>5.0
Serum albumin (g/dL)	>3.5	2.8–3.5	<2.8
International normalized ratio	<1.7	1.7–2.2	>2.2
Ascites	None	Controlled with medication	Treatment refractory
Encephalopathy	None	Grades I–II or controlled with medication	Grades III–IV or treatment refractory
Sum total points for each component:			
	Total Points	Surgical Mortality	
Class A	5–6	10%	
Class B	7–9	30%	
Class C	10–15	80%	

Adapted from Child CG, Turcotte JG. Surgery and portal hypertension. *Major Probl Clin Surg* 1964;1:1–85; and Pugh RN, Murray-Lyon IM, Dawson JL, et al. Transection of the oesophagus for bleeding oesophageal varices. *Br J Surg* 1973;60(8):646–649.

Perioperative Management

Pulmonary complications may be reduced by optimizing status of patients with preexisting lung disease, lung expansion maneuvers, and smoking cessation.

Patients with chronic lung disease should be optimized prior to elective surgery with longer-acting controller medications. Aerosolized β_2-adrenergic receptor agonists, inhaled anticholinergics, and inhaled and systemic corticosteroids may be used to improve

pulmonary function.[49] Preoperative management of poorly controlled asthma includes eliminating wheezing, cough or dyspnea, and targeting peak expiratory flows >80% of predicted or the patient's personal best.[124] Elective surgery should be delayed for signs of acute infection, including increased secretions or change in character of sputum.

Lung expansion maneuvers reduce postoperative reductions in FRC by augmenting alveolar recruitment. Common modalities, including incentive spirometry, deep-breathing exercises, and continuous positive airway pressure (CPAP), have been demonstrated to improve postoperative pulmonary outcomes.[49,125] In patients undergoing CABG, postoperative pneumonia was reduced by 2 weeks of preoperative inspiratory muscle conditioning.[126] Concentrating education during preoperative sessions may increase patient compliance and enhance improvements in high-risk patients.[126,127] Patients with lobar collapse or high-volume secretions may benefit from additional postural drainage and chest physiotherapy, but these maneuvers may also exacerbate bronchospasm.

Hepatic

Postoperative risk in liver disease is related to the severity of underlying liver disease and the extent of the surgical procedure.[128] Patients are living longer with chronic liver disease and they may present as relatively asymptomatic with normal liver function tests even with substantial degrees of hepatic dysfunction. In addition, occult chronic liver disease with silent cirrhosis may be present. Nonalcoholic steatohepatitis affects 2% to 5% of Americans, primarily middle-aged, overweight, or obese patients. In a series of patients undergoing bariatric surgery, 6% were found to have unsuspected cirrhosis in the setting of fatty liver.[129]

The presence of cirrhosis is associated with high risk of complications and death; hepatic decompensation can follow routine surgery. While the liver is usually protected from ischemia due to dual portal and systemic blood flow, in disease states, alterations in splanchnic and autonomic vascular regulation increase vulnerability to hypoperfusion and ischemic injury. Avoidance of shock states is imperative for at-risk patients.

Risk Stratification

Overall surgical risk in cirrhotic patients appears to correlate with established scoring systems. Risk stratification extrapolates scoring based on studies in cirrhotic patients undergoing portal decompression (Modified Child–Pugh–Turcotte [CPT] score; Table 15-14)[130,131] and survival models for patients with end-stage liver disease (Model for End-Stage Liver Disease, MELD score; Table 15-15).[132–134] Both MELD and CPT scores may correlate with postoperative mortality and are useful to guide preoperative counseling.[135,136]

Table 15-15 Model End-Stage Liver Disease Score

MELD score = (9.6 × $\log_e$ [creatinine mg/dL]) + (3.8 × $\log_e$ [bilirubin mg/dL]) + (11.2 × $\log_e$ [international normalized ratio]) + 6.4
Minimum laboratory value is 1.0 (for laboratory values less than 1.0, use value of 1.0)
Maximum creatinine is 4.0 (for creatinine >4.0, use value of 4.0)
if patient has had dialysis twice within the previous week, use value of 4.0
Round final score to nearest whole number
Maximum score is 40

90-Day Mortality for Hospitalized Patients

MELD Score	Mortality
>40	100%
30–39	83%
20–29	76%
10–19	27%
<10	4%

Adapted from Davenport DL, Bowe EA, Henderson WG, et al. National Surgical Quality Improvement Program (NSQIP) risk factors can be used to validate American Society of Anesthesiologists Physical Status Classification (ASA PS) levels. *Ann Surg* 2006;243(5):636–641; discussion 641–644.

Historically, surgery in Child class A patients carries a mortality of 10%, Child class B, 30% and Child class C, 76% to 82%.[137,138] The rate of postoperative complications, including liver failure, encephalopathy, bleeding infection, renal failure, hypoxia and intractable ascites, also increases with class. Poorer outcomes are associated with anemia, ascites, the presence of encephalopathy, hypoalbuminemia, hypoxia, malnutrition, concomitant infection, preoperative upper GI bleeding, intraoperative hypotension, associated renal failure or COPD, and emergency, cardiac, hepatic resection, or abdominal procedures.[128,139] In general, mortality rates for patients undergoing emergency surgery and patients with portal hypertension are higher.

Preoperative Evaluation

History and physical examination may reveal unsuspected liver disease. History of prior hepatitis, prior anesthetic toxicity, biliary disease, hereditary metabolic disorders, bleeding, or prior alcohol or substance abuse should be sought. Physical examination may reveal stigmata of portal hypertension, including hepatomegaly, splenomegaly, ascites, abdominal wall varices, asterixis, and palmar erythema. Thrombocytopenia secondary to splenic sequestration may be an early sign of previously undiagnosed portal hypertension. If liver disease is suspected during routine preoperative evaluation, elective surgery should be deferred for further workup.[140]

Acute conditions for which elective surgery is contraindicated include acute liver failure, acute viral hepatitis, alcoholic hepatitis, liver disease with associated acute renal failure, cardiomyopathy, hypoxemia, or severe coagulopathy.[128] Hepatic recovery may occur following an initial insult and elective surgery should be deferred for a period of several weeks to optimize the patient's condition. For acute alcoholic hepatitis, abstinence from alcohol for 12 weeks before elective surgery has been recommended.

For patients with known chronic liver disease and cirrhosis, surgical morbidity and mortality correlate with the degree of hepatic dysfunction. Patients with compensated chronic liver disease generally tolerate most surgery well; however, patients with decompensated cirrhosis may have substantial perioperative risk proportional to the degree of hepatic dysfunction. A suggested preoperative evaluation for hepatic disease is presented in Algorithm 15-4.[141]

Surgical Considerations

Intra-abdominal surgery[142,143] and cardiac surgery[144] have been associated with high mortality rates in cirrhotics. In one series, patients with cirrhosis undergoing surgery had a 30-day mortality of 11.6% and an overall complication rate of 30%.[139] The most frequent complication was pneumonia, with other complications including bleeding, hepatic decompensation, sepsis, and renal failure. Umbilical hernia may be aggravated in the presence of uncontrolled ascites and nonoperative management may be warranted. Percutaneous interventions for drainage of biliary obstruction are preferred over surgical approaches. Biliary surgery may be performed safely in Child Class A patients, following optimization in Class B patients and preferably avoided in Class C patients.[128] Formal hepatic resection in cirrhosis carries a high mortality rate that is elevated in patients with postresectional liver failure.[145]

Perioperative Management

Perioperative management includes optimization of liver function, including management of portal hypertension, cholestasis and coagulopathy, and avoidance of further hepatic injury secondary to hypoperfusion and ischemia. Direct evidence that medical management affects subsequent outcomes is lacking in randomized studies.

Anesthetic management is directed at preservation of hepatic perfusion. The choice of inhalational agent depends on avoiding direct hepatotoxicity and depressed cardiac output; halothane is historically associated with direct injury and isoflurane and sevoflurane may be the preferred agents. Perioperative management also includes careful consideration of altered drug metabolism and toxicity. Sedative and narcotic metabolism may be reduced and careful dose titration or use of propofol may reduce oversedation.

A preoperative checklist for patients with portal hypertension has been published.[146] Patients with portal hypertension are at risk for bleeding from visceral and retroperitoneal varices; meticulous hemostasis is necessary and may prolong expected operative times. Impaired aldosterone metabolism leads to increased sodium conservation with subsequent volume overload. Peripheral shunting and vasodilation complicate management of acute volume shifts and intraoperative invasive hemodynamic monitoring or transesophageal echocardiography may permit goal-directed resuscitation. Surgical procedures with anticipated right-sided heart failure may worsen hepatic congestion and thus may be contraindicated. β-Blockade and octreotide may be of use in reducing splanchnic hypertension; the role of preoperative TIPS is unclear and its use cannot be routinely recommended.

Coagulopathy may exist from decreased synthetic function and may be monitored with

PT and measurement and replacement of individual coagulation factors. In the presence of biliary obstruction or poor nutrition, deficiencies of vitamin K-dependent clotting factors may be reduced with oral or intravenous supplementation or factor transfusion with fresh frozen plasma or concentrated factor replacement. Enthusiasm for off-label use of Factor rVIIa to treat coagulopathy has waned in the wake of reports of adverse thrombotic events.[147] Thrombocytopenia from splenic sequestration may aggravate surgical bleeding and response to platelet transfusion may be blunted. Increased fibrinolysis may be present secondary to low-grade disseminated intravascular coagulation (DIC). Monitoring with thromboelastography may appropriately direct factor replacement with fresh frozen plasma, prothrombin complex concentrate or Factor rVIIa, or administration of antifibrinolytics.

Wound healing and surgical wound infection are associated with malnutrition, malignancy, and sepsis. Protein calorie malnutrition, hypomagnesemia, and hypophosphatemia may aggravate this. Empiric thiamine, folate, and multivitamin replacement should be administered. Perioperative nutritional support may be limited by intolerance of enteral protein loading and cholestatic changes from parenteral nutrition. Uncontrolled ascites can be managed with volume restriction, active diuresis once acute resuscitation is complete, and paracentesis to minimize abdominal hypertension and local wound disruption.

The development of postoperative liver dysfunction may manifest days to weeks following surgery. Encephalopathy may initially manifest as subtle cognitive changes and progress to substantial changes in mental status. Serum ammonia levels are not correlated with extent of cognitive disturbance. The European Association for the Study of the Liver (EASL) has published guidelines regarding diagnosis and management of hepatic encephalopathy.[148] Medical management consists of careful oversight of volume shifts, judicious sedation use, enteral lactulose titrated to 2 to 3 loose stools daily and oral antibiotics, such as rifaximin, to minimize colonic bacterial amine transformation and reduce bacterial translocation.

Patients with a history of alcohol abuse may undergo acute withdrawal following surgery. Classic delirium tremens (DTs) is seen 72 hours after cessation of alcohol use but may be seen at any time. Symptoms of autonomic instability, agitation, and delirium should be managed symptomatically with β-blockade, clonidine, and benzodiazepines. Protocolized symptom-triggered regimens are associated with lower total medication dose compared to standing regimens.[149] DT prophylaxis with round-the-clock medication is not indicated outside of high-risk cases or a history of prior DTs.

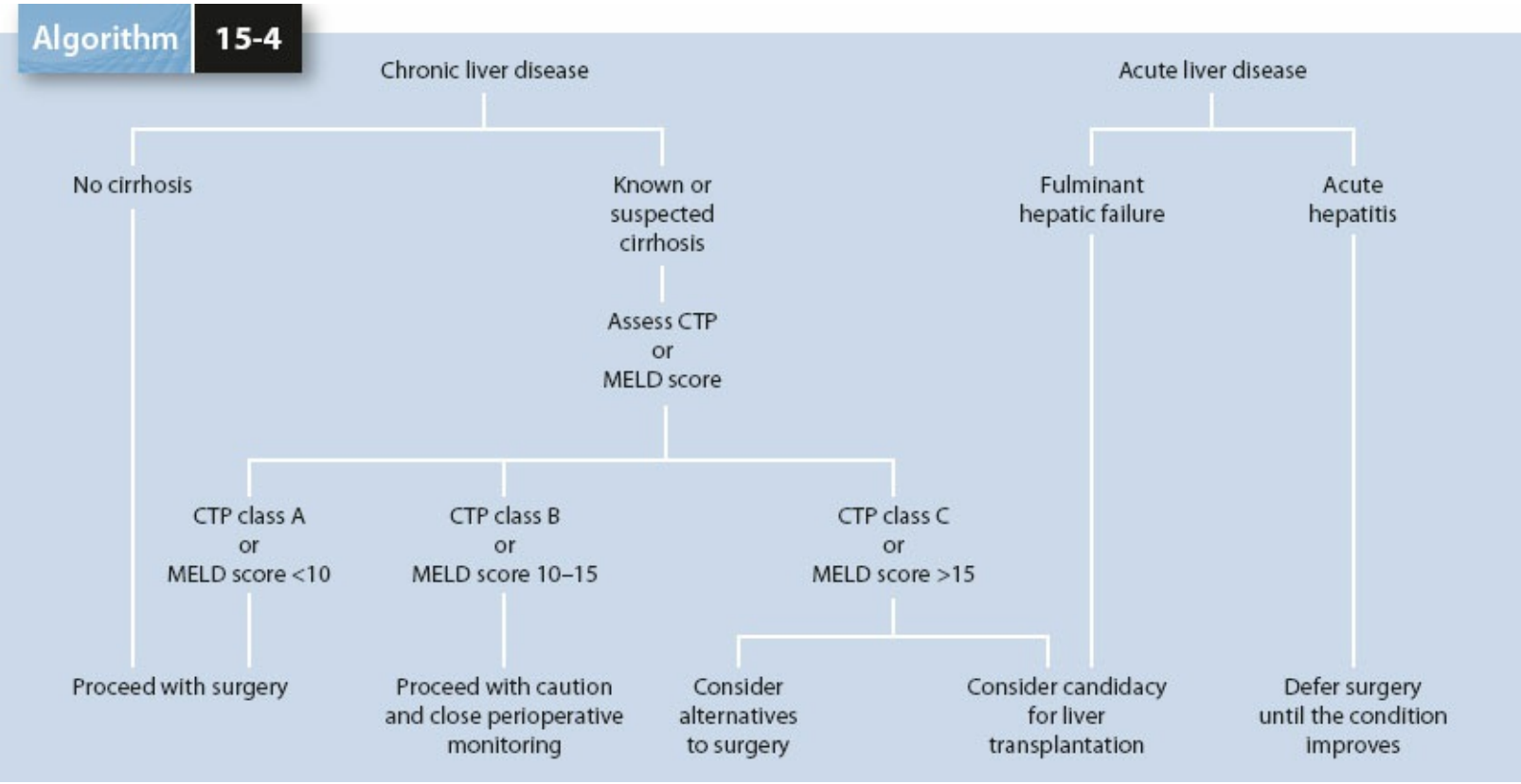

Algorithm 15-4. Proposed algorithm for preoperative evaluation of patients with liver disease. (Adapted from Hanje AJ, Patel T. Preoperative evaluation of patients with liver disease. *Nat Clin Pract Gastroenterol Hepatol* 2007;4(5):266–276.)

Renal

Surgery may worsen preexisting renal dysfunction. There is increasing recognition that new renal failure manifested by even small, transient increases in serum creatinine during the postoperative period is associated with later mortality.[150] Therefore, preoperative evaluation should be based not only on determining current status of chronic or acute renal disease but also on the potential for further deterioration.

Risk Stratification

The strongest risk factor for development of postoperative acute kidney injury is the presence of preexisting chronic renal disease.[151] The development of postoperative renal failure is in turn strongly associated with increased mortality.[150,152,153] A single episode of acute kidney injury (AKI) as defined by RIFLE criteria is associated with long-term mortality in proportion with the severity of injury. In a large noncardiac surgery series,[154] anemia (hemoglobin < 12.0 g/dL) and a decrease in postoperative hemoglobin greater than 1.1 g/dL were associated with higher risk for renal failure. Using a large intraoperative data set, risk factors for the development of acute kidney injury in noncardiac surgical patients were identified and used to model an Acute Kidney Index scoring system (Table 15-16).[153]

Preoperative Evaluation

The presence of underlying renal disease should be suspected on the basis of history. Chronic renal disease in the adult population is not uncommon, with an estimated prevalence at 13%.[155] Common systemic conditions such as hypertension, diabetes mellitus, and arteriosclerosis may lead to end organ damage. Renal impairment must be considered in the context of the presence of associated systemic disease.

Determination of renal function is based on the glomerular filtration rate (GFR), estimated by equations such as the Cockcroft–Gault equation.[156] As the GFR is reduced to <30% of baseline, electrolyte, volume, and red cell homeostasis are altered. Medication excretion will be decreased and drug dosing should be titrated by levels to minimize toxicity.

Defining Acute Kidney Injury

In a noncardiac general surgical population, the incidence of postoperative renal failure may be as high as 1%.[153] The majority of perioperative studies have used differing definitions of postoperative renal failure and direct comparisons are difficult. Small increases in creatinine, as little as 0.3 mg/kg, may increase risk.[157] The search for a consistent definition continues. Criteria utilized in the ICU setting are being validated as predictors of renal outcomes in cardiac, general, and vascular surgery outcomes.[150,158] In 2004, the Acute Dialysis Quality Initiative group developed the RIFLE (Risk, Injury, Failure, Loss, End-Stage) consensus definition of renal failure (Table 15-17).[159] Subsequent refinements (the Acute Kidney Injury Network and Kidney Disease Improving Global Outcomes) have been proposed as an attempt to further incorporate oliguria, as

well as relative and absolute changes in serum creatinine to the RIFLE framework. Promising biomarkers for predicting and measuring acute renal failure have been identified and it is likely that future definitions will incorporate these.

Prevention of Acute Kidney Injury

Strategies for prevention of postoperative renal failure include stabilization of homeostatic imbalances, maintenance of adequate renal perfusion, avoidance of intraoperative hypotension, and judicious use of nephrotoxic agents, including aminoglycosides, ace-inhibitors, intravenous contrast agents, and NSAIDs. In patients with known chronic renal disease, careful evaluation of electrolyte abnormalities, anemia, and intravascular volume should be performed.

The mainstay of prevention strategies is to ensure adequate renal perfusion by avoiding hypotension from hypovolemia. In diabetic patients receiving IV contrast dye, preemptive saline hydration reduced the risk of renal failure; the addition of prophylactic sodium bicarbonate was not demonstrably superior to saline hydration alone.[160]

Despite extensive clinical testing, no pharmacologic intervention has been found to successfully improve postoperative renal outcomes. Preoperative statin,[161] prophylactic or therapeutic acetylcysteine,[162] ANP,[163] insulin-like growth factor[164] tight glycemic control, and antiplatelet drugs have all failed to show efficacy. In the POISE-2 trial, neither aspirin nor clonidine reduced the risk of renal failure in noncardiac surgery, although each drug had increased rates of complications (bleeding, hypotension) associated with higher rates of renal failure.[157] Calcium channel blockers have been associated with renoprotection in transplant surgery[165] but have been associated with increased renal failure rates after cardiac surgery.[166] Forced diuresis with low-dose dopamine and furosemide can maintain urinary flow but do not improve intrinsic renal function.[167] A recent randomized trial of fenoldopam in cardiac surgery demonstrated no reduction in need for renal replacement therapy or 30-day mortality but did show a higher incidence of hypotension.[168]

Table 15-16 General Surgery Acute Kidney Injury Risk Index Classification System

Derivation Cohort, N = 57,080				Validation Cohort, N = 18,872		
Preoperative Risk Class	Total Patients, n	AKI Incidence, % (n)	Hazard Ratio (95% Confidence Interval)	Total Patients, n	AKI Incidence, % (n)	Hazard Ratio (95% Confidence Interval)
Class I (0–2 risk factors)	31,500	0.2 (66)	—	10,301	0.2 (25)	—
Class II (3 risk factors)	12,570	0.8 (104)	4.0 (2.0–5.4)	4,218	0.6 (32)	3.1 (1.0–5.3)
Class III (4 risk factors)	7,033	1.6 (144)	6.8 (0.0–11.5)	2,025	2.0 (53)	8.5 (5.3–13.7)
Class IV (5 risk factors)	3,015	3.3 (118)	10.1 (11.0–21.5)	1,244	3.6 (45)	15.4 (0.4–25.2)
Class V (6+ risk factors	1,450	8.0 (120)	40.3 (34.2–62.0)	484	9.5 (40)	40.2 (26.3–70.9)
Patient receives 1 point for each Risk Factor						
Age ≥56 yrs						
Male sex						
Active congestive heart failure						
Ascites						
Hypertension						
Emergency surgery						
Intraperitoneal surgery						
Renal insufficiency, preoperative serum creatinine >1.2 mg/dL						
Diabetes mellitus, on oral or insulin therapy						

From Kheterpal S, Tremper KK, Heung M, et al. Development and validation of an acute kidney injury risk index for patients undergoing general surgery: results from a national data set. *Anesthesiology* 2009;110(3):505–515.

Perioperative Management

Preoperative hyperkalemia may exist in up to 38% of patients with chronic renal failure.[169] Acute ECG changes should be immediately stabilized with administration of intravenous calcium and intracellular shifts with sodium bicarbonate or insulin and glucose. Removal of excess potassium may be accomplished with exchange resins or acute dialysis.

Anemia is well tolerated in patients with chronic renal failure. Erythropoietin-stimulating agents are recommended for patients on and approaching dialysis; black box warnings have been issued for use in oncologic patients and advise against high hemoglobin targets. Associated coagulopathy related to uremic platelet dysfunction may be managed with desmopressin acetate, platelet transfusion, or dialysis.

Volume overload may accompany acute and chronic oliguric renal failure. Following surgery, volume resuscitation should be goal directed and hydroxyethyl starch[170] and hyperchloremic solutions should be avoided.[171] Hyperresuscitation may result in development of abdominal compartment syndrome; if prerenal oliguria persists despite medical management, decompressive laparotomy may be required to restore renal perfusion.[172]

Table 15-17 The RIFLE Classification for Acute Renal Failure

	Urine Output Criteria	GFR Criteria
Risk (R)	<0.5 mL/kg/hr × 6 hrs	Increased [creat] × 1.5, or GFR decrease of >25%
Injury (I)	<0.5 mL/kg/hr × 12 hrs	Increased [creat] × 2, or GFR decrease of >50%
Failure (F)	<0.5 mL/kg/h × 24 hrs, or anuria for 12 hrs	Increased [creat] × 3, or GFR decrease of >75%, or [creat] > 4 mg/dL
Loss (L)	NA	Persistent ARF ("F") for > 4 wks but less than 3 mo
End-stage renal disease (E)	NA	Persistent ARF ("F") for >3 mo

ARF, acute renal failure; [creat], Serum creatinine concentration; GFR, glomerular filtration rate; NA, not applicable.
Adapted from Kellum JA, Bellomo R, Ronco C. Classification of acute kidney injury using RIFLE: what's the purpose?; *Crit Care Med* 2007;35(8): 1983–1984.

Once renal failure occurs, substantial alterations in drug metabolism and excretion must be considered. From an anesthetic standpoint, sedative and narcotic dosing must be adjusted for elevated half-life and prolonged neuromuscular blockade may occur with agents acting at the neuromuscular junction. Succinylcholine is contraindicated in the presence of hyperkalemia. Agents undergoing peripheral Hoffman degradation may be used preferentially in the face of renal dysfunction. Meta-analysis in cardiac surgery has suggested that the use of volatile anesthetics may also be associated with lower absolute increases in serum creatinine.[173]

Renal replacement therapy is indicated emergently for correction of acidosis, symptomatic hyperkalemia, severe volume overload, or uremic pericarditis. Dialysis may be undertaken preoperatively to optimize volume and electrolyte status prior to surgery. Once GFR falls below 5 to 10 mL/min, hemodialysis is usually indicated for clearance. Continuous venovenous hemodialysis may permit volume removal in the hemodynamically unstable patient. Consideration should be given to the location of temporary dialysis access; subclavian and upper extremity access should be avoided in patients who may eventually go on to require permanent dialysis access.

ADDITIONAL CONSIDERATIONS, FUTURE DIRECTIONS

Considerable progress has been made in refining preoperative risk assessment; however, the majority of the risk factors identified to date have been nonmodifiable (i.e., age, need for emergent surgery, and type of surgery required). As electronic health data collection becomes more prevalent and facile, new predictors of surgical risk that permit targeted interventions may be uncovered and present opportunities for study.

In the meantime, the preoperative visit should continue to function as an opportunity to initiate care for patients identified as high-risk. Process of care practices with broad proven benefit can be protocolized as part of routine presurgical orders; an example would be compliance with the Surgical Care Initiative Project (SCIP) performance measures in the domains of infection prophylaxis and deep venous thrombosis (DVT) prophylaxis. Studies evaluating early “prehabilitation” or “training for surgery” for patients with functional deficits are in progress. Advance in preoperative assessment will continue to contribute to the best outcomes for surgical patients.

References

1. Goldman L, Caldera DL, Nussbaum SR, et al. Multifactorial index of cardiac risk in noncardiac surgical procedures. *N Engl J Med* 1977;297(16):845–850.
2. Chassin MR. Is health care ready for Six Sigma quality? *Milbank Q* 1998;76(4):565–591, 510.
3. Finlayson EV, Birkmeyer JD. Operative mortality with elective surgery in older adults. *Eff Clin Pract* 2001;4(4):172–177.
4. Semel ME, Lipsitz SR, Funk LM, et al. Rates and patterns of death after surgery in the United States, 1996 and 2006. *Surgery* 2012;151(2):171–182.
5. Khuri SF, Henderson WG, Daley J, et al. Successful implementation of the Department of Veterans Affairs' National Surgical Quality Improvement Program in the private sector: the Patient Safety in Surgery study. *Ann Surg* 2008;248(2):329–336.
6. Pearse RM, Moreno RP, Bauer P, et al. Mortality after surgery in Europe: a 7 day cohort study. *Lancet* 2012;380(9847):1059–1065.
7. Kohn LT, Corrigan JM, Donaldson MS, eds. *To Err Is Human: Building a Safer Health System.* Washington, DC: the National Academies Press; 2000.
8. Silber JH, Rosenbaum PR, Trudeau ME, et al. Changes in prognosis after the first postoperative complication. *Med Care* 2005;43(2):122–131.
9. Glance LG, Osler TM, Mukamel DB, et al. Effect of complications on mortality after coronary artery bypass grafting surgery: evidence from New York State. *J Thorac Cardiovasc Surg* 2007;134(1):53–58.
10. Khuri SF, Henderson WG, DePalma RG, et al. Determinants of long-term survival after major surgery and the adverse effect of postoperative complications. *Ann Surg* 2005;242(3):326–341; discussion 341–343.
11. Ghaferi AA, Birkmeyer JD, Dimick JB. Variation in hospital mortality associated with inpatient surgery. *N Engl J Med* 2009;361(14):1368–1375.
12. Dimick JB, Weeks WB, Karia RJ, et al. Who pays for poor surgical quality? Building a business case for quality improvement. *J Am Coll Surg* 2006; 202(6):933–937.
13. Eappen S, Lane BH, Rosenberg B, et al. Relationship between occurrence of surgical complications and hospital finances. *JAMA* 2013;309(15):1599–1606.
14. Joynt KE, Gawande AA, Orav EJ, et al. Contribution of preventable acute care spending to total spending for high-cost Medicare patients. *JAMA* 2013;309(24):2572–2578.
15. Kassin MT, Owen RM, Perez SD, et al. Risk factors for 30-day hospital readmission among general surgery patients. *J Am Coll Surg* 2012;215(3):322–330.
16. Morris MS, Deierhoi RJ, Richman JS, et al. The relationship between timing of surgical complications and hospital readmission. *JAMA Surg* 2014;149(4):348–354.
17. Wick EC, Shore AD, Hirose K, et al. Readmission rates and cost following colorectal

surgery. *Dis Colon Rectum* 2011;54(12):1475–1479.
18. Dindo D, Demartines N, Clavien PA. Classification of surgical complications: a new proposal with evaluation in a cohort of 6336 patients and results of a survey. *Ann Surg* 2004;240(2):205–213.
19. Clavien PA, Barkun J, de Oliveira ML, et al. The Clavien-Dindo classification of surgical complications: Five-year experience. *Ann Surg* 2009;250(2):187–196.
20. Kwok AC, Semel ME, Lipsitz SR, et al. The intensity and variation of surgical care at the end of life: a retrospective cohort study. *Lancet* 2011;378(9800):1408–1413.
21. Rowell KS, Turrentine FE, Hutter MM, et al. Use of national surgical quality improvement program data as a catalyst for quality improvement. *J Am Coll Surg* 2007;204(6):1293–1300.
22. Hall BL, Hamilton BH, Richards K, et al. Does surgical quality improve in the American College of Surgeons National Surgical Quality Improvement Program: an evaluation of all participating hospitals. *Ann Surg* 2009;250(3):363–376.
23. Cohen ME, Liu Y, Ko CY, et al. Improved surgical outcomes for ACS NSQIP hospitals over time: evaluation of hospital cohorts with up to 8 years of participation. *Ann Surg* 2016;263(2):267–273.
24. Osborne NH, Nicholas LH, Ryan AM, et al. Association of hospital participation in a quality reporting program with surgical outcomes and expenditures for Medicare beneficiaries. *JAMA* 2015;313(5):496–504.
25. Etzioni DA, Wasif N, Dueck AC, et al. Association of hospital participation in a surgical outcomes monitoring program with inpatient complications and mortality. *JAMA* 2015;313(5):505–511.
26. Gupta PK, Gupta H, Sundaram A, et al. Development and validation of a risk calculator for prediction of cardiac risk after surgery. *Circulation* 2011;124(4):381–387.
27. Bilimoria KY, Liu Y, Paruch JL, et al. Development and evaluation of the universal ACS NSQIP surgical risk calculator: a decision aid and informed consent tool for patients and surgeons. *J Am Coll Surg* 2013;217(5):833–842; e831–e833.
28. Fleisher LA, Fleischmann KE, Auerbach AD, et al. 2014 ACC/AHA Guideline on Perioperative Cardiovascular Evaluation and Management of Patients Undergoing Noncardiac Surgery: Executive Summary: a report of the American College of Cardiology/American Heart Association Task Force on Practice Guidelines. *Circulation* 2014;130(24):2215–2245.
29. Halaszynski TM, Juda R, Silverman DG. Optimizing postoperative outcomes with efficient preoperative assessment and management. *Crit Care Med* 2004;32(4)(suppl):S76–S86.
30. Brumfield VC, Kee CC, Johnson JY. Preoperative patient teaching in ambulatory surgery settings. *AORN J* 1996;64(6):941–946, 948, 951–952.
31. Smetana GW, Macpherson DS. The case against routine preoperative laboratory

testing. *Med Clin North Am* 2003;87(1):7–40.
32. Kaplan EB, Sheiner LB, Boeckmann AJ, et al. The usefulness of preoperative laboratory screening. *JAMA* 1985;253(24):3576–3581.
33. Benarroch-Gampel J, Sheffield KM, Duncan CB, et al. Preoperative laboratory testing in patients undergoing elective, low-risk ambulatory surgery. *Ann Surg* 2012;256(3):518–528.
34. Kachalia A, Berg A, Fagerlin A, et al. Overuse of testing in preoperative evaluation and syncope: a survey of hospitalists. *Ann Intern Med* 2015; 162(2):100–108.
35. Roberts S, Spain B, Hicks C, et al. Telemedicine in the Northern Territory: an assessment of patient perceptions in the preoperative anaesthetic clinic. *Aust J Rural Health* 2015;23:136–141.
36. Amrock LG, Neuman MD, Lin HM, et al. Can routine preoperative data predict adverse outcomes in the elderly? Development and validation of a simple risk model incorporating a chart-derived frailty score. *J Am Coll Surg* 2014;219(4):684–694.
37. Hilditch WG, Asbury AJ, Jack E, et al. Validation of a pre-anaesthetic screening questionnaire. *Anaesthesia* 2003;58(9):874–877.
38. Hilditch WG, Asbury AJ, Crawford JM. Pre-operative screening: criteria for referring to anaesthetists. *Anaesthesia* 2003;58(2):117–124.
39. Davenport DL, Bowe EA, Henderson WG, et al. National Surgical Quality Improvement Program (NSQIP) risk factors can be used to validate American Society of Anesthesiologists Physical Status Classification (ASA PS) levels. *Ann Surg* 2006;243(5):636–641; discussion 641–644.
40. Smetana GW, Lawrence VA, Cornell JE. Preoperative pulmonary risk stratification for noncardiothoracic surgery: systematic review for the American College of Physicians. *Ann Intern Med* 2006;144(8):581–595.
41. Rodgers A, Walker N, Schug S, et al. Reduction of postoperative mortality and morbidity with epidural or spinal anaesthesia: results from overview of randomised trials. *BMJ* 2000;321(7275):1493.
42. Khuri SF, Daley J, Henderson W, et al. Risk adjustment of the postoperative mortality rate for the comparative assessment of the quality of surgical care: results of the National Veterans Affairs Surgical Risk Study. *J Am Coll Surg* 1997;185(4):315–327.
43. Daley J, Khuri SF, Henderson W, et al. Risk adjustment of the postoperative morbidity rate for the comparative assessment of the quality of surgical care: results of the National Veterans Affairs Surgical Risk Study. *J Am Coll Surg* 1997;185(4):328–340.
44. Russo CA, Andrews RM, Barrett ML. *Racial and Ethnic Disparities in Hospital Patient Safety Events, 2005.HCUP Statistical Brief* #53. Rockville, MD: Agency for Healthcare Research and Quality; June 2008.
45. Sukumar S, Ravi P, Sood A, et al. Racial disparities in operative outcomes after major

cancer surgery in the United States. *World J Surg* 2015;39(3):634–643.
46. World Health Organization. 10 facts on ageing and the life course. http://www.who.int/features/factfiles/ageing/en/. Published 2015.
47. Chow WB, Rosenthal RA, Merkow RP, et al. Optimal preoperative assessment of the geriatric surgical patient: a best practices guideline from the American College of Surgeons National Surgical Quality Improvement Program and the American Geriatrics Society. *J Am Coll Surg* 2012;215(4):453–466.
48. Nicholas JA. Preoperative optimization and risk assessment. *Clin Geriatr Med* 2014;30(2):207–218.
49. Qaseem A, Snow V, Fitterman N, et al. Risk assessment for and strategies to reduce perioperative pulmonary complications for patients undergoing noncardiothoracic surgery: a guideline from the American College of Physicians. *Ann Intern Med* 2006;144(8):575–580.
50. Sheetz KH, Krell RW, Englesbe MJ, et al. The importance of the first complication: Understanding failure to rescue after emergent surgery in the elderly. *J Am Coll Surg* 2014;219(3):365–370.
51. Bettelli G. Preoperative evaluation in geriatric surgery: comorbidity, functional status and pharmacological history. *Minerva Anestesiol* 2011;77(6):637–646.
52. Lee TH, Marcantonio ER, Mangione CM, et al. Derivation and prospective validation of a simple index for prediction of cardiac risk of major noncardiac surgery. *Circulation* 1999;100(10):1043–1049.
53. Welten GM, Schouten O, van Domburg RT, et al. The influence of aging on the prognostic value of the revised cardiac risk index for postoperative cardiac complications in vascular surgery patients. *Eur J Vasc Endovasc Surg* 2007;34(6):632–638.
54. Ogden CL, Carroll MD, Kit BK, et al. Prevalence of obesity in the United States, 2009–2010 *NCHS Data Brief* 2012;(82):1–8.
55. Mullen JT, Moorman DW, Davenport DL. The obesity paradox: Body mass index and outcomes in patients undergoing nonbariatric general surgery. *Ann Surg* 2009;250(1):166–172.
56. American Society of Anesthesiologists Task Force on Perioperative Management of patients with obstructive sleep apnea. Practice guidelines for the perioperative management of patients with obstructive sleep apnea: an updated report by the American Society of Anesthesiologists Task Force on Perioperative Management of patients with obstructive sleep apnea. *Anesthesiology* 2014;120(2):268–286.
57. Gross JB, Bachenberg KL, Benumof JL, et al. Practice guidelines for the perioperative management of patients with obstructive sleep apnea: a report by the American Society of Anesthesiologists Task Force on Perioperative Management of patients with obstructive sleep apnea. *Anesthesiology* 2006;104(5):1081–1093; quiz 1117–1118.

58. Beattie WS, Karkouti K, Wijeysundera DN, et al. Risk associated with preoperative anemia in noncardiac surgery: a single-center cohort study. *Anesthesiology* 2009;110(3):574–581.
59. Hebert PC. Transfusion requirements in critical care (TRICC): a multicentre, randomized, controlled clinical study. Transfusion Requirements in Critical Care Investigators and the Canadian Critical care Trials Group. *Br J Anaesth* 1998;81(suppl 1):25–33.
60. Murphy GJ, Pike K, Rogers CA, et al. Liberal or restrictive transfusion after cardiac surgery. *N Engl J Med* 2015;372(11):997–1008.
61. Carson JL, Terrin ML, Noveck H, et al. Liberal or restrictive transfusion in high-risk patients after hip surgery. *N Engl J Med* 2011;365(26):2453–2462.
62. Lin DM, Lin ES, Tran MH. Efficacy and safety of erythropoietin and intravenous iron in perioperative blood management: a systematic review. *Transfus Med Rev* 2013;27(4):221–234.
63. Hirst C, Williamson L. Preoperative blood transfusions for sickle cell disease. Cochrane Database Syst Rev. 2012;1:CD003149.
64. Lacroix J, Hebert PC, Fergusson DA, et al. Age of transfused blood in critically ill adults. *N Engl J Med* 2015;372(15):1410–1418.
65. Koch CG, Li L, Sessler DI, et al. Duration of red-cell storage and complications after cardiac surgery. *N Engl J Med* 2008;358(12):1229–1239.
66. Reilly DF, McNeely MJ, Doerner D, et al. Self-reported exercise tolerance and the risk of serious perioperative complications. *Arch Intern Med* 1999;159(18):2185–2192.
67. Jette M, Sidney K, Blumchen G. Metabolic equivalents (METs) in exercise testing, exercise prescription, and evaluation of functional capacity. *Clin Cardiol* 1990;13(8):555–565.
68. Lachs MS, Feinstein AR, Cooney LM Jr, et al. A simple procedure for general screening for functional disability in elderly patients. *Ann Intern Med* 1990;112(9):699–706.
69. Fried LP, Tangen CM, Walston J, et al. Frailty in older adults: evidence for a phenotype. *J Gerontol A Biol Sci Med Sci* 2001;56(3):M146–M156.
70. Oresanya LB, Lyons WL, Finlayson E. Preoperative assessment of the older patient: a narrative review. *JAMA* 2014;311(20):2110–2120.
71. Mortensen K, Nilsson M, Slim K, et al. Consensus guidelines for enhanced recovery after gastrectomy: enhanced Recovery After Surgery (ERAS(R)) Society recommendations. *Br J Surg* 2014;101(10):1209–1229.
72. Uppal S, Igwe E, Rice LW, et al. Frailty index predicts severe complications in gynecologic oncology patients. *Gynecol Oncol* 2015;137(1):98–101.
73. Sepehri A, Beggs T, Hassan A, et al. The impact of frailty on outcomes after cardiac surgery: a systematic review. *J Thorac Cardiovasc Surg* 2014;148(6):3110–3117.

74. Miller AL, Min LC, Diehl KM, et al. Analytic morphomics corresponds to functional status in older patients. *J Surg Res* 2014;192(1):19–26.
75. Waits SA, Kim EK, Terjimanian MN, et al. Morphometric age and mortality after liver transplant. *JAMA Surg* 2014;149(4):335–340.
76. Lee JS, He K, Harbaugh CM, et al. Frailty, core muscle size, and mortality in patients undergoing open abdominal aortic aneurysm repair. *J Vasc Surg* 2011;53(4):912–917.
77. Makary MA, Segev DL, Pronovost PJ, et al. Frailty as a predictor of surgical outcomes in older patients. *J Am Coll Surg* 2010;210(6):901–908.
78. Quill TE, Holloway R. Time-limited trials near the end of life. *JAMA* 2011;306(13):1483–1484.
79. Neuman MD, Allen S, Schwarze ML, Uy J. Using time-limited trials to improve surgical care for frail older adults. *Ann Surg* 2015;261(4):639–641.
80. Ang-Lee MK, Moss J, Yuan CS. Herbal medicines and perioperative care. *JAMA* 2001;286(2):208–216.
81. Kaye AD, Clarke RC, Sabar R, et al. Herbal medicines: current trends in anesthesiology practice—a hospital survey. *J Clin Anesth* 2000;12(6):468–471.
82. Cui J, Garle M, Eneroth P, Bjorkhem I. What do commercial ginseng preparations contain? *Lancet* 1994;344(8915):134.
83. Whinney C. Perioperative medication management: general principles and practical applications. *Cleve Clin J Med* 2009;76(suppl 4):S126–S132.
84. Rosenman DJ, McDonald FS, Ebbert JO, et al. Clinical consequences of withholding versus administering renin-angiotensin-aldosterone system antagonists in the preoperative period. *J Hosp Med* 2008;3(4):319–325.
85. Guyatt GH, Akl EA, Crowther M, et al. Executive summary: antithrombotic Therapy and Prevention of Thrombosis, 9th ed: American College of Chest Physicians Evidence-Based Clinical Practice Guidelines. *Chest* 2012;141(2) (suppl):7S–47S.
86. Ansell J, Hirsh J, Hylek E, et al. Pharmacology and management of the vitamin K antagonists: American College of Chest Physicians Evidence-Based Clinical Practice Guidelines (8th edition). *Chest* 2008;133(6) (suppl):160S–198S.
87. Devereaux PJ, Mrkobrada M, Sessler DI, et al. Aspirin in patients undergoing noncardiac surgery. *N Engl J Med* 2014;370(16):1494–1503.
88. O'Riordan JM, Margey RJ, Blake G, et al. Antiplatelet agents in the perioperative period. *Arch Surg* 2009;144(1):69–76; discussion 76.
89. Furnary AP, Wu Y, Bookin SO. Effect of hyperglycemia and continuous intravenous insulin infusions on outcomes of cardiac surgical procedures: the Portland Diabetic Project. *Endocr Pract* 2004;10(suppl 2):21–33.
90. Papadopoulos S, Cook AM. You can withdraw from that? The effects of abrupt discontinuation of medications. *Orthopedics* 2006;29(5):413–417.
91. Subramanian V, Pollok RC, Kang JY, et al. Systematic review of postoperative complications in patients with inflammatory bowel disease treated with

immunomodulators. *Br J Surg* 2006;93(7):793–799.

92. Subramanian V, Saxena S, Kang JY, et al. Preoperative steroid use and risk of postoperative complications in patients with inflammatory bowel disease undergoing abdominal surgery. *Am J Gastroenterol* 2008;103(9):2373–2381.
93. Marik PE, Varon J. Requirement of perioperative stress doses of corticosteroids: a systematic review of the literature. *Arch Surg* 2008;143(12):1222–1226.
94. Mashour GA, Shanks AM, Kheterpal S. Perioperative stroke and associated mortality after noncardiac, nonneurologic surgery. *Anesthesiology* 2011;114(6):1289–1296.
95. Healy KO, Waksmonski CA, Altman RK, et al. Perioperative outcome and long-term mortality for heart failure patients undergoing intermediate- and high-risk noncardiac surgery: impact of left ventricular ejection fraction. *Congestive Heart Fail* 2010;16(2):45–49.
96. Kazmers A, Cerqueira MD, Zierler RE. Perioperative and late outcome in patients with left ventricular ejection fraction of 35% or less who require major vascular surgery. *J Vasc Surg* 1988;8(3):307–315.
97. Nishimura RA, Otto CM, Bonow RO, et al. 2014 AHA/ACC Guideline for the Management of Patients With Valvular Heart Disease: Executive summary: a report of the American College of Cardiology/American Heart Association Task Force on Practice Guidelines. *Circulation* 2014; 129(23):2440–2492.
98. Minai OA, Yared JP, Kaw R, et al. Perioperative risk and management in patients with pulmonary hypertension. *Chest* 2013;144(1):329–340.
99. Ramakrishna G, Sprung J, Ravi BS, et al. Impact of pulmonary hypertension on the outcomes of noncardiac surgery: predictors of perioperative morbidity and mortality. *J Am Coll Cardiol* 2005;45(10):1691–1699.
100. Warnes CA, Williams RG, Bashore TM, et al. ACC/AHA 2008 Guidelines for the Management of Adults with Congenital Heart Disease: executive Summary: A report of the American College of Cardiology/American Heart Association Task Force on Practice Guidelines (writing committee to develop guidelines for the management of adults with congenital heart disease). *Circulation* 2008;118(23):2395–2451.
101. Bouri S, Shun-Shin MJ, Cole GD, et al. Meta-analysis of secure randomised controlled trials of beta-blockade to prevent perioperative death in non-cardiac surgery. *Heart* 2014;100(6):456–464.
102. Durazzo AE, Machado FS, Ikeoka DT, et al. Reduction in cardiovascular events after vascular surgery with atorvastatin: a randomized trial. *J Vasc Surg* 2004;39(5):967–975; discussion 975–976.
103. Devereaux PJ, Sessler DI, Leslie K, et al. Clonidine in patients undergoing noncardiac surgery. *N Engl J Med* 2014;370(16):1504–1513.
104. Manku K, Bacchetti P, Leung JM. Prognostic significance of postoperative in-hospital complications in elderly patients. I. Long-term survival. *Anesth Analg* 2003;96(2):583–589, table of contents.

105. Arozullah AM, Daley J, Henderson WG, et al. Multifactorial risk index for predicting postoperative respiratory failure in men after major noncardiac surgery. The National Veterans Administration Surgical Quality Improvement Program. *Ann Surg* 2000;232(2):242–253.
106. Canet J, Gallart L, Gomar C, et al. Prediction of postoperative pulmonary complications in a population-based surgical cohort. *Anesthesiology* 2010;113(6):1338–1350.
107. Jeong BH, Shin B, Eom JS, et al. Development of a prediction rule for estimating postoperative pulmonary complications. *PloS One* 2014;9(12):e113656.
108. Warner DO, Warner MA, Barnes RD, et al. Perioperative respiratory complications in patients with asthma. *Anesthesiology* 1996;85(3):460–467.
109. Sorensen LT. Wound healing and infection in surgery: the pathophysiological impact of smoking, smoking cessation, and nicotine replacement therapy: a systematic review. *Ann Surg* 2012;255(6):1069–1079.
110. Turan A, Mascha EJ, Roberman D, et al. Smoking and perioperative outcomes. *Anesthesiology* 2011;114(4):837–846.
111. Wong J, Lam DP, Abrishami A, et al. Short-term preoperative smoking cessation and postoperative complications: a systematic review and meta-analysis. *Can J Anaesth* 2012;59(3):268–279.
112. Barrera R, Shi W, Amar D, et al. Smoking and timing of cessation: Impact on pulmonary complications after thoracotomy. *Chest* 2005;127(6):1977–1983.
113. Nakagawa M, Tanaka H, Tsukuma H, et al. Relationship between the duration of the preoperative smoke-free period and the incidence of postoperative pulmonary complications after pulmonary surgery. *Chest* 2001;120(3):705–710.
114. Shi Y, Warner DO. Brief preoperative smoking abstinence: is there a dilemma? *Anesth Analg* 2011;113(6):1348–1351.
115. Shi Y, Warner DO. Surgery as a teachable moment for smoking cessation. *Anesthesiology* 2010;112(1):102–107.
116. Thomsen T, Villebro N, Moller AM. Interventions for preoperative smoking cessation. *Cochrane Database Syst Rev* 2014;3:CD002294.
117. Colice GL, Shafazand S, Griffin JP, et al. Physiologic evaluation of the patient with lung cancer being considered for resectional surgery: ACCP evidenced-based clinical practice guidelines (2nd edition). *Chest* 2007; 132(3) (suppl):161S–177S.
118. IRoselli EE, Murthy SC, Rice TW, et al. Atrial fibrillation complicating lung cancer resection. *J Thorac Cardiovasc Surg* 2005;130(2):438–444.
119. Lawrence VA, Cornell JE, Smetana GW. Strategies to reduce postoperative pulmonary complications after noncardiothoracic surgery: systematic review for the American College of Physicians. *Ann Intern Med* 2006;144(8):596–608.
120. Licker MJ, Widikker I, Robert J, et al. Operative mortality and respiratory complications after lung resection for cancer: impact of chronic obstructive

pulmonary disease and time trends. *Ann Thorac Surg* 2006;81(5):1830–1837.

121. Elkouri S, Gloviczki P, McKusick MA, et al. Perioperative complications and early outcome after endovascular and open surgical repair of abdominal aortic aneurysms. *J Vasc Surg* 2004;39(3):497–505.
122. Von Dossow V, Welte M, Zaune U, et al. Thoracic epidural anesthesia combined with general anesthesia: the preferred anesthetic technique for thoracic surgery. *Anesth Analg* 2001;92(4):848–854.
123. Nelson R, Tse B, Edwards S. Systematic review of prophylactic nasogastric decompression after abdominal operations. *Br J Surg* 2005;92(6):673–680.
124. Sweitzer BJ, Smetana GW. Identification and evaluation of the patient with lung disease. *Med Clin North Am* 2009;93(5):1017–1030.
125. Zarbock A, Mueller E, Netzer S, et al. Prophylactic nasal continuous positive airway pressure following cardiac surgery protects from postoperative pulmonary complications: a prospective, randomized, controlled trial in 500 patients. *Chest* 2009;135(5):1252–1259.
126. Hulzebos EH, Helders PJ, Favie NJ, et al. Preoperative intensive inspiratory muscle training to prevent postoperative pulmonary complications in high-risk patients undergoing CABG surgery: a randomized clinical trial. *JAMA* 2006;296(15):1851–1857.
127. Torrington KG, Henderson CJ. Perioperative respiratory therapy (PORT). A program of preoperative risk assessment and individualized postoperative care. *Chest* 1988;93(5):946–951.
128. Friedman LS. Surgery in the patient with liver disease. *Trans Am Clin Climatol Assoc* 2010;121:192–204; discussion 205.
129. Brolin RE, Bradley LJ, Taliwal RV. Unsuspected cirrhosis discovered during elective obesity operations. *Arch Surg* 1998;133(1):84–88.
130. Child CG, Turcotte JG. Surgery and portal hypertension. *Major Probl Clin Surg* 1964;1:1–85.
131. Pugh RN, Murray-Lyon IM, Dawson JL, et al. Transection of the oesophagus for bleeding oesophageal varices. *Br J Surg* 1973;60(8):646–649.
132. Kamath PS, Wiesner RH, Malinchoc M, et al. A model to predict survival in patients with end-stage liver disease. *Hepatology* 2001;33(2):464–470.
133. Northup PG, Wanamaker RC, Lee VD, et al. Model for end-stage liver disease (MELD) predicts nontransplant surgical mortality in patients with cirrhosis. *Ann Surg* 2005;242(2):244–251.
134. Farnsworth N, Fagan SP, Berger DH, et al. Child-Turcotte-Pugh versus MELD score as a predictor of outcome after elective and emergent surgery in cirrhotic patients. *Am J Surg* 2004;188(5):580–583.
135. Schroeder RA, Marroquin CE, Bute BP, et al. Predictive indices of morbidity and mortality after liver resection. *Ann Surg* 2006;243(3):373–379.

136. Cucchetti A, Ercolani G, Vivarelli M, et al. Impact of model for end-stage liver disease (MELD) score on prognosis after hepatectomy for hepatocellular carcinoma on cirrhosis. *Liver Transplant* 2006;12(6):966–971.
137. Garrison RN, Cryer HM, Howard DA, et al. Clarification of risk factors for abdominal operations in patients with hepatic cirrhosis. *Ann Surg* 1984;199(6):648–655.
138. Mansour A, Watson W, Shayani V, et al. Abdominal operations in patients with cirrhosis: still a major surgical challenge. *Surgery* 1997;122(4):730–735; discussion 735–736.
139. Ziser A, Plevak DJ, Wiesner RH, et al. Morbidity and mortality in cirrhotic patients undergoing anesthesia and surgery. *Anesthesiology* 1999; 90(1):42–53.
140. O'Leary JG, Yachimski PS, Friedman LS. Surgery in the patient with liver disease. *Clin Liver Dis* 2009;13(2):211–231.
141. Hanje AJ, Patel T. Preoperative evaluation of patients with liver disease. *Nat Clin Pract Gastroenterol Hepatol* 2007;4(5):266–276.
142. Meunier K, Mucci S, Quentin V, et al. Colorectal surgery in cirrhotic patients: assessment of operative morbidity and mortality. *Dis Colon Rectum* 2008;51(8):1225–1231.
143. Lehnert T, Herfarth C. Peptic ulcer surgery in patients with liver cirrhosis. *Ann Surg* 1993;217(4):338–346.
144. Suman A, Barnes DS, Zein NN, et al. Predicting outcome after cardiac surgery in patients with cirrhosis: a comparison of Child-Pugh and MELD scores. *Clin Gastroenterol Hepatol* 2004;2(8):719–723.
145. van den Broek MA, Olde Damink SW, Dejong CH, et al. Liver failure after partial hepatic resection: Definition, pathophysiology, risk factors and treatment. *Liver Int* 2008;28(6):767–780.
146. Im GY, Lubezky N, Facciuto ME, et al. Surgery in patients with portal hypertension: A preoperative checklist and strategies for attenuating risk. *Clin Liver Dis* 2014;18(2):477–505.
147. O'Connell KA, Wood JJ, Wise RP, et al. Thromboembolic adverse events after use of recombinant human coagulation factor VIIa. *JAMA* 2006;295(3):293–298.
148. American Association for the Study of Liver Diseases; European Association for the Study of the Liver. Hepatic encephalopathy in chronic liver disease: 2014 practice guideline by the European Association for the Study of the Liver and the American Association for the Study of Liver Diseases. *J Hepatol* 2014;61(3):642–659.
149. Jaeger TM, Lohr RH, Pankratz VS. Symptom-triggered therapy for alcohol withdrawal syndrome in medical inpatients. *Mayo Clin Proc* 2001;76(7):695–701.
150. Bihorac A, Yavas S, Subbiah S, et al. Long-term risk of mortality and acute kidney injury during hospitalization after major surgery. *Ann Surg* 2009;249(5):851–858.
151. Waikar SS, Liu KD, Chertow GM. Diagnosis, epidemiology and outcomes of acute kidney injury. *Clin J Am Soc Nephrol* 2008;3(3):844–861.

152. Chertow GM, Levy EM, Hammermeister KE, et al. Independent association between acute renal failure and mortality following cardiac surgery. *Am J Med* 1998;104(4):343–348.

153. Kheterpal S, Tremper KK, Heung M, et al. Development and validation of an acute kidney injury risk index for patients undergoing general surgery: results from a national data set. *Anesthesiology* 2009;110(3):505–515.

154. Walsh M, Garg AX, Devereaux PJ, et al. The association between perioperative hemoglobin and acute kidney injury in patients having noncardiac surgery. *Anesth Analg* 2013;117(4):924–931.

155. Coresh J, Selvin E, Stevens LA, et al. Prevalence of chronic kidney disease in the United States. *JAMA* 2007;298(17):2038–2047.

156. Cockcroft DW, Gault MH. Prediction of creatinine clearance from serum creatinine. *Nephron* 1976;16(1):31–41.

157. Garg AX, Kurz A, Sessler DI, et al. Perioperative aspirin and clonidine and risk of acute kidney injury: a randomized clinical trial. *JAMA* 2014;312(21):2254–2264.

158. Kuitunen A, Vento A, Suojaranta-Ylinen R, et al. Acute renal failure after cardiac surgery: evaluation of the RIFLE classification. *Ann Thorac Surg* 2006;81(2):542–546.

159. Bellomo R, Ronco C, Kellum JA, et al. Acute renal failure—definition, outcome measures, animal models, fluid therapy and information technology needs: the Second International Consensus Conference of the Acute Dialysis Quality Initiative (ADQI) Group. *Crit Care* 2004;8(4):R204–R212.

160. Brar SS, Shen AY, Jorgensen MB, et al. Sodium bicarbonate vs sodium chloride for the prevention of contrast medium-induced nephropathy in patients undergoing coronary angiography: a randomized trial. *JAMA* 2008;300(9):1038–1046.

161. Argalious MY, Dalton JE, Sreenivasalu T, et al. The association of preoperative statin use and acute kidney injury after noncardiac surgery. *Anesth Analg* 2013;117(4):916–923.

162. Fishbane S. N-acetylcysteine in the prevention of contrast-induced nephropathy. *Clin J Am Soc Nephrol* 2008;3(1):281–287.

163. Allgren RL, Marbury TC, Rahman SN, et al. Anaritide in acute tubular necrosis. Auriculin Anaritide Acute Renal Failure Study Group. *N Engl J Med* 1997;336(12):828–834.

164. Hirschberg R, Kopple J, Lipsett P, et al. Multicenter clinical trial of recombinant human insulin-like growth factor I in patients with acute renal failure. *Kidney Int* 1999;55(6):2423–2432.

165. Wagner K, Albrecht S, Neumayer HH. Prevention of posttransplant acute tubular necrosis by the calcium antagonist diltiazem: A prospective randomized study. *Am J Nephrol* 1987;7(4):287–291.

166. Young EW, Diab A, Kirsh MM. Intravenous diltiazem and acute renal failure after cardiac operations. *Ann Thorac Surg* 1998;65(5):1316–1319.

167. Mahesh B, Yim B, Robson D, et al. Does furosemide prevent renal dysfunction in high-risk cardiac surgical patients? Results of a double-blinded prospective randomised trial. *Eur J Cardiothorac Surg* 2008;33(3):370–376.

168. Bove T, Zangrillo A, Guarracino F, et al. Effect of fenoldopam on use of renal replacement therapy among patients with acute kidney injury after cardiac surgery: a randomized clinical trial. *JAMA* 2014;312(21):2244–2253.

169. Krishnan M. Preoperative care of patients with kidney disease. *Am Fam Physician* 2002;66(8):1471–1476, 1379.

170. Bagshaw SM, Chawla LS. Hydroxyethyl starch for fluid resuscitation in critically ill patients. *Can J Anaesth* 2013;60(7):709–713.

171. Yunos NM, Bellomo R, Hegarty C, et al. Association between a chloride-liberal vs chloride-restrictive intravenous fluid administration strategy and kidney injury in critically ill adults. *JAMA* 2012;308(15):1566–1572.

172. Cheatham ML, Malbrain ML, Kirkpatrick A, et al. Results from the International Conference of Experts on Intra-abdominal Hypertension and Abdominal Compartment Syndrome. II. Recommendations. *Intensive Care Med* 2007;33(6):951–962.

173. Cai J, Xu R, Yu X, et al. Volatile anesthetics in preventing acute kidney injury after cardiac surgery: a systematic review and meta-analysis. *J Thorac Cardiovasc Surg* 2014;148(6):3127–3136.

Chapter 16

Measuring the Quality of Surgical Care

Justin B. Dimick and John D. Birkmeyer

Key Points

1 Quality measures fall into three categories: structure, process, and outcomes. Healthcare structure refers to fixed attributes of the system in which patients receive care. Process of care measures are the clinical details of care provided to patients. Outcome measures reflect the end result of care, from a clinical perspective or as judged by the patient.

2 Composite measures, created by combining multiple individual quality indicators, are becoming increasingly used in the assessment of surgical quality. Most existing value-based purchasing programs use composite measures of some type to assess the quality of care.

3 No quality measure is perfect. Clinical leaders, patient advocates, payers, and policy makers will have to make decisions about when imperfect measures are good enough to act upon. A measure should be implemented only with the expectation that acting on it will result in net improvement in health quality.

4 It is important to ensure a good match between the performance measure and the primary goal of measurement. The right measure depends on whether the underlying goal is (a) quality improvement – raising the level of performance for all providers or (b) selective referral – directing patients to higher-quality hospitals and/or providers.

5 For quality improvement purposes, a good performance measure must be actionable. Measurable improvements in the given process should translate to clinically meaningful improvements in patient outcomes.

6 With selective referral, a good measure will steer patients to better hospitals or physicians. As a basic litmus test, a measure based on prior performance should reliably identify providers likely to have superior performance now and in the future.

7 One of the biggest limitations of surgical quality measurement is the statistical "noise" from the small sample sizes at most hospitals. This problem makes it difficult to isolate the quality signal from the background statistical noise. An emerging technique, reliability adjustment, directly addresses this problem. This technique, based on hierarchical modeling, quantifies and subtracts statistical noise from the measurement process.

8 Another significant limitation of existing approaches to surgical quality assessment is a lack of good measures of global quality. As payers and purchasers of health care move

forward with value-based purchasing, there is a growing need for better composite scores. In this chapter, we discuss an emerging technique for creating empirically weighted composite measures of surgical performance.

9 An emerging technique for creating empirically weighted composite measures of surgical performance is improving the quality and efficiency of surgical care. Quality measures are only useful if they inform improvement efforts. Future refinements in measurement should therefore aim to meet the diverse needs of the improvement efforts of patients, payers, and providers.

With growing recognition that the quality of surgical care varies widely, good measures of performance are in high demand. Patients and their families need accurate information to help them choose the safest hospitals for surgery.[1] Employers and payers need reliable measures for their value-based purchasing programs.[2] Motivated in part by these external pressures, clinical leaders need better measures to guide their quality improvement efforts.[3]

Despite a broadening array of measures, there remains considerable uncertainty about which measures are most useful.[4,5] Current measures are remarkably heterogeneous, encompassing different elements of healthcare structure, process, and outcomes. With the proliferation of value-based purchasing, which requires a global assessment of quality, there has been a rapid growth in the use of composite measures.[6] Although each of these types of performance measures has strengths, each is also associated with conceptual, methodological, and/or practical problems (Table 16-1).

This chapter provides an overview of existing quality indicators followed by a review of the main strengths and limitations of each type of measure: structure, process, outcomes, and composites. The chapter then closes with recommendations for selecting the right measure and a description of emerging techniques that address some of the limitations of existing quality measures.

OVERVIEW OF CURRENT MEASURES

An ever-broadening array of performance measures has been developed for assessing surgical quality. Over the past few years, the National Quality Forum (NQF) has emerged as the leading organization endorsing quality measures. While the NQF is the central organization for evaluating candidate measures, many other organizations continue to create their own quality indicators. For example, the Center for Medicare and Medicaid Services (CMS) Surgical Care Improvement Program (SCIP), which includes process measures related to prevention of surgical site infections, postoperative cardiac events, venous thromboembolism, and respiratory complications, are routinely collected and publicly reported on the Hospital Compare website for most US hospitals.

The Agency for Healthcare Research and Quality (AHRQ) has focused on quality measures that can be used with administrative data. For example, the AHRQ maintains and distributes state and national administrative data as part of their Healthcare Cost and Utilization Project (HCUP). Processes of care are generally not available in these datasets, so the AHRQ measures focus mainly on structure (e.g., hospital volume) and outcomes (e.g., mortality rates).

Table 16-1 Examples, Strengths, and Limitations of Different Approaches to Measuring Surgical Performance

	Examples	Strengths	Limitations
Structure	Hospital or surgeon volume Surgeon specialty training	Inexpensive and readily available Strong relationship to important outcomes	Not actionable for quality improvement Not good at discriminating individual provider performance
Process	Appropriate selection, timing, and duration of antibiotic prophylaxis Use of internal mammary artery for coronary artery bypass grafting	Actionable as targets for improvement Everybody can achieve 100% compliance	Most known processes relate to secondary outcomes High-leverage processes are unknown for most procedures
Outcome	Risk-adjusted mortality Risk-adjusted morbidity	Seen as the bottom line of patient care Buy-in from providers	Sample sizes too small at individual hospitals
Composite	The Leapfrog Group's Survival Predictor STS Composite score for coronary artery bypass grafting	Addresses problems with small sample size Makes sense of multiple conflicting measures	Too broad to identify specific areas that need improvement

STS, Society of Thoracic Surgeons.

The Leapfrog Group, a coalition of large employers and healthcare purchasers, has issued perhaps the most visible set of surgical quality indicators for its value-based purchasing initiative. Although originally focused exclusively on structural measures, including volume standards, their current standards also include selected processes and risk-adjusted outcomes. More recently, the Leapfrog Group began publicly reporting a composite measure of operative mortality and hospital volume as the primary measure for their evidence-based hospital referral initiative on their website.[7] We will discuss composite measures in detail later in this chapter.

INDIVIDUAL QUALITY MEASURES

1 Quality measures fall into three categories: structure, process, and outcomes.

Structure

Healthcare structure refers to fixed attributes of the system in which patients receive care. Many structural measures describe hospital-level attributes, such as the resources or staff coordination and organization (e.g., nurse-to-patient ratios, hospital teaching status). Other structural measures reflect attributes of individual physicians (e.g., subspecialty board certification, procedure volume).

Strengths

Structural measures of quality have several attractive features. First, they are strongly related to patient outcomes. For example, with esophagectomy and pancreatic resection, operative mortality rates at high-volume hospitals are often 10% lower, in absolute terms, than low-volume centers.[8,9] In some instances, structural measures such as procedure volume are more predictive of subsequent hospital performance than any known processes of care or even direct mortality measures (Fig. 16-1).

Perhaps the most important advantage of structural variables is the ease with which they can be assessed. Many can be determined using readily available sources, such as administrative billing data. Although some structural measures require surveying hospitals or providers, such data are much less expensive to collect than measures requiring detailed patient-level information.

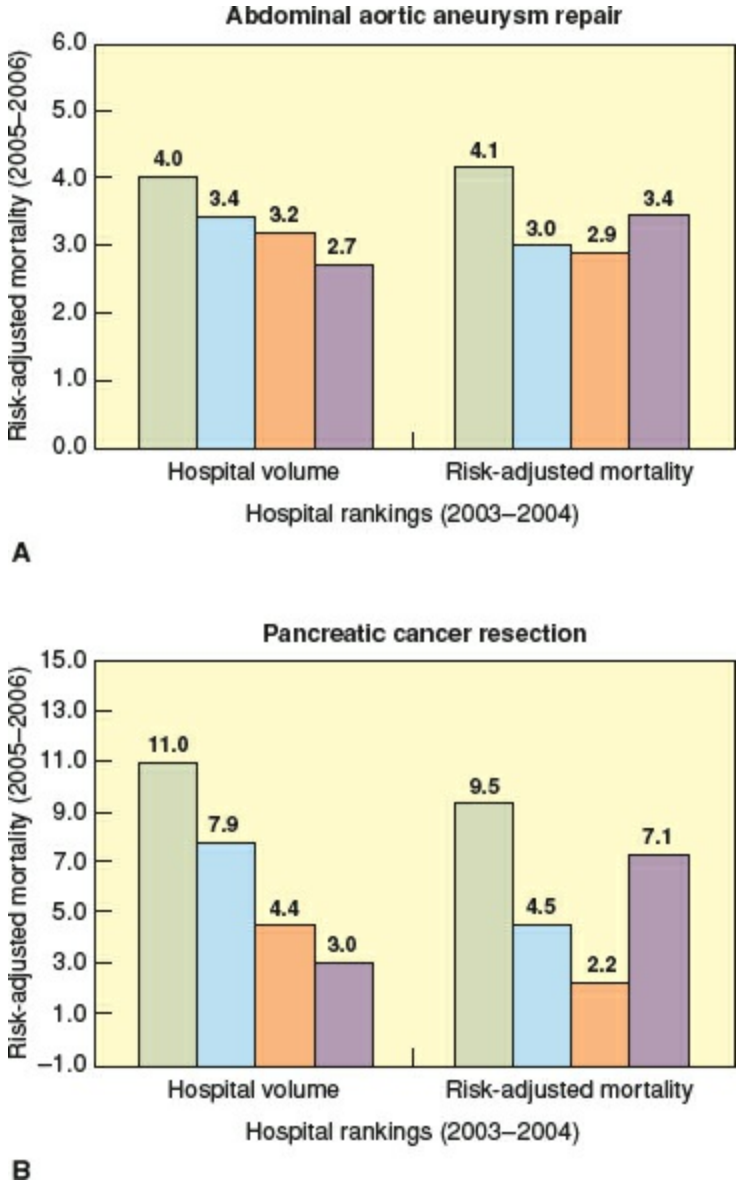

Figure 16-1. Ability of hospital rankings based on 2003–2004 mortality rates and hospital volume to predict risk-adjusted mortality in 2005–2006. Data shown for abdominal aortic aneurysm repair (**A**) and pancreatic cancer resection (**B**). Source: National Medicare data.

Limitations

Perhaps the greatest limitation of structural measures is that they are not readily actionable. For example, a small hospital cannot readily make itself a high-volume center. Thus, while selected structural measures may be useful for selective referral initiatives, they have limited value for quality improvement purposes. Structural measures are also limited in their ability to discriminate the performance of individual providers. For example, in aggregate, high-volume hospitals have much lower mortality rates than lower-volume centers for pancreatic resection.[8,9] However, some individual high-volume hospitals may have high mortality rates, and some low-volume hospitals may have low mortality rates.[10] Although the true performance of individual hospitals is difficult to confirm empirically (for sample size reasons), this lack of discrimination is one reason structural measures are often viewed as “unfair” by many providers.

Process of Care

Process of care measures are the clinical details of care provided to patients. Although long the predominant quality indicators for medical care, their popularity in surgery is growing rapidly. Perhaps the best example of the trend toward using process measures is the CMS's SCIP. As previously mentioned, this quality measurement initiative focuses exclusively on processes related to prevention of surgical site infections, postoperative cardiac events, venous thromboembolism, and respiratory complications.

Strengths

Since processes of care reflect the care actually delivered by physicians, they have face validity and enjoy greater buy-in from providers. They are also directly actionable and provide good substrate for quality improvement activities. Although risk adjustment may be important for outcomes, it is not required for many process measures. For example, the appropriate prophylaxis against postoperative venous thromboembolism is a widely used process measure. Since virtually all patients undergoing open abdominal surgery should be offered some form of prophylaxis, there is little need to collect detailed clinical data for risk adjustment.

Limitations

The biggest limitation of process measures is the lack of correlation between processes of care and important outcomes.[4] There is a growing body of empirical data showing very little correlation between processes of care and important outcomes.[11–13] Most data come from literature on medical diagnoses, such as acute myocardial infarction. For example, the Joint Commission and CMS process measures for acute myocardial infarction explained only 6% of the observed variation in risk-adjusted mortality for acute myocardial infarction.[12]

Emerging evidence demonstrates a similar relationship for surgical process measures, especially for SCIP measures, with no measurable relationship between these widely collected process measures and important outcomes.[13]

There are several reasons why existing process measures explain very little of the variation in important surgical outcomes. First, most process measures currently used in surgery relate to secondary outcomes. While none would dismiss the value of prophylactic antibiotics in reducing risks of superficial wound infection, this process is not related to the most important adverse events of major surgery, including death.

Second, process measures in surgery often relate to complications that are very rare. For example, there is consensus that venous thromboembolism prophylaxis is necessary and important. The SCIP measures, endorsed by the NQF, include the use of appropriate venous thrombosis prophylaxis. However, pulmonary embolism is very uncommon, and improving adherence to these processes will, therefore, not avert many deaths. Until we understand which processes of care account for those adverse events leading to death, process measures will have limited usefulness in surgical quality measurement.[4,11–14]

Outcomes

Outcome measures reflect the end result of care, from a clinical perspective or as judged by the patient. Although mortality is by far the most commonly used measure in surgery, other outcomes that could be used as quality indicators include complications, hospital readmission, and a variety of patient-centered measures of quality of life or satisfaction. The best example of this type of measurement is found in the American College of Surgeons National Surgical Quality Improvement Program (ACS-NSQIP).[15] The ACS-NSQIP is a surgeon-led clinical registry for feeding back risk-adjusted morbidity and mortality rates to participating hospitals. After its successful implementation in Veterans Affairs (VA) hospitals, it was introduced into the private sector with good results.[16] Under the guidance of the American College of Surgeons, hospital participation in the NSQIP continues to grow, with more than 400 hospitals currently participating. Several innovations to the ACS-NSQIP measurement platform in the past few years will no doubt help make the program less expensive and more useful.[3]

Strengths

There are at least two key advantages of outcome measures. First, outcome measures have obvious face validity, and thus are likely to get the greatest "buy-in" from hospitals and surgeons. Surgeon enthusiasm for the ACS-NSQIP and the continued dissemination of the program clearly underline this point. Second, the act of simply measuring outcomes may lead to better performance – the so-called Hawthorne effect. For example, surgical morbidity and mortality rates in VA hospitals have fallen dramatically since implementation of the NSQIP two decades ago.[15] No doubt many surgical leaders at individual hospitals made specific organizational or process improvements after they began receiving feedback on their hospitals' performance. However, it is very unlikely that even a full inventory of these specific changes would explain such broad-based and substantial improvements in morbidity and mortality rates.

Limitations

Hospital- or surgeon-specific outcome measures are severely constrained by small sample sizes. For the large majority of surgical procedures, very few hospitals (or surgeons) have sufficient adverse events (numerators) and cases (denominators) for meaningful, procedure-specific measures of morbidity or mortality. For example, Dimick et al.[17] used data from the Nationwide Inpatient Sample to study seven procedures for which mortality rates have been advocated as quality indicators by the AHRQ. For six of the seven procedures, a very small proportion of US hospitals had adequate caseloads to rule out a mortality rate twice the national average (Fig. 16-2). Although identifying poor-quality outliers is an important function of outcome measurement, focusing on this goal alone significantly underestimates problems with small sample sizes. Discriminating among individual hospitals with intermediate levels of performance is even more difficult.

Another significant limitation of outcome assessment is the expense of data collection. Reporting outcomes requires the costly collection of detailed clinical data for risk

adjustment. For example, it costs over $100,000 annually for a private sector hospital to participate in the ACS-NSQIP. Because of the expense of data collection, the ACS-NSQIP currently collects data on only a sample of patients undergoing surgery at each hospital. Although this sampling strategy decreases the cost of data collection, it exacerbates the problem of small sample size with individual procedures.

COMPOSITE MEASURES

2 Composite measures, created by combining multiple individual quality indicators, are becoming increasingly used in the assessment of surgical quality.[6,7,18] Most existing pay-for-performance efforts, including the CMS pilot, use composite measures to assess the quality of medical and surgical diagnoses. The Society of Thoracic Surgeons (STS) Measurement Taskforce has created a new composite score that combines elements of outcomes and processes of care into a single measure.[18] With growing enthusiasm for this approach, the AHRQ recently published a technical review of composite measures.[19]

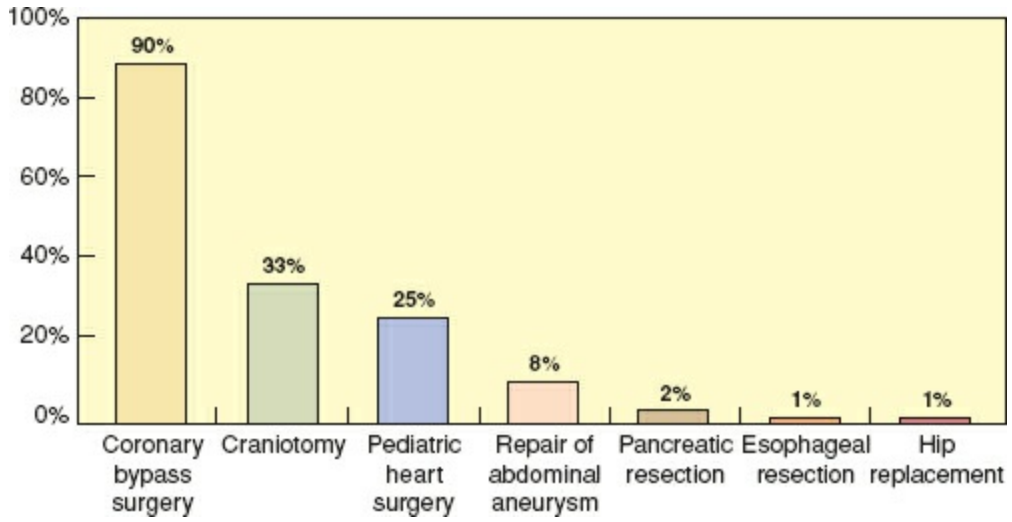

Figure 16-2. Big problems with small samples: the proportion of hospitals in the United States with sufficient caseloads (sample size) to reliably use mortality rates to measure quality.

Strengths

Composite measures have two main advantages over individual quality indicators. First, pooling multiple measures overcomes the problem with small sample sizes described earlier. Second, this approach deals with the problem of multiple conflicting measures, and simplifies quality measurement by providing a single, summary measure of performance. For example, the STS measure for cardiac surgery combines several measures of process and outcomes to create a single score with three categories: one star, two stars, and three stars.[18]

Limitations

Composite measures have both technical and practical limitations. Perhaps the biggest technical challenge is weighting the input measures. Most existing composite measures are created using equal weighting, expert opinion, or the "all or none" approach. For example, the STS cardiac surgery composite score calculates a domain-specific score for morbidity, mortality, process of care, and perioperative medications, and then places equal weight on each domain.[18] Unfortunately, these simplistic weighting schemes do not take into account the simple fact that some measures are more important than others. Ideally, input measures would be weighted empirically, based on how strongly they are related to important outcomes.[19] An emerging technique for creating such empirically weighted composite measures of surgical performance will be discussed at the end of the chapter.[20,21]

Composite measures also have a practical limitation. By design, composite measures reflect global performance with a procedure or specialty. It is hard to know exactly where improvement is needed with this global assessment. Thus, it is important to deconstruct the composite measures into the individual process and outcome measures. Actionable targets for improvement (e.g., high complication rates or failure to adhere to specific processes) can then be addressed.

CHOOSING THE RIGHT MEASURE

3 No quality measure is perfect. Clinical leaders, patient advocates, payers, and policy makers will have to make decisions about when imperfect measures are good enough to act upon. A measure should be implemented only with the expectation that acting on it will result in net improvement in health quality. Thus, the direct benefits of implementing a particular measure cannot be outweighed by the indirect harms. Unfortunately, these benefits and harms are often difficult to measure and heavily influenced by the specific context and who – patients, payers, or providers – is doing the accounting. For this reason, there is no simple answer for where to "set the bar."

4 It is important to ensure a good match between the performance measure and the primary goal of measurement. The right measure depends on whether the underlying goal is (a) quality improvement – raising the performance of all providers or (b) selective referral – directing patients to higher-quality hospitals and/or providers. Although many pay-for-performance initiatives have both goals, one often predominates. For example, the ultimate objective of the CMS's pay-for-performance initiative with prophylactic antibiotics is improving quality at all hospitals (quality improvement). Conversely, the Leapfrog Group's efforts in surgery are primarily aimed at getting patients to hospitals likely to have the best outcomes (selective referral).

5 For quality improvement purposes, a good performance measure must be actionable. Measurable improvements in the given process should translate to clinically meaningful improvements in patient outcomes. Although quality improvement activities are rarely "harmful," their major downsides relate to their opportunity cost. Initiatives hinged on bad measures divert resources (e.g., time and focus of physicians and other staff) away from more productive activities.

6 With selective referral, a good measure will steer patients to better hospitals or physicians. As a basic litmus test, a measure based on prior performance should reliably identify providers likely to have superior performance now and in the future. At the same time, an ideal measure would not incentivize perverse behaviors (e.g., surgeons doing unnecessary procedures to meet a specific volume standard) or negatively affect other domains of quality (e.g., patient autonomy, access, and satisfaction).

Many believe that a good performance measure must discriminate performance at the individual level. From the provider perspective in particular, a "fair" measure must reliably reflect the performance of individual hospitals or physicians. Unfortunately, as described earlier, small caseloads (and sometimes case mix variation) conspire against this objective for most procedures. Patients, however, should value information that improves their odds of good outcomes on average. Many measures meet this latter interest while failing on the former (e.g., hospital volume standards). There may be no simple solution to resolving the basic tension implied by performance measures that are unfair to providers yet informative for patients. However, it underscores the importance of being clear about both the primary purpose (quality improvement or selective referral) and whose interests are receiving top priority (provider or patient).

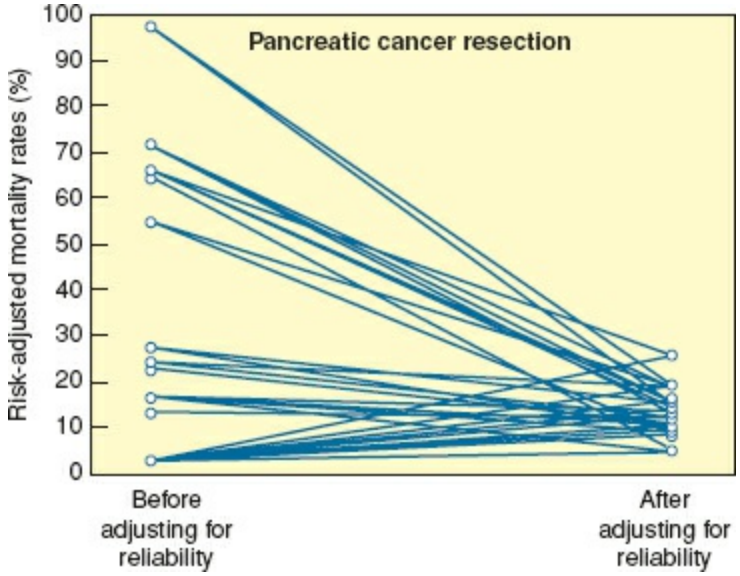

Figure 16-3. Variation in hospital mortality rates before and after adjusting for reliability. Twenty randomly sampled hospitals are shown. Source: National Medicare data, 2005–2006.

DEVELOPING BETTER MEASURES

7 Although great progress has been made, the science of quality measurement is in its infancy. In fact, there are solutions on the horizon for many of the limitations discussed earlier. One of the biggest limitations of surgical quality measurement is the statistical "noise" from the small sample sizes at most hospitals. This problem makes it difficult to isolate the quality signal from the background statistical noise. In other words, it is often hard to know whether hospitals or surgeons have poor performance because they provide low-quality care or because they were unlucky. For obvious reasons, labeling surgeons and hospitals correctly is extremely important.

An emerging technique, reliability adjustment, directly addresses the problem of statistical noise.[22,23] This technique, based on hierarchical modeling, quantifies and subtracts statistical noise from the measurement process. Essentially, it "shrinks" providers' performance back toward average unless they deviate to such an extreme that it is safe to assume they are truly different. In this way, it gives providers the benefit of doubt. Figure 16-3 shows the risk-adjusted mortality rates for pancreatic resection in Medicare patients before and after reliability adjustment. Prior to reliability adjustment, the mortality rates varied from 0% to 100%. After reliability adjustment, the mortality rates only vary from 2% to 22%, yielding a range of performance that is clinically more realistic. Reliability adjustment is gaining popularity outside surgery (e.g., ambulatory care) and is becoming widely recognized as a valid tool for improving the accuracy of quality measurement.[22,23]

Despite wide use in other fields, reliability adjustment is only beginning to find application in surgery. Perhaps the most prominent example is the Massachusetts state cardiac surgery report card, which publishes "smoothed" mortality rates for each hospital.[24] These are obtained with reliability adjustment using hierarchical modeling techniques, as described earlier. This approach was also recently applied to the morbidity and mortality rates in the ACS's NSQIP, as described with other changes in a recent "Blueprint" for a new ACS NSQIP.[3] As the advantages of this technique become more widely known, there is no doubt it will become the standard technique for reporting risk-adjusted outcomes.

8, **9** Another significant limitation of existing approaches to surgical quality assessment is a lack of good measures of global quality. As payers and purchasers of health care move forward with value-based purchasing, there is a growing need for better composite scores. Unfortunately, as discussed earlier, most approaches are not thoughtful about how they weight input measures. However, there is an emerging technique for creating empirically weighted composite measures of surgical performance.[20,21] To create these measures, a "gold standard" quality measure is first identified (e.g., risk-adjusted mortality). The relationships between all input measures and this "gold standard" measure are then determined. A composite is then created that weights the input measures based on how reliable they are (a measure of precision) and how closely they are related to the "gold standard" outcome. Dimick et al.[20,21] recently published the methods for creating these measures using a range of surgical procedures. They found

that a composite measure of risk-adjusted mortality and hospital volume, combined with risk-adjusted mortality for other, related procedures explained a large proportion of hospital-level variation in mortality and was better at predicting future performance than any individual measure (Fig. 16-4).

Although both of these emerging techniques will enhance our ability to profile hospitals on technical quality, we also need to develop better measures of surgical decision making. Wide geographic variations in the use of surgical procedures imply substantial underuse, misuse, and overuse. Escalating healthcare costs are at least in part due to overuse and misuse of surgical interventions. Measures of appropriateness or utilization will need to become part of our armamentarium if meaningful attempts at reducing these variations are to be made. Although appropriateness criteria have been extensively studied, there is growing consensus that they are impractical on a large scale.[25] The task of tabulating all of the potential scenarios in which a procedure is "appropriate" or "inappropriate" is daunting. Even when these exhaustive lists are created, reasonable clinicians may still disagree in a large proportion of cases.[25] Appropriateness criteria should be limited to "low-hanging fruit," those procedures with a few, well-agreed-upon indications for operation.

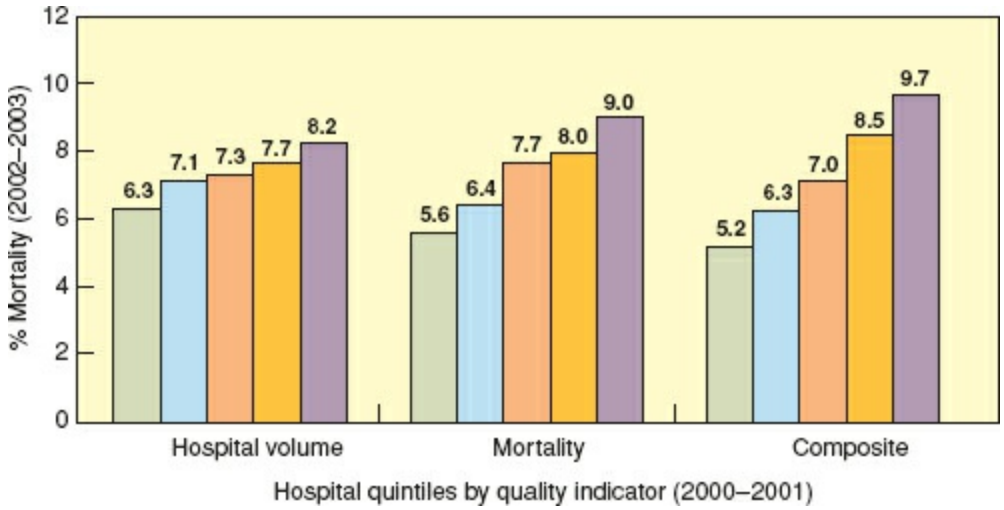

Figure 16-4. Ability of various historical (2000–2001) quality indicators to forecast subsequent (2002–2003) risk-adjusted mortality with aortic valve replacement (AVR). Hospitals sorted into quintiles according to hospital volume alone, risk-adjusted mortality alone, and composite measure based on AVR mortality, AVR hospital volume, and mortality and volume with other cardiac procedures.

For the majority of procedures, however, another approach is needed. One potential approach is the measurement of utilization at the level of the Accountable Care Organization (ACO). ACOs are organization of physicians and/or hospitals that assume care for a group of patients. ACOs are felt by some health policy experts to be the right level of accountability for measuring the quality of the extended healthcare system.[26,27] Most current ACO models fall far short of full capitation, which would undoubtedly lower rates of discretionary procedures, but there are many other ways these organizations could approach overutilization. For example, rates of surgery for each ACO could be used for public reporting, value-based purchasing, or tiered health plans. This approach would

allow patients to choose hospitals based on how “aggressive” they are. Public disclosure of surgery rates would also put downward pressure on hospitals with high rates of surgery, potentially discouraging expanding capacity when it may not be necessary.

The near future will no doubt bring other major advances in the science of quality measurement. The accelerating pace of technology will surely play a role. As electronic medical records become more widely adopted, clinical data will be more easily abstracted from the patient record. Such improvements in technology will provide cost-efficient risk adjustment and more practicable approaches for assessing the adherence to important processes of care. While improvements in technology and infrastructure are of great benefit, involvement of surgeons in health services research will also be important. Studies using tools of clinical epidemiology are needed to generate evidence linking high-leverage processes of care to important outcomes. These processes of care could then be applied to existing quality measurement platforms. Surgeon-scientists with scholarship in quality improvement will be instrumental in providing these insights and leading this high-impact academic field forward.

When measuring quality, it is important to keep in mind the ultimate goal: improving the quality and efficiency of surgical care. Quality measures are only useful if they inform improvement efforts. Future refinements in measurement should therefore aim to meet the diverse needs of the improvement efforts of patients, payers, and providers. In the previous chapter, the three dominant approaches for improving surgical quality were discussed: selective referral, process compliance, and outcome measurement. These three policy approaches roughly mirror the three types of quality measures (structure, process, and outcomes), providing real-world examples of how various stakeholders weigh the pros and cons of quality indicators, and ultimately choose an assessment approach by matching the measure to the purpose.

References

1. Lee TH, Meyer GS, Brennan TA. A middle ground on public accountability. *N Engl J Med* 2004;350:2409–2412.
2. Galvin R, Milstein A. Large employers' new strategies in health care. *N Engl J Med* 2002;347:939–942.
3. Birkmeyer JD, Shahian DM, Dimick JB, et al. Blueprint for a new American College of Surgeons: National Surgical Quality Improvement Program. *J Am Coll Surg* 2008;207:777–782.
4. Birkmeyer JD, Dimick JB, Birkmeyer NJ. Measuring the quality of surgical care: structure, process, or outcomes? *J Am Coll Surg* 2004;198: 626–632.
5. Landon BE, Normand SL, Blumenthal D, et al. Physician clinical performance assessment: prospects and barriers. *JAMA* 2003;290(9):1183–1189.
6. O'Brien SM, DeLong ER, Dokholyan RS, et al. Exploring the behavior of hospital composite performance measures: an example from coronary artery bypass surgery. *Circulation* 2007;116:2969–2975.
7. Dimick JB, Staiger DO, Baser O, et al. Composite measures for predicting surgical mortality in the hospital. *Health Aff* 2009;28:1189–1198.
8. Halm EA, Lee C, Chassin MR. Is volume related to outcome in health care? A systematic review and methodologic critique of the literature. *Ann Intern Med* 2002;137:511–520.
9. Dudley RA, Johansen KL, Brand R, et al. Selective referral to high volume hospitals: estimating potentially avoidable deaths. *JAMA* 2000;283:1159–1166.
10. Rathore SS, Epstein AJ, Volpp KG, et al. Hospital coronary artery bypass graft surgery volume and patient mortality, 1998–2000. *Ann Surg* 2004;239:110–117.
11. Fonarow GC, Abraham WT, Albert NM, et al. Association between performance measures and clinical outcomes for patients hospitalized with heart failure. *JAMA* 2007;297:61–70.
12. Bradley EH, Herrin J, Elbel B, et al. Hospital quality for acute myocardial infarction: correlation among process measures and relationship with short-term mortality. *JAMA*2006;296:72–78.
13. Stulberg JJ, Delaney CP, Neuhauser DV, et al. Adherence to surgical care improvement project measures and the association with postoperative infections. *JAMA* 2010;303:2479–2485.
14. Hawn MT, Itani KM, Gray SH, et al. Association of timely administration of prophylactic antibiotics for major surgical procedures and surgical site infection. *J Am Coll Surg* 2008;206:814–819.
15. Khuri SF, Daley J, Henderson W, et al. The Department of Veterans Affairs' NSQIP: the first national, validated, outcome-based, risk-adjusted, and peer-controlled program for the measurement and enhancement of the quality of surgical care. National VA Surgical Quality Improvement Program. *Ann Surg* 1998;228:491–507.

16. Fink AS, Campbell DA Jr, Mentzer RM Jr, et al. The National Surgical Quality Improvement Program in non-Veterans Administration hospitals: initial demonstration of feasibility. *Ann Surg* 2002;236:344–353.
17. Dimick JB, Welch HG, Birkmeyer JD. Surgical mortality as an indicator of hospital quality: the problem with small sample size. *JAMA* 2004;292:847–851.
18. O'Brien SM, Shahian DM, DeLong ER, et al. Quality measurement in adult cardiac surgery: part 2 – statistical considerations in composite measure scoring and provider rating. *Ann Thorac Surg* 2007;83(suppl 4):S13–S26.
19. AHRQ Inpatient Quality Indicators Composite Measure. Draft technical report. Available at: http://qualityindicators.ahrq.gov/news/AHRQ_IQI_Composite_Draft.pdf. Accessed June 27, 2007.
20. Dimick JB, Staiger DO, Osborne NH, et al. Composite measures for rating hospital quality with major surgery. *Health Serv Res* 2012;47:1861–1679.
21. Dimick JB, Staiger DO, Hall BL, et al. Composite measures for profiling hospitals on surgical morbidity. *Ann Surg* 2013;257:67–72.
22. Dimick JB, Staiger DO, Birkmeyer JD. Ranking hospitals on surgical mortality: the importance of reliability adjustment. *Health Serv Res* 2010;45:1614–1629.
23. Dimick JB, Ghaferi AA, Osborne NH, et al. Reliability adjustment for reporting hospital outcomes with surgery. *Ann Surg* 2012;255:703–707.
24. Adult Coronary Artery Bypass Graft Surgery in the Commonwealth of Massachusetts. Fiscal Year 2006 Report, October 1, 2005–September 30, 2006. Available at: http://www.massdac.org/reports/CS%20FY2006.pdf. Accessed June 17, 2010.
25. Casparie AF. The ambiguous relationship between practice variation and appropriateness of care: an agenda for further research. *Health Policy* 1996; 35:247–265.
26. Bynum JP, Bernal-Delgado E, Gottlieb D, et al. Assigning ambulatory patients and their physicians to hospitals: a method for obtaining population-based provider performance measurements. *Health Serv Res* 2007;42:45–62.
27. Fisher ES, Staiger DO, Bynum JP, et al. Creating accountable care organizations: the extended hospital medical staff. *Health Aff (Millwood)* 2007; 26:w44–w57.

Chapter 17

Policy Approaches to Improving Surgical Quality

John D. Birkmeyer and Justin B. Dimick

Key Points

1 Center of excellence programs implemented by private payers and CMS have failed to identify hospitals with superior outcomes because they rely on weak process of care measures or inaccurate, self-reported data.

2 Pay-for-performance programs in surgery have been successful in increasing hospital compliance with evidence-based practice in perioperative care. It is not clear that they have improved patient outcomes, however.

3 Focusing on a few discrete steps in the care of surgical patients underestimates the complexity of surgical care. Higher leverage measures, including those that reflect important aspects of surgical decision making or technical skill, are needed.

4 Outcome measurement and feedback may provide early benefits by capitalizing on the surgical "Hawthorne effect," but their impact may be limited if they are tied to coordinated efforts aimed at changing practice.

5 With Qualified Clinical Data Registries, surgeons may be eligible for CMS pay-for-performance incentive payments by participating in ACS-NSQIP and other society-led registries.

6 Although prophylactic strategies aimed at avoiding complications in the first place are obviously important, "rescuing" patients once a complication has occurred may be even more critical in reducing current variations in hospital mortality rates.

INTRODUCTION

Improving the quality of surgical care is a public health imperative. As many as 100,000 patients die every year undergoing surgery in the United States; an order of magnitude more experience serious complications.[1] Despite recent studies suggesting that surgery is becoming safer over time,[2] a large body of literature suggests that a large proportion of surgical morbidity and mortality may be avoidable. In its seminal 1999 report *To Err is Human,* the Institute of Medicine estimated that between 44,000 and 98,000 Americans die every year as a result of medical errors, at least half of whom are surgical patients.[3,4] Evidence that morbidity and mortality vary widely across hospitals and surgeons further implies opportunities for improvement. In addition to variation among individual providers, [5–7] surgical outcomes differ according to a number of provider attributes, including procedure volume, surgeon subspecialty training, and other factors.[8–10]

In response, payers, policy makers, and professional organizations have launched a broad array of strategies aimed at improving surgical quality.[11] Some of these efforts, including the so-called Centers of Excellence (COE) programs, aim to direct surgical patients to hospitals or surgeons with the best results.[12] With pay-for-performance programs, payers are instead aiming to incentivize improvements at all hospitals, providing financial rewards (and penalties) to hospitals and/or surgeons meeting performance targets on both outcomes and process of care measures.[13] And finally, surgical professional societies and state organizations are hoping to improve surgical quality through clinical outcome registries, performance feedback, and collaborative quality improvement activities.[14–16]

Although hospitals and surgeons also engage in improvement activities at the local level, these three strategies – COE programs, pay for performance, and outcome feedback – represent the major, policy-level approaches to improving surgical quality at the present time. In this chapter, we review the relative strengths and weaknesses of each approach (Table 17-1). We close by reviewing new research on mechanisms underlying variation in surgical outcomes across hospitals and surgeons, and its implications for quality improvement in the future.

CENTERS OF EXCELLENCE

COE programs hope to identify hospitals and/or surgeons with the best results with selected procedures and direct as many patients as possible to these settings. In some instances, payers restrict insurance approval to narrow networks of approved providers. In others, they implement tiered health plans and benefits packages that give patients financial incentives (e.g., lower copays) to select higher-quality providers. Such programs generally make public comparative information about hospital and surgeon performance, hoping to further motivate patients to "shop for quality."

Among the most prominent examples of active COE programs, Blue Cross Blue Shield Association identifies the so-called "Blue Distinction" centers for cancer care, cardiovascular surgery, organ transplantation, and bariatric surgery, based on periodic surveys of hospital performance on multiple different measures with each specialty area. The CMS until recently restricted bariatric surgery to hospitals designated as COE by either the American College of Surgeons (ACS) or the American Society of Metabolic and Bariatric Surgeons. Although led by employers and purchasers rather than payers, the Leapfrog Group is promoting "evidence-based hospital referral" for aortic valve replacement and complex cancer surgery, based on both procedure volume criteria and hospital mortality rates.[17]

Such strategies reflect the natural response of payers (and many patients) to data indicating variation in provider performance with surgery. Among other advantages, selective referral can often be implemented expediently and inexpensively, particularly when based on simple structural measures of quality (e.g., procedure volume). For many procedures, commonly used quality indicators can reliably identify groups of hospitals and surgeons with superior outcomes. For example, data readily obtained from administrative sources, including procedure volume and hospital mortality, not only describe past performance, but also forecast future performance with many procedures.[18] A recent national study suggests the potential benefits of concentrating complex procedures in COEs. Based on national Medicare data, mortality with high-risk cancer surgery fell almost 20% between 1999 and 2008.[2] Approximately half of that mortality decline could be attributed to market concentration – more procedures being done in high-volume hospitals.

Table 17-1 Characteristics of Three Different Models for Reducing Variation and Improving Surgical Quality

	Centers of Excellence Programs	Pay for Performance	Surgeon-Led Quality Measurement and Improvement
Goal/mechanism	Steer patients to high-quality hospitals or surgeons	Payers implement financial incentives that reward hospitals and surgeons for better outcomes or other measures of performance	Improve care in all settings by providing feedback on surgical outcomes; hospitals and surgeons implement improvement efforts at local level
Examples	Leapfrog Group evidence-based hospital referral program Payers' Centers of Excellence programs in cardiac and bariatric surgery	Hospital Value-Based Purchasing Program of the Center for Medicare and Medicaid Services (CMS) CMS' Physician Value-Based Modifier Payments	National registries/improvement programs administered by Society of Thoracic Surgery and American College of Surgeons Insurer-funded collaboratives in Michigan and other states
Advantages	Inexpensive, expedient Traction with patients and payers	Can facilitate rapid improvements in many aspects of perioperative care	High degree of surgeon buy-in Robust registries are important tool in identifying best practices
Disadvantages	Highly polarizing (for surgeons) For most procedures, hard to reliably identify "best" hospitals and surgeons with existing data	Provides no insights on how to improve Though effective on process measures, little effect to date in improving outcomes	Expensive Difficult to scale

1 Despite their conceptual appeal and potential benefits, the results of many COE initiatives have been largely disappointing. For example, analyses by Mehrotra et al.[19] found no evidence that the Blue Distinction Centers had better outcomes than nondesignated hospitals with spine surgery and total joint replacement. In another study examining the effects of CMS' 2006 policy restricting bariatric surgery to COEs, Dimick et al.[20] found no evidence that COEs had better performance than non-COEs, or that the CMS policy had improved outcomes overall. As a result of that study and others reaching similar conclusions,[12,21] CMS decided to rescind its policy restricting bariatric surgery to COEs in 2013. These examples highlight problems with current approaches to assessing the comparative quality of hospitals and surgeons for COE purposes. These challenges include using administrative data to assess outcomes other than mortality, putting too much weight on hospital attributes and processes of care not tightly linked to outcomes, and relying on self-reported data.[22]

Measurement challenges aside, COE programs have other downsides. Strategies that displace patients from their usual site of care and regular physicians may interfere with coordination of care. They tend to be highly polarizing, dividing hospitals and surgeons into winners and losers. In alienating the latter, a price of COE programs may be lost opportunities for engaging physicians in other types of quality improvement efforts. And finally, such programs improve outcomes exclusively to the extent that they steer care away from poor performers. It provides no mechanism for helping non-COE hospitals and surgeons improve their outcomes.

PAY FOR PERFORMANCE

Another approach to improving surgical outcomes is to encourage hospitals and surgeons to provide higher-quality care with financial incentives. Both public and private payers have active pay-for-performance programs involving surgery. CMS has both a Value-Based Purchasing program aimed at hospitals and a more recent effort targeting physicians – the so-called Physician Value-Based Payment Modifier program.[23] Although such programs are moving toward specialty-specific outcome-based measures (as described later), pay-for-performance programs have until now focused on adherence to evidence-based practices related to perioperative care. For example, many private payers link hospital reimbursement to process measures established by the Surgical Care Improvement Project (SCIP),[24] including practices aimed at reducing rates of surgical site infection, postoperative cardiac events, venous thromboembolism, and ventilator-associated pneumonia.

Among their strengths, pay-for-performance initiatives aimed at improving compliance with specific processes of care are considerably less polarizing than selective referral. In theory, anyone can "win." To the extent that surgeons can "play to the quiz," process-based pay-for-performance programs have the potential to achieve rapid and significant improvements in many aspects in perioperative care. Studies in primary care suggest that pay-for-performance programs may be particularly effective in improving process compliance among poor performers and thus reducing overall variation.[13,25] In surgery, evidence to date suggests similar improvements in compliance with SCIP measures.[26]

2 Nonetheless, the extent to which improvements in evidence-based practice compliance translate to improvements in surgical outcomes remains uncertain. Studies to date have generally failed to demonstrate a strong correlation between provider performance with specific process measures and patient outcomes. For example, hospitals successful in examining at least 12 lymph nodes from the surgical specimens of patients undergoing colectomy for colon cancer, one popular measure, did not have better 5-year survival rates than those scoring worse on this quality indicator.[27] Even when hospital performance is measured across multiple, evidence-based practices related to a specific postoperative complication, process compliance is not well correlated with patient outcomes. In examining national data compiled by CMS' Hospital Compare program, for example, Nicholas et al.[28] found that hospital compliance with the "bundles" of SCIP process measures related to surgical site infection and venous thromboembolism varied widely. Moreover, hospital compliance rates were not related to the incidence of those two postoperative complications.

A more recent study by Shih et al.[29] provides the most direct evaluation of the overall effects of surgical pay-for-performance programs. Focusing on coronary bypass surgery and total joint replacement, Medicare's Premier Hospital Quality Incentive Demonstration (HQID) was intended to incentivize quality and quality improvement by increasing reimbursements to both top performing hospitals and those demonstrating the greatest degree of improvement over time.[30] While mortality and complication rates for cardiac and orthopedic patients decreased significantly over time in premier hospitals,

improvements of similar magnitude were observed in nonparticipating hospitals.[29]

3 Together, these studies do not invalidate the importance of timely antibiotics and other well-tested prophylactic measures against surgical complications. Rather, they underscore the complexity of surgical care and the limitations of focusing exclusively on a small number of discrete steps in managing a surgical patient. As we describe later, these studies also highlight that surgical outcomes also depend on aspects of care not traditionally addressed in pay-for-performance programs, like surgeons' technical skill and their proficiency in managing complications after they have occurred.

OUTCOME FEEDBACK

In contrast to strategies led by payers and policy makers, surgeons and their professional organizations are focusing primarily on registry-based quality improvement programs.[14,15,31] Their goal is to provide hospitals and surgeons with rigorous feedback about their outcomes relative to those of their peers. Some of these programs have centralized approaches to coordinating quality improvement activities, while others focus primarily on performance feedback, leaving improvement work at the local level.

The Scientific Registry of Transplant Recipients and the Adult Cardiac Surgery Database of the Society of Thoracic Surgeons were among the earliest and most recognized surgical outcome registries. The large majority of US hospitals involved in those two specialties now contribute to those databases.[32,33] Originally developed by the Department of Veterans Affairs, the American College of Surgeons-National Surgical Quality Improvement Program (ACS-NSQIP) has become the largest outcome measurement platform for noncardiac surgery.[14,34] Often supported by payers, state and regional collaborative improvement programs – based on either society-developed or "home-grown" outcome registries – have become increasingly popular.

This model of performance feedback and data-driven quality improvement has particular appeal among surgeons. As they represent the "bottom line" of success, outcome measures tend to be more meaningful to surgeons than process measures. When coupled with coordinated programs aimed at effecting practice change, registry-based improvement programs in surgery can be highly effective. In Michigan, for example, Blue Cross Blue Shield of Michigan has supported collaborative improvement programs across numerous surgical specialties.[35] Though not every initiative supported by the Michigan collaborative has been well studied, Michigan hospitals have substantially outperformed national benchmarks in cardiac, general, and bariatric surgery.[16]

4 Whether performance feedback alone improves outcomes remains less clear, however. Early studies support the existence of a surgical "Hawthorne effect" – that the process of measurement spurs improvement. For example, surgical morbidity rates at VA hospitals fell over 40% almost immediately after implementation of NSQIP in the early 1990s,[6] before any systematic attempt to change practice across that system. Mortality rates with cardiac surgery have fallen dramatically over the past 20 years, coincident with national dissemination of the STS registry.[36] The extent to which secular trends toward declining surgical mortality can be attributed to society-led registries and reporting systems is uncertain, however. Using national Medicare data, we compared hospitals participating in ACS-NSQIP to a matched group of nonparticipating hospitals. Though hospitals in the former group had lower mortality rates at the time they enrolled in ACS-NSQIP, both groups improved at the same rate between 2006 and 2012.

Surgeon-led outcome registries and improvement programs have other limitations. Though this issue may fade in the future as electronic medical record data become more accessible, current programs rely on extensive and expensive manual data collection, which has limited their dissemination in most specialties. Outcome measures, particularly when assessed at the level of specific procedures, are often hindered by small sample

sizes and can be too “noisy” to inform hospitals and surgeons of their true performance.[37] And finally, as currently implemented, most registry-based improvement programs have several important “blind spots,” such as addressing the appropriateness of surgical procedures, variation in surgeon technical skill, and management of patients with postoperative complications.

SUMMARY

5 Although this chapter has laid out some of the distinct features, advantages and disadvantages with each strategy, the field is fast evolving and the lines between COE programs, pay for performance, and outcome feedback are blurring over time. Connecting the first and third strategy, for example, the STS recently decided to allow hospitals participating in its registry program to publicly report their outcomes for COE programs and other purposes. In another example, CMS is expanding measurement options for physicians participating in its physician-based P4P program, allowing them to submit specialty-specific outcome data through the so-called Qualified Clinical Data Registries, including those administered by surgical societies.

Each of the three strategies would benefit from advances in quality measurement and improvement. COE programs in particular would benefit from measures that more reliably discriminate performance among individual hospitals and surgeons. As described elsewhere, individual measures of structure (including procedure volume), process of care, and outcomes have major limitations in reflecting provider-specific quality.[38] Composite quality measures, which empirically combine information from several quality domains, appear very promising.[39,40] As described by Dimick et al.[41] such measures far surpass existing quality indicators in capturing true variation in provider performance. More importantly, empirically derived composite measures perform extremely well in forecasting a hospital's future outcomes, a key litmus test given the underlying goals of COE programs.

6 Although better statistical methods for assessing postoperative morbidity and mortality will help, it may be even more important that future initiatives target a broader range of performance domains. First, given that the use of surgical procedures varies as much as outcomes, practical measures of appropriateness – and the quality of surgeons' decisions to operate in the first place – are essential. Second, rather than focusing exclusively on aspects of perioperative care, quality measurement and improvement initiatives should target surgeons' operative proficiency. Recent research suggests that, at least for some procedures, the technical skill of the operating surgeon varies widely and may be the single most important predictor of patient outcomes after surgery.[42] And finally, improving surgical quality will require reducing rates of the so-called "failure to rescue." A growing body of research suggests that hospital mortality rates are explained less by their complication rates than by their case-fatality rates among patients with serious complications.[43,44] Thus, ensuring timely recognition and effective management of complications once they have occurred may be even more important to the success of strategies aimed at reducing surgical mortality.

References

1. Goodney PP, Siewers AE, Stukel TA, et al. Is surgery getting safer? National trends in operative mortality. *J Am Coll Surg* 2002;195:219–227.
2. Finks JF, Osborne MH, Birkmeyer JD. Trends in hospital volume and operative mortality for high-risk surgery. *N Engl J Med* 2011;364:2128–2137.
3. Kohn LT, Corrigan JM, Donaldson MS, eds. *To Err is Human: Building a Safer Health System.* Washington, DC: National Academy Press; 1999.
4. Gawande AA, Thomas EJ, Zinner MJ, et al. The incidence and nature of surgical adverse events in Colorado and Utah in 1992. *Surgery* 1999;126(1):66–75.
5. Hannan EL, Kilburn H Jr, O'Donnell JF, et al. Adult open heart surgery in New York State. An analysis of risk factors and hospital mortality rates. *JAMA* 1990;264(21):2768–2774.
6. Khuri SF, Daley J, Henderson WG. The comparative assessment and improvement of quality of surgical care in the Department of Veterans Affairs. *Arch Surg* 2002;137(1):20–27.
7. O'Connor GT, Plume SK, Olmstead EM, et al. A regional prospective study of in-hospital mortality associated with coronary artery bypass grafting. *JAMA* 1991;266:803–809.
8. Dudley RA, Johansen KL, Brand R, et al. Selective referral to high volume hospitals: estimating potentially avoidable deaths. *JAMA* 2000;283:1159–1166.
9. Halm EA, Lee C, Chassin MR. Is volume related to outcome in health care? A systematic review and methodologic critique of the literature. *Ann Int Med* 2002;137:511–520.
10. Houghton A. Variation in outcome of surgical procedures. *Br J Surg* 1994; 81:653–660.
11. Birkmeyer NJ, Birkmeyer JD. Strategies for improving surgical quality–should payers reward excellence or effort? *N Engl J Med* 2006;354(8):864–870.
12. Livingston EH. Bariatric surgery outcomes at designated centers of excellence vs nondesignated programs. *Arch Surg* 2009;144(4):319–325; discussion 325.
13. Rosenthal MB, Frank RG, Li Z, et al. Early experience with pay-for-performance: from concept to practice. *JAMA* 2005;294(14):1788–1793.
14. Fink A, Campbell DJ, Mentzer RJ, et al. The National Surgical Quality Improvement Program in non-veterans administration hospitals: initial demonstration of feasibility. *Ann Surg* 2002;236:344–353.
15. Rowell KS, Turrentine FE, Hutter MM, et al. Use of national surgical quality improvement program data as a catalyst for quality improvement. *J Am Coll Surg* 2007;204:1293–1300.
16. Share DA, Campbell DA, Birkmeyer NJ, et al. How a regional collaborative of hospitals and physicians in Michigan cut costs and improved the quality of care. *Health Aff* 2011;30(4):636–645.

17. http://www.leapfroggroup.org/about_us/leapfrog-factsheet. Last accessed September 1, 2014.
18. Birkmeyer JD, Dimick JB, Staiger DO. Operative mortality and procedure volume as predictors of future hospital performance. *Ann Surg* 2006;243:411–417.
19. Mehrotra A, Sloss, EM, Hussey PS, et al. Evaluation of centers of excellence programs for knee and hip replacement. *Med Care* 2013;51(1):28–36.
20. Dimick JB, Nicholas LH, Ryan AM, et al. Bariatric surgery complications before vs after implementation of a national policy restricting coverage to centers of excellence. *JAMA* 2013;309(8):792–799.
21. Birkmeyer NJ, Dimick JB, Share D, et al. Hospital complication rates with bariatric surgery in Michigan. *JAMA* 2010;304(4):435–442.
22. Dimick JB, Birkmeyer NJ. Rethinking eligibility criteria for bariatric surgery. *JAMA* 2014;312(9):953–954.
23. Chien AT, Rosenthal MB. Medicare's physician value-based payment modifier – will the tectonic shift create waves. *N Engl J Med* 2013;369:2076–2078.
24. Gold JA, Gold JA. The surgical care improvement project. *WMJ* 2005; 104(1):73–74.
25. Rosenthal MB, Dudley RA. Pay-for-performance: will the latest payment trend improve care? *JAMA* 2007;297(7):740–744.
26. Ingraham AM, Cohen ME, Bilimoria KY, et al. Association of surgical care improvement project infection-related process measure compliance with risk-adjusted outcomes: implications for quality measurement. *J Am Coll Surg* 2010;211(6):705–714.
27. Wong SL, Ji H, Hollenbeck BK, et al. Hospital lymph node examination rates and survival after resection for colon cancer. *JAMA* 2007;298(18):2149–2154.
28. Nicholas LH, Osborne NH, Birkmeyer JD, et al. Hospital process compliance and surgical outcomes in medicare beneficiaries. *Arch Surg* 2010; 145(10):999–1004.
29. Shih T. Nicholas LH, Thumma JR, et al. Does pay-for-performance improve surgical outcomes? *Ann Surg* 2014;259(4):677–681.
30. Centers for Medicare & Medicaid Services. Premier Hospital Quality Incentive Demonstration Rewarding Superior Quality Care Fact Sheet December 2011. Available at http://www.cms.gov/Medicare/Quality-Initiatives-Patient-Assessment-Instruments/HospitalQualityInits/Downloads/HospitalPremierPressRelease-FactSheet.pdf. Accessed September 1, 2014.
31. Birkmeyer JD, Shahian DM, Dimick JB, et al. Blueprint for a new American College of Surgeons: National Surgical Quality Improvement Program. *J Am Coll Surg* 2008;207:777–782.
32. Massie AB, Kuricka LM, Segev DL. Big data in organ transplantation: registries and administrative claims. *Am J Transplant* 2014;14(8):1723–1730
33. Shahian DM, Edwards FH, Ferraris VA, et al. Quality measurement in adult cardiac surgery: part 1–Conceptual framework and measure selection. *Ann Thorac Surg*

2007;83(4 Suppl):S3–S12.
34. Khuri SF, Daley J, Henderson W, et al. Risk adjustment of the postoperative mortality rate for the comparative assessment of the quality of surgical care: results of the National Veterans Affairs Surgical Risk Study. *J Am Coll Surg* 1997;185:315–327.
35. Birkmeyer NJ, Share D, Campbell DA Jr, et al. Partnering with payers to improve surgical quality: the Michigan plan. *Surgery* 2005;138(5):815–820
36. O'Connor GT, Plume SK, Morton JR, et al. Results of a regional prospective study to improve the in-hospital mortality associated with coronary artery bypass grafting. *JAMA* 1996;275:841–846.
37. Dimick JB, Welch HG, Birkmeyer JD. Surgical mortality as an indicator of hospital quality: the problem with small sample size. *JAMA* 2004;292(7):847–851.
38. Birkmeyer JD, Birkmeyer NJ, Dimick JB. Measuring the quality of surgical care: structure, process, or outcomes? *J Am Coll Surg* 2004;198:626–632.
39. O'Brien SM, Shahian DM, DeLong ER, et al. Quality measurement in adult cardiac surgery: part 2–Statistical considerations in composite measure scoring and provider rating. *Ann Thorac Surg* 2007;83:S13–S26.
40. Staiger DO, Dimick JB, Baser O, et al. Empirically derived composite measures of surgical performance. *Med Care* 2009;47(2):226–233.
41. Dimick JB, Staiger DO, Osborne NH, et al. Composite measures for rating hospital quality with major surgery. *Health Serv Res* 2012;47(5):1861–1879.
42. Birkmeyer JD, Finks JF, O'Reilly A, et al. Surgical skill and complication rates after bariatric surgery. *N Engl J Med* 2013;369:1434–1442.
43. Ghaferi AA, Birkmeyer JD, Dimick JB. Variation in hospital mortality associated with inpatient surgery. *N Engl J Med* 2009;361:1368–1375.
44. Ghaferi AA, Birkmeyer JD, Dimick JB. Complications, failure to rescue, and mortality with major inpatient surgery in medicare patients. *Ann Surg* 2009;250(6):1029–1034.

Chapter 18

Patient Safety

Darrell A. Campbell, Jr.

Key Points

1. Safety means “freedom from harm”; in the context of patient care, safety means freedom from harm associated with any medical action or treatment.
2. Even though the system should be constructed to back up human fallibilities, it is instructive to recognize these fallibilities. This subject is hard to quantify, but a good list, developed in a family practice environment, reads as follows: hurry, distraction, lack of knowledge, premature closure of the diagnostic process, and inadequate aggressiveness in patient management.
3. In the acute hospital setting, as opposed to the outpatient environment in family practice, safety problems typically involve poor handoffs, failures of teamwork, excess workload, and fatigue.
4. Another approach to the implementation of safe practices is to educate and train physicians and nurses within the context of a team.
5. The future of the patient safety movement depends on the development of an effective safety reporting mechanism.

IMPORTANT DEFINITIONS: SAFETY VERSUS QUALITY

1 The terms *quality* and *safety* have important bearings on any discussion of patient care. These are related subjects but have different meanings, and these differences should be underscored before any dialog about patient safety begins. Safety means “freedom from harm”; in the context of patient care, safety means freedom from harm associated with any medical action or treatment. Quality is a more global term referring to a “degree of excellence.” It is theoretically possible for a hospital to be safe, but for quality to be average or poor. It is not possible for a hospital to be of high quality and unsafe. In this chapter, we focus primarily on the subject of patient safety, but admit that some aspects of the subject drift into the area of quality as well.

THE PROBLEM

By now, all are familiar with the report issued by the Institute of Medicine (IOM) in 2000 entitled *To Err Is Human.*[1] The report was an exhaustive review of the status of safety in our nation's hospitals. The bottom line – which served as a "burning platform" for the patient safety movement – was the astonishing calculation that between 44,000 and 98,000 Americans died annually in hospitals as the result of preventable medical error. The report produced a flurry of outrage from consumer groups and denials and refutations from medical groups, but when the dust settled, what was left was the recognition, by all groups, that something was seriously wrong in our medical care delivery system.

Comparisons are often made between the safety of airline travel and medical care. One airline disaster every 2 or 3 years produces calls for new regulation, better airports, more frequent mechanical checks, and earlier retirement for pilots. But consider medical care. If even the lower number of preventable deaths extrapolated by the IOM report (44,000 annually) were seen as accurate, and one accepted that an average of 350 passengers were on board every major commercial aircraft flight, deaths from medical error would be equivalent to 63 separate midair collisions per year in the airline industry, or 5 per month. Imagine the public outcry this would produce, the laws that would be quickly passed, and the boon to train travel that would result. With these staggering numbers as a backdrop, the IOM asserted that "it would be irresponsible to expect anything less than a 50% reduction in errors over 5 years." Sadly, 15 years later, only a modest improvement has been seen, and this is evident only in the most recent 3 years.[2] Why the tepid response? It is safe to say that the government and the medical community have been slow to acknowledge, and even slower to respond to the safety imperative.

CULTURE

Fundamental improvements in patient safety rest on establishing a robust safety culture, in which caregivers view the safety of patients as their most important mission. Culture is defined as "how we do things around here." That is, there is a certain level of acceptance, or complacency, for what goes on in a given hospital. Complacency is the result of two assumptions, which in the past have not been challenged. One assumption is that medical errors exist because "humans will always make mistakes." While superficially true, this statement fails to acknowledge that modern human factors engineering strategies can militate against commonly encountered errors. A concrete example of how human factors engineering can be brought into play involves something as simple as a connector for medical tubing. If the connector is designed such that it is not physically possible to connect an O_2 line to a CO_2 valve, a potentially catastrophic mistake becomes impossible. More globally, work hour restrictions for medical trainees, which reduce fatigue, could be expected to result in fewer errors by exhausted and stressed doctors. To date, human factors engineering has not been brought into the delivery of medical care effectively. While humans will always be capable of making mistakes, the number of mistakes will be reduced if design is targeted to what we know about human fallibilities.

The second assumption accounting for complacency is the notion that a medical error is the result of poor individual performance rather than an imperfect system of care. If an individual made the error, in isolation, the only thing to do about it would be to fire the hapless caregiver, or immerse him or her in intensive remedial education. The problem with this approach is that it does not apply to the next hapless caregiver faced with the same situation. And so, since there is a high turnover in most medical environments, mistakes continue to happen, caregivers continue to be fired, and nothing really changes. This sequence has been ingrained in the medical culture, and is an important reason why the medical community has been slow to respond to the safety crisis.

SWISS CHEESE AND MEDICAL ERRORS

A popular paradigm in the medical safety area is the “Swiss cheese” model, introduced by James Reason (Fig. 18-1).[3] This model is a visual representation of the multiple system layers that could prevent a medical error from occurring. A beam of light, representing a latent medical error, passes through a hole in the cheese, which represents system vulnerability. The latent error passing through the system via vulnerability will result in a medical error. If enough systems are set up with vulnerabilities, but in different locations, it becomes progressively harder for the latent error to get all the way through, and to become manifest clinically. The point here is that, while we recognize that both humans and systems of care have vulnerabilities, the prevention of error lies at the door of hospital leadership. Positive results come from the establishment of a strong safety culture, and the establishment of effectively redundant systems of error prevention. This concept is a major paradigm shift in the patient safety movement.

2 Even though the system should be constructed to back up human fallibilities, it is instructive to recognize these fallibilities because systems do not always work. This subject is hard to quantify, but a good list, developed in a family practice environment, reads as follows: hurry, distraction, lack of knowledge, premature closure of the diagnostic process, and inadequate aggressiveness in patient management.[4] The first three issues are probably obvious, but premature closure of the diagnostic process is a problem needing emphasis. Humans often fall into this trap. We see issues as black and white in an attempt to make sense out of complex circumstances. Hurry, distraction, and lack of knowledge contribute. Relevant pieces of Swiss cheese, which could counteract this tendency, include electronic diagnosis and decision-making aids; an institutional policy fostering physician interactions, teamwork, and second opinions; and setting and adhering to reasonable workload standards.

3 Depending on the environment, other fallibilities are exposed. In the acute hospital setting, as opposed to the outpatient environment in family practice, safety problems typically involve poor handoffs, failures of teamwork, excess workload, and fatigue.[5]

But what about the concept of individual responsibility? One cannot show up for work with a careless attitude, engage in irresponsible actions, and expect to be held unaccountable for poor performance because of the emphasis on systems. This is a delicate balance for any health care system. The underlying principle here is that most employees of a hospital wake up each morning wanting to do a good job, and to avoid mistakes, and hence (with exceptions) the general philosophy should be that a major improvement in safety will be at the level of system engineering rather than individual fallibility. When the onus of individual fallibility is lessened (not removed entirely), there then emerges a new sense of system responsibility, with increased willingness to identify system errors and to participate in safety enhancement as a group. This collaborative participation does not occur when one is worried about punitive consequences for reporting and the possibility of job loss.

LEADERSHIP AND POLICY

A robust safety culture is essential, but how does one change a culture? This is not done easily. There are two crucial elements, which, if effective, can change the culture direction positively. The first element is set by the example of hospital leadership. When the rank and file sees that the hospital CEO places patient safety at the top of the list and backs this priority up with funding, a lot of good things happen. When the CEO emphasizes a change in hospital policy, with an emphasis on safety, the change is reinforced. We introduced two policies that serve as examples to make this point. The first, the "full disclosure" policy, stipulated that employees were obligated (not just encouraged) to disclose fully to patients important errors made in rendering their care. Remarkably, this policy resulted in fewer malpractice claims against the system, but more importantly, it underscored for employees the institutional emphasis on openness and honesty.[6] The second policy change implemented was the "speak up with safety concerns" policy, which stipulated that no caregiver could be punished for voicing a concern involving patient safety, regardless of feelings hurt or hierarchy violated. Again, this written policy clearly articulated a health system goal – that patient safety trumped all other considerations.

One manifestation of an improved safety culture is an increased error reporting rate. Clearly, the error reporting rate will not go up if there exists widespread fear of retribution for reporting. What is desired is an increased rate of error reporting, but a decreasing rate of events resulting in temporary or permanent harm. This pattern suggests that caregivers are vigilant, care about safety, and are reporting on "near misses." The data from "near misses" represent a treasure chest of information that can be used to prevent actual mistakes. We have seen increased reporting in association with the purchase of a new electronic reporting format. Whether a change in culture or a change in reporting format is responsible for the increased level of reports is hard to say, but we believe that it is some combination of both (Fig. 18-2).

ASSESSING THE CULTURE

If one places priority on “improving” a safety culture, it is necessary that the “culture” can be measured. Validated culture surveys exist, which, if applied periodically in a hospital environment, give important insight into the success of safety culture initiatives. We use the Agency for Healthcare Research and Quality (AHRQ) safety culture instrument primarily and survey all caregivers at approximately 2-year intervals. We use the resulting information in three ways. First, we use the aggregate response to answer the question, “Are we improving the safety culture?” and, if not, “What are the areas that need to be addressed institutionally?” On our last survey, a clear sore point at our institution was difficulty with “handoffs,” that is, the transfer of information between caregivers and teams. We then developed a taskforce focused on fixing the problem, over both the short and long term. The long-term solution is an electronic one; the short-term solution is a paper-based handoff tool. This effort was a direct result of information gained from the safety culture survey.

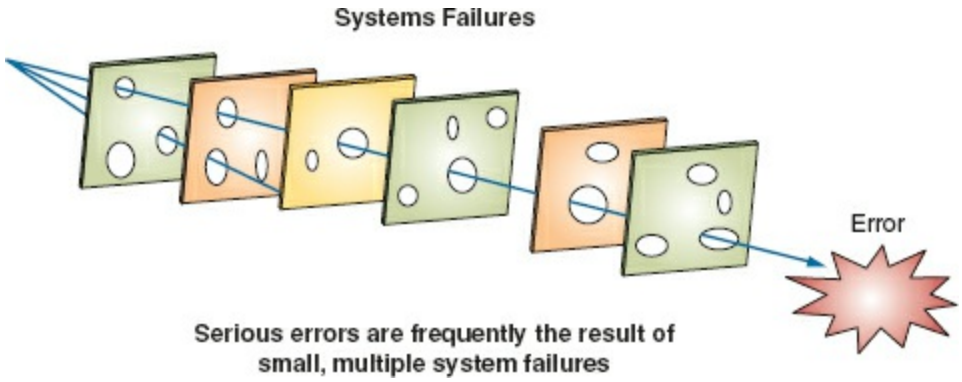

Figure 18-1. Systems failures.

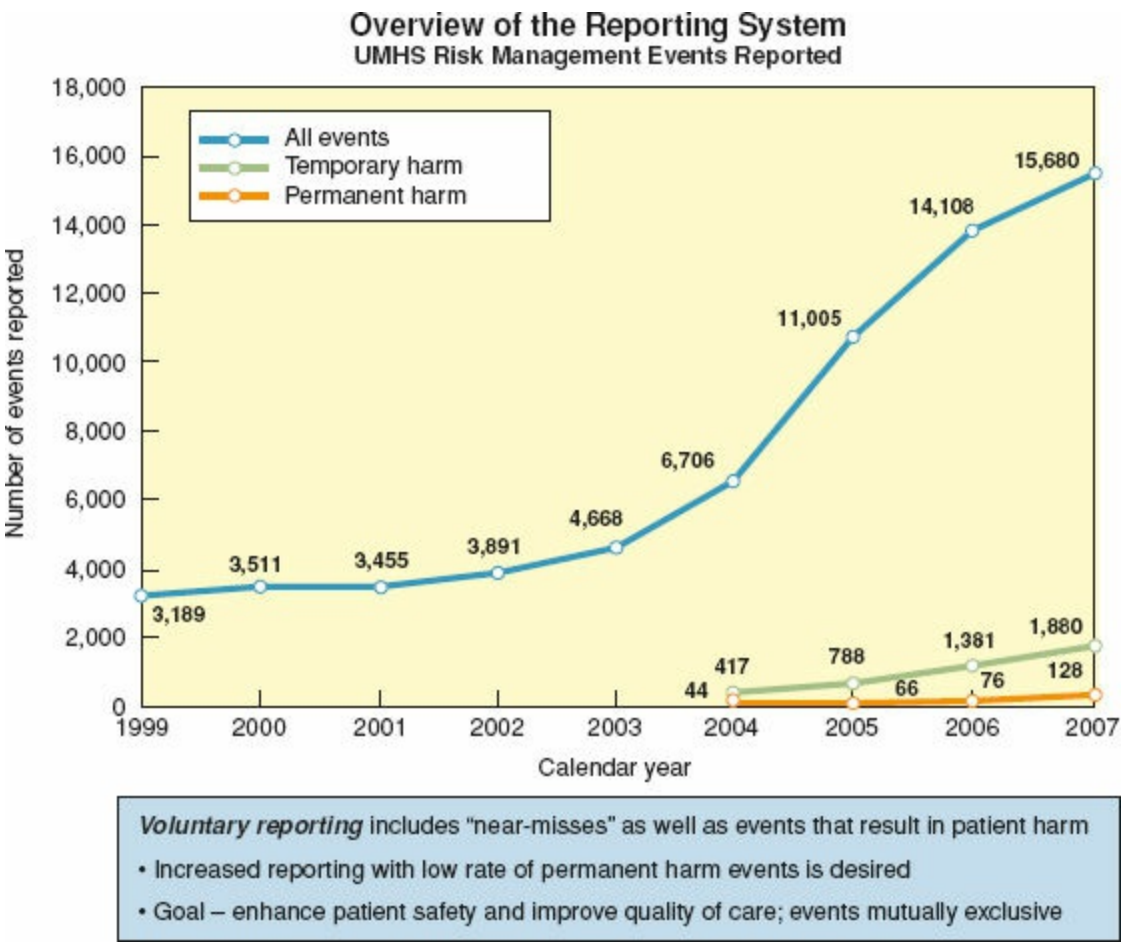

Figure 18-2. Overview of the reporting system.

A second way we use the safety culture survey data is to identify specific hospital units that are struggling with a dispirited or complacent attitude toward the safety effort. Such problems often result from poor nurse leadership, disruptive physicians, or a lack of perceived resources. Armed with information about the safety culture (or lack of it), the institution can implement a focused strategy customized to the problem. Figure 18-3 shows results from our survey arranged by individual nursing unit, demonstrating certain units in need of help with error reporting and, conversely, units where the culture is good and institutional resources are not needed. A third source of information derived from the survey comes from narrative comments entered by individual caregivers. This is a very rich source of information and, since it is anonymous, often draws a fine line under issues that are hard to talk about in any other forum. Issues of suspected physician impairment, abusive behavior, or lack of leadership skills are sometimes identified.

Two important questions regarding safety culture and our efforts to improve it remain. First, using the AHRQ tool, have we seen an aggregate improvement over the past two survey intervals? Many safety initiatives have been instituted over this period of time, and yet the aggregate culture data have not shown much change. We interpret this information to mean that much more work needs to be done, and that changing a culture is a hard thing to do, akin to changing direction of an aircraft carrier. Also, over the period of time we have been studying our culture, our institutional activity has gone up dramatically, the complexity of our patients has increased, and nursing turnover has been high. Under these circumstances, no change in the safety culture data might be viewed

more optimistically.

A second question is, “Are there individual strategies we have used that influence the safety culture positively?” If so, we could use these strategies more broadly. The answer to this question is yes. Patient safety rounds have been an important strategy that has improved the safety culture. Over the course of the past several years, we have made safety rounds on over 200 occasions, at 2-week intervals. Safety rounds are carried out by leadership (chief medical officer, chief of nursing, CEO, etc.) and a pointed 45-minute discussion ensues with the unit caregivers, including nurses, aides, clerks, and transporters. The culture effects of this endeavor are profound. When caregivers believe that the leadership is willing to listen, takes safety very seriously, and will put resources behind the articulated concerns, an overall feeling of confidence and support of the safety effort follows. Figure 18-4 demonstrates that caregivers having participated in patient safety rounds viewed the patient safety environment much more positively than those who had not.[7]

But, is a positive safety culture actually associated with improved safety? The assumption is yes, but data were hard to come by until recently. In Michigan, a multihospital collaborative was initiated (the Keystone Project), the objective of which was to implement evidence-based practices known to decrease the incidence of bloodstream infections (BSIs).[8] A total of 107 hospitals were involved, and caregivers responded to the Safety Attitudes Questionnaire (SAQ), similar to the AHRQ tool described previously. Results (incidence of BSIs) were correlated with answers to the SAQ. The results are seen in Figure 18-5. There was an important association noted between the best results (percent reduction in BSIs) and the most positive answers to SAQ questions. This is only an association (and subject to the usual caveats about associations vs. cause and effect), but important nonetheless. These results support the underlying hypothesis that when leadership prioritizes safety and implements actions to support safety, caregivers reflect this in their answers to the SAQ and this is associated with improved patient safety.

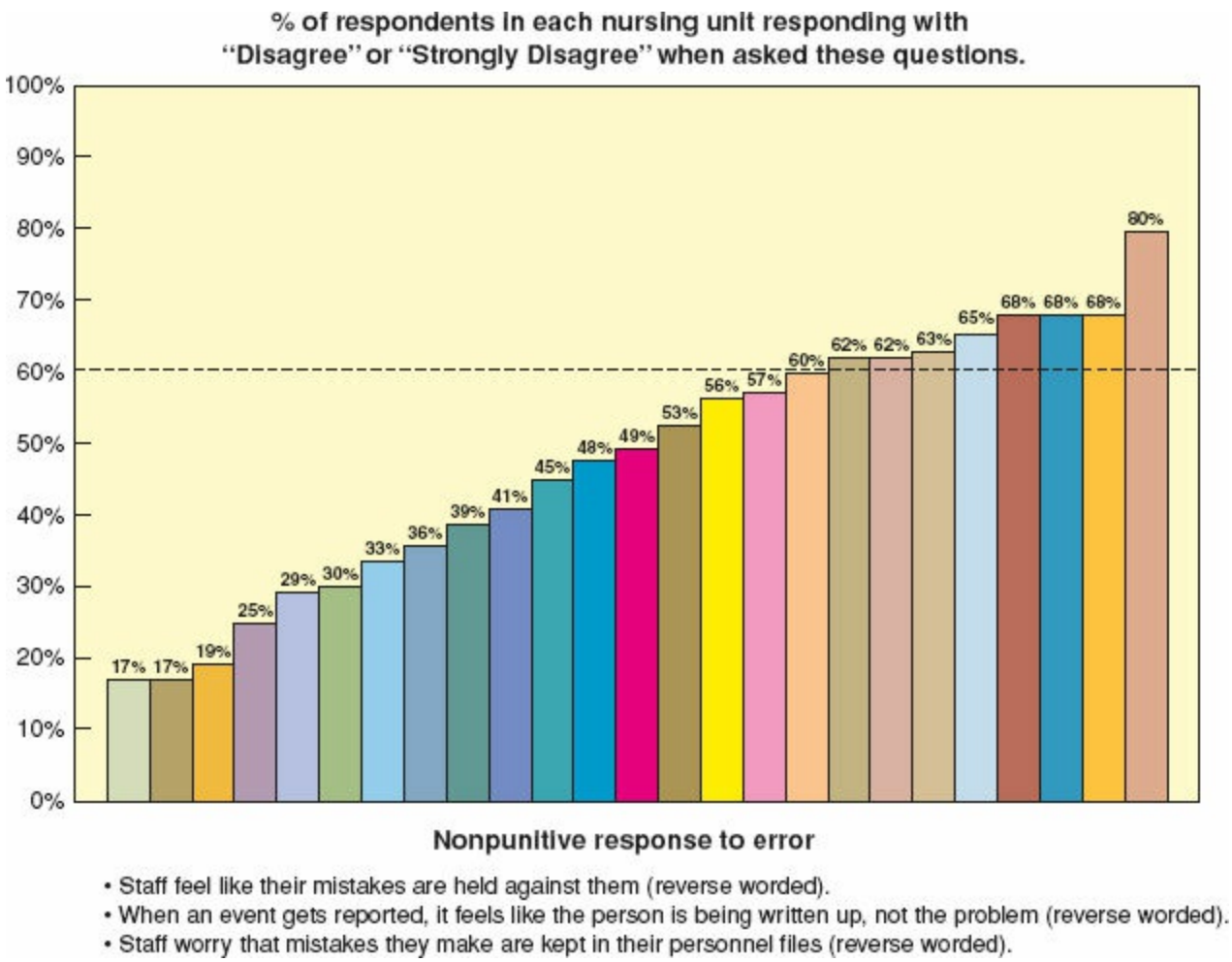

Figure 18-3. Nonpunitive response to error.

THE EVIDENCE BASE FOR PATIENT SAFETY

As important as it is to lay a strong foundation in safety culture, the energy and enthusiasm of caregivers to provide safe patient care must be rooted in activities that have been found to be effective. Unfortunately, there does not exist at this point a large base of evidence in patient safety, largely because the field is relatively young. The World Health Organization (WHO) convened a group to carefully analyze existing studies and highlight effective strategies with an evidence base.[9] These are listed in Table 18-1. Comments about specific evidence-based actions follow.

With regard to the administration of perioperative beta-blockers to prevent postoperative myocardial ischemia, it is very clear that patients already on such medications must be given them postoperatively. However, an initial interest in beta-blocker administration for patients never having received them previously evaporated as the result of the POISE trial.[10] This was an international randomized controlled trial focusing on this specific issue, and the result, after analyzing many thousands of patients, was that giving beta-blockers perioperatively to naive patients caused more harm than good. Specifically, treated patients developed more troublesome bradycardia and hypotension than controls, and this resulted in a higher incidence of stroke, obviating the potential benefit of the drug in preventing myocardial ischemia.

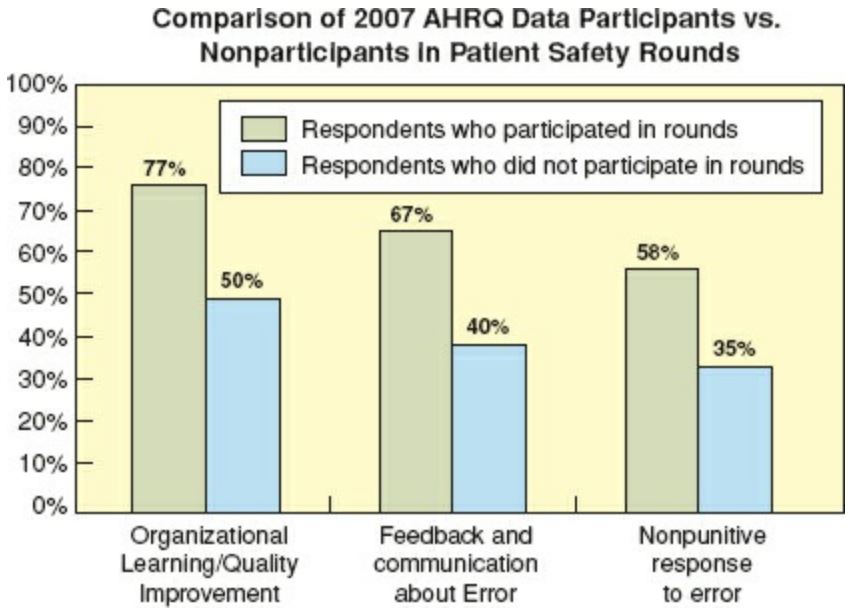

Figure 18-4. Comparison of 2007 Agency for Healthcare Research and Quality (AHRQ) data participants versus nonparticipants in patient safety rounds.

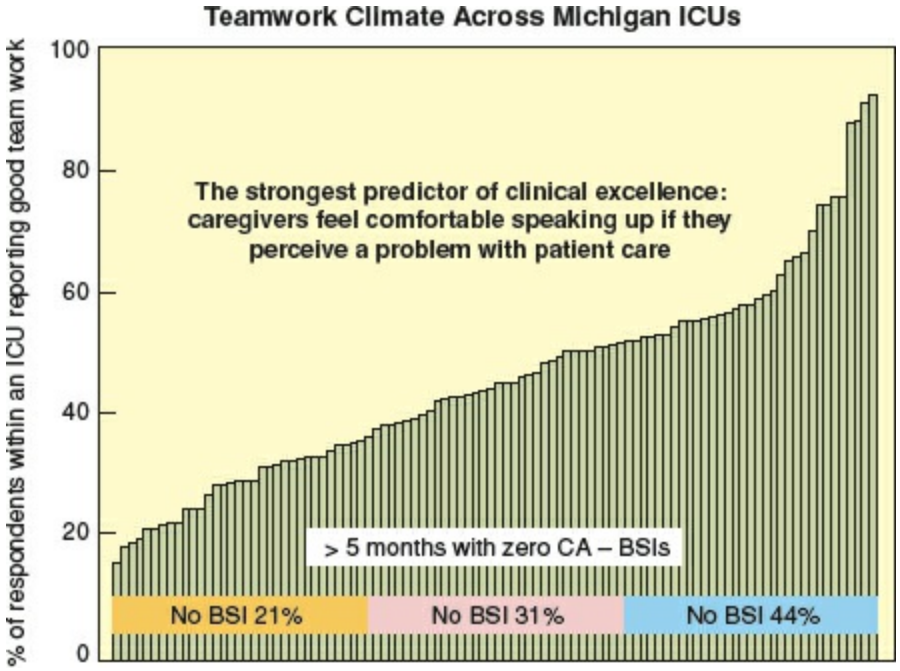

Figure 18-5. Teamwork climate across Michigan intensive care units.

Using maximum sterile barriers for central venous pressure (CVP) catheter insertion to prevent BSI may seem obvious, and the implementation of this protocol has resulted, in many studies, in a dramatic fall in the incidence of this complication. This strategy is complemented by the use of antibiotic-impregnated CVP catheter lines and the use of chlorhexidine in the daily maintenance of the insertion site. The use of ultrasound to help guide CVP catheter line insertion is clearly effective.

Prevention of the feared complication of ventilator-associated pneumonia is a very important consideration, since this development has a high fatality rate and is very expensive to treat. There is some evidence that the continuous aspiration of subglottic secretions is important. Our institution has been successful in decreasing the ventilator-associated pneumonia rate dramatically (Fig. 18-6) using the multipronged strategy described in Table 18-2.

Table 18-1 Evidence-based Interventions for Safe Patient Care

- Appropriate use of prophylaxis to prevent venous thromboembolism
- Use of perioperative beta-blockers in appropriate patients to prevent perioperative morbidity and mortality
- Use of maximum sterile barriers while placing central intravenous catheters to prevent infections
- Asking that patients recall and restate what they have been told during the informed consent process
- Continuous aspiration of subglottic secretions to prevent ventilator-associated pneumonia
- Use of pressure-relieving bedding materials to prevent pressure ulcers
- Use of real-time ultrasound guidance during central line insertion to prevent complications
- Patient self-management for warfarin to achieve appropriate outpatient anticoagulation and prevent complications
- Appropriate provision of nutrition, with a particular emphasis on early enteral nutrition in critically ill and surgical patients
- Use of antibiotic-impregnated central venous catheters to prevent catheter-related infections

DEVELOPING CONSENSUS

Given the paucity of real evidence to achieve what we think of as safe patient care, and because there is an urgent need to act, another strategy has been to develop consensus guidelines. Although such guidelines are not based on randomized trials, there is value in getting the best and most experienced minds together to synthesize what all would agree to be best practices. Trials may come later to support or refute consensus.

A very influential group that develops consensus guidelines is the National Quality Forum (NQF), an organization of a wide variety of experts, consumers, government officials, and corporate directors. The NQF several years ago published its list of "30 Safe Practices" recommended for implementation. Because this chapter is oriented toward surgery, Table 18-3 lists a selection of the 30 Safe Practices germane to the inpatient setting.

Consensus and Accreditation

The NQF works closely with the Joint Commission. When the NQF has reached consensus on a specific safety practice, this is often translated into a Joint Commission requirement for hospital accreditation, in this setting recognized as Joint Commission "patient safety goals." These goals are more specific than consensus guidelines and have more "bite" to them, in that all hospitals need to fulfill these requirements in order to be accredited. For example, goal 7, "Reduce the risk of health care–associated infections," stipulates, among other things, that hospitals have specific strategies in place to prevent surgical site infections (SSIs); that they provide regular feedback about SSI rates to caregivers, with follow-up for 30 days; that they discontinue the use of shaving as a method of preoperative hair removal; and so on. Goal 8, "Reduce the risk of patient harm resulting from falls," stipulates that each hospital implement a specific falls reduction program.

Table 18-2 University of Michigan Protocol for Prevention of Ventilator-Associated Pneumonia (VAP)

Hand washing/hand sanitizing
Chlorhexidine oral rinse prior to intubation, then q12h on 0900–2100 schedule
Oral care with swabs q2–3h
Head of bed elevated 30–45 degrees on all patients at all times, unless medically contraindicated
Extubate early – as soon as safely possible
Turn off tube feedings when placing patients flat for turning or for procedures, unless small-bore feeding tube post pyloric
Endotracheal tube tape changed every 48 h
Minimal use of saline lavage
Change ventilator tubing only when soiled
Staff education and updates on VAP

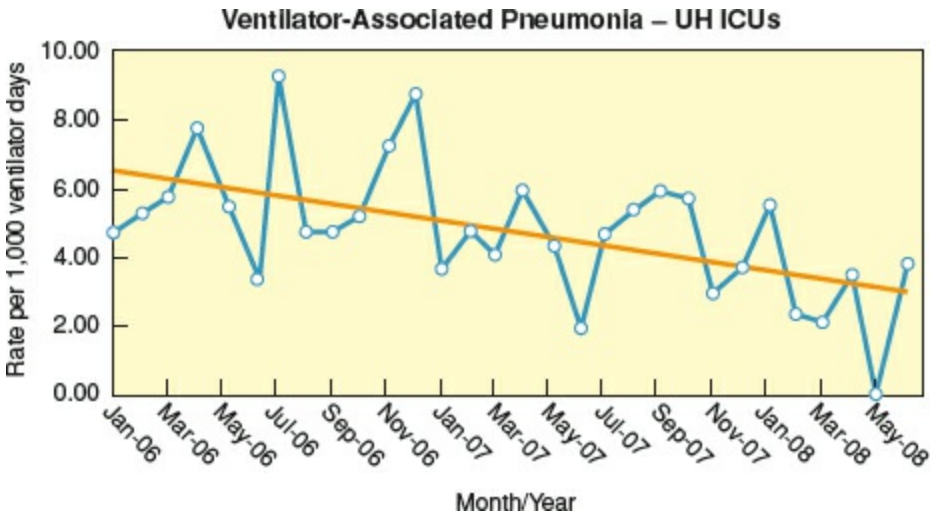

Figure 18-6. Ventilator-associated pneumonia – University Hospital intensive care units.

Consensus, Accreditation, and Payment

The Centers for Medicare and Medicaid Services (CMS) has a lot to say about implementation of safety practices in that they pay a large fraction of the nation's health care bill. As it regards safety in surgery and hospital care, CMS has embarked on two important strategies. The first is the Surgical Care Improvement Project (SCIP), initiated in 2006, whose stated goal was to reduce the incidence of selected surgical complications by 25% by the year 2010. To do this, CMS produced several specific process measures required to be met by hospitals before receiving full payment for services. Private insurers soon followed suit. SCIP measures are listed in Table 18-4. In contrast to the more broadly defined consensus guidelines, agreed-upon SCIP measures had a strong evidence base. Whether this effort will be translated into national improvement in results remains to be determined. The Joint Commission has also integrated certain SCIP measures into its evaluation requirements.

Table 18-3 National Quality Forum Safe Practices

- Create a culture of safety
- Obtain explicit informed consent
- ICU patients managed by critical care certified providers
- Implement computerized physician order entry
- Implement protocol for wrong side/site prevention
- Evaluate for venous thromboembolism/implement prophylactic protocols
- Develop facility-wide anticoagulation services
- Adhere to effective measures for preventing bloodstream infections
- Implement appropriate methods (antibiotic administration) for the prevention of surgical site infection
- Evaluate each patient at admission for the risk of malnutrition
- Develop effective hand sanitizing policies

ICU, intensive care unit.

Results have been mixed. In some cases, a statistically meaningful relationship between adherence to selected measures (antibiotic timing, appropriate antibiotic) was associated with reduced rates of SSI.[11,12] In contrast, a very large study involving over 60,000 patients within the Veterans Administration hospitals showed remarkable improvement in compliance with five SCIP measures, but without appreciable effect in reducing SSI, casting doubt on the value of this effort in the overall CMS strategy for improving patient safety.[13]

Another important strategy embarked upon by the CMS is known as "nonpayment for hospital-acquired conditions," otherwise referred to as the "never event" policy. In this strategy, the CMS has determined that it will not reimburse for flagrant medical errors, such as wrong patient, wrong side, or wrong site surgery. Administrators and surgeons do not object to this policy as far as it goes. But great concern has been raised about other conditions on the "never event" list, such as venous thromboembolism (VTE) or patient falls. The controversy arises because in these cases there does not exist an evidence base that would allow a hospital to eliminate these events entirely. Perfectly appropriate VTE

prophylaxis, for example, only reduces the incidence of postoperative VTE by 50%. This situation seems unfair, and the list of "never event" conditions is progressively growing longer. Whether this strategy will really improve quality and make patients safer remains to be proven.

Table 18-4 Surgical Care Improvement Program (SCIP) Process and Outcome Measures

Infection (INF)

- SCIP INF 1: Prophylactic antibiotic received within 1 h prior to surgical incision
- SCIP INF 2: Prophylactic antibiotic selection for surgical patients
- SCIP INF 3: Prophylactic antibiotics discontinued within 24 h after surgery end time (48 h for cardiac patients)
- SCIP INF 4: Cardiac surgery patients with controlled 6 AM postoperative blood glucose
- SCIP INF 6: Surgery patients with appropriate hair removal
- SCIP INF 7: Colorectal surgery patients with immediate postoperative normothermia

Venous Thromboembolism (VTE)

- SCIP VTE 1: Surgery patients with recommended venous thromboembolism prophylaxis ordered
- SCIP VTE 2: Surgery patients who received appropriate venous thromboembolism prophylaxis without 24 h prior to surgery to 24 h after surgery

PATIENT SAFETY INDICATORS

The AHRQ is another national group, funded by the National Institutes of Health. Several years ago the AHRQ developed 21 patient safety indicators (PSIs), which are thought to reflect on an institution's safety. These indicators are captured from a hospital's coding system, using International Classification of Diseases-9 (ICD-9) codes after patient discharge. The PSIs are listed in Table 18-5. While useful information can be obtained from this system, a disadvantage is that the data are obtained from medical billing coders, and may not accurately reflect whether a complication was actually preventable. An example might be the PSI labeled "accidental puncture and laceration." An enterotomy made during the course of a difficult dissection in an irradiated and multiply operated abdomen would fit into this category and be interpreted by nonsurgeons as an "accident." The surgeon who was carefully dissecting under these circumstances would definitely not agree. Despite such limitations, the AHRQ PSIs will be publicly reported as a safety indicator by the government next year, and already form the basis of certain proprietary safety indices, such as those put forth by HealthGrades.com or the University Health System Consortium.

EFFORTS FROM THE WORLD HEALTH ORGANIZATION

Recognizing that patient safety should be a global imperative, the WHO, working with the Joint Commission, has embarked on an ambitious project to reduce the incidence of medical errors internationally. One effort, known as the "high 5's" initiative, focuses on reducing five prevalent types of medical errors, over a 5-year period, in at least seven countries. The identified problem areas are: (a) managing concentrated injectable medicines, (b) ensuring medication accuracy at transitions of care, (c) improved communication during patient care handovers, (d) improved hand hygiene, and (e) performance of the correct procedure at the correct body site.

Table 18-5 Agency for Healthcare Research and Quality Patient Safety Indicators

1. Hospital-level patient safety indicators
   - Complications of anesthesia
   - Death in low-mortality DRGs
   - Decubitus ulcer
   - Failure to rescue
   - Foreign body left in during procedure
   - Iatrogenic pneumothorax
   - Selected infections due to medical care
   - Postoperative hip fracture
   - Postoperative hemorrhage or hematoma
   - Postoperative physiologic and metabolic derangements
   - Postoperative respiratory failure
   - Postoperative pulmonary embolism or deep vein thrombosis
   - Postoperative sepsis
   - Postoperative wound dehiscence in abdominopelvic surgical patients
   - Accidental puncture and laceration
   - Transfusion reaction
   - Birth trauma – injury to neonate
   - Obstetric trauma – vaginal delivery with instrument
   - Obstetric trauma – vaginal delivery without instrument
   - Obstetric trauma – cesarean delivery
2. Area-level patient safety indicators
   - Foreign body left in during procedure
   - Iatrogenic pneumothorax
   - Selected infections due to medical care
   - Postoperative wound dehiscence in abdominopelvic surgical patients
   - Accidental puncture and laceration
   - Transfusion reaction
   - Postoperative hemorrhage or hematoma

DRGs, diagnosis-related groups.

The WHO has focused on surgical care specifically through a separate effort referred to as the "Safe Surgery Saves Lives" campaign. One very tangible result of this effort is the Surgical Safety Checklist, shown in Table 18-6.[14] Now being tested in eight countries, the vision is that a standardized forum for intraoperative communication will be adopted internationally, much in the same way that the international aviation community has endorsed standardized flight checklists.

IMPLEMENTATION STRATEGIES

Establishing a safe culture is important, and emphasizing an evidence base and consensus guidelines is important, but ensuring implementation of what is known to be safe practice is critical and may be the most difficult of all safety strategies to accomplish. Several strategies have been helpful in our environment.

Adding Pharmacists to Rounds

Our medical center is a tertiary care referral center; the complexity of cases is high and always going higher. Transplants, complex oncologic problems, extracorporeal membrane oxygenation (ECMO) patients, and others with multisystem organ failure fill a large portion of our beds. The pharmacologic aspects of these cases are complex. Adding to the difficulty of managing such patients is the educational aspect of our enterprise, which guarantees a constant supply of new faces on rounds. To address these issues and to prevent errors, we have implemented a policy of adding a clinical pharmacist to each of our high-complexity services. The role of this individual is to suggest appropriate drugs, screen for allergies and incompatibilities, and monitor for important side effects. The program has been invaluable in improving patient safety at our institution and at others.[15]

Rapid Response Team

Mortality rates for in-hospital cardiac arrest have been high for decades, despite advances in cardiopulmonary resuscitation (CPR) techniques and cardiotropic medications. This is true particularly for "floor arrests," those cases of arrest occurring outside of the intensive care unit (ICU). In our center, and in many others, analysis of CPR cases has led to frustration that insufficient attention had been paid to the patient's condition in the hours prior to the arrest, at a time when interventions could conceivably have been very helpful.

One approach to this problem has been to develop a rapid response team (RRT), which is activated when certain physiologic parameters fall outside a specified range. Such parameters identified at our center are heart rate (<40 or >140 with new symptoms), respiratory rate (<8 or >36), blood pressure (systolic <80 or >220, diastolic >110 with symptoms), and unexplained change in cognition or neurologic status of adult inpatients. A key feature of the RRT activation is that it is seen as mandatory for nursing; no judgment is required. If the parameters are exceeded, the RRT is activated. This relieves some of the anxieties experienced by nurses in the past about communication with physicians, particularly at odd hours. In our center, activation of the RRT results in the timely arrival of an experienced surgical ICU nurse and a respiratory therapist. If the conditions are found to warrant it, a hospitalist is called. This occurs in 15% of cases. There is controversy in the literature as to whether the RRT effort actually is effective.[16] However, the concept has so much face validity that most hospitals have accepted it as an important strategy to improve a safety culture.

Table 18-6 World Health Organization Surgical Safety Checklist

Before Induction of Anesthesia	Before Skin Incision	Before Patient Leave Operating Room
Sign In	**Time Out**	**Sign Out**

■ Patient has confirmed:
  ■ Identity
  ■ Site
  ■ Procedure
  ■ Consent
■ Site marked/not applicable
■ Anesthesia safety check completed
■ Pulse oximeter on patient and functioning
■ Does patient have:
  ■ A known allergy?
  ■ No
  ■ Yes
  ■ Difficult airway/aspiration risk?
  ■ No
  ■ Yes
■ Risk of >500 mL blood loss (7 mL/kg in children)?
  ■ No
  ■ Yes, and adequate intravenous access and fluids planned
	■ Confirm all team members have introduced themselves by name and role
	■ Surgeon, anesthesia professional, and nurse verbally confirm
	  ■ Patient
	  ■ Site
	  ■ Procedure
	■ Anticipated critical events
	■ Surgeon reviews: What are the critical or unexpected steps, operative duration, anticipated blood loss?
	■ Anesthesia team reviews: Are there any patient-specific concerns?
	■ Nursing team reviews: Has sterility (including indicator results) been confirmed? Are there equipment issues or any concerns?
	■ Has antibiotic prophylaxis been given within the last 60 min?
	  ■ Yes
	  ■ Not applicable
	■ Is essential imaging displayed?
	  ■ Yes
	  ■ Not applicable
		■ Nurse verbally confirms with the team:
		  ■ The name of the procedure recorded
		  ■ That instrument, sponge, and needle counts are correct (or not applicable)
		  ■ How the specimen is labeled (including patient name)
		  ■ Whether there are any equipment problems to be addressed
		■ Surgeon, anesthesia professional, and nurse review the key concerns for recovery and management of this patient

An interesting, and entirely unexpected, offshoot of the RRT has been the process, by the RRT team, of visiting nursing floors on a shift-by-shift basis prior to any RRT activation. This process lets the team become more familiar with patients who might subsequently warrant RRT activation. Visits often foster a discussion among caregivers and family as to whether any intervention is appropriate or warranted.

Crew Resource Management

4 Another approach to the implementation of safe practices is to educate and train physicians and nurses within the context of a team. The team is defined, goals are set, and individual responsibilities are assigned. The completion of tasks (or omission) is apparent to members of the team, which provides a fail-safe structure. There has been considerable interest in crew resource management in the area of medicine since it has been conclusively shown to add value to aviation cockpit training. Crew resource management is probably best applied in small, well-defined areas, with relatively consistent staffing patterns, such as an operating room. In one report, a perioperative crew resource management training program consisted of an e-learning module, the development of laminated checklists and pocket-sized cards, briefing scripts, a communication whiteboard, and a hands-on training program facilitated by experienced personnel. Even with focused effort at crew resource management, perioperative safety practice implementation was found to be less than perfect, but the field, at least in medicine, is in its infancy, and it will probably be an important part of safety strategies in the years to come.[17]

Developing Collaborative Groups of Hospitals

Under conditions where motivated hospitals get together to discuss safety, the result is often a more consistent implementation of safety practices and better results. The development of a collaborative group directed at safety and/or quality allows for comparative evaluation of quality and safety, and often results in a spirit of friendly competition, which improves the aggregate level of safety.

A prominent example of such collaboration was mentioned previously, the Michigan Hospital Association–sponsored Keystone Initiative. Here, evidence-based practice for the care of patients in the ICU was monitored and found to be low across the state. A protocol was adopted for over 100 ICU groups, which included elevation of the head of the bed 30 degrees, ulcer prophylaxis, regular respiratory weaning trials, and a central line insertion protocol, with line maintenance involving chlorhexidine patches. When the latter protocol was implemented, a profound drop in the incidence of BSIs across the state was seen, and the estimated cost savings exceeded $160 million.[8]

In a different example, 64 Michigan hospitals formed the Michigan Surgical Quality Collaborative. These hospitals convene at 3-month intervals and share information about identified “best practices” and correlation with surgical results. Hospitals with the fewest complications in a specific area discuss why they feel they have been successful. “Best practices” are then distributed in a network including through the internet and a hardcopy newsletter. Each hospital implements strategies it feels are appropriate for its situation. The result has been a sharp drop in the incidence of surgical complications. The results suggest that a collaborative quality organization, with regular and intensive sharing of data and best practices, is an essential vehicle for quality improvement.

PATIENT AND FAMILY INVOLVEMENT

One element of the patient safety movement that will become more important in the future is the involvement of the patient in various hospital safety strategies. A valuable source of information, and an important feedback mechanism, is lost when the patient, or family, is not a part of the care process. Two examples of the value of patient involvement involve hand washing and urgent care.

For hand washing, an effective hospital strategy prompts patients to ask physicians, "Have you washed your hands?" when they come into the patient's room. Physicians frequently wear buttons in this effort, which say, "Ask me if I've washed my hands." While it may seem trivial and somewhat demeaning to the physicians, the fact remains that the percentage of physicians and nurses washing their hands prior to patient contact remains far below 100%, and the prevalence of patient infection with *Clostridium difficile,* vancomycin-resistant *Enterococcus,* and other hospital-acquired infections remains high. In this context, patient involvement could be seen as a very important piece of Swiss cheese.

Another example of patient and family involvement in the care process is the concept of "family activation" of the RRT. Family members are often more aware of changes in a patient's condition than nurses or doctors, for the obvious reason that they know the personality and traits of the patient in detail. "He wouldn't complain about this unless it was really bad" is an important source of information from a wife. In the past, this clue to an evolving situation was sometimes lost on caregivers more focused on vital signs and urine output. In "family activation" of the RRT, family members are allowed to call a phone number activating the RRT if they feel that more attention is needed to a given situation. While it might seem that this would let loose a flood of such calls, in actuality, this has not been the case.

DEVELOPING A TAXONOMY FOR PATIENT SAFETY

Ultimately, comparative data on the safety of patient care in this country will be available to the public, much in the same way that the safety of retail products, medications, and automobiles is currently reported. For any reporting system to be valuable and fair, the definitions of safety events need to be refined and agreed upon. It is not possible to compare the safety of different hospitals if definitions used are not standardized. Many national organizations are working on this topic. The WHO has recently developed an "International Classification for Patient Safety" designed to "define, harmonize, and group patient safety concepts into an internationally agreed upon classification in a way that is conducive to learning and improve patient safety across systems." This work, while difficult, is essential for the patient safety movement.[18]

PUBLIC REPORTING OF SAFETY DATA

5 We live in an age of transparency. The public wants – and deserves – information about the safety record of a given hospital. And yet, such information is hard to find. The future of the patient safety movement depends on the development of an effective safety reporting mechanism. This is because, in the absence of a large-scale database, information is not disseminated effectively, and one hospital may easily make the same mistake as its sister hospital down the street. One major impediment to the development of a national safety database is the lack of a standardized taxonomy of patient safety events. This problem is being addressed, as was just described.

Public reporting has been initiated using both voluntary and mandatory designs. Two examples of successful voluntary reporting systems are the National Nosocomial Infection Survey, a branch of the Centers for Disease Control and Prevention, and the MEDMARX program of the U.S. Pharmacopeia. Mandatory safety reporting systems are often state initiated and provide various sanctions for hospitals known to be engaged in unsafe practices. This penalty provides a disincentive to report, however. Only a few states have successful mandatory reporting systems.

One very successful example of a voluntary reporting system, albeit in the field of aviation, is the Aviation Safety Reporting System. This system analyzes 30,000 reports annually. Its success has depended on these factors: the system is simple, it is safe (for the reporting pilots), and it provides value. The patient safety movement would do well to emulate this system. When it does, and the taxonomy is standardized, doctors, nurses, and administrators will be considerably more willing to make safety data available to the public.

References

1. Kohn LT, Corrigan JM, Donaldson M, eds. *Committee on Quality of Health Care in America IoM. To Err Is Human: Building a Safer Health System.* Washington, DC: National Academy Press; 2000.
2. http://www.ahrq.gov/professionals/quality/safety/pfp/interimhacrate2013.pdf
3. Reason J. Education and debate. Human errors: models and management. *BMJ* 2000;320:768–770.
4. Ely JW, Levinson W, Elder NC, et al. Perceived causes of family physicians' errors. *J Fam Pract* 1995;40:337–344.
5. Singh H, Thomas E, Petersen L, et al. Medical errors involving trainees: a study of closed malpractice claims from 5 insurers. *Arch Intern Med* 2007;167(19):2030–2036.
6. Boothman RC, Blackwell AC, Campbell DA Jr, et al. A better approach to medical malpractice claims? The University of Michigan Experience. *J Health Life Sci Law* 2009;2(2):125–159.
7. Campbell DA., Thompson M, Patient safety rounds: description of an inexpensive but important strategy to improve the safety culture. *Am J Med Qual* 2007;22:26–33.
8. Pronovost P, Needham D, Berenholtz S, et al. An intervention to decrease catheter-related bloodstream infections in the ICU. *N Engl J Med* 2007; 356(25):2660.
9. Ovretveit J. Which interventions are effective for improving patient safety? A synthesis of research and policy issues. WHO HEN Copenhagen and MMC. Stockholm, Sweden: Karolinska. http://homepage.mac.com.
10. POISE Study Group. Effects of extended-release metoprolol succinate in patients undergoing non-cardiac surgery (POISE trial): a randomized controlled trial. *Lancet* 2008;371:1839–1847.
11. Cataife G, Weinberg DA, Wong HH, et al. The Effect of Surgical Care Improvement Project (SCIP) compliance on surgical site infections (SSI). *Med Care* 2014;52(2 Supp 1):S66–S73.
12. Munday GS, Deveaux P, Roberts H, et al. Impact of Implementation of the Surgical Care Improvement Project and future strategies for improving quality in surgery. *Am J Surg* 2014;208:835–840.
13. Hawn MT, Vick CC, Richman J, et al. Surgical Site Infection Prevention : time to move beyond the surgical care improvement program. *Ann Surg* 2011;254:494–499.
14. World Alliance for Patient Safety Progress Report 2006–2007. Geneva, Switzerland: World Health Organization; 2008.
15. Kucukarslan SN, Peters MP, Mlynarek M, et al. Pharmacists on rounding teams reduce preventable adverse drug events in hospital general medicine units. *Arch Intern Med* 2003;163:2014–2018.
16. Hillman K, Chen J, Cretikos M, et al.; MERIT Study Investigators. Introduction of the medical emergency team (MET) system: a cluster-randomised controlled trial. *Lancet* 2005;365:2091–2097.

17. France D, Leming L, Jackson T. An observational analysis of surgical team compliance with perioperative safety practices after crew resource management training. *Am J Surg* 2008;195:546–553.
18. Leape L. Reporting of adverse events. *N Engl J Med* 2002;347(20): 1633–1638.

Part Two **Surgical Practice**

SECTION A: TRAUMA

Chapter 19

Trauma and Trauma Care: General Considerations

Hasan B. Alam

Key Points

1. Injuries are the leading cause of death in young Americans, and account for 1 out of every 10 deaths in the world.
2. Deaths due to penetrating trauma and motor vehicle collisions are decreasing whereas fall-related fatalities are rapidly rising reflecting the aging population.
3. Establishment of trauma systems that use evidence-based triage and treatment protocols saves lives.
4. Bleeding is the number 1 cause of preventable deaths.
5. The vast majority of trauma-related deaths are within the first few hours (< 6 hours) after sustaining injuries.
6. Early hemorrhage control is the major priority along with balanced resuscitation using an appropriate ratio of blood products.
7. Recent military conflicts have rapidly advanced trauma care in many domains, and these developments are now being transferred to the civilian trauma settings.

BURDEN OF DISEASE

1 Injuries and violence affect everyone, regardless of age, race, or economic status. More young Americans (under 46 years of age) die of injuries than any other cause.[1] According to the Centers for Disease Control and Prevention, National Center for Injury Prevention and Control, about a quarter of all the emergency department visits are due to injuries (27 million in 2013),[2] resulting in 3 million hospitalizations and nearly 193,000 deaths – 1 person every 3 minutes.[3] As opposed to cancers, cardiovascular diseases, and strokes, injuries disproportionally strike people in the prime of their lives. In fact, 59% of all deaths among people of 1 to 44 years of age in the United States are due to injuries, which is more than all noncommunicable diseases and infectious diseases combined. Figure 19-1 shows the top 10 causes of death in different age groups in the United States, whereas Figure 19-2 highlights the unintentional causes. Young males are the highest risk groups, not due to any specific physiologic disposition, but due to the propensity to engage in high-risk activities. Similarly, factors that increase risk taking and impair judgment (e.g., alcohol, drugs, crime, conflicts) further exaggerate the chances to get injured.

Although striking, the death data do not tell the entire story. Millions of injured people survive, but they face lifelong mental, physical, and financial problems that add to the societal burden. The resultant economic toll on our society is staggering. In 2013, the total cost of injuries in the United States was estimated to be $671 billion. The costs associated with fatal injuries was $214 billion while nonfatal injuries accounted for over $457 billion.[4] This problem also has global dimensions. According to the World Health Organization, injuries kill more than 5 million people, which is nearly 1.7 times the number of fatalities that result from malaria, tuberculosis, and human immunodeficiency virus, combined.[5]

EVOLVING MECHANISMS OF INJURIES WITH CHANGING POPULATION DEMOGRAPHICS

2 Motor vehicle collisions (MVC), firearms, falls, cutting/piercing instruments, poisoning, and burns are among the leading mechanisms (Table 19-1).[6] Their relative positions on the list are evolving. Over the last decade, better roads, safer cars, more frequent use of seatbelts, and so forth have resulted in a decrease in MVC fatality despite a marked increase in the number of cars on the roads and overall miles driven (Fig. 19-3).[7] Drug overdose, suicide, and prescription medication abuse on the other hand are on the rise. For example, the age-adjusted suicide rate in the United States was 24% higher in 2014 than in 1999, and increases were observed for both females and males in all age groups under 75 years of age.[8] In fact, we are witnessing a 30-year peak in suicide rates in the United States. Falls are also rapidly becoming a major health care issue due to increasing age of the population.[9] Currently, in the United States, 1 in 9 Americans is aged 65 or older, which by 2050 will increase to 1 in 5 (Fig. 19-4).[10] The fall rates are already climbing (Fig. 19-5) and are expected to jump up even more dramatically over the next few decades. These patients also have many more co-morbid problems, and the various age-related anatomic, physiologic, and immunologic changes makes it especially challenging to take care of these patients.[11,12] Violent crimes were near record high from the 1970s to 1990s, but have shown a steady decline in the recent years (Fig. 19-6). When considering 5- and 10-year trends, the total 2013 estimated violent crime rate was 12.3% below the 2009 level, and 14.5% below the 2004 level.[13] Despite the focus by the media on violent crimes, by most measures, we are now witnessing one of the safest eras in the American history.

CHANGING PATTERNS OF DEATH

3, **4**, **5** The classical trimodal distribution of trauma deaths was described by Trunkey[14] in 1983, based upon the patterns of post-traumatic deaths in several counties of Northern California. In that report, nearly half of the deaths occurred within minutes after injury due to disruption of major blood vessels, devastating central nervous system (CNS) injuries or combination. The only practical solution for this group appears to be better prevention strategies, as these deaths often occurred before any medical care could be delivered. A smaller second peak, lasting a few hours, followed that first major peak in mortality (~30% of the deaths) where depending upon the mechanism of trauma, ongoing hemorrhage and CNS injuries played an almost equal role. This group has been the impetus for the development of better trauma delivery systems (emergency medical services, rapid transport mechanisms, and dedicated trauma centers) across the world. In fact, data strongly show that preventable mortality is significantly lower in geographical areas that have well-established trauma systems.[15,16] The third peak was noted days to weeks after injury due to infections, multiple organ failure (MOF) and various late complications. In more contemporary studies, the trimodal distribution has evolved into essentially a bimodal distribution, where 61% of the deaths are immediate, 29% early, and only 10% are late.[17] Compared with the classical description, the percentage of immediate deaths remained unchanged, and early deaths occurred much earlier (median 52 vs. 120 minutes). However, unlike the classic trimodal distribution, the late peak has markedly diminished, most likely due to significant improvements in surgical intensive care. Mortality rates for many of the reasons for late death are rapidly dropping with wider adoption of best care practices for managing critical care illnesses.[18–20] For example, due to more judicious resuscitation practices severe respiratory failure after trauma has become a fairly rare occurrence.[21] Clearly, critical care is resource intensive and adds significantly to our health care costs, but it has "flattened" the third peak. In other words, not only the incidence of late complications has dropped, but our ability to "rescue" patients even if they develop the complications has markedly improved. Today, even in massively bleeding patients (without head injuries) mortality beyond the first 24 hours is only ~10%.[22] Unfortunately, the area where we have failed to alter the mortality remains the period immediately following the injury, including the prehospital phase. The majority of these deaths are due to hemorrhage and/or traumatic brain injury (TBI).[23–26] Of these two conditions, bleeding is clearly more treatable, which makes it the number one cause of *preventable* deaths. Despite numerous advances in trauma care, a recent multinational trial of more than 20,000 patients [27] once again demonstrated that the majority of deaths (even in developing and under developed countries) occur within a few hours after injuries, with <2.5% of the injured succumbing to MOF.

	Age Groups										
Rank	<1	1–4	5–9	10–14	15–24	25–34	35–44	45–54	55–64	65+	Total
1	Congenital Anomalies 4,746	Unintentional Injury 1,216	Unintentional Injury 730	Unintentional Injury 750	Unintentional Injury 11,836	Unintentional Injury 17,357	Unintentional Injury 16,048	Malignant Neoplasms 44,834	Malignant Neoplasms 115,282	Heart Disease 489,722	Heart Disease 614,348
2	Short Gestation 4,173	Congenital Anomalies 399	Malignant Neoplasms 436	Suicide 425	Suicide 5,079	Suicide 6,569	Malignant Neoplasms 11,267	Heart Disease 34,791	Heart Disease 74,473	Malignant Neoplasms 413,885	Malignant Neoplasms 591,699
3	Maternal Pregnancy Comp. 1,574	Homicide 364	Congenital Anomalies 192	Malignant Neoplasms 416	Homicide 4,144	Homicide 4,159	Heart Disease 10,368	Unintentional Injury 20,610	Unintentional Injury 18,030	Chronic Low. Respiratory Disease 124,693	Chronic Low. Respiratory Disease 147,101
4	SIDS 1,545	Malignant Neoplasms 321	Homicide 123	Congenital Anomalies 156	Malignant Neoplasms 1,569	Malignant Neoplasms 3,624	Suicide 6,706	Suicide 8,767	Chronic Low. Respiratory Disease 16,492	Cerebro-vascular 113,308	Unintentional Injury 136,053
5	Unintentional Injury 1,161	Heart Disease 149	Heart Disease 69	Homicide 156	Heart Disease 953	Heart Disease 3,341	Homicide 2,588	Liver Disease 8,627	Diabetes Mellitus 13,342	Alzheimer's Disease 92,604	Cerebro-vascular 133,103
6	Placenta Cord. Membranes 965	Influenza & Pneumonia 109	Chronic Low. Respiratory Disease 68	Heart Disease 122	Congenital Anomalies 377	Liver Disease 725	Liver Disease 2,582	Diabetes Mellitus 6,062	Liver Disease 12,792	Diabetes Mellitus 54,161	Alzheimer's Disease 93,541
7	Bacterial Sepsis 544	Chronic Low Respiratory Disease 53	Influenza & Pneumonia 57	Chronic Low Respiratory Disease 71	Influenza & Pneumonia 199	Diabetes Mellitus 709	Diabetes Mellitus 1,999	Cerebro-vascular 5,349	Cerebro-vascular 11,727	Unintentional Injury 48,295	Diabetes Mellitus 76,488
8	Respiratory Distress 460	Septicemia 53	Cerebro-vascular 45	Cerebro-vascular 43	Diabetes Mellitus 181	HIV 583	Cerebro-vascular 1,745	Chronic Low. Respiratory Disease 4,402	Suicide 7,527	Influenza & Pneumonia 44,836	Influenza & Pneumonia 55,227
9	Circulatory System Disease 444	Benign Neoplasms 38	Benign Neoplasms 36	Influenza & Pneumonia 41	Chronic Low Respiratory Disease 178	Cerebro-vascular 579	HIV 1,174	Influenza & Pneumonia 2,731	Septicemia 5,709	Nephritis 39,957	Nephritis 48,146
10	Neonatal Hemorrhage 441	Perinatal Period 38	Septicemia 33	Benign Neoplasms 38	Cerebro-vascular 177	Influenza & Pneumonia 549	Influenza & Pneumonia 1,125	Septicemia 2,514	Influenza & Pneumonia 5,390	Septicemia 29,124	Suicide 42,773

Figure 19-1. Ten leading causes of death by age group in the United States (2014). Source: Centers for Disease Control and Prevention.

	Age Groups										
Rank	<1	1–4	5–9	10–14	15–24	25–34	35–44	45–54	55–64	65+	Total
1	Unintentional Suffocation 991	Unintentional Drowning 388	Unintentional MV Traffic 345	Unintentional MV Traffic 384	Unintentional MV Traffic 6,531	Unintentional Poisoning 9,334	Unintentional Poisoning 9,116	Unintentional Poisoning 11,009	Unintentional Poisoning 7,013	Unintentional Fall 27,044	Unintentional Poisoning 42,032
2	Homicide Unspecified 119	Unintentional MV Traffic 293	Unintentional Drowning 125	Suicide Suffocation 225	Homicide Firearm 3,587	Unintentional MV Traffic 5,856	Unintentional MV Traffic 4,308	Unintentional MV Traffic 5,024	Unintentional MV Traffic 4,554	Unintentional MV Traffic 6,373	Unintentional MV Traffic 33,736
3	Homicide Other Spec., Classifiable 83	Homicide Unspecified 149	Unintentional Fire/Burn 68	Suicide Firearm 174	Unintentional Poisoning 3,492	Homicide Firearm 3,260	Suicide Firearm 2,830	Suicide Firearm 3,953	Suicide Firearm 3,910	Suicide Firearm 5,367	Unintentional Fall 31,959
4	Unintentional MV Traffic 61	Unintentional Suffocation 120	Homicide Firearm 58	Homicide Firearm 115	Suicide Firearm 2,270	Suicide Firearm 2,829	Suicide Suffocation 2,057	Suicide Suffocation 2,321	Unintentional Fall 2,558	Unintentional Unspecified 4,590	Suicide Firearm 21,334
5	Undetermined Suffocation 40	Unintentional Fire/Burn 117	Unintentional Other Land Transport 36	Unintentional Drowning 105	Suicide Suffocation 2,010	Suicide Suffocation 2,402	Homicide Firearm 1,835	Suicide Poisoning 1,795	Suicide Poisoning 1,529	Unintentional Suffocation 3,692	Suicide Suffocation 11,407
6	Unintentional Drowning 29	Unintentional Pedestrian, Other 107	Unintentional Suffocation 34	Unintentional Fire/Burn 49	Unintentional Drowning 507	Suicide Poisoning 800	Suicide Poisoning 1,274	Unintentional Fall 1,340	Suicide Suffocation 1,509	Unintentional Poisoning 1,993	Homicide Firearm 10,945
7	Homicide Suffocation 26	Homicide Other Spec., Classifiable 73	Unintentional Natural/ Environment 22	Unintentional Other Land Transport 49	Suicide Poisoning 363	Undetermined Poisoning 575	Undetermined Poisoning 637	Homicide Firearm 1,132	Unintentional Suffocation 698	Adverse Effects 1,554	Suicide Poisoning 6,808
8	Unintentional Natural/ Environment 17	Homicide Firearm 47	Unintentional Pedestrian, Other 18	Unintentional Suffocation 33	Homicide Cut/Pierce 314	Homicide Cut/Pierce 430	Unintentional Fall 504	Undetermined Poisoning 820	Undetermined Poisoning 539	Unintentional Fire/Burn 1,151	Unintentional Suffocation 6,580
9	Undetermined Unspecified 16	Unintentional Struck by or Against 38	Unintentional Struck by or Against 16	Unintentional Poisoning 22	Undetermined Poisoning 229	Unintentional Drowning 399	Unintentional Drowning 363	Unintentional Suffocation 452	Homicide Firearm 538	Suicide Poisoning 1,028	Unintentional Unspecified 5,848
10	Unintentional Fire/Burn 15	Unintentional Natural/ Environment 35	Unintentional Firearm (Tied) 14	Homicide Cut/Pierce 19	Unintentional Other Land Transport 177	Unintentional Fall 285	Homicide Cut/Pierce 313	Unintentional Drowning 442	Unintentional Unspecified 530	Suicide Suffocation 880	Unintentional Drowning 3,406

Figure 19-2. Ten leading causes of death by age group in the United States (2014), highlighting unintentional causes. Source: Centers for Disease Control and Prevention.

Table 19-1 Death Rates by Mechanisms (United States 2013)[a]

Mechanisms	Number	Rate (Per 100,000 Population)
All Injuries	192,945	61
Cut/Pierce	2,576	0.8
Drowning	4,056	1.3
Fall	31,240	9.9
Fire/hot objects	3,220	1.0
Firearm	33,636	10.6
Machinery	588	0.2
Motor vehicle traffic	33,804	10.7
Natural/ environmental	1,535	0.5
Poisoning	48,545	15.4
Struck by or against	936	0.3
Suffocation	17,316	5.5

[a]Data obtained from the National Vital Statistics Reports, Vol 64 no 2, February 2016 (Table 18, pages 84–85). The causes are listed alphabetically and the four most frequent are highlighted.

6 Despite obvious differences in the mechanisms of injuries, hemorrhage and TBI remain the leading causes of death not only in civilian but also in combat trauma,[28] and

effective treatment strategies have the potential to save many lives in the battlefield.[29] Traditionally, management of a bleeding patient focuses on the replacement of lost blood, along with standard cardiopulmonary resuscitative strategies. The type of fluid used for resuscitation has evolved since it was introduced nearly a century ago. Toward the end of World War I and during World War II, transfusion of whole blood was the primary approach in the treatment of military traumatic hemorrhage. However, after World War II, the separation of whole blood into its components became widely accepted and replaced the whole-blood transfusion for logistical and financial reasons. During the Vietnam War era, use of salt-based solutions (crystalloids) became popular. Over the next 3 decades we saw a major rise in the volume of salt-water administration in trauma patients. Although it is cheap, easy to store and administer, from the very start there were concerns about the suitability of crystalloid fluids as a substitute for the lost blood. Blood is a complex fluid that contains thousands of proteins, cells that carry oxygen to the tissues (red blood cells) and generate clot to stop bleeding (red blood cells and platelets), various clotting factors, buffers, enzymes, and hormones. As crystalloids lack all of these, their administration results in rapid dilution of cells, clotting factors, and proteins, which can worsen bleeding. Thus, aggressive crystalloid resuscitation, especially in the absence of early hemorrhage control, is impractical, inadequate, and potentially harmful in many circumstances.[30–33] Not only it lacks any specific pro-survival properties, large volume crystalloid infusion can exacerbate bleeding and worsens cellular injury.[34] It should be emphasized that survival in these patients requires definitive control of bleeding, and most deaths today are caused by delays in controlling the source of bleeding, and not due to inadequate delivery of resuscitation fluids. These challenges are compounded in austere circumstances such as a battlefield, where 87% of deaths occur before patients reach a medical facility,[28] yet nearly a quarter of these injuries are considered potentially survivable (PS). Not surprisingly, the PS category is largely (91%) made up of hemorrhage-related deaths, with most being truncal (67%).[28] In the injured that live long enough to reach a medical facility, the percentage of PS deaths increases to 51%, with hemorrhage accounting for 80%.[29] Thus, novel therapies that could improve hemorrhage control, and keep the injured alive long enough to get to higher echelons of care, have the potential to make the biggest difference.

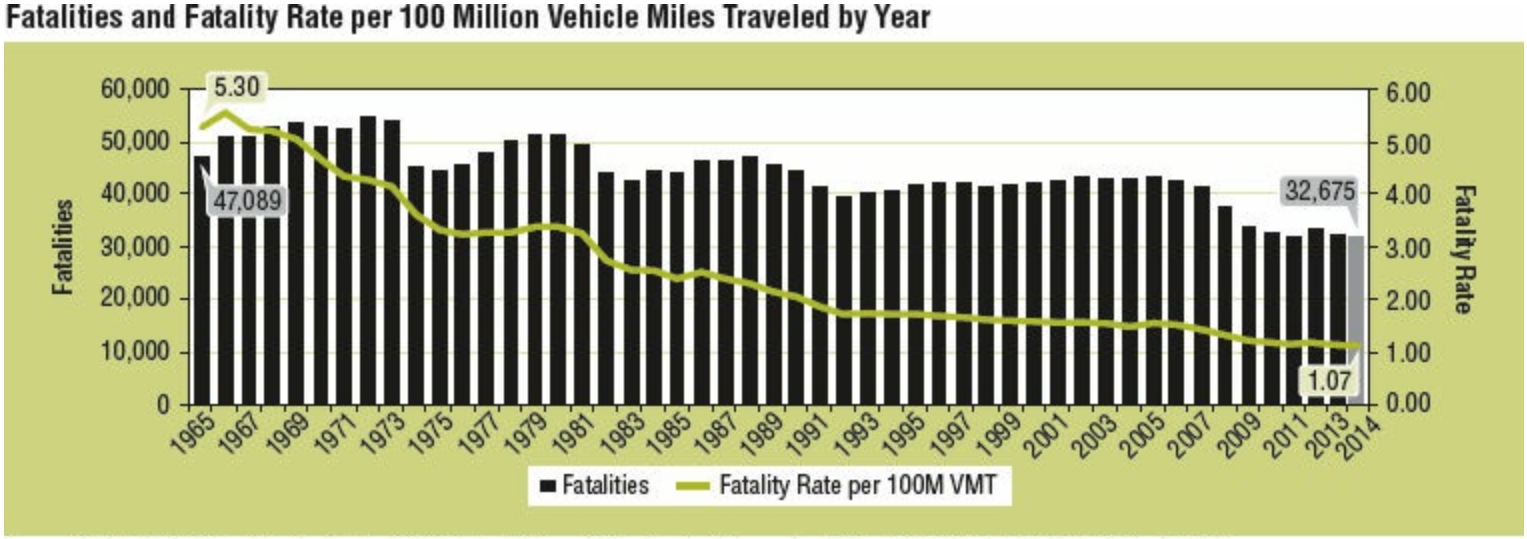

Figure 19-3. Motor vehicle-related fatalities over time in the United States. From US Department of Transportation. NHTSA. 2014 Motor Vehicle Crashes: Overview. http://www-nrd.nhtsa.dot.gov/Pubs/812246.pdf.

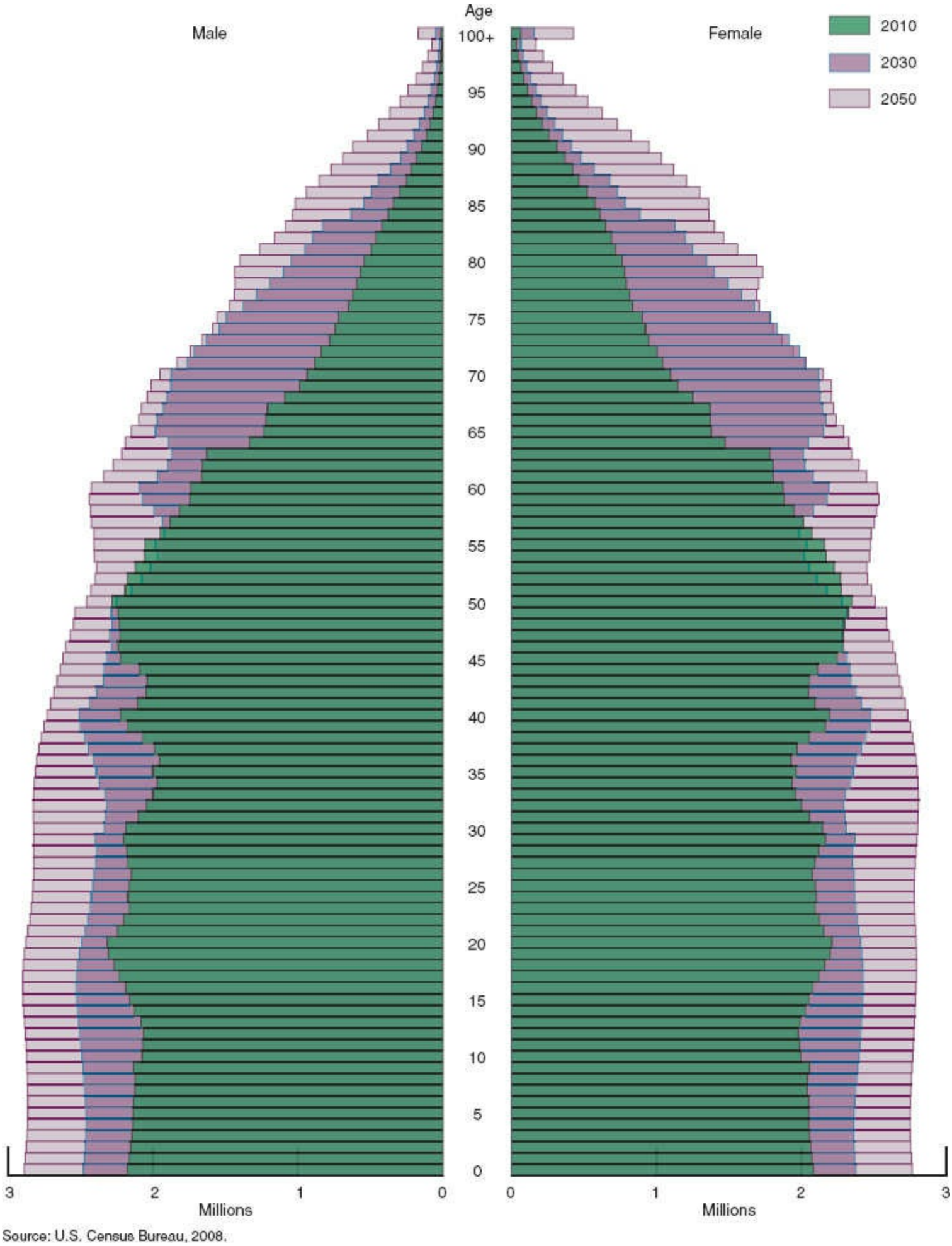

Figure 19-4. Age and sex distribution of the United Sates population: 2010, 2030, and 2050. From Vincent GK, Velkoff VA. The next four decades, the older population in the United States: 2010 to 2050. Current Population Reports, pages

25–1138. Washington, DC: US Census Bureau; 2010.

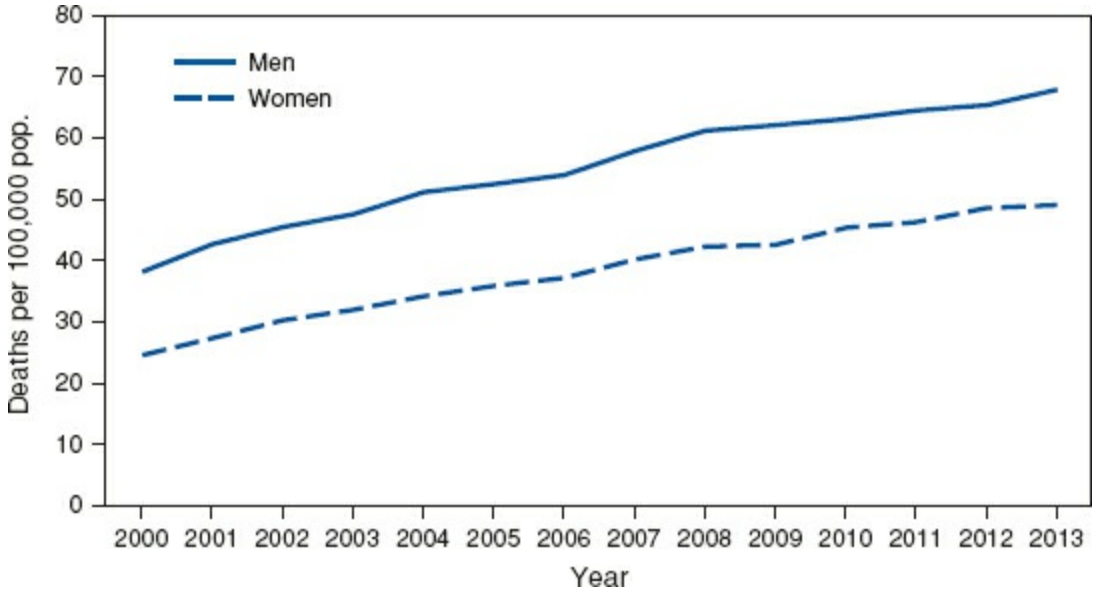

Figure 19-5. Death rates from unintentional falls. The figure is a line chart showing that during 2000–2013, age-adjusted death rates from unintentional falls increased steadily for both men and women aged ≥65 years, with consistently higher rates observed among men. During this period, death rates from falls increased from 38.2 per 100,000 population in 2000 to 67.9 in 2013 among men and from 24.6 to 49.1 among women. From National Vital Statistics System mortality data. Available at http://www.cdc.gov/nchs/deaths.htm.

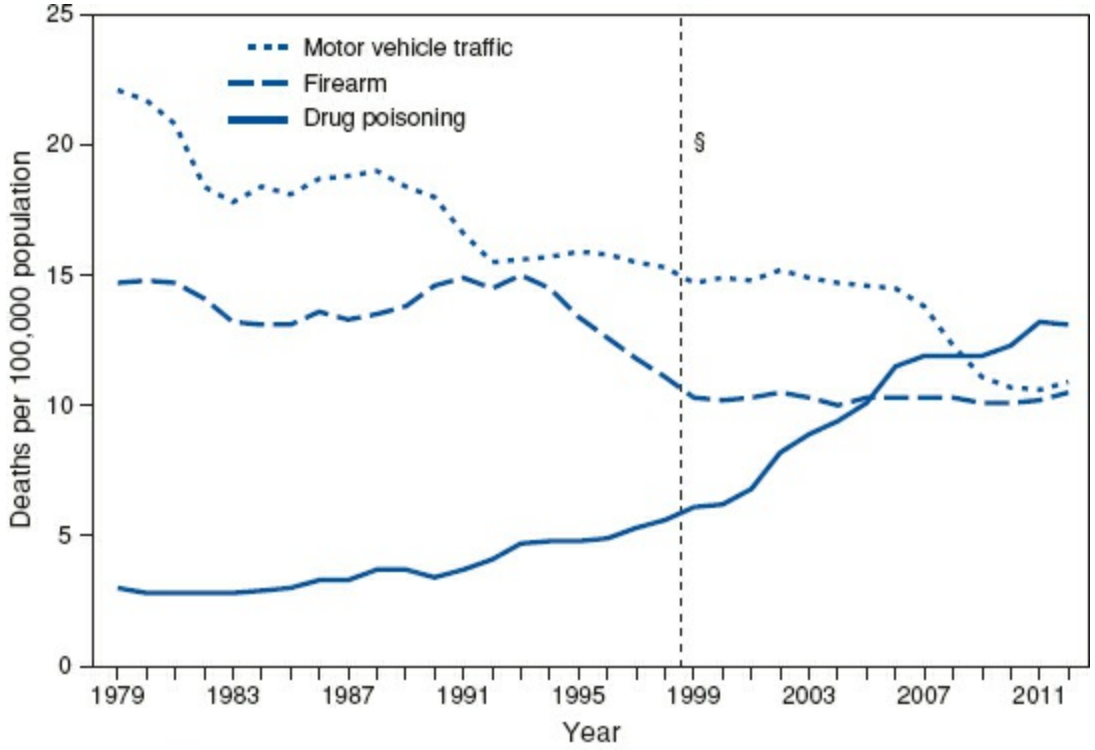

*Per 100,000, age-adjusted to the 2000 U.S. standard population.

Figure 19-6. Death Rates for Three Selected Causes of Injury – National Vital Statistics System, United States, 1979–2012. In 2012, a total of 41,502 drug poisoning deaths, 34,935 motor vehicle traffic deaths, and 33,563 firearm deaths occurred. The age-adjusted death rate for drug poisoning more than quadrupled from 3 per 100,000 in 1979 to 13.1 in 2012. In contrast, the age-adjusted rate dropped from 22.1 to 10.9 for motor vehicle traffic deaths and from 14.7 to 10.5 for firearm deaths during this period. The age-adjusted drug poisoning death rate exceeded the motor vehicle traffic death rate beginning in 2009. From CDC WONDER, compressed mortality file, underlying cause-of-death, available at http://wonder.cdc.gov/mortsql.html.

BIOMECHANICS OF INJURY

It is important to realize that at its most basic level injuries result from deformation of tissues that results in damage. In general, injuries can be categorized as penetrating (sharp objects or firearms) or blunt. There are clearly differences between these mechanisms that must be kept in mind while evaluating the patient. Penetrating trauma causes injury to the objects that are in the path of the foreign body, whereas blunt trauma causes damage either through crush or shear forces. The diagnostic and management approach is therefore very different.

Blunt trauma is best understood by applying the rules of kinetic energy transfer: $KE = (M \times V)/2$, where KE is kinetic energy, M is mass of the object, and V is velocity. Thus, a head on collision between two large sport utility vehicles (~6,000 lb each) traveling at 65 mph can generate enormous amounts of forces. Various safety mechanisms in the modern vehicles direct this force away from the occupants of the vehicle, but the clinicians have a tendency to underappreciate the forces and the vectors involved in the collision. With frontal impact, the vehicle stops abruptly and the occupants continue to move forward (if not belted) and either hit the steering wheel or slide under to hit their knees against the dashboard resulting in classic injury patterns (Fig. 19-7). In a rear impact, the kinetic injury generated depends upon the differences between the velocities of the two vehicles, and the occupant of the front vehicle abruptly accelerates forward resulting in cervical spine hyperextension ("whiplash"). Lateral impact imparts rotational forces and often results in significant protrusion of the passenger compartment. In addition to limb trauma, this can result in major torso (chest, abdomen, and pelvis) injuries. The rotational forces are also more likely to cause torsion injury where the mobile areas join relatively fixed structures (e.g., aortic laceration, cervical spinal ligamentous injuries). Rollover crashes are especially dangerous as the vehicle is impacted from various angles repeatedly during the process. The occupants of the vehicle are thrown around and may even be ejected from the vehicle. Ejection increases the chances of death by ~10 fold. Similarly, death of another occupant is considered a high-risk event, as it is a surrogate for the severity of impact or the complexity of the forces involved. The clinician also must specifically look for clinical evidence of energy transfer. For example, a "seat belt" sign across the abdomen must raise suspicion for energy transfer across the bowel, mesentery, pancreas, and the lumbar spine. Similarly, wedge fracture of L1 vertebra in this setting mandates ruling out a pancreatic injury as the pancreatic body drapes across the anterior aspect of L1. In fact, orthopedic injuries should be considered markers of kinetic energy transfer and make the clinicians proactively look for injuries to adjacent organs, nerves, vessels, and tendons (Table 19-2).

Penetrating trauma should broadly be considered in two categories based upon the mechanism. Sharp objects can cause lacerations or puncture wounds. Lacerations are relatively more straightforward as the structures in the depth of the wound can be examined and injuries to critical organs ruled out by careful inspection. Puncture wounds (or stabs), on the other hand, are challenging when it comes to ruling out occult injury to deeper structures. For example, stab wound to the neck can cause injuries to the airway,

esophagus, blood vessels, thyroid gland, or intrathoracic organs. Similarly, stab wound to the abdomen, chest, flank, and so forth must be evaluated for potential intracavity vascular, solid organ or hollow viscus injuries. Historically, most of these patients used to get surgical explorations but now with better imaging techniques, carefully selected stable patients are often evaluated with advanced imaging studies and/or endoscopy, and managed nonoperatively.[35–39] Clearly, there has been a recent increase in the use of computerized tomography (CT) scans in the evaluation of trauma patients,[40] and careful use of CT scan can reveal additional findings that may not be otherwise apparent.[41] This, however, does not apply to stab wounds to the abdomen, where CT scan has been shown to add no value to the serial physical examinations and close observation.[42] In this prospective study of 249 patients with stab wounds to the abdomen, the CT scan findings did not alter the clinical decision making. Forty-five patients (18.1%) underwent immediate laparotomy, 27 (10.8%) had superficial injuries allowing immediate discharge, and the remaining 177 (71.1%) underwent CT. Of these, 154 (87.0%) were successfully observed, with 20 (11.3%) requiring laparotomy, 2 (1.1%) thoracotomy, and 1 (0.6%) sternotomy. Of the 20 laparotomies, 16 (80.0%) were therapeutic. *All* patients who underwent therapeutic laparotomy did so based on their physical examination alone. The sensitivity and specificity of physical examination were 100% and 98.7%, respectively, while those of CT were 31.3% and 84.2%, respectively. Thus, even in this era of ubiquitous radiographic imaging, the burden is on the clinician to carefully evaluate the patient and make a clinical decision in the trauma bay. One reason CT scans can be misleading in stab wounds is because unlike the gunshot wounds where the track is easier to appreciate due to surrounding tissue injury and cavitation effect, the depth of stab wounds is notoriously difficult to determine on the CT scan. Often, the tissues come back together when the knife is withdrawn, making it difficult to determine the precise depth of penetration (often the knife has penetrated much deeper than the track that is visible on the scan). Thus, in stable patients, nonoperative management of penetrating abdominal trauma is not unreasonable, even if they have solid organ injuries,[43] but it is not a simple radiographic decision. In fact, it remains a *clinical* decision that should be made by an experienced trauma surgeon. These patients also require close observation, serial examinations, and monitoring of laboratory parameters for the next 12 to 24 hours. In settings where this is not possible (e.g., lack of 24/7 clinician availability), the safer option would be to explore the injured body cavity (either laparoscopic or open). Bullet wounds differ from stab wounds not only in the fact that the bullets impart significant kinetic energy depending upon their velocity and weight (Table 19-3) but can also cause “cavitation” effect. Cavitation occurs as tissues impacted by the bullet recoil and transmit the kinetic energy outward, creating a cavity due to the rapid acceleration and deceleration. This can injure organs/tissues that are adjacent to the bullet track even if not hit directly by the projectile. In addition to the kinetic energy, the actual area of injury is influenced by factors such as profile of the bullet, tumble (spin and yaw), and fragmentation. A jacketed bullet does not deform much whereas a hollow point bullet fragments, spreads, and deforms (increasing the area of damage). Similarly, tumbling of the bullet increases the area of energy exchange and much larger zone of damage.

Generally, low-velocity (<1,200 ft/s) or medium velocity (1,200 to 2,000 ft/s) firearms are more common in urban trauma, with high-velocity wounds seen typically in combat settings. The cavitation effect is significantly more pronounced in high-velocity injuries, and the kinetic energy differences translate into a much larger area of destruction, more devitalized tissues, and contamination (cavitation can pull in debris, clothes etc. into the wound). Injuries to multiple organs and structures, even in different body cavities, is possible with bullet wounds. In the operating room, it is important to set clear priorities, and to approach the injuries in a logical fashion. The first priority should be to control the hemorrhage quickly (clamps, catheters, packing, etc.), followed by a quick assessment to identify and treat other life-threatening injuries (pneumothorax, cardiac tamponade, etc.). This should be followed by control of contamination. Then the physiologic status of the patient should be assessed to determine whether definitive repair of all the injuries is feasible versus a "damage control approach" (Table 19-4) where only an abbreviated operation is done and patient brought back to the operating room later for additional interventions (after full resuscitation). While looking for injured organs in penetrating trauma, topography for anatomic proximity must be kept in mind. For example, penetrating injury to the carotid mandates that we exclude injury to adjacent organs such as jugular, trachea, esophagus, and the spine. Similarly, one hole in the bowel should prompt us to look for another hole (through and through injury) that may not be obvious, as well as examining other adjacent organs. For example, a bullet injury to the anterior wall of the stomach can easily pass through the posterior wall, through the pancreas, duodenum, vena cava, and the kidney, depending upon the trajectory. While trying to determine the trajectory, it is important to *not* assume that the subject was in a "normal" anatomical position (standing straight front facing with arms by his side) when shot. Typically, victims assume a variety of odd positions in an effort to avoid getting hit. In addition, bullets do not necessarily travel in a linear track and can bend and bounce off in atypical directions. Thus, gunshot wound to the chest can easily result in injuries not only in the chest (ipsilateral or contralateral), but also in the abdomen, pelvis, or the neck depending upon the course of the projectile. It is also wrong to notice two holes and assume that they represent a through and through gunshot wound. It is equally likely to be two separate gunshot wounds with both bullets still inside the body. As a general rule, the number of gunshot wounds and the number of retained bullets should add up to an even number; otherwise, you are either missing a hole or a bullet. Even in critically ill patients, quick x-rays of the chest/abdomen/pelvis, as a "bullet survey" can be very helpful before rushing to the operating room. This information can be critically important in planning the surgical approach, and in deciding which body cavity to tackle in what sequence.

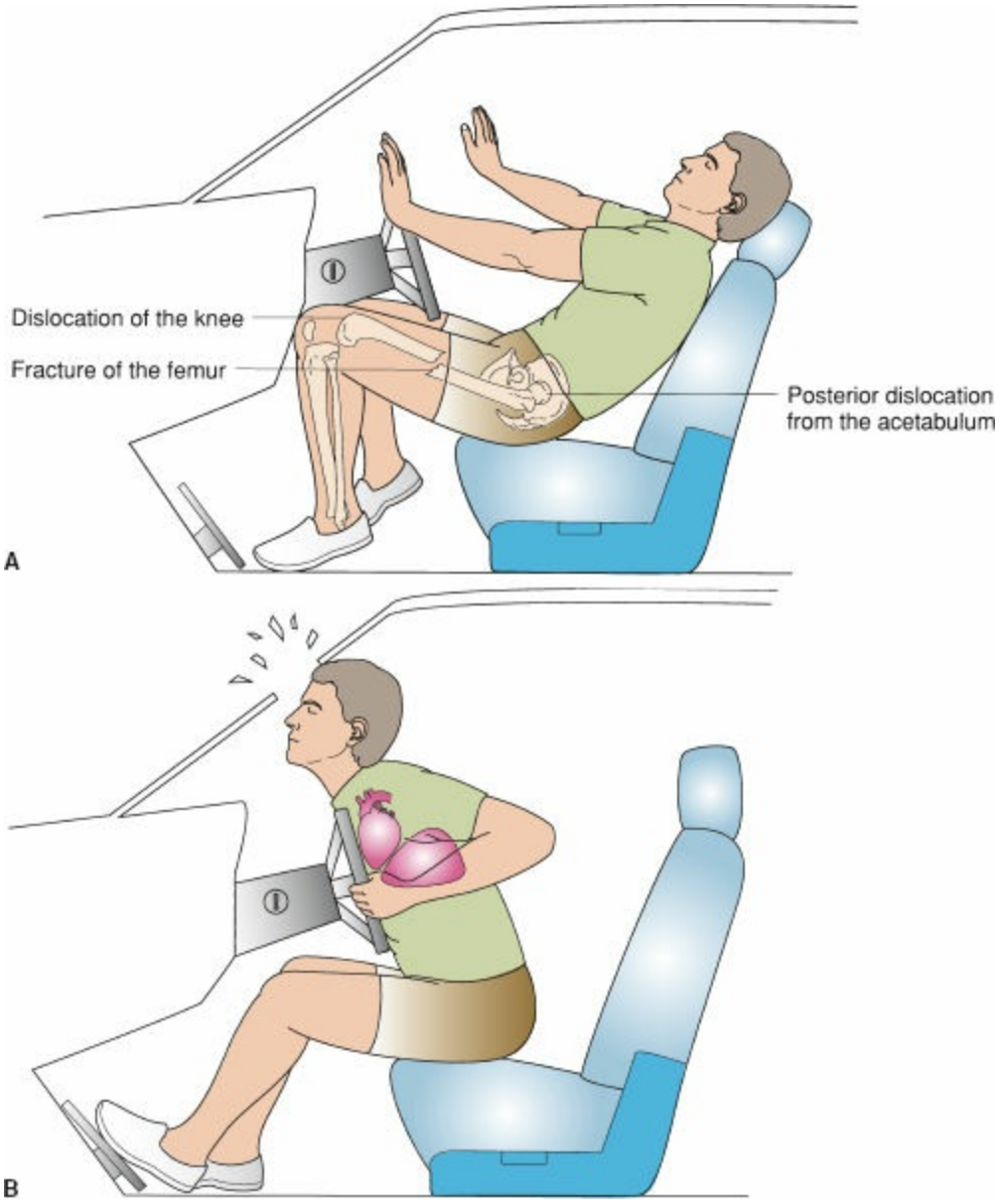

Figure 19-7. **A, B:** Frontal deceleration impact.

Table 19-2 Patterns of Injury to the Head, Neck, Trunk, and Extremities Associated with Orthopedic Injuries

Diagnosed Injury	Associated Injury
Fracture – temporal, parietal bone	Epidural hematoma
Maxillofacial fracture	Cervical spine fracture
Sternal fracture	Cardiac contusion
First and second rib fracture	Descending thoracic aorta, intra-abdominal bleeding
Fractured scapula	Pulmonary contusion
Fractured ribs 8–12, right	Lacerated liver
Fractured ribs 8–12, left	Lacerated spleen
Fractured pelvis	Ruptured bladder, urethral transection
Fractured humerus	Radial nerve injury
Supracondylar humerus	Brachial artery injury fracture
Distal radius fracture	Median nerve compression
Supracondylar femur fracture	Popliteal artery thrombosis
Anterior dislocation shoulder	Axillary nerve injury
Posterior dislocation of hip	Sciatic nerve injury
Posterior dislocation of knee	Popliteal artery thrombosis

Table 19-3 Muzzle Velocity, Kinetic Weight of Projectile, and Approximate Maximum Kinetic Energy of Frequently Used Firearms

Description (Caliber)	Projectile Weight (g)	Muzzle Velocity (ft/s)	Kinetic Energy (ft/lb)
Pistols			
22 Short	29	1,000	72
38 Special	158	870	263
9-mm Luger	125	1,150	440
45	250	860	410
357 Magnum	158	1,430	695
44 Magnum	240	1,470	1,150
Rifles			
22 Long	40	1,150	150
56-mm M-16	55	3,200	1,248
30-30 Winchester	170	2,200	1,830

Table 19-4 List of Proposed Indications for Damage Control, Including Range of Values Reported in Various Articles

1. Core temperature <35°C (34°C–35°C)
2. pH <7.20 (7.10–7.30)
3. Base deficit >14
4. Systolic blood pressure persistently <80 mm Hg (70 mm Hg–90 mm Hg)
5. Blood transfusion >10 units packed red blood cells
6. Estimated blood loss >4 L
7. Operating room fluid replacement >10 L
8. Associated life-threatening injuries in second anatomical location
9. Vascular injuries in inaccessible locations
10. Inability to close the abdomen due to visceral edema
11. Clinical evidence of coagulopathy (nonsurgical bleeding)

FIELD TRIAGE DECISIONS AND EARLY PRIORITIES

Broadly speaking, the trauma patients can be divided into three categories: patients with (a) rapidly fatal injuries, (b) potentially fatal injuries, and (3) all others. A key component of effective prehospital triage is to properly place the injured into these categories based on the available data (mechanism of injury, age of the patient, co-morbid diseases, physiologic status, and injury patters), and then make a rapid decision about what type of facility is the most appropriate for the patient. Committee on Trauma for the American College of Surgeons (ACS-COT) has developed detailed criteria for designating hospitals into different levels depending upon the resource availability, from the highest (level I) to the lowest (level IV). These criteria can easily be found in the Resources for Optimal Care of the Injured Patient – 2014.[44] Working with the Centers for Disease Control and Prevention, ACS-COT has also developed a guideline for the prehospital triage of the injured patients (Algorithm 19-1).[45] The document also contains very detailed guidelines about which patients should be transferred from lower-level to higher-level trauma centers (Table 19-5).[44] The key priorities during the prehospital phase are the ABCs of trauma care (airway, breathing, and circulation), with a major focus on hemorrhage control (direct compression, advanced hemostatic dressings, and tourniquets etc.). In patients that are in hemorrhagic shock but are breathing and maintaining adequate airway/oxygenation, intubation and mechanical ventilation should be avoided (especially for short prehospital times) as administration of sedating drugs and an increase in the intrathoracic pressure (due to positive pressure ventilation) further decreases the preload, which could precipitate an arrest. Judicial administration of crystalloid fluids is acceptable, but aggressive fluid resuscitation in the absence of hemorrhage control can worsen the outcomes. The proof of this concept in humans was published in the New England Journal of Medicine in 1994.[33] In that study, hypotensive patients with *penetrating injury* to the torso were randomized to routine fluid resuscitation, or resuscitation was delayed until bleeding had been surgically controlled. The results showed a survival advantage in the delayed resuscitation group (70% vs. 62%, $p = 0.04$). In fact, a systematic analysis of all the published data failed to find any support in favor of (or against) large volume crystalloid resuscitation in bleeding trauma patients.[46] As these studies had focused on young patients with penetrating trauma, the question remains whether these findings can be generalized to the blunt trauma population. The blunt trauma patients are typically older, may have a higher incidence of coronary and carotid stenosis, and about 20% to 30% have associated TBI (which can worsen due to hypotension). Furthermore, as opposed to penetrating trauma, the sources of bleeding can be multiple and not always surgically fixable in the blunt trauma victims. Because of all these reasons, limited volume ("controlled") resuscitation rather than no resuscitation is logical in this population. This is also supported by an early pilot prospective randomized trial where 192 patients with an out-of-hospital systolic blood pressure (SBP) of 90 mm Hg or lower were randomized to receive controlled resuscitation (CR) or standard resuscitation (SR).[47] CR patients received 250 mL of fluid if they had no radial pulse or an SBP of lower than 70 mm Hg, and additional 250-mL

boluses were given only to maintain a radial pulse or an SBP of 70 mm Hg or greater. The SR group patients received 2 L initially and additional fluid as needed to maintain an SBP of 110 mm Hg or greater. This protocol was maintained until hemorrhage control or 2 hours after arrival in the hospital. The results showed that among the cohort of patients with blunt trauma, 24-hour mortality was 3% and 18% in CR and SR groups, respectively, with an adjusted odds ratio of 0.17(0.03 to 0.92).[47] At present, published data only support careful small volume crystalloid resuscitation to keep the injured alive during transport, and aggressive crystalloid resuscitation should be avoided. In the future, preserved blood products or specialized life-saving drugs may become available, but for now rapid transport to a specialized trauma center ("scoop and run") is the most reasonable strategy in urban environments where the transport times are relatively short. In fact, a prospective comparison between Advanced Life Support (ALS) and Basic Life Support (BLS) transport[48] showed that patients transported by ALS units more often underwent prehospital interventions (97% vs. 17%; $p < 0.01$), including endotracheal intubation, needle thoracostomy, cervical collar, IV placement, and crystalloid resuscitation. While ALS ambulance on-scene time was significantly longer than that of BLS ($p < 0.01$), and had more prehospital interventions (1.8 ± 1.0 per ALS patient vs. 0.2 ± 0.5 per BLS patient; $p < 0.01$), 69.5% ALS patients and 88.4% of BLS patients ($p < 0.01$) survived to hospital discharge. The message is clear – less is more in the prehospital arena, and time to definitive care is the most critical variable. Others studies also support the argument that rapid transport to the trauma center is more important than prehospital interventions in urban victims of penetrating trauma.[49]

Table 19-5 Criteria for Consideration of Transfer from Level III Centers to Level I or II Centers

1. Carotid or vertebral arterial injury.
2. Torn thoracic aorta or great vessel.
3. Cardiac rupture.
4. Bilateral pulmonary contusion with PaO_2:FiO_2 ratio less than 200.
5. Major abdominal vascular injury.
6. Grade IV or V liver injuries requiring transfusion of more than 6 U of red blood cells in 6 hours.
7. Unstable pelvic fracture requiring transfusion of more then 6 U of red blood cells in 6 hours
8. Fracture or dislocation with loss of distal pulses.
9. Penetrating injuries or open fracture of the skull.
10. Glasgow Coma Scale score of less than 14 or lateralizing.
11. Spinal fracture or spinal cord deficit.
12. Complex pelvis/acetabulum fractures.
13. More than two unilateral rib fractures or bilateral rib fractures with pulmonary contusion (if no critical care consultation is available).
14. Significant torso injury with advanced comorbid disease (such as coronary artery disease, chronic obstructive pulmonary).

Source: American College of Surgeons, Committee on Trauma. Resources for Optimal Care of the Injured Patient 2014.

Algorithm 19-1

Measure vital signs and level of consciousness

1

Glasgow coma scale	≤13
Systolic blood pressure (mm Hg)	<90 mm Hg
Respiratory rate	<10 or >29 breaths per minute, or need for ventilatory support (<20 in infant aged <1 year)

No

Assess anatomy of injury

2

- All penetrating injuries to head, neck, torso, and extremities proximal to elbow or knee
- Chest wall instability or deformity (e.g., flail chest)
- Two or more proximal long-bone fractures
- Crushed, degloved, mangled, or pulseless extremity
- Amputation proximal to wrist or ankle
- Pelvic fractures
- Open or depressed skull fracture
- Paralysis

Yes — **Transport to a trauma center.** Steps 1 and 2 attempt to identify the most seriously injured patients. These patients should be transported preferentially to the highest level of care within the defined trauma system.

No

Assess mechanism of injury and evidence of high-energy impact

- **Falls**
  - — Adults: >20 feet (one story is equal to 10 feet)
  - — Children: >10 feet or two or three times the height of the child
- **High-risk auto crash**

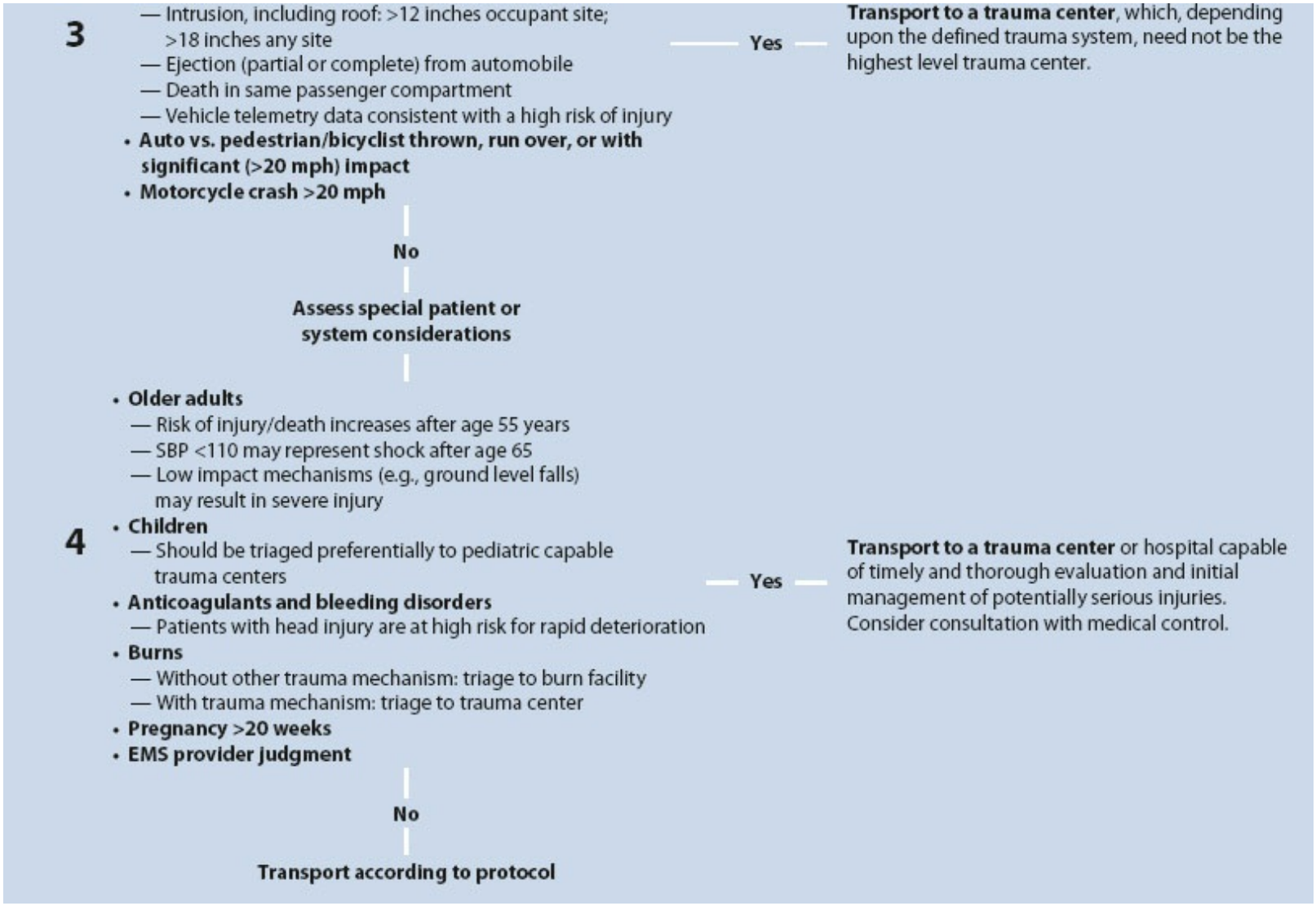

Algorithm 19-1. 2011 Guidelines for the Field Triage of the Injured Patients. Source: Sasser SM, Hunt RC, Faul M, et al. Centers for Disease Control and Prevention. Guidelines for field triage of injured patients: recommendations of the National Expert Panel on Field Triage, 2011. *MMWR Recomm Rep* 2012;61(RR-1):1–20. Available at: https://stacks.cdc.gov/view/cdc/23038/Share.

EARLY HOSPITAL CARE AND PRIORITIES

The Advanced Trauma Life Support (ATLS) program has put together a systematic, concise approach to the care of a trauma patient. ATLS was developed by the American College of Surgeons, Committee on Trauma (COT) and was first introduced in 1980, and is now taught in 60 countries across the world. The ATLS program provides participants with a safe, reliable method for immediate management of the injured patient and the basic knowledge necessary to:

1. Assess the patient's condition rapidly and accurately
2. Resuscitate and stabilize the patient according to priority
3. Determine if the patient's needs exceed a facility's capacity
4. Arrange appropriately for the patient's interhospital transfer (who, what, when, and how)
5. Assure that optimum care is provided and that the level of care does not deteriorate at any point during the evaluation, resuscitation, or transfer process.

The basic concepts of ATLS include a primary survey focusing on the ABCDE (airway, breathing, circulation, disability, and exposure) to identify and address the life-threating issues, followed by a secondary survey to identify all the injuries. The specific treatments of various injuries have been addressed in the different chapters that follow. However, the key points to emphasize are that the two main killers during the early hospital period ("golden hour") are the same as the prehospital setting – *bleeding and TBI.* As treatments for TBI remain mostly supportive, bleeding remains the number 1 cause of *preventable* deaths during the first 6 hours following trauma. In a bleeding patient, the priorities are to identify and control the source of bleeding in the shortest possible period of time. Sometimes the bleeding source is obvious and can be controlled by direct compression (e.g., stab wound to the femoral artery in the groin), tourniquets (e.g., mangled extremity), or sutures (e.g., scalp laceration), but often it is inside a body cavity. Localization of the hemorrhage source is relatively easy for penetrating trauma that is limited to a specific body region, but is notoriously difficult in the blunt polytrauma patients. In these patients, it helps to remember that a person can only lose significant volumes of blood in five locations: (1) pleural space, (2) intra-abdominal, (3) pelvis/retroperitoneal space, (4) soft tissues at the site of long bone fractures/sheer injuries, and (5) externally. With a quick examination and a chest x-ray, three of these possibilities can be easily ruled out, and the choice typically comes down to deciding between the abdomen and the pelvis. If the pelvic x-ray shows a significant pelvic fracture then the possibility of pelvic bleeding source is significant, and a pelvic binder should be applied promptly (or pelvis wrapped tightly with a sheet) for appropriate fracture patterns (e.g., suitable for open book fracture but potentially harmful for severe lateral compression). Focused assessment with sonography for trauma (FAST) can also be helpful in determining the source of hemorrhage. If it shows free fluid in the abdomen in a hypotensive patient then emergent laparotomy for hemorrhage control is justified.

However, FAST has been reported to have a significant false negative rate even in experienced hands.[50] Although diagnostic peritoneal lavage has largely been abandoned, a bedside diagnostic peritoneal aspiration (DPA) can be very helpful in these patients. Percutaneous DPA can be performed in 1 minute, and it has been shown to be accurate, safe, and superior to FAST for the diagnosis of abdominal blood as the source of hemodynamic instability in multitrauma patients.[51] In addition to hemorrhage control, massive transfusion protocol (MTP) should be activated in patients that are actively bleeding to avoid development of trauma associated coagulopathy (TAC). Normal coagulation homeostasis depends on a delicate balance between clot formation and breakdown. Normally, trauma tilts the balance in favor of clot formation at the site of injuries to stop the bleeding. However, major injuries, excessive blood loss, prolonged tissue hypoperfusion, and TBI with disruption of the blood–brain barrier have all been shown to upset the normal coagulation homeostasis, resulting in TAC.[52,53] This can manifest as abnormal clot formation and/or excessive or rapid clot breakdown (fibrinolysis). Unless treated promptly, this coagulopathy leads to further bleeding, which sets up a vicious cycle resulting in the "lethal triad" of coagulopathy, acidosis, and hypothermia that is associated with an extremely high mortality.[54] An analysis of trauma-associated coagulopathy suggests that depletion coagulopathy results in abnormalities of traditional coagulation parameters (international normalized ratio, partial thromboplastin time) and predicts mortality, whereas fibrinolytic coagulopathy predicts infection, end-organ failure, and mortality, without a detectable difference in international normalized ratio or partial thromboplastin time.[55]

Damage Control Resuscitation (DCR) or Hemostatic Resuscitation has recently emerged as a potential solution for the prevention and reversal of trauma-associated coagulopathy.[30,56,57] This approach advocates early hemorrhage control, permissive hypotension (until control of hemorrhage), avoidance of crystalloids, and early use of blood components such as fresh frozen plasma (FFP) and platelets (in 1:1 or 1:2 ratios). A recent prospective randomized multi-institutional trial enrolled 680 patients with severe trauma and major bleeding to test two different blood component ratios.[22] In this study, early administration of plasma, platelets, and red blood cells in a 1:1:1 ratio compared with a 1:1:2 ratio did not result in significant differences in mortality at 24 hours or at 30 days. However, more patients in the 1:1:1 group achieved hemostasis and fewer experienced death due to exsanguination by 24 hours.[22] It must be emphasized, however, that high-ratio protocols do not improve survival in patients who do not require massive transfusion (10 U of packed red blood cells [PRBCs] in 24 hours).[58] In fact, inappropriate infusion of plasma in patients who are not massively bleeding can worsen their outcomes.[59] So, while the exact ratio of PRBCs to FFP and platelets may be debatable, contemporary resuscitation practices have moved to early delivery of component therapy in the setting of massive bleeding, using standardized protocols (see below). Also, it should be emphasized that resuscitation is an adjunct to early hemorrhage control and not a substitute. In a bleeding patient, initiating DCR is a great idea, but the patient's eventual survival depends on the ability (or inability) to obtain rapid and reliable hemorrhage control. In addition, prevention and active reversal of hypothermia (e.g., use

of fluid warmers, body warming devices) and correction of acidosis and hypocalcemia are critically important while resuscitation protocols are carried out.

We also know that development of a clot is just the initial part of the process, and rapid breakdown of the clot may be equally detrimental. It has been shown that development of fibrinolysis is a highly lethal event in severely injured patients,[60,61] and treatment with blood products alone is incapable of reversing this process. Despite ongoing debate about precise ratios of blood products,[62] there is general agreement that blood products should be administered in the form of a MTP to optimize the processes of care and to improve outcomes. Cotton et al.[63] tested the effectiveness of a trauma exsanguination protocol by comparing patients treated with the protocol (n = 94 over 18 months) to a cohort of similar patients admitted during the prior 18 months (n = 117). The study found that implementation of the protocol reduced 30-day mortality (51% vs. 66%, $P < 0.03$), decreased intraoperative crystalloid administration (4.9 L vs. 6.7 L, $P = 0.002$), and reduced postoperative blood product use (2.8 U of PRBCs vs. 8.7 U, $P < 0.001$; 1.7 U of FFP vs. 7.9 U, $P < 0.001$; 0.9 U of platelets vs. 5.7 U, $P < 0.001$). Dente et al.[64] conducted a similar study of an MTP (1:1:1 ratio of platelets, FFP, and PRBCs) by comparing matched patients during a 1-year period before and after implementation of protocol (73 patients in the protocol group and 84 matched controls). Implementation of the protocol was found to reduce mortality in the first 24 hours (17% with MTP vs. 36% pre-MTP, $P = 0.008$) and at 30 days (34% vs. 55%, $P = 0.04$), with a more pronounced impact in the patients with blunt trauma.[64] This study also showed that MTP patients required fewer overall transfusions of PRBCs and FFP after the first 24 hours (2.7 vs. 9.3 U of PRBCs, $P < 0.0001$; 3 vs. 7.5 U of FFP, $P < 0.05$). The University of Michigan MTP is provided for reference (Fig. 19-8).[65] It should be emphasized that to be effective these protocols should not only incorporate the best available evidence, which is constantly changing, but also reflect the resources and realities of the individual institutions.

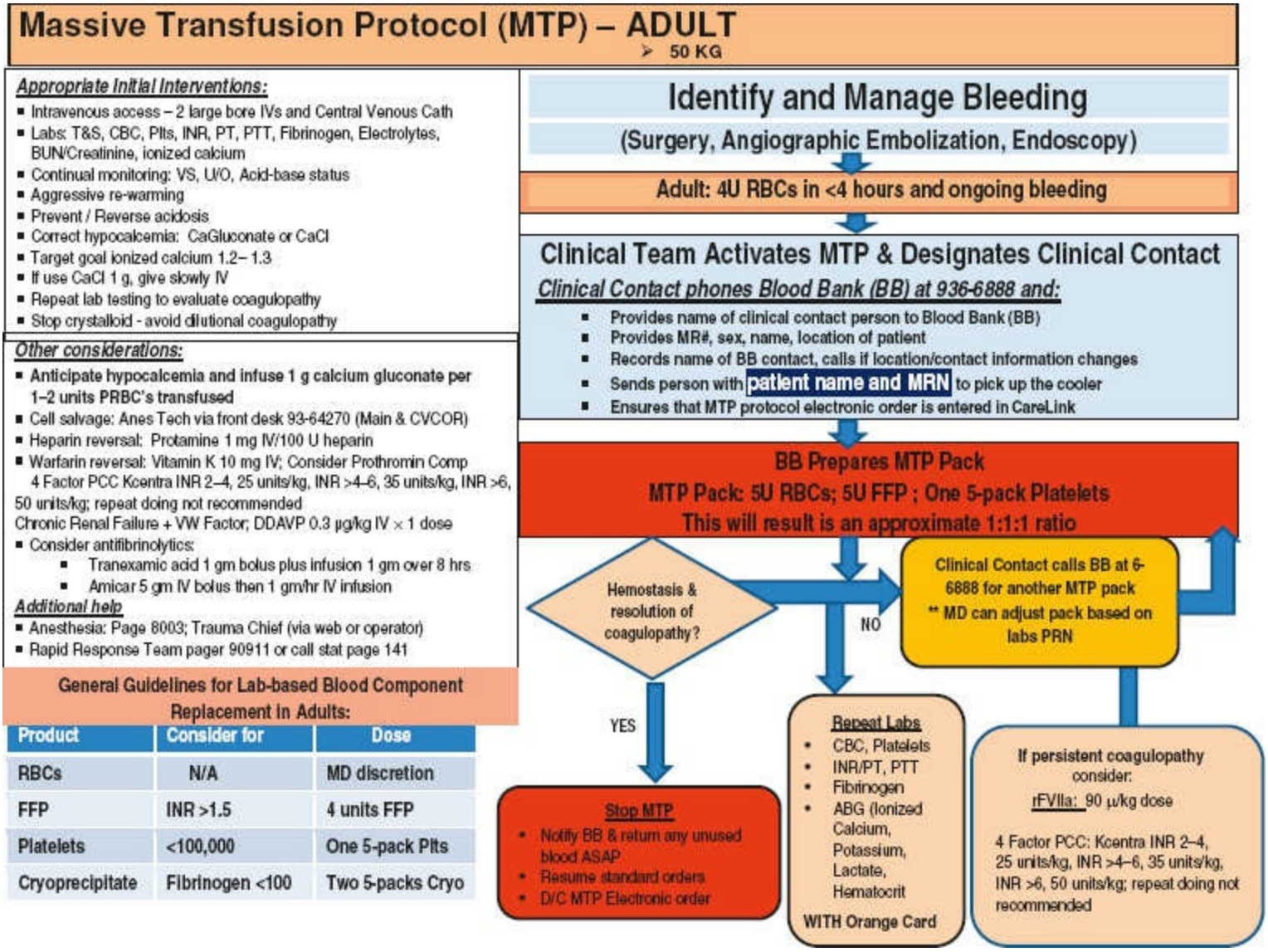

Figure 19-8. Massive transfusion protocol (MTP). BB, blood bank; BUN, serum urea nitrogen; CBC, complete blood count; Cryo, cryoprecipitate; FFP, fresh frozen plasma; INR, international normalized ratio; PCC, prothrombin complex concentrates; Plts, platelets; PRBCs, packed red blood cells; PT, prothrombin time; PTT, partial thromboplastin time; rFVIIa, recombinant factor VIIa. T&S, type and screen; VS, vital signs; U/O, urine output; CVCOR, cardiovascular center operating room; DDAVP, Desmopressin (*1-desamino-8-D-arginine vasopressin*); PRN, as needed (Pro re nata); ABG, arterial blood gas; D/C, discontinue. Reproduced with permission from the University of Michigan Hospitals and Health Centers.[65]

LESSONS LEARNED FROM THE BATTLEFIELD

7 Every major war has catalyzed rapid advances in trauma care. As the medical systems grapple with the challenges of taking care of massive numbers of injured people (military and civilian), often in very austere settings, they quickly evolve, adapt, and improvise. Wars also prompt significant financial investment by the governments in research and development, and attract some of the best minds to the field. Many of the things (various operative interventions, drugs, fluids, dressings, rapid transport systems, trauma teams, in-field care, and many more) that are taken for granted today in the civilian trauma centers can be traced back to the wars of the past. Interestingly, as the war medicine improves and evolves to take care of worse injuries, the war industry responds by developing more lethal weaponry. Thus, the percentage of injured that die in the battlefield (Killed in action or KIA rate) has remained relatively static during the 20th century, hovering around 25% (Table 19-6). The current conflict is the first time in modern warfare that the KIA rate has dropped down to 10%.[66,67] This dramatic drop is clearly multifactorial in etiology, and reflects the focus on prevention strategies with widespread use of superior protective body armor, and deployment of better-designed military vehicles. In addition, the current ongoing conflicts have fundamentally altered how we take care of the injured, which has resulted not only in improved survival rates but also markedly superior functional outcomes. A brief list of the key advancements would include the following:

a. *Prevention:* Explosions (many due to improvised explosive devices or IEDs) have caused a greater percentage of injuries in Iraq and Afghanistan than in any other large-scale conflict. Compared to historical data, improvements in body armor have clearly changed the injury profile of the service personnel.[68] Kevlar helmets, protective eyewear, and body armor is now routinely used. Many direct hits to the to the head and torso that used to be lethal in the previous wars are now potentially survivable. TBI has become the “signature injury” of the current conflict, but increasingly large numbers of individuals survive these injuries. An analysis of 4,623 combat explosion episodes in Iraq between March 2004 and December 2007 showed that the most frequent single injury type was a mild TBI (10.8%).[69] Other frequent injuries were open wounds in the lower extremity (8.8%) and open wounds of the face (8.2%), which includes tympanic membrane rupture. The extremities were the body regions most often injured (41.3%), followed by head and neck (37.4%) and torso (8.8%). Majority of the explosions resulted in more than one injury, and the variety of injuries across nearly every body region and injury type reflects the complex nature of explosion injuries. The fact that large number of US military personnel involved in these explosions survive is a testament to the sophisticated vehicle and personal body armor that is being used by the US and NATO forces, and to superb medical care. For example, mortality from direct chest trauma has dropped down to 10% with the most common injury pattern being pulmonary contusion rather than lethal injury to the critical organs.[70]

b. *Early hemorrhage control:* This is another area where we have seen major improvements. At the start of the conflict the battlefield dressings that were in the individual first aid kits were not a whole lot different from the ones used by the Roman Legions centuries ago. Cotton-based compression dressings and tourniquets had not changed much until the start of the conflict but then underwent a very rapid evolution. A number of advanced hemostatic bandages were quickly developed, rigorously tested, and expeditiously deployed by the military.[71] These advanced hemostatic dressings were widely used during the early years of the Iraq and Afghanistan wars and saved many lives. Since then, second generation dressings have been developed and tested,[72] and incorporated into the Tactical Combat Casualty Care (TCCC) guidelines.[73,74] Many of these dressings that were developed for military use are now widely available, and are commonly used by the civilian emergency medical response providers. When anatomically possible, even more secure hemorrhage control can be obtained by placing a tourniquet. A review of 10 years of data from a military registry showed that of 4,297 casualties with extremity trauma, 30% underwent application of tourniquets.[75] Over this period, tourniquet use increased by 10-fold, and survival rates improved markedly for casualties that had injuries suitable for tourniquets. Typical tourniquets are not effective for really proximal injuries,[76] but in recent years, a number of junctional tourniquets have been developed, and two of these [Combat Ready Clamp (CRoC; http://www.combatmedicalsystems.com) and SAM Junctional Tourniquet (SJT; http://www.sammedical.com/products)] performed well when tested by military medics.[77] Development of advanced dressings and new military tourniquet (windlass devices that can be self-applied and tightened using a single hand) has changed early battlefield care.[78] However, civilian trauma systems have been alarmingly slow in adopting these lessons and developing uniform guidelines.[79] This was at full display after the Boston Marathon bombing when most of the tourniquets used were improvised (and inefficient) devices rather than the military versions.[80] Our experiences with mass casualties underline how important it is for all the emergency medical personnel and physicians to learn the proper use of tourniquets and advanced hemostatic dressings. Austere military settings with focus on damage control procedures have also generated interest in the use of intraluminal occlusive balloons.[81] A variety of balloons and catheters have historically been used by trauma and vascular surgeons for the temporary control of bleeding. Recently, this concept has been taken to the next level as a result of collaborative efforts between the civilian and military surgeons, where the aorta (thoracic or abdominal) is controlled with the bedside application of a resuscitative endovascular balloon occlusion of the aorta (REBOA) device.[82] The balloon-carrying catheter can be inserted using percutaneous techniques, typically via the femoral artery, advanced (without need for fluoroscopy) into the aorta, and inflated to interrupt the aortic flow below the balloon. In this way, REBOA functions essentially similar to an aortic cross-clamp that is applied during resuscitative thoracotomy. Although these tools are not yet widely used, courses have been developed to teach these new life-saving skills to the surgical community.[83] While the strategy is promising,[84] and good results have been reported by the US trauma

centers,[85] data from Japan where emergency medicine physicians typically use the REBOA technology have shown some concerning outcomes.[86] Wider use would require additional work to identify the best target population, the most effective method for deployment, and optimal training requirement for the users.

Table 19-6 Lethality of War Wounds among US Soldiers

	No. Wounded or Killed in Action	No. Killed in Action	Lethality of War Wounds (%)
Revolutionary War, 1775–1783	10,623	4,435	42
War of 1812, 1812–1815	6,765	2,260	33
Mexican War, 1846–1848	5,885	1,733	29
Civil War (Union Force), 1861–1865	422,295	140,414	33
Spanish–American War, 1898	2,047	385	19
World War I, 1917–1918	257,404	53,402	21
World War II , 1941–1945	963,403	291,557	30
Korean War, 1950–1953	137,025	33,741	25
Vietnam War, 1961–1973	200,727	47,424	24
Persian Gulf War, 1990–1991	614	147	24
Current conflicts[a], 2001–April 29, 2016	52,432	5,387	10

Sources: Gawande A. Casualties of War – Military Care for the Wounded from Iraq and Afghanistan. *N Engl J Med* 2004;351:2471–2475.
U.S. casualty status. Washington, D.C.: Department of Defense, 2004. (Accessed April 29, 2016, at http://www.defenselink.mil/news/casualty.pdf.)
[a]Includes data reported publicly by the Department of Defense that are available at http://www.defense.gov/casualty.pdf. Last accessed on April 29, 2016. These data include the following military operations: OPERATION IRAQI FREEDOM, OPERATION NEW DAWN, OPERATION ENDURING FREEDOM, OPERATION ENDURING FREEDOM, OPERATION INHERENT RESOLVE, OPERATION FREEDOM'S SENTINEL.

c. *DCR/Prevention and treatment of coagulopathy:* Just like massive crystalloid resuscitation has been associated with the Vietnam war, where "shock lung/Da Nang lung" (later termed acute respiratory distress syndrome or ARDS) was first described in soldiers that received massive crystalloid resuscitation, the current conflict would be remembered for advancing the concept of DCR. The pendulum has clearly swung toward balanced resuscitation, in large parts based upon the battlefield resuscitation practices. It is informative to briefly review how our clinical practices changed during the war even in the absence of good class I/II clinical evidence. It should also be pointed out that logistical issues (weight, volume, storage requirements etc.) are often a major driver of change in the military. Historically, many DoD agencies, such as the Office of Naval Research (ONR), the US Army Medical Research and Material Command (MRMC), and Defense Advanced Research Projects Agency (DARPA) just to name a few, have been long-standing sponsors of resuscitation research. Primarily as a result of leadership and funding by the ONR, three significant consensus conferences were held where experts analyzed the available data on fluid resuscitation, and recommendations were made to improve clinical practice and to guide future research. The first meeting was held under the supervision of the Institute of Medicine (IOM) in 1998. The IOM report concluded that the current resuscitation strategies were inadequate, potentially harmful, and needed radical changes. It identified numerous

areas of future research, and recommended that combat casualties should be resuscitated with 250 mL bolus of 7.5% saline.[87] Unfortunately, the US Food and Drug Administration (FDA) had not approved this fluid for clinical use. In the follow-up meeting (June 2001, Uniformed Services University, Bethesda, MD) a number of clinical recommendations were made including who should (and should not) be resuscitated, appropriate end points of resuscitation, as well as the optimal fluid for resuscitation.[88] As the choice was deliberately limited to FDA-approved agents (available in the United States), Hetastarch (hydroxyethyl starch) was narrowly recommended as the fluid of choice for use in the battlefield. In the third meeting (October 2001, Toronto, Canada), the scope was widened to include fluids that were available in the NATO countries (even if not available in the United States).[89] At that meeting a combination fluid (7.5% saline and 6% dextran-hypertonic saline dextran) was recommended as the initial fluid of choice.[90] At all of these meetings experts agreed that aggressive resuscitation is deleterious, an "ideal" fluid is yet not available, and that low-volume resuscitation (hypertonic, colloid, or combination) is the most logical choice for the military needs. Proceedings of the last two meetings were published as a special supplement of the Journal of Trauma (May 2003), including the recommendations for the initial fluid resuscitation of combat casualties.[91] Over the next decade, the concepts of DCR became more well established, and this change is clearly reflected in the latest recommendations by the Tactical Combat Casualty Care guidelines for Fluid Resuscitation for Hemorrhagic Shock[92]: "(1) dried plasma (DP) is added as an option when other blood components or whole blood are not available; (2) the wording is clarified to emphasize that Hextend is a less desirable option than whole blood, blood components, or DP and should be used only when these preferred options are not available; (3) the use of blood products in certain Tactical Field Care (TFC) settings where this option might be feasible (ships, mounted patrols) is discussed; (4) 1:1:1 DCR is preferred to 1:1 DCR when platelets are available as well as plasma and red cells; and (5) the 30-minute wait between increments of resuscitation fluid administered to achieve clinical improvement or target blood pressure (BP) has been eliminated. Also included is an order of precedence for resuscitation fluid options. Maintained as recommendations are an emphasis on hypotensive resuscitation in order to minimize (1) interference with the body's hemostatic response and (2) the risk of complications of over resuscitation. Hextend is retained as the preferred option over crystalloids when blood products are not available because of its smaller volume and the potential for long evacuations in the military setting." It should be pointed out that although these guidelines have been designed specifically for the battlefield environment, many of these recommendations are now becoming an integral part of the civilian trauma care (e.g., avoidance of crystalloids, early blood product use, high ratios of plasma and platelets to red cells). Many of the landmark studies such as PROMMTT[57] and PROPPR,[22] were also supported by the DoD funds, and their findings have significantly changed our practices. Another area where military data have advanced the field is in defining the appropriate use of antifibrinolytic agents. An organized clot, histologically, is a clump of blood cells in a mesh of fibrin strands,

which is the final product of the coagulation cascades. Plasmin breaks down the fibrin strands to initiate clot resolution. Normally, clot formation and breakdown are precisely balanced to prevent excessive thrombosis or coagulopathy. Trauma-associated coagulopathy disrupts this balance and leads to poor clot formation and rapid breakdown. Antifibrinolytic drugs such as aprotinin, tranexamic acid (TXA), and ε-aminocaproic acid stabilize the blood clot, which can slow down the bleeding. Due to safety concerns, aprotinin was withdrawn from world markets in May 2008, but TXA and ε-aminocaproic acid are in fairly wide clinical use and appear to be free of serious adverse effects.[93] TXA is a lysine analog that binds with plasminogen to prevent its activation,[94] and in higher concentrations is a noncompetitive inhibitor of plasmin (actions similar to those of ε-aminocaproic acid but about 10 times more potent in vitro). In the recent Clinical Randomization of an Antifibrinolytic in Significant Hemorrhage (CRASH-2) trial,[27] which is one of the largest prospective randomized trials in trauma patients, 20,211 patients at 274 hospitals in 40 countries (mostly underdeveloped) were randomized to receive either TXA or placebo within 8 hours of injury. All-cause mortality in TXA-treated patients was significantly lower compared with placebo (14.5% and 16% in TXA and control groups, respectively; $P = 0.0035$), as was the risk due to bleeding (4.9% and 5.7% in TXA and control groups, respectively; $P = 0.0077$). Subgroup analysis showed that the benefit was found only in patients who were given the drug early (within 3 hours of injury) and were severely hypotensive (SBP $\leq$75 mm Hg). Skeptics point out that the overall survival improvement, although statistically significant, was rather modest (1.5%). There were some other concerns, including the fact that only half the patients in this study required any blood transfusion, suggesting that most were not severely injured. As this study was conducted in developing countries where DCR is not in common use, it is unclear how the results would be influenced by early use of blood component therapy. Critical data about the physiological status of the patients, monitoring methods, blood loss, imaging studies, operative interventions, and complications were not gathered. Also, the role of TXA in the setting of TBI was not determined as only one-third of the patients had a Glasgow Coma Scale score of 12 or lower on admission. Finally, this study was not designed to identify underlying protective mechanisms. These limitations led some experts (military and civilian) to question the robustness and generalizability of the findings, especially in the setting of massive bleeding.[95] In this area of uncertainty, new data from the battlefield have helped clarify the way forward. One important study was a retrospective observational analysis of prospectively collected data in 896 battlefield casualties (377 civilian and 519 military patients) who received at least 1 U of PRBCs (within 24 hours of admission) at a military hospital in Afghanistan.[9] A third of the patients received massive transfusion ($\geq$10 units of PRBC). Unadjusted mortality rates were lower in TXA-treated patients (17.4% and 23.9% in TXA and no-TXA groups, respectively; $P = 0.03$). The benefit was most pronounced in patients who received massive transfusion (14.4% and 28.1% in TXA and no-TXA groups, respectively; $P = 0.004$). TXA was also independently associated with higher odds of survival (odds ratio = 7.2) and less coagulopathy ($P = 0.003$). A

follow-up study (Military Application of Tranexamic Acid in Trauma Emergency Resuscitation [MATTERs II]) showed that the addition of cryoprecipitate independently added to the benefits of TXA in the seriously injured in the battlefield.[97] A closer look at the data from these studies raises some potential safety concerns. In CRASH-2, mortality due to bleeding increased if TXA treatment was given after 3 hours (3.1% and 4.4%, in <3 hours and >3 hours, respectively; $P = 0.0049$). In the MATTERs trial, a statistically significant increase was noted in pulmonary embolism (TXA 2.7% vs. no TXA 0.3%, $P = 0.001$) and deep venous thrombosis (TXA 2.4% vs. no TXA 0.2%, $P = 0.001$). It is unclear whether this simply reflects sicker patients in the TXA group or a real increase in the incidence of adverse events. Experts in the field have therefore developed evidence-based guidelines for the use of TXA[98] that recommend the use of TXA in adult trauma patients with severe hemorrhagic shock (SBP <75 mm Hg), with known predictors of fibrinolysis, or with documented fibrinolysis on thromboelastography. In these patients, TXA should be administered only if the time from injury is less than 3 hours, and the dose of TXA should be 1 g over 10 minutes followed by another 1-g IV infusion over 8 hours. Although we are likely to see ongoing debates about the concepts of DCR and whether and when to use adjunctive agents such as TXA, cryoprecipitate, desmopressin, and prothrombin complex concentrates, the research supported either directly or indirectly by the military over the last 10 to 15 years has clearly changed how we treat the massively bleeding patients today (Fig. 19-8).

d. *Rapid Evacuation and Long-distance Transport:* Rapid air evacuation by specially trained teams was popularized by the US military in the Korean War with great results. Although the war patterns have changed to be more urban, nonlinear, and with a smaller foot-print, rapid evacuation is no less important in the current era. In fact, after the US Secretary of Defense Robert M. Gates mandated in 2009 that the prehospital helicopter transport of critically injured combat casualties should be 60 minutes or less, the evacuation systems became even more efficient. An analysis of battlefield data (21,089 US military casualties) before and after the mandate showed that for the total casualty population, the percentage killed in action (16.0% [386 of 2411] vs. 9.9% [964 of 9755]; $P < 0.001$) and the case fatality rate ([CFR] 13.7 [469 of 3429] vs. 7.6 [1344 of 17660]; $P <0 .001$) were higher before versus after the mandate, while the percentage died of wounds (4.1% [83 of 2025] vs. 4.3% [380 of 8791]; $P = 0.71$) remained unchanged.[99] Decline in CFR after the mandate was associated with an increasing percentage of casualties transported in 60 minutes or less (regression coefficient, -0.141; $P <0 .001$), with projected versus actual CFR equating to 359 lives saved. Among 4,542 casualties (mean injury severity score, 17.3; mortality, 10.1% [457 of 4542]) with detailed data, there was a decrease in median transport time after the mandate (90 min vs. 43 min; $P <0.001$) and an increase in missions achieving prehospital helicopter transport in 60 minutes or less (24.8% [181 of 731] vs. 75.2% [2867 of 3811]; $P <0 .001$). Even more impressive are the results of long-distance transport. One of the unique aspects of the military medical care system

that emerged during Operation Iraqi Freedom and Operation Enduring Freedom has been the opportunity to apply existing civilian trauma system standards to the provision of combat casualty care across an evolving theater of operations. Review of the Critical Care Air Transport Team (CCATT) and Joint Theater Trauma Registry databases shows that for severely injured (mean ISS 23.7) that were evacuated to Landstuhl Regional Medical Center in Germany, the en route mortality rate was less than 0.02%.[100] This is a huge testament to the superb skills, tools, training, and resources that the military has provided for the care of the injured. It also proves that rapid movement of critically injured casualties within hours of wounding appears to be effective, with a minimal mortality incurred during transport and overall 30-day mortality of 2%.[100] Many of these lessons will be translated into the general trauma practice as these medics and physicians transition to civilian work.

e. *Rehabilitation:* Lower-extremity injuries continue to be the most common injuries in the current conflict. In fact, they account for 60% of all injuries to the US troops in Iraq and Afghanistan, which are to the lower extremities, mostly due to explosive devices.[101] But unlike previous wars, the tools and technologies available today are markedly different. Not only are temporary vascular shunts being used widely,[102,103] but also early vascular reconstruction is being performed more frequently with excellent outcomes.[104,105] Liberal use of temporary vascular shunts to control bleeding and restore distal flow during transport to higher echelons of care is clearly a logical approach. It is also a practical solution when dealing with combined vascular and orthopedic injuries, and when the surgeon providing the initial care lacks the skills to perform the definitive vascular repairs.[106] Development and implementation of comprehensive rehabilitation strategies,[107] and cutting edge technology in prosthetic limbs[108] to treat the injured service members with complex lower-extremity trauma from combat has resulted in some of the best functional outcomes in the history of warfare. The civilian trauma system would clearly be the beneficiary of these developments in the future.

NEW DEVELOPMENTS IN INTRACAVITY HEMORRHAGE CONTROL

Current trauma training and equipment is sufficient to care for 53% of the potentially survivable deaths, but novel methods of intravenous or intracavitary noncompressible hemostasis (combined with rapid surgery) are required for the remaining 47% of the decedents.[109] This is the next frontier in hemorrhage control, and many researchers are addressing the challenge of controlling intracavity bleeding especially in the prehospital setting. There was some initial enthusiasm for using systemic therapies such as recombinant clotting factors (factor VIIa), but randomized clinical trials have failed to show a benefit in trauma patients.[110] Recently, the focus has shifted to local/mechanical methods. In addition to devices such as REBOA,[86] approaches such as expanding foams,[111,112] insufflation,[113] and compression devices[114] are being tested. If successful, these could be the game changers that we have been looking for decades.

FUTURE DIRECTIONS

Despite numerous advances, we have failed to make a significant impact on the early trauma deaths. Many of these individuals have underlying injuries that are potentially survivable, but they die before getting definitive care. While resuscitation restores tissue perfusion, it does not have any specific prosurvival properties. By the time the injured gets to the hospital nothing can be done to reverse the "irreversible shock." A much more exciting approach would be to improve the survival by administering specific pharmacological agents in the field that could immediately upregulate prosurvival genes and proteins to create a *prosurvival phenotype,*[115] or use strategies to induce a state of "suspended animation" to keep the organs preserved until the source of hemorrhage can be controlled.[116,117]

In the not too distant future, early trauma resuscitation may be very different from what we currently practice. In addition to early hemorrhage control and DCR, we are also likely to see:

a. Use of specific prosurvival drugs that can be given in the prehospital setting to keep the injured alive long enough to get evacuated to higher levels of care (effective "bridge to definitive care").
b. Early use of preserved plasma products, platelets, and red blood cells.
c. Availability of blood "farming" to eliminate the logistical barriers to supply.
d. Development of safe and effective nonblood oxygen carrying fluids that can be easily administered.
e. Ability to temporarily "suspend" life using hypothermia or hibernation strategies for patients that have potentially survivable injuries, but need more time for surgery or transfer.
f. Individualized therapy with administration of specific pharmacological agents based upon the individual's cellular disturbances.
g. Monitoring of response to therapy that goes beyond measurement of physiology, and looks at the reversal of cellular disturbances.

References

1. Rhee P, Joseph B, Pandit V, et al. Increasing trauma deaths in the United States. *Ann Surg* 2014;260(1):13–21.
2. Centers for Disease Control and Prevention, National Center for Injury Prevention and Control. *Web-based Injury Statistics Query and Reporting System (WISQARS) Nonfatal Injury Data.* (2015). http://www.cdc.gov/injury/wisqars/nonfatal.html. Last accessed 4.25.16
3. Centers for Disease Control and Prevention, National Center for Injury Prevention and Control. *Web-based Injury Statistics Query and Reporting System (WISQARS) Fatal Injury Data.* (2015). http://www.cdc.gov/injury/wisqars/fatal.html. Last accessed 4.25.16
4. Florence C, Simon T, Haegerich T, et al. Estimated lifetime medical and work loss costs of fatal injury, United States 2013. *MMWR* 2015;64(38). http://www.cdc.gov/mmwr/preview/mmwrhtml/mm6438a4.htm?s_cid=mm6438a4_w. Last accessed 4.25.16
5. World Health Organization. *Injuries and Violence: the Facts 2014.* http://www.who.int/violence_injury_prevention/media/news/2015/Injury_violence_f Last accessed 4.25.16
6. Xu J, Murphy SL, Kochanek KD, et al. Deaths: final data for 2013. *National Vital Statistics Reports.* 2016;64(2):84–85.
7. US Department of Transportation. NHTSA. *2014 Motor Vehicle Crashes: Overview.* http://www-nrd.nhtsa.dot.gov/Pubs/812246.pdf. Last accessed 4.25.16.
8. Centers for Disease Control and Prevention, National Center for Health Statistics. *Suicide Rates for Females and Males by Race and Ethnicity: United States, 1999 and 2014.* http://www.cdc.gov/nchs/data/hestat/suicide/rates_1999_2014.htm. Last accessed 4.25.16.
9. Halaweish I, Alam HB. Changing demographics of the American population. *Surg Clin North Am* 2015;95(1):1–10.
10. Vincent GK, Velkoff VA. The next four decades, the older population in the United States: 2010 to 2050. Current Population Reports, page 25–1138. Washington, DC: US Census Bureau; 2010. https://www.census.gov/prod/2010pubs/p25–1138.pdf. Last accessed 4.25.16.
11. DeGrauw X, Annest JL, Stevens JA, et al. Unintentional injuries treated in hospital emergency departments among persons aged 65 years and older, United States, 2006–2011. *J Safety Res* 2016;56:105–109.
12. Ramly E, Kaafarani HM, Velmahos GC. The effect of aging on pulmonary function. Implications for monitoring and support of the surgical and trauma patients. *Surg Clin N Am* 2015;95(1):53–69.
13. Federal Bureau of Investigation. *Uniform Crimes Reports.* www.fbi.gov/about-us/cjis/ucr/crime-in-the-u.s/2013/crime-in-the-u.s.-2013/violent-crime/violent-

crime-topic-page/violentcrimemain_final. Last accessed 4.25.16.
14. Trunkey DD. Trauma. *Sci Am* 1983;249:28–35.
15. Celso B, Tepas J, Langland-Orban B, et al. A systematic review and meta-analysis comparing outcome of severely injured patients treated in trauma centers following the establishment of trauma systems. *J Trauma* 2006;60(2):371–378.
16. MacKenzie EJ, Rivara FP, Jurkovich GJ, et al. A national evaluation of the effect of trauma-center care on mortality. *N Engl J Med* 2006;354(4):366–378.
17. Gunst M, Ghaemmaghami V, Gruszecki A, et al. Changing epidemiology of trauma deaths leads to a bimodal distribution. *Proc (Bayl Univ Med Cent)* 2010;23(4):349–354.
18. Dellinger RP, Levy MM, Rhodes A, et al; Surviving Sepsis Campaign Guidelines Committee including the Pediatric Subgroup. Surviving sepsis campaign: international guidelines for management of severe sepsis and septic shock: 2012. *Crit Care Med* 2013;41(2):580–637.
19. Levy MM, Rhodes A, Phillips GS, et al. Surviving Sepsis Campaign: association between performance metrics and outcomes in a 7.5-year study. *Crit Care Med* 2015;43(1):3–12.
20. Petrucci N, De Feo C. Lung protective ventilation strategy for the acute respiratory distress syndrome. *Cochrane Database Syst Rev* 2013;2:CD003844.
21. Plurad D, Martin M, Green D, et al. The decreasing incidence of late posttraumatic acute respiratory distress syndrome: the potential role of lung protective ventilation and conservative transfusion practice. *J Trauma* 2007;63(1):1–7.
22. Holcomb JB, Tilley BC, Baraniuk S, et al; PROPPR Study Group. Transfusion of plasma, platelets, and red blood cells in a 1:1:1 vs a 1:1:2 ratio and mortality in patients with severe trauma: the PROPPR randomized clinical trial. *JAMA* 2015;313(5):471–482.
23. Shackford SR, Mackersie RC, Holbrook TL, et al. The epidemiology of trauma death: a population based analysis. *Arch Surg* 1993;128:571–575.
24. Sauaia A, Moore FA, Moore EE, et al. Epidemiology of trauma deaths: a reassessment. *J Trauma.* 1995;38:185–193.
25. Acosta JA, Yang JC, Winchell RJ, et al. Lethal injuries and time to death in a level I trauma center. *J Am Coll Surg* 1998;186:528–533.
26. Demetriades D, Murray J, Charalambides K, et al. Trauma fatalities: time and location of hospital deaths. *J Am Coll Surg* 2004;198:20–26.
27. CRASH-2 trial collaborators. Effects of tranexamic acid on death, vascular occlusive events, and blood transfusion in trauma patients with significant haemorrhage (CRASH-2): a randomised, placebo-controlled trial. *Lancet* 2010;376:23–32.
28. Eastridge BJ, Mabry RL, Seguin P, et al. Death on the battlefield (2001–2011): implications for the future of combat casualty care. *J Trauma Acute Care Surg* 2012;73(6 suppl 5):S431–S437.

29. Eastridge BJ, Hardin M, Cantrell J, et al. Died of wounds on the battlefield: causation and implications for improving combat casualty care. *J Trauma* 2011;71(1 suppl):S4–S8.
30. Alam HB, Velmahos GC. New trends in resuscitation. *Curr Probl Surg* 2011;48:531–564.
31. Mattox KL, Feliciano DV. Role of external cardiac compression in truncal trauma. *J Trauma* 1982;22:934–936.
32. Liberman M, Mulder D, Sampalis J. Advanced or basic life support for trauma: meta-analysis and critical review of the literature. *J Trauma* 2000;49:584–599.
33. Bickell WH, Wall MJ, Pepe PE, et al. Immediate versus delayed fluid resuscitation for hypotensive patients with penetrating torso injuries. *N Engl J Med* 1994;331:1105–1109.
34. Santry H, Alam HB. Fluid resuscitation: past, present and the future. *Shock* 2010;33:229–241.
35. Kevric J, O'Reilly GM, Gocentas RA, et al. Management of haemodynamically stable patients with penetrating abdominal stab injuries: review of practice at an Australian major trauma centre. *Eur J Trauma Emerg Surg* 2015.
36. Peev MP, Chang Y, King DR, et al. Delayed laparotomy after selective non-operative management of penetrating abdominal injuries. *World J Surg* 2015;39(2):380–386.
37. Lamb CM, Garner JP. Selective non-operative management of civilian gunshot wounds to the abdomen: a systematic review of the evidence. *Injury* 2014;45(4):659–666.
38. Zafar SN, Rushing A, Haut ER, et al. Outcome of selective non-operative management of penetrating abdominal injuries from the North American National Trauma Database. *Br J Surg* 2012;99 Suppl 1:155–164.
39. Burgess CA, Dale OT, Almeyda R, et al. An evidence based review of the assessment and management of penetrating neck trauma. *Clin Otolaryngol* 2012;37(1):44–52.
40. Sierink JC, Saltzherr TP, Beenen LF, et al.; REACT-2 study group. A multicenter, randomized controlled trial of immediate total-body CT scanning in trauma patients (REACT-2). *BMC Emerg Med* 2012;12:4.
41. Salim A, Sangthong B, Martin M, et al. Whole body imaging in blunt multisystem trauma patients without obvious signs of injury: results of a prospective study. *Arch Surg* 2006;141(5):468–473.
42. Inaba K, Okoye OT, Rosenheck R, et al. Prospective evaluation of the role of computed tomography in the assessment of abdominal stab wounds. *JAMA Surg* 2013;148(9):810–816.
43. Demetriades D, Hadjizacharia P, Constantinou C, et al. Selective nonoperative management of penetrating abdominal solid organ injuries. *Ann Surg* 2006;244(4):620–628.
44. American College of Surgeons, Committee on Trauma. *Resources for Optimal Care of*

the Injured Patient-2014. https://www.facs.org/~/media/files/quality%20programs/trauma/vrc%20resources/resources%20for%20c Last accessed 4.26.16.

45. Sasser SM, Hunt RC, Faul M, et al; Centers for Disease Control and Prevention. Guidelines for field triage of injured patients: recommendations of the National Expert Panel on Field Triage, 2011. *MMWR Recomm Rep* 2012;61(RR-1):1–20. Available at: www.facs.org/quality-programs/trauma/vrc/resources
46. Kwan I, Bunn F, Roberts I. Timing and volume of fluid administration for patients with bleeding. *Cochrane Database of Systematic Reviews* 2003;(3):Art. No.: CD002245.
47. Schreiber MA, Meier EN, Tisherman SA, et al.; ROC Investigators. A controlled resuscitation strategy is feasible and safe in hypotensive trauma patients: results of a prospective randomized pilot trial. *J Trauma Acute Care Surg* 2015;78(4):687–695.
48. Seamon MJ, Doane SM, Gaughan JP, et al. Prehospital interventions for penetrating trauma victims: a prospective comparison between Advanced Life Support and Basic Life Support. *Injury* 2013;44(5):634–638.
49. Rappold JF, Hollenbach KA, Santora TA, et al. The evil of good is better: Making the case for basic life support transport for penetrating trauma victims in an urban environment. *J Trauma Acute Care Surg* 2015;79(3):343–348.
50. Miller MT, Pasquale MD, Bromberg WJ, et al. Not so FAST. *J Trauma* 2003;54(1):52–59.
51. Kuncir EJ, Velmahos GC. Diagnostic peritoneal aspiration—the foster child of DPL: a prospective observational study. *Int J Surg* 2007;5(3):167–171.
52. Sixta SL, Hatch QM, Matijevic N, et al. Mechanistic determinates of the acute coagulopathy of trauma (ACoT) in patients requiring emergency surgery. *Int J Burns Trauma* 2012;2:158–166.
53. Frith D, Brohi K. The pathophysiology of trauma-induced coagulopathy. *Curr Opin Crit Care* 2012;18:631–636.
54. Gerecht R. The lethal triad. Hypothermia, acidosis & coagulopathy create a deadly cycle for trauma patients. *JEMS* 2014;39(4):56–60.
55. Kutcher ME, Ferguson AR, Cohen MJ. A principal component analysis of coagulation after trauma. *J Trauma Acute Care Surg* 2013;74:1223–1230.
56. Dutton RP. Haemostatic resuscitation. *Br J Anaesth* 2012;109(suppl 1):i39–i46.
57. Holcomb JB, del Junco DJ, Fox EE, et al.; PROMMTT Study Group. The prospective, observational, multicenter, major trauma transfusion (PROMMTT) study: comparative effectiveness of a time-varying treatment with competing risks. *JAMA Surg* 2013;148(2):127–136.
58. Sambasivan CN, Kunio NR, Nair PV, et al. High ratios of plasma and platelets to packed red blood cells do not affect mortality in nonmassively transfused patients. *J Trauma* 2011;71(2 suppl 3):S329–S336.
59. Inaba K, Branco BC, Rhee P, et al. Impact of plasma transfusion in trauma patients

who do not require massive transfusion. *J Am Coll Surg* 2010;210:957–965.
60. Ives C, Inaba K, Branco BC, et al. Hyperfibrinolysis elicited via thromboelastography predicts mortality in trauma. *J Am Coll Surg* 2012;215:496–502.
61. Cotton BA, Harvin JA, Kostousouv V, et al. Hyperfibrinolysis at admission is an uncommon but highly lethal event associated with shock and prehospital fluid administration. *J Trauma Acute Care Surg* 2012;73:365–370.
62. Gregory JA, Huitron SS, George AA, et al. Optimizing transfusion ratios in massive transfusion protocols: An argument against the 1:1:1 dogma and approach to trauma resuscitation. *Lab Med* 2015 Spring;46(2):e46–e52.
63. Cotton BA, Gunter OL, Isbell J, et al. Damage control hematology: the impact of a trauma exsanguination protocol on survival and blood product utilization. *J Trauma* 2008; 64:1177–1182.
64. Dente CJ, Shaz BH, Nicholas JM, et al. Improvements in early mortality and coagulopathy are sustained better in patients with blunt trauma after institution of a massive transfusion protocol in a civilian level I trauma center. *J Trauma* 2009;66:1616–1624.
65. University of Michigan Hospitals and Health Centers. Massive transfusion protocol. https://www.pathology.med.umich.edu/static/apps/cms/ckfinder/userfiles/238/files Accessed 4.27.16
66. Gawande A. Casualties of war—military care for the wounded from Iraq and Afghanistan. *N Engl J Med* 2004;351:2471–2475
67. *U.S. casualty status.* Washington, D.C.: Department of Defense; 2004. (Accessed April 27, 2016, at http://www.defenselink.mil/news/casualty.pdf.)
68. Breeze J, Lewis EA, Fryer R, et al. Defining the essential anatomical coverage provided by military body armour against high energy projectiles. *J R Army Med Corps* 2015. pii: jramc-2015–000431.
69. Eskridge SL, Macera CA, Galarneau MR, et al. Injuries from combat explosions in Iraq: injury type, location, and severity. *Injury* 2012;43(10):1678–1682.
70. Keneally R, Szpisjak D. Thoracic trauma in Iraq and Afghanistan. *J Trauma Acute Care Surg* 2013;74(5):1292–1297.
71. Pusateri AE, Holcomb JB, Kheirabadi BS, et al. Making sense of the preclinical literature on advanced hemostatic products. *J Trauma* 2006;60(3):674–682.
72. Kheirabadi BS, Scherer MR, Estep JS, et al. Determination of efficacy of new hemostatic dressings in a model of extremity arterial hemorrhage in swine. *J Trauma* 2009;67(3):450–459.
73. Sims K, Montgomery HR, Dituro P, et al. Management of external hemorrhage in tactical combat casualty care: The adjunctive use of XStat™ compressed hemostatic sponges: TCCC guidelines change 15–03. *J Spec Oper Med* 2016 Spring;16(1):19–28.
74. Bennett BL, Littlejohn LF, Kheirabadi BS, et al. Management of external hemorrhage in tactical combat casualty care: Chitosan-based hemostatic gauze dressings - TCCC

guidelines-change 13–05. *J Spec Oper Med* 2014 Fall;14(3):40–57.
75. Kragh JF Jr, Dubick MA, Aden JK, et al. U.S. Military use of tourniquets from 2001 to 2010. *Prehosp Emerg Care* 2015;19(2):184–190.
76. Kragh JF Jr, Dubick MA, Aden JK 3rd, et al. U.S. Military experience with junctional wounds in war from 2001 to 2010. *J Spec Oper Med* 2013;13(4):76–84.
77. Kragh JF Jr, Parsons DL, Kotwal RS, et al. Testing of junctional tourniquets by military medics to control simulated groin hemorrhage. *J Spec Oper Med* 2014;14(3):58–63.
78. Butler FK. Military history of increasing survival: The U.S. military experience with tourniquets and hemostatic dressings in the Afghanistan and Iraq conflicts. *Bull Am Coll Surg* 2015;100(1 Suppl):60–64.
79. Ramly E, Runyan G, King DR. The state of the union: Nationwide absence of uniform guidelines for the prehospital use of tourniquets to control extremity exsanguination. *J Trauma Acute Care Surg* 2016;80(5):787–791.
80. King DR, Larentzakis A, Ramly EP; Boston Trauma Collaborative. Tourniquet use at the Boston Marathon bombing: Lost in translation. *J Trauma Acute Care Surg* 2015;78(3):594–599.
81. Holcomb JB, Fox EE, Scalea TM, et al. Current opinion on catheter-based hemorrhage control in trauma patients. *J Trauma Acute Care Surg* 2014; 76(3):888–893.
82. Brenner ML, Moore LJ, DuBose JJ, et al. A clinical series of resuscitative endovascular balloon occlusion of the aorta for hemorrhage control and resuscitation. *J Trauma Acute Care Surg* 2013;75(3):506–511.
83. Villamaria CY, Eliason JL, Napolitano LM, et al. Endovascular Skills for Trauma and Resuscitative Surgery (ESTARS) course: curriculum development, content validation, and program assessment. *J Trauma Acute Care Surg* 2014;76(4):929–935.
84. Williams TK, Neff LP, Johnson MA, et al. Extending REBOA: Endovascular Variable Aortic Control (EVAC) in a lethal model of hemorrhagic shock. *J Trauma Acute Care Surg* 2016. Apr 8. [Epub ahead of print]
85. DuBose JJ, Scalea TM, Brenner M, et al; AAST AORTA Study Group. The AAST Prospective Aortic Occlusion for Resuscitation in Trauma and Acute Care Surgery (AORTA) Registry: Data on contemporary utilization and outcomes of aortic occlusion and resuscitative balloon occlusion of the aorta (REBOA). *J Trauma Acute Care Surg* 2016 Apr 5. [Epub ahead of print]
86. Inoue J, Shiraishi A, Yoshiyuki A, et al. Resuscitative endovascular balloon occlusion of the aorta might be dangerous in patients with severe torso trauma: A propensity score analysis. *J Trauma Acute Care Surg* 2016 Apr;80(4):559–567.
87. Committee on fluid resuscitation for combat casualties. Fluid resuscitation: state of the science for treating combat casualties and civilian trauma. Report of the Institute of Medicine. Washington, DC: National Academy Press; 1999.

88. Uniformed Services University of the Health Sciences. *Combat Fluid Resuscitation*. Bethesda, MD: Sponsored by US Office of Naval Research; US Army Medical Research and Material Command; Department of Surgery; Department of Military and Emergency Medicine; 2001.
89. Defense and Civil Institute of Environmental Medicine. *Fluid Resuscitation in Combat*. Toronto, Ontario: Sponsored by Defense R & D Canada, Defense and Civil Institute of Environmental Medicine, Department of Surgery, University of Toronto; and the Office of Naval Research; —2001.
90. Champion HR. Combat fluid resuscitation: Introduction and overview of conferences. *J Trauma* 2003;54(supp):7–12.
91. Rhee P, Koustova E, Alam HB. Searching for the optimal resuscitation method: recommendations for the initial fluid resuscitation of combat casualties. *J Trauma* 2003;54(supp):52–62.
92. Butler FK, Holcomb JB, Schreiber MA, et al. Fluid resuscitation for hemorrhagic shock in tactical combat casualty care: TCCC guidelines change 14–01 - 2 June 2014. *J Spec Oper Med* 2014 Fall;14(3):13–38.
93. Henry DA, Carless PA, Moxey AJ, et al. Anti-fibrinolytic use for minimising perioperative allogeneic blood transfusion. *Cochrane Database Syst Rev* 2011; (3):CD001886.
94. Silva MM, Thelwell C, Williams SC, et al. Regulation of fibrinolysis by C-terminal lysines operates through plasminogen and plasmin but not tissue plasminogen activator (tPA). *J Thromb Haemost* 2012;10:2354–2360.
95. Pusateri AE, Weiskopf RB, Bebarta V, et al.; The US DoD Hemorrhage and Resuscitation Research and Development Steering Committee. Tranexamic acid and trauma: current status and knowledge gaps with recommended research priorities. *Shock* 2013;39:122–126.
96. Morrison JJ, Dubose JJ, Rasmussen TE, et al. Military application of tranexamic acid in trauma emergency resuscitation (MATTERs) study. *Arch Surg* 2012;147:113–119.
97. Morrison JJ, Ross JD, Dubose JJ, et al. Association of cryoprecipitate and tranexamic acid with improved survival following wartime injury: findings from the MATTERs II Study. *JAMA Surg* 2013;148:218–225.
98. Napolitano LM, Cohen MJ, Cotton BA, et al. Tranexamic acid in trauma: how should we use it? *J Trauma Acute Care Surg* 2013;74:1575–1586.
99. Kotwal RS, Howard JT, Orman JA, et al. The effect of a golden hour policy on the morbidity and mortality of combat casualties. *JAMA Surg* 2016;151(1):15–24.
100. Ingalls N, Zonies D, Bailey JA, et al. A review of the first 10 years of critical care aeromedical transport during operation Iraqi freedom and operation enduring freedom: the importance of evacuation timing. *JAMA Surg* 2014;149(8):807–813.
101. Connolly M, Ibrahim ZR, Johnson ON 3rd. Changing paradigms in lower extremity reconstruction in war-related injuries. *Mil Med Res* 2016;3:9.

102. Gifford SM, Aidinian G, Clouse WD, et al. Effect of temporary shunting on extremity vascular injury: an outcome analysis from the Global War on Terror vascular injury initiative. *J Vasc Surg* 2009;50(3):549–555
103. Rasmussen TE, Clouse WD, Jenkins DH, et al. The use of temporary vascular shunts as a damage control adjunct in the management of wartime vascular injury. *J Trauma* 2006;61(1):8–12.
104. Vertrees A, Fox CJ, Quan RW, et al. The use of prosthetic grafts in complex military vascular trauma: a limb salvage strategy for patients with severely limited autologous conduit. *J Trauma* 2009;66(4):980–983.
105. Casey K, Sabino J, Weiss JS, et al. Limb salvage after vascular reconstruction followed by tissue transfer during the Global War on Terror. *J Vasc Surg* 2015;61(3):734–740.
106. Alam HB, DiMusto PD. Management of lower extremity vascular trauma. *Curr Trauma Rep* 2015;1(1):61–68. Available at http://link.springer.com/article/10.1007/s40719–014–0007–2
107. Hoyt BW, Pavey GJ, Pasquina PF, et al. Rehabilitation of lower extremity trauma: A review of principles and military perspective on future directions. *Curr Trauma Rep* 2015;1(1):50–60. Available at http://link.springer.com/article/10.1007/s40719–014–0004–5
108. Fergason J, Keeling JJ, Bluman EM. Recent advances in lower extremity amputations and prosthetics for the combat injured patient. *Foot Ankle Clin* 2010;15(1):151–174.
109. Holcomb J, Caruso J, McMullin N, et al. Causes of death in US special operations forces in the global war on terrorism: 2001–2004. *Ann Surg* 2007;245(6):986–991.
110. Hauser CJ, Boffard K, Dutton R, et al. Results of the CONTROL trial: efficacy and safety of recombinant activated factor VII in the management of refractory traumatic hemorrhage. *J Trauma* 2010;69:489–500.
111. Rago AP, Sharma U, Sims K, et al. Conceptualized use of self-expanding foam to rescue special operators from abdominal exsanguination: Percutaneous damage control for the forward deployed. *J Spec Oper Med* 2015 Fall;15(3):39–45.
112. Mesar T, Martin D, Lawless R, et al. Human dose confirmation for self-expanding intra-abdominal foam: A translational, adaptive, multicenter trial in recently deceased human subjects. *J Trauma Acute Care Surg* 2015;79(1):39–46.
113. Velmahos GC, Spaniolas K, Tabbara M, et al. Abdominal insufflation decreases blood loss without worsening the inflammatory response: implications for prehospital control of internal bleeding. *Am Surg* 2008;74(4):297–301.
114. Tiba MH, Draucker GT, McCracken BM, et al. Use of pelvic hemostasis belt to control lethal pelvic arterial hemorrhage in a swine model. *J Trauma Acute Care Surg* 2015;78(3):524–529.
115. Halaweish I, Nikolian V, Georgoff P, et al. Creating a “prosurvival phenotype” through histone deacetylase inhibition: Past, present, and future. *Shock* 2015;44

Suppl 1:6–16.

116. Alam HB, Pusateri AE, Kindzelski A, et al.; HYPOSTAT workshop participants. Hypothermia and hemostasis in severe trauma: A new crossroads workshop report. *J Trauma Acute Care Surg* 2012;73(4):809–817.

117. Alam HB. Translational barriers and opportunities for emergency preservation and resuscitation in severe injuries. *Br J Surg* 2012;99 Suppl 1:29–39.

Chapter 20

Prehospital and New Advances in Resuscitation

John R. Taylor III, John B. Holcomb, and Bryan A. Cotton

Key Points

1 Prehospital care is an evolving field with more options to get early treatment to acutely injured patients.

2 Prehospital care does not have to be done by EMS personnel only; the emphasis is now on care given by other citizens on site.

3 Early and aggressive blood product resuscitation has transformed how we care for critically injured patients.

4 Technologic advances to include end-tidal CO_2 monitoring, ultrasound, tourniquets, and REBOA will continue to advance the field.

5 Further research into optimal type, timing, and amount of resuscitative fluid will change how we treat our patients in the field.

INTRODUCTION

Trauma continues to be the leading cause of death for 1 to 44 year olds and is the overall fifth leading cause of death for all age groups.[1] The care of the injured patient is a tightly integrated exercise combining the expertise of the prehospital care team and the trauma team once they arrive at the hospital. The likelihood of patient survival is vastly increased by timely transport and proper intervention in the acutely injured patient. The care of the injured patient begins immediately following injury. This may be rendered initially by nearby civilian bystanders or a variety of trained first responders. The recently published Hartford Consensus III outlines that it is the shared responsibility of the medical professionals as well as the noninjured, or minimally injured, patients at the scene to provide care to those injured, specifically addressing cessation of ongoing hemorrhage.[2] The main goal of a prehospital system is to provide timely appropriate care for the sick or injured patient and get them to the most appropriate hospital for definitive care as quickly and safely as possible. At times the most appropriate hospital may be the closest and at others it may be more distant, but with the capabilities more suitable to a particular patient. Most commonly, a phone call placed to a 9-1-1 dispatcher activates the emergency medical system (EMS) and quickly allocates resources to the location where help is needed.

PREHOSPITAL CARE

Personnel

Prehospital personnel are comprised of emergency medical technicians (EMTs), paramedics, firefighters, police, nurses, and less commonly physicians. The recently released Hartford Consensus III places nonmedical civilians on the forefront of hemorrhage control as a ready force of immediate responders. There are multiple levels of EMTs. The EMT-B or basic level has training capable of providing basic life support (BLS). BLS maneuvers include external hemorrhage control, spine immobilization, noninvasive cardiopulmonary resuscitation, and administration of supplementary oxygen, and application of an automated external defibrillator (AED). Paramedics require additional training, upward of 1200 hours, and may administer advanced life support (ALS) techniques. Prehospital ALS was first employed as a "mobile intensive care unit" in 1967.[3] In addition to the maneuvers administered by BLS personnel an ALS unit can provide cardiac drugs, pain control, blood pressure management, glucose control, needle decompression of tension pneumothoraxes, and anticonvulsant medication. There is much debate as to whether ALS is superior to BLS in the prehospital setting. Recent meta-analysis concluded that ALS provides a survival advantage only to nontrauma patients.[4]

In certain US cities a physician medical director of EMS is available at all times to respond to ground crews and dispatch centers for advice. The physician may also respond in person to certain calls as needed. Their role includes providing quality control, education, and approval of drug administration outside of set protocols. Outside of the United States some countries have full time physicians riding with ambulance crews at all time. While physician presence increases transport time there is evidence which indicates an increase in survival in patients with acute myocardial infarction and respiratory distress.[5]

Scoop and Run Versus Stay and Play

The two paradigms that dictate the amount and type of care that patients receive in the prehospital setting are the "Scoop and Run" and the "Stay and Play." The overarching premise of the Scoop and Run technique is to get the injured patient to a facility that can provide definitive care in the shortest period of time. The proponents of this system cite the increasing amount of evidence that prehospital interventions are fraught with complications from both their intervention as well as the resultant delay in arriving at a trauma facility.[6] Stay and Play advocates feel that the early control of life-threatening injuries is considered of critical importance in the management of the injured patient, and initiating therapy for such injuries in the prehospital environment may improve patient survival.[7] The true answer to which paradigm is best for the patient most likely lies somewhere in the middle of the two. In an urban setting with readily accessible, and multiple, trauma facilities it makes sense to extract the patient and get them to the closest center, performing limited, but lifesaving interventions during transport. In a rural environment, where access to a hospital may be greatest distances by road or prolonged wait for rotary wing care, it may be best to provide care on site allowing for stabilization of the patient's injuries. Further studies are necessary to decide which of these two paradigms provide the best care for the patient.

Table 20-1 Prehospital Assessments and Interventions

A	Chin-lift/jaw thrust, oropharyngeal airway, nasopharyngeal airway
B	LMA, king-tube, surgical airway, needle decompression, chest tube, capnography
C	Tourniquet, needle decompression, permissive hypotension, early blood products
D	C Spine immobilization, backboard placement, splinting of extremity fractures
E	Clothing removal, exposure of wounds, warming devices

SCENE ASSESSMENT AND MANAGEMENT PRIORITIES

Airway

1 It is paramount once on scene for the EMT to determine the status of the patient's airway. Evaluating the patient's Glasgow Coma Scale (GCS), chest rise, extent and nature of injuries provides vital insight into whether or not the patient is and will be able to maintain their airway (Tables 20-1 and 20-2). Supplemental maneuvers such as suctioning, chin lift/jaw thrust, placement of oropharyngeal airways, and use of bag-mask devices can temporarily restore oxygenation in the acutely injured patient. These maneuvers will usually maintain airway patency for the patient during their transport to definitive care; for those who are unable to do so, advanced airway maneuvers are key to securing a patent airway. Tracheal intubation provides a definitive airway with a cuffed endotracheal tube that will facilitate oxygenation, ventilation, and prevent aspiration. The skills required to successfully intubate are difficult to achieve and require remediation and oversight to maintain.[8] There is conflicting literature to support field intubation. Winchell and Hoyt completed a retrospective review of blunt trauma patients with severe head injury in San Diego that found statistically significant decrease in mortality between patients intubated in the field and those who were not.[6] The only randomized controlled trial of prehospital intubation versus bag-mask ventilation occurred in 2000 with pediatric patients, and it showed that the addition of out-of-hospital intubation did not improve survival or neurologic outcomes.[9] A retrospective review of prehospital intubation versus bag-mask ventilation by Stockinger and McSwain showed no survival advantage to intubation and an increased prehospital time.[8] The majority of literature suggests that prehospital intubation does not improve survival and may prolong time to definitive care.[10] One meta-analysis evaluating emergency intubation for the acutely ill showed no survival benefit in nontraumatic cardiac arrest prehospital intubation, as well as no evidence of prehospital intubation benefitting trauma patients in the urban environment.[11] While the majority of situations in the prehospital setting do not require intubation, there are some that make sense to secure an airway. Patients who have evidence of extensive facial trauma, patients who will require long transport times to reach definitive care, and those patients who are apneic due to suspected cervical injury are appropriate to intubate in the prehospital setting. The reflexive intubation to "protect" the airway should be avoided, and further randomized studies are required to truly answer the question of who and when to intubate in the prehospital setting.

Table 20-2 Listening to the Patient

Patient Complaint	Clinical Problem
"I can't breathe!"	Ventilatory dysfunction
"I need to sit up!"	Hypoxia Ventilatory dysfunction Tamponade
"I can't swallow!" "I'm choking!"	Airway dysfunction
"I'm gonna die!" "Please help me!"	Hypoxia Hemorrhage
"I'm thirsty!"	Hemorrhage

There are alternative measures that can be taken for those who need to establish an airway but do not have the skills for intubation. Laryngeal mask, Combitube, and King Airway all require less training and skill for insertion, however, they have never been shown to increase survival. While the invention of video-assisted airway insertion devices has taken hold in the hospital setting for "difficult" airways, its use in the prehospital setting has not been studied in depth. A retrospective review of patients in Europe showed the prehospital use of the Glidescope facilitated successful intubation when conventional direct laryngoscopy failed.[12] This study is limited by its small size and retrospective nature, however, as technology advances the use of video-assisted airway devices may allow for more successful prehospital intubation. Whether or not these devices will increase survival in patients is unknown at this time. A surgical cricothyroidotomy (CRIC) can provide an emergency airway in the hands of skilled practitioners. This maneuver requires much training and is usually utilized by military personnel in austere environments, or after failed orotracheal intubation efforts. A retrospective review by the Israeli Defense Force showed a 93% success rate with CRIC for patients requiring an emergency airway.[13]

Breathing

Assessment of patient's breathing occurs simultaneously with airway assessment. Evaluation of symmetric chest rise, obvious signs of chest trauma, and presence of bilateral breath sounds give the first responder an idea of the patient's status. The presence of a tension pneumothorax is a life-threatening event that may lead to obstructive shock, hemodynamic collapse, and potentially death. EMTs may also identify a patient with a tension pneumothorax with the presence of tracheal deviation, neck vein distention, and cyanosis. Prompt decompression of the thoracic cavity with a needle is necessary to reverse the tension effect. While the traditional landmark has been the midclavicular line, cadaver and computerized tomography evaluations had demonstrated more consistent evacuation of air using the anterior axillary, especially in females.[14] Further management with tube thoracostomy will be evaluated once the patient arrives at their receiving facility. Large sucking chest wounds, that permit the rapid equilibration of pleural and atmospheric pressure, can be rapidly fatal. These wounds prevent the lung from expanding and preclude alveolar ventilation. These large wounds cause hemodynamic collapse rapidly unless an airway is obtained that allows for positive pressure ventilation. The very rare smaller open chest wounds are amenable to a three-sided dressing that allows for gas to exit from the chest wall defect but prevents gas from entering the chest wall. These can be fashioned in a field expedient manner and function as a temporizing action until definitive therapy with a chest tube, in a sterile environment, can be achieved.

In addition to gross disturbances and threats to oxygenation and ventilation, prehospital personnel should be aware of these specific interventions as occasionally they can lead to greater harm than the injury itself. Over the last decade, the trauma literature has shown that the manner in which we previously cared for the airway in traumatic brain injury (TBI) may have done more harm than good.[15,16] Hyperventilation in the prehospital setting had been previously advocated, and is unfortunately still occasionally practiced, leading to acute vasospasm in the cerebral blood flow causing an overall decrease in the cerebral blood flow in patients with a severe TBI. This has since been abandoned in favor of normocapnea, decreasing the actual increase in overall cerebral blood flow (and worse outcomes) with hyperventilation.[15,17] Warner et al. in the Journal of Trauma showed that end-tidal CO_2 monitoring in the prehospital setting poorly correlated with the actual arterial blood gas analysis pCO_2, and as such suggested that using it to guide prehospital ventilation status may lead to inadvertent hypercapnia.

Given that many prehospital personnel ventilate patients via bag-valve devices connected to either a facemask or directly to an endotracheal tube, experts in the field and numerous investigators have advocated for the use of end-tidal CO_2 monitoring in these settings.[18,19] Silvestri et al. showed that there were no misplaced endotracheal tubes in patients who had continuous end-tidal CO_2 monitoring (0/93) whereas 23.5% of misplaced (14/60) prehospital intubation did not use monitoring in the prehospital setting. With bag volumes in excess of 1,200 mL, uncontrolled bag ventilation can easily lead to inadvertent hyperventilation. In fact, researchers have shown that almost 80% of

end-tidal CO_2 values for intubated TBI patients are <30 mm Hg in the field.[20] Patients with severe TBI were shown to have decreased mortality when their $PaCO_2$ was maintained between 30 and 35, 21.2% versus 33.7% by Warner et al. This paper suggests that prehospital monitoring, along with close continued monitoring of arterial blood gases after admission to the hospital will lead to interval decrease in mortality.

Circulation

Evaluation and treatment of circulatory status in the prehospital setting has undergone much change in the past 10 years. The experiences from the Global War on Terror have rapidly changed the way in which we think about prehospital circulation and how we treat the abnormalities in circulation. Evaluation of circulatory status begins with initial evaluation of mental status and inspection for obvious signs of active hemorrhage. Direct pressure and hemostatic dressings can be used for control of hemorrhage; however, large volume extremity hemorrhage may need to be addressed with placement of a tourniquet. A prospective evaluation of tourniquets applied during Operation Iraqi Freedom showed increased survival with tourniquet placement and no subsequent limb loss due to their use.[21] Passos et al. reviewed the use of emergency tourniquet use in the civilian setting and found that they prevented exsanguination in the setting of both blunt and penetrating extremity trauma.[20]

Once the circulatory status of the patient has been addressed, sites of rapid compressible exsanguination identified and treated, the decision is made for intravenous access and possible use of intravenous fluid. In 2009 the Eastern Association for the Surgery of Trauma published their practice management guidelines regarding prehospital fluid resuscitation of the injured patient. These guidelines support placement of peripheral IV or intraosseus access only if it does not delay the transport of the patient, as well as small fluid boluses of 250 cc of hypertonic (3% or 7.5%) saline being equivalent to volume resuscitation with 0.9% normal saline or lactated ringers.[22] These guidelines also support minimizing fluid resuscitation until hemorrhage is addressed and not resuscitating those patients with penetrating torso trauma. There is, however, data from the Resuscitation Outcomes Consortium (ROC) that resuscitation with hypertonic fluids versus normal saline did not result in improved 28-day survival.[23] The patients were randomized 250 mL boluses of either hypertonic saline (7.5%) versus hypertonic saline per 6% dextran versus 0.9% normal saline. The study was stopped early due to potential safety concern based on increased mortality in the group that received hypertonic saline. As such, current clinical guidelines do not recommend the regular use of hypertonic saline resuscitation in the severely injured patient.

Further evaluation has led researches to push for earlier transfusion of blood product components as in the prehospital setting. Studies from severe combat casualties showed that an aggressive approach to prehospital blood transfusion was associated with large improvement in mortality; however, further randomized studies were necessary.[24] Severely injured patients are now receiving blood transfusion in the civilian setting while en route to facilitate early hemostatic resuscitation and prevention of coagulopathy complications. Brown and colleagues conducted a retrospective, case-controlled analysis of patients who received prehospital packed red blood cells (240 patients) against those who did not (480 patients).[25] Their study showed an increased likelihood of 24-hour survival, lower odds of shock, and lower overall 24-hour blood transfused. A subsequent paper from these investigators evaluated over 2,000 blunt trauma patients arrived at one of eight subject institutions within 2 hours of injury.[26] Of the 2007 patients, 50 (3.5%)

received blood in the prehospital setting, and they were compared to controls who did not. Those patients who received prehospital blood had a 95% reduction in the odds of 24-hour mortality, 64% reduction in 30-day mortality, and an 88% reduction in the incidence of trauma-induced coagulopathy.

In patients without evidence of hemorrhage or in prehospital settings where blood and blood products are not available, numerous choices of fluid are available. However, most fluid options are actually poor choices for resuscitation of injured patients. Normal saline (0.9% sodium chloride) has an average pH of 5.5, with a sodium and chloride concentration of 154 mEq/L. Normal saline is often preferred as a universal solution for prehospital settings as it is "compatible with blood," contains no potassium, and is cheap to carry; with a low overall cost and extended shelf life. Lactated Ringer's, initially developed to support organs in the lab (because of calcium content) and later championed for treating cholera, has only a slightly better physiologic profile. Lactated Ringer's gives the clinician a better average pH of 6.5, with lower sodium (130 mEq/L) and chloride content (109). The optimal fluid, however, is Plasmalyte®/Normosol® which has an average pH of 7.4 and an electrolyte content that resembles a normal metabolic profile (sodium – 140 mEq/L, potassium – 5.0 mEq/L, chloride – 98 mEq/L, and magnesium – 3.0 mEq/L). In addition to its superior profile, Plasmalyte® is compatible with all blood products and has been shown in a randomized trial to result in improved acid–base status and less hyperchloremia at 24 hours postinjury.[27] There is increased interest in the use of plasma as a prehospital fluid, be it conventional or freeze dried, and this is reflected in the ongoing Prehospital Use of Plasma in Traumatic Hemorrhage (PUPTH trial).[28] The aim of this study is to compare prehospital resuscitation with plasma versus normal saline in patients who are found to be in shock from either blunt or penetrating mechanisms. While results are pending, hopefully this study will shed more light on the ideal type and amount of prehospital fluid for resuscitation.

TRIAGE

Triage is an active process that takes into account multiple factors with the goal of transporting the patient to the correct trauma center in the shortest amount of time. The Centers for Disease Control and Prevention have published guidelines helping to facilitate proper triage of injured patients since 1999. These guidelines underwent their most recent update in 2011 and use physiologic, anatomic, and the mechanisms of the injury to guide the triage of the patient.[29] Changes specific to the 2011 update include lowering GCS for the physiologic criteria, broadening the definition of injuries in the anatomic criteria, and addressing the differences in older adult trauma patients relative to young trauma patients. The implementation of these guidelines is key to preventing both under- and overtriage of the acutely injured patient. Undertriage is the practice of sending an acutely injured patient to a lower than needed tier in the trauma system. This leads to prolongation to definitive care for injuries, multiple transfers to identify the correct level of care, and overall worse care of the patient. Overtriage is transferring a patient to a highest-level trauma system when their injuries do not warrant that level of care. This allocates scarce resources to patients who ultimately do not need them, and as such may prevent those who need that resource appropriately from getting it. In 2011, a review of the triage guidelines from 1999 compared to 2006 showed a statistically significant decrease in the number of patients who were overtriaged when the guidelines were followed appropriately.

A special triage situation occurs when multiple patients are injured. A multicasualty event occurs when a hospital is able to manage the number of casualties with local resources. The majority of level 1 trauma centers are able to take care of a small multicasualty event without significant strain on their work environment. A mass-casualty event exists when the numbers, severity, and diversity of injuries overwhelm the local medical resources. A recent example of a mass-casualty event is the April 15, 2013 bombing of the Boston Marathon. A terrorist attack by two terrorists, bent on causing fear and destruction, deployed two homemade improvised explosive devices (IEDs) near the finish line of the race. Two hundred sixty-four patients sought treatment for injuries from the event; there were three fatalities on scene and numerous patients transferred to the five level 1 trauma centers located in Boston.[30] An active onsite triage team was able to identify those patients who needed immediate transfer based on criteria and send them to one of the awaiting hospitals for immediate treatment. Specifically, the Brigham and Women's Hospital received a total of 31 patients immediately following the bombing, of which 23 arrived within the first hour.[31] Of those transported to the Brigham that day, fifteen patients were admitted to the hospital, nine went to the operating room, and none died. Mass-casualty events require coordination at the state and national level, and extensive practice at implementing triage criteria. Interestingly, in 2002 the city of Boston completed a citywide mass-casualty practice event in response to the 9/11 Attack. Some credit for the successful actions that due has been given to the experience gained from this practice and other drills.

ADVANCES AND CONTROVERSIES

Rapid Sequence Intubation Versus Non-RSI

The use of rapid sequence intubation (RSI) in the prehospital setting is one that engenders much discussion in the prehospital setting. A standard of care in the inpatient setting, the use of RSI in the prehospital setting is both supported and refuted by the literature over time. The drugs that are used for RSI, while no one standard is accepted by everyone, include combinations of the following: diazepam, succinylcholine, vecuronium, midazolam, rocuronium, lidocaine, ketamine, and etomidate. Many argue that the complications that are associated with RSI, including the consequences of multiple failed intubation attempts, unnecessary exposure of patients to dangerous procedure, and complications of the medications do not value the implementation of RSI in the prehospital setting.

A 2005 paper published on the use of RSI in the out-of-hospital setting was unable to predict which patients had severe TBI and over half the patients experienced a desaturation during the RSI procedure, while only one-quarter of they were hypoxic before RSI.[32] A further study from the United Kingdom showed an incidence of 18.3% for hypoxemia during prehospital RSI and 13% developed hypotension lower than pre-RSI blood pressures.[16] This paper attributes its lower incidence of hypoxemia and hypotension to the fact that in the United Kingdom board certified Physicians preform all the prehospital RSI and intubations, while in the San Diego paper the entire procedure was carried out by EMTs. Using a propensity-adjusted model, investigators showed no statistical difference in mortality between prehospital intubations with and without RSI. Further randomized, prospective trials are necessary to prove a benefit to prehospital RSI.

Aggressive Fluids Versus Permissive Hypotension

The concept of permissive hypotension involves keeping the blood pressure low enough to avoid exsanguination while maintaining perfusion of end organs.[33] It is an integral part of the new Damage Control Resuscitation protocols that are being implemented; however, its root goes as far back as World War I. The work of Walter Cannon and John Fraser while serving with the Harvard Medical Unit in France involved the observation that artificial elevations in blood pressure may overcome the clot preventing further hemorrhage, and the patient will lose sorely needed blood.[34] Fast forward to 1994 when the plenary paper by Bickell et al. showed in a randomized prospective control trial delayed fluid resuscitation in adults with penetrating torso injuries lead to greater survival and overall shorter hospital length of stay.[35] These results have been repeated in further subsequent studies by other authors showing no benefit to early aggressive resuscitation, especially to supernormal levels. Finally, Holcomb et al. in 2007 published the plenary paper on damage control resuscitation outlining the two important principles of resuscitating to a systolic blood pressure no greater than 90 and using thawed plasma in a 1:1 or 1:2 ratio with PRBC to restore intravascular volume.[36]

The concept of permissive hypotension is directly contradictory to the guidelines found in the ATLS manual that advocate for 2 L of crystalloid resuscitation early in those patients manifesting signs of shock. However, a recent multicenter, randomized study by the ROC suggests that a restrictive strategy is warranted in blunt trauma patients as well.[37] The investigators randomized hypotensive trauma patients to receive small boluses of fluid (250 mL) if they had no radial pulse or a systolic blood pressure lower than 70 mm Hg or to receive the standard 2-L fluid bolus and additional fluid needed to maintain a systolic of 110 mm Hg or greater. Patients in the hypotensive resuscitation group (fluid for systolic $<$70 mm Hg) had a lower 24-hour mortality compared to standard resuscitation group (3% vs. 18%).

Schreiber et al. conducted a randomized prehospital trial placing patients into either of two groups: (1) standard resuscitation patients who received 2 L of crystalloid initially and fluid as needed to maintain a systolic blood pressure of 110 mm Hg or greater, or (2) controlled resuscitation patients who received 250 mL of fluid if they had no radial pulse or an SBP lower than 70 mm Hg, with additional 250-mL boluses to maintain a radial pulse or SBP of 70 mm Hg or greater. The controlled resuscitation group received 1 L less of fluid, had less deaths (5% vs. 15%) at 24 hours after admission, and among patients with blunt abdominal trauma 24-hour mortality was 3% versus 18%, all statistically significant. This paper showed that controlled resuscitation in the out-of-hospital setting may offer an early survival advantage to the blunt trauma patient. There was, however, no difference in mortality among patients with penetrating trauma.

2 Further studies are necessary to cement at which level the resuscitation should be stopped; however, we now know that minimal intravenous fluids, tolerating systolic blood pressures in the 75 to 90 mm Hg range, and not resuscitating to supernormal values with crystalloid is the paradigm prehospital trauma workers should follow.

Prehospital Blood Protocols

The lessons from the Global War on Terrorism have changed many paradigms regarding the prehospital care of the acutely injured patient. Some argue that the advent of prehospital blood product transfusion protocols will make the greatest impact on civilian trauma management. Early studies identified the prehospital setting as an ideal place to begin early resuscitation with blood products, as hemorrhage was identified to cause 33% to 56% of the prehospital casualties. In a multicenter study of over 1,400 injured patients with evidence of shock, Brown and colleagues demonstrated an increase in both 24-hour and 30-day survival, as well as less coagulopathy on arrival in those patients receiving prehospital red blood cell (RBC) transfusions.[38] Building on this, the Houston group published their aeromedical experience with prehospital plasma and RBC, which began in 2011.[39] Similar to the data published from the wars in Iraq and Afghanistan, the investigators noted in their study of almost 1,700 patients that placing RBCs and plasma products in the prehospital setting, allowing for earlier infusion of life-saving products to critically injured patients, was associated with improved early outcomes.

3 The more recent PROPPR trial included patients who received blood transfusion en route and showed that more patients resuscitation in the 1:1:1 group versus 1:1:2 group achieved hemostasis and fewer experienced death due to exsanguination by 24 hours.[40] This study will hopefully spur further prospective, randomized control trials trying to identify the proper type and amount of blood product resuscitation in the prehospital setting.

$ETCO_2$ Monitoring

4 The use of end-tidal CO_2 ($ETCO_2$) as a means for measurement of exhaled CO_2 is the standard found in the operating room and emergency room; however, its use in the prehospital setting was not commonplace 10 years ago. $ETCO_2$ is a reflection of metabolism, circulation, and ventilation. As technology has advanced, the ease of use and application of $ETCO_2$ monitoring has become more commonplace. $ETCO_2$ was first used as a way to confirm placement of endotracheal tubes in the prehospital setting using colorimetric CO_2 detector.[8] The use of the colorimetric detector in conjunction with auscultation and symmetric chest rise make the likelihood of esophageal intubation near zero. This must be prevented as esophageal intubation rates have been reported as high as 17% to 25% in emergency airway management of nonarrest patients.[41] In-line capnography in the nonintubated patient is key to assessing the adequacy of chest compressions in patients undergoing CPR. $ETCO_2$ has been shown to correlate linearly with coronary artery perfusion pressure, and hence is a simple and noninvasive method to measure blood flow during CPR and can indicate return of spontaneous circulation. In 2009 a study of out of Harborview Hospital showed that documented $ETCO_2$ in prehospital intubations did not correlate to ABG $PaCO_2$, with patients most likely being under ventilated ($PaCO_2$ >40) 80% of the time and severely underventilated ($PaCO_2$ >50) 30% of the time.[42] As such, the use of $ETCO_2$ is to assess for proper endotracheal intubation as well as ascertain effectiveness of CPR is established, however, its ability to predict $PaCO_2$ will need further study.

Tourniquet Use in the Field

5 Tourniquet use for injury has documentation as far back as 6 BC in Hindu text for the treatment of a snakebite.[43] Over time it has fallen in and out of favor in the prehospital setting, however, experiences during the recent Global War on Terror support its use as far forward as possible in the prehospital setting. In the Vietnam War surgeons recognized that of the casualties killed in the war, 2,590 lives could have been saved with better prehospital care namely tourniquets.[21] Analysis of the casualties of Operation Gothic Serpent, the 1993 battle fought between U.S. forces and the militias in Somalia, showed 7% of fatalities resulted from penetrating extremity trauma and that hemorrhage control in the form of tourniquet use should be more widely adopted.[43] The current conflict in Iraq and Afghanistan brought out the strongest data supporting the use of prehospital tourniquets. A prospective study of casualties over a 7-month period in 2006 at a combat hospital in Baghdad showed tourniquet application with the abscence of shock was strongly associated with survival, no amputations resulted solely from tourniquet use, and only four nerve palsies at the level of the tourniquet occurred all of which resolved without issue.[21] Further papers have gone on to show civilian application of this concept also saves lives and limbs. In 2015, Scholl et al. published a retrospective review of civilian trauma patients admitted with a prehospital tourniquet at nine institutions. Their data show overall mortality and limb amputation rate in statistically similarly injured patients was less than that seen in military data previously documented. A final, more fatal, type of hemorrhage is junctional hemorrhage defined as bleeding from the pelvis, groin, perineum, axilla, and neck. These wounds were seen extensively in the Global War on Terrorism as the use of IED increased. Holcomb et al. reviewed preventable causes of death in U.S. Special Forces Soldiers in 2007 and found that junctional or noncompressible trauma was implicated in 47% of deaths.[44] A future place for research, the junctional tourniquet has shown in healthy volunteers to occlude blood flow to the lower extremity.[45] While these experiences are mainly from combat environments, application to the civilian field has been successfully implemented.[46] A paper out of the trauma group at USC showed that prehospital use of tourniquet, be it Combat Application Tourniquet, field expedient tourniquet, or pneumatic tourniquet placed in the emergency room, is associated with no increased rate of complications.[47] Of note from this study, only 50.6% of the tourniquets were placed in the prehospital setting, leading to further question as to whether or not full implementation of prehospital tourniquets would lead to further success in preventing mortality and decreasing complications from traumatic extremity injuries. A subsequent multi-institutional retrospective analysis of prehospital tourniquet use showed lower overall mortality and limb amputation rates when compared to historical combat data.[48] This paper showed that extrapolation of military data, as well as practices, to the civilian trauma patient leads to increased survival and limb salvation.

Resuscitative Endovascular Balloon Occlusion of Aorta

Resuscitative endovascular balloon occlusion of aorta (REBOA) is a balloon placed via the femoral artery to occlude the aorta and prevent life-threatening hemorrhage (Fig. 20-1). While the technology is new, the idea is not as it is described in an article in the journal *Surgery* in 1954 for controlling intra-abdominal hemorrhage. Multiple animal studies have shown that REBOA is superior to emergency thoracotomy with aortic clamping to control hemorrhagic shock in the porcine model.[49] Control of hemorrhage far forward in the military combat environment is the goal of the REBOA. A retrospective analysis of UK combat casualties, 18.5% had an indication for REBOA when reviewing their injuries.[50] While it is rapidly gaining popularity as a substitute for resuscitative thoracotomy, it is probably best suited for quickly controlling pelvic hemorrhage (before the patient has lost pulses) prior to embolization and interventional radiology availability. Research is now being produced that shows a benefit to REBOA use for hemorrhage control. Brenner et al. published a series of six cases in 2013 that outlined the successful implementation for hemorrhage control of REBOA.[51] Successful implementation of REBOA in these six cases showed that endovascular aortic occlusion supports myocardial and cerebral perfusion until resuscitation can be initiated and hemostasis obtained, the same goals of aortic cross clamping in a markedly less invasive manner. Further research published in 2015 compared the outcomes of REBOA versus resuscitative thoracotomy for noncompressible truncal hemorrhage. In clinically similar groups, the REBOA group had fewer early deaths, improved overall survival (37.5% vs. 9.7%, $p = 0.003$) with less morbidity than the resuscitative thoracotomy group.[52] While this took place in only two centers with advanced skills with REBOA, it is feasible that continued training in endovascular skills during both the training and attending years may lead to greater implementation of this skill. The Japanese have published a retrospective review of their experience with the safety and feasibility of REBOA for trauma in 2014.[53] Their data show that REBOA was feasible for trauma resuscitation, however, there was an increased risk of lower limb ischemia and possible amputation that occurred in 12.5% of their patients. New technologic advances producing small sheaths and smaller balloons may eliminate the need to close an arteriotomy required of larger sheaths and thus decrease this risk. Further forward management of REBOA in the field environment may be on the horizon, however, for now its implementation to control traumatic hemorrhage is still in its infancy and the risk–benefit of placing these in the most skilled hands (much less in undertrained personnel or in the prehospital setting) has not been determined.[54]


Percutaneous Entry Thinwall Needle
One-Part
REF SDN-18-7.0
REF G00166
18G / 7cm
Rx only
STERILE EO
2017-12
LOT 3921163
2012-12
A


Rosen Curved Wire Guide
REF G01264
REF THSCF-35-180-1.5-ROSEN
.035"
1.5mm
LOT 3632013
2012-09
2017-09
STERILE EO
B


Coda® Balloon Catheter
REF G53025
REF CODA-2-10.0-35-120-40
.035" (0.89mm)
10Fr (3.3mm)
40mm
38mm
120cm
STERILE EO
2014-11
Rx only
LOT 2888393
2011-11
C


Boston Scientific
0.035in x260cm
Amplatz Super Stiff™
STRAIGHT TIP
SHORT TAPER
Guidewire
(1)
260cm
1cm
0.035in (≤0.91mm)
REF 46-509
2014-10
UPN M001465090
LOT 14736527
D


E

Figure 20-1. Performance of REBOA. Steps of Insertion:

1. Use the percutaneous entry thin wall needle to access the common femoral artery via cutdown, percutaneous access, or wired exchange of existing arterial line (**A**).
2. Insert the Rosen guide wire (0.035) through the needle, then remove the needle (**B**).
3. Open the CODA catheter kit: dilate with the gray 10-Fr then the 12-Fr dilator (**C**).
4. Through the 12-Fr dilator, exchange the 0.035 guidewire for the Amplatz super stiff guidewire.
5. Dilate with the 14-Fr dilator and then assemble the introducer sheath by placing the 14-Fr dilator through the sheath (like a Cordis). Insert the dilator/sheath unit over the guidewire. Place the sheath to a premeasured distance (arterial puncture to umbilicus) then remove the dilator but not the guidewire (**D**).
6. Open CODA balloon (yellow) and remove black tip. *Do NOT test balloon* (**E**).
7. Insert balloon catheter to premeasured distance + 10 cm.
8. Place three-way stopcock (packaged separately in balloon kit) to the end of the balloon catheter.
9. Gently inflate balloon through the sideport until loss of contralateral femoral pulse (can confirm with Doppler US). Do not exceed 40 mL (can use air, saline, or 50% contrast diluted with saline). (**E**).
10. Secure catheter to the patient and document positioning with KUB or fluoroscopy.

CONCLUSION

Prehospital trauma care is a constantly evolving field. Much of our advances from recent military conflicts are being rapidly implemented in the civilian prehospital setting. Further research and developments are necessary to continue the previous success seen in saving the critically injured trauma patient.

References

1. *National Vital Statistics Reports.* Vol. 62. No. 2. 2015. Available from: www.cdc.gov/injury/images/lc-charts/leading_causes_of_death_age_group_2014_1050w760h.gift
2. Jacobs LM; Joint Committee to Create a National Policy to Enhance Survivability from Intentional Mass-Casualty and Active Shooter Events. The Hartford consensus III: Implementation of bleeding control: if you see something do something. *Bull Ame Coll Surg* 2015;100:40–46.
3. Beuran M, Paun S, Gaspar B, et al. Prehospital trauma care: a clinical review. *Chirurgia* 2012;107:564–570.
4. Lerner EB, Shah MN, Swor RA, et al. Comparison of the 1999 and 2006 trauma triage guidelines: where do patients go? *Prehosp Emerg Care* 2011;15(1):12–17.
5. Haas B, Nathens AB. Pro/con debate: is the scoop and run approach the best approach to trauma services organization? *Crit Care* 2008;12:224–240.
6. Winchell RJ, Hoyt DB. Endotracheal intubation in the field improves survival in patients with severe head injury. *Arch Surg* 1997;132(6):592–597.
7. Gausche M, Lewis RJ, Stratton SJ, et al. Effect of out-of-hospital pediatric endotracheal intubation on survival and neurological outcome: a controlled clinical trial. *JAMA* 2000;283:783–790.
8. Stockinger ZT, McSwain NE Jr. Prehospital endotracheal intubation for trauma does not improve survival over bag-valve-mask ventilation. *J Trauma* 2004;56(3):531–536.
9. Struck MF, Wittrock M, Nowak A. Prehospital glidescope video laryngoscopy for difficult airway management in a helicopter rescue program with anesthetists. *Eur J Emerg Med* 2011;18:282–284.
10. Katzenell U, Lipsky AM, Abramovich A, et al. Prehospital intubation success rates among Israel Defense Forces providers: epidemiologic analysis and effect on doctrine. *J Trauma Acute Care Surg* 2013;75(suppl 2):S178–S183.
11. Lecky F, Bryden D, Little R, et al. Emergency intubation for acutely ill and injured patients. *Cochrane Database Syst Rev* 2008;(2):CD001429.
12. Donald MJ, Paterson B. End tidal carbon dioxide monitoring in prehospital and retrieval medicine: A review. *Emerg Med J* 2006;23:728–730.
13. Davis DP, Vadeboncoeur TF, Ochs M, et al. The association between field Glasgow come scale score and outcome in patients undergoing paramedic rapid sequence intubation. *J Emerg Med* 2005;29(4):391–397.
14. Inaba K, Branco BC, Eckstein M, et al. Optimal positioning for emergent needle thoracostomy: a cadaver-based study. *J Trauma* 2011;71:1099–1103; discussion 1103.
15. Warner KJ, Cuschieri J, Copass MK, et al. Emergency department ventilation effects outcome in severe traumatic brain injury. *J Trauma* 2008;64:341–347.
16. Cudnik MT, Newgard CD, Daya M, et al. The impact of rapid sequence intubation on

trauma patient mortality in attempted prehospital intubation. *J Emerg Med* 2010;38(2):175–181.

17. Kerby JD, Cusick MV. Prehospital emergency trauma care and management. *Surg Clin North Am* 2012;92:823–841.
18. Silvestri S, Ralls GA, Krauss B, et al. The effectiveness of out-of-hospital use of continuous end-tidal carbon dioxide monitoring on the rate of unrecognized misplaced intubation within a regional emergency medical services system. *Ann Emerg Med* 2005;45(5):497–503.
19. Davis DP, Hoyt DB, Ochs M, et al. The effect of paramedic rapid sequence intubation on outcome in patients with severe traumatic brain injury. *J Trauma* 2003;54(3):444–453.
20. Passos E, Dingley B, Smith A, et al. Tourniquet use for peripheral vascular injuries in the civilian setting. *Injury* 2014;45(3):573–577.
21. Kragh JF Jr, Walters TJ, Baer DG, et al. Survival with emergency tourniquet use to stop bleeding in major limb trauma. *Ann Surg* 2009;249(1):1–7
22. Cotton BA, Jerome R, Collier BR, et al. Guidelines for prehospital fluid resuscitation in the injured patient. *J Trauma* 2009;67(2):389–402.
23. Bulger EM, May S, Kerby JD, et al. Out-of-hospital hypertonic resuscitation after traumatic hypovolemic shock: A randomized, placebo controlled trial. *Ann Surg* 2011;253(3):431–441.
24. O'Reilly DJ, Morrison JJ, Jansen JO, et al. Prehospital blood transfusion in the en route management of severe combat trauma: A matched cohort study. *J Trauma Acute Care Surg* 2014;77(3 suppl 2):114–120.
25. Brown JB, Sperry JL, Fombona A, et al. Pre-trauma center red blood cell transfusion is associated with improved early outcomes in air medical trauma patients. *J Am Coll Surg* 2014;78(1):781–790.
26. Brown JB, Cohen MJ, Minei JP, et al. Pretrauma center red blood cell transfusion is associated with reduced mortality and coagulopathy in severely injured patients with blunt trauma. *Ann Surg* 2015;261(5):997–1005.
27. Young JB, Utter GH, Schermer CR, et al. Saline vs plasma-lyte A in initial resuscitation of trauma patients: A randomized trial. *Ann Surg* 2014;259(2):255–262.
28. Reynolds PS, Michael MJ, Cochran ED, et al. Prehospital Use of Plasma in Traumatic Hemorrhage (The PUPTH Trial): study protocol for a randomized controlled trials. *Trials* 2015;16:321.
29. Sasser SM, Hunt RC, Faul M, et al.Centers for Disease Control and Prevention Guidelines for Field Triage of Injured Patients: Recommendations of the National Expert Panel on Field Triage, 2011. *MMWR Recomm Rep* 2012;61:1–20.
30. Gates JD, Arabian S, Biddinger P, et al. The initial response to the Boston marathon bombing: Lessons learned to prepare for the next disaster. *Ann Surg* 2014;260(6):960–966.

31. Walls RM, Zinner MJ. The boston marathon response: Why did it work so well? *JAMA* 2013;309(23):2441–2442.
32. Newton A, Ratchford A, Khan I. Incidence of adverse events during prehospital rapid sequence intubation: A review of one year on the London helicopter emergency medical service. *J Trauma* 2008;64:487–492.
33. Geeraedts LM Jr, Kaasjager HA, van Vugt AB, et al. Exsanguination in trauma: A review of diagnostics and treatment options. *Injury* 2009; 40(1):11–20.
34. Beuran M, Negoi I, Paun S, et al. [History of trauma care]. *Chirurgia(Bucur)* 2011;106(5):573–580
35. Bickell WH, Wall MJ Jr, Pepe PE, et al. Immediate versus delayed fluid resuscitation for hypotensive patients with penetrating torso Injuries. *N Engl J Med* 1994;331:1105–1109.
36. Holcomb JB, Jenkins D, Rhee P, et al. Damage control resuscitation: Directly addressing the early coagulopathy of trauma. *J Trauma* 2007;62(2):307–310.
37. Schreiber MA, Meier EN, Tisherman SA, et al. A controlled resuscitation strategy is feasible and safe in hypotensive trauma patients: Results of a prospective randomized pilot trial. *J Trauma Acute Care Surg* 2015;78(4):687–695.
38. Brown JB, Sperry JL, Fombona A, et al. Pre-trauma center red blood cell transfusion is associated with improved early outcomes in air medical trauma patients. *J Am Coll Surg* 2015;220(5):797–808.
39. Holcomb JB, Donathan DP, Cotton BA, et al. Prehospital transfusion of plasma and red blood cells in trauma patients. *Prehosp Emerg Care* 2015;19(1):1–9.
40. Holcomb JB, Tilley BC, Baraniuk S, et al. Transfusion of plasma, platelets, and red blood cells in a 1:1:1 vs a 1:1:2 ratio and mortality in patients with severe trauma: The PROPPR randomized clinical trial. *JAMA* 2015;313(5):471–482.
41. Bair AE, Smith D, Lichty L. Intubation confirmation techniques associated with unrecognized non-tracheal intubations by pre-hospital providers. *J Emerg Med* 2005;28(4):403–407.
42. Hamrick JL, Hamrick JT, Lee JK, et al. Efficacy of chest compressions directed by end-tidal CO_2 feedback in a pediatric resuscitation model of basic life support. *J Am Heart Assoc* 2014;3(2):117–125.
43. Mabry RL, Holcomb JB, Baker AM, et al. United States Army Rangers in Somalia: An analysis of combat casualties on an urban battlefield. *J Trauma* 2000;49(3):515–528.
44. Holcomb J, Caruso J, McMullin N, et al. Causes of death in US Special Operation forces in the global war on terrorism: 2001–2004. *US Army Med Dep J* 2007:24–37.
45. Lyon M, Johnson D, Gordon R. Use of a novel abdominal aortic and junctional tourniquet to reduce or eliminate flow in the brachial and popliteal arteries in human subjects. *Prehosp Emerg Care* 2015;19(3):405–408.
46. Scerbo MH, Mumm JP, Gates K, et al. Safety and appropriateness of tourniquets in 105 civilians. *Prehosp Emerg Care* 2016;31:1–11.

47. Inaba K, Siboni S, Resnick S, et al. Tourniquet use for civilian extremity trauma. *J Trauma Acute Care Surg* 2015;79(2):232–237.
48. Schroll R, Smith A, McSwain NE Jr, et al. A multi-institutional analysis of prehospital tourniquet use. *J Trauma Acute Care Surg* 2015;79(1):10–14.
49. Morrison JJ, Ross JD, Houston R 4th, et al. Use of resuscitative endovascular balloon occlusion of the aorta in a highly lethal model of noncompressible torso hemorrhage. *Shock* 2014;41(2):130–137.
50. Morrison JJ, Galgon RE, Jansen JO, et al. A systematic review of the use of resuscitative endovascular balloon occlusion of the aorta in the management of hemorrhagic shock. *J Trauma Acute Care Surg* 2016;80(2):324–334.
51. Brenner ML, Moore LJ, DuBose JJ, et al. A clinical series of resuscitative endovascular balloon occlusion of the aorta for hemorrhage control and resuscitation. *J Trauma Acute Care Surg* 2013;75(3):506–511.
52. Moore LJ, Brenner M, Kozar RA, et al. Implementation of resuscitative endovascular balloon occlusion of the aorta as an alternative to resuscitative thoracotomy for noncompressible truncal hemorrhage. *J Trauma Acute Care Surg* 2015;79(4):523–530.
53. Norii T, Crandall C, Terasaka Y. Survival of severe blunt trauma patients treated with resuscitative endovascular balloon occlusion of the aorta compared with propensity score-adjusted untreated patients. *J Trauma Acute Care Surg* 2015;78(4):721–728.
54. Inoue J, Shiraishi A, Yoshiyuki A, et al. Resuscitative endovascular balloon occlusion of the aorta might be dangerous in patients with severe torso trauma: A propensity score analysis. *J Trauma Acute Care Surg* 2016;80(4):559–567.

Chapter 21

Head Trauma

Phiroz E. Tarapore, Geoffrey T. Manley, and Randall M. Chesnut

Key Points

1. Care must be taken to avoid hypotension and hypoxia, as these cause secondary injury.
2. In the setting of hypotension, ample volume resuscitation is the first line of therapy.
3. In the absence of intracranial hypertension, ventilation should be maintained with a target $PaCO_2$ >35 mm Hg.
4. Hemoglobin should be maintained at or above 7 g/dL.
5. Traumatic CSF leak should be observed initially, without antibiotic prophylaxis. Persistent leak may require temporary CSF diversion and, if that fails, operative management.

INTRODUCTION

In the field of trauma, other than for exsanguinating injuries, traumatic brain injury (TBI) is the injury most commonly responsible for mortality, accounting for about half of deaths at the scene. In the United States alone, the annual incidence is 2.5 million, and TBI results in over 52,000 deaths per year.[1] The injuries are generally blunt, occurring most frequently in motor vehicle crashes (MVCs). As many as two-thirds of all MVC victims sustain some degree of brain injury. The incidence of TBI is also increasing globally, driven mainly by the increasing use of automobiles.

These data are generally applicable to children as well. Although the mechanisms vary, head injuries are the major cause of morbidity and mortality in childhood trauma victims, accounting for an annual mortality rate of 1 per 1,000 in this age group.[2] Falls are the leading cause of TBI in those under age 14 years.

Interestingly, falls are also the leading cause of TBI in those over age 65 years. With the aging of the baby-boomer generation, a new spectrum of brain injury is blossoming. For persons 65 years and older, TBI-related hospital admissions increased more than 50% between the periods of 2001–2002 and 2009–2010.[3] These patients have less inherent neurologic plasticity, limiting their recovery potential. Furthermore, they tend to have significant comorbidities and may be on one or more anticoagulants. The management of these patients is often different from that which is optimal for the younger population.

In patients with TBI, extracranial trauma is present in over half of cases. In these polytrauma patients, the best predictor of outcome is severity of the TBI.[4] It is therefore critical for a polytrauma patient to be expeditiously transported to a trauma center that can offer the multidisciplinary specialized care that is required. Patients with severe TBI, in particular, should be managed at a center with immediate CT capability, neurosurgical care, and ICP monitoring capability.[5] For these patients, direct transport to a level I or level II is associated with up to a 50% decrease in mortality.[6]

PATHOPHYSIOLOGY

Traumatic injury to the brain involves a primary brain injury that occurs at impact and leads to disruption of brain substance and blood vessels. In addition, secondary brain injury may result from hypoxia, hypotension, hyperventilation, pyrexia, the effects of increased intracranial pressure (ICP), and altered cellular biochemical processes that are often ongoing long after the primary insult.

Primary Injury

Energy transfer to the head causes direct disruption of neurons, glia cells, and microvasculature localized at the area of impact. As the brain rebounds within the skull, it is also vulnerable to impact with the opposite inner table. Therefore, countercoup injury to the contralateral brain is relatively common, in some cases being more severe than the damage at the primary impact site.

Particularly when the mechanism includes rotational forces, head trauma can result in widespread disruption of white matter axons throughout the brain, producing the condition termed *diffuse axonal injury* (DAI). Such injuries often damage a large number of widely distributed neurologic systems. When such injuries involve ascending pathways in both hemispheres or in the brainstem, the result is a depressed level of consciousness. The brain is also subject to torsion injury resulting from rotation around the fixed brainstem. This type of injury can damage the reticular activating system, producing unconsciousness.

Intracranial hemorrhage can take many forms. Direct laceration of epidural arteries from impact fractures or bleeding from fracture lines produces epidural hematomas, which damage the brain by compression. Disruption of bridging subdural veins and bleeding from cortical tissue damage produces a subdural hematoma, which is generally associated with disruption of underlying brain tissue. Intracerebral contusions, lacerations, and hematomas are caused by direct tissue disruption with associated vascular injury, producing neuronal damage and intraparenchymal bleeding.

Penetrating injury damages the brain through tissue injury caused directly by the projectile and, in the case of projectiles with relatively high velocity, result in disruption of neural tissue at a greater distance from the track via cavitation injury. In survivors, the extent and degree of the cavitation injury (related linearly to the mass and in a squared fashion to the velocity of the projectile) are often the primary determinant of outcome. Another source of morbidity is vascular injury, producing aneurysms, pseudoaneurysms, and other vascular anomalies that may present immediately or be delayed.

Whether a projectile or direct impact causes contusion, subdural hematoma, epidural hematoma, or DAI, currently little can be done therapeutically to change the magnitude or location of the primary injury once it has occurred. As such, most of our present care focus is on secondary injuries.

Secondary Injury

Once a primary brain injury has occurred, it sets off a variety of pathologic processes including neurotransmitter release, gene activation, mitochondrial dysfunction, and neuroinflammatory responses over the course of hours and days. These cascades, along with intracranial hypertension and cerebral ischemia, can cause secondary brain injury. The prevention of these secondary injuries is the goal of both medical and surgical management of TBI.

Biochemical and Genomic Processes

Primary tissue injury initiates a variety of biochemical processes, including free radical–mediated lipid peroxidation, excitotoxic "superactivation" of glutamate-aspartate neurotransmitter systems, and alterations in membrane receptor and ionic channel characteristics, among others. A variety of genomic processes are also activated, including apoptotic cell death. These processes can proceed for significant periods of time following primary injury and often are self-sustaining. The goal of the numerous clinical trials involving treatment of patients with brain trauma with various pharmacologic agents is to determine the means by which these processes may be attenuated or reversed. Unfortunately, to date, no clinically useful tools have been obtained from such research.

Cerebral Hypoperfusion and Hypoxia

1 The most dangerous secondary injury processes that occur following brain injury are systemic hypotension and hypoxia. Hypotension is the number one treatable determinant of severe head injury. A single episode of systolic blood pressure less than 90 mm Hg occurring during the period from injury through resuscitation doubles the mortality and significantly increases the morbidity of any given brain injury.[7,8] Furthermore, an early hypotensive episode strongly increases the probability of later intracranial hypertension. For these reasons, rapid and complete restoration of blood pressure is the most important goal in the resuscitation of the brain-injured patient.

Hypoxia (apnea or cyanosis in the field or a partial pressure of arterial oxygen [PaO_2] 60 mm Hg) is also an independent predictor of poor outcome.[7–9] The frequency and magnitude of hypoxia have been notably decreased by modern airway management techniques, particularly endotracheal intubation and assisted ventilation, in addition to ensuring adequate oxygen-carrying capacity through the avoidance of anemia. Recent studies suggest that intubation is safest in the hospital setting, and most emergency medical systems will not intubate patients in the field so long as they are ventilating and oxygenating adequately and transport time to the hospital is short.[10–13]

Cerebral tissue oxygen tension ($PBtO_2$) can be measured directly using implantable Clark electrodes. This makes it possible to follow the partial pressure of oxygen in the brain tissue. Although absolute thresholds have not been rigorously determined, values above 15 to 20 mm Hg are generally considered adequate and values below 5 mm Hg are associated with increasingly poor outcome in a duration-dependent fashion.[14,15] The major limitation of this system is the focal nature of its monitoring – it offers a single

value relevant to a small volume of brain that is usually outside the region of injury. Although there is theoretical attractiveness to monitoring at the border of focal injuries (the "penumbra"), most monitoring is performed within normal brain. With the addition of a jugular venous oxygen saturation monitor (JVO_2), it becomes possible to measure global cerebral oxygen extraction and distinguish hypermetabolic, high extraction states from hyperemic, low extraction states. Thus these two oxygen monitoring tools are complimentary.

Intracranial Hypertension

ICP is a function of the aggregate volumes of brain, cerebrospinal fluid (CSF), and blood within the fixed intracranial compartment. Mild or slow expansion of one or two of these compartments can be buffered by compensatory decreases in either the CSF or blood compartments (into the spinal subarachnoid space or the venous sinuses, respectively). When this buffering capacity is exceeded, the compliance of the brain is compromised and small additional increases in any intracranial compartmental volume will produce marked elevations in ICP.

Intracranial hypertension is considered deleterious via two somewhat separable mechanisms: herniation and ischemia. Herniation occurs when a pressure gradient exists across an incomplete barrier, such as the tentorium, falx cerebri, or foramen magnum. It is deleterious because of the tissue damage that occurs and direct compression of adjacent vessels. Transtentorial herniation, the most recognized form, is manifest by anisocoria, motor posturing, autonomic disturbances, and death. The specter of herniation is the major determinant of the absolute threshold of ICP management, which is generally accepted as 20 to 25 mm Hg (although this range has not been well determined empirically).

The second deleterious aspect of intracranial hypertension is elevated resistance to cerebral blood flow (CBF), resulting in or exacerbating cerebral ischemia. This resistance can be very roughly approximated by cerebral perfusion pressure (CPP), which is defined as the difference between mean arterial blood pressure and ICP:

$$\text{CPP} = \text{mean arterial pressure} - \text{ICP}$$

Under normal circumstances, cerebral pressure autoregulation maintains CBF stable over a wide range of CPP (approximately 50 to 150 mm Hg) (Fig. 21-1). Following injury to the brain, this autoregulation is generally disrupted. This disruption can be complete, resulting in a pressure-passive system.[16] Failure of autoregulation is associated with worse outcome in patients with TBI.[17] More frequently, the disruption is incomplete, characterized by a normal sigmoid shape but with abnormal elevation of the lower breakpoint above the normal value of 50 mm Hg (sigmoid dashed line). A probable consequence of this disruption is that a CPP that is satisfactory for uninjured patients may be associated with a lower CBF following head trauma (range of hypoperfusion).

In a pressure-passive system, cerebral blood volume (CBV) will increase in proportion to CPP. In such an instance, the goal is to keep the CPP just above the level of cerebral ischemia, thereby minimizing iatrogenic intracranial hypertension driven by increased

CBV. In the situation of incomplete disruption, the goal is to keep CPP within the range of autoregulation, because this not only avoids ischemia but also may decrease ICP if autoregulatory vasoconstriction in response to increased CPP serves to decrease CBV.

Keeping the CPP in a physiologically normal range of 50 to 70 mm Hg is the recommendation of the most recent revision of the Guidelines for the Management of Severe Brain Injury.[18,19] A CPP less than 50 mm Hg should be avoided. Driving CPP greater than 70 mm Hg with fluids and vasopressors should also be avoided because of the risk of adult respiratory distress syndrome.[20] The CPP target for an individual patient depends on the status of cerebral autoregulation and determination of the optimal CPP can be facilitated with neuromonitoring. Furthermore, since CPP is calculated from MAP – ICP, a low CPP may be a result of low MAP and/or elevated ICP. Interventions taken to address low CPP must therefore be targeted at the relevant component: blood pressure support in case of low MAP, and ICP reduction for elevated ICP.

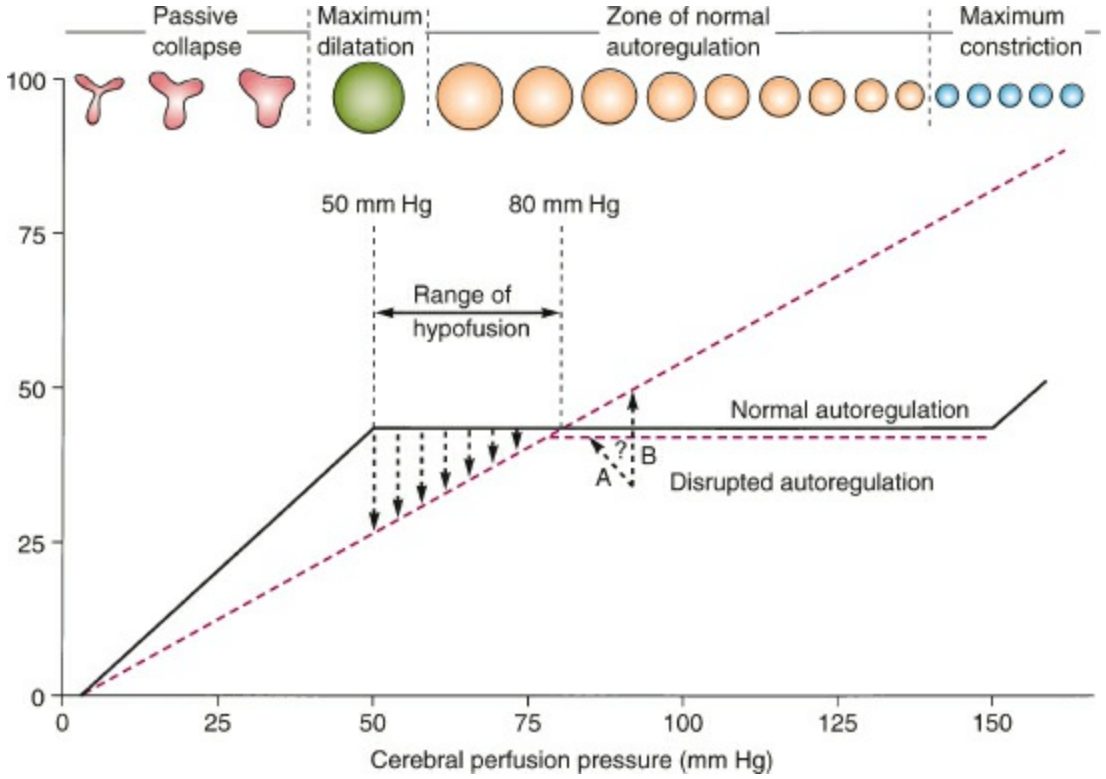

Figure 21-1. Cerebral pressure autoregulation. The normal relationship is indicated by the *solid line* with autoregulatory breakpoints at 50 and 150 mm Hg. Two disrupted states are also diagrammed. Complete loss of autoregulation (*straight dashed line B*) results in a pressure-passive system wherein cerebral blood flow (CBF) (and cerebral blood volume [CBV]) increases linearly with cerebral profusion pressure (CPP). The more common form of disruption is indicated by the sigmoid (*dashed line A*) where the major alteration is a right shift in the lower breakpoint. The *circles* at the top of the figure represent the diameters of the resistance vessels in the normal situation. The area of the circles represents CBV. Shifting this relationship to the right by 30 mm Hg would represent the partially disrupted state. (© R.M. Chesnut, MD, reproduced with permission.)

CLINICAL ASSESSMENT

The objectives during early clinical assessment of the patient with head injury are multiple and must be accomplished simultaneously. These include establishing adequate oxygenation, ventilation, and circulatory stability and evaluating the extent of brain injury while treating ICP elevations. Although some evidence indicates that systemic hypotension may infrequently be the result of a head injury, always initially presume that hypotension in a trauma patient is the result of hypovolemia. It is a significant error to withhold volume resuscitation in a misdirected effort to control cerebral edema.

During initial assessment, mental status changes cannot be presumed to be the result of drugs or alcohol, although routine toxicology screening is appropriate. It should be presumed that any change in mental status or the neurologic examination in general, or any evidence of herniation (e.g., anisocoria), suggests an expanding intracranial mass lesion. Under such circumstances, therapeutic ICP reduction becomes the first priority and diagnostic imaging or surgical decompression must be accomplished emergently.

Do not assume that apparent neurologic unresponsiveness represents a lack of sensitivity to pain. Noxious stimuli, such as placement of urinary drainage catheters, nasogastric tubes, or IV catheters, can precipitate ICP peaks during resuscitation. These procedures should be done quickly and efficiently, optimally after sedation. Endotracheal intubation is particularly likely to induce herniation in borderline cases. Whenever practical, consider premedication with analgesics, sedatives, or IV or endotracheal lidocaine before airway instrumentation.

With regard to the brain injury, several critical assessments are necessary and should be precisely recorded because trends are at least as important as any single observation. The three key parameters are level of consciousness, pupillary reflexes and size, and the motor examination.

Glasgow Coma Scale

The single most important assessment for a patient with head injury is to evaluate the level of consciousness. In this regard, the Glasgow Coma Scale (GCS) has become an international standard that is easily, rapidly, and reliably obtained (Algorithm 21-1).[21] Components of the GCS include assessment of eye opening (E), verbal response (V), and motor response (M). The Guidelines for the Prehospital Care of Severe Brain Injury support the use of the GCS for all prehospital care providers.[22] Special training has been developed by the Brain Trauma Foundation to optimize its accuracy (http://www.braintrauma.org/).

For individual patients, it is recommended that all three components be reported separately (e.g., E4V5M6) instead of a sum score (e.g., GCS = 15).[23] The derived sum score is more relevant for comparisons at the group level, and for classification and prognosis. For triage purposes, patients can be stratified using their GCS scores into those with severe injuries (GCS $\leq$8), moderate injuries (GCS 9 to 12), or mild injuries (GCS $\geq$13; see Algorithm 21-1).

Assessment requires either a spontaneous response or response following application of a stimulus. At more severely disturbed levels of consciousness, the motor score has better discrimination, but in milder injuries the eye and verbal components are more relevant. Thus each component of the scale provides complementary information. Strengths of the GCS are that it covers a broad spectrum of disorders of consciousness, is widely applicable, and offers an important tool for monitoring changes in the level of consciousness. Standardized approaches to both its assessment and its reporting are required in order to be able to compare evaluations over time or when communicating with other healthcare professionals. Spontaneous responses are first observed without stimulating the patient in any way. First verbal stimuli are applied, such as asking a patient to obey commands and at the same time observing whether, for example, an eye opening occurs. If a patient is not responsive, a stimulus is applied to elicit a response. The location of the stimulus (central or peripheral) should be standardized and used consistently. To describe the motor response, only the reaction of the arms should be observed, not the legs.[24]

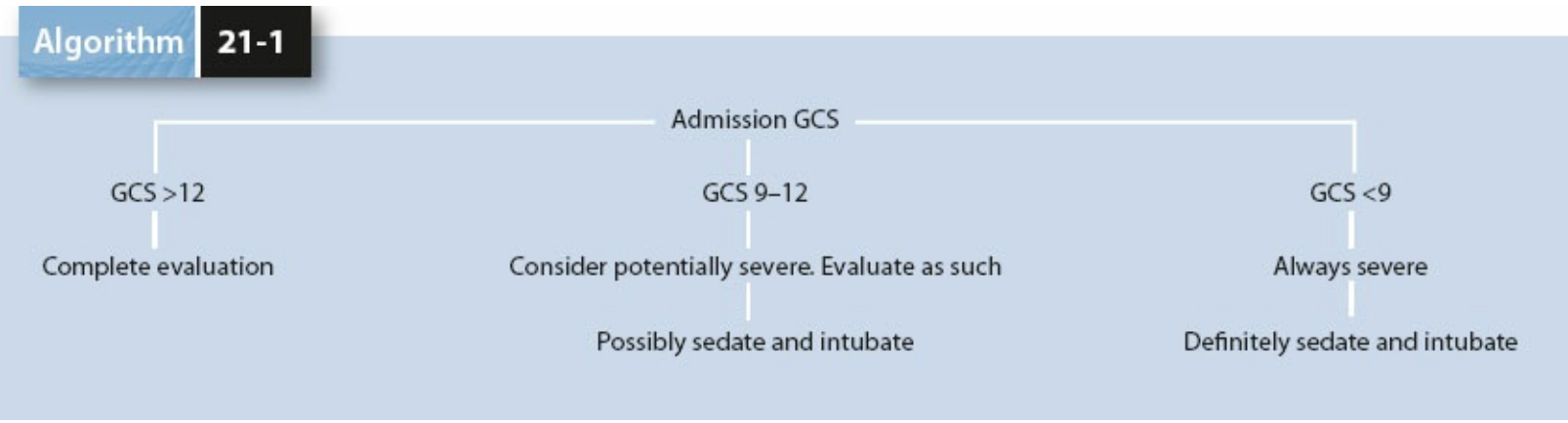

Algorithm 21-1. Glasgow Coma Scale (GCS) triage guide for initial evaluation of head injury. For the motor scale, the best response for any limb is recorded.

If a GCS component is untestable due to intubation, sedation, or other confounder, the reason for this should be recorded (e.g., E1VTM2, with “T” indicating “intubated” and not a testable verbal component). A score of “1” should not be assigned because differentiation between a “true 1” and an untestable component is relevant.

Pupils

Pupillary asymmetry, dilation, or loss of light reflex in an unconscious patient usually reflects herniation because of the mass effect from intracranial hemorrhage ipsilateral to the dilated pupil. The probability of an intracranial mass lesion can be roughly approximated given the degree of anisocoria (1 mm or 3 mm), the mechanism of injury (MVC), and age (Fig. 21-2).[21] Occasionally, pupillary signs may indicate direct second or third nerve injury or trauma to the globe, but this must always be a diagnosis of exclusion. An unequal and nonreactive pupil is the cardinal sign that herniation is occurring, and rapid lowering of ICP is essential. An ovoid pupil is also ominous and is associated with injuries that result in herniation in approximately 15% to 20% of patients.

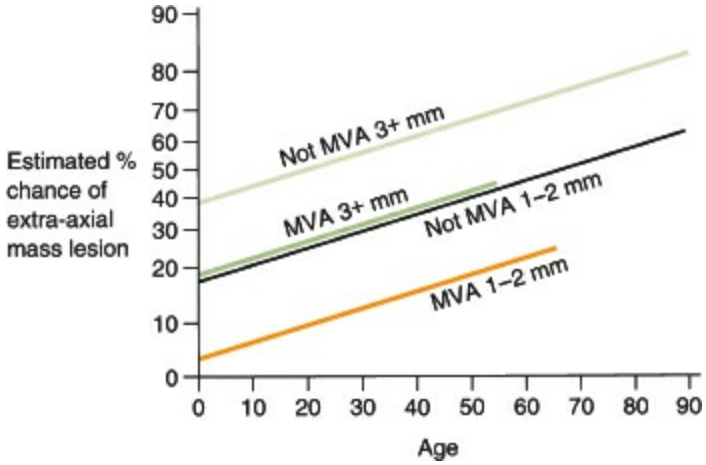

Figure 21-2. Estimated percentage chance of an extra-axial intracranial mass lesion greater than 25 mL as a function of degree of anisocoria, age, and mechanism of injury. Mechanism of injury was defined as motor vehicle accident (MVA) or other mechanism (not MVA). (Reproduced with permission from Chesnut RM, Gautille T, Blunt BA, et al. The localizing value of asymmetry in pupillary size in severe head injury: relation to lesion type and location. *Neurosurgery* 1994;34:840–845.)

Recently, handheld pupillometry has gained acceptance as a method for quantifying pupillary response. Traditionally, the measurement of pupil function has been subjective, using a flashlight and pupil gauge with a qualitative assessment of reactivity, often resulting in poor interrater reliability.[25] The currently available devices measure the rate and degree of pupillary contraction and calculates a normalized neurologic pupillary index, or NPi.[26,27] NPi >4 is indicative of normal function, while NPi <4 raises suspicion for pupil contractility dysfunction. It should be noted that, although one etiology of decreased NPi is increased ICP, other causes such as direct cranial nerve III dysfunction or diabetic pupillary paresis must also be considered.

Motor Examination

The motor system is examined for asymmetry, abnormal posturing, or lack of movement. Hemiparesis, paraparesis, or quadriparesis suggests a cervical or thoracolumbar spine fracture with spinal cord injury. Hemiparesis secondary to brainstem herniation from the mass effect may be either ipsilateral or contralateral to the side of the dilated pupil or an intracranial mass lesion.[21] Hemiparesis may also result from significant brain contusion. In the unconscious patient, a painful stimulus should be used to evaluate motor function. All four extremities should be examined and the results noted, because only the response of the best limb will be reflected in the GCS score.

RADIOGRAPHIC DIAGNOSIS

Neurosurgical evaluation and assessment are initiated as soon as the potential for significant head injury is realized. Prompt radiographic evaluation is essential and CT scanning is the imaging modality of choice for virtually all acute neurologic conditions. Patients with mild head injuries can usually be observed with sequential examinations and radiographic evaluation may be unnecessary unless the results determine whether the patient can be discharged from the hospital. In contrast, however, a cogent argument can be made for the liberal application of CT scanning to even patients with minimal evidence of TBI as a method of making safe, efficient, and economic triage decisions.[30] In any instance, evidence of neurologic deterioration or the occurrence of a situation wherein the neurologic examination cannot be followed (e.g., the need for general anesthesia) mandates CT scanning, intraoperative ICP monitoring, or both. General indications for neurologic imaging (generally, CT scanning) are listed in Table 21-1.

Patients with moderate or severe injuries require prompt neurosurgical consultation and rapid radiographic evaluation using the CT scanner. Hemodynamically stable patients with significant neurologic deterioration should go to the CT scanner immediately following ATLS resuscitation. In hemodynamically unstable patients who require immediate surgical intervention to sustain intravascular volume, lifesaving exploratory thoracotomy or laparotomy must take precedence. In such cases, it is a mistake to delay further investigation of the intracranial compartment pending the end of the case and transport to the CT scanner. A number of methods can be employed to evaluate the intracranial compartment during such lifesaving, extracranial surgery, including insertion of an ICP monitor or ventriculostomy (with air ventriculography, if deemed necessary), transcranial Doppler evaluation, or even placement of exploratory burr holes in the instance of herniation. For this reason, neurosurgical consultation should be initiated on arrival in theater rather than at the finish of the case.

Table 21-1 Indications For Neurologic Imaging

- Suspected skull penetration by a foreign body
- Discharge of cerebrospinal fluid (CSF), blood, or both from the nose
- Hemotympanum or discharge of blood or CSF from the ear
- Protracted unconsciousness
- Altered state of consciousness at the time of examination
- Focal neurologic signs or symptoms
- Any situation precluding proper surveillance
- Head injury plus additional trauma
- Possible head injury in the presence of additional pathologic findings, such as stroke
- Head injury with alcohol or drug intoxication

At the other end of the spectrum, in cases where there is an obvious surgical brain injury, the choice and timing of diagnostic systemic maneuvers should be subject to modification. Such patients should be transported directly to theater and examinations such as focused assessment with sonography in trauma (FAST) or diagnostic peritoneal

lavage performed as the patient is being prepped for craniotomy. In such instances, obviously, early communication between the trauma surgery and neurosurgery departments is critical.

The spine should be cleared radiographically or immobilized and protected in every patient with a severe head injury. Although only 13% of patients with severe head injuries have spinal cord injuries, the potentially devastating consequences of an overlooked spine injury require constant vigilance.

Plain Skull Radiographs

With the routine availability of 24-hour CT scanning capabilities, plain skull radiography has largely become obsolete in TBI. The likelihood of a surgical intracranial hematoma is strongly correlated with the presence or absence of a skull fracture if the neurologic examination is factored in.[31] Nevertheless, the superiority of CT imaging in all aspects of evaluating TBI has relegated the use of skull films to unusual circumstances.

Computed Tomography

The CT finding that correlates most highly with intracranial hypertension is compression or obliteration of the basilar cisterns (Fig. 21-3). Not only does this finding portend a stormy ICP course, but also the primary predictor of outcome in patients with this CT picture is the peak level of intracranial hypertension occurring during the first 72 hours.[32,33] When cisternal compression is paired with a midline shift of more than 5 mm, the prognosis is even more ominous. ICP monitoring should be immediately initiated in any patient with cisternal compression and intracranial hypertension should be vigorously treated. Such patients, particularly those with minimal evidence of contusions, die primarily from secondary brain insults, which implies that they are potentially salvageable.



Figure 21-3. A computed tomography scan that is highly predictive of intracranial hypertension. The basilar cisterns are obliterated and the sulci are flattened.

Acute epidural hematomas correlate well with skull fractures. The most common association is a linear, nondisplaced fracture in the temporoparietal region, crossing the middle meningeal artery. The classic clinical course involving a lucid interval following a brief loss of consciousness with subsequent suspicion must remain high. The typical CT appearance is a high- or mixed-density concave extra-axial hematoma with smooth borders (Fig. 21-4).



Figure 21-4. Typical computed tomography scan appearance of mixed-density, lens-shaped, acute epidural hematoma with mass effect.

Acute subdural hematomas occur over the convexity of the brain. The hematoma may evolve from rupture of bridging cortical veins or bleeding from the underlying parenchymal injury, the latter being a common source. It is this subjacent tissue damage that generally determines the neurologic outcome of patients not succumbing to intracranial hypertension. On CT scan, a subdural hematoma appears as an extra-axial high- or mixed-density crescentic mass that spreads out over the hemisphere, following the cortical irregularities (Fig. 21-5). The midline shift may be out of proportion to the size of the hematoma because of the contributing mass effect from an underlying brain contusion or hemispheric swelling.

Intracerebral hemorrhage and cerebral contusion are common after trauma and are readily visualized with CT scanning. Brain contusion appears as a focal, heterogeneous density with hemorrhage interspersed with injured tissue (Fig. 21-6). Intracerebral hematomas are generally more homogeneous in their high-density appearance. Both of these lesions tend to "blossom" over time because of some continued hemorrhage and the development of edema. It is important, therefore, to closely observe and monitor the ICP of such patients because significant and hazardous mass effect may evolve, requiring surgical extirpation.

With temporal or deep frontal contusions, late deterioration may occur, generally because of progressive edema development. The peak of such deterioration appears to be around 1 week, although cases have occurred as late as 10 to 14 days. Most of these patients will complain of severe or increasing headache or their CT images will show progressive edema formation. As such, a high index of suspicion must be accompanied by

liberal use of follow-up CT imaging and, in particular, not dropping the level of surveillance until both the clinical situation and the CT appearance are stable. In the instance of such lesions showing progressive mass effect, the insertion of an ICP monitor may be considered, even in a patient with a relatively high GCS score.

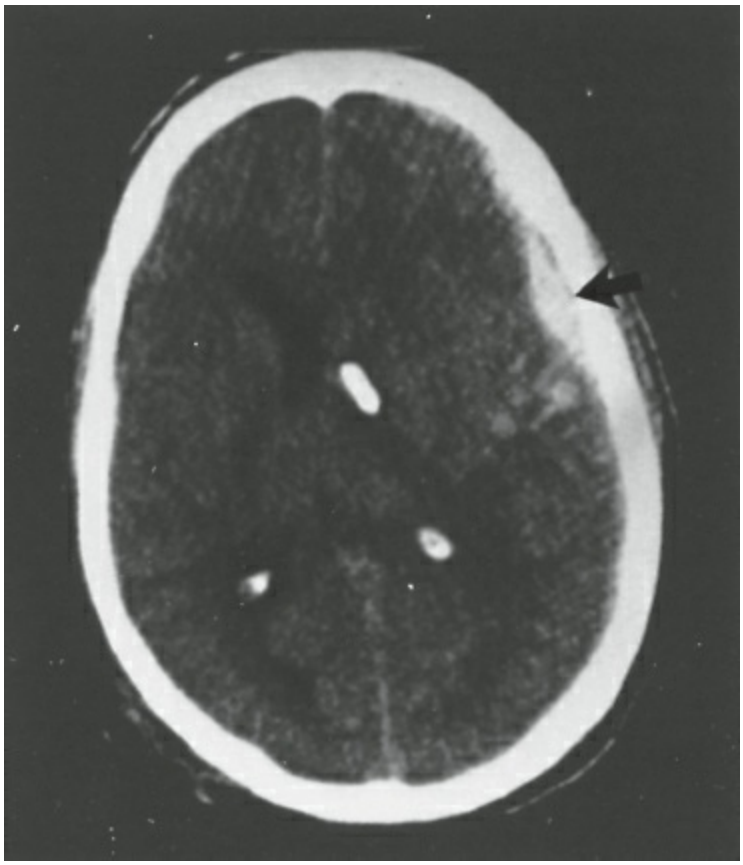

Figure 21-5. Usual computed tomography scan appearance of a crescent-shaped, high-density blood collection conforming to the contour of the cerebral hemisphere in a subdural hematoma.



Figure 21-6. Contusion and associated intracerebral hematoma in the frontotemporal area.

The typical CT appearance of subarachnoid hemorrhage is a layer of blood over the cerebral cortex, layering over the tentorium and commonly filling the basal cisterns. Cerebral edema appears as areas of decreased density, which may be either focal or diffuse. Posttraumatic edema formation generally takes hours to days to develop unless compounded by hypoxia or hypotension. The "swollen brain" commonly seen in the setting of trauma may be caused by edema or increased CBV (unclotted, intravascular blood is low density). DAI, typical of acute acceleration–deceleration injury, appears on CT scan as small areas of focal hemorrhage in the brainstem, thalamus or deep nuclear region, corpus callosum, and hemispheric white matter and may be accompanied by cerebral swelling. Finally, gunshot wounds or other penetrating injuries can be evaluated with CT scanning to allow accurate preoperative assessment of the anatomic injury for prognostic and therapeutic planning purposes.

One significant issue of recent origin is the "blossoming" or appearance of new lesions subsequent to CT images obtained at very short intervals following injury. Most of the "classic" TBI studies presented initial CT data from studies done hours following trauma. With improved prehospital transport and the ready availability of CT imaging, many initial studies are now performed 15 to 30 minutes after injury. As a result of such ultra-early CT scanning, there is now a risk of missing significant intracranial lesions by obtaining imaging before their appearance or during an early phase of their evolution. For this reason, in any patient with moderate or severe TBI, intracranial hypertension, or anticoagulation/antiplatelets, we routinely obtain an early follow-up CT image at 4 to 6 hours after admission. In patients with mild TBI who have a stable neurologic

examination and none of the aforementioned risk factors, routine repeat head CT rarely changes management and may be skipped.[28–31]

It should be noted that absence of CT findings in a patient with a history of TBI does rule out a TBI. Recent data suggest that a significant number of patients seen at a level I trauma center with a negative CT will have pathologic findings with 3T MRI imaging.[32] Advanced MRI techniques, such as diffusion tensor imaging and functional MRI hold great promise for improved diagnosis and prognosis, especially in mild TBI/concussion.[33]

Ancillary Imaging

As noted earlier, there is a significant association between TBI and injury to the axial skeleton, particularly to the cervical spine. In addition, particularly when associated with basilar skull fractures or facial fractures, TBI suggests the possibility of damage to the major arteries of the neck. As such, particular attention should be given to careful radiographic clearance of the spine and consideration of studies such as CT angiography of the great vessels rostral to the aortic arch.

MANAGEMENT

Evidence-based Medicine and the Management of Traumatic Brain Injury

Wherever possible, the recommendations in this text are evidence based. For details, the reader is referred to the source documents.

The publication of the first edition of the Guidelines for the Management of Severe Brain Injury in 1996 represented a significant step in standardizing the management of TBI based on published, peer-reviewed literature.[22] This document represents the application of a strict evidence-based process to 14 topics relevant to TBI care. Following an exhaustive, explicitly defined literature search covering each topic, the recovered literature was carefully classified along a three-point continuum of scientific rigor. As such, each article was ranked as class I, class II, or class III and the analysis of the scientific basis of each topic was predicated on the most scientifically rigorous (highest literature class) reports available. This process produced a set of standards, guidelines, and options for treatment where **standards** (based on class I evidence) represent principles with a high degree of clinical certainty, **guidelines** (based on class II evidence) reflect principles with a moderate degree of clinical certainty, and **options** (based on class III evidence) reflect principles for which unclear clinical certainty exists. By specifically defining the scientific foundation on TBI management issues, the Guidelines for the Management of Severe Brain Injury provided an unbiased reference focused on facilitating scientific management of TBI.

Since the initial publication of the Guidelines for the Management of Severe Brain Injury, it has undergone updating and revision[10,11] encompassing more recently published data and revising earlier practice recommendations where indicated as well as expanding the scope of covered topics. The same evidence-based process has also been applied in the generation of other sets of brain injury guidelines. The Guidelines for the Prehospital Management of Traumatic Brain Injury were published in 2002,[20] spawning the training efforts mentioned previously. In 2001, the Guidelines for the Management of Penetrating Brain Injury (PBI) were published.[23] The Guidelines for the Management of Pediatric Brain Injury were published in 2003.[18] The Guidelines for the Surgical Management of Traumatic Brain Injury were published in 2001.[24] The third edition of the Guidelines were published in 2007[34] and work on the fourth edition is now underway.

General Considerations

Although there is no present technology for its quantification before the insertion of an ICP monitoring device, early intracranial hypertension may certainly exert a detrimental influence on outcome. Not only do all treatment modalities for intracranial hypertension have serious potential complications, but also many of them can directly interfere with resuscitation procedures (e.g., use of osmotic diuretics). The efficacy of successful systemic resuscitation in improving the likelihood of survival from trauma in general is well accepted. In addition, the acknowledged negative influence of secondary insults (e.g., hypotension and hypoxia) on outcome from severe head injury renders systemic resuscitation essential. Therefore, all treatment must be consistent with optimal systemic resuscitation.

The composition and volume of the IV fluids used to resuscitate patients with head injuries should be selected with the purpose of restoring intravascular blood volume. Although the widely disseminated but scientifically unsupported adage of "keeping TBI patients dry" has now been discarded, the concept of restricting free water remains desirable. As such, isotonic crystalloid solution in the form of 0.9% normal saline (NS) is preferable to lactated Ringer solution as a resuscitation fluid for TBI.[35] For some time, a growing body of indirect scientific support appeared to support the use of 250 mL of 7.5% hypertonic saline as the first resuscitation fluid in TBI victims. However, a recent randomized controlled trial from Australia has suggested that this may not be of benefit under optimal resuscitation conditions.[28]

The endpoints of resuscitation do not change depending on the presence or absence of a head injury. Blood volume should be normal, with an appropriate blood pressure and central venous pressure, adequate urine output and peripheral perfusion, and progressive improvement of any base deficit. The systolic blood pressure should never be allowed to drop below 90 mm Hg. Some evidence indicates an advantage to targeting a mean arterial pressure of 80 to 90 mm Hg during resuscitation until ICP monitoring can be initiated. Once ICP is available, a minimal CPP of 60 mm Hg should initially be the goal.

Initial Resuscitation

Resuscitation in the Absence of Clinical Signs of Herniation

2, 3 Algorithm 21-2 is based on the Guidelines for the Management of Severe Brain Injury and the Guidelines for the Prehospital Management of Severe Brain Injury for use by prehospital and initial at-hospital care providers and emergency physicians to guide decision making in resuscitating TBI victims and determining the necessity of ICP-lowering therapy.[22,34] "Signs of increased ICP" implies pupillary abnormalities, motor posturing, or neurologic deterioration not related to medications. When these signs are not present, mannitol is not given and the goal of ventilation is eucapnia (i.e., no hyperventilation). When signs of herniation are present, the patient is hyperventilated to a $PaCO_2$ of 30 to 35 mm Hg and mannitol may be given if the patient's volume status is normal.

Algorithm 21-3 is based on the Guidelines for the Management of Severe Brain Injury for evaluation and treatment of the severe TBI patient from arrival at the trauma center prior to the placement of an ICP monitor.[34] As with any trauma patient, the first step is Advanced Trauma Life Support (ATLS) resuscitation. When appropriate, brain-specific therapies are incorporated into the treatment course. Brain-friendly initial ICU management should lead directly to monitoring of ICP.

Elevating the head of the bed (reverse Trendelenburg position in the absence of clearance of the axial skeleton), a standard maneuver to improve cerebral venous outflow and reduce ICP, has also been shown to generally lower the CPP in the absence of adequate volume resuscitation. Because the reduction in CPP may elevate the ICP per se, it is not advised until complete resuscitation has been accomplished.

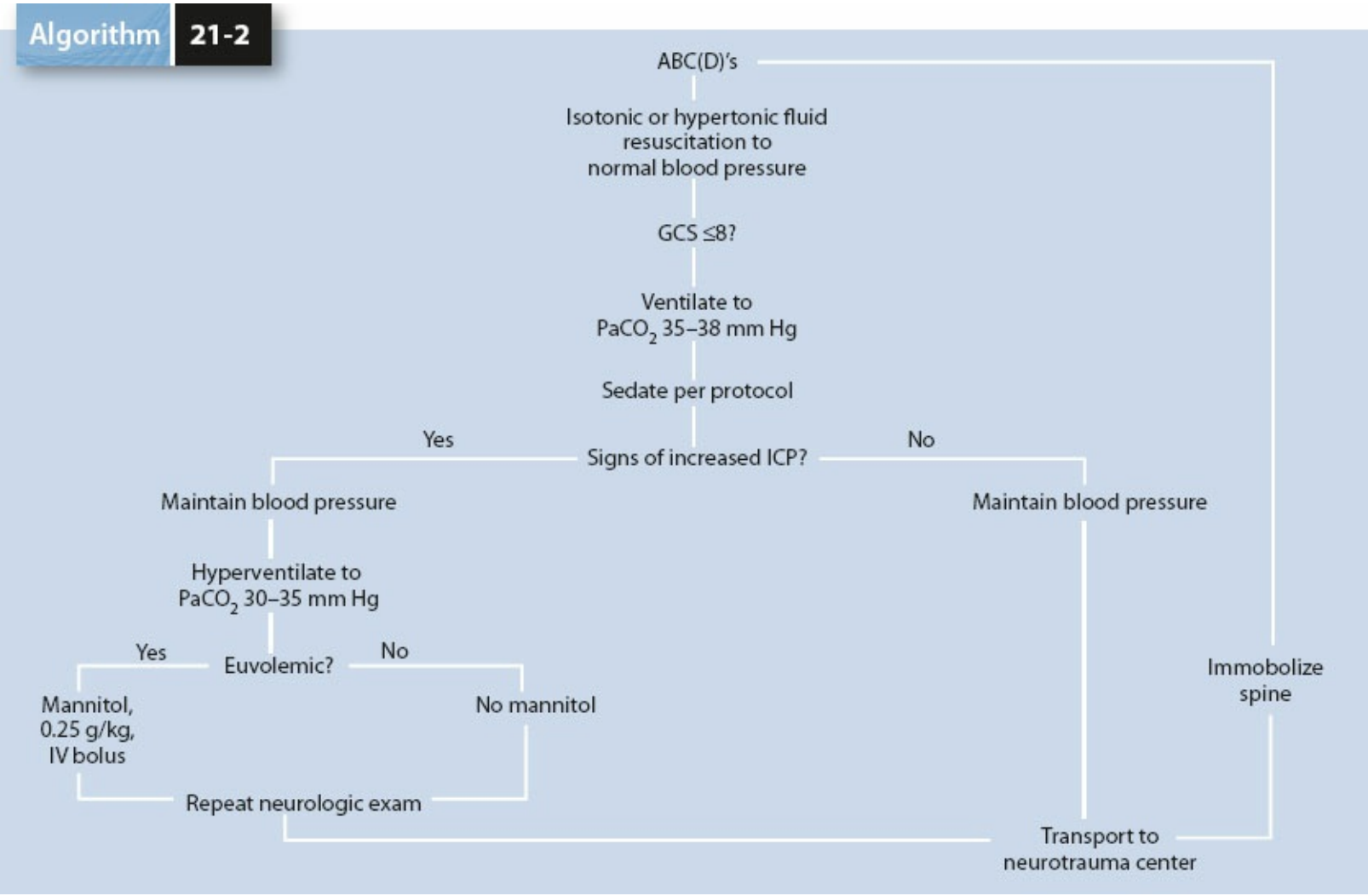

Algorithm 21-2. Prehospital evaluation and treatment of a patient with severe traumatic brain injury. "Signs of increased ICP" is the decision point for determining the necessity of intracranial pressure (ICP)-lowering therapy. These signs include pupillary abnormalities, motor posturing, or neurologic deterioration not related to medications. The order of steps is determined by the risk–benefit ratio for individual treatment maneuvers. This algorithm should be viewed as "expert opinion" and used as a framework, which may be useful in guiding an approach to field management of such patients. (© R.M. Chesnut, MD, FCCM, reproduced with permission.)

The confusion and agitation often associated with head injury can increase intracranial hypertension. Therefore, patients with suspected head injury should generally receive sedatives and analgesics whenever possible. Particularly in the TBI patient, the difference between sedation and analgesia should be kept in mind and the two agents titrated specific to their respective indications. Short-acting agents such as propofol are preferable in the interest of following the neurologic examination.

In addition to eliminating any possibility of spontaneous ventilation and mandating complete ventilatory control, pharmacologic relaxation has the undesirable effect of limiting the neurologic examination to the pupils and the CT scan. Its use in the absence of evidence of herniation, therefore, should be limited to situations where sedation and analgesia alone are not sufficient to optimize safe and efficient patient transport and resuscitation.

The "prophylactic" administration of mannitol is not suggested, because of its volume-depleting diuretic effect. In addition, although it is desirable to approximate the lower

end of the normal range of $PaCO_2$ during transport of a patient suspected of having brain injury, the risk of exacerbating early ischemia by vigorous hyperventilation outweighs the questionable benefit in the patient without evidence of herniation. Therefore, ventilation parameters consistent with optimal oxygenation and "normal" ventilation are recommended. The minute ventilation should be targeted at 100 mL/kg per minute until quantitative measurement of end-tidal carbon dioxide ($EtCO_2$) or $PaCO_2$ is available. The Guidelines for the Prehospital Management of Severe Brain Injury suggest the use of $EtCO_2$ monitoring during prehospital resuscitation and transport whenever possible. In the absence of signs of intracranial hypertension, ventilation should be adjusted to accomplish a $PaCO_2$ of 35 mm Hg when arterial gas values become available.

Resuscitation in the Presence of Clinical Signs of Herniation

Signs of intracranial hypertension consist of evidence of transtentorial herniation (pupillary dilation or loss of reactivity or motor posturing or flaccidity) or progressive neurologic deterioration not attributable to other causes (e.g., sedation). When such signs occur, aggressive treatment of suspected intracranial hypertension is indicated. Hyperventilation to a $PaCO_2$ target of approximately 30 mm Hg should be accomplished by increasing the minute ventilation to approximately 120 to 140 mL/kg per minute or as directed by quantitative CO_2 monitoring. Because hypotension can produce both neurologic deterioration and intracranial hypertension, the use of mannitol is less desirable unless adequate volume resuscitation has been accomplished. If such is the case, however, mannitol should be administered by bolus infusion to establish the optimal osmotic gradient. Under such circumstances, it is critical that the diagnosis and treatment of the neurologic injury be accomplished with utmost haste.

Aggressive restoration of intravascular volume, maintenance of adequate CPP, and avoidance of hypoxia are essential for the management of intracranial hypertension. Volume resuscitation should be vigorous and thorough, with a target of euvolemia. Restrict free water by using isotonic fluids, which makes NS preferable to lactated Ringer solution. Optimally, continuous monitoring of central venous and arterial pressures should be instituted early.

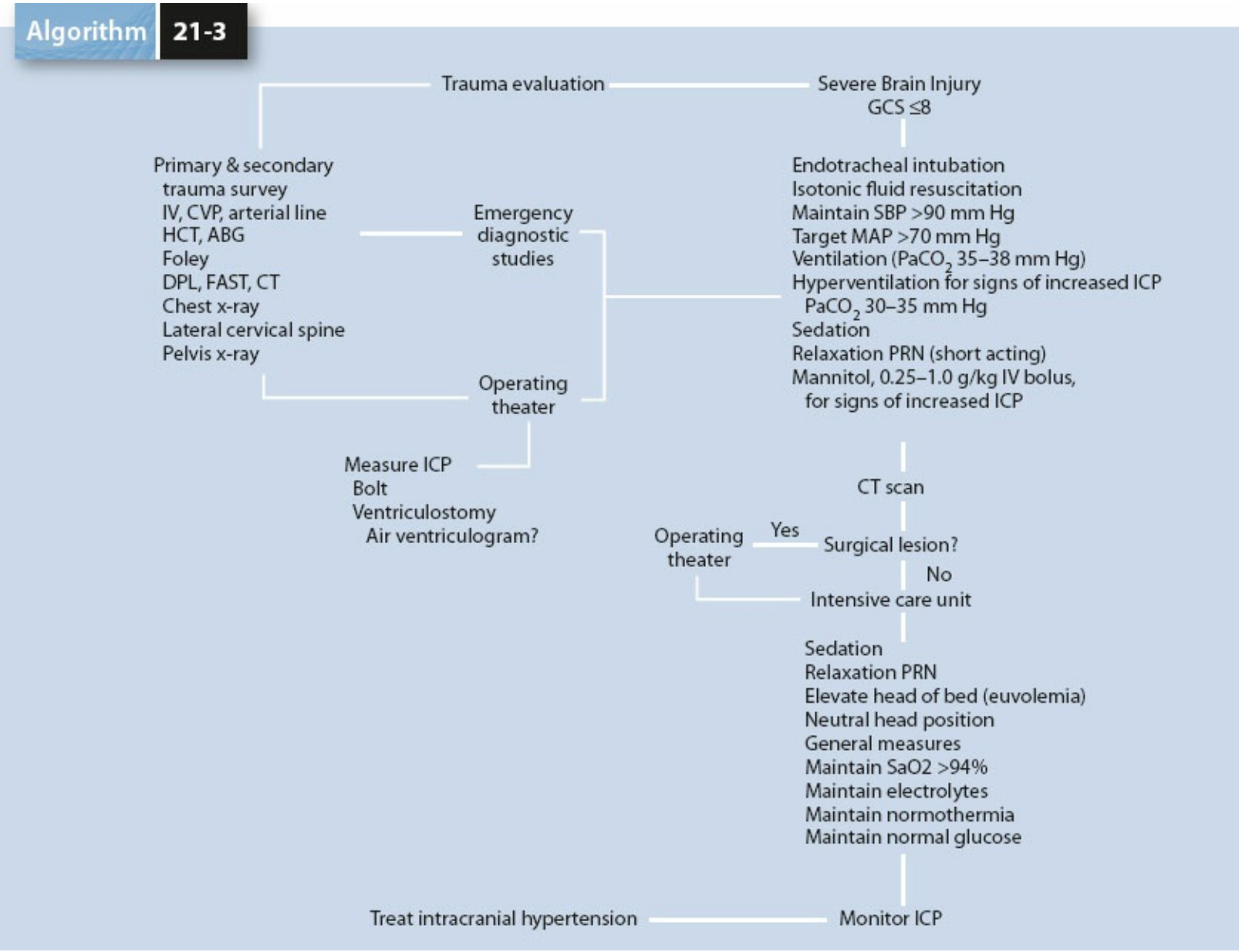

Algorithm 21-3. Evaluation and treatment of the patient with severe traumatic brain injury on arrival at the trauma center. The order of steps is determined by the risk–benefit ratio for individual treatment maneuvers. This algorithm should be viewed as "expert opinion" and used as a framework, which may be useful in guiding an approach to initial hospital management of such patients prior to the initiation of ICP monitoring. (© R.M. Chesnut, MD, reproduced with permission.)

Neuromonitoring

Intracranial Pressure Monitoring

All patients with survivable, severe brain injuries and a significant percentage of those with moderate injuries require continuous ICP monitoring. The most recent revision of the Guidelines for the Management of Severe Brain Injury indicates that class II evidence supports monitoring of all patients with a postresuscitation GCS score equal to or less than 8 who have any CT evidence of intracranial pathology.[36] Class III level evidence supports monitoring in patients with severe TBI and a normal CT scan if they have two or three of the following: (a) age older than 40 years, (b) any history of hypotension, or (c) abnormal motor posturing. ICP monitoring in other patients is left to the discretion of the physician. ICP monitoring should be considered in any patient with a GCS score of 12 or less who cannot be closely monitored clinically or whose CT scan demonstrates evidence of intracranial hypertension (i.e., mass lesion, obscured or absent basal cisterns, or midline shift).

Although many techniques are available, the most common involve small fiberoptic or strain gauge catheter tip pressure sensors placed several millimeters into the brain or fluid-coupled catheters placed into the lateral ventricles. The minimally invasive catheters are reliable and have a very low complication rate,[37] making them an ideal choice in instances where a minimum-risk ICP monitoring technique is desired (e.g., in a moderate head injury that needs general anesthetic). They are also useful when the ventricles are too small to cannulate or there is an uncorrected coagulopathy. Ventriculostomy catheters have the added capability of allowing CSF drainage for ICP control. They are technically more difficult to place, and the complication rate is somewhat higher at 1% to 7%.[38] Rarely, however, do catheter-associated hemorrhages require surgical drainage.

Monitoring ICP not only provides early warning of herniation but also, by allowing calculation of CPP, opens up the possibility of more precisely optimizing CBF and preventing ischemic secondary brain injury. Because all methods of lowering ICP or raising CPP have potentially harmful side effects, using such agents to treat suspected intracranial hypertension without monitoring ICP is not recommended. In hospital settings where ICP monitoring is not possible, recent evidence suggests that hourly neurologic examination by a physician may serve as a proxy for ICP monitoring. In most of the developed world, such routine reevaluation by a physician would be extremely resource intensive, and invasive ICP monitoring remains the preferred method when it is available.[39,40]

Monitoring of Cerebral Perfusion and Oxygenation

Preventing cerebral ischemia is a mainstay in the management of severe TBI patients. There are currently several methods that are readily available for ICU measurement of the adequacy of cerebral oxygen delivery.

Placing a catheter into the jugular bulb via a retrograde venous route allows sampling of the saturation of oxygen in the blood leaving the brain. Jugular venous oxygen saturation values below 50% are associated with cerebral ischemia and worsened

recovery, whereas saturations above approximately 85% suggest hyperemic flow.[41] It should be noted that this method averages a large volume of the brain and does not include blood from all of the supratentorial parenchyma so that it cannot completely rule out ischemia.

An alternative monitoring method is the insertion of an oxygen-sensing (Clark) electrode into the brain parenchyma to measure $PBtO_2$. $PBtO_2$ values of less than 20 mm Hg are associated with reduced CBF and poor oxygenation.[42,43] There is a growing body of evidence supporting the utility of this method, and $PBtO_2$-directed therapy has been associated with improved outcomes.[44,45] This technique samples only a very small, focal volume of tissue, so is typically placed into normal brain with the intent of preserving healthy tissue.

Cerebral microdialysis constitutes a third method of monitoring for evidence of cerebral metabolism by allowing the measurement of tissue lactate and pyruvate and calculating the lactate/pyruvate ratio. Like $PBtO_2$ monitoring, this newer technique also samples a very focal region. At present, although cerebral microdialysis is very sensitive and is being used with growing frequency,[46] it is primarily considered as a research tool.

Monitors that directly measure CBF are also available for clinical use. These monitors measure flow through a thermal dilution method, and can also provide real-time brain temperature and tissue thermal conductivity, which is a measure of parenchymal water content. In conjunction with CPP data, a CBF monitor can help determine the status of a patient's autoregulatory function.[47] Additionally, noninvasive optical techniques for measuring CBF are showing promising preliminary results, although they have yet to be adopted into mainstream clinical practice.[48–51]

Of note, these monitors are not mutually exclusive. They may be used to supplement each other or to verify findings from one technique that are suspect. Such a consideration becomes particularly important when significant prolongation or escalation of therapy is being considered based on an abnormal value from one monitoring system. In many practices, cerebral oxygenation monitors are placed in any patient who receives an ICP monitor.

Medical Intervention

Neurocritical Care after Stabilization

Once stabilized, most patients with a positive CT scan merit observation in a neurologic intensive care unit for hourly observation for at least 24 hours. For patients with severe TBI, the length of ICU stay is typically several days. In these patients, the importance of meticulous general critical care is important, because the protracted ICU stay and the necessity for intubation, mechanical ventilation, and other artificial support systems significantly increase the risk of nosocomial and iatrogenic complications.

Venous drainage of the brain should be facilitated by avoiding constriction of the jugular system in the neck and elevating the head of the bed in euvolemic patients. In addition, attention should be paid to intrathoracic pressures, particularly when considering the use of positive end-expiratory pressure (PEEP) or continuous positive airway pressure (CPAP). Increased intra-abdominal pressure can also decrease venous return, compromise jugular drainage, and elevate ICP.

Fever will elevate ICP and is independently correlated with decreased recovery in severe TBI. Local measures (e.g., cooling blankets, fans) should be used in conjunction with acetaminophen to keep temperatures below 37.5°C to 38°C when ICP requires treatment.

In patients presenting with radiographic evidence of intracranial injury or GCS less than 8, administration of prophylactic antiepileptic drugs is indicated for 7 days postinjury to prevent early seizures.[52] Patients with early seizures should continue antiepileptics and follow up with an epilepsy specialist for subsequent management.

4 Recent investigations in the trauma population have demonstrated an increased risk of complications in patients who undergo blood transfusion, such as the acute respiratory distress syndrome and the systemic inflammatory response syndrome. A recent randomized controlled trial demonstrated more complications when patients were transfused to maintain a hemoglobin of 10 g/dL versus 7 g/dL.[53] Based on this trial, hemoglobin should be maintained at or above 7 g/dL.

Control of Established Intracranial Hypertension

All of the previously discussed “pre-ICP monitoring” steps may be used in direct response to intracranial hypertension, their application and intensity tapered to achieve ICP control. These interventions should be considered the basic steps in this respect and should be optimized prior to adding further treatments.

CSF drainage, hyperventilation, mannitol, barbiturates, and so on are the mainstays of therapy to control intracranial hypertension. Each, however, has significant potential complications, which can obviate their beneficial effects. Therefore, they should not be employed unless intracranial hypertension is established by monitoring ICP, and caution and vigilance must attend their usage. Although the treatment of intracranial hypertension is not the primary focus of this chapter, some brief comments will be useful.

As noted, the treatment of intracranial hypertension should be initiated on a base of adequate sedation and analgesia, control of fever, and optimization of systemic

physiologic conditions that might exacerbate ICP elevation (e.g., intrathoracic pressure). Neuromuscular blockade may be added to sedation and analgesia if further ICP control is desired. It does not always work, so a trial should be initiated to determine whether the patient is a "responder" before considering long-term use. Blockade to the level of one to two twitches out of a train-of-four is a reasonable target in this population.

Treatment for intracranial hypertension in adults from the original edition of the Guidelines for the Management of Severe Brain Injury is outlined in Algorithm 21-4. When consulting this algorithm, remember that it represents a consensus opinion (class III evidence) and that, for this reason, a treatment algorithm was not included in the 2008 revision. When this algorithm was developed, the role of hypertonic saline was not addressed. More recently, a consensus-based best practices for TBI was developed by the American College of Surgeon's Trauma Quality Improvement Program.[24] These best practices are an extension of the Severe Brain Injury Guidelines and are meant to provide expert opinion where class I and II evidences are lacking. A depiction of how these guidelines might be applied in clinical practice is depicted in Figure 21-7.

When available via ventriculostomy, CSF drainage should be the first method of managing intracranial hypertension. There is no consensus on what pattern of drainage is most efficacious. It must be noted that ICP measurement cannot be performed when the ventricular catheter is open to drain. For this reason, we generally drain intermittently for several minutes, then reclamp the catheter and measure the ICP. Requiring such cycling more than five times in 1 hour constitutes a need for consideration of therapeutic escalation.

Cerebral Edema and Osmolar Therapy

Cerebral edema during the early postinjury period is generally cytotoxic (intracellular). Later, vasogenic (extracellular) edema may also play a role in brain swelling. Although resulting from different mechanisms (cellular membrane dysfunction and blood–brain barrier breakdown), our present treatment for cerebral edema in trauma is limited to the administration of osmotic agents, most classically mannitol. Generalizing the documented efficacy of corticosteroids to decrease tumor-related cerebral edema to the setting of trauma-induced edema has proven to be ineffective and actually harmful and is now considered contraindicated.[54]

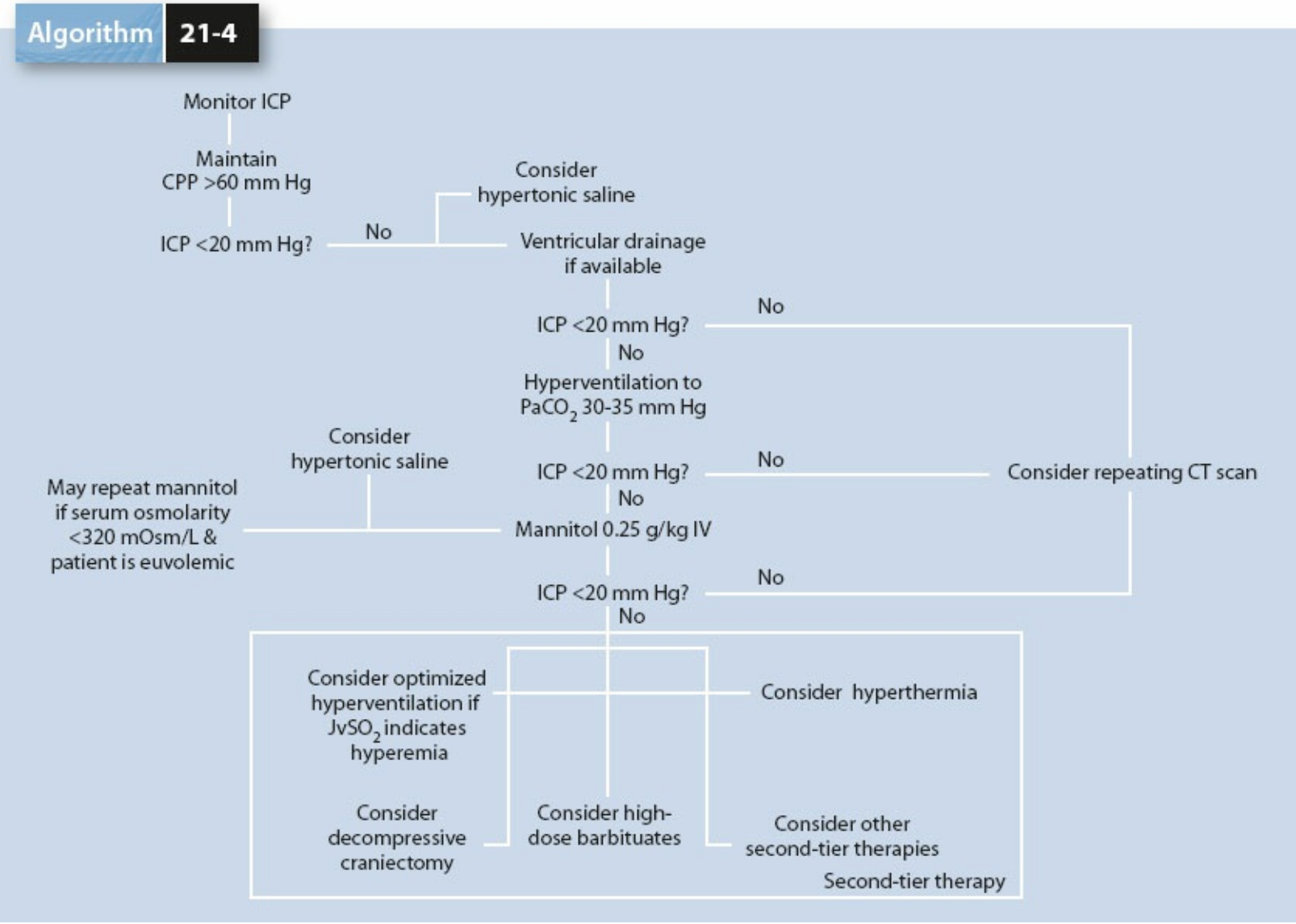

Algorithm 21-4. Treatment of established intracranial hypertension, based on the Guidelines for the Management of Severe Brain Injury. The order of steps is determined by the risk-benefit ratio for individual treatment maneuvers. This algorithm should be viewed as "expert opinion" and used as a framework, which may be useful in guiding an approach to elevated ICP.

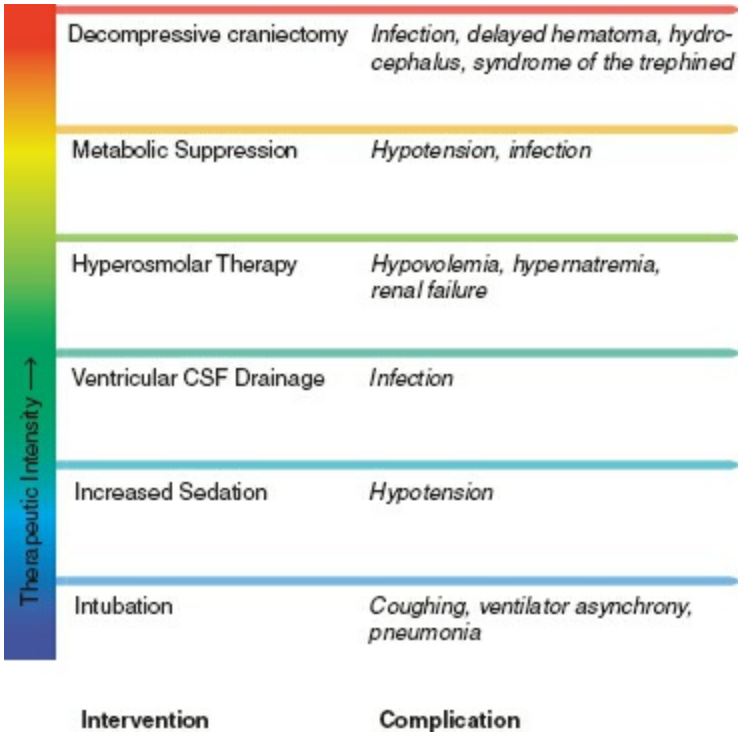

Figure 21-7. A tiered approach to management of intracranial hypertension: increasing levels of intervention are associated with increased complications.

Hyperosmolar agents increase the osmotic gradient, drawing fluid from the interstitial compartment into plasma, thereby reducing brain volume. In regions where the blood–brain barrier has been disrupted, however, such agents are minimally effective and can actually leak into tissues.[55] The extravasated hyperosmolar agent then functions as an osmotic sink, drawing in free water and paradoxically increasing parenchymal edema. Fortunately, the area of blood–brain barrier breakdown is generally much smaller than the area of edema that it creates so that hyperosmolar therapy is generally effective in lowering ICP. Caution should be exercised, however, as mannitol can produce significant diuresis. The resulting hypovolemia can result in hypotension which, as described above, can be deleterious to patient outcomes.

More recently, the use of hypertonic saline to elevate serum osmolarity has become increasingly incorporated into pediatric TBI management. In this population, it can help control intracranial hypertension, although its use has not yet been confirmed with rigorous clinical study. In those studies, 3% sodium chloride solution has generally been used, infused at 0.5 to 1.0 mL/kg per hour. As a result of such publications, the Guidelines for the Management of Severe Pediatric Brain Injury contained recommendations placing the use of hypertonic saline–based osmotherapy at the same level as the use of mannitol, leaving the choice to the physician.[56]

In the treatment of adult TBI, no evidence exists for the routine usage of hypertonic saline infusion to induce iatrogenic hypernatremia. In bolus form, 23.4% saline is effective in acutely lowering ICP, while at the same time increasing the intravascular volume. Because it does not cause diuresis, it may be preferred over mannitol when hypotension is present. Rigorous, randomized comparison data on its relative efficacy and duration with respect to mannitol are lacking.[57,58] There is some data to suggest there is a

dose-dependent effect on the duration of ICP control.[59] Regardless of which agent is chosen, hyperosmolar agents are most effective at controlling ICP when given as a bolus. It should be noted, however, that rapid infusion of higher concentrations of hypertonic saline through a central line can produce temporary asystole.

If hyperosmolar agents have been administered multiple times, when withdrawing therapy, the serum sodium and osmolarity should be allowed to return to within normal limits prior to removing the ICP monitor. The risk of rebound intracranial hypertension associated with the administration of hypotonic solutions such as half-NS or lactated Ringer solution can thereby be minimized.

Barbiturate Coma and Paralysis

In patients who have failed to respond to the above methods, barbiturate coma and paralysis can be effective methods for controlling intracranial hypertension.[60–62] These interventions do have the drawback of reducing the neurologic examination to just pupillary response. In such cases, neuromonitoring data such as ICP, $PBrO_2$, and JVO_2 must be used to evaluate whether the patient has responded adequately to the intervention, or if surgical intervention is required. Barbiturate coma can also cause hypotension, so care should be taken to maintain adequate MAP and CPP in during its use.[63]

Surgical Intervention

When ICP control does not respond to medical management steps, surgical management must be considered. Indeed, with each escalation in medical therapy, surgical intervention should be considered: large mass lesions, for example, or widespread cerebral contusions will often require eventual surgical decompression, so it is preferable to operate before all medical options are exhausted.

Skull Fracture (Including Basal Skull Fractures)

Skull fractures are a common result of head trauma and, when closed and not displaced, rarely require treatment per se. Depressed skull fractures are easily seen on plain frontal or lateral skull films and on CT. The mechanism of injury is usually a direct blow to the skull by a blunt object. Closed depressed skull fractures that are comminuted and those with a fragmented outer margin displaced beneath the inner table have characteristically been treated surgically, although growing evidence indicates that many may be treated nonoperatively if there is no neurologic dysfunction or CT evidence of underlying tissue injury. The best available evidence does not support elevation for the prevention or treatment of epilepsy.

Open fractures are also generally treated surgically, although, again, growing evidence indicates that fresh, noncomminuted fractures without neurologic deficit, CSF or brain extrusion, gross contamination, or underlying tissue injury can be closed and treated with prophylactic antibiotics. When surgery is indicated, the primary goal is to avoid infection by containing CSF, and closing the wound in a manner to ensure healing. Cosmesis is a secondary consideration. Once a fracture has been determined to be operative, early operation is recommend to reduce the incidence of infection. All management strategies for open (compound), depressed fractures should include antibiotics regardless of whether surgery is undertaken. The exact nature of the antibiotics used and the duration of treatment remain inadequately delineated in the existing literature. The general tendency is the use of broad-spectrum antibiotics (vs. gram-positive and gram-negative aerobic and anaerobic bacteria) for 5 days if soft tissue coverage is achieved.[64–67] In cases where soft tissue coverage is impossible, the duration of antibiotic usage is not well studied, but should probably continue for at least 2 weeks. Indications for nonoperative management are given in Table 21-2.

Table 21-2 Indications for Nonoperative Management of Compound Depressed Skull Fractures

No clinical or radiographic evidence of:

- Gross wound contamination
- Significant intracranial hematoma
- Gross cosmetic deformity
- Frontal sinus involvement
- Dural penetration
- Depression >1 cm
- Wound infection
- Pneumocephalus

5 Basilar skull fractures are usually diagnosed with CT imaging or on clinical evidence, as they are poorly visualized on plain films. Clinical signs include otorrhea or rhinorrhea, subcutaneous ecchymoses overlying the mastoid region (Battle sign), bilateral periorbital ecchymoses (raccoon eyes), or hemotympanum. A basilar skull fracture may involve the paranasal sinuses, piriform sinus, petrous bone, sphenoid sinus, or sella turcica. Injuries to adjacent structures, such as the seventh or eighth cranial nerves, brainstem, and carotid or basilar arteries, are not uncommon. These are generally visualized with CT scanning, although special protocols may be required. If vascular injury is suggested (such as by fracture lines involving the carotid canal), CT or catheter angiography should be considered. In the acute CSF leak, no specific therapy is indicated. The leak should not be tamponaded unless it is brisk. Antibiotics should not be administered solely for prophylaxis of meningitis. Most CSF leaks stop spontaneously with minimal treatment (e.g., elevating the head of the bed). Leaks that continue more than 72 hours generally require temporary CSF diversion (e.g., via lumbar drainage or ventriculostomy). CSF drainage that does not respond to diversion will require surgery.[68] Although most instances of rhinorrhea cease without surgery, the most common operation for persistent CSF leaks is exploration of the floor of the frontal fossa. The goal of such surgery is to identify the dural defect (often associated with herniation of a small tongue of brain tissue) and either close it primarily, patch it, or otherwise isolate the subarachnoid compartment from the skull base.

Epidural Hematomas

Epidural hematomas are frequently of arterial origin and have a tendency to expand. Prognosis varies directly with level of consciousness at time of surgery, ranging from 0% mortality for patients conscious throughout, to 27% with the classic lucid interval, to over 50% if the patient never regains consciousness. Aggressive surgical management has resulted in an overall mortality of about 9%.[33]

The recommendations regarding the management of epidural hematomas contained in the Guidelines for the Surgical Management of Traumatic Brain Injury[24] can be summarized as follows: an epidural hematoma larger than 30 mL, clot thickness greater than 15 mm, or midline shift over 5 mm should be surgically evacuated regardless of the patient's GCS score. In patients with a GCS score of 8 or less, evacuation should be emergent. If the GCS score is higher than 8, evacuation should be done as soon as possible but must not interfere with other resuscitative efforts unless there is evidence of progressive deterioration. It is strongly recommended that patients with any acute epidural hematoma with anisocoria undergo surgical evacuation as soon as possible. Epidural hematomas of less than 30 mL, clot thickness below 15 mm, and midline shift less than 5 mm should be considered for evacuation because the risk of evacuation appears less than the dangers of enlargement and neurologic injury. Epidural hematomas of this size in patients with GCS scores above 8 may be considered for nonoperative management, including frequent neurologic monitoring in an ICU setting and serial CT imaging. Although the mean time for enlargement of such lesions is approximately 8 hours after trauma, they may occur at intervals up to 36 hours.

Subdural Hematomas

Subdural hematomas are the more common extra-axial mass lesion, particularly in non–motor vehicle trauma. For acute subdural hematomas, the prognosis is less optimistic, with mortality rates of approximately 50%. To a great extent, this is related to the often significant injury to the underlying brain.

The recommendations regarding the management of subdural hematomas contained in the Guidelines for the Surgical Management of Traumatic Brain Injury[24] can be summarized as follows: an acute subdural hematoma with a thickness greater than 10 mm or midline shift above 5 mm on CT should be surgically evacuated, regardless of the patient's GCS score. Evacuation should be on an emergency basis if the initial GCS score is less than 8. In patients with higher GCS scores, evacuation should be as soon as reasonably possible. A comatose patient (GCS score 8) with a subdural hematoma with less than 10 mm thickness and midline shift below 5 mm should undergo surgical evacuation of the lesion if any of the following apply:

- The GCS score decreased between the time of injury and hospital admission by 2 or more GCS points.
- The patient presents with asymmetric or fixed and dilated pupil(s).
- The ICP exceeds 20 mm Hg for more than 5 to 10 minutes.

Patients with subdural hematomas of less than 10 mm thickness and midline shift below 5 mm and GCS scores greater than 8 can be treated nonoperatively, but should be closely observed.

It appears that outcome from subdural hematomas is proportional to the timing of evacuation. When surgery is planned, it should be performed within 4 hours whenever possible.[69] If surgical evacuation of an acute subdural hematoma in a comatose patient (GCS score 8) is indicated, it should be done using a full craniotomy with or without bone flap removal and duraplasty.

Frequently, consideration is given to leaving off the bone flap following the evacuation of acute subdural hematomas, particularly when the surgeon feels that there is evidence of brain swelling (e.g, brain herniation above craniotomy), or a perceived risk of subsequent brain swelling (e.g., significant preoperative midline shift). Unfortunately, there is a relative dearth of information on this group of patients.

Parenchymal Lesions

Surgery for intraparenchymal mass lesions remains controversial. Arguments against surgery include the risks of the operation itself as well as damage to tissue that may otherwise go on to recover. Arguments for surgery focus on preventing the hazards of intracranial hypertension caused by the lesion itself or progressive edema formation as the lesion matures. Much of the difficulty in determining the applicability of surgery in individual situations arises from our inability to consistently predict which patients will rapidly deteriorate (e.g., proceed on to herniation) or fail nonoperative therapy by developing intracranial hypertension refractory to medical therapy.

Recommendations regarding the management of traumatic parenchymal lesions

contained in the Guidelines for the Surgical Management of Traumatic Brain Injury[24] can be summarized as follows: in general, patients with any lesion greater than 50 mL in volume should be treated operatively. Additionally, patients who have parenchymal mass lesions and signs of progressive neurologic deterioration referable to the lesion, medically refractory intracranial hypertension, or signs of mass effect on CT scan should be considered for surgery.

Patients with GCS scores of 6 to 8 should be treated operatively if they have frontal or temporal contusions greater than 20 mL in volume with either midline shift over 5 mm or cisternal compression on CT scan.

Patients with parenchymal mass lesions may be managed nonoperatively if they do not show evidence for neurologic compromise, have controlled ICP, and have no significant signs of mass effect on CT scan. Such patients should be managed with intensive monitoring, frequent clinical examination, and serial imaging. Surgery should be readdressed if difficulties with control of intracranial hypertension lead to consideration of "higher-tier" therapies (e.g., hypothermia or barbiturate coma) so as to avoid the secondary complications of such therapy. In all nonoperatively treated patients with parenchymal mass lesions, surgery should be considered before reaching the medical "point of failure."

Surgical management may involve decompression to "make room" for the lesion-induced swelling, evacuation and débridement of the offending lesions, or a combination. Because evacuation of such lesions does not always eliminate the development of intracranial hypertension, extensive craniotomy with expansible duraplasty and without replacing the bone flap should be considered at the time of operation.

Diffuse Injury

The mortality rate of diffuse brain injury is directly related to the significance of the associated intracranial hypertension. As such, the mortality rate of diffuse injury with open basilar cisterns is approximately 13%, whereas compression or absence of cisterns has an associated mortality rate of about 38%. Diffuse injuries are not amenable to surgical therapy unless decompressive craniectomy is indicated for control of intractable intracranial hypertension. Although a recent study suggested that decompressive bifrontal craniectomy led to unfavorable outcomes in these patients, flaws in its design (most notably, significant dissimilarity in the severity of neurologic injury between the treatment and the control groups) called into question the validity of its conclusions.[70–72]

DAI is a reasonably distinct subset of diffuse brain injury. It is characterized on CT scan as small areas of focal hemorrhage in the brainstem, thalamus or deep nuclear region, corpus callosum, and hemispheric white matter, which may be associated with cerebral swelling. Intracranial hypertension is an inconsistent part of this syndrome. When ICP is elevated, however, successful management improves outcome. These patients tend to recover to varying extents; many of them will significantly improve in their level of consciousness but will generally be left with diffuse neurologic deficits (e.g., spasticity, cognitive impairments). Although a favorable prognosis seems to be correlated with fewer lesions on imaging studies and early improvement in level of consciousness,

prognostication is difficult in individual cases of DAI.

Posterior Fossa Lesions

Posterior fossa lesions are particularly dangerous because the progression from a benign lesion to a critical lesion is so precipitous and deadly. Patients may rapidly deteriorate from awake and alert to comatose, with signs of herniation ("upward" [caused by uncompensated swelling in the posterior fossa] or "downward" [from hydrocephalus]). Because of difficulties with the technology and uncertainty as to what pressures might be critical, monitoring of posterior fossa ICP is rarely performed. Vigilant clinical observation, tempered with a high degree of preemptive concern, therefore, represents the only form of monitoring currently applicable.

The recommendations regarding the management of traumatic posterior fossa lesions contained in the Guidelines for the Surgical Management of Traumatic Brain Injury[24] can be summarized as follows: rapid suboccipital craniectomy for evacuation of acute traumatic posterior fossa mass lesions is recommended in patients with neurologic dysfunction or deterioration referable to the lesion or mass effect on CT scan. Mass effect on CT scan appears as distortion, dislocation, or obliteration of the fourth ventricle; compression or loss of visualization of the basal cisterns; or presence of obstructive hydrocephalus.

In general, surgery is recommended for any clot larger than 3 cm in diameter, whereas conservative management may be considered with clots smaller than 3 cm when not associated with acute subdural or epidural hematomas. Because of the potential for rapid, unheralded deterioration, evacuation should be performed as soon as possible in patients with indications for surgical intervention.

Penetrating Injuries

Penetrating injuries to the brain present several unique management problems, including the prophylaxis and treatment of intracranial infection, the possibility of epilepsy, and the risk of occult vascular injuries. The recommendations regarding the management of penetrating brain trauma contained in the Guidelines for the Management of PBI[23] can be summarized as follows: Although plain radiographs may be useful in determining intracranial trajectory, CT scanning of the head is the modality of choice in PBI. In addition to the standard axial views with bone and soft tissue windows, coronal sections may be helpful in patients with skull base or high convexity involvement.

Angiography or CT angiography should be considered in patients with PBI. It is strongly recommended in cases in which the wound's trajectory passes through or near the Sylvian fissure, supraclinoid carotid, cavernous sinus, or a major venous sinus because of the increased risk of traumatic aneurysm or arteriovenous malformation. Sentinel signs of vascular abnormalities are large initial hematomas or the delayed development of substantial and otherwise unexplained subarachnoid hemorrhage or hematoma. When discovered, such vascular lesions should be definitively managed.

A major complication of penetrating injury is infection, both meningitis and abscess. Most infections occur within 3 weeks (55%) to 6 weeks (90%). The major risk factors

appear to be CSF leaks, air sinus wounds, or wound dehiscence. The incidence of infection with the use of broad-spectrum antibiotic treatment ranges from 1% to 11%. Although the main causative agent appears to be *Staphylococcus,* gram-negative bacteria are also frequent and *Clostridium* or other anaerobic organisms may be found with appropriate culture techniques. As such, antibiotic prophylaxis is indicated in all penetrating injuries. Broad-spectrum regimens, including anaerobic coverage, lasting for 7 to 14 days appear to be a reasonable approach.

Seizures are much more frequent following PBI than nonpenetrating injury in general. Between 30% and 50% of patients with PBI develop seizures. Although class I data are lacking, the increased incidence of early seizures has led to the recommendation that antiseizure medications (e.g., phenytoin, carbamazepine, valproate, phenobarbital) should be used during the first week after PBI. Prophylactic treatment with anticonvulsants beyond the first week after PBI has not been shown to prevent the development of new seizures and is not recommended.

The surgical management of penetrating wounds to the brain has undergone significant evolution over the past two decades. At present, surgical débridement of the missile tract in the brain is not recommended in the absence of significant mass effect. As well, routine surgical removal of fragments lodged distant from the entry site or reoperation solely to remove retained bone or missile fragments is not recommended.

Treatment of small bullet entrance wounds to the head in patients whose scalp is not devitalized and have no significant intracranial pathology should consist of local wound care and closure. In more extensive wounds with nonviable scalp, bone, or dura, surgical management with more extensive débridement followed by primary closure or grafting to secure a watertight wound is recommended. Closure of the dura and prevention of CSF leakage are extremely important goals in managing penetrating wounds. In patients with significant fragmentation of the skull, débridement of the cranial wound with either craniectomy or craniotomy is recommended.

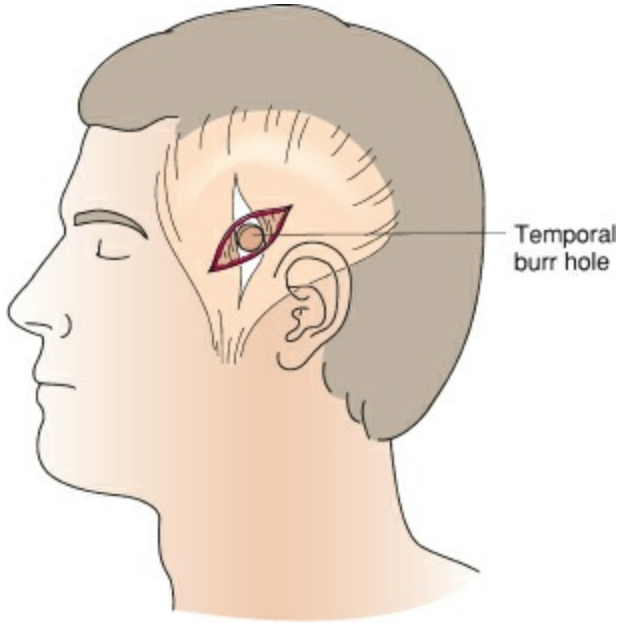

Figure 21-8. Location for placement of initial exploratory burr hole in the temporal region for emergency diagnosis and decompression.

Mass lesions should be surgically managed to prevent intracranial hypertension. As such, débridement of necrotic brain tissue and safely accessible bone fragments is recommended when they produce significant mass effect. As well, evacuation of intracranial hematomas is recommended if they produce significant mass effect as defined by the production of midline shift of over 5 mm or intracranial hypertension. This is one of the reasons that monitoring of ICP in penetrating injuries is an important adjunct to surgical decision making.

Repair of an open air sinus injury with watertight closure of the dura is recommended.

Exploratory Burr Holes/Craniotomy

If there is a high clinical suspicion for a mass lesion and CT imaging is unavailable, exploratory burr holes can be a useful and lifesaving option. If signs of herniation are present, all attempts should be made to reverse it medically (with hyperventilation and hyperosmolar agents as described above) so that the patient may be transferred to a facility equipped with CT capabilities.

If no such facility is reachable, or if herniation is refractory to medical management, emergency burr holes is a useful and lifesaving option. The first burr hole is placed in the ipsilateral temporal region and the dura is opened if an epidural hematoma is not in evidence (Fig. 21-8). If this exploration is negative, a second hole is placed in the opposite temporal region, then at the region of the parietal boss and the frontal convexity, first on the ipsilateral side, then contralaterally. A burr hole exploration is considered negative when six holes have been drilled. Any positive burr hole is turned into a craniotomy, and the hematoma is thoroughly evacuated.

Decompressive Craniectomy for Control of Intracranial Hypertension

In the eventuality that lower-tier interventions have been unsuccessful at controlling intracranial hypertension, decompressive hemicraniectomy should be considered. By effectively expanding the intracranial volume, decompressive hemicraniectomy allows the swollen brain additional room to expand and can improve ICP.

These craniectomies involve intentionally removing large, fronto-temporo-parietal bone flaps, leaving them out, and widely opening the dura to prevent it from constraining the bulging brain. The most common scenario is that of diffuse swelling wherein the more affected side is chosen for decompression. In cases where edema is bilaterally symmetric, bilateral decompressive craniectomies can be performed. In a recent randomized controlled trial, bilateral frontal hemicraniectomy was not found to improve outcomes,[70] but this result is controversial because of technical flaws in the study.[72] Regardless of which method is chosen, the bone flaps are as large as possible and particular attention is paid to decompressing the temporal lobe by removing the temporal bone forming the lateral wall of the middle cranial fossa.

Complications related to surgical management of TBI, especially after craniectomies, occur in a predictable temporal progression.[73] In the hours and days following surgery, pre-existing hemorrhagic lesions may undergo expansion partly because this is their natural history, and partly because of decreased tamponade on the lesion itself.[74] Wound infection and CSF leaks are most commonly seen in the initial week following surgery, and the incidence of complication ranges from 4% to 35%.[75,76] Posttraumatic hydrocephalus is a delayed complication presenting weeks to months following injury. Ventriculomegaly, secondary to encephalomalacia of injured brain tissue or alterations of CSF dynamics after TBI, is found in up to 45% of patients with hemicraniectomy following severe TBI.[77,78]

Given the high rates of morbidity from hemicraniectomy, this procedure should be applied cautiously, and only after an honest appraisal of the patient's recovery potential. Patients who have suffered prolonged periods of hypotension or hypoxemia, patients without evidence of brainstem function, and patients with advanced age or multiple medical comorbidities have increased postsurgical and overall risk and are less likely to benefit from surgery.[79] Additionally, patients on anticoagulation or antiplatelet agents that are irreversible are unlikely to benefit from hemicraniectomy. Finally, patients with catastrophic injury on computerized tomography scan, as quantified by the prognostically oriented Rotterdam score, make poor surgical candidates.[80] Judiciously applied, surgical decompression can be a lifesaving operation that has an acceptable risk profile given a severe TBI.

References

1. TBI: Get the Facts. 2016. Available from: http://www.cdc.gov/traumaticbraininjury/get_the_facts.html
2. Faul M, Coronado V. Epidemiology of traumatic brain injury. *Handb Clin Neurol* 2015;127:3–13.
3. National Hospital Discharge Survey. 2015. Available from: http://www.cdc.gov/nchs/nhds.htm
4. Gennarelli TA, Champion HR, Copes WS, et al. Comparison of mortality, morbidity, and severity of 59,713 head injured patients with 114,447 patients with extracranial injuries. *J Trauma* 1994;37(6):962–968.
5. Badjatia N, Carney N, Crocco TJ, et al. Guidelines for prehospital management of traumatic brain injury 2nd edition. *Prehosp Emerg Care* 2008;12(suppl 1):S1–S52.
6. Hartl R, Gerber LM, Iacono L, et al. Direct transport within an organized state trauma system reduces mortality in patients with severe traumatic brain injury. *J Trauma* 2006;60(6):1250–1256; discussion 1256.
7. Chesnut RM, Marshall LF, Klauber MR, et al. The role of secondary brain injury in determining outcome from severe head injury. *J Trauma* 1993; 34(2):216–222.
8. Manley G, Knudson MM, Morabito D, et al. Hypotension, hypoxia, and head injury: frequency, duration, and consequences. *Arch Surg* 2001;136(10):1118–1123.
9. Jones PA, Andrews PJ, Midgley S, et al. Measuring the burden of secondary insults in head-injured patients during intensive care. *J Neurosurg Anesthesiol* 1994;6(1):4–14.
10. Bossers SM, Schwarte LA, Loer SA, et al. Experience in prehospital endotracheal intubation significantly influences mortality of patients with severe traumatic brain injury: a systematic review and meta-analysis. *PLoS One* 2015;10(10):e0141034.
11. Gaither JB, Spaite DW, Bobrow BJ, et al. Balancing the potential risks and benefits of out-of-hospital intubation in traumatic brain injury: the intubation/hyperventilation effect. *Ann Emerg Med* 2012;60(6):732–736.
12. Karamanos E, Talving P, Skiada D, et al. Is prehospital endotracheal intubation associated with improved outcomes in isolated severe head injury? A matched cohort analysis. *Prehosp Disaster Med* 2014;29(1):32–36.
13. Tuma M, El-Menyar A, Abdelrahman H, et al. Prehospital intubation in patients with isolated severe traumatic brain injury: a 4-year observational study. *Crit Care Res Pract* 2014;2014:135986.
14. Kiening KL, Unterberg AW, Bardt TF, et al. Monitoring of cerebral oxygenation in patients with severe head injuries: brain tissue PO2 versus jugular vein oxygen saturation. *J Neurosurg* 1996;85(5):751–757.
15. van Santbrink H, Maas AI, Avezaat CJ. Continuous monitoring of partial pressure of brain tissue oxygen in patients with severe head injury. *Neurosurgery* 1996;38(1):21–31.
16. Lang EW, Chesnut RM. A bedside method for investigating the integrity and critical

thresholds of cerebral pressure autoregulation in severe traumatic brain injury patients. *Br J Neurosurg* 2000;14(2):117–126.

17. Czosnyka M, Miller C; Participants in the International Multidisciplinary Consensus Conference on Multimodality Monitoring. Monitoring of cerebral autoregulation. *Neurocrit Care* 2014;21(suppl 2):S95–S102.
18. Brain Trauma Foundation, American Association of Neurological Surgeons, Congress of Neurological Surgeons, et al. Guidelines for the management of severe traumatic brain injury. I. Blood pressure and oxygenation. *J Neurotrauma* 2007;24(suppl 1):S7–S13.
19. Brain Trauma Foundation, American Association of Neurological Surgeons, Congress of Neurological Surgeons, et al. Guidelines for the management of severe traumatic brain injury. IX. Cerebral perfusion thresholds. *J Neurotrauma* 2007;24(suppl 1):S59–S64.
20. Robertson CS, Valadka AB, Hannay HJ, et al. Prevention of secondary ischemic insults after severe head injury. *Crit Care Med* 1999;27(10):2086–2095.
21. Teasdale G, Jennett B. Assessment of coma and impaired consciousness. A practical scale. *Lancet* 1974;2(7872):81–84.
22. Gabriel EJ, Ghajar J, Jagoda A, et al. Guidelines for prehospital management of traumatic brain injury. *J Neurotrauma* 2002;19(1):111–174.
23. Teasdale G, Maas A, Lecky F, et al. The Glasgow Coma Scale at 40 years: standing the test of time. *Lancet Neurol* 2014;13(8):844–854.
24. Best Practices in the Management of Traumatic Brain Injury. Trauma Quality Improvement Program. 2015: *American College of Surgeons*. Available on: https://www.facs.org/~/media/files/quality%20programs/trauma/tqip/traumatic%2
25. Du R, Meeker M, Bacchetti P, et al. Evaluation of the portable infrared pupillometer. *Neurosurgery* 2005;57(1):198–203; discussion 198–203.
26. Chen JW, Gombart ZJ, Rogers S, et al. Pupillary reactivity as an early indicator of increased intracranial pressure: the introduction of the Neurological Pupil index. *Surg Neurol Int* 2011;2:82.
27. Chen JW, Vakil-Gilani K, Williamson KL, et al. Infrared pupillometry, the Neurological Pupil index and unilateral pupillary dilation after traumatic brain injury: implications for treatment paradigms. *Springerplus* 2014;3:548.
28. Aziz H, Rhee P, Pandit V, et al. Mild and moderate pediatric traumatic brain injury: Replace routine repeat head computed tomography with neurologic examination. *J Trauma Acute Care Surg* 2013;75(4):550–554.
29. Bata SC, Yung M. Role of routine repeat head imaging in paediatric traumatic brain injury. *ANZ J Surg* 2014;84(6):438–441.
30. Joseph B, Aziz H, Pandit V, et al. Low-dose aspirin therapy is not a reason for repeating head computed tomographic scans in traumatic brain injury: a prospective study. *J Surg Res* 2014;186(1):287–291.

31. Joseph B, Friese RS, Sadoun M, et al. The BIG (brain injury guidelines) project: defining the management of traumatic brain injury by acute care surgeons. *J Trauma Acute Care Surg* 2014;76(4):965–969.
32. Yuh EL, Mukherjee P, Lingsma HF, et al. Magnetic resonance imaging improves 3-month outcome prediction in mild traumatic brain injury. *Ann Neurol* 2013;73(2):224–235.
33. Yuh EL, Hawryluk GW, Manley GT. Imaging concussion: a review. *Neurosurgery* 2014;75(suppl 4):S50–S63.
34. Brain Trauma Foundation, American Association of Neurological Surgeons, Congress of Neurological Surgeons, et al. Guidelines for the management of severe traumatic brain injury. Methods. *J Neurotrauma* 2007;24(suppl 1):S3–S6.
35. Rowell SE, Fair KA, Barbosa RR, et al. The impact of pre-hospital administration of lactated ringer's solution versus normal saline in patients with traumatic brain injury. *J Neurotrauma* 2016.
36. Brain Trauma Foundation, American Association of Neurological Surgeons, Congress of Neurological Surgeons, et al. Guidelines for the management of severe traumatic brain injury. VI. Indications for intracranial pressure monitoring. *J Neurotrauma* 2007;24(suppl 1):S37–S44.
37. Poca MA, Sahuquillo J, Arribas M, et al. Fiberoptic intraparenchymal brain pressure monitoring with the Camino V420 monitor: reflections on our experience in 163 severely head-injured patients. *J Neurotrauma* 2002;19(4):439–448.
38. Bauer DF, Razdan SN, Bartolucci AA, et al. Meta-analysis of hemorrhagic complications from ventriculostomy placement by neurosurgeons. *Neurosurgery* 2011;69(2):255–260.
39. Chesnut RM. Intracranial pressure monitoring: headstone or a new head start. The BEST TRIP trial in perspective. *Intensive Care Med* 2013; 39(4):771–774.
40. Chesnut RM, Temkin N, Carney N, et al. A trial of intracranial-pressure monitoring in traumatic brain injury. *N Engl J Med* 2012;367(26):2471–2481.
41. Robertson CS, Gopinath SP, Goodman JC, et al. SjvO2 monitoring in head-injured patients. *J Neurotrauma* 1995;12(5):891–896.
42. Rosenthal G, Hemphill JC 3rd, Manley G. Brain tissue oxygen tension is more indicative of oxygen diffusion than oxygen delivery and metabolism in patients with traumatic brain injury. *Crit Care Med* 2009;37(1):379–380.
43. Rosenthal G, Hemphill JC, Sorani M, et al. The role of lung function in brain tissue oxygenation following traumatic brain injury. *J Neurosurg* 2008;108(1):59–65.
44. Nangunoori R, Maloney-Wilensky E, Stiefel M, et al. Brain tissue oxygen-based therapy and outcome after severe traumatic brain injury: a systematic literature review. *Neurocrit Care* 2012;17(1):131–138.
45. Oddo M, Levine JM, Mackenzie L, et al. Brain hypoxia is associated with short-term outcome after severe traumatic brain injury independently of intracranial

hypertension and low cerebral perfusion pressure. *Neurosurgery* 2011;69(5):1037–1045; discussion 1045.

46. Sanchez JJ, Bidot CJ, O'Phelan K, et al. Neuromonitoring with microdialysis in severe traumatic brain injury patients. *Acta Neurochir Suppl* 2013;118:223–227.
47. Rosenthal G, Sanchez-Mejia RO, Phan N, et al. Incorporating a parenchymal thermal diffusion cerebral blood flow probe in bedside assessment of cerebral autoregulation and vasoreactivity in patients with severe traumatic brain injury. *J Neurosurg* 2011;114(1):62–70.
48. Lin BS, Wang CC, Chang MH, et al. Evaluation of traumatic brain injury by optical technique. *BMC Neurol* 2015;15:202.
49. Wang CC, Kuo JR, Chen YC, et al. Brain tissue oxygen evaluation by wireless near-infrared spectroscopy. *J Surg Res* 2016;200(2):669–675.
50. Davies DJ, Su Z, Clancy MT, et al. Near-infrared spectroscopy in the monitoring of adult traumatic brain injury: a review. *J Neurotrauma* 2015;32(13):933–941.
51. Plomgaard AM, van Oeveren W, Petersen TH, et al. The SafeBoosC II randomized trial: treatment guided by near-infrared spectroscopy reduces cerebral hypoxia without changing early biomarkers of brain injury. *Pediatr Res* 2016;79(4):528–535.
52. Temkin NR, Dikmen SS, Wilensky AJ, et al. A randomized, double-blind study of phenytoin for the prevention of post-traumatic seizures. *N Engl J Med* 1990;323(8):497–502.
53. Robertson CS, Hannay HJ, Yamal JM, et al. Effect of erythropoietin and transfusion threshold on neurological recovery after traumatic brain injury: a randomized clinical trial. *JAMA* 2014;312(1):36–47.
54. Edwards P, Arango M, Balica L, et al. Final results of MRC CRASH, a randomised placebo-controlled trial of intravenous corticosteroid in adults with head injury-outcomes at 6 months. *Lancet* 2005;365(9475):1957–1959.
55. Kaufmann AM, Cardoso ER. Aggravation of vasogenic cerebral edema by multiple-dose mannitol. *J Neurosurg* 1992;77(4):584–589.
56. Adelson PD, Bratton SL, Carney NA, et al. Guidelines for the acute medical management of severe traumatic brain injury in infants, children, and adolescents. Chapter 11. Use of hyperosmolar therapy in the management of severe pediatric traumatic brain injury. *Pediatr Crit Care Med* 2003;4(3 suppl):S40–S44.
57. Burgess S, Abu-Laban RB, Slavik RS, et al. A systematic review of randomized controlled trials comparing hypertonic sodium solutions and mannitol for traumatic brain injury: implications for emergency department management. *Ann Pharmacother* 2016;50(4):291–300.
58. Wakai A, McCabe A, Roberts I, et al. Mannitol for acute traumatic brain injury. *Cochrane Database Syst Rev* 2013;8:CD001049.
59. Sorani MD, Morabito D, Rosenthal G, et al. Characterizing the dose-response relationship between mannitol and intracranial pressure in traumatic brain injury

patients using a high-frequency physiological data collection system. *J Neurotrauma* 2008;25(4):291–298.

60. Marshall GT, James RF, Landman MP, et al. Pentobarbital coma for refractory intracranial hypertension after severe traumatic brain injury: mortality predictions and one-year outcomes in 55 patients. *J Trauma* 2010;69(2):275–283.
61. Pérez-Bárcena J, Llompart-Pou JA, Homar J, et al. Pentobarbital versus thiopental in the treatment of refractory intracranial hypertension in patients with traumatic brain injury: a randomized controlled trial. *Crit Care* 2008;12(4):R112.
62. Eisenberg HM, Frankowski RF, Contant CF, et al. High-dose barbiturate control of elevated intracranial pressure in patients with severe head injury. *J Neurosurg* 1988;69(1):15–23.
63. Majdan M, Mauritz W, Wilbacher I, et al. Barbiturates use and its effects in patients with severe traumatic brain injury in five European countries. *J Neurotrauma* 2013;30(1):23–29.
64. Luce EA. Discussion: severe infectious complications following frontal sinus fracture: the impact of operative delay and perioperative antibiotic use. *Plast Reconstr Surg* 2013;132(1):163–164.
65. Zix J, Schaller B, Iizuka T, et al. The role of postoperative prophylactic antibiotics in the treatment of facial fractures: a randomised, double-blind, placebo-controlled pilot clinical study. Part 1: orbital fractures in 62 patients. *Br J Oral Maxillofac Surg* 2013;51(4):332–336.
66. Schaller B, Soong PL, Zix J, et al. The role of postoperative prophylactic antibiotics in the treatment of facial fractures: a randomized, double-blind, placebo-controlled pilot clinical study. Part 2: mandibular fractures in 59 patients. *Br J Oral Maxillofac Surg* 2013;51(8):803–807.
67. Bellamy JL, Molendijk J, Reddy SK, et al. Severe infectious complications following frontal sinus fracture: the impact of operative delay and perioperative antibiotic use. *Plast Reconstr Surg* 2013;132(1):154–162.
68. Rodriguez ED, Stanwix MG, Nam AJ, et al. Twenty-six-year experience treating frontal sinus fractures: a novel algorithm based on anatomical fracture pattern and failure of conventional techniques. *Plast Reconstr Surg* 2008;122(6):1850–1866.
69. Seelig JM, Becker DP, Miller JD, et al. Traumatic acute subdural hematoma: major mortality reduction in comatose patients treated within four hours. *N Engl J Med* 1981;304(25):1511–1518.
70. Cooper DJ, Rosenfeld JV, Murray L, et al. Decompressive craniectomy in diffuse traumatic brain injury. *N Engl J Med* 2011;364(16):1493–1502.
71. Sahuquillo J, Martinez-Ricarte F, Poca MA. Decompressive craniectomy in traumatic brain injury after the DECRA trial. Where do we stand? *Curr Opin Crit Care* 2013;19(2):101–106.
72. Honeybul S, Ho KM, Lind CR. What can be learned from the DECRA study. *World*

Neurosurg 2013;79(1):159–161.

73. Stiver SI. Complications of decompressive craniectomy for traumatic brain injury. *Neurosurg Focus* 2009;26(6):E7.
74. Flint AC, Manley GT, Gean AD, et al. Post-operative expansion of hemorrhagic contusions after unilateral decompressive hemicraniectomy in severe traumatic brain injury. *J Neurotrauma* 2008;25(5):503–512.
75. Yang XF, Wen L, Shen F, et al. Surgical complications secondary to decompressive craniectomy in patients with a head injury: a series of 108 consecutive cases. *Acta Neurochir (Wien)* 2008;150(12):1241–1247; discussion 1248.
76. Sughrue ME, Bloch OG, Manley GT, et al. Marked reduction in wound complication rates following decompressive hemicraniectomy with an improved operative closure technique. *J Clin Neurosci* 2011;18(9):1201–1205.
77. Poca MA, Sahuquillo J, Mataró M, et al. Ventricular enlargement after moderate or severe head injury: A frequent and neglected problem. *J Neurotrauma* 2005;22(11):1303–1310.
78. Honeybul S, Ho KM. Incidence and risk factors for post-traumatic hydrocephalus following decompressive craniectomy for intractable intracranial hypertension and evacuation of mass lesions. *J Neurotrauma* 2012;29(10):1872–1878.
79. Steyerberg EW, Mushkudiani N, Perel P, et al. Predicting outcome after traumatic brain injury: development and international validation of prognostic scores based on admission characteristics. *PLoS Med* 2008;5(8):e165; discussion e165.
80. Maas AI, Hukkelhoven CW, Marshall LF, et al. Prediction of outcome in traumatic brain injury with computed tomographic characteristics: a comparison between the computed tomographic classification and combinations of computed tomographic predictors. *Neurosurgery* 2005;57(6):1173–1182; discussion 1173–1182.

Chapter 22

Maxillofacial Injuries

Batya R. Goldwaser, Leonard B. Kaban, and Maria J. Troulis

Key Points

1 Due to the widespread use of seatbelts and airbags, the overall incidence of MVC-related injuries has decreased, but improved survival has resulted in increased complexity of injuries requiring treatment.

2 Life-threatening maxillofacial injuries involve upper airway obstruction and/or hemorrhage.

3 Identification of injuries to specialized structures including the facial nerve, parotid duct, the globe and lacrimal system is critical.

4 Fractures of the maxilla and mandible are unique because of the presence of teeth which are the most important landmark for reduction. The primary goal of treatment is restoration of the dental occlusion.

5 Maxillary fractures involve the pterygoid plates and are classified as Le Fort I, II or, III depending on the superior extent of the injury.

6 Indications for operative treatment of zygomaticomaxillary complex (ZMC) fractures include cosmetic deformity, enophthalmos or diplopia, paresthesia, and limitation of mouth opening from coronoid impingement.

7 The status of the medial canthal ligament and its attachment to bone is the key to proper diagnosis and treatment of naso-orbital–ethmoid (NOE) fractures.

8 Retrobulbar hematoma and extraocular muscle entrapment are surgical emergencies that require immediate treatment to prevent permanent visual deficits.

9 Indications for operative treatment of frontal sinus fractures include cosmetic deformity, intracranial extension, and nasofrontal outflow tract obstruction. Complications include meningitis and mucocele formation which can occur even years later.

10 Indications for open treatment of mandible fractures include edentulism, severe displacement, or comorbid conditions that preclude closed reduction with maxillomandibular fixation, or the presence of concomitant midface fractures.

11 All mandible fractures of the tooth-bearing region are considered open fractures and antibiotic treatment must be instituted.

12 In panfacial fractures, various treatment approaches including “top-down,” “bottom-up,” and “outside-in” exist, and are chosen based on the specific injury pattern.

1 The etiology of facial trauma in adults is most commonly motor vehicle crashes, followed by interpersonal violence, sports injuries, and falls, with the exact incidence varying by geographic location. Among children, falls predominate followed by sports injuries and motor vehicle collisions.[1] Although firearm-related deaths have declined, head and neck injuries continue to make up approximately 15% of gunshot wounds, often a result of suicide or homicide.[2] Young males (age 20 to 30) make up the largest group demographically for all causes of facial trauma, while children account for less than 10%.[3] In adults, the most commonly injured structures are the nose, dentoalveolar complex, zygoma, and mandible given their protrusive position relative to the rest of the face. Orbit and midface (i.e., Le Fort level) injuries are less common. The opposite is true in children whose cranium grows rapidly and results in a prominent forehead and orbits and a larger skull-to-face ratio with the midface relatively protected. Mandibular, nasal and dentoalveolar trauma is most common.[4] Due to the widespread use of seatbelts and airbags, the incidence of MVC-related injuries has decreased. However, severely injured patients have improved survival resulting in an increase in the complexity of midface and mandibular fractures and overlying soft tissue injuries now seen.[5,6]

2 The initial management of a patient with facial trauma, like all trauma patients, begins with the standard ATLS protocol including breathing, airway, and circulation.[7] Specific life-threatening maxillofacial injuries involve upper airway obstruction and/or hemorrhage and must be addressed acutely.[8,9] Aspiration of blood or foreign bodies (including teeth, dentures, debris, and stomach contents), the tongue position especially in unconscious patients or those with certain unstable mandible fractures (i.e., "bucket-handle"), or midface fractures with resultant impaction of the maxilla can obstruct the airway. The high correlation between facial trauma and C-spine injuries requires clinical and radiographic exclusion of concomitant fractures and/or ligamentous injury.

Facial injuries causing significant bleeding are not common, with the exception of scalp and tongue lacerations which must be addressed quickly. The ethmoidal arteries as well as branches of the internal maxillary artery can also be a source of significant bleeding (Fig. 22-1). Hemostasis is usually attained with head elevation, pressure and packing with gauze, an inflated Foley catheter, or Rhinorockets. If bleeding continues despite these measures, diagnostic imaging such as CTA, and fracture reduction and immobilization, with or without direct ligation or embolization may be required (Fig. 22-2).[9–12]

3 The secondary survey involves examination of soft tissue and bony injuries, including specialized structures such as the facial nerve, the parotid duct, the globe, and the lacrimal system. Stepoffs and/or mobility of the orbital rims, malar eminences, zygomatic arch, nasal bones, and mandible signify displaced fractures. Mobility of the maxilla should be determined and all teeth should be accounted for, either by direct visualization or ruling out aspiration by chest x-ray. Nerve paralysis, any sensory deficits, or malocclusion almost always correlate with a significant facial injury.

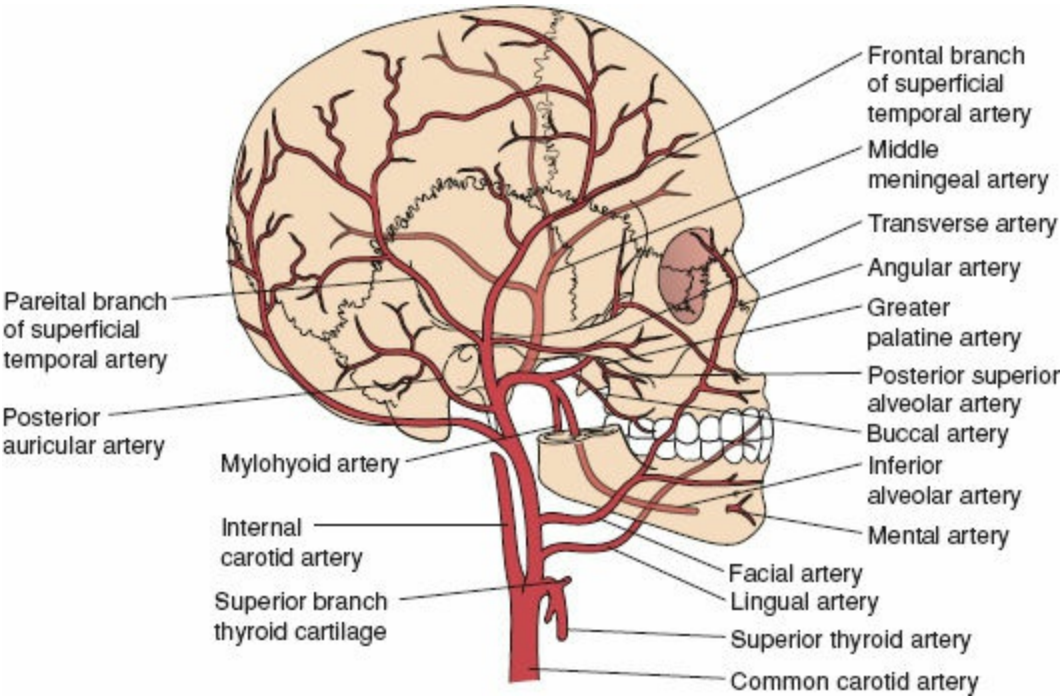

Figure 22-1. Sources of bleeding in facial trauma.

SOFT TISSUE INJURIES

Important anatomic regions of the face that must be precisely reapproximated include the vermillion border of the lip, the eyebrow, and the eyelid where even small inaccuracies in repair can become larger deformities later. Defects of up to 25% of the lip or eyelid can be closed primarily with good results. Eyelid lacerations involving the medial third must be closely evaluated to identify the punctum and canaliculus which drains into the nasolacrimal duct to the inferior meatus in the nose. Retrobulbar hematoma is a surgical emergency that must be immediately decompressed to prevent permanent vision loss. Signs include decreasing visual acuity, elevated intraocular pressure (IOP) (>40), pain, tense globe, proptosis, and often a visible hematoma on imaging. Treatment is with immediate lateral canthotomy and cantholysis for decompression (Figs. 22-3 and 22-4).[13]

The nasal septum and ear pinna must be checked for hematoma which can lead to cartilage necrosis (with subsequent “saddle nose deformity” or “cauliflower ear”) if not evacuated. Following drainage, a bolster should be placed to prevent reaccumulation. Any injury along the course of the facial nerve proximal to the lateral canthus should be suspect for injury to a major branch and repaired primarily (Fig. 22-5).

Injuries to the parotid gland and duct must be identified. To identify ductal injury or continuity defects, the Stenson duct orifice (best found at the papilla adjacent to the maxillary second molar) is visualized while simultaneously “milking” the parotid gland from extraorally in the direction of salivary flow. If the duct is intact, saliva should be visible flowing from the orifice into the mouth. However, lack of salivary flow does not confirm ductal injury, as flow can be minimal in multiple conditions such as dehydration or autoimmune disorders. Comparison to the contralateral or uninjured side can help in differentiating acute injury. Another maneuver that can be diagnostic is cannulating the duct using a lacrimal probe and following the path as far proximally as possible. If the duct has been transected, the probe may be visible within the facial wound. Midductal injuries require proximal and distal segment reanastamosis, usually over a catheter which is left in place for 10 to 14 days. Distal ductal injuries can be left open to the mouth with creation of a neoorifice.[14,15] For intraglandular injury, the parotid capsule may be closed and a pressure dressing placed to prevent development of a sialocele (Fig. 22-6).

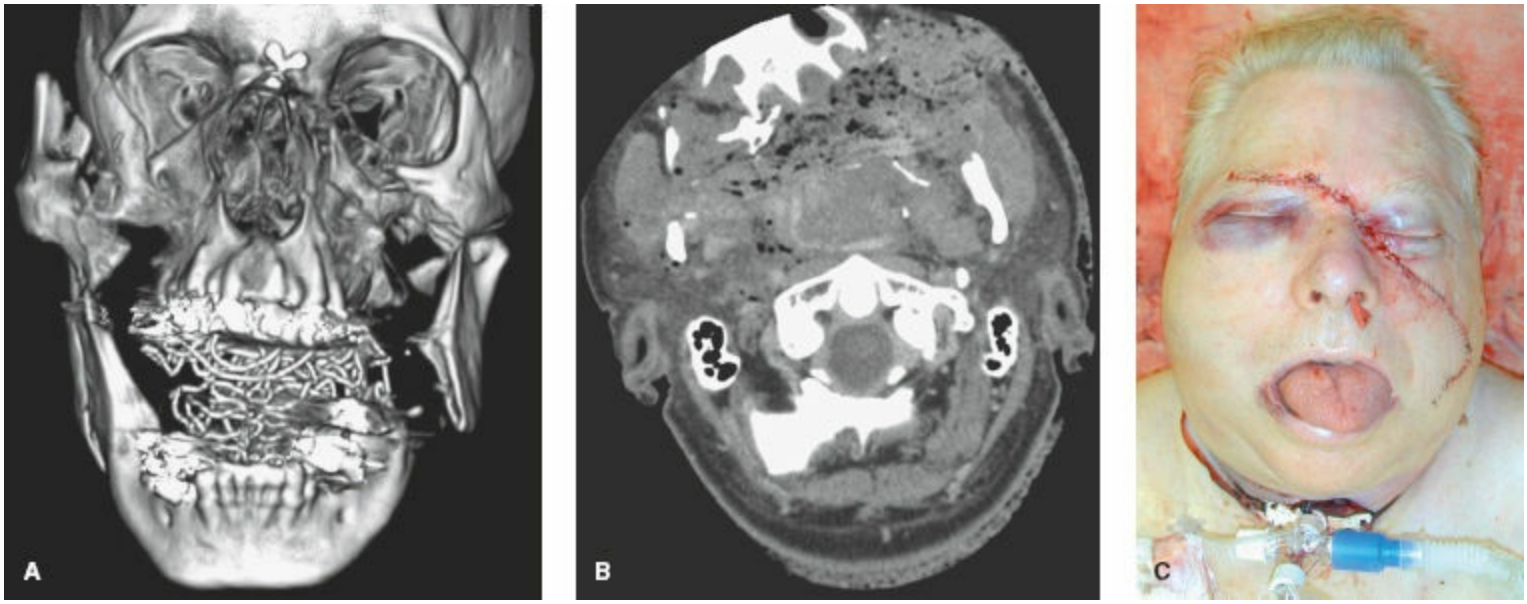

Figure 22-2. The patient was acutely stabilized by the trauma service (Drs DeMoya and Velmahos). **A,B:** Bleeding was acutely controlled by packing for the ascending pharyngeal artery, cauterization of the ethmoidal arteries, and immobilization of the midface. **C:** The laceration was temporarily closed.

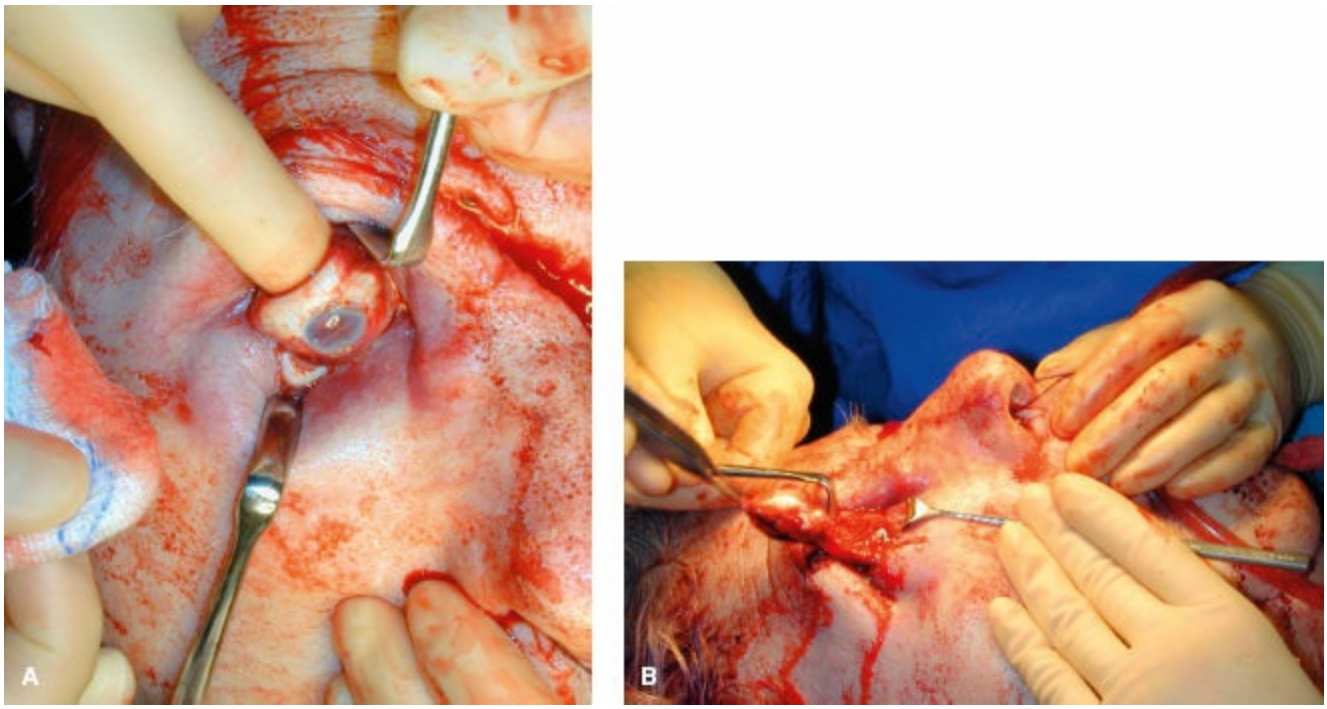

Figure 22-3. **A,B:** At the initial operation, the right globe was found to be ruptured and thus exenterated. The left globe had increased intraocular pressure, was tense and had limited extraocular movements on forced duction so an emergent lateral canthotomy was performed with immediate decompression. The nasolacrimal apparatus was cannulated by the oculoplastics service and noted to be severed.

4 Fractures of the maxilla and mandible differ from other fractures because of the presence of teeth which are the most important landmark for reduction and render fractures as "open." The goal of treatment is not only reduction, fixation, and immobilization, improved contour, and range of motion, but also restoration of occlusion. Although in the acute or emergent setting the airway should be secured by any means necessary, when planning definitive treatment, the requirement for access to the

occlusion will determine whether oral, nasal, or submental intubation is most appropriate. An oral tube can be used if the patient is edentulous or has many missing teeth without a reproducible occlusion. Nasal intubation is generally safe even with significant midface trauma, but is best performed under direct visualization with fiberoptic guidance to prevent inadvertent intracranial injury. When nasal intubation is not possible and the occlusion must be established, submental intubation is a useful alternative. Oral intubation is followed by passing the oral end of the endotracheal tube through an incision in the floor of mouth and submental neck. Postoperatively, the tube is passed back into the mouth and the patient can be extubated. If prolonged assisted ventilation is anticipated, an elective tracheostomy should be considered preoperatively.

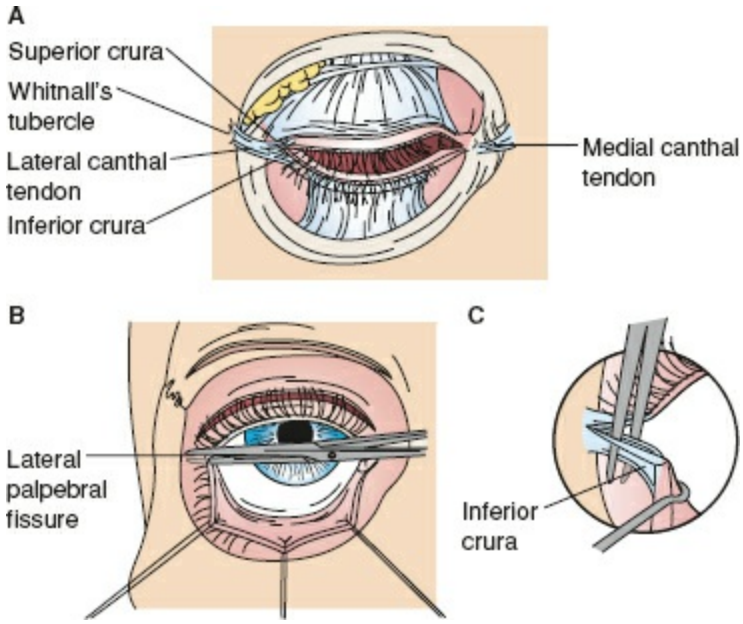

Figure 22-4. Lateral canthotomy. **A:** Canthal tendon anatomy. **B:** Lateral canthotomy. After clamping the tissue for hemostasis, a horizontal cut is made with scissors through skin, orbicularis oculi, and conjunctiva of the lateral palpebral fissure. This is usually not sufficient to reduce intraocular pressure (IOP). **C:** Inferior cantholysis. Next, the lower lid is retracted to expose the inferior limb of the canthal tendon which is oriented horizontally. After dissecting it free, the tendon is cut with scissors oriented vertically. Though not usually required, if IOP is still elevated, the superior limb can be dissected free and transected as well.

Related to choice of airway, fractures of the tooth-bearing maxilla and/or mandible require the patient to be on a nonchew diet for 6 weeks. After a 1-week inflammatory phase, a soft callus forms over 2 to 3 weeks. At this point the fracture is stable enough to prevent shortening but it is still susceptible to angular forces. A hard callus then replaces the soft callus and can take up to 3 to 4 months. For this reason, it is generally recommended to limit chewing forces for 6 weeks (in adults) and to avoid additional trauma for 3 months.[16] If there are minimal concomitant injuries, most patients are able to maintain nutritional requirements with enteral intake, often with oral supplements. If there are other significant injuries, especially those resulting in altered mental status or prolonged ICU stay, a nasogastric tube or gastrostomy tube may be needed.

MAXILLARY FRACTURES

5 The famous study by Rene Le fort in 1901 is the basis for the current classification system of maxillary fractures (Fig. 22-7).[17] Physical examination reveals periorbital ecchymosis and edema, epistaxis, a retruded midface, palatal ecchymosis, malocclusion, numbness in the V2 distribution, mobility of the maxilla at the piriforms, nasofrontal or zygomaticotemporal sutures. Epiphora results if the nasolacrimal duct is obstructed.

Computed tomography (CT) is the imaging modality of choice for midface injuries, especially if the orbit is involved or if an operation is planned. Treatment includes reduction, and usually disimpaction of the maxilla, using the occlusion as a guide when possible, followed by immobilization (either maxillomandibular fixation or rigid fixation to an adjacent stable facial structure) (Fig. 22-8).

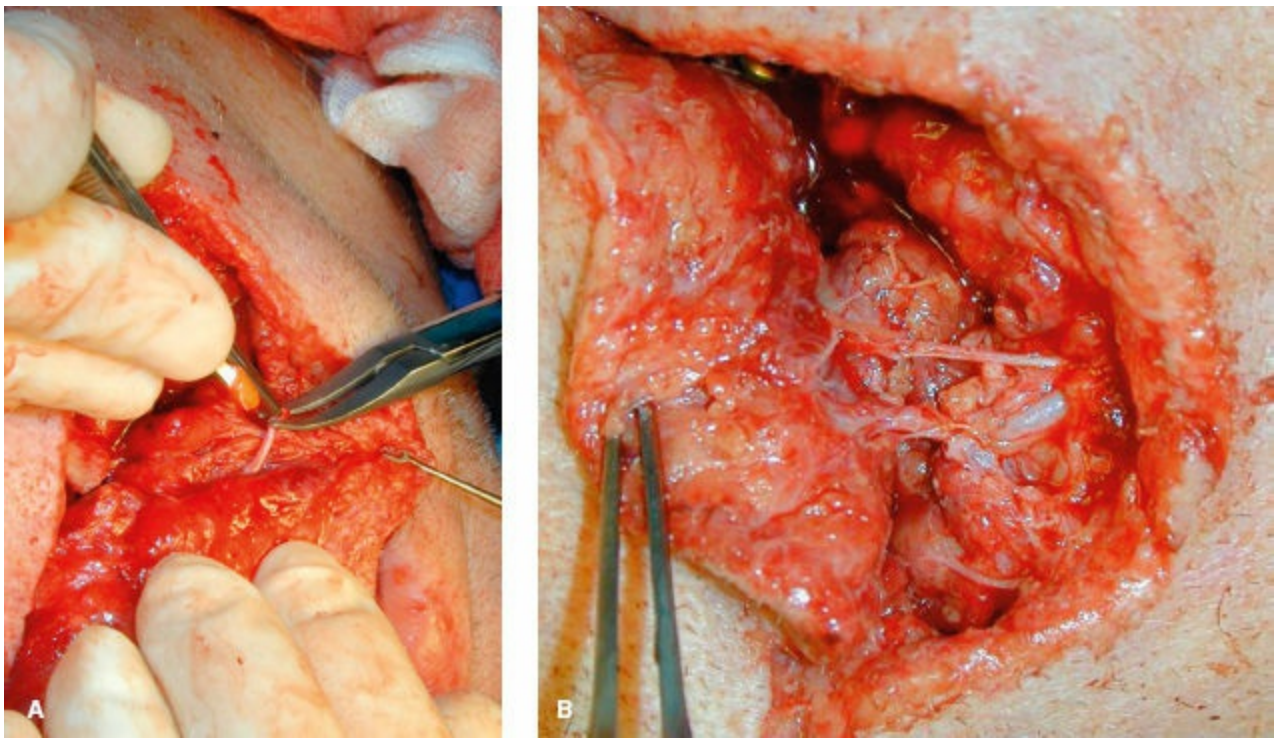

Figure 22-5. **A,B:** The left facial nerve was explored given the location of the laceration (i.e., proximal to the lateral canthus) and a severed branch to the upper lip was anastomosed under microscopic visualization by Dr. Hadlock.

ZYGOMATICOMAXILLARY COMPLEX FRACTURES

The zygoma articulates with the frontal, sphenoid, temporal and maxillary bones, forming a "complex" (Fig. 22-9). It also forms the infraorbital rim and orbital floor. Physical examination shows periorbital ecchymosis and edema, flattening of the cheek, downslanting of the lateral canthus, enophthalmos, or stepoff at the infraorbital rim. Paresthesia of the infraorbital distribution suggests nerve entrapment in the line of fracture. Less common is limitation of mouth opening which occurs if the zygomatic arch is depressed and impinges on the coronoid process of the mandible. Because of the close association with the orbit, a preoperative ophthalmology examination is prudent.[18]

CT scan is the gold standard in order to best appreciate the degree of rotation and/or depression, as well as to evaluate the orbital floor component. Historically, the Water view radiograph was used, and it is with this image that the well-known and still used Knight and North Classification system was developed.[19] This classification system which describes zygomaticomaxillary complex (ZMC) fractures by rotation, depression, and comminution, predicts fracture stability after reduction. With the use of CT scans and rigid fixation, this classification system may not be as relevant. Another classification system developed by Manson in 1990 divides ZMC fractures into low-energy, mid-energy, and high-energy fractures.[20]

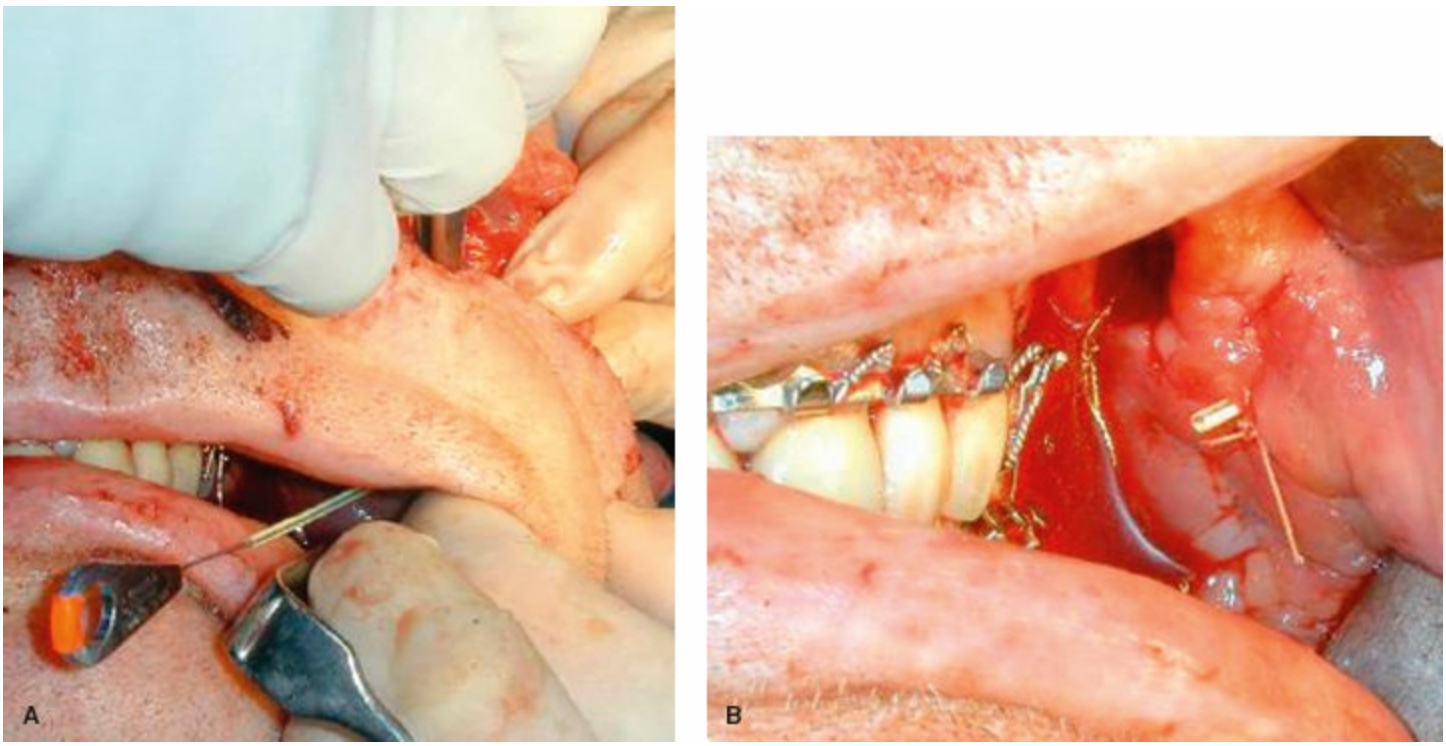

Figure 22-6. **A,B:** The left parotid duct was cannulated and clear salivary flow identified. A stent was left in place for 21 days.

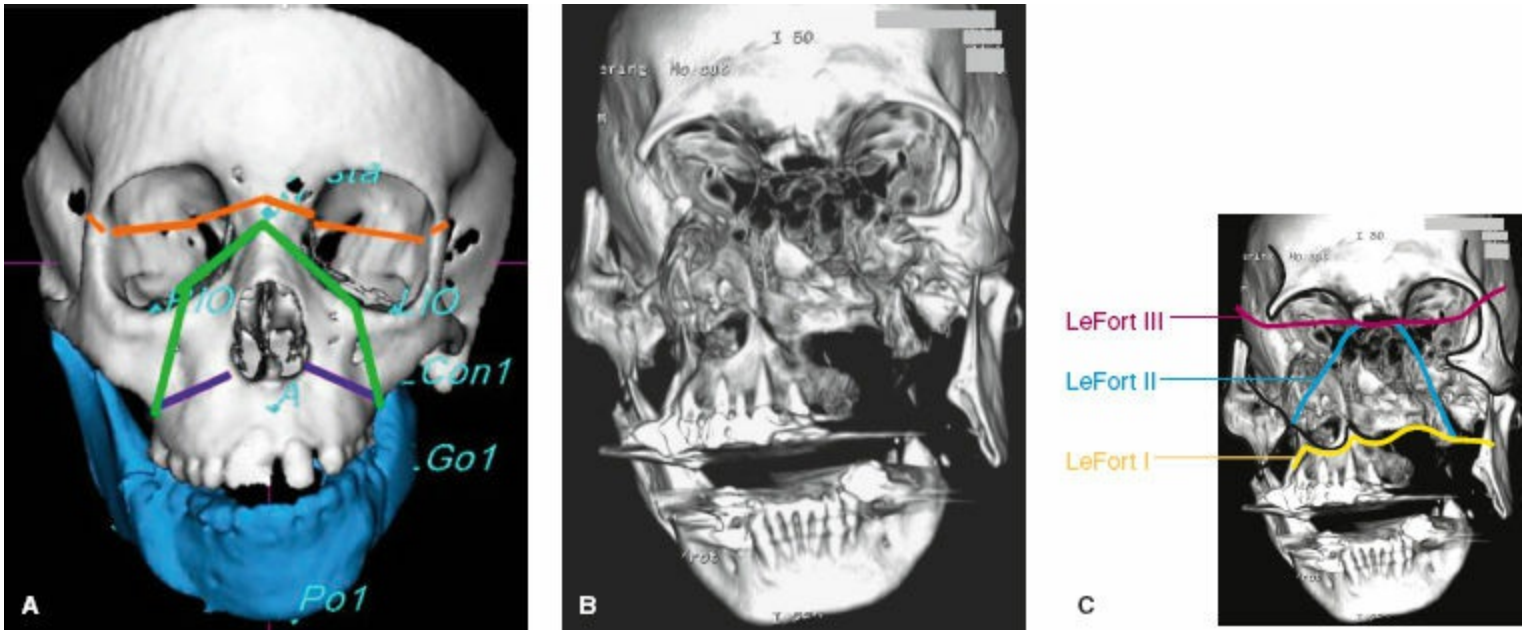

Figure 22-7. **A:** Le Fort I fractures are horizontal fractures that span across the piriform rims along the floor of the nose, through the maxillary sinus around to the pterygoid plates posteriorly. Le Fort II fractures are pyramidal in shape and include the nasal bones, infraorbital rims, in addition to the zygomaticomaxillary buttress and pterygoid plates. Le Fort III is a separation of the entire face from the skull base and includes the nasofrontal suture and medial orbit, zygomaticotemporal suture at the lateral orbit around to the pterygoid plates. **B,C:** Maxillofacial CT of the same patient as above, showing Le Fort I, II, III level fractures and significantly displaced bilateral mandibular body fractures. A CTA and subsequent angiogram showed transection of the bilateral internal maxillary arteries without a target for embolization.

6 Surgical treatment is usually delayed until swelling resolves to better evaluate any cosmetic deformity and to allow easier surgical access if needed. Nondisplaced, stable fractures can be observed. Indications for open treatment include cosmetic deformity, enophthalmos, or diplopia when the orbital floor component is significant, paresthesia of the V2 distribution and limitation of mouth opening from coronoid impingement. If there is enophthalmos, or high likelihood of future enophthalmos secondary to herniation of orbital contents into the maxillary sinus, dystopia, or diplopia that does not resolve once the swelling goes down, the orbital floor will also require reconstruction (see also orbital fractures) (Figs. 22-8 and 22-10).[21–24]

NASO-ORBITAL–ETHMOID FRACTURES

Naso-orbital–ethmoid (NOE), a term coined in 1973, describes a facial subunit that is widely considered to be the most complex of all facial fractures that is uncommonly injured, comprising only 2% to 15% of all facial fractures, and rarely occurs in isolation (usually accompanied by midface or frontal sinus fractures).[25] The complex consists of the medial orbital walls, nasal bones, frontal process of the maxilla, nasal process of the frontal bone, and the ethmoid sinuses. Bleeding may be secondary to injury of the anterior or posterior ethmoidal arteries along the medial orbital wall. The clinical examination is most notable for periorbital ecchymosis and edema, subconjunctival hemorrhage, a depressed nasal radix with a wide or flattened dorsum and upturned tip, and telecanthus with increased intercanthal distance to over 35 mm. CSF rhinorrhea may be present if the cribiform plate is involved, as can enophthalmos, depending on the degree of medial orbital volume increase. Epiphora may also be present if there is damage to the lacrimal drainage system. A complete ophthalmologic examination is required to rule out ocular injury.[18]

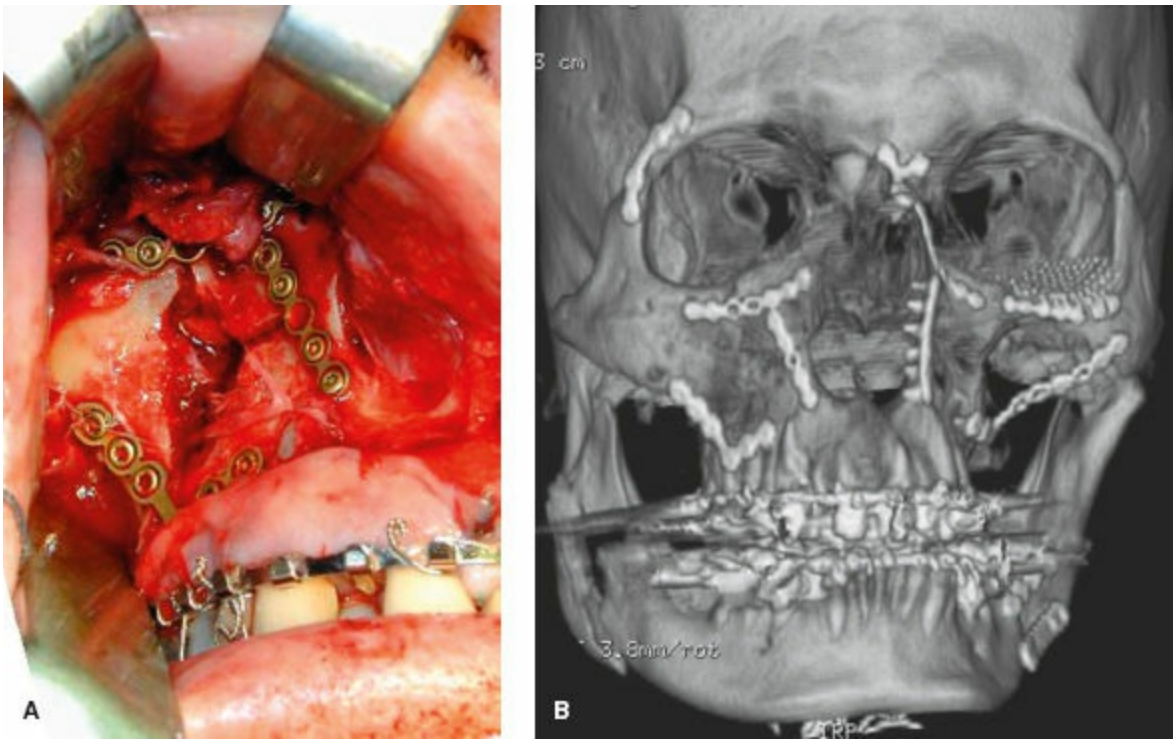

Figure 22-8. Same patient after open reduction and internal fixation of the bilateral Le Fort I, II, and III fractures, after repairing the mandible and using the occlusion as a guide to work from bottom-up. **A:** Intraoperative photos of Le Fort I ORIF. **B:** Postop CT scan.

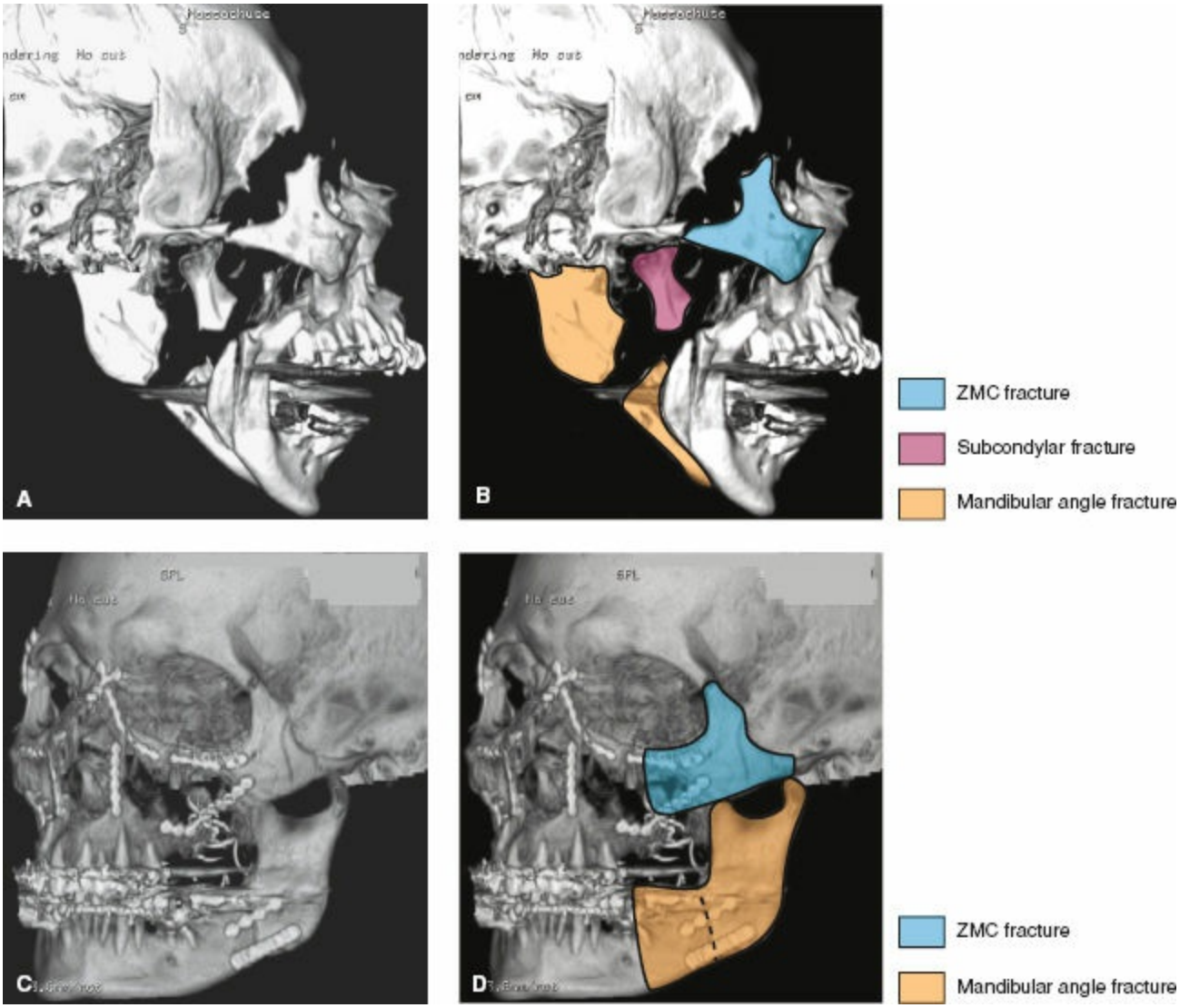

Figure 22-9. **A:** Lateral view of CT scan from same patient showing partial facial amputation. **B:** ZMC fracture and mandibular subcondylar and angle fractures highlighted. **C,D:** Postop CT scan showing reduction and fixation of ZMC and mandible fracture.

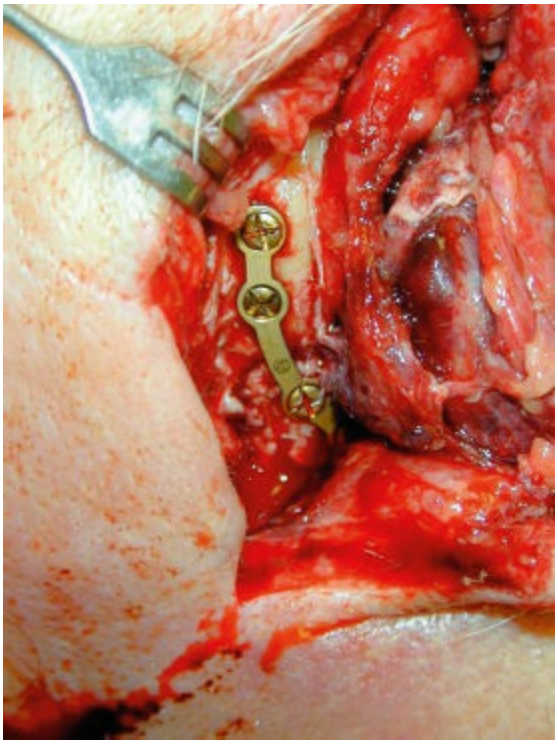

Figure 22-10. The zygomaticofrontal suture was reduced and plated. After releasing the infraorbital nerve from the fractured orbital floor, the zygomas were rigidly fixated at the piriform rims, the zygomaticomaxillary buttresses and infraorbital rims.

7 The status of the medial canthus and its attachment to bone is the key to proper diagnosis and treatment. In 1991, Markowitz and Manson published one of the most well-known studies on NOE fractures (Fig. 22-11).[26] CT scan is the gold standard for diagnosing and classifying NOE fractures. Though it is difficult to visualize the tendon itself, the fracture can be classified based on the degree of comminution.

Definitive treatment can be delayed for swelling or stabilization of other injuries, but ideally not beyond 2 weeks as reduction becomes difficult. The goals of treatment include restoring the intercanthal distance, orbital volume, dorsal support, and nasal tip projection and length. Incompletely reduced telecanthus is one of the most difficult complications to treat so overcorrection should always be attempted.[27–32]

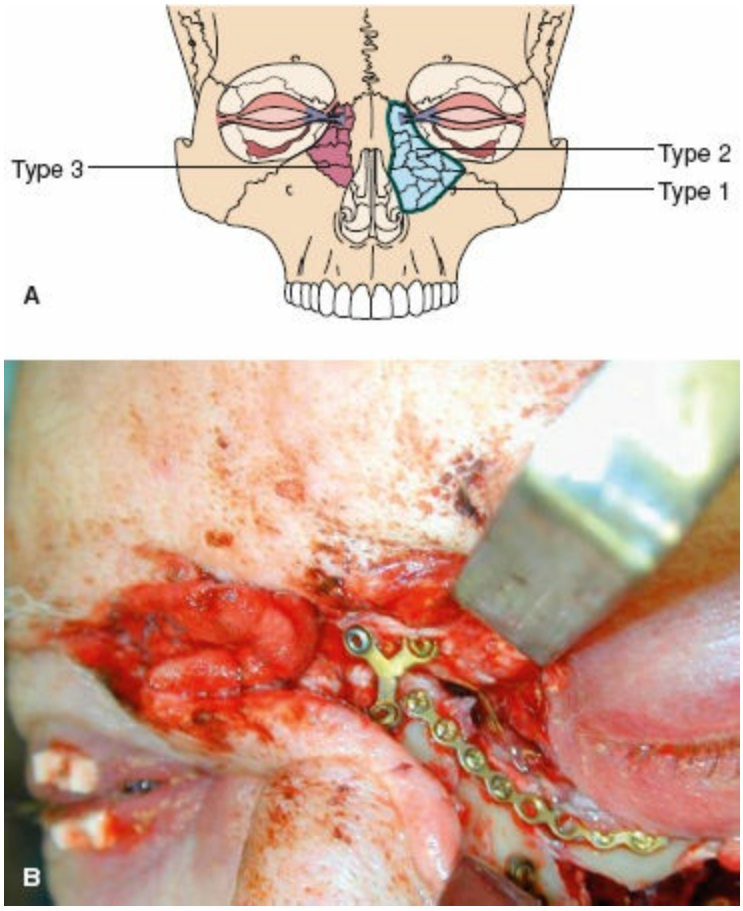

Figure 22-11. **A:** They classified fractures into type I (medial canthal tendon attached to a single large segment of bone), type II (comminuted bony segment but canthus remains attached to sizeable fragment) and type III (severe comminution and/or avulsion of the canthal tendon). **B:** Intraoperative view of same patient showing reduction and fixation of nasofrontal suture and left infraorbital rim. The medial canthal tendon was also identified and resuspended under the nasal bones to the contralateral medial orbit.

ORBITAL FRACTURES

Related to, and often part of both ZMC and NOE fractures are orbital fractures. The superior, lateral, and inferior orbital rims are very dense, while the medial orbital rim and wall, as well as the orbital floor are very thin, often less than 0.5 mm; therefore, trauma to the orbit usually results in fracture of the thin floor or medial wall, termed "blow-out" fractures if isolated (Fig. 22-12).

8 Extraocular muscle entrapment is a surgical emergency, evaluated by testing extraocular movements in the awake patient, or forced duction testing in a noncooperative or comatose patient, in all ZMC, NOE, and isolated orbital fractures. Entrapment is most common in young patients who have elastic bone and periosteum with a small "trapdoor" seen on CT scan of the floor or medial orbit (Fig. 22-13).

The other indication for open treatment is enophthalmos. This can be treated in a delayed fashion and can often be predicted based on CT findings even before the swelling has resolved if the defect is large (>50%), there is significant herniation of orbital contents into the sinus or if the orbital rim is displaced. Immediate (within 2 weeks) versus delayed repair often depends on surgeon preference (Fig. 22-8).[33–35]

FRONTAL SINUS INJURIES

9 Frontal sinus fractures often occur in conjunction with NOE or other midface fractures. Anterior table fractures may result in significant cosmetic deformity if displaced. The nasofrontal outflow tract drains the frontal sinus to the ethmoid sinuses. If this passage is found to be obstructed, it must be sealed off with temporalis fascia, pericranium, cranial bone, or tissue sealants, followed by obliteration of the sinus mucosa and filling the dead space to prevent infection and delayed mucocele formation.

Posterior table fractures can cause intracranial injury and should be evaluated in conjuction with neurosurgery. If the displacement is significant or there is evidence of dural tear or frontal lobe injury, the posterior table should be removed along with the sinus mucosa and the nasofrontal outflow tract obstructed. Then the sinus is cranialized and the anterior table can be reconstructed.[36–38]

MANDIBLE FRACTURES

The diagnosis of a mandible fracture can usually be made by history and physical examination alone. In addition, a panoramic radiograph (actually a sagittal view) is underappreciated in terms of its ability to show the presence and type of fracture. The panoramic x-ray, together with another plain film at 90 degrees (i.e. PA skull film), identifies the degree and direction of displacement, and can obviate the need for a CT scan. In reality however, a CT is often obtained in the emergency room for screening of other injuries.

On examination, findings often include numbness of the inferior alveolar nerve distribution (if the fracture is between the mandibular and mental foramina), malocclusion, gross mobility, jaw deviation, and gingival lacerations or sublingual ecchymosis. Bleeding from the external auditory meatus should raise suspicion for a mandibular condyle or temporal bone fracture. Because the mandible is U-shaped, force from one blow is distributed around the arch and often results in a second fracture. Common patterns include a blow to the symphysis resulting in bilateral condylar fractures, or a blow to the parasymphysis resulting in a contracoup injury to the opposite condyle. The presence of teeth also impact fracture pattern, the most common of which is the third molar, especially if impacted, which increases the risk of a mandibular angle fracture. Teeth in the line of fracture may be left in place as they can aid in reduction; if they impede reduction, extraction is required.[39,40]

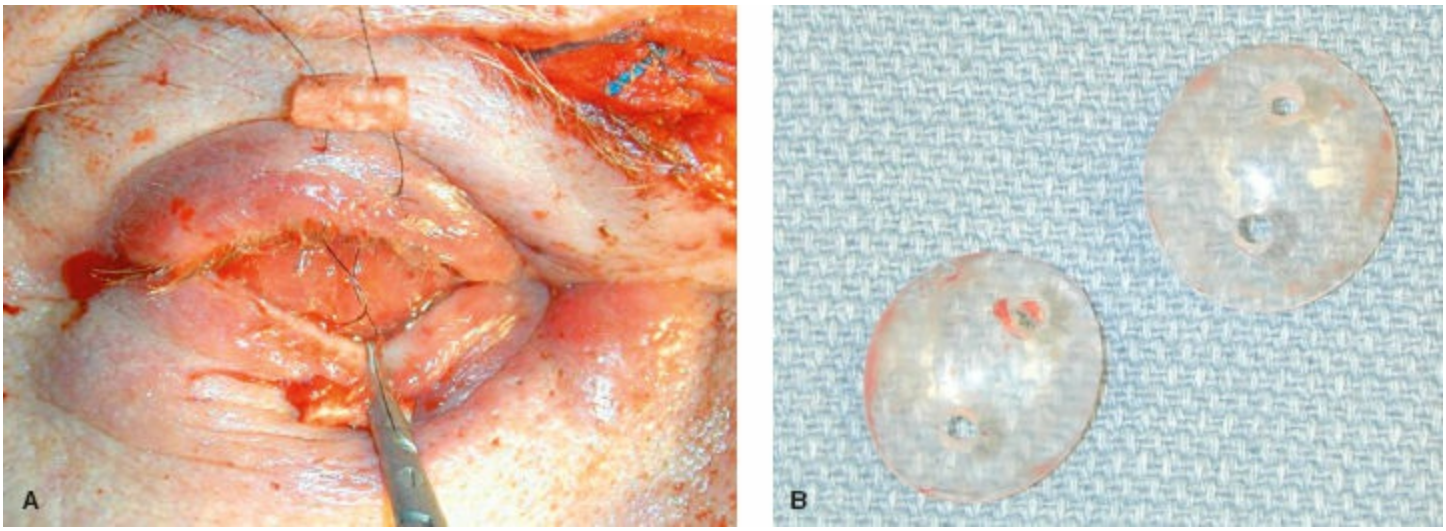

Figure 22-12. **A,B:** The left orbital floor was explored and reconstructed with titanium mesh. A silastic implant holder was placed into the right orbit to provide contour for a future prosthetic implant by the oculoplastics team.

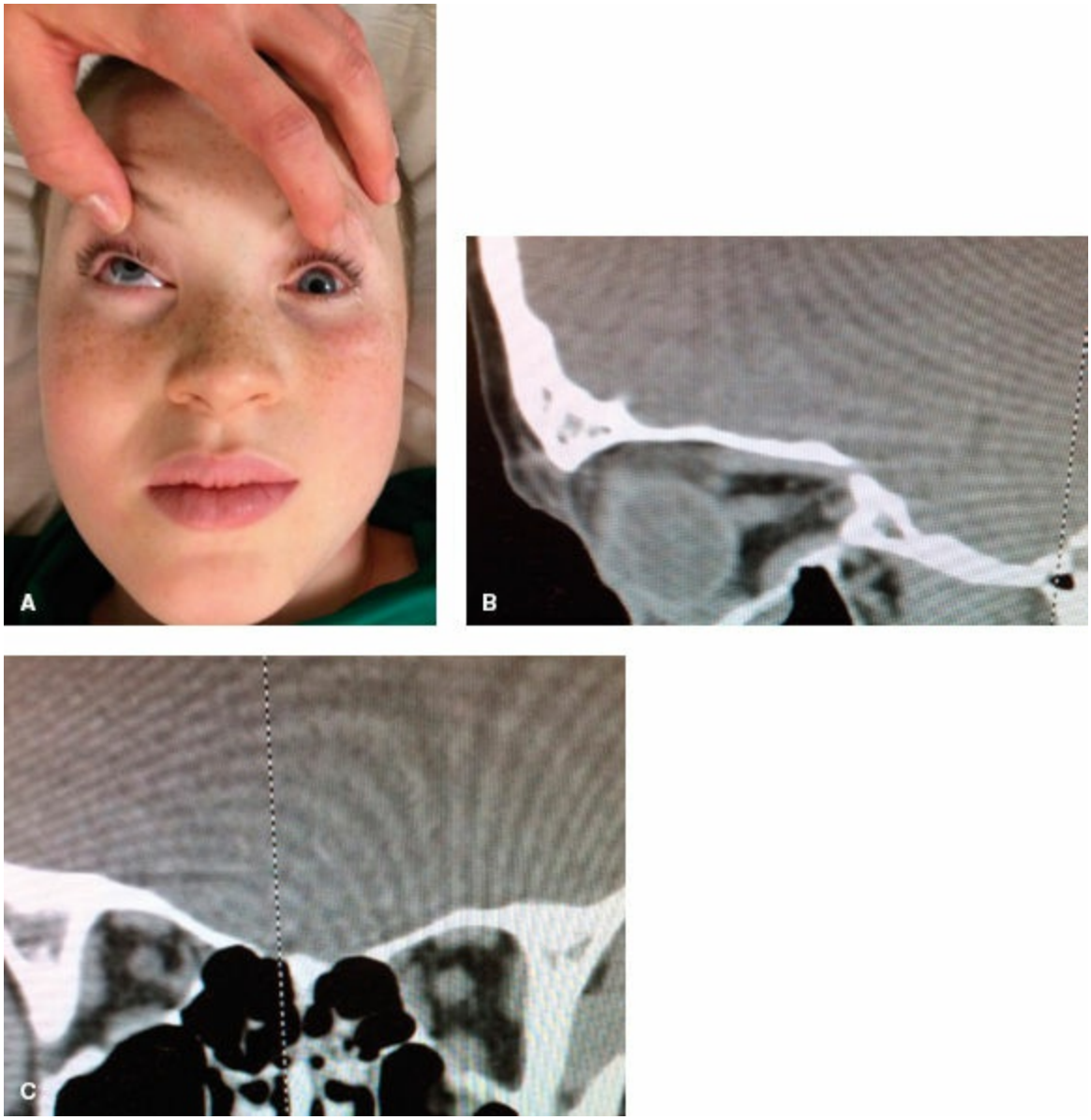

Figure 22-13. A different patient who sustained a left orbital floor blow-out fracture with entrapment of the inferior rectus muscle. **A:** Clinical photo demonstrating limitation of upward gaze. **B:** Sagittal reformat of CT showing entrapment of left inferior rectus. **C:** Coronal reformat showing the same.

Some mandible fractures can be treated with closed reduction and maxillomandibular fixation in dentate patients. Severely comminuted fractures, such as in a gunshot wound, may also be treated closed, to avoid stripping the periosteum and therefore blood supply from small fragments (Fig. 22-14). Immobilization is maintained for 4 to 6 weeks in adults, 6 to 8 weeks in the elderly, and 2 to 4 weeks in children (Fig. 22-15).

10 Indications for open treatment include fractures in edentulous patients as there are no teeth to guide reduction and the bone is often atrophic, requiring load-bearing rigid fixation. Other indications include severe displacement that is not easily reduced, or comorbid conditions that preclude wiring the patient closed (i.e., seizure disorder, alcoholism, and psychiatric issues). In the presence of concomitant midface fractures, a mandible fracture may be treated open in order to establish a stable landmark and building block to work from (Figs. 22-8, 22-9, and Fig. 22-15).[41–46]

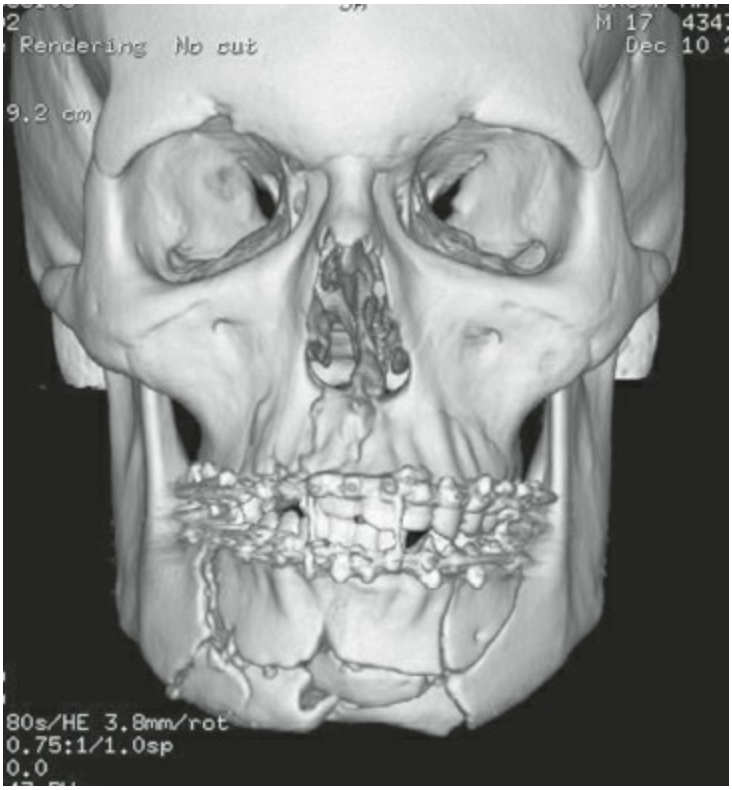

Figure 22-14. Patient with comminuted mandible fracture treated with closed reduction and maxillomandibular fixation to avoid stripping small bone fragments of periosteal blood supply.

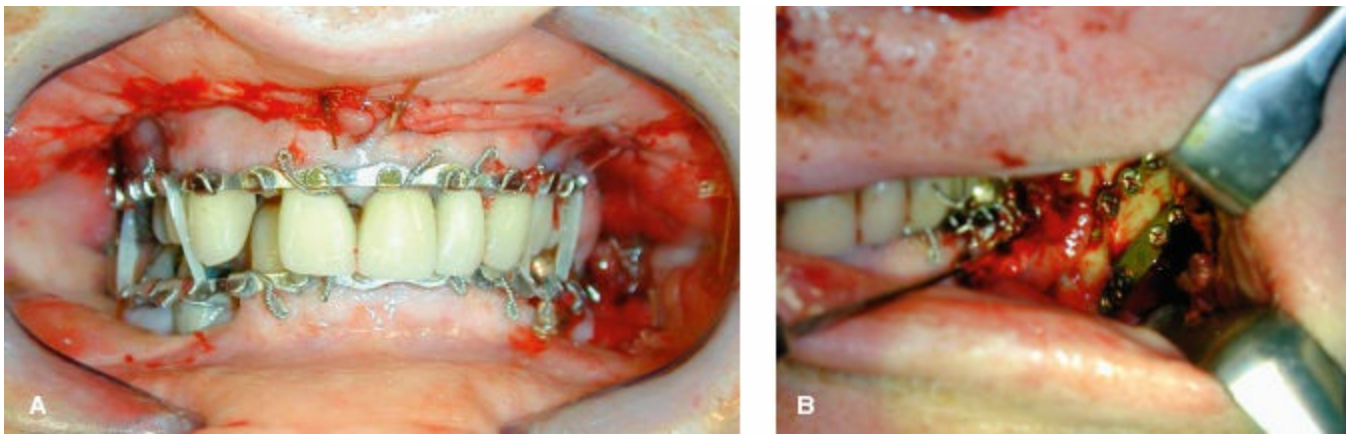

Figure 22-15. **A:** Reduction and immobilization was performed using maxillomandibular fixation. **B:** The left mandibular angle fracture was rigidly fixated. The right subcondylar fracture (see above) was treated with closed reduction and immobilization.

Treatment of mandibular condyle fractures remains with some controversy in maxillofacial trauma. In general, high subcondylar or intracapsular fractures are generally treated closed as there is little bone to plate and bleeding into the joint increases the risk of ankylosis.[47–52] These fractures are treated with early mobilization to maintain range of motion. Low subcondylar fractures are generally treated similar to other extra-articular mandibular fractures. In the past few decades, minimally invasive endoscopic approaches to treatment of mandibular condyle fractures have been used for open treatment with good results.[53–55]

11 Because any fracture within the tooth-bearing segments is considered an open fracture, and is at higher risk of infection, antibiotics and immobilization should be

initiated as soon as possible. Postop antibiotics, while common practice, have not been shown to decrease the infection risk.[56] Long-term complications following mandible fractures include malocclusion, infected hardware, or osteomyelitis. Delayed initial treatment or inadequate immobilization increases the risk.



Figure 22-16. The patient recovered well. His residual deficits were left facial nerve weakness as well as loss of the right eye.

APPROACH TO PANFACIAL FRACTURES

12 Various approaches including “top-down,” “bottom-up,” and “outside-in” exist and are chosen based on the specific injury pattern. In general, the uninjured cranial base is used as the building block for repair of the upper face while the maxillomandibular complex is used to rebuild the lower face. Then these two subunits are unified at the Le Fort I level. For the cranio-orbital subunit, reduction can commence at lateral orbital rims and move inward, or at the NOE and move outward. The dentition is the most useful landmark for rebuilding the maxillomandibular subunit in conjunction with establishing the posterior vertical facial height by reducing the mandibular ramus/condyle unit (Fig. 22-16).[20,57–61] Lack of sufficient projection is the usual problem (Fig. 22-17).

In summary, maxillofacial trauma presents a wide range of diagnostic and treatment challenges. Following acute treatment of life-threatening airway and bleeding concerns, definitive treatment involves careful repair of hard and soft tissue structures, ideally within 2 weeks. With improved survival, presenting injuries are more complex and successful reconstruction requires an appreciation of facial subunits and their interconnection.

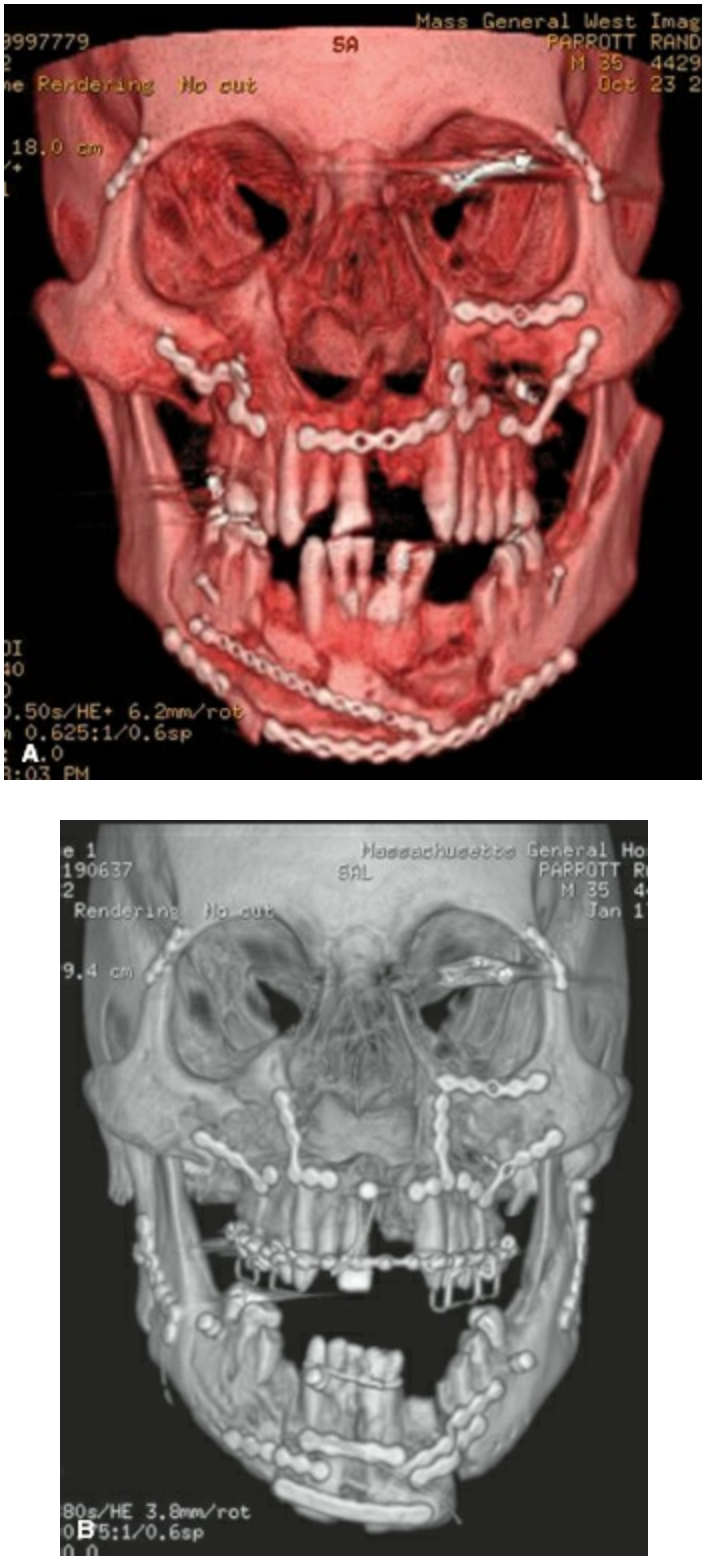

Figure 22-17. **A:** Patient treated after 5-story fall. Inadequate projection and resultant facial widening. **B:** Reoperation with osteotomies and bone repositioning lead in better projection and normalized width.

References

1. Gassner R, Tuli T, Hachl O, et al. Cranio-maxillofacial trauma: a 10 year review of 9543 cases with 21067 injuries. *J Cranio-Maxillofac Surg* 2003;31(1):51.
2. Kraft A, Abermann E, Stigler R, et al. Craniomaxillofacial trauma: synopsis of 14,654 cases with 35,129 injuries in 15 years. *Craniomaxillofac Trauma Reconstr* 2012;5(1):41.
3. Mendes M, Borba M, Sawazaki R, et al. Maxillofacial trauma and seat belt: a 10-year retrospective study. *J Oral Maxillofac Surg* 2013;17:21.
4. Perry M. Advanced Trauma Life Support (ATLS) and facial trauma: can one size fit all?: Part 1: dilemmas in the management of the multiply injured patient with coexisting facial injuries. *Int J Oral Maxillofac Surg* 2008;37:209.
5. Perry M, Morris C. Advanced Trauma Life Support (ATLS) and facial trauma: can one size fit all?: Part 2: ATLS, maxillofacial injuries and airway management dilemmas. *Int J Oral Maxillofac Surg* 2008;37:309.
6. Perry M, Moutray T. Advanced Trauma Life Support (ATLS) and facial trauma: can one size fit all? Part 4: 'can the patient see?' timely diagnosis, dilemmas and pitfalls in the multiply injured, poorly responsive/unresponsive patient. *Int J Oral Maxillofac Surg.* 2008;37(6):505.
7. Crecelius C: Soft tissue trauma. *Atlas Oral Maxillofacial Surg Clin North Am* 2013;21:49e60.
8. Goetsch KE, Annest JJ, Mercy JA, et al. Surveillance for fatal and nonfatal firearm related injuries: United States, 1993–1998. *MMWR Morb Mortal Wkly Rep* 2001;50:1.
9. Kaban LB. Diagnosis and treatment of fractures of the facial bones in children 1943–1993. *J Oral Maxillofac Surg* 1993;51:722.
10. Forshey J, Troulis MJ, Kaban LB. Changing Treads in CMF Trauma AAOMS. 1999.
11. Bynoe RP, Kerwin AJ, Parker HH, et al. Maxillofacial injuries and life-threatening hemorrhage: treatment with transcatheter arterial embolization. *J Trauma* 2003;55:74.
12. Yang WG, Tsai TR, Hung CC, et al. Life threatening bleeding in a facial fracture. *Ann Plast Surg* 2001;46:159.
13. Mehrotra ON, Brown GE, Widdowson WP, et al. Arteriography and selective embolization in the control of life-threatening haemorrhage following facial fractures. *Br J Plast Surg* 1984;37:482.
14. Demetriades D, Chawan S, Gomez H, et al. Initial evaluation and management of gunshot wounds to the face. *J Trauma* 1998;45:39.
15. Steinberg MJ, Herrera AF. Management of parotid duct injuries. *Oral Surg Oral Med Oral Pathol Oral Radiol Endod* 2005;99:136.
16. Ito, K, Perren SM. Biology of fracture healing. In: Ruedi TP, Buckley RE, Moran CG, eds. *AO Principles of Fracture Management.* New York, NY: Thieme Publishing Group;2007.

17. Le Fort R. Experimental study of fractures of the upper jaw: parts I and II. *Rev Chir Paris* 1901;23:208.
18. Peacock ZS, Boulos T, Miller JB, et al. Orbital fractures and ocular injury: is a postoperative ophthalmology examination necessary? *J Oral Maxillofac Surg* 2014;72(8):1533.
19. Knight JS, North JF. The classification of malar fractures: an analysis of displacement as a guide to treatment. *Br J Plast Surg* 1961;13:325.
20. Manson PN, Markowitz B, Mirvis S, et al. Toward CT-based facial fracture treatment. *Plast Reconstr Surg* 1990;85(2):202.
21. Ellis E 3rd, el-Attar A, Moos KF. An analysis of 2,067 cases of zygomatico-orbital fracture. *J Oral Maxillofac Surg* 1985;43(6):417.
22. Ellis E, Kittidumkerng W. Analysis of treatment for isolated zygomaticomaxillary complex fractures. *J Oral Maxillofac Surg* 1996;54:386.
23. Ellis E, Perez D. An Algorithm for the treatment of isolated zygomatico-orbital fractures. *J Oral Maxillofac Surg* 2014;72(10):1975.
24. Kelley P, Hopper R, Gruss J. Evaluation and treatment of zygomatic fractures. *Plast Reconstr Surg* 2007;120:5S.
25. Cunningham LL, Haug RH. Frontal Sinus and NOE fractures. In: Miloro M, ed. *Peterson's Principles of Oral and Maxillofacial Surgery*. 2nd ed. Hamilton, Ontario: BC Decker Inc;2004.
26. Markowitz BL, Manson PN, Sargent L, et al. Management of the medial canthal tendon in nasoethmoid orbital fractures: the importance of the central fragment in classification and treatment. *Plast Reconstr Surg* 1991;887(5):843.
27. Papadopoulos H, Salib NK. Management of naso-orbital-ethmoidal fractures. *Oral Maxillofacial Surg Clin North Am* 2009;21:221.
28. Ellis E. Sequencing treatment for naso-orbito-ethmoid fractures. *J Oral Maxillofac Surg* 1993;51:543.
29. Heine RD, Catone GA, Bavitz JB, et al. Naso-orbital-ethmoid injury: report of a case and review of the literature. *Oral Surg Oral Med Oral Pathol* 1990;69:542.
30. Pawar SS, Rhee JS. Frontal sinus and naso-orbital-ethmoid fractures. *JAMA Facial Plastic Surg* 2014;16(4):284.
31. Nguyen M, Koshy JC, Hollier LH. Pearls of nasoorbitoethmoid trauma management. *Semin Plast Surg* 2010;24:383.
32. Herford AS, Ying T, Brown B. Outcomes of severely comminuted (type III) nasoorbitoethmoid fractures. *J Oral Maxillofac Surg* 2005;63:1266.
33. Burnstine MA. Clinical recommendations for repair of isolated orbital floor fractures. *Ophthalmology* 2002;109:1207.
34. Coyle P, Boyd V, Banergi S, et al. Comprehensive management of orbital fractures. *Plast Reconstr Surg* 2007;120:57S.
35. Raskin EM, Millman AL, Lubkin V, et al. Prediction of late enopthlamos by

volumetric analysis of orbital fractures. *Ophthal Plast Reconst Surg* 1998;14(1):19.
36. Rodriguez ED, Stanwix MG, Nam AJ, et al. Twenty-six year experience treating frontal sinus fractures : a novel algorithm based on anatomical fracture pattern and failure of conventional techniques. *Plast Reconstr Surg* 2008;122(6):1850.
37. Manolidis S, Hollier LH. Management of frontal sinus fractures. *Plast Reconstr Surg* 2007;120:32S.
38. Echo A, Troy JS, Hollier LH. Frontal sinus fractures. *Semin Plast Surg* 2010;24:375.
39. Ellis E. Outcomes of patients with teeth in the line of mandibular angle fractures treated with stable internal fixation. *J Oral Maxillofac Surg* 2002;60:863–865.
40. Stacey DH, Doyle JF, Mount DL, et al. Management of mandible fractures. *Plast Reconstr Surg* 2006;117:48e.
41. Madsen MJ, Haug RH, Christenen BS, et al. Management of atrophic mandible fractures. *Oral Maxillofacial Surg Clin North Am* 2009;21:175.
42. Van Sickels JE, Cunningham LL. Management of atrophic mandible fractures: are bone grafts necessary? *J Oral Maxillofac Surg* 2010;68:1392.
43. Bruce RA, Ellis E. The second Chalmers J. Lyons Academy study of fractures of the edentulous mandible. *J Oral Maxillofac Surg* 1993;51:904.
44. Ellis E, Price C. Treatment protocol for fractures of the atrophic mandible. *J Oral Maxillofac Surg* 2008;66:421.
45. Cawood JI, Howell RA. A classification of the edentulous jaws. *Int J Oral Maxillofac Surg* 1998;17:232.
46. Luhr HG, Reidick R, Merten HA. Results of treatment of fractures of the atrophic edentulous mandible by compression plating: a retrospective evaluation of 84 consecutive cases. *J Oral Maxillofac Surg* 1996;54:250.
47. Lindahl L. Condylar fractures of the mandible: classification and relation to age, occlusion and concomitant injuries of the teeth and teeth-supporting structures and fractures of the mandibular body. *In J Oral Surg* 1977;6:12.
48. Walker RV. Condylar fractures: nonsurgical management. *J Oral Maxillofac Surg* 1994;52:1185.
49. Walker RV, Kerr HR. The consultant. *J Oral Surg* 1966;24:367.
50. Haug RH, Dodson TB, Morgan JP. *"Trauma surgery"—Parameters and Pathways: Clinical Practice Guidelines for Oral and Maxillofacial Surgery.* Rosemont, IL: AAOMS; 2001:p TRA/15.
51. Zide MF, Kent JN. Indications for open reduction of mandibular condyle fractures. *J Oral Maxillofac Surg* 1983;41(2):89.
52. Brandt MT, Haug RH. Open versus closed reduction of adult mandibular condyle fractures: a review of the literature regarding the evolution of current thoughts on management. *J Oral Maxillofac Surg* 2003;61:1324–1332.
53. Troulis MJ, Kaban LB. Endoscopic approach to the ramus/condyle unit: clinical applications. *J Oral Maxillofac Surg* 2001;59:503.

54. Troulis MJ. Endoscopic open reduction and internal rigid fixation of subcondylar fractures. *J Oral Maxillofac Surg* 2004;62:1269.
55. Kellman RM. Endoscopically assisted repair of subcondylar fractures of the mandible: an evolving technique. *Arch Facial Plast Surg* 2003;5(3):244–250.
56. Miles BA, Potter JK, Ellis E. The efficacy of postoperative antibiotic regimens in the open treatment of mandibular fractures: a prospective randomized trial. *J Oral Maxillofac Surg* 2006;64(4):576.
57. Manson PN, Hoopes JE, Su CT. Structural pillars of the facial skeleton : an approach to the management of Le Fort fractures. *Plast Reconstr Surg* 1980; 66:54.
58. Markowtiz BL, Manson PN. Panfacial fractures : organization of treatment. *Clin Plast Surg* 1989;16:105.
59. Gruss JS, Mackinnon SE. Complex maxillary fractures : role of buttress reconstruction and immediate bone grafts. *Plast Reconstr Surg* 1986;78:9.
60. Gruss JS, Phillips JH. Complex facial trauma : the evolving role of rigid fixation and immediate bone graft reconstruction. *Clin Plast Surg* 1989;16:93.
61. He D, Zhang Y, Ellis E. Panfacial fractures: analysis of 33 cases treated late. *J Oral Maxillofac Surg* 2007;65(12):2459.

Chapter 23

Neck Injuries

Brandon R. Bruns and Thomas M. Scalea

Key Points

1 An intimate understanding of the neck anatomy is imperative for optimal management.

2 Obtaining a secure airway is vital for management of all injuries, especially those in the neck.

3 Gentle digital pressure or balloon tamponade presents opportunities to control life-threatening hemorrhage from vascular injuries in the neck.

4 Though classic teaching mandated exploration of zone II injuries, modern practice has strayed from this concept.

5 Blunt cerebrovascular injury must be considered, diagnosed, and treated in patients at risk for the disease.

6 Blunt cerebrovascular injury is often present in patients who do not manifest traditional screening criteria.

7 A combination of endoscopy and contrast-enhanced radiography presents the best opportunity to diagnose esophageal injury when present.

1 Many vital structures reside within the neck and exist in close proximity to one another. These include aerodigestive, vascular, bony, and neurologic organs. These intimate relationships can lead to multiple injuries of varying complexity in a wide variety of structures within a relatively small area. Of penetrating injuries to the neck, the vast majority are caused by stab wounds.[1–3] Blunt injury to the neck is the result of various mechanisms of injury including direct blows, automobile shoulder belts, and various hanging mechanisms with neck hyperextension. The anatomic complexity and diverse injury mechanisms make diagnosing and treating neck injuries challenging.

FUNCTIONAL ANATOMY

The exterior anatomic barriers of the neck include the lower border of the mandible anteriorly to the nuchal line of the occipital bone posteriorly. Inferiorly, the clavicles serve as the anterior border with a line drawn toward the seventh cervical vertebral spinous process encompassing the posterior border.

Triangles are classically used to divide the neck into zones, however they are only rarely used to classify and plan treatment in the trauma patients. The posterior triangles are bordered by the sternocleidomastoid muscles anteriorly, the trapezius muscles posteriorly, and the clavicles inferiorly. The anterior triangles are bordered by the sternocleidomastoid muscles, the midline, and the angles of the mandible bilaterally.

In 1969, Monson and colleagues[4] arbitrarily divided the neck into three anatomic zones: zone I consisted of the area below the sternal notch, zone II was the area between the clavicles and the mandibles, and zone III was described as the upper cervical region and consisted of the area above the mandibles. Roon and Christensen[5] introduced a more modern version of the neck zones in 1979 and defined zone II as the area between the cricoid and the angle of the mandible, zone I as the area below the cricoid cartilage, and zone III remained the area above the mandibular angle (Fig. 23-1).

The zones of the neck are important as the approach to injury within each zone is different. This is particularly true when one considers vascular exposure. All major vascular structures in zone II can be readily accessed via a standard sternocleidomastoid neck incision. Via a single incision, proximal and distal vascular control can both be obtained within zone II and injuries repaired.

However, proximal control for zone I injuries requires control within the chest. A variety of incisions can be used depending on the location of the injury. A full sternotomy provides access to the mediastinal great vessels and the proximal left subclavian artery, along with the origin of the left common carotid artery. If a smaller incision is indicated, a partial sternotomy allows control of the innominate artery. A periclavicular incision provides access to the bilateral subclavian arteries. In short, a variety of incisions may be needed for full exposure. After proximal control, subsequent distal control can then be obtained in zone II.

Proximal control for zone III injuries can be obtained in zone II without much difficulty. However, distal control may be very difficult as the mandible and skull base prevent wide exposure. Several methods such as mandibular subluxation or osteotomy have been described to control the carotid artery at the base of the skull.[6] A muscle splitting incision can also help give access to the carotid artery and the base of the skull.[7]

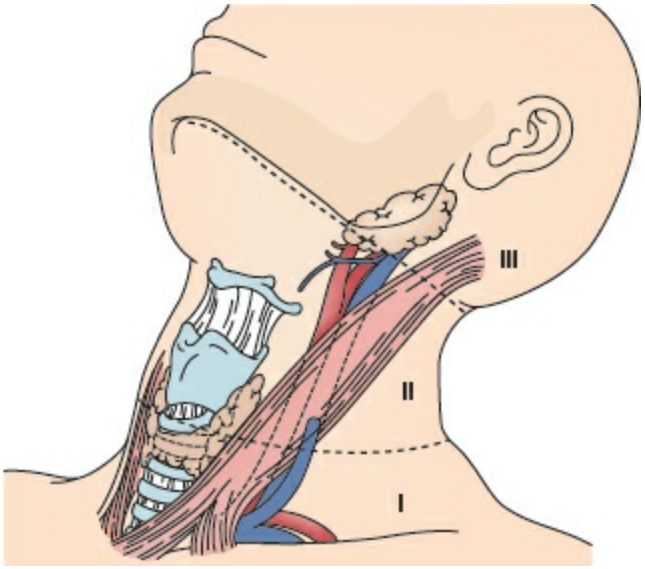

Figure 23-1. Zones of the neck.

The inferior and lateral extensions of zone I are often contested and debated. While this is not well described, our practice is to classify lateral and inferior (superior mediastinal) injuries by zone I principles. Because proximal control involves a thoracic incision, we believe zone I extends to the junction of the subclavian and axillary arteries laterally and inferiorly to the mediastinal great vessels.

Injury to the posterior neck should be treated differently than injury to the anterior neck. It makes sense that tracheal and esophageal injuries would be less common with posterior injury, as they are protected by the spine. Injuries to the spine should be more common in this anatomic region.

Often, more than one zone can be injured by a single trajectory; such as an injury through both zone II and zone I. Management of these “multizone” injuries is guided by the standard principles used for the more challenging zone, usually zone I or zone III.

The platysma muscle envelops the neck and originates from the pectoralis major and deltoid muscles. Though clinical practice has evolved, most classic algorithms of treating penetrating neck trauma stated that injuries penetrating the platysma muscle in zone II of the neck mandated direct operative intervention, whereas those penetrating the platysma in zones I and III mandated additional studies via either angiography or other imaging modalities.[5]

INITIAL MANAGEMENT

2 Basic trauma management of patients with injury to the neck should proceed as outlined in the American College of Surgeons course Advanced Trauma Life Support (ATLS).[8] Initial priority is given to securing the patient's airway. Every patient with a neck injury should be considered for early airway control. A wise clinician should plan airway control in all patients with evidence of neck injury and select the few in whom airway control is not needed. Even in seemingly stable and hemostatic patients, rebleeding can produce sudden and disastrous symptoms and sequlae. An airway that had previously been straightforward to control is now much more complicated and may require advanced techniques.

Obvious injury to the neck, with the presence of an expanding hematoma or other hard signs of vascular injury, should lead the provider to obtain definitive endotracheal access as the first step in the resuscitation. Similarly, air bubbling through the wound, hoarseness, or an obviously transected trachea, should guide the treatment team toward immediate and definitive airway control.

In the event that orotracheal intubation cannot proceed (rapidly expanding hematoma, destructive laryngeal trauma, patient habitus, excessive debris within the oropharynx, etc.); an emergent surgical airway should be expeditiously obtained. Cricothyroidotomy and emergency tracheostomy remain the safest and most reliable methods of emergent surgical control of the airway. Some investigators have shown promising results with percutaneous tracheostomy performed in the emergency setting, though this should only be contemplated by experienced clinicians.[9] If tracheal transection is visualized in the wound, intubation of the distal tracheal segment with an endotracheal tube or any available airway device can be lifesaving (Fig. 23-2).

Though obtaining a safe and definitive airway is the priority in all injured patients with airway compromise, awareness of potential concomitant cervical spine injury must be considered in patients with blunt trauma. Maintaining cervical stabilization during movement and intubation is paramount and is best accomplished by maintaining the head and neck in neutral position with the help of a competent assistant trained in such maneuvers. The same caution is not needed in patients with penetrating trauma, as patients presenting alive and neurologically intact are highly unlikely to have unstable cervical spine fractures.[10,11]

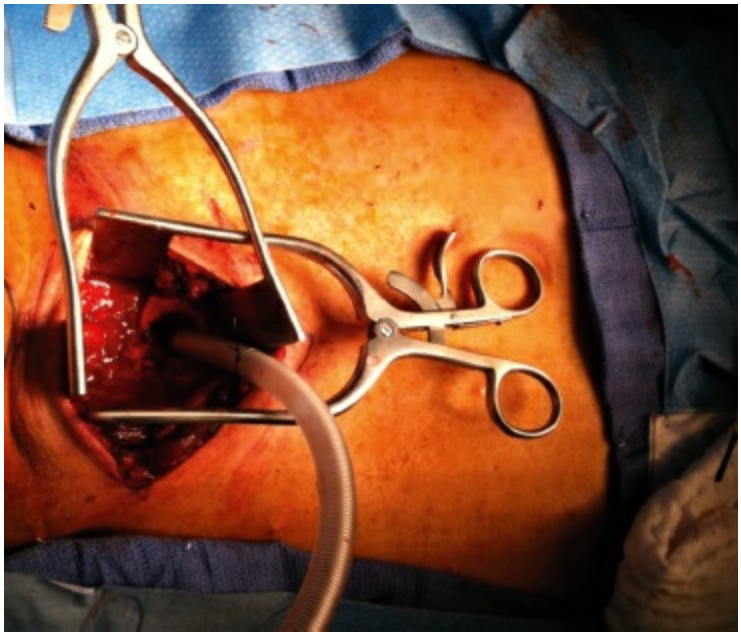

Figure 23-2. Intubation of a distal tracheal transection in the neck.

3 After securing an adequate airway, patient care should proceed in an orderly fashion by using ATLS principles with the next priories being breathing and circulation. In evaluating the chest, the clinician must remain aware that penetrating injury to zone I can violate the cupula of the lung and result in pneumothorax or hemothorax, which may require evacuation. Circulatory issues focus on intravenous access with resuscitation and assessment of the blood pressure, but it also entails control of any obviously bleeding focus. Pulsatile bleeding emanating from a neck wound is best managed with gentle digital compression. Occasionally, a urinary catheter or a Fogarty catheter can be delicately placed into a bleeding neck wound with gradual inflation of the balloon in an attempt to tamponade hemorrhage. The catheter should be inserted as far as it goes easily and the balloon is then inflated and the catheter gently pulled back until bleeding eases.

A rapid assessment of the neurologic state of the patient can give insight into the nature of a neck injury, as a dense hemiplegia may be the result of carotid arterial injury and subsequent ischemic stroke. It is imperative to recognize the patient with a lateralizing neurologic defect early, as revascularization may result in hemorrhagic conversion of a cerebral infarction.

After the primary survey and adjunctive radiographic procedures (chest radiograph, abdominal sonography), a thorough secondary survey should be performed, with focus on the structures of the neck. A hematoma across the base of the neck, which was caused by an automobile seatbelt, may portend a blunt cerebrovascular injury (BCVI). Extensive subcutaneous emphysema in the tissues of the neck usually represents air tracking up from a pneumothorax, but can represent an injury to the airway. Injury to the esophagus is possible, but subcutaneous air is rarely the only symptom of esophageal injury. Similarly, an audible bruit or palpable thrill may indicate major vascular injury that requires prompt attention.

SELECTIVE VERSUS MANDATORY EXPLORATION

Few would argue that penetrating injuries to the neck, with hard signs of injury (pulsatile hemorrhage, expanding hematoma, shock, air emanating from the wound, massive hemoptysis), mandate immediate surgical exploration. In the absence of these hard signs of injury, most favor a selective approach with clinical examination and diagnostic radiographs.

Overall Approach

4 Early surgical teaching mandated exploration for penetrating zone II neck injuries that violate the platysma muscle, regardless of the presence or absence of hard signs of injury.Those who support the concept of mandatory exploration have cited the low incidence of significant morbidity with surgical exploration, despite the high likelihood of negative exploration.[2,12] Proponents also point to the lack of physical examination findings in patients that did proceed to surgical exploration that had injuries present at operation.[3] In contradistinction to mandatory exploration, many investigators advocate a more selective approach to operative therapy, suggesting surgery only in symptomatic patients. Authors supportive of the more limited approach cite a low morbidity and mortality associated with observation of zone II injuries and high likelihood of negative exploration.[1]

While diagnostic exploration may make sense for zone II injuries, diagnostic preoperative evaluation certainly makes sense for injuries in zone I and zone III. Penetrating injury in zone I puts vascular structures, trachea, and esophagus at risk. Physical examination can be misleading and different incisions may be needed depending on which structures are injured and the level at which they are injured. Thus, in stable patients, diagnostic work up is wise. This generally involves endoscopy, contrast studies, or both to investigate the possibility of an esophageal injury. While asymptomatic tracheal injuries are quite rare, many have favored a diagnostic bronchoscopy in these injuries. In the past, vascular structures were investigated by means of catheter angiography, with noninvasive axial imaging as the most common modality in the current era.

Unfortunately, in unstable patients with a zone I trajectory, localization of the injury may not be possible preoperatively. In such a case, the clinician should make an estimate as to which structures are most likely to be injured. The initial incision should be tailored to quickly expose that area. If exposure is inadequate or a different structure has been injured, the incision should be lengthened, or a second incision should be made. This process continues until the injury is controlled or the patient has died.

Aerodigestive injuries are not an issue in zone III; however the difficulty in surgical management of vascular injuries in zone III makes preoperative imaging very attractive. In the past, angiography was used as the sole diagnostic test in stable patients. If patients are unstable, clinicians must weigh the difficulty of diagnostic exploration against the time it would take to use alternative hemostatic methods. In some cases, if catheter hemostasis is immediately available, temporary control with finger pressure or a balloon, as a bridge to rapid diagnostic angiography and catheter hemostasis may actually be quicker than direct operative exploration. In most areas of the world, this approach is only appropriate in a few highly advanced centers. In most centers, while difficult, direct surgical exploration is the wisest course in the unstable patient.

Current Imaging Technology

In recent years, computed tomography (CT) has become much more widely used to evaluate the possibility of neck injury. CT is extremely attractive as it is a single study that is rapidly available in virtually every center and provides a three-dimensional evaluation of the neck. In patients with injury patterns that put the upper mediastinal structures at risk as well, CT can evaluate both areas for potential injury, simultaneously. CT may be very effective at excluding injuries in some cases. For example, a patient with a gunshot wound to the neck that has a clearly demonstrated CT trajectory that avoids all vital structures, most likely only needs observation and no additional diagnostic testing. Other patients, such as those with significant amounts of subcutaneous air or a trajectory that is close to vital structures, such as the carotid artery and/or the esophagus, may need additional diagnostic testing.

Penetrating Neck Trauma

In 2002, Gonzalez et al. prospectively evaluated patients with penetrating injury to zone II of the neck that did not have an indication for emergent surgical exploration.[13] Patients then underwent dynamic CT imaging and had a barium esophagram, followed by mandatory surgical exploration of the neck. Investigators noted a total of four esophageal injuries, two of which were seen on surgical exploration only and were not identified on either CT scan or esophagram. However, both injuries missed on diagnostic evaluation were less than 0.5 cm and were the result of stab wounds. The authors speculated that the injuries may have healed spontaneously. The most commonly missed injury by CT scan was jugular venous injury; which likely needed no therapy.[13]

In a large prospective study involving Los Angeles County, University of Southern California Medical Center, and the R Adams Cowley Shock Trauma Center at the University of Maryland, all asymptomatic patients presenting with a penetrating neck injury and no signs of injury were safely observed and investigators reported zero missed injuries. In the same series, patients with soft signs of injury (venous oozing, nonexpanding or nonpulsatile hematomas, minor hemoptysis, dysphonia, dysphagia, and subcutaneous emphysema) underwent multidetector CT angiography (CTA). Investigators achieved 100% sensitivity and 97.5% specificity in detecting all clinically significant injuries.[14]

Blunt Neck Trauma

Plain film radiography is not adequate to identify injuries to structures in the neck. However pneumothorax, hemothorax, air in the subcutaneous tissues, nasogastric tube displacement, or mediastinal widening are all indicative of significant force that would be sufficient to injure structures within the neck.

BCVI diagnosis deserves special mention, as disagreement still persists as to the optimal screening test for diagnosis. In the past, BCVI was usually diagnosed late, after the patient had suffered a stroke. Diagnostic angiography then virtually always demonstrated an internal carotid artery injury. Therapy included anticoagulation, but was mainly supportive as the damage had already been done. Additionally, catheter angiography is invasive and carries some risk of iatrogenic vascular injury and/or periprocedural stroke.

5 As screening protocols were developed, the incidence of BCVI seemed to increase, even in patients with no identifiable risk factors for BCVI.[15] As CTA became more entrenched as a diagnostic tool, the rate of vascular injury again seemingly radically increased.[16,17] It seems obvious that the patients did not change, but our ability to diagnose injuries did. This is very similar to recent experience with pulmonary embolism, where our ability to diagnose these conditions is greatly increased with the use of CTA. This obviated the need for multiple diagnostic studies such as ventilation perfusion scans and/or pulmonary angiography. One must question whether some of these injuries, particularly those of low grade, have significant clinical importance.

Additional debate has focused on the ideal test for diagnosis of BCVI, with some suggesting angiography and some CTA. In a study of 146 patients at risk for BCVI, investigators imaged all patients with 16-slice CTA and four-vessel cerebral angiography. They noted a sensitivity of 97.7% and a specificity of 100% with the utilization of CTA for the diagnosis of BCVI.[18] However, authors in Memphis examined 684 patients and found the sensitivity of CTA to be 51% with a specificity of 97%.[19] Despite the disparate findings, survey results illustrate that 90% of trauma surgeons utilize CTA as their preferred diagnostic modality for BCVI.[20]

MANAGEMENT OF SPECIFIC INJURIES

Blunt Cerebrovascular Injury (BCVI)

Blunt injuries to the carotid and vertebral arteries are the result of a direct blow to the vessel itself or an extreme flexion, extension, or lateral rotational injury. If located in the carotid artery, these injuries typically occur at the base of the skull. Vertebral artery injury usually is located in the portion of the vessel protected by the cervical spine. These areas are difficult to explore surgically.

6 BCVI is reported to occur in 1% to 2% of blunt trauma patients and the incidence of stroke is approximately 25%, with a mortality rate of up to 13%, if left untreated.[16,21,22–24] Treatment for these injuries is centered on antiplatelet therapy and systemic anticoagulation to decrease the risk of stroke. Early recognition and initiation of treatment has been shown to decrease the rate of cerebral ischemia.[25,26]

The work of Biffl and colleagues in 1999[21,24] highlighted the importance of screening for BCVI when certain anatomic injuries or injury patterns were observed (Table 23-1). Subsequently, organizational guidelines have been disseminated by the Eastern Association for the Surgery of Trauma (EAST) based on review of the literature with the aim of guiding screening practices for BCVI (Table 23-2).[27] Investigators have shown that up to 30% of patients diagnosed with BCVI may have no radiographic or clinical risk factor that would guide the clinician to screen for these injuries.[15] Recent data has also identified an association between BCVI and nontraditional risk factors such as serious chest injury.[17] Thus, a high index of suspicion must be maintained in order to effectively diagnose and treat BCVI.

Given the seeming inability of screening guidelines to accurately identify patients at risk for BCVI, some centers have gone to blanket screening.[15] All polytrauma patients with a blunt mechanism of injury undergo CT scan of the cervical spine with contrast timed to image the carotid and vertebral arteries in conjunction with a chest and abdominal CT scan, obviating the need for a second contrast study. While data on this blanket screening is limited, it does enable the identification of injuries early in the course of workup and identifies injuries in patients that would otherwise not be screened secondary to lack of criteria.[15] Patients with identified injuries generally receive a formal CT angiogram as their follow-up study.

If stroke can be avoided with prompt initiation of therapy, functional outcomes after BCVI are good.[28] However, many patients with BCVI have multisystem trauma and are thus not deemed suitable for antiplatelet therapy or systemic anticoagulation. In a 2009 study, almost one-third of patients with BCVI were identified as not candidates for therapy, with an overall stroke rate of 12%. Stroke-related mortality was 50%.[16]

Table 23-1 Signs and Symptoms of Blunt Cerebrovascular Injury

Hemorrhage of potential arterial origin
Expanding cervical hematoma
Cervical bruit in a patient <50 years old after trauma
Unexplained lateralizing neurologic deficits, transient ischemic attack, amaurosis fugax, or Horner syndrome after trauma
Cranial neurologic deficits incongruous with brain CT findings
Evidence of cerebral infarction on CT scan

From Biffl WL, Moore EE, Elliott JP et al. Blunt Cerebrovascular Injuries. *Curr Probl Surg* 1999;36(7):505–99.

Table 23-2 Screening Criteria for Blunt Cerebrovascular Injury

Injury mechanism
Severe cervical hyperextension/rotation or hyperflexion, particularly if associated with
Displaced midface or complex mandibular fracture
Closed head injury inconsistent with diffuse axonal injury
Near hanging result in anoxic brain injury
Physical signs
Seat belt abrasion or other soft tissue injury of the neck resulting in swelling or altered mental status
Fracture in proximity to internal carotid or vertebral artery
Basilar skull fracture involving the carotid canal
Cervical vertebral body fracture

From Bromberg WJ, Collier BC, Diebel LN, et al. Blunt cerebrovascular injury practice management guidelines: The eastern association for the surgery of trauma. *J Trauma* 2010;68(2):471–477.

It is tempting to assign treatment for BCVI to a relatively lower priority. Patients with BCVI often have concomitant injuries such as intra-abdominal solid visceral injury or traumatic brain injuries. The traditional approach has been to simply decide that these patients are not candidates for anticoagulation and defer therapy. While this may be acceptable with low-grade injuries, given the relatively high rate of stroke with higher-grade injuries, this may not be wise. Recent data suggest that in Grade IV carotid injuries (complete occlusion), recanalization and subsequent stroke is extremely common.[29] This would seem to suggest that the presence of higher-grade injuries mandates therapy. For instance, in a patient with splenic injury and carotid artery injury, one should consider whether splenectomy followed by anticoagulation is wiser than nonoperative management and withholding treatment for the BCVI.

OPERATIVE EXPLORATION

After making the decision to proceed to the operating room, the operating surgeon and surgical team should quickly consider the various anatomic injuries which may be present. This is important as many general surgeons do not commonly operate in the neck. Simply considering what may be found and reviewing treatment options may help.

The patient should be positioned in a supine manner with a full surgical prep from the chin to the knees. Utilizing a widely prepped surgical field enables the surgical team to expeditiously access various body cavities as the operation mandates. If unilaterality of injury is assumed or known, it may be beneficial to position the patient's head in the direction opposite to the injury, which opens the surgical field for better exploration. Given the very real possibility of a "multizone" injury, a sternal saw should be immediately available for possible entry into the mediastinum. Similarly, a chest retractor and deep vascular instruments should be immediately available.

Penetrating Vascular Injury

The presentation of penetrating vascular injury in the neck is dependent on the vessel injured and its location. Arterial injuries, specifically the carotid arteries, present with pulsatile arterial hemorrhage emanating from the wound or a rapidly expanding hematoma. Venous injuries tend to have a more insidious presentation and may be clinically undetectable. Penetrating vertebral artery injury is rarer given the relatively protected position of the artery within the osseous spinal canal.

Cerebral ischemia secondary to carotid artery injury can lead to stroke and long-term neurologic sequelae, or even death. In some series, patients who present in hemorrhagic shock have a mortality of 41%, but have 50% mortality when presenting with stroke.[30] Patients presenting with any neurologic deficit short of coma should undergo carotid arterial repair with revascularization if technically feasible, as results are improved with revascularization. In patients presenting with a glasgow coma score (GCS) <8 (coma), a poor outcome is likely regardless of the therapy selected.[31,32]

Often, carotid artery injury is diagnosed intraoperatively, as there is no time for preoperative imaging. These injuries are usually cared for using the standard principles to treat vascular injuries. The neck is explored through a generous sternocleidomastoid incision. The proximal carotid artery is controlled at the base of zone II. If possible, it is wise to control the artery distally, before entering the hematoma. Unfortunately, this is often not possible. As the neck is a compact structure, during dissection to control the distal carotid, the contained hematoma often ruptures. Digital control can then be used to prevent exsanguinating hemorrhage while the distal dissection is carried out. Once the distal carotid artery, whether it is the internal carotid artery or distal common artery, is controlled, distal pressure can be released and more careful dissection continued.

Injuries to the common carotid artery can sometimes be repaired primarily, particularly if the injury is caused by a stab wound. More complex injuries, as those from gunshot wounds, usually require resection. Sometimes, even gunshot wound injuries can be managed with primary repair. Full mobilization of the common carotid artery will often give additional length. For injuries located more distally, ligating the external carotid artery will give additional mobility to the common carotid artery. If primary repair is not feasible, a bypass graft using either saphenous vein or PTFE is equally acceptable. PTFE, of course, should be avoided in the event of contamination or concomitant tracheal or esophageal injury.

Internal carotid artery injury represents a distinct subset of carotid artery injuries. Unlike common carotid artery injury, the initial neurologic presentation is not a good predictor of final neurologic presentation. Injuries to the internal carotid artery have 20% mortality and the majority of these deaths are secondary to cerebral ischemia.[26] Interventional techniques including embolism may be effective in some injuries, thus obviating the need for exploration.[27]

Control of the internal carotid artery proceeds along the same principles as with common carotid artery injuries, though distal control may be problematic. During the dissection, one must take care not to injure the hypoglossal nerve, which passes across

the distal internal carotid artery. The surgeon should ascertain adequacy of back bleeding from the distal internal carotid artery. Pulsatile back bleeding confirms patency of the circle of Willis. In patients with poor back bleeding, use of a shunt should be considered. We routinely use full dose IV heparin unless there is a contraindication.

The internal carotid artery can be repaired using the same principles as mentioned for the common carotid artery, though several scenarios require special mention. If there is injury to the proximal internal carotid artery and the distal vessel is thrombosed, dissection should be carried out as distal as possible. If the vessel is thrombosed, as far as surgically accessible, the surgeon should avoid the temptation to do catheter thrombectomy as this is virtually never complete and, once revascularized, the patient has significant risks of embolic stroke. In addition, one should avoid ligating the thrombosed internal carotid artery at the base. If one forcefully ligates the internal carotid artery, there is high likelihood that distal clot will be dislodged, causing a stroke of clinical significance.

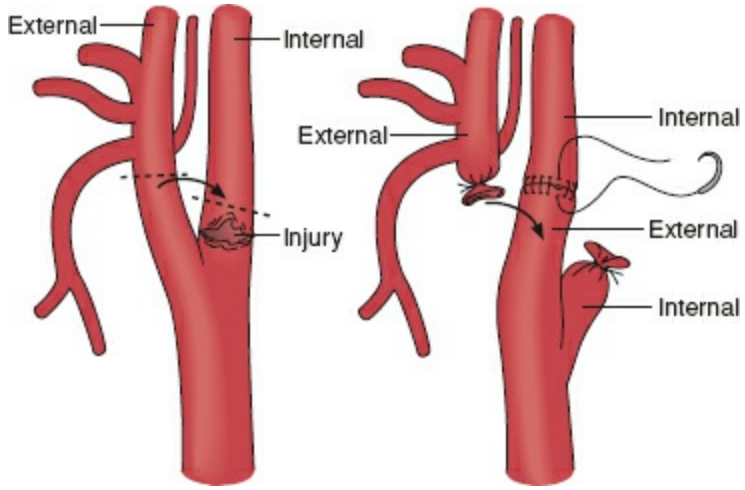

Figure 23-3. A proximal internal carotid artery injury managed with resection and transposition of the external carotid artery to obtain inflow to the native internal carotid artery.

Occasionally, one will encounter an injury in the very proximal internal carotid artery. Once the vessels are controlled, consideration should be given to use the external carotid artery as the conduit, if primary repair is not feasible. The damaged internal carotid artery can be dissected down to the level of the bifurcation (Fig. 23-3). The external carotid can be ligated at the level of the first branch and the external carotid artery rotated over to use as the conduit. A single vascular suture line then connects the external to the internal carotid artery.

The external carotid artery, for the most part, is expendable. If an external carotid artery injury is diagnosed at the time of surgical exploration, it can simply be ligated. Those that are diagnosed preoperatively, with images, are often amenable to catheter-based hemostatic techniques.[29] If there is a distal injury to a branch of an external carotid artery, such as the facial or lingual arteries, particularly if caused by penetrating facial trauma, catheter-based hemostasis is by far the most attractive option. Proximal ligation of the external carotid artery will decrease inflow, but the robust collateral circulation

from the contralateral external carotid may be sufficient to cause continued hemorrhage. Angiographic options are then essentially nil, as the ligated external carotid prevents an angiographic solution.

Secondary to the posterior anatomic location and protection provided by the cervical spine, penetrating vertebral artery injuries are less likely. Additionally, injuries to the vertebral arteries are less likely to cause neurologic sequelae than those to the carotids.[30] Operative exposure of the vertebral artery is quite difficult secondary to its protected location in the posterior neck. If necessary, it is best approached via an anterior approach with proximal ligation of vertebral artery.[31] Combined carotid and vertebral artery penetrating injuries are very morbid, with mortality rates of approximately 50%.[32] Occasionally, a vertebral artery injury will be discovered at the time of diagnostic neck exploration. This is an extremely challenging situation, as direct pressure will only temporarily control the artery. Rather than attempting to expose the artery by unroofing the cervical spine over the vessel, we have generally maintained digital pressure or controlled the artery temporarily with a Fogarty balloon, after which the patient can then be transported to a site where angiographic embolization is possible.

Trachea and Larynx

Blunt laryngotracheal trauma is uncommon[33] and low-grade injuries, can be clinically occult. Thus, it requires a high index of suspicion for accurate diagnosis and initiation of treatment. The most typical mechanism of injury involves an anterior to posterior vector of force that drives the thyroid cartilage into the rigid cervical spine. Such forces can be the result of a motor vehicle collision with compression of the neck against the steering wheel or dash of the automobile. The most common symptoms include hoarseness, dyspnea, and dysphagia.[33,34] Careful attention must be paid to the airway as laryngotracheal separation can be catastrophic. Definitive diagnosis is made with a combination of CT scanning and endoscopy and definitive airway management is best obtained with tracheostomy, if endotracheal intubation is not prudent.[35]

The presentation of penetrating laryngotracheal injuries are less subtle, as impressive symptoms and physical findings almost always present in high-grade injuries. Management is focused on rapid airway control, either via endotracheal intubation or via a surgical airway. In the rare instance of tracheal transection in the neck with two visible lumens, the distal lumen should be intubated with any available airway device. Concomitant esophageal injury is a source of major morbidity; therefore the esophagus should be evaluated with endoscopy early or operative exploration in the course of treatment.[36]

Cervical tracheal injuries, particularly if they are isolated, are best approached via a collar incision performed approximately two fingerbreadths above the sternal notch. If other injuries are present and/or if full exploration is needed, the trachea can be exposed and repaired using a sternocleidomastoid incision. If a collar incision is used, subplatysmal flaps are created and the strap muscles are then divided in the midline. The thyroid isthmus can be retracted cephalad and the entire cervical trachea is then clearly visualized. If the location of the tracheal injury in the neck is clearly in zone II, surgical exploration confirms the diagnosis and allows for prompt therapy.

However, sometimes the injury is located closer to the thoracic inlet. In those cases, preoperative bronchoscopy is vital in order to plan the best operative course. If the injury is located in the upper mediastinum, several options exist. The patient can be explored via a collar incision and the anterior trachea identified. The trachea can be mobilized using digital dissection into the upper mediastinum. The trachea can then be grasped with a tracheal hook and retracted up into the neck. It is possible to mobilize the trachea for approximately three rings, thus allowing the surgeon to repair these injuries with a relatively small incision. However, injuries that are located in the more distal mediastinum are best approached with a right-sided posterolateral thoracotomy.

Occasionally, tracheal injuries will be located at a level above the endotracheal balloon. When performing diagnostic bronchoscopy, the endotracheal tube must be withdrawn over the bronchoscope, up to the level of the vocal cords. This allows complete visualization of the proximal trachea. Not doing this, risks missing the proximal tracheal injury.

Injuries to the posterior membranous trachea are relatively difficult to approach. In

patients with blunt trauma, small injuries may be simply observed. However, if repair is thought to be prudent, the best way to approach this is via the anterior trachea. The anterior trachea is opened transversely at the level of the injury and the injury is then visualized and repaired. The anterior trachea is then closed primarily. Intraoperative bronchoscopy can help locate the level of the injury.

The blood supply to the trachea enters posterolaterally on both sides. Therefore, circumferential mobilization of the trachea, risks causing ischemia, which may manifest either as tracheal necrosis, dehiscence of a repair, or postoperative tracheal stenosis. In addition, the recurrent laryngeal nerve runs in the tracheoesophageal groove and care must be taken to avoid damage to it during mobilization or tracheal repair. Postoperatively, patients should be extubated as soon as possible. It is often tempting to think that the tracheal repair is protected with longer-term tracheal intubation, but the chances of complication are less if the patient is extubated at the end of the operative procedure. One should avoid a tracheostomy in a patient with tracheal repair, because stenosis at the level of tracheostomy and the level of tracheal repair can make future reconstruction exceedingly difficult.

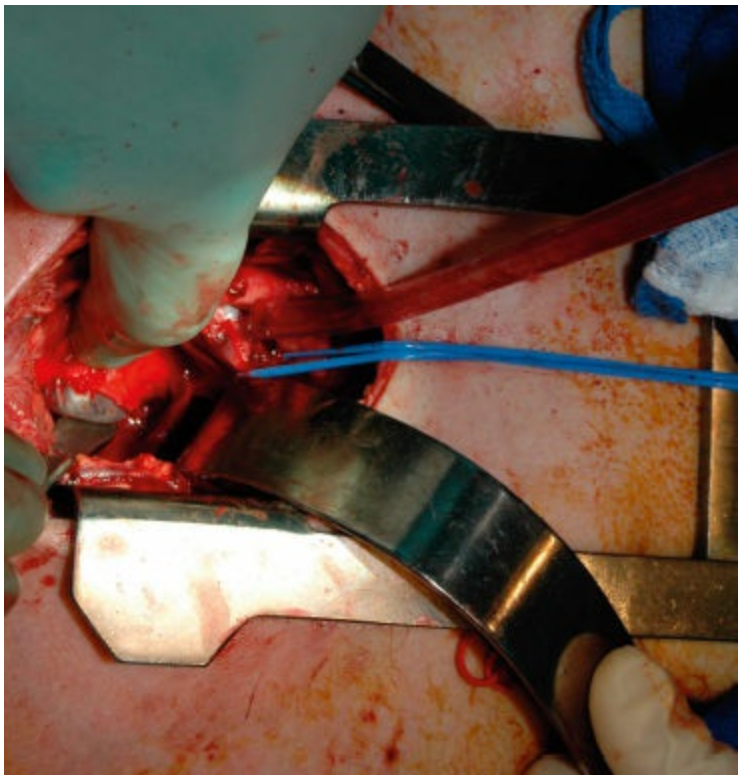

Figure 23-4. Partial sternal split for evaluation of tracheal injury. The endotracheal tube balloon is visualized within the lumen of the injured trachea.

In the event that the injury extends into the thoracic inlet, a partial sternal split (Fig. 23-4) or full sternotomy can be performed for better visualization. Tracheal injuries are preferentially repaired primarily with single layer absorbable suture, though resection of up to 2 to 4 cm with primary anastomosis is technically feasible. Suture lines are buttressed with autologous, well-vascularized tissue such as strap muscle (Fig. 23-5).

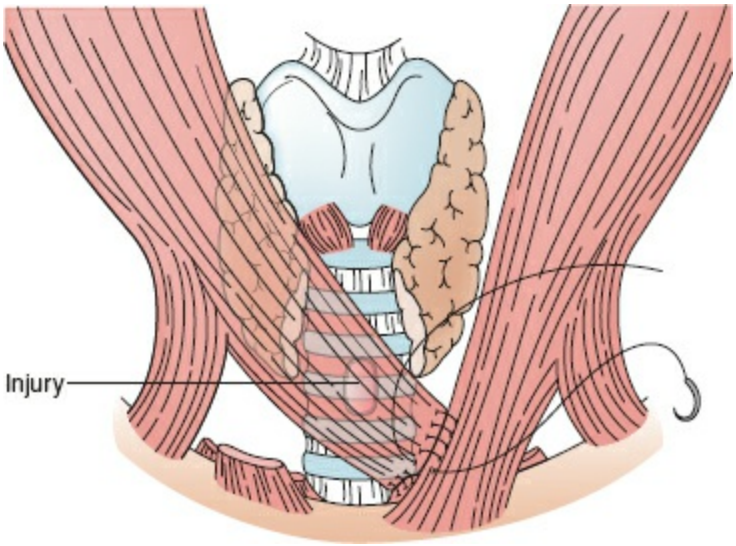

Figure 23-5. Divided strap muscle utilized to buttress tracheal injury/repair.

Expeditious diagnosis of esophageal injury is imperative, as missed injury and/or a delay in diagnosis can lead to disastrous consequences. In a review of 109 penetrating esophageal injuries, the mortality rate was 2% with immediate operation. Mortality increased to 44% with delayed diagnosis and operation. In this same series, mortality increased to 100% for patients with a delayed diagnosis and no operative procedure.[37]

As the course of the esophagus is relatively superficial within the neck, diagnosis can occasionally be made on physical examination findings alone. Food particles or salivary secretions within the wound are highly suggestive of esophageal injury. Additional physical examination findings may include esophageal or oropharyngeal bleeding, subcutaneous emphysema, and neck hematoma. Plain film radiographic findings may include air within the subcutaneous tissues and pneumomediastinum.[38] In a review of 77 patients with noniatrogenic esophageal injury, 58% occurred in the cervical esophagus but physical examination findings were present in only 26% of the cohort.[39]

7 Given the pervasive nature of CT scanning in the trauma patient, investigators have evaluated the utility of this imaging modality for esophageal injury. A study from the Aga Khan University Hospital showed 53% sensitivity for CT scanning in diagnosing esophageal injuries.[40] The gold standard for diagnosis of most esophageal injuries remains a combination of esophagoscopy and contrast-enhanced esophagography. When these two imaging modalities are used in combination, an accuracy of almost 100% is achieved.[41] The sensitivity of esophagography alone varies from 50% to 90% while the sensitivity of endoscopy alone varies from 29% to 100%.[42]

As with the trachea, the location of the esophageal injury defines the approach for repair. Those injuries that are clearly in zone II can easily be approached via a sternocleidomastoid incision. Those in the chest are best approached via a posterolateral right thoracotomy. As with the trachea, localization of the injury, particularly those at the junction between the neck and chest, is the easiest way to ensure optimal exposure. Intraoperative endoscopy can be very helpful in positively identifying the location of an

injury and helping to direct therapy.

Small, nondestructive injuries in the hypopharyngeal region can occasionally be managed nonoperatively with antibiotics, upright positioning, limited oral intake, and close clinical observation.[43] However, the vast majority of cervical esophageal injuries are best managed operatively. Cervical esophageal injuries are most easily approached via a left anterior sternocleidomastoid incision. If a collar incision has been initiated, it can be extended to the left, along the anterior border of the sternocleidomastoid muscle to facilitate better exposure. Preoperative placement of a nasogastric tube may assist with identification of the esophagus in the neck, as the hard nasogastric tube can be palpated within the lumen. After lateral retraction of the sternocleidomastoid muscle, the dissection progresses medially until the esophagus is encountered. Care must be taken to avoid injury to the recurrent laryngeal nerve in the tracheoesophageal groove.

Circumferential dissection of the esophagus and placement of large rubber drain around the organ can facilitate retraction and mobilization. As the blood supply of the esophagus runs vertically within the muscle, the esophagus can be circumferentially mobilized without risk of ischemia. Thus, injuries located in the superior mediastinum can be mobilized into the neck and repaired. After repair, liberal drainage of the injured area is highly recommended in an effort to avoid salivary fistula and deep neck infection.[38,43] Delays in diagnosis of more than 12 hours are associated with poor outcomes and in these cases, proximal diversion and wide drainage may be the safest option.

Primary repair of the injury is the goal in most circumstances. During repair, the entirety of the mucosal injury must be visualized, as it may extend beyond the field of view under the longitudinal outer muscle of the esophagus. Debridement of all devitalized tissue is required. Repairs are typically performed in two layers with absorbable sutures, though single-layer repair is possible.[38,44] Similar to tracheal repair, a well-vascularized muscle is highly recommended to buttress the repair. Given the likelihood that the patient will be on a restricted oral diet, placement of a small-bore enteral tube, distal to the repair, should be considered intraoperatively. Imaging repairs at 7 to 10 days with a contrast-enhanced swallow study is recommended prior to removal of drains.

Table 23-3 Common Complications After Neck Injury

Pneumonia and ventilator dependent respiratory failure
Surgical site infection
Anastomotic dehiscence and repair breakdowns
Suture granulomas
Tracheoesophageal fistula

COMPLICATIONS

As in all forms of injury, neck injuries are associated with a variety of morbidities (Table 23-3). The most common complications after tracheal repair include postoperative suture granuloma, pneumonia, and surgical site infection.[45] Complications after tracheal repair were once thought to be numerous; modern studies have questioned this supposition. In a 2013 paper, investigators showed that complications after tracheal injury alone were associated with an exceedingly low rate of complications. In patients with combined tracheal and esophageal injuries, the rate of complications is drastically increased.[46]

Tracheoesophageal fistula occurs when an abnormal passage forms between the trachea and esophagus, manifesting as respiratory distress and recurrent pulmonary infections. Management includes a variety of operative techniques aimed at restoring the continuity of both the trachea and esophagus and the interposition of well-vascularized tissue flaps between the repairs. Though endoluminal stenting is discussed, its utility is currently minimal.[47]

Esophageal leak from repair dehiscence and anastomotic breakdown creates an ongoing source of intrathoracic infection and inflammation, which makes primary management and repair exceedingly difficult. Though relatively early in the experience, the use of endoluminal stenting in this situation has shown promise and avoids the need for full operative exploration.[48] Leaks in the neck are more easily controlled by opening of the wound and wide drainage with avoidance of enteral nutrition past the site of injury. In rare instances, cervical esophagostomy may be required.

SUMMARY

Management of injuries to the neck requires a thorough understanding of three-dimensional anatomy and an appreciation for the severity of injuries possible in this region. A relatively small anatomic region, the neck contains many structures vital to meaningful survival. Attention to airway is of the utmost importance, because without a secure airway, the remainder of workup is meaningless. In the presence of vascular injury, all management options must be rapidly reviewed and the most easily obtained and efficacious maneuver should be chosen. As nonoperative management of many traumatic injuries continues to expand, it is the obligation of the surgeon to remember basic surgical principles and apply them in an expeditious and safe manner as the situation mandates.

References

1. Nason RW, Assuras GN, Gray PR, et al. Penetrating neck injuries: analysis of experience from a Canadian trauma centre. *Can J Surg* 2001;44(2):122–126.
2. Bishara RA, Pasch AR, Douglas DD, et al. The necessity of mandatory exploration of penetrating zone II neck injuries. *Surgery* 1986;100(4):655–660.
3. Saletta JD, Lowe RJ, Lim LT, et al. Penetrating trauma of the neck. *J Trauma* 1976;16(7):579–587.
4. Monson DO, Saletta JD, Freeark RJ. Carotid vertebral trauma. *J Trauma* 1969;9(12):987–999.
5. Roon AJ, Christensen N. Evaluation and treatment of penetrating cervical injuries. *J Trauma* 1979;19(6):391–397.
6. Simonian GT, Pappas PJ, Padberg FT Jr, et al. Mandibular subluxation for distal internal carotid exposure: technical considerations. *J Vasc Surg* 1999;30(6):1116–1120.
7. Shaha A, Phillips T, Scalea T, et al. Exposure of the internal carotid artery near the skull base: the posterolateral anatomic approach. *J Vasc Surg* 1988; 8(5):618–622.
8. American College of Surgeons - Committee on Trauma. Initial Assessment and Management. In: *Advanced Trauma Life Support - Student Course Manual.* 9th ed. Chicago, IL:American College of Surgeons;2012:2–21.
9. Davidson SB, Blostein PA, Walsh J, et al. Percutaneous tracheostomy: a new approach to the emergency airway. *J Trauma Acute Care Surg* 2012;73(2 Suppl 1):S83–S88.
10. Medzon R, Rothenhaus T, Bono CM, et al. Stability of cervical spine fractures after gunshot wounds to the head and neck. *Spine (Phila Pa 1976)* 2005; 30(20):2274–2279.
11. Ramasamy A, Midwinter M, Mahoney P, et al. Learning the lessons from conflict: pre-hospital cervical spine stabilisation following ballistic neck trauma. *Injury* 2009;40(12):1342–1345.
12. Jones RF, Terrell JC, Salyer KE. Penetrating wounds of the neck: An analysis of 274 cases. *J Trauma* 1967;7(2):228–237.
13. Gonzalez RP, Falimirski M, Holevar MR, et al. Penetrating zone II neck injury: does dynamic computed tomographic scan contribute to the diagnostic sensitivity of physical examination for surgically significant injury? A prospective blinded study. *J Trauma* 2003;54(1):61–64; discussion 64–65.
14. Inaba K, Branco BC, Menaker J, et al. Evaluation of multidetector computed tomography for penetrating neck injury: a prospective multicenter study. *J Trauma Acute Care Surg* 2012;72(3):576–583; discussion 583–584; quiz 803–804.
15. Bruns BR, Tesoriero R, Kufera J, et al. Blunt cerebrovascular injury screening guidelines: what are we willing to miss? *J Trauma Acute Care Surg* 2014; 76(3):691–695.

16. Stein DM, Boswell S, Sliker CW, et al. Blunt cerebrovascular injuries: does treatment always matter? *J Trauma* 2009;66(1):132–143; discussion 143–144.
17. Lohrer L, Vieth V, Nassenstein I, et al. Blunt cerebrovascular injuries in acute trauma care: a screening protocol. *Eur Spine J* 2012;21(5):837–843.
18. Eastman AL, Chason DP, Perez CL, et al. Computed tomographic angiography for the diagnosis of blunt cervical vascular injury: is it ready for primetime? *J Trauma* 2006;60(5):925–929; discussion 929.
19. DiCocco JM, Emmett KP, Fabian TC, et al. Blunt cerebrovascular injury screening with 32-channel multidetector computed tomography: more slices still don't cut it. *Ann Surg* 2011;253(3):444–450.
20. Harrigan MR, Weinberg JA, Peaks YS, et al. Management of blunt extracranial traumatic cerebrovascular injury: a multidisciplinary survey of current practice. *World J Emerg Surg* 2011;6:11–7922–6–11.
21. Biffl WL, Moore EE, Elliott JP, et al. Blunt cerebrovascular injuries. *Curr Probl Surg* 1999;36(7):505–599.
22. Miller PR, Chang MC, Hoth JJ, et al. Colonic resection in the setting of damage control laparotomy: is delayed anastomosis safe? *Am Surg* 2007;73(6):606–609; discussion 609–610.
23. Cothren CC, Moore EE, Biffl WL, et al. Anticoagulation is the gold standard therapy for blunt carotid injuries to reduce stroke rate. *Arch Surg* 2004;139(5):540–545; discussion 545–546.
24. Biffl WL, Moore EE, Offner PJ, et al. Blunt carotid arterial injuries: implications of a new grading scale. *J Trauma* 1999;47(5):845–853.
25. Fabian TC, Patton JH Jr, Croce MA, et al. Blunt carotid injury. Importance of early diagnosis and anticoagulant therapy. *Ann Surg* 1996;223(5):513–522; discussion 522–525.
26. Eastman AL, Muraliraj V, Sperry JL, et al. CTA-based screening reduces time to diagnosis and stroke rate in blunt cervical vascular injury. *J Trauma* 2009;67(3):551–556; discussion 555–556.
27. Bromberg WJ, Collier BC, Diebel LN, et al. Blunt cerebrovascular injury practice management guidelines: the eastern association for the surgery of trauma. *J Trauma* 2010;68(2):471–477.
28. DiCocco JM, Fabian TC, Emmett KP, et al. Functional outcomes following blunt cerebrovascular injury. *J Trauma Acute Care Surg* 2013;74(4):955–960.
29. Lauerman M, Feeney T, Sliker C, et al. Lethal now or lethal later: the natural history of Grade IV blunt cerebrovascular injury. Abstract. American Association for the Surgery of Trauma Annual Meeting. Philadelphia, PA; 2014.
30. Ramadan F, Rutledge R, Oller D, et al. Carotid artery trauma: a review of contemporary trauma center experiences. *J Vasc Surg* 1995;21(1):46–55; discussion 55–56.

31. Feliciano DV. Management of penetrating injuries to carotid artery. *World J Surg* 2001;25(8):1028–1035.
32. Liekweg WG Jr, Greenfield LJ. Management of penetrating carotid arterial injury. *Ann Surg* 1978;188(5):587–592.
33. Sofferman RA. Management of laryngotracheal trauma. *Am J Surg* 1981;141(4):412–417.
34. Myers EM, Iko BO. The management of acute laryngeal trauma. *J Trauma* 1987;27(4):448–452.
35. Fuhrman GM, Stieg FH 3rd, Buerk CA. Blunt laryngeal trauma: classification and management protocol. *J Trauma* 1990;30(1):87–92.
36. Grewal H, Rao PM, Mukerji S, et al. Management of penetrating laryngotracheal injuries. *Head Neck* 1995;17(6):494–502.
37. Sankaran S, Walt AJ. Penetrating wounds of the neck: principles and some controversies. *Surg Clin North Am* 1977;57(1):139–150.
38. Glatterer MS Jr, Toon RS, Ellestad C, et al. Management of blunt and penetrating external esophageal trauma. *J Trauma* 1985;25(8):784–792.
39. Defore WW Jr, Mattox KL, Hansen HA, et al. Surgical management of penetrating injuries of the esophagus. *Am J Surg* 1977;134(6):734–738.
40. Kazi M, Junaid M, Khan MJ, et al. Utility of clinical examination and CT scan in assessment of penetrating neck trauma. *J Coll Physicians Surg Pak* 2013;23(4):308–309.
41. Weigelt JA, Thal ER, Snyder WH 3rd, et al. Diagnosis of penetrating cervical esophageal injuries. *Am J Surg* 1987;154(6):619–622.
42. Carducci B, Lowe RA, Dalsey W. Penetrating neck trauma: consensus and controversies. *Ann Emerg Med* 1986;15(2):208–215.
43. Stanley RB Jr, Armstrong WB, Fetterman BL, et al. Management of external penetrating injuries into the hypopharyngeal-cervical esophageal funnel. *J Trauma* 1997;42(4):675–679.
44. Winter RP, Weigelt JA. Cervical esophageal trauma. Incidence and cause of esophageal fistulas. *Arch Surg* 1990;125(7):849–851; discussion 851–852.
45. Miller BS, Shafi S, Thal ER. Damage control in complex penetrating tracheal injury and silicone T-tube. *J Trauma* 2008;64(2):E18–E20.
46. Lyons JD, Feliciano DV, Wyrzykowski AD, et al. Modern management of penetrating tracheal injuries. *Am Surg* 2013;79(2):188–193.
47. Muniappan A, Wain JC, Wright CD, et al. Surgical treatment of nonmalignant tracheoesophageal fistula: a thirty-five year experience. *Ann Thorac Surg* 2013;95(4):1141–1146.
48. David EA, Kim MP, Blackmon SH. Esophageal salvage with removable covered self-expanding metal stents in the setting of intrathoracic esophageal leakage. *Am J Surg* 2011;202(6):796–801; discussion 801.

Chapter 24

Thoracic Trauma

Marc de Moya and George Velmahos

Key Points

1 The mortality associated with penetrating thoracic trauma is higher than blunt trauma.

2 The most common thoracic injury is rib fracture and the most effective pain relief is thoracic epidural analgesia.

3 Not all pneumothoraces need to be drained but when necessary drainage can be accomplished effectively with a pigtail catheter.

4 Hemothoraces may be drained by 28-Fr chest tubes and if there is significant retained hemothorax early intervention with video-assisted thoracoscopy should be employed.

5 Aortic injury repair may be delayed and the injury medically managed in the face of significant associated injuries.

INTRODUCTION

1 Thoracic trauma is a common occurrence with an incidence of approximately 25% of all traumas.[1] Thoracic injuries are also commonly associated with head and abdominal trauma with a blunt mechanism. The most common thoracic injury is rib fracture and mortality/morbidity increases as the number of ribs fractured increases. Mortality is most pronounced in the elderly where there is a 19% increase in mortality with each additional rib fracture.[2] Penetrating trauma accounts for the majority of deaths related to thoracic trauma but overall 85% of penetrating trauma to the chest can be managed with a chest tube. Regardless of the mechanism or obvious injuries one should always proceed with a systematic approach to the trauma patient, via Advanced Trauma Life Support (ATLS).

INITIAL IMAGING

The initial imaging in the trauma bay for suspected chest trauma is the screening chest X-ray (CXR) and the extended FAST (eFAST) examination. The CXR is typically a supine anterioposterior (AP) single film that helps the clinician determine if there are any bone fractures (ribs/clavicle/scapula), mediastinal hematoma (widened mediastinum >8 cm, loss of aortic knob, loss of aortopulmonary window, depression of left mainstem bronchus >110 degrees, deviation of nasogastric tube, apical cap, or tracheal deviation), pneumothorax, hemothorax, lung contusions, elevated diaphragm, large diaphragmatic rupture, or confirm position of endotracheal tube/any central lines in internal jugular or subclavian positions.[3] If the spine is cleared then an upright AP film may be obtained, which increases sensitivity for hemothoraces and pneumothoraces. These films are often limited due to movement, clothing, backboards, or inadequate exposure but serve as reasonable screening image.

The FAST (Focus Assessment with Sonography for Trauma) has become a standard adjunct in the trauma bay. ATLS[4] now has a module focused on the FAST examination and therefore, all physicians or advanced practitioners who care for trauma patients should become familiar with how to perform the FAST examination. The FAST examination views include the right upper quadrant, left upper quadrant, pelvic view, and the pericardium. For the purposes of this chapter the pericardial view is the view that will demonstrate hemopericardium. Hemopericardium is typically the result of penetrating trauma to the heart but may also be due to blunt rupture of the heart.[5] Rozycki et al.[6] used the FAST examination to determine if there was pericardial fluid in 1,540 patients with truncal injuries, with 100% sensitivity and 99.3% specificity. The eFAST includes the evaluation of lung to determine presence or absence of a large pneumothorax and evaluation for hemothoraces. The sensitivity of ultrasound to detect a pneumothorax is approximately 90% and is more sensitive than the screening supine CXR.[7]

Computed tomographic scans (CT scans) are often employed after the secondary survey and provide important information. They are highly sensitive for hemo/pneumothoraces, bone fractures, vascular injuries, and lung contusions/lacerations. CT scans are typically performed with intravenous contrast to better visualize vascular injuries and lung parenchyma.

COMMON INJURIES

Rib Fractures

The most common injury in thoracic trauma is the rib fracture. There is a spectrum of injury patterns ranging from single nondisplaced rib fractures to large flail segments with severe displacement. There are two general patterns of injury related to age and degree of flexibility of ribs. The younger population has innately more mobile/flexible ribs and therefore requires a higher force to create fractures. This higher force also translates to a higher degree of underlying lung contusion. The older population with more brittle ribs requires less force to fracture the ribs and therefore may not have as severe of an underlying lung contusion. The diagnosis is usually made by initial physical examination (tenderness and chest wall paradoxical movement for flails) and CXR (Fig. 24-1). However, CXR only visualizes 30% of rib fractures. CT scan is extremely sensitive for rib fractures and also allows one to quantify any associated hemothorax/pneumothorax.

Flail chests is defined as three or more segments of consecutive ribs broken in two or more places. These segments move independently and may exhibit a "mechanical" flail which is the paradoxical movement of the flail segment. As the patient inspires and expands the chest to produce a negative pressure, the flail segment is pulled toward the lung. The opposite occurs during expiration and the flail segment bulges outward (Fig. 24-2). The respiratory compromise that occurs in the face of a flail segment is multifactorial; (1) underlying lung contusion, (2) pain with respirations, and (3) mechanical disadvantage. The pain and the contusion are the most influential on clinical outcomes when compared to the mechanical disadvantage.

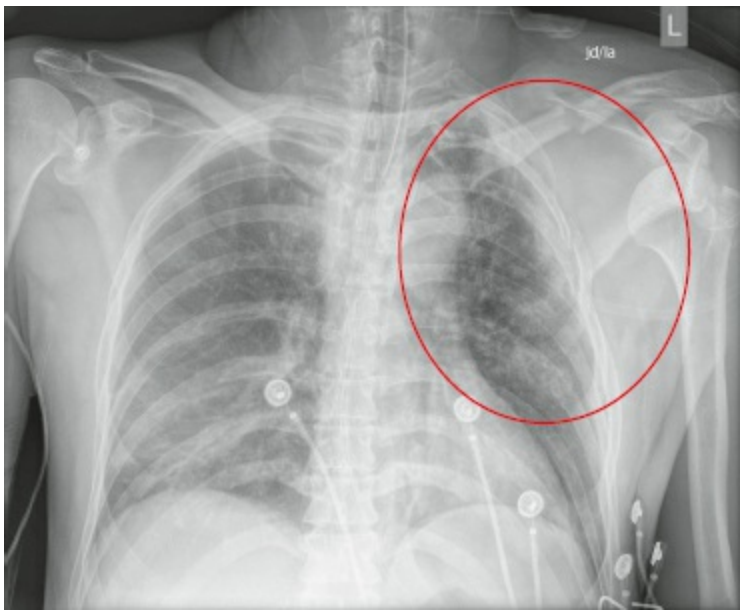

Figure 24-1. Rib fractures on CXR.

Treatment

2 The most important aspect of care for rib fractures is pain management. The majority of complications are directly related to lack of pain control. There are multiple studies

suggesting that thoracic epidurals are superior to intravenous narcotics for treatment of pain related to rib fractures.[8,9] Pain relief can also be provided by intercostal blocks, paravertebral blocks, or lidocaine patches but these methods are not as effective as administration of thoracic epidural analgesia. An aggressive pain management program will allow the patient to be more mobile and promote good pulmonary toilet to remove secretions and improve expansion of the lung.

There are two randomized clinical studies comparing surgical repair of ribs (open reduction and internal fixation) versus mechanical ventilation alone.[10,11] Both studies suggest a benefit in surgical repair in terms of days on the ventilator, pneumonia, and function at 6 and 12 months. Therefore, it is recommended for those with large flail chest (five or more ribs) on mechanical ventilation without a reason for prolonged intubation, that is, severe traumatic brain injury, to undergo rib fixation. This conclusion has also been supported by other nonrandomized trials.[12,13] There are multiple types of rib fixators available (Fig. 24-3) and no repair has proven superior. The majority of ribs repaired are number 4 to 9, approached via a thoracotomy incision (Fig. 24-4).

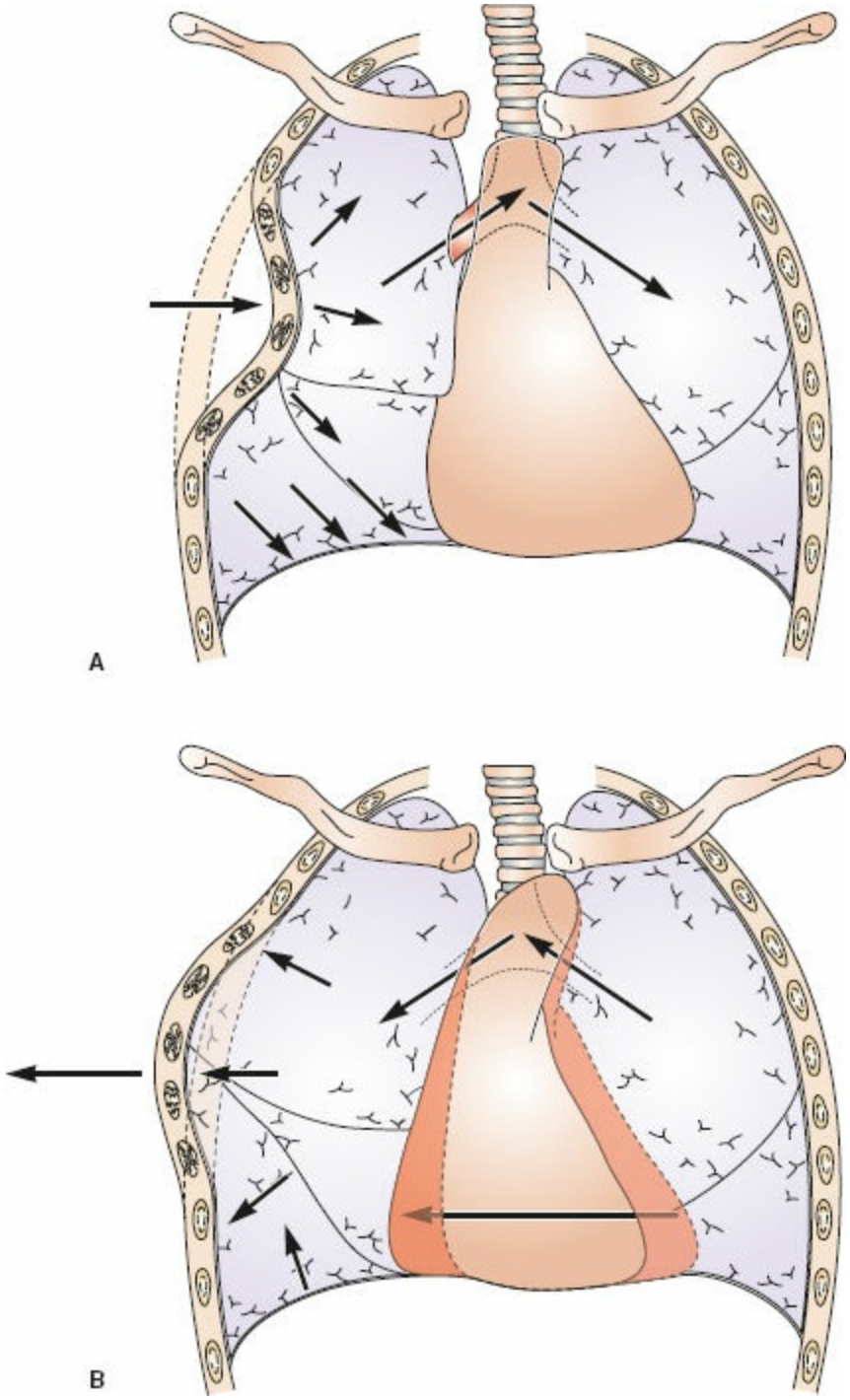

Figure 24-2. Pathophysiology of flail chest. **A:** Inspiratory phase: chest wall collapses inward, causing air to move out of the bronchus of the involved lung into the trachea and bronchus of the uninvolved lung, causing a shift of mediastinum to the uninvolved side. **B:** Expiratory phase: chest wall balloons outward so that air is expelled from the lung on the uninvolved side and enters the lung on the involved side with an associated shift of mediastinum to the involved side.

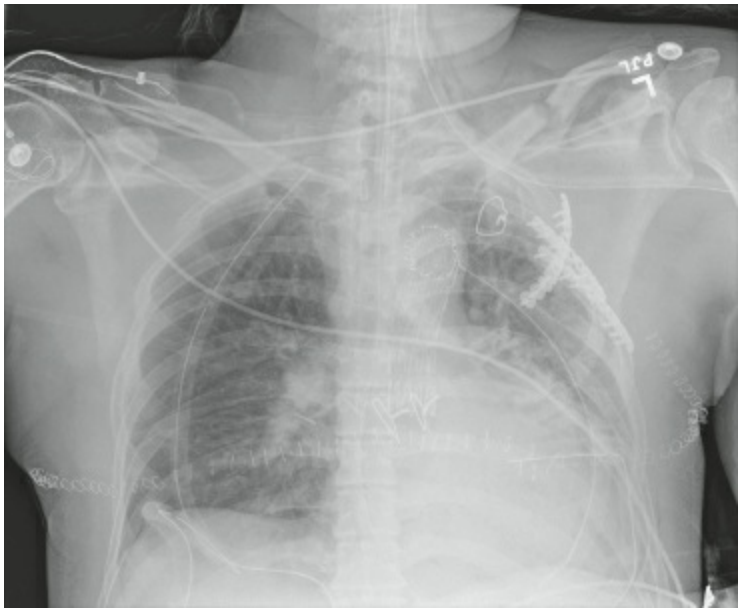

Figure 24-3. Rib fixation with plates.

For patients who do not have large flail chests, which is the majority, the indications for rib fixation remain elusive. In general, the author's approach is to consider rib fixation for any patient with three or more ribs fractured with severe displacement (more than the width of a rib). The patient population that would significantly benefit from fixation is unclear and at this point the decision is made on a case-specific basis.

Pneumothorax

Pneumothoraces can be classified into three subtypes: occult, simple, and tension. The initial diagnosis can be made with physical examination by auscultation. Auscultation is the first diagnostic test performed during the "Breathing" portion of the primary survey. One should be sure to auscultate the chest in two primary positions (bilateral midaxillary lines). This provides the examiner with the greatest specificity since these positions represent the most distant portions of the hemithorax from the contralateral hemithorax. Anterior positions can often be falsely positive for breath sounds secondary to overlapping pleura or transmitted sounds from the contralateral side.

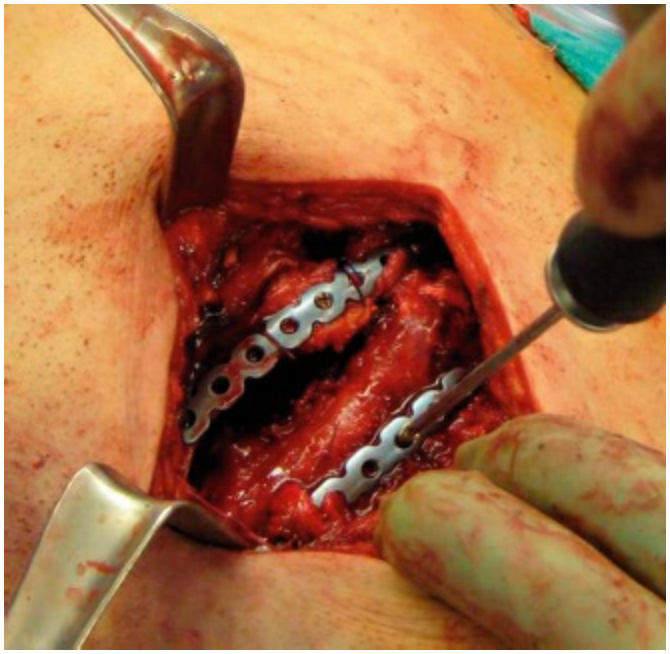

Figure 24-4. Rib Fixation with plates (photo).

The next most commonly used diagnostic test is ultrasound during the extended FAST examination looking specifically for lung sliding. Lung sliding has a high sensitivity and specificity (78.6% and 98.4%)[14] for the presence or absence of a pneumothorax as described above. The standard of care in the trauma bay is upright (if spine is cleared) or supine AP X-ray if the spine is not cleared. Although radiographs are less sensitive than ultrasound for small pneumothoraces they are used to screen for other associated injuries as described above.

An occult pneumothorax is one that is seen on CT scan (which is the most sensitive test for pneumothorax) but not seen on CXR (Fig. 24-5A, B). Subcutaneous emphysema is a sign that should alert the clinician to pneumothorax (Fig. 24-6). A simple pneumothorax is one that is seen on either CT scan or CXR but is not associated with hemodynamic compromise. Those patients with a pneumothorax and hemodynamic compromise must be considered a tension pneumothorax until proven otherwise. Tension pneumothorax is not a radiologic diagnosis but rather a clinical diagnosis. A tension pneumothorax is a pneumothorax that has progressed to the point that the mediastinum is shifted compromising in-flow to the heart. Kinking of the great vessels is the pathophysiology

that leads to an acute decrease in cardiac output and shock. Unless tension is released the patient will die. Signs and symptoms of a tension pneumothorax include; shortness of breath, dyspnea, tachypnea, hypotension, distended neck veins, and tracheal deviation (away from the site of injury). If any of these signs are present immediate decompression is necessary.

Treatment of Pneumothorax

If the patient is unstable and a tension pneumothorax is suspected needle decompression may be considered. A large–bore, 14- to 16-gauge angiocatheter is inserted into either the anterior second intercostal space in the midclavicular line or the fifth intercostal space in the midaxillary line. There is some cadaveric data that suggests that the fifth intercostal space in the midaxillary line has the least distance from the skin to the pleural cavity and therefore, may be superior to the anterior position.[15] This converts the tension pneumothorax to a simple pneumothorax which can subsequently be drained with a proper tube.

3 If one has access to a chest tube quickly there is no need to perform a needle decompression. Classically an open chest tube in the zone of safety may be placed. The zone of safety is outlined by the pectoralis major lateral border, the nipple line in men (two fingerbreadths above the inframammary fold, women), and the anterior border of the latissimus dorsi. The triangle formed by these borders is a guide for the practitioner for placement of the chest tube (Fig. 24-7). If the tube is placed too far caudal it can easily enter the abdominal cavity. A standard 28-Fr chest tube may be placed as there is no difference between a 36 Fr and 28 Fr in ability to adequately drain the chest of either pneumothorax or hemothorax.[16] In those patients with a pure pneumothorax a 14-Fr pigtail catheter is also acceptable and may be superior given the significantly less pain/discomfort of the tube as described in a randomized clinical trial.[17] Pigtail catheters are placed using a Seldinger technique in the identical areas as the open chest tube technique.

For those patients who have a simple (or occult) pneumothorax one should be guided by progression of the pneumothorax or the development of signs/symptoms of cardiopulmonary compromise. In a series of 146 patients with pneumothoraces, 90% of pneumothoraces that were 3.5 cm in widest dimension were successfully observed. This holds true in the intubated patient on positive pressure ventilation as well.[18] Therefore, as a general rule, if the patient is stable one should repeat the CXR and if the pneumothorax is significantly larger (definition of significantly larger varies) or if the patient becomes symptomatic then a tube should be placed to reexpand the lung. No longer is there a need for a mandatory chest tube for pneumothoraces, even for those on positive pressure ventilation.

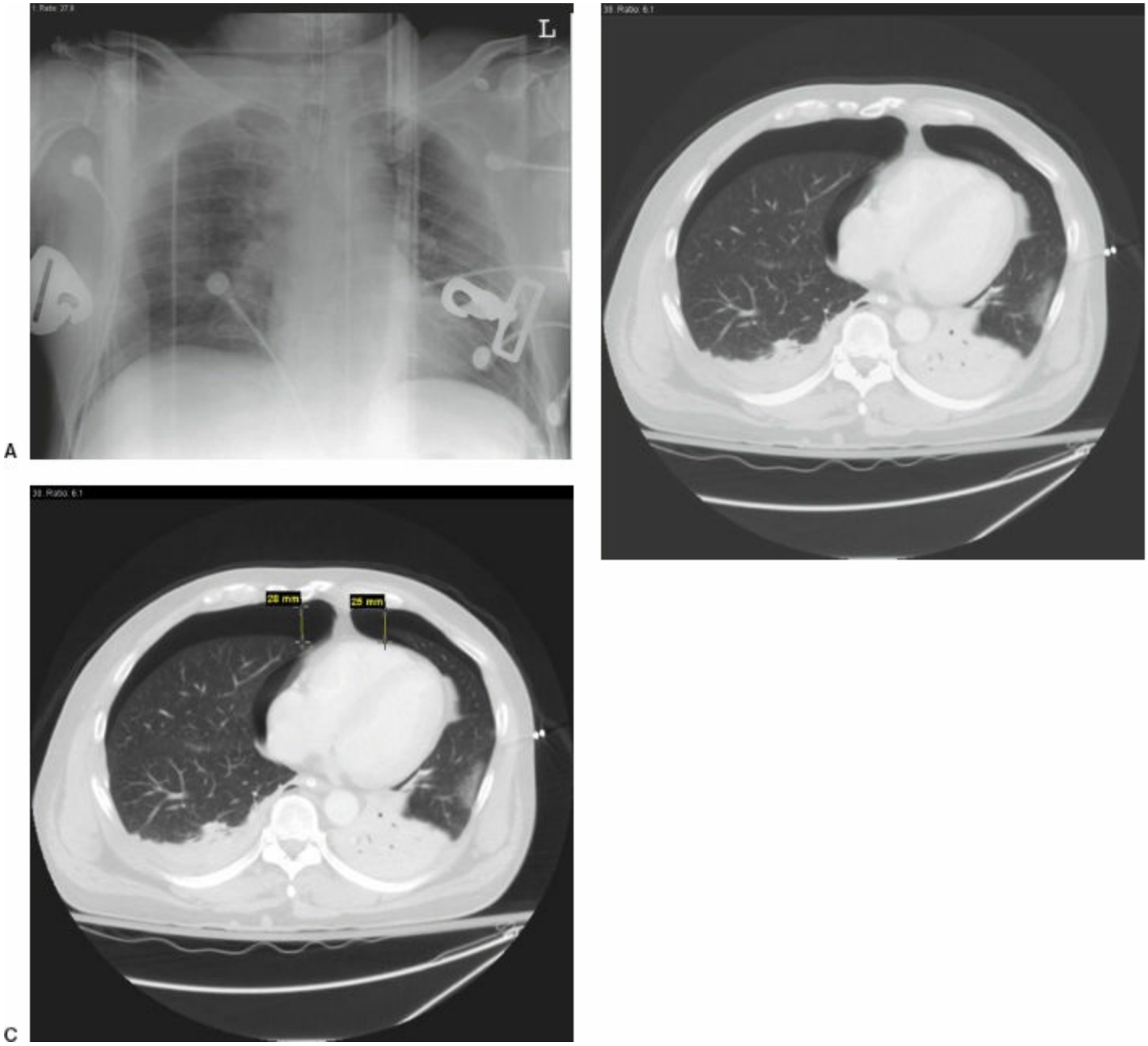

Figure 24-5. **A:** AP CXR in trauma bay with no evidence of pneumothorax. **B:** Occult pneumothorax seen on CT scan **C:** Measurement of largest air pocket in a line drawn perpendicular to the chest wall.

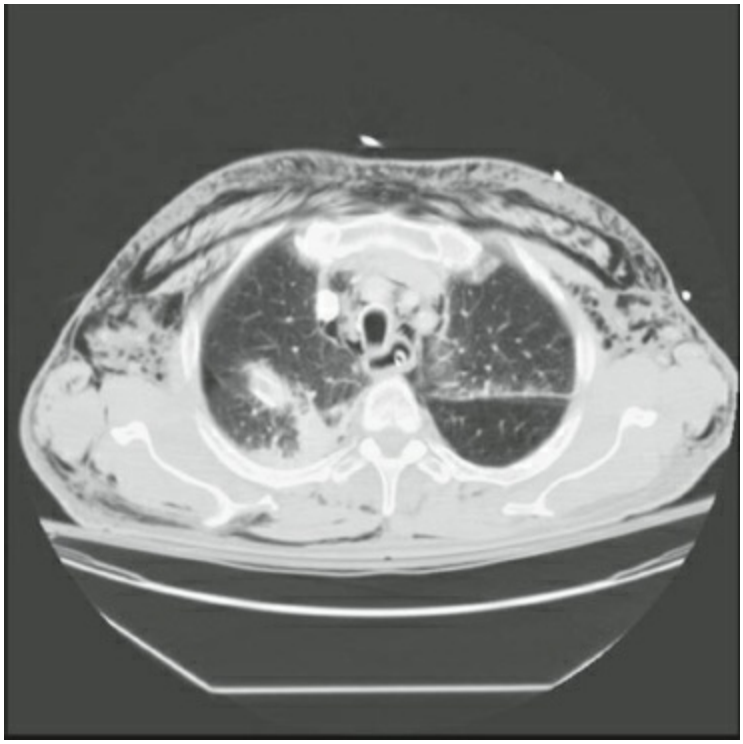

Figure 24-6. Subcutaneous emphysema.

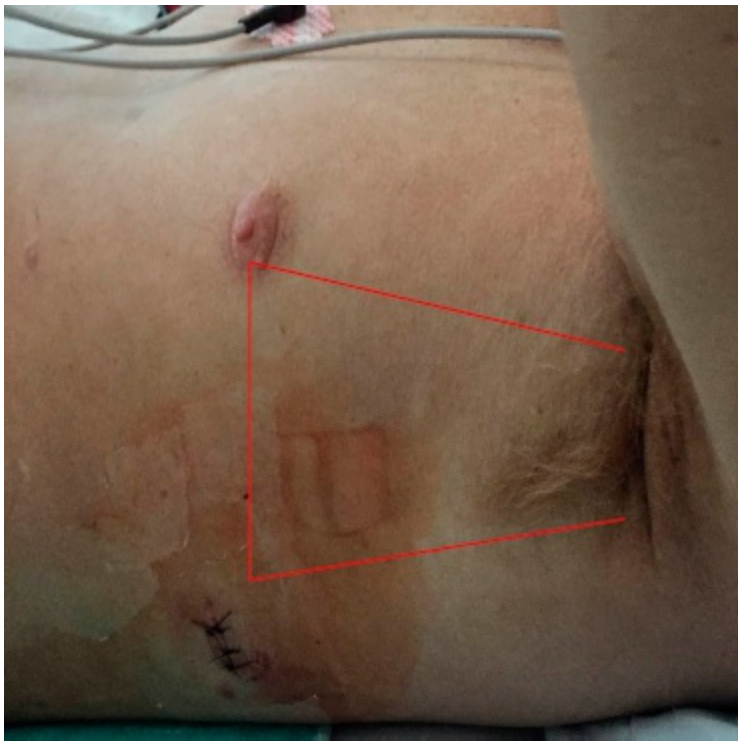

Figure 24-7. Zone of safety.

Pulmonary Contusion

In the presence of flail chest or multiple rib fractures one may observe a significant decrease in the PaO_2/FiO_2 ratio. Rather than a function of the mechanics of the chest wall this is most consistently a result of underlying lung contusion. Lung contusion is the extravasation of blood into the interstitial space of the lung parenchyma. Bleeding may extend to the alveolar space as well in severe cases.

Treatment

The treatment for lung contusion complicated by hypoxia is primarily supportive, with administration of positive end-expiratory pressure (PEEP). PEEP may be applied either noninvasively (face mask) or through an endotracheal tube. In a small study, it was found that 100% of patients who had five or more ribs fractures, two-thirds or more of lung affected by contusion, and a decrease in mental status (GCS $\leq$14) required intubation.[19] Intubations did not necessarily occur on the first day but often on the second day. Therefore, it is important to identify patients at risk for intubation and place them in a higher level of care. Other key aspects of care include minimizing intravenous crystalloid fluids, early mobilization, and encouraging cough/deep breathing.

Hemothorax

Initial imaging is the screening CXR. This x-ray is often a supine AP film that may make the diagnosis of a hemothorax challenging. In the supine film the blood layers in the posterior recess of the hemithorax and the x-ray may appear hazy when compared to the contralateral side. In the face of a large hemothorax the x-ray can appear as a white out. Ultrasonography during the extended FAST examination has a high sensitivity for detecting a hemothorax.

The causes of hemothorax are varied, the most common being rib fractures/intercostal muscle to intercostal artery laceration, pulmonary laceration, or cardiac injury with communication to the pleura via injury to the pericardium. The urgency of the treatment is dictated by the physiologic state of the patient with rapid control of hemorrhage is the first priority.

4 Hemothoraces associated with hemodynamic instability or those that drain $>1{,}500$ cc immediately or >200 cc/hour for >4 hours after placement of a chest tube should be taken directly to the operating room for exploratory thoracotomy. The size of chest tubes has decreased over time and contemporary data suggests that there is no difference in the ability of the 28-Fr versus the 36-Fr chest tube to effectively drain a hemothorax. Some have advocated a 14-Fr pigtail catheter for drainage of a hemothorax. In terms of chest tube position, there is little convincing evidence to suggest that the position of the chest tube, anterior or posterior, makes a difference in the ability of the tube to drain a hemothorax.[20] This is likely a result of the pleura being a closed system and therefore, suction applied to one area will apply equal amounts of pressure to other areas of the pleural space. The liquid component of the hemothorax will be drained from any position. Clotted blood will not be effectively drained even if the tube is in the middle of the clot. In general, patients with a moderate to large volume hemothorax should be drained, approximately 300 cc when estimated using the following formula: Estimated volume (cc) $= d^2 \times l$, where d equals the greatest dimension in centimeters from the chest wall to the lung or mediastinum across the largest fluid pocket, and l is the craniocaudal height (number of axial slices on the CT scan $\times$ the thickness of those slices in centimeter.[21]

Retained Hemothorax

Retained hemothoraces may occur in 30% of the patients.[22] A retained hemothorax is defined as hemothorax that persists despite an attempt at drainage. If the hemothorax is not adequately drained in a 24-hour period it may be necessary to differentiate the hemothorax from atelectasis. A CT scan will help the surgeon differentiate between the two and allow one to calculate the amount retained.

If the amount is moderate to large there are two options; (1) early video-assisted thoracostomy to evacuate the clot or (2) tissue plasminogen activator (TPA) with or without DNAase. The key point is that early intervention allows the clot to be evacuated and prevent a fibrothorax from forming. Ideally, surgical drainage should be performed within 7 days to optimize the ability to successfully perform thoracoscopy.

Aortic Injury

Those patients with evidence of mediastinal hematoma on CXR, as described above, or those with a high-risk mechanism, that is, same-side motor vehicle collision (t-bone collision) should have a CT scan of the chest with intravenous contrast. CT scan has become the standard of care for diagnosis and classification of aortic injuries. Aortic injuries most commonly occur at points of fixation. These locations in decreasing order of occurrence include; (1) ligamentum arteriosa (just distal to the left subclavian artery), (2) diaphragmatic hiatus, and (3) root of the aorta (these usually die at the scene). The current classification of aortic injuries divides the extent of injury into four grades; (1) small intimal tear, (2) intramural hematoma (3) pseudoaneurysm (Fig. 24-8A,B), (4) periaortic rupture. The treatment of these injuries has evolved.

5 Small injuries are placed on aspirin for 6 months. Types 2, 3, and 4 are treated with placement of covered stent grafts via an endovascular approach. When compared to open clamp and sew repairs the incidence of paraplegia is much lower in the endovascular treatment group, which has resulted in its adoption as the contemporary standard of care (Fig. 24-9).[23] These injuries do not need to be repaired immediately as long as there is control of heart rate and blood pressure. The goal HR is <80 and goal systolic blood pressure is <110 mm Hg. This control is achieved with the administration of short acting beta-blocker (i.e., esmolol) followed by nitroprusside. The beta-blocker must precede the nitroprusside because of the possible tachycardic side effects of nitroprusside. Patients should have an immediate arterial line placed, esmolol begun and titrated carefully to achieve the target hemodynamic parameters. This allows time for other associated injuries to be managed, that is, head injury, intra-abdominal bleeding, severe pelvic fracture. Then in the following 24 to 48 hours as the initial resuscitation and urgent treatments are achieved, repair of the aorta may follow. For those with high-grade aortic injuries, repair should take a higher level of priority but remains balanced with other conflicting priorities.

Diaphragmatic Injuries

Injuries may be the result of either penetrating or blunt trauma. The average size of a diaphragmatic injury for penetrating trauma is approximately 2 cm and the average size of the injury for blunt trauma is 8 cm. In a 2015 review, there were 3,873 diaphragmatic injuries among the sample size of 833,309 giving an incidence of 0.46%.[24] Initial imaging begins with CXR and is often followed by CT scan. The sensitivity for diaphragmatic injuries on CT scan is approximately 70% (range is from 50% to 90%). For penetrating trauma CXR and CT scan have very poor sensitivities and one must maintain a high index of suspicion depending upon the trajectory of the knife or bullet. If there is a penetrating trauma to the thoracoabdominal region (nipple line to costal margin) particularly on the left side one should perform a diagnostic laparoscopy after a 24-hour window. This 24-hour window allows the surgeon to effectively exclude an associated hollow viscus injury since these patients would manifest as peritonitis prior to 24 hours.

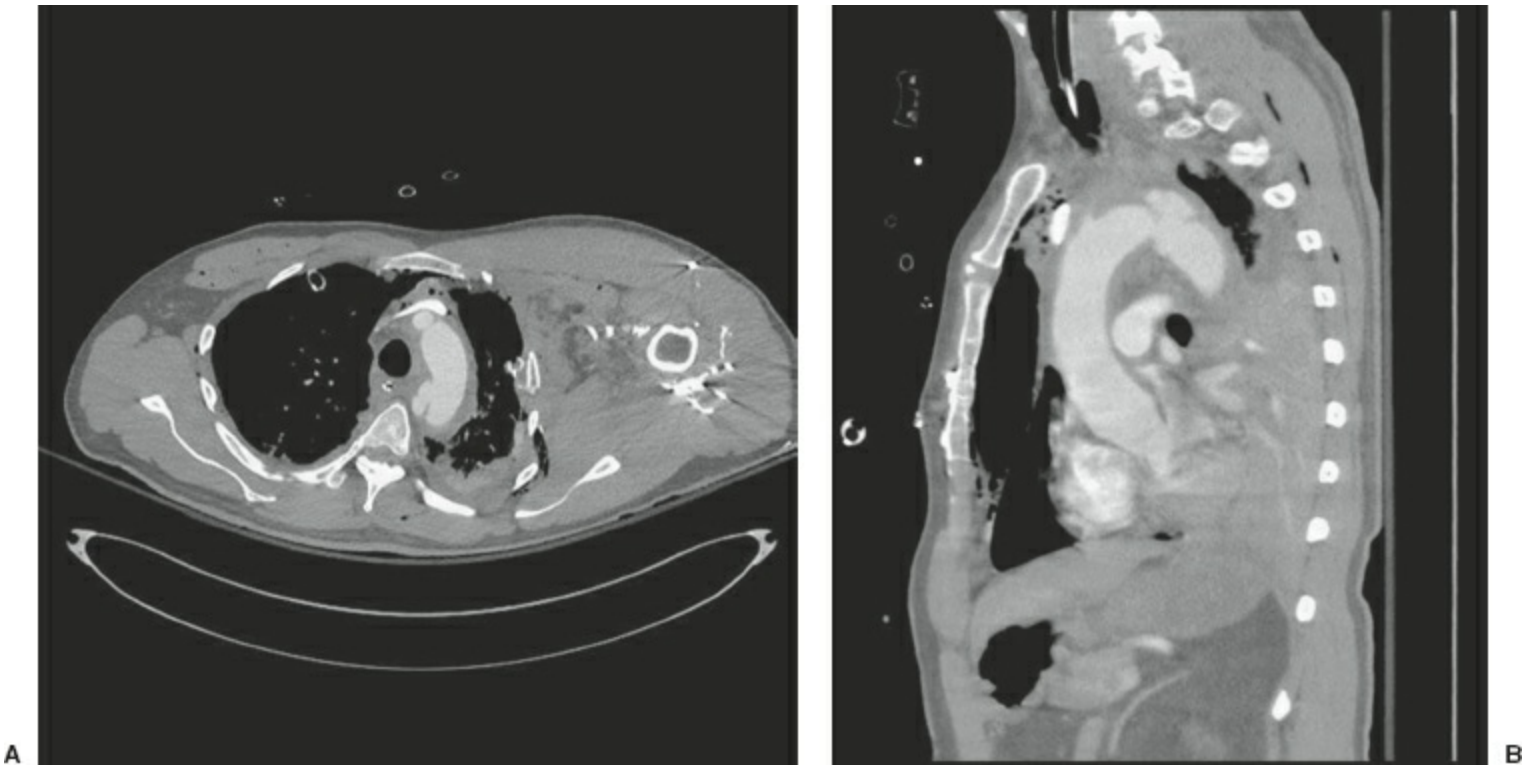

Figure 24-8. **A:** Axial view of type III blunt aortic injury with pseudoaneurysm. **B:** Sagital view of type III blunt aortic injury with pseudoaneurysm.

Treatment

Once the diagnosis is made the patient should be taken to the operating room for repair. In the case of the penetrating trauma patient who is undergoing a diagnostic laparoscopy the repair can proceed laparoscopically via the abdomen. For those with an acute rupture following blunt trauma the repair is usually undertaken via the abdomen in order to inspect abdominal organs for injury. For chronic hernia defects, one may consider repairing from the chest via a thoracotomy or via video-assisted thoracoscopy.

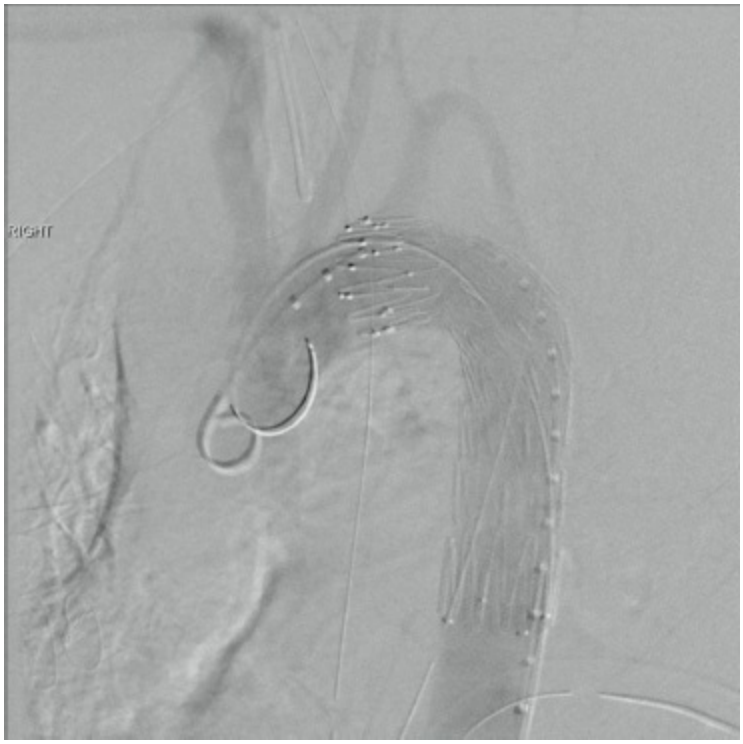

Figure 24-9. Aortic stent graft for blunt rupture.

The repair is with a nonabsorbable suture in either an interrupted or running fashion. The classic repair is with an interrupted horizontal mattress but can be a figure of eight or running suture. The repair must be air tight and a chest tube is usually placed at the time of the repair. It is important to lavage the chest and ensure complete evacuation of any hemothorax via the hole in the diaphragm. In patients where primary repair of the diaphragm is not possible due to tissue loss a mesh (synthetic or biologic) may be used or the diaphragm can be sown to a lower rib, in essence transposing it to a slightly lower position to achieve closure of the hemithorax.

Cardiac

Lacerations can occur with either penetrating or blunt mechanisms. The most common chamber affected with penetrating injury is the right ventricle since it has the largest anterior surface area. The right atrium is the most common chamber that ruptures from blunt mechanisms because of its thin wall. The diagnosis of hemopericardium is usually made via the bedside FAST examination. The FAST examination is 95% sensitive and specific for hemopericardium, and is an important adjunct in the trauma bay. Hemopericardium is diagnosed by ultrasound but tamponade is diagnosed by the combination of hemopericardium and hypotension. The presence of distended neck veins, hypotension, and hemopericardium defines cardiac tamponade and should be treated emergently.

Treatment

If a patient is deteriorating (with loss of consciousness) or has lost vital signs then an ED thoracotomy is indicated. This provides quick access to the pericardium and allows the surgeon to decompress the tamponade, gain control of the hole and potentially repair the injury in the trauma bay. If the patient is awake or vital signs are not quickly deteriorating then an emergent transport to the operating room is preferred. There is very limited role for pericardiocentesis in the acute trauma scenario, given the difficulties in evacuating clot from the pericardium. A pericardial window is a diagnostic test and is restricted to those patients who have a possible confounding issue and are stable, that is, HIV-positive patients with chronic pericardial effusions. Otherwise, a positive pericardial FAST mandates surgical exploration via a sternotomy or thoracotomy.

It is important to understand that in cardiac tamponade when the patient is placed under general anesthesia and placed on positive pressure ventilation the subsequent drop in preload may cause the patient to lose vital signs. Therefore, the surgical team must be ready to quickly perform a median sternotomy. The patient should be prepped and draped from the chin to the thighs, in case there is the need to enter the neck or the abdomen. Once the patient is prepped and draped then anesthesia is induced and the operation commences. This allows the team to be ready with the sternal saw and equipment prior to induction just in case the patient loses vital signs.

Once in the chest via the preferred incision, median sternotomy, the pericardium is opened and the injury identified. The injury can usually be controlled with a finger or two. Other adjuncts are then employed to close the wound, that is, skin stapler, Foley catheter (careful not to rip the thin right ventricle with the balloon), or two stay sutures on either side of the injury that are crossed to close the wound. Once temporary control is obtained one may then place additional sutures which are usually 3-0 silk or prolene. It is helpful to ask for a suture with a large needle. The hole is then closed with or without pledgets in an interrupted fashion. One must take note of the relationship of the injury to the coronary vessels. If the injury is juxtaposed to a coronary vessel, one should perform a horizontal mattress and pass the needle deep to the coronary artery. If the coronary vessel is injured by the trauma it must be bypassed or repaired if it involves the proximal

two-thirds. If the distal third of a coronary is involved it is possible to simply ligate the artery.

Postoperative echocardiography should be performed to evaluate the function of the valves to ensure there is no significant injury to valvular function.

Blunt Cardiac Contusion

There is a spectrum of blunt cardiac contusion, better named blunt cardiac injury. Injuries may cause mild dysrhythmias or lead to wall rupture (Fig. 24-10) and death. Any patient that undergoes a rapid deceleration is at risk of having a traumatic blunt cardiac contusion. These patients are screened with a 12-lead ECG and if completely normal one can rest assured that there is no significant contusion. If the patient has any dysrhythmias including sinus tachycardia serial troponin levels will provide the additional sensitivity to diagnose contusion.

Treatment

These patients are placed on telemetry and observed. If ST segment changes occur a cardiac catheterization is necessary to rule out coronary dissection. If the patient is unstable but with normal ST segments an echo should be performed to identify structural injuries, that is, valve damage or septal defects.

Open Pneumothorax

In circumstances where there is a loss of a portion of the chest wall the normal negative pressure pleural space is lost. The chest wall defect is usually secondary to a high-velocity bullet or close range shot-gun blast. Due to the intrinsic nature of the lung parenchyma to collapse, there must be negative pressure in the chest wall to allow for reexpansion. In an open pneumothorax (sucking chest wound) the lung collapses and the patient has difficulty with ventilation.

Treatment

As a temporary measure, perhaps during transport, a partially occluding dressing can be applied. This dressing is sealed in a way that allows air to escape from a corner of the dressing while preventing atmospheric air from entering the pleural space. However, if encountered in the trauma bay or the operating room the trauma surgeon should close the defect and place a chest tube in a separate space. The chest tube will create the negative pressure required to reexpand the lung with the defect closed. If the defect is large a rotational flap may be necessary to close the defect or the chest wall may require reconstruction with mesh.

Tracheobronchial Injury

Injury can occur from either blunt or penetrating mechanisms and usually presents with a large pneumothorax and air leak. More proximal intrathoracic injuries can be easily visualized via bronchoscopy. At times the patients may be difficult to ventilate due to large air leaks. In rare cases there may be the need for selective lung ventilation with a bronchoscopically placed bronchial blocker or may even require extracorporeal membrane oxygenation (ECMO).

Treatment

The majority of intrathoracic injuries are to the right mainstem bronchus and therefore a right posteriolateral thoracotomy is the best approach. The location of the injury on bronchoscopy will provide direction for surgical exposure. Once exposed the bronchus or trachea can be primarily repaired using a 3-0 absorbable suture. Chest tubes are placed and extubation is guided by the underlying lung contusion and hypoxia. Ideally, these patients should be taken off positive pressure ventilation as soon as possible, even immediately postoperatively.

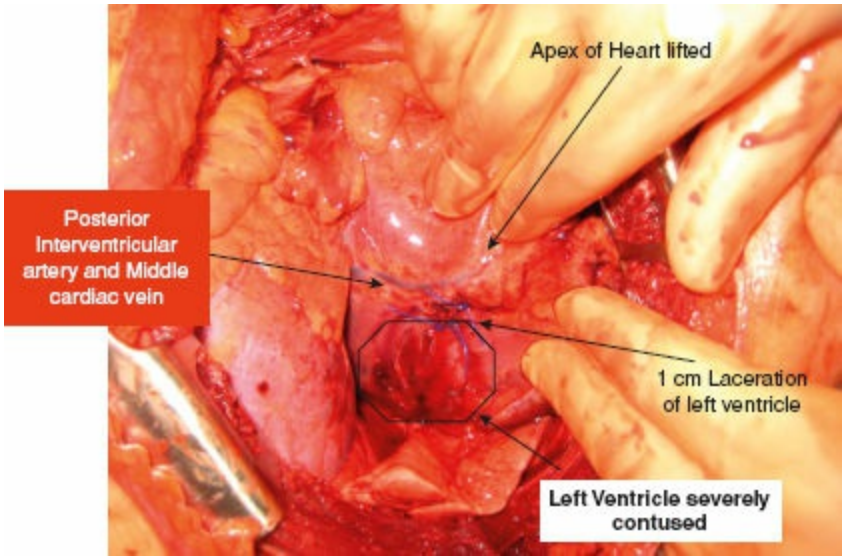

Figure 24-10. Blunt cardiac rupture/contusion.

Thoracic Esophageal Injury

Esophageal injuries are secondary to penetrating trauma. A blunt rupture of the esophagus is exceedingly rare. The signs and symptoms of an acute injury are nonspecific and include hematemesis and chest pain. If the trajectory of the knife or gun-shot wound is such that it crosses the midline, the mediastinum must be evaluated. If the patient is unstable from a thoracic gun-shot wound a rapid trip to the operating room is warranted for exploration and hemorrhage control. If the patient is stable one may perform imaging studies to evaluate the esophagus.

The initial imaging study is a CT scan of the chest with IV contrast to better delineate the track of the missile (Fig. 24-11A). Secondary signs of an esophageal injury may be present including pneumomediastinum, pleural effusion, or mediastinal hematoma. If the missile track is in close proximity to the esophagus (<2 cm) then additional imaging with a water-soluble followed by a barium-contrast study is warranted. The water-soluble contrast is used first in case there is a large leak (Fig. 24-11B). If no obvious leak is identified then the water-soluble contrast should be followed up with a barium study to increase the sensitivity for a small leak. If the barium esophageal imaging is negative one can be assured there is no full-thickness injury to the esophagus. If an injury is identified as an esophageal leak urgent exploration is necessary to minimize contamination of the chest. There is a direct correlation between time to repair and morbidity/mortality, therefore any delay must be minimized.

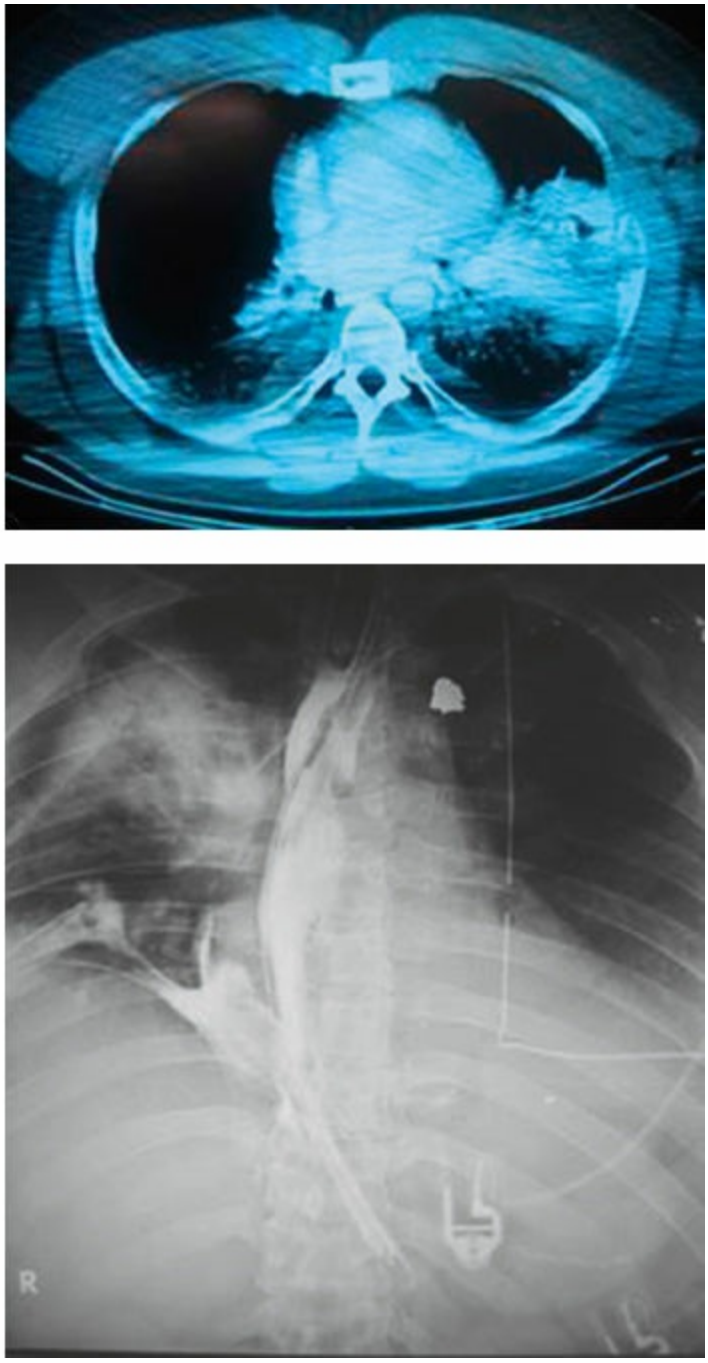

Figure 24-11. **A:** Tract of bullet coursing to posterior mediastinum. **B:** Contrast leaking from an injury to the esophagus.

If the distal one-thirds of the thoracic esophagus is injured a left thoracotomy is the approach of choice. If the proximal two-thirds is involved then a right thoracotomy is performed, which allows one to dissect the esophagus up to the thoracic outlet since the aortic arch is not obscuring the view. Once the esophageal injury is identified, it should be debrided and repaired in a full-thickness single layer. The repair should be buttressed with either a pedicled intercostal muscle flap or a pleural patch. Some have used a tongue of omentum for distal esophageal repairs. Of note, single lung ventilation is necessary to adequately visualize the injury and ensure a safe repair.

EMERGENCY DEPARTMENT THORACOTOMY VERSUS OPERATIVE THORACOTOMY, TIPS/TRICKS

ED thoracotomy is a procedure done to gain primary vascular control of an injured vessel, it also allows one to open the pericardium, perform internal massage, relieve cardiac tamponade, repair cardiac injury, gain control of the pulmonary hilum, and clamp the aorta if necessary. The ED thoracotomy is a left anterolateral thoracotomy (Fig. 24-12). The survival from ED thoracotomy is as high as 60% in victims of penetrating trauma that arrive in the trauma bay with a palpable pulse. The survival decreases to about 4% if the patient arrives without a pulse, assuming a less than 15-minute cardiac arrest time. In blunt trauma the odds of regaining a blood pressure in those who lose vital signs in the trauma bay is about 4% but drops to 0.2% if lost in the field. For these reasons the generally accepted indications for an ED thoracotomy in penetrating trauma is if the patient loses vital signs in the trauma bay or within 15 minutes of arrival. For blunt trauma, the only accepted indication is patients who lose vital signs in the trauma bay. ED thoracotomy is a futile maneuver (and should be avoided) in patients who suffer cardiopulmonary arrest, although some advocate ED thoracotomy if the patient loses signs within 10 minutes of arrival.

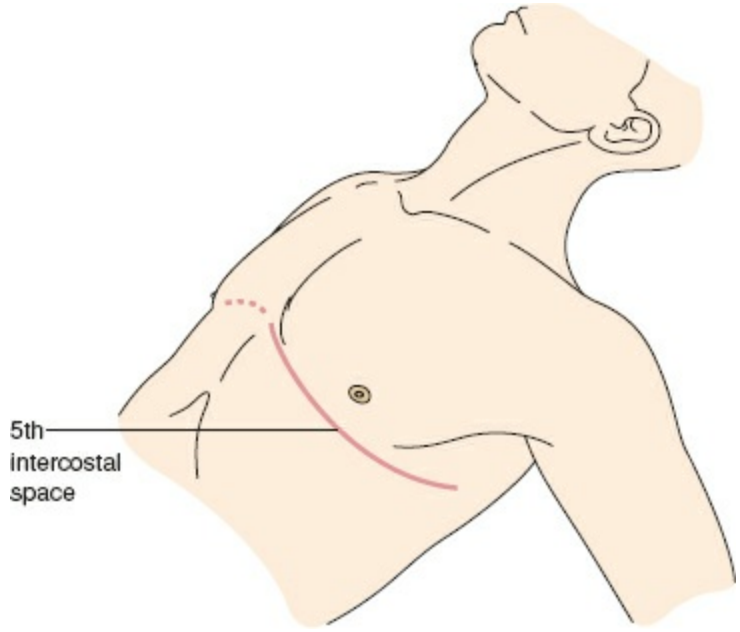

Figure 24-12. Left anterolateral thoracotomy incision.

The indications for a formal operative thoracotomy are if the initial chest tube drains >1,500 cc of blood or >200 cc/hr × 4 hours. The other indication is if there is ongoing hemodynamic instability with continued chest tube drainage.

Control of an intercostal artery can be difficult if low in the chest and posterior. At times it may be necessary to encircle the rib proximal and distal to the bleeding vessel to compress the vessel indirectly. This suture can be absorbable or even brought out through the full thickness of the chest wall and cut in 48 hours. At times one may be dealing with a deep hole from a gun-shot wound into the musculature of the posterior chest wall.

Under these circumstances aggressive and tight packing may suffice or a Foley catheter may be placed in the tract and inflated to tamponade the bleeding. The Foley may even exit the chest wall via a separate stab incision and be deflated 24 to 48 hours later and removed while the patient is observed for recurrent bleeding.

The other common injury that may be found on exploration is a laceration of the lung. It is important to understand that bleeding from the track of a penetrating trauma must not be closed superficially. Closing the entrance or exit holes may simply cause more bleeding into the bronchi or allow air to embolize from the bronchi to the pulmonary venous system. Patients will die from cardiac arrest from air emboli that enter the coronary vessels. Instead the pulmonary tract should be opened (tractotomy) with either clamps or GIA stapling devices. This opens the tract where the raw surface area can be oversewn or stapled while saving lung tissue. Peripheral lesions can simply have wedge resections performed.

CONCLUSION

Thoracic injuries are a common entity with rib fractures being the most common injury. A careful and systematic approach to the trauma patient is key to uncovering significant thoracic injuries. Life-threatening injuries, that is, massive hemorrhage, tension pneumothorax, or cardiac tamponade must be identified within the trauma bay and treated without delay.

References

1. LoCiecero J III, Mattox KL. Epidemiology of chest trauma. *Surg Clin North Am* 1989;69(1):15–19.
2. Bulger EM, Arneson MA, Mock CN, et al. Rib fractures in the elderly. *J Trauma* 2000;48(6):1040–1046.
3. Wong YC, Ng CJ, Wang LJ, et al. Left mediastinal width and mediastinal width ratio are better radiographic criteria than general mediastinal width for predicting blunt aortic injury. *J Trauma* 2004;57(1):88–94.
4. American College of Surgeons. *ATLS Manual.* 9th ed. Chicago, IL: American College of Surgeons; 2012.
5. Maenza RL, Seaberg D, D'Amico F. A meta-analysis of blunt cardiac trauma; ending mycardial confusion. *Am J Emerg Med* 1996;14:237–241.
6. Rozycki G, Ballard R, Feliciano D, et al. Surgeon performed ultrasound for assessment of truncal injuries. *Ann Surg* 1998;228:16–28.
7. Kirkpatrick AW, Sirois M, Laupland KB, et al. Hand-held thoracic sonography for detecting post-traumatic pneumothoraces: the Extended Focused Assessment with Sonography for Trauma (EFAST). *J Trauma* 2004;57(2):288–295.
8. Bulger EM, Edwards T, Klotz P, et al. Epidural analgesia improves outcome after multiple rib fractures. *Surgery* 2004;136:426–430.
9. Moon MR, Luchette FA, Gibson SW, et al. Prospective, randomized comparison of epidural versus parenteral opioid analgesia in thoracic trauma. *Ann Surgery* 1999;229:684–691.
10. Tanaka H, Yukioka T, Yamaguti Y, et al. Surgical stabilization of internal pneumatic stabilization? A prospective randomized study of management of severe flail chest patients. *J Trauma* 2002;52:727–732.
11. Granetzny A, Abd El-Aal M, Emam E, et al. Surgical versus conservative treatment of flail chest: evaluation of the pulmonary status. *Interact Cardiovasc Thorac Surg* 2005;4:583–587.
12. Ahmed Z, Mohyuddin Z. Management of flail chest injury: internal fixation versus endotracheal intubation and ventilation. *J Thorac Cardiovasc Surg* 1995;110:1676–1680.
13. Nirula R, Allen B, Layman R, et al. Rib fracture stabilization in patients sustaining blunt chest injury. *Am Surg* 2006;72:307–309.
14. Alrajab S, Youssef AM, Akkus NI, et al. Pleural ultrasonography versus chest radiography for the diagnosis of pneumothorax: review of the literature and meta-analysis. *Crit Care* 2013;17(5):R208.
15. Inaba K, Branco BC, Eckstein M, et al. Optimal positioning for emergent needle thoracostomy: a cadaver-based study. *J Trauma* 2011;71(5):1099–1103.
16. Inaba K, Lustenberger T, Recinos G, et al. Does size matter? A prospective analysis of 28–32 versus 36–40 French chest tube size in trauma. *J Trauma Acute Care Surg*

2012;72(2):422–427.
17. Kulvatunyou N, Erickson L, Vijayasekaran A, et al. Randomized clinical trial of pigtail catheter versus chest tube in injured patients with uncomplicated traumatic pneumothorax. *Br J Surg* 2014;101:17–22.
18. Cropano C, Mesar T, Turay D, et al. Pneumothoraces on CT scan: Observation using the 35 millimeter rule is safe. *Panamer J Trauma Acute Care Surg* 2015; in press.
19. de Moya MA, Manolakaki D, Chang Y, et al. Blunt pulmonary contusion: admission computed tomography scan predicts mechanical ventilation. *J Trauma* 2011;71(6):1543–1547.
20. Benns MV, Egger ME, Harbrecht BG, et al. Does chest tube location matter? An analysis of chest tube position and the need for secondary interventions. *J Trauma Acute Care Surg* 2015;78(2):386–390.
21. Mergo PJ, Helmberger T, Didovic J, et al. New formula for quantification of pleural effusions from computed tomography. *J Thorac Imaging* 1999;14:122–125.
22. Dubose J, Inaba K, Demetriades D, et al. Management of post-traumatic retained hemothorax: a prospective, observational, multicenter AAST study. *J Trauma Acute Care Surg* 2012;72(1):11–22.
23. Moainie SL, Neschis DG, Gammie JS, et al. Endovascular stenting for traumatic aortic injury:an emerging new standard of care. *Ann Thorac Surg* 2008;85(5):1625–1629.
24. Fair KA, Gordon NT, Barbosa RR, et al. Traumatic diaphragmatic injury in the American Colleges of Surgeons National Trauma Data Bank; a new examination of a rare diagnosis. *Am J Surg* 2015;209(5):864–868.

Chapter 25

Abdominal Trauma

Kenji Inaba, Elizabeth R. Benjamin, and Demetrios Demetriades

Key Points

1 Clinical examination is the cornerstone of the diagnostic workup after blunt abdominal trauma and any patient with peritonitis or instability with a positive FAST requires immediate laparotomy. CT is a high-yield diagnostic modality for the intra-abdominal contents with high degree of sensitivity and specificity for clinically significant injuries.

2 For stable, evaluable patients without peritonitis or evisceration after penetrating abdominal trauma, selective non-operative management is an acceptable treatment option. For those undergoing non-operative management of a gunshot wound, CT scanning is essential. For both stab wounds and gunshot wounds, close clinical observation is utilized to detect those patients with an occult injury that will ultimately require laparotomy and repair.

3 Rapid access to an operating room with immediate access to the instrumentation, consumables and support services such as the blood bank and radiology are required for the successful treatment of patients with abdominal trauma.

4 Standard positioning is supine, however, for injuries in stable patients where the rectum or perineum is at risk, lithotomy may be utilized. The initial incision is usually a midline laparotomy. Extension into the subcostal regions and across the inguinal ligament or into the thoracic cavity may be required to facilitate exposure.

5 Damage control laparotomy, which consists of rapid bleeding and contamination control, followed by temporary closure and resuscitation with delayed definitive repair of injuries should be considered for any patient who is physiologically depleted, has a burden of injury which will result in compromise if definitive repair is attempted, or has an injury profile beyond the scope of the surgeon or facility skillset.

6 Abdominal compartment syndrome is after trauma laparotomy and all patients should be monitored closely with bladder pressures in the recovery area. Any elevation in the intra-abdominal pressures warrants consideration of decompressive laparotomy.

7 Angioembolization is an important adjunct for patients who are undergoing damage control surgery and may be of particular benefit for patients with ongoing bleeding from complex hepatic trauma.

INTRODUCTION

For patients who have sustained a stab wound (SW), gunshot wound (GSW), or blunt multisystem injury, the abdomen remains a high-risk cavity with the potential to hide occult but life-threatening injuries. Unlike the extremity or neck for example, where bleeding occurs externally, for the abdomen, significant bleeding and enteric spillage can occur with minimal symptoms until late. In patients presenting after both blunt and penetrating traumas, injury to the abdominal contents is common. In the National Trauma Data Bank, the largest repository of trauma registry data that exists in the United States, from 2008 to 2012, of the approximately 3,146,401 patients entered, 10.6% had an abdominal injury.

Broken down by regional abbreviated injury scale (AIS), 34.0% of these had an AIS 1, 31.4% an AIS 2, 21.8% an AIS 3, 9.9% an AIS 4, and 2.9% an AIS 5 injury. This injury severity breakdown for all patients was consistent with the data seen for blunt trauma. In comparison, when penetrating injuries were examined, whereas only 9.6% of blunt trauma patients had an abdominal injury with 33.5% having an AIS ≥ 3, a full 25.2% of penetrating patients had an abdominal injury with 39.7% of these having an AIS ≥ 3.

Abdominal injuries are therefore common and a systematic approach to the rapid diagnosis and treatment of these injuries is essential. This chapter will provide a pragmatic approach to the patient with abdominal trauma, focusing on the acute resuscitation, diagnosis, and treatment of clinically relevant injuries to the abdominal structures.

BLUNT INITIAL EVALUATION AND DIAGNOSTICS

Resuscitation

For the patient that sustains abdominal trauma, unlike the extremity, where a tourniquet can be placed, there are currently no validated prehospital methods for direct or indirect hemorrhage control. With the increasing interest in resuscitative endovascular balloon occlusion of the aorta,[1] in the appropriate clinical setting with trained personnel, this procedure could theoretically be performed in the prehospital setting. Experimental work looking at the use of abdominal insufflation with air or foam also shows some promise but is not yet ready for clinical implementation at this time. Rapid transport to definitive care therefore remains the primary goal. The general principles of resuscitation that apply to all trauma patients as outlined elsewhere in this textbook should be followed. Specific to patients with abdominal trauma, whenever possible, venous access should be gained in the upper limbs or torso. Resuscitation through a femoral central venous catheter is suboptimal as the return of blood products into the systemic circulation is compromised if the patient has an injury to the iliac system or vena cava. In the resuscitation area, once the diagnosis of an intra-abdominal injury requiring operative repair has been made, travel to the OR should take precedence over continued resuscitative efforts which can be continued concurrent to definitive hemorrhage control.

Diagnostics

1 The diagnostic workup of a blunt multisystem injury patient is often more difficult than for a penetrating injury patient. The following discussion focuses on the isolated abdominal trauma patient however, practically, for most patients the remainder of the torso must also be considered. In general, the most practical approach to the patient in the resuscitation area depends on hemodynamic status. Patients can be categorized into those that are arresting, unstable, or stable.

For any arresting patient, if the decision to intervene is made, airway control, venous access with blood product infusion, and resuscitative thoracotomy with concurrent right chest tube insertion are the immediate priorities. The outcomes for resuscitative thoracotomy performed for traumatic arrest due to blunt trauma are poor,[2] especially if the source of hemorrhage is in the abdomen, and at many centers, would not even be considered. Survival to discharge and organ donation are possible however, and at our center, thoracotomy is performed liberally. If a resuscitative thoracotomy is performed, and the primary source of hemorrhage is in the abdomen, aortic cross-clamping is designed to mitigate intra-abdominalblood loss. If the procedure is successful and a perfusing rhythm is regained, there is no role for any imaging or further workup. The patient should be taken immediately to the OR for laparotomy and definitive injury management.

For the unstable patient, aggressive resuscitation with blood products should be initiated immediately, and the patient will either stabilize, in which case a complete workup can be performed as described below, or they will arrest, as discussed above or they will remain unstable. If they remain unstable despite resuscitative efforts, bilateral diagnostic chest tubes should be inserted if a chest x-ray (CXR) is not immediately available. Concurrent with the ongoing resuscitation, a focused assessment with sonography in trauma (FAST) should be performed. If free abdominal fluid is visualized, the patient should immediately be taken to the OR and a laparotomy should be performed. If the FAST is negative, a confirmatory diagnostic peritoneal aspirate (DPA) looking for gross blood should be performed. If this is positive, the patient undergoes laparotomy. If negative, alternative sources for the hemorrhage are sought. It is possible that the source of hemorrhage is a contained retroperitoneal vascular injury which would be missed by both DPA and FAST however, for blunt trauma, in the absence of a pelvic fracture, this would be extremely rare.

In the stable patient, a complete diagnostic workup can be completed. This begins with an external examination for any soft tissue evidence of injury. A seatbelt sign for example has been associated with an eightfold increase in the incidence of intra-abdominal injuries, impacting both the solid organs and hollow viscus.[3,4] While not sufficient to warrant mandatory laparotomy, a very low threshold for imaging with CT should be maintained and the patient should undergo a mandatory period of observation. With this mechanism, the seatbelt can cause a “bucket-handle” type injury (Fig. 25-1) where the mesentery is sheared away from the more elastic bowel wall causing ischemia. Clinical evidence of the ischemic GI tract injury can take hours to manifest and close observation

is warranted.

If on initial examination, the patient already has peritonitis, in the setting of trauma, immediate laparotomy should be performed. This is a high-yield indication for operation. Although data were accrued in penetrating trauma, the urgency of peritonitis was made clear in a study examining 139 patients who were hemodynamically stable with peritonitis as the sole indication for operation. Of these, 97% had an intra-abdominal injury, with 11% having between 750 and 1,500 mL and 7% having >1,500 mL of blood on opening with 25% sustaining intraoperative hypotension and 39% requiring blood transfusions despite being hemodynamically normal at presentation.[5]

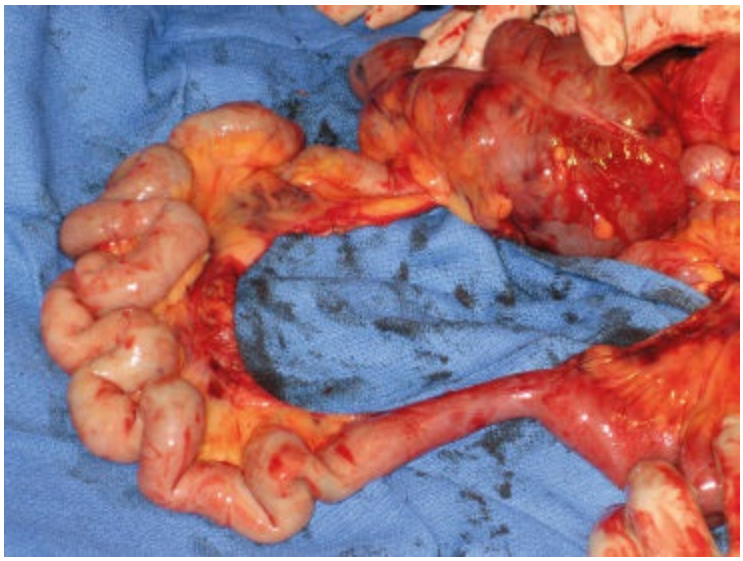

Figure 25-1. Bucket handle–type injury of small bowel.

For patients without peritonitis, the initial imaging modality is FAST. Because cardiac rupture causing an effusion is so rare in blunt trauma patients presenting alive to the hospital,[6] the abdominal windows are of primary importance after blunt trauma. The presence of free fluid is assumed to be blood. The presence of free fluid should trigger additional imaging with CT. For blunt trauma, there is no role for plain radiographs of the abdomen. In unstable patients, a pelvic x-ray can identify a potential source of ongoing blood loss and should be performed early in the resuscitation bay. For the stable patient, a pelvic x-ray is unnecessary especially if the patient is to undergo CT as it is unlikely to impact management. Although specific trauma protocols vary between institutions, CT scans should be performed with IV contrast. PO contrast is not required for the initial CT. A baseline creatinine level for all patients and a pregnancy test in females of child-bearing age should be obtained prior to the test. In general, a CT should be considered in the stable patient when there is external evidence of significant force transfer to the abdomen such as a seatbelt sign, or with free fluid on FAST or when there is significant abdominal tenderness on examination. Mechanism as a sole criterion for deciding which patients require CT scanning is unreliable, but a high-energy mechanism is often considered when making this decision. For the asymptomatic patient with a negative FAST who is fully examinable, cooperative, and can be observed, CT can be omitted. Based on the CT results, patients can be categorized into three groups, those

with no injury, those with an injury, and those with an equivocal finding. If the patient has a fully adequate CT demonstrating no abnormalities, the likelihood of a clinically significant injury is extremely low and the patient can be prepared for discharge once the remainder of the body areas is cleared. For patients with a CT that demonstrates injury, the nature of the injury will determine management. Any hollow viscus injury including the GI tract or bladder, will require operative repair. For solid organ injuries, the indications for operative management will depend on the extent of injury, the physiologic status of the patient including comorbidities, and their tolerance for blood loss and associated injuries. In general, the majority of solid organ injuries can be successfully managed non-operatively.[7,8] In centers where there is access to interventional radiology, endovascular solutions, such as stenting or embolization and percutaneous management of complications such as a biloma can also be used as an adjunct to non-operative management. This will be further elucidated in the following organ-specific sections. This then leaves the patient with equivocal findings of a hollow viscus injury on CT. Equivocal findings would include subtle findings such as mesenteric fat stranding, free fluid without solid organ injury, and bowel wall thickening. These patients should be observed clinically, ideally by a single provider and collateral evidence of injury such as the WBC count, heart rate, temperature, and abdominal examination are used to detect worsening, indicative of a hollow viscus injury requiring operative intervention. The exact period of time required for observation is unknown, however, it is expected that a patient who is improving at 24 hours has a low likelihood of a clinically significant missed injury.

PENETRATING INJURY – INITIAL EVALUATION AND DIAGNOSTICS

General Approach to Penetrating Abdominal Injury

Following the experience of World Wars I and II, with the high rates of destructive injuries, penetrating abdominal trauma was historically treated with universal surgical exploration. Starting in the 1960s, with SWs, followed by GSWs, this paradigm began to shift.[9–11] Patient selection for operative versus non-operative management based on the clinical picture and radiologic evidence began to evolve. With improved access, and quality of the images and the growing body of evidence regarding the potential morbidity of nontherapeutic operations, contemporary evidence now supports a non-operative approach to the management of penetrating abdominal trauma in select circumstances.[12]

2 The balance between prompt surgical management of traumatic injury and avoiding unnecessary operation remains a central diagnostic and management challenge in penetrating abdominal injury. Patients who present *in extremis,* with hemodynamic instability, peritonitis, or are unevaluable mandate immediate operation. For the remaining patients, the practice of universal exploration would result in a high rate of nontherapeutic laparotomy. Although mortality after negative trauma laparotomy is low, morbidity attributed to negative laparotomy is as high as 20%.[13,14] In addition, late complications including hernias and bowel obstructions are likely underreported given the challenges of long-term follow-up. Finally, not only is there a decrease in patient-centered outcomes, from a trauma resource utilization viewpoint, negative laparotomy is associated with an increase in unnecessary operative costs and hospital length of stay.[13,15–17] The introduction of selective non-operative management of penetrating abdominal trauma has been shown to result in a tangible cost savings.[18]

Although a subset of patients with penetrating abdominal trauma will ultimately require exploration, a significant number can be managed without operative intervention and thus be spared the potential morbidity and mortality of a negative laparotomy. In a retrospective analysis of abdominal SWs, mandatory exploration was associated with a negative laparotomy rate of 37%.[13] A Western Trauma Association Multicenter Study including 359 patients with anterior abdominal SWs found that 64% of patients did not require laparotomy.[19] The need for laparotomy is even lower after SWs to the back with only 15% of patients noted to have clinically significant injury.[20] GSWs to the abdomen are more likely to require operative exploration, but the presence of gunshot injury alone does not necessitate mandatory laparotomy. In an analysis of 1,856 patients with abdominal GSWs, had a policy of mandatory laparotomy been employed, 47% of patients would have undergone an unnecessary laparotomy.[18] Similar to SWs, posterior and transpelvic injuries are less likely than anterior injuries to require exploration.[18,21–22]

Indications and Contraindications to Selective Non-operative Management

In the modern era of selective non-operative management of abdominal trauma, several absolute indications for operative intervention remain. Hemodynamic instability in the setting of penetrating abdominal trauma requires laparotomy. In the hemodynamically stable patient, physical examination remains critical to patient triage, and peritonitis is an absolute indication for laparotomy. Although soft tissue injury can cause local tenderness, diffuse peritonitis after penetrating abdominal trauma is associated with a 97% chance of intra-abdominal injury at laparotomy.[5] Given the central role of physical examination in patient triage, unevaluable patients including those with concomitant head or spinal cord injury or those undergoing urgent nonabdominal operations are not candidates for selective non-operative management. Although not an absolute contraindication to selective non-operative management, patients with omental or visceral evisceration after penetrating abdominal trauma should be strongly considered for operative intervention. Significant intra-abdominal injury is present in 46% to 85% of patients with omental evisceration, and even higher rates with visceral evisceration.[17,19,23,24]

Peritoneal penetration alone after penetrating trauma is not an absolute indication for operative exploration. For this reason, invasive evaluation including diagnostic laparoscopy for the sole purpose of determining peritoneal violation is not indicated.

Diagnostics

Radiologic imaging is a key component of the diagnostic workup of patients who have sustained penetrating abdominal trauma, especially those undergoing a trial of non-operative management. In hemodynamically stable evaluable patients without peritonitis, a detailed evaluation of the external wounds and retained fragments using plain radiographs is imperative to plot missile trajectories. External wounds do not always correspond to internal injury and, especially in the setting of multiple missiles, trajectory may be misleading from external wounds alone. For example, an abdominal GSW may have a cranial trajectory resulting in a mediastinal injury. Alternatively, paired lateral abdominal wall bullet wounds may represent a superficial tangential trajectory or two separate transabdominal injuries with retained missiles. In both scenarios, management will change significantly based on the internal trajectory.

FAST examination is a central component of the early assessment after blunt trauma. The utility of this imaging modality in penetrating trauma, however, is less uniformly accepted. The primary use of the FAST examination in penetrating abdominal trauma is to evaluate for pericardial fluid as a marker of cardiac injury. Especially in the setting of an unknown missile trajectory, the cardiac FAST is a critical component of the initial trauma evaluation. A positive cardiac FAST after penetrating trauma mandates immediate median sternotomy. For the intra-abdominal fluid windows, while the FAST examination is highly specific for fluid, the sensitivity is poor ranging from 46% to 67%.[25–27] In the hemodynamically *unstable* patient with multiple cavitary sources of hypotension, a positive FAST can still be helpful as a rapid tool for operative incision planning. For *stable* patients however, it rarely impacts clinical decision-making as the patient either meets criteria for selective non-operative management and will be undergoing CT, or will be going to the OR, irrespective of the FAST findings.

CT has become universally accepted as an integral component in the evaluation of the penetrating trauma patient undergoing selective non-operative management. For patients undergoing exploration, CT is unnecessary and should not be routinely obtained. For patients with a GSW who are stable, evaluable, and without peritonitis and are undergoing a trial of non-operative management however, CT is a requisite next step.

GSWs follow a linear path and have an associated air bubble tract that allows for trajectory identification on CT scan. Understanding the missile trajectory provides critical information regarding potentially injured structures and those to which injury is unlikely. CT scan imaging after abdominal GSWs has been shown to be highly reliable for injury identification, with a sensitivity and specificity of 90.5% to 96% and 95% to 96%, respectively.[28,29] The injury tract on CT scan is often more subtle after SWs due to the lower velocity and smaller volume of air bubbles along the tract, and as a result, CT scan has been shown to be a less useful[30] adjunct in patient triage.[30,31]

Based on the CT scan findings, patients may be divided into four groups. (1) Patients with no peritoneal violation on CT scan. In this population, it is exceedingly rare that operative intervention will be required. (2) Patients with peritoneal violation but no obvious intra-abdominal injury on CT scan. This is the ideal patient population for

selective non-operative management with serial abdominal examinations and observation. (3) Patients with peritoneal violation and evidence of vascular or hollow viscus injury on CT scan. Although there are no strict criteria for diagnosing hollow viscus injury on CT scan, findings concerning for injury include bowel wall edema, missile trajectory traversing bowel, extraluminal fluid, air, or contrast. In this group, laparotomy is mandatory. (4) Patients with peritoneal violation and solid organ injury. In the absence of hollow viscus injury, solid organ injury alone does not mandate laparotomy.[32,33] For patients meeting all other criteria for non-operative management, this remains a treatment option with a high rate of success.

For patients with a GSW and an equivocal finding on CT or for patients with a SW undergoing non-operative management, clinical observation becomes the next important step. This is the most time-consuming aspect of non-operative management and one of the primary reasons it is not feasible in all practice settings. This observation should be performed by a consistent team, ideally by the same provider, who can carefully examine for changes in abdominal pain, collateral markers of occult injury such as tachycardia or fever, and laboratory abnormalities such as an increasing white blood cell count. During this observation period, it is expected that a certain percentage of patients initially selected for non-operative management will progress to operative intervention based on imaging or changes in clinical examination. Selective non-operative management hinges on the ability to perform frequent, consistent physical examinations. Patients should receive no narcotics, anesthetics, or antibiotics and undergo serial hemodynamic and laboratory testing including white blood cell count, lactate, and hemoglobin levels. Strict adherence to a protocol is necessary to ensure early identification of patients who fail non-operative management and require operative intervention.

In patients selected for non-operative management after penetrating abdominal wounds, the duration of observation is individualized based upon the clinical scenario. After abdominal GSWs, a review of 270 patients found that all injuries requiring laparotomy were apparent within 24 hours of observation.[34,35] Similar results have been described for abdominal SWs with injuries requiring laparotomy detected within 12 hours of observation.[36]

Penetrating left thoracoabdominal injuries, bounded by the nipple, scapular tip, and costal margin, present a unique challenge due to the risk of occult diaphragmatic injury. Diaphragmatic injuries are notoriously difficult to diagnose on CT scan and are often asymptomatic in the early, postinjury setting. Over time, as the injury expands, the patient will be at risk for visceral herniation and strangulation. This complication is less likely after right-sided injuries due to buttressing of the injury by the liver but is a serious consideration after left-sided injury. The incidence of diaphragmatic injury after thoracoabdominal injury is as high as 17% to 40%.[37–39] For this reason, patients treated non-operatively for left thoracoabdominal penetrating injuries should undergo a period of clinical observation. If peritonitis develops, the diaphragm can be directly examined at laparotomy. If the patient passes the period of observation, the patient can be offered diagnostic laparoscopy to specifically evaluate the diaphragm on the left side. As the patient has already been clinically evaluated and other intra-abdominal injury excluded,

laparoscopy can be focused on diaphragmatic evaluation and a full exploration is not necessary. Insufflation for this procedure should be done carefully with close monitoring of the vital signs. With any evidence of the development of tension physiology due to a diaphragmatic injury, immediate release of pressure and insertion of a chest tube should be performed before proceeding.

3 For any hospital that cares for trauma patients, the ability to emergently perform an operative intervention is critical. Preparation before the critically ill patient arrives is key. An operating room that is easily accessible from the resuscitation area as well as the ICU should be earmarked for use in these situations. A plan for securing the room for high-profile patients should be in place and there should be a designated waiting area for family members. A contingency plan for multiple casualty situations should be available, with operating rooms located in close proximity to facilitate surgical, anesthesia, and nursing cross-coverage. Transportation of critically ill patients is a high-risk situation, and preplanned routes that minimize distance, elevator use, and public exposure should be well known to all providers. Instruments and disposables should be centrally located and redundant so that multiple casualty situations can be dealt with effectively. Having a dedicated trauma pack that allows for a laparotomy and thoracotomy, with add on sets for a sternotomy, amputation, and peripheral vascular injuries will facilitate circulator efficiency. With the high rate of retained foreign bodies after emergent trauma cases, the use of radiofrequency detection device embedded fabric is recommended. In higher-volume centers, access to a satellite blood bank with uncross-matched packed red blood cells and plasma is ideal, otherwise a system for communication with the main blood bank and product delivery to the OR should be developed and practiced. If a hybrid room is available, the operative team and nursing team should be familiar with the indications for starting an emergent case in this room. For all rooms, access to fluoroscopy and plain films is critical. Because of service line cross-coverage, ongoing in-servicing of the nursing and support staff is important to ensure that practices such as massive transfusion protocols, are universally understood.

4 For all emergent laparotomies, the patient should be placed in the supine position with arms abducted at 90 degrees. Even with a concomitant thoracic injury, this is the preferred starting position. Rarely, for patients with a penetrating injury with a transpelvic trajectory, where endoscopic evaluation may be required, the lithotomy position may be used. Likewise, in the blunt trauma patient where there is external perineal injury, this may be considered. At a minimum, the torso, neck, and upper half of the lower extremities should be prepared into the field for maximum flexibility. With any concurrent limb injuries, the entire extremity should be prepared. If there is any concern of a urethral or bladder injury, the Foley catheter should be prepared into the field to allow manipulation by the surgeon. Forced air warming on the lower half of the extremities, and other warming adjuncts should be utilized. All preoperative patient preparation including venous and arterial access, catheterization, and confirmation of patient identification should be a team effort with full participation by the surgical team.

The trauma laparotomy incision extends from the xiphoid process to the symphysis pubis. Traditionally made with a scalpel, unless emergent, electrocautery can be utilized to minimize bleeding. This extensile midline incision can be extended across the right or left inguinal ligament for distal iliac vascular injuries. Superiorly, a subcostal extension can be added to improve access to the liver on the right, especially with retrohepatic

venous injuries, or to the left for gastroesophageal (GE) junction injuries. The incision can be extended into a sternotomy for concurrent thoracic cavity injuries or to facilitate suprahepatic vena cava control for high-grade liver injuries not amenable to packing. If the patient has a pre-existing right thoracotomy, this can be joined to the laparotomy with incision of the diaphragm to afford the same view of the liver, retrohepatic venous structures, and intrapericardial vena cava.

On entry to the abdomen, the falciform should be taken down so as to minimize traction damage to the liver. Traditionally, blind four quadrant packing was advocated. In reality, this maneuver is not very helpful. In order to prevent iatrogenic damage, it is preferable to remove large amounts of central clotted blood, followed by selected packing of any areas with active bleeding. A rapid examination of the retroperitoneum should also be performed. Focusing on an obvious bowel injury that is encountered first while a retroperitoneal vascular injury remains unattended to is a pitfall. The goal of the initial packing and survey of contents is to identify and temporize any major sources of bleeding. A plan for surgical control can then be made. This includes notifying the circulator of any necessary additional equipment and close communication with anesthesia to optimize the resuscitation needs of the patient. Early consideration of damage control, addressed later in the chapter should be considered. The need for adjunctive services such as angiography prior to proceeding to the SICU should be considered and initiated early to allow lead-time for preparation. Once active hemorrhage has been temporized, a careful and complete survey of all of the abdominal contents should be performed. In the exsanguinating patient who is undergoing a damage control procedure, this may not be possible, but in the stable patient, this is critical. The potential for a missed injury can be mitigated by a systematic approach to the abdominal contents. We recommend that the entire abdomen be reviewed in the same manner for every case, regardless of the mechanism. For example, even a patient with a clear transpelvic GSW trajectory should have their upper abdomen inspected because a fragment undetected on the preoperative imaging may have caused an unexpected colon injury or, a concurrent blunt splenic injury may have been sustained by the patient and not elicited on the initial history. Specific areas warrant extra care during the examination. For blunt injuries without preoperative imaging, duodenal injuries may present with only a subtle hematoma in the retroperitoneum. For hematomas in this area, a right visceral medial rotation should be performed. For penetrating injuries, especially those due to shotguns, colonic, rectal, and small bowel injuries, especially on the mesenteric surface may only be visible as a small bloodstain or hematoma in the overlying fat. These need to be inspected carefully. The posterior surface of the stomach is also a common area for missed injuries and should be inspected carefully.

While exceedingly uncommon for blunt injuries, for both SWs and GSWs, ureteric injuries can be difficult to diagnose and for any trajectories in this region, care should be taken to inspect the at-risk segment of the ureter without devascularizing the structure. Likewise, whereas blunt bladder injuries are often large and located near the dome, penetrating injuries, even those that are intraperitoneal, can be small and asymptomatic. Most small extraperitoneal injuries can be managed non-operatively with urinary catheter

drainage however, large injuries, especially those with an intact connection to the skin can be problematic. If there is an intraperitoneal component of bladder injury, this can be extended and the interior of the bladder visualized. If not, we recommend injection of methylene blue containing sterile water into the bladder retrograde to look for any gross extravasation. If this is identified, the bladder should be taken down and these injuries repaired.

For retroperitoneal hematomas, the abdomen is traditionally broken down into three zones. Zone I is the central portion from the aortic hiatus to the sacral promontory encompassing the aorta, IVC, and major branches. Zone II covers the lateral retroperitoneum which contains the kidneys. Zone III is the pelvis, which encompasses the sacral venous plexus and iliac vessels. For penetrating injuries, all zones undergo exploration. For blunt injuries, traditionally, all zone I hematomas would be explored with zones II and III only warranting exploration if the hematoma was large, expanding or pulsatile. The retrohepatic area is distinct from the remaining areas and we often refer to this as zone IV, containing the retrohepatic IVC and major hepatic veins. This area is difficult to expose and control and as such, if controllable with packing, should not be explored for either blunt or penetrating injuries.

DAMAGE CONTROL LAPAROTOMY

5 Damage control[40] has become a common practice in the management of patients with complex abdominal trauma and has been credited with saving more lives than many of the other surgical techniques developed over the last two decades. Abdominal damage control techniques should always be combined with damage control resuscitation, which includes permissive hypotension, early empiric balanced blood component therapy minimizing crystalloid usage, and the prevention and treatment of hypothermia. Abdominal damage control includes three key components: (a) temporary rapid control of bleeding and contamination with early termination of the operation, (b) postoperative resuscitation with correction of coagulopathy, hypothermia, and acidosis, and (c) subsequent definitive repair of injuries.

The standard indications for damage control include: (a) patients with severe physiologic compromise with coagulopathy, hypothermia, or acidosis, (b) bleeding from difficult to control injuries or an injury burden which will result in physiologic compromise if treated definitively at the index operation, and (c) austere environments with limited resources or surgeon skillset, such as in a rural or combat setting. There is evidence that early damage control, even prior to physiologic decompensation, may be associated with better survival and as such, patients with a large injury burden at risk of becoming physiologically depleted should also be considered as candidates for damage control surgery. The exact timing of damage control should be determined by the complexity of the injuries, the physiologic condition of the patient, the available resources, and the experience of the surgical team.

Effective temporary hemorrhage control can be achieved by mechanical compression or gauze packing in most cases where there is bleeding from surfaces such as complex liver injuries, the retroperitoneum, or the pelvis. However, packing is usually not effective for major vascular injuries and surgical control with ligation or shunting[41] may be necessary. For deep tracts, for example in the liver, balloon tamponade[42] can be very effective (Fig. 25-2). Angioembolization may be a useful adjunct for abdominal damage control and should be considered early, immediately following the operation. A hybrid operating room may be a valuable tool, facilitating simultaneous operation in the abdomen and angioembolization of difficult bleeding sites.

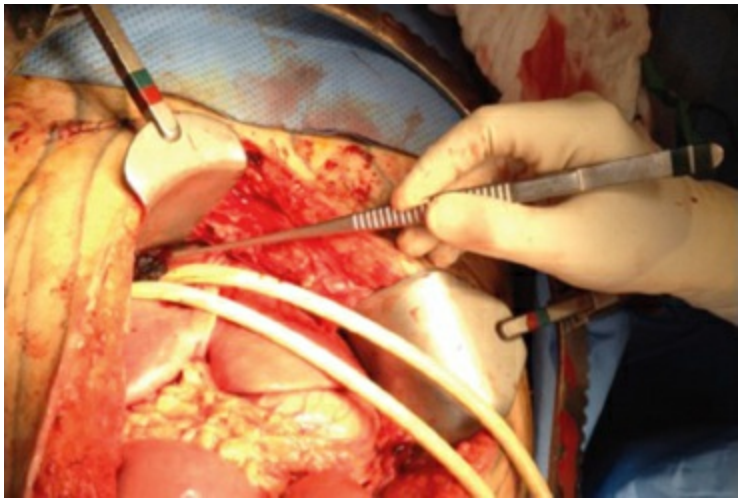

Figure 25-2. Gunshot injury through the center of liver requiring balloon tamponade using Foley catheters for damage control.

Control of intestinal spillage is also an integral part of abdominal damage control. It has been suggested that ligation or stapling of the injured bowel, without reestablishing continuity, should be considered as part of damage control for intestinal injuries requiring resection. Definitive reconstruction is performed at a later stage, once the patient is stabilized, often 24 to 36 hours after the initial operation. There are concerns that this approach may create a complete intestinal obstruction, which may promote bacterial and toxin translocations or aggravate bowel ischemia, especially in patients requiring vasopressors. Although not always possible, reconstruction of the bowel or creation of an ostomy for diversion should be considered at the index operation if tolerated by the patient.

Damage control should be performed in an organized and orderly fashion, making sure that no significant injuries are missed and that there is effective control of hemorrhage and contamination. The procedure should not be terminated if there is persistent bleeding.

6 Following damage control, the abdominal fascia or skin should never be closed because of the high risk of intra-abdominal hypertension and abdominal compartment syndrome.[43] The abdomen should be temporarily closed. The ideal method of temporary abdominal closure should prevent evisceration, preserve the fascia and abdominal wall domain, facilitate reoperation, allow effective removal of toxin-loaded intraperitoneal fluid, reduce the risk of enteroatmospheric fistulas, and help achieve early definitive fascia closure (Fig. 25-3).

Numerous materials and techniques have been used for temporary abdominal closure over the last decade. A widely used technique in the past was passive closure with simple materials, such as a sterile x-ray cassette cover, which is stapled or sutured to the fascia or the skin. This method does not allow effective removal of any contaminated or toxin and cytokine-rich intraperitoneal fluid, and does not prevent the loss of abdominal wall domain. Most contemporary systems now include the addition of negative pressure. This can be made using perforated plastic sheeting, adhesive drapes, drains and laparotomy packs, or a commercially available device. There is evidence that these negative pressure

dressings may improve survival and increase the success rate of primary fascia closure.

Once the patient has had their initial abbreviated procedure and temporary abdominal wall closure, they can then be taken to the ICU for continuation of the resuscitation which was started in the OR. After physiologic status has normalized, the patient can then return to the OR for definitive exploration and repair of all injuries. Even prior to normalization of the patient's physiology, if significant bleeding is noted in the negative pressure system, the pressure should be immediately discontinued and the patient returned to the operating room for reexploration and bleeding control. Although rare, even with a temporary abdominal wall closure in place, intra-abdominal hypertension may still occur. It is important that bladder pressures are monitored routinely during the first few hours after laparotomy, even if it was a damage control procedure with the abdomen left open.



Figure 25-3. Temporary abdominal closure after damage control laparotomy.

DIAPHRAGM

Anatomy

The diaphragm consists of a central aponeurotic portion which fuses with the pericardium and a peripheral muscular portion which is attached to the lower sternum, the lower six ribs, and the lumbar spine. During exhalation, the diaphragm rises to the level of the nipples at the fourth to fifth intercostal space. Penetrating injuries of the lower chest or insertion of a thoracostomy tube below the nipple, therefore has the potential to cause injury to the diaphragm.

Epidemiology

In a prospective study of 119 consecutive patients with penetrating injuries to the left thoracoabdominal region (nipple and tip of the scapula superiorly, costal margin inferiorly), undergoing laparotomy or laparoscopy,[38] a diaphragmatic injury was identified in 59% of GSWs and 32% of SWs. There were no differences between anterior, lateral, or posterior injuries. Blunt trauma may cause diaphragmatic injury through three different mechanisms which include a sudden increase in intra-abdominal pressure causing a bursting of the diaphragm, fractured ribs perforating the diaphragm, and deceleration injuries causing detachment of the diaphragm from the ribs. For blunt trauma, a diaphragmatic injury is found in approximately 7% of all laparotomies and in about 7.5% of autopsy studies. The left hemidiaphragm is involved in approximately 70% of cases and the right in 30% presumably due to the protective presence of the liver. Blunt tears (Fig. 25-4) are usually 7- to 10-cm long as compared with 2 to 3 cm for penetrating trauma (Fig. 25-5). A right diaphragmatic rupture indicates a more severe traumatic insult and in almost all cases there are associated intra-abdominal injuries, compared to 77% for left diaphragmatic ruptures.

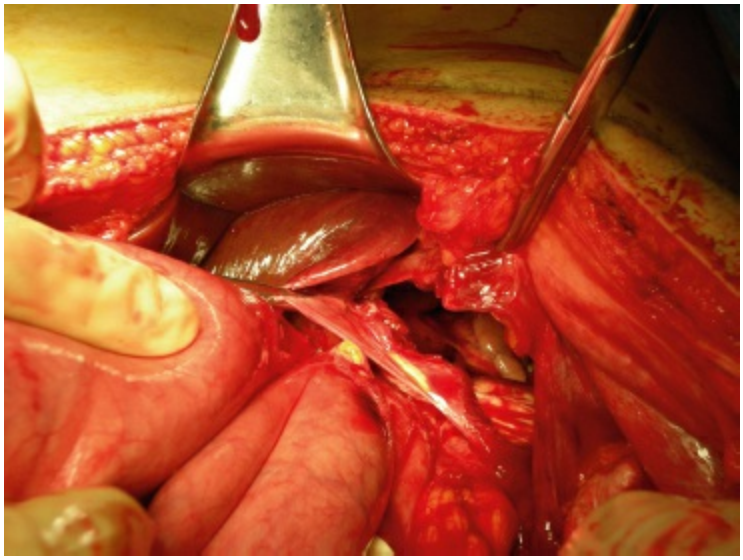

Figure 25-4. Large blunt diaphragm injury.

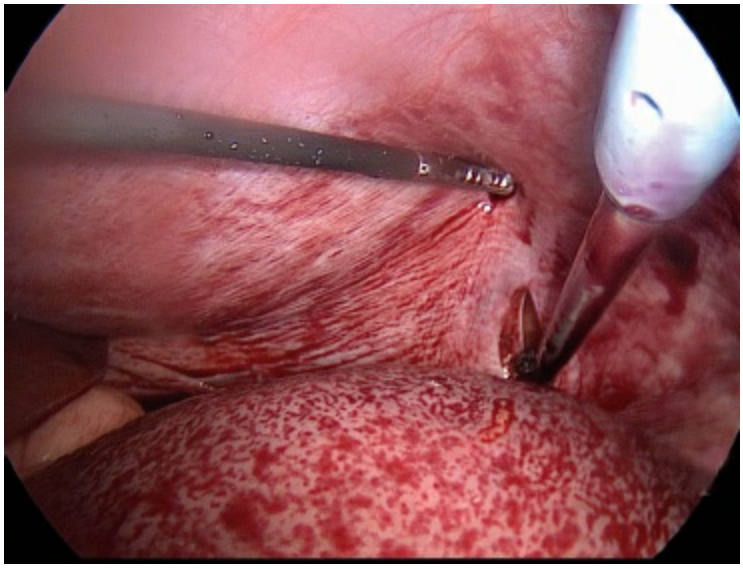

Figure 25-5. Small diaphragm injury after a stab wound to the left thoracoabdominal region.

Diagnostics

Isolated and uncomplicated diaphragmatic injuries are difficult to diagnose as they may be completely asymptomatic or present with minor, nonspecific abdominal signs. The classic signs and symptoms normally associated with diaphragmatic injury such as shortness of breath, bowel sounds in the chest, GI obstruction, or ischemia, are relatively rare, and require acute herniation of abdominal contents.

The natural history of unrecognized diaphragmatic injuries is unknown and although some small injuries may heal, this is not uniform. For right hemidiaphragm injuries, the presence of the liver generally protects against diaphragmatic herniation. However, for the left side, unrepaired diaphragm injuries commonly result in a diaphragmatic hernia, which may present within hours, days, weeks, months, or even years after the injury.

Due to the occult presentation and the risks of unrecognized diaphragmatic injuries, for penetrating trauma, all patients with a wound to the left thoracoabdominal area, defined as the area between the nipple and scapula superiorly and the costal margin inferiorly, should be aggressively evaluated for diaphragm injury. Plain chest x-ray and CT are unreliable in detecting uncomplicated diaphragm injuries as the injuries are often very small. For patients undergoing laparotomy, care should be taken to inspect the diaphragm. If the patient is to be managed non-operatively, as mentioned earlier in the chapter, delayed laparoscopic evaluation is warranted.

For larger blunt injuries, imaging can be more useful. Plain radiologic findings suspicious of diaphragmatic injury include an elevated diaphragm, an irregular diaphragmatic contour, and nonvisualization of the diaphragm. Classically, an NG tube may be seen in the thoracic cavity. Once GI tract herniation has occurred, chest x-ray (Fig. 25-6) and CT (Fig. 25-7) have higher sensitivity. CT scan is the highest-yield investigation because it also includes any associated intra-abdominal injuries and has a higher sensitivity than plain radiographs, especially for newer multidetector CT scans.[44]

Treatment

For patients where there is suspicion of a diaphragmatic injury with herniation, care should be taken to avoid perforation of any hollow viscus in the chest. All diaphragm injuries should ultimately have the abdominal contents reduced and the defects repaired. Acutely, diaphragmatic injuries should be approached through a laparotomy to facilitate exploration of the remaining intra-abdominal contents. In chronic, elective cases, access and repair of the hernia can be performed through a thoracotomy. The repair should be performed using nonabsorbable sutures and if there is contamination of the pleural cavity, extending the incision and washing the cavity out prior to closure are warranted. Tube thoracostomy should be considered in most cases. In rare cases where there is loss of diaphragmatic tissue, synthetic prosthetic reconstruction can be utilized. If the diaphragm has been avulsed from the chest wall, careful reconstruction of the diaphragmatic architecture utilizing nonabsorbable sutures is required. In some cases where there is significant tissue loss, apposition of the remaining diaphragm to the chest wall several rib spaces up may be required to create a tension-free repair.



Figure 25-6. Chest x-ray demonstrating blunt left diaphragmatic injury with herniating gastrointestinal tract.

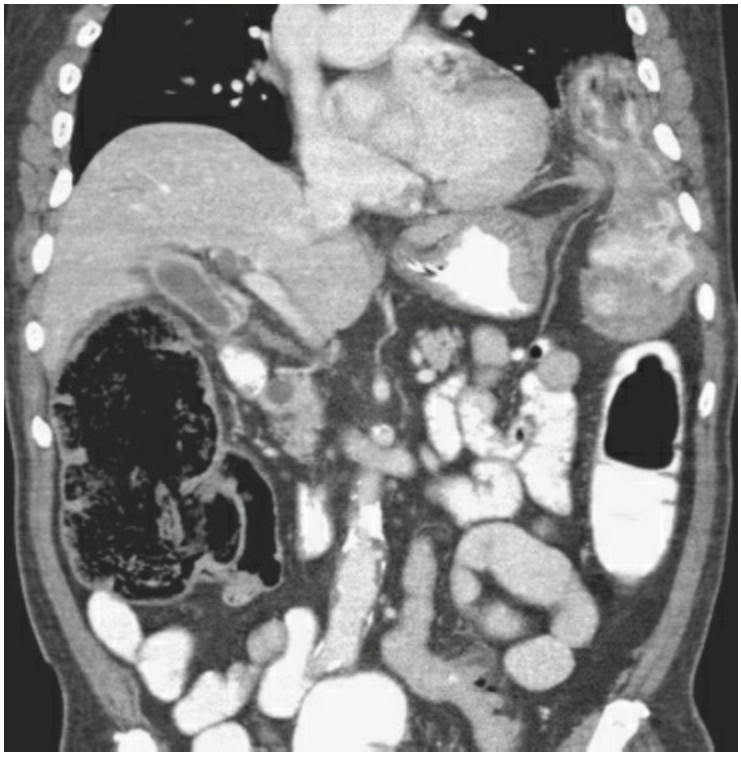

Figure 25-7. CT demonstrating left blunt diaphragmatic injury with herniating gastrointestinal tract contents.

LIVER AND BILIARY TRACT

Anatomy

The anatomical division of the liver into the eight classicCouinaud segments has no practical application in trauma. Parenchymal resection should be minimized and does not follow any anatomical boundaries. An understanding of the blood supply however is important. The retrohepatic IVC is approximately 8- to 10-cm long and in most patients is partially covered by the liver parenchyma. In approximately 7% of individuals the IVC is completely embedded in the liver. For outflow, there are three major hepatic veins (right, middle, and left), with numerous accessory veins. Only the proximal 1 to 2 cm of the major hepatic veins are extrahepatic. In approximately 70% of individuals, the middle hepatic vein joins the left hepatic vein, near the IVC. The portal vein provides approximately 70% of hepatic blood flow, and 50% of the hepatic oxygenation. It divides into right and left branches at the level of the liver parenchyma. The common hepatic artery originates from the celiac artery. In most individuals it branches into the left and right hepatic arteries at the hilum of the liver. In some individuals the right hepatic artery originates from the superior mesenteric artery. The left hepatic artery may originate from the left gastric artery. The porta hepatis contains the hepatic artery to the left, and the common bile duct to the right. The portal vein lies posteriorly and between the common bile duct and the hepatic artery. The left hepatic bile duct, the left hepatic artery, and the left portal vein enter the undersurface of the liver, near the falciform ligament.

Epidemiology

The liver is one of the most commonly injured intra-abdominal organs following blunt trauma. The mechanisms of injury include direct blunt force compression, penetration by a fractured rib, and deceleration with avulsion of the ligaments or the hepatic veins. In penetrating trauma the liver is the most commonly injured solid organ. Low-velocity missiles cause limited tissue damage and are life-threatening only if they cause injury to a major vessel. High-velocity missiles can cause massive tissue destruction and are associated with high mortality. The AAST-OIS grading system (Table 25-1) ranges from a mild grade I injury to a grade VI total hepatic avulsion which is lethal.[45]

Table 25-1 OIS-AAST Grading Scale for the Liver

Grade[a]	Type	Injury Description
I	Hematoma Laceration	Subcapsular, <10% surface area Capsular tear, <1 cm parenchymal depth
II	Hematoma Laceration	Subcapsular, 10–50% surface area; intraparenchymal, <10 cm in diameter 1–3 cm parenchymal depth, <10 cm in length
III	Hematoma Laceration	Subcapsular, >50% surface area or expanding; ruptured subcapsular or parenchymal hematoma; intraparenchymal hematoma, >10 cm or expanding >3 cm parenchymal depth
IV	Laceration	Parenchymal disruption involving 25–75% of hepatic lobe or 1–3 Couinaud segments within a single lobe
V	Laceration Vascular	Parenchymal disruption involving >75% of hepatic lobe or >3 Couinaud segments within a single lobe Juxtahepatic venous injuries; that is, retrohepatic vena cava/ central major hepatic veins
VI	Vascular	Hepatic avulsion

[a]Advance one grade for multiple injuries, up to grade III.
Moore EE, Cogbill TG, Jurkovich GJ, et al. Organ injury scaling: spleen and liver (1994 revision). *J Trauma* 1995;38:323–324.

Diagnostics

A FAST will detect free intraperitoneal bleeding, but it does not provide any information about the source of this bleeding. A formal ultrasound performed by an experienced radiologist may provide additional information regarding the grade of the hepatic injury but this is not practical for acutely injured patients. An abdominal CT scan with intravenous contrast is the most widely used and highest-yield modality. CT provides accurate information about the architecture of the injury, the amount of intraperitoneal blood, the presence of active bleeding, pseudoaneurysms or arteriovenous fistulas, and the presence of associated injuries. CT is a valuable tool in the selection of patients for operation, angiographic embolization, or observation (Fig. 25-9).

Treatment

Selective non-operative management of blunt liver trauma is the only acceptable contemporary standard of care. The selection of patients for non-operative management should incorporate clinical examination, CT scan findings, and the presence or absence of associated injuries. Hemodynamic stability and the absence of peritonitis are absolute requirements for non-operative management. The success rate of non-operative management for blunt hepatic trauma, including those with high-grade injuries, is high.[46,47] In a recent National Trauma Data Bank study of 6,402 patients with grade IV or V blunt liver injuries, 68% were managed non-operatively.[48] For these high-grade injuries, especially with evidence of contrast extravasation (Fig. 25-8), angiointervention has been shown to be an independent predictor of survival and should be used liberally as a postoperative adjunct. Most failures of non-operative management occur within the first 24 hours of admission. There is some evidence that patients with high injury severity score (ISS), severe grade IV or V liver injuries, multiple transfusions, major associated injuries, and associated chronic conditions such as cirrhosis, are at an increased risk for failure of non-operative management. Angiographic embolization may be a significant adjunctive therapeutic modality which increases the success rate of non-operative management of high-grade injuries.[47,49] Although non-operative management of blunt liver trauma has become the standard of care, many centers still treat penetrating injuries operatively. However, there is good evidence that at experienced trauma centers, selected cases with penetrating trauma due to SWs or GSWs (Fig. 25-9), can safely be managed non-operatively.[32,33] For both blunt and penetrating injuries being managed non-operatively, continuous close monitoring in an ICU environment and frequent serial clinical examinations are critical for success.

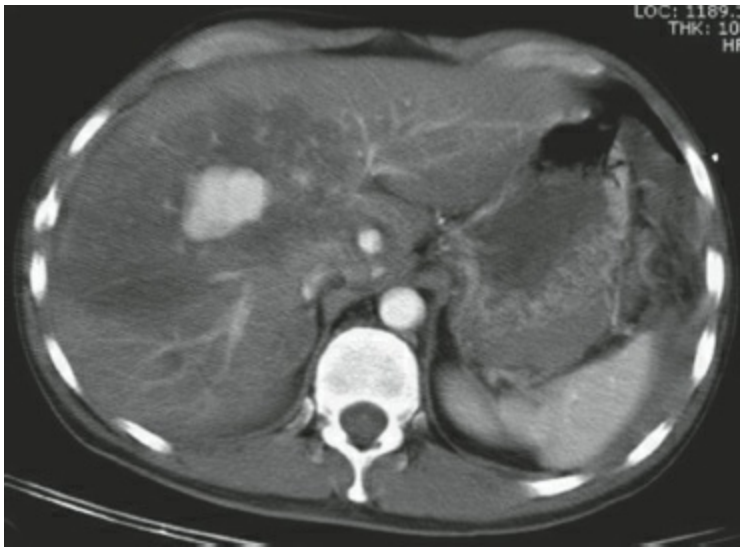

Figure 25-8. High-grade blunt liver injury with active contrast extravasation.

For operative management, the initial incision should be a midline laparotomy because it provides adequate exposure of the liver in the majority of cases and allows systematic exploration of the abdomen. For improved access to posterolateral liver injuries, a right subcostal incision may be required. In rare occasions, addition of a sternotomy may be

required in order to obtain access to the intrapericardial inferior vena cava for total vascular isolation of the liver (Fig. 25-10), or exposure of the heart for placement of an atriocaval shunt (Fig. 25-11). Alternatively, as discussed earlier in the chapter, if the patient has a right thoracotomy, usually in the setting of a gunshot injury which presented with a massive hemothorax due to decompression of a high-grade liver injury through the diaphragm, the thoracotomy and laparotomy can be joined with incision of the diaphragm for unimpeded access to the posterior liver and suprahepatic segment of the IVC.

In this case a cuff of diaphragm should be left so that if the patient survives, reconstruction is facilitated. In approximately 80% to 85% of patients undergoing operation, the liver injury can be managed by relatively simple surgical techniques, such as application of local hemostatic agents, electrocoagulation, or superficial suturing. Bleeding from deep liver lacerations can be controlled by clipping or suture ligation of any major vessels, followed by deep, figure-of-eight sutures, on a large blunt liver needle. Omental packing of large liver defects is useful in eliminating any dead space. Significant bleeding from deep bullet or knife tracts in the liver may require a tractotomy for peripheral wounds or balloon catheter tamponade and perihepatic packing for central wounds.



Figure 25-9. Gunshot injury to the liver successfully managed non-operatively.

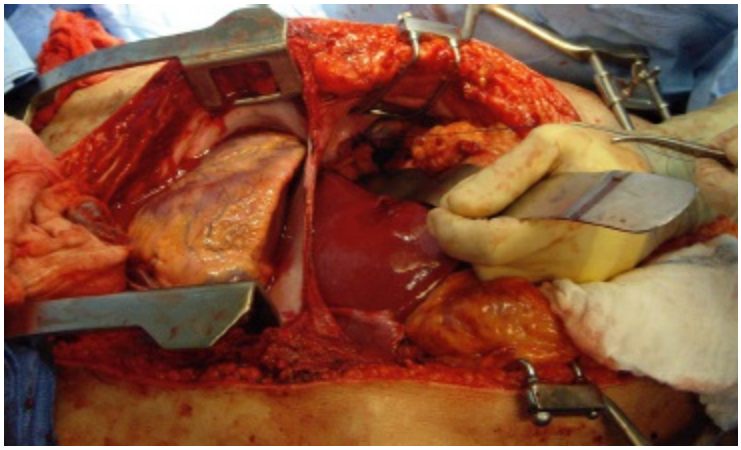

Figure 25-10. Laparotomy and sternotomy demonstrating excellent access to the liver and the intrapericardial segment of the suprahepatic IVC.

7 Severe blunt trauma or high-velocity GSWs associated with extensive parenchymal damage are not amendable to deep suturing. Bleeding control in these cases may be achieved with perihepatic packing, with or without liver resection. Perihepatic packing and damage control is a significant advancement in the management of complex liver injuries. In order to be effective it needs to be performed early, before the patient becomes unstable. The presence of intact hepatic ligaments enhances the effectiveness of the perihepatic packing and they should not routinely be divided. Laying a piece of absorbable mesh on the raw surface of the liver prior to packing facilitates pack removal at the take back as the mesh with its integrated clot can be left undisturbed once the packs are removed. Angioembolization following perihepatic packing should be considered early postoperatively and ideally, intraoperatively, if a hybrid operating room (Fig. 25-12) is available. The perihepatic packing should be removed after correction of coagulopathy and other physiologic abnormalities, usually within 24 to 36 hours of the index operation. Delaying the removal of the packs for more than 48 hours may be associated with an increased risk of infection. Nonanatomic liver resection may be needed in cases where there is a destructive injury, and perihepatic packing is not effective.[50] In general however, packing is highly effective and major anatomic hepatic resections are rarely indicated acutely. Once the patient has stabilized, and the liver has demarcated and the patient is able to tolerate resection, any nonviable parenchyma can be resected. If required acutely, the liver resection can be performed with finger dissection of the parenchyma, with suture ligation of vessels and biliary branches, or with the use of an electrothermal bipolar vessel sealing system. Selective hepatic artery ligation or clipping may be a useful adjunct to packing in rare cases and should be considered if packing by itself is insufficient and temporary occlusion results in reduction of the bleeding. The combination of hepatic artery occlusion, extensive parenchymal injury, and hypotension increases the risk of hepatic necrosis.

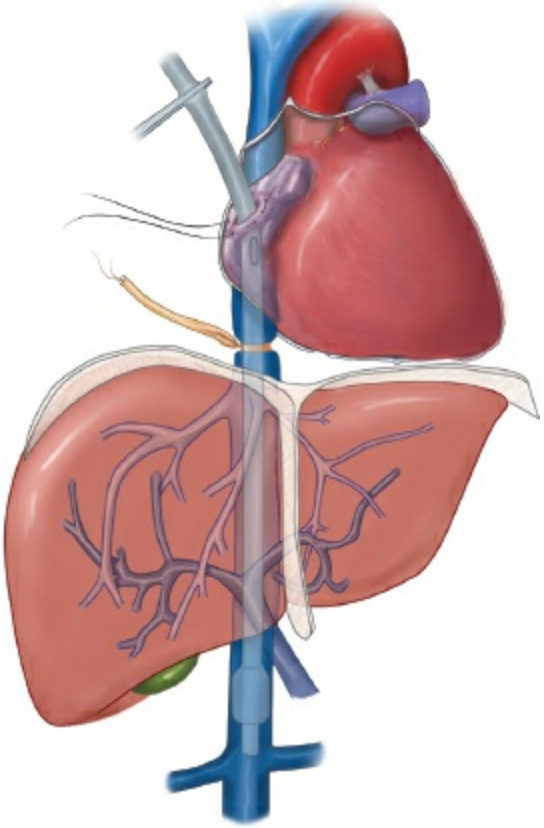

Figure 25-11. Schematic demonstrating an atriocaval shunt. (From Demetriades D, Inaba K, Velmahos G, eds. *Atlas of Surgical Techniques in Trauma.* New York, NY: Cambridge University Press; 2015, with permission.)



Figure 25-12. Hybrid operating room.

In the rare situation where perihepatic packing is not effective, often due to major retrohepatic venous injuries, total vascular isolation of the liver may be required to achieve temporary bleeding control, allowing identification and ligation of the injured vessels. The procedure consists of cross-clamping of the infradiaphragmatic aorta, the suprahepatic and infrahepatic inferior vena cava, and the porta hepatis. Control of the suprahepatic IVC is extremely challenging in the intra-abdominal segment as this is usually where the primary source of bleeding necessitating the procedure has occurred. Consequently, it is recommended that the intrapericardial segment as described earlier is

accessed for control.

Injury to the retrohepatic venous structures should be suspected in the presence of retrohepatic bleeding or hematoma, especially if the bleeding becomes worse when the liver is retracted anteriorly. Characteristically, the bleeding is reduced with posterior compression of the liver. A noncontained retrohepatic venous injury is highly lethal because of the difficult surgical exposure. As discussed earlier, contained retrohepatic hematomas should not be explored because of the risk of uncontrollable hemorrhage. This applies to both blunt and penetrating injuries. However, in the presence of active bleeding not controlled by packing and posterior compression of the liver, exploration and repair or ligation of the bleeding vessel are mandatory. Addition of a subcostal incision improves exposure of the liver and the retrohepatic veins. Division of the falciform and coronary ligaments allows inferior-medial rotation of the liver and direct visualization of the inferior vena cava and the right hepatic vein. As described earlier, an alternative to the subcostal incision is a median sternotomy or if the patient already has a right anterolateral thoracotomy, division of the diaphragm, straight down to the inferior vena cava.

The use of an intracaval shunt may be considered in selected complex retrohepatic venous injuries which cannot be controlled with simpler approaches. The procedure involves extension of the laparotomy incision into a median sternotomy and opening of the pericardium. A tape tourniquet is then applied around the intrapericardial IVC. A purse–string suture (2-0 silk) is placed in the right atrial appendage and a size 8 endotracheal tube with a side hole cut at approximately 8 to 10 cm from the clamped proximal end, is then inserted through the purse–string and guided into the IVC. The balloon of the tube is then inflated just above the renal veins and the tape tourniquet around the intrapericardial IVC is tightened.[51] Alternatively, a 36-Fr chest tube, with fenestrations cut into the proximal segment of the tube to allow blood flow from the IVC into the right atrium may be used. The intracaval shunt may reduce bleeding but in reality, rarely achieves complete hemostasis. The reported results with atriocaval shunts are generally poor, and should be considered if all other techniques have failed.

For completion, other techniques which have been used in the management of retrohepatic venous injuries include intravascular balloons inserted through the femoral vein, extracorporeal venovenous bypass, hypothermic circulatory arrest, and liver transplantation.[52]

The incidence of postoperative liver-related complications after high-grade liver injuries has been reported to be as high as 50%.[53] The clinical presentation of these complications may vary from a few days to many months. Complications include early or late hemorrhage, pseudoaneurysm, arteriovenous fistula, biloma, biliary fistula, liver necrosis, liver abscess, hemobilia, and intrahepatic biliary strictures. Approximately 35% of patients with significant liver-related postoperative complications are asymptomatic and have the complication diagnosed on CT.[53] The majority of these complications can safely be managed non-operatively, with percutaneous endovascular or endoluminal interventional radiology-based or ERCP-guided solutions.

Extrahepatic Biliary Tract Injury

Trauma to the extrahepatic biliary tree is rare and is usually due to a penetrating mechanism. Bile duct injuries are usually diagnosed during laparotomy, although some cases may present late, occurring even days after injury. The diagnosis may be confirmed with a hepatobiliary iminodiacetic acid (HIDA) scan, MRCP, or ERCP. The management of injuries to the biliary tree is determined by the location and extent of the biliary injury, the time of diagnosis, and the presence of associated intra-abdominal injuries. Injuries to the gallbladder are treated by cholecystectomy. Complete duct transections are best managed with a Roux-en-Y biliary-enteric anastomosis because primary repair is associated with a high stricture rate.

Incomplete injuries to the extrahepatic ductal system discovered intraoperatively, can be managed with primary repair, if the transection involves less than 50% of the duct circumference. Placement of a T-tube through a separate choledochotomy facilitates the repair. Transections involving more than 50% of the circumference of the duct, especially with questionable tissue viability, should be treated like a complete transection. All repairs of the biliary tract should be drained externally with closed suction drains.

In the damage control setting, the duct may be ligated or an external catheter may be placed into the proximal duct and exteriorized through the skin. Definitive repair can be performed after physiologic stabilization of the patient or once expert assistance becomes available.

SPLEEN

Anatomy

The spleen is held in place by four ligaments which include the splenogastric ligament medially, the splenocolic ligament inferiorly, and the splenophrenic and splenorenal ligaments posterolaterally. The splenogastric ligament is the only vascular ligament and contains five to seven short gastric vessels, which originate from the distal splenic artery. The tail of the pancreas is in close proximity to the splenic hilum and is at risk of injury during splenectomy or hilar clamping. The splenic artery courses superior to the pancreas and near the splenic hilum it divides into upper and lower pole arteries. The splenic vein is located posterior and inferior to the splenic artery, receives the inferior mesenteric vein and joins the superior mesenteric vein to form the portal vein.

Epidemiology

The spleen is a commonly injured intra-abdominal organ following blunt trauma and the second most commonly injured solid organ after penetrating trauma. The severity of splenic injury is graded by the OIS-AAST spleen injury scale, which is based on CT, as well as operative findings (Table 25-2). Generally, grades I and II are considered minor injuries, grade III a moderate injury, and grades IV and V are severe injuries.

Diagnostics

The clinical presentation of a spleen injury depends on the volume of blood loss and the presence of associated injuries. Many low-grade splenic injuries may be asymptomatic or have only minor local tenderness and the diagnosis is made on CT. If associated with significant blood loss the patient may present with tachycardia and hypotension. Classically, those with large splenic hematomas may experience pain in the left upper quadrant, radiating to the left shoulder (Kehr sign), especially when placed in the Trendelenburg position. Although plain chest x-rays are not diagnostic, the presence of fractures of the left lower ribs or an elevated left hemidiaphragm can be associated with an increased possibility of splenic injury. The FAST may show free fluid around the spleen. Abdominal CT scan with intravenous contrast is the most widely used and highest-yield investigation (Figs. 25-13 and 25-14). It provides accurate information about the grade of injury, the amount of intraperitoneal bleeding, evidence of active bleeding, and associated injuries.

Table 25-2 OIS-AAST Grading Scale for the Spleen

Grade[a]	Type	Injury Description
I	Hematoma Laceration	Subcapsular, <10% surface area Capsular tear, <1 cm parenchymal depth
II	Hematoma Laceration	Subcapsular, 10–50% surface area, <5 cm in diameter 1–3 cm parenchymal depth not involving a trabecular vessel
III	Hematoma Laceration	Subcapsular, >50% surface area or expanding; ruptured subcapsular or parenchymal hematoma; intraparenchymal hematoma, ≥5 cm or expanding >3 cm parenchymal depth or involving trabecular vessels
IV	Laceration	Laceration involving segmental or hilar vessels producing major devascularization (>25% of the spleen)
V	Laceration Vascular	Shattered spleen Hilar vascular injury with devascularized spleen

[a]Advance one grade for multiple injuries, up to grade III.
Moore EE, Cogbill TH, Jurkovich GJ, et al. Organ injury scaling: spleen and liver (1994 revision). *J Trauma* 1995;38:323–324.



Figure 25-13. CT image of a high-grade spleen injury.

Treatment

Approximately 80% of blunt splenic injuries in adults and 90% to 95% in children can be safely managed non-operatively.[54] Recent studies suggest that approximately 10% of all penetrating splenic injuries may also be managed non-operatively.[55] The selection of patients for non-operative management should be based on clinical examination and CT scan findings. The patient should be hemodynamically stable and have no signs of peritonitis. Although associated head trauma is not an absolute contraindication for non-operative management, it should lower the threshold for operative intervention, because head trauma-related coagulopathy increases the risk of splenic bleeding and the splenic bleeding may cause hypotension which would be detrimental to the injured brain.

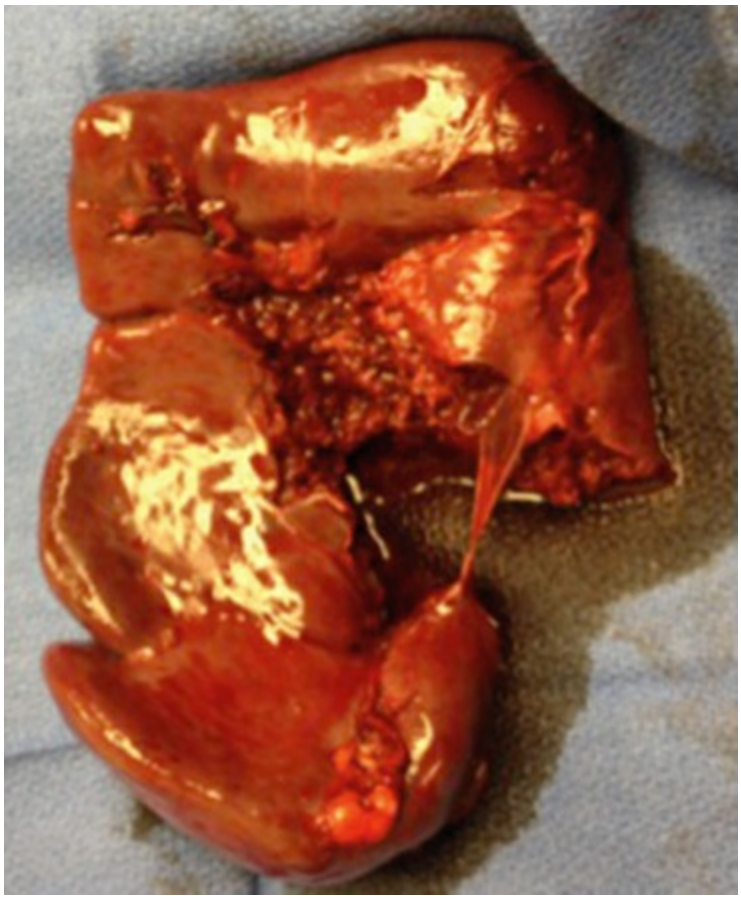

Figure 25-14. Spleen after removal as seen on CT in Figure 25-13.

Low-grade splenic injuries are much more likely to be successfully managed non-operatively, but many high-grade injuries may still be managed non-operatively. Patients with higher-grade splenic injuries selected for non-operative management should be observed in the ICU. Development of hemodynamic instability, peritonitis or the need for blood transfusion should trigger operative exploration. Most failures occur within the first few days, although in some cases, especially those with subcapsular hematomas or pseudoaneurysms, delayed bleeding may occur days to weeks after the injury. Patients with severe splenic injuries selected for non-operative management should receive prophylactic vaccinations against *Streptococcus pneumonia, Neisseria meningitidis,* and *Haemophilus influenza,* in case conservative management fails and the patient requires

splenectomy.

A follow-up CT scan should be performed for all grade III to V splenic injuries within 2 to 3 days of admission to rule out the development of a pseudoaneurysm or progression of the hematoma. Subsequent follow-up CT scan evaluation should be considered in selected cases with high-grade injuries, especially those with subcapsular hematomas.

The duration of avoidance of vigorous physical activities and contact sports should be individualized, taking into account the severity of the spleen injury, the findings on follow-up CT scan, and patient's lifestyle. Most surgeons recommend a period of approximately 4 to 6 weeks before resumption of heavy duties.

Angioembolization has been used as an adjunct to non-operative management in high-grade splenic injuries. For patients with CT scan evidence of active contrast extravasation or pseudoaneurysm, angioembolization should be considered. Proximal splenic artery embolization consists of coil occlusion of the splenic artery distal to the dorsal pancreatic artery and promotes hemostasis by reducing blood flow to the spleen. Distal selective embolization consists of coil or gelfoam deployment as close to the bleeding site as possible. The available evidence is inconclusive and suggests that the two approaches may be equally effective in preventing significant rebleeding. Both techniques are associated with the same incidence of infarctions and infections requiring splenectomy. Distal embolization is associated with a higher rate of asymptomatic segmental infarctions.[56] A Western Trauma Association multicenter trial which included 140 splenic artery embolizations reported an overall complication rate of 32%, including splenic infarctions in 21% and splenic abscess in 4.3%.[57]

For operative management, midline laparotomy is the incision of choice for accessing the spleen. After entering the peritoneal cavity any free blood is evacuated and the left upper quadrant is packed for temporary bleeding control. This allows a rapid evaluation of the rest of the abdomen to rule out any other major injuries which may require immediate attention. The next step is the assessment of the type and severity of the splenic injury, in order to determine if the spleen is salvageable. After removal of the temporary packing, the organ is rotated inferomedially. Several laparotomy pads are then placed under the left diaphragm and behind the spleen, aiding in the exposure of the spleen. Excessive traction on the stomach or the splenic flexure of the colon or excessive medial rotation of the spleen may cause avulsion of the delicate splenic capsule, resulting in bleeding and decreasing the possibility of splenic preservation.

Profuse bleeding from the spleen can temporarily be controlled with digital compression of the hilum or direct digital compression of the splenic parenchyma. A vascular clamp can also be placed across the hilum, taking care not to injure the tail of the pancreas.

The critical move for a quick and safe splenectomy is adequate mobilization and inferomedial rotation of the spleen. This is achieved by sharp division of the splenophrenic and splenorenal ligaments posterolaterally and medial rotation of the spleen. The next step is division and ligation of the vascular gastrosplenic ligament, as far away from the stomach as possible, in order to avoid injury or ischemic necrosis of the gastric wall. Likewise, the splenic artery and vein should be ligated as close to the hilum

as possible, in order to avoid injury to the tail of the pancreas. The final step is division of the splenocolic ligament. Although this stepped approach to mobilization of the spleen is applicable to most patients, the order of taking down the splenic ligaments should be determined by the anatomy and may vary from patient to patient. In fact, for acutely injured spleens, many of these ligaments may already be avulsed.

Preservation of the spleen should be considered in low-grade injuries if the patient is hemodynamically stable with a low overall injury burden. In cases with avulsion of the splenic capsule or minor lacerations, hemostasis can be achieved with electrocautery and local hemostatic agents. Splenic lacerations may be repaired with absorbable figure-of-eight or horizontal mattress sutures, on a blunt liver needle. The presence of an intact splenic capsule makes the placement of the sutures technically easier. If the parenchyma is fragile and does not hold sutures, pledgets may be used. An absorbable splenic mesh can also be used (Fig. 25-15) as an adjunct to splenorrhaphy, especially in cases with multiple stellate parenchymal injuries.

Early local postsplenectomy complications include recurrent bleeding, pancreatic complications (pancreatitis, pseudocyst, and pancreatic fistula), gastric complications (gastroparesis, necrosis of the greater curvature), subdiaphragmatic abscess, splenic vein thrombosis, splenic arteriovenous fistula, left lower lobe atelectasis, or pleural effusion. Complications after splenorrhaphy include intrasplenic hematoma or abscess, splenic infarcts, and pseudoaneurysms or arteriovenous fistulas. A follow-up CT scan with intravenous contrast should be performed in all high-grade splenic injuries managed with splenorrhaphy. Early postsplenectomy hematologic changes include leukocytosis and thrombocytosis. The leukocytosis is usually moderate, rarely exceeding 16,000 to 18,000/mm3 and may last several weeks. More severe leukocytosis may indicate an infectious complication, especially in the presence of fever or tachycardia.[58] Thrombocytosis is usually moderate, may last for a few weeks and in most cases is clinically irrelevant.

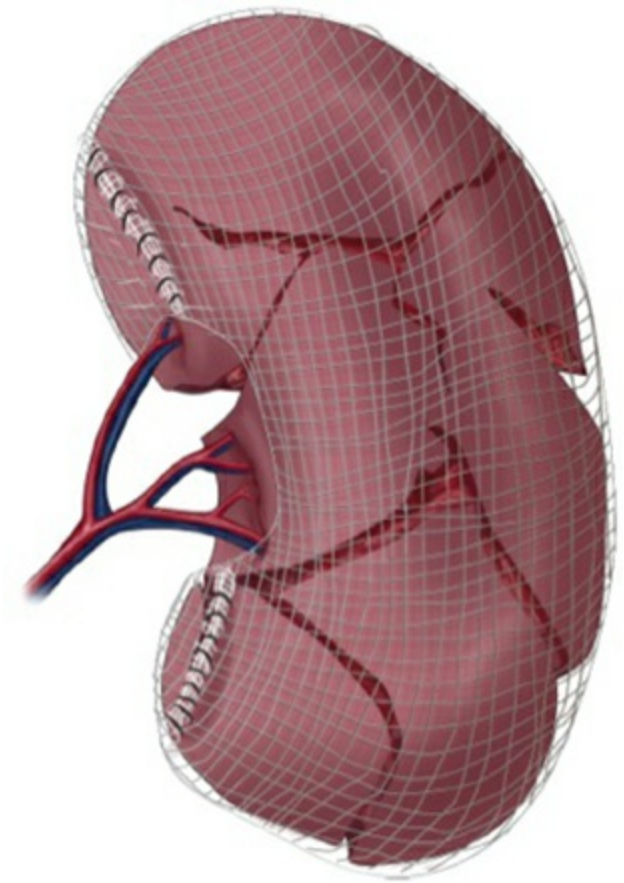

Figure 25-15. Splenic preservation with use of an absorbably mesh bag. (With permission Demetriades D, Inaba K, Velmahos G, eds. *Atlas of Surgical Techniques in Trauma.* New York, NY: Cambridge University Press; 2015.)

Postsplenectomy infections may occur early or late. There is evidence that splenectomy is associated with an increased risk of early postsplenectomy infections. A recent prospective observational, multicenter study of 269 patients with blunt splenic injury surviving at least 72 hours, reported that splenectomy had a significantly higher incidence of infectious complications than splenic preservation.[59] A regression analysis identified splenectomy as an independent risk factor for infectious complications.

Overwhelming postsplenectomy infection (OPSI) is a rare but life-threatening complication, especially in children. The reported mortality varies from 10% to 80%. Encapsulated organisms, such as *Haemophilus influenza, Streptococcus pneumonia,* and *Neisseria meningococcus* are the most common pathogens. Although the majority of infections occur within the first 3 to 4 years, OPSI may occur at any time after splenectomy. The Surgical Infection Society recommends that all splenectomized patients 2 to 64 years old receive the 23-valent pneumococcal vaccine.[60] In addition, high-risk patients should receive *Haemophilus influenza* and Meningococcal vaccines. The timing of administration of the vaccines after trauma may be optimal at 14 days after splenectomy.[61] There is no evidence to support routine long-term prophylactic antibiotic administration in splenectomized patients. Patients should be educated on postsplenectomy sepsis, wear a medical alert bracelet, inform caregivers of their asplenic state, and be advised to seek medical care with the onset of any signs of infection.

PANCREAS

Anatomy

The pancreas is a retroperitoneal organ with its head directly situated over the inferior vena cava and its neck over the superior mesenteric vessels and the proximal portal vein. The body extends over the suprarenal aorta and the left renal vessels, closely related to the splenic artery and vein. The uncinate process wraps around the superior mesenteric vessels. As described for the spleen, the splenic vein courses inferior to the splenic artery and joins the superior mesenteric vein at a right angle to form the portal vein behind the neck of the pancreas. The inferior mesenteric vein drains into the splenic vein behind the body of the pancreas (Figs. 25-16 and 25-17).

The major pancreatic duct of Wirsung travels down the entire length of the pancreas and drains into the ampulla of Vater, approximately 8 cm downstream from the pylorus. The lesser duct of Santorini branches off the superior aspect of the major duct, at the level of the neck of the pancreas. This drains into the duodenum, approximately 2 to 3 cm proximal to the ampulla of Vater. The pancreatic head and the proximal duodenum receive their blood supply from the anterior and posterior pancreaticoduodenal arcades. Because these arcades lie on the surface of the pancreas, close to the duodenal loop, separating these can result in ischemic damage to the duodenum.

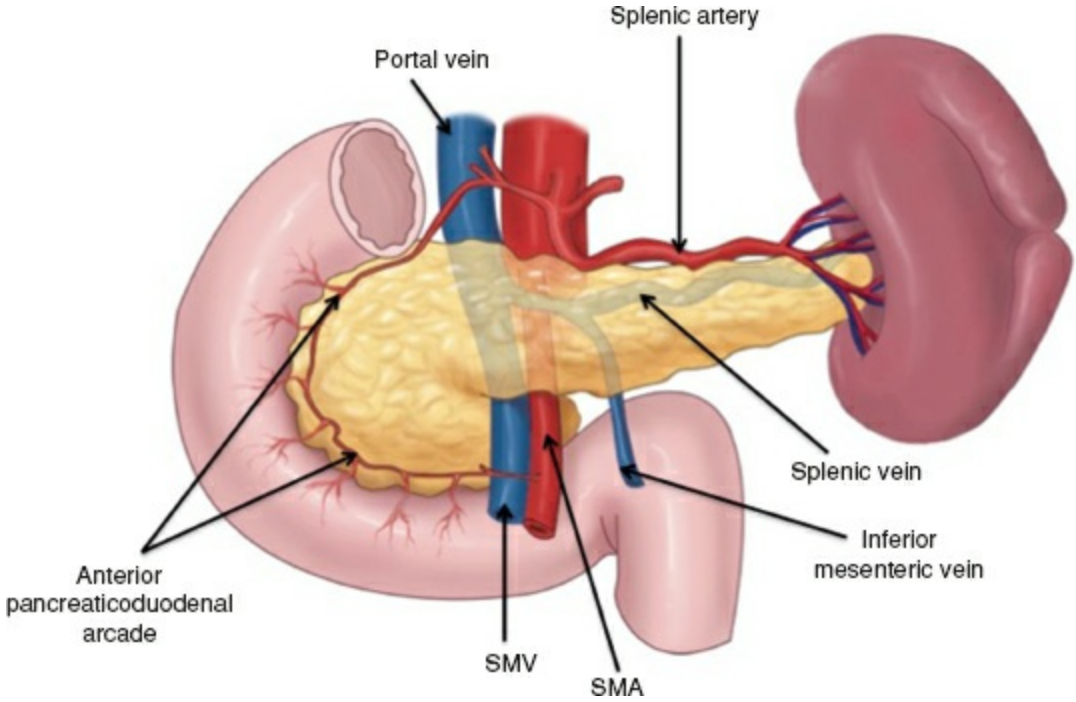

Figure 25-16. Pancreatic anatomy demonstrating relationship to vascular structures and spleen. (With permission Demetriades D, Inaba K, Velmahos G, eds. *Atlas of Surgical Techniques in Trauma.* New York, NY: Cambridge University Press; 2015.)

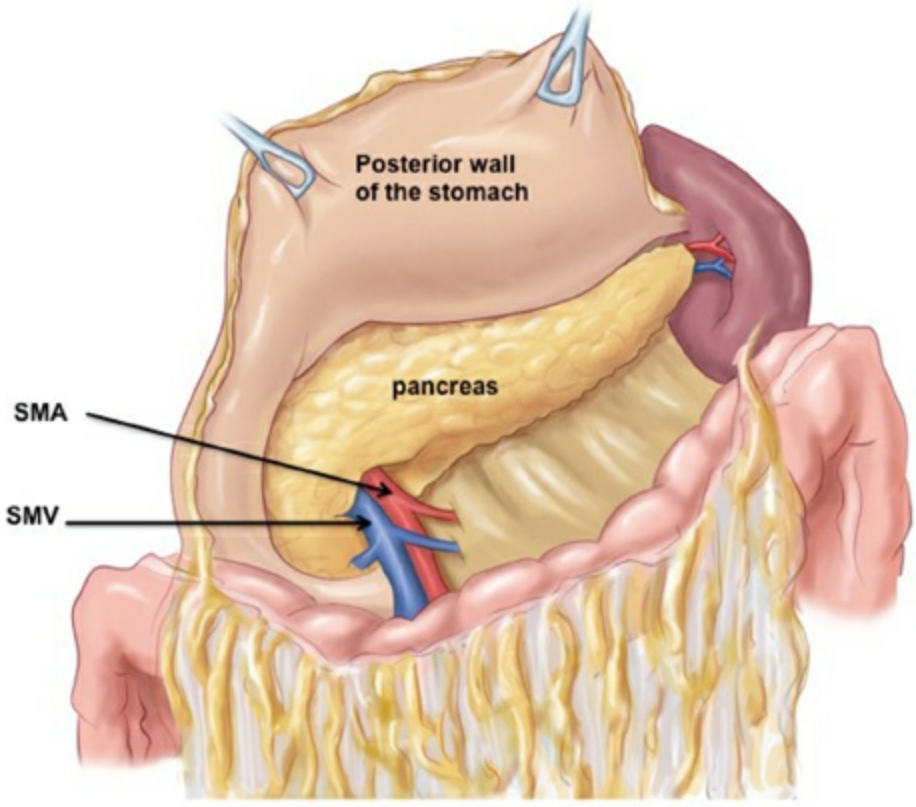

Figure 25-17. Pancreatic anatomy demonstrating relationship to stomach. (With permission Demetriades D, Inaba K, Velmahos G, eds. *Atlas of Surgical Techniques in Trauma.* New York, NY: Cambridge University Press; 2015.)

Epidemiology

Pancreatic trauma is seen in approximately 0.2% of blunt trauma and about 1% of penetrating trauma patients. Overall, about 60% of patients with blunt trauma and about 90% with penetrating trauma will have associated intra-abdominal injuries. The most commonly associated injury in blunt trauma is the spleen. Duodenal injuries are found in less than 10% of the patients. In penetrating trauma, the most commonly associated injuries are the stomach, closely followed by the liver. Associated intra-abdominal vascular injuries are common in penetrating injuries and are found in more than 75% of penetrating injuries to the head of the pancreas. A concomitant major vascular injury increases the likelihood of a poor outcome. The most widely used grading system (Table 25-3) is the OIS-AAST.[45] The classification is based on CT and operative findings.

Table 25-3 OIS-AAST Grading Scale for the Pancreas

Grade[a]	Type	Injury Description
I	Hematoma	Minor contusion without duct injury
	Laceration	Superficial laceration without duct injury
II	Hematoma	Major contusion without duct injury or tissue loss
	Laceration	Major laceration without duct injury or tissue loss
III	Laceration	Distal transection or parenchymal injury with duct injury
IV	Laceration	Proximal transection or parenchymal injury involving ampulla
V	Laceration	Massive disruption of pancreatic head

[a]Advance one grade for multiple injuries to the same organ.
Moore EE, Cogbill TH, Malangoni MA, et al. Organ injury scaling, II: pancreas, duodenum, small bowel, colon, and rectum. *J Trauma* 1990;30:1427–1429.

Diagnostics

The diagnosis of penetrating pancreatic injury is usually made intraoperatively. The diagnosis in blunt trauma, especially for isolated injuries, may be difficult because the initial symptoms may be occult. Clinical signs may take hours or even days to manifest. Serial serum amylase and lipase levels may be useful as a screening test for pancreatic trauma but isolated values have poor sensitivity and specificity. Contrast-enhanced CT scan (Fig. 25-18) is the investigation of choice in suspected pancreatic trauma.[62,63] Its accuracy increases with time from injury and in cases with an equivocal initial test, a repeat CT scan 6 to 8 hours after the initial investigation should be considered. MRCP or ERCP can be considered in selected cases with pancreatic trauma to establish the integrity of the pancreatic duct.[64,65]

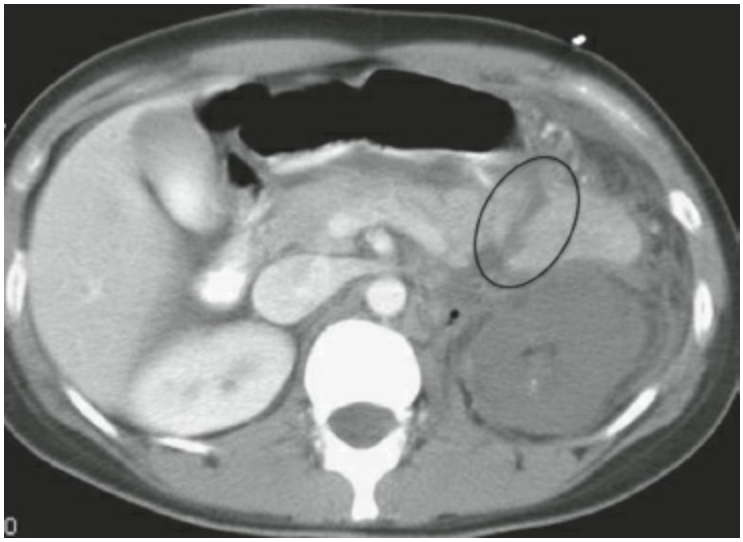

Figure 25-18. CT image of pancreatic transection after blunt trauma. Oval demonstrates the pancreatic transection.

Treatment

The management of pancreatic trauma is determined by the mechanism of injury and the presence or absence of pancreatic duct injury. All penetrating injuries require operative management. However, most patients with isolated blunt trauma to the pancreas with an intact pancreatic duct can safely be managed non-operatively. A National Pediatric Trauma Registry study of pancreatic injuries in 154 children, reported that non-operative management was successful in approximately half of high-grade injuries and in approximately 80% of low-grade injuries.[66] Other studies have confirmed the safety and high success rate of non-operative management in children.[67,68] The success rate of non-operative managment in adults however is significantly lower, in part due to the higher incidence of pancreatic duct injury which is less than 1% in children, but approximately 15% in adults. The safety of selective non-operative managment in adults has been confirmed in many studies.[69,70]

Non-operative management is safe for low-grade injuries and many selected higher-grade injuries, especially in children. For higher-grade injuries, the integrity of the pancreatic duct should be evaluated with ERCP or MRCP. ERCP can also be therapeutic with pancreatic duct stent placement, as definitive treatment. Complications associated with non-operative management include pancreatic pseudocyst and pancreatitis. There is no evidence that the use of somatostatin analogs increases the success rate of non-operative management and they should not be used routinely.

For patients undergoing operative management, the pancreas is exposed through the lesser sac. This allows access to the anterior, superior, and inferior surfaces of the body and tail of the pancreas. The posterior aspect of the pancreas can be mobilized by incising the peritoneum over the inferior border of the pancreas and retracting upward. If more extensive mobilization is required for the distal pancreas, this can be achieved by en-block mobilization and medial rotation of the spleen and tail of the pancreas. For the head and uncinate processes, exposure is achieved with an extended Kocher maneuver.

As a general rule, all peripancreatic hematomas should be explored to examine for any underlying ductal injuries. However, hematomas localized to the head of the pancreas may be left undisturbed, because the duct in this area is deep in the parenchyma and exploration is difficult and potentially dangerous. These injuries should be drained externally with closed drains and postoperatively the integrity of the duct can be evaluated using MRCP or ERCP and treated with stenting.[65,71]

Low-grade injuries without obvious ductal disruption should be treated with the debridement of nonviable tissue, hemostasis, and wide external drainage. For severe parenchymal injuries with known or suspected ductal disruption, the optimal procedure will depend on the condition of the patient and the site of the pancreatic injury (head and neck vs. tail). Severe pancreatic injuries involving the body to the left of the superior mesenteric vessels are best treated by distal pancreatectomy, with or without splenic preservation (Fig. 25-19). For destructive injuries to the head of the pancreas, especially with concurrent duodenal injury, if the operative procedure is to undergo damage control, or if this is beyond the skill set of the operating surgeon, the safest option is

hemostasis and external drainage. Damage control packing and temporary abdominal closure with delayed resection and reconstruction can be performed. If however, a pancreaticoduodenectomy is to be performed, even for hemodynamically stable patients with an experienced surgeon, a two-stage procedure is highly recommended. The initial operation includes temporary control of bleeding by means of packing and in the appropriate cases, arterial shunting or if there is a concomitant venous injury, ligation. The duodenal and pancreatic head resection is performed and the common bile duct is ligated or drained externally. The definitive reconstruction should be performed only after normalization of the patient's physiology. The reconstruction, which includes pancreaticojejunostomy, choledochojejunostomy, and gastroenterostomy, is similar to that in elective cases and should be performed with expert assistance in an optimized patient.

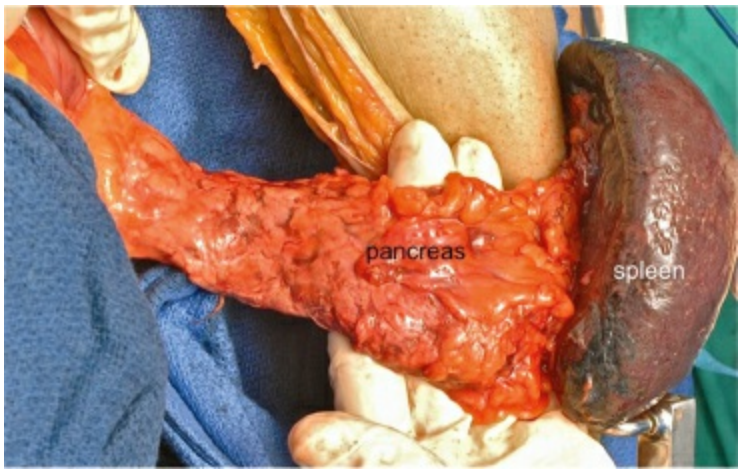

Figure 25-19. Distal pancreatectomy specimen with splenectomy specimen after blunt trauma.

Pancreas-related local complications occur in about 25% of patients and include pancreatic fistulas, pseudocysts, pancreatitis, and perihepatic infection. Most of these complications can successfully be managed non-operatively or with percutaneous drainage and endoscopic stenting of the duct.[71] Endocrine and exocrine pancreatic insufficiencies may occur after major pancreatic resections, but the true incidence of this remains unknown. Patients undergoing major pancreatic resections should be monitored on a regular basis, at least during the first few months after the operation. For those who underwent a pancreaticoduodenectomy and survived, late stricture of the choledochojejunostomy is not uncommon, because of the small size of the common bile duct. The stricture may manifest many months after the operation and thus it is recommended that these patients are followed regularly, especially during the first few months after the injury.

STOMACH

Anatomy

The stomach is a hollow viscus organ located in the left upper quadrant of the abdomen with the fundus, GE junction, and often a significant portion of the body lying above the costal margin. The stomach has a robust blood supply including the left and right gastric arteries, the right and left gastroepiploic arteries, and the short gastric arteries. This level of vascularity can result in significant bleeding after injury but also provides redundancy, making devascularization and necrosis of the stomach relatively rare after trauma.

Diagnostics

Gastric injury usually results from either significant blunt force trauma or after penetrating trauma to the left upper abdomen or lower chest. Presence of blood upon placement of an NG tube is concerning for gastric injury. The majority of patients with full-thickness gastric injury after trauma will present with spillage of gastric contents and peritonitis resulting in direct transfer to the operating room. Blunt injury to the stomach can cause local contusion with gastric wall hematoma or hollow viscus rupture, similar to bladder rupture, with a large full-thickness defect.

After blunt or penetrating trauma, in the absence of peritonitis or hemodynamic instability, additional diagnostic workup with CT imaging is appropriate. CT scan findings concerning gastric injury include extraluminal contrast, air, blood, or fluid, or localized thickening, or enhancement and discontinuity of the gastric wall.[72–74]

Treatment

Gastric repair is generally well tolerated due to the redundancy of tissue and blood supply of the stomach. After penetrating injury, if a single gastric injury is identified, the operating surgeon must assume there is an additional injury corresponding to the entry or exit site. A single gastric injury is exceedingly rare and even a linear laceration should not be mistaken for a tangential wound unless meticulous inspection has ruled out an additional enterotomy. The anterior border of the stomach is fully inspected from the esophagus to the pylorus. The left lobe of the liver may need to be retracted or mobilized for better visualization of the proximal third of the stomach. The posterior aspect of the stomach is evaluated by accessing the lesser sac below the gastroepiploic vessels. The posterior gastric wall must be fully evaluated and visualized all the way up to the GE junction to avoid missed injury. Blood or fluid upon entry into the lesser sac should alert the surgeon to a likely gastric and/or pancreatic injury. Care must be taken when inspecting the GE junction and greater curvature not to apply excess tension on the gastric fundus as this may result in iatrogenic splenic capsular tear or laceration.

Low-grade injuries including hematomas and contusions should be evaluated and evacuated as appropriate. After hematoma evacuation and hemostasis is achieved, the area may be reinforced with Lembert sutures. Full-thickness injuries can be repaired in one or two layers. A two-layered repair includes an inner layer of running absorbable suture and an outer layer of Lembert sutures. Injuries of the greater curvature or larger injuries of the body can be controlled with a stapling device and wedge resection. In gunshot injuries, it is important to debride the devitalized tissue surrounding the injury prior to repair. Given the tissue redundancy of the stomach, stapling devices may be used liberally for wedge resection. Care must be taken, however, to avoid narrowing the GE junction or pylorus. Injuries involving the pylorus may be incorporated into a pyloroplasty for repair.

Significant destructive injuries or those involving the GE junction or pylorus may require a proximal or distal gastrectomy with reconstruction. In rare cases, a total gastrectomy with esophagojejunostomy is required. Proximal gastric injuries or those at the GE junction may present a technical challenge for surgeons not accustomed to these operations. Attempts to repair these complex injuries without appropriate experience can lead to significant morbidity and mortality for the patient. In such cases, a two-staged procedure should be considered. At the initial operation, the distal esophagus or proximal stomach may be stapled and internally drained with a nasogastric tube thus controlling the injury in a damage control manner. An additional staple line distal to the injury will prevent reflux contamination. The area may be drained and the patient stabilized with a delayed reconstruction performed under optimal conditions with all of the requisite expertise present.

DUODENUM

Anatomy

The duodenum is the first portion of the small intestine and forms a C-loop around the head of the pancreas. The duodenum is divided into four parts, an anatomic distinction that can help guide management of traumatic injury. The first portion is intraperitoneal and associated with the portal structures and the gastroduodenal artery. The second and third portions are retroperitoneal and curve around the head of the pancreas. The common bile and pancreatic ducts drain into the ampulla in the second portion of the duodenum. The fourth portion of the duodenum ascends to the ligament of Treitz to join the jejunum.



Figure 25-20. Gunshot injury to duodenum just proximal to the ligament of Treitz.

Epidemiology

Duodenal trauma is rare, occurring in less than 5% of all trauma patients, and is associated with a high morbidity and mortality.[75–77] Patients with duodenal trauma frequently have additional intra-abdominal injury, most commonly of the liver, pancreas, and small bowel.

Treatment

Most low-grade duodenal hematomas secondary to blunt trauma without perforation can be managed conservatively with NG tube decompression and supplemental nutrition. The majority of duodenal trauma, however, is secondary to penetrating injury (Fig. 25-20) and is identified during operative exploration. Duodenal hematomas encountered intraoperatively require exploration to evaluate for underlying perforation.

Mobilization of the duodenum is most commonly achieved with a Kocher maneuver. This allows for medialization of the second and third portions of the duodenum, evaluation of the posterior wall, and exposure of the underlying vascular structures to examine for injury. Separation of the second portion of the duodenum from the head of the pancreas is not advised as disruption of the blood supply puts the duodenum at high risk of ischemia.

Most duodenal injuries can be repaired primarily in one or two layers with a transverse closure to avoid luminal narrowing. Segmental resection is rarely needed but, in the event of injury $>50\%$ of the duodenal circumference, resection with primary, end-to-end anastomosis may be performed when appropriate. Segmental resection is not recommended for the second portion of the duodenum due to the presence of the ampulla and inability to mobilize the medial wall. In complex injuries, pyloric exclusion with gastrojejunostomy may be utilized to protect the repair, however, routine exclusion should not be used for all duodenal injuries. In an analysis of 193 consecutive patients with duodenal injuries, pyloric exclusion offered no morbidity or mortality benefit over primary repair.[78] If performed, external stapling of the pylorus with a TA stapler and internal cerclage with a suture are both acceptable techniques for pyloric exclusion. Most frequently, a gastrojejunostomy to restore continuity is performed. Additional surgical adjuncts include a serosal patch and duodenojejunostomy. In the unstable patient, damage control techniques may be safely applied to duodenal injury with delayed repair or diversion.[79] The traumatic Whipple is rarely indicated and carries a high mortality.[80,81] This should be considered only in patients with complex destructive injuries to the duodenum and pancreas. In these cases, the provider should focus on a damage control procedure with control of contamination and associated hemorrhage as the goals of the index operation. The subsequent reconstruction should be performed in a stabilized patient, most commonly in a staged manner, with expert assistance available. Liberal use of closed suction drainage is recommended after duodenal injury and/or repair.

One of the major complications after duodenal injury repair is fistula formation, occurring in 4% to 33% of patients.[76,79,82] These are managed, when possible, with percutaneous drainage. In rare cases, reoperation and repair or diversion is required.

COLON

Epidemiology

Colon injuries occur in approximately 30% of abdominal GSWs and 20% of SWs undergoing laparotomy. In blunt trauma, approximately 10% of patients undergoing laparotomy will have a colon injury. Many of the blunt trauma injuries are superficial with only 3% of patients undergoing laparotomy having a full-thickness perforation. The presence of an external seatbelt mark sign is associated with an increased risk of colon injury.

Diagnostics

The definitive diagnosis of colon injury is almost always made intraoperatively. Preoperative diagnosis of colon injury following blunt trauma is difficult, especially in unevaluable patients. If a CT is obtained, mesenteric stranding, bowel wall thickening, and unexplained fluid can be seen, increasing the level of suspicion for a bowel perforation. Free extraluminal air is rare. Intraoperatively, all colonic hematomas should be explored to rule out any underlying colon injury without devascularizing the wall. Particular care should be taken for penetrating injuries, especially due to shotgun wounds, where the injury can be hidden within the fat.

The severity of colon injury can be graded by the OIS-AAST colon injury scale (Table 25-4), which is based on the operative findings.[45] A practical classification used by many surgeons breaks injuries down into two severity groups, nondestructive injuries involving $<50\%$ of the bowel wall without devascularization versus destructive injuries which involve $>50\%$ of the bowel wall or demonstrate devascularization.

Treatment

The management of colon injuries has undergone major changes over the last two decades.[83–85] For nondestructive injuries there is sufficient class I and class II evidence supporting primary repair irrespective of risk factors, such as the site of colon injury, associated injuries, or physiologic status.[86–88]

For destructive colon injuries, defined as those with loss of >50% of the bowel wall circumference or with devascularization, segmental colonic resection is required. The management of these cases is controversial. These injuries were traditionally managed with diversion because of the perceived high risk for anastomotic leak and intra-abdominal sepsis. Although the safety of primary anastomosis was demonstrated in several small studies,[86–88] for specific circumstances such as a penetrating abdominal trauma index ≥25 or hypotension or large-volume blood transfusions or patient comorbidities, the potential benefit of diversion remains unclear.[88,89]

Table 25-4 OIS-AAST Grading Scale for the Colon

Grade[a]	Type	Injury Description
I	Hematoma	Contusion or hematoma without devascularization
	Laceration	Partial thickness, no perforation
II	Laceration	Laceration <50% of circumference
III	Laceration	Laceration ≥50% of circumference without transection
IV	Laceration	Transection of the colon
V	Laceration	Transection of the colon with segmental tissue loss
	Vascular	Devascularized segment

[a]Advance one grade for multiple injuries to the same organ.
Moore EE, Cogbill TH, Malangoni MA, et al. Organ injury scaling, II: pancreas, duodenum, small bowel, colon, and rectum. *J Trauma* 1990; 30:1427–1429.

The Eastern Association for the Surgery of Trauma (EAST) guidelines based largely on class III evidence recommended that diversion be considered in patients with shock, significant associated injuries, peritonitis, or underlying disease.[90] Since these were published, a more recent American Association for the Surgery of Trauma prospective multicenter study examined 297 patients with penetrating colon injuries requiring resection.[91] This was a prospective observational study examining the outcomes associated with diversion versus primary anastomosis without diversion. The overall colon-related mortality was 1.3% and all deaths occurred in the diversion group. The incidence of anastomotic leaks was 6.6%. Multivariate analysis identified severe fecal contamination, >4 units of blood transfusions within the first 24 hours, and antibiotic choice as independent risk factors for abdominal complications. The method of colon management, anastomosis, or diversion did not impact outcomes. In addition, delay of operation >6 hours, shock at admission, site of colon injury, penetrating abdominal

trauma index >25, ISS >20, or associated intra-abdominal injuries were also found to have no association with a negative outcome. Based on the available data, for both blunt and penetrating destructive injuries, if the patient meets criteria for a damage control procedure, contamination control with stapling of the colon should be performed. Whenever possible, an anastomosis should be performed at the index operation, but this is only if the patient is able to tolerate the additional operative burden. For stable patients not requiring damage control, the anastomosis should be performed without diversion. The choice of a stapled versus hand-sewn anastomosis has been shown not to make a difference.[92] In a prospective study of 207 patients undergoing resection and anastomosis, the leak rate was 7.8% for hand-sewn and 6.3% for stapled anastomoses. For edematous bowel, often seen at the take back after an initial damage control resection, a hand-sewn anastomosis may be preferred.

Abdominal complications after colon injuries are common, with an abdominal sepsis rate of approximately 20%. Independent risk factors associated with an increased incidence of abdominal sepsis include fecal spillage, blood transfusions exceeding four units of blood within the first 24 hours, and the presence of chronic comorbid conditions. Retained bullets that have passed through the colon are not associated with an increased risk of infection and therefore their routine removal is not required.[93]

Colonic leaks causing abdominal sepsis after repair or resection and anastomosis have been examined in detail. For primary repairs, in a review of 35 prospective or retrospective studies including 2,964 primary repairs, a leak rate of 2.2% was seen.[94] For patients undergoing resection and anastomosis, which are more likely to leak, the rate was 5.5%.[94] In the multicenter AAST study of 197 patients undergoing resection and primary anastomosis, the leak rate was 6.6%.[91] Anastomotic leaks occur more commonly with a colon–colon anastomosis when compared to an ileocolic anastomosis. In the AAST study the leak rate was 4.2% for ileocolostomies and 8.9% for colocolostomies.[91]

The majority of leaks can be managed non-operatively with percutaneous drainage. They are usually small and seal off on their own. CT imaging should be obtained to examine for the presence of any intra-abdominal collections and to guide drainage. Reexploration of the abdomen for drainage and either fecal diversion or resection and reanastomosis is only required if the patient fails percutaneous drainage or develops evidence of generalized peritonitis.

For patients who require a colostomy, there is a significant complication burden associated with the colostomy itself as well as the subsequent closure. In a large series of 528 stomas performed in the trauma setting, approximately 22% of patients sustained an early complication and 3% a late complication.[95] In another study of 110 colostomy closures, a local complication rate of 14.5% was noted.[96]

RECTUM

Anatomy

As the colon continues downstream, the rectum begins where the tenia coli coalesce as the terminal part of the large intestine. The rectum is approximately 12- to 15-cm long and is both intra- and extraperitoneal. Anteriorly, the upper two-thirds and laterally the upper one-third are intraperitoneal, with the lower third being completely extraperitoneal. The blood supply is derived from the superior rectal artery branching from the inferior mesenteric artery, the middle rectal artery from the internal iliac artery, and the inferior rectal artery which is from the internal pudendal artery.

Epidemiology

Most rectal injuries result from a penetrating mechanism, usually secondary to GSWs although anally inserted foreign body trauma and endoscopic trauma are also seen. Because of its protected location, blunt injury is only seen in approximately 5% to 10% of injuries, and is often associated with a pelvic fracture.

Diagnostics

The clinical presentation of rectal injuries that are intraperitoneal does not differ from that of colon injuries. For extraperitoneal injuries, the clinical symptomatology can be masked by containment of the perforation in the retroperitoneal tissues. As a direct consequence, operative exploration, direct visualization on anoscopy and sigmoidoscopy, or CT rather than clinical examination is used to make the diagnosis.

For blunt trauma patients, because the majority of injuries are in the intraperitoneal segment, the same diagnostic principles for colonic injuries apply. For penetrating injuries, both intraperitoneal and extraperitoneal injuries can occur. The diagnostic approach depends on the patient's clinical presentation. Patients with peritonitis, instability, or who are unexaminable should proceed directly to the operating room. For unstable patients, positioning should be supine with an emphasis on the laparotomy and hemorrhage control. Intraoperative sigmoidoscopy and anoscopy can be performed to examine the extraperitoneal segment of the rectum. For those that have peritonitis or instability, the patient may be placed in lithotomy to facilitate sigmoidoscopy and anoscopy. For those who are stable and who meet the criteria for a trial of non-operative management, the highest-yield initial examination is CT (Fig. 25-21). On the CT, the bullet trajectory is tracked. If the trajectory appears to traverse the rectum, the patient can be brought to the operating room, placed in lithotomy and a laparotomy performed. Preoperative or intraoperative sigmoidoscopy and anoscopy can be performed to examine the extraperitoneal segment of the rectum. If the tract is clear of the rectum on CT, no further investigations or treatment is required. For the equivocal CT scan where there is a questionable rectal injury, several options exist. The patient can be brought to the operating room for a laparotomy, sigmoidoscopy, and anoscopy. Another option is to perform diagnostic laparoscopy to look for intraperitoneal breach as well as a sigmoidoscopy and anoscopy. Any entry into the peritoneal cavity can then trigger a laparotomy and closer evaluation.

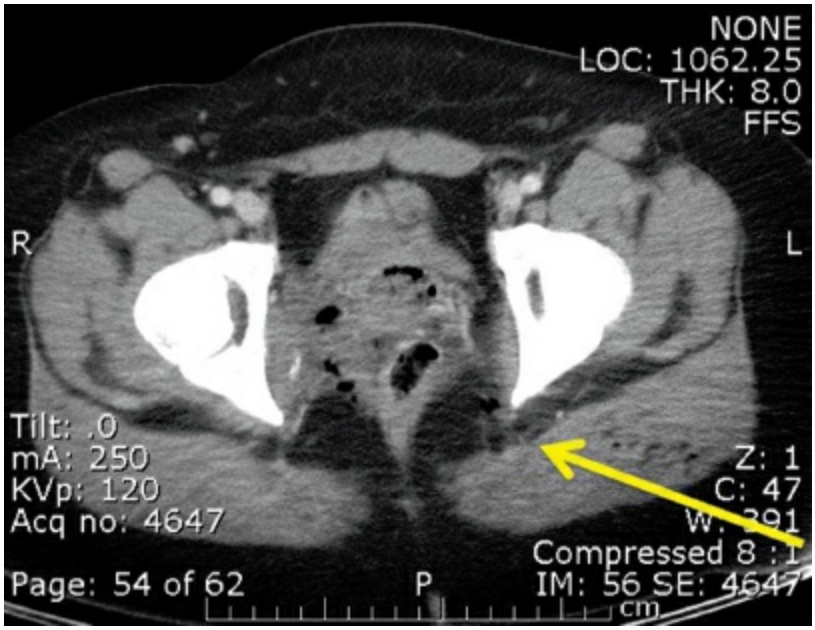

Figure 25-21. CT demonstrating a gunshot wound tract traversing the rectum, *arrow* demonstrates bullet tract.

For intraperitoneal injuries, the management principles are the same as those that apply to colon injuries. The vast majority undergo primary repair without the need for diversion. For extraperitoneal injuries, the management has evolved over the last decade. The classic approach to rectal injuries which included diversion, presacral drainage, and distal rectal washout is no longer performed.[97–106]

For distal extraperitoneal injuries that are accessible through a transanal approach, local repair can be performed without colostomy.[99,105,106] For higher extraperitoneal injuries inaccessible in this manner, the primary treatment is fecal diversion without taking down the rectum and repairing the injury.[103,104] This can even be done laparoscopically with a low rate of morbidity. In fact, the absolute need for colostomy has not even been demonstrated. Theoretically, diversion allows for decreasing the fecal flow past the unrepaired injury augmenting the healing process. Even after diversion, as there is some fecal flow past the injury at least initially during the early phases of healing, the true value of colostomy is questionable.

If there is an associated bladder injury, a tissue barrier using omentum should be placed between the suture lines as a method of decreasing rectovesical fistula formation, a complication seen in upward of a quarter of patients with combined injuries.[107] In the rare case where there is a combined destructive anorectal injury (Fig. 25-22), acutely, hemostasis and diversion are recommended. Once the patient has been stabilized, assessment of the anal sphincter function should be performed, and semielective reconstruction should be performed by a colorectal specialist.



Figure 25-22. Large perineal and groin avulsion injury after pedestrian struck by train.

References

1. Stannard A, Eliason JL, Rasmussen TE. Resuscitative endovascular balloon occlusion of the aorta (REBOA) as an adjunct for hemorrhagic shock. *J Trauma* 2011;71(6):1869–1872.
2. Rhee PM, Acosta J, Bridgeman A, et al. Survival after emergency department thoracotomy: review of published data from the past 25 years. *J Am Coll Surg* 2000;190(3):288–298.
3. Velmahos GC, Tatevossian R, Demetriades D. The “seat belt mark” sign: a call for increased vigilance among physicians treating victims of motor vehicle accidents. *Am Surg* 1999;65(2):181–185.
4. Sharma OP, Oswanski MF, Kaminski BP, et al. Clinical implications of the seat belt sign in blunt trauma. *Am Surg* 2009;75(9):822–827.
5. Brown CV, Velmahos GC, Neville AL, et al. Hemodynamically “stable” patients with peritonitis after penetrating abdominal trauma: identifying those who are bleeding. *Arch Surg* 2005;140(8):767–772.
6. Teixeira PG, Inaba K, Oncel D, et al. Blunt cardiac rupture: a 5-year NTDB analysis. *J Trauma* 2009;67(4):788–791.
7. Gaines BA. Intra-abdominal solid organ injury in children: diagnosis and treatment. *J Trauma* 2009;67(2 suppl):S135–S139.
8. Schroeppel TJ, Croce MA. Diagnosis and management of blunt abdominal solid organ injury. *Curr Opin Crit Care* 2007;13(4):399–404.
9. Shaftan GW. Selective conservatism in penetrating abdominal trauma. *J Trauma* 1969;9(12):1026–1028.
10. Jansen JO, Inaba K, Resnick S, et al. Selective non-operative management of abdominal gunshot wounds: survey of practise. *Injury* 2013;44(5):639–644.
11. Navsaria PH, Nicol AJ, Edu S, et al. Selective nonoperative management in 1106 patients with abdominal gunshot wounds: conclusions on safety, efficacy, and the role of selective CT imaging in a prospective single-center study. *Ann Surg* 2015;261(4):760–764.
12. Inaba K, Demetriades D. The nonoperative management of penetrating abdominal trauma. *Adv Surg* 2007;41:51–62.
13. Leppaniemi A, Salo J, Haapiainen R. Complications of negative laparotomy for truncal stab wounds. *J Trauma* 1995;38(1):54–58.
14. Renz BM, Feliciano DV. Unnecessary laparotomies for trauma: a prospective study of morbidity. *J Trauma* 1995;38(3):350–356.
15. Renz BM, Feliciano DV. The length of hospital stay after an unnecessary laparotomy for trauma: a prospective study. *J Trauma* 1996;40(2):187–190.
16. Hasaniya N, Demetriades D, Stephens A, et al. Early morbidity and mortality of non-therapeutic operations for penetrating trauma. *Am Surg* 1994;60(10):744–747.

17. Arikan S, Kocakusak A, Yucel AF, et al. A prospective comparison of the selective observation and routine exploration methods for penetrating abdominal stab wounds with organ or omentum evisceration. *J Trauma* 2005;58(3):526–532.
18. Velmahos GC, Demetriades D, Toutouzas KG, et al. Selective nonoperative management in 1,856 patients with abdominal gunshot wounds: should routine laparotomy still be the standard of care? *Ann Surg* 2001;234(3):395–402; discussion 402–403.
19. Biffl WL, Kaups KL, Pham TN, et al. Validating the Western Trauma Association algorithm for managing patients with anterior abdominal stab wounds: a Western Trauma Association multicenter trial. *J Trauma* 2011;71(6):1494–1502.
20. Demetriades D, Rabinowitz B, Sofianos C, et al. The management of penetrating injuries of the back. A prospective study of 230 patients. *Ann Surg* 1988;207(1):72–74.
21. Velmahos GC, Demetriades D, Foianini E, et al. A selective approach to the management of gunshot wounds to the back. *Am J Surg* 1997;174(3):342–346.
22. Velmahos GC, Demetriades D, Cornwell EE 3rd. Transpelvic gunshot wounds: routine laparotomy or selective management? *World J Surg* 1998;22(10):1034–1038.
23. Burnweit CA, Thal ER. Significance of omental evisceration in abdominal stab wounds. *Am J Surg* 1986;152(6):670–673.
24. Nagy K, Roberts R, Joseph K, et al. Evisceration after abdominal stab wounds: is laparotomy required? *J Trauma* 1999;47(4):622–624; discussion 624–626.
25. Soffer D, McKenney MG, Cohn S, et al. A prospective evaluation of ultrasonography for the diagnosis of penetrating torso injury. *J Trauma* 2004;56(5):953–957; discussion 957–959.
26. Udobi KF, Rodriguez A, Chiu WC, et al. Role of ultrasonography in penetrating abdominal trauma: a prospective clinical study. *J Trauma* 2001;50(3):475–479.
27. Boulanger BR, Kearney PA, Tsuei B, et al. The routine use of sonography in penetrating torso injury is beneficial. *J Trauma* 2001;51(2):320–325.
28. Velmahos GC, Constantinou C, Tillou A, et al. Abdominal computed tomographic scan for patients with gunshot wounds to the abdomen selected for nonoperative management. *J Trauma* 2005;59(5):1155–1160; discussion 1160–1161.
29. Munera F, Morales C, Soto JA, et al. Gunshot wounds of abdomen: evaluation of stable patients with triple-contrast helical CT. *Radiology* 2004;231(2):399–405.
30. Inaba K, Okoye OT, Rosenheck R, et al. Prospective evaluation of the role of computed tomography in the assessment of abdominal stab wounds. *JAMA Surg* 2013;148(9):810–816.
31. Salim A, Sangthong B, Martin M, et al. Use of computed tomography in anterior abdominal stab wounds: results of a prospective study. *Arch Surg* 2006;141(8):745–750; discussion 750–752.
32. Demetriades D, Hadjizacharia P, Constantinou C, et al. Selective nonoperative

management of penetrating abdominal solid organ injuries. *Ann Surg* 2006;244(4):620–628.

33. DuBose J, Inaba K, Teixeira PG, et al. Selective non-operative management of solid organ injury following abdominal gunshot wounds. *Injury* 2007;38(9):1084–1090.
34. Inaba K, Branco BC, Moe D, et al. Prospective evaluation of selective nonoperative management of torso gunshot wounds: when is it safe to discharge? *J Trauma Acute Care Surg* 2012;72(4):884–891.
35. Inaba K, Barmparas G, Foster A, et al. Selective nonoperative management of torso gunshot wounds: when is it safe to discharge? *J Trauma* 2010;68(6):1301–1304.
36. Alzamel HA, Cohn SM. When is it safe to discharge asymptomatic patients with abdominal stab wounds? *J Trauma* 2005;58(3):523–525.
37. Murray JA, Demetriades D, Asensio JA, et al. Occult injuries to the diaphragm: prospective evaluation of laparoscopy in penetrating injuries to the left lower chest. *J Am Coll Surg* 1998;187(6):626–630.
38. Murray JA, Demetriades D, Cornwell EE 3rd, et al. Penetrating left thoracoabdominal trauma: the incidence and clinical presentation of diaphragm injuries. *J Trauma* 1997;43(4):624–626.
39. Leppaniemi A, Haapiainen R. Occult diaphragmatic injuries caused by stab wounds. *J Trauma* 2003;55(4):646–650.
40. Rotondo MF, Schwab CW, McGonigal MD, et al. 'Damage control': an approach for improved survival in exsanguinating penetrating abdominal injury. *J Trauma* 1993;35(3):375–382; discussion 382–383.
41. Subramanian A, Vercruysse G, Dente C, et al. A decade's experience with temporary intravascular shunts at a civilian level I trauma center. *J Trauma* 2008;65(2):316–324; discussion 324–326.
42. Demetriades D. Balloon tamponade for bleeding control in penetrating liver injuries. *J Trauma* 1998;44(3):538–539.
43. Raeburn CD, Moore EE, Biffl WL, et al. The abdominal compartment syndrome is a morbid complication of postinjury damage control surgery. *Am J Surg* 2001;182(6):542–546.
44. Bocchini G, Guida F, Sica G, et al. Diaphragmatic injuries after blunt trauma: are they still a challenge? Reviewing CT findings and integrated imaging. *Emerg Radiol* 2012;19(3):225–235.
45. Moore EE, Moore FA. American Association for the Surgery of Trauma Organ Injury Scaling: 50th anniversary review article of the Journal of Trauma. *J Trauma* 2010;69(6):1600–1601.
46. Pachter HL, Knudson MM, Esrig B, et al. Status of nonoperative management of blunt hepatic injuries in 1995: a multicenter experience with 404 patients. *J Trauma* 1996;40(1):31–38.
47. Velmahos GC, Toutouzas KG, Radin R, et al. Nonoperative treatment of blunt injury

to solid abdominal organs: a prospective study. *Arch Surg* 2003;138(8):844–851.
48. Sivrikoz E, Teixeira PG, Resnick S, et al. Angiointervention: an independent predictor of survival in high-grade blunt liver injuries. *Am J Surg* 2015;209(4):742–746.
49. Wahl WL, Ahrns KS, Brandt MM, et al. The need for early angiographic embolization in blunt liver injuries. *J Trauma* 2002;52(6):1097–1101.
50. Strong RW, Lynch SV, Wall DR, et al. Anatomic resection for severe liver trauma. *Surgery* 1998;123(3):251–257.
51. Khaneja SC, Pizzi WF, Barie PS et al. Management of penetrating juxtahepatic inferior vena cava injuries under total vascular occlusion. *J Am Coll Surg* 1997;184(5):469–474.
52. Plackett TP, Barmparas G, Inaba K, et al. Transplantation for severe hepatic trauma. *J Trauma* 2011;71(6):1880–1884.
53. Demetriades D, Karaiskakis M, Alo K, et al. Role of postoperative computed tomography in patients with severe liver injury. *Br J Surg* 2003;90(11):1398–1400.
54. Peitzman AB, Heil B, Rivera L, et al. Blunt splenic injury in adults: multi-institutional study of the Eastern Association for the Surgery of Trauma. *J Trauma* 2000;49(2):177–187; discussion 187–189.
55. Berg RJ, Inaba K, Okoye O, et al. The contemporary management of penetrating splenic injury. *Injury* 2014;45(9):1394–1400.
56. Schnuriger B, Inaba K, Konstantinidis A, et al. Outcomes of proximal versus distal splenic artery embolization after trauma: a systematic review and meta-analysis. *J Trauma* 2011;70(1):252–260.
57. Haan JM, Biffl W, Knudson MM, et al. Splenic embolization revisited: a multicenter review. *J Trauma* 2004;56(3):542–547.
58. Toutouzas KG, Velmahos GC, Kaminski A, et al. Leukocytosis after posttraumatic splenectomy: a physiologic event or sign of sepsis? *Arch Surg* 2002;137(8):924–928; discussion 928–929.
59. Demetriades D, Scalea TM, Degiannis E, et al. Blunt splenic trauma: splenectomy increases early infectious complications: a prospective multicenter study. *J Trauma Acute Care Surg* 2012;72(1):229–234.
60. Howdieshell TR, Heffernan D, Dipiro JT. Surgical infection society guidelines for vaccination after traumatic injury. *Surg Infect (Larchmt)* 2006;7(3):275–303.
61. Shatz DV, Romero-Steiner S, Elie CM, et al. Antibody responses in postsplenectomy trauma patients receiving the 23-valent pneumococcal polysaccharide vaccine at 14 versus 28 days postoperatively. *J Trauma* 2002;53(6):1037–1042.
62. Teh SH, Sheppard BC, Mullins RJ, et al. Diagnosis and management of blunt pancreatic ductal injury in the era of high-resolution computed axial tomography. *Am J Surg* 2007;193(5):641–643; discussion 643.
63. Bradley EL 3rd, Young PR Jr, Chang MC, et al. Diagnosis and initial management of blunt pancreatic trauma: guidelines from a multiinstitutional review. *Ann Surg*

1998;227(6):861–869.
64. Ragozzino A, Manfredi R, Scaglione M, et al. The use of MRCP in the detection of pancreatic injuries after blunt trauma. *Emerg Radiol* 2003; 10(1):14–18.
65. Kim HS, Lee DK, Kim IW, et al. The role of endoscopic retrograde pancreatography in the treatment of traumatic pancreatic duct injury. *Gastrointest Endosc* 2001;54(1):49–55.
66. Keller MS, Stafford PW, Vane DW. Conservative management of pancreatic trauma in children. *J Trauma* 1997;42(6):1097–1100.
67. Stringer MD. Pancreatic trauma in children. *Br J Surg* 2005;92(4):467–470.
68. Canty TG Sr, Weinman D. Management of major pancreatic duct injuries in children. *J Trauma* 2001;50(6):1001–1007.
69. Duchesne JC, Schmieg R, Islam S, et al. Selective nonoperative management of low-grade blunt pancreatic injury: are we there yet? *J Trauma* 2008;65(1):49–53.
70. Subramanian A, Dente CJ, Feliciano DV. The management of pancreatic trauma in the modern era. *Surg Clin North Am* 2007;87(6):1515–1532, x.
71. Recinos G, DuBose JJ, Teixeira PG, et al. Local complications following pancreatic trauma. *Injury* 2009;40(5):516–520.
72. Khan I, Bew D, Elias DA, et al. Mechanisms of injury and CT findings in bowel and mesenteric trauma. *Clin Radiol* 2014;69(6):639–647.
73. Brofman N, Atri M, Hanson JM, et al. Evaluation of bowel and mesenteric blunt trauma with multidetector CT. *Radiographics* 2006;26(4):1119–1131.
74. Kim HC, Yang DM, Kim SW, et al. Gastrointestinal tract perforation: evaluation of MDCT according to perforation site and elapsed time. *Eur Radiol* 2014;24(6):1386–1393.
75. Asensio JA, Demetriades D Berne JD, et al. A unified approach to the surgical exposure of pancreatic and duodenal injuries. *Am J Surg* 1997;174(1):54–60.
76. Velmahos GC, Kamel E, Chan LS, et al. Complex repair for the management of duodenal injuries. *Am Surg* 1999;65(10):972–975.
77. Talving P, Nicol AJ, Navsaria PH. Civilian duodenal gunshot wounds: surgical management made simpler. *World J Surg* 2006;30(4):488–494.
78. Velmahos GC, Constantinou C, Kasotakis G. Safety of repair for severe duodenal injuries. *World J Surg* 2008;32(1):7–12.
79. Ordonez C, Garcia A, Parra MW, et al. Complex penetrating duodenal injuries: less is better. *J Trauma Acute Care Surg* 2014;76(5):1177–1183.
80. van der Wilden GM, Yeh D, Hwabejire JO, et al. Trauma Whipple: do or don't after severe pancreaticoduodenal injuries? An analysis of the National Trauma Data Bank (NTDB). *World J Surg* 2014;38(2):335–340.
81. Asensio JA, Petrone P, Roldan G, et al. Pancreaticoduodenectomy: a rare procedure for the management of complex pancreaticoduodenal injuries. *J Am Coll Surg* 2003;197(6):937–942.

82. Cogbill TH, Moore EE, Feliciano DV, et al. Conservative management of duodenal trauma: a multicenter perspective. *J Trauma* 1990;30(12):1469–1475.
83. Demetriades D. Colon injuries: new perspectives. *Injury* 2004;35(3):217–222.
84. Greer LT, Gillern SM, Vertrees AE. Evolving colon injury management: a review. *Am Surg* 2013;79(2):119–127.
85. Steele SR, Maykel JA, Johnson EK. Traumatic injury of the colon and rectum: the evidence vs dogma. *Dis Colon Rectum* 2011;54(9):1184–1201.
86. Sasaki LS, Allaben RD, Golwala R, et al. Primary repair of colon injuries: a prospective randomized study. *J Trauma* 1995;39(5):895–901.
87. Chappuis CW, Frey DJ, Dietzen CD, et al. Management of penetrating colon injuries. A prospective randomized trial. *Ann Surg* 1991;213(5):492–497; discussion 497–498.
88. Stewart RM, Fabian TC, Croce MA, et al. Is resection with primary anastomosis following destructive colon wounds always safe? *Am J Surg* 1994;168(4):316–319.
89. Murray JA, Demetriades D, Colson M, et al. Colonic resection in trauma: colostomy versus anastomosis. *J Trauma* 1999;46(2):250–254.
90. Pasquale M, Fabian TC. Practice management guidelines for trauma from the Eastern Association for the Surgery of Trauma. *J Trauma* 1998;44(6):941–956; discussion 956–957.
91. Demetriades D, Murray JA, Chan L, et al. Penetrating colon injuries requiring resection: diversion or primary anastomosis? An AAST prospective multicenter study. *J Trauma* 2001;50(5):765–775.
92. Demetriades D, Murray JA, Chan LS, et al. Handsewn versus stapled anastomosis in penetrating colon injuries requiring resection: a multicenter study. *J Trauma* 2002;52(1):117–121.
93. Demetriades D, Charalambides D. Gunshot wounds of the colon: role of retained bullets in sepsis. *Br J Surg* 1993;80(6):772–773.
94. Curran TJ, Borzotta AP. Complications of primary repair of colon injury: literature review of 2,964 cases. *Am J Surg* 1999;177(1):42–47.
95. Park JJ, Del Pino A, Orsay CP, et al. Stoma complications: the Cook County Hospital experience. *Dis Colon Rectum* 1999;42(12):1575–1580.
96. Berne JD, Velmahos GC, Chan LS, et al. The high morbidity of colostomy closure after trauma: further support for the primary repair of colon injuries. *Surgery* 1998;123(2):157–164.
97. Herzig DO. Care of the patient with anorectal trauma. *Clin Colon Rectal Surg* 2012;25(4):210–213.
98. Johnson EK, Steele SR. Evidence-based management of colorectal trauma. *J Gastrointest Surg* 2013;17(9):1712–1719.
99. Velmahos GC, Gomez H, Falabella A, et al. Operative management of civilian rectal gunshot wounds: simpler is better. *World J Surg* 2000;24(1):114–118.
100. Steinig JP, Boyd CR. Presacral drainage in penetrating extraperitoneal rectal injuries:

is it necessary? *Am Surg* 1996;62(9):765–767.

101. Gonzalez RP, Falimirski ME, Holevar MR. The role of presacral drainage in the management of penetrating rectal injuries. *J Trauma* 1998;45(4):656–661.
102. Navsaria PH, Graham R, Nicol A. A new approach to extraperitoneal rectal injuries: laparoscopy and diverting loop sigmoid colostomy. *J Trauma* 2001;51(3):532–535.
103. Navsaria PH, Shaw JM, Zellweger R, et al. Diagnostic laparoscopy and diverting sigmoid loop colostomy in the management of civilian extraperitoneal rectal gunshot injuries. *Br J Surg* 2004;91(4):460–464.
104. Navsaria PH, Edu S, Nicol AJ. Civilian extraperitoneal rectal gunshot wounds: surgical management made simpler. *World J Surg* 2007;31(6):1345–1351.
105. Levine JH, Longo WE, Pruitt C, et al. Management of selected rectal injuries by primary repair. *Am J Surg* 1996;172(5):575–578; discussion 578–579.
106. McGrath V, Fabian TC, Croce MA, et al. Rectal trauma: management based on anatomic distinctions. *Am Surg* 1998;64(12):1136–1141.
107. Franko ER, Ivatury RR, Schwalb DM. Combined penetrating rectal and genitourinary injuries: a challenge in management. *J Trauma* 1993;34(3):347–353.

Chapter 26

Genitourinary Trauma

Hunter Wessells

Key Points

1. Upper urinary tract injury is an infrequent result of trauma and the majority result from blunt mechanism.
2. Renal injury after blunt trauma requires further evaluation for all cases of gross hematuria; cases of microscopic hematuria associated with an episode of hypotension in adults; significant microscopic hematuria in children.
3. Renal imaging is required with any degree of hematuria after penetrating trauma.
4. Most renal injuries are managed nonoperatively, with indications for exploration being symptomatic renal hemorrhage causing hypotension, expanding or pulsatile retroperitoneal hematoma at laparotomy, and grade V injury.
5. Ureteral injuries due to external violence are rare and require CT imaging or direct exploration; missed injuries are common due to lack of consistent physical findings.
6. Injuries to the bladder require prompt diagnosis and catheter drainage, with intraperitoneal and complicated extraperitoneal injuries necessitating surgical repair.
7. Initial management of urethral injuries varies based on location (anterior vs. posterior) and severity, the most severe requiring urinary diversion with suprapubic cystostomy.
8. Immediate repair of urethral injuries in patients with complex pelvic fractures is not standard of care, and early endoscopic realignment should be undertaken only by a surgeon experienced with this technique.

The incidence of trauma is rising and the World Health Organization estimates that without change or intervention, road traffic injuries will be the sixth leading cause of death by the year 2020 worldwide.[1] Based on U.S. Census data, we estimate that 15,000 persons would sustain renal injuries requiring hospital evaluation annually. The number of bladder and urethral injuries is estimated between 5,000 and 10,000. While injuries to the genitourinary system as a whole are rarely life threatening, the potential morbidity is high and resultant effects on quality of life are marked. Genitourinary injuries have predictable clinical presentations, and imaging modalities have improved our ability to identify and treat these injuries. We review the fundamental principles guiding the evaluation and treatment of genitourinary trauma, including the American Urological

Association *Practice Guidelines on Urotrauma.*[2] This recent publication incorporates a rigorous evidence review and standardized approach to guideline development.

UPPER URINARY TRACT INJURY

Kidney

Injury to the upper urinary tract (kidney, ureter) is rare following trauma, with an incidence of renal injury of 4.89 per 100,000 persons.[3] Recognizing the factors that predispose to urinary tract injury facilitates early diagnosis and management, which is associated with improved outcomes. The majority of blunt traumatic injury is the result of motor vehicle collision, with fall and motor vehicle–pedestrian collision being second and third, respectively. Penetrating injury predominantly is due to firearm and less often stab wound.[3] Findings on physical examination concerning significant renal injury include rib fracture, significant flank ecchymosis, and penetrating wounds of the abdomen, flank, or lower chest.[2] Anatomically, the kidneys lie in the retroperitoneum, surrounded by the ribcage, retroperitoneal fat, perirenal fat within Gerota capsule, and overlying viscera (right: liver, colon, duodenum, and adrenal; left: spleen, colon, adrenal, and pancreas). Injury may occur as a result of interaction of the surrounding "protective" bony and soft tissue structures with the kidney.[4] The collecting system begins within the kidney, forms the renal pelvis and concentrically narrows at the ureteropelvic junction (UPJ) to become the ureter. The ureter then traverses the retroperitoneum inferiorly, protected by retroperitoneal fat and the psoas muscle. After crossing over the common iliac vessels, the ureter descends into the pelvis, coursing caudad to the base of the bladder, entering the trigone obliquely at the ureterovesical junction (UVJ).

1 Hematuria is the most sensitive clinical sign of renal injury, yet the degree does not predict injury severity (an algorithm for the evaluation and management of renal trauma is shown in Algorithm 26-1). Clinicians should perform diagnostic imaging with intravenous (IV) contrast-enhanced computed tomography (CT) to identify significant renal injuries in blunt trauma patients with (1) gross hematuria or (2) microscopic hematuria, and any recorded systolic blood pressure <90 mm Hg.[2] Penetrating injuries with any degree of hematuria or a trajectory in proximity to the kidney also require imaging if the patient is hemodynamically stable. Imaging decisions in hemodynamically unstable patients require close coordination with the trauma surgery team and are beyond the scope of this chapter (see similar chapter on GSW to abdomen). CT provides the most accurate staging of upper urinary tract injuries and corresponds closely with the American Association for the Surgery of Trauma (AAST) Organ Injury Scale (OIS) (Table 26-1, Fig. 26-1).[5] The scan consists of early venous phase contrast-enhanced images, detecting intravascular contrast extravasation (ICE), renal parenchymal perfusion and integrity, and perinephric and retroperitoneal hematoma. Delayed (5 to 10 minutes) imaging is essential for identifying the collecting system injury (urinary extravasation, hydronephrosis) and ureteral continuity to the bladder. The use of intravenous urography to stage injuries is limited because of lower accuracy for clinical staging.[2,6] Focused abdominal ultrasound for trauma (FAST) is used primarily to detect intraperitoneal bleeding in unstable blunt trauma patients; its use for detecting urologic injury is inferior to CT.[7–9] Renal arterial angiography should not be used diagnostically, but therapeutically is indicated to treat

isolated, symptomatic (early or late) renal bleeding, arteriovenous fistula, or pseudoaneurysm using embolization.[10]

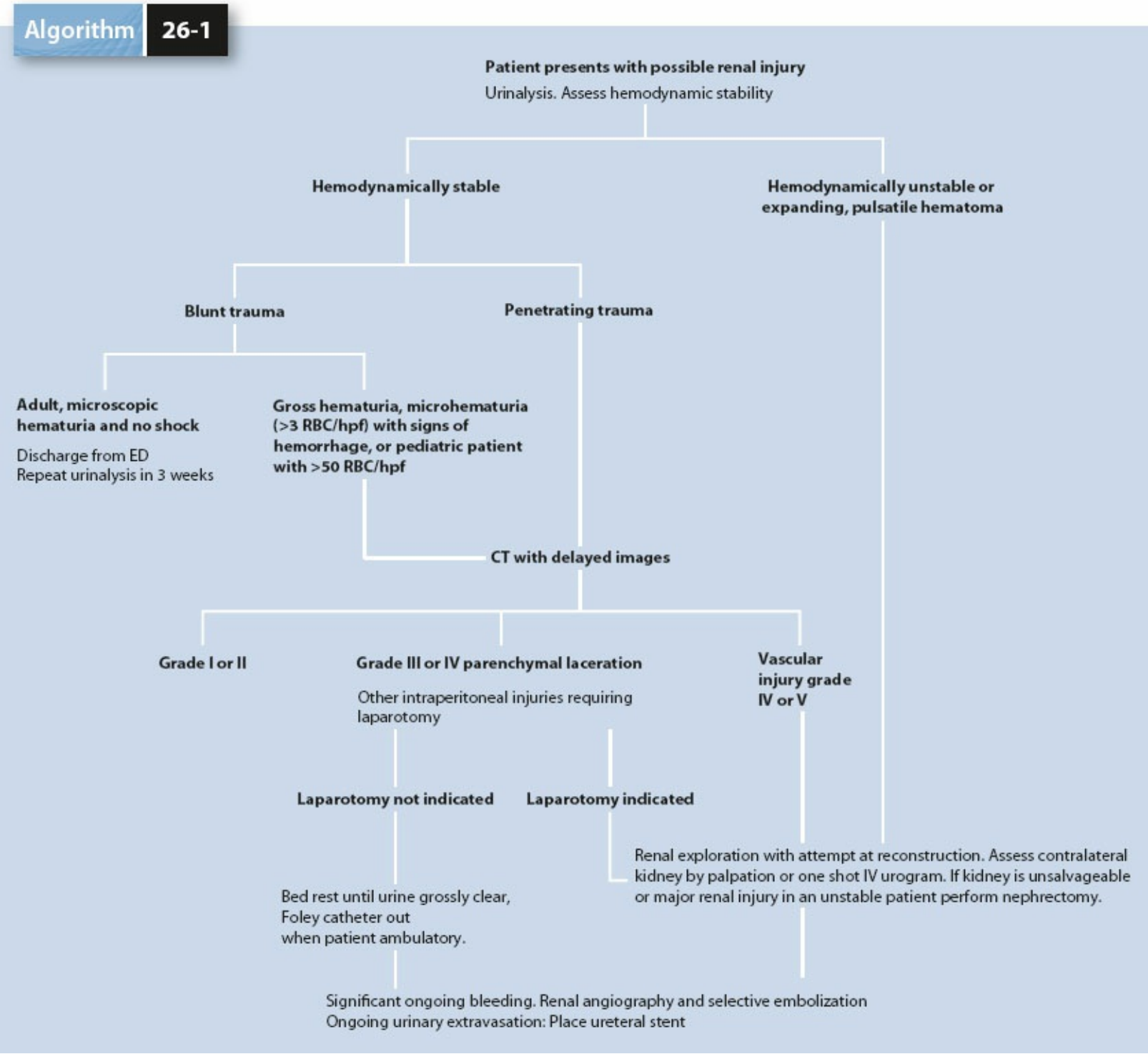

Algorithm 26-1. Algorithm for the evaluation and management of renal injury.

2 Grade I and II injuries rarely require further management. The bulk of blunt grade III and nonvascular grade IV injuries should be managed nonoperatively, whereas only selected penetrating injuries in hemodynamically stable patients can be managed on observation protocols.[11,12] Lacerations with associated collecting system injury (i.e., grade IV) can initially be managed with observation, although a subset of patients will require ureteral stenting due to persistent urinary extravasation. A proposed modification

to the AAST OIS stratifies major renal lacerations into “high risk” and “low risk” based on the likelihood of intervention for hemodynamic instability.[13] The CT imaging criteria of ICE, medial parenchymal laceration, and perirenal hematoma rim distance >3.5 cm have been validated to predict the need for intervention and may lead to further refinement in nonoperative management.[14]

3 The surgical team must perform immediate intervention (surgery or angioembolization in selected situations) in hemodynamically unstable patients with no or transient response to resuscitation.[2] Unstable patients will usually be found to have an expanding or pulsatile retroperitoneal hematoma at laparotomy, and occasionally have hilar injury or pedicle avulsion. In patients undergoing laparotomy for concomitant intraperitoneal injuries, exploration should only be considered judiciously for grade III or IV renal injury due to higher rates of nephrectomy under such circumstances.[15] If renal exploration is contemplated or necessary, demonstration of contralateral renal function is important in the event of ipsilateral nephrectomy. This can be achieved by manual palpation or preferably by intraoperative single-shot intravenous urogram (KUB 10 minutes following intravenous injection of 2 mL/kg contrast).[6] Reasons for failure to demonstrate contrast excretion from the contralateral kidney may indicate solitary kidney, hilar injury, hypoperfusion, or global renal insufficiency secondary to chronic renal disease. Exploration of a solitary kidney should be performed only when absolute indications exist.

Table 26-1 American Association for the Surgery of Trauma Organ Injury Scale

Injured Structure	AAST Grade	Characteristics of Injury
Kidney[a]	I	Contusion with microscopic or gross hematuria, urologic studies normal; nonexpanding subcapsular hematoma without parenchymal laceration
	II	Nonexpanding perirenal hematoma confined to renal retroperitoneum; laceration <1 cm parenchymal depth of renal cortex without urinary extravasation
	III	Laceration >1 cm parenchymal depth of renal cortex without collecting system rupture or urinary extravasation
	IV	Parenchymal laceration extending through renal cortex, medulla, and collecting system with urinary extravasation; injury to main renal artery or vein with contained hemorrhage
	V	Completely shattered kidney; avulsion of renal hilum that devascularizes kidney
Ureter[a]	I	Contusion or hematoma without devascularization
	II	<50% transection
	III	50% transection
	IV	Complete transection with <2 cm devascularization
	V	Avulsion with >2 cm devascularization
Bladder[b]	I	Contusion, intramural hematoma; partial-thickness laceration
	II	Extraperitoneal bladder wall laceration <2 cm
	III	Extraperitoneal bladder wall laceration >2 cm or intraperitoneal bladder wall laceration <2 cm
	IV	Intraperitoneal bladder wall laceration >2 cm
	V	Intraperitoneal or extraperitoneal bladder wall laceration extending into bladder neck or ureteral orifice (trigone)
Urethra	I	Contusion with blood at urethral meatus and normal urethrography
	II	Stretch injury with elongation of urethra, but without extravasation of urethrography contrast material
	III	Partial disruption with extravasation of urethrography contrast material at injury site with visualization in the bladder
	IV	Complete disruption with <2 cm urethral separation and extravasation of urethrography contrast material at injury site, without visualization in the bladder
	V	Complete transection with 2 cm urethral separation or extension into the prostate or vagina

[a]Advance one grade for multiple injuries, up to grade III.
[b]Advance one grade for multiple injuries, up to grade III.
Adapted from Wessells H. Injuries to the urogenital tract. In Souba WW, Fink MP, Jurkovich GJ, et al., eds. *ACS Surgery.* 6th ed. New York, NY: WebMD; 2002;10:3.

The kidney and upper urinary tract are accessed through a midline abdominal incision, and the author obtains preliminary isolation of the renal vessels before renal exploration. Using the inferior mesenteric vein (IMV) as a landmark, a posterior peritoneal window is created medial to the IMV overlying the aorta, which allows access, dissection, and control of the proximal renal vasculature.[16] When immediate nephrectomy is required, reflection of the right or left colon provides rapid access to the renal hilum.[17] If this method is employed, manual compression followed by vascular clamping may be required. Renal cooling is not routinely employed due to time constraints and potential for worsening hypothermia. Once Gerota fascia is exposed and open, the kidney can be freed of its associated perinephric fat. The capsule of the kidney is routinely preserved for closure following renal reconstruction. During renal exploration, sharp debridement, hemostasis, collecting system repair, and bolstered closure of the renal capsule using absorbable suture is performed. A perinephric suction drain is placed away from the repair in the retroperitoneum and removed when drainage subsides, usually less than 50 mL/day. If concern exists as the nature of the drainage, an aliquot of fluid can be sent for creatinine concentration to evaluate for the presence of urine.

In the case of renal artery thrombosis, surgical revascularization is rarely helpful

because of the time delay from injury to revascularization. Intervention is commonly limited to patients with solitary kidney or bilateral injuries.[5] An emerging therapy is vascular stent placement across the injury or thrombosis; however, most series are limited and results mixed.[18] Venous injuries often result in massive bleeding and may require nephrectomy. Isolated proximal left renal vein injuries can potentially be managed by ligation of the renal vein because collateral drainage is present via the gonadal, adrenal, and lumbar veins. Right renal venous injury requires repair, if feasible, or nephrectomy due to lack of collateral circulation.

Clinicians should perform follow-up imaging for renal trauma patients with deep lacerations (AAST grades III, IV, and V) and clinical signs of complications (e.g., fever, worsening flank pain, ongoing blood loss, and abdominal distention).[2] CT best delineates delayed bleeding, persistent urinary extravasation, urinoma, and infection.[5] Secondary bleeding after nonoperative or surgical repair, which usually is caused by a pseudoaneurysm, should be managed angiographically. Ureteral stenting or percutaneous drainage is indicated for persistent leak or abscess. Late complications are uncommon and include renin-mediated hypertension from chronic renal ischemia, arteriovenous malformations, and segmental arteriolar pseudoaneurysm.

Ureter

Ureteral injuries are rare (1%), with fewer than 10 presenting annually in busy trauma centers.[19] These injuries often present without clear signs or symptoms, and many are missed at the initial assessment (an algorithm for the evaluation and management of ureteral trauma is shown in Algorithm 26-2). Clinicians should perform IV contrast-enhanced abdominal/pelvic CT with delayed imaging for stable trauma patients with suspected ureteral injuries.[2] In the adult population, gunshot wounds followed distantly by stab wounds are the most frequent source of injury associated with external violence.[20,21]

4 Injury should be suspected when organs anatomically related to the ureter sustain injury: iliac vessels, bladder, colon, and lumbar spine or transverse processes. Significant deceleration and hyperextension mechanisms can result in ureteral avulsion as well. In children, the avulsion injury occurs at the UPJ due to increased hyperextensibility of the spine.

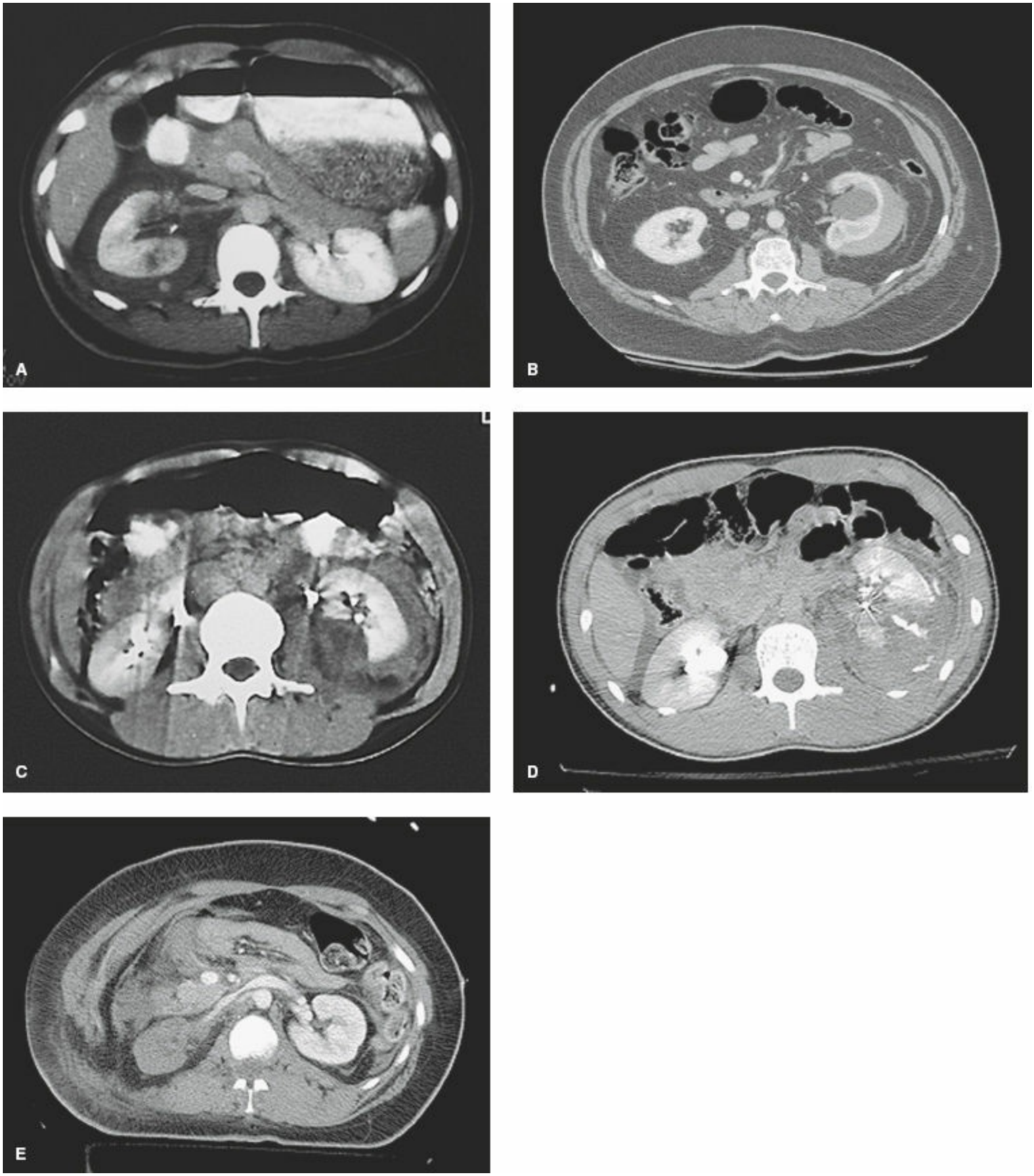

Figure 26-1. Grading of renal injury by computed tomography. **A:** Grade I, contusion; **B:** Grade II; **C:** Grade III; **D:** Grade IV, contrast extravasation; **E:** Grade V, devascularized.

Anatomically, the ureters begin posterior to the renal hilum at the UPJ. They course inferiorly through the retroperitoneum, along the anterior aspect of the psoas muscle. Upon entering the pelvis, the ureters run behind the gonadal vessels before crossing over

the iliac vessels. Finally, the ureters continue caudally, and enter the inferior aspect of the bladder obliquely. The blood supply is segmental and arises from the adjacent anatomic structures within the retroperitoneum and pelvis (proximal-lateral, mid/true pelvis-medial, and inferior-posteriolateral).

Often, patients with penetrating ureteral injuries undergo surgical exploration for associated injuries. Surgeons should directly inspect the ureters during laparotomy in patients with suspected ureteral injury who have not had preoperative imaging.[2] Traumatic ureteral contusions are best managed at the time of laparotomy with ureteral stenting or resection and primary repair depending on ureteral viability and clinical scenario.[2]

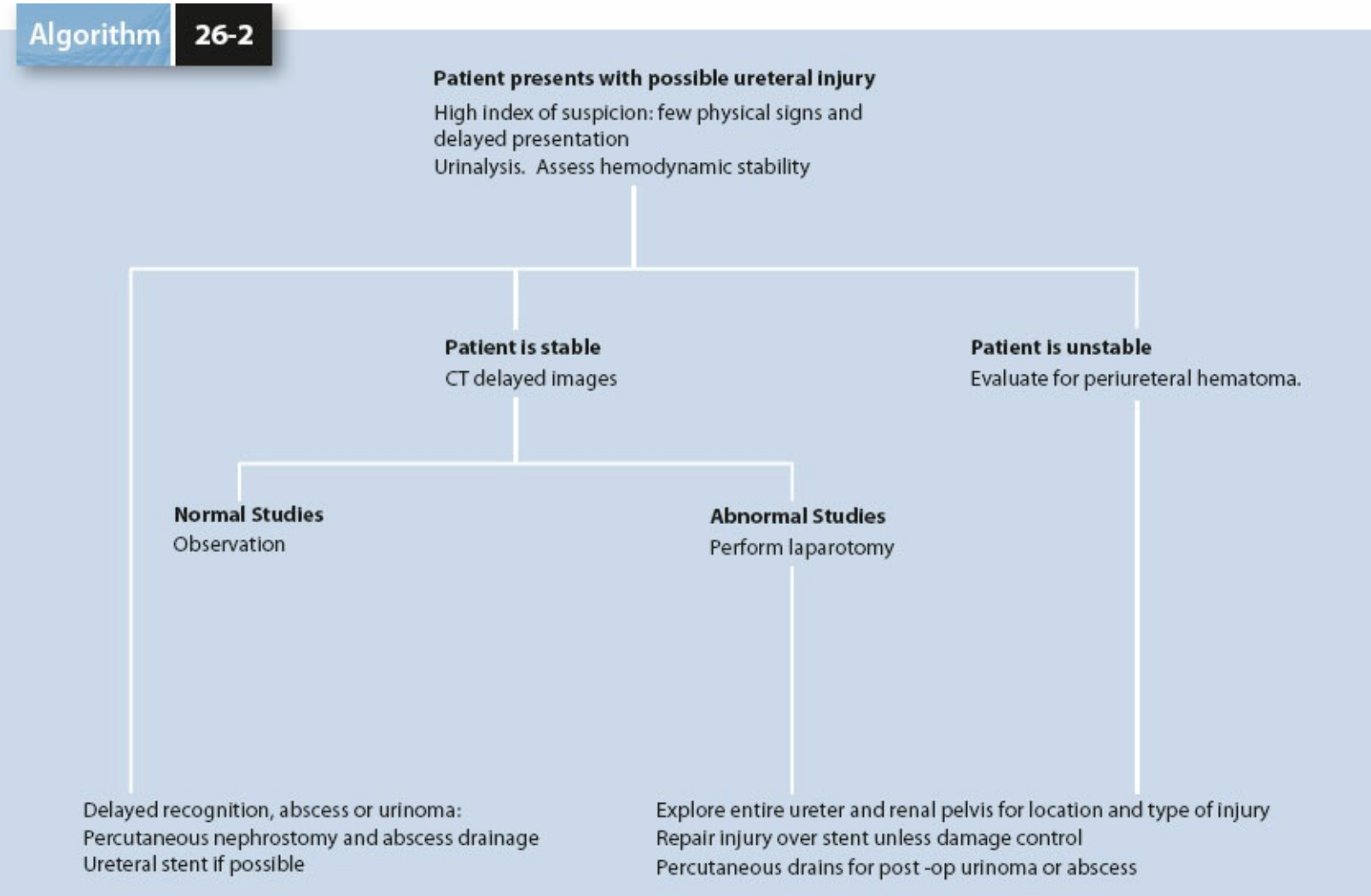

Algorithm 26-2. Algorithm for the evaluation and management of ureteral injury.

Surgeons should repair traumatic ureteral lacerations at the time of laparotomy in stable patients.[2] Debridement as indicated precedes ureter reconstruction, and the level and length of ureteral defect dictates the type of repair (Fig. 26-2). UPJ disruptions require formal reconstruction by reanastomosis or ureteropyelostomy. For injuries occurring in the proximal to midureter without associated renal injury, simple mobilization of the colon without hilar control can be used to expose the ureters. Short upper and midureteral injuries are repaired by primary repair or spatulated reanastomosis

over a stent, whereas low pelvic ureteric injuries are repaired by ureteroneocystostomy (Fig. 26-3). A refluxing implant is acceptable in children and adults.

When patients are hemodynamically unstable, surgeons should elect temporary urinary drainage followed by delayed definitive management.[2] Damage control techniques for urinary diversion include debridement, drainage of the bladder and retroperitoneum, cutaneous ureterostomy diversion with a feeding tube, or ligation of the ureter with percutaneous nephrostomy tube placement.

Patients presenting with a delay in diagnosis often have symptoms of fever, flank pain, fullness, tenderness, atelectasis, or oliguria as a result of urinoma, hematoma, or abscess.[19] Operative intervention at the time of delayed diagnosis can result in nephrectomy. Therefore, management options include ureteral stenting, nephrostomy tube placement, percutaneous urinoma drainage, and Foley catheter insertion. Reconstruction is planned at 3 to 6 months to allow for resolution of periureteral inflammation. Long-term complications of unrecognized ureteral injury include fistula, fluid collections, ureteral stricture, and obstructive uropathy.

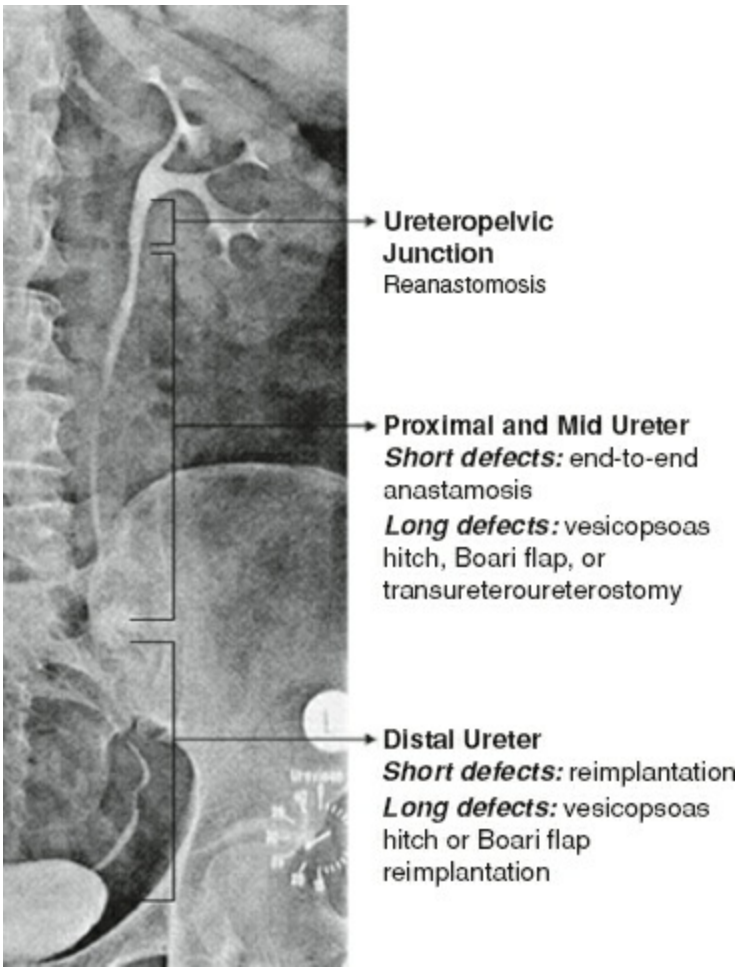

Figure 26-2. Ureteral reconstruction by location of injury.

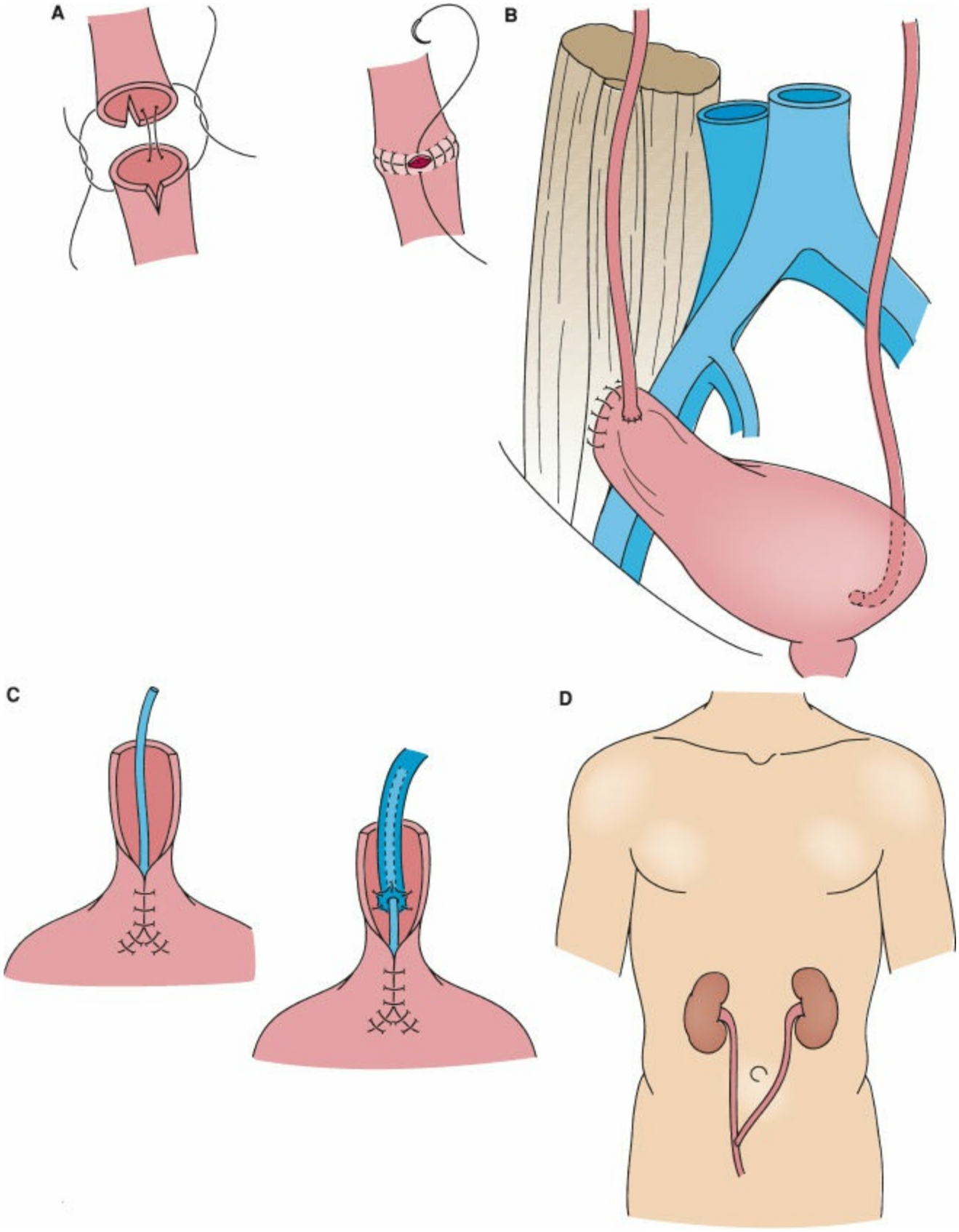

Figure 26-3. Techniques of ureteral repair. **A:** End-to-end ureteroureterostomy; **B:** Vesicopsoas hitch reconstruction with reimplantation performed by suturing of the bladder to psoas tendon after mobilization; **C:** Boari flap performed using a tubularized bladder flap based on the ipsilateral superior vesical artery; **D:** Transureterureterostomy (TUU). For all repairs the principles include tension free, watertight, stented, spatulated, mucosa-to-mucosa anastomosis using absorbable suture with drain placement.

Individuals who have sustained major injury to the ureter require follow-up imaging in

the form of renal ultrasonography, radionuclide scanning or CT urography to evaluate for development of stricture or fistula.[19] Interval ultrasound to evaluate for urinoma or abscess is an acceptable imaging modality and limits radiation exposure.

LOWER URINARY TRACT INJURY

Bladder

Blunt trauma accounts for the majority of bladder injuries, with penetrating mechanisms comprising the remainder.[22] Pelvic fractures are frequently associated with lower urinary tract injuries, although only 5 to 10% of pelvic fractures result in bladder injury.[23] In pelvic fracture two mechanisms predominate as causes of bladder injury, usually resulting in extraperitoneal rupture. The first involves shearing forces at deceleration resulting in injury at the fixed sites of pelvic fascial attachment. The second mechanism involves direct injury from pelvic bone fragments causing laceration of the bladder. Intraperitoneal blunt injury is due to rapid deceleration creating a rapid rise in intravesical pressure resulting in a "burst"-type injury. Extraperitoneal injuries account for 54% to 55% of bladder injuries, intraperitoneal injuries are 38% to 40%, and combined injuries account for 5% to 8%.[24] In the pediatric population, a larger proportion of injuries are intraperitoneal because of the relative intra-abdominal location of the bladder. However, the overall incidence is lower. The incidence of pelvic fracture is also lower in children, but, in contradistinction to adults, bladder neck injuries are more common in boys with a pelvic crush injury rather than urethral injuries as seen in adults.[25]

Gross hematuria is a reliable sign occurring in 95% of patients with bladder injury. Imaging must be performed in the setting of gross hematuria and pelvic fracture, and should be performed when mechanism suggests injury or in the face of pelvic ring fractures and clinical indicators of bladder rupture (i.e. >30 RBC/hpf on urinalysis or physical findings).[2,26] Isolated acetabular fractures without pelvic ring involvement do not need cystography without other indications.[26]

Acutely, patients presenting with bladder injury may complain of inability to void or suprapubic pain, although these symptoms may be masked by pain from more significant injuries.[22] With delayed presentation, frequent symptoms are abdominal distension, ileus, fever, or urinary ascites as a result of persistent leakage, pelvic urinoma, or abscess formation. Laboratory analysis demonstrates acidosis, hyperkalemia, hyperchloremia, hypernatremia, and uremia with intraperitoneal bladder injuries. Particular attention is paid to thorough evaluation of the lower urinary tract for concurrent injury, because of the frequency of these injuries with pelvic fracture. Penetrating and iatrogenic trauma to the pelvis or perineum generally results in associated visceral, urethral, or genital injuries, but without bony disruption.[27]

Imaging of the bladder, if indicated, consists of retrograde cystography, and is performed in the clinically stable patient. For CT cystography, the bladder is filled retrograde with contrast and the scan is performed after 300- to 400-mL contrast is instilled. Static cystography remains an acceptable means of assessing for bladder rupture. Extraperitoneal contrast extravasation is confined to the pelvis on CT and appears as a "flame-shaped" opacity on static cystography (Fig. 26-4). Characteristic patterns of intraperitoneal contrast extravasation include pooling in the cul-de-sac, paracolic gutter,

or retrohepatic space on CT or outlining of bowel loops on static cystography (Fig. 26-5).

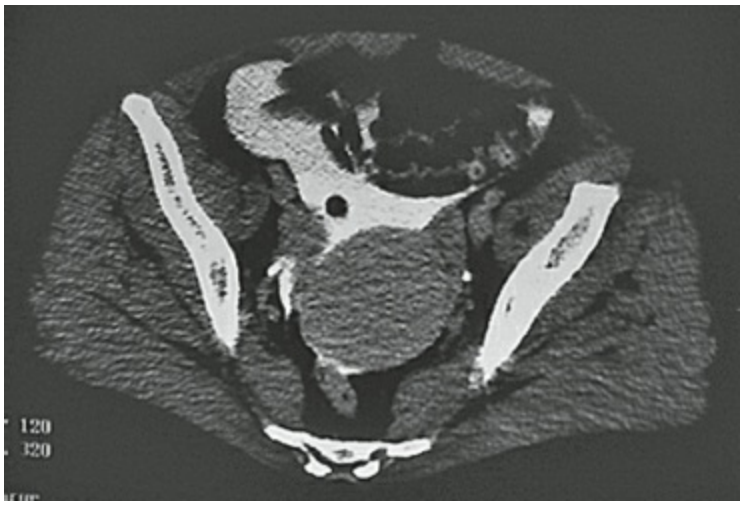

Figure 26-4. CT cystography for intraperitoneal bladder injury.

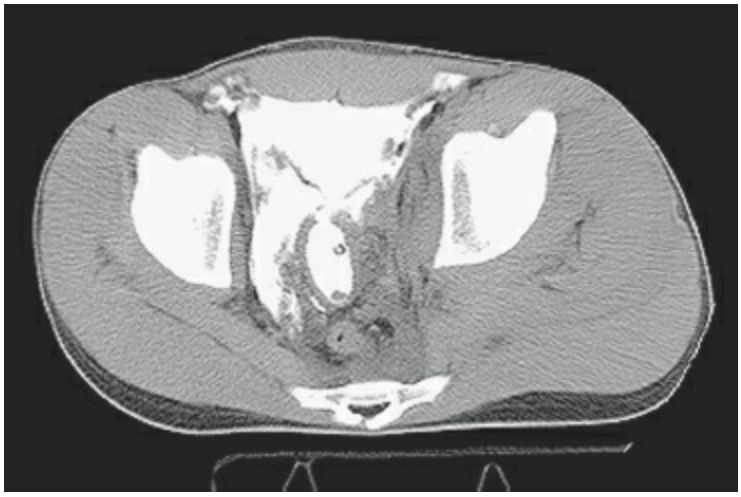

Figure 26-5. CT cystography for extraperitoneal bladder injury.

5, **6** Surgeons must perform surgical repair of intraperitoneal bladder rupture in the setting of blunt or penetrating external trauma.[2] The size of these ruptures generally precludes nonoperative approaches. Uncomplicated extraperitoneal bladder injuries should be managed with catheter drainage. Surgeons should perform surgical repair in patients with complicated extraperitoneal bladder injury. These are considered complex in the following circumstances[2]: exposed bone spicules in the bladder lumen; rectal or vaginal lacerations; and bladder neck injuries. In the case of open reduction internal fixation of pelvic fracture or repair of abdominal injuries, clinicians should perform bladder repair.

Bladder exploration includes assessment of the bladder wall, bladder neck, and ureteral orifices, which are inspected through an anterior cystotomy or the laceration/injury itself. Sites of injury are closed in a two-layer running fashion using 2-0 synthetic absorbable suture. Urethral catheter drainage is sufficient in most cases.[2] Suprapubic catheter diversion is reserved for extensive bladder injuries in which ongoing bleeding or complex repairs require additional drainage. Closed suction drains are placed away from the site of

repair and can be removed in 48 hours unless the drainage fluid demonstrates a creatinine level higher than serum. The urethral catheter is left in place for 7 to 10 days and removed following cystogram demonstrating a healed, watertight repair.

Urethra

The anatomy of the urethra varies throughout its course and is divided for practical purposes into the anterior and posterior segments (Fig. 26-6). The type of injury varies depending on the segment, but most commonly is due to blunt mechanism. Anterior urethral injuries are the result of straddle-type falls or blows to the perineum. Posterior urethral injuries are often associated with pelvic fracture and involve varying degrees of prostatomembranous distraction.[28] Female urethral injuries are uncommon and are usually associated with pelvic fracture.[29] Gross blood at the urethral meatus in males is the most reliable sign and warrants evaluation for injury (an algorithm for the evaluation and management of urethral trauma is shown in Algorithm 26-3). Further examination includes digital rectal examination evaluating for hematoma, bony spicules, hemoccult blood, or a "high-riding prostate." These findings on examination and the presence of perineal ecchymosis or scrotal hematoma suggest anterior pelvic disruption and urethral injury. Females with vaginal bleeding and pelvic fracture should be evaluated for gynecologic as well as urethral injuries.

7 Clinicians should perform retrograde urethrography (RUG) in patients with blood at the urethral meatus after pelvic trauma.[2,30] RUG is readily performed using portable fluoroscopy in the emergency department or operating room. The fossa navicularis is occluded with the partially filled (2- to 3-mL) balloon tip of a Foley catheter, the penis is stretched, and contrast is gently injected to opacify the urethra. Oblique images are taken, when possible, to establish the absence of or the presence and location of extravasation, which is indicative of injury. If no extravasation is present, the catheter is advanced into the bladder. Clinicians should establish prompt urinary drainage in patients with pelvic fracture urethral injury.[2] Initial management involves urinary diversion with suprapubic cystostomy.

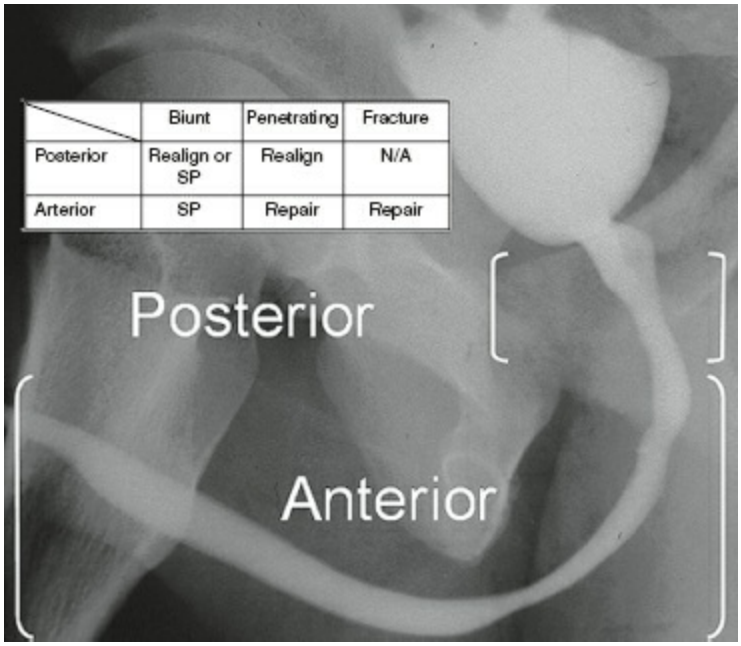

Figure 26-6. Urethral Injury. Normal retrograde urethrogram and urethral injury management by segment and mechanism of injury.

Clinicians may perform primary realignment in hemodynamically stable patients with pelvic fracture urethral injury.[2] Techniques of early endoscopic realignment show promise in potentially decreasing rates of stricture formation while providing equivalent results with regard to continence and erectile dysfunction.[31,32] Early realignment is achieved employing endoscopes and fluoroscopy, then placing a catheter, by Seldinger technique, over a guidewire. Clinicians should not perform prolonged attempts at endoscopic realignment in patients with pelvic fracture urethral injury.[2] Whether a patient receives a suprapubic cystostomy or a urethral catheter as drainage, an appropriate plan of follow-up for tube changes, removals, and definitive reconstructive efforts is imperative, due to potential morbidities including infection, encrustation, hematuria, stricture and obstructive uropathy.

8 Anterior urethral injuries can be divided into blunt straddle-type injury and penetrating mechanisms. Surgeons should perform prompt surgical repair in patients with uncomplicated penetrating trauma of the anterior urethra.[2] In contrast, clinicians should establish prompt urinary drainage, usually via suprapubic cystostomy in patients with straddle injury to the anterior urethra.[2] Similarly, high-velocity injuries should be managed with suprapubic cystostomy and delayed reconstruction.[30]

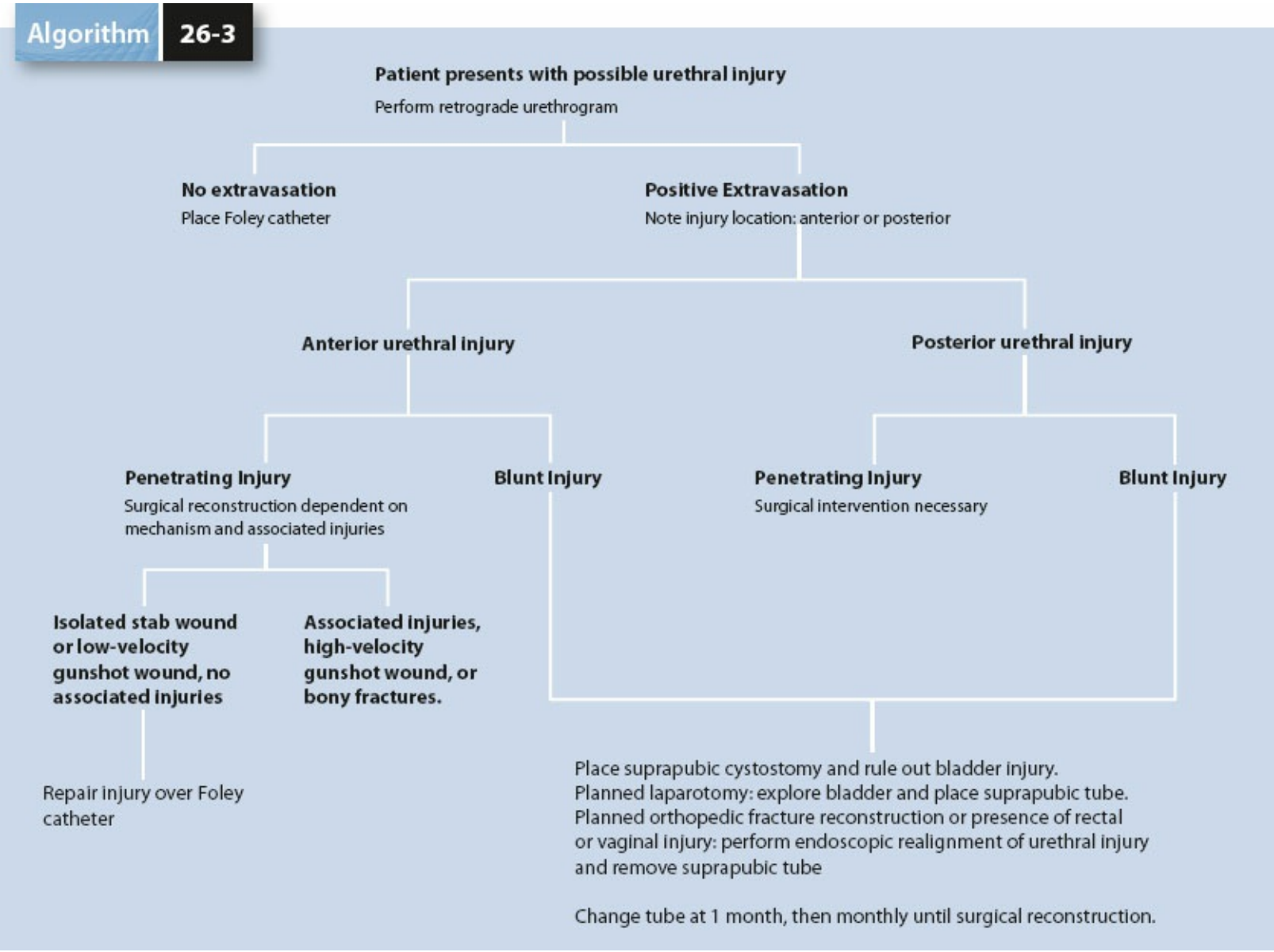

Algorithm 26-3. Algorithm for the evaluation and management of urethral injury.

References

1. Peden M, et al. *World Report on Road Traffic Injury Prevention.* Geneva, Switzerland: World Health Organization; 2004.
2. Morey AF, Brandes S, Dugi DD 3rd, et al. Urotrauma: AUA Guidelines. *J Urol* 2014;192(2):327–335.
3. Wessells H, Suh D, Porter JR, et al. Renal injury and operative management in the United States: results of a population-based study. *J Trauma* 2003;54(3):423–430.
4. Snedeker JG, Barnstuble BB, Iaizzo PA, et al. A comprehensive renal injury concept based on a validated finite element model of the human abdomen. *J Trauma* 2007;62(5):1240–1249.
5. Santucci RA, Wessells H, Bartsch G, et al. Evaluation and management of renal injuries: consensus statement of the renal trauma subcommittee. *BJU Int* 2004;93(7):937–954.
6. Morey AF, McAninch JW, Tiller BK, et al. Single shot intraoperative excretory urography for the immediate evaluation of renal trauma. *J Urol* 1999; 161(4):1088–1092.
7. McGahan JP, Richards JR, Jones CD, et al. Use of ultrasonography in the patient with acute renal trauma. *J Ultrasound Med* 1999;18(3):207–213; quiz 215–216.
8. Perry MJ, Porte ME, Urwin GH. Limitations of ultrasound evaluation in acute closed renal trauma. *J R Coll Surg Edinb* 1997;42(6):420–422.
9. Körner M, Krötz MM, Degenhart C, et al. Current role of emergency US in patients with major trauma. *Radiographics* 2008;28(1):225–242.
10. Hotaling JM, Sorensen MD, Smith TG 3rd, et al. Analysis of diagnostic angiography and angioembolization in the acute management of renal trauma using a national data set. *J Urol* 2011;185(4):1316–1320.
11. Hammer CC, Santucci RA. Effect of an institutional policy of nonoperative treatment of grades I to IV renal injuries. *J Urol* 2003;169(5):1751–1753.
12. Wessells H, McAninch JW, Meyer A, et al. Criteria for nonoperative treatment of significant penetrating renal lacerations. *J Urol* 1997;157(1):24–27.
13. Dugi DD 3rd, Morey AF, Gupta A, et al. American Association for the Surgery of Trauma grade 4 renal injury substratification into grades 4a (low risk) and 4b (high risk). *J Urol* 2010;183(2):592–597.
14. Figler B, Malaeb BS, Voelzke B, et al. External validation of a sub-stratification of the American Association for the Surgery of Trauma renal injury scale for grade IV injuries. *J Am Coll Surg* 2013;217(5):924–928.
15. Wright J, Nathens AB, Rivara FP, et al. Renal and extrarenal predictors of nephrectomy from the national trauma data bank. *J Urol* 2006;175(3 Pt 1):970–975; discussion 975.
16. Carroll PR, Klosterman P, McAninch JW. Early vascular control for renal trauma: a critical review. *J Urol* 1989;141(4):826–829.

17. Gonzalez RP, Falimirski M, Holevar MR, et al. Surgical management of renal trauma: is vascular control necessary? *J Trauma* 1999;47(6):1039–1042; discussion 1042–1044.
18. Lopera JE, Suri R, Kroma G, et al. Traumatic occlusion and dissection of the main renal artery: endovascular treatment. *J Vasc Interv Radiol* 2011;22(11):1570–1574.
19. Brandes S, Coburn M, Armenakas N, et al. Diagnosis and management of ureteric injury: an evidence-based analysis. *BJU Int* 2004;94(3):277–289.
20. Elliott SP, McAninch JW. Ureteral injuries from external violence: the 25-year experience at San Francisco General Hospital. *J Urol* 2003;170(4 Pt 1):1213–1216.
21. Perez-Brayfield MR, Keane TE, Krishnan A, et al. Gunshot wounds to the ureter: a 40-year experience at Grady Memorial Hospital. *J Urol* 2001; 166(1):119–121.
22. Gomez RG, Ceballos L, Coburn M, et al. Consensus statement on bladder injuries. *BJU Int* 2004;94(1):27–32.
23. Brandes S, Borrelli J Jr. Pelvic fracture and associated urologic injuries. *World J Surg* 2001;25(12):1578–1587.
24. Corriere JN Jr, Sandler CM. Diagnosis and management of bladder injuries. *Urol Clin North Am* 2006;33(1):67–71, vi.
25. Tarman GJ, Kaplan GW, Lerman SL, et al. Lower genitourinary injury and pelvic fractures in pediatric patients. *Urology* 2002;59(1):123–126; discussion 126.
26. Avey G, Blackmore CC, Wessells H, et al. Radiographic and clinical predictors of bladder rupture in blunt trauma patients with pelvic fracture. *Acad Radiol* 2006;13(5):573–579.
27. Franko ER, Ivatury RR, Schwalb DM. Combined penetrating rectal and genitourinary injuries: a challenge in management. *J Trauma* 1993;34(3):347–353.
28. Basta AM, Blackmore CC, Wessells H. Predicting urethral injury from pelvic fracture patterns in male patients with blunt trauma. *J Urol* 2007;177(2):571–575.
29. Black PC, Miller EA, Porter JR, et al. Urethral and bladder neck injury associated with pelvic fracture in 25 female patients. *J Urol* 2006;175(6):2140–2144; discussion 2144.
30. Chapple C, Barbagli G, Jordan G, et al. Consensus statement on urethral trauma. *BJU Int* 2004; 93(9):1195–1202.
31. Mouraviev VB, Coburn M, Santucci RA. The treatment of posterior urethral disruption associated with pelvic fractures: comparative experience of early realignment versus delayed urethroplasty. *J Urol* 2005;173(3):873–876.
32. Leddy L, Dhakad U. Outcomes of endoscopic realignment of pelvic fracture associated urethral injuries at a level 1 trauma center. *J Urol* 2012;188(1):174–178.

Chapter 27

Vascular Trauma

Adriana Laser, Shahab Toursavadkohi, and Todd E. Rasmussen

Key Points

1. Vascular disruption and hemorrhage is a leading cause of mortality and morbidity in the civilian and military setting.
2. Vascular injuries are categorized as occurring from either blunt or penetrating mechanisms.
3. Motor vehicle crashes are the main cause of blunt vascular trauma in the civilian setting.
4. Examining the patient is the most important step in evaluation of suspected vascular injury.
5. Hard signs of vascular injury suggest near or complete disruption of the vessel in question and include pulsatile bleeding, expanding hematoma, palpable thrill, audible bruit, and or evidence of acute ischemia distal to the injury site.
6. Contrast-enhanced computed tomography angiography (CTA) is the most available and common imaging modality used in the emergency setting including the evaluation of patients suspected of having vascular trauma.
7. In the trauma patient, hemorrhage leads to both the overall metabolic consequences of total-body ischemia and end-organ ischemia of the specific injured vessel.
8. Damage control resuscitation involves allowing permissive hypotension with a goal of a palpable radial pulse (in patients without head injury).
9. Elevated fascial compartment pressures can be due to reperfusion, hematoma, swelling from crush injury, or major fractures.
10. When discussing neck trauma, there are three regions classically used to describe anatomic location. Zone I is below the cricoid cartilage, zone II is between the cricoid cartilage and the angle of the mandible, whereas zone III is above the angle of the mandible.
11. Control of bleeding from vascular disruption within the torso is not readily amenable to control with direct pressure and is therefore referred to as noncompressible torso hemorrhage.
12. Proximal and distal control is essential when managing suspected vascular injury.

BACKGROUND

1 Vascular disruption and hemorrhage is a leading cause of mortality and morbidity in the civilian and military setting.[1–3] Because of their proximate anatomic nature, arterial and venous injuries often occur in conjunction with one another and are often associated with injury to other vital structures. To optimally manage scenarios in which there is suspicion for vascular injury or cases in which clear evidence of vascular disruption exists, it is necessary to possess an understanding of the epidemiology and anatomic distribution of this injury pattern, considerations associated with different mechanisms and key tenants of diagnosis and management. The objective of this chapter is to familiarize the reader with current knowledge pertaining to the topic of vascular trauma including commonality of the problem, circumstances in which vascular injury occurs, and different approaches to diagnosis. Additionally, this chapter will provide guidance on the management of different patterns of vascular injury focusing on the categories of extremity, torso, and cervical.

EPIDEMIOLOGY AND MECHANISMS OF VASCULAR TRAUMA

The epidemiology of vascular trauma can be broadly categorized into contextual circumstances (military and civilian), mechanism of injury (iatrogenic, blunt, penetrating, blast, and combination injuries), and anatomical site or location of injury (extremity, torso, and junctional).

Wartime Vascular Injury

Contemporary data confirm that exsanguination is the major cause of death in wounded service personnel and that the prevalence of wartime vascular trauma seems to have increased markedly over the past century (Figs. 27-1 and 27-2).[1–3] Estimates from allied surgeons in World War I (WWI) suggested overall vascular trauma rates of 0.4% to 1.3%.[4] DeBakey characterized vascular injury burden in World War II (WWII) as affecting 0.96% of all patients and for the Korean and Vietnam wars the rate of vascular injury was judged to be slightly higher at 2% to 3%.[4–6]

Coalition militaries engaged in recent combat operations in Afghanistan and Iraq have reported rates of vascular trauma higher than in the previously mentioned military campaigns.[2,7–9] In a study reporting US military experience, White and colleagues analyzed vascular cases entered in to the United States Joint Theater Trauma Registry (JTTR) from 2002 to 2009 (Fig. 27-2).[2] Defining the denominator as battle-related injuries sufficiently severe to prevent return to duty in the combat theater, the specific incidence of vascular injury (defined as the *total incidence injury*) was found to be 12% (1,570 of 13,076 cases). The incidence of injuries requiring an operation (defined as the *operative incidence*) was found to be 9% (1,212 of 13,076 cases). Injuries were most common in the extremities (79%) followed by those in the torso (12%) and cervical regions (8%). Of extremity vascular injuries two-thirds were documented in the lower extremities (most commonly femoral artery) while one-third occurred in the upper extremities (most commonly brachial artery).[2] In the torso, the most frequently injured vessels were the iliacs (3.8%) followed by the aorta (2.9%) and subclavian arteries (2.3%), and inferior vena cava (IVC) (1.4%). In the neck, 109 carotid injuries accounted for 7% of the total.

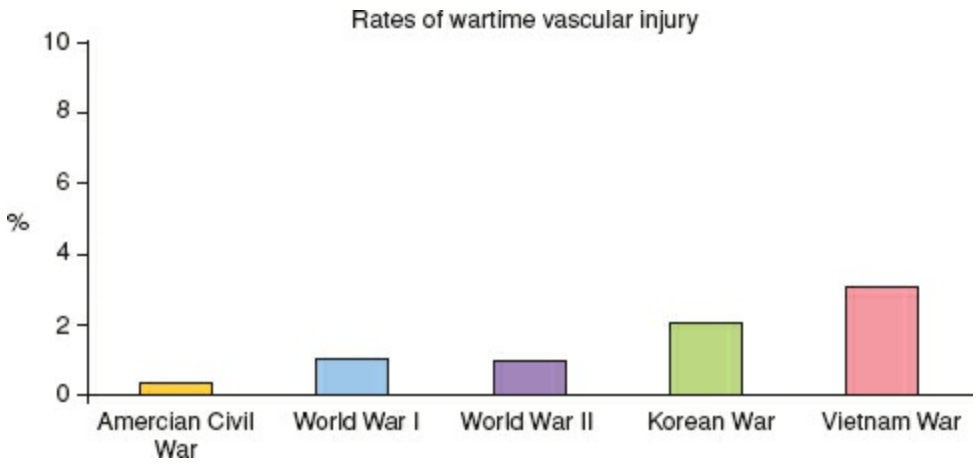

Figure 27-1. The rate of vascular injury reported from the wars of the previous two centuries. (From White J, Stannard A, Burkhardt GE, et al. The epidemiology of vascular injury in the wars in Iraq and Afghanistan. *Ann Surg* 2011;253(6):1184–1189.)

In the study by White and colleagues, it was noted that the vascular injury burden in the extremities in Iraq and Afghanistan was similar to that noted in World War II, although the higher modern rate of cervical and aortic injury was attributed to increased survivability and shortened medical evacuation (MEDEVAC) times.[2,8] Overall, the authors

concluded that the rate of vascular injury in these modern wars was five times that previously reported from Vietnam and Korea (Figs. 27-1 and 27-2). It is important to note that many of these reports from the wars in Afghanistan and Iraq did not include nonoperative cases and were generally confined to descriptions of vascular cases identified in the theater of war. Other studies, including one by Fox and colleagues, document the rate of wartime vascular injury from the perspective of military hospitals back in the United States, which also account for injuries that were diagnosed in a delayed fashion (i.e., delayed presentation or diagnosis of fistula, pseudoaneurysm or occlusion). In characterizing rates among patients having been evacuated to the United States, Fox and colleagues[9] described a 7% prevalence of vascular injury.

In a similar but smaller British study, Stannard and colleagues scrutinized records of 1,203 injured UK servicemen between 2003 and 2008.[7] Unlike the US JTTR, the British dataset also included patients who were *killed in action* (KIA), that is those who died prior to reaching a treatment facility.[7] In this study, it was reported that 110 (9%) of the cohort sustained injuries to named vessels, of which more than two-thirds had extremity vascular injuries. Blast wounds accounted for 54% and 76% of patients sustaining torsocervical and extremity wounds, respectively. Some 66 of the 110 died before surgical intervention could be undertaken, indicating the highly lethal nature of this wounding pattern. In particular, no patient with a combination of vascular injuries affecting more than one body region (torso, extremity, and cervical) survived to an operation.[7] Cervical vascular injuries also proved lethal, with 13 of 17 patients succumbing. On the other hand, of 76 patients with extremity injuries, 37 survived to surgery with one postoperative death. Interventions on 38 limbs included 19 damage control procedures (15 primary amputations, 4 vessel ligations in a group with a median mangled extremity score of 9) and 19 definitive limb revascularization procedures (11 interposition vein grafts, 8 direct repairs), with a limb salvage rate of 84%. This study concluded that while limb salvage is achievable in casualties able to withstand revascularization, torso vascular injury is often not amenable to successful intervention.[7]

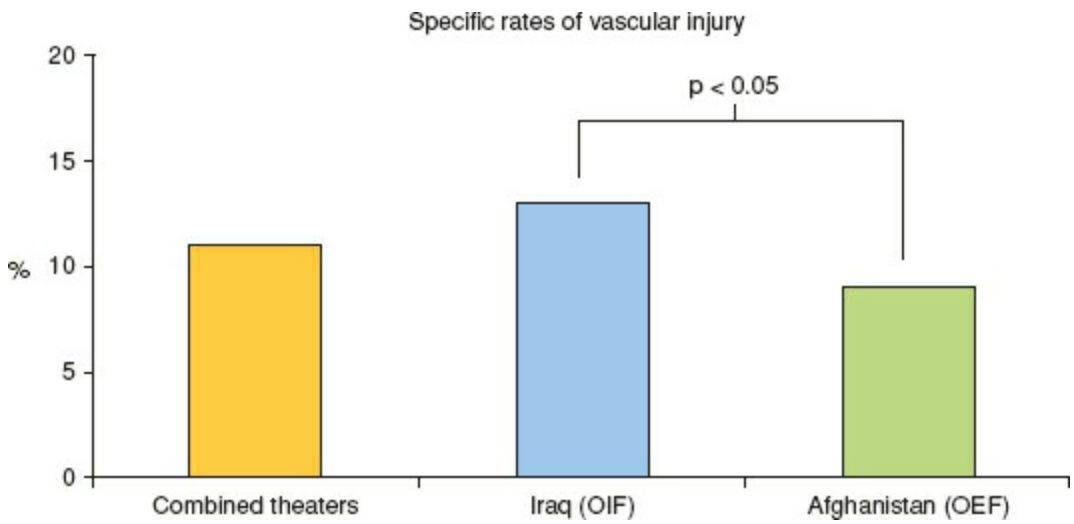

Figure 27-2. The rate of vascular injury reported during the wars in Afghanistan and Iraq. This specific rate refers to the 1,570 US service personnel identified within the Department of Defence Joint Theater Trauma Registry (JTTR) as having sustained vascular injury during the wars (between 2002 and 2009). Note that the overall rate of 12% is several-fold higher than the rate of vascular injury reported in previous wars. (From White J, Stannard A, Burkhardt GE, et al. The epidemiology of vascular injury in the wars in Iraq and Afghanistan. *Ann Surg* 2011;253(6):1184–1189.)

Civilian Population Vascular Trauma

The impact of vascular trauma in the civilian setting is less well characterized than that which occurs in conjunction with combat-related activities. Most societies are not afforded large trauma-specific data repositories or registries which allow characterization of this injury pattern. Even in the United States, which is served by the National Trauma Data Bank® (NTDB®) large-scale studies are limited in number and mostly retrospective. According to data from the National Center for Injury and Prevention, in 2011 in the United States, injuries accounted for 51.3% of all deaths among persons ages 1–44 years of age which is more deaths than those caused by noncommunicable and infectious diseases combined.[10] There is a significant increase in the number of admissions for both general and vascular trauma as the number of motor vehicle accidents increases and traffic density grows. Fatalities stem mainly from motor vehicle accidents (32%), gunshot wounds (22%), and falls (9%). Vascular injuries represent 1% to 2% of total trauma patients but they account for more than 20% of all trauma-related deaths and have the highest utilization of resources among the trauma population.[3]

In 2010, Demetriades and colleagues characterized vascular injury in 22,089 patients, including children, drawn from a population of more than 1.8 million in the NTDB®.[11] Accepting reporting bias that accompanies analysis of such retrospective data, it was determined that the incidence of vascular injury (2002 to 2006) was 1.6%. Four-fifths of the injured were male and the average age was 34 years. Half of the patients (51%) sustained a penetrating mechanism; the top 4 mechanisms of injury were motor vehicle collisions, firearms, stab wounds, and falls. Just under a quarter of patients presented in hemorrhagic shock and over half had an Injury Severity Score of more than 15.[11] Abdominal and chest injuries accounted for more than 25% and 24% of the injury burden, respectively, with arm and leg injuries contributing 26% and 18%. Mortality among those with vascular trauma was 23% and vessels associated with the highest rates of amputation were the axillary (upper limb amputation rate of 6%) and popliteal arteries (lower limb amputation rate of 15%).[11]

In other reports of vascular trauma from civilian centers in New York and El Paso, the rates of injury, in the context of all presenting to each trauma center, were 2.3% and 3.4%, respectively.[12,13] These reports confirm the “at-risk demographic” to be young and male and demonstrate that mortality in those with vascular trauma is twice that of patients without this injury pattern. Not surprisingly, penetrating mechanisms seem to be overrepresented in patients with vascular injury. The El Paso authors reported that of patients with vascular injury, 40% had a penetrating mechanism whereas only 10% of those with nonvascular trauma were injured in such a manner.[13] The largest single center study of vascular trauma in the United States was published from Houston in 1988.[3] This study encompassed a 30-year period, describing 5,760 injuries in 4,459 patients and confirmed that the burden of vascular trauma was borne by young men (86% male gender of average age 30 years), 90% of whom had been injured by firearms (gunshot 52%; shotgun 7%) or knives (31%).[3] The Houston study also showed that the wounding pattern in civilian circumstances, even where ballistic penetrating injury is common, does

not follow that seen in wartime. Torso and neck injuries accounted for two-thirds of all injuries, while lower extremity injuries (including the groin) comprised only 20%. Whereas very few soldiers with injuries to the large vessels of the abdomen are seen by military surgeons, trauma to the abdominal vasculature accounted for 34% of the injury cohort seen in Houston, a fact attributed to the maturation of the city's Emergency Medical Services.[3]

Mechanism of Vascular Trauma

2, **3** Vascular injuries are categorized as occurring from either blunt or penetrating mechanisms either of which can disrupt, to varying degrees of severity, the normal integrity of the layers of the blood vessel wall (intima, media, and adventitia). Blunt vascular trauma is produced by local tissue compression and/or acceleration–deceleration resulting in disruptive shear forces. Motor vehicle crashes are the main cause of blunt vascular trauma in the civilian setting and these patients usually have injuries to other areas of the body including extremity fracture or dislocation, brain injury, and injury to structures in the abdomen or thorax. Although a blunt mechanism is more commonly associated with torso vascular injury (i.e., aortic disruption), this mechanism is also recognized to be associated with a few specific extremity fracture or dislocation patterns near (e.g., posterior knee dislocation, tibial plateau fracture and supracondylar fracture of humerus) is a common location for vascular disruption.

Penetrating mechanisms typically result in direct injury of the vessel(s) causing either laceration or contusion of the wall as well as separation or destruction of soft tissues along the path of the object and those directly surrounding the vessel. Penetrating vascular injury may result from simple, low-velocity sharp objects (i.e., knife or glass), irregular fragments from explosives mechanism or higher velocity, and uniform munitions fired from a weapon. For the later of these, damage to the vessel and surrounding soft tissue often results from a concussive shockwave that is conducted through the tissues as the object moves through the body dissipating energy. Unlike closed blunt injuries, which more commonly affect torso vascular structures, penetrating injuries more commonly affect the extremity vasculature, and this mechanism mandates management of the associated soft tissue wound.

DIAGNOSIS OF VASCULAR INJURY

Physical Examination

4 Examining the patient is the most important step in evaluation of suspected vascular injury.[14,15] Most vascular injuries can be diagnosed with this step if it is performed in an intentional manner, being cognizant of the mechanism and while making use of a few enabling tools such as blood pressure measurement, basic radiography, continuous wave Doppler, and ultrasound. The physical examination should include exposing and palpating the extremities assessing for evidence of extremity fracture or dislocation, penetrating soft tissue wound and/or hematoma. The extremity vascular examination should also include assessment of distal perfusion, examining the appearance of the extremities, and palpating for the presence of pulses. In addition to assessing for penetrating wounds, examination of the abdomen and thorax (front and back) is important to identifying blood or fluid in these cavities with palpation and auscultation. Similarly, the neck and cervical region should be examined for signs of penetrating wounds, the presence of carotid pulses and/or bruising or hematoma.[14,15]

5 When considering physical evidence of vascular trauma, especially during in the extremities, it is useful to categorize it into hard and soft signs. Hard signs of vascular injury suggest near or complete disruption of the vessel in question and include pulsatile bleeding, expanding hematoma, palpable thrill, audible bruit, and or evidence of acute ischemia distal to the injury site. Depending on the degree of extremity ischemia, a patient may exhibit one or more of the classic six “P’s” including pulselessness, pain, pallor, paresthesia, paralysis, and poikilothermia. Soft signs of vascular injury suggest only partial disruption of the vessel in question and include the history or evidence of moderate hemorrhage that has stopped, trauma in proximity to a named vessel (i.e., certain fracture or dislocation patterns) (Figs. 27-3 and 27-4), diminished pulse distal to the site of injury, nonexpanding hematoma or severe bruising, and a peripheral neurologic deficit. Although torso vascular injury is more difficult to diagnose with just the physical examination, it should be suspected in patients with asymmetric arm pulses or pressures and those with severe hypotension and evidence of fluid in the peritoneum or thoracic cavity. As mentioned, patients having survived a high-speed motor vehicle crash or lengthy fall should be considered for a blunt aortic injury.[14,15]

Adjuncts to the Physical Examination

Several simple, noninvasive tools exist which can greatly enhance one's ability to diagnose vascular injury starting with the blood pressure cuff and measurement of pressure in both arms. A persistent discrepancy of more than 20 mm Hg between arm pressures suggests a proximal vascular injury to the subclavian or axillary arteries. A plain chest radiograph is also quick and useful as an adjunct in the diagnosis of blunt aortic injury. The classic signs of this injury pattern include a widened mediastinum (greater than 8 to 10 cm), an apical cap, loss of the characteristic aortic nob, downward displacement of the left mainstem bronchus, and a pleural effusion. Although multiple rib fractures are not a sign of aortic injury itself, it is a marker of severe blunt injury with significant shear and should raise one's index of suspicion for injury to the thoracic aorta.

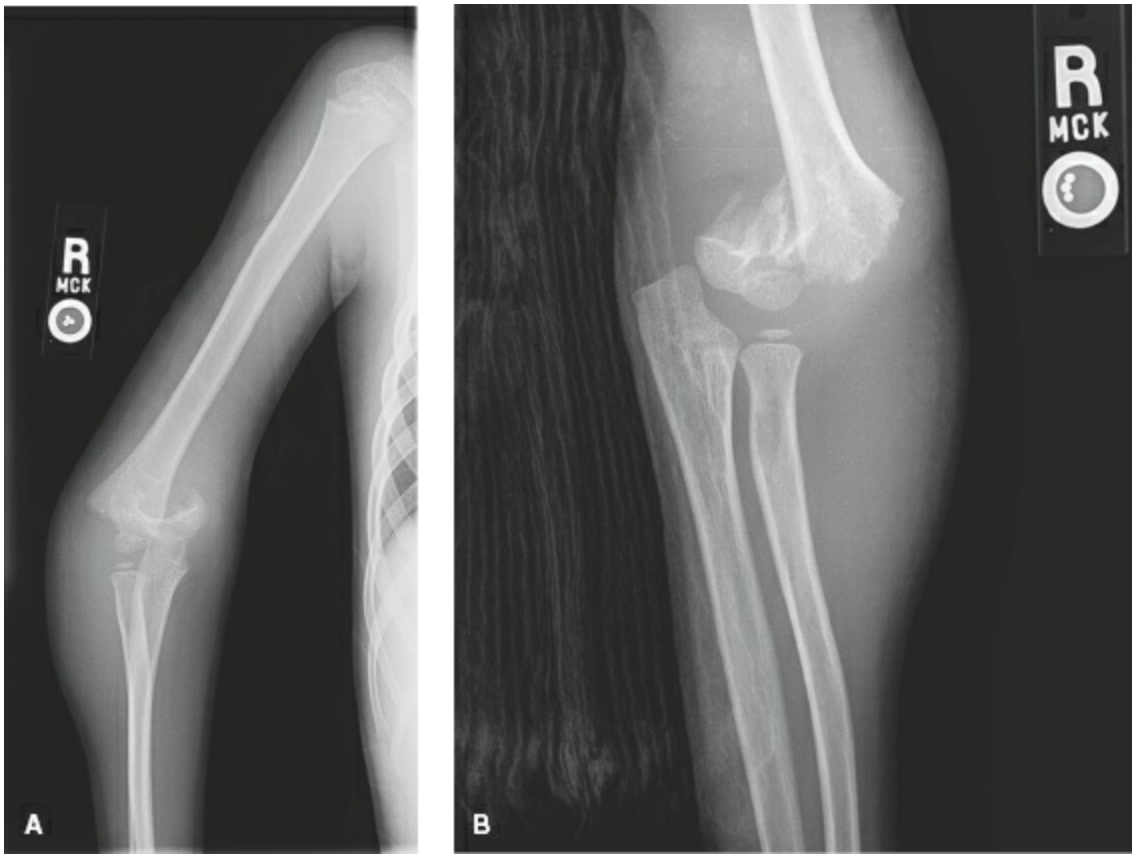

Figure 27-3. **A,B:** Radiographic images of a Gartland type III fracture of the right supracondylar humerus which is commonly associated with brachial artery injury.

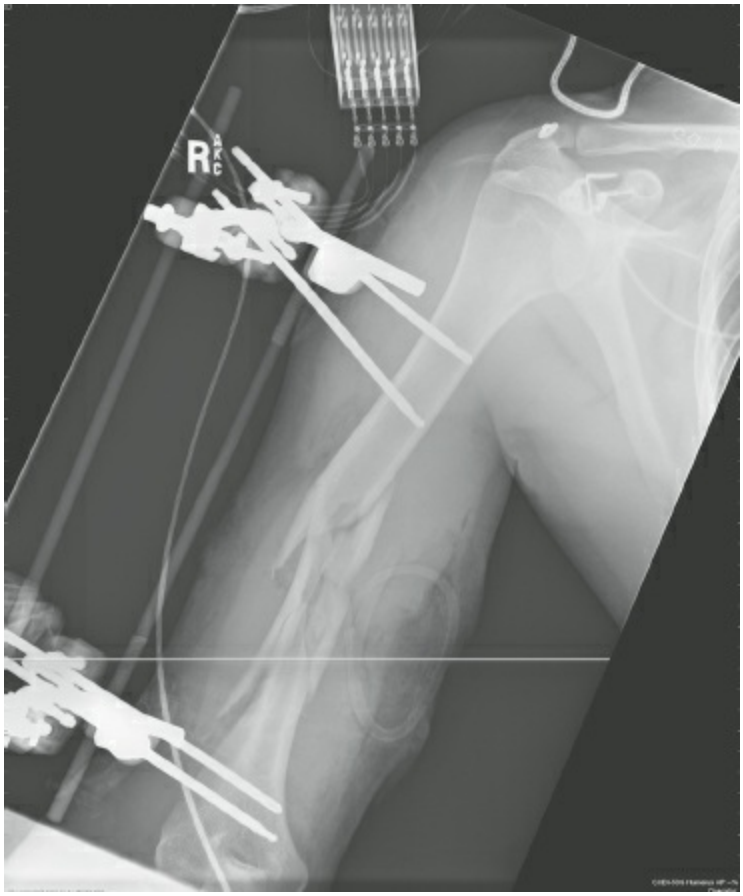

Figure 27-4. Radiograph of right upper extremity showing open humerus fracture and a temporary vascular shunt in the brachial artery which was severed by the fracture. The temporary vascular shunt was placed as a damage control adjunct to restore perfusion prior placement of the external fixator and patient evacuation to a higher echelon of care.

Continuous wave Doppler – with or without a manual blood pressure cuff – is another adjunct to the physical examination of patients in whom there is a concern for vascular injury. Doppler signals in the distal extremity should be recorded as present or absent and, if present, graded as strong and bi- or triphasic or weak and monophasic.[16,17] In the lower extremity, signals should be assessed in the dorsalis pedis and posterior tibial arteries while in the upper extremity, signals should be examined over the radial, ulnar, and brachial arteries. While describing the quality of Doppler signals can be somewhat subjective, identifying the presence of extremity perfusion by noting even the presence of an arterial signal is an important step that is typically less subjective than palpation for a pulse with one's finger.

The best use of continuous wave Doppler in the evaluation of the extremity is in conjunction with a manual blood pressure cuff, which allows one to record an arterial occlusion pressure adding a degree of sensitivity and objectivity to the process. In these instances, the blood pressure cuff is positioned on the distal portion of the lower or upper extremity (leg or forearm, respectively) proximal to the arteries which are to be examined. The Doppler probe is placed over a distal artery in the injured extremity until the arterial signal is audible. At this point, the blood pressure cuff is inflated to the point at which the signal is no longer present. The pressure at which the Doppler signal disappears is recorded as the arterial pressure in that extremity. This ankle or wrist pressure is then compared with the occlusion pressure of the arterial signal in another,

noninjured extremity and the ratio of the occlusion pressure in the injured compared to that in the noninjured extremity is recorded as the injured extremity index or IEI. When comparison of arterial occlusion pressures is performed for a lower extremity injury – comparison of the lower to the upper extremity – it can also be referred to as the ankle-brachial index (ABI). The normal ABI or IEI is 0.9 or greater although caution should be used in interpreting the ratio in patients who are hypotensive, in severe pain, or hypothermic.[15–17] Peripheral vasoconstriction is a normal response to significant trauma and shock and may result in a transiently decreased ABI or IEI in the absence of an injured axial vessel. In this context, assessment of the Doppler occlusion pressures and measurement of ratios should be viewed as dynamic and repeated after resuscitation, administration of pain control, and/or rewarming.

Ultrasound is another noninvasive modality that can be used in the evaluation of patients for vascular trauma. Brightness or B-mode ultrasound is ubiquitous in most emergency departments and critical care settings and allows one to make basic assessments that provide insight into the presence and severity of some patterns of vascular injury.[14,15] The focused assessment with sonography for trauma or FAST examination of the abdomen is based on B-mode ultrasound and is commonly used to determine the presence or absence of fluid in the peritoneum following severe injury. Although not specific for vascular injury, if the FAST examination is positive in a patient who is severely hypotensive following trauma, one can deduce that the fluid is blood. In these cases, ultrasound is identifying the result of vascular disruption from within the parenchyma of a solid organ (liver, kidney, or spleen), a larger named vessel or some other source within the abdomen.

Duplex ultrasound combines B-mode imaging with pulsed Doppler and provides a more sensitive and specific method of assessment for vascular trauma. Duplex is less practical in the immediate or initial physical examination as these machines are typically less prevalent than basic Doppler or ultrasound and they traditionally require more technical support to perform (i.e., vascular technician). Increasingly, small and mobile ultrasound machines in the acute care setting are incorporating duplex into their platforms allowing for more widespread use of this diagnostic modality without the restrictions that traditionally limited its application. If available, duplex is particularly useful in evaluating the extremity and cervical vasculature and provides not only a B-mode image of the vessel lumen but also an assessment of the direction and velocity of flow. A full description of the capability and performance of Duplex ultrasound is beyond the scope of this chapter. However, it is an incrementally more powerful diagnostic, surveillance, and follow-up tool as it relates to vascular trauma and gaining familiarity with its use is recommended.

Computed Tomography and Magnetic Resonance Imaging for Vascular Trauma

Contrast-enhanced computed tomography angiography (CTA) and magnetic resonance imaging (MRI) or angiography (MRA) are sensitive tools used in the diagnosis of vascular trauma.[18] The relative ubiquitous nature of these modalities means that they are often performed in severely injured patients as a matter of routine or screening (i.e., "pan-scan") and not for the specific diagnosis of suspected vascular injury. In this context, practitioners must be aware of incidental CTA findings not correlated with the clinical case or mechanism of injury. In these cases, the incidental finding must be acknowledged but should also be put in context of the mechanism and pattern of injury, the history and physical examination, and the surgeon's overall clinical experience. From the standpoint of diagnosis of suspected vascular injury, CTA and MRA are most useful in patients with soft signs on physical examination or those who have a high-risk mechanism or patterns of trauma.[18]

6 Contrast-enhanced CTA is the most available and common imaging modality used in the emergency setting including the evaluation of patients suspected of having vascular trauma. Multidetector CTA with high-speed helical scanning has reduced the time required to conduct the imaging and improved image quality. CTA has a high degree of sensitivity in identifying vessel dissection (i.e., separation of layers of the vessel wall), occlusion (i.e., thrombosis), and/or extravasation of blood into a contained space (i.e., pseudoaneurysm) or into an open space or cavity. CTA is particularly useful in the assessment of anatomic regions where physical and Doppler examination of the vasculature is limited (i.e., the torso, cervical and junctional regions). There is growing experience with CTA in the assessment of the peripheral vasculature and several clinical reports now demonstrate this modality's sensitivity and specificity in the diagnosis of extremity vascular injury.[19] Extremity CTA is appealing for the polytrauma patient who has soft signs of vascular injury as it can be accomplished concurrent with imaging of other body regions (i.e., head, neck, abdomen, and pelvis).[19]

MRI or MRA also possesses a high degree of sensitivity as it relates to the diagnosis of vascular trauma. However, the more cumbersome nature of MRA, including the slower acquisition and interpretation of images makes it less well suited for use in the acute and early phases of trauma care. Currently, MRA is mostly reserved for select cases of cervical vascular injury (i.e., carotid and vertebral) in which CTA is equivocal or in which there is a significant intracranial component of the injury or its sequela (i.e., stroke). Although contrast-enhanced MRA of the extremity vasculature has excellent definition, it thus far offers no significant practical advantage over other proven modalities such as duplex ultrasound, CTA, or conventional contrast arteriography.

Contrast Angiography

Angiography is the direct imaging of any vascular structure using a contrast agent with fluoroscopy while arteriography and venography refer specifically to imaging of arteries or veins, respectively. Like CTA, angiography is often most useful in patients with soft signs of vascular injury or those having sustained a particularly high-risk injury mechanism. Angiography can be useful in patients with hard signs of vascular injury and in this scenario is often used as an intraoperative technique in those taken immediately to the operating room for surgical repair. Unlike CTA, this imaging modality is more invasive and requires a higher level of technical expertise to accomplish. However, contrast arteriography has the advantage of being able to be performed in the operating room at the time during which resuscitation can be accomplished and other injuries addressed.[20] Contrast angiography also has the advantage of being a precursor for endovascular therapies such as embolization and placement of covered stents or stent grafts.

Intravascular injection of contrast agents allows visualization of anatomy and can be accomplished after direct vascular puncture and placement of a needle or an endovascular catheter. Basic angiographic techniques should be a standard part of any general, trauma, and vascular surgical practice and are typically applied in the resuscitation or operating room. Diagnostic studies and interventions are also performed by radiologists in specialized imaging suites. Transcatheter or catheter-based arteriography provides the highest-resolution imaging of most vascular beds including anatomic definition and a road map for surgical planning or intervention (open or endovascular). Vascular injury can be demonstrated as extravasation of contrast if bleeding from the vessel(s) is brisk and ongoing. However, extravasation may not be visualized if the bleeding is slow or under tamponade. Bleeding may also be missed if the contrast bolus is too small, if it is injected into a different vessel, or if image acquisition is terminated too soon. Angiographic interruption of vessel continuity usually indicates disruption or occlusion (i.e., thrombosis). With sufficient contrast, distal reconstitution of flow (i.e., beyond the disrupted segment) from collateral vessels can typically be demonstrated. Imaging of distal arterial beds can be compromised by hypoperfusion and vasoconstriction, typical manifestations of shock. Vasospasm, with tapering of arteries (sometimes to occlusion) and slow flow, can be more prominent in young patients who have a greater degree of vasomotor reactivity.[18,20]

Early venous filling after intra-arterial contrast injection indicates the presence of an arteriovenous fistula. Traumatic pseudoaneurysms result from focal disruption of arterial-wall integrity, with blood flow contained by adventitia or surrounding tissues. A pseudoaneurysm appears as a focal outpouching of contrast beyond the normal artery wall. Intimal flaps and focal segments of nonocclusive thrombosis may be detected as filling defects or lucencies within the contrast column, sometimes with a delay in distal contrast flow.

MANAGEMENT OF THE PATIENT WITH VASCULAR TRAUMA

Trauma Patient Pathophysiology

7 In the trauma patient, hemorrhage leads to both the overall metabolic consequences of total-body ischemia and end-organ ischemia of the specific injured vessel. Ischemia of both types results in anoxic cell death. Resuscitation is directed toward minimizing ischemia and the "lethal triad" of acidosis, hypothermia, and coagulopathy. Hypoperfusion, or ischemia, leads to acidosis, which causes platelet morphology changes and dysfunction and declining coagulation factor activity leading to decreased thrombin generation and the degradation of fibrinogen. Resuscitation with 0.9% NaCl also leads down a similar path of acidosis. Hypothermia likewise causes platelet dysfunction, less coagulation factor activity, and the induction of fibrinolysis. Both of these pathways lead to coagulopathy and endothelial damage. Nonbalanced massive blood transfusions can also lead to tissue injury, hypoperfused vascular beds, hemo dilution, and depletion/dilution of clotting factors and platelets, which can all contribute to a coagulopathic state.

Counterintuitively, the goal of resuscitation and repair, reperfusion, can precipitate another slew of metabolic insults on the trauma patient. Reperfusing ischemic tissues releases reactive oxygen species and sets off multiple proinflammatory processes including lipid peroxidation. This causes injury to the microvasculature which increases cell permeability and edema. An increase in interstitial pressure in turn leads to more stasis in microvasculature and therefore worsened ischemia, Ensuing cell lysis (e.g., rhabdomyolysis) leads to hyperkalemia, metabolic acidosis, and eventually myoglobin-induced renal failure.

Resuscitation of the Trauma Patient

After the usual ABCD is completed and an inventory of injuries is initially acquired, priorities of injury management can be set. Physical examination should include assessment for hard and soft signs of vascular injury. Examination can be performed almost simultaneously with plain radiographs when needed. General hard signs include active pulsatile bleeding or shock from blood loss, expanding/pulsatile hematoma, pulselessness, audible bruit over an artery, and palpable thrill. Hard signs mandate immediate trip to the OR for hemorrhage control and/or restoration of flow to the ischemic limb. These patients should not have CT/CTA done except in special cases. Unnecessary imaging delays definitive care and worsens outcome. If needed, on-table angiography can be used. Soft signs can include history of hemorrhage prearrival, venous ooze, nonexpanding/nonpulsatile hematoma, neurologic abnormality or decreased pulse as compared to contralateral limb, delayed capillary refill, and other additional site-specific signs. Venous access is also part of the initial management of the trauma patient. Large-bore catheters in peripheral veins of uninjured extremities are ideal, and preferred over central access in the emergent setting. Vein cutdowns, including veins otherwise ideal for later use as venous conduit, are sometimes necessary. Radial or femoral arterial lines are also often accessed for hemodynamic monitoring.[21]

8 Damage control resuscitation, a term coined in 2005, involves allowing permissive hypotension with a goal of a palpable radial pulse (in patients without head injury).[22] It also includes limiting crystalloid infusion and an early institution of massive transfusion protocol with higher rates of plasma and platelets to prevent/reverse coagulopathy.[23]

General Intraoperative Considerations and Pearls

Often the theory of “damage control” and “life over limb” takes precedence in the chaotic trauma bay and operating room. But there are basic tenants to follow when thinking beyond: control hemorrhage, restore blood flow, and prevent further injury.

1. Prep widely, considering any possible procedure including the need to obtain vascular conduit (i.e., saphenous vein). With leg injuries, prep circumferentially, and include the shoulders, chest, and abdomen. With chest or abdominal injuries, prep both groins. With neck or upper extremity wounds, prep the chest.
2. Patients should receive preoperative antibiotics, based on local guidelines.
3. Longitudinal incisions that are parallel with neurovascular bundles should be used for the widest exposure and best control. They may need to be S shaped over joint spaces. Minimization of the devitalization of intervening tissues can improve arterial and venous collateral flow, and provide coverage after repair.
4. Proximal and distal control for any vascular injury is critical. This may be obtained with a digit, vessel loop, vascular clamps, or a Foley or Fogarty balloon. Consider remote proximal control when hematomas or open blast wounds impede visualization. Shunts should also be considered to decrease ischemic time when orthopedic stabilization or other life-saving procedures must occur first. Nonbleeding wounds should not be disturbed including removing debris or foreign objects until surgical control is possible. Temporary application of a lower extremity tourniquet may be helpful with multiple wounds or before control is attained. An inappropriately applied tourniquet inflated to venous pressure can increase exsanguinating hemorrhage; it may need to be increased to stop bleeding that may recommence once resuscitation is underway and systemic blood pressure increases.
5. Injury may require orthopedic surgeons to perform fracture reduction and limb stabilization prior to vascular, nerve, or soft tissue repair. This will often improve vessel spasm and vascular examination should be repeated.
6. Systemic heparin use is individualized and depends on multiple factors: preoperative blood loss, hemodynamic stability, amount of ongoing bleeding, presence of brain injury, and status of patient with regard to acidosis, hypothermia, and coagulopathy. Local administration of heparin and papaverine can also be used in the wound and as vessel flushes. In general, systemic heparin is not indicated in young patients with good vascular repairs who otherwise have healthy vessels (no chronic atherosclerotic disease).
7. Exposure of the injury and vessels depends on the location, and can involve aggressive debridement of devitalized tissue for adequate visualization and postoperative healing (Table 27-1).

Table 27-1 Exposures in Vascular Trauma Surgery

Vessel Injured	Exposure/Maneuver
Right subclavian artery Ascending aorta Innominate artery	Median sternotomy
Left subclavian artery Descending thoracic aorta	Left thoracotomy
Paravisceral, infrarenal aorta Left renal artery Left iliac artery	Left colon mobilization
Inferior vena cava Right renal artery Right iliac artery	Right colon mobilization, extended Kocher maneuver (duodenal mobilization)

8. Inflow and outflow must be assessed before beginning an anastomosis; thrombectomy with a Fogarty embolectomy catheter may be required.
9. Ensure bleeding has stopped, reassess hemodynamic status of patient, and complete repairs with correct prioritization (including artery before veins in most situations).
10. Decision is made on which tension free repair to execute (Table 27-2).
11. Appropriate conduit is obtained, if applicable. Reversed greater saphenous vein of the uninvolved leg is an ideal conduit.
12. Repair is performed with nonabsorbable, monofilament running suture in most cases, and hemostasis is obtained. Hemostatic agents can be parenteral (e.g., tranexamic acid for hyperfibrinolysis;) or topical (Table 27-3).
13. Repair should be assessed in the operating room with Doppler and possible arteriogram.
14. Muscle and/or soft tissue coverage over repairs should be utilized when feasible to decrease contamination, dessication, and disruption.
15. Compartment syndrome must be considered, and fasciotomies performed as needed.
16. Wound care, physical and occupational therapy must be robust and intensive postoperatively.

Table 27-2 Options for Treatment of Vascular Injuries

Type of Repair	Uses, Indications
Lateral repair	<25% vessel compromise
Patch angioplasty	<50% vessel compromise
End-to-end anastomosis	<2 cm defect, ends mobilized, spatulated (smaller vessels)
Interposition graft	>2 cm defect, reversed vein or PTFE (if would be tension)
Extra-anatomic bypass	Extensive defect, multiple level injury, contamination

MANAGEMENT OF SPECIFIC INJURY PATTERNS—EXTREMITY

For all extremity trauma, management algorithms follow as listed in a previous section starting with advanced trauma life support protocols, controlling hemorrhage, alleviating ischemia, and limb stabilization to minimize future disability, in that order.[24] Injuries with hard signs of vascular injury will be taken immediately to the operating room for open and/or endoluminal diagnosis and interventions once life supporting measures allow, without further workup. Presence of hard signs has an almost 100% sensitivity of existing vascular injury. Whereas soft signs, with only a 5% specificity for detecting arterial injuries, allow time for further workup, imaging, and decisions into operative, endovascular, or nonsurgical observation categories.[25]

Generally, the sequence should be stabilization of the extremity with or without the use of a temporary vascular shunt, revascularization, and then as patient condition allows debridement, nerve repair, and soft tissue coverage. Temporary vascular shunts have been shown in many military studies as a successful adjunct in damage control situations with reduced rate of amputations (Figs. 27-4 and 27-5).

An additional issue relevant to all extremity trauma is whether to repair venous injuries. It depends on resources, comorbidities, other injuries, and of course, stability of patient. Ligation of veins is better tolerated in upper extremities than lower. When harvesting the greater saphenous vein for conduit, it should be from the uninjured leg when feasible to allow full venous drainage of injured leg (Fig. 27-6).

Table 27-3 Topical Hemostatic Agents

	Indications	Agent Potency/Mechanism	Uses	Examples
Level I (mechanical hemostat)	Min or mild bleeding, localized	Contact activation ± platelet aggregation	Capillary, arteriolar ooze	Gelfoam, procine gelatin, bovine collagen, surgical, nu-knit, Arista
Level II (Thrombin)	Min or mild bleeding diffuse	Converts fibrinogen to fibrin activated platelet aggregation Contact activation + fibrinogen converted to fibrin	Capillary, ooze Capillary, arteriolar ooze, spurting	Bovine thrombin, recombinant thrombin Collagen or gelatin + thrombin; Floseal, Surgiflo
Level III (fibrin sealant, combination hemostat)	Mild bleeding diffuse; moderate bleeding	Fibrin sealant, replicates final stage of clotting cascade Synthetic sealant, covalently and mechanically bond Other	Capillary, arteriolar ooze High pressure sealing	Thrombin + fibrinogen ± fibrinolysis inhibitor; Tisseel, Evicel PEG polymer; coseal Bioglue

Adapted from Shander A, Kaplan LJ, Harris MT, et al. Topical hemostatic therapy in surgery: bridging the knowledge and practice gap. *J Am Coll Surg.* 2014;219(3):570–579.

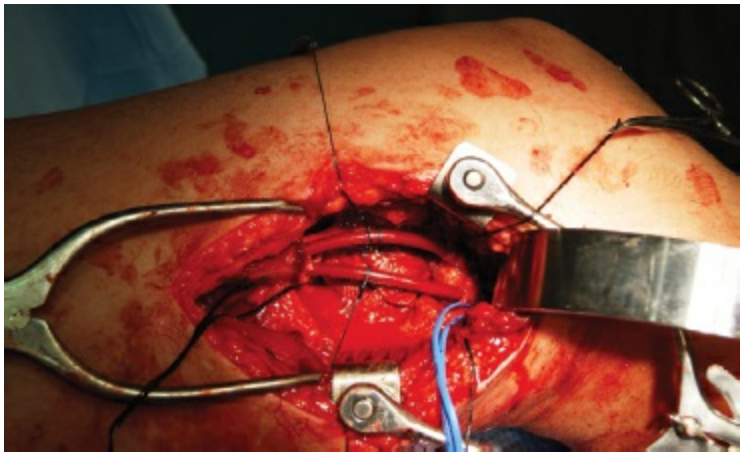

Figure 27-5. Operative photograph showing temporary vascular shunts placed as a damage control maneuver in the proximal popliteal artery and vein of the left lower extremity. The shunts had been secured with silk suture ties, and both were patent with Doppler flow several hours after the injury. Note also the operative approach to the left above-knee popliteal fossa that includes a proximal Wietlaner retractor and a distal Henly popliteal retractor, and short handheld Wylie renal vein retractor.

9 A critical issue in all extremity trauma management is evaluation of compartment syndrome. Elevated fascial compartment pressures can be due to reperfusion, hematoma, swelling from crush injury or major fractures. There must be a low threshold for performing fasciotomy, based on clinical suspicion of present or pending compartment syndrome. Diagnosis is based on a high index of suspicion suggested by any of the following: >4 to 6 hours of ischemia, crush injuries, combined arterial and venous injuries, vessel ligation, tense compartments, pain out of proportion and on passive motion, poikilothermy, pallor, paralysis, paresthesia, and finally, pulselessness. Compartment pressures can be measured as an adjunctive aid in diagnosis. A commonly used cutoff is 30 mm Hg, but normal pressures with a concerning examination should not deter from pursuing treatment with fasciotomy.

Postoperative considerations include starting aspirin as soon as possible, DVT prophylaxis, elevation of the injured extremity, 24 hour of antibiotics, and starting rehabilitation as soon as appropriate in patient's condition. Systemic heparinization is usually not required postoperatively, and DVT prophylaxis and/or antiplatelet agents can suffice.

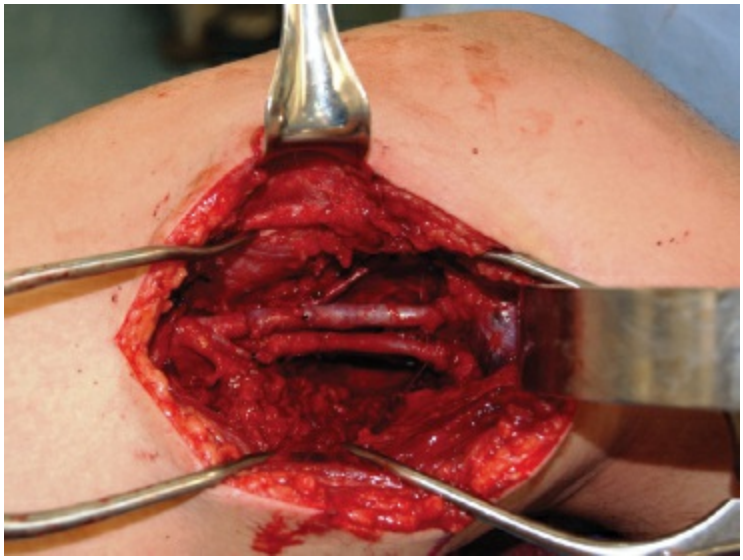

Figure 27-6. Operative photograph showing interposition vein graft repair of the left proximal popliteal artery and vein. The interposition grafts were performed after removal of the temporary vascular shunts and consisted of greater saphenous vein from the right (contralateral) lower extremity.

Upper Extremity

Anatomically, the axillary artery is defined proximally by the lateral margin of the first rib and distally by the lateral edge of the teres major muscle. The artery is protected proximally within the shoulder from penetrating injury, but susceptible to forceful blunt trauma due to its fixation. It is difficult to expose proximally due to the artery's location under the clavicle and may require either infra- and supraclavicular incisions to gain control, or a more proximal intrathoracic or mediastinal approach of the subclavian artery. The mid- and distal axillary artery can be approached through a traditional infraclavicular incision. The complications with more distal exposure are due to increasing branches and associated nerves leading to the shoulder and arm. Employing endovascular techniques for temporary balloon occlusion or placement of stent grafts may be advantageous in either of these locations.[26]

The axillary artery becomes the brachial artery, which runs in the anterior compartment of the arm with the median nerve. Two veins accompany, and often cross over, the artery – the basilic and brachial veins. Exposure of the brachial artery is simple compared to the axillary, in the medial grove between the biceps and triceps muscles. The brachial artery is most often injured during penetrating trauma, but should be considered with any humerus fracture, especially posterior or lateral fractures. The brachial artery's main proximal branch, the profunda brachii, can provide significant perfusion to the distal upper extremity if it remains intact.

The radial artery is a terminal branch of the brachial just distal to the elbow and travels in the anterior compartment to become the deep palmar arch. The ulnar artery is the larger terminal branch of the brachial artery and runs to the wrist to form the superficial palmar arch and joins the deep arch. If temporary control of bleeding is needed, a blood pressure cuff can be used as a tourniquet; clamps should never be placed blindly into a bleeding wound due to the high risk of nerve injury. Evaluation should include the previously described neurovascular examination with addition of the Allen test to determine patency of the palmar arch. Some believe a single vessel injury with no ischemic changes can be ligated if the palmar arch is intact. If both forearm arteries are injured, the usually dominant ulnar repair is preferred, primarily or with vein from ipsilateral arm or dorsal foot vein. There is limited to no role for acute management of traumatic forearm injuries by endovascular means.

Lower Extremity

Femoral trauma constitutes 20% of all traumatic arterial injuries. Supracondylar femur and tibial plateau fractures are associated with distal superficial femoral artery and popliteal artery injuries. Acute ligation of the femoral artery leads to 50% amputation rate.[27] Previously stated management principles should be followed for the lower extremity as well with some site-specific caveats. Some situations may require control of hemorrhage via an assistant's digit prepped into field, a temporary balloon catheter or tourniquet, or exposure of the distal external iliac artery in the preperitoneal space with compression against iliac fossa for femoral triangle injuries. Incision should be longitudinal just distal to the inguinal ligament. Primary repair or interposition grafts are the mainstay of therapy. Although vein conduit is always preferred, prosthetic graft can be used when necessary, in larger vessels with good muscle coverage. Heavy contamination (such as a bowel injury) may make an extra-anatomic bypass necessary, at least temporarily. Endovascular techniques can be employed in certain circumstances in the femoral and popliteal region including coiling arteriovenous fistulae or pseudoaneurysms, stenting pseudoaneurysms or transections that can be crossed.

Popliteal trauma is classically due to posterior knee dislocation. Historically, amputation rates were 20% for both penetrating and blunt popliteal injuries.[28] While failure to repair a popliteal occlusion results in over 60% amputation rate. Incision should be medial, employ the use of a bump under the slightly flexed leg, and utilize deep self-retaining retractors (Figs. 27-5 and 27-6). Repair is primary, interposition graft, or with a stent. Primary repair should be attempted only if defect is <1 cm. Completion angiography is recommended in most situations.

Reportedly, a single terminal vessel can be ligated in the lower extremity in a patient with no signs of ischemia and no peripheral vascular disease. Whenever possible, preserving three artery perfusion to the foot is preferred. When all three arteries are damaged, repair should focus on the posterior tibial via a medial incision or anterior tibial via a lateral incision.

MANAGEMENT OF SPECIFIC INJURY PATTERNS – CERVICAL

The carotid artery travels in the anterior cervical triangle of the neck, specifically the carotid triangle bordered by the sternocleidomastoid muscle, the superior belly of the omohyoid muscle, and the posterior belly of the digastric muscle. Of course, besides hemorrhage from carotid artery, jugular veins and branches, injury to nerves (vagus, hypoglossal), trachea, and esophagus must also be considered. The vertebral artery, which supplies blood to the posterior brain, travels first in the transverse foramina of the cervical vertebrae and then in the vertebral canal.

10 When discussing neck trauma, there are three regions classically used to describe anatomic location. Zone I is below the cricoid cartilage, zone II is between the cricoid cartilage, and the angle of the mandible, whereas zone III is above the angle of the mandible. The carotid and vertebral arteries are at risk in all three zones.[29]

Neck trauma is also divided into penetrating and blunt injuries. Zone II of the neck is the most commonly injured region at 47% of penetrating neck injuries. The most commonly injured structure within the neck is blood vessel, with a 20% incidence of major vascular injury in penetrating neck trauma. These injuries lead to a 7% to 27% stroke rate and 7% to 50% mortality rate; 80% of deaths due to penetrating neck injuries are attributed to stroke.[30] Evaluation of these injuries used to include a mantra “operate if penetrated the platysma” but this is no longer the rule as it has been shown to lead to a 50% to 90% negative exploration rate. Currently, CTA is used whenever the patient is deemed stable enough to travel to CT scan. The CTA should include the neck and head, with extension through the aortic arch if a zone I injury is suspected. CTA has a 90% sensitivity and 100% specificity rate for vascular injuries that require treatment.[31]

As stated, treatment of injuries with hard signs in zone II is emergent operative exploration. This can be undertaken often via a cervical incision. Stab wounds can often be repaired primarily or with a patch, while ballistic injuries typically require segmental resection with interposition graft. Greater saphenous vein should be used as conduit whenever possible. Internal jugular can be ligated in an emergent setting, but otherwise should be repaired, especially if injury is bilateral. External jugular and facial veins can be ligated without significant consequence, as can the external carotid artery. Internal carotid artery should be repaired as there is a high mortality with ligation (45%).[30] Heparinization with or without shunting is employed during these repairs unless major contraindications exist in the multi-injured trauma patient.

Zone I and III injuries are much more difficult to expose using an open approach. Thus, they are often managed with open surgery, endovascular intervention, or a hybrid combined approach depending on location, comorbid conditions, other injuries, stability of patient, and availability of resources. Endovascular approaches have become particularly appealing for injuries at the thoracic outlet and skull base, which are especially difficult to access during open surgery.

Zone I injuries with hard signs of vascular injury typically involve the great vessels.

These need to be managed with either an endovascular approach (cover stents and endografts) or open clamp for proximal control via median sternotomy, high anterior thoracotomy, or clavicular resection. Common carotid can be controlled via a sternotomy, and portends a lower risk of stroke than clamping the internal carotid due to collateral flow via external carotid and the circle of Willis.

Open control of zone III injuries can require subluxation of the mandible (jaw dislocation), mandibulotomy, and other morbid exposures so endoluminal control is appealing in this region as well. A temporary occlusive balloon while exposure and hemostasis is obtained, coil embolization, and a covered stent placement over the injury are strategies that have been used. Covered stent have been described in the treatment of traumatic carotid injuries. The results are inconsistent and based on small studies. One study placed stents in 10 patients with carotid dissections, neurologic changes and contraindication for or failure of anticoagulation with good overall results. Whereas a contemporary study of 23 patients who underwent carotid stent placement for traumatic pseudoaneurysm documented a 21% complication rate and 45% occlusion rate, both higher rates than the patients treated with antithrombotic therapy alone.[29,32]

Vertebral artery injuries are less common, and more difficult to expose and control operatively, than carotid artery injuries. Vertebral artery injuries are most often associated with cervical spine transverse process fractures, subluxations, or penetrating injuries to the back of the neck. Only medical management is needed if the injury is not bleeding. Endovascular means of embolization has been employed for pseudoaneurysms and intimal disruption (and is technically a better option whenever possible), if the vessel is not already thrombosed. Open access to the vertebral artery may be necessary to control bleeding if endovascular approach cannot be used for any reason (not available or not enough time, etc.). This involves an exposure similar to that for the carotid artery, and after the sternocleidomastoid and anterior scalene muscles are mobilized, vertebral artery can be isolated and ligated. In this procedure, care must be taken to avoid injury to the phrenic nerve and thoracic duct. To obtain proximal and distal control of a more distal vertebral artery injury may require employing similar techniques as with a zone III carotid injury. The expected stroke rate of ligation of the vertebral artery in the spine literature is 0% to 8%. However, whenever possible, medical therapy with antithrombotics is still the primary treatment modality.

Blunt vascular trauma to the neck is usually considered as blunt cerebrovascular injury (BCVI) and encompasses both carotid and vertebral injuries (often discussed as one). BCVI represents $<1\%$ of admissions for blunt trauma, but the impact is great when considering these injuries lead to a 12% to 58% stroke rate and 31% to 59% mortality rate when untreated.[33] The goal of management is thrombosis prevention, therefore treatment with antithrombotic therapy is recommended. Two such examples reported a reduction in stroke rate from 64% to 6.8%, and 46% to 0% in blunt carotid injury patients treated with any antithrombotic agent.[34] However, the optimal drug(s) and duration for each injury grade has not yet been determined by prospective data. This could include aspirin, clopidogrel, anticoagulation, for a set time versus life long. Retrospective data have shown equivalence in injury outcomes with antiplatelet and anticoagulation

treatment regimens.

MANAGEMENT OF SPECIFIC INJURY PATTERNS – TORSO

11 Control of bleeding from vascular disruption within the torso is not readily amenable to control with direct pressure and is therefore referred to as noncompressible torso hemorrhage (NCTH). Civilian studies demonstrating that NCTH accounts for 60% to 70% of mortality following otherwise survivable injuries clearly emphasize the lethality of this injury pattern. Hemorrhage is also a significant problem in the wartime setting, accounting for up to 60% of deaths in potentially survivable injury scenario. The distinction between compressible extremity hemorrhage and NCTH is notable. There has been a demonstrable reduction in mortality from extremity injury with a better understanding of its epidemiology and the need to rapidly control hemorrhage with tourniquets and/or topical hemostatic agents. To date, there has been no such reduction in mortality in the setting of NCTH.[35] Vascular disruption with bleeding can arise from an array of anatomic sites:

- Large axial vessels
- Solid organ injuries
- Pulmonary parenchymal injuries
- Complex pelvic fractures

As such, the definition of NCTH begins with the presence of vascular disruption from one or more of four anatomic categories listed above.

Management of Torso Hemorrhage

12 Despite advances in surgical understanding, technique, and technology, one fundamental tenet remains: Proximal and distal control is essential when managing suspected vascular injury. The majority of patients with these types of injuries qualify for management in a damage-control fashion and the appropriate surgical maneuvers depend primarily on the location of hemorrhage within the torso.

Thoracic Cavity

Vascular trauma to the aortic arch and its major branch vessels is rare and the majority of patients present in shock, requiring immediate surgical intervention in the form of tube thoracostomy, resuscitative thoracotomy (RT), or median sternotomy. Aortic arch injuries are often associated with multiple other vascular injuries, including vena cava, innominate vein, and pulmonary artery injuries and a median sternotomy is the operative exposure of choice. Sternotomy followed by division of the innominate vein allows the pericardium to be opened for release of any associated cardiac tamponade. Exposure of aortic branches can be facilitated by extending the sternotomy incision proximally as a supraclavicular incision with division of the sternocleidomastoid muscle.

For hemorrhage control within the thoracic cavity, access to the ipsilateral side is best via an anterolateral thoracotomy, through the fourth interspace, with the patient in the supine position, tilted up on a roll. This approach also allows extension of this incision across the sternum into the right hemithorax or the clam-shell incision, permitting access to either of the other two compartments in the chest (mediastinum and contralateral thoracic cavity) if required. It is important that a surgeon performing this maneuver must also have the ability to concomitantly explore the abdomen, so this must be included when preparing the surgical field.

Once within the chest, hemorrhage control is the priority. Pulmonary bleeding can be controlled using several techniques, depending on location. Injury to the periphery of the lung can be stapled off in a nonanatomic fashion using a linear stapler. If hemorrhage from the lung is from the deeper hilar structures, the lung itself (after mobilization) can be compressed or even twisted on itself to occlude the hilar vessel. In cases where the injury significantly compromises a patient's pulmonary reserve, extracorporeal life support (ECLS) may also be a useful adjunct.

Abdominal Cavity

The abdomen should be opened through a midline incision from the xiphoid process to the pubic symphysis to permit access to all 4 quadrants. Initial packing remains the best method of initial hemostasis, allowing for the resuscitation to restore the circulating volume. An additional useful adjunct for patients in extremis is resuscitative aortic occlusion of the aorta at the diaphragmatic hiatus. The next key steps are sequential evaluation of the abdomen, decisions regarding local control of hemorrhage and contamination and the type of reconstruction required for any large vessel injury (Fig. 27-7).

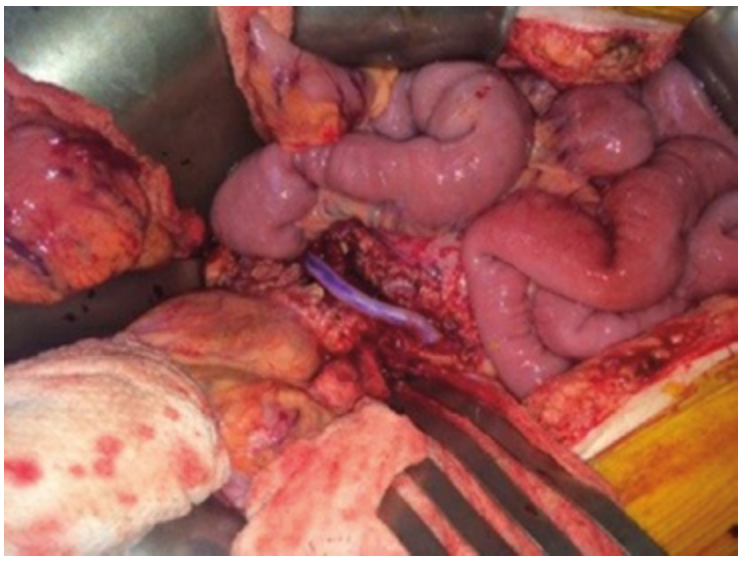

Figure 27-7. End-to-end interposition graft repair of mid-superior mesenteric artery injury with great saphenous vein.

Hemorrhage from the solid organs of the abdomen is managed differently, depending on the organ in question. Exposure and removal of the spleen is fairly straightforward and well tolerated by the patient, and thus splenectomy is the favored maneuver for the hemorrhaging spleen. By contrast, hemorrhage from the liver necessitates packing to control venous bleeding in most instances. Control of the porta hepatus at the gastrohepatic ligament and application of the Pringle maneuver is often used as an adjunct to liver packing to control inflow to the organ. Depending on the nature of the wound and the location of the hepatic bleeding, the liver can be mobilized by dividing the coronary and triangular ligaments and allowing the left and right lobes to be drawn or compressed together.

Retroperitoneum

Posterior to the peritoneal sac lies the retroperitoneum, which can be divided into four zones. Zone I is centrally located and contains the aorta and IVC. Hemorrhage often manifests as a hematoma and should always be explored in this zone. Management of such injuries should adhere to standard principles of proximal and distal control of the vessel. The aorta can be widely exposed through a left medial visceral rotation – also referred to as the Mattox maneuver by mobilizing the left colon and kidney. The IVC can be explored through a right visceral rotation – also referred to as the Cattell–Braasch maneuver – by mobilizing the large and small bowel fully to the root of the mesentery.

Approaching large-vein injuries in the abdomen is often more challenging than controlling and repairing arterial hemorrhage. Like bleeding from large arteries, one must be prepared with multiple suction devices and a good retraction device, and be sure that the anesthesia team is prepared with warmed rapid transfusion devices. Because large veins often do not tolerate clamps in the setting of trauma and hematoma, direct pressure should be applied with sponge-sticks or the smaller Kittner dissector sponges. These devices substitute for manual pressure and allow one to create more visibility in the operative field.

Zone II is perirenal in location and generally should be managed conservatively in blunt trauma, provided there is no expansion and the patient is hemodynamically stable. Penetrating trauma requires a different approach, with an emphasis on exploration and repair of the kidney if possible, or nephrectomy. If there is concern of injury to or violation of the collecting system, drains should be left in the perinephric or retroperitoneal space.

Zone III originates from within the pelvis, although these injuries can be extensive, tracking all the way up to the supracolic compartment. Pelvic hematomas are best managed conservatively in blunt trauma, and opening them should be avoided. Further management options are outlined below. In penetrating, vascular control is vital, especially if a direct vessel injury is suspected, and may require mobilization of the terminal aorta.

Operative management of bleeding from the portal-retrohepatic zone (sometimes referred to as zone IV) is fraught with difficulty. Control of bleeding from the retrohepatic vena cava is especially challenging and is associated with high mortality. Contained hematomas should be left undisturbed, and expanding lesions should be packed in the first instance.

Pelvis

The pelvis is a complex compartment containing several unique anatomic structures typically managed in the elective setting by specialists from a range of disciplines (e.g., urology, orthopedic surgery, vascular surgery, and general/colorectal surgery). Operative exposure of the pelvic space can be achieved through either a transperitoneal approach at the time of laparotomy or with an extraperitoneal approach, which can be accomplished through a midline or a Pfannenstiel incision. The former is the quicker approach, enabling access to both the abdomen and the pelvis and permitting access to the aorta and distal vascular along with the hollow viscera within that region. The extraperitoneal approach allows access to the external iliac vasculature for suprainguinal arterial control and for packing of the preperitoneal space. The latter is a useful adjunct to managing venous bleeding in complex pelvic fractures once bony stabilization has been achieved. Arterial bleeding from the pelvis is most commonly managed with endovascular techniques such as coil embolization in cases of complex pelvic fracture. In rare instances of pelvic fracture or open fragmentation or gunshot wounds to the pelvis, ligation of the internal iliac artery is necessary as a hemorrhage-control maneuver.

A proportion of patients with NCTH present with circulatory collapse, either profoundly hypotensive or in cardiac arrest. Management of patients presenting in such a fashion has been extensively studied. The current civilian standard of care is to perform a RT, which permits the following maneuvers:

- Release of cardiac tamponade
- Management of thoracic bleeding
- Control of massive air-leaks
- Internal cardiac massage
- Thoracic aortic occlusion

The latter maneuver is undoubtedly the most practiced, as aortic control theoretically enhances cerebral and myocardial perfusion. Aortic occlusion can also be achieved by endovascular balloon occlusion, as demonstrated by the use of percutaneous devices used to control the neck of abdominal aortic aneurysms during endovascular repair.[36] This technique enables the physiologic benefit to be realized without the additional burden of entering a body cavity. Such a technique has been used in trauma as early as the Korean War and since.[37] With recent improvements in endovascular devices and resuscitation in general, there is a renewed interest in this approach, which has been termed resuscitative endovascular balloon occlusion of the aorta (REBOA) (Fig. 27-8).[38,39]

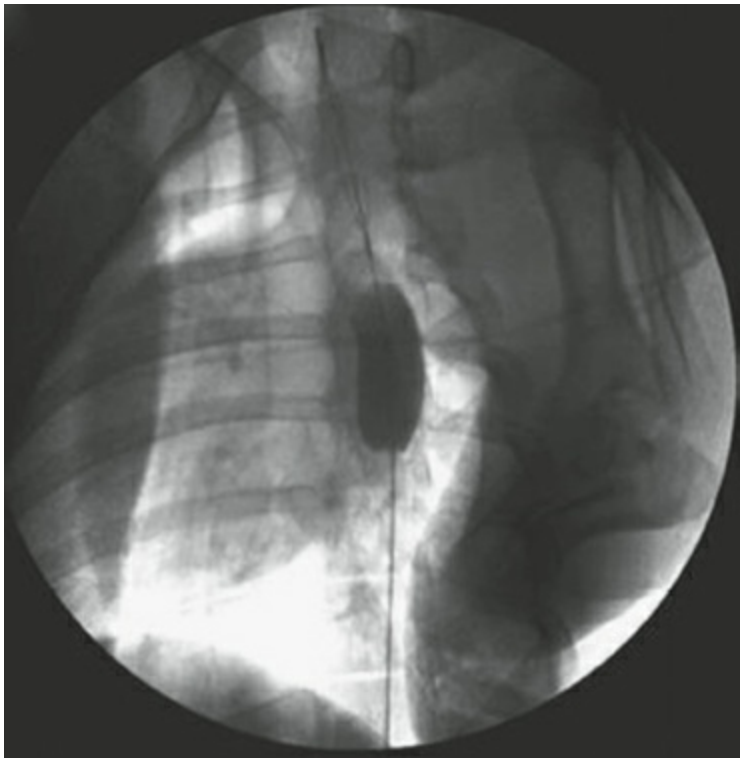

Figure 27-8. Fluoroscopic image of a compliant balloon inflated in the descending thoracic aorta as part of the maneuver referred to as resuscitative endovascular balloon occlusion of the aorta or REBOA. This endovascular maneuver was accomplished through a percutaneous sheath in the right femoral artery and can be accomplished in certain scenarios instead of an open resuscitative thoracotomy with aortic clamping to restore proximal central aortic pressure and mitigate distal bleeding. (From Scott DJ, Eliason JL, Villamaria C, et al. A novel fluoroscopy-free, resuscitative endovascular aortic balloon occlusion system in a model of hemorrhagic shock. *J Trauma Acute Care Surg* 2013;75:122–128.)

CONCLUSION

Vascular trauma remains a leading cause of mortality and morbidity following civilian and military injuries. A large volume of military supported epidemiologic and translational research stemming from the wars in Afghanistan and Iraq has advanced the understanding and treatment of this injury pattern. Evidence suggests that the commonality of vascular trauma is increasing at a time during which familiarity with its management (open and endovascular) is on the decline. Supported by an understanding of modern epidemiologic patterns of injury, including mechanisms and specific scenarios, and knowledge of the range of options available to examine and image patients, providers will be able to effectively diagnose or exclude the presence of vascular trauma. This foundational understanding will also aid providers in their approach to resuscitating severely injured patients and knowing when to intervene and when not to intervene. The operative management of vascular trauma has changed with the growth of endovascular approaches to hemorrhage control and resuscitation as well as the specific treatment of several injury patterns. Still, many of the original principles underpinning the safe and effective management of vascular injury – from damage control to definitive treatment – find themselves in knowledge of traditional open operative exposure, with control and repair of the vessels (Fig. 27-7). Regardless of experience and training level, the foundational principles provided in this chapter will support one's attempts to improve his or her effectiveness in managing what is arguably the most challenging injury pattern following significant trauma.

References

1. Eastridge BJ, Mabry RL, Seguin P, et al. Death on the battlefield (2001–2011): implications for the future of combat casualty care. *J Trauma Acute Care Surg* 2012;73:S431–S437.
2. White JM, Stannard A, Burkhardt GE, et al. The epidemiology of vascular injury in the wars in Iraq and Afghanistan. *Ann Surg* 2011;253:1184–1189.
3. Mattox KL, Feliciano DV, Burch J, et al. Five thousand seven hundred sixty cardiovascular injuries in 4459 patients: epidemiologic evolution 1958 to 1987. *Ann Surg* 1989;209:698–705.
4. DeBakey ME, Simeone FA. Battle injuries of the arteries in World War II: an analysis of 2471 cases. *Ann Surg* 1946;123:534–579.
5. Hughes CW. The primary repair of wounds of major arteries: an analysis of experience in Korea in 1953. *Ann Surg* 1955;141:297–303.
6. Rich NM, Baugh JH, Hughes CW. Acute arterial injuries in Vietnam: 1,000 cases. *J Trauma* 1970;10:359–369.
7. Stannard A, Brown K, Benson C, et al. Outcome after vascular trauma in a deployed military trauma system. *Br J Surg* 2011;98:228–234.
8. Clouse WD, Rasmussen TE, Peck MA, et al. In-theater management of vascular injury: 2 years of the Balad vascular registry. *J Am Coll Surg* 2007;204:625–632.
9. Fox CJ, Gillespie DL, O'Donnell SD, et al. Contemporary management of wartime vascular trauma. *J Vasc Surg* 2005;41:638–644.
10. Norton R, Kobusingye O. Injuries. *N Engl J Med* 2013;368:1723–1730.
11. Barmparas G, Inaba K, Talving P, et al. Pediatric vs adult vascular trauma: a National Trauma Databank review. *J Pediatr Surg* 2010;45:1404–1412.
12. Loh SA, Rockman CB, Chung C, et al. Existing trauma and critical care scoring systems underestimate mortality among vascular trauma patients. *J Vasc Surg* 2011;53:359–366.
13. Galindo RM, Workman CR. Vascular trauma at a military level II trauma center. *Curr Surg* 2000;57:615–618.
14. Sise MJ. Diagnosis of vascular injury. In: Rasmussen TE, Tai NRM, eds. *Vascular Trauma.* 3rd ed. Philadelphia, PA: Elsevier, Inc; 2016:35–43.
15. Fox N, Rajani RR, Bokhari F, et al. Eastern Association for the Surgery of Trauma. Evaluation and management of penetrating lower extremity arterial trauma: an Eastern Association for the Surgery of Trauma practice management guideline. *J Trauma Acute Care Surg* 2012;73(5 suppl 4):S315–S320.
16. Frykberg ER, Dennis JW, Bishop K, et al. The reliability of physical examination in the evaluation of penetrating extremity trauma for vascular injury: results at one year. *J Trauma* 1991;31:502–511.
17. Frykberg ER. Advances in the diagnosis and treatment of extremity vascular trauma.

Surg Clin North Am 1995;75(2):207–223.

18. Dawson DL. Imaging for the evaluation and treatment of vascular trauma. In: Rasmussen TE, Tai NRM, eds. *Vascular Trauma.* 3rd ed. Philadelphia, PA: Elsevier, Inc; 2016:44–55.
19. Miller-Thomas MM, West OC, Cohen AM. Diagnosing traumatic arterial injury in the extremities with CT angiography: pearls and pitfalls. *Radiographics* 2005;25(suppl 1):S133–S142.
20. Holcomb JB, Fox EE, Scalea TM, et al. Current opinion on catheter-based hemorrhage control in trauma patients. *J Trauma Acute Care Surg* 2014; 76:888–893.
21. Dua A, Desai SS, John B, et al., eds. *Clinical Review of Vascular Trauma.* Springer Berlin Heidelberg;2014.
22. Dutton RP. Resuscitative strategies to maintain homeostasis during damage control surgery. *Br J Surg* 2012;99:21–28.
23. Hess JR, Holcomb JB, Hoyt DB. Damage control resuscitation: the need for specific blood products to treat the coagulopathy of trauma. *Transfusion* 2006;46(5):685–686.
24. Shander A, Kaplan LJ, Harris MT, et al. Topical hemostatic therapy in surgery: bridging the knowledge and practice gap. *J Am Coll Surg* 2014;219(3):570–579.
25. Dua A, Patel B, Desai SS, et al. Comparison of military and civilian popliteal artery trauma outcomes. *J Vasc Surg* 2014;59(6):1628–1632.
26. Gill H, Jenkins W, Edu S, et al. Civilian penetrating axillary artery injuries. *World J Surg* 2011;35(5):962–966.
27. Moore WS. *Vascular and Endovascular Surgery: A Comprehensive Review.* 7th ed. Philadelphia, PA: Saunders Elsevier; 2006.
28. Wagner WH, Calkins ER, Weaver FA, et al. Blunt popliteal artery trauma: one hundred consecutive injuries. *J Vasc Surg* 1988;7(5):736–743.
29. Núñez DB Jr, Torres-León M, Múnera F. Vascular injuries of the neck and thoracic inlet: helical CT-angiographic correlation. *Radiographics* 2004;24(4):1087–1098.
30. du Toit DF, van Schalkwyk GD, Wadee SA, et al. Neurologic outcome after penetrating extracranial arterial trauma. *J Vasc Surg* 2003;38(2):257–262.
31. Munera F, Soto JA, Nunez D. Penetrating injuries of the neck and the increasing role of CTA. *Emerg Radiol* 2004;10(6):303–309.
32. Cohen JE, Ben-Hur T, Rajz G, et al. Endovascular stent-assisted angioplasty in the management of traumatic internal carotid artery dissections. *Stroke* 2005;36(4):e45–e47.
33. Biffl WL, Moore EE, Ryu RK, et al. The unrecognized epidemic of blunt carotid arterial injuries: early diagnosis improves neurologic outcome. *Ann Surg* 1998;228(4):462–470.
34. Biffl WL, Ray CE Jr, Moore EE, et al. Treatment-related outcomes from blunt cerebrovascular injuries: importance of routine follow up arteriography. *Ann Surg* 2002;235(5):699–706.

35. Kotwal RS, Montgomery HR, Kotwal BM, et al. Eliminating preventable death on the battlefield. *Arch Surg* 2011;146(12):1350–1358.
36. Stannard A, Eliason JL, Rasmussen TE. Resuscitative endovascular balloon occlusion of the aorta (REBOA) as an adjunct for hemorrhagic shock. *J Trauma* 2011;71(6):1869–1872.
37. Hughes CW. Use of an intra-aortic balloon catheter tamponade for controlling intraabdominal hemorrhage in man. *Surgery* 1954;36:65–68.
38. Brenner ML, Moore LJ, DuBose JJ, et al. A clinical series of resuscitative endovascular balloon occlusion of the aorta for hemorrhage control and resuscitation. *J Trauma Acute Care Surg* 2013;75(3):506–511.
39. Moore LJ, Brenner M, Kozar RA, et al. Implementation of resuscitative endovascular balloon occlusion of the aorta as an alternative to resuscitative thoracotomy for noncompressible truncal hemorrhage. *J Trauma Acute Care Surg* 2015;79(4):523–530.

Chapter 28

The Principles of Orthopedic Surgery for Trauma

Raymond Malcolm Smith

Key Points

1 Establishing bony stability significantly reduces local bleeding.

2 Major pelvic fractures occur in recognizable patterns that predict other injuries.

3 Obtaining bony stability can significantly reduce pelvic bleeding and is an essential part of their initial care.

4 Early stabilization of major fractures in polytrauma patients facilitates other care and saves lives.

5 Early radical management of open fractures with adequate debridement, bony stabilization, and specifically early healthy soft tissue cover significantly reduces the risk of infection and decreases morbidity.

6 Establishing reliable bony stability is the key for local soft tissue healing.

7 The principles of accurate reduction, stable fixation, preservation of a healthy soft tissue envelope, and early rehabilitation with joint and patient mobility are the keys to general fracture management.

INTRODUCTION – AIMS AND PRIORITIES IN ORTHOPEDIC TRAUMA CARE

In recent years, the subspecialty of Orthopedic traumatology has become well established dealing with not only more routine fractures but also the more complex problems presented by very severe localized high-energy injury and combination multisystem polytrauma. In critical multisystem injury, it is very important to correctly manage the orthopedic injuries which must not be underestimated. Their management has a critical role in ensuring survival of the patient and ensuring practical overall clinical management. In severe local injury, useful limb salvage needs critically appropriate orthopedic management often combined with plastic surgeons to manage the severe soft tissue injury. Beyond this, in the vast majority of less severely injured patients the orthopedic surgeon's care should limit the medium- and long-term disability caused by fractures and severe peripheral soft tissue injuries. This general point of view is illustrated in Table 28-1. It is useful to consider the role of the orthopedic surgeon in this regard.

ORTHOPEDIC TRAUMA SURGERY TO SAVE LIFE

Many orthopedic injuries present as part of severe multisystem trauma cases and as such are a major part of the trauma burden and the threat to life. This threat comes from hemorrhage (from individual or multiple injury sites), the general effect of multiple major skeletal injuries, specific early associated injuries or complications such as vascular injury and compartment syndrome or later complications such as issues related to infection, immobility, and thromboembolic disease.[1]

Hemorrhage

1 The most immediate and absolute need for surgery in trauma is the control of bleeding. For the orthopedic traumatologist this takes two important forms, first a massive general bleeding insult associated with multiple high-energy fractures and second that associated with a specific major injury, most typically to the pelvis. Bleeding from multiple fractures is common and often underestimated. In general good transfusion protocols and early fracture management controls the situation. Bleeding from fractures will invariably slow and usually stop spontaneously when the fracture is reduced, stabilized, and the compartment tension restored. However, it is very easy to underestimate the collective blood loss from multiple injuries and get too far behind in resuscitation. Aggressive transfusion protocols with appropriate attention to replacing volume and clotting factors with early use of blood with plasma and platelets are essential but emergency orthopedic intervention with provision of skeletal stabilization for early hemorrhage control is equally important.[2] This may involve wound debridement and hemostasis in the complex open injury or early long-bone stabilization in multiple closed fractures. Occasionally, temporary external fixation may be required to provide rapid skeletal stabilization when the more extensive surgery required for definitive stabilization would be inappropriate.

The Bleeding Pelvis

2 Put simply, patients with major pelvic ring injuries bleed to death. Often presenting after a high-energy injury, the pelvis as the source major hemorrhage may be obvious with massive local swelling and clear instability. At presentation, a primary plain pelvic x-ray remains the best way to quickly understand the fracture. It will allow immediate assessment of the fracture pattern, energy involved, degree of displacement and lead to an estimate of the risk of local bleeding and presence of local or distal associated injuries.[4–8] Today many patients have a binder applied in the field for transport. This is a very effective way to initially control pelvic volume and tamponade bleeding but may reduce the deformity and lead to the initial x-ray underestimating the degree of injury.

Pelvic fractures can be classified by two major systems. Young and Burgess[4,5] (Fig. 28-1) presented a classification system based on the implied direction of the initial force. They defined injuries essentially as anterior–posterior compression (APC), lateral compression (LC), and vertical shear (VS) injuries. This allows an assessment of the direction of the force applied, the resultant instability and can predict mortality, transfusion requirements, and associated injuries. It remains very useful in this regard, for example, a severe LC fracture on the left is likely to be seen after a high-energy motor vehicle crash (MVC) in which there was a major intrusion into the car on the side of injury. It is therefore likely to be associated with a major head injury and bleeding mainly from elsewhere; specifically, the associated ipsilateral chest and abdominal injury. A major AP injury will classically come from a motorcycle crash and will often produce major bleeding in the pelvis itself. The Tile (after Penall)[9,10] (Fig. 28-1) system considers the injury with regard to the resultant instability and has now been adopted by the AO Foundation (AO) and Orthopedic Trauma Association (OTA). An “A”-type fracture has a stable pelvic ring and essentially includes more minor avulsion fractures and undisplaced mechanically stable pelvic ring injuries (includes APC I & LC I). “B”-type injuries are rotationally unstable but vertically stable with an intact posterior soft tissue hinge providing some stability (corresponding to APC II or LC II/III injuries) while “C”-type injuries are both rotationally and vertically unstable, implying that the posterior hinge is torn (corresponding to APC III and VS injuries). The latter carry the highest risk of bleeding and death.

Table 28-1 Why We Operate on Fractures: Priorities in Trauma Care

- Orthopedic surgery to save a life
- Orthopedic surgery to save a limb
- Orthopedic surgery to limit disability

From a surgical management perspective, A-type injuries are unlikely to be a source of major bleeding while B type and specifically C types are increasingly life-threatening. After initial assessment, primary radiology, and consideration of the response to initial resuscitation, pelvic fractures can be considered by the mechanical stability resulting from the injury and the resultant hemodynamic response (Table 28-2).

Table 28-2 Principles of Management of Major Pelvic Ring Injuries

	Mechanically Stable Pelvis	Mechanically Unstable Pelvis
Hemodynamically stable	Nonoperative	Early, planned operative stabilization of pelvic ring
Hemodynamically unstable	Likely extrapelvic cause Angiography/ embolization	Emergent provision of mechanical stability +/– Packing/angio

When considered in this way the orthopedic care follows a logical pattern. The essential contribution of the orthopedic surgeon is to assess the injury with regard to the local and associated problems it will produce and to provide pelvic mechanical stability when required. Clearly, the hemodynamically stable patient with a stable pelvic ring injury does not require major active orthopedic management although it should be noted that even the most apparently simple injury can rarely cause local bleeding and transfusion may be required.[11] The hemodynamically stable patient with a mechanically unstable pelvic ring injury needs early but nonemergent surgery to restore mechanical stability to the pelvis for pain relief, normal daily care, and mobilization. Hemodynamically unstable patients need emergent care to restore their physiologic stability. If the pelvis is mechanically stable, orthopedic intervention has little to offer, either there is an extrapelvic cause for the bleeding or hemostasis should be obtained by provision of appropriate clotting factors and platelets or angiographically.

3 The patient in hemorrhagic shock with a major unstable pelvic ring is a very different problem.[11,12] Early coordinated multidisciplinary care is essential with appropriate resuscitation within an established massive transfusion protocol. It is well established that the site of hemorrhage in most bleeding major pelvic fractures is from the fractured bone surfaces and extensive soft tissue injury, and rarely from major named arteries. Fortunately, the majority of this will slow significantly or stop when skeletal stability is achieved. Unfortunately, rapid stabilization of the pelvic ring is a major expert intervention at best and is commonly not easily achievable in the acute bleeding situation. Initial reduction, stability and some local tamponade is provided by a pelvic binder. In critical cases it should not be removed without an available alternative method to provide stability. Internally rotating the hips, slightly flexing the knees and binding the legs at the thigh should also be used if possible and provides additional effective control. The provision of early pelvic fixation or a primary angiographic approach depends on local expertise and protocol. Recently, a move to emergent operative provision of skeletal stability and packing of bleeding areas has entered practice and is suggested to be a major advance.[2,3] This considers the major bleeding pelvic injury similar to a bleeding liver and where local hemostasis can rarely be achieved and general hemorrhage control with packing for local pressure and provision of appropriate clotting factors is essential. For the severe pelvic injury, a systematic protocol with pelvic stabilization and packing at the end of an appropriate decision-making tree is essential.[2,3] Emphasizing the importance of

not getting out of control or reacting too late, "The Denver Protocol"[2,3] begins with a patient with shock, a pelvic ring injury, and a failure to respond to 2 L of crystalloid resuscitation and 2 units of blood transfusion (Algorithm 28-1). The essential principle is early aggressive surgical management for hemorrhage control with preperitoneal packing and rapid blood and factor replacement before the patient becomes grossly coagulopathic. From the orthopedic point of view, restoring skeletal stability is a critical part of this process and close cooperation with the general traumatologist is essential.

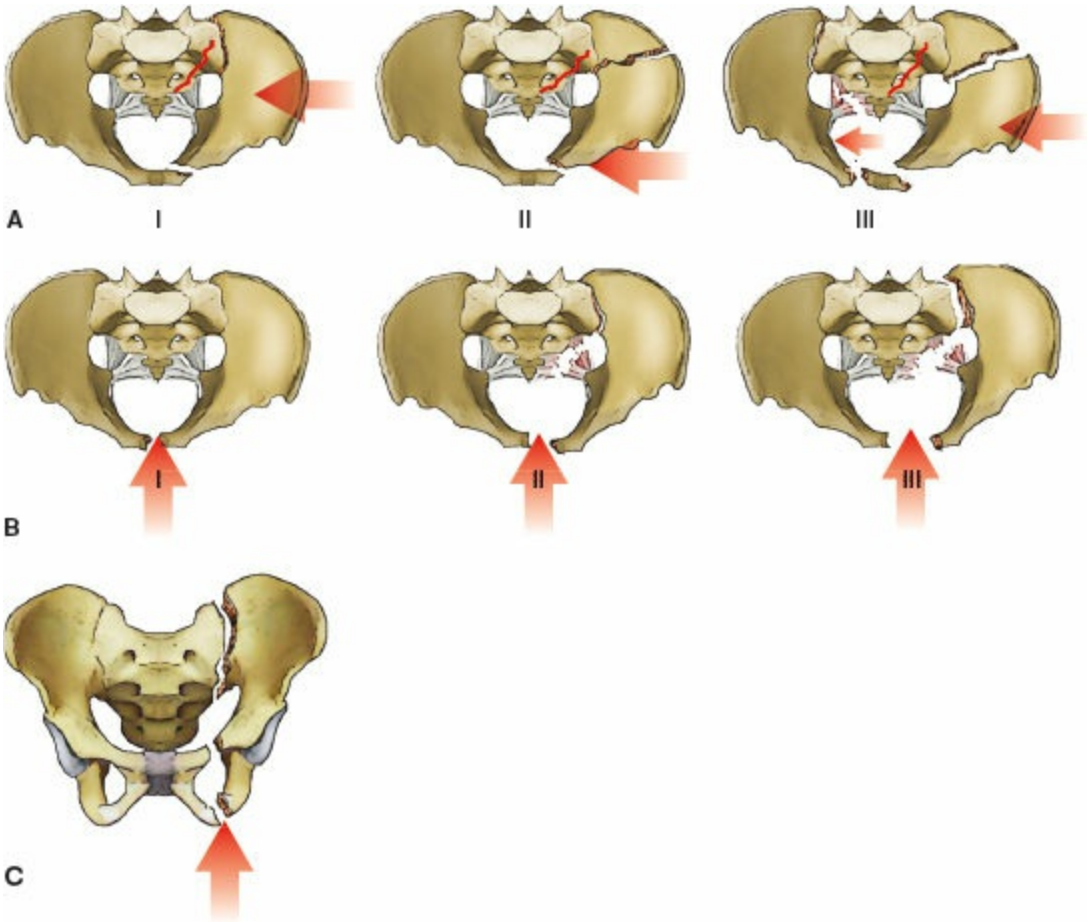

Figure 28-1. **A–C:** Young and Burgess and Tile (AO-OTA) classifications of pelvic fractures (from Wiss DA. *Master Techniques in Orthopaedic Surgery: Fractures*. 3rd ed. Philadelphia, PA: Wolters Kluwer Health; 2012.)

Pelvic Packing

The procedure of packing a pelvis for hemorrhage is not complicated and well within the capabilities of most surgeons but some form of pelvic bony stability has to be achieved first to give a solid base to pack into. In the emergency situation this commonly means the application of an anterior external fixation frame although if available and possible, internal fixation has many advantages. Occasionally, emergency provision of posterior stability with emergent percutaneous sacroiliac fixation or application of a “C clamp” can be dramatically effective in restoring stability and markedly slowing bleeding. Preperitoneal packing is done through a small anterior incision just above the pubis. After separating the rectus muscles (which may be avulsed from the pubis), the cavity created by the trauma is entered, the hematoma evacuated and rapid mechanical stability obtained (often temporarily, with an immediate anterior clamp across the pubis). The cavity is then packed with as many packs required. These should be placed as far back into the true pelvis as possible. The hematoma cavity created by the injury will be obvious and it is not required or desirable to extend the dissection outside this area but it is essential to get the packs right to the back of the cavity. Assuming hemostasis is achieved, the packs are left in, often for 48 hours and under an open but sealed abdomen before they are changed or simply removed depending on the physiologic response.

Complicated Pelvic Injuries – Open Fractures or Associated Visceral Injury

The initial assessment of any patient with a pelvic fracture must include an inspection of the perineum with rectal and vaginal examination to check for complex open injuries or associated urologic injuries. Open pelvic fractures and those complicated by damage to the local viscera need specific treatment based on the wound or specific visceral damage sustained.[13,14] While the mortality and complexity increases with the risk of contamination and infection the orthopedic principles of open fracture care remain the same. Any open fracture is considered contaminated and dealt with along the principles described below of debridement and lavage, establishment of bony stability and early, healthy soft tissue cover as required. However, in major pelvic injuries there is usually a massive trauma cavity where contamination and infection would prove fatal. Aggressive decontamination and protection of this extensive zone of injury from further contamination by diversion of the fecal stream may be essential.

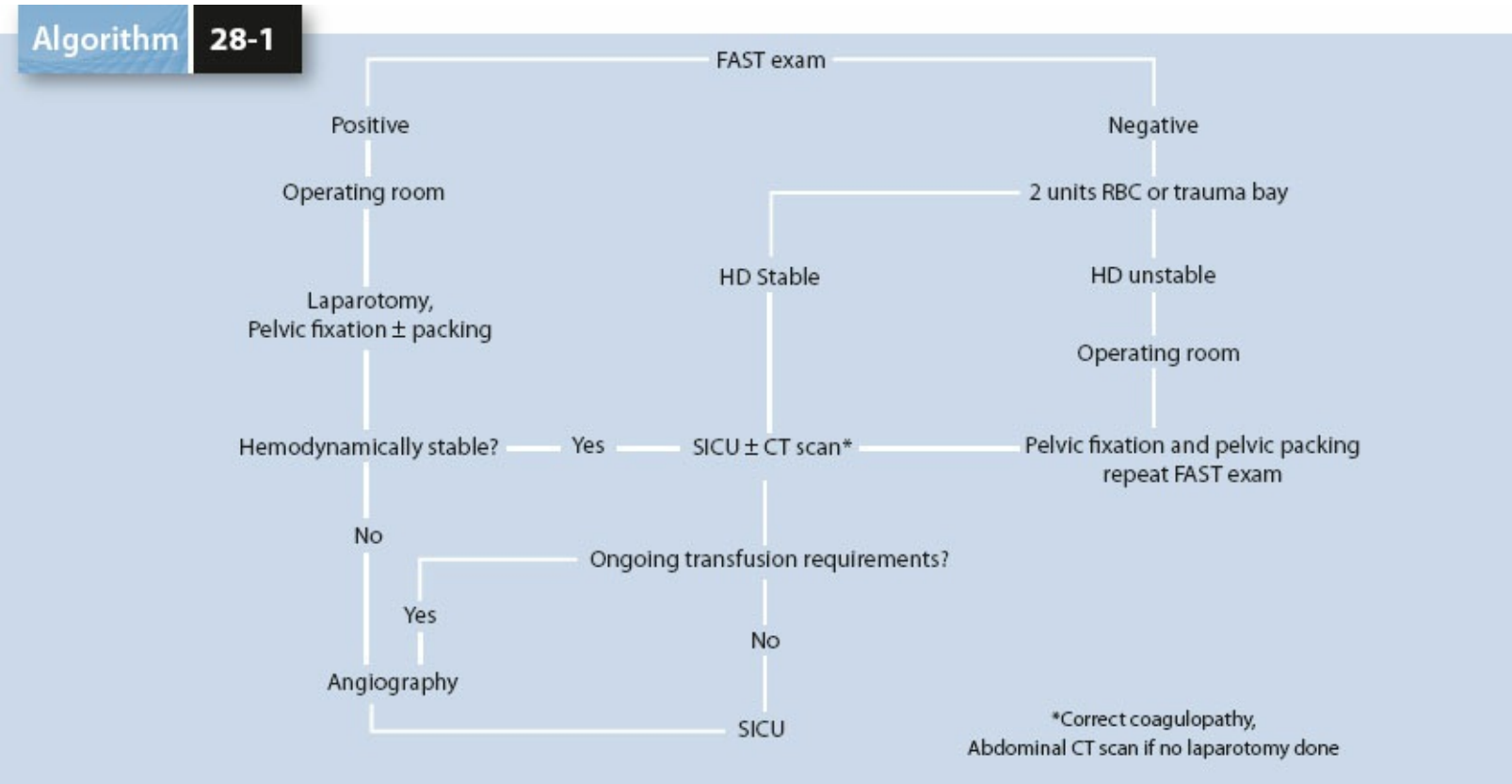

Algorithm 28-1. The Denver Protocol for management of major pelvic fractures. (Reproduced with permission and copyright © of the British Editorial Society of Bone and Joint Surgery. Mauffrey C, Cuellar DO 3rd, Pieracci F, et al. Strategies for the management of hemorrhage following pelvic fractures and associated trauma-induced coagulopathy. *Bone Joint J* 2014;96(9):1143–1154.)

Complex urologic injuries are commonly seen with specific patterns of pelvic fracture. A significant APC injury is commonly associated with an extraperitoneal bladder rupture of the anterior bladder wall directly in line with the plane of injury. LC injuries may be associated with urethral tears as the inferior ramus cuts the male membranous urethra as

it is forced across the midline by the injury. In all cases the presence of hematuria or blood at the meatus is the pathognomonic sign of injury and necessitates appropriate investigation and joint management with the urologic service. Again from the orthopedic point of view no soft tissue reconstruction can work without an underlying stable bony skeleton to support the repair and prevent reinjury. In many situations, the best access the urologist will have is at the time of the primary bony stabilization and early urologic repair or diversion avoids many problems. While a staged urologic procedure may be required, very early combined surgery has much to recommend it.

The Orthopedic Management of Major Polytrauma

4 Major trauma is a surgical problem, and the essence of management is to take control and stay in control of the trauma and do no further iatrogenic harm. From the orthopedic point of view, this means that it is essential to gain control by stabilizing the skeleton. This understanding has developed through quite opposite phases to now consider all elements of the injury and physiologic priorities. The management protocols have focused on the changing opinions about stabilization of the femur fracture which has become the index injury in this regard. Essentially, despite the development of long-bone nailing by Kuntscher[15] in the 1940s, through till the late 1980s most Western surgeons believed that seriously injured patients were "too sick to operate on" and used traction devices as the primary mode of treatment for major fractures. Concern that this was not the best mode of treatment led to the term "Horizontal Crucifixion" and several early publications[15–17] suggesting a major advantage of early surgical stabilization of the fractures, specifically with femoral nailing. Johnson[18] confirmed this effect and showed that it appeared to be greater the more severely the patient was injured and in 1989 Bone[19] published his landmark paper, a prospective randomized trial of early against late femoral nailing after severe injury. Essentially he showed that there was a major advantage in early nailing and the pendulum swung to enthusiastic universal early skeletal stabilization after polytrauma. The patient was now considered "too sick not to operate on" and a management philosophy now termed "Early Total Care" developed. This practice was soon questioned, specifically in Germany where the orthopedic trauma surgeon is closely involved with intensive care and inevitably observed the combined effect of other injures. Pape et al.[20] again considering the femur, looked specifically at the effect of early and late femoral nailing in severe polytrauma and showed the deleterious effect of an associated chest injury in association with femur fractures treated by early reamed nailing. While statistically the effect seemed more related to the chest injury than the nailing, this alerted the profession to the combination effect of these injuries and stimulated an outpouring of research looking at the general and immunologic effects of orthopedic procedures and specifically of reaming the femur.[21–36] Eventually, a concept of the general effects of polytrauma and bony injury has become more widely accepted and a concept of the appropriate surgery (damage control orthopedics – DCO) for the most severely injured patients developed.

Essential Damage Control Surgery in Orthopedics

Damage control in orthopedics means taking control of the musculoskeletal elements of the injury without creating an increased trauma load due to increased surgical bleeding or a lengthy surgery associated with definitive care of complex fractures (Fig. 28-2). After essential hemorrhage and wound management this involves restoring major skeletal stability usually by the rapid application of external fixators. The basic physiologic parameters are then normalized in a critical care environment unit and definitive stabilization is delayed until the peritraumatic immunologic storm has settled.[25,26,28,29] The most critical element is the speed and accuracy of the initial surgery as the critical injured patient cannot tolerate a long orthopedic procedure. However, it cannot be underemphasized how important the principle of establishing early skeletal stability remains; this was the major lesson of the early Johnson/Bone papers[18,19] and has never been disputed, the issue is not if, but how this is obtained. In situations where the patient can tolerate it, there are major advantages in early definitive skeletal stabilization. The question is, how do we identify which patients are too sick and for what? Long orthopedic procedures and protracted bleeding must be avoided and nailing the femur seems to be particularly excessively stimulating. A variety of parameters have been investigated to help with this decision.[25] Measurement of interleukin-6 (IL6)[24] has not achieved its initial promise and today a spectrum of parameters considering the patient's general condition are commonly used.[30] This essentially means close communication and protocol agreement with the anesthetic/general trauma team but is primarily a surgical decision as the anesthetic team is less likely to be trauma specialized. Basic parameters to be considered include the hemoglobin/hematocrit, ventilation parameters, platelet count and coagulation studies, patient temperature and a measure of acidosis, usually the lactate level. The latter has been widely used as measure of resuscitation and as the primary decision-making parameter by many orthopedic surgeons. Initially, a level of 2.5 mmol/L was considered the value above which surgery should not proceed but the more recent work from Vallier et al.[30] has suggested a lactate level of 4 mmol/L is a safe cutoff. However, surgical decision making in critical illness does not occur in isolation and improvements in early resuscitation and critical care management mean constant reappraisal and probably another future swing in the pendulum (Table 28-3).



Figure 28-2. Early damage control of extensive limb injuries with external fixation.

Table 28-3 Essential Priorities in Orthopedic Damage Control

Principle	Example
Surgical hemorrhage control	Direct control, pelvic packing, long-bone stabilization
Cavity decompression	Compartment syndrome
Debridement/ decontamination	Major open wounds/fractures
Revascularization	Repair vascular injury to revascularize the limb if patient is well enough, if not amputate
Fracture stabilization	Usually rapid external fixation of major long-bone injury/pelvis
Critical care	Ongoing resuscitation, rewarming, and factor replacement prior to delayed secondary surgery
Delay reconstructive surgery	Conversion of external fixation to nails, definitive joint reconstruction

Special Polytrauma Situations – Head Injury

The orthopedic priorities change in specific scenarios the most obvious being the associated head injury. When the brain is at risk the primary aim is to maintain cerebral oxygenation and cerebral perfusion pressure (CPP); accordingly, orthopedic procedures especially those that would lead to bleeding, swings in blood pressure and thus episodes of reduced CPP should be avoided. However, there are definite advantages in having a stable skeleton and being able to sit the patient up which will help oxygenation and general critical care such that after appropriate discussions bony stabilization at the right time is strongly indicated.[37,38]

Special Polytrauma Situations – Chest Injury and Femur Fractures

The effect of the chest injury is discussed above. It was emphasized by Pape and Tscherne and innumerable papers that followed.[20] While multiple studies have shown the advantages of early skeletal stabilization there is no doubt that the lungs are vulnerable to further insults after injury, and that the acute lung injury can be worsened by fat embolization especially during femoral canal instrumentation. While improvements in reamer design reduce canal pressurization and smaller nails have been advocated, delaying definitive nailing for 4 to 5 days after initial external fixation in the most critical patient is probably the standard of care. The effect seems to be dose dependent such that the patient with bilateral femur fractures is at a significantly increased risk and some surgeons avoid bilateral femoral nailing at the same time even in healthy patients.[39–42]

Specific Orthopedic Scenarios

Major Wounds

5 The ongoing septic effect of major wounds can be critical. In the first instance, debridement of necrotic tissue from the trauma is essential and commonly inadequately done at the initial surgery. Wounds will never stabilize until adequately debrided and when associated with fractures will not heal until bony stability has been established. The management of complex open fractures is described below; in polytrauma cases the principles remain the same but the ability to obtain early soft tissue cover is compromised by the patient's general situation.

Table 28-4 Open Fracture Surgical Principles

Debridement to healthy margins and profuse lavage/ decontamination
Bony stabilization
Early, healthy soft tissue cover

ORTHOPEDIC TRAUMA SURGERY TO SAVE LIMBS

Open Fracture Principles

Open fractures can range from simple to destructive injuries but in all the important feature is that the fracture hematoma communicates with the outside environment and the fracture is thus potentially contaminated. As such, their specific management revolves around limiting the chance of this contamination converting to established infection. General measures include the provision of tetanus cover, early broad spectrum antibiotics, early splintage, wound dressing, and specific surgical management. The latter is designed to reduce the degree of contamination, to remove necrotic or threatened tissue likely to become infected and to protect the limb by making it unlikely to develop further infection due to an unstable open wound (Tables 28-4 and 28-5).

Appropriate and adequate open fracture debridement is one of the most difficult surgical procedures, it should not be relegated to inexperienced staff and if possible not attempted at night unless the limb is very seriously threatened. The whole zone of injury must be assessed and all dead and dying tissue removed, only nerve and vessel must be preserved and poor muscle specifically removed. Any free bone or fragments attached by flimsy soft tissue should also be removed and the resulting defect dealt with accordingly, although only rarely is a significant defect produced. Wound extensions need to be placed with specific consideration for the later closure and must not make the soft tissue reconstruction more complex. An adequate appropriate debridement must be performed the first time. Repeated debridements "to make sure" are a result of an inadequate initial operation and massively increase delay and the infection rate. This should be avoided at all costs.

6 Establishing early bone stability is essential, and ideally the definitive bone stabilization should be performed at the primary procedure. This reduces the chance of late infection and facilitates the subsequent soft tissue reconstruction. In truth, the ability to perform an adequate debridement and the best bony reconstruction depends directly on the orthopedic surgeons' confidence in the subsequent soft tissue closure and thus the working relationship with the plastic surgery team. While soft tissue reconstruction is often delayed for practical reasons there is excellent evidence that the earlier a healthy closure is obtained the better. This is true to the extent that the best data in the most complex (IIIb) injuries are with immediate flap cover after an adequate initial debridement and definitive bony reconstruction as one primary procedure (Fig. 28-3). Few units can achieve this at primary presentation, such that definitive debridement, fracture stabilization, and appropriate soft tissue assessment at the primary procedure followed by definitive soft tissue cover at the second visit to the OR (at about 48 hours) after the patient has been appropriately counseled are probably the best achievable standard. Cooperative care with the plastic surgical service from the start is essential.[44–49]

Table 28-5 Open Fracture Classification (after Gustillo & Anderson[43])

Grade I	Small low-energy wound, <1 cm no high-energy features
Grade II	Small low-energy laceration over fracture 1–10 cm no high-energy features
Grade IIIa	High-energy open fracture (degloving, periosteal stripping, bone comminution) with adequate soft tissue cover
Grade IIIb	High-energy open fracture with inadequate soft tissue cover
Grade IIIc	Any open fracture with a vascular injury requiring repair for viability

Vascular Injuries

An acutely ischemic limb with a fracture or dislocation is major surgical emergency. At presentation, all fractures must have the distal circulation assessed and documented; if the blood supply is affected the fracture or dislocation must be rapidly reduced. Fortunately, this commonly results in restoration of circulation and normal fracture care can continue. If not an emergent, combined vascular–orthopedic procedure is required. Sometimes a temporary shunt will be used to obtain distal flow while a bony reconstruction is performed. Bony stability at the correct length must be obtained before definitive vascular reconstruction, both to allow the vascular repair to be at the correct level and tension, and to protect it from disruption. Any subsequent reconstruction must be done with provision for awareness and care of the vascular repair.

Compartment Syndrome

A compartment syndrome is a major surgical emergency as the muscle is acutely ischemic due to an increased compartment pressure reducing tissue perfusion to below a critical level. Accordingly, the classical presentation is pain out of proportion to the injury due to the muscle ischemia. The compartment may be obviously hard with loss of muscle function and distal neurologic symptoms due to pressure on the nerves passing through the compartment. Loss of arterial flow through the compartment is exceedingly rare and not useful diagnostically, the presence of a distal pulse does not contribute to the diagnosis of compartment syndrome. While the diagnosis is often clinical and straightforward a formal measurement of the perfusion pressure of the compartment (similar to CPP in head injuries) has been popularized by McQueen.[50] Assessing mainly the anterior compartment of the lower leg after tibial fractures with constant compartment pressure monitoring, they showed that if the compartment pressure remained at least 30 mm of mercury below the diastolic blood pressure (known as the D $p > 30$) the consequences of compartment syndrome (muscle necrosis and contractures) did not occur. Accordingly, today the definitive test for compartment syndrome is a direct measurement of the compartment pressure and comparison to the diastolic pressure. This is particularly seen in situations when the patient is not able to respond appropriately to pain. These include, during anesthesia, particularly under regional anesthesia, patients sedated on intensive care, patients where any strong analgesia is being used, or if the patient poorly responsive after a medication overdose. The diagnosis must not be missed, as immediate fasciotomy is needed to restore muscle perfusion.

Rarely compartment syndromes present late when muscle necrosis is established. There will be a high creatinine kinase level, myoglobinuria, and even frank renal failure if several compartments are involved and the presentation is delayed. If compartment syndrome is established at presentation, perhaps if diagnosed after 12 to 24 hours, fasciotomy is not indicated as it will only expose the necrotic compartment to infection. Unless deemed that muscle debridement is the only way to reduce the myoglobin level and reduce the renal damage the tight limb should be simply observed and the subsequent distal contracture more safely dealt with later by specific muscle or tendon releases.[52]



Figure 28-3. **A–E:** Management sequence of a major open fracture. This is a III-C injury in a 12 year old treated by immediate "fix and flap" incorporating the anastomosis for the Lattimus Dorsi free flap into the vascular repair. The subsequent course shows good soft tissue and bony healing.

Indications for Amputation/Failure of Reconstruction

The indications for amputation can be remembered as the three “D’s” referring to a limb that is “Dead,” “Dangerous” or a “Damn” nuisance. In the early trauma situation, this may be clearly obvious and early amputation may be lifesaving while the latter refers to later reconstructive scenarios. While limb salvage is always an aim the surgery required may be protracted such that salvage should not be attempted if it puts life at risk. This requires experienced decision making at the acute stage and when possible agreement between staff surgeons. With an isolated injury situation, the decision essentially depends on the degree and site of necrotic tissue and reconstructive functional potential of the limb. If not grossly necrotic, this can be a most difficult decision and should be made by a surgeon experienced in reconstructive options and their functional outcome. In many situations, an amputee will function as well if not better than a poor reconstruction especially if several muscle compartments have been lost. This is clearly a decision for experienced staff and should involve the patient as much as possible. The application of a temporary external fixator to the severely mangled limb with a view to appropriate discussion prior to initiating a limb salvage course has much to recommend it.

ORTHOPEDIC TRAUMA SURGERY TO LIMIT DISABILITY – MANAGEMENT OF FRACTURES

7 The management of fractures has been a core medical discipline for millennia and has developed from primitive bone setting, through the guild of army barber surgeons to the modern day orthopedic traumatologist. In general orthopedic practice today, almost half of the work is the care of injury and in most the modern trauma centers taking a large percentage of blunt trauma 80% to 90% of the surgical care of the injured falls to the orthopedic service.

Fortunately, fractures have an intrinsic tendency to heal and bone is one of only two tissues to heal by reforming its own tissue and not with a scar. There are four essential phases in fracture management: assessment, position, healing, and rehabilitation. The first is self-explanatory but mandates a full limb assessment with documentation of the relevant clinical signs. This must include assessment and documentation of the neurovascular state of the distal limb. X-rays need to be taken of the whole bone involved and centered on the fracture. For example, an x-ray of the humerus which includes the shoulder is inadequate to assess a specific shoulder injury and separate views of the relevant part must be obtained. These views must include an AP and appropriate lateral. In many situations, the anatomy is still not adequately defined by these views and specific additional x-ray views or a computed tomography (CT) scan will be required to detail the anatomy to fully understand the injury and for surgical planning. Fracture management then centers on obtaining and holding the position of the fracture through healing. Essentially middiaphyseal fractures need to be held in a position to maintain overall length, alignment, and rotation but do not need an anatomical reduction of individual fragments. They are usually treated by long bridging techniques that hold the bone at each end without an open reduction of the fracture area. In modern practice, this is usually achieved by intramedullary nailing which also provides the relative stability needed at the fracture site and facilitates healing with callus (Fig. 28-4). As a contrast, articular fractures usually need a direct open approach to ensure accurate reduction of the joint surface and the absolute stability of the fixation. The recovery of joint function is directly related to the quality of the reduction and provision of stable fixation to allow early motion. In this situation, the bone at the joint would be expected to heal by primary bone union without callus (Fig. 28-5).

Essentially, the method chosen to hold the position of the fracture will be more or less stable depending on how firmly it holds the bone. A traditional cast on the tibia will provide only relative stability but should lead to a high rate of healing with callus. There can be a very good functional recovery if an adequate position is maintained and cast complications are avoided but it essentially provides a less reliable hold than an implant directly applied to the bone. Accordingly, the patient undergoing nonoperative management in cast has to be followed closely, often with weekly x-rays for up to a month or until the position is deemed stable. The cast then stays until bone healing is considered adequate to maintain the position faced with functional loads and the cast can

be removed. A stable, painless fracture on clinical examination suggests adequate healing to stay out of cast which should be confirmed by good bone healing on x-ray.

Nonoperative fracture management is an art that has been practiced for years but is used today only for stable relatively undisplaced fractures. This includes undisplaced articular fractures, low-energy nonarticular fractures, and many fractures in children who have a large capacity for remodeling during and after bone healing and obtain bony healing in about half the time adults with excellent function results (Table 28-6).

The phase of bone healing from fracture to a stable skeleton progresses from an inflammatory reaction through fibrous tissue and cartilage formation before immature bone and finally mature remodeling. A number of biologic stimulatory molecules and specific mechanical features then drive the normal healing response. Overall there is a progressive stiffening of the fracture environment until bone can form when the local strain is at or below 2%.[53,54] This may be produced by the gradual tissue stiffening provided by the natural healing process or by an orthopedic implant that creates a local strain environment in conjunction with the specific fracture anatomy and intrinsic fracture stability. Normal healing with splintage or with devices that produce relative stability (some fracture motion under physiologic loads) lead to the progressive stiffening effect described briefly above and healing by callus when the strain reduces to a level where bone can form. If an implant confers absolute stability, usually through direct compression of the fracture surfaces, the strain is less than 2% from the start and the bone heals by a modified remodeling process termed “primary bone healing,” callus does not form. In planning a bony reconstruction the surgeon specifically decides what degree of stability is required to treat a specific fracture and the appropriate implant to do this. This follows basic AO[55,56] principles which are the key to fracture surgery. Essentially, diaphyseal fractures need treatment with relative stability and indirect reduction techniques to maximize the local healing process. In contrast, articular fractures require usually a direct reduction for perfect anatomy and subsequent fixation with absolute stability (no deformation occurs under physiologic load) to facilitate joint recovery.

The rehabilitation process should be considered from the immediate decision-making process and begins as soon as the soft tissues are stable enough to allow dependency and joint motion. This confers the major advantages of mobility to the limb and whole patient. With articular fractures the cartilage is only nourished by diffusion from joint fluid which is effectively pumped into the hyaline cartilage as a secondary effect of motion. Accordingly, fracture fixation must be stable enough to allow early range-of-motion (ROM) exercises as tolerated but weight bearing is usually limited to protect the reconstruction from early displacement.

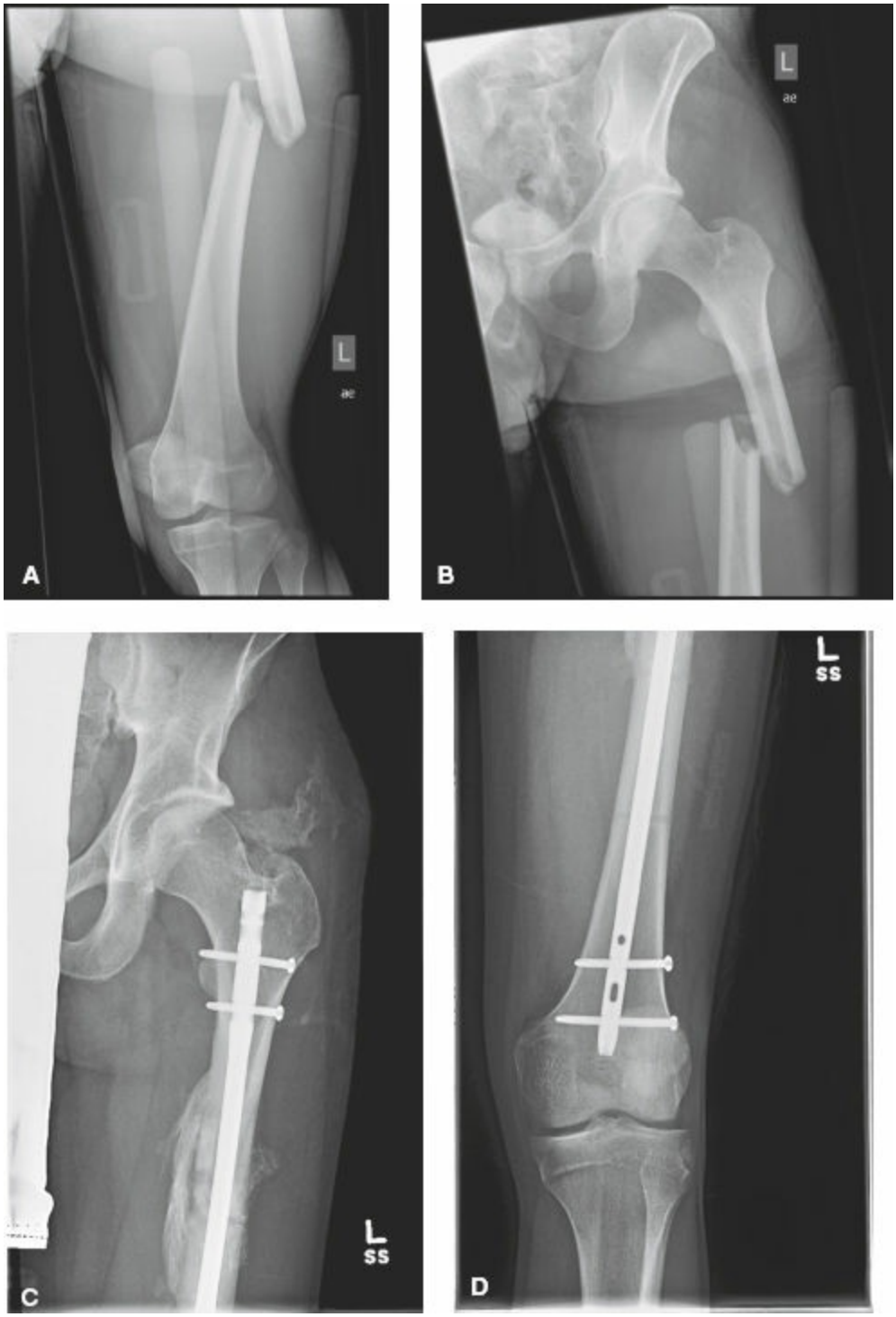

Figure 28-4. Assessment and surgical management of a diaphyseal fracture of the femur. **A,B:** Anterioposterior x-rays of a diaphyseal femur fracture **C,D:** Reamed fully locked intramedullary nailing of a diaphyseal femur fracture showing progressive healing.

Complex Articular Fractures

Major joint injuries are significant joint-threatening injuries and can be very complex.[57–59] The aim of care involves articular reconstruction with perfect joint anatomy and stable fixation with absolute stability. Surgical reconstruction often requires detailed preoperative assessment with a CT scan and application of specific implants often designed for the specific joint and side involved. The basic principles used for surgical reconstruction of these injuries were developed over 50 years ago by the AO and have only seen minimal modifications since. However, modern implants and particularly the development of locking plates have improved the capability of our implants to hold fractures securely and specifically a cantilever hold of local fragments that allows fractures to be held well in position with less extensile exposures. The modern implant offers major mechanical advantages and the more limited approach reduces the chance of additional surgical damage to the injured bone and thus maximizes its healing potential. Occasionally the primary injury (even if closed) is associated with significant degloving of the local soft tissues, manifest by early fracture blisters and precludes an early open surgical approach.[60] Surgical management then takes the form of temporary bridging external fixation, applied outside the zone of injury which confers some stability and allows the soft tissues to settle prior to conversion to an internal fixation often after 1 to 2 weeks. However, in most fractures excellent results can be obtained by much earlier surgery which is much easier than a delayed reconstruction.[61]

Special Fracture Groups – Proximal Femur

Like many injuries, fractures of the proximal femur have a bimodal distribution with rarer high-energy injuries in the young and extremely common bone fragility fractures in the elderly. As a public health issue, osteoporosis and its related fractures are at epidemic proportions with many fracture units admitting one or two patients every day.[62] The general medical care of the elderly dominates the clinical picture where across the board the mortality is of the order of 15% to 20% in the 3 months after fracture. Major efforts to optimize the care of this group of patients are essential both on an individual and community basis. Massive numbers of injured frail elderly patients produce a major load on hospital and rehabilitation services. In addition, specific attention to long-term bone health is essential. The orthopedic issues of proximal femoral fracture take two forms and produce specifically different problems and solutions. The fractures essentially occur inside (intracapsular) or outside the hip capsule (extracapsular). Intracapsular fractures carry a risk of avascular necrosis (AVN) of the femoral head depending on the displacement of the fracture, while intratrochanteric fractures are mechanically unstable due to the anatomy and offset of the proximal femur creating marked mechanical instability with a tendency to collapse into varus.



Figure 28-5. Assessment and surgical management of a complex articular fracture of the distal tibia (pilon). Despite virtually anatomic reduction it progresses to degenerative arthritis in the medium term. **A,B:** AP and lateral x-rays of an intra-articular fracture of the distal articular surface of the tibia. **C,D:** CAT scans show the marked damage and displacement at the joint surface, underappreciated by initial x-rays. **E:** Open reduction and internal fixation to restore the joint surface for function and joint longevity. **F:** After healing and removal of the majority of the hardwear there is significant degenerative arthritis of the joint that may need joint arthrodesis.

Table 28-6 Bone Healing Timeframes

Guideline Fracture Healing Times (In Cast)	Upper Limb	Lower Limb
Children	3 wks	6 + wks
Adults	6 wks	12 wks

Intracapsular fractures (femoral neck) are classically classified by Garden.[63] Garden grade 1&2 injuries are essentially undisplaced and carry a low risk of AVN, they are usually treated by fixation unless the patient's bone quality is considered too poor for fixation. In that situation and in displaced fractures (Garden grade 3&4) a replacement of the femoral head with hemiarthroplasty or total hip replacement in a biologically younger patient is required.[64,65]

Extracapsular fractures (trochanteric) are mechanically unstable. They will collapse into varus without fixation and have a tendency to settle and shorten with healing due to the intrinsic bone weakness and pull of local muscles. Accordingly, fixation devices need the ability to mechanically control the angle of the femoral neck and accommodate some shortening without protrusion of the device into the hip. The instability is associated with the degree and position of any comminution which also indicates which device is appropriate to use. Essentially a sliding hip screw device can be used for any trochanteric fracture unless the lateral wall is incompetent (reverse obliquity injuries or their equivalent) or where there is subtrochanteric extension. In these cases an intramedullary nail with a retrograde locking device is specifically indicated although many surgeons use these nails for most fractures. When using a sliding hip screw for a trochanteric fracture it is essential to get the tip of the screw within a 1 cm of the articular surface to avoid failure.[66,67]

Complications

Infection Nonunion and Malunion

Specific healing problems may require later specialist care.[68] Infection is unfortunately common after complex fracture care, especially if the initial injury was open. Failure of healing (nonunion) is not usually diagnosed before 6 months and commonly suggested by persistence of pain on loading and failure of progression of bone healing on x-Ray. Malunion is assessed with regard to the specific problem produced and may require specific corrective surgery for limb alignment, joint function, or longevity. While these complications are minimized by good primary fracture care, they still occur and many specialist services attract referrals of these problems. Commonly they are combined with infection and failure of bone healing often occurring together. In principle, infection after fracture creates a similar situation to osteomyelitis with acute and chronic clinical pictures. In general, the management of infection involves the same principles as the management of open fractures with debridement and lavage, skeletal stability and healthy soft tissue cover; with the addition of long-term antibiotics guided by perioperative cultures and under the supervision of an infectious disease specialist. Again adequate debridement of the poor often dead infected bone, the provision of bony stability and healthy soft tissue cover is the key to management.

Surgical management of the acute infection before fracture healing involves urgent washout of the wound, biopsy, cultures, appropriate antibiotics, and healthy wound management, often necessitating delayed primary closure after a secondary washout. While unstable fixation should be removed and stability regained stable fracture fixation should be maintained even if superficially contaminated until adequate fracture union. An implant can then be safely removed and usually any residual infection eradicated. Chronic infection with a united fracture needs similar treatment but in this scenario the fracture is stable. The key here is removal of a contaminated implant and debridement of dead bone to remove the source of infection. Subsequent, local profuse washout and healthy soft tissue closure then proceeds as above. However, in the chronic situation affected tissues are stiff and nonpliable such that bone and soft tissue debridement may produce a dead space, soft tissue defect, or skeletal instability with a bony defect. Filling a soft tissue defect will require appropriate soft tissue to be imported and commonly the help of a plastic surgeon. If a bony defect is created there are multiple potential options for treatment ranging from bone grafting through use of a cement spacer and the Masquelet technique[69] to bone transport with an Ilizarov device.[70] or complex free bone/soft tissue transfer. Unfortunately, often limb salvage may end up being protracted and not be the best option for the patient.

Malunions cause considerable disability and can be very rewarding to correct (Fig. 28-6). Each needs to be fully assessed for the specifics of the deformity and consideration to a variety of methods of correction given. There are champions of a variety of acute correction methods with an osteomy and fixation or gradual correction usually with a ring fixation device.

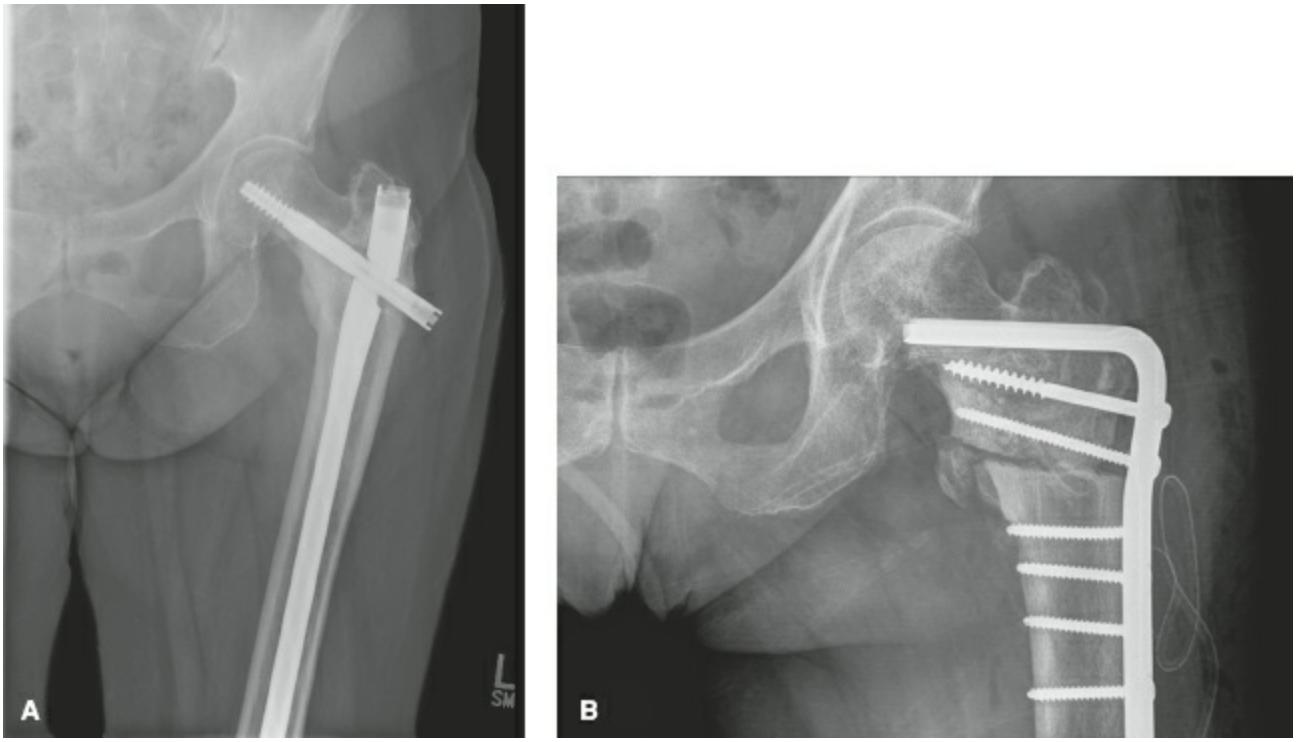

Figure 28-6. Assessment and surgical management of a proximal femoral malunion after implant failure. **A:** Proximal femoral malunion (collapsed in to varus) with a broken implant in place. **B:** Correction of the malunion with a Valgus osteotomy held with a blade plate.

Orthopedic Injury/Disaster Triage

Given the predominance of orthopedic injuries in the injured patient and the frequency of multiple patient events surgeons are often faced with prioritizing the care of a number of injuries in one complex patient or of a number of patients at the same time. In common day practice a major motor vehicle crash with several victims can stress a system and require appropriate prioritization. In major international disasters these situations can be extreme. In these situations simple reliable rules are needed to guide staff through the process especially when there are multiple problems to consider and the situation is critical. ATLS dealt with this superbly with the A, B, C, alphabetic system for the primary survey. While this remains an excellent system for initial patient evaluation and can guide some immediate surgical decisions it does not help the surgeon who will have to make critical priority decisions beyond this. From the orthopedic traumatology point of view the variety of injuries often cover the whole spectrum of clinical need and produce complex decision-making situations. The easiest way for the supervising surgeon to plan the care of an individual is to stand back and work along simple priority guidelines, asking "what is needed here to save the life," "what is needed to save a limb," and "what is disability limiting." Considering each injury in turn then allows a logical plan to be made to prioritize the care required. In multiple patient scenarios the process is the same but modified by the number of patients involved and the medical resources available. With adequate resources each patient's problems are dealt with individually as needed and no consideration to major disaster triage is required. If resources are reasonable although stressed, patients with life-threatening problems are dealt with first prioritized by their individual acuity while others with important but initially stable issues can be managed safely later. In the massive disaster situation priorities change, resources are overwhelmed, and first priority is given to the group of patients who will gain the most while not tying up or exhausting scarce resources. The critical patient who would often be dealt with first when if more resources were available are not prioritized as their care would swamp the resources available and not allow simpler care to many others.[52] Going in to situations (such as the immediate medical relief after the 2010 Haiti earthquake) without preplanning or the experience to deal with difficult decisions like this is not advisable.

References

1. Bucholz RW, Heckman JD, Court-Brown CM, eds. *Rockwood & Green's Fractures in Adults* 6th ed. Lippincott Williams & Wilkins. Philadelphia, PA: 2006.
2. Mauffrey C, Cuellar DO 3rd, Pieracci F, et al. Strategies for the management of haemorrhage following pelvic fractures and associated trauma-induced coagulopathy. *Bone Joint J* 2014;96B:1143–1154.
3. Biffl WL, Smith WR, Moore EE, et al. Evolution of a multidisciplinary clinical pathway for the management of unstable patients with pelvic fractures. *Ann Surg* 2001;233(6):843–850.
4. Burgess AR, Eastridge BJ, Young JW, et al. Pelvic ring disruptions: effective classification systems and treatment protocols. *J Trauma* 1990;30:848–856.
5. Dalal SA, Burgess AR, Siegel JH, et al. Pelvic fracture in multiple trauma: classification by mechanism is key to pattern of organ injury, resuscitative requirements and outcome. *J Trauma* 1989;29(7):981–1000.
6. Poole GV, Ward EF, Muakkassa FF, et al. Pelvic fracture from major blunt trauma: outcome is determined by associated injuries. *Ann Surg* 1991;213(6):532–538.
7. Demetriades D, Karaiskakis M, Toutouzas K, et al. Pelvic fractures: epidemiology and predictors of associated abdominal injuries and outcomes. *J Am Coll Surg* 2002;195(1):1–10.
8. Starr AJ, Griffin DR, Reinert CM, et al. Pelvic ring disruptions: prediction of associated injuries, transfusion requirement, pelvic arteriography, complications and mortality. *J Orthop Trauma* 2002;16(8):553–561.
9. Tile M, Pennal GF. Pelvic disruption: Principles of Management. *Clin Orthop Relat Res* 1980;151:56–64.
10. Tile M. Classification of fractures of the pelvis and acetabulum. In: Tile M, ed. *Fractures of the Pelvis and Acetabulum.* 2nd ed. London: Williams and Wilkins; 1995:66–101.
11. Bramos A, Velmahos GC, Butt UM, et al. Predictors of bleeding from stable pelvic fractures. *Arch Surg* 2011;146(4):407–411.
12. Gruen GS, Leit ME, Gruen RJ, et al. The acute management of hemodynamically unstable multiple trauma patients with pelvic ring fractures. *J Trauma* 1994;36(5):706–711.
13. Rothenberger DA, Fischer RP, Strate RG, et al. The mortality associated with pelvic fractures. *Surgery* 1978;84(3):356–361.
14. Rothenberger D, Velasco R, Strate R, et al. Open pelvic fracture: a lethal injury. *J Trauma* 1978;18(3):184–187.
15. Kuntscner G. The intramedullary nailing of fractures. *Clin Orthop Relat Res* 1968;60:5–12.
16. Riska EB, von Bonsdorff H, Hakkinen S, et al. Primary operative fixation of long bone fractures in patients with multiple injuries. *J Trauma* 1977;17(2):111–121.

17. Goris RJ, Gimbrere JS, van Niekerk JL, et al. Early osteosynthesis and prophylactic mechanical ventilation in the multitrauma patient. *J Trauma* 1982;22:895–903.
18. Johnson KD, Cadambi A, Seibert GB. Incidence of adult respiratory distress syndrome in patients with multiple musculoskeletal injuries: effect of early operative stabilization of fractures. *J Trauma* 1985;25:375–384.
19. Bone LB, Johnson KD, Weigelt J, et al. Early versus delayed stabilization of femoral fractures. A prospective randomized study. *J Bone Joint Surg Am* 1989;71(3):336–340.
20. Pape HC, Auf'm'Kolk M, Paffrath T, et al. Primary intramedullary femur fixation in multiple trauma patients with associated lung contusion–a cause of posttraumatic ARDS?*J Trauma* 1993;34(4):540–547.
21. Bosse MJ, MacKenzie EJ, Riemer BL, et al. Adult respiratory distress syndrome, pneumonia, and mortality following thoracic injury and a femoral fracture treated either with intramedullary nailing with reaming or with a plate. A comparative study. *J Bone Joint Surg Am* 1997;79(6):799–809.
22. Pape HC, Hildebrand F, Pertschy S, et al. Changes in the management of femoral shaft fractures in polytrauma patients: from early total care to damage control orthopedic surgery. *J Trauma* 2002;53(3):452–461.
23. Giannoudis PV, Smith RM, Banks RE, et al. Stimulation of inflammatory markers after blunt trauma. *Br J Surg* 1998;85:986–990.
24. Giannoudis PV, Smith RM, Bellamy MC, et al. Stimulation of the inflammatory system by reamed and unreamed nailing of femoral fractures; an analysis of the second hit. *J Bone Joint Surg Br* 1999;81(2):356–361.
25. Pape HC, Grimme K, Van Griensven M, et al. Impact of intramedullary instrumentation versus damage control for femoral fractures on immunoinflammatory parameters: prospective randomized analysis by the EPOFF Study Group. *J Trauma* 2003;55(1):7–13.
26. Harwood PJ, Giannoudis PV, van Griensven M, et al. Alterations in the systemic inflammatory response after early total care and damage control procedures for femoral shaft fracture in severely injured patients. *J Trauma* 2005;58(3):446–452.
27. Giannoudis PV, Pape HC, Cohen AP, et al. Review: systemic effects of femoral nailing: From Kuntscher to the immune reactivity era. *Clin Orthop Relat Res* 2002; (404):378–386.
28. Pape HC, Rixen D, Morley J, et al; EPOFF Study Group. Impact of the method of initial stabilization for femoral shaft fractures in patients with multiple injuries at risk for complications (borderline patients). *Ann Surg* 2007;246(3):491–499.
29. Nahm NJ, Vallier HA. Timing of definitive treatment of femoral shaft fractures in patients with multiple injuries: a systematic review of randomized and nonrandomized trials. *J Trauma Acute Care Surg* 2012;73(5):1046–1063.
30. Vallier HA, Wang X, Moore TA, et al. Timing of orthopaedic surgery in multiple trauma patients: development of a protocol for early appropriate care. *J Orthop*

Trauma 2013;27(10):543–551.

31. Vallier HA, Cureton BA, Ekstein C, et al. Early definitive stabilization of unstable pelvis and acetabulum fractures reduces morbidity. *J Trauma* 2010;69(3):677–684.
32. Nahm NJ, Como JJ, Wilber JH, et al. Early appropriate care: definitive stabilization of femoral fractures within 24 hours of injury is safe in most patients with multiple injuries. *J Trauma* 2011;71(1):175–185.
33. Vallier HA, Super DM, Moore TA, et al. Do patients with multiple system injury benefit from early fixation of unstable axial fractures? The effects of timing of surgery on initial hospital course. *J Orthop Trauma* 2013;27(7):405–412.
34. O'Toole RV, O'Brien M, Scalea TM, et al. Resuscitation before stabilization of femoral fractures limits acute respiratory distress syndrome in patients with multiple traumatic injuries despite low use of damage control orthopedics. *J Trauma* 2009;67(5):1013–1021.
35. Canadian Orthopaedic Trauma Society. Reamed versus unreamed intramedullary nailing of the femur: comparison of the rate of ARDS in multiple injured patients. *J Orthop Trauma* 2006;20(6):384–387.
36. Weninger P, Figl M, Spitaler R, et al. Early unreamed intramedullary nailing of femoral fractures is safe in patients with severe thoracic trauma. *J Trauma* 2007;62(3):692–696.
37. Brundage SI, McGhan R, Jurkovich GJ, et al. Timing of femur fracture fixation: effect on outcome in patients with thoracic and head injuries. *J Trauma* 2002;52(2):299–307.
38. Giannoudis PV, Veysi VT, Pape HC, et al. When should we operate on major fractures in patients with severe head injuries? *Am J Surg* 2002;183(3):261–267.
39. Giannoudis PV, Abbott C, Stone M, et al. Fatal systemic inflammatory response syndrome following early bilateral femoral nailing. *Intensive Care Med* 1998;24:641–642.
40. Copeland CE, Mitchell KA, Brumback RJ, et al. Mortality in patients with bilateral femoral fractures. *J Orthop Trauma* 1998;12(5):315–319.
41. Nork SE, Agel J, Russell GV, et al. Mortality after reamed intramedullary nailing of bilateral femur fractures. *Clin Orthop Relat Res* 2003;(415):272–278.
42. Kobbe P, Micansky F, Lichte P, et al. Increased morbidity and mortality after bilateral femoral shaft fractures: myth or reality in the era of damage control?*Injury* 2013;44(2):221–225.
43. Gustilo RB, Anderson JT. Prevention of infection in the treatment of one thousand and twenty-five open fractures of long bones: retrospective and prospective analyses. *J Bone Joint Surg Am* 1976;58(4):453–458.
44. Blachut PA, Meek RN, O'Brien PJ. External fixation and delayed intramedullary nailing of open fractures of the tibial shaft. A sequential protocol. *J Bone Joint Surg Am* 1990;72(5):729–734.

45. Gopal S, Majumder S, Batchelor AG, et al. Fix and Flap: The radical orthopaedic and plastic treatment of severe open fractures of the tibia. *J Bone Joint Surg Br* 2000;82:959–966.
46. Gopal S, Giannoudis PV, Murray A, et al. The functional outcome of severe, open tibial fractures managed with early fixation and flap coverage. *J Bone Joint Surg Br* 2004;86(6):861–867.
47. Wood T, Sameem M, Avram R, et al. A systematic review of early versus delayed wound closure in patients with open fractures requiring flap coverage. *J Trauma Acute Care Surg* 2012;72(4):1078–1085.
48. Hull PD, Johnson SC, Stephen DJ, et al. Delayed debridement of severe open fractures is associated with a higher rate of deep infection. *Bone Joint J* 2014;96:379–384.
49. Lack WD, Karunaker MA, Angerame MR, et al. Type III open tibia fractures: immediate antibiotic prophylaxis minimizes infection. *J Orthop Trauma* 2015;29(1):1–6.
50. McQueen MM, Court-Brown CM. Compartment monitoring in tibial fractures: the pressure threshold for decompression. *J Bone Joint Surg Br* 1996;78:99–104.
51. Harrington P, Bunola J, Jennings AJ, et al. Acute compartment syndrome masked by intravenous morphine from a patient-controlled analgesia pump. *Injury* 2000;31:387–389.
52. Smith RM, Dyer GS, Antonangeli K, et al. Disaster triage after the Haitian earthquake. *Injury* 2012;43(11):1811–1815.
53. Perren SM. Physical and biological aspects of fracture healing with special reference to internal fixation. *Clin Orthop Relat Res*1979;138:175–196.
54. Perren SM. Evolution of the internal fixation of long bone fractures. The scientific basis of biological internal fixation: choosing a new balance between stability and biology. *J Bone Joint Surg Br* 2002;84(8):1093–1110.
55. Mueller ME, Allgower M, Schneider R, et al. *Manual of Osteosynthesis.* Berlin/Heidelberg/New York: Springer Verlag; 1970.
56. Helfet DL, Haas NP, Schatzker J, et al. AO philosophy and principles of fracture management-its evolution and evaluation. *J Bone Joint Surg Am* 2003;85(6):1156–1160.
57. Schatzker J, McBroom R, Bruce D. The tibial plateau fracture. The Toronto experience 1968–1975. *Clin Orthop Relat Res* 1979;(138):94–104.
58. Matta JM. Fractures of the acetabulum: accuracy of reduction and clinical results in patients managed operatively within three weeks after the injury. *J Bone Joint Surg Am* 1996;78:1632–1645.
59. Moed BR, Yu PH, Gruson KI. Functional outcomes of acetabular fractures. *J Bone Joint Surg Am* 2003;85(10):1879–1883.
60. Sirkin M, Sanders R, DiPasquale T, et al. A staged protocol for soft tissue

management in the treatment of complex pilon fractures. *J Orthop Trauma* 1999;13(2):78–84.

61. White TO, Guy P, Cooke CJ, et al. The results of early primary open reduction and internal fixation for treatment of OTA 43.C-type tibial pilon fractures: a cohort study. *J Orthop Trauma* 2010;24(12):757–763.
62. Donaldson LJ, Cook A, Thomson RG. Incidence of fractures in a geographically defined population. *J Epidemiol Community Health* 1990;44(3):241–245.
63. Garden RS. Low-angle fixation in fractures of the femoral neck. *J Bone Joint Surg Br.* 1961;43 :647–663.
64. Parker MJ, Gurusamy K. Arthroplasties (with and without bone cement) for proximal femoral fractures in adults. *Cochrane Database Syst Rev* 2006;(3):CD001706.
65. Bhandari M, Devereaux PJ, Swiontowski MF. Internal fixation compared with arthroplasty for displaced fractures of the femoral neck: a meta-analysis. *J Bone Joint Surg Am* 2003;85:1673–1681.
66. Queally JM, Harris E, Handoll HH, et al. Intramedullary nails for extracapsular hip fractures in adults. *Cochrane Database Syst Rev* 2014;9:CD004961.
67. Baumgaertner MR, Curtin SL, Linskog DM, et al. The value of the tip apex distance in prediciting failure of fixation of peritrochanteric fractures of the hip. *J Bone Joint Surg Am* 1995;77(7):1058–1064.
68. Schatzker J. Intra-articular malunions and nonunions.*Orthop Clin North Am* 1990;21(4):743–757.
69. Masquelet AC, Begue T. The concept of induced membrane for reconstruction of long bone defects. *Orthop Clin North Am* 2010;41(1):27–37.
70. García-Cimbrelo E, Martí-González JC. Circular external fixation in tibial nonunions. *Clin Orthop Relat Res* 2004;(419):65–70.

Chapter 29

Pediatric Trauma

Elizabeth S. Soukup and Peter T. Masiakos

Key Points

1 **Epidemiology:** Pediatric trauma significantly impacts the lives of children and families in the United States and around the world. Traumatic injuries remain the no. 1 killer of children and adolescents in the United States. Injury, both intentional and unintentional, accounts for more than 50% of deaths in children younger than 18 years. Therefore, pediatric trauma is a significant public health problem, with management strategies that should include not only emergency medical care but also injury prevention and systems of trauma care to meet the needs for pediatric patients.

2 **ABCs:** As in adults, the primary survey should focus on the identification of acute life-threatening injuries. Attention to the airway, breathing, and circulation (ABCs) supersedes all other interventions in the initial resuscitation phase. All centers that care for children should have sequestered resuscitation equipment designed for children, that is, endotracheal tubes, laryngoscopes, catheters, and passive warming lamps. Room temperature should be kept warm to limit insensible heat losses in small children. The Broselow Pediatric Emergency Tape aides in estimating the weight of the child by measuring his or her length and is used to facilitate pediatric resuscitation.

3 **C-spine clearance:** Much of the imaging that is done to clear the c-spine in a child is unnecessary. The clinical evaluation of pediatric trauma patients with suspected c-spine injury is quite effective in predicting which subset of patients will benefit from cross-sectional imaging. Simple clinical criteria, like Glasgow Coma Scale, used in concert with the physical examination, can safely predict cervical spine injury in children, safely reducing the dependence on clinical imaging for the vast majority of patients (even the very young).

4 **Nonaccidental trauma:** Nonaccidental trauma is a leading cause of trauma in children, with 650,000 confirmed cases of physical abuse annually in the United States, accounting for 1,500 deaths per year, mostly in children younger than 4 years.[105] Nonaccidental trauma and abuse may be difficult to recognize, and a high index of suspicion is needed when evaluating children with injuries. The American Academy of Pediatrics guidelines published in 2015 provide a resource to help identify these children, because unrecognized cases of abuse can represent with serious or even fatal injuries.

5 **Injury prevention:** As policy makers struggle to allocate limited resources in order to improve population health, injury prevention programs will play a particularly important role. The rationale is straightforward: regulatory efforts specifically aimed at injury primary and secondary prevention, if well designed, can be very successful at health care cost reduction, thereby freeing resources for other concerns.

INTRODUCTION AND EPIDEMIOLOGY

1 Pediatric trauma significantly impacts the lives of children and families in the United States and around the world. Traumatic injuries remain the no. 1 killer of children and adolescents in the United States. Injury, both intentional and unintentional, accounts for more than 50% of deaths in children younger than 18 years.[1] The pediatric mortality rate from trauma in the United States is double that of other developed countries, and for every pediatric death there were more than 2,000 emergency department visits.[2] In the United States alone, more than 50,000 children are permanently disabled after trauma, most commonly the result of traumatic brain injury (TBI).[2] Injuries account for almost a third of the total burden of disease in children by disability-adjusted life years.[2] According to data that are now longer than 20 years, these disabilities account for $14 billion in lifetime medical spending and $66 billion in future wages lost.[3] Therefore, pediatric trauma is a significant public health problem, with management strategies that should include not only emergency medical care but also injury prevention and systems of trauma care to meet the needs for pediatric patients.[3]

Although there is a rise in the incidence of penetrating trauma, which now accounts for up to 10% to 20% of trauma activations, the vast majority of pediatric injuries result from blunt trauma with associated closed head injuries that require nonoperative management.

TRAUMA SYSTEMS

The concept of a trauma system was shaped by the publication of a US government report in 1966 “Accidental Death and Disability: the Neglected Disease of Modern Society”[4] and has led to improvements in infrastructure, processes of emergency response, communication, and outcome measurements and quality indicators of responding hospital centers. The Committee on Trauma first categorized Trauma Center designations in 1976.[2] The first Pediatric trauma centers were organized in the 1970–1980s; however, even today in the United States, there are too few designated pediatric trauma centers to care for all pediatric trauma patients. There are 35 level I and 32 level II pediatric trauma centers verified by the American College of Surgeons and a handful of other pediatric trauma centers that are verified by their own states. Because the vast majority of pediatric patients are cared for at adult trauma centers,[5,6] the exchange of ideas between adult and pediatric trauma centers and the development of integrated regional trauma systems remain critically important for our care of injured children.[2,7]

Inclusive trauma systems include all facilities within a region according to a tiered-triage system. Each participating facility receives a level designation, and this is used to appropriately triage and refer patients as necessary. Along with these regionalization efforts, advances in pediatric transport have also improved how we care for injured children. Inclusive systems have been shown to improve outcomes because more timely and appropriate transfers can occur. It has become increasingly important to develop and study various “performance indicators” of the quality of care that is delivered to injured pediatric patients. For example, rate of successful splenic salvage is a commonly cited quality indicator in pediatric trauma, and there are reports that children cared for at an adult trauma center have a fivefold higher risk of splenectomy than those at pediatric trauma center.[6,8,9] In addition, beyond simply benchmarking mortality rates, other measurable quality indicators include availability of a pediatric intensive care unit with in-house intensivists; radiation exposure from imaging; early neurosurgical intervention for severe head injury; early fixation of femur fractures; operative rates for solid organ injuries; and participation in registry databases to monitor performance over time, such as the Trauma Quality Improvement Program set up by the American College of Surgeons-Committee on Trauma.[10,11] It is unclear whether superior care is offered to injured children in a dedicated pediatric hospital, compared to an adult hospital; however, it has been demonstrated that pediatric trauma certification and expertise in care of trauma patients are both important factors in optimal care.[12–17]

Pediatric trauma centers should provide a broad range of pediatric-specific expertise, including pediatric emergency medicine, pediatric surgery and surgical specialties, pediatric anesthesiologists, and pediatric medical subspecialists, most importantly pediatric intensivists with a dedicated pediatric intensive care unit for intensive monitoring and care of critically ill pediatric patients. Furthermore, pediatric imaging protocols, sedation and pain management protocols, and overall principles of family centered care add a layer of safety to the care of the child. Child-life specialists and personnel to help transfer to posthospital all work to improve the care of the pediatric

patient. The youngest and sickest children should preferentially be transferred to these higher-level designated pediatric trauma centers.[3]

INITIAL ASSESSMENT, RESUSCITATION, AND STABILIZATION

The evaluation and treatment of traumatic injuries of infants and children requires specific knowledge of pediatric physiology and the physiologic response to injury. Generally, the trauma resuscitation of children follows similar rules that have been described for adults by advanced trauma life support standards. However, there are several special considerations in the initial assessment and subsequent care for children and specific paradigms regarding ancillary studies that are different from those in adults. These special considerations will be discussed here.



Figure 29-1. Broselow pediatric emergency resuscitation tape.

2 As in adults, the primary survey should focus on the identification of acute life-threatening injuries. Attention to the airway, breathing, and circulation (ABCs) supersedes all other interventions in the initial resuscitation phase. All centers that care for children should have sequestered resuscitation equipment designed for children, that is, endotracheal tubes (ETTs), laryngoscopes, catheters, and passive warming lamps. Room temperature should be kept warm to limit insensible heat losses in small children. The Broselow Pediatric Emergency Tape aides in estimating the weight of the child by measuring his or her length. A color-coded bar on the tape measures the length of the child and indicates the appropriate equipment sizes and medication doses to perform emergency resuscitation on the child. Designated resuscitation equipment is contained in corresponding, color coded equipment pouches or drawers (Fig. 29-1).

Pediatric vital signs vary by age (Table 29-1). Children are able to maintain normal blood pressures until late hemorrhagic shock (>30% blood loss), and, therefore, subtle changes in heart rate and respiratory rate must be noted. As a general rule, the lower limit of acceptable systolic blood pressure = Age × 2) + 70 mm Hg. For newborns, acceptable systolic blood pressure is 60 mm Hg or greater.

Airway control (“A”) is the first priority. Cardiac arrest in a child is most often of

respiratory etiology, and an injured child who is obtunded, unresponsive, or combative may need to be intubated. An uncooperative child who needs radiologic imaging may also need to be intubated. Intubation must be performed with the jaw thrust technique and in-line cervical stabilization. Keep in mind these key anatomic differences for intubation in children: larger tongue, more narrow and anterior glottis, and shorter trachea. You may find that a straight Miller blade is easier than the curved Mac blade because the epiglottis is floppy (less cartilaginous). The appropriate size of ETT can be estimated by the size of pinkie finger (or the formula = [age + 16]/4). The Broselow Pediatric Emergency Resuscitation Tape is also a useful tool to estimate ETT (and other device) size and medication doses, given a child's height or weight. Use an uncuffed ETT in a young child (<8 years of age or approximately 60 lb), because the subglottic trachea is narrow and provides a sufficient seal. However, cuffed ETT may be used (except in newborns), if appropriate cuff pressures are used. Rapid sequence intubation is similar to adults, including preoxygenation with 100% FiO_2, medication administration, cricoid pressure, cervical spine stabilization, laryngoscopy, and advancement of tube to an appropriate distance beyond the cords. Confirm exhaled CO_2 and secure the tube. In the rare event of acute airway obstruction, needle cricothyroidotomy with a 14 g catheter is preferential to open cricothyroidotomy because of the increased incidence of subglottic stenosis.

Table 29-1 Pediatric Vital Signs

	Pulse (Beats/Min)	Systolic Blood Pressure (mm Hg)	Respiration (Breaths/Min)
Newborn (<1 mo)	95–145	60–90	30–60
Infant (1 mo to 1 yr)	125–170	75–100	30–60
Toddler (1–2 yrs)	100–160	80–110	24–40
Preschool (3–4 yrs)	70–110	80–110	22–34
School age (4–12 yrs)	70–110	85–120	18–30
Adolescent (>12 yrs)	55–100	95–120	12–16

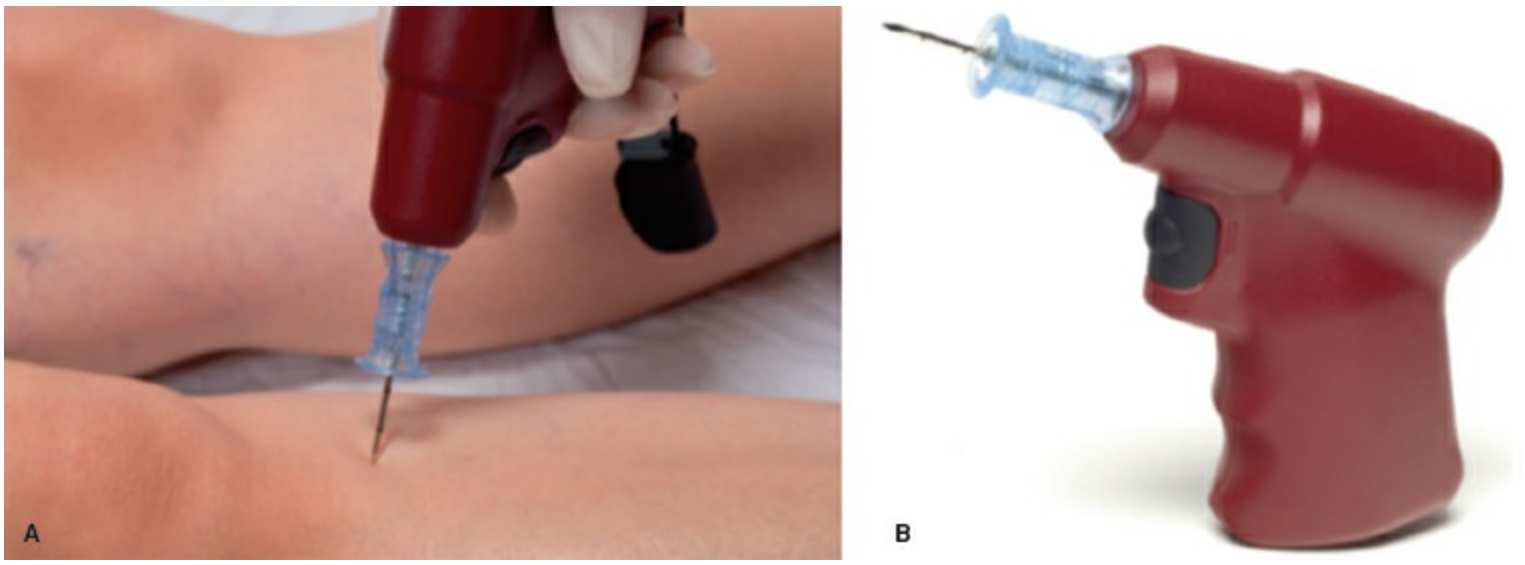

Figure 29-2. **A:** Intraosseous line placement. **B:** EZ-IO drive.

After securing the airway, assess the child's breathing ("B"). If there is difficulty with respiration, assist the ventilation and assess for potential life-threatening thoracic injuries: pneumothorax (open chest wound or tension pneumothorax), hemothorax, flail chest/pulmonary contusions, and rib fractures with splinted breathing. The mediastinum of a child is very compliant and can lead to rapid decline from a tension pneumothorax. These life-threatening injuries must be rapidly identified and treated. Children are diaphragmatic breathers and, therefore, gastric distension can be an unrecognized contributor to respiratory distress, especially in the young child who is distended from swallowing air while crying. If there are concerns for abdominal distension, a nasogastric tube should be placed to decompress the stomach. Use an orogastric tube in babies, who are obligate nose breathers.

Hemorrhage is the most common etiology of Circulatory compromise ("C") in trauma, but do not overlook obstructive etiologies (cardiac tamponade and tension pneumothorax) and distributive etiologies (neurogenic shock). Assessment of volume status and shock is difficult in the child. Children have impressive physiologic reserve and can maintain systolic blood pressure until late-stage hypovolemic shock (>30% blood loss). Tachycardia, tachypnea, altered level of consciousness, and poor peripheral perfusion (mottled cool extremities, weak thready pulses, narrowed pulse pressure, delayed capillary refill) are early but subtle signs of blood loss. Establishing vascular access in an injured child is a priority and can be challenging. Peripheral intravenous lines are ideal, but when they cannot be obtained, intraosseous lines are quick, reliable, and allow high-volume infusion of any fluid (crystalloid, blood products, and even medications, including pressors). An intraosseous line is placed in the anteromedial tibia, 2- to 3-cm distal to the tibial tuberosity after a quick skin preparation for sterility (Fig. 29-2). Avoid wounds, fractures, or infected areas. They should ideally be placed with a single attempt because multiple holes can lead to leakage of infusion fluids and resultant compartment syndrome. If contraindicated, definitive intravenous (IV) access can be obtained with a central line in the femoral vein or a peripheral vein cut down (i.e., saphenous vein).

Initial fluid resuscitation is indicated when there are signs of hypovolemic shock. Initial bolus consists of 20 mL/kg of warmed normal saline or lactated Ringer's solution. This may be repeated if there is no response or only a transient response. All subsequent volume resuscitation should be performed with blood products (10 mL/kg = "1 unit") (Table 29-2). If there is no time for cross-matched, type-specific blood, "O-negative" blood is indicated. Massive transfusion protocols may be initiated at this time if indicated and should include hemostatic resuscitation with packed red blood cells, fresh frozen plasma, and platelets, targeting high plasma-to-red blood cell and platelet-to-red blood cell ratios.[18] In the most recent advanced trauma life support protocols, this has become known as "damage control resuscitation,"[19] espousing permissive hypotension, minimizing crystalloid resuscitation, and promoting early blood product administration for the treatment of the lethal triad (acidosis, coagulopathy, and hypothermia) of severe uncontrolled hemorrhage. There is, however, no evidence-based support for permissive hypotension strategies in pediatric trauma patients. As in adults, ongoing hemodynamic

instability from blood loss in a child must be controlled expeditiously. Sources of bleeding can be thought of in terms of body compartments: including the chest, peritoneal cavity, retroperitoneum/pelvis, femur fracture/thigh compartment, and external injury (especially the scalp). In an infant, prior to suture closure of the skull, intracranial hemorrhage may produce hemodynamic instability. Once resuscitated, maintenance fluid requirements (Table 29-2) can be estimated using the "4-2-1" rule and should be administered as D5 1/2NS (or D10 1/2NS for neonates).

Table 29-2 Fluid Management in Children

Resuscitation Fluids (NS or LR)	
If hypotension or signs of shock:	Bolus 20 mL/kg. Repeat if transient or no response and then switch to blood transfusions (10 mL/kg).
Daily Maintenance Fluid Requirements (D5 1/2NS or D10 1/2NS)	
Weight <10 kg	100 mL/kg/day
Weight 11–20 kg	1,000 mL + 50 mL/kg/day (for every kg over 10)
Weight >20 kg	1,500 mL + 20 mL/kg/day (for every kg over 20)

A brief neurologic assessment is part of the primary survey ("D" for disability). Head injury accounts for the highest degree of morbidity and mortality in children and is the principle determinant of outcome after trauma. However, children have the potential for more frequent and fuller recovery from even serious head injury, when compared to similar injuries in adults.[20] Therefore, careful attention to preventing secondary injury and maximizing tissue perfusion to the brain can greatly improve outcome. These secondary insults include ischemia, hypoxia, hypotension, hyperthermia, hypercapnia, acidosis, and increased intracranial pressure (ICP). The Glasgow Coma Scale (GCS) is modified in young children who are preverbal to measure neurologic function and prognosis. The motor response scale tends to provide the most reliable assessment of function in a preverbal or intubated child (Table 29-3).

In preparation for the secondary survey, the child must be Exposed ("E") completely for a complete head-to-toe physical examination. Keep in mind that they also have a larger body surface area ratio and, therefore, lose heat and water quickly and can become hypothermic. Use warm fluids, bare huggers, warming lights, and warm ambient room temperature to prevent heat loss in a child and the secondary coagulopathy that is associated with hypothermia.

Only after the primary assessment is complete, and ABCs are secured, do we move on to the full secondary survey. In reality, with a team approach to management of the pediatric trauma patient, much of the supportive care happens concurrently with the primary and secondary surveys, including placement of intravenous lines, drawing laboratories, applying monitors and oxygen, and obtaining ancillary diagnostic tests. Adjunct diagnostic modalities and imaging may be used to provide additional information

in the evaluation of a pediatric trauma patient. Although diagnostic peritoneal aspiration has been traditionally used to evaluate intra-abdominal injuries in the unstable patient, it has no role in the pediatric population where solid organ injuries are unlikely to require surgery. Focused assessment with sonography in trauma (FAST) examination has significant advantages over more invasive diagnostic maneuvers: the FAST examination can be performed quickly and exposes the patient to no potential harm from delay or ionizing radiation. However, children with intra-abdominal injuries are more frequently managed nonoperatively, and thus the need for rapid decision making regarding operative management is less common. Children also have a relatively higher incidence of solid organ injury without free fluid, and consequently, a negative FAST examination may not obviate the need for an abdominal computed tomography (CT) when there is a clinical suspicion of significant injury. The FAST examination should not be relied on as a stand-alone screening tool in the pediatric population.[21,22] Findings from chest radiography, anteroposterior pelvis radiography, and the FAST examination, along with the primary and secondary surveys, guide decisions regarding further radiographic examination, including CT or plain radiography.

In addition to a full physical examination, a brief history is essential and is often provided by emergency medical services (EMS) personnel or the parents. An "AMPLE" history helps the provider focus on essential information such as Allergies, Medications, Past medical history, Last meal, and Events surrounding the traumatic incident. Blunt trauma is the most common mechanism after which children present for evaluation. Children are more prone to multisystem trauma due to their small body size and more compliant body (less protective bones, muscle, and torso fat). Blunt trauma can result in injury patterns that resemble penetrating injuries, without significant external signs of trauma. Careful attention to a bruise on the abdominal wall resulting from a bicycle handlebar should lead to a more thorough investigation of the abdomen. A lap belt mark across the abdomen may raise concerns of lumbar spine fracture (Chance fracture), with an associated risk of small bowel injury. A history of significant hemorrhage at the scene may instigate a more thorough investigation of the vessels in the proximity of injury in an otherwise hemodynamically stable patient who has no hard signs of vascular injury. Therefore, a thorough history, mechanism of injury, and focused examination of the entire child is mandated so that signs of forceful impact can be elucidated.

Table 29-3 Modified Glasgow Coma Scale in Children

	Infant	Child
Eye opening		
4	Spontaneous	Spontaneous
3	To verbal stimuli	To verbal stimuli
2	To pain only	To pain only
1	None	None
Verbal response		
5	Coos and babbles	Oriented, appropriate
4	Irritable cries	Confused
3	Cries to pain	Inappropriate words
2	Moans to pain	Incomprehensible sounds
1	None	None
Motor response[a]		
6	Moves spontaneously and purposefully	Obeys commands
5	Withdraws to touch	Localizes painful stimuli
4	Withdraws in response to pain	Withdraws in response to pain
3	Abnormal flexion posture to pain	Flexion in response to pain
2	Abnormal extension posture to pain	Extension in response the pain
1	None	None

[a]If patient is intubated, unconscious, or preverbal, the most important part of this scale is motor response and should be closely evaluated.

MANAGEMENT OF SPECIFIC INJURIES

Traumatic Brain Injury

Traumatic brain injury is the leading cause of death and disability in children,[20,23,24] and is an important determinant of outcome. Physical abuse such as shaken baby syndrome is the most common cause of head injury in children younger than 2 years, and blunt head trauma from motor vehicle accidents, falls, or bicycle/pedestrian accidents are responsible for most injuries in children older than 2 years. Injury prevention strategies are necessary for improving outcomes of the primary TBI. However, reduction of secondary injury patterns is critical in children, who have impressive physiologic reserve and potential for rehabilitation after brain injury. Focus must be on preserving cerebral oxygenation and perfusion and mitigate toxic exposures to minimize secondary brain injury. This includes treating or preventing hypotension, hypoxia, hyper or hypocarbia, hyperoxia with generation of ischemia reperfusion free-radicals, hyperthermia, seizures, and intracranial hypertension.

Mild Traumatic Brain Injury

Children with minor head trauma can present the greatest challenge to emergency department personnel. Eastern Association for the Surgery of Trauma (EAST) guidelines define mild traumatic brain injury (MTBI) to be interchangeable with the term "Concussion," involving a blunt force mechanism with alteration in brain function (i.e., GCS score of 13 to 15) but by definition must have a normal head CT if performed.[25] Significant brain injuries need to be identified early and treatment instituted rapidly. CT scans provide the most accurate and expeditious means of diagnosis but expose many pediatric patients to unnecessary radiation. Evidence-based clinical decision tools have helped identify the population of children who benefit most from radiologic evaluation. The TBI study group for PECARN (Pediatric Emergency Care Applied Research Network) has developed tools for assessment of children after blunt head injury.[25–30] The "PECARN Rules,"[26] (Algorithm 29-1) identify children at very low risk ($<0.05\%$) of having clinically important TBI requiring intervention. These patients can avoid CT and be discharged safely with appropriate instructions. Children with abnormal GCS score (GCS score of ≤ 14) or evidence of skull fracture are at the highest risk for clinically important injury and should be evaluated emergently by CT scan. If there is a history of loss of consciousness, severe injury mechanism, abnormal behavior to the parent or nonfrontal scalp location (<2 years), or vomiting and severe headache (≥ 2 years), then further observation or CT should be offered as reasonable management options. Subsequent analyses also identified children with only isolated loss of consciousness (and no other PECARN predictors) to be at very low risk for clinically important TBI.[27] Children with MTBI (GCS score of 14 to 15) who underwent CT can be safely discharged home without further neurologic monitoring, if their head CT scan is normal.[25,28] Even those with an isolated skull fracture can be discharged home from the emergency department with strict discharge instructions and return precautions.[29,30,31,32] At this point, routine structural or

functional imaging modalities such as magnetic resonance imaging, functional magnetic resonance imaging, or positron emission tomography for diagnosis or prognosis of MTBI are not supported.[25]

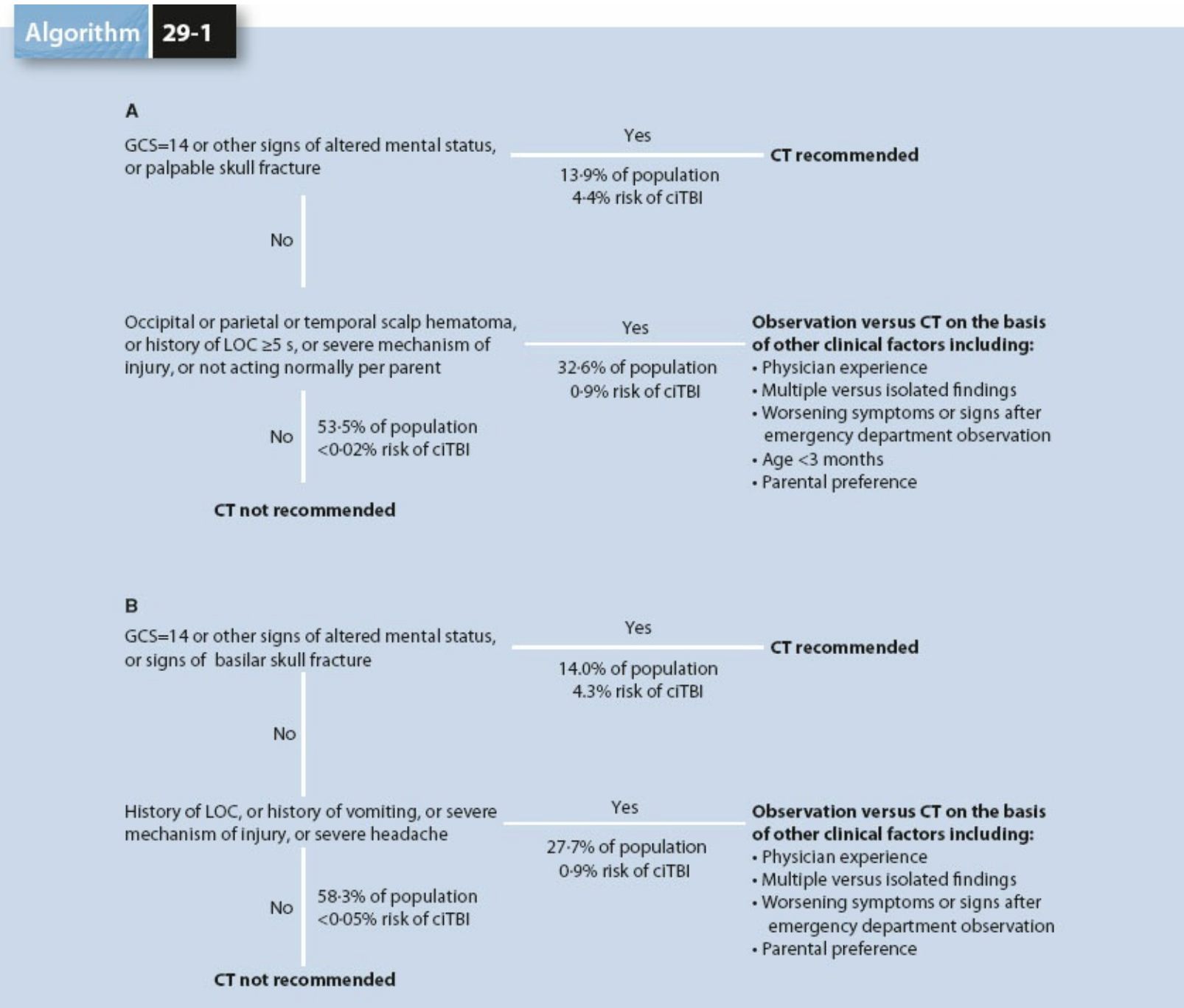

Algorithm 29-1. PECARN rules to identify children at very low risk of clinically important TBI. CT algorithm for children younger than 2 years (**A**) and for those aged 2 years and older (**B**) with GCS scores of 14–15 after head trauma. ciTBI, clinically important traumatic brain injury; GCS, Glasgow Coma Scale; LOC, loss of consciousness. (From Kuppermann N, Holmes JF, Dayan PS, et al. Identification of children at very low risk of clinically-important brain injuries after head trauma: A prospective cohort study. *Lancet* 2009;374(9696):1160–1170.)

Prognosis and outcome in MTBI, especially as it relates to "return to learn or return to play" after concussion, is still hotly debated. Most studies agree that patients with MTBI return to baseline within 3 months (majority within 10 to 14 days), but certainly symptom resolution can take longer. Lingering symptoms of headache, dizziness, fatigue,

sleep disturbance, impairment in memory and concentration, irritability, anxiety, or depression are referred to as the "postconcussive syndrome," which is not a well-understood entity.[25] Standardized tools exist, such as the Immediate Postconcussion Assessment and Cognitive Testing Battery (ImPACT), to aid clinicians in functional assessment of patients with MTBI.[33] The well-known NCAA Concussion Study from 2003 found that high-level athletes were more likely to sustain repeat concussions, which were associated with a longer recovery time,[34] and it has been increasingly recognized that repeat concussions can have permanent and sometimes devastating effects. In 2010, the American Academy of Pediatrics officially endorsed the International Conference on Concussion in Sport recommendations for a graduated "Return to Play" protocol (available online: http://www.ncbi.nlm.nih.gov/pmc/articles/PMC4004129/table/T1/, last accessed April 5, 2016).[35,36] The CDC HEADS UP guidelines also incorporate these recommendations[37] and provide resources for schools, coaches, and primary care providers on returning to school and sports after a concussion. Data are lacking in the efficacy of these guidelines and their role in preventing recurrent concussions.[38]

Moderate to Severe TBI

More serious head injury needs to be evaluated and treated expeditiously. The GCS (and modified GCS for infants) is a universal tool that can be used for rapid assessment of neurologic function and is based on verbal response, motor function, and eye opening. Moderate TBI is considered GCS score of 9 to 12 or 13 and severe TBI includes GCS score of ≤ 8, the definition of a coma. The goal of initial assessment and resuscitation in a severely brain injured patient is to minimize or prevent secondary brain injury. Attention to ABCs is critical, with maintenance of normotension and normoxia. Management of severe TBI in the pediatric intensive care unit is largely focused on management of elevated ICP and maintenance of cerebral perfusion pressure.[39] In 2003 and again in 2012, guidelines for the acute medical management of severe TBI in infants, children, and adolescents were published, which represented the first recommendations made specifically for pediatric patients (Tables 29-4 and 29-5).[40–43] These guidelines, composed mostly of class II or III evidence, included recommendations on management of intracranial hypertension, hypoxia/airway management, indications for ICP monitoring, thresholds for treatment and management of cerebral perfusion pressure, and hypotension. It also addressed therapies such as cerebrospinal fluid drainage, hyperosmolar therapies, hyperventilation, barbiturates, decompressive surgery, temperature control, corticosteroids, and supportive care such as sedatives/neuromuscular antagonists and nutrition, although the guidelines are mostly based on expert panel opinion rather than large clinical trials. Prehospital management focused on the benefit of pediatric trauma centers rather than adult trauma centers for children with severe TBI. Supplemental oxygen should be administered. There was no superiority of endotracheal intubation versus bag-mask ventilation in the prehospital setting, but if endotracheal intubation is to be undertaken, specialized training and the use of end-tidal CO_2 monitoring is encouraged. Hyperventilation with hypocarbia (pCO_2 <30 to 35) is to be avoided. There was class II support for ICP monitoring for children

with GCS score of 8 or less; using an ICP threshold of 20 mm Hg and a cerebral perfusion pressure of 40 to 65 mm Hg; efficacy of hypertonic saline solutions in lowering ICP; and the role for decompressive surgery in the treatment of elevated ICP. From these guidelines, an algorithm for the management of acute intracranial hypertension was developed on the basis of the expert opinions of the committee (Algorithm 29-2), which has served as a template for clinical protocols for patient care and research. The 2012 guidelines changed a few of the recommendations (Table 29-5). Only hyperosmolar therapy was supported by two small studies (class II data); the remaining therapeutics could not be supported by the literature, including use of corticosteroids, immune-modulating diets, and induction of moderate hypothermia ("Cool Kids" trial).[44,45] Other topics with class III evidence were added including advanced neuromonitoring (using a brain–tissue oxygen partial pressure of 10 mm Hg), neuroimaging (avoiding routine repeat head CT unless neurologic deterioration), cerebrospinal fluid drainage, and the use of antiseizure prophylaxis (phenytoin prophylaxis) to reduce posttraumatic seizures. For a variety of other topics, including glycemic control, cerebrospinal fluid drainage, and analgesics/sedatives/neuromuscular blockade, definitive recommendations could not be made on the basis of the available literature. Overall, there is still a paucity of high-quality evidence to make specific treatment plans for children with severe TBI, but this allows for a wide variety of clinical approaches that are considered within the guidelines of pediatric care.

3 Cervical spine injuries (CSI) in blunt trauma pediatric patients occur in less than 2% of seriously injured children. Despite this low incidence, it is clear that many clinicians obtain radiographs in order to exclude CSI. The added benefit of routine imaging in the pediatric trauma evaluation is debatable. In recent years, concerns have been raised about the liberal use of plain films, CT scans, and magnetic resonance images in children with reference to imaging-related short- and long-term morbidity, resource consumption, and cost. The increased risk of fatal and nonfatal cancers associated with CT-related radiation has gained attention both by physicians and also by consumers. Both the U.S. Food and Drug Administration Center for Devices and Radiological Health (FDA) and the National Cancer Institute have published guidelines designed to limit unnecessary imaging in children. Although proponents of liberal imaging argue that a single missed CSI may cost more than multiple diagnostic tests, the use of non–evidence-based tests may inspire suboptimal practice with an undefined risk-benefit ratio.

Two seminal studies (NEXUS and Canadian Cervical Spine Rules [CCR])[46,47] have examined whether clinical criteria (neurologic deficit, cervical spine tenderness, intoxication, decreased mental status, and distracting injuries) can rule out CSI in adults without the need of imaging. These criteria have been applied to pediatric patients in a manuscript by Viccellio and colleagues,[48] who evaluated 3,065 blunt trauma patients younger than 18 years and found that nearly 20% of patients fell into the "low-risk" category where imaging could have been avoided. In another retrospective review of 206 pediatric patients (from birth to 16 years of age), Jaffe and colleagues[49] suggested that the absence of eight clinical criteria (neck pain; neck tenderness; abnormality of reflexes, strength, or sensation; direct trauma to the neck; limitation of neck mobility; abnormal mental status) enabled a clinician to detect CSI in children with a sensitivity of 98% and a specificity of 54%. The PECARN group has also reported on its series of 540 cervical spine injuries in children, presenting a model with eight predictors to identify children who should be evaluated for CSIs after blunt trauma.[50] These include altered mental status, focal neurologic deficits, complaint of neck pain, torticollis, substantial torso injury, predisposing condition, diving, and high-risk motor vehicle crash, with a sensitivity of 98%.

Table 29-4 Summary of Standards, Guidelines, and Options Generated from the 2003 Pediatric TBI Guidelines

Topic	Level of Evidence	Recommendation
Trauma systems, pediatric trauma centers, and the neurosurgeon	Guideline	"In a metropolitan area, pediatric patients with severe TBI should be transported directly to a pediatric trauma center, if available"
	Option	"…should be treated in a pediatric trauma center or in an adult trauma center with added qualifications to treat children in preference to a level I or II adult trauma center without added qualifications…"
Prehospital airway management	Guideline	"Hypoxia must be avoided…and attempts made to correct it immediately. Supplemental oxygen should be administered…no evidence to support an advantage of endotracheal intubation over bag-valve-mask ventilation…"
	Option	"If prehospital endotracheal intubation is instituted…, then specialized training and use of end-tidal CO_2 detectors is necessary"
Resuscitation of blood pressure and oxygenation	Guideline	"Hypotension should be identified and corrected…defined as systolic blood pressure below fifth percentile for age or by clinical signs of shock…"
	Option	"Airway control should be obtained in children with a GCS ≤8 to avoid hypoxemia, hypercarbia and aspiration…hypoxia should be identified and corrected…blood pressure should be monitored frequently and accurately…"
Indications for intracranial pressure monitoring	Option	"ICP monitoring is appropriate…(GCS ≤8). The presence of an open fontanelle and/or sutures does not preclude the development of intracranial hypertension or negate the utility of ICP monitoring"
Threshold for treatment of intracranial hypertension	Option	"Treatment for intracranial hypertension…should begin at an ICP ≥20 mm Hg"
Intracranial pressure–monitoring technology	Option	"…a ventricular catheter or an external strain gauge transducer or catheter tip pressure transducer device is an accurate and reliable method of monitoring ICP"
Cerebral perfusion pressure	Guideline	"A CPP >40 mm Hg…should be maintained"
	Option	"A CPP between 40 and 65 mm Hg probably represents an age-related continuum for optimal treatment threshold…Hypotension should be avoided"
Sedation and neuromuscular blockade	Option	"…the choice and dosing of sedatives, analgesics and neuromuscular blocking agents…should be left to the treating physician…"
Hyperosmolar therapies	Option	"Hypertonic saline is effective at control of increased ICP…Mannitol is effective for control of increased ICP…"
Hyperventilation	Option	"…Prophylactic hyperventilation…should be avoided. Mild hyperventilation ($PaCO_2$ 30–35 mm Hg) may be considered for longer periods of intracranial hypertension…Aggressive hyperventilation ($PaCO_2$ <30 mm Hg) may be considered as a second tier option in the setting of refractory intracranial hypertension…"
Barbiturates	Option	"High-dose barbiturate therapy may be considered in hemodynamically stable patients with refractory intracranial hypertension…appropriate hemodynamic monitoring and cardiovascular support are essential…"
Temperature control	Option	"…Hyperthermia should be avoided…"
Surgical treatment of intracranial hypertension	Option	"Decompressive craniectomy should be considered…."
Corticosteroids	Guideline	"The use of steroids significantly reduces endogenous cortisol production…may have an associated increased risk of complications of infection"
	Option	"The use of steroids is not recommended for improving outcome or reducing ICP…"
Nutritional support	Option	"Replace 130%–160% of resting metabolism expenditure…nutritional support should begin by 72 h with full replacement by 7 d"

CPP, cerebral perfusion pressure (mean arterial blood pressure minus intracranial pressure); GCS, Glasgow Coma Scale; ICP, intracranial pressure; $PaCO_2$, partial pressure of carbon dioxide; TBI, traumatic brain injury.
From Bell MJ, Kochanek PM. Pediatric traumatic brain Injury in 2012: The year with new guidelines and common data elements. *Crit Care Clin* 2013;29(2):223–238, with permission.

Table 29-5 Summary of Evidence Generated from the 2012 Pediatric TBI Guidelines

Topic	Level of Evidence	Recommendation
Indications for ICP monitoring	Level III	"Use of ICP monitoring may be considered…"
Threshold for the treatment of intracranial hypertension	Level III	"Treatment of ICP may be considered at a threshold of 20 mm Hg"
Cerebral perfusion pressure thresholds	Level III	"A minimum CPP of 40 mm Hg may be considered…A CPP threshold of 40–50 mm Hg may be considered…"
Advanced neuromonitoring	Level III	"If brain oxygenation monitoring is used, maintenance of a partial pressure of brain-tissue oxygen ($Pbto_2$) ≥10 mm Hg may be considered"
Neuroimaging	Level III	"In the absence of neurologic deterioration…routine repeat CT scan…may not be indicated…"
Hyperosmolar therapy	Level II	"Hypertonic saline should be considered…for intracranial hypertension…effective doses…range between 6.5 and 10 mL/kg"
	Level III	"Hypertonic saline should be considered…effective doses as a continuous infusion of 3% saline range between 0.1 and 1.0 mL/kg/h administered on a sliding scale…"
Temperature control	Level II	"Moderate hypothermia…for only 24 h duration should be avoided…moderate hypothermia starting within 8 h after injury and lasting for 48 h duration should be considered to reduce ICP…rewarming at a rate of 0.5°C/h should be avoided"
	Level III	"Moderate hypothermia…for 48 h duration may be considered"
Cerebrospinal fluid drainage	Level III	"CSF drainage through an externalized ventricular drain…may be considered…The addition of a lumbar drain may be considered…"
Barbiturates	Level III	"High-dose barbiturate therapy may be considered in hemodynamically stable patients with refractory intracranial hypertension…continuous arterial blood pressure monitoring and cardiovascular support to maintain adequate CPP are required"
Decompressive craniectomy for the treatment of intracranial hypertension	Level III	"Decompressive craniectomy with duraplasty…may be considered for pediatric patients…showing early signs of neurologic deterioration or herniation or are developing intracranial hypertension refractory to medical management…"
Hyperventilation	Level III	"Avoidance of prophylactic severe hyperventilation to a $PaCO_2$ <30 mm Hg may be considered within the first 48 h…If hyperventilation is used…advanced neuromonitoring for evaluation of cerebral ischemia may be considered"
Corticosteroids	Level II	"The use of corticosteroids is not recommended to improve outcome or lower ICP…"
Glucose and nutrition	Level II	"The evidence does not support the use of an immune-modulating diet…to improve outcome"
	Level III	"…glycemic control…should be left to the treating physician"
Antiseizure prophylaxis	Level III	"Prophylactic treatment with phenytoin may be considered to reduce the incidence of early posttraumatic seizures…"

CPP, cerebral perfusion pressure (mean arterial blood pressure minus intracranial pressure); CSF, cerebrospinal fluid; CT, computed tomographic; ICP, intracranial pressure; $PaCO_2$, partial pressure of carbon dioxide.
From Bell MJ, Kochanek PM. Pediatric traumatic brain injury in 2012: Tthe year with new guidelines and common data elements. *Crit Care Clin* 2013;29(2):223–238, with permission.

Location of Injury

Conventional wisdom has taught that the position of a CSI in children was related to age with the predominance of upper c-spine injuries seen in infants and toddlers and lower c-spine injuries seen in adolescents. This was thought to be a result of the mechanism of injury (flexion/extension and axial load, respectively). However, in a recent evaluation of

the pediatric national trauma database, Polk et al.[51] identified a greater percentage of injuries to the lower c-spine than previously reported. A large database study evaluated the tendency for injuries to occur at certain levels of the cervical spine over a 5 year period and found that younger children ($\leq$10 years of age) sustained upper (C1–C4) CSI more frequently than lower (C4–C7) CSI (87% vs. 57%).[49] Data from a 24-year retrospective study of patients admitted with CSI to a level 1 trauma center similarly concluded that for younger patients ($\leq$8 years of age), significantly more injuries occurred in the upper cervical spine.[46] However, the National Trauma Data Bank (NTDB) data for this study revealed that the number of fractures to the upper c-spine and lower c-spine was nearly equal (53% and 47%), and that more than half of cervical spinal cord injuries were located in the lower c-spine (53%).[51]

Algorithm 29-2a

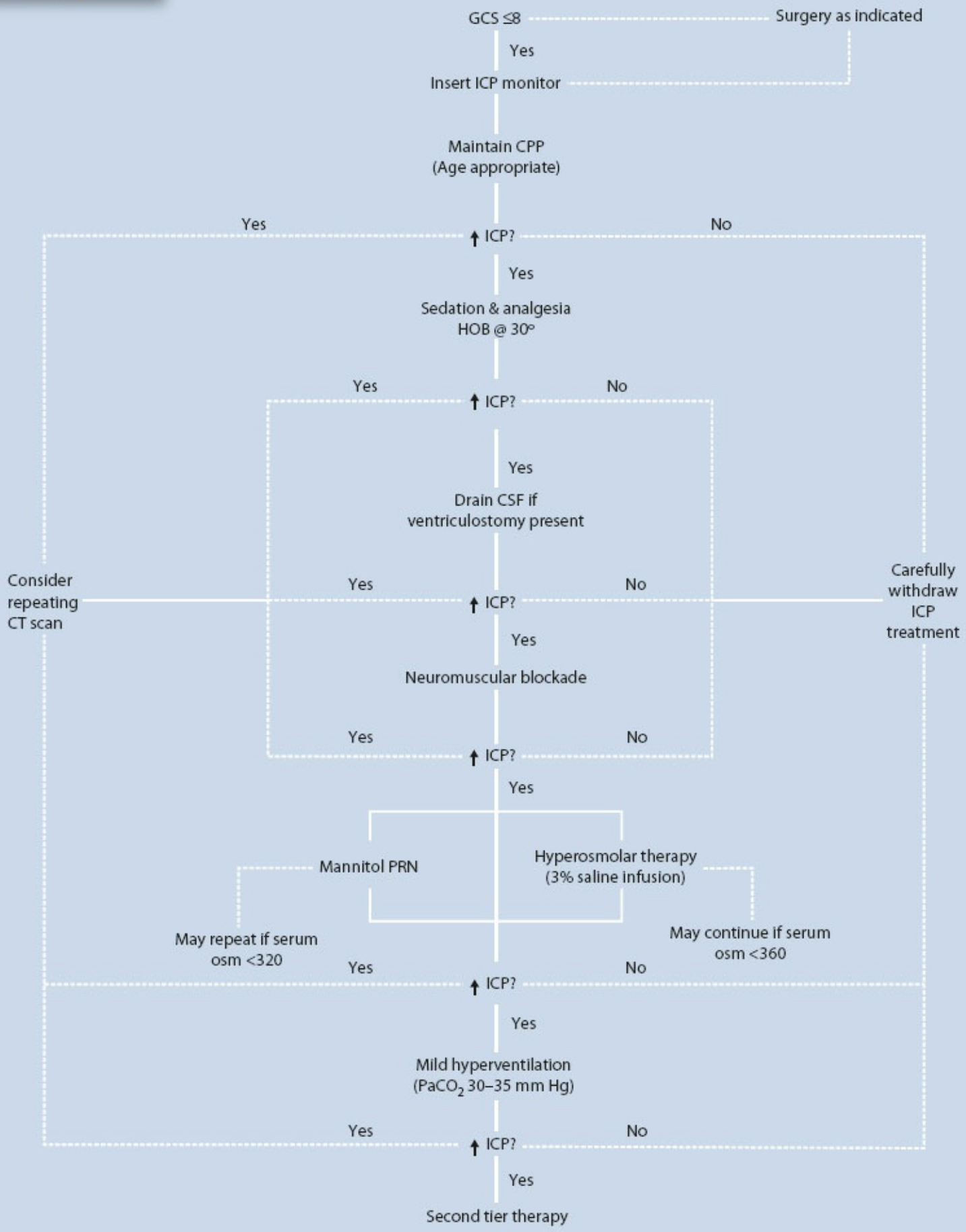

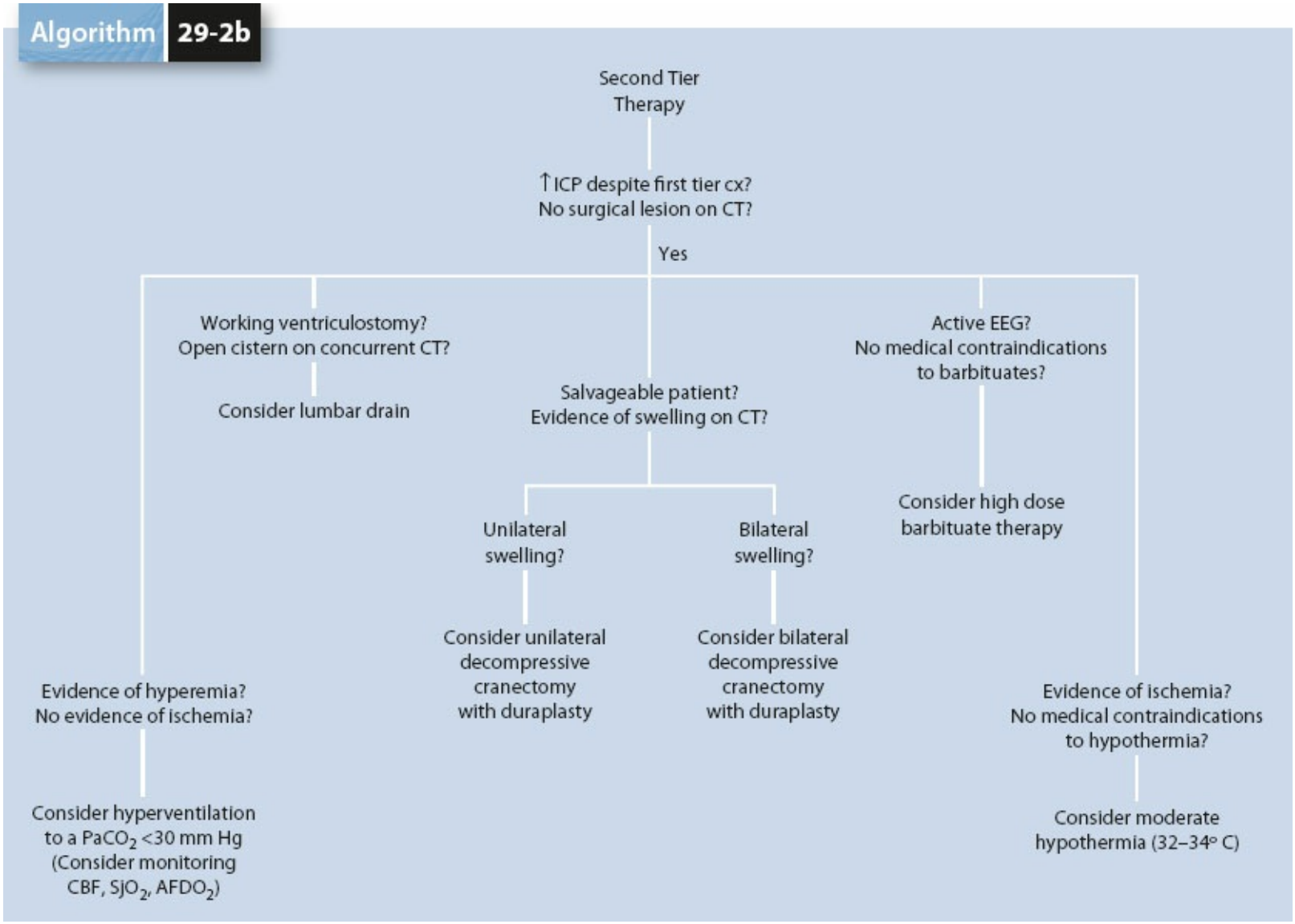

Algorithm 29-2a. Algorithm generated by the Brain Trauma Foundation Committee for the first edition of the *Guidelines for the Medical Management of Severe Traumatic Brain Injury in Infants, Children, and Adolescents* for first-tier therapies (**A**) and second-tier therapies (**B**). $AFDO_2$, arteriovenous difference in oxygen; CBF, cerebral blood flow; CPP, cerebral perfusion pressure; CSF, cerebrospinal fluid; CT, computed tomography; EEG, electroencephalogram; GCS, Glasgow Coma Scale; HOB, head of bed; ICP, intracranial pressure; $PaCO_2$, partial pressure of carbon dioxide; PRN, as needed; SjO_2, jugular bulb venous oxygen saturation. (From Bell MJ, Kochanek PM. Pediatric traumatic brain injury in 2012: The year with new guidelines and common data elements. *Crit Care Clin* 2013;29(2):223–238, with permission.)

Mechanism of Injury

Motor Vehicle Crash (MVC) remains the most common mechanism of CSI for the youngest age group.[46–49,52] A study of children younger than 14 years observed that while MVC was the most common mechanism for this large age group, when ages were further stratified, MVC ranked the highest for infants.[53] This same study also found that falls were the most common mechanism for the 2 to 9 years age group. While the focus on children younger than 3 years in this study was unique, conclusions about mechanism of injury remained consistent with previous literature. The frequency of MVC as mechanism for blunt trauma CSI is significantly greater than all other mechanisms, with falls ranking second (66% and 15%, respectively). Given that this patient population is just learning to

walk, falls are a concern. However, the high energy of an MVC has greater potential for major neurologic impairment and mortality.

The observations generated from analysis of the NTDB data suggest that the lower C-spine needs to be adequately evaluated on the basis of the near equal distribution of injuries. In addition, the association of CSI with high-energy mechanisms (i.e., MVAs) warrants a higher index of suspicion of this subset of young pediatric patients. In addition, those patients requiring at scene intubation and/or admission to the intensive care unit (ICU) should also be evaluated thoughtfully. Despite the low incidence of CSI, until the cervical spine is cleared, it should be immobilized, ideally with an age/size appropriate hard collar. Such collars should be stocked in all trauma centers that care for pediatric patients.

The authors of the reviewed paper[53] implemented a similar clinical guidelines strategy emphasizing the use of physical examination and NEXUS criteria in order to clear the cervical spine in children presenting after trauma. The primary outcome measure was to determine the use of CT scans in children younger than 15 years and to compare the extent of use of CT scans for cervical spine clearance 12 months before and after implementation of these guidelines. A total of 233 children were evaluated during the 2-year period (128 before guidelines were in place and 105 afterward). For children clearable by NEXUS criteria, the implementation guidelines had an immediate effect, decreasing CT use by 23%. Furthermore, there were no missed injuries. These results offer even more evidence that much of the imaging that is done to clear the c-spine in a child is unnecessary. The clinical evaluation of pediatric trauma patients with suspected c-spine injury is quite effective in predicting which subset of patients will benefit from cross-sectional imaging. Simple clinical criteria, like GCS, used in concert with the physical examination, can safely predict CSI in children, safely reducing the dependence on clinical imaging for the vast majority of patients (even the very young).

Spinal Cord Injury without Radiographic Abnormality

Spinal cord injury without radiographic abnormality was first defined in a series of children with signs of acute traumatic spinal cord injury in the absence of bony findings on cervical spine radiographs, flexion–extension films, or CT scans.[54] The authors noted that these patients had neurologic deficits or a history of transient paresthesias, numbness, or paralysis, and a delay of symptoms occurred in approximately half of the patients.

In recent years, as attention to limit ionizing radiation exposure in children has increased, magnetic resonance imaging has become a mainstay in the workup of children with presumed CSI or neurologic deficits on physical examination. As a result, more children have been found to have demonstrable injury to the spinal cord, soft tissue components of the spinal column vertebral body growth plates.[55,56] As a result of this advent of new neuroimaging paradigms, the diagnosis of spinal cord injury without radiographic abnormality has become questionable. Although the trend in the workup has been to limit radiography in children (with good reason), it is important to remember that young patients with blunt trauma who have a history of any transient neurologic

symptom may have a significant injury to the spinal cord and/or spinal column, and these children warrant thorough radiographic evaluation.

Cerebrovascular Injury

Blunt trauma force to the neck or cervical spine fractures can result in vascular injuries to the carotid or vertebral arteries. Stroke and permanent neurologic deficit is the most feared outcome from this rare injury, and in children, because of ill-defined screening criteria, neurologic deficit is the most common presenting symptom for diagnosis. 2010 EAST guidelines are aimed at adult patients and provide little evidence toward screening criteria or management in either adults or children.[57] Risk factors for cerebrovascular injury include injury mechanism with severe hyperextension or hyperflexion with rotation, maxillary or mandibular injuries, TBI with diffuse axonal injury, near hanging, “seat belt sign” or other soft tissue contusion to the neck, and fractures involving the carotid canal or cervical vertebral body, particularly the vertebral foramen. A recent meta-analysis of pediatric blunt cerebrovascular injury recommended screening high-risk pediatric patients with CT angiography of the neck and treatment with anticoagulation in patients with confirmed injuries.[58]

Thoracic Trauma

Blunt trauma, most commonly from motor vehicle crashes, is the most common mechanism for thoracic trauma in pediatric patients. Children have a more flexible, cartilaginous rib cage, and, therefore, serious intrathoracic injuries can occur in the absence of obvious external trauma or rib fractures. Children also have a more mobile mediastinum, predisposing them to tension pneumothorax with subsequent cardiopulmonary collapse from impaired venous return. The primary survey is designed to identify these acute life-threatening thoracic injuries such as airway injury, tension pneumothorax, open pneumothorax, hemothorax, flail chest with pulmonary contusion, or cardiac tamponade, which require immediate intervention (Table 29-6).[59] Once bilateral breath sounds and adequate ventilation and oxygenation are confirmed, CXR is an urgent part of any pediatric trauma evaluation and can identify most other acute thoracic injuries. FAST examination can evaluate for pericardial fluid and in experienced hands can identify pneumothorax or pleural effusion. Many injuries can be observed or managed with tube thoracostomy.

Pulmonary contusions are one of the most common thoracic injuries after blunt trauma. The diagnosis is made on CXR in which infiltrates are identified that do not follow anatomic boundaries. Parenchymal edema peaks at 24 to 36 hours postinjury, as the contusion "blossoms" on CXR, and requires admission for monitoring, oxygen therapy, or intubation and respiratory support if needed. Any evidence of hemothorax or pneumothorax seen on CXR should be managed initially with tube thoracostomy. Stable patients with an occult pneumothorax (seen only on CT scan but not on CXR) may be safely observed without thoracostomy drainage, even if requiring positive pressure ventilation. Traditional indications for thoracotomy in adults include an initial chest tube output of 1,500 mL and a persistent output of 150 to 200 mL/hr for 4 hours. In children, this equates to a chest tube output of approximately 20% of the patient's estimated blood volume, or ongoing output of 2 to 3 mL/kg/hr. However, patient physiology should be the primary indication for surgical treatment rather than the absolute blood output. The thoracoscopic approach has become increasingly acceptable in stable patients for the management of retained hemothorax, persistent air leak, or select diaphragmatic injuries after penetrating thoracoabdominal trauma. The EAST practice management guidelines for thoracic trauma provide a good overview of the evidence for management of thoracic trauma in adults, but no specific guidelines exist for pediatric patients.[60]

Emergency bedside thoracotomy is indicated for patients who present pulseless to the emergency department with signs of life and penetrating thoracic trauma. The evidence is more controversial for patients who do not have signs of life or who sustained penetrating extrathoracic injuries or blunt trauma and should be based on clinical judgment. There is no role for emergency thoracotomy for patients without signs of life after blunt trauma.[61] Advanced trauma life support guidelines recommend application of these guidelines to children on the basis of existing literature,[62,63] but these data are sparse.

Table 29-6 Acute Life-Threatening Thoracic Injuries

Injury	Diagnosis	Management
Airway obstruction	Apnea or stridor, maxillofacial trauma.	Definitive tracheal intubation (oro- or nasotracheal) or cricothyroidotomy.
Flail chest	Paradoxical chest wall motion.	Positive pressure ventilation.
Tension pneumothorax (PTX)	Respiratory distress, tracheal deviation, hypotension, distended neck veins, absent unilateral breath sounds, hyperresonance to percussion.	Needle decompression (2nd interspace, midclavicular line), followed by placement of chest tube (4th interspace, anterior axillary line).
Open pneumothorax	Open wound into chest→"sucking chest wound."	Sterile gauze (secure on three sides) and placement of chest tube.
Hemothorax	Absent breath sounds, dullness to percussion, hypotension.	Chest tube placement. Massive hemothorax necessitates thoracotomy.
Cardiac tamponade	Distended neck veins, muffled heart sounds, hypotension (Beck's triad), pulsus paradoxus.	Pericardiocentesis (or emergency thoracotomy if pulseless).

Other serious thoracic injuries are very rare in children but include blunt aortic injury and blunt cardiac injury. Aortic injury can be effectively diagnosed with CT scan with IV contrast (CT angiogram). Widened mediastinum on CXR from a physiologic thymic shadow is quite commonly seen in young children. However, with the appropriate mechanism, including blunt thoracic trauma with a significant deceleration mechanism, and abnormal contour of mediastinum, CT chest angiography with contrast may be required to rule out this injury.[64,65] Treatment, as in adults, relies on strict antihypertensive therapy and operative repair, including the endovascular approach in those children who are big enough to accommodate a stent (although this has not been standardized in pediatric patients). Blunt cardiac injury (most commonly myocardial contusion) can also be challenging to diagnose but occurs most commonly after motor vehicle collision or pedestrian trauma. Abnormalities on EKG are the main findings in myocardial contusion. Traditional risk factors such as sternal fracture or upper rib fractures do not appear to correlate with blunt cardiac injury. The new EAST guidelines, although designed for adult patients, recommend an EKG and troponin I if blunt cardiac injury is suspected. If both studies are normal, this effectively rules it out. If either is abnormal, the child should be admitted to a monitored bed. Echocardiogram is recommended only for patients with hypotension or arrhythmias.[66]

Traumatic asphyxia occurs in children because of their flexible thoracic wall in the setting of direct blunt compression, most often after a motor vehicle collision or crush injury. At the time of injury, if the glottis is closed and the thoracoabdominal muscles are tensed, the increased intrathoracic pressure is transmitted through the central venous system (inferior and superior vena cava) to the brain and solid organs. Typical signs of traumatic asphyxia include subconjunctival hemorrhage and petechiae of the chest, shoulders, and head, with subsequent bronze discoloration of the skin. Supportive care in a monitored setting is the standard of care for these children, watching for signs of airway edema.

Abdominal Trauma

Blunt mechanism of injury is the most common cause of abdominal trauma in children. Assessment of abdominal trauma in pediatric patients can be challenging. Vomiting, abdominal tenderness, and seat belt signs are signs and symptoms that increase the likelihood of abdominal injuries. FAST examination is a standard assessment in adult trauma patients, but its role in pediatric patients is still controversial. In an unstable patient, FAST examination can help identify the presence hemoperitoneum and triage a patient to the operating room or interventional radiology suite. CT scan with IV contrast is the best assessment for abdominal trauma in a stable pediatric patient. Despite concerns for radiation exposure, this is an important study if indicated. PECARN has similarly developed rules and algorithms to identify a low-risk patient who can safely avoid abdominal CT.[67–69] If an examinable child (GCS score of >13) had no evidence of abdominal or chest wall trauma (including seat belt sign), no abdominal pain, tenderness or vomiting, and normal bilateral breath sounds, the rule had a 99.9% negative predictive value for intra-abdominal injuries requiring intervention[67,69] and was more sensitive than clinical suspicion.[68] After a normal abdominal CT scan, most patients can safely be discharged if otherwise stable (sensitivity 97.8%). However, most missed injuries were hollow viscous injuries, which are difficult to identify on CT and should be suspected in patients with seat belt sign, free fluid on CT, or leukocytosis.[70]

Penetrating abdominal trauma is much less common in children than in adults but should be managed similarly. There is increasing evidence toward a nonoperative, conservative approach to abdominal stab wounds that penetrate the fascia, relying on serial examinations and imaging to guide operative approach. Laparotomy is still largely recommended for gunshot wounds to the abdomen on the basis of the most recent 2010 EAST guidelines, although this area remains controversial.[71]

Damage control laparotomy is an established operative approach for hemodynamically unstable trauma patient in hemorrhagic shock and is utilized in approximately 5% of all laparotomies for trauma in both adults and children. The goal of this approach is to avoid the onset of the lethal triad: hypothermia, coagulopathy, and acidosis. The procedure is abbreviated and focused on maintaining the priorities of hemorrhage control, followed by control of contamination and temporary abdominal closure, with plans to return for definitive repairs after resuscitation and warming in the ICU, usually 24 to 48 hours later. The decision for damage control should be made early in the operative course in order to minimize exposure time in the operating room and avoid irreversible shock and its sequelae. Although well described and widely adopted within the adult trauma population, data are less available in the pediatric population but theoretically of even greater importance as children have small circulating blood volumes and are more prone to hypothermia.[72] As discussed in a previous section, damage control resuscitation is managed in parallel, with a focus on initiating the massive transfusion protocol, minimizing crystalloid fluids, and resuscitating with blood products using a high ratio of plasma and platelets for each unit of red blood cells transfused.[72]

Solid Organ Injuries

Most solid organ injuries (spleen, liver, and kidney) are managed nonoperatively after blunt trauma.[73] Most of these injuries are identified or evaluated by CT and can be graded according to American Association for the Surgery of Trauma (AAST) grading system for prognostic value.[74] In a large series of pediatric patient with solid organ injury, 11% received a blood transfusion, 1.4% underwent angiographic embolization, and 4% required laparotomy.[75] Laparotomy rates ranged from 5.4% at adult trauma centers to 2.8% at freestanding children's hospitals, raising concerns for optimal and consistent management of pediatric patients who are cared for in adult centers.[75–77] Across all institutions, there is wide variability of care of pediatric patients with solid organ injuries. In those managed successfully with nonoperative management, there is no standard of care for level of monitored care (whether children are admitted to ICU vs. floor vs. home), frequency of blood draws, duration of bed rest or bowel rest, and timing of discharge home and resumption of activities.[75] In the 1990s, the American Pediatric Surgical Association proposed an algorithm for posttrauma management of solid organ injuries, which has commonly been adopted by institutions but has never been rigorously verified (Table 29-7[78]). These recommendations include ICU admission only for grade IV solid organ injury, observation on the pediatric floor for a duration of injury grade +1 days, liberation of diet and ambulation once the hematocrit has stabilized (and hematuria resolved in renal injuries), and exertional activity restriction for a duration of injury grade +2 weeks. No routine reimaging of injuries is recommended.[78] Indications for laparotomy include hemodynamic instability, ongoing blood loss (hematocrit drop) with blood transfusion requirement of greater than 20 mL/kg, or evidence of hollow viscous injury. More recently, the American College of Surgeons' pediatric trauma consortium (ATOMAC) developed a practice management guideline for solid organ injury, which is now used at many additional pediatric trauma centers throughout the United States.[79] The guidelines support management on the basis of hemodynamic status rather than injury grade. Transfusion triggers have been debated and although there are no class I data to support a number at which blood should be given, it is generally agreed that transfusion should be considered at a threshold of 7.0 g/dL. It supports abbreviated bed rest and earlier discharge than the older APSA guidelines (Algorithm 29-3). The approach to angiographic embolization for splenic salvage is still controversial in pediatric patients and has a wide variability among institutions.[79–82]

Table 29-7 Original American Pediatric Surgical Association Guidelines for Posttrauma Management of Pediatric Solid Organ Injury

	CT Grade			
	I	II	III	IV
ICU stay (days)	None	None	None	1
Hospital stay (days)	2	3	4	5
Predischarge imaging	None	None	None	None
Postdischarge imaging	None	None	None	None
Activity restriction (weeks)[a]	3	4	5	6

[a]Return to full-contact, competitive sports (i.e., football, wrestling, hockey, lacrosse, mountain climbing) should be at the discretion of the individual pediatric trauma surgeon. The proposed guidelines for return to unrestricted activity include "normal" age-appropriate activities. From Stylianos S. Evidence-based guidelines for resource utilization in children with isolated spleen or liver injury. *J Pediatr Surg* 2000;35(2):164–169, with permission.

The role of FAST examination for diagnosis of solid organ injury in children is still unclear. Whereas its use has long been the standard of care in adults, recent PECARN data of pediatric trauma centers suggest that only 13% of pediatric trauma patients with a suspicion for intra-abdominal injuries undergo FAST examination.[83,84] Sensitivity in pediatric patients ranges from 50% to 92%, with a rigorous meta-analysis suggesting the sensitivity to be around 66%.[21,22,85–87] Specificity is also very low, and in a hemodynamically stable patient, a positive FAST examination should be followed up with an urgent CT. Bedside FAST may have utility in hemodynamically unstable patients to rapidly identify or rule out intraperitoneal hemorrhage when patients cannot undergo CT, but decision making should include other features such as patient physiology, mechanism, clinical suspicion, and responsiveness to initial resuscitation measures.[22,88] As its use in children increases, it is likely that FAST will become more reliable, with greater sensitivity and specificity. Until a prospective study is done, it should remain a screening tool and that physical examination findings should dictate next steps.

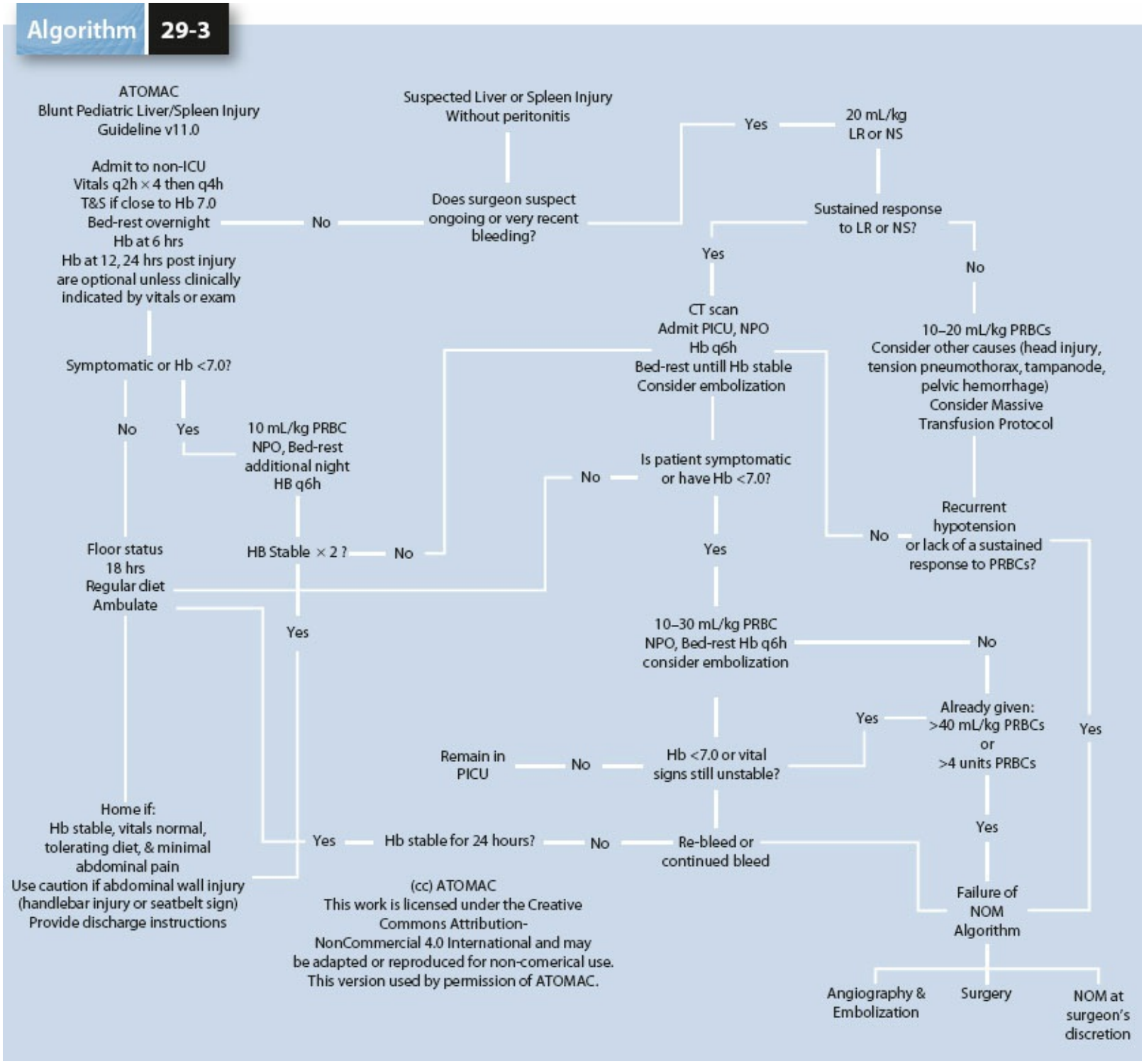

Algorithm 29-3. New ATOMAC guidelines for management of pediatric solid organ injury. Hb, hemoglobin; ICU, intensive care unit; LR, lactated ringers; NOM, nonoperative management; NPO, non per os; NS, normal saline; PICU, pediatric intensive care unit; PRBC, packed red blood cell; q6h, every 6 hours. (From Notrica DM, Eubanks JW III, Tuggle DW, et al. Nonoperative management of blunt liver and spleen injury in children: Evaluation of the ATOMAC guideline using GRADE. *J Trauma Acute Care Surg* 2015;79(4):683–693, with permission.)

Hollow Viscous Injury

Hollow viscous injuries occur after blunt trauma, in particular bicycle handlebar injuries, lap belt injuries (often with seat belt sign and associated with Chance vertebral fracture), and direct blows to the abdomen. Diagnosis is challenging with current radiographic techniques. Subtle findings on CT must be elicited, including free fluid in the absence of

solid organ injuries, free intraperitoneal air, or extravasation of oral contrast. In the setting of abdominal wall ecchymosis (seat belt sign), leukocytosis, or abdominal tenderness, patients should be closely monitored with serial abdominal examinations and blood count. Evidence for evolving peritonitis, fever, leukocytosis, or systemic inflammatory response syndrome physiology should prompt surgical exploration, either laparoscopic or by laparotomy. Intramural duodenal hematomas are managed conservatively without surgical intervention but may take several weeks to completely resolve, requiring nasogastric tube (NG) drainage and Total Parenteral Nutrition (TPN) in the interim. Delayed stricture after partial thickness luminal injury or mesenteric injury can present days to weeks after an injury, with symptoms of partial or complete small bowel obstruction.

Pancreatic and Biliary Injury

Pancreatic injury classification by AAST injury grade divides patients into those without ductal injury (grades 1 to 2) and those with duct disruption (grades 3 to 5). Currently there is no universal standard for management of pancreatic trauma in pediatric patients, but evidence is beginning to emerge.[89–97] Amylase and lipase are useful to screen for pancreatic injury but may be normal immediately after trauma; by 3 hours after trauma, they are universally elevated (100% sensitivity), although with low specificity.[91] CT scan of the abdomen can help determine the integrity of the duct, but endoscopic retrograde cholangiopancreotography (ERCP) may be a useful adjunct in some patients. In general, higher-grade pancreatic injuries with duct disruption result more frequently in operative intervention. Although early literature promoted nonoperative management for pediatric pancreatic injuries,[91–95] recent reports and multi-institutional studies have suggested improved outcomes, reduced need for drainage procedures, and decreased length of stay (LOS) for operative intervention, most commonly distal pancreatectomy.[89,96,97]

Biliary injury is rare in children, representing $<0.1\%$ of all trauma patients, and includes intrahepatic and extrahepatic ductal injuries, biloma, and gallbladder injury. Literature is sparse but many injuries can be managed nonoperatively with ERCP with biliary stent placement and percutaneous peritoneal drainage. These patients are at risk for delayed stricture and require close follow-up. Hepaticojejunostomy remains the definitive repair for extrahepatic biliary tract transections.[98]

Anorectal Injuries

Anorectal injuries are uncommon in children and usually occur after penetrating mechanism. Isolated anal trauma can be repaired primarily, including sphincter repair. Extraperitoneal rectal injuries should be repaired primarily if possible and often require fecal diversion and/or presacral drainage. Intraperitoneal rectal injuries can be managed similarly to colon injuries, with or without fecal diversion. Associated genitourinary injuries should be sought with examination under anesthesia.[99,100]

Pelvic Fracture and Extremity Trauma

Fractures represent one of the most common injuries in pediatric trauma patients. Children have more malleable bones, more absorptive cartilage, and a higher potential for bone remodeling and healing than adults. Anatomic differences in radiology of pediatric bones can make recognition of injuries challenging. Injury to the growth plates can result in premature fusion and asymmetric limb growth. Greenstick fractures occur when the bone bends before it breaks. Options for stabilization include casting, splinting, traction, internal fixation, or external fixation. A thorough neurovascular examination is essential. Although vascular injury requiring repair is rare, children are more prone to vascular spasm, resulting in asymmetric pulse examination and transient ischemic symptoms.[101]

Pelvic fractures are a source of morbidity and mortality in pediatric patients and occur most commonly after high-mechanism blunt trauma such as MVC or pedestrians struck. Pelvic fractures are usually present in the setting of multiple injuries including TBI, abdominal injuries, and genitourinary trauma. The Young-Burgess Classification system for pelvic fractures is most commonly used in adults and categorizes injuries into lateral compression, anterior–posterior compression, and vertical shear injuries to the pelvic ring. Pediatric classifications exist but are not standard. The pediatric pelvis is more elastic, allowing for significant displacement before fracture. Pelvic hematoma and ongoing hemorrhage requiring angiographic intervention or preperitoneal packing occurs less commonly in children than in adults but should be a major consideration in the hemodynamically unstable child. The 2011 EAST guidelines for the treatment of hemorrhage in pelvic fracture are limited to adult data, but many principles can be extrapolated to the pediatric population.[102] These guidelines recommend the use of early external stabilization, particularly with a size-appropriate pelvic orthotic device, to stabilize fractures, reduce pelvic volume, and theoretically limit blood loss. The hemodynamically unstable pediatric patient with a pelvic fracture represents a diagnostic challenge – does one proceed to the operating room for abdominal exploration or to the angiography suite for embolization? FAST examination does not have the sensitivity to rule out abdominal hemorrhage. If stable enough, a CT scan of the abdomen and pelvis is preferable to help identify the injuries and determine treatment course. Despite classification systems, fracture patterns on anteroposterior pelvic plain film do not predict bleeding or need for angiographic embolization. Angiographic embolization should be considered in hemodynamically unstable patients after other sources of hemorrhage have been ruled out. In the adult literature, arterial contrast extravasation on CT scan warrants empiric embolization, even in a stable patient, but these data are unclear in the pediatric population. Similarly, preperitoneal packing is a newer technique for the control of pelvic hemorrhage, and its use can be considered alongside pelvic embolization.[102] Treatment of pelvic fractures in children is usually nonoperative with non–weight bearing, Spica casts, or traction. In some cases, external fixation or open reduction, internal fixation (ORIF) is necessary. Fractures involving the acetabulum are complex, especially when the triradiate cartilage complex is involved, as premature fusion can result in long-term problems with

leg-length discrepancy and acetabular failure.

Venous Thromboembolism

The incidence of venous thromboembolism in pediatric trauma patients is very low, ranging from 0.02% to 0.3%.[103] Although evidence in adult trauma populations supports chemical prophylaxis, such as low–molecular-weight heparin, no standard evidence-based guidelines exist for pediatric patients. Recommendations are based on small series and retrospective data. A recent meta-analysis and review of the literature suggests that older and more severely injured patients are at higher venous thromboembolism risk.[103] In particular, those with spine or spinal cord injury, or major vascular injuries are at the highest risk. Other risk factors include admission to an ICU, presence of a central venous catheter, lower extremity or pelvic fracture, or TBI, and when one or more of these are present, pediatric patients should be considered for prophylaxis. Clinical prediction tools based on large databases, such as the National Trauma Data Bank, have been proposed but require validation.[104]

Nonaccidental Trauma (Child Abuse)

4 Nonaccidental trauma is a leading cause of trauma in children, with 650,000 confirmed cases of physical abuse annually in the United States, accounting for 1,500 deaths per year, mostly in children younger than 4 years.[105] Nonaccidental trauma and abuse may be difficult to recognize and a high index of suspicion is needed when evaluating children with injuries. The American Academy of Pediatrics guidelines published in 2015 provide a resource to help identify these children, because unrecognized cases of abuse can represent with serious or even fatal injuries. Features of the history that should increase suspicion include unexplained significant injury, denial of trauma, changes in the story or differences in the story by different witnesses, explanation that is inconsistent with the pattern, age or severity of injury or with the child's developmental capabilities, and delay in seeking medical care. Findings on examination that may suggest abuse include any injury in a preambulatory infant, multiple organ system injuries or multiple injuries at different stages of healing, patterned injuries, injuries to unusual locations (mnemonic "TEN-4" = injury to torso, ears, or neck in a child younger than 4 years), or other evidence of neglect (failure to thrive, dental caries, poor hygiene). Burns with sharply demarcated edges, bite marks, cigarette burns, and other markers of being hit with an object are high-risk injuries. Certain fracture patterns should raise concern for nonaccidental trauma including fractures in nonambulatory infants, multiple fractures, rib fractures, infants and toddlers with midshaft femur or humerus fractures, and other unusual fractures such as scapular and metaphyseal fractures. Skeletal survey is recommended in children younger than 2 years who have suspicion for abuse (see Indications for Obtaining a Skeletal Survey available online from the study by Christian[105]; see Skeletal Survey Guidelines available from the study by Wood et al.[106]). If there is a reasonable suspicion that a child has been abused, a report to child protective services for further investigation is mandated by law. See Christian, CW[105] for outlines recommending workup in a child suspected of nonaccidental trauma, including blood work, imaging, and consultation of specialists such as ophthalmology, in order to identify injury and obtain forensic evidence.

INJURY PREVENTION

5 In 1911, the Triangle Shirtwaist Company in New York City's Greenwich Village became the site of the deadliest industrial disaster in US history. In a fire that engulfed the 10-story building, 146 sweatshop workers (mostly young women) died when elevators and fire escapes failed. Following this incident, the labor movement was born and policy makers began to take a hard look at working conditions and addressed safety in the work place by passing meaningful legislation. Although the concept of injury prevention legislation can be dated back to the early 20th century, it was not until 1964 when the four major US auto manufacturers installed two front-seat lap belts as standard equipment did injury prevention develop into a true science. In 1968, the National Traffic and Motor Vehicle Safety Act established the National Highway Traffic Safety Administration, which has influenced the improvement of road infrastructure, automobile, and driver and passenger safety, resulting in precipitous drops in roadway fatalities.

There are many examples where comprehensive state and federal laws have resulted in statistical drops in injuries and deaths.[107–109] In the following section, we provide several examples where federal mandates and state laws have been implicated in the reduction of pediatric injuries. In many cases, surgeon advocates where integral in the legislative process.

Smoke Detectors and Carbon Monoxide Detectors

Smoke detectors have been legislated into building codes in all 50 states. As a result, the early warnings of a fire are thought to have prevented thousands of deaths. More than 10,000 Americans are poisoned by carbon monoxide and more than 500 people in the United States die annually from carbon monoxide poisoning. As of August 2015, 30 states have enacted statutes regarding carbon monoxide detectors, and another 11 have promulgated regulations on CO detectors. Several states now require CO detectors in hotels and schools.

Drunken Driving Laws

Alcohol is known to play a role in many MVCs. Drivers younger than 21 years are more likely than older drivers to be involved in fatal crashes, and alcohol use adds to the risk of fatal crashes. This group has been the target of several interventions to reduce alcohol-impaired driving, including “zero tolerance” blood alcohol concentration standards for drivers under the legal drinking age with mandatory license revocation after a first offense.[110]

Junior Driver Laws/Safe Driving Laws

The increased risk of car crashes associated with texting and cell phone use has been well documented – among adults and teens alike. But for teens, who are immersed in a world of smart phones and texting, these types of laws send a powerful message that driving demands their undivided attention. Although not exclusive to children or adolescents, "safe driving laws" ban text messaging for all drivers, prohibit junior drivers from using cell phones, and institute new license renewal procedures for mature drivers, among other provisions. Graduated driver licensing programs that require new drivers to progress through stages allowing them increased driving privileges as they gain experience have, in some form, been enacted in all 50 states. Many states have also incorporated parental education and curfews to these laws and have seen up to a 40% decrease in the number of injuries and fatalities as novice drivers have become engaged in this process.[111,112]

Child Passenger Restraints

Seat belt use around the country has steadily increased. There is mounting evidence that seat belt use and airbag implementation have been the greatest cause for decreased road fatalities per miles driven, which is at an all-time low according to National Highway Traffic Safety Administration statistics. Furthermore, there is evidence that educating pediatricians improves the use of car seats for children. Although the rate of use of car seats for newborns and infants is approximately 75%, their use in toddlers is estimated at only 29%, and more than half of car seats for children are not used correctly. In the child older than 4 years or 40 lb, there is ample evidence that booster seats should be used rather than adult-type restraints. Many states now have legislation aimed at this population.

All-Terrain Vehicle Laws

In the United States, all-terrain vehicle crashes account for a rising number of injuries and deaths in all age. Approximately 30% of the injured/dead are children. In 1988, in response to this trend, the Consumer Product Safety Commission and the all-terrain vehicle industry agreed upon a set of standards designed to limit injury. This agreement included regulations that restricted operators younger than 16 years halted the sale of three-wheeled vehicles and included a mandatory educational safety training module and improved safety warnings. However, in 1998, 10 years after they were established, these consent decrees expired and since that time, the rate of injuries has risen steeply. Several states have recently enacted restrictions on ridership and in Massachusetts, where these restrictions have included an age cutoff, the number of injuries have fallen dramatically (unpublished data).

Finally, as policy makers struggle to allocate limited resources in order to improve population health, injury prevention programs will play a particularly important role. The rationale is straightforward: regulatory efforts specifically aimed at injury primary and secondary prevention, if well designed, can be very successful at health care cost reduction, thereby freeing resources for other concerns.

References

1. Osterman MJ, Kochanek KD, MacDorman MF, et al. Annual summary of vital statistics: 2012–2013. *Pediatrics* 2015;135(6):1115–1125.
2. Wesson DE. Pediatric trauma centers: Coming of age. *Tex Heart Inst J* 2012; 39(6):871–873.
3. American Academy of Pediatrics Section on Orthopaedics; American Academy of Pediatrics Committee on Pediatric Emergency Medicine; American Academy of Pediatrics Section on Critical Care; American Academy of Pediatrics Section on Surgery; American Academy of Pediatrics Section on Transport Medicine; American Academy of Pediatrics Committee on Pediatric Emergency Medicine; Pediatric Orthopaedic Society of North America, Krug SE, Tuggle DW. Management of pediatric trauma. *Pediatrics* 2008;121(4):849–854.
4. Committee on Trauma and Committee on Shock, Division of Medical Sciences, National Academy of Sciences, Nation Research Council. *Accidental Death and Disability: The Neglected Disease of Modern Society*. Washington, DC: The National Academies Press; 1966.
5. Segui-Gomez M, Chang DC, Paidas CN, et al. Pediatric trauma care: an overview of pediatric trauma systems and their practices in 18 US states. *J Pediatr Surg* 2003;38:1162–1169.
6. Simpson AJ, Rivara FP, Pham TN. Quality care in pediatric trauma. *Int J Crit Illn Inj Sci* 2012;2(3):149–155.
7. Kelly ML, Banerjee A, Nowak M, et al. Decreased mortality in traumatic brain injury following regionalization across hospital systems. *J Trauma Acute Care Surg* 2015;78(4):715–720.
8. Bowman SM, Zimmerman FJ, Christakis DA, et al. Hospital characteristics associated with the management of pediatric splenic injuries. *JAMA* 2005;294:2611–2617.
9. Hamlat CA, Arbabi S, Koepsell TD, et al. National variation in outcomes and costs for splenic injury and the impact of trauma systems: a population-based cohort study. *Ann Surg* 2012;255:165–170.
10. http://www.emscnrc.org/emsc-resources/toolboxes/emergency-department-pediatric-performance-measures-toolbox. Accessed June 27, 2016.
11. http://www.emscnrc.org/~/media/emsc/files/pdf/emsc_resources/hospitalbased_perla=en. Accessed June 27, 2016.
12. Lorch SA, Myers S, Carr B. The regionalization of pediatric health care. *Pediatrics* 2010;126:1182–1190.
13. MacKenzie EJ, Rivara FP, Jurkovich GJ, et al. A national evaluation of the effect of trauma-center care on mortality. *N Engl J Med* 2006;354:366–378.
14. Densmore JC, Lim HJ, Oldham KT, et al. Outcomes and delivery of care in pediatric injury. *J Pediatr Surg* 2006;41:92–98; discussion 92–98.

15. Amini R, Lavoie A, Moore L, et al. Pediatric trauma mortality by type of designated hospital in a mature inclusive trauma system. *J Emerg Trauma Shock* 2011;4:12–19.
16. Hulka F, Mullins RJ, Mann NC, et al. Influence of a statewide trauma system on pediatric hospitalization and outcome. *J Trauma* 1997;42:514–519.
17. Pracht EE, Langland-Orban B, Tepas JJ III et al. Analysis of trends in the Florida Trauma System (1991–2003): changes in mortality after establishment of new centers. *Surgery* 2006;140:34–43.
18. Camazine MN, Hemmila MR, Leonard JC, et al. Massive transfusion policies at trauma centers participating in the American College of Surgeons Trauma Quality Improvement Program. *J Trauma Acute Care Surg* 2015; 78(6 suppl 1):S48–S53.
19. Hughes NT, Burd RS, Teach SJ. Damage control resuscitation: Permissive hypotension and massive transfusion protocols. *Pediatr Emerg Care* 2014;30(9):651–666; quiz 657–658.
20. Daley BJ, Lee S, Raju R, et al. Emedicine. Considerations in pediatric trauma. Available from: http://emedicine.medscape.com/article/435031-overview#a1. Accessed September 9, 2015.
21. Murphy R, Ghosh A. Towards evidence based emergency medicine: best BETs from the Manchester Royal Infirmary. The accuracy of abdominal ultrasound in paediatric trauma. *Emerg Med J* 2001;18(3):208–209.
22. Scaife ER, Rollins MD, Barnhart DC, et al. The role of focused abdominal sonography for trauma (FAST) in pediatric trauma evaluation. *J Pediatr Surg* 2013;48(6):1377–1383.
23. National Center for Injury Prevention and Control. *Traumatic Brain Injury in the United States: Assessing Outcomes in Children.* Atlanta, GA: Centers for Disease Control and Prevention; 2006.
24. http://www.cdc.gov/TraumaticBrainInjury/. Accessed November 2, 2015.
25. Barbosa RR, Jawa R, Watters JM, et al. Eastern Association for the Surgery of Trauma. Evaluation and management of mild traumatic brain injury: An Eastern Association for the Surgery of Trauma practice management guideline. *J Trauma Acute Care Surg* 2012;73(5 suppl 4):S307–S314.
26. Kuppermann N, Holmes JF, Dayan PS, et al. Pediatric Emergency Care Applied Research Network (PECARN). Identification of children at very low risk of clinically-important brain injuries after head trauma: a prospective cohort study. *Lancet* 2009;374(9696):1160–1170.
27. Lee LK, Monroe D, Bachman MC, et al. Traumatic Brain Injury (TBI) Working Group of Pediatric Emergency Care Applied Research Network (PECARN). Isolated loss of consciousness in children with minor blunt head trauma. *JAMA Pediatr* 2014;168(9):837–843.
28. Holmes JF, Borgialli DA, Nadel FM, et al. TBI Study Group for the Pediatric Emergency Care Applied Research Network. Do children with blunt head trauma and

normal cranial computed tomography scan results require hospitalization for neurologic observation? *Ann Emerg Med* 2011;58(4):315–322.

29. Powell EC, Atabaki SM, Wootton-Gorges S, et al. Isolated linear skull fractures in children with blunt head trauma. *Pediatrics* 2015;135(4):e851–e857.
30. Dayan PS, Holmes JF, Hoyle J Jr, et al. Pediatric Emergency Care Applied Research Network (PECARN). Headache in traumatic brain injuries from blunt head trauma. *Pediatrics* 2015;135(3):504–512.
31. Metzger RR, Smith J, Wells M, et al. Impact of newly adopted guidelines for management of children with isolated skull fracture. *J Pediatr Surg* 2014;49(12):1856–1860.
32. Blackwood BP, Bean JF, Sadecki-Lund C, et al. Observation for isolated traumatic skull fractures in the pediatric population: unnecessary and costly. *J Pediatr Surg* 2016;51(4):654–658.
33. Schatz P, Pardini JE, Lovell MR, et al. Sensitivity and specificity of the ImPACT Test Battery for concussion in athletes. *Arch Clin Neuropsychol* 2006;21(1):91–99.
34. McCrea M, Guskiewicz KM, Marshall SW, et al. Acute effects and recovery time following concussion in collegiate football players: The NCAA Concussion Study. *JAMA* 2003;290(19):2556–2563.
35. Halstead ME, Walter KD; Council on Sports Medicine and Fitness. American Academy of Pediatrics. Clinical report–sports-related concussion in children and adolescents. *Pediatrics* 2010;126(3):597–615.
36. May KH, Marshall DL, Burns TG, et al. Pediatric sports specific return to play guidelines following concussion. *Int J Sports Phys Ther* 2014; 9(2):242–255.
37. http://www.cdc.gov/headsup/index.html. Accessed November 2, 2015.
38. Cancelliere C, Hincapié CA, Keightley M, et al. Systematic review of prognosis and return to play after sport concussion: results of the International Collaboration on Mild Traumatic Brain Injury Prognosis. *Arch Phys Med Rehabil* 2014;95(3 suppl):S210–S229.
39. Dawes AJ, Sacks GD, Cryer HG, et al. Los Angeles County Trauma Consortium. Intracranial pressure monitoring and inpatient mortality in severe traumatic brain injury: a propensity score-matched analysis. *J Trauma Acute Care Surg* 2015;78(3):492–501; discussion 501–502.
40. Adelson PD, Bratton SL, Carney NA, et al. Guidelines for the acute medical management of severe traumatic brain injury in infants, children, and adolescents. Chapter 5. Indications for intracranial pressure monitoring in pediatric patients with severe traumatic brain injury. *Pediatr Crit Care Med* 2003;4(suppl 3):S19–S24.
41. Kochanek PM, Carney N, Adelson PD, et al. Chapter 4. Threshold for treatment of intracranial hypertension. *Pediatr Crit Care Med* 2012;13: S18–S23.
42. Bell MJ, Kochanek PM. Pediatric traumatic brain injury in 2012: the year with new guidelines and common data elements. *Crit Care Clin* 2013;29(2):223–238.

43. Kochanek PM, Carney N, Adelson PD, et al. Guidelines for the acute medical management of severe traumatic brain injury in infants, children and adolescents: Second edition. *Pediatr Crit Care Med* 2012;13(suppl 1):S1–S82.
44. Hutchison JS, Ward RE, Lacroix J, et al. Hypothermia therapy after traumatic brain injury in children. *N Engl J Med* 2008;358(23):2447–2456.
45. Adelson PD, Wisniewski SR, Beca J, et al. Paediatric Traumatic Brain Injury Consortium. Comparison of hypothermia and normothermia after severe traumatic brain injury in children (Cool Kids): a phase 3, randomised controlled trial. *Lancet Neurol* 2013;12(6):546–553.
46. Hoffman JR, Wolfson AB, Todd K, et al. Selective cervical spine radiography in blunt trauma: Methodology of the National Emergency X-Radiography Study (NEXUS). *Ann Emerg Med* 1998;32(4):461–469.
47. Steill IG, Wells GA, Vandemheen KL, et al. The Canadian C-Spine rule for radiography in alert and stable trauma patients. *JAMA* 2001;286(15):1841–1848.
48. Viccellio P, Simon H, Pressman BD, et al. A prospective multicenter study of cervical spine injury in children. *Pediatrics* 2001;108(2):E20.
49. Jaffe DM, Binns H, Radkowski MA, et al. Developing a clinical algorithm for early management of cervical spine injury in child trauma victims. *Ann Emerg Med* 1987;16(3):270–276.
50. Leonard JC, Kuppermann N, Olsen C, et al. Pediatric Emergency Care Applied Research Network. Factors associated with cervical spine injury in children after blunt trauma. *Ann Emerg Med* 2011;58(2):145–155.
51. Polk-Williams A, Carr BG, Blinman TA, et al. Cervical spine injury in young children: A National Trauma Data Bank review. *J Pediatr Surg* 2008;43(9):1718–1721.
52. Leonard JR, Jaffe DM, Kuppermann N, et al. Pediatric Emergency Care Applied Research Network (PECARN) Cervical Spine Study Group. Cervical spine injury patterns in children. *Pediatrics* 2014;133(5):e1179–e1188.
53. Pieretti-Vanmarcke R, Velmahos GC, Nance ML, et al. Clinical clearance of the cervical spine in blunt trauma patients younger than 3 years: a multi-center study of the American association for the surgery of trauma. *J Trauma* 2009;67(3):543–549; discussion 549–550.
54. Pang D, Wilberger JE Jr. Spinal cord injury without radiographic abnormalities in children. *J Neurosurg* 1982;57:114–129.
55. Pang D. Spinal cord injury without radiographic abnormality in children, 2 decades later. *Neurosurgery* 2004;55:1325–1342; discussion 1342–1343.
56. Yucesoy K, Yuksel KZ. SCIWORA in MRI era. *Clin Neurol Neurosurg* 2008;110:429–433.
57. Bromberg WJ, Collier BC, Diebel LN, et al. Blunt cerebrovascular injury practice management guidelines: The Eastern Association for the Surgery of Trauma. *J Trauma* 2010;68(2):471–477.

58. Malhotra A, Wu X, Kalra VB, et al. Screening for pediatric blunt cerebrovascular injury: Review of literature and a cost-effectiveness analysis. *J Pediatr Surg* 2015;50(10):1751–1757.
59. Sharma MS, Kupferschmid J. Pediatric thoracic trauma. http://emedicine.medscape.com/article/905863-overview#a1. Updated September 15, 2013. Accessed November 6, 2015.
60. Mowery NT, Gunter OL, Collier BR, et al. Practice Management guidelines for management of hemothorax and occult pneumothorax. *J Trauma* 2011;70(2):510–518.
61. Seamon MJ, Haut ER, Van Arendonk K, et al. An evidence-based approach to patient selection for emergency department thoracotomy: a practice management guideline from the Eastern Association for the Surgery of Trauma. *J Trauma Acute Care Surg* 2015;79(1):159–173.
62. Easter JS, Vinton DT, Haukoos JS. Emergent pediatric thoracotomy following traumatic arrest. *Resuscitation* 2012;83(12):1521–1524.
63. Working Group, Ad Hoc Subcommittee on Outcomes, American College of Surgeons, Committee on Trauma. Practice management guidelines for emergency department thoracotomy. Working Group, Ad Hoc Subcommittee on Outcomes, American College of Surgeons-Committee on Trauma. *J Am Coll Surg* 2001;193:303–309.
64. Fox N, Schwartz D, Salazar JH, et al. Evaluation and management of blunt traumatic aortic injury: a practice management guideline from the Eastern Association for the Surgery of Trauma. *J Trauma Acute Care Surg* 2015;78(1)136–146.
65. Anderson SA, Day M, Chen MK, et al. Traumatic aortic injuries in the pediatric population. *J Pediatr Surg* 2008;43(6):1077–1081.
66. Clancy K, Velopulos C, Bilaniuk JW, et al. Screening for blunt cardiac injury: An Eastern Association for the Surgery of Trauma practice management guideline. *J Trauma Acute Care Surg* 2012;73(5 suppl 4):S301–S306.
67. Holmes JF, Lillis K, Monroe D, et al. Pediatric Emergency Care Applied Research Network (PECARN). Identifying children at very low risk of clinically important blunt abdominal injuries. *Ann Emerg Med* 2013; 62(2):107–116.e2.
68. Mahajan P, Kuppermann N, Tunik M, et al. Intra-abdominal Injury Study Group of the Pediatric Emergency Care Applied Research Network (PECARN). Comparison of clinician suspicion versus a clinical prediction rule in identifying children at risk for intra-abdominal injuries after blunt torso trauma. *Acad Emerg Med* 2015;22(9):1034–1041.
69. Adelgais KM, Kuppermann N, Kooistra J, et al. Intra-Abdominal Injury Study Group of the Pediatric Emergency Care Applied Research Network (PECARN). Accuracy of the abdominal examination for identifying children with blunt intra-abdominal injuries. *J Pediatr* 2014;165(6):1230–1235.e5.
70. Kerrey BT, Rogers AJ, Lee LK, et al. Pediatric Emergency Care Applied Research Network. A multicenter study of the risk of intra-abdominal injury in children after

normal abdominal computed tomography scan results in the emergency department. *Ann Emerg Med* 2013;62(4):319–326.

71. Como JJ, Bokhari F, Chiu WC, et al. Practice management guidelines for selective nonoperative management of penetrating abdominal trauma. *J Trauma* 2010;68(3):721–733.
72. Lamb CM, MacGoey P, Navarro AP, et al. Damage control surgery in the era of damage control resuscitation. *Br J Anaesth* 2014;113(2):242–249.
73. Stassen NA, Bhullar I, Cheng JD, et al. Selective nonoperative management of blunt splenic injury: an Eastern Association for the Surgery of Trauma practice management guideline. *J Trauma Acute Care Surg* 2012; 73(5):S294–S300.
74. Injury Scoring Scales: A Resource for Trauma Care Professionals. http://www.aast.org/library/traumatools/injuryscoringscales.aspx. Accessed November 8, 2015.
75. Wisner DH, Kuppermann N, Cooper A, et al. Management of children with solid organ injuries after blunt torso trauma. *J Trauma Acute Care Surg* 2015;79(2):206–214; quiz 332.
76. Bowman SM, Bulger E, Sharar SR, et al. Variability in pediatric splenic injury care: Results of a national survey of general surgeons. *Arch Surg* 2010;145(11):1048–1053.
77. Safavi A, Skarsgard ED, Rhee P, et al. Trauma center variation in the management of pediatric patients with blunt abdominal solid organ injury: A national trauma data bank analysis. *J Pediatr Surg* 2016;51(3):499–502.
78. Stylianos S. Evidence-based guidelines for resource utilization in children with isolated spleen or liver injury. The APSA Trauma Committee. *J Pediatr Surg* 2000;35(2):164–169.
79. Notrica DM, Eubanks JW III, Tuggle DW, et al. Nonoperative management of blunt liver and spleen injury in children: Evaluation of the ATOMAC guideline using GRADE. *J Trauma Acute Care Surg* 2015;79(4):683–693.
80. Gross JL, Woll NL, Hanson CA, et al. Embolization for pediatric blunt splenic injury is an alternative to splenectomy when observation fails. *J Trauma Acute Care Surg* 2013;75(3):421–425.
81. Cloutier DR, Baird TB, Gormley P, et al. Pediatric splenic injuries with a contrast blush: Successful nonoperative management without angiography and embolization. *J Pediatr Surg* 2004;39(6):969–971.
82. Kiankhooy A, Sartorelli KH, Vane DW, et al. Angiographic embolization is safe and effective therapy for blunt abdominal solid organ injury in children. *J Trauma* 2010;68(3):526–531.
83. Menaker J, Blumberg S, Wisner DH, et al. Intra-abdominal Injury Study Group of the Pediatric Emergency Care Applied Research Network (PECARN). Use of the focused assessment with sonography for trauma (FAST) examination and its impact on abdominal computed tomography use in hemodynamically stable children with blunt

torso trauma. *J Trauma Acute Care Surg* 2014;77(3):427–432.
84. Scaife ER, Fenton SJ, Hansen KW, et al. Use of focused abdominal sonography for trauma at pediatric and adult trauma centers: A survey. *J Pediatr Surg* 2009;44(9):1746–1749.
85. Soudack M, Epelman M, Maor R, et al. Experience with focused abdominal sonography for trauma (FAST) in 313 pediatric patients. *J Clin Ultrasound* 2004;32(2):53–61.
86. Ben-Ishay O, Daoud M, Peled Z, et al. Focused abdominal sonography for trauma in the clinical evaluation of children with blunt abdominal trauma. *World J Emerg Surg* 2015;10:27.
87. Holmes JF, Gladman A, Chang CH. Performance of abdominal ultrasonography in pediatric blunt trauma patients: a meta-analysis. *J Pediatr Surg* 2007;42(9):1588–1594.
88. Holmes JF, Brant WE, Bond WF, et al. Emergency department ultrasonography in the evaluation of hypotensive and normotensive children with blunt abdominal trauma. *J Pediatr Surg* 2001;36(7):968–973.
89. Mattix KD, Tataria M, Holmes J, et al. Pediatric pancreatic trauma: Predictors of nonoperative management failure and associated outcomes. *J Pediatr Surg* 2007;42(2):340–344.
90. East Guidelines for the Diagnosis and Management of Pancreatic Trauma. Eastern association for the surgery of trauma practice management guidelines. https://www.east.org/education/practice-management-guidelines/pancreatic-trauma-diagnosis-and-management-of. Accessed November 8, 2015.
91. Adamson WT, Hebra A, Thomas PB, et al. Serum amylase and lipase alone are not cost-effective screening methods for pediatric pancreatic trauma. *J Pediatr Surg* 2003;38(3):354–357; discussion 354–357.
92. Bass J, Di Lorenzo M, Desjardins JG, et al. Blunt pancreatic injuries in children: The role of percutaneous external drainage in the treatment of pancreatic pseudocysts. *J Pediatr Surg* 1988;23(8):721–724.
93. Shilyansky J, Sena LM, Kreller M, et al. Nonoperative management of pancreatic injuries in children. *J Pediatr Surg* 1998;33(2):343–349.
94. Nadler EP, Gardner M, Schall LC, et al. Management of blunt pancreatic injury in children. *J Trauma* 1999;47(6):1098–1103.
95. Wales PW, Shuckett B, Kim PC. Long-term outcome after nonoperative management of complete traumatic pancreatic transection in children. *J Pediatr Surg* 2001;36(5):823–827.
96. Iqbal CW, St. Peter SD, Tsao K, et al. Pancreatic Trauma in Children (PATCH) Study Group. Operative vs nonoperative management for blunt pancreatic transection in children: Multi-institutional outcomes. *J Am Coll Surg* 2014;218(2):157–162.
97. Wood JH, Partrick DA, Bruny JL, et al. Operative vs nonoperative management of

blunt pancreatic trauma in children. *J Pediatr Surg* 2010;45(2):401–406.
98. Soukup ES, Russell KW, Metzger R, et al. Treatment and outcome of traumatic biliary injuries in children. *J Pediatr Surg* 2014;49(2):345–348.
99. Russell KW, Soukup ES, Metzger RR, et al. Fecal continence following complex anorectal trauma in children. *J Pediatr Surg* 2014;49(2):349–352.
100. Samuk I, Steiner Z, Feigin E, et al. Anorectal injuries in children: A 20-year experience in two centers. *Pediatr Surg Int* 2015;31(9):815–819.
101. Mommsen P, Zeckey C, Hildebrand F, et al. Traumatic extremity arterial injury in children: Epidemiology, diagnostics, treatment and prognostic value of Mangled Extremity Severity Score. *J Orthop Surg Res* 2010;5:25, 1–8.
102. Cullinane DC, Schiller HJ, Zielinski MD, et al. Eastern Association for the Surgery of Trauma practice guidelines for hemorrhage in pelvic fracture—update and systematic review. *J Trauma* 2011;71(6):1850–1868.
103. Thompson AJ, McSwain SD, Webb SA, et al. Venous thromboembolism prophylaxis in the pediatric trauma population. *J Pediatr Surg* 2013;48(6):1413–1421.
104. Connelly CR, Laird A, Barton JS, et al. A clinical tool for the prediction of venous thromboembolism in pediatric trauma patients. *JAMA Surg* 2016;151(1):50–57.
105. Christian CW; Committee on Child Abuse and Neglect, American Academy of Pediatrics. The evaluation of suspected child physical abuse. *Pediatrics* 2015;135(5):e1337–e1354.
106. Wood JN, Fakeye O, Feudtner C, et al. Development of guidelines for skeletal survey in young children with fractures. *Pediatrics* 2014;134(1):45–53.
107. Mendelson KG, Fallat ME. Pediatric injuries: Prevention to resolution. *Surg Clin North Am* 2007;87:207–228, viii.
108. Brussoni M, Towner E, Hayes M. Evidence into practice: combining the art and science of injury prevention. *Inj Prev* 2006;12:373–377.
109. Tepas JJ III. The national pediatric trauma registry: a legacy of commitment to control of childhood injury. *Semin Pediatr Surg* 2004;13:126–132.
110. Brehaut JC, Miller A, Raina P, et al. Childhood behavior disorders and injuries among children and youth: a population based study. *Pediatrics* 2003;111(2):262–269.
111. Kaafarani H, Lee J, Cropano C, et al. The impact and sustainability of the graduated driver licensing program in preventing motor vehicle crashes in Massachusetts. *J Trauma Acute Care Surg* 2015;78(2):265–270; discussion 270–271.
112. Rajaratnam SM, Landrigan CP, Wang W, et al. Teen crashes declined after Massachusetts raised penalties for graduated licensing law restricting night driving. *Health Aff (Millwood)* 2015;34(6):963–970.

Chapter 30

Geriatric Trauma

Carlos V.R. Brown, Zara Cooper, and Ali Salim

Key Points

1 The physiology of aging affects nearly every organ system including cardiovascular, pulmonary, renal, and gastrointestinal. Altered physiology may also be associated with comorbid conditions in the elderly patient including hypertension, cardiac disease, chronic obstructive pulmonary disease (COPD), chronic renal insufficiency, and altered drug metabolism.

2 The American Geriatrics Society has published the Beers Criteria for potentially inappropriate medication use in older adults that can be used to refine inpatient medication management for elderly trauma patients.

3 Falls are far and away the most common mechanism of injury in elderly trauma patients, causing almost 75% of injuries in elderly patients; 90% of elderly falls are ground level falls.

4 An underreported but important mechanism of injury in elderly trauma patients is elderly abuse.

5 Imaging with head CT in elderly trauma patients should be used liberally.

6 Severely injured older patients may not display standard signs of hemodynamic instability.

7 Due to the broad range of age-related factors that can contribute to injury and adversely affect recovery in geriatric patients, injured individuals should receive a comprehensive geriatric assessment during their hospital stay.

8 Frailty is a syndrome of decreased physiologic reserve distinct from the normal aging process and other comorbidities. Frailty is associated with higher mortality and complications, and worse functional outcomes after trauma, and is more predictive than age or injury severity of hospital complications, in-hospital mortality, or discharge to an institution.

9 Palliative care is appropriate in the management of a broad range of injured patients who die or suffer with acute and chronic pain, functional disability, or life-limiting conditions such as severe frailty and underlying organ failure.

10 Four-fifths of in-hospital deaths among geriatric trauma patients involve decisions to withdraw or withhold of life-sustaining therapies.

INTRODUCTION

The elderly population in the United States is steadily growing and Americans >65 years old are expected to number more than 80 million by the year 2050, more than double the population in 2012.[1] Trauma and acute care surgeons will be increasingly responsible for caring for this complex population of patients. Even prior to injury, the elderly patient brings unique challenges including altered physiology, numerous comorbid conditions, and preinjury medications. The epidemiology and triage complexities of elderly trauma patients make it challenging to ensure these patients are transported to the appropriate receiving facility. Elderly patients are most often injured by a blunt mechanism and are particularly at risk for falls from standing. In addition, they sustain unique injuries that may escape diagnosis during the initial evaluation. Trauma centers may need to alter activation criteria for elderly trauma patients in order to avoid the pitfall of undertriage that is associated with poor outcomes in this population. Though the initial trauma evaluation for elderly patients is similar to younger adults, the trauma surgeon must understand the nuances associated with caring for the injured elderly patient. The elderly trauma patient more frequently has issues that relate end-of-life care in the postinjury period.

PHYSIOLOGY, COMORBIDITY, AND PREINJURY MEDICATIONS

1 Elderly individuals present with a vast array of body systems affected by the deranged physiology associated with aging. The physiology of aging affects nearly every organ system including cardiovascular, pulmonary, renal, and gastrointestinal. Altered physiology may also be associated with comorbid conditions in the elderly patient including hypertension, cardiac disease, chronic obstructive pulmonary disease (COPD), chronic renal insufficiency, and altered drug metabolism.

Cardiovascular

The cardiovascular system is most commonly affected by the physiology of aging and has a significant impact on care of the injured elderly patient. Alterations to physiology of the vascular system in the aging adult are primarily the result of changes in the large arteries including elongation, dilatation, and arterial wall thickening as a result of changes in the intima and media.[2] Changes in large arteries lead to decreased compliance, stiffness, and hypertension or other cardiovascular diseases in elderly adults. The aging process will affect cardiac physiology including reduced systolic and diastolic functions of the right ventricle as well as left ventricular hypertrophy with associated impaired contractility and relaxation. Resting cardiac output and ejection fraction are preserved.[3] While there are significant changes in cardiac and vascular physiology in elderly patients at baseline, the lack of cardiovascular response to stress may be the most important component of altered cardiovascular physiology in elderly patients, especially in the setting of hemorrhagic shock. The blunted response to alpha-adrenergic stimulation limits vasoconstriction[2,4] while lack of response to beta-adrenergic stimulation limits the ability to mount a tachycardic response.[3,5] Elderly individuals are also at increased risk to develop atrial fibrillation, ischemic heart disease, and congestive heart failure.

Table 30-1 Changes in Cardiovascular and Pulmonary Physiology and Commonly Encountered Comorbidities in the Elderly

System Involved	Physiologic Changes	Common Comorbidity
Cardiovascular	Elongation, dilatation, and wall thickening of large arteries Decreased arterial compliance and stiffness Reduced systolic and diastolic function of right ventricle Left ventricular hypertrophy Lack of cardiovascular response	Hypertension Ischemic heart disease Atrial fibrillation Congestive heart failure
Pulmonary	Kyphosis Decreased intervertebral height Decreased muscular strength Loss of elasticity and recoil Emphysematous changes Dysfunction of mucociliary system Alterations in lung volumes, gas exchange, and respiratory drive Diminished physiologic response to hypoxia and hypercapnia	Chronic obstructive pulmonary disease (COPD) Asthma Obstructive sleep apnea

Pulmonary

The aging process also brings significant baseline anatomic and physiologic changes to the pulmonary system.[6] The chest wall of the elderly individual changes over time with increasing kyphosis as well as decreasing height of intervertebral spaces. There is a decrease in strength of the intercostal muscles and diaphragm. After trauma, these anatomic changes place elderly patients at risk for earlier or more rapid respiratory failure as well as difficulty in liberation from the ventilator.[6–8] In addition to alterations in the chest wall, there are several changes in the pulmonary parenchyma of elderly individuals. These changes lead to increased compliance due to loss of elasticity and elastic recoil, emphysematous changes, and dysfunction of the mucociliary system. While anatomic changes are important, the altered pulmonary physiology of aging may lead to significant clinical implications when caring for the injured elderly patient. The elderly individual will have changes to pulmonary physiology including alterations in lung volumes, gas exchange, and respiratory drive.[6] Lung volumes in elderly patients will have increased residual volume and functional residual capacity but decreased vital capacity and FEV1.[9,10] Alterations of pulmonary gas exchange in elderly patients include increased ventilation–perfusion mismatch as well as decreased diffusion across the alveolar–arterial membrane, both associated with a decrease in baseline PaO_2.[11,12] Due to deranged respiratory drive seen with aging, elderly patients will have a diminished physiologic response to both hypoxemia and hypercapnia.[13] Some of the most common pulmonary comorbidities in the elderly trauma patients include COPD, asthma, and obstructive sleep apnea. Table 30-1 displays changes in cardiovascular and pulmonary physiology as well as common comorbidities encountered in the elderly trauma patient.

Renal and Gastrointestinal

Aging causes deterioration in renal function over time due to alterations in renal vasculature, microanatomy, as well as changes in renal physiology.[14] Elderly patients commonly have low-grade and/or undiagnosed chronic renal insufficiency putting them at risk for development of acute kidney injury after trauma. Avoiding nephrotoxic agents, intravenous contrast, hyperglycemia, and hypovolemia can help prevent acute kidney injury in elderly trauma patients. Gastrointestinal derangements in the elderly patient may include dysphagia, gastroesophageal reflux, gastroparesis, and diarrhea or constipation.[15] In addition, many elderly trauma patients will present in a state of malnutrition established long before the time of injury. It is important to screen elderly trauma patients for nutritional status and begin enteral nutrition early in the postinjury course.

Elderly trauma patients present with a wide array of altered physiology and comorbid conditions. These pre-existing medical conditions are usually treated in the outpatient setting by primary care providers, and the mainstay of treatment is often a long list of medications. These preinjury medications can have a profound effect on the management and outcomes of elderly trauma patients. In addition, elderly individuals have an altered ability to metabolize the medications they encounter prior to injury as well as during their hospitalization.

Medications

Elderly trauma patients may be taking a variety of medications that may affect initial presentation, evaluation and treatment, and eventually outcomes. As hypertension is the most common comorbidity, elderly trauma patients will often be taking preinjury antihypertensive medications. Diuretics will cause patients to present in a hypovolemic state prior to injury or hemorrhage. Preinjury beta-blockers will blunt the tachycardic response and may confound the initial presentation.[16] The most significant preinjury medications in elderly trauma patients are anticoagulants and antiplatelet agents. Elderly patients may be on anticoagulants or antiplatelet agents for a variety of conditions including atrial fibrillation, ischemic cardiac disease, valvular heart disease, cerebrovascular accidents, or thromboembolic disease. The most common outpatient anticoagulant is coumadin (vitamin K antagonist), but there have been several newer anticoagulants brought to market recently. These include the direct thrombin inhibitor dabigatran as well as the Xa inhibitors, rivaroxaban and apixaban. The most common antiplatelet agents include aspirin (cyclo-oxygenase inhibitor) and clopidogrel (ADP inhibitor). Newer antiplatelet agents include newer ADP inhibitors, prasugrel and ticagrelor.

Table 30-2 Common Preinjury Anticoagulants in the Elderly

Mechanism of Action	Drugs	Reversal Strategies
Vitamin K antagonist	Warfarin	FFP or PCC
Direct thrombin inhibitor	Dabigatran	Reversed with Idarucizumab (Praxbind) Intragastric charcoal Hemodialysis Consider PCC
Xa inhibitors	Rivaroxaban Apixaban	Reversal agent Andexanet alfa under investigation Intragastric charcoal Consider PCC
Antiplatelet agents	Aspirin Clopidogrel Prasugrel Ticagrelor	DDAVP Platelet transfusion

Reversal of anticoagulants and antiplatelet agents in elderly trauma patients can be a challenging and complex clinical scenario. The clinician must balance reversal to eliminate hemorrhage and thromboembolic complications associated with reversing anticoagulation or antiplatelet agents. Coumadin may be reversed with either fresh frozen plasma (FFP) or prothrombin complex concentrate (PCC).[17,18] There is limited evidence regarding reversal of direct thrombin inhibitors or Xa inhibitors.[19–22] Dabigatran may be reversed with Idarucizumab (Praxnind). Intragastric activated charcoal may be administered if drug has been taken within 2 hours of presentation or hemodialysis may

be considered. PCC may be considered for reversal of dabigatran but FFP is unlikely to have any therapeutic effect. Reversal agents for Xa inhibitors (Adnexanet alfa) are currently under investigation. Activated charcoal may be used or PCC may also be considered. Antiplatelet agents may be reversed with either DDAVP or platelet transfusion, but the indications for either therapy have not been elucidated.[21,23,24] Table 30-2 displays common preinjury anticoagulants and antiplatelet agents in the elderly trauma patient.

2 Once hospitalized, particular attention must be paid to medications ordered for the elderly trauma patient. Elderly patients have changes in pharmacokinetics and pharmacodynamics including alterations in absorption, bioavailability, distribution, metabolism, and elimination.[25] The American Geriatrics Society has published the Beers Criteria for potentially inappropriate medication use in older adults that can be used to refine inpatient medication management for elderly trauma patients.[26] Of particular importance to the management of the elderly trauma patients is the plan for pain control. Pain medications may have significant side effects in elderly patients including delirium, nausea, vomiting, constipation, renal dysfunction, and gastrointestinal bleeding. A multimodal approach with the lowest effective dose for pain control should be used for elderly trauma patients.[25]

MECHANISM AND INJURIES

3 Mechanisms of injury for elderly trauma patients are most often a result of blunt trauma with falls, motor vehicle crashes, and pedestrian struck by auto being the most frequent. Falls are far and away the most common mechanism in elderly trauma patients, causing almost 75% of injuries.[16] Fully, 90% of elderly falls are ground level falls. After hospitalization, older patients are at further risk for inpatient falls.[27] There are a variety of reasons that elderly individuals are at risk for falls including weakness, deconditioning from chronic illness, vision loss, gate and balance disturbances, slowed reaction time, and cognitive impairments.[16] The American Geriatrics Society has developed clinical practice guidelines (Table 30-3) for the prevention of falls in older adults.[28]

Elderly Abuse

4 An underreported but extremely important mechanism of injury in elderly trauma patients is abuse. Elderly abuse is committed by an individual who has a relationship with and is responsible for the well being of an elderly individual. Perpetrators of elderly abuse may include family members or care givers either in the home or at an assisted living facility. Abuse of the elderly is associated with depression, cognitive impairment, loss of functional capacity, and increased morbidity and mortality.[29] Several risk factors and warning signs for elderly abuse have been identified and are listed in Table 30-4.[30] If elderly trauma patients appear to be at risk for or display warning signs of possible abuse they may be assessed using a variety of available screening tools[30] including the American Medical Association (AMA) screening tool, the Conflict Tactics Scale (CTS), the Brief Abuse Screen for the Elderly (BASE), the Elder Assessment Instrument (EAI), or the Comprehensive Geriatric Assessment (CGA).

Traumatic Brain Injury

5 Traumatic brain injury (TBI) is a significant cause of morbidity and mortality in elderly trauma patients.[31,32] TBI in elderly patients leads to almost 100,000 emergency department visits each year with the large majority requiring hospitalization. The most common mechanism causing TBI in elderly patients is falls (51%) followed by motor vehicle–related injuries (9%). All other causes combined make up 18% of TBI and about 20% are from an unknown cause. Imaging with head CT in elderly trauma patients should be used liberally for several reasons: (1) elderly patients have progressive brain atrophy leading to stretching of bridging veins and increased risk of subdural hemorrhage after trauma,[33] (2) clinical tools such as the New Orleans Criteria and Canadian CT Head Rule exclude elderly patients,[34,35] and (3) neurologic examination may be unreliable in elderly trauma patients.[36,37] The catastrophic combination of TBI and preinjury anticoagulation should prompt to rapid reversal of anticoagulation.[38,39]

Fractures

Elderly patients have decreased cortical bone mass increasing their risk for fractures at lower levels of kinetic energy. As a consequence, older patients have increased risk of rib, spinal, pelvic, and extremity fractures after falls and other low impact mechanisms than younger patients.

Rib fractures are a significant cause of morbidity and mortality among older patients.[40] Retrospective studies show that in-hospital mortality for patients >65 years is double that of younger patients.[41,42] The risk of mortality and pneumonia increases with increasing number of ribs fractured, and patients with more than three fractures have worse outcomes.[41,43] Up to a third of older patients with rib fractures develop pneumonia and rib fractures are associated with mechanical ventilation and ICU length of stay.[41]

Osteoporosis, prior fracture, and functional impairment are all risk factors for pelvic fracture.[44] Over 80% of pelvic fractures are caused by falls, and morbidity and mortality after pelvic fractures is significant. In-hospital mortality approaches 8% and is up to five times higher than for younger patients.[45] Many patients after pelvic fracture require a cane or a walker, up to one-third are institutionalized, and 27% will die within a year of injury.[44]

Table 30-3 AGS/BGS Clinical Practice Guideline: *Prevention of Falls in Older Persons*

Summary of Recommendations
Screening and Assessment
1. All older individuals should be asked whether they have fallen (in the past year).
2. An older person who reports a fall should be asked about the frequency and circumstances of the fall(s).
3. Older individuals should be asked if they experience difficulties with walking or balance.
4. Older persons who present for medical attention because of a fall, report recurrent falls in the past year, or report difficulties in walking or balance (with or without activity curtailment) should have a multifactorial fall risk assessment.
5. Older persons presenting with a single fall should be evaluated for gait and balance.
6. Older persons who have fallen should have an assessment of gait and balance using one of the available evaluations.
7. Older persons who cannot perform or perform poorly on a standardized gait and balance test should be given a multifactorial fall risk assessment.
8. Older persons who have difficulty or demonstrate unsteadiness during the evaluation of gait and balance require a multifactorial fall risk assessment.
9. Older persons reporting only a single fall and reporting or demonstrating no difficulty or unsteadiness during the evaluation of gait and balance do not require a fall risk assessment.
10. The multifactorial fall risk assessment should be performed by a clinician (or clinicians) with appropriate skills and training.
11. The multifactorial fall risk assessment should include the following:

Focused History

a. History of falls: detailed description of the circumstances of the fall(s), frequency, symptoms at time of fall, injuries, and other consequences
b. Medication review: all prescribed and over-the-counter medications with dosages
c. History of relevant risk factors: acute or chronic medical problems (e.g., osteoporosis, urinary incontinence, cardiovascular disease)

Physical Examinations

a. Detailed assessment of gait, balance, and mobility levels and lower extremity joint function
b. Neurologic function: cognitive evaluation, lower extremity peripheral nerves, proprioception, reflexes, and tests of cortical, extrapyramidal, and cerebellar function
c. Muscle strength (lower extremities)
d. Cardiovascular status: heart rate and rhythm, postural pulse, blood pressure, and, if appropriate, heart rate and blood pressure responses to carotid sinus stimulation
e. Assessment of visual acuity
f. Examination of the feet and footwear

Functional Assessment

a. Assessment of activities of daily living (ADL) skills including use of adaptive equipment and mobility aids, as appropriate
b. Assessment of the individual's perceived functional ability and fear related to falling (assessment of current activity levels with attention to the extent to which concerns about falling are protective [i.e., appropriate given abilities] or contributing to deconditioning and/or compromised quality of life [i.e., individual is curtailing involvement in activities he or she is safely able to perform due to fear of falling])

Environmental Assessment

a. Environmental assessment including home safety

Table 30-4 Risk Factors and Warning Signs for Elderly Abuse

History
Advanced age (>80 years)
Disability in self-care
Dementia
Depression
History of hip fracture
History of stroke
Social isolation
Poor socioeconomic status
External family stressors
Unfavorable caretaker characteristics (mental illness, substance abuse, history of violent or antisocial behavior, depression, or financial dependency on the victim)
Institutional staffing shortages
Inappropriate or excessive medications; failure to get needed medications; lack of appropriate monitoring of medications and their effects
Substance abuse
Physical/Mental Status Examination
Indicators of sexual abuse: pain, bruises, lacerations, bleeding in anal–genital areas; bruised breasts or abdomen; signs of venereal diseases
Lacerations (including large skin tears, abrasions, burns, and bruises) without adequate explanation, especially on the trunk or other unusual locations
Suspicious fractures in sites other than those seen in osteoporotic fractures, that is, wrist, hip or vertebral body
Malnutrition
Focal findings on neurologic examination
Signs of dehydration
Pressure ulcers
Dementia, psychiatric disorders, lack of mental capacity

Spinal trauma is increasingly common in elderly patients.[46] The risk of cervical fracture after falls increases with age due to higher rates of cervical stenosis and degenerative disk disease.[47] An estimated 5% to 10% will sustain spinal injury and permanent neurologic deficit after cervical fracture, and 1-year mortality is estimated to be 20% to 30%.[48]

Fourteen percent of elderly patients who sustain hip fracture after falls die within 6 months and almost one-fourth dies within a year.[49,50] Most do not regain prior functional abilities, and patients after hip fracture are five times more likely to live in an institution a year after injury. Hip fracture in older patients often leads to depression,[51] social isolation, and worse overall health. Up to half of patients with hip fracture experience pain for many months after injury.[52] Shorter time to surgery is associated with decreased mortality and fewer complications.[53]

TRIAGE CRITERIA FOR OLDER PATIENTS

6 Trauma center care reduces in-hospital mortality for older trauma patients,[54,55] and the benefit of treatment at trauma centers for older patients increases with age.[56] However, triage of older patients can be quite challenging. Even severely injured older patients may not display standard signs of hemodynamic instability. Furthermore, because older patients cannot tolerate large blood loss and shock, some have advocated that systolic blood pressure $\leq$120 mm Hg should trigger trauma activation to prompt earlier intervention.[57] The Centers for Disease control suggest that injured patients $>$55 years should be transferred to a trauma center, regardless of injury severity.[58] The Eastern Association for Trauma (EAST) guidelines recommend that trauma centers should lower threshold for trauma team activation for elderly patients. Further, the guidelines suggest that older patients should be transferred to a level I center if they have a base deficit of –6 or greater, or one body system AIS is $>$3.[59] In a retrospective study using the National Trauma Data Bank, Pandit et al.[60] showed that shock index (HR/SBP) $>$1 was associated with higher rates of blood transfusions, exploratory laparotomy, in-hospital complications, and in-hospital mortality. Based on these findings, the authors recommend that patients with a shock index $>$1 should be transferred to level I trauma centers.

Despite evidence supporting higher triage, multiple studies show that older patients are routinely undertriaged. Data from the Washington State database showed that the likelihood of being transferred to a trauma center decreased above age 45.[61] Compared to younger patients in the cohort, patients 81 years and older were only 11% as likely to be transported to a level I trauma center from the scene, and only 24% as likely to be transferred from a lower level center to a level I center. The relationship between trauma center admission and longer-term outcome is controversial. One study of severely injured older patients (ISS $>$15) in three counties in California showed that older patients were less likely to receive care at trauma centers, yet mortality at 60 days after injury was no different.[62]

EVALUATION AND MANAGEMENT

Comprehensive Geriatric Assessment

Older patients are much more likely to have medical comorbidities, extensive lists of medications and social needs that require special attention. A retrospective study of older trauma patients showed that 69% of patients age 75 to 79 years and 90% of those >80 years have comorbidities.[63] The most common are cardiopulmonary (coronary disease, hypertension, congestive heart failure, and COPD). Geriatric syndromes such as dementia and frailty also play important roles and are frequently the primary contributors in falls and motor vehicle crashes. Malnutrition, hearing loss, vision loss, incontinence, polypharmacy, and osteoporosis all increase the risk of falls; weakness from sarcopenia and sensory deficits also place elders at high risk for being either struck by motor vehicles, or driving in motor vehicle crashes. Alcohol and substance abuse are under-recognized contributors to injury in geriatric trauma patients.[64]

7 Due to the broad range of age-related factors that can contribute to injury and adversely affect recovery in geriatric patients, patients should receive a comprehensive geriatric assessment (CGA) during their hospital stay. This is a multidimensional and multidisciplinary evaluation including functional ability, physical health, cognition and mental health, and medication review. A recent meta-analysis of 22 randomized trials showed that hospitalized elders who receive a CGA are less likely to die in hospital, have higher rates of discharge home, and improved long-term functional outcomes.[65] Functional status is evaluated with a review of activities of daily living (ADL) (eating, dressing, bathing, transfers, toileting, continence) and instrumental ADL (housework, bills, meal preparation, medication management, using the telephone).[66] Physical and occupational therapists can assess gait, balance, home safety, and ability to carry out ADL.

Medications commonly used in older patients can exacerbate injury. Postural hypotension is a common condition in older adults, leading to falls, and can be caused by medication side effects (diuretics, antiarrhythmics, benzodiazepines, antidepressants, and psychotropic agents).[67,68] Antidepressants and psychotropic agents can cause gait impairment. Most patients should receive a nutritional assessment because malnutrition in elderly patients is highly prevalent; 38% of community-dwelling elders are either malnourished or at risk of malnourishment.[69] Social workers can assess social supports, caregiver needs, financial assets and identify resources for the patient and family after hospital discharge. Poverty rates are highest for those 85 and older, and rates are increasing.[70] Social isolation is also a major contributor to poor health in this age group.[71] Those without social support have more frequent hospitalizations and higher healthcare costs near the end-of-life.[72] They are also more likely to be discharged to institutions. In cases where it is impractical to thoroughly evaluate each condition during hospitalization, patients should be referred for outpatient follow-up at discharge.

Assessing Frailty

8 Frailty is a syndrome of decreased physiologic reserve distinct from the normal aging process and other comorbidities. Frailty is associated with higher mortality and complications, and worse functional outcomes after trauma, and is more predictive than age or injury severity as a predictor of hospital complications, in-hospital mortality, or discharge to an institution.[73] The prevalence of frailty increases with age: 7% of 65 year olds are frail whereas 30% of patients 80 and older are frail.[74] Components of the frailty syndrome include shrinkage, weakness, exhaustion, low physical activity, and slowness. Presence of three or more of these indicates frailty.[75] Multimorbidity and side effects from certain medications may exacerbate frailty.

Screening for frailty identifies patients at risk for adverse outcomes, but frailty remains difficult to quantify. Frailty can be assessed using a number of different measures.[76] Investigators at the University of Arizona recently developed a frailty index using 50 preadmission variables that included data about demographics, comorbidities, medications, social history, ADLs, and mood. A frailty index was calculated based on the proportion of the 50 variables that were present; high score was indicative of frailty. These investigators demonstrated that after adjusting for age injury severity score and Glasgow coma score, higher frailty index predicted increased odds of unfavorable discharge (death or skilled nursing facility).[73,77] Other investigators have considered sarcopenia, a loss of muscle leading to decreased strength and impaired mobility, as a surrogate measure of frailty in trauma patients. Sarcopenia is associated with more days on the ventilator, and higher postacute care needs.[78] Sarcopenia can be measured using the cross-sectional area of the psoas muscle on abdominal CT, a measure which is inversely related to functional dependence.[79] The Vulnerable Elders-13 Survey, an assessment of functional status, has been validated as a screening tool to predict discharge to nursing facility, and surgical complication or death in trauma patients 65 years or older. In a prospective study of 63 geriatric trauma patients, each VES-13 point increased the odds of complication by 1.53.[80]

Patient Management

Data are emerging that unique expertise, and specialized pathways and processes of care improve outcomes in injured geriatric patients. A retrospective study of the Pennsylvania State database found that trauma centers with the highest volume of geriatric patients, rather than the highest overall trauma volume, had lower mortality, fewer complications, and lower rates of failure-to-rescue, suggesting that experience with older patients at the center level improves outcome.[81] A recent meta-analysis in hip fracture patients showed that routine geriatric consultation, comanagement, or geriatric admission with orthopedic consultation reduced in-hospital mortality by 40% and longer-term mortality by 17%.[82] Among trauma patients, triggered or proactive, geriatric consultation is associated with lower rates of delirium, fewer consults to medicine and psychiatry, and fewer discharges to facilities among patients who were admitted from home.[83] In another pre–post study of routine geriatric consult in trauma patients over 65 years, Tillou et al.[84] showed that patients who received a geriatric consultation had better functional recovery at 6 and 12 months after injury than patients without the consultation.

Some centers have reported success in developing clinical pathways for geriatric trauma patients. Bradburn et al.[85] implemented a high-risk geriatric protocol at their level II trauma center. As part of the protocol, patients received arterial blood gas determination at the time of trauma activation, were admitted to the ICU, and received a geriatric consultation. If the initial base deficit was >6, it was rechecked every 4 hours until normalized. Patients treated under the protocol had 40% lower mortality than those who did not receive the protocol. Bar-Or et al.[86] also showed improved mortality among trauma patients >65 years who routinely received serial venous lactate measurement and early surgical consultation. Mangram et al.[87] created the dedicated G-60 unit at their level II trauma center for trauma patients over 60 years who were admitted within 48 hours of injury. Patients were evaluated by a surgeon and a hospitalist at the time of trauma activation, and admitted to the surgical service. Other services including physical medicine and rehabilitation, palliative care, physical and occupational therapy, respiratory therapy, the G-60 nurse supervisor, social work, nutrition, pharmacy were also notified at the time of activation and evaluated patients within 24 hours of admission. Surgeon-led multidisciplinary rounds occurred twice weekly. As compared to historical controls, patients on the G-60 service had significantly shorter ED length of stay, time to OR, hospital length of stay, and ICU length of stay. Although mortality was unchanged, there were also significantly lower rates of medical complications.

OUTCOMES

Mortality Outcomes

The relationship between age and adverse outcomes among older trauma patients is well recognized.[88] As compared to younger patients, in-hospital mortality for older patients are 4.4% versus 1.6% for low severity injuries and 5.9% versus 1.4% for moderate severity injuries. Moreover, mortality among older trauma patients increases with the number of comorbidities; patients with minor injuries and comorbidities are at increased risk of death compared to age-matched counterparts without comorbidities.[89] It is important for clinicians to recognize that significant numbers of geriatric trauma patients die shortly after hospital discharge, and patients have higher mortality than age-matched counterparts for years after injury. Clark et al.[90] showed that mortality at 30 days was nearly double the in-hospital mortality. Fleischman et al.[91] found that 89% of postinjury mortality occurs by 60 days and that mortality rates level off at 6 months. Davidson et al.[92] found that while all trauma patients had higher mortality up to 3 years after injury than age-matched controls, older patients and those discharged to skilled nursing facilities fared particularly poorly.

Functional Outcomes

Most older trauma patients will return to their prior level of function, and thus an initial aggressive approach to treatment in a trauma center is warranted.[59] A significant portion experiences long-term functional decline after injury. A follow-up study of blunt trauma patients showed that 87% were functionally independent 1 to 3 years after injury, and another with mean follow-up 2.8 years after injury showed that 63% remained independent but with reduced function.[93] Studies with 12 months or less follow-up show higher rates of decreased functional abilities. In a prospective study of 37 patients >65 years, Kelley-Quon et al.[94] showed that most patients had lost 1 ADL at 12 months. More recent data from this group show that a geriatric consultation during the index hospitalization is associated with less long-term functional decline.[84] Quality of life in older patients is significantly impaired. Among patients 1 year after hip fracture 90% have reduced mobility, 69% have pain, and 33% who were independent live in a nursing home. As compared to patients without TBI, a cohort of patients >50 years old had poorer cognitive and psychosocial function a year post injury.

PALLIATIVE AND END-OF-LIFE CARE IN THE GERIATRIC TRAUMA PATENT

9 Palliative care is an approach to medical care aimed at relieving suffering and improving quality of life for patients with serious illness and for their families. Palliative care is appropriate in the management in a broad range of injured patients who die or suffer with acute and chronic pain, functional disability, or life-limiting conditions such as severe frailty and underlying organ failure.[95] Clinical domains of palliative care encompass symptom management. Spiritual, religious, psychosocial, and bereavement support can be delivered alongside aggressive life prolonging care and should not be limited to only those patients near the end-of-life.[96] Thus palliative care can be provided to patients who are “cured” of their illnesses or recover from injury. Palliative care should not be confused with hospice care which is an administrative benefit provided to patients with terminal illness and typically provided to patients expected to survive less than 6 months.

End-of-Life Care

10 Four-fifths of in-hospital deaths among geriatric trauma patients involve decisions to withdraw or withhold of life-sustaining therapies.[97] Advanced directives, including living wills and proxy forms are intended to guide medical decisions in the event a patient loses capacity to make decisions. Unfortunately, many patients, even those with terminal illness, do not have advanced directives or the advanced directives are too specific or too broad to be useful.[98] Therefore, it is critically important that clinicians make every effort to engage patients and their families in conversations about the overall goals of care and expectations for recovery. Patients may forego heroic measures and prolonged life-sustaining treatments if all possible outcomes are not acceptable to them.[99] It is advisable for clinicians to identify healthcare proxies and address code status early in the hospital stay and ideally with the patient.

Physicians play an important role in providing a comfortable death experience for patients and families. In death, patients want to minimize discomfort, to avoid a prolonged dying process, to achieve a sense of control, and time to strengthen relationships with loved ones.[100] Survivors and surrogates suffer high rates of depression, posttraumatic stress disorder, and complicated grief after a loved one dies in the ICU.[101] Better outcomes for survivors are achieved when they feel that they have been well informed and had appropriate responsibility in decision-making.[102] It is important for physicians to provide emotional support for surrogates who are often conflicted and distressed.

In cases where the primary goal is comfort, liberal use of opioids can reduce pain and dyspnea. Some clinicians may be reluctant to use opioids for fear of causing respiratory depression and death. Opioid use is ethically justifiable in these scenarios as long as the intent is symptom relief and not euthanasia. Patients should receive doses adequate to achieve comfort; target respiratory rate is 15 to 20 breaths per minute. When patients die, physicians should be available to answer questions and address bereavement needs. The way death is communicated is important. In a study of survivors of patients who died in the ICU, failure to find the physician comforting was most strongly associated with developing a psychiatric diagnosis in the year after death.[101] In another study of 70 survivors of cancer patients, feeling unprepared was a predictor of major depressive disorder up to 9 months.[103]

Hospice

Hospice is an interdisciplinary approach to care that provides comprehensive, medical, nursing, counseling, and bereavement to terminally ill patients and their families. Referral for hospice care is appropriate when patients have a limited prognosis and the primary goal is comfort and symptom management. In the care of geriatric trauma patients, hospice may be relevant to patients with severe TBI or patients who sustain injury in the setting of other advanced serious underlying illnesses with life expectancy 6 months or less. Hospice care is associated with better quality of life, better bereavement outcomes, lower healthcare costs, and either equivalent or improved survival in patients with a terminal diagnosis.[104–107] The impact of transition to hospice on trauma center mortality reporting is unclear. Kozar et al. found wide variation among 167 trauma centers enrolled in the Trauma Quality Improvement Project as to whether they reported patients discharged to hospice as in-hospital deaths or survivors. The authors advised that hospice discharge should be considered death across centers to prevent distortion of actual performances.[108]

References

1. Ortman JM, Velkoff VA. An aging nation: the older population in the United States. U.S. Department of Commerce, Economics and Statistics Administration; May, 2014.
2. Villella E, Cho SJ. Effect of aging on the vascular system plus monitoring and support. *Surg Clin N Am* 2015;95:37–51.
3. Martin RS, Farrah JP, Chang MC. Effect of aging on cardiac function plus monitoring and support. *Surg Clin North Am* 2015;95:23–35.
4. Elliott HL, Sumner DJ, McLean K, et al. Effect of age on the responsiveness of vascular alpha-adrenoceptors in man. *J Cardiovasc Pharmacol* 1982;4(3):388–392.
5. Christou DD, Seals DR. Decreased maximal heart rate with aging is related to reduced {beta}-adrenergic responsiveness but is largely explained by a reduction in intrinsic heart rate. *J Appl Physiol (1985)* 2008;105(1):24–29.
6. Ramly E, Kaafarani HM, Velmahos G. The effect of aging on pulmonary function: implications for monitoring and support of the surgical and trauma patient. *Surg Clin North Am* 2015;95:53–69.
7. Sevransky JE, Haponik EF. Respiratory failure in elderly patients. *Clin Geriatr Med* 2003;19(1):205–224.
8. Sprung J, Gajic O, Warner DO. Review article: age related alterations in respiratory function—anesthetic considerations. *Can J Anaesth* 2006;53(12):1244–1257.
9. Zaugg M, Lucchinetti E. Respiratory function in the elderly. *Anesthesiol Clin North America* 2000;18(1):47–58, vi.
10. Knudson RJ, Slatin RC, Lebowitz MD, et al. The maximal expiratory flow-volume curve. Normal standards, variability, and effects of age. *Am Rev Respir Dis* 1976;113(5):587–600.
11. Cardus J, Burgos F, Diaz O, et al. Increase in pulmonary ventilation-perfusion inequality with age in healthy individuals. *Am J Respir Crit Care Med* 1997;156(2 Pt 1):648–653.
12. Guenard H, Marthan R. Pulmonary gas exchange in elderly subjects. *Eur Respir J* 1996;9(12):2573–2577.
13. Kronenberg RS, Drage CW. Attenuation of the ventilatory and heart rate responses to hypoxia and hypercapnia with aging in normal men. *J Clin Invest* 1973;52(8):1812–1819.
14. Baldea AJ. Effect of aging on renal function plus monitoring and support. *Surg Clin North Am* 2015;95:71–83.
15. Nohra E, Bochicchio GV. Management of the gastrointestinal tract and nutrition in the geriatric surgical patient. *Surg Clin North Am* 2015;95:85–101.
16. Bonne S, Schuerer DJ. Trauma in the older adult. Epidemiology and evolving geriatric trauma principles. *Clin Geriatr Med* 2013;29:137–150.
17. Holbrook A, Schulman S, Witt DM, et al. Evidence-based management of

anticoagulant therapy. *Chest* 2012;141(2):e152S–e184S.
18. Sarode R, Milling TJ, Refaai MA, et al. Efficacy and safety of a 4-factor prothrombin complex concentrate in patients on vitamin K antagonists presenting with major bleeding. *Circulation* 2013;128:1234–1243.
19. Kaatz S, Kouides PA, Garcia DA, et al. Guidance on the emergent reversal of oral thrombin and factor Xa inhibitors. *Am J Hematol* 2012;87:S141–S145.
20. Heidbuchel H, Verhamme P, Alings M, et al. European Society of Cardiology practical guide on the use of new oral anticoagulants in patients with non-valvular atrial fibrillation. *Eur Heart J* 2013;15:625–651.
21. Spahn DR, Bouillon B, Cerny V, et al. Management of bleeding and coagulopathy following major trauma: an updated European Guidelines. *Crit Care* 2013;17(2):R76.
22. Eerenberg ES, Kamphuisen PW, Sijpkens MK, et al. Reversal of rivaroxaban and dabigatran by prothrombin complex concentrate: a randomized, placebo-controlled, crossover study in healthy subjects. *Circulation* 2011; 124(14):1573–1579.
23. Levi M, Eerenberg E, Kamphuisen PW, et al. Bleeding risk and reversal strategies for old and new anticoagulants and antiplatelet agents. *J Thromb Haemost* 2011;9(9):1705–1712.
24. Makris M, Van Veen JJ, Tait CR, et al. Guideline on the management of bleeding in patients on antithrombotic agents. *Br J Haematol* 2012;160:35–46.
25. Then J, Tisherman SA. Pharmacology for the geriatric surgical patient. *Surg Clin North Am* 2015;95:139–147.
26. American Geriatrics Society 2012 Beers Criteria Update Expert Panel. American Geriatrics Society updated Beers criteria for potentially inappropriate medication use in older adults. *J Am Geriatr Soc* 2012;60(4):616–631.
27. Brown CV, Ali S, Fairley R, et al. Risk factor for falls among hospitalized trauma patients. *Am Surg* 2013;79(5):465–469.
28. Panel on Prevention of Falls in Older Persons, American Geriatrics Society and British Geriatrics Society. Summary of the Updated American Geriatrics Society/British Geriatrics Society clinical practice guideline for prevention of falls in older persons. *J Am Geriatr Soc* 2011;59(1):148–157.
29. Lachs MS, Pillemer K. Elder abuse. *Lancet* 2004;364(9441):1263.
30. Halphen JM, Dyer CB. Elder mistreatment: abuse, neglect, and financial exploitation. In: Schmader KE, Sokol HN, eds. *UpToDate*. Waltham, MA: Wolters Kluwer; Accessed on December 31, 2014.
31. Thompson HJ, McCormick WC, Kagan SH. Traumatic brain injury in older adults: epidemiology, outcomes, and future implications. *J Am Geriatr Soc* 2006;54(10):1590–1595.
32. Langlois JA, Rutland-Brown W, Thomas KE. *Traumatic Brain Injury in the United States: Emergency Department Visits, Hospitalizations, and Deaths.* Atlanta, GA: National Center for Injury Prevention and Control; 2004.

33. Adhiyaman V, Asghar M, Ganeshram KN, et al. Chronic subdural haematoma in the elderly. *Postgrad Med J* 2002;78(916):71–75.
34. Haydel MJ, Preston CA, Mills TJ, et al. Indications for computed tomography in patients with minor head injury. *N Engl J Med* 2000;343(2):100–105.
35. Stiell IG, Wells GA, Vandemheen K, et al. The Canadian CT Head Rule for patients with minor head injury. *Lancet* 2001;357:1391–1396.
36. Rathlev NK, Medzon R, Lowery D, et al. Intracranial pathology in elders with blunt head trauma. *Acad Emerg Med* 2006;13(3):302–307.
37. Mack LR, Chan SB, Silva JC, et al. The use of head computed tomography in elderly patients sustaining minor head trauma. *J Emerg Med* 2003;24(2):157–162.
38. Goldstein JN, Thomas SH, Frontiero V, et al. Timing of fresh frozen plasma administration and rapid correction of coagulopathy in warfarin-related intracerebral hemorrhage. *Stroke* 2006;37:151–155.
39. Ivascu FA, Janczyk RJ, Junn FS, et al. Treatment of trauma patients with intracranial hemorrhage on preinjury warfarin. *J Trauma* 2006;61(2):318–321.
40. Sharma OP, Oswanski MF, Jolly S, et al. Perils of rib fractures. *Am Surg* 2008;74(4):310–314.
41. Bulger EM, Arneson MA, Mock CN, et al. Rib fractures in the elderly. *J Trauma* 2000;48(6):1040–1046; discussion 1046–1047.
42. Bergeron E, Lavoie A, Clas D, et al. Elderly trauma patients with rib fractures are at greater risk of death and pneumonia. *J Trauma* 2003;54(3):478–485.
43. Holcomb JB, McMullin NR, Kozar RA, et al. Morbidity from rib fractures increases after age 45. *J Am Coll Surg* 2003;196(4):549–555.
44. Rapp K, Cameron ID, Kurrle S, et al. Excess mortality after pelvic fractures in institutionalized older people. *Osteoporos Int* 2010;21(11):1835–1839.
45. O'Brien DP, Luchette FA, Pereira SJ, et al. Pelvic fracture in the elderly is associated with increased mortality. *Surgery* 2002;132(4):710–714; discussion 714–715.
46. Kannus P, Niemi S, Palvanen M, et al. Continuously increasing number and incidence of fall-induced, fracture-associated, spinal cord injuries in elderly persons. *Arch Intern Med* 2000;160(14):2145–2149.
47. Bonne S, Schuerer DJ. Trauma in the older adult. Epidemiology and evolving geriatric trauma principles. *Clin Geriatr Med* 2013;29:137–150.
48. Harris MB, Reichmann WM, Bono CM. Mortality in elderly patients after cervical spine fractures. *J Bone Joint Surg Am* 2010;92(3):567–574.
49. Hannan EL, Magaziner J, Wang JJ, et al. Mortality and locomotion 6 months after hospitalization for hip fracture: risk factors and risk-adjusted hospital outcomes. *JAMA* 2001;285(21):2736–2742.
50. Lu-Yao GL, Baron JA, Barrett JA, et al. Treatment and survival among elderly Americans with hip fractures: a population-based study. *Am J Public Health* 1994;84(8):1287–1291.

51. Lenze EJ, Munin MC, Skidmore ER, et al. Onset of depression in elderly persons after hip fracture: implications for prevention and early intervention of late-life depression. *J Am Geriatr Soc* 2007;55(1):81–86.
52. Herrick C, Steger-May K, Sinacore DR, et al. Persistent pain in frail older adults after hip fracture repair. *J Am Geriatr Soc* 2004;52(12):2062–2068.
53. Zuckerman JD, Skovron ML, Koval KJ, et al. Postoperative complications and mortality associated with operative delay in older patients who have a fracture of the hip. *JBone Joint Surg Am* 1995;77(10):1551–1556.
54. Meldon SW, Reilly M, Drew BL, et al. Trauma in the very elderly: a community-based study of outcomes at trauma and nontrauma centers. *J Trauma* 2002;52(1):79–84.
55. Mann NC, Mullins RJ, MacKenzie EJ, et al. Systematic review of published evidence regarding trauma system effectiveness. *J Trauma* 1999;47(3 suppl):S25–S33.
56. Goodmanson NW, Rosengart MR, Barnato AE, et al. Defining geriatric trauma: when does age make a difference? *Surgery* 2012;152(4):668–674; discussion 674–665.
57. Oyetunji TA, Chang DC, Crompton JG, et al. Redefining hypotension in the elderly: normotension is not reassuring. *Arch Surg* 2011;146(7):865–869.
58. Centers for Disease Control and Prevention. 2011 guidelines for field triage of injured patients. 2011. http://www.cdc.gov/fieldtriage/pdf/decisionscheme_poster_a.pdf. Accessed December 29, 2014.
59. Jacobs DG, Plaisier BR, Barie PS, et al. Practice management guidelines for geriatric trauma: the EAST Practice Management Guidelines Work Group. *J Trauma Acute Care Surg* 2003;54(2):391–416.
60. Pandit V, Rhee P, Hashmi A, et al. Shock index predicts mortality in geriatric trauma patients: an analysis of the National Trauma Data Bank. *J Trauma Acute Care Surg* 2014;76(4):1111–1115.
61. Gage AM, Traven N, Rivara FP, et al. Compliance with Centers for Disease Control and Prevention field triage guidelines in an established trauma system. *J Am Coll Surg* 2012;215(1):148–154; discussion 154–156.
62. Staudenmayer KL, Hsia RY, Mann NC, et al. Triage of elderly trauma patients: a population-based perspective. *J Am Coll Surg* 2013;217(4):569–576.
63. Milzman DP, Boulanger BR, Rodriguez A, et al. Pre-existing disease in trauma patients: a predictor of fate independent of age and injury severity score. *J Trauma* 1992;32(2):236–243; discussion 243–244.
64. Zautcke JL, Coker SB Jr, Morris RW, et al. Geriatric trauma in the State of Illinois: substance use and injury patterns. *Am J Emerg Med* 2002;20(1):14–17.
65. Ellis G, Whitehead MA, Robinson D, et al. Comprehensive geriatric assessment for older adults admitted to hospital: meta-analysis of randomised controlled trials. *BMJ* 2011;343:d6553.

66. Katz S, Ford A, Moskowitz RW, et al. Studies of illness in the aged. The index of ADL: a standardized measure of biological and psychosocial function. *JAMA* 1963;185:914–919.
67. Leipzig RM, Cumming RG, Tinetti ME. Drugs and falls in older people: a systematic review and meta-analysis: II. Cardiac and analgesic drugs. *J Am Geriatr Soc* 1999;47(1):40–50.
68. Hartikainen S, Lönnroos E, Louhivuori K. Medication as a risk factor for falls: critical systematic review. *J Gerontol A Biol Sci Med Sci* 2007;62(10):1172–1181.
69. Kaiser MJ, Bauer JM, Rämsch C, et al. Frequency of malnutrition in older adults: a multinational perspective using the mini nutritional assessment. *J Am Geriatr Soc* 2010;58(9):1734–1738.
70. Employee Benefit Research Institute Notes. Time trends in poverty for Older Americans between 2001–2009. 2012. http://www.ebri.org/pdf/notespdf/ebri_notes_04_apr-12.eldpovty.pdf. Accessed January 10, 2015.
71. Perissinotto CM, Cenzer IS, Covinsky KE. Loneliness in older persons: a predictor of functional decline and death. *Arch Intern Med* 2012;172(14):1078–1084.
72. Kelley AS, Ettner SL, Morrison RS, et al. Determinants of medical expenditures in the last 6 months of life. *Ann Intern Med* 2011;154(4):235–242.
73. Pandit V, Joseph B, Rhee PM, et al. Frailty is superior to age in predicting outcomes in geriatric trauma patients: a prospective analysis. *J Am Coll Surg* 2013;217(3 suppl):S59.
74. Singh M, Alexander K, Roger VL, et al. Frailty and its potential relevance to cardiovascular care. Paper presented at: Mayo Clinic Proceedings; 2008.
75. Fried LP, Tangen CM, Walston J, et al.; Cardiovascular Health Study Collaborative Research Group. Frailty in older adults: evidence for a phenotype. *J Gerontol A Biolo Sci Med Sci* 2001;56(3):M146–M157.
76. Clegg A, Young J. The frailty syndrome. *Clin Med* 2011;11(1):72–75.
77. Joseph B, Pandit V, Rhee P, et al. Predicting hospital discharge disposition in geriatric trauma patients: is frailty the answer? *J Trauma Acute Care Surg* 2014;76(1):196–200.
78. Moisey LL, Mourtzakis M, Cotton BA, et al.; Nutrition and Rehabilitation Investigators Consortium (NUTRIC). Skeletal muscle predicts ventilator-free days, ICU-free days, and mortality in elderly ICU patients. *Crit Care* 2013;17(5):R206
79. Fairchild B, Webb T, Xiang Q, et al. Sarcopenia and frailty in elderly trauma patients. *World J Surg* 2015;39(2):373–379.
80. Min L, Ubhayakar N, Saliba D, et al. The vulnerable elders survey-13 predicts hospital complications and mortality in older adults with traumatic injury: a pilot study. *J Am Geriatr Soc* 2011;59(8):1471–1476.
81. Matsushima K, Schaefer EW, Won EJ, et al. Positive and negative volume-outcome

relationships in the geriatric trauma population. *JAMA Surg* 2014;149(4):319–326.
82. Grigoryan KV, Javedan H, Rudolph JL. Ortho-geriatric care models and outcomes in hip fracture patients: a systematic review and meta-analysis. *J Orthop Trauma* 2014;28(3):e49–e55.
83. Lenartowicz M, Parkovnick M, McFarlan A, et al. An evaluation of a proactive geriatric trauma consultation service. *Ann Surg* 2012;256(6):1098–1101.
84. Tillou A, Kelley-Quon L, Burruss S, et al. Long-term postinjury functional recovery: outcomes of geriatric consultation. *JAMA Surg* 2014;149(1):83–89.
85. Bradburn E, Rogers FB, Krasne M, et al. High-risk geriatric protocol: improving mortality in the elderly. *J Trauma Acute Care Surg* 2012;73(2):435–440.
86. Bar-Or D, Salottolo KM, Orlando A, et al. Association between a geriatric trauma resuscitation protocol using venous lactate measurements and early trauma surgeon involvement and mortality risk. *J Am Geriatr Soc* 2013;61(8):1358–1364.
87. Mangram AJ, Mitchell CD, Shifflette VK, et al. Geriatric trauma service: a one-year experience. *J Trauma Acute Care Surg* 2012;72(1):119–122.
88. Grossman M, Scaff DW, Miller D, et al. Functional outcomes in octogenarian trauma. *J Trauma* 2003;55(1):26–32.
89. McGwin G Jr, MacLennan PA, Fife JB, et al. Preexisting conditions and mortality in older trauma patients. *J Trauma* 2004;56(6):1291–1296.
90. Clark DE, DeLorenzo MA, Lucas FL, et al. Initial presentation of older injured patients to high-volume hospitals is not associated with lower 30-day mortality in Medicare data. *Crit Care Med* 2007;35(8):1829–1836.
91. Fleischman RJ, Adams AL, Hedges JR, et al. The optimum follow-up period for assessing mortality outcomes in injured older adults. *J Am Geriatr Soc* 2010;58(10):1843–1849.
92. Davidson GH, Hamlat CA, Rivara FP, et al. Long-term survival of adult trauma patients. *JAMA* 2011;305(10):1001–1007.
93. Inaba K, Goecke M, Sharkey P, et al. Long-term outcomes after injury in the elderly. *J Trauma* 2003;54(3):486–491.
94. Kelley-Quon L, Min L, Morley E, et al. Functional status after injury: a longitudinal study of geriatric trauma. *Am Surg* 2010;76(10):1055–1058.
95. Grossman MD, Miller D, Scaff DW, et al. When is an elder old? Effect of preexisting conditions on mortality in geriatric trauma. *J Trauma* 2002;52(2):242–246.
96. Surgeons ACo. *ST-50 Statement of Principles of Palliative Care.* Vol 90. Chicago, IL: Surgeons ACo; 2005.
97. Plaisier BR, Blostein PA, Hurt KJ, et al. Withholding/withdrawal of life support in trauma patients: is there an age bias? *Am Surg* 2002;68(2):159–162.
98. Goodman MD, Tarnoff M, Slotman GJ. Effect of advance directives on the management of elderly critically ill patients. *Crit Care Med* 1998;26(4):701–704.
99. Barnato AE, Herndon MB, Anthony DL, et al. Are regional variations in end-of-life

care intensity explained by patient preferences?: a study of the US Medicare Population. *Med Care* 2007;45(5):386–393.

100. Steinhauser KE, Clipp EC, McNeilly M, et al. In search of a good death: observations of patients, families, and providers. *Ann Intern Med* 2000; 132(10):825–832.
101. Siegel MD, Hayes E, Vanderwerker LC, et al. Psychiatric illness in the next of kin of patients who die in the intensive care unit. *Crit Care Med* 2008;36(6):1722–1728.
102. Gries CJ, Engelberg RA, Kross EK, et al. Predictors of symptoms of posttraumatic stress and depression in family members after patient death in the ICU. *Chest* 2010;137(2):280–287.
103. Wright AA, Zhang B, Ray A, et al. Associations between end-of-life discussions, patient mental health, medical care near death, and caregiver bereavement adjustment. *JAMA* 2008;300(14):1665–1673.
104. Teno JM, Clarridge BR, Casey V, et al. Family perspectives on end-of-life care at the last place of care. *JAMA* 2004;291(1):88–93.
105. Teno JM, Shu JE, Casarett D, et al. Timing of referral to hospice and quality of care: length of stay and bereaved family members' perceptions of the timing of hospice referral. *J Pain Symptom Manage* 2007;34(2):120–125.
106. Obermeyer Z, Makar M, Abujaber S, et al. Association between the Medicare hospice benefit and health care utilization and costs for patients with poor-prognosis cancer. *JAMA* 2014;312(18):1888–1896.
107. Wright AA, Keating NL, Balboni TA, et al. Place of death: correlations with quality of life of patients with cancer and predictors of bereaved caregivers' mental health. *J Clin Oncol* 2010;28(29):4457–4464.
108. Kozar RA, Holcomb JB, Xiong W, et al. Are all deaths recorded equally? The impact of hospice care on risk-adjusted mortality. *J Trauma Acute Care Surg* 2014;76(3):634–639.

Chapter 31

Trauma in Pregnancy

Felix Y. Lui and Kimberly A. Davis

Key Points

1 Unique challenges exist in the management of the pregnant patient that need to be addressed in order to achieve optimal outcomes for both the mother and child.

2 Anatomic and physiologic changes in the maternal trauma patient evolve over the course of pregnancy and require modifications in management based on gestational age.

3 Patient care should be tailored for the anatomic and physiologic changes in the gravid trauma patient, but priorities remain the same as for the nongravid patient.

4 Relative hypervolemia of pregnancy can mask large-volume hemorrhagic losses and requires rapid identification and aggressive resuscitation.

5 Compression of the inferior vena cava (IVC) and decreased cardiac output can result from supine positioning. Proper positioning and use of a wedge is recommended.

6 A Kleihauser–Betke test should be performed in all pregnant trauma patients with greater than 12 weeks of gestation and prophylactic anti-D immune globulin given within 72 hours for high-risk patients.

7 Radiation exposure should be minimized in all pregnant trauma patients. Ultrasound (including FAST) exposes the mother and fetus to no radiation and is reliable, has good negative predictive value, and can be followed serially over time.

8 Angiography and angioembolization may be useful in life-threatening hemorrhage, recognizing the risks of increased radiation exposure.

9 Pregnant patients are at an increased risk for deep venous thrombosis (DVT) and should be given unfractionated subcutaneous heparin for prophylaxis.

10 Providers should have a low threshold for screening maternal trauma patients for intimate partner violence (IPV) and substance abuse.

INTRODUCTION

Trauma is the leading cause of nonobstetric death in pregnant patients worldwide. As the risk of death due to pregnancy-related complications has declined, trauma now accounts for nearly half of maternal deaths in the United States annually, with an up to fourfold increase in fetal mortality in some series.[1,2] Pregnant trauma patients have increased rates of preterm labor and placental abruption, and their infants are at increased risk of respiratory distress and fetal death.[3]

The trauma evaluation of the pregnant patient presents unique challenges including alterations in anatomy and physiology that evolve continuously throughout pregnancy, pregnancy-specific patterns of injury, and pregnancy-specific challenges in critical care and surgical management.

Pregnant patients also present special social and ethical issues in trauma. Interpersonal violence against the pregnant female is an underrecognized phenomenon worldwide and has long-lasting effects on both mother and child. While management of the pregnant trauma patient focuses on the resuscitation of the mother, consideration of fetal survival and outcome must be considered in the management of these patients.

1 Trauma in the pregnant patient presents as a unique situation in which treatment is required in two (or more) patients simultaneously. In order to provide the optimal level of care to both the mother and child, the practitioner needs to recognize the unique anatomical and physiologic changes of the gravid patient as the pregnancy progresses, and how they alter the treatment of these patients.

EPIDEMIOLOGY OF INJURY DURING PREGNANCY

Up to 37% to 46.3% of gravid maternal deaths in the United States are attributable to trauma, resulting in over one million deaths annually worldwide. An estimated 5% to 7% of pregnancies are complicated by trauma, and 0.3% to 0.4% of all pregnant females required hospitalization for treatment of injuries.[4–7] The majority of trauma occurs later in pregnancy, with greater than 50% occurring during the third trimester. Motor vehicle–related injuries are the most common cause of trauma and injury (up to 33.6%), followed by falls and interpersonal violence.[8] Although motor vehicle collisions are no more common in pregnancy, they remain the leading cause of fetal death due to frequency of maternal trauma.[9,10] Fetal death occurs in up to 50% of life-threatening traumatic injury to the mother, but due to the frequency of minor trauma, the majority of fetal loss occurs after minor traumatic injuries.[11] Violence due to domestic abuse is an underrecognized cause of maternal and fetal injury and death. Interpersonal violence between intimate partners occurs in up to 30% of pregnant women, with a fetal mortality of 5%. While most common in first 18 weeks of gestation, violence is prevalent throughout gestation. The risk of IPV is greatest immediately after delivery of a child.[12–14]

PATTERNS OF INJURY

2 The development of the fetus and enlargement of the uterus throughout pregnancy affects the patterns of injury experienced depending on stage of development. Until the 12th week of gestation, the uterus is thick walled and is well protected by the surrounding pelvis. By the 20th week of gestation, the uterus extends out of the true pelvis up to the umbilicus and by the 34th week, the costal margins. As the uterus grows, the protection conferred by the bony pelvis is lost and the fetus becomes increasingly vulnerable to direct trauma and injury. Later in pregnancy the relative thickness of the uterine wall decreases, as does the relative volume of amniotic fluid surrounding the fetus, further limiting the protective barrier surrounding the fetus and predisposing the uterus to shear forces and rupture.

Motor vehicle collisions remain the most common mechanism of significant blunt trauma in the pregnant patient. Maternal seatbelt use is associated with improved outcomes and decreased fetal mortality.[15] As the growing uterus emerges out of the pelvis after the 12th week of gestation, the fetus is increasingly exposed to direct blunt trauma by seat belt or steering wheel injuries. Trauma to the fetus commonly results in skull fracture or intracranial hemorrhage, especially late in pregnancy. Placental abruption, resulting from shear of the relatively inelastic placenta against the flexible uterine wall, is the most common cause of fetal demise from trauma. Uterine rupture is fortunately rare, but carries a rate of fetal demise near 100% and maternal mortality of 10%. Pelvic fractures are a sign of high-energy forces and can result in severe retroperitoneal hemorrhage of the mother with hypotension, and severe direct injury to the fetal head as it descends into the pelvic inlet late in pregnancy.

Penetrating trauma to the pregnant patient carries a high rate of fetal mortality, ranging from 40% to 80%, depending on mechanism, gestational age, and location.[16–18] Up to 9.5% of trauma in pregnant patients is intentional, with 73% of penetrating abdominal wounds in pregnancy resulting from gunshot wounds.[17] Gunshot wounds to the abdomen mandate exploratory laparotomy, whereas stab wounds may be managed selectively depending on the presence or absence of fascial disruption.[19] Fetal injury occurs in 70% of gunshot wounds to the pregnant abdomen. Diagnostic peritoneal lavage may be useful in evaluating these patients, though focused abdominal sonography for trauma (FAST) has largely supplanted its use. FAST ultrasound in the pregnant patient has a sensitivity of 61% to 83% and a specificity of 94% to 100% in detecting intraperitoneal injuries.[20–22] Direct trauma to the uterus can be associated with large-volume blood loss due to the engorged uterine vessels.

EVALUATION OF THE PREGNANT TRAUMA PATIENT

3 The evaluation of the pregnant trauma patient follows the same principles as for the nonpregnant patient as outlined in the American College of Surgeons' Advanced Trauma Life Support guidelines.[23] The evaluation and resuscitation begins with the primary survey, utilizing a systematic ABCDE approach, and followed by a complete assessment of injuries in the secondary survey. Basic tenets of surgical intervention and "damage control" techniques should be followed. The best outcomes for the fetus are achieved by the optimal evaluation, resuscitation, and treatment of the mother.

Chart 31-1 Frequency of Injury in Fetal Trauma Deaths

Injury Pattern	Frequency
Placental abruption	20%
Excessive bleeding	3.3%
Breech/malpresentation	2.1%
Placenta previa	0.8%

The main priorities in prehospital care continue to be the avoidance of hypoxia and hypotension in the mother. Maintenance of an adequate airway, as well as provision of supplemental oxygen, is essential in avoiding fetal hypoxia. Circulatory support with crystalloids is recommended and should be initiated early. The relative hypervolemic state of pregnancy means that a large-volume blood loss can occur prior to the development of signs of shock. Displacement of the uterus off the inferior vena cava (IVC) or tilting of the patient with a wedge may be required to augment cardiac return. A detailed obstetric history including length of gestation, prenatal care, complications, and names of care providers can be valuable information for the trauma team.

During the trauma evaluation, the priorities in patient management remain the same in the pregnant patient as in the nonpregnant patient. Adequate oxygenation of the mother, by ensuring an adequate maternal airway with supplemental oxygen, best ensures the adequate oxygenation of the fetus. Access for resuscitation can be achieved with peripheral IVs or subclavian or jugular venous central access. Blood loss should be treated with crystalloid and blood transfusion following the principles of damage control and balanced resuscitation, with an emphasis on early use of blood and blood products in the event of life-threatening hemorrhage.[24,25]

In the secondary survey, a complete physical examination is essential. In addition to a complete examination for maternal injuries, complete examination of the fetus includes estimation of uterine size and fundal height, examination for vaginal bleeding, rupture of membranes, presence of bulging perineum, contractions, or abnormal fetal heart rate (FHR) or rhythm. Vaginal bleeding may be an indicator of premature cervical dilation, early labor, abruption placentae, or placenta previa. Cloudy white or green fluid from the cervical os may represent amniotic sac rupture. A vaginal speculum examination should be performed to assess for cervical dilatation and bleeding from the cervical os. Strong

contractions, or bulging of the perineum (due to the presenting part of the fetus) can signal imminent delivery (or abortion in early pregnancy).

A thorough medical and obstetric history is required for all patients in whom it can be obtained. An accurate date of last menstrual period and expected delivery aids in measurement of uterine size, height, and position. A history of complications of the present or previous births, such as hypertension, preterm labor, abruption placentae, or placenta previa aids in evaluation and management, due to the high rate of recurrence.

Options for evaluation of the fetus include Doppler FHR monitoring or ultrasound. Normal FHR ranges from 120 to 160 beats/min. Tachycardia (>160 beats/min) is seen during stress, hypoxia, or hypotension, however bradycardia (<120 beats/min) also indicates fetal distress and mandates immediate maternal resuscitative efforts including supplemental oxygen, fluid, or blood administration. Fetal heart monitoring should be performed in all potentially viable fetuses involved in a traumatic abdominal injury.

Airway

Increased metabolic needs of the mother and fetus lead to a 30% to 60% increase in oxygen consumption. This in combination with decreases in functional expiratory reserve volume and functional residual capacity due to the enlarged uterus and upward pressure on the maternal diaphragms leads to decreased overall respiratory reserve and can result in rapid onset of hypoxia of mother and fetus.

The average pregnant patient gains about 17% of body weight during pregnancy.[26] This results in an overall increase in BMI from fat and protein deposition, blood volume, interstitial fluid, and uterine size. The resulting increase in Mallanpati scores may complicate airway management and result in morbidity due to failed intubations.[27] Raised progesterone levels also increase total-body water and result in generalized edema, including edema of the airway. Edema of the tongue, oropharynx, and trachea may impair visualization and intubation of the airway, further complicating intubation. These changes progressively increase with increasing gestational age.[28] Gastric compression due to increased fundal height and lower esophageal sphincter dysmotility contribute to an increased risk of aspiration and early intubation should be considered for at-risk patients. Preoxygenation, cricoid pressure, and avoidance of bag-mask ventilation when possible are recommended.

Cardiovascular System

4 Beginning at 10 weeks of gestation, intravascular blood volume increases steadily over the course of pregnancy, reaching up to 50% above normal by term.[29] The increase in plasma volume is relatively greater than the approximately 15% increase in red blood cell (RBC) mass initially; therefore a relative physiologic anemia is seen during early pregnancy. However, erythrocyte production increases later in pregnancy, and after a nadir at 30 to 32 weeks, hematocrits are near normal by term. The relative hypervolemia of pregnancy can mask large-volume hemorrhagic losses and up to 35% of maternal blood loss can be lost prior to signs and symptoms of shock. Pulse rates increase by 10 to 15 beats/min and remain elevated until delivery.

5 As the gravid uterus increases in size, supine positioning can result in "supine hypotensive syndrome" resulting in compression of the IVC and decreased blood return to the heart, resulting in up to a 30% decrease in cardiac output. Symptoms include lightheadedness, dizziness, pallor, tachycardia, and hypotension. Displacing the uterus laterally to the left of the patient, either manually or by use of a wedge to tilt the patient >15 degrees to the patient's left can restore perfusion.

Fluid resuscitation is the first-line therapy for the unstable pregnant trauma patient. Catecholamine release preserves the maternal blood pressure through maternal peripheral vasoconstriction, but decreases fetal blood flow via placental vasoconstriction. Adequate access is essential in the injured pregnant patient, as decreased fetal blood flow precedes maternal hypotension.[30] Two large bore intravenous lines, preferably above the diaphragm, should be placed initially. Adjustments must be made for the relative hypervolemia of pregnancy and fetal distress can precede maternal instability. Blood and blood product transfusion should be considered early in the unstable trauma patient. Type O, Rh-negative blood should be used until type specific or cross-matched blood is available. In the resuscitated, euvolemic patient, if pressor support is required, ephedrine and phenylephrine have the least effect on uterine-placental vasculature and are recommended for initial pressor support in pregnant patients. Additional pressors such as norepinephrine and epinephrine can be considered in the unstable patient, especially in those without a viable pregnancy.[31]

Compression of the IVC by the gravid uterus decreases venous return to the heart and can decrease cardiac output by up to 30%. During cardiopulmonary resuscitation (CPR), lateral displacement of the uterus to the patient's left can improve hemodynamics and CPR efforts. In late pregnancy (>24 weeks), use of a foam wedge or padding to tilt the patient up to 30 degrees to her left can be helpful, though CPR is only 80% effective in this position. Standard Advanced Cardiac Life Support (ACLS) voltage should be used if defibrillation is required.

Pulmonary System

Increased intra-abdominal pressure from the growing uterus causes elevation of the diaphragm and results in a decrease in total lung capacity and functional residual capacity. This results in a compensatory chronic hyperventilation with 30% to 40% increase in minute ventilation. The resultant chronic respiratory alkalosis facilitates transfer of fetal CO_2 to the maternal circulation. Overaggressive correction of respiratory acidosis in the mother can have deleterious effects on the fetus.[32] Hypocapnia ($PaCO_2$ of <30 mm Hg) is common in pregnancy and a "normal" CO_2 (~ 40 mm Hg) may be a sign of imminent respiratory failure. Oxygen consumption is increased approximately 20% in pregnancy and needs to be accounted for in oxygen supplementation.

Elevation of the diaphragm late in pregnancy requires care to be taken when thoracostomy tube placement or thoracentesis is required. Chest tubes for hemo- or pneumothoraces require higher placement and should be inserted in the third or fourth intercostal space.

Ventilatory support, when required, should be individualized to optimize oxygenation and avoid acidosis. There are no studies addressing the ideal way to manage ventilatory support in pregnant patients with acute lung injury or ARDS. While lung protective strategies may be beneficial, hypercapnea in these patients should be avoided.

Gastrointestinal System

The growing uterus causes progressive gastric compression as the pregnancy progresses. Increased progesterone levels in pregnancy result in decreased function and tone of the lower esophageal sphincter, as well as decreases in gastric tone and motility. This places the mother at increased risk of aspiration, especially during intubation. During intubation, rapid sequence induction is recommended given the high risk of aspiration. High levels of progesterone decrease gallbladder contractions and lead to bile stasis and formation of gallstones.

Genitourinary System

Renal function increases to meet the demands of increased circulatory volume during pregnancy. Renal blood flow and glomerular filtration rates (GFRs) increase by 50% to 60% and levels of blood urea nitrogen (BUN), creatinine, urate, and bicarbonate are decreased. Increased water retention causes decreased plasma osmolality. Relaxation of the bladder smooth muscle increases capacity, stasis, and the risk of development of urinary tract infections and pyelonephritis.[33,34]

Hematologic System

Increased intravascular volume relative to RBC production leads to a physiologic anemia with an average hematocrit of 32 during the first two trimesters. This corrects to near normal hematocrit levels by term. White blood cell counts (WBCs) also are relatively increased and can range from 9,800 to 15,000/mm3.

Increased estrogen levels lead to increased production of factors VII, VIII, IX, X, and XII and plasma fibrinogen levels are elevated about 30% to 50%. Plasminogen activator levels are decreased. Protein S activity is decreased and protein C activity is increased.[35] This leads to the "hypercoagulable" state of pregnancy and places these patients at increased risk of deep venous thrombosis (DVT) and pulmonary embolism (PE), with slower resolution and lysis of clot. Normal levels of coagulation factors should raise the suspicion of disseminated intravascular coagulation (DIC).

6 During trauma, entry of fetal Rh+ blood (as little as 0.07 mL) into the blood stream of an Rh− mother results in formation of antibodies. These antibodies, while harmless to the mother, can reenter the bloodstream of the fetus (or subsequent pregnancies) and cause hemolysis of the fetal RBCs. Prophylactic anti-D immune globulin (RhoGAM™) should be given within 72 hours of trauma when significant risk of maternofetal hemorrhage exists. A Kleihauer–Betke (KB) analysis should be performed for all pregnant patients with >12 weeks of gestation.[36,37] A study out of University of Maryland showed a positive KB was the single predictive risk factor for preterm labor with a likelihood ratio of 20.8.[38]

Chart 31-2 Frequency of Injury by Mechanism

Mechanism	Frequency
Motor vehicle collision (MVC)	48.6%
Falls	25.4%
Assault	17.5%
Gunshot	4.3%
Suicide	3.4%
Burns	0.7%

Adapted from El-Kday D, Gilbert WM, Anderson J, et al. Trauma during pregnancy: an analysis of maternal and fetal outcomes in a large population. *Am J Obstet Gynecol* 2004;190(6):1661–1668.

MONITORING AND EVALUATION OF THE FETUS

Pregnancies beyond 24 weeks of gestation are considered viable, and an expedient estimation of gestational age is required. Patient history, fundal height, or ultrasonographic measurement of femur length (in the third trimester) or biparietal measurements can be used.

Optimal management of the pregnant mother results in the best chance of survival of the fetus. However, studies showing fetal death rates can be several fold greater than maternal deaths rates in trauma suggest that maternal survival in itself is not sufficient. Close monitoring of the viable fetus is necessary. Continuous fetal monitoring is the only way to identify fetal distress in the acute setting.[39] The Eastern Association of Surgery for Trauma (EAST) guidelines recommend monitoring of all pregnant female with gestation >20 weeks for at least 6 hours after significant trauma.[40] Early involvement of the neonatal intensive care staff is recommended.

RADIOGRAPHIC IMAGING IN TRAUMA

The ideal diagnostic imaging test in the pregnant patient should be fast, readily available, safe, and accurate. Selection of the appropriate test needs to balance the need for expedient diagnosis while minimizing risk to mother and fetus. During pregnancy, radiation exposure should be avoided or minimized whenever possible. Exposure to less than 5 rad of radiation has not been associated with fetal anomalies or pregnancy loss, and is safe at any gestation age.[41] With proper shielding, however, minimal radiation is transmitted to the fetus with plain films (Chart 31-4).

7 Sonographic evaluation of both the mother and fetus is safe and useful in determining the extent of injuries. FAST ultrasound has excellent specificity and negative predictive value in detecting pericardial, pleural, and peritoneal free fluid in the hemodynamically unstable mother and poses no risk to the fetus.[42] Ultrasound is particularly useful in the evaluation of intrauterine contents, but can miss 50% to 80% of placental abruptions.[43] Fetal ultrasound should be performed to assess for gestational age, cardiac activity, and movement.

CT scans are rapid and sensitive for evaluation of traumatic injuries. CT scans of the head and neck can be performed with minimal radiation exposure to the fetus. As radiation exposure levels from CT scans of the chest, abdomen, and pelvis can be variable, the use of CT should be minimized whenever possible. However, CT imaging should be performed when appropriate for complete evaluation of traumatic injuries. Practitioners should utilize radiation reduction strategies whenever possible.[44]

Magnetic resonance imaging (MRI) poses minimal risk to the fetus and may have a role in the evaluation for ligamentous injuries of the spine and spinal cord injuries. However, use of this modality is limited due to availability and length of time required to perform. Additionally, the MRI scanner is often remote from the resuscitation area, and ongoing resuscitative efforts may not be feasible when the patient is undergoing MRI. Therefore, MRI should only be utilized in hemodynamically normal patients without ongoing resuscitation requirements.

8 Angiography and angioembolization may be useful in the event of life-threatening hemorrhage, but radiation dose increases with increasing duration and extent of evaluation. Typical exposure ranges from 2 to 10 rad/min, and the risk versus benefit needs to be carefully weighed, and patients appropriately counseled. Embolization of the gravid uterus is not recommended, however embolization of the nonuterine vessels is feasible and can be life-saving in pelvic fractures with ongoing hemorrhage.[40]

In counseling patients and families, healthcare providers should emphasize that the radiation exposure from a single diagnostic test is not sufficient to cause harmful effects to the fetus, and that concerns regarding possible effects of radiation should not prevent the use of medically indicated diagnostic studies.[45]

SPECIAL CONSIDERATIONS

Pelvic Fractures

Pelvic fractures in pregnancy are associated with a high rate of hemorrhage and up to 35% fetal mortality in trauma.[46] Engorgement of the pelvic venous complex during the relative hypervolemia of pregnancy can result in massive, life-threatening hemorrhage in the event of pelvic trauma, including fetal death due to maternal shock.[7] Direct injury to the uterus can result in placental abruption or injury to the fetus. The most common fetal injury is traumatic brain injury, especially late in pregnancy as the fetal head descends into the pelvic inlet. Angiography and angioembolization are useful adjuncts in the management of life-threatening pelvic hemorrhage.

Chart 31-3 Physiologic Changes in Pregnancy

Cardiovascular	Increased heart rate Decreased systemic vascular resistance Decreased blood pressure (first and second trimesters) Increased plasma volume
Pulmonary	Elevated diaphragm Increased tidal volume Increased minute ventilation Decreased functional residual capacity Decreased PCO_2
Gastrointestinal	Decreased lower esophageal sphincter competency Decreased gastric motility Increased transaminase levels Impaired gallbladder contractions
Genitourinary	Increased glomerular filtration rate Increased renal plasma flow Decreased blood urea nitrogen levels Decreased creatinine levels Hydronephrosis/hydroureter
Hematologic	Relative anemia with increased overall RBC volume Leukocytosis Increased factors VII, VIII, IX, X, XII (hypercoagulability) Decreased fibrinolytic activity (hypercoagulability) Increased fibrinogen

Chart 31-4 Estimated Fetal Radiation Doses from Common Imaging Studies

Diagnostic Test	Fetal Dose (Rad)
Chest x-ray	<0.01
Abdominal x-ray	0.1–0.3
Pelvis x-ray	0.04–0.24
Extremity x-ray	<0.01
CT head	<0.05
CT chest	0.1–0.45
CT abdomen	0.24–2.6
CT pelvis	0.73–4.6

Adapted from Williams PM, Fletcher S. Health effects of prenatal radiation exposure. *Am Fam Physician* 2010;82:488–493.

Abruptio Placentae

Disruption of the placenta from the uterine wall is the most common cause of late maternal bleeding and the leading cause of fetal demise after trauma.[47] Fetal mortality ranges from 30% to 70%. Shearing of the inelastic placenta off the relatively elastic uterine wall from direct trauma or deceleration leads to separation of the placenta–uterine interface and results in maternal bleeding and disruption of blood flow to the fetus. Disruption of greater than 50% of the placental surface is uniformly fatal to the fetus. However, fetal distress may not manifest until greater than 30% of disruption occurs. Risk factors for abruptio placentae include hypertension, diabetes mellitus, advanced age, multiparity, tobacco use, and cocaine use. Symptoms include abdominal pain, intense uterine contractions, vaginal bleeding, and back pain. Vaginal bleeding with abdominal pain after trauma mandates prompt ultrasonographic evaluation. Massive bleeding can occur with hemodynamic collapse, but even occult bleeding can lead to plasminogen activator–mediated fibrinolysis and DIC.[48] Delayed presentation of abruptio placentae can occur and patients with blunt injury to the abdomen should be closely monitored.[49]

Uterine Rupture

Traumatic rupture due to blunt trauma is uncommon, with an incidence of approximately 0.6%, but is associated with up to 10% mortality of the mother and almost 100% mortality of the fetus.[11,50] Most result from direct high-energy trauma to the abdomen and are associated with concurrent injuries. Risk factors include prior caesarean section or prior uterine surgery.[51] Diagnosis can be challenging, as abdominal pain, often without vaginal bleeding, can be the only sign of underlying uterine rupture. Excellent outcomes in subsequent pregnancies can be achieved in those with prior uterine rupture who undergo uterine repair.[52] An attempt at repair and subsequent vaginal delivery should be encouraged.

Amniotic Fluid Embolism

Embolism of the amniotic fluid into the maternal venous circulation is a rare, but often fatal complication of abdominal trauma or placental abruption. Mortality rates of up to 80% have been reported. Amniotic fluid embolization is characterized by sudden onset of hypoxemia, hypotension, and coagulopathy. Diagnosis is mostly clinical, though chest radiography may show evidence of pulmonary edema or bilateral scattered infiltrates characteristic of acute respiratory distress syndrome (ARDS). DIC occurs in 30% of these patients. Treatment is supportive with optimization of hemodynamics, oxygenation, and treatment of resulting coagulopathy.[53]

Preeclampsia/Eclampsia

Preeclampsia is infrequent, occurring in up to 5% of pregnancies. Risk factors include nulliparity, diabetes mellitus, chronic hypertension, renal disease, advanced maternal age (>35 years), obesity, prior or family history of preeclampsia.[54] Signs of this syndrome include hypertension, edema, proteinuria, and hyperactive reflexes, though patients may present only with hypertension without other signs. Eclampsia, the onset of seizures with preeclampsia, occurs rarely in about 0.05% to 0.2% of pregnancies, but mandates immediate treatment with magnesium sulfate, and consideration of emergent caesarian section. An alteration in mental status in the pregnant trauma patient mandates consideration of eclampsia as an underlying cause.

Disseminated Intravascular Coagulation

Major trauma, especially those involving massive hemorrhage, abruption, preeclampsia/eclampsia, HELLP (hemolysis, elevated liver enzymes, low platelet count), amniotic fluid embolism, or SIRS (systemic inflammatory response syndrome), can lead to disruption of the hemostatic cascade. In healthy patients, tissue factor binds to factor VIIa, generating Xa. Xa binds to cofactor Va, converting prothrombin. Regulation of this cascade is complex, involving tissue factor pathway inhibitor, antithrombin, and activated protein C. Dysfunction of this regulatory mechanism leads to unchecked thrombin production, with diffuse intravascular fibrin deposition (causing end-organ damage and failure) and fibrinolysis, resulting in depletion of coagulation factors and platelets (leading to a profound bleeding diathesis). Placental abruption can release thromboplastin into the maternal circulation, resulting in severe DIC. Treating involves expedient correction of clotting deficits and emptying of the uterus.

EMERGENT CAESARIAN SECTION

Vaginal delivery is preferred whenever possible, even if labor begins during evaluation and treatment for traumatic injuries, including exploratory laparotomy and surgical intervention.[55] Indications for emergent caesarian section include maternal shock, massive exsanguination, facilitation of maternal treatment, high risk of fetal demise, and unstable thoracolumbar spinal injuries. Perimortem caesarian section can be considered if the estimated gestational age is over 26 weeks. However, the decision to perform a caesarian section must be made in an expedient manner. If performed within 5 minutes of maternal demise, survival of over 75% can be achieved in viable fetuses with fetal heart tones and >26 weeks of gestation.[56,57] Case reports also show that 60% of mothers had either improved hemodynamics or return of spontaneous circulation after performance of perimortem caesarian section. The 2010 American Heart Association guidelines recommend perimortem caesarian section for the viable fetus, in the event of maternal cardiac arrest without return of spontaneous circulation by 4 minutes.[58] These recommendations are widely supported by national and international associations including the American College of Obstetricians and Gynecologists and the Royal College of Obstetricians and Gynaecologists.[59,60] Early involvement of the obstetrics team facilitates the decision to perform an emergent caesarian section and ensures the timeliest delivery of the child should one be necessary.

DEEP VENOUS THROMBOSIS AND PULMONARY EMBOLISM

9 Pregnant patients are at increased risk for DVT and PE. These patients may have venous stasis from decreased mobility, relative vena cava compression, as well as hypercoagulability due to increased production of coagulation factors. Endothelial injury is common in trauma and adds to the increased risk in these patients (Virchow's Triad). Unfractionated subcutaneous heparin, in addition to sequential compression device use and early ambulation, is recommended in pregnancy and should be initiated once stable. Low–molecular-weight heparin appears to be safe in the treatment of DVT/PE with at least one small, randomized controlled trial showing safety and effectiveness with less bleeding complications. Coumadin is not recommended for use in treatment of DVT/PE due to difficult regulation of anticoagulation. When given in the first trimester, up to a 29% incidence of warfarin embryopathies can be seen, including mental retardation, optic atrophy, ventral midline dysplasia, and central nervous system (CNS) abnormalities. Late pregnancy administration is associated with significant risk of fetal bleeding and mortality.[61] Low–molecular-weight heparin does not cross the placenta and is not associated with increased teratogenicity or fetal bleeding, and is recommended by the American College of Chest Physicians for thromboembolism prophylaxis and treatment in pregnant patients.[62] Placement of a vena cava filter should be considered when the extent of thrombosis is extensive or patients at high risk for PE.

SOCIAL AND ETHICAL CONSIDERATIONS

10 IPV affects up to 324,000 women each year, and 4% to 9.5% of all pregnancies.[6,63–65] IPV affects women across all age groups, religions, ethnic backgrounds, socioeconomic level, education, and sexual orientation. Care providers need to have low thresholds for screening pregnant patients for IPV, especially when patients present with multiple episodes of trauma, suspicious patterns of injury, or injury that does not correspond to the given history. Although screening during trauma evaluation can be challenging, even brief screening tools have found to be effective. Early detection and intervention, with the assistance of social work and local resources, best ensures the safety of both mother and fetus.[66,67]

Substance abuse is increasingly seen in pregnant trauma patients. In two major urban centers, 50% to 80% of admitted female trauma patients tested positive for cocaine and/or heroin.[68] Data from the American College of Surgeons National Trauma Data Bank showed 12.9% and 19.6% of traumas in pregnant women were associated with alcohol and drug use, respectively.[69] Alcohol abuse is associated with decreased use of seatbelt restraint systems (22% vs. 46% in sober patients).[68] While seatbelt use by pregnant women is higher than in the general populace, improved education may improve outcomes given half of all fetal losses could have been prevented with proper seatbelt use.[15]

TEAM APPROACH TO TRAUMA IN THE PREGNANT PATIENT

A coordinated approach involving prehospital providers, the Emergency Medicine team, Nursing, Obstetrics, Obstetric Nursing, Critical Care and Surgery is key to the proper management of these patients. Involvement of the obstetric team (even prior to arrival of the patient) can be invaluable and consideration should be given for early notification.

SUMMARY

The optimal treatment of the pregnant patient requires special attention to the evolving anatomical and physiologic changes that occur during pregnancy. Evaluation and management should be tailored to the stage of pregnancy and requires a multidisciplinary, team approach. While fetal survival is best achieved by appropriate resuscitation and care of the mother, recognition of the unique patterns and complications of traumatic injury ensure the best possible outcome for the mother and fetus.

References

1. Fildes J, Reed L, Jones N, et al. Trauma: the leading cause of maternal death. *J Trauma* 1992;32:643–645.
2. El Kady D. Perinatal outcomes of traumatic injuries during pregnancy. *Clin Obstet Gynecol* 2007;50:582–591.
3. Schiff MA, Holt VL. Pregnancy outcomes following hospitalization for motor vehicle crashes in Washington State from 1989 to 2001. *Am J Epidemiol* 2005;161:503–510.
4. Peckham CH, King RW. A study of intercurrent conditions observed during pregnancy. *Am J Obstet Gynecol* 1963;87:609–624.
5. Kuczkowski KM. Trauma during pregnancy: a situation pregnant with danger. *Acta Anaeth Belg* 2005;56:13–18.
6. Drost TF, Rosemurgy AS, Sherman HF, et al. Major trauma in pregnant women: maternal/fetal outcome. *J Trauma* 1990;30:574–578.
7. Lavin JP, Polsky SS. Abdominal trauma during pregnancy. *Clin Perinatol* 1983;10:423–438.
8. Crosby WM. Traumatic injuries during pregnancy. *Clin Obstet Gynecol* 1983;26:902–912.
9. Weiss H. Pregnancy associated injury in Pennsylvania, 1995. *Ann Emerg Med* 1995;34:626–636.
10. Weiss HB, Songer TJ, Fabio A. Fetal deaths related to maternal injury. *JAMA* 2001;286:1863–1868.
11. Mattox KL, Goetzl L. Trauma in pregnancy. *Crit Care Med* 2005;33(suppl 10):S385–S389.
12. Weiss HB, Lawrence BA, Miller TR. Pregnancy-associated assault hospitalizations. *Obstet Gynecol* 2002;100(4):773–780.
13. Poole GV, Martin JN Jr, Perry KG Jr, et al. Trauma in pregnancy: the role of interpersonal violence. *Am J Ostet Gynecol* 1996;174:1873–1878.
14. Rogers FB, Rozycki GS, Osler TM, et al. A multi-institutional study of factors associated with fetal death in injured pregnant patients. *Arch Surg* 199;134:1274–1277.
15. Klinich KD, Flannagan CA, Rupp JD, et al. Fetal outcome in motor-vehicle crashes: effects of crash characteristics and maternal restraint. *Am J Obstet* 2008;198(4):450.e1–e9.
16. Franger AL, Buschbaum HJ, Peaceman AM. Abdominal gunshot wounds in pregnancy. *Am J Obstet Gynecol* 1989;160:1124–1128.
17. Petrone P, Talving P, Browder T, et al. Abdominal injuries in pregnancy:155 month study at two level 1 trauma centers. *Injury* 2011;42:47–49.
18. Iliya FA, Hajj SN, Buchsbaum HJ. Gunshot wounds of the pregnant uterus: report of two cases. *J Trauma* 1980;290:90–92.

19. Brooks DC, Oxford C. Chapter: The pregnant surgical patient. *ACS Surg Princ Pract* 2007:1–21.
20. Richards JR, Ormsby EL, Romo MV, et al. Blunt abdominal injury in the pregnant patient: detection with US. *Radiology* 2004;233(2):463–470.
21. Goodwin H, Holmes JF, Wisner DH. Abdominal ultrasound examination in pregnancy blunt trauma patients. *J Trauma* 2001;50(4):689–693.
22. Brown MA, Sirlin CB, Farahmand N, et al. Screening sonography in pregnant patients with blunt abdominal trauma. *J Ultrasound Med* 2005;24(2):175–181.
23. American College of Surgeons' Committee on Trauma. *Advanced Trauma Life Support, Student Manual.* 9th ed. Chicago: American College of Surgeons; 2012.
24. Xue X, Liu L, Rao Z. Management of postpartum hemorrhagic shock and disseminated intravascular coagulation with damage control resuscitation. *Am J Emerg Meg* 2013;31:1291.e1–e2.
25. Cotton BA, Au BK, Nunez TC, et al. Predefined massive transfusion protocols are associated with a reduction in organ failure and postinjury complications. *J Trauma* 2009;66:41–48.
26. Dennehy KC, Pian-Smith MC. Airway management of the Parturient. *Int Anesthesiol Clin* 2000;38:147–159.
27. Pilington S, Carli F, Dakin MJ, et al. Increase in Mallampati score during pregnancy. *Br J Anaesth* 1994;74:638–642.
28. Reisner LS, Benumof JL, Cooper SD. The difficult airway: risk, prophylaxis and management. In Chestnut DH, ed. *Obstetric Anesthesia: Principles and Practice.* St. Louis, MO: Mosby;1999:590–620.
29. Hytten FE, Leitch I. *The Physiology of Human Pregnancy.* 2nd ed. Oxford, England: Blackwell Scientific Publications; 1971;18.
30. Morkovin V. Trauma in pregnancy. In Farrell RG, ed. *Ob/Gyn emergencies: The first 60 minutes.* Rockville, MD: Aspen Publications; 1986;71.
31. Dildy G, Belfort M, Saade G, et al. *Critical Care Obstetrics.* 4th ed. Malden, MA: Blackwell Publishing; 2004:691.
32. Gordon MC. Maternal physiology in pregnancy. In Gabbe SG, Niebyl JR, Simpson JL, eds. *Obstetrics: Normal and Problem Pregnancies.* 4th ed. Philadelphia, PA: Churchill Livingston; 2002:63–91.
33. Chesley LC. Renal function during pregnancy. In: Carey HM, ed. *Modern trends in Human Reproductive Physiology.* Vol 1. London: Butterworths; 1963:205–214.
34. Chestnutt AN. Physiology of normal pregnancy. *Crit Care Clin* 2004;20:609–615.
35. Said JM, Ignjatovic V, Monagle PT, et al. Altered reference ranges for protein C and protein S during early pregnancy: implications for the diagnosis of protein C and protein S deficiency in pregnancy. *Thromb Haemost* 2010; 103:984–988.
36. Perlman MD, Tintinalli JE, Lorenz RP. A prospective controlled study of outcome after trauma during pregnancy. *Am J Obstet Gynecol* 1990;162:1502–1507.

37. Muench MV, Baschart AA, Reddy UM, et al. Pregnancy is not a sufficient indicator for trauma team activation. *J Trauma* 2004;57:1094–1098.
38. Muench MV, Baschat AA, Reddy UM, et al. Kleihauer-Betke testing is important in all cases of maternal trauma. *J Trauma Inj Infect Crit Care* 2003;57:1094–1098.
39. Curet MJ, Schermer CR, Demarest GB, et al. Predictors of outcome in trauma during pregnancy: identification of patients who can be monitored for less than 6 hours. *J Trauma Inj Infect Crit Care* 2000;49:18–25.
40. Barraco ED, Chiu WC, Clancy TV, et al. Practice management guidelines for the diagnosis and management of injury in the pregnant patient: the EAST practice management guidelines group. *J Trauma* 2010;69:211–214.
41. Brent RL. The effect of embryonic and fetal exposure to x-ray, microwaves, and ultrasound: counseling the pregnant and nonpregnant patient about these risks. *Semin Oncol* 1989;16:347–368.
42. Kirkpatrick A, Ball C, D'Amours S, et al. Acute resuscitation of the unstable adult trauma patient: bedside diagnosis and therapy. *Can J Surg* 2008;51:57–69.
43. Bernstein MP. Imaging of traumatic injuries in pregnancy. *Am Roentgen Radiol Soc* 2008;2:203–210.
44. McCollough CH, Primak AN, Braun N, et al. Strategies for reducing radiation dose in CT. *Radiol Clin North Am* 2009:47:27–40.
45. ACOG Committee on Obstetric Practice. ACOG Committee Opinion #299. Guidelines for diagnostic imaging during pregnancy. *Obstet Gynecol* 2004; 104;647–651.
46. Leggon RE, Wood CG, Indeck MC. Pelvic fractures in pregnancy: factors influencing maternal and fetal outcomes. *J Trauma* 2002;53:796–804.
47. Crosby WM. Trauma in the pregnant patient. *Conn Med* 1986;50:251–258.
48. Hill C, Pickinpaugh J. Trauma and surgical emergencies in the obstetric patient. *Surg Clin North Am* 2008;88:421–440.
49. Higgins SD, Garite TJ. Late abruptio placentae in trauma patients: implications for monitoring. *Obstet Gynecol* 1984;63:10S–12S.
50. Weintraub AY, Leron E, Manor M. The pathophysiology of trauma in pregnancy: a review. *J Matern Fetal Neonatal Med* 2006;19:601–605.
51. Schrinsky DC, Benson RC. Rupture of the pregnant uterus: a review. *Obstet Gynecol Surv* 1978;33:217–232.
52. Fox NS, Gerber RS, Mourad M, et al. Pregnancy outcomes in patients with prior uterine rupture or dehiscence. *Obstet Gynecol* 2014;123(4):785–789.
53. Judich A. Kuriansky J, Engelberg I, et al. Amniotic fluid embolism following blunt abdominal trauma in pregnancy. *Injury* 1998;29:475–477.
54. Duckitt K, Harrington D. Risk factors for pre-eclampsia at antenatal booking: systemic review of controlled studies. *BMJ* 2005;330:565.
55. Dyer I, Barclay DL. Accidental trauma complicating pregnancy and delivery. *Am J Obstet Gynecol* 1962;83:907.

56. Morris JA, Rosenbower TJ, Jurkovich GJ, et al. Infant survival after cesarean section for trauma. *Ann Surg* 1996;223:481–491.
57. Rothengerer D, Quattlenbaum FW, Perry JF. Blunt maternal trauma: a review of 103 cases. *J Trauma* 1978;18:173–179.
58. Vanden Hoek TL, Morrison LJ, Schuster M, et al. Part 12: cardiac arrest in special situations: 2010 American Heart Association Guidelines for Cardiopulmonary Resuscitation and Emergency Cardiovascular Care. *Circulation* 2010;122:S829–S836.
59. American College of Obstetricians and Gynecologists. ACOG Practice Bulletin No. 100: critical care in pregnancy. *Obstet Gynecol* 2009;113:443–450.
60. Royal College of Obstetricians and Gynaecologists. RCOG Green-top Guidelines No. 56: Maternal Collapse in Pregnancy and the Puerperium. 2011. Available online at https://www.rcog.org.uk/en/guidelines-research-services/guidelines/gtg56/. [Online]. Accessed September 10, 2014.
61. Ginsberg JS, Hirsch J. Use of antithrombotic agents during pregnancy. *Chest* 1998;114:524S–530S.
62. Bates SM, Gree IA, Pabinger I, et al. Venous thromboembolism, thrombophilia, antithrombotic therapy and pregnancy: American College of Chest Physicians Evidence-Based Clinical Practice Guidelines (8th Edition). *Chest* 2012;141(2 suppl):e691S–736S.
63. Kissinger DP, Rozycki GS, Morris JA, et al. Trauma in pregnancy: predicting pregnancy outcomes. *Arch Surg* 1991;126:1079–1086.
64. Hoff WS, D'Amelio FL, Tinkoff GH, et al. Maternal predictors of fetal demise in trauma during pregnancy. *Surg Gynecol Obstet* 1991;172:175–180.
65. Tinker SC, Reefhuis J, Dellinger AM, et al. Epidemiology of maternal injuries during pregnancy in a population-based study, 1997–2005. *J Womens Health* 2010;19(12):2211–2218.
66. McFarlane H, Parker B, Soeken K, et al. Assessing for abuse during pregnancy. Severity and frequency of injuries and associated entry into prenatal care. *JAMA* 1992;267(23):3176–3178.
67. Krimm J, Heinzer MM. Domestic violence screening in the emergency department of an urban hospital. *J Natl Med Assoc* 2002;94(6):484–491.
68. Patteson SK, Snider CC, Meyer DS, et al. The consequences of high risk behaviors: trauma during pregnancy. *J Trauma* 2007;62:1015–1020.
69. Ikossi DG, Lazar AA, Morabito D, et al. Profiles of mothers at risk: an analysis of injury and pregnancy loss in 1195 trauma patients. *Am Coll Surg* 2005; 200:49–56.

Chapter 32

Postinjury Management

Bellal Joseph and Peter Rhee

Key Points

1 Damage control resuscitation is critical to avoid the lethal triad of trauma: dilutional coagulopathy, hypothermia, and acidosis.

2 Permissive hypotension, liberal use of blood products instead of isotonic fluids, and early correction of coagulopathy are the principles of damage control resuscitation.

3 Massive transfusion protocols and early use of red cells, fresh frozen plasma, and platelets in a 1:1:1 ratio minimizes the risk of dilutional coagulopathy.

4 Attempts to achieve supernormal resuscitation endpoints should be avoided to prevent complications such as abdominal compartment syndrome.

5 Traumatic brain injury (TBI) remains the leading cause of death from trauma. Neurologic examination is a valuable tool and can replace repeat head CT scans in mild TBI. Initial laboratory data have prognostic value in TBI outcomes.

6 Preinjury coagulopathy with home medications is common in patients with TBI and knowledge of home medications is important.

7 Early use of enteral nutrition is desirable.

8 Organ donation is a legitimate outcome in trauma patients. Early involvement of organ procurement networks and social services as well as aggressive resuscitation protocols improves procurement rates.

INTRODUCTION

Trauma is now the leading cause of death for ages 46 and below in the United States.[1] Hemorrhagic shock is the most common cause of mortality during the first 6 hours following trauma and 16% to 80% of those deaths may be preventable.[2] Postinjury management predominantly focuses on two goals, early control of bleeding and resuscitation.

ACUTE TRAUMATIC COAGULOPATHY

Coagulopathy is known to worsen posttraumatic hemorrhage and is associated with increased mortality and worse outcomes. Interestingly, up to 25% of trauma patients are already coagulopathic upon arrival to the hospital.[3,4] Current data suggest that coagulopathy develops in the early posttraumatic period even before resuscitation begins and is now referred to as acute traumatic coagulopathy.[4–6] Diffuse endothelial damage, activation of the protein C pathway, and massive catecholamine release are some of the proposed mechanisms for acute traumatic coagulopathy.[7] Acute traumatic coagulopathy may be exacerbated by hypothermia, acidosis, and dilution of clotting factors.

1 Hypothermia in trauma patients results from a multitude of factors that include radiant heat losses to the environment, failure of shivering response during anesthesia, intraoperative heat loss from exposed peritoneal surfaces, and tissue hypoxia during hemorrhagic shock with decreased metabolism. Another major cause of hypothermia is the use of relatively cool room temperature resuscitation fluids or cold refrigerated blood products that were not warmed before infusion.[8–10] These cumulative factors produce qualitative and quantitative defects in platelet function and decrease coagulation factor activity.[11–13] In addition to reducing coagulation factor activity, dilutional coagulopathy from large-volume crystalloid resuscitation and acidosis from prolonged tissue hypoxia perpetuates the bloody vicious cycle.[14,15] The combined presence of three factors, hypothermia, acidosis, and coagulopathy, is known as the “lethal triad.” Modern trauma resuscitation is defined as damage-controlled resuscitation and aimed at reducing the iatrogenic development of this “lethal triad.”

DETECTION OF TRAUMATIC COAGULOPATHY

The early identification of acute traumatic coagulopathy remains a challenge. Conventional coagulation assays like PT, aPTT, and INR are insensitive and unreliable in trauma patients, as they do not provide an accurate assessment of the in vivo state of coagulation. Moreover, these assays are performed at physiologic pH and temperature; because of this they are unable to account for the effects of hypothermia and acidosis on coagulation.[7] Acute traumatic coagulopathy involves changes in both coagulation and fibrinolytic pathways, and detection requires a more dynamic view of all components of the coagulation cascade, which is provided by viscoelastic tests, that is, thromboelastography and rotational thromboelastometry. These assays rely on changes in clot strength to detect coagulation defects and provide an in vivo picture of the coagulation and fibrinolytic processes. These tests also assess the interaction between coagulation factors and platelets and can detect functional changes in platelet function even with normal platelet counts. They can be performed with much more rapidity and have been shown to detect coagulation abnormalities with higher sensitivity as compared to conventional coagulation assays.[16–18] Viscoelastic tests have also shown to be more accurate in predicting blood product requirements and massive transfusion and can therefore guide blood transfusion in trauma patients.[19,20] Despite these advantages, viscoelastic tests come with inherent disadvantages such as cost and the need for greater expertise in performance and interpretation.

DAMAGE CONTROL RESUSCITATION

The primary objective of resuscitation following hemorrhage is to restore effective circulating volume to allow adequate tissue perfusion and oxygenation. Historically, the standard of practice has been to aggressively resuscitate patients with high volumes of crystalloids to restore volume and blood pressure. In recent years, there has been a paradigm shift away from the large-volume resuscitation. Current strategies combine the principles of permissive hypotension, liberal use of blood products instead of isotonic fluids, the use of hypertonic saline to pull water back into the vascular system, and early correction of coagulopathy with blood products as well as drugs (Table 32-1).

2 Permissive hypotension aims at restoring systolic blood pressure to 90 mm Hg so that adequate tissue perfusion can be maintained while not exacerbating blood loss, before definitive hemorrhage control is achieved. Large-volume resuscitation with crystalloids before definitive hemostasis can raise blood pressure which can "pop off" the clot and worsen hemorrhage.[21] A target mean arterial pressure (MAP) of around 60 mm Hg is thought to maintain adequate tissue perfusion without the potential for increased blood loss.[22,23,24,25]

A brief period of hypotension with a MAP around 60 mm Hg can be safely maintained for short periods of time without risk of irreversible damage or an increase in mortality.[26] Permissive hypotension has been shown to reduce the risk of death and development of coagulopathy.[3,27] However, in patients with hemorrhagic shock and concurrent traumatic brain injury (TBI), the safety of permissive hypotension has not been demonstrated and thus it is not yet recommended.[28]

Up to 5% of civilian trauma patients require massive transfusion, defined as the need for more than 10 units of red blood cells in 24 hours. These patients are at greatest risk for developing dilutional coagulopathy from large volumes of resuscitation even if packed red cell transfusion is used early in the resuscitation phase. Damage control resuscitation (DCR) utilizes massive transfusion protocols and early use of red cells, fresh frozen plasma, and platelets in a 1:1:1 ratio in an attempt to reconstitute whole blood. The use of blood products early in the course of resuscitation is not only an attempt to combat the coagulopathy in trauma patients requiring massive transfusion but to also minimize the use of crystalloids and colloids.[29–31]

The use of predefined massive transfusion protocols has shown improved survivals and decrease in adverse outcomes.[32,33] This approach requires the ability to predict the need for massive transfusion in trauma patients at the time of arrival which is often difficult even for experienced surgeons. Multiple scoring systems have been developed to help define the cohort requiring massive transfusion.[34,35]

3 The appropriate ratios of packed red cells, fresh frozen plasma, and platelets in exsanguinating trauma patients have been debated. The concept of a 1:1:1 ratio stems from military data which show improved survival with the use of fresh whole blood. Since civilian trauma centers do not have fresh whole blood available, component therapy is an attempt to reconstitute whole blood by giving red cells, fresh frozen plasma, and

platelets in a nearly physiologic ratio. Most studies have shown improved mortality with the use of high plasma and pRBC ratios with even greater survival in those with early (6 to 12 hours) use of high ratios.[5,8,36–41] The use of a 1:1 ratio for pRBC and platelets has also shown improved survival.[38] Despite the survival advantage with the use of a 1:1:1 ratio for transfusion, the potentially lethal complications of blood transfusion need to be kept in mind. The PROPPR trial which was a multicenter prospective randomized study in hemorrhagic trauma patients demonstrated an early survival benefit when the patients were resuscitated with a 1:1:1 ratio compared to a 2:1:1 ratio but the 28-day mortality was not statistically significantly different.

Table 32-1 Components of Damage Control Resuscitation

- Permissive hypotension
- Early definitive hemorrhage control
- Reduced crystalloid use
- Use of hypertonic saline
- Early correction of coagulopathy with drugs (Factor VIIa, PCC, TXA)
- Increased use of blood products in 1:1:1 ratios

PCC, Prothrombin complex concentrate; TXA, Tranexamic acid.

Hypertonic saline has many potential advantages in that it can resuscitate with low volume by pulling water into the vascular space and thus avoids excess water during resuscitation. This concept has advantages especially in the military field environment. Hypertonic saline is also thought to be an immune modulator that potentially decreases inflammation associated with resuscitation injury.[42] However, a multicenter prospective trial in trauma patients with hemorrhagic shock was halted before completion as the outcome was similar between the groups. Overall there was no survival disadvantage in the hypertonic saline arm of the study except in a small subset of patients who did not require blood transfusion. This subset of patients had higher mortality if given hypertonic saline in the field. There was also a subset that required ICU treatment that showed higher survival and decreased multiple organ failure when hypertonic saline was given.[43] Since 7.5% hypertonic saline is not commercially available, an alternative is to use 5% hypertonic saline. Those who use 5% hypertonic saline administer it as a one-time bolus in the initial phase of resuscitation. This approach may be beneficial in patients with TBI. The safety of using 5% hypertonic saline has been shown in two studies.[44,45] A caveat of using hypertonic saline is that it causes hyperchloremic acidosis, but clinical significance has not yet been demonstrated. Because of the capability of increasing intravascular volume, the ideal time and place for hypertonic saline use may be in the field, especially in the military setting.[46]

Hyperfibrinolysis associated with traumatic coagulopathy may decrease levels of fibrinogen. High plasma:pRBC ratios adequately replenish the fibrinogen pool required for adequate hemostasis and thus the use of cryoprecipitate rich in fibrinogen as an adjunct to DCR is rational.[8] The use of cryoprecipitate has additional advantages as it provides particles that act as a low-volume colloid resuscitation and draw water into the

vascular system, and is an adjunct in resuscitation. Tranexamic acid is an antifibrinolytic agent found to be safe and effective in reducing the risk of bleeding if used within 3 hours of injury.[47] The military Tactical Combat Casualty Care Committee has recommended its use in the military setting. Several other novel strategies have also been used as an adjunct in DCR including the use of activated recombinant factor VII (rFVIIa). rFVIIa activates factor Xa at the site of tissue injury by complexing with tissue factor on the surface of platelets. Use of rFVIIa has shown to effectively reduce blood loss and mortality in massive trauma patients; its use is limited by high costs.[48,49] Prothrombin complex concentrate (PCC) is another cost-effective option that reverses coagulopathy in traumatic injury.[50]

The discussion of DCR should also include damage control laparotomy. After injury, when a trauma patient requires laparotomy, some patients may require abbreviated laparotomy in order to better resuscitate the patient so that the prolonged initial surgery does not harm the patient. Although damage control laparotomy has been widely accepted as the standard of care for trauma patients, it was adopted without rigorous proof of concept. One hallmark study suggested that damage control laparotomy is of benefit in trauma patients with numerous major visceral injuries that also have vascular injury; this study also showed that damage control laparotomy in patients without major injuries was associated with worse outcome.[51] Definitive laparotomy may have survival benefit with decrease in morbidities known to accompany damage control laparotomy such as open abdomens and enterocutaneous fistulas. Because of the decreased number of surgeries and morbidities, the cost benefits were significant.[52,53]

ENDPOINTS OF RESUSCITATION

The ultimate goal of resuscitation is to ensure adequate oxygen delivery to tissues. Prolonged tissue hypoxia is associated with multiorgan dysfunction syndrome, risk of infection, and increased mortality.

Advanced Trauma Life Support guidelines define the correction of vital signs like blood pressure and heart rate as markers of adequate resuscitation. However, up to 82% of severely injured patients with normalized vital signs have ongoing occult ischemia that is associated with adverse outcomes.[54] While normalization of vital signs may describe the current perfusion status, they do not assess oxygen debt, defined as ongoing oxygen deficits that have accumulated during the period of shock. Oxygen debt is known to be associated with increased mortality.[55,56] Arterial lactate and base deficit may serve as indicators for severity of shock and may help to stratify patients. Trends in serum lactate levels indicate adequacy of resuscitation.

Invasive monitoring with central venous pressure (CVP) and pulmonary artery catheter (PAC) have been extensively used to guide resuscitation. CVP and pulmonary capillary wedge pressure monitoring provide information regarding the intravascular volume, but concurrent factors like mechanical ventilation and changes in ventricular compliance from myocardial dysfunction limit their efficacy in accurately guiding resuscitation.[57] Moreover, PAC use in critically ill trauma patients has not been shown to improve outcomes.[58]

$ScVO_2$ and SVO_2 measure central venous oxygen saturation from the upper body and mixed venous oxygen saturation from both the upper and lower body, respectively. Inadequate oxygen supply from ongoing shock or increased oxygen demand leads to an increased tissue extraction of oxygen, which is reflected as a decrease in the values of $ScVO_2$ and SVO_2. SVO_2 of less than 65% even in the presence of normal vital signs indicates blood loss and need for transfusion to optimize oxygen supply and demand.[59] Therefore, $ScVO_2$ and SVO_2 provide a real-time picture of tissue perfusion and are able to detect very subtle changes in oxygen delivery. The ideal marker for resuscitation may be to determine blood volume, but there is currently no simple way to determine ideal circulating blood volume.

ABDOMINAL COMPARTMENT SYNDROME

4 Abdominal compartment syndrome is an undesired consequence of elevated intra-abdominal pressure and a cause of morbidity and mortality.[60] The incidence of abdominal compartment syndrome is decreasing with recent evolution in resuscitation strategy, suggesting a possible iatrogenic etiology.[61] Intra-abdominal hypertension is defined as a pressure of greater than or equal to 12 mm Hg. Intra-abdominal hypertension is graded based on increasing intra-abdominal pressure (Table 32-2). Abdominal compartment syndrome is defined as a sustained intra-abdominal pressure greater than 20 mm Hg (with or without an abdominal perfusion pressure of less than 60 mm Hg) with new organ dysfunction or failure.[62] Experimental data indicate that hepatic arterial, portal venous, and hepatic microcirculatory blood flow are markedly reduced when intra-abdominal pressure is increased.[62,63] Typically, abdominal compartment syndrome is observed after severe abdominal trauma with intra-abdominal hemorrhage, severe liver and kidney injuries, and in both operatively and nonoperatively managed settings (primary abdominal compartment syndrome).[64–66] Excessive large-volume resuscitation, even in the absence of any direct abdominal trauma, can also lead to abdominal compartment syndrome (secondary abdominal compartment syndrome).[67–69] Recurrent or tertiary abdominal compartment syndrome refers to a condition following a previously treated primary or secondary abdominal compartment syndrome.[62] Risk factors for development of abdominal compartment syndrome include diminished abdominal wall compliance, increased intraluminal and intra-abdominal content, crystalloid resuscitation/leak, and other risk factors such as age, shock, high BMI, coagulopathy, and mechanical ventilation.[70–80] Abdominal compartment syndrome can even occasionally occur in patients with an open abdomen. The diagnosis often begins with findings of a tense and distended abdomen in the presence of high end-inspiratory airway pressures and other signs of organ dysfunction (i.e., oliguria, rising serum creatinine). Additional clinical signs consistent with abdominal compartment syndrome are a reduced cardiac output, elevated systemic vascular resistance, and elevated pulmonary capillary wedge pressure with simultaneous low or normal calculated estimates of end-diastolic volume. The standard for monitoring intra-abdominal pressure is bladder pressure measurement via intravesical technique. Bladder pressure is measured in end-expiration with the patient supine, by distending the bladder with 25 mL of sterile saline.[81,82]

Table 32-2 Grades of Intra-abdominal Hypertension

Grade	Intra-Abdominal Pressure
I	12–15 mm Hg
II	16–20 mm Hg
III	21–25 mm Hg
IV	>25 mm Hg

Surgical decompression of the abdomen is an option for established abdominal

compartment syndrome with associated organ dysfunction and persistent shock with no absolute thresholds for urine output and airway pressure.[83] Protocols on fluid resuscitation are recommended to avoid a sustained increase in intra-abdominal pressure.[84] In addition to decompressive laparotomy for abdominal compartment syndrome, numerous medical and minimally invasive therapies have been proposed such as sedation and analgesia for anxiety relief and brief trials of neuromuscular blockade as temporizing measures. Body positioning and colonic/nasogastric decompression are also suggested noninvasive treatment options.[85–87] Patients with abdominal compartment syndrome may have ascites and drainage of fluid with various catheters can be tried before performing decompressive laparotomy as a less invasive alternative. A common factor among all cases of abdominal compartment syndrome seems to be the use of aggressive crystalloid resuscitation causing resuscitation injury. Use of excessive crystalloid resuscitation is discouraged in DCR and studies show decreased rates of abdominal compartment syndrome in association with decreased rates of crystalloid resuscitation.[61] Attempts to achieve "supranormal" endpoints (cardiac index of >4 L/min/m^2 or oxygen delivery index of >600 mL/min/m^2), while theoretically desirable, have not been shown to be effective as this often requires excessive resuscitation volumes that contribute to abdominal compartment syndrome.[88] As resuscitation has changed with DCR, the incidence of abdominal compartment syndrome has been decreasing. In the trauma setting, abdominal compartment syndrome has been disappearing rapidly but in the general surgery setting, it is more common. Sepsis as a source of inflammation can create abdominal compartment syndrome even when resuscitation injury is minimized. Source control of the bacterial contamination is the best treatment for abdominal compartment syndrome. End organ failure with microcirculatory disruption and endothelial leak is another source of the syndrome.

TRAUMATIC BRAIN INJURY

5 TBI remains one of the leading causes of injury-related deaths. Initial management of TBI includes hyperosmolar resuscitation, intracerebral pressure (ICP) monitoring, and prevention of hypoxia and hypotension.

Secondary Brain Injury

Injury prevention and better safety are the mainstays for primary brain injury. After the initial insult, the main goal is to prevent or minimize secondary brain injury. Secondary brain injury can be influenced by a cascade of inflammatory responses, occurring as a consequence of the primary injury. Secondary brain injury is also exacerbated by potentially preventable factors such as hypotension, hyperthermia, seizure activity, hyperglycemia, and hypoxemia.

Hypotension at any point (even brief time periods) is associated with a doubling of mortality in patients with severe TBI.[89,90] Although hyperventilation temporarily reduces intracranial pressure and may help to prevent herniation, evidence suggests that excessive hyperventilation may be harmful for patients with TBI. Therefore, brief hyperventilation is only recommended in order to reduce ICP temporarily until surgical decompression can be performed.

Imaging in Traumatic Brain Injury

Computed tomography (CT) scanning remains an essential tool in the initial evaluation and postinjury management of TBI. Patients with mild and moderate TBI who are examinable and not on any anticoagulant medications can be monitored by clinical examination without the need for routine serial CT scans of the head.[91–93] With technologic improvements made to the CT scanners around the world, the incidence of TBI has been increasing. Small insignificant intracranial radiologic findings are the main reason for the increase in the diagnosis of TBI. With increased awareness of mild TBI and with the increased attention to mild TBI with posttraumatic stress disorder, CT scans of the head are being ordered more often and routinely. In trauma, the single most common reason for obtaining a CT scan of the head has been loss of consciousness. Thus increased screening for TBI and improved technology identifying small clinically insignificant intracranial injuries has resulted in the increase of incidence of TBI. TBI is a clinical diagnosis and not just a radiographic diagnosis. There are patients with TBI with normal CT scans of the head who have cognitive deficits as well as posttraumatic stress disorder and there are many with radiographic TBI that do not have clinical deficits. Therefore, significant deterioration in neurologic examination should be considered in the decision for whether repeat head CT scan or consultation of a neurosurgeon is needed. CT scans and neurosurgical consultations are valuable resources with costs to the health care system as well as to the patient. The use of routine repeat head CT and neurosurgical consultations should be restricted to patients on prehospital antiplatelet and anticoagulants, and those with depressed skull fractures. A Brain Injury Guideline has been developed which helps guide when the resources should be used (Table 32-3).[94–96]

Progression of lesions on repeat head CT can promptly identify patients who require more invasive neurosurgical interventions and medical therapies. Routine repeat head CT is still recommended for those patients with GCS less than 8 and for those who do not have a reliable clinical examination such as patients that are under general anesthesia or patients that are in the ICU under sedation.

Coagulopathy in TBI

A decreased platelet count (less than 100,000/μL) and/or impaired platelet function after TBI is associated with progression of intracranial hemorrhage, need for neurosurgical intervention, and mortality.[97–99] Admission INR greater than 1.5 also predicts progression of intracranial hemorrhage. The treatment of coagulopathy after TBI is multipronged due to the complexity of the problem. Therapeutic strategies should focus on the treatment of the primary cause and controlling the progression of intracranial bleeding. fresh frozen plasma, platelets, recombinant factor VII, and PCC can be used in various combinations to improve outcomes.[100,101]

Antiplatelet and Anticoagulation Therapy in TBI

6 Antiplatelet medications, anticoagulants, and nonsteroidal anti-inflammatory drugs are among the most frequently encountered medications in TBI patients, especially the elderly. Existing evidence shows an increased risk of progression of intracranial bleeding in patients on high-dose aspirin and clopidogrel, whereas low-dose aspirin and ibuprofen do not cause progression on CT or neurologic examination.[102–104] A platelet count of less than 135,000/μL in patients on antiplatelet therapy is predictive of both radiographic and clinical worsening.[105] Reversal of the effect of anticoagulants and antiplatelets is suggested to improve the outcomes.

Table 32-3 Brain Injury Guideline

Variables	BIG 1[a]	BIG 2
Neurologic examination	Normal	Normal/abnormal
Intoxication	Yes/no	Yes/no
CAMP	No	Yes/no
Skull Fracture	No/simple, nondisplaced	Other
SDH	≤4 mm	>4 mm
EDH	≤4 mm	>4 mm
IPH/Contusion	One location and ≤4 mm	Other
SAH	Trace/pinpoint	Other
Therapeutic Plan		
Neurosurgical Consult	No	Yes
RHCT	No	Yes
ICU admission	No	Yes

[a]Patients should meet all Criteria for BIG 1.
Intoxication, alcohol/drugs; CAMP, coumadin, aspirin, motrin, plavix; SDH, subdural hematoma; EDH, epidural hematoma; IPH, intraparenchymal hemorrhage; SAH, subarachnoid hemorrhage; IVH, intraventricular hemorrhage; RHCT, repeat head CT; NSC, neurosurgical consult.

Use of newer oral anticoagulants like direct thrombin inhibitors and factor Xa inhibitors is increasing. Despite their safety advantage over coumadin, concerns for progression of intracranial bleed and adverse outcomes exist in TBI patients.[106,107] No specific reversal agents are yet available for newer oral anticoagulants. Oral charcoal administration, hemodialysis, PCC, and rFVIIa have shown some efficacy in the reversal of these agents.[108–113]

Seizure Prophylaxis after TBI

Posttraumatic seizures increase the cerebral metabolic rate, ICP, and may cause secondary brain injury. Seizures after TBI are associated with worse outcome. It is not known if poor outcomes are due to underlying injury which is associated with posttraumatic seizures or if posttraumatic seizures exacerbate injury. Studies have shown that prophylactic therapy with phenytoin during the first 7 days after injury is effective in reducing the number of early posttraumatic seizures.[114] Long-term use of prophylactic anticonvulsants has not been shown to be of benefit. Anticonvulsant prophylaxis is not indicated for late onset posttraumatic seizures (after 7 days). Because phenytoin is cumbersome to use, as it requires frequent drug-level monitoring and can lead to neurodepressive side effects, the use of levetiracetam has become common. However, recent studies have shown that the seizure rate after TBI is very low and the use of levetiracetam has not equated to reduced seizures.[115]

Penetrating Brain Injury

Gunshot wounds to the brain are the most lethal of all firearm injuries. Aggressive postinjury resuscitation is associated with significant improvement in both survival and organ donor eligibility.[116,117] Early aggressive management includes blood products, hyperosmolar therapy, vasopressors, and/ or PCC. Early aggressive T4 (levothyroxine) therapy and correction of coagulopathy increases the organ donation rate in nonsurvivable patients.[116,118]

NUTRITIONAL AND METABOLIC SUPPORT

Nutritional support after injury imparts significant acute and long-term effects on outcomes. Understanding of the nutritional and metabolic derangements following injury has increased exponentially over the past few decades. This has resulted in a more focused and goal-oriented approach toward nutritional support. Once patients are stabilized and recovered from shock, attention should be directed to metabolic and nutritional support.

The route of administration and timing of initiation of nutritional support have been issues of controversy. Current evidence supports the use of enteral nutrition in all trauma patients as soon as possible.[119–124] There are certain situations where enteral nutrition is not a feasible option; in such patients total parenteral nutrition is an alternative. Even in cases where enteral nutrition cannot be administered due to frequent or impending operative intervention or intolerance of enteral feeding, total parenteral nutrition should be used as a bridging measure. The literature on nutritional support in critically injured trauma patients consistently reports higher septic morbidity in patients on total parenteral nutrition.[122–125] Current guidelines on the nutritional support provide a level 1 recommendation on the advantages of enteral nutrition over nutritional support via the parenteral route.[126]

7 Recent recommendations aim for early enteral nutrition. The definition of early varies in the literature, ranging from a few hours after injury up to 72 hours.[124,125] Although the benefits are yet to be established, safety of early (within 24 hours of injury) enteral feeding is well documented.[126] In patients with severe burns it is recommended to initiate enteral feeding within 18 hours of injury.[127] Early feeding in this group of patients reduces the risk of gastroparesis. In the case of severe TBI enteral feeding is safe and should be administered early.[128–130]

Nasogastric and nasojejunal routes are the preferred modes of initial nutritional access. If long-term nutritional support is required, the planning of feeding access should be based on individual patient circumstances. In patients undergoing laparotomy, insertion of a surgical feeding tube either in the stomach or small intestine is a feasible option. For patients in need of long-term nutritional support and not requiring surgical intervention the preferred route is via endoscopically guided percutaneous feeding tube. The percutaneous endoscopic route is increasingly popular, but the literature is not well established on its safety and complications.[131,132] While choosing one route over the other, special consideration should be given to individual patient factors as there is no single feeding access that stands out among the others for safety and efficacy.[133–136]

The goal of nutritional support during postinjury phase is twofold, first to provide enough calories to meet basal energy expenditure and second to complement the special micronutrient requirements of ongoing inflammation. Basal energy expenditure during postinjury phase ranges from 30 to 35 kcal/kg/day. Basal energy expenditure is higher in TBI patients and lower in spinal cord injury patients. The estimation of basal energy expenditure in critically ill patients remains challenging and current calculators frequently overestimate caloric requirements. A high-caloric dietary supplementation is associated

with hyperglycemia, hypercapnia, and higher in-hospital complications.[137] While underfeeding is also a concern in critically ill patients, a more balanced approach is permissive underfeeding. Permissive underfeeding focuses more on maintaining nitrogen balance than meeting caloric requirements alone. Diets containing higher protein content and lower caloric value than target serve such a purpose. Permissive underfeeding results in better glycemic control, rapid recovery, and overall better in-hospital patient outcomes.[138–140]

In the setting of trauma and critical illness, the ongoing catabolic response demands special micronutrients and dietary considerations along with standard protein and caloric replacement. Nonessential amino acids such as arginine and glutamine become conditionally essential. Addition of these amino acids along with omega-3 fatty acids to standard dietary formulas has been shown to improve outcomes and immune function. Enhanced diets containing higher protein content, and including a combination of arginine, glutamine, omega-3 fatty acids, minerals (zinc, copper, etc.), nucleic acids, and vitamins have shown to improve overall immune function.[141–144]

The assessment of nutritional requirement in critically ill patients is primarily done by the indirect calorimetry method. The standard measure of nutritional requirement uses a metabolic cart, but this is expensive and cumbersome.[145] An alternative approach uses predictive equations but these are imprecise and often over- or underestimate the nutritional requirement.[146] In recent years, several hand-held indirect calorimeters have been marketed. They provide ease of use as they are portable and relatively accurate.[147] To assess the adequacy of nutritional supplementation, anthropometric measurements and biochemical data can be utilized. While there is no single measure which accurately predicts adequacy of nutritional support, prealbumin levels provide a reliable estimate compared to albumin, transferrin, and retinol-binding protein.[148]

ORGAN DONATION

Trauma donors are the major contributor in the organ donation pool.[149] There remains great potential to enhance the conversion rate in this group of trauma donors. Over the past decade significant changes occurred in resuscitation protocols in general and specifically in potential organ donors. These changes in resuscitation have resulted in better organ donation in this group of potential donors.

Wide spread acceptance of DCR has led to better end-organ preservation, which not only improves outcomes in surviving patients but can improve overall organ donation rates in patients who become brain dead. The guidelines defining organ donor management recommend continuation of this aggressive resuscitative support even after declaration of brain death.[118,150]

A feasible goal for resuscitating any potential donors is to follow a rule of 100's that is, maintaining a systolic blood pressure of >100 mm Hg, heart rate of <100 bpm, urinary output >100 mL/hr, and paO_2 >100 mm Hg. Along with hemodynamic resuscitation, focus should also be given to pulmonary edema, coagulopathy, and hypothermia. Coagulopathy and hypothermia are not only associated with adverse outcomes in trauma patients but also render them ineligible for organ donation.[151]

The focus of resuscitative efforts after declaration of brain death shifts from cerebral preservation to organ preservation. The shift in resuscitation focus is a continuum of ongoing resuscitation.[152] Donors should be managed in a critical care setting and attention should be directed toward moderation of postbrain death physiologic changes. Along with ongoing resuscitation, initiation of a T4 protocol should ensue. T4 protocol or hormone replacement therapy takes into account the disruption of hypothalamic–pituitary axis.[153] The essential components of the T4 protocol include methylprednisolone, triiodothyronine (T3)/levothyroxine (T4), arginine, vasopressin, and insulin. The goal of this resuscitative cocktail is to prevent potential cardiac arrhythmias, diabetes insipidus, hypotension, and metabolic acidosis. Early initiation of hormonal therapy has shown improved organ donation rates and should be considered in all brain-dead potential organ donors.[154–156]

8 Organ donation is a legitimate outcome in trauma patients. As aggressive resuscitation protocols for trauma patients closely align with donor management goals, the spectrum of care in potential organ donors can easily be extended to address organ preservation. Trauma patients presenting with previously fatal neurologic injuries provide an excellent cohort where aggressive resuscitation can not only improve survival rates but also the organ donation rates.[118,157] The care of a potential organ donor is a multidisciplinary task. Involvement of organ procurement networks and social services can improve the communication between the treatment team, procurement agency, and the donor's relatives. Bridging this gap is of utmost importance as family decline still remains a major cause of loss of potential donors.

References

1. Rhee P, Joseph B, Pandit V, et al. Increasing trauma deaths in the United States. *Ann Surg* 2014;260:13–21.
2. Spinella PC, Holcomb JB. Resuscitation and transfusion principles for traumatic hemorrhagic shock. *Blood Rev* 2009;23:231–240.
3. Maegele M, Lefering R, Yucel N, et al. Early coagulopathy in multiple injury: an analysis from the German Trauma Registry on 8724 patients. *Injury* 2007;38:298–304.
4. MacLeod JB, Lynn M, McKenney MG, et al. Early coagulopathy predicts mortality in trauma. *J Trauma* 2003;55:39–44.
5. Maegele M, Lefering R, Paffrath T, et al. Red-blood-cell to plasma ratios transfused during massive transfusion are associated with mortality in severe multiple injury: a retrospective analysis from the Trauma Registry of the Deutsche Gesellschaft für Unfallchirurgie. *Vox Sang* 2008;95:112–119.
6. Brohi K, Singh J, Heron M, et al. Acute traumatic coagulopathy. *J Trauma* 2003;54:1127–1130.
7. Palmer L, Martin L. Traumatic coagulopathy–part 1: pathophysiology and diagnosis. *J Vet Emerg Crit Care (San Antonio)* 2014;24:63–74.
8. Duchesne JC, Hunt JP, Wahl G, et al. Review of current blood transfusions strategies in a mature level I trauma center: were we wrong for the last 60 years? *J Trauma* 2008;65:272–276; discussion 6–8.
9. Burch JM, Denton JR, Noble RD. Physiologic rationale for abbreviated laparotomy. *Surg Clin North Am* 1997;77:779–782.
10. Kirkpatrick AW, Chun R, Brown R, et al. Hypothermia and the trauma patient. *Can J Surg* 1999;42:333–343.
11. Rohrer MJ, Natale AM. Effect of hypothermia on the coagulation cascade. *Crit Care Med* 1992;20:1402–1405.
12. Valeri CR, Feingold H, Cassidy G, et al. Hypothermia-induced reversible platelet dysfunction. *Ann Surg* 1987;205:175–181.
13. Vella MA, Jenner C, Betteridge DJ, et al. Hypothermia-induced thrombocytopenia. *J Royal Soc Med* 1988;81:228–229.
14. Meng ZH, Wolberg AS, Monroe DM 3rd, et al. The effect of temperature and pH on the activity of factor VIIa: implications for the efficacy of high-dose factor VIIa in hypothermic and acidotic patients. *J Trauma* 2003;55:886–891.
15. Dirkmann D, Hanke AA, Gorlinger K, et al. Hypothermia and acidosis synergistically impair coagulation in human whole blood. *Anesth Analg* 2008;106:1627–1632.
16. Doran CM, Woolley T, Midwinter MJ. Feasibility of using rotational thromboelastometry to assess coagulation status of combat casualties in a deployed setting. *J Trauma* 2010;69(Suppl 1):S40–S48.

17. Levrat A, Gros A, Rugeri L, et al. Evaluation of rotation thrombelastography for the diagnosis of hyperfibrinolysis in trauma patients. *Br J Anaesth* 2008;100:792–797.
18. Martini WZ, Cortez DS, Dubick MA, et al. Thrombelastography is better than PT, aPTT, and activated clotting time in detecting clinically relevant clotting abnormalities after hypothermia, hemorrhagic shock and resuscitation in pigs. *J Trauma* 2008;65:535–543.
19. Cotton BA, Faz G, Hatch QM, et al. Rapid thrombelastography delivers real-time results that predict transfusion within 1 hour of admission. *J Trauma* 2011;71:407–414; discussion 14–17.
20. Plotkin AJ, Wade CE, Jenkins DH, et al. A reduction in clot formation rate and strength assessed by thrombelastography is indicative of transfusion requirements in patients with penetrating injuries. *J Trauma* 2008;64:S64–S68.
21. Alam HB. An update on fluid resuscitation. *Scand J Surg* 2006;95:136–145.
22. Kentner R, Safar P, Prueckner S, et al. Titrated hypertonic/hyperoncotic solution for hypotensive fluid resuscitation during uncontrolled hemorrhagic shock in rats. *Resuscitation* 2005;65:87–95.
23. Sondeen JL, Coppes VG, Holcomb JB. Blood pressure at which rebleeding occurs after resuscitation in swine with aortic injury. *J Trauma* 2003;54:S110–S117.
24. Alam HB, Koustova E, Rhee P. Combat casualty care research: from bench to the battlefield. *World J Surg* 2005;29:S7–S11.
25. Alam HB, Rhee P. New developments in fluid resuscitation. *Surg Clin North Am* 2007;87(1):55–72.
26. Palmer L, Martin L. Traumatic coagulopathy–part 2: resuscitative strategies. *J Vet Emerg Crit Care (San Antonio)* 2014;24:75–92.
27. Mapstone J, Roberts I, Evans P. Fluid resuscitation strategies: a systematic review of animal trials. *J Trauma* 2003;55:571–589.
28. Chesnut RM, Marshall LF, Klauber MR, et al. The role of secondary brain injury in determining outcome from severe head injury. *J Trauma* 1993; 34:216–222.
29. Alam HB, Stanton K, Koustova E, et al. Effect of different resuscitation strategies on neutrophil activation in a swine model of hemorrhagic shock. *Resuscitation* 2004;60:91–99.
30. Rhee P, Koustova E, Alam HB. Searching for the optimal resuscitation method: recommendations for the initial fluid resuscitation of combat casualties. *J Trauma* 2003;54(5):S52–S62.
31. Koustova E, Stanton K, Gushchin V, et al. Effects of lactated Ringer's solutions on human leukocytes. *J Trauma* 2002;52:872–878.
32. Cotton BA, Au BK, Nunez TC, et al. Predefined massive transfusion protocols are associated with a reduction in organ failure and postinjury complications. *J Trauma* 2009;66:41–48; discussion 8–9.
33. Cotton BA, Gunter OL, Isbell J, et al. Damage control hematology: the impact of a

trauma exsanguination protocol on survival and blood product utilization. *J Trauma* 2008;64:1177–1182; discussion 82–83.

34. Yucel N, Lefering R, Maegele M, et al. Trauma Associated Severe Hemorrhage (TASH)-Score: probability of mass transfusion as surrogate for life threatening hemorrhage after multiple trauma. *J Trauma* 2006;60:1228–1236; discussion 36–37.
35. Nunez TC, Voskresensky IV, Dossett LA, et al. Early prediction of massive transfusion in trauma: simple as ABC (assessment of blood consumption)? *J Trauma* 2009;66:346–352.
36. Borgman MA, Spinella PC, Perkins JG, et al. The ratio of blood products transfused affects mortality in patients receiving massive transfusions at a combat support hospital. *J Trauma* 2007;63:805–813.
37. Gunter OL Jr, Au BK, Isbell JM, et al. Optimizing outcomes in damage control resuscitation: identifying blood product ratios associated with improved survival. *J Trauma* 2008;65:527–534.
38. Holcomb JB, Wade CE, Michalek JE, et al. Increased plasma and platelet to red blood cell ratios improves outcome in 466 massively transfused civilian trauma patients. *Ann Surg* 2008;248:447–458.
39. Snyder CW, Weinberg JA, McGwin G Jr, et al. The relationship of blood product ratio to mortality: survival benefit or survival bias? *J Trauma* 2009;66:358–362; discussion 62–64.
40. Sperry JL, Ochoa JB, Gunn SR, et al. An FFP:PRBC transfusion ratio $\geq$1:1.5 is associated with a lower risk of mortality after massive transfusion. *J Trauma* 2008;65:986–993.
41. Teixeira PG, Inaba K, Shulman I, et al. Impact of plasma transfusion in massively transfused trauma patients. *J Trauma* 2009;66:693–697.
42. Junger WG, Coimbra R, Liu FC, et al. Hypertonic saline resuscitation: a tool to modulate immune function in trauma patients? *Shock* 1997;8:235–241.
43. Bulger EM, May S, Kerby JD, et al. Out-of-hospital hypertonic resuscitation after traumatic hypovolemic shock: a randomized, placebo controlled trial. *Ann Surg* 2011;253:431–441.
44. DuBose JJ, Kobayashi L, Lozornio A, et al. Clinical experience using 5% hypertonic saline as a safe alternative fluid for use in trauma. *J Trauma* 2010;68(5):1172–1177.
45. Joseph B, Aziz H, Snell M, et al. The physiologic effects of hyperosmolar resuscitation: 5% vs. 3% hypertonic saline. *Am J Surg* 2014;208(5):697–702.
46. Rhee P. Noncolligative properties of intravenous fluids. *Curr Opin Crit Care* 2010;16(4):317–322.
47. Williams-Johnson JA, McDonald AH, Strachan GG, et al. Effects of tranexamic acid on death, vascular occlusive events, and blood transfusion in trauma patients with significant haemorrhage (CRASH-2) a randomised, placebo-controlled trial. *West Indian Med J* 2010;59:612–624.

48. Perkins JG, Schreiber MA, Wade CE, et al. Early versus late recombinant factor VIIa in combat trauma patients requiring massive transfusion. *J Trauma* 2007;62:1095–1099; discussion 9–101.
49. Spinella PC, Perkins JG, McLaughlin DF, et al. The effect of recombinant activated factor VII on mortality in combat-related casualties with severe trauma and massive transfusion. *J Trauma* 2008;64:286–293; discussion 93–94.
50. Joseph B, Hadjizacharia P, Aziz H, et al. Prothrombin complex concentrate: an effective therapy in reversing the coagulopathy of traumatic brain injury. *J Trauma Acute Care Surg* 2013;74:248–253.
51. Rotondo MF, Schwab CW, McGonigal MD, et al. 'Damage control': an approach for improved survival in exsanguinating penetrating abdominal injury. *J Trauma* 1993;35:375–382; discussion 82–83.
52. Hatch QM, Osterhout LM, Ashraf A, et al. Current use of damage-control laparotomy, closure rates, and predictors of early fascial closure at the first take-back. *J Trauma* 2011;70:1429–1436.
53. Hatch QM, Osterhout LM, Podbielski J, et al. Impact of closure at the first take back: complication burden and potential overutilization of damage control laparotomy. *J Trauma* 2011;71:1503–1511.
54. Abou-Khalil B, Scalea TM, Trooskin SZ, et al. Hemodynamic responses to shock in young trauma patients: need for invasive monitoring. *Crit Care Med* 1994;22:633–639.
55. Bishop MH, Shoemaker WC, Appel PL, et al. Prospective, randomized trial of survivor values of cardiac index, oxygen delivery, and oxygen consumption as resuscitation endpoints in severe trauma. *J Trauma* 1995;38:780–787.
56. Shoemaker WC, Appel PL, Kram HB. Tissue oxygen debt as a determinant of lethal and nonlethal postoperative organ failure. *Crit Care Med* 1988;16:1117–1120.
57. Trauma TEAftSo. Resuscitation Endpoints - Practice Management Guideline. 2014.
58. Barmparas G, Inaba K, Georgiou C, et al. Swan-Ganz catheter use in trauma patients can be reduced without negatively affecting outcomes. *World J Surg* 2011;35(8):1809–1817.
59. Scalea TM, Hartnett RW, Duncan AO, et al. Central venous oxygen saturation: a useful clinical tool in trauma patients. *J Trauma* 1990;30:1539–1543.
60. Ivatury RR, Porter JM, Simon RJ, et al. Intra-abdominal hypertension after life-threatening penetrating abdominal trauma: prophylaxis, incidence, and clinical relevance to gastric mucosal pH and abdominal compartment syndrome. *J Trauma* 1998;44(6):1016–1021.
61. Joseph B, Zangbar B, Pandit V, et al. The conjoint effect of reduced crystalloid administration and decreased damage-control laparotomy use in the development of abdominal compartment syndrome. *J Trauma Acute Care Surg* 2014;76(2):457–461.
62. Kirkpatrick AW, Roberts DJ, De Waele J, et al. Intra-abdominal hypertension and the

abdominal compartment syndrome: updated consensus definitions and clinical practice guidelines from the World Society of the Abdominal Compartment Syndrome. *Intensive Care Med* 2013;39(7):1190–1206.

63. Diebel LN, Wilson RF, Dulchavsky SA, et al. Effect of increased intra-abdominal pressure on hepatic arterial, portal venous, and hepatic micro-circulatory blood flow. *J Trauma* 1992;33(2):279–282.
64. Morris JA Jr, Eddy VA, Blinman TA, et al. The staged celiotomy for trauma. Issues in unpacking and reconstruction. *Ann Surg* 1993;217(5):576–584.
65. Chen RJ, Fang JF, Chen MF. Intra-abdominal pressure monitoring as a guideline in the nonoperative management of blunt hepatic trauma. *J Trauma* 2001;51(1):44–50.
66. Yang EY, Marder SR, Hastings G, et al. The abdominal compartment syndrome complicating nonoperative management of major blunt liver injuries: recognition and treatment using multimodality therapy. *J Trauma* 2002;52(5):982–986.
67. McKinley BA, Kozar RA, Cocanour CS, et al. Normal versus supranormal oxygen delivery goals in shock resuscitation: the response is the same. *J Trauma* 2002;53(5):825–832.
68. Hobson KG, Young KM, Ciraulo A, et al. Release of abdominal compartment syndrome improves survival in patients with burn injury. *J Trauma* 2002;53(6):1129–1133.
69. Biffl WL, Moore EE, Burch JM, et al. Secondary abdominal compartment syndrome is a highly lethal event. *Am J Surg* 2001;182(6):645–648.
70. Balogh ZJ, Martin A, van Wessem KP, et al. Mission to eliminate postinjury abdominal compartment syndrome. *Arch Surg* 2011;146:938–943.
71. Reintam Blaser A, Parm P, Kitus R, et al. Risk factors for intra-abdominal hypertension in mechanically ventilated patients. *Acta Anaesthesiol Scand* 2011;55:607–614.
72. Dalfino L, Tullo L, Donadio I, et al. Intra-abdominal hypertension and acute renal failure in critically ill patients. *Intensive Care Med* 2008;34:707–713.
73. Balogh Z, McKinley BA, Holcomb JB, et al. Both primary and secondary abdominal compartment syndrome can be predicted early and are harbingers of multiple organ failure. *J Trauma* 2003;54:848–859 (discussion 859–861).
74. Madigan MC, Kemp CD, Johnson JC, et al. Secondary abdominal compartment syndrome after severe extremity injury: are early, aggressive fluid resuscitation strategies to blame? *J Trauma* 2008;64:280–285.
75. Kirkpatrick AW, Pelosi P, De Waele JJ, et al. Clinical review: intra-abdominal hypertension: does it influence the physiology of prone ventilation? *Crit Care* 2010;14:232.
76. Hering R, Vorwerk R, Wrigge H, et al. Prone positioning, systemic hemodynamics, hepatic indocyanine green kinetics, and gastric intramucosal energy balance in patients with acute lung injury. *Intensive Care Med* 2002;28:53–58.

77. Hering R, Wrigge H, Vorwerk R, et al. The effects of prone positioning on intraabdominal pressure and cardiovascular and renal function in patients with acute lung injury. *Anesth Analg* 2001;92:1226–1231.
78. Vidal MG, Ruiz Weisser J, Gonzalez F, et al. Incidence and clinical effects of intra-abdominal hypertension in critically ill patients. *Crit Care Med* 2008; 36:1823–1831.
79. Ke L, Ni HB, Sun JK, et al. Risk factors and outcome of intra-abdominal hypertension in patients with severe acute pancreatitis. *World J Surg* 2012;36:171–178.
80. Kim IB, Prowle J, Baldwin I, et al. Incidence, risk factors and outcome associations of intra-abdominal hypertension in critically ill patients. *Anaesth Intensive Care* 2012;40:79–89.
81. Lui F, Sangosanya A, Kaplan LJ. Abdominal compartment syndrome: clinical aspects and monitoring. *Crit Care Clin* 2007;23(3):415–433.
82. Malbrain ML, Cheatham ML, Kirkpatrick A, et al. Results from the International Conference of Experts on Intra-abdominal Hypertension and Abdominal Compartment Syndrome. I. Definitions. *Intensive Care Med* 2006;32(11):1722–1732.
83. Hong JJ, Cohn SM, Perez JM, et al. Prospective study of the incidence and outcome of intra-abdominal hypertension and the abdominal compartment syndrome. *Br J Surg* 2002;89(5):591–596.
84. Cheatham ML, Safcsak K. Is the evolving management of intra-abdominal hypertension and abdominal compartment syndrome improving survival? *Crit Care Med* 2010;38:402–407.
85. Ouellet JF, Leppaniemi A, Ball CG, et al. Alternatives to formal abdominal decompression. *Am Surg* 2011;77(Suppl 1):S51–S57.
86. De Keulenaer BL, De Waele JJ, Malbrain ML. Nonoperative management of intra-abdominal hypertension and abdominal compartment syndrome: evolving concepts. *Am Surg* 2011;77(Suppl 1):S34—S34.
87. Cheatham ML. Nonoperative management of intraabdominal hypertension and abdominal compartment syndrome. *World J Surg* 2009;33:1116–1122.
88. Sperry JL, Minei JP, Frankel HL, et al. Early use of vasopressors after injury: caution before constriction. *J Trauma* 2008;64(1):9–14.
89. Winchell RJ, Simons RK, Hoyt DB. Transient systolic hypotension. A serious problem in the management of head injury. *Arch Surg* 1996;131(5):533–539.
90. Manley G, Knudson MM, Morabito D, et al. Hypotension, hypoxia, and head injury: frequency, duration, and consequences. *Arch Surg* 2001;136(10):1118–1123.
91. Joseph B, Sadoun M, Aziz H, et al. Repeat head computed tomography in anticoagulated traumatic brain injury patients: still warranted. *Am Surg* 2014;80(1):43–47.
92. Joseph B, Aziz H, Pandit V, et al. A three-year prospective study of repeat head computed tomography in patients with traumatic brain injury. *J Am Coll Surg* 2014;219(1):45–51.

93. Aziz H, Rhee P, Pandit V, et al. Mild and moderate pediatric traumatic brain injury: replace routine repeat head computed tomography with neurologic examination. *J Trauma Acute Care Surg* 2013;75(4):550–554.
94. Joseph B, Friese RS, Sadoun M, et al. The BIG (brain injury guidelines) project: defining the management of traumatic brain injury by acute care surgeons. *J Trauma Acute Care Surg* 2014;76(4):965–969.
95. Joseph B, Aziz H, Sadoun M, et al. Acute care surgery model: managing traumatic brain injury without an inpatient neurosurgical consultation. *J Trauma Acute Care Surg* 2013;75(1):102–105.
96. Joseph B, Pandit V, Aziz H, et al. Mild traumatic brain injury defined by Glasgow Coma Scale: is it really mild?*Brain Inj* 2015;29:11–16.
97. Schnüriger B, Inaba K, Abdelsayed GA, et al. The impact of platelets on the progression of traumatic intra-cranial hemorrhage. *J Trauma* 2010;68:881–885.
98. Nekludov M, Bellander BM, Blombäck M, et al. Platelet dysfunction in patients with severe traumatic brain injury. *J Neurotrauma* 2007;24:1699–1706.
99. Joseph B, Aziz H, Zangbar B, et al. Acquired coagulopathy of traumatic brain injury defined by routine laboratory tests: which laboratory values matter? *J Trauma Acute Care Surg* 2014;76(1):121–125.
100. Joseph B, Aziz H, Pandit V, et al. Prothrombin complex concentrate versus fresh-frozen plasma for reversal of coagulopathy of trauma: is there a difference? *World J Surg* 2014;38(8):1875–1881.
101. Joseph B, Hadjizacharia P, Aziz H, et al. Prothrombin complex concentrate: an effective therapy in reversing the coagulopathy of traumatic brain injury. *J Trauma Acute Care Surg* 2013;74(1):248–253.
102. Zangbar B, Pandit V, Rhee P, et al. Clinical outcomes in patients on preinjury ibuprofen with traumatic brain injury. *Am J Surg* 2015;209:921–926.
103. Joseph B, Pandit V, Aziz H, et al. Clinical outcomes in traumatic brain injury patients on preinjury clopidogrel: a prospective analysis. *J Trauma Acute Care Surg* 2014;76(3):817–820.
104. Joseph B, Aziz H, Pandit V, et al. Low-dose aspirin therapy is not a reason for repeating head computed tomographic scans in traumatic brain injury: a prospective study. *J Surg Res* 2014;186(1):287–291.
105. Joseph B, Pandit V, Meyer D, et al. The significance of platelet count in traumatic brain injury patients on antiplatelet therapy. *J Trauma Acute Care Surg* 2014;77(3):417–421.
106. Schaefer JH, Leung W, Wu L, et al. Translational insights into traumatic brain injury occurring during dabigatran or warfarin anticoagulation. *J Cereb Blood Flow Metab* 2014;34:870–875.
107. Joseph B, Ditillo M, Pandit V, et al. Dabigatran therapy: minor trauma injuries are no longer minor. *Am Surg* 2014;80(4):116–118.

108. Eerenberg ES, Kamphuisen PW, Sijpkens MK, et al. Reversal of rivaroxaban and dabigatran by prothrombin complex concentrate: a randomized, placebo-controlled, crossover study in healthy subjects. *Circulation* 2011;124:1573–1579.
109. Godier A, Miclot A, Le Bonniec B, et al. Evaluation of prothrombin complex concentrate and recombinant activated factor VII to reverse rivaroxaban in a rabbit model. *Anesthesiology* 2012;116:94–102.
110. Marlu R, Hodaj E, Paris A, et al. Effect of nonspecific reversal agents on anticoagulant activity of dabigatran and rivaroxaban: a randomised crossover ex vivo study in healthy volunteers. *Thromb Haemost* 2012;108:217–224.
111. Solbeck S, Meyer MA, Johansson PI, et al. Monitoring of dabigatran anticoagulation and its reversal in vitro by thrombelastography. *Int J Cardiol* 2014;176:794–799.
112. van Ryn J, Stangier J, Haertter S, et al. Dabigatran etexilate–a novel, reversible, oral direct thrombin inhibitor: interpretation of coagulation assays and reversal of anticoagulant activity. *Thromb Haemost* 2010;103:1116–1127.
113. Warkentin TE, Margetts P, Connolly SJ, et al. Recombinant factor VIIa (rFVIIa) and hemodialysis to manage massive dabigatran-associated postcardiac surgery bleeding. *Blood* 2012;119:2172–2174.
114. Temkin NR, Dikmen SS, Wilensky AJ, et al. A randomized, double-blind study of phenytoin for the prevention of posttraumatic seizures. *N Engl J Med* 1990;323(8):497–502.
115. Inaba K, Menaker J, Branco BC, et al. A prospective multicenter comparison of levetiracetam versus phenytoin for early posttraumatic seizure prophylaxis. *J Trauma Acute Care Surg* 2013;74(3):766–771.
116. Joseph B, Aziz H, Pandit V, et al. Improving survival rates after civilian gunshot wounds to the brain. *J Am Coll Surg* 2014;218(1):58–65.
117. Gressot LV, Chamoun RB, Patel AJ, et al. Predictors of outcome in civilians with gunshot wounds to the head upon presentation. *J Neurosurg* 2014;121(3):645–652.
118. Joseph B, Aziz H, Sadoun M, et al. Fatal gunshot wound to the head: the impact of aggressive management. *Am J Surg* 2014;207(1):89–94.
119. Peterson VM, Moore EE, Jones TN, et al. Total enteral nutrition versus total parenteral nutrition after major torso injury: attenuation of hepatic protein reprioritization. *Surgery* 1988;104:199–207.
120. Moore FA, Moore EE, Jones TN, et al. TEN versus TPN following major abdominal trauma–reduced septic morbidity. *J Trauma* 1989;29:916–922; discussion 22–23.
121. Moore FA, Feliciano DV, Andrassy RJ, et al. Early enteral feeding, compared with parenteral, reduces postoperative septic complications. The results of a meta-analysis. *Ann Surg* 1992;216:172–183.
122. Kudsk KA, Croce MA, Fabian TC, et al. Enteral versus parenteral feeding. Effects on septic morbidity after blunt and penetrating abdominal trauma. *Ann Surg* 1992;215:503–511; discussion 11–13.

123. Mochizuki H, Trocki O, Dominioni L, et al. Mechanism of prevention of postburn hypermetabolism and catabolism by early enteral feeding. *Ann Surg* 1984;200:297–310.
124. Kompan L, Kremzar B, Gadzijev E, et al. Effects of early enteral nutrition on intestinal permeability and the development of multiple organ failure after multiple injury. *Int Care Med* 1999;25:157–161.
125. Moore EE, Jones TN. Benefits of immediate jejunostomy feeding after major abdominal trauma–a prospective, randomized study. *J Trauma* 1986;26:874–881.
126. Jacobs DG, Jacobs DO, Kudsk KA, et al. Practice management guidelines for nutritional support of the trauma patient. *J Trauma* 2004;57:660–678; discussion 79.
127. Raff T, Hartmann B, Germann G. Early intragastric feeding of seriously burned and long-term ventilated patients: a review of 55 patients. *Burns* 1997;23:19–25.
128. Hadley MN, Grahm TW, Harrington T, et al. Nutritional support and neurotrauma: a critical review of early nutrition in forty-five acute head injury patients. *Neurosurgery* 1986;19:367–373.
129. Borzotta AP, Pennings J, Papasadero B, et al. Enteral versus parenteral nutrition after severe closed head injury. *J Trauma* 1994;37:459–468.
130. Klodell CT, Carroll M, Carrillo EH, et al. Routine intragastric feeding following traumatic brain injury is safe and well tolerated. *Am J Surg* 2000; 179:168–171.
131. Blomberg J, Lagergren J, Martin L, et al. Complications after percutaneous endoscopic gastrostomy in a prospective study. *Scand J Gastroenterol* 2012;47:737–742.
132. Glazer ES, Kulvatunyou N, Green DJ, et al. Contemporary acute care surgery percutaneous endoscopic gastrostomy tube placement: an extreme bumper height and complications. *J Trauma Acute Care Surg* 2013;75:859–863.
133. Adams GF, Guest DP, Ciraulo DL, et al. Maximizing tolerance of enteral nutrition in severely injured trauma patients: a comparison of enteral feedings by means of percutaneous endoscopic gastrostomy versus percutaneous endoscopic gastrojejunostomy. *J Trauma* 2000;48:459–464; discussion 64–65.
134. Kortbeek JB, Haigh PI, Doig C. Duodenal versus gastric feeding in ventilated blunt trauma patients: a randomized controlled trial. *J Trauma* 1999;46:992–996; discussion 6–8.
135. Singh N, Sharma B, Sharma M, et al. Evaluation of early enteral feeding through nasogastric and nasojejunal tube in severe acute pancreatitis: a noninferiority randomized controlled trial. *Pancreas* 2012;41:153–159.
136. Gómez AM. Testing the cycle of violence hypothesis: child abuse and adolescent dating violence as predictors of intimate partner violence in young adulthood. *Youth Soc* 2010;43(1):171–192.
137. Dickerson RN. Optimal caloric intake for critically ill patients: first, do no harm. *Nutr Clin Pract* 2011;26:48–54.

138. Arabi YM, Haddad SH, Aldawood AS, et al. Permissive underfeeding versus target enteral feeding in adult critically ill patients (PermiT Trial): a study protocol of a multicenter randomized controlled trial. *Trials* 2012;13:191.
139. Arabi YM, Tamim HM, Dhar GS, et al. Permissive underfeeding and intensive insulin therapy in critically ill patients: a randomized controlled trial. *Am J Clin Nutr* 2011;93:569–577.
140. Owais AE, Kabir SI, Mcnaught C, et al. A single-blinded randomised clinical trial of permissive underfeeding in patients requiring parenteral nutrition. *Clinical Nutrition* 2014;33(6):997–1001.
141. Moore FA, Moore EE, Kudsk KA, et al. Clinical benefits of an immune-enhancing diet for early postinjury enteral feeding. *J Trauma* 1994;37:607–615.
142. Taylor SJ, Fettes SB, Jewkes C, et al. Prospective, randomized, controlled trial to determine the effect of early enhanced enteral nutrition on clinical outcome in mechanically ventilated patients suffering head injury. *Crit Care Med* 1999;27:2525–2531.
143. Kudsk KA, Minard G, Croce MA, et al. A randomized trial of isonitrogenous enteral diets after severe trauma. An immune-enhancing diet reduces septic complications. *Ann Surg* 1996;224:531.
144. Marimuthu K, Varadhan KK, Ljungqvist O, et al. A meta-analysis of the effect of combinations of immune modulating nutrients on outcome in patients undergoing major open gastrointestinal surgery. *Ann Surg* 2012; 255:1060–1068.
145. Davis KA, Kinn T, Esposito TJ, et al. Nutritional gain versus financial gain: the role of metabolic carts in the surgical ICU. *J Trauma* 2006;61:1436–1440.
146. Mueller C, Compher C, Ellen DM. A.S.P.E.N clinical guidelines nutrition screening, assessment, and intervention in adults. *JPEN J Parenter Enteral Nutr* 2011;35:16–24.
147. Hipskind P, Glass C, Charlton D, et al. Do handheld calorimeters have a role in assessment of nutrition needs in hospitalized patients? A systematic review of literature. *Nutr Clin Pract* 2011;26:426–433.
148. Beck FK, Rosenthal TC. Prealbumin: a marker for nutritional evaluation. *Am Fam Phys* 2002;65:1575–1580.
149. Saidi RF, Markmann JF, Jabbour N, et al. The faltering solid organ donor pool in the United States (2001–2010). *World J Surg* 2012;36:2909–2913.
150. Salim A, Velmahos GC, Brown C, et al. Aggressive organ donor management significantly increases the number of organs available for transplantation. *J Trauma* 2005;58:991–994.
151. Joseph B, Khalil M, Pandit V, et al. Hypothermia in organ donation: A friend or foe? *J Trauma Acute Care Surg* 2014;77:559–563.
152. McKeown DW, Bonser RS, Kellum JA. Management of the heartbeating brain-dead organ donor. *Br J Anaesth* 2012;108(Suppl 1):i96–i107.
153. Novitzky D, Cooper DK, Morrell D, et al. Change from aerobic to anaerobic

metabolism after brain death, and reversal following triiodothyronine therapy. *Transplantation* 1988;45:32–36.

154. Joseph B, Aziz H, Pandit V, et al. Levothyroxine therapy before brain death declaration increases the number of solid organ donations. *J Trauma Acute Care Surg* 2014;76:1301–1305.

155. Salim A, Martin M, Brown C, et al. Using thyroid hormone in brain-dead donors to maximize the number of organs available for transplantation. *Clin Transplant* 2007;21:405–409.

156. Rosendale JD, Kauffman HM, McBride MA, et al. Aggressive pharmacologic donor management results in more transplanted organs. *Transplantation* 2003;75:482–487.

157. Croezen DH, Van Natta TL. Presentation and outcomes for organ donation in patients with cerebral gunshot wounds. *Clin Transplant* 2001;15(Suppl 6):11–15.

Chapter 33

Environmental Injuries

J. Patrick Walker and Gregory J. Jurkovich

Key Points

1 Of the 3,000 species of snakes worldwide, only 600 are venomous, with approximately 6 deaths per year in the United States caused by snakebite. In contrast, there are over 150,000 species of Hymenoptera in the world that cause approximately 40 deaths per year, mostly as a result of severe anaphylactic reactions.

2 Snakebite morbidity depends on the type of snake and the degree of envenomation. Venoms consist of numerous polypeptides that can disrupt endothelial cells and blood flow, produce neuromuscular blockade, or generate a coagulopathy via procoagulants. Some snakes (particularly Elapids [represented by the coral snakes in North America]) also have direct neurotoxins and cardiotoxins.

3 Snakebite produces immediate pain, edema, and erythema at the site. Spread of the swelling greater than 30 cm/hr indicates severe envenomation. Initial incision and suction and the use of a proximal tourniquet are contraindicated. Use of purified ovine antivenin is effective for serious Crotalidae envenomation and has replaced equine antivenin with its associated risk of serum sickness. Because of the presumed safety of the newer antivenom, overuse is more likely.

4 Spider bites produce toxicity by local tissue necrosis (brown recluse and hobo spiders) and painful muscle contractions (black widow spider). Death may be caused by stinging Hymenoptera, including bees (particularly aggressive Africanized bees), fire ants, and scorpions. The death is usually secondary to anaphylaxis, but occasionally massive envenomation occurs – especially with Africanized honeybees. The estimated lethal dose is approximately 20 stings/kg in most mammals.

5 Hypothermia risk is high in the severely injured patient as a result of exposure, loss of normal protective metabolism (i.e., shivering), rapid massive infusion of cold fluids/blood, and open thoracic and abdominal cavities.

6 The initial response to hypothermia is an intensive sympathetic type reaction with tremulousness, profound vasoconstriction, marked increase in oxygen consumption, and accelerated heart rate and minute ventilation. As core temperature falls to 33°C and 30°C this response is lost, and deeper core hypothermia rapidly develops.

7 Hypothermia increases risk of mortality at every level of traumatic injury. There is no improvement in outcome when applied to the severe TBI, and patients rapidly rewarmed require less resuscitation volume and have improved survival.

8 Treating hypothermia begins by preventing further heat loss and allowing endogenous rewarming. Active rewarming has many adjuncts, including warm blankets, heating pads and lights, and immersion in warm water or internally by core rewarming. Internal core rewarming is more effective, and includes heated intravenous fluids; heated body cavity lavage; heated moist inhaled air; extracorporeal circulatory rewarming (ECMO or CPB) or closed circuit intravascular countercurrent heat-exchange devises.

9 Frostbite involves ice crystal formation and unpredictable loss of tissue. Early definitive rewarming (avoiding refreezing) by submersion in 40°C to 42°C water is preferable with subsequent meticulous care, awaiting demarcation, and avoidance of early débridement to optimize outcomes and tissue salvage.

10 Early thrombolytic therapy might be beneficial in select frostbite patients.

Although most of us will not suffer a gunshot wound or a small bowel obstruction, we will all receive insect bites and those of us who frequent the outdoors will be exposed to many other facets of the environment. This chapter is about those encounters – the heat, the cold, venomous bites and stings. It is essential that all physicians know the basics of care for injuries produced in this manner.

ENVENOMATION

Snakebite

The legends and lore of snakes are spread across history; with serpents mentioned in 42 Bible verses, implicated in the death of Cleopatra, and the medical field – the snake is essential to the rod of Aesculapius and the Caduceus. Few emergencies have been surrounded with as many types of treatment (some very innovative – electrical shock and TASER, tourniquets with ice emersion, crosscut of the bite with suction of the wound) and little scientific fact as a snakebite. We will attempt to address the management of envenomation with as much evidence as possible.

There are over 1.8 million poisonous snakebites in the world annually with almost 100,000 deaths.[1] In the United States, the CDC estimates there are 7,000 to 8,000 bites per year with 5 to 6 deaths.[2] Most of the deaths are secondary to Rattlesnake envenomation, with only two fatalities from Copperhead snakebite in the past 5 years.

1 More than 3,000 species of snakes exist in the world of which approximately 600 are venomous. They range in size from 10 cm to greater than 9 m.[3] Nonvenomous snakes predominate on all continents with the exception of Australia. There are five families of poisonous snakes worldwide: Colubridae, Elapidae, Hydrophidae, Viperidae, and Atractaspididae. The boomslang and the bird snake represent the Colubridae – found mostly in Africa. The Elapids are found throughout the world and include snakes, such as mambas, kraits, adders, and cobras. The only Elapids in North America are the coral snakes. The Hydrophidae are the sea snakes. The Viperids have long hinged fangs. They include the pit vipers that, like the Boidae family (boas and pythons), have infrared sensors in a nasal pit that is located between the nose and the eye (Fig. 33-1). These are excellent sensitive organs that can differentiate a temperature differential of 0.003°C. All venomous snakes in North America with the exception of the coral snakes are in this family. Poisonous snakes in North America are therefore of the phylum Chordata, class Reptilia, order Squamata, suborder Serpentes, and of the Crotalidae (subfamily Crotalinae) or Elapidae family. Venomous snakes are distributed throughout the United States with at least one species in every state with the exception of Hawaii, Alaska, and Maine. Water moccasins are found primarily in the Southeastern United States. Copperheads are found from Massachusetts westerly to Illinois and to the south from Florida to Texas. Rattlesnakes are found coast to coast. The genus Crotalus – the true rattlesnakes – are found only in the New World.



Figure 33-1. Heat sensor – nasal pit. (Photo courtesy of Ronny Stewart, MD.)

Snakes are easily identifiable reptiles, marked anatomically by the large number (greater than 120) of precloacal vertebral bodies. They also have a reduced (almost absent) left lung, a single ventricle (no ventricular septum), and no muscles in the ciliary body of the eye. Despite the absence of a ventricular septum, oxygenated and deoxygenated blood channels fairly separately though the heart.[4] All snakes are strictly carnivores. The size of the snake dictates the size of the prey.

The pit vipers (the genus Crotalus, Sistrurus, and Agkistrodon) are morphologically distinguished by elliptical pupils, a triangular head, (Fig. 33-2) and retractable fangs. The fangs are tubular; injecting venom similar to a hypodermic needle. This is in contradistinction to the Elapids in which the fangs are fixed and grooved – wicking the venom into the victim. Venomous snakes have a single row of caudal plates distal to the anal plate, whereas harmless snakes have a double row of caudal plates. There are 32 species of rattlesnakes in the New World, ranging from southern Alberta to central Argentina.[5–7] Rattlesnakes are only found in the Americas. All true rattlesnakes have a rattle (with the exception of an endangered species in Mexico – the Santa Catalina rattlesnake, which has only a vestigial rattle). The rattle is a series of interlocking segments. A new segment is added with each shedding of the skin, which may occur 2 to 3 times per year. There are two genus of rattlesnakes; Crotalus – the true rattlesnakes and Sistrurus – the pigmy rattlers. There are 14 species of Crotalus (Table 33-1) in North America. The largest species of rattlesnake in North America is the eastern diamondback (*Crotalus adamanteus*), which is slightly larger than its cousin the western diamondback (*Crotalus atrox*). There are eight members of the Agkistrodon genus – moccasins and copperheads (Table 33-2).



Figure 33-2. Triangular shape of pit viper head. (Photo courtesy of Ronny Stewart, MD.)

By far the most critical step in management of snakebite is identification of the offending species. The majority of snakebites are nonvenomous and require no treatment. Some bites, such as those of copperheads (Fig. 33-3) and pigmy rattlers (Table 33-3), are almost always self-limiting and require little more than observation. Others such as the diamondback (Fig. 33-4) and Mojave rattlers can require intense medical management, occasional surgical management, and even rarely cause death. Identification of the species by the patient is notoriously invalid; however, a detailed description of the offending snake should be taken. The only snake where color is useful in identifying is the coral snake–red and yellow kill a fellow, red and black venom lack (Fig. 33-5). Note that this is true only in North America, as there are venomous coral snakes in Central and South America that have red bands touching black bands. Other clues, such as geography and topography (proximity to water), can also at least help with identification of the genus. All snakebites should, at least initially, be considered an event with potential morbidity and possible mortality.

Table 33-1 Crotalus Species

US Rattlesnakes – Genus *Crotalus*
Timber rattlesnake (Canebrake) – *Crotalus horridus*
Eastern diamondback – *Crotalus adamanteus*
Western diamondback – *Crotalus atrox*
Prairie rattlesnake – *Crotalus viridis*
Mojave rattlesnake – *Crotalus scutulatus*
Rock rattlesnake – *Crotalus lepidus*
Black-tailed rattlesnake – *Crotalus molossus*
Red diamond rattlesnake – *Crotalus ruber*
Speckled rattlesnake – *Crotalus mitchellii*
Sidewinder rattlesnake – *Crotalus cerastes*
Tiger rattlesnake – *Crotalus tigris*
Twin spotted rattlesnake – *Crotalus pricei*
Ridge nose rattlesnake – *Crotalus willardi*
Western rattlesnake – *Crotalus oreganus*

Table 33-2 Agkistrodon Species

US Copperheads and Moccasins
Northern copperhead – *Agkistrodon contortrix mokasen*
Osage copperhead – *Agkistrodon contortrix phaeogaster*
Southern copperhead – *Agkistrodon contortrix contortrix*
Broad-banded copperhead – *Agkistrodon contortrix laticinctus*
Trans-pecos copperhead – *Agkistrodon contortrix pictigaster*
Eastern cottonmouth – *Agkistrodon piscivorus piscivorus*
Florida cottonmouth – *Agkistrodon piscivorus conanti*
Western cottonmouth – *Agkistrodon piscivorus leucostoma*

As snakes are cold-blooded animals, snakebites generally occur in the warm months, with a particular increase in incidence in the spring and fall. The majority of snakebites occur in young men, with up to 60% of bites occurring in victims that were deliberately provoking the snakes.

2 Venom is produced in Duvernoy glands on the dorsal sides of the head (corresponding to parotid glands) enhancing the triangular appearance. During envenomation the venom is forced through the fangs by the palantine muscles. If a fang is broken off, it will be replaced by the next in a row of "proto-fangs." Any clothing may limit the amount and depth of envenomation. The purpose of the venom is to immobilize or kill the prey and begin digestion. Pit viper venoms are complex – with up to 50 different proteins and enzymes identified.[8–10] Over 90% of the dry weight of venom is proteinaceous in nature. Although it is common to classify the venoms as neurotoxic or digestive in nature, all snakes have varying compositions of venoms. The Crotalids will have a higher percentage of digestive/enzymatic type proteins than the Elapids, which will contain a higher percentage of neurotoxins. Common enzymes are phospholipases, metalloproteases, collagenase, and hyaluronidase (Table 33-4). These peptides and polypeptides act by damaging vascular endothelium and other cellular membranes.

Compliment is activated, fibrin is degraded, and platelets are activated. The increased permeability of the membranes leads to peripheral and pulmonary edema, hemorrhage, and hypotension. L-amino acid oxidase splits fibrinogen contributing to the induction of DIC. The Elapids in particular contain a higher percentage of proteins that block acetylcholine receptor sites. This can lead to dysphagia, slurred speech, seizures, coma, and death. Despite the very high toxicity of coral snake venom, only one fatality has been recorded in the United States in the past 50 years.



Figure 33-3. Copperhead. (Photo courtesy of Ronny Stewart, MD.)

Table 33-3 *Sistrurus* Species

US Rattlesnakes – Genus *Sisturus* (Ground Rattlers/Swamp Rattlers)
Massasauga – *Sistrurus catenatus*
Eastern – Subsp *catenatus*
Western – Subsp *tergeminus*
Desert – Subsp *edwardsii*
Western pigmy rattlesnake – *Sistrurus miliarius streckeri*
Carolina pigmy rattlesnake – *Sistrurus miliarius miliarius*
Dusky pigmy rattlesnake – *Sistrurus miliarius barbouri*

3 When evaluating the snakebite victim, it is important to document both local and systemic signs and symptoms. Vital signs should be recorded, and repeated at intervals guided by the clinical response. Pain, edema, and erythema at the site are common. Secondary symptoms include muscle twitching, perioral paresthesias, and a metallic taste in the mouth. Marking lines at the site of documented discoloration (Fig. 33-6) can help the clinician follow the progression of the envenomation. Swelling in the affected digit or limb should be measured (circumference) and followed closely. The amount of local tissue destruction is an accurate marker of the degree of envenomation. It is probable that if there is no pain or erythema by the time that the patient arrives in the ED, no

envenomation has occurred. Intravenous access should be obtained. Laboratory evaluation should include a CBC with platelet count, PT, PTT, CPK, fibrinogen level, creatinine, BUN, and urinalysis. Up to 30% of Crotalid envenomations will show an abnormality in the coagulation profile, although clinical bleeding is exceedingly rare.[11] In Lovonas 2004 review of 400 copperhead bites from the Carolinas: no hypotension, no respiratory failure, and no deaths occurred.[15] Eight patients did have laboratory abnormalities, but none developed bleeding complications. However, in severe envenomation by one of the larger rattlesnakes, diffuse capillary leakage can lead to pulmonary edema, hypotension, and shock.[12] A consumptive coagulopathy may rapidly develop. Such patients may bleed spontaneously from any site. Acute renal failure may result from directs nephrotoxins as well as myoglobinuria. An electrocardiogram, or at least continuous cardiac monitoring should be considered. If there appears to be no evidence of envenomation, the patient may be observed in the emergency department for several hours and discharged home. With evidence of envenomation our recommendation is for admission to the hospital, preferably a monitored bed, for observation and possible intervention for at least 24 hours.



Figure 33-4. Western diamondback.



Figure 33-5. Coral snake.

Table 33-4 Composition of Venom

Main Enzymes of Snake Venom
Dehydrogenase lactate
L-Amino acid oxidase
Catalase
Alanine amino transferase
Phospholipase A2
Lysophospholipase
Acetylcholinesterase
5′-Nucleotidase
Phosphodiesterase
Deoxyribonuclease
Ribonuclease 1
Adenosine triphosphatase
Hyaluronidase
NAD-Nucleotidase
Factor-X activator
α-Fibrinogenase
Prothrombin activator
Collagenase
Elastase



Figure 33-6. Demarcation of hemolysis after bite.

As noted above treatment is largely dictated by the species of snake and the initial clinical presentation. Although a number of series have noted the appropriate treatment of Agkistrodon (copperhead and moccasin) bite is observation only,[13–15] extrapolation of this data to rattlesnakes could be misleading. In the rattlesnake bite victim with a moderate or severe envenomation, early use of antivenom is appropriate, and should be strongly considered (see below). Although there are a number of snakebite severity indices (grading systems) published, a modification of the simple system proposed by Dart in 1996 is probably the most useful.[16] A grade 1 envenomation is limited to the immediate bite site, a grade 2 envenomation extends onto less than a full extremity and may have non–life-threatening symptoms such as nausea, vomiting, mild tachycardia, and mild hypotension. A grade 3 envenomation involves more than an extremity and includes systemic signs such as severe hypotension/tachycardia or blood dyscrasias or clinically significant clotting abnormalities. Although enzyme-linked immunosorbent assays (ELISAs) have been developed that can directly measure serum venom antigens as well as identify the offending snake, clinical applicability of these types of tests are limited.[17]

Initial first aid on the scene should involve immobilization and splinting. Although there are no data to confirm this will limit the spread of venom, it might be more comfortable. The application of ice or heat seems to have little effect on results. A number of historical treatments should specifically be avoided. Incision and suction, advocated for years, is no longer recommended.[18] A surgical incision in the field by a nonsurgeon can possibly involve vessels, tendons, and nerves and increase morbidity, and only a small amount of venom can actually be extracted with suction. Limited cooling of the extremity may have some benefit, although a version of this – ligation cryotherapy – is associated with a high rate of amputation.[19,20] Although placement of a constrictor band may be of benefit in Australia (where Elapids predominate) to prevent rapid dissemination of a deadly neurotoxin, it is probably of little benefit in North America where the offending species is almost certainly a Crotalid. The use of a compression bandage has been shown to slow the systemic absorption of venom.[21,22] This may make it the treatment of choice in the field for a nonnecrotizing envenomation, such as produced by an Elapid. It may however increase local necrosis when used to treat the bite of a pit viper.

The wound should be cleansed and the location of the puncture sites documented. The distance between the two fang marks is related to the size of the snake. The tetanus

immunization status of the patient should be reviewed and updated. Steroids have no benefit in humans although these are often used by veterinarians.[23,24] Steroids do have a role in treating the infrequent acute allergic as well as delayed-onset serum sickness that may occur after the use of sheep-derived antivenom, as noted below.

The prophylactic use of antibiotics has been evaluated by several studies and does not seem to reduce infection rates.[25–28] Infection after snakebite is surprisingly uncommon and while patients are often given an antibiotic, there is no good clinical evidence for their use. Although many patients will have erythema, edema, and tissue necrosis and will appear infected, these are usually sterile; culture-proven infection occurring after snakebite should be treated appropriately. Culture of organisms in the mouth of the rattlesnake include *Pseudomonas, Enterobacteracie, Staphylococcus,* and *Clostridia.*[29]

If the species is a coral snake or a nonindigenous Elapid, the administration of cholinergic agonists should occur at the first sign of symptoms. Calcium infusion may reduce the onset of seizures.

Certainly the most controversial decision point in management of snakebite is the administration of antivenom. Although hundreds of antivenoms are available worldwide for various species, for all practical purposes in North America we are only dealing with envenomation by Crotalids. Snakebite by coral snakes are uncommon, and while the venom is exceedingly toxic, the treatment is only supportive as antivenom is no longer available. Prior to 2000, the primary antivenom available in the United States for the bite of a Crotalid was a hyperimmune serum produced by envenomation of horses. Its use was associated with a high incidence of side effects: anaphylaxis, hypersensitivity, and delayed serum sickness.[30] In 2000, CroFab (Crotalidae Polyvalent Immune Fab [Ovine]) was introduced obviating the use of now unavailable horse serum products.[12,31]

CroFab is truly an elegant drug. It is produced by immunizing sheep with the venom from the western diamondback rattlesnake (*Crotalus atrox*), the eastern diamondback rattlesnake (*Crotalus adamanteus*), the Mojave rattlesnake (*Crotalus scutulatus*) or the cottonmouth water moccasin (*Agkistrodon*). The monovalent immunoglobulin from the sheep is prepared by fractionation of the immunoglobulin from the serum, digesting it with papain, and then utilizing ion exchange and affinity chromatography to separate the Fab fragments specific to each species.[32] The Fc portion of IgG is generally thought to be responsible for high rates of hypersensitivity and serum sickness seen with the horse serum product developed by Wyeth in 1954, and hence this ovine (sheep) version is generally considered safer. The four different monospecific antivenins are then mixed (Table 33-5). In a murine model there is good antigenic crossover in treating other North American Crotalid envenomations.[33]

Utilizing CroFab to treat Crotalid envenomation is somewhat controversial, primarily because of the cost/benefit ratio. The cost of this drug is a significant factor with wholesale prices up to $2,000 per vial. Certainly any patient with life-threatening symptoms should immediately be given 4 to 6 vials of the antivenom.[34] Treatment is not based on the body mass of the patient – as the antivenom neutralizes the poison that is injected – this will vary with each envenomation. The lyophilized powder is reconstituted with 18 mL of normal saline, followed by dilution in 250 mL. Each dose is given over 1

hour. It is thought that venom is rapidly tissue bound, therefore the earlier the antivenom can be given, the more likely a favorable response. The packaging information states that treatment should begin within 6 hours of the bite. There is however at least one report of effective use of antivenom after significant delay.[35] Thus is the conundrum – there are certainly snakebites that initially appear innocuous that later become life-threatening. This has lead physicians in the emergency room to over treat large numbers of patients who do not require therapy, and why it is so important that every attempt be made to identity the offending species. If one can ascertain that the snake is one of the less virulent types (Agkistrodon or Sistrurus species) the patient can almost certainly be treated without the use of antivenom.[14,36] However, in the patient with a deteriorating clinical condition, treatment should always be given. Repeated dosing should be given until clinical stability is achieved; although this is highly unlikely after 30 to 40 vials. The patient should be monitored for recurrence of symptoms and retreated if necessary.[37] CroFab has an estimated half-life of 12 to 23 hours.

Table 33-5 Components of Antivenom–CroFab Antibodies

LD50 Neutralizing Units
Crotalus atrox (Western diamondback) 1,350
Crotalus adamanteus (Eastern diamondback) 800
Crotalus scutulatus (Mojave rattler) 5,210
Agkistrodon piscivorus (Cottonmouth water moccasin) 460

LD50, median lethal dose.

Immediate adverse drug reactions will occur in 6% to 8% of patients.[38,39] This may be related to the rate of infusion.[40] Although anaphylaxis would occur in up to 50% of patients treated with the older equine antivenin, it is an uncommon occurrence with CroFab – maybe up to 14% of patients.[41] It should be treated aggressively when occurring: The antivenin infusion should be stopped and a combination of antihistamines (diphenhydramine), epinephrine, and steroids administered, depending on the severity of the response. The airway should be assessed and secured if necessary. Appropriate volume resuscitation should be instituted. Steroid dosing ranges from a single 125 mg intravenous bolus of methylprednisolone to short-course prednisone pulse dosing (60 mg daily for 5 days).[40]

Serum sickness will occur in 13% to 16%[39,41] of patients treated with ovine antivenom (CroFab), certainly less common than with the older Wyeth equine antivenom.[30] Serum sickness is a type III hypersensitivity reaction in which soluble antigen–antibody complexes are deposited diffusely in the presence of antigen excess. Symptoms such as urticaria, itching, nephritis, and arthralgia can occur for weeks after the infusion. The treatment for serum sickness is a pulse of corticosteroids tapered over 7 to 14 days.

There is no question that the purified ovine antivenin (CroFab) is much safer than the older horse product.[8,42] This has led to some indiscriminate usage in emergency departments across the country. It should be recognized that the vast majority of

snakebite victims will recover uneventfully with only supportive treatment. Each patient must be individually clinically evaluated and limit antivenom use to those in whom the potential benefits outweighs the risk of side effect.

CroFab has been used extensively in children as young as 14 months.[43–45] There are beginning to be reports of overuse of CroFab in children as well as adults.[46] A special consideration should be use of antivenom in the pregnant patients. Certainly coagulopathy could be lethal to the mother and fetus. There have been limited reports of use of CroFab in pregnancy.[47] Reports of fetal loss of up to 20% are noted in the worldwide literature with snakebites of a variety of species. This seems to be improved with the use of antivenom.[47,48] Certainly the risk/benefit ratio must be carefully weighed, but the general recommendation is to treat pregnant women with CroFab when indicated.

In the rare patient that develops clinical bleeding; such as hemoptysis, intracranial hemorrhage, or gastrointestinal bleeding, correction of the coagulopathy should be undertaken with appropriate blood products. Antivenom should be given in these patients as initial therapy. Do not routinely treat thrombocytopenia or severe coagulopathy in the absence of bleeding. Coagulopathy can recur up to 2 weeks late.[37]

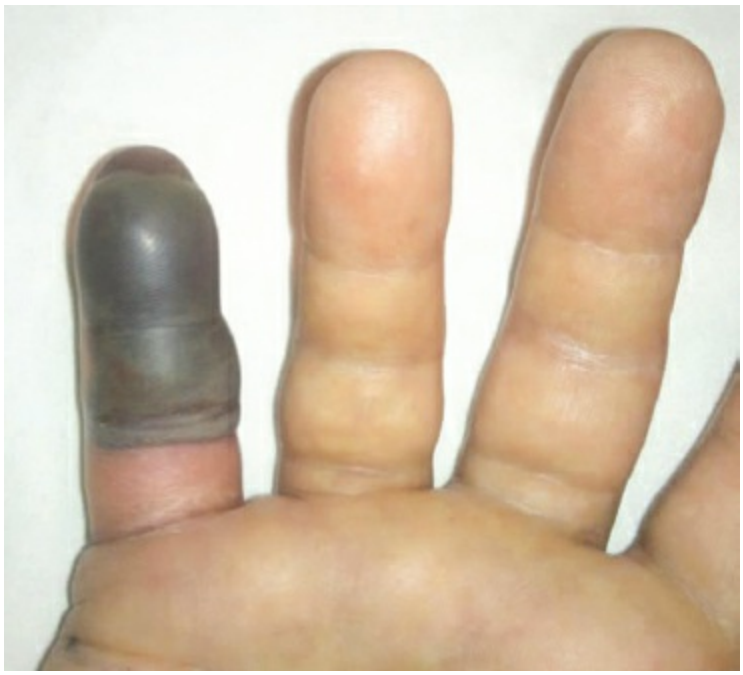

Figure 33-7. Hemorrhagic bullae.

The use of surgery in the management of snakebite has a limited role. Although historically snakebite has been treated with various surgical procedures,[19,49] it should be in an unusual patient that more than simple debridement is needed. Crosscut and aspiration of the puncture sites was utilized for years, but this is no longer recommended. Several studies have shown the limitations of this practice. In dogs, up to one-half of the venom can be removed if incision and suction are begun within 3 minutes.[17] In rabbits up to 37% of antivenom can be removed. However, in human studies only about 11% of the venom may be removed.[50,51] It is rapidly bound to tissues and is difficult to be removed by suction. Laceration of vessels and nerves by well-meaning people at the scene is likely

to increase morbidity as well as increase the risk of infection. Both partial and radical surgical excision of the involved bite area has likewise been attempted with no proven benefit.[52–55] A common finding is a local cytolytic response (Fig. 33-7), that produces a hemolytic bullae and requires debridement (Figs. 33-8 and 33-9). This can be expected to heal by secondary intention with a satisfactory cosmetic response (Fig. 33-10).

Another use of CroFab is in the patient with impending compartment syndrome. The great majority of snakebites deposit venom in the subcutaneous tissues, not subfascial. It can sometimes be difficult to differentiate a swollen painful extremity from a true compartment syndrome. When in doubt compartment pressures should be measured.[55,56] With rising pressures (greater than 30 to 40 mm), antivenom therapy should be initiated (or repeated). With failure of response to adequate dosing of antivenom, appropriate surgical fasciotomy can save extremities. Prophylactic fasciotomy has no role in treatment. Stewart and colleagues at the University of Texas Health Science Center in San Antonio have an extensive experience with rattlesnake bites.[57] They have randomized animals to receive an intracompartmental injection of venom from the western diamondback rattlesnake. The animals received fasciotomy with debridement alone, antivenom alone, or antivenom with fasciotomy and debridement. Antivenom therapy prevented muscle loss and improved survival. Surgery alone did not. It was noted that muscle that had been debrided would have survived if treated with antivenom alone. Fasciotomy may increase the severity of local tissue loss.[58,59] When fasciotomy is required because of rising compartment pressures that do not respond to antivenom, consideration for postoperative negative-pressure wound therapy should be given.



Figure 33-8. First debridement.



Figure 33-9. Second debridement.

Creative attempts at treating envenomation have even included the use of electrical current to neutralize the venom.[60] The use of current from the generator of an outboard motor and an automotive battery has even been attempted. As innovative and entertaining as these efforts may be, there is no improved outcome.[61] The TASER® or conductive electrical weapon (stun gun) is a small hand-held device that produces a very high voltage with a low current. It is used primarily by law enforcement agencies to temporarily immobilize attackers. A group of physicians practicing in Ecuador reported a series of 34 patients in letters to the editor of Lancet.[62,63] They claimed an immediate improvement with no mortality. The snakebites were most likely *Bothrops atrox* – the Fer-de-lance – a pit viper. Unfortunately this reported treatment was not a controlled study. Several animal studies have since proven electrical shock therapy to be ineffective in snakebite.[64–66]



Figure 33-10. Healed wound.

Special Consideration of Elapid Envenomation

As noted there are only three species of Elapids in the United States – the eastern coral snake, the Texas coral snake, and the Arizona coral snake. The Eastern coral snake (*Micrurus fulvius*) is found in the southeastern United States up to Kentucky and North Carolina. The Texas coral snake (*Micrurus tener*) is found in west of the Mississippi across Arkansas, through Louisiana into eastern Texas. The Eastern and Texas coral snakes inhabit forests and shrubbery. The Arizona coral snake (*Micruroides euryxanthus*) is found in the desert climates of the southwestern United States into Mexico. Coral snakes are more active at night and hide under ground cover. Their behavior is elusive and they will generally try to flee when disturbed. This family of snakes has a common feature – bilateral upper maxillary fangs that are fixed into position and angled down and back. The fangs are grooved for instillation of the venom, which is predominately a neurotoxin. The snakes are oviparous and have round pupils. Their head is flat, with a smooth tapered tale and of course no rattles. They have characteristic coloration which is mimicked by several other nonvenomous species (such as the king snake and the scarlet king snake) in a biologic phenomenon referred to as Batesian mimicry.[67] Although the North American coral snakes are relatively small (less than 5 ft), some Elapids from other continents are very large; the Black mamba is 14 to 15 ft and the King Cobra can be up to 18 ft and weigh 25 lb. Although nonnative elapids bites have a substantial risk for death, only one known death from a Coral snake has occurred in the United States in the last 50 years (Bonita Springs Florida 2006).[68]

The bite of an Elapid is likely to produce much less tissue injury than the bite of a Crotalid.[69] There may be minimal pain. Envenomation may result in immediate neurotoxicity (within 15 to 30 minutes in the case of the mamba or Australian brown snake) or be delayed a bit (2 to 5 hours with coral snakes). There is no longer any antivenom available for North American coral snakes, but local zoos may be able to provide antivenom for more exotic Elapidae. First aid should involve a compression bandage over the wound. The poison generally spreads by lymphatics; therefore field compression to occlude lymph flow at the site of envenomation can slow toxicity. Symptoms will be related to the neurotoxicity – confusion, muscle spasm, nausea, vomiting, and dizziness. Blurred vision and difficulty with speech will occur. Finally, respiratory paralysis of the diaphragm occurs with resultant death. Cardiovascular and pulmonary support is essential to salvage patients that progress to this state.[70] It should be noted that venom of an Elapid is incredibly toxic. The Taipan and Belcher sea snakes have an LD50 in mice of as little as 0.025 mg/kg of venom.[71] Any suspected Elapid bite should be managed with the possibility of rapid demise of the patient. If the bite is of a nonnative Elapid, antivenom (if it can be found) should be administered promptly at the first sign of clinical demise. Death rates for untreated nonnative Elapids varies from 20% to 30% for cobras to nearly 100% for the mambas.[72] Antivenom for exotic snakebites may be obtained from the local zoo or through their national organization – the Association of Zoos and Aquariums (https://www.aza.org) or through the Poison Control Center at 1-800-222-1222.



Figure 33-11. Gila monster.

Venomous Lizards

There are two venomous lizards in North America: the Gila monster (*Heloderma suspectum*) and the Mexican beaded lizard (*Heloderma horridum*). Both species have heavy bodies with large heads. The Gila monster is found in the southwestern United States, ranging primarily in Arizona, extending into southeastern California, southwestern Utah and New Mexico, and into northern Mexico. There are two subspecies: the banded Gila monster (Fig. 33-11) that is found in the northern portion of the habitat and the reticulated that exists in the southern portion of the range. It is the largest lizard in the United States with a length of up to 56 cm. The Gila monster has generated substantial lore in the southwestern United States, because of its characteristic appearance and apparent fetid breath. It lives below ground and spends most of its life in or near its burrow. It is primarily seen in the spring, in the morning hours during breeding season. It has powerful jaws and the bite is characterized by the tendency to hang on with the animal difficult to dislodge. The lizard has eight labial glands on either side of the lower jaw. The venom is secreted into the floor of the mouth where it is wicked into the victim via grooved lower canine teeth. Envenomation is limited and deaths are virtually unknown.[73] The morbidity is usually secondary to local effects from the toxins present: serotonin, phospholipase A, amine oxidases, hyaluronidase, and proteases.[74] These produce pain at the site that usually resolves in less than 24 hours. Hypotension, coagulopathy, and myocardial infarction have been reported.[75] Nausea and vomiting can occur. Malaise may persist for several days. The patient should be admitted for observation and a low threshold for surgical exploration/debridement be given because the teeth often shed into the bite and can serve as a nidus for infection.[76]

The Mexican beaded lizard is found from Sonora to Guatemala and is represented by four subspecies. They are larger than the North American Gila monster; with a maximum size of up to 91 cm. They have similar venom as the Gila monster and bites should be managed in a supportive fashion.

Insect Bites and Stings

4 Although the bite of a venomous snake will certainly draw more attention in the emergency department, in fact insects kill many more Americans (greater than 100 deaths per year)[77] than snakes (about 5 deaths per year). Although most of these deaths are from anaphylactic reactions, some are from overwhelming envenomation, particularly from those of the Africanized honey bee (the “killer” bee). Most of the treatment recommendations below are from expert opinion; few randomized trials have been performed.

Spiders

There are six genera of spiders in the United States that can produce painful bites, tissue necrosis, and rarely death. These fall into three groups – the brown recluse (Fig. 33-12), the black widow (Fig. 33-13), and the hobo spiders.[78]



Figure 33-12. Brown recluse.

Brown Recluse

There are 13 species of *Loxosceles,* of which 5 have been known to produce tissue necrosis. Probably the species producing the most pathology is the brown recluse (*Loxosceles reclusa*). Envenomation by the hobo spiders (*Tegenaria agresis*) produces a similar wound. The brown recluse is generally found in the southern states.[79] Hobo spiders are found in the Pacific Northwest.[80] Bites from these two species generally are initially painless and the victim may not recall being bit. Pain and erythema develop over the next 6 hours. The venom can produce a painful, necrotic, slow healing wound over the next 48 to 72 hours.[79,81] Two to 7 days after the bite an eschar develops with surrounding soft tissue induration. The eschar can conceal an underlying tissue necrosis that can persist for months.[79,82] These can require extensive debridement leading to skin grafting and even amputation.

The venom is both hemolytic and cytotoxic. The enzyme that is thought to produce the "desmonecrotic arachnidosis" is sphingomyelinase D. The venom also contains hyaluronidase, lipase, arachidonic acid, and prostaglandins.[83,84] Systemic symptoms occur in less than 10% of victims, more commonly in children. Rarely hemolysis, hemodynamic instability, and death have occurred.[85] Initial treatment should include analgesia, wound care, and tetanus prophylaxis. Antibiotics should be reserved for infection/cellulitis. Early debridement should be withheld. Consideration for oral dapsone therapy should be given. Dapsone is thought to work as an inhibitor of polymorphonuclear leukocyte chemotaxis. It has significant side effects and can produce hemolysis in G6PD-deficient patients. Its use is somewhat controversial. It has been shown to reduce the size of the skin lesion and lessen the amount of surgical debridement, but these are not prospective studies.[86] A controlled study of dapsone, electroshock therapy and no treatment in guinea pigs showed some improvement with dapsone, but none with the electrical therapy.[87] Hyperbaric oxygen has been studied in rabbits and pigs and failed to demonstrate significant improvement.[88] A trial of hyperbaric oxygen, dapsone, and cyproheptadine in rabbits failed to show any improvement.[89] Systemic steroids and antihistamines likewise have not been shown to help. Initial surgical excision of the lesion has no clear benefit.[90] Delayed excision of the area of necrosis with skin grafting can be necessary. Recurrent necrosis in the same site can return even years later.



Figure 33-13. Black widow.

Black Widow Spiders

There are 31 species of the genus *Lactrodectus,* the Black Widow spider, of which 4 are found in North America. These are marked by a prominent red hourglass figure on the ventral aspect of the thorax. Although both the male and the female possess venom, only the bite of the female can penetrate human skin. The female is four times the size of the male. The female of the species is known for eating the male after mating, which may or may not occur. The bite may produce only minimal local symptoms, with only a small area of redness, or a "target" appearance. The venom contains alpha-latrotoxin, which is neurotoxic. This produces chest and abdominal pain, and the patient's presentation may be confused as an acute surgical abdomen.[91] Marked cramping and abdominal rigidity may be present. Fasciculations of facial muscles with ptosis and spasm may occur producing a particular facie. Hyperreflexia, paresthesia, cutaneous hyperesthesia, and nausea may also occur. Symptoms may occur within an hour and resolve over several days.[92] The muscle spasm should initially be treated with benzodiazepines. Antivenin is available, and should be considered in the very young or ill patient. The dose is one ampule given in 50 mL of saline. The antivenom is equine and hypersensitivity testing should be done prior to giving the antivenom.[93,94] A 1-mL test dose of horse serum is included with the antivenom for topical conjunctival testing. Calcium gluconate was often given in the past, but is no longer recommended. Mortality is exceedingly rare.

Hymenoptera

More than 100,000 species of Hymenoptera exist. This includes bees, wasp, hornets, and fire ants. The venom injected by these insects is at least as toxic as that of the rattlesnake, but the volume is much less. The venom is primarily a hemolysin and neurotoxin. Anaphylaxis is a common clinical problem produced by the envenomation. Approximately 0.4% of the human population is at risk of anaphylaxis from Hymenoptera stings.[95] The anaphylaxis is modulated by preformed IgE that activates mast cells leading to massive histamine release. This leads to laryngeal edema, pulmonary edema, and cardiovascular collapse. This must be treated aggressively with intravenous diphenhydramine and epinephrine as well as with management of the airway and supplemental oxygen. Most stings are mild, however, resulting in only dermal reactions – pain, erythema, and edema. The stinger should be removed and ice applied to the site. Application of meat tenderizer might be of some benefit. Patients with a history of insect sting anaphylaxis should be given a prescription for an epinephrine pen and be considered for venom immunotherapy. This is almost 100% successful in desensitization, but can take up to 3 years.

Killer Bees

Africanized honeybees (killer bees) are hybrids of the African honeybee and the European honeybee, the one commonly found in the United States. The Africanized honeybee was originally brought from Tanzania to Brazil in 1957, with the hope of better honey production. The bees have spread up through Central America, Mexico, and into Texas. They are continuing to advance at about 100 miles per year.[96,97] Africanized honeybees are indistinguishable from the European honeybee, so DNA (usually mitochondrial DNA) analysis is necessary to differentiate the subspecies.[98] They are termed "killer bees" because of increased aggressive traits. They show greater defensiveness of the hive, they have a bigger "alarm" area, and they deploy in greater numbers and will pursue perceived threats over much greater distances. Although their venom is of the same potency as the European bees, the number of stings received will usually be much greater. With more than 50 stings, nausea, vomiting, shock, hemolysis, rhabdomyolysis, coagulopathy, coma, and death may occur. Usually most patients will just complain of pain, but delayed toxic reactions – 6 to 48 hours – may also occur. It is recommended that any patient presenting with more than 50 stings be hospitalized and observed.[99] Laboratory evaluation with coagulation studies, platelet count, and liver function studies should be obtained.

Fire Ants

Fire ants are wingless members of the Hymenoptera order. They were brought to the United States from South America around 1918.[100] The red imported fire ants appear to have come over on a ship through Mobile, Alabama. Shipments of infested nursery stock and other agricultural products, natural mating flights, and floating on flood waters have contributed to their spread. Two species of imported fire ant now infect large areas of the Gulf Coast states.[101] Fire ants aggressively attack any perceived danger to themselves or their mound.[102] Each ant can produce multiple stings. The venom is a dialkylpiperidine that induces the release of histamine from increased mast cell reactivity. The fire ant sting produces a sterile pustule, which does not usually require antibiotic therapy. Infectious complications can occur at the site that may be more common in diabetic or immunocompromised individuals. Fire ant venom shares at least four antigenic proteins with bees and wasps. More than 80 fatalities have been reported from fire ant anaphylaxis, notably in Australia and southern United States. The treatment is the same as with bee/wasp sting anaphylaxis.[77]

Scorpions

More than 1,500 species of scorpions can be found worldwide. Only about 20 or 25 are considered dangerous. They are in the class Arachnidia; close relatives of ticks, mites, and spiders. Their characteristic shape makes them readily identifiable. Scorpions prefer dry habitats but may be found throughout the southern United States. Scorpions are nocturnal, hiding during the day and becoming active at night. This behavior helps them manage their temperature and water balance, important for survival in their dry habitats. The scorpion's body has a 5-segmented tail that can be arched over the back and becomes more slender toward the end. On the end of the tail is the bulb-like poison gland/stinger. Between the last pair of legs are comb like structures called the pectines – sensory organs used to sense surface textures and detect prey. The venom toxicity varies greatly depending on the species, season, and age of the scorpion. Stings from dangerous species may cause paralysis, severe convulsions, cardiac irregularities, breathing difficulties, and death. In the United States most scorpion bites are not life-threatening and only result in local effects. In parts of Brazil, Mexico, North Africa, and Israel, however, the sting may be lethal. In Brazil the mortality rate is as high as 12% for adults and 60% in children.[103] In India, of 34 children admitted to a hospital for a scorpion sting, 14 had hypertension, 9 had acute pulmonary edema, 5 had a myocardial infarction, and 4 died.[104] Antivenins are typically available in area where dangerous species are found, either from a local zoo or state or university agricultural extension departments. One species in the North America is particularly venomous – the Arizona bark scorpion (*Centuroides sculpturatus*) (Fig. 33-14). The sting produces a dramatic neuromotor syndrome and respiratory insufficiency. It has produced several deaths in the United States and hundreds in Mexico. An antivenin is available in Mexico, but not in the United States.



Figure 33-14. Arizona bark scorpion.

Centipedes and Millipedes

There are approximately 3,000 species of centipedes in the world. They are arthropods with a single set of legs on each body segment. The front pair of legs are modified to deliver venom. One of the largest members of this class is the giant desert centipede (*Scolopendra gigantea*). It can grow to 26 cm in length. Significant morbidity, including EKG changes and rhabdomyolysis, can occur from centipede bites, but death is exceedingly rare. The most common symptoms include erythema, swelling, and pain.[105] Treatment is largely symptomatic, with reports of both ice and heat improving symptoms.[106] There are approximately 7,000 species of millipedes. They have 2 pairs of legs on each body segment. Millipedes do not have a mechanism to inject a venom, but instead secrete an irritating liquid from pores covering their body.[107] This can produce a superficial burn that is self-limiting. Only symptomatic therapy is indicated.

Asp Caterpillars

The asp is a venomous caterpillar found in the southern United States. It is the larval stage of the Southern Flannel Moth (*Megalopyge opercularis*) (Fig. 33-15). It has the appearance of soft furry ball, encouraging the unwary to touch it. The long hairs of the asp conceal shorter spikes that discharge venom. Typically an intense throbbing and pain occurs almost immediately. Erythematous spots occur at the site of envenomation. Symptoms include headache, nausea, vomiting, and the development of lymphadenopathy. Chest pain occurs occasionally. Rarely shock and respiratory distress have been reported. Death is exceedingly rare and is almost certainly because of a hypersensitivity reaction.[108–110] A similar caterpillar found in South America – *Lonomia* – has a death rate of 1.7%. The initial treatment should be to apply adhesive tape and pull it off to remove the spines. Ice packs and antihistamines may provide symptomatic relief. Intravenous calcium and steroids have been suggested as a treatment regimen.[111]



Figure 33-15. Asp caterpillar.

Hypothermia

5 Humans will always attempt to maintain a constant body temperature despite changes in environmental temperature. Normal body temperature is 37°C sublingually, 38°C in the rectum, 32°C at the skin, and 38.5°C deep in the liver, with normal daily (circadian) variation of about 0.5°C to 1°C; we tolerate poorly even minor deviations from these norms.[112] Although humans have a remarkable capacity to dissipate heat by evaporating body water, our tropical evolutionary heritage has provided us with far less ability to cope with cold conditions. As a result, hypothermia can occur in a variety of clinical settings and from a number of causes (Table 33-6).

Table 33-6 Clinical Definitions of Hypothermia and Examples of Settings in Which They Occur

Type	Settings
Accidental	Recreational environmental exposure, cold-water immersion
Therapeutic	Treatment of Reye syndrome, cardiopulmonary bypass, organ preservation
Drug induced	Alcohol, anesthetics, barbiturates, phenothiazines, morphine, other drugs
Central nervous system dysfunction	Transection of spinal cord, hypopituitarism, cerebrovascular accidents
Hypothalamic dysfunction	Wernicke encephalopathy, anorexia nervosa, head trauma, pinealoma, other tumors
Metabolic	Hypoglycemia, hypothyroidism, hypoadrenalism, malnutrition
Dermal dysfunction	Burns, erythrodermas
Traumatic	Occurs after any major injury

Adapted from Jurkovich GJ. Hypothermia in the trauma patient. *Adv Trauma* 1989;4:111–140.

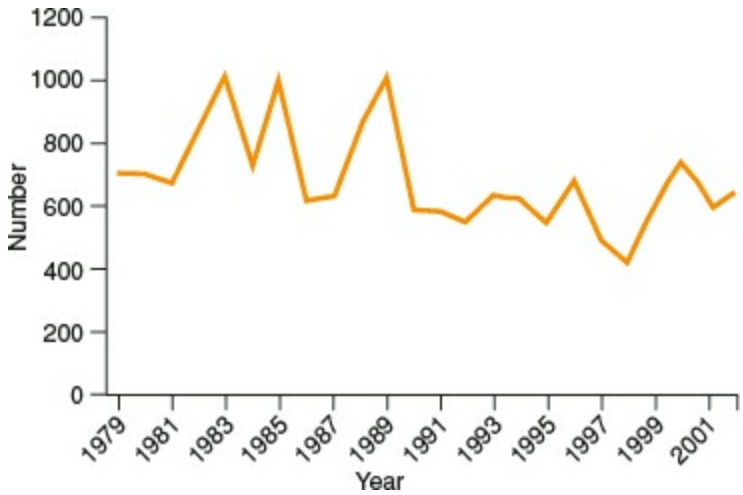

Figure 33-16. Number of hypothermia-related deaths by year in the United States, 1979–2002. (After Hypothermia-related deaths—United States, 2003–2004. *MMWR Morb Mortal Wkly Rep* 2005;54:173–175.)

Hypothermia is considered to be present in humans if the core temperature drops

below 35°C (95°F). Hypothermia is usually classified by temperature zones: mild (32°C to 35°C); moderate (28°C to 32°C); or severe (<28°C). Primary accidental hypothermia is defined as a decrease in core temperature that occurs as a result of overwhelming environmental cold stress, such as recreational misadventures that lead to cold-water immersion or prolonged environmental exposure. Secondary accidental hypothermia occurs in patients with abnormal heat production or thermoregulation, who become cold despite only mild cold stress. The most significant risk factors are advanced age, mental impairment, and substance abuse (alcohol, primarily), although hypothyroidism, hypoadrenalism, trauma, and hypoglycemia are other risk factors.[113,114] Chronic hypothermia develops in patients with impaired heat generation (i.e., the elderly and infirm) who live in unheated apartments, are under continual cold stress, and after a time are found to have a chronically low temperature as if they have autoregulated to a new, lower-set core temperature.

A multicenter review of 428 cases of accidental hypothermia reported an overall mortality rate of 17%,[115] although other reports document mortality rates as high as 80%, primarily a result of infection and underlying illness. Treatment of accidental hypothermia remains highly variable. A report from an academic medical center in Amsterdam highlights this, as they reported that over an 8-year period (2000 to 2008) a total of 84 patients with accidental hypothermia were treated with 14 different rewarming techniques, with an overall mortality of 28.6%.[116] It is estimated that each year about 1,500 patients in the United States have hypothermia listed on their death certificate, although the exact incidence of primary and secondary hypothermia and the associated morbidity and mortality remain uncharacterized.[114] From 1979 to 2002, the CDC reported that a total of 16,555 deaths in the United States, an average of 689 per year (range 417 to 1,021), were attributed to exposure to excessive natural cold (Fig. 33-16).[113] From 1999 to 2002, a total of 4,607 death certificates in the United States had hypothermia-related diagnoses listed as the underlying cause of death for an annual incidence of 4 per 1,000,000 population.[113] Most reported hypothermia-related deaths (67%) occurred in males (Fig. 33-17), but the overall death rate is the same for both males and females. Notable is that deaths occur in all states, even those that generally are considered to have warm climates. Hypothermia-related deaths are reported by states with characteristically milder climates that experience rapid temperature changes and by western states that have high elevations and experience considerable changes from daytime to nighttime temperatures. States with the greatest overall death rates caused by hypothermia are Alaska, New Mexico, Wyoming, and Montana (Fig. 33-18).

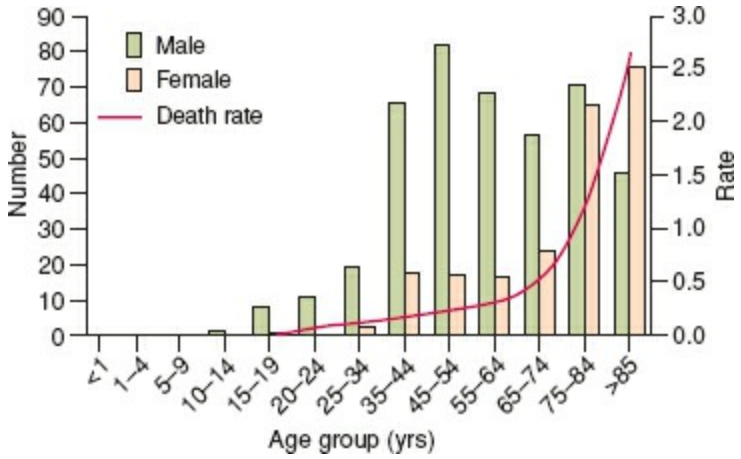

Figure 33-17. Number and rate (per 100,000 population) of hypothermia-related deaths, by age group and gender, in the United States, 1979–2002. (After Hypothermia-related deaths United States, 2003–2004. *MMWR Morb Mortal Wkly Rep* 2005;54:173–175.)

6 The physiologic response to hypothermia is one of transitional changes, with few exact temperature-dependent responses (Fig. 33-19). Broadly speaking, the transition from a "safe zone" of hypothermia (in which physiologic adaptations to heat loss are working) to a "danger zone" of hypothermia (in which shivering is abolished, metabolism decreases, and heat loss is passively accepted) occurs between 33°C and 30°C. The initial effects of hypothermia mimic intense sympathetic stimulation, with tremulousness, profound vasoconstriction, tremendous increases in oxygen consumption, and acceleration of heart rate and minute ventilation.[77] When core body temperature cannot be measured, a four-stage hypothermia classification based on vital signs and level of consciousness has been developed by Swiss clinicians.[114,117] It should be emphasized that the purpose of the Swiss clinical grading is to direct treatment in the absence of the ability to actually measure core body temperature, so it should have its primary purpose in the austere or field care environment.

The cardiovascular response to hypothermia begins with tachycardia, but followed by progressive bradycardia, which starts at approximately 34°C and results in a 50% heart rate decrease at 28°C. Cardiac output initially increases with the tachycardia, and then progressively decreases, with a concomitant fall in blood pressure. The conduction system is particularly sensitive to hypothermia: the PR interval, then the QRS complex, and finally the QT interval become progressively prolonged.[118] As temperature falls below 30°C, atrial fibrillation, bradycardia, and ventricular dysrhythmia become common, with asystole occurring at temperatures below 25°C. Perhaps the most challenging management of an accidental hypothermia patient is the one with temperatures between 28°C and 32°C (Swiss stage 2), as these patients are prone to develop poorly perfusing arrhythmias, yet they often can be rewarmed with active external and environmental rewarming if such arrhythmias do not occur. Hence gentle manipulation of such patients is required. Because palpating pulses or measuring blood pressure in cold, stiff, hypothermic patients is difficult, the presence of an organized cardiac electrical rhythm should be taken as a sign of life that contraindicates cardiopulmonary resuscitation chest compressions, despite the absence of a palpable pulse. Such a rhythm may provide

diminished but sufficient circulation in patients with severely reduced metabolism, and it is likely that vigorous chest compressions will convert this perfusing rhythm to fibrillation. Rewarming should occur with close monitoring of rhythm, pulse, and blood pressure. If cardiac arrest occurs (Swiss stage 3 or 4), extracorporeal cardiopulmonary bypass (CPB) or extracorporeal membrane oxygenation (ECMO) for perfusion and rewarming is indicated.[114,119,120] Among patients with what is likely Swiss stage 4, those treated with ECMO or CPB have a reported survival rate without neurologic impairment of 47% to 63%, compared to 37% for similar patients treated without active core rewarming and oxygenation techniques.[114] One report noted excellent long-term functional outcomes in 15 of 32 young patients successfully rewarmed with CPB.[119] All patients were intubated and ventilated and had received ongoing cardiac massage during transportation, and all 15 survivors had documented circulatory arrest (ventricular fibrillation or asystole) and fixed, dilated pupils. The mean interval from discovery of the patient to rewarming with cardiopulmonary bypass was 141 ± 50 minutes; the mean temperature was 21.8°C ± 2.5°C. A report from Finland documents a 61% (14 of 23) survival to hospital discharge for adults undergoing cardiopulmonary bypass after a mean of 70 minutes of cardiopulmonary resuscitation following hypothermic arrest primarily from cold-water immersion or exposure.[121]

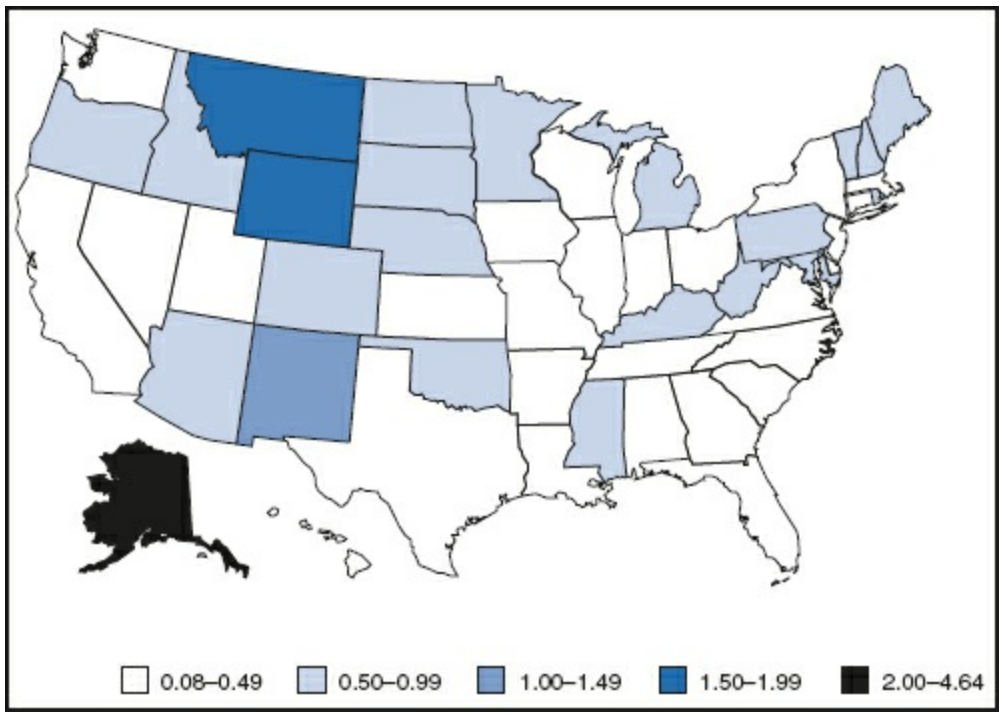

Figure 33-18. Average annual rate per 100,000 of hypothermia-related deaths by state, 1999–2002.

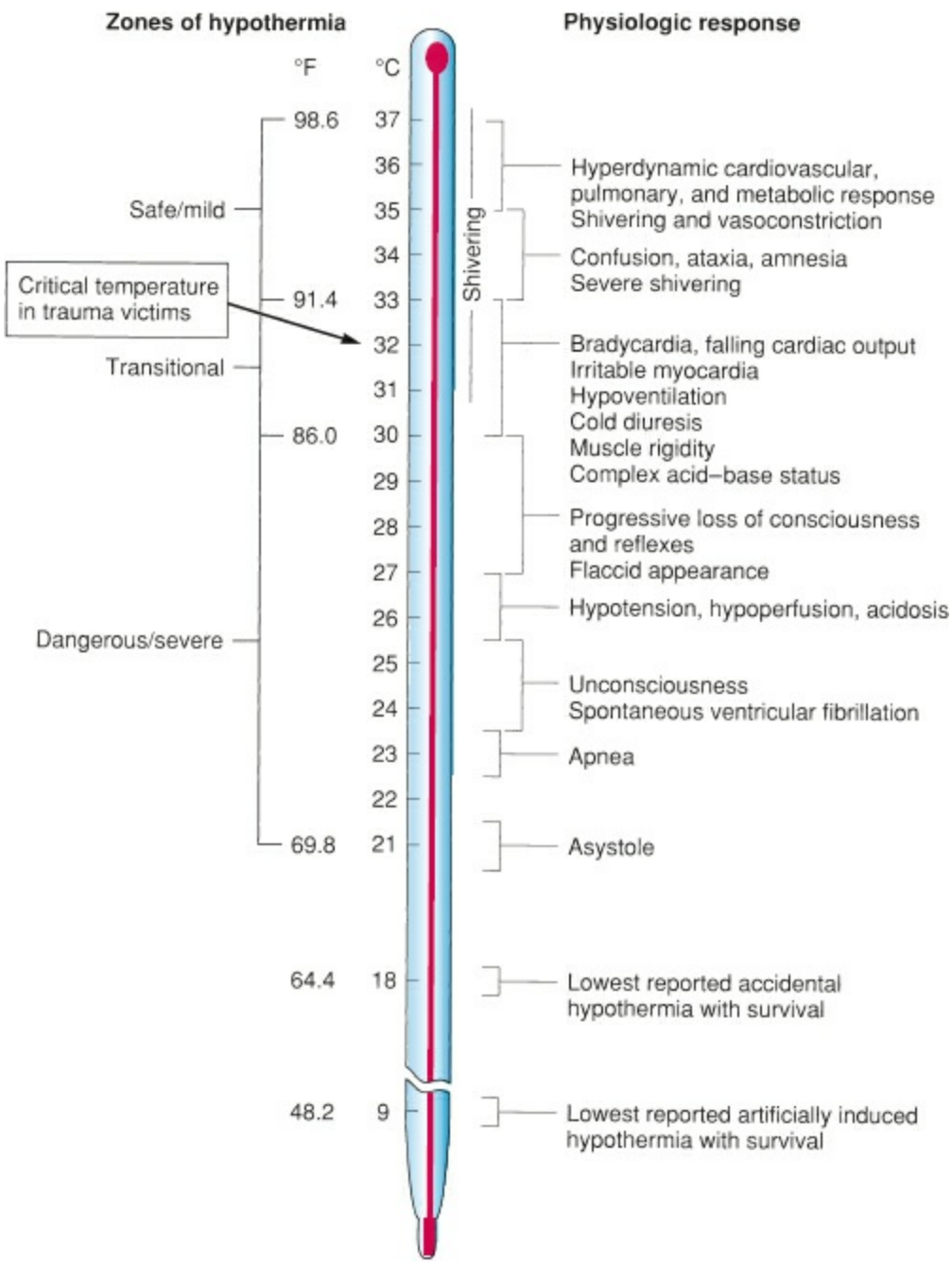

Figure 33-19. Zones of hypothermia and corresponding physiologic responses. Wide biologic variability accounts for physiologic changes rarely occurring at the exact temperatures noted. (After Jurkovich GJ. Hypothermia in the trauma patient. *Adv Trauma* 1989;4:111–140.)

7 Respiratory drive is increased during the early stages of hypothermia, but below 33°C progressive respiratory depression occurs, resulting in a decrease in minute ventilation. This decrease is not usually a significant problem until temperatures below 29°C is reached. Occasionally, hypothermia results in the production of a large amount of mucus (cold bronchorrhea).[122] This development predisposes to atelectasis and aspiration as ciliary action and the cough reflex are also depressed. Noncardiogenic pulmonary edema is also occasionally reported, especially in elderly patients and especially after prolonged periods of hypothermia.[123]

The effect of core hypothermia on arterial blood gas interpretation warrants a comment. Arterial blood gas samples are typically warmed to 37°C before measurement. A nomogram of Severinghaus mathematical corrections is then used to estimate the blood

gas values at the patient's actual body temperature. With each 1°C temperature reduction, the P_{CO_2} decreases by 4.4% and the P_{O_2} decreases by 7.2%. As an example, lets say a blood gas from a hypothermic 32°C patient is measured at 37°C showing a P_{CO_2} of 40 mm Hg and a P_{O_2} of 70 mm Hg; using the above correction techniques results in a reported P_{CO_2} of 32 mm Hg and a P_{O_2} of 48 mm Hg. The decrease in partial pressure is related to the increased solubility of gases in cold fluids and is not a result of a change in carbon dioxide content, oxygen content, or serum bicarbonate level. Clinicians often assume that the normal P_{CO_2} and P_{O_2} at 37°C are the values that should be attained at all temperatures. However, if normothermic endpoints for P_{CO_2} were attained in a hypothermic patient, they would have increased total-body CO_2 stores, which would manifest by a rising P_{CO_2} and a falling pH during rewarming. Likewise, attempts at increasing a P_{O_2} that reflects normal oxygen content at a lower temperature are also inappropriate. A far simpler strategy is to assess the blood gases at 37°C without temperature correction. Values that are normal and acceptable when reported at 37°C (without temperature correction) correspond to normal values and contents when "corrected" for hypothermic temperatures.

Temperature correction of blood gases for pH management is also unnecessary.[124] A pH of 7.40 at 37°C would be temperature corrected to 7.47 in a 32°C patient. At 37°C, the acid–base balance of water is neutral (pH is equal to pOH) when the pH is 6.8, and the body functions optimally when its pH is offset 0.6 pH units above the neutral point of water and has a relatively alkaline pH of 7.40. The pH of water rises with cooling, causing the pH of blood to rise by 0.015 pH units/°C, without a change in bicarbonate content.[125] Treating a patient with a temperature of 30°C with a pH of 7.40 instead of 7.47 fails to maintain the normal pH offset above the neutral point of water (relative alkalinity) and results in an acidotic cellular and chemical environment that has a multiplicity of effects on enzyme systems. Because blood with a pH of 7.40 assessed at 37°C is reported as having a pH of 7.47 when temperature corrected to 32°C, the simplest strategy when confronted with a patient with a temperature of 32°C is to assess the blood gas at 37°C only and to use the 37°C uncorrected pH value for management.[126–128]

The neurologic response to hypothermia is heralded by progressive loss of lucidity and deep tendon reflexes and, eventually, by flaccid muscular tone. Patients are often amnestic below 32°C, and between 31°C and 27°C they usually lose consciousness. Pupillary dilatation and loss of cerebral autoregulation occur at temperatures below 26°C, and electroencephalography becomes silent at 19°C to 20°C.[129] These findings, combined with an unobtainable pulse and apparent rigor mortis, may cause the patient to appear dead. It is important to remember that patients have been revived from core temperatures as low as 14°C[130] and hence the saying "No one is dead until warm and dead."[131] An exception to this admonition probably includes the patient who has sustained an anoxic event while still normothermic and has a serum potassium level greater than 10 mmol/L, although the Bernese criteria for trauma and hypothermia have picked a level of 12 mmol/L as being nonsalvageable.[114,117,121,132] The role of hypothermia in brain death determination remains controversial. Brain death is a medically and legally accepted

mechanism of death in the United States and worldwide. Yet significant variability in individual institutional policies regarding the determination of brain death occurs. In 2010 the American Academy of Neurology (AAN) issued guidelines on the determination of brain death.[133] A recent study examined how well 52 organ procurement organizations and 508 unique hospitals have adopted these guidelines, determining that among other variables in policy, only 181 of 228 policies (80%) required the absence of hypothermia (temperature $>36^{\circ}C$) in brain death determination.[134]

In classic surgical physiology research, Moyer and Debakey showed that with hypothermia, reduction in blood pressure and cardiac output decreases glomerular filtration rate, but urinary output is maintained because of impairment in renal tubular Na^+ reabsorption (cold diuresis).[135,136] Vasoconstriction also results in an initial increase in central blood volume that prompts a diuresis. Ileus, bowel wall edema, depressed hepatic drug detoxification, punctate gastric erosions (Wischnevsky ulcers), hyperamylasemia, and, rarely, hemorrhagic pancreatitis are hallmarks of the intestinal response to hypothermia. Hypothermia inhibits insulin release and insulin uptake at receptor sites, making hyperglycemia a relatively common finding, especially at temperatures below 30°C.[137] Exogenous insulin administration is unwarranted because it may result in rebound hypoglycemia during rewarming. Serum electrolyte changes are unpredictable, but serum potassium is often slightly increased in hypothermic patients because of renal tubular dysfunction, acidosis, and the breakdown of liver glycogen.[138] Hypothermia also appears to affect endothelial cell adhesion molecule function, which may partially explain increased infectious complications in hypothermic patients.[139] One study demonstrated a drop of 1.9°C core hypothermia triples the incidence of surgical wound infection following colon resection and increases the duration of hospitalization by 20%, leading to the now standard perioperative checklist monitoring of body temperature during surgery.[140]

Body temperature has a significant effect on oxygen uptake. Oxygen consumption (VO_2) initially increases dramatically with any fall in body temperature. When involuntary muscle contractions in the form of shivering occur, oxygen consumption increases by as much as three- to fivefold.[141,142] This process is inefficient because shivering produces heat near the surface of the body, causing most of the heat to be lost to the environment, with less than 45% being retained by the patient. As core temperatures fall to between 33°C and 30°C, shivering is abolished, and the patient will rapidly sink to ambient temperature.

The thermoregulatory drive is such a powerful one that it takes precedence over many other homeostatic functions. The resultant increase in oxygen utilization may result in anaerobic metabolism, acidosis, and significant cardiopulmonary stress. One study noted a 35% increase in oxygen consumption and a 65% increase in CO_2 production in postoperative patients after resolution of anesthesia, when the thermostatic drive reappeared.[143,144] In another study, a core temperature decrease of as little as 0.3°C in postoperative patients was associated with a 7% increase in VO_2, and temperature reductions between 0.3°C and 1.2°C were associated with a 92% increase in VO_2, with

proportional increases in minute ventilation. Shivering can be iatrogenically abolished with low doses of meperidine (Demerol®) and possibly ondansetron (Zofran®, Zuplenz®). Further details of the specific organ system responses to hypothermia are beyond the scope of this chapter, but the interested reader is referred to several excellent indepth monographs.[112,145,146]

Hypothermia in Trauma Patients

Mild hypothermia is very common after traumatic injury. The thermoneutral environment for humans is a humid and warm 28°C (82.5°F) (think tropical islands). When ambient temperature falls below the thermoneutral temperature (i.e., the temperature at which no thermogenesis or heat dissipation is necessary), an increase in heat production is required to maintain a normal body temperature. Combustion is the only source of endogenous heat production, and this process requires an increase in oxygen utilization. After shock or injury, however, oxygen supplies are often limited and further heat loss occurs owing to cold emergency department and operating room environments, cold fluid resuscitation, and open thoracic and abdominal cavities. Anesthetic and neuromuscular blocking agents that prevent the heat-producing shivering response further aggravate this. Thus, the occurrence of hypothermia in surgical or critically injured patients is most often a form of secondary accidental hypothermia.

One study found that 57% of trauma patients admitted to a level 1 trauma center were hypothermic at some time and that temperature loss was most significant in the emergency department.[147] Another study reported that the average initial temperature for 94 intubated major trauma victims was 35°C, with no seasonal variation.[148] Of patients in this study, 66% were hypothermic on admission; 43% were mildly hypothermic (34°C to 36°C), and 23% had temperatures below 34°C. Likewise, Jurkovich and Luterman reported that 42% of 71 adult trauma victims with an injury severity score (ISS) of 25 or higher had core temperatures below 34°C and in 13% the core temperature fell below 32°C.[149] Importantly, there were no survivors when core body temperature was below 32°C. Inaba reported that of 118 patients requiring emergent surgery following traumatic injury, hypothermia (<35°C) was present in nearly 30% of patients upon presentation to the operating room, and that a continued decrease in core temperature was associated with increased mortality. This mortality rose to 50% if temperature fell below 32°C.[150] Both mortality rate and the incidence of hypothermia increase with higher ISS, massive fluid resuscitation, and the presence of shock, but controlling for these variables still demonstrates that the mortality rate of the hypothermic trauma patient is greater than that of the warm trauma patient.[151] Although the mortality rate for moderate (28°C to 32°C) degrees of primary accidental hypothermia is approximately 20%,[114,115] moderate levels of hypothermia in trauma and critically ill patients are associated with a much higher mortality rate. Rutherford et al.[152] reported that 9.4% of surgical intensive care unit patients had a core body temperature less than 35°C; the mortality rate of the hypothermic trauma patients was 53%. In fact, compared with other patient populations, the mortality rate associated with hypothermia in the trauma victim is so high that the definition of mild, moderate, and severe hypothermia in

the trauma patient warrants special classification (Table 33-7).[112]

Table 33-7 Zones of Severity for Hypothermia

Zone	Temperature
Mild hypothermia	36°C–34°C (<96.8°F–93.2°F)
Moderate hypothermia	34°C–32°C (<93.2°F–89.6°F)
Severe hypothermia	<32°C (<89.6°F)

Hypothermia appears to occur primarily in victims of relatively severe trauma. Little and Stoner,[153] while reporting on a heterogeneous group of 82 trauma patients, observed that hypothermia occurred only in those patients with an ISS greater than 12. Skin temperature fell from 32.0°C to 31.7°C, whereas core temperature fell from 37.3°C to 36.5°C. Hypothermia did not occur in less severely injured patients, and shivering, which should be expected, was noted in only one of the hypothermic patients. Mild degrees of injury have, in fact, been associated with small elevations in core body temperature, particularly when the shivering response mechanism has not been abated.[112,154] It is notable that over the past two decades, considerable attention has been given to preventing hypothermia in trauma patients. Prior to the 1993 version of Advanced Trauma Life Support, the student and instructor course books did not include the prevention of hypothermia in the primary survey. The recognition that hypothermia can be prevented has resulted in substantial changes in the management of the acute injured patient. As a result, the "lethal triad" of coagulopathy, acidosis, and hypothermia is much less frequently observed.[155]

The detrimental effect of hypothermia in the human trauma victim is contrasted by a large body of experimental evidence in animals suggesting that hypothermia has a protective role in shock. This extensive body of literature is reviewed elsewhere,[112] but in general, animals subjected to combined hypothermia and shock (hemorrhage, burn, and blunt trauma) usually survive longer than similarly injured but actively warmed animals. Blalock and Mason (1941) were among the first in modern times to recognize the ability of hypothermia to prolong survival times after shock,[156] but they emphasized that the overall survival rate was unchanged, an observation reaffirmed in 2003.[157] However, increases in both survival times and survival rates have been shown in a number of animal models of induced hypothermia after hemorrhagic shock.[158,159] The protective effects of hypothermia in preventing ischemia–reperfusion injury have been described in a number of models, including muscle, intestine, and rabbit ear.[160–162] These observations have prompted some to suggest that there is a role for iatrogenic-induced hypothermia in severe trauma patients, with the goal being a reduction of oxygen consumption in the setting of limited oxygen delivery (hypovolemic shock) to allow surgeons time to repair injured structures and then rewarm and resuscitate the patients.[163–165]

Hypothermia has also utilized in attempts to protect the traumatically injured brain.

The use of therapeutic hypothermia in a patient with traumatic brain injury was first reported in 1943[166] and sporadically over the ensuing 2 decades[120] in 2001, Clifton et al. reported a randomized, multicenter, controlled trial of core body hypothermia in trauma patients with severe closed head injury.[167] Select trauma patients (GCS 3 to 7) were intentionally cooled within 6 hours of injury to 32°C to 33°C for 48 hours after injury and then rewarmed. The outcome was poor (defined as severe disability, a vegetative state, or death) in 57% of the patients in both groups. Mortality was 28% in the hypothermia group and 27% in the normothermia group ($p = 0.79$). The patients in the hypothermia group had more hospital days with complications than the patients in the normothermia group. This study has led most authorities to conclude that treatment with total-body hypothermia is not effective in improving outcomes in patients with severe brain injury. Other authors have also reported higher rates of pneumonia and diabetes insipidus in patients with severe head injury and induced hypothermia.[168] Evidence further supporting the harmful effect of hypothermia in the trauma patient is provided by a prospective, randomized trial of rapid rewarming versus conventional rewarming of 57 multiple-trauma patients.[168] In this study, trauma patients who were rapidly rewarmed with continuous arteriovenous rewarming (CAVR) from less than 34.5°C to greater than 36°C required less resuscitation fluid volume and had a lower early mortality rate than those rewarmed more slowly. Failure to rewarm in either group was uniformly fatal. The survival rate at 3 days after injury was 82% in the rapid rewarm group versus 62% in conventionally managed patients. Approximately 50% of the patients in both groups had a severe head injury, defined as a head abbreviated injury severity score of 3 or greater. In this well-controlled study, maintenance of hypothermia not only failed to confer an advantage but also was detrimental to early survival.

The use of hypothermia in the treatment of acute cardiac arrest is beyond the scope of this chapter. It is discussed in Chapter 20. However, the principle of this increasingly common technique is the same as the principle of organ preservation for transplantation – cooling of the body decreased oxygen consumption and may allow for a longer period of relative anoxia with good recovery.[169–171] The advantage in these patients, or rather the difference between the acute care arrhythmia patient and the patient with trauma is likely the total-body tissue injury and its effect in coagulation and the inflammatory response. But the attraction for the concept of “suspended animation” with induced hypothermia in trauma remains seductive.

The role of hypothermia in the injured patient remains complex. It is apparent that the physiologic consequence of severe trauma is a drop in core body temperature, either as a protective response to shock or the result of diminished heat production caused by failing metabolism. The frequent presence of lactic acid accumulation in cold, seriously injured patients supports the latter hypothesis. Clinical studies indicate that even mild hypothermia in the trauma patient is predictive of a poor outcome, given our current capabilities of surgical repair of injured organs. Hypothermia does diminish metabolic demands and oxygen consumption, but the price appears to be malfunction of enzymes and physiologic systems necessary to recover from injury.

The systems most affected by hypothermia in victims of injury are those involved in

clotting. Focused attention on the coagulation mechanisms in trauma patients over the past decade has exposed the lack of a comprehensive understanding of the complex relationship between injury, inflammation, and coagulopathy.[172] Temperature is yet another variable in this complexity. Reports of coagulation abnormalities in patients with apparently normal clotting factor levels surfaced shortly after the introduction of hypothermic cardioplegia for cardiac surgery.[173,174] Although hemodilution with volume expanders deficient in clotting factors and platelets is the usual cause of nonsurgical bleeding, cold platelets are known to undergo morphologic changes that affect adherence, including loss of shape, cytoplasmic swelling, and dissolution of cytoplasmic microtubules necessary for normal motility.[175] Platelet activation is also associated with activation of cell membrane phospholipases that hydrolyze phospholipids to arachidonic acid, a precursor to prostaglandin endoperoxides and thromboxane A_2, a potent vasoconstrictor necessary for normal platelet aggregation[176] Valeri et al.[177] induced systemic hypothermia to 32°C in baboons, but kept one forearm warm using heating lamps and a warming blanket. Simultaneous bleeding time measurements in the warm and cold arm were 2.4 and 5.8 minutes, respectively. This effect, which was reversible with rewarming, appeared to be mediated by cold-induced slowing of the enzymatic reaction rate of thromboxane synthetase, which resulted in decreased production of thromboxane A_2. Bleeding observed at mildly reduced temperatures (33°C to 37°C) results primarily from a platelet adhesion defect and not reduced enzyme activity or platelet activation; however, at temperatures below 33°C, both reduced platelet function and enzyme activity likely contribute to the coagulopathy,[178] perhaps helping to explain why 32°C is such a critical temperature in the coagulopathic injured patient.

As with blood gases, clinical tests of coagulation are temperature standardized to 37°C. Fibrometers contain a thermal block that heats the plasma and reagents to 37°C before initiating the assay. Thus, tests of coagulation reflect clotting factor deficiencies but are corrected for any potential effect of hypothermia on clotting factor function. A detailed study of the kinetic effects of hypothermia on clotting factor function has been undertaken by Reed et al.[179] He performed clotting tests (PT, PTT, and thrombin time) on reference human plasma–containing normal clotting factor levels at temperatures ranging from 25°C to 37°C. The results showed a significant slowing of all coagulation tests at temperatures below 35°C that was proportional to the degree of hypothermia. The prolongation of clot formation occurred at clinically relevant levels of hypothermia and was equivalent to that seen in normothermic patients with significant clotting factor depletion. For example, assays conducted at 35°C, 33°C, and 31°C prolonged the PTT to the same extent as would occur in a euthermic patient with reductions in factor IX levels to 66%, 32%, and 7% of normal, respectively.

Clotting factor supplementation is not the answer to a hypothermia-induced coagulopathy; rewarming is. However, in many seriously injured patients, clotting factor depletion exists in conjunction with hypothermia. A potentiating effect of hypothermia on coagulation dysfunction occurs in plasma of patients with deficient clotting factor levels, although there does not appear to be synergy between the two conditions.[180]

Hypothermic, coagulopathic trauma patients still benefit from coagulation profile testing. If prolongation of PT and PTT is evident in plasma warmed to 37°C, clotting factor replacement is indicated. If PT and PTT are near normal, rewarming alone reverses the clinically apparent coagulopathy.

Treatment

8 Rewarming techniques are usually classified as passive external rewarming, active external rewarming, or active core rewarming.[181] Passive external rewarming simply implies allowing spontaneous rewarming to occur with the patient removed from a hypothermic environment and is usually used only for the mildly hypothermic patient. Active external rewarming techniques include surrounding the patient with warm blankets or heating pads, infrared heating lights, and immersion in warm water. Active core rewarming includes heated intravenous fluids, as well as heated peritoneal or thoracic lavage; heated gastric, bladder, or colonic lavage; heated and water-saturated inhaled air; and extracorporeal circulatory rewarming. Blood rewarming is currently limited to a maximum temperature of 42°C by the American Association of Blood Banks, but rewarming to 49°C with inline microwave blood rewarmers has been reported as safe, as has intravenous fluid rewarming to 65°C.[182,183]

The advantages and disadvantages of each technique are regularly debated, particularly regarding the role of external versus core rewarming. It is clear, however, that the rate of heat transfer to the hypothermic patient is greatest using active core rewarming, particularly extracorporeal circulation rewarming. This may be a critical factor in surgical patients for whom rapid restoration of clotting and cardiac function is necessary.

The technique of rewarming the hypothermic victim by extracorporeal circulation has been described by numerous authors, initially based on small personal experiences and using cardiopulmonary bypass techniques of open-heart surgery.[119–121] This technique has appeal in cases of primary accidental hypothermia, in which maintenance of circulation, correction of hypoxia, and replenishment of intravascular volume may play a role as large as correcting the temperature change itself. The need for systemic anticoagulation has, however, generally limited the usefulness of full cardiopulmonary bypass rewarming in the trauma patient. More recently the use of ECMO for core hypothermia rewarming has been the subject of numerous publications as more centers become more experienced with this tool.[184]

A simplified technique of extracorporeal active core rewarming is CAVR.[185] This technique makes use of the patient's own blood pressure to drive an extracorporeal circuit through an efficient, but small countercurrent heat-exchange device. Systemic anticoagulation is not necessary if the tubing is heparin-bonded and trauma patients are relatively anticoagulated. The relative ease of use made this device widely applicable in rewarming severely hypothermic patients with an intact circulation and, in a prospective, randomized trial of rewarming trauma patients, demonstrated its efficacy by improved survival.[168] Unfortunately, the product used in that referenced study by Gentilello et al. is no longer in commercial production.

Direct intracirculation rewarming can be accomplished with commercially available devises that employ either an intra–vena caval countercurrent heat-exchange devise (InnerCool RTx®, Phillips Healthcare, Best, The Netherlands) or balloon catheters with large surface areas (Alsius/Zoll Medical Irvine, CA). The ownership and design of these devises change rapidly, as the clinical need is limited. Although initially developed to cool patients for neurosurgical procedures, they are now used primarily for inducing and maintaining hypothermia following sudden cardiac arrest; rewarming can be accomplished by simply changing the temperature of the closed-loop circulating fluid. Requirements are the commercial bedside console and the specialized endovascular temperature control catheter, inserted via the femoral vein to the vena cava, usually with a larger size introducer (10 to 12 Fr). Data on rewarming cold patients suggest that rewarming can occur up to 3°C per hour compared to 6°C to 9°C per hour with ECMO or CPB.[114,186]

The use of body cavity lavage with warm solutions is a simple, less invasive method of accomplishing active core rewarming; however, rewarming rates with body cavity lavage vary greatly based on initial core temperature, dialysate temperature, infusion rate, and dwell time. Several studies support the notion that active core rewarming by peritoneal lavage is preferable to active external rewarming.[187] Moss examined three techniques of rewarming hypothermic and cardiac-arrested dogs, concluding that both peritoneal lavage (55°C dialysate) and partial extracorporeal circulation were faster than active external rewarming with a heating blanket.[188] A frequently stated disadvantage of external rewarming is that the peripheral tissues are rewarmed in advance of the still cool "core," resulting in peripheral vasodilation. In the presence of inadequate volume resuscitation, this rewarming method may result in vascular collapse ("rewarming shock") and a subsequent fall in central temperature ("afterdrop") as the cold peripheral blood returns to the core. Whether this process is the mechanism of the core afterdrop is debatable because a core afterdrop has been noted to occur in animal models even during complete circulatory arrest. Volume contraction caused by vasoconstriction, cold diuresis, and cellular swelling coupled with inadequate fluid resuscitation may be a more appropriate explanation for circulatory collapse during rewarming.

The thermodynamic principles of heat transfer to the hypothermic patient are reviewed in greater detail elsewhere, but a sense of rewarming rates and quantity of heat transferred by various techniques is instructional.[181,189] Ventilating a patient with a core temperature of 32°C with water-saturated air at 41°C results in a maximum heat transfer rate of 9 kcal/hr. For comparison, basal metabolic heat generation produces approximately 70 kcal/hr, and shivering produces up to 250 kcal/hr. Given the specific heat of the body (0.083 kcal/kg/°C), 58 kcal is required to raise the temperature of a 70-kg patient by 1°C. Thus, more than 6 hours would be required to warm a 32°C patient using 41°C humidified inspired air.

Heat transfer rates using body cavity lavage can be similarly calculated based on the specific heat of water (1 kcal/kg/°C). If 1 L of 44°C water infused into a body cavity dwells long enough to exit at 40°C, 4 kcal of heat will have been transferred to the patient. Thus, over 14 L of fluid is needed to increase core temperature by 1°C. However,

warming becomes less efficient as the patient rewarms because a longer dwell time is required to reduce the temperature of the infusate to 40°C.

Warming by cardiopulmonary bypass or ECMO or CAVR is the most efficient method of core heating. With flow rates of 15 to 30 L/hr, it is possible to deliver 120 to 240 kcal/hr if the reinfused blood is heated to 40°C, a rate of heat transfer over 10 times that of the other methods. In any case, the urgency with which rewarming must be accomplished depends on how adversely the hypothermia is affecting the patient. With the exception of extracorporeal circulatory methods, most rewarming techniques serve primarily to prevent loss of endogenously generated heat and are ineffective in circumstances in which rapid rewarming is indicated. Early and direct attention to preventing heat loss is therefore essential in surgical patients. With more widespread adoption of ECMO capabilities for treating severe lung disease, centers are starting to report on the use of this modality as a rewarming technique. The combination of injury and hypothermia represents a particular challenge. Swiss physicians with experience in treating injured and hypothermia avalanche victims have developed the Bernese Hypothermia Algorithm, a detailed approach to rewarming techniques and injury care priorities in this population.[190]

Cold Injury and Frostbite

9 Frostbite is a cold injury limited to digits, extremities, or exposed surfaces that is the result of direct tissue freezing. Chilblain (aka pernio) and trenchfoot are the result of more chronic exposure to an environment just above freezing. Both of these types of cold injury have been a major cause of morbidity during war experiences. They resulted in more than 7 million lost soldier fighting days by Allied forces in World War II and were reportedly the most common major injury sustained by British soldiers in the Falklands expedition.[138]

The terms *chilblain* and *pernio* describe a form of local cold injury characterized by pruritic, red-purple papules, macules, plaques, or nodules on the skin. The lesions are often associated with edema or blistering and are caused by a chronic vasculitis of the dermis[191]; this entity does not appear to be related to hereditary protein C or S deficiency.[192] This pathologic process is provoked by repeated exposure to cold, but not freezing, temperatures. This injury typically occurs on the face, the anterior surface of the tibia, or the dorsum of the hands and feet, areas poorly protected or chronically exposed to the environment. With continued exposure, ulcerative or hemorrhagic lesions may appear and progress to scarring, fibrosis, and atrophy. Treatment consists of sheltering the patient, elevating the affected part on sheepskin, and allowing gradual rewarming at room temperature. Rubbing and massage are contraindicated because they can cause further damage and secondary infection.

Trench foot or cold immersion foot (or hand) describes a nonfreezing injury of the hands or feet, typically in sailors, fishermen, or soldiers, that is caused by chronic exposure to wet conditions and temperatures just above freezing.[193] It appears to involve an alternating arterial vasospasm and vasodilatation, with the affected tissue first cold and anesthetic and then hyperemic after 24 to 48 hours of exposure. With the hyperemia comes an intense, painful burning and dysesthesia, and tissue damage is characterized by edema, blistering, redness, ecchymosis, and ulceration. Complications of local infection or cellulitis, lymphangitis, and gangrene may occur. A posthyperemic phase occurs 2 to 6 weeks later and is characterized by tissue cyanosis with increased sensitivity to cold. Treatment is best started during or before the reactive hyperemia state and consists of immediate removal of the extremity from the cold, wet environment with exposure of the feet (or hands) to warm, dry air. Elevation to minimize edema, protection of pressure spots, and local and systemic measures to combat infection are indicated. Massage, soaking of the feet, or rapid rewarming is not indicated. Demyelination of nerves, muscle atrophy, fallen arches, and osteoporosis may all present long-term complications, and a tendency toward marked vasospasm during subsequent exposure to cold develops in some patients.[194]

Frostnip is the mildest form of cold injury. It is characterized by initial pain and pallor, with subsequent numbness of the affected body part. Skiers and other winter outdoor enthusiasts are most likely to experience this cold injury to the nose, ears, or tips of digits. The injury is reversible and warming of the cold tissue results in return of sensation and function with no tissue loss.

Frostbite is a more severe and common form of cold injury. Frostbite damage is caused by direct ice crystal formation at the cellular level with cellular dehydration and microvascular occlusion. Frostbite is traditionally classified into four grades of injury severity (Table 33-8).

The affected body part nearly always initially appears hard, cold, white, and anesthetic, regardless of the depth of injury. Because the appearance of the lesion changes frequently during the course of treatment and because the initial treatment regimen is applicable for all degrees of insult, some authorities suggest discarding this classification as a prognostic impossibility and simply classifying frostbite as either superficial or deep.[195]

Weather conditions, altitude, degree of protective clothing, duration of exposure, and degree of tissue wetness are all contributing external factors to the development of frostbite injury. Because sensory nerve activity is abolished at 7°C to 9°C, the disappearance of pain is an early warning sign of cold injury. Acclimation to cold may be protective, whereas a previous history of frostbite probably predisposes to another cold tissue injury. Smoking and a history of arterial disease also are contributing factors. In urban environments, more than 50% of frostbite injuries are alcohol-related and in one report, 16% of these patients also had a significant underlying psychiatric illness.[196]

Evidence suggests that frostbite injury has two components – the initial freeze injury and a reperfusion injury that occurs during rewarming. The initial response to tissue cooling is vasoconstriction and arteriovenous shunting, intermittently relieved (every 5 to 7 minutes) by vasodilation, the so-called hunting response.[197] With prolonged exposure, this response fails, and the temperature of the freezing tissue approximates ambient temperature until –2°C. At this point, extracellular ice crystals form, and as these crystals enlarge, the osmotic pressure of the interstitium increases resulting in movement of intracellular water out of cells and into the interstitium. Cells begin to shrink and become hyperosmolar, disrupting cellular enzyme function. If freezing is rapid (>10°C/min), intracellular ice crystal formation will occur, resulting in immediate cell death.[198] In addition, endothelial cell disruption and red cell sludging associated with freezing result in cessation of circulation.

CLASSIFICATION

Table 33-8 Classification of Frostbite

Degree	Description of Frostbite
First	Tissue freezing with hyperemia and edema but without blistering
Second	Tissue freezing with hyperemia, edema, and characteristic large, clear blisters
Third	Tissue freezing with death of subcutaneous tissues and skin, resulting in hemorrhagic vesicles that are in general smaller than second-degree blisters
Fourth	Tissue necrosis, gangrene, and eventual full-thickness tissue loss

During rewarming, red cell, platelet, and leukocyte aggregation occurs and results in patchy thrombosis of the microcirculation. These accumulated blood elements are thought to release, among other products, the toxic oxygen free radicals and the arachidonic acid metabolites PGF_{2a} and thromboxane A_2, which further aggravate vasoconstriction and platelet and leukocyte aggregation.[199,200] However, the exact mechanism of tissue destruction and death after freeze injury remains poorly defined. Animal studies suggest that vascular injury in the form of endothelial cell damage and subsequent interstitial edema, but not vessel thrombosis, predominate as initial events in rewarming injury.[201] A substantial component of severe cold injury may be neutrophil mediated, as suggested by the observation that a monoclonal antibody to neutrophil–endothelial and neutrophil–neutrophil adherence can markedly ameliorate the pathologic process of a severe cold injury.[202] In this rabbit model, animals treated with anti-CD11/CD18 adhesion molecule after cold injury (30 minutes at –15°C) but before rewarming (39°C water bath) had significantly less tissue loss and edema. The implication of these observations is that much of the injury of severe frostbite occurs during rewarming or reperfusion, although the efficacy of intra-arterial thrombolytic therapy suggests that endovascular clotting does occur and can be reversed.[203–206]

Treatment

Prehospital or field care of the victim of cold injury should focus on removing the patient from the hostile environment and protecting the injured body part from further damage. Rubbing or exercising the affected tissue does not augment blood flow and risks further cold injury or mechanical trauma. Because repeated bouts of freezing and thawing worsen the injury, it is preferable for the patient with frostbite of the hands or feet immediately to seek definitive shelter and care rather than rewarm the tissue in the field and risk refreezing. Although the initial symptoms may be mild and overlooked by the patient, severe pain, burning, edema, and even necrosis and gangrene may appear with rewarming. With severe injury the range of motion progressively decreases and edema becomes prominent. The injury may progress to numbness and, eventually, to loss of all sensation in the affected tissue.

The emergency room treatment of a frostbite victim should first focus on the basic ABCs (airway, breathing, and circulation) of trauma resuscitation and then systemic hypothermia should be identified and corrected. Most patients are dehydrated, and resuscitation with warm fluids is an important part of early management. Fractures are often accompanied by frostbite in mountaineers, and although manipulation may be required to treat vascular compromise, open reduction is hazardous, and application of traction should be delayed until after postthawing edema has been assessed.

Rapid rewarming is the goal. Gradual, spontaneous rewarming is inadequate, particularly for deeper injuries, and rubbing the injured part in ice or snow often delays warming and results in marked tissue loss.[207] Rapid rewarming should be achieved by immersing the tissue in a large water bath of 40°C to 42°C (104°F to 108°F). The water should feel warm, but not hot, to the normal hand. The bath should be large enough to prevent rapid loss of heat, and the water temperature should be maintained. Dry heat is not advocated because it is difficult to regulate, and the result of using excessive heat is often disastrous. The rewarming process should take approximately 30 to 45 minutes for digits, with the affected area appearing flushed when rewarming is complete and good circulation has been reestablished. Narcotics are required because the rewarming process can be quite painful.

The skin should be gently but meticulously cleansed and air-dried and the affected area elevated to minimize edema. A tetanus toxoid booster should be administered as indicated by immunization history. Sterile cotton is placed between toes or fingers to prevent skin maceration and extreme care taken to prevent infection and avoid even the slightest abrasion. The affected tissue should be protected by a tent or cradle, and pressure spots must be prevented. In one review, infection developed in 13% of urban frostbite victims, but one-half of these infections were present at the time of admission.[196] Most clinicians reserve antibiotics for identified infections.[208]

After rewarming, the treatment goals are to prevent further injury while awaiting the demarcation of irreversible tissue destruction. All patients should be hospitalized and affected tissue gently cleansed once or twice a day in warm (38°C) whirlpool baths, with some clinicians adding an antiseptic such as chlorhexidine or an iodophor to the bath.

Based on the findings of arachidonic acid metabolites in the blisters of frostbite victims, some authors advocate the use of topical aloe vera (thromboxane inhibitor) and systemic ibuprofen or aspirin. Heggers et al. report in a nonrandomized trial in which 56 patients treated with these agents, plus prophylactic penicillin, had less tissue loss, a lower amputation rate, and a shorter hospital stay than 98 patients treated with warm saline, silver sulfadiazine, or sulfamylon dressings (Bertek Pharmaceuticals, Research Triangle Park, NC).[209] Another report on frostbite treatment in rabbits demonstrated improved tissue viability when systemic pentoxifylline and topical aloe vera cream were used.[210] Uninfected blebs should be left intact because they provide a sterile biologic dressing for 7 to 10 days and protect underlying epithelialization. After resolution of edema, digits should be exercised during the whirlpool bath and physical therapy begun. Tobacco, nicotine, and other vasoconstrictive agents must be withheld. Weight bearing is prohibited until complete resolution of edema.

Numerous adjuvants have been tried in an effort to restore blood supply to frostbitten areas. The intense vasoconstrictive effect of cold injury has focused attention on increased sympathetic tone. Sympathetic blockade and even surgical sympathectomy continues to be advocated by some authors based on the theory that it releases the vasospasm that precipitates thrombosis in the affected tissue.[211,212] This method of treatment has produced inconsistent results and is difficult to evaluate clinically, with no prospective, randomized trials available. Although sympathectomy appears to mollify the pain and hyperhidrosis and vasospasm of cold injuries, it may increase vascular shunting and adversely affect healing. In one series, a more proximal demarcation of injury in sympathectomized limbs was noted than in nonsympathectomized ones, despite apparently equal bilateral injury.[207]

Experience with intra-arterial vasodilatory drugs, such as reserpine, tolazoline, and papaverine, has also been unrewarding. For example, Bouwman et al.[212] demonstrated in a controlled clinical study that immediate (mean 3 hours) ipsilateral intra-arterial reserpine infusion coupled with early (mean 3 days) ipsilateral operative sympathectomy failed to alter the natural history of acute frostbite injury compared with the contralateral limb. Iloprost, a synthetic analog of prostacyclin PGI_2 has also been used in an effort to vasodilate microvascular arcades.[206] Low–molecular-weight dextran has been shown to alleviate postthawing circulatory obstruction as late as 2 hours after thawing and markedly reduced tissue loss in rabbit feet,[213] but similar results in humans has not been demonstrated. Heparin, thrombolytic agents, and hyperbaric oxygen have also failed to demonstrate any substantial treatment benefit, but hyperbaric enthusiasts continue to tout its role.[214] None of these adjuncts is considered routine care.

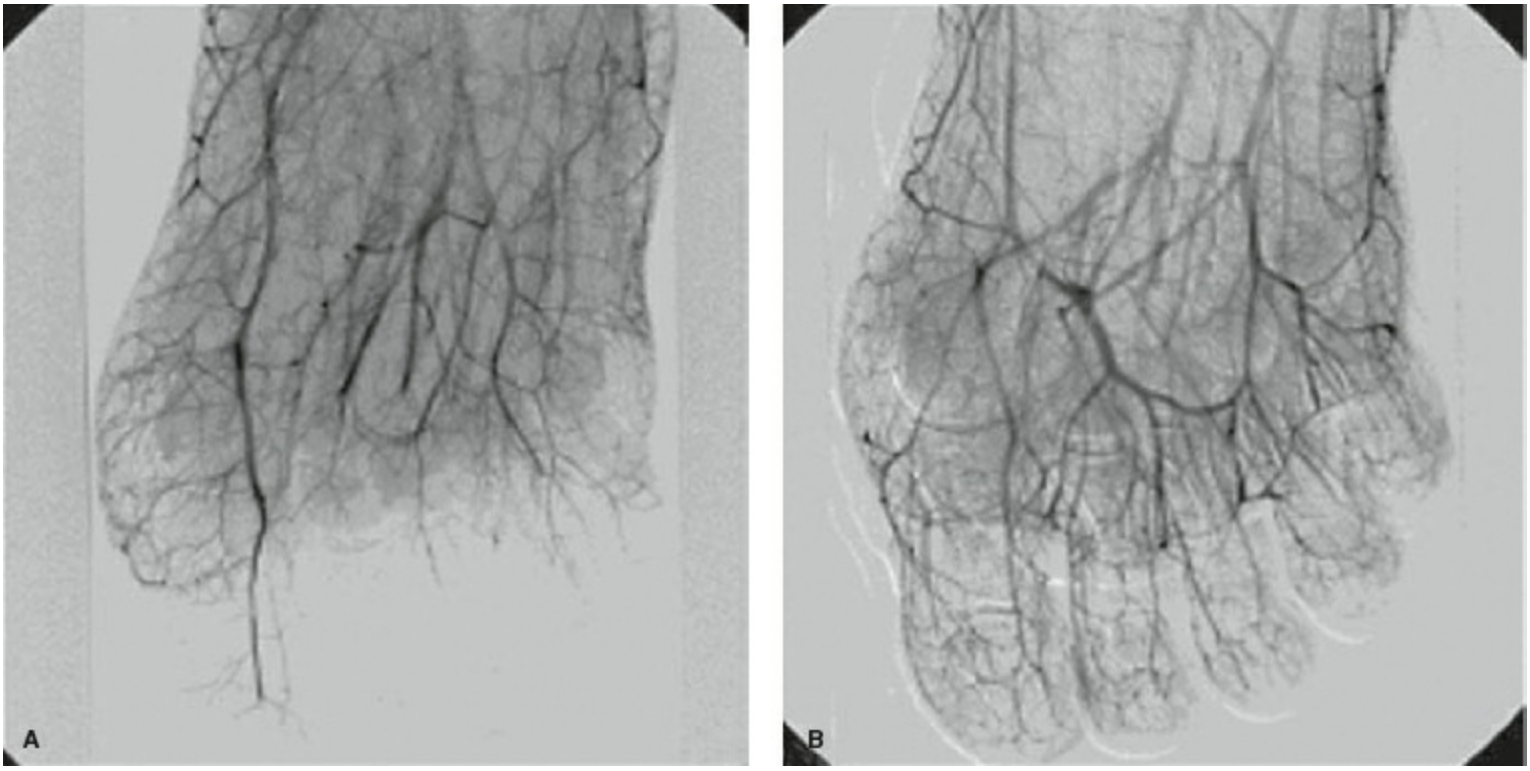

Figure 33-20. Digital angiography of a 19-year-old woman who sustained bilateral lower extremity frostbite following vehicle breakdown. **A:** The image demonstrates poor distal perfusion to the left toes. **B:** Following administration of tissue plasminogen activator via bilateral femoral catheters, angiography demonstrates return of perfusion. All 10 of her toes were saved. (Reproduced with permission from Bruen KJ, Ballard JR, Morris SE, et al. Reduction of the incidence of amputation in frostbite injury with thrombolytic therapy. *Arch Surg* 2007;142:546–553.)

10 The most recent adjunct to the management of frostbite is the intra-arterial infusion of tissue plasminogen activator (tPA). In a nonrandomized study of a small number (n = 7) of patients who received intra-arterial tPA, the burn team at the University of Utah demonstrated that tPA infusion improved tissue perfusion and reduced amputations (10% vs. 41%) when administered within 24 hours of injury (6 of the 7), as compared with 25 patients managed in a more traditional fashion.[203] Since this 2007 report, isolated case reports have also suggested that this therapy is effective.[205,215] Candidates for this therapy should have minimal risk of bleeding from other injuries, have the tPA administered (intra-arterial or intravenously) within 24 hours of frostbite, with no episodes of rewarming or refreezing between injury and treatment, and have clear evidence of full-thickness tissue involvement, as well as abnormal perfusion on either angiogram or pyrophosphate scanning (Fig. 33-20, Table 33-9).

The difficulty in determining the depth of tissue destruction in cold injury has led to a conservative approach to the care of frostbite injuries.[208,216] For digit frostbite, the Hennepin score may provide a useful way to track progress and compare experimental therapies.[217] As a general rule, amputation and surgical débridement are delayed for 2 to 3 months unless infection with sepsis intervenes, hence the adage: “frostbite in January, amputate in June.” The natural history of a full-thickness frostbite injury is the gradual demarcation of the injured area with dry gangrene or mummification clearly delineating nonviable tissue. Often the permanent tissue loss is much less than originally suspected.

In an Alaskan series, only 10.5% of patients required amputation, usually involving only phalanges or portions of phalanges.[193] The need for emergency surgery is unusual, but vigilance should be maintained during the rewarming phase for the development of a compartment syndrome requiring fasciotomy. Open amputations are indicated in patients with persistent infection and sepsis that is refractory to débridement and antibiotics. Mills convincingly demonstrated that of all the factors in the treatment of frostbite that may influence outcome, premature surgical intervention by any means, in any amount, was by far the greatest contributor to poor results.[218]

Table 33-9 Amputation Outcomes of Patients Treated With Tissue Plasminogen Activator (tPA) Compared With All Other Patients by Frostbite

Agent	No. of Patients	No. of Involved Extremities	Extremities Requiring Amputation, No. (%)			No. of Digits Amputated/Total Digits Involved (%)
			None	Proximal	Digits only	
No agent[a]	26	57	25 (45)	14 (25)	18 (29)	97/234 (41)
tPA administration, <24 hrs	6	13	10 (77)	0	3 (23)	6/59 (10)[b]
Total	32	70	35 (50)	14 (20)	21 (30)	103/293 (35)

[a]Includes one patient who received tPA starting 48 hours after exposure.
[b]$p < 0.50$ using Mann–Whitney U test.
Reproduced with permission from Bruen KJ, Ballard JR, Morris SE, et al. Reduction of the incidence of amputation in frostbite injury with thrombolytic therapy. *Arch Surg* 2007;142:546–553.

The use of technetium-99m methylene diphosphonate bone scanning has shown some promise in the early detection of eventual bone and soft tissue viability[219] as has the use of magnetic resonance imaging.[220,221] Technetium-99m "triple-phase" scanning (at 1 minute, 2 hours, and 7 hours) performed beginning 48 hours after admission has been used to assess early tissue perfusion and viability, in an attempt to define the extent of fatally damaged tissues and to allow for early débridement and wound closure.[222,223] The utility of this diagnostic modality continues to evolve, however, with one recent study suggesting that the moderate to severe frostbite lesion identified by technetium-99m scans can be "hibernating" (viable) tissue, which can show improvement up to 6 months following injury.[208,224]

Frostbitten tissues seldom recover completely. Some degree of cold insensitivity invariably remains. Hyperhidrosis (in up to 72% of patients), neuropathy, decreased nail and hair growth, and a persistent Raynaud phenomenon in the affected part are frequent sequelae to cold injury.[204,224,225] The affected tissue remains at risk for reinjury and should be carefully protected during any cold exposure. As mentioned previously, chilblain (or chronic pernio) is a specific form of a dermopathy secondary to cold-induced skin vasculitis. Treatment with antiadrenergic agents (prazosin hydrochloride, 1 to 2 mg/d) or calcium channel blockers (nifedipine, 30 to 60 mg/d) and careful protection from further exposure is often helpful.[191,224] However, few therapies afford significant relief to the chronic symptoms after tissue freeze injury, although β- and α-adrenergic blocking agents, calcium channel blockers, topical and systemic steroids, and a host of

home remedies have been tried with occasional individual success.

References

1. Estimation of the global burden of snakebite [Internet]. 2008 [cited March 1, 2016]. Available at: http://www.cdc.gov/niosh/topics/snakes.
2. Centers for Disease Control and Prevention. Necrotic arachnidism–Pacific Northwest, 1988–1996. *JAMA* 1996;275(24):1870–1871.
3. Mattison C. Snake: The essential visual guide to the world of snakes. New York, NY: Dorling Kindersley Ltd; 2006.
4. Pough F. *Herpetology*. Upper Saddle River, NJ: Pearson/Prentice Hall; 2004.
5. Conant R, Collins J. Peterson field guide: Reptiles and amphibians: Eastern and central North American. Boston, MA: Houghton Mifflin; 1998.
6. Stebbins R. Peterson field guides: Western reptiles and amphibians. New York, NY: Houghton Mifflin; 2003.
7. Tennant A, Salmon G, King R. *Snakes of North America: Eastern and Central Regions*. Lanham, MD: Lone Star; 2003.
8. Gold BS, Dart RC, Barish RA. Bites of venomous snakes. *N Engl J Med* 2002;347(5):347–356.
9. Ruha AM, Curry SC, Albrecht C, et al. Late hematologic toxicity following treatment of rattlesnake envenomation with crotalidae polyvalent immune Fab antivenom. *Toxicon* 2011;57(1):53–59.
10. Ownby C. Structure, function, and biophysical aspects of the myotoxins from snake venoms. *J Toxicol - Toxin Rev* 1998;172(2):213–238.
11. Hutton RA, Warrell DA. Action of snake venom components on the haemostatic system. *Blood Rev* 1993;7(3):176–189.
12. Lavonas EJ, Gerardo CJ, O'Malley G, et al. Initial experience with Crotalidae polyvalent immune Fab (ovine) antivenom in the treatment of copperhead snakebite. *Ann Emerg Med* 2004;43(2):200–206.
13. Burch JM, Agarwal R, Mattox KL, et al. The treatment of crotalid envenomation without antivenin. *J Trauma* 1988;28(1):35–43.
14. Walker JP, Morrison RL. Current management of copperhead snakebite. *J Am Coll Surg* 2011;212(4):470–474; discussion 474–475.
15. Whitley RE. Conservative treatment of copperhead snakebites without antivenin. *J Trauma* 1996;41(2):219–221.
16. Dart RC, Hurlbut KM, Garcia R, et al. Validation of a severity score for the assessment of crotalid snakebite. *Ann Emerg Med* 1996;27(3):321–326.
17. Bucher B, Canonge D, Thomas L, et al. Clinical indicators of envenoming and serum levels of venom antigens in patients bitten by Bothrops lanceolatus in Martinique. Research Group on Snake Bites in Martinique. *Trans R Soc Trop Med Hyg* 1997;91(2):186–190.
18. Stewart ME, Greenland S, Hoffman JR. First-aid treatment of poisonous snakebite:

Are currently recommended procedures justified? *Ann Emerg Med* 1981;10(6):331–335.

19. McCullough N, Gennaro J Jr. Treatment of venomous snake bites in the United States. *Clin Toxicol* 1970;3:483–500.
20. Stahnke HL, McBride A. Snake bite and cryotherapy. *J Occup Med* 1966;8(2):72–76.
21. Anker RL, Straffon WG, Loiselle DS, et al. Retarding the uptake of "mock venom" in humans: Comparison of three first-aid treatments. *Med J Aust* 1982;1(5):212–214.
22. Meggs WJ, Courtney C, O'Rourke D, et al. Pilot studies of pressure-immobilization bandages for rattlesnake envenomations. *Clin Toxicol (Phila)* 2010;48(1):61–63.
23. Clark R. Cryotherapy and corticosteroids in the treatment of rattlesnake bite. *Mil Med* 1971;136:42–44.
24. Schottler WH. Antihistamine, ACTH cortisone, hydrocortisone and anesthetics in snake bite. *Am J Trop Med Hyg* 1954;3(6):1083–1091.
25. Blaylock RS. Antibiotic use and infection in snakebite victims. *S Afr Med J* 1999;89(8):874–876.
26. Clark RF, Selden BS, Furbee B. The incidence of wound infection following crotalid envenomation. *J Emerg Med* 1993;11(5):583–586.
27. Kularatne SA, Kumarasiri PV, Pushpakumara SK, et al. Routine antibiotic therapy in the management of the local inflammatory swelling in venomous snakebites: results of a placebo-controlled study. *Ceylon Med J* 2005;50(4):151–155.
28. LoVecchio F, Klemens J, Welch S, et al. Antibiotics after rattlesnake envenomation. *J Emerg Med* 2002;23(4):327–328.
29. Ledbetter E, Kutscher A. The aerobic and anaerobic flora of rattlesnake fangs and venom: therapeutic implications. *Arch Environ Health* 1969; 50(4):151–155.
30. Jurkovich GJ, Luterman A, McCullar K, et al. Complications of Crotalidae antivenin therapy. *J Trauma* 1988;28:1032–1037.
31. Dart RC, Seifert SA, Boyer LV, et al. A randomized multicenter trial of crotalinae polyvalent immune Fab (ovine) antivenom for the treatment for crotaline snakebite in the United States. *Arch Intern Med* 2001; 161(16):2030–2036.
32. Chippaux JP, Goyffon M. Venoms, antivenoms and immunotherapy. *Toxicon* 1998;36(6):823–846.
33. Consroe P, Egen NB, Russell FE, et al. Comparison of a new ovine antigen binding fragment (Fab) antivenin for United States Crotalidae with the commercial antivenin for protection against venom-induced lethality in mice. *Am J Trop Med Hyg* 1995;53(5):507–510.
34. Lavonas EJ, Ruha AM, Banner W, et al. Unified treatment algorithm for the management of crotaline snakebite in the United States: results of an evidence-informed consensus workshop. *BMC Emerg Med* 2011;11:2.
35. Bebarta V, Dart RC. Effectiveness of delayed use of crotalidae polyvalent immune Fab (ovine) antivenom. *J Toxicol Clin Toxicol* 2004;42(3):321–324.

36. White RR 4th, Weber RA. Poisonous snakebite in central Texas. Possible indicators for antivenin treatment. *Ann Surg* 1991;213(5):466–471; discussion 71–72.
37. Bogdan GM, Dart RC, Falbo SC, et al. Recurrent coagulopathy after antivenom treatment of crotalid snakebite. *South Med J* 2000;93(6):562–566.
38. Holstege CP, Wu J, Baer AB. Immediate hypersensitivity reaction associated with the rapid infusion of Crotalidae polyvalent immune Fab (ovine). *Ann Emerg Med* 2002;39(6):677–679.
39. Schaeffer TH, Khatri V, Reifler LM, et al. Incidence of immediate hypersensitivity reaction and serum sickness following administration of Crotalidae polyvalent immune Fab antivenom: a meta-analysis. *Acad Emerg Med* 2012;19(2):121–131.
40. Clark RF, McKinney PE, Chase PB, et al. Immediate and delayed allergic reactions to Crotalidae polyvalent immune Fab (ovine) antivenom. *Ann Emerg Med* 2002;39(6):671–676.
41. Cannon R, Ruha AM, Kashani J. Acute hypersensitivity reactions associated with administration of crotalidae polyvalent immune Fab antivenom. *Ann Emerg Med* 2008;51(4):407–411.
42. Corneille MG, Larson S, Stewart RM, et al. A large single-center experience with treatment of patients with crotalid envenomations: outcomes with and evolution of antivenin therapy. *Am J Surg* 2006;192(6):848–852.
43. Pizon AF, Riley BD, LoVecchio F, et al. Safety and efficacy of Crotalidae Polyvalent Immune Fab in pediatric crotaline envenomations. *Acad Emerg Med* 2007;14(4):373–376.
44. Farrar HC, Grayham T, Bolden B, et al. The use and tolerability of Crotalidae Polyvalent Immune FAB (Ovine) in pediatric envenomations. *Clin Pediatr (Phila)* 2012;51(10):945–949.
45. Goto CS, Feng SY. Crotalidae polyvalent immune Fab for the treatment of pediatric crotaline envenomation. *Pediatr Emerg Care* 2009;25(4):273–9; quiz 280–282.
46. Correa JA, Fallon SC, Cruz AT, et al. Management of pediatric snake bites: Are we doing too much? *J Pediatr Surg* 2014;49(6):1009–1015.
47. Lin HL, Lin TY, Lee WC. Snakebite: use of antivenom in a pregnant woman. *Am J Emerg Med* 2011;29(4):457.
48. Langley RL. Snakebite during pregnancy: a literature review. *Wilderness Environ Med* 2010;21(1):54–60.
49. Glass T. Early debridement in pit viper bites. *JAMA* 1976;235(23):2513–2516.
50. Alberts M, Shalit M, LoGalbo F. Suction for venomous snakebite: a study of “mock venom” extraction in a human model. *Ann Emerg Med* 2004;43(2):181–186.
51. Bush SP, Hegewald KG, Green SM, et al. Effects of a negative pressure venom extraction device (Extractor) on local tissue injury after artificial rattlesnake envenomation in a porcine model. *Wilderness Environ Med* 2000;11(3):180–188.
52. Huang T, Lynch J, Larson D. The use of excisional therapy in management of

snakebite. *Ann Surg* 1974;179(35):598–607.
53. Lawrence W, Giannopoulos A, Hansen A. Pit viper bites: rational management in locales in which copperheads and cottonmouths predominate. *Ann Plast Surg* 1996;36:276–285.
54. McCullough N, Gennaro J. Evaluation of venomous snake bite in southern United States. *J Fla Med Assoc* 1963;40:959–967.
55. Garfin S. Rattlesnake bites and surgical decompression: results using a laboratory model. *Toxicon* 1984;22:177–184.
56. Curry S, Kraner J, Kunkel D, et al. Noninvasive vascular studies in management of rattlesnake envenomations to extremities. *Ann Emerg Med* 1985;14:1081–1084.
57. Stewart RM, Page CP, Schwesinger WH, et al. Antivenin and fasciotomy/debridement in the treatment of the severe rattlesnake bite. *Am J Surg* 1989;158(6):543–547.
58. Hall EL. Role of surgical intervention in the management of crotaline snake envenomation. *Ann Emerg Med* 2001;37(2):175–180.
59. Tanen DA, Danish DC, Grice GA, et al. Fasciotomy worsens the amount of myonecrosis in a porcine model of crotaline envenomation. *Ann Emerg Med* 2004;44(2):99–104.
60. Osborn C. Multiple HVDC shocks as first aid or therapy for venomous bites and stings. *J Okla State Med Assoc* 1992;85:331–343.
61. Dart RC, Lindsey D, Schulman A. Snakebites & shocks. *Ann Emerg Med* 1988;17(11):1262.
62. Guderian R, MacKenzie C, Williams J. High voltage shock treatment for snake bite. *Lancet* 1986;2:229–231.
63. Pearson CA. High-voltage shock treatment for snake bite. *Lancet* 1986; 2(8504):461.
64. Howe N, Meisenheimer J. Electric shock does not save snakebitten rats. *Ann Emerg Med* 1988;17(3):22–124.
65. Johnson EK, Kardong KV, Mackessy SP. Electric shocks are ineffective in treatment of lethal effects of rattlesnake envenomation in mice. *Toxicon* 1987;25(12):1347–1349.
66. Ben Welch E, Gales BJ. Use of stun guns for venomous bites and stings: a review. *Wilderness Environ Med* 2001;12(2):111–117.
67. Pfennig DW, Harcombe WR, Pfennig KS. Frequency-dependent Batesian mimicry. *Nature* 2001;410(6826):323.
68. *List of fatal snake bites in the United States.* Wikipedia; 2016. Available at: https://en.wikipedia.org/wiki/List_of_fatal_snake_bites_in_the_United_States. Accessed September 5, 2016.
69. Kitchens CS, Van Mierop LH. Envenomation by the Eastern coral snake (Micrurus fulvius fulvius). A study of 39 victims. *JAMA* 1987;258(12):1615–1618.
70. Parrish H. Incidence of treated snakebites in the United States. *Public Health Rep*

1966;81:269–276.
71. Chippaux J. Snake bites: appraisal of the global situation. *Bull World Health Organ* 1998;76(5):515–524.
72. WHO/SEARO. Guidelines for the clinical managment of snake bites in the Southeast Asian region. *Southeast Asian J Trip Med Public Health* 1999;30(suppl 1):1.
73. Strimple PD, Tomassoni AJ, Otten EJ, et al. Report on envenomation by a Gila monster (Heloderma suspectum) with a discussion of venom apparatus, clinical findings, and treatment. *Wilderness Environ Med* 1997; 8(2):111–116.
74. Hooker KR, Caravati EM, Hartsell SC. Gila monster envenomation. *Ann Emerg Med* 1994;24(4):731–735.
75. Preston C. Hypotension, myocardial infarction, and coagulopathy following Gila monster bite. *J Emerg Med* 1989;7:37–40.
76. Cantrell FL. Envenomation by the Mexican beaded lizard: A case report. *J Toxicol Clin Toxicol* 2003;41(3):241–244.
77. Health NIfOSa. *Insects and Scorpions: Centers for Disease Control.* 2016. Available at: http://www.cdc.gov/niosh/topics/insects/. Accessed September 5, 2016.
78. Saucier JR. Arachnid envenomation. *Emerg Med Clin North Am* 2004;22(2):405–22, ix.
79. Swanson DL, Vetter RS. Bites of brown recluse spiders and suspected necrotic arachnidism. *N Engl J Med* 2005;352(7):700–707.
80. Necrotic arachnidism–Pacific Northwest, 1988–1996. *MMWR Morb Mortal Wkly Rep* 1996;45(21):433–436.
81. Walker JS, Hogan DE. Bite to the left leg. Necrotic ulcer from a brown recluse spider bite. *Acad Emerg Med* 1995;2(3):223; 231; 234–237.
82. Wilson DC, King LE, Jr. Spiders and spider bites. *Dermatol Clin* 1990; 8(2):277–286.
83. Futrell JM. Loxoscelism. *Am J Med Sci* 1992;304(4):261–267.
84. Patel KD, Modur V, Zimmerman GA, et al. The necrotic venom of the brown recluse spider induces dysregulated endothelial cell-dependent neutrophil activation. Differential induction of GM-CSF, IL-8, and E-selectin expression. *J Clin Invest* 1994;94(2):631–642.
85. Sams HH, Dunnick CA, Smith ML, et al. Necrotic arachnidism. *J Am Acad Dermatol* 2001;44(4):561–573; quiz 573–576.
86. Bryant SM, Pittman LM. Dapsone use in Loxosceles reclusa envenomation: Is there an indication?*Am J Emerg Med* 2003;21(1):89–90.
87. Barrett SM, Romine-Jenkins M, Fisher DE. Dapsone or electric shock therapy of brown recluse spider envenomation?*Ann Emerg Med* 1994;24(1):21–25.
88. Strain GM, Snider TG, Tedford BL, et al. Hyperbaric oxygen effects on brown recluse spider (Loxosceles reclusa) envenomation in rabbits. *Toxicon* 1991;29(8):989–996.
89. Phillips S, Kohn M, Baker D, et al. Therapy of brown spider envenomation: a controlled trial of hyperbaric oxygen, dapsone, and cyproheptadine. *Ann Emerg Med*

1995;25(3):363–368.
90. Rees RS, Altenbern DP, Lynch JB, et al. Brown recluse spider bites. A comparison of early surgical excision versus dapsone and delayed surgical excision. *Ann Surg* 1985;202(5):659–663.
91. Clark RF, Wethern-Kestner S, Vance MV, et al. Clinical presentation and treatment of black widow spider envenomation: a review of 163 cases. *Ann Emerg Med* 1992;21(7):782–787.
92. Muller GJ. Black and brown widow spider bites in South Africa. A series of 45 cases. *S Afr Med J* 1993;83(6):399–405.
93. Suntorntham S, Roberts JR, Nilsen GJ. Dramatic clinical response to the delayed administration of black widow spider antivenin. *Ann Emerg Med* 1994;24(6):1198–1199.
94. Antivenin Latrodectus Mactans (Black Widon Spider Antivenin). Food and Drug Administration. 2014.
95. Reisman RE. Stinging insect allergy. *Med Clin North Am* 1992;76(4):883–894.
96. Kim KT, Oguro J. Update on the status of Africanized honey bees in the western states. *West J Med* 1999;170(4):220–222.
97. Schumacher MJ, Egen NB. Significance of Africanized bees for public health. A review. *Arch Intern Med* 1995;155(19):2038–2043.
98. Szalanski A, Magnus R. Mitochondrial DNA characterization of Africanized honey bee (Apis mellifera L.) populations from the USA. *J Apicult Res Bee* 2010;49(2):177–185.
99. Kolecki P. Delayed toxic reaction following massive bee envenomation. *Ann Emerg Med* 1999;33(1):114–116.
100. Kemp SF, deShazo RD, Moffitt JE, et al. Expanding habitat of the imported fire ant (Solenopsis invicta): a public health concern. *J Allergy Clin Immunol* 2000;105(4):683–691.
101. Stafford CT. Fire ant allergy. *Allergy Proc* 1992;13(1):11–16.
102. Goddard J, Jarratt J, de Castro FR. Evolution of the fire ant lesion. *JAMA* 2000;284(17):2162–2163.
103. Yarom R. Scorpion venom: a tutorial review of its effects in man and experimental animals. *Clin Toxicology* 1970;3(4):561–569.
104. Bawaskar HS, Bawaskar PH. Cardiovascular manifestations of severe scorpion sting in India (review of 34 children). *Ann Trop Paediatr* 1991;11(4):381–387.
105. Bush SP, King BO, Norris RL, et al. Centipede envenomation. *Wilderness Environ Med* 2001;12(2):93–99.
106. Chaou CH, Chen CK, Chen JC, et al. Comparisons of ice packs, hot water immersion, and analgesia injection for the treatment of centipede envenomations in Taiwan. *Clin Toxicol (Phila)* 2009;47(7):659–662.
107. Radford AJ. Millipede burns in man. *Trop Geogr Med* 1975;27(3):279–287.

108. Foot NC. Pathology of the dermatitis caused by megalopyge opercularis, a Texan caterpillar. *J Exp Med* 1922;35(5):737–753.
109. Neustater BR, Stollman NH, Manten HD. Sting of the puss caterpillar: an unusual cause of acute abdominal pain. *South Med J* 1996;89(8):826–827.
110. Norris R. Caterpillar envenomations 2014. Available at: http://emedicine.medscape.com/article/772949-overview. Accessed September 5, 2016.
111. Rosen T. Caterpillar dermatitis. *Dermatol Clin* 1990;8(2):245–252.
112. Jurkovich G. Hypothermia in the trauma patient. *Adv Trauma* 1989;4:111–1140.
113. Hypothermia-related deaths – United States 1999–2002 and 2005. *MMWR Morb Mortal Wkly Rep* 2006;55(10):282–4.
114. Brown D, Brugger H, Boyd J, et al. Accidental Hypothermia. *N Engl J Med* 2012;367:1930–1938.
115. Danzl D, Pozos R, Auerbach P, et al. Multicenter hypothermia survery. *Ann Emerg Med* 1987;16:1042–1055.
116. van der Ploeg G, Gosloings J, et al. Accidental hypothermia: rewarming treatment, complications and outcomes from one university medical centre. *Resuscitation* 2010;81(11):1550–1555.
117. Deslarzes T, Rousson V, Yersin B, et al. An evaluation of the Swiss staging model for hypothermia using case reports from the literature. *Scand J Trauma Resusc Emerg Med* 2016;24(1):16.
118. Trevino A, Razi B, Beller BM. The characteristic electrocardiogram of accidental hypothermia. *Arch Intern Med* 1971;127(3):470–473.
119. Walpoth BH, Walpoth-Aslan BN, Mattle HP, et al. Outcome of survivors of accidental deep hypothermia and circulatory arrest treated with extracorporeal blood warming. *N Engl J Med* 1997;337(21):1500–1555.
120. Hauty MG, Esrig BC, Hill JG, et al. Prognostic factors in severe accidental hypothermia: experience from the Mt. Hood tragedy. *J Trauma* 1987;27(10):1107–1112.
121. Silfvast T, Pettila V. Outcome from severe accidental hypothermia in Southern Finland–a 10-year review. *Resuscitation* 2003;59(3):285–290.
122. Cohen DJ, Cline JR, Lepinski SM, et al. Resuscitation of the hypothermic patient. *Am J Emerg Med* 1988;6(5):475–478.
123. Ledingham IM, Mone JG. Treatment of accidental hypothermia: a prospective clinical study. *Br Med J* 1980;280(6222):1102–1105.
124. Swain JA, White FN, Peters RM. The effect of pH on the hypothermic ventricular fibrillation threshold. *J Thorac Cardiovasc Surg* 1984;87(3):445–451.
125. White FN. Reassessing acid-base balance in hypothermia–a comparative point of view. *West J Med* 1983;138(2):255–257.
126. White FN. A comparative physiological approach to hypothermia. *J Thorac Cardiovasc*

Surg 1981;82(6):821–831.

127. Ream AK, Reitz BA, Silverberg G. Temperature correction of PCO_2 and pH in estimating acid-base status: an example of the emperor's new clothes? *Anesthesiology* 1982;56(1):41–44.
128. Hansen JE, Sue DY. Should blood gas measurements be corrected for the patient's temperature?. *N Eng J Med* 1984;303:341.
129. Orlowski JP, Erenberg G, Lueders H, Cruse RP. Hypothermia and barbiturate coma for refractory status epilepticus. *Crit Care Med* 1984;12(4):367–72.
130. Dobson JA, Burgess JJ. Resuscitation of severe hypothermia by extracorporeal rewarming in a child. *J Trauma* 1996;40(3):483–485.
131. Iyer A, Rajkuman V, Sadasivan S, et al. No one is dead until warm and dead. *J Thorac Cardiovasc Surg* 2007;134:1042–1043.
132. Schaller MD, Fischer AP, Perret CH. Hyperkalemia. A prognostic factor during acute severe hypothermia. *JAMA* 1990;264(14):1842–1845.
133. Wijdicks EF, Varelas PN, Gronseth GS, et al; American Academy of N. Evidence-based guideline update: determining brain death in adults: Report of the Quality Standards Subcommittee of the American Academy of Neurology. *Neurology* 2010;74(23):1911–1918.
134. Greer D, Wang J, Robinson J, et al. Variability of brain death policies in the United States. *JAMA Neurol* 2016;73(2):213–218.
135. Moyer JH, Heider C, Morris GC Jr, et al. Hypothermia. III. The effect of hypothermia on renal damage resulting from ischemia. *Ann Surg* 1957;146(2):152–166.
136. Debakey ME, Morris G, Moyer JH. Hypothermia. I. Effect on renal hemodynamics and on excretion of water and electrolytes in dog and man. *Ann Surg* 1957;145(1):26–40.
137. Curry DL, Curry KP. Hypothermia and insulin secretion. *Endocrinology* 1970;87(4):750–755.
138. Axelrod DR, Bass DE. Electrolytes and acid-base balance in hypothermia. *Am J Physiol* 1956;186(1):31–34.
139. Haddix TL, Pohlman TH, Noel RF, et al. Hypothermia inhibits human E-selectin transcription. *J Surg Res* 1996;64(2):176–183.
140. Kurz A, Sessler DI, Lenhardt R. Perioperative normothermia to reduce the incidence of surgical-wound infection and shorten hospitalization. Study of Wound Infection and Temperature Group. *N Engl J Med* 1996; 334(19):1209–1215.
141. Pozos R, Wittmers L. *The Nature and Treatment of Hypothermia.* Minneapolis: University of Minnesota Press; 1983.
142. Iampietro PF, Vaughan JA, Goldman RF, et al. Heat production from shivering. *J Appl Physiol* 1960;15:632–634.
143. Goldberg MJ, Roe CF. Temperature changes during anesthesia and operations. *Arch*

Surg 1966;93(2):365–369.
144. Roe CF. Temperature regulation and energy metabolism in surgical patients. *Prog Surg* 1973;12:96–127.
145. Paton B. Accidental hypothermia. *Pharmacol Ther* 1983;22:331–337.
146. Gentilello LM. Advances in the management of hypothermia. *Surg Clin North Am* 1995;75(2):243–256.
147. Gregory JS, Flancbaum L, Townsend MC, et al. Incidence and timing of hypothermia in trauma patients undergoing operations. *J Trauma* 1991; 31(6):795–798; discussion 798–800.
148. Luna G, Maier R, Pavlin E, et al. Incidence and effect of hypothermia in seriously injured patients. *J Trauma* 1987;27(9):1014–1018.
149. Jurkovich G, Greiser W, Luterman A, et al. Hypothermia in trauma victims: An ominous predictor of survival. *J Trauma* 1987;27:1019–1024.
150. Inaba K, Berg R, Barmparas G, et al. Prospective evaluation of ambient operating room temperature on the core temperature of injured patients undergoing emergent surgery. *J Trauma Acute Care Surg* 2012;73(6):1478–1483.
151. Psarras P, Ivatury R, Rohman M, et al, eds. Hypothermia in trauma: Incidence and prognostic significance. Presentation before the Eastern Association for the Surgery of Trauma, Longboat Key, FL: 1988.
152. Rutherford EJ, Fusco MA, Nunn CR, et al. Hypothermia in critically ill trauma patients. *Injury* 1998;29(8):605–608.
153. Little R, Stoner H. Body temperature after accidental injury. *Br J Surg* 1981;68:221–224.
154. Hardy J, Randini I. Some physiologic aspects of surgical trauma. *Am Surg* 1952;136:345.
155. Perlman R, Callum J, Laflamme C, et al. A recommended early goal-directed management guideline for the prevention of hypothermia-related transfusion, morbidity, and mortality in severely injured trauma patients. *Crit Care* 2016;20(1):107.
156. Blalock A, Mason M. A comparison of the effects of heat and those of cold in the prevention and treatment of shock. *Arch Surg* 1945;42:1054–1059.
157. Wu X, Drabek T, Tisherman SA, et al. Emergency preservation and resuscitation with profound hypothermia, oxygen, and glucose allows reliable neurological recovery after 3 h of cardiac arrest from rapid exsanguination in dogs. *J Cereb Blood Flow Metab* 2008;28(2):302–311.
158. Sori A, El-Assuooty A, Rush B, et al. The effect of temperature on survival in hemorrhagic shock. *Am Surg* 1987;53:706–710.
159. Alam HB, Bowyer MW, Koustova E, et al. Learning and memory is preserved after induced asanguineous hyperkalemic hypothermic arrest in a swine model of traumatic exsanguination. *Surgery* 2002;132(2):278–288.

160. Cornejo CJ, Kierney PC, Vedder NB, et al. Mild hypothermia during reperfusion reduces injury following ischemia of the rabbit ear. *Shock* 1998;9(2):116–120.
161. Jurkovich G, Pitt R, Curreri P, et al. Hypothermia prevents increased capillary permeability following ischemia-reperfusion injury. *J Surg Res* 1988;44:514–521.
162. Wright JG, Kerr JC, Valeri CR, et al. Regional hypothermia protects against ischemia-reperfusion injury in isolated canine gracilis muscle. *J Trauma* 1988;28(7):1026–1031.
163. Finkelstein RA, Alam HB. Induced hypothermia for trauma: current research and practice. *J Intensive Care Med* 2010;25(4):205–226.
164. Tisherman SA. Salvage techniques in traumatic cardiac arrest: thoracotomy, extracorporeal life support, and therapeutic hypothermia. *Curr Opin Crit Care* 2013;19(6):594–598.
165. Nozari A, Safar P, Wu X, et al. Suspended animation can allow survival without brain damage after traumatic exsanguination cardiac arrest of 60 minutes in dogs. *J Trauma* 2004;57(6):1266–1275.
166. Fay T. Observations on generalized refrigeration in cases of severe cerebral trauma. *Ass Res Nerv Ment Dis Proc* 1943;(24):611–619.
167. Clifton GL, Miller ER, Choi SC, et al. Lack of effect of induction of hypothermia after acute brain injury. *N Engl J Med* 2001;344(8):556–563.
168. Gentilello LM, Jurkovich GJ, Stark MS, et al. Is hypothermia in the victim of major trauma protective or harmful? A randomized, prospective study. *Ann Surg* 1997;226(4):439–447; discussion 447–449.
169. Bernard SA, Gray TW, Buist MD, et al. Treatment of comatose survivors of out-of-hospital cardiac arrest with induced hypothermia. *N Engl J Med* 2002;346(8):557–563.
170. Nielsen N, Wetterslev J, Cronberg T, et al. Targeted temperature management at 33 degrees C versus 36 degrees C after cardiac arrest. *N Engl J Med* 2013;369(23):2197–2206.
171. Mikkelsen ME, Christie JD, Abella BS, et al. Use of therapeutic hypothermia after in-hospital cardiac arrest. *Crit Care Med* 2013;41(6):1385–1395.
172. Cohen MJ, Kutcher M, Redick B, et al. Clinical and mechanistic drivers of acute traumatic coagulopathy. *J Trauma Acute Care Surg* 2013;75(1 suppl 1):S40–S47.
173. Bachmann F, McKenna R, Cole ER, et al. The hemostatic mechanism after open-heart surgery. I. Studies on plasma coagulation factors and fibrinolysis in 512 patients after extracorporeal circulation. *J Thorac Cardiovasc Surg* 1975;70(1):76–85.
174. Harker LA, Malpass TW, Branson HE, et al. Mechanism of abnormal bleeding in patients undergoing cardiopulmonary bypass: acquired transient platelet dysfunction associated with selective alpha-granule release. *Blood* 1980;56(5):824–834.
175. Kattlove HE, Alexander B. The effect of cold on platelets. I. Cold-induced platelet aggregation. *Blood* 1971;38(1):39–48.

176. Patt A, McCroskey BL, Moore EE. Hypothermia-induced coagulopathies in trauma. *Surg Clin North Am* 1988;68(4):775–785.
177. Valeri CR, Feingold H, Cassidy G, et al. Hypothermia-induced reversible platelet dysfunction. *Ann Surg* 1987;205(2):175–181.
178. Wolberg AS, Meng ZH, Monroe DM 3rd, et al. A systematic evaluation of the effect of temperature on coagulation enzyme activity and platelet function. *J Trauma* 2004;56(6):1221–1228.
179. Reed RL 2nd, Bracey AW Jr, Hudson JD, et al. Hypothermia and blood coagulation: dissociation between enzyme activity and clotting factor levels. *Circ Shock* 1990;32(2):141–152.
180. Gubler KD, Gentilello LM, Hassantash SA, et al. The impact of hypothermia on dilutional coagulopathy. *J Trauma* 1994;36(6):847–851.
181. Gentilello L, Jurkovich G, Moujaes S. Hypothermia and injury: thermodynamic principles of prevention and treatment. In: Levine B, ed. *Perspectives in Surgery*. St. Louis, MO: Quality Medical Publishers; 1991.
182. Sheaff CM, Fildes JJ, Keogh P, et al. Safety of 65 degrees C intravenous fluid for the treatment of hypothermia. *Am J Surg* 1996;172(1):52–55.
183. Herron DM, Grabowy R, Connolly R, et al. The limits of bloodwarming: maximally heating blood with an inline microwave bloodwarmer. *J Trauma* 1997;43(2):219–226; discussion 226–228.
184. Darocha T, Jarosz A, Zietkiewicz M, et al. ECMO in Treating patients in critical, life-threatening medical condition brought on by severe hypothermia-criterion standard. *Ann Emerg Med* 2016;67(4):558–559.
185. Gentilello LM, Cobean RA, Offner PJ, et al. Continuous arteriovenous rewarming: rapid reversal of hypothermia in critically ill patients. *J Trauma* 1992;32(3):316–325; discussion 325–327.
186. Laniewicz M, Lyn-Kew K, Silbergleit R. Rapid endovascular warming for profound hypothermia. *Ann Emerg Med* 2008;51(2):160–163.
187. Patton JF, Doolittle WH. Core rewarming by peritoneal dialysis following induced hypothermia in the dog. *J Appl Physiol* 1972;33(6):800–804.
188. Moss J. Accidental severe hypothermia. *Surg Gynecol Obstet* 1986;162:501–513.
189. Gentilello LM, Moujaes S. Treatment of hypothermia in trauma victims: thermodynamic considerations. *J Intensive Care Med* 1995;10(1):5–14.
190. Monika BM, Martin D, Balthasar E, et al. The Bernese Hypothermia Algorithm: a consensus paper on in-hospital decision-making and treatment of patients in hypothermic cardiac arrest at an alpine level 1 trauma centre. *Injury* 2011;42(5):539–543.
191. Jacob JR, Weisman MH, Rosenblatt SI, et al. Chronic pernio. A historical perspective of cold-induced vascular disease. *Arch Intern Med* 1986; 146(8):1589–1592.
192. Benchikhi H, Roujeau JC, Levent M, et al. Chilblains and Raynaud phenomenon are

usually not a sign of hereditary protein C and S deficiencies. *Acta Derm Venereol* 1998;78(5):351–352.

193. Auerbach P. Disorders due to physical and environmental agents. In: Mills J, Ho MT, Salber PR, et al., eds. *Current Emergency Diagnosis and Treatment.* Los Altos, California: Lange Medical Publications; 1985.
194. Francis TJ, Golden FS. Non-freezing cold injury: the pathogenesis. *J R Nav Med Serv* 1985;71(1):3–8.
195. Mills WJ Jr. Frostbite. A discussion of the problem and a review of the Alaskan experience. 1973. *Alaska Med* 1993;35(1):29–40.
196. Urschel J. Frostbite: predisposing factors and predictors of poor outcome. *J Trauma* 1990;30(3):340–343.
197. Dana H, Rex I, Samitz M. The hunting reaction. *Arch Dermatol* 1969; 99:441.
198. Britt LD, Dascombe WH, Rodriguez A. New horizons in management of hypothermia and frostbite injury. *Surg Clin N Am* 1991;71(2):345–370.
199. Murphy JV, Banwell PE, Roberts AH, et al. Frostbite: pathogenesis and treatment. *J Trauma* 2000;48(1):171–178.
200. Ozyazgan I, Tercan M, Melli M, et al. Eicosanoids and inflammatory cells in frostbitten tissue: prostacyclin, thromboxane, polymorphonuclear leukocytes, and mast cells. *Plast Reconstr Surg* 1998;101(7):1881–1886.
201. Bourne M, Piepkorn M, Clayton F, et al. Analysis of microvascular changes in frostbite injury. *J Surg Res* 1986;40:26–35.
202. Mileski WJ, Raymond JF, Winn RK, et al. Inhibition of leukocyte adherence and aggregation for treatment of severe cold injury in rabbits. *J Appl Physiol* (1985) 1993;74(3):1432–1436.
203. Bruen KJ, Ballard JR, Morris SE, et al. Reduction of the incidence of amputation in frostbite injury with thrombolytic therapy. *Arch Surg* 2007;142(6):546–551; discussion 551–553.
204. Heil K, Thomas R, Robertson G, et al. Freezing and non-freezing cold weather injuries: a systematic review. *Br Med Bull* 2016;117(1):79–93.
205. Ibrahim AE, Goverman J, Sarhane KA, et al. The emerging role of tissue plasminogen activator in the management of severe frostbite. *J Burn Care Res* 2015;36(2):e62–e66.
206. Groechenig E. Treatment of frostbite with iloprost. *Lancet* 1994; 344(8930):1152–1153.
207. Mills WJ Jr, Whaley R. Frostbite: experience with rapid rewarming and ultrasonic therapy: Part I, II, III 1960. *Alaska Med* 1993;35(1):1–27.
208. Petrone P, Kuncir EJ, Asensio JA. Surgical management and strategies in the treatment of hypothermia and cold injury. *Emerg Med Clin North Am* 2003;21(4):1165–1178.
209. Heggers J, Robson M, Weingarten M, et al. Experimental and clinical observations on frostbite. *Ann Emerg Med* 1987;16(9):1056–1062.

210. Miller MB, Koltai PJ. Treatment of experimental frostbite with pentoxifylline and aloe vera cream. *Arch Otolaryngol Head Neck Surg* 1995; 121(6):678–680.
211. Rakower SR, Shahgoli S, Wong SL. Doppler ultrasound and digital plethysmography to determine the need for sympathetic blockade after frostbite. *J Trauma* 1978;18(10):713–718.
212. Bouwman DL, Morrison S, Lucas CE, et al. Early sympathetic blockade for frostbite–is it of value? *J Trauma* 1980;20(9):744–749.
213. Purdue GF, Hunt JL. Cold injury: a collective review. *J Burn Care Rehabil* 1986;7(4):331–342.
214. Higdon B, Youngman L, Regehr M, et al. Deep Frostbite treated with hyperbaric oxygen and thrombolytic therapies. *Wounds* 2015;27(8):215–223.
215. Twomey JA, Peltier GL, Zera RT. An open-label study to evaluate the safety and efficacy of tissue plasminogen activator in treatment of severe frostbite. *J Trauma* 2005;59(6):1350–1354; discussion 1354–1355.
216. Edlich RF, Chang DE, Birk KA, et al. Cold injuries. *Compr Ther* 1989;15(9):13–21.
217. Nygaard RM, Whitley AB, Fey RM, et al. The Hennepin score: quantification of frostbite management efficacy. *J Burn Care Res* 2015.
218. Mills WJ Jr. Summary of treatment of the cold injured patient: frostbite. 1983. *Alaska Med* 1993;35(1):61–66.
219. Mehta RC, Wilson MA. Frostbite injury: prediction of tissue viability with triple-phase bone scanning. *Radiology* 1989;170:511–514.
220. Barker JR, Haws MJ, Brown RE, et al. Magnetic resonance imaging of severe frostbite injuries. *Ann Plast Surg* 1997;38(3):275–279.
221. Raman SR, Jamil Z, Cosgrove J. Magnetic resonance angiography unmasks frostbite injury. *Emerg Med J* 2011;28(5):450.
222. Cauchy E, Marsigny B, Allamel G, et al. The value of technetium 99 scintigraphy in the prognosis of amputation in severe frostbite injuries of the extremities: a retrospective study of 92 severe frostbite injuries. *J Hand Surg Am* 2000;25(5):969–978.
223. Cauchy E, Chetaille E, Lefevre M, et al. The role of bone scanning in severe frostbite of the extremities: a retrospective study of 88 cases. *Eur J Nucl Med* 2000;27(5):497–502.
224. Rustin MH, Newton JA, Smith NP, et al. The treatment of chilblains with nifedipine: the results of a pilot study, a double-blind placebo-controlled randomized study and a long-term open trial. *Br J Dermatol* 1989;120(2):267–275.
225. Heil KM, Oakley EH, Wood AM. British Military freezing cold injuries: a 13-year review. *J R Army Med Corps* 2016:pii: jramc-2015-000445.

SECTION B: TRANSPLANTATION

Chapter 34

Clinical Transplant Immunology

Amit K. Mathur and Satish N. Nadig

Key Points

1 Understanding clinical transplant immunology is predicated on understanding mechanisms of innate and adaptive immunity, as well as T- and B-cell signal pathways.

2 T cells are responsible for regulatory and effector mechanisms in the immune response. T-cell effector activity is coordinated by regulatory cells driven by three signals of antigen presentation.

3 Clinical immunosuppression involves induction and maintenance therapies.

4 Induction therapies are used to prevent early acute rejection of allografts, and are generally aimed at reducing T-cell signaling. Commonly used drugs are lymphocyte depletion agents, IL-2 receptor antibodies, agents to block costimulatory signals.

5 Maintenance immunosuppression consists of calcineurin inhibitors, mTOR inhibitors, antimetabolite agents, and steroids. All agents have a clinically significant side effect profile.

6 Acute rejection has a clinical phenotype and may involve cellular infiltration of the allograft as well as antibody-mediated mechanisms. Chronic rejection, or chronic transplant dysfunction, is driven by immune and nonimmune mechanisms and results in progressive graft fibrosis that is heretofore irreversible.

7 Major side effects of chronic immunosuppression include calcineurin inhibitor–related nephrotoxicity, major and minor infections, and cancer.

8 Clinical tolerance is the holy grail of transplantation, and novel targets in regulatory immunocytes have emerged as a promising focus of future research.

INTRODUCTION

Modern clinical transplantation has rapidly evolved over the last 50 years. The fortitude of surgeons in the early development of surgical techniques and basic science have enabled thousands of patients to realize the gift of a solid organ transplant. The long-term benefit to adults and children who are on the verge of death from kidney, liver, intestinal, pancreatic, pulmonary, or cardiac failure is directly linked to our cumulative understanding of clinical transplant immunology. The discovery of the immune response to alloantigens and the identification of molecular targets for modern immunosuppressive agents have solidified clinical transplantation as the treatment of choice for patients with organ failure.

Management of the transplant recipient is predicated on understanding the mechanisms and clinical manifestations of the graft immune response, and applying principles of clinical transplant immunology to abate deleterious effects on graft function. Graft injury begins as a result of several complex interactions between inflammatory mediators related to the obligatory ischemia–reperfusion injury tied to surgical recovery, organ preservation, and implantation in the recipient. This inflammatory injury overlaps with graft-host immune interactions, and ultimately promotes graft immunogenicity. This process affects graft function by proliferation of antigen presentation and up-regulation of cell signaling to recruit effector cells that lead to organ injury. These reactions also play a role in the development of chronic rejection of the organ, which may lead to the need for repeat transplant or shortened recipient life expectancy.

The application of transplant immunology principles in the creation of immunosuppression protocols requires an in-depth understanding of the molecular mechanisms that lead to acute and chronic rejection. Transplant rejection is the clinical phenotype of organ injury brought on by the recipient immune system's recognition of allogeneity. The rejection phenotype is the culmination of several signals initiated by antigen presentation and effector mechanisms that operate through humoral- and cell-mediated immune responses. Our growing understanding of transplant immunobiology has been directly responsible for the development of clinical therapeutics used in immunosuppression induction, as well as maintenance therapy to prevent rejection, and in salvage situations to treat rejection once it has occurred.

The aim of this chapter is to review the scientific principles behind the use of modern immunosuppressive agents, the interplay between cell types involved in the alloimmune response, and an in-depth discussion of modern therapeutics applied to the clinical management of the transplant patient. Additionally, the complications of immunosuppressive therapy and evolving therapies will be discussed.

SCIENTIFIC BASIS OF MODERN CLINICAL IMMUNOSUPPRESSION

The Immune Response to a Solid Organ Transplant

1 The interaction of a host's immune system with foreign antigen is central to understanding the pathways that modulate organ-directed effector responses. *Operational tolerance is* defined as the immunologic acceptance of an organ allograft while maintaining global immune system integrity; down-regulation of host effector mechanisms must be maintained while minimizing the suppression of recipient defence mechanisms. T- and B-cell activation and regulatory pathways are primary targets for conventional immunosuppressive regimens. Immunosuppressive regimens have been developed to impact isolated pathways in T-cell activation by recipient antigen-presenting cells (APCs). As the field of transplantation has matured, these pharmacotherapies have become more specific and less toxic to the host immune system.

The development of mature T cells begins with nascent thymocytes. Thymocytes contain T-cell receptors (TCR) arranged and rearranged in a random individual-specific manner. These TCR-containing thymocytes are challenged by "self" antigen and undergo programmed cell death if they express "high affinity" and activate. In contrast, these immature cells are programmed not to proliferate if they express "too low" an affinity. Thymocytes with an intermediate affinity are fostered to survive and differentiate into specific CD4- and CD8-expressing cells which interact with self-restricted major histocompatibility complexes (MHCs) on APCs, such as dendritic cells, in the peripheral blood.

The foundation of the adaptive immune response lies in the presentation of antigen to T cells which takes place via macrophages, B cells, and dendritic cells. Dendritic cells present antigen via their MHC class I or II molecules to $CD8^+$ T cells and $CD4^+$ T cells respectively. The most common scenario occurs when a T cell interacts with an APC–MHC complex presenting "self" antigen. In normal (nonautoimmune) circumstances, this is usually a very weak bond and the T cell removes itself from the interaction and begins to recirculate. In the context of infection or transplantation, the APC–MHC complex presents a foreign peptide which the T cells recognize as "nonself" and begin the cascade of activation as well as clonal expansion.

2 T cells are activated by a process that requires three sequential signals. The "three signal" process of T-cell activation begins with signal 1 as the TCR interacts with the MHC–foreign peptide complex presented by an APC. T cells become maximally activated only after a threshold number of TCRs have been occupied.[1] Once this occurs, multiple costimulatory supporting molecules on the periphery of both the APC and T cells "ride" lipid rafts to the synapse of the TCR–MHC interaction.[2,3] Once these costimulation molecules have reached the immunologic synapse they begin to interact with each other, comprising signal 2. The engagement of TCR by MHC–peptide complexes in combination with the interaction of costimulatory, accessory, and adhesion molecules results in a cascade of signaling pathways including activation of NFκB and translocation of the

nuclear factor of activation and transcription (NFAT) to the nucleus of the T cell which translates and transcribes proteins such as interleukin-2 (IL-2).[4] IL-2, formerly known as T-cell growth factor, then contributes to the clonal expansion of other T-cell populations allowing for cellular expansion to fight against the inciting foreign antigen. IL-2 also engages with CD25 on the T cell itself thereby activating a doublet complex known as the mammalian target of rapamycin, or mTOR. Signaling through mTOR constitutes "signal 3" of activation which affects cell cycling and cytokine production, cellular proliferation, and T-cell differentiation into an effector cell against the grafted organ. This pathway initiates the slower, more sophisticated, adaptive immune response (Fig. 34-1).[5]

Immediately following implantation and reperfusion of an organ allograft, markers of inflammation are up-regulated which act as homing signals to effector T cells. These inflammatory mediators also allow for a more efficient uptake of antigen by dendritic cells. Organ-derived dendritic cells are released to the host's secondary lymphoid tissue. Termed "passenger leukocytes," these dendritic cells are primed to present antigen to naïve host T cells.[6,7] These activated $CD4^+$ T cells specialize into subsets of helper T cells each identified by a distinct signature of cytokines. Interferon-γ (IFNγ) secreting T_H1 cells are central to various cell-mediated rejection responses including acute and chronic or delayed-type hypersensitivity responses. T_H2 cells support B-cell production of antibody and secrete cytokines with a suppressive capacity such as IL-4 and IL-10.[7] T_H17 cells secrete IL-17, which is a potent instigator of tissue injury in the setting of transplantation and autoimmune diseases.[8]

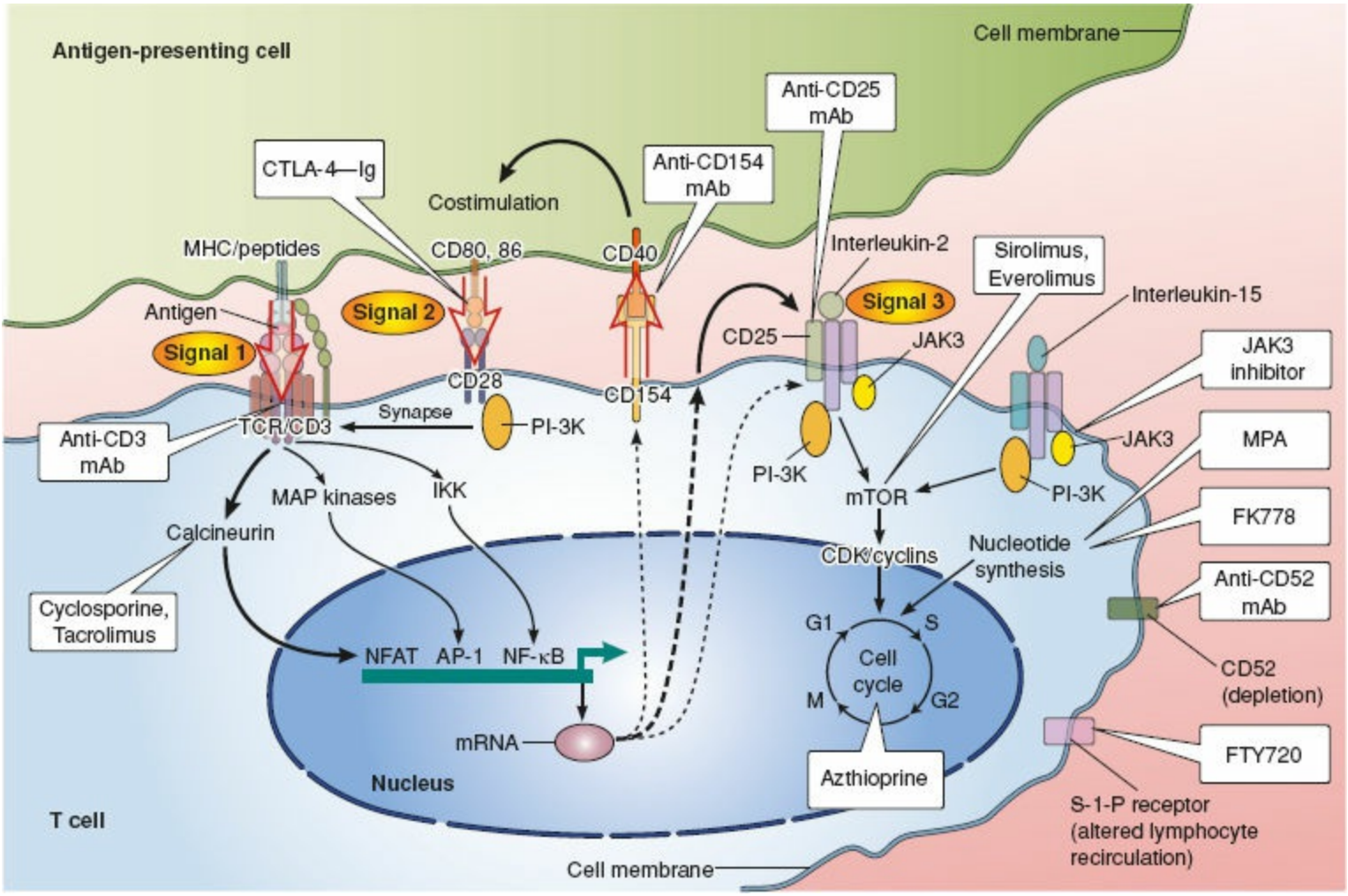

Figure 34-1. The signal hypothesis of T-cell activation and molecular targets of modern clinical immunosuppression. T-cell activation requires three signals to initiate an effector response: antigen presentation of nonself MHC, costimulatory signal, and regulation of cytokine signaling at the cell surface. These three signals are thus targets for therapeutic drugs used in modern clinical immunosuppression in both induction and maintenance phases, as well as in the treatment of rejection. The figure demonstrates the site of action of these agents.

Memory T-cell subsets react in a more rapid manner to the graft and incite an accelerated rejection response. Seminal studies investigating memory responses to allografts proved that antigen-experienced memory T-cell subsets can cause graft destruction in the absence of secondary lymphoid tissue.[9] Clinically, these "memory" T cells are generated throughout the lifespan of a potential recipient due to various infections that the patient may have experienced. Memory T-cell subsets that have been generated by these infections may then react against an organ at the time of transplant if the antigenic response from the organ mimics that of the previous infectious episodes. This concept of "heterologous immunity" may account for early rejection responses in patients who have not been classically sensitized by foreign human antigen by transfusion, pregnancy, or previous transplant.[10] Studies have also suggested that certain induction therapies may eradicate naïve host T cells yet spare memory subsets which may also contribute to potential early rejection responses and express resistance to tolerance induction.[11–13]

Immunosuppression Induction in Solid Organ Transplantation

Human immunity depends on innate and adaptive responses to foreign antigen. The innate response is rapid and nonspecific when foreign antigen is encountered; the adaptive response develops over time and harbors the ability to recall pathogens upon each successive insult. Therefore, adaptive immunity becomes more efficient with each antigenic interaction. The innate immune response usually sets the scene for the adaptive response but it is the antigen specificity of the adaptive response that allows for activation and proliferation of effector cells to rid the system of the pathogenic insult. Current therapies in clinical immunosuppression target this global activation and proliferation of T cells.

3 Induction immunosuppression is used intraoperatively and/or perioperatively as a prophylactic treatment to attenuate acute rejection responses in the first few months after transplant when the risk is highest.[14] Various induction strategies have been developed in order to spare the use of toxic calcineurin inhibitors (CNIs) and steroids.

CELL SURFACE RECEPTOR BLOCKADE

4 Each of the three signals in T-cell activation is uniquely important and each depends on the other for cellular proliferation and effector cell differentiation (Fig. 34-1).[15,16] If one signal acts in isolation without the others, anergic or apoptotic signal ensues.[17,18] With this knowledge, various pharmacotherapies have been developed to block signal 2, or costimulation, in order to inhibit the clonal proliferation of the effector T cell. Several pathways are involved in the make-up of the second signal in lymphocyte activation. Costimulation pathways have been targeted by various types of biologics including monoclonal antibodies as well as recombinant fusion proteins.

A specific APC-T–cell interaction is crucial. The engagement of APC-derived CD80/86 (B7 molecules) with CD28 on T cells (members of the Ig superfamily) is integral to positive costimulation.[5] Pharmacotherapies targeting other costimulatory pathways are in various phases of development and include monoclonal antibodies to CD40 as well as CD2. Although costimulation blockade has been successfully utilized for the induction of tolerance in rodent models, this has not been realized in humans. Costimulation blockade has proven to be beneficial when used as maintenance immunosuppression.[19]

The initiation of signal 3 begins with the engagement of IL-2 on CD25 located on the surface of the T cell. IL-2 receptor blockade has become standard of therapy in the perioperative period (day 0 and day 4) to allow for early allograft acceptance and reduced usage of nephrotoxic CNIs. Early clinical trials proved that induction therapy with IL-2 receptor blockade significantly reduced acute rejection rates in renal transplant recipients when compared to placebo groups and in combination with standard CNIs and steroids.[20]

B7/CD28 CTLA4 Blockade

The expression of CD80 (B7.1) and CD86 (B7.2) on the surface of APCs provides T cells with either activation signals, if engaged to CD28, or inhibitory signals, if ligating cytotoxic T-lymphocyte antigen 4 (CTLA4). CD80 and CD86 interact preferentially with CTLA4 (CD152) when compared to CD28.[18,21] CTLA4 is also up-regulated following the activation process and its ligation results in inhibition of activation thereby controlling clonal expansion.[22,23] Additionally, CTLA4 is constitutively expressed on regulatory T cells.[24] Blockade of each B7 molecule as monotherapy has not led to significant allograft survival in nonhuman primate models. In contrast, blockade of both B7 molecules together did lead to prolonged graft survival but was not able to induce tolerance as rejection occurred once therapy was stopped.[25–27] An immunoglobulin fusion protein of CTLA4 (abatacept), has been shown to inhibit graft rejection in xenogeneic and allogeneic systems.[28,29] These promising early results have prompted the development of CTLA4-Ig variants.

LEA29Y (belatacept) is a second-generation molecule, derived as a result of mutating two amino acids of CTLA4-Ig. Belatacept possesses a twofold greater ligation capacity for both CD80 and CD86. The increase in avidity allows for a more complete blockade of the B7 molecules and a 10-fold greater suppression in in vitro assays.[30] Belatacept has shown improved renal function, reduction in chronic allograft nephropathy, decreased calcineurin-related toxicity, and no thromboembolic complications in phase II trials.[31] Phase III trials have evaluated the efficacy and renal protection of belatacept in standard (BENEFIT) and expanded criteria donors (BENEFIT-Ext). There was an increased incidence of posttransplant lymphoproliferative disease in Epstein–Barr virus (EBV)-seronegative patients and acute rejection at 1 year in the belatacept treatment groups compared to CNIs. Additional results revealed an improved glomerular filtration rate (GFR) and lipid profile over a 5-year period.[32–35]

IL-2 Receptor Blockade

Basiliximab is a chimeric mouse/human IgG1 monoclonal antibody to the alpha chain of CD25 (IL-2 receptor) which has proven to reduce acute rejection rates in adult and pediatric renal and pancreas transplant recipients. In clinical trials with 6-month follow-up, basiliximab had a significant impact on acute rejection rates with no increase in infectious complications.[36] Often used in kidney transplant patients as induction therapy, and in liver transplantation in order to spare the nephrotoxic effects of tacrolimus, long-term follow-up remains to be provided.[37–39] In a randomized, prospective, placebo-controlled trial of patients investigating immunoprophylaxis in liver transplantation, investigators identified a lower acute rejection rate in HCV-negative patients at 6-month follow-up in patients treated with basiliximab in combination with standard CNI therapy.[40]

LEUKOCYTE DEPLETION

In order to achieve tolerance to an organ transplant, it may be necessary to maximize the potential of engraftment by depleting the alloreactive effector T cells (and B cells in some therapeutic regimens) which mediate a rejection response. Many investigators have identified the value of monoclonal or polyclonal antibodies designed to bind to peripheral alloreactive lymphocytes. The short-term depletion of leukocytes using antithymocyte globulin, anti-CD3, anti-CD2, anti-CD4, and anti-CD8 has proven successful in terms of long-term graft survival in animal models; these results are further enhanced with thymectomy prior to transplantation in order to prevent posttransplantation peripheral effector cell repopulation.[41,42] In nonhuman primate models, anti-CD3 conjugated to diphtheria immunotoxin administered alone prior to transplantation or in conjunction with sirolimus (rapamycin) or deoxyspergualin, inhibitor monocytes and macrophages, produced tolerance via T-cell depletion.[43–45] Clinical trials in kidney transplant recipients using anti-CD52 antibody (alemtuzemab)–mediated leukocyte depletion alone and in combination with deoxyspergualin were not able to induce tolerance.[46,47] In subsequent trials, alemtuzumab therapy allowed for the use of low-dose immunosuppression in steroid-free regimens in order to control effector responses; alemtuzumab is now a commonly used and inexpensive induction agent.[48–52] Memory T cells are the most resistant to depletion with alemtuzumab therapy.[13,53]

Polyclonal leukocyte-depleting antibodies, such as thymoglobulin (rabbit antithymocyte globulin [rATG]), are useful as induction agents, and are mainstays of induction therapy in renal transplant recipients.[54] Upon binding various T-cell epitopes, rATG lyses leukocytes using complement-dependent pathways and opsonization leading to mononuclear cell phagocytosis of T cells.[55] rATG also binds to surface receptors on dendritic cells, which impair antigen presentation.[55] Polyclonal antithymocyte globulin is wrought with serious side effects including a predisposition to posttransplant lymphoproliferative disorder and the cytokine release syndrome.[56,57]

Depleting the recipient of leukocytes creates a window of opportunity for an allograft to “settle in” without attack by effector immunocytes. The recipient’s transient immunodeficiency is dictated by the strength and duration of depletion. T-cell depletion strategies have paved the way for future studies involving administration of donor antigen along with leukocyte depletion in an attempt to achieve chimeric states.[58]

CLINICAL THERAPEUTICS FOR MAINTENANCE IMMUNOSUPPRESSION IN SOLID ORGAN TRANSPLANTATION

Calcineurin Inhibitors

5 One of the greatest medical discoveries of 20th century was the identification of the CNIs with their effects on T-cell signaling, and their alterations in cell-mediated immunity. This class of agents has potent biologic activity and minimal myelosuppressive effects, which were a significant limitation in early clinical transplantation. Cyclosporine A was the first of these drugs identified, initially found in a soil sample from the fungus *Tolypocladium inflatum*. Cyclosporine is a cyclical fungal peptide composed of 11 amino acids, with significant immunosuppressive effects.[59,60] Subsequently, the clinical efficacy of cyclosporine A was demonstrated in human kidney transplantation, opening the gates to a new era for clinical organ transplantation. Cyclosporine remained the mainstay of clinical immunosuppression for several years, and was used across organ types by thousands of patients. In 1984, FK506 (tacrolimus) was identified as another CNI with a similar mechanism of action. FK506 is a macrolide immunosuppressant that was approved by the U.S. Food and Drug Administration for use in liver transplantation.[61–63] Tacrolimus has become the mainstay of maintenance immunosuppression in solid organ transplant programs due to a gentler side effect profile and potency of immunosuppression, and is used in virtually all solid organ types.

CNIs, as a class, disrupt regulatory T-cell signaling and lead to a down-regulation of IL-2 production, which eventually decreases the activity of cytotoxic T cells. Antigen presentation at the TCR leads to an increase in cytoplasmic calcium levels through a protein kinase and G-protein reaction within regulatory T cells. This calcium binds to calmodulin, a regulatory subunit of the phosphatase calcineurin, prevalent in immunocompetent lymphocytes and nerve cells. Calcineurin is responsible for cleaving the phosphate bound to NFAT (nuclear factor of activated T-cells) which in its activated form traverses the T-cell nuclear membrane and promotes transcription of IL-2. Inhibition of calcineurin occurs through the activation of immunophilins, such as cyclophilin and FK-binding protein, which are endogenous cytosolic peptides. The cyclosporine–cyclophilin complex and its counterpart, the FK506–FKBP12 complex, prevent dephosphorylation of NFAT, which in turn leads to reduced IL-2 production and diminished T-cell signal transduction to effector lymphocytes.

Side Effects

CNIs have a variety of side effects which present challenges in the clinical management of transplant recipients. One of the issues relates to drug interactions for patients on tacrolimus or cyclosporine. Common interactions that may boost levels of CNIs occur in patients requiring antifungal therapy, particularly in the azole class, as well as other drugs metabolized by hepatic/intestinal cytochrome P450 3A4 enzyme. As implied by the

name, calcineurin is also present in nerve tissue as well as lymphocytes. Drug activity in nerve tissue leads to several clinical effects including tremors, seizures, and posterior reversible encephalopathy syndrome.[64] Additional side effects include hyperkalemia, hypercholesterolemia, and gastrointestinal dysfunction including diarrhea. Cyclosporine has also been associated with gingival hyperplasia that is seen less frequently with tacrolimus. The most significant long-term effects include chronic nephrotoxicity that may precipitate end-stage renal disease, as well as new-onset diabetes mellitus after transplantation. Consultation with a transplant pharmacist is integral to the successful management of the posttransplant patient to prevent toxicity and achieve therapeutic immunosuppression goals.

mTOR Inhibitors

The first discovered mTOR inhibitor was sirolimus. Sirolimus, or rapamycin, is a bacterial macrolide derived from *Streptomyces hygroscopicus,* found initially in a soil sample from Easter Island (Rapa Nui). Like CNIs, its mechanism of action leads to decreased IL-2 proliferation. Sirolimus binds to FK-binding protein 12, as does tacrolimus. The site of action of the sirolimus–FKBP12 complex is known as the mammalian target of rapamycin, or mTOR. Despite having structural similarity to tacrolimus, sirolimus has limited activity on calcineurin when bound to FKBP12. The complex disrupts signal transduction of the IL-2 receptor and decreases nuclear transcription of molecules active in lymphocyte homing.[65] Sirolimus also has significant antiproliferative properties, and inhibits cell cycle activity in lymphocytes and fibroblasts.[66–68]

Sirolimus has been adopted in a variety of clinical protocols. Sirolimus is currently used primarily in place of CNIs, most commonly in patients who are weeks to months out from the transplant operation.[69] Sirolimus has less nephrotoxicity than CNIs, but has been associated with a higher risk of acute rejection in some studies. In liver transplantation, conversion from tacrolimus to sirolimus in patients with reduced kidney function was associated with more acute rejection episodes but did not have a tangible benefit in terms of kidney function in a randomized control trial.[70] Some have advocated for lower-dose CNIs as maintenance therapy in patients with impaired renal function compared to sirolimus monotherapy,[71] and studies have demonstrated the potential of low-dose CNIs in conjunction with sirolimus for maintenance immunosuppression. Importantly, there is an FDA black box warning against using sirolimus in conjunction with higher-dose CNIs due to higher risk of mortality and graft loss in liver transplantation, as well as an increased risk of hepatic artery thrombosis within the first month after transplant.

Everolimus is another mTOR inhibitor that has recently been approved for use in kidney and liver transplantation. Everolimus is a hydroxylated derivative of sirolimus, and its preserved structure allows for a similar mechanism of action via FKBP12 binding and mTORC1 inhibition. Its immediate appeal was its lower risk of nephrotoxicity. In a recent multicenter prospective clinical trial, patients with reduced-dose tacrolimus and everolimus had improved GFR at 2 years posttransplant compared to patients on standard tacrolimus-based regimens, without any higher risk of biopsy-proved acute rejection or major side effects.[72,73] This improvement in GFR has also been identified retrospectively in patients converted to everolimus in maintenance immunosuppression.[74]

Side Effects of mTOR Inhibitors

Sirolimus has been associated with impaired wound healing after transplant, including anastomotic dehiscence in lung transplantation, surgical site infections, and fascial union problems.[75–80] Surgeons confronted with transplant patients who are on mTOR inhibitors should consult with transplant professionals prior to operative intervention if possible, in order to guide alterations in immunosuppressive therapy to minimize complications. Several other complications have been noted in patients on mTOR inhibitors. Pulmonary toxicity manifested as pneumonitis has been identified, and caution should be taken in

administering the drug to patients with pre-existing lung disease. Metabolic complications including hyperlipidemia and new-onset diabetes mellitus after transplant have also been identified as significant side effects.[81] In low- to moderate-risk renal transplant recipients, conversion from tacrolimus to mTOR inhibitors was associated with a higher risk of acute rejection, higher rates of proteinuria, hypercholesterolemia, and anemia.[81]

Antimetabolite Drugs

Antimetabolite drugs in solid organ transplantation comprise a class of agents aimed at suppressing lymphocyte proliferation by reducing the rate of de novo purine synthesis, which prevents effective nucleotide synthesis and DNA transcription. Typically, these drugs are used in combination with CNIs and steroids. One of the first antimetabolite drugs applied in clinical transplantation was azathioprine. Azathioprine has been applied in a multitude of disease states including inflammatory bowel disease and autoimmune diseases such as rheumatoid arthritis and systemic lupus erythematosus. While it is effective in reducing T-cell and B-cell propagation, azathioprine is also a potent suppressive agent of bone marrow, increases the risk of anemia, and is also associated with pancreatitis.

A newer antimetabolite, mycophenolic acid (MPA), has emerged as a mainstay in solid organ transplantation. MPA was identified in a *Penicillium* fungal species, and is hepatically metabolized. MPA has less myelosuppressive activity than azathioprine, but side effects are common.

Side Effects of Antimetabolite Drugs

Myelosuppression and leukopenia are common side effects of this class of agents. Mycophenolate is also associated with a significant risk of gastrointestinal dysfunction including diarrhea, nausea, and vomiting. Azathioprine has been recognized as a group 1 carcinogen by the National Toxicology Program in the United States, related to length of use and dosage.[82–85] Mycophenolate should be avoided in pregnancy or in transplant recipients trying to conceive due to the risk of miscarriage and congenital malformations.[86–90]

Steroids

Steroids have represented the mainstay of immunosuppressive therapy since the beginning of clinical transplantation. Glucocorticoids are steroids that arise from the zona fasciculata in the adrenal gland. These molecules have a plethora of effects in humans, and their receptors are omnipresent across human cell types. In lymphocytes, glucocorticoids act on cytosolic receptors that in turn lead to a variety of intracellular signals that are responsible for gene transcription, and decrease the expression of several cytokines, including IL-2. Glucocorticoids also reduce the number and function of both T cells and B cells.

Side Effects of Steroid Therapy

Steroid therapy is used in a variety of clinical treatments including maintenance immunosuppression and in high doses as a rescue therapy in patients presenting with acute rejection. There are several side effects to chronic corticosteroid use, which have prompted transplant clinicians and researchers to develop protocols that reduce the need for chronic steroid use. Common side effects include glucose intolerance, weight gain, skin and tissue frailty, osteopenia and osteoporosis, muscle breakdown, neuropsychiatric dysfunction, glaucoma and cataracts, secondary hypercortisolemia, and other effects. Many transplant programs are shifting toward steroid avoidance in maintenance immunosuppression in low-risk patients.[91–93]

TREATING REJECTION IN SOLID ORGAN TRANSPLANTATION

6 Immunologic rejection can occur minutes to years after an organ transplant. The early phases of rejection, termed hyperacute rejection, can occur on the operating room table to 24 hours after surgery and is mediated by the humoral immune system. Acute rejection is a cell-mediated phenomenon which often manifests days to months after transplant. Chronic rejection occurs in the months to years after transplant and continues to be one of the leading causes of graft loss in the long term. Acute and chronic antibody-mediated rejection (AMR) is a separate phenomenon that may occur days to years after transplant and remains an important barrier to successful engraftment of organs.

Hyperacute Rejection

Hyperacute rejection is a rare clinical entity in modern clinical transplantation. Hyperacute rejection is generally attributed to ABO blood group incompatibility or the presence of preformed anti-HLA antibodies. In the allograft, the capillary endothelium expresses blood group antigens which may join with circulating antibodies to A and B glycoproteins. For example, a blood group B transplant candidate would have circulating anti-A IgG antibodies in blood. If a blood group A kidney allograft were transplanted into that recipient without any other treatment, these antibodies would react with the donor endothelium and activate complement and humoral immunity effector mechanisms, which would lead to endothelial injury, thrombosis, as well as intraparenchymal hemorrhage. This response usually happens within minutes after reperfusion of the allograft, and requires removal of the allograft in order to prevent a systemic inflammatory response which may lead to multiorgan failure. Prevention of this type of rejection is central to the practice of clinical transplantation, and mandates confirmation of donor and recipient compatibility via ABO blood group verification and cross-matching prior to implantation of the allograft.

Acute Rejection

Induction protocols in combination with immunosuppressive therapy successfully prevent the relatively quick onset of acute rejection episodes. In the case of renal transplantation, induction therapies in combination with potent maintenance therapies have fostered a significant improvement of 1-year outcomes.[94] Less than 10% of organs experience clinically significant acute cellular rejection (ACR) episodes leading to graft loss at 1 year.[95] As discussed above, ACR is an adaptive response characterized by T-cell interactions with donor antigens either presented directly by the donor APC or indirectly by the recipient professional presenting cells.[96] Once clonal expansion occurs “effector” T cells then infiltrate the graft and mediate various methods of organ injury.

The gold standard in pathologic categorization of renal transplant rejection is the Banff classification model. The Banff classification originated at a consensus conference in 1991 aimed at ranking the levels of rejection seen on kidney transplant biopsies based on degree of structural damage, such as tubulitis, arteritis, and cellular infiltrate.[97] In renal transplantation, the diagnosis of ACR occurs with tissue confirmation after ruling other causes for declining graft function. Treatment of ACR is usually dictated by the Banff classification. For example, borderline rejection characterized by Banff class IA or IB is often treated with pulse corticosteroids and increases in maintenance immunosuppression whereas, more severe ACR is more often treated with multiple doses of thymoglobulin. Today, ACR is often the result of inadequate immunosuppression due to noncompliance/adherence or early immunosuppression withdrawal/underdosing. Repeated episodes of acute rejection are associated with chronic dysfunction and early graft failure.

Chronic Rejection

The clinical sequelae of chronic rejection (more recently termed chronic transplant dysfunction or CTD) are varied and organ specific. The unifying factor of CTD among all organs transplanted is the histopathologic effect of arterial intimal thickening in the vessels supplying the organ, termed transplant arteriosclerosis or transplant vasculopathy. Both immune and nonimmune stimuli may up-regulate pathways leading to progressive graft fibrosis. Immune-dependent mechanisms, including HLA mismatching, inadequate immunosuppression, and episodes of acute rejection, promote the development of CTD and eventual graft failure. Additionally, immune-independent mechanisms, such as prolonged ischemia time and usage of brain dead donor organs, as well as recipient factors such as native hypertension may also play a role in the onset of CTD. Various studies suggest that the development of vascular fibrosis progressing to parenchymal fibrosis is multifactorial and includes effector responses mediated by complement, $CD4^+$ T cells, $CD8^+$ T cells, and alloreactive antibodies.[98–102]

Type of Rejection	Time of Onset	Mechanism	Morphology
Hyperacute	Minutes to few hours	Preformed antibodies bind to graft endothelium	Vessel thrombosis; Ischemic necrosis
Acute Cellular	Days to weeks, months to years	T cells injure graft by direct cytotoxicity and type IV hypersensitivity	Interstitial infiltrates of lymphocytes; Focal necrosis of graft tissue
Acute Humoral (Rejection Vasculitis)	Days to weeks, months to years	Antidonor antibodies against graft antigens	Vasculitis; Intimal thickening; Thrombosis
Chronic	Months to years (Irreversible)	T cell cytokines stimulate vascular smooth muscle proliferation	Arteriosclerosis; Ischemic atrophy; Interstitial fibrosis

Figure 34-2. Time course, mechanism, and morphology of transplant rejection. Allograft rejection responses have many different phenotypes, which also lead to different therapies. This figure provides a summary of the types of clinically significant rejection episodes, the root cause behind them, and histopathologic features identified on biopsy.

Clinically, the manifestations of CTD depend on the type of organ allograft. Recipients of renal allografts with CTD often manifest with proteinuria, decreases in GFR, increases in plasma creatinine, and arterial hypertension. Patients who have undergone liver transplantation may present with abnormal liver function tests or an increase in serum bilirubin secondary to the so-called *vanishing bile duct syndrome*. Bronchiolitis obliterans, detected by computed tomography and altered pulmonary function tests indicate the onset of CTD in lung transplant recipients. Patients receiving cardiac allografts may present with a range of symptoms from arrhythmias to fatal myocardial infarction.[103]

The timing, mechanism, and morphology of hyperacute, acute, and chronic rejections are summarized in Figure 34-2.

Antibody-Mediated Rejection

Antibody-mediated rejection or AMR can occur in both the acute and chronic phases of transplantation. Increasingly, AMR has been shown to occur in multiple organs including liver and heart.[104] AMR starts with production of donor-specific antibody (DSA) directed to the endothelial lining of organ allografts. DSA–endothelial cell interactions lead to complement activation as well as innate responses resulting in allograft injury.[105,106] In the chronic setting, persistent DSA leads to microthrombotic events and late graft failure. Diagnostically, along with serum titers of circulating DSA, tissue biopsy reveals deposition of complement split products including C4d and inflammation of capillaries and renal tubules. AMR has also been diagnosed using newer endothelial, cell-specific biomarkers of capillaritis.[107] Liver allografts have shown susceptibility to AMR and DSA in recent studies.[108]

The treatment of acute AMR is based on removal of inciting antibodies (Fig. 34-3). Although there are no high-quality evidence-based treatments for acute AMR, strategies include plasmapheresis, immunoadsorption, use of B-cell toxic antibodies such as rituximab, newer proteasome inhibitors such as bortezomib, and even splenectomy.[109] In patients with drug-resistant AMR, monoclonal antibodies to complement C5 (eculizumab) have been used off-label with some encouraging results although the extreme expense of the drug has hindered its investigation in randomized control trials.[109]

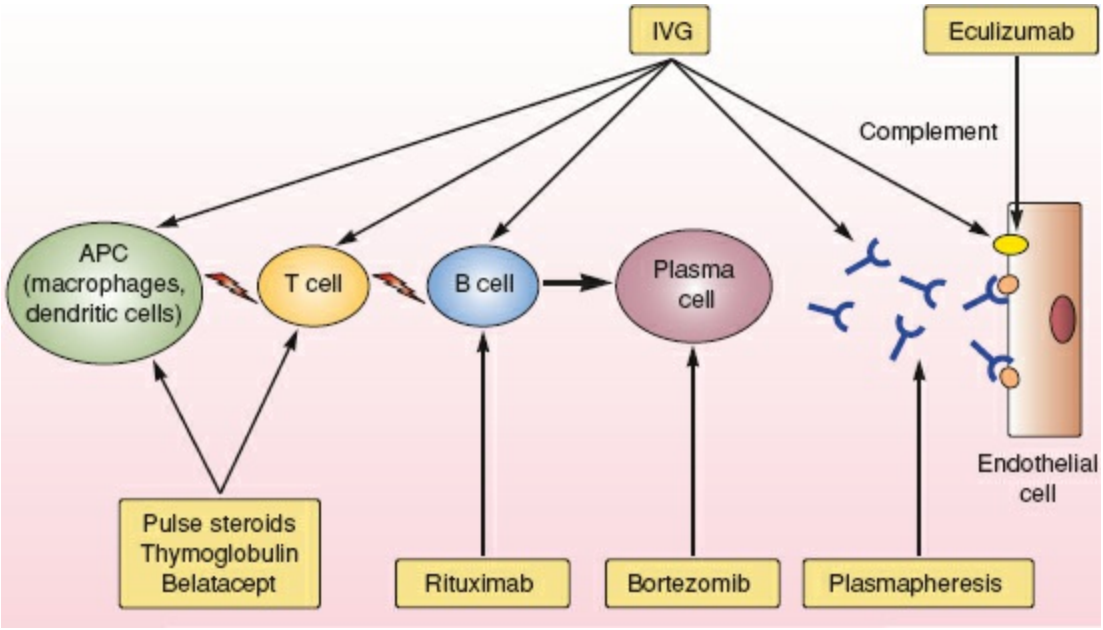

Figure 34-3. Current strategies to treat various phases of antibody-mediated rejection. Antibody-mediated rejection involves antigen presentation, T-cell signaling, and effector responses that result in stimulation of B cells, antibody formation and release, and antibody deposition and initiation of the innate immune response via complement activation. This figure demonstrates the site of action of drugs and treatments common to antibody-mediated rejection treatment protocols, which are ultimately aimed at reducing antibody. (Adapted from Djamali, Kaufman DB, Ellis TM, et al. Diagnosis and management of antibody-mediated rejection: current status and novel approaches. *Am J Transplant* 2014; 14:25514;plantand management.)

COMPLICATIONS OF IMMUNOSUPPRESSIVE THERAPY

7 The need for continued immunosuppression after transplant is a necessary evil in clinical transplantation. In order to maintain long-term graft function, the immune system is suppressed as discussed using a variety of agents. Long-term exposure to these agents does carry a risk of serious complications that must be discussed with any patient considering a transplant for the treatment of end organ failure.

Renal Failure with Calcineurin Inhibitors

The nephrotoxic effects of CNIs have long been recognized in clinical transplantation, and several protocols have been designed to reduce the risk of acute and chronic renal failure in the renal and nonrenal solid organ transplantation. Registry analyses suggest that 7% to 21% of nonrenal transplant recipients are at risk for renal failure, and patients treated with CNIs are at significantly increased risk of requiring dialysis treatment in the months and years after transplant.[110]

In the acute setting immediately after transplant, CNIs may cause renal dysfunction by affecting renal blood flow via several mechanisms including vasoactive/nitric oxide-dependent pathways, as well as activation of the renin/angiotensin system. These mechanisms result in increased renal vascular resistance and lower GFR. In the early posttransplant setting, these nephrotoxic effects are typically reversed with reduction in CNI dosage, and seem to be independent of plasma concentration.

CNI-related renal dysfunction may also result in chronic organ injury. Histologically, kidneys demonstrate interstitial fibrosis and tubular atrophy. Cyclosporine has been implicated in up-regulation of TGF-beta, a profibrotic cytokine.[111] Reduction in CNI dosage does not improve renal function in the long term in patients with global fibrosis, and patients may require renal replacement therapy. In liver transplantation, the need for long-term dialysis represents a significant increase in posttransplant mortality risk and attenuates the survival benefit of the initial transplant.[112–115] In order to preempt CNI-associated effects on kidney function, patients with pre-existing renal insufficiency and other end organ failure are often considered for combined nonrenal and renal transplantation if they meet certain criteria.

Infections after Transplant

Posttransplant infections are directly related to the level of immunosuppression in the host. In the early period after transplant, when levels of immunosuppression are high and proximal to the use of T-cell depleting induction agents, the risk of opportunistic infections is high and management is focused on antimicrobial prophylaxis. Further from transplant, less immunosuppression is typically required, and prophylaxis is not necessary. However, the prevalence and incidence of infectious diseases in solid organ transplant recipients mandate close monitoring of clinical signs and symptoms, and appropriate diagnostic testing when a clinical suspicion arises of a bacterial, viral, parasitic, or fungal infection. Infections after transplant may consist of donor-derived infections transmitted with the organ, recipient-derived infections due to colonization or other pretransplant exposure, nosocomial infections acquired in the healthcare setting, and community-acquired infections.[116] Figure 34-4 demonstrates the peak incidence of common opportunistic infections as a function of time after transplant. When faced with a transplant patient with a high clinical suspicion of an infection, transplant providers and infectious disease specialists use this information, clinical history, affected organs and systems, and a battery of cause-oriented diagnostic tests to establish the diagnosis and treatment strategy (Fig. 34-5).

Donor-Derived Infections

Deceased organ donors may be exposed to community-acquired infections prior to death, infectious risk related to lifestyle exposures (i.e., intravenous drug abuse), as well as nosocomial infections acquired during hospital care. Several infectious transmissions have occurred as a result of donor transmission, including human immunodeficiency virus (HIV), West-Nile virus, rabies, Chagas disease, and lymphocytic choriomeningitis virus. Careful attention must be paid to the circumstances surrounding the donor's death as well as reported signs and symptoms such as fever and altered mental status. Prior to organ recovery, organ donors are routinely serologically screened for several infectious pathogens, including HIV, hepatitis, cytomegalovirus (CMV), EBV, and syphilis. Routine blood, urine, and sputum cultures may be used in premortem care. Serologic testing consists of antibody testing, which is not 100% sensitive, but the recent inclusion of nucleic acid testing in many centers may help mitigate risk in organ acceptance and aid patient counseling.[117] In the case of CMV, hepatitis, and EBV serologic testing, serologic matching between donors and recipients drives the perception of posttransplant infectious risk and guides antimicrobial prophylaxis decisions and selection of immunosuppression.

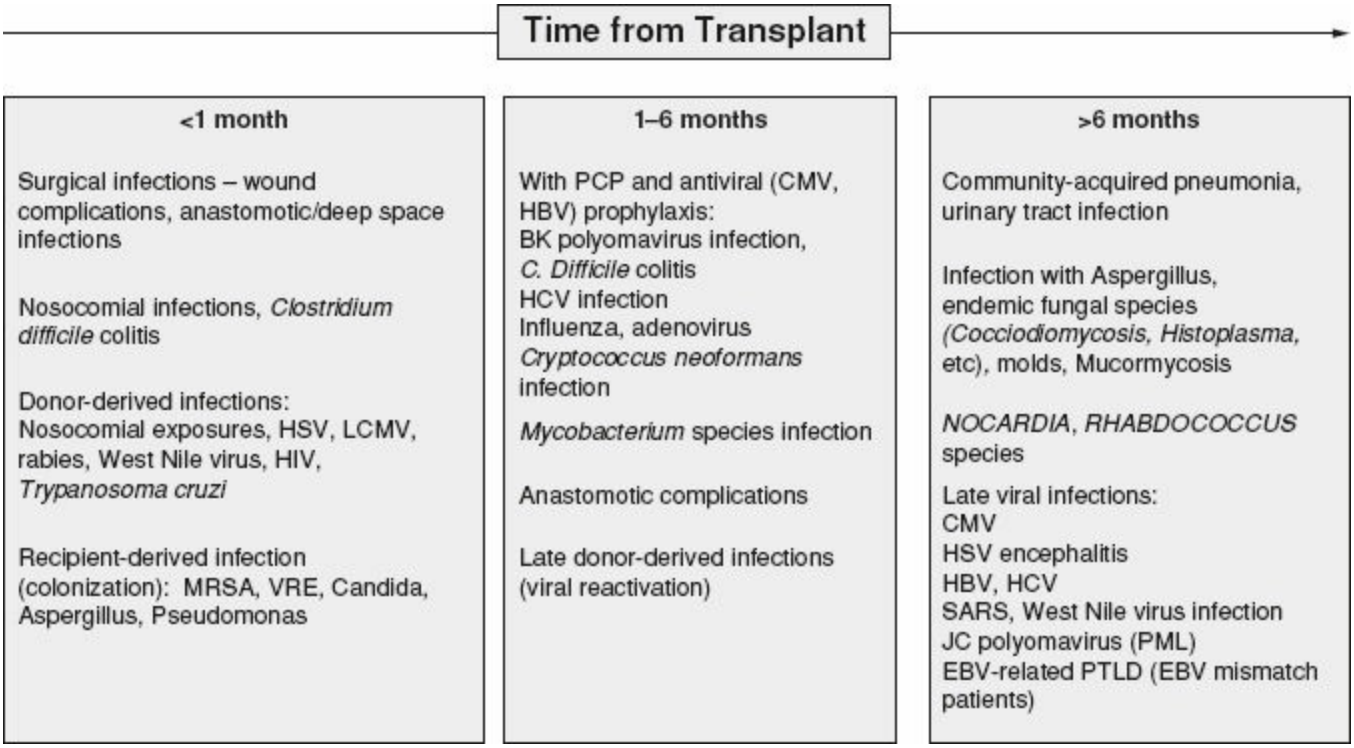

Figure 34-4. Timeline of common infections after transplantation. Immunosuppression predisposes transplant recipients to infection by deterring host defenses. In this context, bacterial, viral, and fungal infections may arise which have distinct peaks of onset. Treatment of these infections usually involves withdrawal or reduction of immunosuppression in most cases, particularly when infections are life-threatening or are causing significant morbidity. (Adapted from Fishman JA. Infection in solid-organ transplant recipents. *N Eng J Med* 2007;357:2601–2614.)

Recipient-Derived Infections

The incidence of posttransplant infections that arises from pretransplant exposure to the recipient is increasingly recognized. Transplanting patients with active infections should be undertaken with extreme caution due to the risk of dissemination of disease with early immunosuppression.

Nosocomial pathogens may colonize the recipient prior to transplant, when healthcare utilization may be high due to organ failure, or may infect patients at any point after transplant. Pathogens may acquire antibiotic resistance which may make treatment difficult, such as in cases with vancomycin-resistant *Enterococcus,* methicillin-resistant *Staphylococcus,* azole-resistant *Candida,* as well as in *Clostridium difficile colitis,* several gram-negative enteric pathogens, and fungi.[116] Recipient exposure via travel or residence in geographically endemic areas can also be a risk for infection (fungal infections such as histoplasmosis, aspergillosis, coccidiomycosis, atypical bacterial infections such as *Mycobacterium tuberculosis,* parasitic infections caused by *Strongyloides* or *Trypanosoma cruzi*), as well as reactivation of dormant viruses (hepatitis, CMV, or varicella-zoster virus). Exposures to relatively benign pathogens may result in major infections after transplant. Respiratory viruses may further weaken natural tissue defenses in the bronchopulmonary tree and lead to superinfection with other pathogens. Fungal infections derived from the soil such as *Nocardia* or *Aspergillus* may arise in this fashion, and require changes in immunosuppression to prevent exacerbation of infection.

Pathogen	Site of Disease	Disease Manifestations	Prophylaxis	Treatment
Cytomegalovirus (CMV)	CNS, Respiratory, GI tract, Bone marrow	Fever, neutropenia, pneumonitis, diarrhea, mucosal ulceration, chorioretinitis, meningoencephalitis, graft dysfunction	Low risk patients: Acyclovir High Risk patients: Valganciclovir	Valganciclovir Ganciclovir CMV-immunoglobulin Minimization of immunosuppression
Epstein–Barr Virus (EBV)	Bone marrow, spleen, CNS	B-cell–derived post transplant lymphoproliferative disease (PTLD)	Antiviral prophylaxis such as acyclovir or valganciclovir	Minimization of immunosuppression Chemotherapy Radiation Therapy (CNS) Anti-CD20 antibody therapies
BK Virus	Kidney	Renal Dysfunction	None	Minimization of immunosuppression Experimental antiviral therapies (cidofovir)
Pneumocystis	Respiratory	Pneumonia/pneumonitis	Trimethoprim/ sulfamethoxazole Pentamidine Dapsone	

Figure 34-5. Common infections after transplantation, prophylaxis, and treatment strategies. After transplant, while predisposed to multiple infections related to immunosuppression, certain infections are particularly common and virulent. Clinical decisions regarding prophylaxis against these pathogens and how this affects immunosuppression are key decision points in managing the posttransplant patient.

While the spectrum of potential infectious pathogens is broad, infectious epidemiology in the immunocompromised population guides targeted prophylaxis strategies. Common posttransplant infections are listed in Figure 34-5. Immunosuppression management in the infected transplant recipient is often challenging, and dependent on the relative immunogenicity of the organ transplanted, the virulence of the pathogen, and the presence or potential of disseminated disease. Minimization of immunosuppression is a mainstay during infectious episodes, but must be balanced with the risk of intervening acute rejection.

Cancer

Chronic immunosuppressive therapy weakens host defenses against neoplastic processes. There is well-established evidence that solid organ transplant recipients of every type have an increased risk of malignancy, both related to immunosuppression and oncogenic viral infections.[118] The most common cancers incurred by solid organ transplant recipients are skin cancers, followed by posttransplant lymphoproliferative disease.[118,119] In this context, posttransplant patients are strongly recommended to have yearly skin examinations by a dermatologist. Screening for malignancy in chronically immunosuppressed patients follows general screening guidelines. Treatment of cancers is driven by site and extent of disease, but in all cases includes reduction in the amount of immunosuppression.

APPROACHES TO TOLERANCE

8 The perpetual goal of clinical transplant immunology is the induction of tolerance. Several advances have been made in identifying potential cellular and molecular targets and pathways on a basic science level, and case reports of maintaining transplant recipients with normal graft function without any or very little immunosuppression are well known. While clinical tolerance remains out of reach in the current era, several potential mechanisms are the focus of research and drug development.

Immunodeletion

Experimental strategies to deplete graft-specific effector T cells have been employed both centrally, in the thymus, as well as in the periphery. These methods take advantage of developing T cells by exposing them to donor-specific antigens at an early stage such that they are deleted to the graft during transplantation. This has been achieved with the use of intrathymic administration of donor-specific antigen such as bone marrow in large animal models of kidney and skin transplantation in conjunction with total lymphoid irradiation.[120–122] Infusion of intrathymic alloislets in combination with peripheral lymphocyte depletion has also been shown to reverse diabetes in experimental animal models.[123] More recently, studies have demonstrated this concept in models of autoimmunity.[124] These observations suggest that centrally inoculated donor antigen or allopeptides combined with peripheral leukocyte depletion may lead to the successful induction of tolerance.[125–127]

Immunoregulation

Postthymic immunomodulatory strategies to induce graft acceptance are often referred to as "peripheral tolerance." Various approaches exist to induce peripheral tolerance. Since the discovery of $CD4^+$ T cells expressing the biomarkers $CD25^+$ $CD127^{low}$ and the master gene regulator $Foxp3^+$, the field of immunoregulation has expanded to include $CD8^+$ regulatory cells, regulatory dendritic cells, and B-regulatory cells.[100,128–130]

Regulatory T cells (Tregs) have shown the most promise and exert suppressive capabilities over effector-type T cells in various ways.[131–133] Naturally occurring Tregs make up 1% to 2% of the T-cell repertoire and clonally expand when needed; when removed from immunocompetent individuals the lack of these cells leads to spontaneous autoimmunity in both mouse and man.[128,134] Their suppressive ability ranges from direct toxic effects on effector cells using granzyme/perforin pathways, to secretion of suppressive cytokines such as IL-10 and TGF-β, to modulation of donor APCs.[135] Human Treg cells may be isolated, expanded ex vivo, and then reintroduced as therapy in vivo to inhibit chronic rejection responses using human cells and tissue.[100] These findings have allowed Tregs to be introduced into various clinical trials.[136] Studies have also suggested that existing immunotherapies, such as sirolimus, may also allow for the expansion of these suppressive T-cell subsets.[137,138] Along with naturally occurring Tregs, inducible Tregs may arise in the presence of donor antigen and may be generated by naïve T cells even in the absence of their naturally occurring counterpart.[139–141] Tregs have proven to be essential for graft-specific self-tolerance and the expansion of pure populations of these cells will almost certainly be the key to efficient clinical translation.

Immunologic Anergy and Exhaustion

Mechanisms of T- and B-cell anergy are important to the development of graft-specific tolerance. Anergic responses occur within lymphocytes when incomplete activation takes place and all three signals of activation are not fully engaged. Anergic responses have also been associated with regulatory activity. Blockade of accessory molecules and costimulation may also lead to anergic-type lymphocyte responses.[121] T-cell exhaustion occurs when donor antigen load exceeds the activation capacity of recipient T cells thereby overwhelming their activation and clonal expansion capabilities. This concept has been invoked to explain the tolerant effects of liver and multiorgan transplants given the high donor antigen load and chronic stimulation.[142]

Chimerism

The introduction of donor-type immunocytes within a recipient prior to allograft transplantation has been the subject of many investigations over recent years. Combinations of donor and recipient cell types in a single host have been thought to confer a state of operational tolerance to organ allografts. Historically, stable mixed chimerism of donor and recipient cells was a concept limited to the field of bone marrow transplantation. Long-term allograft acceptance without the need for chronic immunosuppression in bone marrow transplant recipients who subsequently received renal allografts from the bone marrow donor encouraged the use of experimental macrochimeric models in the investigation of tolerance.[143–146] Although bone marrow transplantation is not feasible or appropriate for patients on transplant waiting lists, in vivo models of tolerance utilizing the principles of macrochimerism have demonstrated that it is essential in the tolerogenic potential of mixed chimerism. *Macro*chimerism, has been shown to result in tolerant states but requires the use of cytoreductive therapy to ensure hematopoietic stem cell engraftment.[147,148] Conditions necessary to achieve stable chimerism include the use of lymphoablative therapy alone or in conjunction with bone marrow infusion. Under these conditions, tolerance to allografts has been reported in rodent and nonhuman primate models.[149,150] The requirement for lymphoid irradiation has limited the translation of these models to the clinic, and has resulted in a search for effective nonmyeloablative strategies. In an attempt to circumvent the use of irradiation conditioning, many groups have attempted the experimental use of costimulation blockade or T-cell depletion in conjunction with high-dose bone marrow infusions to delete donor reactive cells in the thymus. Results from these nonmyeloablative regimens have proven to be encouraging in mouse models and some large animal models.[151–155]

Immunomodulating Stem Cells

Recent reports have focused on the suppressive capacity of mesenchymal stem cells (MSCs). MSCs have shown great promise in both small and large animal models of transplantation.[156] Mechanistically, MSCs have been shown to down-regulate costimulation molecules on APC thereby inducing anergic responses in T cells, keeping APC in an immature, and thus tolerogenic state.[157] Additionally, MSCs have shown the ability to engraft and incorporate into healing tissues. MSCs also inhibit T- and B-cell expansion by dampening the metabolic activity of T cells with the production of indolamine 2,3-dioxygenase which deprives lymphocytes of nutritional tryptophan, inducing cell death.[156,158] Furthermore, MSCs have also been shown to synergize with standard therapies of costimulation blockade to induce Treg and tolerogenic phenotypes making them a target for future clinical translation.[159]

References

1. Valitutti S, Lanzavecchia A. Serial triggering of TCRs: a basis for the sensitivity and specificity of antigen recognition. *Immunol Today* 1997;18(6):299–304.
2. Horejsi V. Lipid rafts and their roles in T-cell activation. *Microbes Infect* 2005;7(2):310–316.
3. Manes S, Viola A. Lipid rafts in lymphocyte activation and migration. *Mol Membr Biol* 2006;23(1):59–69.
4. Kovacs B, Parry RV, Ma Z, et al. Ligation of CD28 by its natural ligand CD86 in the absence of TCR stimulation induces lipid raft polarization in human CD4 T cells. *J Immunol* 2005;175(12):7848–7854.
5. Larsen CP, Knechtle SJ, Adams A, et al. A new look at blockade of T-cell costimulation: a therapeutic strategy for long-term maintenance immunosuppression. *Am J Transplant* 2006;6(5 Pt 1):876–883.
6. Larsen CP, Morris PJ, Austyn JM. Migration of dendritic leukocytes from cardiac allografts into host spleens. A novel pathway for initiation of rejection. *J Exp Med* 1990;171(1):307–314.
7. Janeway CA, Travers P, Walport M, et al. *Immunobiology: The Immune System in Health and Disease 6th Edition.* 6th ed. Janeway, CA: Garland Science Publishing; 2005.
8. Chen Y, Wood KJ. Interleukin-23 and TH17 cells in transplantation immunity: does 23 + 17 equal rejection? *Transplantation* 2007;84(9):1071–1074.
9. Chalasani G, Dai Z, Konieczny BT, et al. Recall and propagation of allospecific memory T cells independent of secondary lymphoid organs. *Proc Natl Acad Sci U S A* 2002;99(9):6175–6180.
10. Adams AB, Pearson TC, Larsen CP. Heterologous immunity: an overlooked barrier to tolerance. *Immunol Rev* 2003;196:147–160.
11. Yang J, Brook MO, Carvalho-Gaspar M, et al. Allograft rejection mediated by memory T cells is resistant to regulation. *Proc Natl Acad Sci U S A* 2007;104(50):19954–19959.
12. Brook MO, Wood KJ, Jones ND. The impact of memory T cells on rejection and the induction of tolerance. *Transplantation* 2006;82(1):1–9.
13. Pearl JP, Parris J, Hale DA, et al. Immunocompetent T-cells with a memory-like phenotype are the dominant cell type following antibody-mediated T-cell depletion. *Am J Transplant* 2005;5(3):465–474.
14. Kirk AD. Induction immunosuppression. *Transplantation* 2006;82(5):593–602.
15. Bretscher P, Cohn M. A theory of self-nonself discrimination. *Science* 1970;169(950):1042–1049.
16. Lafferty KJ, Cunningham AJ. A new analysis of allogeneic interactions. *Aust J Exp Biol Med Sci* 1975;53(1):27–42.

17. Schwartz RH. A cell culture model for T lymphocyte clonal anergy. *Science* 1990;248(4961):1349–1356.
18. Snanoudj R, de Preneuf H, Creput C, et al. Costimulation blockade and its possible future use in clinical transplantation. *Transpl Int* 2006;19(9):693–704.
19. Pilat N, Schwarz C, Wekerle T. Modulating T-cell costimulation as new immunosuppressive concept in organ transplantation. *Curr Opin Organ Transplant* 2012;17(4):368–375.
20. Nashan B, Moore R, Amlot P, et al. Randomised trial of basiliximab versus placebo for control of acute cellular rejection in renal allograft recipients. CHIB 201 International Study Group. *Lancet* 1997;350(9086):1193–1198.
21. Thompson CB. Distinct roles for the costimulatory ligands B7-1 and B7-2 in T helper cell differentiation? *Cell* 1995;81(7):979–982.
22. Bluestone JA. Is CTLA-4 a master switch for peripheral T cell tolerance? *J Immunol* 1997;158(5):1989–1993.
23. Thompson CB, Allison JP. The emerging role of CTLA-4 as an immune attenuator. *Immunity* 1997;7(4):445–450.
24. Stamper CC, Zhang Y, Tobin JF, et al. Crystal structure of the B7-1/CTLA-4 complex that inhibits human immune responses. *Nature* 2001;410(6828):608–611.
25. Ossevoort MA, Ringers J, Kuhn EM, et al. Prevention of renal allograft rejection in primates by blocking the B7/CD28 pathway. *Transplantation* 1999;68(7):1010–1018.
26. Kirk AD, Tadaki DK, Celniker A, et al. Induction therapy with monoclonal antibodies specific for CD80 and CD86 delays the onset of acute renal allograft rejection in non-human primates. *Transplantation* 2001;72(3):377–384.
27. Birsan T, Hausen B, Higgins JP, et al. Treatment with humanized monoclonal antibodies against CD80 and CD86 combined with sirolimus prolongs renal allograft survival in cynomolgus monkeys. *Transplantation* 2003;75(12):2106–2113.
28. Lenschow DJ, Zeng Y, Thistlethwaite JR, et al. Long-term survival of xenogeneic pancreatic islet grafts induced by CTLA4lg. *Science* 1992;257(5071):789–792.
29. Larsen CP, Elwood ET, Alexander DZ, et al. Long-term acceptance of skin and cardiac allografts after blocking CD40 and CD28 pathways. *Nature* 1996;381(6581):434–438.
30. Larsen CP, Pearson TC, Adams AB, et al. Rational development of LEA29Y (belatacept), a high-affinity variant of CTLA4-lg with potent immunosuppressive properties. *Am J Transplant* 2005;5(3):443–453.
31. Vincenti F, Larsen C, Durrbach A, et al. Costimulation blockade with belatacept in renal transplantation. *N Eng J Med* 2005;353(8):770–781.
32. Satyananda V, Shapiro R. Belatacept in kidney transplantation. *Curr Opin Organ Transplant* 2014;19(6):573–577.
33. Durrbach A, Pestana JM, Pearson T, et al. A phase III study of belatacept versus cyclosporine in kidney transplants from extended criteria donors (BENEFIT-EXT study). *Am J Transplant* 2010;10(3):547–557.

34. Vincenti F, Charpentier B, Vanrenterghem Y, et al. A phase III study of belatacept-based immunosuppression regimens versus cyclosporine in renal transplant recipients (BENEFIT study). *Am J Transplant* 2010;10(3):535–546.
35. Rostaing L, Vincenti F, Grinyo J, et al. Long-term belatacept exposure maintains efficacy and safety at 5 years: results from the long-term extension of the BENEFIT study. *Am J Transplant* 2013;13(11):2875–2883.
36. Adu D, Cockwell P, Ives NJ, et al. Interleukin-2 receptor monoclonal antibodies in renal transplantation: meta-analysis of randomised trials. *BMJ* 2003;326(7393):789.
37. Penninga L, Wettergren A, Wilson CH, et al. Antibody induction versus corticosteroid induction for liver transplant recipients. *Cochrane Database Syst Rev* 2014;5:CD010252.
38. Schmeding M, Sauer IM, Kiessling A, et al. Influence of basiliximab induction therapy on long term outcome after liver transplantation, a prospectively randomised trial. *Ann Transplant* 2007;12(3):15–21.
39. Turner AP, Knechtle SJ. Induction immunosuppression in liver transplantation: a review. *Transpl Int* 2013;26(7):673–683.
40. Neuhaus P, Clavien PA, Kittur D, et al. Improved treatment response with basiliximab immunoprophylaxis after liver transplantation: results from a double-blind randomized placebo-controlled trial. *Liver Transpl* 2002;8(2):132–142.
41. Waldmann H. Manipulation of T-cell responses with monoclonal antibodies. *Annu Rev Immunol* 1989;7:407–444.
42. Monaco AP, Wood ML, Russel PS. Studies on heterologous anti-lymphocyte serum in mice: III. Immunologic tolerance and chimerism produced across the H-2 locus with adult thymectomy and anti-lymphocyte serum. *Ann N Y Acad Sci* 1966;129:190.
43. Golshayan D, Buhler L, Lechler RI, et al. From current immunosuppressive strategies to clinical tolerance of allografts. *Transpl Int* 2007;20(1):12–24.
44. Knechtle SJ, Vargo D, Fechner J, et al. FN18-CRM9 immunotoxin promotes tolerance in primate renal allografts. *Transplantation* 1997;63(1):1–6.
45. Armstrong N, Buckley P, Oberley T, et al. Analysis of primate renal allografts after T-cell depletion with anti-CD3-CRM9. *Transplantation* 1998;66(1):5–13.
46. Kirk AD, Mannon RB, Kleiner DE, et al. Results from a human renal allograft tolerance trial evaluating T-cell depletion with alemtuzumab combined with deoxyspergualin. *Transplantation* 2005;80(8):1051–1059.
47. Kirk AD, Hale DA, Mannon RB, et al. Results from a human renal allograft tolerance trial evaluating the humanized CD52-specific monoclonal antibody alemtuzumab (CAMPATH-1H). *Transplantation* 2003;76(1):120–129.
48. Tzakis AG, Tryphonopoulos P, Kato T, et al. Preliminary experience with alemtuzumab (Campath-1H) and low-dose tacrolimus immunosuppression in adult liver transplantation. *Transplantation* 2004;77(8):1209–1214.
49. Vathsala A, Ona ET, Tan SY, et al. Randomized trial of alemtuzumab for prevention

of graft rejection and preservation of renal function after kidney transplantation. *Transplantation* 2005;80(6):765–774.

50. Watson CJ, Bradley JA, Friend PJ, et al. Alemtuzumab (CAMPATH 1H) induction therapy in cadaveric kidney transplantation–efficacy and safety at five years. *Am J Transplant* 2005;5(6):1347–1353.
51. Trzonkowski P, Zilvetti M, Friend P, et al. Recipient memory-like lymphocytes remain unresponsive to graft antigens after CAMPATH-1H induction with reduced maintenance immunosuppression. *Transplantation* 2006;82(10):1342–1351.
52. Morris PJ, Russell NK. Alemtuzumab (Campath-1H): a systematic review in organ transplantation. *Transplantation* 2006;81(10):1361–1367.
53. Barth RN, Janus CA, Lillesand CA, et al. Outcomes at 3 years of a prospective pilot study of Campath-1H and sirolimus immunosuppression for renal transplantation. *Transpl Int* 2006;19(11):885–892.
54. Brennan DC, Daller JA, Lake KD, et al. Rabbit antithymocyte globulin versus basiliximab in renal transplantation. *N Eng J Med* 2006;355(19):1967–1977.
55. Naujokat C, Berges C, Fuchs D, et al. Antithymocyte globulins suppress dendritic cell function by multiple mechanisms. *Transplantation* 2007;83(4):485–497.
56. Caillard S, Dharnidharka V, Agodoa L, et al. Posttransplant lymphoproliferative disorders after renal transplantation in the United States in era of modern immunosuppression. *Transplantation* 2005;80(9):1233–1243.
57. Hardinger KL. Rabbit antithymocyte globulin induction therapy in adult renal transplantation. *Pharmacotherapy* 2006;26(12):1771–1783.
58. Kean LS, Gangappa S, Pearson TC, et al. Transplant tolerance in non-human primates: progress, current challenges and unmet needs. *Am J Transplant* 2006;6(5 Pt 1):884–893.
59. Stahelin HF. The history of cyclosporin A (Sandimmune) revisited: another point of view. *Experientia* 1996;52(1):5–13.
60. Cheng M. Hartmann Stahelin (1925-2011) and the contested history of cyclosporin A. *Clin Transplant* 2013;27(3):326–329.
61. Fung JJ, Starzl TE. FK506 in solid organ transplantation. *Ther Drug Monit* 1995;17(6):592–595.
62. Warty V, Diven W, Cadoff E, et al. FK506: a novel immunosuppressive agent. Characteristics of binding and uptake by human lymphocytes. *Transplantation* 1988;46(3):453–455.
63. Zeevi A, Duquesnoy R, Eiras G, et al. In vitro immunosuppressive effects of FK506 in combination with other drugs. *Transplant Proc* 1988;20(1 suppl 1):220–222.
64. Kuo PC, Schroeder RA, eds. *Clinical Management of the Transplant Patient.* New York, NY: Oxford University Press; 2001.
65. Thomson AW, Turnquist HR, Raimondi G. Immunoregulatory functions of mTOR inhibition. *Nat Rev Immunol* 2009;9(5):324–337.

66. Akselband Y, Harding MW, Nelson PA. Rapamycin inhibits spontaneous and fibroblast growth factor beta-stimulated proliferation of endothelial cells and fibroblasts. *Transplant Proc* 1991;23(6):2833–2836.
67. Biecker E, De Gottardi A, Neef M, et al. Long-term treatment of bile duct-ligated rats with rapamycin (sirolimus) significantly attenuates liver fibrosis: analysis of the underlying mechanisms. *J Pharmacol Exp Ther* 2005;313(3):952–961.
68. McKenna GJ, Trotter JF, Klintmalm E, et al. Limiting hepatitis C virus progression in liver transplant recipients using sirolimus-based immunosuppression. *Am J Transplant* 2011;11(11):2379–2387.
69. Schena FP, Pascoe MD, Alberu J, et al. Conversion from calcineurin inhibitors to sirolimus maintenance therapy in renal allograft recipients: 24-month efficacy and safety results from the CONVERT trial. *Transplantation* 2009;87(2):233–242.
70. Abdelmalek MF, Humar A, Stickel F, et al. Sirolimus conversion regimen versus continued calcineurin inhibitors in liver allograft recipients: a randomized trial. *Am J Transplant* 2012;12(3):694–705.
71. DuBay D, Smith RJ, Qiu KG, et al. Sirolimus in liver transplant recipients with renal dysfunction offers no advantage over low-dose calcineurin inhibitor regimens. *Liver Transpl* 2008;14(5):651–659.
72. Saliba F, De Simone P, Nevens F, et al. Renal function at two years in liver transplant patients receiving everolimus: results of a randomized, multicenter study. *Am J Transplant* 2013;13(7):1734–1745.
73. De Simone P, Nevens F, De Carlis L, et al. Everolimus with reduced tacrolimus improves renal function in de novo liver transplant recipients: a randomized controlled trial. *Am J Transplant* 2012;12(11):3008–3020.
74. Saliba F, Dharancy S, Lorho R, et al. Conversion to everolimus in maintenance liver transplant patients: a multicenter, retrospective analysis. *Liver Transpl* 2011;17(8):905–913.
75. Knight RJ, Villa M, Laskey R, et al. Risk factors for impaired wound healing in sirolimus-treated renal transplant recipients. *Clin Transplant* 2007;21(4):460–465.
76. Schaffer M, Schier R, Napirei M, et al. Sirolimus impairs wound healing. *Langenbecks Arch Surg* 2007;392(3):297–303.
77. Grim SA, Slover CM, Sankary H, et al. Risk factors for wound healing complications in sirolimus-treated renal transplant recipients. *Transplant Proc* 2006;38(10):3520–3523.
78. Kuppahally S, Al-Khaldi A, Weisshaar D, et al. Wound healing complications with de novo sirolimus versus mycophenolate mofetil-based regimen in cardiac transplant recipients. *Am J Transplant* 2006;6(5 Pt 1):986–992.
79. Flechner SM, Zhou L, Derweesh I, et al. The impact of sirolimus, mycophenolate mofetil, cyclosporine, azathioprine, and steroids on wound healing in 513 kidney-transplant recipients. *Transplantation* 2003;76(12):1729–1734.

80. Chua AP, Budev M, Mehta AC. Late airway anastomotic dehiscence associated with sirolimus and migratory staples in a lung transplant recipient. *Transplantation* 2010;89(10):1293–1294.
81. Murakami N, Riella LV, Funakoshi T. Risk of metabolic complications in kidney transplantation after conversion to mTOR inhibitor: a systematic review and meta-analysis. *Am J Transplant* 2014;14(10):2317–2327.
82. Kwong YL. Azathioprine: association with therapy-related myelodysplastic syndrome and acute myeloid leukemia. *J Rheumatol* 2010;37(3):485–490.
83. Perrett CM, Harwood CA, McGregor JM, et al. Carcinogenic mechanisms related to immunosuppressive therapy. *Cancer Treat Res* 2009;146:123–132.
84. Nguyen T, Vacek PM, O'Neill P, et al. Mutagenicity and potential carcinogenicity of thiopurine treatment in patients with inflammatory bowel disease. *Cancer Res* 2009;69(17):7004–7012.
85. Karran P, Attard N. Thiopurines in current medical practice: molecular mechanisms and contributions to therapy-related cancer. *Nat Rev Cancer* 2008;8(1):24–36.
86. Gerosa M, Meroni PL, Cimaz R. Safety considerations when prescribing immunosuppression medication to pregnant women. *Expert Opin Drug Saf* 2014;13:1–9.
87. Vos R, Ruttens D, Verleden SE, et al. Pregnancy after heart and lung transplantation. *Best Pract Res Clin Obstet Gynaecol* 2014;28(8):1146–1162.
88. Rostas S, Kim M, Gabardi S. Risk evaluation and mitigation strategies: a focus on the mycophenolic acid preparations. *Prog Transplant* 2014;24(1):33–36.
89. Hou S. Pregnancy in renal transplant recipients. *Adv Chronic Kidney Dis* 2013;20(3):253–259.
90. Kim M, Rostas S, Gabardi S. Mycophenolate fetal toxicity and risk evaluation and mitigation strategies. *Am J Transplant* 2013;13(6):1383–1389.
91. Pascual J, Zamora J, Galeano C, et al. Steroid avoidance or withdrawal for kidney transplant recipients. *Cochrane Database Syst Rev* 2009;(1):CD005632.
92. Montagnino G, Sandrini S, Iorio B, et al. A randomized exploratory trial of steroid avoidance in renal transplant patients treated with everolimus and low-dose cyclosporine. *Nephrol Dial Transplant* 2008;23(2):707–714.
93. Heilman RL, Mazur MJ, Reddy KS, et al. Steroid avoidance immunosuppression in low-risk kidney transplant recipients. *Transplant Proc* 2005;37(4):1785–1788.
94. Hariharan S, Johnson CP, Bresnahan BA, et al. Improved graft survival after renal transplantation in the United States, 1988 to 1996. *N Eng J Med* 2000;342(9):605–612.
95. Heeger PS, Dinavahi R. Transplant immunology for non-immunologist. *Mt Sinai J Med* 2012;79(3):376–387.
96. Vesley D, Norlien KG, Nelson B, et al. Significant factors in the disinfection and sterilization of flexible endoscopes. *Am J Infect Control* 1992;20(6):291–300.

97. Solez K, Racusen LC. The Banff classification revisited. *Kidney Int* 2013;83(2):201–206.
98. Moseley EL, Atkinson C, Sharples LD, et al. Deposition of C4d and C3d in cardiac transplants: a factor in the development of coronary artery vasculopathy. *J Heart Lung Transplant* 2010;29(4):417–423.
99. Warnecke G, Bushell A, Nadig SN, et al. Regulation of transplant arteriosclerosis by CD25 + CD4 + T cells generated to alloantigen in vivo. *Transplantation* 2007;83(11):1459–1465.
100. Nadig SN, Wieckiewicz J, Wu DC, et al. In vivo prevention of transplant arteriosclerosis by ex vivo-expanded human regulatory T cells. *Nat Med* 2010;16(7):809–813.
101. Pober JS, Jane-wit D, Qin L, et al. Interacting mechanisms in the pathogenesis of cardiac allograft vasculopathy. *Arterioscler Thromb Vasc Biol* 2014;34(8):1609–1614.
102. Lee RS, Yamada K, Houser SL, et al. Indirect recognition of allopeptides promotes the development of cardiac allograft vasculopathy. *Proc Natl Acad Sci U S A* 2001;98(6):3276–3281.
103. Hillebrands JL, Rozing J. Chronic transplant dysfunction and transplant arteriosclerosis: new insights into underlying mechanisms. *Expert Rev Mol Med* 2003;5(2):1–23.
104. Campbell P. Clinical relevance of human leukocyte antigen antibodies in liver, heart, lung and intestine transplantation. *Curr Opin Organ Transplant* 2013;18(4):463–469.
105. Hidalgo LG, Sellares J, Sis B, et al. Interpreting NK cell transcripts versus T cell transcripts in renal transplant biopsies. *Am J Transplant* 2012;12(5):1180–1191.
106. Sis B, Halloran PF. Endothelial transcripts uncover a previously unknown phenotype: C4d-negative antibody-mediated rejection. *Curr Opin Organ Transplant* 2010;15(1):42–48.
107. Haas M, Sis B, Racusen LC, et al. Banff 2013 meeting report: inclusion of c4d-negative antibody-mediated rejection and antibody-associated arterial lesions. *Am J Transplant* 2014;14(2):272–283.
108. O'Leary JG, Michelle Shiller S, Bellamy C, et al. Acute liver allograft antibody-mediated rejection: an inter-institutional study of significant histopathological features. *Liver Transplant* 2014;20(10):1244–1255.
109. Djamali A, Kaufman DB, Ellis TM, et al. Diagnosis and management of antibody-mediated rejection: current status and novel approaches. *Am J Transplant* 2014;14(2):255–271.
110. Ojo AO, Held PJ, Port FK, et al. Chronic renal failure after transplantation of a nonrenal organ. *N Eng J Med* 2003;349(10):931–940.
111. Goldfarb DA. Expression of TGF-beta and fibrogenic genes in transplant recipients with tacrolimus and cyclosporine nephrotoxicity. *J Urol* 2003;169(6):2436–2437.
112. Sharma P, Goodrich NP, Schaubel DE, et al. Patient-specific prediction of ESRD after

liver transplantation. *J Am Soc Nephrol* 2013;24(12):2045–2052.

113. Sharma P, Schaubel DE, Guidinger MK, et al. Impact of MELD-based allocation on end-stage renal disease after liver transplantation. *Am J Transplant* 2011;11(11):2372–2378.
114. Sharma P, Welch K, Eikstadt R, et al. Renal outcomes after liver transplantation in the model for end-stage liver disease era. *Liver Transpl* 2009;15(9):1142–1148.
115. Sharma P, Goodrich NP, Zhang M, et al. Short-term pretransplant renal replacement therapy and renal nonrecovery after liver transplantation alone. *Clin J Am Soc Nephrol* 2013;8(7):1135–1142.
116. Fishman JA. Infection in solid-organ transplant recipients. *N Eng J Med* 2007;357(25):2601–2614.
117. Theodoropoulos N, Jaramillo A, Ladner DP, et al. Deceased organ donor screening for HIV, hepatitis B, and hepatitis C viruses: a survey of organ procurement organization practices. *Am J Transplant* 2013;13(8):2186–2190.
118. Engels EA, Pfeiffer RM, Fraumeni JF Jr, et al. Spectrum of cancer risk among US solid organ transplant recipients. *JAMA* 2011;306(17):1891–1901.
119. Krynitz B, Edgren G, Lindelof B, et al. Risk of skin cancer and other malignancies in kidney, liver, heart and lung transplant recipients 1970 to 2008–a Swedish population-based study. *Int J Cancer* 2013;132(6):1429–1438.
120. Manilay JO, Pearson DA, Sergio JJ, et al. Intrathymic deletion of alloreactive T cells in mixed bone marrow chimeras prepared with a nonmyeloablative conditioning regimen. *Transplantation* 1998;66(1):96–102.
121. Getts DR, Shankar S, Chastain EM, et al. Current landscape for T-cell targeting in autoimmunity and transplantation. *Immunotherapy* 2011;3(7):853–870.
122. Horton PJ, Hawthorne WJ, Walters S, et al. Tolerance induction in a large-animal model using total lymphoid irradiation and intrathymic bone marrow. *Transplantation* 2008;86(12):1830–1836.
123. Posselt AM, Barker CF, Tomaszewski JE, et al. Induction of donor-specific unresponsiveness by intrathymic islet transplantation. *Science* 1990;249(4974):1293–1295.
124. Hosseini H, Oh DY, Chan ST, et al. Non-myeloablative transplantation of bone marrow expressing self-antigen establishes peripheral tolerance and completely prevents autoimmunity in mice. *Gene Ther* 2012;19(11):1075–1084.
125. Jones ND, Fluck NC, Mellor AL, et al. The induction of transplantation tolerance by intrathymic (i.t.) delivery of alloantigen: a critical relationship between i.t. deletion, thymic export of new T cells and the timing of transplantation. *Int Immunol* 1998;10(11):1637–1646.
126. Oluwole SF, Chowdhury NC, Ingram M, et al. Mechanism of acquired thymic tolerance induced by a single major histocompatibility complex class I peptide with the dominant epitope: differential analysis of regulatory cytokines in the lymphoid

and intragraft compartments. *Transplantation* 1999;68(3):418–429.

127. Turvey SE, Hara M, Morris PJ, et al. Mechanisms of tolerance induction after intrathymic islet injection: determination of the fate of alloreactive thymocytes. *Transplantation* 1999;68(1):30–39.
128. Sakaguchi S, Sakaguchi N, Asano M, et al. Immunologic self-tolerance maintained by activated T cells expressing IL-2 receptor alpha-chains (CD25). Breakdown of a single mechanism of self-tolerance causes various autoimmune diseases. *J Immunol* 1995;155(3):1151–1164.
129. Sakaguchi S. Naturally arising CD4+ regulatory t cells for immunologic self-tolerance and negative control of immune responses. *Annu Rev Immunol* 2004;22:531–562.
130. Wood KJ, Bushell A, Hester J. Regulatory immune cells in transplantation. *Nat Rev Immunol* 2012;12(6):417–430.
131. Bacchetta R, Passerini L, Gambineri E, et al. Defective regulatory and effector T cell functions in patients with FOXP3 mutations. *J Clin Invest* 2006;116(6):1713–1722.
132. Ng WF, Duggan PJ, Ponchel F, et al. Human CD4(+)CD25(+) cells: a naturally occurring population of regulatory T cells. *Blood* 2001;98(9):2736–2744.
133. Baecher-Allan C, Brown JA, Freeman GJ, et al. CD4+CD25high regulatory cells in human peripheral blood. *J Immunol* 2001;167(3):1245–1253.
134. Wildin RS, Freitas A. IPEX and FOXP3: clinical and research perspectives. *J Autoimmun* 2005;25(suppl):56–62.
135. Wood KJ, Sakaguchi S. Regulatory T cells in transplantation tolerance. *Nat Rev Immunol* 2003;3(3):199–210.
136. Juvet SC, Whatcott AG, Bushell AR, et al. Harnessing regulatory T cells for clinical use in transplantation: the end of the beginning. *Am J Transplant* 2014;14(4):750–763.
137. Hester J, Schiopu A, Nadig SN, et al. Low-dose rapamycin treatment increases the ability of human regulatory T cells to inhibit transplant arteriosclerosis in vivo. *Am J Transplant* 2012;12(8):2008–2016.
138. Battaglia M, Stabilini A, Roncarolo MG. Rapamycin selectively expands CD4+CD25+FoxP3 +regulatory T cells. *Blood* 2005;105(12):4743–4748.
139. Hara M, Kingsley CI, Niimi M, et al. IL-10 is required for regulatory T cells to mediate tolerance to alloantigens in vivo. *J Immunol* 2001;166(6):3789–3796.
140. Kretschmer K, Apostolou I, Hawiger D, et al. Inducing and expanding regulatory T cell populations by foreign antigen. *Nat Immunol* 2005;6(12):1219–1227.
141. Karim M, Kingsley CI, Bushell AR, et al. Alloantigen-induced CD25+CD4+ regulatory T cells can develop in vivo from CD25-CD4+ precursors in a thymus-independent process. *J Immunol* 2004;172(2):923–928.
142. Bishop GA, Sun J, Sheil AG, et al. High-dose/activation-associated tolerance: a mechanism for allograft tolerance. *Transplantation* 1997;64(10):1377–1382.

143. Sayegh MH, Fine NA, Smith JL, et al. Immunologic tolerance to renal allografts after bone marrow transplants from the same donors. *Ann Intern Med* 1991;114(11):954–955.
144. Jacobsen N, Taaning E, Ladefoged J, et al. Tolerance to an HLA-B,DR disparate kidney allograft after bone-marrow transplantation from same donor. *Lancet* 1994;343(8900):800.
145. Sorof JM, Koerper MA, Portale AA, et al. Renal transplantation without chronic immunosuppression after T cell-depleted, HLA-mismatched bone marrow transplantation. *Transplantation* 1995;59(11):1633–1635.
146. Wood K, Sachs DH. Chimerism and transplantation tolerance: cause and effect. *Immunol Today* 1996;17(12):584–587; discussion 8.
147. Monaco AP. Prospects and strategies for clinical tolerance. *Transplant Proc* 2004;36(1):227–231.
148. Monaco AP. The beginning of clinical tolerance in solid organ allografts. *Exp Clin Transplant* 2004;2(1):153–161.
149. Slavin S, Strober S, Fuks Z, et al. Induction of specific tissue transplantation tolerance using fractionated total lymphoid irradiation in adult mice: long-term survival of allogeneic bone marrow and skin grafts. *J Exp Med* 1977;146(1):34–48.
150. Myburgh JA, Smit JA, Stark JH, et al. Total lymphoid irradiation in kidney and liver transplantation in the baboon: prolonged graft survival and alterations in T cell subsets with low cumulative dose regimens. *J Immunol* 1984;132(2):1019–1025.
151. Wekerle T, Sykes M. Induction of tolerance. *Surgery* 2004;135(4):359–364.
152. Wekerle T, Kurtz J, Ito H, et al. Allogeneic bone marrow transplantation with co-stimulatory blockade induces macrochimerism and tolerance without cytoreductive host treatment. *Nat Med* 2000;6(4):464–469.
153. Guo Z, Wang J, Dong Y, et al. Long-term survival of intestinal allografts induced by costimulation blockade, busulfan and donor bone marrow infusion. *Am J Transplant* 2003;3(9):1091–1098.
154. Huang CA, Fuchimoto Y, Scheier-Dolberg R, et al. Stable mixed chimerism and tolerance using a nonmyeloablative preparative regimen in a large-animal model. *J Clin Invest* 2000;105(2):173–181.
155. Adams AB, Durham MM, Kean L, et al. Costimulation blockade, busulfan, and bone marrow promote titratable macrochimerism, induce transplantation tolerance, and correct genetic hemoglobinopathies with minimal myelosuppression. *J Immunol* 2001;167(2):1103–1111.
156. Ebrahimi A, Rahim F. Recent immunomodulatory strategies in transplantation. *Immunol Invest* 2014;43(8):829–837.
157. Oh W, Kim DS, Yang YS, et al. Immunological properties of umbilical cord blood-derived mesenchymal stromal cells. *Cell Immunol* 2008;251(2):116–123.
158. Chinnadurai R, Copland IB, Patel SR, et al. IDO-independent suppression of T cell

effector function by IFN-gamma-licensed human mesenchymal stromal cells. *J Immunol* 2014;192(4):1491–1501.

159. Takahashi T, Tibell A, Ljung K, et al. Multipotent mesenchymal stromal cells synergize with costimulation blockade in the inhibition of immune responses and the induction of Foxp3+ regulatory T cells. *Stem Cells Transl Med* 2014;3(12):1484–1494.

Chapter 35

Organ Procurement and Preservation

Michael J. Englesbe

Key Points

1. *Organ donation:* Efforts to expand organ donation are critical to save lives. Organ donation must be done within a regulated system that is deeply rooted in ethical standards of care.
2. *Organ selection:* A careful balance must be maintained between using every viable donor organ and assuring each patient a chance of a successful posttransplant outcome.
3. *Organ procurement techniques:* The organ procurement operation requires coordination of a multidisciplinary team including surgeons, anesthesiologists, nurses, and organ perfusion technicians. Careful procurement and perfusion techniques are mandatory for successful transplant recipient outcomes.
4. *Applied sciences of organ preservation:* Organ procurement and storage results in significant alterations in the homeostasis of the organ. The degree of organ preservation injury contributes to the degree to which normal organ function is delayed or prevented following transplantation. Novel organ preservation techniques aim to mitigate organ preservation injury.

Organ transplantation has become a standard of care for end-organ failure. For the majority of recipients, organ transplantation is the only life-saving therapy available. With improvements in outcomes and expansion of indications for both donation and transplantation, the demand for transplantation continues to expand. As of August 2014, there were 123,256 patients waiting for an organ transplant in the United States and 6,315 patients died while waiting for a life-saving organ in the previous year.[1–3] In certain regions of the United States, wait times for kidney transplantation exceeds 10 years.

The successful procurement and preservation of these life-saving organs is critical.

ORGAN DONATION

Living Donation

Considering high wait-list mortality and long wait times, early transplant for patients with end-organ failure has significant benefits. For example, patients who receive a kidney transplant prior to initiating dialysis (a preemptive transplant) have a lower rate of allograft failure and mortality and a higher quality of life compared to patients who receive a transplant after beginning dialysis.[4,5] Living donation facilitates early transplantation and these recipients have better outcomes. The 5-year graft survival of patients receiving a living donor transplant is 79.8% versus 66.6% for recipients of deceased donor transplants.[2] In the United States, 25.6% of liver and kidney transplants are done with living donor organs, though there is a trend toward less living organ donation, likely related to mounting concerns about donor safety (Fig. 35-1).[2] In certain cultures, deceased donation is not well accepted and living donation is the primary source of life-saving organs.

In kidney transplantation, living donation is preferable for most recipients. Efforts should be made to encourage potential recipients to secure a living donor organ. Significant advances have facilitated living donation. These include the use of social media to link potential donors with recipients and paired exchange transplant programs. In a paired exchange, a potential recipient secures a willing donor. If this pair is incompatible (blood type or recipient–donor antibody sensitization), then organs are exchanged with another donor–recipient pair (Fig. 35-2). Criteria for living donation are strict. Living donors must be excellent surgical candidates with minimal comorbidities (medical and psychiatric) and must decide upon donation autonomously.

Deceased Donation

In 2013 in the United States, the majority (79.3%) of organs used for transplantation came from deceased donors.[1] In general, organ donors are brain-dead, previously in good health, and free of life-threatening communicable disease. Permission for organ donation is obtained from the patient's next of kin prior to organ donation.

Considering the strong demand for life-saving organs, regulations are necessary to assure fair and equitable distribution across populations and to assure that every suitable organ is procured from every organ donor. Organ donation must be managed by a not-for-profit entity (organ procurement organization or OPO) that is not directly involved in the care of the patient. The OPO as well as the transplant surgical team must be separated from the declaration of death process. Patients who are not brain dead may donate following cessation of cardiac function; this is known as donation after cardiac death or DCD donation.

Declaration of Death

1 In the United States, a patient is considered dead when they have irreversible cessation of brain function (brain dead) or irreversible cessation of circulatory and respiratory functions. The definition of brain death is established locally by hospitals using rules that conform to the *Harvard Criteria.*[6] Established criteria for brain death are detailed in Table 35-1. The caring physician must rule out potentially reversible causes of coma including hypothermia, shock, sedation, or pharmacologic paralysis. Once the clinical diagnosis of brain death is made, a confirmatory test must be completed before organ donation. Most frequently, nuclear scintigraphy is used to confirm brain death. This test can be done at the bedside, avoiding the transport of the potentially unstable brain-dead patient through the hospital.

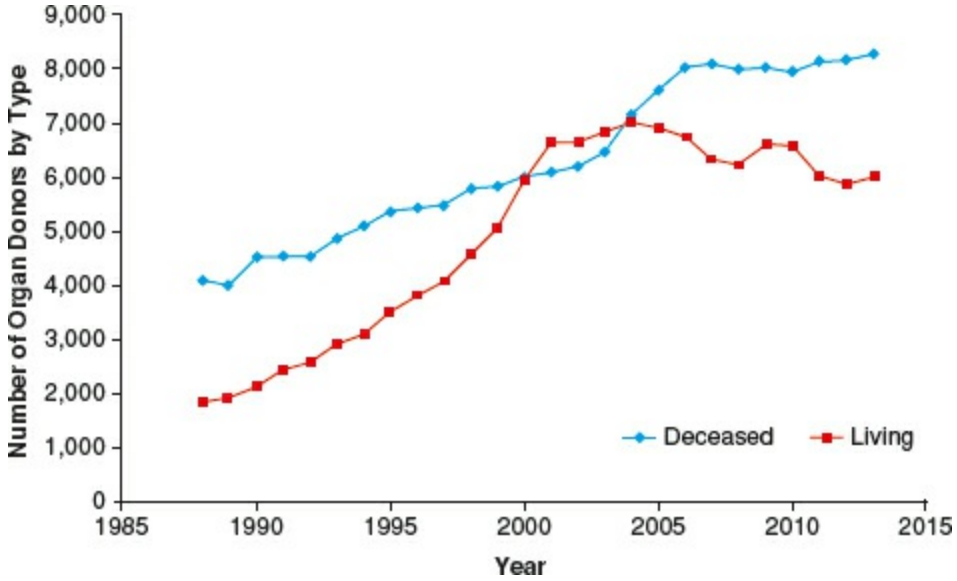

Figure 35-1. The number of living and deceased organ donors in the United States.[2]

In response to the shortage of donor organs, advances have been made to enable the utilization of organs following cardiac death.[7] These patients have a devastating

neurologic injury but do not fulfill criteria for brain death. Family members who intend to withdrawal support (inotropes and mechanical ventilation) may wish to consider DCD donation. Following informed consent, ventilator and circulatory support are withdrawn. The patient is declared dead by the caring physician upon cessation of circulation. It is critical that members of the transplant teams are not involved in the process of declaration of death. Each hospital establishes policies and protocols for procurement of DCD donors. In general, the patient is given systemic anticoagulation prior to withdrawal. After the patient is declared dead, 5 additional minutes are usually allowed to elapse prior to organ procurement surgery. If the patient does not reach criteria for death within 60 to 90 minutes, kidney recovery is not pursued. For liver and lung procurement, the maximal acceptable agonal time (time from withdraw to death) is approximately 30 minutes. The transplant surgeon rapidly recovers the organs using a similar technique as brain-dead donor procurement. DCD organs have acceptable but inferior outcomes.[7]

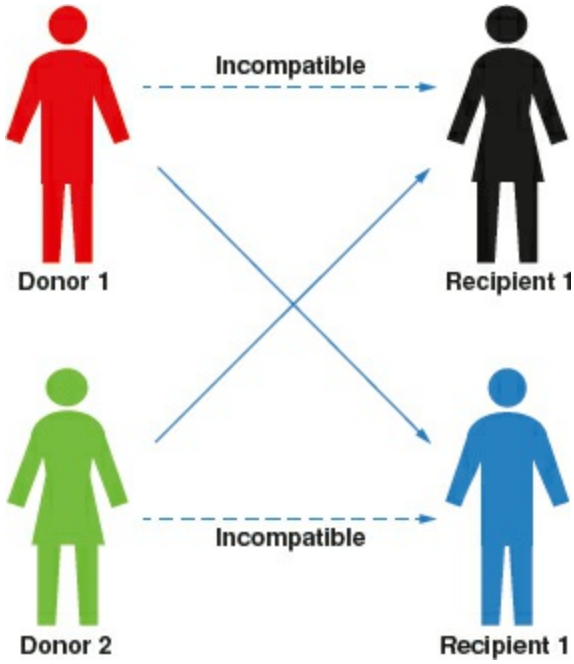

Figure 35-2. Schematic for paired exchange kidney transplantation.

Consent for Donation

Effective efforts to augment organ donation have focused on increasing organ donor registration, usually associated with automobile licensing. A signed and witnessed organ donor card is sufficient indication of the decedent's wishes to allow organ donation. Despite this declaration, the family's consent is routinely obtained even when a valid organ donor card is present. Many hospitals have specific team members who seek consent for donation. It is critical that this request is done with great care. Explanation of the organ donation process by an empathetic party not directly involved in the care of the deceased patient yields the highest consent rates.

ORGAN SELECTION

2 Organ quality is closely linked to recipient outcomes. A careful balance must be maintained between using every viable donor organ and assuring each patient a chance of a successful posttransplant outcome. The surgeon should assess general health issues of the donor as well as organ-specific function. Donor age is also relevant, as older organs have inferior long-term outcomes and thus are better suited for older recipients.[2]

Donor History of Cancer: Potential organ donors should be cured of cancer. Transmission of cancer to the organ recipient results in rapid death related to cancer progression in the setting of severe illness and systemic immunosuppression. Criteria and guidelines for suitability for donation among cancer survivors are well detailed in the literature.[8,9] Donors with a history of melanoma, leukemia, lymphoma, or small-cell carcinoma are excluded from donation. For most major cancers associated with systemic progression, organ donors should be disease free for 5 years. Some donor cancers have been shown to have minimal risk of transmission to the recipient. These include nonmelanoma skin cancers without nodal involvement, small renal cell and prostate cancers, and many intracranial malignancies that have not recently had intracranial surgical intervention.

Table 35-1 Criteria for Brain Death[6]

All reversible causes of coma excluded
Loss of all function of the entire brain confirmed ■ No pupillary light reflex ■ No corneal reflex ■ No oculocephalic reflex ■ No spontaneous respirations
Confirmatory diagnostic tests (one must be completed) ■ Electroencephalogram (EEG) with electrocerebral silence ■ No blood flow to the brain on nuclear scintigraphy ■ No flow on four vessel cerebral angiogram

Donor History of Infectious Disease: All donors are screened for communicable disease. The predonation work-up is detailed in Table 35-2. Many donors have been critically ill for many days prior to donation and hospital acquired infections are common. Donors with a recent history of systemic bacteremia are acceptable while donors with fungemia are not. The transplant center needs to follow donor cultures and make sure that the recipient is appropriately treated.

Donor transmission of HIV, hepatitis B, or hepatitis C can lead to disastrous outcomes in the recipient. Donor history of an ongoing viral infection must be carefully assessed. All donors are tested for an antibody response to HIV. Nucleic acid testing (NAT) for HIV is also done in most cases. NAT testing reduces the “window period” for false-negative test results.[10] Recipients with a previous history of these viruses can receive organs that are infected with them. For example, HIV-positive patients on the waitlist can receive HIV-positive donor organs. Similarly, hepatitis C-positive donor organs without significant liver disease have excellent outcomes in hepatitis C-positive liver transplant

recipients.[11] With advances in the viral therapies, many hepatitis C-positive patients will no longer have systemic viremia, though they remain antibody positive for hepatitis C. These individuals should not receive hepatitis C-positive organs. Similarly, the HCV viral genotype of the recipient should be considered when deciding to accept a HCV-positive donor organ. Organs from donors with the previous history of hepatitis B infection can transmit the infection to recipients. These organs should be used in recipients who have been immunized against hepatitis B. In liver and kidney transplantation, donors who test positive for hepatitis B core antibody but negative surface antigen can be used in most recipients with excellent results.[12] The recipient does require long-term antiviral therapy.

Other important infectious pathogens can be transmitted during organ transplantation.[9] Many of these are endemic to specific communities. A cause of death that is suspicious for a communicable disease (such as rabies, encephalitis, etc.) is a red flag against organ donation. The transplant surgeon should discuss infectious disease issues with a transplant infectious disease expert prior to accepting any questionable organs.

Table 35-2 Standard Organ Donor Work-up

- Consent for donation
- Confirmation of brain death in brain-dead donors
- Complete history and physical
- Determination of "CDC high-risk" status related to social history
- Comprehensive and serial laboratory evaluation including frequent blood gases, renal function tests, and liver function tests
- Toxicology screen
- Cultures
- Details of hemodynamics and pressor requirements
- Serologies – Anti-HBcAb, Anti-HCV, Anti-HIV I/II, HIV NAT, Anti-HTLV I/II, HBsAg, Anti-CMV, RPR/VDRL, HBsAb, EBV (IgG), EBV (IgM)
- Chest X-ray
- Echocardiogram and EKG
- Bronchoscopy
- Blood gas on 100% O_2
- Liver biopsy (selectively)
- Cardiac catheterization (selectively)

Organ-Specific Issues

In addition to a global assessment of the donor, each organ has specific considerations.

- **Kidney** – Primary considerations include donor age, history of hypertension, diabetes, cardiovascular disease, or renal dysfunction. Patients with acute renal failure are suitable donors, though such grafts are more frequently associated with delayed graft function (DGF). Renal biopsy to assess for glomerular fibrosis can aid in graft selection.[13] High circulatory resistance while on organ preservation pump is associated with inferior outcomes. Kidneys with significant arterial plague or multiple arteries can be technically more complex to transplant, but rarely do these issues preclude use of the allograft. Efforts should be made to keep the cold ischemia time less than 24 hours.
- **Liver** – Primary considerations include donor age and history of liver disease. Donor elevations in transaminases or bilirubin should be considered; preterminal liver injury is associated with primary nonfunction of the allograft. Allograft size is an important consideration, especially in smaller recipients. A preprocurement liver biopsy is frequently available on patients with risk factors for liver disease. Greater than 30% macrosteatosis and/or parenchymal fibrosis may preclude transplantation. More than a grade 2 traumatic liver laceration generally precludes transplantation. Efforts should be made to keep the cold ischemia time less than 12 hours.
- **Pancreas** – Selection of pancreas allografts must be done with care since recipient complications and allograft failure are relatively common events. Donor age should be less 40 and donors should be free of major comorbidities and be hemodynamically stable. The pancreas should be soft to palpation (a firm pancreas suggests previous injury) without significant fat infiltration. Donor iliac vessels used for the vascular conduit should be free of atherosclerotic disease. Pancreatic branches from the splenic artery and superior mesenteric artery must be intact (Fig. 35-3). Injury to pancreatic parenchyma precludes use of the organ. Efforts should be made to keep the cold ischemia time less than 12 hours.
- **Heart** – Primary considerations include donor age and history of cardiovascular disease. Predonation work-up includes an echocardiogram; significant structural cardiac disease or abnormal cardiac function precludes donation. Potential donors with risk factors for cardiac disease undergo cardiac catheterization to rule out significant coronary artery disease. The relationship between the donor and recipient body size should be considered. Prior to procurement, the procuring surgeon should examine the beating heart for size and function before the recipient surgeon begins the heart transplant operation. Efforts should be made to keep the cold ischemia time less than 4 hours.
- **Lungs** – Primary considerations include donor age, history of smoking, history of pulmonary disease, and events surrounding death (i.e., aspiration or accident with chest injury). Predonation work-up includes chest X-rays, arterial blood gases, CT scan, and a bronchoscopy with airway cultures. Lung contusions or pneumonia may preclude transplantation. Donors are ventilated on 100% oxygen to assure high blood oxygen levels. The relationship between the donor and recipient body size are considered. At the time of procurement, the donor surgeon performs a repeat bronchoscopy and a

median sternotomy to physically inspect the lungs for damage, infection, or underlying lung disease. Efforts should be made to keep the cold ischemia time less than 6 hours.

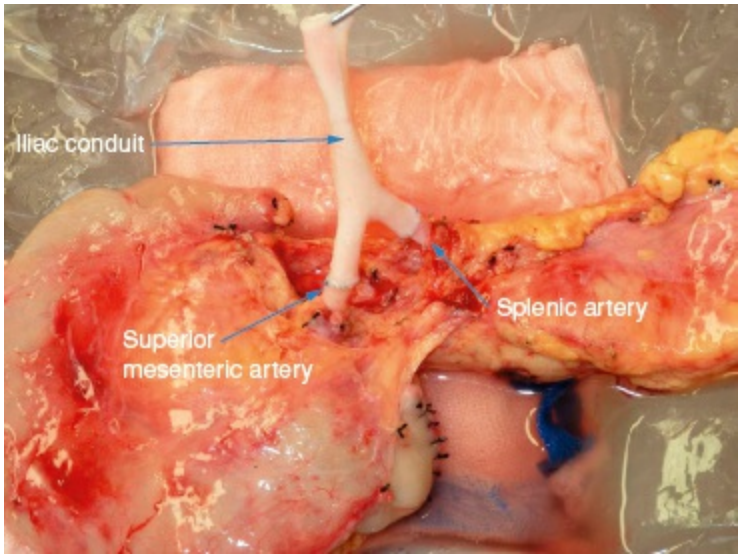

Figure 35-3. Donor superior mesenteric artery and splenic artery with arterial conduit created from the donor iliac artery.

THE ORGAN PROCUREMENT OPERATION

3 The organ procurement operation requires coordination of a multidisciplinary team including surgeons, anesthesiologists, nurses, and organ perfusion technicians. By convention, transplant centers send their own teams to procure the heart, liver, lungs, and pancreas. The kidneys are procured by one of the other abdominal teams and are shipped to the appropriate transplant center. In most cases, procurement teams travel to the hospital where the donor is admitted; both air and ground transportation is usually required. In some regions, the donors are transported to a centralized procurement facility. This has been shown to reduce costs, travel time, and cold ischemia times.[14] The recipient liver, lung, and heart operations usually begin before organs return to the transplant center; thus continuous communication and coordination are needed between transplant centers and the procurement teams.

Upon arrival to the donor operating room, the transplant surgeon must check the appropriate documentation. This includes identification of the donor, consent for donation, and the donor medical chart. The surgery teams should discuss hemodynamic and anticoagulation management with the anesthesia team.

The surgeons should tuck the arms to facilitate four surgeons being able to work on the donor simultaneously. After induction of general anesthesia, an incision is made from the sternal notch to the symphysis pubis and the abdomen and sternum are opened (Fig. 35-4). Even if the thoracic organs are not being procured, a median sternotomy facilitates exposure for the abdominal operation. The key organ-specific steps are detailed below.

Liver Procurement: The right colon and small bowel are mobilized to expose the entirety of the retroperitoneum, including the intrahepatic vena cava and the aorta. The superior mesenteric artery is encircled at the root of the mesentery close to the aorta. The gallbladder is opened and all of the bile is removed. The left lateral segment of the liver is mobilized and the pars flaccida is inspected for a replaced or accessory left hepatic artery. If an artery is noted, the surgeon must carefully dissect all of the branches from the proximal left gastric artery, staying close to the lesser curvature of the stomach. Failure to properly manage these small branches will result in a postreperfusion hematoma around this artery, potentially causing arterial thrombosis. The porta hepatis is palpated to assess the location of the arteries. If present, a replaced right hepatic artery is noted right and posterior to the common bile duct.

The aorta is dissected at its bifurcation to facilitate proximal and distal control (Fig. 35-5). The surgeon should assure that there are no renal arteries from the distal aorta or iliac arteries. If there are, the cannulation should occur distal to these arteries to make sure they are flushed. The supraceliac aorta is exposed by retracting the caudate lobe and the left lateral segment of the liver to the right, grasping the crux of the diaphragm, and dividing it with electrocautery. Circumferential control of the supraceliac aorta is not needed, though sufficient exposure for occlusive clamping is a necessity.

When all teams are ready, the donor is given systemic heparin and the aorta is cannulated (Fig. 35-6). The supraceliac aorta is clamped and the abdominal organs are flushed with cold preservation solution. The inferior vena cava is incised in the chest to

drain the perfusate and blood. The liver is surrounded with ice and flushed with approximately 5 L of preservation solution.

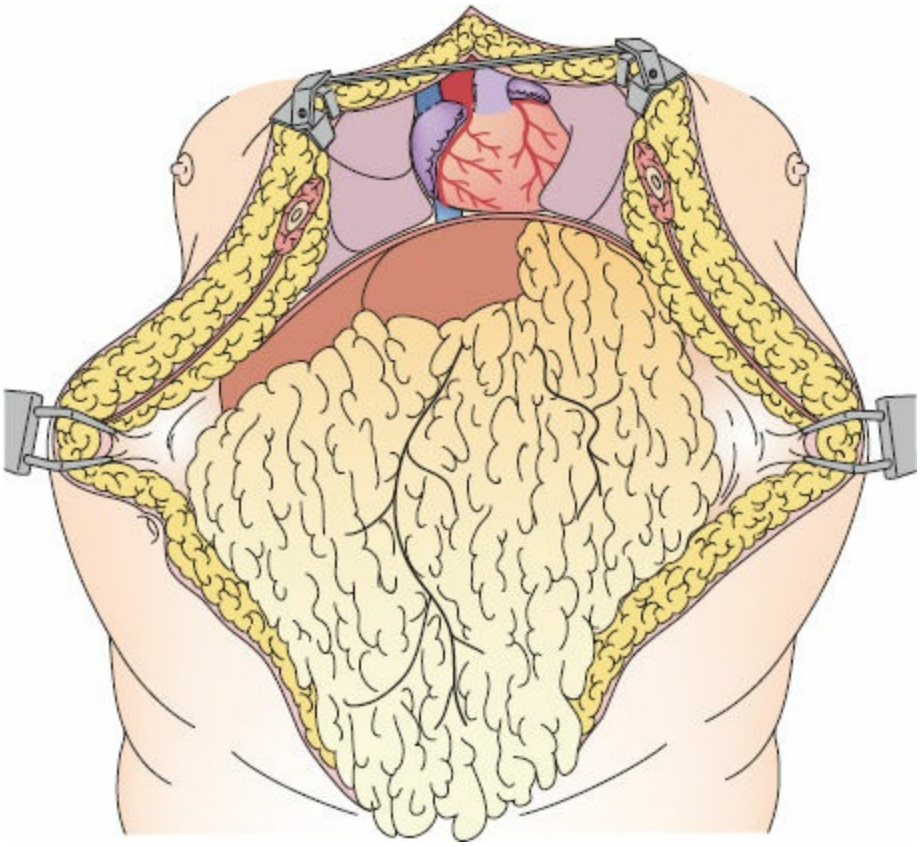

Figure 35-4. Exposure for the organ procurement operation.

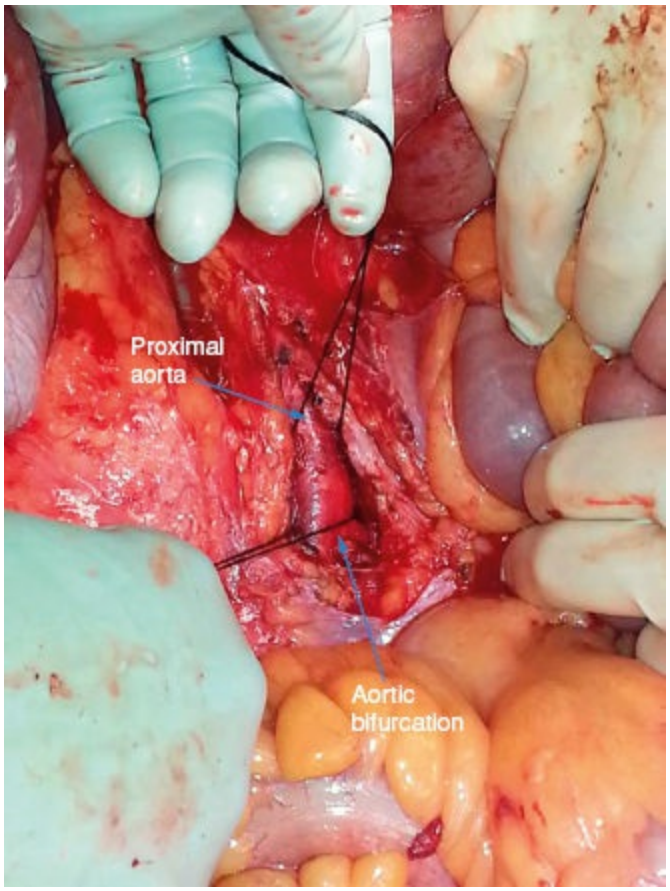

Figure 35-5. Exposure of the distal abdominal aorta in preparation for aortic cannulation.

Once the flush is complete, the diaphragm is divided leaving a cuff around the suprahepatic inferior vena cava. The infrahepatic inferior vena cava is divided approximately 1 cm above the renal veins. The bile duct and portal vein are divided in the porta (if the pancreas is being used) or the entire head of the pancreas is excised, assuring maximal length of the portal vein. The superior mesenteric artery and the aorta are divided. The surgeon must be sure to not divide the aorta below the orifice of the superior mesenteric artery; the renal arteries are close to the superior mesenteric artery origin and easy to injure. The liver is removed and the portal vein and bile duct are flushed on the back table. Tissue surrounding the liver is removed on the back table to prepare the organ for transplantation.

Arterial anatomy has many variations and, failure to identify variation may jeopardize the transplant operation (Fig. 35-7). On occasion, dissection of the replaced right hepatic artery can jeopardize the pancreas allograft, but usually both teams can agree to an acceptable dissection plane. There are several options for reconstruction of a replaced right hepatic artery. The replaced vessel can be sewn end to end to the gastroduodenal artery. If the replaced right hepatic artery is large, anastomosis to the splenic artery may result in a better reconstruction. A cuff of superior mesenteric artery along with the replaced right hepatic artery can be sewn to the celiac.

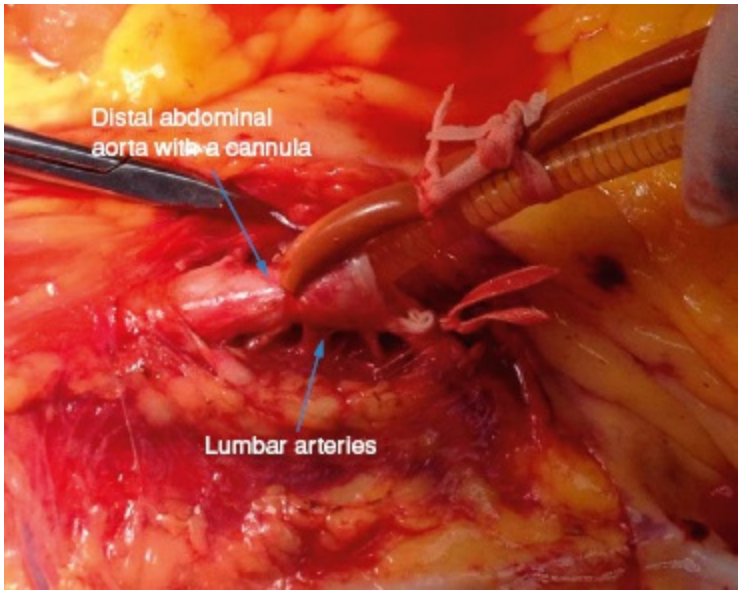

Figure 35-6. Aorta cannula securely fixed to the distal abdominal aorta.

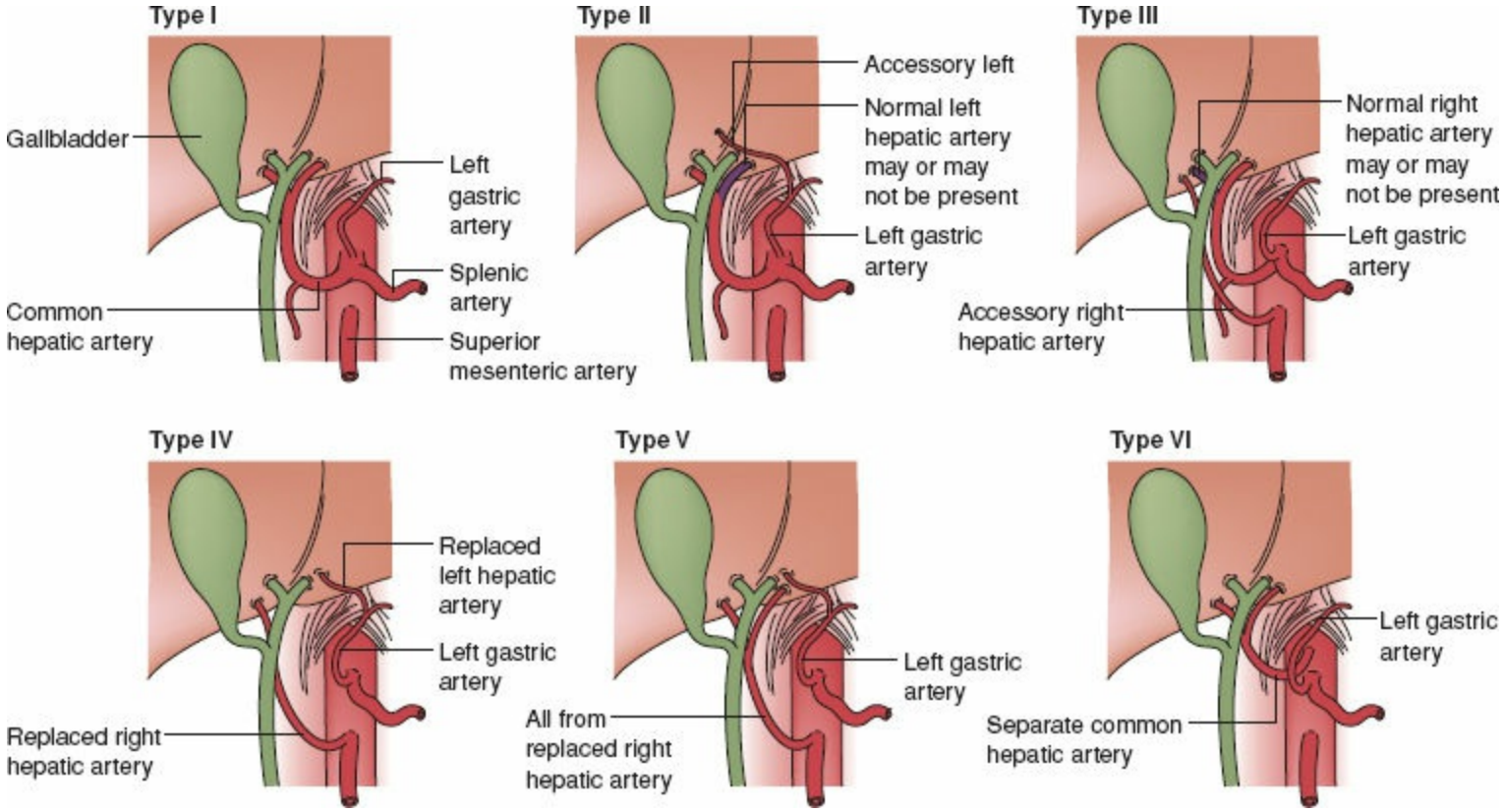

Figure 35-7. Variations in hepatic arterial anatomy. Lack of identification of this anatomy may jeopardize the transplant operation.



Figure 35-8. Upon dividing the ureter in the pelvis, a robust amount of periureteral tissue is left around the ureter.

Kidney Procurement: Kidney procurement is the final step in the procurement operation. Kidney procurement is significantly easier if the liver has been removed. If the liver has

not been removed and will not be used for transplantation, the portal triad and the right diaphragm should be divided. This results in the liver falling into the right chest, greatly facilitating the kidney procurement.

The supraceliac and the infrarenal aorta should be exposed as described in the liver procurement section. Arterial cannulation should occur distal to all renal arteries, even if they arise from the iliac arteries. The kidneys are mobilized bilaterally out of the retroperitoneum to facilitate packing with ice at the time of cold perfusion. Heparin administration and clamping is coordinated with the other procurement teams. The abdominal viscera are flushed as described in the liver section.

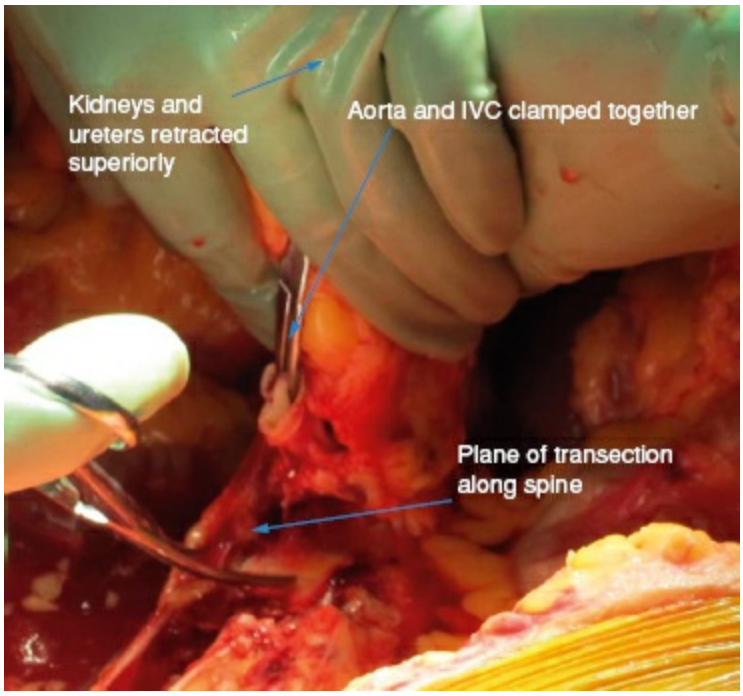

Figure 35-9. Method of procuring the kidneys. Retraction of both kidneys and ureters superiorly while clamping the distal aorta and inferior vena cava together. Division of tissue on the spine, posterior to the great vessels.

The ureters are divided bilaterally in the pelvis and mobilized toward the kidney. The periureteral tissue should be left intact in order to maintain the blood supply to the ureter (Fig. 35-8). The inferior vena cava and the aorta are divided at the bifurcation and the two vessels are clamped together with a single large clamp (Fig. 35-9). The ureters, kidneys, and vessels are retracted superiorly and the tissue posterior to the kidneys is incised. The left renal vein is divided just off of the inferior vena cava, leaving the entire inferior vena cava with the right kidney. The aorta is divided in the midline, providing an aortic cuff to all renal arteries (Fig. 35-10). The kidneys are flushed on the back table and carefully examined for vascular disease and parenchymal lesions. The kidneys are placed in cold storage or on a perfusion pump.

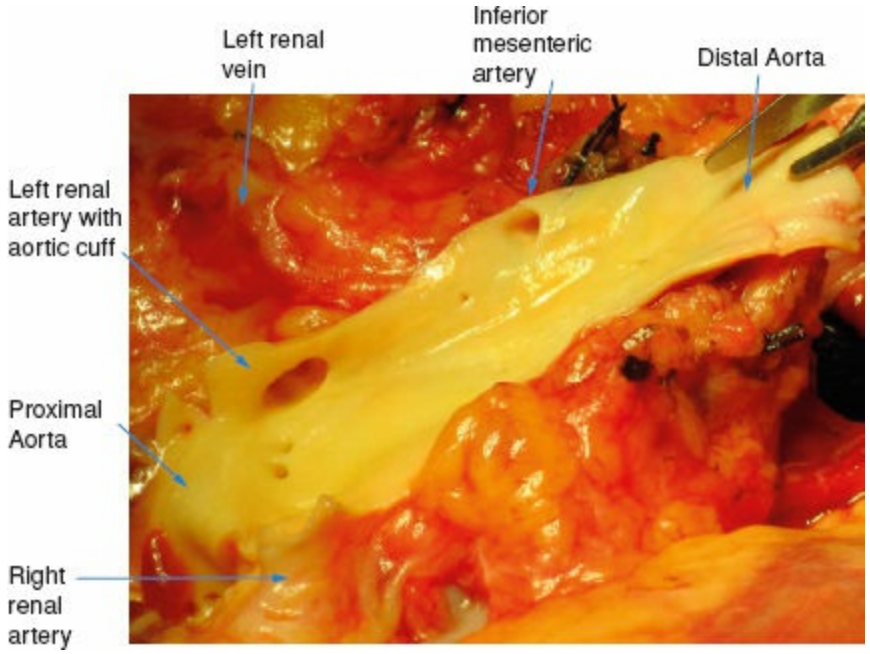

Figure 35-10. Division of the aorta in the midline leaving an aortic cuff around each renal artery.

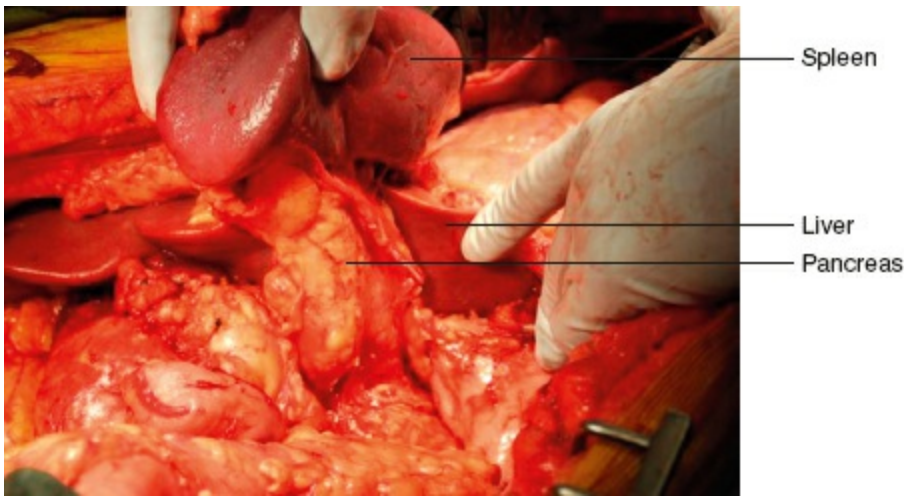

Figure 35-11. Retraction of the pancreas allograft out of the retroperitoneum during the procurement operation.

Pancreas Procurement: All of the steps necessary for the liver procurement up to the point of perfusion are completed. The pancreas must be mobilized out of the retroperitoneum with care. This can be done in the cold following flushing, but mobilization prior to flushing allows a careful examination of the organ as well as assuring that the vasculature is ligated.

The short gastric vessels are divided to widely expose the pancreas. The gland is assessed for fatty infiltration or firmness, both of which may preclude transplantation. The retroperitoneal tissue inferior to the pancreas and behind the spleen is incised. The spleen is retracted both anteriorly and medially (Fig. 35-11). The tissue behind the spleen and pancreas is divided until the aorta is reached. The duodenum is divided distal to the pylorus (Fig. 35-12). A vessel loop is placed around the splenic artery. The retrograde cold perfusion is described in the liver section. After approximately 3 L of cold profusion, the splenic artery is occluded to avoid over perfusion, which may result in edema of the pancreas.

Once perfusion is complete, the pancreas is removed in situ or en bloc along with the liver. The proximal jejunum is divided as it exits the retroperitoneum. It is critical that the root of the mesentery is securely divided with a vascular stapler. Division of the portal vein, the superior mesenteric artery, and splenic artery should be done in communication with the liver surgeon (Fig. 35-13). The iliac artery is procured for creation of the Y graft for the transplant operation (Fig. 35-3). The iliac vein is procured in case an extension graft is needed for the portal vein.

Heart and Lung Procurement: A bronchoscopy is done to examine anatomy, remove secretions and rule out pneumonia. A median sternotomy is performed and a retractor placed. The thymus gland is dissected and the innominate vein is identified in the superior aspect of the chest. The pericardium is incised and stay sutures are placed. The aorta is mobilized, freeing it from the main pulmonary artery and the right pulmonary artery. The superior and inferior vena cava are mobilized (Fig. 35-14). The chest and abdominal teams must agree on where to drain the inferior vena cava. The heart and lung teams must agree on where to drain the left side of the heart. This is usually accomplished by making an incision at the junction of the left atrium and the left superior pulmonary vein, or by transecting the left atrial appendage.

When all teams are ready, systemic heparin is administered. The aortic root is cannulated with a standard needle-tipped cannula. A purse-string suture is placed on the distal main pulmonary artery. A hole is made in the center of this suture and an “L”-shaped cannula is placed in the pulmonary artery. Prostaglandin is administered into the pulmonary artery. The superior vena cava is ligated, the inferior vena cava is incised, an incision is made to vent the heart, and the aortic cross-clamp is placed distal to the coronary perfusion cannula (Fig. 35-15). The heart and lung cold perfusion is started and the organs are surrounded with ice.

Once perfuse is complete, left atrium is divided, leaving an oval cuff of atrial tissue for the pulmonary veins on each lung (Fig. 35-16). The superior and inferior vena cava are divided in collaboration with the liver surgeon. The pulmonary artery is divided, taking care not to damage the left main pulmonary artery. The aorta is divided just distal to the aortic arch and the heart is removed. The lateral and posterior borders of the pericardium are divided, including the posterior wall of the left atrium. The innominate vein is divided and the anterior trachea is identified. The trachea is encircled as high in the chest as possible. The lungs are inflated and the main bronchus and left main bronchus are stapled. The trachea is divided proximal to the staple line and the inflated lungs are removed (Fig. 35-17A,B). The lungs are retrogradely flushed on the back table.

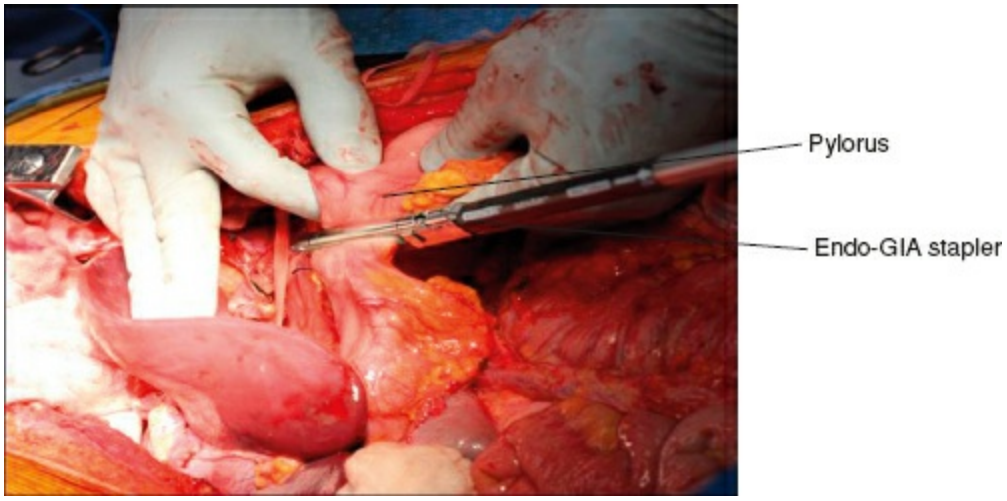

Figure 35-12. Division the duodenum just distal to the pylorus.

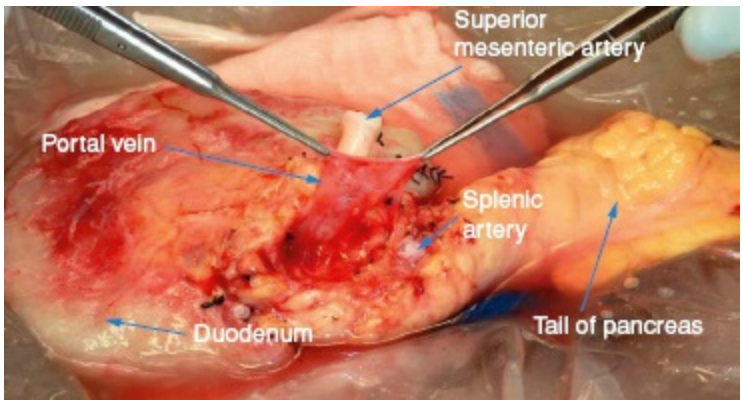

Figure 35-13. Pancreas allograft following procurement, with ample length of portal vein, superior mesenteric artery, and splenic artery.

APPLIED SCIENCES IN ORGAN PRESERVATION

4 Organ procurement and storage result in significant alterations in the homeostasis of the organ. The degree of organ preservation injury contributes to the degree to which normal organ function is delayed or prevented following transplantation. Organ preservation injury is largely mediated by ischemia and hypothermia. The duration when the organ is in cold storage is termed “cold ischemia time.” Minimizing this time as well as careful organ preservation is critical for successful outcomes. The core concepts of organ preservation are detailed in the Table 35-3.

Cold ischemia and warm reperfusion cause much of the organ damage. As a result, novel strategies for warm perfusion of organs are being used. These techniques involve perfusion with blood or a blood-like analog with or without oxygenation. These perfusion models are mostly investigational at this time, but offer promise for better organ preservation in the future.

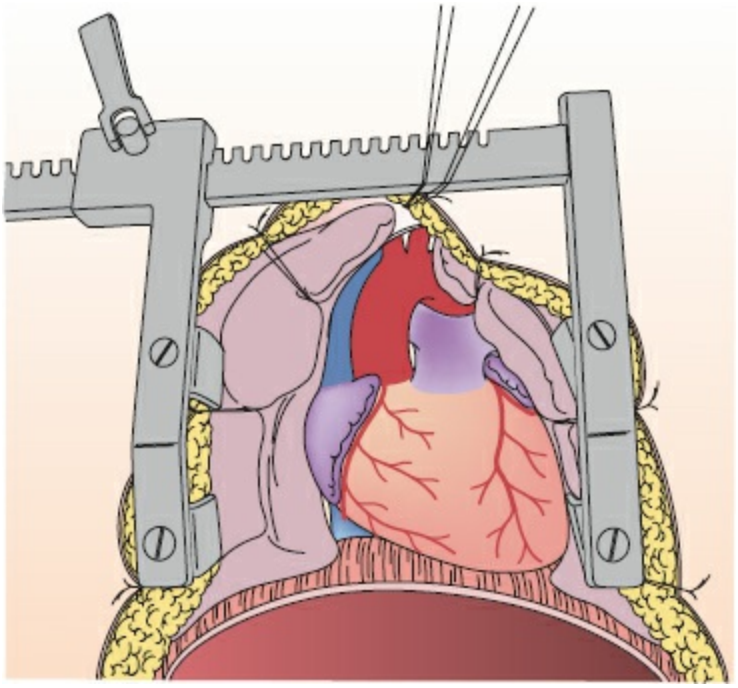

Figure 35-14. Chest exposure for the heart- and lung procurement operation.

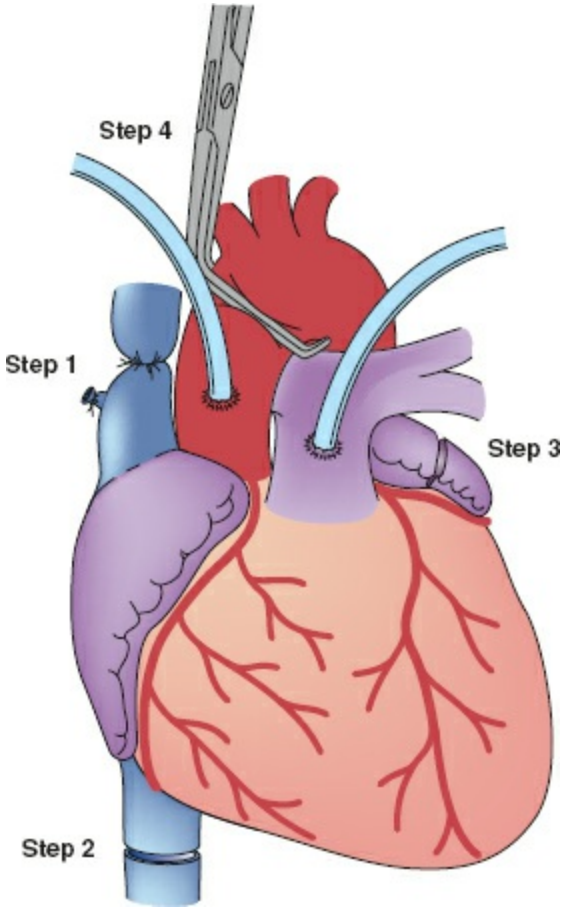

Figure 35-15. Steps in the thoracic procurement operation. Clamping in a counter-clockwise manner, beginning with the superior vena cava and ending with the aorta.

- Step 1: Ligation of the superior vena cava, assuring that the azygous is either ligated or the clamp is below the azygous vein.
- Step 2: Division of the inferior vena cava at the pericardial reflection within the chest to drain the right heart adequately. This line of transection must be discussed with the liver surgeon.
- Step 3: An incision to vent the left heart by cutting across the base of the left atrial appendage.
- Step 4: An aortic cross-clamp distal to the coronary perfusion cannula.

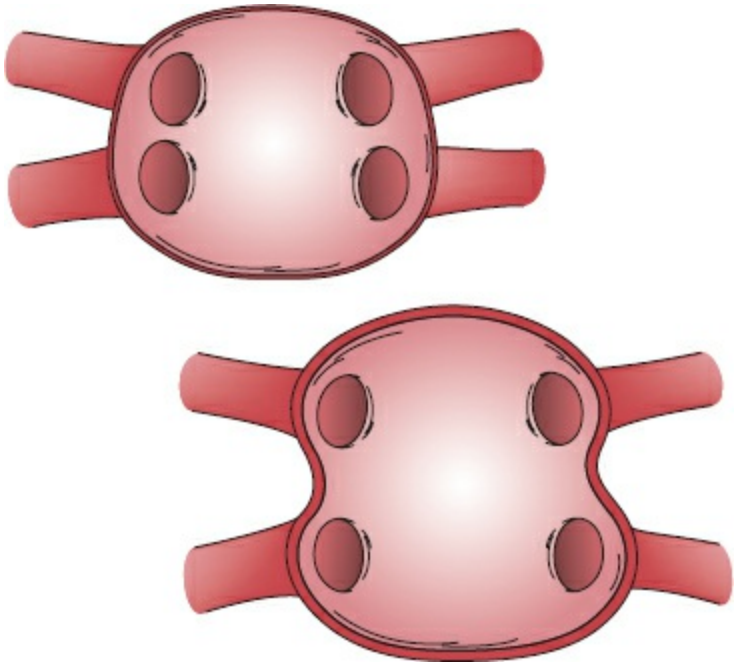

Figure 35-16. Preparation of the pulmonary vein cuffs during the lung procurement operation.

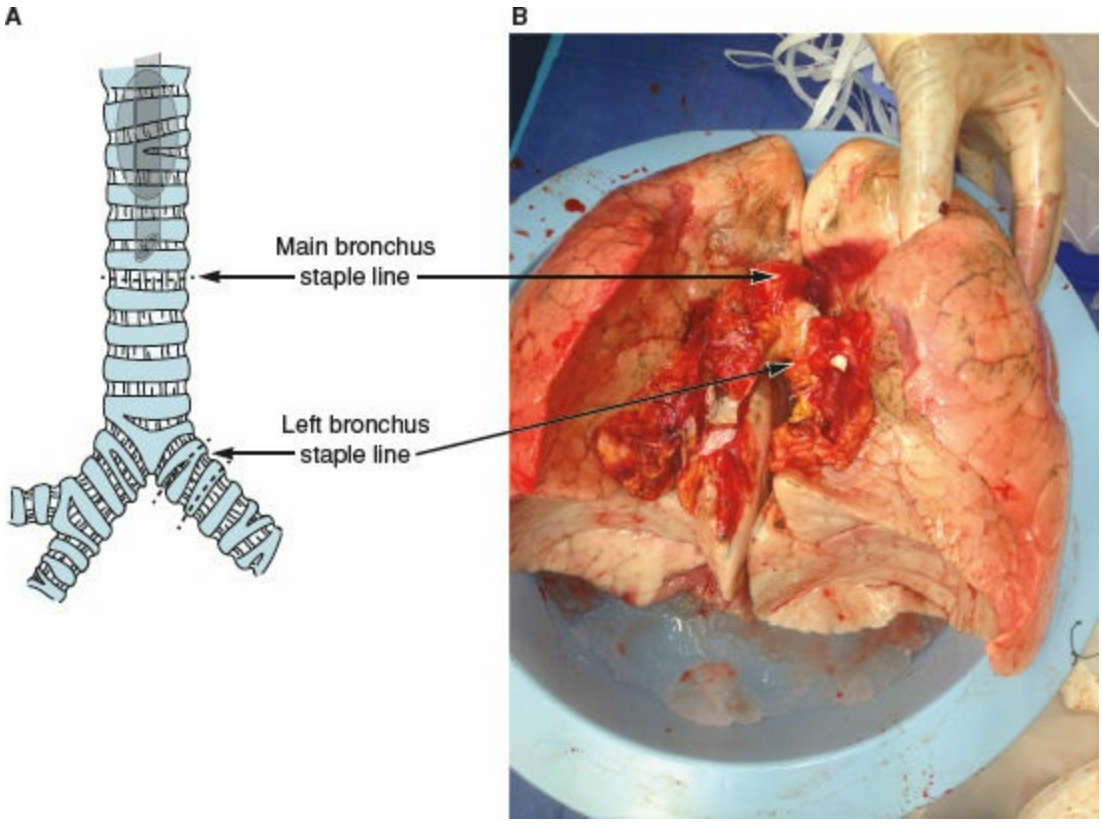

Figure 35-17. Stapling of the main bronchus and left main bronchus (**A** and **B**). The lungs are then divided between these staple lines.

Several strategies have been developed to mitigate the effects of ischemia on organs obtained following DCD procurement procedures. These include the infusion of antifibrinolytics into the donor organ at the time of flush or transplant.[15] Early reports suggest these strategies result in fewer postliver transplant biliary complications. Another approach is to resume normothermic perfusion of the abdominal viscera following death using an extracorporeal membrane oxygenation (ECMO) circuit. This strategy has several

benefits including enabling withdraw of support in the ICU with the family present, resuscitation of the organs following the agonal period, and avoidance of urgency in the procurement operation. A diagram of the ECMO circuit used for DCD procurement is detailed in Figure 35-18.

Machine cold perfusion is now commonly done in clinical transplantation, and in some regions is the standard of care for renal preservation (Fig. 35-19). Some of the injury during cold ischemia and reperfusion is related to the accumulation of metabolites; perfusion may mitigate these effects by washing out deleterious metabolites and by maintaining patency of the microvasculature of the organ. Machine cold perfusion is now used on nearly 50% of deceased donor kidneys in the United States.[16] Early trials of cold perfusion of high-risk livers and lungs have also been successful (Fig. 35-20).[3,17,18] Such strategies may expand usable organs, provide therapeutic interventions directly to the organ during the perfusion process, and rehabilitate damaged organs.

Table 35-3 Key Concepts in Organ Preservation

Prevent thrombosis	■ Anticoagulation of the donor ■ Rapid and complete organ flush following cessation of circulation
Maintain organ structural integrity	■ Maintenance of stable configuration of cell membrane lipid bilayer ■ Cold storage results in conformational changes of cell membrane resulting in cell swelling ■ Hypertonic preservation solutions mitigate some of these effects
Maintain ionic composition	■ Preservation solution electrolyte composition is similar to intercellular composition of Na^+ and K^+ ■ H^+ accumulates as a result of anaerobic glycolysis ■ Preservation solution buffers H^+ effects
Maintain cellular energy	■ Hypothermia reduces metabolism 12-fold ■ Hypothermia affects the activity of mitochondrial enzymes ■ Mitochondrial dysfunction results in changes and cellular energy
Reperfusion injury – oxygen free radicals	■ The majority of organ injury happens at reperfusion and not during cold ischemia ■ The sudden availability of O_2 results in the production of reactive oxygen intermediates (O_2- and $OH^·$) ■ Free radicals cause cellular injury – largely through lipid peroxidation ■ Glutathione protects against peroxidation and is useful in preservation solutions
Reperfusion injury – cytokines	■ Tissue injury results in the release of cytokines ■ Tumor necrosis factor (TNF), interferon-gamma, interleukin-1, and interleukin-8 are released at reperfusion ■ Cytokine exposure results in the up-regulation of adhesion molecules, resulting in platelet plugging and leukocyte adherence to the endothelium

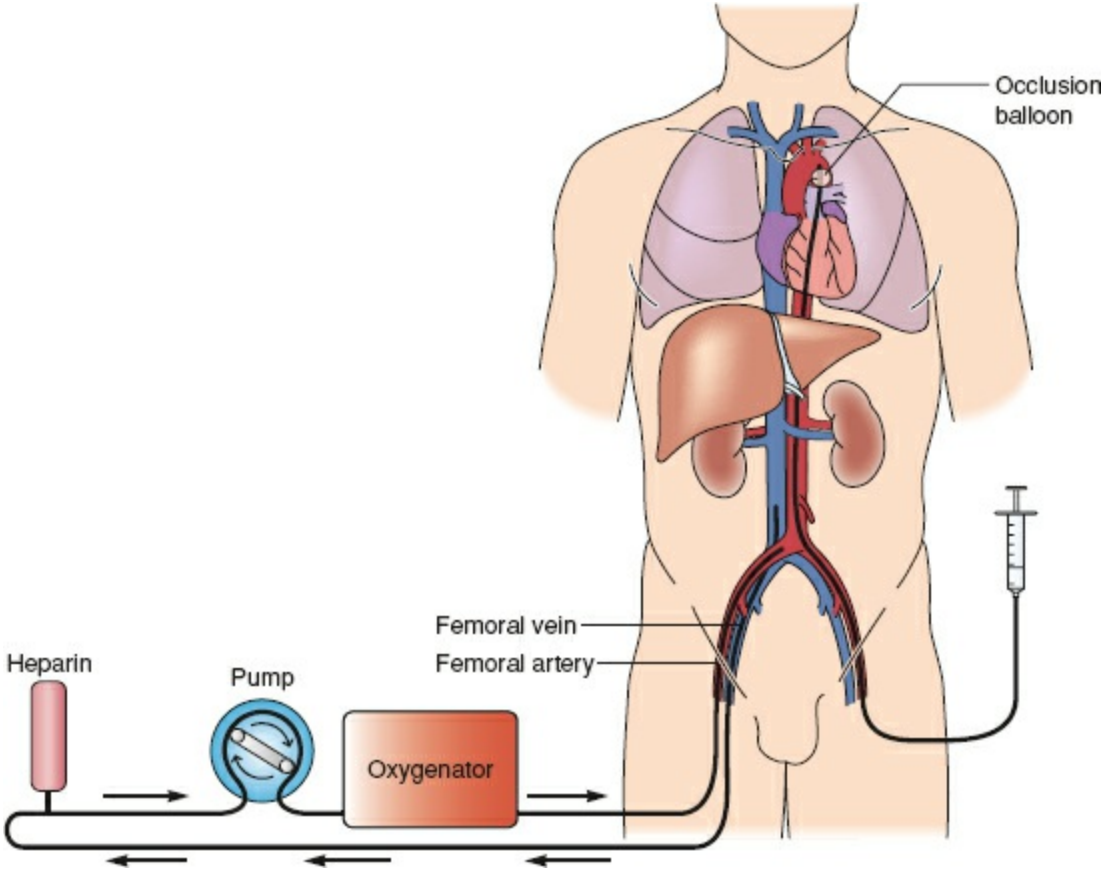

Figure 35-18. Extracorporeal membrane oxygenation circuit used to perfuse the abdominal viscera following withdraw of support and death in DCD procurement procedures.

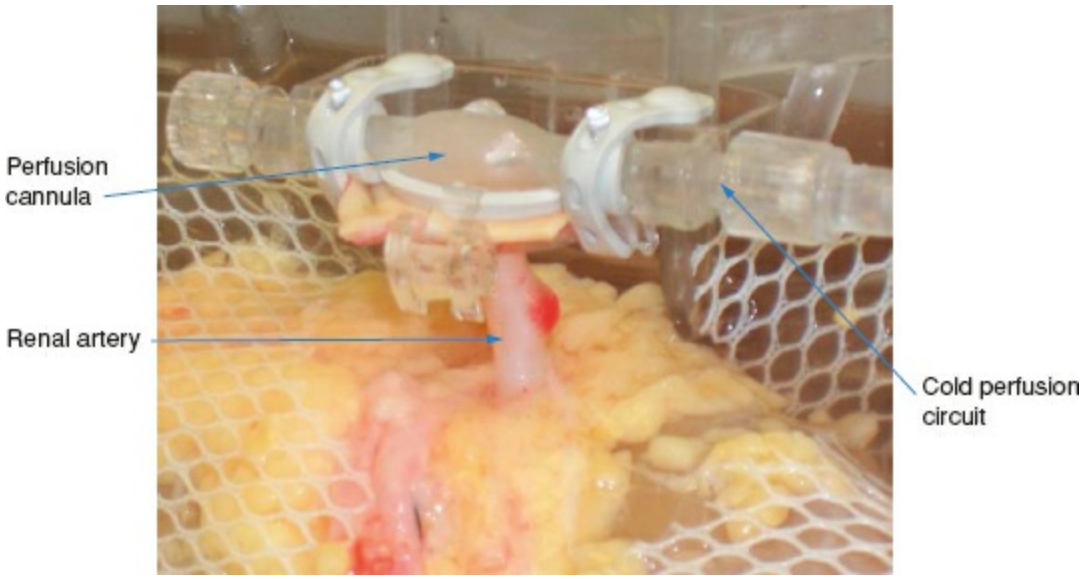

Figure 35-19. Renal machine cold-perfusion circuit with renal artery cannula.

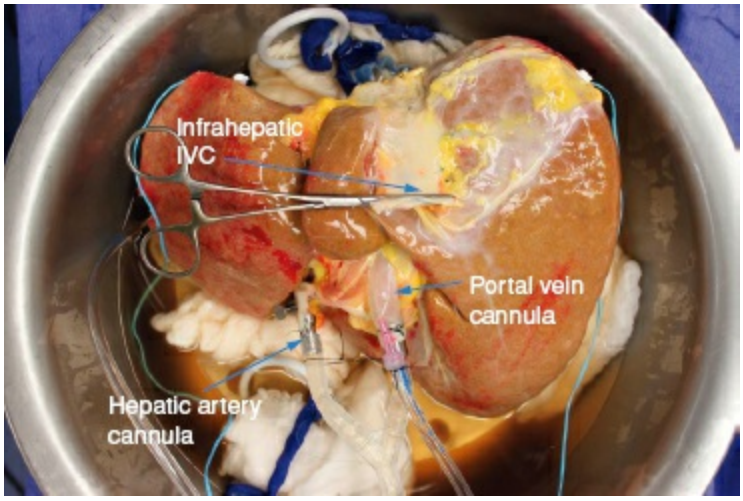

Figure 35-20. Machine liver cold-perfusion circuit with hepatic artery and portal vein cannulas.

References

1. United Network for Organ Sharing - Annual Data Assessment 2014. Available from: http://www.unos.org. Accessed October 9, 2014.
2. The Scientific Registry of Transplant Recipients - Annual Report 2014. Available from: http://www.srtr.org. Accessed October 9, 2014.
3. Graham JA, Guarrera JV. “Resuscitation” of marginal liver allografts for transplantation with machine perfusion technology. *J Hepatol* 2014;61(2):418–431.
4. Mange KC, Joffe MM, Feldman HI. Effect of the use or nonuse of long-term dialysis on the subsequent survival of renal transplants from living donors. *N Eng J Med* 2001;344(10):726–731.
5. Weng FL, Mange KC. A comparison of persons who present for preemptive and nonpreemptive kidney transplantation. *Am Journal Kidney Dis* 2003; 42(5):1050–1057.
6. Harvard criteria: an appraisal. *JAMA* 1972;221(1):65.
7. Morrissey PE, Monaco AP. Donation after circulatory death: current practices, ongoing challenges, and potential improvements. *Transplantation* 2014; 97(3):258–264.
8. Nalesnik MA, Woodle ES, Dimaio JM, et al. Donor-transmitted malignancies in organ transplantation: assessment of clinical risk. *Am J Transplant* 2011;11(6):1140–1147.
9. Ison MG, Nalesnik MA. An update on donor-derived disease transmission in organ transplantation. *Am J Transplant* 2011;11(6):1123–1130.
10. Ison MG, Llata E, Conover CS, et al. Transmission of human immunodeficiency virus and hepatitis C virus from an organ donor to four transplant recipients. *Am J Transplant* 2011;11(6):1218–1225.
11. Northup PG, Argo CK, Nguyen DT, et al. Liver allografts from hepatitis C positive donors can offer good outcomes in hepatitis C positive recipients: a US National Transplant Registry analysis. *Transplant Int* 2010;23(10):1038–1044.
12. Fabrizio F, Bunnapradist S, Martin P. Transplanting kidneys from donors with prior hepatitis B infection: one response to the organ shortage. *J Nephrol* 2002;15(6):605–613.
13. De Vusser K, Lerut E, Kuypers D, et al. The predictive value of kidney allograft baseline biopsies for long-term graft survival. *J Am Soc Nephrol* 2013; 24(11):1913–1923.
14. Doyle MB, Vachharajani N, Wellen JR, et al. A novel organ donor facility: a decade of experience with liver donors. *Am J Transplant* 2014;14(3):615–620.
15. Hashimoto K, Eghtesad B, Gunasekaran G, et al. Use of tissue plasminogen activator in liver transplantation from donation after cardiac death donors. *Am J Transplant* 2010;10(12):2665–2672.
16. Cannon RM, Brock GN, Garrison RN, et al. To pump or not to pump: a comparison of machine perfusion vs cold storage for deceased donor kidney transplantation. *J Am*

Coll Surg 2013;216(4):625–633; discussion 33–34.

17. Guarrera JV. Assist devices: machine preservation of extended criteria donors. *Liver Transplant* 2012;18(Suppl 2):S31–S33.
18. Cypel M, Keshavjee S. Strategies for safe donor expansion: donor management, donations after cardiac death, ex-vivo lung perfusion. *Curr Opin Organ Transplant* 2013;18(5):513–517.

Chapter 36

Renal Transplantation

Chris E. Freise and Peter G. Stock

Key Points

1. The major barriers to successful renal transplantation include ABO compatibility and the human leukocyte antigen (HLA) system.
2. Before a renal transplant is undertaken, histocompatibility of the donor and recipient is determined.
3. Methods to expand the donor pool of kidneys include the use of donation after cardiac death donors and high kidney donor profile index kidneys.
4. The etiology of kidney disease resulting in end-stage failure, and the necessity for transplantation is led by glomerulonephritis, diabetes, and hypertension.
5. The kidney transplant is heterotopically placed in the extraperitoneal iliac fossa.
6. Surgical complications of kidney transplantation include vascular, urologic, lymphocele, and wound problems.
7. Hyperacute rejection is humorally mediated by preformed anti-HLA antibodies. Hyperacute rejection occurs within minutes to hours following reperfusion of the kidney.
8. Acute cell-mediated rejection most typically occurs between 1 week and 3 months following transplantation.
9. Chronic rejection leads to loss of graft function over the course of months to several years.

Renal transplantation has evolved to become the preferred therapeutic modality for patients with end-stage renal failure. Improved patient survival and quality of life as compared with dialysis has been established, with cost effectiveness achieved after a minimum of 18 months of allograft function. The importance of minimizing time on dialysis, compounded by the exponential growth of patients on the wait list, has led to several strategies to increase the number of deceased and living-donor organs in an effort to decrease waiting time and mortality on the wait list. These new strategies have been the focus of clinical research in kidney transplantation and will be discussed in this chapter. Other important topics that will be reviewed include immunologic considerations specific to kidney transplantation; preoperative assessment of kidney allograft recipients; the standard surgical approach in kidney transplantation and advances in laparoscopic

technology for the donor; current strategies in immunosuppression; management of the technical and immunosuppressive complications; new kidney allocation policies affecting waitlist management; and future trends.

IMMUNOLOGY OF RENAL TRANSPLANTATION

The immunologic response to allografted tissue is well defined and under the influence of both T-cell– and B-cell–derived reactions. The cells and cytokines responsible for rejection vary with time posttransplant (hyperacute, acute, and chronic rejection) and have a differential response to currently available immunosuppressive agents.

1 The major barriers to successful renal transplantation include ABO compatibility and the human leukocyte antigen (HLA) system. In general, renal transplantation is done between ABO-compatible donor and recipients using the same guidelines as for blood transfusion. However, because of the shortage of donors, cadaver kidneys are nearly always used in recipients of identical blood type. Recently, ABO-incompatible living-donor transplants have been performed on an experimental basis secondary to excessive wait times for ABO-compatible deceased-donor transplants.[1,2]

The HLA system is made up of well-defined antigens present on most cell types that are genetically determined for each patient and are termed the *major histocompatibility complex*. These genes reside on chromosome 6 and are distributed in a Mendelian fashion to offspring. The HLA system includes several loci, but the most commonly characterized are the HLA-A, HLA-B, and HLA-D regions. Given that each human has two alleles for each locus, there are six potential HLA antigens of clinical significance. These are characterized using tissue-typing techniques and can be used to determine the degree of matching between a donor and potential recipient, that is, one-antigen match to six-antigen match. Improved results of graft survival are seen when the degree of matching reaches the six-antigen level and long-term results may be less favorable with matching to a lesser degree.

Class I antigens include the HLA antigens A, B, and C, whereas class II antigens include the D and DR loci. Class I antigens act as targets for cytotoxic T lymphocytes, and class II antigens are important for antigen presentation. Class II antigens are also responsible for triggering lymphocyte proliferation in the mixed lymphocyte culture system.

2 Before a renal transplant is undertaken, histocompatibility of the donor and recipient are determined. Standard pretransplant workup consists of several assays that will help to determine future compatibility with a potential donor. First, donors and recipients undergo tissue typing, which involves characterization of their respective HLA type. Secondly, recipient serum is tested against a panel of antigens that contain the known HLA types, to identify anti-HLA antibodies. The sensitivity for detecting anti-HLA antibodies continues to improve and newer technology uses single antigen beads to detect antibodies against a specific HLA antigen. The amount of reactivity that a potential recipient has against a panel of HLA antigens is indicative of the degree of sensitization. Based on the number of anti-HLA antibodies detected, a calculated percent reactive antibodies (cPRA) can be estimated. A cPRA of 70% would suggest that the potential recipient would have anti-HLA antibodies against 70% of the potential donor pool. Sensitization to HLA antigens occurs as a result of previous exposure to foreign HLA antigen either from pregnancy, previous blood transfusion, or a previous organ

transplant. A patient who is highly sensitized is more difficult to transplant because of the greater likelihood of having antibodies to a potential donor.

The last critical test performed prior to transplantation is commonly known as the *final crossmatch*. This final crossmatch can be performed in several ways. Recipient serum samples collected at different times are mixed with donor lymphocytes in a culture system. This assay will detect preformed cytotoxic antibodies that would result in a hyperacute rejection if the transplantation were performed (see Rejection, later). A more sensitive method of detecting these antibodies uses a fluorescent-activated cell scanner crossmatch and is commonly used when evaluating potential recipients who are highly sensitized or receiving second transplants. Many transplant centers have adopted "virtual crossmatching" based on the detection of anti-HLA antibodies present in a given recipient. The most sensitive technology will be used to detect the presence of anti-HLA antibodies in a given recipient. Based on these antibodies, each recipient will have a list of unacceptable donor antigens. Compatibility with each donor will be determined in the absence of the serum-based final crossmatch by eliminating a potential donor based on the presence of unacceptable antigens. This strategy facilitates an expedited transplant and minimization of cold ischemia times, as it avoids the additional time and expense associated with the serum-based final crossmatch. The use of the virtual crossmatching is particularly beneficial for determining potentially compatible kidneys allocated to highly sensitized recipients, a scenario occurring with increasing frequency as a result of the new kidney allocation algorithm initiated in December 2014. Widespread acceptance of the virtual crossmatch will require further confirmation that all donor antigens are sufficiently identified using the single antigen bead technology. Currently, at least for highly sensitized recipients, most centers will still perform a serum-based final crossmatch to verify the virtual crossmatch result.[3]

THE DONOR POOL: LIVING DONORS, DECEASED DONORS, DONATION AFTER CARDIAC DEATH

There is marked improvement in graft survival for both living and deceased donors when a transplant can be completed before the initiation of dialysis.[4] The significantly better outcomes achieved with preemptive transplantation and minimizations of dialysis times have given rise to several strategies to increase the number of available kidneys.

Living Donors

The first long-term success in renal transplantation over 60 years ago involved a live-donor transplant between twin brothers. The number of living donors has increased significantly in the last few years, in part as a result of the increased use of the laparoscopic technique for donor nephrectomies. For the first time, in 2001 the number of living donors exceeded the number of deceased donors, although deceased-donor transplants still represent the majority of kidney transplants done today.[5] This trend toward increased live donation may also be the result of the excessive waiting times for deceased-donor transplants, now more than 8 years for blood type O and B recipients in many parts of the United States. Despite initial concerns about the safety and efficacy of the laparoscopic technique for the donor procedure, morbidity and mortality rates (0.03%) remain low and comparable with those of the open technique.[6,7]

The evaluation of a potential living kidney donor begins with a brief overall assessment of physical condition because potential donors must be in good health with normal kidney function. Diabetes, hypertension, and cardiovascular disease generally rule out a potential donor. ABO is also determined before further workup, because ABO incompatibility has been a relative contraindication to donation. A crossmatch test is usually performed at this time to ensure donor and recipient immunologic compatibility. After this initial screen, a careful medical and psychosocial screen takes place to confirm donor suitability. Following a normal physical examination, further studies should include chest radiography, electrocardiogram, urinalysis, and blood work. During this phase, any conditions that could predispose to later renal insufficiency need to be ruled out. For example, donors from families with a history of type II diabetes are at a significant risk for the development of diabetes and glucose tolerance testing is justified as part of the screening process. A history of renal stones warrants stone analysis to assess likelihood for recurrent stones. Any inherited disorders of kidney disease must also be ruled out, particularly in potential living-related donors when the recipient has polycystic kidney disease.

The psychosocial history is directed at assessing the motivation of the donor, and to ensure that there are adequate resources for the donor to proceed with the surgery and recovery. Many centers require a relationship between the donor and intended recipient, although it is becoming increasingly common to have general members of the public show interest in being evaluated as a donor, with no particular recipient identified. These nondirected donors require the same careful scrutiny as any living donor and the psychosocial evaluation is especially important. The motivation for donation should be clear and not be connected in any way to financial gain. As a further safety measure living donors are also evaluated and counseled by an Independent Living Donor Advocate, usually a social worker, who is not directly involved in the recipient care, and can assess for any psychosocial issues or donor concerns that may interfere with a smooth donation and recovery process. It is also the duty of the physician evaluating the potential donor to review the current statistics on morbidity and mortality. The final testing of a potential donor involves anatomic definition of the two kidneys and is typically done with either a

computed tomography angiogram or MR angiogram, both of which avoid the arterial needle stick and catheters associated with a conventional angiogram. The results of these studies are used to detect any anatomic abnormalities that would exclude a donor and to decide which kidney will be removed. In general, the left kidney is favored for transplant because it has a longer renal vein.

Several strategies are currently being considered to increase the frequency of living donation. Potential donors with well-controlled hypertension on a single antihypertensive agent are being considered, although this remains controversial. Controversy also exists regarding the potential reimbursement for living donors, specifically providing financial compensation regarding lost wages during the donation. Consideration is also being given to providing health insurance to living donors for complications related to the donor procedure. The extent of the reimbursement provided to living donors continues to be debated by medical ethicists and transplant professionals. Finally, a national exchange system is currently being designed that matches living donors who were incompatible with their intended recipient (either because of ABO incompatibility or a positive crossmatch test) with other recipients with incompatible living donors. Such exchange systems have already been successful on a regional and national level, and extending this to a single national system will permit many more successful exchanges and further expand the living donor pool. The creation of a single national exchange system is still a work in progress. The advantage of having greater numbers of donor and recipient pairs in the "pool" is to increase the likelihood that a highly sensitized recipient will be able to be matched to a compatible donor. There have also been some preliminary attempts at including compatible donor and recipient pairs in the pool, with their consent, in an effort to facilitate transplantation of highly sensitized recipients.[8]

Deceased Donors

3 Procurement of kidneys from brain-dead deceased donors has not increased at the same pace as the rapid growth of the national wait list (Fig. 36-1). Although most deceased donors are brain dead, there has been an increased use of kidneys from donors who do not meet the strict definitions of brain death but have cardiopulmonary support withdrawn because of a severe brain injury or high spinal cord injury, with little hope of living without the use of ongoing mechanical ventilation and/or the possibility of existing in a persistent vegetative state. Organs are recovered after withdrawal of support, once the heart stops beating, hence the terminology of *donors by cardiac death* or *DCD donors.* Usually support is withdrawn in a controlled setting so that the time of warm ischemia and poor organ perfusion can be minimized. Minimizing the time from cessation of the heart to perfusion of organs with preservation fluid requires an experienced procurement team, and the successful use of these organs is dependent on rapid procurement. Although the use of livers from DCD donors appears to be associated with a higher incidence of biliary tract complications following transplantation, kidneys procured from DCD donors are proving to be an important source of donor kidneys.[9] Several studies from the United States and Japan have demonstrated comparable graft success between kidneys procured from DCD donors and brain-dead donors, although the incidence of initial delayed graft function is higher in DCD kidneys.[10] The percentage of DCD donors in the United States has progressively increased over the last decade and presently represents about 10% of deceased donors.

Placement of deceased-donor kidneys is guided by a series of complex allocation rules established by the United Network for Organ Sharing (UNOS). Unfortunately, the number of people being added to waiting lists continues to be significantly greater than the number of people being removed following transplantation. UNOS has recently implemented a new kidney allocation algorithm, although it is unlikely that it will have a significant impact on the overall waiting times for deceased kidney transplants, now approximating 7 to 8 years for certain blood types in several parts of the country. Nonetheless, there are some significant changes which will impact the allocation process. Donor kidneys are now assigned a kidney donor profile index (KDPI) score, the lower the score the better predicted survival of the kidney (better quality kidney). The new allocation system attempts to match the predicted longevity of the deceased-donor organ quantified by the KDPI with the estimated posttransplant survival (EPTS) of the recipient. The top 20% of kidneys (KDPI scores less than 20%) will be transplanted to recipients with longest EPTS (top 20%). In the new allocation scheme, the highest KDPI kidneys (KDPI $>85\%$) will be allocated to recipients who have consented to receive an expanded criteria donor. Highly sensitized patients will receive a significant number of allocation points, so if in the rare event that a compatible kidney becomes available (based on the virtual crossmatch), that kidney will be allocated to the compatible highly sensitized recipient. Highly sensitized recipients with cPRA's of 99% or 100% will get access to the regional and national lists respectively to increase the chances of finding a compatible kidney. Finally, waiting times will be backdated to the time of the initiation of dialysis,

although patients can still be listed when the glomerular filtration rates drop below 20 mL/min.[11]

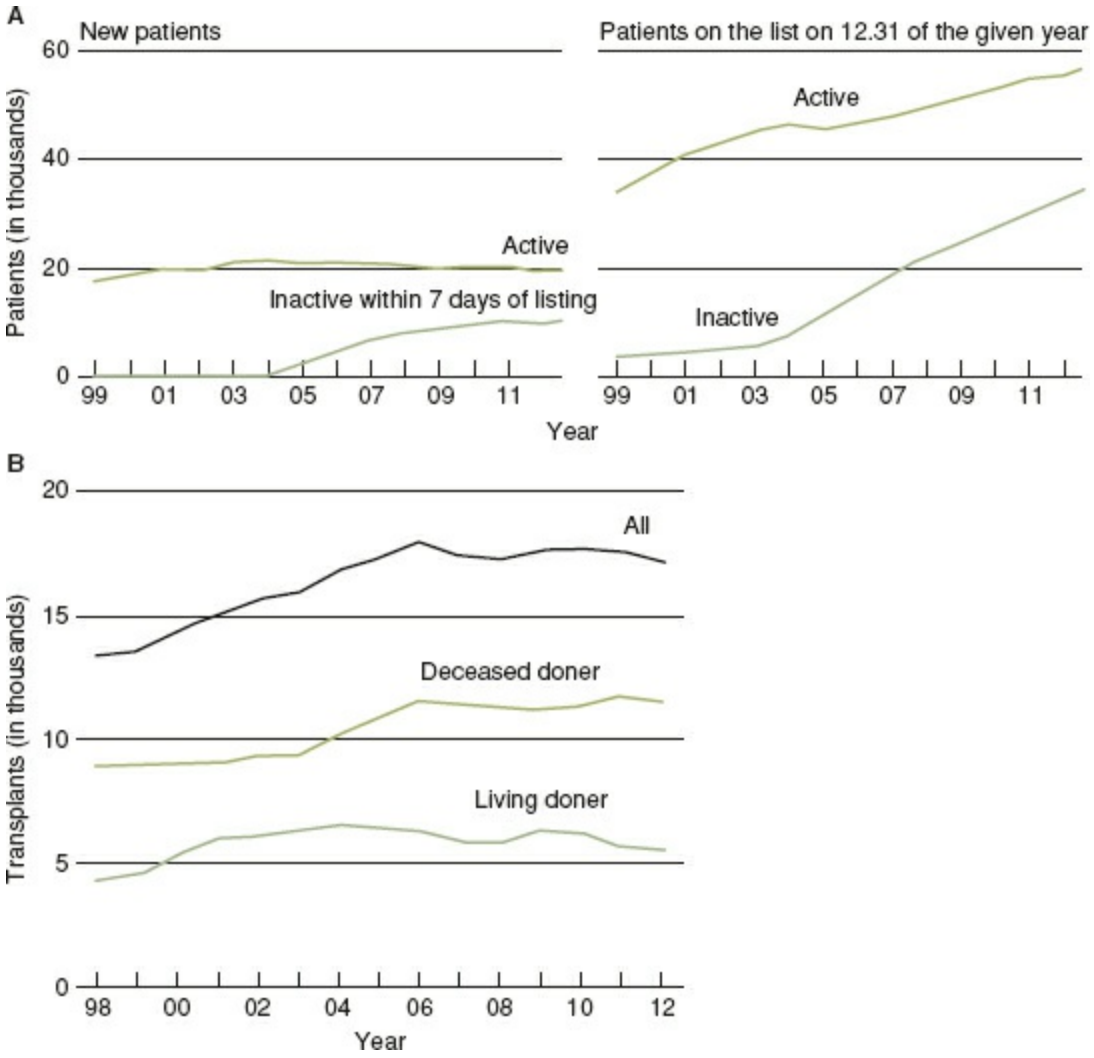

Figure 36-1. The growth in the number of patients awaiting transplant (**A**) has exceeded the relatively stagnant rate of deceased-donor kidney transplants leading to progressively increasing waiting times over the last decade. Living donors had a slight increase early in the last decade, which may be in part due to the introduction of the laparoscopic donation procedure, but rates of living donation are currently flat (**B**). (Adapted from: SRTR and OPTN Annual Data Report, 2012, available at: http://srtr.transplant.hrsa.gov/annual_reports/2012/Default.aspx. Accessed July 15, 2015)

Further Strategies for Increasing the Number of Donor Kidneys

Many of the unique approaches for increasing the number of potential donors have come from Japan, where cultural beliefs have limited the number of available deceased-donor transplants. Several groups have reported successful kidney transplantation across ABO blood group barriers, using aggressive pretransplant immunosuppression, plasmapheresis to decrease anti-ABO titers, and in some cases splenectomy.[1,2] This strategy has been implemented with increasing frequency in the United States as a result of the marked increases in the waiting times for blood group O and B recipients.[12] While this strategy may be effective for living-donor pairs that are ABO incompatible in the United States, it is more common to place these ABO-incompatible pairs into one of the kidney exchange programs.

For donor recipient pairs that are incompatible due to a positive crossmatch, an important strategy currently being implemented in the United States, as well as internationally, involves the use of desensitization protocols to facilitate transplantation across a known positive anti-HLA crossmatch. These protocols may involve pretransplant infusion of gamma globulin in the recipient to bind circulating antibody, plasmapheresis of the recipient to remove circulating antibody, and/or the use of agents, such as rituximab, to decrease antibody production. These protocols could potentially impact the increasing number of sensitized patients on waiting lists who have little hope of finding a compatible donor.[13] Lastly, a hybrid approach for the highly sensitized recipient with a crossmatch-incompatible donor could involve finding a kidney that is “less incompatible” through an exchange program, and then converting the positive crossmatch to a compatible crossmatch with desensitization techniques. Further strategies have recently been implemented to expand the number of kidneys procured from deceased donors. In addition to the use of kidneys from DCD donors described earlier, transplant centers have considered using kidneys from donors that are less than optimal, previously designated as expanded criteria donors (ECD). In the previous allocation scheme, these donors were between age 50 and 59, and had two out of three other clinical feature: history of hypertension, died of a cerebrovascular injury, or had a terminal creatinine of greater than 1.5 mg/dL. Additionally, any donor over age 60 was considered an ECD. These kidneys clearly had a shorter survival compared to younger, healthier donors and therefore potential recipients were required to give consent to receive these kidneys before transplant. The advantage to certain patient groups who were predicted to do poorly on dialysis (i.e., older patients or patients with diabetes) was an increased overall patient survival if they received a timely transplant with an ECD kidney, rather than wait a prolonged time on the list. In the newer allocation scheme, ECD kidneys are now defined as KDPI $>85\%$. In the new allocation system, kidneys with KDPI $>85\%$ will be allocated to an expanded list (regional versus local) in order to increase organ utilization and minimize the chance of discard. The increased use of “kidney pumping” may help to determine the quality of these ECD kidneys by observing flow rates on the pump, and may also decrease the rates of posttransplant delayed graft function.[14]

THE TRANSPLANT PROCEDURE

Recipient Preoperative Assessment

4 The etiologies of kidney disease resulting in end-stage failure and the necessity for transplantation are led by glomerulonephritis, diabetes, and hypertension (Table 36-1).[15] Because of the high incidence of cardiovascular disease associated with many of these conditions, most notably diabetes, a careful assessment of the cardiovascular status of the potential recipient is critical. For patients at risk, this assessment should include at a minimum an echocardiogram and an exercise or pharmacologic stress test as a screen for reversible ischemia requiring cardiac catheterization. Controversy remains with regard to the accuracy of noninvasive studies in terms of identifying significant disease of the coronary arteries, particularly in diabetic patients. Nonetheless, for most centers this remains the standard screening strategy, and updated studies should be obtained within 1 year of the transplant procedure. If either coronary artery bypass or stenting has taken place in preparation for renal transplantation, follow-up angiograms and/or stress tests should be repeated within 1 to 2 years of the actual transplant. If stenting of the coronary arteries is required, patients with drug eluting stents will commonly require clopidogrel (Plavix) for an extended period of time. Although controversial, many centers will proceed with transplantation while recipients are on Plavix, within 6 months of the stenting procedure.

Table 36-1 Etiology of Renal Disease as Indications for Renal Transplantation, Ranked in Order of Prevalence

Diabetes mellitus (types I and II)
Hypertension
Polycystic kidney disease
IgA nephropathy
Chronic glomerulonephritis
Focal sclerosis
Systemic lupus
Membranous glomerulonephritis
Pyelonephritis
Focal segmental glomerulosclerosis
Congenital obstructive uropathy
Nephritis
Alport syndrome
Hypoplasia, dysplasia
Wegener granulomatosis
Postinfectious glomerulonephritis
Obstructive uropathy
Hemolytic uremia
Membranoproliferative glomerulonephritis
Goodpasture syndrome
Membranous nephropathy
Analgesic nephropathy
Prune belly syndrome
Medullary cystic disease
Henoch–Schönlein purpura
Nephronophthisis
Scleroderma
Sickle cell anemia
Amyloidosis
Oxalosis

Adapted from Cecka JM. The OPTN/UNOS renal transplant registry. In: Cecka JM, Terasaki PI, eds. *Clinical Transplants 2003*. Los Angeles, CA: UCLA Immunogenetics Center; 2004:1–12, with permission.

Although the evaluation of potential recipients is focused on the assessment of cardiovascular status, further studies must exclude malignancies and infections that would contraindicate transplantation and immunosuppression. Potential kidney recipients who are infected with hepatitis C should be evaluated by a hepatologist to determine the risks of immunosuppression causing progression to end-stage liver disease. Potential kidney recipients with evidence of advanced liver disease should be evaluated for a combined liver and kidney transplant. For patients with less advanced liver disease, consideration could be given to treatment with newer antiviral drugs before proceeding with kidney transplantation to provide the opportunity for viral clearance.[16] Kidney transplantation was previously contraindicated in people with HIV infection secondary to concerns of exacerbating an already immunologically compromised state. Recent advances in antiretroviral therapy and the ability to provide effective prophylaxis against opportunistic infections has prompted several centers to perform transplantation in

people with end-stage renal disease and HIV infection. Early results suggest that progression of HIV to AIDS has not been seen following transplantation and immunosuppression, with early allograft success rates comparable to those in non–HIV-positive recipients.[17] Potential patients with a previous history of tuberculosis or conversion to purified protein derivative positivity should be evaluated for active disease.

Colonoscopy, mammography, and Pap smear should be performed as dictated by age-specific standard guidelines. For most malignancies, a disease-free interval of 5 years is recommended before kidney transplantation. Controversy exists about pretransplant waiting times for certain malignancies, such as early stage breast cancer or prostate cancer, and some centers will not require any pretransplant waiting. Similarly, pretransplant wait times are probably not necessary for nonmelanoma skin cancers and early stage renal cancers. For patients with congenital abnormalities as the cause of renal failure, a complete workup of the genitourinary systems is necessary, including urodynamics and voiding cystourethrograms. These studies are particularly important in children with end-stage disease resulting from posterior urethral valves, to ensure that the bladder will serve as an adequate conduit for the kidney transplant. For patients with severe reflux disease and chronic pyelonephritis, native nephroureterectomy may be required to prevent posttransplant infection secondary to chronic reflux into the native ureters. For patients with inadequate bladder capacity and function, pretransplant reconstructive procedures such as ileal augmentation or ileal conduits may be required.

For patients with suspected clotting disorders based on a previous history of thromboembolic events (frequent clotting problems with dialysis access) or diseases associated with an increased frequency of clotting disorders (i.e., lupus), a hematologic workup is necessary to determine the necessity for anticoagulation at the time of the transplant. The length of time for anticoagulation is dependent on the severity of the clotting disorder and a history of a previous thrombotic event. This workup should include a determination of serum levels of protein C, protein S, anticardiolipin antibody, factor V Leiden, antithrombin III levels, and the G20210 A prothrombin gene mutation.

Living-Donor Nephrectomy: Open and Laparoscopic

A living kidney donor operation is a unique surgical procedure for two reasons. First, the donor has no medical reason to be in the operating room, and the process is driven only by his or her willingness to help another person with the gift of donation. Second, the removed tissue must be in perfect condition because it will be reimplanted into the recipient. These two features, therefore, necessitate that the donor operation is done safely and done well. The original donor operation was done through a generous flank incision, allowing for good exposure and careful dissection of the renal vessels. Unfortunately, this flank approach generally left a large incision, with its accompanying morbidity, pain, and sometimes adverse cosmetic result. The development of the laparoscopic procedure to remove kidneys has revolutionized the field, although its initial introduction was met with trepidation because of concerns over donor safety. With the explosive growth and dissemination of this procedure, it has now become the standard for donor nephrectomy.

The procedure is most commonly done through a transperitoneal approach, although some surgeons prefer to remain retroperitoneal. Once the operative space is expanded with carbon dioxide gas and the scope is inserted, two to three additional ports are placed to allow for the passage of instruments to dissect the kidney (Fig. 36-2). Some centers also favor the use of a gastight "hand-port," which allows placement of the surgeon's hand in the operative space to assist in exposure and to have available if sudden bleeding is encountered. Once the kidney vessels are transected and the vessel stumps are controlled by laparoscopic staples, the kidney can be removed through a 2- to 3-in incision, which can be placed in a position that leaves minimal scarring and avoids cutting muscle tissue. Most commonly this is via a Pfannenstiel incision, and recently the use of natural orifice approaches has been described. Additionally, some centers have adopted the use of a robotic assisted technique, to facilitate the dissection of important vascular structures. Donors who undergo the laparoscopic procedure typically have reduced pain medicine requirements, have a slightly shorter hospital stay, and are able to return to their usual activities sooner.[6,7]

The safety of this relatively new procedure has been established, in addition to the demonstration that kidneys recovered through a laparoscopic approach function as well as kidneys removed in an open operation. There has been an increased interest in live donation, coincident with the introduction of the laparoscopic procedure, suggesting that this procedure has removed some of the disincentives of the donation process.

Recipient Operative Procedure

The kidney transplant is heterotopically placed in the extraperitoneal iliac fossa. Although this is a less technically demanding procedure than either liver or pancreas transplants, attention to detail is imperative to optimize immediate graft function and avoid technical complications resulting in loss of the kidney transplant.

5 The operation is initiated by exposure of the iliac fossa through a curvilinear incision and can be done on either the right or left side. The incision extends from 1 cm above the symphysis pubis to approximately 2 cm medial to the anterior iliac spine (Fig. 36-3). The fascia is divided along the lateral border of the rectus sheath, and the contents of the peritoneal cavity are reflected cephalad and medially, exposing the iliac vessels in the retroperitoneum. Lymphatics overlying the iliac vessels are ligated and divided to prevent the development of lymphoceles. In males, the spermatic cord is secured with a vessel loop and can be retracted away from the operative field. In females, the round ligament is suture ligated and divided. The inferior epigastric artery and vein are typically divided to prevent potential compression of the transplanted ureter. Placement of a mechanical retractor should avoid compression of the iliac artery and vein as well as the femoral nerve to prevent neuropraxias.

The living- or deceased-donor kidney is inspected for the presence of multiple vessels, duplication of the urinary collecting system, and parenchymal abnormalities. The artery and vein are dissected from surrounding structures to provide the necessary length for transplantation. In the case of multiple arteries, a decision must be made as to whether to perform ex vivo reconstruction to achieve a single implantable conduit versus implanting the vessels separately. This decision is in part dependent on the quality of the recipient vessels and an assessment as to whether the anastomosis of multiple vessels directly into the recipient would require an unacceptable period of warm ischemia to the kidney. In general, in an adult the anastomosis of the renal artery and vein are performed in an end-to-side fashion to the external iliac vessels, although occasionally the presence of atherosclerotic disease requires transplantation to the common iliac vessels. In children who weigh less than 20 kg, or for third transplants in adults, an intraperitoneal approach is used and the vascular anastomoses are frequently performed to the aorta and inferior vena cava. For kidneys from deceased donors, a Carrel patch of aorta is used to prevent stenosis and to provide a common patch for multiple arteries. Warm ischemia time should be minimized to prevent delayed graft function. Ensuring adequate intravascular volume and stable hemodynamics at the time of reperfusion is extremely important to achieve optimal function of the transplant.

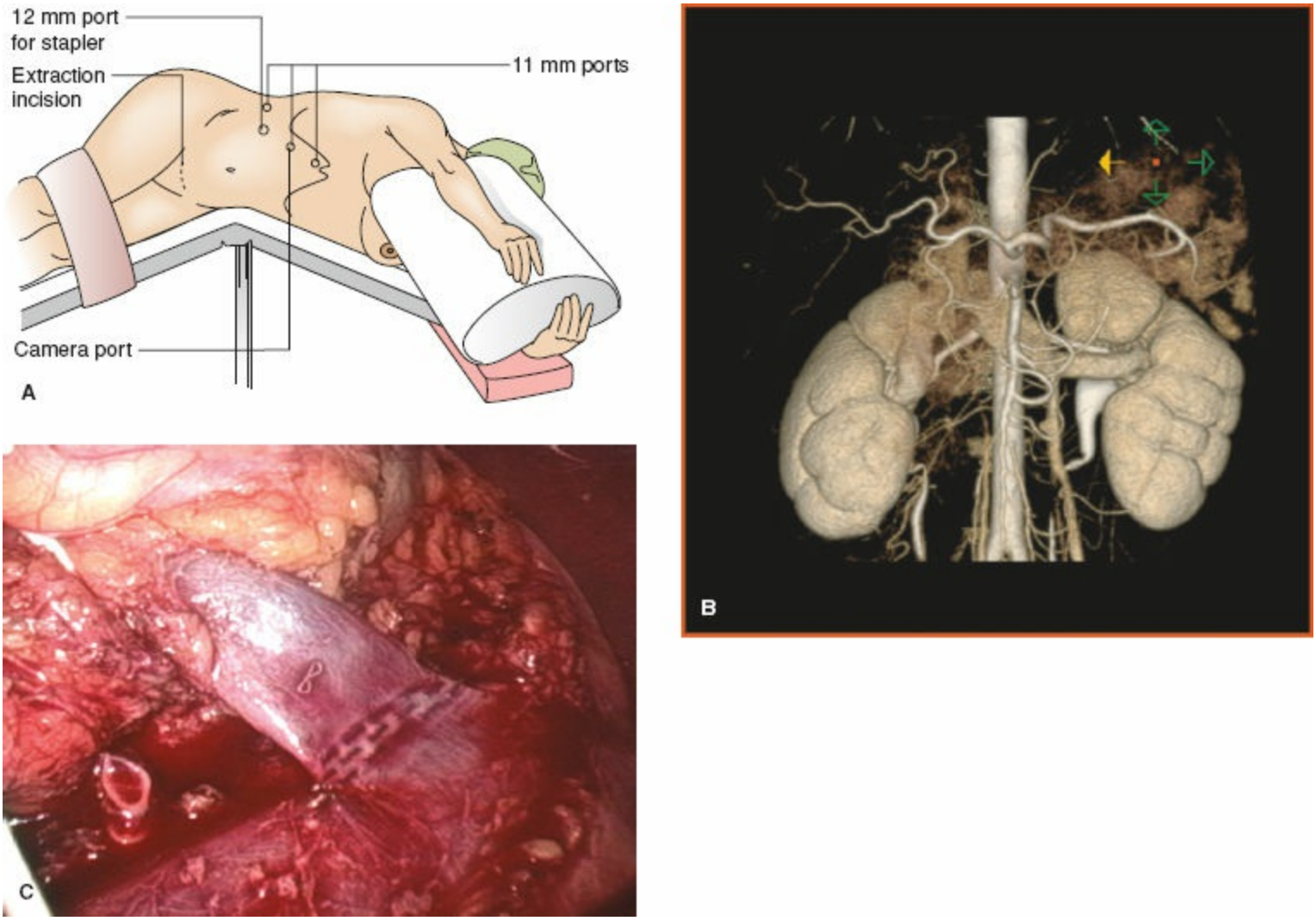

Figure 36-2. **A:** The laparoscopic donor procedure is performed with the donor in a lateral position, typically using three to four ports, with extraction of the kidney through a 6- to 8-cm incision. **B:** Preoperative computed tomography angiogram revealing the arterial and venous anatomy. **C:** Intraoperative photograph of laparoscopic view of right kidney just prior to transection of the renal vein. The artery has already been divided.

The reimplantation of the ureter is most frequently performed through an extravesicular technique. Following positioning of the revascularized kidney in the iliac fossa and assurance of hemostasis, the ureter is shortened to permit a tension-free anastomosis with adequate blood supply to the distal ureter. In men, the ureter is placed under the spermatic cord to prevent ureteral obstruction. The bladder is distended with an antibiotic solution to identify a suitable area for ureteral implantation on the dome of the bladder, and a cystotomy is made at this site. An anastomosis between the mucosa of the bladder and transplanted ureter is constructed using an absorbable suture to prevent stone formation. A second layer of the bladder musculature is closed over the distal portion of the ureter to prevent reflux during micturition.

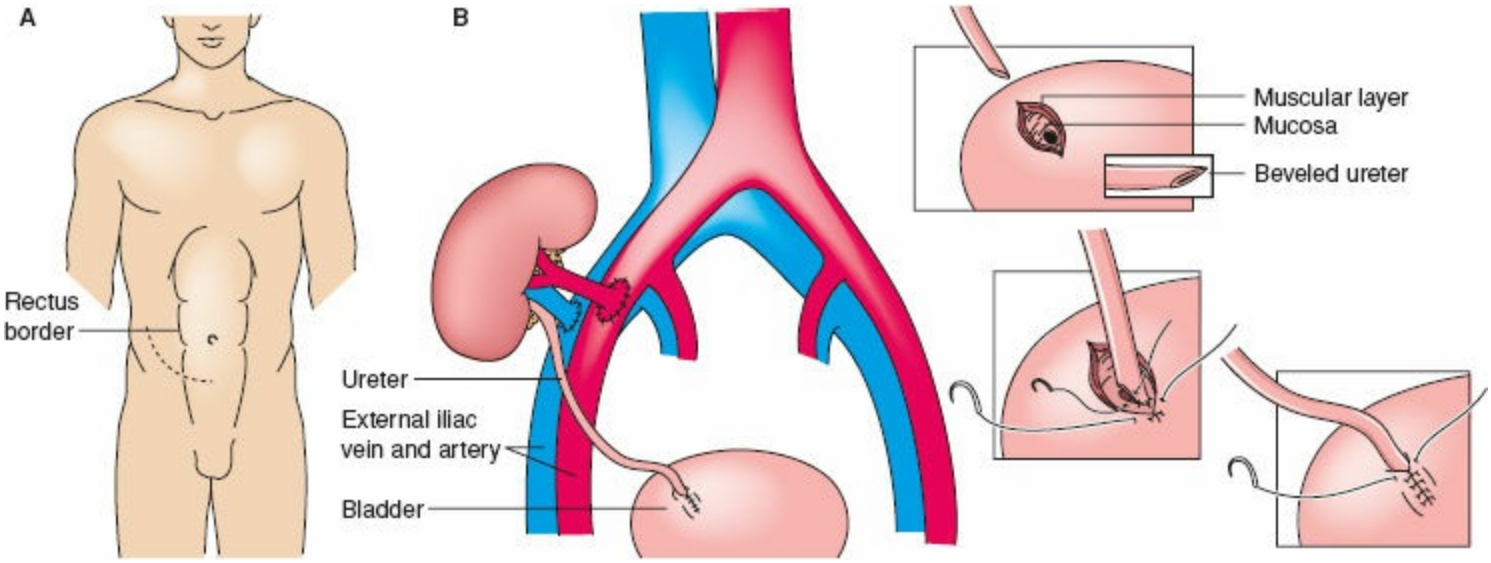

Figure 36-3. **A:** Curvilinear iliac fossa incision used for the kidney transplant recipient procedure. **B:** Vascular anastomoses completed between the recipient external iliac artery and vein and donor renal artery and vein. *Insets:* ureteral anastomosis performed using the external ureteroneocystostomy technique.

There are alternative techniques to reimplant the ureter, including the Politano–Leadbetter transvesical ureteroneocystostomy. This technique involves tunneling the ureter through the bladder wall from the inside of the bladder. This technique is still preferred by some surgeons who believe the long-term prevention of reflux is superior with the transvesicular approach. However, this technique requires a second cystotomy, and posttransplant hematuria is more common than with the extravesicular technique. A third technique for ureteral implantation in recipients with normal native ureters is ureteroureterostomy over a double-J stent. In general, this technique is reserved as a salvage procedure for reimplantation of transplanted ureters with distal strictures secondary to ischemia. It can also be used as a primary technique if there are questions regarding the blood supply to the distal ureter at the time of transplant. This technique is preferred if the donor ureter was damaged or inadvertently stripped of its blood supply at the time of procurement but is dependent on the availability of normal native ureters to serve as an adequate conduit. The routine placement of a double-J stent is center dependent, with some centers reserving placement of the stent for challenging extravesicular anastomosis to poor quality bladders.

The surgical procedure has changed little over the last 60 years, with the exception of limited reports of implantation of the kidney with the use of a robotic-assisted laparoscopic approach. The purported advantage is smaller incisions, which appear to have an advantage in obese patients, avoiding some of the frequent wound complications. Widespread adaptation of this technique has not occurred.[18]

COMPLICATIONS

Early Graft Dysfunction

Most kidneys begin to function immediately after implantation, especially in the case of a living donor. When the initial function results in only a slow drop in serum creatinine, the diagnosis of slow graft function is made. When dialysis is needed in the first week because of poor function, the diagnosis of delayed graft function is made. Delayed graft function typically occurs in 15% to 30% of deceased-donor transplants. The diagnosis of slow graft function or delayed graft function is important to establish because other problems, such as rejection, vascular occlusion, or ureteral obstruction, can also result in low urine output and need for dialysis. These other causes must be eliminated before the diagnosis of slow graft function or delayed graft function can be made.

In the immediate postoperative period, careful attention to fluid status is critical. In cases of immediate graft function, fluid orders should include replacement for urine output as well as a maintenance fluid rate. This approach ensures that the patient does not become volume depleted and compromise perfusion to the new kidney. In cases of delayed graft function, fluid should be restricted and dialysis instituted when electrolyte imbalance or fluid overload are evident.

A decrease in urine output in the early postoperative period requires immediate diagnostic and therapeutic intervention. A stepwise algorithm to assist in diagnosing the etiology of oliguria is shown in Figure 36-1. Once mechanical obstruction of the indwelling Foley catheter has been excluded by irrigation, the volume status of the patient should be assessed, preferably with a central venous pressure line or pulmonary artery catheter. Fluid replacement to restore intravascular volume should be initiated in the volume-depleted patient.

Radiologic evaluation using various imaging techniques is required if urine output remains low in the face of adequate volume status. Ultrasonography is most helpful to diagnose ureteral obstruction caused by technical complications at the anastomosis or fluid collections that may be obstructing the ureter by extrinsic compression. With the addition of duplex and color Doppler imaging, blood flow to the kidney can be evaluated and technical problems with the vessels can be assessed. Nuclear medicine techniques are also valuable for assessing renal function. Technetium 99m diethylenetriamine pentaacetic acid (DTPA) and iodine-131 iodohippurate (Hippuran) are the two major radionuclides used in the evaluation of renal allograft function. DTPA renal scans evaluate the vascular flow pattern of the kidney as well as the gross anatomy of the ureter and bladder. Scans are performed over 30 minutes, with uptake of contrast within 6 seconds indicating adequate flow to the graft. Peak activity in the parenchyma should be reached within 2 minutes, followed by a gradual decline in radioactivity in the renal parenchyma and an increase in radioactivity in the urinary collecting system and bladder. Iodine-131 iodohippurate scans are more sensitive in evaluating renal function. Peak activity is also reached in 2 to 4 minutes, with gradual decline over the next 30 minutes. In rejection, acute tubular necrosis and drug toxicity poor uptake and poor excretion are the typical

findings with a nuclear medicine scan.

If these imaging techniques do not provide an explanation for poor urine output, the diagnosis of delayed graft function is made. Immunosuppression can then be adjusted to minimize or avoid the calcineurin inhibitors, which can prolong the recovery from delayed graft function, and also to initiate antibody therapy to protect the kidney from rejection. The combination of delayed graft function and early rejection is clearly associated with worse outcome in the long term, and an early biopsy of the kidney that is functioning poorly is helpful to diagnose rejection and guide therapy.

Technical Complications

6 Most surgical complications are experienced in the immediate postoperative period. The two main types of complications can be classified as vascular and urologic.

Renal artery thrombosis is a rare complication occurring in about 1% of transplants. The risk of this complication is higher with size mismatch of donor renal artery and recipient internal iliac artery when an end-to-end anastomosis is performed, in kidneys with multiple renal arteries, in kidneys traumatized because of rough handling, and in the presence of an unidentified renal artery intimal flap. Sudden loss of urinary output, not the result of an obstructed Foley catheter or inadequate vascular volume, should necessitate a workup with duplex Doppler ultrasound. Loss of signal is indicative of no flow to the kidney. Alternatively, a nuclear medicine renal scan is informative, with lack of isotope uptake by the kidney indicating no blood flow. Prompt return to the operating room for correction of a technical problem is imperative, but often the diagnosis is not made quickly enough to salvage the kidney.

Renal artery stenosis occurs in up to 15% of transplanted kidneys. Difficult-to-control hypertension should suggest the possibility of stenosis. Diagnosis with renal duplex ultrasound followed by arteriography to better define the anatomy and degree of stenosis should be done before operative repair or angioplasty. Initial success rates for both methods are similar (75% to 80%), but the restenosis rate following angioplasty is not well defined. Anastomotic strictures respond less well to angioplasty and probably should be repaired by operative intervention.

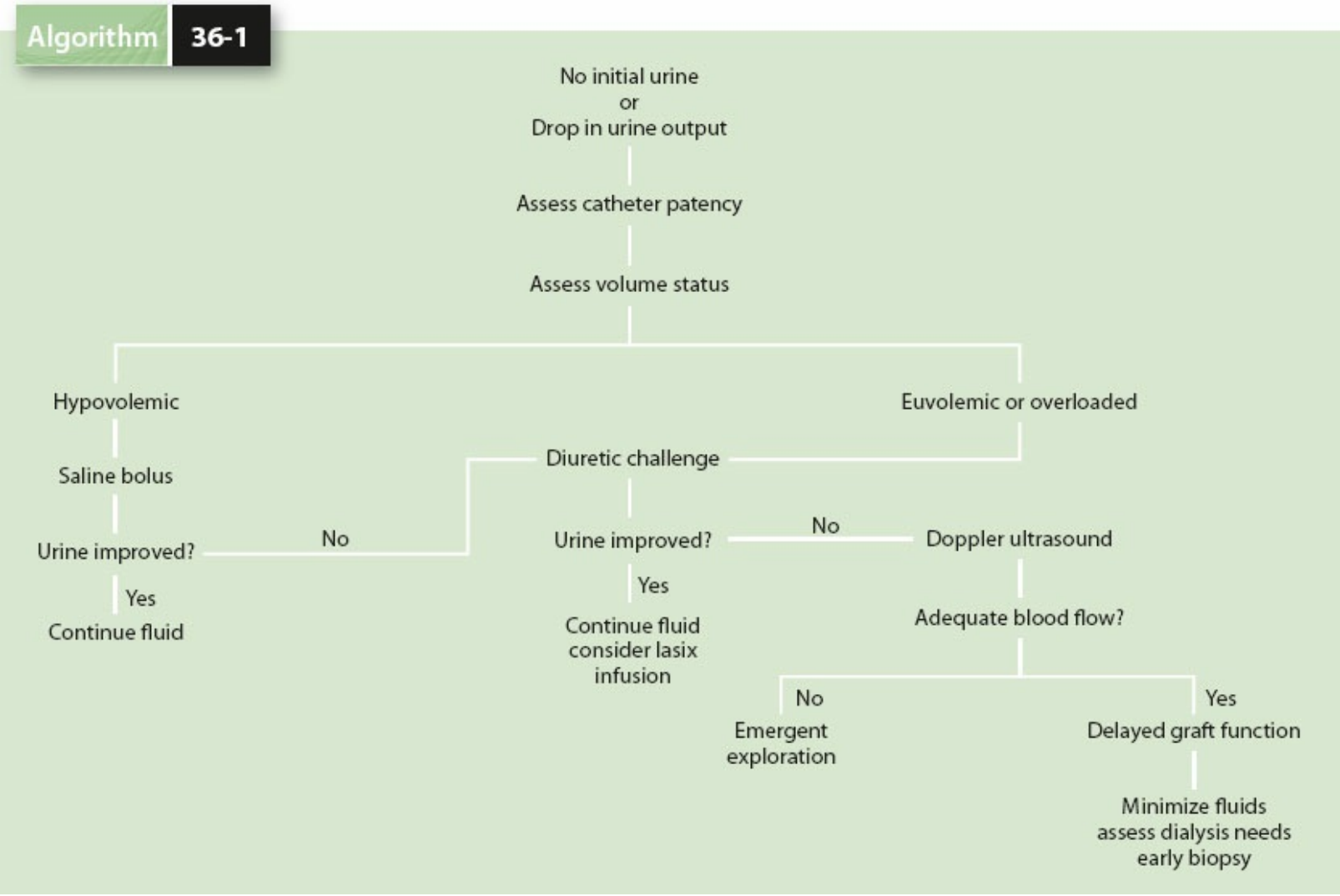

Algorithm 36-1. Stepwise approach to the management of decreased low urine output posttransplant.

Aneurysms that occur in the renal artery are either pseudoaneurysms at the anastomotic site or mycotic aneurysms secondary to bacterial or fungal infection. A rapidly expanding, tender pulsatile mass in the region of the kidney suggests a mycotic aneurysm. Arteriography is confirmatory for diagnosis. Treatment consists of appropriate antibiotics and removal of the transplanted kidney.

Venous complications are less frequent, with thrombosis occurring in 1% to 4% of transplants. Causative factors include intimal damage during retrieval, kinking at the iliac vein anastomosis, or pressure secondary to a lymphocele, urinoma, or hematoma. Occasionally, severe rejection can result in venous occlusion. Heparin infusion for incomplete occlusion and transplant nephrectomy for complete occlusion are the indicated therapies. Occasionally, graft salvage is possible if the diagnosis is made before progression of clot into the kidney itself. The classic sign of new onset hematuria may be an early hint of a renal vein problem and should lead to an ultrasound.

Urologic complications include ureteral obstruction, urinary fistula, or bladder leak. These complications all present with decreased urine output and a rise in serum creatinine. With a urine leak, pain in the region of the transplant may be severe. Mechanical obstruction of the Foley catheter must first be eliminated. Ureteral obstruction occurs in 1% to 9% of transplants, and diagnosis can be made with

ultrasonography demonstrating hydronephrosis. A leak is usually diagnosed with a nuclear medicine renal scan. Further definition of a leak or stricture can be obtained via an antegrade pyelogram (Fig. 36-4). Early obstruction of the transplant ureter at the site of the bladder anastomosis may respond to internal stenting. Late strictures usually require reoperation, and urine and blood polymerase chain reaction for the polyoma virus should be done in that circumstance, because polyoma viral infection can lead to ureteral stricture. The surgical correction of a ureteral stricture may require reimplantation of the ureter into the bladder, the creation of a Boari flap, or the use of the recipient's native ureter for a ureteroureterostomy (Fig. 36-5).

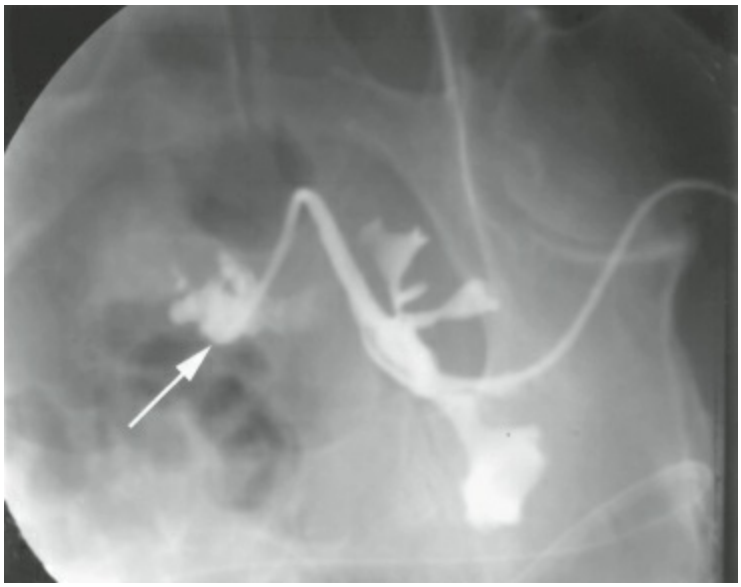

Figure 36-4. Percutaneous nephrostogram revealing a urine leak from the ureterovesical anastomosis.

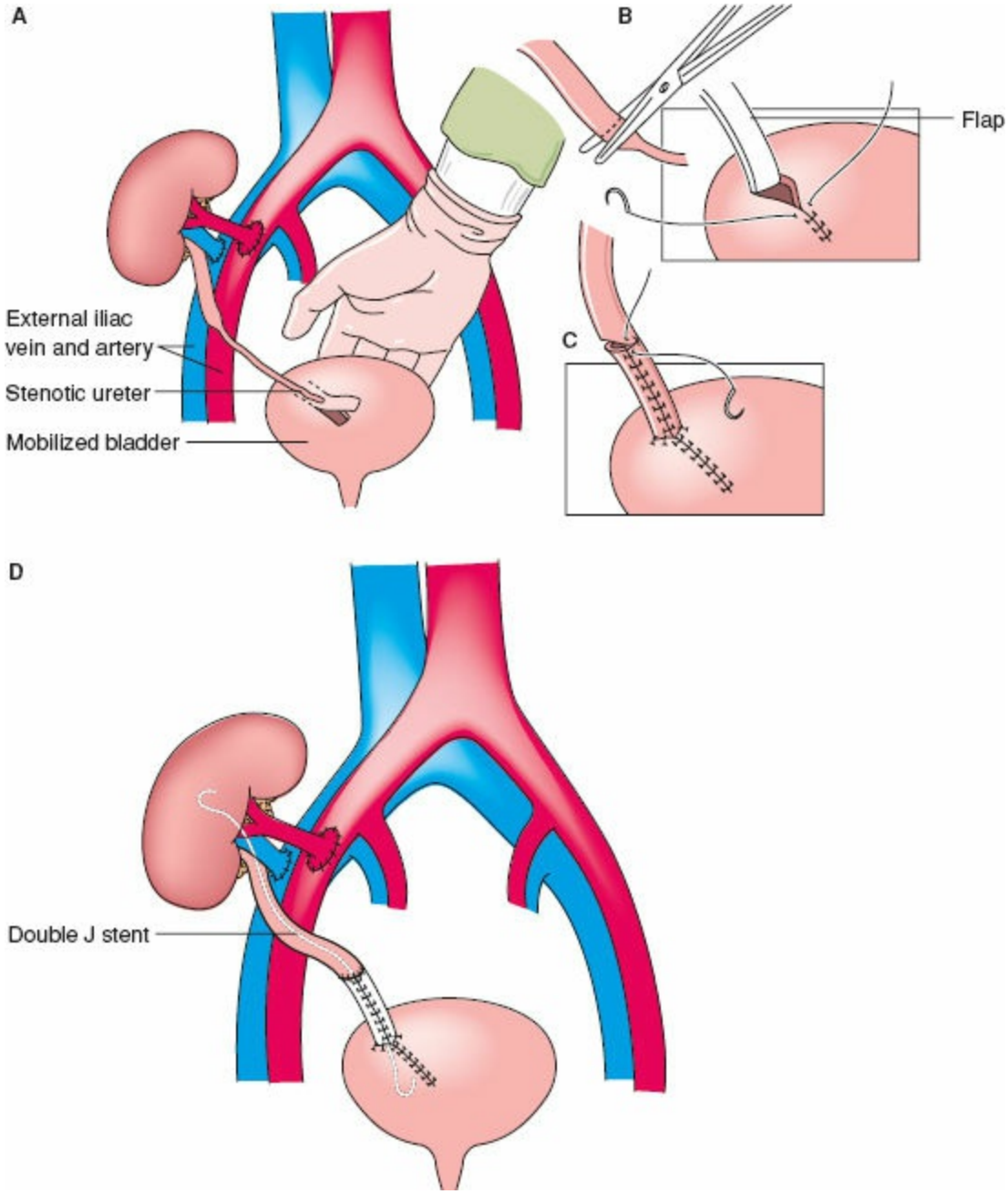

Figure 36-5. **A:** Reconstruction of a stenotic donor ureter, showing resection of the stenotic segment and mobilization of the bladder. **B–D:** A Boari flap is constructed from a tabularized segment of bladder wall and anastomosed end-to-end to the proximal donor ureter.

IMMUNOSUPPRESSION, REJECTION, AND IMMUNOSUPPRESSIVE COMPLICATIONS

Immunosuppression

Major advances in the ability to block immune-mediated destruction of the kidney have taken place in the past few years, resulting in a significant decrease in the incidence of acute rejection and improvement in long-term allograft survival rates.[15] This advance is the result of numerous agents that have been added during the past decade to the immunosuppressive armamentarium of prednisone, azathioprine, and cyclosporine A. These agents include tacrolimus, mycophenolate mofetil, sirolimus, and everolimus (mTOR inhibitors), anti-interleukin-2 receptor blockers, antithymocyte globulin (a polyclonal anti–T-cell agent), rituximab (an anti-CD20 monoclonal agent), and most recently costimulatory blockade with CTLA4-Ig. The addition of various newer drugs targeting different pathways in the alloimmune cascade has permitted the development of regimens that are less dependent on the calcineurin inhibitors or prednisone.[19]

Newer strategies in the immunosuppressive pipeline are targeted to block: costimulatory pathways; signaling pathways that activate T cells and T-cell proliferation; and trafficking and recruitment of immune cells. The most promising biologic agents targeted to block the costimulatory pathways include a second-generation CTLA4Ig (LEA29Y), a humanized anti-CD11-a (anti-LFA1), and a humanized anti-B7.1/B7.2. Promising agents designed to block T-cell activation and proliferation are the inhibitors of the Janus protein tyrosine kinase (JAK3) and the leflunomide analog FK778. Finally, drugs to block the trafficking and recruitment of immune cells are antagonists against the chemokine receptors CCR1, CXCR3, and CCR5. The chemokine antagonists have been effective in experimental transplantation and will likely be transitioned to clinical trials in the near future.[20]

Rejection

7 Hyperacute rejection is extremely rare and is humorally mediated by preformed anti-HLA antibodies. Hyperacute rejection occurs within minutes to hours following reperfusion of the kidney, whereas classic cell-mediated rejection typically does not occur until 1 to 2 weeks after the transplant. In hyperacute rejection, the anti-HLA antigens bind to the vascular endothelium of the kidney transplant, resulting in activation of the complement cascade and rapid graft thrombosis. The kidney appears blue-black with poor tissue turgor despite adequate blood flow. The characteristic histologic appearance includes the triad of polymorphonuclear leukocytes in the glomerular capillary loops, fibrin deposition, and platelet thrombi. The kidney cannot be salvaged, and a transplant nephrectomy is necessary. The presence of anti-HLA antibodies should be detected in the pretransplant crossmatch, and with the sensitivity of current immunologic assays, hyperacute rejection is usually a result of technical or clerical errors in the crossmatch procedure. A more common and less intense form of humoral rejection occurring within a few days of transplantation is a result of reactivation of memory B cells following reexposure to alloantigen. The histologic findings are defined by positive C4d staining on vascular endothelium, although lymphocytic infiltrates consistent with classic cell-mediated rejection can be present. Treatment of this aggressive rejection can include plasmapheresis, the anti–B-cell agent rituximab (anti-CD20 monoclonal antibody), and polyclonal antilymphocyte preparations (antithymocyte globulin).

8 Classic acute cell-mediated rejection typically occurs between 1 week and 3 months following transplantation. Most patients with rejection episodes present with decreasing urine volumes and increases in serum creatinine values. Low-grade fever and allograft tenderness may be present, but significant physical symptoms frequently are absent. Immediate workup of increasing serum creatinine should be initiated, beginning with an ultrasound to rule out ureteral obstruction or technical vascular complications as the cause of the deteriorating function. Similarly, toxicity from calcineurin inhibitors needs to be determined by checking drug levels. A percutaneous kidney biopsy is performed to confirm rejection. The severity of the rejection episode is based on the presence of lymphocytes in renal tubules (tubulitis) and vascular endothelium (vasculitis). Mild rejection is generally treated with pulse corticosteroids and maximizing the maintenance immunosuppression to ensure therapeutic levels of calcineurin inhibitors. More severe rejection with both tubulitis and vasculitis, as well as steroid-resistant rejection, is treated with antilymphocyte antibody preparations, most frequently with rabbit polyclonal antilymphocyte preparations. If the rejection episode occurred while the patients had therapeutic drug levels, maintenance therapy is frequently altered following the antibody therapy. For example, if maintenance therapy consisted of cyclosporine A, the calcineurin inhibitor could be switched to tacrolimus. Other potential strategies include the addition of an mTOR inhibitor to the immunosuppressive regimen, particularly for cases where there is evidence of calcineurin inhibitor toxicity on biopsy.

9 Each rejection episode takes a toll on long-term function of the kidney transplant. Even well-controlled acute rejection episodes initiate a cascade of events leading to

interstitial fibrosis and proliferative changes affecting the vascular endothelium. These histologic and progressive degenerative changes are classified as chronic rejection or chronic allograft nephropathy. These changes lead to loss of graft function over the course of months to several years. Current strategies minimizing calcineurin inhibitor nephrotoxicity are being used to prolong function in kidneys with these chronic changes and involve the addition of TOR inhibitors to replace the calcineurin inhibitors. It remains unclear whether the marked decrease in acute rejection episodes, from greater than 50% to less than 20% observed in the past 5 years, will translate to better long-term function of transplants. Nonetheless, it is evident that immunosuppression strategies minimizing prednisone and calcineurin inhibitors are providing safer and more effective immunosuppression for kidney-transplant recipients while decreasing long-term toxicities associated with immunosuppression.

Immunosuppressive Complications

It would be naive to assume that the intensification of immunosuppressive regimens resulting in decreased acute and chronic rejection rates can be accomplished without sequelae. Infections and malignancy remain significant complications associated with long-term immunosuppression and are the driving force for drug-minimization strategies. Early infections during the perioperative period are commonly iatrogenic and involve bladder infections or intravenous catheter use. Higher doses of immunosuppressive drugs used in the early postoperative period predispose patients to these infections and emphasize the importance of maintaining sterility during Foley catheter placement and insertion of intravenous catheters. Pneumonia related to mechanical ventilation and poor postoperative inspiratory effort can occur in the early postoperative period, and early incentive spirometry should be encouraged to decrease the potential for this infection. Wound infections are relatively uncommon, although diabetes and obesity are both associated with a much higher incidence of wound complications. Weight reduction to achieve a body mass index of less than 35 is strongly recommended to facilitate the operative procedure and minimize the risks of wound complications, particularly in the recipient with diabetes mellitus.

Cytomegalovirus (CMV), a herpesvirus, remains a problematic infection in the immunosuppressed patient and can become symptomatic 1 to 2 months following the transplant. CMV-seronegative patients who receive a kidney from a CMV-seropositive donor are at the highest risk for infection, although prophylaxis with acyclovir or ganciclovir is generally provided for all recipients for a period of 3 to 6 months following the transplant. Despite prophylaxis, activation of CMV can occur, accompanied by fever, malaise, pneumonia, gastrointestinal distress, or dysfunction of the kidney transplant. The effective treatment of blood- or tissue-invasive CMV has been one of the major advances in the management of kidney transplant patients within the past two decades. What was a life-threatening disease in the early era of solid organ transplantation can today be effectively managed with oral antibiotics.

Prophylaxis against *Candida albicans* with fluconazole and *Pneumocystis carinii* with trimethoprim–sulfamethoxazole is also part of most management strategies posttransplant. Other potentially life-threatening opportunistic organisms that can affect the chronically immunosuppressed transplant recipient include *Aspergillus, Cryptococcus, Listeria, Nocardia,* and *Mycobacterium.*

More potent immunosuppression regimens used in the current era have been associated with the emergence of polyoma or BK virus, a previously rare infection that may cause graft loss in up to 5% of infected patients. Reduction in immunosuppression is necessary to prevent progression of viral tubulitis. There has been some experience with the use of leflunomide, ironically an immunosuppressive agent, but with an active metabolite, A77 1726, that has substantial antiviral activity in vitro and in animals. Another potential medication, cidofovir, is a nucleotide analogue that inhibits viral DNA polymerase but unfortunately is also nephrotoxic, and its in vivo efficacy has not been proved. Probably the best method to prevent graft loss due to polyoma is the use of monitoring of urine

and serum levels of BK virus, with lowering of immunosuppression when early evidence of polyoma is detected.

Patients with a previous history of active tuberculosis or conversion to purified protein derivative positivity should receive appropriate prophylaxis for 6 months to 1 year following the transplant procedure.

More potent immunosuppression regimens will also have an impact on the development of neoplasms following transplantation.[21] Skin cancers are the most common malignancy following transplantation, with more than 90% being squamous or basal cell cancers. The incidence of skin cancers is staggering, with 50% or more of white recipients ultimately developing lesions. The immunosuppressed patient also has a higher incidence of nodal spread, and educating the patient about the importance of avoiding direct sun exposure is essential. Other malignancies that have a particularly high incidence in transplant recipients include non-Hodgkin lymphomas and carcinomas of the anogenital areas. The etiology of anogenital carcinoma is related to the presence of human papilloma virus. Although there have been no prospective trials to date, there is some evidence that TOR inhibitors are advantageous in the setting malignancies as the preferred immunosuppressive agent based on their antiproliferative qualities. Conversion to mTOR inhibitors and minimization of calcineurin inhibitors is a strategy that has been used with increasing frequency in the scenario of malignancies following transplantation.

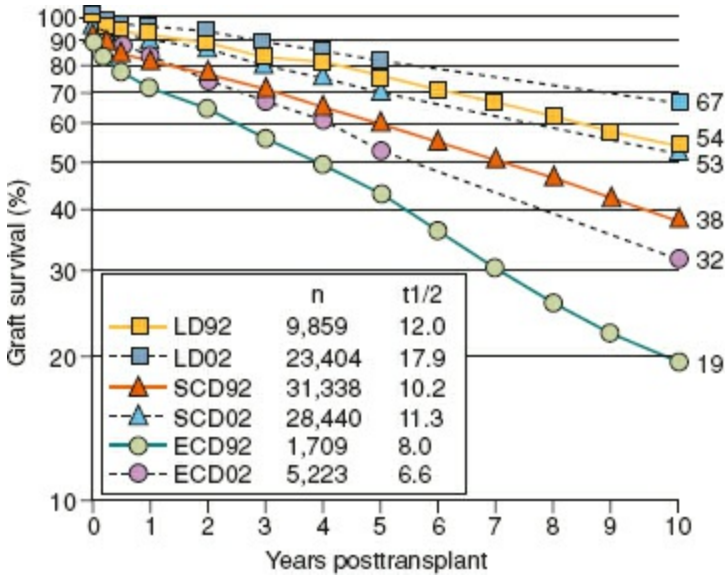

Figure 36-6. Comparison of graft survival and graft half-life ($t_{1/2}$) in 1992 and 2002 for different donor types (age >60 years in 1992 group, age >50 years with hypertension, elevated creatinine, or donor death from cerebrovascular accident in 2002 group). There has been an improvement in survival for all donor types, with the best long-term results with living-donor kidneys. ECD, expanded criteria donor; LD, living donor; SCD, standard deceased donor.

Posttransplant lymphoproliferative disease is the second most common form of malignancy in transplant recipients and is associated with Epstein–Barr virus. These lymphoproliferative syndromes present as a spectrum of pathology, extending from polyclonal lymphoproliferation to monoclonal B-cell lymphomas. Polyclonal disease has been managed by decreasing or withdrawing immunosuppression, whereas progression to

monoclonal lymphomas has required chemotherapy. CD20-positive lymphomas have been successfully managed with rituximab, an anti-CD20 antibody, with no significant side effects.

CURRENT RESULTS AND FUTURE TRENDS

Over the past three decades, progressive improvement has been made in patient and graft survival, independent of donor source. This progression is best shown in Figure 36-6 for the period of time spanning 1992 to 2002. Overall graft survival, as well as the half-life of the graft, improved incrementally for live-donor transplants, standard deceased-donor transplants, and even deceased-donor transplants using suboptimal or expanded criteria donors.[15] This change is related to improved organ preservation, perfected operative technique, and most important, improved immunosuppressive agents. Current 1-year actuarial graft survival rates for living and deceased-donor transplants are 94.8% and 88.9%, respectively.[22] These remarkable 1-year results continue to be overshadowed by the specter of late graft loss due to chronic rejection. This problem remains unsolved in renal transplantation, and future improvement in long-term survival will be achieved only when the mechanisms of this process are understood.

The exponential growth in waiting lists compounded by the ongoing critical shortage of organs will continue to stimulate creative means of increasing both the living- and deceased-donor pools. Expansion in the number and types of immunosuppressive agents has resulted in marked decreases in the incidence of acute rejection, which it is hoped will translate to prolongation in the long-term function of kidney transplants. Newer strategies in immunosuppressive regimens that minimize nephrotoxic cyclosporine and tacrolimus by adding nonnephrotoxic agents will also benefit the long-term function of transplanted kidneys. The effect of ischemia-reperfusion injury on both early and late graft function, as well as its impact on the development of chronic rejection and transplant glomerulopathy, is an area of active research, and potential therapeutic interventions to minimize this injury are being evaluated. The induction of tolerance to foreign antigen remains the “holy grail” of transplantation. A paucity of tolerizing regimens have been applied clinically, although the use of donor bone marrow or stem cells will likely have a future role in achieving the elusive goal of transplantation tolerance.

References

1. Tanabe K, Tokumoto T, Ishida H, et al. Excellent outcome of ABO-incompatible living kidney transplantation under pretransplantation immunosuppression with tacrolimus, mycophenolate mofetil, and steroid. *Transplant Proc* 2004;36(7):2175–2177.
2. Takahashi K, Saito K, Takahara S, et al. Excellent long-term outcome of ABO-incompatible living donor kidney transplantation in Japan. *Am J Transplant* 2004;4(7):1089–1096.
3. Tait BD, Susal C, Gebel HM, et al. Consensus guidelines on the testing and clinical management issues associated with HLA and non-HLA antibodies in transplantation. *Transplantation* 2013;95:19–47.
4. Meier-Kriesche HU, Kaplan B. Waiting time on dialysis as the strongest modifiable risk factor for renal transplant outcomes: a paired donor kidney analysis. *Transplantation* 2002;74(10):1377–1381.
5. Rosendale JD. Organ donation in the United States: 1988–2002. *Clin Transpl* 2003:65–76.
6. Ahearn AJ, Posselt AM, Kang SM, et al. Experience with laparoscopic donor nephrectomy among more than 1000 cases: low complication rates, despite more challenging cases. *Arch Surg* 2011;146(7):859–864.
7. Nogueira JM, Jacobs SC, Haririan A, et al. A single center comparison of long-term outcomes of renal allografts procured laparoscopically versus historic controls procured by the open approach. *Transpl Int* 2008;21(9):908–914.
8. Gurkan A, Kacar S, Varilsuha C, et al. Exchange donor transplantation: ethical option for living renal transplantation. *Transplant Proc* 2011;43(3):795–797.
9. Cooper JT, Chin LT, Krieger NR, et al. Donation after cardiac death: the university of wisconsin experience with renal transplantation. *Am J Transplant* 2004;4(9):1490–1494.
10. Aull MJ, Kapur S. Kidney paired donation and its potential impact on transplantation. *Surg Clin North Am* 2013;93:1407–1421.
11. Israni AK, Salkowski N, Gustafson S, et al. New national allocation policy for deceased donor kidneys in the United States and possible effect on patient outcomes. *J Am Soc Nephrol* 2014;25:1842–1848.
12. Warren DS, Zachary AA, Sonnenday CJ, et al. Successful renal transplantation across simultaneous ABO incompatible and positive crossmatch barriers. *Am J Transplant* 2004;4:561–568.
13. Jordan SC, Tyan D, Stablein D, et al. Evaluation of intravenous immunoglobulin as an agent to lower allosensitization and improve transplantation in highly sensitized adult patients with end-stage renal disease: report of the NIH IG02 trial. *J Am Soc Nephrol* 2004;15:3256–3262.
14. Jochmans I, Moers C, Smits JM, et al. Machine perfusion versus cold storage for the preservation of kidneys donated after cardiac death: a multicenter, randomized,

controlled trial. *Ann Surg* 2010;252:756–764.
15. Cecka JM. The OPTN/UNOS Renal Transplant Registry 2003. *Clin Transpl* 2003:1–12.
16. Terrault NA, Stock PG. Management of hepatitis C in kidney transplant patients: on the cusp of change. *Am J Transplant* 2014;14(9):1955–1957.
17. Stock PG, Barin B, Murphy B, et al. Outcomes of kidney transplantation in HIV-infected recipients. *N Engl J Med* 2010;363:2004–2014.
18. Tzvetanov I, Giulianotti PC, Bejarano-Pineda L, et al. Robotic-assisted kidney transplantation. *Surg Clin North Am* 2013;93:1309–1323.
19. Vincenti F. Immunosuppression minimization: current and future trends in transplant immunosuppression. *J Am Soc Nephrol* 2003;14(7):1940–1948.
20. Vincenti F, Kirk AD. What's next in the pipeline. *Am J Transplant* 2008; 8:1972–1981.
21. Morath C, Mueller M, Goldschmidt H, et al. Malignancy in renal transplantation. *J Am Soc Nephrol* 2004;15:1582–1588.
22. Wynn JJ, Distant DA, Pirsch JD, et al. Kidney and pancreas transplantation. *Am J Transplant* 2004;4(Suppl 9):72–80.

Chapter 37

Hepatic Transplantation

Theodore H. Welling

Key Points

1. The main indication forliver transplantation is end-stage liver disease, defined as the clinical scenario in which a pathologic process or multiple processes have resulted in a damaged liver that has minimal function and no potential for recovery.
2. The Organ Procurement and Transplantation Network uses the Model of End-stage Liver Disease score as a method of prioritizing liver transplant recipients. The Model of End-stage Liver Disease score is an integer value based on three objective laboratory studies: creatinine, bilirubin, and the international normalized ratio.
3. The degree of preoperative debilitation and the complexity of the operative procedure make complications following hepatic transplantation very common.
4. Approximately 2% to 4% of transplanted livers function so poorly in the immediate postoperative period that death is likely in the absence of retransplantation, a condition referred to as primary nonfunction of the allograft.
5. For reasons that are not completely understood, liver transplant recipients require less immune suppression than patients with other types of allografts, such as heart, lung, and kidney recipients.
6. Typical acute rejection in liver transplant recipients is usually cell mediated.
7. Chronic rejection is characterized by relentless immune attack on small bile ducts. Histologically, small bile ducts are obliterated or completely absent, termed *vanishing bile duct syndrome.*
8. The patient survival rate following liver transplantation in the United States at 1 year is more than 85% for adults and nearly 90% for children.

Liver transplantation has evolved over the past four decades to be the standard treatment for patients with a variety of acute and chronic liver diseases. The first successful liver transplant was performed on a moribund child with a hepatoma by Dr. Thomas Starzl at the University of Colorado in 1967.[1] This child lived more than a year before succumbing to recurrent tumor. Over the next 12 years, liver transplants continued to be performed at a modest rate. Despite 1-year survival rates of less than 50%, it was clear that some patients benefited from the procedure.

In 1979 cyclosporine was introduced into clinical organ transplantation by Sir Roy

Calne.[2] Almost immediately 1-year patient survival rates jumped to over 70%. As a result, liver transplantation programs began to appear worldwide. Today more than 10,000 liver transplants are performed annually in the United States, and survival rates exceed 85% at 1 year and 70% at 5 years, primarily varying on liver disease indication.[3,4]

The clinical expanse of liver transplantation is now primarily limited by the availability of suitable donor organs. Every year more patients are listed for liver transplantation than receive transplants. In the future it is likely that this problem will worsen because of the large number of individuals with chronic hepatitis C infection, a significant portion of whom will eventually develop cirrhosis and hepatocellular carcinoma (HCC), and the expanding numbers of patients with either HCC or nonalcoholic steatohepatitis (NASH).[5] Attention continues to be focused on methods to increase the available supply of livers for transplantation. Notable efforts to improve the supply of available organs include the work by the Department of Health and Human Services, which recently took up the cause of organ donation vigorously. This effort, termed the Organ Donation Breakthrough Collaborative,[6] focused on improving the success rate of organ donation efforts at the hospitals that have most potential organ donors nationwide. The Center for Medicare and Medicaid Services also joined the effort by declaring specific Conditions of Participation for all hospitals that treat Medicare patients in the United States.[7] This effort focused on encouraging methods of approaching donor families that have been shown to be optimally effective.

Many other methods to increase the number of donor livers are currently being practiced. These methods include the utilization of older liver donors, steatotic donor livers, the development of techniques to allow a single liver graft to be split into two grafts, and the utilization of liver grafts from donors that donate after cardiac death (DCD). Many centers have continued the development of safe surgical techniques that allow healthy, living volunteers to donate a segment of their liver to a recipient in need of a liver transplant.[8,9]

GENERAL INDICATIONS FOR HEPATIC TRANSPLANTATION

1 The most common indication for liver transplantation is end-stage liver disease. The term *end-stage* refers to the clinical scenario in which a pathologic process or multiple processes have resulted in a damaged liver that has minimal function and no potential for recovery. The diagnosis of end-stage liver disease is made primarily on the basis of clinical findings. Additional information about the etiology of the liver disease and thus its natural history can often be obtained by supplementary investigations including serologic studies and histologic examination of a liver biopsy specimen. It is important that potential liver transplant recipients are evaluated by a hepatologist and surgeon with expertise in end-stage liver disease, because many other diseases may present similar clinical pictures.

The severity of liver disease in an individual is highly variable, from mild cirrhosis and no symptoms to severe decompensation resulting in deterioration of mental status and frank renal failure. The rate of progression of liver disease from a functional state to invalidism and death is variable and may be rapid or may take several years. The challenge facing liver transplant professionals is to identify patients who will benefit from transplantation. Hepatic transplantation may result in wonderful and dramatic results, but at the same time it is always a high-risk procedure. In situations in which patients enjoy full performance status, and are only minimally symptomatic, transplantation is an inappropriate therapeutic measure. A liver transplant is a major surgical procedure on a profoundly ill individual with unavoidable risk that also requires chronic, lifelong immunosuppression. Despite advances in immunosuppressive medications developed over the past four decades, immunosuppression remains a treatment that induces a state of vulnerability in the recipient by virtue of the fact that the recipient's natural resistance to infection and malignancy is compromised. It is thus critical that patients be carefully selected who will benefit from the procedure.

Table 37-1 MELD and PELD Score

MELD score	$= 0.957 \times \text{Log}_e(\text{Creatinine [mg/dL]}) + 0.378 \times \text{Log}_e(\text{Total bilirubin [mg/mL]}) + 1.120 \times \text{Log}_e(\text{INR}) + 0.643$
PELD score	$= 0.436$ (Age younger than 1 year = 1, Older = 0) $- 0.687 \times \text{Log}_e(\text{Albumin [g/dL]}) + 0.480 \times \text{Log}_e(\text{Total bilirubin [mg/mL]}) + 1.857 \times \text{Log}_e(\text{INR}) + 0.667$ (Growth Failure = 1)

2 How is it possible to properly select patients and properly time transplantation so that the benefit of transplantation is assured? In 2002, the Organ Procurement and Transplantation Network began using the Model of End-stage Liver Disease (MELD)[10] score as a method of prioritizing liver transplant recipients. The MELD score is an integer value based on three objective laboratory studies: creatinine, bilirubin, and the international normalized ratio (INR) (Table 37-1). This has been adapted to pediatric patients as the Pediatric End-Stage Liver Disease (PELD) utilizing the variables in MELD

along with albumen instead of creatinine and including age as well as the presence of growth failure (Table 37-1). Analysis done by the Scientific Registry of Transplant Recipients (SRTR) has shown that patients with MELD scores of less than 15 have a mortality rate on the waiting list that is less than the mortality rate of the transplant procedure in the same population.[11] This suggests that patients with a MELD score of less than 15 do not receive an absolute survival benefit from transplantation whereas patients with higher MELD scores have the potential to receive a survival benefit with liver transplantation. In other words, there is no evidence that patients who are very ill from liver disease do not benefit from liver transplantation, but patients who have stable, mild liver disease should not receive a transplant until their disease has progressed to a more severe state.

Surprisingly, MELD more accurately predicts mortality than clinical factors that were previously thought to be ominous signs of reduced (6 months or less) survival. Such factors, including the presence of ascites, hepatic encephalopathy, spontaneous bacterial peritonitis, or variceal hemorrhage, do not add to the predictive value of MELD.[10] This finding may be related to the difficult nature of accurately quantifying clinical variables in registry databases or to the fact that MELD is such an accurate way of measuring functional hepatic capacity that no additional clinical variables are more relevant.

As will be discussed later, the transplant community has agreed upon certain exceptions to the MELD score for patients with chronic liver disease. It is generally supported that patients with diseases such as HCC, hepatopulmonary syndrome (HPS), primary oxaluria, and familial amyloidosis benefit from additional MELD points by regional review boards. Other diseases or complications such as portal vein thrombosis or portopulmonary hypertension (PPHTN) remain less clear and are handled on a case-by-case basis.[12]

Table 37-2 Urgent Listing Criteria for Liver Transplantation

Status 1A:	*FHF* (encephalopathy within 8 wks of liver disease and ICU status with ventilator dependence, renal replacement therapy, INR >2.0, or acute Wilson disease) *Hepatic artery thrombosis of liver transplant* (AST >3,000 U/mL and INR >2.5 or acidosis within 7 d) *Primary nonfunction of liver transplant* (AST >3,000 U/mL and INR >2.5 or acidosis within 7 d) *Anhepatic state* (graft removal for any reason)
Status 1B:	Age <18, chronic liver disease in ICU with MELD/PELD >25 plus one of the following: ventilator dependence, GI bleeding, renal replacement therapy, GCS <10

The improved ability to predict mortality for patients with liver failure allowed the development of national allocation policies that direct livers to those patients that will benefit. Importantly, the implementation of the MELD system of liver allocation from deceased donors has been associated with a decrease in the death rate on the waiting

list.[13] Further refinements of our understanding will undoubtedly occur as improved long-term follow-up data on waiting list mortality become available and as quality of life considerations are added to the analysis.

These considerations apply to the chronic forms of liver failure, but not to the important emergency decisions about transplantation that must be made when a patient presents with fulminant hepatic failure (FHF), which is defined as the progression from good health to liver failure with hepatic encephalopathy within 8 weeks. Without transplantation, the mortality rate for FHF is approximately 75%.[14] Death often occurs rapidly once patients progress to stage II (confusion), stage III, (stuporous), or stage IV (unresponsive) hepatic encephalopathy. In these cases, the decision to perform transplantation is based on clinical grounds. Current liver transplant allocation policy allows for the rapid transplantation of patients with fulminant hepatic failure. These patients can be listed as "status 1A," (Table 37-2) which gives them higher priority for available livers than patients with chronic liver disease who are prioritized based on MELD score.

CONTRAINDICATIONS TO LIVER TRANSPLANTATION

The number of absolute contraindications to hepatic transplantation has steadily decreased during the past several years as experience with the procedure has increased. Many clinical situations once considered to be absolute contraindications for transplantation are now either no longer considered to be contraindications or to be only relative contraindications. A thrombosed portal vein is no longer a contraindication to transplantation because techniques have been devised to effectively deal with this condition (see Liver Transplantation: Surgical Procedure).[15] The presence of juvenile-onset diabetes mellitus formerly precluded transplantation. In current practice, this is not usually the case, depending on the patient's physiologic status at the time of evaluation. Similarly, advanced age causes concern, but in most centers the physiologic state of the patient is a more important consideration than the chronologic age.

The inability to withstand the operative procedure, usually for cardiovascular or pulmonary reasons, is still generally considered to be a contraindication to liver transplantation. Specific examples include patients with depressed ejection fraction secondary to ischemic cardiomyopathy, significant pulmonary hypertension, and significant chronic obstructive pulmonary disease. Cardiac disease that is not amenable to percutaneous therapy poses a particular problem because these patients are frequently unable to withstand a corrective cardiac procedure because of their severe liver disease. In highly selected patients it may be possible to perform combined heart and liver transplantation or combined lung and liver transplantation.

Recent intracranial hemorrhage is almost always a contraindication because during the liver transplant procedure, coagulopathy is often present along with significant alterations in arterial blood pressure. The risk of a catastrophic exacerbation of intracranial bleeding during a transplant is therefore high in this setting. However, the meaning of "recent" is not defined in either the transplant or the neurosurgical literature. Profound, irreversible neurologic impairment is also considered to be a contraindication. Active substance abuse remains a contraindication, as is the lack of the necessary social support network.

HIV infection, long considered a contraindication, is no longer an absolute exclusion due to the development of highly effective antiretroviral therapies.[16,17] Active sepsis or untreated infection and active extrahepatic malignancy continue to be contraindications.

Although renal insufficiency increases the risk of liver transplantation, it is not a contraindication. Patients who have hepatorenal syndrome (HRS) frequently experience recovery of renal function following liver transplantation. However, patients who have longstanding hepatorenal failure and patients with known renal parenchymal disease requiring renal replacement therapy are often best served by combined liver/kidney transplantation.

DISEASE-SPECIFIC INDICATIONS AND OUTCOMES

While the MELD score assessment plays a critical role in evaluating and listing patients that might benefit from liver transplantation, patients that develop liver disease–specific complications, regardless of MELD, are also appropriate to consider liver transplantation. Some of these complications along with other liver-specific metabolic diseases are listed in Table 37-3. Hepatitis C is currently the most common disease for which liver transplantation is currently performed in the United States (33%) (Fig. 37-1). Alcoholic liver disease, NASH, and cholestatic liver diseases are the next most common ranging from 10% to 14% of cases. However, this trend is believed to be changing with a greater proportion of liver transplants being performed for NASH (Fig. 37-2).[5] Outcomes following liver transplantation are best for pediatric patients with biliary atresia, while patients with cholestatic liver diseases experience the best survival among adults (Fig. 37-3). Patients with hepatitis C or HCC experience worse survival secondary to disease recurrence although recent advances in hepatitis C antiviral therapy may change this trend.[18] Disease-specific indications, outcomes, and considerations will be discussed in the following sections.

Alcoholic Liver Disease

Excessive alcohol consumption can lead to several hepatic abnormalities, ranging from alcoholic hepatitis to steatosis, hepatic fibrosis, and cirrhosis. Alcoholic liver disease was once thought to occur only in individuals who consumed large quantities of alcohol over long periods of time. It has recently become recognized that even moderate amounts of alcohol consumption can induce liver injury, suggesting that hereditary and or environmental factors are probably important. Hepatitis C viral infection, found in 15% to 25% of patients with alcoholic liver disease, appears to exacerbate alcohol-induced liver injury and vice versa.

Table 37-3 Liver Disease Complications and Liver-Specific Metabolic Diseases

Complications:
Ascites
Encephalopathy
Refractory variceal hemorrhage or portal gastropathy
HCC
Hepatopulmonary syndrome (HPS)
Portopulmonary hypertension (PPHTN)
Fulminant hepatic failure (FHF)
Metabolic diseases:
Wilson disease
Alpha-1 antitrypsin disease
Familial amyloidosis
Urea cycle enzyme deficiencies
Glycogen storage disease
Tyrosemia
Primary oxaluria

When liver transplantation emerged as a standard therapy for end-stage liver disease in the 1980s, intense debates occurred surrounding the issue of offering liver transplantation. There were two broad areas of concern. First, many were skeptical that patients with a history of longstanding alcoholism would be able to successfully comply with the rigorous long-term medical treatment required of patients who receive lifelong immunosuppression. On a broader level, concern was expressed that scarce societal resources should not be used to treat patients with "self-induced" diseases. With more experience in this area, it has been recognized that the incidence of recidivism after transplantation is low, and both short- and long-term results in this category are as good as for nonalcohol-related categories. It has also become understood that determining worthiness for receiving a lifesaving organ by making a judgment about past behavior is neither ethical nor possible.

Today, the same methods of determining suitability for transplantation are used for patients with alcoholic liver disease as with other diagnoses with one proviso. Alcohol-induced liver injury frequently regresses following cessation of alcohol consumption as long as cirrhosis is not yet present. Patients with a history of recent alcohol abuse should therefore be observed for a minimum of 6 months to ensure that their hepatic dysfunction

is not reversible. In addition, all patients with a history of substance abuse must be evaluated by individuals with expertise in addiction and found to have good insight into their past self-destructive behavior and a stable social support network for the posttransplant phase.

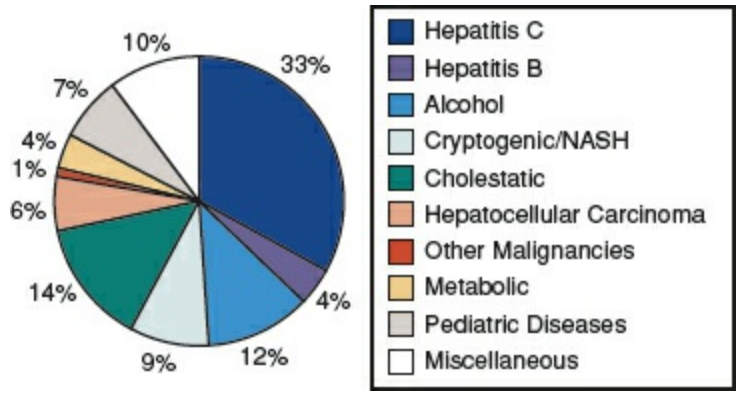

Figure 37-1. Percentage of liver transplants for each etiology. (From O'Leary JG, Lepe R, Davis G. Indications for liver transplantation. *Gastroenterology* 2008;134:1764–1776.)

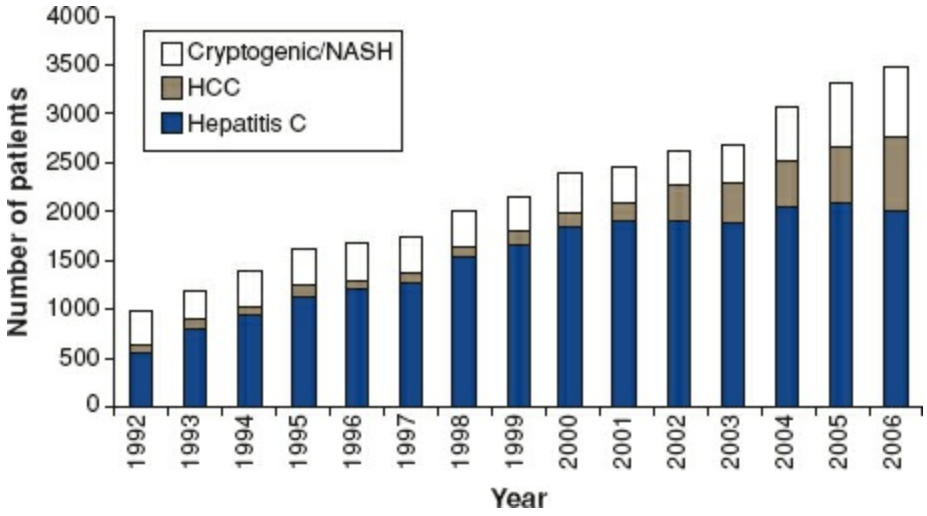

Figure 37-2. Changing incidence of liver transplantation for NASH, HCC, and Hepatitis C. (From O'Leary JG, Lepe R, and Davis GL. Indications for liver transplantation. *Gastroenterology* 2008;134:1764–1776.)

Viral Hepatitis

Most patients who become infected with hepatitis B develop an immunologic response to the virus that results in complete viral clearance. Patients who do not clear the hepatitis viral antigen may persist as carriers or may develop chronic hepatitis, which progresses to fibrosis and cirrhosis. In the 1980s, transplantation for hepatitis B was associated with universal recurrence of viral infection posttransplant and survival rates were poor. Fortunately, transplantation for this indication was revolutionized by the development of effective posttransplant prophylaxis using long-term, high-dose, hepatitis B immune globulin and the nucleoside inhibitors lamivudine or entecavir.[19,20] Today, outcomes for transplantation for hepatitis B–induced liver failure, while varying based on genotype, are equivalent to or better than those for other conditions.[21]

Hepatitis C has become the most common etiology among patients receiving liver transplants.[5] Antiviral therapy using pegylated interferon and ribavirin for early hepatitis C infection has been demonstrated to have clinically important responses seen in over half of patients treated. However, complete clearance of HCV from the serum can only be achieved in a minority of patients which is largely related to viral genotype and whether significant toxicities to therapy develop.[22,23] Fortunately, multiple new anti-HCV medications have now been FDA approved and show much improved complete response rates and improved tolerability. These recent developments will serve to change the landscape for patients with chronic HCV, eliminating the need for transplantation in many cases, and offer new options to treat HCV recurrence following transplantation.[18]

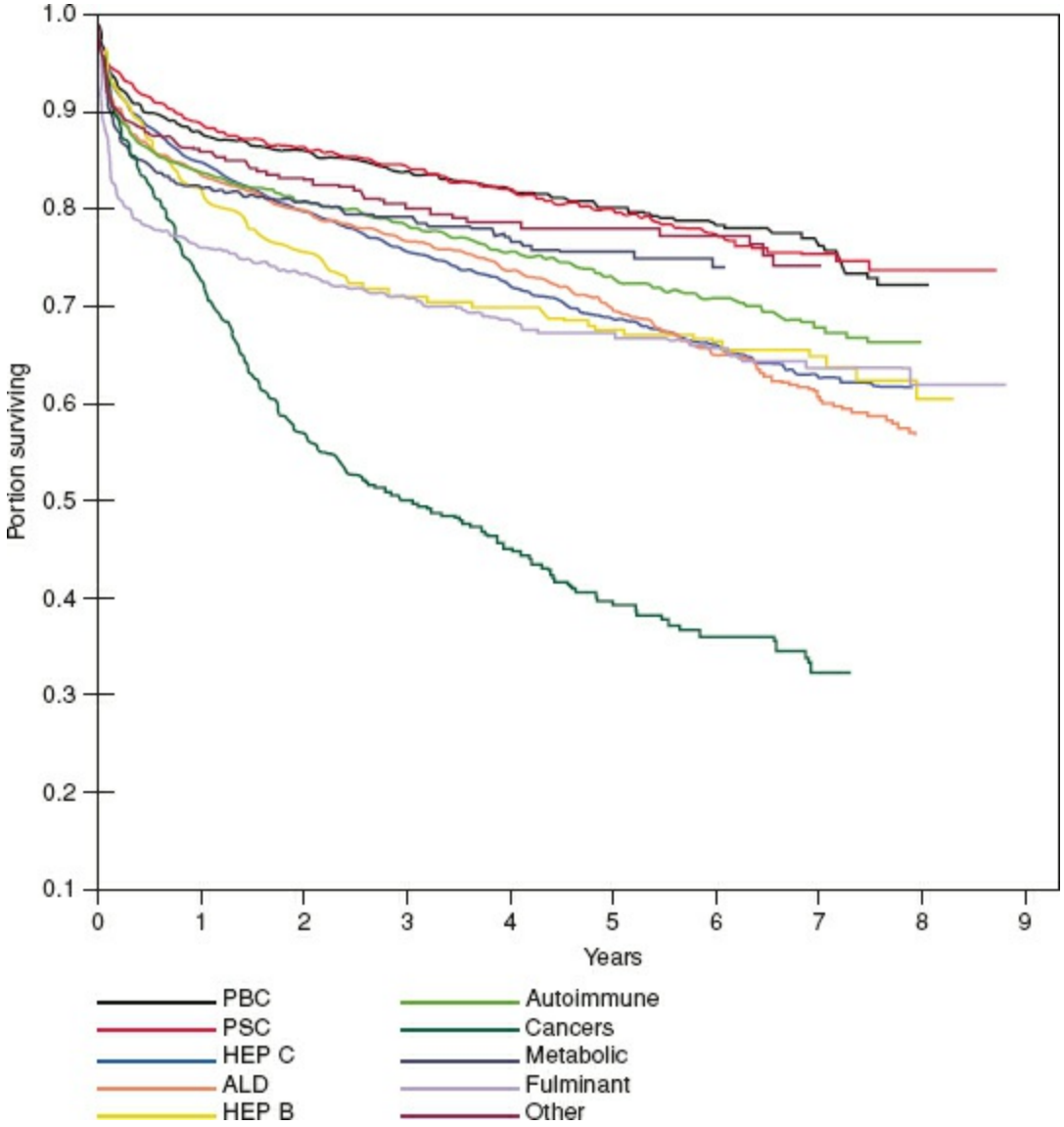

Figure 37-3. Disease-specific survival following liver transplantation. (From Roberts MS, Angus DC, Bryce CL, et al. Survival after liver transplantation in the United States: a disease-specific analysis of the UNOS database. *Liver Transpl* 2004;10:886–897.)

Following liver transplantation, recurrence of HCV hepatitis in the transplanted liver occurs universally unless the virus was eradicated pretransplant with therapy.[24] Although some patients experience an indolent course, most patients experience a more rapid progression to liver failure once cirrhosis has developed posttransplant. These patients can progress to end-stage liver failure within 6 months. Short-term results of transplantation for this disease are comparable to those for the other noninfectious conditions. However, approximately 25% of patients develop recurrent cirrhosis within 5 years posttransplant, and long-term survival is less likely compared with patients who do not have hepatitis C infection. Use of livers from donors of increased age are thought to contribute to poorer results in hepatitis C patients.[25] Treatment of recurrent hepatitis C posttransplant is presently being attempted with some of the new antiviral therapies available and clinical trials underway.[18,26] Despite recurrence, transplantation appears to provide a substantial and worthwhile survival benefit to most patients with hepatitis C.

Hepatocellular Carcinoma and Other Hepatic Malignancy

Cirrhosis is a major risk factor for the development of HCC, and the majority of HCCs develop in patients who have cirrhosis. Curative resection is unsafe in the setting of advanced cirrhosis, and it does not eliminate the high likelihood of recurrent malignancy. Because most patients with HCC die of liver failure, rather than metastatic disease, it was reasoned that transplantation would be potentially curative. This approach yielded poor survival rates, and during the early 1990s primary hepatic malignancy was considered a contraindication to liver transplantation by many centers. This circumstance changed when Mazzaferro et al.[27] reported an 85% 4-year survival rate for patients who had cirrhosis and either stage I or stage II HCC (Table 37-4). Transplantation is now considered standard therapy for HCC and cirrhosis if there is no evidence of extrahepatic disease, vascular invasion, and if the tumor burden does not exceed stage II (single tumor ≤ 5 cm in diameter, or 2 to 3 tumors, none >3 cm in diameter). While some advocate transplantation of patients with larger tumors,[28,29] this practice is still controversial due to concerns of overall lower disease-free survival. Many centers now adopt a downstaging strategy with local regional therapies such as radiofrequency ablation (RFA) or transarterial chemoembolization (TACE) to bring patients down to stage II in order to list for liver transplantation.[30] Transplantation is clearly not beneficial in the presence of known positive nodal or distant metastases (stage IV disease). To create relative equality for a scarce resource, MELD allocation points are standardly allocated to HCC patients meeting the Milan criteria so as to minimize waitlist dropouts due to disease progression and at the same time not over utilize donor livers from the remainder of the recipient candidate pool. However, in recent reviews of outcomes of liver transplantation as reported by the SRTR,[4] the adjusted 3-year survival rate for HCC patients was 74% and was statistically lower than non-HCC recipients (81%) during the MELD era while at the same time one of the lowest waitlist drop-off rates and higher transplant rate among other disease indications for transplantation,[4,31] suggesting that the allocation policy may need further refinements.

Table 37-4 TNM Classification and Staging of Hepatocellular Carcinoma

Classification	
T1	One nodule ≤1.9 cm
T2	One nodule 2.0–5.0 cm; two or three nodules, all <3.0 cm
T3	One nodule >5.0 cm; two or three nodules, at least one >3.0 cm
T4a	Four or more nodules, any size
T4b	T2, T3, or T4a plus gross intrahepatic portal or hepatic vein involvement on imaging
N0	No evidence of regional nodal involvement
N1	Regional (porta hepatitis) nodal involvement
M0	No evidence of metastatic disease
M1	Evidence of metastatic disease
Stage Grouping	
Stage I	T1
Stage II	T2
Stage III	T3
Stage IV A1	T4a
Stage IV A2	T4b
Stage IV B	Any N1, any M1

From Facciuto ME, Rochon C, Pandey M, et al. Surgical dilemma: liver resection or liver transplantation for hepatocellular carcinoma and cirrhosis. Intention-to-treat analysis in patients within and outwith Milan criteria. HPB (Oxford). 2009 Aug;11(5):398–404.

Other primary tumors of the liver include hepatoblastoma, cholangiocarcinoma, and primary sarcoma. Hepatoblastoma occurs primarily in children with resection or transplantation being used as potential curative options.[32] Transplantation is utilized for patients who are unresectable because of bilobar disease or hilar location. Hepatoblastoma can respond partially to chemotherapy, but complete and sustained tumor regression is uncommon. Patients are often treated with chemotherapy until the time of transplantation to prevent extrahepatic growth prior to the definitive treatment. Hepatoblastoma is relatively unique among liver tumors in that long-term survival has been reported even in children who have had distant metastatic spread.

Cholangiocarcinoma has historically been considered a contraindication to transplantation because 5-year survival rates have been reported at less than 20%. Recently, success similar to other recipients has been reported for patients who have limited disease (<2.5 cm, no lymph node disease) and have received neoadjuvant chemotherapy and radiation along with aggressive staging prior to transplantation.[33,34]

Although there are anecdotal reports of long-term survival following transplantation for primary sarcoma of the liver, the majority of experiences indicate that transplantation is not a curative therapy for this condition. Liver transplantation is generally not appropriate for patients who have secondary (metastatic) hepatic malignancy, because long-term survival rates are very poor due in part to the observation that immunosuppression promotes tumor growth. The possible exception to this rule is patients who have metastatic carcinoid or neuroendocrine tumor that is limited to the liver. These tumors can progress very slowly and local cure of the primary tumor is

frequently possible. While it is still controversial when compared to other standard therapies, long-term disease-free survival following liver transplantation is possible in selected circumstances.[35]

Nonalcoholic Fatty Liver Disease (NAFLD)

NAFLD may be the most common liver disease in the United States. It has a high incidence in obese patients and those with adult-onset diabetes mellitus. The disease resembles alcoholic liver disease, but patients do not report a significant history of alcohol use. The degree of hepatic injury varies from benign elevations of serum hepatic transaminases in association with hepatic steatosis or steatohepatitis to fibrosis and cirrhosis. A majority of patients previously classified as having cryptogenic cirrhosis probably have longstanding steatohepatitis. It is estimated that at least two-thirds of the obese population in the United States has hepatic steatosis and close to one-fifth have steatohepatitis.[36] Patients who develop cirrhosis and progress to end-stage liver disease are appropriate candidates for liver transplantation. Recurrence of steatohepatitis leading to graft dysfunction is possible. Recipient diabetes or obesity appears to be independent negative prognostic indicators for survival after liver transplantation.[36]

Fulminant Hepatic Failure

Acute hepatic failure, defined as the development of altered mental status, coagulopathy and hepatic dysfunction within 8 weeks of the onset of an acute hepatic disease, is a rare, but lethal disease.[14,37] There are over 2,000 cases of acute hepatic failure per year in the United States. The mortality rate approaches 80% in patients who do not receive liver transplants. The causes of acute hepatic failure include viral hepatitis, toxins such as aflatoxins from the poisonous mushroom family *Amanita phalloides,* acute fatty liver of pregnancy, acute Budd–Chiari syndrome, and drug toxicities. Drug toxicities include both idiosyncratic reactions and drugs with predictable toxicity when taken in excess. Drugs that have been reported to induce idiosyncratic liver failure include isoniazid, halothane, valproate, disulfram, and phenytoin, among many others. The over-the-counter analgesic, acetaminophen, causes dose-dependent hepatic failure and is now the single most common cause of acute hepatic failure in the United States.

The most generally accepted criteria for transplantation of patients with FHF were described by the group at the King's College hospital in London, England (Table 37-5).[38] While the King's College criteria has been separately validated in other studies, more recent studies have begun to evaluate whether other scoring systems may have improved abilities to measure severity of illness. MELD has come under recent investigation in this regard and has been found to be additive to the King's College criteria in predicting outcome following FHF.[39,40] The current United National Organ Sharing (UNOS) listing criteria for patients with FHF is in Table 37-2. The outcomes following transplantation have shown overall higher perioperative mortality, compared to other diseases, with overall similar long-term survival (Fig. 37-3).[3]

Biliary Atresia

Biliary atresia is a congenital disorder of infants, occurring in about 1 of 15,000 births, that is characterized by biliary obstruction resulting from obliteration or discontinuity of the extrahepatic biliary system resulting in progressive hyperbilirubinemia, cirrhosis, and hepatic failure. Other anatomic anomalies can also be coassociated with this disorder such as a preduodenal portal vein. The etiology is not completely defined yet is the most common indication for hepatic transplantation in pediatric patients. Standard treatment includes creation of a portoenterostomy (Kasai procedure), if this can be done before 3 months of age. After this point, success rates diminish markedly. Response to the portoenterostomy procedure is highly variable. Patients may develop cirrhosis within the first 6 months of life or live into their twenties before developing synthetic dysfunction and portal hypertension. Approximately 75% of children will require transplantation by 6 years of age.

Table 37-5 King's College Criteria for Liver Transplantation

Acetaminophen	Nonacetaminophen
pH <7.3	PT >100 s (INR >6.5)
Or all three of: Grade 3–4 encephalopathy PT >100 s (INR >6.5) Cr >3.4 mg/dL	Or any three of: Age <10 or >40 y Etiology (non-A, non-B hepatitis, halothane, drug reaction, Wilson disease) Period of transition from jaundice to encephalopathy <7 d PT >50 s (INR >3.5) Total bilirubin >17.5 mg/dL

It is critical that these patients are managed by an experienced pediatric gastroenterologist so that the correct window for effective transplantation can be identified and so they receive appropriate attention to their specialized nutritional needs. Specifically, deficiencies of fat-soluble vitamins that depend on bile for absorption are common and treatable. Transplantation is appropriate when children manifest growth and nutritional failure, when ascites develops, and when portal hypertension progresses to the point of variceal hemorrhage. Recurrent cholangitis is also thought to be an indication for liver transplantation. Transplantation for this population overall has had excellent results with >85% 10-year survival being achieved in the United States.[41] Factors that have been associated with improved survival include living donor transplants and older recipient age. Patients with significant growth failure generally have poorer outcomes.

Primary Biliary Cirrhosis

Primary biliary cirrhosis (PBC), thought to be autoimmune in nature, is characterized by gradually increasing serum bilirubin levels, progressive fatigue, and cirrhosis. Early stages of the disease are usually asymptomatic, and disease progression may evolve over 20 years. Treatment with ursodeoxycholic acid appears to slow the progression of the disease, but immunosuppression does not. It was once thought that PBC does not recur, however, histologic analysis has shown that the incidence of recurrence is approximately 15% within 5 years of transplantation.[42] Eventual progression to graft failure requiring retransplantation is possible, though rare.

Primary Sclerosing Cholangitis

Primary sclerosing cholangitis (PSC) is an autoimmune disease that is characterized by gradually progressive inflammation of the biliary tree, eventually resulting in cirrhosis. It is associated with ulcerative colitis, but removal of the colon does not affect progression of the disease. In most cases, colectomy for associated inflammatory bowel disease is done after successful transplantation because the failing liver makes the patient a poor candidate for a large abdominal procedure. PSC is also associated with the development of cholangiocarcinoma. Patients who experience a course that becomes rapidly progressive should be examined by endoscopic retrograde cholangiopancreatography (ERCP) with brushings to evaluate for cholangiocarcinoma. In addition to the usual considerations about the timing of transplantation, it is important to note that these patients are susceptible to bacterial cholangitis, which can cause systemic sepsis and rapid hepatic decompensation. Episodes of cholangitis that do not respond to suppressive antibiotic therapy should prompt early consideration for transplantation. Overall, patients with PBC or PSC experience the best outcomes with transplantation when compared to adults with other liver diseases, however, disease recurrence remains higher in PSC patients than in PBC patients.[3,43]

Inherited Metabolic Disorders

Numerous inherited metabolic disorders are treatable by liver transplantation (Table 37-3). Some enzymatic deficiencies in this group result in destruction of the liver, so transplantation may resolve the liver failure as well as supply the missing enzyme. Disorders in this category include Wilson disease, alpha-1 antitrypsin deficiency, tyrosinemia, and type I glycogen storage disease. In other cases, the liver is not affected by the disease, either structurally or functionally. In these circumstances transplantation is undertaken solely as enzyme replacement therapy. Diseases that have been cured by hepatic transplantation in this category include hemophilia A or B, homozygous familial hypercholesterolemia, Niemann–Pick disease, oxalosis, familial amyloid polyneuropathy, and numerous enzymatic deficiencies of urea cycle metabolism.[44] Determination of eligibility for transplantation depends on determining that transplantation will cure the disease, or at least halt its progression, and that the consequences of the disease without transplantation are devastating, making transplantation appropriate.

Budd–Chiari Syndrome

Budd–Chiari syndrome is characterized by obliteration of the hepatic veins. It may be due to congenital webs of the hepatic veins or suprahepatic cava or may be caused by spontaneous thrombosis of the hepatic veins. The latter condition is associated with polycythemia vera and other hypercoagulable states. Diagnosis is made by inferior vena cavagram or magnetic resonance venography. The classic presentation is a triad of right upper quadrant pain, hepatomegaly, and ascites. Patients may present with FHF during acute Budd–Chiari and have symptoms of encephalopathy and coagulopathy, or they may present in a more indolent fashion with ascites as the predominant feature. The natural history of the indolent form of Budd–Chiari syndrome is the eventual development of cirrhosis.

Patients who present with intact hepatic function should undergo an assessment to determine whether the liver has evidence of cirrhosis. A transjugular intrahepatic portosystemic shunt (TIPS) is the preferred therapy for patients who do not have evidence of synthetic failure and have not yet developed cirrhosis. Transplantation is reserved for cases where portal decompressive shunting is not possible or for patients who have advanced cirrhosis. Long-term anticoagulation to prevent recurrent hepatic vein thrombosis in the liver graft is routinely recommended.

Other Considerations

HPS and PPHTN are two other manifestations of cirrhosis whereby transplantation is justified. Similar to HCC, these two diseases can occur in cirrhosis despite overall preserved hepatic function and appear to involve dysregulation of vasoactive mediators such as nitric oxide. Therefore, MELD exception scores are often sought when either HPS or PPHTN are present.[12] HPS is diagnosed on the basis of unexplained hypoxia in the presence of cirrhosis along with a positive "bubble" study for pulmonary shunt on echocardiography. PPHTN is diagnosed on the basis of pulmonary hypertension in the setting of cirrhosis without any other explainable etiology such as underlying pulmonary pathology. Recipient selection and management is critical to achieve reasonable success with liver transplantation. Patients with HPS experience the best outcomes if preoperative PaO_2 is greater than 50 mm Hg.[45] Patients with PPHTN likewise must have mean pulmonary artery pressures less than 35 mm Hg with or without medical therapy to experience a reasonable chance of recovery following liver transplantation.[46,47]

In addition to isolated liver disease, liver transplantation is occasionally considered along with other solid organ transplantation. The two most notable examples are combined kidney and liver transplantation as well as combined liver and intestine transplantation.[4] Intestine transplantation is usually performed in cases where intestinal failure is present along with progressive cholestatic liver failure secondary to hyperalimentation.[48] Since HRS frequently occurs with advanced cirrhosis and also frequently resolves with successful liver transplantation, the indications for combined liver and kidney transplantation are more controversial.[49] It is widely accepted that pre-existing end-stage renal disease along with significant cirrhosis or the existence of HRS requiring eight or greater weeks of renal replacement therapy warrant consideration of combined liver and kidney transplantation. Ongoing investigations are required to define patients with HRS who are less likely to recover renal function following liver transplantation.

LIVER TRANSPLANTATION: SURGICAL PROCEDURE

Anesthetic Management

An anesthesiologist with experience in liver transplantation is invaluable to the transplant team and liver transplant anesthesiology is rapidly becoming a subspecialty. Proper anesthetic management and effective communication between the surgery and anesthesiology teams is necessary to optimize patient care during the surgical procedure. While an extensive outpatient preoperative evaluation is usually performed, including cardiac risk stratification, many liver candidates report from home when a liver becomes available. If adequate time for fasting has not occurred, consideration of rapid sequence induction should be given to prevent aspiration. After induction and intubation, general anesthesia is maintained with a combination of inhalational agents as well as the administration of paralytic agents and analgesics. For adult patients, cardiac monitoring is often performed either by pulmonary artery catheterization or intraoperative transesophageal echocardiography. An arterial catheter is placed for blood pressure monitoring. Adequate vascular access, often including central venous catheters, is required for the administration of blood products and the potential for rapid resuscitation in the case of massive blood loss. A device for rapid infusion and the ability to warm blood products or intravenous fluids is required. Low central venous pressures maintained during the hepatectomy phase of the procedure may help avoid excess bleeding.

Intraoperative Management of Coagulopathy

Liver transplantation has the potential for massive blood loss for several reasons. Liver transplant candidates with cirrhosis often have synthetic deficiencies in circulating coagulation factors as well as severe portal hypertension associated with thrombocytopenia and extensive venous collaterals. Intraoperative coagulopathy may be worsened during the anhepatic phase of the procedure. Finally, liver transplantation involves extensive dissection of major vascular structures including the inferior vena cava, portal vein, and hepatic artery, all with an inherent risk for torrential bleeding.

Intraoperatively, coagulation is monitored by frequent determination of standard parameters including prothrombin time, partial thromboplastin time, platelet count, and fibrinogen. Abnormalities of these laboratory values associated with intraoperative bleeding are often corrected with fresh frozen plasma, platelets, or cryoprecipitate. Normal coagulation is also helped by maintaining normal pH, calcium levels, and normothermia. While the administration of recombinant factor VII intraoperatively can rapidly and effectively stop nonsurgical bleeding, its use has a theoretical risk of postoperative thrombotic complication including hepatic arterial thrombosis. In addition, no definitive data has been demonstrated to decrease the need for intraoperative blood transfusions.[50,51] Therefore, its use is only recommended in emergent situations.

Following reperfusion of the donor liver, a fibrinolytic state may be encountered. This is related to the lack of production of fibrinolysis inhibitors during the anhepatic phase and the inability of the liver to metabolize profibrinolytic compounds. This state may be identified either by thromboelastography, recurrence of bleeding where hemostasis had been previously obtained (such as the wound edge), or by extensive and refractory bleeding after revascularization. This state may be treated with the use of antithrombolytic agents including ε-aminocaproic acid, tranexamic acid, or aprotinin.

Surgical Technique

Transplantation of the liver is among the most technically demanding surgical procedures. During induction and placement of the appropriate monitoring lines by the anesthesiology team, the donor liver is prepared on the back table for implantation (Fig. 37-4). Bench preparation includes resection of the donor diaphragm and adrenal gland off of the bare area of the liver and vena cava. Meticulous ligation of tributaries from the vena cava (adrenal vein, phrenic vein, and lumbar branches) is performed. The artery is dissected free from the Carrel patch of the aorta up to the gastroduodenal artery. Dissection near the right or left hepatic arteries is avoided to prevent unnecessary injury. The portal vein is circumferentially dissected free. The gallbladder may be removed at this stage or following reperfusion. Tissues surrounding the common bile duct are left intact to avoid injury of the blood supply.

Following this, the recipient's abdomen and bilateral groins are prepped and draped in a standard fashion. The most commonly used incision is a unilateral or bilateral subcostal incision with a midline extension to the xiphoid process (Fig. 37-4). After dividing the fascia, ascites, which can occasionally be present in a large volume, is evacuated. The ligamentum teres hepatis is carefully divided between clamps and ligated because a large recannulized umbilical vein is often present in patients with severe portal hypertension. After dividing the falciform ligament with cautery, a mechanical retractor is used to retract the bilateral costal margins anteriorly and superiorly for excellent exposure of the upper abdomen. The abdominal cavity and liver are then inspected for any abnormalities including unsuspected malignancy, particularly within the cirrhotic liver which is a risk factor for HCC. Following this, liver transplantation occurs in three stages: (1) recipient hepatectomy, (2) anhepatic phase, and (3) postrevascularization.

Recipient Hepatectomy

During the recipient hepatectomy phase, the liver is mobilized from its ligamentous attachments and the porta hepatis is skeletonized. Attention is first directed to dissecting and skeletonizing the structures of the portal triad. The peritoneum overlying the portal triad is divided with electrocautery near the liver edge. The right and left hepatic arteries are dissected free, ligated, and divided leaving adequate length to form a branch patch for the arterial anastomosis. The proper hepatic artery is also dissected free to the level of the gastroduodenal artery allowing enough length for clamping during the anastomosis. Because portal venous flow of blood to the liver may be hepatofugal (away from the liver), division of the artery may leave the patient functionally anhepatic. If a prolonged period of time is expected for mobilization of the liver, such as when extensive adhesions are present, the artery may be dissected free but left in continuity to allow whatever synthetic capacity the native liver has to continue. A replaced or accessory right hepatic artery, which arises as a branch of the superior mesenteric artery and travels in a posterior position to the common bile duct and lateral to the portal vein, can usually be palpated if present and can be ligated and divided. When the replaced right hepatic artery is relatively large and the proper hepatic artery is diminutive in size, the replaced right hepatic artery can be left long and used for arterial inflow for the donor liver. A replaced or accessory left hepatic artery arises from the left gastric artery if present and can be identified by inspection of the pars flaccida of the lesser omentum along the lesser curvature of the stomach (Fig. 37-5).

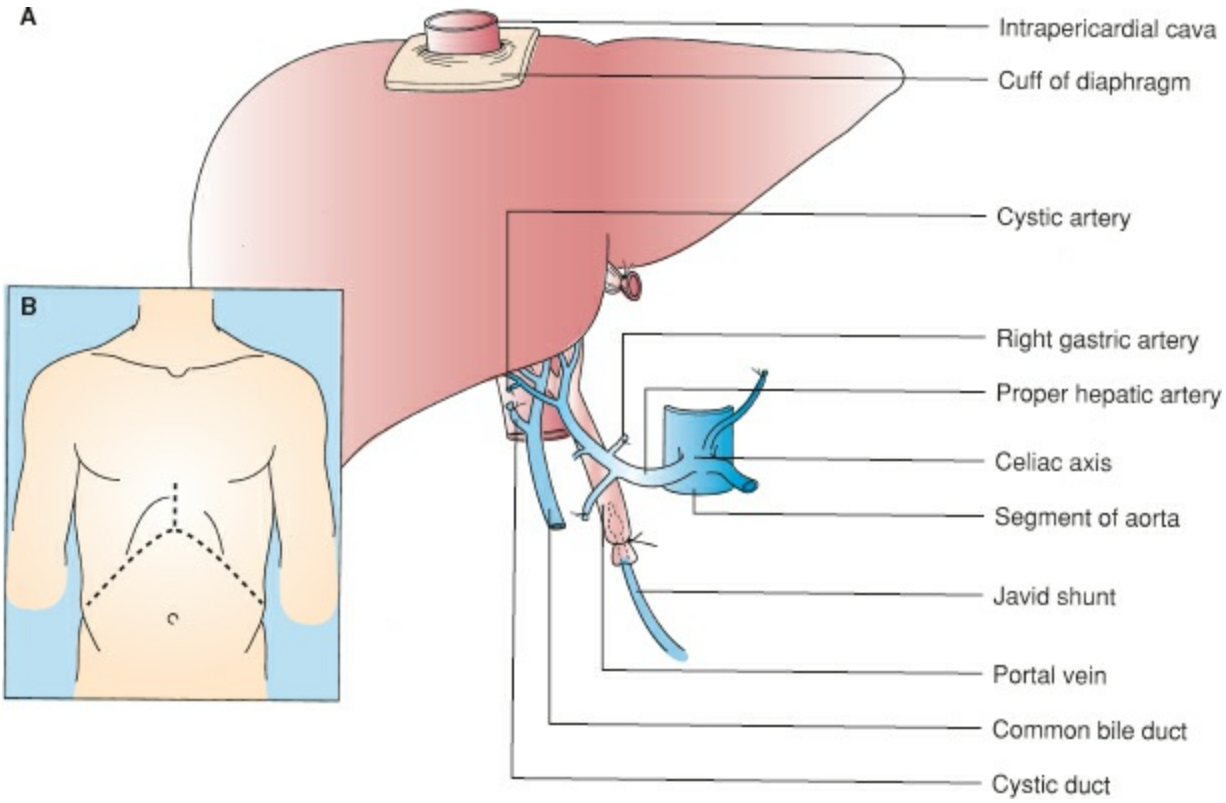

Figure 37-4. **A:** The donor liver after excision and before transplantation. **B:** Bilateral subcostal incision with a subxiphoid extension.

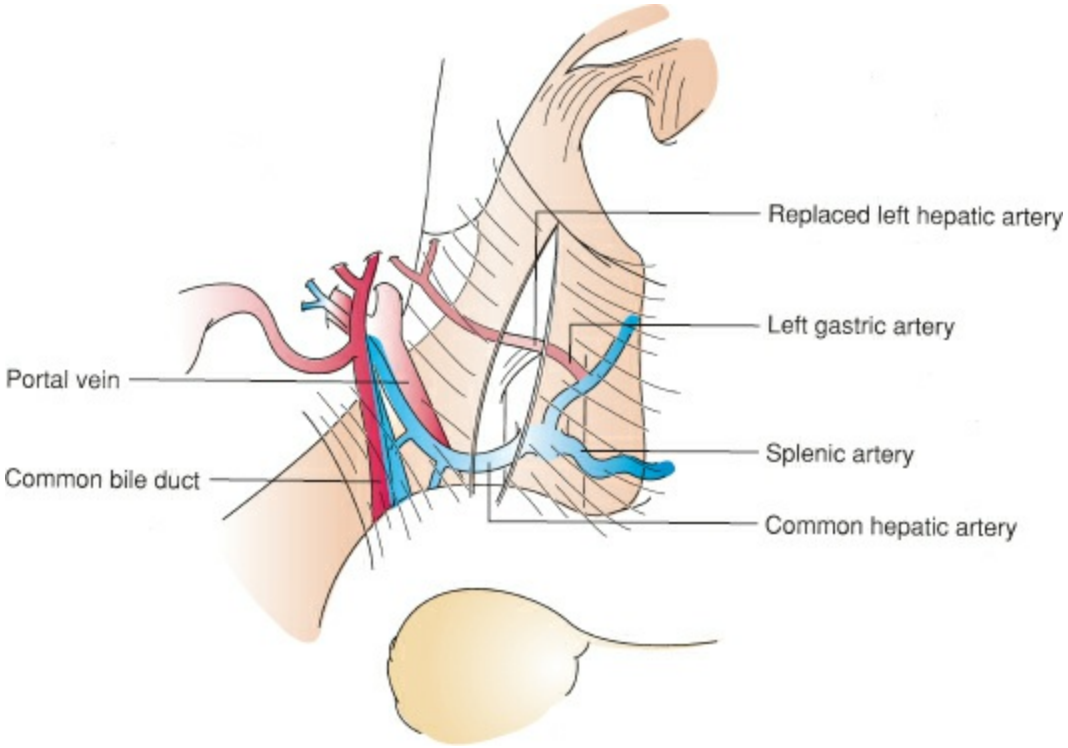

Figure 37-5. A replaced left hepatic artery usually arises as a branch of the left gastric artery, traversing the pars flaccida of the lesser omentum from left to right toward the left lobe of the liver.

Conceptually, the common bile duct and common hepatic duct should be dissected free with as much length as possible and without injuring the blood supply to the bile duct. Leaving the recipient bile duct as long as possible allows the length of the donor bile duct, which may have a tenuous blood supply, to be shorter and still avoid tension at the time of anastomosis. This is accomplished by first ligating and dividing the cystic duct. The common bile duct and common hepatic duct are then circumferentially dissected free leaving the surrounding tissue to preserve the bile duct blood supply. The common hepatic duct is then ligated as close to the native liver as possible.

Once the bile duct and the hepatic artery are freed from surrounding tissues, the portal vein can be easily approached from its anterior, medial, and lateral aspects. In general, the portal vein is freed circumferentially from the edge of the duodenum up to its bifurcation of the right and left portal veins. Small branches may arise near the pancreas and excessive bleeding may arise if these are inadvertently injured. Most patients with severe portal hypertension will not develop hypotension, small bowel edema, or ischemia if the portal vein is clamped and divided because of the presence of portal venous collaterals. However, patients without portal hypertension such as those undergoing liver transplantation for fulminant hepatic failure, metabolic deficiency, or those who have had a transjugular intrahepatic portosystemic shunt (TIPS) for a prolonged period of time, may develop extensive small bowel edema or hypotension when the portal vein is clamped. Small bowel edema can lead to limited exposure in the right upper quadrant making implantation of the liver extremely difficult. In these situations, the portal vein should be left in continuity for as long as possible, particularly when the use of venovenous bypass is not intended. For those patients with portal vein thrombosis, portal venous flow can be restored in most cases. Often, the thrombus can be evacuated with the

use of forceps or by placing a Yankauer suction tip within the lumen of the portal vein. If the thrombus is more mature, an eversion endovenectomy may be necessary.[52] If these maneuvers are unsuccessful, the junction of the splenic vein and superior mesenteric vein may be patent. Dissection of the portal vein behind the pancreas to this junction can then be performed to allow for future anastomosis. Dissection to the confluence of the splenic and superior mesenteric veins is sometimes necessary in pediatric recipients because of the small caliber of the portal vein within the porta hepatis. In rare cases, all of these maneuvers may be unsuccessful and a venous bypass graft from the superior mesenteric vein may be necessary. If the superior mesenteric vein is also occluded, the inferior vena cava or left renal vein can be used for portal inflow, a procedure termed cavoportal or renoportal transposition.[53] This procedure is associated with acceptable outcome despite the fact that portal hypertension may not be alleviated. A fourth option is arterialization of the portal vein, using a conduit created by anastomosing donor iliac vessels to the recipient aorta and connecting this to the donor portal vein.[54]

The ligamentous attachments of the liver, including the left and right triangular and coronary ligaments are then divided using electrocautery. The bare area of the liver is dissected along a plane just superficial to the capsule of the liver. Care must be taken to avoid injury to the phrenic or hepatic veins when freeing the suprahepatic inferior vena cava where it traverses the diaphragm. The hepatocaval ligament along the right lateral aspect of the vena cava can be divided using a combination of cautery and ligation as a phrenic venous branch is often present within this ligament. The liver is then dissected off of the anterior aspect of the inferior vena cava. Small venous branches from the inferior vena cava to the caudate lobe are ligated and divided. Larger branches, such as an accessory right hepatic vein, are clamped, divided, and oversewn. Division of the portal vein facilitates exposure for this dissection but is not required. The liver may be gradually retracted and dissected from either the right or left aspects until the right, middle, and left hepatic veins are reached. If a bicaval venous anastomosis technique will be used, the vena cava can be circumferentially mobilized near the diaphragm above the hepatic veins as well as in an infrahepatic position. However, if a piggyback or cavocavostomy (side-to-side caval anastomosis) technique is intended; the dissection of the posterior aspect of the vena cava should be avoided to prevent encountering unnecessary bleeding from collateral or lumbar venous branches in this area.

Anhepatic Phase and Implantation of the Donor Liver

At this point, the liver has been completely mobilized except for its attachments of the hepatic veins to the inferior vena cava and in some cases, the portal vein. The decision should now be made whether to use venovenous bypass. Most patients will tolerate clamping of both the portal vein and the inferior vena cava without difficulty.[55] At this point, communication with the anesthesiologist is essential and the vena cava should be test clamped before division to make sure that adequate cardiac filling and blood pressure can be maintained. If the patient becomes hypotensive during test clamping, the clamp should be removed and additional volume or pressor support can be administered. Occasionally patients will require venovenous bypass, but its use is no longer routine at most centers.

If necessary, venovenous bypass can be accomplished from both the portal vein and inferior vena cava simultaneously, or a single cannula in either the portal vein or the inferior vena cava may be used (Fig. 37-6). There are several accepted methods of placing cannulas for venovenal bypass. Cannulas may be placed percutaneously in the internal jugular vein and femoral vein prior to beginning the procedure. These cannulas are advanced into the superior and inferior vena cava, respectively. Alternatively, one or both of the bypass cannulas may be placed by cutdown on the axillary and/or the greater saphenous vein. Inferior vena caval and mesenteric blood is delivered to the superior vena cava by a centrifugal pump. The cannulas, tubing, and centrifugal pump head are heparin bonded to reduce the chance of thrombus formation and subsequent embolism without the use of anticoagulation. Flow rates of 1 to 2 L/min are usual.

Once venovenous bypass has been established or the decision to forego bypass has been made, the recipient hepatectomy is completed. If still intact, the portal vein is divided as high in the hilum as possible. Three methods are commonly used for orthotopic liver transplantation: (1) the bicaval technique, (2) the piggyback technique, (3) cavocavostomy (side-to-side caval technique).

1. For the bicaval technique, the recipient liver is excised en bloc with the retrohepatic inferior vena cava after caval clamps have been placed in a suprahepatic and infrahepatic position. The hepatic veins are divided within the substance of the liver to allow the creation of a large suprahepatic cuff compromising the left, middle, and right hepatic veins (Fig. 37-7). This technique has the disadvantages of: (a) totally obstructing inferior vena cava flow resulting in renal ischemia and decreased cardiac filling with associated hypotension possibly leading to the requirement of venovenous bypass, (b) requires two vena caval anastomoses prolonging the warm ischemic time, (c) requires dissection posterior to the vena cava possibly leading to bleeding. However, complete dissection of the caudate lobe off of the vena cava is not necessary making the recipient hepatectomy phase somewhat easier and faster.

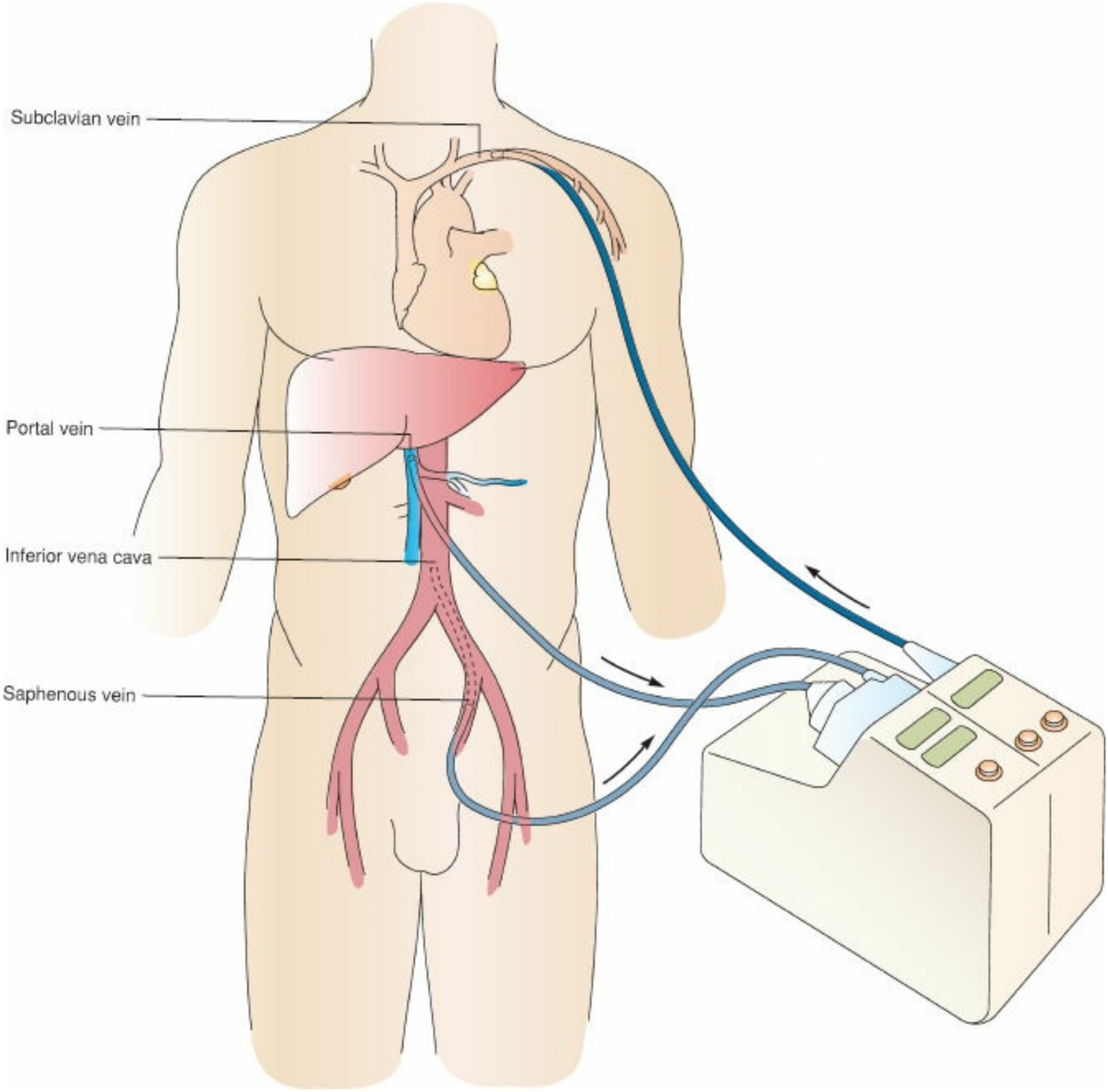

Figure 37-6. Setup for venovenous bypass during hepatic transplantation. Cannulas are placed into the portal vein to decompress the splanchnic bed and inferior vena cava (through the greater saphenous vein) to decompress the lower extremities and kidneys during the anhepatic phase of the transplantation. A centrifugal pump is used to deliver bypassed blood to the central circulation by means of a cannula passed into the axillary vein.

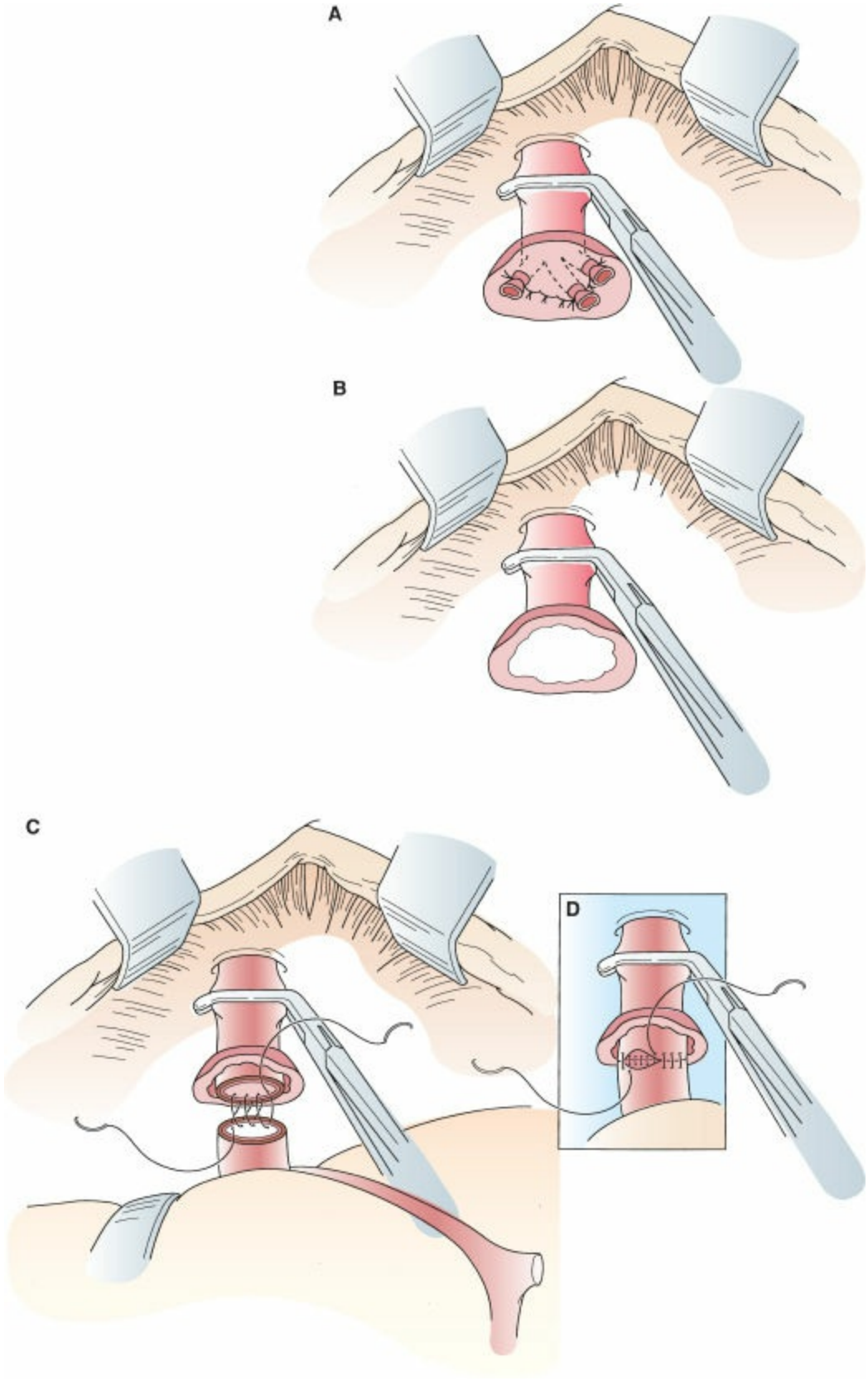

Figure 37-7. **A:** The diseased recipient liver is removed by incising the liver below the level of the hepatic veins. **B:** The hepatic veins are then opened to form a large suprahepatic cuff for anastomosis. The suprahepatic vena caval anastomosis: posterior suture line (**C**); anterior suture line (**D**).

2. For the piggyback technique, a clamp is placed transversely, partially occluding the vena cava at the level of the hepatic veins. The vena cava is left in continuity and the hepatic veins are divided within the substance of the liver allowing the creation of a common patch of the right, middle, and left hepatic veins for a wide anastomosis.

While the intention is to only partially occlude the vena cava allowing venous return to the heart, often a clamp placed for the piggyback technique either occludes or nearly occludes the inferior vena cava. This technique does have the advantage of only requiring a single vena caval anastomosis helping to limit warm ischemic time. However, torsion may occur if the right upper quadrant is relatively large, such as when a large volume of ascites is present, and the donor right hepatic lobe is relatively small. This may lead to right hepatic vein or inferior vena caval stenosis.

3. For the cavocavostomy technique, clamps can be placed on the right hepatic vein as well as the junction of the left and middle hepatic veins. The liver is excised and these venous branches are oversewn and the clamps are removed. Alternatively, the hepatic veins can be divided using an Endo GIA stapler (Fig. 37-8). Advantages of the cavocavostomy anastomosis include: (a) minimalization of the time that the vena cava is clamped, (b) the vena caval clamp is placed longitudinally only occluding the anterior third of the vena cava leading to minimal or no changes in the recipient's hemodynamics, (c) a cavoplasty is performed limiting the likelihood of caval stenosis, (d) a long anastomosis is performed, often over 6 cm in length, minimizing the risk for hepatic vein outflow complications, (e) exposure during suturing of the anastomosis is considerably improved compared to the piggyback or bicaval technique.

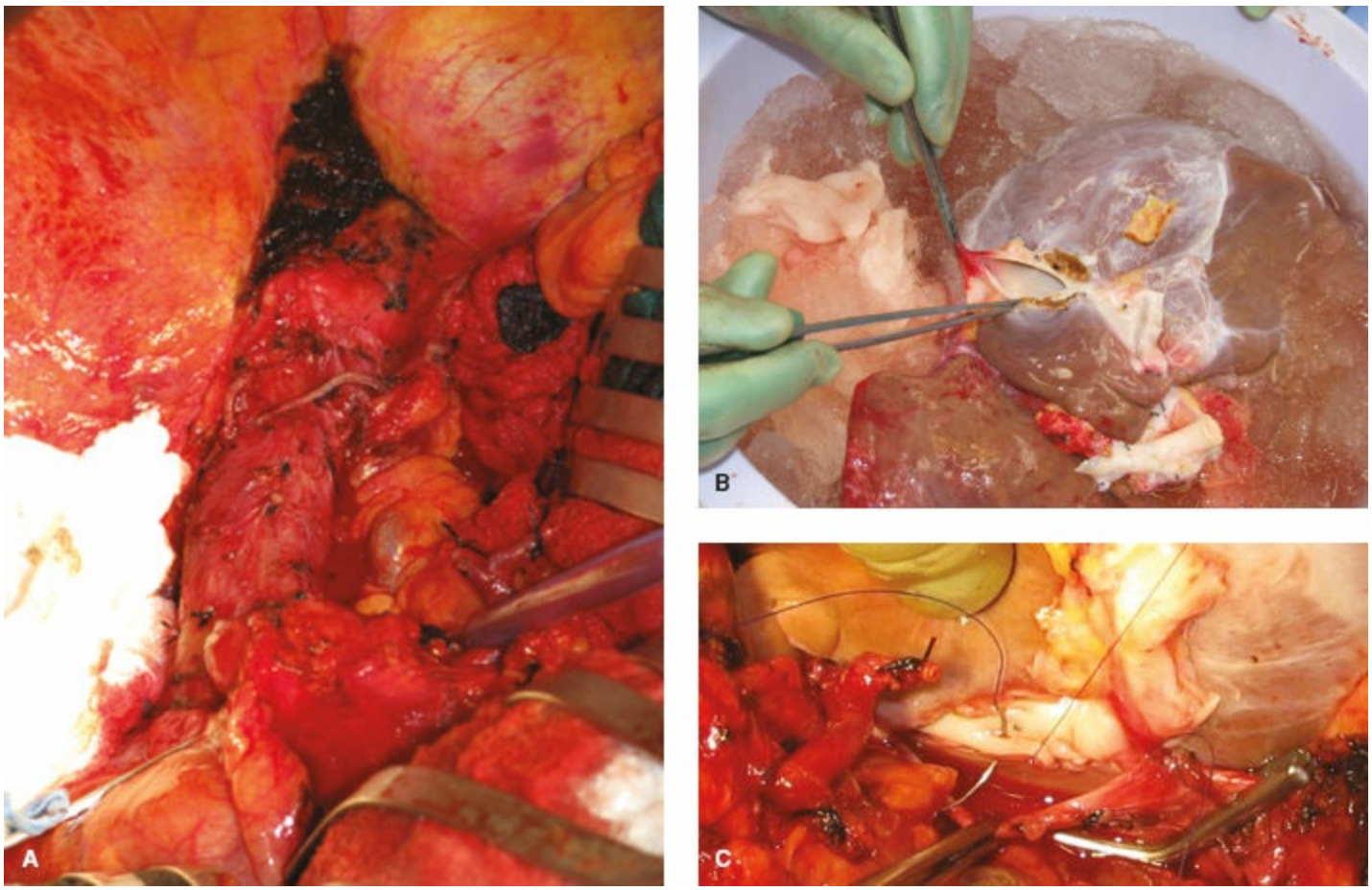

Figure 37-8. Cavocavostomy. **A:** The recipient right and junction of the middle and left hepatic veins are stapled and the inferior vena cava is left in continuity. **B:** The supra- and infrahepatic vena cavae are stapled and a venotomy is made longitudinally on the posterior aspect of the donor liver. **C:** A side-to-side caval anastomosis is performed with a running suture.

After removal of the recipient liver, the right upper quadrant is carefully inspected and hemostasis is obtained. Complete hemostasis in the bare area is essential at this time because this region is easily visualized when the liver is absent but may be relatively inaccessible once the donor liver is implanted, especially if the donor liver is relatively large or the recipient is obese. Argon beam coagulation can also be used to aid in hemostasis at this point.

The donor liver is then brought onto the operative field. The vascular anastomoses are performed using a running monofilament polypropylene suture. If a bicaval technique is planned, two caval anastomoses are required. The suprahepatic vena caval anastomosis is first performed by suturing the posterior walls from within the lumen using an imbricating technique (Fig. 37-7). The anterior wall is then completed. The infrahepatic anastomosis is then completed in a similar fashion. Redundancy in the donor vena cava is avoided to prevent the potential for kinking. The completion of the anastomosis may be left until the time of hepatic revascularization to provide a vent for air, acidotic or hyperkalemic blood, and for residual preservation solution. Venting of blood prior to reperfusion is most important if preservative solutions containing a high concentration of potassium, such as University of Wisconsin solution, were used. Venting of blood is less critical if preservative solutions that do not contain high concentrations of potassium are used, but care must still be taken to avoid the rapid bolus of air or cold blood to the heart. For the piggyback technique, the donor infrahepatic vena cava is either oversewn or stapled. The donor infrahepatic vena cava is then sewn in an end-to-side fashion to the recipient hepatic vein cuff (Fig. 37-9). As described above, an imbricating suture technique is often helpful to prevent gaps in the anastomosis and to compensate for size discrepancies. Venting at the time of reperfusion can either be performed through the suprahepatic anastomosis or at the donor infrahepatic vena cava. For the side-to-side caval technique, a clamp is placed longitudinally on the anterior third of the recipient vena cava. A longitudinal venotomy is made on the anterior surface of the recipient vena cava. The donor supra- and infrahepatic vena cavae are either oversewn or stapled closed. A longitudinal posterior venotomy was then made matching the length of the recipient venotomy. The liver then placed in the right upper quadrant in the left lateral segment is elevated. The two vena cavae are then sutured in a side-to-side fashion with the lateral wall sutured from within the lumen and the medial wall sutured from outside the lumen (Fig. 37-8). Venting can be performed from either the suprahepatic donor vena cava or the medial wall of the anastomosis. During the caval anastomosis, the donor liver may be perfused with cold fluid via a cannula placed within the donor portal vein to wash out the preservation solution and to help maintain the cold temperature of the liver. This step is not required but may be considered if the liver was preserved with a solution containing a high concentration of potassium or if a prolonged warm ischemic time is anticipated.

Once the caval anastomosis or anastomoses are completed, either the portal anastomosis, arterial anastomosis, or both can be performed prior to reperfusion. In theory, reperfusion with arterial blood would limit the extent of warm ischemia to the biliary tree which, unlike the remainder of the liver, receives its blood supply exclusively from the arterial blood and not along with portal venous blood. However, neither

sequence has been clearly shown to be an advantage over the other, so the choice is made based on the surgeon's preference and the patient's anatomy. Most commonly, the portal venous anastomosis is completed and the liver is reperfused. If portal bypass has been used, the portal limb of the venovenous bypass circuit is removed. The portal anastomosis is usually performed in an end-to-end fashion using a running technique. To avoid narrowing and allow for expansion under venous flow, an air knot is used when the suture is tied.

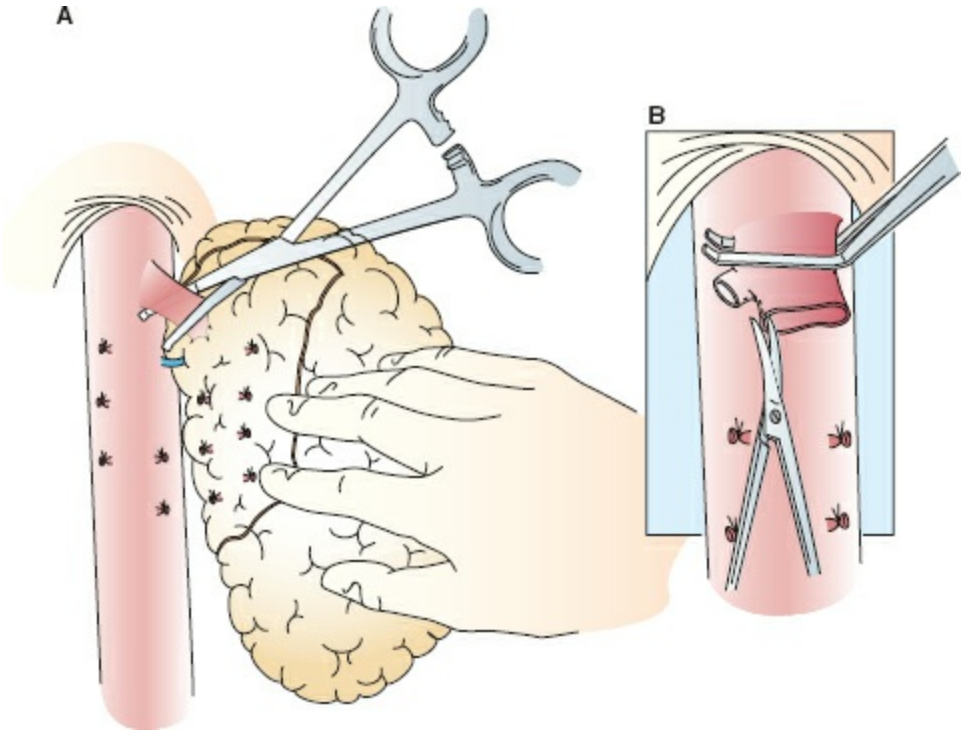

Figure 37-9. **A:** Recipient liver is dissected off native inferior vena cava by dividing veins draining directly into the inferior vena cava up to the level of the hepatic veins. **B:** Clamp placed on recipient hepatic veins in preparation of excision of the recipient's native liver and performance of a piggyback anastomosis.

At the time of revascularization, flow is restored to the liver through the portal vein and/or the hepatic artery. The first several hundred cc of blood may be vented through the infrahepatic vena cava and the knot can be tied completing the caval anastomosis. Alternatively, the caval clamp can be briefly opened and the anastomosis inspected for bleeding and, repaired if present. If blood is not vented through the infrahepatic cava, portal blood should be restored gradually to minimize cardiac irritability, bradycardia, and hypotension, all of which routinely result from cold blood circulating through the donor liver and going directly into the right atrium. Close coordination between the surgeon and anesthesiologist is necessary during this phase as hypotension and bradycardia are routinely encountered and cardiac arrest may rarely occur. If venovenous bypass has been used during the anhepatic phase, it can now be discontinued.

Once hemostasis is obtained and the patient has stabilized, attention can now be turned toward the arterial anastomosis if it has not already been performed. Conceptually, the arterial anastomosis can be performed in one of two ways. The anastomosis can be performed with the artery being very long, which allows the artery to lie with a smooth

and gentle curve or loop (Fig. 37-10). For this technique, all branches on the donor artery are ligated and the donor aortic Carrel patch, celiac artery, or branch patch of the celiac and splenic artery are anastomosed in an end-to-end fashion to a branch patch of the recipient right and left hepatic arteries (Fig. 37-11). Alternatively, the artery can be cut to just the right length and sewn in an end-to-end fashion. This is often performed by forming branch patches between the donor gastroduodenal and recipient proper hepatic arteries and performing the anastomosis in an end-to-end fashion. However, when the retractor is released, the liver may shift position and kinking of the artery may occur. Therefore, judging the proper length of the arteries may be difficult and this technique may be more technically demanding than the method which leaves the artery very long. If the artery is somewhat long but not long enough to allow a gentle or smooth curve or loop, kinking and obstruction to blood flow may occur. For both techniques, the anastomosis can be performed using a fine, nonabsorbable, monofilament, running suture. If the recipient arterial inflow is inadequate, an aortic conduit may be constructed. This is often performed using a graft consisting of the donor common and external (or internal) iliac artery. A partially occluding aortic clamp can either be placed in a supraceliac or infrarenal position and the common iliac artery is sutured in an end-to-side fashion to the recipient aorta. The donor Carrel patch can then be sutured in an end-to-end fashion to the external iliac artery of the conduit.

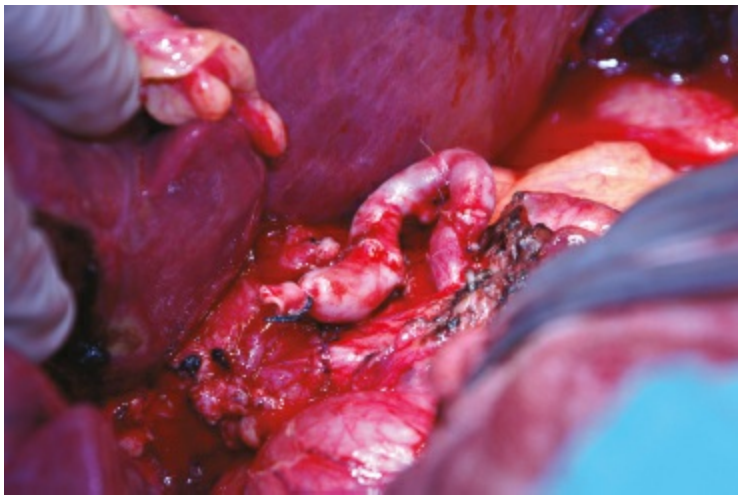

Figure 37-10. Hepatic artery anastomosis where the artery is left long to allow for a gentle loop or curve to form.

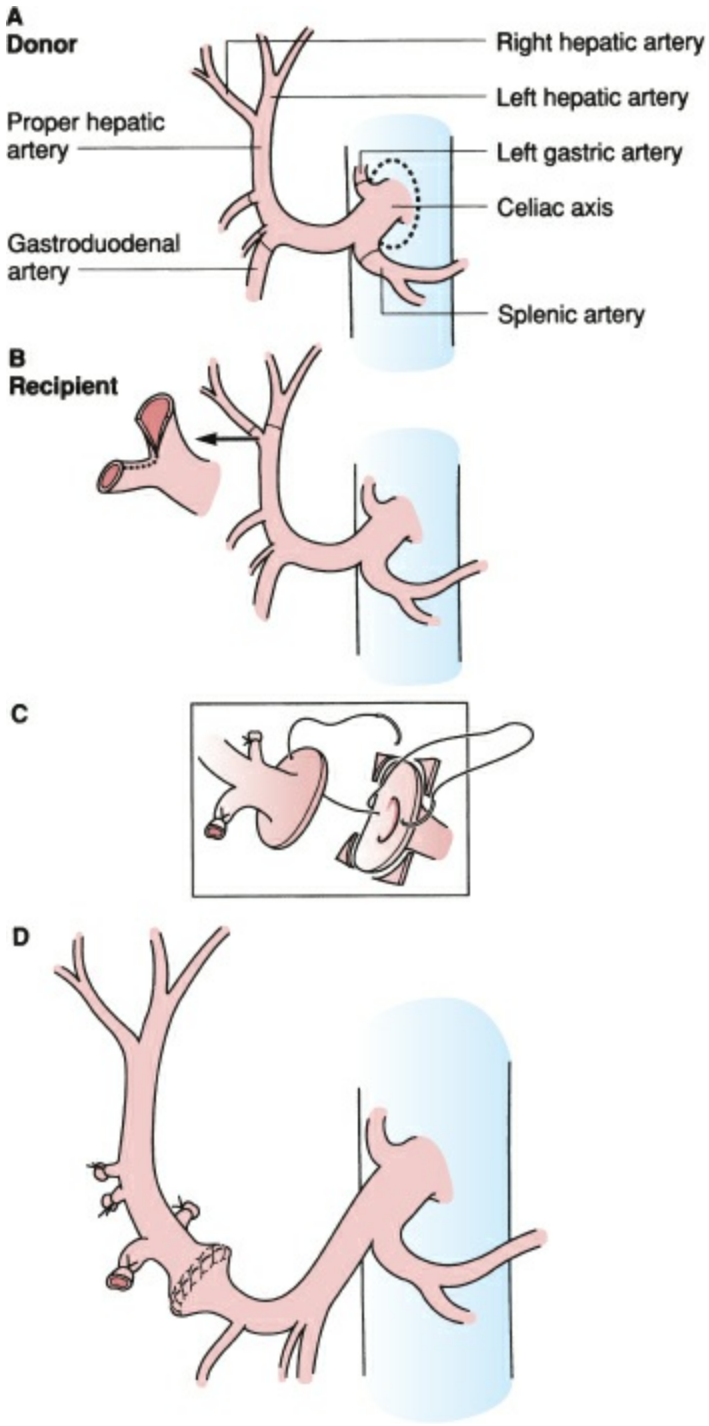

Figure 37-11. **A:** The donor hepatic artery is procured with a Carrel patch of aorta. **B:** The recipient hepatic artery bifurcation is used to fashion a branch patch for a larger anastomosis. **C:** The anastomosis is carried out using continuous monofilament suture material. **D:** The completed anastomosis.

Postrevascularization Phase

Following revascularization, the liver should assume a normal color and consistency within several minutes. If the liver remains pale or is overly soft, problems with portal inflow should be considered. Alternatively, if the liver becomes edematous and overly firm, outflow obstruction should be excluded. Bile production should be seen while in the operating room and is among the first evidence for liver function. In contrast, watery or milky fluid from the bile duct raises concern for primary nonfunction. Inspection for surgical bleeding should be performed and entails examination of the vascular anastomoses as well as a search for branches of the major vessels that may not have been ligated. If bleeding continues after all surgical bleeding has been resolved, attention should be directed toward correction of coagulopathy as described above.

While biliary reconstruction does not carry the same risk for intraoperative complications when compared to the recipient hepatectomy and reperfusion, it is associated with considerable postoperative morbidity and mortality and requires the same diligence and attention as other step of the operation. Because of the relatively high complication rate associated with biliary reconstruction, it has been referred to as the Achilles heel of liver transplantation. There are several options for biliary reconstruction. In the past, the Calne conduit, or the use of the donor gallbladder, was used but has been abandoned due to the high rate of biliary complications associated with it. The simplest and most common technique is currently an end-to-end choledochocholedochostomy from the donor to the recipient bile duct (Fig. 37-12). If a size discrepancy exists, the narrower duct can be spatulated. Running or interrupted sutures can be used. Absorbable monofilament suture is most commonly used to avoid a nidus for future stone formation within the bile duct. While T. tubes were commonly used in the past to stent the anastomosis, evidence now shows that more leaks or strictures develop as a result of the T tube than are prevented. Internal biliary stents may be used and may help prevent leaks or strictures.[56] Alternative biliary reconstruction methods may be necessary for those with a bile duct of inadequate quality or size or in those whose primary disease is biliary pathology such as PSC or biliary atresia. The most common option employed in these situations includes a standard Roux-en-Y choledochojejunostomy. If a prior choledochojejunostomy had been performed in the past, the limb of small bowel used may often be salvaged and used for biliary drainage of the new liver. Placement of drains is optional but may help identify and treat biliary leaks. Abdominal wall and skin closure is then performed in the standard fashion.

Technique for Reduced Size and Split Liver Transplantation

In the 1980s, the waiting list mortality for small, pediatric liver candidates was relatively high because the number of suitably sized small liver donors was inadequate. As a result, techniques to reduce the size of an adult liver, based on Couinaud segmental anatomy (Fig. 37-13), were developed so that the left lobe, left lateral segment, or even a single segment could be used for a recipient more than 10 times smaller by weight than the donor.[57,58] During the early experience, the donor hepatectomy was performed in a standard fashion and the liver was brought back to the recipient hospital. The needed segments of the liver were cut down on the back table with the organ on ice, the vessels were left intact to the future transplant graft, and the remainder of the liver was discarded. Techniques have now developed so that both sides of the liver can be transplanted into two recipients, either a child and an adult or two adults.[59,60] In addition, the liver may be split in situ at the donor hospital, allowing coagulation of the cut edge of the liver so that bleeding is minimized following reperfusion. Perfusion to both sides of the liver can be inspected prior to flushing ensuring that blood flow to all segments of each future graft has been preserved. Because of technical and practical issues, both the cut down technique and in situ splitting of the liver are still employed. Split liver transplantation has been associated with a decreased survival rate and the potential for increased risk of complications, including primary nonfunction, hepatic artery thrombosis, and biliary complications. Because of this, while widespread adoption of allocation policies to encourage greater utilization of split liver grafts in the adult population has been suggested, split liver transplantation only accounts for a small proportion of transplants performed. In addition, only grafts from “ideal donors” are thought to be suitable to this form of transplantation. Criteria supported by the UNOS for splitting currently include donor age less than 40 years of age, on a single or no pressors, transaminases no greater than three times normal, and a body mass index of 28 or less.

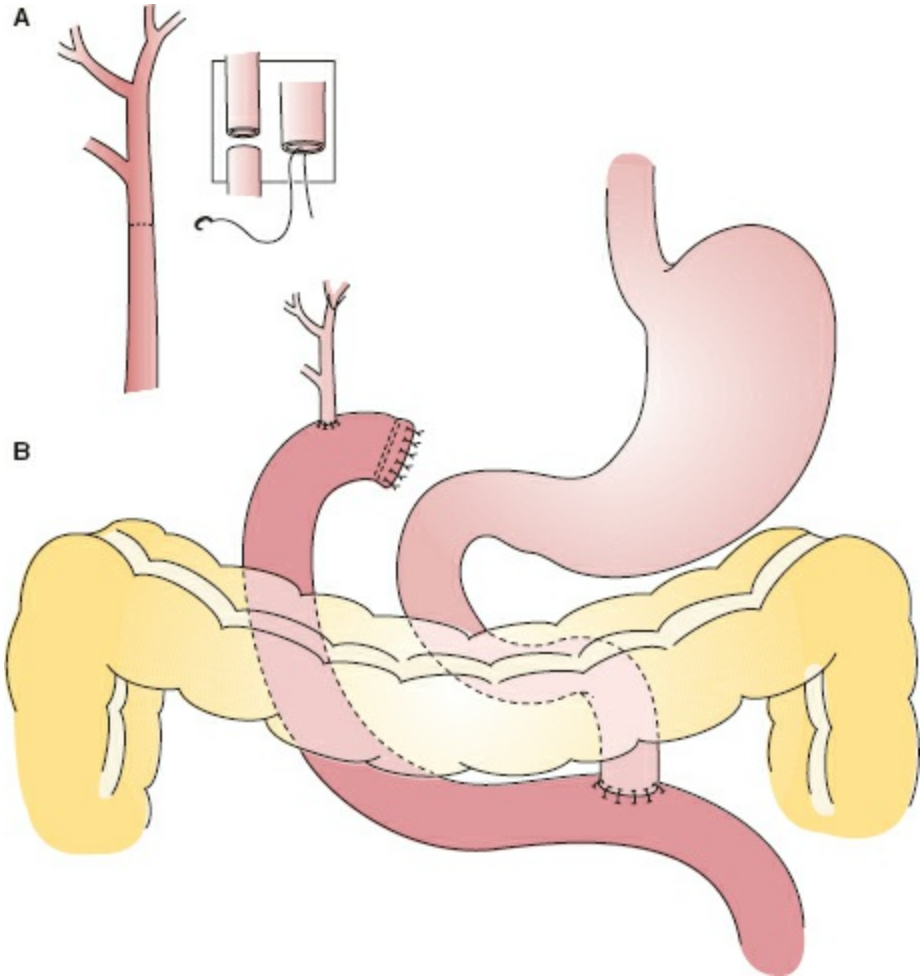

Figure 37-12. **A:** In most cases, a choledochocholedochostomy is performed, possibly over an internal stent. **B:** Patients with a diseased or unsuitable common bile duct may require biliary reconstruction with a Roux-en-Y choledochoenterostomy.

Living Donor Liver Transplantation

Experiences with deceased donor split liver transplantation as well as the success with living donor kidney transplantation led to the adoption of the techniques for split liver transplantation to living donor liver transplantation. The first living donor liver transplantation allowed an adult volunteer to donate the left lateral segment of the liver to a child. Based on the success of living donation in the pediatric population as well as the increased waiting list mortality rate for adults, these techniques have also been applied to adult recipients receiving either the right or left lobe from an adult volunteer.[61] Living donor liver transplantation was progressively developing in the United States until a well-publicized donor mortality occurred.[62] Living donor liver transplantation now accounts for approximately 5% of all liver transplants performed in the United States. In Japan and other areas of the Far East, where deceased donor transplantation has developed slower because of cultural difficulties with the concept of brain death, living donor transplant are the rule rather than the exception.

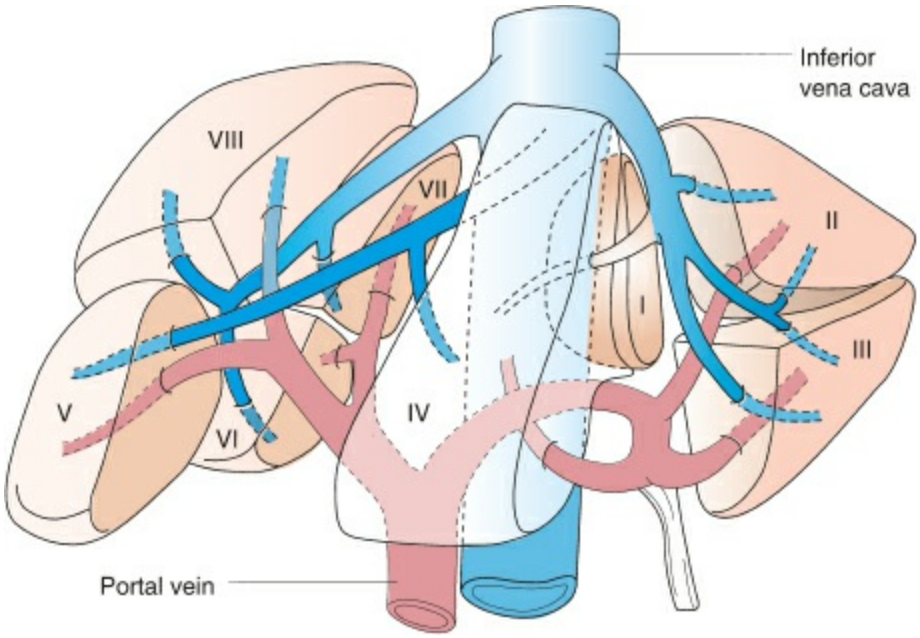

Figure 37-13. Segmental anatomy of the liver as based on Couinaud nomenclature.

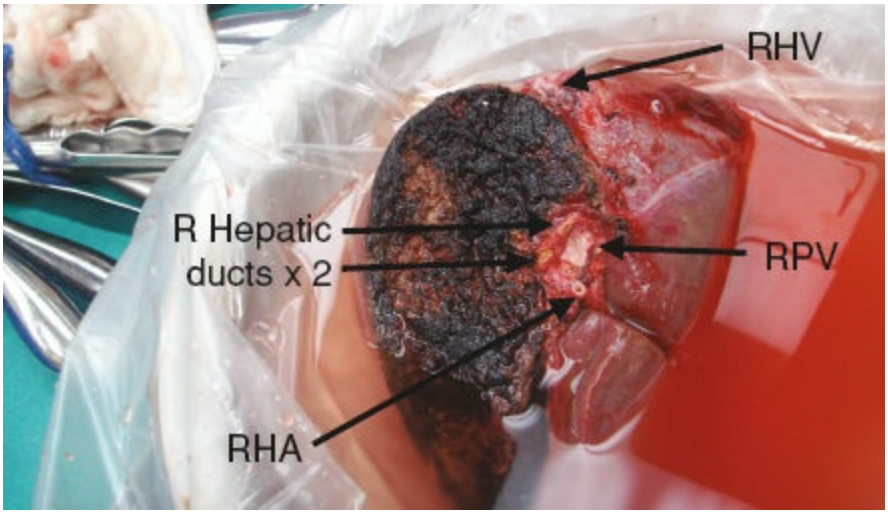

Figure 37-14. Living donor right hepatic lobe allograft demonstrating the right hepatic vein (RHV), right portal vein (RPV), right hepatic artery (RHA), and two right hepatic ducts.

In many respects, transplantation of a graft from a living donor is similar to transplantation of a whole liver from a deceased donor. However, a bicaval technique is not possible given that the donor vena cava is not available for replacement of the recipient's retrohepatic inferior vena cava (Fig. 37-14). Therefore, the recipient vena cava must be left intact. A direct hepatic vein to vena caval anastomosis is used (Figs. 37-15 and 37-16). Establishing adequate outflow of hepatic venous blood is necessary to help prevent edema of inadequately drained segments of the liver possibly leading to small-for-size syndrome. Therefore, any accessory veins greater than 5 mm in diameter should be reconstructed either by direct anastomosis to the vena cava or using an interposition graft. In addition, the length of the portal vein, hepatic artery, and bile duct on the donor graft is considerably shorter than that available from a deceased donor. Therefore, during the recipient hepatectomy, considerable care should be given to preserving the length of the recipient bile duct as well as the right and/or left hepatic artery and portal vein which are intended for future anastomosis.

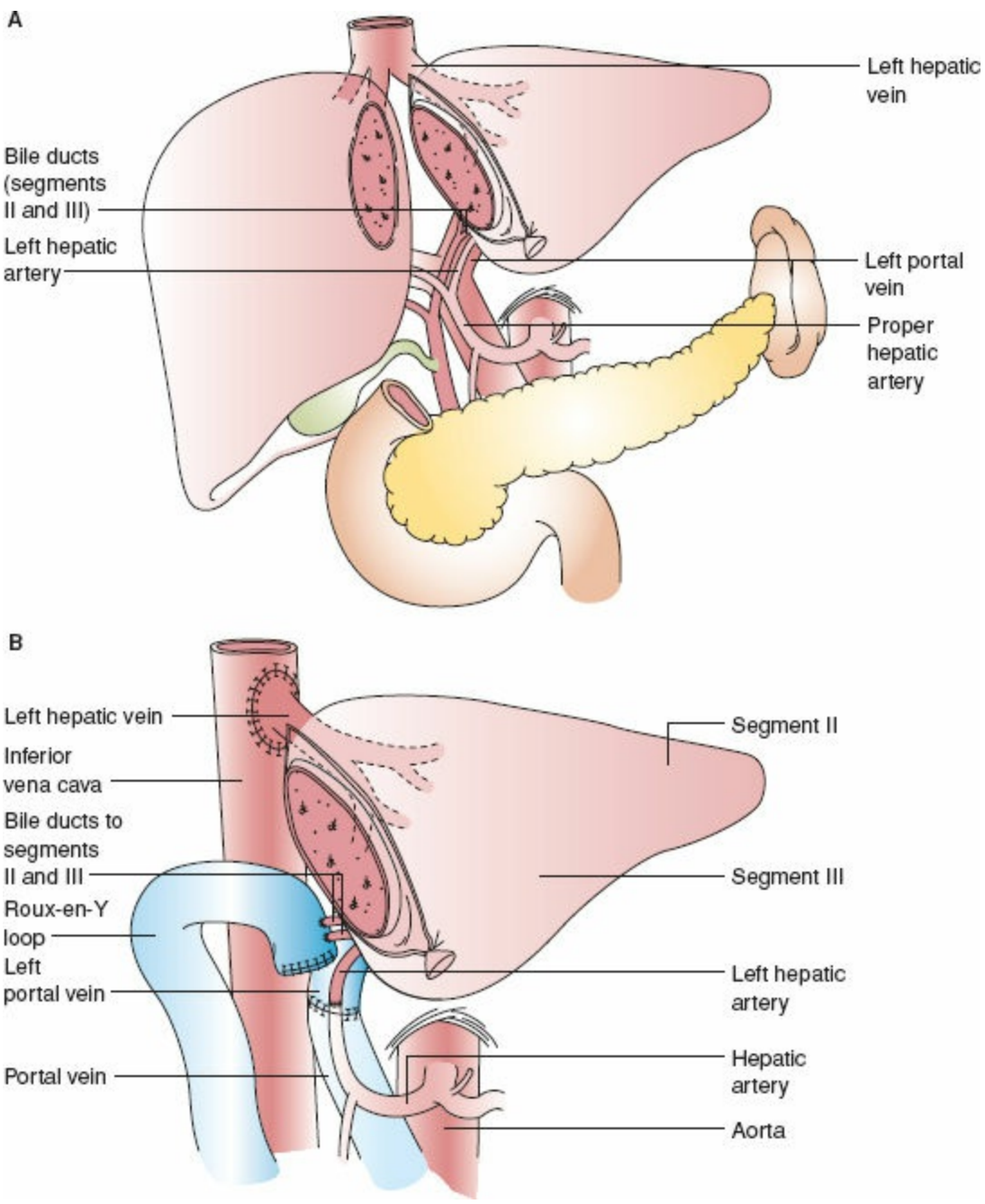

Figure 37-15. Left lateral segment (segments II and III) living donor transplantation. **A:** Donor operation. **B:** Recipient operation completed.

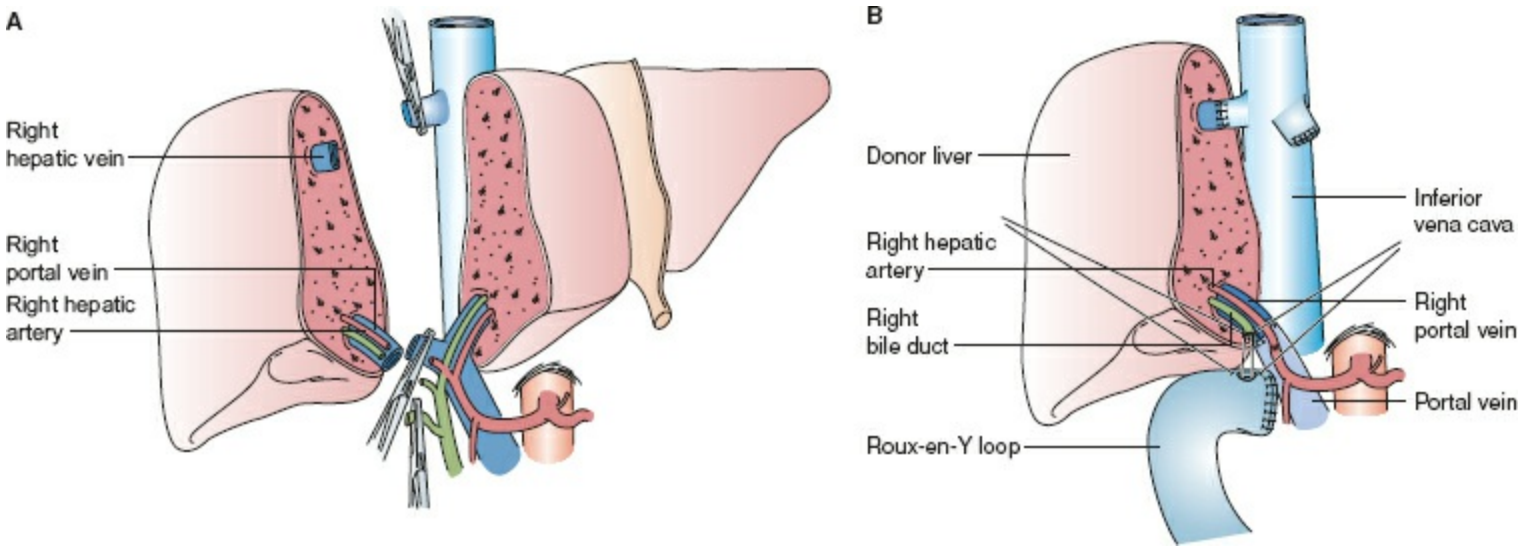

Figure 37-16. Right lobe (segments V to VIII) living donor transplantation. **A:** Donor operation. **B:** Recipient operation completed.

Auxiliary Liver Transplantation

Under select circumstances, there is a good rationale for placing the donor allograft in a heterotopic rather than orthotopic position, leaving the native liver in place. This procedure is known as auxiliary liver transplantation. Auxiliary liver transplantation has occasionally been used for cases in which liver transplantation is indicated for somatic genetic deficiency but the native liver is otherwise normal in all other respects. It is also been used in cases of FHF where the liver candidate is expected to die in the near future without transplant but if adequate time was allowed, the native liver may recover and return to normal. In this situation, immunosuppression can slowly be weaned, the transplanted liver will atrophy, and the recipient can be taken off of all immunosuppression. Figure 37-17 demonstrates one technique used. Another option, auxillary partial orthotopic liver transplantation (APOLT) has been developed. For this technique, part of the native liver is resected, often the right trisegment, leaving only the left lateral segment intact. The donor liver is then transplanted in an orthotopic position. If the native left lateral segment recovers, immunosuppression can be weaned leading to hypertrophy of the left lateral segment and involution of the allograft.

Complications

3 The degree of preoperative debilitation and the complexity of the operative procedure make complications following liver transplantation very common. Prompt recognition and treatment are essential. However, the usual signs or symptoms that would be expected in the general population are often absent or present to a lesser degree, and therefore, a high level of suspicion must be maintained. Early warnings, such as fever, leukocytosis, or pain may be suppressed as a result of immunosuppression. In addition, the burden of immunosuppression predisposes to additional problems not usually encountered in other areas of surgery. Complications associated with immunosuppression, which are predominantly infectious, are detailed in another chapter. In the following sections, some of the major surgical complications that occur after liver transplantation are described.

Primary Nonfunction

4 About 2% to 4% of transplanted livers function so poorly in the immediate postoperative period, from an unknown etiology that death is likely in the absence of retransplantation and is referred to as primary nonfunction. Most cases of primary nonfunction likely occur as a result of ischemic injury, occurring either in the donor or the recipient,[63] or from poor preservation. Donor factors known to predispose to primary nonfunction include allograft steatosis, advanced donor age, and prolonged cold ischemic time. In addition, donor race and the need for portal vein reconstruction have also been demonstrated to be risk factors for primary nonfunction.[64]

Early evidence for primary nonfunction include poor bile production of the liver intraoperatively, refractory acidosis, progressive coagulopathy, and hepatic encephalopathy. In a short period of time, these early signs are often followed by acute renal insufficiency and eventually cardiopulmonary collapse. Serial factor V levels may be helpful to determine if a liver allograft is functioning in a patient who has received a massive transfusion of fresh frozen plasma. In this setting, the INR may reflect transfused coagulation factors rather than factors synthesized by the liver graft. Fresh frozen plasma contains relatively little factor V because this factor is relatively unstable in cold storage. Therefore, a steady increase in the factor V level suggests production by the liver rather than transfusion with fresh frozen plasma.

Liver transplant recipients in the United States with primary nonfunction, currently defined as those who were transplanted within 7 days and are anhepatic developed an AST above 3,000 along with either an INR above 2.5 and/or an acidosis, can be relisted as a status 1A. Patients listed as a status 1A receive regional priority over less ill patients and frequently wait only a period of few days for an appropriate donor to become available. Despite this preferential listing for retransplantation, primary nonfunction is associated with a mortality rate of more than 50%.[64]

Postoperative Hemorrhage

Postoperative hemorrhage requiring laparotomy occurs in approximately 5% to 15% of liver transplant recipients. Postoperative bleeding should be suspected in any liver recipient during the immediate posttransplant period that develops tachycardia, volume-dependent hypotension, oliguria, and abdominal distention. Because many liver transplant recipients may have had a large volume of ascites preoperatively (sometimes more than 10 to 20 L), a considerable amount of bleeding may occur before developing an abdominal compartment syndrome. In general, attempts to correct coagulopathy should be made and reexploration should occur in patients with refractory hypotension, abdominal compartment syndrome, or ongoing need for blood transfusion. At exploration, a specific bleeding point often cannot be identified, suggesting that bleeding may be related more to coagulopathy than failure of surgical hemostasis. Therefore, waiting until coagulopathy is corrected before reexploration may be wise assuming that the recipient is otherwise reasonably stable.

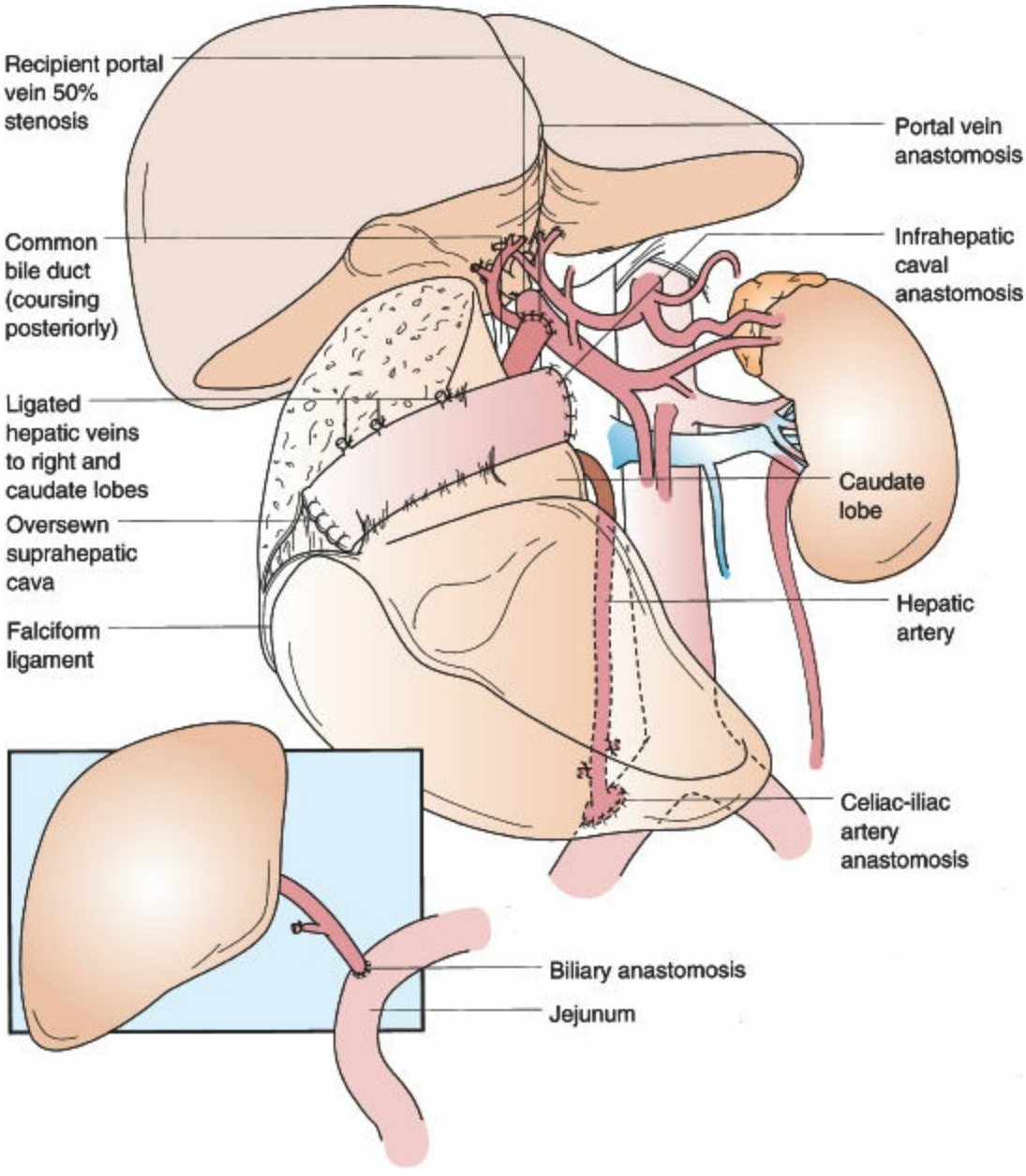

Figure 37-17. Heterotopic auxiliary liver transplantation using a reduced-size allograft.

Hepatic Artery Thrombosis

The incidence of hepatic artery thrombosis ranges from 1% to 2% up to 10% in some populations. The incidence of hepatic artery thrombosis is higher in pediatric recipients as well as recipients of living donors or split livers. Other risk factors include receiving a liver from a donor who is significantly smaller than the recipient, the need for reconstructive arterioplasty in the presence of nonstandard donor anatomy, acute rejection within the first week posttransplant, placement of cytomegalovirus (CMV)-positive organs into CMV-negative recipients, and a recipient history of smoking.[65] The association between rejection and hepatic artery thrombosis may be the result of a decrease in hepatic arterial flow that occurs when the liver is swollen and edematous or to release procoagulations into the microcirculation in association with the inflammatory injury of graft rejection.

Hepatic artery thrombosis can occur in the early, arbitrarily defined as within 30 days, or late posttransplant periods. Early hepatic artery thrombosis is usually identified within the first 10 days posttransplant. The diagnosis is suspected in the setting of unexpectedly high liver enzymes, an elevation in liver enzymes rather than a gradual decline, or poor synthetic function during the first week to 10 days posttransplant. Other signs of biliary ischemia from hepatic arterial thrombosis include the development of biliary leaks, strictures, or intrahepatic abscesses. Doppler ultrasonography is usually used to confirm flow within the extrahepatic and intrahepatic arteries. If inappropriate waveforms or no flow is identified, the diagnosis can be confirmed by angiography or reexploration. At exploration, flow can be restored within the hepatic artery approximately 80% of the time if the diagnosis is made early. However, despite restoring arterial flow, many of these recipients will still develop biliary complications.

Hepatic artery thrombosis that occurs months to years following liver transplantation does not always lead to graft failure. Although some patients develop biliary strictures and/or hepatic abscesses, approximately a third of patients do well without intervention.[66]

The arterial blood flow in the reconstructed hepatic artery is an important determinant of long-term patency. It is believed that children are predisposed to hepatic artery thrombosis because they have smaller vessels and lower mean arterial blood pressure than adults. Pediatric patients with an arterial diameter of less than 3 mm have the highest incidence of hepatic artery thrombosis. However, the experience with pediatric living donor transplantation, where very small arteries are routinely encountered, has indicated that with microsurgical technique it is possible to achieve a low hepatic artery thrombosis rate.[67]

A postoperative hypercoagulable state associated with hepatic transplantation may predispose to hepatic artery thrombosis. Relatively poor hepatic production of natural regulatory anticoagulants, such as proteins C and S and antithrombin III, immediately after transplantation promotes coagulation because production of procoagulant factors, such as factor V and VII, occurs more rapidly after revascularization.[68] This observation has prompted some centers to administer fresh frozen plasma as a source of antithrombin

III and proteins C and S in the postoperative period. Most centers recommend prophylactic aspirin to prevent hepatic artery thrombosis in children.

Portal Vein Thrombosis

Postoperative portal vein thrombosis is much less common than hepatic artery thrombosis, occurring in 1% to 3% of cases. A higher incidence of portal vein problems is seen in patients that have had previous portal vein operations or prior thrombosis of the portal system. Factors that decrease antegrade portal flow also predispose to portal vein thrombosis. Patients with chronic portal hypertension often spontaneously develop large retroperitoneal collaterals from the portal venous system to the renal vein and inferior vena cava. A previous surgically created splenorenal shunt should be disconnected at the time of transplantation because it usually is associated with reduced flow through the portal vein. This can be accomplished easily during a liver transplant by dissecting down the vena cava and ligating the left renal vein at its origin. This maneuver does not compromise the function of the left kidney. This maneuver can also be useful to improve portal flow if preoperative imaging discloses large spontaneous portosystemic shunts to the left renal vein.

Portal vein thrombosis should be suspected when the recipient develops symptoms of portal hypertension or ascites that is unusually difficult to control. Doppler ultrasound examination is usually the first diagnostic tool, but magnetic resonance imaging is also an option, as are standard mesenteric arteriography with portal phase views and direct percutaneous transhepatic portography. Transhepatic portography is particularly useful if a stenosis, rather than thrombosis, is identified because it is possible to both measure the pressure gradient across a stenotic area and treat a stenotic area with angioplasty and/or stent placement.

When portal vein thrombosis is identified in the immediate postoperative period, reexploration and attempted thrombectomy are usually indicated. Thrombectomy is more likely to be successful if a technical flaw in the anastomosis is present and can be corrected. When performing thrombectomy, it is advisable to avoid using balloon embolectomy catheters to remove clot from the mesenteric venous system, because these veins are very fragile and rupture of mesenteric veins deep in the mesentery can be catastrophic.

Hepatic Vein or Inferior Vena Cava Stenosis

Thrombosis of the inferior vena cava is a rare complication after liver transplantation, but hepatic vein outflow obstruction occurs in 2% to 4% of patients. Restrictions of hepatic blood flow may result from kinking of the suprahepatic cava. This is particularly problematic when the donor is small relative to the recipient and when the suprahepatic anastomosis is left long. Hepatic outflow problems can present with ascites and renal dysfunction. Presentation may be early in the first week after transplantation or months later. The diagnosis may be suspected on the basis of Doppler ultrasonography, but definitive diagnosis usually requires inferior cavography with measurement of pressure gradients. The incidence of caval complications utilizing the piggyback technique appears to be higher than the incidence with the bicaval technique, at approximately 4%.[69] Outflow stenosis appears to be more common if the combined orifice of two, rather than three, hepatic veins is used for the anastomotic site on the recipient when the piggyback technique is used. In many cases, hepatic vein or suprahepatic caval stenosis can be successfully treated noninvasively with the use of balloon angioplasty and stenting.[70,71]

Biliary Leak or Stricture

Biliary leak or obstruction is a common surgical complication encountered after hepatic transplantation with an incidence of approximately 10% to 30%.[56,72] Most biliary complications probably relate to ischemia of the donor biliary tree (Fig. 37-18). The transected donor bile duct is totally dependent on arterial flow from the liver graft. Therefore, when a biliary leak is identified, it is appropriate to interrogate the hepatic vasculature to rule out the presence of hepatic artery stenosis or thrombosis.

Although anastomotic biliary complications can result in mortality from sepsis, these most commonly lead to short-term morbidity. The initial management of biliary complications can generally be nonoperative. In most cases, the problem can be both diagnosed and treated by ERCP. If the biliary reconstruction was made using a Roux-en-Y hepaticojejunostomy, of if ERCP is unsuccessful, biliary leaks can be diagnosed and treated by interventional radiology using percutaneous transhepatic cholangiography and percutaneous placement of a biliary stent. In addition to stenting the anastomosis, it may be necessary to place a percutaneous drain if there is a significant extrahepatic collection of bile. In cases where initial studies show a large defect and in cases where the leak is not controlled through percutaneous measures, operative revision may be indicated.

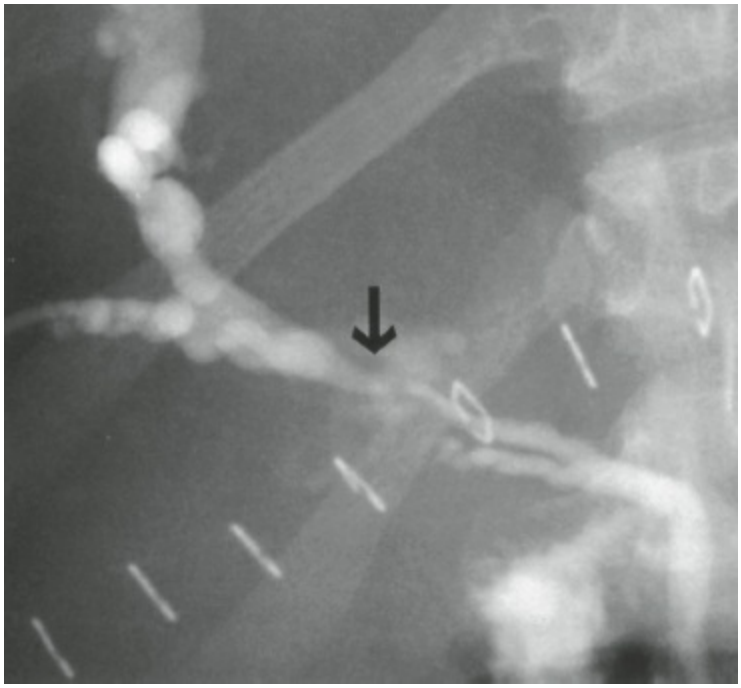

Figure 37-18. Bile leak (*arrow*) from the choledochocholedochostomy after hepatic transplantation.

Biliary obstruction resulting from anastomotic strictures can also generally be managed nonoperatively by using percutaneous cholangioplasty or ERCP. When anastomotic strictures persist beyond two attempts at balloon dilatation and stent replacement, operative repair may be an option as long as the entire biliary stricture is extrahepatic and there are no intrahepatic strictures.

While anastomotic strictures are less likely to cause long-term morbidity, intrahepatic biliary strictures, also referred to as intrahepatic cholangiopathy, can be progressive and lead to allograft dysfunction, cholangitis, and ultimately to either death or retransplantation. Intrahepatic cholangiopathy is largely related to ischemic injuries and occurs in the setting of hepatic artery thrombosis and occurs in approximately 20% of donation following cardiac death (DCD) liver recipients.

Intra-Abdominal Sepsis

Intra-abdominal sepsis presents as diffuse peritonitis or localized abscess and occurs in about 5% of patients who undergo liver transplantation. The most common cause of peritonitis is leakage of the biliary anastomosis. Abscesses may also develop spontaneously in the right upper quadrant or elsewhere in the abdomen. Most isolated infected fluid collections can be managed by percutaneous placement of drains guided by ultrasound or CT scanning, along with broad-spectrum intravenous antibiotics. Generalized infected ascitic fluid is managed with paracentesis and antibiotics. Surgical drainage may be necessary if leakage of enteric contents is suspected based on the finding of extravasated oral contrast in the peritoneal cavity on CT scan, or if the patient does not respond to percutaneous drainage.

Neurologic Complications

A number of preoperative and postoperative factors predispose to impaired consciousness and seizure activity after transplantation. Patients who have significant preoperative encephalopathy are more likely to suffer from postoperative neurologic symptoms. In the extreme, patients who are in hepatic coma from fulminant liver failure can sometimes take weeks to regain complete consciousness. Patients undergoing liver transplants are also at risk for watershed cerebral infarcts if significant intraoperative hypotension occurs. The effects of transient cerebral ischemia are worsened by the large amount of intravenous fluids that are often necessary during and after transplantation, which can exacerbate cerebral edema. Air embolism is also a risk if venous bleeding occurs from the inferior vena cava or hepatic veins at a time when the patient is relatively hypovolemic. If the patient has a patent foramen ovale, air embolism can result in cerebral ischemia if large bubbles lodge in the cerebral circulation. If the patient fails to awaken promptly after transplantation, and particularly if the transplant is functioning well, an urgent CT scan of the head should be obtained to rule out intracranial hemorrhage and to assess the degree of cerebral edema.

Seizures are reasonably common after transplantation. The calcineurin inhibitors cyclosporine and tacrolimus both lower seizure threshold and are associated with seizures following liver transplantation. Patients with a history of seizures are particularly predisposed to postoperative seizure activity. Seizures are treated with benzodiazepines acutely. Many long-term anticonvulsants alter the metabolism of calcineurin inhibitors. Therefore, levetiracetam is often used in substitution for these other anticonvulsants. To prevent recurrence of seizure activity it is usually necessary to decrease the dosage of calcineurin inhibitor to a lower target blood level. Frequently it is also necessary to change to a different calcineurin inhibitor altogether, or even to change the patient's maintenance immunosuppression to a regimen that does not include a calcineurin inhibitor.

REJECTION AND IMMUNOSUPPRESSION

5 For reasons that are not understood, liver transplant recipients require less immune suppression than patients with other types of allografts, such as heart, lung, and kidney recipients. This is somewhat surprising given that the mass of the liver is so great compared with the mass of the other organs. With current immunosuppressive therapy, graft loss from rejection is rare.

Antibody-Mediated Rejection

The liver is relatively resistant to injury from recipient antibodies, regardless of whether they are present at the time of transplant or develop later. This is very different compared with renal and cardiac recipients who experience rapid graft destruction, termed *hyperacute rejection,* if performed in a patient who has complement-fixing antibodies directed against the donor organ in significant concentrations at the time of transplantation. Hepatic graft injury from pre-existing antibodies directed at donor ABO determinants does occur, but in a much less pronounced fashion than in the context of renal transplantation. The overall results of ABO-incompatible liver transplants are somewhat inferior to those of ABO-compatible transplantations, but only by about a 10% to 20% decrease in 1-year graft survival rates compared to ABO-compatible grafts. Some of this decrease in graft survival rate may be due to the fact that ABO-incompatible transplants are usually performed only in dire circumstances where the patient is so ill that he or she may not survive the wait for a compatible organ. Because preformed antibodies do not seem to be clinically important, most transplantation programs do not perform prospective cross-matches between recipient serum and donor cells before transplantation, and determination of recipient and donor HLA type is no longer considered mandatory.

Why the liver is less susceptible to antibody-mediated destruction than the kidney is not clearly understood. One factor may be the vastly different microcirculation that the liver has compared with the kidney, with a preponderance of sinusoidal channels and a smaller capillary network. It is probable that antibody-mediated injury affects blood flow through the delicate capillary network of the kidney more than it does to the liver sinusoids. In addition, each hepatocyte is exposed to two sinusoidal channels, presumably permitting survival if only one sinusoid is occluded. Finally, differences in HLA antigen expression are known to exist in the two organs, with the kidney the more antigenic of the two.

Cell-Mediated Rejection

6 Typical acute rejection in liver transplant recipients is usually cell mediated and occurs frequently but is effectively blunted by antirejection therapy. Acute rejection occurs most commonly in the first two postoperative months. In modern practice, cell-mediated rejection is a less common cause of graft loss than are primary nonfunction or hepatic artery thrombosis. Still, the effectiveness of antirejection treatment assumes a relatively early diagnosis and treatment of acute rejection, which is in turn the result of careful monitoring by the transplantation physician and compliance by the patient with frequent laboratory testing. Treatment of acute rejection with enhanced immunosuppressive therapy is highly effective, and an episode of rejection does not affect long-term graft survival. This is very different from renal transplantation, where an episode of rejection decreases long-term graft survival markedly.

The diagnosis of cell-mediated rejection is made primarily on a histologic basis. Clinical features can include low-grade fever and malaise, but frequently the patient is completely asymptomatic. Laboratory evaluation of peripheral blood may demonstrate leukocytosis and occasionally eosinophilia. Biochemical changes associated with rejection include elevated and rising levels of serum transaminases and alkaline phosphatase. A prolonged serum prothrombin time and an abnormal serum bilirubin also suggest the possibility of rejection, but frequently these parameters are normal if rejection is detected early. Any of these findings should prompt a biopsy.

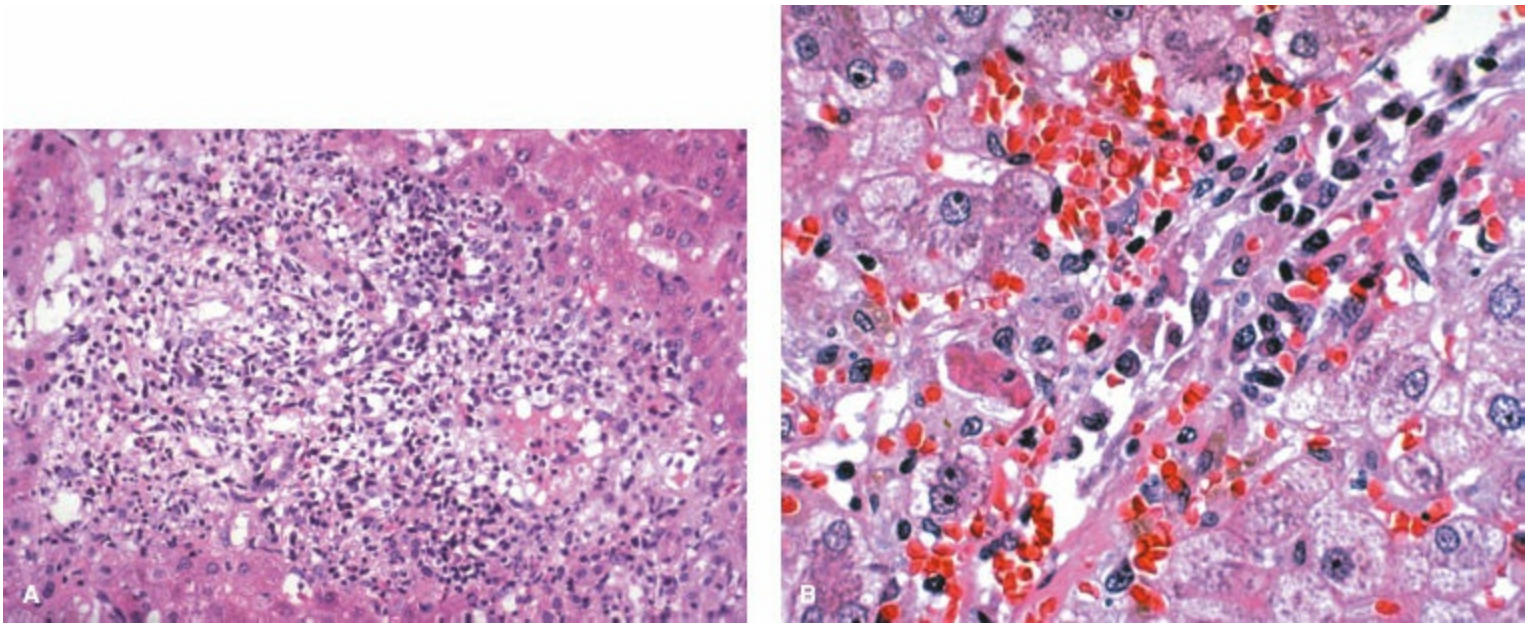

Figure 37-19. Acute rejection of a liver transplant. **A:** A portal tract is expanded by a polymorphous inflammatory infiltrate consisting of large and small lymphocytes, plasma cells, macrophages, and neutrophils. The bile ducts (*arrows*) are damaged and inflamed. **B:** A central vein from the same biopsy exhibits endothelialitis, characterized by swollen endothelial cells and infiltrating lymphocytes. (From Thung SN, Gerber MA. Histopathology of liver transplantation. In: Fabry TL, Klion FM, eds. *Guide to Liver Transplantation.* New York: Igaku-Shoin Medical Publishers; 1988.)

The diagnosis of cell-mediated rejection rests on the finding of a triad of portal lymphocytosis, endotheliitis (subendothelial deposits of mononuclear cells), and bile duct

infiltration and damage (Figs. 37-19 and 37-20). Various classification schemes have been devised to grade the severity of the rejection process based on the degree of cellular involvement or injury in these areas. Cell characterization studies have documented that the cells in the portal triads are primarily T cells, with fewer macrophages and neutrophils. Bile duct epithelial cells appear to be a prime target of immune attack, and they are known to express large amounts of class II HLA antigen.

If the recipient has hepatitis C, it is critical that recurrent hepatitis C is differentiated from acute rejection. At times the difference can be subtle, and a pathologist with experience in the interpretation of allograft biopsies is extremely valuable. Enhanced immunosuppression is associated with accelerated rates of hepatitis C viral replication; it is, therefore, important that immunosuppression is kept to a minimum for these patients.

Chronic Rejection

7 Chronic rejection is characterized by relentless immune attack on small bile ducts. Clinically, the pattern is one of gradual elevation of alkaline phosphatase and bilirubin, in the absence of obstruction of the large bile ducts. Histologically, small bile ducts are obliterated or completely absent, with a less pronounced cellular infiltrate than is seen with acute rejection. This finding has been termed *vanishing bile duct syndrome* when bile ducts are absent in 15 of 20 portal triads examined.[73] The loss of small bile ducts is partly the result of lymphocyte-directed attack on biliary epithelium. Relative to other cells in the liver, biliary epithelium tends to express more class I antigen. Thus, biliary epithelial cells are vulnerable targets for host attack because of their antigenicity. Loss of bile ducts may also occur indirectly as the result of ischemia secondary to immune-mediated obliteration of small to medium arteries. As in the case of renal transplantations, there is no effective treatment for chronic rejection except retransplantation.

Immunosuppression Induction and Maintenance

Multiple immunosuppressive protocols achieve acceptable suppression of allograft rejection for liver transplant recipients. Induction with antithymocyte globulin is no longer considered to be mandatory but is used at some centers. Similarly prednisone therapy, once considered a mainstay of a successful immunosuppressive protocol, is no longer considered absolutely necessary and when used is often tapered off rapidly. Treatment with a calcineurin inhibitor, either cyclosporine or tacrolimus is still considered to be imperative for most liver transplant recipients. These agents are associated with significant long-term morbidity, particularly the development of chronic renal failure. Dosages of these agents have gradually been reduced both to prevent renal insufficiency and to avoid the rapid and aggressive recurrence of hepatitis C infection. Induction antibody therapy with either polyclonal antilymphocyte preparations or with inhibitors of the receptor for IL-2 are still used commonly in the perioperative setting to avoid the nephrotoxicity associated with the immediate use of calcineurin inhibitors.

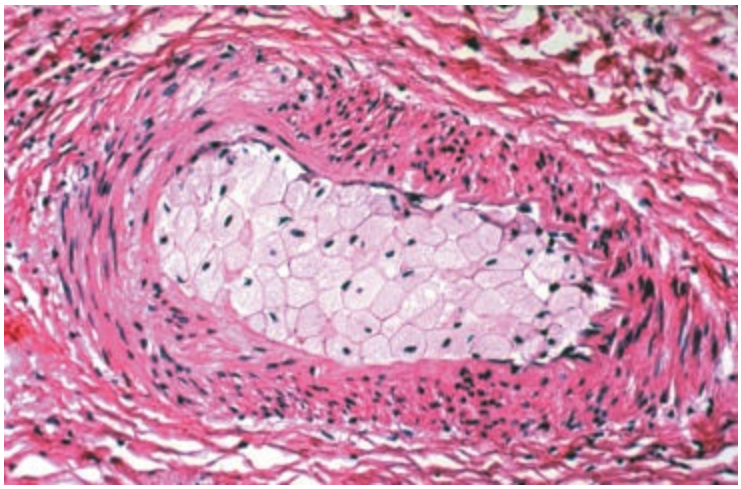

Figure 37-20. Arterial lesion of chronic hepatic rejection. Subintimal foam cells, intimal sclerosis, and myointimal hyperplasia obliterate the arterial lumen. (From Rubin E, Farber JL. *Pathology.* 3rd ed. Philadelphia: Lippincott Williams & Wilkins; 1999.)

Because immunosuppression predisposes to infection, prophylactic anti-infective drugs are usually administered. Trimethoprim–sulfamethoxazole, dapsone, or pentamidine is recommended to prevent *Pneumocystis carinii* infection. Oral Mycostatin or fluconazole therapy is used to prevent fungal infections, particularly esophageal *Candida albicans.* Either ganciclovir or valganciclovir is prescribed for patients who are at risk for CMV infection, which includes any patient exposed to CMV in the past and any patient transplanted with organs from a donor who has been exposed to CMV. Patients who are CMV negative who receive CMV-negative organs are not at high risk for CMV infection but should still receive prophylaxis against disseminated herpes simplex infections with acyclovir therapy. The duration of prophylactic anti-infective therapy has not been rigorously defined by evidenced-based trials and is therefore dependent on each center's experience with the prevalence of these infections in its patient population.

Treatment of Acute Rejection

Despite the overall effectiveness of the regimen described, acute rejection does occur and must be treated promptly. Several options are available for treatment of acute rejection, depending on the clinical circumstances. Traditionally, high doses of methylprednisolone are administered (usually 500 mg to 1 g) intravenously on a daily basis for 3 days. This treatment is effective in reversing most acute rejection episodes. Alternatively, increased doses of oral prednisone, a calcineurin inhibitor, or the addition of an antimetabolite drug, such as mycophenolate mofetil, will also reverse most episodes of rejection, particularly if the rejection is mild. Rejection that is resistant to these maneuvers or severe is treated with antilymphocyte therapy, either a monoclonal antibody directed at the T3 determinant common to all mature T cells (Orthoclone, OKT3) or polyclonal antilymphocyte treatments such as Atgam or Thymoglobulin. These treatments are typically administered daily for 5 to 10 days. These agents are highly effective, and it is unusual to lose an allograft secondary to acute rejection. However, these treatments are associated with profound and long-lasting immunosuppression, and it is usually advisable to restart prophylactic anti-infective therapies when they are initiated.

RESULTS

8 The patient survival rate following liver transplantation in the United States at 1 year is more than 85% for adults and nearly 90% for children. Patients who survive the first year following a liver transplantation experience approximately a 3% annual mortality rate thereafter, so 3-year survival rates for adults and children are currently 78% and 83%, respectively.

The most important predictors of survival following liver transplantation are whether the patient has previously undergone transplantation and whether the patient was in the intensive care unit at the time of transplantation. Although not as important as the condition of the patient at transplantation, the cause of liver failure is also an important determinant of success. Five-year survival varies from approximately 60% for patients transplanted for malignancy to 70% for patients transplanted for viral and alcoholic cirrhosis. The best 5-year survival rates of around 80% are seen with patients transplanted for metabolic liver disease, biliary atresia, and cholestatic liver diseases (PBC and PSC).[37] The volume of liver transplants performed at a given transplant center is also associated with patient survival, with higher-volume programs exhibiting higher adjusted overall patient survival rates.[74]

References

1. Starzl TE, Groth CG, Brettschneider L, et al. Orthotopic homotransplantation of the human liver. *Ann Surg* 1968;168:392–415.
2. Calne RY, Rolles K, White DJ, et al. Cyclosporin A initially as the only immunosuppressant in 34 recipients of cadaveric organs: 32 kidneys, 2 pancreases, and 2 livers. *Lancet* 1979;2:1033–1036.
3. Roberts MS, Angus DC, Bryce CL, et al. Survival after liver transplantation in the United States: a disease-specific analysis of the UNOS database. *Liver Transpl* 2004;10:886–897.
4. Freeman RB Jr, Steffick DE, Guidinger MK, et al. Liver and intestine transplantation in the United States, 1997–2006. *Am J Transplant* 2008;8:958–976.
5. O'Leary JG, Lepe R, Davis GL. Indications for liver transplantation. *Gastroenterology* 2008;134:1764–1776.
6. Punch JD, Hayes DH, LaPorte FB, et al. Organ donation and utilization in the United States, 1996–2005. *Am J Transplant* 2007;7:1327–1338.
7. Centers for Medicare & Medicaid Services (CMS), HHS. Medicare and Medicaid programs; conditions for coverage for organ procurement organizations (OPOs). Final rule. *Fed Regist* 2006;71:30981–31054.
8. Olthoff KM, Merion RM, Ghobrial RM, et al. Outcomes of 385 adult-to-adult living donor liver transplant recipients: a report from the A2ALL Consortium. *Ann Surg* 2005;242:314–323, discussion 323–325.
9. Trotter JF, Wachs M, Everson GT, et al. Adult-to-adult transplantation of the right hepatic lobe from a living donor. *N Engl J Med* 2002;346:1074–1082.
10. Kamath PS, Wiesner RH, Malinchoc M, et al. A model to predict survival in patients with end-stage liver disease. *Hepatology* 2001;33:464–470.
11. Merion RM, Schaubel DE, Dykstra DM, et al. The survival benefit of liver transplantation. *Am J Transplant* 2005;5:307–313.
12. Freeman RB GR, Harper A, Davis GL, et al. Model for end-stage liver disease (MELD) exception guidelines: results and recommendations from the MELD exception study group and conference (MESSAGE) for the approval of patients who need liver transplantation with diseases not considered by the standard MELD formula. *Liver Transpl* 2006;12:S128–S136.
13. Freeman RB, Wiesner RH, Edwards E, et al. Results of the first year of the new liver allocation plan. *Liver Transpl* 2004;10:7–15.
14. Sass DA, Shakil AO. Fulminant hepatic failure. *Liver Transpl* 2005;11:594–605.
15. Stieber AC, Zetti G, Todo S, et al. The spectrum of portal vein thrombosis in liver transplantation. *Ann Surg* 1991;213:199–206.
16. Roland ME, Barin B, Carlson L, et al. HIV-infected liver and kidney transplant recipients: 1- and 3-year outcomes. *Am J Transplant* 2008;8:355–365.

17. Mindikoglu AL, Regev A, Magder LS. Impact of human immunodeficiency virus on survival after liver transplantation: analysis of United Network for Organ Sharing database. *Transplantation* 2008;85:359–368.
18. Pawlotsky JM. New hepatitis C therapies: the toolbox, strategies, and challenges. *Gastroenterology* 2014;146:1176–1192.
19. Wong SN, Chu CJ, Wai CT, et al. Low risk of hepatitis B virus recurrence after withdrawal of long-term hepatitis B immunoglobulin in patients receiving maintenance nucleos(t)ide analogue therapy. *Liver Transpl* 2007;13:374–381.
20. Chu CJ, Fontana RJ, Moore C, et al. Outcome of liver transplantation for hepatitis B: report of a single center's experience. *Liver Transpl* 2001;7:724–731.
21. Gaglio P, Singh S, Degertekin B, et al. Impact of the hepatitis B virus genotype on pre- and post-liver transplantation outcomes. *Liver Transpl* 2008;14:1420–1427.
22. Bruno S, Stroffolini T, Colombo M, et al. Sustained virological response to interferon-alpha is associated with improved outcome in HCV-related cirrhosis: a retrospective study. *Hepatology* 2007;45:579–587.
23. Manns MP, McHutchison JG, Gordon SC, et al. Peginterferon alfa-2b plus ribavirin compared with interferon alfa-2b plus ribavirin for initial treatment of chronic hepatitis C: a randomised trial. *Lancet* 2001;358:958–965.
24. Everson GT, Trotter J, Forman L, et al. Treatment of advanced hepatitis C with a low accelerating dosage regimen of antiviral therapy. *Hepatology* 2005;42:255–262.
25. Lake JR, Shorr JS, Steffen BJ, et al. Differential effects of donor age in liver transplant recipients infected with hepatitis B, hepatitis C and without viral hepatitis. *Am J Transplant* 2005;5:549–557.
26. Fontana RJ, Hughes EA, Bifano M, et al. Sofosbuvir and daclatasvir combination therapy in a liver transplant recipient with severe recurrent cholestatic hepatitis C. *Am J Transplant* 2013;13:1601–1605.
27. Mazzaferro V, Regalia E, Doci R, et al. Liver transplantation for the treatment of small hepatocellular carcinomas in patients with cirrhosis. *N Engl J Med* 1996;334:693–699.
28. Onaca N, Davis GL, Goldstein RM, et al. Expanded criteria for liver transplantation in patients with hepatocellular carcinoma: a report from the International Registry of Hepatic Tumors in Liver Transplantation. *Liver Transpl* 2007;13:391–399.
29. Schwartz M. Liver transplantation for hepatocellular carcinoma. *Gastroenterology* 2004;127:S268–S276.
30. Golfieri R, Cappelli A, Cucchetti A, et al. Efficacy of selective transarterial chemoembolization in inducing tumor necrosis in small (<5 cm) hepatocellular carcinomas. *Hepatology* 2011;53:1580–1589.
31. Kim WR, Stock PG, Smith JM, et al. OPTN/SRTR 2011 Annual Data Report: liver. *Am J Transplant* 2013;13(Suppl 1):73–102.
32. Finegold MJ, Egler RA, Goss JA, et al. Liver tumors: pediatric population. *Liver*

Transpl 2008;14:1545–1556.

33. Mantel HT, Rosen CB, Heimbach JK, et al. Vascular complications after orthotopic liver transplantation after neoadjuvant therapy for hilar cholangiocarcinoma. *Liver Transpl* 2007;13:1372–1381.
34. Darwish Murad S, Kim WR, Harnois DM, et al. Efficacy of neoadjuvant chemoradiation, followed by liver transplantation, for perihilar cholangiocarcinoma at 12 US centers. *Gastroenterology* 2012;143:88–98e3; quiz e14.
35. van Vilsteren FG, Baskin-Bey ES, Nagorney DM, et al. Liver transplantation for gastroenteropancreatic neuroendocrine cancers: defining selection criteria to improve survival. *Liver Transpl* 2006;12:448–456.
36. Burke A, Lucey MR. Non-alcoholic fatty liver disease, non-alcoholic steatohepatitis and orthotopic liver transplantation. *Am J Transplant* 2004;4:686–693.
37. Mas A, Rodes J. Fulminant hepatic failure. *Lancet* 1997;349:1081–1085.
38. O'Grady JG, Alexander GJ, Hayllar KM, et al. Early indicators of prognosis in fulminant hepatic failure. *Gastroenterology* 1989;97:439–445.
39. Dhiman RK, Jain S, Maheshwari U, et al. Early indicators of prognosis in fulminant hepatic failure: an assessment of the Model for End-Stage Liver Disease (MELD) and King's College Hospital criteria. *Liver Transpl* 2007;13:814–821.
40. Yantorno SE, Kremers WK, Ruf AE, et al. MELD is superior to King's college and Clichy's criteria to assess prognosis in fulminant hepatic failure. *Liver Transpl* 2007;13:822–828.
41. Barshes NR, Lee TC, Balkrishnan R, et al. Orthotopic liver transplantation for biliary atresia: the U.S. experience. *Liver Transpl* 2005;11:1193–1200.
42. Sylvestre PB, Batts KP, Burgart LJ, et al. Recurrence of primary biliary cirrhosis after liver transplantation: histologic estimate of incidence and natural history. *Liver Transpl* 2003;9:1086–1093.
43. Maheshwari A, Yoo HY, Thuluvath PJ. Long-term outcome of liver transplantation in patients with PSC: a comparative analysis with PBC. *Am J Gastroenterol* 2004;99:538–542.
44. Kayler LK, Rasmussen CS, Dykstra DM, et al. Liver transplantation in children with metabolic disorders in the United States. *Am J Transplant* 2003;3:334–339.
45. Arguedas MR, Abrams GA, Krowka MJ, et al. Prospective evaluation of outcomes and predictors of mortality in patients with hepatopulmonary syndrome undergoing liver transplantation. *Hepatology* 2003;37:192–197.
46. Ashfaq M, Chinnakotla S, Rogers L, et al. The impact of treatment of portopulmonary hypertension on survival following liver transplantation. *Am J Transplant* 2007;7:1258–1264.
47. Swanson KL, Wiesner RH, Nyberg SL, et al. Survival in portopulmonary hypertension: Mayo Clinic experience categorized by treatment subgroups. *Am J Transplant* 2008;8:2445–2453.

48. Pomfret EA, Fryer JP, Sima CS, et al. Liver and intestine transplantation in the United States, 1996–2005. *Am J Transplant* 2007;7:1376–1389.
49. Eason JD, Gonwa TA, Davis CL, et al. Proceedings of Consensus Conference on Simultaneous Liver Kidney Transplantation (SLK). *Am J Transplant* 2008;8:2243–2251.
50. Lodge JP, Jonas S, Jones RM, et al. Efficacy and safety of repeated perioperative doses of recombinant factor VIIa in liver transplantation. *Liver Transpl* 2005;11:973–979.
51. Planinsic RM, van der Meer J, Testa G, et al. Safety and efficacy of a single bolus administration of recombinant factor VIIa in liver transplantation due to chronic liver disease. *Liver Transpl* 2005;11:895–900.
52. Dumortier J, Czyglik O, Poncet G, et al. Eversion thrombectomy for portal vein thrombosis during liver transplantation. *Am J Transplant* 2002;2:934–938.
53. Tzakis AG, Kirkegaard P, Pinna AD, et al. Liver transplantation with cavoportal hemitransposition in the presence of diffuse portal vein thrombosis. *Transplantation* 1998;65:619–624.
54. Charco R, Margarit C, Lopez-Talavera JC, et al. Outcome and hepatic hemodynamics in liver transplant patients with portal vein arterialization. *Am J Transplant* 2001;1:146–151.
55. Lerut J, Ciccarelli O, Roggen F, et al. Cavocaval adult liver transplantation and retransplantation without venovenous bypass and without portocaval shunting: a prospective feasibility study in adult liver transplantation. *Transplantation* 2003;75:1740–1745.
56. Welling TH, Heidt DG, Englesbe MJ, et al. Biliary complications following liver transplantation in the model for end-stage liver disease era: effect of donor, recipient, and technical factors. *Liver Transpl* 2008;14:73–80.
57. Otte JB, de Ville de Goyet J, Alberti D, et al. The concept and technique of the split liver in clinical transplantation. *Surgery* 1990;107:605–612.
58. Brolsch CE, Stevens LH, Whitington PF. The use of reduced-size liver transplants in children, including split livers and living related liver transplants. *Eur J Pediatr Surg* 1991;1:166–171.
59. Emond JC, Whitington PF, Thistlethwaite JR, et al. Transplantation of two patients with one liver. Analysis of a preliminary experience with ‘split-liver’ grafting. *Ann Surg* 1990;212:14–22.
60. Humar A, Khwaja K, Sielaff TD, et al. Technique of split-liver transplant for two adult recipients. *Liver Transpl* 2002;8:725–729.
61. Marcos A, Fisher RA, Ham JM, et al. Right lobe living donor liver transplantation. *Transplantation* 1999;68:798–803.
62. Miller C, Florman S, Kim-Schluger L, et al. Fulminant and fatal gas gangrene of the stomach in a healthy live liver donor. *Liver Transpl* 2004;10:1315–1319.

63. Strasberg SM, Howard TK, Molmenti EP, et al. Selecting the donor liver: risk factors for poor function after orthotopic liver transplantation. *Hepatology* 1994;20:829–838.
64. Oh CK, Sawyer RG, Pelletier SJ, et al. Independent predictors for primary non-function after liver transplantation. *Yonsei Med J* 2004;45:1155–1161.
65. Pungpapong S, Manzarbeitia C, Ortiz J, et al. Cigarette smoking is associated with an increased incidence of vascular complications after liver transplantation. *Liver Transpl* 2002;8:582–587.
66. Bhattacharjya S, Gunson BK, Mirza DF, et al. Delayed hepatic artery thrombosis in adult orthotopic liver transplantation-a 12-year experience. *Transplantation* 2001;71:1592–1596.
67. Furuta S, Ikegami T, Nakazawa Y, et al. Hepatic artery reconstruction in living donor liver transplantation from the microsurgeon's point of view. *Liver Transpl Surg* 1997;3:388–393.
68. Stahl RL, Duncan A, Hooks MA, et al. A hypercoagulable state follows orthotopic liver transplantation. *Hepatology* 1990;12:553–558.
69. Parrilla P, Sanchez-Bueno F, Figueras J, et al. Analysis of the complications of the piggy-back technique in 1,112 liver transplants. *Transplantation* 1999;67:1214–1217.
70. Borsa JJ, Daly CP, Fontaine AB, et al. Treatment of inferior vena cava anastomotic stenoses with the Wallstent endoprosthesis after orthotopic liver transplantation. *J Vasc Interv Radiol* 1999;10:17–22.
71. Frazer CK, Gupta A. Stenosis of the hepatic vein anastomosis after liver transplantation: treatment with a heparin-coated metal stent. *Australas Radiol* 2002;46:422–425.
72. Feller RB, Waugh RC, Selby WS, et al. Biliary strictures after liver transplantation: clinical picture, correlates and outcomes. *J Gastroenterol Hepatol* 1996;11:21–25.
73. Wiesner RH, Batts KP, Krom RA. Evolving concepts in the diagnosis, pathogenesis, and treatment of chronic hepatic allograft rejection. *Liver Transpl Surg* 1999;5:388–400.
74. Axelrod DA, Guidinger MK, McCullough KP, et al. Association of center volume with outcome after liver and kidney transplantation. *Am J Transplant* 2004;4:920–927.

Chapter 38

Cardiac Transplantation

Richard N. Pierson III

Key Points

1 Over the past 50 years, heart transplantation has evolved from public spectacle to accepted therapeutic modality based on improved tools to diagnose rejection and infection and an expanded armamentarium of treatment options.

2 Heart transplantation is offered to patients who are at higher risk of death without transplant than with it, and for whom no other reasonable treatment options exist, while excluding those whose comorbid conditions are likely to significantly limit length or quality of life.

3 The mortality rate for patients awaiting transplant has improved significantly over recent decades due to improvements in (a) patient selection, (b) medical therapy of patients awaiting transplantation, (c) mechanical support as a bridge to transplant, and (d) donor management and allocation algorithms.

4 Of the four techniques for performing heart transplantation, orthotopic transplant using bicaval right atrial connections has emerged as the most popular.

5 A "triple-drug" regimen including a calcineurin inhibitor, an antimitotic agent, and a steroid, with or without antilymphocyte "induction," is employed to prevent graft injury due to acute rejection.

6 Prophylaxis against opportunistic infections includes agents targeted at common bacterial, viral, and protozoal pathogens.

7 Although the number of heart transplants performed worldwide has declined due to a donor organ shortage, operative survival has improved over the past 20 years, and both patient and graft 1-year survival rates now exceed 87% for adults.

8 Rejection and infection together account for most of the mortality during the first year after transplant, whereas long-term survival is limited by cardiac allograft vasculopathy (a manifestation of chronic rejection) and malignancy.

9 Current initiatives in the field include development of improved immunosuppression (perhaps leading to graft "tolerance") and alternatives to heart allotransplantation, such as "destination" mechanical support or heart "xenografts" from genetically modified pigs.

1 Since 1964, clinical cardiac transplantation has evolved from a sensational, perilous

experiment to become conventional therapy for end-stage heart disease, the paradigm of successful but expensive “high-tech” medicine. This remarkable transformation stemmed from fundamental surgical innovations supported by incremental improvements in the diagnosis and management of common problems. Current challenges revolve around donor supply and allocation, improving long-term outcomes, developing alternative therapies, and related ethical issues.

HISTORICAL PERSPECTIVE

Based on significant contributions by many surgical pioneers,[1–8] the first clinical heart transplant was performed in 1964 by Hardy,[9] who attempted to salvage a man dying from cardiogenic shock by replacing his heart with one from a chimpanzee. Then, before the concept of brain death achieved wide social or legal acceptance, in 1967 Christian Barnard et al.[10] captured the imagination of the world with the first operative survival, using the heart of a resuscitated cadaveric donor. This case, and many others that were performed shortly thereafter, demonstrated not only the physiologic capacity of the transplanted human heart allograft to support the recipient's circulation but also the difficulty of diagnosing and managing subsequent immunologic and infectious complications. After a worldwide flurry of activity, generally dismal outcomes at many prominent cardiac surgery centers made clear the need for more thoughtful approaches to what was clearly a difficult constellation of problems beyond effective circulatory support.

A few pioneering programs persisted in cautious clinical application supported by parallel laboratory investigation. Recognizing the need for a more sensitive and specific diagnostic technique to diagnose rejection, Phillip Caves, working with Shumway et al. at Stanford, developed the technique of transvenous endomyocardial biopsy.[11] Frequent, representative surveillance sampling of the graft allowed early detection of pathogenic host immune responses. Perivascular lymphocytic infiltrates were found to accurately diagnose acute cellular rejection in its presymptomatic phase; when detected early, rejection usually responded to enhanced immunosuppression. Equally important, when rejection was not seen, immunosuppression could be tapered to minimize drug toxicities and reduce the incidence of opportunistic infection. Coupled with important advances in the diagnosis, prevention, and treatment of infectious pathogens in immunosuppressed patients and in selection and management of patients with end-stage heart failure, patient survival at 1 year improved gradually, from about 20% in the 1960s to about 70% by 1980.[12]

However, even as recently as the early 1980s, when rejection persisted or recurred despite high-dose steroids, alternative treatments (total lymphoid irradiation, intramuscular antilymphocyte preparations, thoracic duct ligation, splenectomy) were often toxic or invasive and accompanied by a high incidence of major short- and long-term complications. In this context the discovery and clinical development of the first calcineurin inhibitor (CNI), cyclosporin A (CsA),[13,14] catalyzed the next major improvement in outcomes. CsA's primary mechanism of action and toxicity profile were fundamentally different from those of azathioprine, the most commonly used antimitotic agent, or anti-inflammatory steroids and combination "triple" therapy allowed each agent to be used at lower doses and thus more safely. Meanwhile, antithymocyte and antilymphocyte preparations were adapted for safe intravenous use, either as prophylactic "induction" therapy ("quadruple therapy") or as treatment for steroid-resistant rejection. Based primarily on these pharmacologic innovations in the regulation of the immune response, expected 1-year survival following heart transplant gradually rose from about

70% to almost 90% between 1980 and the present, despite increasing reliance on older donors for older and sicker recipients.[15,16]

CANDIDATE EVALUATION

End-stage heart failure is the primary indication for heart transplantation in adults, with coronary artery occlusive disease and myopathy of various etiologies each accounting for about 45% of cases. Congenital heart disease is the primary indication for infants, whereas myopathy predominates in older children.

2 heart transplant evaluation process seeks to identify patients who are at higher risk of death without transplant than with it and for whom no other reasonable treatment options exist, while excluding those whose comorbid conditions are likely to significantly limit length or quality of life. In 1993, a National Institutes of Health consensus conference developed recipient selection guidelines for cardiac transplantation, based on objective criteria known to predict poor outcome without transplantation[17]; these guidelines (Tables 38-1–38-3) continue to evolve in the context of improving heart failure therapy.[18–20] Among patients with heart failure symptoms, maximal oxygen consumption (MVO_2) is more sensitive and specific than ejection fraction in gauging prognosis, and blunted cardiac output response to exercise may further stratify patients into high- and low-risk groups.[18]

When no clear survival advantage is apparent for transplantation or an alternative management strategy, quality of life and other subjective factors are weighed. Contemporary studies defining relative risks, along with basic considerations in the medical management of end-stage heart failure, are well summarized in recent reviews.[19,20]

Table 38-1 Indications for Heart Transplant

General indications
End-stage heart disease without a lower-risk treatment alternative
Absence of any noncardiac condition likely to: 1. Limit survival independent of cardiac function 2. Preclude safe, reliable administration of adequate immunosuppression 3. Predispose to life-threatening infection or malignancy with immunosuppression
Specific indications 1. Heart failure of various etiologies a. Myopathy: ischemic, idiopathic, viral, familial, restrictive b. Valvular c. Congenital d. Failed transplant e. Early: primary nonfunction, acute rejection f. Late: cardiac allograft vasculopathy 2. Other indications a. Angina not amenable to revascularization b. Arrhythmia, failed conventional therapy c. Hypertrophic cardiomyopathy d. Restrictive cardiomyopathy e. Primary cardiac tumor (completely resectable)

Table 38-2 Selection Criteria for Stratifying Risk and Survival Results

Survival Benefit Established
MVO_2 <10 mL/kg/min
Class IV CHF symptoms despite maximal medical therapy
Requiring mechanical circulatory support
Refractory angina without therapeutic alternative
Refractory ventricular arrhythmia without alternative
Survival Benefit Likely
MVO_2 10–14 with blunted CO response to exercise
Instability of fluid balance or renal function despite documented compliance
EF <20% with class III HF symptoms on maximal medical therapy
Survival Benefit Not Established
MVO_2 10–14 with preserved CO response to exercise
MVO_2 >14, EF <20% without other indication
History of CHF or arrhythmia, controlled with medical therapy
Quality-of-life considerations may influence selection of recipients for whom survival benefit is not established.

CHF, congestive heart failure; CO, carbon monoxide; EF, ejection fraction; MVO_2, maximal oxygen consumption.

DONOR SELECTION AND MANAGEMENT

The ideal donor is a young, previously healthy individual without cardiac disease or hypertension, who is well matched in size to the intended recipient and whose hemodynamics have been carefully managed during the evolution of his or her lethal central nervous system (CNS) injury. Some programs have advocated use of older donors, donors who may transmit infection or malignancy to the recipient, and grafts with hypertensive myocardial hypertrophy for particular recipients.[21] Some aggressive programs have even proposed that hemodynamically significant coronary stenoses can be bypassed at the time of transplant.[22] These approaches to donor selection are associated with less favorable short- and long-term outcomes, but the increased risk may be considered acceptable for patients in whom the short-term prognosis is poor without transplant.[15,23,24] Successful use of hearts resuscitated after cessation of cardiac activity in the donor has recently been described, and may prove to be safely enabled by functional and metabolic evaluation during normothermic ex vivo perfusion.[25] Survival of genetically modified pig hearts beyond 2 years in a preclinical model demonstrates significant progress toward an alternative potential solution to the organ donor shortage.[26]

Donor management requires skill and experience to successfully address the complex physiologic perturbations associated with brain death. Reflex hypertensive and hypotensive responses to intracranial pressure changes, fluid and electrolyte imbalances consequent to the diabetes insipidus from pituitary death, and additional stresses related to hemorrhage, trauma, and surgery often cause hemodynamic and metabolic instability, which may injure a previously healthy heart. The neurohumoral milieu of CNS catastrophe may also adversely affect other fundamental cell regulatory functions, such as those dependent on thyroid hormone. Despite controversy regarding the mechanisms involved, thyroid hormone is often administered to the donor as a continuous infusion, hoping to correct a “sick euthyroid” syndrome and optimize cardiac metabolism prior to explant. Although evidence to date is largely anecdotal, inotrope requirements can often be reduced after thyroid infusion is begun, and donor hemodynamic lability is less common, suggesting improved cardiac and vasoregulatory function.[27,28]

Table 38-3 Contraindications to Cardiac Transplantation

Absolute contraindications[a]
High pulmonary vascular resistancea
Transpulmonary gradient >15, fixed (unresponsive to Rx, mechanical unloading)
Pulmonary vascular resistance index >5–6 Woods Units
Irreversible renal insufficiency (CrCl <40)[a]
Active infection (viral or bacterial)
Active peptic ulcer disease
Diabetes with end-organ damage, renal insufficiency, neuropathy, retinopathy
Symptomatic extracardiac vascular disease
CVOD with recent TIA, CVA
PVOD with claudication, rest pain, or tissue loss
Mesenteric vascular disease with symptoms
Current malignancy or recent treatment (generally <2 yrs) for life-threatening malignancy
Disease of another organ system that would probably limit survival
Established cirrhosis, cardiac or other etiology
Symptomatic COPD; chronic bronchitis
High risk for inability to comply with complex medical regimen
Not firmly committed to transplantation
Inadequate cognitive capacity to comply with postop regimen, coupled with inadequate compensatory social support
Documented psychiatric instability
Recurrent drug or alcohol abuse
Demonstrated noncompliance with therapeutic recommendations
Relative contraindications
Age over 65
Established renal failure on stable dialysis (transplant-eligible)
Diabetes without end-organ disease
Asymptomatic or previously treated extracardiac vascular disease
COPD with FEV_1 or DLCO <60% predicted without referable symptoms
Remote malignancy, in remission (generally >4 yrs with no evidence of disease)
High pulmonary vascular resistance, reversible with Rx
Disease of another organ system that would limit quality or length of life
Difficulty complying with complex medical regimen

[a]On optimal medical therapy and/or mechanical circulatory support.
COPD, chronic obstructive pulmonary disease; CrCl, creatinine clearance; CVA, cardiovascular accident; CVOD, cerebrovascular obstructive disease; DLCO, carbon monoxide diffusing capacity; FEV_1, forced expiratory volume in 1 second; PVOD, pulmonary veno-occlusive disease; TIA, transient ischemic attack.

Cardiac echocardiography has become a standard component of donor assessment to measure ejection fraction and to exclude structural abnormalities or hypertrophy suggestive of hypertensive myopathy. Cardiac catheterization may be requested for donors over age 45, especially for those with a strong family history of coronary artery disease, for smokers, or when regional wall motion abnormalities are appreciated on echocardiography.

MATCHING DONOR TO RECIPIENT

Once a potential donor is identified, priority among blood type–compatible recipients is determined first by relative severity of illness ("status") and then by length of time on the waiting list among those at each status in the donor's geographic area. In the United States, this information is currently tracked and collated by a central, national registry operated by the United Network for Organ Sharing. The heart is first offered to the program whose candidate has priority on the list and whose registered height and weight range include the potential donor. Donor inotrope requirements and functional assessment, recipient pulmonary vascular resistance, possible infection transmission risks (known hepatitis or potential human immunodeficiency virus [HIV] exposure in the donor), and other logistical considerations (expected graft ischemic time) influence the recipient team's decision regarding acceptance of an organ for an individual patient. If the first program declines the offer for the first patient, the process is repeated for the patient next on the list until the heart is accepted.

Tissue typing, the time-consuming process by which donor and recipient are matched for shared transplant antigens, is not currently used for hearts. The probability is low of identifying a "close" match among the relatively small number of blood type–compatible potential recipients within the geographic radius (usually $<$1,500 miles) defined by a 4-hour projected ischemic time. In addition, the demonstrated benefit of partial human leukocyte antigen (HLA) matching is small relative to the added risk of prolonged graft ischemia, a risk augmented by increasing donor age.[16,29]

RECIPIENT MANAGEMENT BEFORE TRANSPLANT

3 The medical therapy of patients awaiting transplantation has improved significantly over the past decade, centered around aggressive afterload reduction and diuresis, anticoagulation, and beta blockade.[18–20] This trend, coupled with improved mechanical support and improved donor allocation algorithms (discussed later), has reduced the mortality rate for patients awaiting transplantation. As waiting lists have grown faster than the donor pool and average time waiting has similarly escalated, cardiac decompensation among patients on the waiting list is frequent. In most areas of the United States and Europe, the majority of hearts go to patients who are sick enough to require hospitalization for intensive diuresis and intravenous inotrope administration.[15,16]

When inotropic therapy proves inadequate, as gauged by progressive deterioration in renal and other end-organ function, temporary intra-aortic balloon pump counterpulsation and mechanical ventilation can stabilize some patients. These interventions are associated with important risks; the relative risk of death is increased threefold in patients who are ventilator dependent at the time of transplant.[15,16] Consequently, mechanical circulatory support using ventricular assist device (VAD) blood pumps has emerged as an effective and generally preferred bridging strategy. Particularly in emergency circumstances or in the setting of progressive or refractory extracardiac organ dysfunction, temporary support with a paracorporeal (pump external to the body) VAD, an intravascular axial flow device (Impella), or with a venoarterial extracorporeal membrane oxygenator (ECMO) device, is used as a short-term "bridge to decision." Fully implanted pumps are reserved for patients for whom end-organ function seems likely to recover, and "bridge to transplant" (BTT) or definitive ("destination") VAD therapy is therefore deemed likely to extend life of a quality acceptable to the patient. Although many VAD-bridged patients incur serious complications (stroke, renal or hepatic failure, systemic infection, device malfunction) and some exhibit behaviors (noncompliance, substance abuse) that may preclude transplantation, about three quarters are successfully transplanted, with excellent outcomes relative to patients not requiring this intervention.[16] Patients with biventricular failure can often be adequately supported with left ventricular support, with or without addition of temporary paracorporeal right heart support. Various total artificial heart devices can be implanted in place of the native heart and have been applied successfully in small numbers.[30,31] This approach is most likely to find a niche as an alternative to heart transplantation in patients not supportable with a left VAD, such as those with fixed pulmonary hypertension, although BTT is the only application currently clinically approved by FDA. Over the past decade relatively small axial turbine (Jarvik 2000, HeartMate II) or bearing-free centrifugal (HeartWare) continuous-flow (nonpulsatile) VADs have largely supplanted bulkier (Novacor) or less durable (HeartMate I) pulsatile devices for both short-term paracorporeal (CentriMag) and longer-term applications. Continuous-flow assist systems have shown sufficient promise in clinical trials to earn FDA approval, with 1-year survival in both BTT patients and in carefully selected nontransplant-eligible "destination therapy" patients now approaching that observed after heart transplantation.[32,33]

HEART PROCUREMENT

Cardiac allograft protection depends primarily on hypothermia, which reduces myocardial energy requirements while the heart graft has no nutritive coronary blood flow. Other important principles include avoidance of distention and warm ischemia in both the donor and the recipient and induction of diastolic (flaccid) cardiac arrest. These goals are accomplished by interrupting systemic venous return for decompression, placing a clamp across the distal ascending aorta, and infusing a hyperkalemic preservation solution proximal to the clamp, and thus selectively into the coronary arteries. Both the inferior vena cava and left atrium are incised ("vented") to prevent distention of either ventricle. Some preservation solutions incorporating free radical scavenging molecules or other cytoprotective agents are associated with improved early graft function.[34,35]

Every effort is made to minimize the ischemic interval – the time between initial interruption of coronary flow by aortic cross-clamping in the donor and removal of the cross-clamp in the recipient – since recipient morbidity and mortality increase with each additional hour of "cold ischemic time." Although laboratory studies and isolated clinical reports suggest that good results may be expected with storage times of 8 hours or more using various preservation solutions, increased ischemic time remains a strong and important independent risk factor for poor recipient outcome.[15,16] Normothermic (~34 to 37°C) ex vivo organ perfusion during transport is being explored in clinical trials as a potential alternative to static cold storage (~4°C).[36]

OPERATIVE RECIPIENT MANAGEMENT

Timing of the recipient operation requires careful coordination with the procurement team. Anesthesia is induced after the donor heart is visually inspected and found suitable. Venous access is obtained, which will permit rapid volume resuscitation and invasive cardiac monitoring after the new heart is implanted. Prior cardiac surgery may complicate coordination of operative timing and is associated with increased risk of bleeding.

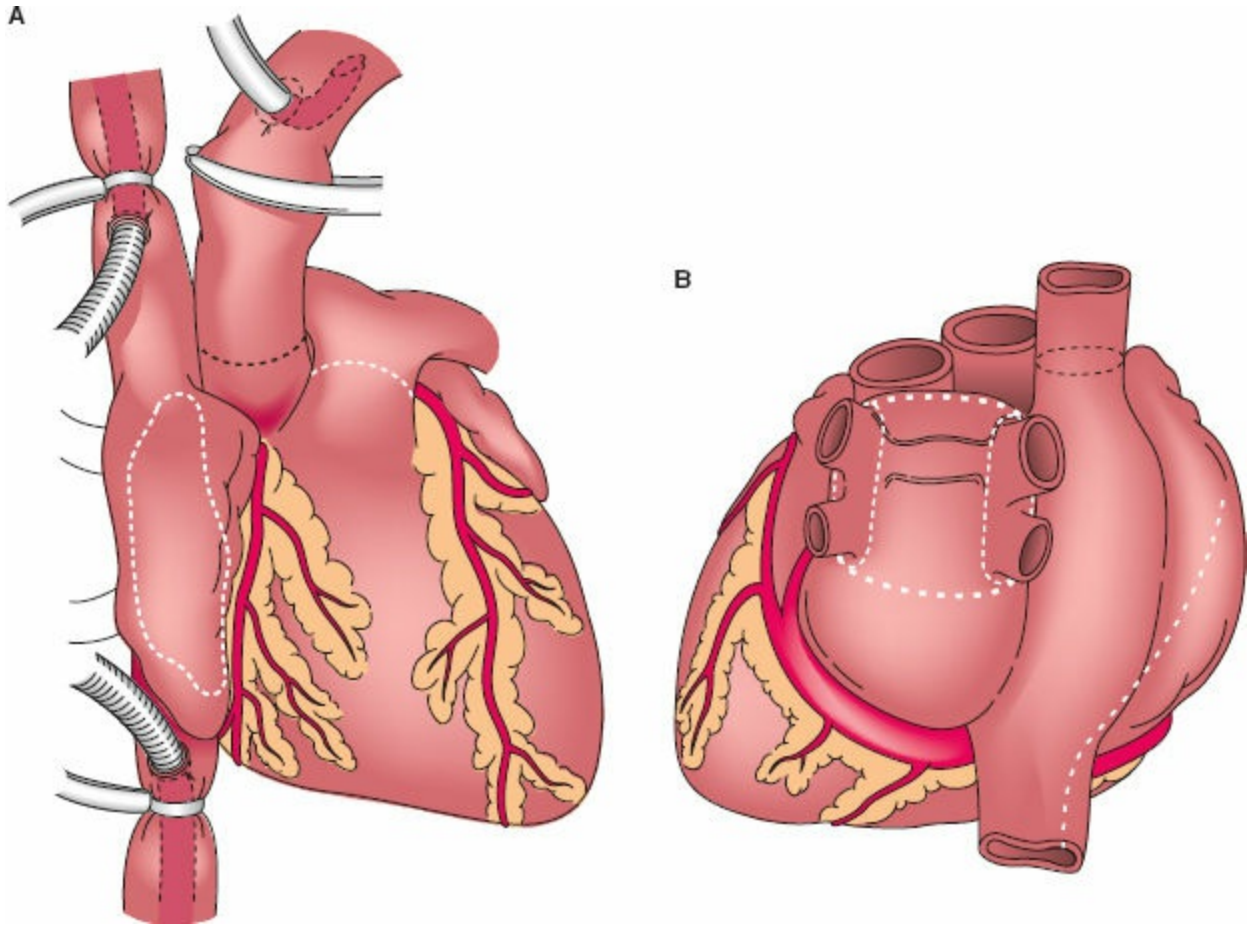

Figure 38-1. Native cardiectomy and donor graft preparation. **A:** Recipient pericardium after institution of cardiopulmonary bypass and ascending aortic occlusion, with caval snares secured. The diseased native heart can then be safely excised by transecting the recipient aorta and pulmonary artery, and the atria divided as appropriate for the intended implant technique. Shown is the right atrial incision for the traditional Lower/Shumway right atrial cuff. **B:** Posterior view of the explanted donor heart, indicating various incisions used for atrial cuff preparation. Donor atrial cuff incisions made in preparation for traditional Lower/Shumway biatrial implant are indicated by the *heavy white dashed line*. The superior vena cava (SVC) is ligated or oversewn. Right and left pulmonary vein (*light white dashed line*) and superior vena cava (*black dashed line*) incisions are indicated for the total atrioventricular implant technique. For the bicaval technique, the donor SVC (*black dashed line*) and inferior vena cava are retained as for the total atrioventricular technique (Fig. 38-4), and the donor left atrial cuff trimmed as for the traditional biatrial approach (*heavy white dashed line*).

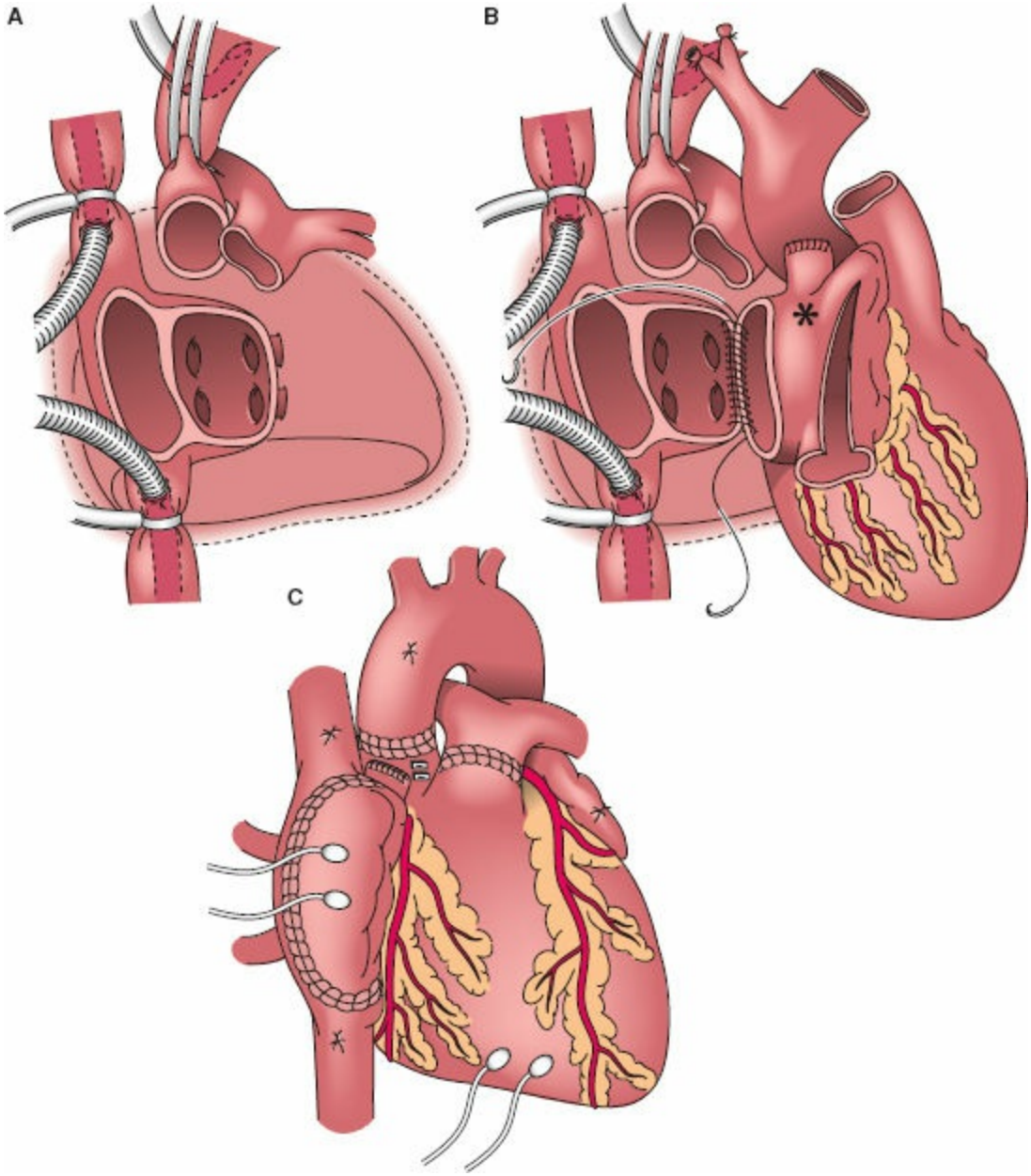

Figure 38-2. Traditional Lower/Shumway biatrial technique. **A:** Recipient cuffs, prepared for bicaval atrial implant technique. After completion of the left atrial anastomosis (**B**), the right atrial cuffs are joined. Care is taken to avoid carrying the right atrial incision or suture line close to the donor sinoatrial node, at the superior vena cava/right atrial junction (*asterisk*). **C:** Appearance of the operative field after completion of great vessel anastomoses, weaning from cardiopulmonary bypass, and decannulation.

If appropriate, Coumadin effects are reversed with fresh frozen plasma, vitamin K, or prothrombin complex concentrates. ε-Aminocaproic acid or tranexamic acid, and des-deoxyargine vasopressin (DDAVP) are often used to inhibit fibrinolysis and promote coagulation at physiologically appropriate sites, respectively, after prior cardiac surgery or associated with hepatic congestion. (Aprotinin, a serine protease inhibitor formerly in routine use to prevent coagulopathic bleeding, was withdrawn from the market because of safety concerns.) Increased inotropic infusion, antiarrhythmic agents, or mechanical circulatory support may be required to maintain adequate systemic perfusion prior to institution of cardiopulmonary bypass.

Vascular access for bypass is accomplished by cannulation of the superior and inferior

vena cavae so as to completely divert systemic venous blood to the cardiopulmonary bypass circuit. The ascending aorta, common femoral, or subclavian artery is used for arterial return from the circuit to the patient. Technical misadventures – such as entry into the heart or great vessels before bypass is established or induction of ventricular arrhythmias – are more common with reoperative procedures, and can greatly complicate the intraoperative course and postoperative management.

Once the proximate arrival of the donor heart is ensured, the recipient is placed on bypass and cooled. Snares are secured around the caval cannulae, the ascending aorta clamped, and the native heart excised (Fig. 38-1A). Vascular cuffs are preserved and tailored appropriately for implantation of the donor heart (Figs. 38-2A, 38-3A, and 38-4A). The donor heart is then prepared according to the implant technique to be used (Fig. 38-1B).

Implant techniques and the sequence of vascular anastomosis vary widely between surgeons, as do strategies used to protect the ischemic organ during implantation. The biatrial orthotopic heart transplant technique is simple, easy to teach, and still used by many surgeons (Fig. 38-2A–C).[8] The donor atria are spatulated open, trimmed if necessary, and laid over the recipient's atrial remnants. The left atrial suture line is everted to achieve endothelial apposition and to avoid leaving epicardial fat or muscle exposed in the lumen as a potential nidus for thromboemboli. Sinoatrial node dysfunction can usually be prevented by keeping the donor right atriotomy well anterior on the right atrial appendage, away from the sinoatrial node and its blood supply (Fig. 38-2B), and by optimizing graft preservation.[35] Even if most of the dilated native atrium is excised, atrioventricular (AV) valve annular geometry may be distorted, causing tricuspid regurgitation; or the area around the sinus node may be placed under tension, leading to atrial arrhythmias or sinus node dysfunction.

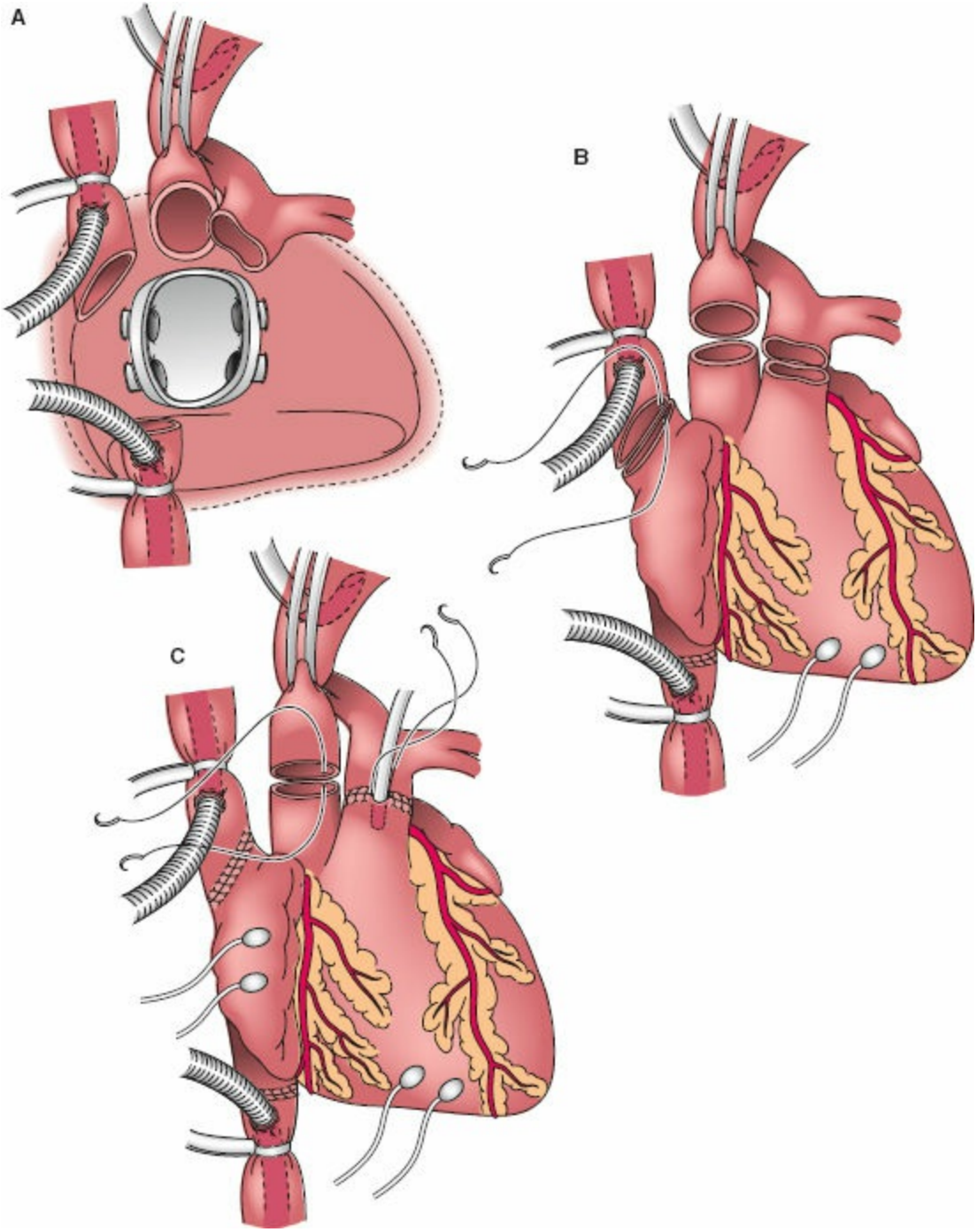

Figure 38-3. Bicaval right atrial implant technique. **A:** During explantation of the native heart, the interatrial septum may be excised, for end-to-end anastomosis of the cavae (**B**), or left in place (as in Fig. 38-2A), allowing the back walls of the donor cavae to be laid into those of the recipient. **C:** Technique for pulmonary artery venting through an opening in the anterior aspect of this anastomosis, which is useful for de-airing and decompressing the right heart. Alternatively, the aorta may be anastomosed earlier in the operation and the aortic cross-clamp removed, to minimize graft ischemic time.

4 During the 1990s, these considerations led to evaluation of alternate atrial anastomotic techniques, including bicaval right atrial connections (Fig. 38-3A–C) and total atrioventricular replacement (two caval and two pulmonary vein anastomoses) (Fig. 38-4A, B). In a prospective, randomized trial (bicaval)[37] and several retrospective analyses,[38,39] the incidence of atrial arrhythmias and AV valve regurgitation was reduced, and hemodynamic results and survival were improved with either the bicaval or total

atrioventricular technique. Tricuspid valve annuloplasty may decrease early or later tricuspid regurgitation and reduce the incidence of right heart dysfunction.[40]

Independent of whether the aorta or pulmonary artery connection is performed first, the anterior aspect of the pulmonary artery anastomosis is usually left open or vented, to allow decompression of the right heart after reperfusion (Fig. 38-3C). The size mismatch between donor and recipient aortas is often dramatic, but can usually be accommodated by beveling the smaller vessel (usually the more pliable donor) to increase its effective circumference and by distributing the discrepancy evenly over the length of each anastomosis. Occasionally it is necessary to tailor down the larger vessel to reduce its effective diameter, or to replace an aneurysmal ascending aorta with donor tissue or a prosthetic graft. Functional supravalvular pulmonary stenosis is avoided by trimming back both donor and recipient sufficiently to prevent redundancy or kinking.

An alternate “heterotopic” implantation technique places a second heart in the circulation, in parallel with the retained native heart.[41] In principle, leaving the native heart affords protection in the event that the graft fails. The operation is technically demanding, usually produces compressive atelectasis in the right lung, and is associated with a high risk of stroke, perhaps due to stasis of blood in the native heart.[42] Notwithstanding, this surgical approach may be considered for patients with high pulmonary vascular resistance unresponsive to vasodilators, and may in the future also find a role in the initial application of cardiac xenografts.

After completion of the anastomoses, the heart is reperfused and allowed to resume contracting without being required to function as a pump (“rested”) as the recipient and graft are rewarmed. Atrial and ventricular pacing wires are placed. Cardiac output of the denervated transplant is highly dependent on rate. In addition, the shorter cardiac filling time associated with higher heart rate prevents graft distention. One commonly used protocol initiates isoproterenol prior to weaning from bypass at a dose of 0.005 to 0.02 μg/kg/min, titrated to achieve a heart rate of about 110 beats/min.

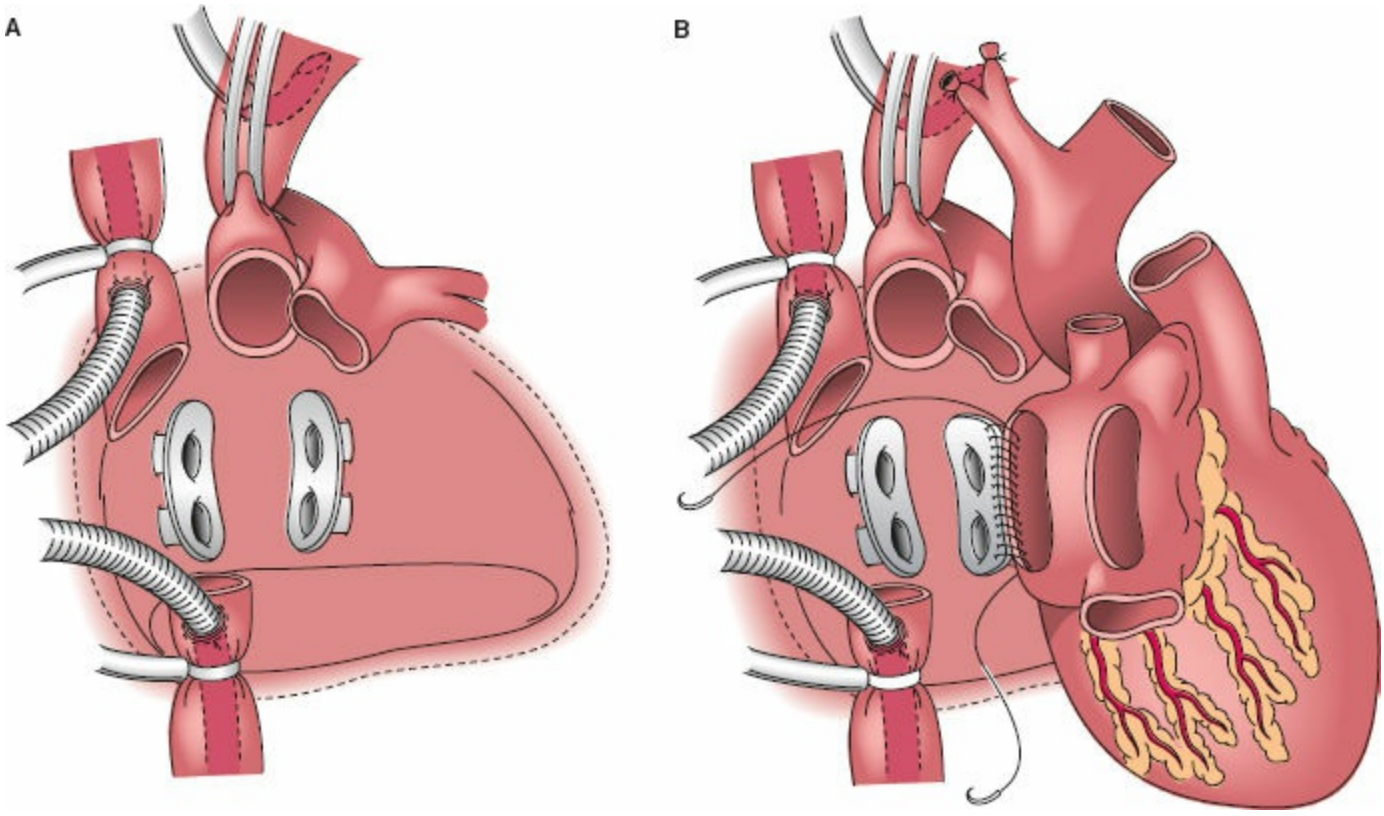

Figure 38-4. Total atrioventricular transplant technique. **A:** Recipient pericardial well after preparation of bilateral pulmonary vein pedicles and caval cuffs, for total atrioventricular heart transplant. **B:** Construction of left pulmonary vein anastomosis. As with other left atrial anastomotic approaches, atrial walls or vein cuffs are everted to minimize exposure of thrombogenic fat or muscle to the blood.

Patients with high preoperative pulmonary vascular resistance may be particularly difficult to wean from cardiopulmonary bypass, even with excellent function of the donor heart, as the "normal" donor right ventricle may acutely dilate and fail when confronted by a high-resistance pulmonary vascular bed. Resting the recently ischemic heart on cardiopulmonary bypass, establishing a stable sinus or AV sequentially paced rhythm, instituting inotropic support, and intra-aortic balloon counterpulsation are useful in managing this problem. Traditional pharmacologic approaches to reducing pulmonary vascular resistance, such as prostaglandins E_1 or I_2 and sodium nitroprusside, may cause transpulmonary shunting of deoxygenated blood; these agents also reduce systemic vascular resistance and thus coronary perfusion pressure. Inhaled nitric oxide or prostacyclin selectively dilates the pulmonary vascular bed before being rapidly inactivated, and is very helpful to selectively reduce pulmonary vascular resistance without adverse effects on systemic vascular resistance, oxygenation, or myocardial function.[43,44] Poor graft function may necessitate institution of mechanical support (VAD support of one or both ventricles, or venoarterial ECMO) as a bridge to graft recovery or to retransplantation.

Postoperatively, ventilator and inotropic support is weaned, immunosuppression is instituted, and diuretic and antihypertensive agents are initiated as necessary. When used, isoproterenol is continued for about 5 days. Theophylline may be used transiently (for days to weeks after transplant) to sustain a resting heart rate over 70. The first

surveillance endomyocardial biopsy is typically performed 7 to 14 days after surgery and repeated about every 2 weeks for the first 3 months. Patient and caregiver education with regard to medication schedules and physiologic monitoring facilitates early discharge for patients without complications. Biologic monitoring of peripheral blood gene or protein expression or lymphocyte function and electrical approaches to monitor the immune response to the graft have shown promise to safely reduce dependence upon routine invasive monitoring.[45–48]

IMMUNOSUPPRESSION

5 The goal of immunosuppressive therapy is to prevent immune-mediated injury to the graft while minimizing associated complications, including opportunistic infection and drug-related toxicities. Most programs employ a "triple-drug" regimen, including a CNI, an antimitotic agent, and steroids. This approach allows each individual drug to be used within its therapeutic window (Table 38-4). Some centers add antibody "induction" with anti-interleukin-2 (anti-IL-2) receptor antibodies, polyclonal antilymphocyte serum, or other agents.[15,16,49–54] Once wound healing has occurred, an inhibitor of the mammalian target of rapamycin (mTOR) may be introduced.[55] The mechanisms of action and side effect profiles of these agents are well described in an earlier chapter of the transplantation section of this text.

6 Medical management after heart transplantation is focused on anticipation and prevention of common complications. Hypertension and hyperlipidemia are prevalent due to predisposition in the recipient patient population and as side effects of various immunosuppressive agents. Prophylaxis against opportunistic infections includes agents targeted at common protozoal and viral pathogens (Table 38-4). Surveillance biopsies are performed according to a scheduled routine and additional biopsies are performed to exclude rejection in the event of hemodynamic instability or unexplained fever. Typically, patients are able to leave the hospital within 10 days of uncomplicated operation, to be followed regularly in outpatient clinic. Monitored physical rehabilitation facilitates optimal cardiovascular and musculoskeletal recuperation,[56] and occupational rehabilitation may offer important psychological and social benefits.

Table 38-4 Typical Immunosuppressive Protocol and Associated Medical Treatment Following Adult Heart Transplantation

Calcineurin inhibitors	Cyclosporine	2–4 mg/kg PO bid or 1–4 mg/h IV target trough level 250–500
	FK506	0.025–0.15 mg/kg PO bid target trough level 4–12
Side effects	Hypertension, renal insufficiency, tremor, neurotoxicity (FK>CsA)	
	Hirsutism (cyclosporine A only), gingival hyperplasia, diabetes (FK only)	
Antimitotic agents	Azathioprine	1–2 mg/kg/d qd
	Mycophenolate mofetil	500–1,500 mg/d bid *occasionally regulated by drug levels*
Side effects	Marrow suppression, nausea, abdominal cramps, diarrhea	
	Dosing typically titrated based on bone marrow suppression	
Mammalian target of rapamycin inhibitors	Sirolimus, Everolimus	0.5–5 mg/kg PO bid target trough level 4–12
Side effects	Delayed wound healing; Lymphedema; deep venous thrombosis; thrombotic microangiopathy	
Glucocorticoids	Methylprednisolone IV, then Prednisone PO	
Side effects	Hypertension, insulin resistance, osteoporosis, mood swings	
	Central obesity, Cushingoid habitus	
Antiprotozoal	Trimethoprim–sulfamethoxazole (*Pneumocystis;* toxoplasmosis)	
Side effects	*Marrow suppression, renal insufficiency*	
Antiviral	Acyclovir (herpes)	
	Ganciclovir, valganciclovir (cytomegalovirus)	
Side effects	*Marrow suppression*	
Antihypertensives	Angiotensin-converting enzyme inhibitor or receptor blocker	
	Diltiazem (retards CNI metabolism)	
	α-Receptor blockers	
Antilipid agents	Statin class agent	

COMPLICATIONS

Complications of antirejection therapy relate primarily to the side effects of the specific immunosuppressive agents currently used. Infections tend to occur in patients with the greatest degree of preoperative debility and malnutrition, or in conjunction with additional stressors such as perioperative bleeding or hepatorenal dysfunction. Bacterial pathogens are common in the first several weeks, particularly in the lung and related to surgical or vascular access sites. Opportunistic viral and fungal infections usually predominate later. Increasingly effective prophylaxis for cytomegalovirus and herpes infections has markedly reduced the morbidity associated with these common pathogens. When infection occurs, immunosuppression is tapered as aggressively as possible based on myocardial biopsy results.

Acute rejection occurs in the majority of patients and is graded histologically according to standardized criteria developed by the International Society for Heart and Lung Transplantation (ISHLT).[57,58] When detected at an early histologic stage (ISHLT grade 1R, Fig. 38-5) in an asymptomatic patient on surveillance biopsy, rejection will often respond to augmented oral steroids and/or an increased dose of CNI. When a higher grade of rejection is found (Fig. 38-6), when the infiltrate fails to resolve in response to initial interventions, or in the setting of depressed cardiac function or shock, high-dose intravenous steroids are administered and antilymphocyte therapy often added. Inotropic or mechanical support is instituted as needed in hopes of rescuing graft and patient. Antibody-mediated "vascular" rejection is now a well-recognized entity that, when suspected or confirmed based on immunohistochemical techniques or detection of increasing titers of antidonor antibody, may warrant introduction of cyclophosphamide or other agents with increased activity against B cells.[58]

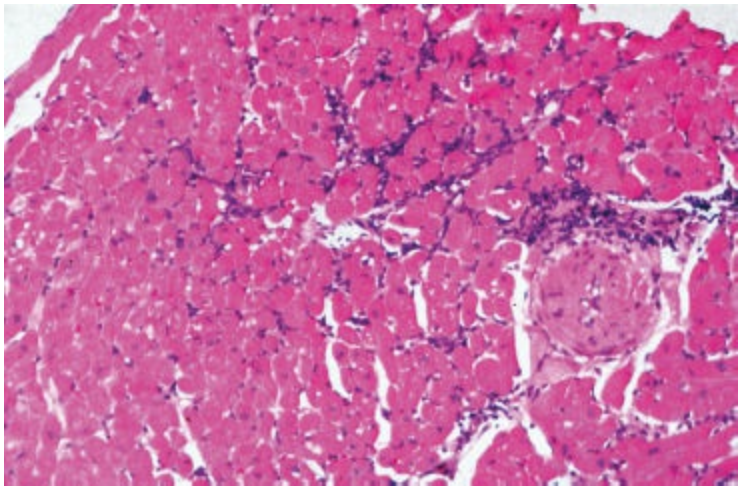

Figure 38-5. International Society for Heart and Lung Transplantation grade 1R – diffuse interstitial or focal perivascular infiltrate with rare or absent myocyte damage is characteristic of mild acute cellular rejection.

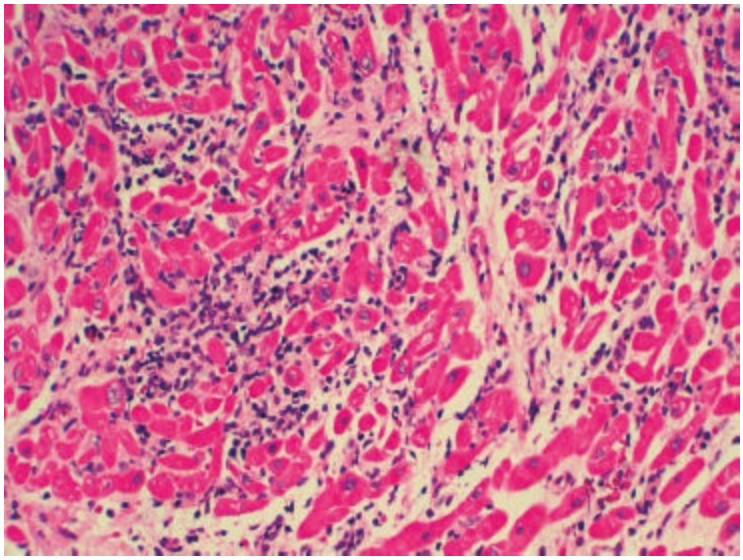

Figure 38-6. International Society for Heart and Lung Transplantation grade 3R – multifocal cellular infiltrate with focal myocyte necrosis, typical of severe acute cellular rejection.

Bradycardia is prevalent in the denervated heart for the first weeks after transplant, but a resting heart rate over 70 can usually be achieved by initiating a β-agonist such as isoproterenol or theophylline. Persistent bradycardia may be caused by ischemic, surgical, or immunologic injury to the sinus or AV nodes or by amiodarone leaching from stores accumulated preoperatively in body fat; pacemaker implantation may be necessary. Atrial flutter or fibrillation may occur spontaneously or herald acute rejection. This dysrhythmia can be difficult to manage because vagal denervation attenuates digoxin modulation of the typical rapid ventricular response. Most other agents traditionally used to treat atrial arrhythmias depress AV node conduction or myocardial contractility, particularly undesirable side effects in a recent heart recipient. Amiodarone is generally better tolerated, controls heart rate and promotes conversion to sinus rhythm, and has been used widely in this circumstance once absence of acute rejection has been confirmed.

Among patients who survive beyond the first year, the primary limits to long-term survival are cardiac allograft vasculopathy (CAV) and malignancy[15,16,24] (Fig. 38-7). Current understanding of the pathogenesis of CAV is incomplete.[59–61] Widely presumed to be a consequence of "chronic rejection," this process has an incidence of approximately 5% per year. CAV may cause progressive insufficiency of coronary flow, myocardial infarction, and ultimately death. Recent research has drawn attention to the importance of donor stress associated with brain death and ischemia/reperfusion injury in the incidence and severity of CAV in animal models.[62] In contrast to the usual pattern of focal proximal lesions in conventional atherosclerosis, coronary arteries are diffusely involved and conventional revascularization techniques are not generally feasible. This process has proven stubbornly refractory to immunosuppressive or antiproliferative interventions.[55,63] Both CAV and increased risk of malignancy would likely be prevented if durable tolerance were successfully induced, but this objectives has thus far proven elusive for the heart as for other organs.[64]

RESULTS

7 Due to a decline in the number of donor hearts that are considered acceptable, the number of heart transplants performed worldwide has declined, from a peak of about 4,070 in 1995 to fewer than 3,200 reported in each year since 2000, a 20% decrease. While some decrease in reporting from European centers may have resulted from the absence of an incentive to contribute to international registries, reported U.S. activity – which is federally mandated by organ allocation regulations – decreased by about 15% between 1997 and 2004 despite a steady increase in average donor age.[15,24] A slight upward trend in U.S. heart transplant activity during the past decade (from 2,000 to 2,200 cases annually between 2004 and 2014) may reflect the influence of a Health Resources and Services Administration organ donor initiative,[15,65,66] and implementation in 2006 of a donor allocation algorithm that emphasizes recipient disease acuity over proximity to the donor hospital or other factors.

8 Operative survival in adults has improved over the past 20 years to above 90%, and both patient and graft 1- and 5-year survival rates exceed 87% and 75%, respectively (Fig. 38-8).[15,16] The most important risk factors for death within the first year include previous transplant, increased donor age (with age older than 60 conferring greater risk than age older than 45), need for ventilator or left VAD support before transplant, and recipient age older than 60. Among common complications, rejection and infection together account for most of the mortality during the first year and contribute approximately equally (Table 38-5). Beyond the first year, malignancy including posttransplant lymphoproliferative disease and chronic rejection emerge as prominent additional factors limiting long-term survival. Extrapolating from current early results, more than 50% of recent recipients can expect to be alive 10 years after transplant, with actuarial graft half-life over 12 years.[15,16,24,29]

Repeat heart transplantation accounts for less than 2% of all heart transplants done. When performed within the first 6 months, typically for early failure of the first graft, 1-year survival is less than 50%. When performed later, usually for cardiac allograft vasculopathy, 1-year survival is over 80%, and has improved significantly over the past decade. Overall, actuarial graft half-life following retransplant is about 4.6 years, and is over 9 years in those who survive the first year.[16] While these outcomes are significantly inferior to other transplant indications, retransplantation offers significant survival advantage for carefully selected patients.



Figure 38-7. Autopsy specimen of an epicardial coronary artery demonstrating a moderately severe concentric fibroproliferative intimal lesion characteristic of cardiac allograft vasculopathy. (Courtesy of Dr. James Atkinson, Vanderbilt University School of Medicine, Nashville, TN.)

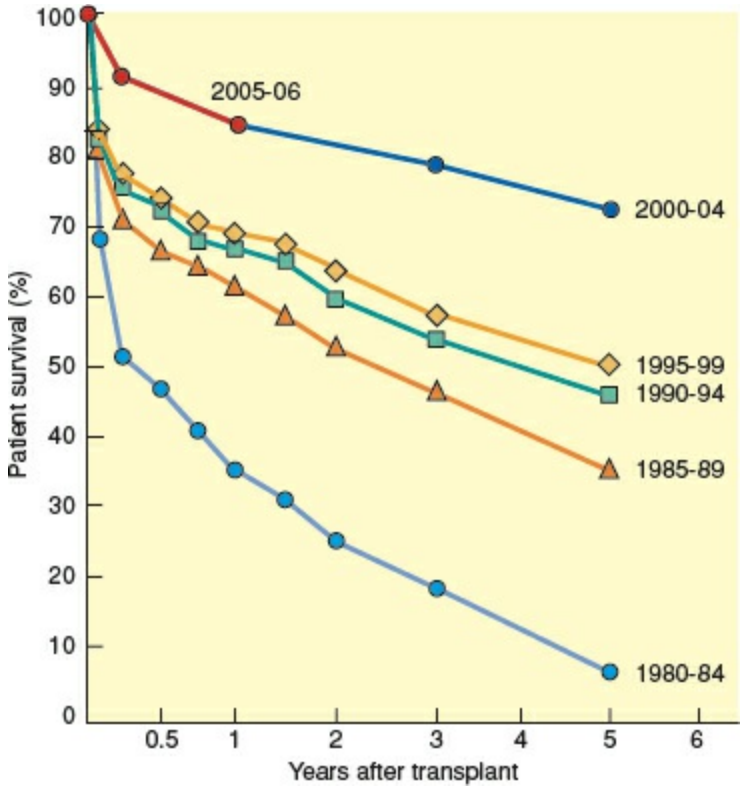

Figure 38-8. Heart Transplant Survival, 1980–2015. Survival following heart transplantation in recipients, grouped by era of operation, analyzed by the Kaplan–Meier method. Operative survival accounts for much of the steady improvement in outcomes over the past two decades. The subsequent rate of attrition appears to have changed little over the past 35 years, likely reflecting the effect of competing influences such as an older, sicker recipient population and improving patient management strategies. (Figure created from data provided by the United Network for Organ Sharing and International Society for Heart and Lung Transplantation, including follow-up information available as of April 2015.) Current demographics and statistics may be found at International Society for Heart and Lung Transplantation website (www.ishlt.org).

Table 38-5 Complications Following Heart Transplantation

Primary graft failure (<5%) Technical (inadequate tissue preservation; reperfusion injury) Immunologic (hyperacute rejection) Donor selection (myocardial, valvular, or coronary obstructive disease in donor)
Technical Size mismatch (too large, too small) Bleeding (surgical, medical) Anastomotic (narrowing, aneurysm, disruption)
Infection Bacterial (various) Viral (herpes, cytomegalovirus, Epstein–Barr virus) Protozoal (toxoplasmosis, *Nocardia*) Fungal (*Candida*, *Aspergillus*)
Treatment effects Hypertension (99% by 10 yrs) Hyperlipidemia (93% by 10 yrs) Diabetes (37% by 10 yrs) Renal failure (acute; chronic) (39% by 10 yrs; 6% dialysis or transplant recipient) Malignancy (31% by 10 yrs)
Skin Visceral (lung, colon, prostate/breast, other) Lymphoproliferative disease

Adolescent (11 to 17 year olds) pediatric heart transplantation recipients fare better (>80% 1-year survival) than do younger children (1 to 10 year olds: ~77%) or infants (younger than 1 year old: ~68%). Less favorable short-term outcomes may be ascribed to pulmonary hypertension and anatomic challenges posed by congenital heart disease, and to monitoring and compliance challenges characteristic of these age groups. Nonetheless, the graft half-life for pediatric patients (11.4 to 13 years) is similar to that for adults.[15,16,24,29]

ETHICS

Ethical considerations are important to every aspect of heart transplantation. The donor pool is limited and appears to be shrinking despite extended donor acceptance criteria, restricting the number of patients who can undergo transplantation. This shortage forces consideration of ways to limit recipient candidacy (age limits), to increase the donor pool (presumed consent, advertising initiatives, community outreach), and to develop alternatives (mechanical devices, xenografts, bioengineered hearts).[26,33,67–70]

The heart transplant community has taken the lead in standardizing patient selection and management guidelines and has established policies for equitable organ allocation. Those given an opportunity to receive the "gift of life" are chosen from a much larger population who might benefit. Recipient candidacy decisions are made by a multidisciplinary group based on objective and subjective input from many individuals who come to know the patient and family in depth. Some recipient selection criteria are fundamentally arbitrary: for example, age is retained as a criterion because of the limited supply of donor organs and based on the consensus view that younger patients deserve preferred access. Recipient selection criteria only become unfair if they are applied unequally or inconsistently at different programs or between various regions of the country.

Some of the most difficult decisions made by the heart transplant team involve medically marginal candidates with outstanding and effective social support or medically suitable candidates with marginal social support. While the majority of such patients will do well, outcomes in either case can, on average, be expected to fall below outcome benchmarks. For every marginal patient transplanted, a candidate who meets all the criteria may die. Thus, the "right" decision for an individual patient is difficult or impossible to know in advance and may conflict with the best interests of the population of potential recipients.

CURRENT ISSUES

Quantifiable, objective measures of efficacy beyond survival, such as improvement in exercise capacity, freedom from complications, and reduced costs are becoming the standards by which individual heart transplantation programs are judged. Most important to the patient are subjective factors such as quality of life and productivity, for which standardized measurement tools are being developed. Meanwhile, the efficacy of any proposed alternative to transplantation must be measured against survival, cost, and quality-of-life benchmarks established by this once-experimental procedure.[71,72]

The most important factor currently restricting the application of heart transplantation is the limited supply of donor organs. Consent is obtained from the donor's legal representatives in only about 25% to 50% of cases where hearts are appropriate based on acceptable physiologic parameters. Various proactive approaches, such as institution of presumed consent, have been associated with high per capita donation rates in some countries. However, presumed consent is ethically dubious and may violate basic cultural or religious precepts of individuals or ethnic groups. An adverse societal response to imposition of this unpopular approach as national policy might paradoxically cripple efforts to maintain organ donation even at current levels. Well-conceived efforts to increase the rate of consent, by passing laws requiring hospitals to facilitate and document the request, by allowing trained individuals to manage the request process, and by educating the public about "the gift of life," have boosted per capita donation in several U.S. organ procurement regions.

9 Efforts to develop improved immunosuppressive drugs are important and are likely to yield incremental near-term improvements in the incidence of chronic rejection. Ideally, one could induce tolerance – permanent graft acceptance without requirement for indefinite immunosuppressive therapy. Modulation, rather than suppression, of host responses to donor antigens may allow achievement of this goal.[73,74]

Even if every physiologically suitable donor heart were available, only a minority of patients for whom transplantation would offer a survival advantage could be cared for using this modality. As technical innovations and management strategies evolve to address issues related to transcutaneous power delivery, thromboembolism, infection risk, and reliability, definitive "destination" therapy with VADs has become a viable option for some patients.[33] Progress has also been made toward use of porcine "xenografts" in man. The initial immunologic barrier, hyperacute rejection, appears surmountable using organs from pigs genetically modified to express human complement regulatory proteins and "knocked out" for the gene encoding Galα1,3Gal, the main carbohydrate target recognized by human antipig antibodies.[26,69,75–79] Control of subsequent antipig antibody responses and coagulation pathway dysregulation phenomena has been achieved in animal models, with recent survival of multitransgenic heart grafts beyond 2 years using an "experimental" but clinically applicable immunosuppressive regimen.[26] Meanwhile, fully life-supporting function of renal xenografts (for 3 months) and heart xenografts (for 1 month) have been demonstrated in primates using an intensive regimen of "conventional" immunosuppressive agents.[78,79]

Heart transplantation is one of the most resource-intensive modalities in modern medicine when assessed as cost per year of life saved. The procedure itself, the increasingly common in-hospital and/or VAD bridge care before transplantation, and maintenance of program infrastructure are very expensive. Ongoing pharmacy charges and surveillance procedure costs are also substantial. Paradoxically, patients physically able to return to work often cannot do so because they rely on medical disability benefits to pay for medications and follow-up care. Whether heart transplantation will continue to receive wide support is a function of societal acceptance of these costs, as currently reflected by coverage policies established by public and private health care insurers.[71] In the future the application of heart transplantation and related technologies may be limited more by what society chooses to afford, rather than what is medically possible.

References

1. Carrel A, Guthrie CC. The transplantation of veins and organs. *Am Med (Philadelphia)* 1905;10:1101.
2. Carrel A. The surgery of blood vessels. *Bull Johns Hopkins Hosp* 1907;18:18.
3. Neptune WB, Cookson BA, Bailey CP, et al. Complete homologous heart transplantation. *Arch Surg* 1953;66:174–178.
4. Webb WR, Howard HS, Neely WA. Practical methods of homologous cardiac transplantation. *J Thorac Surg* 1959;37:361–366.
5. Goldberg M, Berman EF, Akman LC. Homologous transplantation of the canine heart. *J Int Coll Surg* 1958;30:575–586.
6. Cass MH, Brock R. Heart excision and replacement. *Guys Hosp Rep* 1959;108:285–290.
7. Demikhov VP. *Experimental Transplantation of Vital Organs [in Russian].* Haigh B, trans-ed. New York, NY: Consultant's Bureau; 1962.
8. Lower RR, Stofer RC, Shumway NE. Homovital transplantation of the heart. *J Thorac Cardiovasc Surg* 1961;41:196–204.
9. Hardy JD, Chavez CM, Kurrus FE, et al. Heart transplantation in man: developmental studies and report of a case. *JAMA* 1964;188:1132–1140.
10. Barnard CN. The operation. A human cardiac transplant: an interim report of a successful operation performed at Groote Schuur Hospital, Cape Town. *S Afr Med J* 1967;41:1271–1274.
11. Caves PK, Stinson EB, Braham AF, et al. Percutaneous transvenous endomyocardial biopsy. *JAMA* 1973;225:288–291.
12. Kaye MP, Elcombe SA, O'Fallon WM. The international heart transplantation registry. The 1984 report. *J Heart Transplant* 1985;4(3):290–292.
13. Calne RY, White DJ, Rolles K, et al. Prolonged survival of pig orthotopic heart grafts treated with cyclosporin A. *Lancet* 1978;1:1183–1185.
14. Reitz BA, Bieber CP, Raney AA, et al. Orthotopic heart and combined heart and lung transplantation with cyclosporin-A immune suppression. *Transplant Proc* 1981;13:393–396.
15. Colvin-Adams M, Smith JM, Heubner BM, et al. OPTN/SRTR 2013 Annual Data Report: heart. *Am J Transplant* 2015;15(Suppl 2):1–28.
16. Lund LH, Edwards LB, Kucheryavaya AY, et al. The registry of the International Society for Heart and Lung Transplantation: thirty-first official adult heart transplant report—2014; focus theme: retransplantation. *J Heart Lung Transplant* 2014;33(10):996–1008.
17. O'Connell JB, Gunnar RM, Evans RW, et al. Task force 1: organization of heart transplantation in the US. *J Am Coll Cardiol* 1993;22:8–14.
18. Chomsky DB, Lang CC, Rayos GH, et al. Hemodynamic exercise testing. A valuable

tool in the selection of cardiac transplantation candidates. *Circulation* 1996;94(12):3176–3183.

19. Mehra MR, Kobashigawa J, Starling R, et al. Listing criteria for heart transplantation: International Society for Heart and Lung Transplantation guidelines for the care of cardiac transplant candidates—2006. *J Heart Lung Transplant* 2006;25(9):1024–1042.
20. Kinkhabwala MP, Mancini D. Patient selection for cardiac transplant in 2012. *Expert Rev Cardiovasc Ther* 2013;11(2):179–191.
21. Jeevanandam V, Furukawa S, Prendergast TW, et al. Standard criteria for an acceptable donor heart are restricting heart transplantation. *Ann Thorac Surg* 1996;62(5):1268–1275.
22. Drinkwater DC, Laks H, Blitz A, et al. Outcomes of patients undergoing transplantation with older donor hearts. *J Heart Lung Transplant* 1996;15(7):684–691.
23. Tenderich G, Koerner MM, Stuettgen B, et al. Extended donor criteria: hemodynamic follow-up of heart transplant recipients receiving a cardiac allograft from donors > or = 60 years of age. *Transplantation* 1998;66(8):1109–1113.
24. Pierson RN III, Barr ML, McCullough KP, et al. SRTR report on the state of transplantation: thoracic organ transplantation. *Am J Transplant* 2004;4(suppl 9):93–105.
25. Dhital KK, Iyer A, Connellan M, et al. Adult heart transplantation with distant procurement and ex-vivo preservation of donor hearts after circulatory death: a case series. *Lancet* 2015;385(9987):2585–2591.
26. Mohiuddin MM, Singh AK, Corcoran PC, et al. Genetically engineered pigs and target-specific immunomodulation provide significant graft survival and hope for clinical cardiac xenotransplantation. *J Thorac Cardiovasc Surg* 2014;148(3):1106–1113; discussion 1113–1114.
27. Novitsky D, Cooper DK, Reichart B. Hemodynamic and metabolic responses to hormonal therapy in brain-dead potential organ donors. *Transplantation* 1987;43:852–854.
28. Novitzky D, Mi Z, Sun Q, et al. Thyroid hormone therapy in the management of 63,593 brain-dead organ donors: a retrospective analysis. *Transplantation* 2014;98(10):1119–1127.
29. Opelz G. Results of cardiac transplantation and factors influencing survival based on the collaborative heart transplant study. In: Cooper DK, Miller LW, Patterson GA, eds. *The Transplantation and Replacement of Thoracic Organs.* 2nd ed. Hingham, MA: Kluwer Academic Press; 1996:417–427.
30. Copeland JG, Smith RG, Arabia FA, et al. CardioWest Total Artificial Heart Investigators. Cardiac Replacement with a total artificial heart as a bridge to transplantation. *N Engl J Med* 2004;351(9):859–867.
31. Cohn WE, Timms DL, Frazier OH. Total artificial hearts: past, present, and future. *Nat Rev Cardiol* 2015;12(10):609–617.

32. John R, Kamdar F, Liao K, et al. Improved survival and decreasing incidence of adverse events with the HeartMate II left ventricular assist device as bridge-to-transplant therapy. *Ann Thorac Surg* 2008;86(4):1227–1234.
33. Jorde UP, Kushwaha SS, Tatooles AJ, et al. Results of the destination therapy post-food and drug administration approval study with a continuous flow left ventricular assist device: a prospective study using the INTERMACS registry (Interagency Registry for Mechanically Assisted Circulatory Support). *J Am Coll Cardiol* 2014;63(17):1751–1757.
34. Vega JD, Ochsner JL, Jeevanandam V, et al. A multicenter, randomized controlled trial of Celsior for flush and hypothermic storage of cardiac allografts. *Ann Thorac Surg* 2001;71(5):1442–1447.
35. Jeevanandam V, Barr ML, Auteri JS, et al. University of Wisconsin solution versus crystalloid cardioplegia for human donor heart preservation. A randomized blinded prospective clinical trial. *J Thorac Cardiovasc Surg* 1992;103(2):194–198.
36. Ardehali A, Esmailian F, Deng M, et al. Ex-vivo perfusion of donor hearts for human heart transplantation (PROCEED II): a prospective, open-label, multicentre, randomised non-inferiority trial. *Lancet.* 2015;385(9987):2577–2584.
37. el Gamel A, Yonan NA, Grant S, et al. Orthotopic cardiac transplantation: a comparison of standard and bicaval Wythenshawe techniques. *J Thorac Cardiovasc Surg* 1995;109(4):721–729.
38. Aziz T, Burgess M, Khafagy R, et al. Bicaval and standard techniques in orthotopic heart transplantation: medium-term experience in cardiac performance and survival. *J Thorac Cardiovasc Surg* 1999;118(1):115–122.
39. Trento A, Takkenberg JM, Czer LS, et al. Clinical experience with one hundred consecutive patients undergoing orthotopic heart transplantation with bicaval and pulmonary venous anastomoses. *J Thorac Cardiovasc Surg* 1996;112(6):1496–1550.
40. Jeevanandam V, Russell H, Mather P, et al. Donor tricuspid annuloplasty during orthotopic heart transplantation: long-term results of a prospective controlled study. *Thorac Surg* 2006;82(6):2089–2095
41. Cooper DK, Taniguchi S. Heterotopic heart transplantation—indications, surgical techniques and special considerations. In: Cooper DK, Miller LW, Patterson GA, eds. *Transplantation and Replacement of Thoracic Organs.* 2nd ed.Hingham, MA: Kluwer Academic Press; 1996:353–365.
42. Tagusari O, Kormos RL, Kawai A, et al. Native heart complications after heterotopic heart transplantation: insight into the potential risk of left ventricular assist device. *J Heart Lung Transplant* 1999;18(11):1111–1119.
43. Maxey TS, Smith CD, Kern JA, et al. Beneficial effects of inhaled nitric oxide in adult cardiac surgical patients. *Ann Thorac Surg* 2002;73(2):529–532.
44. Khan TA, Schnickel G, Ross D, et al. A prospective, randomized, crossover pilot study of inhaled nitric oxide versus inhaled prostacyclin in heart transplant and lung transplant recipients. *J Thorac Cardiovasc Surg* 2009; 138(6):1417–1424.

45. Marboe CC, Billingham M, Eisen HJ, et al. Refining pathological classification of acute rejection in cardiac allograft recipients: a multicenter study using peripheral blood gene expression profiling. *J Heart Lung Transplant* 2004; 23(2S):S42.
46. Kobashigawa JA, Kiyosaki KK, Patel JK, et al. Benefit of immune monitoring in heart transplant patients using ATP production in activated lymphocytes. *J Heart Lung Transplant* 2010;29(5):504–508.
47. Deng MC, Elashoff B, Pham MX, et al. IMAGE Study Group. Utility of gene expression profiling score variability to predict clinical events in heart transplant recipients. *Transplantation* 2014;97(6):708–714.
48. Knosalla C, Grauhan O, Muller J, et al. Intramyocardial electrogram recordings (IMEG) for diagnosis of cellular and humoral mediated cardiac allograft rejection. *Ann Thorac Cardiovasc Surg* 2000;6(2):89–94.
49. Starnes VA, Oyer PE, Stinson EB, et al. Prophylactic OKT3 used as induction therapy for heart transplantation. *Circulation* 1989;80(5 Pt 2):III79–III83.
50. Gelder T, Baan CC, Balk AH, et al. Blockade of the interleukin (IL)-2/IL-2 receptor pathway with a monoclonal anti-IL-2 receptor antibody (BT563) does not prevent the development of acute heart allograft rejection in humans. *Transplantation* 1998;65(3):405–410.
51. Carey JA, Frist WH. Use of polyclonal antilymphocytic preparations for prophylaxis in heart transplantation. *J Heart Transplant* 1990;9(3 Pt 2):297–300.
52. Aliabadi A, Grömmer M, Cochrane A, et al. Induction therapy in heart transplantation: where are we now? *Transpl Int* 2013;26(7):684–695.
53. Penninga L, M⊘ller CH, Gustafsson F, et al. Immunosuppressive T-cell antibody induction for heart transplant recipients. *Cochrane Database Syst Rev* 2013;12:CD008842.
54. Mazimba S, Tallaj JA, George JF, et al. Infection and rejection risk after cardiac transplantation with induction vs. no induction: a multi-institutional study. *Clin Transplant* 2014;28(9):946–952.
55. Eisen HJ, Kobashigawa J, Starling RC, et al. Everolimus versus mycophenolate mofetil in heart transplantation: a randomized, multicenter trial. *Am J Transplant* 2013;13(5):1203–1216.
56. Kobashigawa JA, Leaf DA, Lee N, et al. A controlled trial of exercise rehabilitation after heart transplantation. *N Engl J Med* 1999;340(4):272–277.
57. Stewart S, Winters GL, Fishbein MC, et al. Revision of the 1990 working formulation for the standardization of nomenclature in the diagnosis of heart rejection. *J Heart Lung Transplant* 2005;24(11):1710–1720.
58. Berry GJ, Burke MM, Andersen C, et al. The 2013 International Society for Heart and Lung Transplantation Working Formulation for the standardization of nomenclature in the pathologic diagnosis of antibody-mediated rejection in heart transplantation. *J Heart Lung Transplant* 2013; 32(12):1147–1162.

59. Pierson RN III, Miller GM. Late graft failure: lessons from clinical and experimental thoracic organ transplantation. *Graft* 2000;3(2):88–93.
60. Caforio AL, Tona F, Fortina AB, et al. Immune and nonimmune predictors of cardiac allograft vasculopathy onset and severity: multivariate risk factor analysis and role of immunosuppression. *Am J Transplant* 2004;4(6):962–970.
61. Valantine H. Cardiac allograft vasculopathy after heart transplantation: risk factors and management. *J Heart Lung Transplant* 2004;23(5S):S187–S193.
62. Schmid C, Heemann U, Tilney NL. Factors contributing to the development of chronic rejection in heterotopic rat heart transplantation. *Transplantation* 1997;64(2):222–228.
63. Kaufman DB, Shapiro R, Lucey MR, et al. Immunosuppression: practice and trends. *Am J Transplant* 2004;4(suppl 9):38–53.
64. Pierson RN 3rd. Tolerance after heart transplantation: the Holy Grail, or an attainable goal? *Heart Fail Clin* 2007;3(1):17–29.
65. Marks WH, Wagner D, Pearson TC, et al. Organ donation and utilization, 1995–2004: entering the collaborative era. *Am J Transplant* 2006;6(5):1101–1110.
66. Shafer TJ, Wagner D, Chessare J, et al. US organ donation breakthrough collaborative increases organ donation. *Crit Care Nurse Q* 2008;31(3):190–210.
67. Rose EA, Gelijns AC, Moskowitz AJ, et al. Long-term mechanical left ventricular assistance for end-stage heart failure. *N Engl J Med* 2001;345(20):1435–1443.
68. Cooper DK, Keogh AM, Brink J, et al. Report of the Xenotransplantation Advisory Committee of the International Society for Heart and Lung Transplantation: the present status of xenotransplantation and its potential role in the treatment of end-stage cardiac and pulmonary diseases. *J Heart Lung Transplant* 2000;19:1125–1165.
69. Pierson RN 3rd, Dorling A, Ayares D, et al. Current status of xenotransplantation and prospects for clinical application. *Xenotransplantation* 2009; 16(5):263–280.
70. Tapias LF, Ott HC. Decellularized scaffolds as a platform for bioengineered organs. *Curr Opin Organ Transplant* 2014;19(2):145–152.
71. Evans RW. Socioeconomic aspects of heart transplantation. *Curr Opin Cardiol* 1995;10(2):169–179.
72. Evans RW. The economics of big game hunting: using a rifle to get a clear shot at transplantation. *Transplantation* 2003;75(10):1626–1627.
73. Weaver TA, Charafeddine AH, Kirk AD. Costimulation blockade: towards clinical application. *Front Biosci* 2008;13:2120–2139.
74. Ferrer IR, Hester J, Bushell A, et al. Induction of transplantation tolerance through regulatory cells: from mice to men. *Immunol Rev* 2014;258(1):102–116.
75. Cozzi E, White DJ. The generation of transgenic pigs as potential organ donors for humans. *Nat Med* 1995;1(9):964–966.
76. McGregor CG, Davies WR, Oi K, et al. Cardiac xenotransplantation: recent preclinical progress with 3-month median survival. *J Thorac Cardiovasc Surg* 2005;130(3):844–

851.
77. Kuwaki K, Tseng YL, Dor FJ, et al. Transplantation of hearts from α1,3-galactosyltransferase gene-knockout (GalT-KO) pigs into baboons. *Nat Med* 2005;11:29–31.
78. Zaidi A, Schmoeckel M, Bhatti F, et al. Life-supporting pig-to-primate renal xenotransplantation using genetically modified donors. *Transplantation* 1998;65(12):1584–1590.
79. Schmoeckel M, Bhatti FN, Zaidi A, et al. Orthotopic heart transplantation in a transgenic pig-to-primate model. *Transplantation* 1998;65(12):1570–1577.

Chapter 39

Pulmonary Transplantation

Jules Lin and Andrew C. Chang

Key Points

1 Candidates for lung transplantation have significant functional impairment that interferes with their activities of daily living. In patients with restrictive or obstructive pulmonary disease, gas exchange is impaired requiring supplemental oxygen while in pulmonary vascular disease, manifestations of right ventricular failure predominate.

2 Initiation of the Lung Allocation Score (LAS) has decreased waitlist times and waitlist mortality while posttransplant survival has continued to improve. With an increased emphasis on waitlist survival and transplant benefit, there has been a shift in the primary diagnosis from emphysema to pulmonary fibrosis.

3 Patients being listed for transplant are sicker than in the past with an increasing percentage of patients with an LAS score >50, and with acute inpatient evaluations becoming more common, it is critical to avoid deconditioning by using aggressive physical therapy, early tracheostomy, and ambulatory extracorporeal membrane oxygenation (ECMO) when necessary.

4 Advances in donor management and lung preservation have increased the number and quality of donor lungs and is likely responsible for the increase in the number of lung transplants performed over the last 10 years. Ex vivo perfusion of marginal donor lungs and the use of DCD lungs (donation after cardiac death [DCD]) may allow further increases in the percentage of recoverable lungs.

5 Posttransplant lung injury results from the ischemic insult and subsequent reperfusion of the donor lung as well as the host immunologic response and other mediators of non–alloimmune-related injury.

6 By the end of the first year after transplantation, approximately 80% of recipients report no limitations in activity.

7 Long-term survival after lung transplant is lower when compared to outcomes after transplantation of other solid organs. The lack of effective medical therapy for chronic rejection remains a significant barrier and is the focus of ongoing research.

8 Reflux in lung transplant patients has been associated with aspiration, impaired lung function, and decreased survival. Antireflux surgery decreases immune factors associated with bronchiolitis obliterans syndrome (BOS), preserves overall pulmonary function, and can be safely performed in lung transplant patients.

INTRODUCTION

The first lung transplant was performed by James Hardy in 1963 at the University of Mississippi in a patient with lung cancer who died 18 days later from renal failure.[1] Over 40 lung transplants were performed in the next 20 years with no long-term survivors. With time, pulmonary vascular and bronchial anastomotic techniques were refined including the telescoping bronchial anastomosis and wrapping the anastomosis with omentum to provide neovascularization. Steroids were found to inhibit bronchial healing,[2] and with the availability of cyclosporine and its decreased toxicity,[3] the first successful lung transplant was performed in 1983 by Joel Cooper at the University of Toronto. The number of lung transplants continues to increase with approximately 3,640 lung transplants performed worldwide in 2011.[4] Pulmonary transplantation comprises 4% of the organs transplanted in the United States.

Over the past 30 years, outcomes have improved dramatically, but even with advances in immunosuppression, surgical technique, and perioperative and posttransplant care, long-term survival following pulmonary transplantation remains less than that of other solid organ transplants. The major factors limiting long-term survival include donor availability, recipients with more advanced disease, infection, acute rejection, impaired anastomotic healing,[5] and chronic rejection with bronchiolitis obliterans.[6] Survival continues to increase, and the median survival in 2013 was up to 5.6 years from 5.3 years in 2010.[4,7]

The lung has a dual blood supply as a result of distinct bronchial and pulmonary arterial circulation. Bronchial artery reanastomosis has been proposed as a way to decrease ischemia to the anastomosis, but since bronchial artery anatomy and caliber vary greatly, most transplant surgeons have not advocated reanastomosis in order to limit prolonged ischemia times. Bronchial anastomotic healing is dependent on retrograde perfusion from collaterals from the pulmonary arterial circulation. Consequently, the bronchial anastomosis is more profoundly ischemic after transplantation and susceptible to airway dehiscence, typically within 3 weeks after transplantation. The combination of anastomotic ischemia and other factors such as infection and postreperfusion edema hindered initial efforts to develop successful clinical programs in pulmonary transplantation.

The first combined heart and lung transplantation was performed successfully in 1981, but this procedure is currently rarely performed, with only 23 performed in the United States in 2013. Combining cardiac and pulmonary transplantation introduced new issues including those associated with heart transplantation, especially accelerated coronary artery atherosclerosis. Impaired tracheal anastomotic healing is less common, possibly because the bronchial artery collaterals in the subcarinal space are preserved. The discrepancy between available donor organs and the increasing number of patients on the waiting list for heart or lung transplantation as well as lower short- and intermediate-term survival among heart–lung transplant recipients compared to heart or lung transplant alone are factors which have decreased the performance of heart–lung transplantation.

Investigators have defined factors contributing to failure in pulmonary transplantation.[8] These factors include a significant detrimental effect of corticosteroids on airway healing. Investigators have also shown that cyclosporine did not have this adverse effect and that delaying the administration of maintenance corticosteroids was advantageous. Wrapping the bronchial anastomosis with a pedicle of omentum was initially thought to encourage capillary growth and promote airway healing, although this has not correlated with a reduction in anastomotic dehiscence.[9]

Another factor contributing to the improved success of lung transplantation was recognition of the importance of careful recipient selection. Most early attempts at pulmonary transplantation involved critically ill, ventilator-dependent patients who had already suffered significant physical debilitation. Poor short-term outcomes highlighted the importance of assessing preoperative functional status and implementing intense pulmonary rehabilitation pretransplant. Thorough patient evaluation and preparation, in addition to advances in operative techniques and immunosuppression, have improved outcomes and broadened the indications for pulmonary transplantation.

As lung transplantation became more widely accepted in the treatment of end-stage lung diseases, the worsening discrepancy between donor organ availability and patients listed for transplantation resulted in increasing waitlist mortality. Initial lung allocation policies were based on ABO blood type compatibility, geographic proximity to the donor hospital, and the accumulated waiting time since listing. In 1998, the Final Rule was issued by the U.S. Department of Health and Human Services requiring increased organ sharing with development of an organ allocation system that would be more equitable and that would reduce the use of waitlist time as a criterion for allocation.[10] In 2005, the Lung Allocation Score (LAS) was implemented, incorporating waiting list and posttransplant survival probabilities, in order to minimize waiting list mortality, increase the benefit of transplantation among recipients, and ensure equitable allocation of lungs to lung transplantation candidates. Since implementation of the LAS, there has been a dramatic reduction in the duration of median waiting list time prior to transplantation, from 792 days in 2004 to 199 and 132 days in 2005 and 2006, respectively.[11] Waiting list mortality also declined from 134.6 per 1,000 patient-years in 2004 to 114.9 per 1,000 patient-years and 97.2 per 1,000 patient-years in 2005 and 2006, respectively.

INDICATIONS

1 Transplantation is indicated for patients with isolated organ dysfunction who have limited life expectancy despite maximal medical therapy (Table 39-1). A patient should be referred for lung transplantation when expected survival after transplant exceeds the expected survival without transplantation. Improvements in patient selection, operative techniques, organ preservation, immunosuppression, and posttransplant management have led to better survival after transplantation. The overall median survival after transplantation is approximately 5 years, and the timing of transplant is an important consideration for maximizing transplant benefit. Prior to May 2005, allocation of donor lungs was based on time on the waiting list. With the large discrepancy between the number of listed transplant candidates and the limited availability of donor lungs, referral for transplant often occurred well before patients had become severely debilitated from poor respiratory function. With the institution of the LAS, the severity of disease has become a more important factor than waitlist times alone.

Lung transplantation can also provide considerable palliation for dyspnea. Due to the limited availability of donors, quality-of-life improvement has been considered secondary to survival benefit, although improved outcomes in terms of oxygen dependence, physical activity, and return to work remain important in assessing the success of pulmonary transplantation.

CONTRAINDICATIONS

Table 39-2 lists absolute and relative contraindications to lung transplant. The absolute contraindications are consistent with the risks associated with immunosuppression and the physical and social challenges of maintaining a complex medical regimen after transplantation. With respect to body mass index (BMI), extremes in weight have been associated with lower short-term survival in heart transplant patients.[12] These findings have been reinforced by studies of lung transplantation where extremes in BMI have been shown to confer a three- to fivefold increase in 90-day mortality.[13,14]

Overall survival for patients over the age of 65 is significantly lower than for younger cohorts.[15,16] A consensus report in 2006 recommended that age >65 be a relative contraindication[17] due to lower survival with a median survival of 3.6 years and a 5-year survival of 38%. Many centers will limit listing recipients to those who are 65 years of age or younger. Despite this, the number of transplants in older patients has continued to increase, and single-institution studies have demonstrated similar 1- and 3-year survival in highly selected older patients.[18–20] Since the implementation of the LAS, recipients age 65 or older have increased most rapidly from 2.9% in 1998 to 19% in 2008 and 25.9% in 2012.[4,21–23]

Postoperative recovery after lung transplant can be particularly challenging. Incisional pain, impaired ventilatory mechanics, malnutrition, and deconditioning directly impact lung function as with any pulmonary operation. In the early days of lung transplantation, it became apparent that posttransplant survival was poor for ventilator-dependent patients or those with immunosuppression-related myopathy. Preoperative pulmonary rehabilitation and improved selection of ambulatory patients led to a significant improvement in survival in the 1990s. With improvements in critical care, pulmonary transplantation may still be appropriate in highly selected ventilator-dependent patients as demonstrated in small single-center series including patients who have had rapid deterioration in lung function and who have had only brief periods of debilitation. Adjuncts to mechanical ventilatory support, particularly tracheostomy or venovenous extracorporeal membrane oxygenation (ECMO),[24] may allow patients to continue efforts to maintain preoperative conditioning. While patients with end-stage extrapulmonary organ dysfunction are generally not candidates for lung transplant, limited experience has demonstrated acceptable survival in patients with coronary artery disease amenable to coronary artery bypass grafting or percutaneous coronary intervention.[25]

Table 39-1 Pulmonary Disease Diagnosis Groups

Group A	Group B	Group C	Group D
Chronic obstructive pulmonary disease	Primary pulmonary hypertension	Cystic fibrosis	Idiopathic pulmonary fibrosis
Alpha-1 antitrypsin deficiency	Pulmonary thromboembolic disease	Hypogammaglobulinemia	Interstitial pneumonias
Sarcoidosis (mean PA pressure <30 mm Hg)	Pulmonary veno-occlusive disease	Common variable immune deficiency	Sarcoidosis (mean PA pressure >30 mm Hg)
Bronchiectasis	Eisenmenger syndrome		Connective tissue diseases
Lymphangioleiomyomatosis	Pulmonic stenosis		Amyloidosis
			Eosinophilic granuloma
			ARDS/pneumonia

PA, pulmonary arterial; ARDS, acute respiratory distress syndrome.

Table 39-2 Contraindications to Lung Transplantation

Absolute Contraindications
Recent malignancy other than skin cancer (nonmelanoma)
End-stage extrapulmonary organ dysfunction (i.e., cirrhosis, dialysis-dependent renal failure)
Active sepsis
Active HIV infection
Active hepatitis B or C infection with histologic evidence of liver damage
Current or recent tobacco use
History of alcohol or drug abuse/addiction
Severe psychiatric illness
History of noncompliance with medical therapies
Malnutrition (BMI <18)
Relative Contraindications
Age >65
Debilitation (6-min hall walk <150 m)
Mechanical ventilation
Extrapulmonary organ dysfunction
Uncorrectable coronary artery disease
Severe esophageal dysmotility
Severe osteoporosis
Poorly controlled chronic medical conditions (e.g., diabetes, hypertension)
Chronic high-dose steroid dependence
Chest or spinal deformity
Obesity (BMI >32)
Severe pleural disease including empyema, fungal infection, and pleurodesis
Chronic infection with HIV or hepatitis B or C

BMI, body mass index; HIV, human immunodeficiency virus.

Disease-Specific Indications

Disease-specific indications for lung transplantation are listed in Table 39-3.

Chronic Obstructive Pulmonary Disease

Chronic obstructive pulmonary disease (COPD) was the most common indication for lung transplantation prior to the institution of the LAS score, accounting for 35.4% of transplants from 1990 to 2004 and decreasing to 30.9% after 2005.[15] Advances in medical therapy for patients with emphysema that can prolong survival include smoking cessation, long-acting bronchodilators, oxygen supplementation, optimization of nutrition, pulmonary rehabilitation, and vaccination for pneumonia and influenza. In addition, lung volume reduction surgery confers a survival benefit in patients with upper lobe–predominant disease, impaired exercise capacity, and the absence of high-risk factors including forced expiratory volume in 1 second (FEV_1) less than 20% or carbon monoxide diffusing capacity (DLCO) less than 20%.[26] Patients who deteriorate despite maximal therapy and who are not candidates for lung volume reduction should be referred for transplantation.

Factors associated with poor survival in patients with COPD include respiratory exacerbation with hypercapnia, hypoxia, pulmonary hypertension, increasing age, decreasing FEV_1, decreasing DLCO, and increased BMI.[27] A prospectively validated index based on *b*ody mass, airflow *o*bstruction, degree of *d*yspnea, and *e*xercise tolerance (BODE) has been proposed as a robust predictor of mortality in patients with COPD. A BODE index of greater than 7 on a scale from 0 to 10 was associated with a median survival of 3 years.[28]

Idiopathic Pulmonary Fibrosis

Usual interstitial pneumonia (UIP) is the pathologic correlate of idiopathic pulmonary fibrosis (IPF) and is the most common subtype of interstitial lung disease. While IPF accounted for 28% of single lung transplants and 14% of bilateral lung transplants from 1995 to 2007, pulmonary fibrosis has become the most common indication for lung transplantation after the initiation of the LAS with 32% of all lung transplants performed for IPF in 2006 and 36.5% in 2013.[16,29]

Table 39-3 Disease-specific Considerations for Lung Transplantation

Chronic Obstructive Pulmonary Disease
BODE index >7 or hospitalization for exacerbation with hypercapnia ($PaCO_2$ >50 mm Hg)
Pulmonary hypertension
FEV_1 <20% and either DLCO <20% or non–upper-lobe-predominant emphysema
Idiopathic Pulmonary Fibrosis
Histologic or radiographic evidence of UIP and:
DLCO <39%
>10% decrease in FVC on 6-mo follow-up
SaO_2 <88% during a 6-min walk test
"Honeycombing" on HRCT (fibrosis score ≥2)
Cystic Fibrosis
FEV_1 <30% or rapid decline in FEV_1 on follow-up
Exacerbation requiring ICU stay
Increasing frequency of exacerbations
Refractory or recurrent pneumothorax
Increasing oxygen requirements
Hypercapnia
Pulmonary hypertension
Idiopathic Pulmonary Hypertension
NYHA class III or IV on maximal therapy
Low or declining 6-min walk test
Cardiac index <2.0
Right atrial pressure >15

BODE, *b*ody mass, airflow *o*bstruction, degree of *d*yspnea, and *e*xercise tolerance; DLCO, carbon monoxide diffusing capacity; FEV_1, forced expiratory volume in 1 second; HRCT, high-resolution computed tomography; NYHA, New York Heart Association; UIP, usual interstitial pneumonia. Taken from Orens JB, Estenne M, Arcasoy S, et al. International guidelines for the selection of lung transplant candidates: 2006 update—a consensus report from the Pulmonary Scientific Council of the International Society for Heart and Lung Transplantation. *J Heart Lung Transplant* 2006;25(7):745–755.

Although the options for effective medical therapy for IPF are limited and patient mortality is high with a median survival of 3 to 4 years following diagnosis, patients experience a variable clinical course, with some patients progressing rapidly and others with a more gradual decline. Risk factors for poor survival include a pathologic diagnosis of UIP as opposed to other types of interstitial lung disease, severe fibrosis by high-resolution CT scan, the presence and severity of pulmonary hypertension, and acute pulmonary exacerbations.

Assessment of pulmonary function and exercise capacity can also be used to identify patients at higher risk for mortality. A baseline DLCO of less than 39% and a greater than 10% decrease in DLCO or forced vital capacity (FVC) over a 6- to 12-month period are associated with an increased risk of death.[30,31] Oxygen desaturation and a shorter 6-minute walk distance independently predicted increased mortality in patients with pulmonary fibrosis.[32]

Lung transplant improves survival and quality of life in patients with end-stage interstitial lung disease with a median survival of 4.5 years which may be affected by the increased age at diagnosis.[33] Prior to the LAS, IPF patients had the highest waitlist mortality rate[34,35] and decreased survival in the early posttransplant period compared to

other diagnoses.[36] The development of pulmonary hypertension significantly increases the risk of complications and decreases survival.[37] LAS scores have increased since 2005 for patients with IPF to 43.3 compared to 38.3 with no change in postoperative mortality while waiting times have decreased from 266 days to 78 days.[29]

Cystic Fibrosis/Bronchiectasis/Infection-Related End-Stage Lung Disease

Cystic fibrosis (CF) is the third most common indication for lung transplantation, accounting for 16.3% of lung transplants performed in the last 15 years with a median survival of 7.8 years, with most recipients undergoing bilateral transplantation due to the risk of bacterial seeding of the transplanted lung.[16] Colonization of the airway with resistant organisms is common in these patients and is not an absolute contraindication to transplantation, although sepsis is an absolute contraindication. Single-institution studies have identified colonization with *Burkholderia cepacia* genomovar III (redesignated as *Burkholderia cenocepacia*) to be associated with a 30% to 40% increase in posttransplant mortality, although this finding has not been validated in a multi-institutional setting.

Among patients with pulmonary disease due to CF, the time course of respiratory deterioration is highly variable making the criteria for pulmonary transplantation in this population difficult to define by risk modeling. Deterioration of FEV_1 to below 30% of predicted remains an indication for referral for evaluation, although not necessarily for immediate listing.[38,39] Other factors to consider include increasing oxygen requirements, hypercapnia, and pulmonary hypertension.[40]

Pulmonary Artery Hypertension

Idiopathic pulmonary artery hypertension (PAH) has a median survival of less than 3 years if untreated, and the cause of death in most patients is progressive right-sided heart failure. Pulmonary hypertension was a more common indication for transplantation in the past, and after the initiation of the LAS, the percentage of transplant patients waitlisted has decreased from 14.7% in 2002 to 10.8% in 2007 and 6.4% in 2012.[23] There has been some concern that the LAS may not adequately prioritize these patients. Increasing use of medical vasodilator therapy including inhaled iloprost and oral sildenafil, prostacyclin analogs, phosphodiesterase 5 inhibitors, endothelin receptor antagonists, and guanylate cyclase stimulators have improved survival in this population and may also be responsible for the decrease in transplants performed for PAH. Patients with a history of right heart failure or poor pretreatment functional status and those with either no response or functional deterioration despite vasodilator therapy should be referred for transplantation. Recent guidelines emphasize progressive deterioration of right heart function despite maximal medical therapy as an indication for referral.[40]

Cardiac index is an independent predictor for improvement in survival in patients with PAH.[7] Patients with left ventricular heart failure requiring inotropic support may not be suitable candidates for pulmonary transplantation alone but instead should be considered for heart–lung transplantation. Patients with PAH made up 23% of heart-lung transplant

recipients from 2000 to 2012.[4]

Lung Allocation and Transplant Benefit

Lung Allocation Score

The goal of the lung allocation system should be to maximize the net benefit for donated lungs. Before 1995, allocation was based solely on wait times, geography, and blood type. In 1995, an exemption was created for an additional 90 days for idiopathic pulmonary fibrosis due to increased mortality for these patients on the waitlist. However, this did not account for differences in mortality for other pulmonary diseases. The allocation system preferentially selected patients with a longer survival, and the waitlist times were greater than 2 years for the majority of listed patients. Due to the increasing number of waitlist deaths, the Final Rule was instituted in 1998 and mandated that medical necessity be considered in organ allocation.[35,41]

In compliance with the Final Rule, the LAS was developed and has been one of the most significant changes in the practice of lung transplantation over the past 10 years. The LAS was implemented in 2005 and takes into account the urgency (1-year risk of dying on the waitlist without a transplant) and utility (1-year survival posttransplant) giving a net transplant benefit. The normalized LAS ranges from 0 (lowest priority) to 100 (highest priority) for recipients older than 12. The waitlist mortality is given a greater weight in the LAS score. Variables included in the LAS score are listed in Table 39-4.

Lung allocation currently depends on the LAS, blood type, recipient and donor size, geographic location, and age, with donor lungs being offered first to local candidates who are ABO identical and then to patients that are ABO compatible. The donor lungs are then offered to zones A–E, increasingly further away from the donor center. Since the initiation of the LAS, $PaCO_2$ values and bilirubin were added in 2008 while FVC was removed for all groups except group D. The bilirubin has a high impact on potential recipients with idiopathic pulmonary hypertension (group B).

Table 39-4 Selected Components of the Lung Allocation Score

Age
Bilirubin
Cardiac index, CVP
Diagnosis group
Functional status
Diabetes
Assisted ventilation
Supplemental oxygen
FVC% predicted (Group D)
PA systolic
PA mean
PA wedge
$PaCO_2$ (≥40 or increase ≥15%)
6-min walk
Creatinine

FVC, forced vital capacity; PA, pulmonary artery.

Transplant Benefit

Egan et al.[10] analyzed over 4,000 patients on the lung transplant waiting list in order to identify markers of waitlist mortality in the Scientific Registry of Transplant Recipients (SRTR).The listing diagnoses for these patients, including COPD, IPF, CF, and PAH, accounted for 80% of the transplants performed at the time. Transplant candidate demographics, hemodynamic parameters, measures of pulmonary function, and other clinical variables were used to create a regression model. Substantial differences in waitlist mortality were found, with patients listed for emphysematous diseases experiencing a 1-year waitlist mortality of less than 14% compared with 1-year waitlist mortality between 28% and 33% among patients listed with the other three primary diagnoses. These results were confirmed in the International Society of Heart and Lung Transplantation (ISHLT) Registry data from 2005 showing that patients with IPF, PAH, and sarcoidosis had an increased relative risk for 1-year waitlist mortality and a waitlist mortality of 9.7%, 13.1%, 17.8%, and 23.1% for group A, B, C, and D diagnostic groups from 2001 to 2002.[15] Before the LAS, patients with COPD were more likely to undergo transplantation since they had a greater chance of surviving to transplant; however, after the initiation of the LAS, incorporating waitlist urgency into lung allocation, IPF has now become the most common indication for lung transplant.

2 The LAS has had a clear impact on waitlist outcomes in lung transplantation. The number of active waitlist patients declined by 54% since early listing no longer conferred an advantage. Waiting time to transplantation has decreased from 792 days in 2004 to 141 days in 2007. The median waitlist time in 2012 was 4 months with 65.3% of recipients transplanted within 1 year.[23] Mortality rates on the waiting list have decreased since implementation of the LAS but have started to increase recently to 15.4 per 100 waitlist years from 2010 to 2012, possibly due to an overall increase in the acuity and age of patients on the waiting list.[23] The median age of recipients has increased from 45 years in 1985 to 55 years after the institution of the LAS, with 27.2% of recipients older than 65 in 2012.[4,22,23] According to a recent report, 20.7% of patients on the waiting list were older than 65 in 2012 compared with 2.5% in 2002 (Fig. 39-1).[23]

An analysis of all transplant patients with COPD, IPF, and CF from 1992 to 1994 demonstrated a survival benefit for patients with IPF and CF but not with COPD.[42,43] A similarly powered analysis of the European transplant experience demonstrated a survival benefit for all lung transplant groups.[44] Other studies have also called into question the transplant benefit for children with CF listed between 1992 and 2002.[45] Overall early survival (30-day and 1-year) has slowly improved since 1995, which has continued through the implementation of the LAS in 2005 with improvements in operative and postoperative care. A predictive model for posttransplant survival was also developed.[10] When these models were applied to evaluate survival in 2,484 patients with these four primary diagnoses, factors including increasing recipient age, intensive care unit (ICU) admission, and the need for mechanical ventilation were significant predictors of 1-year mortality.

Other risk factors for earlier posttransplant mortality included donor/recipient BMI,

recipient creatinine, bilirubin, and PA systolic pressure. Malnutrition increases morbidity and mortality after lung transplant. An albumin less than 3 g/dL has been correlated with an increased mortality at 1 year[46]; 9% to 25% of lung transplant patients are malnourished. Allen et al.[47] found decreased survival in patients who were either under- or overweight.

Results of studies evaluating posttransplant survival after initiation of the LAS are conflicting. Since the initiation of the LAS, sicker patients are being transplanted (Fig. 39-1), and an increasing LAS has been associated with a lower 1-year survival. Transplanted patients with an LAS score less than 35 had a 1-year survival of 85.7%, whereas those with an LAS score greater than 60 had a 1-year survival of 71.3%.[48] The median LAS continues to increase to 40.8 in 2011 with 6.3% of patients with LAS scores greater than 50 compared with a median LAS of 36.6 in 2005 with less than 2% greater than 50.[49] A study in 2008 showed an increased incidence of primary graft dysfunction and increased ICU stays after initiation of the LAS although the 1-year survival was similar.[50] McCue et al.[51] reported no difference in posttransplant morbidity with a small statistically significant improvement in 1-year survival. One-year survival improved from 70% in 1988 to 1994 to 87% from 2007 to 2012.[22,23] Thabut et al.[52] evaluated the survival benefit of transplant patients with CF after initiation of the LAS and found that lung transplant decreased the risk of death by 69%, and a higher LAS was associated with an increased survival benefit.

Reevaluation and revision of the criteria that determine the LAS remains one of the objectives of the Thoracic Organ Transplantation Committee of the OPTN. Data will continue to be analyzed through large studies including REVEAL (Registry to Evaluate Early and Long-term Pulmonary Arterial Hypertension Disease Management) and the Lung Retrospective Data Collection Projects, and the LAS will continue to evolve to maximize the net lung transplant benefit.[53,54] The first comprehensive revision of the LAS was approved in November 2012 by the OPTN Board of Directors but has yet to be implemented. The revision includes changes to the variables included in the LAS such as cardiac index, CVP, and serum creatinine and the weight given to each variable in the LAS calculation. These changes will have the greatest effect on patients in diagnosis group B.[53]

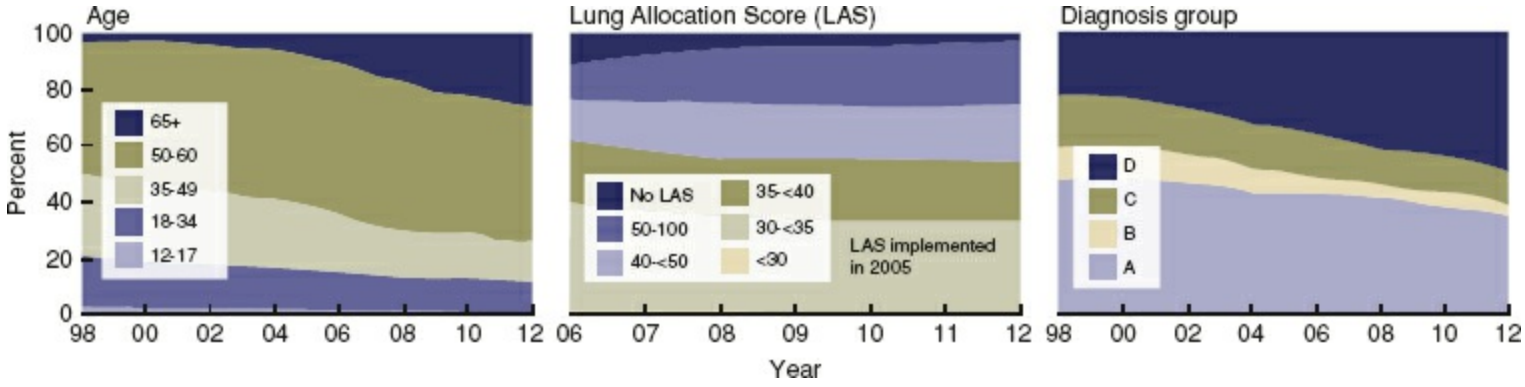

Figure 39-1. Since the initiation of the Lung Allocation Score (LAS) in 2005, the percentage of waitlist patients older than 65 has markedly increased. Patients are also sicker with an increasing percentage of patients with an LAS score >50. Meanwhile, COPD (group A), with a lower waitlist mortality, has decreased as an indication for lung transplant while idiopathic pulmonary fibrosis (group D) has grown to become the most common indication. (Adapted from the 2012 OPTN/SRTR Annual Report.)

Critically Ill Patients

Before the institution of the LAS, critically ill patients were at a disadvantage because the primary criterion was time on the waiting list. Under the LAS, the risk of waitlist mortality carries a greater weight than posttransplant survival.[10] A study by Russo et al.[49] evaluated associations between the LAS and postoperative morbidity and mortality. They found that an LAS of greater than 75 was correlated with a decreased 1-year survival and increased perioperative complications. There was no difference in mortality at 1 and 3 years. With the LAS, there has been some concern that the increased impact of predicted waitlist mortality will result in allocation of donor lungs to patients with a lower posttransplant survival. Russo et al.[49]found that patients with an LAS score between 90 and 100 had a survival rate of 1.56 years while those between 80 and 90 LAS had a survival of 2.28 years. A higher LAS score was also associated with primary graft dysfunction (PGD) and decreased graft survival.[22] The rate at which the LAS changed over a patient's course affected survival with changes greater than five associated with a worse survival.[55]

Extracorporeal Membrane Oxygenation

The use of ECMO can be lifesaving in cases of severe PGD posttransplant. Some centers prefer venoarterial ECMO in order to reduce blood flow to the donor lung thus limiting the degree of pulmonary edema[56] while others prefer venovenous ECMO due to the lower complication rate. ECMO is now available in more than 200 centers.[57,58] Using ECMO as a bridge to lung transplant has been associated with poor outcomes in the past.[59–61] However, outcomes have improved with developments in oxygenator technology using polymethylpentene membranes to reduce plasma leakage, dual lumen cannulas and smaller pumps and oxygenators allowing ambulatory ECMO, centrifugal pumps, and improvements in critical care.

In venovenous ECMO blood is drawn from the central venous system, passed through the pump and oxygenator, and returned to the right atrium. Newer dual lumen cannulas

allow this to be performed through a single cannulation site, often using the jugular vein. Patients with high pulmonary arterial pressures and right heart failure may require conversion to venoarterial ECMO or an atrial septostomy. In venoarterial ECMO, blood is withdrawn from a central vein and returned to a peripheral or central artery providing hemodynamic and respiratory support. The configuration and cannulation depend on the patient's needs and mobility. Venovenous ECMO is a good choice in patients with hypercapnic or hypoxemic respiratory failure without significant right heart dysfunction, such as most patients with CF. A single dual lumen cannula with insertion in the jugular vein allows patients to ambulate. Physical therapy should be consulted as soon as possible. Ambulating patients require close coordination with the ECMO specialist, respiratory therapist, nursing, and the critical care team. Some patients can be extubated while on ECMO, with the goal to keep patients comfortable so they are able to participate in physical therapy. It is also important to avoid blood transfusions when possible to avoid development of antibodies that can limit donor organ availability, only transfusing patients when the hemoglobin is <6 g/dL, if there is hemodynamic instability, or if patients are hypoxemic despite ECMO support. For CO_2 clearance alone, a pumpless system driven by the patient's own arterial pressure can be used with groin cannulation, decreasing ventilator-induced trauma.[62,63]

Venovenous ECMO may be insufficient for patients with significant right heart dysfunction and pulmonary hypertension. Venoarterial ECMO or pulmonary artery to left atrial cannulation may be more beneficial by unloading the right ventricle. Central cannulation is avoided when possible to prevent complicating the subsequent lung transplant. Femoral arterial cannulation makes ambulation more difficult and does not oxygenate the carotids and coronary arteries as well. Axillary arterial cannulation using a 6- to 8-mm vascular graft provides more effective upper body oxygenation.

3 Since the initiation of the LAS, patients on mechanical ventilation have higher scores and are more likely to undergo a transplant. These patients are also more likely to be deconditioned and have decreased posttransplant survival. In a study from 2010, patients undergoing transplant on mechanical ventilation had a significantly lower survival of 57% versus 70% at 1 year, although survival is similar after 6 months.[64] Ambulatory ECMO can be used to help prevent deconditioning of these patients prior to transplant.

The decision-making process must include a multidisciplinary team including the ECMO and critical care intensivist, transplant surgeon, pulmonologist, and social work. The goals of care include establishing adequate CO_2 removal, oxygenation, and circulatory support. Whether ECMO is being used as a bridge to recovery or to lung transplant should be established when possible before initiating ECMO. Factors to consider include the patient's age, the underlying pulmonary disease, social support, other organ dysfunction, the presence of infection, and variables affecting the potential waiting times including the patient's size and panel of reactive antibodies (PRA). Patients who have completed their transplant evaluation or are in the process of being evaluated, younger patients, and those who were listed prior to an acute exacerbation generally have better outcomes. Timing is important and the initiation of ECMO should not be delayed to the

point where the patient is no longer a transplant candidate due to deconditioning. Their pulmonary disease should have progressed to the point where it is unlikely that they will improve, but patients must have sufficient functional reserve. Active bacteremia or highly resistant infections are contraindications. Patients with renal, hepatic, and cardiac failure are also not candidates for ECMO. It is important to carefully discuss the decision to proceed to ECMO with the patient and family, as well as considering the possibility of withdrawal from ECMO in the event that the patient is no longer a transplant candidate due to complications including sepsis, renal, liver, or left heart failure, stroke, or worsening functional status despite circulatory support. Daily clinical assessment is important to ensure that the patient continues to meet transplant criteria.

Due to the severity of pulmonary disease, patients with an LAS that is greater than 90 have a postoperative mortality that is higher than expected. In a study from 2005, ECMO was used as a bridge to transplant in 31 patients with 25 surviving to transplantation.[65] The 2-year survival rate was 74% in both the unsupported and the bridge to transplant groups. The rate of PGD was higher in the ECMO group.[65] In a study from 2013, 31 patients were successfully bridged to lung transplant, including 19 who were ambulatory, with an 80% 3-year survival.[66] In another study, 30 of 36 patients on ECMO were bridged to lung transplant with a 2-year survival rate of 60.5%. Survival was greater among patients with CF at 71% compared to idiopathic pulmonary fibrosis at 27.3%.[67] The duration of ECMO also affects morbidity and mortality. One study showed a 76% 1-year survival with patients on ECMO less than 14 days having a significantly improved survival.[68] Fuehner et al. evaluated 26 patients bridged to lung transplant compared to 34 historical control patients on mechanical ventilation. Survival at 6 months was higher in the ECMO group at 80% versus 50%.[69] While transplant outcomes for patients undergoing ECMO as a bridge to transplant have been acceptable, larger cohort studies are needed to optimize selection criteria for patients bridged to transplant.

DONOR CONSIDERATIONS

Donor Selection

While the number of lung transplants has steadily increased, with 1,830 transplants in 2011, and waitlist times and waitlist death rates have decreased, the total number of patients on the waitlist has continued to increase to 2,200 highlighting the shortage of acceptable donors. The reasons that fewer lungs are available compared to other organs are multiple. Death from head injury or intracranial bleeding may lead to neurogenic pulmonary edema, while chest trauma can result in contusions or pneumothorax. All brain-dead donors are intubated and at risk for aspiration and nosocomial pneumonia, especially if there is a prolonged interval between hospitalization and declaration of brain death. In addition, hemodynamic instability, whether from herniation or trauma, often results in significant volume resuscitation that can contribute to acute lung injury. Criteria for an ideal lung donor include age <55 years, less than 20 pack-year smoking history, $<$ 48 hours on the ventilator, a PaO_2:FiO_2 ratio >300, and no evidence of edema or infection (Table 39-5).[70,71]

Bronchoscopy allows for direct examination of the bronchial tree and for microbiologic examination of the bronchoalveolar lavage (BAL), the results of which may influence later treatment of the recipient. Chest radiography and computed tomography are useful to evaluate for effusions, pulmonary infiltrates, consolidation, and contusions that could contribute to donor hypoxemia. Unlike other solid organ transplants, lungs are unique in carrying a relatively high risk of infection (i.e., pneumonia) following transplant. Because all brain-dead patients have endotracheal tubes and are on mechanical ventilation, there is a high likelihood that the airway is either colonized with bacteria or that there is ongoing pulmonary infection.

Not infrequently, the donor lungs may not be suitable because of infiltrates when all other organs are acceptable. Significant infiltrates typically preclude the use of donor lungs. However, a bilateral lung transplant may still be considered, in a recipient with a higher LAS, when there is a small infiltrate in one lung without evidence of purulent secretions and the contralateral lung appears normal. In addition, unilateral pulmonary infiltrates do not necessarily preclude use of the normal contralateral lung for a single lung transplant.[72]

Aspiration at the time of the initial insult resulting in brain death is a common cause of pulmonary infiltrates in potential donors. Signs of aspiration may not be evident on a chest radiograph for 24 to 48 hours, underscoring the importance of the bronchoscopic examination. Characteristic early bronchoscopic evidence of aspiration includes erythematous tracheobronchial mucosa, purulent secretions, and occasionally the presence of food particles.

Table 39-5 Criteria for Ideal Lung Donors

Age <55 years
ABO compatibility
Height match within 20% of recipient
Clear chest radiograph
PaO_2 >300 on FiO_2 of 1.0, PEEP 5 cm H_2O
Tobacco history of <20 pack-years
Absence of chest trauma
No evidence of aspiration or pulmonary sepsis
No previous cardiothoracic surgery
Negative sputum Gram stain
Absence of purulent secretions

PEEP, positive end-expiratory pressure.

Major pulmonary contusion resulting from blunt chest trauma may also eliminate lungs from donor consideration, but minor to moderate unilateral contusions are often acceptable. Evaluating the full extent of the contusions at the time of donor procurement can be difficult because the interval from injury to determination of brain death and donation may be short. Although the detrimental effect on gas exchange caused by a pulmonary contusion is usually transient, further bleeding into the lung parenchyma could occur if cardiopulmonary bypass is required to perform the transplant. Pulmonary edema may occur as a result of massive head injury and may be exacerbated by donor management protocols directed at maintaining satisfactory perfusion and function of nonpulmonary organs.

The limitation in overall donor organ availability is further compounded by the relatively smaller number of usable donor lungs. The standard criteria for an acceptable donor lung are particularly stringent (Table 39-5).[73] There are limited data available to validate these criteria, and multiple single-institution retrospective reports evaluating "extended criteria" donors have shown conflicting short- and long-term outcomes for almost every criterion. Clinically, these selection criteria provide an overall indication of the quality of the donor lungs. When multiple criteria are not met, the risks of transplanting such lungs likely outweigh the benefits. However, if one aspect of the donor lungs is marginal, the lungs may still be acceptable, and the risks must be weighed against recipient acuity and the likelihood of receiving another offer, taking the patient's size and antigenic status into account.

There are several caveats that have come into "standard" practice. Although leukocytes or occasional bacteria on sputum Gram stain can be acceptable, the presence of gross pus or fungal elements confers a high risk of perioperative complications.[74] In the annual report of lung transplant outcomes, increasing donor age modestly increased the risk of 5-year mortality.[16] Analysis of a large cohort of more than 750 lung and heart–lung recipients demonstrated significantly worse long-term survival with ischemic times greater than 330 minutes. Hazard ratios for death were threefold higher in patients with ischemic times of 8 hours and nearly eightfold higher when ischemia reached 10 hours.[75] The detrimental effects of older donor age and longer ischemic times appear to be additive.[76]

Donor Management

4 Despite the inability to identify "extended" donor criteria that reliably provide acceptable grafts, donor management optimization has allowed an increase in donor recovery and is likely responsible for the increase in the overall number of transplants performed over the last decade.The number of donor lungs recovered has increased from 0.25 lungs per donor in 2000 to 0.39 lungs per donor in 2012.[23] Algorithm 39-1 outlines the donor management algorithm used at the University of Michigan. Key principles include the early use of steroids and thyroxine to prevent neurogenic pulmonary edema and to maintain cardiovascular stability, aggressive alveolar recruitment with positive end-expiratory pressure (PEEP) for patients with a partial pressure of arterial oxygen (PaO_2) less than 350 mm Hg, optimization of intravascular volume, maneuvers to prevent aspiration, and lung-protective ventilation utilizing high frequency, low tidal volumes, and PEEP to prevent volutrauma and barotrauma to the lungs. Using these maneuvers has been shown to double the organ recovery rate without detrimental effects on 30-day or 1-year survival.[77]

Investigators at the Texas Organ Sharing Alliance identified 330 potential lung donors over a 4-year period preceding initiation of an active donor management protocol and 381 potential donors managed on the protocol in the subsequent 4 years.[77] Overall, 1.7 organs per donor were procured in 19% (136/711) of potential donors. Prior to initiation of the management protocol, organ procurement occurred in only 12% (38/330), recovering 1.6 lungs per donor. In contrast, with lung-protective donor management, organ procurement occurred in 26% (98/381), recovering 1.7 organs per donor.



Algorithm 39-1. The donor management algorithm used at the University of Michigan in coordination with the organ procurement organization, Gift of Life. Optimal PEEP is determined by increasing PEEP 2 cm of H_2O every 3 to 5 minutes until compliance decreases. Recruitment maneuvers include CPAP at 30 cm of H_2O for 30 seconds every 20 minutes × 3. P/F, PaO_2/FiO_2; IBW, ideal body weight; TV, tidal volume; APRV, airway pressure release ventilation; CPAP, continuous positive airway pressure.

Following initial organ acceptance, the lungs might be declined if the procurement team identifies significant purulent secretions during bronchoscopy, if arterial blood gases deteriorate significantly to a P/F ratio <300 or if the donor lungs are found to have poor compliance. On-site measurement of selective pulmonary vein blood gases at the time of donor procurement can aid the procuring team in determining whether donor hypoxemia is due to unilateral or bilateral lung compromise.[78] Size of the donor lungs is less important when the recipient suffers from emphysema, in which each hemithorax is large, compared to pulmonary fibrosis, in which the hemithorax can be significantly contracted. The most important size consideration is a reasonable match between donor and recipient height.

Lung Preservation

Unlike the kidney, liver, or pancreas, immediate acceptable function of the transplanted lung is vital for survival of the recipient. PGD occurs in 10% to 25% of cases and is the most common cause of 30-day mortality after lung transplantation. PGD is associated with higher rates of chronic rejection (bronchiolitis obliterans syndrome [BOS]) and correlates with increased 1- and 5-year mortality.[79]

5 Ischemia-reperfusion injury refers to the cellular and architectural changes that occur after cross-clamp of the donor aorta to release of the recipient pulmonary arterial clamp (ischemic phase) through the immediate restoration of systemic gas exchange (reperfusion phase). Minimizing ischemia-reperfusion injury is crucial to ensuring good early graft function. Advances in donor lung preservation techniques have led to more consistent quality of the donor allograft and lower rates of PGD.

Current preservation techniques depend on cold static preservation to decrease metabolic activity using topical cooling and cold pulmonary perfusion. A major development in lung preservation has been the widespread clinical use of a preservation solution specifically designed for lung procurement. Traditional preservation solutions such as Euro-Collins solution were designed to maintain intracellular ion balance and cell wall integrity. Low-potassium dextran (Perfadex, Vitrolife, Goteborg, Sweden) has an extracellular fluid ion balance and has been shown to have beneficial effects on endothelial cell function and pulmonary microcirculation. Five single-institution reports have demonstrated significantly better initial lung function with low-potassium dextran, while one study showed no difference.[80]

The donor allograft is cooled to minimize cellular metabolism while maintaining vital cellular function. Although small animal studies have demonstrated better postischemic function at preservation temperatures between 15°C and 23°C, practical limits have led to the common practice of cooling to 4°C to 8°C (the temperature of ice water). Other techniques that have traditionally been employed to ensure rapid homogeneous cooling of the lung include topical cooling, antegrade flush through the pulmonary artery, and techniques to maintain patency of the microcirculation including the administration of prostaglandins prior to cross-clamp and the maintenance of ventilation after cross-clamp. Retrograde flush through the pulmonary veins purges the pulmonary and bronchial circulations, has a more homogeneous distribution, and can evacuate pulmonary arterial clots or fat emboli. Clinically, retrograde perfusion in combination with the antegrade flush has been shown to improve immediate posttransplant oxygenation.[81]

Optimal storage techniques have also evolved. After flushing of the pulmonary circulation, the lungs are recruited to expand atelectatic areas, and the trachea is stapled and divided prior to separation from the donor and storage for transport. Methods of lung recruitment have been studied in animal models and have shown that ventilation with less than 50% oxygen and maintenance of airway pressure between 15 and 20 cm H_2O have beneficial effects on capillary leak, lipid peroxidation, and barotrauma.[82–84]

Lung injury likely results not only from the ischemic insult but also from reperfusion of the ischemic lung. Several experimental models of acute lung injury implicate oxygen free

radicals as a factor in reperfusion injury. A significant early increase in lung permeability is seen after an ischemic period followed by reperfusion, which improves within several hours. After single lung transplantation, changes in the contralateral, nonischemic lung are presumably the result of substances released during reperfusion of the ischemic lung. Animal models have demonstrated that gradual pressure-controlled reintroduction of blood flow and a protective ventilation strategy of high frequency and low tidal volume reduce lung injury.[85,86]

Expanding the Donor Pool

Ex Vivo Lung Perfusion

Currently only 20% of brain death donor lungs are used for transplantation due to damage from trauma or complications related to brain death and critical care including barotrauma and edema.[87,88] The number of patients on the waiting list exceeds the number of donor lungs available. With current cold static preservation techniques, it is difficult to assess lung function after organ procurement. Normothermic ex vivo lung perfusion (EVLP) (Fig. 39-2) allows for objective evaluation of marginal lungs in an optimized environment leading to improved utilization of available donor lungs.

Early attempts at EVLP failed due to the development of pulmonary edema.[89] Steen et al.[90] initially evaluated EVLP as a means to evaluate donor lungs from uncontrolled donation after cardiac death (DCD) circumstances. They developed an optimized colloid lung perfusate solution that keeps fluid within the intravascular space and also provides nutrition during lung perfusion (Steen Solution, XVIVO, Sweden).[91] The perfusion period was initially short, at around 60 minutes, and the solution was mixed with red blood cells. The Toronto group first described stable long-term perfusion for 12 hours using an acellular Steen solution, protective perfusion with only 40% of the cardiac output, and physiologic left atrial positive pressure.[92]

Lung injury is reflected in the development of pulmonary edema during EVLP. Parameters used to evaluate the donor lungs include the perfusate pO_2, airway pressure, lung compliance, and pulmonary vascular resistance. While PaO_2 is one of the most important *in vivo* donor parameters, pO_2 is less useful *ex vivo*. Dynamic compliance is the most sensitive parameter for the development of pulmonary edema ex vivo.[93] Parameters are monitored over a 3- to 4-hour period, and it is important to take the trends into account in addition to the absolute values. A delta pO_2 (pulmonary vein pO_2 – pulmonary artery pO_2) of greater than 300 mm Hg on 100% is used as criteria for lung acceptance for transplantation. Chest x-rays, bronchoscopies, and deflation tests are also performed.



Figure 39-2. The donor lungs have been placed on ex vivo lung perfusion with pulmonary arterial and left atrial cannulation and the change in pO_2, compliance, and pulmonary vascular resistance will be evaluated to determine if the lungs are acceptable for transplantation.

Several prospective trials have recently been completed or are underway including the NOVEL trial (United States; XVIVO), the HELP trial (Toronto; XVIVO), the INSPIRE and EXPAND trials (Europe and the United States; Transmedics), the Perfusix trial (United States; Perfusix), the Vienna trial (Vienna; XVIVO), and the DEVELOP trial (United Kingdom; Vivoline). Different technologies and techniques are used in the various trials. While the NOVEL, HELP, DEVELOP, EXPAND, and Perfusix trials are evaluating extended criteria lungs, the INSPIRE and Vienna trials are evaluating standard criteria lungs. In the HELP trial, 80% of the lungs from brain dead and DCD donors that were not initially acceptable for transplantation were transplanted after EVLP with outcomes equivalent to standard controls.[94,95] The incidence of PGD grade 3, airway complications, and the need for ECMO has been $<5\%$.

EVLP also provides the potential for rehabilitating injured lungs. Specific therapies could be used depending on the type of lung injury. Terbutaline increases clearance of alveolar fluid during EVLP[96] while applying surfactant to porcine lungs injured by aspiration improved graft function.[97] Treatment of donor lungs with high-dose antibiotics could also be useful with the large number of lungs rejected for pneumonia.[98,99] For donors with acute pulmonary emboli, tissue plasminogen activator has been used to lyse emboli with good outcomes after transplant.[100] Gene therapy with IL-10 is also being studied using adenoviral vectors in rejected donor lungs and has shown improved function.[101] In addition, the application of stem cells has been reported to restore endothelial barrier permeability after lung injury.[102]

Donation after Cardiac Death

DCD may be valuable in increasing the donor pool with only 20% of donor lungs acceptable for transplant. The lung is unique compared to other organs since it does not depend solely on perfusion for oxygen, and cell viability can be maintained by mechanical ventilation after cardiac arrest. Cadaveric lungs have been shown experimentally to remain viable for 1 hour to 90 minutes after arrest with function declining after 2 hours although this does not account for the agonal phase, which can vary in duration and the degree of hypoxia and hypotension.[103–105] On the other hand, DCD donor lungs may actually have better function, since they are not exposed to the catecholamine surge and neurogenic pulmonary edema associated with brain death and may be less sensitive to ischemia-reperfusion injury.[106] The Toronto group reported that lungs from brain-dead donors had higher levels of proinflammatory cytokines than DCD lungs.[107]

Currently only 2% of DCD lungs are utilized in the United States.[108] However 13.3% of lung transplants in the United Kingdom and 22.5% in Canada are from DCD donors.[109] DCD donors are classified using the Maastricht classification into four groups: I, dead on arrival; II, failed resuscitation; III, awaiting cardiac arrest; IV, cardiac arrest in a brain-dead donor.[110] Controlled DCD (category III and IV) is the approach of choice and includes withdrawal of life support in the ICU or operating room so the organs can be allocated in advance with the ability to evaluate graft function and discuss donation with the family. DCD donors generally have an irreversible cerebral injury, high spinal cord injury, or end-stage muscular disorder and are expected to die within 1 hour of the

withdrawal of support. Predictive models have been developed to predict the potential for expiration based on the need for pressors, cardiopulmonary status, age, BMI, Glasgow Coma Scale, peak and inspiratory pressures, and the PaO_2/FiO_2 ratio.[111–113]

Death of the donor, with irreversible cessation of respiration and circulation, must be declared before organ retrieval can begin, and the retrieval process must not alter or hasten death. One of the main differences from brain death donation is the addition of a warm ischemia period. The length of the agonal phase, from the withdrawal of care until the declaration of death which includes a 2- to 5-minute no touch period after circulatory arrest, varies among donors and is associated with impaired graft function and longer hospital stays.[114,115] Most DCD protocols limit the agonal phase to 60 minutes for lung donation. Heparin is generally given before cardiac arrest although some donor hospitals restrict its use since heparin can hasten death in donors with intracranial hemorrhage. Heparin given postarrest can prevent pulmonary thromboemboli, and retrograde perfusion is helpful in clearing any emboli[116,117] with no difference in thrombus formation.[118–121] After arrest, the donor lungs can be rapidly cooled topically, through chest tubes or after exposure of the lungs, followed by antegrade perfusion with cold Perfadex and retrograde perfusion through the pulmonary veins.

EVLP may increase the use of DCD lungs by allowing evaluation after cardiac death in optimized conditions, which is especially useful in DCD cases since in vivo evaluation is more limited and the warm ischemia time is variable. There is also the potential to improve lung function. The Toronto group transplanted lungs using 20 donor lungs placed on EVLP, including 9 DCD lungs, with no significant difference in 30-day mortality, ICU or hospital length of stay. Although the use of EVLP remains controversial since DCD lung transplants can also be performed with good outcomes without EVLP.[108,109]

The first successful lung transplant from a DCD donor was reported in 1995.[122] Early and midterm outcomes after transplantation of lungs from controlled DCD donors are comparable to standard lung transplantation.[123–125] Although the incidence of PGD grade 3 was not significantly different, in some series there was a trend toward increased early graft dysfunction with improvement within 72 hours and more frequent ECMO usage.[125,126] The incidence of BOS is similar but was more frequent in the brain death group at 1 year in a series from the Netherlands.[127] In a series of uncontrolled DCDs from Madrid, the incidence of BOS at 5 years was 45%, which was significantly higher, although outcomes were improved after using EVLP to evaluate donor lung function.[128]

TRANSPLANTATION OPERATION

Single Versus Bilateral Lung Transplant

Over the past decade the ratio of bilateral lung transplants has continued to increase from 49.9% of all lung transplants in 2002 to 67.3% in 2012.[23] Bilateral lung transplant is required for septic lung diseases, including CF, due to the risk of contaminating the transplanted lung. Whether to perform a single or bilateral lung transplant for other diseases remains controversial, and short- and long-term outcomes as well as benefits to society should be considered.[129,130] While double lung transplants may provide greater benefits to the recipient, single lung transplants may maximize the benefit to society by allowing two patients to be transplanted.

The decision to proceed with single or bilateral lung transplantation depends on several factors including the primary diagnosis, the presence of pulmonary hypertension, recipient age, and donor lung availability. Patients with chronic infection, such as those with CF or immunoglobulin deficiency disorders, require bilateral transplant. Single lung transplantation can be considered for patients with restrictive physiology (pulmonary fibrosis), particularly if there is no evidence of secondary pulmonary hypertension. The decision on which side to transplant is based on both donor lung availability and the recipient's quantitative ventilation perfusion scan.

In patients with end-stage obstructive lung disease, specifically emphysema, there was concern initially that single lung transplantation would be associated with altered physiology due to hyperventilation of the overly compliant native lung and that mediastinal shift would result in significant ventilation and perfusion mismatch and compromised function of the transplanted lung. It has been demonstrated that single lung transplantation is acceptable in patients with emphysema,[131] especially for older patients, with significant improvements in mean 6-minute walk results (Fig. 39-3). However, bilateral lung transplant recipients appear to have greater improvement in FEV_1 at 3-month (Fig. 39-4) and 1-year follow-up.[132]

A single lung transplant is simpler technically and avoids a sternotomy. While some studies have found improved early 30-day and 3-month survival with single lung transplant,[133,134] others have found no difference in survival[135,136] or other postoperative outcomes including mechanical ventilation and ICU stay.[137,138] Bilateral lung transplantation, when indicated, has been simplified by the development and refinement of the sequential rather than the *en bloc* double lung technique, which required a tracheal anastomosis with cardiopulmonary bypass and resulted in significant perioperative morbidity and mortality.[139] Bilateral sequential lung transplant can be approached either by median sternotomy or bilateral thoracotomies using cardiopulmonary bypass when necessary depending on the degree of pulmonary hypertension and impairment in gas exchange. A bilateral thoracosternotomy ("clamshell") incision permits easier exposure of the hilum especially on the left but tends to be more painful.

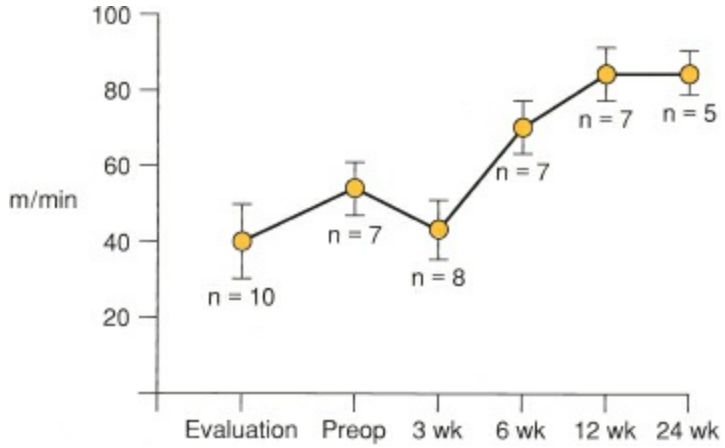

Figure 39-3. Mean 6-minute walk results for patients undergoing single lung transplantation for emphysema. There is significant improvement at 6 weeks with continued improvement after 12 weeks.

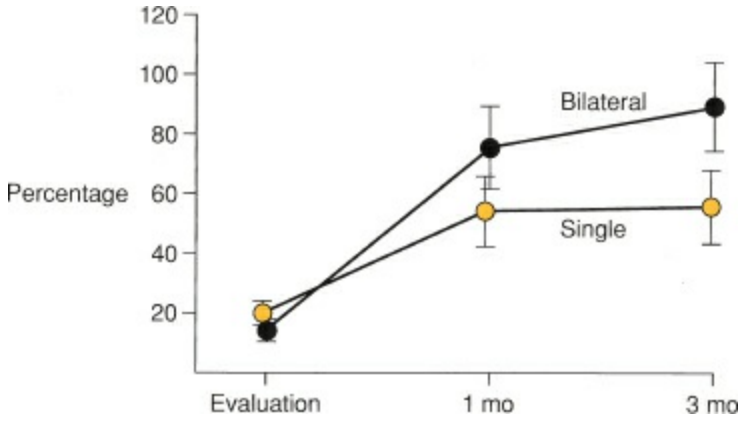

Figure 39-4. Comparison of the percent predicted forced expiratory volume in 1 second (FEV1) in 14 patients undergoing single and 10 patients undergoing bilateral pulmonary transplantation for chronic obstructive pulmonary disease.

In patients with pulmonary hypertension, single lung transplantation historically had been felt to be adequate to unload the right ventricle by reducing pulmonary artery pressures leading to improved right ventricular function. Although no significant survival benefit has been demonstrated between patients receiving single, bilateral, or heart–lung transplantation, most patients undergo bilateral sequential transplantation unless there is evidence for inotrope-dependent left ventricular heart failure.[140] Patients with pulmonary arterial hypertension listed for lung transplantation tend to be younger, and thus may be more likely to obtain more durable improvement in lung function following bilateral lung transplantation. In addition, perioperative management and improved hemodynamic performance appear to be facilitated by bilateral rather than single lung transplantation. Although seemingly contradictory, bilateral lung transplantation for this population also might improve organ utilization, since marginal bilateral lungs are likely more readily available than an "ideal" single donor lung.

Bilateral lung transplant results in greater improvements in spirometry.[129,141] A study by Anyanwu et al. shows that over 3 years, quality of life was improved to a greater degree after bilateral versus single lung transplant while Gerbase et al. found no significant difference in quality of life.[129] Meyer et al.[136] evaluated 2,260 patients

undergoing lung transplant for COPD in the United Network for Organ Sharing (UNOS) database and found that long-term survival was better following bilateral lung transplant for recipients less than 60. Thabut et al.[142] evaluated 9,883 patients with COPD and found that median survival was longer after bilateral transplant but not for patients older than 60. Nwakanma[143] also found no significant difference in long-term survival in 1,656 patients older than 60.

In a study of 821 patients with IPF, there was no significant difference in survival between single and bilateral lung transplants with a trend favoring single lung transplant.[133] Force et al. evaluated 3,860 patients with IPF in the UNOS database and found no survival advantage on multivariate analysis, but the 1-year survival for those living at least 1 year was greater after bilateral transplant. Risk factors for early mortality included recipient age greater than 57 and donor age greater than 36.[144] The authors concluded that bilateral transplant should be considered for younger patients with IPF. Patients undergoing bilateral transplant from 1994 to 2011 had a greater median survival compared to single lung transplants (6.9 vs. 4.6 years).[145]

Bilateral transplant has also been found to have a survival benefit in sicker patients with a higher LAS with a 14.4% lower 1-year mortality after a bilateral transplant.[146] Black et al.[147] evaluated 8,778 patients in the UNOS database and found that in patients with an LAS >75, the 1-year survival was significantly lower in patients undergoing a single lung transplant. While several smaller studies have found an increased risk of BOS after single lung transplant,[129,130,148] Meyer et al.,[136] found no difference in the risk of BOS in 2,260 patients with COPD in the UNOS database at 3-year follow-up.

While no randomized or prospective, controlled studies have been performed, the ratio of bilateral lung transplants has continued to increase over the past decade. Based on the available data, our approach has been to perform bilateral lung transplants in most patients younger than 60 while a single lung transplant is performed in older patients with IPF or COPD especially if pulmonary pressures are only mildly elevated and there is a significant difference in perfusion between the two lungs.

OPERATIVE TECHNIQUE

Single Lung Transplantation

In the recipient operation, a standard fourth intercostal space posterolateral thoracotomy is performed. In patients with emphysematous disease, a muscle-sparing axillary thoracotomy can be performed, but this approach might not afford suitable exposure for patients who have significant volume loss due to severe pulmonary fibrosis, a previous thoracotomy, or pleurodesis. The groin should always be included in the sterile field. If necessary, cardiopulmonary bypass can be performed by cannulating the femoral vessels in the groin or the right atrium and ascending aorta either through a right thoracotomy or a clamshell incision. The hilar dissection (Fig. 39-5) differs from that of a pneumonectomy in that the main pulmonary artery should be mobilized and divided distal to the origin of the first segmental trunk, and the pulmonary veins should be divided at the main segmental tributaries as they return to the superior or inferior veins. Care should be taken to preserve the peribronchial lymphatic and areolar tissue in order to maintain the vascular supply of the mainstem bronchus just proximal to the origin of the upper lobe bronchus. In addition, injury to the phrenic nerve must be avoided, especially in the setting of pleural adhesions from previous surgery, severe emphysema, or pulmonary fibrosis, to avoid diaphragmatic dysfunction, which can adversely affect posttransplant functional recovery.

The donor lung is prepared by dissecting the left atrial cuff and the proximal pulmonary artery from the surrounding tissues. Retrograde perfusion is then administered by perfusing the superior and inferior pulmonary veins with cold Perfadex while the lung is still inflated. The bronchial cuff is prepared by transecting the mainstem bronchus approximately two cartilaginous rings from the orifice of the upper lobe bronchus to maximize retrograde perfusion to the bronchial anastomosis.

Implantation of the donor lung begins with the anastomosis between the donor and recipient bronchus. An end-to-end anastomosis is performed with a running 4-0 polydioxanone suture on the membranous airway and figure-of-eight 4-0 polydioxanone sutures to reapproximate the cartilaginous airway.[149,150] Absorbable sutures are used rather than polypropylene to reduce the risk of suture granuloma formation. The peribronchial areolar and lymphatic tissue can be reapproximated between the donor and recipient, particularly anteriorly, in order to separate the bronchial and pulmonary arterial anastomoses. Advocates of bronchial arterial revascularization with a native internal mammary artery have reported decreased bronchial anastomotic complications in small series, but this technique has not received widespread acceptance due to the increased complexity and ischemic times.[151–153]

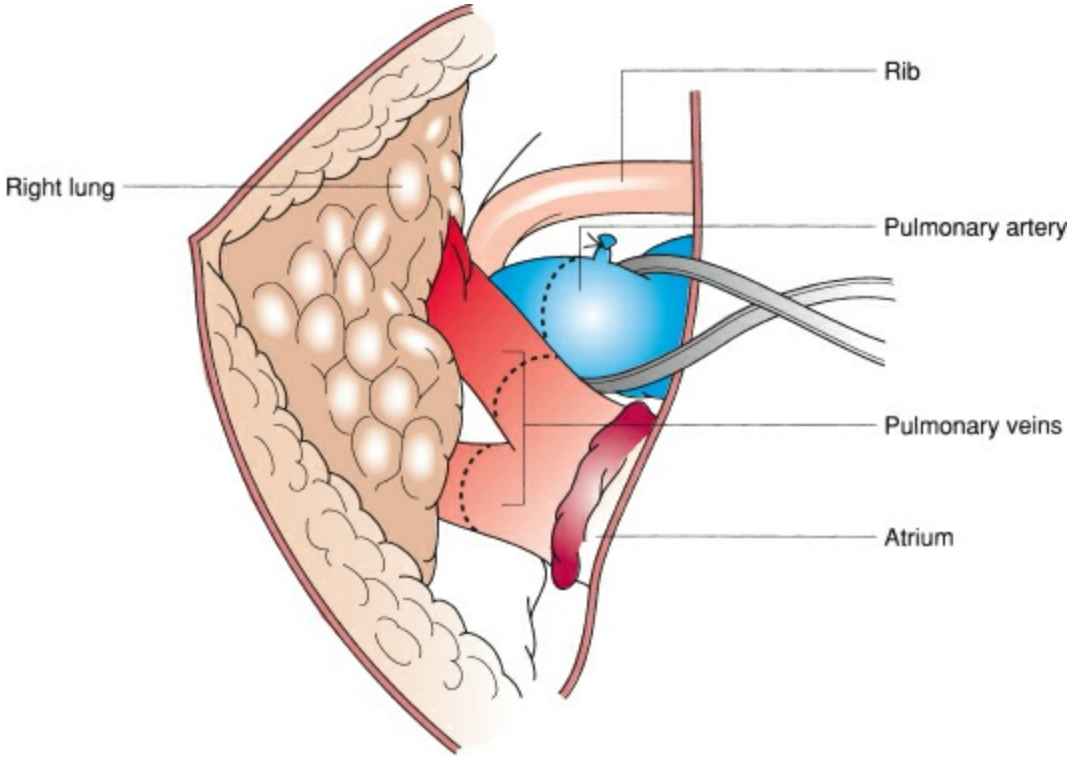

Figure 39-5. Mobilization of the hilum of the right lung. The pulmonary artery is encircled, and the first branch is ligated and divided. The superior and inferior pulmonary veins have been exposed. Both the artery and veins are taken as close to the lung as possible. The bronchus is divided at the level of the takeoff of the upper lobe to minimize ischemia of the airway.

The vascular anastomoses are then performed sequentially using running 4–0 or 5–0 nonabsorbable polypropylene sutures. Our preference has been to first perform the left atrial anastomosis followed by the pulmonary arterial anastomosis. The pericardium is opened around the left atrial cuff allowing the left atrium to be clamped centrally to the branch point of the superior and inferior veins. The recipient pulmonary vein stumps are prepared by unifocalization into one left atrial cuff to reduce the risk of pulmonary venous obstruction. In constructing the pulmonary arterial anastomosis, care must be taken to trim the donor pulmonary artery to the appropriate length to avoid kinking of the low-pressure vessel. Once the vascular anastomoses are completed, the lungs are gently ventilated as the vessels are deaired with the patient in the Trendelenburg position, first removing the pulmonary arterial clamp followed by the left atrial clamp prior to tying the anastomotic sutures. The chest is closed in standard fashion.

Bilateral Lung Transplantation

The technique of double lung transplantation has evolved considerably since the late 1980s from an *en bloc* technique to a bilateral, sequential technique.[139,154] With the patient in the supine position, this operation can be performed through a median sternotomy, bilateral thoracosternotomy (clamshell) incision (Fig. 39-6), bilateral anterior thoracotomies without sternal division, or bilateral muscle-sparing axillary thoracotomies. The bilateral thoracosternotomy incision provides the widest exposure facilitating dissection and mobilization of the hilar structures as well as cannulation of the right atrium and ascending aorta if cardiopulmonary bypass is necessary. This exposure is particularly important in recipients with diffuse dense pleural adhesions as is often seen in patients with chronic infections with bronchiectasis or CF, previous pleurodesis, or with severe apical adhesions after lung volume reduction in patients with emphysema.

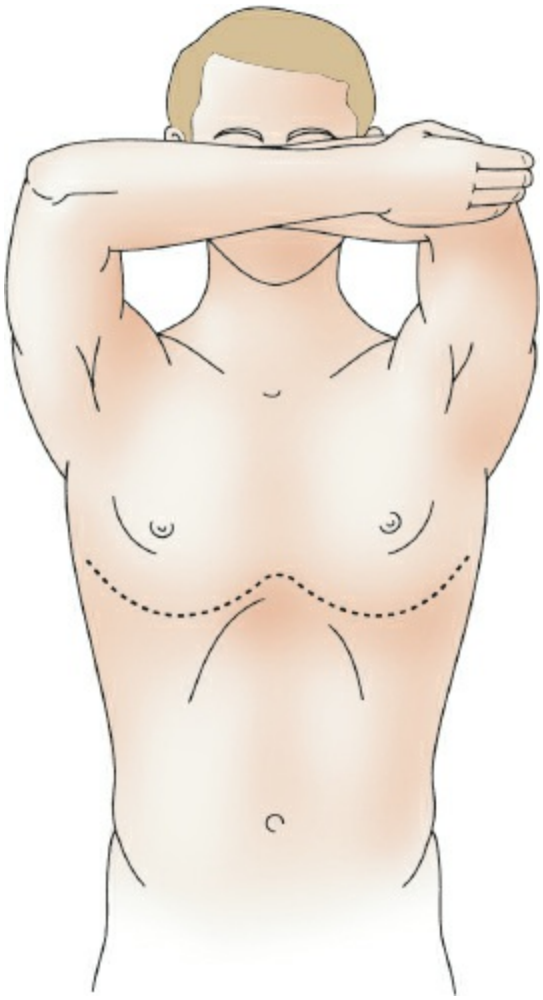

Figure 39-6. Patient positioning for a bilateral, sequential lung transplant. Bilateral anterior thoracotomies are made in the fourth intercostal space with a transverse sternotomy when needed for exposure (clamshell incision).

Although both lungs are replaced, the operation can often be performed without cardiopulmonary bypass unless the recipient has significant pulmonary hypertension or severely limited gas exchange. By replacing the lung with the least function first, based on the quantitative ventilation perfusion scan, oxygenation and ventilation can be maintained by the native lung. If the patient is unable to tolerate single lung ventilation

due to inadequate gas exchange or worsening right ventricular dysfunction with increasing pulmonary hypertension (near or suprasystemic), then cardiopulmonary bypass is initiated. If recipient hemodynamics are significantly impaired during retraction and exposure of the left atrial anastomosis, particularly during left lung recipient pneumonectomy and implantation, opening the recipient pericardium can be sufficient to permit safe manual cardiac retraction or application of an apical cardiac stabilizer.[155] In patients with severe mediastinal shift due to volume loss from pulmonary fibrosis, cardiopulmonary bypass may be necessary to provide sufficient cardiac decompression in order to obtain adequate exposure to complete the anastomoses.

The donor lungs are prepared leaving a cuff of left atrium around the pulmonary veins on each side. The recipient pneumonectomy is performed one side at a time with the patient maintained using single lung ventilation of the contralateral lung. Each donor lung is implanted using the same technique as described for single lung transplantation. The bronchial anastomosis is completed first, followed by the left atrial and pulmonary arterial anastomoses. Once perfusion and ventilation are restored to the first implanted lung, this lung then supports the patient while the remaining lung is removed and the second lung is implanted.

RESULTS

1. Based on OPTN data, 27,043 lung transplants were performed between 1988 and 2013. In 2012, 52.5% of transplanted patients were from diagnosis group D, including pulmonary fibrosis, which is now the most common indication for lung transplant (Fig. 39-1).[23] LAS scores continue to increase with 12.7% of transplant candidates with an LAS of 50 to 100 in 2006 compared to 22.5% in 2012. Of those patients listed, only 2% were listed for a heart–lung transplant. In 2012, 1,783 lung transplants were performed with 68% bilateral transplants and 5.5% retransplants. By the end of the first year after transplantation, approximately 80% of recipients report no limitations in activity.

6 Overall, survival after transplant has steadily improved with time. Between 1988 and 1994, median survival was 3.9 years while the median survival in 2012 was 5.3 years.[23] For patients who survived at least 1 year, the survival was 6.7 years. In this most recent era of lung transplant, the overall 1-year survival rate following lung transplant was 81.4% and the 5-year survival was 53.5%. Patients receiving bilateral lung transplant survive significantly longer than patients after single lung transplant (median survival of 6.2 vs. 4.5; $p < 0.0001$). In general, younger recipients have a longer survival than older patients. Patients with CF have the best median survival (6.4 years) as they comprise a younger population and in general will receive two lungs secondary to their infectious lung disease. Median survival for patients with pulmonary fibrosis is significantly lower at 4.1 years, and that of patients with COPD is 5 years.

For all recipients, the factors associated with the highest risk of 1-year mortality were the era in which patients were transplanted, intravenous inotropes, and mechanical ventilation. The most significant risk factor for 5-year mortality was the development of BOS within the first year of transplant.[16]

IMMUNOSUPPRESSION

Immunosuppression is initiated in the immediate perioperative period and continued for the remainder of the recipient's life. Regimens typically include a calcineurin inhibitor, either cyclosporine or tacrolimus; a purine synthesis antagonist, either azathioprine or mycophenolate mofetil; and a corticosteroid, either methylprednisolone (intravenous) or prednisone (oral). In an open-label randomized trial of 90 patients who received either cyclosporine or tacrolimus,[156] subjects who were treated with tacrolimus experienced significantly less acute rejection. Lymphocytic bronchitis was also less frequent among patients receiving tacrolimus. In addition, fewer patients developed stage 0-p BOS (not statistically significant). The investigators used a composite endpoint including cumulative acute rejection score, cumulative lymphocytic bronchitis score, or the development of BOS stage 0-p (10% or greater decrease in FEV_1). No difference in graft survival was seen. Although diabetes was slightly more prevalent among subjects treated with tacrolimus, there were no differences observed between the two treatment groups in terms of hypertension, chronic renal disease, posttransplant malignancy, or total number of infections. In 2012, more than 90% of lung transplant recipients were treated with tacrolimus.[23] Rapamycin (sirolimus) is a serine/threonine kinase inhibitor that can be used as a second-line agent for treatment of acute rejection, sometimes in combination with calcineurin inhibitors, but such use is considered off-label and not recommended. In addition, rapamycin is absolutely contraindicated in the early posttransplantation period because of an association with fatal bronchial anastomotic dehiscence.

In other solid organs, use of induction (perioperative) antithymocyte regimens appears to be beneficial in reducing both acute and chronic rejection. There are limited data supporting the use of such agents in lung transplantation. In a study of 44 patients randomized to conventional triple-drug immunosuppression with or without rabbit antithymocyte globulin, a significant reduction in early acute rejection from 41% to 5% was observed with the use of rabbit antithymocyte globulin, but there was no apparent effect on the total number of rejection episodes. Compared to induction immunosuppression, the time to onset of BOS was earlier and graft survival was worse with conventional therapy alone, but these differences were not statistically significant. Several studies comparing antithymocyte globulin with T-cell–specific interleukin-2 (IL-2) receptor (CD25) monoclonal antibody suggest that outcomes, including early acute rejection and freedom from rejection, are equivalent[157] if not worse[158,159] for patients treated with IL-2 receptor antibody. Treatment-related complications, particularly cytomegalovirus infection, appear to be equivalent for these induction agents. These studies do not provide sufficient evidence, and lack sufficient power, to determine whether their use is beneficial for the prevention of acute or chronic rejection. However, the use of induction therapy has increased from 23% in 1998 to 55% in 2012 with IL-2 receptor antagonists being the most commonly used agents.[23]

COMPLICATIONS

Complications after pulmonary transplantation occur frequently, may be severe, and occasionally result in death (Table 39-6). Compared to other solid organ transplants, lung recipients have the highest rates of rehospitalizations for complications at 43.7 per 100 patients.[23] Intraoperative complications include technical problems with the vascular or bronchial anastomoses, injury to the phrenic or recurrent laryngeal nerves, and myocardial infarction. Early postoperative complications include PGD, infection, and problems with airway healing and acute rejection. The most common late complications are infection and bronchiolitis obliterans (chronic rejection). Intra-abdominal complications are not uncommon while wound infection occurs rarely. Two important issues regarding standard immunosuppressive therapy are the various side effects associated with these agents and their interactions with other commonly prescribed medications.[160] Despite the progress made in operative techniques and early postoperative care, noninfectious, nonpulmonary complications related to long-term immunosuppression remain common. Five years after transplant, 66.7% of patients have hypertension, 53.8% hyperlipidemia, 49.8% renal dysfunction, 42.5% diabetes, and 18.3% have developed a malignancy with the risk of cancer three- to fourfold higher in patients after transplant.[23,161]

Table 39-6 Complications

Short Term
Bleeding
Airway complications (dehiscence)
Kinking of the pulmonary artery
Venous outflow obstruction
Primary graft dysfunction
Infection
Pleural space complications (pneumothorax, effusion, empyema)
Acute rejection
Long Term
Infection
Airway complications (stenosis, granulation, malacia)
Malignancy (posttransplant lymphoproliferative disorder, skin cancers)
Chronic rejection/bronchiolitis obliterans

Causes of recipient death can be categorized according to the time frame in which they occur. Early deaths (less than 30 days following transplant) most commonly result from primary graft failure (28.2%).[16] Infection is the second most common cause of early death (20.3%), followed by heart failure (11.1%). Rejection accounts for 4.3% of deaths in the early posttransplantation period. Hemorrhage and airway dehiscence each are responsible for 8.3% of early postoperative deaths. Infection accounts for about 39.5% of deaths within the first year of transplant (after 90 days). About one-third of deaths result from manifestations of chronic rejection and obliterative bronchiolitis, the single most

significant barrier to long-term survival following lung transplantation. Respiratory failure and malignancy are the next most common causes of late mortality.

Primary Graft Dysfunction

Mild, transient pulmonary edema is common in the freshly transplanted allograft. In approximately 15% of cases, the injury is sufficiently severe to cause PGD. While ischemia-reperfusion injury is the likely cause, surgical trauma and lymphatic disruption may also be contributing factors. The diagnosis rests on the presence of widespread infiltrates on chest radiographs, severe hypoxemia within 72 hours after transplantation, and the exclusion of other causes of graft dysfunction, such as volume overload, pneumonia, rejection, occlusion of the venous anastomosis, and aspiration. Treatment is supportive relying principally on conventional mechanical ventilation. Independent lung ventilation, inhaled nitric oxide, and ECMO have been used as adjunctive measures. Mortality rates of up to 60% have been reported, and among those who survive, the recovery period is often prolonged, but achievement of normal allograft function is possible. The results of emergency retransplantation in such cases have been poor.[160,162,163]

The impact of PGD on lung transplant outcomes has been historically unclear due to variability in the definition. A consensus statement in 2005 sought to standardize the definition and severity of PGD (Table 39-7).[164] Studies examining outcome utilizing the current grading system have demonstrated a direct correlation with severity of PGD and ICU mortality, in-hospital mortality, 1-year survival, and freedom from BOS.[165,166]

Table 39-7 Grading of Primary Graft Dysfunction Severity

Grade	PaO_2/FIO_2	Radiographic Infiltrate Consistent with Pulmonary Edema
0	>300	Absent
1	>300	Present
2	200–300	Present
3	<200	Present

Rejection

Acute rejection episodes often occur soon after transplantation, usually between posttransplantation days 5 and 7. Two or three rejection episodes can occur within the first month. Mild temperature elevation, perihilar fluffy infiltrates, or a minimal decrease in oxygenation as measured by arterial oxygen tension may indicate the onset of acute rejection. Because rejection occurs so frequently during this period, the distinction between infection and rejection may be difficult. Often, the distinguishing factor between these two entities is that rejection responds positively to the administration of corticosteroids. Treatment of early rejection involves the use of bolus corticosteroids given on 3 consecutive days. Within 12 to 18 hours after the first corticosteroid dose symptoms relating to rejection usually resolve including clearing of infiltrates on chest radiograph.

Transbronchial biopsies are performed to diagnose and monitor rejection, but the number of biopsies required to maximize specificity is large. One group recommends obtaining 18 separate transbronchial biopsy specimens to achieve 95% specificity. Transbronchial lung biopsy can also be used when the issue of rejection versus infection is not resolved after steroid administration. Flexible bronchoscopy can be performed at the bedside, and 6 to 10 separate biopsies can be obtained under fluoroscopic guidance. When symptoms or signs of rejection persist despite adequate treatment, open lung biopsy may be considered.

Infection

Infection in the posttransplantation period continues to be a significant cause of morbidity and mortality and is the most common overall cause of death. Posttransplant prophylaxis strategies targeting gram-positive and gram-negative bacteria, *Pneumocystis pneumoniae,* cytomegalovirus, and *Aspergillus* have been shown to decrease the morbidity and mortality from infectious complications. Bacterial pneumonia usually responds to appropriate antibiotic therapy, and patients are maintained on broad-spectrum antibiotics until specificities are determined by culture from the donor and recipient bronchus sent at the time of transplantation. Antibiotic administration is particularly important if one predominant organism is grown from the donor bronchus, and the recipient is maintained on an appropriate antibiotic or combination of antibiotics for at least 1 week. The most common organism recovered from donor bronchial washings is *Staphylococcus aureus.* In a series of 32 transplants, this organism was recovered from donors 11 times and subsequently from 4 transplant recipients.[167] Other commonly recovered pathogens include *Enterobacter* species and *Candida albicans.* The presence of organisms cultured from donor bronchial washings, however, does not absolutely predict the development of invasive infection in recipients. Less than half of recipients from whom organisms were recovered developed invasive infections.

The second most significant pathogen is cytomegalovirus (CMV). The diagnosis of CMV is usually made from culture of BAL fluid or tissue obtained from transbronchial lung biopsy. In the pulmonary transplantation population, CMV pneumonitis is the predominant form of CMV infection, although CMV enteritis and retinitis also occur. This observation corresponds to that seen in cardiac and cardiopulmonary transplant recipients. About half of lung recipients develop documented CMV infection. Ganciclovir has proved particularly effective and is the drug of choice for CMV infection in this circumstance. The drug is well tolerated in most patients, with neutropenia accounting for most of the toxicity. CMV prophylaxis with ganciclovir can be used for CMV-positive recipients or in those recipients who receive a lung from a CMV-positive donor. The mortality rate from life-threatening CMV infections treated with ganciclovir has been reported at 10%, far better than the 40% or greater mortality reported before this agent was available.[168] Life-threatening CMV infection can occur in CMV-negative recipients who receive a lung from a CMV-positive donor (primary infection) or in recipients who are already CMV positive (secondary infection). Cytolytic therapy especially with muromonab-CD3 is associated with an increased risk and severity of CMV infection. Mismatched donor–recipient CMV status also appears to be a significant univariate risk factor for mortality following retransplantation.[169] Attempts to match a CMV-negative recipient with a CMV-negative donor lung, given the shortage of donor organs, can prolong candidate waiting times. Based on the 2012 OPTN Annual Data Report, the donor and recipient CMV status was either matched (positive-positive or negative-negative) or mismatched with a CMV-positive recipient and a CMV-negative donor in 70% of lung transplants performed from 2008–2012.[23]

An analysis of UNOS outcomes data demonstrated that donor–recipient CMV serologic

mismatch, particularly donor-positive/recipient-negative (D−/R–) serologic status, was a significant adverse risk factor for posttransplantation mortality in earlier eras (1990 to 1994 and 1995 to 1999) but not in a more recent era (2000 to 2004) of pulmonary transplantation, when compared with donor-negative/recipient-negative transplants.[170] These findings suggest that donor–recipient CMV mismatch can be an adverse factor for posttransplant survival but that this effect can be significantly decreased with the introduction of more effective CMV antiviral therapy.[171]

Infection with *Aspergillus* species is the most common fungal infection after lung transplant and occurs in 15% to 35% of recipients. Overall mortality is high (52%), especially with invasive infections (80%).[172] Preemptive antifungal therapy has been shown to decrease the incidence of clinical fungal infection from 69% to 31%.[173]

Airway Complications

Airway complications can significantly affect quality of life with repeated procedures, office visits, and hospitalizations. Airway complications can be categorized by the time course of occurrence (early vs. late) and the type of complication (stenosis, dehiscence, granulation, fistula, or infection). The incidence of airway complications has decreased substantially over time. This is likely due to improvements in lung preservation, surgical technique, and antibiotic prophylaxis. Airway complications are associated with persistent ischemia, infection, and rejection.

During the early pulmonary transplantation experience, problems with airway healing occurred in 60% to 80% of patients and resulted in death in 2% to 3%.[174] Patients often did well for the first 3 weeks after transplantation, and then the bronchial anastomosis dehisced, often with erosion into the pulmonary artery. Bronchial anastomotic healing was initially facilitated by withholding maintenance corticosteroids until after the first posttransplantation week and using an omental pedicle wrapped around the anastomosis. Historically, most problems with airway healing occurred after *en bloc* double lung transplants, which involves a tracheal anastomosis. Double lung transplantation required extensive dissection in the subcarinal space, resulting in the disruption of a number of bronchial collateral vessels. Since this operation was modified to one involving bilateral, sequential lung implantation with two bronchial anastomoses, airway problems are now infrequent, occurring in 10% to 15%, and rarely result in recipient deaths.[175,176] The development of cyclosporine, advances in lung preservation, and better postoperative care have also improved airway healing. Immunosuppression, especially with high-dose steroids, may increase the risk of infection and decrease wound healing,[177,178] and sirolimus should be avoided perioperatively for 90 days due to significantly increased rates of airway dehiscence.[178–180]

The use of a telescoping bronchial anastomosis, in which the donor bronchus is intussuscepted into the recipient bronchus or vice versa, obviated the need for the omental pedicle wrap, allowed for immediate use of corticosteroids and reduced the anastomotic dehiscence rates. However, the telescoping anastomosis can increase the rate of anastomotic stenosis with complications in up to 48%[181] and a stenosis rate of 7%.[181,182] Recently there has been a trend toward the use of primary end-to-end anastomosis using figure-of-eight sutures with the anastomosis performed as close to the secondary carina as possible.[149,183] Initial results demonstrate a lower incidence of stenosis with an equivalent rate of dehiscence of approximately 2%.[149,150] Minimizing the length of the donor bronchus is important since perfusion of the anastomosis depends initially on retrograde collaterals from the pulmonary artery.[184–186]

Risk factors for airway complications include the duration of donor mechanical ventilation, height mismatch, length of the donor bronchus, type of anastomosis, size mismatch, infections, airway ischemia, immunosuppression used, PGD, positive pressure ventilation, and acute rejection.[178,179,181,185,187] Infections may increase inflammation and decrease healing, and resistant bacteria and fungal colonization are frequently present at the time of the anastomosis.

Management options depend on the type, location, timing, and severity of airway complication. Complications can occur at the anastomosis or more distally in 2.5% to 3% of patients with the extreme case being the vanishing bronchus syndrome with a mean survival of 25 months.[188,189] Bronchial stenosis is the most common and occurs in 1.6% to 32% of transplants.[181,189,190] Necrosis and dehiscence result in bronchial strictures. Some degree of dehiscence occurs in 1% to 10% of cases.[191] Infections such as *Aspergillus* and early rejection have also been associated with stenosis.[192] Patients may present with cough, postobstructive pneumonia, dyspnea, atelectasis or lobar collapse on chest x-ray, and worsening FEV1 on spirometry. Other types of airway complications include malacia, dehiscence, and fistula. A persistent air leak, pneumothorax, or pneumomediastinum may suggest airway dehiscence, and the most severe cases may require open repair, flap bronchoplasty, or even retransplant,[193] although a partial dehiscence may heal without further intervention.

Chest CT with 3D reconstructions can be helpful in planning interventions.[194,195] Bronchoscopy plays a key role in diagnosing, and managing airway complications. Dilation can be performed using a balloon, rigid bronchoscope, or various dilators including Savary or olive tip dilators. Balloon dilation is the only procedure required in 26% of cases[196] and relieves symptoms in 94% of patients,[197] although most patients require repeat procedures. Rigid bronchoscopic dilation allows for direct visualization of the stricture and ventilation during dilation. Ablation can be performed with laser, argon plasma coagulation, or cryotherapy. For refractory lesions, submucosal injection of steroids or topical mitomycin-C may help prevent recurrence.[198–200]

Stenting should be considered when other more conservative interventions have failed. Stents can provide symptomatic relief in 80% to 94% of patients with long-term patency in 45%.[197,201] However, complication rates up to 54% have been reported[202–204] and should be carefully considered when placing a foreign body in an immunocompromised patient. Bacterial colonization is seen in up to 78% of cases,[201,205,206] and complications include infection, granulation tissue, and stent migration. Stents have also been associated with higher rates of respiratory infections in cancer patients.[207] Metal stents can become embedded in granulation tissue making removal hazardous. Covered stents should be used when possible and should be removed once they are no longer needed. Stents can also be used to temporarily cover a dehiscence to allow healing over several weeks[208] although care must be taken not to extend the injury during stent placement and removal.

Self-expanding stents are easy to place through a flexible scope; however, silicone stents offer certain advantages including decreased granulation tissue, the ability to customize and modify the stents, and the ease of removing the stents,[209] although stent migration and mucous plugging are still possible. If endoscopic therapies are unsuccessful, sleeve resection, lobectomy, and pneumonectomy have been reported but carry significant risks of morbidity and mortality.

Bronchomalacia may occur with loss of cartilaginous support of the airway due to ischemia or infection. Patients have a “barking” cough, shortness of breath, wheezing, and recurrent infections. Bronchoscopy and dynamic CT with inspiration and expiration images are important for diagnosis. Patients are treated with mucolytics and noninvasive

positive pressure ventilation. In severe cases, stents may be used and can increase spirometry results.[196]

The lungs have a dual blood supply with perfusion from systemic bronchial arteries as well as the pulmonary arteries, although generally only the pulmonary arterial circulation is restored during transplantation. The anatomy of the bronchial arteries is variable with 1 to 4 arteries arising from the descending aorta and the upper right intercostal arteries.[210] Bronchial artery revascularization may improve airway healing and decrease airway complications.[211–214] The largest series from Copenhagen showed an improved 5-year survival of 69% after bronchial artery revascularization versus 57% without.[215] There are also studies showing decreased incidence of pulmonary infections and a trend toward increased freedom from BOS at 24 months.[216] Bronchial artery revascularization is technically challenging, leading to longer ischemic times and increased risk of bleeding, and with the limited published data, has not been widely adopted.

Bronchiolitis Obliterans

7 Acute and chronic rejection continues to be higher after lung transplant than other solid organs. Bronchiolitis obliterans remains the leading cause of late mortality following lung transplantation with nearly 30% of deaths beyond the first year of transplantation attributed to the fibroproliferative changes and airway destruction of this disorder. BOS is present in the first year in 7.9% of patients and in 43% by 5 years,[23] and remains a significant cause of morbidity. Following heart–lung transplantation, nearly 50% of deaths beyond the first year are attributable to bronchiolitis obliterans and pulmonary graft failure.[17]

BOS is defined as a decline in FEV_1 of greater than 20% from baseline determined on at least two separate measurements obtained at least 3 weeks apart.[217] The histologic appearance of bronchiolitis obliterans is characterized by progressive small airway destruction, an inflammatory exudate, and fibrosis. This complication is likely a form of chronic rejection, although its exact etiology remains unknown. If diagnosed early, enhancing immunosuppression may either halt the process or slow its progression. Factors associated with BOS include repeated episodes of acute rejection, chronic rejection, infection, and gastroesophageal reflux disease.[218–220] It has been hypothesized that the development of obliterative bronchiolitis in cardiopulmonary transplantation patients is related to a human major histocompatibility complex (human leukocyte antigen)–A2 antigen mismatch. Others believe that CMV infection or early lung injury, such as that arising from PGD, may be implicated.[221] Once diagnosed, it is important to increase immunosuppression to prevent what is usually an insidiously progressive disorder. Unfortunately, in patients who have developed obliterative bronchiolitis and then undergo retransplantation, the pathology can recur in the newly transplanted lungs. Obliterative bronchiolitis remains the major problem in patients surviving for greater than 2 years following transplantation. Overall, long-term survival for lung transplantation is not likely to improve significantly until effective strategies for the prevention and treatment of obliterative bronchiolitis are identified.

New terminology has been recently introduced to include other chronic forms of decreased lung function after transplant.[222] Chronic allograft dysfunction, or CLAD, is defined as an irreversible decline in FEV1 to $<$ 80% of baseline. In addition to BOS, restrictive allograft syndrome presents with restrictive findings on PFTs including a decline in total lung capacity to $<$90% of baseline and has a worse survival than other patients with CLAD.[223]

GASTROESOPHAGEAL REFLUX

8 After lung transplantation, patients have a higher rate of gastroesophageal reflux disease,[224] and the incidence is increased after bilateral transplant and retransplantation.[225,226] Reflux is found in 90% of patients with CF[7,227] and high rates of reflux and dysmotility are associated with connective tissue disorders.[228] Compared to nontransplant patients, pepsin is increased in BAL fluid in patients after lung transplant.[229,230] Increased reflux may be a result of immunosuppressive medications or changes from the surgical procedure itself, possi bly due to the proximity of the vagus nerve.[231–233] Reflux in lung transplant patients has been associated with aspiration, impaired lung function, and decreased survival. Bronchiolitis obliterans has been associated with gastroesophageal reflux.[220,230,234–236] Cytokines and cellular activation are increased in BAL fluid secondary to chronic gastroesophageal reflux and may lead to the production of alloantigens and BOS.[237,238] Decrease in mucociliary clearance in transplant patients may also make the effects of aspiration worse.[232,239] Reflux may lead to chemical injury,[240] and bile acids may inhibit immune mechanisms by lowering levels of surfactant involved in regulating cytokines and the immune response.[234] Studies have found an association between reflux and episodes of acute rejection.[230,235,237,241]

Lung transplant patients with abnormal pH probe testing have an increased rate of decline in their FEV1, and the decline is worse when patients do not undergo antireflux surgery.[220] One study of 215 patients found that abnormal preoperative pH testing was associated with significantly decreased survival.[242] Nonacid reflux is also increased after lung transplant, and heartburn symptoms were poor at predicting the presence of pepsin or bile in BAL fluid.[243,244] In addition, suppressing acid with H2 blockers or proton pump inhibitors did not stop the effects of aspiration or the development of bronchiolitis obliterans.[245] Antacid therapy may result in silent aspiration and also contribute to bacterial overgrowth, which could increase injury from aspiration.[246] Thirty-six percent of patients with reflux also had esophageal dysmotility.[225] Gastroparesis is present in 50% of lung transplant patients before transplant, increasing to 74% postoperatively; a significant number of patients return to normal function with time.[247]

Antireflux surgery decreases both acid and nonacid reflux and can be safely performed in lung transplant patients[228,233,248,249] either prior to or after their transplant depending on their functional status. Antireflux surgery decreases immune factors associated with BOS and preserves overall pulmonary function[220,233,250,251]; data on any survival benefit is limited with only one study showing a survival benefit at 1 year after early fundoplication within 90 days.[252]

FUTURE CONSIDERATIONS

The number of lung transplants continues to increase with 1,922 lung transplants performed in 2013 and 2,474 patients added to the waiting list. Pulmonary transplantation has evolved from an experimental therapy to the standard of care for patients with certain end-stage pulmonary diseases. The number of transplanted patients older than 65 has increased substantially over the past 10 years, and patients are sicker with a higher median LAS. Careful patient selection by a multidisciplinary team is essential. As waitlisted patients become sicker, with acute inpatient evaluations becoming more common, the use of ambulatory ECMO may increase to help prevent these patients from becoming deconditioned. Work also continues on developing long-term paracorporeal support devices including the artificial lung.

Donor availability remains a limiting factor and efforts to increase the number of acceptable donor lungs will continue including aggressive donor management, evaluation of marginal lungs using EVLP, and consideration of DCD lungs. Future developments in EVLP may also allow biomarker assessment to evaluate donor lung injury as well as therapeutic interventions during ex vivo perfusion.[87] Research is also being done to regenerate decellularized lung scaffolds using EVLP.[253,254]

References

1. Hardy JD. The first lung transplant in man (1963) and the first heart transplant in man (1964). *Transplant Proc* 1999;31:25–29.
2. Samano MN, Minamoto H, Junqueira JJ, et al. Bronchial complications following lung transplantation. *Transplant Proc* 2009;41:921–926.
3. Morris PJ. The impact of Cyclosporin A on transplantation. *Adv Surg* 1984;17:99–127.
4. Yusen RD, Christie JD, Edwards LB, et al. The Registry of the International Society for Heart and Lung Transplantation: thirtieth adult lung and heart-lung transplant report–2013; focus theme: age. *J Heart Lung Transplant* 2013;32:965–978.
5. Egan TM, Cooper JD. Lung transplantation. *Ann Thorac Surg* 1989;48:741–742.
6. Estenne M, Maurer JR, Boehler A, et al. Bronchiolitis obliterans syndrome 2001: an update of the diagnostic criteria. *J Heart Lung Transplant* 2002; 21:297–310.
7. Christie JD, Edwards LB, Kucheryavaya AY, et al. The Registry of the International Society for Heart and Lung Transplantation: twenty-seventh official adult lung and heart-lung transplant report–2010. *J Heart Lung Transplant* 2010;29:1104–1118.
8. Lima O, Cooper JD, Peters WJ, et al. Effects of methylprednisolone and azathioprine on bronchial healing following lung autotransplantation. *J Thorac Cardiovasc Surg* 1981;82:211–215.
9. Khaghani A, Tadjkarimi S, al-Kattan K, et al. Wrapping the anastomosis with omentum or an internal mammary artery pedicle does not improve bronchial healing after single lung transplantation: results of a randomized clinical trial. *J Heart Lung Transplant* 1994;13:767–773.
10. Egan TM, Murray S, Bustami RT, et al. Development of the new lung allocation system in the United States. *Am J Transplant* 2006;6:1212–1227.
11. Mulligan MS, Shearon TH, Weill D, et al. Heart and lung transplantation in the United States, 1997-2006. *Am J Transplant.* 2008;8:977–987.
12. Grady KL, White-Williams C, Naftel D, et al. Are preoperative obesity and cachexia risk factors for post heart transplant morbidity and mortality: a multi-institutional study of preoperative weight-height indices. Cardiac Transplant Research Database (CTRD) Group. *J Heart Lung Transplant* 1999;18:750–763.
13. Culver DA, Mazzone PJ, Khandwala F, et al. Discordant utility of ideal body weight and body mass index as predictors of mortality in lung transplant recipients. *J Heart Lung Transplant* 2005;24:137–144.
14. Madill J, Gutierrez C, Grossman J, et al. Nutritional assessment of the lung transplant patient: body mass index as a predictor of 90-day mortality following transplantation. *J Heart Lung Transplant* 2001;20:288–296.
15. Christie JD, Edwards LB, Kucheryavaya AY, et al. The registry of the International Society for Heart and Lung Transplantation: twenty-eighth adult lung and heart-lung transplant report–2011. *J Heart Lung Transplant* 2011;30:1104–1122.
16. Hertz MI, Aurora P, Christie JD, et al. Registry of the International Society for Heart

and Lung Transplantation: a quarter century of thoracic transplantation. *J Heart Lung Transplant* 2008;27:937–942.

17. Trulock EP, Edwards LB, Taylor DO, et al. Registry of the International Society for Heart and Lung Transplantation: twenty-second official adult lung and heart-lung transplant report–2005. *J Heart Lung Transplant* 2005;24:956–967.
18. Mahidhara R, Bastani S, Ross DJ, et al. Lung transplantation in older patients? *J Thorac Cardiovasc Surg* 2008;135:412–420.
19. Smith PW, Wang H, Parini V, et al. Lung transplantation in patients 60 years and older: results, complications, and outcomes. *Ann Thorac Surg* 2006;82:1835–1841; discussion 1841.
20. Vadnerkar A, Toyoda Y, Crespo M, et al. Age-specific complications among lung transplant recipients 60 years and older. *J Heart Lung Transplant* 2011;30:273–281.
21. Yusen RD, Shearon TH, Qian Y, et al. Lung transplantation in the United States, 1999-2008. *Am J Transplant* 2010;10:1047–1068.
22. Valapour M, Paulson K, Smith JM, et al. OPTN/SRTR 2011 Annual Data Report: lung. *Am J Transplant* 2013;13(suppl 1):149–177.
23. Valapour M, Skeans MA, Heubner BM, et al. OPTN/SRTR 2012 Annual Data Report: lung. *Am J Transplant* 2014;14(suppl 1):139–165.
24. Baz MA, Palmer SM, Staples ED, et al. Lung transplantation after long-term mechanical ventilation : results and 1-year follow-up. *Chest.* 2001;119:224–227.
25. Patel VS, Palmer SM, Messier RH, et al. Clinical outcome after coronary artery revascularization and lung transplantation. *Ann Thorac Surg* 2003;75:372–377; discussion 377.
26. Fishman A, Martinez F, Naunheim K, et al. A randomized trial comparing lung-volume-reduction surgery with medical therapy for severe emphysema. *N Eng J Med* 2003;348:2059–2073.
27. Oga T, Nishimura K, Tsukino M, et al. Analysis of the factors related to mortality in chronic obstructive pulmonary disease: role of exercise capacity and health status. *Am J Respir Crit Care Med* 2003;167:544–549.
28. Celli BR, Cote CG, Marin JM, et al. The body-mass index, airflow obstruction, dyspnea, and exercise capacity index in chronic obstructive pulmonary disease. *N Eng J Med* 2004;350:1005–1012.
29. De Oliveira NC, Osaki S, Maloney J, et al. Lung transplant for interstitial lung disease: outcomes before and after implementation of the united network for organ sharing lung allocation scoring system. *Eur J Cardiothorac Surg* 2012;41:680–685.
30. Latsi PI, du Bois RM, Nicholson AG, et al. Fibrotic idiopathic interstitial pneumonia: the prognostic value of longitudinal functional trends. *Am J Respir Crit Care Med* 2003;168:531–537.
31. Mogulkoc N, Brutsche MH, Bishop PW, et al. Pulmonary function in idiopathic pulmonary fibrosis and referral for lung transplantation. *Am J Respir Crit Care Med*

2001;164:103–108.
32. Lama VN, Flaherty KR, Toews GB, et al. Prognostic value of desaturation during a 6-minute walk test in idiopathic interstitial pneumonia. *Am J Respir Crit Care Med* 2003;168:1084–1090.
33. O'Beirne S, Counihan IP, Keane MP. Interstitial lung disease and lung transplantation. *Semin Respir Crit Care Med* 2010;31:139–146.
34. Garrity ER, Moore J, Mulligan MS, et al. Heart and lung transplantation in the United States, 1996-2005. *Am J Transplant* 2007;7:1390–1403.
35. OPTN/SRTR. Annual reports of the US organ procurement and transplantation network and the scientific registry of transplant. recipients: transplant data 1999–2008. Bethesda, MD: Health Resources and Services Administration, US Department of Health and Human Services; 2009.
36. Orens JB, Shearon TH, Freudenberger RS, et al. Thoracic organ transplantation in the United States, 1995-2004. *Am J Transplant* 2006;6:1188–1197.
37. Whelan TP, Dunitz JM, Kelly RF, et al. Effect of preoperative pulmonary artery pressure on early survival after lung transplantation for idiopathic pulmonary fibrosis. *J Heart Lung Transplant* 2005;24:1269–1274.
38. Kerem E, Reisman J, Corey M, et al. Prediction of mortality in patients with cystic fibrosis. *N Eng J Med* 1992;326:1187–1191.
39. Kreider M, Kotloff RM. Selection of candidates for lung transplantation. *Proc Am Thorac Soc* 2009;6:20–27.
40. Orens JB, Estenne M, Arcasoy S, et al. International guidelines for the selection of lung transplant candidates: 2006 update–a consensus report from the Pulmonary Scientific Council of the International Society for Heart and Lung Transplantation. *J Heart Lung Transplant* 2006;25:745–755.
41. Department of Health and Human Services. Final rule, 42 CFR 121: Organ procurement and transplantation network. *Federal Register 42 CFR (Part 121)* 1999:56649–56661.
42. Hosenpud JD, Bennett LE, Keck BM, et al. Effect of diagnosis on survival benefit of lung transplantation for end-stage lung disease. *Lancet* 1998;351:24–27.
43. Titman A, Rogers CA, Bonser RS, et al. Disease-specific survival benefit of lung transplantation in adults: a national cohort study. *Am J Transplant* 2009;9:1640–1649.
44. De Meester J, Smits JM, Persijn GG, et al. Lung transplant waiting list: differential outcome of type of end-stage lung disease, one year after registration. *J Heart Lung Transplant* 1999;18:563–571.
45. Liou TG, Adler FR, Cox DR, et al. Lung transplantation and survival in children with cystic fibrosis. *N Eng J Med* 2007;357:2143–2152.
46. Chamogeorgakis T, Mason DP, Murthy SC, et al. Impact of nutritional state on lung transplant outcomes. *J Heart Lung Transplant* 2013;32:693–700.
47. Allen JG, Arnaoutakis GJ, Weiss ES, et al. The impact of recipient body mass index

on survival after lung transplantation. *J Heart Lung Transpl* 2010;29:1026–1033.
48. McCurry KR, Shearon TH, Edwards LB, et al. Lung transplantation in the United States, 1998-2007. *Am J Transplant* 2009;9:942–958.
49. Russo MJ, Iribarne A, Hong KN, et al. High lung allocation score is associated with increased morbidity and mortality following transplantation. *Chest* 2010;137:651–657.
50. Kozower BD, Meyers BF, Smith MA, et al. The impact of the lung allocation score on short-term transplantation outcomes: a multicenter study. *J Thorac Cardiovasc Surg* 2008;135:166–171.
51. McCue JD, Mooney J, Quail J, et al. Ninety-day mortality and major complications are not affected by use of lung allocation score. *J Heart Lung Transplant* 2008;27:192–196.
52. Thabut G, Christie JD, Mal H, et al. Survival benefit of lung transplant for cystic fibrosis since lung allocation score implementation. *Am J Respir Crit Care Med* 2013;187:1335–1340.
53. OPTN. Proposal to revise the lung allocation score (LAS) system. 2013.
54. McGoon M, Miller D. REVEAL registry: registry to evaluate early and long-term PAH disease management. Available at: http://clinicaltrials.gov/ show/NCT00370214. 2006.
55. Tsuang WM, Vock DM, Finlen Copeland CA, et al. An acute change in lung allocation score and survival after lung transplantation: a cohort study. *Ann Intern Med* 2013;158:650–657.
56. Lang G, Aigner C, Winkler G, et al. Prolonged venoarterial extracorporeal membrane oxygenation after transplantation restores functional integrity of severely injured lung allografts and prevents the development of pulmonary graft failure in a pig model. *J Thorac Cardiovasc Surg* 2009; 137:1493–1498.
57. Rehder KJ, Turner DA, Hartwig MG, et al. Active rehabilitation during extracorporeal membrane oxygenation as a bridge to lung transplantation. *Respir Care* 2013;58:1291–1298.
58. Turner DA, Cheifetz IM, Rehder KJ, et al. Active rehabilitation and physical therapy during extracorporeal membrane oxygenation while awaiting lung transplantation: a practical approach. *Crit Care Med* 2011;39:2593–2598.
59. Jackson A, Cropper J, Pye R, et al. Use of extracorporeal membrane oxygenation as a bridge to primary lung transplant: 3 consecutive, successful cases and a review of the literature. *J Heart Lung Transplant* 2008;27:348–352.
60. Nosotti M, Rosso L, Palleschi A, et al. Bridge to lung transplantation by venovenous extracorporeal membrane oxygenation: a lesson learned on the first four cases. *Transplant Proc* 2010;42:1259–1261.
61. Olsson KM, Simon A, Strueber M, et al. Extracorporeal membrane oxygenation in nonintubated patients as bridge to lung transplantation. *Am J Transplant*

2010;10:2173–2178.
62. Strueber M, Hoeper MM, Fischer S, et al. Bridge to thoracic organ transplantation in patients with pulmonary arterial hypertension using a pumpless lung assist device. *Am J Transplant* 2009;9:853–857.
63. Fischer S, Simon AR, Welte T, et al. Bridge to lung transplantation with the novel pumpless interventional lung assist device NovaLung. *J Thorac Cardiovasc Surg* 2006;131:719–723.
64. Gore A, Hatch O. National Organ Transplant Act of 1984. In: Senate 2048–98th Congress: Sec. 101-Sec, vol. 401. *Weekly Compilation of Presidential Documents, Presidential statement.* Washington, DC: 1984:98–507.
65. Lewandowski K, Rossaint R, Pappert D, et al. High survival rate in 122 ARDS patients managed according to a clinical algorithm including extracorporeal membrane oxygenation. *Intens Care Med* 1997;23:819–835.
66. Kopp R, Dembinski R, Kuhlen R. Role of extracorporeal lung assist in the treatment of acute respiratory failure. *Minerva Anestesiol* 2006;72:587–595.
67. Morris AH, Wallace CJ, Menlove RL, et al. Randomized clinical trial of pressure-controlled inverse ratio ventilation and extracorporeal CO2 removal for adult respiratory distress syndrome. *Am J Respir Crit Care Med* 1994;149:295–305.
68. Jurmann MJ, Haverich A, Demertzis S, et al. Extracorporeal membrane oxygenation as a bridge to lung transplantation. *Eur J Cardiothorac Surg* 1991;5:94–97; discussion 98.
69. Fuehner T, Kuehn C, Hadem J, et al. Extracorporeal membrane oxygenation in awake patients as bridge to lung transplantation. *Am J Respir Crit Care Med* 2012;185:763–768.
70. Meyers BF, Lynch J, Trulock EP, et al. Lung transplantation: a decade of experience. *Ann Surg* 1999;230:362–370; discussion 370-371.
71. Merlo C, Orens J. Selection of candidates for lung transplantation. *Curr Opin Organ Transpl* 2007;12:749–784.
72. Puskas JD, Winton TL, Miller JD, et al. Unilateral donor lung dysfunction does not preclude successful contralateral single lung transplantation. *J Thorac Cardiovasc Surg* 1992;103:1015–1017; discussion 1017–1018.
73. Orens JB, Boehler A, de Perrot M, et al. A review of lung transplant donor acceptability criteria. *J Heart Lung Transplant* 2003;22:1183–1200.
74. Zenati M, Dowling RD, Dummer JS, et al. Influence of the donor lung on development of early infections in lung transplant recipients. *J Heart Transplant* 1990;9:502–508; discussion 508–509.
75. Thabut G, Mal H, Cerrina J, et al. Graft ischemic time and outcome of lung transplantation: a multicenter analysis. *Am J Respir Crit Care Med* 2005;171:786–791.
76. Weill D. Donor criteria in lung transplantation: an issue revisited. *Chest* 2002;121:2029–2031.

77. Angel LF, Levine DJ, Restrepo MI, et al. Impact of a lung transplantation donor-management protocol on lung donation and recipient outcomes. *Am J Respir Crit Care Med* 2006;174:710–716.
78. Botha P, Trivedi D, Searl CP, et al. Differential pulmonary vein gases predict primary graft dysfunction. *Ann Thorac Surg* 2006;82:1998–2002.
79. Arcasoy SM, Fisher A, Hachem RR, et al. Report of the ISHLT Working Group on Primary Lung Graft Dysfunction part V: predictors and outcomes. *J Heart Lung Transplant* 2005;24:1483–1488.
80. de Perrot M, Keshavjee S. Lung preservation. *Semin Thorac Cardiovasc Surg* 2004;16:300–308.
81. Venuta F, Rendina EA, Bufi M, et al. Preimplantation retrograde pneumoplegia in clinical lung transplantation. *J Thorac Cardiovasc Surg* 1999; 118:107–114.
82. DeCampos KN, Keshavjee S, Liu M, et al. Optimal inflation volume for hypothermic preservation of rat lungs. *J Heart Lung Transplant* 1998;17:599–607.
83. Fukuse T, Hirata T, Ishikawa S, et al. Optimal alveolar oxygen concentration for cold storage of the lung. *Transplantation* 2001;72:300–304.
84. Haniuda M, Hasegawa S, Shiraishi T, et al. Effects of inflation volume during lung preservation on pulmonary capillary permeability. *J Thorac Cardiovasc Surg* 1996;112:85–93.
85. de Perrot M, Imai Y, Volgyesi GA, et al. Effect of ventilator-induced lung injury on the development of reperfusion injury in a rat lung transplant model. *J Thorac Cardiovasc Surg* 2002;124:1137–1144.
86. Pierre AF, DeCampos KN, Liu M, et al. Rapid reperfusion causes stress failure in ischemic rat lungs. *J Thorac Cardiovasc Surg* 1998;116:932–942.
87. Munshi L, Keshavjee S, Cypel M. Donor management and lung preservation for lung transplantation. The Lancet. *Respir Med* 2013;1:318–328.
88. Punch JD, Hayes DH, LaPorte FB, et al. Organ donation and utilization in the United States, 1996-2005. *Am J Transplant* 2007;7:1327–1338.
89. Jirsch DW, Fisk RL, Couves CM. Ex vivo evaluation of stored lungs. *Ann Thorac Surg* 1970;10:163–168.
90. Steen S, Sjoberg T, Pierre L, et al. Transplantation of lungs from a non-heart-beating donor. *Lancet* 2001;357:825–829.
91. Steen S, Ingemansson R, Eriksson L, et al. First human transplantation of a nonacceptable donor lung after reconditioning ex vivo. *Ann Thorac Surg* 2007;83:2191–2194.
92. Cypel M, Yeung JC, Hirayama S, et al. Technique for prolonged normothermic ex vivo lung perfusion. *J Heart Lung Transplant* 2008;27:1319–1325.
93. Yeung JC, Cypel M, Machuca TN, et al. Physiologic assessment of the ex vivo donor lung for transplantation. *J Heart Lung Transplant* 2012;31:1120–1126.
94. Cypel M, Yeung JC, Machuca T, et al. Experience with the first 50 ex vivo lung

perfusions in clinical transplantation. *J Thorac Cardiovasc Surg* 2012;144:1200–1206.
95. Cypel M, Yeung JC, Liu M, et al. Normothermic ex vivo lung perfusion in clinical lung transplantation. *N Eng J Med* 2011;364:1431–1440.
96. Frank JA, Briot R, Lee JW, et al. Physiological and biochemical markers of alveolar epithelial barrier dysfunction in perfused human lungs. *Am J Physiol Lung Cell Mol Physiol* 2007;293:L52–L59.
97. Inci I, Ampollini L, Arni S, et al. Ex vivo reconditioning of marginal donor lungs injured by acid aspiration. *J Heart Lung Transplant* 2008;27:1229–1236.
98. Andreasson A, Karamanou DM, Perry JD, et al. The effect of ex vivo lung perfusion on microbial load in human donor lungs. *J Heart Lung Transplant* 2014;33:910–916.
99. Boffini M, Bonato R, Rinaldi M. The potential role of ex vivo lung perfusion for the diagnosis of infection before lung transplantation. *Transpl Int* 2014;27:e5–e7.
100. Machuca TN, Hsin MK, Ott HC, et al. Injury-specific ex vivo treatment of the donor lung: pulmonary thrombolysis followed by successful lung transplantation. *Am J Respir Crit Care Med* 2013;188:878–880.
101. Cypel M, Liu M, Rubacha M, et al. Functional repair of human donor lungs by IL-10 gene therapy. *Sci Transl Med* 2009;1:4ra9.
102. Lee JW, Fang X, Gupta N, et al. Allogeneic human mesenchymal stem cells for treatment of E. coli endotoxin-induced acute lung injury in the ex vivo perfused human lung. *Proc Natl Acad Sci U S A* 2009;106:16357–16362.
103. Egan TM, Lambert CJ Jr, Reddick R, et al. A strategy to increase the donor pool: use of cadaver lungs for transplantation. *Ann Thorac Surg* 1991;52:1113–1120; discussion 1120–1121.
104. Van Raemdonck DE, Jannis NC, De Leyn PR, et al. Warm ischemic tolerance in collapsed pulmonary grafts is limited to 1 hour. *Ann Surg* 1998;228:788–796.
105. Greco R, Cordovilla G, Sanz E, et al. Warm ischemic time tolerance after ventilated non-heart-beating lung donation in piglets. *Eur J Cardiothorac Surg* 1998;14:319–325.
106. Neyrinck AP, Van De Wauwer C, Geudens N, et al. Comparative study of donor lung injury in heart-beating versus non-heart-beating donors. *Eur J Cardiothorac Surg* 2006;30:628–636.
107. Kang CH, Anraku M, Cypel M, et al. Transcriptional signatures in donor lungs from donation after cardiac death vs after brain death: a functional pathway analysis. *J Heart Lung Transplant* 2011;30:289–298.
108. Wigfield CH, Love RB. Donation after cardiac death lung transplantation outcomes. *Curr Opin Organ Transplant* 2011;16:462–468.
109. Levvey BJ, Harkess M, Hopkins P, et al. Excellent clinical outcomes from a national donation-after-determination-of-cardiac-death lung transplant collaborative. *Am J Transplant* 2012;12:2406–2413.
110. Kootstra G, Daemen JH, Oomen AP. Categories of non-heart-beating donors. *Transplant Proc* 1995;27:2893–2894.

111. Bernat JL, D'Alessandro AM, Port FK, et al. Report of a National Conference on Donation after cardiac death. *Am J Transplant* 2006;6:281–291.
112. Lewis J, Peltier J, Nelson H, et al. Development of the University of Wisconsin donation After Cardiac Death Evaluation Tool. *Prog Transplant* 2003;13:265–273.
113. DeVita MA, Brooks MM, Zawistowski C, et al. Donors after cardiac death: validation of identification criteria (DVIC) study for predictors of rapid death. *Am J Transplant* 2008;8:432–441.
114. Cypel M, Sato M, Yildirim E, et al. Initial experience with lung donation after cardiocirculatory death in Canada. *J Heart Lung Transplant* 2009;28:753–758.
115. Snell GI, Levvey BJ, Oto T, et al. Early lung transplantation success utilizing controlled donation after cardiac death donors. *Am J Transplant* 2008;8:1282–1289.
116. Okazaki M, Date H, Inokawa H, et al. Optimal time for post-mortem heparinization in canine lung transplantation with non-heart-beating donors. *J Heart Lung Transplant* 2006;25:454–460.
117. Akasaka S, Nishi H, Aoe M, et al. The effects of recombinant tissue-type plasminogen activator (rt-PA) on canine cadaver lung transplantation. *Surg Today* 1999;29:747–754.
118. Keshava HB, Farver CF, Brown CR, et al. Timing of heparin and thrombus formation in donor lungs after cardiac death. *Thorac Cardiovasc Surg* 2013;61:246–250.
119. Van De Wauwer C, Neyrinck AP, Geudens N, et al. Retrograde flush following warm ischemia in the non-heart-beating donor results in superior graft performance at reperfusion. *J Surg Res* 2009;154:118–125.
120. Sanchez PG, Bittle GJ, Williams K, et al. Ex vivo lung evaluation of prearrest heparinization in donation after cardiac death. *Ann Surg* 2013;257:534–541.
121. Brown CR, Shafii AE, Farver CF, et al. Pathologic correlates of heparin-free donation after cardiac death in lung transplantation. *J Thorac Cardiovasc Surg* 2013;145:e49–e50.
122. D'Alessandro AM, Hoffmann RM, Knechtle SJ, et al. Successful extrarenal transplantation from non-heart-beating donors. *Transplantation* 1995;59:977–982.
123. Mason DP, Brown CR, Murthy SC, et al. Growing single-center experience with lung transplantation using donation after cardiac death. *Ann Thorac Surg* 2012;94:406–411; discussion 411–412.
124. Zych B, Popov AF, Amrani M, et al. Lungs from donation after circulatory death donors: an alternative source to brain-dead donors? Midterm results at a single institution. *Eur J Cardiothorac Surg* 2012;42:542–549.
125. De Oliveira NC, Osaki S, Maloney JD, et al. Lung transplantation with donation after cardiac death donors: long-term follow-up in a single center. *J Thorac Cardiovasc Surg* 2010;139:1306–1315.
126. Puri V, Scavuzzo M, Guthrie T, et al. Lung transplantation and donation after cardiac death: a single center experience. *Ann Thorac Surg* 2009;88:1609–1614; discussion

1614–1615.
127. Van De Wauwer C, Verschuuren EA, van der Bij W, et al. The use of non-heart-beating lung donors category III can increase the donor pool. *Eur J Cardiothorac Surg* 2011;39:e175–e180; discussion e180.
128. Gomez-de-Antonio D, Campo-Canaveral JL, Crowley S, et al. Clinical lung transplantation from uncontrolled non-heart-beating donors revisited. *J Heart Lung Transplant* 2012;31:349–353.
129. Gerbase MW, Spiliopoulos A, Rochat T, et al. Health-related quality of life following single or bilateral lung transplantation: a 7-year comparison to functional outcome. *Chest* 2005;128:1371–1378.
130. Neurohr C, Huppmann P, Thum D, et al. Potential functional and survival benefit of double over single lung transplantation for selected patients with idiopathic pulmonary fibrosis. *Transpl Int* 2010;23:887–896.
131. Kaiser LR, Cooper JD, Trulock EP, et al. The evolution of single lung transplantation for emphysema. The Washington University Lung Transplant Group. *J Thorac Cardiovasc Surg* 1991;102:333–339; discussion 339–341.
132. Pochettino A, Kotloff RM, Rosengard BR, et al. Bilateral versus single lung transplantation for chronic obstructive pulmonary disease: intermediate-term results. *Ann Thorac Surg* 2000;70:1813–1818; discussion 1818–1819.
133. Meyer DM, Edwards LB, Torres F, et al. Impact of recipient age and procedure type on survival after lung transplantation for pulmonary fibrosis. *Ann Thorac Surg* 2005;79:950–957; discussion 957–958.
134. Chang AC, Chan KM, Lonigro RJ, et al. Surgical patient outcomes after the increased use of bilateral lung transplantation. *J Thorac Cardiovasc Surg* 2007;133:532–540.
135. Meyers BF, Lynch JP, Trulock EP, et al. Single versus bilateral lung transplantation for idiopathic pulmonary fibrosis: a ten-year institutional experience. *J Thorac Cardiovasc Surg* 2000;120:99–107.
136. Meyer DM, Bennett LE, Novick RJ, et al. Single vs bilateral, sequential lung transplantation for end-stage emphysema: influence of recipient age on survival and secondary end-points. *J Heart Lung Transplant* 2001;20:935–941.
137. Minambres E, Llorca J, Suberviola B, et al. Early outcome after single vs bilateral lung transplantation in older recipients. *Transplant Proc* 2008;40:3088–3089.
138. Gammie JS, Keenan RJ, Pham SM, et al. Single- versus double-lung transplantation for pulmonary hypertension. *J Thorac Cardiovasc Surg* 1998;115:397–402; discussion 402–403.
139. Pasque MK, Cooper JD, Kaiser LR, et al. Improved technique for bilateral lung transplantation: rationale and initial clinical experience. *Ann Thorac Surg* 1990;49:785–791.
140. Toyoda Y, Thacker J, Santos R, et al. Long-term outcome of lung and heart-lung transplantation for idiopathic pulmonary arterial hypertension. *Ann Thorac Surg*

2008;86:1116–1122.
141. Mason DP, Rajeswaran J, Murthy SC, et al. Spirometry after transplantation: how much better are two lungs than one? *Ann Thorac Surg* 2008;85:1193–1201, 1201.e1–e2.
142. Thabut G, Christie JD, Ravaud P, et al. Survival after bilateral versus single lung transplantation for patients with chronic obstructive pulmonary disease: a retrospective analysis of registry data. *Lancet* 2008;371:744–751.
143. Nwakanma LU, Simpkins CE, Williams JA, et al. Impact of bilateral versus single lung transplantation on survival in recipients 60 years of age and older: analysis of United Network for Organ Sharing database. *J Thorac Cardiovasc Surg* 2007;133:541–547.
144. Force SD, Kilgo P, Neujahr DC, et al. Bilateral lung transplantation offers better long-term survival, compared with single-lung transplantation, for younger patients with idiopathic pulmonary fibrosis. *Ann Thorac Surg* 2011;91:244–249.
145. Anyanwu AC, McGuire A, Rogers CA, et al. Assessment of quality of life in lung transplantation using a simple generic tool. *Thorax* 2001;56:218–222.
146. Weiss ES, Allen JG, Merlo CA, et al. Survival after single versus bilateral lung transplantation for high-risk patients with pulmonary fibrosis. *Ann Thorac Surg* 2009;88:1616–1625; discussion 1625–1626.
147. Black MC, Trivedi J, Schumer EM, et al. Double lung transplants have significantly improved survival compared with single lung transplants in high lung allocation score patients. *Ann Thorac Surg* 2014; 98:1737–1741.
148. Hadjiliadis D, Davis RD, Palmer SM. Is transplant operation important in determining posttransplant risk of bronchiolitis obliterans syndrome in lung transplant recipients? *Chest* 2002;122:1168–1175.
149. Garfein ES, Ginsberg ME, Gorenstein L, et al. Superiority of end-to-end versus telescoped bronchial anastomosis in single lung transplantation for pulmonary emphysema. *J Thorac Cardiovasc Surg* 2001;121:149–154.
150. Schroder C, Scholl F, Daon E, et al. A modified bronchial anastomosis technique for lung transplantation. *Ann Thorac Surg* 2003;75:1697–1704.
151. Baudet EM, Dromer C, Dubrez J, et al. Intermediate-term results after en bloc double-lung transplantation with bronchial arterial revascularization. Bordeaux Lung and Heart-Lung Transplant Group. *J Thorac Cardiovasc Surg* 1996;112:1292–1299; discussion 1299–1300.
152. Pettersson G, Norgaard MA, Arendrup H, et al. Direct bronchial artery revascularization and en bloc double lung transplantation–surgical techniques and early outcome. *J Heart Lung Transplant* 1997;16:320–333.
153. Sundset A, Tadjkarimi S, Khaghani A, et al. Human en bloc double-lung transplantation: bronchial artery revascularization improves airway perfusion. *Ann Thorac Surg* 1997;63:790–795.

154. Lau CL, Patterson GA. Technical considerations in lung transplantation. *Chest Surg Clin N Am.* 2003;13:463–483.
155. Lau CL, Hoganson DM, Meyers BF, et al. Use of an apical heart suction device for exposure in lung transplantation. *Ann Thorac Surg* 2006;81:1524–1525.
156. Hachem RR, Yusen RD, Chakinala MM, et al. A randomized controlled trial of tacrolimus versus cyclosporine after lung transplantation. *J Heart Lung Transplant* 2007;26:1012–1018.
157. Mullen JC, Oreopoulos A, Lien DC, et al. A randomized, controlled trial of daclizumab vs anti-thymocyte globulin induction for lung transplantation. *J Heart Lung Transplant* 2007;26:504–510.
158. Burton CM, Andersen CB, Jensen AS, et al. The incidence of acute cellular rejection after lung transplantation: a comparative study of anti-thymocyte globulin and daclizumab. *J Heart Lung Transplant* 2006;25:638–647.
159. Hachem RR, Chakinala MM, Yusen RD, et al. A comparison of basiliximab and anti-thymocyte globulin as induction agents after lung transplantation. *J Heart Lung Transplant* 2005;24:1320–1326.
160. Arcasoy SM, Kotloff RM. Lung transplantation. *N Eng J Med* 1999;340:1081–1091.
161. Amital A, Shitrit D, Raviv Y, et al. Development of malignancy following lung transplantation. *Transplantation* 2006;81:547–551.
162. Christie JD, Kotloff RM, Ahya VN, et al. The effect of primary graft dysfunction on survival after lung transplantation. *Am J Respir Crit Care Med* 2005;171:1312–1316.
163. Novick RJ, Stitt LW, Al-Kattan K, et al. Pulmonary retransplantation: predictors of graft function and survival in 230 patients. Pulmonary Retransplant Registry. *Ann Thorac Surg* 1998;65:227–234.
164. Christie JD, Carby M, Bag R, et al. Report of the ISHLT Working Group on Primary Lung Graft Dysfunction part II: definition. A consensus statement of the International Society for Heart and Lung Transplantation. *J Heart Lung Transplant* 2005;24:1454–1459.
165. Prekker ME, Nath DS, Walker AR, et al. Validation of the proposed International Society for Heart and Lung Transplantation grading system for primary graft dysfunction after lung transplantation. *J Heart Lung Transplant* 2006;25:371–378.
166. Whitson BA, Prekker ME, Herrington CS, et al. Primary graft dysfunction and long-term pulmonary function after lung transplantation. *J Heart Lung Transplant* 2007;26:1004–1011.
167. Low DE, Kaiser LR, Haydock DA, et al. The donor lung: infectious and pathologic factors affecting outcome in lung transplantation. *J Thorac Cardiovasc Surg* 1993;106:614–621.
168. Ettinger NA, Bailey TC, Trulock EP, et al. Cytomegalovirus infection and pneumonitis. Impact after isolated lung transplantation. Washington University Lung Transplant Group. *Am Rev Respir Dis* 1993;147:1017–1023.

169. Novick RJ, Schafers HJ, Stitt L, et al. Recurrence of obliterative bronchiolitis and determinants of outcome in 139 pulmonary retransplant recipients. *J Thorac Cardiovasc Surg* 1995;110:1402–1413; discussion 1413–1414.
170. Russo MJ, Sternberg DI, Hong KN, et al. Postlung transplant survival is equivalent regardless of cytomegalovirus match status. *Ann Thorac Surg* 2007;84:1129–1134; discussion 1134–1135.
171. Monforte V, Lopez C, Santos F, et al. A multicenter study of valganciclovir prophylaxis up to day 120 in CMV-seropositive lung transplant recipients. *Am J Transplant* 2009;9:1134–1141.
172. Sole A, Salavert M. Fungal infections after lung transplantation. *Transplant Rev* 2008;22:89–104.
173. Husain S, Zaldonis D, Kusne S, et al. Variation in antifungal prophylaxis strategies in lung transplantation. *Transpl Infect Dis* 2006;8:213–218.
174. Santacruz JF, Mehta AC. Airway complications and management after lung transplantation: ischemia, dehiscence, and stenosis. *Proc Am Thorac Soc* 2009;6:79–93.
175. Shofer SL, Wahidi MM, Davis WA, et al. Significance of and risk factors for the development of central airway stenosis after lung transplantation. *Am J Transplant* 2013;13:383–389.
176. Dutau H, Vandemoortele T, Laroumagne S, et al. A new endoscopic standardized grading system for macroscopic central airway complications following lung transplantation: the MDS classification. *Eur J Cardiothorac Surg* 2014;45:e33–e38.
177. Bloom RD, Goldberg LR, Wang AY, et al. An overview of solid organ transplantation. *Clin Chest Med* 2005;26:529–543, v.
178. Schafers HJ, Wagner TO, Demertzis S, et al. Preoperative corticosteroids. A contraindication to lung transplantation? *Chest* 1992;102:1522–1525.
179. Groetzner J, Kur F, Spelsberg F, et al. Airway anastomosis complications in de novo lung transplantation with sirolimus-based immunosuppression. *J Heart Lung Transplant* 2004;23:632–638.
180. King-Biggs MB, Dunitz JM, Park SJ, et al. Airway anastomotic dehiscence associated with use of sirolimus immediately after lung transplantation. *Transplantation* 2003;75:1437–1443.
181. Garfein ES, McGregor CC, Galantowicz ME, et al. Deleterious effects of telescoped bronchial anastomosis in single and bilateral lung transplantation. *Ann Transplant* 2000;5:5–11.
182. Schmid RA, Boehler A, Speich R, et al. Bronchial anastomotic complications following lung transplantation: still a major cause of morbidity? *Eur Respir J* 1997;10:2872–2875.
183. Murthy SC, Blackstone EH, Gildea TR, et al. Impact of anastomotic airway complications after lung transplantation. *Ann Thorac Surg* 2007;84:401–409,

409.e401–e404.
184. Van De Wauwer C, Van Raemdonck D, Verleden GM, et al. Risk factors for airway complications within the first year after lung transplantation. *Eur J Cardiothorac Surg* 2007;31:703–710.
185. Shennib H, Massard G. Airway complications in lung transplantation. *Ann Thorac Surg* 1994;57:506–511.
186. Mulligan MS. Endoscopic management of airway complications after lung transplantation. *Chest Surg Clin N Am* 2001;11:907–915.
187. Murthy SC, Gildea TR, Machuzak MS. Anastomotic airway complications after lung transplantation. *Curr Opin Organ Transplant* 2010;15:582–587.
188. Hasegawa T, Iacono AT, Orons PD, et al. Segmental nonanastomotic bronchial stenosis after lung transplantation. *Ann Thorac Surg* 2000;69:1020–1024.
189. Marulli G, Loy M, Rizzardi G, et al. Surgical treatment of posttransplant bronchial stenoses: case reports. *Transplant Proc* 2007;39:1973–1975.
190. Herrera JM, McNeil KD, Higgins RS, et al. Airway complications after lung transplantation: treatment and long-term outcome. *Ann Thorac Surg* 2001;71:989–993; discussion 993–984.
191. Usuda K, Gildea TR, Pandya C, et al. Bronchial dehiscence. *J Bronchology Interv Pulmonol* 2005;12:164–165.
192. Castleberry AW, Worni M, Kuchibhatla M, et al. A comparative analysis of bronchial stricture after lung transplantation in recipients with and without early acute rejection. *Ann Thorac Surg* 2013;96:1008–1017; discussion 1017–1008.
193. Kshettry VR, Kroshus TJ, Hertz MI, et al. Early and late airway complications after lung transplantation: incidence and management. *Ann Thorac Surg* 1997;63:1576–1583.
194. Garg K, Zamora MR, Tuder R, et al. Lung transplantation: indications, donor and recipient selection, and imaging of complications. *Radiographics* 1996;16:355–367.
195. Quint LE, Whyte RI, Kazerooni EA, et al. Stenosis of the central airways: evaluation by using helical CT with multiplanar reconstructions. *Radiology* 1995;194:871–877.
196. Chhajed PN, Malouf MA, Tamm M, et al. Interventional bronchoscopy for the management of airway complications following lung transplantation. *Chest* 2001;120:1894–1899.
197. De Gracia J, Culebras M, Alvarez A, et al. Bronchoscopic balloon dilatation in the management of bronchial stenosis following lung transplantation. *Respir Med* 2007;101:27–33.
198. Brodeur I, Goulet I, Tremblay CS, et al. Regulation of the Fanconi anemia group C protein through proteolytic modification. *J Biol Chem* 2004;279:4713–4720.
199. Erard AC, Monnier P, Spiliopoulos A, et al. Mitomycin C for control of recurrent bronchial stenosis: a case report. *Chest* 2001;120:2103–2105.
200. Penafiel A, Lee P, Hsu A, et al. Topical mitomycin-C for obstructing endobronchial

granuloma. *Ann Thorac Surg* 2006;82:e22–e23.

201. Saad CP, Ghamande SA, Minai OA, et al. The role of self-expandable metallic stents for the treatment of airway complications after lung transplantation. *Transplantation* 2003;75:1532–1538.
202. Madden BP, Loke TK, Sheth AC. Do expandable metallic airway stents have a role in the management of patients with benign tracheobronchial disease? *Ann Thorac Surg* 2006;82:274–278.
203. Murgu SD, Colt HG. Complications of silicone stent insertion in patients with expiratory central airway collapse. *Ann Thorac Surg* 2007;84:1870–1877.
204. Gildea TR, Murthy SC, Sahoo D, et al. Performance of a self-expanding silicone stent in palliation of benign airway conditions. *Chest* 2006;130:1419–1423.
205. Bolliger CT, Sutedja TG, Strausz J, et al. Therapeutic bronchoscopy with immediate effect: laser, electrocautery, argon plasma coagulation and stents. *Eur Respir J* 2006;27:1258–1271.
206. Kapoor BS, May B, Panu N, et al. Endobronchial stent placement for the management of airway complications after lung transplantation. *J Vasc Interv Radiol* 2007;18:629–632.
207. Grosu HB, Eapen GA, Morice RC, et al. Stents are associated with increased risk of respiratory infections in patients undergoing airway interventions for malignant airways disease. *Chest* 2013;144:441–449.
208. Mughal MM, Gildea TR, Murthy S, et al. Short-term deployment of self-expanding metallic stents facilitates healing of bronchial dehiscence. *Am J Respir Crit Care Med* 2005;172:768–771.
209. Thistlethwaite PA, Yung G, Kemp A, et al. Airway stenoses after lung transplantation: incidence, management, and outcome. *J Thorac Cardiovasc Surg* 2008;136:1569–1575.
210. Schreinemakers HH, Weder W, Miyoshi S, et al. Direct revascularization of bronchial arteries for lung transplantation: an anatomical study. *Ann Thorac Surg* 1990;49:44–53; discussion 53–54.
211. Couraud L, Baudet E, Nashef SA, et al. Lung transplantation with bronchial revascularisation. Surgical anatomy, operative technique and early results. *Eur J Cardiothorac Surg* 1992;6:490–495.
212. Daly RC, McGregor CG. Routine immediate direct bronchial artery revascularization for single-lung transplantation. *Ann Thorac Surg* 1994;57:1446–1452.
213. Daly RC, Tadjkarimi S, Khaghani A, et al. Successful double-lung transplantation with direct bronchial artery revascularization. *Ann Thorac Surg* 1993;56:885–892.
214. Pettersson G, Arendrup H, Mortensen SA, et al. Early experience of double-lung transplantation with bronchial artery revascularization using mammary artery. *Eur J Cardiothorac Surg* 1994;8:520–524.
215. Burton CM, Milman N, Carlsen J, et al. The Copenhagen National Lung Transplant

Group: survival after single lung, double lung, and heart-lung transplantation. *J Heart Lung Transplant* 2005;24:1834–1843.

216. Pettersson GB, Karam K, Thuita L, et al. Comparative study of bronchial artery revascularization in lung transplantation. *J Thorac Cardiovasc Surg* 2013;146:894–900.e893.
217. Sato M, Keshavjee S. Bronchiolitis obliterans syndrome: alloimmune-dependent and -independent injury with aberrant tissue remodeling. *Semin Thorac Cardiovasc Surg* 2008;20:173–182.
218. Chalermskulrat W, Neuringer IP, Schmitz JL, et al. Human leukocyte antigen mismatches predispose to the severity of bronchiolitis obliterans syndrome after lung transplantation. *Chest* 2003;123:1825–1831.
219. Keller CA, Cagle PT, Brown RW, et al. Bronchiolitis obliterans in recipients of single, double, and heart-lung transplantation. *Chest* 1995;107:973–980.
220. Hartwig MG, Anderson DJ, Onaitis MW, et al. Fundoplication after lung transplantation prevents the allograft dysfunction associated with reflux. *Ann Thorac Sur* 2011;92:462–468; discussion 468–469.
221. Daud SA, Yusen RD, Meyers BF, et al. Impact of immediate primary lung allograft dysfunction on bronchiolitis obliterans syndrome. *Am J Respir Crit Care Med* 2007;175:507–513.
222. Todd JL, Jain R, Pavlisko EN, et al. Impact of forced vital capacity loss on survival after the onset of chronic lung allograft dysfunction. *Am J Respir Crit Care Med* 2014;189:159–166.
223. Sato M, Waddell TK, Wagnetz U, et al. Restrictive allograft syndrome (RAS): a novel form of chronic lung allograft dysfunction. *J Heart Lung Transplant* 2011;30:735–742.
224. Young LR, Hadjiliadis D, Davis RD, et al. Lung transplantation exacerbates gastroesophageal reflux disease. *Chest* 2003;124:1689–1693.
225. Davis CS, Shankaran V, Kovacs EJ, et al. Gastroesophageal reflux disease after lung transplantation: pathophysiology and implications for treatment. *Surgery* 2010;148:737–744; discussion 744–735.
226. Fisichella PM, Davis CS, Shankaran V, et al. The prevalence and extent of gastroesophageal reflux disease correlates to the type of lung transplantation. *Surg Laparosc Endosc Percutan Tech* 2012;22:46–51.
227. Mendez BM, Davis CS, Weber C, et al. Gastroesophageal reflux disease in lung transplant patients with cystic fibrosis. *Am J Surg* 2012;204:e21–e26.
228. Gasper WJ, Sweet MP, Golden JA, et al. Lung transplantation in patients with connective tissue disorders and esophageal dysmotility. *Dis Esophagus* 2008;21:650–655.
229. Ward C, Forrest IA, Brownlee IA, et al. Pepsin like activity in bronchoalveolar lavage fluid is suggestive of gastric aspiration in lung allografts. *Thorax* 2005;60:872–874.
230. Stovold R, Forrest IA, Corris PA, et al. Pepsin, a biomarker of gastric aspiration in

lung allografts: a putative association with rejection. *Am J Respir Crit Care Med* 2007;175:1298–1303.

231. Shafi MA, Pasricha PJ. Post-surgical and obstructive gastroparesis. *Curr Gastroenterol Rep* 2007;9:280–285.
232. Berkowitz N, Schulman LL, McGregor C, et al. Gastroparesis after lung transplantation. Potential role in postoperative respiratory complications. *Chest* 1995;108:1602–1607.
233. Robertson AG, Krishnan A, Ward C, et al. Anti-reflux surgery in lung transplant recipients: outcomes and effects on quality of life. *Eur Respir J* 2012;39:691–697.
234. D'Ovidio F, Mura M, Ridsdale R, et al. The effect of reflux and bile acid aspiration on the lung allograft and its surfactant and innate immunity molecules SP-A and SP-D. *Am J Transplant* 2006;6:1930–1938.
235. Fisichella PM, Davis CS, Lundberg PW, et al. The protective role of laparoscopic antireflux surgery against aspiration of pepsin after lung transplantation. *Surgery* 2011;150:598–606.
236. Hadjiliadis D, Duane Davis R, Steele MP, et al. Gastroesophageal reflux disease in lung transplant recipients. *Clin Transplant* 2003;17:363–368.
237. Li B, Hartwig MG, Appel JZ, et al. Chronic aspiration of gastric fluid induces the development of obliterative bronchiolitis in rat lung transplants. *Am J Transplant* 2008;8:1614–1621.
238. Meltzer AJ, Weiss MJ, Veillette GR, et al. Repetitive gastric aspiration leads to augmented indirect allorecognition after lung transplantation in miniature swine. *Transplantation* 2008;86:1824–1829.
239. D'Ovidio F, Mura M, Tsang M, et al. Bile acid aspiration and the development of bronchiolitis obliterans after lung transplantation. *J Thorac Cardiovasc Surg* 2005;129:1144–1152.
240. Neujahr DC, Uppal K, Force SD, et al. Bile acid aspiration associated with lung chemical profile linked to other biomarkers of injury after lung transplantation. *Am J Transplant* 2014;14:841–848.
241. Shah N, Force SD, Mitchell PO, et al. Gastroesophageal reflux disease is associated with an increased rate of acute rejection in lung transplant allografts. *Transplant Proc* 2010;42:2702–2706.
242. Mason DP, Little SG, Nowicki ER, et al. Temporal pattern of transfusion and its relation to rejection after lung transplantation. *J Heart Lung Transplant* 2009;28:558–563.
243. Blondeau K, Mertens V, Vanaudenaerde BA, et al. Gastro-oesophageal reflux and gastric aspiration in lung transplant patients with or without chronic rejection. *Eur Respir J* 2008;31:707–713.
244. Reder NP, Davis CS, Kovacs EJ, et al. The diagnostic value of gastroesophageal reflux disease (GERD) symptoms and detection of pepsin and bile acids in

bronchoalveolar lavage fluid and exhaled breath condensate for identifying lung transplantation patients with GERD-induced aspiration. *Surg Endosc* 2014;28:1794–1800.

245. Tang T, Chang JC, Xie A, et al. Aspiration of gastric fluid in pulmonary allografts: effect of pH. *J Surg Res* 2013;181:e31–e38.
246. Theisen J, Nehra D, Citron D, et al. Suppression of gastric acid secretion in patients with gastroesophageal reflux disease results in gastric bacterial overgrowth and deconjugation of bile acids. *J Gastrointest Surg* 2000;4:50–54.
247. Raviv Y, D'Ovidio F, Pierre A, et al. Prevalence of gastroparesis before and after lung transplantation and its association with lung allograft outcomes. *Clin Transplant* 2012;26:133–142.
248. Abbassi-Ghadi N, Kumar S, Cheung B, et al. Anti-reflux surgery for lung transplant recipients in the presence of impedance-detected duodenogastroesophageal reflux and bronchiolitis obliterans syndrome: a study of efficacy and safety. *J Heart Lung Transplant* 2013;32:588–595.
249. Fisichella PM, Davis CS, Gagermeier J, et al. Laparoscopic antireflux surgery for gastroesophageal reflux disease after lung transplantation. *J Surg Res* 2011;170:e279–e286.
250. Neujahr DC, Mohammed A, Ulukpo O, et al. Surgical correction of gastroesophageal reflux in lung transplant patients is associated with decreased effector CD8 cells in lung lavages: a case series. *Chest* 2010;138:937–943.
251. Fisichella PM, Davis CS, Lowery E, et al. Pulmonary immune changes early after laparoscopic antireflux surgery in lung transplant patients with gastroesophageal reflux disease. *J Surg Res* 2012;177:e65–e73.
252. Cantu E, 3rd, Appel JZ, 3rd, Hartwig MG, et al. J. Maxwell Chamberlain Memorial Paper. Early fundoplication prevents chronic allograft dysfunction in patients with gastroesophageal reflux disease. *Ann Thorac Surg* 2004;78:1142–1151; discussion 1142–1151.
253. Ott HC, Clippinger B, Conrad C, et al. Regeneration and orthotopic transplantation of a bioartificial lung. *Nat Med* 2010;16:927–933.
254. Petersen TH, Calle EA, Zhao L, et al. Tissue-engineered lungs for in vivo implantation. *Science* 2010;329:538–541.

Chapter 40

Pancreas and Islet Transplantation

Randall S. Sung

Key Points

1. The Diabetes Control and Complications Trial (DCCT) demonstrated that tight control of blood glucose and minimization of hemoglobin A1C delays the progression of secondary complications of diabetes.
2. Recipients with functioning pancreas transplants have normal glycemic control without the need for exogenous insulin, and pancreas transplantation has a beneficial impact on diabetic complications.
3. Pancreas graft survival rates are 90% at 1 year.
4. Most pancreas transplants are performed in patients with end-stage renal disease (ESRD), either concomitant with or following a kidney transplant.
5. In general, eligibility criteria for pancreas transplantation are more stringent than for kidney transplantation alone.
6. Pancreas transplant outcome is dependent on the careful selection of donors and on meticulous pancreas procurement technique.
7. Immunosuppression for pancreas transplantation is similar to that for kidney transplantation.
8. In contrast to kidney transplants, the effect of a pancreas transplant on patient survival is probably only modest.
9. Islet transplantation does not require an operative procedure.
10. Although early outcomes are excellent at major islet centers, long-term rates of insulin independence are worse than whole-pancreas transplants, but continue to improve.

Diabetes mellitus is a spectrum of impaired glucose tolerance that ranges from gestational glucose intolerance to severe hyperglycemia and ketoacidosis. Diabetes, which affects approximately 8% of the U.S. population, can be divided into two major classifications. Type 1, previously referred to as insulin-dependent diabetes, is an autoimmune disease characterized by the eventual loss of all pancreatic β-cell function. Type 2 diabetes, previously referred to as non–insulin-dependent diabetes or adult-onset diabetes, characteristically presents in obese patients over age 40.[1] Many of these individuals eventually require insulin therapy. The incidence of type 2 diabetes is increasing as the prevalence of obesity increases, especially in younger age groups. The annual percentage

change for age-adjusted prevalence and incidence of diagnosed diabetes did not change significantly during the 1980s, but increased sharply each year during 1990 to 2008 before leveling off with no significant change during 2008–2012.[2] Analyses of nationally representative data from 1980 to 2012 suggest a doubling of the incidence and prevalence of diabetes during 1990–2008, and a plateauing between 2008 and 2012. There appear to be continued increases in the prevalence or incidence of diabetes among subgroups, including non-Hispanic black and Hispanic subpopulations and those with a high school education or less.

While the mean age of onset is in the early teenage years, the disease may present as early as the first year of life. Type 1 diabetes afflicts approximately one in every 400 to 500 children and adolescents.[3] Patients may present as late as the fourth decade of life, and these patients may be misclassified as type 2 diabetics, despite clearly possessing the physiology of type 1 diabetes. The disease classically presents in a lean patient with polyuria, polydipsia, and polyphagia. It may present at the time of a concurrent illness. While there may be a brief “honeymoon” period after presentation where insulin is not required, exogenous insulin is always required to replace that lost by the complete destruction of β-cell mass. While hyperglycemic episodes from poorly controlled diabetes, or hypoglycemic events from insulin, may be life threatening, the major morbidity of type 1 diabetes stems from the myriad long-term manifestations of the disease, particularly those that are due to accelerated atherosclerosis.

PATHOPHYSIOLOGY

The classic pathophysiology of diabetes is that of insulin secretory failure in type 1 diabetes and peripheral insulin resistance in patients with type 2 diabetes. The etiology, epidemiology, and pathogenesis of diabetes are much more complex than is reflected in early characterizations of the disease. Type 1 diabetes is classically described as an autoimmune disorder manifest by destruction of β-cells, with proinsulin being the most likely primary target.[4] Although there are rare monogenic, immune-mediated forms of type 1 diabetes, the common form is thought to be determined by multiple genetic and environmental factors. The concordance for type 1 diabetes in monozygotic twins is less than 100%, and although type 1 diabetes aggregates in some families, it does not segregate with any clear mode of inheritance.[5]

There is multigenic susceptibility to type 1 diabetes. Genes within the HLA region, especially those that encode antigen-presenting molecules, confer the greatest part of the genetic risk of type 1 diabetes. The likelihood that these many genes may individually only have weak effects make them more difficult to identify precisely, and may explain the heterogeneity of inheritance of type 1 diabetes. This genetic susceptibility background is thought to interact with environmental triggers, perhaps infectious, that lead to autoimmunity and insulitis, the characteristic pathologic lesion of type 1 diabetes, although definitive proof of these triggers is lacking.

The incidence of type 1 diabetes has been progressively increasing during the past several decades, particularly among children younger than 5 years. In children at genetic risk, diabetes-related autoantibodies appear, followed by the evolution of metabolic abnormalities and the eventual clinical appearance of the disease. If individuals identified by genetic markers subsequently undergo seroconversion and develop two or more diabetes-related autoantibodies, their risk of progression to type 1 diabetes is 75% over 10 years and appears to be almost certain over 20 years.[6] Attempts at primary prevention before seroconversion, and secondary prevention in those with diabetes-related autoantibodies, have not been successful.[7] The interventions evaluated to date have been very low risk since they are designed to be used in at-risk individuals who may or may not progress to type 1 diabetes.

Mucosal tolerance has been exploited in secondary prevention studies using nasal insulin and in secondary prevention and recent-onset type 1 diabetes studies using oral insulin.[8] However, these studies have not been successful in altering the course of the disease. In the Diabetes Prevention Trial–Type 1 (DPT-1), a secondary prevention study of oral insulin, those with high levels of insulin autoantibodies at baseline had a projected 4.5- to 5-year delay in the development of clinical diabetes. A subsequent analysis showed continued beneficial effects even after oral insulin was discontinued.

In type 2 diabetes, while β-cell hypersecretion initially may exist, ultimately loss of β-cell mass ensues. β-Cell apoptosis is mediated by glucotoxicity from insulin resistance, and is exacerbated by fatty acids, lipoproteins, leptins, and cytokines, all of which are elevated in type 2 diabetes and obesity.[9] Because of peripheral insulin resistance, many patients require insulin in amounts that exceed one unit per kilogram, far greater than

typically required by type 1 diabetics.

The observation that type 1 and type 2 diabetes frequently cooccur in the same family has raised the possibility that they are opposite ends of the same disease spectrum, and ample evidence suggests the two are more similar than initially believed.[10,11] Families with mixed diabetes histories tend to have an intermediate diabetes phenotype: insulin resistance in type 1 and lower BMI and C-peptide concentrations in type 2 patients. β-Cell destruction is common to both types, and obesity and insulin resistance have both been shown to be risk factors for childhood type 1 as well as type 2 diabetes. The "accelerator hypothesis" of diabetes proposes three determinants of disease in all types of diabetes: the intrinsic rate of β-cell apoptosis, insulin resistance, and autoimmunity (which would apply only to a subset). Genetic studies suggest there may be a common predisposition. However, the cytokines, signal transduction pathways, and other soluble mediators of apoptosis are quite different between the insulitis of type 1 diabetes and the lipotoxic or glucotoxic processes of type 2 diabetes, and thus at minimum represent distinct mechanisms of β-cell destruction.[12]

The relatively recent discovery of the replicative potential of a variety of adult tissue types, and their roles in the pathogenesis of disease, has relevance to the pathogenesis of diabetes. In such a model, diabetes occurs due to a failure of regeneration of β-cells, and individual variation in the ability to regenerate β-cells is an important determinant of diabetes development. This hypothesis is partially supported by the finding of associations of type 2 diabetes with genes having identified roles in cellular development. While it is broadly agreed that failure of β-cell replication is an important contributor to diabetes development, increased susceptibility of replicating β-cells to apoptosis in a proapoptotic environment may also lead to loss of β-cell mass. There is also evidence that deficits of β-cell secretion are as important as those of replication. Furthermore, the range of β-cell mass in adult diabetic and nondiabetic humans is very wide, and exceeds the apparent capacity for expansion of β-cell mass in response to regenerative stimuli. Thus it appears more likely that insufficient growth of β-cell mass during development may be more likely to have a role in the predisposition to diabetes than specific deficits in regeneration.[13]

Alternatively, β-cell dedifferentiation, rather than death, may be the mechanism responsible for β-cell failure in type 2 diabetes.[14] When normal β-cells are challenged by mild hyperglycemia or insulin resistance, they produce and secrete more insulin, thus maintaining euglycemia. Current thinking suggests that oxidative stress and/or endoplasmic-reticulum stress results in β-cell dysfunction, leading to increased secretion of incompletely processed proinsulin, which may trigger apoptosis. Stressed β-cells may undergo dedifferentiation, decreasing expression of β-cell–specific genes, including the enzyme that processes proinsulin; this may explain increased proinsulin secretion in type 2 diabetes. Dedifferentiation may also promote expression of embryonic progenitor-cell markers, and these cells may later secrete non–β-cell hormones such as somatostatin and glucagon.

SECONDARY COMPLICATIONS OF DIABETES

Diabetes mellitus is responsible for tens of thousands of deaths each year in the United States. The high incidence of cardiovascular complications in diabetics is primarily responsible for the twofold increase in the risk of death in diabetics compared with those without diabetes.[2] Clinical complications of diabetes include end-stage renal disease (ESRD), retinopathy, peripheral vascular disease, coronary artery disease, and neuropathy. Diabetic nephropathy is responsible for nearly half of all cases of ESRD; diabetes is also the leading cause of blindness and amputations in the United States.[15] In 2012, 1 in 5 healthcare dollars was spent to support the care of patients with diabetes at a total estimated cost of $245 billion.[16]

Improvements in diabetes care have reduced the long-term impact to some extent. Rates of all five major diabetes complications (acute myocardial infarction, hyperglycemic crisis, stroke, amputations, and ESRD) declined between 1990 and 2010, with the smallest decline in end-stage renal disease. However, when expressed as rates for the overall population, in which a change in prevalence also affects complication rates, there was a decline in rates of acute myocardial infarction and death from hyperglycemic crisis, but not in rates of amputation, stroke, or ESRD. Thus, while rates of diabetes-related complications have declined substantially in the past two decades, a large burden of disease persists because of the continued increase in the prevalence of diabetes.[17]

While diabetic complications have a multifactorial etiology, they are ultimately secondary to structural alterations in nerves, blood vessels, and connective tissue. Excess glucose is converted to sorbitol by aldose reductase, leading to the reduction of cellular content of myoinositol, abnormal phosphoinositide metabolism, and reduction in Na^+-K^+-ATPase activity. In experimental animals, aldose reductase inhibitors prevent diabetic neuropathy, cataracts and retinopathy.[18] The accumulation of advanced glycosylation end products (AGEs), due to abnormal nonenzymatic glycosylation of proteins, and extensive crosslinking of these proteins, is likely to be pathogenic.[19] Ligation of endothelial cell receptors by AGEs results in the release of proinflammatory cytokines and activation of the coagulation cascade. Microangiopathy is characterized by thickening of capillary basement membranes, which increases with the duration of disease, and altered capillary permeability.

1 The Diabetes Control and Complications Trial (DCCT) demonstrated that tight control of blood glucose prevents and delays the progression of secondary complications of diabetes.[20,21] This study, in which patients with type 1 diabetes were randomized to conventional treatment with one or two doses of daily insulin versus intensive treatment with three or more injections per day, demonstrated a dramatic reduction in the risk of progression of retinopathy, microalbuminuria, albuminuria, peripheral neuropathy, and cardiovascular disease in the subjects randomized to intensive treatment. However, the major side effect of intensive treatment was a threefold increase in the risk of severe hypoglycemic episodes; approximately 10% of patients in the intensive insulin therapy cohort experienced five or more episodes of seizure or coma during the study period.

Even in the absence of overt brain injury, multiple episodes of severe hypoglycemia have been associated with cerebral perfusion abnormalities and poor neuropsychiatric performance. In addition, there is a significant risk of accident during hypoglycemic episodes. Frequently, as hypoglycemia becomes more frequent and autonomic neuropathy worsens, patients may develop a syndrome of unawareness to hypoglycemia where the typical symptoms of tremor and anxiety do not occur. Such patients with hypoglycemic unawareness may develop profound hypoglycemia, especially if left unsupervised, and risk severe neurologic and traumatic injury.

In a similar trial, patients randomized to intensive insulin therapy, compared to those randomized to conventional therapy, had lower all-cause mortality. The most common causes of death were cardiovascular disease (22%), cancer (20%), and acute complications (18%).[22] The long-term risk of an impaired glomerular filtration rate (GFR) was significantly lower among persons treated early in the course of type 1 diabetes with intensive diabetes therapy than among those treated with conventional diabetes therapy.[23] Notably, all-cause mortality was significantly higher among those with higher mean hemoglobin A1C (HbA1C) levels and with renal disease during the 20-year follow-up.[22]

The overall management of diabetes is focused upon maintaining blood glucose as close to normal range as possible while attempting to minimize significant hypoglycemic episodes. Although the frequency and extent of hyperglycemia is important in the assessment of glucose management, long-term glycemic control is best assessed by evaluation of blood levels of hemoglobin A1C which measures the extent of glycosylation of hemoglobin. Although the incidence of diabetes is increasing, the overall treatment efficacy has improved. The use of subcutaneous insulin pumps is being increasingly employed, inhaled insulin has been used in selected patients, and infusion devices which also assess serum glucose and automatically adjust insulin dose accordingly are being developed.[24,25] Fully automated artificial-pancreas systems have been developed which link glucose sensors with insulin pumps through computerized control algorithms, which dictate insulin delivery in response to real-time sensor data.[26] Recent studies that have been carried out in hospitals have shown that such systems can improve glucose control and reduce the risk of nocturnal hypoglycemia in children, adolescents, and adults. Although such studies are encouraging, the major challenge ahead is successful implementation of such systems outside the hospital.

In practice it is the rare diabetic who can maintain tight glucose control without hypoglycemic complications. In fact, in a study of type 2 diabetics designed to reduce cardiovascular complications through normalization of glycemic control, intensive therapy was associated with increased early mortality and no reduction of cardiovascular events.[27] Most type 1 diabetics, even if on optimal insulin therapy, are unable to maintain hemoglobin A1C levels in the normal range, and most will ultimately develop progressive diabetic complications.

PANCREAS TRANSPLANTATION

Overview

2 Pancreas transplantation, while not technically a cure, represents an important therapeutic insulin replacement option for many type 1 diabetics. Recipients with functioning pancreas transplants have normal glycemic control without the need for exogenous insulin. Initial experience with pancreas transplantation, from the first pancreas transplant performed by Kelly and Lillehei in 1966 until the 1980s, was marked by low success rates and high mortality.[28] In 1980 the 1-year graft survival rate for pancreas transplantation was only 21%, and there was tremendous skepticism about the utility of the procedure.

3 Advances in surgical technique and immunosuppression have dramatically improved current graft survival rates to around 90% at 1 year. In addition to the development of cyclosporine, the introduction of bladder drainage of the donor pancreas, first introduced by Sollinger in 1985 using a button of donor duodenum, and subsequently modified by Corry in 1986 using an entire segment of duodenum anastomosed to the urinary bladder, dramatically improved the results of pancreas transplantation (Fig. 40-1).[29,30] Graft survival continued to improve throughout the 1980s and 1990s, especially for isolated pancreas transplantation (pancreas transplant alone [PTA], or pancreas after kidney transplantation [PAK]), the results of which have been historically inferior to simultaneous kidney–pancreas transplants (SPK). Both short- and long-term survival of pancreas transplants have slowly improved over the past decade. Because bladder drainage is associated with significant morbidity, most pancreas transplants are currently performed with enteric exocrine drainage and venous drainage into the systemic circulation. However, pancreas transplantation may also be performed by draining pancreatic venous blood into the recipient portal circulation, usually via the superior mesenteric vein.

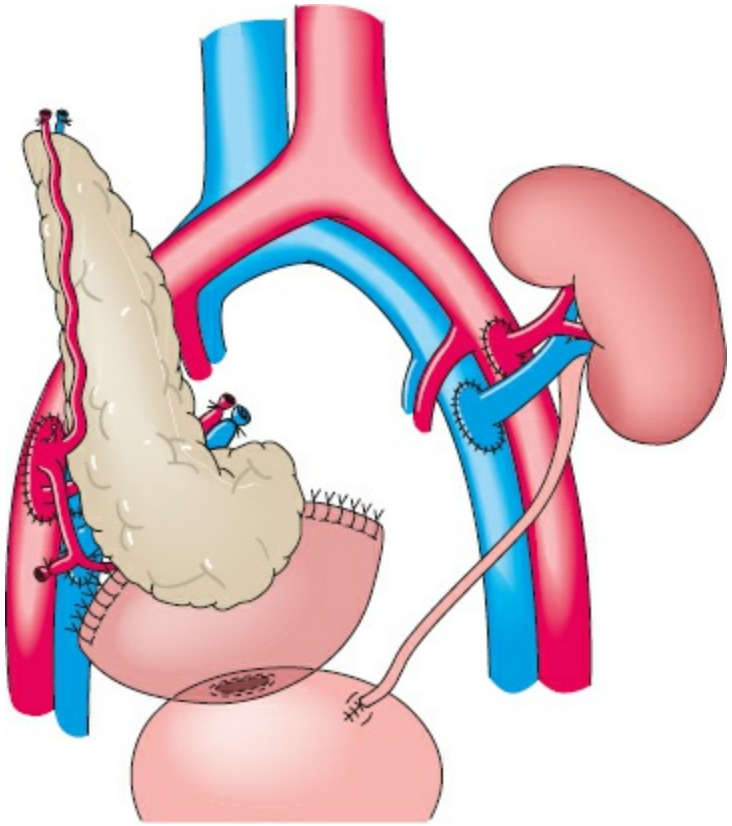

Figure 40-1. Simultaneous pancreas kidney transplantation performed with drainage of the pancreatic exocrine secretions into the urinary bladder (bladder drainage). This technique has been predominant until recently. Note that a segment of the second portion of the duodenum is left attached to the pancreas. Despite its heterotopic location, the transplanted pancreas responds to gastrointestinal hormones with a marked increase in secretion of pancreatic juice that has very high bicarbonate content. Also note that the portal vein drains into the iliac vein (i.e., systemic venous drainage). In healthy individuals 50% of the secreted insulin is extracted from the circulation in the first pass through the liver. Transplant recipients with systemic venous drainage have peripheral insulin levels two to two and one half times higher than normal.

Patient Selection

Pancreas transplantation is usually performed in patients with type 1 diabetes. The diagnosis of type 1 diabetes is relatively straightforward for most individuals. A history of juvenile or young adult onset, diabetic ketoacidosis, a lean body habitus, and a low insulin requirement (<0.7 units/kg) all support the diagnosis of type 1 diabetes. In contrast, older age of onset, obesity, an interval of treatment with diet or oral agents, or high insulin requirements are all suggestive of type 2 diabetes. A subset of adult-onset diabetics will display characteristics otherwise associated with type 1 diabetes, including absence of insulin production. Whether these individuals are properly classified as type 1 or type 2 diabetics may be subject to debate, but these individuals may certainly benefit from pancreas transplantation. Individuals with type 1 physiology but adult age of onset and low but detectable C-peptide secretion may also be considered for pancreas transplantation. Approximately 5% of pancreas transplant recipients are classified as having type 2 diabetes, and outcomes for these recipients are similar to those with type 1 diabetes.[31] As these are typically highly selected individuals without significant insulin resistance, most type 2 diabetics would not be considered candidates. Some type 1 diabetics may develop insulin resistance as a result of years of insulin therapy; this is frequently accompanied by increased body weight and insulin requirements. While insulin resistance may improve after transplantation in such patients, or may be managed with additional oral hypoglycemic agents, these patients are at higher risk for remaining on insulin after pancreas transplantation.[32] While provocative tests for insulin resistance exist, they are not commonly employed.

A small percentage of pancreas transplant recipients do not have type 1 diabetes, but have diabetes from other causes. Several have undergone pancreatectomy for chronic pancreatitis or other conditions.[33] Some pancreas transplants (<1%) are performed as part of a multivisceral transplant that includes liver and small intestine in patients who do not have diabetes; in these transplants, the pancreas is included in the graft to facilitate the technical conduct of the operation and to reduce complications.[34]

4 Most individuals evaluated for pancreas transplantation have chronic renal disease. These patients may present prior to onset of dialysis, while currently receiving dialysis, or following kidney transplantation. For individuals without a functioning kidney transplant, potential options include simultaneous deceased donor kidney/pancreas transplantation (SPK), living donor kidney transplantation followed by PAK, simultaneous living donor kidney–deceased donor pancreas transplantation (SPLK), or simultaneous living donor kidney–pancreas transplantation. Of these options the former two are by far the most common.

Simultaneous Kidney–Pancreas Transplantation

SPK from a deceased donor is the most commonly performed pancreas transplant option, with the number exceeding all other types combined. An SPK transplant has the advantage of requiring only one operation for both transplants. Since alloreactivity against the transplanted pancreas tends to be concordant with activity against the kidney, pancreas rejection may be heralded by signs of kidney rejection, which are more sensitive and present earlier. Consequently, SPK pancreas outcomes have been historically superior to those of solitary pancreas transplants.

Pancreas After Kidney Transplantation

If a living kidney donor is available, candidates have the option of receiving a living donor transplant, followed by a deceased donor pancreas transplant. This approach has the disadvantage of requiring two separate operations, but the recipient enjoys the benefit of a living donor kidney transplant that in many circumstances occurs sooner than would an SPK from a deceased donor. Since the primary survival benefit of the kidney–pancreas transplant comes from the restoration of renal function, this is a significant advantage. However, since a PAK is essentially a solitary pancreas transplant immunologically distinct from the kidney transplant, pancreas outcomes are worse than for SPK.

Simultaneous Living Donor Kidney–Deceased Donor Pancreas Transplantation

SPLK is another option performed at a few centers.[35] Candidates with identified living donors are listed for deceased donor pancreas transplantation. When a deceased donor pancreas becomes available, the living kidney donor transplant is performed at the same time as the pancreas transplant. This approach has the advantages of sequential living donor kidney followed by PAK transplants while requiring only one operation. It does require that the potential living donor be available to donate at any time, a requirement that excludes some donors from this approach. It also has the disadvantage of potentially delaying a kidney transplant for the recipient if the waiting time for a deceased donor pancreas is long. However, since waiting times for solitary pancreas in some areas of the country can be quite short, the advantages may be substantial.

Living Donor Kidney–Pancreas Transplantation

A few centers perform living donor kidney–pancreas transplantation, with a single living donor donating the tail of the pancreas as well as the kidney (Fig. 40-2). This approach has all the advantages of a single operation, a single donor, and no waiting time. Results have been comparable to deceased donor SPK transplants.[36,37] Widespread adoption of this approach has been limited by concerns about donor morbidity from the pancreatectomy. Serious complications such as pancreatitis, fistula, abscess, or pseudocyst can occur. Glucose intolerance and frank diabetes have occurred, although this problem has been nearly eliminated with more stringent donor selection criteria.[37,38]

Pancreas transplant candidates with renal failure may be counseled in a variety of ways depending on the availability of a living donor. How individuals are counseled depends in part on factors particular to the potential living donor and recipient, and also on the expected waiting time for SPK and PAK transplantation, which vary greatly by geographic region. Since the mortality benefit of a kidney–pancreas transplant derives primarily from the kidney transplant, priority is generally given to achieving kidney transplantation expeditiously. In geographic regions where the waiting time for SPK is long (5 years is not unusual), living donor kidney transplantation is advised. Recipients of living donor kidney transplant can then be listed for PAK which can be performed following recovery from the living donor kidney transplant. Individuals without living donors or those with borderline living donors in areas with short waiting times can be listed for SPK. Interestingly, there does not appear to be the same adverse impact in outcome with a limited interval of pretransplant dialysis (less than 2 years) in SPK recipients that is observed in kidney-alone recipients, whether deceased or living donor.[39] Therefore, even candidates with living donors may reasonably opt for SPK if anticipated waiting times are short.

Pancreas-Alone Transplantation

A small number of type 1 diabetics are evaluated for PTA. These individuals are generally extremely labile diabetics who have progressive complications but do not have nephropathy. In these individuals the risk–benefit equation is quite different than those uremic diabetics evaluated for kidney–pancreas transplantation. For nonuremic diabetics evaluated for pancreas transplantation the risk of immunosuppression in addition to the surgical procedure must be weighed against the potential benefits from transplantation. This contrasts to uremic diabetics, where the risk of immunosuppression is already assumed by virtue of the need for a kidney transplant. This risk includes renal failure due to chronic calcineurin inhibitor use. This is commonly cited as justification to not perform PTA, and recent evidence suggests the 10-year risk is at least 20% and is related to pretransplant GFR.[40] Whether PTA for type 1 diabetes results in a significant survival benefit is controversial. PTA in most centers is generally offered only in the most exceptional cases, the most common indication being frequent life-threatening hypoglycemic events. However, several transplant programs exist that have a different philosophical outlook on the risks and benefits of PTA, and these referral centers generally perform large numbers of PTA. Most PTAs are from deceased donors, with a small number of centers offering living donor PTA. Living donor pancreas transplants carry a higher rate of technical failure but a lower rate of immunologic failure.[41,42]

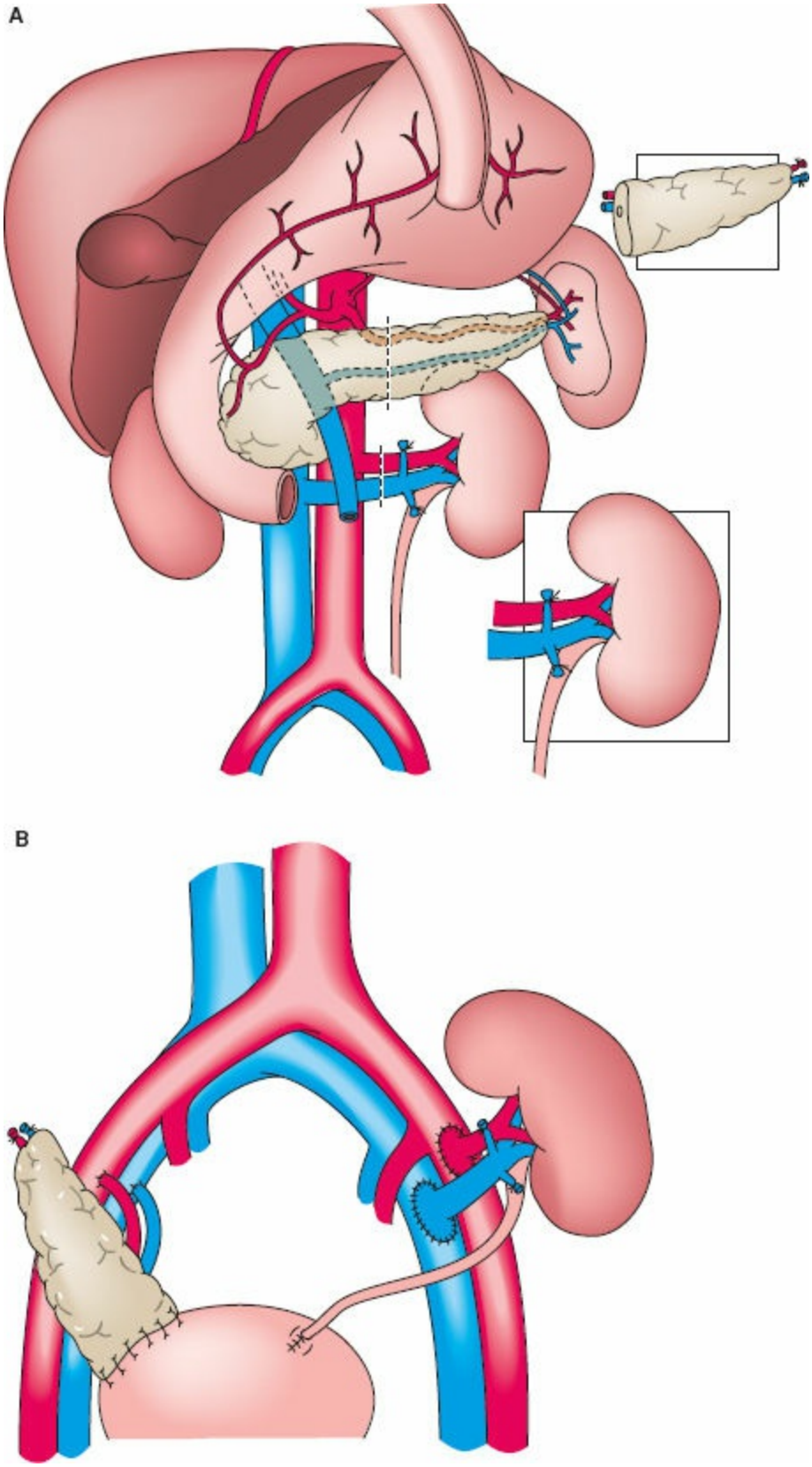

Figure 40-2. Live donor pancreas and kidney transplantation. **A:** Provided that the donor has a normal glucose tolerance test, a living donor may donate the segment of the pancreas that is to the left of the superior mesenteric vessels. **B:** Transplantation of tail of the pancreas is based on the splenic artery and vein.

Evaluation and Screening

5 In general, eligibility criteria for pancreas transplantation are more stringent than for kidney transplantation alone, since the operation and recovery are more rigorous, the potential complications more serious, and the benefits less pronounced compared with kidney transplantation. Candidates should have excellent functional status in anticipation of the more extensive surgery and more frequent complications. Age is not tightly related to outcome, but patients over the age of 60 are carefully scrutinized.[43] A detailed history of the patient's diabetes and treatment is obtained, including current glycemic control, hypoglycemic events, secondary complications, insulin requirements, and overall quality of life. Obesity in and of itself is not a contraindication, as outcomes for carefully selected obese (BMI >30) recipients are similar to nonobese recipients, although surgical complications and the likelihood of remaining insulin dependent may be slightly higher.[44] Selection practices vary widely—for some centers, pancreas transplantation is reserved for those with significant complications and poor glycemic control who have failed alternative treatments, while for others the presence of type 1 diabetes and a full understanding of the risks and benefits are sufficient, with patient preferences playing a significant role. In general, because of the added need for immunosuppression in PTA, these diabetes-related criteria are much more stringent than for SPK or PTA, where the risk of immunosuppression is already assumed by virtue of the kidney transplant.

All candidates, in addition to assessment of the potential benefit of pancreas transplantation, should have at the least noninvasive cardiac stress testing such as dobutamine stress echocardiography or adenosine thallium stress scintigraphy. Potential candidates with reversible myocardial defects undergo coronary angiography, and many centers perform angiography on all candidates. The decision to perform pretransplantation coronary revascularization must be made with consideration of both peritransplant mortality and long-term survival. Although survival outcomes are diminished in recipients with coronary artery disease,[45] a history of coronary revascularization is not necessarily a contraindication; individuals with extensive myocardium at risk and without revascularization options are frequently excluded.

Screening for peripheral vascular occlusive disease is often performed. Although distal peripheral vascular occlusive disease is characteristic of longstanding diabetes, aortoiliac disease and femoral popliteal vascular disease may also be present. Femoral popliteal disease is generally not a contraindication to transplantation, unless there are clinical signs of arterial insufficiency such as severe claudication or nonhealing ulcers. The presence of iliac disease is more problematic, as it can compromise inflow to the transplanted organs or increase the risk for postoperative arterial complications. In addition, diabetics may have significant vascular calcification which could preclude transplantation even in the absence of flow abnormalities. Screening for peripheral vascular occlusive disease, in addition to a thorough physical examination, may include noninvasive flow studies and/or CT scanning to evaluate vascular calcification. Candidates with a history or examination findings suggestive of cerebrovascular disease should be screened for hemodynamically significant carotid occlusive disease.

Other evaluations, as with other types of organ transplants, are tailored to the individual medical history, and differ among centers. Screening for malignancy commonly includes mammography and pap smears for women, prostate-specific antigen levels in men, and colonoscopy. Individuals with a prior history of treated cancer and who are judged to be at low risk for recurrence are usually candidates following an appropriate disease-free interval. This interval is decreasing as greater experience with transplantation in individuals with a history of cancer has accumulated, and can be as little as 2 years for many solid epithelial tumors to none for carcinoma in situ or early prostate cancer.[46] Screening for chronic viral infections such as hepatitis B, hepatitis C, and HIV is commonly performed, and pancreas transplants in selected individuals with chronic hepatitis are being performed with increasing frequency.[47,48] As with liver and kidney transplantation, early experience with pancreas transplantation in carefully selected individuals with HIV infection has been encouraging.[49] Social work and/or psychiatric evaluation is performed to rule out psychiatric disease, inadequate social environments, and other issues that may impact the recipient's ability to participate in posttransplantation management.

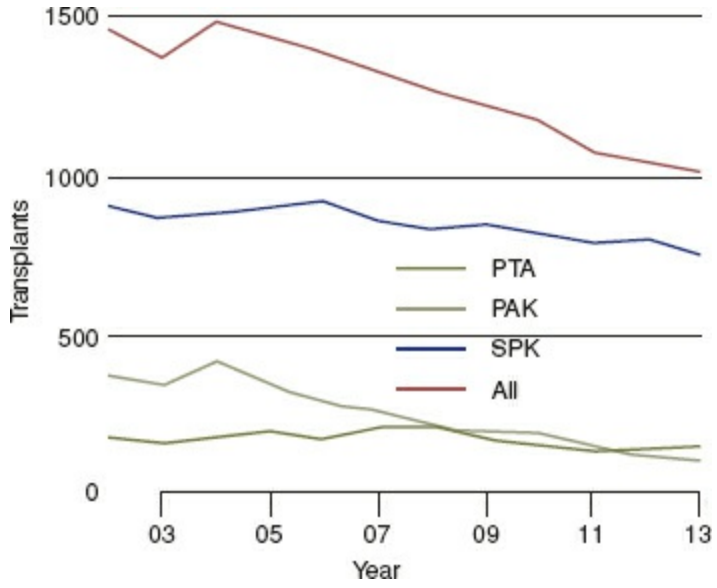

Figure 40-3. Number of U.S. simultaneous pancreas–kidney (SPK), pancreas after kidney transplantation (PAK), and pancreas transplantation alone (PTA) pancreas transplants performed by year. (Data from Scientific Registry of Transplant Recipients. 2013 Annual Report. Rockville, MD: Health Resources and Services Administration, Department of Health and Human Services; 2015).

The Kidney–Pancreas Waiting List and Recipients

The number of patients on the waiting list for a simultaneous kidney–pancreas transplant has decreased from a peak of 2,396 in 2005 to 2,076 in 2012.[50] The majority of patients are white (60%), though the percentages of white candidates is decreasing, while the percentage of African-American (24%) and Hispanic/Latino patients (13%) continues to increase. The number of patients on the waiting list has decreased since 2000 for all adult age groups except those in 50 to 64, and the age distribution has shifted upward. While the majority are ages 35 to 49 (57% in 2012), the percentage who are ages 50 to 64 is increasing (23% in 2012) and the percentage who are ages 18 to 34 (19% in 2012) is decreasing. The annual death rate on the SPK waiting list was 69 per 1,000 patient years in 2012, compared with 96 in 2006.

The number of SPK transplants performed has declined from 924 in 2006 to 801 in 2012 (Fig. 40-3). Median times to SPK have increased from 14.8 months for those registered in 2006–2007 to 16.2 months for those registered in 2010–2011. Time to transplant is longer for African-American and Hispanic/Latino recipients. While the majority of SPK recipients are white (65%) and males (64%), the percentage of SPK recipients who are African American (20% in 2012) and Hispanic (12% in 2010) in increasing. The age distribution of recipients parallels that of the waiting list.

The Pancreas Transplant Waiting List and Recipients

The number of patients awaiting isolated pancreas transplants in 2012 is also decreasing, with 413 patients awaiting PTA versus 528 in 2006 and 583 awaiting PAK versus 986 in 2006.[50] The increase in the number of patients waiting for isolated pancreas transplant in the last 5 years is largely due to a sharp decrease in the numbers of new registrations rather than an increase in transplants performed.

The great majority of patients awaiting isolated pancreas transplants are white (80% for PTA, 75% for PAK); there have been significant increases in the percentage of African Americans on the PAK and PTA lists over the last several years. Although women continue to constitute 54% of the PTA waiting list in 2012, they are only 46% of the PAK waiting list. The majority of patients awaiting both PTA and PAK are between 35 and 49 years old, but as with SPK candidates, the percentage of older patients listed for PAK and PTA has increased, with 36% and 30%, respectively, of the waiting list in 2012 being between the age of 50 and 64 years.

The median time to transplant for PAK has increased over the last 5 years, with the mean waiting time for candidates registered in 2008–2009 now being 36.9 months. This is greater than the median time to transplant for SPK registrants. Wait times for PTAs have also increased, nearly doubling since 2007–2011 to 19.1 months for those registered in 2010–2011.

The age and race of recipients of solitary pancreas transplants reflect the waiting list. In 2012, 88% of PTA and 72% of PAK and recipients were white. More PAK recipients (64%) were male, but more PTA recipients (63%) were women, and this gender gap has widened in the past 5 years.

Deceased Donor Pancreas Allocation

As with many organs, deceased donor pancreas allocation is determined primarily by geography, with most organs offered to centers in the Donation Service Area (DSA) of donor origin. The base organ allocation unit is the organ procurement organization (OPO) which serves the population within the DSA. The 58 DSAs are organized into 11 regions, which serve as the second-tier of organ allocation. As with other organs, pancreata are allocated according to nationally determined policies.[51] There is mandatory sharing of pancreata to highly sensitized candidates that are completely matched to the donor; beyond this, pancreata are allocated to these pancreas candidates first locally, then regionally, then nationally based primarily on waiting time.

If the pancreas candidate is an SPK candidate, then a kidney from the same donor is usually also allocated to the SPK candidate, regardless of the candidate's place on the kidney waiting list. While such a policy promotes pancreas utilization, it has been somewhat controversial, since preferential allocation of kidneys to simultaneous kidney–pancreas (SPK) candidates prevents allocation to kidney-alone candidates who have generally been waiting longer. Solitary pancreata are more difficult to place compared with SPK because their outcomes are slightly worse, but are more easily shared voluntarily since OPOs have no obligation to share kidneys along with pancreas for outside SPK candidates; since pancreas donors are carefully selected, the kidneys from these donors are usually able to be transplanted into a local kidney candidate. Thus, shared pancreata are generally restricted to PTA or PAK candidates.[52]

Pancreas allocation is also complicated by the fact that the pancreas donor selection criteria for islet transplant and whole-organ transplant overlap, leading to competition among certain types of organs. In determining whether a given pancreas will be allocated to a solid organ or islet transplant candidate, donor age and BMI are considered. Donors under age 50 and with BMI <30 are allocated for whole-organ pancreas transplant locally. If there is no local acceptance, the pancreas is offered regionally and then nationally. If there is no candidate for whole pancreas, the pancreas is then allocated for islets. For donors older than age 50 or with BMI >30, whose pancreata are rarely used for whole-organ transplant, the organ is first offered for pancreas transplant locally; if there are no local candidates, the pancreas is then offered for islets.[51]

Pancreata are significantly underutilized compared to other solid organs such as liver and kidney. As discussed below, donor selection criteria are more rigorous. Restrictions on cold ischemia time for whole-pancreas transplantation and particularly for islet transplantation make the placement of pancreata that are not used by the recovering center difficult. There is significant geographic variation in pancreas use, which correlates with activity by local transplant centers.[53]

Donor Evaluation

6 The selection of appropriate pancreas donors is perhaps the most important determinant of successful pancreas transplantation. Many of the early complications of pancreas transplantation are thought to be secondary to processes related to organ quality and preservation, rather than the technical conduct of the recipient operation. While the ideal donor is young, nonalcoholic and nonobese, very few donors meet this description, and the surgeon frequently needs to consider pancreata from imperfect donors. Donor selection criteria may vary among surgeons and transplant centers, and may depend upon past experience, waiting time, and recent outcomes. Primary criteria are the age of the donor, donor BMI, donor cause of death, and the gross appearance of the organ at the time of recovery. Additional information that may influence the decision include aspects of the medical and social history, donor hemodynamics, laboratory values, HLA matching, and anticipated preservation time. As with donor selection with other organs, the decision-making process often involves consideration of multiple factors in aggregate.

The importance of donor age on graft outcomes has been confirmed by multiple studies, and the maximum age threshold is significantly lower than for liver and kidney transplantation.[54,55] Many centers use an age threshold, which may range from 40 to 50, above which donors are selected very carefully. The mechanism by which age affects outcomes is not firmly established: age appears to influence both early technical and late graft loss.[55,56]

Donor BMI has been found to be a determinant of graft failure by single-center and transplant registry analyses.[57,58] Very few pancreata from donors with BMI greater than 30 are used for solid-organ transplant, and are more likely to be recovered for islet transplant.[52] Interestingly, for overweight but not obese donors (BMI 25 to 30), a large single-center study found a higher rate of technical failure for donors who also had a cerebrovascular attack as cause of death.[57] It is not known whether associations with BMI relate to fatty infiltration of the pancreas or by a separate mechanism.

The circumstances of death and the condition of the donor influence donor selection. Pancreata from donors with stroke as a cause of death have reduced graft survival. Although experience from donors after cardiac death (DCD) remains relatively limited (only 1.5% of all pancreas transplants in 2011), outcomes have been good with careful donor selection.[50,59,60] Laboratory values, including serum amylase and lipase, play a relatively minor role in donor selection. Insulin administration is generally not considered a contraindication to pancreas donation. While the presence of donor hyperglycemia may raise concerns about latent diabetes, in most donors this reflects the rapid administration of dextrose-containing solutions, corticosteroids for cerebral edema, and high-dose catecholamines for blood pressure support rather than latent pancreatic endocrine insufficiency. Abnormal HbA1C has been utilized as a relative contraindication, but is not well studied and is not uniformly available for use. Evidence of injury to other organs such as liver and kidneys, as a marker of abdominal ischemia, while not ordinarily a contraindication, may be considered in marginal cases.

Donors with a history of type 2 diabetes, excessive alcohol use or pancreatitis may be

used. A history of cardiovascular disease or cardiac risk factors are also not contraindications but may influence decision making or be associated with mesenteric atherosclerotic disease. A social history which suggests an increased risk of transmission of hepatitis or HIV should be evaluated, as with other organs, in the context of the degree of perceived risk relative to the benefit of the transplant.

Intraoperative evaluation of the donor organ is said to be the most important determinant of donor selection. Evidence of inflammation or fibrosis, which may manifest as focal or diffuse firmness to palpation, is considered to be a contraindication. Fatty infiltration of the pancreas, trauma and pancreatic edema are also adverse findings, although the latter may be correctable with donor management. Traumatic injury to the pancreas or hematoma within the substance of the pancreas would preclude transplantation. However, a prior splenectomy is not a contraindication, provided that the tail can be dissected atraumatically.

Factors not intrinsic to the donor may bear on the decision to perform a transplant. The higher risk of graft failure associated with solitary pancreas transplants leads some centers to have more stringent selection criteria for PTA and PAK. While cold ischemia is a risk factor for graft survival, pancreata from selected donors can be transplanted with cold ischemic times approaching 24 hours with good outcomes. Attention to HLA matching varies widely by center; the many analyses performed suggest that any relationships between matching and graft outcome that may exist are not likely to be very significant.[56,58,61]

As for deceased donor livers and kidneys, a Donor Risk Index for pancreas has been described.[53] The pancreas DRI (PDRI) is based on 10 factors demonstrated to have significant impact on pancreas transplant outcomes. These include age, gender, race (black or Asian), BMI, height, CVA as cause of death, cold ischemia time, DCD, and terminal creatinine greater than 2.5 (Table 40-1). There is great variation in outcome by PDRI: the difference in graft survival at 1 year between the lowest 20% of PDRI (best outcomes) and the highest 20% is about 11% for SPK transplants and 16% to 17% for solitary transplants (Table 40-2). In addition to predicting outcomes for individual patients, indices like the PDRI are useful in assessing trends in pancreas utilization, which is quite variable by geography and by transplant center.[53]

Procurement Technique

The importance of the pancreatic procurement cannot be overstated. It is thought by many pancreas transplant surgeons to be more critical to the success of the transplant than the recipient procedure. Because the pancreas is susceptible to traumatic injury, it must be carefully dissected and manipulated to avoid injury to the pancreatic parenchyma. Typically the pancreas is procured along with the liver and kidneys. This is performed in standard fashion through a midline incision which extends from the sternal notch to the pubic symphysis. After a generous Kocher maneuver, mobilization of the right colon, and isolation of the distal and supraceliac aorta to prepare these vessels for clamping, the pancreas is mobilized. This is most commonly achieved by entering the lesser sac, dividing the gastrocolic omentum. This dissection continues with division of the short gastric vessels and the avascular gastrosplenic ligament. The pancreas is dissected from the pancreatic bed using the spleen as a handle. The tail is lifted from the pancreatic bed using blunt dissection and the occasional use of electrocautery. The proximal jejunum is dissected at the ligament of Treitz. An antibiotic and/or betadine containing solution are frequently instilled into the duodenum through a nasogastric tube for decontamination. The duodenum is divided both at the ligament of Treitz and at the pylorus using a stapler. Division of the middle colic vessels permits exposure of the proximal small bowel mesentery, which is divided distal to the pancreas with a vascular stapler. The mobilization of the pancreas may be performed either prior to or following the aortic perfusion procedure described below.

Perfusion of the pancreas is generally achieved through an intra-arterial cannula placed in the distal aorta following clamping of the supraceliac aorta and the aortic bifurcation. This is typically achieved with approximately 3 L of University of Wisconsin or HTK (histidine–tryptophan–ketoglutarate) solution while the entire abdominal organs are packed in saline slush. Preservation solutions are generally regarded to be equivalent, although a few studies suggest slightly worse outcomes with HTK.[58,62,63] Some centers will also perfuse the abdominal viscera with a portal perfusion cannula, typically through the inferior mesenteric vein, although some surgeons maintain that overperfusion of either the arterial or the venous circulation may result in pancreatic edema and an increased risk of complications.

Table 40-1 Summary of Pancreas DRI

Donor Characteristics	Reference Donor (DRI = 1.00)	Change Factor Value to	DRI
Gender	Male	Female	0.87
Age	28	45	1.56
Black race	No	Yes	1.27
Asian race	No	Yes	1.17
BMI	24	30	1.17
Height (cm)	173	190	0.9
Cause of death: CVA/stroke	No	Yes	1.23
Cause of death: CVA/stroke in PAK	No	Yes	0.93
Pancreas preservation time (hrs)	12	20	1.13
DCD	No	Yes	1.39
SCr >2.5	No	Yes	1.22

Equation: pDRI = exp(–0.13792 × I[Female Donor]) – 0.034455 × I[Donor Age <20] × [Donor Age – 20] + 0.026149 × [Donor Age – 28] + 0.19490 × I[Donor Creatinine > 2.5] + 0.23951 × I[Donor Black Race] + 0.15711 × I[Donor Asian Race] – 0.000986347 × [Donor BMI – 24] + 0.033274 × I[Donor BMI > 25] × [Donor BMI – 25] –0.006073879 × (Donor Height – 173) + 0.21018 × I[Donor COD CVA] – 0.28137 × I[Donor COD CVA for PAK txp] + 0.014678 × [Preservation Time – 12] + 0.33172 × I[DCD]).[40]

Table 40-2 Results: Unadjusted 1-year Pancreas Allograft Survival by DRI and Transplant Type

	SPK		PAK		PTA	
DRI Group	Adjusted% Graft Survival	95% Confidence Limits	Adjusted% Graft Survival	95% Confidence Limits	Adjusted% Graft Survival	95% Confidence Limits
0.64–0.85	88	(87, 90)	84	(81, 87)	84	(76, 89)
0.86–1.15	87	(86, 89)	77	(73, 79)	82	(77, 87)
1.16–1.56	82	(79, 84)	75	(70, 79)	70	(61, 77)
1.57–2.11	78	(75, 81)	69	(61, 75)	68	(57, 77)
2.12–2.86	77	(70, 82)	67	(46, 81)		

The pancreas can be removed either en bloc with the liver and kidneys, en bloc with the liver, or separately, following removal of the liver. Whatever the technique, the portal triad is dissected out in cooperation with the liver procurement team. Typically the portal vein is shared by dividing it at the level of the coronary vein. Only in the rarest of circumstances should there be any difficulty using both the liver and the pancreas from the same donor even in the presence of hepatic arterial anomalies. In the presence of a replaced right hepatic artery, the superior mesenteric artery (SMA) can be divided just distal to the replaced right hepatic artery, leaving a very short cuff of SMA on the pancreas. Alternatively, the replaced right hepatic artery, if large enough to be safely reconstructed by the liver transplant team without a cuff of SMA, can be transected as it exists superiorly from behind the head of the pancreas. This is also true in the rare case where a completely replaced hepatic artery emerges from the superior aspect of the head of the pancreas; usually the artery in this case is long enough and large enough to be used for liver transplant without a celiac axis or aortic cuff. The bile duct and gastroduodenal artery are ligated on the pancreas side and divided on the liver side. Dissection then proceeds along the superior aspect of the pancreas along the proper hepatic artery. The splenic artery, which constitutes the other arterial blood supply to the pancreas, is

divided a few millimeters from its origin to allow for adequate length on the pancreas while allowing the stump to be oversewn without compromising flow to the liver. Once the pancreas is removed or split from the liver, the pancreas is packed in preservation solution; the entire common iliac artery and its two main branches, the internal and external iliac arteries, are packaged along with the pancreas for back-table reconstruction. A graft of donor iliac vein is also included in case the portal vein needs to be extended, which is done by some surgeons. Although most centers transplant the pancreas as soon as possible, up to 24 hours of cold ischemia time (time between perfusate infusion and organ reperfusion) has not been associated with reduced graft survival in carefully selected donors.[53,56]

Back-Table Preparation of the Pancreas

The pancreas is placed on ice and remains cold at all times on the back table. The spleen is removed by dividing all vessels near the spleen, either by ligature or stapling, taking care to avoid injury to the tail of the pancreas which should be clearly identified. Some surgeons elect to wait until reperfusion of the pancreas in the recipient to remove the spleen. Significant peripancreatic fat, if left on at the time of procurement, should be trimmed. Both ends of the distal duodenum are shortened to the point where they are immediately adjacent to the head of the pancreas. Both stapled ends of the duodenum may be oversewn with silk or polypropylene sutures. Some surgeons elect to reinforce the mesenteric staple line by oversewing with polypropylene suture. The iliac artery Y-graft is typically attached by anastomosis of the internal iliac artery to the splenic artery and anastomosis of the externally iliac artery to the SMA (Fig. 40-4). In the absence of a Y-graft, the splenic artery may be implanted in end-to-side fashion to the SMA. The portal vein is mobilized by freeing from surrounding adventitial tissue to the confluence of the splenic vein and superior mesenteric vein. This should allow an adequate length of portal vein for anastomosis, as only 1 to 2 cm of portal vein length is generally needed.

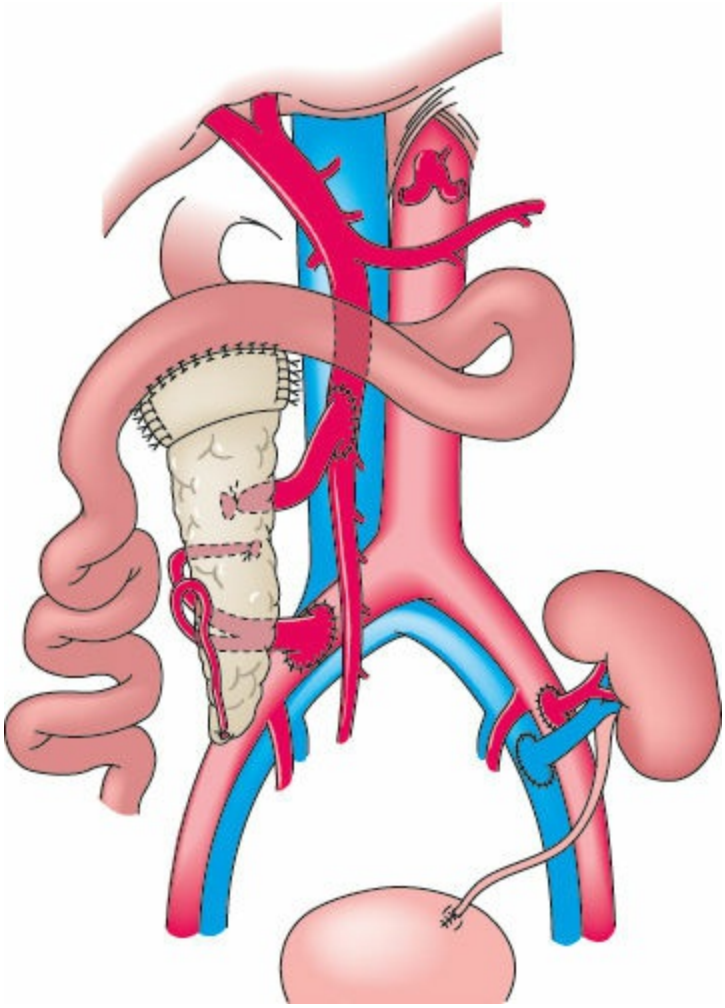

Figure 40-4. Simultaneous pancreas–kidney transplantation performed with drainage of the pancreatic exocrine secretions into the proximal jejunum (enteric drainage). This technique has been adopted by most transplant centers in the United States for simultaneous pancreas–kidney transplants. For solitary pancreas transplantation, some centers still utilize bladder drainage to allow monitoring of the urinary amylase. Note that the donor portal vein drains into the recipient superior mesenteric vein (portal venous drainage), preventing peripheral hyperinsulinemia. Many centers continue to place the pancreas in the pelvis, combining enteric drainage and systemic venous drainage. This placement requires enteric anastomosis to a more distal segment of jejunum or ileum.

Recipient Operation

The pancreas transplant is typically performed through a midline incision, although a lower quadrant incision similar to a kidney transplant incision may be used. The recipient should receive broad spectrum antibiotics preoperatively. The pancreas transplant, for systemic venous drainage, is placed in the iliac fossa, preferably on the right side. After dissection of the recipient artery and vein, the portal vein is anastomosed in end-to-side fashion to the systemic vein. The distal inferior vena cava, common iliac vein, or external iliac vein may be used; the recipient vein segment should be mobile enough for the portal vein to reach without tension. The common iliac artery component of the donor Y-graft is then anastomosed in end-to-side fashion to either the recipient external iliac artery or common iliac artery; the distal aorta can also serve as the site of anastomosis. A pancreas placed on the left side in the recipient may be placed either medial or lateral to the sigmoid colon. Multiple variations have been described.

Because of concerns about the systemic hyperinsulinemia that invariably develops with systemically drained pancreas transplants, portal venous drainage is also utilized (Fig. 40-5). As 50% of insulin is removed with the first pass through the liver, systemic drainage leads to elevated peripheral insulin levels, which is not observed following portal venous drainage. Since hyperinsulinemia has been associated with dyslipidemia and accelerated atherosclerosis, portal venous drainage theoretically ought to decrease cardiovascular risk compared with systemic drainage.[64] Portal drainage is associated with stimulation of the IGF-I/GH axis, contributing to glucose control despite lower insulin levels.[65] However, despite a nearly 10-year experience with the procedure, no effect on cardiac morbidity or mortality has been shown, and graft and patient survival are essentially equivalent.[66–68]

Although the type of venous drainage typically depends on the preferences of individual surgeons or transplant centers, the decision to perform portal or systemic drainage may also depend upon the anatomy of an individual patient. Patients with multiple previous abdominal operations or who have a thickened mesentery may be more suited for systemic venous drainage. Alternatively, patients who have had multiple transplants or other operations on the iliac vessels may be candidates for portal venous drainage.

For portal venous drainage the superior mesenteric vein is dissected out just below the transverse mesocolon.[69] The right common iliac artery is almost completely dissected. An end-to-side anastomosis of the donor portal vein to the recipient superior mesenteric vein is performed with the duodenum oriented superiorly and the tail pointed inferiorly. The iliac artery graft of the donor is then passed through a hole created in the small bowel mesentery, and anastomosed to the recipient common iliac artery.

Most centers currently use enteric exocrine drainage for simultaneous kidney/pancreas transplant and some centers use enteric drainage for all transplants including solitary pancreas transplantation. This shift to enteric drainage occurred as a result of the significant morbidity associated with bladder-drained pancreas transplants. Morbidity includes recurrent urinary tract infections, hematuria, chemical urethritis, severe bicarbonate wasting, and dehydration. Historically, approximately 25% of individuals

who receive a bladder-drained pancreas transplants require enteric conversion because of persistent complications,[70] but an additional percentage endure significant morbidity early after transplant. The major advantage of bladder drainage is the ability to monitor urinary amylase, a decrease in which can be associated with rejection. This can be helpful in solitary pancreas transplants, but is not as important for simultaneous pancreas/kidney transplants where graft function may be monitored by serum creatinine. Improved immunosuppression and an increased utilization of biopsy to diagnose rejection have led to a decreased reliance on urinary amylase.[71]

Enteric drainage is achieved by creating a side-to-side or end-to-side anastomosis of donor duodenum to recipient jejunum. This may be a loop of jejunum, or a Roux-en-Y configuration may be created. For bladder drainage a side-to-side anastomosis between the donor duodenum and the bladder is performed. Enteric drainage is always used for pancreas transplants with portal venous drainage because the orientation of the pancreas precludes anastomosis of the duodenum to the bladder.

If a simultaneous kidney–pancreas transplant is performed, the kidney transplant is usually placed in the left iliac fossa. The anastomoses, as with a kidney transplant via a retroperitoneal incision, are typically to the external iliac artery and external iliac vein. The kidney is typically placed in an intraperitoneal location, which increases the potential for torsion of the kidney on its vascular pedicle compared with kidney-alone transplants which are usually placed in a retroperitoneal location. Some surgeons prefer to raise a retroperitoneal flap to place the kidney retroperitoneally after implantation. Advantages to this approach include improved percutaneous access should biopsy be required, and a decreased risk of postbiopsy hemorrhage.

Following revascularization of the pancreas, attention is paid to bleeding from the pancreas which can be quite brisk. This is controlled with ties or suture ligatures. Since thrombosis is a common complication of pancreas transplantation, anticoagulation in the perioperative period is frequently employed, particularly for solitary pancreas transplantation. Thrombosis is less frequent in simultaneous pancreas–kidney transplantation, where uremic platelet dysfunction is protective. The extent of anticoagulation may range from the intraoperative administration of heparin prior to clamping of vessels, followed up by low-dose heparin infusion and warfarin anticoagulation, to more conservative approaches such as the use of low-dose heparin for a limited interval postoperatively, or the use of aspirin or other antiplatelet agents. Hypercoagulability states may predispose to graft thrombosis in a significant number of individuals, although definitive data are lacking; anticoagulation is individualized based on risk.[72] Whatever the approach, patients should be monitored for bleeding, since as many as 10% of patients experience postoperative hemorrhage requiring reoperation.[73]

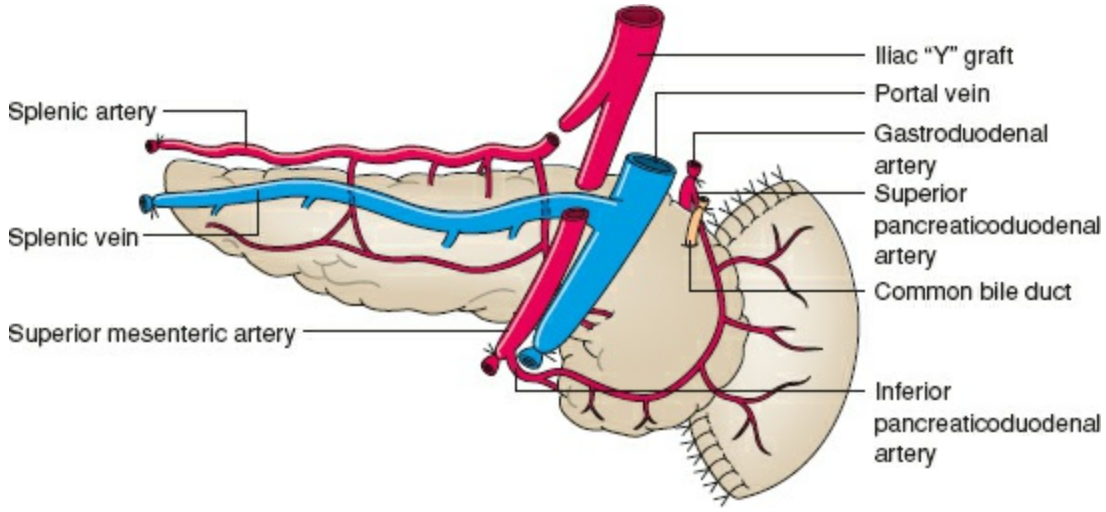

Figure 40-5. Back-table preparation of the pancreas. Before transplantation, the pancreas must be prepared in a slush-filled basin to maintain cold preservation. Preparation includes unifying the arterial blood supply of the pancreas by anastomosis of the donor external iliac artery to the superior mesenteric artery and the donor internal iliac artery to the splenic artery. The donor common iliac artery is used for anastomosis to the recipient iliac artery. During back-table preparation, donor splenectomy is performed.

Following revascularization serum glucose levels are obtained hourly. It is common for the blood glucose to decline significantly following revascularization, and it is not uncommon for it to fall to normal levels soon after the patient's arrival in the recovery room. At some point intravenous fluids should be converted to dextrose-containing solution in order to prevent hypoglycemia. Pancreas transplant recipients with enteric drainage require only maintenance fluid with consideration of third-space losses. Simultaneous kidney–pancreas transplant recipients may require the additional fluid replacement that would be administered following kidney transplantation alone. Individuals who receive bladder-drained pancreas transplants require replacement of pancreatic exocrine losses, which can be quite profound in the early postoperative period.

Immunosuppression

7 Immunosuppression for pancreas transplantation is similar to that for kidney transplantation. The immunogenicity of a pancreas transplant is considered to be greater than the majority of solid-organ transplants because of the extensive lymphoid component of the gland. In addition, the difficulty in diagnosing rejection compared to other solid-organ transplants makes the choice of immunosuppression more significant for pancreas transplants. Most centers use some forms of triple maintenance therapy utilizing a calcineurin inhibitor, an antiproliferative agent, and steroids, although steroid-free regimens are becoming more common. According to data from the Scientific Registry of Transplant Recipients, 92% of kidney–pancreas recipients in 2012 received tacrolimus as maintenance therapy, compared to only 3.5% who received cyclosporine.[50] Mycophenolate mofetil is the antiproliferative agent of choice in pancreas transplantation; the use of sirolimus declined from a peak of 19% in 2001 to 7% in 2012. The use of steroids for pancreas transplantation, while still much lower than prior to 2000, increased from 61% in 2007 to 68% in 2012.

The use of induction therapy to inhibit lymphocyte function is common. Several large randomized multicenter trials utilizing either T-cell–depleting antibody induction (OKT3, ATGAM, and thymoglobulin) or interleukin-2 (IL-2) receptor antibody inhibition (daclizumab and basiliximab) showed a reduction in the incidence of acute rejection but failed to demonstrate a significant effect on patient or graft survival.[74,75] Despite this modest impact on overall graft outcome, 89% of kidney–pancreas transplant recipients received induction therapy in 2012, 79% T-cell–depleting agents, and 12% IL-2 receptor antibody.[50] The International Pancreas Transplant Registry (IPTR) has demonstrated a lower risk of pancreas graft loss in all categories of pancreas transplantation with the use of tacrolimus, and also demonstrated similar associations with the use of mycophenolate mofetil.[56] Consistent with the multicenter trials, IPTR analyses also fail to demonstrate a beneficial effect of induction therapy on patient and graft survival.

Several groups have reported excellent intermediate-term patient and graft outcomes utilizing steroid minimization protocols.[76–78] These protocols generally employ an induction agent (usually a depleting T-cell antibody), tacrolimus, and either MMF or sirolimus. Steroids are given for a maximum of 3 days. These steroid minimization protocols, as in kidney transplantation, aim to avoid the significant short- and long-term side effects associated with corticosteroids. Regimens employing maintenance monotherapy have also been successfully employed, although based on registry data, these appear to be falling into disfavor.[50,79]

Complications

Thrombosis of the pancreas transplant is the most common cause of graft loss in the early postoperative period, occurring in 5% to 10% of transplants. Why pancreas transplants are more prone to thrombosis than other solid-organ transplants is uncertain. The most likely mechanism is that ischemia reperfusion injury in the pancreas, characterized by the release of cytokines and activation of pancreatic enzymes, leads to accelerated injury and a procoagulant state. Diabetic patients have impaired fibrinolysis and are, therefore, relatively hypercoagulable. The relatively low venous flow through the portal vein, which leads to diminished flow velocity, may be contributory. Thrombosis is slightly more common in solitary pancreas transplantation than in SPK, probably due to the absence of uremic platelet dysfunction present in SPK recipients. The risk of thrombosis has been associated with donor factors such as older patient age, renal dysfunction, cold ischemic time, body mass index, DCD status, and cerebrovascular cause of death.[55,80,81]

Pancreas transplant thrombosis is usually heralded by a sudden rise in blood glucose in a pancreas that was previously functioning. Confirmation of the diagnosis is usually obtained with duplex ultrasound. Although anecdotal reports have described successful surgical and angiographic thrombectomy or thrombolysis in restoring flow to the pancreas,[82,83] the usual treatment is removal of the infarcted pancreas. While this usually occurs immediately after diagnosis, some centers opt to relist the patient urgently and wait until another pancreas transplant becomes available. Depending on the waiting time for another pancreas, the added morbidity of delaying the graft pancreatectomy is usually not significant. In contrast, asymptomatic thrombosis, whether partial or even complete, has been successfully managed with anticoagulation, especially if late in onset.[84,85] Because of the high risk of thrombosis, some degree of anticoagulation is frequently employed after pancreas transplantation.[86] It is likely due to these efforts and improvements in immunosuppression that the thrombosis rate for simultaneous pancreas–kidney transplants has decreased to less than 5% for simultaneous pancreas–kidney transplant and to less than 10% for isolated pancreas transplants (Fig. 40-6).

Bleeding is another frequent cause for reoperation in the early postoperative period. Because of the large number of vessels that enter and exit the pancreas, bleeding following reperfusion is not unusual. While readily controllable, it is not uncommon for bleeding points to emerge later in the procedure, and postoperatively. This can be minimized by meticulous attention to ligating vascular structures during pancreas procurement. The use of anticoagulation in the perioperative period, as described above, adds to the bleeding risk. Pancreas transplant recipients are monitored carefully in the early postoperative period for signs and symptoms of intra-abdominal hemorrhage.

The other major early complication is leak from the donor duodenum. Duodenal leaks occur in approximately 5% to 10% of cases, usually 1 to 2 weeks after the transplant.[87] A leak may present as fever, abdominal pain, leukocytosis, lower abdominal tenderness, and persistent ileus. The diagnosis may be supported by the finding of a focal fluid collection near the head of the pancreas on CT scanning or ultrasound. Alternatively, diffuse peritonitis may reflect disseminated contamination. For bladder-drained pancreas

transplants, the diagnosis may be made by cystography.

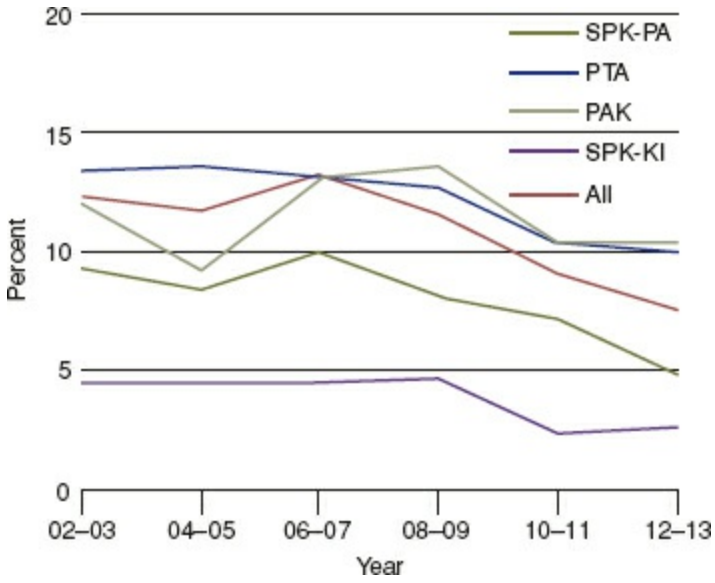

Figure 40-6. Technical graft failure rates for U.S. pancreas transplant recipients by year. (Data from Scientific Registry of Transplant Recipients. 2013 Annual Report. Rockville, MD: Health Resources and Services Administration, Department of Health and Human Services; 2015).

The management of a suspected duodenal leak is operative. Peripancreatic sepsis or abscess can occur in the absence of a frank duodenal leak. This is caused by the growth of organisms transmitted into the peritoneal cavity during performance of the duodenal anastomosis. The peritoneum should be lavaged and all necrotic debris removed. If a leak is present it is usually at the stapled end of the duodenum rather than at the anastomosis. The likelihood of success for repair of a duodenal leak depends on the viability of the duodenum at the point of the leak, the patient's overall hemodynamic stability, and the degree of surrounding inflammation. Usually one attempt at repair is made, but failure may necessitate removal of the pancreas in order to control life-threatening sepsis. Some surgeons have adopted a practice of managing leaks from duodenal enteric anastomoses by conversion to bladder drainage. This minimizes the risk of recurrent contamination of the peritoneal cavity with enteric contents and allows for Foley catheter decompression of the duodenum, but has the morbidity associated with bladder drainage. Occasionally a fluid collection or leak which presents late and without systemic sepsis can be treated with percutaneous CT-guided drainage.[88] In addition, drainage of infection without primary repair of the duodenal leak has been successfully employed in situations where inflammation is so profound that the leak could not be primarily repaired. However, the morbidity associated with these duodenal fistulas dictates that these options be employed only when definitive repair is not possible.

In contrast to renal transplantation, the complications of pancreas transplantation can be severe and life threatening if not properly managed. Even in the most experienced centers, occasional patients who suffer extended intensive care unit stays and even death are not unusual. This is a consequence of both the tenuous medical status of longstanding diabetics and the substantial morbidity of pancreas transplant complications. Therefore,

given the limited survival benefit of pancreas transplantation, particularly compared with kidney transplantation, patients should be counseled frankly about the potential magnitude of these complications so that they have a realistic expectation of outcomes. Even with honest discussion and informed consent, most individuals will elect pancreas transplantation, and many will pursue multiple pancreas transplants even with a history of significant complications from previous pancreas transplants.

Diagnosis and Treatment of Rejection

The timely and accurate diagnosis of pancreas transplant rejection is one of the most important and challenging aspects of posttransplant management. As with kidney transplant rejection, pancreas rejection, whether acute cellular rejection or antibody-mediated rejection, is associated with inferior graft survival.[89] Furthermore, both pre- and posttransplant donor-specific antibody (DSA) are associated with antibody-mediated rejection and reduced pancreas and kidney graft survival.[89,90] The incidence of pancreas rejection is about 20% to 25% in the first 2 years.[50] Therefore, the implications of delayed or missed antirejection treatment can be profound.

There is no single laboratory abnormality capable of diagnosing rejection. Amylase and lipase serum levels are commonly elevated, and can arouse suspicion, but are not specific. Hyperglycemia is also nonspecific, and if due to rejection occurs late, signifies significant pancreatic endocrine injury and has a dismal prognosis. While imaging modalities including ultrasound may identify abnormalities in parenchyma or perfusion, they are neither sensitive nor specific.[91] Hence, the diagnosis of rejection is best made with histologic examination of a pancreatic biopsy specimen.[92] The pancreas graft in SPK transplants may be monitored by following the serum creatinine, as the concordance rate for rejection between kidney and pancreas grafts is believed to be high, although isolated pancreas rejection clearly occurs.[93,94] Improvements in the outcome of solitary pancreas transplants are attributable to improvements in overall quality of immunosuppression, and to more accurate diagnosis and treatment of pancreas rejection.

The technique of pancreas transplant biopsy has evolved over the years. In the era of bladder-drained pancreas transplants, cystoscopic biopsy of both the pancreas and transplant duodenum was common.[95] As more enteric-drained pancreas transplants have been performed, a greater reliance on percutaneous biopsy has developed, using either ultrasound or CT-guided techniques.[96] Laparoscopic-assisted or open pancreas biopsy may be utilized for patients whose pancreas transplant is not accessible to percutaneous approaches, although the need for operative biopsy is decreasing as the percutaneous procedure has become more routine.[97] Enteroscopic biopsy has been described, and a high jejunal anastomosis can facilitate utilization of this method.[98] The indications for pancreatic biopsy include hyperamylasemia, hyperlipasemia, hyperglycemia, or unexplained pain in the vicinity of the pancreas transplant. The differential diagnosis includes pancreatitis, cytomegalovirus (CMV) infection, and toxicity from calcineurin inhibitors and, in the early postoperative period, peripancreatic infection. The histologic grading system developed at the University of Maryland for determining rejection grade in pancreas biopsies is generally used (Table 40-3).[99] Indeterminate rejection may be treated with increases in calcineurin inhibitor dose or pulse corticosteroids. More substantial rejection is generally treated with depleting antilymphocyte antibody therapy, either OKT3 or Thymoglobulin.

As long-term survival of pancreas transplants becomes more commonplace, chronic rejection is emerging as an important problem.[100] Unfortunately, as with kidney transplantation, while newer agents have improved short-term survival by preventing

acute rejection, improvement of short-term survival has not translated into improved long-term graft survival.[101] Chronic rejection is histologically characterized as expansion of fibrous septa within the pancreatic parenchyma. This may progress to lobular atrophy or loss of both acini and β-cells. Although there are parallels to chronic allograft nephropathy, whether chronic calcineurin inhibitor toxicity contributes to chronic pancreas rejection is unknown.

Table 40-3 Diagnosis: Revised Banff Classification for Diagnosis and Grading Pancreas Allograft Rejection[86]

Category	Findings
1. Normal	Absent inflammation *or* inactive septal, mononuclear inflammation not involving ducts, veins, arteries or acini. There is no graft sclerosis. The fibrous component is limited to normal septa and its amount is proportional to the size of the enclosed structures (ducts and vessels). The acinar parenchyma shows no signs of atrophy or injury.
2. Indeterminate	Septal inflammation that appears active but the overall features do not fulfill the criteria for mild cell-mediated acute rejection.
3. Acute T-cell-mediated rejection	Grade I/Mild acute T-cell–mediated rejection—Active septal inflammation (activated, blastic lymphocytes and ±eosinophils) involving septal structures: venulitis (subendothelial accumulation of inflammatory cells and endothelial damage in septal veins), ductitis (epithelial inflammation and damage of ducts), *and/or* focal acinar inflammation. No more than two inflammatory foci per lobule with absent or minimal acinar cell injury. Grade II/Moderate acute T-cell–mediated rejection (requires differentiation from AMR)—Multifocal (but not confluent or diffuse) acinar inflammation (≥3 foci per lobule) with spotty (individual) acinar cell injury and dropout *and/or* mild intimal arteritis (with minimal, <25% luminal compromise). Grade III/Severe acute T-cell–mediated rejection (requires differentiation from AMR)—Diffuse (widespread, extensive) acinar inflammation with focal or diffuse multicellular/confluent acinar cell necrosis *and/or* moderate or severe intimal arteritis, >25% luminal compromise *and/or* transmural inflammation—necrotizing arteritis.
4. Antibody-mediated rejection	Confirmed circulating donor-specific antibody (DSA)—Morphologic evidence of tissue injury (interacinar inflammation/capillaritis, acinar cell damage swelling/necrosis/apoptosis/dropout, vasculitis, and thrombosis). C4d positivity in interacinar capillaries (IAC, ≥5% of acinar lobular surface). Acute AMR 3 of 3 diagnostic components—Consistent with acute AMR 2 of 3 diagnostic components. Requires exclusion of AMR 1 of 3 diagnostic components. Chronic active antibody-mediated rejection—Combined features of categories 4 and 6 in the absence of features of category 3.
5. Chronic allograft arteriopathy	Arterial intimal fibrosis with mononuclear cell infiltration in fibrosis.
6. Chronic allograft rejection/graft fibrosis	Stage I (mild graft fibrosis)—Expansion of fibrous septa; the fibrosis occupies less than 30% of the core surface but the acinar lobules have eroded, irregular contours. The central lobular areas are normal. Stage II (moderate graft fibrosis)—The fibrosis occupies 30–60% of the core surface. The exocrine atrophy affects the majority of the lobules in their periphery (irregular contours) and in their central areas (thin fibrous strands criss-cross between individual acini). Stage III (severe graft fibrosis)—The fibrotic areas predominate and occupy more than 60% of the core surface with only isolated areas of residual acinar tissue and/or islets present.
7. Islet pathology	Recurrence of autoimmune DM (insulitis and/or selective ß-cell loss). Islet amyloid (amylin) deposition.
8. Other histologic diagnosis	Pathologic changes not considered to be due acute and/or chronic rejection. For example, CMV, pancreatitis, PTLD.

Recurrent Autoimmunity

Selective β-cell destruction in pancreas transplants may occur in a pattern similar to the insulitis seen in type 1 diabetes. This pattern is histologically distinct from cellular rejection. Although recurrent autoimmunity has been documented in both immunosuppressed pancreas transplant recipients and nonimmunosuppressed living donor recipients from identical twin siblings, well-documented case series have been infrequent. A variety of associations have been suggested with autoantibodies to glutamic acid decarboxylase (GAD-65) and islet cells (IA-2), but patterns of autoantibody expression have not proven reliable enough to establish their etiologic relevance or prognostic value.[102,103]

Posttransplant Viral Infections

The higher level of immunosuppression given to pancreas transplant recipients compared with kidney transplant recipients, particularly with respect to lymphocyte-depleting induction therapy, places pancreas transplant recipients at risk for conditions known to be influenced by overall immunosuppressive exposure. While rates of CMV infection are generally higher than for kidney recipients, especially when the donor is known to carry the virus, the use of intravenous and oral ganciclovir has reduced the incidence of significant CMV-associated disease.[104,105] The incidence of CMV disease may also be lower in those recipients receiving steroid-free immunosuppression.[105] Data are mixed with respect to the incidence of polyoma-associated, or BK, nephropathy, with some analyses suggesting a higher rate and other an equivalent incidence in SPK recipients compared with kidney-alone recipients.[106,107] As with kidney-alone recipients, those SPK recipients with BK nephropathy have inferior kidney graft survival. Posttransplant lymphoproliferative disorder (PTLD), often associated with Epstein–Barr virus (EBV) infection, has a 5-year incidence of approximately 2%, which is similar to or higher than kidney recipients.[108,109] Pancreas recipients with PTLD have a worse prognosis than other abdominal organ transplants recipients with PTLD.

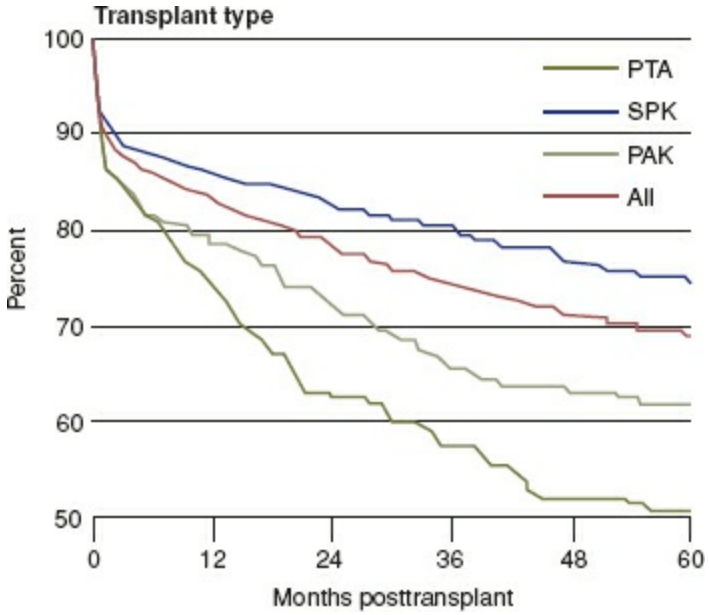

Figure 40-7. Pancreas graft survival among adult pancreas transplant recipients, 2008. (Data from Scientific Registry of Transplant Recipients. 2013 Annual Report. Rockville, MD: Health Resources and Services Administration, Department of Health and Human Services; 2015).

Results of Kidney–Pancreas Transplantation

Current kidney graft survival at 1 and 5 years following SPK transplantation is 96% and 80%, respectively.[50] African Americans have historically had somewhat poorer 5-year graft survival than whites. Kidneys from older donors have the poorest graft survival; 5-year graft survival from donors older than 50 is 68% compared with approximately 80% from donors aged 11 to 34. As opposed to previous decades, 5-year kidney graft survival is not associated with HLA matching.

Pancreas graft survival at 1 and 5 years following SPK transplantation is 86% and 73%, respectively (Fig. 40-7). Worse 5-year graft survival is seen in African-American recipients compared with whites. Recipients with a previous transplant (kidney, pancreas, or both) have worse pancreas graft survival. As with kidney survival, there is no difference in 5-year pancreas graft survival with increasing levels of HLA mismatch.

Registry analyses demonstrate a mortality benefit of SPK transplantation compared with dialysis[110] or deceased donor kidney transplantation alone.[111] These benefits diminish with higher-risk donors, particularly older donors.[112] Patient survival at 1 year and 5 years following SPK transplantation is 98% and 92%, respectively. Race, ethnicity, gender, and transplant center volume are not associated with decreased patient survival at 5 years, and patient survival has improved since 1995 but not appreciably in the past 10 years.[50]

Results of Solitary Pancreas Transplantation

The 1-year pancreas graft survival for recipients of a PAK transplant has improved in the last 5 years, from 78% for PAK transplants performed in 2005 to 88% for transplants performed in 2011.[50] Graft survival for PAK at 5 years is currently 53%. One-year pancreas graft survival for PTA has improved in the last 5 years to 80%. The unadjusted graft survival for PTA at 5 years is 53%. Graft survival rates for PTA are better than PAK early, but the rate of graft failure in the long term is greater for PTA than for PAK. Patient survival for both SPK and PAK recipients is excellent, $>90\%$ at 1 year and $>80\%$ at 5 years.

8 Whether pancreas transplantation positively impacts patient mortality is controversial. One study reported that registrants on the waiting lists for PAK and PTA had better survival rates than recipients who underwent these procedures.[110] Subsequently, another group, using a similar cohort but different analytical methods, reported better survival rates for recipients of solitary pancreas transplantation than registrants on the waiting list.[113] These discrepancies are in part related to the differing methodologies used in the two studies with respect to deaths among those removed from the waitlist and also to variability in the year-to-year death rates on the waiting list. In contrast, both studies demonstrated a conclusive benefit for SPK recipients compared with remaining on the waiting list, which illustrates the importance of restoration of kidney function in this population, as with kidney-alone transplant. While opinions on the specific benefit of the pancreas transplant differ in light of the differing conclusions of these two studies, together the studies indicate any survival benefit conferred by the pancreas transplant is likely to be modest. In fact, most studies do not demonstrate a graft or patient survival advantage of SPK over living donor kidney transplant.[111,114] The survival benefit of SPK over deceased donor kidney transplant alone has been recently further quantified, and while statistically significant, the survival benefit was not considered clinically meaningful.[115]

Effect of Pancreas Transplantation on Secondary Complications of Diabetes Mellitus

There are data that clearly demonstrate the impact of pancreas transplantation on the course of secondary complications of diabetes. This could be predicted from the results of the DCCT, in that pancreas transplantation leads to a complete normalization of blood glucose and glycosylated hemoglobin levels that are vastly superior to those achievable by intensive insulin therapy. Therefore, it should not be surprising that pancreas transplantation has an impact on diabetic complications.

For example, while type 1 diabetic recipients of kidney transplants alone show typical findings of diabetic nephropathy following transplantation, SPK transplantation prevents the development of recurrent diabetic nephropathy.[116] In addition, native diabetic nephropathy, including microvascular structural abnormalities has been demonstrated to reverse 10 years following successful isolated pancreas transplantation.[117,118] These reports demonstrate convincingly that pancreas transplantation has a significant impact on diabetic nephropathy.

Effects on diabetic neuropathy have also been documented using nerve conduction studies, which are significantly improved following pancreas transplantation and SPK.[119] Small corneal nerve fiber regeneration can be detected.[120,121] Furthermore, clinical progression of diabetic neuropathy is significantly diminished compared to nontransplanted controls. However, no study has been able to demonstrate clinical improvement in existing diabetic neuropathy following transplantation. There is also an impact on autonomic neuropathy, with clinical improvement in epinephrine responses to hypoglycemia.[122]

While the DCCT demonstrated a relationship between glycemic exposure and retinopathy, the effect of pancreas transplantation on retinopathy is only modest. While stabilization of moderate retinopathy has been demonstrated, long-term graft function (>3 years) is required.[123,124] Many pancreas transplant candidates have advanced retinopathy, and an effect has not been demonstrated in these individuals. Early acceleration of retinopathy, a phenomenon that has been noted with other methods of improving glycemic control, can occur in the first 6 to 12 months following transplant.

Pancreas transplantation also appears to have a modest impact of cardiovascular disease parameters. Despite the findings of the DCCT trial, assessment of the clinical impact of pancreas transplantation on the progression of cardiovascular disease lacks a definitive large scale study. Positive effects on lipid profiles, blood pressures and left ventricular ejection fraction have been demonstrated.[125] Some centers have demonstrated a positive impact on peripheral vascular occlusive disease, with others demonstrating a worsening of disease.[126,127]

Regardless of the magnitude of objectively demonstrable benefits of pancreas transplantation, most recipients enjoy a dramatic improvement in quality of life.[94,128,129] While many diabetics can adapt quite well to the dramatic glucose fluctuations and the associated morbidity of diabetes, the freedom from insulin and the avoidance of hyper- and hypoglycemia offered by a functioning pancreas transplant is a primary motivator for

many recipients. The fervor with which many candidates pursue pancreas transplantation, especially retransplantation is an indication of the enormous benefit on quality of life for these individuals.

ISLET TRANSPLANTATION

Overview

9 The notion that insulin-producing β-cells could be physically separated from the pancreas and transplanted for the treatment of diabetes has long been recognized. Islet transplantation, as a cellular transplant, has significant potential advantages over whole-organ pancreas transplantation. Islet transplantation does not require an operative procedure.[130] In addition, the potential ability to preserve islets opens up possibilities with regard to distribution, allocation, transportation, and preparation of the islet recipient. Pretreatment of the graft to reduce immunogenicity or enhance survival and function is also possible.[131] Recipients of successful islet transplants can have glucose metabolism and insulin secretion profiles that are close to normal, and maintain metabolic control in a manner equivalent to whole-pancreas transplantation.[132] Although effects on long-term mortality and progression of diabetic complications are unproven, these benefits are also anticipated. From a long-range perspective, the development of islet transplantation sets some of the procedural, technical, and regulatory groundwork for the eventual establishment of stem-cell derived β-cell transplantation. Furthermore, technologic advances in islet isolation for allotransplantation have been very successfully utilized in autotransplantation following pancreatic resection.

History

The development of islet transplantation was historically limited by poor graft survival. The first human islet allograft in a type 1 diabetic was performed in 1974 by the University of Minnesota.[133] The first islet autograft for the treatment of chronic pancreatitis was performed at Minnesota in 1977. Despite intense research in islet transplantation over three decades, until 2000 clinical islet transplantation met with minimal success.[134] While transplanted islets were capable of physiologic function, as evidenced by the 66% rate of insulin independence at 1 year in the 163 recipients of islet autografts from 1974 to 1995, even these recipients had significantly reduced functional β-secretory reserve.[135] Allotransplantation presented an even greater hurdle; in the 96 islet allograft recipients with type 1 diabetes from 1990 to 1994, C-peptide production and insulin independence at 1 year were 25% and 7%, respectively.[134] Of the 270 recipients until 1999, only six had achieved insulin independence for greater than 2 years.

The dramatic improvement in islet transplant outcome reported by the Edmonton Group in 2000 stimulated an increase in islet transplant activity.[136] Several important refinements in islet isolation and immunosuppression have been credited for the improvement in outcomes, including careful attention to pancreas procurement; minimization of cold ischemia time of the pancreas prior to isolation; avoidance of xenoproteins in the islet isolation process; and avoidance of steroids in the immunosuppressive regimen. The use of sequential infusions to achieve insulin independence has been critical to success for many centers. Subsequently, the enthusiasm that accompanied this success was tempered by the inability for many new centers to replicate the success of more established centers,[137] the disappointing long-term survival of the transplants,[138] and the costs associated with islet transplants, which are still not reimbursed by third-party payers and Medicare.[139] As a result, the volume of islet transplants has contracted in the past decade, as have the number of centers performing transplants.[140] Nevertheless, incremental improvement in efficacy and long-term outcomes in selected centers has resulted in sustained optimism that this procedure will ultimately be regarded as an alternative to pancreas transplantation.[141,142]

Islet Isolation

The precise separation of the islets from the other tissues of the pancreas (exocrine cells, lymphatics, and vascular structures), is the most important determinant of successful islet transplantation. One of the limitations of islet isolation is the difficulty in getting a large number of high-quality islets, and consistent success in islet isolation is a combination of science, art, and experience. Although a variety of methods have been utilized, most currently employ some modification of the semiautomated method described by Ricordi in 1988.[143] This method combines mechanical distension with enzymatic digestion of the pancreas. After cleaning the pancreas of surrounding fat, the pancreatic duct is cannulated with an angiocatheter and the pancreas is distended and loaded with warm collagenase solution, which digests the pancreas.[144] The pancreas is then placed into a sterile chamber, which also contains a number of stainless steel or glass spheres. Additional collagenase solution is added, and the chamber is attached to a shaking apparatus or agitated by hand. The collagenase solution is recirculated and kept at 37°C as the chamber is agitated. Agitation of the chamber allows the spheres to continue to disrupt the structural integrity of the pancreas as it digests. Following digestion, the separation of islets from nonislet tissue is performed via density gradient centrifugation. After suspension in culture media, islets are counted and assessed for sterility, purity, viability, and functional capacity. As islet isolation in the United States is regulated by the U.S. Food and Drug Administration, stringent product release criteria are in place to ensure the quality of the transplanted islets.

The percentage of islet isolations that result in a transplantable preparation varies widely among centers, between 25% and 70%, and depends both on donor selection practices and the experience and expertise of the particular center. Many elements of the process, such as collagenase batch or type, gradient preparation, the use of culture and culture conditions, and additives to prevent islet loss, are not standardized. This variability reflects both the need for improvements in isolation efficiency and the art/science currently inherent in the process. The ultimate goal is to develop a reproducible process with enough fidelity to allow islet preparations to be biologically licensed, which appears to be a major barrier to federal funding for the procedure, which will be necessary for broader application.

Patient Selection

Candidates for islet transplantation are selected in a similar manner as for whole-organ pancreas transplantation. Islet transplantation is currently limited to adult type 1 diabetics with progressive diabetic complications who have failed intensive insulin therapy. Because islet transplantation remains experimental therapy with limited availability, the procedure is generally offered only to ideal candidates with minimal medical conditions other than diabetes. Most centers require evaluation and/or a period of treatment by an experienced endocrinologist specializing in diabetes. Candidates with coronary artery disease, chronic infections, including hepatitis B and C, or a prior solid-organ transplant are excluded. Nonuremic candidates must be free of renal insufficiency, due to concerns about aggravation of nephropathy by calcineurin inhibitors. Since efficacy of the islet transplant appears to be related to the number of islets transplanted per kilogram of recipient body weight, only lean (<70 kg or BMI <28) recipients are selected. Although most islet transplants are currently performed in nonuremic diabetics, islet transplants either concurrent with or following kidney transplantation are also performed.[145,146]

Donor Selection/Procurement/Preservation

Donor selection for islet isolation differs from that for whole-pancreas transplantation in several respects. While the ideal donor for islet isolation is still young and healthy, the age and weight criteria are less stringent than for whole-pancreas transplantation. Donors greater than age 50, donors on vasopressors, and especially obese donors are all perfectly suitable for islet isolation. Since the ideal pancreas is easily distensible and digestible, fatty pancreata are felt to be especially suitable, whereas fibrotic pancreata are not. As previously mentioned, pancreata from older and obese donors (which are infrequently used for whole pancreas) are preferentially allocated for islet transplantation rather than for regional and national sharing for whole-pancreas transplantation.[52]

The pancreas is procured in a manner similar to whole-pancreas transplantation. However, less attention to preservation of vascular structures is required. Attention is paid to surface cooling following flushing of preservation solution, and avoidance of pancreatic injury. A number of reports have highlighted the importance of a dedicated team trained in pancreas procurement in the success of islet isolation.[147,148] Expanded use of the two-layer technique of pancreas preservation, using both standard preservation solution (UW solution or HTK) and oxygenated perfluorocarbon solution, has resulted in increased islet yields.[149–152] The two-layer technique also permits the successful use for islet transplantation of pancreata subjected to prolonged cold ischemia as long as 18 hours. Success with pancreata from DCD has been reported.[153]

Transplant Techniques

The portal circulation of the liver is currently the preferred site for islet transplantation (Fig. 40-8).[154] This can be performed by a minilaparotomy, with infusion of the islets into a peripheral mesenteric vein. However, most centers utilize interventional radiology techniques, avoiding both a surgical incision and general anesthesia. Percutaneous transhepatic portal vein catheterization is done under ultrasound and fluoroscopic guidance, with usually a small gauge (4-French) catheter. The islets are infused into the portal vein through the catheter by either gravity from an infusion bag or by hand injection, and the islets lodge in the hepatic parenchyma. Portal vein pressure is monitored intermittently throughout the procedure. Following infusion of the islets, hemostasis is usually achieved using a combination of coils and gelfoam. Recipients receive heparin in the islet preparation, systemically during the procedure, and in the perioperative period as prophylaxis against portal vein thrombosis, a now rare but serious complication.

Perioperative Care

Although islet transplantation is in theory an outpatient procedure, it is not uncommon for recipients to receive a few days of inpatient care for monitoring purposes. Immediately following the islet transplant, patients are maintained on bed rest for a short interval and monitored for bleeding. Liver function tests are monitored, and a liver ultrasound is frequently done to assess portal venous flow and to check for hematoma. It has been demonstrated that intensive glycemic control with insulin in the immediate posttransplant period is beneficial for islet function.[155] Hence, many centers will give insulin postoperatively to keep the serum glucose tightly controlled, in order to "rest" the islets. Additional adjuncts to prevent the instant blood-mediated inflammatory reaction (IBMIR), which results in early islet loss and reduced β-cell mass in the recipient, may include antioxidants such as Vitamin E, etanercept (anti-TNFα antibody), anakinra (IL-1β antagonist), reparixin (CXCR1/2 inhibitor), pentoxifylline, and others.[156]

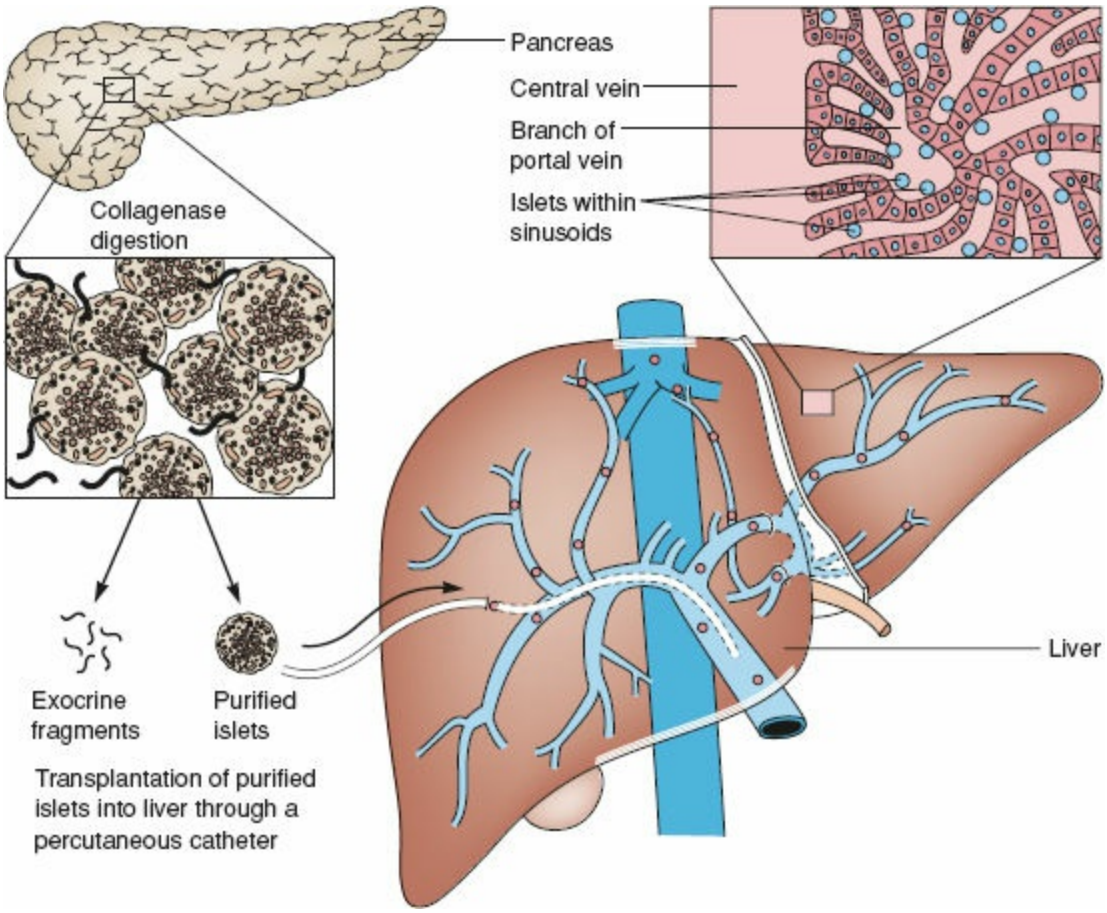

Figure 40-8. Islet transplantation. The pancreas is procured as a whole organ from the donor. The islets are isolated from the pancreas and are purified and infused into a cannula placed in a branch of the recipient's portal vein.

Immunosuppression

Current thinking focuses on the importance of the elimination of steroids from the immunosuppressive regimen, which typically uses basiliximab induction, and maintenance therapy with low-dose tacrolimus and sirolimus. Regimens employing mycophenolate mofetil and cyclosporine are also used, and thymoglobulin is an alternative induction agent. The best results for islet–kidney transplantation are cases where steroids are avoided or eliminated at the time of islet transplantation. While long-term effects of either the islet transplant or steroid elimination on kidney function are not known, steroid avoidance in kidney transplant recipients is now routine.[50] Regimens that avoid both steroid and calcineurin inhibitors have been successfully used.[157]

Metabolic Control

Islet recipients show significant improvement in metabolic function and glycemic reserve, although hormonal counter regulation to hypoglycemia is diminished, actual hypoglycemic events are rare.[158] Data from the Collaborative Islet Transplant Registry show that at 1 year, approximately 59% of all transplant recipients were free of severe hypoglycemic events and maintained hemoglobin A1C (HbA1C) level of $<6.5\%$. Of these 1-year responders, 69%, 54%, and 44% maintained this composite endpoint at 2, 3, and 4 years, respectively. Ninety-one percent of all recipients were free of severe hypoglycemic episodes at 1 year, and 80% at 4 years.[141] Islet recipients also demonstrate a reduction in behaviors adopted in avoiding hypoglycemia and attenuation in concerns about hypoglycemic episodes.[159] Islet transplantation also results in improved insulin sensitivity mediated by effects at both the liver and skeletal muscle.[160] However, islet recipients have significantly diminished β-cell reserve than do recipients of whole-pancreas transplants, which may account for their reduced long-term survival.[161] Acute insulin response to intravenous glucose is commonly used to determine islet engraftment, and is a robust early metabolic marker to predict return to insulin therapy.[162] Analyses of the impact on diabetic complications and mortality await further experience.

Complications

Morbidity from islet transplantation is substantial but much less than for whole-pancreas transplantation. The most common serious complication is bleeding (1% to 5%). Most cases of bleeding can be managed nonoperatively with adjustments in anticoagulation, though occasionally laparotomy is required. The side effects of immunosuppression, such as hyperlipidemia and mouth ulcers in sirolimus-containing regimens, are much more common and can significantly affect quality of life.[163] Renal insufficiency is an uncommon but serious consequence.[138] Transient elevations of portal venous pressure during islet infusion and elevations of liver function tests following infusion are common and usually well tolerated.[164,165] However, reduction in liver perfusion during the islet infusion has been linked to premature graft failure.[166] The demonstration of late steatosis has raised concerns about chronic liver disease; to date this has not been reported.[167] CMV infection is rare. Mortality is virtually nil.

Sensitization and the development of posttransplant DSA, which was originally thought not to occur following allogenic islet transplantation, are now recognized as a significant challenge. Recent experience has shown that most recipients showed DSA or autoantibody increases (de novo expression or titer increase) after islet transplantation. Recipients who have a posttransplant antibody increase have similar initial performance but significantly lower graft survival than patients without an increase.[168] Patients with complete graft loss who discontinue immunosuppression had significantly higher levels of anti-HLA antibodies than those with functioning grafts still on immunosuppression.[169] Ways to minimize sensitization in these recipients includes minimizing the number of islet donors used per recipient, and in the absence of donor-specific anti-HLA antibodies, repeating HLA mismatches with subsequent islet infusions.

Results

10 The short-term results of islet transplantation at high-volume centers are approaching that of whole-pancreas transplantation. The most successful centers achieve insulin independence rates of 80% to 90% at 1 year.[136,170–171] In the Immune Tolerance Network multicenter trial of the Edmonton Protocol, success rates at the most successful centers (Edmonton, Minnesota, and Miami) were significantly higher than at the other centers.[137] However, long-term rates of insulin independence are worse than whole-pancreas transplants, but continue to improve. Overall, insulin independence at 3 years after transplant improved from 37% in the years 2003–2006 to 44% in the years 2007–2010, and the islet reinfusion rate was lower: 48% by 1 year in 2007–2010 versus 60% to 65% in 1999–2006. While in most centers less than 50% of recipients are insulin-free at 3 years, in experienced centers the 5-year insulin independence rate approaches 50% which approaches the graft survival of PTA.[138,141,142]

One of the shortcomings of islet transplantation compared with whole-pancreas transplantation is the inability to reverse diabetes with the islets from one pancreas. Most of the recipients in the modern era have required two or more islet infusions to achieve insulin independence. However, some centers have successfully employed single-donor islet transplantation by utilizing careful donor and recipient selection, usually by transplanting islets from pancreata from large donors into small recipients.[170,172–173] As long-term outcome appears to be related to β-cell mass, which is likely to be lower for single-donor infusions, these recipients may return to insulin or require retransplants earlier.[174] At the recipient level, administration of anti-inflammatory agents, whether nonspecific or directed at specific molecular targets, has become the mainstay of perioperative treatment. The ability to maximize the use of islets and minimize islet requirements and pancreas utilization for an individual recipient is critical if islet transplantation is to compare favorably with whole-pancreas transplantation.

Graft Failure

Graft failure appears to occur earlier than for whole-pancreas transplants. This may be related to a lower initial islet mass or the inability to histologically diagnose and treat islet rejection, since the islets are scattered about the liver parenchyma. As with pancreas graft failure, there is no true agreement on what constitutes graft failure, since recipients may require insulin yet make C-peptide and have superior metabolic control compared with pretransplant. Most outcome measures focus on insulin independence as the most stringent, and C-peptide production as the least stringent. Recent findings indicate that immunologic markers of rejection or recurrent autoimmunity, and metabolic indicators may identify recipients at risk for inferior outcomes and impending graft failure, although treatment algorithms based on these predictors are not standardized.[162,168,175–176] A number of investigators have demonstrated the ability to label and identify islets in vivo in recipients in order to monitor functional islet mass—an example of this is ferucarbotran-labelling of islets, which enables their long-term noninvasive visualization by MRI and correlates with sustained C-peptide production.[177]

Recipients with prior graft function who have returned to insulin are candidates for retransplantation. In fact, some centers have used transplanted islets from isolations where yields are insufficient for a primary transplant as retransplants, where the islet requirement may be less if there is still sufficient residual graft function.

Alternative Methods

As the current method of islet allotransplantation has made great progress toward clinical application over a long period of time, other alternative methods have also advanced. There continues to be a great deal of interest in the use of encapsulated islets. These capsules can be made from a variety of materials designed to be permeable enough to permit the passage of insulin and glucose, but to isolate the islet from the immune system. Several pilot clinical trials in humans, with transplantation into the peritoneal cavity without immunosuppression have been reported, which confirms the safety of the procedure and the demonstration of graft function, if not insulin independence.[178,179] No allo- or autoantibody has been detected in this small number of recipients. Human islets can also be shipped safely for long distances after encapsulation and culture without compromising viability and function.[180] The major barriers to graft function and longevity have been the tendency of the capsules to cluster and fibrose, which limits their efficacy.

Animal studies suggest that bone marrow precultured with human islets may enhance the survival and function of transplanted islets, thus significantly improving the therapeutic efficacy of islet transplantation.[181] Other work has cotransplanted mesenchymal stem cells with islets, which may be beneficial for islet engraftment by promoting cell survival/angiogenesis and reducing inflammation.[182,183]

THE FUTURE OF PANCREAS AND ISLET TRANSPLANTATION

Many challenges remain in determining the ideal insulin replacement therapy for type 1 diabetics. While the current allocation system designed to maximize whole-pancreas transplantation ensures the most efficient use of donor pancreata, improvements in the efficiency of islet isolation may require that further refinements be made to allocation policy. Current outcomes support the prioritization of whole-pancreas transplantation over islet transplantation, and sufficient long-term survival reproducible among a larger number of centers may be required before islet transplantation can move further into the mainstream. If this occurs, the reduced morbidity of islet transplantation may mean that a large number of candidates who are not surgical candidates for pancreas transplantation may be islet candidates in the future. Many centers have taken the philosophical step to offer islet transplantation primarily to diabetics who would not otherwise receive immunosuppression, that is, nonuremic diabetics. This is somewhat in contrast to PTA transplantation, which is offered to only the most exceptional candidates. Taken further, islet transplantation could theoretically be open to a large number of type 1 diabetics that would surely exhaust the limited supply of human donor pancreata. However, the experience gained by the development of islet transplantation would surely apply to technologies not affected by donor supply, such as islet xenografts or engineered β-cells, which could have a profound impact on the devastating effects of diabetes on the public health worldwide.

References

1. American Diabetes Association. *National Diabetes Statistics.* Accessed December 1, 2008. http://www.diabetes.org/diabetes-statistics.jsp
2. Geiss LS, Wang J, Cheng YJ, et al. Prevalence and incidence trends for diagnosed diabetes among adults aged 20 to 79 years, United States, 1980–2012. *JAMA* 2014;312(12):1218–1226.
3. Engelgau MM, Geiss LS, Saaddine JB, et al. The evolving diabetes burden in the United States. *Ann Intern Med* 2004;140:945–950.
4. Faideau B, Larger E, Lepault F, et al. Role of beta-cells in type 1 diabetes pathogenesis. *Diabetes* 2005;54(suppl 2):S87–S96.
5. Concannon P, Rich SS, Nepom GT. Genetics of type 1A diabetes. *N Engl J Med* 2009;360:1646–1654.
6. Ziegler AG, Rewers M, Simell O, et al. Seroconversion to multiple islet autoantibodies and risk of progression to diabetes in children. *JAMA* 2013;309(23):2473–2479.
7. Skyler JS. Primary and secondary prevention of type 1 diabetes. *Diabet Med* 2013;30(2):161–169.
8. Skyler JS, Krischer JP, Wolfsdorf J, et al; Diabetes Prevention Trial–Type 1 Diabetes Study Group. Effects of oral insulin in relatives of patients with type 1 diabetes mellitus. *Diabetes Care* 2005;28:1068–1076.
9. Donath MY, Ehses JA, Maedler K, et al. Mechanisms of β-cell death in type 2 diabetes. *Diabetes* 2005;54(suppl 2):S108–S113.
10. Tuomi T. Type 1 and type 2 diabetes. What do they have in common? *Diabetes* 2005;54(suppl 2):S40–S45.
11. Boitard C, Efendic S, Ferrannini E, et al. A tale of two cousins: type 1 and type 2 diabetes. *Diabetes* 2005;54(suppl 2):S1–S3.
12. Cnop M, Welsh N, Jonas J-C, et al. Mechanisms of pancreatic b-cell death in type 1 and type 2 diabetes. *Diabetes* 2005;54(suppl 2):S97–S107.
13. Butler PC, Meier JJ, Butler AE, et al. The replication of beta-cells in normal physiology, in disease and for therapy. *Nat Clin Pract End Metab* 2007;3(11):758–768.
14. Dor Y, Glaser B. Beta-cell dedifferentiation and type 2 diabetes. *N Engl J Med* 2013;368:572–573.
15. Rubin RJ, Altman WM, Mendelson DN. Health care expenditures for people with diabetes mellitus, 1992. *J Clin Endocrinol Metab* 1994;78:809A–809F.
16. American Diabetes Association. Economic costs of diabetes in the US in 2012. *Diabetes Care* 2013;36(4):1033–1046.
17. Gregg EW, Li Y, Wang J, et al. Changes in diabetes-related complications in the United States, 1990–2010. *N Engl J Med* 2014;370:1514–1523.
18. Greene DA, Lattimer S, Ulbrecht J, et al. Glucose-induced alterations in nerve

metabolism: current perspective on the pathogenesis of diabetic neuropathy and future directions for research and therapy. *Diabetes Care* 1985;8:290–299.

19. Sheetz MJ, King GL. Molecular understanding of hyperglycemia's adverse effects for diabetic complications. *JAMA* 2002;288:2579–2588.
20. DCCT Research Group. The effect of intensive treatment of diabetes on the development and progression of long-term complications in insulin-dependent diabetes mellitus. *N Engl J Med* 1993;329:977–986.
21. Nathan DM, Cleary PA, Backlund JY, et al; Diabetes Control and Complications Trial/Epidemiology of Diabetes Interventions and Complications (DCCT/EDIC) Study Research Group. Intensive diabetes treatment and cardiovascular disease in patients with type 1 diabetes. *N Engl J Med* 2005;353(25):2643–2653.
22. Livingstone SJ, Levin D, Looker HC, et al. Estimated life expectancy in a Scottish cohort with type 1 diabetes, 2008–2010. *JAMA* 2015;313(1):37–44.
23. The DCCT/EDIC Research Group. Intensive diabetes therapy and glomerular filtration rate in type 1 diabetes. *N Engl J Med* 2011;365:2366–2376.
24. Garg S, Zisser H, Schwartz S, et al. Improvement in glycemic excursions with a transcutaneous, real-time continuous glucose sensor: a randomized controlled trial. *Diabetes Care* 2006;29(1):44–50.
25. Ceglia L, Lau J, Pittas AG. Meta-analysis: efficacy and safety of inhaled insulin therapy in adults with diabetes mellitus. *Ann Int Med* 2006;145(9):665–675.
26. Phillip M, Battelino T, Atlas E, et al. Nocturnal glucose control with an artificial pancreas at a diabetes camp. *N Engl J Med* 2013;368:824–833.
27. Action to Control Cardiovascular Risk in Diabetes Study Group; Gerstein HC, Miller ME, Byington RP, et al. Effects of intensive glucose lowering in type 2 diabetes. *N Engl J Med* 2008;358(24):2545–2559.
28. Kelly WD, Lillehei R, Merkel F, et al. Allotransplantation of the pancreas and duodenum along with the kidney in diabetic nephropathy. *Surgery* 1967;61:827–837.
29. Sollinger HW, Cook K, Kamps D, et al. Clinical and experimental experience with pancreaticocystostomy for exocrine pancreatic drainage in pancreas transplantation. *Transplant Proc.* 1984;16:749–751.
30. Nghiem DD, Corry RJ. Technique of simultaneous renal pancreatoduodenal transplantation with urinary drainage of pancreatic secretion. *Am J Surg* 1987;153:405–406.
31. Nath DS, Gruessner AC, Kandaswamy R, et al. Outcomes of pancreas transplants for patients with type 2 diabetes mellitus. *Clin Transplant* 2005:19:792–797.
32. Dean PG, Kudva YC, Larson TS, et al. Posttransplant diabetes mellitus after pancreas transplantation. *Am J Transplant* 2008;8(1):175–182.
33. Gruessner RW, Sutherland DE, Drangstveit MB, et al. Pancreas allotransplants in patients with a previous total pancreatectomy for chronic pancreatitis. *J Am Coll Surg* 2008;206:458–465

34. Scientific Registry of Transplant Recipients, special analysis for the Organ Procurement and Transplantation Network Pancreas Committee, 2008.
35. Farney AC, Cho E, Schweitzer EJ, et al. Simultaneous cadaver pancreas living-donor kidney transplantation: a new approach for the type 1 diabetic uremic patient. *Ann Surg* 2000;232:696–703.
36. Gruessner RW, Kendall DM, Drangstveit MB, et al. Simultaneous pancreas-kidney transplantation from live donors. *Ann Surg* 1997;226:471–482.
37. Gruessner RW. Living donor pancreas transplantation. In: Gruessner RW, Sutherland DE, eds. *Transplantation of the Pancreas.* New York, NY: Springer; 2004:429.
38. Gruessner RW, Pugliese A, Reijonen HK, et al. Development of diabetes mellitus in living pancreas donors and recipients. *Expert Rev Clin Immunol* 2011;7(4):543–551.
39. Wiseman AC, Huang E, Kamgar M, et al. The impact of pre-transplant dialysis on simultaneous pancreas-kidney versus living donor kidney transplant outcomes. *Nephrol Dial Transplant* 2013;28(4):1047–1058.
40. Kim SJ, Smail N, Paraskevas S, et al. Kidney function before pancreas transplant alone predicts subsequent risk of end-stage renal disease. *Transplantation* 2014;97(6):675–680.
41. Boggi U, Amorese G, Marchetti P, et al. Segmental live donor pancreas transplantation: review and critique of rationale, outcomes, and current recommendations. *Clin Transplant* 2011;25(1):4–12.
42. Sutherland DE, Radosevich D, Gruessner R, et al. Pushing the envelope: living donor pancreas transplantation. *Curr Opin Organ Transplant* 2012;17(1):106–115.
43. Shah AP, Mangus RS, Powelson JA, et al. Impact of recipient age on whole organ pancreas transplantation. *Clin Transplant* 2013;27(1):E49–E55.
44. Afaneh C, Rich B, Aull MJ, et al. Pancreas transplantation considering the spectrum of body mass indices. *Clin Transplant* 2011;25(5):E520–E529.
45. Mangus RS, Powelson J, Kinsella SB, et al. Pretransplant coronary artery disease associated with worse clinical outcomes in pancreas transplantation. *Clin Transplant* 2013;27(4):E442–E447.
46. Morath C, Mueller M, Goldschmidt H, et al. Malignancy in renal transplantation. *J Am Soc Nephrol* 2004;15:1582–1588.
47. Stehman-Breen CO, Psaty BM, Emerson S, et al. Association of hepatitis C virus infection with mortality and graft survival in kidney–pancreas transplant recipients. *Transplantation* 1997;64:281–286.
48. Honaker MR, Stratta RJ, Lo A, et al. Impact of hepatitis C virus status in pancreas transplantation: a case controlled study. *Clin Transplant* 2002; 16:243–251.
49. Stock P, Roland M, Carlson L, et al. Solid organ transplantation in HIV-positive patients. *Transplant Proc* 2001;33:3646–3648.
50. Scientific Registry of Transplant Recipients. In: Rockville MD, eds. *2012 Annual Report.* Health Resources and Services Administration, Department of Health and

Human Services; 2004.
51. Organ Procurement and Transplantation Network. Organ distribution: pancreas allocation. Policy 11.
52. Stegall MD, Dean PG, Sung RS, et al. The rationale for the new deceased donor pancreas allocation schema. *Transplantation* 2007;83:1156–1162.
53. Axelrod DA, Sung RS, Meyer K, et al. Systematic evaluation of pancreas allograft quality, outcomes, and geographic variation in utilization. *Am J Transplant* 2010;10:837–845.
54. Douzdjian V, Gugliuzza KG, Fish JC. Multivariate analysis of donor risk factors for pancreas allograft failure after simultaneous pancreas-kidney transplantation. *Surgery* 1995;118:73–81.
55. Humar A, Ramcharan T, Kandaswamy R, et al. Technical failures after pancreas transplants: why grafts fail and the risk factors–a multivariate analysis. *Transplantation* 2004;78:1188–1192.
56. Gruessner AC, Gruessner RW. Pancreas transplant outcomes for United States (US) and non-US cases as reported to the United Network for Organ Sharing (UNOS) and the International Pancreas Transplant Registry (IPTR) as of June 2004. *Clin Transplant* 2005;19:433–455.
57. Humar A, Ramcharan T, Kandaswamy R, et al. The impact of donor obesity on outcomes after cadaver pancreas transplants. *Am J Transplant* 2004;4:605–610.
58. Scientific Registry of Transplant Recipients. *Final Analysis for Data request for the Outcomes Model Review Sub-Committee of the OPTN Pancreas Transplantation Committee Meeting of March 5, 2008.*
59. Salvalaggio PR, Davies DB, Fernandez LA, et al. Outcomes of pancreas transplantation in the United States using cardiac-death donors. *Am J Transplant* 2006;6:1059–1065.
60. Fernandez LA, Di Carlo A, Odorico JS, et al. Simultaneous pancreas-kidney transplantation from donation after cardiac death: successful long-term outcomes. *Ann Surg* 2005;242(5):716–723.
61. Berney T, Malaise J, Morel P, et al; The Euro SPK Study Group. Impact of HLA matching on the outcome of simultaneous pancreas–kidney transplantation. *Nephrol Dial, Transplant* 2005;20:ii48-ii53.
62. Fridell JA, Agarwal A, Milgrom ML, et al. Comparison of histidine-tryptophan-ketoglutarate solution and University of Wisconsin solution for organ preservation in clinical pancreas transplantation. *Transplantation* 2004;77:1304–1306.
63. Stewart ZA, Cameron AM, Singer AL, et al. Histidine-Tryptophan-Ketoglutarate (HTK) is associated with reduced graft survival in pancreas transplantation. *Am J Transplant* 2009;9:217–221
64. Rosenlof LK, Earnhardt RC, Pruett TL, et al. Pancreas transplantation. An initial experience with systemic and portal drainage of pancreatic allografts. *Ann Surg*

1992;215:586–597.
65. Frystyk J, Ritzel RA, Maubach J, et al. Comparison of pancreas-transplanted type 1 diabetic patients with portal-venous versus systemic-venous graft drainage: impact on glucose regulatory hormones and the growth hormone/insulin–like growth factor-I axis. *J Clin Endocrinol Metab* 2008;93:1758–1766.
66. Petruzzo P, Lefrancois N, Berthillot C, et al. Impact of pancreatic venous drainage site on long-term patient and graft outcome in simultaneous pancreas-kidney transplantation. *Clin Transplant* 2008:22:107–112.
67. Stratta RJ, Shokouh-Amiri MH, Egidi MF, et al. A prospective comparison of simultaneous kidney-pancreas transplantation with systemic-enteric versus portal-enteric drainage. *Ann Surg* 2001;233:740–751.
68. Bazerbachi F, Selzner M, Marquez MA, et al. Portal venous versus systemic venous drainage of pancreas grafts: impact on long-term results. *Am J Transplant* 2012;12(1):226–232..
69. Gaber AO, Shokouh-Amiri H, Grewal HP, et al. A technique for portal pancreatic transplantation with enteric drainage. *Surg Gynecol Obstet* 1993;177:417–419.
70. Sollinger HW, Sasaki TM, D'Alessandro AM, et al. Indications for enteric conversion after pancreas transplantation with bladder drainage. *Surgery* 1992;112:842–846.
71. Benedetti E, Najarian JS, Gruessner AC, et al. Correlation between cystoscopic biopsy results and hypoamylasuria in bladder-drained pancreas transplants. *Surgery* 1995;118:864–872.
72. Adrogue HE, Matas AJ, McGlennon RC, et al. Do inherited hypercoagulable states play a role in thrombotic events affecting kidney/pancreas transplant recipients? *Clin Transplant* 2007:21:32–37.
73. Troppmann C, Gruessner AC, Dunn DL, et al. Surgical complications requiring early relaparotomy after pancreas transplantation: a multivariate risk factor and economic impact analysis of the cyclosporine era. *Ann Surg* 1998;227:255–268.
74. Stratta RJ, Alloway RR, Lo A, et al. Two-dose daclizumab regimen in simultaneous kidney-pancreas transplant recipients: primary endpoint analysis of a multicenter, randomized study. *Transplantation* 2003;75:1260–1266.
75. Kaufman DB, Iii GW, Bruce DS, et al. Prospective, randomized, multi-center trial of antibody induction therapy in simultaneous pancreas-kidney transplantation. *Am J Transplant* 2003;3:855–864.
76. Freise CE, Kang SM, Feng S, et al. Excellent short-term results with steroid-free maintenance immunosuppression in low-risk simultaneous pancreas-kidney transplantation. *Arch Surg* 2003;138:1121–1126.
77. Kaufman DB, Leventhal JR, Koffron AJ, et al. A prospective study of rapid corticosteroid elimination in simultaneous pancreas-kidney transplantation: comparison of two maintenance immunosuppression protocols: tacrolimus/mycophenolate mofetil versus tacrolimus/sirolimus. *Transplantation*

2002;73:169–177.
78. Kaufman DB, Leventhal JR, Gallon LG, et al. Alemtuzumab induction and prednisone-free maintenance immunotherapy in simultaneous pancreas-kidney transplantation comparison with rabbit antithymocyte globulin induction – long-term results. *Am J Transplant* 2006;6:331–339.
79. Thai NL, Khan A, Tom K, et al. Alemtuzumab induction and tacrolimus monotherapy in pancreas transplantation: one- and two-year outcomes. *Transplantation* 2006;82:1621–1624.
80. Troppmann C, Gruessner AC, Benedetti E, et al. Vascular graft thrombosis after pancreatic transplantation: univariate and multivariate operative and nonoperative risk factor analysis. *J Am Coll Surg* 1996;182:285–316.
81. Finger EB, Radosevich DM, Dunn TB, et al. A composite risk model for predicting technical failure in pancreas transplantation. *Am J Transplant* 2013;13(7):1840–9.
82. Gilabert R, Fernandez-Cruz L, Real MI, et al. Treatment and outcome of pancreatic venous graft thrombosis after kidney-pancreas transplantation. *Br J Surg* 2002;89:355–360.
83. Ciancio G, Julian JF, Fernandez L, et al. Successful surgical salvage of pancreas allografts after complete venous thrombosis. *Transplantation* 2000;70:126–131.
84. Kim YH, Park JB, Lee SS, et al. How to avoid graft thrombosis requiring graftectomy: immediate posttransplant CT angiography in pancreas transplantation. *Transplantation* 2012;94(9):925–930.
85. Garcia-Roca R, Samame J, Garcia-Criado MA. et al. Preservation of pancreas graft function after complete venous thrombosis: report of four cases treated conservatively. *Transplantation* 2012;93(2):214–218.
86. Scheffert JL, Taber DJ, Pilch NA, et al. Clinical outcomes associated with the early postoperative use of heparin in pancreas transplantation. *Transplantation* 2014;97(6):681–685.
87. Sollinger HW, Odorico JS, Knechtle SJ, et al. Experience with 500 simultaneous pancreas-kidney transplants. *Ann Surg* 1998;228:284–296.
88. Nath DS, Gruessner A, Kandaswamy R, et al. Late anastomotic leaks in pancreas transplant recipients – clinical characteristics and predisposing factors. *Clin Transplant* 2005:19:220–224.
89. Niederhaus SV, Leverson GE, Lorentzen DF, et al. Acute cellular and antibody-mediated rejection of the pancreas allograft: incidence, risk factors and outcomes. *Am J Transplant* 2013;13(11):2945–2955.
90. Cantarovich D, De Amicis S, Akl A, et al. Posttransplant donor-specific anti-HLA antibodies negatively impact pancreas transplantation outcome. *Am J Transplant* 2011;11(12):2737–2746.
91. Kersting S, Ludwig S, Ehehalt F, et al. Contrast-enhanced ultrasonography in pancreas transplantation. *Transplantation* 2013;95(1):209–214.

92. Kuo PC, Johnson LB, Schweitzer EJ, et al. Solitary pancreas allografts. The role of percutaneous biopsy and standardized histologic grading of rejection. *Arch Surg* 1997;132(1):52–57.
93. Bartlett ST, Schweitzer EJ, Johnson LB, et al. Equivalent success of simultaneous pancreas kidney and solitary pancreas transplantation. A prospective trial of tacrolimus immunosuppression with percutaneous biopsy. *Ann Surg* 1996;224:440–452.
94. Sutherland DER, Gruessner RWG, Dunn DL, et al. Lessons learned from more than 1,000 pancreas transplants at a single institution. *Ann Surg* 2001;233(4):463–501.
95. Carpenter HA, Engen DE, Munn SR, et al. Histologic diagnosis of rejection by using cystoscopically directed needle biopsy specimens from dysfunctional pancreatoduodenal allografts with exocrine drainage into the bladder. *Am J Surg Pathol* 1990;14:837–846.
96. Atwell TD, Gorman B, Larson TS, et al. Pancreas transplants: experience with 232 percutaneous US-guided biopsy procedures in 88 patients. *Radiology* 2004;231:845–849.
97. Kayler LK, Merion RM, Rudich SM, et al. Evaluation of pancreatic allograft dysfunction by laparoscopic biopsy. *Transplantation* 2002;74:1287–1289.
98. Margreiter C, Aigner F, Resch T, et al. Enteroscopic biopsies in the management of pancreas transplants: a proof of concept study for a novel monitoring tool. *Transplantation* 2012;93(2):207–213.
99. Drachenberg CB, Torrealba JR, Nankivell BJ, et al. Guidelines for the diagnosis of antibody-mediated rejection in pancreas allografts-updated Banff grading schema. *Am J Transplant* 2011;11(9):1792–1802.
100. Humar A, Khwaja K, Ramcharan T, et al. Chronic rejection: the next major challenge for pancreas transplant recipients. *Transplantation* 2003;76:918–923.
101. Waki K, Sugawara Y, Tamura S, et al. Simultaneous pancreas-kidney transplantation in the United States: an analysis of the UNOS registry. *Clin Transpl* 2010;20:35–44.
102. Ringers J, van der Torren CR, van de Linde P, et al. Pretransplantation GAD-autoantibody status to guide prophylactic antibody induction therapy in simultaneous pancreas and kidney transplantation. *Transplantation* 2013;96(8):745–752.
103. Assalino M, Genevay M, Morel P, et al. Recurrence of type 1 diabetes after simultaneous pancreas-kidney transplantation in the absence of GAD and IA-2 autoantibodies. *Am J Transplant* 2012;12(2):492–495.
104. Ricart MJ, Malaise J, Moreno AN, et al; Fernandez-Cruz L the Euro-SPK Study Group. Cytomegalovirus: occurrence, severity, and effect on graft survival in simultaneous pancreas–kidney transplantation. *Nephrol Dial Transplant* 2005;20(suppl 2):ii25–ii32.
105. Axelrod D, Leventhal JR, Gallon LG, et al. Reduction of CMV disease with steroid-free immunosuppresssion in simultaneous pancreas–kidney transplant recipients. *Am J Transplant* 2005;5:1423–1429.

106. Gupta G, Shapiro R, Thai N, et al. Low Incidence of BK virus nephropathy after simultaneous kidney pancreas transplantation. *Transplantation* 2006;82:382–388.
107. Lipshutz GS, Mahanty H, Feng S, et al. BKV in simultaneous pancreas-kidney transplant recipients: a leading cause of renal graft loss in first 2 years posttransplant. *Am J Transplant* 2005;5:366–373.
108. Paraskevas S, Coad JE, Gruessner A, et al. Posttransplant lymphoproliferative disorder in pancreas transplantation: a single-center experience. *Transplantation* 2005;80:613–622.
109. Caillard S, Lamy FX, Quelen C, et al. French transplant centers. Epidemiology of posttransplant lymphoproliferative disorders in adult kidney and kidney pancreas recipients: report of the French registry and analysis of subgroups of lymphomas. *Am J Transplant* 2012;12(3):682–93.
110. Venstrom JM, McBride MA, Rother KI, et al. Survival after pancreas transplantation in patients with diabetes and preserved kidney function. *JAMA* 2003;290:2817–2823.
111. Reddy KS, Stablein D, Taranto S, et al. Long-term survival following simultaneous kidney-pancreas transplantation versus kidney transplantation alone in patients with type 1 diabetes mellitus and renal failure. *Am J Kidney Dis* 2003;41:464–470.
112. Kayler LK, Wen X, Zachariah M, et al. Outcomes and survival analysis of old-to-old simultaneous pancreas and kidney transplantation. *Transpl Int* 2013;26(10):963–972.
113. Gruessner RWG, Sutherland DER, Gruessner AG. Mortality assessment for pancreas transplants. *Am J Transplant* 2006;4(12):2018–2026.
114. Ojo AO, Meier-Kriesche HU, Hanson JA et al. The impact of simultaneous pancreas-kidney transplantation on long-term patient survival. *Transplantation* 2001;71:82–90.
115. Sung RS, Zhang M, Schaubel DE, et al. A reassessment of the survival advantage of simultaneous kidney-pancreas versus kidney-alone transplantation. *Transplantation* 2015;99(9):1900.
116. Bilous RW, Mauer SM, Sutherland DE, et al. The effects of pancreas transplantation on the glomerular structure of renal allografts in patients with insulin-dependent diabetes. *N Engl J Med* 1989;321:80–85.
117. Fioretto P, Steffes MW, Sutherland DE, et al. Reversal of lesions of diabetic nephropathy after pancreas transplantation. *N Engl J Med* 1998;339:69–75.
118. Khairoun M, de Koning EJ, van den Berg BM, et al. Microvascular damage in type 1 diabetic patients is reversed in the first year after simultaneous pancreas-kidney transplantation. *Am J Transplant* 2013;13(5):1272–1281.
119. Kennedy WR, Navarro X, Goetz FC, et al. Effects of pancreatic transplantation on diabetic neuropathy. *N Engl J Med* 1990;322:1031–1037.
120. Tavakoli M, Mitu-Pretorian M, Petropoulos IN, et al. Corneal confocal microscopy detects early nerve regeneration in diabetic neuropathy after simultaneous pancreas and kidney transplantation. *Diabetes* 2013;62(1):254–260.
121. Mehra S, Tavakoli M, Kallinikos PA, et al. Corneal conforcal microsopy detects early

nerve regeneration after pancreas transplantation in patients with type 1 diabetes. *Diabetes Care* 2007;30:2608–2612.

122. Kendall DM, Rooney DP, Smets YF, et al. Pancreas transplantation restores epinephrine response and symptom recognition during hypoglycemia in patients with long-standing type I diabetes and autonomic neuropathy. *Diabetes* 1997;46:249–257.
123. Walsh AW. Effects of pancreas transplantation on secondary complications of diabetes: retinopathy. In: Gruessner RWG, Sutherland DER, eds. *Transplantation of the Pancreas.* New York, NY:Springer; 2004:462–470.
124. Giannarelli R, Coppelli A, Sartini MS, et al. Pancreas transplant alone has beneficial effects on retinopathy in type 1 diabetic patients. *Diabetologia* 2006;49:2977–2982.
125. Boggi U, Vistoli F, Amorese G, et al. Long-term (5 years) efficacy and safety of pancreas transplantation alone in type 1 diabetic patients. *Transplantation* 2012;93(8):842–846.
126. Morrissey PE, Shaffer D, Monaco AP, et al. Peripheral vascular disease after kidney-pancreas transplantation in diabetic patients with end-stage renal disease. *Arch Surg* 1997;132:358–362.
127. Knight RJ, Schanzer H, Guy S, et al. Impact of kidney-pancreas transplantation on the progression of peripheral vascular disease in diabetic patients with end-stage renal disease. *Transplant Proc* 1998;30:1947–1949.
128. Nakache R, Tyden G, Groth CG. Quality of life in diabetic patients after combined pancreas-kidney or kidney transplantation. *Diabetes* 1989;38(suppl 1):40–42.
129. Gross CR, Limwattananon C, Matthees BJ. Quality of life after pancreas transplantation: a review. *Clin Transplant* 1998;12:351–361.
130. Owen RJ, Ryan EA, O'Kelly K, et al. Percutaneous transhepatic pancreatic islet cell transplantation in type 1 diabetes mellitus: radiologic aspects. *Radiology* 2003;229:165–170.
131. Lau H, Reemtsma K, Hardy MA. Prolongation of rat islet allograft survival by direct ultraviolet irradiation of the graft. *Science* 1984;223:607–609.
132. Ryan EA, Lakey JR, Paty BW, et al. Successful islet transplantation: continued insulin reserve provides long-term glycemic control. *Diabetes* 2002;51:2148–2157.
133. Sutherland DE, Matas AJ, Goetz FC, et al. Transplantation of dispersed pancreatic islet tissue in humans: autografts and allografts. *Diabetes* 1980;29(suppl 1):31–44.
134. Brendel MD, Hering BJ, Schultz AO, et al, eds. *International Islet Transplant Registry 2001.* 2001;8:1.
135. Teuscher AU, Kendall DM, Smets YF, et al. Successful islet autotransplantation in humans: functional insulin secretory reserve as an estimate of surviving islet cell mass. *Diabetes* 1998;47:324–340.
136. Shapiro AM, Lakey JR, Ryan EA, et al. Islet transplantation in seven patients with type 1 diabetes mellitus using a glucocorticoid-free immunosuppressive regimen. *N Engl J Med* 2000;343:230–238.

137. Shapiro AM, Ricordi C, Hering BJ, et al. International trial of the Edmonton protocol for islet transplantation. *N Engl J Med* 2006;355(13):1318–1330.
138. Ryan EA, Paty BW, Senior PA, et al. Five year follow-up after clinical islet transplantation. *Diabetes* 2005;54:2060–2069.
139. Markmann JF, Kaufman DB, Ricordi C, et al. Financial issues constraining the use of pancreata recovered for islet transplantation: a white paper. *Am J Transplant* 2008;8(8):1588–1592.
140. Close N, Alejandro R, Hering B, et al. Second annual analysis of the collaborative islet transplant registry. *Transplant Proc* 2007;39:179–182.
141. Tiwari JL, Schneider B, Barton F, et al. Islet cell transplantation in type 1 diabetes: an analysis of efficacy outcomes and considerations for trial designs. *Am J Transplant* 2012;12:1898–1907.
142. Shapiro AM. Islet transplantation in type 1 diabetes: ongoing challenges, refined procedures, and long-term outcome. *Rev Diabet Stud* 2012;9:385–406.
143. Ricordi C, Lacy PE, Firike EH, et al. Automated method for isolation of human pancreatic islets. *Diabetes* 1988;37:413–420.
144. Linetsky E, Bottino R, Lehmann R, et al. Improved human islet isolation using a new enzyme blend, LiberaseTM. *Diabetes* 1997;46:1120–1123.
145. Gerber PA, Pavlicek V, Demartines N, et al. Simultaneous islet-kidney versus pancreas–kidney transplantation in type 1 diabetes mellitus: a 5 year single centre follow-up. *Diabetologia* 2008;51(1):110–119.
146. Kaufman DB, Baker MS, Chen X, et al. Sequential kidney/islet transplantation using prednisone-free immunosuppression. *Am J Transplant* 2002;2:674–677.
147. Lakey JR, Warnock GL, Rajotte RV, et al. Variables in organ donors that affect the recovery of human islets of langerhans. *Transplantation* 1996;61:1047–1053.
148. Kneteman NM, Lakey JR, Kizilisik TA, et al. Cadaver pancreas recovery technique. Impact on islet recovery and in vitro function. *Transplantation* 1994;58:1114–1119.
149. Lakey JR, Tsujimura T, Shapiro AM, et al. Preservation of the human pancreas before islet isolation using a two-layer (UW solution-perfluorochemical) cold storage method. *Transplantation* 2002;74:1809–1811.
150. Ricordi C, Fraker C, Szust J, et al. Improved human islet isolation outcome from marginal donors following addition of oxygenated perfluorocarbon to the cold-storage solution. *Transplantation* 2003;75:1524–1527.
151. Hering BJ, Matsumoto I, Sawada T, et al. Impact of two-layer pancreas preservation on islet isolation and transplantation. *Transplantation* 2002;74:1813–1816.
152. Paushter DH, Qi M, Danielson KK, et al. Histidine-tryptophan-ketoglutarate and University of Wisconsin solution demonstrate equal effectiveness in the preservation of human pancreata intended for islet isolation: a large-scale, single-center experience. *Cell Transplant* 2013; 22:1113–1121.
153. Markmann JF, Deng S, Desai NM, et al. The use of non-heart-beating donors for

isolated pancreatic islet transplantation. *Transplantation* 2003;75:1423–1429.

154. Weimar B, Rauber K, Brendel MD, et al. Percutaneous transhepatic catheterization of the portal vein: a combined CT- and fluoroscopy-guided technique. *Cardiovasc Intervent Radiol* 1999;22:342–344.
155. Bretzel RG, Brandhorst D, Brandhorst H, et al. Improved survival of intraportal pancreatic islet cell allografts in patients with type-1 diabetes mellitus by refined peritransplant management. *J Mol Med* 1999;77:140–143.
156. Citro A, Cantarelli E, Maffi P, et al. CXCR1/2 inhibition enhances pancreatic islet survival after transplantation. *J Clin Invest* 2012;122:3647–3651.
157. Posselt AM, Szot GL, Frassetto LA, et al. Clinical islet transplantation at the University of California, San Francisco. *Clin Transpl* 2010;235–243.
158. Paty BW, Ryan EA, Shapiro AM, et al. Intrahepatic islet transplantation in type 1 diabetic patients does not restore hypoglycemic hormonal counterregulation or symptom recognition after insulin independence. *Diabetes* 2002;51:3428–3434.
159. Radosevich DM, Jevne R, Bellin M, et al. Comprehensive health assessment and five-yr follow-up of allogeneic islet transplant recipients. *Clin Transplant* 2013;27:E715–E724.
160. Rickels MR, Kong SM, Fuller C, et al. Improvement in insulin sensitivity after human islet transplantation for type 1 diabetes. *J Clin Endocrinol Metab* 2013;98:E1780–E1785.
161. Frank A, Deng S, Huang X, et al. Transplantation for type I diabetes: comparison of vascularized whole-organ pancreas with isolated pancreatic islets. *Ann Surg* 2004;240(4):631–640.
162. Hirsch D, Odorico J, Danobeitia JS, et al. Early metabolic markers that anticipate loss of insulin independence in type 1 diabetic islet allograft recipients. *Am J Transplant* 2012;12(5):1275–1289.
163. Hirshberg B, Rother KI, Digon BJ 3rd, et al. Benefits and risks of solitary islet transplantation for type 1 diabetes using steroid-sparing immunosuppression: the National Institutes of Health experience. *Diabetes Care* 2003;26:3288–3295.
164. Casey JJ, Lakey JR, Ryan EA, et al. Portal venous pressure changes after sequential clinical islet transplantation. *Transplantation* 2002;74:913–915.
165. Rafael E, Ryan EA, Paty BW, et al. Changes in liver enzymes after clinical islet transplantation. *Transplantation* 2003;76:1280–1284.
166. Esposito A, Palmisano A, Maffi P, et al. Liver perfusion changes occurring during pancreatic islet engraftment: a dynamic contrast-enhanced magnetic resonance study. *Am J Transplant* 2014;14:202–209.
167. Markmann JF, Rosen M, Siegelman ES, et al. Magnetic resonance-defined periportal steatosis following intraportal islet transplantation: a functional footprint of islet graft survival? *Diabetes* 2003;52:1591–1594.
168. Piemonti L, Everly MJ, Maffi P, et al. Alloantibody and autoantibody monitoring

predicts islet transplantation outcome in human type 1 diabetes. *Diabetes* 2013;62:1656–1664.

169. Naziruddin B, Wease S, Stablein D, et al. HLA class I sensitization in islet transplant recipients: report from the collaborative islet transplant registry. *Cell Transplant* 2012;21:901–908.
170. Hering BJ, Kandaswamy R, Harmon JV, et al. Transplantation of cultured islets from two-layer preserved pancreases in type 1 diabetes with anti-CD3 antibody. *Am J Transplant.* 2004;4:390–401.
171. Froud T, Ricordi C, Baidal DA, et al. Islet transplantation in type 1 diabetes mellitus using cultured islets and steroid-free immunosuppression: Miami experience. *Am J Transplant* 2005;5(8):2037–2046.
172. Gangemi A, Salehi P, Hatipoglu B, et al. Islet transplantation for brittle type 1 diabetes: the UIC protocol. *Am J Transplant* 2008;8:1250–1261.
173. Markmann JF, Deng S, Huang X, et al. Insulin independence following isolated islet transplantation and single islet infusions. *Ann Surg* 2003; 237:741–750.
174. Keymeulen B, Gillard P, Mathieu C, et al. Correlation between b-cell mass and glycemic control in type 1 diabetic recipients of islet cell graft. *PNAS* 2006;103(46):17444–17449.
175. Han D, Xu X, Pastori RL, et al. Elevation of cytotoxic lymphocyte gene expression is predictive of islet allograft rejection in nonhuman primates. *Diabetes* 2002;51:562–566.
176. Shapiro AM, Hao EG, Lakey JR, et al. Novel approaches toward early diagnosis of islet allograft rejection. *Transplantation* 2001;71:1709–1718.
177. Saudek F, Jirak D, Girman P, et al. Magnetic resonance imaging of pancreatic islets transplanted into the liver in humans. *Transplantation* 2010;90:1602–1606.
178. Jacobs-Tulleneers-Thevissen D, Chintinne M, Ling Z, et al. Beta Cell Therapy Consortium EU-FP7. Sustained function of alginate-encapsulated human islet cell implants in the peritoneal cavity of mice leading to a pilot study in a type 1 diabetic patient. *Diabetologia* 2013;56:1605–1614.
179. Basta G, Montanucci P, Luca G, et al. Long-term metabolic and immunological follow-up of nonimmunosuppressed patients with type 1 diabetes treated with microencapsulated islet allografts: four cases. *Diabetes Care* 2011;34:2406–2409.
180. Vaithilingam V, Barbaro B, Oberholzer J, et al. Functional capacity of human islets after long-distance shipment and encapsulation. *Pancreas* 2011;40:247–252.
181. Luo JZ, Xiong F, Al-Homsi AS, et al. Allogeneic bone marrow cocultured with human islets significantly improves islet survival and function in vivo. *Transplantation* 2013;95:801–809.
182. Yeung TY, Seeberger KL, Kin T, et al. Human mesenchymal stem cells protect human islets from pro-inflammatory cytokines. *PLoS ONE* 2012;7:e38189.
183. Ding Y, Bushell A, Wood KJ. Mesenchymal stem-cell immunosuppressive capabilities:

therapeutic implications in islet transplantation. *Transplantation* 2010;89:270–273.

SECTION C: HEAD AND NECK

Chapter 41

Head and Neck

J. Kenneth Byrd and Robert L. Ferris

Key Points

1 Squamous cell carcinoma (SCC) is the most common malignancy of the head and neck region. Tobacco, alcohol, and human papillomavirus are the major risk factors.

2 A cystic neck mass in an adult represents a neck metastasis until proven otherwise, and should not be incised and drained.

3 A multidisciplinary team should evaluate patients with a suspected head and neck tumor for treatment options.

4 Functional reconstruction is equally important as oncologic resection in head and neck surgery.

5 Patients with new hoarseness for more than 2 weeks should be evaluated by a physician capable of performing flexible fiberoptic laryngoscopy.

INTRODUCTION

The head and neck is a complex anatomical subsite, containing the major structures responsible for sight, hearing, smell, speech, and swallowing. Disorders of the head and neck can therefore cause detriment to quality of life by interfering with these functions. Knowledge of the anatomy of the region is crucial to treat patients who present with complaints involving the head and neck, whether benign or malignant. The following chapter will provide an overview of common presentations of head and neck disorders, including head and neck cancer, which accounts for over 50,000 cases per year.

PATIENT EVALUATION

1 As in any clinical evaluation, a careful patient history should be taken, paying particular attention to the timing of onset, severity, progression, and associated symptoms. Table 41-1 lists some of the more common presenting signs and symptoms of head and neck cancer. Social history is of particular importance in head and neck patients, as tobacco and alcohol use synergistically increase the risk of head and neck squamous cell carcinoma (SCC).[1] The clinician should document type, frequency, and duration of use on any patient suspected to have a head and neck disorder. Sexual history may also be of some interest, as the number of oral sexual partners has been associated with an increased risk of HPV-related oropharyngeal cancer.[2]

On physical examination, the physician should proceed systematically through each area of the head and neck. Gross deformity, skin lesions, previous incisions or scars, and radiation sequelae should be noted. The physician should pay attention to any breathing difficulty, including stridor, stertor, and nasal obstruction.

Each mucosal subsite of the head and neck region should be thoroughly inspected (Table 41-2). A headlight or headlamp should be used to inspect the oral cavity, oropharynx, and larynx/hypopharynx (if indirect mirror laryngoscopy is performed). Dentures should be removed prior to bimanual examination of the oral cavity and oropharynx using tongue blades to check all mucosal surfaces.

Although some otolaryngologists prefer indirect laryngoscopy to visualize the larynx and hypopharynx, patients with large tongues and/or hyperactive gag reflexes may be difficult to examine. In the setting of possible malignancy, we recommend that all patients undergo flexible fiberoptic laryngoscopy, which provides excellent dynamic visualization and the ability to record images and video when coupled with appropriate equipment. Additionally, flexible or rigid endoscopy provides a more detailed view of the nasal cavity than anterior rhinoscopy. Figure 41-1 demonstrates the view of the larynx provided by in-office stroboscopy.

The cervical lymph nodes should be palpated carefully, taking note of the location in levels I to V of the neck, as described by Robbins et al. (Fig. 41-2),[3] as well as lateral and superior–inferior mobility. Pulsatility of the mass may suggest a vascular pathology, and should not be biopsied prior to imaging. The laryngeal and tracheal framework should be examined to determine any disruption to the normal architecture, as well as the position relative to the sternum. The thyroid gland should also be palpated as part of every head and neck examination, although this is addressed in a separate chapter.

In the neurologic examination, particular attention should be paid to the cranial nerves. In sinonasal pathology, hyposmia may be due to nasal obstruction, or alternatively due to direct involvement of the olfactory nerve. Extraocular movement abnormalities can result from orbital or skull base pathology. Temporal wasting or facial numbness may be a sign of perineural spread in the trigeminal nerve, and facial weakness or twitching in the setting of a parotid mass suggests malignancy. Ipsilateral vocal paralysis or impaired palatal elevation may suggest involvement of the vagus nerve, important to note in skull base paragangliomas. Preoperative shoulder weakness in the setting of lymphadenopathy

may prompt the surgeon to counsel the patient about the need for radical neck dissection, as the spinal accessory nerve may be involved by tumor.

WORKUP

In the setting of an accessible tumor (e.g., oral tongue, tonsil) biopsy may be performed in the office under local anesthesia. In more distal subsites, operative direct laryngoscopy is required. For palpable salivary or cervical masses, fine-needle aspiration is easily performed without image guidance. In most patients with head and neck pathology, CT with contrast is the preferred imaging modality. MRI can be of value in some cases, such as when perineural spread is a concern, to evaluate for invasion of intrinsic tongue musculature in oral or oropharyngeal cancer, and for orbital and dural assessment. When malignancy is diagnosed, metastatic workup with PET/CT or chest CT should be performed in stage III/IV pathology.

Table 41-1 Differential Diagnosis of the Neck Mass

Congenital	Branchial cleft
	Vascular malformation
	Thyroglossal duct cyst
	Dermoid
Infectious	Tuberculosis
	Atypical mycobacteria
	Cat scratch disease
	Mononucleosis
	Odontogenic
	Sialadenitis
Inflammatory	Sarcoidosis
	Sialadenosis
Trauma	Hematoma
	Laryngocele
Neoplasm	Epithelial (SCC, melanoma, adenocarcinoma)
	Salivary
	Neurogenic
	Sarcoma
	Lipoma
	Lymphoproliferative

Table 41-2 Subsites of Head and Neck

Skin	
Anterior skull base	Nasal cavity Paranasal sinuses Orbit
Oral cavity	Tongue/floor of mouth Gingiva/retromolar trigone Hard palate
Pharynx	Nasopharynx Oropharynx Hypopharynx
Larynx	Supraglottis Glottis Subglottis
Salivary	Parotid Submandibular Sublingual Minor
Lateral skull base	Parapharyngeal space Infratemporal fossa Temporal bone

AIRWAY MANAGEMENT

Although the anesthesia team is primarily responsible for evaluating the airway, the surgeon should share some responsibility in patients with head and neck disorders. A number of patient factors have been described in the anesthesia literature as predictors of difficult laryngoscopy, including sternomental distance, Mallampati score, thyromental distance, and mouth opening.[4] However, the head and neck surgeon will be more aware of the endoscopic airway anatomy as a result of preoperative imaging and laryngoscopy. Bulky supraglottic and oropharyngeal masses may lead to failure of mask ventilation and difficulty passing an orotracheal tube; lesions prone to bleeding may cause similar problems. Patients with fibrosis from prior radiation or chemoradiation may have impaired laryngeal excursion, in addition to trismus. In a prospective study of intubation in patients with head and neck pathology, one group found that prior radiotherapy, a diagnosis of cancer, and supraglottic or glottic subsite were predictive of airway difficulty.[5] Indeed, it is imperative that the surgeon and anesthesiologist communicate about the airway plan prior to induction.



Figure 41-1. In-office stroboscopy demonstrates a normal larynx with glottis open. Stroboscopy allows for dynamic visualization of the mucosal wave and arytenoid movement.

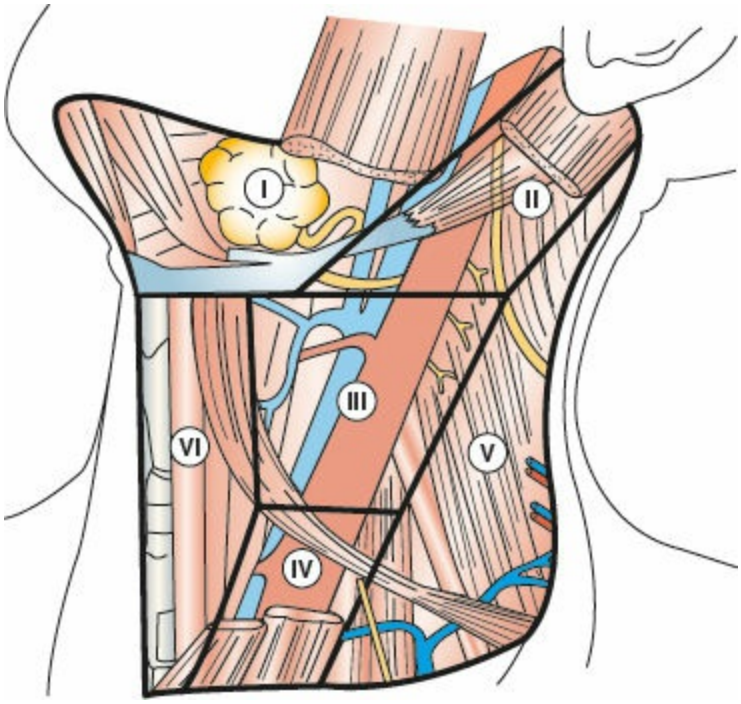

Figure 41-2. The cervical lymph nodes are divided into six groups, or levels.

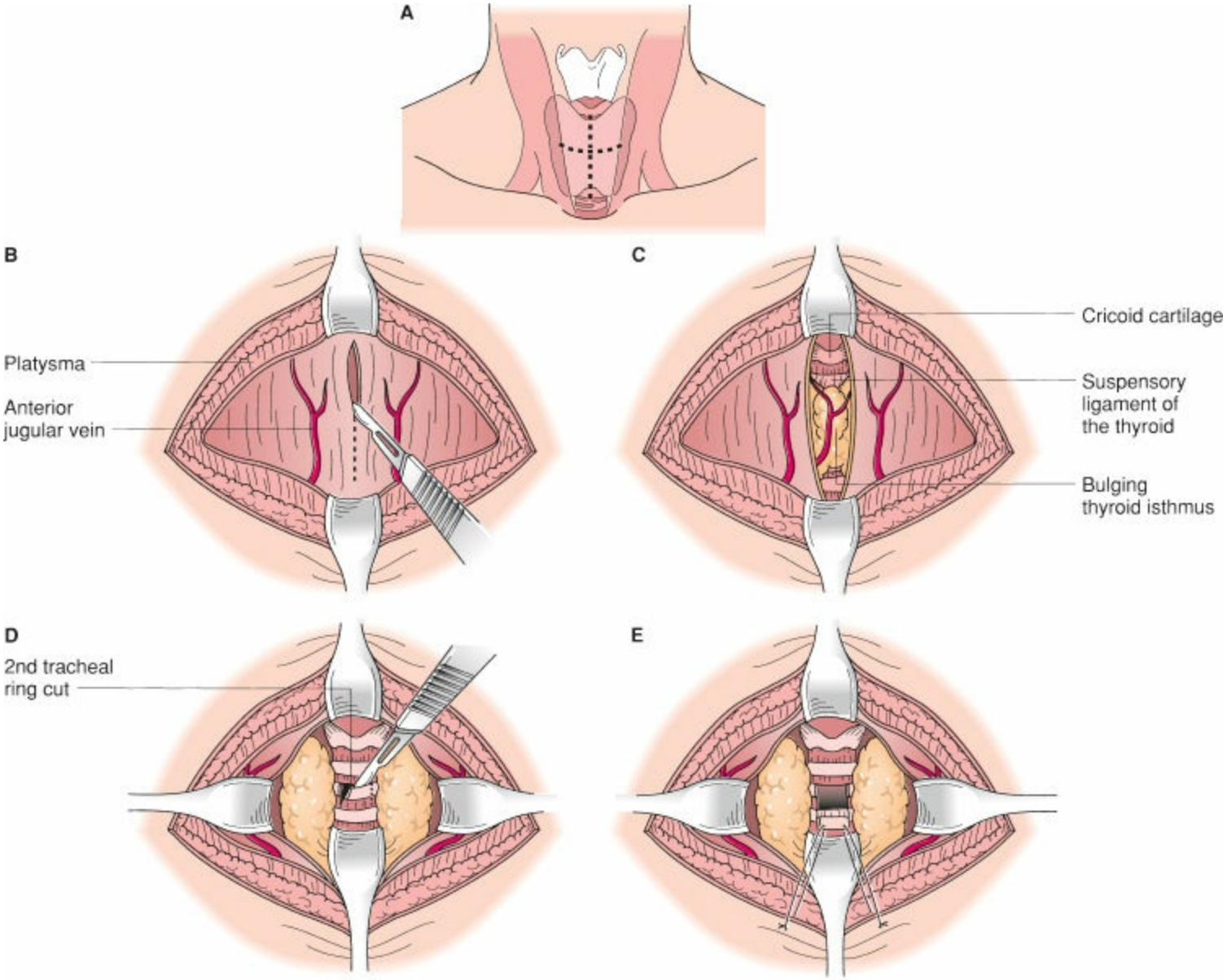

Figure 41-3. Tracheostomy. **A:** The incision for an elective tracheostomy is typically placed on a horizontal axis, approximately two finger breadths above the sternal notch. A vertical incision allows for less bleeding when the procedure must be performed emergently. **B:** The strap muscles are separated in the midline. The thyroid isthmus may bulge into the wound (**C**), necessitating inferior retraction or division (**D**). **E:** After the second tracheal ring is cleaned off, an inferiorly based flap (i.e., Bjork flap) is developed in the tracheal wall and sutured to the skin. This allows for easy access to the trachea while the tract is maturing.

In patients for whom difficulty is predicted, fiberoptic nasotracheal or orotracheal intubation may be safely performed with the patient spontaneously breathing with topical anesthesia and sedation. Alternatively, planned awake tracheotomy is an option in patients with severe obstruction and abnormal anatomy. Additionally, a tracheotomy kit should always be nearby for emergent cricothyrotomy or tracheotomy, should it be necessary. Figure 41-3 demonstrates the typical sequence of steps in a tracheotomy.

INFECTIOUS

Pharyngitis and Abscesses

Acute pharyngitis is a common presentation in outpatient offices and the emergency department. Although group A streptococcus is a concern due to its potential complications, it accounts for only 10% to 15% of pharyngeal infections in adults; the majority are viral. Patients with fever, tonsillar exudates, absence of cough, and cervical lymphadenopathy are more likely to have bacterial pharyngitis, and should be tested for streptococcus and subsequently treated with amoxicillin, clindamycin, or a macrolide.[6] Those without streptococcal pharyngitis may generally be treated with hydration and analgesics, although antibiotics may be indicated if atypical bacteria are suspected or if symptoms fail to improve.

The most common head and neck abscess is the peritonsillar abscess, which typically arises from untreated bacterial pharyngitis that leads to bacterial invasion of the parapharyngeal space if not drained. Patients typically present with throat pain, trismus, dysphagia and odynophagia, and a muffled voice. Physical examination reveals palatal and tonsillar bulging and uvular deviation toward the unaffected side. Imaging is often unnecessary but may be useful in equivocal cases. Drainage is performed at bedside after topical anesthetic spray and injected lidocaine or bupivacaine are used to anesthetize the area; trismus is often greatly improved after local is administered, facilitating drainage. An 18-gauge needle can be of use to localize the pus collection and plan the incision. An 11 or 15 blade is then used to make an incision, which is enlarged with a hemostat when the abscess is localized. Palpation of the tonsil with the hemostat or a cotton swab will express the remaining fluid (Fig. 41-4). Antibiotics with broad coverage (e.g., amoxicillin-clavulanate or clindamycin) should be prescribed for 10 to 14 days.[7] Patients with a history of multiple peritonsillar abscesses should be considered for tonsillectomy.

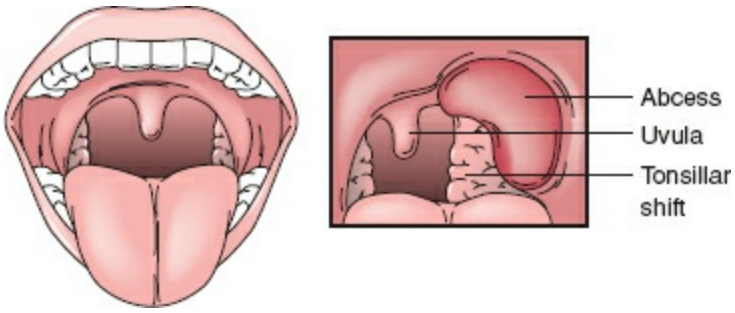

Figure 41-4. Schematic representation of a peritonsillar abscess. Purulence develops between the tonsillar capsule and the superior pharyngeal constrictor muscle. As a result, the palate bulges and the tonsil is deviated medially. Inflammation in the region of the pterygoid muscles results in pain and trismus which may be significant.

In evaluating the patient with pharyngitis or a peritonsillar abscess, it is important to differentiate from epiglottitis. Patients may present similarly, with odynophagia, a muffled voice, and drooling. However, patients with acute bacterial epiglottitis are more toxic in appearance and have impending airway compromise. Plain film radiographs of the neck will display the “thumbprint” sign, or an edematous epiglottis. If the patient is

tolerant, transnasal flexible laryngoscopy can be used to confirm the diagnosis, but early securing of the airway in the operating room with tracheotomy or fiberoptic intubation is paramount.

Progression of odontogenic or pharyngeal infections can lead to deep neck space infections, as well. Early evaluation of the patient's airway is paramount in deep neck infections, as they may rapidly progress, particularly in the immunocompromised (e.g., diabetics). Elective intubation is often required, and tracheotomy may be necessary in the setting of prolonged airway edema. Of particular concern are infections involving the floor of mouth, or Ludwig angina, which can quickly progress bilaterally, and cause airway compromise via posterior displacement of the base of tongue and trismus. In this setting, awake fiberoptic transnasal intubation may be attempted, but the surgeon should be prepared for awake tracheotomy. Infections in other neck spaces, including the Danger Space and Prevertebral Space, may spread quickly through the entire neck and cause rapid decompensation. Figure 41-5 lists the relevant deep neck spaces and paths of spread.

Operative intervention is usually required for deep neck infections, involving incision and drainage of the affected spaces. Copious irrigation with placement of suction drains is recommended to decrease the likelihood of reaccumulation, and reexploration is occasionally needed. Additionally, the odontogenic source of the infection should be addressed, ideally at the same time as the incision and drainage.

SINUSITIS

In the clinical setting, patients and caregivers often lump upper respiratory infection (URI) and "sinusitis" together. Indeed, the common cold virus is the most common infection associated with URI, which concomitantly involves the nasal mucosa and paranasal sinuses. Rhinosinusitis is therefore a better term than "sinusitis." Rhinosinusitis is classified as acute, subacute, and chronic based on length of duration: less than 4 weeks, 4 to 12 weeks, and greater than 12 weeks, respectively.[8]

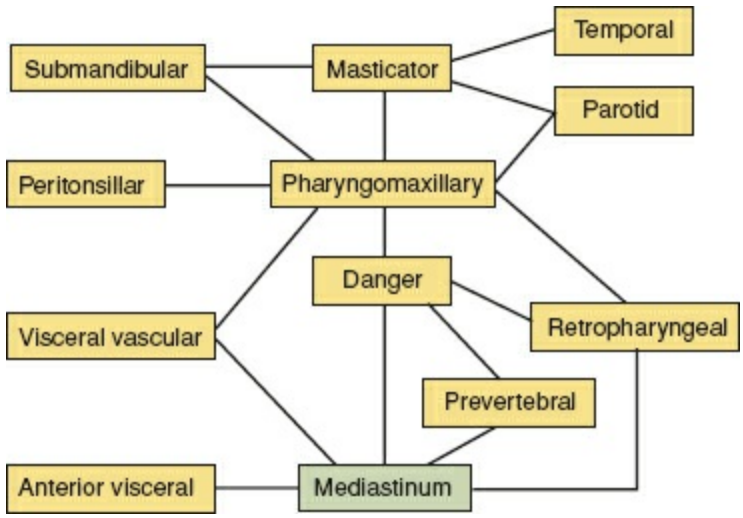

Figure 41-5. The deep spaces of the neck are distinct but interconnected compartments. Infections in any one of these may spread to involve other potential spaces and critical structures contained therein.

In the acute setting, it is important to differentiate between viral and bacterial rhinosinusitis, as both will present with fever, facial pressure and/or pain, nasal obstruction, and purulent or discolored nasal discharge. The American Academy of Otolaryngology-Head and Neck Surgery Clinical Practice Guideline for adult sinusitis notes that the vast majority of URIs are viral, and that bacterial rhinosinusitis should be suspected when symptoms persist after 10 days or worsen after a period of improvement.[8]

In the setting of presumed viral rhinosinusitis, patients should be treated with antipyretics and analgesics, and decongestants may be considered. For acute bacterial rhinosinusitis, amoxicillin was recommended as the first-line antibiotic in the 2007 guidelines; however, some now recommend amoxicillin-clavulanate for 5 to 7 days due to the increasing prevalence of resistance. A fluoroquinolone or doxycycline may be used as first-line treatment in patients with penicillin allergy.[9]

Surgery is not indicated for patients with acute sinusitis, unless orbital or intracranial involvement occurs, or in the setting of an immunocompromised patient who fails to respond to medical treatment. Similarly, imaging is recommended against, except in the aforementioned situations.[8] However, *complicated* acute bacterial rhinosinusitis (Table 41-3) should be suspected when visual, mental status, or neurologic changes are present. Proptosis, chemosis, and periorbital edema may signify extension of infection into the orbit (Fig. 41-6). Contrasted CT is useful to determine the extent of disease, and may be

complemented by MRI. Prompt consultation with ophthalmology and/or neurosurgery is warranted for these cases.

Acute, severe, evolving sinonasal complaints in the immunocompromised should raise concern for acute invasive fungal sinusitis, which is rapidly progressive and fatal if untreated. Patients with HIV, organ transplant, chemotherapy-induced neutropenia, and even uncontrolled diabetes mellitus may be susceptible. The organisms most commonly associated are from the *Aspergillus, Rhizopus, Mucor, Rhizomucor,* and *Absidia* genera.[10] Nasal endoscopy should be performed at the bedside, and which will demonstrate pale or black, necrotic mucosa, typically involving the turbinates or septum. Frozen section biopsy is performed, rather than fungal cultures, as immediate diagnosis is imperative. The patient should be emergently and aggressively debrided to bleeding, vascularized tissue in the operating room, and concomitant consultation of an Infectious Disease specialist with initiation of antifungal drugs is advised. Reversal of the underlying immunocompromised state will improve prognosis, as well.

COMPLICATIONS

Table 41-3 Complications of Sinusitis

Local
Mucocele
Pott puffy tumor
Osteomyelitis
Orbital
Preseptal cellulitis
Orbital (postseptal) cellulitis
Subperiosteal abscess
Orbital abscess
Cavernous sinus thrombosis
Intracranial
Meningitis
Epidural abscess
Subdural abscess
Intracerebral abscess
Cavernous sinus thrombosis
Superior sagittal sinus thrombosis

From Epstein VA, Kern RC. Invasive fungal sinusitis and complications of sinusitis. *Otolaryngol Clin North Am.* 2008;41:497, with permission.

SIALADENITIS

Patients with sialadenitis present with acute onset pain in the parotid or submandibular areas. Patients who are debilitated, dehydrated, or have decreased salivary flow due to medications or other factors (e.g., previous radiation) are predisposed to salivary gland infection. Sialadenitis is a clinical diagnosis, based on reproducible pain with palpation of the affected gland(s), temporal course, and presence of purulence in Warthin or Stensen duct. Sialadenitis may be viral or bacterial, viral infections (mumps, HIV, etc.) having a tendency to affect multiple glands bilaterally. In acute bacterial sialadenitis, symptoms tend to present quickly, with purulent salivary secretions, tense, erythematous skin, fever, and leukocytosis. Most infections are caused by *Staphylococcus aureus,* although a variety of anaerobes and other oral pathogens may be cultured.[11]



Figure 41-6. Contrasted coronal CT demonstrates a right-sided periorbital abscess (*asterisk*) arising in a child with acute bacterial ethmoid sinusitis. Urgent ophthalmologic consultation was obtained, which revealed increased intraocular pressure. The child was taken for endoscopic ethmoidectomy and orbital decompression.

Patients with uncomplicated sialadenitis should be treated with hydration, sialogogues, gland massage, and broad spectrum antibiotics if bacterial pathogens are suspected. If purulent saliva is noted, cultures may be sent. Worsening of symptoms after initiation of therapy should prompt consideration of abscess development, and imaging with ultrasound or CT should be performed. Recurrent or chronic salivary infections less often result from chronic infection, but rather structural or inflammatory disorders are more common. Connective tissue disorders, such as Sjogren syndrome, rheumatoid arthritis, and sarcoidosis may present with or develop salivary gland involvement, and should prompt consultation with a rheumatologist if suspected. Alternatively, a history of repeated episodes of sialadenitis or gland fullness can be due to sialolithiasis. Physical examination with palpation of the submandibular and parotid ducts will reveal a palpable mass in cases with large, distal stones. These are best approached via intraoral cutdown

on a lacrimal probe. However, smaller stones in the hilum or gland parenchyma may require imaging for diagnosis.

Although parotidectomy or submandibular gland excision has long been the treatment for such stones and strictures, improvements in fiberoptic technology have led to increasing adoption of sialendoscopy to implement gland-sparing interventions. A recent meta-analysis demonstrated a high proportion of success and low incidence in complications for patients undergoing sialendoscopy for obstructive disease.[12]

Finally, it is important to rule out neoplasia in patients with repeated salivary complaints, as tumors can cause transient obstruction, as well.

CYSTIC NECK INFECTIONS

2 A variety of head and neck infections may present atypically. While it is true that adult patients may *rarely* manifest infectious, cystic neck lesions, they should be presumed malignant until proven otherwise because of the high prevalence cystic lymph node metastasis in SCC, particularly the HPV-related disease (Fig. 41-7). Large, necrotic lymph nodes may become painful and swollen if hemorrhage or superinfection occurs, mimicking benign disease. It is important to note that incision and drainage of cancerous lymph nodes can hinder cure due to widespread tumor seeding.

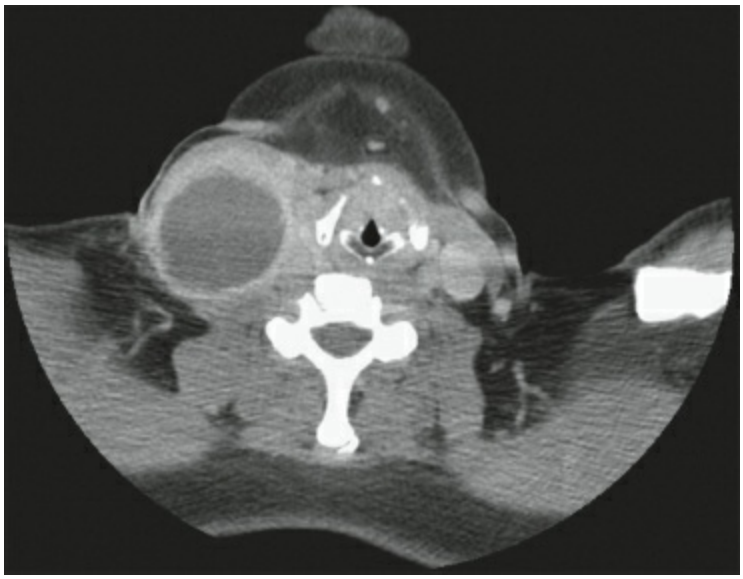

Figure 41-7. Contrasted axial CT demonstrates a large, rim-enhancing mass involving the right level III and IV neck. Image-guided FNA was required to confirm HPV-related squamous cell carcinoma due to its cystic nature.

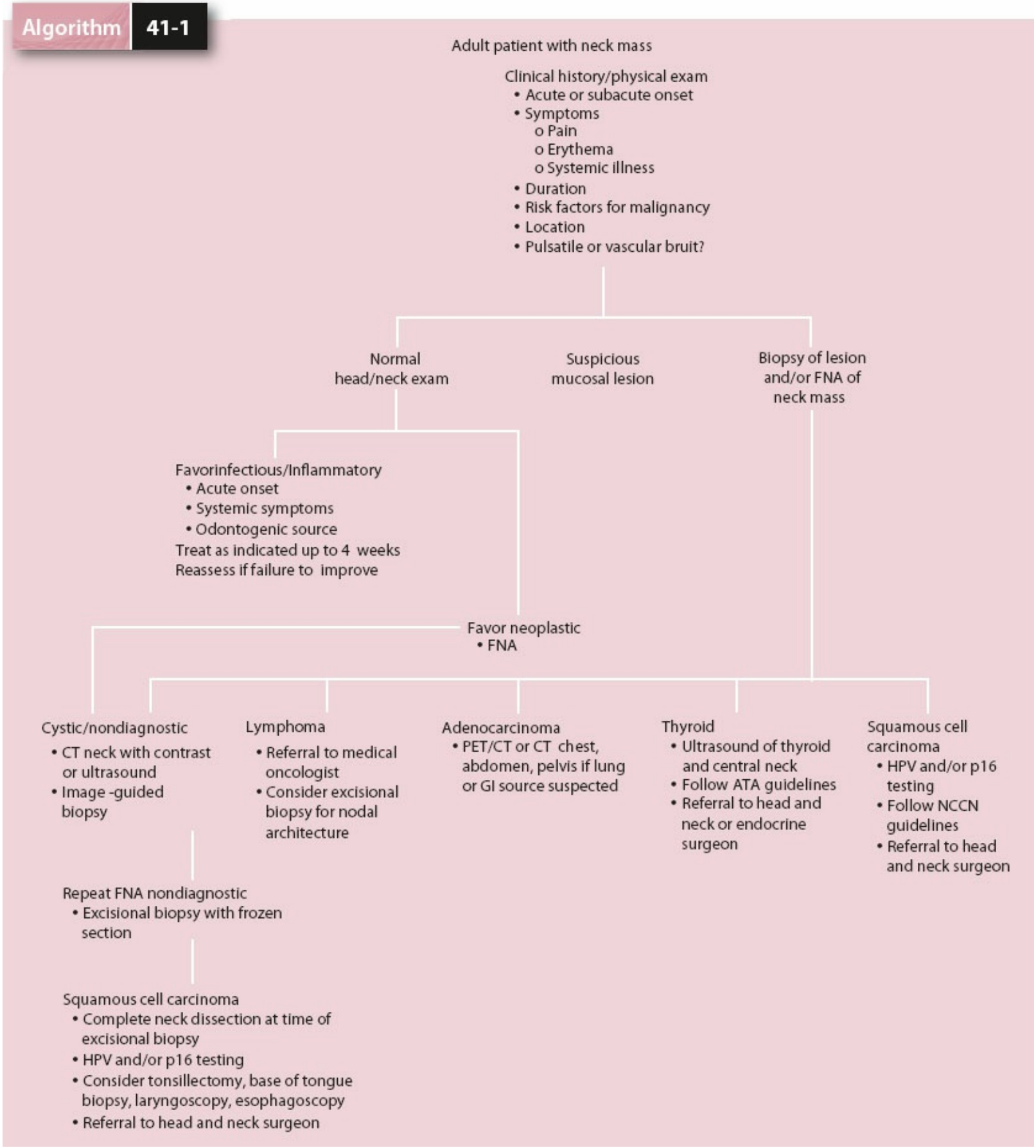

Algorithm 41-1. Workup of a Neck Mass in an Adult Patient.

With the previous caveats, the infrequent adult patient may present with atypical suppurative lymphadenitis or an infected, previously unrecognized branchial cleft cyst. If history and physical examination are suspicious for this, a limited trial of antibiotics may

be initiated for 1 to 2 weeks to monitor for improvement. However, further workup, including complete physical examination, imaging, and fine-needle aspiration should be simultaneously undertaken to prevent delays in diagnosis. If a cystic neck mass is to be removed for diagnosis, a frozen section should be sent at the time of surgery, with completion neck dissection planned if SCC is present. Algorithm 41-1 is a suggested approach to the adult with a lateral neck mass.

HEAD AND NECK NEOPLASMS

3 Patients with diagnosed head and neck tumor should be referred to a center with a multidisciplinary care team, including head and neck surgeons, radiation oncologists, medical oncologists, dentists, pathologists, radiologists, speech therapy, and social work. Treatment of head and neck neoplasms, whether surgical or nonsurgical, is likely to have an impact on speech, swallowing, and overall quality of life, and anticipation and aggressive treatments of these aspects are crucial.

Table 41-4 Salivary Tumors

Benign	Malignant	Malignant Nonsalivary
Pleomophic adenoma	Mucoepidermoid carcinoma	Lymphoma
Warthin tumor (papillary cystadenoma lymphomatosum)	Adenoid cystic carcinoma	Squamous cell carcinoma
Basal cell adenoma	Adenocarcinoma	Melanoma
Oncocytoma	Acinic cell carcinoma	
Hemangioma	Carcinoma ex-pleomorphic adenoma	
	Salivary duct carcinoma	
	Malignant mixed tumor	

SALIVARY

Salivary tumors, although rare, encompass a large number of benign and malignant pathologies (Table 41-4). The parotid is the most commonly involved gland, followed by minor salivary glands, the submandibular gland, and the sublingual gland. The majority of parotid tumors (~75%) are benign, the most common type being pleomorphic adenoma.[13,14] However, there is an inverse relationship between frequency of gland involvement and rate of malignancy, with approximately 50% malignant pathology in the submandibular gland and up to 86% in the sublingual gland. The most common malignant tumor is mucoepidermoid carcinoma, followed by adenoid cystic carcinoma (ACC) and adenocarcinoma.[13] Table 41-5 lists the T-staging for parotid malignancies according to the American Joint Committee on Cancer.[15] Additionally, the parotid gland contains lymph nodes that receive lymphatic drainage from the scalp and face.

Salivary tumors commonly present with painless swelling, and the most typical location is in the parotid tail. However, tumors that arise in the deep lobe of the parotid (deep to the plane of the facial nerve) may extend into the parapharyngeal space and grow quite large before they are noticed, and may cause trismus or a pharyngeal bulge. Warthin tumors are associated with male gender and smoking, and may be bilateral or multifocal.[16] Although most salivary tumors are benign, the presence of pain, trismus, or facial weakness should raise the clinician's suspicion of malignancy.

In the setting of a small tumor without atypical symptoms, routine imaging is not necessarily required, as it is unlikely to change the surgical plan. When imaging is desired, CT is the mainstay of imaging due to its widespread availability and ease to obtain, although MRI can be useful to further delineate the extent of a mass and perineural invasion.[17] Figure 41-8A,B demonstrates MRI characteristics of a pleomorphic adenoma on contrasted MRI.

Table 41-5 Staging of Major Salivary Gland Tumors

T1	<2 cm, without extraparenchymal extension
T2	2–4 cm, without extraparenchymal extension
T3	>4 cm, and/or with extraparenchymal extension
T4a	Involvement of skin, mandible, ear canal, or facial nerve
T4b	Encases carotid artery or invades skull base

Used with the permission of the American Joint Committee on Cancer (AJCC), Chicago, Illinois. The original source for this material is the AJCC Cancer Staging Manual, Seventh Edition (2010) published by Springer Science and Business Media LLC, www.springer.com

Fine-needle aspiration may be performed prior to surgery, based on surgeon preference. In practice, FNA may be useful for counseling patients in whom malignancy is found that a more aggressive surgery will be performed, or to avoid surgery in patients with inflammatory disease or lymphoid malignancies. However, the surgeon should be aware that the specificity for neoplasia and malignancy is high, however the sensitivity is lower and more variable for both.[18]

For benign lesions, partial superficial parotidectomy, taking just the tissue immediately around the tumor, is sufficient. Additionally, there is some evidence that, in experienced hands, extracapsular dissection without facial nerve identification may be equally effective and less morbid than superficial parotidectomy.[19,20] Figure 41-9 demonstrates the steps performed in superficial parotidectomy with facial nerve dissection.

Although “total parotidectomy” is typically recommended for malignancy, tumors may not be found to be malignant until final pathology.[21] Furthermore, a total parotidectomy is very difficult to perform en bloc with preservation of the facial nerve, which should always be attempted if it is functional. In small tumors localized to the superficial lobe, a superficial parotidectomy with an ample cuff of normal gland is adequate. Tumors in the deep lobe require superficial parotidectomy for nerve identification and mobilization, which may cause a temporary paresis due to retraction. If tumor involvement necessitates nerve sacrifice, it should be reconstructed with a nerve graft.

PATHOLOGY-SPECIFIC CONCERNS

Pleomorphic adenoma is typically a well-encapsulated, enhancing, round lesion with a tendency to recur if incompletely excised or if there is tumor spillage. Malignant transformation occurs in approximately 6%, and increases with the length of observation.[22] Although benign, up to 40% may have extension beyond the capsule ("tumor pseudopodia"), and incomplete capsules have also been described.[23] Therefore, it is generally recommended to take a cuff of parotid with the tumor, although the surgeon frequently finds that it is necessary to dissect the tumor capsule directly off the facial nerve. In cases that recur, surgical salvage is recommended, but radiation may aid in local control for patients who are not surgical candidates.

The prognosis and treatment of mucoepidermoid carcinoma and ACC are largely affected by histologic grade. Mucoepidermoid carcinoma is classified as low grade or high grade, and sometimes as intermediate grade depending on the grading system used. High-grade tumors tend to be more aggressive, recurring locally and metastasizing frequently. Similarly, ACC can be subdivided by histologic type, tubular being the most indolent and solid being the least. ACCs have a great propensity for perineural invasion, and therefore MRI should be performed to evaluate for nerve involvement, and frozen sections should be taken to clear nerves when they are involved.

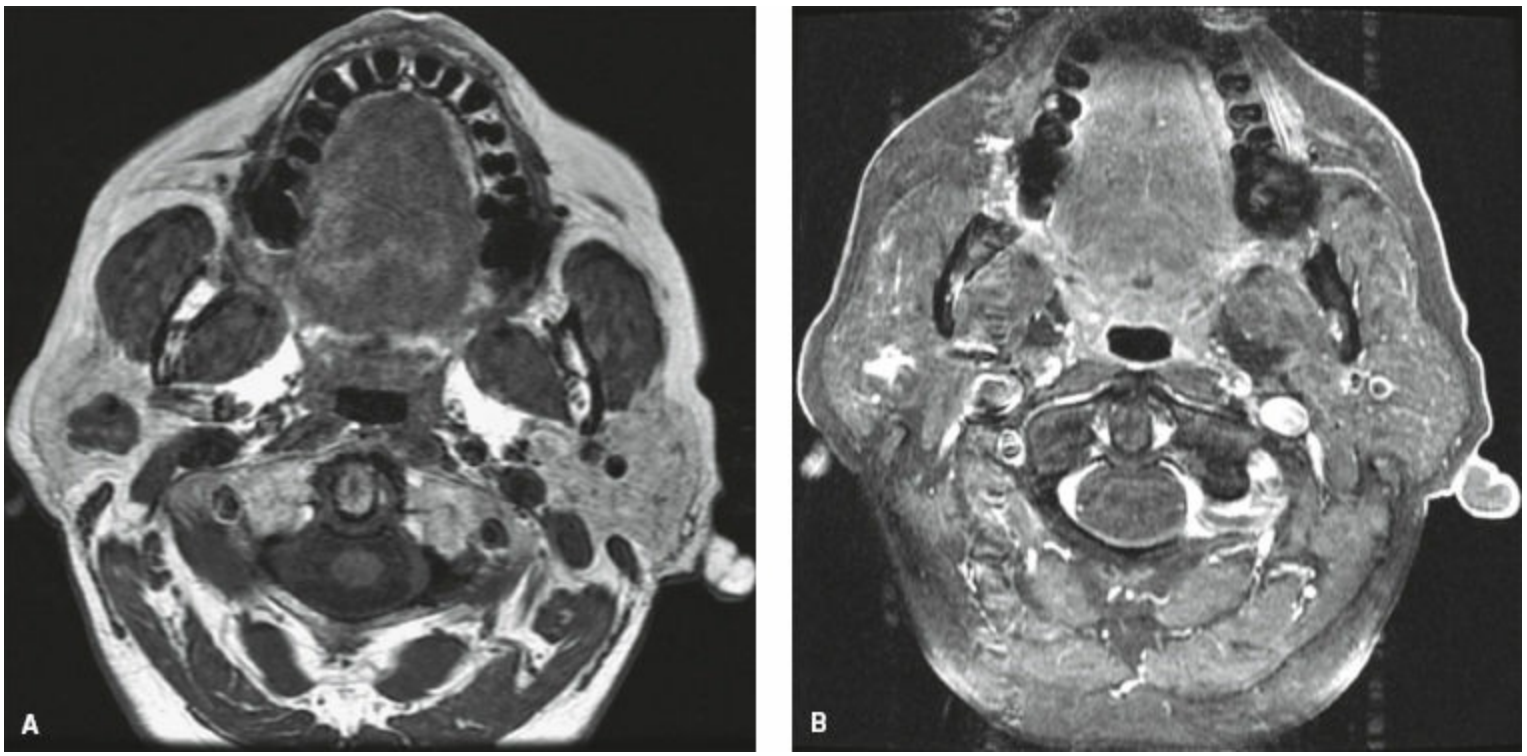

Figure 41-8. Precontrast (**A**) and postcontrast (**B**) T1 MRI demonstrate a lobulated, heterogeneous mass within the right parotid gland just posterior to the retromandibular vein, consistent with a pleomorphic adenoma.

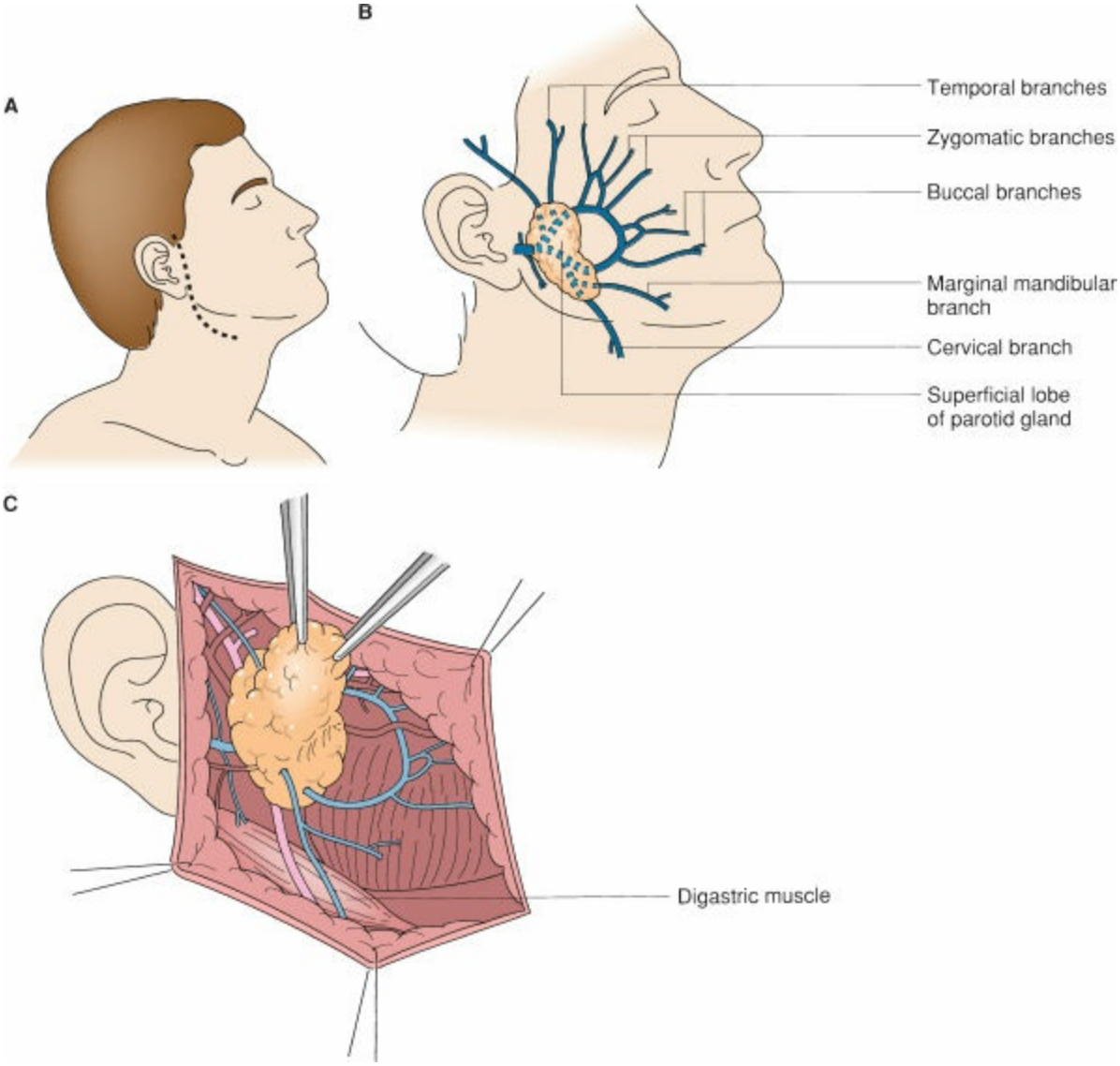
A
B
Temporal branches
Zygomatic branches
Buccal branches
Marginal mandibular branch
Cervical branch
Superficial lobe of parotid gland
C
Digastric muscle

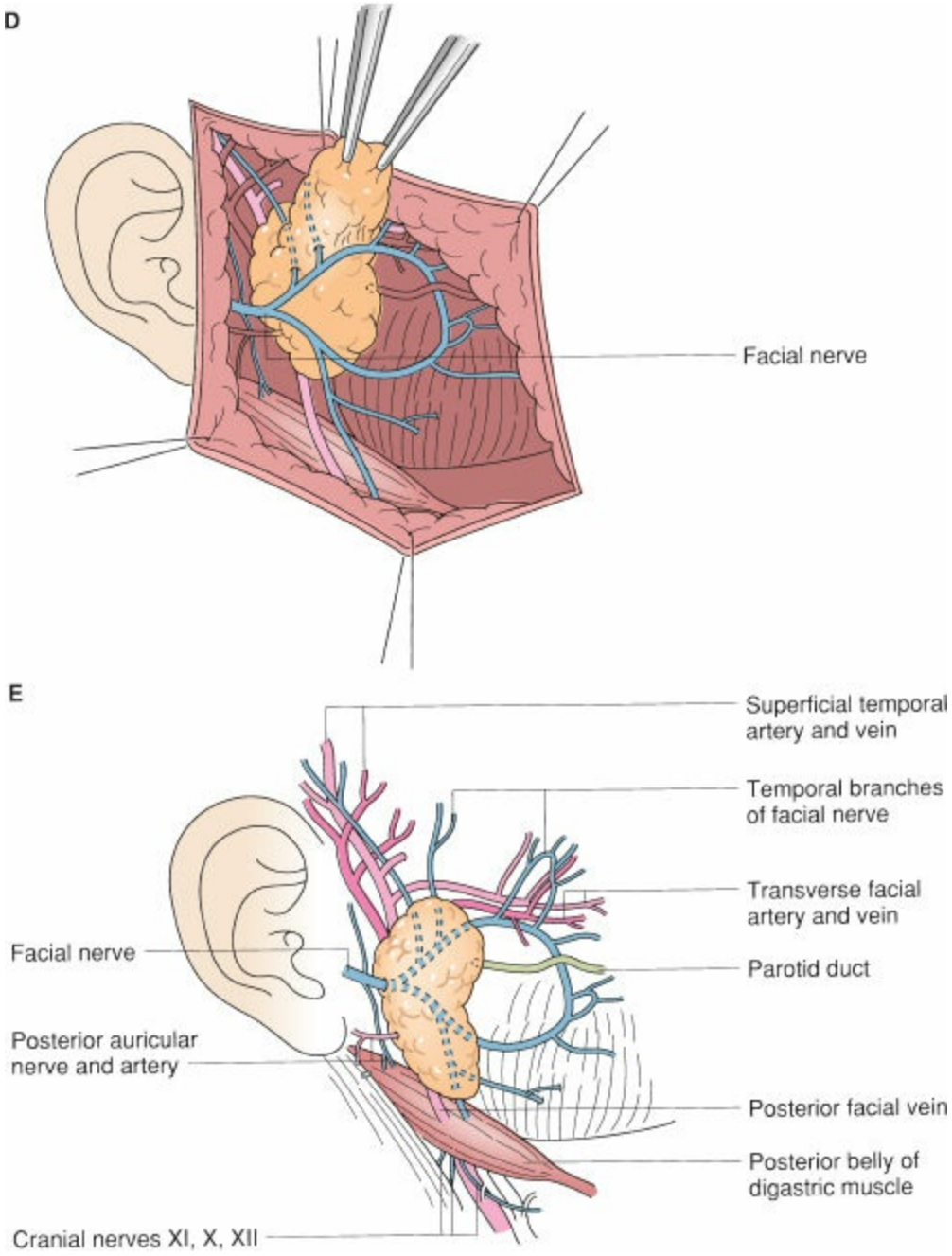

Figure 41-9. Superficial parotidectomy. **A:** The standard Blair incision or the cosmetically superior rhytidectomy incision may be employed. **B:** Branches of the facial nerve course between the superficial and deep lobes of the parotid. **C:** The main trunk of the facial nerve is identified 8 mm deep to the tympanomastoid suture line and at the same level as the digastric muscle. **D:** The nerve is then dissected distally, separating it from the substance of the parotid. **E:** Schematic representation of the relationship between the parotid and surrounding structures.

In general, ipsilateral neck dissection should be performed when lymphadenopathy is present, and in the N0 neck when there is high-grade pathology (salivary duct carcinoma, high-grade MEC, SCC, adenocarcinoma except for polymorphous low-grade adenocarcinoma, carcinoma ex-pleomorphic adenoma). Postoperative radiation should be used for stage III/IV disease, high-grade pathology, and perineural or extensive tissue invasion.

SINONASAL

Sinonasal tumors may present with vague symptoms, including nasal obstruction, epistaxis, decreased smell, or nasal discharge. Sinonasal tumors are rare, the most common being the benign inverted papilloma, with a yearly incidence between 0.2 and 0.6 per 100,000. However, there are over 70 pathologies that may involve the paranasal sinuses, over half of which are malignant.[24] The maxillary sinus is most commonly affected, followed by the ethmoid, sphenoid, and frontal sinuses.[25]

Rigid endoscopy is required to evaluate the patient with a possible sinonasal tumor. Imaging of the sinuses and skull base with fine-cut CT is advisable prior to biopsy to evaluate for the integrity of the orbits, vasculature, and skull base, and to rule out odontogenic origin for maxillary sinus pathology. MRI is also valuable to assess for dural, intraorbital, and neural integrity. Figure 41-10 is a contrasted T1 image of a sinonasal mucosal melanoma; MRI provides evidence that both the dura and the periorbita are intact, allowing for an endoscopic resection without craniotomy or orbital exenteration.

When possible, inverted papilloma should be resected in its entirety with drilling of its site of attachment to prevent recurrence, which may be as high as 70% without complete resection. The specimen should be sent for pathologic evaluation due approximately 10% risk of concurrent or delayed malignancy.[26] However, when tumor involves critical structures (optic nerve, carotid artery, etc.), they should be preserved and the patient followed closely.

For sinonasal malignancies, surgery is the mainstay for most lesions. SCC is the most common (40% to 50%), followed by adenocarcinoma and ACC.[27] “Round blue cell” tumors are less common, but represent several different pathologies, including esthesioneuroblastoma, sinonasal undifferentiated carcinoma (SNUC), neuroendocrine carcinoma, small cell carcinoma, mucosal melanoma, lymphoma, and various sarcomas. Rhabdomyosarcoma is most common in the pediatric population, and should be treated nonsurgically as primary therapy. Consultation with a head and neck pathologist is particularly important in patients with small blue cell tumors because high-grade pathologies (SNUC, small cell) tend to metastasize early and are also often treated with induction chemotherapy and radiation, or concurrent chemoradiation.

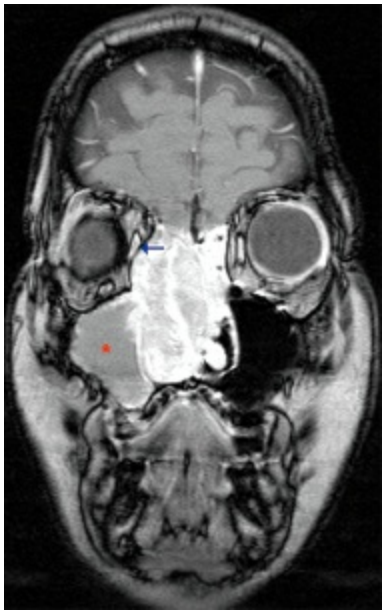

Figure 41-10. Postcontrast T1 coronal image of a sinonasal mucosal melanoma. MRI allows for the distinction between the vascular tumor and trapped secretions in the maxillary sinus (*asterisk*), and provides evidence that the periorbita is intact (*arrow*).

The widespread adoption of endoscopic sinus surgery in the 1990s has led to increasing comfort with minimally invasive techniques for sinonasal tumors. For inverted papilloma, the endoscopic approach is associated with a decrease in both recurrence rate and morbidity for inverted papilloma compared to open approaches.[26,28] Similarly, evidence is building that T1 and T2 sinonasal tumors may be safely and effectively removed with the endoscopic approach, and that endoscopic resection may complement open surgery in combined cases.[29,30]

HEAD AND NECK SQUAMOUS CELL CARCINOMA

SCC is the most common malignancy of the upper aerodigestive tract, and is associated with approximately 50% overall survival due to its aggressive nature and the tendency for patients to present with advanced stage. The staging criteria for the common head and neck tumor subsites are available in the American Joint Commission on Cancer or the National Cancer Comprehensive Network.[15,31] Staging is based on the size and invasiveness of the primary tumor site, the number, size, and location of metastatic lymph nodes, and the presence or absence of distant metastases. Tables 41-6 to 41-9 list the TNM staging for the oral cavity, oropharynx, and larynx, which are grouped into an overall stage of I to IV (Table 41-10). Patients with AJCC stage I/II tumors may be treated with single modality therapy, radiation, or surgery. Those with stage III/IV will require multimodality treatment. It is of particular importance that higher-stage patients undergo multidisciplinary evaluation due to combination therapy and the need for aggressive functional rehabilitation after treatment.

Table 41-6 Oral Cavity Staging

T1a	<2 cm
T2	2–4 cm
T3	>4 cm
T4a	Invades bone, floor of mouth, inferior alveolar nerve, extrinsic tongue musculature, skin of face, or maxillary sinus
T4b	Involves masticator space, pterygoid plate, skull base, or surrounds internal carotid artery

Used with the permission of the American Joint Committee on Cancer (AJCC), Chicago, Illinois. The original source for this material is the AJCC Cancer Staging Manual, Seventh Edition (2010) published by Springer Science and Business Media LLC, www.springer.com

Table 41-7 Oropharynx Staging

T1	<2 cm
T2	2–4 cm
T3	>4 cm
T4a	Invades larynx, extrinsic tongue musculature, medial pterygoid muscle, mandible, or hard palate
T4b	Involves lateral pterygoid muscle, pterygoid plates, lateral nasopharynx, skull base, or surrounds internal carotid artery

Used with the permission of the American Joint Committee on Cancer (AJCC), Chicago, Illinois. The original source for this material is the AJCC Cancer Staging Manual, Seventh Edition (2010) published by Springer Science and Business Media LLC, www.springer.com

ORAL CAVITY

4 The subsites of the oral cavity include the lip, oral tongue, floor of mouth, hard palate, gingival mucosa and retromolar trigone, and buccal mucosa. Although patients are given the choice between surgical and nonsurgical treatment in most head and neck cancers, surgery is considered the primary treatment for oral cancer because of its ease of access and because of the risk of osteoradionecrosis of the mandible when high-dose radiation or chemoradiation is used in the region. Microvascular reconstruction is very important to restore the structure and function of the structures of the oral cavity to preserve speech and swallowing and minimize cosmetic deformity for larger tumors, and may require bone, soft tissue, or a combination of both.

Table 41-8 Larynx Staging

Supraglottis	
T1	Limited to one supraglottic subsite, with normal vocal cord mobility
T2	Tumor involves >1 subsite of epiglottis, or involves one adjacent mucosal subsite outside of epiglottis
T3	Vocal cord fixation, pre-epiglottic or paraglottic space involvement, or invasion of inner cortex of thyroid cartilage
T4a	Tumor invades outer cortex of thyroid cartilage, or invades tissues beyond larynx
T4b	Invasion of prevertebral fascia, mediastinal structure, or encasement of carotid artery
Glottis	
T1a	Tumor limited to one vocal cord, with normal mobility
T1b	Tumor involves both vocal cords, with normal mobility
T2	Extension into supraglottis or subglottis, or with impaired cord mobility
T3	Vocal cord fixation, paraglottic space involvement, or invasion of inner cortex of thyroid cartilage
T4a	Tumor invades outer cortex of thyroid cartilage, or invades tissues beyond larynx
T4b	Invasion of prevertebral fascia, mediastinal structure, or encasement of carotid artery

Used with the permission of the American Joint Committee on Cancer (AJCC), Chicago, Illinois. The original source for this material is the AJCC Cancer Staging Manual, Seventh Edition (2010) published by Springer Science and Business Media LLC, www.springer.com

Table 41-9 Nodal Staging for Salivary Cancers and Squamous Cell Carcinoma of Oral Cavity, Oropharynx, Larynx

N0	No regional lymph node metastases
N1	Single ipsilateral lymph node metastasis, <3 cm
N2a	Single ipsilateral lymph node metastasis, 3–6 cm
N2b	Multiple ipsilateral lymph node metastases, <6 cm
N2c	Bilateral or contralateral lymph node metastases, <6 cm
N3	Metastasis in a lymph node >6 cm
M0	No evidence of distant metastasis
M1	Distant metastasis present

Used with the permission of the American Joint Committee on Cancer (AJCC), Chicago, Illinois. The original source for this material is the AJCC Cancer Staging Manual, Seventh Edition (2010) published by Springer Science and Business Media LLC, www.springer.com

Site-specific considerations are important oncologically and functionally for oral cavity cancer. Lower lip carcinoma, which is most common and often due to sun exposure, has a very low incidence of occult cervical metastases (<15%), and may be observed in stage I/II with clinically negative nodes.[31] In contrast, the upper lip has unilateral drainage, but a higher incidence of nodal involvement. Reconstruction of the lip may involve primary closure or local advancement for small lesions (<1/3 of length), and local or free flap reconstruction for larger tumors.[32]

In oral tongue cancer, depth of invasion is clinically important. Very thin tumors (<2 mm) have a low likelihood to spread to regional lymphatics, in contrast to thick tumors (>8 to 9 mm). Although a definitive consensus has not been reached, many surgeons advocate elective neck dissection for patients with T1 tumors and depth of invasion >4 mm.[33] T1–T2 tongue tumors may be resected and closed primarily or with a skin or acellular dermis graft; larger lesions require microvascular reconstruction with enough bulk to allow for speech and deglutition. Similarly, small floor of mouth resections may be closed primarily, and grafts may be used when the floor of mouth musculature is preserved, but additional tissue is needed for larger tumors to prevent orocutaneous fistula when simultaneous neck dissection is performed.

Table 41-10 AJCC Stage Grouping for Cancers of the Head and Neck (Excluding Thyroid and Nasopharynx)

Stage	Stage Grouping
0	Tis, N0, M0
I	T1, N0, M0
II	T2, N0, M0
III	T3, N0, M0 T1–T3, N1, M0
IVA	T4a, N0–1, M0 T1–T4a, N2, M0
IVB	T4b, Any N, M0 Any T, N3, M0
IVC	Any T, Any N, M1

From American Joint Committee on Cancer. *Cancer Staging Manual.* 6th ed. New York: Springer-Verlag; 2002, with permission.

Lesions of the retromolar trigone and buccal mucosa/space present a challenge due to early involvement of the muscles of mastication. Pterygoid and/or masseter may cause severe trismus, making preoperative examination and intraoperative exposure difficult. Marginal mandibulectomy (removal of the inner cortex) may be necessary when the tumor is attached to mandibular periosteum. Composite resection of a segment of mandible is required when the integrity of the bone is compromised on preoperative imaging, or when tumor has infiltrated via a tooth root or neural foramen. Microvascular osteocutaneous reconstruction has become the standard of care for most segmental defects due to the cosmetic and functional deformity of nonreconstruction ("mandibular swing"), and because of delayed hardware extrusion that occurs after several years with plating and soft tissue coverage alone.

NASOPHARYNX

Nasopharyngeal carcinoma (NPC) is an uncommon entity in most of the world, but is endemic to certain parts of Asia, most notably southern China. Although environmental and dietary factors play a role in the development of NPC, the most important causal factor is Epstein–Barr virus.[34–36] The World Health Organization subclassifies NPC into three types: keratinizing SCC (I), nonkeratinizing SCC (II), and undifferentiated carcinoma (III).[24] Endemic NPC is 95% type III, which is associated with the best prognosis, and types I and II are more common in nonendemic areas.

Because the nasopharynx is not easily visualized, and because tumors tend to metastasize early, the most common presenting symptom is bulky lymphadenopathy. Of note, large lymphadenopathy is less prognostic in NPC than involvement of the supraclavicular fossa, which is reflected in a different nodal staging than for other head and neck subsites.[15] Other possible complaints at presentation include nasal obstruction, speech changes, and hearing loss due to involvement of the eustachian tube. Cranial nerve palsies signify extension into the skull base, suggesting advanced disease.

Biopsy of the nasopharynx or lymph nodes to confirm NPC should be accompanied by imaging with CT and MRI to evaluate the skull base and infratemporal fossa. The primary treatment for NPC is nonsurgical, and concurrent chemoradiation has been shown to be superior to radiation alone in advanced disease.[37,38] Surgery is reserved for failure of chemoradiation, and can be successful in patients with localized disease. In a large series of 312 patients undergoing salvage nasopharyngectomy, the 5-year overall survival was 62%,[39] although the majority of patients required a transfacial approach with maxillary disarticulation. With the advent of endoscopic techniques, some recurrences may be salvaged without traditional open approaches via the transnasal or transpterygoid approach, although control of the internal carotid artery is a concern.[40] Similarly, transoral robotic surgery has been reported for recurrences limited to soft tissue, although division of the soft palate is necessary, and there are no currently available robotic instruments that are suited to remove bone.[41]

OROPHARYNX

The oropharynx is comprised of the palatine tonsillar fossae and tonsils, base of tongue, soft palate, and posterior pharyngeal wall. While the incidence of head and neck SCC of other subsites has decreased with the prevalence of smokers in the United States, oropharyngeal cancer incidence has risen over the past two decades. This correlates with our understanding that the human papillomavirus, particularly subtypes 16 and 18, play a pathogenic role in squamous carcinoma of the oropharynx, and it is now believed that HPV is responsible for approximately 80% of oropharyngeal cancer.[42] In contrast to the poor prognosis of HPV-negative carcinoma of the oropharynx, HPV-associated cancer is associated with a favorable prognosis.[43,44]

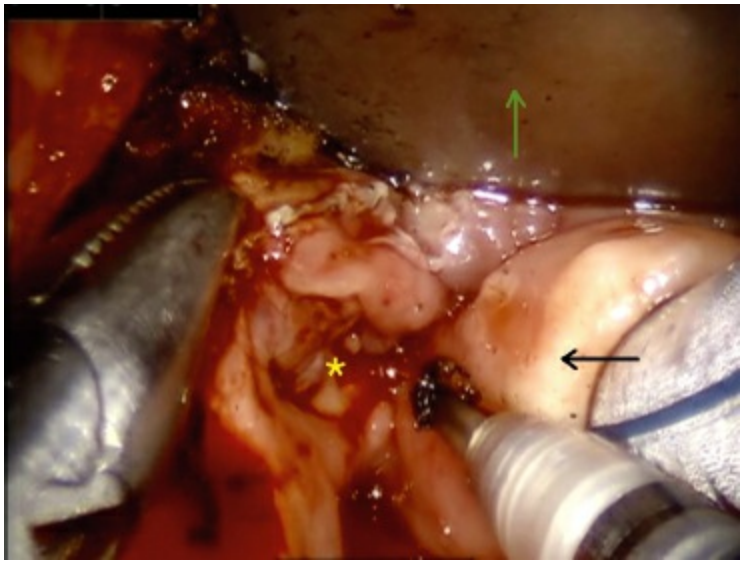

Figure 41-11. Transoral robotic surgery for a tongue base tumor. The retractor (*green arrow*) retracts the oral tongue. The lateral cut has been made 1 cm away from the tumor (*yellow asterisk*); the epiglottis (*black arrow*) is retracted to visualize the vallecula.

Although small T1–T2 tumors of the tonsils are often amenable to transoral excision,[45] radiation and concurrent chemoradiation have been used since the 1990s to treat less accessible and larger tumors due to equivalent effectiveness and decreased morbidity and mortality compared to the traditional open approaches, which involved transcervical, transpharyngeal, or transmandibular resection.[46] However, the rising prevalence of younger HPV-positive patients with favorable prognosis and the advent of minimally invasive approaches have led to increased interest in surgery as primary treatment, due to the long-term sequelae of radiation and chemotherapy.

Transoral laser microsurgery (TLM) and transoral robotic surgery have emerged in the past 10 years as techniques to treat T1–T3 tumors transorally with acceptable oncologic and functional outcomes.[47,48] Advanced optics and instrumentation allow for complete tumor resection without requiring morbid open approaches (Figs. 41-11 and 41-12). Currently two prospective NCI funded trials, ECOG 3311(HPV+ $n = 377$) and RTOG 1221 (HPV– $n = 144$), are underway to determine the role of surgical treatment for HPV positive and negative oropharyngeal cancer.[49]

HYPOPHARYNX

The hypopharynx, comprised of the pyriform sinuses, postcricoid mucosa, and posterior pharyngeal wall below the level of the hyoid, is the area between the oropharynx and cervical esophagus. For the purposes of this chapter, cervical esophageal cancer will not be discussed. Cancer of the hypopharynx may present insidiously, with gradually increasing dysphagia, hoarseness due to laryngeal involvement, or ear pain referred through cranial nerves IX and X via Jacobson and Arnold nerves.

Compared to other subsites, the hypopharynx has a poorer prognosis, with an overall survival of only 30% to 35% in early stage cancer,[50] and a rate of distant metastases of up to 60%.[51] Because of its proximity to laryngeal structures, hypopharyngeal cancer is typically treated nonoperatively, as most tumors would require removal of the larynx. Although induction chemotherapy followed by definitive radiation may be used in these patients, many institutions prefer concurrent chemoradiation, extrapolating the improved outcomes of concurrent CRT over sequential treatment in trials of other subsites. Small hypopharyngeal tumors of the posterior wall or pyriform sinus may be treated with transoral laser or robotic techniques,[52,53] although bilateral neck dissection is required for regional control. Recurrent hypopharyngeal cancer may require total laryngectomy with partial pharyngectomy, or laryngopharyngectomy with microvascular reconstruction of the neopharynx.

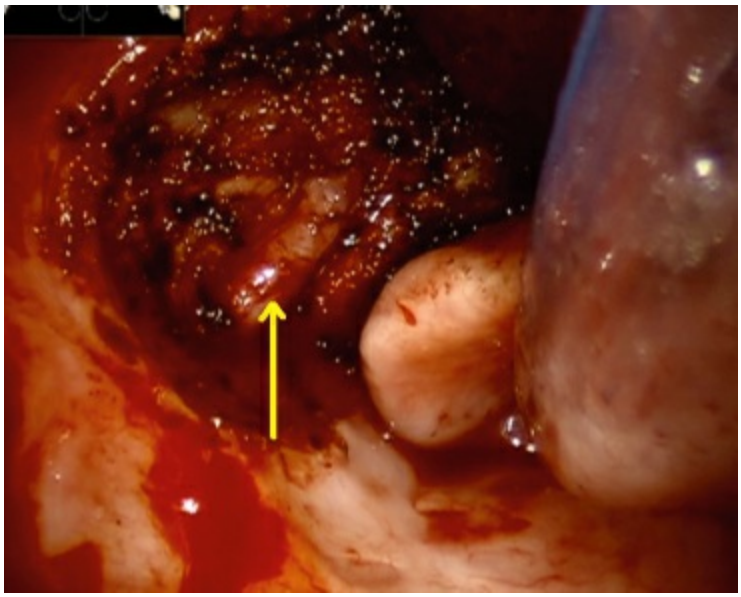

Figure 41-12. Resultant defect from TORS resection, demonstrating the lingual artery in situ, which was coagulated later with bipolar cautery to prevent bleeding.

LARYNX

Tobacco and alcohol have a dose-dependent, synergistic carcinogenic effect on the epithelium of the larynx. The glottis, or true vocal cords, is the most common subsite involved, followed by the supraglottis (tip of the epiglottis to the laryngeal ventricle), and subglottis (1 cm below ventricle to the inferior border of the cricoid cartilage). In contrast to the respiratory epithelium of the rest of the upper aerodigestive tract, the glottis is comprised of stratified squamous nonkeratinizing epithelium overlying a complex lamina propria over the thyroarytenoid ligament and muscle. Due to the fibroelastic support of the conus elasticus and quadrangular membrane, early glottic tumors have a very low propensity for spread to regional lymph nodes, in contrast to the supraglottis and subglottis.

5 Early-stage carcinoma of the glottis (T1–T2) can be treated with single modality radiation or surgery, with approximately 90% cure for T1 and 75% for T2; early recognition and diagnosis at this stage therefore is key. Surgical treatment is performed via transoral resection, often using the CO_2 laser, which has no statistically significant difference in overall or disease-free survival or local control compared to radiation, although laryngeal preservation rates appear to be higher in the surgical group based on retrospective studies.[54–56] Transoral resection of early glottic and supraglottic cancer has the advantage of requiring only one treatment, compared to the 6 to 7 weeks of radiation needed. However, supraglottic carcinoma has a high incidence of occult nodal metastasis, as well as bilateral drainage, and therefore planned bilateral level 2–4 neck dissection is recommended for patients who undergo surgery for the primary tumor.

For advanced laryngeal cancer (T3–T4), either surgery followed by radiation or concurrent chemoradiation may be offered, based on two randomized clinical trials. The so-called “VA Trial” demonstrated equivalent survival between surgery and radiation versus induction chemotherapy followed by radiation, with 64% laryngeal preservation in the nonsurgical arm.[57] This was followed by the RTOG 91–11 trial, which demonstrated the superiority of concurrent chemoradiation compared to radiation alone or after induction chemotherapy for laryngectomy-free survival and local control.[58] However, the 10-year follow-up to this study did not demonstrate an advantage of concurrent CRT versus induction chemotherapy and radiation in overall survival, local control, or overall laryngeal preservation.[59]

For advanced stage laryngeal cancer, surgery generally involves total laryngectomy with bilateral lymphadenectomy, with local tissue or free tissue transfer as needed for pharyngeal reconstruction. This procedure functionally separates the airway from the digestive tract, but allows for effective verbal communication via esophageal speech, tracheoesophageal puncture with prosthesis, or electrolarynx. Open partial laryngeal surgeries, including supraglottic or supracricoid partial laryngectomy, may be used in selected cases, but have prolonged recovery of swallowing and airway protection.

Additional factors must be considered in choosing a treatment modality for patients with advanced stage laryngeal cancer. Radiation is less effective in cartilage and bone, and therefore thought to be inferior to surgery in T4 laryngeal cancer.[60] Additionally,

patients who present with extensive paraglottic spread and vocal cord fixation will not regain function of the larynx with treatment, and are likely to remain tracheostomy-dependent if tracheotomy is performed prior to nonsurgical treatment.[61] Similarly, patients with poor pretreatment swallowing are likely to worsen, and may become permanently gastrostomy-dependent.

NECK DISSECTION

Head and neck SCC has a propensity to travel to the cervical lymphatics, the risk of which increases with T-stage. Pharyngeal tumors, especially those of the nasopharynx and hypopharynx, may present with a cervical neck mass. In cases when a patient presents with a neck mass for more than 2 weeks, the clinician should have a high suspicion for metastatic SCC, rather than an infectious or congenital etiology, and workup should entail imaging, fine-needle aspiration, and endoscopy.

In any patient presenting with SCC, consideration of therapeutic or elective treatment of the neck is imperative. In general, the cervical lymph nodes are treated with the same modality as the primary tumor; if surgery is undertaken for an oral cavity primary, for example, simultaneous neck dissection is performed. Similarly, the radiation oncologist will contour the treatment field to incorporate the relevant nodal basins in patients treated nonsurgically. Elective neck dissection or elective neck irradiation in the absence of clinically positive nodes is performed when the risk of occult nodal metastasis is greater than 15% (Table 41-11).

MANAGEMENT

Table 41-11 Indications for Elective Treatment of the Neck Based on Anatomic Locale and T Stage

Subsite	T Stages with >20% Risk of Occult Nodal Metastases
Oral cavity	T2, T3, T4
Oropharynx	T1, T2, T3, T4
Hypopharynx	T1, T2, T3, T4
Supraglottic larynx	T1, T2, T3, T4
Glottic larynx	T2, T3, T4

From Frank DK, Sessions RB. Management of the neck-surgery. In: Harrison LB, Sessions RB, Hong WK, eds. *Head and Neck Cancer: A Multidisciplinary Approach*. 3rd ed. Philadelphia, PA: Lippincott Williams & Wilkins; 2009:189, with permission.

The techniques for neck dissections have evolved with time, initially being developed in the late 19th century as an en bloc procedure for removal of cervical lymphatics. Crile and Martin subsequently popularized the radical neck dissection, removal of the cervical lymphatics with sacrifice of the sternocleidomastoid muscle, internal jugular vein, and spinal accessory nerve. The modified radical neck dissection, removal of levels I to V with preservation of one or more of the three structures, then gave way to the idea of oncologic lymphadenectomy with decreased morbidity.[62] Currently, selective neck dissection, the removal of the at-risk nodal basins with preservation of the SCM, internal jugular, and accessory nerve, is most commonly as the standard of care, as it preserves oncologic principles and minimizes morbidity.[63] The patterns of lymphatic drainage from each subsite are well described based on the publications of Lindberg and Shah.[64,65] In general, dissection of levels II to IV is performed for cancers of the larynx, oropharynx,

and hypopharynx, while levels I to III and possibly IV are addressed for oral cavity cancer (Fig. 41-13). Level V is rarely involved except in NPC and skin cancer.

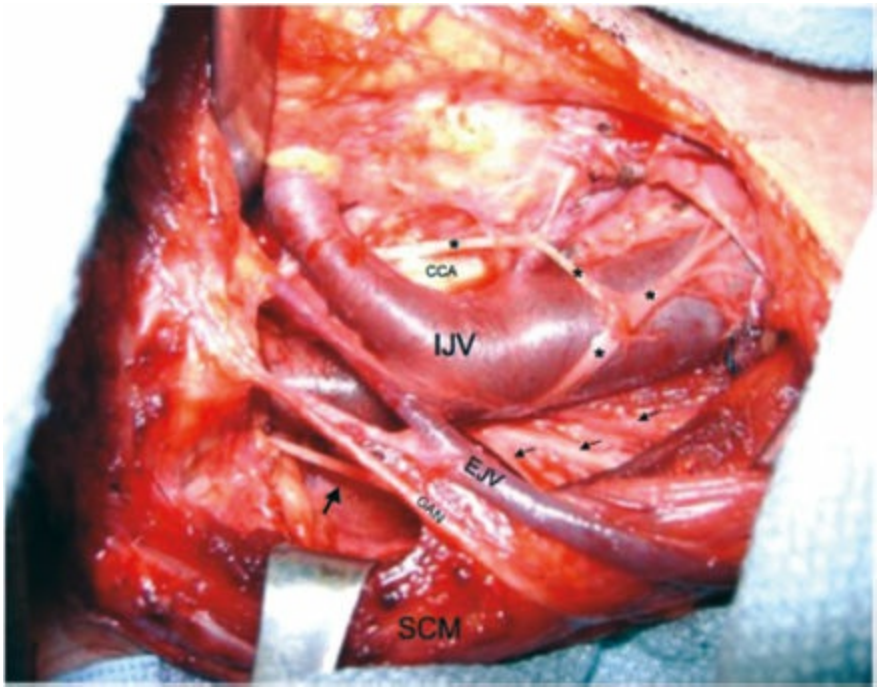

Figure 41-13. Intraoperative photograph demonstrating the left neck after performance of a selective (supraomohyoid) neck dissection. Selective neck dissection is generally a low morbidity procedure. Vital structures such as the internal jugular vein (IJV), common carotid artery (CCA), and spinal accessory nerve (*large arrow*) are carefully preserved. In the context of an N0 neck, other nonvital structures such as the sternocleidomastoid muscle (SCM), external jugular vein (EJV) greater auricular nerve (GAN), cervical sensory rootlets (*small arrows*) and ansa cervicalis (*asterisks*) may also be spared.

Table 41-12 Complications of Common Head and Neck Surgeries

Tonsillectomy/Adenoidectomy
Hemorrhage
Velopharyngeal insufficiency
Lingual neuropraxia
Endoscopic Sinus Surgery
Intranasal adhesions
Hyposmia
Epistaxis
Orbital injury/hematoma
Cerebrospinal fluid leak
Internal carotid artery injury
Parotidectomy
Great auricular nerve injury
Hematoma/seroma
Frey syndrome (gustatory facial sweating)
Facial nerve injury
Submandibular Gland Removal
Hematoma/seroma
Marginal mandibular nerve injury
Lingual nerve injury
Neck Dissection
Spinal accessory nerve injury
Marginal mandibular nerve injury
Hypoglossal nerve injury
Great vessel injury
Chyle leak
Total Laryngectomy
Pharyngocutaneous fistula
Parathyroid injury with hypocalcemia
Hypoglossal nerve injury
Esophageal stricture

As in central neck dissection for thyroid cancer, a systematic, comprehensive approach should be used to perform neck dissection, rather than "node-plucking." The boundaries for the common "lateral neck dissection," encompassing levels II to IV, should extend from the digastric muscle's insertion on the mastoid with the SCM superiorly to the plane of the clavicle inferiorly, and from the posterior edge of the SCM to the strap muscles anteriorly. The floor of dissection is the cervical sensory rootlets in level III and the fascia overlying the deep musculature in level II (levator scapulae) and in level IV (anterior and middle scalenes). Care should be taken in level IV to avoid the phrenic nerve and brachial plexus, as well as the thoracic duct and right lymphatic duct. When level IB is included in the specimen, the marginal mandibular nerve must be elevated off the submandibular gland and protected to allow for safe resection of the gland and nodes along the facial vessels. Level V dissection requires identification of the spinal accessory nerve just below Erb point; it is then traced to its entry into the trapezius to protect it along its course.

COMPLICATIONS OF HEAD AND NECK SURGERY

Due to the intricate, complex anatomy of the region, surgery of the head and neck may be fraught with complications and morbidity. Although better understanding of anatomy and refined surgical techniques have fostered “functional” and “minimally invasive” approaches, complications occur, even in experienced hands. Salvage surgery after radiation or chemoradiation may be particularly difficult due to the extensive fibrosis that occurs. Table 41-12 lists common and serious, rare complications of common head and neck procedures. When performing these procedures, the surgeon should be aware of critical structures in the area, and thorough discussion with the patient should be a part of the informed consent process.

References

1. Sankaranarayanan R, Masuyer E, Swaminathan R, et al. Head and neck cancer: a global perspective on epidemiology and prognosis. *Anticancer Res* 1998;18(6B):4779–4786.
2. D'Souza G, Kreimer AR, Viscidi R, et al. Case-control study of human papillomavirus and oropharyngeal cancer. *N Engl J Med* 2007;356(19):1944–1956.
3. Robbins KT, Medina JE, Wolfe GT, et al. Standardizing neck dissection terminology. Official report of the Academy's Committee for Head and Neck Surgery and Oncology. *Arch Otolaryngol Head Neck Surg* 1991;117(6):601–605.
4. Crosby ET, Cooper RM, Douglas MJ, et al. The unanticipated difficult airway with recommendations for management. *Can J Anaesth* 1998;45(8):757–776.
5. Iseli TA, Iseli CE, Golden JB, et al. Outcomes of intubation in difficult airways due to head and neck pathology. *Ear Nose Throat J* 2012;91(3):E1–E5.
6. Snow V, Mottur-Pilson C, Cooper RJ, et al. Principles of appropriate antibiotic use for acute pharyngitis in adults. *Ann Intern Med* 2001;134(6):506–508.
7. Apostolopoulos NJ, Nikolopoulos TP, Bairamis TN. Peritonsillar abscess in children. Is incision and drainage an effective management? *Int J Pediatr Otorhinolaryngol* 1995;31(2–3):129–135.
8. Rosenfeld RM, Andes D, Bhattacharyya N, et al. Clinical practice guideline: adult sinusitis. *Otolaryngol Head Neck Surg* 2007;137(3 Suppl):S1–S31.
9. Chow AW, Benninger MS, Brook I, et al. IDSA clinical practice guideline for acute bacterial rhinosinusitis in children and adults. *Clin Infect Dis* 2012;54(8):e72–e112.
10. Duggal P, Wise SK. Chapter 8: Invasive fungal rhinosinusitis. *Am J Rhinol Allergy* 2013;27(Suppl 1):S28–S30.
11. Fattahi TT, Lyu PE, Van Sickels JE. Management of acute suppurative parotitis. *J Oral Maxillofac Surg* 2002;60(4):446–448.
12. Strychowsky JE, Sommer DD, Gupta MK, et al. Sialendoscopy for the management of obstructive salivary gland disease: a systematic review and meta-analysis. *Arch Otolaryngol Head Neck Surg* 2012;138(6):541–547.
13. Spiro RH. Salivary neoplasms: overview of a 35-year experience with 2,807 patients. *Head Neck Surg* 1986;8(3):177–184.
14. Eveson JW, Cawson RA. Salivary gland tumours. A review of 2410 cases with particular reference to histological types, site, age and sex distribution. *J Pathol* 1985;146(1):51–58.
15. American Joint Committee on Cancer. *American Joint Committee for Cancer Staging Manual.* 7th ed. 2010.
16. Pinkston JA, Cole P. Cigarette smoking and Warthin's tumor. *Am J Epidemiol* 1996;144(2):183–187.
17. Razfar A, Heron DE, Branstetter BF, et al. Positron emission tomography-computed

tomography adds to the management of salivary gland malignancies. *Laryngoscope* 2010;120(4):734–738.

18. Schmidt RL, Hall BJ, Wilson AR, et al. A systematic review and meta-analysis of the diagnostic accuracy of fine-needle aspiration cytology for parotid gland lesions. *Am J Clin Pathol* 2011;136(1):45–59.
19. Mantsopoulos K, Koch M, Klintworth N, et al. Evolution and changing trends in surgery for benign parotid tumors. *Laryngoscope* 2015;125(1):122–127.
20. Albergotti WG, Nguyen SA, Zenk J, et al. Extracapsular dissection for benign parotid tumors: a meta-analysis. *Laryngoscope* 2012;122(9):1954–1960.
21. Walvekar RR, Andrade Filho PA, Seethala RR, et al. Clinicopathologic features as stronger prognostic factors than histology or grade in risk stratification of primary parotid malignancies. *Head Neck* 2011;33(2):225–231.
22. Di Palma S. Carcinoma ex pleomorphic adenoma, with particular emphasis on early lesions. *Head Neck Pathol* 2013;7(Suppl 1):S68–S76.
23. Zbaren P, Stauffer E. Pleomorphic adenoma of the parotid gland: histopathologic analysis of the capsular characteristics of 218 tumors. *Head Neck* 2007;29(8):751–757.
24. Shanmugaratnam K. Nasal cavity and paranasal sinuses. In: Shanmugaratnam K, Sobin L, eds. *Histological Typing of Tumours of the Upper Respiratory Tract and the Ear.* 2nd ed. Berlin: Springer; 1991:3–5.
25. Khademi B, Moradi A, Hoseini S, et al. Malignant neoplasms of the sinonasal tract: report of 71 patients and literature review and analysis. *Oral Maxillofac Surg* 2009;13(4):191–199.
26. Krouse JH. Endoscopic treatment of inverted papilloma: safety and efficacy. *Am J Otolaryngol* 2001;22(2):87–99.
27. Gotte K, Hormann K. Sinonasal malignancy: what's new? *ORL J Otorhinolaryngol Relat Spec* 2004;66(2):85–97.
28. Reh DD, Lane AP. The role of endoscopic sinus surgery in the management of sinonasal inverted papilloma. *Curr Opin Otolaryngol Head Neck Surg* 2009;17(1):6–10.
29. Hanna E, DeMonte F, Ibrahim S, et al. Endoscopic resection of sinonasal cancers with and without craniotomy: oncologic results. *Arch Otolaryngol Head Neck Surg* 2009;135(12):1219–1224.
30. Higgins TS, Thorp B, Rawlings BA, et al. Outcome results of endoscopic vs craniofacial resection of sinonasal malignancies: a systematic review and pooled-data analysis. *Int Forum Allergy Rhinol* 2011;1(4):255–261.
31. NCCN Clinical Practice Guidelines in Oncology: Head and Neck Cancers. 2014; 5/2014:http://www.nccn.org
32. Papel ID, Frodel JL, Richard Holt G, et al.,. Lip reconstruction. In: DeFatta RJ, Williams III EF, eds. *Facial Plastic and Reconstructive Surgery.* 3rd ed: Thieme; 2009.
33. Huang SH, Hwang D, Lockwood G, et al. Predictive value of tumor thickness for

cervical lymph-node involvement in squamous cell carcinoma of the oral cavity: a meta-analysis of reported studies. *Cancer* 2009;115(7):1489–1497.

34. de-The G. Epstein-Barr virus behavior in different populations and implications for control of Epstein-Barr virus-associated tumors. *Cancer Res* 1976;36(2 pt 2):692–695.
35. Tsao SW, Tsang CM, To KF, et al. The role of Epstein-Barr virus in epithelial malignancies. *J Pathol* 2015;235(2):323–333.
36. Chang ET, Adami HO. The enigmatic epidemiology of nasopharyngeal carcinoma. *Cancer Epidemiol Biomarkers Prev* 2006;15(10):1765–1777.
37. Al-Sarraf M, LeBlanc M, Giri PG, et al. Chemoradiotherapy versus radiotherapy in patients with advanced nasopharyngeal cancer: phase III randomized Intergroup study 0099. *J Clin Oncol* 1998;16(4):1310–1317.
38. Lee AW, Tung SY, Chua DT, et al. Randomized trial of radiotherapy plus concurrent-adjuvant chemotherapy vs radiotherapy alone for regionally advanced nasopharyngeal carcinoma. *J Natl Cancer Inst* 2010;102(15):1188–1198.
39. Chan JY. Surgical management of recurrent nasopharyngeal carcinoma. *Oral Oncol* 2014;50(10):913–917.
40. Al-Sheibani S, Zanation AM, Carrau RL, et al. Endoscopic endonasal transpterygoid nasopharyngectomy. *Laryngoscope* 2011;121(10):2081–2089.
41. Tsang RK, To VS, Ho AC, et al. Early results of robotic assisted nasopharyngectomy for recurrent nasopharyngeal carcinoma. *Head Neck* 2015;37(6):788–793.
42. Chaturvedi AK, Engels EA, Pfeiffer RM, et al. Human papillomavirus and rising oropharyngeal cancer incidence in the United States. *J Clin Oncol* 2011;29(32):4294–4301.
43. Ang KK, Harris J, Wheeler R, et al. Human papillomavirus and survival of patients with oropharyngeal cancer. *N Eng J Med* 2010;363(1):24–35.
44. Posner MR, Lorch JH, Goloubeva O, et al. Survival and human papillomavirus in oropharynx cancer in TAX 324: a subset analysis from an international phase III trial. *Ann Oncol* 2011;22(5):1071–1077.
45. Walvekar RR, Tyler PD, Tammareddi N, et al. Robotic-assisted transoral removal of a submandibular megalith. *Laryngoscope* 2011;121(3):534–537.
46. Parsons JT, Mendenhall WM, Stringer SP, et al. Squamous cell carcinoma of the oropharynx: surgery, radiation therapy, or both. *Cancer* 2002; 94(11):2967–2980.
47. Grant DG, Hinni ML, Salassa JR, et al. Oropharyngeal cancer: a case for single modality treatment with transoral laser microsurgery. *Arch Otolaryngol Head Neck Surg* 2009;135(12):1225–1230.
48. Leonhardt FD, Quon H, Abrahao M, et al. Transoral robotic surgery for oropharyngeal carcinoma and its impact on patient-reported quality of life and function. *Head Neck* 2012;34(2):146–154.
49. Shaw RJ, Holsinger FC, Paleri V, et al. Surgical trials in head & neck oncology: Renaissance and revolution? *Head Neck* 2015;37(7):927–930.

50. Lefebvre JL, Chevalier D, Luboinski B, et al. Larynx preservation in pyriform sinus cancer: preliminary results of a European Organization for Research and Treatment of Cancer phase III trial. EORTC Head and Neck Cancer Cooperative Group. *J Natl Cancer Inst* 1996;88(13):890–899.
51. Kotwall C, Sako K, Razack MS, et al. Metastatic patterns in squamous cell cancer of the head and neck. *Am J Surg* 1987;154(4):439–442.
52. Park YM, Kim WS, De Virgilio A, et al. Transoral robotic surgery for hypopharyngeal squamous cell carcinoma: 3-year oncologic and functional analysis. *Oral Oncol* 2012;48(6):560–566.
53. Karatzanis AD, Psychogios G, Waldfahrer F, et al. T1 and T2 hypopharyngeal cancer treatment with laser microsurgery. *J Surg Oncol* 2010;102(1):27–33.
54. Higgins KM, Shah MD, Ogaick MJ, et al. Treatment of early-stage glottic cancer: meta-analysis comparison of laser excision versus radiotherapy. *J Otolaryngol Head Neck Surg* 2009;38(6):603–612.
55. Hartl DM, Ferlito A, Brasnu DF, et al. Evidence-based review of treatment options for patients with glottic cancer. *Head Neck* 2011;33(11):1638–1648.
56. Caicedo-Granados E, Beswick DM, Christopoulos A, et al. Oncologic and functional outcomes of partial laryngeal surgery for intermediate-stage laryngeal cancer. *OtolaryngolHead Neck Surg* 2013;148(2):235–242.
57. Induction chemotherapy plus radiation compared with surgery plus radiation in patients with advanced laryngeal cancer. The Department of Veterans Affairs Laryngeal Cancer Study Group. *N Eng J Med* 1991;324(24):1685–1690.
58. Forastiere AA, Goepfert H, Maor M, et al. Concurrent chemotherapy and radiotherapy for organ preservation in advanced laryngeal cancer. *N Eng J Med* 2003;349(22):2091–2098.
59. Forastiere AA, Zhang Q, Weber RS, et al. Long-term results of RTOG 91–11: a comparison of three nonsurgical treatment strategies to preserve the larynx in patients with locally advanced larynx cancer. *J Clin Oncol* 2013;31(7):845–852.
60. Gourin CG, Conger BT, Sheils WC, et al. The effect of treatment on survival in patients with advanced laryngeal carcinoma. *Laryngoscope* 2009; 119(7):1312–1317.
61. Tennant PA, Cash E, Bumpous JM, et al. Persistent tracheostomy after primary chemoradiation for advanced laryngeal or hypopharyngeal cancer. *Head Neck* 2014;36(11):1628–1633.
62. Harrison BL, Sessions BR, Kies MS. *Head and Neck Cancer: A Multidisciplinary Approach.* 4th ed. Philadelphia, PA: Wolters Kluwer/Lippincott-Raven; 2014.
63. Byers RM. Modified neck dissection. A study of 967 cases from 1970 to 1980. *Am J Surg* 1985;150(4):414–421.
64. Lindberg R. Distribution of cervical lymph node metastases from squamous cell carcinoma of the upper respiratory and digestive tracts. *Cancer* 1972;29(6):1446–1449.

65. Shah JP. Patterns of cervical lymph node metastasis from squamous carcinomas of the upper aerodigestive tract. *Am J Surg* 1990;160(4):405–409.

SECTION D: ESOPHAGUS

Chapter 42

Esophageal Anatomy and Physiology and Gastroesophageal Reflux Disease

Daniel S. Oh and Steven R. DeMeester

Key Points

1 The esophagus can be considered to have distinct anatomical locations in the neck, chest, and abdomen with distinct physiologic and pathophysiologic considerations.

2 The esophageal wall is composed of three distinct layers – the mucosa, submucosa, and muscularis propria. The mucosa is separated from the submucosa by the muscularis mucosae. Tumors lying within the mucosal layer may be managed endoscopically.

3 The mucosal lining of the esophagus is squamous mucosa at birth. Repeated injury of the esophageal squamous mucosa with reflux may lead to metaplastic change to columnar mucosa such as cardiac mucosa, oxyntocardiac mucosa, or cardiac mucosa with intestinal metaplasia (goblet cells).

4 Barrett esophagus is defined as having both an endoscopic columnar segment and a microscopic finding of cardiac mucosa with goblet cells or intestinal metaplasia.

5 During a swallow, the peristaltic wave begins in the upper esophageal sphincter. The lower esophageal sphincter relaxes at the initiation of the swallow and remains relaxed until the peristaltic wave progresses down the esophageal body and through the lower sphincter.

6 The lower esophageal sphincter retains its competence as a barrier to gastric contents by three factors: its length, its resting pressure, and its position.

7 The function of the esophagus can be evaluated by endoscopy, radiology (fluoroscopy), and manometry. Measurement of acid exposure in the esophagus can be performed with ambulatory pH monitoring.

8 The endoscopist should note three critical landmarks during an EGD: the squamocolumnar junction (SCJ), the gastroesophageal junction (GEJ), and the crura or hiatus.

9 Preoperative functional assessment of the esophagus and lower esophageal sphincter are mandatory when considering antireflux surgery to tailor the operation to the appropriate circumstances of the patient.

10 Ambulatory pH monitoring remains the gold standard for documenting

gastroesophageal reflux and should be used to confirm the diagnosis of GERD.

ESOPHAGEAL ANATOMY AND FUNCTION

The esophagus is a muscular tube that starts as the continuation of the pharynx with the upper esophageal sphincter (UES) or cricopharyngeus and ends with the lower esophageal sphincter at the fundus of the stomach (Fig. 42-1). Knowledge of the anatomy of the esophagus and its relationship with other organs and structures is essential for the surgeon to evaluate the location of lesions seen by endoscopy, barium swallow study, or computed tomography (CT); to interpret esophageal function studies; and to safely expose the esophagus during surgery.

Cervical Esophagus

The cervical portion of the esophagus is approximately 3 to 5 cm long. It starts below the cricopharyngeus muscle and appears as a continuation of the inferior constrictor muscle of the pharynx. A space between the right and left inferior constrictor muscles posteriorly just above the cricopharyngeus muscle is an area of natural weakening and referred to as Killian triangle, the site where a Zenker diverticulum develops (Fig. 42-2). The beginning of the cervical esophagus is marked by the level of C6, and the end by the lower border of T1. The cervical esophagus curves slightly to the left as it descends. Anteriorly, it abuts the trachea and larynx and can be dissected off both organs. Posteriorly, the cervical esophagus lies on the vertebral bodies in a prevertebral or retroesophageal space. This space is continuous with the retropharyngeal space superiorly and the posterior mediastinum inferiorly, which is the primary route of descending mediastinitis from oropharyngeal infections. Laterally, the omohyoid muscle crosses the cervical esophagus obliquely, and it is usually necessary to divide this to expose that portion of the esophagus. The carotid sheaths lie laterally, and the lobes of the thyroid and the strap muscles lie anteriorly. The recurrent laryngeal nerves lie in the grooves between the esophagus and the trachea. The right recurrent nerve runs a more lateral and oblique course to reach the groove and is more prone to anatomic variation. Although the surgical approach to the cervical esophagus may be from either side of the neck through an incision along the medial border of the sternocleidomastoid muscle, the left-sided approach is preferred to avoid injury to the more variable course of the right recurrent nerve.

Thoracic Esophagus

The thoracic portion of the esophagus is approximately 18 to 20 cm long (Fig. 42-1) and starts at the thoracic inlet. In the upper portion of the thorax, it is closely related to the posterior membranous wall of the trachea. This close relationship is responsible for the early spread of cancer of the upper esophagus into the trachea, and it may limit the surgeon's ability to resect such a tumor. Above the level of the tracheal bifurcation, the esophagus courses to the right of the aortic arch and the descending aorta and then deviates to the left, passing behind the tracheal bifurcation and the left main bronchus. In the lower portion of the thorax, the esophagus remains deviated to the left and passes anteriorly through the diaphragmatic hiatus. There are three natural areas of constriction in the thoracic esophagus: the cricopharyngeus or UES, the bronchoaortic constriction as it crosses behind the aortic arch and left mainstem bronchus, and the lower esophageal sphincter.

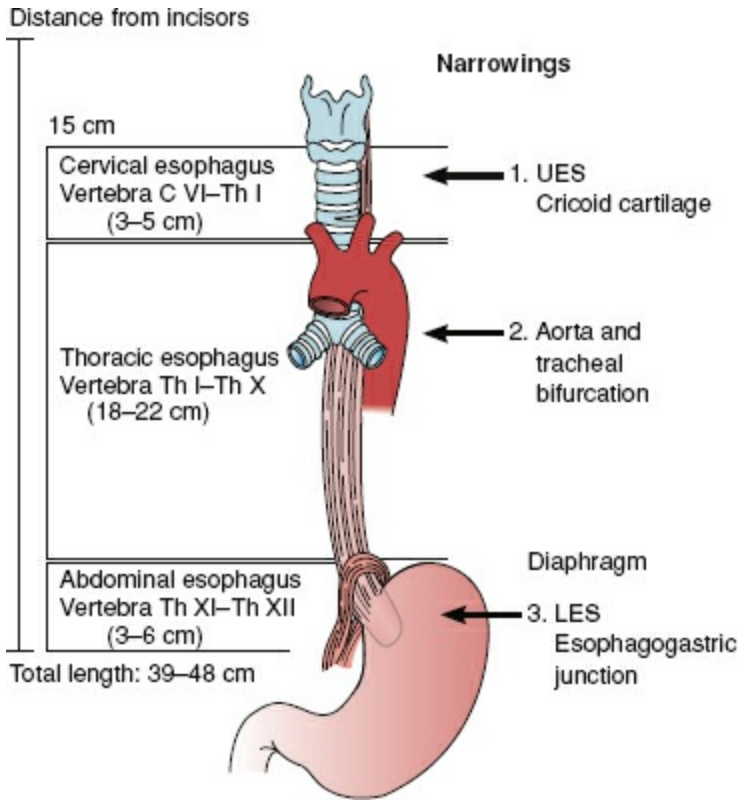

Figure 42-1. Anatomy of the esophagus.

Unlike the remainder of the gastrointestinal tract, the esophagus does not have a serosal layer and its strength is derived from its mucosa. The thoracic esophagus is covered only by parietal pleura, making this portion the weakest and the most common site of perforation in Boerhaave syndrome, usually on the left side where there is a lack of support from adjacent structures.

The azygos vein is closely related to the right of the esophagus as it ascends from the abdomen and then arches from its paraspinal position over esophagus and the right main bronchus to enter the superior vena cava.

The thoracic duct ascends behind and to the right of the distal thoracic esophagus

between the azygos vein and aorta. At approximately the level of T5, it passes alongside the aorta and ascends on the left side of the esophagus to enter behind the junction of the left internal jugular and subclavian veins. Due to the possibility of disrupting the thoracic duct during its course across the mediastinum during an esophagectomy, ligation of the duct is generally performed low in the chest where it comes through the aortic hiatus.

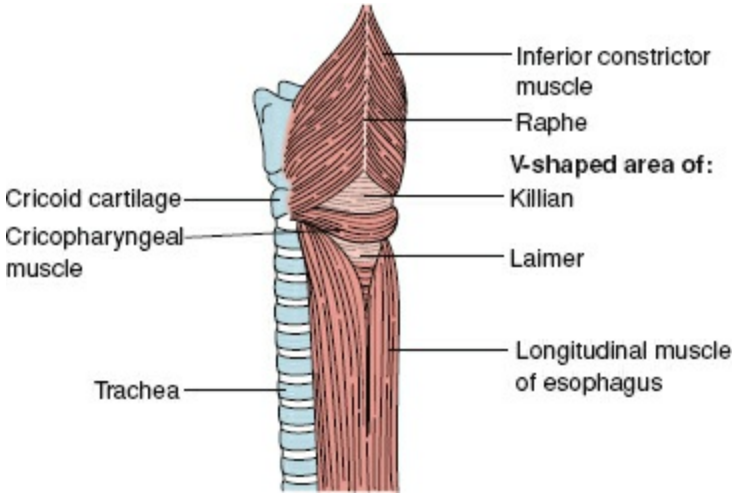

Figure 42-2. Posterior view of cervical esophagus.

Abdominal Esophagus

The abdominal portion of the esophagus is approximately 3 to 6 cm long and consists of the abdominal portion of the LES. It begins as the esophagus passes through the diaphragmatic hiatus and is surrounded by the phrenoesophageal membrane, a fibroelastic ligament that arises from the subdiaphragmatic fascia as a continuation of the transversalis fascia lining the abdomen (Fig. 42-3). The upper leaf of the membrane attaches in a circumferential fashion around the esophagus about 1 to 2 cm above the level of the hiatus. The lower leaf of the phrenoesophageal membrane blends with the serosa of the stomach, and its end is marked anteriorly by a prominent fat pad, which corresponds approximately with the gastroesophageal junction. The lower esophageal sphincter is a zone of high pressure 3 to 4 cm long at the lower end of the esophagus[1] and does not correspond to any visible macroscopic anatomic landmark either on the external surface of the esophagus, nor in the endoscopic appearance of the mucosa. Its function is derived from the microscopic architecture of the muscle fibers. The esophageal hiatus is surrounded by the right and left crura, which together form a sling of diaphragmatic skeletal muscle around the esophagus that originates from tendinous bands attached to the anterolateral surface of the first lumbar vertebra (Fig. 42-4). The relative contribution of the right and left crura to this sling is variable. Posterior to the esophagus, the crura are united by a tendinous arch, the median arcuate ligament, which lies just anterior to the aorta.

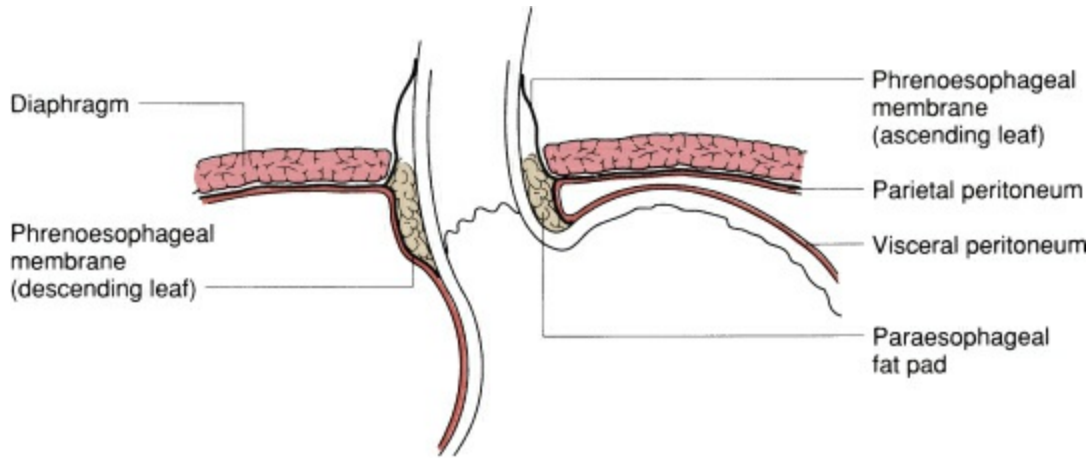

Figure 42-3. Anatomy of the esophageal hiatus and relationship to the phrenoesophageal membrane.

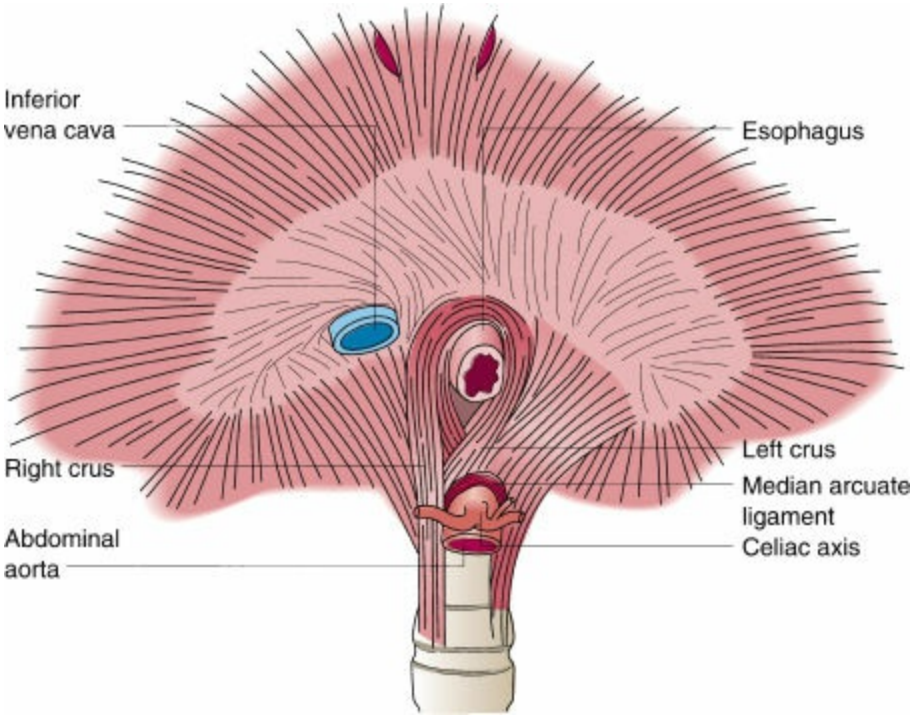

Figure 42-4. Inferior view of diaphragm and anatomy of the esophageal hiatus.

Structure of the Esophageal Wall and Mucosa

The esophagus is composed of three primary layers – mucosa, submucosa, and muscularis propria. The mucosal layer is normally composed of nonkeratinized stratified squamous epithelium, as opposed to the stomach where columnar epithelium is present. In the distal aspect of the esophagus within the lower esophageal sphincter, repeated exposure of the squamous epithelium to gastric contents can result in metaplasia of esophageal squamous mucosa to a columnar epithelium called cardiac mucosa. This nomenclature was originally used to describe what was mistakenly thought to be the proximal stomach or cardia, but there is now convincing evidence that this is in fact metaplastic esophageal mucosa.[2] With further injury and exposure to refluxed gastric juice such as bile acids, cardiac mucosa may further transform into intestinal metaplasia or Barrett esophagus, characterized by the presence of goblet cells within cardiac mucosa. Alternatively, cardiac mucosa can also differentiate further to acquire parietal cells and is known as oxyntocardiac mucosa.[3]

A critical layer within the mucosa for determining the biologic behavior of a superficial cancer is the muscularis mucosa. This thin, poorly developed layer lies below the basement membrane and above the submucosa. It is often duplicated in patients with Barrett esophagus, and can lead to confusion during pathologic evaluation of the depth of tumor invasion in endoscopic resection (ER) specimens.[4] The significance of the muscularis mucosa is that tumors confined to this layer rarely are associated with lymph node metastases, but once tumors penetrate through this layer into the submucosa the frequency of lymph node metastases increases substantially.

The submucosa is characterized by a rich lymphatic plexus that extends throughout the esophagus. Lymphatic collecting branches arise from within the submucosa and pierce the muscularis propria to communicate with regional lymph nodes and the thoracic duct outside of the esophagus. This network of lymphatics allow for significant longitudinal spread of esophageal cancers and a high rate of skip metastases. Clinically, tumor invasion beyond the muscularis mucosa into the submucosa is significant due to this lymphatic system, with the rate of regional lymph node metastases increasing from $<5\%$ with intramucosal tumors to 20% to 50% for submucosal tumors.[5] Finally, the submucosa of the esophagus also harbors mucous glands that drain into the lumen. These glands are helpful for determining the true extent of the esophagus when metaplasia of the mucosa occurs.

The muscularis propria is composed of an inner circular layer and an outer longitudinal layer. The muscles are striated in the upper portion and transition to completely smooth muscle near the upper third of the esophagus. The longitudinal muscle layer courses down in an elongated spiral pattern, turning approximately 90 degrees as it descends to the stomach. The circular muscle layer is thicker than the longitudinal layer, which also takes on an elliptical or spiral orientation (Fig. 42-5). This arrangement of muscle is responsible for the wormlike drive of peristalsis.

Blood Supply, Lymphatics, and Innervation

The cervical portion of the esophagus receives its main blood supply from the inferior thyroid artery. The thoracic portion receives blood from the bronchial and esophageal arteries. Seventy-five percent of individuals have one right-sided and two left-sided bronchial arteries, and usually two esophageal branches arise directly from the aorta. There are rarely aortic branches directly to the esophagus in the lower half of the esophagus in the chest, allowing the surgeon to perform an en bloc dissection of all of the periesophageal tissue directly off the plane of the aortic adventitia from the right to the left pleural spaces. The blood supply of the abdominal portion of the esophagus comes from the ascending branch of the left gastric artery and from the right and left inferior phrenic arteries (Fig. 42-6). After the vessels have entered the muscular wall of the esophagus, branching occurs at right angles to provide an extensive longitudinal vascular plexus. The rich blood supply provided by this vascular plexus allows mobilization of the esophagus from the stomach to the aortic arch without causing ischemic injury.[6]

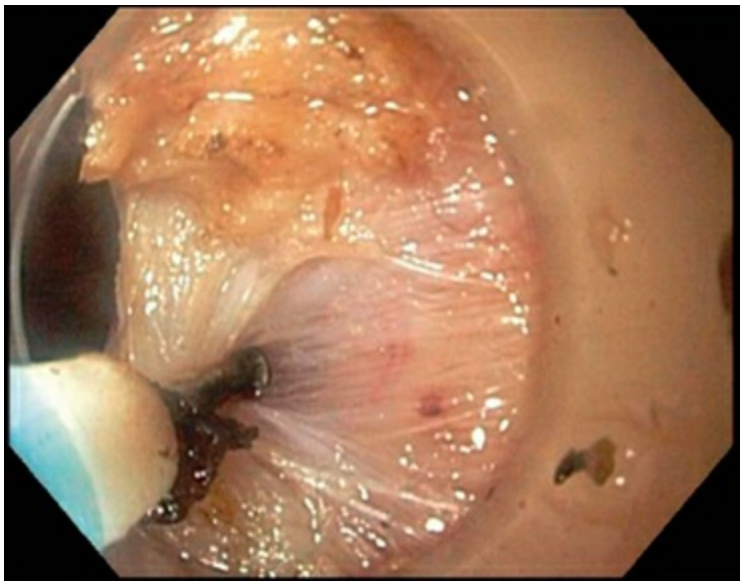

Figure 42-5. Endoscopic view of esophageal muscle layers during a peroral endoscopic myotomy (POEM) for achalasia. The endoscopic knife is lifting and cutting the circumferential circular muscle fibers, leaving the longitudinal muscle fibers intact.

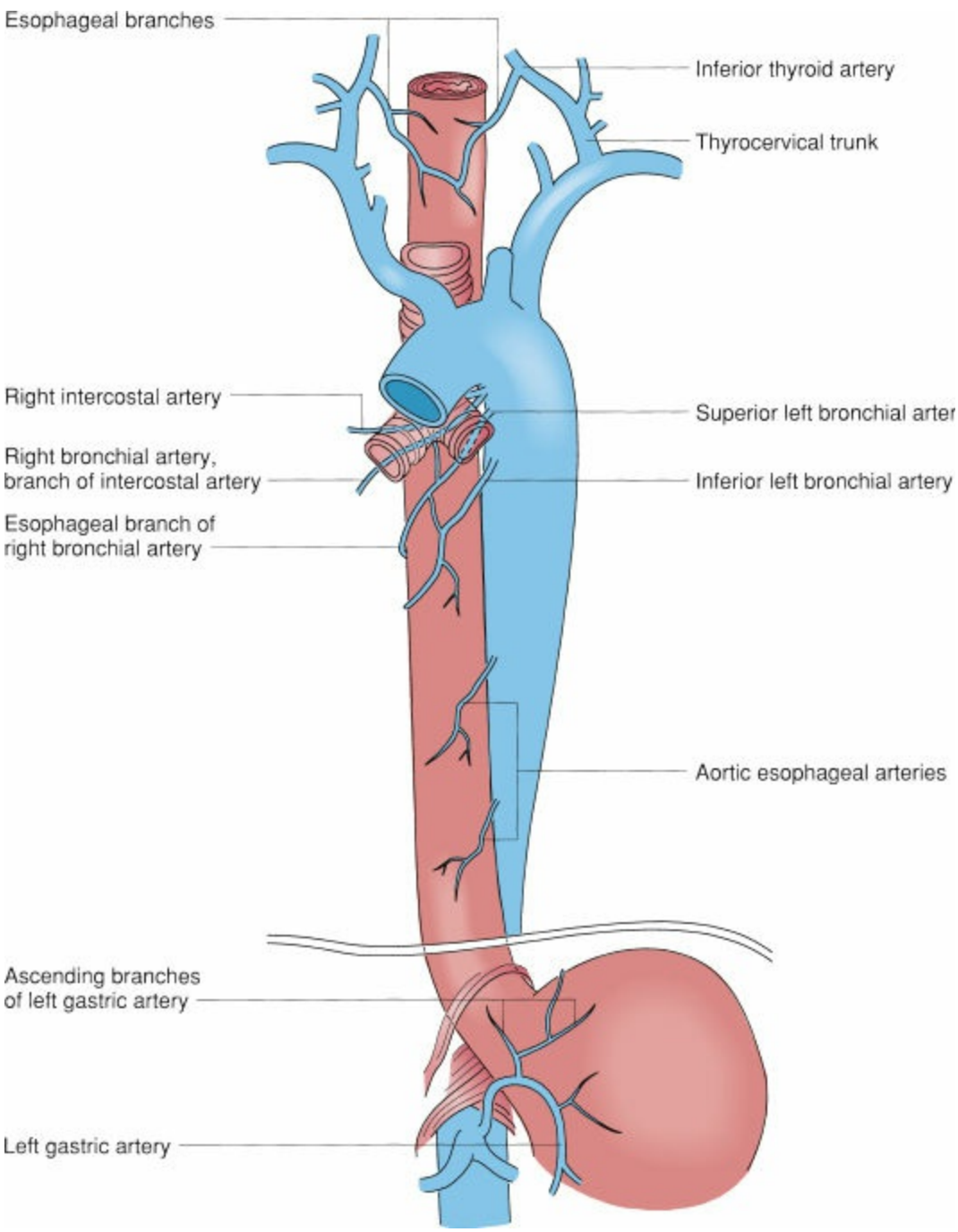

Figure 42-6. Arterial anatomy of the esophagus.

The capillaries of the esophagus drain into a submucosal and periesophageal venous plexus, from which the esophageal veins originate. In the cervical region, the esophageal veins empty into the inferior thyroid vein; in the thoracic region, they empty into the bronchial, azygos, or hemiazygos veins; and in the abdominal region, they empty into the coronary vein (Fig. 42-7).

The lymphatic channels are located almost exclusively below the muscularis mucosa in the submucosa of the esophagus, constituting a dense and interconnected plexus with more lymph vessels than blood capillaries (Fig. 42-8). Lymph flow in the submucosal plexus runs in a longitudinal direction, and after the injection of a contrast medium, the longitudinal spread is six times that of the transverse spread. In the upper two-thirds of the esophagus, the lymphatic flow is mostly cephalad; in the lower third, it is mostly caudal. In the thoracic portion of the esophagus, the submucosal lymph plexus extends

over a long distance in a longitudinal direction before penetrating the muscle layer to enter lymph vessels in the adventitia. As a consequence of this nonsegmental lymph drainage, the lymphatic spread of tumor cells can extend for a considerable distance superiorly and inferiorly within the submucosal lymphatics before the cells pass through lymphatic channels in the muscularis and on into the regional lymph nodes. There is a high rate of skip metastases in esophageal cancer due to this arrangement. By contrast, the cervical esophagus has a more segmental lymph drainage into the regional lymph nodes, and as a result, tumors in this portion of the esophagus have less submucosal extension.

Lymph from the cervical esophagus drains into the paratracheal and deep cervical lymph nodes, whereas lymph from the upper thoracic esophagus flows mainly into the paratracheal lymph nodes. The lymph from the lower thoracic esophagus drains into the subcarinal and inferior pulmonary nodes. Lymph from the distal thoracic and abdominal portion of the esophagus drains into the parahiatal and perigastric nodes.[7]

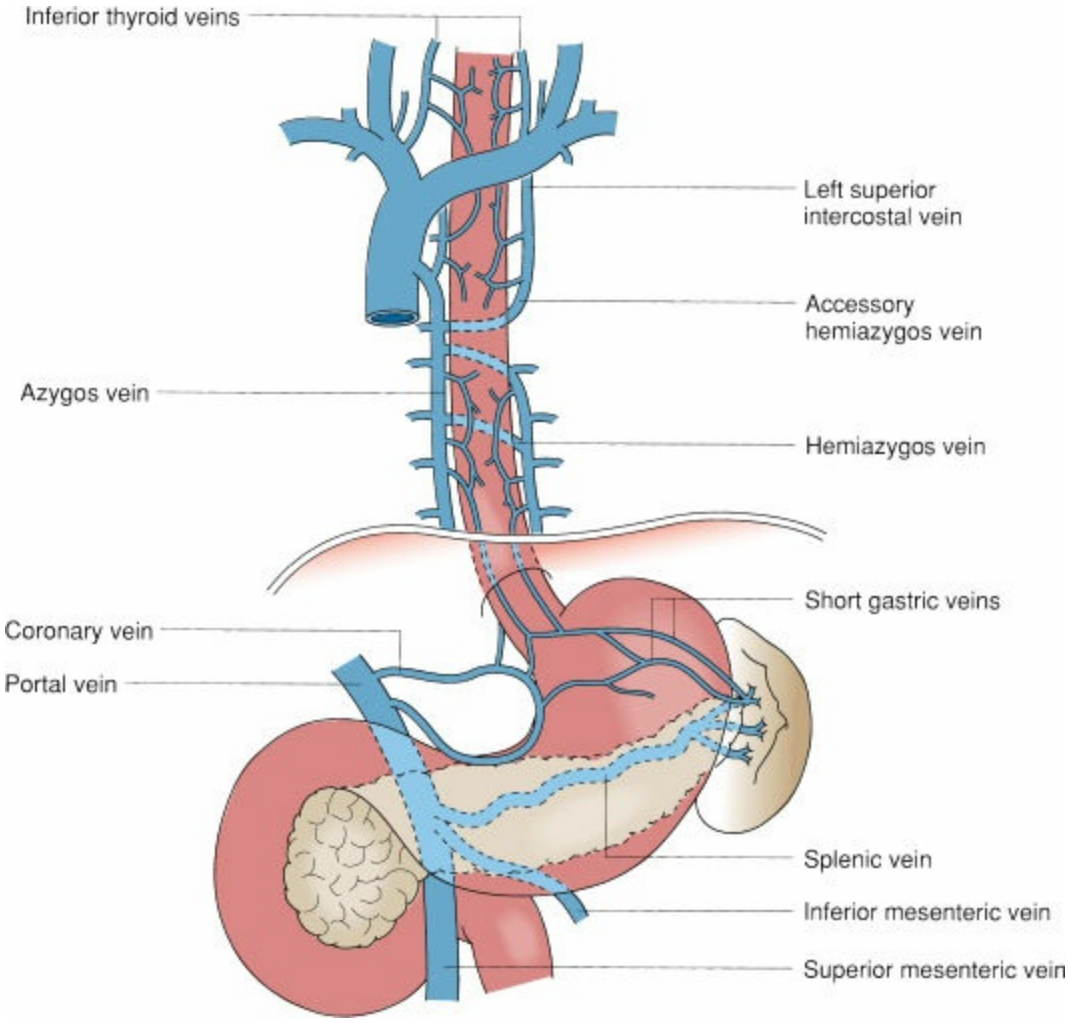

Figure 42-7. Venous anatomy of the esophagus.

The parasympathetic innervation of the pharynx and esophagus is provided mainly by cranial nerve X or the vagus nerves. The constrictor muscles of the pharynx receive branches from the pharyngeal plexus, which is located on the posterior lateral surface of the middle constrictor muscle and is formed by pharyngeal branches of the vagus nerve,

with a small contribution from cranial nerves IX and XI. The cricopharyngeal sphincter and the cervical portion of the esophagus receive branches from both the right and left recurrent laryngeal nerves originating from the vagus nerves (Fig. 42-9). Damage to these recurrent nerves interferes not only with the movement of the vocal cords but also with the function of the cricopharyngeal sphincter and the motility of the cervical esophagus, predisposing the patient to pulmonary aspiration on swallowing. The upper thoracic esophagus receives innervation from the left recurrent laryngeal nerve and both vagus nerves. As the right and left vagus nerves descend into the mediastinum, they join the outer surface of the esophagus. The esophageal plexus, which is formed by the branches of the right and left vagus nerves and thoracic sympathetic chain, lies on the anterior and posterior walls of the esophagus and innervates the lower thoracic portion.[8] The branches of the plexus coalesce into the left (anterior) and right (posterior) vagal trunks.

Afferent visceral sensory fibers from the esophagus end without synapse in the first four segments of the thoracic spinal cord by a combination of sympathetic and vagal pathways. These pathways are also occupied by afferent visceral sensory fibers from the heart, which explains the similarity of symptoms in esophageal and cardiac diseases.

PHYSIOLOGY

To comprehend the mechanics of alimentation, it is useful to visualize the gullet as a series of pumps and valves. In the pharyngeal segment, the tongue and pharyngeal muscle function as pumps, whereas the soft palate, the epiglottis, and the cricopharyngeus serve as the valves that regulate flow. In the esophageal segment, the esophageal body functions as the pump to propel the food bolus, whereas the lower esophageal sphincter serves as a valve to allow transport into the stomach and to prevent the flow of gastric contents back into the esophagus.

The Swallowing Mechanism

Swallowing can be started at will, or it can be reflexively elicited by the stimulation of the anterior and posterior tonsillar pillars or the posterior lateral walls of the hypopharynx. The afferent sensory nerves of the pharynx are the glossopharyngeal nerves and the superior laryngeal branches of the vagal nerves. Once it is aroused by stimuli entering through these nerves, the swallowing center in the medulla coordinates the complete act of swallowing by discharging impulses through cranial nerves V, VII, X, XI, and XII and the motor neurons of C1 through C3. Discharges through these nerves always occur in a specific pattern and last for approximately 0.5 second. Little is known about the swallowing center except that it can trigger swallowing after a variety of different inputs. Once it is triggered, the swallow response is always a rigidly ordered pattern of outflow neurogenic impulses.

The act of alimentation requires the passage of food and drink from the mouth into the stomach. Food is taken into the mouth in a variety of bite sizes, after which it is broken up by the teeth, mixed with saliva, and lubricated. When food is ready for swallowing, the tongue, acting as a pump, moves the bolus into the posterior oropharynx and forces it into the hypopharynx (Fig. 42-10). Concomitantly with the posterior movement of the tongue, the soft palate is elevated, thereby closing the passage between the oropharynx and nasopharynx. With the initiation of the swallow, the hyoid moves superiorly and anteriorly, thereby elevating the larynx and enlarging the retropharyngeal space. At the same time, the epiglottis covers the laryngeal inlet to prevent aspiration.

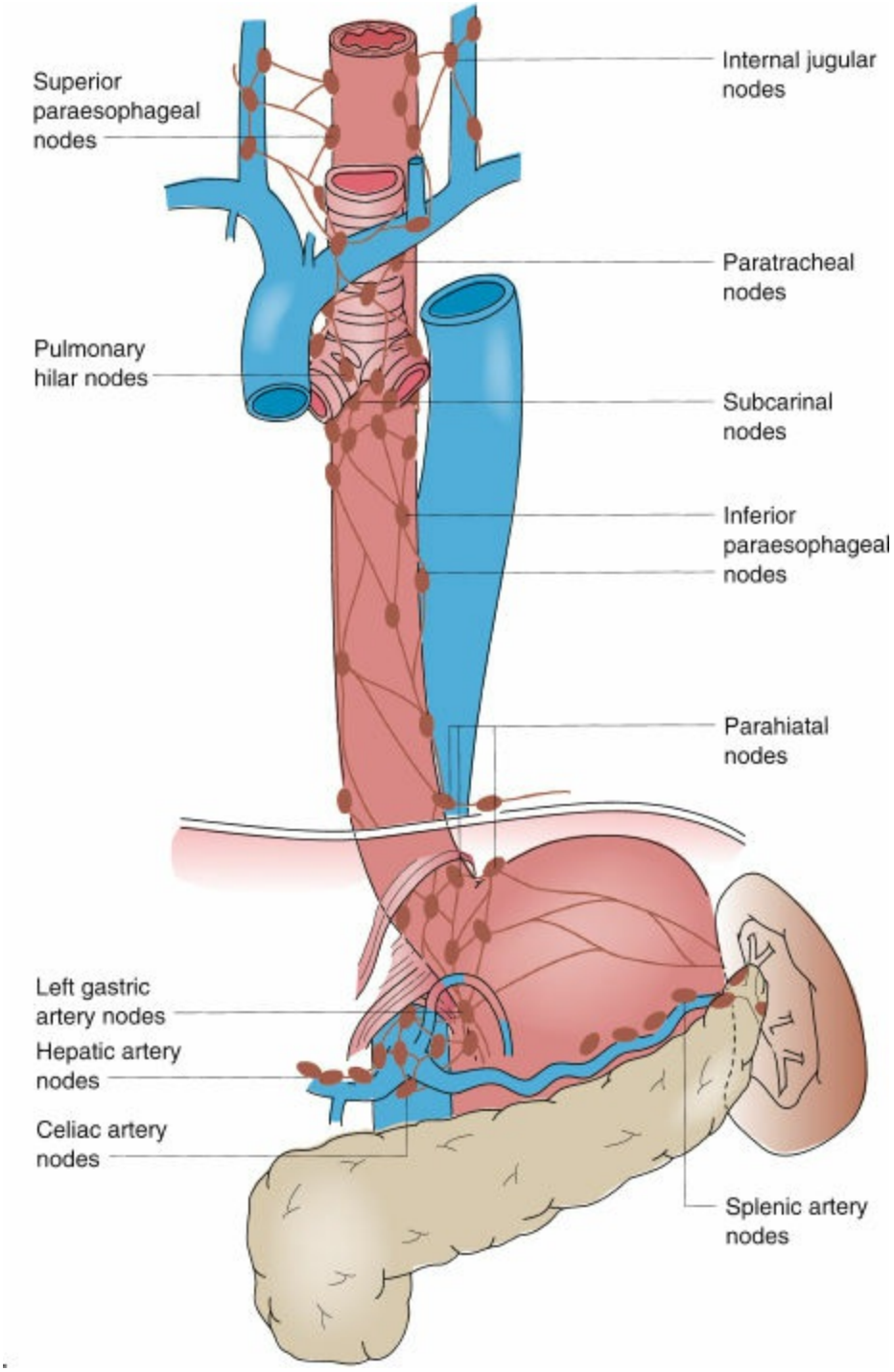

Figure 42-8. Lymphatic anatomy of the esophagus.

During swallowing, the pressure in the hypopharynx rises abruptly to 60 mm Hg as a result of the backward movement of the tongue and contraction of the posterior pharyngeal constrictors. A sizable pressure difference develops between the hypopharyngeal pressure and the subatmospheric midesophageal or intrathoracic pressure (Fig. 42-11). This pressure gradient speeds the movement of food from the hypopharynx into the esophagus when the cricopharyngeus or UES relaxes. The bolus is both propelled by the peristaltic contraction of the posterior pharyngeal constrictors and sucked into the thoracic esophagus by this pressure gradient.

Critical to receiving the bolus is the compliance of the cervical esophageal muscle and the timing and degree of relaxation of the UES. Abnormalities of compliance and UES opening can result in pharyngeal dysphagia. During the transfer of the bolus from the

mouth into the esophagus, the UES is mechanically pulled open. Elevation of the larynx by muscles attached to the hyoid bone pulls the UES open at the same time that relaxation of the UES is occurring. The active relaxation of the UES is caused by a reduction in the tone of the tonic constriction of the cricopharyngeus muscle, and it is dependent on a neurologically mediated reflex. This is an all-or-nothing event; partial relaxation does not normally occur. The UES closes within 0.5 second of the initiation of the swallow, with a postrelaxation contraction pressure that is approximately twice the resting pressure of 30 mm Hg. The postrelaxation contraction continues down the esophagus as a peristaltic wave (Fig. 42-12). The high closing pressure and the initiation of the peristaltic wave prevent reflux of the bolus from the esophagus into the pharynx. After completion of the swallow, the pressure of the UES returns to its normal resting pressure.

The pharyngeal activity in swallowing initiates the esophageal phase of swallowing. Because of the helical arrangement of its circular muscles, the body of the esophagus functions as a worm-drive propulsive pump, and it is responsible for transmitting a bolus of food into the stomach. With the act of swallowing, the longitudinal muscle of the esophageal body shortens, thus enlarging the lumen to accept the bolus (the "on response"), after which the circular smooth muscle contraction forms the peristaltic wave (the "off response"). During the esophageal phase of swallowing, the bolus is moved into the stomach over a gradient of 12 mm Hg (i.e., from a negative intrathoracic pressure environment of −6 mm Hg to a positive intra-abdominal pressure environment of +6 mm Hg). Effective and coordinated smooth muscle function in the lower two-thirds of the esophageal body is important to allow this movement to occur.

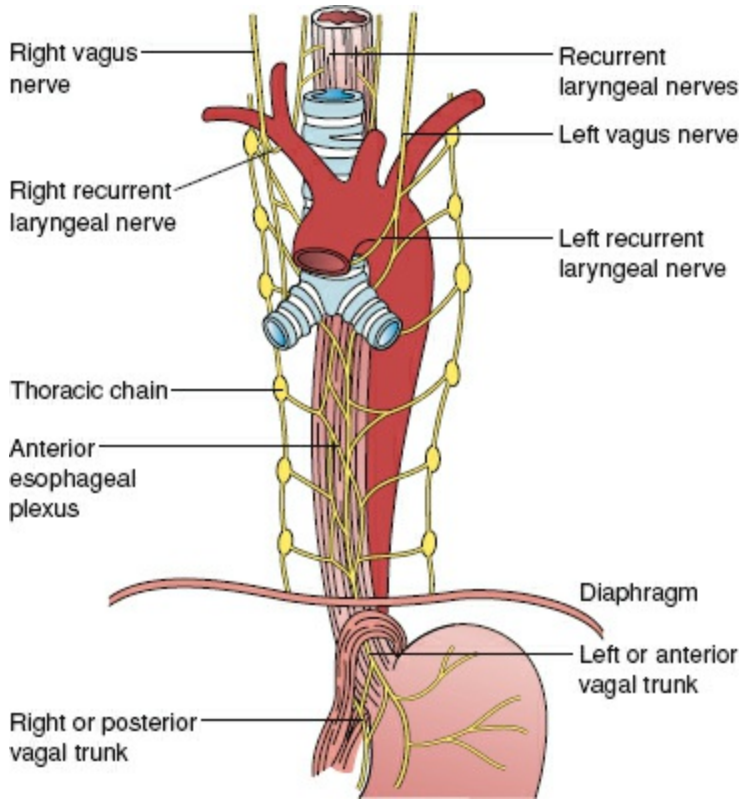

Figure 42-9. Relationship of the esophagus to the vagus nerves and their branches.

The peristaltic wave generates an occlusive pressure that varies from 30 to 120 mm Hg. The wave rises to a peak in 1 second, remains at the peak for about 0.5 second, and then subsides in about 1.5 seconds. The whole course of the rise and fall of an occlusive contraction may occupy one point in the esophagus for 3 to 5 seconds.[9,10] The peak of the primary peristaltic contraction moves down the esophagus at a rate of 2 to 4 cm per second and reaches the distal esophagus about 9 seconds after swallowing starts. The lower esophageal sphincter relaxes at the initiation of the peristaltic wave and remains open until the peristaltic wave passes through the body and into the sphincter muscle, and this is followed by a distinctive postrelaxation contraction of the lower esophageal sphincter. A consecutive swallow after 20 seconds produces a similar primary peristaltic wave; however, if repetitive swallowing occurs sooner, the esophagus becomes unresponsive (*deglutitive inhibition*).

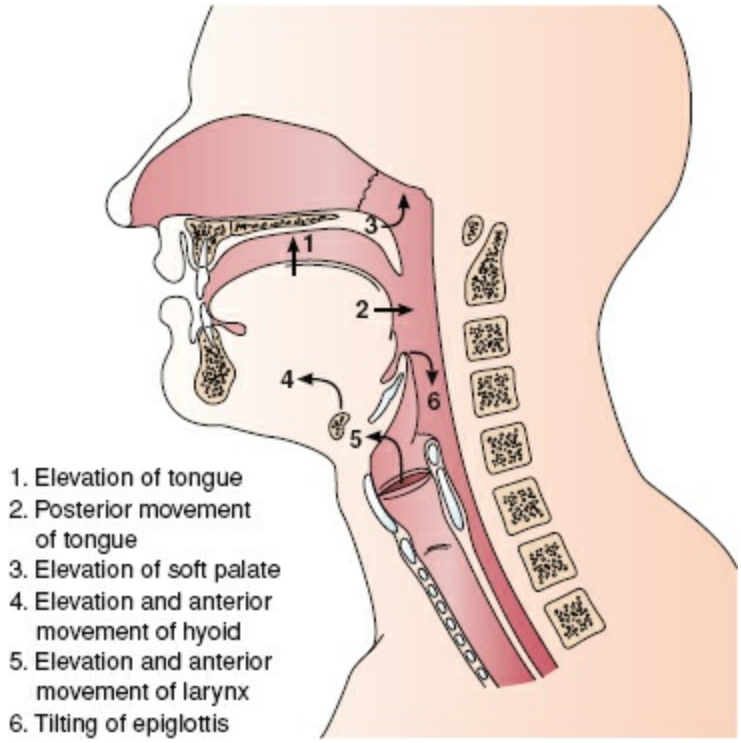

Figure 42-10. Overview of the act of swallowing.

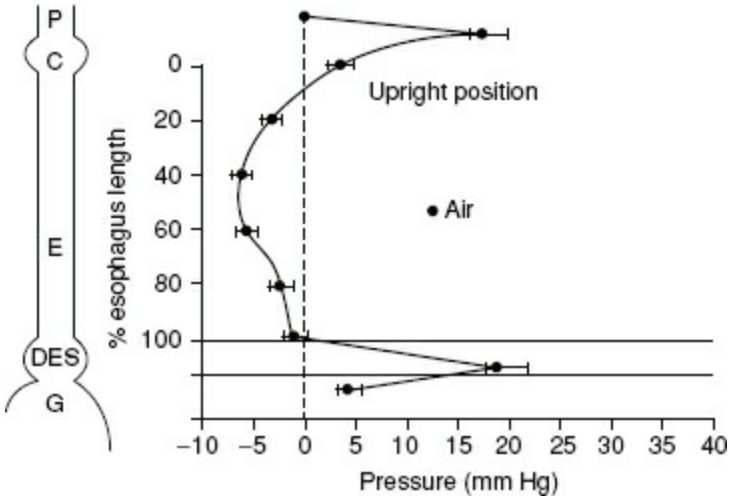

Figure 42-11. Pressure profile of the esophagus in the neck, chest, and abdomen. (From Waters PF, DeMeester TR. Foregut motor disorders and their surgical management. *Med Clin North Am* 1981;65:1237, with permission.)

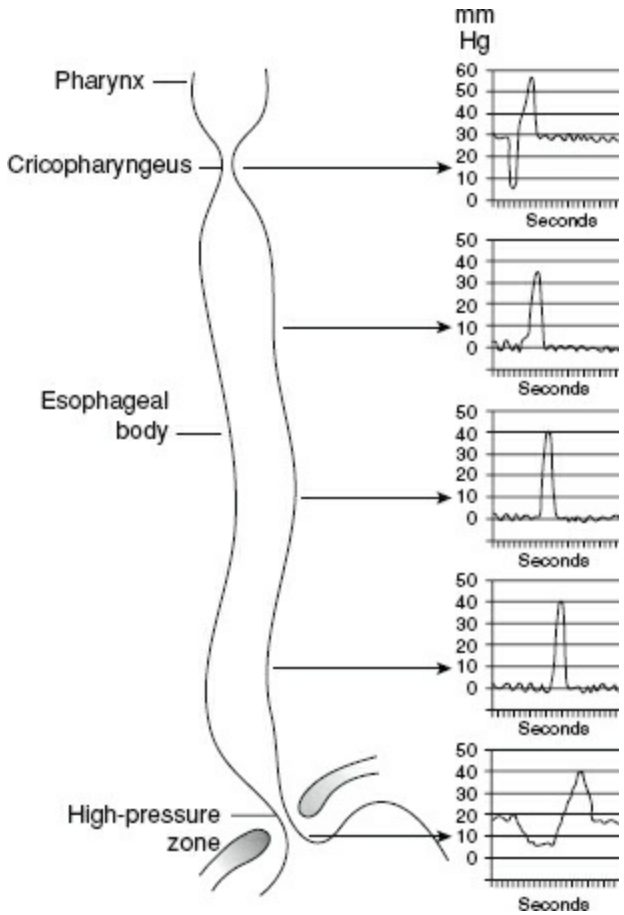

Figure 42-12. Overview of esophageal body peristalsis. (From Waters PF, DeMeester TR. Foregut motor disorders and their surgical management. *Med Clin North Am* 1981;65:1237, with permission.)

To be effective, peristaltic contractions must be of sufficient amplitude to occlude the esophageal lumen and sufficiently organized in a peristaltic waveform to propel a bolus toward the stomach. Low-amplitude contractions that do not occlude the lumen merely indent a semisolid bolus rather than propel it, and simultaneous contractions throughout the body of the esophagus result in splitting the bolus or propelling it orally which can be observed on a barium esophagram as bolus segmentation or cephalic escape.

Clinically, defects in peristalsis occur in three broad categories, depending on which

major feature is the most impaired. First, there is a neural abnormality that results in the defective organization of the peristaltic wave; this is recognized by the presence of simultaneous contractions with a loss of the peristaltic sequence and results in typical primary motility disorders (e.g., diffuse esophageal spasm). The second category defect is evident when there is a reduction of the amplitude of the contraction but the peristaltic sequence remains; this is usually due to muscle damage and the formation of fibrous tissue within the muscle. Examples include end-stage gastroesophageal reflux disease (GERD) and connective tissue disorders such as scleroderma. The third category defect results from altered anatomy of the esophageal body. A loss in the efficiency of the peristaltic sequence can result when the esophagus is not anchored distally, as occurs with a large paraesophageal hernia (PEH); which can result in the appearance of an accordion esophagus on a barium swallow esophagram with ineffective clearance of barium.

Lower Esophageal Sphincter

The LES represents the barrier that confines the gastric juice to the stomach and protects the acid-sensitive squamous esophageal mucosa from injury by refluxed gastric juice. As is true for any valve, failure of the LES can occur in two completely opposite ways, which lead to two distinct clinical disease entities. Regardless of the type of LES failure, the secondary effects are produced proximally in the esophagus. Failure of the LES to relax or to open appropriately leads to the inability of the esophagus to propel food into the stomach, esophageal distention, and the condition known as achalasia. On the other hand, failure of the LES to remain closed leads to an increased exposure of the squamous epithelium to gastric juice and the condition known as GERD.

The LES has no anatomic landmarks and cannot be seen endoscopically; it is identified on manometry as a rise in pressure over gastric baseline pressure. This high-pressure zone is normally present except in two situations: (1) after a swallow, when it is momentarily dissipated or relaxes to allow passage of food into the stomach; and (2) during a belch, when it allows gas to be vented from a distended fundus. The common denominator for virtually all episodes of gastroesophageal reflux is the loss of this normal high-pressure zone or barrier. When the barrier is absent, resistance to the flow of gastric juice from an environment of higher pressure (the stomach) to an environment of lower pressure (the esophagus) is lost. In early GERD, this is usually caused by a transient loss of the barrier. In advanced GERD, there is usually a permanent loss of the barrier.[11]

There are three characteristics of the LES or high-pressure zone that maintain its function as a barrier to intragastric and intra-abdominal pressure challenges. Two of these characteristics – the overall length and pressure of the LES – work together and depend on each other to provide resistance to the flow of gastric juice from the stomach into the esophagus.[12] The shorter the overall length, the higher the pressure must be for the LES to maintain sufficient resistance to remain competent (Fig. 42-13). Consequently, the effect of a normal LES pressure can be nullified by a short overall LES length, and the effect of a normal overall LES length can be nullified by a low LES pressure. A fundamental principle for surgeons to understand is that the length of the barrier or LES is critical to its function.

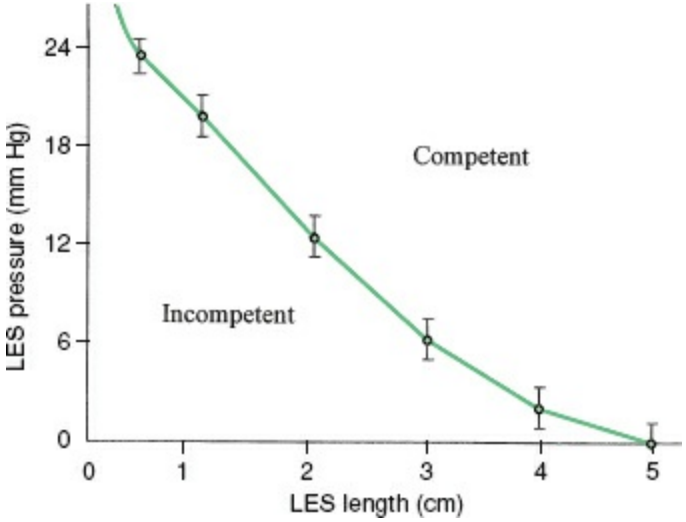

Figure 42-13. Relationship of the length and pressure of the lower esophageal sphincter in maintaining competence of the gastroesophageal barrier.

Foreshortening of LES length occurs naturally with gastric filling as the terminal esophagus is "taken up" by the expanding fundus (Fig. 42-14);[13] this is similar to the shortening of the neck of a balloon as it is inflated. With excessive gastric distention (e.g., with overeating), the length of the LES shortens to a critical point at which it gives way, the pressure drops precipitously, and reflux occurs (Fig. 42-15).[14] If the length of the LES is permanently shortened, then further shortening caused by the normal gastric distention with normal-volume meals results in postprandial reflux. In this situation, competency of the barrier is an ever-constant clinical problem. The observation that gastric distention results in shortening of the LES down to a critical length so that the pressure dissipates, the lumen opens, and reflux occurs provides a mechanical explanation for transient LES relaxations without invoking a neuromuscular reflex. If only the LES pressure and not its length is measured (e.g., with a Dent sleeve), the event appears as a spontaneous relaxation of LES pressure.[15] In reality, it is the progressive shortening of the LES rather than the transient LES relaxations that results in the loss of LES pressure.

Variations in the anatomy of the cardia, from a normal acute angle of His to an abnormal dome architecture of a sliding hiatal hernia, influence the ease with which the sphincter is shortened by gastric distention. A hernia can result from the pulsion force of abdominal pressure on the esophageal hiatus or from the traction produced by inflammatory fibrosis of the esophageal body. The resulting alteration in the geometry of the cardia places the sphincter at a mechanical disadvantage in maintaining its length with progressive degrees of gastric distention. Greater gastric distention is necessary to open the barrier in patients with an intact angle of His than in those with a hiatal hernia.[16] The reason is that the dome or funnel shape of a hiatal hernia allows the wall tension forces that pull open the barrier with gastric distention to be more effectively applied to the gastroesophageal junction,[17] and it accounts for the common association of a hiatal hernia with GERD. Kahrilas et al.[18] demonstrated this mechanical disadvantage by studying the effect of intragastric air infusion on the number of transient LES relaxations or "shortenings" per hour. Patients with hiatal hernias had significantly more transient LES relaxations per hour than did control subjects without hernias. The

reduction in length became significant 20 to 30 minutes after the beginning of air infusion and occurred in a distal to cephalad direction before a loss of LES pressure was observed.

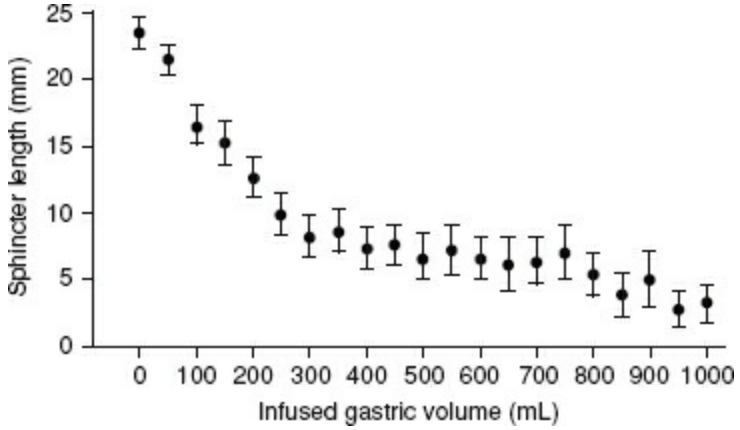

Figure 42-14. Effect of increasing gastric volume on the shortening of the lower esophageal sphincter length. As the stomach expands, the gastric body takes up the inferior aspect of the sphincter causing its length to shorten. (From Mason RJ, Lund RJ, DeMeester TR, et al. Nissen fundoplication prevents shortening of the sphincter during gastric distention. *Arch Surg* 1997;132:719–726, with permission.)

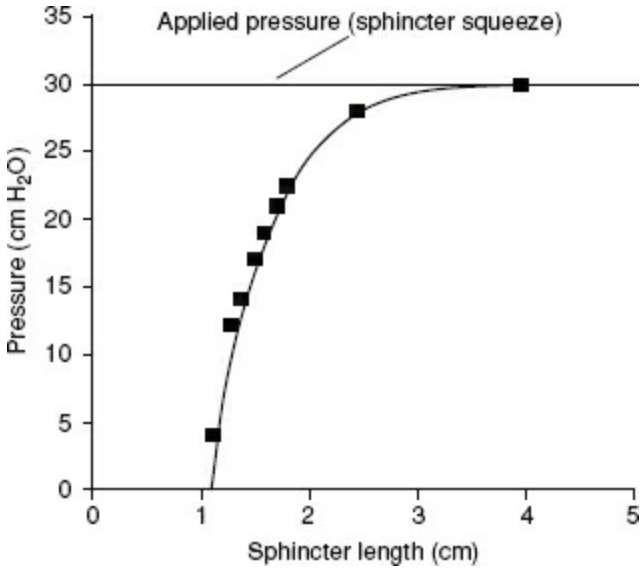

Figure 42-15. Representation of the loss of competence of the lower esophageal sphincter with shortening of its length. As a critical length is reached, there is a precipitous drop in sphincter pressure reflecting loss of competence. (From Pettersson GB, Bombeck CT, Nyhus LM. The lower esophageal sphincter: mechanisms of opening and closure. *Surgery* 1980;88:307–314, with permission.)

The third characteristic of the LES high-pressure zone is its position. A portion of the overall length of the high-pressure zone is normally exposed to the positive intra-abdominal pressure environment and is commonly referred to as the abdominal length of the LES.[19] During periods of increased intra-abdominal pressure, the resistance of the LES would easily be overcome if its position were such that abdominal pressure was unable to be applied equally to the LES and the stomach.[20–22] This is analogous to sucking on a soft soda straw immersed in a bottle of liquid; the positive hydrostatic pressure of the fluid and the negative pressure inside the straw from sucking cause the straw to collapse

instead of allowing the liquid to flow up the straw in the direction of the negative pressure. When the abdominal length of the LES is inadequate, increases in intra-abdominal pressure will be applied to the stomach but not the LES thereby encouraging reflux to occur. Studies have shown that the critical length of abdominal LES is 1 cm, below which almost no LES pressure will be sufficient to maintain competency of the sphincter.[15]

In the fasting state deficits in LES pressure, overall length, or abdominal length will lead to an increased likelihood of sphincter incompetence. An LES defective in all three parameters is particularly likely to be associated with increased reflux of gastric juice into the esophagus. This reflux can result in inflammatory injury to the mucosa and ultimately to the muscularis propria of the esophageal body, thereby causing a reduced contraction amplitude of the esophageal body and interrupted or dropped peristaltic sequences. Continued reflux can lead to progressive loss of effective esophageal clearance, protracted esophageal exposure to the refluxed material and ultimately further organ injury (Fig. 42-16).[23,24]

Causes and Consequences of the Failure of the Gastroesophageal Barrier

Early GERD is initiated by increased transient losses of the barrier as a result of gastric overdistention from excessive air and food ingestion.[11,25] The tension vectors produced by gastric wall distention pull on the gastroesophageal junction, which results in the terminal esophagus being “taken up” into the stretched fundus, thereby reducing the length of the LES. With overeating, a critical length is reached (usually about 1 to 2 cm) at which the sphincter gives way; its pressure drops precipitously, and reflux occurs (Fig. 42-15). If the swallowed air is vented, gastric distention is reduced, the length of the LES is restored, and competency returns until subsequent distention again shortens it and further reflux occurs. Aerophagia is common in patients with GERD because they swallow their saliva more frequently to neutralize the acidic gastric juice that is refluxed into the esophagus.[26] Together, the actions of overeating and air swallowing result in the common complaint of postprandial bloating, repetitive belching, and heartburn in patients with early GERD. The high prevalence of the disease in the Western world is thought to be a result of the eating habits of Western society.[27] Gastric distention from overeating, along with delayed gastric emptying resulting from the increased ingestion of fatty foods, leads to prolonged periods of postprandial gastric distention with shortening of the LES and repetitive transient loss of the barrier. Surgical correction with a fundoplication prevents the shortening of the barrier with progressive degrees of gastric distention by diverting the forces that pull on the gastroesophageal junction.[14]

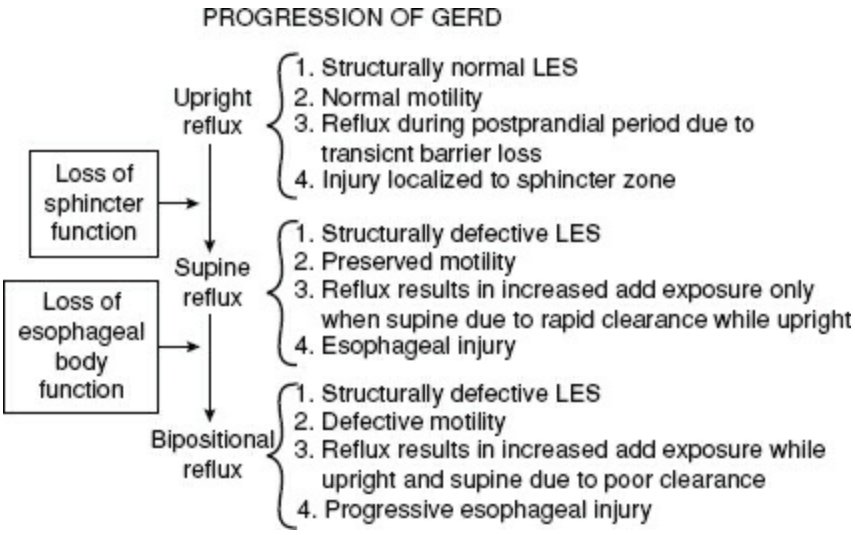

Figure 42-16. Overview of the progressive nature of GERD and the effect of the lower esophageal sphincter and esophageal body on reflux in the upright and supine positions.

In advanced GERD, permanent loss of sphincter length occurs from inflammatory injury that extends from the mucosa into the muscular layers of the LES. Fletcher et al.[28] showed that in the fasting state, there is a persistent region of high acidity in the area of the gastroesophageal junction and that this region of acidity migrates 2 cm proximally after meals.[29] This migration occurs from distention of the stomach with eating and pulling apart of the distal high-pressure zone or LES, thus allowing the area of high acidity to move proximal to the squamocolumnar junction. This proximal movement exposes the distal esophageal squamous mucosa to acid and results in the formation of cardiac mucosa. Cardiac mucosa is an acquired mucosa that replaces chronically injured squamous mucosa in the terminal esophagus.[30] The inflammatory process can extend into the muscular layer of the LES, thereby resulting in muscle cell injury with permanent shortening of the high-pressure zone or LES and a concomitant reduction in the amplitude of the high-pressure zone or barrier pressure.[30–32] A defective barrier is recognized when the length or pressure of the LES measured during the fasting state is below the 2.5 percentile of normal.[33]

For clinicians, the finding of a permanently defective LES has several implications. First, symptoms in patients with a defective LES can be difficult to manage, and mucosal damage may persist with medical therapy.[34] Surgery is usually required to achieve consistent long-term symptom relief in these patients to restore a gastroesophageal barrier and interrupt the natural history of the disease. It has been shown repeatedly that a laparoscopic Nissen fundoplication can consistently restore the length and pressure of the LES to normal parameters.[35] Newer techniques of sphincter augmentation such as with a magnetic bracelet is an alternative means of restoring the LES that is gaining in popularity.[36] Second, a permanently defective LES is commonly associated with reduced contractility and abnormal wave progression of the esophageal body.[37] For this reason, careful evaluation of the esophageal body is critical in the evaluation for antireflux surgery for potential tailoring of the operation with a partial fundoplication. Third, a permanently defective LES and the loss of effective esophageal clearance can lead to

mucosal injury such as erosive esophagitis or Barrett metaplasia, repetitive regurgitation and aspiration events and ultimately pulmonary fibrosis. Without reestablishing a barrier, chronic use of acid suppression therapy may simply mask the symptoms due to modification of the pH; however, in the setting of a structurally defective LES, reflux will continue unabated.[38]

EVALUATION OF ESOPHAGEAL FUNCTION

A thorough understanding of the patient's underlying anatomic and functional deficits is fundamental to the successful treatment of esophageal disease. The diagnostic tests that are employed to evaluate the esophagus are those used to visualize structural abnormalities, to detect functional abnormalities, and to measure esophageal exposure to gastric juice. At the authors' center a panel of four diagnostic tests are used routinely in the evaluation of known or suspected reflux disease: barium esophagram, upper endoscopy, high-resolution esophageal manometry, and ambulatory pH monitoring.

Radiographic Evaluation

Radiographic assessment of the anatomy and function of the esophagus and stomach is one of the most important aspects of the esophageal evaluation, provided the surgeon has a working knowledge of esophageal physiology. Classically, the barium esophagram has been described as a road map for the esophagus. The first diagnostic test in patients with suspected esophageal disease should be a barium swallow that includes a full assessment of the stomach and the duodenum.[39] Video recording of the study greatly aids in the evaluation by providing the surgeon with a real-time visualization of bolus transport and the size and reducibility of the hiatal hernia. The study also provides anatomic information, such as the presence of obstructing lesions and structural abnormalities of the foregut.

The pharynx and the UES are evaluated in the upright position, allowing assessment of the timing and coordination of the events of pharyngeal transit.[40] This includes oropharyngeal bolus transport, pharyngeal contraction, opening of the pharyngoesophageal segment, and degree of airway protection during swallowing. It readily identifies a diverticulum, stasis of the contrast medium in the valleculae, cricopharyngeal bar, or narrowing of the pharyngoesophageal segment. These are anatomic manifestations of neuromuscular disease and result from the loss of muscle compliance from the deinnervation of the skeletal muscle of the pharynx and the cervical esophagus.[41]

The assessment of bolus transport on video esophagography often adds to or complements the information obtained by esophageal manometry. Esophageal clearance is optimally assessed by observing several individual swallows of barium with the patient in both the upright and supine positions; the study can be performed with both liquid and solid bolus material. During normal swallowing, a primary peristaltic wave is generated that completely strips the bolus out of the esophagus and into the stomach. Residual material rarely stimulates a secondary peristaltic wave; rather, an additional pharyngeal swallow is usually required.

The protocol developed and utilized at the authors' institution has previously been reported.[42] Normal subjects in the prone position should be able to clear at least three of five 10-mL liquid barium boluses with one swallow and have only one episode of proximal escape or distal retention of a barium bolus with the five swallows. Normal subjects can also clear a solid barium bolus with four or fewer swallows in the upright position. Motility disorders with disorganized or simultaneous esophageal contraction give a segmented appearance to the barium column. This can often give a beading or corkscrew appearance to the barium within the esophagus. In patients with dysphagia, the use of a barium-impregnated marshmallow, piece of bread, or hamburger can identify an esophageal transport disturbance that is not evident on the liquid barium study. A 13-mm barium tablet is another useful adjunct that can be used to determine how well solid material can clear the esophagus, and identify areas of clinically significant narrowing since solid food dysphagia typically is present with luminal narrowing below 13 mm.

A hiatal hernia is present in a high percentage of patients with gastroesophageal

reflux.[43] These are best demonstrated with the patient in the prone position; the increased intra-abdominal pressure produced in this position promotes displacement of the hernia above the diaphragm. The hiatal hernia is an important component of the underlying pathophysiology of reflux. A large (>5 cm) or irreducible hiatal hernia may be associated with chronic reflux and esophageal foreshortening. The diagnosis of reflux disease is not accurately made on video esophagram. Spontaneous reflux to the level of the thoracic inlet seems to correlate with a positive pH test, but evoked reflux and spontaneous reflux into the distal esophagus are not. Moreover, failure to observe reflux during a video esophagram does not indicate the absence of disease.

A full-column technique with distention of the esophageal wall can discern extrinsic compression of the esophagus, and a fully distended esophagogastric region is necessary to identify narrowing from a Schatzki ring, stricture, or obstructing lesion. Mucosal relief or double-contrast films can be obtained to enhance the detection of small neoplasms, esophagitis, and varices. Assessment of the stomach and duodenum during the barium study is helpful for the evaluation of the patient with esophageal symptoms (ESs). A gastric or duodenal ulcer, a neoplasm, or poor gastroduodenal transit can mimic many of the symptoms that are suggestive of an esophageal disorder.

Endoscopic Examination

Endoscopic evaluation of the esophagus is essentially the physical examination of the foregut. It is a critical part of the assessment of a patient with esophageal disease and is indicated in essentially every patient who is being evaluated for GERD. A barium study obtained before esophagoscopy is helpful to the endoscopist by directing attention to locations of subtle change and alerting the examiner to such potential danger spots as a cervical vertebral osteophyte, an esophageal diverticulum, a deeply penetrating ulcer, or a carcinoma. Regardless of the radiologist's interpretation of an abnormal finding, each structural abnormality of the esophagus should be examined visually with an endoscope.

During every endoscopic examination, the locations of three specific landmarks are routinely obtained relative to the front incisors: the squamocolumnar junction, gastroesophageal junction, and the diaphragmatic crura. The crura are usually evident by having the patient sniff. The gastroesophageal junction is the location at which the gastric rugal folds meet the tubular esophagus; it is normally aligned with the squamocolumnar junction. The squamocolumnar junction is the location at which the velvet and darker rose-colored columnar epithelium changes to the lighter squamous epithelium. When this junction is not clear, narrow band imaging (NBI), a feature that is standard on all modern endoscopic systems, is extremely helpful in distinguishing columnar from squamous mucosa. Particular effort should be made to detect any tongues, islands, or a circumferential segment of columnar-lined esophagus (CLE) in the distal esophagus.

When erosive esophagitis is found, an objective grading system should be utilized to communicate the severity of the findings. Currently, the Los Angeles classification is the most commonly utilized system.[44] Grade A is defined as one or more mucosal break ≤ 5 mm that does not extend between the tops of mucosal folds. Grade B is defined as one or more mucosal break >5 mm that does not extend between the tops of the mucosal folds. Grade C is defined as one or more mucosal break that is continuous between the tops of two or more mucosal folds but involves $<75\%$ of the circumference. Grade D is defined as one or more mucosal break that involves $\geq 75\%$ of the circumference.

Barrett esophagus is a pathologic condition in which the tubular esophagus is lined with columnar epithelium as opposed to the normal squamous epithelium. It is suspected at endoscopy when there has been separation of the squamocolumnar junction from the gastroesophageal junction. When columnar metaplasia is observed, it must be biopsied to confirm the presence of intestinal metaplasia in order to make the diagnosis of Barrett esophagus; the finding of cardiac metaplasia without goblet cells does not meet this criteria in the United States. On histologic examination, it appears as columnar mucosa with goblet cells and is called intestinal metaplasia. Early metaplasia is often manifest as an irregular or eccentric squamocolumnar junction. Routine four-quadrant biopsies with jumbo forceps are necessary every 2 cm of columnar metaplasia. In addition, the likelihood of identifying goblet cells is greatest at the cephalad portion of a columnar segment, especially at the squamocolumnar junction.[45] Barrett esophagus is susceptible to ulceration, bleeding, stricture formation, and malignant degeneration. The earliest histologic sign of malignant degeneration is high-grade dysplasia (HGD) or intramucosal

adenocarcinoma. These dysplastic changes have a patchy distribution, so a minimum of four biopsy specimens every 2 cm should be taken from the Barrett mucosa–lined portion of the esophagus. A study of intramucosal adenocarcinomas arising in Barrett esophagus showed that most of the tumors arose in the distal Barrett segment, closer to the stomach.[46]

Abnormalities of the cardia or gastroesophageal junction can be visualized by retroflexion of the endoscope and provide a complementary assessment regarding the competency of the gastroesophageal barrier. Hill et al. have graded the appearance of the gastroesophageal valve from I to IV according to the degree of unfolding or deterioration of the normal architecture (Fig. 42-17).[47] This commonly used grading system has allowed endoscopists to maintain uniformity in their reporting. The Hill grade correlates well with the competence of the gastroesophageal barrier, with increasing acid exposure prevalent in patients with worsening Hill grade.

A hiatal hernia is diagnosed by observing separation of the gastroesophageal junction from the crura. By definition, a hiatal hernia is present when at least 2 cm of the top of the rugal folds has migrated above the pinch of the diaphragmatic crura. A prominent sliding hiatal hernia is frequently associated with GERD. When a hernia is observed, particular care is taken to exclude Cameron ulcers or gastritis within the herniated stomach.

As the endoscope is slowly withdrawn, the esophagus is again examined, and biopsy samples are taken. The location of the cricopharyngeus is identified, and the larynx and vocal cords are visualized. Acid reflux may result in inflammation of the larynx. Vocal cord movement should also be recorded, both as a reference for subsequent surgery and as an assessment of the patient’s ability to protect the airway.

Esophageal Manometry

Fundamental to the evaluation of a patient with benign esophageal disease is the assessment of esophageal contractility, coordination, and sphincter function. Manometry is indicated whenever an abnormality of the esophagus is suggested by the symptoms of dysphagia, odynophagia, chest pain, heartburn, and regurgitation. It is particularly necessary to confirm the diagnosis of specific primary esophageal motility disorders, such as achalasia, diffuse esophageal spasm, nutcracker esophagus, or hypertensive LES. It can also identify ineffective esophageal body motility as a result of GERD or systemic diseases such as scleroderma, dermatomyositis, polymyositis, or mixed connective tissue disorders. In patients with symptomatic GERD, esophageal manometry can identify a mechanically defective LES and evaluate the adequacy of the esophageal body contraction amplitudes and waveform. Finally, manometry is mandatory for accurate placement of an ambulatory pH monitor in relationship to the upper border of the LES.

High-resolution manometry (HRM) has now become standard technology over the past several years and represents an improvement in methodology that leads to a more detailed data collection and simpler data interpretation, especially with regard to the esophageal body. The concept behind this technology is that by vastly increasing the number of sensors and reducing the space between the sensors, it can provide representation of the entire pressure profile along the esophagus from the pharynx to the proximal stomach without the need to reposition or to pull back the catheter as in conventional manometry.

The most commonly used HRM system is a solid-state manometric assembly with 36 circumferential sensors spaced at 1-cm intervals and are available from different manufacturers. These transducers detect the pressure over a length of 25 mm in each of 12 radially dispersed sectors. The recorded pressure at each sector is then averaged, making each of the 36 sensors a circumferential pressure detector with the extended frequency response characteristic of solid-state manometric systems and free of the hydrostatic influence characteristic of water-perfused systems. The increased number of circumferential pressure sensors results in a vastly greater amount of data and detail. Interpretation of the data has been simplified by a sophisticated topographic plotting algorithm that converts the traditional linear waveform tracings into an esophageal pressure topography or Clouse plot (Fig. 42-18). Sphincter characteristics and esophageal motor function are represented by isocontour manometric plots, eliminating the need for the tedious analysis of the increased waveform data that are generated by the 36 sensors.

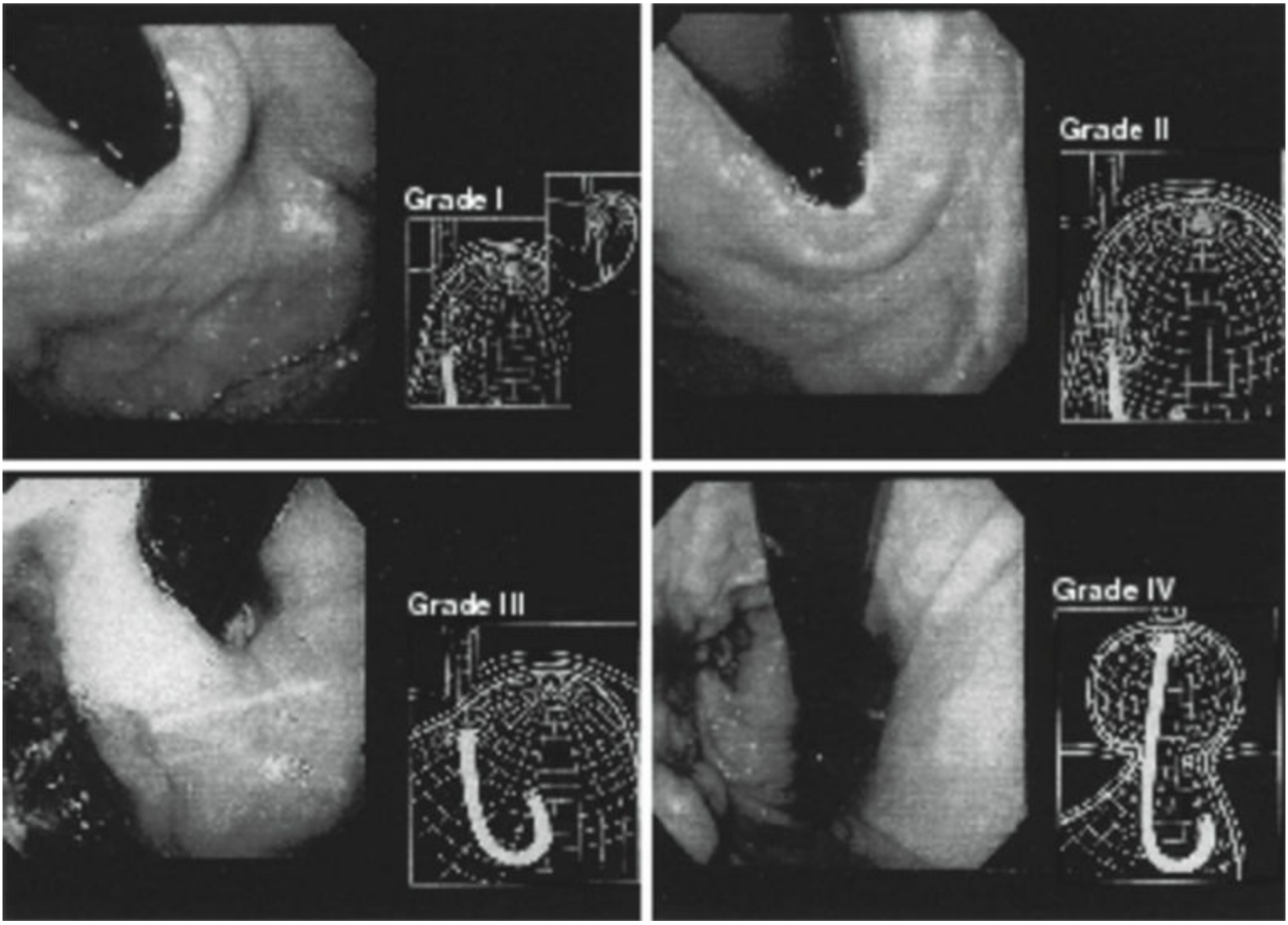

Figure 42-17. Endoscopic grading of the gastroesophageal junction during the retroflex view. (From Oberg S, Peters JH, DeMeester TR, et al. Endoscopic grading of the gastroesophageal valve in patients with symptoms of gastroesophageal reflux disease (GERD). *Surg Endoscopy* 1999;13(12):1184–1188, with permission.)

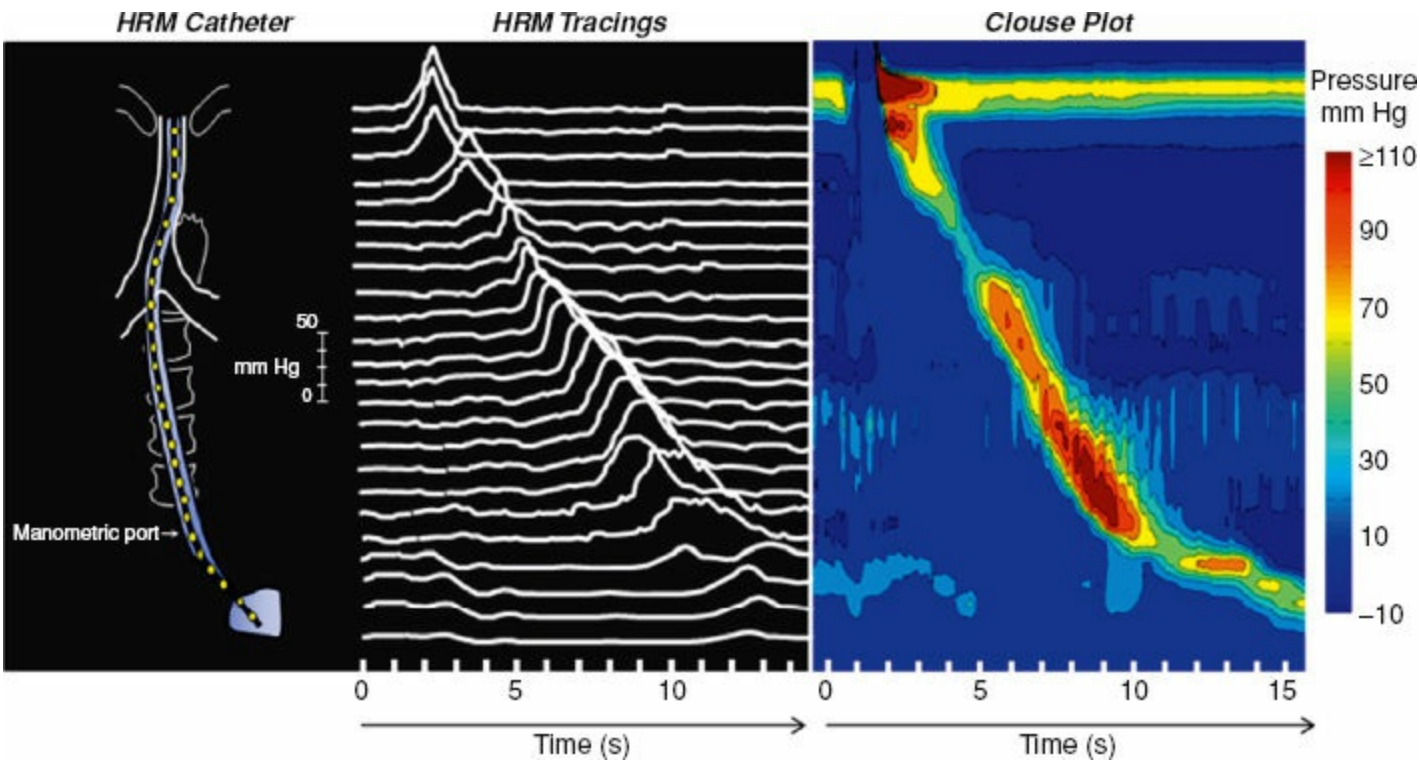

Figure 42-18. High-resolution manometry with line tracings and converted pressure topography or Clouse plot view. (From Pandalfino JE, Roman S. High-resolution manometry: an atlas of esophageal motility disorders and findings of GERD using esophageal pressure topography. *Thor Surg Clin* 2011;21:465–475, with permission.)

The manometry procedure is performed by passing the catheter into the stomach and esophagus to measure contraction pressures and waveform in the esophageal body and the sphincters' resting pressure and response to swallowing. The lubricated catheter is passed through the nostril and into the esophagus. The catheter is advanced until a portion of the sensors are in the stomach. In patients who have a dilated or tortuous esophagus such as suspected achalasia or a large PEH, it is recommended that the catheter be passed endoscopically to ensure that it is properly positioned into the stomach and not coiled in the esophagus. The pressure topogram is assessed to ensure that the catheter is completely traversing the UES and the LES. Unlike with traditional manometry, a HRM study can be performed with 10 swallows without the need to repeatedly move the catheter back and forth for different portions of the examination. The patient is then asked to refrain from swallowing for 30 seconds with quiet breathing, which allows the capture of a landmark frame for assessment of the resting UES and LES. The patient is positioned supine with the head elevated and is asked to swallow 5 mL aliquots of water separated by a minimum of 30 seconds to prevent deglutitive inhibition. A complete manometric study includes the assessment of the structural characteristics of the LES, the degree of LES relaxation, the esophageal body coordination, contraction amplitude and waveform, and the UES function.

Lower Esophageal Sphincter

The resting LES is assessed during the landmark frame (Fig. 42-19). The lower (distal) border of the LES is the point at which the resting pressure rises above the gastric baseline; the upper border is the point at which sphincter pressure reaches the esophageal

baseline. The respiratory inversion point is identified when the positive excursions that occur with breathing in the abdominal environment change to negative deflections in the thoracic environment. The respiratory inversion point is the functional division between the abdomen and thorax. The resting pressure of the LES is the pressure above gastric baseline measured during midrespiration at the respiratory inversion point. The overall length of the sphincter is the distance from the distal border to the proximal border. The abdominal length is the distance from the distal border to the respiratory inversion point and represents the portion of the LES that is subject to fluctuations in intra-abdominal pressure. The measurements for each of these components from each transducer are expressed as an average during the landmark frame, which extends for 30 seconds.

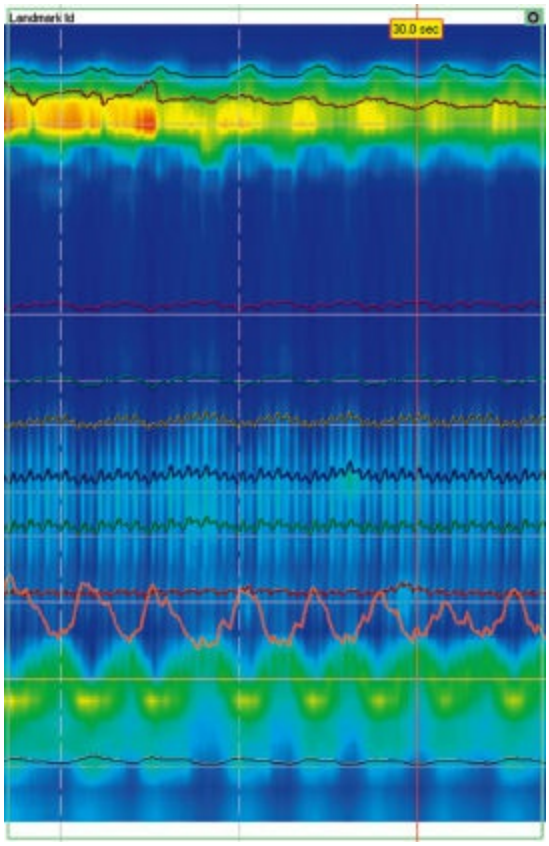

Figure 42-19. High-resolution esophageal manometry showing the landmark frame. The upper and lower esophageal sphincters are observed at the top and bottom of the frame, respectively. Resting pressure and length measurements of the sphincters can be determined in this portion of the study while the patient is refraining from any swallowing. (From Pandalfino JE, Roman S. High-resolution manometry: an atlas of esophageal motility disorders and findings of GERD using esophageal pressure topography. *Thor Surg Clin* 2011;21:465–475, with permission.)

A structurally defective sphincter is identified by one that has low resting pressure or short length. Based on conventional manometry in normal volunteers, the following characteristics have traditionally been used to identify a structurally defective LES: (1) an average LES pressure of less than 6 mm Hg, (2) an average abdominal length of less than 1 cm, and (3) an average overall length of less than 2 cm. Based on normative data, these values are below the 2.5 percentile. A defect in one or even two components of the LES may be compensated by good esophageal body function, but when all three components are defective, excessive esophageal acid exposure is inevitable. With the HRM technique,

normal overall LES length should be 2.7 to 4.8 cm and mean basal resting pressure of the LES should be 13 to 43 mm Hg.

It should be noted that while HRM has revolutionized the assessment of the esophageal body due to improved resolution of contraction waves, the assessment of the LES has been less optimal. This is primarily due to the nature of the HRM catheter, which functions as a sleeve manometry catheter and results in circumferential averaging of pressure data. For this reason, length assessment of the LES and UES is believed to be less detailed than that obtained with conventional manometry with a manually pulled through catheter.[48] It is believed that the newly developed 3D HRM catheter will allow more precise or detailed evaluation of the LES structure, but clinical experience is necessary to fully evaluate its additive value.

Lower Esophageal Sphincter Relaxation

The LES pressure normally drops to gastric baseline immediately after initiation of a swallow, and remains open until the oncoming peristaltic wave reaches the stomach (Fig. 42-18). A characteristic postrelaxation contraction of the LES is subsequently observed as the LES closes with passage of the bolus. Using HRM, relaxation is assessed during a 4-second segment of the time between initiation of the swallow and when the peristaltic wave reaches the LES. This 4-second window is often captured in a noncontiguous manner during the swallow to eliminate the effect of respiratory variation from the crura and is termed the integrated relaxation pressure (IRP). An IRP >15 mm Hg is considered elevated and may result in clinically significant outflow resistance through the LES.

Esophageal Body Motility

The esophageal body is evaluated by assessing contraction amplitude, duration, slope, velocity, and morphology (i.e., single, double, or triple peaked). A physiologic gap in contraction or proximal peristaltic break typically occurs in the upper one-third of the esophagus, and corresponds to the transition zone between the striated muscle above and smooth muscle below. Pathologic breaks are those that are >2 cm long or if a break occurs in the distal esophagus. HRM has had its greatest improvement in the assessment of esophageal body function. It is important to allow 30 seconds between swallows to prevent deglutitive inhibition of the body, a physiologic dampening or absence of peristalsis with repetitive swallowing.

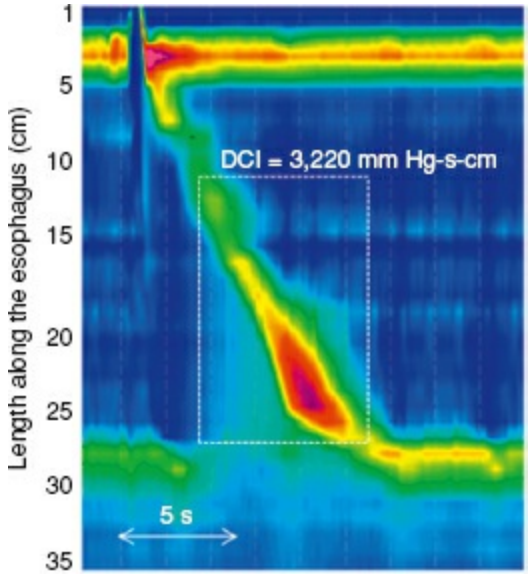

Figure 42-20. High-resolution esophageal manometry during a swallow. The initiation of swallowing is reflected by transient relaxation of the UES followed by a peristaltic pressure wave progressing down the esophageal body. Note the LES relaxes at the initiation of swallowing. A characteristic peristaltic break is observed in the upper third of the esophageal body at the transition zone between the striated and smooth muscle. (From Pandalfino JE, Roman S. High-resolution manometry: an atlas of esophageal motility disorders and findings of GERD using esophageal pressure topography. *Thor Surg Clin* 2011;21:465–475, with permission.)

Further improvement in assessing esophageal body function with HRM has been the use of the distal contractile integral (DCI) which gives a global assessment of esophageal contractile function. This is an integrated summation of the contractile pressures generated between the proximal peristaltic break and the upper border of the LES and is calculated as the product of amplitude (mm Hg) × duration (seconds) × length (cm), with normal values ranging from 500 to 4,300 (Fig. 42-20). Based on conventional manometry, it was believed that a minimum of distal contraction amplitude of >20 mm Hg 5 cm above the LES was necessary to overcome the resistance of an antireflux procedure. With HRM it is currently believed that a DCI >500 mm Hg*sec*cm is necessary to minimize the possibility of postoperative dysphagia; however, clinical validation of this cutoff has not been performed.

Upper Esophageal Sphincter

The position, length, and resting pressure of the UES and its relaxation with swallowing are assessed with a technique similar to that used for the LES. The key features to be assessed are the adequacy of pharyngeal contraction and the timing and extent of UES relaxation. An indirect measure of UES stiffness or loss of compliance is the intrabolus pressure, which appears as a pressure rise or shoulder on the upstroke of the pharyngeal contraction.

High-Resolution Impedance

Even with the addition of high-resolution topography, manometric data often does not correlate with the effective passage of the swallowed bolus. To overcome this

shortcoming, the barium video esophagram has been used to complement manometry; however, one drawback is that these tests cannot be performed simultaneously. Not infrequently, a discrepancy may exist between these studies with a normal video esophagram but poor esophageal body manometry characteristics, or vice versa. Currently, the authors are utilizing combined HRM with high-resolution impedance to gain additional information on bolus transport.

Ambulatory pH Monitoring

The development of ambulatory pH monitoring by DeMeester and Johnson[49] was a major advance in the unraveling of the pathophysiology of GERD. All previous tests had relied on the identification of reflux by a provocative maneuver, which had little relevance to the patient's daily activities. The 24-hour pH monitoring test allowed objective assessment of esophageal exposure to gastric juice in a patient in a continuous setting. It is considered the gold standard for the diagnosis of GERD because it has the highest sensitivity and specificity of all tests currently available. It is indicated in any patient with symptoms suggestive of GERD, unless the symptoms are trivial or permanently abolished by a short course of acid suppression therapy. The need for continued acid suppression should stimulate objective study. A 24-hour pH monitoring study is especially important in patients who are being considered for antireflux surgery. Atypical presentations of GERD are also a common indication; they include such symptoms as noncardiac chest pain (i.e., pain despite a normal cardiac evaluation) and respiratory symptoms (RSs) such as shortness of breath, cough, nocturnal wheezing, and chronic hoarseness. In such patients, 24-hour pH monitoring allows confirmation of the diagnosis of GERD and can relate the occurrence of the symptoms to an episode of reflux.

To perform the standard pH test, a thin catheter containing a pH electrode is passed transnasally into the esophagus and placed 5 cm above the upper border of the LES, a position that has been previously determined by manometry. Different probes are available, but bipolar glass electrodes are preferred for their greater reliability and their elimination of the need for an external reference electrode. The electrode is connected to an external portable digital storage device that is kept at the patient's side, and pH values are continuously recorded at 6-second intervals for 24 hours (i.e., a complete circadian cycle). Precalibration and postcalibration of the system to pH levels of 1 and 7 is important to exclude electrode drift. A gastric "dipstick" maneuver is performed prior to securing the location of the catheter to confirm acid in the stomach and that the patient does not have atrophic gastritis. The patient is then instructed to carry out normal daily activities but to avoid strenuous exertion. He or she is asked to remain in the upright position while awake during the day, lying down supine only at night while sleeping, and to ingest two meals at the usual time. The diet is standardized only by its absence of food and beverages with a pH value of less than 5.0 and greater than 6.0. The patient notes in a diary the times of meals, retiring for sleep, and rising the following morning as well as the presence and duration of any symptoms. At the authors' institution, patients are also asked to consume a challenge meal consisting of a hamburger, French fries, and a milk shake. It has been found that a refluxogenic meal can often uncover early acid reflux disease that would not ordinarily be detected during a typical 24-hour period.[50] Figure 42-21 shows typical 24-hour pH tracings from a healthy subject and from a patient with GERD. Medications such as H_2 blockers and prokinetics should be discontinued for 48 hours before the testing begins. Proton pump inhibitors (PPIs) (e.g., omeprazole) should be stopped for 2 weeks before pH monitoring because of their long-lasting action.

It is important to emphasize that 24-hour esophageal pH monitoring should not be

considered a test for reflux; rather, it is a measurement of the esophageal exposure to gastric juice. The measurement is expressed as the percentage of time that the esophageal pH was below 4 during the 24-hour period. Just measuring the percentage of time that the pH is less than 4, although concise, does not reflect how the exposure has occurred; for example, it may have occurred in a few long or several short reflux episodes. Consequently, two other assessments are necessary: (1) the frequency of the reflux episodes and (2) their duration. For this reason, esophageal exposure to gastric juice is best assessed by the following measurements:

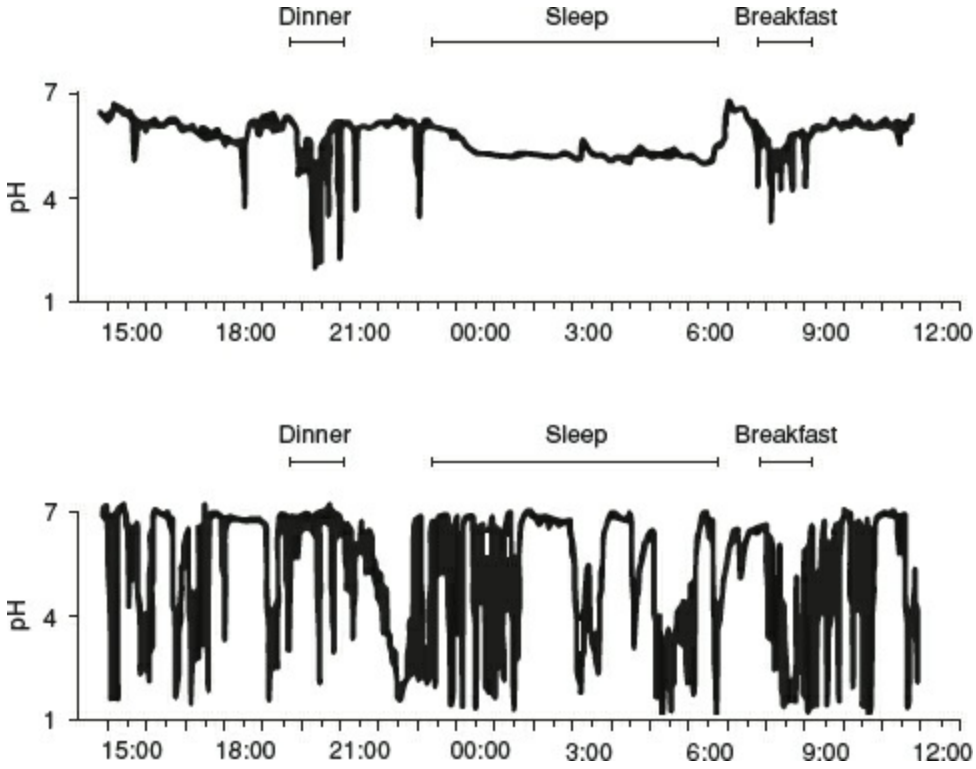

Figure 42-21. Dual-probe 24-hour pH tracing of patient. The top tracing is of the pH sensor located below the upper esophageal sphincter and the bottom tracing is of the pH sensor located 5 cm above the top of the lower esophageal sphincter. Episodes of pH <4 are considered acid events. In this example the patient has abnormal acid exposure in the distal esophagus with several reflux events extending into the proximal esophagus.

- The cumulative time that the esophageal pH is below 4 expressed as the percentage of the total, upright, and supine monitored times;
- The frequency of reflux episodes, when the pH drops below 4, expressed as the number of episodes per 24 hours;
- The number of episodes during which the pH remained below 4 for longer than 5 minutes per 24 hours; and
- The time in minutes of the longest recorded reflux episode, the longest time the pH consistently remained below 4.

Normal values for these six components of the 24-hour record were derived from 50 asymptomatic control subjects. The upper limits of normal were established at the 95th percentile.[51] If the values of symptomatic patients are outside of the 95th percentile of normal subjects, they are considered to be abnormal for the component measured. There

is a uniformity of normal values for these six components as reported by centers throughout the world. The normal values for the six components obtained from 50 healthy volunteers are shown in Table 42-1. A composite scoring system was developed by DeMeester and Johnson that integrates the different components of the pH record into a single measurement of esophageal acid exposure. This composite score is calculated from the six parameters with use of their standard deviations as weighing factors.[51]

Advances in technology have made pH testing more comfortable for the patient with the development of a catheter-free miniaturized pH electrode. The Bravo system (Medtronic, Minneapolis, MN) allows the transnasal or transoral deployment of a small capsule that attaches to the esophageal mucosa and transmitting pH data by radiotelemetry to a pager-sized receiver, thus eliminating the need for an unpleasant transnasal catheter. It may also provide a more accurate physiologic picture by allowing patients to perform their normal daily activities without the social and behavioral restrictions imposed by the catheter. Another major advantage of the Bravo capsule is the ability to record for prolonged periods, and routine monitoring of 48 hours is now performed with improved diagnostic capabilities.[52] New normal thresholds have been defined and validated for the 48-hour Bravo pH test, with the normal composite score for the first 24 hours being 14.0, the second 24 hours being 14.0, and the combined 48-hour score being 16.0.[51]

Table 42-1 Normal Manometric Values of the Distal Esophageal Sphincter in 50 Subjects

Median Parameter	Value	2.5th Percentile	97.5th Percentile
Pressure (mm Hg)	13	5.8	27.7
Overall length (cm)	3.6	2.1	5.6
Abdominal length (cm)	2	0.9	4.7

In patients with symptoms of chronic cough, hoarseness, or pulmonary aspiration, placement of an additional pH electrode in the proximal part of the esophagus or pharynx can be helpful.[53] Such dual-probe catheters are particularly helpful in determining if gastroesophageal reflux events extend proximally, which could give indirect evidence of acid exposure into pharyngeal area and subsequent irritation. If the accumulated acid exposure in the proximal esophagus is greater than 1% or the number of reflux episodes is more than 24 (particularly if there is a temporal relationship between the reflux episodes and the onset of the symptoms), reflux can be documented and assumed to be the cause of the patient's RSs.[53] A composite score has been developed for proximal pH monitoring, analogous to that developed for the distal probe, with the normal threshold composite score being 16.4.[52]

Additional testing is sometimes necessary if the standard methods of assessing esophageal function fail to yield conclusive results, particularly when investigating the relationship of acid reflux and extraesophageal symptoms. A novel pharyngeal pH system

has been developed that allows a pH probe to be positioned directly into the pharynx just below the uvula (Restech pH probe, Respiratory Technology Corp, San Diego, CA, USA).[53] This probe utilizes a novel antimony sensor that allows measurement of pH within the humidified air of that environment without drying out and creating artifacts. Early clinical experience with this technique indicates that it is a useful adjunct diagnostic test in patients suspected of having laryngopharyngeal reflux (LPR).

Testing for reflux that is nonacidic or weakly acidic can be gained by multichannel intraluminal esophageal impedance monitoring. This type of measurement determines the resistance to the flow of current through a given medium (impedance). The impedance to current changes as the composition of the medium in which the current is traveling changes (i.e., air, liquids, or solids). Coupled with a pH probe, it can differentiate acid reflux from nonacid reflux, which may be particularly useful in patients who remain symptomatic on acid suppression therapy.

Lastly, the assessment of gastric function can be important in many patients with ESs. Disorders of gastric emptying frequently can contribute to or be confused with esophageal disease, especially GERD. Nuclear medicine radioisotope with solid food matter such as scrambled eggs has been utilized for this purpose, and is indicated in any patient being evaluated for GERD who also has a history of nausea, early satiety, and vomiting. Such information may be invaluable to prevent performing an antireflux operation in the setting of gastroparesis. The most reliable results are obtained with the use of a 4-hour study rather than one that just determines a half-time of emptying.

CONCLUSIONS

Although seemingly simple, the anatomy and physiology of the esophagus is complex. Understanding the anatomic relationships is critical to enable safe surgery on the esophagus. Functional studies allow identification of abnormalities in the upper or lower esophageal sphincter as well as the esophageal body, and pH testing can determine the presence of increased exposure of the esophagus to refluxed gastric juice. An understanding of the relevant pathophysiology is critical to allow functional restoration of LES competence in patients with reflux disease, or to reduce the LES outflow resistance in patients with achalasia. While complex, restoration of esophageal function can bring tremendous improvements in quality of life and social satisfaction for patients, and is gratifying for esophageal surgeons.

GASTROESOPHAGEAL REFLUX DISEASE

Definition and Epidemiology

GERD is a very common disease, but developing an accurate definition of GERD is surprisingly difficult. In 2004, a group of experts came together in Montreal and concluded that GERD can be best defined as "a condition which develops when the reflux of stomach contents causes troublesome symptoms and/or complications."[54] Population-based studies have reported that one-third of Western populations experience the symptoms of GERD at least once a month, with 4% to 7% of the population experiencing daily symptoms.[55,56] Its prevalence varies considerably around the globe and is highest in North America, Australia, and Western Europe and lowest in Africa and Asia.[57] It is also likely that both the prevalence and severity of GERD are increasing in many parts of the world. Time trend analyses have shown that the prevalence of GERD symptoms has increased progressively in most longitudinal studies, including those from the United States, Singapore, and China (Fig. 42-22).[58] Further, recent data reported by the Agency for Healthcare Research and Quality (AHRQ) indicate a marked increase (103%) in hospitalizations for treating disorders caused by GERD; a 216% increase in hospitalization of patients who, in addition to the ailment for which they were admitted, have milder forms of GERD; and a 39% increase in admission for GERD with severe symptoms including anemia, weight loss, and vomiting.[59] These data suggest that the current therapeutic approach to GERD may be inadequate.

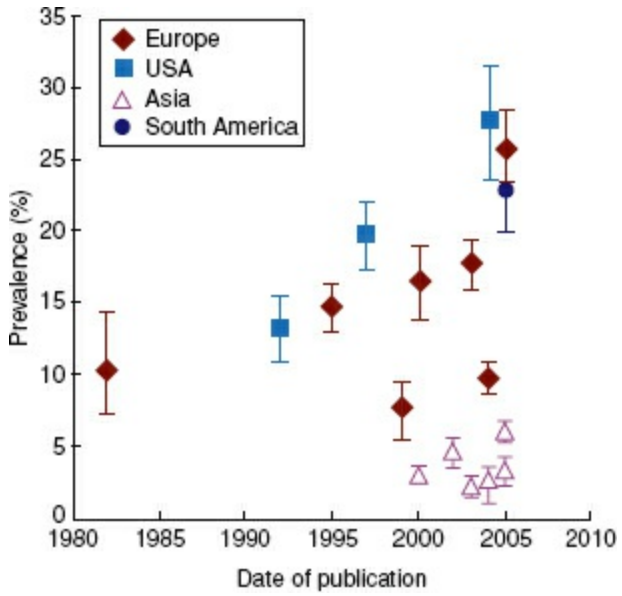

Figure 42-22. Time trends for the prevalence of weekly heartburn from 1980 to 2005. (Reproduced with permission from El-Serag H. Time trends of gastroesophageal reflux disease: a systematic review. *Clin Gastroenterol Hepatol* 2007;5:17–26.)

Most patients with mild symptoms self-medicate with over-the-counter antacids or antisecretory agents, whereas those with more severe and persistent symptoms seek out medical attention. In contrast to duodenal ulcer disease, where the prevalence has markedly decreased, the prevalence and severity of GERD seem to be increasing (Fig. 42-

23).[60] The diagnosis of a CLE is also increasing at a rapid rate, and deaths from end-stage benign esophageal disease are on an upward trend.[61] These changes have occurred despite dramatic improvements in the efficacy of treatment options.

Two epidemiologic trends may be contributing to the increasing prevalence and severity of GERD over the past several decades. Population-based studies have shown that GERD is positively associated with obesity and negatively associated with gastric colonization with *Helicobacter pylori*. Over the past 20 to 30 years, the former has increased and the latter has decreased markedly in most Western countries. The relationship between GERD and body mass index (BMI) has been evaluated in a number of well-designed clinical studies. The frequency, duration, and severity of reflux symptoms were studied in 10,500 women of the Nurses' Health Study and a dose-dependent relationship between increasing BMI frequency of GERD symptoms was identified.[62] Compared to normal-weight women (BMI 20 to 22.4), underweight women (BMI <20) were one-third less likely and overweight women (BMI 25 to 27.4) two times more likely to have frequent GERD symptoms. Obese women (BMI >30) had a nearly three times higher risk of frequent GERD symptoms. Recent meta-analyses confirm these findings, with studies from the United States demonstrating an association between increasing BMI and the presence of GERD.[63] High-resolution motility studies have shown a significant correlation with BMI and both intragastric pressure and gastroesophageal pressure gradients, providing a physiologic explanation for the BMI–GERD association.[64] These studies suggest that obese subjects are more likely to have esophagogastric junction disruption and abnormal pressure gradients favoring the development of reflux. Finally, the risk of Barrett esophagus has been correlated with the presence of central obesity. Measures of central obesity, including waist circumference and waist-to-hip ratios, were associated with both short- and long-segment Barrett esophagus, with a 4.1 higher odds ratio of long-segment Barrett in patients with a high waist-to-hip ratio.[65]

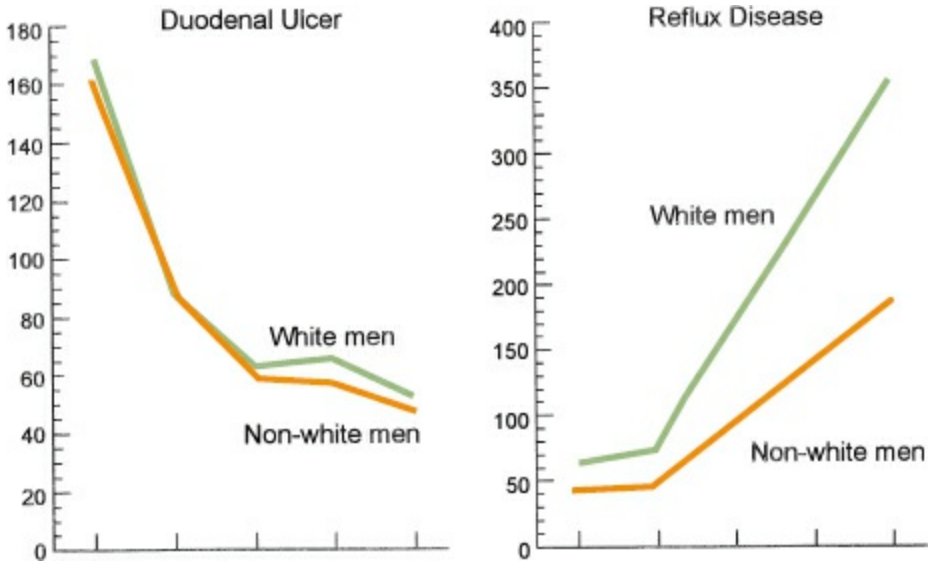

Figure 42-23. Trends in hospitalization for duodenal ulcer and gastroesophageal reflux disease from the 1970s to 1990s in U.S. veterans. (Reproduced with permission from El-Serag HB, Sonnenberg A. Opposing time trends of peptic ulcer and reflux disease. *Gut* 1998;43:327–333.)

The possible pathogenic role of helical-shaped bacteria found in gastric fluids was first suggested in the late 19th century by the Polish scientist Walery Jaworski of the University of Krakow.[66] It was the publication of two Australian scientists in 1983 that convincingly demonstrated the pathogenic role of *H. pylori*.[67] These pioneering studies of Barry Marshall and Robin Warren from Perth, Australia, included self-experiments and were later awarded the Nobel Prize. *H. pylori* induces a significant inflammatory and immune response in the affected host, resulting in persistent inflammation in virtually all infected subjects.

The relationship between *H. pylori* and GERD has been of interest for decades. The observation that gastric mucosal atrophy was less frequent in patients with reflux esophagitis was made well before the *H. pylori* era. Evolutionary hypotheses assume, and the majority of available epidemiologic data show, that the decline of *H. pylori* infection is one of the reasons behind the increasing incidence of GERD-related diseases including esophageal and cardia adenocarcinoma in the Western world. This inverse relationship is strongest between *H. pylori* and esophageal adenocarcinoma, although significant evidence relates *H. pylori* and the development of Barrett esophagus and GERD. Over the period from 1970 to 1995, the incidence of both duodenal ulcer, compared to erosive esophagitis, and distal gastric cancer, compared to gastric cardia cancer, displays strikingly opposing time trends. It has been postulated that *H. pylori*–induced chronic corpus gastritis may protect against the development of GERD and its malignant transformation. A detailed report by Labenz et al.[68] in 1997 provided some of the first evidence in support of this theory. In a case-control study of 460 duodenal ulcer patients, new-onset GERD symptoms were significantly higher in patients who had successful *H. pylori* eradication than in those with persisting infection. Although a number of subsequent studies have raised doubts as to whether a true relationship exists, the available evidence suggests that the prevalence of *H. pylori* infection in patients with GERD is lower than non-GERD control populations and that there is likely an inverse epidemiologic relationship between GERD and *H. pylori*.

The relationship of Barrett esophagus to gastric *H. pylori* colonization is also debated, although most studies show an even stronger inverse relationship than that of GERD alone. Bowrey et al. reported an *H. pylori* prevalence of 27% in patients with Barrett esophagus compared to 41% in healthy control subjects.[69] Werdmuller and Loffeld[70] also found significantly lower *H. pylori* infection rates in Barrett than non-Barrett patients (23% vs. 51%), whereas Loffeld et al.[71] reported very high rates (62%) in a retrospective analysis of 107 consecutive patients with CLE. Investigations focused on the role of subpopulations of *H. pylori* have implicated cagA$^+$ strains as particularly relevant to the development of GE reflux and its complications.[72] Vicari et al.[73] demonstrated that in patients with *H. pylori* infection, the prevalence of cagA$^+$ strains progressively decreased with the severity of GERD, including Barrett esophagus and esophageal adenocarcinoma. Other studies have confirmed an inverse relationship between the presence of cagA positivity and adenocarcinoma of the esophagus and the GE junction.[74] Most authors postulate that cagA$^+$ strains may protect from the development of adenocarcinoma by inducing more severe mucosal inflammation and atrophic gastritis and thereby decreasing

acid reflux. Present data regarding gastric acid secretion are conflicting, however, and further studies are required to test whether this hypothesis is true.

Previously there was a concept that GERD was a categorical disease with little movement between categories. In other words, patients with nonerosive disease (NERD) seldom developed erosive esophagitis. This concept was disproven by one of the most detailed studies on the natural history of GERD from investigators in Europe.[75] The progression or regression of GERD complications was assessed in a cohort of nearly 4,000 patients with predominant heartburn over a 2-year period. After 2 years, 25% of patients with nonerosive GERD progressed to erosive disease, 1.6% with mild erosive esophagitis worsened to more severe esophagitis, and nearly 8% progressed to Barrett esophagus, the latter predominantly in patients with Los Angeles grade C/D erosive disease at baseline. On the other hand, 50% to 60% of patients with baseline esophagitis improved to a milder grade or no erosive disease and 22% were off medications at 2 years. Given that virtually all patients were receiving significant antisecretory therapy, the study shows that a substantial minority of patients will continue to worsen despite pharmacologic treatment. A follow-up study at 5 years on 2,721 of the originally enrolled patients reported that while in most the disease was stable or esophagitis had improved, a sizeable portion of patients progressed.[76] At 5 years, 6% of patients with NERD, 12% with LA grade A/B esophagitis, and 20% of those with LA grade C/D esophagitis had developed Barrett esophagus. On multivariable analysis risk factors for progression to esophagitis or Barrett esophagus were family history of GERD, baseline esophagitis or remaining unhealed after initial treatment, alcohol intake, and regular use of PPI medication.[76]

Investigators in Lausanne, Switzerland, reported an intensive endoscopic follow-up of a defined population of 959 patients over a 30-year period.[77] The study involved only patients who had endoscopic esophagitis and did not include those who had symptoms without mucosal injury. In 42% of patients esophagitis progressed on therapy to more severe mucosal injury. Further, 18% of the initial population acquired a columnar-lined lower esophagus with intestinal metaplasia at late follow-up.

Clinical Presentation

The most common complaints in patients with GERD are heartburn, regurgitation, and dysphagia. These represent the so-called typical symptoms of GERD. Although none of these are specific to GERD, dysphagia may be an indication of more serious underlying pathology, including esophageal carcinoma, and should prompt an upper endoscopy. Heartburn means different things to different people and it is important to ask a patient what heartburn means to them. Typically, heartburn should be characterized as a substernal "burning" discomfort often radiating from the epigastrium to sternal notch. Occasionally patients will refer to it as chest or epigastric pain or indigestion. The typical pattern for early reflux disease is heartburn that occurs postprandially and made worse by "spicy" foods such as tomato sauce, citrus juices, chocolate, coffee, and alcohol. It is commonly relieved by antacids, histamine-2 blockers or PPIs. Importantly, the severity of symptoms is not necessarily related to the severity of the underlying disease (Fig. 42-24).

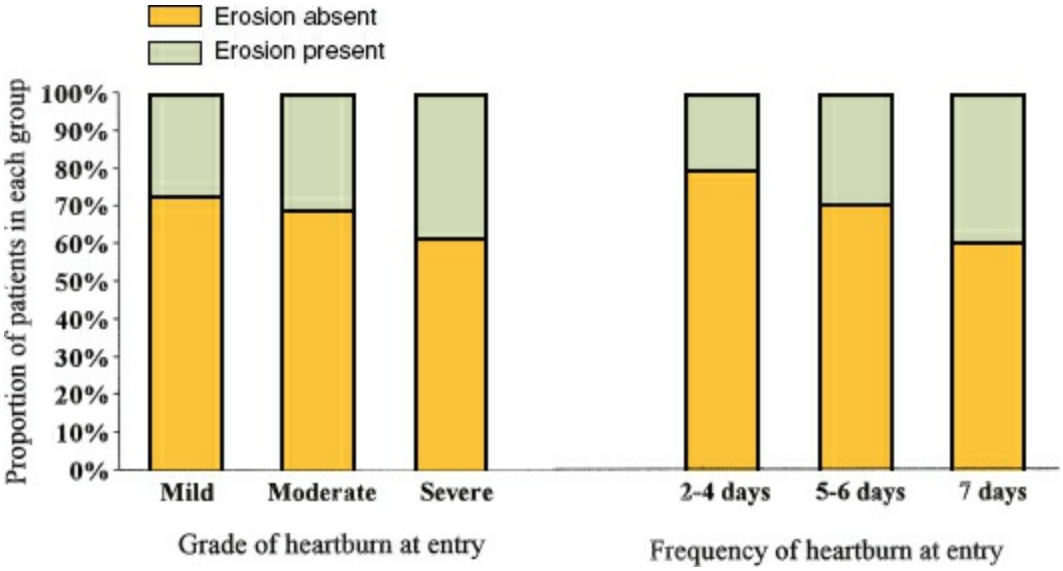

Figure 42-24. Prevalence of erosive esophagitis in 994 patients with varying severity and frequency of reflux symptoms. (Reproduced with permission from Venables TL, Newland RD, Patel AC, et al. Omeprazole 10 mg once daily, omeprazole 20 mg once daily, or ranitidine 150 mg twice daily, evaluated as initial therapy for the relief of symptoms of gastro-oesophageal reflux disease in general practice. *Scand J Gastroenterol* 1997;32:965.)

Regurgitation is the spontaneous return of gastric contents proximal to the GE junction. Its spontaneous nature distinguishes it from vomiting. The patient often gets a sensation that fluid or food is returning into the esophagus, even if it does not reach as high as the pharynx or mouth. It is typically worse at night in the recumbent position or when bending over or lying down after a meal. Patients commonly compensate by not eating late at night or by sleeping partially upright with several pillows or in a chair. This symptom is often less well relieved with antacids or antisecretory agents, although it may change in character from acidic to a more "bland" nature.

Dysphagia is generally manifested by a sensation of food hanging up in the esophagus rather than difficulty transferring the bolus from the mouth to the esophageal inlet (oropharyngeal dysphagia). Classically, dysphagia limited to only solid food, with normal

passage of liquids, suggests a mechanical disorder such as a large hernia, stricture, or tumor, whereas difficulty with both solids and liquids suggests a functional or motor disorder such as achalasia. Dysphagia often develops slowly enough that the patient may adjust his or her eating habits and not be particularly alarmed or aware of the problem. Thus, a thorough esophageal history includes an assessment of the patient's dietary history. Questions should be asked regarding the consistency of food that is typically eaten and whether the patient requires liquids with the meal, is the last to finish, has interrupted a social meal, chokes or vomits with eating, or has been admitted on an emergency basis for food impaction. These assessments, in addition to the ability to maintain nutrition, help to quantify the dysphagia and are important in determining the indications for surgical therapy.

Many patients with GERD often manifest "atypical" or extraesophageal symptoms, such as cough, asthma, hoarseness, and noncardiac chest pain. Atypical symptoms are the primary complaint in 20% to 25% of patients with GERD and are secondarily present in association with heartburn and regurgitation in many more. It is considerably more difficult to prove a cause-and-effect relationship between atypical symptoms and GE reflux than it is to do so for the typical symptoms, and the etiology of these symptoms is often multifactorial. Often a trial of high-dose PPIs is helpful, but it takes several months to evaluate the full impact of the therapy since if GERD is causing the inflammation that leads to the symptoms, it takes time for that inflammation to improve or resolve with GERD therapy. Antireflux surgery can provide excellent symptom relief in these patients, but careful testing to document GERD is critical particularly in those with little or no response to medical therapy.

The diagnosis of GERD based on symptoms alone is correct in only approximately two-thirds of patients.[78] This is because these symptoms are not specific for GE reflux and can be caused by other diseases such as achalasia, diffuse spasm, esophageal carcinoma, pyloric stenosis, cholelithiasis, gastritis, gastric or duodenal ulcer, and coronary artery disease. This fact underscores the need for objective diagnosis before the decision is made for surgical treatment.

Physiology of the Antireflux Barrier

The common denominator for virtually all episodes of gastroesophageal reflux, whether physiologic or pathologic, is the loss of the normal gastroesophageal high-pressure zone and the resistance it imposes to the flow of gastric juice from an environment of higher pressure, the stomach, to an environment of lower pressure, the esophagus. This barrier, composed of both anatomic (flap valve and diaphragm) and physiologic (LES) components, acts to prevent reflux during stressed and unstressed conditions. The key determinates of the barrier include:

1. The frequency of swallow- and non–swallow-induced transient relaxations of the LES
2. The structural integrity of the LES
3. Anatomic alterations of the diaphragmatic crura and gastroesophageal flap valve represented by the angle of His

The presence or absence of pathologic esophageal acid exposure (i.e., abnormal 24-hour pH studies) is not only influenced by the degree of barrier loss but also by esophageal and gastric functional characteristics including esophageal clearance, intra-abdominal pressure, and gastric emptying abnormalities.

Transient Relaxation of the Lower Esophageal Sphincter

The lower esophageal high-pressure zone is normally present except in two situations: (a) after a swallow, when it momentarily relaxes to allow passage of food into the stomach, and (b) when the fundus is distended with gas, and it is reflexly relaxed to allow venting of the gas (a belch). In 1982, Dodds et al.[79] reported that non–swallow-induced transient relaxations of the lower esophageal sphincter (TLESRs) were a significant mechanism of gastroesophageal reflux in normal individuals and patients with GERD. These spontaneous relaxations occurred without pharyngeal contraction, were prolonged (>10 seconds), and, when reflux occurred, were associated with relaxation of the crural diaphragm. Underscoring the importance of the crural diaphragm to barrier integrity, Mittal et al.[80] later showed that pharmacologic elimination of lower esophageal sphincter pressure to zero did not result in reflux unless crural diaphragmatic contraction was also absent. Gastric distention, upright posture, and meals high in fat have all been shown to increase the frequency of TLESRs.[80,81] The latter observations suggest that unfolding of the sphincter may be responsible for the loss of sphincter pressure.

As a result of these findings, TLESRs became commonly accepted as the major mechanism of gastroesophageal reflux regardless of the underlying severity of disease, despite evidence to the contrary. The facts that in over 80% of patients with symptomatic gastroesophageal reflux a hiatal hernia could be identified and that most patients with erosive esophagitis and Barrett esophagus had incompetent lower esophageal sphincter characteristics at rest were largely ignored by many. When these facts are taken into account, particularly in association with the known characteristics of TLESRs, it seems likely that transient relaxations are (a) a physiologic response to gastric distention by food or gas, (b) the mechanism of belching, and (c) responsible for physiologic reflux episodes in individuals with normal lower esophageal sphincter and hiatal anatomy, but not the primary mechanism of GERD. Evidence supporting this has been provided via studies of Van Herwaarden et al.,[82] in which ambulatory esophageal manometry and esophageal pH monitoring were performed on patients with and without hiatal hernia. Patients with hiatal hernia had greater esophageal acid exposure and more reflux episodes, but the frequency of TLESRs, and the proportion associated with reflux, was similar in both groups. They concluded that excess reflux in patients with GERD and hiatal hernia is caused by a combination of low LES pressure, swallow-induced relaxation, and straining.

Structural Integrity of the Lower Esophageal Sphincter

In humans a zone of high pressure can be identified at the junction of the esophagus and stomach. This lower esophageal "sphincter" provides an important component of the barrier between the esophagus and stomach that normally prevents gastric contents from entering the esophagus. It has no anatomic landmarks, but its presence can be identified by a rise in pressure over gastric baseline as a pressure transducer is pulled from the stomach into the esophagus.

There are three characteristics of the lower esophageal sphincter that maintain its resistance or barrier function to intragastric and intra-abdominal pressure challenges. They are its pressure, its overall length, and the length exposed to the positive pressure environment of the abdomen (Table 42-1). The tonic resistance of the lower esophageal sphincter is a function of both its pressure and the length over which this pressure is exerted.[21] The shorter the overall length of the high-pressure zone, the higher the pressure must be to maintain sufficient resistance to remain competent (Fig. 42-13). Consequently, a short overall sphincter length can nullify a normal sphincter pressure.[12] Further, as the stomach fills, the length of the sphincter decreases, rather like the neck of a balloon shortening as the balloon is inflated. If the overall length of the sphincter is abnormally short when the stomach is empty, then with minimal gastric distention there will be insufficient sphincter length for the existing pressure to maintain sphincter competency, and reflux will occur.

The third characteristic of the lower esophageal sphincter is its position, in that a portion of the overall length of the high-pressure zone should be exposed to positive intra-abdominal pressure. During periods of increased intra-abdominal pressure, the resistance of the lower esophageal sphincter would be overcome if the abdominal pressure were not applied equally to the high-pressure zone and stomach. This is akin to sucking on a soft soda straw immersed in a bottle of Coke; the hydrostatic pressure of the fluid and the negative pressure inside the straw due to sucking cause the straw to collapse instead of allowing the liquid to flow up the straw in the direction of the negative pressure. If the abdominal length is inadequate, the sphincter cannot respond to an increase in applied intra-abdominal pressure by collapsing, and reflux is more liable to result. If the high-pressure zone has an abnormal low pressure, a short overall length, or minimal exposure to the abdominal pressure environment in the fasting state, then there is a permanent loss of lower esophageal sphincter resistance and the unhampered reflux of gastric contents into the esophagus throughout the circadian cycle. This is referred to as a *permanently defective sphincter* and is identified by having one or more of the following characteristics: a high-pressure zone with an average pressure of less than 6 mm Hg, an average overall length of 2 cm or less, and an average length exposed to the positive pressure environment of the abdomen of 1 cm or less.[83] Compared with normal subjects, these values are below the 2.5th percentile for each parameter. The most common cause of a permanently defective sphincter is an inadequate abdominal length, most likely a consequence of the development of a hiatal hernia. It is important to note that an inadequate abdominal length or an abnormally short overall length can nullify the

efficiency of a sphincter with a normal pressure.

The presence of a permanently defective sphincter has several implications. First, it is commonly associated with esophageal mucosal injury and predicts that the patient's symptoms may be difficult to control with medical therapy.[23,34] It is now accepted that when the sphincter is permanently defective, it is irreversible, even when the associated esophagitis is healed. The presence of a permanently defective sphincter is commonly associated with reduced esophageal body function,[84] and if the disease is not brought under control, the progressive loss of effective esophageal clearance can lead to severe mucosal injury, repetitive regurgitation, aspiration, and pulmonary failure.

Anatomic Alterations

With the advent of clinical roentgenology, it became evident that a hiatal hernia was a relatively common abnormality although not always accompanied by symptoms. Philip Allison, in his classic treatise published in 1951, suggested that the manifestations of GERD were caused by the presence of a hiatal hernia. For most of the next two decades, hiatal hernia was considered the primary pathophysiologic abnormality leading to GERD. Indeed, the Allison repair, among the first surgical attempts to treat GERD, consisted of a hernia repair only. As techniques of esophageal manometry were developed in the late 1950s and 1960s, allowing identification and study of the lower esophageal sphincter, attention was slowly diverted away from the hernia as the main pathophysiologic abnormality of GERD. In 1971, Cohen and Harris[85] published a study of the contributions of hiatal hernia to lower esophageal sphincter competence in 75 patients, concluding that hiatal hernia had no effect on GE junction competence. This paper, published in the *New England Journal of Medicine,* and the growing use of esophageal manometry shifted the emphasis away from the hernia almost exclusively toward features of the lower esophageal sphincter as the primary abnormality in symptomatic GERD.

Perhaps serendipitously, studies of the phenomenon of TLESRs identified the diaphragmatic crura as an important factor in preventing reflux during periods of loss of LES pressure.[86] In normal subjects, even with absent LES pressure, reflux does not occur without relaxation of the crural diaphragm. Coincidentally, Hill et al.[87] stressed the importance of the physiologic flap valve created by the angle of His as a barrier to gastroesophageal reflux. The endoscopic appearance of the flap valve can be correlated with abnormal esophageal acid exposure, emphasizing that the geometry of the gastroesophageal region is also important to barrier competence.[47] If mechanical forces set in play by gastric distention are important in pulling on the terminal esophagus and shortening the length of the high-pressure zone or “sphincter,” then the geometry of the cardia, that is, the presence of a normal acute angle of His or the abnormal dome architecture of a sliding hiatus hernia, should influence the ease with which the sphincter is pulled open. Evidence that this occurs was provided by Ismail et al.,[16] who showed a close relationship between the degree of gastric distention necessary to overcome the high-pressure zone (yield pressure) and the morphology of the cardia (Fig. 42-25). No relationship between the yield pressure and lower esophageal sphincter resting pressure and length was found. A higher intragastric pressure was needed to open the sphincter in patients with an intact angle of His when compared to patients with a hiatal hernia. The presence of a hiatal hernia also disturbs esophageal clearance mechanisms likely due to loss of anchorage of the esophagus in the abdomen. Kahrilas et al. have shown that complete esophageal emptying was achieved in 86% of swallows in control subjects without a hiatal hernia, 66% in patients with a reducing hiatal hernia, and only 32% of patients with a nonreducing hiatal hernia.[88] Impaired clearance in patients with nonreducing hiatal hernias further supports the contribution of hiatal hernia to the pathogenesis of GERD. Thus, present evidence is overwhelming that hiatal hernia does indeed play a significant, if not primary, role in the pathophysiology of GERD.

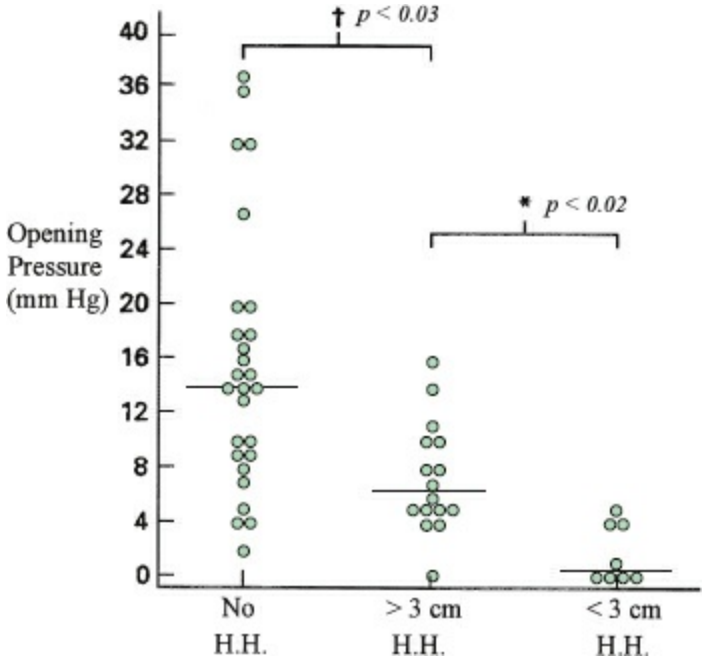

Figure 42-25. The intragastric pressure at which the lower esophagus endoscopically opened in response to gastric distention by air during endoscopy. Note that the dome architecture of a hiatus hernia (HH) influences the ease with which the sphincter can be pulled open by gastric distention. (Reproduced with permission from Ismail T, Bancewicz J, Barlow J. Yield pressure, anatomy of the cardia and gastro-oesophageal reflux. *Br J Surg* 1995;82:943–947.)

A transient loss of the high-pressure zone can also occur and usually results from a functional problem of the gastric reservoir.[33] Excessive air swallowing or food can result in gastric dilatation and, if the active relaxation reflex has been lost, an increased intragastric pressure. When the stomach is distended, the vectors produced by gastric wall tension pull on the GE junction with a force that varies according to the geometry of the cardia; that is, the forces are applied more directly when a hiatal hernia exists than when a proper angle of His is present. The forces pull on the terminal esophagus, causing it to be "taken up" into the stretched fundus and thereby reducing the length of the high-pressure zone or "sphincter." This process continues until a critical length is reached, usually about 1 to 2 cm, when the pressure drops precipitously and reflux occurs. The mechanism by which gastric distention contributes to shortening of the length of the high-pressure zone, so that its pressure drops and reflux occurs, provides a mechanical explanation for "transient relaxations" of the LES without invoking a neuromuscular reflex. Rather than a "spontaneous" muscular relaxation, there is a mechanical shortening of the high-pressure zone, secondary to progressive gastric distention, to the point where it becomes incompetent. These "transient sphincter" shortenings occur in the initial stages of GERD and are the mechanism for the early complaint of excessive postprandial reflux. After gastric venting, the length of the high-pressure zone is restored and competence returns until distention again shortens it and encourages further venting and reflux. This sequence results in the common complaints of repetitive belching and bloating in patients with GERD. The increased swallowing frequency seen in patients with GERD contributes to gastric distention and is due to their repetitive ingestion of saliva in an effort to neutralize the acid refluxed into their esophagus.[26] Thus, GERD may begin in the stomach, secondary to gastric distention resulting from overeating and the increased

ingestion of fried foods, which delay gastric emptying. Both characteristics are common in Western society and may explain the high prevalence of the disease in the Western world.

A recent series of studies from Glasgow assesses the nature of the acid environment at the GE junction,[28] including possible inciting factors in the development of cardia and distal esophageal adenocarcinoma. The studies were initiated to investigate a long-recognized observation that esophageal pH monitoring reveals postprandial esophageal acidification at the same time as the gastric contents are alkalinized. This paradox is hard to explain given that reflux of gastric content into the esophagus is the primary mechanism underlying GERD. Hypothesizing that acidic material must be present somewhere in the upper stomach, the investigators studied luminal pH at 1-cm increments across the upper stomach and lower esophagus in healthy volunteers before and after meals. Surprisingly, they identified a "pocket" of acid at the GE junction unaffected by the buffering action of the meal, which extended across the squamocolumnar junction an average of 1.8 cm into the lumen of the esophagus (Fig. 42-26). The authors concluded that this was the source of postprandial esophageal acid exposure. They expanded these initial studies, confirming that the same process occurs in patients with endoscopy-negative dyspepsia and normal conventional esophageal pH monitoring 5 cm above the upper border of the LES.[89] Perhaps more important, they also identified that dietary nitrate consumed in the form of green vegetables results in the generation of concentrations of nitric oxide at the GE junction high enough to be potentially mutagenic (Fig. 42-27).[90] These observations provide the fundamental basis for the observations of inflammation and other alterations in the epithelium long known to occur at the squamocolumnar junction in both overt and unrecognized GERD.

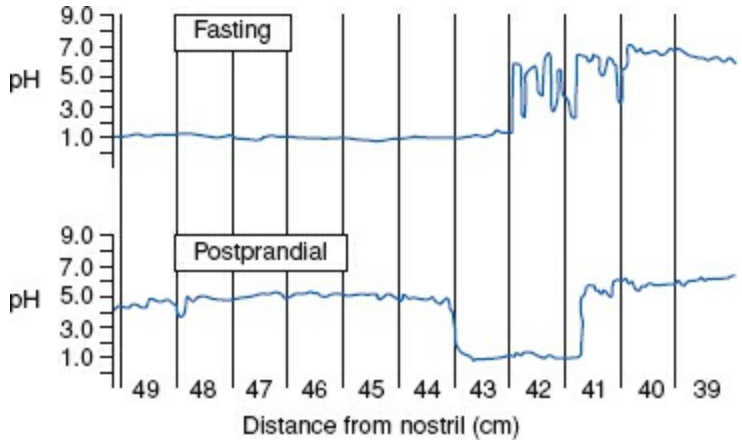

Figure 42-26. Fasting and postprandial gastric and esophageal pH measurements in 1 cm increments during a pull through the gastroesophageal junction. The postprandial tracing reveals an "acid pocket" from 44 to 41 cm from the nares. The fasting tracing reveals this to be the same area as the pH "step-up" corresponding to the transition from the stomach to the esophagus. (Reproduced with permission from Fletcher J, Wirz A, Young J, et al. Unbuffered highly acidic gastric juice exists at the gastroesophageal junction after a meal. *Gastroenterology* 2001;121:775–783.)

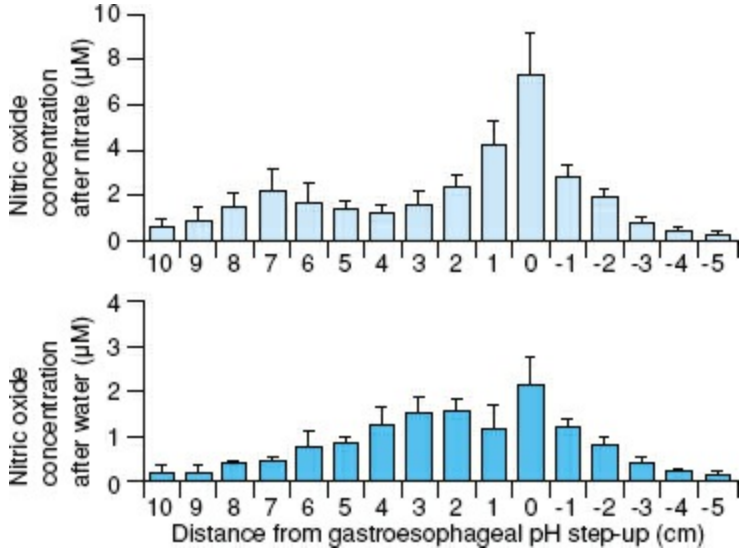

Figure 42-27. Mean (±SEM) nitric oxide concentrations in the upper stomach and lower esophagus after administration of water with 2 mmol nitrate (upper tracing) and water alone (lower tracing) (**$p < 0.01$, *$p < 0.05$ compared with value at gastroesophageal junction pH step-up). (Reproduced with permission from Iljima K, Henry E, Moriya A, et al. Dietary nitrate generates potentially mutagenic concentrations of nitric oxide at the gastroesophageal junction. *Gastroenterology* 2002;122:1248–1257.)

The data support the likelihood that GERD begins in the stomach. Fundic distention occurs because of overeating and delayed gastric emptying secondary to the high-fat Western diet. The distention causes the sphincter to be "taken up" by the expanding fundus, exposing the squamous epithelium with the high-pressure zone, which is the distal 3 cm of the esophagus, to gastric juice. Repeated exposure causes inflammation of the squamous epithelium, columnarization, and carditis. This is the initial step and explains why in early disease the esophagitis is mild and commonly limited to the very distal esophagus. The patient compensates by increased swallowing, allowing saliva to bathe the injured mucosa and alleviate the discomfort induced by exposure to gastric acid. Increased swallowing results in aerophagia, bloating, and repetitive belching. The distention induced by aerophagia leads to further exposure and repetitive injury to the terminal squamous epithelium and the development of cardiac-type mucosa. This is an inflammatory process, commonly referred to as "carditis," and explains the complaint of epigastric pain so often registered by patients with early disease. The process can lead to a fibrotic mucosal ring at the squamocolumnar junction and explains the origin of a Schatzki ring. Extension of the inflammatory process into the muscularis propria causes a progressive loss in the length and pressure of the distal esophageal high-pressure zone associated with an increased esophageal exposure to gastric juice and the symptoms of heartburn and regurgitation. The loss of the barrier occurs in a distal-to-proximal direction and eventually results in the permanent loss of LES resistance and the explosion of the disease into the esophagus with all the clinical manifestations of severe esophagitis. This accounts for the observation that severe esophageal mucosal injury is almost always associated with a permanently defective sphincter. At any time during this process and under specific luminal conditions or stimuli, such as exposure time to a specific pH range, intestinalization of the cardiac-type mucosa can occur and set the stage for malignant

degeneration.

Implications

Implications of recognizing anatomic alterations as component of GE barrier:

1. Transient lower esophageal sphincter relaxation is likely a consequence of sphincter shortening by gastric distention and is the underlying mechanism for belching and physiologic reflux. It does not play a major role in patients with symptomatic gastroesophageal reflux, particularly those with erosive disease, Barrett esophagus, or those referred for surgery.
2. Efforts to augment the gastroesophageal barrier either pharmacologically or endoscopically will commonly fail when a hiatal hernia is present.
3. Patients with abnormal esophageal acid exposure in the presence of normal LES characteristics and no hiatal hernia have an uncommon reason for reflux and these patients require additional evaluation since gastric or esophageal clearance failure may be present and may impair the outcome of a fundoplication.
4. Both reduction of hiatal hernia and augmentation of the lower esophageal sphincter are necessary to maximally restore gastroesophageal barrier competence.
5. Although acid control without regard to barrier incompetence will improve heartburn and heal esophageal erosive disease, it results in increasing numbers of patients with pulmonary manifestations of GERD.

Complications of Gastroesophageal Reflux Disease

The complications of gastroesophageal reflux result from the damage caused by the reflux of gastric juice onto the esophageal mucosa or laryngeal or respiratory epithelium (Fig. 42-28). Complications can be conceptually divided into (a) mucosal complications such as esophagitis and stricture; (b) extraesophageal or respiratory complications such as chronic cough, asthma, and pulmonary fibrosis; and (c) metaplastic (Barrett esophagus) and neoplastic (adenocarcinoma). The prevalence and severity of complications is related to the degree of loss of the gastroesophageal barrier, defects in esophageal clearance, and the content of refluxed gastric juice (Fig. 42-29).

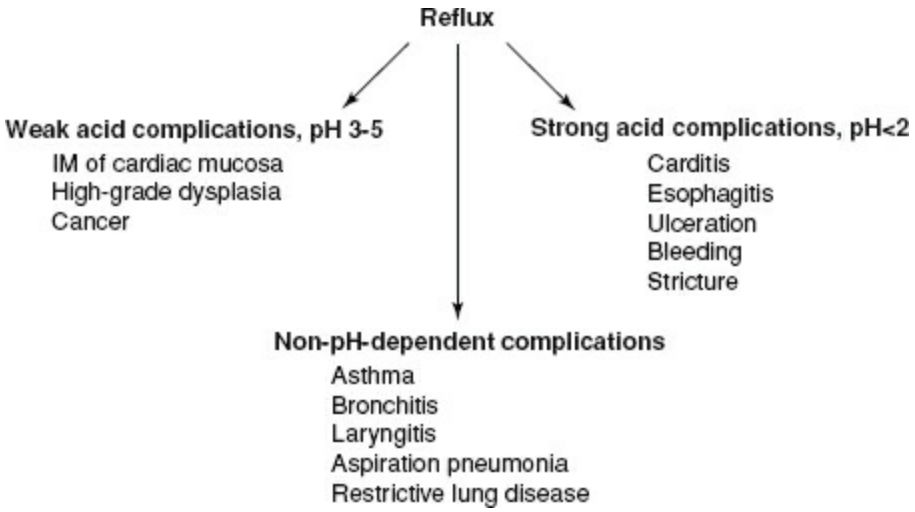

Figure 42-28. Schematic representation of the types of complications of gastroesophageal reflux disease.

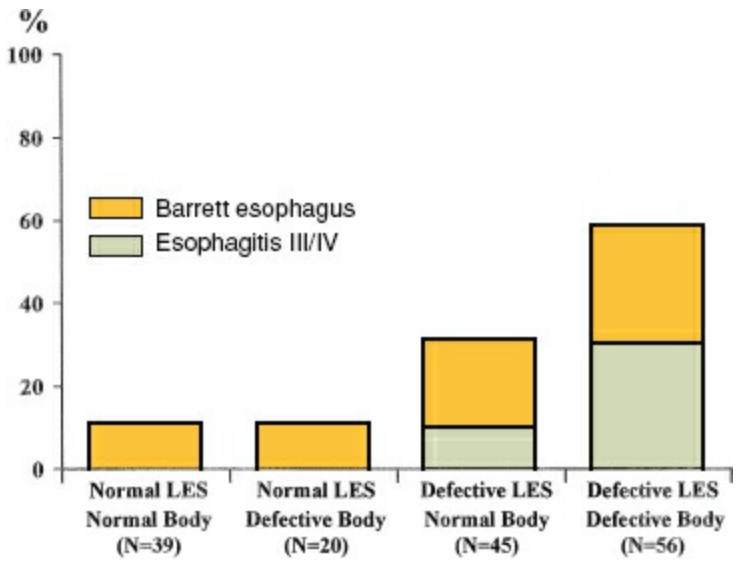

Figure 42-29. Prevalence of esophageal mucosal injury related to the presence of a defective lower esophageal sphincter, esophageal body motility, or both.

Mucosal Complications

The potential injurious components that reflux into the esophagus include gastric secretions, such as acid and pepsin; biliary and pancreatic secretions that regurgitate from the duodenum into the stomach; and toxic compounds generated in the mouth, esophagus,

and stomach by the action of bacteria on dietary substances.

Our current understanding of the role of the various ingredients of gastric juice in the development of esophagitis is based on classic animal studies performed by Lillimoe et al.[91,92] These studies have shown that acid alone does minimal damage to the esophageal mucosa, but the combination of acid and pepsin is highly deleterious. Hydrogen ion injury to the esophageal squamous mucosa occurs only at a pH below 2. In acid refluxate, the enzyme pepsin appears to be the major injurious agent. Similarly, the reflux of duodenal juice alone does little damage to the mucosa, while the combination of duodenal juice and gastric acid is particularly noxious. Reflux of bile and pancreatic enzymes into the stomach can either protect or augment esophageal mucosal injury. For instance, the reflux of duodenal contents into the stomach may prevent the development of peptic esophagitis in a patient whose gastric acid secretion maintains an acid environment, because the bile salts would attenuate the injurious effect of pepsin and the acid would inactivate the trypsin. Such a patient would have bile-containing acid gastric juice that, when refluxed, would irritate the esophageal mucosa but cause less esophagitis than if it were acid gastric juice–containing pepsin. In contrast, the reflux of duodenal contents into the stomach of a patient with limited gastric acid secretion can result in esophagitis, because the alkaline intragastric environment would support optimal trypsin activity and the soluble bile salts with a high pK_a would potentiate the enzyme's effect. Hence, duodenal-gastric reflux and the acid-secretory capacity of the stomach interrelate by altering the pH and enzymatic activity of the refluxed gastric juice to modulate the injurious effects of enzymes on the esophageal mucosa.

This disparity in injury caused by acid and bile alone as opposed to the gross esophagitis caused by pepsin and trypsin provides an explanation for the poor correlation between the symptom of heartburn and endoscopic esophagitis. The reflux of acid gastric juice contaminated with duodenal contents could break the esophageal mucosal barrier, irritate nerve endings in the papillae close to the luminal surface, and cause severe heartburn. Despite the presence of intense heartburn, the bile salts present would inhibit pepsin, the acid pH would inactivate trypsin, and the patient would have little or no gross evidence of esophagitis. In contrast, the patient who refluxed alkaline gastric juice may have minimal heartburn because of the absence of hydrogen ions in the refluxate but have endoscopic esophagitis because of the bile salt potentiation of trypsin activity on the esophageal mucosa. This is supported by recent clinical studies that indicate that the presence of alkaline reflux is associated with the development of mucosal injury.[93]

Although numerous studies have suggested the reflux of duodenal contents into the esophagus in patients with GERD, few have measured this directly. The components of duodenal juice thought to be most damaging are the bile acids, and as such, they have been the most commonly studied. Most studies have implied the presence of bile acids using pH measurements. Studies using either prolonged ambulatory aspiration techniques (Fig. 42-30) or spectrophotometric bilirubin measurement have shown that, as a group, patients with GERD have greater and more concentrated bile acid exposure to the esophageal mucosa than normal subjects.[23,34] This increased exposure occurs most commonly during the supine period while asleep and during the upright period following

meals. Most studies have identified the glycine conjugates of cholic, deoxycholic, and chenodeoxycholic acids as the predominant bile acids aspirated from the esophagus of patients with GERD, although appreciable amounts of taurine conjugates of these bile acids were also found. Other bile salts were identified but in small concentrations. This is as one would expect because glycine conjugates are three times more prevalent than taurine conjugates in normal human bile.

The potentially injurious action of toxic compounds either ingested or newly formed on the mucosa of the gastroesophageal junction and distal esophagus has long been postulated. Until recently, however, few studies have substantiated this possibility. Expanding upon studies of acid exposure at the gastroesophageal junction, investigators from Glasgow, Scotland, have recently shown that dietary nitrate consumed in the form of green vegetables and food contaminated by nitrate-containing fertilizers results in the generation of nitric oxide at the gastroesophageal junction in concentrations high enough to be potentially mutagenic.[90] Previous studies have shown that nitrate ingested in food is reabsorbed in the small bowel, with approximately 25% resecreted into the mouth via the salivary glands. Oral bacteria chemically transforms the relatively innocuous nitrate to the more toxic nitrite, which is swallowed and subsequently converted to nitric oxide and other toxic nitroso-compounds by acid and ascorbic acid in the stomach. Whether this mechanism in fact contributes to injury and/or neoplastic transformation in the upper stomach, gastroesophageal junction, and distal esophagus is currently unknown.

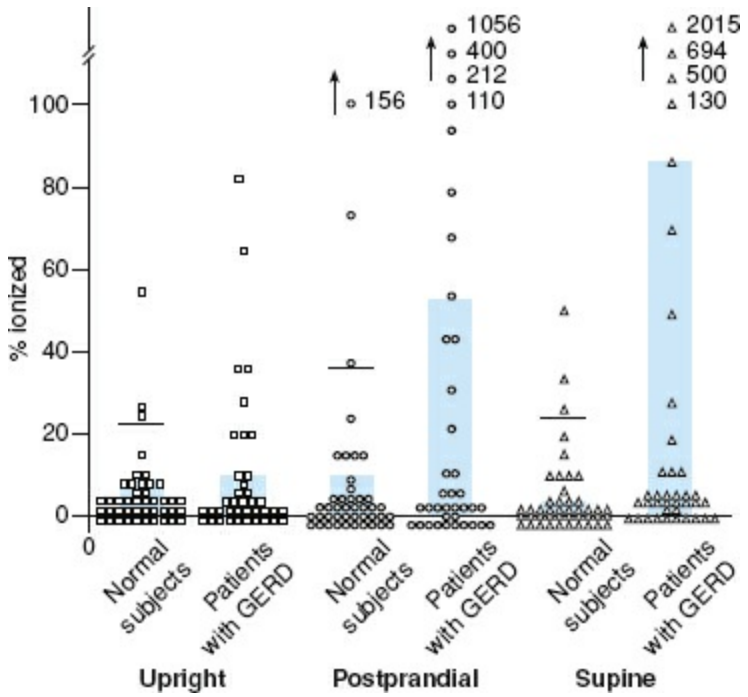

Figure 42-30. Peak bile acid concentration (μmol/L) for patients and normal subjects during upright, postprandial, and supine aspiration periods. The shaded area represents the mean and the bar the 95th percentile values.

Respiratory Complications

It is increasingly recognized that a significant proportion of patients with gastroesophageal reflux will have either primary RSs or RSs in association with more prominent heartburn and regurgitation.[94] Reflux has been implicated as causative of

asthma and idiopathic pulmonary fibrosis (IPF) and can complicate advanced lung diseases including chronic obstructive pulmonary disease (COPD) and cystic fibrosis (CF). Thirty-five to fifty percent of asthmatics have been shown to have abnormal esophageal pH, esophagitis, and a hiatal hernia.[95] Others have shown that the prevalence of reflux symptoms exceeded 50% in patients with asthma and CF.[96,97] In addition, patients with COPD and gastroesophageal reflux are twice as likely to have significant COPD exacerbations than their nonreflux counterparts,[98] and reflux symptoms correlate with airway obstruction in COPD patients. These reports suggest that the frequency of dual pathology is higher than would be expected by chance alone.

Pathophysiology of Reflux-Induced Respiratory Symptoms. Two mechanisms have been proposed as the pathogenesis of reflux-induced RSs. The first, the so-called "reflux" theory, maintains that RSs are the result of the aspiration or microaspiration of gastric contents. The second or "reflex" theory maintains that vagally mediated bronchoconstriction follows acidification of the lower esophagus via a reflex neurologic arc.

The evidence supporting a *reflux* mechanism was shown in animals in the 1950s to 1970s, with studies of acid instillation in the lungs resulting in pneumonitis,[99,100] epithelial damage,[101] and increased airway resistance.[102] The evidence in humans can be categorized as follows. First, there is radiographic evidence. Patients with pulmonary fibrosis have an increased prevalence of hiatal hernia on upper GI series,[103,104] while elderly patients with large hiatal hernias have a significantly increased frequency of pleural scarring on chest CT scans.[105] Second, erosive esophagitis was found at a high frequency in a large series of Veterans Affairs patients with asthma, pneumonia, chronic bronchitis, and pulmonary fibrosis.[94] Third, patients with chronic lung diseases, including asthma and pulmonary fibrosis in particular, have a significantly higher frequency of positive 24-hour pH studies.[105,106] With dual pH monitoring of the proximal and distal esophagus, prolonged exposure of the proximal esophagus to gastric juice occurs at a higher frequency in patients with gastroesophageal reflux and RSs than in patients without respiratory complaints.[107,108] Fourth, simultaneous tracheal and esophageal pH monitoring in patients with reflux disease have documented tracheal acidification in concert with esophageal acidification.[102] Finally, medications used to treat chronic lung diseases, in particular, bronchodilators, relax esophageal sphincter tone.[109]

A *reflex* mechanism is primarily supported by the fact that bronchoconstriction occurs following the infusion of acid into the lower esophagus.[110–112] This can be explained by the common embryologic origin of the tracheoesophageal tract and its shared vagal innervation.

The primary challenge in implementing treatment for reflux-associated RSs lies in establishing the diagnosis. In those patients with predominantly typical reflux symptoms and secondary respiratory complaints, the diagnosis may be straightforward. However, in a substantial number of patients with reflux-induced RSs, the RSs dominate the clinical scenario. Gastroesophageal reflux in these patients is often silent and is only uncovered when investigation is initiated.[106,113] A high index of suspicion is required, notably in

patients with poorly controlled asthma in spite of appropriate bronchodilator therapy. Supportive evidence for the diagnosis can be gleaned from endoscopy and stationary esophageal manometry. Endoscopy may show erosive esophagitis or Barrett esophagus. Manometry may indicate a hypotensive lower esophageal sphincter or ineffective body motility, defined by 30% or more contractions in the distal esophagus of less than 30 mm Hg in amplitude.[114] D'Ovidio et al.[115] studied 78 patients awaiting lung transplant for IPF, scleroderma, COPD, or CF and found that 72% had a hypotensive lower esophageal sphincter, 33% abnormal esophageal body motility, and 38% abnormal 24-hour pH testing, although, interestingly, patients with IPF in other series have been shown to have normal manometry.[108]

The current "gold standard" for the diagnosis of reflux-induced respiratory complaints is ambulatory dual-probe pH monitoring, often combined with multichannel intraluminal impedance (MII-pH). One probe is positioned in the distal esophagus and the other at a more proximal location. Sites for proximal probe placement have included the trachea, pharynx, and proximal esophagus. Most authorities would agree that the proximal esophagus is the preferred site for proximal probe placement. While ambulatory esophageal pH monitoring allows a direct correlation between esophageal acidification and RSs, the chronologic relationship between reflux events and bronchoconstriction is complex. Further, the proximal probe must be positioned close to, but not above, the UES. Failure to properly place the probe can lead to artifact or errors in pH assessment. In addition, the use of a pH threshold of 4 as is used in the distal esophagus is questioned. Normal subjects should have a pH ≥ 7 in the cervical esophagus for at least 19.6% of the monitored period. Looking at pH exposure in reverse, in other words as loss of the normal alkalinity in the cervical esophagus, was shown to be a more sensitive indicator of proximal reflux.[116] Recently the use of a special pH probe designed for the environment of the pharynx has been advocated in patients with RSs to evaluate for proximal reflux. This probe, called the Restech pH probe (Respiratory Technology Corp, San Diego, CA, USA), has been shown to better predict successful relief of extraesophageal RSs with a fundoplication compared to the traditional dual-probe pH test.[117] Of importance, the Restech analysis uses a pH threshold of 5.5 for upright and 5.0 for supine reflux, and the Ryan score is used to determine normal from abnormal pharyngeal reflux exposure.[116] Probably the best pH monitoring method in these patients is to start with a 48-hour Bravo pH and if that is normal on both days then add a Restech pH test.[117]

Laryngopharyngeal Reflux

The term *LPR* is used for a broad category of atypical symptoms that may be secondary to gastroesophageal reflux. These may include laryngitis, pharyngitis, hoarseness, sinusitis, sleep disturbance, dental erosions, and globus.[118,119] Mechanisms for these symptoms are difficult to prove and substantial evidence remains lacking.[120]

Treatment of Extraesophageal Complications. Once gastroesophageal reflux is suspected or thought to be responsible for extraesophageal symptoms, treatment may be with either prolonged PPI therapy or antireflux surgery. Initially, a 3- to 6-month trial of

high-dose PPI therapy (b.i.d. or t.i.d. dosing) may help confirm (by virtue of symptom resolution) the fact that reflux is partly or completely responsible for the symptoms. If symptoms are improved, patients can be treated with maintenance medical therapy or may be offered surgical treatment to control the reflux. The persistence of symptoms despite PPI treatment, however, does not necessarily rule out reflux as being a potential contributor. Algorithm 42-1 bases clinical decisions on the results of dual-probe 24-hour pH monitoring and is a useful starting point.

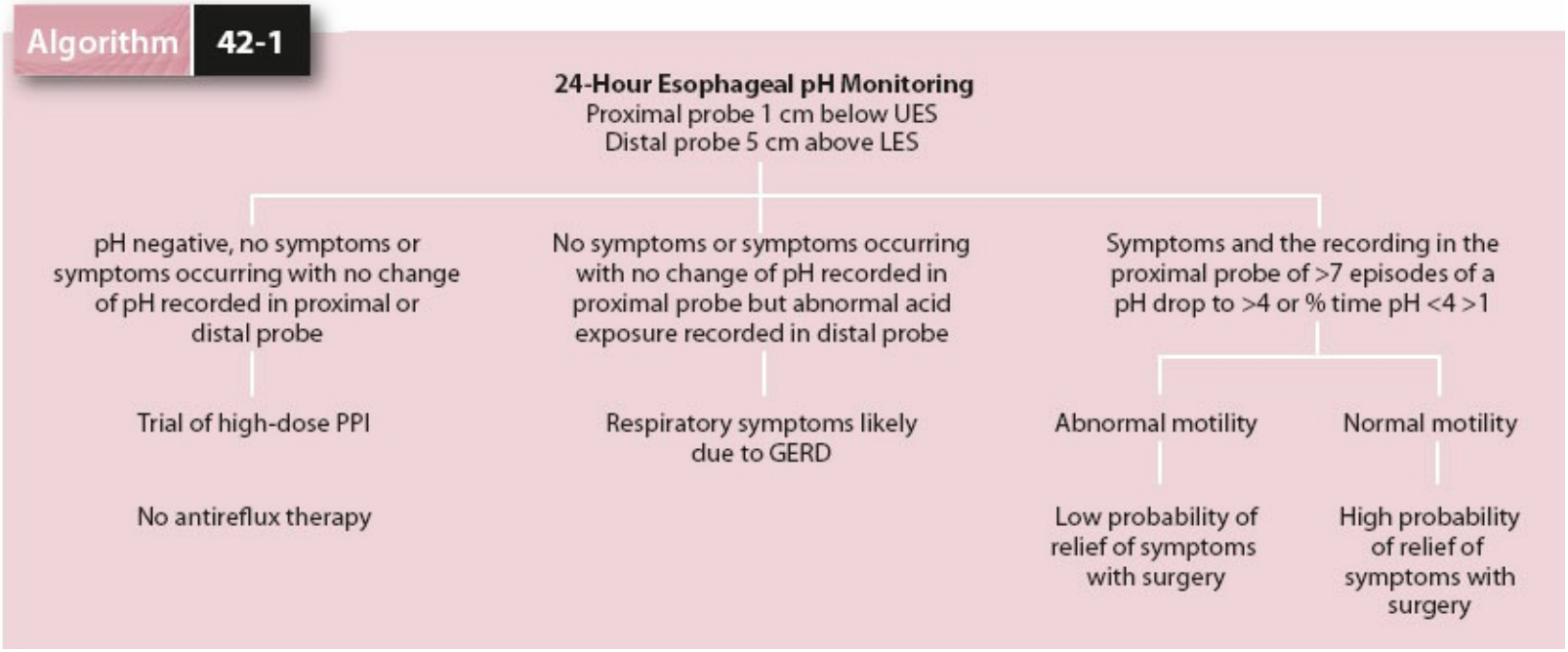

Algorithm 42-1. 24-Hour Esophageal pH Monitoring

Based on reported observations, relief of RSs can be anticipated for 25% to 50% of patients with reflux-induced asthma treated with antisecretory medications,[121–123] although patients with pulmonary fibrosis in particular may have an inherent resistance to standard-dose PPIs.[124] Fewer than 15% of asthmatics with symptom relief, however, can be expected to have objective improvements in their pulmonary function. The reason for this apparent paradox may be that most studies employed relatively short courses of antisecretory therapy (<3 months). This time period may have been sufficient for symptomatic improvement but insufficient for recovery of pulmonary function. The chances of success with medical treatment are likely directly related to the extent of reflux elimination. The conflicting findings of reports of antisecretory therapy may well be due to inadequate control of gastroesophageal reflux in some studies. The literature indicates that antireflux surgery improves RSs in nearly 90% of children and 70% of adults with asthma and reflux disease.[123,125] Improvements in pulmonary function were demonstrated in around one-third of patients. Comparison of the results of uncontrolled studies of each form of therapy and the evidence from the two randomized controlled trials of medical versus surgical therapy indicate that fundoplication is the most effective therapy for reflux-induced asthma.[125] The superiority of the surgical antireflux barrier over medical therapy is probably most noticeable in the supine posture, which

corresponds with the period of acid breakthrough with PPI therapy and is the time in the circadian cycle when asthma symptoms and peak expiratory flow rates are at their worst.

More convincing data establishing the benefit of antireflux surgery in improving RSs and pulmonary function tests derives from the lung transplantation literature. Bronchiolitis obliterans syndrome (BOS), synonymous with chronic rejection of the transplanted lung, is diagnosed by a greater than 20% decline in pulmonary function tests from posttransplant baseline. Lau et al. showed in the early 2000 that 67% of 18 patients with BOS had an improvement in their pulmonary function tests after antireflux surgery.[126] More recently, several groups have reported improvements in oxygen requirements and stabilization of declining pulmonary function tests when pre–lung transplant patients underwent antireflux surgery.[127,128] In addition, pulmonary and other extraesophageal symptoms can improve after laparoscopic Nissen fundoplication with minimal perioperative morbidity.[129]

It is also important to realize that, in asthmatic patients with a non–reflux-induced motility abnormality of the esophageal body, performing an antireflux operation may not prevent the aspiration of orally regurgitated, swallowed liquid or food. This can result in RSs and airway irritation that may elicit an asthmatic reaction. This factor may be the explanation why surgical results appear to be better in children than adults, since disturbance of esophageal body motility is more likely in adult patients.

Metaplastic (Barrett) and Neoplastic (Adenocarcinoma) Complications

The condition whereby the tubular esophagus is lined with columnar epithelium rather than squamous epithelium was first described by Norman Barrett in 1950 (Fig. 42-31).[130] He incorrectly believed it to be congenital in origin. It is now realized that it is an acquired abnormality, occurring in 7% to 10% of patients with GERD, and represents the end stage of the natural history of this disease.[131] It is also understood to be distinctly different from the congenital condition in which islands of mature gastric columnar epithelium are found in the upper half of the esophagus.

The definition of Barrett esophagus has evolved considerably over the past decade.[130–133] Traditionally, Barrett esophagus was identified by the presence of any columnar mucosa extending at least 3 cm into the esophagus. Recent data indicating that specialized intestinal-type epithelium is the only tissue predisposed to malignant degeneration, coupled with the finding of a similar risk of malignancy in segments of intestinal metaplasia less than 3 cm long, have resulted in the diagnosis of Barrett esophagus, given any length of endoscopically visible tissue that is intestinal metaplasia on histology (Fig. 42-32). Whether to call long segments of columnar mucosa without intestinal metaplasia Barrett esophagus is unclear. The hallmark of intestinal metaplasia is the presence of goblet cells. Recent studies have identified a high prevalence of biopsy-proven intestinal metaplasia at the cardia, in the absence of endoscopic evidence of a CLE. The significance and natural history of this finding remain unknown. The term *Barrett esophagus* should currently be used in the setting of an endoscopically visible segment of intestinal metaplasia of any length or columnar replacement of the esophagus of 3 cm or more.

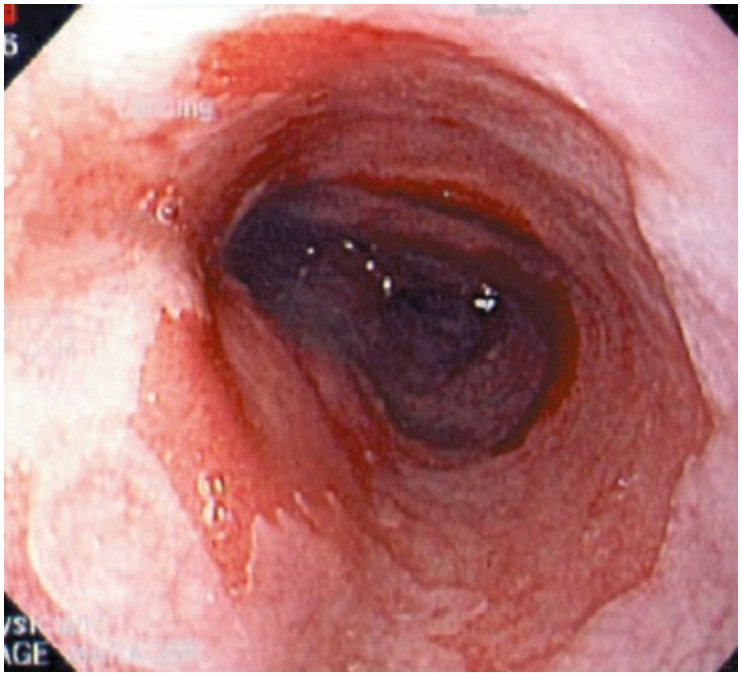

Figure 42-31. Endoscopic appearance of Barrett esophagus. Note the pink metaplastic mucosa as opposed to the normal whitish squamous lining of the esophagus.

Factors predisposing to the development of Barrett esophagus include early-onset GERD, abnormal lower esophageal sphincter and esophageal body physiology, and mixed reflux of gastric and duodenal contents into the esophagus.[133] Direct measurement of esophageal bilirubin exposure as a marker for duodenal juice has shown that 58% of the patients with GERD have increased esophageal exposure to duodenal juice and that this exposure is most dramatically related to Barrett esophagus.[134]

Pathophysiology of Barrett Metaplasia. Recent studies suggest that the metaplastic process at the gastroesophageal junction may begin by conversion of distal esophageal squamous mucosa to cardiac-type epithelium, heretofore presumed to be a normal finding.[132] This is likely due to exposure of the distal esophagus to excess acid and gastric contents via prolapse of esophageal squamous mucosa into the gastric environment. This results in inflammatory changes at the gastroesophageal junction and/or a metaplastic process, both of which may result in the loss of muscle function and a mechanically defective sphincter allowing free reflux with progressively higher degrees of mucosal injury. Intestinal metaplasia within the sphincter may result, as in Barrett metaplasia of the esophageal body. This mechanism is supported by the finding that as the severity of GERD progresses, the length of columnar lining above the anatomic gastroesophageal junction is increased.

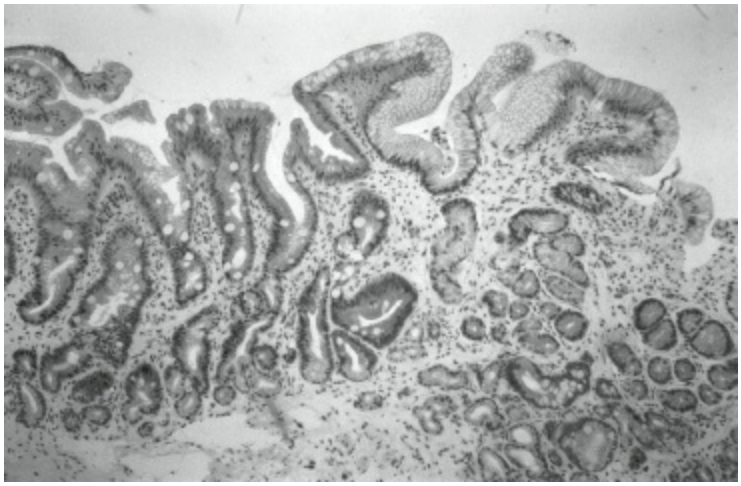

Figure 42-32. Histologic appearance of Barrett esophagus. To the left of the photograph, columnar mucosa with abundant goblet cells is seen. This is intestinal metaplasia, which is the histologic hallmark of Barrett esophagus. To the right of the photomicrograph, cardiac epithelium is present.

Treatment. The relief of symptoms remains the primary force driving antireflux surgery in patients with Barrett esophagus. Healing of esophageal mucosal injury and the prevention of disease progression are important secondary goals. In this regard, patients with Barrett esophagus are no different than the broader population of patients with gastroesophageal reflux. Antireflux surgery should be considered when patient factors suggest severe disease or predict the need for long-term medical management, both of which are almost always true in patients with Barrett esophagus.

PPI therapy, both to relieve symptoms and to control any coexistent esophagitis or stricture, is an acceptable treatment option in patients with Barrett esophagus. Once initiated, however, most patients with Barrett esophagus will require life-long treatment. Complete control of reflux with PPI therapy can be difficult, however, as has been highlighted by studies of acid breakthrough while on therapy. Katzka and Castell, and Ouatu-Lascar and Triadafilopolous have shown that 40% to 80% of patients with Barrett esophagus continue to experience abnormal esophageal acid exposure despite up to 20 mg twice daily of PPI.[135,136] Ablation trials have shown that mean doses of 56 mg of omeprazole are necessary to normalize 24-hour esophageal pH studies.[137] Antireflux surgery likely results in more reproducible and reliable elimination of reflux of both acid and duodenal content, although long-term outcome studies suggest that as many as 25% of patients postfundoplication will have persistent pathologic esophageal acid exposure confirmed by 24-hour pH studies.[138]

An important consideration is that patients with Barrett esophagus generally have severe GERD, with its attendant sequelae such as large hiatal hernia, stricture, shortened esophagus, and poor motility. Compared to mild and nonerosive reflux disease, severe erosive disease and Barrett esophagus are associated with significantly greater loss of the mechanical antireflux barrier because of associated hiatal hernias and a hypotensive lower esophageal sphincter. Surgical treatment with a laparoscopic Nissen fundoplication reduces the hiatal hernia, improves the antireflux barrier, and consequently provides similarly excellent symptom control.[139] Large studies in patients with typical acid reflux

symptoms have been published from the United States and Europe.[140–143] In patients having laparoscopic Nissen fundoplication at Emory University, relief of heartburn and regurgitation occurred in 90%, and 70% were off all reflux medications at a mean follow-up of 11 years.[144] These results emphasize the durability of the procedure as well as the persistent relief of typical symptoms. Risk factors for persistent use of antacids after antireflux surgery include a partial fundoplication, older age, and female gender.[145]

Studies focusing on the symptomatic outcome following antireflux surgery in patients with Barrett esophagus document excellent to good results in 72% to 95% of patients at 5 years following surgery.[138–140] The outcome of laparoscopic Nissen fundoplication in patients with Barrett esophagus has been assessed at 1 to 3 years after surgery. Hofstetter et al. reported the experience at the University of Southern California (USC) in 85 patients with Barrett esophagus at a median of 5 years after surgery. Fifty-nine had long- and 26 short-segment Barrett esophagus and 50 underwent a laparoscopic antireflux procedure.[138] Reflux symptoms were absent postoperatively in 79% of the patients. Postoperative 24-hour pH was normal in 17 of 21 patients (81%). Ninety-nine percent of the patients considered themselves cured or improved and 97% were satisfied with the surgery. In addition to symptomatic improvement in reflux after surgery, there is evidence that mediators of esophageal inflammation implicated in carcinogenesis are decreased as well. Cyclooxygenase-2 (COX-2) gene expression is elevated in the distal esophagus of reflux patients, but the expression of COX-2 and another inflammatory mediator, interleukin 8, can be decreased in the distal esophageal mucosa after a fundoplication.[146–148]

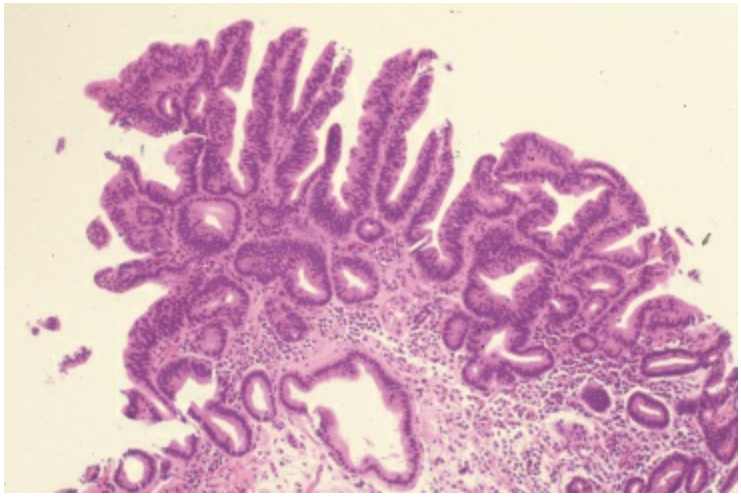

Figure 42-33. Histologic appearance of Barrett esophagus. To the left of the photograph, columnar mucosa with abundant goblet cells is seen. This is intestinal metaplasia, which is the histologic hallmark of Barrett esophagus. To the right of the photomicrograph, cardiac epithelium is present.

The Development of Dysplasia in Barrett Esophagus. The prevalence of dysplasia at diagnosis in patients presenting with Barrett esophagus ranges from 15% to 25%, and approximately 5% of patients will develop dysplasia each year. The identification of dysplasia in Barrett epithelium rests on histologic examination of biopsy specimens. The cytologic and tissue architectural changes are similar to those described in ulcerative

colitis (Fig. 42-33). By convention, Barrett metaplasia is currently classified into four broad categories:

1. No dysplasia
2. Indefinite for dysplasia
3. Low-grade dysplasia
4. High-grade dysplasia

There are few prospective studies documenting the progression of nondysplastic Barrett epithelium to low- or high-grade dysplasia. Those that are available suggest that 5% to 6% per year will progress to dysplasia and 0.5% to 1% per year to adenocarcinoma (Table 42-2). Several newer studies have suggested a lower rate, but these studies excluded patients that progressed within the first year of follow-up, and in one study included those with a CLE with or without intestinal metaplasia. Once identified, Barrett esophagus complicated by dysplasia should undergo aggressive therapy. Patients whose biopsies are interpreted as indefinite for dysplasia should be treated with a medical regimen consisting of 60 to 80 mg of PPI therapy for 3 months and rebiopsied. Importantly, esophagitis should be healed prior to interpretation of the presence or absence of dysplasia. The presence of severe inflammation makes the microscopic interpretation of dysplasia difficult. The purpose of acid suppression therapy is to resolve inflammation that may complicate the interpretation of the biopsy specimen. Persistent indefinite or low-grade dysplasia should be a relative indication for a Nissen fundoplication given the evidence that in most patients low-grade dysplasia reverts to nondysplastic intestinal metaplasia after a fundoplication. Alternatively, or if dysplasia persists after a fundoplication, it should be ablated using radiofrequency or cryotherapy devices given evidence that ablation reduces the risk of progression to cancer in these patients.

Table 42-2 Development of Dysplasia: Prospective Evaluation of 62 Patients

Initial Diagnosis	Final Diagnosis				
	No.	Metaplasia	I/LGD	HGD	CA
Metaplasia	39	27	10	1	1
I/LGD	20	4	8	3	2
HGD	3			1	2

CA, carcinoma; HGD, high-grade dysplasia; I, indeterminate; LGD, low-grade dysplasia.
From Reid BJ, Blount PL, Rubin CE, et al. Flow-cytometric and histological progression to malignancy in Barrett's esophagus: prospective endoscopic surveillance of a cohort. *Gastroenterology* 1992;102:1212–1219.

HGD should be confirmed by two pathologists knowledgeable in GI pathology. Numerous esophagectomy series have shown that approximately 50% of patients thought

to have only HGD will harbor a focus of invasive carcinoma somewhere in the columnar mucosa.[149–151] Any patient with dysplasia, particularly HGD, requires careful endoscopic evaluation preferably with a high-definition endoscope and NBI or similar technology to look for any nodules or lesions. These lesions are sites of potential invasive cancer. If no lesion is present then the columnar mucosa should be ablated since randomized trials have confirmed the benefit of ablation to reduce the risk of progression to cancer in patients with HGD.

If a lesion is present it must be excised using ER techniques to determine if it is malignant and allow assessment of the depth of invasion and tumor characteristics. The aim of EMR is to excise the area of interest including the mucosal and submucosal layers down to the muscularis propria allowing optimal histologic interpretation. Over a decade ago the authors showed in a small series that EMR reliable removed superficial esophageal adenocarcinomas and provided an excellent pathologic specimen for evaluation. Until recently, esophagectomy was considered the standard of care for patients with HGD or a superficial adenocarcinoma. Subsequently, high-volume esophageal centers in Europe and the United States began offering endoscopic therapy for these lesions in appropriate patients. The authors have confirmed that the oncologic outcome is similar in patients with HGD or intramucosal adenocarcinoma whether they were treated with esophagectomy or endoscopic therapy, but the morbidity and mortality rates were significantly lower with endoscopic therapy. The largest study on endoscopic therapy alone for intramucosal adenocarcinoma comes from Wiesbaden, Germany. In this study of 1,000 patients there was no procedure-related mortality and only a 2% major complication rate. After a mean follow-up period of 56.6 months 96% of patients had achieved a complete response. Esophagectomy for failed endotherapy was necessary in only 12 patients (3.7%). Metachronous lesions or local recurrence developed in 140 patients (14.5%), but was successfully retreated endoscopically in 79% of patients. The calculated 10-year overall survival was 75%, and only two patients died from esophageal adenocarcinoma. These excellent results should make endoscopic therapy the preferred therapy for intramucosal adenocarcinoma in appropriate patients. Risk factors for failure of endoscopic therapy are still being identified, but include ultra–long segment (>8 cm) Barrett's, poorly controlled reflux disease, and high-grade tumor differentiation. Tumors associated with an increased risk for lymph node metastases include those with lymphovascular invasion, size >2 cm, and invasion into the submucosa.

Treatment of Gastroesophageal Reflux Disease

Medical Treatment

GERD is one of the most prevalent conditions encountered in general medical practice. As a result, medications for control of GERD comprise one of the largest pharmaceutical markets in the United States and abroad. Since PPIs were introduced in the United States in 1989, a number of different agents have emerged, each with substantial penetration in the marketplace. Data from the year 2004 reveal that, of the top 10 expenditures for medications in the United States, the third highest dollar amount was spent on Prevacid (lansoprazole, TAP Pharmaceutical Products, Inc., Lake Forest, Illinois; $4.0 billion), while the fourth highest was on Nexium (esomeprazole magnesium, AstraZeneca Pharmaceuticals, Wilmington, Delaware; $3.6 billion).[152,153]

GERD is such a common condition that most patients with mild symptoms carry out self-medication, particularly now that generic and over-the-counter H_2-receptor antagonists (H_2RAs) and PPIs have become widely available. When first seen with symptoms of heartburn or regurgitation without obvious complications, patients can reasonably be placed on 8 to 12 weeks of acid suppression therapy before extensive investigations are carried out. In many situations, symptoms successfully resolve. Patients should be advised to elevate the head of the bed; avoid tight clothing; eat small, frequent meals; avoid eating their nighttime meal shortly before retiring; lose weight; and avoid alcohol, coffee, chocolate, and peppermints, which may aggravate the symptoms. Medications to promote gastric emptying, such as metoclopramide, are beneficial in early disease but of little value in more severe disease.

The mainstay of maintenance medical therapy is acid suppression. Patients with persistent symptoms should be given PPIs, such as omeprazole. In doses as high as 40 mg/day, they can effect an 80% to 90% reduction in gastric acidity. Such a regimen usually heals mild esophagitis, but healing may occur in only three-fourths of patients with severe esophagitis. It is important to realize that in patients who reflux a combination of gastric and duodenal juice, inadequate acid suppression therapy may give symptomatic improvement while still allowing mixed reflux to occur. This can result in an environment that allows persistent mucosal damage in an asymptomatic patient. Unfortunately, within 6 months of discontinuation of any form of medical therapy for GERD, 80% of patients have a recurrence of symptoms.[154]

In patients with reflux disease, esophageal acid exposure is reduced by up to 80% with H_2RAs and up to 95% with PPIs. Despite the superiority of the latter class of drug over the former, periods of acid breakthrough still occur.[155,156] Breakthrough occurs most commonly at nighttime and is some justification for a split rather than a single dosing regimen. Katzka et al.[155] studied 45 patients with breakthrough reflux symptoms while on omeprazole 20 mg b.i.d. and found that 36 patients were still refluxing, defined by a total distal esophageal acid exposure greater than 1.6%. Peghini et al.[156] employed intragastric pH monitoring in 28 healthy volunteers and 17 patients with reflux disease and found that nocturnal recovery of acid secretion (more than 1 hour) occurred in 75% of the

individuals. Recovery of acid secretion occurred within 12 hours of the oral evening dose of PPI, the median recovery time being 7.5 hours. This is particularly pertinent because it is during the nighttime and early morning that asthma symptoms are most pronounced and that peak expiratory flow rate is at its lowest. Ranitidine 300 mg at bedtime appears superior to omeprazole 20 mg at bedtime in preventing acid breakthrough, likely due to the abolition of histamine-mediated acid secretion in the fasting state.

An accumulating body of literature suggests potential adverse consequences to long-term acid suppressive therapy. A population-based cohort study from the Netherlands covering the years 1995–2002 revealed higher incidence rates of community-acquired pneumonia in patients using H_2RAs or PPIs compared to those who never used them or those who had used them previously but stopped.[157] The risk was most pronounced for PPIs and showed a clear dose–response relationship. Other studies have focused on the association between acid suppression and the development of osteoporosis-related fractures.[158–160] Of note, a population-based study from the United Kingdom assessed the risk of hip fractures from long-term PPI therapy.[158] The study covered the years 1987–2003 and compared users of PPI therapy to nonusers of any acid suppressive medication. The risk of hip fracture was significantly increased in patients prescribed long-term high-dose PPI, and the strength of the association increased with increasing duration of PPI therapy. The authors conjectured that calcium malabsorption secondary to chronic acid suppression may potentially explain the positive association. Other concerning side effects of PPI use have surfaced and include interactions with antiplatelet medications and a recent association with an increased risk for acute myocardial infarction.

Failure of acid suppression to control symptoms or immediate return of symptoms after stopping treatment suggests that either the diagnosis is incorrect or the patient has relatively severe disease. Endoscopic examination at this stage of the patient's evaluation provides the opportunity for assessing the severity of mucosal damage and the presence of Barrett esophagus. Both of these findings on initial endoscopy predict a high risk for medical failure. A measurement of the degree and pattern of esophageal exposure to gastric juice, with 24-hour pH monitoring, should be obtained at this point. The status of the LES and the function of the esophageal body should also be assessed. These studies identify features that predict a poor response to medical therapy, frequent relapses, and the development of complications and include supine reflux, poor esophageal contractility, erosive esophagitis, a CLE, and a structurally defective sphincter. Patients who have these risk factors should be given the option of surgery as a primary therapy with the expectation of long-term control of symptoms and complications.

Antireflux Surgery

Indications. Antireflux surgery is indicated for the treatment of objectively documented, relatively severe GERD. Candidates for surgery include not only patients with erosive esophagitis, stricture, and Barrett esophagus but also those without severe mucosal injury who are dependent on PPIs for symptom relief. Patients with atypical or RSs who have a good response to intensive medical treatment are also candidates. The option of antireflux surgery should be given to all patients who have demonstrated the need for long-term

medical therapy, particularly if escalating doses of PPIs are needed to control symptoms. Antireflux surgery may be the preferred option in patients younger than 50 years, those who are noncompliant with their drug regimen, those for whom medications are a financial burden, and those who favor a single intervention over long-term drug treatment. It may be the treatment of choice in patients who are at high risk of progression despite medical therapy. Although this population is not well defined, risk factors that predict progressive disease and a poor response to medical therapy include (a) nocturnal reflux on 24-hour esophageal pH study, (b) a structurally deficient LES, (c) mixed reflux of gastric and duodenal juice, and (d) mucosal injury at presentation.[161]

Preoperative Evaluation. Successful antireflux surgery is largely defined by two objectives: the achievement of long-term relief of reflux symptoms and the absence of complications or complaints after the operation. In practice, achieving these two deceptively simple goals is difficult. Both are critically dependent on establishing that the symptoms for which the operation is performed are the result of excess esophageal exposure to gastric juice, as well as the proper performance of the appropriate antireflux procedure. Success can be expected in the vast majority of patients if these two criteria are met. The status of the LES is not as important a factor as in the days of open surgery. Patients with normal resting sphincters are often selected for antireflux surgery in the era of laparoscopic fundoplication. The outcome is not dependent on sphincter function. There are four important goals of the diagnostic approach to patients suspected of having GERD and being considered for antireflux surgery (Table 42-3).

DIAGNOSIS

Table 42-3 Goals of the Diagnostic Approach to Patients Suspected of Having GERD and Being Considered for Antireflux Surgery

Establish that GERD is the underlying cause of the patient's symptoms.
Estimate the risk of progressive disease.
Determine the presence or absence of esophageal shortening.
Evaluate esophageal body function and, occasionally, gastric emptying function.

GERD, gastroesophageal reflux disease.

The introduction of laparoscopic access, coupled with the growing recognition that surgery is a safe and durable treatment for GERD, has dramatically increased the number of patients being referred for laparoscopic fundoplication compared to the prelaparoscopic era. Recent data suggest that the peak use of antireflux surgery in the United States occurred in 1999, with an estimated 15.7 cases per 100,000 adults at that time.[162] Since then, the frequency of antireflux surgery has declined, such that an estimated 11 antireflux procedures were performed per 100,000 adults in 2003. This recent decline may reflect the availability of generic and over-the-counter PPIs, a constantly evolving menu of endoscopic antireflux therapies, increased utilization of

Roux-en-Y gastric bypass for control of GERD in morbidly obese individuals, and the long-term efficacy of fundoplication being called into question. Given the various therapies for GERD, each with its potential advantages and shortcomings, accurate and contemporary data regarding outcomes after antireflux surgery are necessary as a basis against which other established and novel therapies must be judged.

Given the large number of surgical referrals, the importance of selecting patients for surgery who are likely to have a successful outcome cannot be overemphasized. Although a Nissen fundoplication will reliably and reproducibly halt the return of gastroduodenal juice into the esophagus, little benefit is likely if the patient's symptoms are not caused by this specific pathophysiologic derangement. Thus, in large part, the anticipated success rate of laparoscopic fundoplication is directly proportional to the degree of certainty that GERD is the underlying cause of the patient's complaints.

Table 42-4 Predictors of Outcome after Laparoscopic Fundoplication: Stepwise Logistic Regression Results of 199 Patients

Predictor	Status	Adjusted Odds Ratio (95% Confidence Intervals)	Wald's *p* Value
Composite acid score	Increased	5.4 (1.9–15.3)	<0.001
	Normal	—	—
Symptom	Typical	5.1 (1.9–13.7)	<0.001
	Atypical	—	—
Response to medical therapy	Complete/partial	3.3 (1.3–8.7)	0.02
	Minor/none	—	—

Odds ratios and corresponding *p* values are adjusted for age and for all other factors in the model.
From Campos GMR, Peters JH, DeMeester TR, et al. Multivariate analysis of the factors predicting outcome after laparoscopic Nissen fundoplication. *J Gastrointest Surg* 1999;3:292–300.

Three factors predictive of a successful outcome following antireflux surgery have emerged (Table 42-4).[163] These are (a) an abnormal score on 24-hour esophageal pH monitoring; (b) the presence of typical symptoms of GERD, namely, heartburn or regurgitation; and (c) symptomatic improvement in response to acid suppression therapy prior to surgery. It is immediately evident that each of these factors helps to establish that GERD is indeed the cause of the patient's symptoms and that they have little to do with the severity of the disease.

Endoscopic Assessment. Endoscopic visualization of the esophagus equates to the physical examination of the foregut and is a critical part of the preoperative evaluation of patients with GERD. Its main aim is to detect complications of GE reflux, the presence of which may influence therapeutic decisions.

In every patient, the locations of the diaphragmatic crura, the GE junction, and the squamocolumnar junction are determined. These anatomic landmarks are commonly at three different sites in patients with GERD. The crura are usually evident and can be confirmed by having the patient sniff during the examination. The anatomic GE junction is identified as the point where the gastric rugal folds meet the tubular esophagus and is

often below the squamocolumnar junction, even in patients without otherwise obvious Barrett esophagus.

Endoscopic esophagitis is defined by the presence of mucosal erosions (Table 42-5). When present, the grade and length of esophageal mucosal injury are recorded. The presence and length of columnar epithelium extending above the anatomic GE junction is also noted. CLE is suspected at endoscopy when there is difficulty in visualizing the squamocolumnar junction at its normal location and by the appearance of a velvety red luxuriant mucosa. The presence of Barrett esophagus is confirmed by biopsy evidence of specialized intestinal metaplasia involving the tubular esophagus and is considered histologic evidence of GERD. Endoscopic visualization of columnar lining without histologic confirmation of specialized intestinal metaplasia is not considered Barrett esophagus and likely has no premalignant potential. Multiple biopsies should be taken in a cephalad direction to determine the level at which the junction of Barrett epithelium and normal squamous mucosa occurs. Barrett esophagus is susceptible to ulceration, bleeding, stricture formation, and malignant degeneration. Dysplasia is the earliest sign of malignant change. Because dysplastic changes typically occur in a random distribution within the distal esophagus, a minimum of four biopsies (each quadrant) every 2 cm should be obtained from the metaplastic epithelium. Particular attention must be paid to the squamocolumnar junction in these patients, where a mass, ulcer, nodularity, or inflammatory tissue is always considered suspicious for malignancy and requires thorough biopsy or ER. The GE junction is defined endoscopically where the tubular esophagus meets gastric rugal folds, and the squamocolumnar junction is where there is an obvious change from the velvety and darker columnar epithelium to the lighter squamous epithelium.

CLASSIFICATION

Table 42-5 Modified Los Angeles Classification of Esophagitis

Grade	Lesion
A	One (or more) mucosal break of longer than 5 mm that does not extend between the tops of two mucosal folds
B	One (or more) mucosal break more than 5 mm long that does not extend between the tops of two mucosal folds
C	One (or more) mucosal break that is continuous between the tops of two or more mucosal folds but that involves <75% of the circumference
D	One (or more) mucosal break that involves at least 75% of the esophageal circumference

After completion of the esophageal examination, the first and second portions of the duodenum and the stomach are systematically inspected. This is commonly done on withdrawal of the endoscope. When the antrum is visualized, the incisura angularis appears as a constant ridge on the lesser curve. Turning the lens of the scope 180 degrees allows inspection of the fundus and cardia. Attention is paid to the frenulum (angle of

His) of the esophagogastric junction and to the closeness with which the cardia grips the scope. Hill et al.[87] have graded the appearance of this valve on a scale from I to IV according to the degree of unfolding or deterioration of the normal valve architecture. This grading system has been correlated with the presence of increased esophageal acid exposure, occurring predominantly in patients with a grade III or IV valve.

A hiatal hernia is endoscopically confirmed by finding a pouch lined with gastric rugal folds lying 2 cm or more above the margins of the diaphragmatic crura. A prominent sliding hernia is frequently associated with increased esophageal exposure to gastric juice. When a PEH exists, particular attention is given to exclude a gastric ulcer or gastritis within the pouch. The term *Cameron erosions* refers to such mucosal erosions occurring in large sliding or PEHs, typically at the level of the diaphragmatic hiatus. The intragastric retroflex or "J" maneuver is important in evaluating the full circumference of the mucosal lining of the herniated stomach. As the endoscope is removed, the esophagus is again examined and biopsies taken. The location of the cricopharyngeus is identified and the larynx and vocal cords are visualized. Acid reflux may result in inflammation of the larynx. Vocal cord movement is recorded both as a reference for subsequent surgery and an assessment of the patient's ability to protect the airway.

Twenty-Four Hour Ambulatory pH Monitoring. The most direct method of assessing the relationship between symptoms and GERD is to measure the esophageal exposure to gastric juice with an indwelling pH electrode. Miller[164] first reported prolonged esophageal pH monitoring in 1964, although it was not until 1973 that its clinical applicability and advantages were demonstrated by Johnson and DeMeester.[165] Ambulatory pH testing is considered by many to be the "gold standard" for the diagnosis of GERD, because it has the highest sensitivity and specificity of all tests currently available. Some experts have suggested that 24-hour pH monitoring be used selectively, limited to patients with atypical symptoms or no endoscopic evidence of GE reflux. Given present-day referral patterns, more than half of the patients referred for antireflux surgery will have no endoscopic evidence of mucosal injury. For these patients, 24-hour pH monitoring provides the only objective measure of the presence of pathologic esophageal acid exposure. Although it is true that most patients with typical symptoms and erosive esophagitis have a positive 24-hour pH result, the pH study provides other useful information. It quantifies the actual time that the esophageal mucosa is exposed to gastric juice, measures the ability of the esophagus to clear refluxed acid, and correlates esophageal acid exposure with the patient's symptoms. It is the only way to quantitatively express the overall degree and pattern of esophageal acid exposure, both of which may impact the decision toward surgery.[166] Patients with nocturnal or bipositional reflux have a higher prevalence of complications and failure of long-term medical control. For these reasons, we continue to advocate the routine use of pH monitoring in clinical practice.

Table 42-6 Normal Values for Esophageal Exposure to pH <4 in 50 Subjects

Component	Mean	Standard Deviation	95th Percentile
Total time pH <4	1.51	1.36	4.45
Upright time pH <4	2.34	2.34	8.42
Supine time pH <4	0.63	1.0	3.45
No. episodes	19.00	12.76	46.9
No. >5 min	0.84	1.18	3.45
Longest episode	6.74	7.85	19.8

From Johnson LF, DeMeester TR. Development of the 24-hour intraesophageal pH monitoring composite scoring system. *J Clin Gastroenterol* 1986;8(suppl 1):52–58.

Present technology includes both transnasal catheter-based pH probes and an implantable capsule (Bravo pH system, Medtronic Corporation, Minneapolis, Minnesota) placed under endoscopic guidance.[166–168] The units used to express esophageal exposure to gastric juice are (a) cumulative time the esophageal pH is below a chosen threshold, expressed as the percent of the total, upright, and supine monitored time; (b) frequency of reflux episodes above a chosen threshold, expressed as number of episodes per 24 hours; and (c) duration of the episodes, expressed as the number of episodes greater than 5 minutes per 24 hours and the time in minutes of the longest episode recorded. Table 42-6 shows the normal values for these components of the 24-hour record at the whole number pH threshold derived from 50 normal, asymptomatic subjects. The upper limits of normal were established at the 95th percentile. Most centers use pH 4 as the threshold. Combining the result of the six components into one expression that reflects the overall esophageal acid exposure below a pH threshold, a pH score was calculated by using the standard deviation of the mean of each of the six components measured.

Several limitations exist, however, to standard pH monitoring: nonacid reflux events are not detected, the height and quantity of refluxate above the gastroesophageal junction are not defined, and the physical nature of the refluxed material (i.e., liquid, gas, or a mixture) cannot be differentiated. As reflux symptoms such as regurgitation and cough may be present in the absence of demonstrable reflux of acid, improved modalities for detection of nonacid refluxate may be clinically important.

Ambulatory Combined Impedance–pH Monitoring. New technology has been introduced into clinical practice that allows for detection of both acid and nonacid refluxate. The Sleuth system (Sandhill Scientific, Denver, Colorado) combines pH monitoring and intraluminal impedance measurements using a single catheter (Fig. 42-34). The technology identifies refluxate via changes in impedance caused by the presence of a bolus in the esophagus, and the reflux event can be categorized as acid or nonacid by the contemporaneous change in intraluminal pH. Multichannel intraluminal impedance (MII) has been validated as an appropriate method for the evaluation of gastrointestinal function and reflux.[169] All episodes of gastroesophageal reflux can be detected using this technology without regard to their chemical composition. Surprisingly, recent studies using this technology have shown that, in normal subjects, PPI therapy does not alter the number of reflux episodes; it simply converts them to neutral pH.[170] This observation

may have important implications in the treatment of GERD.

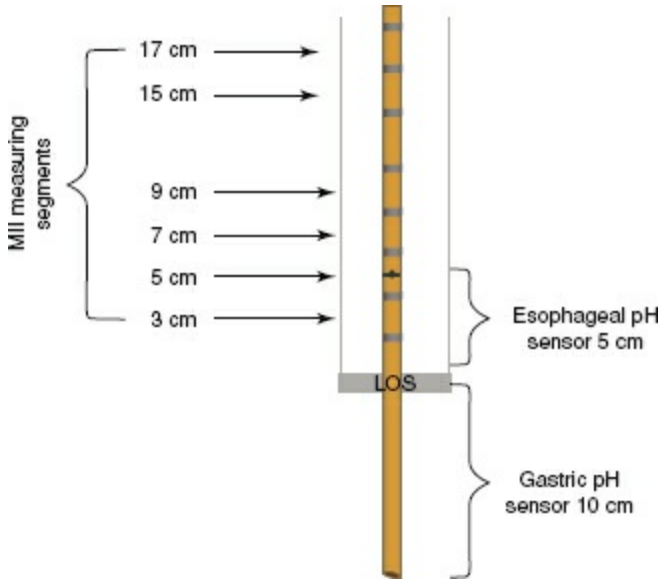

Figure 42-34. Combined multichannel intraluminal impedance–pH catheter. (Reproduced with permission from Mainie I, Tutuian R, Agrawal A, et al. Combined multichannel intraluminal impedance-pH monitoring to select patients with persistent gastro-oesophageal reflux for laparoscopic Nissen fundoplication. *Br J Surg* 2006;93:1483–1487.)

Combined MII-pH monitoring has recently been used to select patients, both with typical and atypical manifestations of GERD and who are resistant to medical treatment, for fundoplication.[171] Patients with a positive symptom index, as assessed by combined MII-pH testing while on PPI therapy, were noted to respond well to surgery. Another recent trial demonstrated that combined MII-pH testing is more accurate for the preoperative assessment of GERD in patients off of PPI therapy compared to pH monitoring alone.[172]

Assessment of Esophageal Length. Esophageal shortening is a consequence of scarring and fibrosis associated with repetitive esophageal injury. Anatomic shortening of the esophagus can compromise the ability to perform an adequate tension-free fundoplication and may result in an increased incidence of breakdown or thoracic displacement of the repair. Esophageal length is best assessed preoperatively using video roentgenographic contrast studies and endoscopic findings. Endoscopically, hernia size is measured as the difference between the diaphragmatic crura, identified by having the patient sniff, and the GE junction, identified as the loss of gastric rugal folds. We consider the possibility of a short esophagus in patients with strictures or those with large hiatal hernias (>5 cm), particularly when the latter fail to reduce in the upright position on a video barium esophagram.[173]

The definitive determination of esophageal shortening is made intraoperatively when, after thorough mobilization of the esophagus, the GE junction cannot be reduced below the diaphragmatic hiatus without undue tension on the esophageal body. Surgeons performing fundoplication have reported varying incidences of esophageal shortening, attesting to the judgment inherent in defining and recognizing “undue tension.” An

advantage of transthoracic fundoplication is the ability to mobilize the esophagus extensively from the diaphragmatic hiatus to the aortic arch. With the GE junction marked with a suture, esophageal shortening is defined by an inability to position the repair beneath the diaphragm without tension. In this situation, a Collis gastroplasty coupled with either a partial or complete fundoplication may be performed.[174]

Potential pitfalls of laparoscopic fundoplication include the elevation of the diaphragm due to pneumoperitoneum, potentially contributing to a false impression that esophageal length is adequate, and the limited ability to mobilize the esophagus relative to the transthoracic approach.[175] In our experience, the failure to appreciate esophageal shortening is a major cause of fundoplication failure and is often the explanation for the "slipped" Nissen fundoplication. In many such instances, the initial repair is incorrectly constructed around the proximal tubularized stomach rather than the terminal esophagus. Surgeons opting to perform fundoplication laparoscopically in the setting of potential esophageal shortening must be vigilant of esophageal tension, technically facile at extensive mediastinal mobilization of the esophagus while preserving vagal integrity, and able to perform a laparoscopic or open transabdominal Collis gastroplasty should esophageal lengthening be necessary.

Radiographic Evaluation. Radiographic assessment of the anatomy and function of the esophagus and stomach is one of the most important parts of the preoperative evaluation. Critical issues are assessed, including the presence of esophageal shortening (Fig. 42-35), the size and reducibility of a hiatal hernia, and the propulsive function of the esophagus for both liquids and solids.

The definition of radiographic GE reflux varies depending on whether reflux is spontaneous or induced by various maneuvers. In only about 40% of patients with classic symptoms of GERD is spontaneous reflux observed by the radiologist (i.e., reflux of barium from the stomach into the esophagus with the patient in the upright position). In most patients who show spontaneous reflux on radiography, the diagnosis of increased esophageal acid exposure is confirmed by 24-hour esophageal pH monitoring. Therefore, the radiographic demonstration of spontaneous regurgitation of barium into the esophagus in the upright position is a reliable indicator that reflux is present. On the contrary, failure to see radiographic reflux does not prove the absence of reflux disease.



Figure 42-35. Barium-filled esophagogastric segment in a patient with a short esophagus. Note that the gastroesophageal junction is well above the hiatus.

Table 42-7 University of Southern California Protocol for Video Esophagram Studies

Patient Position	Purpose	Technique
Prone RAO	Esophageal body function	Five separate 10-mL swallows, 15 s between each, follow bolus on videotape
		Video swallow over thoracic inlet and another over distal third of esophagus without panning
	Esophageal diameter	Rapid swallow of several gulps to distend esophagus maximally
	Gastric function	Video-record activity of stomach and duodenum for 30 s in prone position
Supine	Relationship of GE junction to hiatus	Two or three individual swallows focused on distal esophagus and GE junction
Erect	Cricopharyngeal function	Lateral and anteroposterior views of oropharynx and upper esophagus
	Mucosal injury	Spot of collapsed esophagus for mucosal detail
	Reducibility of hernia	Video images of one or two swallows focused on distal esophagus and GE junction
	Gas distention of distal esophagus	
Erect	Solid bolus transport	Record video images of passage of two contrast-coated hamburger boluses from oropharynx to stomach

GE, gastroesophageal; RAO, right anterior oblique.

A carefully performed video esophagram can provide an enormous amount of

information on the structure and function of the esophagus and stomach. The modern barium swallow emphasizes motion recording (video), utilizes a tightly controlled examination protocol (Table 42-7), and requires an understanding of esophageal physiology.

Videotaping the study greatly aids the evaluation, providing the surgeon with a real-time assessment of swallowing function, bolus transport, and the size and reducibility of an associated hiatal hernia. Given routine review before antireflux surgery, the value of the study becomes increasingly clear. The examination provides structural information including the presence of obstructing lesions and anatomic abnormalities of the foregut. A hiatal hernia is present in more than 80% of patients with GE reflux and is best demonstrated with the patient in the prone position, which causes increased abdominal pressure and promotes distention of the hernia above the diaphragm. The presence of a hiatal hernia is an important component of the underlying pathophysiology of GE reflux. Other relevant findings include a large (>5 cm) or irreducible hernia, suggesting the presence of a shortened esophagus; a tight crural "collar" that inhibits barium transit into the stomach, suggesting a possible cause of dysphagia; and the presence of a PEH.

Lower esophageal narrowing resulting from a ring, stricture, or obstructing lesion is optimally viewed with full distention of the esophagogastric region. A full-column technique with distention of the esophageal wall can be used to discern extrinsic compression of the esophagus. Mucosal relief or double-contrast films should be obtained to enhance the detection of small esophageal neoplasms, mild esophagitis, and esophageal varices. The pharynx and UES are evaluated in the upright position, and an assessment of the relative timing and coordination of pharyngeal transit is possible.

The assessment of peristalsis on video esophagram often adds to, or complements, the information obtained by esophageal motility studies. This is in part because the video barium study can be done both upright and supine and with liquid and solid bolus material, which is not true of a stationary motility examination. This is particularly true with subtle motility abnormalities. During normal swallowing, a stripping wave (primary peristalsis) is generated that completely clears the bolus. Residual material can stimulate a secondary peristaltic wave, but usually a second pharyngeal swallow is required. Motility disorders with disorganized or simultaneous esophageal contractions have "tertiary waves" and provide a segmented appearance to the barium column, often referred to as beading or corkscrewing. In dysphagic patients, a barium-impregnated marshmallow, bread, or hamburger is a useful adjunct, which can discern a functional esophageal transport disturbance not evident on the liquid barium study. Reflux is not easily seen on video esophagram, and motility disorders that cause retrograde barium transport may be mistaken for reflux.

Assessment of the stomach and duodenum during the barium study is a necessity for proper preoperative evaluation of the patient with GERD. Evidence of gastric or duodenal ulcer, neoplasm, or poor gastroduodenal transit has obvious importance in the proper preoperative evaluation.

Assessment of Esophageal Function. The presence of poor esophageal body function

can impact the likelihood of relief of regurgitation, dysphagia, and RSs following surgery and may influence the decision to undertake a partial rather than a complete fundoplication. When peristalsis is absent or severely disordered, many surgeons would opt for a partial fundoplication, although recent studies would suggest a complete fundoplication may be appropriate even in this setting. The less favorable response of atypical, compared with typical, reflux symptoms after fundoplication may be related to persistent poor esophageal propulsive function and the continued regurgitation of esophageal contents.[176,177]

The function of the esophageal body is assessed with esophageal manometry. Conventional water-perfused or solid-state manometry is performed with five pressure transducers located in the esophagus (Fig. 42-36). To standardize the procedure, the most proximal pressure transducer is located 1 cm below the well-defined cricopharyngeal sphincter. With this method, a pressure response along the entire esophagus can be obtained during one swallow. The study consists of recording 10 wet swallows with 5 mL of water. Amplitude, duration, and morphology of contractions following each swallow are all calculated at the five discrete levels within the esophageal body (Fig. 42-37). The delay between onset or peak of esophageal contractions at the various levels of the esophagus is used to calculate the speed of wave propagation and represents the degree of peristaltic activity.

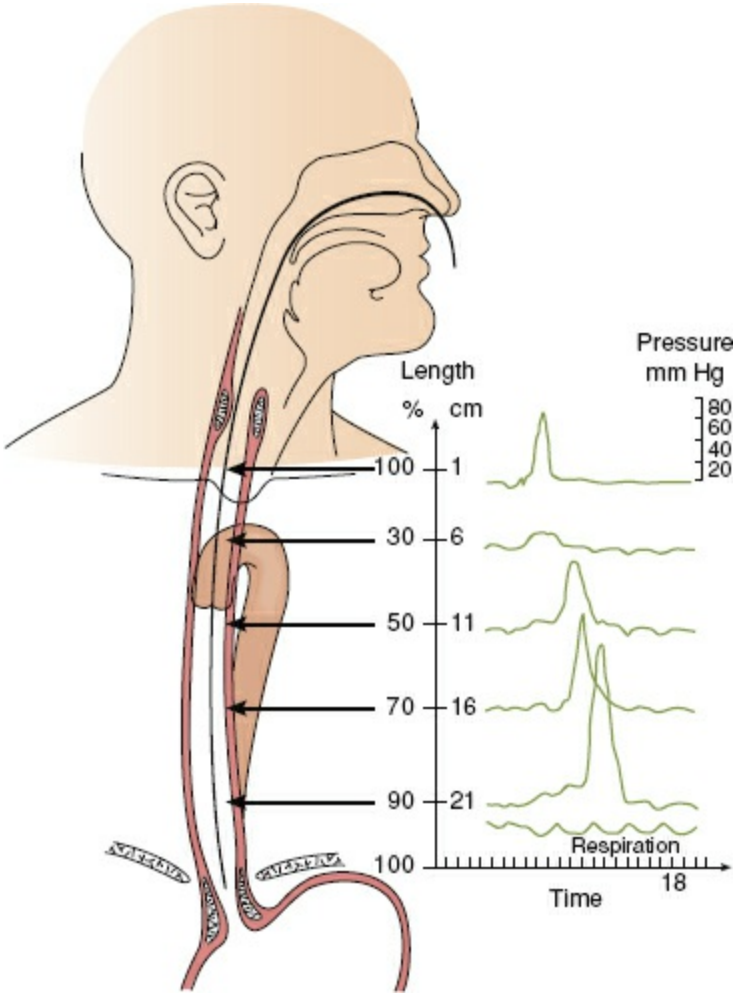

Figure 42-36. Illustration of the position of a five-channel esophageal motility catheter during the esophageal body portion of the study.

Recently, HRM (ManoScan360, Sierra Scientific Instruments, Los Angeles, CA) has been introduced into clinical practice and may possess several advantages over the other manometric systems currently available.[178] The high-resolution catheter is 4.2 mm in diameter and has 36 solid-state transducers spaced at 1-cm intervals, compared to the standard 3- to 5-cm spacing of traditional water-perfused or solid-state catheters. Pressure transduction technology allows each of the sensors to detect pressure over a length of 2.5 mm in 12 radially dispersed sectors. The pressure of each sector is averaged, making each of the 36 sensors a circumferential pressure detector. This construct allows a more thorough and precise evaluation of esophageal function than standard manometry. In addition, given the number and span of transducers across the length of the catheter, the UES, esophageal body, and lower esophageal sphincter can be assessed simultaneously without moving the catheter. Thus, the study can be performed more quickly and with improved patient comfort compared to conventional manometry in that multiple repositionings of the catheter are not required to complete the evaluation. The experience in our laboratory has been that HRM takes, on average, only 8.1 minutes to complete, whereas standard manometry with a solid-state catheter takes 24.4 minutes ($p < 0.0001$).[141] Finally, the color-coded readouts allow for a better, more intuitive, graphic description of the motor activity of the esophagus, the characteristics of the lower esophageal sphincter, and the presence of a hiatal hernia compared to the other technologies (Fig. 42-38). The catheter, however, is expensive with a high replacement cost should it break. With increasing experience and further study, the pros and cons of this new technology will continue to be elucidated.

Assessment of Gastric Function. Esophageal disorders are frequently associated with abnormalities of duodenogastric function. Symptoms suggestive of gastroduodenal pathology include nausea, epigastric pain, anorexia, and early satiety. Abnormalities of gastric motility or increased gastric acid secretion can be responsible for increased esophageal exposure to gastric juice. If not identified before surgery, unrecognized gastric motility abnormalities are occasionally “unmasked” by an antireflux procedure, resulting in disabling postoperative symptoms.[43] Considerable experience and judgment are necessary to identify the patient with occult gastroduodenal dysfunction. The surgeon should maintain a keen awareness of this possibility and investigate the stomach given any suggestion of problems. Tests of duodenogastric function that are helpful when investigating the patient with GE reflux include gastric emptying studies, gastric acid analysis, 24-hour gastric pH monitoring, and ambulatory bilirubin monitoring of the esophagus and stomach.

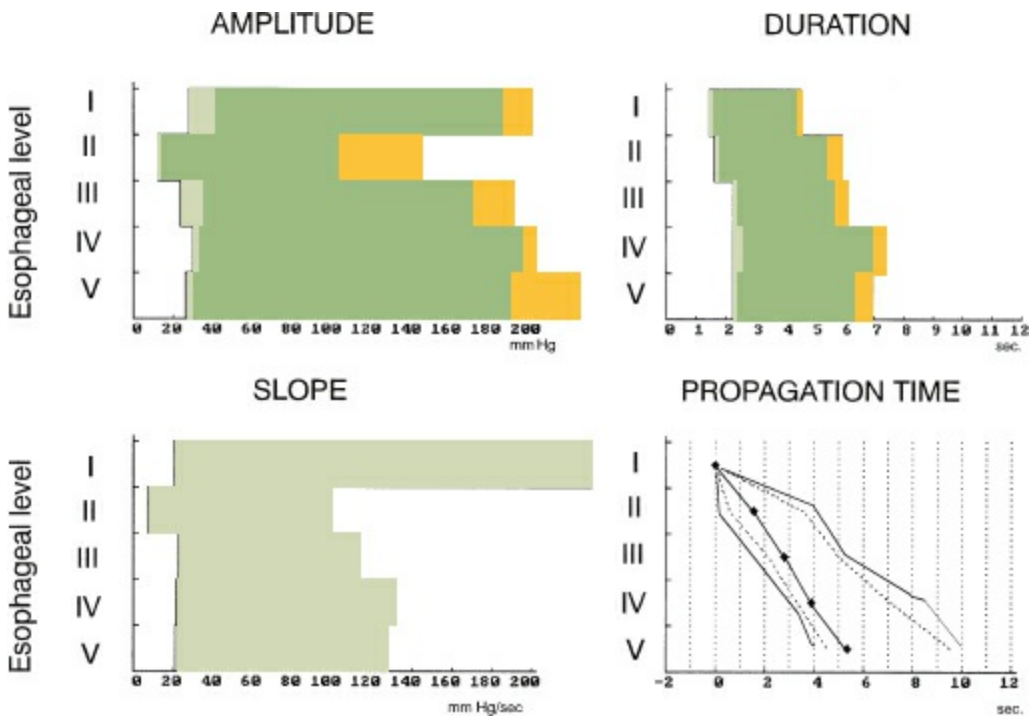

Figure 42-37. Computer-generated graphic representation of esophageal body contraction amplitudes, duration of contraction, and wave progression.

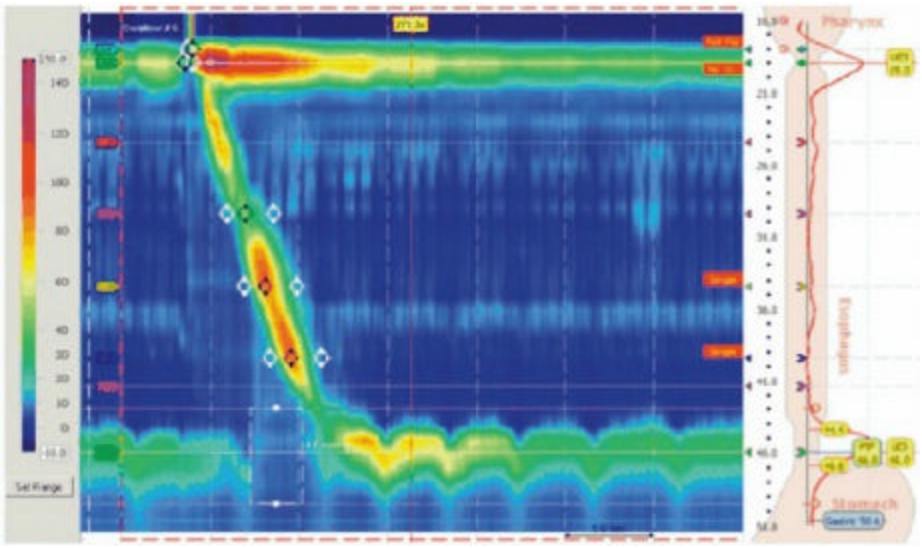

Figure 42-38. High-resolution manometry (HRM) display. Note the color-coded graphic description of esophageal body wave amplitudes and lower esophageal sphincter function.

Poor gastric emptying or transit can provide for reflux of gastric contents into the distal esophagus. Standard gastric emptying studies are performed with radionuclide-labeled meals. They are often poorly standardized and difficult to interpret. Emptying of solids and liquids can be assessed simultaneously when both phases are marked with different tracers. After ingestion of a labeled standard meal, gamma camera images of the stomach are obtained at 5- to 15-minute intervals for 1.5 to 2 hours. After correction for decay, the counts in the gastric area are plotted as percentage of total counts at the start of the imaging. The resulting emptying curve can be compared with data obtained in normal volunteers. In general, normal subjects will empty 59% of a meal within 90 minutes.

Evolving Technologies for Assessment of Extraesophageal Manifestations of GERD. Given the difficulty inherent in proving that GERD is etiologic to extraesophageal symptoms, such as cough, sore throat, or hoarseness, or to more chronic and insidious conditions, such as repetitive aspiration or pulmonary fibrosis, a great interest exists to develop testing modalities that are both more sensitive and more specific than the technologies widely utilized at present. Several recent testing paradigms have emerged that appear promising, despite lacking extensive data.

Simultaneous 24-hour MII-pH and continuous pulse oximetry recently was evaluated in 20 subjects with primary RSs and 10 with primary ESs.[179] Oxygen saturation monitoring was performed using a finger clip probe (Pulsox-300i, Konica Minolta Sensing, Inc., Ramsey, NJ) that measures the arterial oxygen saturation (SpO_2) and pulse rate every second via standard photometrics (Fig. 42-39). An oxygen desaturation event was defined by either (a) SpO_2 less than 90% or (b) SpO_2 drop of 6% or greater (Fig. 42-40). Reflux events, both acid and nonacid, were temporally correlated to desaturation events. Markedly more reflux events were associated with desaturation in patients with RSs (74.5%, 832/1,117 reflux events) than in patients with ESs (30.4%, 223/734 reflux events, $p < 0.0001$) (Fig. 42-41). In addition, the difference in reflux desaturation association was more pronounced with proximal reflux (80.3% with RSs vs. 20.4% with ESs, $p < 0.0001$). While a number of issues still need to be resolved with this technique for it to be considered reliable and useful, the observation of oxygen desaturations in temporal proximity to reflux events, particularly in patients with RSs, is intriguing and may prove meaningful.

A pharyngeal pH catheter (Restech, San Diego, CA) also was recently developed and consists of a thin (1.5-mm diameter) nasally passed catheter that can be positioned in the pharynx with the assistance of a light-emitting diode (LED) mounted on the tip. The catheter, being small, is well tolerated and measures both liquid and aerosolized reflux events. Optimal pH thresholds are currently being evaluated to predict the responsiveness of extraesophageal symptoms to antireflux therapy, either medical or surgical.

Finally, several centers have investigated the utility of salivary/sputum or laryngoscopic biopsy specimen assays for pepsin as a marker for underlying GERD.[180–182] As pepsin is produced only in the gastric mucosa, its presence in the sputum or larynx reflects gastric reflux. Pepsin assays, when compared to ambulatory pH monitoring, showed a high correlation to proximal reflux events. Positive assays were also highly correlated with the presence of LPR symptoms. Still lacking are data showing that a positive sputum or laryngeal pepsin assay predicts a successful symptomatic response to antireflux therapy. With additional study, the utility and reliability of each of these modalities will be determined in the clinical marketplace.

Partial Versus Complete Fundoplication. The decision between partial and complete fundoplication and an open or laparoscopic approach requires considerable judgment. Two randomized studies of unselected patients undergoing laparoscopic fundoplication have shown equivalence of complete and partial fundoplications, anterior in one study[183] and posterior in the other,[83] in terms of operative time, perioperative morbidity, and

hospital stay. Watson et al.[183] noted that resting and residual LES pressures were greater after complete fundoplication and that esophageal clearance of liquid radioisotope was prolonged in these patients compared with after partial fundoplication. Six months after operation, partial fundoplication was linked to a greater overall level of patient satisfaction manifested by a lower incidence of the symptoms of dysphagia, inability to belch, and excessive flatus. Laws et al.[184] did not identify any difference in symptomatic outcome between patients treated by complete and those treated by posterior partial fundoplication at a mean follow-up time of 27 months.



Figure 42-39. Pulsox-300i with finger probe used to assess ambulatory oxygen saturation (Konica Minolta Sensing, Inc.).

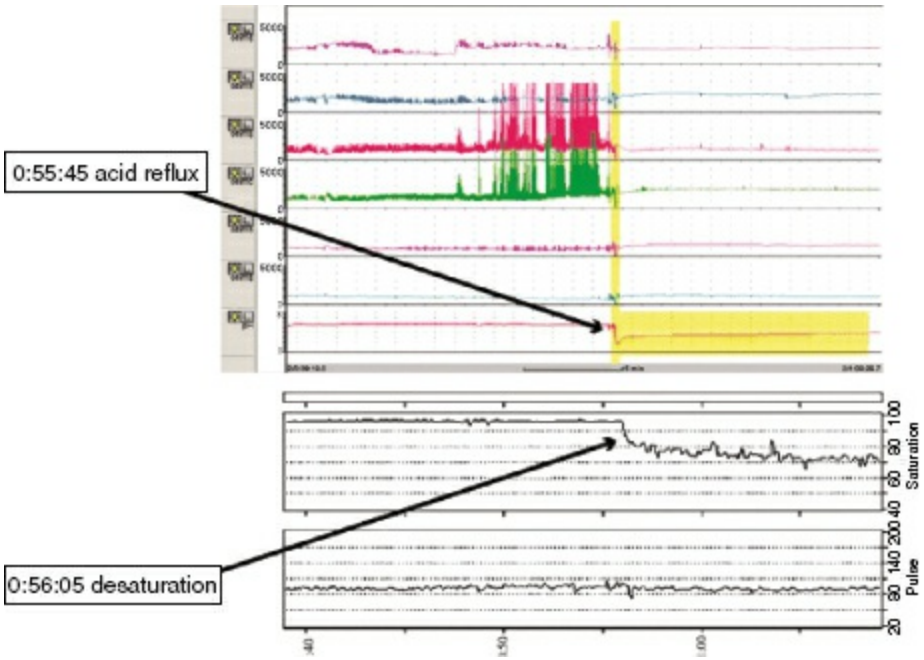

Figure 42-40. Example of the association between a reflux episode detected by multichannel intraluminal impedance–pH study and oxygen desaturation detected by pulse oximetry. (Reproduced with permission from Salvador R, Watson TJ, Herbella F, et al. Association of gastroesophageal reflux and O2 desaturation: a novel study of simultaneous 24-h MII-pH and continuous pulse oximetry. *J Gastrointest Surg* 2009;13:854–861.)

Hagedorn et al.[185] reported on the results of a randomized, controlled trial comparing

total (Nissen-Rossetti) and posterior partial (Toupet) fundoplication in which long-term efficacy was assessed. A total of 110 patients (54 undergoing a total wrap, 56 a partial wrap) completed a median follow-up of 11.5 years. No significant differences were observed between the groups in terms of heartburn, regurgitation, or dysphagia scores. A significant difference, however, was noted in the prevalence of rectal flatus and postprandial fullness, which were reported more often by those having undergone a total fundoplication.

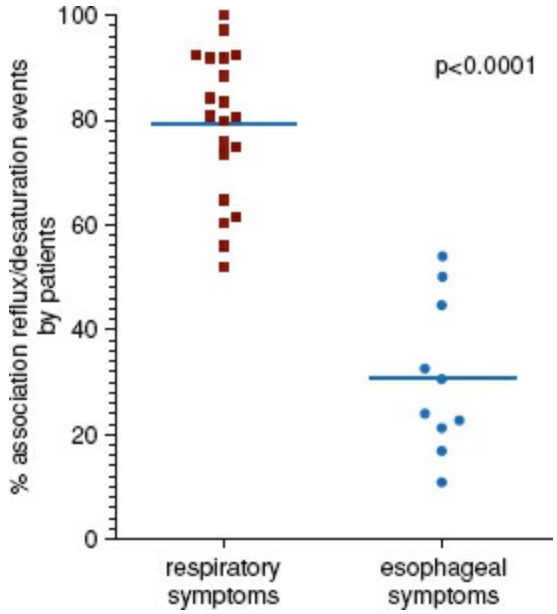

Figure 42-41. Scatterplot of association between reflux episodes and desaturation events by patient group. The prevalence of reflux-associated desaturations was remarkably different between the two groups ($p < 0.0001$). (Reproduced with permission from Salvador R, Watson TJ, Herbella F, et al. Association of gastroesophageal reflux and O2 desaturation: a novel study of simultaneous 24-h MII-pH and continuous pulse oximetry. *J Gastrointest Surg* 2009;13:854–861.)

A recent prospective, randomized trial from Australia comparing laparoscopic Nissen fundoplication to an anterior 180-degree partial fundoplication similarly revealed no significant differences between the two groups with regard to reflux symptoms, dysphagia, abdominal bloating, ability to belch, and overall satisfaction at 10 years' follow-up.[186]

These observations, however, must be tempered by reports questioning the durability of partial fundoplications. Jobe et al.[187] found that 51% of patients studied by 24-hour esophageal pH monitoring after Toupet fundoplication still had pathologic acid exposure. Disturbingly, only 40% of the refluxers were symptomatic. Two studies have identified the presence of a defective LES function, an aperistaltic distal esophagus, and higher grades of esophagitis (Savary-Miller grades 2 to 4) as risk factors for partial fundoplication failure.[185,187] Bell et al.[188] reported recurrent reflux in 14% after Toupet fundoplication. The presence of mild esophagitis and a normal LES were associated with a 3-year success rate of 96%, whereas the presence of complicated esophagitis or a defective LES lowered this value to 50% (Fig. 42-35).

These findings highlight an apparent paradox, in that partial fundoplications afford

suboptimal reflux protection in those most at risk from the effects of unabated GERD. The question arises, therefore, whether total fundoplication should be applied more liberally to patients with severe reflux disease and associated esophageal dysmotility. Patti et al. recently reported on 357 patients undergoing antireflux surgery, 235 undergoing a "tailored approach" with either a partial or total fundoplication depending on the results of preoperative manometry, and 122 more recent patients undergoing a total fundoplication regardless of the quality of esophageal peristalsis.[189] In the first group, heartburn from pathologic reflux, confirmed by postoperative ambulatory esophageal pH monitoring, recurred in 19% after partial fundoplication and in 4% after total fundoplication. In the latter group, heartburn recurred in 4% after total fundoplication. Importantly, the incidence of postoperative dysphagia was similar in the two groups. This recent evidence, as well as our own experience, has led us to utilize the complete fundoplication more readily, particularly in patients with Barrett esophagus. Currently, partial fundoplication is best reserved for patients with severe esophageal dysmotility approaching aperistalsis, such as occurs in scleroderma, or in combination with a distal esophageal myotomy for achalasia.[190]

Laparoscopic Nissen Fundoplication. The performance of laparoscopic fundoplication should include the steps identified in Table 42-8.

Table 42-8 Elements of Laparoscopic Fundoplication

1. Crural dissection, identification and preservation of both vagi including the hepatic branch of the anterior vagus
2. Circumferential dissection of the esophagus
3. Crural closure
4. Fundic mobilization by division of short gastric vessels
5. Creation of a short, loose fundoplication by enveloping the anterior and posterior wall of the fundus around the lower esophagus

Port Placement. Five ports are used. The camera is placed above and to the left of the umbilicus, roughly one-third of the distance to the xiphoid process. In most patients, placement of the camera in the umbilicus is too low to allow adequate visualization of the hiatal structures once dissected. A transrectus location is preferable to midline to minimize the prevalence of port site hernia formation. The liver is retracted with a Nathensen retractor placed through a 5-mm incision on the right side of the xiphoid. A retraction port is placed slightly above the level of the umbilicus, in the left anterior axillary line. Placement of these ports too far lateral or too low on the abdomen will compromise the excursion of the instruments and thus the ability to retract. The left-sided operating port (surgeon's right hand) is placed 1 to 2 cm below the costal margin approximately at the lateral rectus border. Such placement allows triangulation between the camera and the two instruments and avoids the difficulty associated with the instruments being in direct line with the camera. The right-sided operating port

(surgeon's left hand) is placed last, after the left lateral segment of the liver has been retracted. This placement prevents "sword fighting" between the liver retractor and the left-handed instrument. The falciform ligament hangs low in many patients and provides a barrier around which the left-handed instrument must be manipulated.

Hiatal Dissection. In patients without a large or PEH dissection begins with division of the gastrohepatic omentum and identification of the right crus of the diaphragm. Alternatively, when a PEH is present sac excision is started at the 2 o'clock position at the hiatus to avoid injuring the left gastric vessels which are routinely up in the chest on the right side of the hiatus.

Crural Dissection. A large left hepatic artery arising from the left gastric artery is present in up to 25% of patients (Fig. 42-42); it should be identified and can typically be divided without consequence but a pulse in the hepatoduodenal ligament should be confirmed. After incising the gastrohepatic omentum, the outside of the right crus will become evident. The peritoneum overlying the anterior aspect of the right crus is incised and the plane between the esophagus and right crus developed.

Following dissection of the right crus, attention is turned toward the phrenoesophageal ligament anteriorly. These tissues are held upward by the left-handed grasper and the esophagus and anterior vagus nerve are swept downward away from the phrenoesophageal ligament. The anterior crural tissues are then divided and the left crus identified. The anterior vagus nerve often "hugs" the left crus and can be injured in this portion of the dissection if not carefully searched for and protected. The left crus is dissected as completely as possible, including taking down the angle of His and the attachments of the fundus to the left diaphragm (Fig. 42-43). The short gastric vessels are divided along with the posterior pancreatic vessels to completely mobilize the gastric fundus. Failure to do so will result in difficulty encircling the esophagus, and increase the risk of a perforation of the posterior esophagus when developing the retroesophageal window. A window behind the GE junction can generally now be easily created and a Penrose drain passed for esophageal retraction.

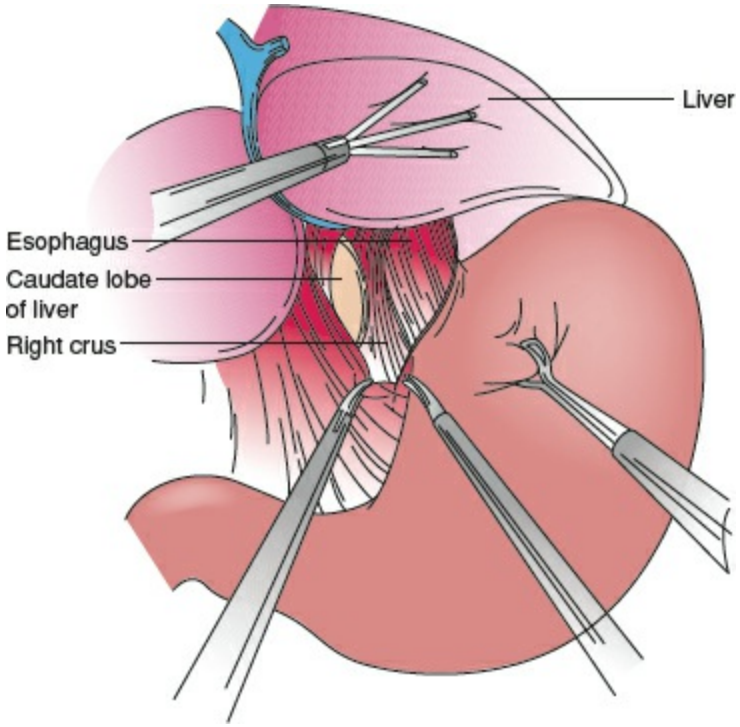

Figure 42-42. Illustration of the initial dissection of the esophageal hiatus. The right crus is identified and dissected toward its posterior confluence with the left crus.

Esophageal Mobilization and Crural Closure. The esophagus is mobilized into the posterior mediastinum for several centimeters to provide maximal intra-abdominal esophageal length. Posterior and right lateral mobilization is readily accomplished. In performing the anterior and left lateral mobilization, the surgeon must take care not to injure the anterior vagus nerve. Gentle traction on the Penrose drain around the GE junction facilitates exposure. The right and left pleural reflection often come into view and should be avoided, although if a pleural opening is created it is well tolerated provided the hole is made large enough to prevent a ball-valve tension pneumothorax from developing. Continue the crural dissection to enlarge the space behind the GE junction as much as possible. Following mobilization and an assessment of intra-abdominal esophageal length, the hiatus is closed in all patients. The esophagus is held anterior and to the left and the crura approximated with two to four interrupted figure-of-eight 0-Ethibond sutures, starting just above the aortic decussation and working anterior. The authors prefer a large needle (CT1) passed down the left upper 10-mm port to facilitate a durable crural closure using absorbable pledgets in a horizontal mattress fashion. The aorta may be punctured while suturing the left crus. Identification of the anterior aortic surface and retracting the left crus via the left-handed grasper will help avoid inadvertent aortic puncture. The authors prefer extracorporeal knot tying using a "tie knot" device (LSI Solutions, Victor, New York). More recently, we have inspected the crural closure at the completion of the procedure following creation of the fundoplication and removal of the bougie. Doing so will often reveal that the bougie has dilated the hiatal opening such that a final stitch should be placed to further approximate it. Although there have been no randomized studies evaluating the role of routine crural closure, there is compelling evidence to indicate that closure should be standard. Watson

et al.[191] identified paraesophageal herniation in 17 of 253 patients (7%), the frequency being 3% in those who had undergone crural repair and 11% in those who had not.

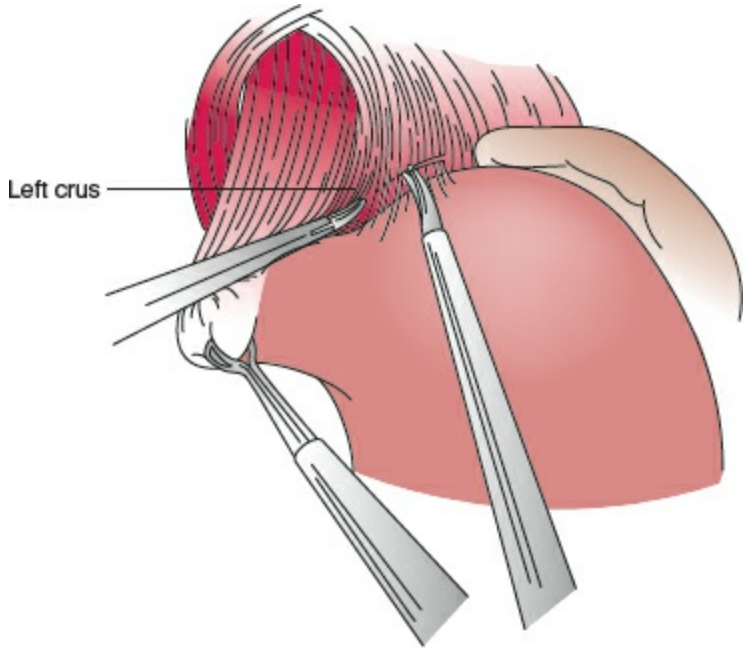

Figure 42-43. Left-sided crural dissection. The left crus is dissected as completely as possible and the attachments of the fundus of the stomach to the diaphragm are taken down.

Creation of the Fundoplication. A short, loose fundoplication is fashioned with particular attention to the geometry of the wrap (Fig. 42-44). The midposterior fundus is grasped and passed left to right behind the esophagus rather than pulling right to left. This ensures that the posterior fundus is used for the posterior aspect of the fundoplication. This is accomplished by placing a Babcock clamp through the left lower port and grasping the midportion of the posterior fundus (Fig. 42-45). One should gently bring the posterior fundus behind the esophagus to the right side with an upward, rightward, and clockwise twisting motion. This maneuver can be difficult, particularly for the novice. If so, placement of a 0-silk suture in the midposterior fundus 6 cm down from the GEJ and grasping it from the right side facilitates bringing the posterior fundus around to create the fundoplication. The anterior wall of the fundus is then folded over the esophagus to meet the posterior at about the 9 o'clock position such that the esophagus is imbricated within the fundus rather than having the fundus twisted or spiraled around the esophagus.

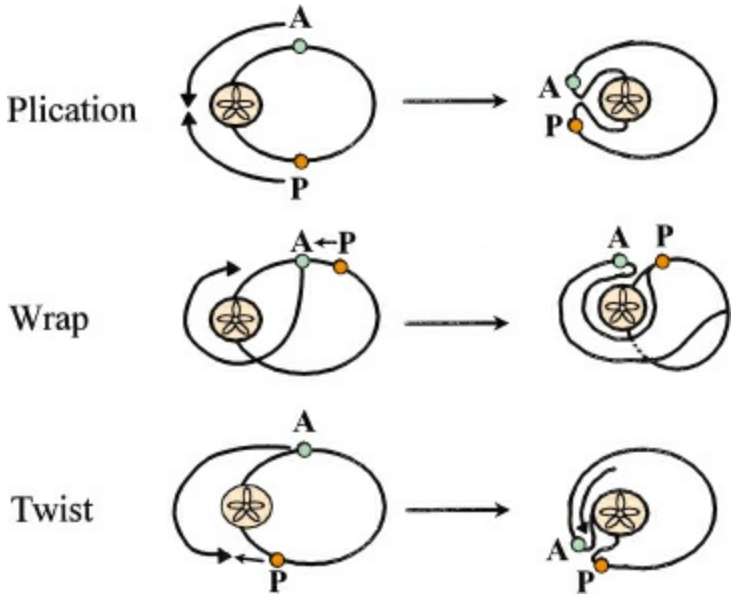

Figure 42-44. Schematic representations of the various possibilities of orientation of a Nissen fundoplication. The top set of figures represents the preferred approach, whereas the bottom two sets can be seen to result in twisting of the fundoplication.

The posterior and anterior fundic lips should be maneuvered (as in a "shoe shine") to allow the fundus to envelope the esophagus without twisting. Laparoscopic visualization has a tendency to exaggerate the size of the posterior opening that has been dissected. Consequently, the space for the passage of the fundus behind the esophagus may be tighter than thought and the fundus relatively ischemic when brought around. If the right lip of the fundoplication has a bluish discoloration, the stomach should be returned to its original position and the posterior dissection enlarged. A 60-French bougie is passed to properly size the fundoplication, and the "lips" of the fundoplication sutured utilizing a single U-stitch of 2-0 Prolene buttressed with absorbable pledgets. The most common error is an attempt to grasp the anterior portion of the stomach to construct the right lip of the fundoplication rather than the posterior fundus. The esophagus should comfortably lie in the untwisted fundus prior to suturing. If the posterior fundus tries to pull away back under the esophagus there is tension likely from inadequate mobilization of the fundus, particularly posteriorly along the pancreas. This should be addressed to release the tension and reduce the risk of disruption of the fundoplication postoperatively. Finally, two anchoring sutures of 2-0 silk or Ethibond are placed above and below the U-stitch to complete the fundoplication. When finished, the suture line of the fundoplication should be facing in a right anterior direction (Fig. 42-46). The abdomen is then irrigated, hemostasis checked, and the Penrose drain and any sponges placed into the abdomen removed.

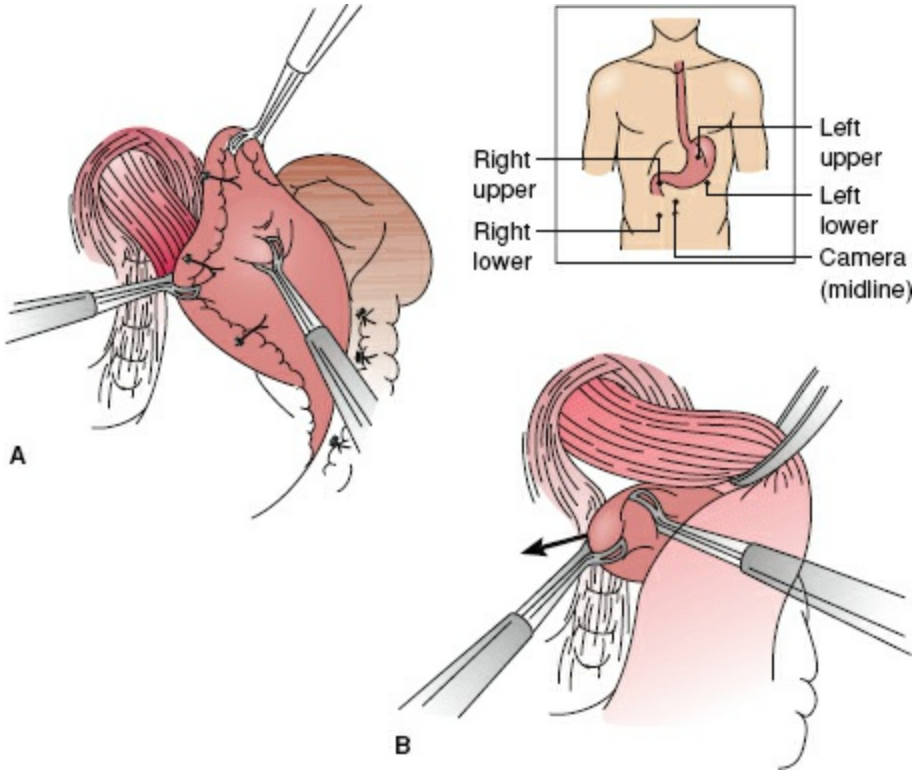

Figure 42-45. Placement of Babcock on the posterior fundus in preparation for passing it behind the esophagus to create the posterior or right lip of the fundoplication. Inset: To achieve the proper angle for passage, the Babcock is placed through the left lower trocar. The posterior fundus is passed left to right and grasped from the right via a Babcock through the right upper trocar. **A:** Location of posterior fundus for passage to the right side. **B:** The posterior fundus passed underneath the esophagus and grasped on the right.

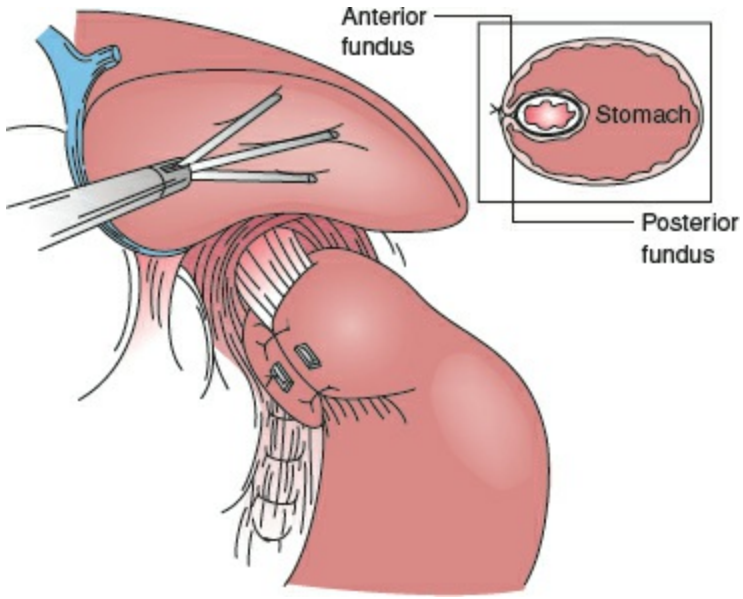

Figure 42-46. Fixation of the fundoplication. The fundoplication is sutured in place with a single U-stitch of 2-0 Prolene pledgeted on the outside. A 60-French mercury-weighted bougie is passed through the gastroesophageal junction prior to fixation of the wrap to ensure a floppy fundoplication. Inset illustrates the proper orientation of the fundic wrap.

Transthoracic Nissen Fundoplication. The indications for performing an antireflux procedure by a transthoracic approach are given in Table 42-9.

In the thoracic approach the hiatus is exposed through a left posterior lateral thoracotomy incision in the sixth intercostal space (i.e., over the upper border of the

seventh rib). When necessary, the diaphragm is incised circumferentially 2 to 3 cm from the lateral chest wall for a distance of approximately 10 to 15 cm. The esophagus is mobilized from the level of the diaphragm to underneath the aortic arch. Mobilization up to the aortic arch is usually necessary to place the repair in a patient with a shortened esophagus into the abdomen without undue tension. Failure to do this is one of the major causes for subsequent breakdown of a repair and return of symptoms. The cardia is then freed from the diaphragm. When all the attachments between the cardia and diaphragmatic hiatus are divided, the fundus and part of the body of the stomach are drawn up through the hiatus into the chest. The vascular fat pad that lies at the GE junction is excised. Crural sutures are then placed to close the hiatus though are not tightened until later. The fundoplication is constructed by enveloping the fundus around the distal esophagus in a manner similar to that described for the abdominal approach. When complete, the fundoplication is placed into the abdomen by compressing the fundic ball with the hand and manually maneuvering it through the hiatus. The previously placed crural stitches are then tightened and knotted.

Collis Gastroplasty. In patients with a short esophagus secondary to a stricture, Barrett esophagus, or a large hiatal hernia, the esophagus is lengthened with a Collis gastroplasty. The gastroplasty lengthens the esophagus by forming a gastric tube or "neoesophagus" along the lesser curvature. The procedure allows a tension-free construction of a total or partial fundoplication around the newly formed gastric tube, with placement of the repair in the abdomen. A gastroplasty can be readily performed via either an abdominal or thoracic approach. A number of techniques have been reported for the laparoscopic performance of Collis gastroplasty, and the surgeon opting to manage the shortened esophagus laparoscopically must be able to perform such a procedure should the need arise.[192] The authors prefer the wedge fundectomy technique initially described by Hunter et al. In a series of 85 patients that had a wedge fundectomy Collis gastroplasty and either a Nissen or Toupet fundoplication there were no staple line leaks or abscesses in the perioperative period, and at a median follow-up of 12 months 93% were free of heartburn. Dysphagia was significantly less common then preoperatively with new-onset dysphagia in only two patients. On upper endoscopy in 54 patients at a median of 6 months postoperatively esophagitis was only present in 11% of patients. These results suggest that a wedge fundectomy can be added safely and with good results in patients where a shortened esophagus is found intraoperatively.

INDICATIONS/CONTRAINDICATIONS

Table 42-9 Indications for Performing an Antireflux Procedure by a Transthoracic Approach

Indication	Explanation
Previous hiatal hernia repair	In this situation, a peripheral circumferential incision in the diaphragm is made to provide simultaneous exposure of the upper abdomen. This allows safe dissection of the previous repair from both the abdominal and thoracic sides of the diaphragm.
Concomitant procedure	Concomitant esophageal myotomy for achalasia or diffuse spasm.
Short esophagus	This is usually associated with a stricture or Barrett esophagus. In this situation, the thoracic approach is preferred to allow maximum mobilization of the esophagus, the performance of a Collis gastroplasty, or, if necessary, placement of the repair without tension below the diaphragm.
Sliding hiatal hernia that does not reduce below the diaphragm during a roentgenographic barium study in the upright position	This can indicate esophageal shortening and, again, a thoracic approach is preferred for maximum mobilization of the esophagus and, if necessary, the performance of a Collis gastroplasty.
Associated pulmonary pathology	The nature of the pulmonary pathology can be evaluated and the proper pulmonary surgery, in addition to the antireflux repair, can be performed.
Obesity	The abdominal repair is difficult because of poor exposure, whereas the thoracic approach gives better exposure and allows a more precise repair.

Outcomes Following Antireflux Surgery. Any discussion regarding results following fundoplication must consider:

1. Perioperative morbidity and mortality
2. Control of typical and atypical symptoms
3. Side effects
4. Objective relief from excessive esophageal acid exposure
5. Anatomic failure rates, such as recurrent hiatal herniation or slippage, and the need for reoperation

Complications of Antireflux Surgery. Carlson and Frantzides[193] reported on complications and results of primary minimally invasive antireflux operations based on a literature review. Included in their analysis were 41 papers comprising 10,489 procedures. Postoperative complications were found to occur in approximately 8% of patients, with the rate of conversion to an open procedure of about 4%. The most common perioperative complication was early wrap herniation (1.3%), defined as occurring within 48 hours of surgery. This is one complication that may be more common with the laparoscopic than open approach. The explanation for this is unclear but may be related to the opening of tissue planes by the pneumoperitoneum, the reduced tendency for adhesion formation after laparoscopic compared to open surgery, and inadequate bites of crural tissue related to the magnified view with the laparoscope. An adequate crural repair is critical in laparoscopic antireflux surgery (LARS).

Both pneumothorax and pneumomediastinum have been reported. The occurrence of pneumothorax is related to breach of either pleural membrane, usually the left, during the hiatal dissection. Chest drain insertion is usually not required because accumulated carbon dioxide rapidly dissipates following release of pneumoperitoneum by a combination of positive pressure ventilation and absorption. Tension pneumothorax intraoperatively is typically related to a ball-valve effect from a small opening in the pleura. In this setting the laparoscopic capnoperitoneum gets into the pleural space with exhalation, but cannot escape rapidly with inhalation. Creating a large pleural defect

solves this issue, and since the anesthesiologist can increase the ventilation pressure above the 15 mm used for laparoscopic pneumoperitoneum there should be no difficulty ventilating the patient adequately.

As with any laparoscopic procedure, instrumental or trocar perforation of a hollow viscera may occur. Esophageal perforation may arise intraoperatively during passage of the bougie, during the retroesophageal dissection, or as a consequence of suture pull-through. Late esophageal perforation is typically related to diathermy or dissection injury at the time of mobilization. Gastric perforations usually result from excessive traction on the fundus particularly when reducing a PEH without first mobilizing the hernia sac. Gastric perforation also occurs during reoperative fundoplication procedures. The key is to recognize the injury and repair it appropriately since generally major complications are a result of unrecognized injuries.

Hemorrhage during the course of laparoscopic fundoplication usually arises from the short gastric vessels or spleen. Rarer causes include retractor trauma to the liver, injury to the left inferior phrenic vein, an aberrant left hepatic vein, or the inferior vena cava. Cardiac tamponade as a result of right ventricular trauma has also been reported. Major vascular injury mandates immediate conversion to an open procedure to achieve hemostasis. One complication that has been virtually eliminated since the advent of laparoscopic fundoplication is incidental splenic injury necessitating splenectomy (0.06%), which occurred with a frequency of around 2% to 5% during the open era. The mortality rate for primary minimally invasive antireflux surgery has fortunately been quite low, reported at 0.08%.

Symptomatic Outcomes Following Antireflux Surgery. Studies of long-term outcome following both open and laparoscopic fundoplication document the ability of laparoscopic fundoplication to relieve typical reflux symptoms (heartburn, regurgitation, and dysphagia) in more than 90% of patients at follow-up intervals averaging 2 to 3 years and 80% to 90% of patients 5 years or more following surgery.[35,194–201] The data include evidence-based reviews of antireflux surgery,[198] prospective randomized trials comparing antireflux surgery to PPI therapy[199] and open to laparoscopic fundoplication,[200] and analysis of U.S. national trends in utilization and outcomes.[201] The results of laparoscopic fundoplication compare favorably with those of the “modern” era of open fundoplication. They also indicate the less predictable outcome of atypical reflux symptoms (cough, asthma, laryngitis) after surgery being relieved in only two-thirds of patients.[202]

A few recent trials deserve emphasis. Results were updated on a prospective, randomized trial comparing PPI therapy to antireflux surgery.[203] The outcome of the study previously had been reported at a follow-up of 5 years,[199] while the latest update provided follow-up of at least 7 years. The proportion of patients in whom treatment did not fail during the 7 years was significantly higher in the surgical arm than in the medical arm. A smaller difference in outcomes was noted after dose adjustments in the medical group. More patients in the surgical cohort, however, complained of side effects such as dysphagia, inability to belch or vomit, and hyperflatulence. Disease control was essentially stable between 5 and 7 years of follow-up. The authors concluded that surgery

was more effective in controlling overall GERD symptoms, though postfundoplication side effects were a concern.

Another prospective trial from the United Kingdom compared laparoscopic Nissen fundoplication to PPI and reported follow-up at a median of 6.9 years.[142] Some patients initially randomized to PPI therapy were offered the opportunity to undergo surgery. While both the medical and surgical cohorts reported an improvement in GERD-related symptoms after 12 months, further symptomatic improvement was noted in those patients subsequently undergoing surgery despite optimal PPI therapy.

A multicenter, European, prospective randomized trial comparing LARS to medical therapy with esomeprazole is ongoing (the LOTUS trial). Three-year outcomes in 288 patients assigned to LARS and 266 assigned to medical therapy were reported in 2008.[204] The proportion of patients remaining in symptomatic remission was similar between the two groups (90% for LARS, 93% for medical therapy in an intention-to-treat analysis, $p = 0.25$). No major perioperative complications were noted and esomeprazole appeared to be well tolerated.

Recent reports have called attention to the observation that many patients are prescribed acid suppression medications after antireflux surgery. Spechler et al.[205,206] reported on the long-term follow-up of patients with complicated GERD enrolled in the Department of Veterans Affairs randomized trial of medical versus surgical therapies. In the first report, almost half (46.9%) of the patients treated by fundoplication had taken acid suppression medications at some point during the 11- to 13-year follow-up period.[205] In the second report, 62% of the surgically treated patients had used medications.[206] The reasons for and the necessity of acid suppression medication usage was not explored in this study. In contrast, Lord et al.[207] reported on 86 patients who had symptoms after Nissen fundoplication severe enough to warrant evaluation with 24-hour ambulatory esophageal pH monitoring. Thirty-seven (43%) of these patients were taking acid suppression medications, and only nine of them (24%) were found to have abnormal pH scores. Heartburn and regurgitation were the only symptoms that were significantly associated with an abnormal pH study. Multivariable logistic regression analysis showed that patients with a disrupted or abnormally positioned fundoplication had a 52.6 times increased risk of abnormal esophageal acid exposure. Based on these data, most patients using acid suppression medications after antireflux surgery do not have abnormal esophageal acid exposure, and objective evidence of reflux should be obtained prior to restarting acid suppression medications in patients with symptoms after a fundoplication.

The goal of surgical treatment for GERD is to relieve abolish reflux by reestablishing the GE barrier. This will alleviate symptoms related to reflux and protect the esophageal and laryngeal mucosa from reflux-related injury. The challenge is to accomplish this without inducing dysphagia or other untoward side effects. Dysphagia that existed prior to surgery usually improves following laparoscopic fundoplication. Temporary dysphagia is common after surgery and generally resolves within 3 months. Dysphagia persisting beyond 3 months has been reported in up to 10% of patients. In our experience, dysphagia, manifested by occasional difficulty in swallowing solids, was present in 7% of patients at 3 months, 5% at 6 months, 2% at 12 months, and a single patient at 24 months

following surgery.[35] Others have observed a similar improvement in postoperative dysphagia with time. Induced dysphagia is usually mild, does not require dilatation, and is temporary, often related to edema from the surgery. Other side effects common to antireflux surgery include the inability to vomit and increased flatulence. Most patients cannot vomit through an intact wrap, though this is rarely clinically relevant. Hyperflatulence is a common and noticeable problem, likely related to increased air swallowing that is present in most patients with reflux disease and the inability to belch.

Objective Outcomes Following Antireflux Surgery. Laparoscopic fundoplication results in a significant increase in LES pressure and length, generally restoring these values to normal. The ability of an antireflux operation to restore esophageal acid exposure to normal depends on the type of fundoplication performed. Complete (Nissen) fundoplications generally are more reliable and durable than partial (e.g., Toupet) fundoplications at preventing pathologic acid reflux. Objective studies have shown that more than 90% of patients will have normal pH studies at 1 to 3 years following complete fundoplication, whereas only 50% of patients will have normal esophageal acid exposure following a partial fundic wrap.[187]

Quality-of-life analyses have become an important part of surgical outcome assessment, with both generic and disease-specific questionnaires in use, in an attempt to quantitate quality of life before and after surgical intervention. In general, these measures relate the effect of disease management to the overall well-being of the patient.[208] Most studies have utilized the Short Form 36 (SF-36) instrument, because it is rapidly administered and well validated. This questionnaire measures 12 different health-related quality-of-life parameters encompassing mental and physical well-being. Data from Los Angeles indicate significant improvements in scores for the area of bodily pain and in a portion of the general health index.[35] Most other measures were improved but failed to achieve statistical significance. Trus et al.[209] have also analyzed SF-36 scores before and after LARS. In contrast to our data, scores in all fields were significantly better after surgery. In this study, preoperative scores were dramatically lower than were found in our study. Thus, the difference is likely to be secondary to the relatively high scores of our patients prior to surgery (perhaps reflecting good disease control on medical therapy) and to our small sample size.

Other investigators have also reported improvement in quality of life following antireflux surgery. Glise et al.[210] utilized two standardized and validated questionnaires, the Psychological General Well-Being Index and the Gastrointestinal Symptom Rating Scale, to evaluate quality of life in a cohort of 40 patients following LARS. Scores with both instruments were improved following antireflux surgery and better than in untreated patients. Of particular note was that scores were as good as or better than those of patients receiving optimal medical therapy. Velonovich et al.,[211] using a 10-item health-related quality-of-life questionnaire specific for GERD, have also shown an improvement in quality of life following antireflux surgery.

Fernando et al.[212] reported on quality of life after antireflux surgery compared with nonoperative management for severe GERD. Follow-up quality of life was measured using

the SF-36, and heartburn severity was measured using the Health-Related Quality-of-Life (QOL) scale. Detailed outcomes were available for 101 surgical patients and 37 medical patients. Mean QOL scores were better in the surgical group. More of the medical patients were dissatisfied with therapy. SF-36 scores were better in six of eight domains for surgical patients. These data support the notion that antireflux surgery, performed on properly selected patients, can significantly improve quality of life and may outperform medical therapy in this regard.

Anatomic Failure Following Antireflux Surgery. An important and often underemphasized point is that the rate of failure of fundoplication is largely dependent upon the size of the underlying hiatal hernia. Repair of large sliding and PEHs is associated with a higher risk of recurrent hiatal herniation compared to fundoplication for GERD in the setting of no or small hiatal hernias. Multiple potential explanations exist to explain this differential, including the presence of a widened hiatus with weakened or attenuated crural fibers that must be brought together under tension, the coexistence of esophageal body shortening, the generally older and frailer nature of patients with a PEH, and underlying anatomic, muscular, or connective tissue deficits that contributed to the pathogenesis of the hernia. In particular, the association between kyphosis and intrathoracic stomach is becoming increasingly recognized, as skeletal abnormalities likely are contributory to the pathogenesis of paraesophageal hiatal herniation.[213]

The need for reoperation after fundoplication for GERD is only approximately 5% over the patient's lifetime, whereas the risk can run as high as 42% after repair of a giant PEH.[214] In a trial from Finland, objective outcomes were assessed by endoscopy and demonstrated a 40% disruption rate following open Nissen fundoplication and a 13% disruption rate following a laparoscopic procedure.[215] Despite these relatively high rates of objective breakdown, only 8% of patients in the open group and 2% in the laparoscopic group had undergone repeat operation for fundoplication failure.

A recent trial compared two techniques of laparoscopic PEH repair, with or without the use of a biologic prosthesis placed at the esophageal hiatus.[216] At 6 months, 9% of patients with the prosthesis and 24% of patients without mesh reinforcement had developed a recurrent hiatal hernia as assessed by a barium upper gastrointestinal examination, underscoring the potential for failure when operation is undertaken for PEHs. However, at a median of 58 months follow-up the authors updated their results and reported that greater than 50% of patients in both the mesh and nonmesh groups had objective evidence of hernia recurrence.[21] This has led to controversy about the role of mesh at the hiatus, particularly in patients with large or paraesophageal-type hiatal hernias. It is likely that mesh use alone is inadequate to prevent hernia recurrence if tension on the crural closure or related to esophageal shortening is unaddressed. If mesh is to be used most experienced esophageal surgeons avoid the use of large or esophageal-encircling permanent mesh to minimize the risk of erosion. A small strip of synthetic mesh placed across the crural closure posterior to the esophagus may have less tendency to erode and lead to a reduction in hernia recurrence. Bridging the crura with synthetic mesh should be avoided since this leads to the highest risk for mesh erosion. An

absorbable or biologic mesh bridge should also be avoided since this will lead to hernia recurrence in essentially all patients. Instead, a diaphragm relaxing incision should be used when the crura cannot be reapproximated or to do so requires excessive tension. Increasingly biologic or bioresorbable mesh reinforcement of the primary crural closure is being reported with good results.[22] However, it is likely that mesh use increases the complexity of a reoperation if necessary, and has been shown to lead to a higher risk for the need for resection rather than redo fundoplication in the reoperative setting.[23]

Relaxing incisions have been used for hernia repairs at other sites in the abdomen, and logically would be useful in patients with a widely splayed hiatus where the crura are unable to be approximated without tension. A right-sided diaphragmatic relaxing incision is easiest and usually suffices, but in a very large hiatus or in reoperations sometimes a left diaphragm relaxing incision is necessary. The defect created in the diaphragm should be repaired with permanent mesh to avoid herniation of abdomen contents into the thorax. The authors prefer a Gore Tex patch for this purpose and reinforce the primary crural closure with an absorbable or biologic mesh.[24]

It is likely that efforts to reduce the high objective hernia recurrence rate after laparoscopic PEH repair will require addressing crural tension, esophageal tension from a shortened esophagus, and mesh reinforcement of the primary crural closure. When these adjunct techniques are added as necessary during a laparoscopic PEH repair the authors have reported a very reasonable short-term objective recurrence rate of 4%.[25]

FUTURE DIRECTIONS

Medical therapy for GERD and antireflux surgery both have inherent drawbacks. Major limitations of acid suppressive medications include the inability to prevent regurgitation of weakly acidic or nonacidic refluxate and the need for chronic, continual therapy, not to mention the cost, inconvenience, potential side effects, and need for ongoing dietary and lifestyle modifications. In addition, current therapy does not address the main pathophysiologic contributor to the presence of GERD, the mechanically defective LES. Fundoplications, while intended to permanently restore the LES, suffer from the potential for perioperative complications, a high initial cost, the risks inherent in general anesthesia, possible short- and long-term side effects, and inconsistent reflux control across centers. In addition, proper patient selection is critical and the operative technique is not well standardized, perhaps adversely affecting outcomes, particularly in inexperienced hands.

For all of these reasons, an interest remains to create means of restoring LES competence by medical or less invasive surgical or endoscopic techniques that are easily applied and highly reproducible. Medications such as baclofen, a γ-aminobutyric $acid_B$ receptor agonist, have been utilized to decrease TLESRs, thereby decreasing GERD.[217] Similar investigational drugs are in the pipeline and likely will reach clinical practice soon. A number of endoluminal therapies have been devised and tested to date, the most promising of which are the transoral endoscopic fundoplication devices (EsophyX, EndoGastric Solutions, Inc., Redmond, Washington and Medigus SRS, Medigus, Ltd., Omer, Israel). A recent randomized control trial has shown that compared to PPI therapy a transoral fundoplication using the EsophyX device was associated with improved regurgitation symptoms.[26]

Magnetic augmentation of the LES via a laparoscopically placed ring of small magnets (TORAX Medical, Inc., Shoreview, Minnesota) has proven efficacy for control of reflux in appropriate patients. The recently completed 5-year follow-up in 85 of an initial cohort of 100 patients showed no device erosions, migrations, or malfunctions. The GERD quality of life scores, frequency of PPI use and regurgitation symptoms were all improved compared to baseline. The ability to belch and vomit if necessary was preserved in all patients, and bothersome gas-bloat symptoms were reduced from baseline with a similar frequency of dysphagia symptoms.[27]

Lastly, a novel device that provides intermittent electrical current to the LES via implanted wires and a pacer device (Endostim) has shown promising results in human trials from outside the United States.[28]

References

1. Gray SW, Rowe JS Jr, Skandalakis JE. Surgical anatomy of the gastroesophageal junction. *Am Surg* 1979;45(9):575–587.
2. Chandrasoma PT, Der R, Ma Y, et al. Histology of the gastroesophageal junction: an autopsy study. *Am J Surg Pathol* 2000;24(3):402–409.
3. Chandrasoma PT, Der R, Dalton P, et al. Distribution and significance of epithelial types in columnar-lined esophagus. *Am J Surg Pathol* 2001;25(9):1188–1193.
4. Abraham SC, Krasinskas AM, Correa AM, et al. Duplication of the muscularis mucosae in Barrett esophagus: an underrecognized feature and its implication for staging of adenocarcinoma. *Am J Surg Pathol* 2007;31(11):1719–1125.
5. Nigro JJ, Hagen JA, DeMeester TR, et al. Prevalence and location of nodal metastases in distal esophageal adenocarcinoma confined to the wall: implications for therapy. *J Thorac Cardiovasc Surg* 1999;117(1):16–23; discussion 23–25.
6. Liebermann-Meffert DM, Luescher U, Neff U, et al. Esophagectomy without thoracotomy: is there a risk of intramediastinal bleeding? A study on blood supply of the esophagus. *Ann Surg* 1987;206(2):184–192.
7. Liebermann-Meffert D. Human foregut anatomy, adjacent structures, and their relation to surgical approaches. In: CJ Yeo, ed. *Shackelford's Surgery of the Alimentary Tract.* Philadelphia, PA: Elsevier Saunders: 2013;9–31.
8. Liebermann-Meffert DM, Walbrun B, Hiebert CA, et al. Recurrent and superior laryngeal nerves: a new look with implications for the esophageal surgeon. *Ann Thorac Surg.* 1999;67(1):217–223.
9. Pouderoux P, Lin S, Kahrilas PJ. Timing, propagation, coordination, and effect of esophageal shortening during peristalsis. *Gastroenterology* 1997; 112(4):1147–1154.
10. Pouderoux P, Shi G, Tatum RP, et al. Esophageal solid bolus transit: studies using concurrent videofluoroscopy and manometry. *Am J Gastroenterol* 1999;94(6):1457–1463.
11. DeMeester TR, Peters JH, Bremner CG, et al. Biology of gastroesophageal reflux disease: pathophysiology relating to medical and surgical treatment. *Ann Rev Med* 1999;50:469–506.
12. Bonavina L, Evander A, DeMeester TR, et al. Length of the distal esophageal sphincter and competency of the cardia. *Am J Surg* 1986;151(1):25–34.
13. Mason RJ, DeMeester TR, Lund RJ, et al. Nissen fundoplication prevents shortening of the sphincter during gastric distention. *Archiv Surg* 1997; 132(7):719–724; discussion 724–726.
14. Pettersson GB, Bombeck CT, Nyhus LM. The lower esophageal sphincter: mechanisms of opening and closure. *Surgery* 1980;88(2):307–314.
15. Dent J. A new technique for continuous sphincter pressure measurement.

Gastroenterology 1976;71(2):263–267.
16. Ismail T, Bancewicz J, Barlow J. Yield pressure, anatomy of the cardia and gastro-oesophageal reflux. *Br J Surg* 1995;82(7):943–947.
17. Marchand P. The gastro-oesophageal sphincter and the mechanism of regurgitation. *Br J Surg* 1955;42(175):504–513.
18. Kahrilas PJ, Shi G, Manka M, et al. Increased frequency of transient lower esophageal sphincter relaxation induced by gastric distention in reflux patients with hiatal hernia. *Gastroenterology* 2000;118(4):688–695.
19. DeMeester TR, Wernly JA, Bryant GH, et al. Clinical and in vitro analysis of determinants of gastroesophageal competence. A study of the principles of antireflux surgery. *Am J Surg* 1979;137(1):39–46.
20. Johnson LF, Lin YC, Hong SK. Gastroesophageal dynamics during immersion in water to the neck. *J Appl Physiol* 1975;38(3):449–454.
21. O'Sullivan GC, DeMeester TR, Joelsson BE, et al. Interaction of lower esophageal sphincter pressure and length of sphincter in the abdomen as determinants of gastroesophageal competence. *Am J Surg* 1982;143(1):40–47.
22. Pellegrini CA, DeMeester TR, Skinner DB. Response of the distal esophageal sphincter to respiratory and positional maneuvers in humans. *Surg Forum* 1976;27(62):380–382.
23. Stein HJ, Barlow AP, DeMeester TR, et al. Complications of gastroesophageal reflux disease. Role of the lower esophageal sphincter, esophageal acid and acid/alkaline exposure, and duodenogastric reflux. *Ann Surg* 1992;216(1):35–43.
24. Zaninotto G, DeMeester TR, Bremner CG, et al. Esophageal function in patients with reflux-induced strictures and its relevance to surgical treatment. *Ann Thorac Surg* 1989;47(3):362–370.
25. Barham CP, Gotley DC, Mills A, et al. Precipitating causes of acid reflux episodes in ambulant patients with gastro-oesophageal reflux disease. *Gut* 1995;36(4):505–510.
26. Bremner RM, Hoeft SF, Costantini M, et al. Pharyngeal swallowing. The major factor in clearance of esophageal reflux episodes. *Ann Surg* 1993;218(3):364–369; discussion 369–370.
27. Iwakiri K, Kobayashi M, Kotoyori M, et al. Relationship between postprandial esophageal acid exposure and meal volume and fat content. *Dig Dis Sci* 1996;41(5):926–930.
28. Fletcher J, Wirz A, Young J, et al. Unbuffered highly acidic gastric juice exists at the gastroesophageal junction after a meal. *Gastroenterology* 2001;121(4):775–783.
29. Ayazi S, Tamhankar A, DeMeester SR, et al. The impact of gastric distension on the lower esophageal sphincter and its exposure to acid gastric juice. *Ann Surg* 2010;252(1):57–62.
30. Oberg S, Peters JH, DeMeester TR, et al. Inflammation and specialized intestinal metaplasia of cardiac mucosa is a manifestation of gastroesophageal reflux disease.

Ann Surg 1997;226(4):522–530; discussion 530–532.
31. DeMeester TR, Wang CI, Wernly JA, et al. Technique, indications, and clinical use of 24 hour esophageal pH monitoring. *J Thorac Cardiovasc Surg* 1980;79(5):656–670.
32. Theisen J, Oberg S, Peters JH, et al. Gastro-esophageal reflux disease confined to the sphincter. *Dis Esophagus* 2001;14(3–4):235–238.
33. DeMeester TR, Ireland AP. Gastric pathology as an initiator and potentiator of gastroesophageal reflux disease. *Dis Esophagus* 1997;10(1):1–8.
34. Kuster E, Ros E, Toledo-Pimentel V, et al. Predictive factors of the long term outcome in gastro-oesophageal reflux disease: six year follow up of 107 patients. *Gut* 1994;35(1):8–14.
35. Peters JH, DeMeester TR, Crookes P, et al. The treatment of gastroesophageal reflux disease with laparoscopic Nissen fundoplication: prospective evaluation of 100 patients with "typical" symptoms. *Ann Surg* 1998;228(1):40–50.
36. Ganz RA, Peters JH, Horgan S. Esophageal sphincter device for gastroesophageal reflux disease. *N Engl J Med* 2013;368(8):719–727.
37. Singh P, Adamopoulos A, Taylor RH, et al. Oesophageal motor function before and after healing of oesophagitis. *Gut* 1992;33(12):1590–1596.
38. Tamhankar AP, Peters JH, Portale G, et al. Omeprazole does not reduce gastroesophageal reflux: new insights using multichannel intraluminal impedance technology. *J Gastrointest Surg,* 2004;8(7):890–897; discussion 897–898.
39. Dodds WJ. 1976 Walter B. Cannon Lecture: current concepts of esophageal motor function: clinical implications for radiology. *AJR Am J Roentgenol* 1977;128(4):549–561.
40. Ekberg O, Wahlgren L. Dysfunction of pharyngeal swallowing. A cineradiographic investigation in 854 dysphagia patients. *Acta Radiol Diagn* 1985;26(4):389–395.
41. Donner MW. Swallowing mechanism and neuromuscular disorders. *Semin Roentgenol* 1974;9(4):273–282.
42. Fuller L, Huprich JE, Theisen J, et al. Abnormal esophageal body function: radiographic-manometric correlation. *Am Surg* 1999;65(10):911–914.
43. Schwizer W, Hinder RA, DeMeester TR. Does delayed gastric emptying contribute to gastroesophageal reflux disease? *Am J Surg* 1989;157(1):74–81.
44. Genta RM, Spechler SJ, Kielhorn AF. The Los Angeles and Savary-Miller systems for grading esophagitis: utilization and correlation with histology. *Dis Esophagus* 2011;24(1):10–17.
45. Theodorou D, Ayazi S, DeMeester SR, et al. Intraluminal pH and goblet cell density in Barrett's esophagus. *J Gastrointest Surg* 2012;16(3):469–474.
46. Oh D, Hagen JA, Chandrasoma PT, et al. Clinical biology and surgical therapy of intramucosal adenocarcinoma of the esophagus. *J Am Coll Surg* 2006;203(2):152–161.
47. Oberg S, Peters JH, DeMeester TR, et al. Endoscopic grading of the gastroesophageal valve in patients with symptoms of gastroesophageal reflux disease (GERD). *Surg*

Endoscopy 1999;13(12):1184–1188.

48. Ayazi S, Hagen JA, Zehetner J, et al. The value of high-resolution manometry in the assessment of the resting characteristics of the lower esophageal sphincter. *J Gastrointest Surg,* 2009;13(12):2113–2120.
49. Johnson LF, Demeester TR. Twenty-four-hour pH monitoring of the distal esophagus. A quantitative measure of gastroesophageal reflux. *Am J Gastroenterology* 1974;62(4):325–332.
50. Mason RJ, Oberg S, Bremner CG, et al. Postprandial gastroesophageal reflux in normal volunteers and symptomatic patients. *J Gastrointest Surg,* 1998;2(4):342–349.
51. Ayazi S, Lipham JC, Portale G, et al. Bravo catheter-free pH monitoring: normal values, concordance, optimal diagnostic thresholds, and accuracy. *Clin Gastroenterol Hepatology* 2009;7(1):60–67.
52. Ayazi S, Hagen JA, Zehetner J, et al. Proximal esophageal pH monitoring: improved definition of normal values and determination of a composite pH score. *J Am Coll Surg* 2010;210(3):345–350.
53. Ayazi S, Lipham JC, Hagen JA, et al. A new technique for measurement of pharyngeal pH: normal values and discriminating pH threshold. *J Gastrointest Surg,* 2009;13(8):1422–1429.
54. Vakil N, van Zanten SV, Kahrilas P, et al. The Montreal definition and classification of gastroesophageal reflux disease; a global evidence-based consensus. *Am J Gastroenterol* 2006;101:1900–1920.
55. Locke GR, Talley NJ, Fett SL, et al. Prevalence and clinical spectrum of gastroesophageal reflux; a population-based study in Olmsted County Minnesota. *Gastroenterology* 1997;112:1448.
56. Isolauri J, Laippala P. Prevalence of symptoms suggestive of gastroesophageal reflux disease in an adult population. *Ann Med* 1995;27:67–70.
57. Sharma P, Wani S, Romero Y, et al. Racial and geographic issues in gastroesophageal reflux disease. *Am J Gastroenterol* 2008;103:2669–2680.
58. El-Serag H. Time trends of gastroesophageal reflux disease: a systematic review. *Clin Gastroenterol Hepatol* 2007;5:17–26.
59. Agency for Healthcare Research and Quality. Hospitalizations for problems caused by severe acid reflux increase by 103 percent. *AHRQ News and Numbers.* Rockville, MD: Agency for Healthcare Research and Quality; 2008. Available at: http://www.ahrq.gov/news/nn/nn010208.htm. Accessed January, 2009.
60. El-Serag HB, Sonnenberg A. Opposing time trends of peptic ulcer and reflux disease. *Gut* 1998;43:327–333.
61. Panos MZ, Walt RP, Stevenson C, et al. Rising death rate from non-malignant disease of the oesophagus (NMOD) in England and Wales. *Gut* 1995;36:488–491.
62. Jacobson BC, Somers SC, Fuchs CS, et al. Body-mass index and symptoms of gastroesophageal reflux in women. *N Eng J Med* 2006;354:2340–2348.

63. Corely DA, Kubo A. Body mass index and gastroesophageal reflux disease: a systematic review and meta-analysis. *Am J Gastroenterol* 2006;108: 2619–2628.
64. Pandolfino JE, El-Serag HB, Zhang Q, et al. Obesity: a challenge to esophagogastric junction integrity. *Gastroenterology* 2006;130:639–649.
65. Edlestein ZR, Farrow DC, Bronner MP, et al. Central obesity and risk of Barrett's esophagus. *Gastroenterology* 2007;133:403–411.
66. Konturek JW. Discovery by Jaworski of Helicobacter pylori and its pathogenetic role in peptic ulcer, gastritis and gastric cancer. *J Physiol Pharmacol* 2003;54(suppl 3):23–41.
67. Marshall BJ, Warren JR. Unidentified curved bacilli in the stomach of patients with gastritis and peptic ulceration. *Lancet* 1984;1:1311–1315.
68. Labenz J, Blum AL, Bayerdorffer E, et al. Curing Helicobacter pylori infection in patients with duodenal ulcer may provoke reflux esophagitis. *Gastroenterology* 1997;112:1442–1447.
69. Bowrey DJ, Williams GT, Clark GW. Interactions between Helicobacter pylori and gastroesophageal reflux disease. *Dis Esophagus* 1998;11: 203–209.
70. Werdmuller BF, Loffeld RJ. Helicobacter pylori infection has no role in the pathogenesis of reflux esophagitis. *Dig Dis Sci* 1997;42:103–105.
71. Loffeld RJ, Ten Tije BJ, Arends JW. Prevalence and significance of Helicobacter pylori in patients with Barrett's esophagus. *Am J Gastroenterol* 1992;87:1598–1600.
72. Weel JF, Van Der Hulst RW, Gerrits Y, et al. The interrelationship between cytotoxin-associated gene A, vacuolating cytotoxin, and Helicobacter pylori-related diseases. *J Infect Dis* 1996;173:1171–1175.
73. Vicari JJ, Peek RM, Falk GW, et al. The seroprevalence of cagA-positive Helicobacter pylori strains in the spectrum of gastroesophageal reflux disease. *Gastroenterology* 1998;115:50–57.
74. Chow WH, Blaser MJ, Blot WJ, et al. An inverse relation between cagA− strains of Helicobacter pylori infection and risk of esophageal and gastric cardia adenocarcinoma. *Cancer Res* 1998;58:588–590.
75. Labenz J, Nocon M, Lind T, et al. Prospective follow-up data for the ProGERD study suggest that GERD is not a categorical disease. *Am J Gastroenterol* 2006;101:2457–2462.
76. Malfertheiner P, Nocon M, Vieth M, et al. Evolution of gastro-oesophageal reflux disease over 5 years under routine medical care – the ProGERD study. *Aliment Pharmacol Ther* 2012;35:154–164.
77. Monnier P, Ollyo JB, Fontolliet C, et al. Epidemiology and natural history of reflux esophagitis. *Semin Laparosc Surg* 1995;2:2–9.
78. Costantini M, Crookes PF, Bremner RM, et al. The value of physiologic assessment of foregut symptoms in a surgical practice. *Surgery* 1993; 114:780–786; discussion 786–787.

79. Dodds WJ, Dent J, Hogan WJ, et al. Mechanisms of gastroesophageal reflux in patients with reflux esophagitis. *N Engl J Med* 1982;307: 1547–1552.
80. Mittal RK, Holloway R, Dent J. Effect of atropine on the frequency of reflux and transient lower esophageal sphincter relaxation in normal subjects. *Gastroenterology* 1995;109:1547–1554.
81. Mittal RK, Hollaway RH, Penagini R, et al. Transient lower esophageal sphincter relaxation. *Gastroenterology* 1995;109:601–610.
82. Van Herwaarden MA, Samson M, Smout AJ. Excess gastroesophageal reflux in patients with hiatal hernia is caused by mechanisms other than transient LES relaxations. *Gastroenterology* 2000;119:1439–1446.
83. Zaninotto G, DeMeester TR, Schwizer W, et al. The lower esophageal sphincter in health and disease. *Am J Surg* 1988;155:104–111.
84. Stein HJ, Eypasch EP, DeMeester TR, et al. Circadian esophageal motor function in patients with gastroesophageal reflux disease. *Surgery* 1990; 108:769.
85. Cohen S, Harris LD. Does hiatus hernia affect competence of the gastroesophageal sphincter. *N Engl J Med* 1971;284:1053–1056.
86. Mittal RK, Fisher MJ. Electrical and mechanical inhibition of the crural diaphragm during transient relaxation of the lower esophageal sphincter. *Gastroenterology* 1990;99:1265–1268.
87. Hill LD, Kozarek RA, Kraemer SJM, et al. The gastroesophageal flap valve: in vitro and in vivo observations. *Gastrointest Endosc* 1996;44:541–547.
88. Kahrilas PJ, Wu S, Shezhang L, et al. Attenuation of esophageal shortening during peristalsis with hiatus hernia. *Gastroenterology* 1995;109:1818–1825.
89. Fletcher J, Wirz A, Henry E, et al. Studies of acid exposure immediately above the gastroesophageal squamocolumnar junction: evidence of short segment reflux. *Gut* 2004;53:168–173.
90. Iljima K, Henry E, Moriya A, et al. Dietary nitrate generates potentially mutagenic concentrations of nitric oxide at the gastroesophageal junction. *Gastroenterology* 2002;122:1248–1257.
91. Lillimoe KD, Johnson LF, Harmon JW. Role of the components of the gastroduodenal contents in experimental acid esophagitis. *Surgery* 1982;92:276–284.
92. Lillimoe KD, Johnson LF, Harmon JW. Alkaline esophagitis: a comparison of the ability of components of gastroduodenal contents to injure the rabbit esophagus. *Gastroenterology* 1983;85:621–628.
93. Kauer WK, Peters JH, DeMeester TR, et al. Mixed reflux of gastric juice is more harmful to the esophagus than gastric juice alone. The need for surgical therapy reemphasized. *Ann Surg* 1995;222:525–533.
94. El-Serag HB, Sonnenberg A. Comorbid occurrence of laryngeal or pulmonary disease with esophagitis in United States Military Veterans. *Gastroenterology* 1997;113:755–760.

95. Havemann BD, Henderson CA, El-Serag HB. The association between gastro-oesophageal reflux disease and asthma: a systematic review. *Gut* 2007;56:1654–1664.
96. Sontag SJ. The spectrum of pulmonary symptoms due to gastroesophageal reflux. *Thorac Surg Clin* 2005;15:353–368.
97. Blondeau K, Dupont L, Mertens V, et al. Gastroesophageal reflux and aspiration of gastric contents in adult patients with cystic fibrosis. *Gut* 2008;57:1049–1055.
98. Rascon-Aguilar IE, Pamer M, Wludyka P, et al. Role of gastroesophageal reflux symptoms in exacerbations of COPD. *Chest* 2006;130:1096–1101.
99. Hamelberg W, Bosomworth PP. Aspiration pneumonitis: experimental studies and clinical observations. *Anesth Analg Curr Res* 1964;170:74–86.
100. Greenfield LJ, Singleton RP, McCaffree DR, et al. Pulmonary effects of experimental graded aspiration of hydrochloric acid. *Ann Surg* 1969; 170:74–86.
101. Glauser FL, Millen JE, Falls R. Effects of acid aspiration on pulmonary alveolar epithelial membrane permeability. *Chest* 1979;76:201–205.
102. Tuchman DN, Boyle JT, Pack AI, et al. Comparison of airway responses following tracheal or esophageal acidification in the cat. *Gastroenterology* 1984;87:872–881.
103. Pearson JE, Wilson RS. Diffuse pulmonary fibrosis and hiatus hernia. *Thorax* 1971;26:300–305.
104. Mays EE, Dubois JJ, Hamilton GB. Pulmonary fibrosis associated with tracheobronchial aspiration: a study of the frequency of hiatal hernia and gastroesophageal reflux in interstitial fibrosis of obscure etiology. *Chest* 1976;69:512–515.
105. Raiha I, Manner R, Hietanen E. Radiographic pulmonary changes of gastro-oesophageal reflux disease in elderly patients. *Age Ageing* 1992;21:250–255.
106. Tobin RW, Pope CE, Pellegrini CA. Increased prevalence of gastroesophageal reflux in patients with idiopathic pulmonary fibrosis. *Am J Respir Crit Care Med* 1988;158:1804–1808.
107. Kauer WK, Stein HJ, Möbius C, et al. Assessment of respiratory symptoms with dual pH monitoring in patients with gastro-oesophageal reflux disease. *Br J Surg* 2004;91:867–871.
108. Raghu G, Freudenberger TD, Yang S, et al. High prevalence of abnormal acid gastro-oesophageal reflux in idiopathic pulmonary fibrosis. *Eur Respir J* 2006;27:136–142.
109. Crowell MD, Zayat EN, Lacy BE, et al. The effects of an inhaled beta(2)-adrenergic agonist on lower esophageal function: a dose-response study. *Chest* 2001;120:1184–1189.
110. Mansfield LE, Hameister HH, Spaulding HS, et al. The role of the vagus nerve in airway narrowing caused by intraesophageal hydrochloric acid provocation and esophageal distention. *Ann Allergy* 1981;47:431–434.
111. Wright RA, Miller SA, Corsello BF. Acid-induced esophagobronchial-cardiac reflexes in humans. *Gastroenterology* 1990;99:71–73.

112. Schan CA, Harding SM, Haile JM, et al. Gastroesophageal reflux-induced bronchoconstriction. An intraesophageal acid infusion study using state-of-the-art technology. *Chest* 1994;106:731–737.
113. Sweet MP, Patti MG, Leard LE, et al. Gastroesophageal reflux in patients with idiopathic pulmonary fibrosis referred for lung transplantation. *J Thorac Cardiovasc Surg* 2007;133:1078–1084.
114. Sweet MP, Herbella FA, Leard L, et al. The prevalence of distal and proximal gastroesophageal reflux in patients awaiting lung transplantation. *Ann Surg* 2006;244:491–497.
115. D'Ovidio F, Singer LG, Hadjiliadis D, et al. Prevalence of gastroesophageal reflux in end-stage lung disease candidates for lung transplant. *Ann Thoracic Surg* 2005;80:1254–1261.
116. Ayazi S, Hagen JA, Zehetner J, et al. Loss of alkalization in proximal esophagus: a new diagnostic paradigm for patients with laryngopharyngeal reflux. *J Gastrointest Surg* 2010;14(11):1653–1659
117. Worrell SG, DeMeester SR, Greene CL, et al. Pharyngeal pH monitoring better predicts a successful outcome for extraesophageal reflux symptoms after antireflux surgery. *Surg Endosc* 2013;27(11):4113–4118.
118. Frank L, Kleinman L, Ganoczy D, et al. Upper gastrointestinal symptoms in North America: prevalence and relationship to healthcare utilization and quality of life. *Dig Dis Sci* 2000;45:809–818.
119. Jailawala JA, Shaker R. Oral and pharyngeal complications of gastroesophageal reflux disease: globus, dental erosions, and chronic sinusitis. *J Clin Gastroenterol* 2000;30(3 suppl):S35–S38.
120. Hungin AP, Raghunath AS, Wiklund I. Beyond heartburn: a systematic review of the extra-oesophageal spectrum of reflux-induced disease. *Fam Pract* 2005;22:591–603.
121. Levin TR, Sperling RM, McQuaid KR. Omeprazole improves peak expiratory flow rate and quality of life in asthmatics with gastroesophageal reflux. *Am J Gastroenterol* 1998;93:1060–1063.
122. Boeree MJ, Peters FT, Postma DS, et al. No effects of high-dose omeprazole in patients with severe airway hyperresponsiveness and symptomatic gastro-oesophageal reflux. *Eur Respir J* 1998;11:1070–1074.
123. Harding SM, Richter JE, Guzzo MR, et al. Asthma and gastroesophageal reflux: acid suppressive therapy improves asthma outcome. *Am J Med* 1996;100:395–405.
124. Raghu G, Yang ST, Spada C, et al. Sole treatment of acid gastroesophageal reflux in idiopathic pulmonary fibrosis: a case series. *Chest* 2006;129: 794–800.
125. Sontag SJ, O'Connell S, Khandelwal S, et al. Asthmatics with gastroesophageal reflux: long term results of a randomized trial of medical and surgical antireflux therapies. *Am J Gastroenterol* 2003;98:987–999.
126. Lau CL, Palmer SM, Howell DN, et al. Laparoscopic antireflux surgery in the lung

transplant population. *Surg Endosc* 2002;16:1674–1678.
127. Linden PA, Gilbert RJ, Yeap BY, et al. Laparoscopic fundoplication in patients with end-stage lung disease awaiting transplantation. *J Thorac Cardiovasc Surg* 2006;131:438–446.
128. Patti MG, Tedesco P, Golden J, et al. Idiopathic pulmonary fibrosis: how often is it really idiopathic? *J Gastrointest Surg* 2005;9:1053–1056.
129. Fernando HC, El-Sherif A, Landreneau RJ, et al. Efficacy of laparoscopic fundoplication in controlling pulmonary symptoms associated with gastroesophageal reflux disease. *Surgery* 2005;138:612–616.
130. Spechler SJ. The columnar lined esophagus: history, terminology and clinical issues. *Gastroenterol Clin North Am* 1997;26:455–466.
131. Peters JH, Hagen JA, DeMeester SR. Barrett's esophagus. *J Gastrointest Surg* 2004;8:1–17.
132. Chandrasoma P. Norman Barrett: so close, yet 50 years away from the truth. *J Gastrointest Surg* 1999;3:7–14.
133. Campos GM, DeMeester SR, Peters JH, et al. Predictive factors of Barrett's esophagus: multivariate analyses of 502 patients with GERD. *Arch Surg* 2001;136:1267–1273.
134. Kauer WK, Stein HJ. Bile reflux in the constellation of gastroesophageal reflux disease. *Thorac Surg Clin* 2005;15:335–340.
135. Katzka DA, Castell DO. Successful elimination of reflux symptoms does not insure adequate control of acid reflux in patients with Barrett's esophagus. *Am J Gastroenterol* 1994;89:989–991.
136. Ouatu-Lascar R, Triadafilopolous G. Complete elimination of reflux symptoms does not guarantee normalization of intraesophageal acid reflux in patients with Barrett's esophagus. *Am J Gastroenterol* 1998;93:711–716.
137. Sampliner RE, Fennerty B, Garewal HS. Reversal of Barrett's esophagus with acid suppression and multipolar electrocoagulation: preliminary results. *Gastrointest Endos* 1996;44:532–535.
138. Hofstetter WA, Peters JH, DeMeester TR, et al. Long term outcome of antireflux surgery in patients with Barrett's esophagus. *Ann Surg* 2001;234:532–539.
139. Lord RV, DeMeester SR, Peters JH, et al. Hiatal hernia, lower esophageal sphincter incompetence, and effectiveness of Nissen fundoplication in the spectrum of gastroesophageal reflux disease. *J Gastrointest Surg* 2009;13:602–610.
140. Farrell TM, Smith CD, Metreveli RE, et al. Fundoplication provides effective and durable symptom relief in patients with Barrett's esophagus. *Am J Surg* 1999;178:18–21.
141. Oelschlager BK, Barreca M, Chang L, et al. Clinical and pathologic response of Barrett's esophagus to laparoscopic antireflux surgery. *Ann Surg* 2003;238:458–466.
142. Mehta S, Bennett J, Mahon D, et al. Prospective trial of laparoscopic Nissen

fundoplication versus proton pump inhibitor therapy for gastroesophageal reflux disease: seven-year follow-up. *J Gastrointest Surg* 2006;10:1312–1316.

143. Dallemagne B, Weerts J, Markiewicz S, et al. Clinical results of laparoscopic fundoplication at ten years after surgery. *Surg Endosc* 2006;20:159–165.
144. Morgenthal CB, Shane MD, Stival A, et al. The durability of laparoscopic Nissen fundoplication: 11-year outcomes. *J Gastrointest Surg* 2007;11:693–700.
145. Wijnhoven BP, Lally CJ, Kelly JJ, et al. Use of antireflux medication after antireflux surgery. *J Gastrointest Surg* 2008;12:510–517.
146. Lurje G, Vallbohmer D, Collet PH, et al. COX-2 mRNA expression is significantly increased in acid-exposed compared to nonexposed squamous epithelium in gastroesophageal reflux disease. *J Gastrointest Surg* 2007;11:1105–1111.
147. Vallböhmer D, DeMeester SR, Oh DS, et al. Antireflux surgery normalizes cyclooxygenase-2 expression in squamous epithelium of the distal esophagus. *Am J Gastroenterol* 2006;101:1458–1466.
148. Oh DS, DeMeester SR, Vallböhmer D, et al. Reduction of interleukin 8 gene expression in reflux esophagitis and Barrett's esophagus with antireflux surgery. *Arch Surg* 2007;142:554–559.
149. Altorki NK, Sunagawa M, Little AG, et al. High-grade dysplasia in the columnar-lined esophagus. *Am J Surg* 1991;161:99–100.
150. Pera M, Trastek VF, Carpenter HA, et al. Barrett's esophagus with high grade dysplasia: an indication for esophagectomy. *Ann Thorac Surg* 1992;54:199–204.
151. Ferguson MK, Naunheim KS. Resection for Barrett's mucosa with high-grade dysplasia: implications for prophylactic photodynamic therapy. *J Thorac Cardiovasc Surg* 1997;114:824–829.
152. www.drugs.com. Accessed September 12, 2006.
153. www.rxlist.com. Accessed September 12, 2006.
154. Sandmark S, Carlsson R, Fausa O, et al. Omeprazole or ranitidine in the treatment of reflux esophagitis. *Scand J Gastroenterol* 1988;23:625–632.
155. Katzka DA, Paoletti V, Leite L, et al. Prolonged ambulatory pH monitoring in patients with persistent gastroesophageal reflux disease symptoms: testing while on therapy identifies the need for more aggressive anti-reflux therapy. *Am J Gastroenterol* 1996;91:2110–2113.
156. Peghini PL, Katz PO, Bracy NA, et al. Nocturnal recovery of gastric acid secretion with twice-daily dosing of proton pump inhibitors. *Am J Gastroenterol* 1998;93:763–767.
157. Laheij RJ, Sturkenboom MC, Hassing R-J, et al. Risk of community-acquired pneumonia and use of gastric acid-suppressive drugs. *JAMA* 2004; 292:1955–1960.
158. Yang Y-X, Lewis JD, Epstein S, et al. Long-term proton pump inhibitor therapy and the risk of hip fracture. *JAMA* 2006;296:2947–2953.
159. Roux C, Briot K, Gossec L, et al. Increase in vertebral fracture risk in postmenopausal

women using omeprazole. *Calcif Tissue Int* 2009;84:13–19.

160. Targownik LE, Lix LM, Metge CJ, et al. Use of proton pump inhibitors and risk of osteoporosis-related fractures. *CMAJ* 2008;179:319–326.
161. Campos GM, Peters JH, DeMeester TR, et al. The pattern of esophageal acid exposure in GERD influences the severity of the disease. *Arch Surg* 1999;134:882–887; discussion 887–888.
162. Finks JF, Wei Y, Birkmeyer JD. The rise and fall of antireflux surgery in the United States. *Surg Endosc* 2006;20:1698–1701.
163. Campos GM, Peters JH, DeMeester TR, et al. Multivariate analysis of the factors predicting outcome after laparoscopic Nissen fundoplication. *J Gastrointest Surg* 1999;3:292–300.
164. Miller FA. Utilization of inlying pH-probe for evaluation of acid-peptic diathesis. *Arch Surg* 1964;89:199–203.
165. Johnson LF, DeMeester TR. Development of the 24-hour intraesophageal pH monitoring composite scoring system. *J Clin Gastroenterol* 1986; 8(suppl 1):52–58.
166. Jamieson JR, Stein HJ, DeMeester TR, et al. Ambulatory 24-h esophageal pH monitoring: normal values, optimal thresholds, specificity, sensitivity, and reproducibility. *Am J Gastroenterol* 1992;87:1102–1111.
167. Pandolfino JE, Richter JE, Ours T, et al. Ambulatory esophageal pH monitoring using a wireless system. *Am J Gastroenterol* 2003;98:740–749.
168. Wenner J, Johansson J, Johnsson F, et al. Optimal thresholds and discriminatory power of 48-h wireless esophageal pH monitoring in the diagnosis of GERD. *Am J Gastroenterol* 2007;102:1862–1869.
169. Tutuian R, Vela MF, Shay SS, et al. Multichannel intraluminal impedance in esophageal function testing and gastroesophageal reflux monitoring. *J Clin Gastroenterol* 2003;37:206–215.
170. Vela MF, Camacho-Lobato L, Srinivasan R, et al. Simultaneous intraesophageal impedance and pH measurement of acid and nonacid gastroesophageal reflux: effect of omeprazole. *Gastroenterology* 2001;120:1599–1606.
171. Mainie I, Tutuian R, Agrawal A, et al. Combined multichannel intraluminal impedance-pH monitoring to select patients with persistent gastro-oesophageal reflux for laparoscopic Nissen fundoplication. *Br J Surg* 2006; 93:1483–1487.
172. Gruebel C, Linke G, Tutuian R, et al. Prospective study examining the impact of multichannel intraluminal impedance on antireflux surgery. *Surg Endosc* 2008;22:1241–1247.
173. Gastal OL, Hagen JA, Peters JH, et al. Short esophagus: analysis of predictors and clinical implications. *Arch Surg* 1999;134:633–636; discussion 637–638.
174. Ritter MP, Peters JH, DeMeester TR, et al. Treatment of advanced gastroesophageal reflux disease with Collis gastroplasty and Belsey partial fundoplication. *Arch Surg* 1998;133:523.

175. DeMeester SR, Sillin LF, Lin HW, et al. Increasing esophageal length: a comparison of laparoscopic versus transthoracic esophageal mobilization with and without vagal trunk division in pigs. *J Am Coll Surg* 2003;197:558–564.
176. Stein HJ, Feussner H, Siewart JR. Failure of antireflux surgery: causes and management. *Am J Surg* 1996;171:36.
177. Johnson WE, Hagen JA, DeMeester TR, et al. Outcome of respiratory symptoms after antireflux surgery on patients with gastroesophageal reflux disease. *Arch Surg* 1996;131:489–492.
178. Salvador R, Dubecz A, Polomsky M, et al. A new era in esophageal diagnostics: the image-based paradigm of high-resolution manometry. *J Am Coll Surg* 2009;208:1034–1044.
179. Salvador R, Watson TJ, Herbella F, et al. Association of gastroesophageal reflux and O2 desaturation: a novel study of simultaneous 24-h MII-pH and continuous pulse oximetry. *J Gastrointest Surg* 2009;13:854–861.
180. Potluri S, Friedenberg F, Parkman HP, et al. Comparison of a salivary/sputum pepsin assay with 24-hour esophageal pH monitoring for detection of gastric reflux into the proximal esophagus, oropharynx, and lung. *Dig Dis Sci* 2003;48:1813–1817.
181. Johnston N, Knight J, Dettmar PW, et al. Pepsin and carbonic anhydrase isoenzyme III as diagnostic markers for laryngopharyngeal reflux disease. *Laryngoscope* 2004;114:2129–2134.
182. Kim TH, Lee KJ, Yeo M, et al. Pepsin detection in the sputum/saliva for the diagnosis of gastroesophageal reflux disease in patients with clinically suspected atypical gastroesophageal reflux disease symptoms. *Digestion* 2008;77:201–206.
183. Watson DI, Jamieson GG, Pike GK, et al. Prospective randomized double-blind trial between laparoscopic Nissen and anterior partial fundoplication. *Br J Surg* 1999;86:123–130.
184. Laws HL, Clements RH, Swillie CM. A randomized, prospective comparison of the Nissen fundoplication versus the Toupet fundoplication for gastroesophageal reflux disease. *Ann Surg* 1997;225:647.
185. Hagedorn C, Lonroth H, Rydberg L, et al. Long-term efficacy of total (Nissen-Rossetti) and posterior partial (Toupet) fundoplication: results of a randomized clinical trial. *J Gastrointest Surg* 2002;6:540–545.
186. Cai W, Watson DI, Lally CJ, et al. Ten-year clinical outcome of a prospective randomized clinical trial of laparoscopic Nissen versus anterior 180° partial fundoplication. *Br J Surg* 2008;95:1501–1505.
187. Jobe BA, Wallace J, Hansen PD, et al. Evaluation of laparoscopic Toupet fundoplication as a primary repair for all patients with medically resistant gastroesophageal reflux. *Surg Endosc* 1997;11:1080–1083.
188. Bell RC, Hanna P, Mills MR, et al. Patterns of success and failure with laparoscopic partial fundoplication. *Surg Endosc* 1999;13:1189–1194.

189. Patti MG, Robinson T, Galvani C, et al. Total fundoplication is superior to partial fundoplication even when esophageal peristalsis is weak. *J Am Coll Surg* 2004;198:863.
190. Horvath KD, Jobe BA, Herron DM, et al. Laparoscopic Toupet is an inadequate procedure for patients with severe reflux disease. *J Gastrointest Surg* 1999;3:583–591.
191. Watson DI, Jamieson GG, Devitt PG, et al. Paraoesophageal hiatus hernia: an important complication of laparoscopic Nissen fundoplication. *Br J Surg* 1995;82:521–523.
192. Terry ML, Vernon A, Hunter JG. Stapled-wedge Collis gastroplasty for the shortened esophagus. *Am J Surg* 2004;188:195–199.
193. Carlson MA, Frantzides CT. Complications and results of primary minimally invasive antireflux procedures: a review of 10,735 reported cases. *J Am Coll Surg* 2001;193:429–439.
194. Hinder RA, Filipi CJ, Wetscher G, et al. Laparoscopic Nissen fundoplication is an effective treatment for gastroesophageal reflux disease. *Ann Surg* 1994;220:472.
195. DeMeester TR, Bonavina L, Albertucci M. Nissen fundoplication for gastroesophageal reflux disease – evaluation of primary repair in 100 consecutive patients. *Ann Surg* 1986;204:9–20.
196. Bammer T, Hinder RA, Klaus A, et al. Five- to eight-year outcome of the first laparoscopic Nissen fundoplications. *J Gastrointest Surg* 2001;5:42–48.
197. Granderath FA, Kamolz T, Schweiger UM, et al. Long-term results of laparoscopic antireflux surgery: surgical outcomes and analysis of failure after 500 laparoscopic antireflux procedures. *Surg Endosc* 2002;16:753–757.
198. Catarci M, Gentileschi P, Papi C, et al. Evidence-based appraisal of antireflux fundoplication. *Ann Surg* 2004;239:325–337.
199. Lundell L, Miettinen P, Myrvold HE, et al. Continued (5-year) follow-up of a randomized clinical study comparing antireflux surgery and omeprazole in gastroesophageal reflux disease. *J Am Coll Surg* 2001;192:172.
200. Nilsson G, Wenner J, Larsson S, et al. Randomized clinical trial of laparoscopic versus open fundoplication for gastroesophageal reflux. *Br J Surg* 2004;91:552–559.
201. Finlayson SR, Laycock WS, Birkmeyer JD. National trends in utilization and outcomes of antireflux surgery. *Surg Endosc* 2003;17:864–867.
202. So JB, Zeitels SM, Rattner DW. Outcomes of atypical symptoms attributed to gastroesophageal reflux treated by laparoscopic fundoplication. *Surgery* 1998;124:28–32.
203. Lundell L, Miettinen P, Myrvold HE, et al. Seven-year follow-up of a randomized clinical trial comparing proton-pump inhibition with surgical therapy for reflux oesophagitis. *Br J Surg* 2007;94:198–203.
204. Lundell L, Attwood SE, Ell C, et al. Comparing laparoscopic antireflux surgery with esomeprazole in the management of patients with chronic gastro-oesophageal reflux

disease: a 3-year interim analysis of the LOTUS trial. *Gut* 2008;57:1207–1213.

205. Spechler SJ. Comparison of medical and surgical therapy for complicated gastroesophageal reflux disease in veterans. The Department of Veterans Affairs Gastroesophageal Reflux Disease Study Group. *N Engl J Med* 1992;326:786–792.
206. Spechler SJ, Lee E, Ahnen D, et al. Long-term outcome of medical and surgical therapies for gastroesophageal reflux disease: follow-up of a randomized controlled trial. *JAMA* 2001;285:2331–2338.
207. Lord RV, Kaminski A, Oberg S, et al. Absence of gastroesophageal reflux disease in a majority of patients taking acid suppression medications after Nissen fundoplication. *J Gastrointest Surg* 2002;6:3.
208. Testa MA, Simonson DC. Assessment of quality-of-life outcomes. *N Engl J Med* 1996;334:835–840.
209. Trus TL, Laycock WS, Waring JP, et al. Improvement in quality of life measures following laparoscopic antireflux surgery. *Ann Surg* 1999;229:331–336.
210. Glise H, Hallerbäck B, Johansson B. Quality-of-life assessments in evaluation of laparoscopic Rossetti fundoplication. *Surg Endosc* 1995;9:183.
211. Velonovich V, Vallance SR, Gusz JR, et al. Quality of life scale for gastroesophageal reflux disease. *J Am Coll Surg* 1996;183:217–224.
212. Fernando HC, Schauer PR, Rosenblatt M, et al. Quality of life after antireflux surgery compared with nonoperative management for severe gastroesophageal reflux disease. *J Am Coll Surg* 2002;194:23–27.
213. Polomsky M, Siddall KA, Salvador R, et al. Association of kyphosis and spinal skeletal abnormalities with intrathoracic stomach: a link toward understanding its pathogenesis. *J Am Coll Surg* 2009;208:562–569.
214. Hashemi M, Peters JH, DeMeester TR, et al. Laparoscopic repair of large type III hiatal hernia: objective follow-up reveals high recurrence rate. *J Am Coll Surg* 2000;190:553–560.
215. Salminen PT, Hiekkanen HI, Rantala AP, et al. Comparison of long-term outcome of laparoscopic and conventional Nissen fundoplication: a prospective randomized study with an 11-year follow-up. *Ann Surg* 2007;246:201–206.
216. Oelschlager BK, Pellegrini CA, Hunter J, et al. Biologic prosthesis reduces recurrence after laparoscopic paraesophageal hernia repair: a multicenter, prospective, randomized trial. *Ann Surg* 2006;244:481–490.
217. Rosen R, Nurko S, Furuta GT. Impeding gastroesophageal refluxate: a new application of an old medication. *Gastroenterology* 2003;125:984–985.

Chapter 43

Esophageal Tumors and Injury

Jonathan D'Cunha and James D. Luketich

Key Points

1 The esophagus lacks a serosal layer. This is distinctive from other parts of the gastrointestinal tract. It is a major factor as tumor growth radially is not limited as in other gastrointestinal cancers.

2 Esophageal perforation is a morbid clinical entity that has increasing incidence due to invasive procedures where iatrogenic injury accounts for over 50% of cases.

3 The management of esophageal perforation is dictated by location of the perforation, the clinical condition of the patient, and the presence of underlying pathology.

4 Esophageal stenting is a newer modality which has a role in esophageal perforation in well-selected clinical cases.

5 The incidence of esophageal adenocarcinoma mirrors the rise in gastroesophageal reflux disease and obesity at an epidemic rate.

6 In advanced stages, neoadjuvant therapy for esophageal adenocarcinoma suggests a survival advantage when chemoradiation is given prior to surgery for advanced disease. Early stage disease with minimal to no nodal involvement may go directly to surgery in selected cases.

7 Surgery remains the primary therapy for esophageal cancer and options include transhiatal esophagectomy, Ivor Lewis esophagectomy, three-field esophagectomy, thoracoabdominal esophagectomy, and minimally invasive esophagectomy.

8 Minimally invasive esophagectomy can be performed safely with excellent oncologic outcomes and lower morbidity than the open procedure.

9 There are numerous palliative options for the patient with advanced esophageal cancer to maintain comfort, afford oral intake, and manage the symptoms of the disease in the end-stage situation.

INTRODUCTION

The esophagus is an active conduit that assists in transfer of food and secretions from the pharynx to the stomach. The esophagus is an organ of motility and provides no absorptive function. It also isolates the food and secretions from the mediastinum during transit.

Although the esophageal anatomy has been reviewed in the previous chapter, there are several points of consideration which need to be outlined as they are particularly relevant to surgical practice. First, three indentations can be identified on esophagram (Fig. 43-1). The cricopharyngeus muscle is the most proximal indentation and is a common location for iatrogenic perforation. The second indentation is the aortic arch which is just to the left of the esophagus and a common location for foreign body or food impaction. The third indentation is the left mainstem bronchus.

In the adult, the length of the esophagus is somewhat variable and certainly becomes relevant in the presence of a perforation, injury, or any requirement for reconstruction. The average overall length of the esophagus is 24 cm, with the esophagus beginning at the cricopharyngeus which is 14 to 16 cm from the incisors in an average-sized adult and ends at the gastroesophageal sphincter which is located 38 to 40 cm from the incisors when measured endoscopically.

The blood supply to the esophagus is segmental. The esophagus is vascularized by numerous arteries coursing through the lateral attachments and has an extensive submucosal collateral circulation. The cervical esophagus receives blood from the superior and inferior thyroid arteries. Multiple aortoesophageal arteries supply the intrathoracic esophagus and connect via collaterals with the inferior thyroid, intercostal, bronchial, inferior phrenic, and left gastric arteries. This blood supply is especially relevant during any operation on the esophagus and control of these segmental vessels is critical for a smooth operative and postoperative course.

1 The esophagus is composed of an outer longitudinal muscle layer and an inner layer of circular muscle. There is no serosal layer and this is a critical consideration when one thinks about disease processes of the esophagus. The lack of serosal layer is a distinguishing feature of the esophagus when compared with other parts of the gastrointestinal tract. The esophagus also has a unique submucosal layer which has a high fat content. This leads to an overlying mobility of the mucosa and propensity for proximal retraction such that care must be taken when placing sutures for reconstruction and minimizing the potential for anastomotic leak. The intramural lymphatic network is predominantly located within the submucosa of the organ. This is a rich lymphatic network which is especially relevant when one considers oncologic spread of tumor. There are also lymphatic channels within the lamina propria of the mucosa. All of this sets the stage for even superficial tumors to be associated with nodal metastases.

The esophagus is innervated by the autonomic nervous system. The cervical esophagus receives parasympathetic innervation through the recurrent laryngeal branches of the vagus nerve. Thus, injury to the recurrent laryngeal nerve not only produces vocal cord dysfunction, but also upper esophageal sphincter dysfunction.

ESOPHAGEAL INJURY

Perforation

Esophageal perforations are a major source of morbidity (10% to 60%) and mortality (4% to 50%); furthermore, following a perforation, 10% to 50% of patients develop strictures requiring dilations.[1–9] To date, no unified approach is available to treat these complex problems. Accurate diagnosis and early treatment are essential to the successful management of these complicated and often significantly ill patients. Some investigators suggest aggressive operative intervention (e.g., surgical exploration and repair or gastric conduit takedown with diversion) for patients with postesophagectomy intrathoracic anastomotic leak, while others recommend nonoperative management with stenting, jejunostomy feeds, perianastomotic drainage, and broad-spectrum antibiotics.[5,10–15] Guidelines for either approach may work depending on the injury and thoracic surgeons must incorporate clinical judgment in the therapeutic decision-making process. The decision is influenced by the location and size of the perforation, the timing and mechanism, the degree of periesophageal soling and extravasation, coexisting pathology of the esophagus, the patient's overall clinical condition and perhaps most importantly, the experience of the surgeon.

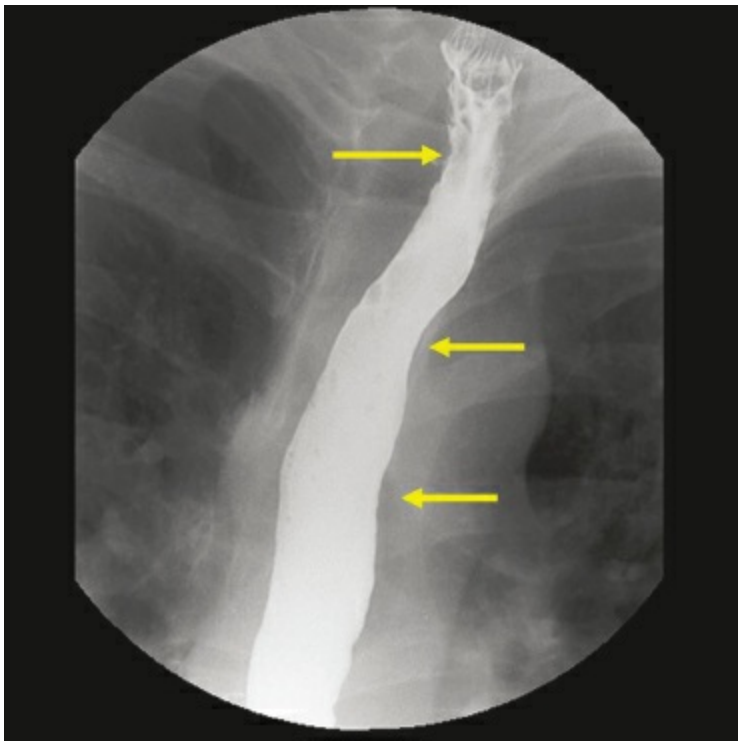

Figure 43-1. Barium contrast esophagography showing the constriction caused by the cricopharyngeal muscle, aortic arch, and the left mainstem bronchus. Indentations of the esophagus made by external structures are important anatomic landmarks and are often the sites of perforation due to instrumentation.

2 The incidence of perforation has risen in the modern era due to the rise in endoscopic interventions. The causes of esophageal perforation are listed in Table 43-1. Generally speaking the incidence of iatrogenic perforation (59%) far outweighs the incidence of spontaneous perforations (15%).[12] Other less common injuries include foreign-body

ingestion (12%) and trauma (9%). Ingestion of foreign bodies or caustic materials most commonly causes perforations in the anatomic areas just proximal or at narrowing (cricopharyngeus, level of aortic arch, and the level of left mainstem bronchus). Also included in the area at risk is the lower esophageal sphincter zone. External penetrating trauma can occur at any level but is seen more commonly in the cervical esophagus as the mediastinal portion is posterior and protected by the thorax. The morbidity and mortality of penetrating esophageal trauma is usually related to associated injuries including major vascular and airway structures.[16] Blunt traumatic perforation of the esophagus is exceedingly rare.

The most commonly referenced and discussed perforation is the spontaneous one. This results from a sudden increase in intraesophageal pressure and associated with hyperemesis, childbirth, seizure, or prolonged coughing. Boerhaave syndrome is of special historical note, wherein patients develop perforation of the distal esophagus following extensive ingestion of food or alcohol. What follows is violent emesis resulting in a distal esophageal perforation, frequently into the left chest. The syndrome was named after Herman Boerhaave, who provided a detailed account of this condition in 1723 through a postmortem correlation of the perforation found in the High Admiral of the Dutch Navy, Baron Van Wassenaer.[17] Legend has it that the admiral attempted to relieve his postprandial discomfort by self-induced vomiting after having feasted on roast duck and beer.

Table 43-1 Causes of Esophageal Perforation

Instrumental
Endoscopy
Dilation
Intubation
Sclerotherapy
Laser therapy
Noninstrumental
Barogenic trauma
Postemetic (Boerhaave syndrome)
Blunt chest or abdominal trauma
Other (e.g., labor, convulsions, defecation)
Penetrating neck, chest, or abdominal trauma
Operative trauma
Esophageal reconstruction (anastomotic disruption)
Vagotomy, pulmonary resection, hiatal hernia repair, esophagomyotomy
Corrosive injuries (acid or alkali ingestion)
Erosion by adjacent infection
Swallowed foreign body

Clinical Features of Esophageal Perforation

The presenting features depend on the location of perforation and the time interval from perforation to presentation. Underlying comorbidities may also have an influence on the presentation and the patient's physiologic reserve. Patients with cervical perforation present with dysphagia, neck pain, dysphonia, and subcutaneous neck emphysema. Intrathoracic perforations present with signs and symptoms of mediastinitis as follows: chest pain, tachycardia, tachypnea, fever, and leukocytosis. Perforations of the intra-abdominal esophagus may present as an acute abdomen with signs and symptoms as follows: pain, tachypnea, tachycardia, fever, and leukocytosis. More significant perforations and longer intervals to presentation contribute to the features of systemic sepsis, shock, and rapid deterioration.

Diagnosis

The diagnosis of esophageal perforation needs to begin with the clinician and their index of suspicion. Any patient who presents with pain following an endoscopic intervention needs to be carefully evaluated for perforation. The initial workup involves careful history and physical examination, laboratory studies including leukocyte count, and chemistry panel for acidosis. Chest x-ray is a good screening test for other diagnoses in the differential. Contrast esophagography remains the gold standard for diagnosis as the study will diagnose and localize the site of the perforation. This study also gives important information about coexisting pathology of the esophagus and the degree of extravasation and its trajectory. Water-soluble contrast (e.g., Gastrografin) is the initial agent utilized, followed by thin barium to enhance the sensitivity of the study. Water-soluble agents demonstrate 50% of cervical perforations and 80% of intrathoracic perforations.[18] Thin barium will identify 60% of cervical and 90% of intrathoracic perforations.[19] If there is a chance of aspiration or high concern of tracheoesophageal fistula, thin barium should be used from the outset because the hyperosmolar water-soluble contrast agents may cause rapid pulmonary edema and respiratory compromise.

Computerized tomography (CT) scan is very useful in the diagnostic evaluation of the patient with concern for esophageal perforation. Often a CT scan is the first test obtained following a chest x-ray as it affords the clinician the ability to narrow the differential diagnosis. CT may be useful for identifying the site of perforation and any associated mediastinal or pleural fluid collections. It is very common for a CT scan finding to prompt thoracic surgical consultation or transfer and there is much additional information about the patient's overall status which is routinely utilized in the management plan. However, it should be emphasized that the barium swallow should be the procedure of choice unless there is a significant risk of aspiration.

Flexible esophagoscopy should be utilized liberally in the diagnostic evaluation of the esophagus and in the planning of treatment options, and in a significant number of cases it can also be used for intervention. The scope is utilized to directly visualize the area of perforation and identify any potential associated pathology. It has a sensitivity of over 95% and a specificity of 80% or even higher depending on the experience of the physician.[20] We routinely perform flexible endoscopy as the initial step in the operating room when considering all options for patient management. Concern has been expressed by some that the instrumentation of the esophagus and insufflation of air can worsen the extent of injury and pathology and we would agree with that in inexperienced hands. With care and experience, however, the flexible scope can be used safely and more effectively delineates the problem to aid in surgical decision-making that follows. The vast majority of patients will require an endoscopic evaluation at some point and the timing of this will depend on clinical presentation and findings on radiologic imaging. For very small leaks present in stable and nontoxic patients, when the contrast study shows little or no extravasation, we may opt to hold off on an endoscopy in select cases.

Management

3 The treatment of esophageal perforation is managed according to the clinical presentation which includes the location of the perforation, the degree of soilage, and the clinical condition of the patient. Generally speaking, the sooner diagnosis and a treatment plan is carried out, the better the outcome. The goal of treatment is to stabilize the patient, stop ongoing soilage, control the infection, and reestablish esophageal continuity. Algorithm 43-1 provides general guidelines to the management of patients with esophageal perforations.

Nonoperative Treatment

For properly selected patients with esophageal perforation, nonoperative management may be appropriate. Generally, as thoracic surgeons, we err on the side of operative exploration intervention given the potential gravity of missing a clinically significant esophageal perforation with mediastinal soilage. Reports of nonoperative management date back to the 1960s in which successful management was accomplished in 18 highly selected patients with only one death.[21] In the late 1970s, criteria were published for nonoperative management.[22] Current guidelines for patients that can be managed nonoperatively include those with no transmural perforation or for whom transmural perforation represents a contained process. There must also be no associated esophageal pathology such as malignancy and no signs of systemic illness. The management of the nonoperative approach begins with the administration of broad-spectrum antibiotics (including antifungals), the suspension of oral intake, and vigilant clinical monitoring. The patient is followed clinically and reimaged as needed, generally within 48 to 72 hours with an esophagram and CT scan. If the patient improves during that time and testing is favorable, the diet may be advanced to clear liquids with the patient eventually being discharged on oral antibiotics and full liquids until reevaluation with imaging in clinic in 2 weeks. Any signs of sepsis such as fever, tachycardia, or leukocytosis suggest failure of this approach and further intervention should be expeditiously considered.

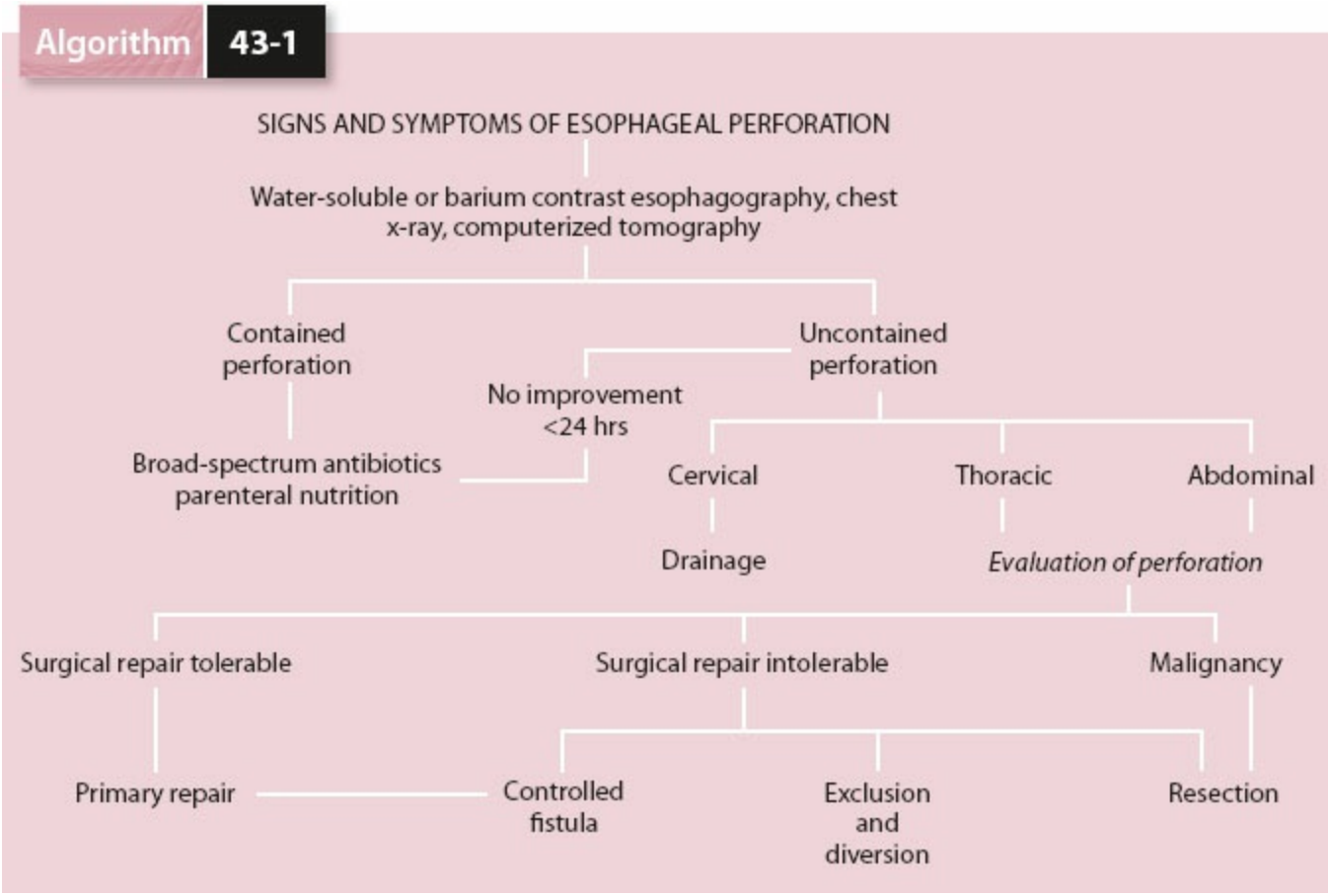

Algorithm 43-1. Evaluation and treatment of esophageal perforation.

Esophageal Stents

4 Endoscopic placement of endoluminal stents for perforations has been a concept which has been discussed for several decades.[23] In the last 10 years, the technology of stents has improved such that deployment is easier and our indications have expanded to include placement for perforations. Starting with small limited series,[24–30] their use has expanded dramatically to the point that they have become one of the main tools in the management of select, contained perforations. Highly selected patients with perforations are candidates for stenting in the context of a thoracic surgical practice according to the principles outlined in this section. Our own investigations and use in our practice has found that esophageal stent placement for perforations facilitates source control, may minimize stricture formation, and frequently allows for early oral intake. However, success depends on a uniform approach that focuses on appropriate patient selection, proper stent placement technique, thorough drainage procedures which cannot be underemphasized, and meticulous postoperative care. Our recommended uniform approach is presented here and this approach has yielded excellent results.[31–33]

DIAGNOSTIC EVALUATION

A computerized tomography (CT) scan, with or without oral and intravenous (IV) contrast, is a good initial diagnostic test. The role of a CT scan is to help determine whether additional source-control measures are needed (e.g., tube thoracostomy, decortication). We frequently perform the contrast esophagram second as the barium may interfere with the CT scan and the only reason we omit this step is in the case of aspiration risk. The barium esophagram is regarded as a real-time image, whereas the contrast delivery of the CT scan does not provide the same functional and anatomic details of the site and tracking of the leak, thus we prefer both when possible.

PATIENT SELECTION

For perforations proximal to the cricopharyngeus, stents have little or no role. For perforations 2 cm or more distal to the cricopharyngeus, a stent may work if the proximal extent seats just below the cricopharyngeus muscle. If the stent seats at or above the cricopharyngeus, patients experience intolerable foreign-body sensations during deglutition and reflux and coughing are generally severe. Also of note, stents placed in the proximal esophagus may cause pressure and compression of the posterior membranous trachea leading to dyspnea and, in severe cases, critical airway compromise. If a stent is considered in the proximal esophagus, the physician should strongly consider performing a simultaneous bronchoscopy to assess airway patency. Perforations below this area may be good candidates for stenting when there is limited perforation, and there is good purchase of esophagus above and below the site of the perforation. This might include perforations associated with malignancy and in benign diseases such as iatrogenic perforation, Boerhaave syndrome, and select cases of achalasia. Patients with perforations from near-obstructing cancers can be ideal candidates for stents as the stent will purchase well against the tumor, leading to sealing of the perforation and relieving any coexisting blockage above or below the perforations. In addition, operating on perforated cancers can be a significant clinical problem as this may occur at the initial diagnosis or the endoscopic ultrasound (EUS), or may occur during chemo and radiation, thus making stenting our procedure of choice in the setting of cancer.

Initial broad-spectrum antimicrobial therapy is directed to cover common gram-negative bacteria, anaerobic bacteria, and fungi. We generally use a beta-lactam agent in combination with fluconazole, which is usually sufficient. We adjust therapy to culture findings. Duration of therapy is patient dependent, but it is typically continued for 10 to 14 days after resolution.

In addition to antimicrobial therapy, we tailor further source control in accordance with clinical, CT scan, endoscopic, and intraoperative findings. We emphasize aggressive source control, and operative drainage of any extraluminal material. Stent placement without drainage in the setting of mediastinal soilage is a risky approach and if it is done, one may question whether the perforation was small enough to need intervention and, if larger, we would typically perform a VATS or thoracotomy to debride any soilage. If patients deteriorate clinically following any treatment, consideration of the presence of undrained sepsis should always be considered. At times, a patient might require several interventions to control the local and regional sepsis.

Source control measures vary depending on clinical and anatomical findings:

Mediastinal air (no fluid): antibiotics only without additional source control measures.

- Mediastinal fluid collection or abscess: operative drainage; the approach varies by anatomical location:
  - Neck and superior mediastinum: lower neck incision with blunt mediastinal dissection, irrigation, open packing, and, if deemed appropriate, drain placement.
  - Posterior mediastinum at any level: right thoracoscopy or thoracotomy with wide

pleural incision, drainage, irrigation, and large-bore chest tube(s) placement.
  - Lower posterior mediastinum only: left thoracoscopic or open drainage.
- Free-flowing pleural effusion: large-bore tube thoracostomy.
- Empyema: thoracoscopic or open decortication.

STENT SELECTION

Numerous stents are available for use. We prefer the Wallflex fully covered stent and find that the longer stents (15 cm) work better to cover defects and minimize migration.

STENT PLACEMENT TECHNIQUE

We perform our procedures in the operating room and with the patients under general endotracheal anesthesia. The key components of our stent placement technique are the following:

1. Position: supine position with the head of the bed elevated 30 degrees.
2. Intraoperative fluoroscopy:
   - Radiopaque skin markers: large-bore IV needles taped to the skin. Lock the fluoroscopy arm into position once the desired image has been obtained and before skin marker placement; moving the fluoroscopy arm after marker placement may lead to inaccurate marking.
   - At times, we will use intraoperative esophagram: if the leak is small, we will inject contrast through the esophagoscope to clearly identify it; we always confirm leak sealing with contrast injection after stent placement. We use isomolar and water-soluble contrast dye (iodixanol [Visipaque]; GE Healthcare Inc, Princeton, NJ) to minimize respiratory complications in case of aspiration.
3. Wire of choice: superstiff, angled or straight tip, 0.035-in (0.8-mm) diameter, 260-cm length.
4. Stent position:
   - Minimum coverage: at least 3 to 4 cm above and below the leak or perforation.
   - Minimum distance from cricopharyngeus muscle (upper esophageal sphincter): 1 to 2 cm.
   - Distal end position: we avoid the distal end from crossing the GE junction.
5. Stent foreshortening or “jumping” on deployment: this varies by stent.
6. Intraoperative evaluation of stent position and proper sealing: every stent is placed and evaluated with fluoroscopic guidance and endoscopy.
7. Tools and techniques for stent repositioning (if stent is too distal or too proximal): the “rattooth” forceps is the best tool to pull the stent proximally if needed after deployment. If we need to advance the stent in a patient with a gastric conduit, then we will advance the gastroscope into the distal stomach, retroflex, lock the “rat-tooth” grasper on the distal end of the stent, and push the gastroscope forward.
8. Indications for immediate stent removal: we never leave a stent in place if it is not in perfect position, angulated too much, or obstructed.

POSTSTENT MANAGEMENT

1. Nutrition: enteral feeding access should be ensured as soon as possible, preferably at the time of endoscopic and operative interventions. We place an operative jejunostomy tube or percutaneous endoscopic jejunostomy tube in the occasional postesophagectomy patient who does not already have enteral feeding access. In patients with perforations, we place a percutaneous endoscopic gastrostomy (PEG) tube at the time of endoscopic or operative intervention but before stent placement. In our experience, placing a PEG tube has no effect on the perforation; placing a PEG tube after stent placement will likely displace the stent.
2. Aspiration and reflux precautions: these precautions are imperative in all postesophagectomy patients and in patients with stents that cross the gastroesophageal junction.
3. Postprocedure follow-up:
   a. Chest radiograph: we obtain chest radiography immediately after the procedure and daily thereafter to monitor for migration.
   b. Sepsis resolved: we wait until the patient is able to swallow appropriately; then we perform an esophagram.
   c. Ongoing sepsis: we thoroughly reassess the patient; ongoing sepsis is generally due to poor source control and/or nonsealing of the leak or perforation. Reintervention is then tailored to the situation but might require aggressive surgical intervention and stent removal and/or replacement.
   d. Stent migration: mandates replacement unless leak has resolved. This is typically not an emergency but should be addressed in a timely fashion.
4. Resumption of oral intake: this depends on the clinical scenario. A speech pathologist evaluates every patient before an esophagram. Only patients who are safe to swallow undergo an esophagram. Oral intake is then resumed.
5. Eventual stent removal or exchange: We generally repeat endoscopy at 3-week intervals and remove the stent. If a small leak persists, we restent so that the distal end of the stent is slightly proximal or distal to that of the previous stent to allow the area of inflamed gastric mucosa to heal.
6. Pain: pain appears to be less common in patients with leaks and perforations than in patients with malignant strictures. Persistent pain should prompt reevaluation, because it might represent ongoing mediastinal or pleural contamination.

Operative Treatment

The operative management of esophageal perforation is dictated by the location of the injury, extent of injury, and underlying pathology. The operative approaches include the following options: drainage alone, primary reinforced repair, esophagectomy with immediate/delayed reconstruction, and esophageal exclusion.

Perforations of the upper third of the esophagus to the level of the carina and treated by cervical drainage that is approached via a left neck incision as depicted in Figure 43-2. Traditionally it is not necessary to find or close the perforation as this will seal during the

process of healing. In order for this to be successful, however, wide and complete drainage must be accomplished. The posterior prevertebral fascia is opened completely to accomplish this. Preoperative imaging via CT scan will aid in ensuring that the important areas of contamination are addressed surgically. In the operating room we liberally use on-table flexible endoscopy to evaluate the defect and the location of the hole. If the hole is identified and it is small, we advocate for closure of the hole. The neck incision is loosely closed with staples over a drain. Postoperatively, broad-spectrum antibiotics are continued. One may consider a gastrostomy or jejunostomy tube for nutritional access during the time the patient is NPO. Typically at 5 to 7 days postoperatively a contrast esophagram is obtained, the patient's diet is advanced, and the drain is removed. If there is continued leak, the patient is left NPO or on clear liquids and restudied in 1 week. There should be no distal obstruction on the contrast study and if there is a stricture that prevents normal contrast flow, we advocate for dilation to aid in eventual closure of the esophageal fistula. As long as there is no underlying pathology and there is distal flow through the esophagus in the presence of adequate drainage, the esophageal perforations will heal spontaneously.

Perforations of the middle third of the esophagus are best approached through the middle third of the esophagus via a right 5th interspace posterolateral thoracotomy. After adequate IV access and arterial line placement, a single-lumen tube is placed and bronchoscopy/esophagoscopy is performed. The single-lumen endotracheal tube is changed to a double-lumen endotracheal tube and the patient is positioned in the left lateral decubitus position. We routinely start thoracoscopically, but typically these patients are very ill and thoracotomy is indicated early. At the time of entry into the chest, an intercostal m. flap is routinely taken. We use papaverine solution to enhance blood flow and great care is taken not to injure the flap when the retractors are placed. A Doppler is routinely used to confirm blood flow in the flap. All pleural collections are drained, the lung is decorticated, and the site of perforation identified after opening the posterior mediastinal pleura. Necrotic tissue at the site of the perforation is debrided and the esophagus is mobilized. A vertical myotomy is performed to expose the mucosa and the full extent of the tear (Fig. 43-3). The mucosa is repaired with interrupted or running absorbable suture. The muscular layer is reapproximated with interrupted fine silk suture. On-table endoscopy is performed to ensure the leak is repaired. The intercostal m. is then secured as an onlay patch. Large chest tubes are placed and a 10-French Jackson–Pratt drain is left in the area of the repair and placed to bulb suction. Typically nutritional access is not addressed at the time of the index operation as the patients are quite ill, and this can be accomplished at a later date. On POD 7, a contrast study is obtained and if there is no leak, the diet is advanced. Persistent leaks are treated with JP drainage, provided CT imaging demonstrates that there are no undrained collections. Esophageal dilation may be required to ensure proper forward flow. Reoperations for adequate drainage may be required. Esophageal stenting may be used to exclude the leak provided that there is adequate drainage and the principals described in the stenting portion of this chapter are followed. If the repair breaks down or there are signs of clinical sepsis, esophageal exclusion may be required with cervical esophagostomy, esophageal

resection, and gastrostomy tube. When the patient recovers and walks into clinic begging for reconstruction (this usually occurs at 6 to 12 months postexclusion), they may be considered for reconstruction most commonly approached as a substernal gastric pull-up.

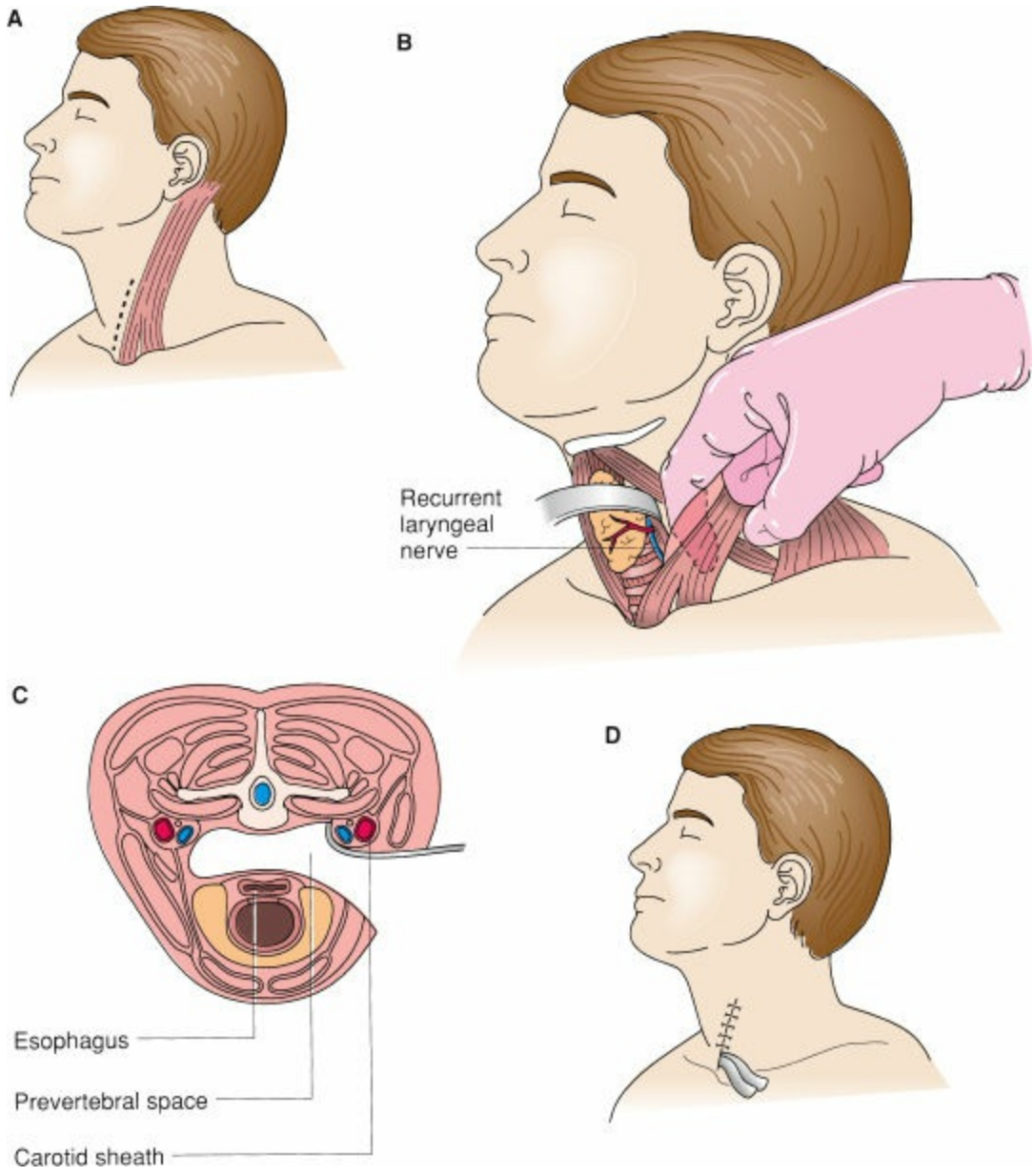

Figure 43-2. Approach for drainage of a cervical esophageal perforation. **A:** Skin incision parallel to the anterior border of the left sternocleidomastoid muscle, extending from the level of the cricoid cartilage to the sternal notch. **B:** With the sternocleidomastoid muscle and carotid sheath retracted laterally and the trachea and thyroid gland medially, blunt dissection along the prevertebral fascia in the superior mediastinum is carried out. Injury to the recurrent laryngeal nerve in the tracheoesophageal groove must be avoided. **C:** Schematic drawing of the prevertebral space drained by this cervical approach. **D:** Two 1-in rubber drains placed into the superior mediastinum are brought out through the neck wound to allow establishment of an esophagocutaneous fistula, which usually heals spontaneously.

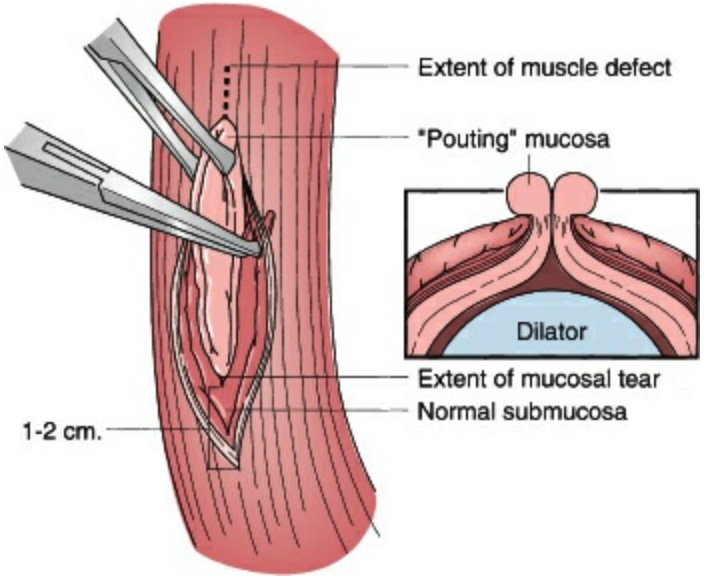

Figure 43-3. Primary repair of esophageal perforation. The edematous mucosa pouting through the muscular defect (*inset*) is grasped with Allis clamps and elevated. A 1-cm vertical esophagomyotomy is made at either end of the muscular defect to expose the entire limits of the tear. This is facilitated by using a right-angle clamp to direct muscularis away from underlying submucosa around the entire circumference of the tear. The result of this mobilization is exposure of a circumferential rim of normal submucosa that can then be closed.

Perforations of the distal third of the esophagus are approached via a left 7th intercostal space thoracotomy. Similar to the approach for middle-third perforations, after adequate IV access and arterial line placement, a single-lumen tube is placed and bronchoscopy/esophagoscopy is performed. The single-lumen endotracheal tube is changed to a double-lumen endotracheal tube and the patient is positioned in the left lateral decubitus position. Thoracoscopy may be an option, but typically these patients are very ill and thoracotomy is indicated. At the time of entry into the chest, an intercostal m. flap is routinely taken and care is taken not to injure it as retractors are placed. The chest is drained, lung decorticated, the perforation identified, and the repair performed as described above.

The operative treatment in the presence of underlying pathology deserves special attention and can be quite challenging. If there is distal obstruction, this must be dealt with. Strictures can be dilated or stented and often support the healing of a proximal perforation. Patients with achalasia who are perforated during pneumatic dilation are especially challenging. Many are candidates for nonoperative intervention as they have small perforations that are asymptomatic and the patients are clinically nontoxic. This is acceptable provided the distal obstruction has been relieved. For those who fail nonoperative management or are not candidates, operative management should be tailored to the individual and their pathology. In patients with preserved motility, the perforation should be repaired primarily and a vertical myotomy should be performed 180 degrees opposite the injury. These patients should have a nonobstructive fundoplication performed. For stable patients with advanced achalasia, esophagectomy should be considered. For unstable patients, esophageal exclusion should be performed.

Unstable patients with advanced pathology such as cancer should undergo esophageal

exclusion. This includes stapled esophageal diversion with resection of the diseased segment of the esophagus. A linear stapler is deployed on the esophagus proximally and at the gastroesophageal junction. The esophagus is resected. An end cervical esophagostomy is created saving as much esophageal length as possible. Pleural drainage is accomplished. Subsequently the patient undergoes placement of gastrostomy (+/– jejunostomy tube) with repair of the diaphragmatic defect from the abdominal side via laparoscopy or laparotomy. The components of operation may be staged based on the severity of patient illness. If the patient survives and is a candidate for reestablishment of continuity, this can be investigated at a later date when they recover. In the current healthcare climate, the presentation of an advanced perforated malignancy, stenting and drainage may have a role. Additionally, consideration should be given to end-of-life discussions depending on the extent of the cancer.

Caustic Injury

Caustic burns of the esophagus result from ingestion of caustic substances. In children, ingestion is typically accidental, but in adults, ingestion is often intentional as part of a suicide attempt. Although prevention programs, consumer product safety commissions, lobbying by the medical profession, and heightened consumer awareness have significantly diminished the devastating effects of caustic ingestions, caustic injury of the esophagus remains a significant medical and social problem. The two most common ingestion scenarios are accidental ingestions in children younger than 5 years old and suicide attempts in individuals 15 to 40 years old. The most commonly ingested agent is an alkaline household liquid cleaner. Although mortality from caustic ingestion is low, the morbidity associated with caustic ingestions is significant. Acute morbidities include perforation and necrosis, and late morbidities, which are more prevalent, include stricture formation and cancer.

The extent of injury to the esophagus caused by ingested caustic material is dependent on the volume and nature of the ingestion. Injuries resulting from ingestion of liquids are much more severe than those caused by ingestion of solids. The patient usually spits particulate matter out and, thus, it rarely moves beyond the oropharynx. Liquid caustic agents contribute to pathology down the length of the esophagus. Strong acid and alkali ingestions comprise the majority of caustic ingestions. These substances are sold in various liquid and solid/particulate forms. The most commonly ingested strong acids include industrial and swimming pool cleaning solutions, battery fluids, and antirust compounds. Commonly ingested strong alkaline-containing substances include household cleaning products and personal hygiene products. The most commonly ingested weak alkali is ammonia hydroxide, which is found in most bleach solutions. Weak alkalis cause much less injury and require far less therapy.

The burns from acid ingestion cause coagulative necrosis and a superficial eschar that protects the deeper layers of the esophagus from damage. Fortunately, acids tend to taste bitter and cause immediate pain, thus the patient will usually spit the substance out well before it reaches the esophagus and stomach. When acids are ingested in liquid form, they move quickly, typically spare the oropharynx, and produce skip injuries to the esophagus. Acids in liquid form cause gastric and duodenal injury more frequently than esophageal injury.

Alkaline burns are characterized by liquefactive necrosis, leading to far greater penetration at the level of the oropharynx and esophagus. Solid alkali has a propensity to adhere to the oropharynx, whereas liquid alkali is rapidly swallowed. Thus, liquid alkali results in more distal esophageal and gastric injury. Frequently there is penetration of all layers of the esophagus causing substantial secondary edema. Commensurate with this, the potential for perforation and circumferential scar formation is greatest with an alkaline ingestion. In contrast to acid ingestion, alkali substances are typically odorless and tasteless, which enhances the potential for deeper injury.

Management

The initial clinical presentation comprises oropharyngeal pain; irritability; and, in severe cases, excessive salivation, dysphagia, and airway compromise. Ingestion of particulate caustic substances results in signs of contact readily visible in the oropharynx. Hoarseness and stridor are signs of serious airway injury that mandate intubation. Retrosternal pain, neck crepitus, and sudden onset of epigastric pain imply full-thickness esophageal damage. Many patients present without symptoms and a significant proportion have injuries that will require intervention. Thus, a 24-hour period of observation is reasonable, even for asymptomatic patients, especially if there is any question about the circumstances of the ingestion or extent of injury.

As with any acute situation, management should begin with the standard assessment of the ABCs (airway, breathing, and circulation) (Algorithm 43-2). Most caustic ingestions involve the oropharynx, lips, and gums. As with most foreign-body ingestions, the most common sites for pathology within the esophagus are its three areas of narrowing: the cricopharyngeus, the level of the aortic arch, and the gastroesophageal junction. A stable patient may undergo imaging via posteroanterior and lateral upright chest and abdominal radiographs to evaluate for pleural effusion or free air. CT of the chest and abdomen can provide important anatomical definition of injury. Patients with no visible symptoms or only lip swelling or redness can be observed in the hospital or a short-stay unit for 24 hours to ensure they can tolerate oral feedings. This is typically for pediatric patients. Patients with oral lesions should undergo esophagoscopy and bronchoscopy. The bedside insertion of a nasogastric or orogastric tube is discouraged when the extent and depth of injury have not been fully evaluated.

After radiographic imaging, rigid or flexible esophagoscopy to characterize the location and extent of injury should be the next course of investigation. This instrumentation should be performed within the first 24 hours as the risk of procedural complication increases with time. The indications for esophagoscopy include stridor, vomiting, drooling, and intentional ingestion. Caution should be used when moving beyond the first sign of pathology below the cricopharyngeus. If there are respiratory symptoms, laryngoscopy and bronchoscopy should be performed. When injury is identified, the standard grading of the esophageal burn should be reported (Table 43-2).

Patients with grade I injuries have superficial burns causing edema and hyperemia. These patients can be observed, a normal diet can be advanced, and the patient ultimately can be followed in an outpatient clinic. Superficial grade I injuries cause mucosal sloughing and should heal without a stricture. Grade II injuries penetrate into the muscular layer of the esophagus and can result in either patchy (IIA) or circumferential (IIB) injury. Ulcerations (superficial and deep) and pseudomembranes are found during endoscopy. Once circumferential injury is identified, the risk of stricture formation increases dramatically. Grade III injuries are full-thickness injuries, and mediastinitis or peritonitis occurs within 48 hours. Grade III findings are characterized by gray mucosal slough, thrombosed submucosal vessels, and black eschar. All grade III burns and >75% of circumferential grade IIB burns cause esophageal stricture and, as expected, are

associated with a higher incidence of infection.

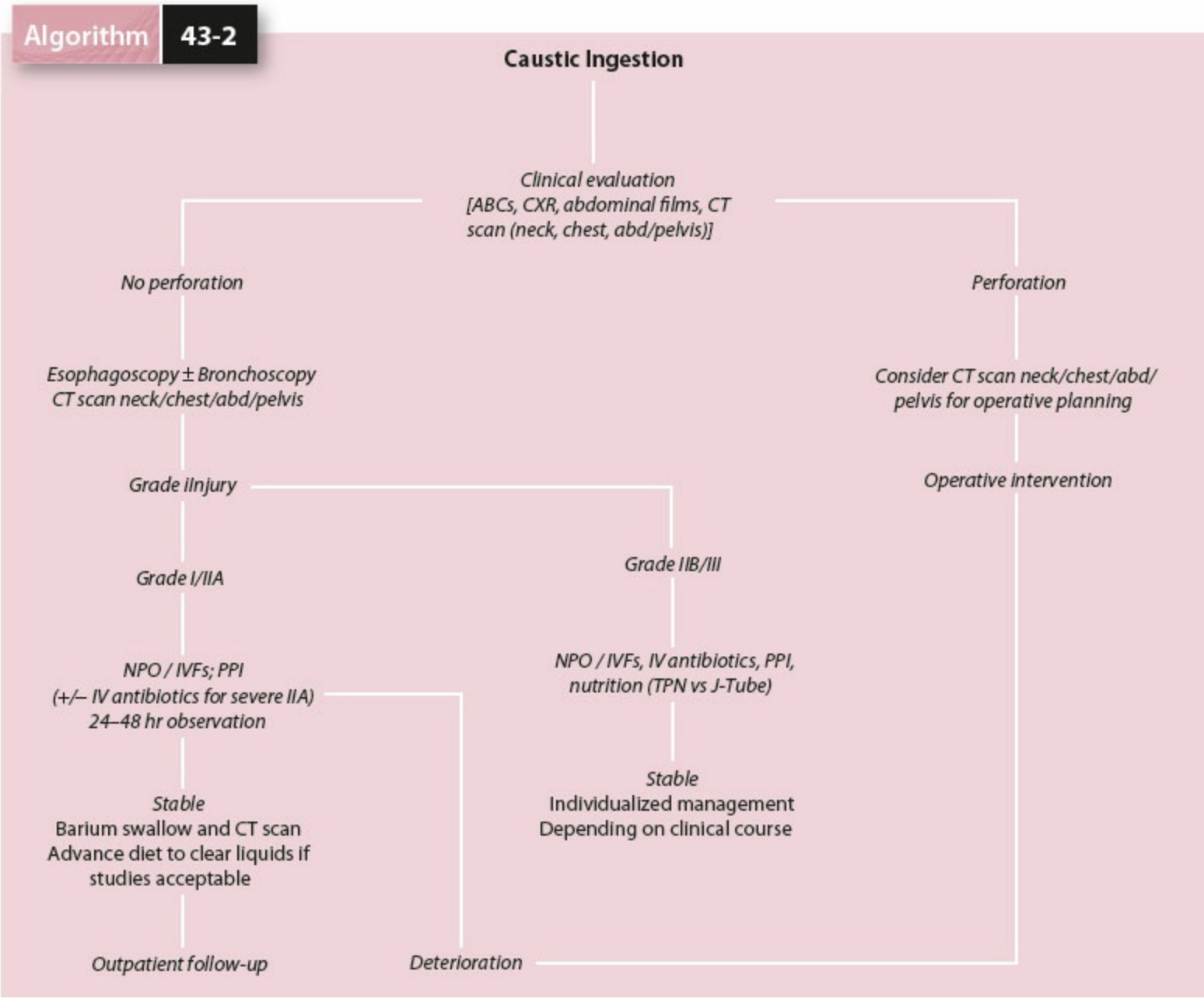

Algorithm 43-2. Proposed algorithm for evaluation and management of acute caustic ingestion.

Acute management of caustic ingestion should be dictated by the endoscopic grading of the esophagus and the clinical status of the patient (Algorithm 43-2). Patients should be evaluated for using endoscopy to grade the injury. If there is no evidence of perforation, patients with mild exposure (e.g., bleach or detergent ingestion) can be observed for 24 to 72 hours (depending on the clinical presentation). Generally, patients should be kept *nil per os* (NPO) until pain free. Enteral feedings can likely be introduced within 48 hours for all patients with grade I or IIA burns.

CLASSIFICATION

Table 43-2 Endoscopic Grading of Acute Caustic Injury to the Esophagus

Injury	Endoscopic	Depth of Grade Appearance Injury
I	Superficial hyperemia	Mucosal
IIA	Sloughing mucosa, superficial ulceration	Patch partial thickness
IIB	Deep ulceration	Circumferential
III	Eschar, necrosis	Full thickness

Patients with grade IIB or grade III esophageal burns without evidence of perforation should be placed in a monitored setting, kept NPO, and given IV fluids and IV antibiotics (penicillin derivative or clindamycin). Patients should also be maintained on proton pump inhibitors to reduce acid exposure of the esophagus as this may decrease the stricture incidence. Steroid administration is controversial, does not prevent stricture formation, and may mask findings in the serial abdominal examination. If corticosteroids (2 to 2.5 mg/kg/d) are used, they should be instituted within the first 24 hours of ingestion and for 3 weeks thereafter. Early introduction of parenteral nutrition is essential for all patients with esophageal perforation and for patients with poor gastric motility. Open gastrostomy is helpful for patients with grade IIB or III burns. Depending on the extent of injury, the patient may require mechanical ventilation. Esophagram (or CT scan with oral contrast) may be used as an adjunct evaluation. If free contrast extravasation into the mediastinum is visualized, drainage of the mediastinum into the pleural space is indicated. Further, esophageal resection may be required with findings of necrosis. On occasion, a contained mediastinal leak, which returns contrast material back into the esophagus, may be observed without the need for immediate drainage. Pneumoperitoneum is an absolute indication for laparotomy and resection of all dead tissues. Laparoscopic evaluation may be useful to evaluate the abdomen if there is isolated mediastinal pathology.

Strictures of varying degrees occur in almost all patients and, thus, careful follow-up is recommended after a caustic ingestion. The esophagus and stomach should be evaluated via barium swallow 3 weeks, 3 months, and 6 months after the ingestion to rule out stricture formation or gastric outlet obstruction. Esophagogastroduodenoscopy (EGD) is typically performed 3 weeks after the ingestion for full evaluation. Early endoscopy is warranted during the phase of cicatrix formation, and dilation is repeated at varying intervals. The interval for intervention is patient dependent and clinically dictated by the amount of dysphagia or interval to recurrence of dysphagia, the initial severity of burn, and findings on radiographic studies.

Operative Considerations

Delay in the diagnosis of esophageal perforation from caustic ingestion is uniformly fatal. Isolated mediastinal air can be managed with direct inspection of the thorax, open débridement of necrotic tissue, and drainage of the mediastinum. Caustic esophageal perforations are best managed with urgent esophagectomy. Removal of the entire esophagus is possible through a transhiatal approach followed by a cervical esophagostomy, gastrostomy, and feeding jejunostomy. Patients with extensive full-thickness esophageal and gastric necrosis should undergo total esophagogastrectomy with cervical esophagotomy and feeding jejunostomy. Of course, any operative intervention should include assessment of other organs involved and complete drainage/resection of necrotic tissue.

In most patients, management of esophageal strictures that develop as a result of caustic burns is the primary operative consideration. Circumferential grade IIB burns can be managed with an open gastrostomy and insertion of a string through the gastrostomy that exits transnasally. Four weeks after the burn, serial dilations using progressive antegrade bougienage from the oropharynx or retrograde stringing bougienage through the gastrostomy is effective. Retrograde string bougienage or antegrade dilations should be performed at 2- to 3-week intervals for consecutive dilations. Optimal caliber bougienage is 48 to 50 for adults and 34 to 36 for children. Esophageal stenting is a newer approach for second-degree esophageal burns, which may be more palatable than string bougienage. A removable, fully covered stent is placed endoscopically and left in place for 3 weeks. It can then be removed. Recent reports have suggested that this is an appropriate intervention to prevent stricture formation in some patients. Injection of the stricture with triamcinolone (30 mg/mL) also may be effective, especially in those strictures that are focal.

Esophageal replacement is usually considered if a stricture fails to resolve after 1 year of dilations, stricture injections, and antacid therapy. Malignant degeneration is possible at the area of the stricture, and esophageal cancer occurs at a 1,000-fold greater frequency in individuals with a caustic injury to the esophagus than in the general population. Any change in symptoms warrants radiographic and endoscopic evaluation. Options for esophageal replacement include reverse gastric tube, gastric pull-up, and colon or jejunal interposition. Most centers today use the gastric pull-up or colon interposition (retrosternal). Short-term complications of replacement are those typical of esophagectomy; anastomotic leak and poor conduit vascularity are the most feared complications. Long-term complications depend on the type of replacement. Stomach conduits have the problem of continued gastric acid secretion and the possibility of reflux and dysplasia. The colon (and the jejunum) can become redundant and require revision. Overall, there is no optimal substitute for one's own esophagus and efforts should be made to preserve it at all costs.

Foreign Body

Foreign-body ingestion and food bolus impaction are common occurrences that physicians can encounter when dealing with the esophagus. A majority of foreign bodies have been known to pass through the gastrointestinal tract spontaneously. However, roughly 10% to 20% of cases may require nonoperative intervention, with <1% requiring surgery.[34–36] A large percentage of objects that do not pass spontaneously remain in the cervical esophagus.

Foreign-body ingestion is most commonly seen in children between the ages of 6 months and 3 years, with over 100,000 new cases occurring in the United States annually.[37] Pediatric foreign-body ingestion is typically accidental and most frequently involve coins, followed by toy parts, batteries, bones, and food.[37] Cases of foreign-body ingestion in adults are seen more commonly among the psychiatric patients, patients with impaired cognition such as the elderly, and incarcerated individuals seeking secondary gain.[34–36]

Endoscopy is the choice of management when nonoperative intervention is a viable option. Timing of endoscopy is indicated by the risk of esophageal wall damage or aspiration, as well as the clinical status of the patient. Urgent intervention using endoscopy may be required in patients with severe distress, unable to swallow their own secretions, or with foreign bodies that are batteries or have sharp edges. Patients who do not fit these criteria and have no evidence of severe obstruction can be handled less urgently as most foreign objects will pass spontaneously.

Retrieval is the goal when dealing with foreign bodies that are not subjected to spontaneous passing. General anesthesia is recommended during the entirety of this procedure. Flexible endoscopy is the preferred method for most foreign bodies. A rigid endoscope is useful in the retrieval of foreign bodies lodged in the proximal esophagus at the level of the cricopharyngeus muscle. Rigid esophagoscopy is a rarer procedure and one should be familiar with the technique. Often senior surgical help should be sought to accomplish the procedure safely and effectively because this technique is rarely used in current training. Using either approach, the object should be reoriented with a grasper and removed safely. When using the flexible esophagoscope, we have found the overtube to be a very useful tool for removal of foreign bodies such that the esophagus is not injured proximally upon extrication of the object. Esophagotomy may be required when the lodged foreign bodies are large, have sharp edges, are embedded in the mucosa, or exceed the diameter of the rigid endoscope in all orientations. Following removal of the foreign body, completion esophagoscopy and contrast esophagoscopy should be performed to rule out injury. If there is a perforation, it should be managed according to the algorithm in Algorithm 43-1.

BENIGN NEOPLASMS

Table 43-3 represents a list of all benign neoplasms of the esophagus. All of these lesions are rare, with leiomyoma making up roughly 60% to 70% of all cases.[38,39] Esophageal polyps are also seen frequently in large referral centers and will be discussed. Other listed benign neoplasms of the esophagus will not be discussed in this chapter, but the possibility of an occurrence should be noted, especially during the formulation of a differential diagnosis.

Leiomyoma

As mentioned above, leiomyomas are by far the most common benign neoplasms of the esophagus, accounting for roughly 60% to 70% of these cases.[38,39] The incidence of leiomyoma of the esophagus reported in autopsy range from 0.005% to 5.1%.[40] Histologically, approximately 80% of leiomyoma originates from the muscularis propria and are located intramurally. Upon visual inspection of the esophagus, they are typically located in the middle and lower esophagus. They have been reported to present as single lesions. Because leiomyomas are slow-growing tumors, the size of these lesions often do not change for many years. Over 50% of these patients often are asymptomatic due to the nature of the growth.[39]

Table 43-3 Classification of Benign Esophageal Tumors

Epithelial Tumors
Papillomas
Polyps
Adenomas
Cysts
Nonepithelial Tumors
Myomas
Leiomyomas
Fibromyomas
Lipomyomas
Fibromas
Vascular tumors
Hemangiomas
Lymphangiomas
Mesenchymal and other tumors
Reticuloendothelial tumors
Lipomas
Myxofibromas
Giant cell tumors
Neurofibromas
Osteochondromas
Heterotopic Tumors
Gastric mucosal tumors
Melanoblastic tumors
Sebaceous gland tumors
Granular cell myoblastomas
Pancreatic gland tumors
Thyroid nodules

From Nemir P Jr, Wallace HW, Fallahnejad M. Diagnosis and surgical management of benign disease of the esophagus. *Curr Probl Surg* 1976;13(3):1–74, with permission.

Algorithm 43-3 depicts the process for evaluating and treating esophageal leiomyomas. Evaluation of a patient suspected of having a leiomyoma should begin with a barium swallow, endoscopy, EUS, and CT scan of the chest. Figure 43-4 depicts the typical appearance of an esophageal leiomyoma located in the midthoracic of the esophagus. This smooth walled characteristic may indicate that mucosa is not involved and that the lesion is contained in the submucosal layer. Figure 43-5 offers the endoscopic appearance of a distal esophageal leiomyoma. The utility of the EUS also gives clinicians the ability to ascertain the layer of origin of the mass. EUS in combination with fine-needle aspiration (FNA) may be used to obtain tissue for histologic studies such as immunohistochemical (IHC) analysis. IHC analysis is helpful in differentiating leiomyomas from other more aggressive pathology such as leiomyosarcomas and gastrointestinal stromal tumors (GISTs) and should be incorporated into the surgical planning for diagnosis.[41] However, FNA should not be routinely performed due to the association between preoperative biopsy and mucosal perforation at the time of surgical enucleation.[42]

Treatment in asymptomatic patients with tumors <3 cm is currently controversial. Nonoperative surveillance or resection should be discussed with patients in this cohort. The surgical removal of an esophageal leiomyoma is indicated with the development of symptoms of dysphagia, an increase in tumor size, mucosal ulcerations, and to definitively rule out a malignant process such as a leiomyosarcoma.

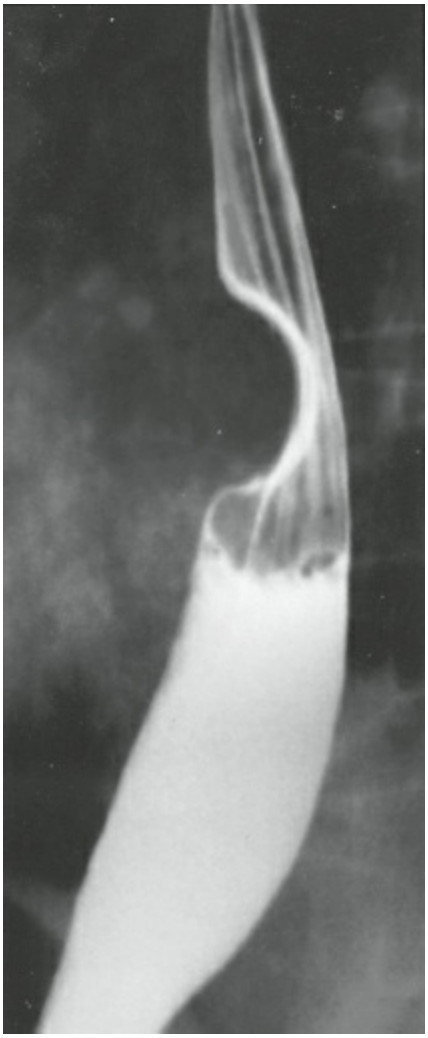

Figure 43-4. Esophagram of a leiomyoma. The acute angle at its junction with the esophageal wall is typical. (Reproduced with permission from Orringer MB. Tumors of the esophagus. In: Sabiston DC Jr, ed. *Textbook of Surgery*. 13th ed. Philadelphia, PA: WB Saunders; 1986:736.)

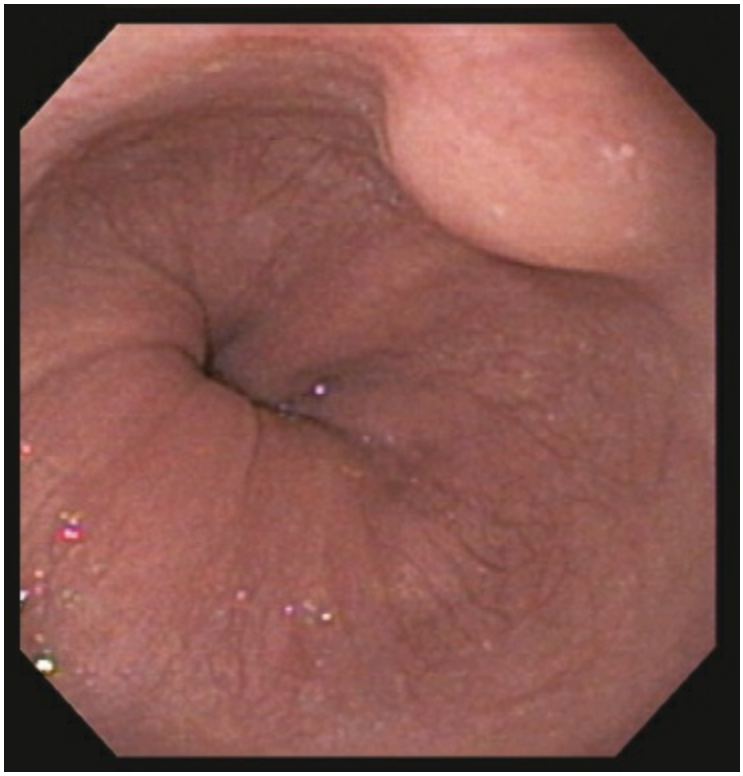

Figure 43-5. Endoscopic appearance of an esophageal leiomyoma at the level of the gastroesophageal junction. (Courtesy of Michael L. Kochman, MD, Hospital of the University of Pennsylvania, Philadelphia.)

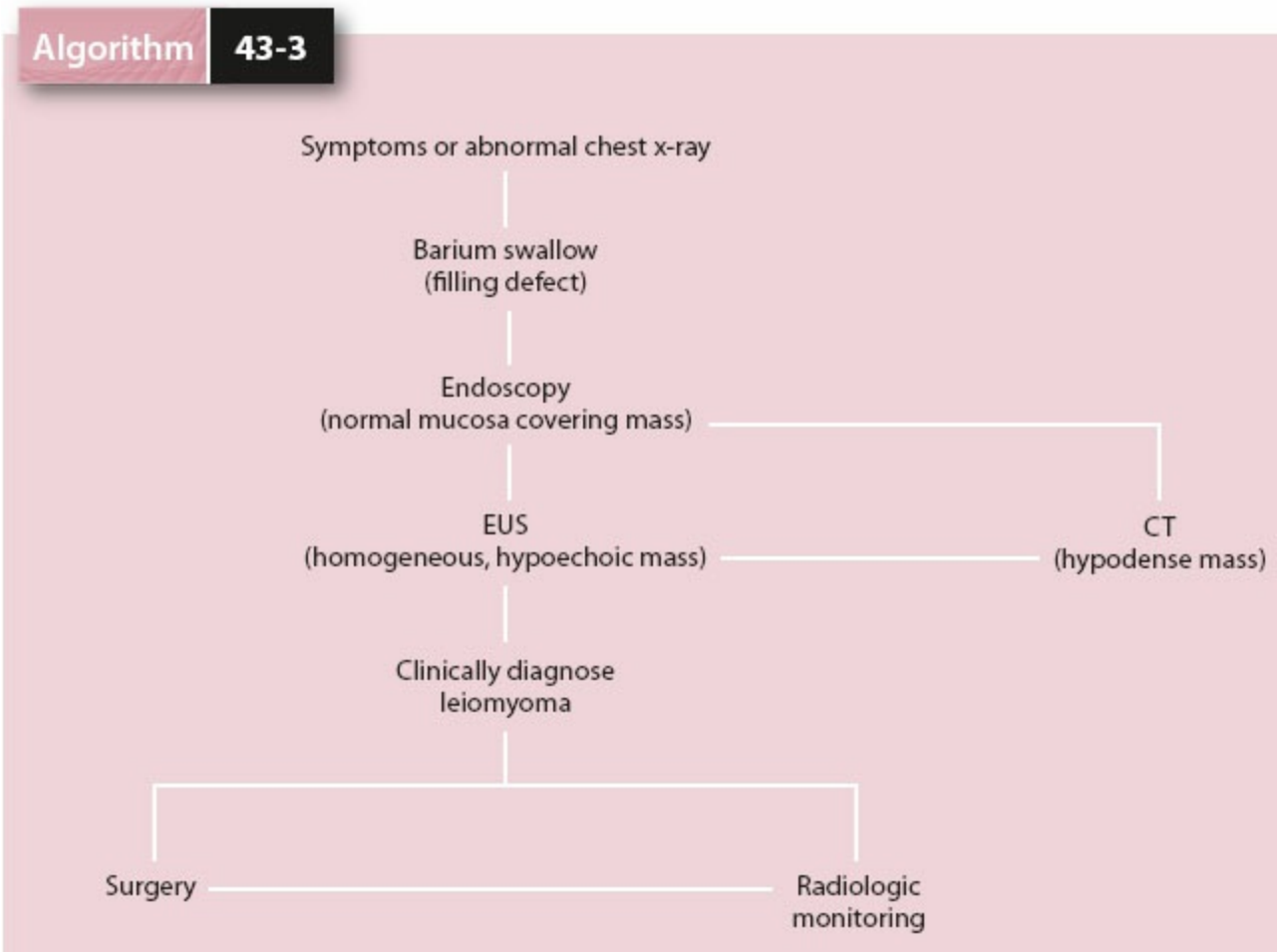

Algorithm 43-3. Evaluation and treatment of esophageal leiomyoma.

Like other lesions of the esophagus, the surgical approach is dependent on tumor

location, size, and characteristics. The typical approach to leiomyomas originating from the mid to distal esophagus is via the right thorax. Surgical extramucosal enucleation is an approach that has shown excellent results with patients with leiomyomas that are less than 8 cm without annular characteristics. Mortality was found to be less than 1% for this approach with over 90% of patients symptom free at 5 years.[43]

Minimally, invasive approaches to enucleation have also been shown to be effective, particularly in tumors smaller than 5 cm. Zaninotto and colleagues performed 11 video-assisted enucleations of leiomyomas of the esophagus with no major morbidities, including death or postoperative leaks.[44] Leiomyomas greater than 8 cm or annular in character usually require esophageal resection. Approaches and techniques to esophageal resection will be covered later in this chapter.

Fibrolipomas and Fibrovascular Polyps

Fibrolipomas and fibrovascular polyps are rare tumors of the esophagus that often present as an intraluminal mass originating from the cervical portion of the esophagus. Clinically, these tumors will decrease intraluminal diameter and volume, and patients will present with dysphagia. The growth of these tumors are influenced by the peristaltic action of the esophagus, causing these lesions to elongate over time.[45] The stalk-like nature of esophageal fibrolipomas can be seen endoscopically and subsequently should be removed. Cervical esophagotomy or right thoracotomy approaches may be required for resection if the size of the lesions restrict mobility. In rare instances, patients can present with their polyp protruding from their mouth after an episode of coughing or emesis (Fig. 43-6). Polyps may also flip and cause blockage of the airways and should be excised to avoid this occurrence.

MALIGNANT NEOPLASMS

Tumors of the esophagus include adenocarcinoma, squamous cell carcinoma, small cell carcinoma, leiomyosarcoma, rhabdomyosarcoma, fibrosarcoma, liposarcoma, lymphomas, and metastatic lesions from the other sites. Adenocarcinoma and squamous cell carcinoma are the most common, with adenocarcinoma emerging in recent years in epidemic type rates of increase (Fig. 43-7). Recent analysis of incidence has demonstrated that there are about 17,000 cases diagnosed each year in the United States. About 14,000 will die annually. The lifetime risk of developing esophageal cancer is 0.5%, with a slightly higher incidence in males. Risk factors include tobacco, alcohol, and obesity. Tylosis is the only recognized family syndrome that predisposes patients to the development of esophageal cancer. It is an autosomal dominant disorder that has been mapped to chromosome 17q25.[40] These patients have a 95% risk of developing squamous cell carcinoma of the esophagus by age 70.



Figure 43-6. This patient presented with a large esophageal polyp protruding from her mouth following an episode of coughing. This polyp was found to originate from a narrow stalk in her cervical esophagus and was removed endoscopically. Of note, she had undergone operative resection of a cervical esophageal polyp earlier in life.

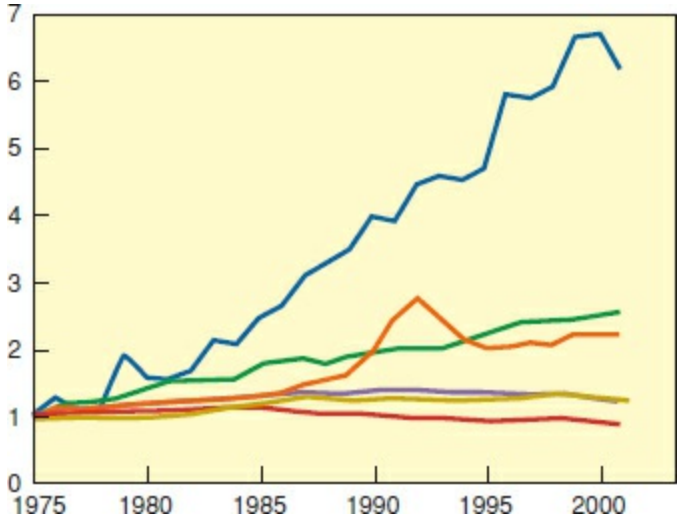

Figure 43-7. Relative change in incidence of esophageal adenocar-cinoma and other malignancies (1975–2001). Data from the National Cancer Institute's Surveillance, Epidemiology, and End Results program with age-adjustment using the 2000 U.S. standard population. Baseline was the average incidence between 1973 and 1975. *Blue line,* esophageal adenocarcinoma; *green line,* melanoma; *orange line,* prostate cancer; *yellow line,* breast cancer; *purple line,* lung cancer; *red line,* colorectal cancer. (Adapted with permission from Pohl H, Welch G. The role of overdiagnosis and reclassification in the marked increase of esophageal adenocarcinoma incidence. *J Natl Cancer Inst* 2005;97:142–146.)

Diagnosis and Staging

The vast majority of cases of esophageal cancer present late. The disease is largely asymptomatic due to the location of the tumor and clinical symptoms do not drive patient presentation until there is a significant degree of obstruction or bleeding. As a muscular conduit, the esophagus is quite accommodating until it is narrowed significantly. Up to 80% of patients present with dysphagia and 20% present with odynophagia. More subtle signs of a problem are often elicited retrospectively when questioning patients, where they admit to retrosternal discomfort and progressive symptoms that have been overlooked. When one investigates further, it is often discovered that the patient has altered their lifestyle or eating habits for a period of time. Typically patients have had difficulty with solids and then liquids as the tumor progresses. The vast majority of patients have significant weight loss on presentation and weight loss of more than 10% is a significant predictor of poor prognosis.[46]

Patients may also present with significant pulmonary symptoms when there is a more advanced process leading to aspiration or there is direct airway invasion by a tumor. Direct airway invasion can occur with midesophageal tumors as the esophagus courses directly posterior to the left mainstem bronchus. New hoarseness is indicative of locally advanced tumor due to vocal cord paralysis. The Virchow node, a palpable left supraclavicular node, may be present in some patients. These findings are all indicators of poor prognosis and advanced disease.

The evaluation of a patient with suspected esophageal cancer involves a number of different tests which are aimed at accurate diagnosis and staging. This is extremely important as therapy decisions are made based on both of these findings. Barium swallow and esophagram are the mainstays of diagnosis for assessment of patients. Barium swallow obtains both anatomic and functional information. Flexible esophagoscopy is used to precisely locate the tumor, and biopsy can be performed to determine histology. In patients with a known tumor, important additional information can be obtained by EUS and this is considered the single most important test for determining T stage of the tumor. EUS successfully predicts T stage in over 80% of cases when performed by an experienced endoscopist. Regional lymph nodes can also be visualized and sampled by FNA. This aids in determining the N stage. The sensitivity of EUS alone to predict N stage is 85% and increases to 95% when FNA is added.[47]

At present there are no serum markers that have been found in esophageal cancer patients that would consistently yield meaningful clinical data. Standard serum cancer markers including CEA, CA19-9, and CA-125 have no value in the preoperative evaluation of the patient with esophageal cancer. The most useful laboratory parameters used clinically outside of a hemoglobin and electrolyte panel include nutritional parameters (albumin, prealbumin).

A CT scan of the chest, abdomen, and pelvis with contrast is a valuable tool for assessing tumor, lymph nodes, and the general anatomy related to the patient. Additionally, metastases to the liver and lung are assessed via this method. Positron emission tomography (PET) with 18F-fluorodeoxyglucose (FDG) is a physiologic unique

test that detects metabolic activity within tissues. It is invaluable in the assessment and clinical staging of patients with esophageal cancer as it provides information on N and M stage to help guide clinical staging. PET scans are routinely obtained for the clinical staging of esophageal cancer patients prior to and after treatment to evaluate for disease and disease progression, respectively.

Additional staging modalities attempt to improve the accuracy of clinical staging. We use laparoscopic staging quite liberally in our practice. This allows us to perform endoscopy and bronchoscopy on every patient. In the laparoscopic staging procedure we can examine the extent of nodal involvement in the celiac lymph nodes and evaluate for local tumor advancement and any diaphragmatic invasion. Importantly, many patients present with significant dysphagia and weight loss, so nutritional needs can be addressed at the time of this procedure either with an esophageal stent or feeding jejunostomy. Finally, a chemotherapy port can be placed for easier access during treatment. We acknowledge that staging laparoscopy is not absolutely required, however we feel there are many advantages that it has to offer if planning further surgical intervention in the future.

Cervical Esophageal Cancer

Cancer of the cervical esophagus represents a very small subset of primary tumors. Direct extension into the esophagus by tumors of the thyroid and trachea are much more common. These tumors are challenging to treat and generally do not respond to surgical resection as a primary modality. Traditionally, chemoradiotherapy has been the standard treatment for these tumors. Those who get treated and have a good response may represent a small subset of patients that are referred esophagectomy with laryngectomy and tracheostomy.

Adenocarcinoma

5 Adenocarcinoma of the esophagus is the most common esophageal tumor in the United States and Western world, accounting for more than 50% of cases. The rise of this histologic subtype correlates with the incidence of gastreoesophageal reflux disease (GERD) and obesity in the Western world, and the overall prevalence of BE appears to be rising within the West. Whether this finding is related to a true increased incidence or heightened surveillance is not clear. Although the overall incidence of BE is unknown, autopsy series have estimated the prevalence to be 376 cases per 100,000 in Olmsted County, MN, USA.[48] Remarkably, this rate is five times the clinical prevalence in the same geographic area (82.6 per 100,000). As a result of findings such as these, it is generally well accepted that the subclinical prevalence is underestimated. These cohort studies suggest that the majority of patients with BE are undiagnosed because they experience minimal to no symptoms.

The sequence leading from chronic GERD to the development of Barrett esophagus, the precursor of adenocarcinoma of the esophagus, is well defined. The esophagus is normally lined by squamous mucosa, and repeated injury from chronic reflux leads to transformation of the normal squamous mucosa into columnar epithelium. This is likely a

two-step process, with the first step involving the transformation of normal esophageal squamous mucosa to simple columnar epithelium. This initial step takes place relatively quickly over the course of a few years, while the second step, the development of intestinal metaplasia, proceeds over 5 to 10 years.[49] Once present, Barrett can progress to low-grade and high-grade dysplasia. With progression to dysplasia, the nuclei become more crowded and the normal glandular architecture is lost. Patients with high-grade dysplasia carry a significant risk of the development of adenocarcinoma, and at 5 years 10% to 30% of patients will develop invasive findings. The annual rate of neoplastic transformation is 0.5%.[50] Patients with recurring symptoms of reflux have an eightfold increase in the risk of adenocarcinoma. Patients with nondysplastic Barrett's have a 0.5% per patient-year rate of progression to esophageal adenocarcinoma.[51,52] At the time of espophagectomy for high-grade dysplasia, invasive carcinoma is identified in as many as 30% to 40% of patients.[53]

Squamous Cell Carcinoma

Squamous cell carcinoma is more frequent world wide with the primary risk factor for development being chronic irritation of the esophageal mucosa. This is hypothesized to be associated most frequently with prolonged alcohol consumption which is believed to be enhanced with concomitant tobacco exposure. Nitrosamines and other nitrosyl compounds found in smoked meats are especially important carcinogens that the native populations rely on heavily. Hot beverages in Asian countries have been theorized to be associated with a high incidence. Medical conditions such as achalasia, caustic strictures, Plummer–Vinson syndrome, and tylosis also increase the risk of incidence. The risk with long-standing achalasia is in the range of 5% to 7%, thus surveillance with biopsies is recommended in these patients.[54]

Staging

In 2009, the American Joint Committee on Cancer (AJCC) published the seventh edition AJCC Cancer Staging Manual. Table 43-4 summarizes the seventh edition AJCC TNM system for staging esophageal cancers. This new staging system has significant revisions from the previous sixth edition which are summarized in Table 43-5. Several stages and categories are redefined and subclassified. Tumors arising in the stomach less or equal to 5 cm away from the esophagogastric (EG) junction and tumors arising from or crossing the EG junction are all staged under this new system. The stage groupings have all been reassigned, with the new pathologic stage relying all on the number of nodes containing metastasis, tumor grade, tumor location, and histologic cell type in the seventh edition staging criteria. The revised staging groupings and current recommended treatment strategies for each stage are displayed in Table 43-6.

The importance of a cancer staging protocol lies in the strong association between stage of the disease and outcomes. The seventh edition AJCC TNM staging system is data driven and harmonized. It will allow physicians to clinical stage esophageal cancers accurately, which is of paramount importance during the formulation of an appropriate treatment plan. Preoperative evaluation is necessary to identify the extent of disease and help elicit the clinical stage. CT scans of the chest and abdomen are crucial to preoperative evaluation and should be ordered in all patients. We also recommend PET scanning in conjunction with CT imaging to detect distant metastatic disease. In the absence of liver, lung, or other distant metastatic disease, esophageal ultrasound should be used to assess regional lymph nodes and define the depth of tumor invasion. Patients with stage-appropriate disease should be optimized from a medical standpoint prior to undergoing resection.

Table 43-4 T, N, and M Status and Histologic Grade Definitions for Esophagus and Esophagogastric Junction Cancer in the Seventh Edition of the American Joint Committee on Cancer (AJCC) Cancer Staging Manual

T status	
Tis	High-grade dysplasia
T1	Invasion into the lamina propria, muscularis mucosae, or submucosa
T2	Invasion into muscularis propria
T3	Invasion into adventitia
T4a	Invades resectable adjacent structures (pleura, pericardium, diaphragm)
T4b	Invades unresectable adjacent structures (aorta, vertebral body, trachea)
N status	
N0	No regional lymph node metastases
N1	1–2 positive regional lymph nodes
N2	3–6 positive regional lymph nodes
N3	7 or more positive regional lymph nodes
M status	
M0	No distant metastases
M1	Distant metastases
Histologic grade	
G1	Well differentiated
G2	Moderately differentiated
G3	Poorly differentiated
G4	Undifferentiated

Used with the permission of the American Joint Committee on Cancer (AJCC), Chicago, Illinois. The original source for this material is the AJCC Cancer Staging Manual, Seventh Edition (2010) published by Springer Science and Business Media LLC, www.springer.com

Neoadjuvant Therapy

The current information on neoadjuvant treatment can be divided into studies evaluating preoperative radiation, preoperative chemotherapy, and combined preoperative chemoradiation therapy. In operable patients with resectable tumors, the results of any preoperative therapy followed by resection must be compared with the results of primary resection alone. It is important that this analysis takes into account the toxicities associated with multimodality therapy and the impact on the intended resection and quality of life. Several randomized trials have failed to show any benefit from preoperative radiation therapy alone. Proponents of preoperative radiotherapy argue that the trials are too small to demonstrate the advantages of this approach. A meta-analysis of available randomized trials comprising 1,147 patients, however, found no improvement in survival with preoperative radiotherapy alone in patients with resectable esophageal cancer.[55] At this time, there is no indication for preoperative radiation therapy alone followed by resection.

Table 43-5 Summary of Changes from AJCC Sixth to Seventh Edition Esophagus and Esophagogastric Junction Cancers Staging System

- Tumor location is simplified, and esophagogastric junction and proximal 5 cm of stomach are included.
- Tis is redefined and T4 is subclassified.
- Regional lymph nodes are redefined. N is subclassified according to the number of regional lymph nodes containing metastasis.
- M is redefined.
- Separate stage groupings for squamous cell carcinoma and adenocarcinoma.
- Stage groupings are reassigned using T, N, M, and G classifications.

Table 43-6 American Joint Committee on Cancer (AJCC) Stage Groupings with Recommended Treatment and 5-Year Survival

Stage	TNM Designation	Treatment	5-Yr Survival (%)
0	Tis, N0, M0, G1	Surgery alone	N/A
IA	T1, N0, M0, G1–2	Surgery alone	87.7
IB	T1, N0, M0, G3 T2, N0, M0, G1–2	Surgery alone	73.3
IIA	T2, N0, M0, G3	Surgery alone	55.3
IIB	T3, N0, M0, G-any T1–2, N1, M0, G-any	Surgery or neoadjuvant treatment followed by surgery	40.1
IIIA	T1–2, N2, M0, G-any T3, N1, M0, G-any T4a, N0, M0, G-any	Surgery or neoadjuvant treatment followed by surgery	24.3
IIIB	T3, N2, M0, G-any	ChemoXRT	11.9
IIIC	T4a, N1–2, M0, G-any T4b, N-any, M0, G-any T-any, N3, M0, G-any	ChemoXRT	3.1
IV	T-any, N-any, M1, G-any	Palliation (chemo, XRT, stenting, or combination)	0.0

The utility of preoperative chemotherapy alone is much more poorly defined. A large multicenter randomized trial in the United States (Intergroup Trial) of 440 patients failed to show any improvement in survival after three cycles of combined cisplatin and fluorouracil followed by surgery and two postoperative cycles when compared to surgery alone.[56] This is in contrast to a large randomized European study (Medical Research Council), which suggested that neoadjuvant chemotherapy resulted in nearly a 10% improvement in survival at 2 years.[57] Unfortunately, the preoperative staging techniques and duration of treatments were quite different, making the two studies difficult to compare. More recently, another European neoadjuvant chemotherapy trial (MAGIC trial) demonstrated improved survival with perioperative chemotherapy versus surgery alone (36% vs. 23% at 5 years).[58] Of note, 75% of the MAGIC trial participants had gastric cancer. Also, only 41.6% of patients randomized to perioperative chemotherapy were able to complete all six prescribed cycles of therapy. In a recent Cochrane review of the topic, 11 randomized controlled trials with 2,051 patients suggested that preoperative chemotherapy plus surgery may offer a survival advantage compared to surgery alone for resectable esophageal cancer.[59] There was no demonstrable difference in the rate of resection, tumor recurrence, or postoperative morbidity. There was some chemotherapy-related morbidity. Presumably based on the relative success of the MRC and MAGIC trials, chemotherapy alone is used quite commonly as neoadjuvant therapy in Europe, whereas combined chemotherapy and radiation is used more commonly in the United States. Several small randomized trials have evaluated combined preoperative chemoradiation followed by surgical resection. The most widely cited trial to justify the use of combined treatment followed by surgery was published by Walsh et al. in 1996.[60] This study projected a 3-year survival of 32% in the neoadjuvant treatment group as compared to 6% in the surgery alone group for patients with adenocarcinoma. Critics were quick to point out the lack of appropriate staging, the poor survival in the surgical group as compared with other surgical series, and the small study size. A more recent

study found equivalent median and 3-year survival in patients with squamous cell carcinoma of the esophagus randomized to either preoperative chemoradiation followed by surgery or surgery alone.[61] An increased complication rate was noted in the patients undergoing preoperative chemoradiation therapy. A recent metaanalysis of 10 randomized controlled trials of neoadjuvant chemoradiotherapy versus surgery alone demonstrated an absolute survival advantage of 13% at 2 years favoring neoadjuvant therapy.[62] Despite a paucity of conclusive data, there seems to be an evolving consensus at most centers that patients with T3 and/or N1 disease should receive neoadjuvant chemoradiation. This issue remains unresolved, and operation remains the standard treatment for localized esophageal cancer outside of a clinical trial. At this time we consider neoadjuvant chemoradiotherapy to be investigational. Unfortunately, a large intergroup trial designed to answer this question was closed because of poor accrual.

More recently, the CROSS Trial enrolled 363 patients from the Netherlands, of which 75% had GE junction adenocarcinoma.[63] They were randomized to chemotherapy with concurrent XRT (41.4 Gy) then surgery versus upfront surgery. Improved survival was seen in the neoadjuvant group at 5 years suggesting that chemoradiotherapy followed by surgery provided a survival advantage. Both arms in the trial were noted to have an unusually high leak rate related to surgery (CRT 22% vs. surgery 30%). This called into question the validity of the surgical standardization in the operative approach as this leak rate is quite high. The long-term results (minimum 5-year follow-up) were recently reported and confirmed the overall survival benefits for neoadjuvant chemoradiotherapy when added to surgery (43 months vs. 27 months, $p < 0.03$) in patients with resectable esophageal or EG junctional cancer.[64]

6 Recently the Society of Thoracic Surgeons released a consensus statement on neoadjuvant therapy for the treatment of esophageal cancer stating the following class IIA recommendations based on level A evidence[65]:

1. “Neoadjuvant platinum-based doublet chemotherapy alone is beneficial before resection for patients with locally advanced esophageal adenocarcinoma.”
2. “Neoadjuvant chemoradiotherapy should be used for locally advanced squamous cell cancer and either neoadjuvant chemotherapy or chemoradiotherapy for locally advanced adenocarcinoma as multimodality therapy has advantages over operation alone.”

SURGICAL CONSIDERATIONS IN APPROACHING THE ESOPHAGUS

The esophagus is generally considered one of the most problematic organs to manage when it comes to the indication for operation, patient fitness, operative approach, and the postoperative consequences of complications. There is no doubt that surgical experience and expertise play a critical role in all phases of esophageal disease ending up in the operating room.

A complete working knowledge of the anatomical relationships between the esophagus and adjacent structures is vital. We feel it is a requirement and marked advantage for those formally trained in general thoracic surgery to be the ones performing these operations. The upper esophagus is in contact with the posterior membranous trachea, the left mainstem bronchus, and the aortic arch. Patients with cancers involving the upper thoracic esophagus must undergo preoperative bronchoscopy to rule out involvement of the airway as this generally precludes safe resection.

From a surgical perspective the esophagus is divided into thirds. The upper third can be reached through a cervical incision. The middle third is best approached through the right chest as access through the left chest is limited by the aortic arch. The distal third of the esophagus is best approached through the left chest. The short segment of intra-abdominal esophagus may be approached through the upper abdomen.

7 When esophagectomy is required, several surgical approaches have been described. Generally speaking, no one surgical approach fits all. These approaches include the transhiatal approach,[66] transabdominal transthoracic approach (Ivor Lewis),[67] the three-stage or “three-field” approach (McKeown),[68] and the thoracoabdominal approach.[69,70] In the current era, both minimally invasive and robotic approaches have been championed and our group has led pioneering efforts in this regard. Each approach has its own set of risks and benefits as well as clear opinions on those merits. Our belief is that selection of the approach should be coupled with surgical expertise and patient pathology. Generally speaking, several studies have shown equivalent outcomes when it comes to removal of the esophagus and one trades one variable for another when critically evaluating the results. Careful review of the literature draws on two important variables: surgeon experience and volume.[71] Failures in technique that occur during the performance of esophagectomy are associated with increased length of stay, in-hospital mortality, and poorer overall long-term survival.[72]

OPERATIVE MANAGEMENT

Approaches to Esophagectomy

There are several surgical approaches to esophagectomy and the master esophageal surgeon should be familiar with all approaches as they have different indications depending on the individual patient, the location of the tumor, and surgeon experience. Options for reconstruction include a gastric tube, colonic interposition, and in selected small cases an intestinal free graft. We opt for the use of colon or small bowel in patients where the stomach is not usable because of the morbidity associated with these conduits. The highlights of the main approaches will be presented along with an in-depth description of the approach to minimally invasive esophagectomy (MIE) to help outline the critical considerations for the steps of the operation.

Transhiatal Esophagectomy

Mark Orringer has championed this approach for esophagectomy with outstanding results and leak rates in the 3% to 5% range.[73] The procedure starts with an upper midline laparotomy and left cervical incision as shown in Figure 43-8. A gastric conduit based on the right gastroepiploic artery is used to establish gastrointestinal continuity. A modified stapled anastomosis is performed to complete the EG anastomosis (Fig. 43-9).

Many surgeons prefer THE in the current era, as historically it has been compared to open Ivor Lewis esophagectomy. Debate continues over the effectiveness of it as a cancer operation, as thoracic lymphadenectomy is not a part of the procedure as seen in the Ivor Lewis Approach. Proponents for the operation argue that the approach has lower morbidity and mortality than the Ivor Lewis approach. Should a leak occur in the neck, it can be treated by simple bedside cervical drainage. A leak in the chest following the Ivor Lewis approach is far more likely to result in severe mediastinitis and other significant complications. The arguments and debates are certainly quite different in the current era with the excitement surrounding MIE.

Ivor Lewis Esophagectomy

The transabdominal transthoracic approach to esophagectomy as initially described is more commonly referred to as the Ivor Lewis esophagectomy. The specific steps are covered in the section on MIE as we perform this operation through minimal access surgery. Following laparotomy and creation of the gastric conduit, the stomach is mobilized and a posterolateral thoracotomy is performed through the 5th interspace. The intrathoracic esophagus is mobilized under direct vision and the EG anastomosis is performed at the level of the azygos vein. This approach is especially useful for bulky tumors or where there are concerns regarding airway injury. As discussed above, critics of this approach point out the increased morbidity of the operation and the potential perils of a chest anastomosis. The lymphadenectomy is clearly superior with this approach and the risk of local recurrence, in theory, reduced.

Three-Field Esophagectomy

This approach is carried out through a separate laparotomy, thoracotomy, and left cervical incision.[68] The anastomosis is performed in the neck. This approach is appropriate for mid-esophageal tumors where there is concern of airway injury during the dissection. Another potential advantage is a three-field lymphadenectomy. In summary, the operation has the potential to provide the patient with a more complete resection and thus improves long-term survival. This claim has not been overtly substantiated in the literature.

Thoracoabdominal Approach

The left thoracoabdominal approach is the least frequently used of all the approaches to the esophagus. It is performed by making an oblique incision from the midpoint between the xiphoid and the umbilicus across the costal arch to the tip of the scapula. The abdomen is opened and the diaphragm divided along the chest wall to spare any phrenic nerve branches. This approach is sometimes useful in those patients who have had hiatal work done previously. For patients with distal tumors and inadequate conduit for esophageal replacement, the anastomosis can be made in the left chest just below the inferior pulmonary vein. For those with adequate conduit, the esophagus can be mobilized and a left cervical anastomosis can be performed. The morbidity of this approach is quite high, however the largest series of 64 patients reported no anastomotic leaks and 2% mortality.[74]

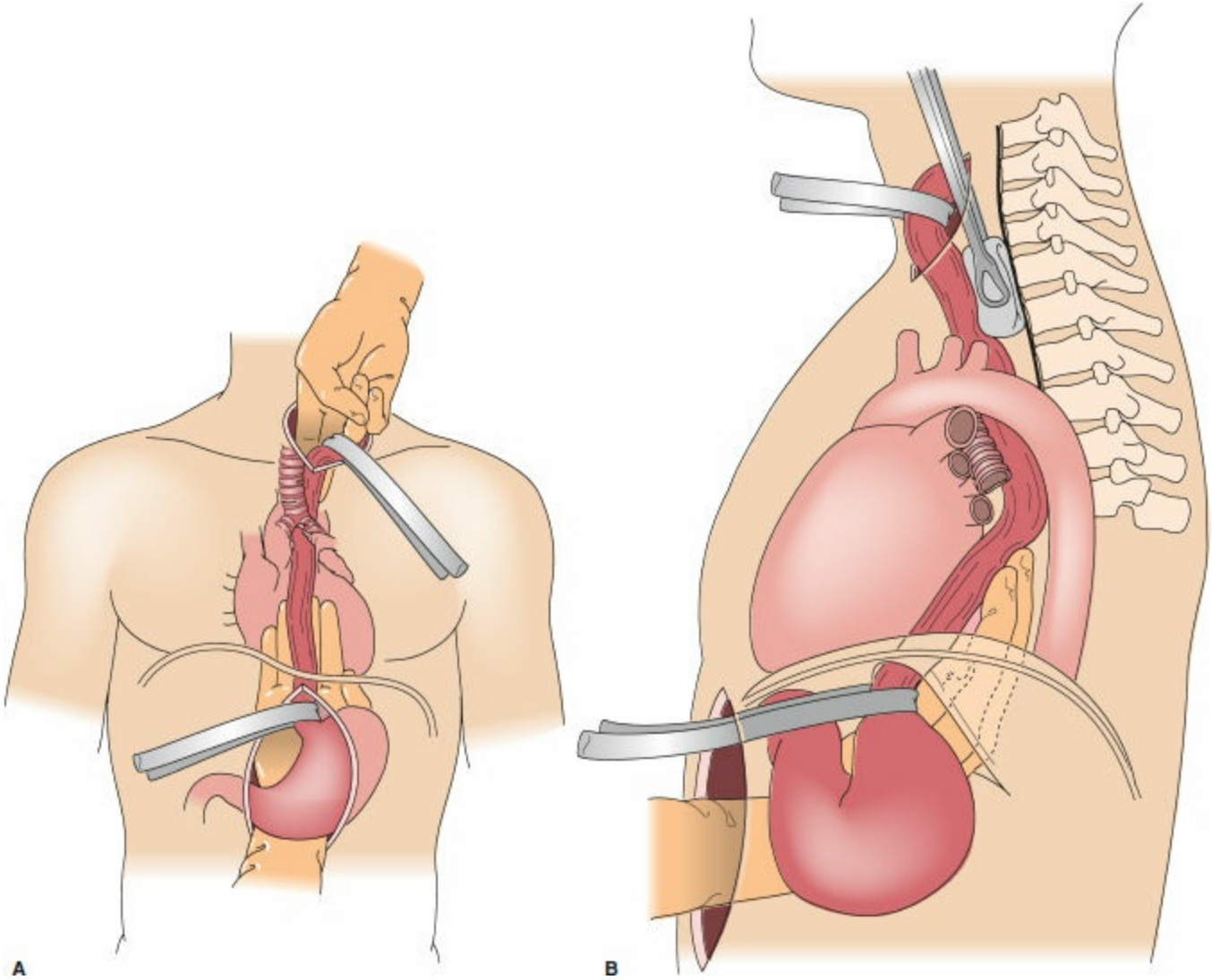

Figure 43-8. **A:** Transhiatal mobilization of the thoracic esophagus from the posterior mediastinum with the use of blunt dissection and traction on rubber drains placed around the esophagogastric junction and cervical esophagus. The volar aspects of the fingers are kept against the esophagus to reduce the risk for injury to adjacent structures. **B:** Lateral view showing transhiatal mobilization of the esophagus away from the prevertebral fascia. Half of a sponge on a stick is inserted through the cervical incision and advanced until it makes contact with the hand inserted from below through the diaphragmatic hiatus. Arterial pressure is monitored as the heart is displaced forward by the hand in the posterior mediastinum.

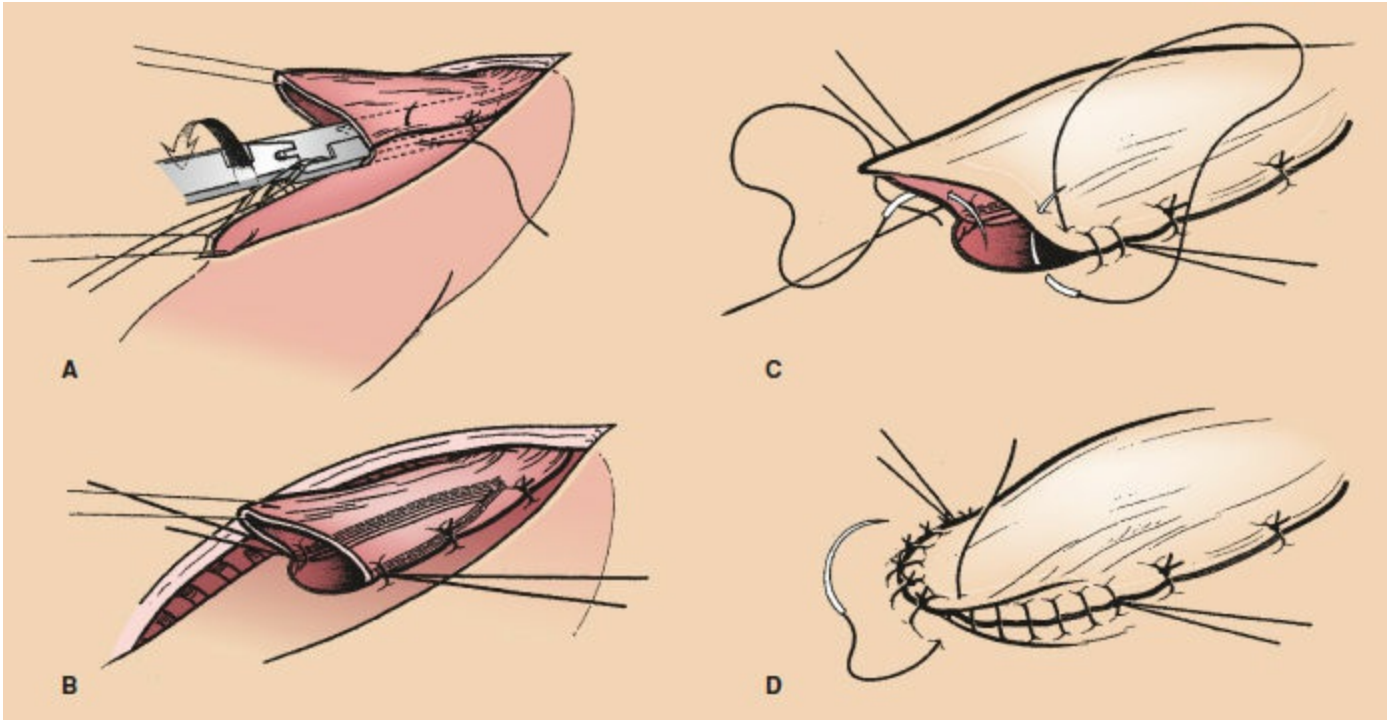

Figure 43-9. The stapled technique for cervical esophageal anastomosis. This technique results in lower anastomotic leak rates and fewer postoperative strictures.

Minimally Invasive Esophagectomy

Some surgeons have combined a thoracoscopic approach with a laparotomy, while others reported a laparoscopic abdominal component with an open thoracotomy for the chest. While these hybrid operations do fall under the umbrella of minimally invasive esophageal resection, a strict definition of minimally invasive esophageal resection avoids both a thoracotomy and a laparotomy completely. In our experience, we initially started with a laparoscopic transhiatal approach (in 15 patients) and attempted to reach our finger dissection from the neck incision. We found this to be quite difficult in most patients. We then converted to a combined thoracoscopic/laparoscopic approach with a neck anastomosis, as it afforded better visualization of the periesophageal structures especially near the main airways and subcarinal areas, was less affected by patient height and body habitus, improved our ability to do a more complete nodal dissection, and greatly improved overall visualization compared with the totally laparoscopic method. This minimally invasive three-field (McKeown approach) operation was our procedure of choice for 6 to 8 years (approximately 500 cases). Following this extensive minimally invasive experience, we moved to a minimally invasive Ivor Lewis approach in which we start laparoscopically and complete using a right thoracoscopic approach and a high thoracic anastomosis. We prefer this approach because the avoidance of a neck dissection essentially eliminates recurrent laryngeal nerve injury. Additionally, minimally invasive Ivor Lewis resection allows a more aggressive gastric resection margin; amputation of the most proximal tip of the newly constructed gastric conduit, which is the most susceptible to ischemia and potential leak; and performance of the anastomosis with a wide view within the chest cavity.[75,76]

8 In 2000, Nguyen et al. compared MIE with open transthoracic esophagectomy and transhiatal esophagectomy (THE). Shorter operative times, less blood loss, and shorter stays in the ICU with no increase in morbidity were documented with the minimally invasive approach as compared with the open approach. Over the past several years, several series have been published on minimally invasive resections that demonstrate comparable survival outcomes compared with large open series.[77]

Indications for the minimally invasive approach for esophagectomy include Barrett esophagus with high-grade dysplasia, end-stage achalasia, esophageal strictures, and esophageal cancer. While most T4 esophageal cancers are generally not amenable to open or minimally invasive surgical approaches, cancers of all other T stages are potentially amenable to MIE in experienced hands. Esophageal cancer that has been downstaged after neoadjuvant chemoradiation is also potentially resectable by a minimally invasive approach but, as with open operations in this setting, can be technically more difficult than nonirradiated fields. Previous thoracic and abdominal surgery is not necessarily a contraindication to MIE depending on the extent of the previous surgery and the experience of the surgeon. The minimally invasive Ivor Lewis esophagectomy works well for most distal esophageal cancers, short-to-moderate length Barrett with high-grade dysplasia, and gastroesophageal junction tumors extending onto the gastric cardia. Total laparoscopic and thoracoscopic Ivor Lewis resections should not be performed for upper

third esophageal cancers with significant proximal extension due to concern for adequate margins of resection. Some midesophageal tumors can be approached with the Ivor Lewis technique, but a very high intrathoracic anastomosis may be needed to gain a negative margin.

Anesthetic Considerations

Anesthetic management during MIE poses specific challenges. Whereas all patients receive an arterial blood pressure monitoring line, central venous catheter placement is not routine. A double-lumen endotracheal tube is placed initially in anticipation of the thoracoscopic phase. In patients with midthoracic or upper thoracic tumors, a single-lumen endotracheal tube is initially placed for preoperative bronchoscopy to evaluate airway involvement.

Patients generally require significant volume loading during the laparoscopic phase secondary to the pneumoperitoneum and steep reverse Trendelenburg positioning. Given the high flow of CO_2 required, the patient can develop significant hypercarbia and acidosis. The surgeon must also be mindful of vasopressors administered by the anesthesiologist because these agents directly affect the viability of the newly created gastric conduit. Simple measures can be undertaken to help correct these problems. Maneuvers to increase preload include lowering the insufflation pressure, decreasing the degree of the reverse Trendelenburg position, and increasing volume loading. In addition to changes in the ventilator settings, hypercarbia can often be corrected by reversing the pneumoperitoneum, allowing the patient time to compensate and clear the excess CO_2. There must be clear and ongoing communication throughout the procedure between the surgeon and the anesthesiologist.

Endoscopic Evaluation

The operation begins with a careful EGD. The location of the tumor is confirmed along with precise measurements of the proximal and distal extent of the lesion. The surrounding esophagus is examined for evidence of Barrett changes proximal to the intended resection margin, with four-quadrant biopsies taken in areas of clinical concern. Careful endoscopic examination of the stomach is also imperative to assess its suitability for use as a conduit in esophageal reconstruction. Air insufflation should be kept to a minimum during the examination to reduce the degree of small bowel distention which may significantly decrease domain and heighten the difficulty of laparoscopy.

Laparoscopic Phase

Positioning and Laparoscopic Port Placement

The patient is positioned supine with the arms out at 60 degrees. A foot board is placed to allow steep reverse Trendelenburg positioning during the hiatal dissection. The costal margin is identified and a line is drawn from the xiphoid to the umbilicus. This line is then divided into thirds. The first port is placed using a direct Hassan cutdown approach in the right paramedian position roughly 2 cm lateral to the midline at the junction of the lower and middle thirds of the described line. A total of five abdominal ports are used for gastric mobilization (12-mm right and left paramedian, 5-mm right and left subcostal, and a second 5-mm right lateral subcostal port for liver retraction (Fig. 43-10) with the remaining ports placed under direct laparoscopic vision. A sixth port is placed in the right paraumbilical region to assist in placement of the feeding jejunostomy tube. All ports should be a hand's breadth apart so as to avoid interference between instruments. In addition, it is important to keep skin and fascial incisions small so as to avoid subcutaneous emphysema.

While working at the hiatus, the camera is placed in the left paramedian port position. The surgeon works from the right side of the table using the right paramedian and subcostal ports. The assistant, on the left of the table, controls the camera as well as a second grasper for retraction (through the left subcostal port). The liver retractor is brought in through the right lateral subcostal port and positioned to elevate the left lobe of the liver and expose the hiatus.

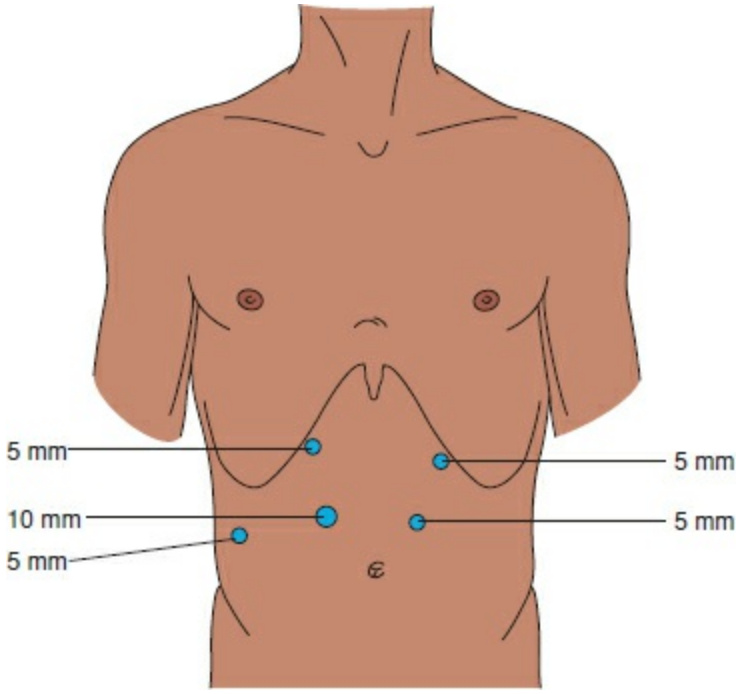

Figure 43-10. Laparoscopic port placement. The 10-mm port is placed first in the right midabdomen using open Hasson trocar insertion technique. An additional 5/11-mm port is placed in the right lower quadrant that is helpful for retraction during pyloroplasty and gastric tube creation.

Gastric Mobilization

Thorough inspection of the abdomen is performed to ensure that no injuries were caused during the process of port placement and to evaluate for intraperitoneal metastasis. The peritoneal lining, omentum, and liver are visually inspected for abnormalities with biopsies taken of any suspicious lesions for frozen-section evaluation. The gastrohepatic ligament is opened and the left gastric vascular pedicle identified (Fig. 43-11). A complete lymph node dissection is then performed, leaving the left gastric and celiac lymph nodes with the specimen. This dissection is continued laterally along the splenic artery and the superior border of the pancreas and superiorly toward the crura along the preaortic plane. If there is a question of potential malignant involvement, these nodes are sent for frozen-section evaluation to aid in determination of resectability. Once ensured that no nodal disease is present, the right crus is dissected, allowing lateral mobilization of the esophagus. This dissection is continued anterior to the esophagus, transecting the phrenoesophageal ligaments and exposing the anterior hiatus. The left crus may be exposed either by the continuation of this anterior dissection along the medial crural border or by first mobilizing the fundus of the stomach by division of the short gastric vessels. Dissection of the left crus is continued posteriorly until the decussation of the right and left crural fibers is noted. This exposes the retroesophageal window and ensures complete mobilization of the superior portion of the lesser curvature and gastroesophageal junction.

After identifying the gastrocolic omentum, the antrum of the stomach is retracted, and a window is created in the greater omentum, thus allowing access to the lesser sac. The remaining short gastric vessels are divided, taking care to preserve the right gastroepiploic arcade. The fundus is retracted to the right and this dissection is continued posteriorly, eventually exposing the left gastric artery and vein and joining the lesser curve dissection plane to complete mobilization of the stomach. Gastric mobilization is carried inferiorly to the pyloroantral region. Meticulous attention must be paid during this phase of the dissection because any injury to the gastroepiploic arcade at this level may render the gastric conduit unusable. This dissection may be especially difficult in patients who have had pancreatitis or a history of prior biliary surgery. Adequate mobilization has been achieved when the pylorus is able to reach the level of the caudate lobe of the liver, which may require either a partial or a complete Kocher maneuver. The left gastric artery and vein are then divided using an endovascular GIA stapler. Care should be taken to ensure that all nodes are swept toward the specimen side and to avoid narrowing of the splenic or hepatic arteries.

Creation of the Gastric Tube

The gastric tube is created prior to the completion of the pyloroplasty and placement of the feeding jejunostomy tube to allow for an assessment of the viability of the gastric conduit. The gastric tube follows the arc of the greater curve of the stomach and is based on the right gastroepiploic artery (Fig. 43-12). An endovascular stapling technique allows for a controlled creation of the gastric tube conduit. The first staple load is placed across

the adipose tissue and vessels along the lesser curve, above the level of the right gastric artery. No stomach is divided in this initial staple firing, which is intended to provide hemostasis. The subsequent staple firings divide the stomach. We prefer 45-mm staple loads for this process (purple loads; Endo GIA Reloads with Tri-staple Technology, Covidien, Mansfield, MA) because the course of the greater curvature can be followed more precisely, resulting in improved conduit length. An additional grasper is brought through the right paraumbilical port at this time to assist in the retraction of the stomach during creation of the gastric tube. It is important to keep the stomach on stretch during this process so as to create a straight conduit. The first assistant grasps the tip of the fundus along the greater curve and gently stretches it toward the spleen. A second instrument from the paraumbilical port grasps the antral area with a slight downward retraction. The stomach is first horizontally divided across the antrum. The staple line is then directed superiorly, toward the fundus, parallel to the line of the greater curve. A conduit width of 4 to 5 cm is preserved (Fig. 43-13). The length of the conduit is shortened if there is concern for extension of the tumor onto the gastric cardia. Sutures may be placed to reinforce the staple line if there is concern about its integrity, although this practice is not routinely necessary.

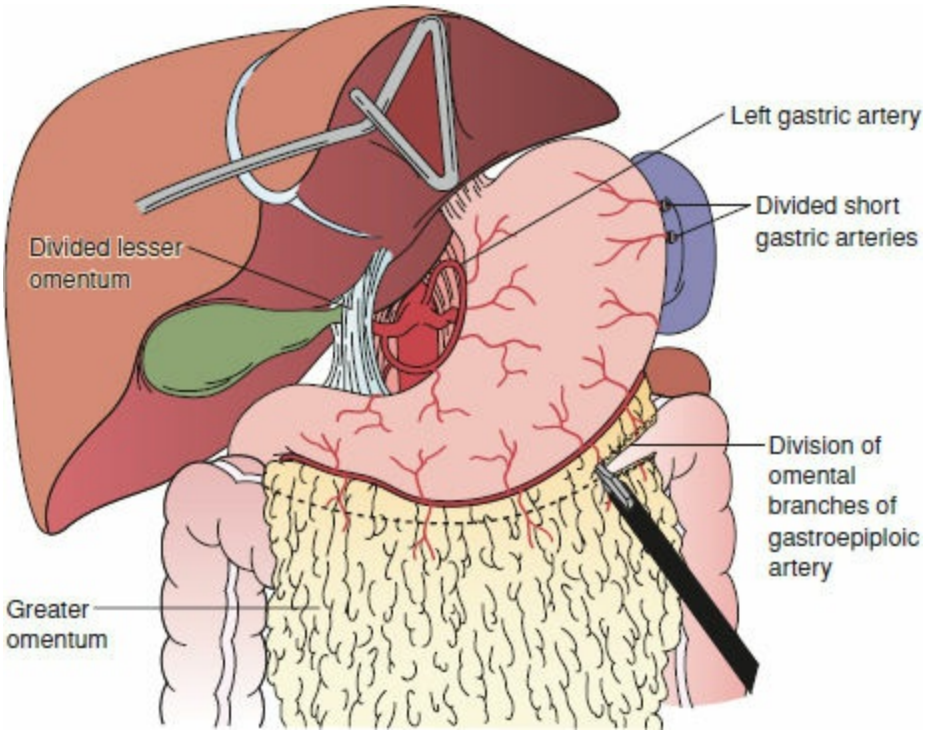

Figure 43-11. Laparoscopic staging, with opening of the gastrohepatic ligament and evaluation of left gastric/celiac lymph nodes.

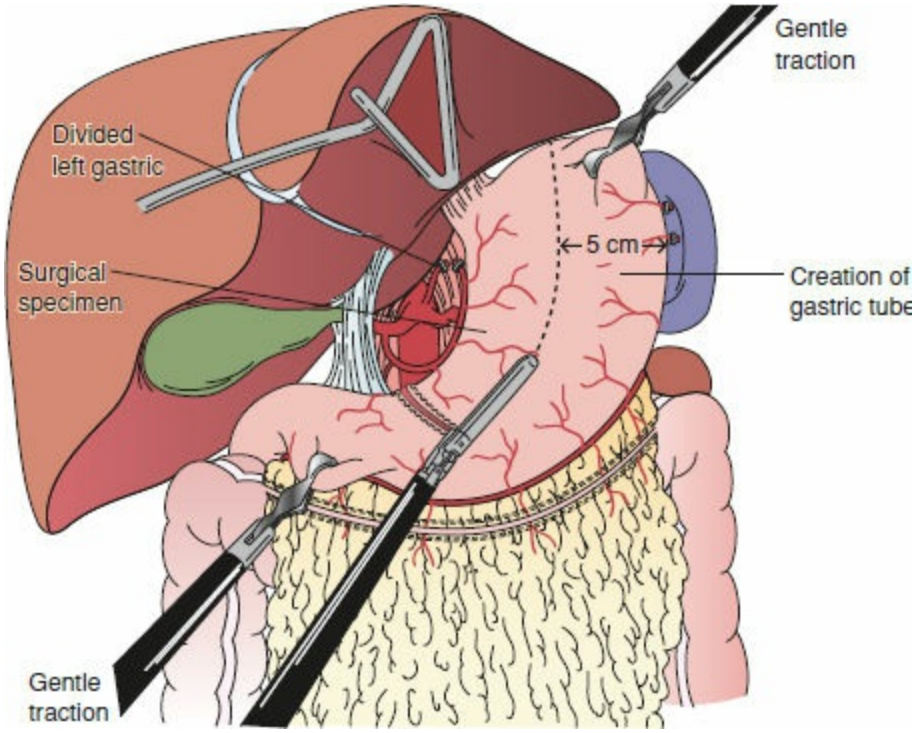

Figure 43-12. Creation of gastric conduit. The first stapler along the lesser curve is a vascular endo GIA stapler after which the thick antrum is divided with the 4.8 mm (green) loads that are 45 mm long fired sequentially. The antrum and the fundus are pulled in opposite direction to provide adequate tension during the gastric conduit creation.

Pyloroplasty

The pylorus is visually identified and 2-0 Surgidac (Covidien, Mansfield, MA) stay sutures are placed on the superior and inferior aspects using the Endostitch device (U.S. Surgical, Norwalk, CT) to place it on stretch (Fig. 43-14). The anterior wall of the pylorus is then transected with ultrasonic shears. The pyloromyotomy is then closed transversely in a Heineke–Mikulicz fashion using simple, interrupted 2-0 Surgidac sutures. An omental patch (with a vascular pedicle if the patient received neoadjuvant treatment) is placed over the pyloroplasty prior to termination of the abdominal portion of the operation.

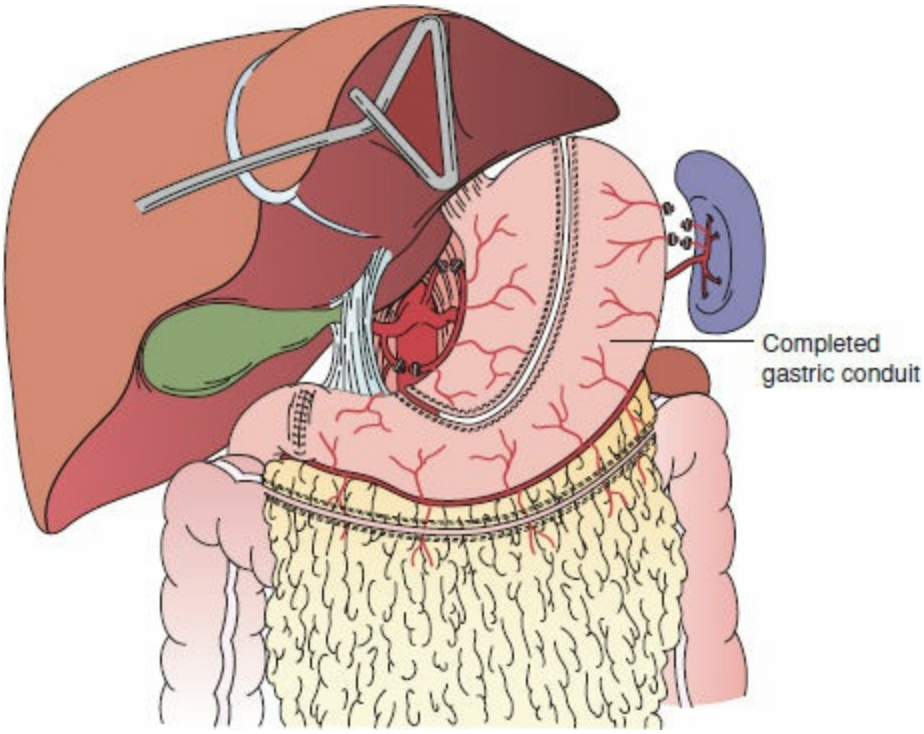

Figure 43-13. Completed gastric conduit with an intact right gastroepiploic arcade and an intact right gastric artery.

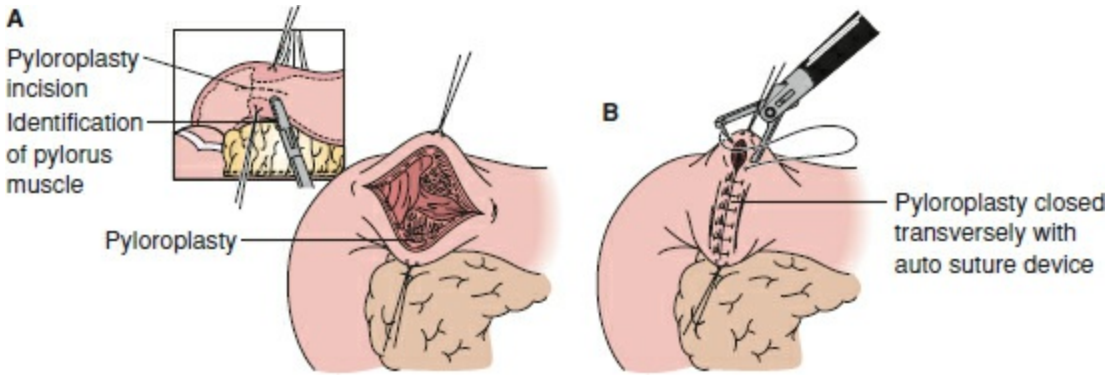

Figure 43-14. Creation of pyloroplasty (**A**) and vertical closure **(B)** in a Heineke–Mikulicz fashion.

Feeding Jejunostomy Tube Placement

A 10-French jejunostomy catheter is placed in the left lower quadrant using a percutaneous technique (Fig. 43-15). The transverse colon is retracted superiorly to expose the ligament of Treitz and a position in the jejunum is identified 30 to 40 cm from this location. The antimesenteric border of the bowel is sutured to the abdominal wall

with a 2-0 Surgidac suture. The 12-mm right paraumbilical port is used by the surgeon with the camera positioned in the right paramedian location. A Seldinger technique is then used to introduce the catheter into the jejunum under direct laparoscopic vision. Air insufflation via the catheter can be used to verify luminal placement. The jejunum is then tacked to the abdominal wall anterior to the catheter entry site to prevent leakage, and an additional suture to the abdominal wall is placed in the distal limb of jejunum to prevent rotation and obstruction.

Preparation for Thoracoscopic Phase

The gastric conduit is again assessed for viability and, if needed, resection of the nonviable portion and further mobilization with extension of the Kocher maneuver are performed at this time. Once viability of the conduit is ensured, the most superior portion of the gastric tube is stitched to the specimen (Fig. 43-16). It is imperative to maintain the alignment of the conduit so that twisting is avoided as the stomach is brought into the chest. We ensure this by suturing the greater curvature along the short gastric vessels to the staple line of the proximal gastric remnant. If an omental flap has been created, the distal end is sutured to the conduit tip. Clips are applied to the staple line as needed for hemostasis. The specimen and gastric conduit are then placed in the lower mediastinum, again taking care to preserve the proper orientation of the gastric conduit (Fig. 43-17). If the hiatal opening appears large, the crura are reapproximated with a stitch to prevent delayed thoracic herniation of the conduit. A nasogastric tube is then placed in the esophagus for decompression in preparation for the thoracic phase of the operation.

Thoracoscopic Phase

Positioning and Port Placement

Turn the patient to the left lateral decubitus position and reconfirm placement of the double-lumen endotracheal tube. The operating surgeon stands on the right side of the table (facing the patient's back) while the assistant stands on the left side of the table. A total of five thoracoscopic ports are used (Fig. 43-18). A 10-mm camera port is placed in the eighth or ninth intercostal space, just anterior to the midaxillary line. The working port is a 10-mm port placed in the eighth or ninth intercostal space, posterior to the posterior axillary line. Another 10-mm port is placed in the anterior axillary line at the fourth intercostal space, through which a fan-shaped retractor aids in retracting the lung to expose the esophagus. A 5-mm port is placed just inferior to the tip of the scapula for the surgeon's left hand. A final 5-mm port is placed at the sixth rib, at the anterior axillary line for suction by the assistant.

Thoracoscopic Dissection and Resection of the Esophagogastric Specimen

Adequate retraction of the diaphragm is essential to the thoracoscopic phase of the dissection. A 48-in, 0 Surgidac suture is placed through the central tendon of the diaphragm using the Endostitch. The suture is brought out through the lateral chest wall at the level of the insertion of the diaphragm through a small stab incision, retracting the diaphragm inferiorly and exposing the distal esophagus. The inferior pulmonary ligament is divided to the level of the inferior pulmonary vein to allow for maximal retraction to the lung. This dissection is carried onto the avascular plane along the surface of the pericardium, which becomes the medial border of the dissection. This dissection is carried superiorly to the subcarinal space, with the lymph nodes kept en bloc with the esophagus (Fig. 43-19). Care must be taken to identify the membranous wall of the right mainstem bronchus because it is easily injured during this phase of the dissection. Removing any suction from the right lung during this dissection will prevent the membranous wall from collapsing and can aid in visualization. The lung is then retracted anteriorly and the pleura incised along the anterior border of the esophagus to the level of the azygos vein. The azygos vein and vagus nerve are divided to facilitate the dissection and prevent traction injuries to the recurrent laryngeal nerve during esophageal mobilization. Above the level of the azygos vein, dissection is kept close to the esophagus to avoid injury to the recurrent nerves. The extent of superior dissection and mobilization depends upon the location of the tumor and the intended site of resection. To facilitate lateral mobilization, the pleura is divided in the groove posterior to the esophagus. This dissection is kept superficial to avoid injury to the thoracic duct and underlying thoracic aorta. Bridging lymphatics and aortoesophageal vessels are controlled with endoclips and subsequently divided with the ultrasonic shears. A careful thoracic duct ligation should be considered if there is concern for trauma to the duct. This lateral dissection is carried along the length of the esophagus from above the azygos vein to the level of the gastroesophageal junction. The contralateral pleura marks the deep margin of the dissection. The left

pleural space may be entered if needed to remove a bulky tumor. The insertion of a Penrose drain to encircle the esophagus can also be useful to provide traction and elevate the esophagus from the mediastinal bed.

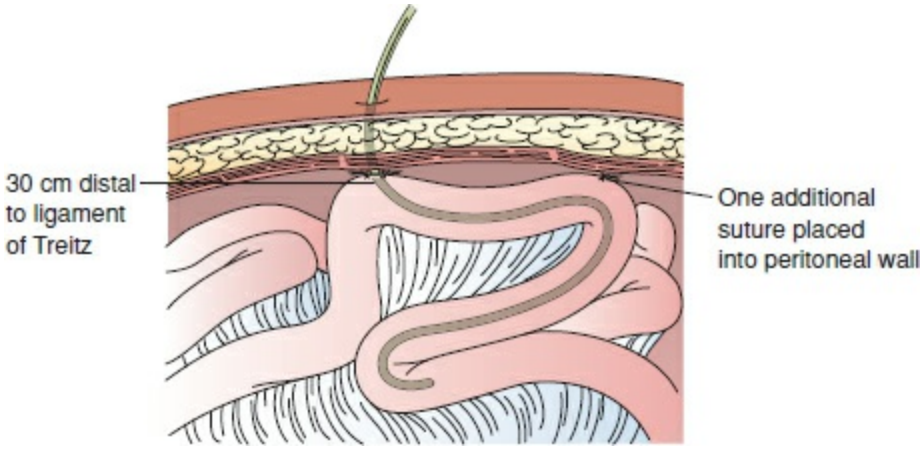

Figure 43-15. Placement of a 10-French needle jejunostomy catheter and an antitorsion stitch 3 to 4 cm distally along the antimesenteric border.

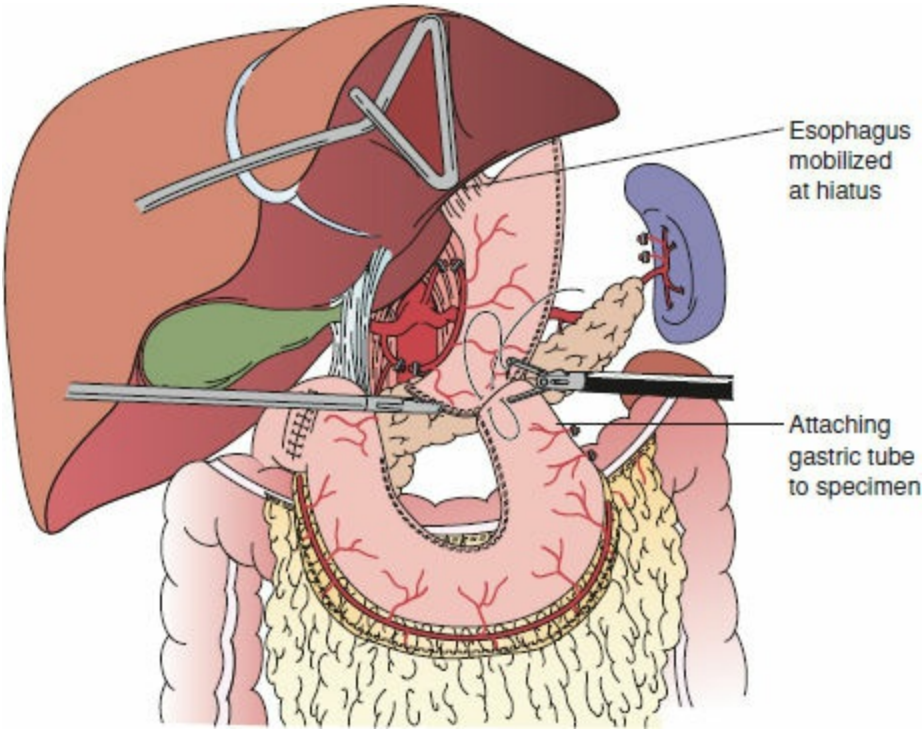

Figure 43-16. The gastric conduit is secured to the specimen along the lesser curve staple line for proper orientation during the thoracoscopic portion with a horizontal U stitch.

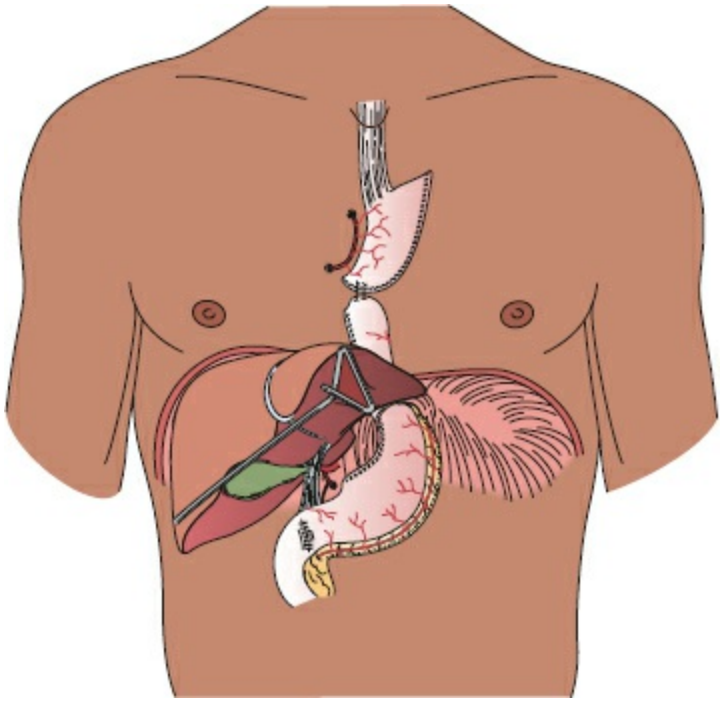

Figure 43-17. Proper orientation of the gastric conduit during the thoracoscopic part.

Once the esophagus has been completely mobilized, the specimen and attached gastric conduit are delivered into the chest, preserving the orientation of the gastric tube. The conduit staple line should be directly facing the lateral chest wall. The stitch between the specimen and the conduit is cut and the tip of the conduit secured to the diaphragm with an Endostitch to prevent it from retracting into the abdomen. The specimen is then retracted anteriorly and superiorly, away from the esophageal bed, and the dissection completed along the contralateral pleural surface. Above the level of the azygos vein, this dissection again moves to the plane along the wall of the esophagus itself to avoid recurrent laryngeal nerve injury. Lymph node sampling is not routinely performed at this level.

Once mobilization of the esophagus is complete, a 4- to 5-cm minithoracotomy is made between the surgeon's working port and the tip of the scapula. A wound retractor (Applied Medical, Rancho Santa Margarita, CA) is placed to protect the skin and chest wall. The esophagus is then sharply transected using laparoscopic scissors at or above the level of the azygos vein as determined by the proximal extent of tumor. The nasogastric tube is pulled back into the proximal esophagus under direct vision as this is done. The esophagogastrectomy specimen is then withdrawn through the wound protector and sent for frozen section evaluation of the resection margins.

Creation of the Gastroesophageal Anastomosis

Attention is next turned to construction of the EG anastomosis. Our preferred technique utilizes an end-to-end anastomosis (EEA) stapling device (Fig. 43-20). The anvil of the stapler is placed in the cut proximal end of the esophagus and secured in place with two pursestring sutures of 2-0 Surgidac. All layers of the esophagus must be included in the suture to ensure a competent anastomosis. Typically, a 28-mm EEA stapler can be used without difficulty. This size will help to minimize stricture formation and potentially

decreases the need for postoperative dilation. If the proximal esophagus does not appear large enough to accommodate the 28-mm anvil, a Foley catheter can be used to gently dilate the esophageal lumen in an attempt to facilitate placement of the anvil before electing a smaller stapler size. The gastric conduit is pulled further into the chest and the tip of the gastric conduit is opened using ultrasonic shears to the right side of the staple line. The EEA stapler is placed through the wound protector and positioned through the gastrotomy inside the conduit. The stapler spike is brought out along the greater curve of the gastric conduit to dock with the anvil. Prior to creating the anastomosis, we carefully estimate the amount of conduit that will lie in the chest. It is a common mistake to bring an excess stomach into the chest with the intent of minimizing tension on the anastomosis. A redundant conduit above the diaphragm can lead to significant problems with conduit emptying. In addition, ensuring proper orientation of the stomach is critical to prevent twisting. The stapler is then opened two complete turns and withdrawn. The tissue rings are inspected to ensure that they are complete prior to proceeding further.

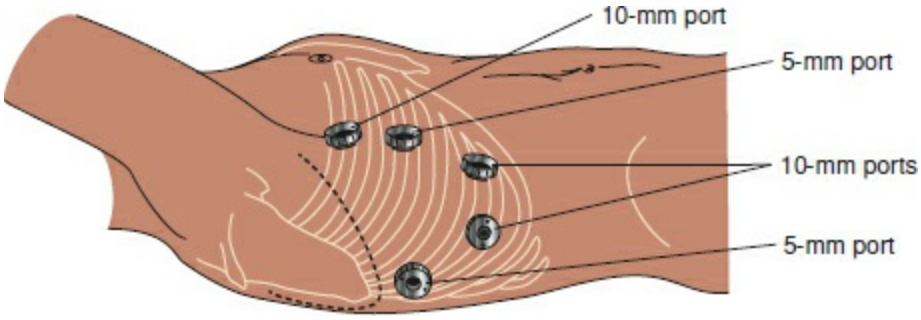

Figure 43-18. Thoracoscopic port placement.

After stapling, the remaining excess gastric tip, including the gastrotomy through which the stapler was introduced, is resected with two or three loads of the endovascular GIA stapler (Fig. 43-21). If an omental flap was created during the abdominal dissection, it is wrapped around the anastomosis and secured in place with two or three sutures. The chest is then thoroughly irrigated and inspected for hemostasis. Final anatomy of the reconstruction is demonstrated in Figure 43-22.

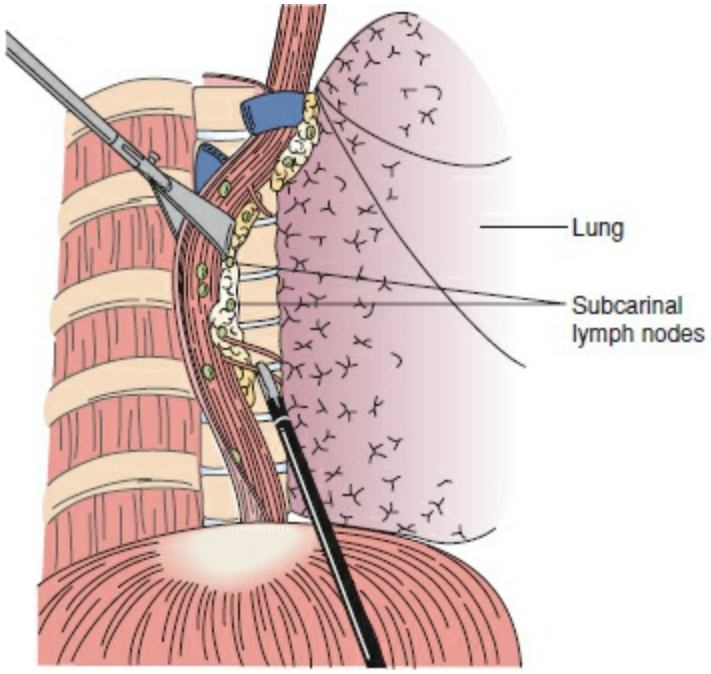

Figure 43-19. Thoracoscopic esophageal mobilization. The lung is retracted anteriorly and the pleura along the esophagus is excised. The subcarinal lymph nodes are excised en bloc along with the specimen.

Drain Placement and Closure

Adequate drainage of the mediastinum and the area surrounding the anastomosis is imperative to mitigate complications related to anastomotic leak. A 10-mm Jackson–Pratt drain is placed posteriorly along the anastomosis and a 28-French chest tube is directed posteriorly toward the apex. The previously placed nasogastric tube is advanced past the anastomosis under thoracoscopic visualization. The gastric conduit is sutured to the right crus with a single 2-0 Endostitch to prevent torsion or delayed herniation of the conduit. A long aspirating needle is used to instill a multilevel intercostal nerve block to aid in postoperative pain control. The minithoracotomy is closed using pericostal sutures with a multilayer soft tissue closure. The Jackson–Pratt drain is secured with multiple sutures to prevent it from becoming dislodged. Once the patient is turned to the supine position, the oropharynx and nasopharynx are suctioned free of all secretions. The double-lumen endotracheal tube is withdrawn and the patient reintubated with a single-lumen endotracheal tube. Use of a tube exchange catheter should be discouraged because this device is placed blindly and may cause injury to the right mainstem bronchus, which is potentially vulnerable owing to the dissection of the thoracic esophagus. A toilet bronchoscopy is then performed using an adult bronchoscope. At this time, both right and left mainstem bronchi are examined for any evidence of airway injury.

Postoperative Care

Patients are taken to the intensive care unit postoperatively and typically remain there for the first postoperative day before transferring to the surgical floor. The typical hospital stay is 7 days in patients with an uncomplicated postoperative course. The nasogastric tube may be removed on day 2 and "trickle" (20 to 30 mL/hr) jejunostomy tube feeds are started. A contrast esophagram is obtained on day 3 to 4 if the patient has adequate pulmonary toilet and a good cough. If there is no evidence of leak, oral intake is initiated in the form of 1 to 2 oz of clear liquids per hour. This is advanced over 2 days to full liquids, no more than 3 to 4 oz/hr along with cycled tube feeds. The chest tube is removed when output low (<150 cc/d) and the clinical course negative for leak. The Jackson–Pratt drain is pulled back 3 to 5 cm on postoperative day 5 and resecured. The drain is removed at the first postoperative clinic visit in 2 weeks' time.

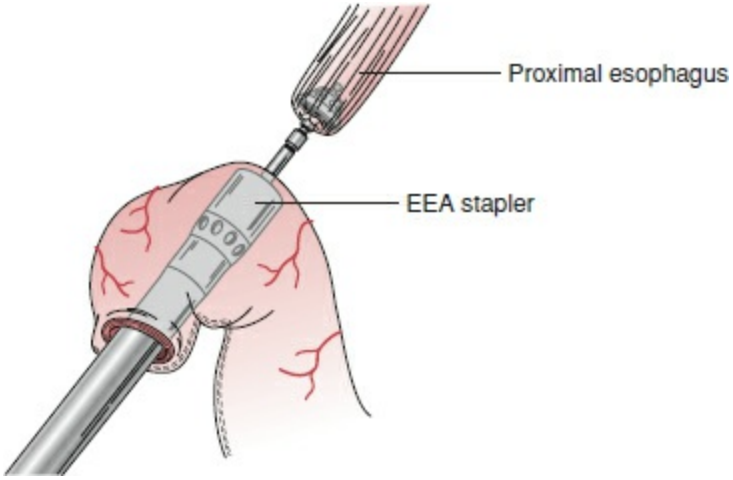

Figure 43-20. Creation of the esophago-gastric anastomosis. The anvil is secured in the proximal esophagus with two purse-string sutures. The EEA stapler is introduced into the conduit via a gastrostomy and is docked with the anvil keeping the conduit aligned with the lesser curve staple line facing the camera.

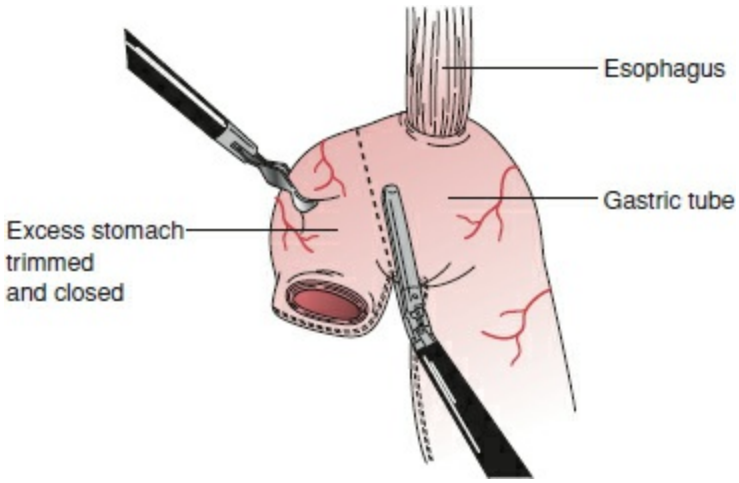

Figure 43-21. The gastrotomy is closed with an Endo GIA stapler and this part of the stomach is sent as final gastric margin. Care is taken not to encroach this staple line too close to the circular EEA staple line. A JP drain is left in the esophageal bed posterior to the anastomosis.

PALLIATIVE OPTIONS IN ADVANCED ESOPHAGEAL CANCER

9 In the event that patients have unresectable disease, metastatic disease, or are medically unfit for surgery, numerous palliative therapies are available. The goal of these therapies is to maintain comfort by restoring as much swallowing function as possible and support nutrition.

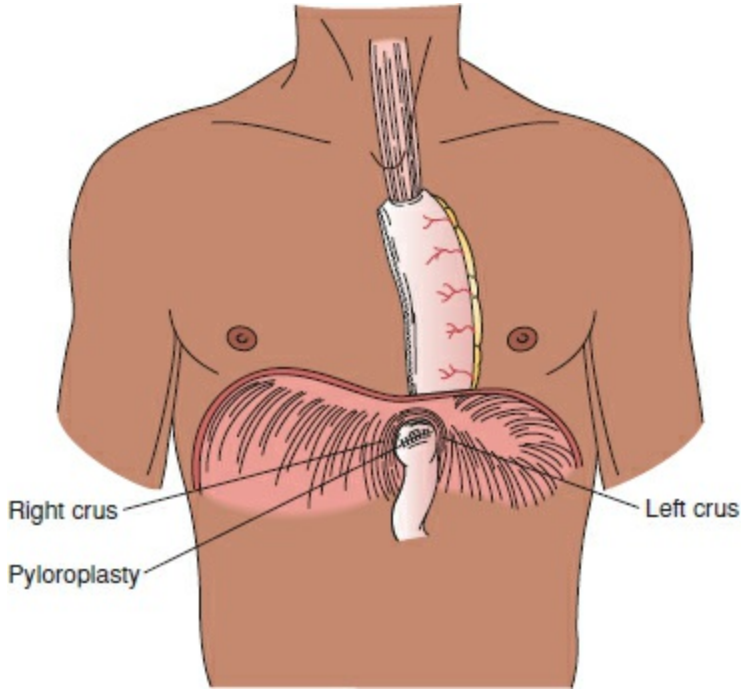

Figure 43-22. Completed reconstruction.

Nutrition support and hydration can be provided through alternative enteral access. PEG or surgical jejunostomy tube should be placed whenever possible under endoscopic guidance. Open gastrostomy or jejunostomy tubes are an alternative in patients with bulky obstructive lesions who cannot receive a PEG.

Chemotherapy

Chemotherapy can also provide palliation in patients with esophageal cancer. Many regimens are available that have been extensively studied. Agents such as fluorouracil and taxanes may be used either alone or in combination with platin-based agents to provide symptomatic relief. Palliative chemotherapy typically requires time to effectively reduce dysphagia. Special attention is needed while implementing these chemotherapeutic agents in usually debilitated, malnourished patients.

Radiation

Radiotherapy can be used for palliative reasons in patients with dysphagia. The typical dosage used is 4,000 to 5,000 cGy delivered over 4 weeks. The goal for this treatment is to allow patients with advanced disease and severe obstructive symptoms to handle secretions and swallow liquids such as dietary supplements. Like with palliative chemotherapy, radiotherapy does not offer immediate relief and will require time in order to reach maximal palliative effect. Patients with life expectancies greater than 3 months can be offered a combination of chemotherapy and radiation to achieve palliation. Side effects of radiation therapy include skin irritation and erythema. Patients may also experience esophagitis with painful swallow, stricture formation, radiation pneumonitis, and fistulization to the airway.

Stenting

Stenting technology has advanced significantly since its initial introduction in the 1970s as a palliative option for inoperable malignant esophageal strictures.[23] Currently, many stents are available on the market included self-expanding coated and uncoated nitinol types. Patients have the option of either inserting them endoscopically or radiologically. Stenting can be done in conjunction with other palliative treatment options including balloon dilation, neodymium; yttrium-aluminum-garnet (Nd:YAG) laser fulguration, and photodynamic therapy (PDT), which we will discuss next.

Neodymium:Yttrium-Aluminum-Garnet Laser Fulguration

In patients with unresectable obstructive tumors, endoscopic Nd:YAG laser fulguration is a surgical option that can provide temporary relief of esophageal obstruction. First, an esophagoscope is used to identify the lesion. The YAG laser energy is delivered through a flexible quartz fiber that is passed through the working channel of the scope. Multiple YAG laser sessions will be required to debulk the lumen of the esophagus to the point where patients may function relatively normally. As with many palliative treatments, laser fulguration is often performed in conjuncture with endoluminal stenting and radiation therapy to achieve better functional success. It can be particularly useful in patients who have undergone prior stenting and are experiencing an ingrowth of tumor through the stent. Tumor ingrowth is less of a problem with many of the current stents because we prefer to use the fully covered stents.

Photodynamic Therapy

Another form of palliative therapy is intraluminal PDT. It is a nonthermal ablative technique that requires the systemic administration of a photosensitizing substance such as hematoporphyrin. Over the course of 48 hours, this photosensitizing substance becomes highly concentrated in malignant cells. Patients will then undergo endoscopic evaluation with application of an argon-pump dye-laser introduced endoluminally in the esophagus to deliver light at a wavelength of 630 nm. This endoluminal light source will cause a chain reaction that generates an overwhelming concentration of oxygen radicals, quickly leading to tumor necrosis and patent luminal area. Perforation is of little concern with PDT because the risk of full-thickness necrosis of the esophagus is rare due to the limited depth of penetration of the light. Unfortunately, photosensitizing agents such as hematoporphyrin are frequently retained by the reticuloendothelial system of the skin. This retention will cause patients to be sensitive to infrared wavelength light, including sunlight, radiant heat, fluorescent light, and strong incandescent light. Patients should be informed of these side effects as they may persist for up to 3 months depending on what agent was used as well as the individual. Because of these long-lasting postoperative effects, endoluminal PDT may not be a favored option for patients with shorter life expectancies.

In a recent series of 215 patients who underwent endoluminal PDT for palliation, investigators reported a procedure-related mortality rate of 1.8%. With a median survival of 4.8 months, this series found this technique to be an effective palliative treatment in 85% of patients with obstructive esophageal tumors.[78] Of note, some of these patients also required stenting for palliation, suggesting that PDT may have a role in a multimodal palliative treatment plan for patients with obstructing esophageal cancers.

References

1. Briel JW, Tamhankar AP, Hagen JA, et al. Prevalence and risk factors for ischemia, leak, and stricture of esophageal anastomosis: gastric pull-up versus colon interposition. *J Am Coll Surg* 2004;198(4):536–541; discussion 541–542.
2. Young MM, Deschamps C, Trastek VF, et al. Esophageal reconstruction for benign disease: early morbidity, mortality, and functional results. *Ann Thorac Surg* 2000;70(5):1651–1655.
3. Vigneswaran WT, Trastek VF, Pairolero PC, et al. Transhiatal esophagectomy for carcinoma of the esophagus. *Ann Thorac Surg* 1993;56(4):838–844; discussion 844–846.
4. Young MM, Deschamps C, Allen MS, et al. Esophageal reconstruction for benign disease: self-assessment of functional outcome and quality of life. *Ann Thorac Surg* 2000;70(6):1799–1802.
5. Crestanello JA, Deschamps C, Cassivi SD, et al. Selective management of intrathoracic anastomotic leak after esophagectomy. *J Thorac Cardiovasc Surg* 2005;129(2):254–260.
6. Parekh K, Iannettoni MD. Complications of esophageal resection and reconstruction. *Semin Thorac Cardiovasc Surg* 2007;19(1):79–88.
7. Kent MS, Schuchert M, Fernando H, et al. Minimally invasive esophagectomy: state of the art. *Dis Esophagus* 2006;19(3):137–145.
8. Alanezi K, Urschel JD. Mortality secondary to esophageal anastomotic leak. *Ann Thorac Cardiovasc Surg* 2004;10(2):71–75.
9. Eroglu A, Turkyilmaz A, Aydin Y, et al. Current management of esophageal perforation: 20 years experience. *Dis Esophagus* 2009;22(4):374–380.
10. Wehrmann T, Stergiou N, Vogel B, et al. Endoscopic debridement of paraesophageal, mediastinal abscesses: a prospective case series. *Gastrointest Endosc* 2005;62(3):344–349.
11. Amir AI, van Dullemen H, Plukker JT. Selective approach in the treatment of esophageal perforations. *Scand J Gastroenterol* 2004;39(5):418–422.
12. Brinster CJ, Singhal S, Lee L, et al. Evolving options in the management of esophageal perforation. *Ann Thorac Surg* 2004;77(4):1475–1483.
13. Muir AD, White J, McGuigan JA, et al. Treatment and outcomes of oesophageal perforation in a tertiary referral centre. *Eur J Cardiothorac Surg* 2003;23(5):799–804; discussion 804.
14. Page RD, Shackcloth MJ, Russell GN, et al. Surgical treatment of anastomotic leaks after oesophagectomy. *Eur J Cardiothorac Surg* 2005;27(2):337–343.
15. Sauvanet A, Baltar J, Le Mee J, et al. Diagnosis and conservative management of intrathoracic leakage after oesophagectomy. *Br J Surg* 1998;85(10):1446–1449.
16. Weiman DS, Walker WA, Brosnan KM, et al. Noniatrogenic esophageal trauma. *Ann Thorac Surg* 1995;59(4):845–849; discussion 849–850.

17. Barrett NR. Spontaneous perforation of the oesophagus; review of the literature and report of three new cases. *Thorax* 1946;1:48–70.
18. Foley MJ, Ghahremani GG, Rogers LF. Reappraisal of contrast media used to detect upper gastrointestinal perforations: comparison of ionic water-soluble media with barium sulfate. *Radiology* 1982;144(2):231–237.
19. Gollub MJ, Bains MS. Barium sulfate: a new (old) contrast agent for diagnosis of postoperative esophageal leaks. *Radiology* 1997;202(2):360–362.
20. Horwitz B, Krevsky B, Buckman RF Jr, et al. Endoscopic evaluation of penetrating esophageal injuries. *Am J Gastroenterol* 1993;88(8):1249–1253.
21. Mengold L KK, Conservative management of esophageal perforation. *Arch Surg* 1965;91:232.
22. Cameron JL, Kieffer RF, Hendrix TR, et al. Selective nonoperative management of contained intrathoracic esophageal disruptions. *Ann Thorac Surg* 1979;27(5):404–408.
23. Atkinson M, Ferguson R. Fibreoptic endoscopic palliative intubation of inoperable oesophagogastric neoplasms. *Br Med J* 1977;1(6056):266–267.
24. Tuebergen D, Rijcken E, Mennigen R, et al. Treatment of thoracic esophageal anastomotic leaks and esophageal perforations with endoluminal stents: efficacy and current limitations. *J Gastrointest Surg* 2008;12(7):1168–1176.
25. Blackmon SH, Santora R, Schwarz P, et al. Utility of removable esophageal covered self-expanding metal stents for leak and fistula management. *Ann Thorac Surg* 2010;89(3):931–936; discussion 936–937.
26. Fischer A, Thomusch O, Benz S, et al. Nonoperative treatment of 15 benign esophageal perforations with self-expandable covered metal stents. *Ann Thorac Surg* 2006;81(2):467–472.
27. Freeman RK, Ascioti AJ, Wozniak TC. Postoperative esophageal leak management with the Polyflex esophageal stent. *J Thorac Cardiovasc Surg* 2007;133(2):333–338.
28. Freeman RK, Van Woerkom JM, Ascioti AJ. Esophageal stent placement for the treatment of iatrogenic intrathoracic esophageal perforation. *Ann Thorac Surg* 2007;83(6):2003–2007; discussion 2007–2008.
29. Karbowski M, Schembre D, Kozarek R, et al. Polyflex self-expanding, removable plastic stents: assessment of treatment efficacy and safety in a variety of benign and malignant conditions of the esophagus. *Surg Endosc* 2008;22(5):1326–1333.
30. Schubert D, Scheidbach H, Kuhn R, et al. Endoscopic treatment of thoracic esophageal anastomotic leaks by using silicone-covered, self-expanding polyester stents. *Gastrointest Endosc* 2005;61(7):891–896.
31. Rueth NM, Shaw D, D'Cunha J, et al. Esophageal stenting and radiotherapy: a multimodal approach for the palliation of symptomatic malignant dysphagia. *Ann Surg Oncol* 2012;19(13):4223–4228.
32. D'Cunha J, Rueth NM, Groth SS, et al. Esophageal stents for anastomotic leaks and perforations. *J Thorac Cardiovasc Surg* 2011;142(1):39–46.e1.

33. D'Cunha J. Esophageal stents for leaks and perforations. *Semin Thorac Cardiovasc Surg* 2011;23(2):163–167.
34. Eisen GM, Baron TH, Dominitz JA, et al. Guideline for the management of ingested foreign bodies. *Gastrointest Endosc* 2002;55(7):802–806.
35. Longstreth GF, Longstreth KJ, Yao JF. Esophageal food impaction: epidemiology and therapy. A retrospective, observational study. *Gastrointest Endosc* 2001;53(2):193–198.
36. Smith MT, Wong RK. Foreign bodies. *Gastrointest Endosc Clin N Am* 2007;17(2):361–382, vii.
37. Kay M, Wyllie R. Pediatric foreign bodies and their management. *Curr Gastroenterol Rep* 2005;7(3):212–218.
38. Hatch GF 3rd, Wertheimer-Hatch L, Hatch KF, et al. Tumors of the esophagus. *World J Surg* 2000;24(4):401–411.
39. Seremetis MG, Lyons WS, deGuzman VC, et al. Leiomyomata of the esophagus. An analysis of 838 cases. *Cancer* 1976;38(5):2166–2177.
40. Postlethwait RW, Musser AW. Changes in the esophagus in 1,000 autopsy specimens. *J Thorac Cardiovasc Surg* 1974;68(6):953–956.
41. Stelow EB, Jones DR, Shami VM.. Esophageal leiomyosarcoma diagnosed by endoscopic ultrasound-guided fine-needle aspiration. *Diagn Cytopathol* 2007;35(3):167–170.
42. Bonavina L, Segalin A, Rosati R, et al. Surgical therapy of esophageal leiomyoma. *J Am Coll Surg* 1995;181(3):257–262.
43. Lee LS, Singhal S, Brinster CJ, et al. Current management of esophageal leiomyoma. *J Am Coll Surg* 2004;198(1):136–146.
44. Zaninotto G, Portale G, Costantini M, et al. Minimally invasive enucleation of esophageal leiomyoma. *Surg Endosc* 2006;20(12):1904–1908.
45. Schuhmacher C, Becker K, Dittler HJ, et al. Fibrovascular esophageal polyp as a diagnostic challenge. *Dis Esophagus* 2000;13(4):324–327.
46. Fein R, Kelsen DP, Geller N, et al. Adenocarcinoma of the esophagus and gastroesophageal junction. Prognostic factors and results of therapy. *Cancer* 1985;56(10):2512–2518.
47. Puli SR, Reddy JB, Bechtold ML, et al. Staging accuracy of esophageal cancer by endoscopic ultrasound: a meta-analysis and systematic review. *World J Gastroenterol* 2008;14(10):1479–1490.
48. Cameron AJ, Zinsmeister AR, Ballard DJ, et al. Prevalence of columnar-lined (Barrett's) esophagus. Comparison of population-based clinical and autopsy findings. *Gastroenterology* 1990;99(4):918–922.
49. Öberg S, Johansson J, Wenner J, et al. Metaplastic columnar mucosa in the cervical esophagus after esophagectomy. *Ann Surg* 2002;235(3):338–345.
50. Shaheen N, Ransohoff DF. Gastroesophageal reflux, barrett esophagus, and

esophageal cancer: Scientific review. *JAMA* 2002;287(15):1972–1981.

51. Sikkema M, de Jonge PJ, Steyerberg EW, et al. Risk of esophageal adenocarcinoma and mortality in patients with Barrett's esophagus: a systematic review and meta-analysis. *Clin Gastroenterol Hepatol* 2010;8(3):235–244; quiz e32.
52. Wani S, Puli SR, Shaheen NJ, et al. Esophageal adenocarcinoma in Barrett's esophagus after endoscopic ablative therapy: a meta-analysis and systematic review. *Am J Gastroenterol* 2009;104(2):502–513.
53. Spechler SJ. Dysplasia in Barrett's esophagus: limitations of current management strategies. *Am J Gastroenterol* 2005;100(4):927–935.
54. Aggestrup S, Holm JC, Sorensen HR. Does achalasia predispose to cancer of the esophagus? *Chest* 1992;102(4):1013–1016.
55. Arnott SJ, Duncan W, Gignoux M, et al. Preoperative radiotherapy for esophageal carcinoma. *Cochrane Database Syst Rev* 2005;(4):Cd001799.
56. Kelsen DP, Ginsberg R, Pajak TF, et al. Chemotherapy followed by surgery compared with surgery alone for localized esophageal cancer. *N Engl J Med* 1998;339(27):1979–1984.
57. Medical Research Council Oesophageal Cancer Working Group. Surgical resection with or without preoperative chemotherapy in oesophageal cancer: a randomised controlled trial. *Lancet* 2002;359(9319):1727–1733.
58. Cunningham D, Allum WH, Stenning SP, et al. Perioperative chemotherapy versus surgery alone for resectable gastroesophageal cancer. *N Engl J Med* 2006;355(1):11–20.
59. Malthaner RA, Collin S, Fenlon D Preoperative chemotherapy for resectable thoracic esophageal cancer. *Cochrane Database Syst Rev* 2006;(3):Cd001556.
60. Walsh TN, Noonan N, Hollywood D, et al. A comparison of multimodal therapy and surgery for esophageal adenocarcinoma. *N Engl J Med* 1996; 335(7):462–467.
61. Bosset JF, Gignoux M, Triboulet JP, et al. Chemoradiotherapy followed by surgery compared with surgery alone in squamous-cell cancer of the esophagus. *N Engl J Med* 1997;337(3):161–167.
62. Gebski V, Burmeister B, Smithers BM, et al. Survival benefits from neoadjuvant chemoradiotherapy or chemotherapy in oesophageal carcinoma: a meta-analysis. *Lancet Oncol* 2007;8(3):226–234.
63. van Hagen P, Hulshof MC, van Lanschot JJ, et al. Preoperative chemoradiotherapy for esophageal or junctional cancer. *N Engl J Med* 2012;366(22):2074–2084.
64. Shapiro J, van Lanschot JJ, Hulshof MC, et al. Neoadjuvant chemoradiotherapy plus surgery versus surgery alone for oesophageal or junctional cancer (CROSS): long-term results of a randomised controlled trial. *Lancet Oncol* 16(9):1090–1098.
65. Little AG, Lerut AE, Harpole DH, et al. The Society of Thoracic Surgeons practice guidelines on the role of multimodality treatment for cancer of the esophagus and gastroesophageal junction. *Ann Thorac Surg* 2014;98(5):1880–1885.

66. Orringer MB, Sloan H. Esophagectomy without thoracotomy. *J Thorac Cardiovasc Surg* 1978;76(5):643–654.
67. Lewis I. The surgical treatment of carcinoma of the oesophagus; with special reference to a new operation for growths of the middle third. *Br J Surg* 1946;34:18–31.
68. McKeown KC. Total three-stage oesophagectomy for cancer of the oesophagus. *Br J Surg* 1976;63(4):259–262.
69. Forshaw MJ, Gossage JA, Ockrim J, et al. Left thoracoabdominal esophagogastrectomy: still a valid operation for carcinoma of the distal esophagus and esophagogastric junction. *Dis Esophagus* 2006;19(5):340–345.
70. Linden PA, Sugarbaker DJ. Section V: Techniques of esophageal resection. *Semin Thorac Cardiovasc Surg* 2003;15(2):197–209.
71. Dimick JB, Pronovost PJ, Cowan JA, et al. Surgical volume and quality of care for esophageal resection: do high-volume hospitals have fewer complications? *Ann Thorac Surg* 2003;75(2):337–341.
72. Rizk NP, Bach PB, Schrag D, et al. The impact of complications on outcomes after resection for esophageal and gastroesophageal junction carcinoma. *J Am Coll Surg* 2004;198(1):42–50.
73. Orringer MB, Marshall B, Iannettoni MD. Eliminating the cervical esophagogastric anastomotic leak with a side-to-side stapled anastomosis. *J Thorac Cardiovasc Surg* 2000;119(2):277–288.
74. Heitmiller RF. Results of standard left thoracoabdominal esophagogastrectomy. *Semin Thorac Cardiovasc Surg* 1992;4(4):314–319.
75. Luketich JD, Pennathur A, Awais O, et al. Outcomes after minimally invasive esophagectomy: review of over 1000 patients. *Ann Surg* 2012;256(1):95–103.
76. Luketich JD, Pennathur A, Franchetti Y, et al. Minimally invasive esophagectomy: results of a prospective phase II multicenter trial-the eastern cooperative oncology group (E2202) study. *Ann Surg* 2015;261(4):702–707.
77. Nguyen NT, Follette DM, Wolfe BM, et al. Comparison of minimally invasive esophagectomy with transthoracic and transhiatal esophagectomy. *Arch Surg* 2000;135(8):920–925.
78. Litle VR, Luketich JD, Christie NA, et al. Photodynamic therapy as palliation for esophageal cancer: Experience in 215 patients. *Ann Thorac Surg* 2003;76(5):1687–1692; discussion 1692–1693.

SECTION E: STOMACH AND DUODENUM

Chapter 44

Gastric Anatomy and Physiology

Michael W. Mulholland

Key Points

1 The stomach is an extremely well-vascularized organ, supplied by a number of major arteries and protected by a large number of extramural and intramural collaterals.

2 Oxyntic glands occupy the fundus and body of the stomach and contain the oxyntic or parietal cells, which are the sites of acid production. Oxyntic glands also contain chief cells, the site of gastric pepsinogen synthesis.

3 The most important stimulant of gastrin release is a meal. Postprandial luminal pH also strongly affects gastrin secretion.

4 The basolateral membrane of the parietal cell contains specific receptors for histamine, gastrin, and acetylcholine, the three major stimulants of acid production.

5 Pepsins are a heterogeneous group of proteolytic enzymes that are secreted by the gastric chief cells.

6 The gastric mucosa is the site of production of intrinsic factor, which is necessary for the absorption of cobalamin from the ileal mucosa. Total gastrectomy is regularly followed by cobalamin malabsorption, as is resection of the proximal stomach or atrophic gastritis that involves the oxyntic mucosa.

GROSS ANATOMY

The stomach and duodenum, along with the esophagus, liver, bile ducts, and pancreas, are derived from the embryonic foregut. During the fifth week of gestation, the future stomach is marked as a dilation in the caudal portion of the foregut. Cranial to this dilation, the trachea forms as a bud from the future esophagus. At this time, the primitive stomach is invested with both ventral and dorsal mesenteries. The embryonic ventral mesentery is represented in postnatal life by the falciform ligament and by the gastrohepatic and hepatoduodenal mesenteries that form the lesser omentum. The celiac artery, the major blood supply to the foregut, passes within the dorsal mesentery. The primitive dorsal mesentery ultimately forms three structures: the gastrocolic ligament, the gastrosplenic ligament, and the gastrophrenic ligament.

During the sixth and seventh weeks of gestation, the typical morphology of the stomach is established. Accelerated growth of the left gastric wall, relative to the right, establishes the greater and lesser curvatures. This unequal growth also rotates the stomach and causes the left vagal nerve trunk to assume its anterior position, whereas the right vagal trunk is located posteriorly. The growth of structures cephalad to the stomach causes the organ to descend. During the sixth week, the primitive stomach lies between the T10 and T12 vertebral segments. By the eighth week, the stomach is located between the T11 and the L4 segments. In adult life, the stomach is most commonly located between the T10 and the L3 vertebral segments.

The stomach can be divided into anatomic regions based on external landmarks (Fig. 44-1). Although this division is commonly referred to in surgical texts and is useful in discussing gastric resective procedures, it does not necessarily reflect the secretory or motor functions of the mucosal and muscular layers of the stomach. The gastric cardia is the region of the stomach just distal to the gastroesophageal junction. The fundus is the portion of the stomach above and to the left of the gastroesophageal junction. The corpus constitutes the region between the fundus and the antrum. The margin between the corpus and antrum is not distinct externally but can be defined arbitrarily by a line from the incisura angularis on the lesser curvature to a point one-fourth the distance from the pylorus to the esophagus along the greater curvature. The gastric antrum is bounded distally by the pylorus, which can be appreciated by palpation as a thickened ring of smooth muscle.

The stomach is mobile in most people and is fixed at only two points, proximally by the gastroesophageal junction and distally by the retroperitoneal duodenum. Therefore, the position of the stomach varies and depends on the habitus of the person, the degree of gastric distention, and the position of the other abdominal organs. Anteriorly, the stomach is in contact with the left hemidiaphragm, the left lobe and the anterior segment of the right lobe of the liver, and the anterior parietal surface of the abdominal wall. The posterior surface of the stomach is related to the left diaphragm; the left kidney and left adrenal gland; the neck, tail, and body of the pancreas; the aorta and celiac trunk; and the periaortic nerve plexuses. The greater curvature of the stomach is near the transverse colon and the transverse colonic mesentery. The concavity of the spleen contacts the left

lateral portion of the stomach.

1 The stomach is an extremely well-vascularized organ, supplied by a number of major arteries and protected by a large number of extramural and intramural collaterals. Gastric viability can be preserved after ligation of all but one primary artery, an advantage that can be exploited during gastric reconstructive procedures. Also, the rich network of anastomosing vessels means that gastric hemorrhage cannot be controlled by the extramural ligation of gastric arteries. Most gastric blood flow is ordinarily derived from the celiac trunk (Fig. 44-2). The lesser curvature is supplied by the left gastric artery, which is the first major branch of the celiac trunk, and by the right gastric artery, which is derived from the hepatic artery. Branches of the left gastric artery also supply the lowermost portion of the esophagus. The greater curvature is supplied by the short gastric and left gastroepiploic arteries, which are branches of the splenic artery, and by the right gastroepiploic artery, a branch of the gastroduodenal artery. In instances of celiac trunk occlusion, gastric blood flow is usually maintained from the superior mesenteric artery collaterally by way of the pancreaticoduodenal arcade. In general, venous effluent from the stomach parallels the arterial supply. The venous equivalent of the left gastric artery is the coronary vein.

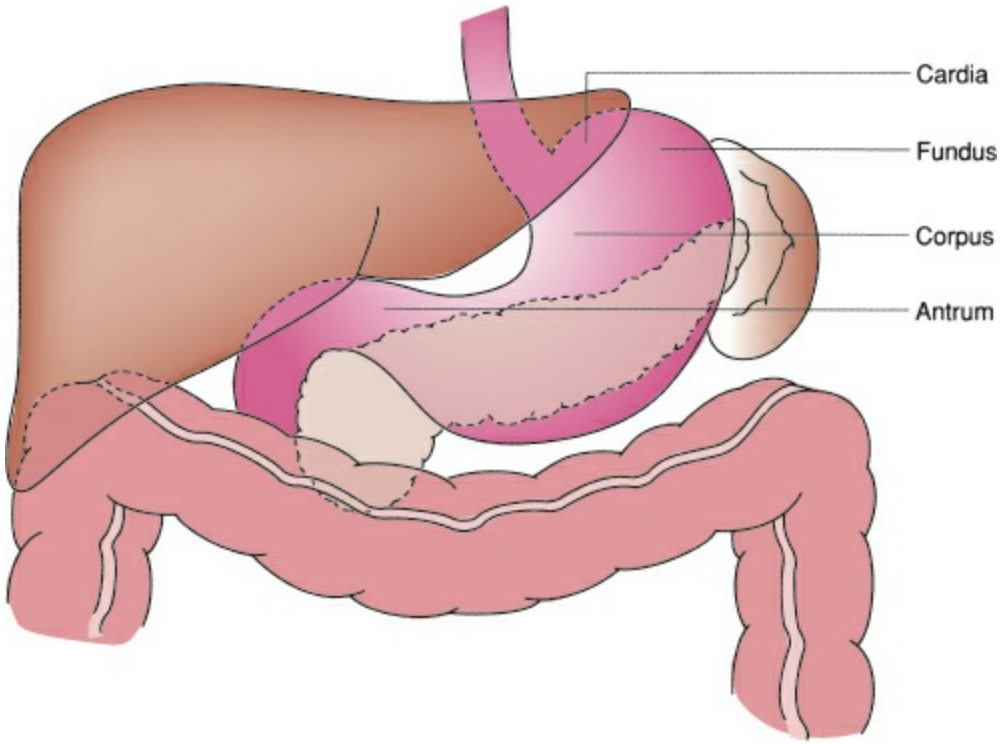

Figure 44-1. Topographic relations of the stomach.

As a first approximation, the lymphatic drainage of the stomach parallels gastric venous return (Fig. 44-3). Lymph from the proximal portion of the stomach along the lesser curvature first drains into superior gastric lymph nodes surrounding the left gastric artery. The distal portion of the lesser curvature drains through suprapyloric nodes. The proximal portion of the greater curvature is supplied by lymphatic vessels that traverse pancreaticosplenic nodes, whereas the antral portion of the greater curvature drains into the subpyloric and omental nodal groups. Secondary drainage from each of these systems

eventually traverses nodes at the base of the celiac axis. These discrete anatomic groupings are misleading. The lymphatic drainage of the human stomach, like its blood supply, exhibits extensive intramural ramifications and a number of extramural communications. As a consequence, disease processes that involve the gastric lymphatics often spread intramurally beyond the region of origin and to nodal groups at a distance from the primary lymphatic zone.

The left and right vagal nerves descend parallel to the esophagus within the thorax before forming a periesophageal plexus between the tracheal bifurcation and the diaphragm. From this plexus, two vagal trunks coalesce before passing through the esophageal hiatus of the diaphragm (Fig. 44-4). The left vagal trunk is usually closely applied to the anterior surface of the esophagus, whereas the posterior vagal trunk is often midway between the esophagus and the aorta. The anterior vagus supplies a hepatic division, which passes to the right in the lesser omentum before innervating the liver and biliary tract. The remainder of the anterior vagal fibers parallels the lesser curvature of the stomach, branching to the anterior gastric wall. The posterior vagus nerve branches into the celiac division, which passes to the celiac plexus, and a posterior gastric division, which innervates the posterior gastric wall.

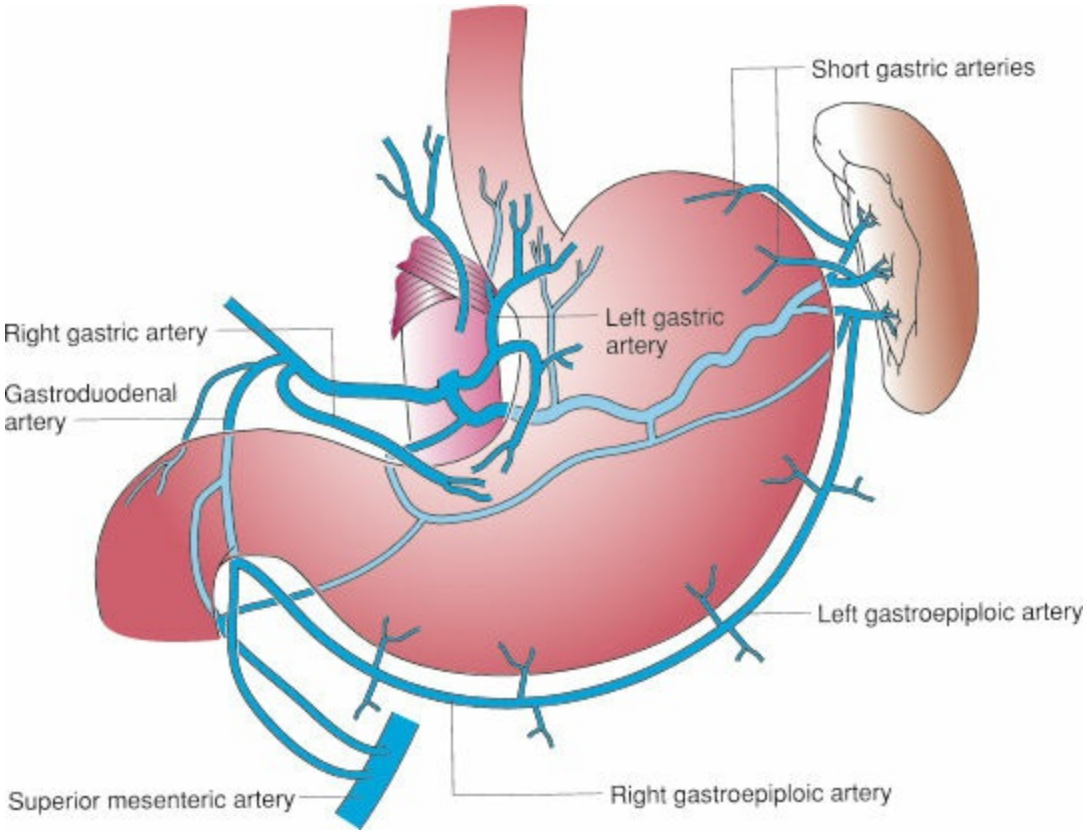

Figure 44-2. Arterial blood supply of the stomach.

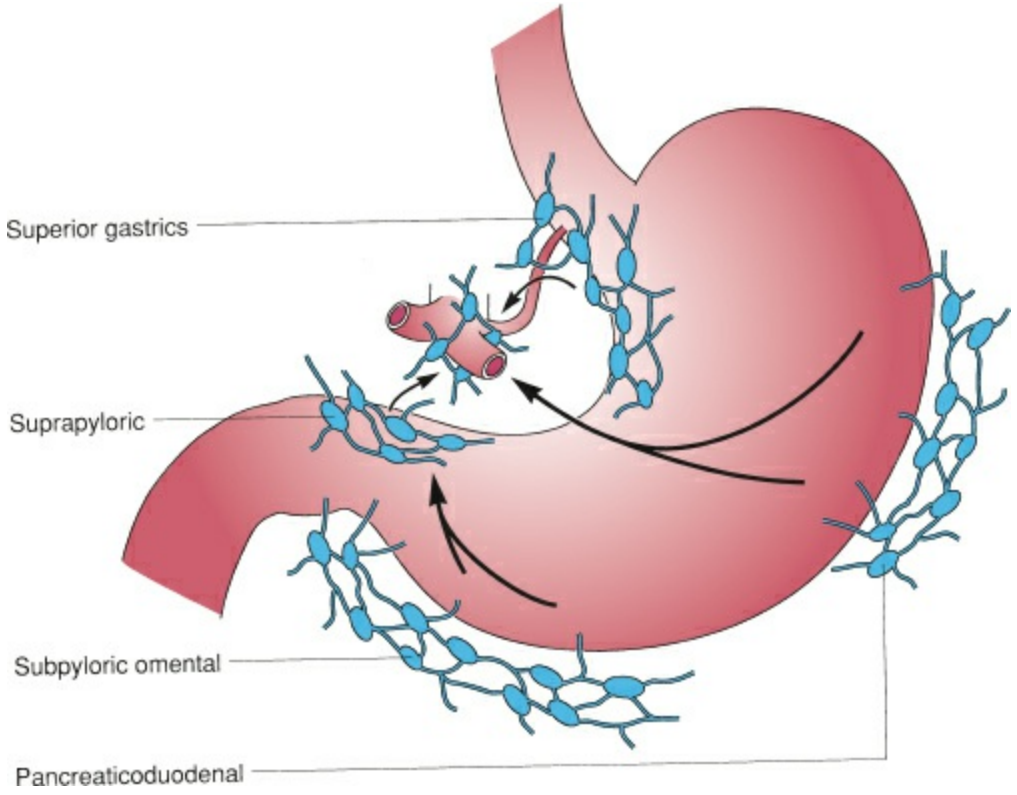

Figure 44-3. Lymphatic drainage of the stomach.

Approximately 90% of the fibers in the vagal trunks are afferent, transmitting information from the gastrointestinal tract to the central nervous system (CNS). Parasympathetic afferent fibers are not responsible for the sensation of gastric pain. Only 10% of vagal nerve fibers are motor or secretory efferents. Parasympathetic efferent fibers contained in the vagus originate in the dorsal nucleus of the medulla. Vagal efferent fibers pass without synapse to contact postsynaptic neurons in the gastric wall in the myenteric and submucous plexuses. Secondary neurons directly innervate gastric smooth muscle or epithelial cells. Acetylcholine is the neurotransmitter of primary vagal efferent neurons.

The gastric sympathetic innervation is derived from spinal segments T5 through T10. Sympathetic fibers leave the corresponding spinal nerve roots by way of gray rami communicantes and enter a series of bilateral prevertebral ganglia (Fig. 44-5). From these ganglia, presynaptic fibers pass through the greater splanchnic nerves to the celiac plexus, where they synapse with secondary sympathetic neurons. Postsynaptic sympathetic nerve fibers enter the stomach in association with blood vessels. Afferent sympathetic fibers pass without synapse from the stomach to dorsal spinal roots. Pain of gastroduodenal origin is sensed through afferent fibers of sympathetic origin.

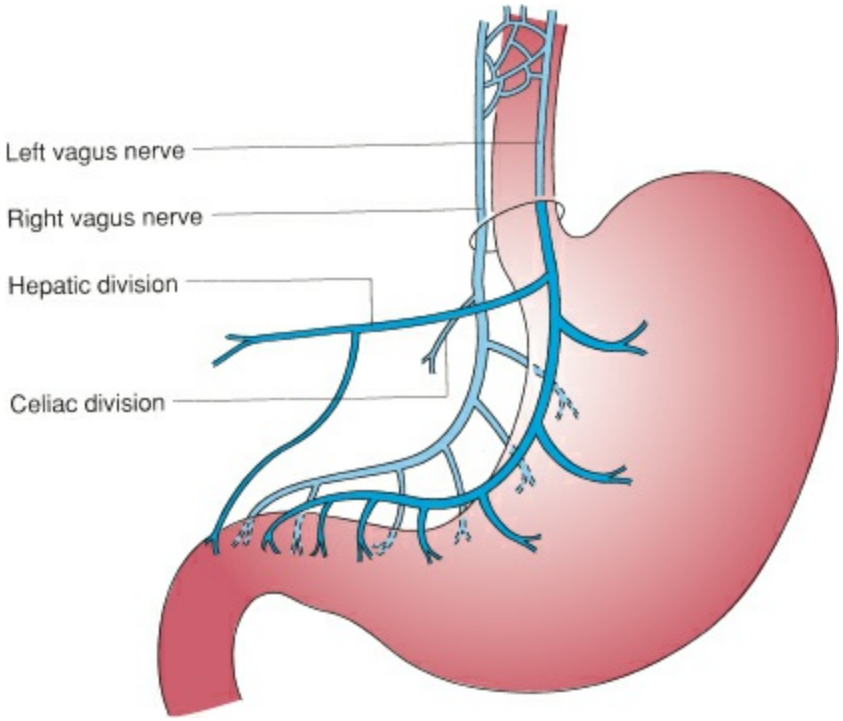

Figure 44-4. Vagal innervation of the stomach.

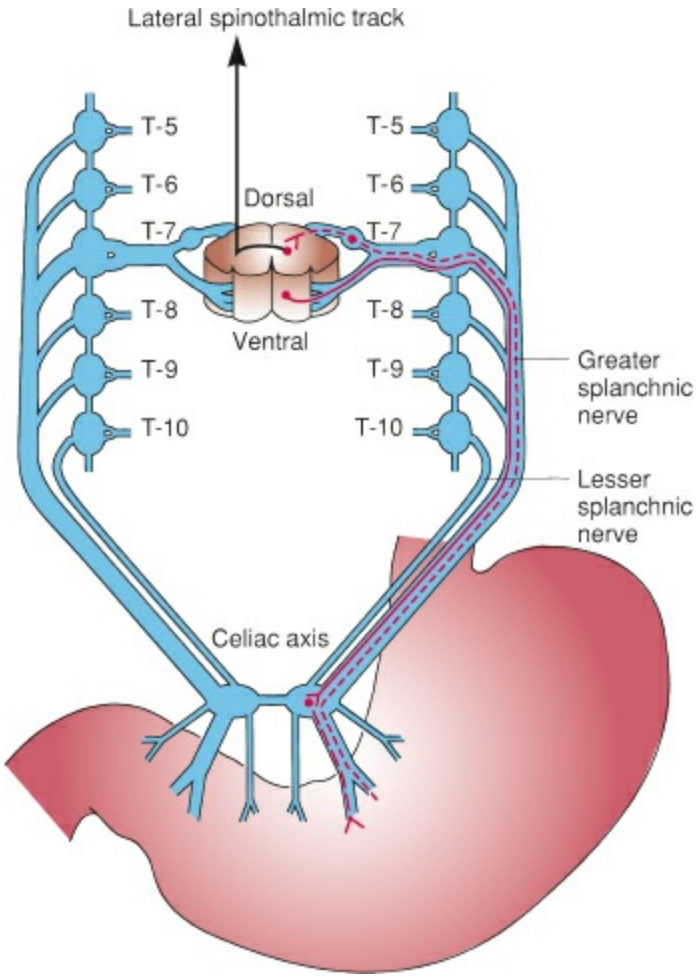

Figure 44-5. Derivation of gastric sympathetic innervation.

MICROSCOPIC ANATOMY

The glandular portions of the stomach are lined by a simple columnar epithelium composed of surface mucous cells. The luminal surface, visualized by scanning electron microscopy, appears cobblestoned, interrupted at intervals by gastric pits. Opening into the gastric pits are one or more gastric glands that impart functional significance to the gastric mucosa. The mucosa of the human stomach is composed of three distinct types of gastric glands – cardiac, oxyntic, and antral.

In humans, cardiac glands occupy a narrow zone adjacent to the esophagus and mark a transition from the stratified squamous epithelium of the esophagus to the simple columnar epithelium of the stomach. The surface and gastric pit mucous cells of the cardia are not distinguishable from those in other areas of the stomach. Cardiac glands contain mucous and undifferentiated and endocrine cells but not the parietal or chief cells that are prominent in the adjacent oxyntic mucosa. Cardiac glands are usually branched and connect with relatively short gastric pits. The functional properties of cardiac glands include the secretion of mucus.

2 Oxyntic glands are the most distinctive feature of the human stomach. They occupy the fundus and body of the stomach and contain the oxyntic or parietal cells, which are the sites of acid production. Oxyntic glands also contain chief cells, the site of gastric pepsinogen synthesis. The tubular oxyntic glands are usually relatively straight but sometimes branch; several glands may empty into a single gastric pit. The glands are divided into three regions: (a) the isthmus, containing surface mucous cells and a few scattered parietal cells; (b) the neck, with a heavy concentration of parietal cells and a few neck mucous cells; and (c) the base of the gland, containing chief cells, undifferentiated cells, a few parietal cells, and some mucous neck cells. Endocrine cells are scattered throughout all three regions of oxyntic glands.

The most distinctive cell of the gastric mucosa is the acid-secreting parietal cell. Parietal cells have an unusual ultrastructural specialization in the form of intracellular canaliculi, a network of clefts extending to the basal cytoplasm and often encircling the nucleus, which is continuous with the gland lumen (Fig. 44-6). The surface area provided by the intracellular secretory canaliculi is large and is further magnified by microvilli lining the canaliculi. In parietal cells that are not stimulated to secrete acid, the secretory canaliculi are collapsed and inconspicuous. On stimulation, a severalfold increase in canalicular surface area occurs, the intracellular clefts become prominent, and the communication with the luminal surface is readily identified. These changes create an intracellular space in communication with the gastric lumen into which hydrogen ions are secreted at high concentration.

The cytoplasm of the parietal cell also contains an abundance of large mitochondria. Mitochondria are estimated to occupy 30% to 40% of the cytoplasmic volume of unstimulated parietal cells, reflecting the extremely high oxidative activity of these cells. The oxygen consumption rate of isolated parietal cells is approximately five times higher than that of gastric mucous cells. The cytoplasm also contains a limited amount of rough endoplasmic reticulum, presumed to be the production site of intrinsic factor, which is

also secreted by parietal cells.

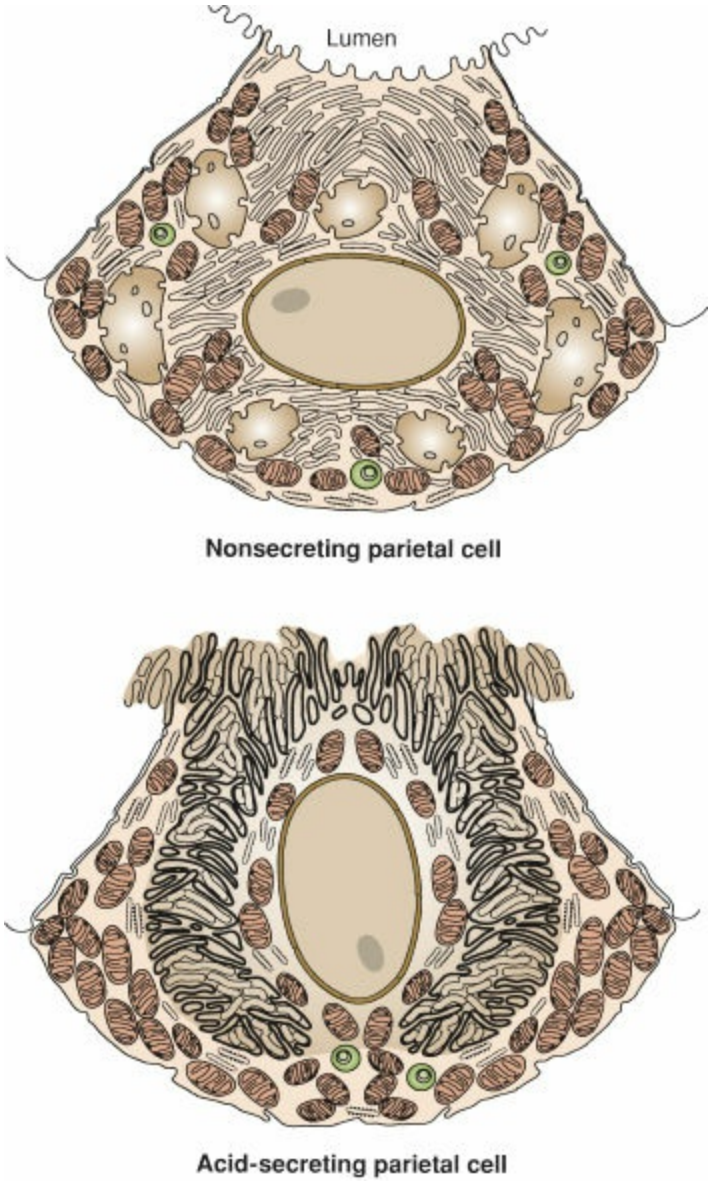

Figure 44-6. Resting and stimulated parietal cell, emphasizing morphologic transformation with increase in secretory canalicular membrane surface area that occurs with acid secretion.

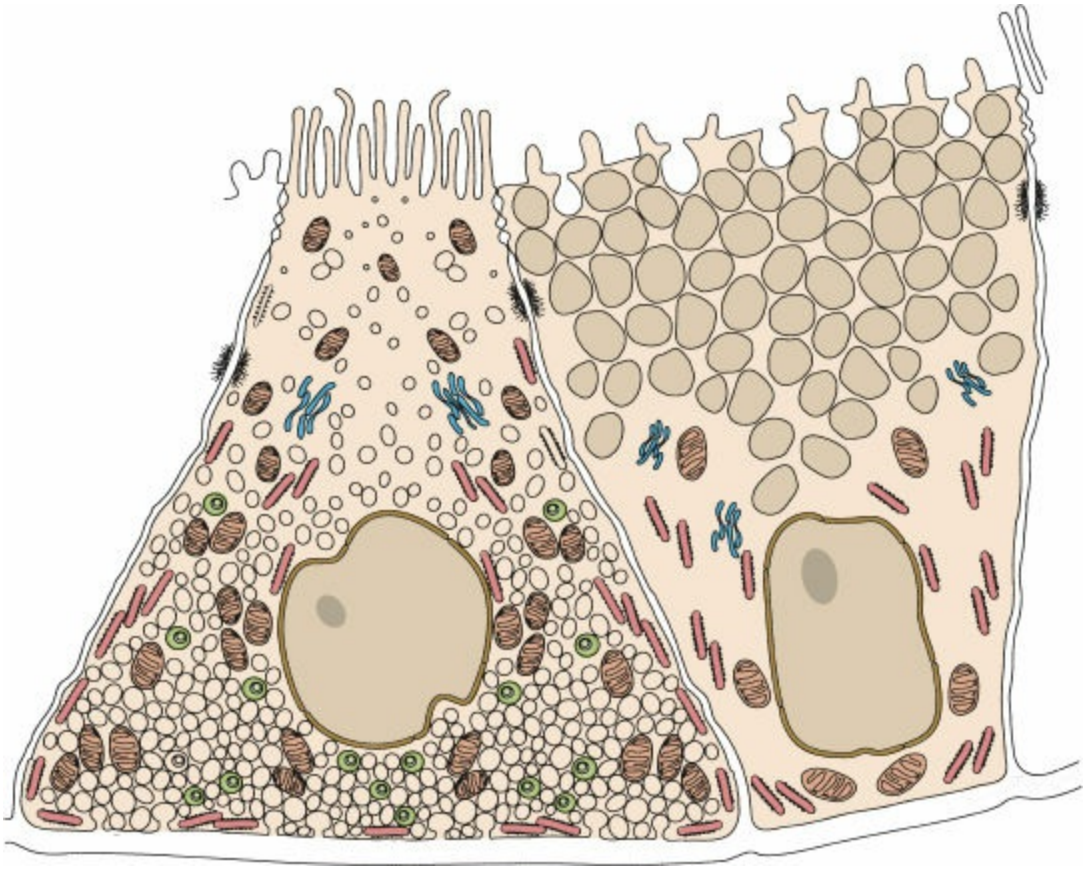

Figure 44-7. Contrasting morphology of antral gastrin cell (*left*) with basally oriented secretory granules, and gastric mucous cell (*right*) with apical mucous granules.

In addition to parietal cells, the oxyntic glands contain the gastric chief cells, which synthesize and secrete pepsinogen. Chief cells are most abundant in the basal region of the oxyntic glands. The cells have a morphology typical of protein-secreting exocrine cells and are similar in ultrastructural appearance to pancreatic acinar cells. Rough endoplasmic reticulum is abundant in the cytoplasm and extends between secretory granules. Zymogen granules containing pepsinogen are most concentrated in the apical cytoplasm. Pepsinogen is released by exocytosis from secretory granules at the apical surface of chief cells.

Antral glands occupy the mucosa of the distal stomach and pyloric channel. Antral glands are relatively straight and often empty through deep gastric pits. Although most cells in the antral glands are mucus secreting, gastrin cells are the distinctive feature of this mucosa. Gastrin cells are pyramid shaped, with a narrow area of luminal contact apically and a broad surface overlying the lamina propria basally (Fig. 44-7). Gastrin cells are identified immunocytochemically by the presence of the peptide. Granules ranging from 150 to 400 nm in diameter are the sites of gastrin storage and are most numerous in the basal cytoplasm. Gastrin is released by exocytotic fusion of the secretory granule with the plasma membrane. In contrast to secretion from chief cells, emptying of gastrin-containing granules occurs at the basal membrane rather than at the apical region of the cell. Gastrin thus released diffuses to and enters submucosal capillaries in close apposition to the lamina propria.

GASTRIC PEPTIDES

The stomach contains a number of biologically active peptides in nerves and mucosal endocrine cells, including gastrin, somatostatin, ghrelin, gastrin-releasing peptide, vasoactive intestinal polypeptide (VIP), substance P, glucagon, and calcitonin gene–related peptide. The peptides with the greatest importance to human disease and clinical surgery are gastrin, somatostatin, and ghrelin.

Gastrin

The synthesis, secretion, and action of gastrin have been extensively studied, and many aspects of the biology of gastrin appear to be shared by other gastrointestinal peptide hormones.[1] The gene that encodes for gastrin was isolated using a human DNA library. The human gastrin gene contains three exons; two exons consist of coding sequences. The major active product is encoded by a single exon. In adults, the gastrin gene is expressed primarily in mucosa cells of the gastric antrum, with lower levels of expression in the duodenum, pituitary, and testis. During embryonic development, the gastrin gene is transiently active in pancreatic islets and colonic mucosa.

The human gene encompasses approximately 4,100 base pairs and directs the synthesis of a peptide of 101 amino acids (Fig. 44-8). The resulting peptide, preprogastrin, contains the sequence of gastrin within its amino acid sequence. Preprogastrin consists of a signal peptide of 21 amino acids, an intervening peptide of 37 amino acids, the 34-residue region of the gastrin molecule, and a carboxyl-terminal extension of nine amino acids. Gastrin is derived from its preprohormone by the sequential enzymatic cleavage of the signal peptide, the intervening peptide, and the carboxyl-terminal extension.

The signal peptide region of preprogastrin consists of a series of hydrophobic amino acids that direct the nascent peptide into the endoplasmic reticulum as it is translated from messenger RNA. After directing the preprogastrin molecule into the rough endoplasmic reticulum, the signal peptide is removed. The remaining peptide is termed *progastrin*. Progastrin is further processed as it traverses the endoplasmic reticulum to mature secretory vesicles. Enzymatic cleavage at a pair of basic amino acid residues proximal to the gastrin 34 (G_{34}) sequence removes the intervening peptide. A similar cleavage removes a six-amino-acid fragment at the carboxyl-terminal end. The peptide that remains has a Gly-Arg-Arg sequence at the carboxyl terminus. Carboxypeptidase cleaves the Arg residues, and the peptide that results is termed *glycine-extended gastrin*. G_{34} is formed by cleavage of the Gly-Arg-Arg sequence and amidation of the carboxyl-terminal phenylalanine. Gastrin, like most gastrointestinal peptide hormones, requires terminal amidation for biologic activity. Gastrin 17 (G_{17}), the most abundant form of gastrin in the human antrum, is formed by further processing that removes the first 17 amino acids at the amino terminus of G_{34}. G_{34} is the predominate molecular form of gastrin in the duodenum.

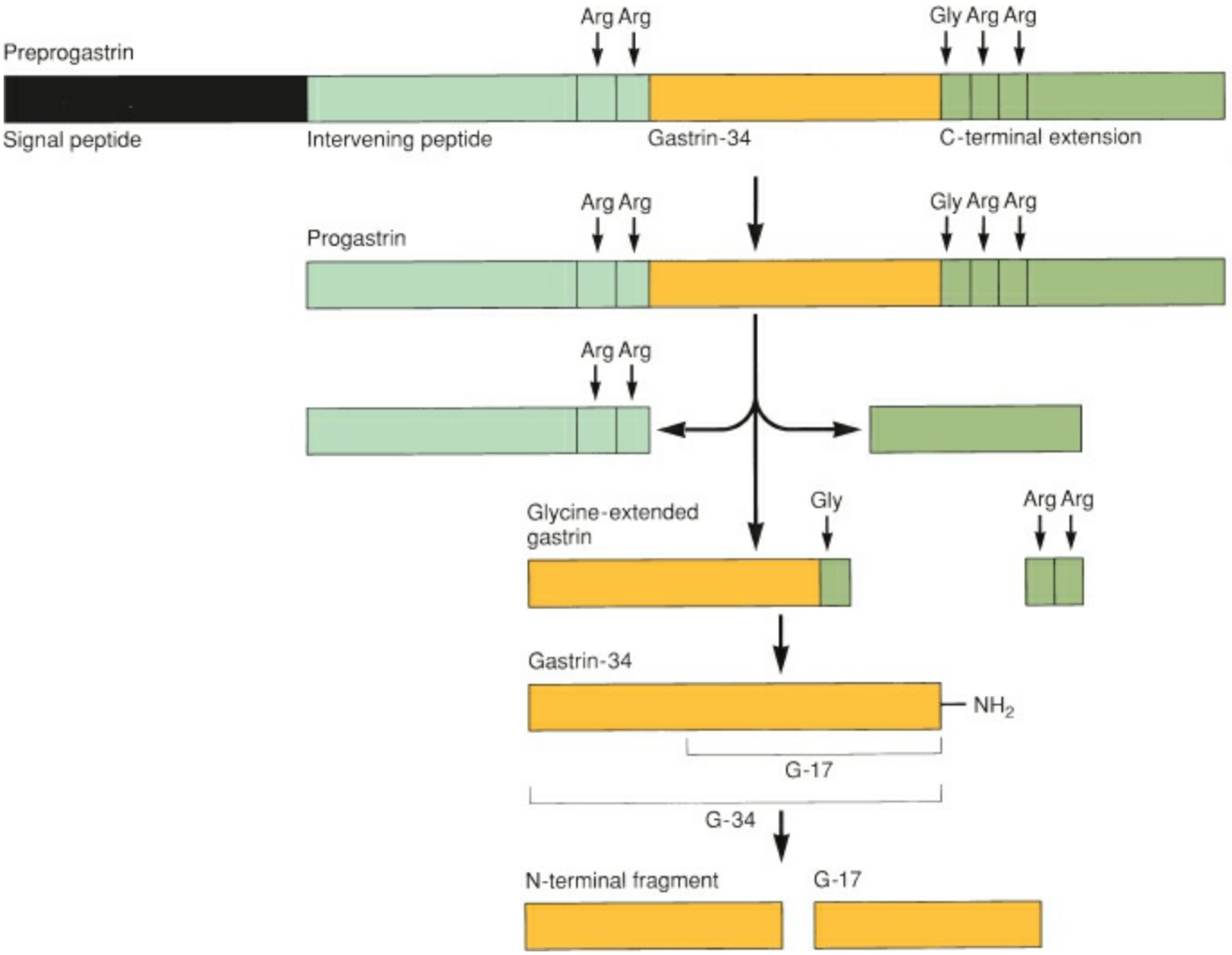

Figure 44-8. Sequential processing of preprogastrin molecule.

3 The most important stimulant of gastrin release is a meal. Small peptide fragments and amino acids that result from intragastric proteolysis are the most important food components that stimulate gastrin release. The most potent gastrin-releasing activities are demonstrated by the amino acids tryptophan and phenylalanine. Ingested fat and glucose do not cause gastrin release. Gastric distention by a meal activates cholinergic neurons and stimulates gastrin release. As the meal empties and distention diminishes, VIP-containing neurons are activated, which stimulate somatostatin secretion and thus attenuate gastrin secretion.

Postprandial luminal pH also strongly affects gastrin secretion. Gastrin release is inhibited when acidification of an ingested meal causes the intraluminal pH to fall below 3.0. Conversely, maintaining intragastric pH above 3.0 potentiates gastrin secretion after ingestion of protein or amino acids.[2] Pernicious anemia and atrophic gastritis, which produce chronic achlorhydria, are associated with fasting hypergastrinemia and an exaggerated gastrin meal response. Release of mucosal somatostatin occurs with gastric acidification and this peptide has been implicated in the inhibition of gastrin release that occurs when luminal pH falls.

The vagus nerve appears to both stimulate and inhibit gastrin release.[3] In humans, vagally mediated stimulation of gastrin release can be demonstrated by sham feeding,

insulin-induced hypoglycemia, and administration of the vagal stimulant gamma-aminobutyric acid. In contrast to these stimulatory vagal effects, hypergastrinemia, observed after vagotomy, suggests that inhibitory vagal effects on gastrin release may also exist. Cholinergic neurons stimulate gastrin secretion directly by actions on gastrin cells. By decreasing somatostatin secretion, cholinergic neurons also indirectly stimulate gastrin release. Evidence suggests that vagal stimulation of gastrin release is mediated by bombesin or its mammalian equivalent, gastrin-releasing peptide, acting as a neurotransmitter in the gastric wall. Adrenergic stimulation has also been noted to increase gastrin release.

Chronic gastric infection with *Helicobacter pylori* causes increased acid secretion by altering gastrin release.[4,5] *H. pylori* has been observed to upregulate proinflammatory cytokines, including interleukin (IL)-6, IL-8, and tumor necrosis factor-α (TNF-α). Several inflammatory mediators have been demonstrated to stimulate gastrin release from isolated gastrin cells. The putative gastrin secretagogues include IL-1, IL-8, TNF-α, interferon-gamma, and leukotrienes C4 and D4. The same factors that affect gastrin release also influence gastrin mRNA expression. Food ingestion increases gastrin mRNA abundance, whereas fasting and somatostatin decrease gastrin mRNA production. Chronic achlorhydria, as seen in pernicious anemia, increases gastrin mRNA production.

In addition to stimulating acid secretion from gastric parietal cells (detailed later in this chapter), gastrin has important physiologic actions in the control of gastrointestinal mucosal growth. The acid-secreting oxyntic mucosa is particularly sensitive to the trophic actions of gastrin, but the mucous membranes of the duodenum, colon, and pancreatic parenchyma are also affected. Stimulation of mucosal growth by gastrin is enhanced by the presence of solid food in the diet. The 17- and 34-amino-acid forms of gastrin are equipotent in stimulating mucosal growth. Prolonged stimulation by high levels of gastrin, as seen in the Zollinger–Ellison syndrome, is associated with hypertrophy of the gastric mucosa. Smaller increases in circulating gastrin, such as those that follow vagotomy, do not cause mucosal hypertrophy.

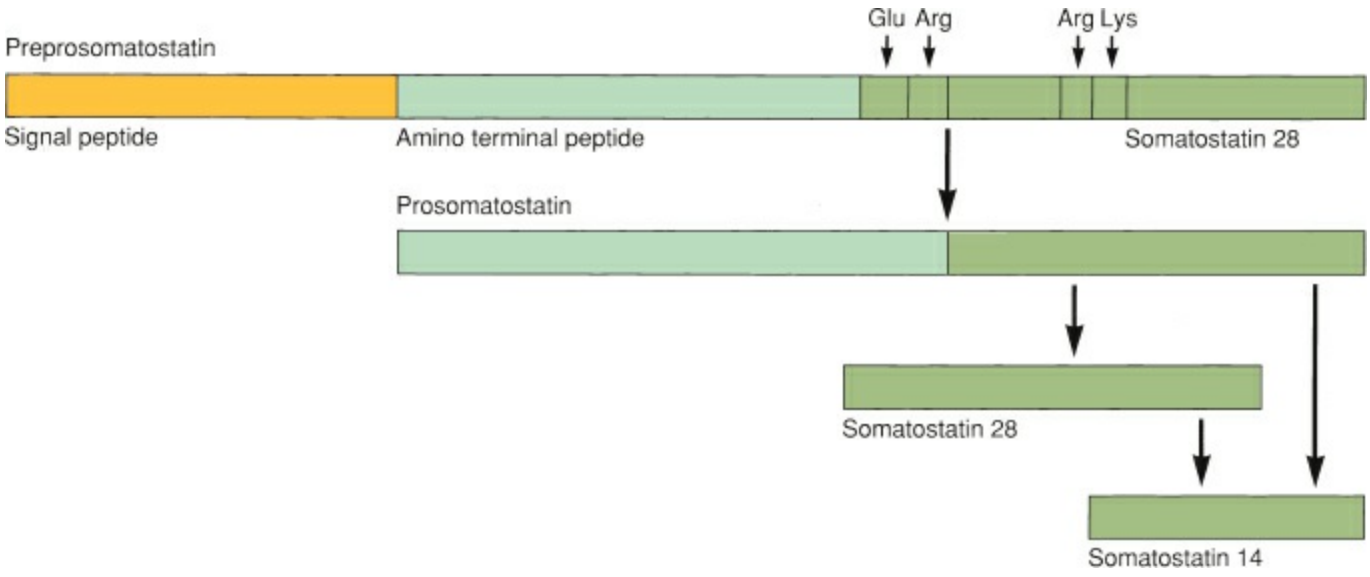

Figure 44-9. Derivation of somatostatin 14 from preprosomatostatin precursor.

Somatostatin

Somatostatin, like gastrin, is very significant in gastric physiology. Somatostatin was first isolated from hypothalamic tissues and was named for its ability to inhibit the release of growth hormone. The peptide was subsequently localized in neurons in central and peripheral nervous systems, and in endocrine cells in the pancreas, stomach, and intestine.[6] The wide tissue distribution of somatostatin suggested important regulatory functions, a concept validated by many investigations.

The human somatostatin gene is located on chromosome 3 and encodes for a precursor of 116 amino acids (Fig. 44-9). The somatostatin molecule is contained in the carboxyl-terminal sequence of this preprohormone. The first 24 amino acids of the amino terminus of preprosomatostatin constitute a signal peptide; cleavage of this signal peptide leaves prosomatostatin. Enzymatic cleavage of an additional 64-amino-acid segment from prosomatostatin forms somatostatin 28. Further processing of somatostatin 28 to somatostatin 14 is tissue-specifically regulated. In the stomach, most somatostatin exists as the shorter peptide.

Gastric somatostatin release responds to luminal, hormonal, and neural signals. Luminal acidification is associated with increased somatostatin release, whereas somatostatin release decreases when luminal pH is increased. A number of peptides have been demonstrated experimentally to release somatostatin from the stomach, including gastrin, cholecystokinin, and secretin. β-Adrenergic agonists have also been shown to release somatostatin. In contrast, electrical stimulation of vagal nerves inhibits somatostatin release, as does the cholinergic agonist methacholine.

The most important gastric function of somatostatin appears to be regulation of acid secretion and gastrin release. Circulating somatostatin appears to be important in modulating gastric acid secretion; locally released somatostatin functions to regulate gastrin release. In each instance, somatostatin serves an inhibitory function, decreasing acid secretion and diminishing the release of gastrin. In animals, antral or duodenal acidification has been associated with an increase in circulating somatostatin. Increases in circulating somatostatin are followed, in turn, by decreased gastric acid secretion. Infusion of exogenous somatostatin in doses that produce somatostatin levels similar to those observed postprandially has also been shown to inhibit acid secretion. In humans, concentrations of somatostatin capable of inhibiting acid secretion can do so without altering serum gastrin levels, indicating a direct action on the acid-secreting fundic mucosa.

Somatostatin is believed to influence gastrin secretion through a locally active intramucosal mechanism. Local actions of somatostatin are supported by ultrastructural studies of antral somatostatin cells, which demonstrate long cytoplasmic processes that make intimate cell-to-cell contact with antral gastrin cells. The presence of somatostatin at these sites of cellular contact implies that somatostatin cells influence the function of gastrin cells through local release of the peptide. Somatostatin can also reach neighboring gastrin cells through diffusion or local blood flow. A number of experiments have suggested that release of somatostatin and gastrin is functionally, although reciprocally,

linked. For example, in anesthetized animals, an increase in gastric pH or ingestion of a meal is associated with increases in gastrin and decreases in somatostatin in antral venous blood. Cholinergic agents stimulate gastrin release while inhibiting somatostatin release. Prostaglandin E_2, in contrast, inhibits gastrin release and stimulates somatostatin secretion. These and similar observations suggest that increases in somatostatin release are often associated with decreased gastrin secretion. A family of five somatostatin receptors has been cloned. Inhibition of gastrin-stimulated gastric acid secretion is mediated by somatostatin receptor subtype 2.[7]

GASTRIC ACID SECRETION

Cellular Events

4 An appreciation of the mechanisms that control gastric acid formation is essential to a discussion of gastric disease. An understanding of the cellular basis of acid secretion by the gastric parietal cell also provides a foundation for discussing the pharmacologic treatment of acid–peptic diseases. The basolateral membrane of the parietal cell contains specific receptors for histamine, gastrin, and acetylcholine, the three major stimulants of acid production.[8] Each stimulant reaches the parietal cell by a different route. Histamine is released from mastlike cells within the lamina propria and diffuses to the mucosa, acetylcholine is released in close proximity to the parietal cells from cholinergic nerve terminals, and gastrin is delivered by the systemic circulation to the fundic mucosa from its source in the antrum and proximal duodenum (Fig. 44-10), activating protein kinase A, which in turn catalyzes protein phosphorylation. The target protein molecules for this phosphorylation, in turn, stimulate acid production.

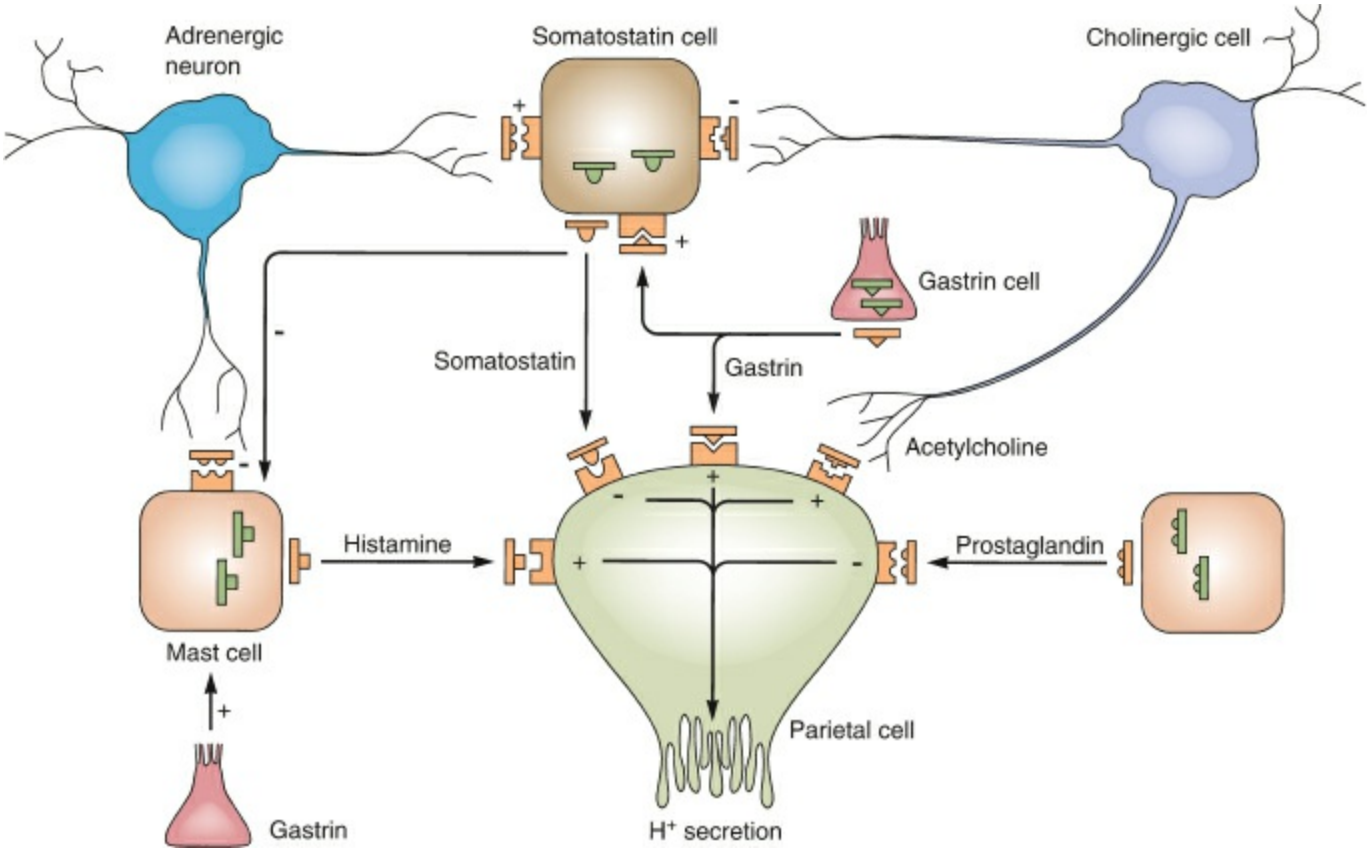

Figure 44-10. Interactions of cell types that affect parietal cell acid secretion.

Acetylcholine and related cholinergic agonists activate parietal cells after binding to muscarinic receptors. The stimulatory effects of acetylcholine and its congeners can be abolished by atropine. The action of acetylcholine is mediated by muscarinic receptor subtype 3 (M_3). Studies suggest that cholinergic stimulation of parietal cell function is coupled to enhanced mobilization of intracellular calcium. The resultant transient increases in intracellular calcium activate mechanisms that stimulate acid secretion (Fig.

44-11). Evidence also indicates that occupation of acetylcholine receptors increases turnover of specific membrane phospholipids termed *phosphatidylinositides.* Acetylcholine–receptor binding is followed by activation of membrane-associated phospholipase C. Phospholipase C acts on phosphatidylinositol-4,5-bisphosphate (PIP_2) within the plasma membrane to liberate water-soluble inositol triphosphate (IP_3) and diacylglycerol. A major action of IP_3 is to increase intracellular calcium, mainly from intracellular stores in the endoplasmic reticulum. The resulting increased cytosolic calcium interacts with calmodulin or other calcium-binding proteins. Calmodulin kinase type II is involved in parietal cell activation by acetylcholine. Intracellular calcium in this form is postulated to modulate parietal cell function through protein phosphorylation or enzyme activation. Diacylglycerol, the second product released by hydrolysis of PIP_2, activates a class of protein kinases that are phospholipid dependent and Ca^{2+} activated, protein kinase C. Protein kinase C in turn acts to phosphorylate a set of proteins that are distinct from those affected by the calmodulin-dependent system. The ultimate result of this protein phosphorylation is parietal cell activation and hydrogen ion secretion.

Parietal cells can also be activated by occupation of specific gastrin receptors. As with cholinergic stimulation, gastrin exposure increases membrane PIP_2 turnover (Fig. 44-11). Like acetylcholine, the actions of gastrin depend highly on increases in intracellular calcium and activation of protein kinase C.

Although histamine, acetylcholine, and gastrin occupy separate receptors on the parietal cell and activate differing second-messenger systems, each secretagogue ultimately acts by means of a specialized ion transport system called the *parietal cell proton pump.* This membrane-bound protein is located in the secretory canaliculus of the parietal cell; the peptide has not been identified in other gastric cells or in significant amounts in other organs. The proton pump is an H^+-K^+-adenosine triphosphatase (ATPase) that electroneutrally exchanges cytosolic H^+ for luminal K^+. Hydrogen ions are concentrated 2.5-million-fold within the secretory canaliculus, and the hydrolysis of ATP is the energy source for transport against the steep electrochemical gradient generated. For each H^+ ion transported to the luminal surface of the canalicular membrane, one K^+ ion is transported to the cytosolic surface (Fig. 44-12). This cotransport requires that K^+ be continuously supplied to the luminal surface of the secretory membrane. This requirement is satisfied by conductance of K^+ across the canalicular membrane from intracellular stores. Chloride ions also enter the secretory canaliculus by diffusion.

Activation of the H^+-K^+-ATPase significantly increases intracellular OH^- generation, with potential cellular toxicity. Carbonic anhydrase, which is associated with the canalicular membrane, converts OH^- to HCO_3^-. The HCO_3^- produced is disposed of by exchange for Cl^- at the basolateral membrane. Intracellular Cl^- thus acquired supplies the necessary Cl^- on a one-to-one basis for each H^+ secreted. The transcellular exchange of H^+ for HCO_3^- ensures that the voluminous secretion of hydrochloride at the luminal surface of the gastric mucosa is matched by an equivalent delivery of base to submucosal capillaries. Parietal cell ionic transport pathways are shown in Figure 44-13.

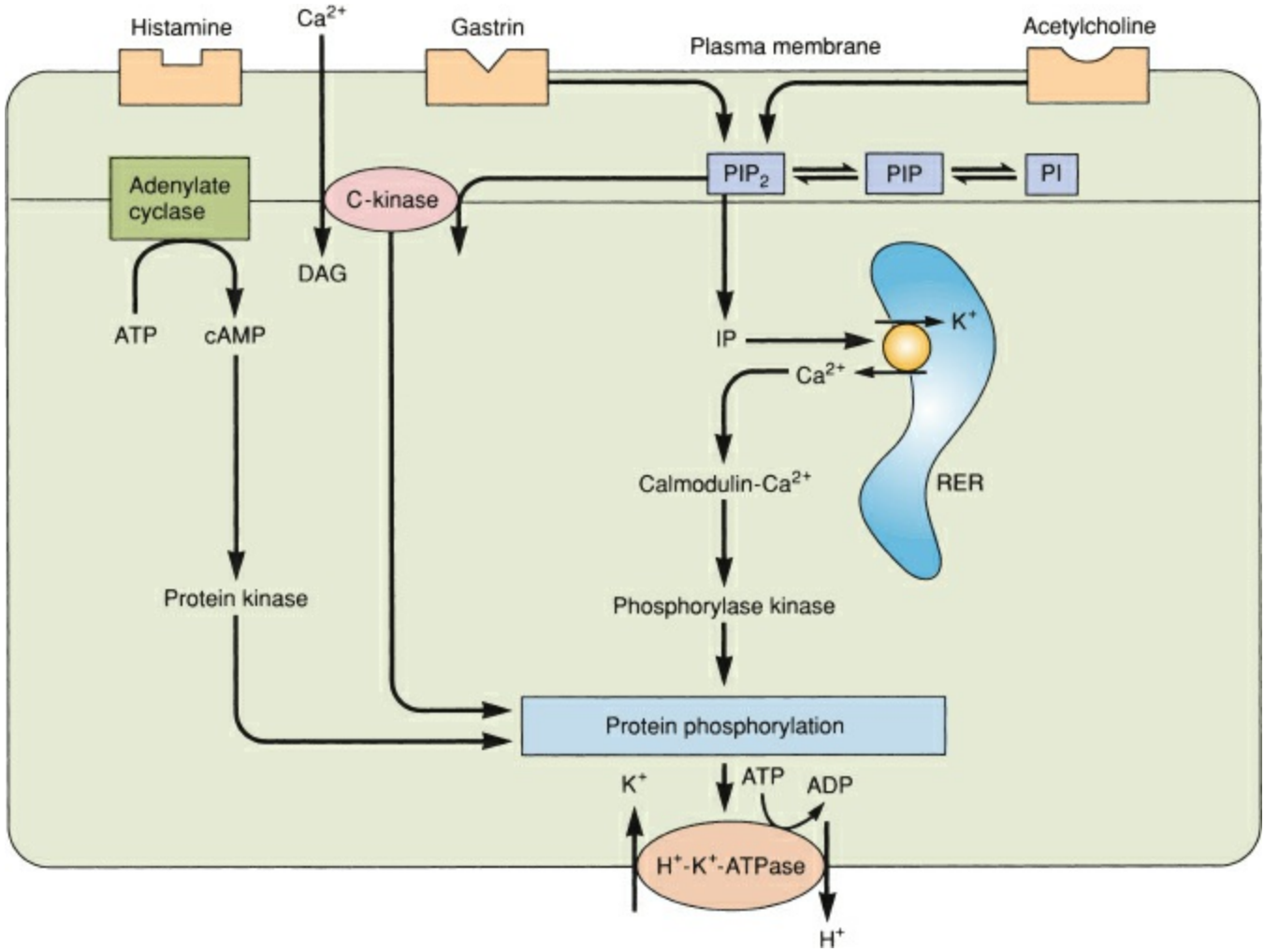

Figure 44-11. Cellular mechanisms controlling parietal cell acid secretion. ADP, adenosine diphosphate; ATP, adenosine triphosphate; cAMP, cyclic adenosine monophosphate; PI, phosphatidylinositol; PIP, phosphatidylinositol-4,5-phosphate; PIP_2, phosphatidylinositol-4,5-bisphosphate; RER, rough endoplasmic reticulum.

The function of the proton pump is highly regulated. In the unstimulated state, the enzyme is sequestered in cytoplasmic structures termed *tubulovesicles* that are not connected to the gastric lumen. Tubulovesicle membranes in this state have a low permeability to KCl. Stimulation of acid secretion causes tubulovesicles to fuse with apical secretory membranes and increases membrane permeability to KCl. In this way, the fusion of tubulovesicle membrane exposes the H^+-K^+ pump to the gastric lumen and simultaneously provides the K^+ substrate necessary for acid secretion.

Parietal cells also contain membrane receptors that inhibit acid secretion. Specific receptors for somatostatin have been identified using isolated gastric cells. Activation of isolated parietal cells by histamine, pentagastrin, or the cholinergic agonist carbachol can be blocked by somatostatin 28. In the case of histamine activation, the inhibitory effects appear to be mediated by the ability of somatostatin to block the production of cyclic adenosine monophosphate (cAMP). Somatostatin appears to inhibit the actions of these agonists at a point distal to second-messenger generation. Gastric parietal cells also contain receptors for prostaglandins, notably prostaglandin E_2 and its derivatives. Prostaglandin E_2 is a potent inhibitor of histamine-stimulated parietal cell activation, probably by a mechanism that inhibits formation of cAMP. Prostaglandin inhibition is

specific for histamine; the actions of gastrin or carbachol are not affected. Epidermal growth factor and transforming growth factor-α also inhibit histamine-stimulated acid secretion through effects on cAMP production.

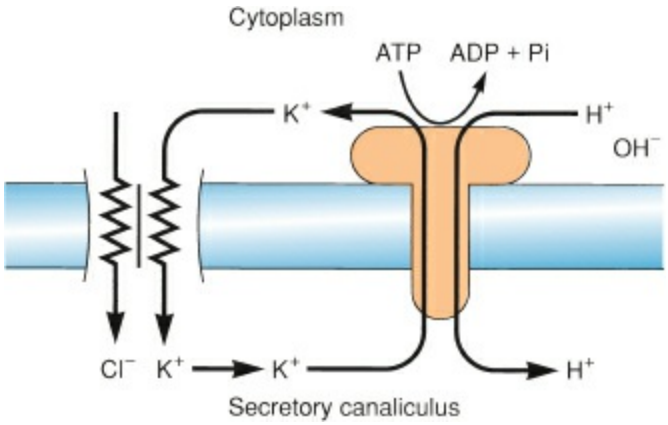

Figure 44-12. Gastric H^+-K^+-adenosine triphosphatase (ATPase). ADP, adenosine diphosphate; ATP, adenosine triphosphate; Pi, phosphate ion.

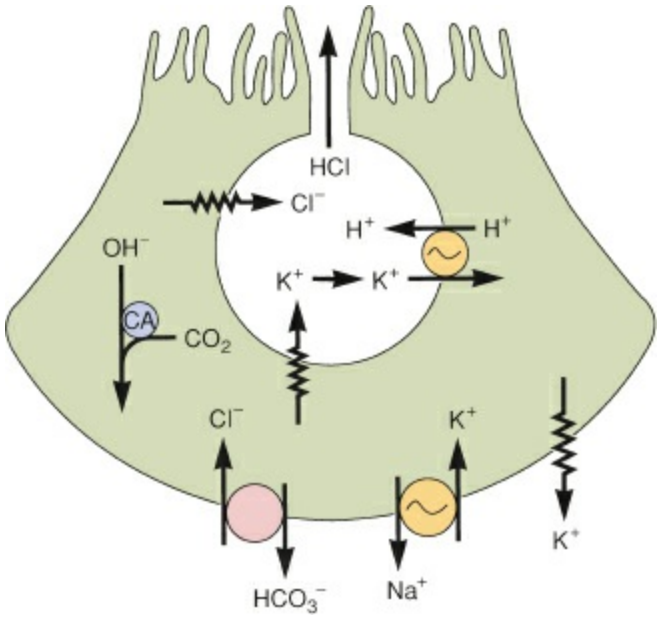

Figure 44-13. Ionic fluxes associated with acid secretion by the parietal cell.

These considerations of the cellular basis of acid production demonstrate how parietal cell function can be altered pharmacologically. Gastric acid production can be blocked by receptor antagonists for each of the three primary stimulants – gastrin, acetylcholine, and histamine. Direct inhibition of acid production can be effected by derivatives of somatostatin or prostaglandin E_2. All forms of stimulated acid production can be blocked by agents that act as inhibitors of the parietal cell proton pump. Agents that act at each of these points have been developed, and their appropriate clinical applications are discussed in subsequent chapters.

Regulation of Acid Secretion

Given the multiple receptors on parietal cells, it is not surprising that a great deal of secretagogue interdependence, both stimulatory and inhibitory, exists in humans. Parietal cell activation, and the resultant acid secretion, is greater in response to a combination of agonists than it is in response to the total effect of agents used singly. This increase in responsiveness is defined as *potentiation*. Potentiating interactions are most apparent when agents are used that act by way of different second-messenger systems. Thus, histamine strongly potentiates the acid-secretory response to pentagastrin or to carbachol in humans. Conversely, blockade of receptors to one stimulant also decreases responsiveness to the other agonists. For example, blocking histamine receptors with agents such as cimetidine decreases responsiveness to pentagastrin, even though gastrin receptors are not directly affected. These inhibitory interactions are exploited therapeutically in the treatment of acid–peptic diseases.

Humans normally secrete 2 to 5 mEq/hr of hydrochloride in the fasting state, constituting basal acid secretion. Both vagal tone and ambient histamine secretion are presumed to be important in determining the rate of basal acid secretion. In humans, truncal vagotomy decreases basal secretion by approximately 85%. Similarly, H_2-receptor antagonists also inhibit basal acid secretion by approximately 80%. Gastrin does not have an important role in determining basal acid secretion in normal people.

Stimulated acid secretion begins with the thought, sight, or smell of food (Fig. 44-14). This cephalic phase of gastric acid secretion is mediated by the vagus nerve. Vagal discharge directs a cholinergic mechanism, and the cephalic phase of acid secretion can be inhibited by administering atropine. Vagal discharge secondary to cephalic stimulation also inhibits the release of somatostatin. Diminished secretion of somatostatin further augments stimulatory vagal effects, presumably by eliminating tonic inhibition of acid secretion exerted by somatostatin. The cephalic component of acid secretion can be measured in normal people by sham feeding and is approximately 10 mEq/hr. The cephalic phase approximates 40% of the maximal acid-secretory response to gastrin infusion.

The gastric phase of acid secretion begins when food enters the stomach. The presence of partially hydrolyzed food constituents, gastric distention, and the buffering capacity of food all stimulate acid secretion. Gastrin is the most important mediator of the gastric phase of acid secretion. In normal humans, acid-secretory rates after a mixed meal average 15 to 25 mEq/hr, approximately 75% of the maximal response achieved with infusion of exogenous gastrin or histamine. The meal response is less than the maximal response to exogenous stimulants because food also causes the release of somatostatin and initiates other inhibitory responses. In humans, 90% of meal-stimulated acid secretion is mediated by gastrin release.[9]

The inhibitory regulation of gastric acid secretion is accomplished by CNS, gastric, and intestinal mechanisms. Stimulated acid secretion can be inhibited experimentally by administering various neuropeptides into the lateral cerebral ventricles, including gastrin-releasing peptide (bombesin), corticotropin-releasing factor, and calcitonin gene–related

peptide. Although the relevance of these observations to human physiology remains to be determined, it is likely that CNS inhibition of acid secretion exists in humans. In this regard, the vagus nerve has both a stimulatory and an inhibitory role in acid secretion and gastrin release. Vagotomy causes fasting and postprandial hypergastrinemia, indicating that an inhibitory regulation of gastrin release normally exists. Hypergastrinemia is sustained long term after vagotomy by hyperplasia of antral gastrin cells. The vagal fibers to the oxyntic region of the stomach appear to mediate this inhibitory effect.

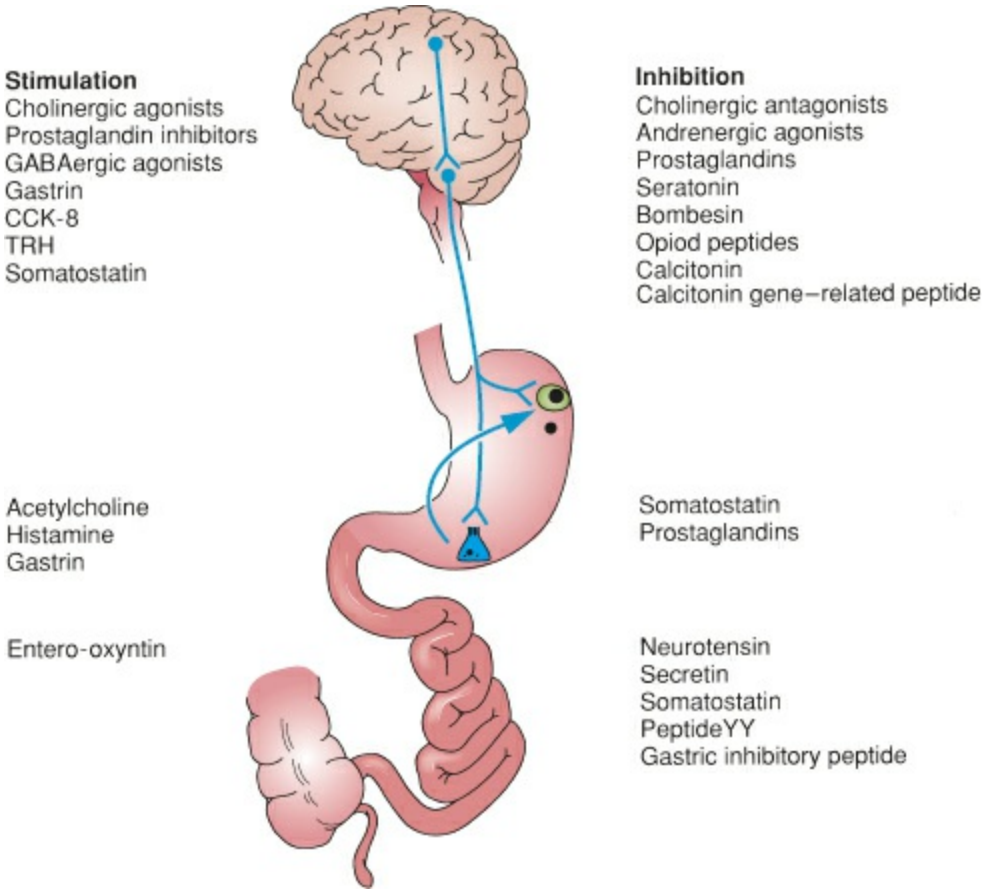

Figure 44-14. Regulation of acid secretion in vivo. TRH, thyroid-releasing hormone.

In humans, the most important and clearly established gastric inhibitory influence is the suppression of gastrin release when the antral mucosa is exposed to acid. When luminal pH falls to 2.0, gastrin release stops. Antral acidification also suppresses the gastrin response to an ingested meal. Somatostatin acting locally in the gastric mucosa as a paracrine agent may mediate this important inhibitory response. Release of gastric somatostatin is reciprocally linked to that of gastrin; acidification of the antrum causes increases in somatostatin release and decreases in gastrin secretion. Antral distention also inhibits stimulated acid secretion.

The entry of digestive products into the intestine begins intestinal-phase inhibition of gastric acid secretion. Acidification of the duodenal bulb inhibits acid secretion, and although exogenous secretin also can inhibit acid secretion, this effect appears to be independent of the release of secretin from the duodenal mucosa. Hyperosmolar solutions and those containing fat also potently inhibit acid secretion. Several peptides, including

secretin, somatostatin, peptide YY, gastric inhibitory peptide, and neurotensin, have been proposed as mediators of the intestinal phase effects.

PEPSIN

5 Pepsins are a heterogeneous group of proteolytic enzymes that are secreted by the gastric chief cells. Pepsin is derived under acidic conditions from pepsinogen by the autocatalytic loss of a variable amino-terminal sequence of the parent compound. This conversion occurs slowly at pH values of 5.0 to 6.0 and occurs rapidly when luminal pH approximates 2.0. Pepsin catalyzes the hydrolysis of a wide variety of peptide bonds that contain acidic residues, with a pH optimum for hydrolysis between 1.5 and 2.5. Once activated, pepsin is sensitive to ambient pH values; it is irreversibly denatured at pH 7.0 or greater.

The most important stimulus for pepsinogen secretion is cholinergic stimulation. Acetylcholine and its derivatives stimulate pepsinogen secretion by a mechanism that can be antagonized by atropine, indicating a muscarinic receptor. The receptor is an M_1 type. Endogenous cholinergic stimulation through the vagal nerve results in the formation of a gastric secretion that is rich in pepsin. Although both exogenous histamine and gastrin can stimulate pepsin secretion, their actions appear to be indirectly due to the concomitant secretion of gastric acid rather than to direct stimulation of chief cells. Chief cells have also been shown to possess cholecystokinin receptors, and cholecystokinin-like peptides appear to have a direct stimulatory action on chief cells. The oxyntic mucosa contains somatostatin cells near chief cells. Pepsinogen secretion in response to a variety of stimuli has been demonstrated to be inhibited by somatostatin.

The major physiologic function of pepsin is to initiate protein digestion. Pepsin is highly active against collagen and may be important in the digestion of animal protein. Intragastric protein hydrolysis by pepsin is incomplete, and relatively large peptides enter the intestine, although amino acids and small peptide fragments are released. These products of partial hydrolysis are important signals for gastrin and cholecystokinin release, which in turn regulate digestive processes. In this way, pepsin also contributes to the overall coordination of the digestive process.

INTRINSIC FACTOR

6 The gastric mucosa is the site of production of intrinsic factor, which is necessary for the absorption of cobalamin from the ileal mucosa. Total gastrectomy is regularly followed by cobalamin malabsorption, as is resection of the proximal stomach or atrophic gastritis that involves the oxyntic mucosa.

Autoradiographic and immunocytochemical techniques have confirmed the parietal cell as the site of intrinsic factor synthesis and storage in humans. Intrinsic factor secretion, like acid secretion, is stimulated by histamine, acetylcholine, and gastrin. Unlike acid production, intrinsic factor secretion peaks rapidly after stimulation and then returns to baseline. The amount of intrinsic factor secreted usually greatly exceeds the amount needed to bind and absorb available dietary cobalamin.

GASTRIC BICARBONATE PRODUCTION

It is generally agreed that the gastric mucosa secretes HCO_3^- in addition to acid. The cells responsible for HCO_3^- production are presumed to be the surface mucous cells facing the gastric lumen, and HCO_3^- transport has been postulated to protect against damage from luminal acid. In theory, H^+ ions diffusing from luminal bulk fluids toward the gastric mucosa could be neutralized by secreted HCO_3^- near the surface (Fig. 44-15). In this way, nearly neutral pH can be maintained at the mucosal surface, even if the total amount of hydrochloride secreted greatly exceeds gastric HCO_3^- production. The occurrence of pH gradients at the surface of the gastric mucosa have been demonstrated in humans using microelectrodes. Drugs or chemicals that inhibit bicarbonate secretion result in acidification of the mucosal surface.

The degree of luminal acidity, reflected by pH, required to stimulate bicarbonate secretion is greater in the stomach than in the duodenum. Direct exposure of the gastric mucosa to pH levels of 2.0 or more increases bicarbonate secretion. In the duodenum, exposure of the mucosa to pH 5.0 doubles bicarbonate secretion, whereas exposure to pH 2.0 increases alkaline secretion 10-fold.

Cholinergic agonists, vagal nerve stimulation, and sham feeding have all been shown to increase gastric HCO_3^- production. The effects of cholinergic stimulation can be blocked by atropine. In the human stomach, exposure to luminal perfusates at pH 2.0 has been associated with increased release of prostaglandin E_2. Prostaglandin E_2 and its synthetic derivatives are also potent stimulants of gastric bicarbonate secretion. Because mucosal bicarbonate production can be decreased in experimental models by indomethacin, endogenous prostaglandins are thought to be important in the mucosal alkaline response.

GASTRIC BLOOD FLOW

Because the gastric mucosa is metabolically highly active, control of mucosal blood flow is of great physiologic importance. In addition, studies have implicated perfusion abnormalities in the development of mucosal lesions during periods of stress. Mucosal blood flow is regulated by neural, hormonal, and locally active influences.

Postganglionic sympathetic nerve fibers reach the stomach in association with its blood supply and richly innervate small mucosal arteries. Mucosal capillaries do not receive adrenergic innervation. Electrical stimulation of sympathetic nerves supplying the stomach is followed by decreased total gastric blood flow, decreased flow in celiac and gastroepiploic vessels, and diminished blood flow to the mucosa. Studies in animals demonstrate that vasoconstriction of the gastric vascular bed is mediated by α-adrenergic receptors and that vasodilation is mediated by β-adrenergic receptors.

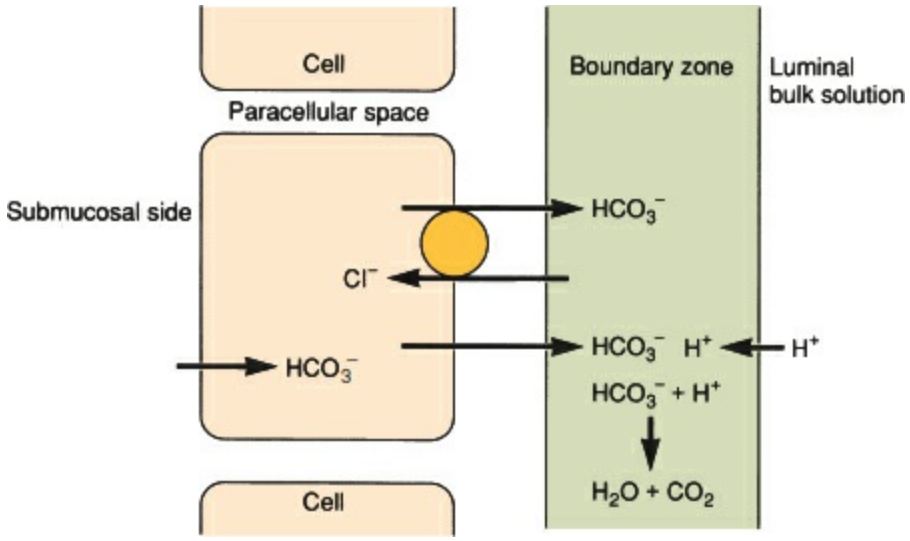

Figure 44-15. Schematic representation of mucosal bicarbonate secretion showing neutralization of luminal hydrogen ions immediately above the mucosal surface.

Stimulation of the vagus nerve is followed by a prompt increase in blood flow, suggesting a dilatory effect of parasympathetic nerves. The effects of vagal stimulation on mucosal blood flow are complicated by accompanying increases in acid secretion. Almost all stimuli that increase acid production also increase blood flow secondarily.

A number of gastrointestinal peptide hormones affect gastric blood flow, most because of their ability to increase or decrease acid secretion. Thus, gastrin, because it is a potent stimulant of acid secretion, also increases mucosal blood flow. Cholecystokinin appears to have direct vasodilatory effects on the gastric vasculature. Vasopressin has been well demonstrated to have direct vasoconstrictor activity.

Nitric oxide modulates basal gastric vascular tone and controls gastric vasodilation and hyperemia. Nitric oxide mediates the hyperemic response that accompanies increases in acid secretion, although the molecule has no direct stimulatory role in acid production.

Prostaglandins are important mucosally produced compounds that have clear effects on the gastric vasculature. Prostaglandins of the E class have been shown in animals and

humans to increase gastric blood flow at doses that decrease acid secretion. Indomethacin, in doses sufficient to inhibit prostaglandin formation, decreases the diameter of submucosal blood vessels and reduces basal blood flow. Complete inhibition of cyclooxygenase activity causes an approximate 50% reduction in resting blood flow. These studies suggest that endogenous, locally produced prostaglandins are crucial to maintaining basal gastric blood flow in humans and probably act in concert with endogenous nitric oxide.

GASTRIC MOTILITY

Gastric Smooth Muscle

Consideration of gastric motility requires that the stomach be viewed in functional terms as two different regions, the proximal one-third and the distal two-thirds. These areas are distinct in terms of smooth muscle anatomy, electrical activity, and contractile function. The regions do not correspond to the traditional anatomic divisions of fundus, corpus, and antrum.

In the proximal stomach, three layers of gastric smooth muscle can be distinguished: an outer longitudinal layer, a middle circular layer, and an inner oblique layer. In the distal two-thirds of the stomach, the longitudinal layer is most clearly defined, and the inner oblique layer is usually not distinct. The gastric smooth muscle ends at the pylorus.

The smooth muscle of the proximal stomach is electrically stable, whereas the smooth muscle of the distal stomach demonstrates spontaneous, repeated electrical discharges. Gastric smooth muscle exhibits myoelectric activity that is based on a highly regular pattern called the *slow wave.*[10] In the stomach, slow waves occur with a frequency of three cycles per minute. Slow waves do not, by themselves, lead to gastric contractions, but they do set the maximum rate of contractions at three per minute. Gastric contractions occur when action potentials are phase locked with the crest of the slow wave.

Extracellular electrical recording from the serosal surface of the stomach also demonstrates the intrinsic electrical activity of the distal stomach in the form of pacesetter potentials. Pacesetter potentials reflect partial depolarization of the gastric smooth muscle cell and are recorded during relatively long periods (2 or 3 seconds). Pacesetters originate along the greater curvature at a point in the proximal third of the stomach. Pacesetter potentials, discharging at a rate of three times per minute in humans, drive cells located distally. Spread of the pacesetter potentials is faster along the greater curvature, so that a ring of electrical activity reaches the pylorus simultaneously along both curvatures. The pacesetter potentials do not result in smooth muscle contraction unless an additional depolarization is superimposed in the form of an action potential. When action potentials occur, a ring of smooth muscle contraction moves peristaltically along the distal stomach toward the pylorus.

Duodenal slow-wave frequency and maximum rate of phasic contractions are higher than those observed in the stomach. The duodenal rate is approximately 12 cycles per minute; the contraction rate declines progressively to nine cycles per minute in the distal ileum.

The smooth muscle activity of the proximal stomach is fundamentally different from that of the distal stomach. There are no pacesetters or action potentials in the proximal stomach. As a result, peristalsis does not occur. Proximal gastric contraction is tonic and prolonged, and increases in luminal pressure are often sustained for several minutes.

Coordination of Contraction

Important vagally mediated reflexes influence intragastric pressure, presumably by affecting contractile activity of smooth muscle in the proximal stomach. The most important reflex is termed *receptive relaxation* and occurs with ingestion of a meal. Increasing gastric volumes are accommodated with little increase in intragastric pressure by relaxation of the proximal stomach. This receptive relaxation allows the proximal stomach to act as a storage site for ingested food in the immediate postprandial period. Afferent impulses, presumed to originate from stretch receptors in the gastric wall, are carried along vagal fibers; efferent vagal discharges are inhibitory. Receptive gastric accommodation is lost after either truncal or proximal gastric vagotomy. After the meal has been ingested, proximal contractile activity increases; alterations in proximal gastric tone cause the compressive movement of gastric content from the fundus to the antrum.

Food that enters the antrum from the proximal stomach is propelled peristaltically toward the pylorus. A number of observations indicate that the pylorus closes 2 or 3 seconds before the arrival of the antral contraction ring. This coordinate closing of the pylorus allows a small bolus of liquid and suspended food particles to pass while retropulsing the main mass of gastric contents back into the proximal antrum. The churning action that results, mixes ingested food particles, gastric acid, and pepsin, and contributes to the grinding function of the stomach. Solid food particles do not ordinarily pass the pylorus unless they are no larger than 1 mm.

A consistent finding in humans ingesting a mixed solid–liquid meal is that liquids empty more quickly than solids. Characteristically, solid food empties only after a lag period, whereas liquid emptying begins almost immediately. A traditional interpretation of these human observations has been that the proximal stomach is the dominant force in determining how quickly a liquid meal empties by the gastroduodenal pressure gradient generated by proximal gastric contractions. The actions of the proximal stomach in liquid emptying are also regulated by the sieving actions of the antropyloric segment and are modified by the nutrient composition of the ingested meal. The distal gastric segment has been postulated to control solid emptying through its grinding and peristaltic actions. This traditional concept of the two-component stomach is useful in considering observations in patients who have undergone gastric operative procedures. Patients who have undergone proximal gastric vagotomy exhibit accelerated emptying of liquids but have normal solid emptying. Because of loss of receptive relaxation, the denervation of the proximal stomach is presumed to increase intragastric pressure and accelerate liquid emptying while leaving the distal gastric segment unaffected. Conversely, vagal denervation of the antrum interrupts gastric emptying of solids to a greater degree than liquids. Although this model of gastric emptying oversimplifies the many mechanisms (gastric, pyloric, and intestinal) that work in concert to control gastric emptying, it provides a useful framework for considering the effects of gastric surgical procedures.

References

1. Von Rosenvinge EC, Raufman J-P. Gastrointestinal peptides and regulation of gastric acid secretion. *Curr Opin Endocrinol Diabetes Obes* 2010;17(1):40–44.
2. Schubert M, Peura D. Control of gastric acid secretion in health and disease. *Gastroenterology* 2008;134(7):1842–1860.
3. Schubert ML. Gastric secretion. *Curr Opin Gastroenterol* 2008;24:(6)659–664.
4. Debas HT, Carvajal SH. Vagal regulation of acid secretion and gastrin release. *Yale J Biol Med* 1994;67:145–151.
5. Cover TL. Role of Heliocobacter pylori CagL in modulating gastrin expression. *Gut* 2012;61:965–966.
6. Corleto VD. Somatostatin and the gastrointestinal tract. *Curr Opin Endocrinol Diabetes Obes* 2010;17:63–68.
7. Theodoropoulou M, Stalla GK. Somatostatin receptors: from signaling to clinical practice. *Front Neuroendocrinol* 2013;34:228–252.
8. Urushidani T, Forte JG. Signal transduction and activation of acid secretion in the parietal cell. *J Membr Biol* 1997;59:99–111.
9. Waldum HL, Brenna E, Kleveland PM, et al. Gastrin—physiological and pathophysiological role: clinical consequences. *Dig Dis* 1995;13:25–38.
10. Quigley EM. Gastric and small intestinal motility in health and disease. *Gastroenterol Clin North Am* 1996;25:113–145.

Chapter 45

Gastroduodenal Ulceration

Michael W. Mulholland

Key Points

1 Mucosal infection with *Helicobacter pylori* is the factor that contributes to ulcer pathogenesis in most patients.

2 *H. pylori* virulence factors include vacuolating cytotoxin A (VacA) and cytotoxin-associated gene A (CagA).

3 As a group, patients with duodenal ulcers have an increased capacity for gastric acid secretion relative to normal people.

4 Current treatment of peptic ulceration involves a combination of an antisecretory drug, usually a proton pump inhibitor, with antibiotics.

5 Hemorrhage is the leading cause of death associated with peptic ulcer. Patients with recurrent hemorrhage and elderly patients are at greatest risk of death.

6 For perforation, current therapy includes omental patch closure with postoperative anti–*H. pylori* therapy. Minimally invasive approaches are becoming standard practice.

7 Major trauma accompanied by shock, sepsis, respiratory failure, hemorrhage, or multiorgan injury is often accompanied by acute stress gastritis.

EPIDEMIOLOGY

Peptic ulceration remains a major public health problem worldwide. Worldwide prevalence of peptic ulcer disease ranges from 0.1% to 4.7% with an overall incidence of 0.2% to 0.3%.[1] With improving public hygiene and effective treatment of *Helicobacter pylori,* most epidemiologic studies are now reporting falling incidence rates. The surgical treatment of peptic ulcer has changed fundamentally. New insights into disease pathogenesis, especially the realization that gastric infection has a role in most cases of peptic ulceration, have been especially exciting. Antibiotics are now front-line antiulcer therapy. A number of powerful antisecretory drugs have been introduced into clinical practice. Medical, endoscopic, and surgical therapies are frequently integrated in the care of individual patients.

PATHOPHYSIOLOGY

1 The pathogenesis of peptic ulceration is complex and multifactorial but increasingly understood. Approximately 75% of peptic ulcer cases are caused by *H. pylori,* with almost all other cases due to use of nonsteroidal anti-inflammatory drugs (NSAIDs).[2] Both NSAID use and *H. pylori* infection are independent risk factors for development of peptic ulcer disease. The development of peptic ulceration is often depicted as a balance between chronic inflammatory injury, acid–peptic secretion, and mucosal defense, with the equilibrium shifted toward disease. Although acid–peptic secretion is crucial in the development of ulcers, usually a defect in mucosal defense induced by bacterial infection also exists to tip the balance away from health. Mucosal infection with *H. pylori* is the factor that contributes to ulcer pathogenesis in most patients.

Helicobacter pylori

The relation between *H. pylori* infection and ulceration is inferential but overwhelmingly strong; a causal relation between *H. pylori* infection and peptic ulceration has not been tested directly. Because *H. pylori* infection is difficult to eradicate with certainty, and because of the potentially serious consequences of infection, the intentional exposure of humans to the organism to establish such a relation is not justified.

Many lines of evidence establish *H. pylori* as a factor in the pathogenesis of duodenal ulceration:

- *H. pylori* is the primary cause of chronic active gastritis, characterized by nonerosive inflammation of the gastric mucosa. Antral gastritis is nearly always present histologically in patients with duodenal ulcer, and *H. pylori* can be isolated from gastric mucosa in almost all cases.
- Gastric metaplasia is extremely common in duodenal epithelium surrounding areas of ulceration. *H. pylori* binds only to gastric-type epithelium, regardless of location; metaplastic gastric epithelium can become colonized by *H. pylori* from gastric sources. Gastric metaplasia of the duodenal bulb is a nonspecific response to damage and is the means by which antral gastritis with *H. pylori* is converted to active chronic duodenitis.
- Eradication of *H. pylori* with antimicrobials that have no effect on acid secretion leads to ulcer healing rates superior to those seen with acid-suppressing agents.
- Relapse of duodenal ulcer after antimicrobial therapy is preceded by reinfection of the gastric mucosa by *H. pylori*.

In addition, half of patients evaluated for dyspepsia, but without ulceration, have histologic evidence of mucosal bacterial infection. Furthermore, 20% of healthy volunteers harbor the bacteria; the incidence of bacterial carriage in the healthy, asymptomatic population increases with age. The occurrence of peptic ulcers in only a small proportion of people who carry the organism suggests that other factors must also act to induce ulceration. The ability of *H. pylori* infection to induce alterations in gastric acid secretion is a prerequisite for ulcer development in most patients.

H. pylori is the most common bacterial infection worldwide. *H. pylori* infection is usually *acquired in childhood and lasts lifelong in the absence of specific therapy*. Epidemiologic studies suggest that *H. pylori* infection occurs via person-to-person contact, usually among family members. Transmission is believed to occur during a bout of gastroenteritis; the highest risk is associated with vomiting.

H. pylori is the only human bacterium to persistently infect the stomach. The organism is actually somewhat fragile, being killed by exposure to high levels of oxygen and to the low pH found in the acidic lumen of the stomach. To avoid the bactericidal activity of the stomach, the organism has evolved mechanisms to move within the gastric environment, to adhere to gastric mucosa, and to protect itself from the harmful effects of acid. Over 300 genes of *H. pylori* are regulated by acid.

H. pylori bacteria are spiral shaped with polar flagella. Most bacilli are free-swimming within the mucous layer covering the gastric epithelium. The organisms orient according

to a pH gradient, moving away from the lower pH of the lumen toward the epithelium. The majority of organisms remain motile within the mucous layer, but contact promotes adherence to epithelial cells, particularly in the region of intercellular junctions. The products of more than 30 genes are expressed on the outer membrane of the bacterium and function as adhesins to promote attachment to the gastric cells' surface. The best-characterized adhesin binds to the Lewis blood group antigen b. Adhesion triggers the expression of other bacterial genes, including bacterial virulence factors.

2 All strains of *H. pylori* cause persistent infection and all strains induce gastric inflammation. Yet, only 15% of infected individuals develop peptic ulceration and only 1% develop gastric adenocarcinoma. Differential expression of bacterial virulence factors is presumed to account for these observations. Two virulence factors are best characterized: vacuolating cytotoxin A (VacA) and cytotoxin-associated gene A (CagA) (Table 45-1).[3]

VacA is a pore-forming cytotoxin. VacA is expressed in all strains of *H. pylori* but is polymorphic with marked variation in two regions. The VacA protein is 88 kD. Upon secretion from the bacterium, the protein moves to the host cell membrane, where it forms a ring structure in the shape of a flower.[4] This ring complex inserts into the membrane of the host cell, creating a pore. VacA pores are permeable to anions and small neutral molecules, including urea. Pore formation may be a mechanism by which the organism obtains nutrients from gastric epithelial cells.

VacA also inserts into endosomal membranes, leading to osmotic swelling. VacA induces gastric cell death through apoptosis. This action is thought to occur via pore formation in mitochondrial membranes. VacA has been reported to interfere with immune T-cell activation and proliferation. This activity may inhibit clearance of the organism by immune mechanisms.

The second major virulence factor in *H. pylori* is termed *CagA*.[5,6] The CagA gene is part of a region of DNA that is inserted into the genome of more virulent strains of *H. pylori,* termed a *pathogenicity island.*[5] The genes in this island that are adjacent to the CagA gene encode proteins, which function as microscopic needles for the transfer of bacterial products into host gastric cells. CagA is transferred to host cells through this injection mechanism.

Table 45-1 *Helicobacter Pylori* Virulence Factors

Vacuolating Cytotoxin A (VacA)

- Forms ring structure in the shape of a flower
- Inserts into gastric cell membrane, forming pore
- Inserts into endosomal membranes, causing cellular swelling
- Damages mitochondrial membranes
- Causes leakage of ions and small molecules

Cytotoxin-Associated Gene A (CagA)

- Contained within pathogenicity island DNA sequence
- Injected into host cells
- Phosphorylated by cellular oncogenes
- Activates growth factor receptor–like signaling
- Disturbs normal proliferation, adhesion, cytoskeletal function
- Disturbs intercellular junctions, causing disruption of epithelial permeability
- Elicits inflammatory response

After CagA protein is transferred to host cells, it becomes phosphorylated on tyrosine residues by host cell kinases. Phosphorylated CagA activates a number of cellular signaling pathways involved in cellular polarity, cytoskeletal protein function, and cellular proliferation and differentiation. As a consequence, infected gastric cells change shape and become more elongated. Apical junctions between cells become disrupted, gaps develop between epithelial cells, and epithelial barrier function is lost. CagA protein also stimulates transcription factors involved in regulation of cellular proliferation. Disturbance of cellular function in favor of apoptosis affects epithelia restitution and may inhibit ulcer healing.

Acid-Secretory Status

3 The formation of duodenal ulcers depends on gastric secretion of acid and pepsin. As a group, patients with duodenal ulcers have an increased capacity for gastric acid secretion relative to normal people (Table 45-2). The maximal acid output of normal men is approximately 20 mEq/h in response to intravenous histamine stimulation, whereas patients with duodenal ulcer secrete an average of approximately 40 mEq/h. Considerable overlap exists between these two groups, and the values for most people with duodenal ulcer fall within the normal range. The increase in acid secretion in some patients with duodenal ulcer has been postulated to be due to an increase in the mass of parietal cells in the acid-secreting gastric mucosa or to an increased sensitivity to circulating gastrin.

Groups of patients with duodenal ulcer demonstrate a prolonged and larger acid-secretory response to a mixed meal than do groups of normal subjects. As with histamine-stimulated acid output, overlap exists between patients with duodenal ulcer and normal subjects. Disturbances in gastric motility can exacerbate meal-stimulated acid-secretory abnormalities.

Patients with duodenal ulcer have accelerated emptying of gastric contents, particularly liquids, after a meal, and duodenal acidification fails to slow emptying appropriately. In such patients, the duodenal mucosa can be exposed to low pH for prolonged periods relative to normal subjects.

Table 45-2 Pathogenesis of Peptic Ulcer

Helicobacter pylori infection

Endocrine Consequences
- Increased basal serum gastrin
- Increased gastrin response to a meal
- Increased responsiveness to gastrin-releasing peptide
- Production of N^{α}-methylhistamine
- Decreased density of somatostatin cells
- Decreased mucosal somatostatin content

Gastric Acid Secretion
- Increased acid = secretory capacity
- Increased basal secretion
- Increased pentagastrin-stimulated output
- Increased meal response
- Abnormal gastric emptying

Mucosal Defense
- Decreased duodenal bicarbonate production
- Decreased gastric mucosal prostaglandin production
- Increased apoptosis of epithelial cells
- Disruption of epithelial barrier function
- Inhibited epithelial restitution

Groups of patients with duodenal ulcer also demonstrate increased basal secretion of acid. Increased basal secretion can be demonstrated by nocturnal collection of gastric secretions.

Studies indicate that most of these secretory abnormalities are a direct consequence of *H. pylori* infection. Paradoxically, the earliest stages of *H. pylori* infection are accompanied by a marked decrease in gastric acid secretion. Acute antral gastritis is followed by fundal inflammation. Fundal inflammation is associated with mucosal production of a number of cytokines, including interleukin (IL)-1β, IL-6, IL-8, and tumor necrosis factor-α (TNF-α). IL-1β is a potent inhibitor of gastric acid secretion. Investigators have postulated that acute reduction in gastric acid secretion facilitates further gastric colonization with *H. pylori.* Acute hypochlorhydria resolves despite persistence of *H. pylori* and is followed by a state of chronically increased acid secretion.

Basal and peak acid outputs are increased in patients with duodenal ulcer infected with *H. pylori* relative to uninfected healthy volunteers. With eradication of *H. pylori* infection, basal acid output returns to normal within 4 weeks, and peak acid output declines to the normal range by 6 months. Peak acid output reflects parietal cell mass; the slow return to normal levels suggests that *H. pylori* infection may stimulate increases in the parietal cell mass.

Abnormalities in acid secretion and parietal cell mass appear to be due to *H. pylori*–induced hypergastrinemia.[7] *H. pylori*–infected patients have increased basal serum gastrin levels, increased gastrin responses to meal stimulation, and an augmented gastrin response to intravenous gastrin-releasing peptide. Eradication of *H. pylori* infection causes serum gastrin levels to return to baseline. Gastric mucosal inflammatory cells and epithelial cells are activated by *H. pylori* infection to release cytokines such as IL-8, interferon-γ, and TNF-α. These cytokines are stimulants of gastrin release from cultured canine gastrin cells.

H. pylori expresses Nα-histamine methyltransferase activity. This enzyme produces Nα-methylhistamine, an abnormal analogue of histamine that can act as a gastric acid-secretory stimulant.

The concentration of somatostatin in the antral mucosa and the number of somatostatin-producing cells in the antrum are diminished in *H. pylori*–infected patients. Treatment of *H. pylori* infection is followed by increases in numbers of somatostatin cells and in mucosal somatostatin messenger RNA levels. These observations suggest that alterations in mucosal somatostatin metabolism may also contribute to the hypergastrinemia seen in *H. pylori*–infected patients by removing the inhibitory effects that somatostatin exerts on gastrin release. Somatostatin release is also suppressed by Nα-methylhistamine.

Mucosal Defense against Peptic Injury

Gastric surface epithelial cells secrete mucus and bicarbonate, creating a pH gradient within the mucous layer that is nearly neutral at the mucous cell surface, even when the lumen is highly acidic. Failure of normal bicarbonate secretion locally would, in theory, result in exposure of surface epithelial cells to the peptic activity of gastric secretions at low pH. Patients with duodenal ulcers have been demonstrated to have significantly lower basal bicarbonate secretion in the proximal duodenum than normal subjects. In addition, in response to a physiologically relevant amount of hydrochloric acid instilled into the duodenal bulb, stimulated bicarbonate output was approximately 40% of the normal response. Abnormalities in duodenal bicarbonate secretion normalize after elimination of *H. pylori* in infected patients. These results suggest one mechanism by which ulceration could occur, even in patients secreting normal amounts of acid.

Diminished mucosal prostaglandin production has also been proposed to exist in subsets of patients with duodenal ulcer. Prostaglandins and prostaglandin analogues have been shown to exert cytoprotective effects, to accelerate healing of established duodenal ulcers, and to decrease acid secretion. In the duodenum, locally produced prostaglandins stimulate mucosal bicarbonate secretion. In patients with active duodenal ulceration, gastric mucosal production of prostaglandin E_2 and other prostanoids has been shown to be diminished. An increase in prostanoid synthesis within the gastric mucosa characterizes ulcer healing. Duodenal bicarbonate responses to prostaglandin E_2 are impaired in patients with duodenal ulcer.

Inflammatory responses to *H. pylori* infection are central to the pathogenesis of peptic ulceration. While *H. pylori* infection always induces inflammation, the patterns of response are not uniform. Three major patterns have been recognized.[8,9] The most common pattern is a mild to moderate inflammation of all regions of the stomach. This form is not associated with major alterations in gastric acidity and most individuals are asymptomatic and do not develop peptic ulceration. Approximately 15% of infected individuals develop an antral-predominant form of gastritis. These individuals exhibit an intense inflammation limited to the antrum without involvement of the mucosa of the gastric corpus. Gastrin levels are elevated and acid secretion is high. Inhibitory control of gastric acid production is impaired in this form of gastritis. As a result, duodenal and prepyloric ulcers are common. The third form of inflammatory response, occurring in 1% of infected individuals, is least common but most serious. This form is characterized by corpus-predominant gastritis, hypochlorhydria, and gastric atrophy. This form of inflammatory response is considered a precursor state for gastric cancer. Individuals with the third pattern of inflammation demonstrate hypergastrinemia, low acid secretion, and diminished secretion of pepsinogen.

Environmental Factors

NSAIDs have emerged as a significant risk factor for the development of acute ulceration. Although acute mucosal injury caused by NSAIDs is more common in the stomach than in the duodenum, NSAID-induced ulcer complications occur with equal frequency in these two sites. NSAIDs produce a variety of lesions, ranging from hemorrhage, to superficial mucosal erosions, to deeper ulcerations. In the duodenum, it appears likely that invasive NSAID-associated ulcers result from underlying peptic ulcer diathesis compounded by the direct injurious effects of these drugs.

The ulcerogenic actions of NSAIDs have been attributed to their systemic suppression of prostaglandin production. Numerous experimental models have demonstrated the ability of NSAIDs to injure the gastroduodenal mucosa. Ulcers resembling those caused by NSAIDs can be produced experimentally by antibodies to prostaglandins. Conversely, NSAID-associated gastric ulcers can be prevented by the coadministration of prostaglandin analogues. Ulcers associated with NSAIDs usually heal rapidly when the drug is withdrawn, corresponding to the reversal of antiprostaglandin effects. All available NSAIDs appear to pose the hazard of gastroduodenal ulceration. Clinically important ulceration (of both the stomach and duodenum) is estimated by the U.S. Food and Drug Administration to occur at a rate of 2% to 4% per patient-year. The risks inherent with NSAID use appear to be increased by a history of *H. pylori* infection, by cigarette smoking, and by alcohol use. The incidence of NSAID-caused ulcer complications is highest in older patients, as is the attendant mortality rate. Peptic ulcer disease is rare in individuals who are *H. pylori* negative and who are not receiving NSAID medications.

A role of NSAIDs in upper gastrointestinal (GI) hemorrhage is widely recognized. The risk of bleeding is particularly acute for peptic ulceration. In three reports, spanning two decades, NSAIDs were linked to 50% to 75% of bleeding peptic ulcers, one-third of deaths due to hemorrhage, and 30% of hospitalizations.[10,11] Use of NSAIDs increases the risk of bleeding from peptic ulcer threefold for those under 65 years of age, but by eightfold for individuals over 75 years of age. The odds ratio for bleeding is 13 for patients with a prior history of bleeding ulcer.

Because of the risk of gastrointestinal side effects, a selective class of cyclooxygenase-2 (COX-2) inhibitors was developed for long-term pain relief and anti-inflammatory therapy. Selective COX-2 inhibitors have reduced potential to injure the gastrointestinal mucosa relative to standard NSAIDs.[11] Concurrent use of aspirin with COX-2 inhibitors significantly undermines the safety advantages of the COX-2 agents, as does smoking.[12]

DIAGNOSIS

The cardinal feature of duodenal ulceration is epigastric pain. The pain is usually confined to the upper abdomen and is described as burning, stabbing, or gnawing. Unless perforation or penetration into the head of the pancreas has occurred, referral of pain is not common. Many patients report pain on arising in the morning. Ingestion of food or antacids usually provides prompt relief. In uncomplicated cases, abnormal physical findings are minimal. The differential diagnosis is broad and includes a variety of diseases originating in the upper gastrointestinal tract. The most common disorders to be distinguished include nonulcerative dyspepsia, gastric neoplasia, cholelithiasis and related diseases of the biliary system, and both inflammatory and neoplastic disorders of the pancreas. In dyspeptic patients, the principal diagnoses that must be differentiated definitively are peptic ulceration and gastric cancer.

The evaluation of patients with suspected peptic ulceration usually involves endoscopy, the standard against which other diagnostic modalities are measured. Endoscopy is employed because it permits biopsy of the esophagus, stomach, and duodenum. Endoscopy must be recommended with discretion because of associated morbidity (approximately 1 per 5,000 cases) and higher costs.

Duodenal ulcer is characterized by lesions that are erosive to the bowel wall. When viewed endoscopically, the ulcers have a typical appearance. The edges are usually sharply demarcated and the underlying submucosa is exposed. The ulcer base is often clean and smooth, although acute ulcers and those with recent hemorrhage can demonstrate eschar or adherent exudate. Surrounding mucosal inflammation is common. The most frequent site for peptic ulceration is the first portion of the duodenum, with the second portion less commonly involved. Ulceration of the third or fourth portions of the duodenum is unusual, and occurrence in these sites should arouse suspicion of an underlying gastrinoma. Ulceration in the pyloric channel or the prepyloric area is similar in endoscopic appearance to duodenal ulceration, and ulcers in these areas demonstrate other clinical features similar to duodenal ulcers. Endoscopic demonstration of a duodenal ulcer should prompt mucosal biopsy of the gastric antrum to demonstrate the presence of *H. pylori* and guide subsequent therapy.

The hallmarks of the histologic appearance of duodenal ulcers are chronicity and invasiveness. Chronic injury is suggested by surrounding fibrosis; collagen is deposited in the submucosa during each round of ulcer relapse and healing. The adjacent mucosa often demonstrates evidence of chronic injury with infiltration of acute and chronic inflammatory cells. Gastric metaplasia, in which the duodenum exhibits histologic features of gastric mucosa, is common in the surrounding nonulcerated mucosa. The ulcer can extend for a variable distance through the wall of the duodenum, including the full thickness of the bowel in cases of perforation.

4 In the absence of active treatment, *H. pylori* infection is lifelong. Spontaneous healing of infected mucosa is very rare, occurring in less than 0.5% per patient-year. Current treatment of peptic ulceration involves a combination of an antisecretory drug, usually a proton pump inhibitor, with antibiotics.[13] This therapy is rational for most patients who are *H. pylori* positive and results in a high rate of sustained ulcer healing.

A large number of drug regimens have been described, but the most widely used treatment protocols combine a proton pump inhibitor, usually omeprazole, with two antibiotics, usually clarithromycin and metronidazole or amoxicillin. A combination of antibiotics is more effective than one antibiotic alone in almost all series. This triple therapy is administered for 7 or 14 days. Triple-drug therapy is cost effective and associated with a low rate of side effects, low rates of antibiotic resistance, and acceptable levels of patient compliance. *H. pylori* eradication rates of greater than 90% have been reported.

After elimination of *H. pylori,* ulcer recurrence rates reflect the rate of reinfection. In developed countries, reinfection rates of less than 10% at 5 years have been reported. Eradication of *H. pylori* improves quality of life, as measured by symptoms, drug prescriptions, physician visits, and days of missed employment. To date, antibiotic resistance has been low, approximately 18% for clarithromycin, 14% for levofloxacin, and 35% for metronidazole. Resistance to amoxicillin has been close to zero.[14]

HISTAMINE-RECEPTOR ANTAGONISTS

Histamine, released into the interstitial fluid by cells in the fundic mucosa, diffuses to the mucosal parietal cell. Histamine stimulates acid production by occupying a membrane-bound receptor and activating parietal cell adenylate cyclase. Histamine is released in response to a number of physiologic stimuli; blockade of histamine receptors inhibits most forms of stimulated acid secretion in humans. Parietal cell histamine receptors are classified as H_2 receptors because they are activated by agonists such as 4-methylhistamine and are selectively blocked by agents such as cimetidine. Some H_2-receptor antagonists also possess nongastric actions by binding to androgen receptors, by interacting with the hepatic microsomal oxidase system, and by crossing the blood–brain barrier. All clinically useful gastric histamine receptor antagonists are of the H_2 type.

H_2-receptor antagonists bind competitively to parietal cell H_2 receptors to produce a reversible inhibition of acid secretion. An enormous worldwide experience has accumulated with the use of H_2-receptor antagonists. The agents are effective and safe when used in the treatment of peptic ulcer. The various compounds have similar efficacy in terms of ulcer healing when used in doses that produce similar reductions in acid output. It is clear that H_2-receptor blockers do not affect the underlying ulcer diathesis; if H_2-receptor antagonists are stopped, recurrent ulceration occurs in more than half of patients within 1 year. The current understanding of the role of *H. pylori* in ulcer pathogenesis has changed the role of H_2-receptor antagonists from primary therapy to that of a substitute for proton pump inhibitors in conjunction with antibiotic treatment.

PROTON PUMP BLOCKERS

Acid secretion by the gastric parietal cells is due to the active transport of hydrogen ions from the parietal cell cytoplasm into the secretory canaliculus in exchange for potassium. Because this so-called *proton pump* is tissue specific, being present only in gastric mucosa, its blockade would be expected to have minimal effects on nongastric functions. Omeprazole is representative of a family of compounds that selectively block the parietal cell proton pump.

Omeprazole is a weak base, with a pKa of approximately 4. The drug is nonionized and lipid soluble at neutral pH, but it becomes ionized and activated at a pH of less than 3. In its activated state, omeprazole binds to the membrane-bound H^+-K^+-adenosine triphosphatase (ATPase) of the parietal cell. Because the compound is a weak base, omeprazole accumulates selectively within the acidic environment of the parietal cell secretory canaliculus; 4 hours after administration, the drug is detectable in appreciable quantities only in the gastric mucosa. If enough drug is administered to occupy all parietal cell–binding sites, anacidity can be produced. Omeprazole, in doses from 20 to 30 mg, causes nearly complete inhibition of stimulated gastric acid secretion within 6 hours. At 24 hours after drug administration, a 60% to 70% reduction in acid secretion persists.

Repeated daily dosing with omeprazole results in increasing inhibitory action on gastric secretion and thus in decreased intragastric degradation of the drug. Acid suppression stabilizes after approximately 3 days. Because of tissue accumulation, the secretory actions of omeprazole do not correlate with plasma levels. Several studies have demonstrated a significant inhibition of peak acid output, marked relief of epigastric pain, and decreased use of supplemental antacids during omeprazole therapy. Direct comparisons with H_2-receptor antagonists have generally favored omeprazole in terms of pain relief and rate of ulcer healing.

OPERATIVE TREATMENT OF ULCER DISEASE

Surgical Goals

Operative intervention is reserved for the treatment of complicated ulcer disease. Three complications are most common and constitute the indications for peptic ulcer surgery – hemorrhage, perforation, and obstruction. The first goal in the surgical treatment of the complications of ulcer disease is treatment of coexisting anatomic complications, such as pyloric stenosis or perforation. The second major goal should be patient safety and freedom from undesirable chronic side effects. To achieve these goals, the gastric surgeon can direct therapy through endoscopic or operative means, the appropriate choice depending on the clinical circumstances.

Operative Procedures

A number of operative procedures have been used to treat peptic ulcer, but with decreasing frequency in the past decade. There is currently no indication for surgical treatment of uncomplicated ulcer disease. Operative treatment of gastric outlet obstruction has decreased by approximately 50%. Most surgical patients are now treated emergently for the complications of bleeding or perforation.

Three procedures – truncal vagotomy and drainage, truncal vagotomy and antrectomy, and proximal gastric vagotomy – were widely used in the past in the operative treatment of peptic ulcer disease. With increasing frequency, surgical therapy of peptic ulcer is directed exclusively at correction of the immediate problem (e.g., closure of duodenal perforation) without gastric denervation. The underlying ulcer diathesis is then addressed after surgery by antibiotic therapy directed at *H. pylori*. This approach is applicable to most patients with peptic ulcer undergoing emergent operation and implies a very limited role for vagotomy in the future.

Division of both vagal trunks at the esophageal hiatus – truncal vagotomy – denervates the acid-producing fundic mucosa as well as the remainder of the vagally supplied viscera (Fig. 45-1). Because denervation impedes normal pyloric coordination and can result in impairment of gastric emptying, truncal vagotomy must be combined with a procedure to eliminate pyloric sphincteric function. Usually, gastric drainage is ensured by performance of a pyloroplasty (Fig. 45-2).

When truncal vagotomy is combined with resection of the gastric antrum there is a further reduction in acid secretion, presumably by removing antral sources of gastrin. The limits of antral resection are usually defined by external landmarks, rather than the histologic transition from fundic to antral mucosae. The stomach is divided proximally along a line from a point above the incisura angularis to a point along the greater curvature midway from the pylorus to the gastroesophageal junction. Restoration of gastrointestinal continuity by a gastroduodenostomy is termed a Billroth I reconstruction. A Billroth II procedure uses a gastrojejunostomy (Fig. 45-3).

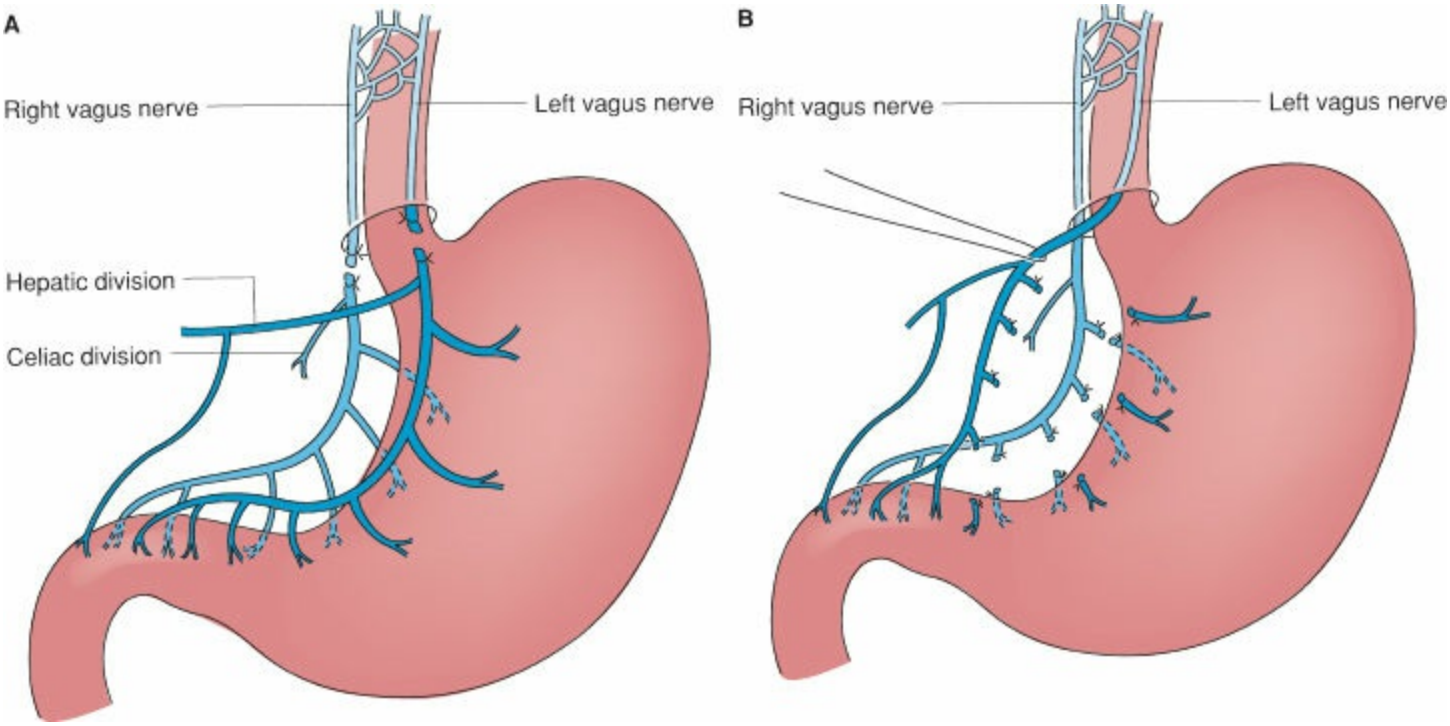

Figure 45-1. Truncal vagotomy and proximal gastric vagotomy. **A:** With truncal vagotomy, both nerve trunks are divided at the level of the diaphragmatic hiatus. **B:** Proximal gastric vagotomy involves division of the vagal fibers that supply the gastric fundus. Branches to the antropyloric region of the stomach are not transected, and the hepatic and celiac divisions of the vagus nerves remain intact.

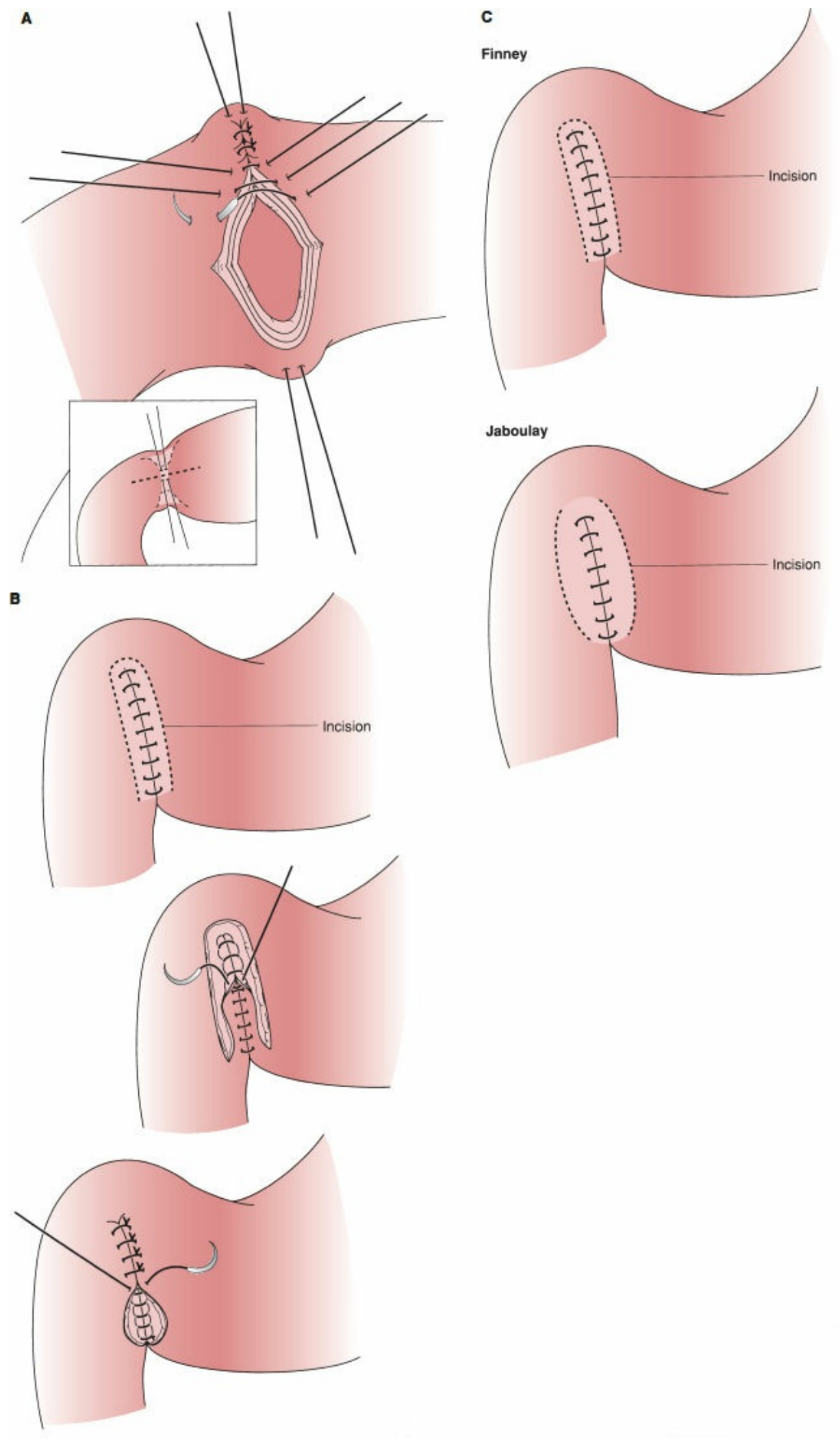
A
B
Incision
C
Finney
Incision
Jaboulay
Incision

Figure 45-2. Pyloroplasty formation. **A:** A Heineke–Mikulicz pyloroplasty involves a longitudinal incision of the pyloric sphincter followed by a transverse closure. **B:** The Finney pyloroplasty is performed as a gastroduodenostomy with division of the pylorus. **C:** The Jaboulay pyloroplasty differs from the Finney procedure in that the pylorus is not transected.

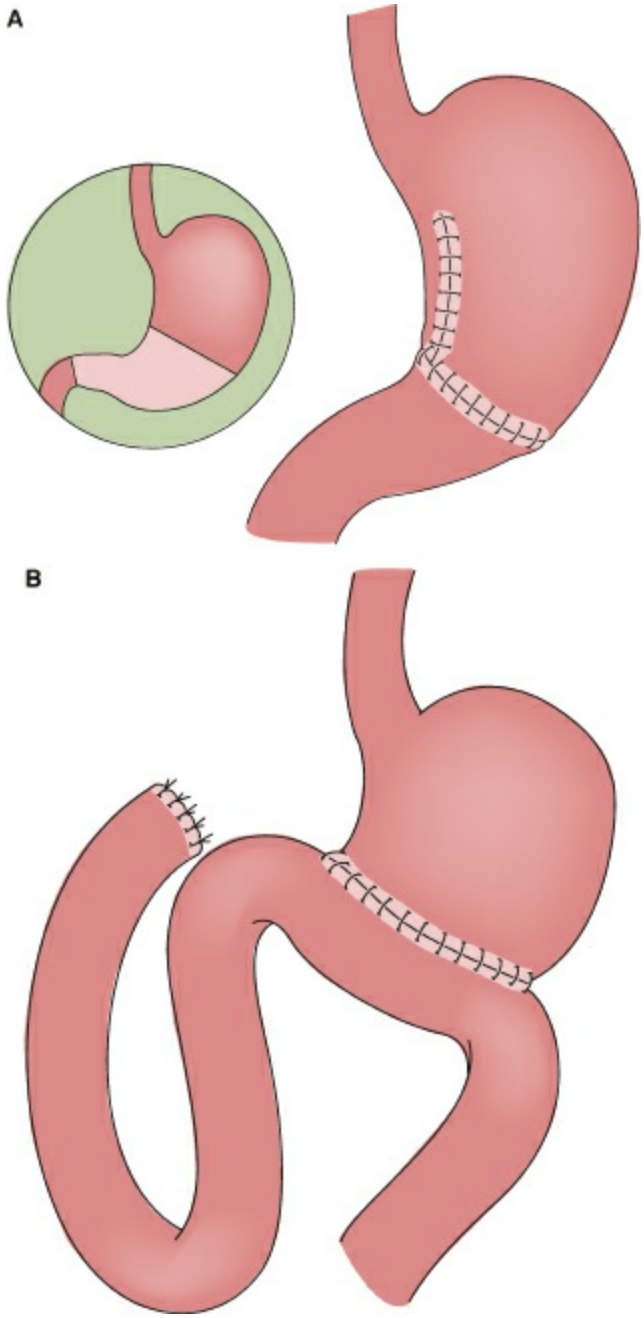

Figure 45-3. Antrectomy involves resection of the distal stomach (pink area in inset). Restoration of gastrointestinal continuity may be accomplished as a Billroth I gastroduodenostomy (**A**) or Billroth II gastrojejunostomy (**B**) reconstruction.

Physiologic Consequences of Operation

Division of efferent vagal fibers directly affects acid secretion by reducing cholinergic stimulation of parietal cells. In addition, vagotomy also diminishes parietal cell responsiveness to gastrin and histamine. Basal acid secretion is reduced by approximately 80% in the immediate postoperative period. Acid secretion increases slightly within months of surgery but remains unchanged thereafter. The maximal acid output in response to exogenously administered stimulants such as pentagastrin is reduced by approximately 70% in the early period after surgery. After 1 year, pentagastrin-stimulated maximal acid output rebounds to 50% of prevagotomy values but remains at this level on subsequent testing. Acid secretion due to endogenous stimulation by a liquid meal is reduced by 60% to 70% relative to normal subjects.

The inclusion of antrectomy with truncal vagotomy causes further reductions in acid secretion. Pentagastrin-stimulated maximal acid output is reduced by 85% relative to values recorded before surgery. Little rebound in acid secretion occurs with the passage of time.

Operations that involve vagotomy alter gastric emptying. Proximal gastric denervation abolishes vagally mediated receptive relaxation. Thus, for any given volume ingested, the intragastric pressure rise is greater and the gastroduodenal pressure gradient is higher than that in normal subjects. As a result, emptying of liquids, which depends critically on the gastroduodenal pressure gradient, is accelerated after proximal gastric vagotomy. Because nerve fibers to the antrum and pylorus are preserved, the function of the distal stomach to mix and triturate solid food is preserved, and emptying of solids is nearly normal in patients who have undergone proximal gastric vagotomy. Truncal vagotomy affects the motor activities of both the proximal and distal stomach. Solid and liquid emptying rates are usually increased when truncal vagotomy is accompanied by pyloroplasty.

Dumping, a postprandial symptom complex of abdominal discomfort, weakness, and vasomotor symptoms of sweating and dizziness, occurs in 10% to 15% of patients with truncal vagotomy and antrectomy in the early postoperative period and is chronically disabling in 1% to 2%. After truncal vagotomy and pyloroplasty, dumping is present initially in 10% and remains severe in approximately 1%. Permanent symptoms of dumping are rare after proximal gastric vagotomy. The incidence of diarrhea, which is presumably caused by denervation of the pylorus and small bowel and by elimination of pyloric function, parallels the incidence of dumping after truncal vagotomy and antrectomy or pyloroplasty. Persistent or disabling diarrhea is present in less than 1% of patients after proximal gastric vagotomy.

Most prospective surgical series were reported in the era before the pathogenic role of *H. pylori* was appreciated. With appropriate use of postoperative antimicrobials directed against *H. pylori,* ulcer recurrence rates are currently much lower than historical standards. Although recurrence rates (without *H. pylori* treatment) as low as 5% have been reported, a more generally accepted figure is 10%. This rate is similar to that of reinfection with *H. pylori* after its successful eradication. The reported ulcer recurrence

rates after proximal gastric vagotomy can be adversely affected by the inclusion of prepyloric and pyloric channel ulcers.

Hemorrhage

5 Hemorrhage is the leading cause of death associated with peptic ulcer, and the incidence of this complication has not changed since the introduction of H_2-receptor antagonists. The lifetime risk of hemorrhage for patients with duodenal ulcer who have not had surgery and who do not receive continuing maintenance drug therapy approximates 15% at 5 years.[15] Most hemorrhages occur during the initial episode of ulceration or during a relapse, and patients who have hemorrhaged previously have a higher risk of bleeding again. Continued or recurrent bleeding occurs in 20% to 30% of patients, and when this happens, mortality varies between 10% and 40%. Patients with recurrent hemorrhage and elderly patients are at greatest risk of death, and these two groups should be resuscitated vigorously, investigated promptly, and treated aggressively.[16,17]

The contemporary risk of mortality from bleeding ulcer approximates 10% to 20%. Operative risk is increased in patients who have shock at admission, recurrent bleeding, delay in operative intervention, or coexisting medical illnesses. Surgical delay may lead to recurrent hypovolemia and, subsequently, multisystem organ failure.

Upper gastrointestinal endoscopy is the appropriate initial diagnostic test when hemorrhage from duodenal ulceration is suspected. Endoscopy can correctly determine the site and cause of bleeding in more than 90% of patients. An ulcer should be accepted as the bleeding source only if it has one of the stigmata of active or recent hemorrhage. Active hemorrhage is defined by an arterial jet, active oozing, or oozing beneath an adherent clot. The signs of recent hemorrhage include an adherent clot without oozing, an adherent slough in the ulcer base, or a visible vessel in the ulcer. The ability of these endoscopic findings to accurately predict recurrent hemorrhage has been extensively validated. Approximately 30% of patients who have stigmata of recent hemorrhage experience rebleeding, and most of the patients who experience recurrent hemorrhage require emergency treatment. These stigmata are not sufficiently accurate to be used alone as indications for surgery. Rather, they serve as a warning that aggressive therapy is needed and close follow-up mandatory. The occurrence of hypovolemic shock, rebleeding during hospitalization, and a posteroinferior location of the ulcer are additional clinical features that have been associated with increased risks of recurrent bleeding. A recent study suggests that rebleeding risk in excess of 30% justifies second-look endoscopy as a means to anticipate, and thus preemptively treat, ulcers at highest risk of recurrent hemorrhage.[18] The role of gastric acidity as a cause for in-hospital rebleeding appears to be inconsequential, and reduction of acid secretion by H_2-receptor antagonists or omeprazole is not sufficient to prevent recurrent hemorrhage.

The ability to visualize bleeding duodenal ulcers endoscopically has led to development of methods to treat hemorrhage endoscopically. There are many different methods of endoscopic therapy, but the most established consist of thermal coagulation, injection of alcohol, or sclerosants. Thermal coagulation can be achieved by bipolar electrocoagulation or direct application of heat through a heater probe. Injection of epinephrine into the base of the bleeding ulcer is also effective in control of ulcer

hemorrhage.

Proof of efficacy, in the form of lowered rebleeding rates and avoidance of operation, has been convincingly demonstrated for all of these methods of endoscopic hemostasis. The analysis of reports of endoscopic treatment of hemorrhage is complicated by the 70% rate of spontaneous, although sometimes temporary, cessation of bleeding without intervention. In addition to endoscopic stigmata, hemodynamic instability, need for continuing transfusion, red stool or hematemesis, age older than 60 years, and serious medical comorbidity are clinical features that mandate endoscopic therapy. Rebleeding during hospitalization and the endoscopic findings of visible vessel, oozing, or bleeding associated with an adherent clot are other indications for endoscopic hemostasis. Ulcers with clean bases require no treatment. Failure of endoscopic hemostasis is usually due to inaccessibility because of scarring, to rapid active bleeding obscuring the endoscopic view, or to an adherent clot. Patients treated endoscopically should be observed closely for further hemorrhage. Patients who rebleed within 72 hours of initial endoscopic control may be successfully retreated without increasing the risk of mortality.[19]

The efficacy of endoscopy is dependent on timing. Early endoscopy correctly identifies patients at low risk for recurrent hemorrhage and permits safe avoidance of hospitalization. Early endoscopy also benefits high-risk patients by directing active hemostatic therapy. Patients treated in this way have been demonstrated to have fewer episodes of rebleeding, lower rates of operation, and shorter hospitalizations.

Table 45-3 lists situations in which operative intervention is appropriate. The need for emergency surgery significantly increases surgical risks; mortality rates are increased approximately 10-fold. Operative therapy should consist of duodenostomy with direct ligation of the bleeding vessel in the ulcer base.

Table 45-3 Situations in Which Operative Intervention is Appropriate

Massive hemorrhage leading to shock or cardiovascular instability
Prolonged blood loss requiring continuing transfusion
Recurrent bleeding during medical therapy or after endoscopic therapy
Recurrent hemorrhage requiring hospitalization

Postoperatively, patients should receive antibiotics directed against *H. pylori*. This treatment paradigm is based on the observation that peptic ulcer hemorrhage recurs in 20% of patients in whom *H. pylori* is not eradicated, whereas rebleeding is reduced to 3% in patients who receive *H. pylori* eradication therapy (Algorithm 45-1).[20] The studies that support this practice were not specifically designed to evaluate postoperative hemorrhage, but the results are so definitive that they support this application (Fig. 45-4).

Perforation

The lifetime risk for perforation in patients with duodenal ulceration who do not receive therapy approximates 10%. In contrast, ulcer perforation is unusual if initial ulcer healing has been achieved.

Perforation of a duodenal ulcer is usually accompanied by sudden and severe epigastric pain. The pain, caused by the spillage of highly caustic gastric secretions into the peritoneum, rapidly reaches peak intensity and remains constant. Radiation to the right scapular region is common because of right subphrenic collection of gastric contents. Occasionally, pain is sensed in the lower abdomen if gastric contents travel caudally through the paracolic gutter. Peritoneal irritation is usually intense and most patients avoid movement to minimize discomfort.

Physical examination reveals low-grade fever, diminished bowel sounds, and rigidity of the abdominal musculature. Usually, upright abdominal radiographs reveal pneumoperitoneum, but up to 20% of perforated ulcers do not show free intraperitoneal air. Computed tomography of the abdomen is very sensitive for demonstrating perforation if pneumoperitoneum is not demonstrated but perforation is still suspected.

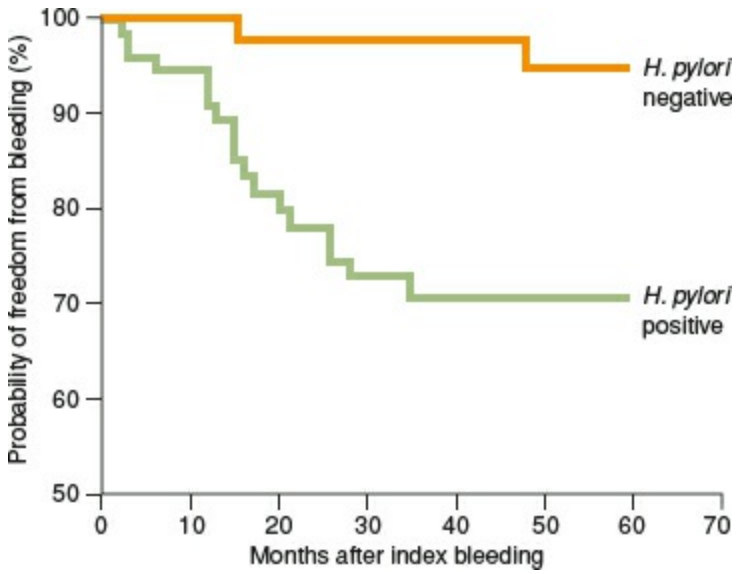

Figure 45-4. Probability of freedom from recurrent hemorrhage according to posttreatment *H. pylori* status.

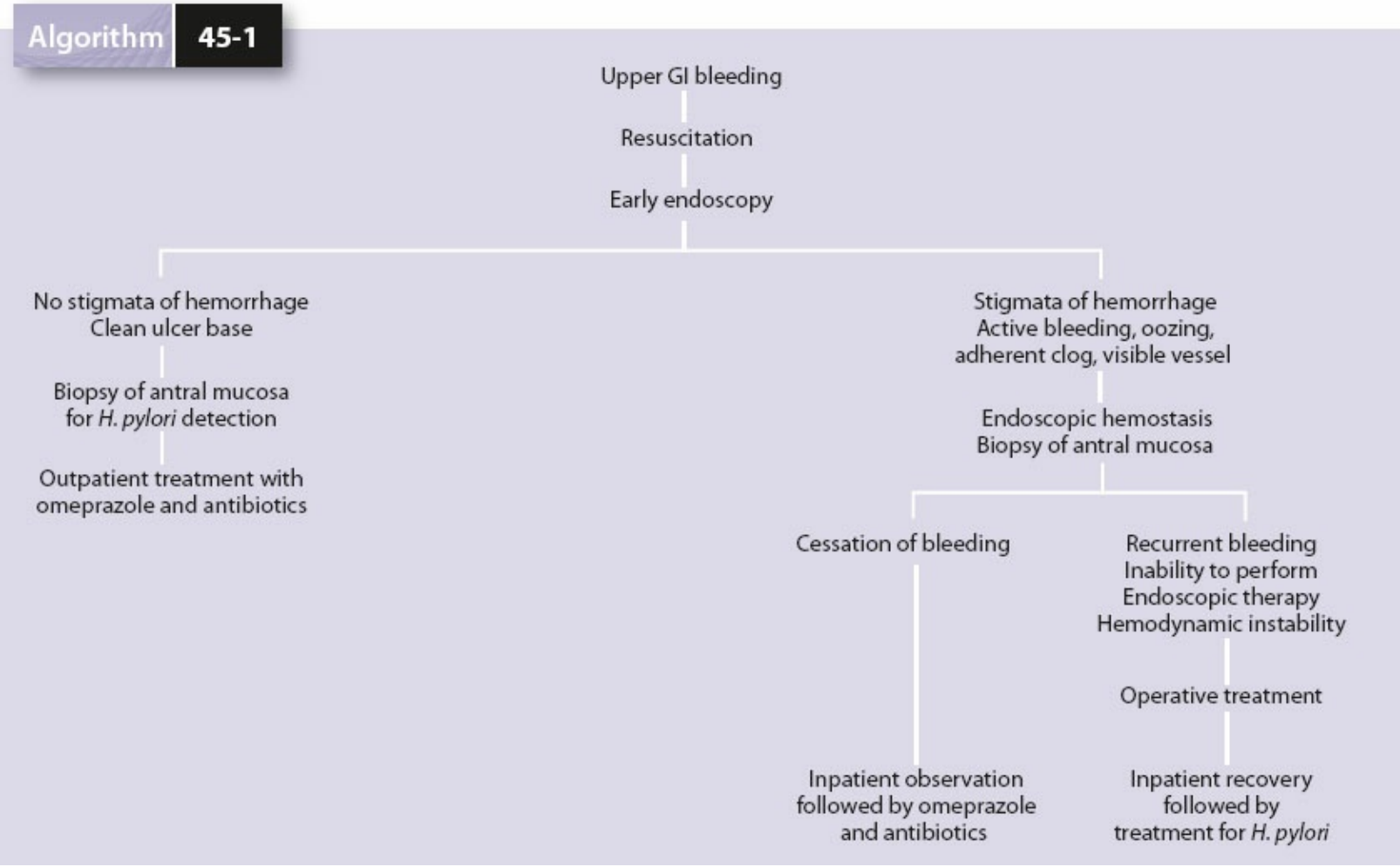

Algorithm 45-1. Treatment of bleeding duodenal ulceration.

Although occasional reports have described the nonoperative treatment of this complication, perforation remains a strong indication for surgery in most circumstances. Laparotomy or laparoscopy affords the opportunity to relieve intraperitoneal contamination and to close the perforation (Fig. 45-5).

Signs of antecedent duodenal ulceration, in terms of history of prior symptoms and anatomic evidence of duodenal scarring, should be sought. A lack of antecedent symptoms is not protective. Reports suggest that patients without antecedent symptoms are also at risk for recurrent ulceration. By 5 to 6 years, symptomatic ulcer recurrence in patients with acute ulcer perforation is similar to that for patients with chronic disease. Before the role of *H. pylori* was appreciated, simple omental closure of duodenal perforation resulting from chronic ulceration did not provide satisfactory long-term results; up to 80% of patients so treated had recurrent ulceration, and 10% experienced reperforation if untreated. Approximately four-fifths of all patients with perforation have *H. pylori* infestation and therefore are at risk of recurrent disease.

The mortality of emergent ulcer operations is most clearly correlated with the following circumstances: preoperative shock, coexisting medical illness, and presence of perforation for more than 48 hours.[21] Mortality increases progressively with the number of prognostic variables present – the so-called Boey Score – being 0%, 10%, 45%, and 100% with zero to three positive. Mortality with perforated peptic ulcer disease has also

been correlated with the American Society of Anesthesiology (ASA) score and the Peptic Ulcer Perforation (PULP) score.[22]

6 Current reports advocate omental patch closure only, often laparoscopically, with postoperative anti–*H. pylori* therapy. This approach presumes that most duodenal ulcers are caused by *H. pylori,* that secure closure of the perforation can be obtained, and that further surgical therapy will be obviated by the effects of medical therapy. Minimally invasive approaches are becoming standard practice.

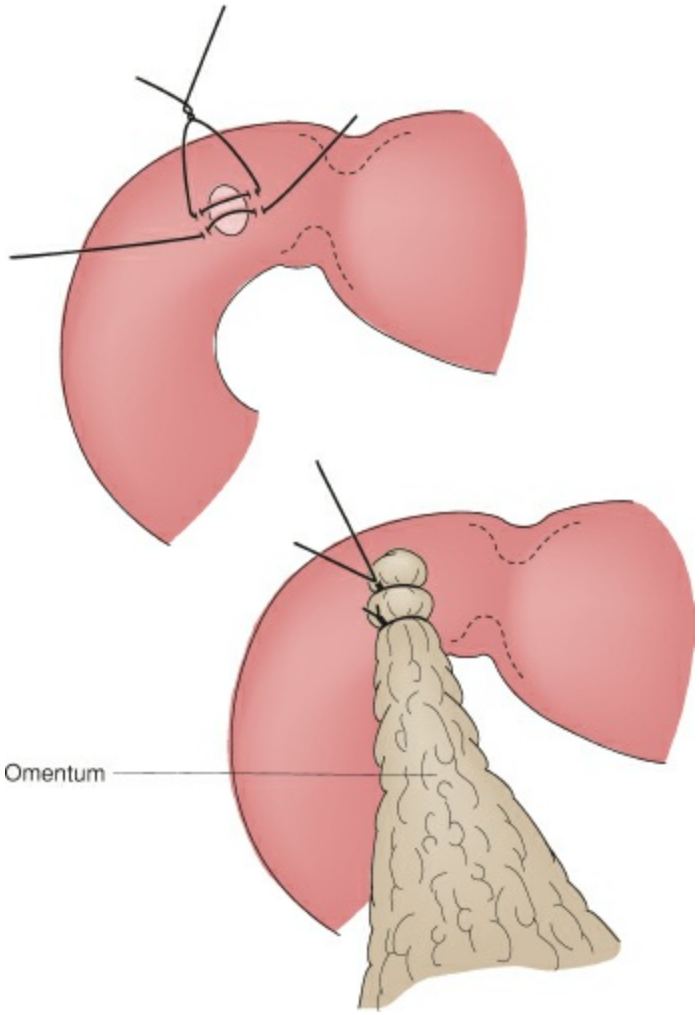

Figure 45-5. Omental patching of perforated duodenal ulcer.

Three meta-analyses of surgical treatment of perforated peptic ulcer have compared open surgical therapy with laparoscopic approaches.[23–25] In terms of operative time, there is no clear superiority of one approach over the other, but trials reported after 2001 have favored laparoscopic repair. While in-hospital analgesic use is less in laparoscopically treated patients, the more important variable of hospital length of stay was not significantly shorter for these patients. Overall rates of postoperative complications were not statistically different between the two approaches. A lower rate of wound infection in the laparoscopic group approached significance. Return to normal daily activities and work favored the laparoscopic group. The pooled estimate of mortality favored laparoscopic repair. Thirty-day mortality risk approximates 15%.[26] Septic complications, organ space infection, and prolonged ventilation are leading causes of postoperative

morbidity.[27]

Obstruction

Gastric outlet obstruction can occur acutely or chronically in patients with duodenal ulcer disease. Acute obstruction is caused by edema and inflammation associated with ulcers in the pyloric channel and the first portion of the duodenum. Pyloric obstruction is suggested by recurrent vomiting, dehydration, and hypochloremic alkalosis due to loss of gastric secretions. Acute gastric outlet obstruction is treated with nasogastric suction, rehydration, and intravenous administration of antisecretory agents. In most instances, acute obstruction resolves with such supportive measures within 72 hours.

Repeated episodes of ulceration and healing can lead to pyloric scarring and a fixed stenosis with chronic gastric outlet obstruction.

Upper endoscopy is indicated to confirm the nature of the obstruction and to exclude neoplasm. Endoscopic hydrostatic balloon dilatation of pyloric stenoses can also be attempted at this time (Fig. 45-6). Approximately 85% of pyloric stenoses are amenable to balloon dilatation. Only 40% of patients with gastric stenoses have sustained improvement by 3 months after balloon dilatation. Recurrent stenoses are presumably due to residual scarring in the pyloric channel. Thus, although pyloric dilatation is occasionally palliative, in most cases operative correction is required.

Operative management of gastric outlet obstruction should be focused on relief of the anatomic abnormality. Antrectomy has been used with success in this circumstance, with low ulcer recurrence rates and with satisfactory restoration of gastric emptying.

GASTRIC ULCER

Benign gastric ulcers are a form of peptic ulcer disease, occurring with one-third the frequency of benign duodenal ulceration. In the United States, gastric ulcer is somewhat more common in men than in women and occurs in a patient cohort approximately 10 years older than for duodenal ulceration.

Endoscopic Diagnosis

Upper gastrointestinal endoscopy is the preferred method for diagnosing gastric ulceration. The ulcer base in benign disease is commonly smooth and flat and often covered by a gray, fibrous exudate. The margin is usually slightly raised, erythematous, and friable. Differentiation of benign and malignant gastric ulcers is reliably made only by histologic examination. Visual endoscopic differentiation of benign from malignant ulcers is not reliable. All gastric ulcers should have multiple biopsies taken from the perimeter of the lesion. The addition of lesional brushings to biopsy increases diagnostic accuracy to approximately 95%.

Benign gastric ulcers may occur in any location in the stomach, but approximately 60% are located along the lesser curvature proximal to the incisura angularis. Less than 10% of benign gastric ulcers are located on the greater curvature. Virtually all gastric ulcers lie within 2 cm of the histologic transition between fundic and antral mucosa. With increasing age, this mucosal transition zone moves proximally along the lesser curvature. Movement of this transition zone is reflected by the greater prevalence of proximal ulcers in elderly patients.

As with benign duodenal ulceration, *H. pylori* plays a central role in the pathogenesis of benign gastric ulcers.[28] Benign gastric ulcers associated with *H. pylori* respond to antibiotic therapy at a rate equivalent to that of duodenal ulceration. The recurrence rate of ulcerations in these patients after *H. pylori* eradication is equal to the rate of reinfection.

A strong association of benign gastric ulceration with the use of NSAIDs has been recognized. Cigarette smoking is associated with development of gastric ulceration, and continued smoking impedes medical therapy. Gastric and duodenal ulcers have been noted in patients receiving hepatic artery chemotherapy in whom improper placement of the catheter permits perfusion of gastric and duodenal mucosae. A variety of agents, including 5-fluorouracil, cisplatin, doxorubicin, and mitomycin C, have been implicated.

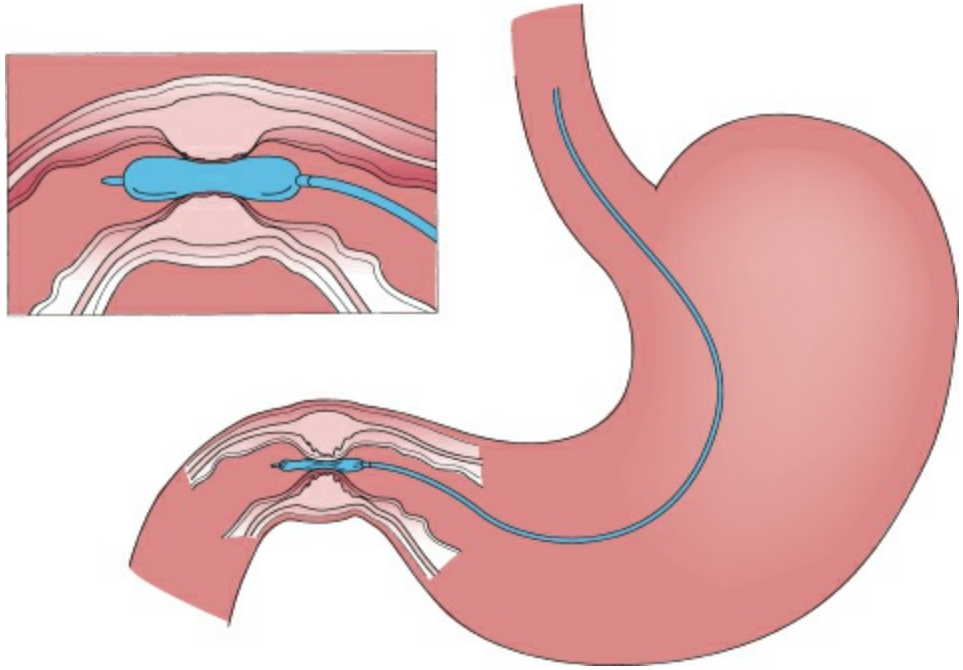

Figure 45-6. Schematic representation of balloon dilatation of pyloric stenosis.

Therapy

The primary therapy for benign gastric ulceration in most patients is antimicrobial treatment of *H. pylori* infection. The treatment protocols are similar to those used for benign duodenal ulceration. For many patients, cessation of NSAID therapy is also required.

Indications for surgical treatment of gastric ulcer include hemorrhage, perforation, failure of a recurrent ulcer to respond to medical therapy, and inability to exclude malignant disease.

For benign gastric ulcers, the elective operation of choice is usually a distal gastrectomy with gastroduodenal (Billroth I) anastomosis. The ulcer should be included in the gastrectomy specimen. With this approach, operative mortality rates of 2% to 3%, with ulcer recurrence rates of less than 5%, have been reported. Because benign gastric ulcers are not associated with gastric acid hypersecretion, inclusion of vagotomy is not necessary.

The occurrence of a gastric ulcer near the gastroesophageal junction represents a difficult surgical problem. When possible, the ulcer should be excised. This usually requires a distal gastrectomy with an extension along the lesser curvature near the esophageal wall and reconstruction with gastrojejunostomy.

Emergency operations performed for hemorrhage or perforation require ulcer excision. Distal gastrectomy, performed with gastroduodenal reconstruction, is usually the procedure of choice. Operative mortality rates average 10% to 20% in the presence of hemorrhage or perforation.

POSTGASTRECTOMY SYNDROMES

A number of syndromes have been described that are associated with distressing symptoms after gastric operations performed for peptic ulcer or gastric neoplasm. The occurrence of severe postoperative symptoms is fortunately low, perhaps 1% to 3% of cases, but the disturbances can be disabling. The two most common postgastrectomy syndromes, categorized according to predominant manifestation, are dumping and alkaline reflux gastritis.

Dumping

The term *dumping* denotes a clinical syndrome with both gastrointestinal and vasomotor symptoms. The precise cause of dumping is not known but is believed to relate to the unmetered entry of ingested food into the proximal small bowel after vagotomy and either resection or division of the pyloric sphincter. Early dumping symptoms occur immediately after a meal and include nausea, epigastric discomfort, borborygmi, palpitations, and, in extreme cases, dizziness or syncope. Late dumping symptoms follow a meal by 1 to 3 hours and can include reactive hypoglycemia in addition to the aforementioned symptoms.

Although a relatively large number of patients experience mild dumping symptoms in the early postoperative period, minor dietary alterations and the passage of time bring improvement in all but approximately 1%. The somatostatin analogue octreotide has been reported to improve dumping symptoms when 50 to 100 mg is administered subcutaneously before a meal. The beneficial effects of somatostatin on the vasomotor symptoms of dumping are postulated to be due to pressor effects of the compound on splanchnic vessels. In addition, somatostatin analogues inhibit the release of vasoactive peptides from the gut, decrease peak plasma insulin levels, and slow intestinal transit, all effects that might be expected to ameliorate dumping symptoms. Octreotide administration before meal ingestion has been shown to prevent changes in pulse, systolic blood pressure, and packed red cell volume during early dumping and blood glucose levels during late dumping.

Alkaline Reflux Gastritis

The term *alkaline reflux gastritis* should be reserved for patients who demonstrate the clinical triad of postprandial epigastric pain often associated with nausea and vomiting, evidence of reflux of bile into the stomach, and histologic evidence of gastritis. One or more of these findings occur transiently in 10% to 20% of patients after gastric resection, but they persist in only 1% to 2%.

The differential diagnosis for a patient with postoperative epigastric pain includes recurrent ulceration, biliary and pancreatic disease, afferent loop obstruction, and esophagitis in addition to alkaline reflux gastritis. Serum gastrin measurements should be determined to exclude Zollinger–Ellison syndrome and retained gastric antrum. Endoscopic examination is essential to exclude recurrent ulcer.

Endoscopically, the gastric mucosa appears red, friable, and edematous. Gastric inflammation is patchy and nonulcerative. Histologic examination shows mucosal and submucosal edema and infiltration of acute and chronic inflammatory cells into the lamina propria. Glandular atrophy and intestinal metaplasia are frequent accompaniments.

No perfect solution to alkaline reflux gastritis exists. H_2-receptor antagonists, proton pump inhibitors, bile acid chelators, and dietary manipulations have not been demonstrated definitely to be beneficial. The only proved treatment for alkaline reflux gastritis is operative diversion of intestinal contents from contact with the gastric mucosa. The most common surgical procedure used for this purpose is a Roux-en-Y gastrojejunostomy with an intestinal limb of 50 to 60 cm constructed to prevent reflux of intestinal contents (Fig. 45-7). This procedure is effective in eliminating bilious vomiting (nearly 100%), but recurrent or persistent pain is reported in up to 30% of patients, and up to 20% of patients are troubled with postoperative delayed gastric emptying.

STRESS GASTRITIS

7 Major trauma accompanied by shock, sepsis, respiratory failure, hemorrhage, or multiorgan injury is often accompanied by acute stress gastritis. Acute stress gastritis is particularly prevalent after thermal injury with greater than 35% total surface area burned.[29] Multiple superficial ulcerations and erosions are noted in the proximal, acid-secreting portion of the stomach, with fewer lesions in the antrum and only rare ulcerations in the duodenum.

The most sensitive diagnostic test for stress ulceration is endoscopic examination. If patients are examined within 12 hours of the onset of injury, acute mucosal ulcerations may be observed that appear as multiple, shallow areas of erythema and friability, often accompanied by focal hemorrhage. The lesions are progressive during the first 72 hours after injury. When lesions are examined histologically, they are seen to consist of coagulation necrosis of the superficial endothelium with infiltration of leukocytes into the lamina propria. Chronic disease, characterized by fibrosis and scarring, is not observed. With resolution of the underlying injury or sepsis, healing is accompanied by mucosal restitution and regeneration.

Clinical observations and a large number of experimental studies suggest that mucosal ischemia is the central event underlying the development of stress gastritis. In clinical practice, most patients who contract stress gastritis do so after an episode of sepsis, hemorrhage, or cardiac dysfunction accompanied by shock. Experimental studies that cause depletion of high-energy phosphate compounds such as ATP predispose to the development of stress gastritis. Luminal gastric acid secretion, although not the sole cause of stress gastritis, appears to be a necessary concomitant process. A number of experimental observations suggest that a critical concentration of luminal acid is required to initiate injury in the setting of mucosal ischemia. The fall in mucosal energy supply permits proton back-diffusion into the mucosa; the resultant decrease in mucosal pH exacerbates ischemic damage.

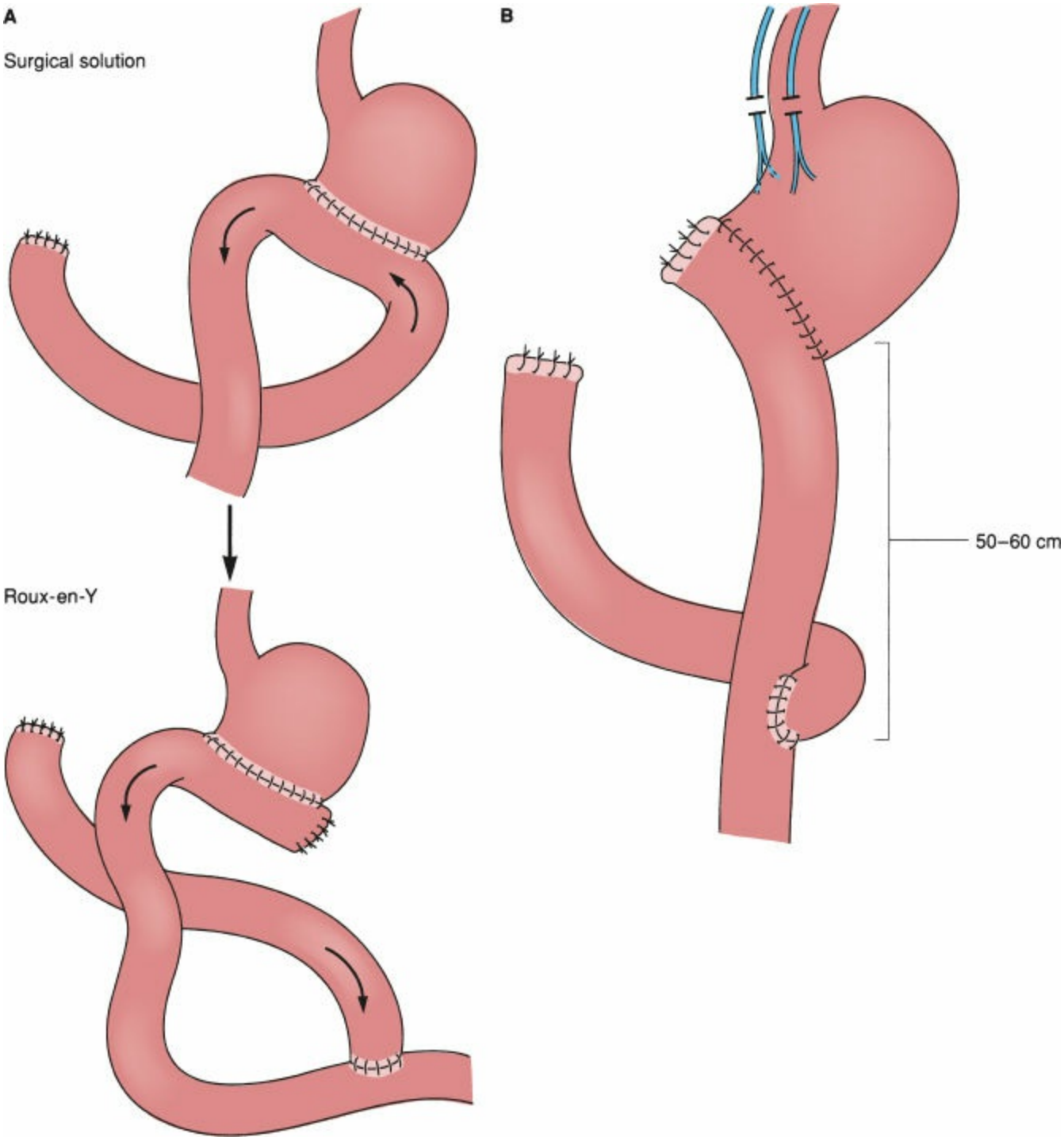

Figure 45-7. Conversion of Billroth II gastrojejunostomy to Roux-en-Y gastrojejunostomy. The afferent limb is divided (**A**) and intestinal continuity is reestablished by anastomosis 50 to 60 cm downstream from the original gastrojejunostomy (**B**).

Clinical risk factors that predict development of stress gastritis include adult respiratory distress syndrome, multiple long-bone fractures, a major burn over 35% of the body surface, transfusion requirement above 6 units, hepatic dysfunction, sepsis, hypotension, and oliguric renal failure. Scoring systems of critical illness, exemplified by the Acute Physiology and Chronic Health Evaluation (APACHE) system, accurately predict risk for acute stress gastritis.

The major complication of stress gastritis is hemorrhage. Admission to an intensive care unit is not an independent risk factor for bleeding. However, the development of respiratory failure or coagulopathy (platelet count less than 50,000/mm3, international

normalized ratio (INR) >1.5, or partial thromboplastin time (PTT) greater than two times normal) imparts the greatest risk for hemorrhage.

Diagnosis

Clinical studies that use bloody nasogastric discharge as a sign of stress gastritis probably underestimate its incidence in critically ill patients. Conversely, studies based on endoscopy overestimate the incidence of clinically important stress gastritis. In one endoscopically controlled study, 100% of patients with life-threatening injuries had evidence of gastric erosions by 24 hours. Severely burned patients have endoscopic evidence of gastric erosions in greater than 90% of cases, whereas significant upper gastrointestinal hemorrhage occurs in between 25% and 50% of patients with burn wound infection.

Treatment and Prophylaxis

Critically ill patients are at risk for development of acute stress gastritis. Because hemorrhage associated with stress gastritis significantly increases mortality, these patients should be treated prophylactically.[29–31] Seven randomized, controlled trials have compared H_2-receptor antagonists with proton pump inhibitors in prophylaxis of bleeding from stress ulceration.[29] The consensus of these studies is that proton pump inhibitors are more effective at maintaining gastric pH above 4.0, but no convincing data exist that one agent is superior to the other in prevention of clinically important bleeding. Stress ulcer prophylaxis with these agents is associated with colonization of the upper GI tract with potentially pathogenic gram-negative organisms. No statistically significant differences in incidence of pneumonia have been noted between H_2-receptor antagonists and proton pump inhibitors when used for stress ulcer prophylaxis. H_2-receptor antagonists are involved in more drug-drug interactions due to inhibitory effects on the cytochrome oxidase system. Prolongation of protime may be noted in patients receiving coumadin. Increased plasma concentrations of diazepam, propranolol, nifedipine, and several antibiotics may also be noted in patients receiving H_2-receptor antagonists.

Early enteral feeding was first introduced as a component of burn care. Enteral feeding was designed to address the hypermetabolic state that develops after burn injury and to prevent visceral protein loss due to catabolic metabolism. Enteral nutrition has also been demonstrated to prevent bacterial translocation across the intestinal wall. In addition, enteral nutrition has been noted to maintain intragastric pH >3.5, suggesting that this modality may be used to prevent gastric hemorrhage from stress ulceration. In burn patients, early enteral feeding decreases upper GI hemorrhage, effects that are not potentiated by the addition of H_2-receptor antagonists. It seems likely that early enteral feeding will become widely employed in critically ill surgical patients, beyond those with thermal injury, as a primary modality for stress ulcer prophylaxis.

References

1. Sung JJ, Kuipers EJ, El-Serag HB. Systematic review: the global incidence and prevalence of peptic ulcer disease. *Aliment Pharmacol Ther* 2009;29:938–946.
2. Sanchez-Delgado J, Gene E, Suarez D, et al. Has H. pylori prevalence in bleeding peptic ulcer been underestimated? A meta-regression. *Am J Gastroenterol* 2011;106;398–405.
3. Shiota S, Suzuki R, Yamaoka Y. The significance of virulence factors in Helicobacter pylori. *J Dig Dis* 2013;14:341–349.
4. Reyrat JM, Rappouli R, Telford JL. A structural overview of the Helicobacter cytotoxin. *Int J Med Microbiol* 2000;290:375–379.
5. Wu J, Xu S, Zhu Y. Helicobacter pylori CagA: a critical destroyer of the gastric epithelial barrier. *Dig Dis Sci* 2013;58:1830–1837.
6. Censini S, Lange C, Xiang Z, et al. Cag, a pathogenicity island of Helicobacter pylori encodes type I-specific and disease-associated virulence factors. *Proc Natl Acad Sci U S A* 1996;93:1259–1264.
7. Gillen D, El-Omar EM, Wirz AA, et al. The acid response to gastrin distinguishes duodenal ulcer patients from Helicobacter pylori-infected healthy subjects. *Gastroenterology* 1998;114:50–57.
8. Amieva MR, El-Omar EM. Host-bacterial interactions in Helicobacter pylori infection. *Gastroenterology* 2008;134;306–323.
9. Cid TP, Fernandez MC, Martinez SB, et al. Pathogenesis of Helicobacter pylori infection. *Helicobacter* 2013;18:12–17.
10. Lanas A, Perex-Aisa MA, Feu F, et al. A nationwide study of mortality associated with hospital admission due to severe gastrointestinal events and those associated with nonsteroidal antiinflammatory drug use. *Am J Gastroenterol* 2005;100:1685–1693.
11. Pilotto A, Franceshi M, Leandro G, et al. NSAID and aspirin use by the elderly in general practice: effect on gastrointestinal symptoms and therapies. *Drugs Aging* 2003;20:701–710.
12. Lanas A, Garcia-Rodriguez LA, Arroyo MT, et al. Risk of upper gastrointestinal ulcer bleeding associated with selective cyclooxygenase-2 inhibitors, traditional non-aspirin non-steroidal anti-inflammatory drugs, aspirin and combinations. *Gut* 2006;55;1731–1738.
13. O'Connor A, Molina-Infante J, Gisbert JP, et al. Treatment of Helicobacter pylori infection 2013. *Helicobacter* 2013;18(suppl 1):58–65.
14. Megraud F, Coenen S, Versporten A, et al. Helicobacter pylori resistance to antibiotics in Europe and its relationship to antibiotic consumption. *Gut* 2013:62:34–42.
15. Zullo A, Hassan C, Campo SM, et al. Bleeding peptic ulcer in the elderly: risk factors and prevention strategies. *Drugs Aging* 2007;24:815–828.
16. Zeiton JD, Rosa-Hezode I, Chryssostalis A, et al. Epidemiology and adherence to

guidelines on the management of bleeding peptic ulcer: a prospective multicenter observational study in 1140 patients. *Clin Res Hepatol Gastroenterol* 2012:36:227–234.

17. Rosenstock SJ, Moller MH, Larsson H, et al. Improving quality of care in peptic ulcer bleeding: nationwide cohort study of 13,498 consecutive patients in the Danish clinical register of emergency surgery. *Am J Gastroenterol*2013;108:1449–1457.
18. Imperiale TF, Kong N. Second-look endoscopy for bleeding peptic ulcer disease: a decision-effectiveness and cost-effectiveness analysis. *J Clin Gastroenterol*2012;46;e71–e75.
19. Hepworth CC, Swain CP. Mechanical endoscopic methods of haemostasis for bleeding peptic ulcers: a review. *Baillieres Clin Gastroenterol* 2000;14:467–476.
20. Sharma VK, Sahai AV, Corderi FA, et al. Helicobacter pylori eradication is superior to ulcer healing with or without maintenance therapy to prevent further ulcer haemorrhage. *Ailment Pharmacol Ther* 2001;15:1939–1947.
21. Boey J, Choi SK, Alagaratnam TT, et al. Risk stratification for perforated duodenal ulcers: a prospective validation of predictive factors. *Ann Surg* 1987;205:22–28.
22. Moller MH, Engebjerg MC, Adamsen S, et al. The peptic ulcer (PULP) score: a predictor of mortality following peptic ulcer perforation. A cohort study. *Acta Anaesthesiol Scand* 2012;56:655–662.
23. Lunevicius R, Morkevicius M. Systematic review comparing laparoscopic and open repair for perforated peptic ulcer. *Br J Surg* 2005;92:1195–1207.
24. Sanabria AE, Morales CH, Villegas MI. Laparoscopic repair for perforated peptic ulcer disease. *Cochrane Database Syst Rev* 2005;(4):CD004778.
25. Antoniou SA, Antoniou GA, Koch OO, et al. Meta-analysis of laparoscopic versus open repair of perforated peptic ulcer. *J Soc Laparoendo Surg* 2013;17:15–22.
26. Hemmer PH, de Schipper JS, van Etten B, et al. Results of surgery for perforated gastroduodenal ulcers in a Dutch population. *Dig Surg* 2011;28:360–366.
27. Burge N, Barton RG, Enniss TM, et al. Laparoscopic versus open repair of perforated gastroduodenal ulcer: a national surgical quality improvement program analysis. *Am J Surg* 2013;206:957–963.
28. Atherton JC. The pathogenesis of Helicobacter pylori-induced gastro-duodenal disease. *Annu Rev Pathol* 2006;1:63–96.
29. Greenwood JE, Pilkington KB, Wagstaff MJ. Prevention of gastrointestinal bleeding due to stress ulceration: a review of current literature. *Anaesth Crit Care* 2012;40:253–259.
30. Alhazzani W, Alenezi F, Jaeschke RZ. Proton pump inhibitors versus histamine 2 receptor antagonists for stress ulcer prophylaxis in critically ill patients: a systematic review and meta-analysis. *Crit Care Med* 2013;41:693–705.
31. Reveiz L, Guerrero-Lozano R, Camacho A, et al. Stress ulcer, gastritis, and gastrointestinal bleeding prophylaxis in critically ill pediatric patients: a systematic review. *Pediatr Crit Care Med* 2010;11:124–132.

Chapter 46

Management of Obesity

Robert W. O'Rourke

Key Points

1. Obesity is defined and categorized using body mass index (BMI, weight [kg]/height [m]^2) based on World Health Organization definitions.
2. BMI directly correlates with the risk of multiple metabolic diseases and long-term mortality.
3. Lifestyle interventions as treatment for obesity, including diet, exercise, and psychological therapy, are of limited efficacy; evolving strategies directed toward environmental manipulation demonstrate potential.
4. Current pharmacotherapy for obesity includes a wide range of agents that act via multiple mechanisms, are prone to side effects, and are of limited efficacy; active research in pharmacotherapy for obesity holds significant promise.
5. Bariatric surgery is highly efficacious in treating obesity and metabolic disease, and includes a wide range of procedures that have evolved over decades.
6. Current dominant bariatric surgery operations include gastric bypass, sleeve gastrectomy, and gastric banding.
7. Classic mechanisms of action of bariatric surgery include restriction of caloric intake and malabsorption of ingested calories, but evolving data suggest that other mechanisms predominate, including but not limited to alterations in gut and satiety hormone homeostasis, bile acid metabolism, and enteroenteric and enterocentral nervous systemic communications.

DIAGNOSIS AND EPIDEMIOLOGY

Obesity and Metabolic Disease

Excess adipose tissue is the defining feature of obesity, and metabolic disease arises in adipose tissue. Metabolic disease is diverse, involving every organ system. The correlation between obesity and metabolic disease, while strong, is not perfect – some patients develop metabolic disease at low body weight, while others who are very obese are protected. Visceral adiposity imparts greater risk than subcutaneous adiposity, and heterogeneity of visceral and subcutaneous adiposities partly explains the imperfect correlation between obesity and metabolic disease. Lean patients also develop metabolic disease, albeit less frequently than the obese, demonstrating that nonadipose tissue-based mechanisms contribute to metabolic disease as well. It is beyond the scope of this chapter to discuss the wide spectrum of specific treatment strategies for individual metabolic diseases. Rather, we will discuss the treatment of obesity itself, the goal of which is reduction in adipose tissue mass, because despite the variable relationship between body weight and metabolic dysfunction, in the vast majority of patients, regardless of initial weight, weight loss has beneficial effects on virtually all metabolic diseases. Treatment options for obesity may be broadly divided into medical and surgical approaches.

Diagnosis

1 Body mass index (BMI, weight [kg]/height [m]^2) is the primary metric used to define obesity. Originally devised in the 19th century as a general measure of human body habitus, BMI was coopted in the 1940s by the insurance industry and used to stratify humans into high- and low-risk subpopulations based on actuarial data for the purpose of setting life insurance rates. The medical community subsequently used BMI to estimate risk of morbidity and mortality. Much debate exists regarding the appropriate BMI cutoff points for optimal health, with various health and professional organizations setting different values. World Health Organization (WHO) definitions, set in 1995 and agreed upon by the U.S. Centers for Disease Control (CDC), are most commonly utilized and define overweight as BMI >25 and <30 and obesity as BMI ≥ 30, and categorize obesity into classes 1 (BMI 30 to 34.9), 2 (BMI 35 to 39.9), and 3 (BMI ≥ 40).[1]

2 BMI correlates with long-term mortality and metabolic disease in a J-shaped curve, the nadir of which is debated, but may be as low as 20 or as high as 25.[2] BMI in the obese range (≥ 30) is clearly associated with an increased risk in long-term mortality and multiple metabolic diseases relative to BMI <30. For individuals with BMI 40 to 50, this risk translates into a 10-year decrease in life expectancy. In contrast to obesity, data demonstrating a correlation between overweight BMI and health risk are conflicting. Analyses are complicated by numerous confounding variables including but not limited to gender, age, ethnicity, smoking, cancer, and diabetes. In addition, the choice of control/referent group alters outcomes; for example, the correlations between overweight BMI and clinical outcomes weaken significantly and may be masked when referent groups span a larger BMI range (e.g., 18 to 25) relative to comparison with referent groups spanning a narrow BMI range (e.g., 21 to 23). Despite these conflicting data, the preponderance of evidence suggests that BMI in the overweight range is associated with an increased risk of long-term mortality, albeit lower than the risk associated with BMI in the obese range.[3] Furthermore, mortality aside, compelling data demonstrate that overweight BMI is associated with an increased risk of cardiovascular disease, diabetes, and other metabolic diseases, and is associated with an increased risk of future progression to frank obesity with its attendant risks. Taken together, these observations suggest that overweight should be considered a serious health risk and a predecessor to obesity.

These complex data demonstrate that BMI is not a perfect measure of adiposity. Indeed, muscular athletes may have BMI within the obese range despite low body fat levels and an absence of metabolic disease, while elderly people with a paucity of muscle mass may have low BMI despite increased adiposity and metabolic disease. Ethnic differences further confound the predictive power of BMI, as certain ethnicities, for example Asians, develop metabolic disease at lower BMI, prompting the WHO in 2004 to propose BMI cutoffs of 23 and 27.5 for overweight and obesity respectively in Asians. In certain subpopulations, including patients with heart failure, renal failure, and other chronic diseases, overweight and obesity are associated with decreased mortality, a phenomenon termed the “obesity paradox.”[4]

These observations have led to a search for other measures of adiposity. Waist circumference and waist–hip ratio are easily measured and in many studies correlate more accurately with metabolic disease than BMI, reflecting the disproportionate effect of visceral adiposity on metabolic disease.[5] Water displacement, dual-energy x-ray absorptiometry scanning, double-labeled isotope water measurement, bioelectrical impedance analysis, and quantitative magnetic resonance imaging may provide more accurate measures of adiposity and better predict metabolic disease, but have not gained widespread acceptance due to cost and complexity. Despite its limitations, BMI remains the most commonly used metric for obesity.

Epidemiology, Disease Burden

Human obesity has existed for millennia as evidenced by prehistoric figurines of obese humans (e.g., Venus of Willendorf) and periodic concerns regarding past obesity "epidemics" over the past two centuries. Nonetheless, the worldwide prevalence of overweight and obesity has increased dramatically over the past 50 years. BMI, like many clinical characteristics, spans a bell curve. Three large US epidemiologic datasets, the National Health and Nutrition Examination Survey (NHANES), the National Health Interview Survey (NHIS), and the Behavioral Risk Factor Surveillance System (BRFSS), demonstrate similar trends, with a rightward shift of the BMI bell curve over the past three decades, mean BMI increasing from 25.5 in the 1970s to 28.5 in 2005, and the prevalence of obesity more than doubling in the same interval.[6] The CDC reports that as of 2010, 69% of US adults were overweight or obese, and 36% of US adults and 17% of US children were obese.[7] Evidence suggests that the prevalence of obesity has plateaued in the past 2 to 3 years in industrialized countries including the US, but continues to rise in developing countries. Gender, ethnic, and regional differences complicate obesity epidemiology. The rate of increase is higher in women compared to men, and while rates of increase are similar across ethnicities, mean BMI is highest in Blacks, followed by Hispanics, then Caucasians. Data regarding the association between obesity and socioeconomic status are conflicting; evidence suggests an inverse correlation between low socioeconomic status and obesity in low- and middle-income countries but a positive correlation in industrialized countries. Obesity prevalence is increased in rural compared to urban environments in the United States, although this relationship is inverted in developing countries.

The disease burden associated with obesity is substantial. Multiple confounders complicate quantification of risk, not the least of which is variability in the degree of obesity itself, with increasing BMI being associated with increasing risk of mortality and disease in a dose-dependent but nonlinear fashion. Obesity is associated with decreased lifespan. Data from the Framingham Heart Study demonstrate a loss of 3 and 6 years of life for overweight and obese men respectively,[8] while NHANES data demonstrate a loss of 13 years of life for severely obese men (BMI >45).[9] Overweight and obesity are associated with an increased risk of multiple diseases, among which type II diabetes is particularly important. The association between obesity and diabetes is robust; relative risks for diabetes range from 2 to 15 for BMI in the overweight range and 20 to 90 for BMI in the obese range. The CDC estimates that in the United States in 2011, the prevalence of type II diabetes was 8.3% among all adults and 27% among those over 65 years of age. Furthermore, 35% of all US adults, and 50% of US adults over 65 years of age have elevated fasting blood glucose or HbA1c consistent with prediabetes. If current trends persist, the prevalence of diabetes in the United States in 2050 will exceed 30%, and worldwide trends parallel these US data.

Obesity is associated with an increased risk of multiple diseases, including atherosclerosis, hypertension, hyperlipidemia, hepatic steatosis and steatohepatitis, sleep apnea, osteoarthritis, gallbladder disease, endocrine disorders, autoimmune disease,

allergy and atopy, multiple types of cancer, and depression. Metabolic disease encompasses all of physiology. Risk ratios for overweight and obesity-related diseases vary substantially depending on BMI, ranging from 2 to 5 for stage I obesity with dramatic dose-dependent increases in risk with increasing BMI. For example, the prevalence of hepatic steatosis in the general population is generally estimated to be approximately 30%, increases progressively with increasing BMI, and exceeds 90% in obese patients with BMI >40. In the NHANES population, the prevalence of sleep apnea was 3% in nonobese men and 12% in obese men (BMI >30),[10] but in a separate study of patients with severe obesity (BMI >40), prevalence exceeded 70%.[11] This disease burden is associated with significant economic costs. While accurate quantification of obesity-related healthcare costs is challenging and complicated by regional variability in payer systems and patient demographics, a recent systematic review estimated that costs directly attributable to overweight and obesity in the United States exceed 100 billion dollars annually and constitute 5% to 10% of total US healthcare spending.

MEDICAL MANAGEMENT

Treatment Strategies

The medical management of obesity falls into two primary categories: lifestyle intervention and pharmacotherapy. Both strategies, with rare exceptions, achieve similar results, with modest weight loss and high recidivism. Nonetheless, both strategies hold significant untapped promise, with advances expected in coming decades, particularly in the areas of environmental engineering and pharmacotherapy.

Lifestyle Interventions

3 Lifestyle interventions for obesity include any or all of three basic components: diet modification, exercise, and psychological therapy. Interventions may be unsupervised or administered under the supervision of clinicians, dieticians, or commercial weight loss plans, and may be individualized or administered in group programs.

Diet modification is the mainstay of lifestyle intervention. Diet strategies vary with respect to macronutrient composition, daily caloric intake, and food and caloric measurement methods, and include low-carbohydrate diets, low-fat diets, meal replacement strategies, Mediterranean diets, very low-calorie diets, and multiple commercial diet plans. No clear evidence demonstrates advantages of any specific diet plan over others. Specifically, macronutrient composition does not impact on weight loss when caloric intake is controlled – total calories, rather than the macronutrient composition of those calories, is the variable that determines weight loss. In contrast to weight loss, conflicting evidence exists regarding the role of macronutrient composition in improvement of metabolic disease, with some evidence suggesting that low-carbohydrate diets (which include low-glycemic index–high-fiber diets and very low-carbohydrate diets), when compared to low-fat diets, may be associated with greater improvements in insulin resistance and triglyceride levels, and higher resting energy expenditure. These studies must be interpreted with caution as follow-up is relatively short, and low-carbohydrate diets may be associated with adverse changes in low-density lipoprotein levels.[12] Low-carbohydrate diets also appear to provide better compliance than other diet strategies over short-term follow-up of less than 6 months, but compliance differences vanish at follow-up exceeding 1 year.

Physical activity is a central component of lifestyle intervention for obesity. Exercise alone achieves only modest weight loss, but exercise and diet potentiate each other. Importantly, exercise reduces obesity-related mortality and cardiovascular disease risk independent of weight loss. Data regarding the optimal type, duration, frequency, and intensity of exercise are conflicting and specific evidence-based guidelines remain elusive. High intensity exercise may be more effective for weight loss, but many obese patients are unable to engage in even moderate intensity exercise due to comorbid diseases such as osteoarthritis. Increased daily nonexercise activities such as walking and stair use nonetheless may provide modest weight loss and cardiovascular health benefits.

Of the wide range of psychological techniques used to treat obesity, cognitive-

behavioral therapy is most common. Cognitive-behavioral therapy achieves modest weight loss in the obese of approximately 2 to 3 kg at 1-year follow-up, with increased weight loss when combined with diet and/or exercise. Increased frequency of psychological intervention and group therapy compared with individual therapy are associated with greater weight loss.

Intensive lifestyle interventions are supervised multicomponent plans that involve a combination of diet, exercise, and behavioral modification, with periodic monitoring by coaches and dieticians, and individual or group psychological counseling. Two NIH-sponsored randomized controlled trials suggest that intensive lifestyle interventions provide more durable results than standard lifestyle interventions, although long-term outcomes of metabolic disease are conflicting. The Diabetes Prevention Program randomized 3,234 overweight or obese insulin-resistant patients (mean BMI 34) to 1 of 3 experimental arms: intensive lifestyle interventions, metformin treatment, or placebo treatment.[13] After a mean follow-up of 2.8 years, average weight loss in the intensive lifestyle interventions group was 5.6 kg compared with 2.1 kg and 0.1 kg for the metformin and placebo groups respectively; at 10 years an average weight loss of 2 kg was maintained in both intensive lifestyle interventions and metformin arms relative to the placebo arm. The cumulative risk of incident diabetes was 34% lower in the intensive lifestyle interventions arm and 18% lower in the metformin arm relative to the placebo arm. The NIH-sponsored Look AHEAD (Action for Health in Diabetes) study randomized 5,145 overweight or obese diabetic patients to a 4-year intensive lifestyle intervention involving diet and exercise modification with regular on-site visits and counseling, or standard primary care provider-supervised diabetes and weight loss education. After 8 years, mean weight loss was 4.7% and 2.1% in the intensive lifestyle intervention and standard care arms respectively.[14] Nonetheless, the study was halted after 11 years after no difference in cardiovascular events was observed. These studies demonstrate that while modest, weight loss may be maintained over long periods with intensive lifestyle interventions, although the effects on metabolic disease are equivocal. Of importance, in Look AHEAD, a subset of patients in each arm (27% and 17% in intensive lifestyle intervention and standard care arms, respectively), maintained a loss of $>10\%$ of total starting weight, suggesting that subpopulations of patients are more responsive than others to lifestyle interventions, and that identification of predictors of responsiveness would permit better allocation of care.

Assessing the overall efficacy of lifestyle interventions for obesity is challenging, as results vary depending on the subgroup studied, follow-up is variable and often short, and program and outcome reporting methods are widely disparate. The resultant complex body of literature limits our current understanding of the efficacy of such interventions. Nonetheless, a preponderance of data suggests that results of lifestyle interventions for obesity are modest, with mean weight loss between 2% and 10% of total body weight over follow-up periods from 6 to 48 months. Unsupervised individual efforts underperform more intensive, multicomponent, supervised, group interventions. Compliance is a critical issue; individual diet programs are associated with attrition that may exceed 90% over a year or more while attrition for intensive supervised efforts is

less. Weight regain after program discontinuation is common and long-term adherence to lifestyle changes is low. Despite these limitations, modest weight loss, or exercise in the absence of weight loss, appears to have measurable if modest beneficial effects on metabolic disease, with a subset of patients being responsive to such interventions. As such, lifestyle interventions should be a component of the treatment of all obese patients, but only rarely achieve dramatic and durable results.

Environmental Interventions – The Future

An understanding of importance of the interaction between environment and human genetics in the pathogenesis of obesity has shifted focus away from individual patient behavior modification and toward manipulation of the *obesogenic built environment*. While rigorous data and proof of causality are emerging, specific characteristics of the built environment have been linked to obesity, including proximity and prevalence of fast food restaurants and full-service grocery stores, access to and quality of exercise facilities, parks, and sidewalks, school and work environment food and exercise resources, and public transit infrastructure. An emerging field of environmental and social engineering will shift the focus of lifestyle intervention from individual to environment, and holds promise as next-generation treatment for obesity.

Pharmacotherapy

4 The history of pharmacotherapy for obesity is replete with drugs that have been introduced with much enthusiasm and variable efficacy but subsequently withdrawn due to unacceptable and in many cases life-threatening side effects that became apparent only after widespread use. Sheep thyroid extract was used in the late 19th century, while in the early 20th century, workers in the dye industry exposed to 2, 4-dinitrophenol were observed to lose weight, leading to its use as a weight loss drug in the 1930s. Amphetamines were popular weight loss drugs in the 1950–60s. All these agents were abandoned due to prohibitive side effects. The modest efficacy of weight loss drugs is testament to the multiple redundant physiologic systems that act to defend adipose tissue stores in the face of interventions designed to reduce those stores. The frequent adverse effects of weight loss drugs speak to the interface between body weight regulation and multiple fundamental physiologic processes, manipulation of which entails substantial risk.

The largest and most important class of weight loss drugs targets monoamine signaling mediators (norepinephrine, serotonin, dopamine, histamine) involved in CNS/hypothalamic control of satiety and hunger. Many of these agents regulate multiple pathways and demonstrate overlapping activities. Sympathomimetic agents that primarily potentiate norepinephrine release include phentermine, introduced in 1959 and still in use today, and phenylpropanolamine, used as a decongestant and also as a weight loss drug since the 1970s, but withdrawn from the market in 2000 after being associated with an increased risk of stroke. Drugs that primarily potentiate serotonin activity include fenfluramine, introduced in 1973 and withdrawn from the market in 1997, sibutramine (Meridia), a serotonin, norepinephrine, and dopamine reuptake inhibitor with primary

effects on serotonin and norepinephrine, introduced in 1997 but withdrawn in 2010 after being linked to increased risks of myocardial infarction and stroke, and lorcaserin (Belviq), a selective serotonin 2C agonist approved by the FDA in 2012. Drugs that target dopamine signaling are currently being studied in clinical trials (e.g., bupropion, tesofensine). Targeting multiple monoamine signaling pathways provides synergy. The combination drug fenfluramine/phentermine ("Fen-phen"), introduced in 1992, demonstrated increased efficacy over either agent alone, but was withdrawn from the market in 1997 after widespread use revealed serious morbidity attributable to fenfluramine, including pulmonary hypertension and cardiac valvular disease. In 2013, the FDA approved a combination drug of phentermine and topiramate, an antiepileptic with multiple CNS activities (Qsymia). A combination formulation of bupropion and naltrexone, an opioid antagonist which stimulates pro-opiomelanocortin neurons, is currently being studied in research trials.

Gut peptides have diverse metabolic functions including regulating satiety and hunger within the hypothalamic feeding center, and include glucagon-like peptide 1 (GLP-1), cholecystokinin, ghrelin, oxyntomodulin, pancreatic polypeptide, and amylin. Drugs based on these mediators show promise. Many gut peptides have short biologic half-lives and research has focused on long-acting analogs or mediators that target degradation pathways. GLP-1, secreted by ileal L cells in response to a meal, induces satiety and potentiates insulin secretion and peripheral insulin sensitivity. Long-acting GLP-1 analogs, including liraglutide (Victoza) and exenatide (Byetta) are FDA approved for treatment of type 2 diabetes and are under investigation as primary weight loss agents.[15] Ghrelin is so far the only known orexigenic hormone, and ghrelin antagonists, agonists of ghrelin degradation pathways, and antighrelin vaccines are in development. Amylin, released by pancreatic beta cells, induces satiety via CNS-based mechanisms and also potentiates peripheral insulin resistance; pramlintide (Symlin), a human amylin agonist, is approved for treatment of diabetes and induces modest weight loss. Orlistat (Xenical), approved by FDA in 1999, is a pancreatic lipase inhibitor that blocks intestinal absorption of fat, and the only drug to date that functions by reducing absorption of ingested calories. Side effects of orlistat include diarrhea, steatorrhea, and increased risks of kidney stones and pancreatitis. Second-generation lipase inhibitors are in development.

Agents designed to manipulate neuropeptide signaling within the hypothalamus, while not yet approved for use in humans, are important targets, and include drugs directed toward leptin, melanocortin-4 receptor (MC4R), neuropeptide Y, and melanin-concentrating hormone. While leptin resistance has confounded development of leptin as a therapeutic agent, recent data from animal models suggest that concomitant treatment of endoplasmic reticulum stress may abrogate leptin resistance,[16] while separate research demonstrates that amylin agonists also restore leptin sensitivity.[17] These lines of research have reinvigorated interest in leptin therapy. Mutations in the MC4R gene, a central hypothalamic satiety mediator, are implicated in up to 5% of cases of common human obesity, and MC4R agonists are currently in development. Other central-acting agents are directed toward endocannabinoid signaling: rimonabant (Acomplia), a selective endocannabinoid antagonist, was denied FDA approval in 2008 despite promising weight

loss results in clinical trials due to an association with depression and suicide, but interest in manipulation of endocannabinoid signaling persists.

Manipulation of thermogenesis and metabolic rate remains an active field of research. Thyroid hormone achieves weight loss by increasing metabolic rate, but is associated with cardiac toxicity and has detrimental effects on glucose homeostasis. Despite these failures, research persists. Many agents discussed above that regulate food intake, most notably the sympathomimetics, also increase metabolic rate, and it is unclear to what extent these effects contribute to weight loss. Agents that regulate steroid metabolism, fatty acid oxidation and other aspects of adipose tissue, and skeletal muscle metabolism are under study. Dietary constituents also regulate thermogenesis, including methylxanthines (e.g., caffeine), polyphenols (e.g., resveratrol, quercetin), capsaicinoids (found in chili peppers and mustards), and medium-chain fatty acids, all of which represent potential therapeutic agents.

Overall efficacy of current obesity pharmacotherapy is modest, achieving weight loss of 3% to 10% of total body weight. Most agents demonstrate synergy with lifestyle interventions. Current drugs approved by the FDA specifically for weight loss include orlistat, the only drug approved for long-term use; phentermine, approved for short-term use (<12 weeks) due to addiction potential and cardiovascular toxicity; lorcaserin, FDA approved for use as an adjunct to lifestyle interventions; and phentermine/topiramate. The XENDOS study (XENical in the Prevention of Diabetes in Obese Subjects) randomized 3,305 patients to lifestyle intervention combined with either orlistat or placebo and at 4 years, and demonstrated a 5.8-kg weight loss in the orlistat arm compared with a 3.0-kg weight loss in the placebo arm, as well as a reduced incidence of diabetes with orlistat therapy.[18] Lorcaserin induced 5% weight loss compared with 3% in placebo-treated patients at 1 year.[19] The phentermine/topiramate combination drug achieved 10.5% weight loss compared with 1.8% in placebo-treated patients at 2-year follow-up.[20]

A complete summary of obesity pharmacotherapy is beyond the scope of this chapter, which has by necessity omitted important areas of research, including drugs that target steroid metabolism, lipid metabolism, adipocyte differentiation and proliferation, and efforts to shift white adipose tissue toward a brown adipose tissue phenotype (the “browning” of adipose tissue). This discussion has focused on agents designed to treat obesity directly with the goal of weight loss, but an important parallel class of drugs target metabolic disease independent of or in conjunction with weight loss. The activities of weight loss drugs are complex and overlapping, with many agents regulating body weight and metabolism via multiple mechanisms. Multiple redundancies in the regulation of energy homeostasis suggest that drug combinations will enhance efficacy. As an understanding of these mechanisms increases, safe and effective pharmacotherapy for obesity and metabolic disease will emerge.

SURGICAL MANAGEMENT

Bariatric Surgery – Beginnings

5 In contrast to lifestyle interventions and pharmacotherapy, surgical management of obesity is highly efficacious. Modern bariatric surgery (Gr. *baros,* heavy, burden) is the result of over a half-century of evolution in surgical technique that has its genesis in the 1940–50s with experiments in animals and isolated operations in humans that employed small intestinal resection and jejunocolic and ileocolic bypasses of various anatomic configurations. These operations involved substantial morbidity and did not achieve widespread acceptance, but set the stage for development of the *jejunoileal bypass,* the first bariatric operation to be widely applied in humans. Jejunoileal bypass involved division of the jejunum 14 inches distal to the ligament of Treitz and creation of a jejunoileostomy 4 inches proximal to the ileocecal valve, and was thus referred to as a "14–4 bypass" (Fig. 46-1). In 1969, Payne and Dewind[21] published the first report describing long-term clinical outcomes in a large group of patients who underwent jejunoileal bypass in the 1950–60s, describing dramatic weight loss ("A total of 10,373 pounds have been lost by the (80) patients") along with improvements in insulin resistance, hypercholesterolemia, and hepatic steatosis. Jejunoileal bypass was widely used throughout the 1960s and early 1970s.

Despite its efficacy, as experience accumulated, it became clear that jejunoileal bypass was associated with significant morbidity. Diarrhea, steatorrhea, dehydration, electrolyte imbalances, and micro- and macronutrient deficiencies resulted from the highly malabsorptive nature of the operation. Patients also suffered a host of complications not obviously linked to malabsorption, including liver disease, nephropathy, arthropathy, neuropathy, and myopathy. While the cause of these latter complications was not completely clear, an immune response directed toward bacterial overgrowth in the blind intestinal limb was implicated. Overall morbidity afflicted as many as 70% of patients and led to abandonment of jejunoileal bypass by the late 1970s. Nonetheless, up to 30% of patients achieved good results, and the clinician may still encounter rare remaining patients. Indications for reversal or conversion to modern bariatric operations are not well established and must be considered on an individual basis, but include progressive liver or kidney disease not attributable to other causes. Some clinicians advocate reversal and conversion to a modern bariatric operation in all patients who are good operative candidates regardless of the presence or absence of complications.

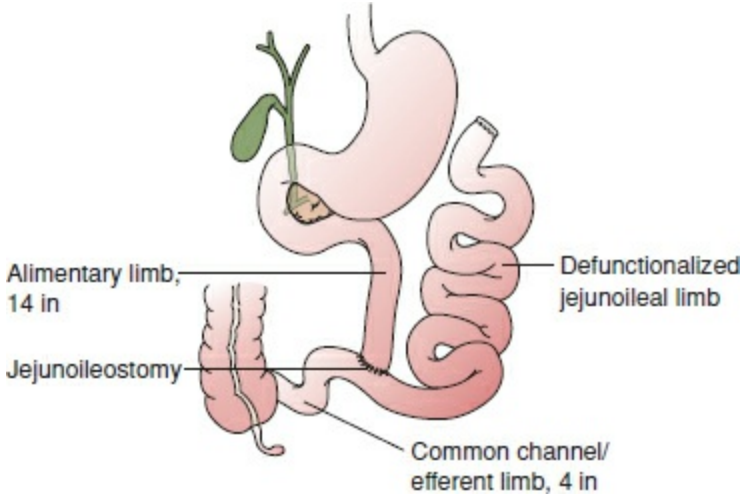

Figure 46-1. Jejunoileal bypass. The jejunum is divided 14 in distal to the ligament of Treitz, and a jejunoileostomy is created 4 in proximal to the ileocecal valve. Note that the defunctionalized jejunoileal limb is out of continuity with biliopancreatic effluent, predisposing to limb stasis.

Gastric Bypass – The Gold Standard

With the decline of jejunoileal bypass, surgeons began searching for alternatives. In the 1960s, Edward Mason at the University of Iowa experimented with operations based on observations that patients who underwent gastric resections for ulcer disease had difficulty maintaining their weight. Mason's efforts led to the development of the *gastric bypass,* for which he earned the title "father of bariatric surgery." Mason's original gastric bypass consisted of a pouch gastroplasty with a loop gastrojejunostomy reconstruction. Gastric bypass subsequently evolved through a number of iterations, all with important clinical implications. Large horizontal fundal-based pouches were replaced with smaller vertical lesser curve-based pouches, which improve gastric emptying. Undivided gastric pouches were associated with high rates of staple-line dehiscence and gastrogastric fistula, and were replaced with divided gastric bypass, expedited by the development of cutting staplers. Roux-en-Y reconstruction, compared to loop reconstruction, reduces tension on the gastrojejunal anastomosis and prevents bile reflux gastritis, but may be associated with higher rates of anastomotic ulcer disease. Retrocolic Roux limbs may improve pouch emptying and generate less tension on the gastrojejunostomy, but at the price of higher rates of mesocolic internal hernias. Banding of the gastrojejunal anastomosis may increase weight loss, but also increases risks of stenosis, obstruction, and erosion. Variations persist, including retrocolic Roux limbs, loop reconstructions ("minigastric bypass"), and prosthetic-banded gastric pouches. The modern gastric bypass practiced by the majority of surgeons today consists of a divided, unbanded, lesser curve-based pouch gastroplasty of 15 to 30 cc with an antecolic Roux-en-Y gastrojejunal reconstruction with a 100-cm Roux/alimentary limb and a 50- to 100-cm afferent/biliopancreatic limb (Fig. 46-2). The modern gastric bypass is a robust operation because within limits, subtle variations in technique, including pouch size and morphology and intestinal limb length and position, do not greatly affect efficacy or morbidity. Gastric bypass remains, as of this writing, the dominant bariatric operation worldwide and the gold standard against which all other operations are measured.

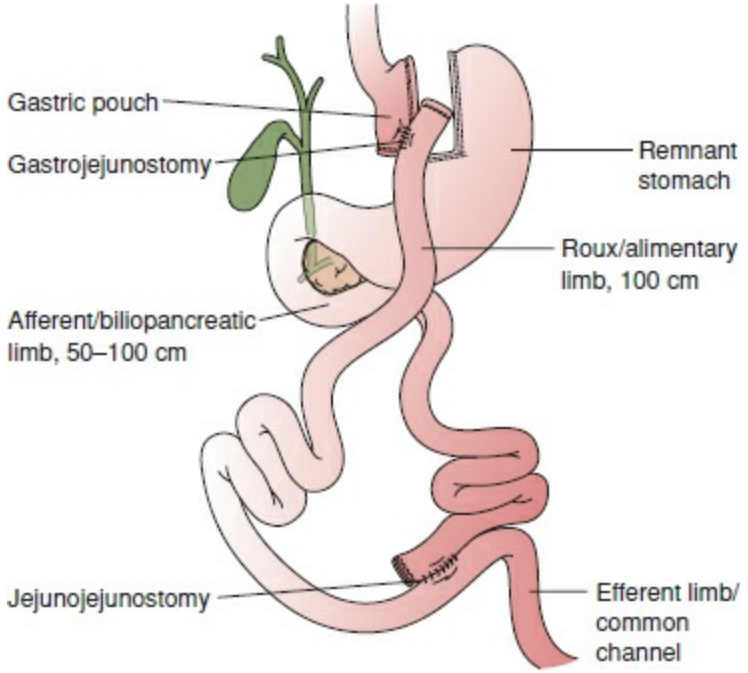

Figure 46-2. Anatomy of modern Roux-en-Y gastric bypass. Modern gastric bypass consists of a divided pouch gastroplasty with Roux-en-Y jejunojejunal reconstruction. The Roux limb is most commonly placed in the antecolic position. Intestinal limbs are termed with either standard Roux (Roux, afferent, efferent) or bariatric (alimentary, biliopancreatic, common channel) nomenclature as shown.

Malabsorption Revisited

Despite the failure of jejunoileal bypass, interest in operations that relied on small intestine bypass persisted. *Biliopancreatic diversion* consists of an antrectomy with a gastrojejunostomy and distal Roux-en-Y jejunoileostomy. The *duodenal switch modification of the biliopancreatic diversion* involves a sleeve gastrectomy, division of the duodenum distal to the pylorus, and a duodenojejunostomy and distal Roux-en-Y jejunoileostomy, thus maintaining the pylorus in the alimentary stream (Fig. 46-3). Biliopancreatic diversion/duodenal switch differs from jejunoileal bypass in two important regards. First, maintenance of forward flow of biliopancreatic effluent in the bypassed afferent limb prevents stasis and bacterial overgrowth. Second, common channel length was increased to 100 cm, reducing malabsorptive complications. Biliopancreatic diversion/duodenal switch provides weight loss and metabolic disease remission equivalent to, and in many series, greater than gastric bypass. Morbidity and mortality for biliopancreatic diversion/duodenal switch span a wide range, with centers with significant expertise reporting low rates similar to gastric bypass. Nonetheless, when the literature as a whole is considered, biliopancreatic diversion/duodenal switch is associated with higher morbidity and mortality than gastric bypass. Perioperative mortality reported by meta-analyses is at least twofold higher than gastric bypass, possibly due to a higher risk of anastomotic dehiscence, as laparoscopic creation of the duodenojejunal anastomosis associated with the duodenal switch modification is technically challenging.[22] Late malabsorptive complications which may require surgical revision, while much improved over jejunoileal bypass, range from 2% to 20%. Unlike gastric bypass, in which small changes in pouch size or limb length do not substantially alter clinical outcome, outcomes of biliopancreatic diversion/duodenal switch are relatively sensitive to differences in efferent limb length, small changes in which may make the difference between poor weight loss and malabsorptive complications. Predicting the correct efferent limb length for an individual patient is challenging. Most surgeons advocate a fixed length of 100 cm, while others advocate an *ad hoc* limb length proportional to total small intestine length. While advocated by select surgeons and associated with good outcomes in centers with significant experience, biliopancreatic diversion/duodenal switch is nonetheless waning in use, currently comprising less than 2% of bariatric operations.

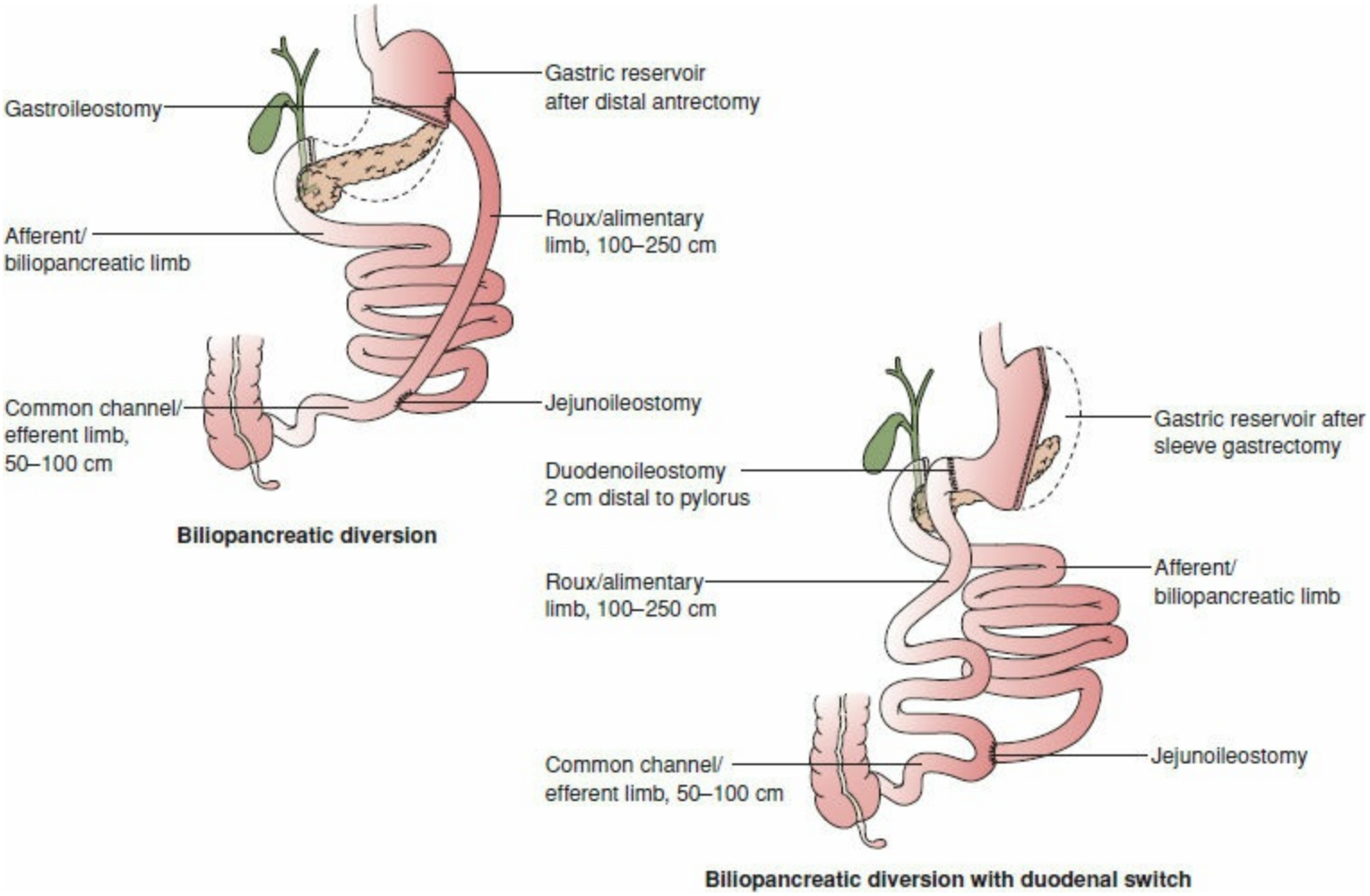

Figure 46-3. Biliopancreatic diversion (BPD). BPD involves a distal antrectomy with a Roux-en-Y jejunoileal reconstruction; BPD + DS involves a sleeve gastrectomy with a Roux-en-Y duodenolieal reconstruction, with the duodenoileostomy created 2 cm distal to the pylorus, thus preserving the pyloric emptying mechanism. Note that, unlike JIBP, the afferent/biliopancreatic jejunoileal limb is in continuity with biliopancreatic effluent, reducing limb stasis.

Pure Restriction

In Mason's era, morbidity from gastric bypass was not trivial. In an effort to design a simpler and safer operation, Mason experimented with gastroplasties that precluded the need for small intestinal reconstruction. Like gastric bypass, these operations evolved through a number of iterations, eventually leading to the modern *vertical banded gastroplasty,* which involves creation of a partitioned upper stomach pouch with a prosthetic band restricting pouch outlet diameter (Fig. 46-4). Vertical banded gastroplasty achieved widespread acceptance and peaked in the 1970–80s. Vertical banded gastroplasty weight loss is substantially less and late weight regain substantially greater compared to gastric bypass, however, and vertical banded gastroplasty has therefore been relegated to a minority operation that is rapidly being eliminated from use.

Study of prosthetic bands applied to the upper stomach to limit food intake began in the late 1970s using devices made from prolene, marlex, and other materials. These devices were nonadjustable and plagued with complications related to erosion, migration, stenosis, and obstruction. Efforts persisted, eventually culminating in the modern *adjustable gastric band,* a silicone device that was FDA approved in the United States in 2001 (Fig. 46-5). A primary advantage of gastric band is its technical simplicity and low rates of major morbidity and mortality. Unlike gastric bypass, which continues to be associated with low but finite rates of anastomotic dehiscence and mortality, gastric band is associated with 5 to 10 lower rates of life-threatening complications and mortality. Much enthusiasm accompanied the introduction of gastric band in the late 1990s, but over the past decade, enthusiasm has waned for two reasons. First, therapeutic efficacy of gastric band in the majority of patients is substantially less than gastric bypass. Second, as years passed, late complication rates have increased. These complications, including band slippage, erosion, and esophageal dilation and development of gastroesophageal reflux disease (GERD), are usually not life-threatening, but range between 10% and 50% and often lead to band removal.[23] Despite these problems, gastric band efficacy, while not as high as gastric bypass, is acceptable. Gastric band remains the bariatric operation with the lowest major morbidity and mortality rates, an appealing quality for risk-averse patients. Gastric band does not require Roux-en-Y reconstruction, an advantage in patients with complex abdominal surgical histories. For these reasons, gastric band remains an important component of the bariatric surgery repertoire.

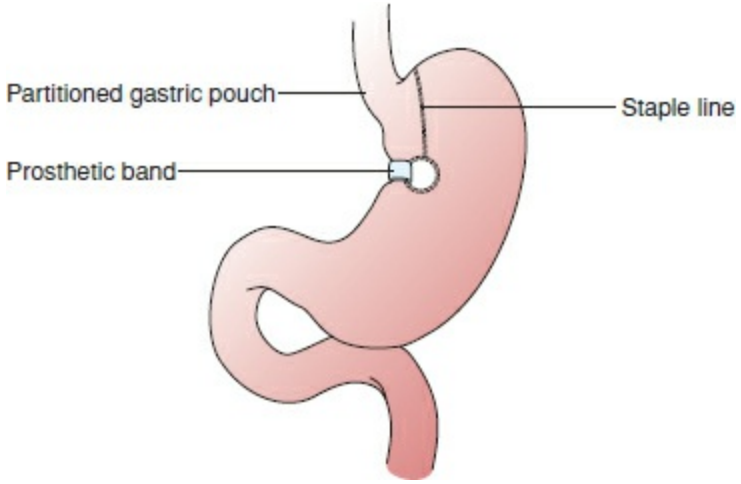

Figure 46-4. Vertical banded gastroplasty. A partitioned proximal gastric pouch is created with a linear stapler, and outflow limited with a prosthetic band. Variations included a divided staple line and different materials used for banding.

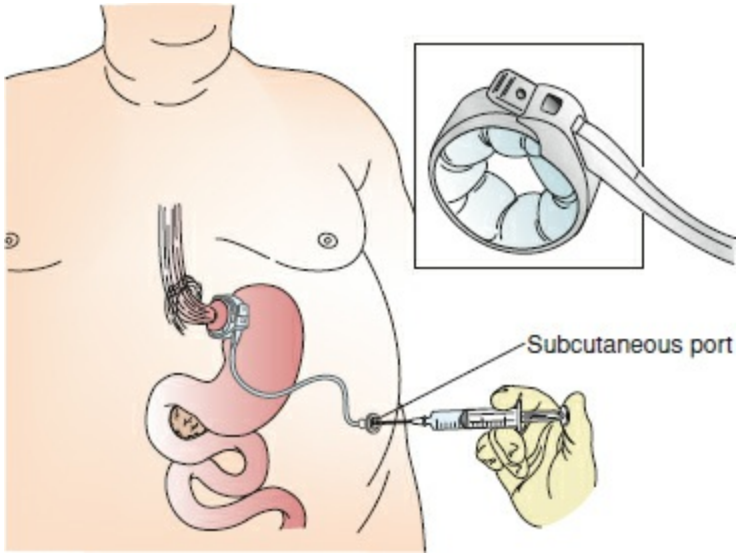

Figure 46-5. Gastric band. A silicone adjustable band is positioned around the upper stomach, creating a gastric pouch. A port attached to the band via silicone tubing is placed in the subcutaneous tissue in the abdominal wall, permitting percutaneous access and adjustment of band diameter.

Sleeve gastrectomy was introduced initially as a component of the duodenal switch modification of biliopancreatic diversion, but did not gain significant attention as a stand-alone bariatric operation until the early 2000s. Sleeve gastrectomy involves a lateral gastrectomy, leaving a narrow "sleeve" of stomach 32 to 40 Fr in diameter (Fig. 46-6). Originally proposed as the first step in a staged approach for high BMI patients prior to definitive gastric bypass, early follow-up data demonstrated excellent results, and long-term efficacy appears similar to gastric bypass. Sleeve gastrectomy is associated with perioperative complication rates similar to gastric bypass, but late complications are rare, in part due to elimination of morbidity associated with alterations in small intestinal anatomy. For these reasons, sleeve gastrectomy has engendered significant enthusiasm and is rapidly increasing in utilization.

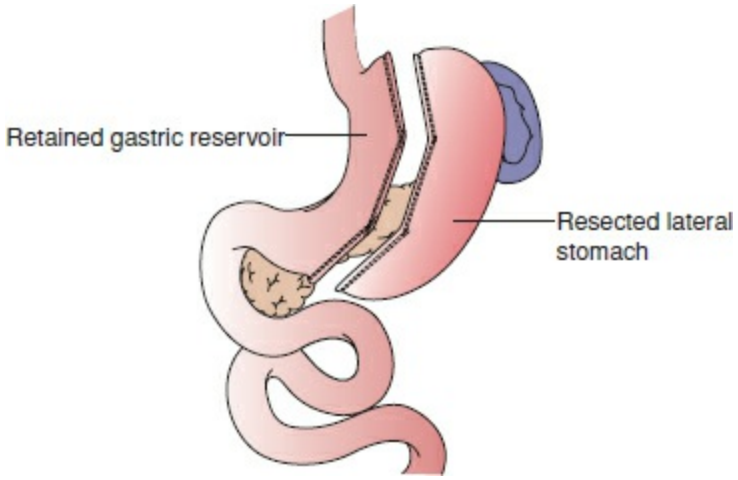

Figure 46-6. Sleeve gastrectomy. A lateral gastrectomy is performed with a linear cutting stapler, creating narrow gastric reservoir 32 to 40 Fr in diameter.

Modern Bariatric Surgery

6 Bariatric operations in addition to those described above exist, including variants of gastric bypass, biliopancreatic diversion/duodenal switch, and vertical banded gastroplasty as well as distinct alternative operations. Currently gastric bypass, sleeve gastrectomy, and gastric band are the mainstays, while biliopancreatic diversion/duodenal switch comprises a waning minority. Worldwide utilization rates in 2011 were gastric bypass 47%, sleeve gastrectomy 28%, gastric band 18%, and biliopancreatic diversion/duodenal switch 2% of all bariatric operations, with a marked increase in sleeve gastrectomy and decrease in gastric band in recent years.[24] The introduction of laparoscopy in the early 1990s provided significant advantages for many surgical patients but perhaps none more so than the obese. Wound infections and ventral hernias afflicted 30% to 90% of patients undergoing bariatric surgery via laparotomy, complications that were virtually eliminated with laparoscopy. Surgeons began exploring laparoscopic gastric bypass in the mid-1990s, but laparoscopy came with a price, introducing technical challenges dissimilar from open bariatric surgery, with a long, arduous learning curve that may exceed 100 cases for laparoscopic gastric bypass. These challenges engendered a response that included fellowship training programs and programmatic efforts to codify technique and care, including certification of bariatric surgery centers by surgical societies. These efforts, along with increasing surgeon experience, have reduced current morbidity and mortality to levels substantially lower than in the prelaparoscopic era. Currently, a laparoscopic approach is considered standard of care for bariatric surgery patients in the absence of a prohibitive prior surgical history.

Efficacy

Bariatric surgery achieves dramatic results. Weight loss is commonly reported as a percent age of *excess weight lost* (EWL), defined as the difference between presurgical weight and ideal weight, with ideal weight calculated for BMI = 25 for height. Weight loss typically peaks 1 to 2 years after surgery and may approach 80% to 90% EWL, followed by partial weight regain 3 to 10 years after surgery, leading to a plateau at 50% to 70% EWL at long-term follow-up.[25] The mechanisms underlying this weight loss pattern are unknown but may involve development of adaptive eating patterns that increase caloric intake over time. For gastric band, weight loss is typically slower and more gradual, with a plateau after 2 to 3 years. These varying patterns of weight loss complicate comparison of results of different operations and analysis of published data due to variable length of follow-up among studies. Analysis is further complicated by significant attrition of patients over long-term follow-up in most studies. Despite these challenges, meta-analyses, controlled trials, and uncontrolled case series provide estimates of the efficacy of bariatric operations (Table 46-1). Weight loss is highest for biliopancreatic diversion/duodenal switch, ranging from 55% to 75% EWL, followed by gastric bypass and sleeve gastrectomy (50% to 70% EWL) and gastric band (40% to 60% EWL).

Table 46-1 Bariatric Surgery Long-Term Weight Loss Responses

Reference	Study Population/Design	Weight Loss			
		GBP	SG	GB	BPD
Buchwald et al.[29]	Meta-analysis	68% EWL	NR	50% EWL	72% EWL
Carlin et al., 2013[40]	Michigan cooperative	67% EWL	56% EWL	44% EWL	NR
Chang et al.[34]	Meta-analysis	−13 BMI	−13 BMI	−9 BMI	NR
Courcoulas et al.[41]	LABS consortium	32% TWL	NR	16% TWL	NR
Garb et al.[32]	Meta-analysis	71% EWL	NR	55% EWL	NR
Lynch et al.[36]	Meta-analysis	72% EWL	NR	39% EWL	NR
Maggard et al.[30]	Meta-analysis	−41 kg	NR	−35 kg	−53 kg
O'Brien et al.[31]	Systematic review	62% EWL	NR	55% EWL	76% EWL
Padwal et al.[33]	Meta-analysis	−9 BMI	NR	−2.4 BMI	−11 BMI
Yip et al.[35]	Meta-analysis	71% EWL	68% EWL	NR	NR

GBP, gastric bypass; SG, sleeve gastrectomy; GB, gastric band; BPD, biliopancreatic diversion; EWL, excess weight loss; NR, not reported; BMI, body mass index; TWL, total weight loss.

Rates of improvement and remission of metabolic diseases parallel weight loss, with gastric bypass, sleeve gastrectomy, and biliopancreatic diversion/duodenal switch associated with higher remission rates than gastric band. Diabetes, steatosis, sleep apnea, hypertension, and hyperlipidemia improvement/remission rates range from 60% to over 90% (Table 46-2). Weight loss is durable, lasting decades in most patients, and accompanied by marked reductions in long-term incident diabetes, cardiovascular disease, and cancer, increased quality of life, reduced long-term healthcare costs, and a 25% to 40% reduction in long-term mortality. Randomized controlled trials demonstrate that bariatric surgery is substantially more efficacious than medical therapy for weight loss and diabetes, and multiple medical societies, including the American Diabetes Association, the International Diabetes Federation, and the American Heart Association, endorse bariatric surgery as treatment for metabolic disease.

Despite its efficacy, results of bariatric surgery are variable, with a substantial minority of patients achieving significantly better than average weight loss and disease response rates, while a similar minority experience suboptimal results. Anywhere from 10% to 30% of patients achieve $<50\%$ EWL, which may be due to failure to lose weight initially, or weight regain after a period of adequate weight loss. Mechanisms underlying such failures are poorly defined, and identification of accurate predictors of response to surgery is an important area of research. While suboptimal results are often attributed to lack of patient compliance with postoperative diet and exercise, these arguments ring false, echoing similar arguments that attribute obesity itself to a lack of "willpower." Instead, compelling evidence implicates genetic and epigenetic mechanisms. Like obesity itself, responses to bariatric surgery are highly hereditable. Ethnicity is a predictor of outcome, with Caucasians and Hispanics experiencing greater weight loss than Blacks and Asians. Multiple single-nucleotide polymorphisms have been linked to surgical outcome. Future research will identify clinical and genetic predictors of response and permit optimization of allocation of surgical resources.

Perioperative Mortality and Morbidity

Morbidity and mortality associated with bariatric surgery have decreased over the past two decades as surgeon experience increased and techniques evolved. Currently, gastric bypass and gastric band are associated with mortality risks similar to hip replacement and laparoscopic cholecystectomy, respectively. Perioperative mortality is highest for biliopancreatic diversion/duodenal switch, followed by gastric bypass and sleeve gastrectomy, then gastric band (Table 46-3**).** Life-threatening perioperative morbidity associated with gastric bypass and sleeve gastrectomy consists primarily of anastomotic dehiscence, staple-line leaks, hemorrhage, thromboembolic events, and cardiac events. Life-threatening perioperative morbidity associated with gastric band is rare and consists primarily of gastric perforation, thromboembolic events, and cardiac events.

The most dire perioperative complication of gastric bypass is anastomotic dehiscence of the gastrojejunostomy which usually occurs within 2 weeks of surgery. Incidences in most series range from 0.1% to 4%, although recent data suggest that anastomotic dehiscence rates are decreasing and high-volume centers report rates in the range of 0.1% to 0.2%. Signs and symptoms are similar to those of anastomotic dehiscence after any intestinal operation, but may be less apparent in the obese. Persistent tachycardia and abdominal pain are important but nonspecific sentinel signs. Upper GI radiographs may be of diagnostic utility but lack sensitivity. Abdominal CT scan, even within a few days of surgery, may be useful, as the lack of a fluid collection near the gastrojejunostomy has a high negative predictive value for leak, while contrast extravasation has a high positive predictive value. Nonetheless, data are conflicting regarding the sensitivity and specificity of radiologic studies for diagnosing anastomotic dehiscence, and laparoscopic reexploration should be employed aggressively in suspected cases. Operative management consists of washout, wide drainage, judicious attempt at repair, and distal enteral access, usually with a gastrostomy tube in the remnant stomach, although a jejunostomy tube in the distal Roux limb or biliary limb is an option if access to the remnant stomach is difficult. Anastomotic dehiscence can be managed laparoscopically in some cases, reducing the high risk of ventral hernia associated with laparotomy. Most will heal if sepsis is controlled.

Staple-line leaks are an equally dire event after sleeve gastrectomy, occurring anywhere from 1–2 weeks to many months after surgery. Leaks may occur at any point along the staple line, but when involving the thicker tissue of the antrum may be less prone to heal, and interval conversion to gastric bypass with resection of the involved portion of gastric sleeve may be necessary. Proper stapler selection and use during primary operation with avoidance of overly narrow sleeves (current consensus recommends 32- to 40-Fr diameter) reduce the risk of sleeve gastrectomy staple-line leaks, which currently occur with an incidence of approximately 1% to 3%. Gastric band is only rarely associated with perioperative septic complications, most often in the form of gastric perforation, which occurs in 0% to 0.5% of cases. Perforation, if not recognized, may be life-threatening and is a primary cause of rare perioperative mortality and major morbidity after gastric band.

Table 46-2 Bariatric Surgery Long-Term Comorbidity Responses

Reference	Study Population/ Design	Diabetes				Hypertension				Sleep Apnea				Hyperlipidemia			
		GBP	SG	GB	BPD	GBP	SG	GB	BPD	GBP	SG	GB	BPD	GBP	SG	GB	BPD
Buchwald et al.[29]	Meta-analysis	84	NR	48	99	87	NR	72	92	95	NR	56	87	96	NR	78	99
Carlin et al.[40]	Michigan cooperative	80	66	37	NR	45	40	18	NR	66	57	29	NR	63	40	27	NR
Chang et al.[34]	Meta-analysis	93	86	68	NR	78	82	63	NR	95	91	71	NR	80	NR	40	NR
Courcoulas et al.[41]	LABS consortium	69	NR	29	NR	41	NR	19	NR	NR	NR	NR	NR	59	NR	24	NR
Lynch et al.[36]	Meta-analysis	72	NR	50	NR	54	NR	17	NR	89	NR	NR	NR	38	NR	12	NR
Yip et al.[35]	Meta-analysis	81	80	NR	NR	NR	NR	NR	NR	NR	NR	NR	NR	NR	NR	NR	NR

Data presented are the percent of patients who experienced improvement or resolution. Some studies include series with data from both open and laparoscopic operations. See primary publications for details. GBP, gastric bypass; SG, sleeve gastrectomy; GB, gastric band; BPD, biliopancreatic diversion; NR, not reported.

Table 46-3 Bariatric Surgery Perioperative Mortality and Morbidity

Reference	Study Population/Design	% Mortality (≤30 Days)				% Morbidity (≤30 Days)			
		GBP	SG	GB	BPD	GBP	SG	GB	BPD
Banka et al.[38]	NIS database	0.1	NR	NR	NR	21	NR	NR	NR
Buchwald et al.[29]	Meta-analysis	0.50	NR	0.10	1.1	NR	NR	NR	NR
Carlin et al.[40]	Michigan cooperative	0.10	0.07	0.07	NR	10	6.3	2.4	NR
Chang et al.[34]	Meta-analysis	0.38	0.29	0.07	NR	12	9	8	NR
Courcoulas et al.[41]	LABS consortium	0.2	NR	0	NR	NR	NR	NR	NR
Finks et al.[39]	Michigan cooperative	0.1	0.1	0.04	0.3	10.1	5.6	2.3	16.3
Flum et al.[42]	LABS consortium	0.2	NR	0	NR	4.8	NR	1.0	NR
Lynch et al.[36]	Meta-analysis	0.3	NR	0.18	NR	NR	NR	NR	NR
Maggard et al.[30]	Meta-analysis	0.3	NR	0.02	0.9	19	NR	13	6
Trastulli et al.[37]	Systematic review	0	0	0	NR	21	12	0	NR

GBP, gastric bypass; SG, sleeve gastrectomy; GB, gastric band; BPD, biliopancreatic diversion; NR, not reported.

Perioperative hemorrhage after gastric bypass occurs with an incidence of 1% to 4%, often originates from staple lines, and may be intraperitoneal or intraluminal. Intraluminal bleeding presents with melena and is often self-limited, requiring only transfusion and observation. Infrequently, endoscopic or operative intervention may be necessary. Hemorrhage after sleeve gastrectomy ranges from 1% to 4%, is usually intraperitoneal from the gastric staple line, and may require operative intervention, although observation in the hemodynamically stable patient is a reasonable initial course. Early small bowel obstruction, and thromboembolic, pulmonary, and cardiac events comprise the majority of the remainder of acute postoperative complications after bariatric surgery. Pathophysiology is not substantially different than after nonbariatric GI operations, although the obese may be at higher risk, reinforcing the importance of preoperative evaluation and preparation.

Late Morbidity

Late morbidity after bariatric surgery is similar to that associated with complex nonbariatric GI operations, may occur months or years later, and often presents with abdominal pain. Gallbladder disease and small bowel obstruction from adhesions and ventral/trocar hernias may occur after all bariatric operations. Other complications are operation specific. While definitions vary, overall late morbidity rates for gastric bypass

range from 5% to 10%. Many late complications of gastric bypass result from Roux-en-Y anatomy. Internal hernias occur in 0.5% to 9% of patients, and are categorized as mesenteric (common to all Roux-en-Y reconstructions, in which bowel passes through the mesenteric split in the Roux limb), mesocolic (specific to retrocolic reconstructions, in which bowel passes through the mesocolic defect created for the Roux limb), and Petersen's (more often associated with antecolic than retrocolic reconstructions, in which bowel passes under the Roux limb and its mesentery) (Fig. 46-7).[26] Although closure of internal hernia defects at primary operation is straightforward and recommended, long-term clinical follow-up data do not demonstrate that this practice reduces hernia rates compared with series in which routine closure was not performed, possibly because of lack of scar tissue formation at the sites of closure, and/or loss of mesenteric adipose tissue with weight loss leading to late patency of previously closed defects. Patients often present years after surgery with a history of severe episodic abdominal pain. Diagnosis may be challenging, as obstipation may be absent and imaging normal even in the face of incarceration, especially if the biliopancreatic limb, which is out of continuity with the alimentary stream, is involved. A low threshold for operative exploration must be maintained in any patient with unrelenting abdominal pain after gastric bypass. Operative reduction and closure of internal hernia defects can usually be performed via a laparoscopic approach.

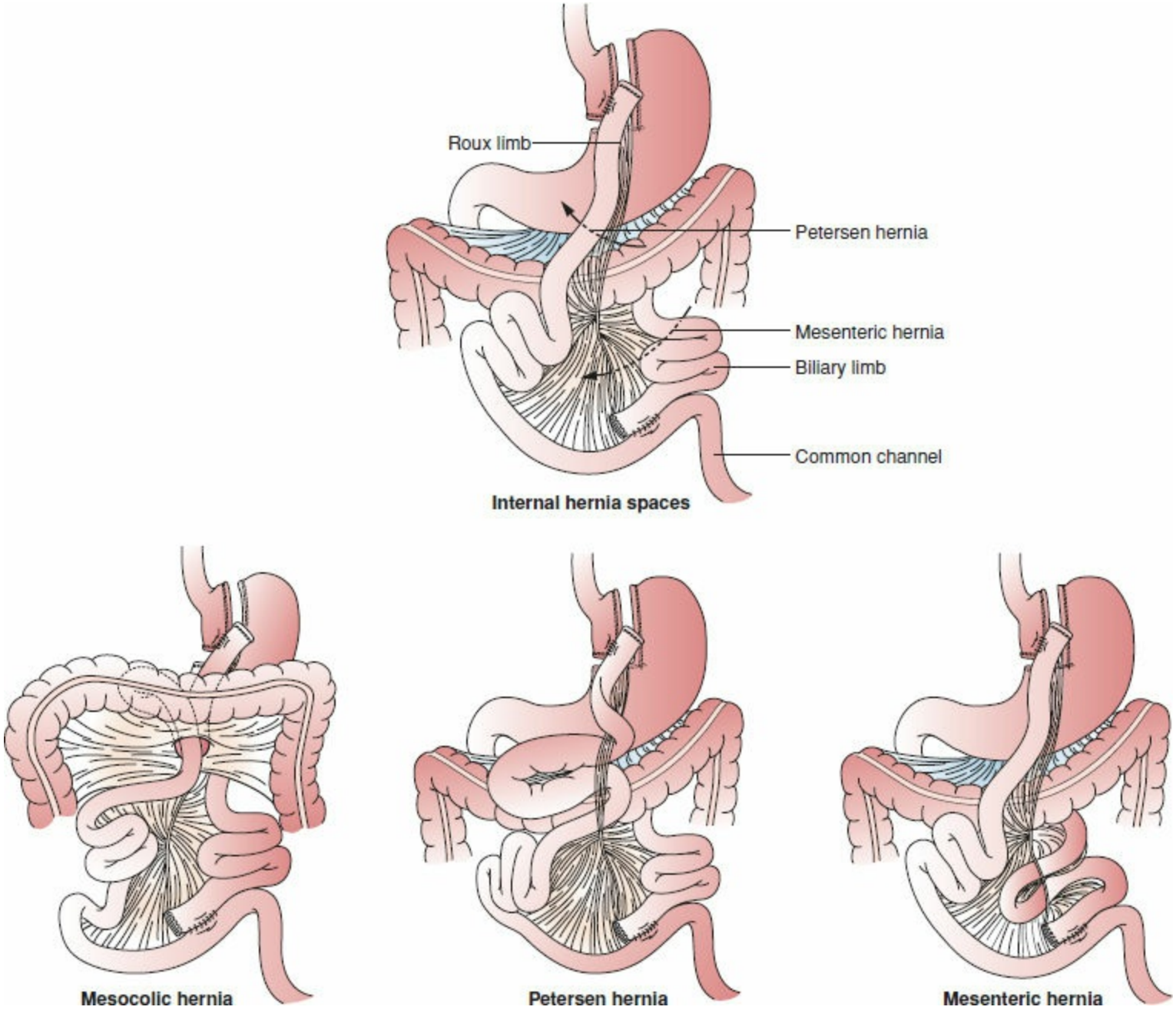

Figure 46-7. Internal hernias. Internal hernias may occur after any Roux-en-Y reconstruction, and include mesenteric, Petersen's, and mesocolic hernias. Weight loss after gastric bypass and loss of adipose tissue in the intestinal mesentery may predispose to internal herniation.

Gastrojejunal anastomotic ulcer occurs in 0.5% to 25% of patients after gastric bypass, with the majority of series reporting incidences between 2% and 8%. Tobacco or NSAID use increases risk, but ulcers may occur in the absence of these risk factors. Diagnosis by upper endoscopy is usually straightforward. Upper GI radiography is advisable to rule out an associated gastrogastric fistula, especially if an ulcer is recalcitrant to medical treatment or is associated with weight regain. Most ulcers heal with high-dose antacid therapy, and once healed, most surgeons recommend maintenance antacid therapy for life, although data supporting this practice are sparse. Rarely, ulcers recalcitrant to medical therapy require resection with anastomotic revision. Large pouches are a risk factor for ulcers due to retention of parietal cells in the distal gastric pouch that do not participate in negative inhibition of gastrin secretion, thus rationalizing pouch resection

and anastomosis revision as a treatment strategy. Gastrogastric fistula occurs with an incidence of 0% to 2% and may be associated with ulcers. Gastrogastric fistula incidence has decreased substantially since the advent of divided gastric bypass. Gastrogastric fistula often results from incomplete division of the gastric pouch from the gastric remnant at primary operation. Stenosis of the gastrojejunostomy typically presents with intolerance of solid foods and vomiting within 1 to 3 months of surgery with a wide range of reported incidences from $<1\%$ to $>20\%$, but most commonly 3% to 7%. Stenosis is usually easily treated with endoscopic dilation, although rare cases may require anastomotic revision. Retrograde intussusception at the jejunojejunostomy is a rare cause of abdominal pain after gastric bypass with a reported incidence of 0.1%. Pathogenesis is likely related to motility disorders resulting from disruption of enteroenteric nerves and divorce of the small intestine from duodenal pacemaker plexi with subsequent development of aberrant ectopic pacemakers in the involved intestinal limbs. Diagnosis may be challenging and imaging unreliable. Treatment consists of either plication/pexy of involved limbs or resection and revision of the jejunojejunostomy, with the latter approach associated with lower rates of recurrence.

The clinical presentation and differential diagnosis of abdominal pain after gastric bypass is diverse and diagnostic imaging may be unreliable. The clinician is not infrequently faced with a gastric bypass patient who presents with persistent pain in the absence of a clear cause after thorough diagnostic evaluation. Exploratory laparoscopy in such patients provides a diagnosis in up to 90% of cases. Even in the absence of intraoperative findings other than patent internal hernia defects without incarceration, closure of defects provides relief in the majority of patients. Less commonly, in the absence of a clear cause, pain is presumed to result from atypical motility disorders associated with Roux-en-Y anatomy and may be difficult to treat (Algorithm 46-1).

Late complications after gastric band are common, afflicting 10% to 50% of patients, may occur years after primary operation, and include band slippage, band erosion, and development of GERD and esophageal motility disorders. Treatment often requires band explant, with late explant rates of 30% to 50% in some series. While long-term data are evolving, late complications after sleeve gastrectomy appear to be uncommon, with infrequent reports of sleeve stenosis (0.5% to 3%) and development of GERD.

Bariatric operations alter absorption of macro- and micronutrients. Protein and lipid malabsorption, steatorrhea, and protein wasting are rare after modern gastric bypass and virtually absent with gastric band and sleeve gastrectomy, but afflict anywhere from 2% to 20% of patients after biliopancreatic diversion/duodenal switch. The elimination of the pyloric emptying mechanism in gastric bypass is associated with dumping and hypoglycemic syndromes, the underlying mechanisms of which are not well understood. Early dumping occurs within 10 to 30 minutes of a meal, and is thought to result from intraluminal fluid shifts and acute intravascular volume depletion secondary to rapid emptying of hyperosmolar gastric contents into the small intestine. Early dumping is associated with tachycardia and diaphoresis. Aberrations in gut hormone secretion, including elevated secretion of vasoactive intestinal polypeptide, enteroglucagon, pancreatic polypeptide, and GLP-1, have been associated with a predisposition to early

dumping. Late dumping occurs hours after a meal and is thought to be due to hypersecretion of insulin with subsequent reactive hypoglycemia; excess secretion of GLP-1 has also been implicated. Dumping and hypoglycemia typically respond to a low-carbohydrate diet and preprandial acarbose therapy. In cases recalcitrant to these measures, pharmacotherapy with agents that reduce insulin secretion, including octreotide, diazoxide, and calcium channel blockers, may be of benefit. Surgical banding of the gastric pouch to delay emptying has been employed with variable efficacy.

Micronutrient deficiencies are underreported after bariatric surgery. The reported prevalences of deficiencies of virtually all micronutrients after surgery span a broad range from 10% to >80% for biliopancreatic diversion/duodenal switch and gastric bypass. Deficiencies are less common after sleeve gastrectomy and gastric band. An understanding of the anatomic sites and mechanisms of micronutrient absorption affected by gastric bypass foregut diversion guides diagnosis and management. Anemia, neurologic, dermatologic, and GI symptoms are common clinical manifestations of many micronutrient deficiencies (Table 46-4). Acute deficiencies may involve dramatic presentations (e.g., thiamine deficiency and Wernicke encephalopathy). Chronic occult micronutrient deficiencies are associated with increased risk of chronic disease. Chronic magnesium deficiency, for example, is associated with an increased risk of type II diabetes. Chronic selenium deficiency has been associated with an increased risk of cancer and cardiovascular disease. The most common deficiencies associated with gastric bypass involve calcium, vitamin D, folate, iron, and B12. Vomiting due to stenosis or gastroenteritis increases the risks of severe micronutrient deficiencies, and nutritional status should be monitored carefully in any bariatric surgery patient with significant vomiting. It is important to note that obesity is associated with multiple micronutrient deficiencies independent of bariatric surgery, which should be identified and corrected in the preoperative period, and which may resurface in the postoperative period.

Patient Selection, Choice of Operation, Preoperative Preparation

Current criteria for candidacy for bariatric surgery are based on a 1991 NIH consensus conference, and include BMI ≥40, or BMI ≥35 with at least one serious comorbidity of obesity. While widely used, these criteria are based on expert opinion rather than definitive epidemiologic data, and were established over two decades ago. Recent data suggest that bariatric surgery provides benefits to diabetic patients with BMI 30 to 34.9.[27] While consensus is evolving, the American Society for Metabolic and Bariatric Surgery (ASMBS) had issued a statement in support of bariatric surgery in this low BMI patient population, and the FDA, as the regulatory body that authorizes device use, approved gastric band for this subgroup in 2011. As data accrue, candidacy criteria will expand. Good outcomes have been reported in carefully selected patients with organ transplants, end-stage renal disease, compensated cirrhosis, HIV, and adolescents. Active uncontrolled cardiac, pulmonary, or psychiatric disease and uncompensated liver disease are generally considered absolute contraindications.

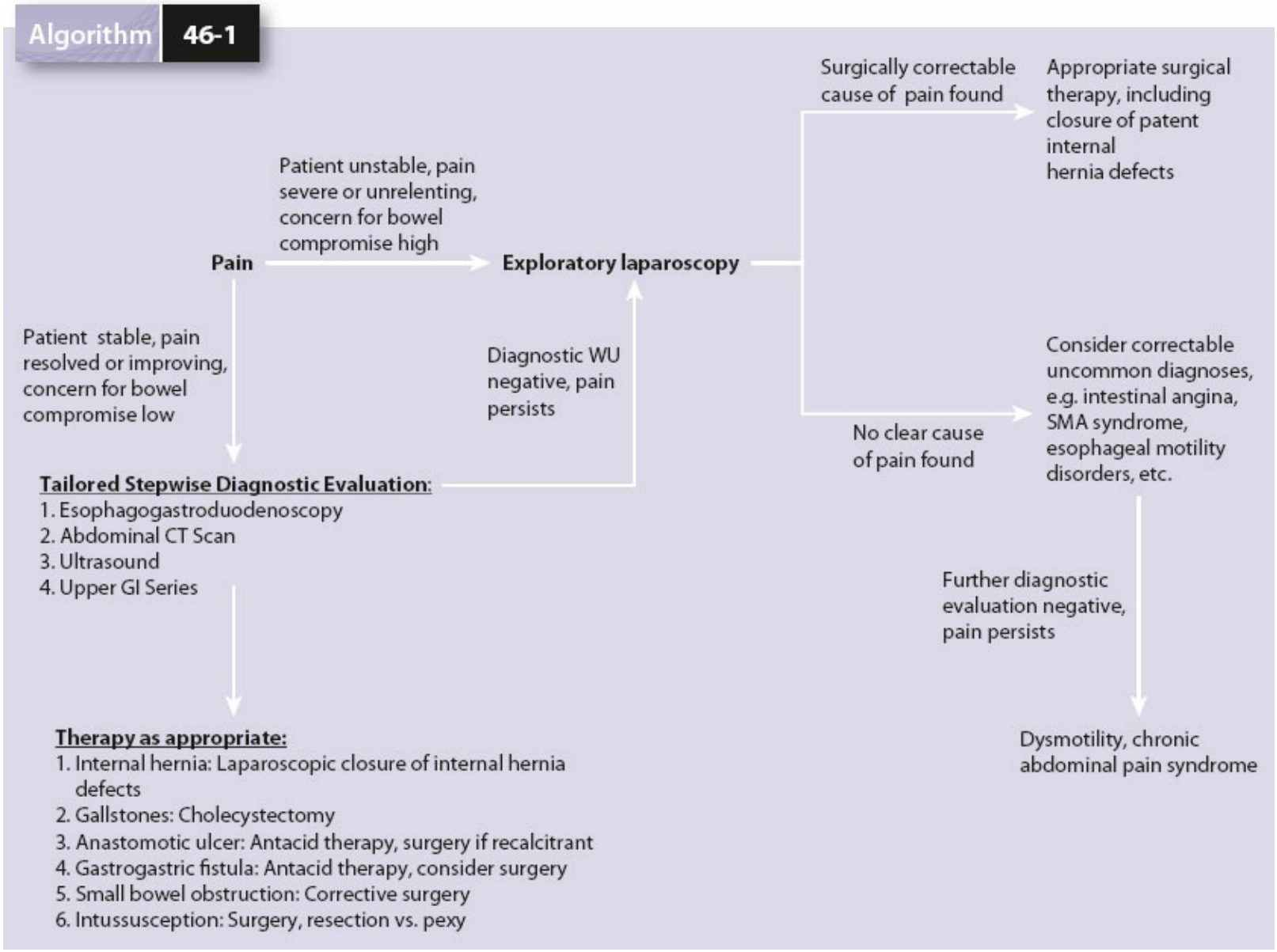

Algorithm 41-6. Algorithm for management of abdominal pain months or years after Roux-en-Y reconstruction.

The choice of bariatric operation is a complex decision. Gastric bypass is considered the gold-standard operation by many, although sleeve gastrectomy may soon supplant gastric bypass in this regard. The high failure rate of gastric band has led some to argue that it should be eliminated from the repertoire, although this is debated. While highly individualized, clinical considerations guide choice of operation. Gastric bypass is highly effective in ameliorating GERD; sleeve gastrectomy and gastric band, in contrast, may exacerbate GERD. Gastric bypass may provide theoretical advantages in the treatment of diabetes (discussed below), but sleeve gastrectomy and to a lesser extent gastric band are also highly efficacious in this regard. Gastric bypass is associated with increased intestinal oxalate absorption and hyperoxaluria, and sleeve gastrectomy or gastric band should therefore be considered in patients with a history of oxalate nephrolithiasis. Patients with severe gastroparesis may benefit from gastric bypass rather than sleeve gastrectomy or gastric band, although data in this subgroup are sparse, and gastric bypass itself may rarely lead to gastroparesis. Gastric band should be avoided in patients with dysphagia or esophageal motility disorders. Sleeve gastrectomy and gastric band avoid the need for

manipulation of the small intestine and thus may be good choices in patients with complex abdominal surgical histories. Despite its high late morbidity and long-term failure rates, gastric band remains an option for risk-averse patients who are unaccepting of the relatively higher risk of perioperative morbidity and mortality associated with gastric bypass and sleeve gastrectomy.

Preoperative preparation includes thorough medical, psychological, and dietary evaluations. Patients should undergo age-appropriate cancer screening, and treatment for active medical issues should be optimized. Sleep apnea testing should be performed in most if not all patients, as the prevalence of sleep apnea in the obese population may exceed 70%, and appropriate treatment with continuous positive airway pressure (CPAP) should be instituted prior to surgery and continued through the perioperative period. Diabetes should be well controlled; while data do not support a specific value, a preoperative HbA1c <8 is a common target. Some degree of preoperative surgeon–supervised diet-induced weight loss should be achieved in most patients, as data suggest that this practice reduces hepatic steatosis, may reduce perioperative complications, and may be associated with improved long-term outcomes. Preoperative testing and treatment for *Helicobacter pylori* is recommended, although data suggesting that this practice decreases postoperative anastomotic ulcer risk is equivocal.

Operative Considerations

A thorough discussion of the technical aspects of bariatric surgery is beyond the scope of this chapter, but a few important issues warrant mention. Obesity is a risk factor for DVT, and aggressive DVT prophylaxis should be employed. Optimal prophylaxis agents and regimens have not been determined, but unfractionated or low–molecular-weight heparin during operation and continued through the hospitalization period is typical. Subtherapeutic dosing of these agents is common in the obese, and the American College of Chest Physicians recommends weight-based dosing.

Table 46-4 Select Micronutrient Deficiencies Associated with Bariatric Surgery

Micronutrient	Signs, Symptoms of Deficiency	Site of Absorption	Mechanism of Absorption, Other Issues
B9 (folate)	Macrocytic megaloblastic anemia, leukopenia, thrombocytopenia, glossitis, elevated homocysteine levels, neural tube defects in pregnancy	Duodenum, jejunum, ileum	Water soluble, conserved via enterohepatic circulation; B12 required for folate activation, B12 deficiency can cause folate deficiency; multivitamin generally sufficient for supplementation after surgery
B1 (thiamine)	Wernicke encephalopathy (ophthalmoplegia, nystagmus, ataxia, dementia), Korsakoff psychosis, beri-beri, peripheral neuropathy	Jejunum, ileum	Water soluble, depletion may occur with 2–3 weeks; rapid weight loss, vomiting increase risk of deficiency; symptoms of acute deficiency may mimic stroke
B6 (pyridoxine)	Seborrheic dermatitis, atrophic glossitis, conjunctivitis, neuropathy	Jejunum, ileum	Water soluble, passive absorption
B12 (cobalamin)	Macrocytic anemia, leukopenia, thrombocytopenia, glossitis, irreversible neuropathies	Ileum	Binds salivary R-proteins which prevent acid hydrolysis, then binds intrinsic factor secreted by parietal cells in gastric antrum; intrinsic factor-B12 complex absorbed in ileum; found in foods of animal origin – be alert for deficiency in vegetarians
C	Scurvy: malaise, myalgias, petechiae, mucosal bleeding, edema; iron deficiency	Jejunum	Symptomatic deficiency rare after bariatric surgery; potentiates iron absorption, should be used in iron deficient patients
D	Fatigue, myalgia, arthralgia, osteopenia	Jejunum, ileum	Fat soluble; deficiency common in obesity independent of surgery in up to 50% of patients
A	Xerophthalmia, night blindness, keratitis	Duodenum, jejunum, ileum	Fat soluble; deficiency associated with malabsorptive procedures
E	Ataxia, paresthesias, myopathy, arthropathy, anemia, retinopathy, immune dysfunction	Jejunum, ileum	Fat soluble; deficiency associated with malabsorptive procedures
K	Coagulopathy	Jejunum, ileum	Fat soluble; deficiency associated with malabsorptive procedures
Calcium	Tetany (Trousseau, Chvostek signs), paresthesias, QT prolongation, cardiac arrhythmias, petechiae, purpura, osteopenia	Duodenum, jejunum	Symptoms of acute deficiency rare; chronic deficiency common, manifests as osteopenia, related to vitamin D deficiency
Copper	Ataxia, anemia, demyelinating neuropathy, paresthesias; chronic deficiency associated with osteoporosis, cardiovascular disease, cancer	Stomach, duodenum	Involved in antioxidant metabolism
Iron	Microcytic anemia, fatigue, cold intolerance, atrophic glossitis, angular stomatitis	Duodenum	Conversion from ferric to ferrous form requires acid hydrolysis; supplements interfere with calcium absorption, should be taken at different times
Magnesium	Alopecia, muscle cramps, hypocalcemia, hypokalemia, hypoparathyroidism, chronic deficiency linked to increased risk of diabetes, cardiovascular disease	Duodenum	Deficiency common in obesity independent of surgery in up to 35% of patients
Selenium	Acute deficiency rare; chronic deficiency linked to increased risk of cancer, diabetes, long-term mortality	Duodenum	Involved in antioxidant metabolism; excess selenium is toxic
Zinc	Alopecia, dermatitis	Duodenum	Deficiency common in obesity independent of surgery in up to 50% of obese patients

Dominant anatomic sites of absorption are listed, but many micronutrients are absorbed throughout the GI tract. In cases of micronutrients absorbed via active transport mechanisms, passive absorption also occurs in lesser amounts, and supplementation with supraphamacologic doses overcomes bypassed active uptake mechanisms via passive absorption (e.g., B12).

Hand-sewn, linear stapler, and circular stapler techniques are used to create the gastrojejunostomy in gastric bypass. No single technique demonstrates a clear advantage, although stenosis rates may be higher with the circular stapler technique. Absorbable suture should be used for all anastomoses, as nonabsorbable suture is a nidus for ulcer formation. Routine intraoperative testing of the gastrojejunal anastomosis with EGD-air insufflation or methylene blue instillation may be associated with reduced anastomotic dehiscence rates and is advisable. The use of drains at the gastrojejunal anastomosis is practiced selectively, and no clear data demonstrate that routine drain placement aids in early detection or reduced morbidity of anastomotic dehiscence. Some data suggest that drains may allow for nonoperative management of such events. Routine closure of internal hernia defects during gastric bypass is controversial, as data do not clearly demonstrate that this practice reduces late hernia incidence. Nonetheless, closure is straightforward, entails low morbidity, and is therefore recommended. Risk–benefit analyses do not support prophylactic cholecystectomy during laparoscopic bariatric surgery in the absence of cholelithiasis, or in the presence of asymptomatic cholelithiasis. It is therefore reasonable to manage cholelithiasis in bariatric surgery patients as in all patients, that is, perform cholecystectomy only if symptoms are present.

As with any laparoscopic operation, conversion to laparotomy is a reasonable option if laparoscopy presents insurmountable technical challenges. That said, bariatric surgeons are well aware that “open” bariatric surgery is not “easier” than laparoscopic surgery, but simply presents qualitatively different technical challenges. Often, hepatomegaly is a major obstacle. Left hepatic lobe size should be assessed at the beginning of every operation, and if adequate liver retraction is not possible, consideration should be given to aborting the planned procedure, especially if significant steatosis is present that might be mitigated by further preoperative diet-induced weight loss.

Perioperative and Postoperative Management

Perioperative care of the bariatric surgery patient is similar to that of any patient undergoing complex GI surgery but must be tailored to the obese. Inpatient, outpatient, and operating room facilities should be equipped with beds, chairs, lifting and transfer apparatuses, and other equipment capable of bearing the weight of obese patients. Anesthesia, nursing, dietician, physical therapy, and other subspecialty staff with experience in the management of obese patients are necessary. Hospital stays after laparoscopic gastric bypass and sleeve gastrectomy are typically 1 to 3 days, while gastric band is generally performed on an outpatient basis.

The dietary regimen in the first few weeks after surgery is designed to prevent food impaction at an edematous surgical site and maintain adequate hydration, and includes clear liquids progressing to soft foods. Caloric intake in the early postoperative period may be less than 500 cal/day, which is acceptable as long as hydration is maintained. Within 2 to 3 weeks of surgery, solid foods may be introduced and caloric intake will slowly rise, with a long-term maintenance target of 1,200 to 1,500 calories and 50 to 70 g of protein per day. Within a few months of surgery, most patients are able to eat any

foods in small quantities with few exceptions. Deviation from this pattern should raise concerns for anastomotic stenosis, ulcer, or other complications. Persistent vomiting, unless clearly associated with a specific food that when eliminated ameliorates symptoms, is abnormal and should prompt a diagnostic workup, usually with UGI and/or EGD.

The incidence of cholelithiasis after bariatric surgery ranges from 15% to over 70%, but only approximately 7% of patients will require cholecystectomy. Prophylactic treatment with ursodeoxycholic acid reduces the risk of postoperative cholelithiasis, from 28% to 9% in one recent meta-analysis. Such therapy entails little morbidity and a 6-month postoperative treatment regimen is common practice. Data are equivocal, however, regarding whether this practice reduces cholecystectomy rates or is cost-effective.

The variability in surveillance practices makes accurate estimation of the incidence of postoperative nutritional deficiencies challenging, and a wide range of supplementation practices exist. Interpretation of the data is made more difficult because obese patients are at high risk for pre-existing micronutrient deficiencies independent of surgery. Vitamin D and zinc deficiencies, for example, afflict over 50% and 30% of obese patients, respectively. Abnormal serum levels of micronutrients after surgery are common, ranging from 10% to >80% depending on the micronutrient, operation, and patient population studied; clinically symptomatic deficiencies are less common. Consensus guidelines from the American Association of Clinical Endocrinologists, the Obesity Society, and the ASMBS recommend that gastric bypass patients undergo annual surveillance of 25-hydroxyvitamin D, calcium, iron, and B12 levels, along with a complete blood count, electrolyte and lipid panels, and liver function tests and periodic bone scans, and receive lifelong daily multivitamin (including folate), calcium citrate, vitamin D, and vitamin B12 supplementation, with iron supplementation in menstruating women.[28] Sleeve gastrectomy patients likely have a lower risk of nutritional deficiencies, but similar regimens are recommended. Gastric band patients receive a daily multivitamin, calcium, and vitamin D supplementation.

Clinical follow-up after bariatric surgery should be lifelong. Primary care providers play a critical role in preoperative and postoperative care. Endocrinology expertise may be required, especially in the early postoperative period when diabetes may resolve rapidly. A medical bariatrician subspecialty is evolving to care for this expanding patient population.

Physiologic Mechanisms Underlying Bariatric Surgery Efficacy

Restriction of caloric intake and nutrient malabsorption are the classic presumed mechanisms of bariatric operations. These mechanisms are important, but their relationship to outcome is complex and nonlinear. For example, data are conflicting regarding the correlation between gastric bypass pouch size and weight loss. In general, pouch volumes <50 cc are associated with good results with little evidence that smaller pouches achieve greater weight loss, while efficacy may decrease substantially as pouch sizes increase beyond 50 cc. Similarly, common channel length teeters on a less well-defined threshold, above which weight loss is poor and below which malnutrition results. Other features of restriction are counterintuitive: more rapid gastric pouch emptying on

oral contrast studies is associated with greater weight loss after gastric bypass while sleeve gastrectomy is associated with increased gastric emptying rates compared to native anatomy. These observations suggest a complex relationship between weight regulation, metabolism, and gut anatomy and motility.

7 Complex mechanisms in addition to restriction and malabsorption contribute to weight loss and improved metabolism after surgery, with qualitatively different responses than those associated with diet-induced weight loss. Satiety is increased, hunger decreased, and metabolic rate increased after bariatric surgery, the opposite of responses observed with diet-induced weight loss. Bariatric surgery somehow "sidesteps" the normal compensatory responses that act to defend body weight with nonsurgical weight loss. The mechanisms underlying these counterintuitive responses are not well established. Among putative mechanisms are changes in gut hormone secretion secondary to altered intestinal anatomy. Decades ago, it was observed that an oral glucose load elicits a greater insulin response than an intravenous glucose load, leading to postulation of the existence of *incretins,* gut hormones secreted in response to a meal that regulate systemic glucose metabolism. Subsequent research led to the discovery of GIP and GLP-1, incretins secreted by duodenal K cells and ileal L cells, respectively, in response to nutrient delivery to the small intestine. Incretins have diverse effects on glucose homeostasis, potentiating central insulin secretion and peripheral insulin sensitivity. Alterations in incretin hormone secretion secondary to gut anatomic derangements were invoked to explain the observation that diabetes often improved within days of gastric bypass, well before substantial weight loss.

The *foregut and hindgut hypotheses* have been proposed to explain this phenomenon: bypass of the alimentary stream from the stomach, duodenum, and proximal jejunum (the foregut hypothesis), and increased caloric delivery to the distal jejunum and ileum (the hindgut hypothesis) alter secretion of gut hormones with improvement in glucose homeostasis. While data are less compelling for GIP and other putative foregut hormones, evidence supports the hindgut hypothesis, including data demonstrating increased serum GLP-1 levels after gastric bypass. While debate persists regarding the magnitude of these effects on diabetes remission after gastric bypass, an understanding of incretin physiology has led to the development of GLP-1 agonists as pharmacologic therapy for diabetes independent of bariatric surgery.

Gut anatomic derangements mediate additional metabolic changes. Gastric bypass and sleeve gastrectomy reduce secretion of the orexigenic hormone ghrelin from the gastric fundus, which may reduce hunger after surgery. Gastric bypass and sleeve gastrectomy are associated with increased secretion of peptide YY and oxyntomodulin, gut hormones secreted by L cells in parallel with GLP-1 in response to a meal that induce satiety and inhibit gut motility and are central mediators of the "ileal brake" mechanism. Roux-en-Y anatomy alters bile acid metabolism, increasing serum levels of conjugated bile acids with beneficial effects on glucose and lipid metabolism. Bariatric surgery disrupts vagal and enteroenteric innervations of the gut and alters CNS satiety responses. Finally, gastric bypass is associated with alterations in gut microbiota that contribute to weight loss and resolution of metabolic disease. The precise mechanisms by which these diverse effects

contribute to weight loss and metabolic disease remission remain unclear.

Mechanisms other than restriction and malabsorption underlie the systemic effects of bariatric surgery. An emerging field of *metabolic surgery* is exploring operations designed to mimic the metabolic effects of gastric bypass (e.g., ileal transposition, foregut exclusion) in animals and lean diabetic humans with promising results. Also in development are endoscopic and laparoscopic gastric plications, intragastric balloon placement, vagal nerve blockade, gastric simulators, and impermeable intraluminal duodenal and jejunal stents designed to prevent caloric absorption. Bariatric surgery in the 21st century will evolve to include a broad array of procedures applied to a diverse patient population as these efforts mature.

References

1. Henderson RM. The bigger the healthier: are the limits of BMI risk changing over time? *Econ Hum Biol* 2005;3(3):339–366.
2. Chen SE, Florax RJ. Zoning for health: the obesity epidemic and opportunities for local policy intervention. *J Nutr* 2010;140(6):1181–1184.
3. Berrington de Gonzalez A, Hartge P, Cerhan JR, et al. Body-mass index and mortality among 1.46 million white adults. *N Engl J Med* 2010;363:2211–2219.
4. Oreopoulos A, Padwal R, Kalantar-Zadeh K, et al. Body mass index and mortality in heart failure: a meta-analysis. *Am Heart J* 2008;156(1):13–22.
5. Ashwell M, Gunn P, Gibson S. Waist-to-height ratio is a better screening tool than waist circumference and BMI for adult cardiometabolic risk factors: systematic review and meta-analysis. *Obes Rev* 2012;13(3):275–286.
6. Lewis CE, McTigue KM, Burke LE, et al. Mortality, health outcomes, and body mass index in the overweight range: a science advisory from the American Heart Association. *Circulation* 2009;119(25):3263–3271.
7. Odgen CL, Carroll MD, Kit BK, et al. *Prevalence of Obesity in the United States, 2009–2010 NCHS Data Brief, No 82.* Hyattsville, MD: National Center for Health Statistics; 2012.
8. Peeters A, Barendregt JJ, Willekens F, et al. Netherlands Epidemiology and Demography Compression of Morbidity Research Group. Obesity in adulthood and its consequences for life expectancy: a life-table analysis. *Ann Intern Med* 2003;138(1):24–32.
9. Fontaine KR, Redden DT, Wang C, et al. Years of life lost due to obesity. *JAMA* 2003;289(2):187–193.
10. Li C, Ford ES, Zhao G, et al. Prevalence of self-reported clinically diagnosed sleep apnea according to obesity status in men and women: National Health and Nutrition Examination Survey, 2005–2006. *Prev Med* 2010;51(1):18–23.
11. Lopez PP, Stefan B, Schulman CI, et al. Prevalence of sleep apnea in morbidly obese patients who presented for weight loss surgery evaluation: more evidence for routine screening for obstructive sleep apnea before weight loss surgery. *Am Surg* 2008;74(9):834–838.
12. Samaha FF, Iqbal N, Seshadri P, et al. A low-carbohydrate as compared with a low-fat diet in severe obesity. *N Engl J Med* 2003;348:2074–2081.
13. Knowler WC, Barrett-Connor E, Fowler SE, et al. Reduction in the incidence of type 2 diabetes with lifestyle intervention or metformin. *N Engl J Med* 2002;346(6):393–403.
14. Wadden TA, Bantle JP, Blackburn G, et al. Eight-year weight losses with an intensive lifestyle intervention: the look AHEAD study. *Obesity (Silver Spring)* 2014;22(1):5–13.
15. Cho YM, Wideman RD, Kieffer TJ. Clinical application of glucagon-like peptide 1 receptor agonists for the treatment of type 2 diabetes mellitus. *Endocrinol Metab*

(Seoul) 2013;28(4):262–274.
16. Ozcan L, Ergin AS, Lu A, et al. Endoplasmic reticulum stress plays a central role in development of leptin resistance. *Cell Metab* 2009;9(1):35–51.
17. Trevaskis JL, Coffey T, Cole R, et al. Amylin-mediated restoration of leptin responsiveness in diet-induced obesity: magnitude and mechanisms. *Endocrinology* 2008;149:5679–5687.
18. Torgerson JS, Hauptman J, Boldrin MN, et al. XENical in the prevention of diabetes in obese subjects (XENDOS) study: a randomized study of orlistat as an adjunct to lifestyle changes for the prevention of type 2 diabetes in obese patients. *Diabetes Care* 2004;27(1):155–161.
19. Smith SR, Weissman NJ, Anderson CM, et al. Behavioral Modification and Lorcaserin for Overweight and Obesity Management (BLOOM) Study Group. Multicenter, placebo-controlled trial of lorcaserin for weight management. *N Engl J Med* 2010;363(3):245–256.
20. Garvey WT, Ryan DH, Look M, et al. Two-year sustained weight loss and metabolic benefits with controlled-release phentermine/topiramate in obese and overweight adults (SEQUEL): a randomized, placebo-controlled, phase 3 extension study. *Am J Clin Nutr* 2012;95(2):297–308.
21. Payne JH, DeWind LT. Surgical treatment of obesity. *Am J Surg* 1969; 118:141–147.
22. Sudan R, Jacobs DO. Biliopancreatic diversion with duodenal switch. *Surg Clin North Am* 2011;91(6):1281–1293.
23. Arapis K, Chosidow D, Lehmann M, et al. Long-term results of adjustable gastric banding in a cohort of 186 super-obese patients with a BMI ≥ 50 kg/m2. *J Visc Surg* 2012;149(2):e143–e152.
24. Buchwald H, Oien DM. Metabolic/bariatric surgery worldwide 2011. *Obes Surg* 2013;23(4):427–436.
25. Sjöström L, Narbro K, Sjöström CD, et al. Swedish Obese Subjects Study. Effects of bariatric surgery on mortality in Swedish obese subjects. *N Engl J Med* 2007;357(8):741–752.
26. O'Rourke RW. Management strategies for internal hernia after gastric bypass. *J Gastrointest Surg* 2011;15(6):1049–1054.
27. Maggard-Gibbons M, Maglione M, Livhits M, et al. Bariatric surgery for weight loss and glycemic control in nonmorbidly obese adults with diabetes: a systematic review. *JAMA* 2013;309(21):2250–2261.
28. Mechanick JI, Kushner RF, Sugerman HJ, et al. American Association of Clinical Endocrinologists, the Obesity Society, and American Society for Metabolic & Bariatric Surgery medical guidelines for clinical practice for the perioperative nutritional, metabolic, and nonsurgical support of the bariatric surgery patient. *Obesity* 2009;17(supp 1):S1–S70.
29. Buchwald H, Avidor Y, Braunwald E, et al. Bariatric surgery: a systematic review and

meta-analysis. *JAMA* 2004;292(14):1724–1737.

30. Maggard MA, Shugarman LR, Suttorp M, et al. Meta-analysis: surgical treatment of obesity. *Ann Intern Med* 2005;142(7):547–559.
31. O'Brien PE, McPhail T, Chaston TB, et al. Systematic review of medium-term weight loss after bariatric operations. *Obes Surg* 2006;16(8):1032–1040.
32. Garb J, Welch G, Zagarins S, et al. Bariatric surgery for the treatment of morbid obesity: a meta-analysis of weight loss outcomes for laparoscopic adjustable gastric banding and laparoscopic gastric bypass. *Obes Surg* 2009;19(10):1447–1455.
33. Padwal R, Klarenbach S, Wiebe N, et al. Bariatric surgery: a systematic review of the clinical and economic evidence. *J Gen Intern Med* 2011; 26(10):1183–1194.
34. Chang SH, Stoll CR, Song J, et al. The effectiveness and risks of bariatric surgery: an updated systematic review and meta-analysis, 2003–2012. *JAMA Surg* 2013;149(3):275–287.
35. Yip S, Plank LD, Murphy R. Gastric bypass and sleeve gastrectomy for type 2 diabetes: a systematic review and meta-analysis of outcomes. *Obes Surg* 2013;23:1994–2003.
36. Lynch J, Belgaumkar A. Bariatric surgery is effective and safe in patients over 55: a systematic review and meta-analysis. *Obes Surg* 2012;22(9):1507–1516.
37. Trastulli S, Desiderio J, Guarino S, et al. Laparoscopic sleeve gastrectomy compared with other bariatric surgical procedures: a systematic review of randomized trials. *Surg Obes Relat Dis* 2013;9(5):816–829.
38. Banka G, Woodard G, Hernandez-Boussard T, et al. Laparoscopic vs. open gastric bypass surgery: differences in patient demographics, safety, and outcomes. *Arch Surg* 2012;147(6):550–556.
39. Finks JF, Kole KL, Yenumula PR, et al. Michigan Bariatric Surgery Collaborative, from the Center for Healthcare Outcomes and Policy. Predicting risk for serious complications with bariatric surgery: results from the Michigan Bariatric Surgery Collaborative. *Ann Surg* 2011;254(4):633–640.
40. Carlin AM, Zeni TM, English WJ, et al. Michigan Bariatric Surgery Collaborative. The comparative effectiveness of sleeve gastrectomy, gastric bypass, and adjustable gastric banding procedures for the treatment of morbid obesity. *Ann Surg* 2013;257(5):791–797.
41. Courcoulas AP, Christian NJ, Belle SH, et al. Longitudinal Assessment of Bariatric Surgery (LABS) Consortium. Weight change and health outcomes at 3 years after bariatric surgery among individuals with severe obesity. *JAMA* 2013;310(22):2416–2425.
42. Flum DR, Belle SH, King WC, et al. Longitudinal Assessment of Bariatric Surgery (LABS) Consortium. Perioperative safety in the longitudinal assessment of bariatric surgery. *N Engl J Med* 2009;361(5):445–454.

Chapter 47

Gastric Neoplasms

Hari Nathan and Rebecca M. Minter

Key Points

1. The presence of a gastric adenomatous polyp is a marker of increased risk for the development of cancer in the remaining gastric mucosa, and therefore these patients should be enrolled in an appropriate endoscopic surveillance program.
2. *Helicobacter pylori* infection is the predominant risk factor for gastric carcinogenesis. However, additional cofactors also play an important role and likely drive the progression from a premalignant condition to adenocarcinoma in most individuals.
3. The symptoms produced by gastric cancer are not specific and can mimic those associated with a number of nonneoplastic gastroduodenal diseases, especially benign gastric ulcer.
4. The extent of gastric resection is determined by the need to obtain a resection margin free of microscopic disease, and examination of a minimum of 15 nodes is suggested for adequate staging.
5. Multimodality treatment should be the standard of care for treating locally advanced resectable gastric cancer.
6. Low-grade gastric MALT lymphomas are usually effectively treated with eradication of *H. pylori* infection alone.
7. Almost all (95%) gastrointestinal stromal tumors (GISTs) express the KIT antigen, and this is an important molecular target for medical therapy.

Gastric cancer is a relatively common, frequently lethal affliction and remains a serious and unsolved problem in general surgery. The disease often is not recognized until it is at an advanced stage. Gastric cancer usually cannot be controlled by surgery alone, and surgical cure rates have remained disappointingly low. Increasingly, a multidisciplinary approach is being applied to these difficult neoplasms, with some modest improvements in outcome finally being observed. Technical innovations and basic scientific investigations continue to be applied to this disease, and cautious optimism for the future is appropriate.

ADENOCARCINOMA

Epidemiology

Starting in 1930, the incidence of gastric cancer declined dramatically in the United States. By 1990, the incidence of gastric cancer (10 cases per 100,000 population) was approximately one-fourth the incidence recorded in 1930.[1] By 2010, gastric cancer accounted for 2% of cancer deaths in the United States, compared with 20% to 30% in the 1930s.[1] Nevertheless, more than 22,000 new cases continue to be diagnosed annually in the United States, with over 10,000 deaths per year attributable to the disease. Worldwide, its impact is much larger, and gastric cancer remains the third leading cause of cancer death among men and the fifth leading cause among women, accounting for 10% of cancer deaths overall.[2] It has long been thought that environmental exposures play a role in gastric carcinogenesis, a notion that is supported by the finding that groups who migrate from regions with high prevalence of gastric cancer to those with low prevalence experience a decreasing incidence of gastric cancer with time.[3,4] It has been theorized that dietary changes and reductions in smoking have contributed to decrease in gastric cancer incidence in some parts of the world.[2] Food preservation methods using large amounts of salt and nitrites have been partially supplanted by improved refrigeration, and fresh fruits and vegetables have become more widely available. The strongest known risk factor for gastric cancer, however, is infection with *Helicobacter pylori,* which is associated with a six-fold increased risk of (noncardia) gastric cancer.[5,6] Approximately 75% of gastric cancer cases are attributable to *H. pylori* infection, making this organism the dominant infectious cause of cancer in the world.[7]

Due at least in part to these environmental factors, there is marked worldwide geographic variability in the incidence of gastric cancer (Fig. 47-1).[8] The highest incidence occurs in Eastern Asia, but Central and Eastern Europe and South America also have high incidence of gastric cancer. The lowest incidence of gastric cancer is seen in Africa and North America.[2] In the United States, higher gastric cancer incidence and mortality are seen in black, Asian American/Pacific Islander, American Indian/Alaska Native, and Hispanic patients as compared with non-Hispanic white patients.[1] The anatomic distribution of gastric cancers also varies, with proximal cancers occurring more commonly in relatively younger, white, and male patients.[9]

Premalignant Lesions

The risk for development of gastric cancer is greater in stomachs that harbor polyps. This risk is related most closely to polyp histologic type, size, and number. Variations in these three factors account for the wide range in reported risk associated with gastric polyps. In terms of malignant potential, gastric polyps can be divided into two broad categories—hyperplastic polyps and adenomatous polyps.

Although not premalignant, hyperplastic polyps are discussed here because they are common, occurring in up to 1% of the general population and accounting for 75% of all gastric polyps. The hyperplastic polyp contains an overgrowth of histologically normal-appearing gastric epithelium. Atypia is rare, and hyperplastic gastric polyps have no neoplastic potential. Hyperplastic polyps are generally asymptomatic. Dyspepsia and vague epigastric discomfort are the most common complaints, although coexistent gastroduodenal disease is also frequently identified. Complications are unusual, and gastrointestinal hemorrhage occurs in less than 20% of patients. When hyperplastic polyps are discovered, endoscopic removal for histologic examination is indicated and is sufficient treatment. Subsequent surveillance is not necessary, given the lack of neoplastic potential in these polyps.

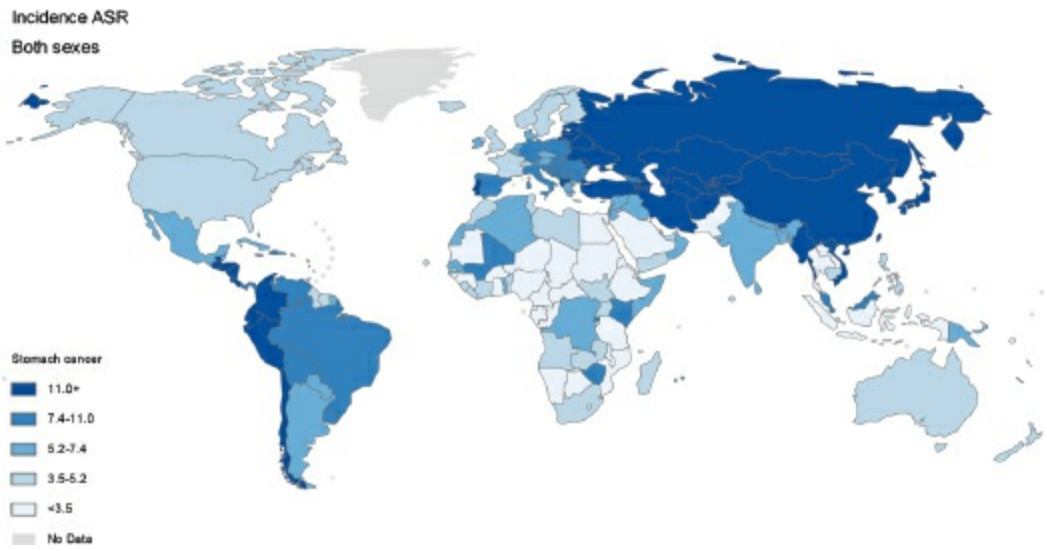

Figure 47-1. Worldwide geographic variability in gastric cancer incidence. (From Ferlay J, Soerjomataram I, Ervik M, et al. *GLOBOCAN 2012 v1.0, Cancer Incidence and Mortality Worldwide: IARC CancerBase No. 11 [Internet]*. Lyon, France: International Agency for Research on Cancer; 2013. Available from: http://globocan.iarc.fr, accessed on August 1, 2015.)

1 Adenomatous polyps also tend to be asymptomatic, but in contrast to hyperplastic polyps, adenomatous polyps carry a distinct risk for the development of malignancy.[10] Mucosal atypia is frequent, and mitotic figures are more common than in hyperplastic polyps. Dysplasia and carcinoma in situ have developed in adenomatous polyps observed over time. The risk for the development of carcinoma has been estimated at 10% to 20% and is greatest for polyps more than 2 cm in diameter. The presence of multiple adenomatous polyps increases the risk of cancer. The presence of an adenomatous polyp is also a marker indicating a diffusely increased risk for the development of cancer in the remainder of the gastric mucosa.

Endoscopic removal is indicated for pedunculated lesions and is sufficient if the polyp is completely removed and shows no evidence of invasive cancer on histologic examination. Operative excision is recommended for sessile lesions larger than 2 cm, for polyps with biopsy-proved invasive carcinoma, and for polyps complicated by pain or bleeding. After removal, repeat endoscopic surveillance is indicated to rule out recurrence at the site of previous excision, evaluate for new or missed polyps or an early carcinoma, and confirm eradication of *H. pylori,* if applicable.

Gastritis

The incidence of both gastric cancer and atrophic gastritis increases with age. Chronic gastritis is frequently associated with intestinal metaplasia and mucosal dysplasia, and these histologic features are often observed in mucosa adjacent to gastric cancer. Gastritis is frequently progressive and severe in the gastric mucosa of patients with cancer.

Gastric malignancy seems to be increased in patients with chronic gastritis associated with pernicious anemia, although the risk appears to have been overstated in the past. This disease, characterized by fundic mucosal atrophy, loss of parietal and chief cells, hypochlorhydria, and hypergastrinemia, is present in 3% of people older than 60 years. For people in whom pernicious anemia has been active for more than 5 years, the risk of gastric cancer is twice that of age-matched control subjects. Patients with pernicious anemia also have an increased risk of gastric carcinoid development. This increased risk warrants aggressive investigation of new symptoms in patients with long-standing pernicious anemia, but it is not high enough to justify repeated endoscopic surveillance.

Intestinal metaplasia, the presence of intestinal glands within the gastric mucosa, is also commonly associated with both gastritis and gastric cancer. The evolution from metaplasia to dysplasia to carcinoma to invasive cancer has been demonstrated in other organs and in adenocarcinoma arising in the gastroesophageal junction. However, no direct evidence has been provided for this progression in gastric cancer.

Helicobacter Pylori

2 As outlined above, infection with *H. pylori* has been unequivocally associated with chronic inflammatory conditions in the stomach, and this association has stimulated interest in the role of chronic infection by this organism in gastric carcinogenesis. Childhood acquisition of *H. pylori* infection is frequent in areas of high gastric cancer incidence, and high rates of infection have been identified in patients with premalignant lesions and invasive cancer. Infection with *H. pylori* is associated with an increased risk of adenocarcinoma of both major histologic types (intestinal and diffuse) and of both the body and the antrum of the stomach.[11] In contrast, *H. pylori* infection is not a risk factor for cancers of the gastroesophageal junction, which are frequently associated with mucosal abnormalities of Barrett esophagus and which seem to follow the metaplasia to dysplasia to carcinoma pattern of development.

The mechanism of carcinogenesis related to *H. pylori* infection is incompletely understood but is thought to be related to the chronic inflammation caused by the organism.[12] However, only ~1% of patients chronically infected with *H. pylori* will develop the gastric cancer phenotype, which consists of corpus-predominant gastritis, multifocal atrophic gastritis, high gastrin levels, hypo/achlorhydria, and low pepsinogen I/II ratio. The majority of subjects infected with *H. pylori* will develop the simple gastritis phenotype which is not associated with any significant clinical outcome, or the duodenal ulcer phenotype (10% to 15% of infected subjects) which consists of antral-predominant gastritis and high gastrin and acid secretion and actually provides protection from developing gastric cancer.[13] Of note, there is variable distribution of these three phenotypes geographically, with particular prevalence of the gastric cancer phenotype in certain parts of Asia where gastric cancer is common.[14] Bacterial virulence factors, environmental exposures, and host genetic factors also clearly play an important role in the pathogenesis of gastric carcinogenesis following infection-related gastritis.[12,13,15] Eradication of *H. pylori* may not prevent the development of gastric cancer once premalignant lesions have already developed.[16]

Previous Gastric Surgery

A number of uncontrolled reports have suggested that gastric cancer is more likely to develop in people who have undergone previous partial gastrectomy, with patients who have undergone a gastrojejunal (Billroth II) anastomosis at apparently higher risk for carcinogenesis than those reconstructed with a gastroduodenal anastomosis (Billroth I).[17,18] The so-called *gastric remnant cancer* is a true clinical entity, although the risk for development of this gastric neoplasm appears to have been overestimated. Several large, prospective studies with long-term follow-up indicate that the relative risk is not increased for up to 15 years after gastric resection, likely due to surgical removal of mucosa at risk for development of gastric cancer, followed by modest increases in cancer risk (three times the control value) observed only after 25 years.[19–22]

The cellular mechanisms that contribute to the development of neoplasia in the remnant stomach are unknown. Decreased luminal pH, bacterial overgrowth with increased production of *N*-nitroso carcinogens, and reflux of bile acids into the stomach have been postulated to promote cancer development, but remains unproved. Vagotomy, often performed in conjunction with gastric surgery for benign disease, does not appear to promote cancer development. A population-based study from Sweden of 7,198 vagotomized patients followed for up to 18 years did not report increased risk.[20]

A recent study explored genetic alterations in gastric remnant cancer and found that the microsatellite instability high (MSI-H) phenotype was much more common (43%) in gastric remnant cancers than in sporadic gastric cancers (6%), and that this incidence was much higher in patients who had undergone a Billroth II anastomosis (67%) as compared to those who had undergone a Billroth I anastomosis (11%). The MSI-H phenotype in these tumors was associated with inactivation of the DNA mismatch repair genes hMLH1 and hMSH2. The significance of this relationship is not yet clear.[23] Reported 5-year survival ranges from only 7% to 33% for gastric remnant cancers, but this poor prognosis is most likely due to the fact that these cancers are usually diagnosed at an advanced stage when treatment options are limited.

Hereditary Syndromes

Approximately 5% to 10% of gastric cancer may have a familial component, and 3% to 5% are associated with known inherited cancer syndromes. Hereditary diffuse gastric cancer (HDGC) is an autosomal dominant syndrome that confers a lifetime risk for the development of gastric cancer by age 80 years of 67% for men and 83% for women.[24] The average age at diagnosis is 37 years, and cancers tend to be of the diffuse type. Germline mutations in CDH1, a tumor suppressor gene that encodes the cell-to-cell adhesion protein E-cadherin, are found in 25% of patients with HDGC.[25] Patients with documented CDH1 mutations and a family history of gastric cancer may be offered prophylactic gastrectomy at a young age. Other familial cancer syndromes associated with an increased risk of gastric cancer include Lynch syndrome, juvenile polyposis syndrome, and Peutz–Jeghers syndrome. Surveillance upper endoscopy may be considered in patients with these syndromes.

Clinical Features

3 The symptoms produced by gastric cancer are nonspecific and can closely mimic those associated with a number of nonneoplastic gastroduodenal diseases, especially benign gastric ulcer (Fig. 47-2). In early gastric cancers, epigastric pain is present in over 70% of patients.[26] The pain is often constant, nonradiating, and unrelieved by food ingestion. In a surprising number of patients, pain can be relieved, at least temporarily, by antacids or gastric antisecretory drugs. Anorexia, nausea, and weight loss are present in less than 50% of patients with early gastric cancers but become increasingly common with disease progression. Dysphagia is present in 20% of patients with proximal gastric lesions. Overt gastrointestinal hemorrhage is present in only 5%. Perforation is uncommon (1%).

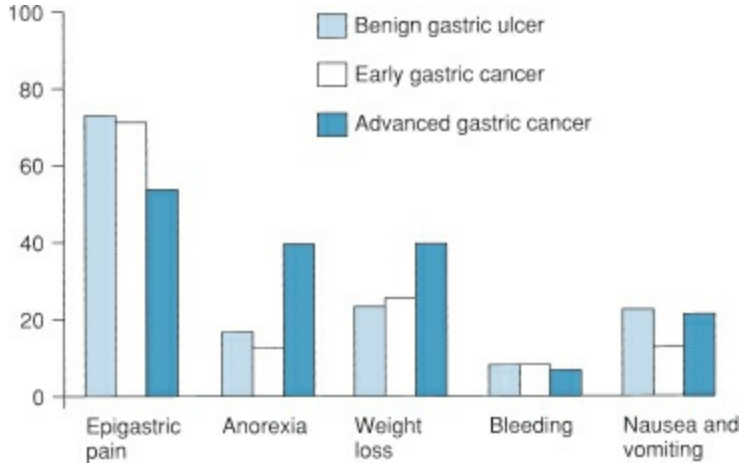

Figure 47-2. Clinical symptom frequency in benign gastric ulcer, early gastric cancer, and advanced gastric cancer. (After Meyer WC, Damiano RJ, Postlethwait RW, et al. Adenocarcinoma of the stomach: changing patterns over the past four decades. *Ann Surg* 1987;205:18.)

In most patients with early gastric cancers, physical examination is unremarkable. Stool tests positive for occult blood in one-third. Abnormal physical findings usually reflect advanced disease (Table 47-1). Cachexia, abdominal mass, hepatomegaly, and supraclavicular adenopathy usually indicate metastasic disease.[27] There are no simple laboratory tests specific for gastric neoplasms.

Diagnosis and Staging

Fiberoptic endoscopy is the most definitive diagnostic method when gastric neoplasm is suspected. In the initial stages, gastric cancers can appear polypoid, as flat, plaquelike lesions, or as shallow ulcers. Advanced lesions are typically ulcerated. The ulcer border can have an irregular, beaded appearance because of infiltrating cancer cells, and the base is frequently necrotic and shaggy. The ulcer can appear to arise from an underlying mass. Although each of these features suggests a malignant ulcer, differentiation of benign from malignant gastric ulcers can be made definitively only with gastric biopsy. Multiple biopsies of any gastric ulcer should be performed. The sensitivity of a single biopsy for diagnosing a gastric cancer is 70%, but performing multiple biopsies can increase the sensitivity to greater than 98%.[28] False-negative results occur in approximately 10% of patients, usually as the result of sampling error or due to the absence of a mucosal abnormality as can occur with linitis plastica; false-positive results are rare. Diagnostic accuracy can be further enhanced by the addition of endoscopic ultrasound (EUS) with fine-needle aspiration biopsy for infiltrative tumors involving the wall of the stomach without obvious mucosal abnormalities.

Table 47-1 Common Symptoms and Physical Findings in Gastric Cancer

Symptoms	Physical Findings
Weight loss	Guaiac-positive stool
Pain	Cachexia
Nausea and vomiting	Abdominal mass
Anorexia	Abdominal tenderness
Dysphagia	Hepatomegaly
Melena	—

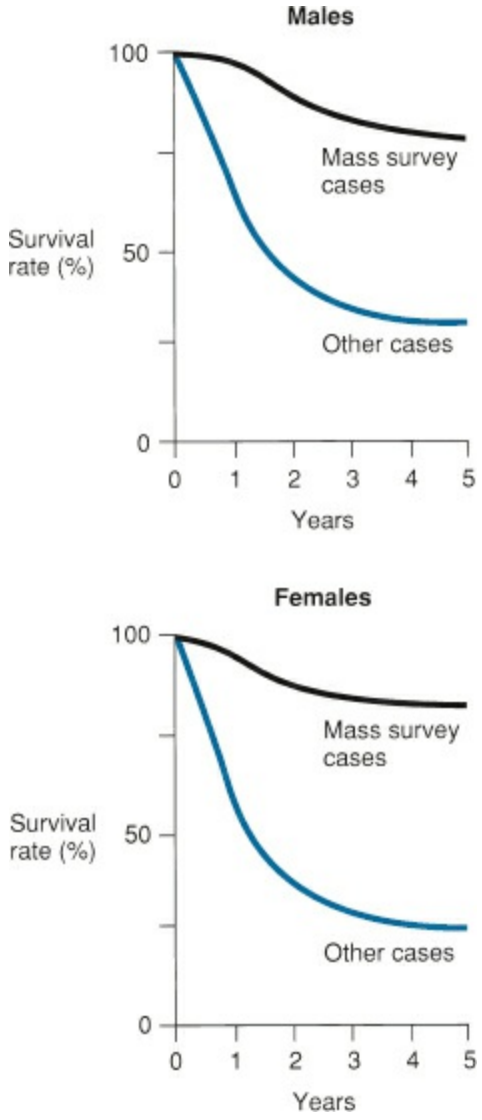

Figure 47-3. Early cancer survival rate in Japan.

Annual mass screening programs have been instituted in some countries (e.g., Japan, Venezuela, Chile) with high incidence of gastric cancer. Whether such programs significantly reduce gastric cancer mortality is unclear. In Japan, compliance with screening has been associated with a 50% decrease in gastric cancer mortality, but most of this benefit is attributable to confounding factors such as baseline general health.[29] A large cohort study failed to show any effect of screening on mortality.[30] Cancers detected in screened patients tend to be earlier cancers with fewer nodal metastases,[31] and patients with resected gastric cancer diagnosed by screening have better survival than those diagnosed after development of symptoms (Fig. 47-3). However, a survival difference between screened and unscreened gastric cancer patients persists even after accounting for stage,[31] suggesting that patient selection confounds the effect of screening on mortality. The Japanese findings that early detection and identification of early gastric cancer can improve survival has been confirmed by European investigations, in which patients with early gastric cancers have been shown to have survival rates equivalent to those of patients with benign gastric ulcer (Fig. 47-4).[26] Mass screening programs have been found to be cost-effective in high-incidence countries such as Japan and China,[32] but they are unlikely to be cost-effective in lower-incidence countries such as the United

States. The cost-effectiveness of the Japanese screening program is likely to change given the significant decrease in the rate of chronic *H. pylori* infection in Japanese under the age of 30 (25% vs. 60% as compared to their parents).[33]

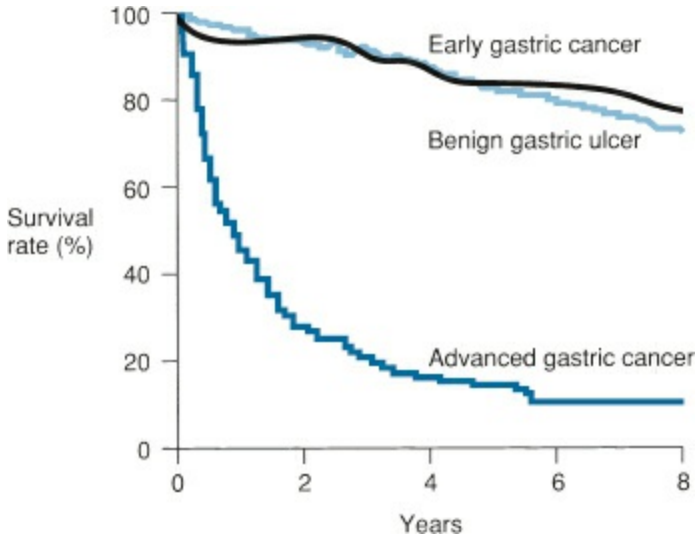

Figure 47-4. Early cancer survival rate in Europe.

Barium-contrast radiographs have, in the past, been the standard method for diagnosing gastric neoplasm. Single-contrast examinations have a diagnostic accuracy of 80%. This diagnostic yield increases to approximately 90% when double-contrast (air and barium) techniques are used. Typical findings include ulceration, the presence of a gastric mass, loss of mucosal detail, and distortion of the gastric silhouette (Fig. 47-5). Contrast radiography has been largely supplanted by endoscopy because of the ability to obtain biopsy material by the latter technique.

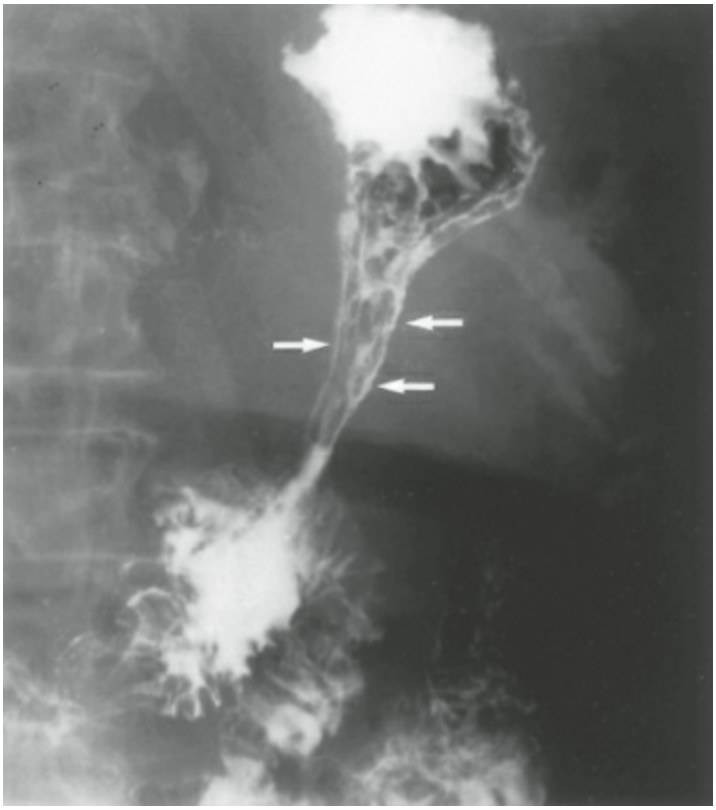

Figure 47-5. Barium-contrast radiograph demonstrating extensive involvement of the gastric body by infiltrating adenocarcinoma (linitis plastica). The gastric silhouette is narrowed (*arrows*), and the stomach is nondistensible.

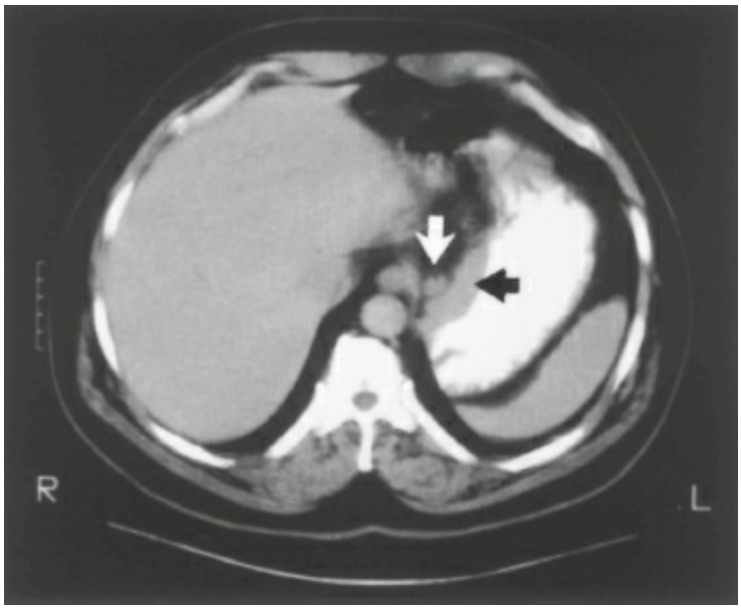

Figure 47-6. Computed tomography scan demonstrating mass along lesser curvature of the stomach (*black arrow*) and associated lymph node enlargement (*white arrow*).

Computed tomography (CT) can provide information both about the primary tumor and visceral metastatic disease. Because it is noninvasive and widely available, it is often the first staging modality that is employed in a patient diagnosed with gastric cancer. Patients who are found to have metastatic disease can be spared further, potentially invasive staging studies. When performed with intraluminal and intravenous contrast, CT can demonstrate infiltration of the gastric wall by tumor, gastric ulceration, and the presence of hepatic metastases (Figs. 47-6 and 47-7). CT may overestimate depth of

invasion, but serosal involvement can be reliably assessed (sensitivity 83% to 100%, specificity 80% to 97%).[34] The technique is less reliable for detection of small peritoneal metastases, which may be missed in 30% of cases.[35] Similarly, evaluation of nodal disease by CT is limited, with accuracy of 70% to 80% even with modern CT techniques.[36]

EUS is another useful method of preoperative evaluation for local staging and diagnosis. EUS can assess subepithelial lesions that may be confused with gastric cancer and guide biopsy of submucosal tumors within the wall of the stomach. Investigation of submucosal masses, infiltrative gastric disorders, and enlarged gastric epithelial folds, as well as differentiation of gastric lymphoma from gastric adenocarcinoma are all aided by EUS. This technique has the ability to assess the depth and pattern of gastric wall penetration by the tumor as well as relationship to adjacent structures, and has good correlation with intraoperative assessment and histologic findings. Perigastric lymph nodes involved with tumor are also reliably identified by EUS, and therefore EUS provides the most accurate assessment of local stage of disease (TN status), with an accuracy of 65% to 90% for staging depth of tumor invasion[34] and 50% to 78% for nodal involvement.[37] EUS is generally not useful for detecting metastatic disease, but it can help identify patients at risk for radiographically occult metastatic disease (e.g., peritoneal metastases) for staging laparoscopy.[35] Therefore, EUS serves as a useful adjunct to cross-sectional imaging and can help guide selection of patients for further staging studies or multimodality therapy.

Metabolic imaging with positive emission tomography (PET) using ^{18}F-fluorodeoxyglucose has been found to be less accurate than cross-sectional imaging and EUS for staging locoregional involvement, but more sensitive for detecting distant metastases in patients with gastric cancer.[37] A meta-analysis comparing PET, ultrasound, CT, and magnetic resonance imaging (MRI) found that PET scan was the most sensitive imaging modality for detecting hepatic metastases.[38] A separate study found that tumors which responded metabolically on PET to neoadjuvant chemotherapy correlated highly with histopathologic response and improved patient survival.[39] Therefore, current recommendations regarding the use of PET for staging gastric cancer are for selective use for patients with locally advanced tumors where the metastatic potential is high, and in cases where neoadjuvant therapy is being considered.[37] In these patients, the addition of PET can result in net cost savings by reducing the number of futile surgical procedures.[40]

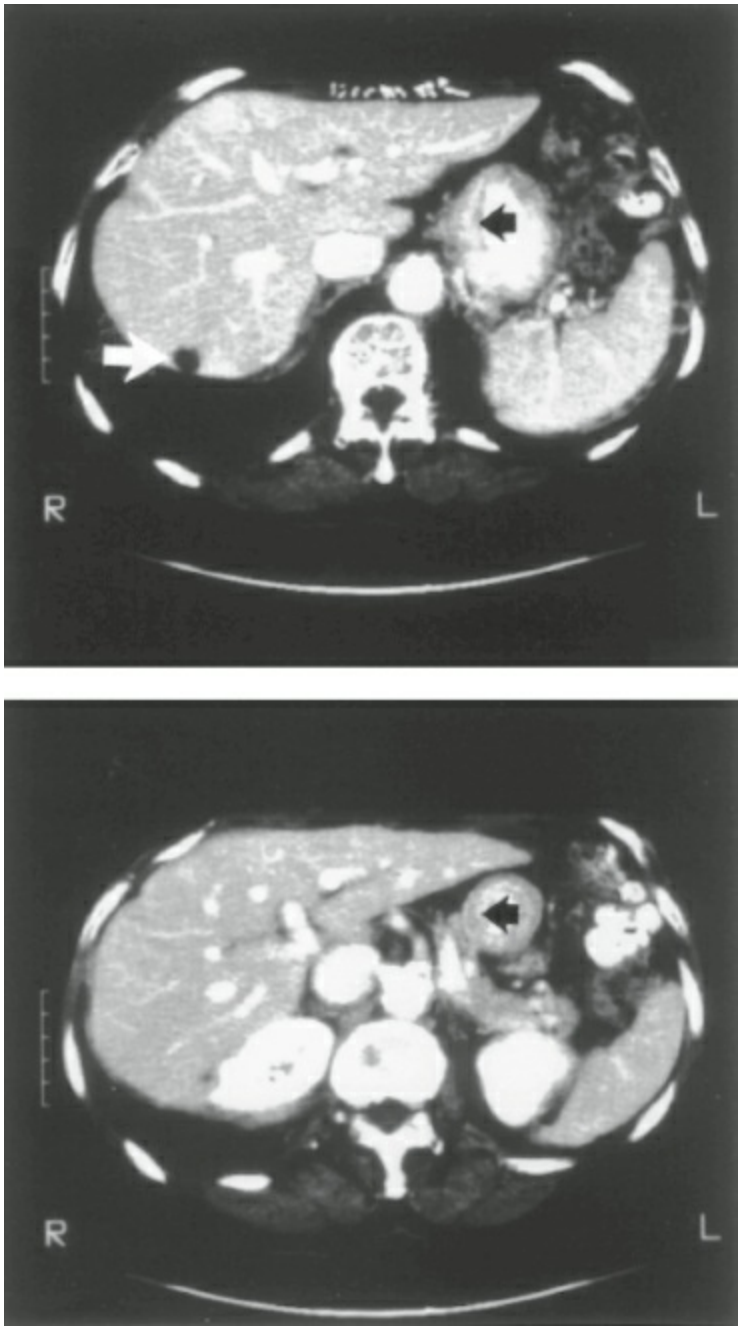

Figure 47-7. Computed tomography scans of the upper abdomen showing extensive thickening of the gastric wall (*black arrows*) caused by infiltrating adenocarcinoma and associated hepatic metastasis (*white arrow*).

Staging Laparoscopy

The peritoneal lining, omentum, and liver capsule are common sites for gastric cancer metastasis that are difficult to evaluate preoperatively by CT scanning. In prospective studies, diagnostic laparoscopy has been superior to preoperative CT or percutaneous ultrasound in detection of peritoneal, hepatic, or lymphatic metastasis.[41] Accurate identification of patients with metastatic disease is important in order to spare them futile, ultimately noncurative surgical procedures. In up to 25% of patients, laparoscopy will detect metastatic disease that precludes curative resection.[42–44] Relative to laparotomy, the shorter hospitalization and reduced operative trauma following laparoscopy may both hasten recovery and facilitate earlier initiation of systemic chemotherapy. Most patients with systemic metastasis can be treated without the need for palliative surgical resection.[45]

In addition to grossly evident intra-abdominal metastatic disease, patients with microscopic metastatic disease are at high risk for early recurrence and death after attempted curative resection.[46,47] Based on this finding, patients with positive cytology in peritoneal washings are considered to have M1 disease. Approximately one-fourth of patients subjected to staging laparoscopy prior to planned curative resection of gastric cancer will have positive peritoneal cytology; one-third of these patients will not have grossly apparent metastatic disease. Patients who clear their initially positive peritoneal cytology after systemic chemotherapy have an improved prognosis, but cure remains highly unlikely.[46]

Diagnostic laparoscopy may be considered in patients being considered for surgical resection without neoadjuvant therapy. In these situations, the procedure can be conducted at the beginning of the planned resection so as to avoid an additional general anesthesia. Patients with locally advanced (T3–T4 or node-positive) tumors who would typically be selected for neoadjuvant therapy should be considered for diagnostic laparoscopy with peritoneal washings prior to initiation of chemotherapy. The finding of positive peritoneal cytology should prompt adoption of a noncurative paradigm of treatment in most cases.

Pathology

Gastric adenocarcinoma occurs in two distinct histologic subtypes—intestinal and diffuse. These subtypes are characterized by differing pathologic and clinical features and by differing patterns of metastatic spread.

In the intestinal form of gastric cancer, the malignant cells tend to form glands. The intestinal form of malignancy is more frequently associated with gastric mucosal atrophy, chronic atrophic gastritis, intestinal metaplasia, and dysplasia. Gastric cancer with the intestinal histologic subtype is more common in populations at high risk (e.g., Japan), and it occurs with increased frequency in men and older patients. Clinical studies suggest that this subtype more frequently demonstrates bloodborne metastases.

The diffuse form of gastric adenocarcinoma does not demonstrate gland formation and tends to infiltrate tissues as a sheet of loosely adherent cells. Lymphatic invasion is common. Intraperitoneal metastases are frequent. The diffuse form of gastric adenocarcinoma tends to occur in younger patients, in women, and in populations with a relatively low incidence of gastric cancer (e.g., the United States). The prognosis is poorer for patients with the diffuse histologic subtype.

Sporadic gastric adenocarcinomas demonstrate a number of chromosomal and genetic abnormalities. Cytometric analysis reveals that gastric tumors with a large fraction of aneuploid cells (with a greater-than-normal amount of nuclear DNA) tend to be more highly infiltrative and have a poorer prognosis. Amplifications of both the HER-2/*neu* and K-*ras* proto-oncogenes have been consistently detected in gastric adenocarcinomas, and in a small percentage of tumors a lack of expression of the tumor suppressor gene *MKK4* is robustly associated with poor survival.[48] The exact mechanisms by which these genetic abnormalities contribute to gastric oncogenesis are currently unclear. Additionally, a number of growth factors, including epidermal growth factor, platelet-derived growth factor, and transforming growth factor-β, are overexpressed in gastric carcinoma cells.[49]

In the United States, the incidence of proximal gastric cancers has been increasing; such that in 2001 the rate of proximal cancers, defined as cancers arising in the cardia and fundus, exceeded that of distal cancers, defined as cancers arising in the antrum and pylorus. Proximal cancers are more likely to occur in young white men and distal cancers are more likely to occur in Asian, African American, and Hispanic patients within the United States. The proportion of tumors involving the proximal stomach has dramatically increased over the past decades; in the 1960s, only 16% involved this region, and a clear explanation for this rise in proximal disease remains elusive. In 10% of cases, the stomach is diffusely involved at the time of diagnosis.[27] Prognosis is poorer for tumors arising from the proximal stomach or for those with diffuse involvement of the organ relative to distal tumors, and these patients are much more likely to need neoadjuvant and adjuvant therapy.[9,50]

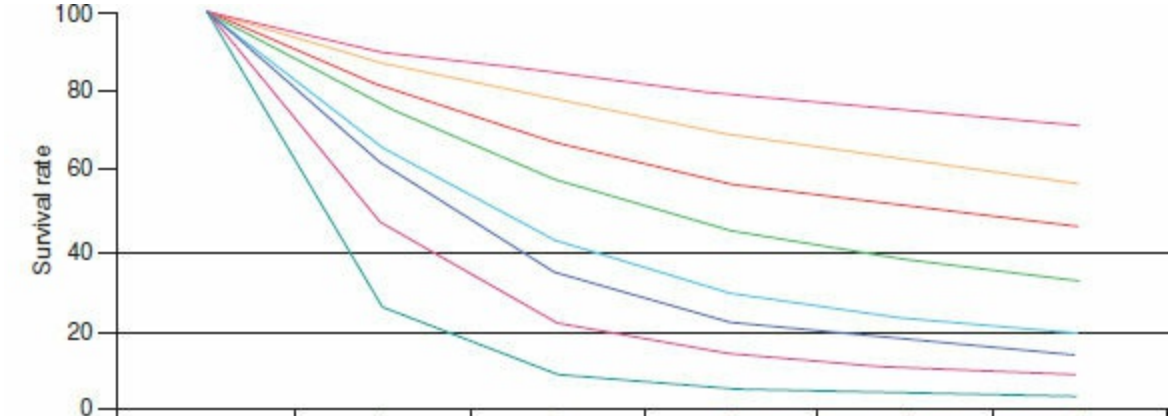

	At Dx	1	2	3	4	5
IA	100.0	90.2	84.8	79.8	74.8	70.8
IB	100.0	87.4	77.9	69.9	62.7	57.4
IIA	100.0	82.1	67.4	57.2	50.2	45.5
IIB	100.0	76.8	58.3	46.0	38.4	32.8
IIIA	100.0	66.5	42.4	29.9	23.5	19.8
IIIB	100.0	61.6	35.4	22.9	17.8	14.0
IIIC	100.0	47.4	21.8	14.2	11.0	9.2
IV	100.0	27.0	10.0	5.6	4.5	4.0

Figure 47-8. Gastric cancer survival by stage. Used with the permission of the American Joint Committee on Cancer (AJCC), Chicago, Illinois. The original source for this material is the AJCC Cancer Staging Manual, Seventh Edition (2010) published by Springer Science and Business Media LLC, www.springer.com

Table 47-2 Seventh Edition AJCC Staging System for Gastric Cancer

Primary Tumor	
T0	No evidence of primary tumor
Tis	Carcinoma in situ; intraepithelial tumor without invasion of the lamina propria
T1a	Tumor invades lamina propria or muscularis mucosae
T1b	Tumor invades submucosa
T2	Tumor invades muscularis propria
T3	Tumor penetrates subserosal connective tissue without invasion of visceral peritoneum or adjacent structures
T4a	Tumor invades serosa (visceral peritoneum)
T4b	Tumor invades adjacent structures
Regional Lymph Node Involvement	
N0	No regional nodal metatasis
N1	Metastasis to 1–2 regional lymph nodes
N2	Metastasis to 3–6 regional lymph nodes
N3	Metastasis in 7 or more regional lymph nodes
Distant Metastasis	
M0	No distant metastasis
M1	Distant metastasis
Stage Grouping	
Stage 0	Tis N0 M0
Stage IA	T1 N0 M0
Stage IB	T1 N1 M0 T2 N0 M0
Stage IIA	T1 N2 M0 T2 N1 M0 T3 N0 M0
Stage IIB	T1 N3 M0 T2 N2 M0 T3 N1 M0 T4a N0 M0
Stage IIIA	T2 N3 M0 T3 N2 M0 T4a N1 M0
Stage IIIB	T3 N3 M0 T4a N2 M0 T4b N1 M0 T4b N0 M0
Stage IIIC	T4a N3 M0 T4b N3 M0 T4b N2 M0
Stage IV	Any T Any N M1

Used with the permission of the American Joint Committee on Cancer (AJCC), Chicago, Illinois. The original source for this material is the AJCC Cancer Staging Manual, Seventh Edition (2010) published by Springer Science and Business Media LLC, www.springer.com

The seventh edition American Joint Committee on Cancer (AJCC) staging system for gastric cancer is presented in Table 47-2.[51] The staging system accurately discriminates prognosis based on pathologic factors for tumors located 5 cm distal to the esophagogastric junction (EGJ) and below or arising within 5 cm of, but not crossing, the

EGJ (Fig. 47-8). The AJCC recommends that cancers arising within 5 cm of the EGJ that cross into the EGJ or esophagus be staged and treated as esophageal cancers. A consideration of staging data illustrates the high frequency with which lymph node metastases are present at the time of diagnosis in the United States, and the severe impact lymphatic involvement has on survival. Even early gastric cancers (tumors restricted to the mucosa and submucosa) have a 15% prevalence of nodal metastasis.

Curative-Intent Treatment

Surgical resection is the only potentially curative therapy for gastric cancer, but an advanced stage of disease at the time of diagnosis precludes curative resection for most patients.

Since the mid-1990s, the surgical treatment of gastric cancer has continued to evolve, with minimally invasive approaches increasingly pursued for early cancers and increasingly radical operations advocated by some for advanced tumors. Japanese surgeons have reported the largest experience with early gastric cancer. The Japanese Gastric Cancer Association defines early gastric cancer as tumor in which invasion is restricted to the mucosa or submucosa.[52] The presence or absence of lymph node metastasis is not considered in this classification. While the presence of lymphatic metastasis cannot be correctly judged by endoscopic findings, it is critically important in prognosis. For tumors confined to the mucosa, lymphatic metastasis is present in 1-3% of cases; with submucosal involvement, the rate of nodal positivity increases to 14-20%.[53,54]

Endoscopic Resection

For intestinal-type mucosal tumors less than 2 cm in size without ulceration or evidence of lymphovascular invasion, endoscopic mucosal resection (EMR) may be performed. With this approach, postoperative bleeding or perforation has been reported in 5%, and in 17% histologic examination revealed submucosal invasion that required further operative treatment.[55] Earlier reports suggested underestimation of tumor invasion in 45% and missed lymphatic metastasis in 9% urged caution before widespread acceptance of this technique.[56] However, in experienced centers good results can be obtained. A Japanese series of 131 patients reported disease-free survival of 99% at 10 years.[57] Endoscopic submucosal dissection (ESD) is an emerging technique that may allow larger tumors to be endoscopically resected than with EMR. In the absence of randomized trials comparing EMR and ESD against surgical resection, surgical resection remains the gold standard for potentially curative therapy in appropriate-risk patients.

Surgical Resection

4The fundamental principle of surgical resection of gastric cancer is complete extirpation of the primary tumor. The extent of gastric resection is determined primarily by the need to obtain a resection margin free of microscopic disease (R0 resection). Microscopic involvement of the resection margin by tumor cells (R1 resection) is associated with poor prognosis.[27] Patients with positive surgical margins are at high risk for development of recurrent disease, and histologically positive margins are strongly correlated with the development of anastomotic recurrence. In the setting of ≥ 5 positive nodes, however, margin positivity does not impact survival,[58] because these patients are at higher risk for systemic recurrence. In contrast to other gastrointestinal malignancies such as colon cancer, gastric cancer frequently demonstrates extensive intramural spread, especially the diffuse type. The propensity for intramural spread is related, in part, to the extensive anastomosing capillary and lymphatic network in the wall of the stomach. Retrospective studies suggest that when performing a subtotal gastrectomy, a margin of 6 cm from the tumor mass proximally and 3 to 5.9 cm distally is necessary to minimize anastomotic recurrence.[59] Frozen section evaluation of resection margins may be obtained prior to proceeding with reconstruction in order to improve the probability that R0 resection can be achieved.

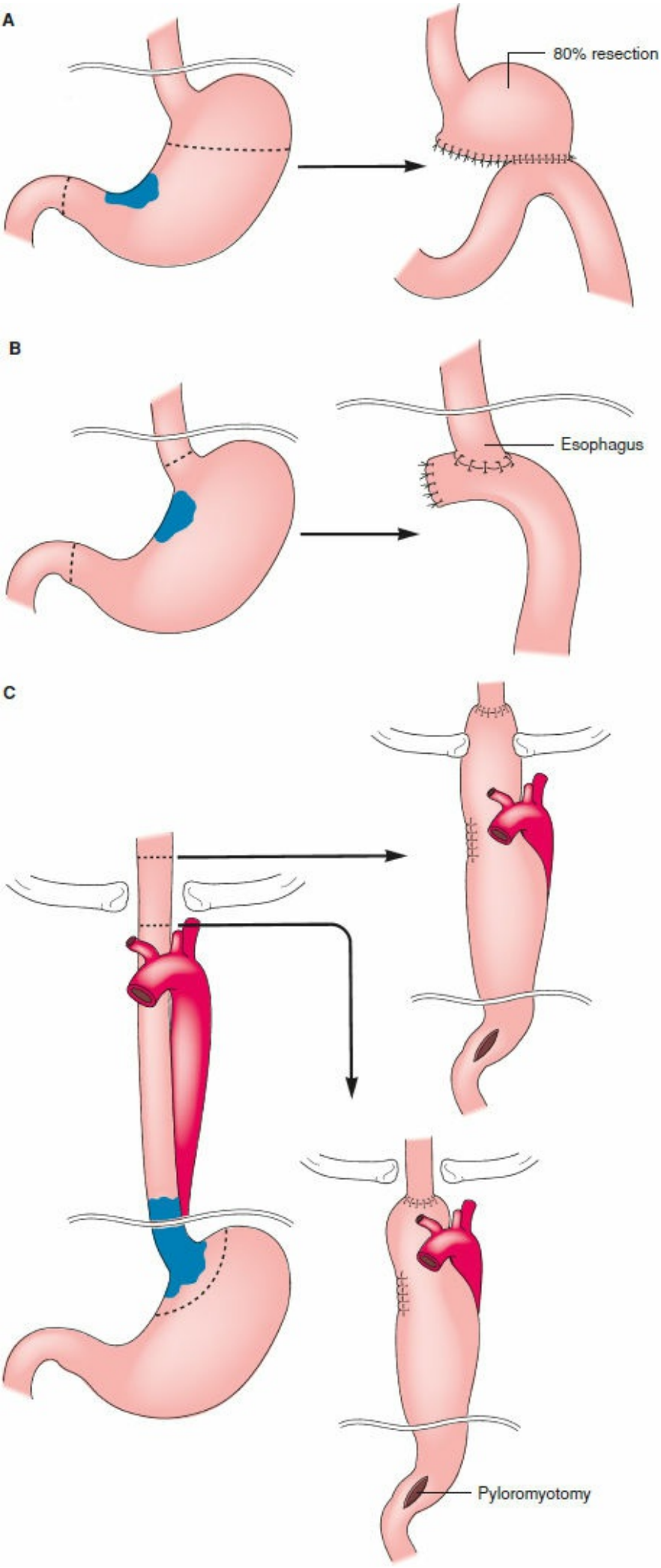
A
80% resection
B
Esophagus
C
Pyloromyotomy

Figure 47-9. Surgical options for resection of gastric neoplasms. **A:** Subtotal gastrectomy with gastrojejunal reconstruction. **B:** Total gastrectomy with esophagojejunostomy. **C:** Esophagogastrectomy with anastomosis in cervical or thoracic position.

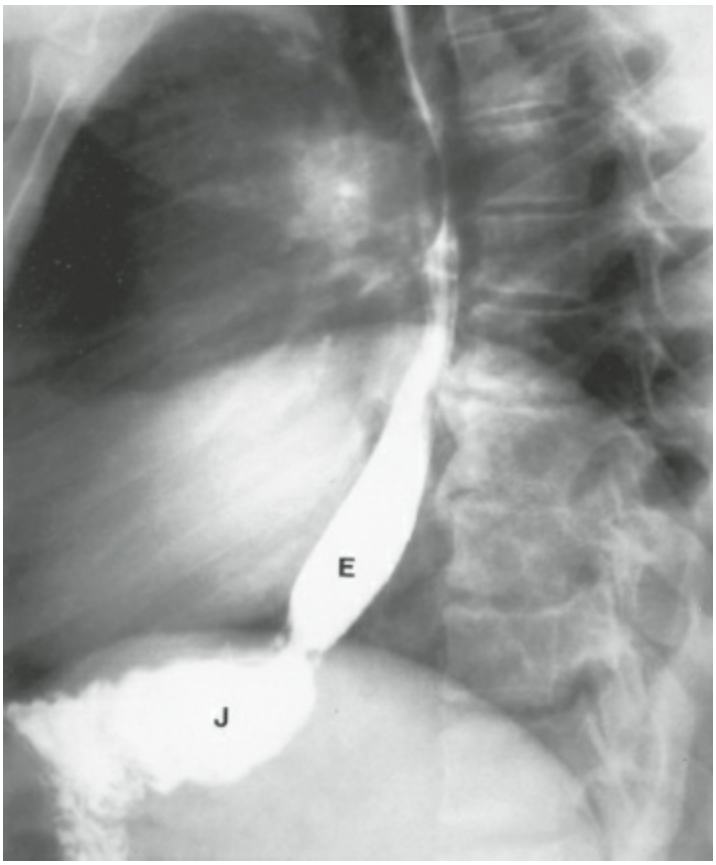

Figure 47-10. Postoperative radiograph after total gastrectomy with esophagojejunal anastomosis, showing esophagus (E) and jejunum (J).

For lesions in the distal two-thirds of the stomach, distal subtotal gastrectomy is usually sufficient for complete removal of the primary tumor. In contrast, lesions in the upper third of the stomach may require total gastrectomy or esophagogastrectomy to encompass the tumor (Figs. 47-9 and 47-10). For tumors involving the cardia without involvement of the gastroesophageal junction, some have advocated proximal gastrectomy as an alternative to total gastrectomy with esophagojejunostomy with the goal of preserving a gastric reservoir to lessen postoperative weight loss. This procedure does not compromise oncologic outcomes,[60,61] but there is a significantly higher incidence of severe reflux esophagitis with proximal gastrectomy.[37] Use of a jejunal interposition has been proposed to mitigate reflux esophagitis, but quality-of-life data are conflicting.

Radical gastric operations can be performed with acceptable morbidity and low mortality rates in the older age groups at greatest risk for gastric cancer. Mortality rates for total gastrectomy range from 3% to 7%.[62] There is some evidence that outcomes are superior at higher-volume centers. Defining what constitutes a high-volume center is problematic, but one review suggests that hospitals with at least 21 gastric cancer resections per year may achieve optimal outcomes.[63] Nutritional support in the immediate postoperative period is an important adjunctive measure as patients resume

oral intake,[64] and many surgeons place a jejunal feeding tube at the time of total gastrectomy to ensure that optimal enteral nutrition can be delivered in the postoperative period. Surgical reconstructions that interpose a small intestinal reservoir between the esophagus and the jejunum have been advocated after total gastrectomy, but a clear nutritional benefit has not been demonstrated.[65–68]

Because gastric cancer metastasizes so frequently to lymph nodes, radical extirpation of draining lymph nodes has both therapeutic and staging implications.[69] The value of routine-extended lymphadenectomy beyond the perigastric lymph nodes in the treatment of gastric adenocarcinoma, however, is controversial. The first favorable experience was reported from Japan.[70,71] Resections in the original Japanese system are shown in Table 47-3, and the current nomenclature used to define extent of lymphadenectomy is shown in Table 47-4 and Figure 47-11. Only retrospective studies of extended perigastric lymphadenectomy have been reported from Japan. Initial reports suggested an improvement of approximately 10%, stage for stage, for patients with advanced disease treated with D2 or D3 operations.[70–73] The benefits of extended lymphadenectomy have not been confirmed in non-Japanese centers, and several randomized trials in Western centers have failed to show a survival benefit for extended lymphadenectomy when the entire patient population was analyzed.[74–78] Long-term (median 15-year) follow-up results from the Dutch trial of D1 versus D2 lymphadenectomy have shown a lower gastric cancer–related death rate in the D2 group (37% vs. 48%) and lower rates of local and regional recurrence.[79] The significance of this finding is unclear given the absence of an overall survival benefit and the long period of time it took for this difference to manifest. Improvements in adjuvant therapy also complicate the interpretation of historical results of extended lymphadenectomy.

Table 47-3 Lymphadenectomy Resections in the Original System of the Japanese Research Society for Gastric Cancer

Level	Description
R1	Resection of stomach, omentum, and perigastric lymph nodes
R2	Resection of stomach, omentum, and en bloc removal of the superior leaf of the transverse mesocolon, the pancreatic capsule and lymph nodes along the branches of the celiac artery and in the infraduodenal and supraduodenal areas
R3	Resection of the above structures plus lymph nodes along the aorta and esophagus, along with the spleen and the tail of the pancreas, and skeletonization of vessels in the porta hepatis

The safety of extended lymphadenectomy is disputed. Data from a national Japanese registry indicate a contemporary mortality of less than 1%.[80] Low mortality risks have been reported from multi-institutional trials conducted in Italy and Germany.[78,81] Investigations from the United States, Britain, and the Netherlands have been less

optimistic, indicating increased short-term morbidity and in-hospital mortality.[74,75]

Table 47-4 Current Nomenclature Used to Describe the Extent of Lymphadenectomy Performed in Conjunction with Gastrectomy

Level	Description
D0	Any lymph node removal that is less than D1
D1	Resection of greater and lesser omenta, including the perigastric nodes along the right and left cardia, nodes along the lesser and greater curvatures, suprapyloric nodes along the right gastric artery, and infrapyloric nodes
D2	D1 dissection plus nodes along the left gastric artery, common hepatic artery, celiac trunk, splenic hilum, and splenic artery
D3	D2 dissection plus nodes in the hepatoduodenal ligament, retropancreatic nodes, and nodes at the root of the mesentery the para-aortic lymph nodes
D4	D3 dissection plus paracolic and para-aortic nodes

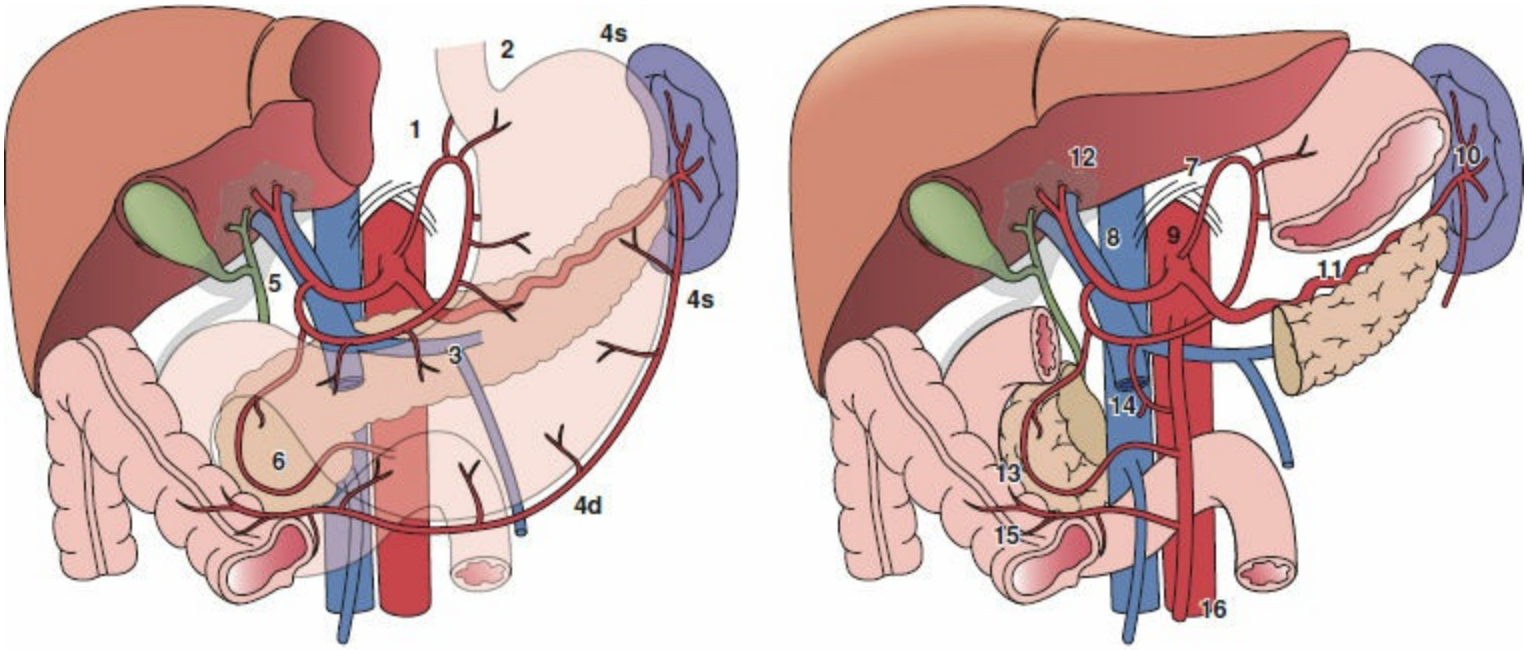

N1 Lymph nodes (perigastric)
1 Right cardiac nodes
2 Left cardiac nodes
3 Nodes along the lesser curvature
4d Lymph nodes along the short gastric and the left gastroepiploic vessels
4s Lymph nodes along the right gastroepiploic vessels
5 Suprapyloric nodes
6 Infrapyloric nodes

N2 Lymph nodes (celiac axis branches)
7 Nodes along root left gastric artery
8 Nodes along common hepatic artery
9 Nodes around celiac axis
10 Nodes at splenic hilum
11 Nodes along splenic artery

N3 Lymph nodes
12 Nodes at the hepatoduodenal ligament
13 Retropancreatic (periduodenal) nodes
14 Nodes at the root of the mesentery

N4 Lymph nodes
15 Nodes along the middle colic vein
16 Para-aortic nodes

Figure 47-11. Lymph node locations and groupings. D1 dissection: removal of N1 nodes. D2 dissection: removal of N1 and N2 nodes. D3 dissection: removal of N1, N2, and N3 nodes. D4 dissection: removal of N1–N4 nodes.[79]

Histologically positive lymph nodes are frequently present in the splenic hilum and along the splenic artery, and routine splenectomy has been practiced in some centers. Splenectomy has not been demonstrated to improve outcome for similarly staged patients.[82,83] Likewise, resection of the tail or body of the pancreas has not been demonstrated to improve survival. Thus, associated splenectomy or pancreatosplenectomy is only beneficial when there is direct extension or bulky adenopathy at the splenic hilum.[84] Resection of adjacent organs may be required for local control if direct invasion has occurred. In this circumstance, operative morbidity is increased and the long-term survival rate is approximately 25%.[85]

In some centers in the United States, greater emphasis has been placed on the total number of nodes removed and histologically examined rather than the location of the nodes (e.g., D1 vs. D2 lymphadenectomy). Current recommendations of the AJCC staging for gastric cancer suggest that a minimum of 15 nodes be evaluated for accurate staging.[51]

Laparoscopic gastrectomy has also been reported for treatment of gastric malignancy, with advantages of reduced pain, shorter hospitalization, and improved quality of life,[86] and studies from Japan, Korea, and Italy have demonstrated that distal, subtotal, and total gastrectomy with lymphadenectomy is feasible with acceptable morbidity and mortality. However, the majority of the patients in these studies had early gastric cancer.[37] A meta-analysis of four small single-institution randomized trials from Asia demonstrated lower nodal harvests with a laparoscopic approach for early gastric cancer. Complication rates were lower in the laparoscopic group but did not translate into differences in time to oral intake or length of stay.[87] A single-institution Western randomized trial of laparoscopic versus open subtotal gastrectomy for distal gastric cancer (both early and locally advanced) did report equivalent lymph node retrieval (33.4 $\pm$ 7.4 in the open group vs. 30 $\pm$ 14.9 in the laparoscopic group), as well as similar rates of perioperative morbidity and mortality. Five-year overall and disease-free survival were also similar for both groups: 55.7% and 54.8% for the laparoscopic group versus 58.9% and 57.3% for the open group.[88] More recently, interim results of a Korean multicenter randomized trial focused on early gastric cancer demonstrated equivalent perioperative morbidity and mortality, but no data on oncologic outcomes have been published to date.[89] As such, there are still no published multi-institutional randomized data to confirm the oncologic equivalency of laparoscopic gastrectomy as compared with the open approach.

Neoadjuvant and Adjuvant Therapies

5 Given the largely disappointing outcomes of locally advanced gastric cancer in Western countries, significant interest has focused on the use of multimodality therapy. Several neoadjuvant and adjuvant approaches have been explored. Although there is no consensus on the optimal approach, it is clear that all patients with locally advanced disease should be considered for multimodality therapy. Two general approaches are popular in the West.

Adjuvant chemoradiotherapy may be considered both for patients known to have locally advanced disease from the outset as well as for those thought to have early gastric cancer who are subsequently upstaged after surgical resection. The largest (n = 556) and most recent trial evaluating this approach was the US Intergroup INT0116 trial, which compared surgical resection followed by 5-fluorouracil (5FU), leucovorin, and external beam radiation versus resection alone in patients with gastric or EGJ cancer.[90] Most patients (69%) had T3/T4 tumors, and 85% had nodal metastases. Three-year overall survival (50% vs. 41%) and 5-year overall survival (43% vs. 28%) were significantly improved with multimodality therapy. Both local and distant failures were reduced by chemoradiation. The primary criticism of this trial was that the extent of lymphadenectomy was not standardized, and less than D1 lymph node dissection was performed in 54% of the patients, which may have contributed to the poor outcomes in the surgery-only group and led to overstatement of the true benefit of chemoradiation. Additionally, one-third of patients were unable to complete their adjuvant chemoradiation due to perioperative complications or treatment-associated toxicities. Finally, due to changes in the staging system for gastric cancer, the benefit of this regimen for patients with T2N0 disease is questionable.

A more common approach in Europe is to administer preoperative chemotherapy, with or without additional postoperative chemotherapy. The most influential trial evaluating this approach was the Medical Research Council Adjuvant Gastric Infusional Chemotherapy (MAGIC) trial, which randomly assigned 503 patients with gastric, distal esophageal, or EGJ adenocarcinomas to surgery plus perioperative chemotherapy or surgery alone.[91] Planned chemotherapy consisted of three preoperative and three postoperative cycles of epirubicin, cisplatin, and 5FU (ECF regimen). Patients with T2 and higher tumors were eligible. This study demonstrated a significant survival benefit in patients receiving perioperative chemotherapy (5-year survival 36% vs. 23%), with reduced local and distant failures. Extent of lymphadenectomy was improved as compared to the Intergroup trial, but there were significantly more patients with T1/2 tumors and N0/1 disease in the perioperative chemotherapy group, suggesting a baseline imbalance in prognosis. Additionally, only 42% of patients completed all courses of chemotherapy. Finally, as with the Intergroup trial it is unclear whether T2N0 patients are as likely to benefit from this approach as those with more advanced disease. Despite the limitations of these studies, the improved survival observed in both trials makes it clear that a multimodality approach is superior to surgery alone. Numerous ongoing studies are investigating the relative benefits of various chemotherapeutic regimens as

well as the incremental benefit of chemoradiotherapy versus chemotherapy alone. Targeted therapies are also being investigated. For example, the Trastuzumab for Gastric Cancer (ToGA) trial demonstrated a modest but statistically significant survival benefit with the addition of trastuzumab to cytotoxic chemotherapy in patients with HER2-positive gastric cancer.[92] Patients with locally advanced resectable gastric cancer are optimally treated in a center where a collaborative multidisciplinary treatment approach can be devised and executed (Algorithm 47-1).

Palliative Treatment

When preoperative evaluation demonstrates disseminated disease, palliation of symptoms becomes a primary consideration. Palliation does not usually require surgery. Obstruction and bleeding can be managed nonoperatively with endoscopic techniques or radiotherapy in selected patients. Dysphagia and bleeding caused by proximal lesions can also be alleviated endoscopically (laser therapy or stenting) in the majority of patients. Nonetheless, for a minority of patients, surgical palliation may be indicated. In the setting of metastatic gastric cancer, palliative resection does not improve survival. Noncurative resection may be indicated, for example, in the setting of intractable bleeding from the primary tumor. Surgical palliation of obstructive symptoms (resection or gastrojejunostomy) should generally be reserved for cases in which less invasive methods are contraindicated, technically infeasible, or unsuccessful. In addition to radiotherapy and endoscopic ablation or stenting, placement of a feeding jejunostomy tube with or without venting gastrostomy may be used to palliate gastric outlet obstruction, especially in patients with limited life expectancy.

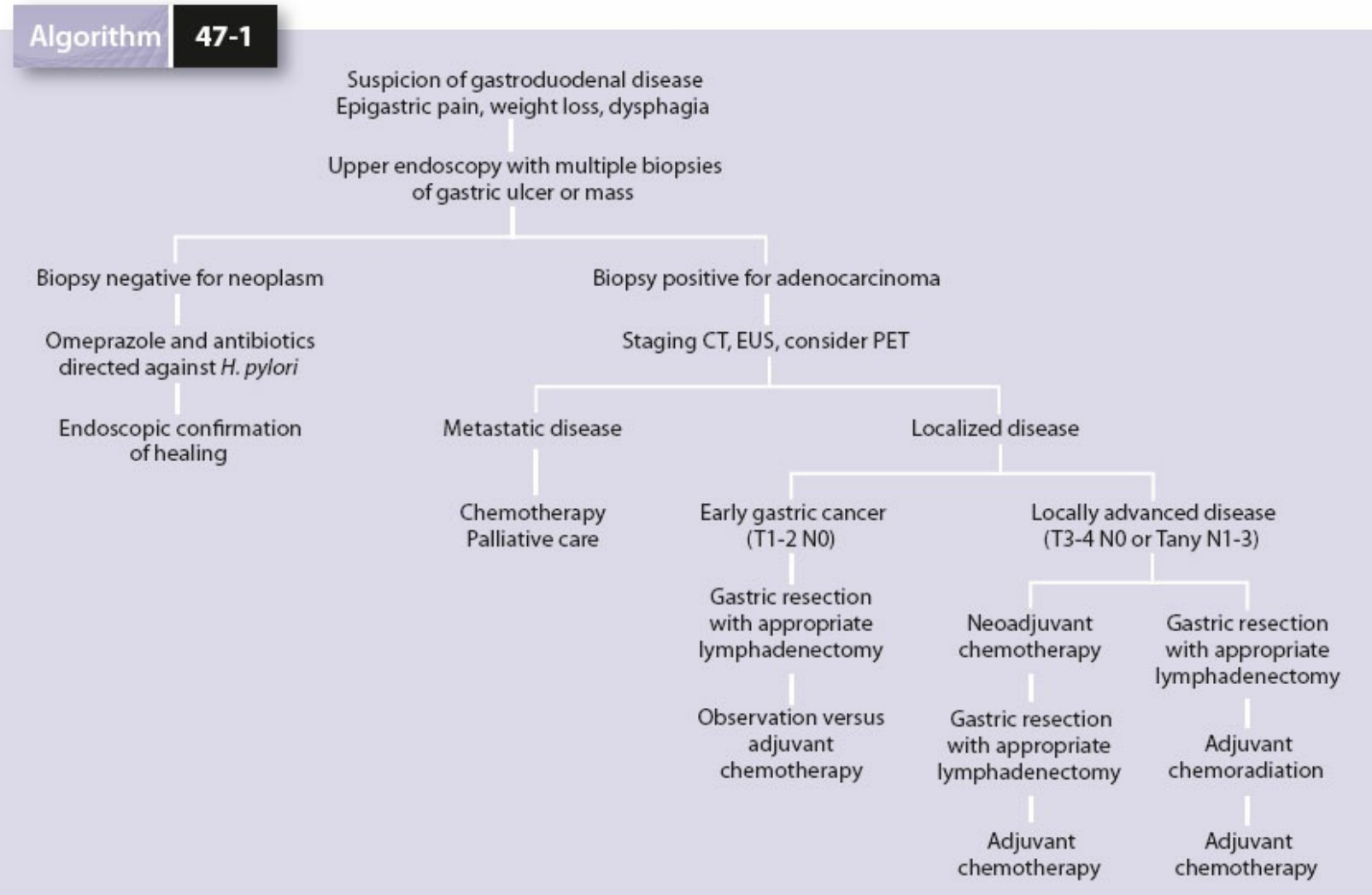

Algorithm 47-1. Treatment of gastric adenocarcinoma.

GASTRIC LYMPHOMA

Clinical Features

The stomach is the site of more than half of gastrointestinal lymphomas and is the most common organ involved in extranodal lymphomas. Non-Hodgkin lymphomas account for approximately 5% of malignant gastric tumors; lymphoma represents an increasing proportion of gastric neoplasms diagnosed currently. Patients are considered to have primary gastric lymphoma if initial symptoms are gastric and the stomach is exclusively or predominantly involved with the tumor. Patients who do not fulfill these criteria are considered to have secondary gastric involvement from systemic lymphoma.

Gastric lymphoma is distinctly uncommon in children and young adults. The peak incidence is in the sixth and seventh decades. Symptoms are usually indistinguishable from those of peptic ulcer disease and gastric adenocarcinoma. Epigastric pain, weight loss, anorexia, nausea, and vomiting are common.[93] Systemic B symptoms such as fever and night sweats occur in a minority of patients but may be suggestive of the diagnosis. Although gross bleeding is uncommon, occult hemorrhage and anemia are observed in more than half of patients. Patients rarely have spontaneous perforation.

Diagnosis

Radiologic findings are similar to those for adenocarcinoma (gastric thickening and lymphadenopathy). Endoscopic examination is the diagnostic method of choice. The endoscopic appearance of lesions may be ulcerated, polypoid, or infiltrative, and this morphology may be further characterized by EUS. Gastric lymphoma is most commonly localized to the middle or distal stomach and unusually involves the proximal stomach, in contrast to gastric adenocarcinoma. Endoscopic biopsy, combined with endoscopic brush cytology and EUS, provides positive diagnosis in 90% of cases. Submucosal growth without ulceration of the overlying mucosa can occasionally render endoscopic biopsy nondiagnostic. EUS-guided biopsy is useful in this circumstance.

Appropriate staging should search for evidence of systemic disease. CT of the chest and abdomen (to detect lymphadenopathy), bone marrow biopsy, and biopsy of enlarged peripheral lymph nodes are all appropriate.

Mucosa-Associated Lymphoid Tissue

The concept that low-grade gastric lymphomas have features resembling mucosa-associated lymphoid tissue (MALT) is a major advance in the understanding of gastric lymphomas. The gastric submucosa does not ordinarily contain lymphoid tissue, and the development of lymphoid tissue resembling small intestinal Peyer patches is believed to occur in response to infection with *H. pylori.*[94] A number of observations support a causal relationship between chronic *H. pylori* infection and gastric lymphoma development. *H. pylori* is present in the stomachs of more than half of patients with gastric lymphoma [95] and 90% of those with gastric MALT lymphoma.[96] As with gastric adenocarcinoma, geographic regions with a high prevalence of *H. pylori* also have a high incidence of gastric lymphoma. Infection with *H. pylori* has been noted to precede development of gastric lymphoma.[97]

Gastric MALT lymphoma is postulated to begin with chronic inflammation due to infection with *H. pylori.* Chronic gastritis leads to the accumulation of CD4+ lymphocytes and B cells in the gastric lamina propria. *H. pylori*-derived antigens drive T-cell activation, interleukin-2 (IL-2) release, and B-cell proliferation.[98] Progressive genetic rearrangements lead to IL-2–independent B-cell proliferation. With cumulative genetic defects, low-grade MALT lymphoma progresses to high-grade disease.

Low-grade MALT lymphomas resemble Peyer patches. Lymphoma cells invade between follicles and into gastric epithelium; invasion of gastric glands forms characteristic lymphoepithelial lesions. Low-grade lesions are often multifocal. Low-grade MALT lesions are less likely than high-grade tumors to invade transmurally, involve perigastric lymph nodes, or invade adjacent organs.[97] Approximately 40% of gastric lymphomas are low-grade MALT lymphomas.[99]

6 The concept that low-grade lymphoma depends on continued *H. pylori* antigenic stimulation supports eradication of *H. pylori* with antibiotics as first-line antineoplastic therapy. Complete regression of low-grade gastric MALT lymphomas with antibiotic treatment has been reported in 70% to 100% of cases.[100,101] The median time to complete response is 5 months.[102] Most patients with partial responses were subsequently determined also to have foci of high-grade lymphoma. Radiation and chemotherapy have been proposed as salvage for antibiotic treatment failures or for the minority of patients with *H. pylori*-negative gastric MALT lymphoma.

Non-MALT Lymphomas

Most non-MALT gastric lymphomas are diffuse large B-cell lymphomas (DLBCL), including those that were previously called "high-grade MALT lymphomas." DLBCL typically exhibit more aggressive behavior and worse prognosis than MALT lymphomas. Other histologies, such as mantle cell, follicular, and peripheral T-cell lymphomas can also be seen. Survival for gastric lymphoma is closely linked to stage at diagnosis (Fig. 47-12). In the past, a multimodality treatment program was used in most centers for primary gastric lymphomas, with gastrectomy as the first step in the therapeutic strategy.[103] This approach evolved empirically, without prospective data to support it. Several advantages of this approach had been cited: (a) more accurate histologic evaluation was possible; (b) in cases with localized tumor, the procedure could be curative; and (c) gastrectomy eliminated the risk of life-threatening hemorrhage or perforation which may occur with the treatment of tumors involving the full thickness of the gastric wall.[104] However, the role of gastrectomy for both staging and treatment of gastric lymphoma has diminished significantly, based in part on results of a randomized trial demonstrating superior outcomes with CHOP (cyclophosphamide, doxorubicin, vincristine, and prednisone) chemotherapy than with surgery, surgery plus radiotherapy, or surgery with CHOP (Fig. 47-13).[105]. It has also been recognized that the incidence of perforation during chemotherapy is only 5%. Most patients are currently treated with chemotherapy (commonly CHOP with rituximab) with or without radiotherapy. Surgical intervention is generally reserved for complications such as obstruction, bleeding, or perforation.

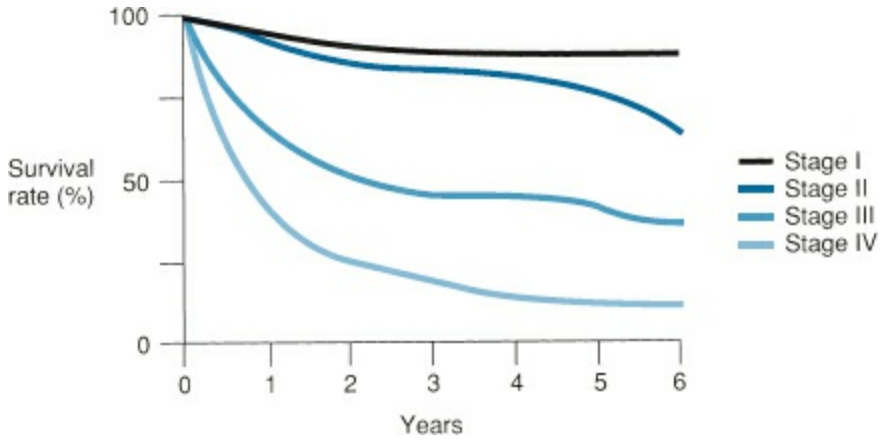

Figure 47-12. Survival with gastric lymphoma, by stage.

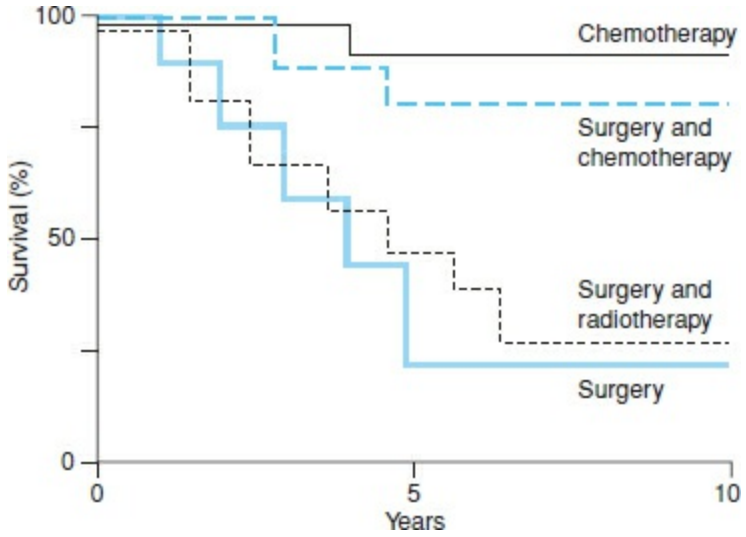

Figure 47-13. Relapse-free survival by treatment assignment for primary gastric diffuse large B-cell lymphoma.

GASTRIC CARCINOIDS

Gastric carcinoid tumors were previously considered to be very rare tumors, but more recent studies have reported that as many as 10% to 30% of all carcinoids occur in the stomach, and they account for at least 1% of all gastric neoplasms.[106] Most patients with small gastric carcinoids are asymptomatic, and these tumors are most commonly diagnosed incidentally. Occasionally, however, larger tumors can present with abdominal pain, bleeding, or symptoms related to the secretion of bioactive substances which can be produced by the tumor. When viewed endoscopically at an early stage, carcinoids are reddish-pink to yellow submucosal nodules in the proximal stomach. Endoscopic biopsy is usually diagnostic if deep enough to sample submucosal tumor cells.

Four types of gastric carcinoids have been described. Type 1 is the most common (70% to 80%) and is associated with chronic atrophic gastritis and pernicious anemia. These tumors tend to be small (<1 cm) and multiple, and their behavior indolent. When they are less than 2 cm in size, they metastasize less than 10% of the time.[107] They can typically be followed and removed endoscopically, but surgery may be necessary for larger or very numerous tumors. Type 2 tumors comprise approximately 5% of gastric carcinoids and occur in patients with Zollinger–Ellison syndrome (gastrinomas), often in the setting of multiple endocrine neoplasia type 1 (MEN1). Like type 1 tumors, they are often small, multiple, and indolent, and they can be treated endoscopically for the most part. Both type 1 and type 2 gastric carcinoid tumors are associated with hypergastrinemia. Type 1 and 2 gastric carcinoids arise from enterochromaffin-like (ECL) cells, which mediate the secretion of histamine and in turn stimulate parietal cells to secrete acid. Hypergastrinemia (due to chronic atrophic gastritis in type 1 and gastrinoma in type 2) is thought to cause ECL cell hyperplasia and lead to the development of gastric carcinoids over time.[108]

Type 3 lesions account for 20% of gastric carcinoids. Type 3 gastric carcinoids tend to be larger, solitary lesions. They are associated with normal gastrin levels and behave much more aggressively than other gsatric carcinoid tumors.[108] Metastases are common, and these tumors can cause an atypical carcinoid syndrome. Type 3 carcinoids are best dealt with by resection and lymphadenectomy, the extent of which depends on the size of the tumor.

GASTROINTESTINAL STROMAL TUMORS OF THE STOMACH

Gastrointestinal stromal tumors (GISTs) were historically misclassified as leiomyomas, leiomyosarcomas, and leiomyoblastomas due to a mistaken belief that they arose from the smooth muscle in the bowel wall. However, it is now recognized that GISTs represent a distinct mesenchymal tumor type, and actually arise from the interstitial cells of Cajal, intestinal pacemaker cells located in and around the myenteric plexus in the bowel wall. While GISTs can arise anywhere within the gastrointestinal tract, approximately 50% of these tumors are found in the stomach. With a slight male predominance, GISTs are typically present in middle-aged and elderly individuals, with a median age at presentation of approximately 60. They are typically asymptomatic and are most commonly identified incidentally during endoscopy performed for other reasons. Their endoscopic appearance is that of a submucosal mass with normal overlying mucosa. If these tumors become large, however, they may present with symptoms of abdominal pain and bleeding. GISTs frequently have prominent extraluminal growth patterns, and central necrosis is common as these tumors become very large and outgrow their blood supply (Fig. 47-14). If the majority of the growth is extraluminal, endoscopic examination may be unrevealing or only demonstrate umbilication of the mucosa suggestive of an underlying mass. EUS or CT imaging may be helpful for diagnosis in these cases. With large tumors, symptoms related to mass effect may occur. Additionally, ulceration of the overlying gastric mucosa may occur with tumor necrosis, and these patients may present with significant and intermittent gastrointestinal hemorrhage.

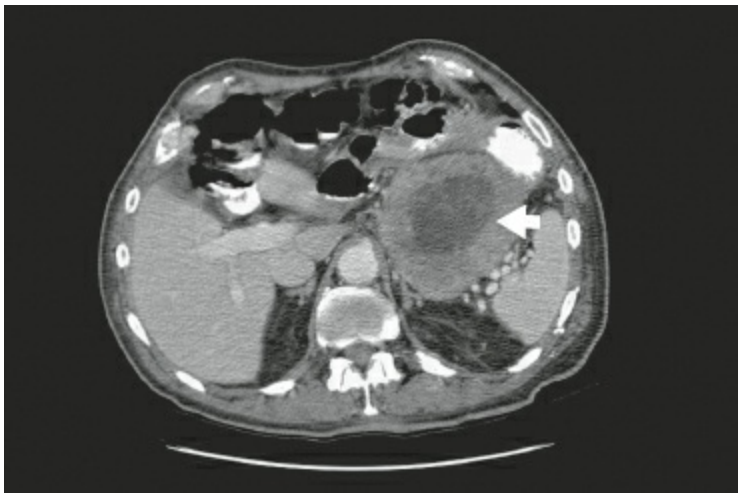

Figure 47-14. CT scan of GIST of stomach arising from lesser curvature. The *arrow* indicates central tumor necrosis. The lesion caused mucosal erosion with gastrointestinal hemorrhage.

7 The molecular hallmark of GISTs is overexpression of the CD117 antigen, which is part of the KIT transmembrane receptor tyrosine kinase. Mutations in *c-kit,* the proto-oncogene that encodes KIT, can lead to constitutive activation of the receptor and abnormal cell proliferation. Approximately 95% of GISTs overexpress KIT. Of those that do not, many have activating mutations in platelet-derived growth factor receptor alpha

(PDGFRA), another receptor tyrosine kinase. However, some GISTs lack mutations in either of these genes, and many of these are characterized by inactivating mutations in the succinate dehydrogenase (SDH) complex. The molecular pathogenesis of GIST is important because of the availability of tyrosine kinase inhibitors (TKIs), such as imatinib and sunitinib, which can inhibit GIST cell growth. However, GISTs that lack KIT or PDGFRA mutations, as well as those with certain types of KIT or PDGFRA mutations, may be variably resistant to TKI therapy.

All GISTs should be considered potentially malignant, especially those >1 cm in size.[109] Tumor size and mitotic index are the most important prognostic variables (Table 47-5).[110] Site of origin is also prognostic, with gastric GISTs behaving less aggressively than intestinal GISTs.[111] For localized GISTs, surgical resection is the treatment of choice. When GISTs do metastasize, they do so by a hematogenous route (most commonly to peritoneal surfaces and the liver). Therefore, associated lymphadenectomy is typically not performed at the time of gastric resection for GIST. Additionally, unlike adenocarcinoma, GISTs do not present with an intramural growth pattern and thus gross margins of 1 to 2 cm are deemed adequate for resection of a GIST. Ultimately the goal of resection is a negative microsopic margin. If the tumor involves adjacent structures, then en bloc resection of nonvital structures should be performed whenever possible. Due to the less radical nature of surgery required for appropriate oncologic resection of these tumors as compared to adenocarcinoma of the stomach, minimally invasive surgical techniques have become widely accepted as an appropriate and acceptable operative approach for these tumors. A nomogram has been developed to allow prediction of outcomes following surgical resection of GISTs.[112]

For patients with metastatic or locally advanced, unresectable GISTs, imatinib is first-line therapy. Although most patients will respond to imatinib therapy, development of resistance is common, likely due to selection of clones with secondary KIT mutations.[113,114] These patients may be managed either with imatinib dose escalation or by using another TKI (e.g., sunitinib). Imatinib is also indicated in the adjuvant setting for tumors at high risk for recurrence. The ACOSOG Z9001 trial evaluated the efficacy of 1 year of adjuvant imatinib versus placebo in patients with resected GIST ≥3 cm in size and KIT-positive.[115] Recurrence-free survival at 1 year was significantly lower in the imatinib arm (98% vs. 83%). No overall survival difference was shown, likely because patients were allowed to cross over to the imatinib arm after the study was unblinded. The Scandinavian Sarcoma Group evaluated the effect of 1 versus 3 years of adjuvant imatinib after resection of high-risk GIST and found differences in 5-year recurrence-free survival (66% vs. 49%) and overall survival (92% vs. 82%).[116] Based on these data, 3 years of imatinib therapy are recommended after resection of high-risk GIST. Rates of recurrence after discontinuation of imatinib therapy are similar to those in untreated patients, suggesting that TKI therapy may simply be delaying recurrences rather than actually preventing them. The use of imatinib in the neoadjuvant setting has been reported in retrospective series and was found to be safe in a phase II trial, but there are currently insufficient prospective data to guide this treatment approach.

Table 47-5 Risk of Aggressive Behavior in Gastrointestinal Stromal Tumors

Risk	Size (cm)	Mitotic Count (per 50 HPF)	Primary Tumor Site
Very low	<2.0	≤5	Any
Low	2.1–5.0	≤5	Any
Intermediate	2.1–5.0 <5.0 5.1–10	>5 6–10 ≤5	Gastric Any Gastric
High	Any >10 Any >5.0 2.1–5.0 5.1–10	Any Any >10 >5 >5 ≤5	Tumor rupture Any Any Any Nongastric Nongastric

HPF, high-powered fields.

References

1. Siegel R, Ma J, Zou Z, et al. Cancer statistics, 2014. *CA Cancer J Clin* 2014;64:9–29.
2. Jemal A, Bray F, Center MM, et al. Global cancer statistics. *CA Cancer J Clin* 2011;61:69–90.
3. Haenszel W, Kurihara M. Studies of Japanese migrants. I. Mortality from cancer and other diseases among Japanese in the United States. *J Natl Cancer Inst* 1968;40:43–68.
4. McMichael AJ, McCall MG, Hartshorne JM, et al. Patterns of gastro-intestinal cancer in European migrants to Australia: the role of dietary change. *Int J Cancer* 1980;25:431–437.
5. Helicobacter and Cancer Collaborative Group. Gastric cancer and Helicobacter pylori: a combined analysis of 12 case control studies nested within prospective cohorts. *Gut* 2001;49:347–353.
6. An international association between Helicobacter pylori infection and gastric cancer. The EUROGAST Study Group. *Lancet* 1993;341:1359–1362.
7. Parkin DM. The global health burden of infection-associated cancers in the year 2002. *Int J Cancer* 2006;118:3030–3044.
8. Ferlay J, Soerjomataram I, Ervik MD, et al. *GLOBOCAN 2012 v1.0, Cancer Incidence and Mortality Worldwide: IARC CancerBase No. 11 [Internet]*. Lyon, France: International Agency for Research on Cancer; 2013. Available from: http://globocan.iarc.fr, accessed on January 13, 2015.
9. Wilkinson NW, Howe J, Gay G, et al. Differences in the pattern of presentation and treatment of proximal and distal gastric cancer: results of the 2001 gastric patient care evaluation. *Ann Surg Oncol* 2008;15:1644–1650.
10. Harju E. Gastric polyposis and malignancy. *Br J Surg* 1986;73:532–533.
11. Uemura N, Okamoto S, Yamamoto S, et al. Helicobacter pylori infection and the development of gastric cancer. *N Engl J Med* 2001;345:784–789.
12. Crowe SE. Helicobacter infection, chronic inflammation, and the development of malignancy. *Curr Opin Gastroenterol* 2005;21:32–38.
13. Amieva MR, El-Omar EM. Host-bacterial interactions in Helicobacter pylori infection. *Gastroenterology* 2008;134:306–323.
14. Naylor GM, Gotoda T, Dixon M, et al. Why does Japan have a high incidence of gastric cancer? Comparison of gastritis between UK and Japanese patients. *Gut* 2006;55:1545–1552.
15. Forman D, Pisani P. Gastric cancer in Japan–honing treatment, seeking causes. *N Engl J Med* 2008;359:448–451.
16. Wong BC, Lam SK, Wong WM, et al. Helicobacter pylori eradication to prevent gastric cancer in a high-risk region of China: a randomized controlled trial. *JAMA* 2004;291:187–194.
17. Caygill CP, Hill MJ, Kirkham JS, et al. Mortality from gastric cancer following

gastric surgery for peptic ulcer. *Lancet* 1986;1:929–931.
18. Lundegardh G, Adami HO, Helmick C, et al. Stomach cancer after partial gastrectomy for benign ulcer disease. *N Engl J Med* 1988;319:195–200.
19. Hansson LE. Risk of stomach cancer in patients with peptic ulcer disease. *World J Surg* 2000;24:315–320.
20. Lundegardh G, Ekbom A, McLaughlin JK, et al. Gastric cancer risk after vagotomy. *Gut* 1994;35:946–949.
21. Tersmette AC, Offerhaus GJ, Giardiello FM, et al. Long-term prognosis after partial gastrectomy for benign conditions. Survival and smoking-related death of 2633 Amsterdam postgastrectomy patients followed up since surgery between 1931 and 1960. *Gastroenterology* 1991;101:148–153.
22. von Holstein CS. Long-term prognosis after partial gastrectomy for gastroduodenal ulcer. *World J Surg* 2000;24:307–314.
23. Aya M, Yashiro M, Nishioka N, et al. Carcinogenesis in the remnant stomach following distal gastrectomy with Billroth II reconstruction is associated with high-level microsatellite instability. *Anticancer Res* 2006; 26:1403–1411.
24. Pharoah PD, Guilford P, Caldas C; International Gastric Cancer Linkage C. Incidence of gastric cancer and breast cancer in CDH1 (E-cadherin) mutation carriers from hereditary diffuse gastric cancer families. *Gastroenterology* 2001;121:1348–1353.
25. Fitzgerald RC, Caldas C. Clinical implications of E-cadherin associated hereditary diffuse gastric cancer. *Gut* 2004;53:775–778.
26. Moreaux J, Bougaran J. Early gastric cancer. A 25-year surgical experience. *Ann Surg* 1993;217:347–355.
27. Wanebo HJ, Kennedy BJ, Chmiel J, et al. Cancer of the stomach. A patient care study by the American College of Surgeons. *Ann Surg* 1993;218:583–592.
28. Graham DY, Schwartz JT, Cain GD, et al. Prospective evaluation of biopsy number in the diagnosis of esophageal and gastric carcinoma. *Gastroenterology* 1982;82:228–231.
29. Mizoue T, Yoshimura T, Tokui N, et al. Prospective study of screening for stomach cancer in Japan. *Int J Cancer* 2003;106:103–107.
30. Inaba S, Hirayama H, Nagata C, et al. Evaluation of a screening program on reduction of gastric cancer mortality in Japan: preliminary results from a cohort study. *Prev Med* 1999;29:102–106.
31. Kunisaki C, Ishino J, Nakajima S, et al. Outcomes of mass screening for gastric carcinoma. *Ann Surg Oncol* 2006;13:221–228.
32. Dan YY, So JB, Yeoh KG. Endoscopic screening for gastric cancer. *Clin Gastroenterol Hepatol* 2006;4:709–716.
33. Marshall BJ, Windsor HM. The relation of Helicobacter pylori to gastric adenocarcinoma and lymphoma: pathophysiology, epidemiology, screening, clinical presentation, treatment, and prevention. *Med Clin North Am* 2005;89:313–344, viii.
34. Kwee RM, Kwee TC. Imaging in local staging of gastric cancer: a systematic review.

J Clin Oncol 2007;25:2107–2116.

35. Power DG, Schattner MA, Gerdes H, et al. Endoscopic ultrasound can improve the selection for laparoscopy in patients with localized gastric cancer. *J Am Coll Surg* 2009;208:173–178.
36. Chen CY, Hsu JS, Wu DC, et al. Gastric cancer: preoperative local staging with 3D multi-detector row CT–correlation with surgical and histopathologic results. *Radiology* 2007;242:472–482.
37. Ly QP, Sasson AR. Modern surgical considerations for gastric cancer. *J Natl Compr Canc Netw* 2008;6:885–894.
38. Kinkel K, Lu Y, Both M, et al. Detection of hepatic metastases from cancers of the gastrointestinal tract by using noninvasive imaging methods (US, CT, MR imaging, PET): a meta-analysis. *Radiology* 2002;224:748–756.
39. Ott K, Herrmann K, Lordick F, et al. Early metabolic response evaluation by fluorine-18 fluorodeoxyglucose positron emission tomography allows in vivo testing of chemosensitivity in gastric cancer: long-term results of a prospective study. *Clin Cancer Res* 2008;14:2012–2018.
40. Smyth E, Schoder H, Strong VE, et al. A prospective evaluation of the utility of 2-deoxy-2-[(18) F]fluoro-D-glucose positron emission tomography and computed tomography in staging locally advanced gastric cancer. *Cancer* 2012;118:5481–5488.
41. Mortensen MB, Scheel-Hincke JD, Madsen MR, et al. Combined endoscopic ultrasonography and laparoscopic ultrasonography in the pretherapeutic assessment of resectability in patients with upper gastrointestinal malignancies. *Scand J Gastroenterol* 1996;31:1115–1119.
42. Blackshaw GR, Barry JD, Edwards P, et al. Laparoscopy significantly improves the perceived preoperative stage of gastric cancer. *Gastric Cancer* 2003;6:225–229.
43. Lowy AM, Mansfield PF, Leach SD, et al. Laparoscopic staging for gastric cancer. *Surgery* 1996;119:611–614.
44. Sarela AI, Miner TJ, Karpeh MS, et al. Clinical outcomes with laparoscopic stage M1, unresected gastric adenocarcinoma. *Ann Surg* 2006;243:189–195.
45. D'Ugo DM, Coppola R, Persiani R, et al. Immediately preoperative laparoscopic staging for gastric cancer. *Surg Endosc* 1996;10:996–999.
46. Mezhir JJ, Shah MA, Jacks LM, et al. Positive peritoneal cytology in patients with gastric cancer: natural history and outcome of 291 patients. *Ann Surg Oncol* 2010;17:3173–3180.
47. Badgwell B, Cormier JN, Krishnan S, et al. Does neoadjuvant treatment for gastric cancer patients with positive peritoneal cytology at staging laparoscopy improve survival? *Ann Surg Oncol* 2008;15:2684–2691.
48. Cunningham SC, Kamangar F, Kim MP, et al. MKK4 status predicts survival after resection of gastric adenocarcinoma. *Arch Surg* 2006;141:1095–1099; discussion 100.
49. Katano M, Nakamura M, Fujimoto K, et al. Prognostic value of platelet-derived

growth factor-A (PDGF-A) in gastric carcinoma. *Ann Surg* 1998; 227:365–371.
50. Harrison LE, Karpeh MS, Brennan MF. Proximal gastric cancers resected via a transabdominal-only approach. Results and comparisons to distal adenocarcinoma of the stomach. *Ann Surg* 1997;225:678–683; discussion 83–85.
51. Edge SB, American Joint Committee on Cancer. *AJCC Cancer Staging Manual.* 7th ed. New York, NY: Springer; 2010.
52. Adachi Y, Shiraishi N, Kitano S. Modern treatment of early gastric cancer: review of the Japanese experience. *Dig Surg* 2002;19:333–339.
53. Kunisaki C, Shimada H, Takahashi M, et al. Prognostic factors in early gastric cancer. *Hepatogastroenterology* 2001;48:294–298.
54. Nakamura K, Morisaki T, Sugitani A, et al. An early gastric carcinoma treatment strategy based on analysis of lymph node metastasis. *Cancer* 1999;85:1500–1505.
55. Ono H, Kondo H, Gotoda T, et al. Endoscopic mucosal resection for treatment of early gastric cancer. *Gut* 2001;48:225–229.
56. Korenaga D, Orita H, Maekawa S, et al. Pathological appearance of the stomach after endoscopic mucosal resection for early gastric cancer. *Br J Surg* 1997;84:1563–1566.
57. Uedo N, Iishi H, Tatsuta M, et al. Longterm outcomes after endoscopic mucosal resection for early gastric cancer. *Gastric Cancer* 2006;9:88–92.
58. Kim SH, Karpeh MS, Klimstra DS, et al. Effect of microscopic resection line disease on gastric cancer survival. *J Gastrointest Surg* 1999;3:24–33.
59. Bozzetti F, Bonfanti G, Bufalino R, et al. Adequacy of margins of resection in gastrectomy for cancer. *Ann Surg* 1982;196:685–690.
60. Harrison LE, Karpeh MS, Brennan MF. Total gastrectomy is not necessary for proximal gastric cancer. *Surgery* 1998;123:127–130.
61. Katai H, Sano T, Fukagawa T, et al. Prospective study of proximal gastrectomy for early gastric cancer in the upper third of the stomach. *Br J Surg* 2003;90:850–853.
62. Schwarz RE, Karpeh MS, Brennan MF. Factors predicting hospitalization after operative treatment for gastric carcinoma in patients older than 70 years. *J Am Coll Surg* 1997;184:9–15.
63. Dixon M, Mahar A, Paszat L, et al. What provider volumes and characteristics are appropriate for gastric cancer resection? Results of an international RAND/UCLA expert panel. *Surgery* 2013;154:1100–1109.
64. Daly JM, Weintraub FN, Shou J, et al. Enteral nutrition during multimodality therapy in upper gastrointestinal cancer patients. *Ann Surg* 1995;221:327–338.
65. Bozzetti F, Bonfanti G, Castellani R, et al. Comparing reconstruction with Roux-en-Y to a pouch following total gastrectomy. *J Am Coll Surg* 1996;183:243–248.
66. Chareton B, Landen S, Manganas D, et al. Prospective randomized trial comparing Billroth I and Billroth II procedures for carcinoma of the gastric antrum. *J Am Coll Surg* 1996;183:190–194.
67. de Almeida AC, dos Santos NM, Aldeia FJ. Long-term clinical and endoscopic

assessment after total gastrectomy for cancer. *Surg Endosc* 1993;7:518–523.
68. Nakane Y, Okumura S, Akehira K, et al. Jejunal pouch reconstruction after total gastrectomy for cancer. A randomized controlled trial. *Ann Surg* 1995;222:27–35.
69. Shiu MH, Moore E, Sanders M, et al. Influence of the extent of resection on survival after curative treatment of gastric carcinoma. A retrospective multivariate analysis. *Arch Surg* 1987;122:1347–1351.
70. Maruyama K, Okabayashi K, Kinoshita T. Progress in gastric cancer surgery in Japan and its limits of radicality. *World J Surg* 1987;11:418–425.
71. Noguchi Y, Imada T, Matsumoto A, et al. Radical surgery for gastric cancer. A review of the Japanese experience. *Cancer* 1989;64:2053–2062.
72. Adachi Y, Kamakura T, Mori M, et al. Role of lymph node dissection and splenectomy in node-positive gastric carcinoma. *Surgery* 1994;116:837–841.
73. Baba H, Maehara Y, Takeuchi H, et al. Effect of lymph node dissection on the prognosis in patients with node-negative early gastric cancer. *Surgery* 1995;117:165–169.
74. Bonenkamp JJ, Hermans J, Sasako M, et al. Extended lymph-node dissection for gastric cancer. *N Engl J Med* 1999;340:908–914.
75. Cuschieri A, Fayers P, Fielding J, et al. Postoperative morbidity and mortality after D1 and D2 resections for gastric cancer: preliminary results of the MRC randomised controlled surgical trial. The Surgical Cooperative Group. *Lancet* 1996;347:995–999.
76. Maeta M, Yamashiro H, Saito H, et al. A prospective pilot study of extended (D3) and superextended para-aortic lymphadenectomy (D4) in patients with T3 or T4 gastric cancer managed by total gastrectomy. *Surgery* 1999;125:325–331.
77. Robertson CS, Chung SC, Woods SD, et al. A prospective randomized trial comparing R1 subtotal gastrectomy with R3 total gastrectomy for antral cancer. *Ann Surg* 1994;220:176–182.
78. Siewert JR, Bottcher K, Stein HJ, et al. Relevant prognostic factors in gastric cancer: ten-year results of the German Gastric Cancer Study. *Ann Surg* 1998;228:449–461.
79. Songun I, Putter H, Kranenbarg EM, et al. Surgical treatment of gastric cancer: 15-year follow-up results of the randomised nationwide Dutch D1D2 trial. *Lancet Oncol* 2010;11:439–449.
80. Lee JS, Douglass HO Jr. D2 dissection for gastric cancer. *Surg Oncol* 1997;6:215–225.
81. Pacelli F, Doglietto GB, Bellantone R, et al. Extensive versus limited lymph node dissection for gastric cancer: a comparative study of 320 patients. *Br J Surg* 1993;80:1153–1156.
82. Otsuji E, Yamaguchi T, Sawai K, et al. End results of simultaneous splenectomy in patients undergoing total gastrectomy for gastric carcinoma. *Surgery* 1996;120:40–44.
83. Stipa S, Di Giorgio A, Ferri M, et al. Results of curative gastrectomy for carcinoma. *J Am Coll Surg* 1994;179:567–572.
84. Kunisaki C, Makino H, Suwa H, et al. Impact of splenectomy in patients with gastric

adenocarcinoma of the cardia. *J Gastrointest Surg* 2007;11:1039–1044.
85. Shchepotin IB, Chorny VA, Nauta RJ, et al. Extended surgical resection in T4 gastric cancer. *Am J Surg* 1998;175:123–126.
86. Cuschieri A. Laparoscopic gastric resection. *Surg Clin North Am* 2000; 80:1269–1284, viii.
87. Ohtani H, Tamamori Y, Noguchi K, et al. A meta-analysis of randomized controlled trials that compared laparoscopy-assisted and open distal gastrectomy for early gastric cancer. *J Gastrointest Surg* 2010;14:958–964.
88. Huscher CG, Mingoli A, Sgarzini G, et al. Laparoscopic versus open subtotal gastrectomy for distal gastric cancer: five-year results of a randomized prospective trial. *Ann Surg* 2005;241:232–237.
89. Kim HH, Hyung WJ, Cho GS, et al. Morbidity and mortality of laparoscopic gastrectomy versus open gastrectomy for gastric cancer: an interim report–a phase III multicenter, prospective, randomized Trial (KLASS Trial). *Ann Surg* 2010;251:417–420.
90. Macdonald JS, Smalley SR, Benedetti J, et al. Chemoradiotherapy after surgery compared with surgery alone for adenocarcinoma of the stomach or gastroesophageal junction. *N Engl J Med* 2001;345:725–730.
91. Cunningham D, Allum WH, Stenning SP, et al. Perioperative chemotherapy versus surgery alone for resectable gastroesophageal cancer. *N Engl J Med* 2006;355:11–20.
92. Bang YJ, Van Cutsem E, Feyereislova A, et al. Trastuzumab in combination with chemotherapy versus chemotherapy alone for treatment of HER2-positive advanced gastric or gastro-oesophageal junction cancer (ToGA): a phase 3, open-label, randomised controlled trial. *Lancet* 2010;376:687–697.
93. Isaacson PG. Gastrointestinal lymphoma. *Hum Pathol* 1994;25:1020–1029.
94. Isaacson PG. Gastric lymphoma and Helicobacter pylori. *N Engl J Med* 1994;330:1310–1311.
95. Parsonnet J, Hansen S, Rodriguez L, et al. Helicobacter pylori infection and gastric lymphoma. *N Engl J Med* 1994;330:1267–1271.
96. Wotherspoon AC, Ortiz-Hidalgo C, Falzon MR, et al. Helicobacter pylori-associated gastritis and primary B-cell gastric lymphoma. *Lancet* 1991;338:1175–1176.
97. Montalban C, Castrillo JM, Abraira V, et al. Gastric B-cell mucosa-associated lymphoid tissue (MALT) lymphoma. Clinicopathological study and evaluation of the prognostic factors in 143 patients. *Ann Oncol* 1995;6:355–362.
98. Hussell T, Isaacson PG, Crabtree JE, et al. The response of cells from low-grade B-cell gastric lymphomas of mucosa-associated lymphoid tissue to Helicobacter pylori. *Lancet* 1993;342:571–574.
99. Yoon SS, Coit DG, Portlock CS, et al. The diminishing role of surgery in the treatment of gastric lymphoma. *Ann Surg* 2004;240:28–37.
100. Bayerdorffer E, Neubauer A, Rudolph B, et al. Regression of primary gastric

lymphoma of mucosa-associated lymphoid tissue type after cure of Helicobacter pylori infection. MALT Lymphoma Study Group. *Lancet* 1995;345:1591–1594.

101. Neubauer A, Thiede C, Morgner A, et al. Cure of Helicobacter pylori infection and duration of remission of low-grade gastric mucosa-associated lymphoid tissue lymphoma. *J Natl Cancer Inst* 1997;89:1350–1355.
102. Pinotti G, Zucca E, Roggero E, et al. Clinical features, treatment and outcome in a series of 93 patients with low-grade gastric MALT lymphoma. *Leuk Lymphoma* 1997;26:527–537.
103. Stephens J, Smith J. Treatment of primary gastric lymphoma and gastric mucosa-associated lymphoid tissue lymphoma. *J Am Coll Surg* 1998; 187:312–320.
104. Bartlett DL, Karpeh MS Jr, Filippa DA, et al. Long-term follow-up after curative surgery for early gastric lymphoma. *Ann Surg* 1996;223:53–62.
105. Aviles A, Nambo MJ, Neri N, et al. The role of surgery in primary gastric lymphoma: results of a controlled clinical trial. *Ann Surg* 2004;240:44–50.
106. Modlin IM, Kidd M, Latich I, et al. Current status of gastrointestinal carcinoids. *Gastroenterology* 2005;128:1717–1751.
107. Soga J. Early-stage carcinoids of the gastrointestinal tract: an analysis of 1914 reported cases. *Cancer* 2005;103:1587–1595.
108. Landry CS, Brock G, Scoggins CR, et al. A proposed staging system for gastric carcinoid tumors based on an analysis of 1,543 patients. *Ann Surg Oncol* 2009;16:51–60.
109. Gold JS, Dematteo RP. Combined surgical and molecular therapy: the gastrointestinal stromal tumor model. *Ann Surg* 2006;244:176–184.
110. Fletcher CD, Berman JJ, Corless C, et al. Diagnosis of gastrointestinal stromal tumors: A consensus approach. *Hum Pathol* 2002;33:459–465.
111. Joensuu H. Risk stratification of patients diagnosed with gastrointestinal stromal tumor. *Hum Pathol* 2008;39:1411–1419.
112. Gold JS, Gonen M, Gutierrez A, et al. Development and validation of a prognostic nomogram for recurrence-free survival after complete surgical resection of localised primary gastrointestinal stromal tumour: a retrospective analysis. *Lancet Oncol* 2009;10:1045–1052.
113. Heinrich MC, Corless CL, Blanke CD, et al. Molecular correlates of imatinib resistance in gastrointestinal stromal tumors. *J Clin Oncol* 2006;24:4764–4774.
114. Wardelmann E, Merkelbach-Bruse S, Pauls K, et al. Polyclonal evolution of multiple secondary KIT mutations in gastrointestinal stromal tumors under treatment with imatinib mesylate. *Clin Cancer Res* 2006;12:1743–1749.
115. Dematteo RP, Ballman KV, Antonescu CR, et al. Adjuvant imatinib mesylate after resection of localised, primary gastrointestinal stromal tumour: a randomised, double-blind, placebo-controlled trial. *Lancet* 2009;373:1097–1104.
116. Joensuu H, Eriksson M, Sundby Hall K, et al. One vs three years of adjuvant imatinib

for operable gastrointestinal stromal tumor: a randomized trial. *JAMA* 2012;307:1265–1272.

SECTION F: SMALL INTESTINE

Chapter 48

Anatomy and Physiology of the Small Intestine

E. Ramsay Camp, Kevin F. Staveley-O'Carroll, Niraj J. Gusani, Jussuf T. Kaifi, and Eric T. Kimchi

Key Points

1 The normal adult anatomy of the small intestine is the result of a complex cascade of embryologic events which result in 270 degrees of total rotation of the bowel around its axis. A failure of these precise steps produces a spectrum of anatomical variants which are grouped together as malrotation of the intestinal tract.

2 There is no clear anatomic boundary between the jejunum and ileum. The proximal two-fifths of the small intestine distal to the ligament of Treitz have been arbitrarily defined as *jejunum* and the distal three-fifths as *ileum*.

3 The enteric nervous system contains two major plexuses:

a. the myenteric (Auerbach) plexus, located between the longitudinal and circular muscle layers

b. the submucosal (Meissner) plexus

4 The small intestine is the largest endocrine organ in the human body. The secretion of numerous hormones and neurotransmitters are specific to distinct anatomic zones within the small intestine.

5 The coordinated movement of the gastrointestinal tract is necessary for the proper digestion of food. Well-timed contraction and relaxation patterns are initiated in gastrointestinal nervous system causing coordinated electrical activity and muscular movements.

6 The lumen of the gastrointestinal tract is connected to the outside environment and comes in direct contact with many potentially pathogenic microorganisms. Consequently, the small intestine needs a complex defense mechanism to battle against these exposures in different ways.

7 The small intestine reabsorbs nearly 80% of the fluid that passes through it. This dynamic process is accomplished by a rapid bidirectional movement of fluid in the intestinal lumen. This ebb and flow of fluid in the intestinal lumen is critical in maintaining normal homeostasis. Minor changes in intestinal permeability or rate of flow of the intestinal contents can result in net secretion and diarrheal states.

8 While the exact mechanisms of many of the interactions between the gut microflora and the small intestinal microenvironment are still speculative, it has become evident that a symbiotic environment is present which, at least in part, is responsible for proper homeostasis of the small intestine.

The small intestine's intrinsic design serves to provide a maximum amount of surface area for absorption of nutrients, water, and electrolytes. Specialized areas provide neurohormonal stimulation to the digestive tract. Its structure and vast surface area also provide an important physical barrier to potential pathogens and certain areas are critical in immune surveillance.

GROSS ANATOMY AND EMBRYOLOGY

1 The small intestine spans from the pylorus to the ileocecal valve, and includes three distinct regions: the duodenum, the jejunum, and the ileum. These areas combined measure approximately 200 to 300 cm in a newborn and 5 to 7 m in an adult; comprising nearly 62% of the entire length of the alimentary tract. The gastrointestinal tract is formed from the endodermal layer of the developing embryo. The small intestine is derived from the distal foregut (proximal duodenum), midgut, and the adjacent splanchnic mesenchyme. Epithelium and glands develop from the embryonic endoderm, while connective tissue, muscle, and serosa develop from the mesoderm. During the 5th and 6th weeks of development, the duodenal lumen is temporarily obliterated due to proliferation of its mucosal lining. During the subsequent weeks, luminal vacuolization and degeneration of some of the proliferating cells result in recanalization of the duodenal lumen. From the 4th to the 10th week of development, a large portion of the midgut is herniated through the umbilicus. This may be due to the rapid growth of the intestinal tract at this time in relation to the abdominal cavity. At approximately 8 weeks of gestation, the midgut begins to rotate in a counterclockwise manner 90 degrees around the axis of the mesenteric vasculature. The extra-abdominal portion of the gut returns to the abdominal cavity approximately 2 weeks later. Around this time point an additional 180-degree rotation occurs. These two rotations provide 270 degrees of total rotation and result in the typical anatomy that is found in humans. A failure of these precise steps produces a spectrum of anatomical variants which are grouped together as malrotation of the intestinal tract.[1]

DUODENUM

The duodenum comprises the first portion of the small intestine and plays an important role in connecting the foregut organs to the midgut. It anatomically begins at the duodenal bulb which is immediately distal to the pylorus and terminates at the ligament of Treitz, where it joins the jejunum. The duodenum is approximately 20 to 30 cm in length and is divided into four distinct areas.

The first portion of the duodenum is approximately 5 cm in length and is referred to as the bulb or cap. This area is directly attached to the pylorus and extends laterally and cephalad. It serves as an attachment for the hepatoduodenal ligament and traverses over the common bile duct, portal vein, pancreatic head, and the gastroduodenal artery. The mucosal surface of the duodenal bulb is smooth until its junction with the second portion of the duodenum, where the concentric Kerckring folds begin. This portion of the duodenum is prone to ulceration, with approximately 90% of duodenal ulcers occurring here. Unfortunately, due to its anatomic positioning, these ulcers may erode into the gastroduodenal artery which lies directly posterior, causing potentially life-threatening bleeding.

The second portion of the duodenum (descending duodenum) extends from the origin of the Kerckring folds to the beginning of the transverse duodenum and travels over the right renal vasculature, the medial aspect of Gerota fascia, the inferior vena cava, and to the right of the L1 and L2 vertebra. It is approximately 10 cm in length and 3 to 5 cm in diameter. The Kerckring folds (plicae circulares) are concentric mucosal folds which are 1 to 2 mm thick and 2 to 4 mm high and are separated by 2 to 4 mm of smooth, flat mucosa. This portion of the duodenum serves as an entry point for pancreatic and biliary secretions into the gastrointestinal tract. This is typically through the major papilla (ampulla of Vater), which is a valvular structure arising in the midportion of the descending duodenum, approximately 7 to 10 cm from the pylorus. Through this point, the confluence of the common bile duct and the main pancreatic duct (duct of Wirsung) join the duodenum. The valvular function of the papilla is regulated through the muscular sphincter of Oddi. The minor pancreatic duct (duct of Santorini) enters through the minor papilla proximal to the ampulla of Vater in 50% to 60% of patients and endoscopically appears as a 1- to 3-mm polypoid structure.

The second portion of the duodenum is important surgically as it represents the entry of the duodenum into the retroperitoneum. Surgical evaluation of this part of the duodenum requires mobilization from its posterior and lateral attachments, described as a Kocher maneuver. This allows for further evaluation of the duodenum, pancreatic head, and bile duct.

The third (transverse) and fourth (ascending) portions of the duodenum complete the duodenal sweep. The third portion of the duodenum is about 10 cm in length and courses transversely from right to left, crossing the midline anterior to the spine, aorta, and inferior vena cava. This portion is closely attached to the uncinate process of the pancreas. The superior mesenteric artery (SMA) and vein (SMV) course anterior to the third portion of the duodenum to provide blood supply to the gut. The transition between

the third and fourth portions of the duodenum is marked by the passage of the SMA in front of the duodenum. The SMA forms an acute angle as it originates from the aorta. An abnormally narrow angle can result in obstruction of the duodenum at this location (SMA syndrome). The fourth portion of the duodenum is approximately 5-cm long and courses upward and obliquely to reach the ligament of Treitz, marking the end of the duodenum and the return of the small bowel to the peritoneal cavity.

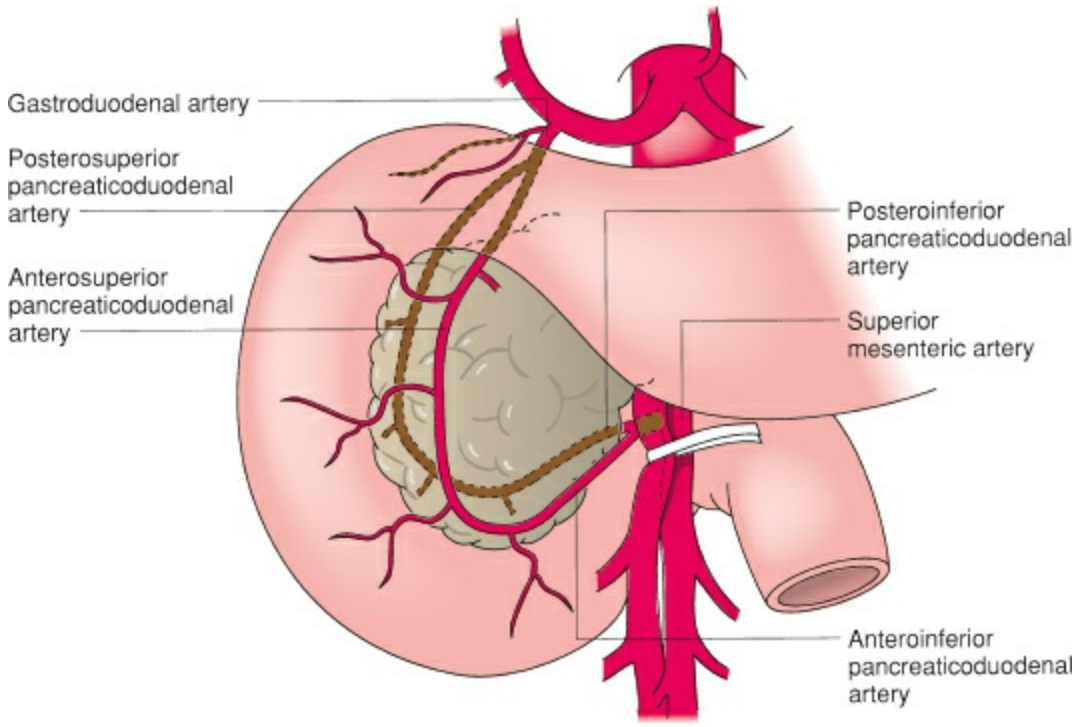

Figure 48-1. Arterial blood supply to the duodenum.

Following its embryologic origins, the vascular supply to the duodenum arises from branches of the celiac trunk for the foregut portion, whereas the distal (midgut origin) duodenum is supplied by branches of the SMA (Fig. 48-1). Venous drainage includes a series of pancreaticoduodenal veins which drain into the SMV–portal vein system. Lymphatic drainage follows the vascular supply with drainage to the pancreaticoduodenal nodes. From here, lymph drains superiorly to the hepatic nodes or inferiorly to the superior mesenteric nodes.

JEJUNUM AND ILEUM

2 Distal to the ligament of Treitz, the jejunum and ileum form the remainder of the small intestine. The boundary between the two is arbitrarily determined such that 40% of the intraperitoneal small intestine comprises jejunum and 60% comprises ileum. This portion of the bowel is suspended within the peritoneal cavity by a thin, broad-based mesentery that is attached to the posterior abdominal wall. The jejunum and ileum are freely mobile within the peritoneal cavity. The jejunum is the widest portion of the small intestine, whose caliber progressively decreases as it approaches the ileocecal valve. The mucosa of the jejunum has a thick lining and is characterized by prominent plicae circulares that become shorter and less frequent in the ileum. The total length of jejunum and ileum varies, but is usually between 5 and 7 m in length. The small intestine terminates in the right lower quadrant at the ileocecal valve. The ileocecal valve exhibits motor characteristics separate from the terminal ileum and colon, postulated to prevent reflux of fecal material from the colon into the small intestine.[2]

The arterial blood supply of the jejunum and the ileum arises from the SMA. The main vascular branches form arcades within the mesentery. The vasa recta, intestinal arterial branches, enter into the intestinal wall without anastamosing. The vasa recta of the jejunum are straight and long, in contrast to the vasa recta of the ileum, which are shorter with greater arborization (Fig. 48-2). The venous and lymphatic drainage follow the arterial supply. The main venous outflow is through the SMV which, along with the splenic vein, becomes the portal vein.

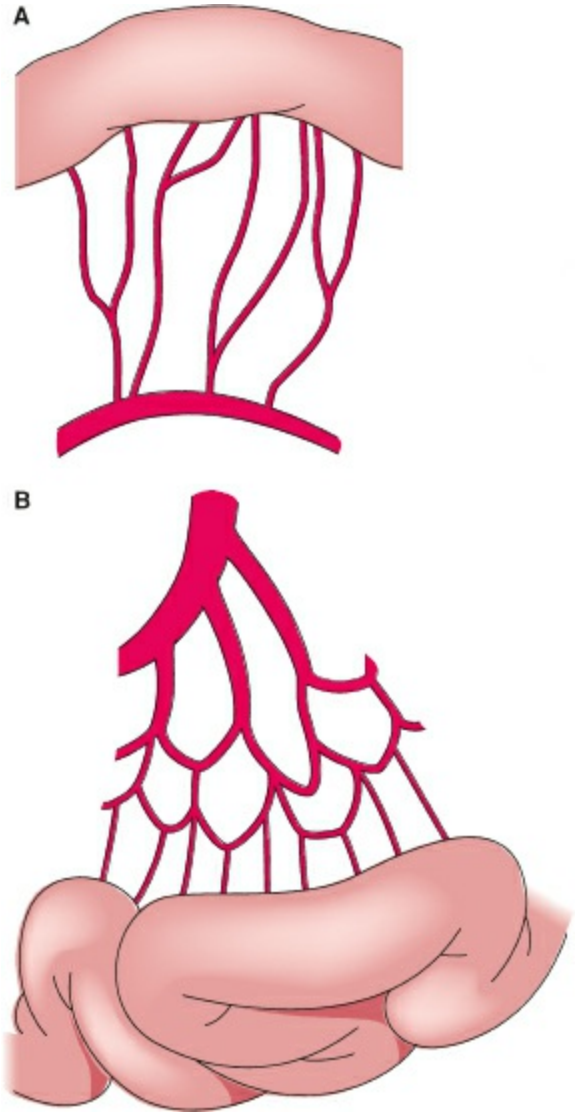

Figure 48-2. The superior mesenteric artery supplies bloodflow into the small intestinal arteries (vasa recta) which branch within the mesentery. In the jejunum (**A**), the vasa recta are straight and long, this is in contrast to the vasa recta within the ileum (**B**), which are shorter with greater arborization.

MICROSCOPIC ANATOMY

General Considerations

3 The wall of the small intestine is composed of four distinct layers—mucosa, submucosa, muscle, and serosa. The role of the mucosa is absorption and secretion. The luminal mucosal surface forms circular folds known as plica circularis or valvulae conniventes in all segments of the small intestine distal to the first portion of the duodenum. The submucosa contains an elaborate network of blood vessels, lymphatics, and nerves. The muscular portion of the wall includes outer longitudinal and inner circular muscle layers. Between the muscle layers lies the myenteric (Auerbach) plexus. The muscular layers are responsible for coordinating peristaltic movements. The outermost layer, the serosa, is composed of a thin layer of mesothelial cells overlying loose connective tissue. The serosa covers only the anterior surface of the retroperitoneal segments of small bowel, but it completely covers the portions of small bowel that are invested with mesentery.

Mucosa

The mucosa lines the luminal surface of the small intestine. It consists of three layers: epithelial cells, lamina propria, and a narrow layer of smooth muscle, the muscularis mucosae. The basic structural unit of the mucosa is the crypt and villus. Villi are finger-like projections of mucosa 0.5 to 1 mm high extending into the intestinal lumen that have a columnar epithelial surface and a cellular connective tissue core of lamina propria. Each villus contains a central lacteal (lymphatic), and a vascular network consisting of a small artery, vein, and capillaries. Ninety percent of the cells of the villi are columnar epithelial cells responsible for absorption and secretion. These cells are 22 to 25 μm high with basally located nuclei. The apices of these cells have microvilli, produced by numerous folds in the apical membrane, which account for the brush border appearance. Microvilli are approximately 1 μm long and 0.08 μm wide. Their surface is coated by glycoproteins rooted in the cell membrane. These glycoprotein filaments are referred to as the glycocalyx and are essential for digestion and absorption.[3] The lateral membranes of neighboring enterocytes are connected by tight junctions, an apparent fusion of adjoining plasma membranes just below the level of the brush border. Movement of ions and water can occur by either a transmembrane or a paracellular route through tight junctions, which behave as selective pores.

Between the villi lie the crypts of Lieberkühn. Stem cells within the crypts of Lieberkühn are the source of the four major types of differentiated cells: the absorptive enterocyte, goblet cells, enteroendocrine cells, and Paneth cells. Absorptive enterocytes differentiate as they migrate from the crypt compartment up toward the tip of the intestinal villus. Cells then undergo apoptosis and are shed into the intestinal lumen. Most of the intestinal lining is renewed over a period of approximately 5 days. Despite the rapid rate of cellular turnover, intestinal epithelial cells exhibit complex patterns of gene expression that vary according to their location on the two main spatial axes of the gut, the vertical (crypt-villus) and horizontal (proximal to distal) axes. For example, cells

destined to become enterocytes do not begin to express a variety of genes important in digestion and absorption until the cells have migrated out of the crypt and up the villus. In addition, many epithelial cell genes are selectively expressed in the proximal small intestine, whereas other genes are specifically expressed only in the ileum.[4]

Several other cell types are present in the mucosa. Mucus-secreting goblet cells are present in both the crypts and villi. Goblet cells have a narrow base containing the nucleus and a wide apical membrane with a large number of granules containing mucin. Mucin is secreted in a merocrine fashion by the goblet cell and functions as a lubricant and has a cytoprotective function.[5]

Paneth cells are pyramidal cells that reside in the crypt base. They contain large eosinophilic secretory granules located at their apical surface. It is thought that Paneth cells play a role in host defense based on their abundant expression of lysozyme and defensins, a family of small peptides that are also found in human neutrophils and exhibit microbicidal activity toward many different bacterial organisms in vitro. However, examination of the role of Paneth cells in the small intestine by lineage ablation in transgenic mice revealed no alteration in host defense mechanisms, thus the actual function of Paneth cells are yet to be delineated.[6]

Enteroendocrine (also referred to as *amine precursor uptake and decarboxylation,* or *APUD*) cells may reside in either the crypts or the villi, depending on the particular neuroendocrine substance they produce. Specific areas of the small intestine have higher concentrations of specific neuroendocrine substances than other areas. These cells do not contact the intestinal lumen, unlike exocrine cells, and their secretory granules are located below the nucleus near the basement membrane. This suggests that these cells secrete their contents into the circulation rather than into the intestinal lumen.

Submucosa

The submucosa is a dense connective tissue layer with a rich network of blood vessels, nerves, and lymphatics. The submucosa contains Meissner plexus and is the strongest layer of the intestinal wall. Brunner glands are found in the submucosa of the duodenum and secrete mucus and bicarbonate into the intestinal lumen. These secretions aid in the neutralization of the gastric acid load which enters the duodenum. Peyer patches are localized collections of lymphoid follicles that are most prominent in the submucosa of the ileum. These are typically 8 to 10 mm in diameter and are most abundant early in life, gradually disappearing with age.

Physiology

4 The small intestine plays important physiologic roles in motility, blood flow, growth, digestion, absorption, immune function, and endocrine secretion. In fact, the small intestine is the largest endocrine organ in the human body.[7] The secretion of numerous hormones and neurotransmitters are specific to distinct anatomic zones within the small intestine (Fig. 48-3). There is no specific cell mass which produces these hormones, but rather individual cells scattered along the gastrointestinal tract.

Gastrin is a peptide produced in the gastric antrum and in the duodenum by the G cells and secreted into the circulation in response to gastric distension, vagal stimulation, amino acids, and hypercalcemia. Gastrin exists in three functional forms (G-34, G-17, and G-14). Its release is inhibited by low intraluminal pH, somatostatin, secretin, gastric inhibitory peptide (GIP), vasoactive intestinal peptide (VIP), glucagon, and calcitonin. Gastrin binds to CCK2/gastrin receptors on ECL cells causing a release of histamine which in turn stimulates the parietal cells in a paracrine fashion. Gastrin also causes an increase in the gastric blood flow and the release of pepsinogen by the chief cells and pancreatic enzymes from the pancreatic centroacinar cells.

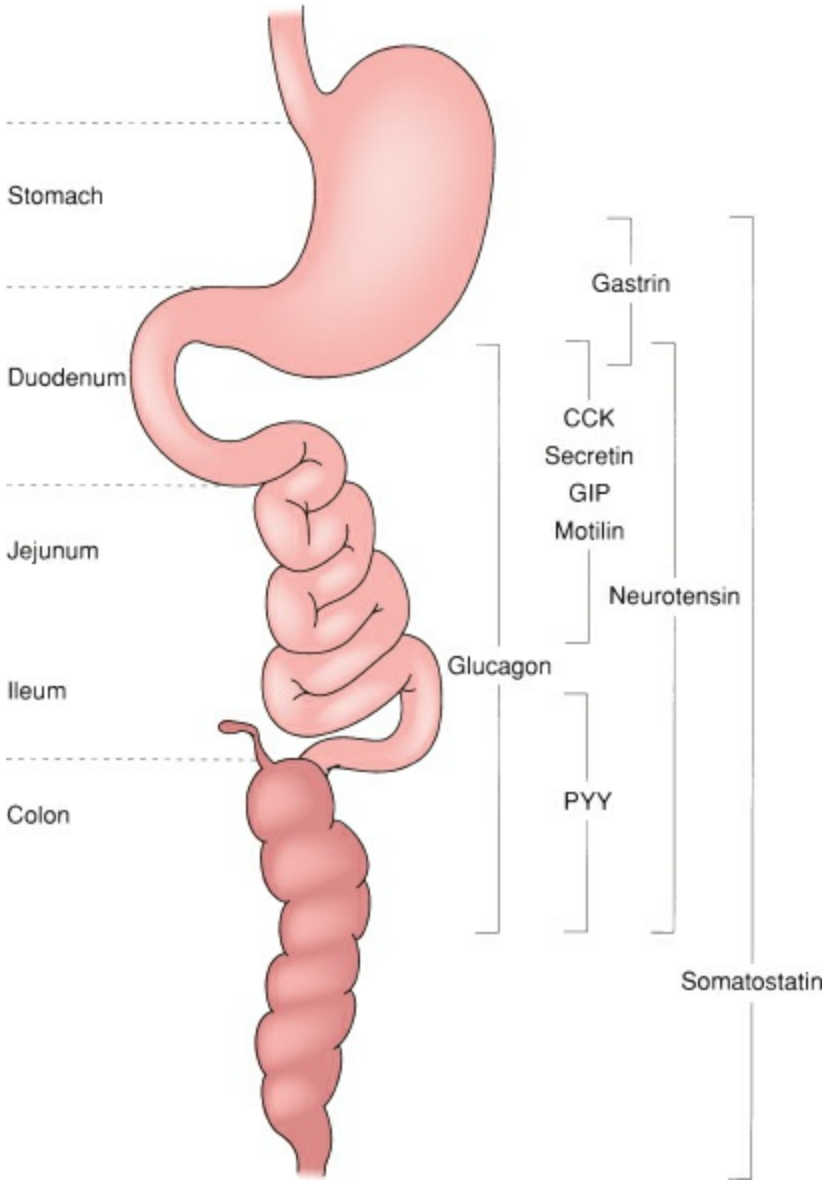

Figure 48-3. Distribution of peptide hormones in the gastrointestinal tract.

Cholecystokinin (CCK) is produced in the proximal two-thirds of the small intestine by the I cells and released into the gut lumen. It has 4 main forms (CCK-58, CCK-39, CCK-33, and CCK-8). It shares the final five amino acids adjacent to the C-terminus with gastrin, and this accounts for its hormonal activity. Stimulation of I cells by amino or fatty acids causes release of CCK, this in turn stimulates contraction and emptying of the gallbladder, increases bile flow, causes relaxation of the sphincter of Oddi, and stimulates pancreatic enzyme secretion. CCK also has trophic effects on the small intestinal mucosa and pancreas.

Secretin, discovered as the first gastrointestinal hormone in 1902, is a 27 amino acid peptide produced by the S cells of the duodenum and jejunum. Secretin is released into the circulation and intestinal lumen in response to low intraluminal pH, fatty acids, and bile salts. Water and bicarbonate are secreted by the pancreas in response to secretin. Bicarbonate is also released from the biliary ductal epithelium and Brunner glands in response to secretin. In turn, pancreatic enzymes are released from the pancreas. The increased pH and the presence of pancreatic enzymes aid in the digestion of lipids. The increased pH also provides a negative feedback loop to inhibit further production of

secretin. Secretin produces a paradoxical release of gastrin in patients with gastrinomas, but does not produce this effect on normal individuals.

Somatostatin is a peptide hormone consisting of 14 or 28 amino acids and is produced by D cells in the pancreatic islets, gastric antrum, and duodenum. Its primary role is inhibition of other gastrointestinal hormones and inhibition of pancreatic, biliary, and gastric secretion. In addition, somatostatin decreases splanchnic and portal blood flow. Somatostatin is stimulated by the presence of fat, proteins, acid, glucose, amino acids, and CCK. Octreotide, a long-acting synthetic somatostatin analog, is used in the treatment of variceal bleeding, hormone secreting neuroendocrine tumors, carcinoid syndrome, and enterocutaneous and pancreatic fistulas.[8]

Gastrin-releasing peptide, the mammalian homolog of bombesin, is a 27 amino acid peptide which is produced by the small intestine and is released in response to vagal stimulation. It is a prostimulatory molecule which causes the release of most gastrointestinal hormones, with the exception of secretin. It also has a promotility effect and stimulates endothelial proliferation. Gastric inhibitory peptide or glucose-dependent insulinotropic peptide (GIP) is a 42 amino acid peptide produced by the K cells of the duodenum and jejunum. It is released in response to glucose, fat, protein, and adrenergic stimulation. It stimulates secretion of insulin and inhibits gastric acid and pepsin production. Type 2 diabetics are resistant to the effects of GIP.

Motilin is a 22 amino acid peptide produced by the enteroendocrine cells in the duodenum and jejunum. Release of motilin occurs during the interdigestive and fasting periods. Release may also be related to alkalinization of the duodenum. Motilin's main function is to stimulate the migrating myoelectric complex. Motilin agonists such as erythromycin, are used clinically as stimulants of gastrointestinal motility.

VIP is a 28 amino acid peptide which is produced by gastrointestinal tract neurons. It serves as a neurotransmitter stimulating pancreatic exocrine and intestinal secretion. Conversely, it has an inhibitory effect on gastric acid secretion. VIP is a potent vasodilator and relaxant of smooth muscle.

Neurotensin is a 13 amino acid peptide that is produced by the N cells primarily in the ileum, but also in the proximal small intestine and colon in response to the presence of intraluminal fat. It stimulates pancreatic bicarbonate secretion and intestinal motility. Neurotensin also serves as a trophic factor on the small intestinal mucosa and inhibits gastric secretion.

Pancreatic glucagon and enteroglucagon are 29 and 37 amino acid peptides produced by the α-islet cells of the pancreas and the L cells of the small intestine, respectively. Pancreatic glucagon is released in response to low serum glucose and subsequently induces glycogenolysis, lipolysis, gluconeogenesis, and ketogenesis. Enteroglucagon is released in response to the presence of a mixed meal and inhibits gastric emptying and small bowel motility.

Motility

5 The coordination of movements of the gastrointestinal tract is necessary for the proper digestion of food. Well-timed contraction and relaxation patterns are initiated in gastrointestinal nervous system causing coordinated electrical activity and muscular movements. This may be influenced by both internal and external factors. The small intestine has motor functions which are distinct from the other parts of the gastrointestinal tract. The intrinsic nerves (myenteric or Auerbach plexus) provide the basis for coordinating the circular and longitudinal smooth muscles of the small intestine. Extrinsic sympathetic (epinephrine) stimulation slows motility while parasympathetic (acetylcholine) stimulation increases motility.

The intrinsic electrical activity of the small intestine is based on the intestinal smooth muscle normal resting potential. This normally is –50 to –70 mV and is maintained by Na^+-K^+-ATPase activity.[9] The resting potential varies by 5 to 15 mV and results in a phasic depolarization which is referred to as slow waves, basic electrical rhythm, or pacemaker potential. These depolarizations occur at regular intervals of approximately 11 to 13 times per minute in the duodenum and decrease to 8 to 10 times in the ileum, but do not directly lead to muscular contractions. The electrical activity is coupled to muscular contraction at the level of gap junctions, which are low resistance cell-to-cell connections. These gap junctions become less regular in the midjejunum and in the distal small intestine. This causes slowing of the frequency of contractions distally, allowing for absorption of more slowly digested intestinal contents, including fats and bile salts.

Spike potentials represent a second mode of electrical stimulation of the small intestine. Spike potentials result in rapid depolarization of the membrane potential. Repeated bursts of spike potentials cause a short area of contraction. In contrast to the always present slow waves, spike potentials occur at discrete time intervals. The coordination of a slow wave and a spike potential leads to the initiation, duration, and frequency of rhythmic migratory small intestinal contractions.

During the interdigestive period between feeding, the small intestine follows a well-defined rhythmic pattern. This pattern consists of muscular contractions that migrate from the stomach or duodenum, continue on to the terminal ileum, and are regulated by the migrating motor complex (MMC). This pattern can be broken down into four distinct phases. Phase I is a period of relative quiescence; phase II is a period of accelerated irregular electrical spiking and muscular activity; phase III is a series of high-amplitude rapid electrical spikes corresponding to rhythmic gut contractions; and phase IV is a period of subsiding activity. This process occurs over a period of 90 to 120 minutes and progresses from the proximal small bowel and terminates in the ileum. Once the MMC reaches the terminal ileum, the process starts over again in the proximal small bowel. The circular muscles provide segmental contraction over a 1-cm length of small intestine. These contractions occur approximately 11 to 13 times per minute in the duodenum and decrease to 8 to 10 times in the ileum. This creates functional compartments where prolonged exposure to the mucosa and mixing of the intestinal chyme occurs, aiding the process of digestion and absorption. The circular muscles are also responsible for the

peristaltic waves which propagate regularly at a rate of 1 to 2 cm/sec. These regular waves may be interspersed with rushes of contractions followed by periods of no motor activity. This rate becomes progressively slower in the distal small intestine. These peristaltic movements serve as a method of propelling chyme through the length of the small intestine. The total transit time from the duodenum to the terminal ileum is approximately 220 minutes (+/–53 minutes).[10] Serum motilin levels have been found to mirror the activity of the MMC. Exogenous motilin administration has been found to increase MMC activity.

During and immediately following times of feeding, the intestinal movements are not rhythmic, with complexes of peristaltic and antiperistaltic contractions. This is thought to be a disruption of the MMC from bolus feeding. This seemingly random pattern of movements allows for effective mixing of chyme. Hormonal changes are thought to play a role in this process. Physiologic doses of neurotensin, insulin, gastrin, and CCK cause an alteration in the MMC similar to bolus feeding. Visual and olfactory feeding cues can also cause a disruption of the MMC. The MMC is more significantly inhibited by fatty meals as opposed to protein or carbohydrate meals of similar caloric value. The intrinsic nervous plexus or Meissner plexus innervating the submucosa helps to regulate mucosal absorption and secretion, but has no control on motility.

IMMUNOLOGY

Principles of Gut Immunology

6 The lumen of the gastrointestinal tract is connected to the outside environment and comes in direct contact with many potentially pathogenic microorganisms. Lymphocytes, macrophages, polymorphic granulocytes and other cells that take part in immune response are distributed throughout the whole gut. The commensal microflora have many benefits to the host by supporting digestion and keeping the appropriate balance among different microbial species.[11] The immune system is highly effective at responding selectively to invading pathogens, yet on the other hand tolerating a much larger number of harmless food antigens and commensal organisms. Many bacteria, viruses and parasites are digested and enter the small intestine every day.[12] Consequently, the small intestine needs a complex defense mechanism to battle against these exposures in different ways.[13]

While the immune system in the small intestine is important for host defense, other mechanisms within the small intestine also participate in host defense. Proteolytic and lipolytic enzymes are produced in high concentrations by extraintestinal cells in the pancreas and degrade different pathogenic agents at an early phase of digestion. In addition, mucin is produced by the enterocytes which is cytoprotective and inhibits bacterial growth. The small intestine can actively increase peristalsis functions to mechanically get rid of pathogenic agents, which may be potentially dangerous to the gut. In addition, tight junctions between epithelial cells prevent penetration of bacteria in between cells. Potential pathogens vary greatly in size, from very small viruses that are nanometer in size, to parasites such as helminths that are macroscopically visible and quite large. To put this into the broader picture of evolution, a large range of defense mechanisms is essential for survival of each individual.

The primary cellular barrier in the gut that prevents antigens from encountering the immune system is the single layer of gut epithelium. The total surface area of the small intestine is 400 m^2, due not only to intestinal length but also due to the formation of millions of villi in the small bowel which contribute significantly to the overall surface area.[14] In the upper small intestine, the bulk of antigen exposure comes from the diet, whereas in the ileum and colon, the additional antigenic load of an abundant and highly complex commensal microflora is prevalent. The epithelial cells of the gut mucosa have developed features that make the intestinal epithelium an active immunologic as well as anatomic barrier. For example, these nonclassical immune cells express major histocompatibility complex (MHC) class I and II molecules, consistent with their ability to participate in adaptive immune recognition of pathogenic bacteria. Small intestinal epithelial cells also express toll-like receptors on their apical surface that enables them to detect bacterial products and to initiate an innate immune response. Antigen-presenting dendritic cells (DCs) also send processes between gut epithelial cells without disturbing tight junction integrity and sample commensal and pathogenic gut bacteria.[15,16] The gut epithelial barrier therefore represents a highly flexible structure that limits antigens from entering the systemic body.

The gut-associated immune system represents one of the largest immunologic compartments in the body. Lymphoid tissue in the gastrointestinal tract is a major part of the whole-body immune system and consists of both aggregated (lymphoid follicles, Peyer patches) and nonaggregated (luminal, intraepithelial and in lamina propria) immune cells. Under physiologic circumstances, oral administration of protein antigens induces systemic unresponsiveness when the same antigen is given parenterally (a phenomenon known as oral tolerance). In animal models, oral tolerance appears to be a specific consequence of the immune environment in the gut, which favors the generation of regulatory T cells.

Nonaggregated and Aggregated Lymphoid Tissue

The gut epithelium and its mucous layer form a major barrier to trap pathogens which are then eliminated when the gut epithelium is shed and replaced by new cells deriving from stem cells in the crypts. Several different cell types face antigenic exposure present in the intestinal lumen and include the epithelium, neutrophils, lymphocytes, and macrophages. These luminal cells represent an initial effector mechanism in the first front directed toward an antigenic exposure. In addition, there are also immigrated intraepithelial lymphocytes, which are found in between epithelial cells beneath the tight junctions. Local defense depends in part on these T lymphocytes that are nestled among gut epithelial cells. These T cells modulate homeostasis of the gut epithelium through local production of cytokines and have cytolytic effects. In fact, the number of intraepithelial lymphocytes can increase dramatically in response to inflammation or infection. After exposure to antigens, these cells reenter the circulation to initiate a systemic immune response. The lamina propria contains nonaggregated, diffusely distributed lymphoid tissue, including different types of immune cells (Fig. 48-4). B cells in the lamina propria undergo cytokine-induced differentiation to become active producers of immunoglobulin A (IgA) that is secreted into the gut lumen. T cells in the lamina propria may have a different role in a helper-inducer function for immunoglobulin production rather than a cytolytic function. Mast cells and eosinophils are also present in the lamina propria in small numbers. They exhibit an important role in allergic and hypersensitivity reactions as well as defense against parasites. Parasites including worms are recognized and tagged using the monovalent immunoglobulin E (IgE) which is mostly bound to host cell surfaces. Actual parasite killing is depending on toxic proteins secreted by eosinophils.

There are also large aggregates of lymphoid tissue found in the small intestine. These so-called Peyer patches are localized collections of lymphoid follicles that are most prominent and macroscopically visible in the submucosa of the ileum. Peyer patches are most prominent in children and gradually disappear with age. Along with the nonaggregated immune system, the enormous quantity and diversity of antigens present within the gut are also processed via Peyer patches in the lamina propria and the mucosa-associated lymphoid tissue (MALT), which in total contains about 70% of the body's lymphoid cells. Another often used term to describe the immune system within the small intestine is gut-associated lymphoid tissue (GALT). Peyer patches do not have any villi, and so-called microfold (M) cells concentrated within the epithelium allow the selective uptake of food antigens and microorganisms (Fig. 48-5). M cells are specific cells in the intestinal epithelium over lymphoid follicles that endocytose antigens. M cells transport them into the underlying tissue, where they are taken up by local DCs and macrophages.[17] DCs and macrophages that receive antigens from M cells present them to T cells in the GALT, leading ultimately to appearance of IgA-secreting plasma cells in the mucosa. B-lymphocyte precursors proliferate in germinal centers within the Peyer patches. DCs below the epithelium can also take up luminal antigens by pushing pseudopods up between epithelial cells.

Immunoglobulin Secretion

At an early level of exposure at the gut epithelium, M cells take up antigen and transport it transcellularly using an endocytic mechanism into the underlying lymphoid tissues of Peyer patches. Lymphocyte activation ensues, and these activated lymphocytes migrate into afferent lymphatics, pass through mesenteric lymph nodes, and enter the circulation through the thoracic duct. During this process, the lymphocytes mature into B and T lymphoblasts with an enriched population of IgA-producing B cells.[18] Passage of viable bacteria from the intact gastrointestinal tract to the mesenteric lymph node and beyond has been termed bacterial translocation, possibly explaining septic complications and multiple organ failure in peritonitis, burn and trauma patients. The immunogenic integrity of the mucosa is significantly damaged by systemic injury of different kinds. A major protective mechanism of the intestinal immune system is synthesis and secretion of IgA. In the intestine, IgA exists as a dimer that is linked with two additional molecules – the J chain – linking two IgA molecules, and the polymeric immunoglobulin receptor, which transports the IgA complex across the cell and allows release of the complex, termed *secretory component,* into the intestinal lumen. The transmembranous immunoglobulin receptor is produced by the intestinal epithelial cell. It is thought that the secretory component may prevent proteolytic degradation of the IgA molecule and may stabilize the structure of the polymeric IgA complex in an environment containing numerous proteolytic enzymes and bacteria that would otherwise rapidly degrade it. Unlike IgG and IgM, IgA does not activate complement and does not promote cell-mediated opsonization. The major function of secretory IgA in host defense is protection against bacteria, viruses, and luminal antigens. Secretory IgA inhibits the adherence of bacteria to epithelial cells. It is well known that a breast-feeding mother transfers secretory IgA to her nursing infant, protecting the infant from bacteria and viruses that were originally present in the mother's gastrointestinal tract.

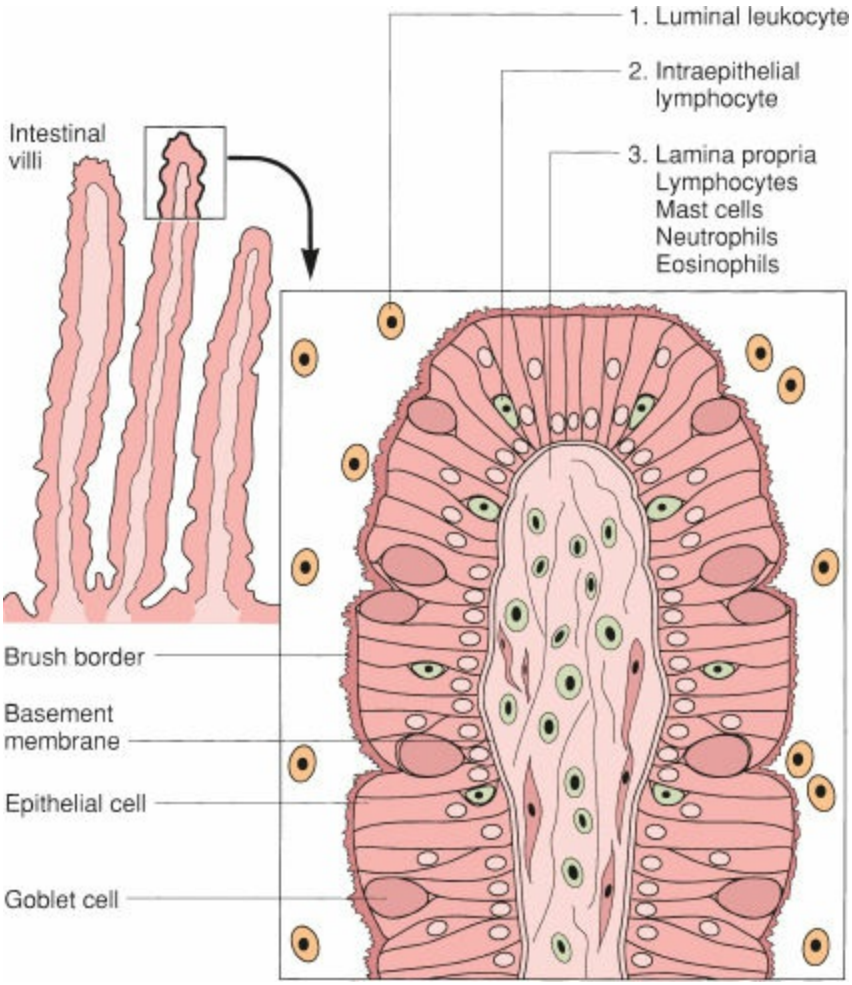

Figure 48-4. Small intestinal villus with associated immunologic cells.

DIGESTION AND ABSORPTION

Absorption of Water and Electrolytes

7 An average person consumes approximately 1 to 1.5 L of water per day. An additional 5 to 10 L is secreted by the gastrointestinal tract: 1 to 2 L of saliva, 2 to 3 L of gastric secretions, 0.5 L of biliary secretions, 1 to 2 L of pancreatic juice, and 1 L of intestinal secretions. The small intestine reabsorbs nearly 80% of the fluid that passes through it. This dynamic process is accomplished by a rapid bidirectional movement of fluid in the intestinal lumen. This ebb and flow of fluid in the intestinal lumen is critical in maintaining normal homeostasis. Minor changes in intestinal permeability or rate of flow of the intestinal contents can result in net secretion and diarrheal states.

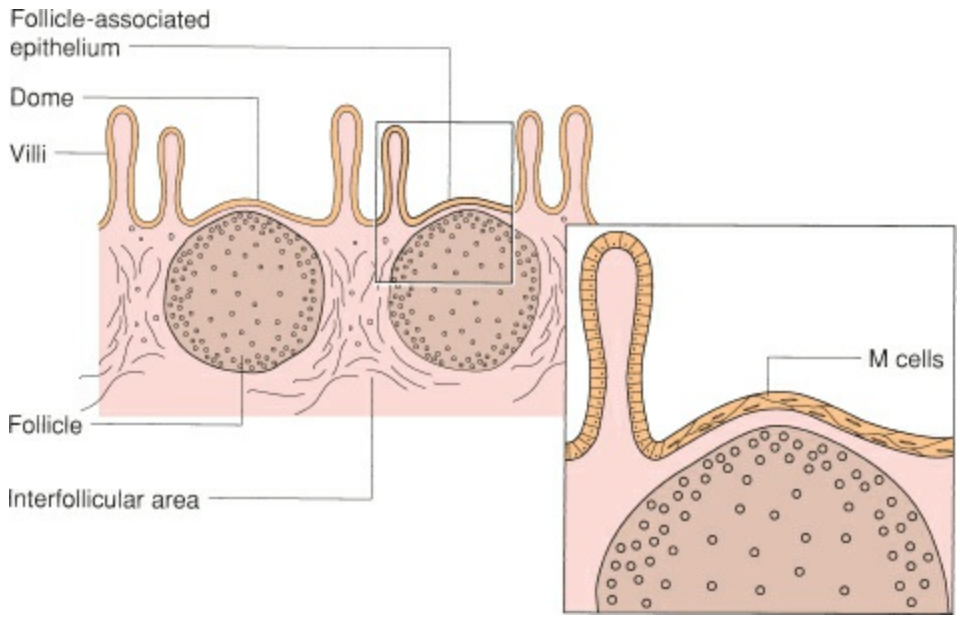

Figure 48-5. Epithelial anatomy in the area of Peyer patches.

The tonicity of the intraluminal contents determines the overall net movement of water. In general, after a meal is consumed, the addition of large amounts of saliva, gastric juice, and hypotonic chime enters the proximal small intestine. Acid gastric contents are neutralized by the secretion of bicarbonate, creating NaCl and water, and decreasing the osmotic pressure. The jejunum is effective at passively reabsorbing water in a paracellular fashion due to its relatively large intercellular pores. As the chyme travels through the length of the small intestine, the intercellular channels become more tightly arranged and the movement of water becomes dependent on the active transport of solutes into the paracellular spaces. A total of 6 to 11 L of water enters the duodenum every day, of this, less than 1 L enters the colon.

Sodium absorption occurs through several different processes. Simple electrogenic absorption, nonelectrolyte-stimulated absorption, and electroneutral absorption are reliant on the Na^+-K^+-ATPase pump on the basolateral membrane of the cell. This pump utilizes the hydrolysis of ATP to provide the necessary energy to move 3 Na^+ ions out of the cell while transporting 2 K^+ ions into the cell against an electrical gradient. This

process maintains a negatively charged low Na^+ intracellular environment, allowing for several mechanisms of absorption at the apical membrane. Simple electrogenic absorption of sodium is the process of an influx of Na^+ ions from the sodium-rich intestinal lumen into the negatively charged low-sodium intracellular environment. This process is indirectly energy dependent, as it relies on the function of the Na^+-K^+-ATPase pump on the basolateral membrane to maintain the low sodium environment and the negative intracellular charge. This process can be inhibited by oubain, a Na^+-K^+-ATPase inhibitor.[19]

Nonelectrolyte-stimulated sodium absorption occurs when sodium is coupled with an organic solute, such as glucose, amino acids, dipeptides, tripeptides, and bile acids. Sodium is preferentially transported down its electrochemical gradient which is created by the Na^+-K^+-ATPase pump on the basolateral membrane of the cell, providing the necessary energy to transport the organic solute against its gradient (Fig. 48-6A). Electroneutral absorption of sodium chloride occurs through a process which couples two neutral ion countertransport mechanisms. Na^+ is exchanged for H^+ and Cl^- is exchanged for HCO_3^-, resulting in no net change in intracellular charge. This process provides an influx of NaCl in exchange for H^+ HCO_3^- efflux. This electroneutral transfer of ions allows for intracellular pH regulation and for sodium and chloride transport (Fig. 48-6B).

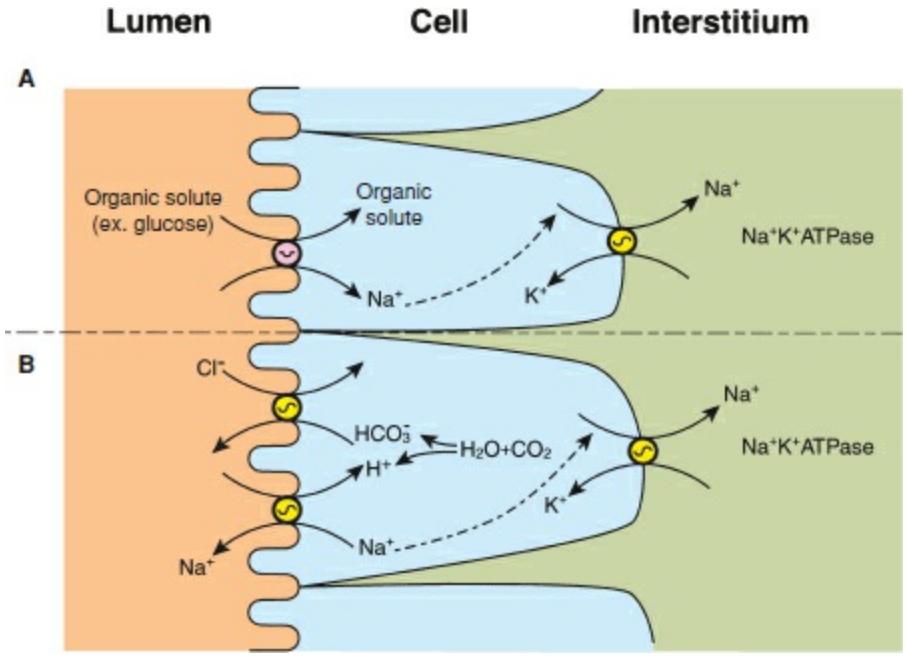

Figure 48-6. Mechanisms of sodium absorption in the small intestine: solute-coupled Na^+ absorption (**A**) and electroneutral NaCl absorption (**B**).

While the majority of chloride is absorbed by electroneutral transfer, chloride is also absorbed by passive diffusion in a paracellular fashion. This is due to the slightly positive interstitium when compared to the gut lumen, allowing the negatively charged chloride ions to be absorbed. An additional important source of chloride transport involves the reabsorption of chloride ions contained within gastric hydrochloric acid secretions. Chloride is a major determinant of the regulation of fluid secretion into the small intestine and in intestinal hydration.[20]

Bicarbonate absorption occurs primarily in the jejunum and requires the formation of carbon dioxide in the intestinal lumen from HCO_3^- and H^+. This creates an increase in the partial pressure of carbon dioxide in the intestinal lumen. Carbon dioxide subsequently diffuses back into the enterocyte and is enzymatically cleaved into H^+ and HCO_3^- by the action of carbonic anhydrase. HCO_3^- diffuses into the interstitium and H^+ is resecreted in exchange for other cations, predominantly Na^+. In the duodenum and ileum, HCO_3^- is secreted in exchange for Cl^-. This efflux of HCO_3^- provides a mechanism to neutralize gastric acid entering into the duodenum. HCO_3^- secretion in the ileum most likely helps maintain acid–base equilibrium, although this process is not well understood.[21]

Approximately 90 mEq/d of potassium is ingested in a normal diet of which 90% is absorbed. An equal amount of potassium is excreted in the urine as is absorbed in the intestine, allowing maintenance of potassium homeostasis. The majority of absorption occurs in the small intestine mainly through passive mechanisms.[22] This process is thought to occur through intercellular pores or through an H^+-K^+ exchange pathway facilitated by the intracellular electrochemical gradient which is created predominantly by the basolateral ATPase pump. Intracellular K^+ then diffuses across the basolateral membrane by a K^+ channel or carrier.

Mineral Absorption

Mineral absorption is necessary for the proper form and function of the human body. These inorganic elements are responsible for approximately 4% to 6% of a person's mass. Calcium accounts for approximately 50% of this mass, phosphate provides an additional 25%, and a variety of other minerals constitute the remaining 25%. Many of these minerals are best absorbed in their ionized forms, which is aided by the presence of hydrochloric acid in the gastric lumen. Calcium, phosphate, magnesium, sulfur, sodium, chloride, and potassium are considered macrominerals, with daily requirements exceeding 100 mg/d. Microminerals (trace minerals) include iron, zinc, copper, manganese, iodine, selenium, fluoride, molybdenum, chromium, and cobalt with daily requirements of less than 15 mg/d.

Approximately 1 g of calcium is consumed per day, mainly from dairy products. Once in its ionized form, calcium is primarily absorbed in the duodenum, although this process occurs throughout the length of the small intestine. When calcium is present intraluminally at low levels, it is transported across the apical membrane of the enterocyte by carrier-mediated facilitated diffusion. Once calcium is in the cytoplasm, it is bound to calcium-binding proteins and delivered to the basal membrane. Calcium is then transferred into the interstitium by a Ca^{2+}-ATPase pump. This process is indirectly regulated by parathyroid hormone (PTH). PTH in low-calcium states promotes conversion of vitamin D to its active form 1,25-$(OH)_2$ vitamin D. This activated form of Vitamin D causes an increase in the expression of both calcium-binding proteins and Ca^{2+}-ATPase, causing an increase in the absorption of calcium by the small intestine.[23,24] When intraluminal calcium is in excess of its capacity to be actively transferred by the apical membrane's carrier-mediated mechanism, passive paracellular calcium absorption occurs in the distal small intestine.

Absorbable dietary sources of iron are typically either contained within a protein, such as heme, or as a ferrous (Fe^{2+}) ion. Iron-containing proteins are usually from ingested meats, whereas ferrous forms are typically present in vegetables, grains, and fruits. Vitamin C (ascorbic acid) increases iron absorption by reducing the ferric (Fe^{3+}) ion into the more soluble ferrous state. Absorption of iron is facilitated by carrier-mediated translocation across the apical membrane of the enterocyte in the duodenum and proximal jejunum. Once in the cytoplasm, the ferrous ion is released by enzymatic cleavage. Ferrous ions may be stored intracellularly by ferritin or transported into the circulation by transferrin. The process of iron absorption is regulated in the enterocyte by hypoxia-inducible factor signaling and iron-regulatory proteins. Systemically, the central iron regulatory hormone is hepatic hepcidin. Hepatic hepcidin regulates iron absorption and mobilization from systemic stores by inhibiting ferroportin, a cellular iron exporter.[25]

Carbohydrate Digestion and Absorption

Carbohydrates are a staple in many diets and provide a major source of daily caloric intake. In Western diets, 400 g of carbohydrates are consumed by the average adult daily, providing 1,600 kcal (4 kcal/g of carbohydrate). Carbohydrates are present in three main digestible forms: complex starches, disaccharides, and simple sugars. Complex starches account for approximately 60% of daily carbohydrate intake. The most common form is amylopectin which consists of glucose linked in a linear fashion with α(1,4)-glycosidic bonds with branch points consisting of α(1,6)-glycosidic linkages occurring after approximately every 20 to 26 glucose moieties. Amylose is a long linear grouping of glucose molecules connected with α(1,4)-glycosidic bonds without branch points. Disaccharides, mainly sucrose and lactose, are the next most common source of dietary carbohydrates, representing nearly a third of daily intake. Sucrose disaccharides are comprised of glucose–fructose dimers, whereas lactose disaccharides consist of glucose–galactose dimers.

The complex starches, amylopectin and amylose, are digested with the aid of salivary and pancreatic amylase. Salivary amylase contributes a small amount to this process as it is inactivated by gastric acid, leaving the remainder of this process to be completed by pancreatic amylase. This process yields maltose, which are glucose dimers with α(1,4)-glycosidic bonds, and maltotriose, which are glucose trimers with α(1,4)-glycosidic bonds. In addition, α-dextrins are produced with an average of 6 glucose moieties with α(1,4)-glycosidic bonds and side branches linked by α(1,6)-glycosidic bonds. This digestive process is usually completed before the carbohydrate bolus leaves the duodenum. These small oligosaccharides along with ingested disaccharides, typically sucrose and lactose, are then further digested by the brush border saccharidases in the jejunum.

The brush border of the small bowel contains specific enzymes which through catalytic reactions hydrolyze these oligo- and disaccharides into their component monosaccharide moieties, such as glucose, galactose, and fructose. Once broken down into their basic subunits, these monosaccharides can be transported across the apical cell membrane. A sodium-dependent hexose transporter (SGLUT-1) is required for the transport of glucose and galactose as they utilize the same carrier mechanism. The cotransportation of these monosaccharides with sodium is dependent on the Na^+-K^+-ATPase pump on the basolateral membrane to maintain a sodium gradient allowing for this influx. Fructose is transported in a carrier mediated diffusion dependent manner by GLUT5 and does not require sodium as a cotransporter (Fig. 48-7). The movement of monosaccharides into the cellular cytoplasm provides an additional gradient by which water is absorbed by the enterocytes from the intestinal lumen. The monosaccharides are then transported across the basolateral membrane by GLUT2. This hexose transporter allows for the diffusion of all three monosaccharides into the extracellular space and ultimately into the portal blood flow. A small portion of these monosaccharides may be used by the enterocyte, but the majority is transported through the cell.

Nondigestible carbohydrates (dietary fiber) such as cellulose are thought to be an

important part of a normal diet even though they do not provide dietary calories. Dietary fiber is present in grains, vegetables, and pulpy fruits. Dietary fiber helps decrease bowel transit time by absorbing water in the intestinal lumen. In addition, fiber can absorb organic materials such as lipids and bile salts and inorganic minerals such as zinc, calcium, and magnesium. These actions of fiber are thought to play a role in preventing carcinogenesis and in helping to maintain normal serum lipid profiles. Unfortunately, fiber is underrepresented in most Western diets.

Protein Digestion and Absorption

Protein consumption is essential to the daily diet. An average adult requires 0.75 g/kg of protein per day, although this requirement may be significantly increased during childhood, pregnancy, and times of significant illness. Protein provides an important caloric energy source as well as the essential building blocks for production of new proteins. A nearly equal amount of protein is ingested daily from dietary sources (70 to 100 g) as is provided by endogenous proteins (50 to 60 g of protein per day) in the small intestine from secreted enzymes, desquamated cells, and plasma protein leakage. Nearly 90% of this protein load is metabolized in a similar fashion to dietary proteins.

The initial digestion of protein begins with the activation of pepsinogen to pepsin in the acid environment of the stomach. Pepsin hydrolyzes protein into its component amino acids; however this action only represents a small part of overall protein digestion. The majority of protein digestion occurs in the small intestine by pancreatic peptidases and proteases. Pancreatic enzymes flow into the duodenum, initiating this phase of protein digestion. These pancreatic proteases are initially released as proenzymes (zymogens). These zymogens are inactive and require a further catalytic process to occur for their activation. This is initiated by the brush border enzyme enteropeptidase (enterokinase) in the duodenum. Endopeptidase cleaves trypsinogen into the active enzyme trypsin. Trypsin in turn activates the other zymogens into their active endopeptidases (trypsin, chymotrypsin, and elastase) which hydrolyze internal peptide bonds. Additional protein digestion is performed by exopeptidases (caroxypeptidase A and B) which are able to cleave amino acids from the C-terminal ends of proteins. Seventy percent of the process results in short oligopeptides of 2 to 6 amino acids and the remaining 30% produces single amino acids.

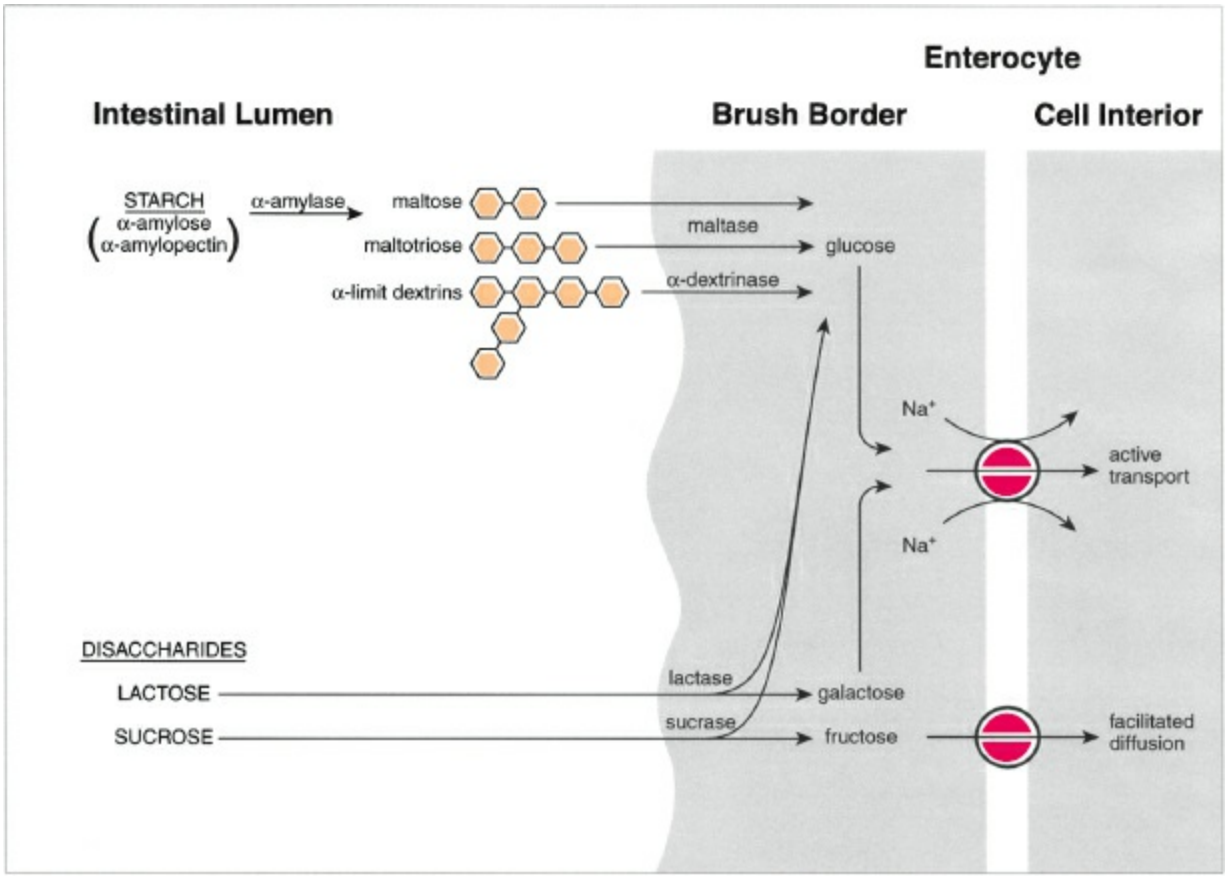

Figure 48-7. Digestion and absorption of carbohydrates.

Short oligopeptides are further digested by enzymes in the brush border of the small intestine or within the cell cytoplasm. Single amino acids, dipeptides, and tripeptides are able to diffuse through the apical membrane into the cytoplasm. Single amino acids are cotransported into the cytoplasm with sodium along an electrochemical gradient. This electrochemical gradient is maintained by the Na^+-K^+-ATPase pump on the basolateral cell membrane. At least four separate transport mechanisms exist for the various electrochemical properties of amino acids which are transported (neutral, dibasic, acidic, and imino). Peptides greater than 3 amino acids in length are broken down into smaller peptides by enzymes in the brush border. The resultant dipeptides and tripeptides are then moved into the cytoplasm along with H^+ by a cotransporter PepT1, where they are hydrolyzed by specific peptidase into their component amino acids. Transport of amino acids into the cytosol provides an osmotic gradient by which water is further absorbed from the intestinal lumen. A small portion of the processed amino acids are utilized by the enterocyte, and the vast majority is shuttled into the portal blood flow via amino acid transporters on the basolateral membrane.

Fat Digestion and Absorption

Forty percent of the average daily caloric intake (60 to 90 g) in a Western diet is in the form of fat. Ninety percent of these ingested fats are triglycerides, while the remainder is comprised of cholesterol, phospholipids, and fat-soluble vitamins. The initiation of lipid digestion occurs when CCK is stimulated by the presence of fatty acids on the duodenal mucosa. CCK in turn stimulates pancreatic secretion of lipase and its cofactor colipase. Lipase hydrolyzes triglycerides at the 1 and 3 positions of the glycerol backbone, yielding two fatty acids and a monoglyceride (a fatty acid esterified to glycerol). Cholesterol and fat-soluble vitamins are hydrolyzed by pancreatic cholesterol esterase and phospholipids by phopholipase A_2. The products of lipolysis interact with bile salts to form water soluble micelles. Mixed micelles are 50 to 400 Å in diameter and are a combination of fatty acids, bile salts, and monoglycerides. The structure of a micelle is composed of an inward facing hydrophobic region and a hydrophilic region facing outward toward the aqueous environment of the intestinal lumen. Due to the hydrophobic core, cholesterol, phospholipids, and fat-soluble vitamins can reside within the micelle structure. Micelles are able to interact with the mucosal cells and empty their contents into the cytoplasm. This occurs by the process of dissolution of the micelles into the lipid bilayer of the mucosal cell. Once this is completed, the components of the micelle are ready to reform with new lipid components to repeat this process. There is no energy consumed directly in the transfer of lipids into the cell cytoplasm.

Once in the cytoplasm, long-chain fatty acids and β-monoglycerides are carried by cytosolic fatty acid–binding proteins to the smooth endoplasmic reticulum (SER). In the SER, resynthesis of triglycerides occurs. These triglycerides are further processed in the Golgi apparatus where a phospholipid and an apoprotein coat are added to form a chylomicron. Chylomicrons are 90% triglyceride; the remaining 10% is composed of phospholipid, cholesterol, and protein. These large particles are 750 to 6,000 Å in diameter. Before exiting the Golgi apparatus, the chylomicrons are packaged into secretory vesicles. They exit the cell membrane by exocytosis and enter the central lacteal of the villus and the intestinal lymphatic system. In addition, enterocytes also produce smaller lipoprotein particles, very low density lipoproteins, which contain a higher cholesterol/triglyceride ratio and provide the major route of entry for dietary cholesterol into the lymphatic system.

Short chain fatty acids contain less than 8 carbon atoms and are water soluble. This allows these molecules to enter and exit the enterocyte by simple diffusion independent of bile micelles or chylomicrons. Medium chain triglycerides consist of 6 to 12 carbon atoms and can be absorbed by simple diffusion or through the previously mentioned process of transport of long chained fatty acids via the formation of bile micelles and chylomicrons. Both short and medium chain fatty acids may enter the portal circulation without entering into the lymphatics. The majority of dietary fat is processed and absorbed in the duodenum and upper jejunum.

Absorption of Bile Salts

Approximately 95% of the bile salts secreted into the intestine are reabsorbed and returned to the liver through the portal circulation. Once in the liver, these bile salts are reprocessed and secreted and stored in the gallbladder in preparation for the next meal. This process of recycling of bile salts is referred to as the enterohepatic circulation. This reabsorption occurs by both passive and active means. A small amount of bile salts are passively reabsorbed along the entire length of the small intestine. The majority of bile salts, however, are reabsorbed though an active Na^+-dependent transport mechanism in the terminal ileum. Bile, which is not reabsorbed, passes into the colon where it is deconjugated by bacteria. This process increases the solubility of the bile and promotes further passive absorption. High concentrations of bile salts within the colon inhibit sodium and water reabsorption, resulting in diarrhea. Patients who have undergone resection of their ileum may suffer from diarrhea due to this process. These patients may be treated with the bile-binding resin, cholestyramine, to help alleviate their symptoms.

Vitamin Absorption

Fat-soluble vitamins (A, D, E, and K) are incorporated into micelles along with fats in order to pass into the enterocyte. These vitamins are then processed and packaged into chylomicrons so that they can exit into the lymphatic system. Water-soluble vitamins are absorbed in the jejunum and ileum through a variety of mechanisms. Vitamin C (ascorbic acid), biotin, and niacin are transported by Na^+-dependent mechanisms. Folate, vitamin B_1 (thiamine), and vitamin B_2 (riboflavin) are absorbed by Na^+-independent mechanisms and vitamin B_6 is absorbed by passive diffusion.[25]

Vitamin B_{12} (cobalamin) absorption is dependent on the presence of intrinsic factor, a glycoprotein produced by the gastric parietal cells. One molecule of intrinsic factor binds two molecules of cobalamin to form a complex which attaches to a specific membrane receptor in the terminal ileum. Unbound cobalamin cannot be absorbed. Cobalamin becomes unbound from its complex in the enterocyte and exits from the cell into the portal circulation with the aid of B_{12}-binding proteins called transcobalamins. Cobalamin is essential for DNA synthesis and a deficiency usually presents with megaloblastic anemia. Inability to absorb sufficient amounts of cobalamin may be due to lack of intrinsic factor after proximal or total gastrectomy, autoimmunity to gastric parietal cells or intrinsic factor, or atrophic gastritis. In addition, cobalamin-intrinsic factor complexes may fail to be absorbed due to distal ileal disease or resection, and cobalamin deficiency may occur from bacterial overgrowth due to bacterial overconsumption of cobalamin.

Small Intestinal Microbiota

8 The importance of the microbiota of the small intestine on metabolism and its impact on health and disease processes are increasingly being realized. The small intestine is not highly populated by bacteria due to its relatively inhospitable environment, which is comprised of a variety of antimicrobial proteins, immunoglobulins, and a low pH. Bacterial populations of the small intestine have been estimated at 10^3/g in the duodenum to 10^8/g in the distal ileum, but despite these relatively low populations there is evidence that there is interplay between the microbes and the intestinal lining that may directly affect intestinal health.[26] The role of microbes and bile acid metabolism is relatively well understood, but new findings about the regulation of bile acid conjugation are cited as possible factors in irritable bowel disease and inflammatory bowel disease.[27] Metabolism of fatty acids, dietary fiber, and amino acids alter the production of microbial anti-inflammatory and proinflammatory factors and is thought to play an important role in mucosal integrity and translocation, as well as, hepatic function and may have a role in the pathogenesis of nonalcoholic fatty liver disease.[28–32] While the exact mechanisms of many of the interactions between the gut microflora and the small intestinal microenvironment are still speculative, it has become evident that a symbiotic environment is present which, at least in part, is responsible for proper homeostasis of the small intestine.

References

1. Kluth D, Jaeschke-Melli S, Fiegel H. The embryology of gut rotation. *Semin Pediatr Surg* 2003;12(4):275–279.
2. Cohen S, Harris LD, Levitan R. Manometric characteristics of the human ileocecal junctional zone. *Gastroenterology* 1968;54(1):72–75.
3. Holmes R, Lobley RW. Intestinal brush border revisited. *Gut* 1989;30(12):1667–1678.
4. Rubin DC. Spatial analysis of transcriptional activation in fetal rat jejunal and ileal gut epithelium. *Am J Physiol* 1992;263(6 Pt 1):G853–G863.
5. Trier JS. Studies on small intestinal crypt epithelium. I. The fine structure of the crypt epithelium of the proximal small intestine of fasting humans. *J Cell Biol* 1963;18:599–620.
6. Garabedian EM, Roberts LJ, McNevin MS, et al. Examining the role of Paneth cells in the small intestine by lineage ablation in transgenic mice. *J Biol Chem* 1997;272(38):23729–23740.
7. Englander E, Greeley J. *Postpyloric Gastrointestinal Peptides.* San Diego: Elsevier; 2005.
8. Weckbecker G, Lewis I, Albert R, et al. Opportunities in somatostatin research: biological, chemical and therapeutic aspects. *Nat Rev Drug Discov* 2003;2(12):999–1017.
9. Casteels R. Membrane potential in smooth muscle cells. In Bulbring E, Brading A, Jones A, eds. *Smooth Muscle: An Assessment of Current Knowledge.* Austin, TX: University of Texas Press; 1981:105–126.
10. Ofori-Kwakye K, Fell JT, Sharma HL, et al. Gamma scintigraphic evaluation of film-coated tablets intended for colonic or biphasic release. *Int J Pharm* 2004;270(1–2):307–313.
11. Xavier RJ, Podolsky DK. Microbiology. How to get along–friendly microbes in a hostile world. *Science* 2000;289(5484):1483–1484.
12. Kraehenbuhl JP, Corbett M. Immunology. Keeping the gut microflora at bay. *Science* 2004;303(5664):1624–1625.
13. Macdonald TT, Monteleone G. Immunity, inflammation, and allergy in the gut. *Science* 2005;307(5717):1920–1925.
14. Hayday A, Viney JL. The ins and outs of body surface immunology. *Science* 2000;290(5489):97–100.
15. Niess JH, Reinecker HC. Lamina propria dendritic cells in the physiology and pathology of the gastrointestinal tract. *Curr Opin Gastroenterol* 2005;21(6):687–691.
16. Pasare C, Medzhitov R. Toll-like receptors: Balancing host resistance with immune tolerance. *Curr Opin Immunol* 2003;15(6):677–682.
17. Niess JH, Brand S, Gu X, et al. CX3CR1-mediated dendritic cell access to the intestinal lumen and bacterial clearance. *Science* 2005;307(5707):254–258.
18. Macpherson AJ, Uhr T. Induction of protective IgA by intestinal dendritic cells

carrying commensal bacteria. *Science* 2004;303(5664):1662–1665.
19. Charney AN, Donowitz M. Functional significance of intestinal Na + -K + -ATPase: In vivo ouabain inhibition. *Am J Physiol* 1978;234(6):E629–E636.
20. Barrett KE, Keely SJ. Chloride secretion by the intestinal epithelium: molecular basis and regulatory aspects. *Annu Rev Physiol* 2000;62:535–572.
21. Minhas BS, Sullivan SK, Field M. Bicarbonate secretion in rabbit ileum: electrogenicity, ion dependence, and effects of cyclic nucleotides. *Gastroenterology* 1993;105(6):1617–1629.
22. Agarwal R, Afzalpurkar R, Fordtran JS. Pathophysiology of potassium absorption and secretion by the human intestine. *Gastroenterology* 1994;107(2):548–571.
23. Cai Q, Chandler JS, Wasserman RH, et al. Vitamin D and adaptation to dietary calcium and phosphate deficiencies increase intestinal plasma membrane calcium pump gene expression. *Proc Natl Acad Sci U S A* 1993; 90(4):1345–1349.
24. Walters JR. Calbindin-D9k stimulates the calcium pump in rat enterocyte basolateral membranes. *Am J Physiol* 1989;256(1 Pt 1):G124–D128.
25. Said HM. Recent advances in carrier-mediated intestinal absorption of water-soluble vitamins. *Annu Rev Physiol* 2004;66:419–446.
26. Leser TD, M⊘lbak L. Better living through microbial action: the benefits of the mammalian gastrointestinal microbiota on the host. *Environ Microbiol* 2009;11(9):2194–2206.
27. Joyce SA, Gahan CG. The gut microbiota and the metabolic health of the host. *Curr Opin Gastroenterol* 2014;30(2):120–127.
28. Elamin EE, Masclee AA, Dekker J, et al. Ethanol metabolism and its effects on the intestinal epithelial barrier. *Nutr Rev* 2013;71(7):483–499.
29. Everard A, Cani PD. Diabetes, obesity and gut microbiota. *Best Pract Res Clin Gastroenterol* 2013;27(1):73–83.
30. Keshavarzian A, Fields JZ, Vaeth J, et al. The differing effects of acute and chronic alcohol on gastric and intestinal permeability. *Am J Gastroenterol* 1994;89(12):2205–2211.
31. Wang HB, Wang PY, Wang X, et al. Butyrate enhances intestinal epithelial barrier function via up-regulation of tight junction protein Claudin-1 transcription. *Dig Dis Sci* 2012;57(12):3126–3135.
32. Willemsen LE, Koetsier MA, van Deventer SJ, et al. Short chain fatty acids stimulate epithelial mucin 2 expression through differential effects on prostaglandin E(1) and E(2) production by intestinal myofibroblasts. *Gut* 2003;52(10):1442–1447.

Chapter 49

Ileus and Bowel Obstruction

David I. Soybel and Ariel P. Santos

Key Points

1 Peritoneal adhesions account for more than half of small bowel obstruction (SBO) cases.

2 In simple obstruction the intestinal lumen is partially or completely occluded without compromise of intestinal blood flow. Simple obstructions may be complete, meaning that the lumen is totally occluded, or incomplete, meaning that the lumen is narrowed but permitting distal passage of some fluid and air. In strangulation obstruction, blood flow to the obstructed segment is compromised and tissue necrosis and gangrene are imminent.

3 Four key symptoms that are associated with acute mechanical bowel obstruction include abdominal pain, vomiting, distention, and obstipation; abdominal pain out of proportion to physical findings should raise concern about rapidly evolving closed-loop obstruction and the need for urgent resuscitation and operation.

4 Use of water-soluble contrast may be both diagnostic and therapeutic.

5 Increasingly, computed tomography (CT) is the "go-to" imaging modality to detect and identify the likely site and source of obstruction.

6 Conservative management consisting of intravenous hydration, nasogastric decompression, and restoration of electrolyte balance is a cornerstone of initial management of any patient suspected of having intestinal obstruction.

7 Open exploratory laparotomy is the gold standard in treating unresolved SBO but laparoscopic management should be considered in select group of patients. Types of intestinal obstruction that are more likely to lead to strangulation and the need for urgent/emergent operation include closed-loop obstructions, obstruction that occurs without a prior history of operation, and obstructions that occur after laparoscopic procedures.

8 Ileus denotes underlying alterations in motility of the gastrointestinal tract, leading to functional obstruction.

9 Postoperative ileus (POI) can be differentiated from SBO with the use of contrast CT and enteroclysis imaging techniques.

10 POI is often self-limiting; less frequent interventions are required for prolonged POI, if proper precautions have been taken during surgery.

INTRODUCTION AND HISTORICAL PERSPECTIVE

The purpose of this chapter is to provide an overview of the pathophysiology, natural history, diagnosis, and management of acute obstruction and ileus of the small and large intestines. The development of the modern approach to intestinal obstruction and ileus paralleled the development of techniques for safe abdominal surgery. Chief among these accomplishments were the discovery of safe general anesthetics, the popularization of aseptic methods in the operating rooms and management of wounds, and the development of techniques for intestinal resection, intestinal anastomosis, and colostomy. The foundations of the recognition and management of intestinal obstruction and ileus are attributed to Frederick Treves.[1–3] In 1884, he published a detailed discussion of the etiologies (including adhesions) and surgical management of mechanical intestinal obstruction.[1] Treves also distinguished mechanical from nonmechanical (i.e., paralytic) causes of intestinal distention, classifying the latter causes under the term *ileus*. From 1880 to 1925, proximal intestinal decompression was recognized to provide relief from the symptoms of mechanical obstruction or ileus.[3] In 1933, Wangensteen and Paine reported the efficacy of gastrointestinal intubation in relieving symptoms of intestinal distention caused by intestinal obstruction or from the ileus that resulted from laparotomy.[4,5] Subsequently, Wangensteen and Rea provided experimental evidence that the source of gaseous distention in cases of obstruction or ileus was swallowed air.[6] The value of intravenous fluid resuscitation in experimental models of intestinal obstruction was recognized as early as 1912[7] and became a principle of care of the patients with intestinal obstruction in the late 1920s. By 1920, plain abdominal radiographs were used in diagnosis of intestinal obstruction.[3] Thus, the principles of early diagnosis, rapid intravenous fluid resuscitation, gastrointestinal decompression, and early operation to avoid intestinal gangrene and peritonitis, were established well before the advent of antibiotic therapy, invasive hemodynamic monitoring, and parenteral nutrition.[8] These early developments were most important in reducing morbidity and mortality of mechanical intestinal obstruction and ileus.[9]

MECHANICAL OBSTRUCTION OF THE INTESTINES

Terminology and Classification

The term *mechanical obstruction* means that luminal contents cannot pass through the gut tube because the lumen is blocked. This obstruction is in contrast with *neurogenic* or *functional* obstructions in which luminal contents are prevented from passing because of disturbances in gut motility that prevent coordinated peristalsis from one region of the gut to the next. This latter form of obstruction is commonly referred to as *ileus* in the small intestine and *pseudo-obstruction* in the large intestine. In *simple* obstruction the intestinal lumen is partially or completely occluded without compromise of intestinal blood flow. Simple obstructions may be *complete,* meaning that the lumen is totally occluded (Fig. 49-1), or *incomplete,* meaning that the lumen is narrowed but permitting distal passage of some fluid and air. In *strangulation* obstruction, blood flow to the obstructed segment is compromised and tissue necrosis and gangrene are imminent. Strangulation usually implies that the obstruction is complete, but some forms of partial obstruction can also be complicated by strangulation.

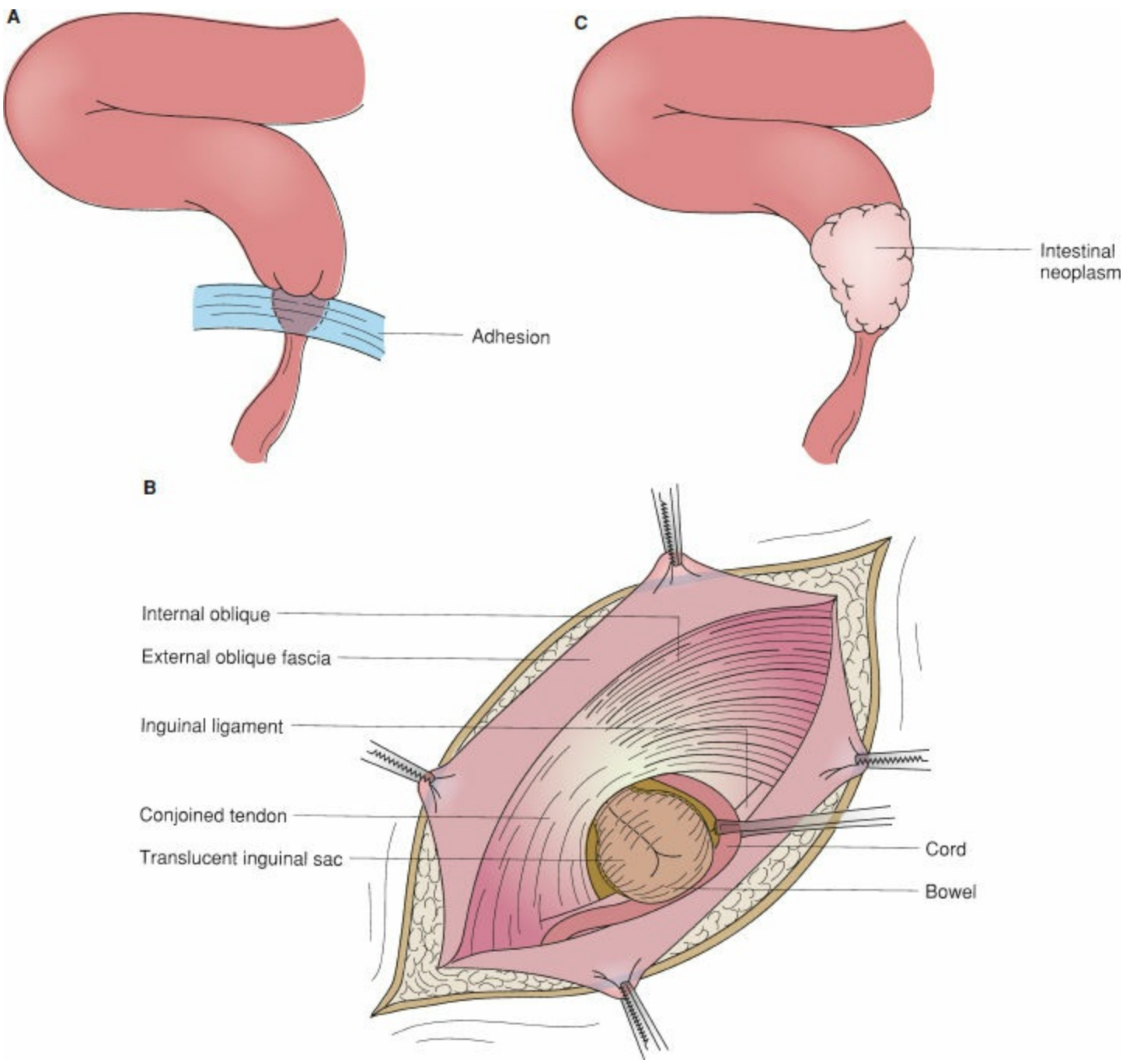

Figure 49-1. Schematic illustration of different forms of simple mechanical obstruction. Simple obstruction is most often due to adhesion (**A**), groin hernia (**B**), or neoplasm (**C**). The hernia can act as a tourniquet, causing a closed-loop obstruction and strangulation.

1 The various forms of mechanical intestinal obstruction can be classified according to different but overlapping schemes. Most commonly, obstruction is classified according to etiology. As detailed in Table 49-1, distinctions are drawn between intraluminal obturators such as foreign bodies or gallstones, intramural lesions such as tumors or intussusceptions, and extrinsic or extramural lesions such as adhesions. Adhesions are the most common cause of intestinal obstruction, accounting for more than half of all cases. In order to highlight the pathophysiology, presentation, and natural history, however, it is useful to classify obstruction according to the location of the obstructing lesion. Proximal or "high" obstructions involve the pylorus, duodenum, and proximal jejunum. Intermediate levels of obstruction involve the intestine from the midjejunum to the

midileum. Distal levels of obstruction arise in the distal ileum, ileocecal valve, and proximal colon whereas the most distant or "low" obstructions would arise in regions beyond the transverse colon. As shown in Table 49-2, clinical symptoms and signs of obstruction (pain, vomiting, abdominal distention, and gas pattern on abdominal radiographs) vary with the level of obstruction.

It is also important to distinguish between *open-loop* and *closed-loop* obstructions. An open-loop obstruction occurs when intestinal flow is blocked but proximal decompression is possible through vomiting. A closed-loop obstruction occurs when inflow to the loop of bowel and outflow from the loop are both blocked. This obstruction permits gas and secretions to accumulate in the loop without a means of decompression, proximally or distally. Examples of closed-loop obstructions are torsion of a loop of small intestine around an adhesive band (Fig. 49-2), incarceration of the bowel in a hernia, volvulus of the cecum or colon, or development of an obstructing carcinoma of the colon with a competent ileocecal valve. The primary symptoms of a closed-loop obstruction of the small intestine are sudden, severe midabdominal pain and vomiting whereas symptoms of the large intestine are pain and sudden abdominal distention. This pain often occurs before associated findings of localized abdominal tenderness or involuntary guarding. When signs of peritoneal irritation or frank peritonitis develop, there is a high level of suspicion that the viability of the bowel is compromised.

Table 49-1 Classification of Adult Mechanical Intestinal Obstructions

Intraluminal	Intramural	Extrinsic
Foreign bodies	Congenital (rare in adult)	Adhesions
Barium inspissation (colon)	Atresia, stricture or stenosis	Congenital: Ladds or Meckel bands
Bezoar	Web	Postoperative
	Intestinal duplication	Postinflammatory (after pelvic inflammatory disease)
	Meckel diverticulum	
Inspissated feces	Inflammatory Process	Hernias
Gallstone ileus	Crohn disease	Abdominal wall
Meconium (cystic fibrosis)	Diverticulitis	Internal
	Stricture from ischemia	Volvulus
	Radiation enteritis or stricture	External mass effect
	Medication-induced (NSAIDs, KCl tablets)	Abscess
Parasites (ascaris, diphyllobothrium)	Neoplasms	Annular pancreas
Enterolith	Primary intestinal or colon (malignant or benign)	Pancreatic pseudocyst
Intussusception		Carcinomatosis
	Secondary (metastasis or carcinomatosis)	Endometriosis
Polypoid and exophytic lesions	Trauma (e.g., intramural hematoma)	Pregnancy

Pathophysiology of Intestinal Obstruction

Local Effects of Bowel Obstruction

When a loop of bowel becomes obstructed, intestinal gas and fluid accumulate. Stasis of luminal content favors bacterial overgrowth, alters intestinal fluid transport properties and motility, and causes variations in intestinal perfusion and lymph flow. Luminal contents and volume, bacterial proliferation, and alterations in motility and perfusion work in concert to determine the rate at which symptoms and complications develop. Each of these factors merits discussion in some detail.

Intestinal Gas. Approximately 80% of the gas seen on plain abdominal radiographs is attributable to swallowed air.[6] Approximately 70% of the gas in the obstructed gut is inert nitrogen.[10] Oxygen accounts for 10% to 12%, CO_2 for 6% to 9%, hydrogen 1%, methane 1%, and hydrogen disulfide 1% to 10%. In the setting of acute pain and anxiety, patients with intestinal obstruction may swallow excessive amounts of air. Passage of such swallowed air distally is prevented by nasogastric suction.

Intestinal Flora. An important contribution to normal digestive function comes from its bacterial population.[11] In patients with normal gastric acid secretion, the chyme entering the duodenum is sterile. The small numbers of bacteria that are found in stomach and proximal intestine are aerobic, gram-positive species found in the oropharynx. Distally, in the ileum and colon, gram-negative aerobes are present and anaerobic organisms predominate. Total bacterial counts in normal feces reach 10^{11} organisms per gram of fecal matter. Control of the bacterial populations depends on intact motor activity of the intestines and the interactions of all species present. This ecology can be disturbed by antibiotic therapy or by surgical reconstructions that result in stasis within intestinal segments. Intestinal bacteria serve several functions, including metabolism of fecal sterols, releasing the small-chain fatty acids that are an important food source for colonocytes; metabolism of fecal bile acids, fat-soluble vitamins (e.g., vitamin K) and vitamin B12; and breakdown of complex carbohydrates and organic matter, leading to formation of CO_2, H_2, and CH_4 gases.[9] Considerable evidence suggests that the normal flora may contribute to baseline levels of intestinal secretion and, perhaps, normal intestinal motility. Under baseline conditions, the small intestines in germfree animals are frequently dilated, fluid filled, and without peristalsis.[12,13]

Table 49-2 Symptoms and Signs of Bowel Obstruction

Symptom/ Sign	Proximal Small Bowel (Open Loop)	Distal Small Bowel (Open Loop)	Small Bowel (Closed Loop)	Colon/Rectum
Pain	Intermittent, intense, colicky, often relieved by vomiting	Intermittent to constant	Progressive, intermittent to constant; rapidly worsens	Continuous
Vomiting	Large volumes, bilious and frequent	Low volume and frequency, progressively feculent with time	May be prominent (reflex)	Intermittent, not prominent; when present, feculent
Tenderness	Epigastric or periumbilical; quite mild, unless strangulation is present	Diffuse and progressive	Diffuse, progressive	Diffuse
Distension	Absent	Moderate to marked	Often absent	Marked
Obstipation	May not be present	Present	May not be present	Present

Adapted from Schuffler MD, Sinanan MN. Intestinal obstruction and pseudo-obstruction. In: Sleisenger MH, Fordtran JS, eds. *Gastrointestinal Disease*. 5th ed. Philadelphia, PA: WB Saunders, Co.; 1993;898–916.

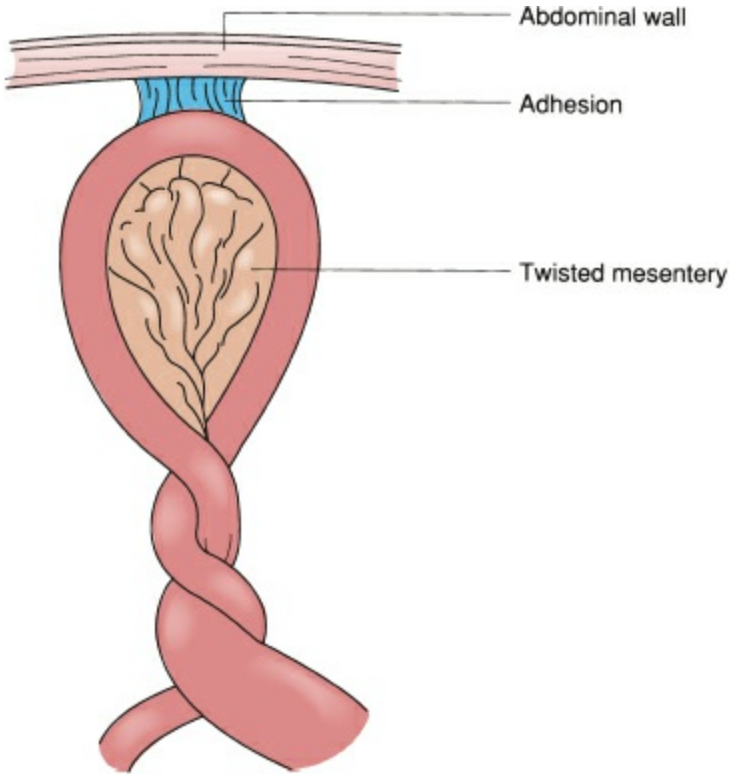

Figure 49-2. Schematic illustration of a closed-loop obstruction. The small intestine twists around its mesentery, compromising inflow and outflow of luminal contents from the loop. Also, the vascular supply to the loop may be compromised due to the twisting of the mesentery. The risk of strangulation is high.

In recent years, the role of bacterial toxins in mediating the mucosal response to obstruction has received increasing attention. In germfree dogs, luminal accumulation of fluid is not observed and absorption continues.[13] In addition, it is well recognized that bacterial endotoxins can stimulate secretion, possibly via release or potentiation of activity of neuroendocrine substances and prostaglandins.[12] Finally, since a substantial part of systemic microvascular and hemodynamic responses to endotoxemia appear to be attributable to heightened synthesis of nitric oxide,[14,15] it seems likely that mucosal response to local inflammation and endotoxin release will also be altered by conditions modifying the synthesis or activity of nitric oxide. The role of nitric oxide in mucosal fluid and electrolyte movements is currently under active investigation.[16,17]

Intestinal Fluid. Classical experimental studies established that fluid accumulates intraluminally with open- or closed-loop small intestinal obstruction.[9,11,18] Factors contributing to the accumulation of fluid include intraluminal distention and pressure, release of prosecretory and antiabsorptive hormones and paracrine substances, changes in mesenteric circulation, and elaboration and luminal release of bacterial toxins. Experimental studies and clinical investigation[19,20] demonstrated that elevation of luminal pressures above 20 cm H_2O inhibits absorption and stimulates secretion of salt and water into the lumen proximal to an obstruction. In closed-loop obstructions, luminal pressures may exceed 50 cm H_2O and may account for a substantial proportion of luminal fluid accumulation.[21] In simple, open-loop obstructions, distention of the lumen by gas rarely leads to luminal pressures higher than 8 to 12 cm H_2O.[22] In open-loop obstructions, the contributions of high luminal pressures to hypersecretion may not be important.

The release of endocrine/paracrine substances remains relatively uncharacterized in states of mechanical bowel obstruction.[23,24] Suggestions have been made that vasoactive intestinal polypeptide (VIP) may be released from the submucosal and myenteric plexuses within the gut wall, promoting epithelial secretion and inhibiting absorption.[24,25] Use of prostaglandin synthesis inhibitors has also implicated excess release of prostaglandins.[23] Further work may be expected to focus on the role of luminal factors such as irritative bile acids, proinflammatory agents such as endotoxin and platelet-activating factor,[26–28] and messengers such as nitric oxide[29,30] in coordinating responses of mucosal secretory and absorptive functions during intestinal obstruction.

Intestinal Blood Flow. Microvascular responses to intestinal obstruction may also play an important role in determining the hydrostatic gradients for fluid transfer across the mucosa into the lumen. In response to heightened luminal pressure, total blood flow to the bowel wall may initially increase.[31] The breakdown of epithelial barrier structures and enzymatic breakdown of stagnant intestinal contents leads to increased osmolarity of luminal contents. In addition to secretory stimulation and absorptive inhibition of the mucosa, the simultaneous changes in hydrostatic and osmotic pressures on the blood and lumen sides of the mucosa favor flow of extracellular fluid into the lumen. Perfusion is then compromised as luminal pressures increase, bacteria invade, and inflammation leads to edema within the bowel wall.[11]

Intestinal Motility. Obstruction of the intestinal lumen does not simply block distal passage of luminal contents. The accumulation of fluid and gas in the obstructed lumen also elicit changes in myoelectrical function of the gut, proximal and distal to the obstructed segment. In response to this distention, the obstructed segment itself may dilate, a process known as *receptive relaxation.*[32] Such changes ensure that, despite accumulation of air and fluid, intraluminal pressures do not amplify easily to the point of compromising blood flow to the intestinal mucosa. At sites proximal and distal to the obstruction, changes in myoelectrical activity are time dependent. Initially, there may be intense periods of activity and peristalsis. Subsequently, myoelectrical activity is diminished and the interdigestive migrating myoelectrical complex pattern, is replaced by

ineffectual and seemingly disorganized clusters of contractions.[33–35] Similar alterations have been observed in experimental models of large bowel obstruction. Subsequent patterns of myoelectrical quiescence may correspond to increasing accumulation of fluid and air proximally and the attempt to prevent luminal pressures from rising. It is likely that many factors contribute to the rate at which these changes in myoelectrical activity occur.[36] These factors would include neurohumoral milieu, bacterial products, and luminal constituents.

Complications and Systemic Effects of Bowel Obstruction

Closed-Loop Obstructions. The complications of closed-loop obstructions evolve rapidly. The reasons for this rapid evolution are best understood by considering the simplest and most common form of closed-loop obstruction, appendicitis. When a fecalith obstructs the blind-ended appendix, secretion of mucus and enhanced peristalsis represent the initial attempt to clear the blockage. Intense crampy abdominal pain focused at the umbilicus results. Nausea and vomiting are not uncommon as a result of luminal obstruction but as a reflexive response to hyperperistalsis and stretching of the mesentery. Over the next 8 to 18 hours, continued secretion of mucus to high intraluminal pressures, stasis, bacterial overgrowth, mucosal disruption, and elevation of luminal pressures convert intermittent cramps to constant and worsening pain. When luminal pressure exceeds mural venous pressure and then capillary perfusion pressures, inflammatory cells are recruited from surrounding peritoneal structures. This sequence of events leads to intense inflammation, release of exudate in the area of the appendix and the first localization of pain from the umbilicus to the area of peritoneum lying nearest the inflamed appendix. Peritoneal findings (localized tenderness, involuntary guarding, rebound, or referred tenderness) and fevers appear. Subsequently, 20 to 24 hours into the illness, the blood supply of the appendix is compromised. Gangrene and perforation follow and, if not contained by surrounding structures, free perforation leads to a rigid abdomen. Toxins from necrotic tissue and bacterial overgrowth are released into the systemic circulation and shock ensures. Torsion of a loop of small intestine around an adhesive band or inside a hernia leads to a similar pattern of events. As discussed below, torsions of the large bowel are usually accompanied by massive distention of the loop by air and feces, but the compromise of intestinal wall perfusion and evolution into peritonitis, systemic toxicity, and shock are similar.

Open-Loop Obstructions. Complications in open-loop obstructions do not necessarily evolve as rapidly as in closed-loop obstructions. Not uncommonly, an open-loop obstruction located in the proximal jejunum can be decompressed by the patient's ability to vomit. Proximal obstruction is characterized by vomiting and loss of gastric, pancreatic, and biliary secretions, with resulting electrolyte disturbances. These disturbances include dehydration, metabolic alkalosis, hypochloremia, hypokalemia, and usually hyponatremia. In contrast, obstructions of the distal ileum may lead only to a slowly progressing distention of the small intestine, with accommodation by intestinal myoelectrical function and minor alterations in fluid and electrolyte balances. Open-loop

obstructions located in the midgut are often complicated by events similar to those seen in closed-loop obstructions or combinations of events seen in high and low obstructions (Table 49-2). Patients with distal jejunal obstruction tend to present with a combination of complications resulting from loss of intestinal contents from vomiting, as well as distention and compromise of intestinal wall perfusion.

2 In simple or uncomplicated obstruction, the intestinal lumen is partially or completely occluded without compromise of intestinal blood flow. Simple obstructions may be complete, meaning that the lumen is totally occluded, or incomplete, meaning that the lumen is narrowed but permitting distal passage of some fluid and air. In strangulation obstruction, blood flow to the obstructed segment is compromised and tissue necrosis and gangrene are imminent.

Clinical Presentation and Differential Diagnosis

3 The four key symptoms associated with acute mechanical bowel obstruction include *abdominal pain, vomiting, distention, and obstipation.* When bowel obstruction is the most likely diagnosis, "abdominal pain out of proportion to physical findings" represents a surgical emergency. Colon obstruction is usually accompanied by varying levels of pain with massive abdominal distention and obstipation. As noted earlier, the signs and symptoms of acute but simple small intestinal obstructions are related to the level of the obstruction and the closed- or open-loop nature of the obstruction. Other abdominal conditions, such as appendicitis, diverticulitis, perforated peptic ulcer, cholecystitis, or choledocholithiasis can usually be distinguished from SBO, by clinical examination and basic laboratory data. It should be emphasized that bowel obstruction can complicate any of these abdominal conditions. The presence of another abdominal process does not exclude the complication of SBO.

Over the years, numerous attempts have been made to use groupings of clinical criteria to establish the diagnosis of complete and irreversible intestinal obstruction, as distinguished from partial intestinal obstruction that might improve without operative intervention or other abdominal pathology. In recent studies, computer-assisted analysis has been used to identify such criteria.[37] Key factors in the history and clinical examination[38] include previous abdominal surgery, quality of pain (colic/intermittent versus steady), abdominal distention, and hyperactivity of bowel sounds. Not surprisingly, the use of such computer-assisted algorithms confirms that the most important clues to the diagnosis of simple obstruction of the small intestine are obtained in a complete and careful history and physical examination. As discussed below, the role of plain abdominal radiographs and other imaging studies is to confirm the clinical diagnosis of simple obstruction. It should be emphasized that, in simple obstruction, laboratory studies do not play a direct role in diagnosis, but aid in understanding the extent of complications such as dehydration, strangulation, and sepsis.

Strangulation obstruction is accompanied by symptoms and signs suggesting peritonitis, large fluid shifts, or systemic toxicity. These symptoms and signs include abdominal tenderness or involuntary guarding localized to the area of the strangulated loop of

bowel, decreasing urine output, fever, and tachycardia. There have been attempts to use common clinical and laboratory test criteria to identify the likelihood that the obstruction is associated with strangulation. Stewardson et al.[39] observed that the risk of strangulation was low in patients with partial (i.e., incomplete) or complete SBO if fever, tachycardia, localized abdominal tenderness, or leukocytosis were not present. These authors suggested that, in a setting consistent with bowel obstruction, any one of these four cardinal signs indicated a small risk for strangulation. The presence of any two of these signs increased the risk of strangulation so high as to warrant immediate surgery. These authorities and others have stressed, however, that when complete obstruction is present, no satisfactory clinical criteria are available to reliably exclude the possibility of strangulation.[39–43]

Different laboratory tests have been advocated for early detection of strangulated intestine. Metabolic (i.e., lactic) acidosis and increases in serum amylase, inorganic phosphate, hexosaminidase, intestinal fatty acid–binding protein, and serum D-lactate levels have all been associated with intestinal ischemia.[44,45] Such laboratory abnormalities may be helpful in diagnosing established strangulation in a small group of patients where the diagnosis of necrotic bowel is not clear. However, a noninvasive and rapid test has not yet been developed that can provide information to suggest that tissue necrosis is imminent but not yet established.[43]

Radiographs and Imaging

Plain Films

The role of plain abdominal radiographs and imaging studies is to confirm the diagnosis of bowel obstruction, locate the site of obstruction, and gain insight into the lesion responsible for the obstruction. On plain radiographs of the abdomen, the key findings of SBO reflect the accumulation of air and fluid proximal, and clearance of fluid and air distal to the point of obstruction. Dilated loops of small intestine are defined as those greater than 3 cm in diameter. Free air represents perforation of a viscus and mandates immediate operation. Such findings include dilated loops of small bowel on the flat plate (Fig. 49-3) and multiple air–fluid levels located at different levels on the upright film or lateral decubitus film (Fig. 49-4). Based on these criteria plain abdominal radiography is diagnostic in 67% to 80% of patients.[46,47] Plain radiographs, however are only accurate in 46% to 85% of the time and can miss SBO in patients without air–fluid levels because of fluid-filled distended loops.[48] In complete obstruction of the small intestine, the colon loops and rectum do not contain air. If there is air in the colon, the obstruction may be complete, but early, or it may be incomplete.

In the colon, tight closed-loop obstructions (i.e., volvulus of the cecum, transverse colon, or sigmoid colon) are accompanied by distention of the obstructed segment (Fig. 49-5). The proximal colon is considered dilated when it reaches 8 to 10 cm; the sigmoid colon is considered dilated at 4 to 5 cm. In contrast, obstruction by carcinoma or diverticulitis presents with massive distention of the entire colon from the point of obstruction to the ileocecal valve. From this standpoint, any large bowel obstruction may represent a “closed loop” if the ileocecal valve is competent. Although plain film findings can be used to differentiate obstruction of the small bowel from that of the large bowel, they are not consistently accurate in localizing the specific site of obstruction.



Figure 49-3. Plain supine abdominal film of a patient with small-intestinal obstruction. Note the multiple dilated loops of small intestine (*black arrow*) in the left upper quadrant, characterized by complete markings of the plicae. Also note the absence of air in colon and rectum.

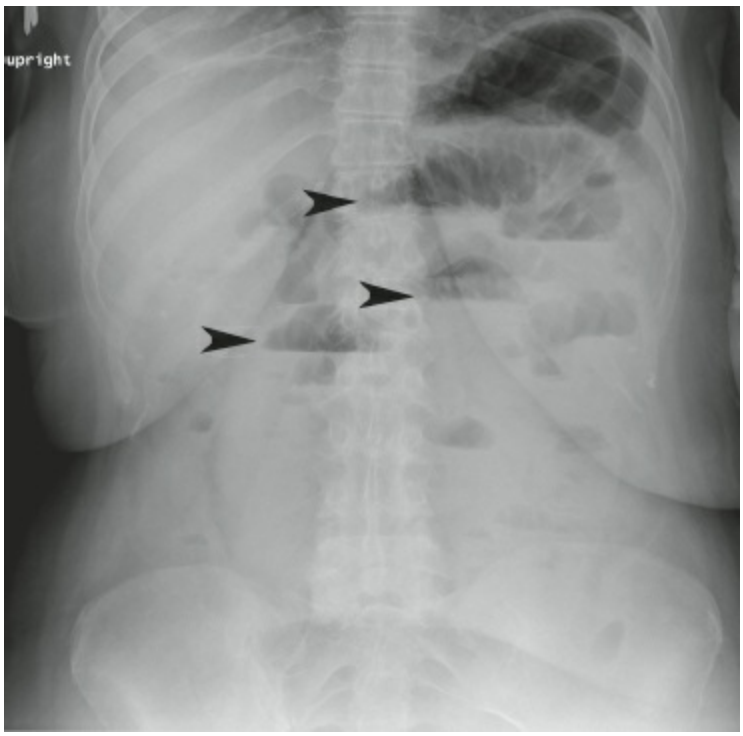

Figure 49-4. Plain upright abdominal film of a patient with small-intestinal obstruction. Note the air–fluid levels in the stomach and multiple dilated loops of small intestine (*black arrows*), and absence of air in the colon or rectum.

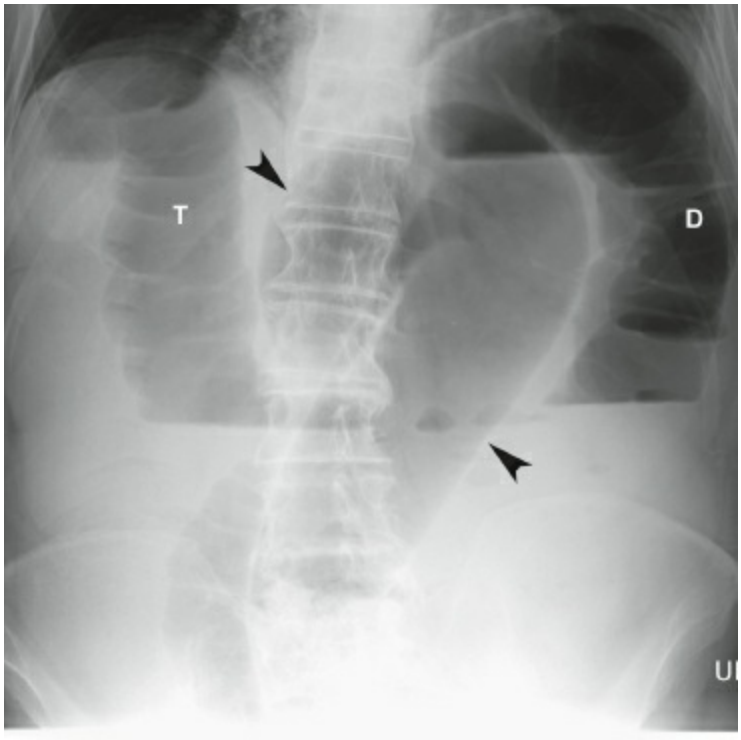

Figure 49-5. Plain upright abdominal film of a patient with sigmoid volvulus. The dilated centrally located sigmoid loop is seen (*arrowheads*). The proximal colon is dilated and gas filled. T, transverse colon; D, descending colon.

Contrast Studies

The diagnosis of bowel obstruction can generally be made by considering the clinical history, physical examination, laboratory, and plain radiograph findings. Contrast studies (i.e., small bowel follow-through, enteroclysis, and contrast enema) may provide specific localization of the point of obstruction and the nature of the underlying lesion. When obstruction of the small intestine is not progressing or resolving, a small bowel follow-through may be performed to confirm the presence and location of the obstruction. Also, even under acute circumstances, diagnosis and management of colonic obstructions are generally enhanced by the use of a contrast enema. Under some circumstances, however, contrast studies are unnecessary and may be contraindicated. For example, in the classic setting of abdominal pain, nausea, vomiting, and a plain film indicating multiple air–fluid levels in the small intestine and colonic collapse, the diagnosis of acute obstruction can be made clinically. Failure to improve in a short period of time will mandate operation and contrast studies are unnecessary. When strangulation or perforations are strongly suspected, contrast studies are contraindicated.

4 The choice of contrast materials includes water-insoluble suspensions of barium and water-soluble agents such as Gastrografin® or Hypaque®. Barium studies provide the clearest images, in both small bowel studies where the contrast is given from above and colon/rectum studies in which the contrast is given by enema. If barium leaks into the peritoneum, it elicits intense peritonitis. If there is any possibility of bowel perforation or gangrene, barium should not be used. Water-soluble agents such as sodium amidotrizoate/meglumine amidotrizoate oral solution (Gastrografin®) or diatrizoate sodium/diatrizoate meglumine (Hypaque®) are hyperosmotic and can elicit fluid

translocation into the gut. When the obstruction of the small intestine is incomplete the use of these agents may facilitate resolution. Gastrografin is hyperosmolar (1,900 mOsm/L). Its administration permits mobilization of fluid into the bowel lumen which decreases edema of the intestinal wall and increases the pressure gradient across obstructive site. It is thought that these fluid and pressure shifts can contribute to resolution in cases of incomplete obstruction. The 2013 Bologna guidelines for diagnosis and management of adhesive SBO recommended a dosage of 50 to 150 mL of Gastrograffin administered either orally or via NGT immediately on admission or after an attempt of conservative treatment for 48 hours.[49] The appearance of contrast in the colon within 4 to 24 hours after administration had a sensitivity of 96% and specificity of 98% in predicting resolution of SBO.[50] A prospective randomized trial confirmed that gastrograffin significantly reduced the need for surgery by 74%.[51] Some studies showed that water-soluble contrast medium reduces hospital stay but does not reduce need for surgery[52,53] but recent meta-analysis showed that it is effective in reducing the need for surgery and shortening length of stay.[50] Use of water-soluble contrast may thus be both diagnostic and can be therapeutic.

Computed Tomography and Other Imaging Modalities

5 The potential benefits of *computed tomography* (CT) scanning in diagnosis of bowel obstruction include the following.[54–57] First, using radiographic contrast, the obstructing segment may be localized and characterized as complete or incomplete. Second, the nature of the obstructing lesion, especially if it is malignant, can be established. Third, additional abdominal pathology (e.g., metastases, ascites, parenchymal liver abnormalities) may be identified. Fourth, anatomic information obtained from the CT can be used in operative planning. There is also evidence that, in special circumstances, CT may improve preoperative detection of strangulation.[42,56] Coronal and sagittal reconstruction improve the ability to identify transition point and IV contrast with delayed imaging should be considered to assess for venous occlusion or delayed bowel wall enhancement.[58] CT findings indicating the site of obstruction and impending ischemia include beak-like narrowing, mesenteric edema, vascular engorgement, moderate to severe intestinal wall thickening (greater than 2 mm) (Fig. 49-6). In addition, high attenuation of bowel wall on unenhanced CT scans, low or reduced attenuation of bowel wall on intravenous contrast CT scans, and presence of intramural air (pneumatosis) or portal venous gas are CT findings suggestive of strangulation. Attenuation reflects increased energy absorption, scattering, beam divergence, and other causes of energy loss. Thus, areas of high attenuation appear darker than areas of low attenuation. CT scan has a 96% sensitivity and 93% specificity with a negative predictive value of 99% in diagnosing intestinal strangulation.[59] Although CT scan need not be routinely performed unless history, physical examination, and plain films are not conclusive for SBO diagnosis,[60] it is increasingly the “go-to” study for confirmation.

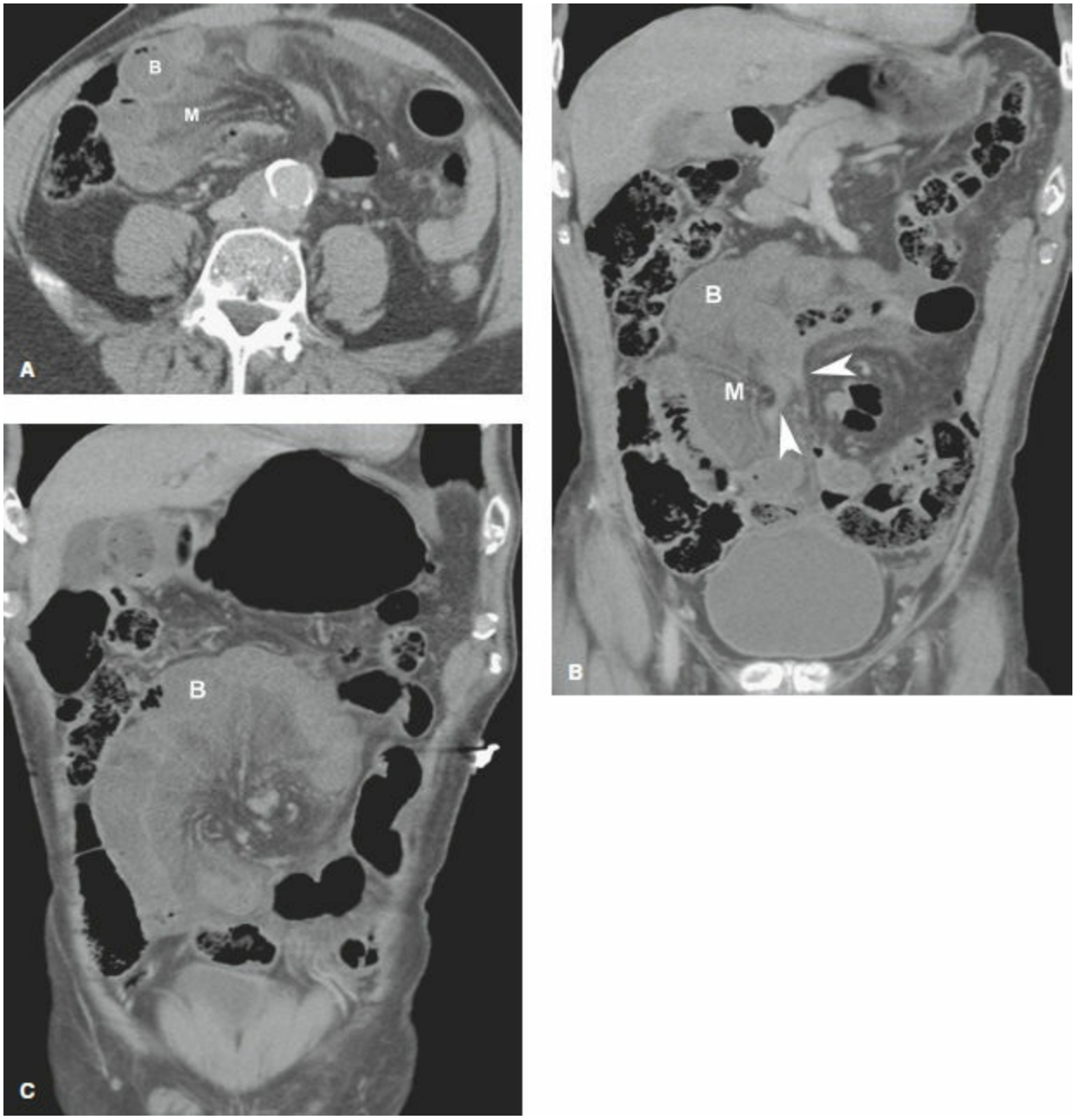

Figure 49-6. Axial (**A**) and coronal (**B**) images of a closed-loop obstruction with strangulated small bowel secondary to a volvulus from an adhesive band. Distended fluid-filled loops of small bowel (*B*) in a radial distribution converge toward the point of torsion (*white arrows*). There is edema within the mesentery (*M*). Shown in (**C**) is a coronal view of vascular engorgement and mesenteric edema in a closed-loop obstruction.

Ultrasound has a very limited use in diagnosing SBO and visualization can be obscured by the intraluminal air but it has been suggested that real-time abdominal sonography could aid in the diagnosis of strangulation obstruction. In studies conducted in two different institutions, Ogata and colleagues[61,62] demonstrated that the presence of significant amounts of peritoneal fluid and of an akinetic and dilated loop of bowel were strongly associated with the presence of strangulation. In patients who had strangulation, but were thought to have simple obstruction only, these findings helped to make the preoperative diagnosis of infarction.

Magnetic resonance imaging (MRI) has the sensitivity comparable to CT scan in diagnosing obstruction but limitations include lack of availability after hours, poor definition of mass lesion, and poor visualization of colonic obstructions.[63] The use of MRI

should be limited to patients who have contraindications to CT or are allergic to contrast material.[49]

It should be emphasized that when the clinical picture suggests strangulation, unnecessary imaging studies should not delay resuscitation or expeditious movement to the operating room. Such studies will not necessarily be helpful when clinical criteria and basic abdominal radiographs have indicated the presence of a simple and complete obstruction. By itself, this diagnosis mandates urgent exploration and the information sought should be weighed against the risk of delay in going to the operating room. In fact, in most studies evaluating the impact of imaging on diagnosis and timing of intervention, clinical diagnosis is seldom incorrect – it is highly specific when multiple clinical signs (tenderness, peritoneal signs, leukocytosis, and profound dehydration) of strangulation are present. However, such a picture represents advanced disease and use of CT scan may detect strangulation before such signs are manifest. These findings reinforce the dictum that when there are clinical signs of strangulation, surgery should be performed without delaying for additional imaging studies. In patients with equivocal findings or uncertain clinical diagnosis, CT can be highly useful in confirming the diagnosis, localizing the site and detecting the cause of intestinal obstruction and strangulation.[56]

General Considerations in Management of the Patient with Bowel Obstruction

Patients with obstruction of the large bowel present with abdominal pain, distention, and obstipation. Vomiting and electrolyte imbalances are sometimes prominent, though usually delayed. Elderly patients, in particular, are prone to dehydration. The presentation of SBO depends on level of obstruction, open- or closed-loop nature, and interval since onset of symptoms. Symptoms and signs of pain, vomiting, obstipation, and distention are present in variable degrees. The overall picture, however, is usually one of a patient with abdominal symptoms that are evolving and getting worse. In the settings described previously, the following questions must be addressed as expeditiously as possible:

1. *Is the abdominal pain disproportionate to the physical findings and laboratory studies?*
2. *How rapidly the symptoms and signs are evolving: minutes, hours, or less acutely?*
3. *Does the patient suffer from dehydration, electrolyte imbalance and acid–base disturbance?*
4. *Is the obstruction complete or incomplete?*
5. *Is there a possibility of strangulation?*

Clinical data and basic laboratory studies will provide reliable information to answer the first three questions. Answering questions 4 and 5 will often depend on close clinical observation and reexamination in the first hours or days after presentation. Abdominal radiographs and imaging studies are frequently used to provide additional information to help answer these latter questions, as well as providing information to identify the obstructing lesion.

Summarized in Table 49-3 are thumbnail sketches of different, but typical, kinds of patients presenting with symptoms and signs consistent with obstruction of the small intestine. The principles of diagnosis and management of each of these patients begins with clinical information that indicates the likelihood of a bowel obstruction. Laboratory studies and plain abdominal films are used to confirm the diagnosis of obstruction and determine the extent of physiologic impairment. The patient's history and clinical course in the first few hours of observation are used to determine the likelihood of strangulation. Indications for surgery include rapid evolution of symptoms and signs and the diagnosis that the obstruction is complete. Contrast or imaging studies are used only when symptoms are not evolving rapidly and when identification of the underlying lesion might alter the operative strategy (see specific lesions later).

Table 49-3 Diagnosis and Decisions in Bowel Obstruction in Three Hypothetical Patients

	Patient I Closed-Loop Obstruction	Patient II Intestinal Obstruction With Strangulation	Patient III Open-Loop Obstruction of the Distal Small Intestine or Cecum
Clinical	Crampy periumbilical pain worsening over last 12 hrs. Two to three episodes of emesis. No distension, minimal flatus	Diffuse, crampy abdominal pain over 2 days with many episodes of vomiting. No bowel movements or flatus. T 100°F, P 100, dehydrated. Mild distension; local tenderness lower abdomen	Progressive abdominal distension over previous 2 wks. Mild discomfort. No vomiting. Few bowel movements and little flatus. Distension prominent, mild tenderness, no peritoneal findings
Lab	No leukocytosis, pH or electrolyte disturbances	WBC 16K. Serum Na^+ low, K^+ low, Cl^- low, pH alkalotic	WBC normal, serum electrolytes mildly decreased
X-ray	Nonspecific gas pattern on plain film	Multiple dilated loops and air–fluid levels. No gas in colon	Multiple dilated small bowel loops and air–fluid levels. Some gas and stool in proximal colon
Differential Dx	Broad: includes appendicitis, closed-loop SBO, pancreatitis, nonsurgical conditions	Narrow: complete SBO likely, strangulation cannot be excluded	Narrow: distal small bowel or proximal colon obstruction likely, possibly incomplete
Initial Rx	Admit with q3–4h reevaluation by clinical examination, WBC. Repeat films q8–12h. NG tube if vomiting persists. IVFs	Admit for rapid resuscitation with IVFs, IV antibiotics. Urinary catheter and NG intubation indicated	Admit for IVFs, NG intubation. Hypaque enema followed by barium to evaluate colon. CT if malignancy suspected
Indications for surgery	If pain worsens, local tenderness or peritoneal signs evolve, WBC rises, and urine output falls	Already present. Patient should be scheduled and brought to OR after adequate resuscitation (dramatic improvement with resuscitation may permit observation for 4 hrs)	Surgery performed when evaluation is complete or if clinical course deteriorates during evaluation

6 The initial management of all patients with suspected bowel obstruction includes designating the patient "NPO" and starting intravenous fluids comprised of isotonic Ringers or normal saline solutions. Restoration of fluid and electrolyte balance is a priority, often requiring frequent evaluation of serum electrolytes and pH. In rapidly evolving cases or patients with significant dehydration, an indwelling urinary catheter should be placed to monitor urine output. Invasive hemodynamic monitoring (e.g., a Swan–Ganz catheter) may be necessary to monitor the response to fluid resuscitation in patients with severe cardiac, pulmonary, or renal insufficiency.

Nasogastric decompression is indicated in most cases. The nasogastric tube, typically a 16- or 18-Fr sump tube, serves to prevent distal passage of swallowed air and minimizes the discomfort of refluxing intestinal content. The use of longer tubes has been advocated in certain settings, especially for patients with chronic but intermittent obstruction arising from Crohn disease, peritoneal carcinomatosis, radiation enteritis, or many previous laparotomies for obstruction. The underlying rationale is that advancement of the tip of the long tube to the obstructed loop would permit more effective decompression, perhaps resulting in relaxation of the loop and relief of the obstruction. A number of studies have failed to document benefits in the use of long tubes[64,65] in helping to resolve partial intestinal obstruction or prolonged ileus. Recently. A more possibly effective version of the long tube has been described, the ileus tube (Create Medic, Tokyo), which is made of silicon is 300 cm in length, is 16 Fr wide and has three channels. This tube is advanced with endoscopic guidance and has been reported in one study to be more effective (89.6 vs. 46.7%) compared to NGT group, specifically with respect to the intervals to resolution of symptoms and radiographic findings.[66] Caution should be undertaken on the potential risk of development of pneumonia and respiratory failure in routine use of NGT.[67]

A randomized controlled trial suggested that resolution of partial SBO could be accelerated with the use of a regimen of oral adjunctive therapy that included magnesium oxide (500 mg), simethicone (40 mg) and Lactobacillus acidophilus (0.3 g tablet) given three times daily via NGT was effective in hastening the resolution of the conservatively treated partial adhesive SBO and shortening the hospital stay with no difference in complication rate and recurrence. Magnesium oxide was used due to its laxative side effects. Simethicone, a defoaming agent, was used because it alters surface tension of gas bubbles and causes them to coalesce, thereby accelerating the passage of gas through the intestinal tract. Lactobacillus, a probiotic, may have multiple benefits, including improved digestion and prevention of overgrowth of pathogenic bacterial species.[67a]

Recent study showed the potential beneficial effects of hyperbaric oxygen (HBO) therapy at a pressure of 2.0 atmospheres absolute with 100% oxygen given once a day up to 7 days. HBO therapy was associated with earlier resumption of oral intake (4.7 days vs. 5.6 days; $p = 0.001$), shorter hospital stay (10.3 days vs. 14.1; $p = 0.001$) and lower operative rate (7.4% vs. 14.8%).[68] It is postulated that intestinal edema is decreased through the osmotic effect of oxygen. Oxygenation under high pressure enhances inert gas diffusion from the closed intestinal lumen into the blood. Relaxation of the distended intestinal loop improves the compromised microcirculation and oxygenation of hypoxic intestinal tissue which leads to preservation of intestinal viability and recovery of motility. This modality may be an option in the management of patients with high anesthesiologic risk.[69] A current study (HOT Trial) is underway to find out the clinical value of HBO therapy in obstruction due to radiation-induced fibrosis (ISRCTN 86894066).

The use of intravenous antibiotics in the initial management of bowel obstruction should be discussed as well. Clinically, it has been recognized that antibiotics can ameliorate the evolution of symptoms and signs of strangulation in closed-loop obstruction and appendicitis. Studies in humans have demonstrated that, even in simple

obstruction, bacterial counts in succus rise from under 10^6 organisms/L to over 10^9 organisms/L[70] and are not necessarily reduced with short-term administration of antibiotics.[71] Moreover, experimental studies indicate that bacteria can translocate across the intestinal mucosa, passing into lymph channels.[72] Further studies have demonstrated that germfree animals can survive strangulation obstruction longer than normal animals and that luminal fluid taken from obstructed segments in germ-free animals is much less toxic than fluid taken from normal animals.[73,74]

For all these reasons, it is a well-established practice to administer antibiotics perioperatively, in order to reduce wound infection and abdominal sepsis rates in patients undergoing operation to relieve intestinal obstruction, simple or strangulated. Once the decision has been made to proceed with surgery, broad-spectrum antibiotics, covering gram-negative aerobes and anaerobes should be given. A second-generation cephalosporin or a combination of a first-generation cephalosporin and metronidazole is a rational practice for perioperative coverage in both simple and strangulation obstruction. Nevertheless, the use of antibiotics in patients who have not yet been committed to operation has not been evaluated systematically. Giving antibiotics to patients who are being observed can obscure the underlying process and, in the end, delay optimal therapy.

The decision to perform abdominal exploration to relieve intestinal obstruction should be made expeditiously, but not in the absence of critical information or before adequate resuscitation (Algorithm 49-1). Indications for surgery are outlined in Table 49-3, for each of the thumbnail vignettes. It should be emphasized that once a diagnosis of complete obstruction is made, simple or strangulated, the operation should proceed without undue delay. It is reasonable to commit the patient to a period of observation when the diagnosis is uncertain (i.e., there is a possibility of a nonsurgical diagnosis or that the obstruction is not complete). A practical point is that obstruction occurring in a patient without a previous history of laparotomy is not likely to be caused by peritoneal adhesions. This is known as *de novo* obstruction and whatever the underlying cause will not usually resolve without operation.

Specific Types of Bowel Obstruction

Chronic Adhesions

As noted previously, peritoneal adhesions account for more than half of SBO cases. Lower abdominal procedures such as appendectomy, hysterectomy, colectomy, and abdominoperineal resection are common precursor operations to adhesive obstruction. Adhesions form after any abdominal procedure, however, including cholecystectomy, gastrectomy, and abdominal vascular procedures. In long-term follow-up, about 5% of patients undergoing laparotomy will develop adhesive obstruction; of these, 10% to 30% will suffer from additional episodes.[75,76] Up to 80% episodes of SBO due to adhesions may resolve nonoperatively.[39,40,53,64] However, an index episode and three recurrences indicate a likelihood of over 80% that there will be more recurrences.[75] Surgical management of an acute episode appears to reduce subsequent recurrence rates from ~15% to ~6%,[76] but no studies have been able to establish whether the immediate benefit of laparotomy for any given episode of simple adhesive obstruction outweighs the overall benefit of expectant management and operation only for serial recurrences. Thus, a previous history of a laparotomy simply provides a reasonable basis for expectant management of patients in whom it is not yet possible to diagnose a complete obstruction. Ultimately, patients who present with signs and symptoms of bowel obstruction are managed according to the CT findings and clinical course.

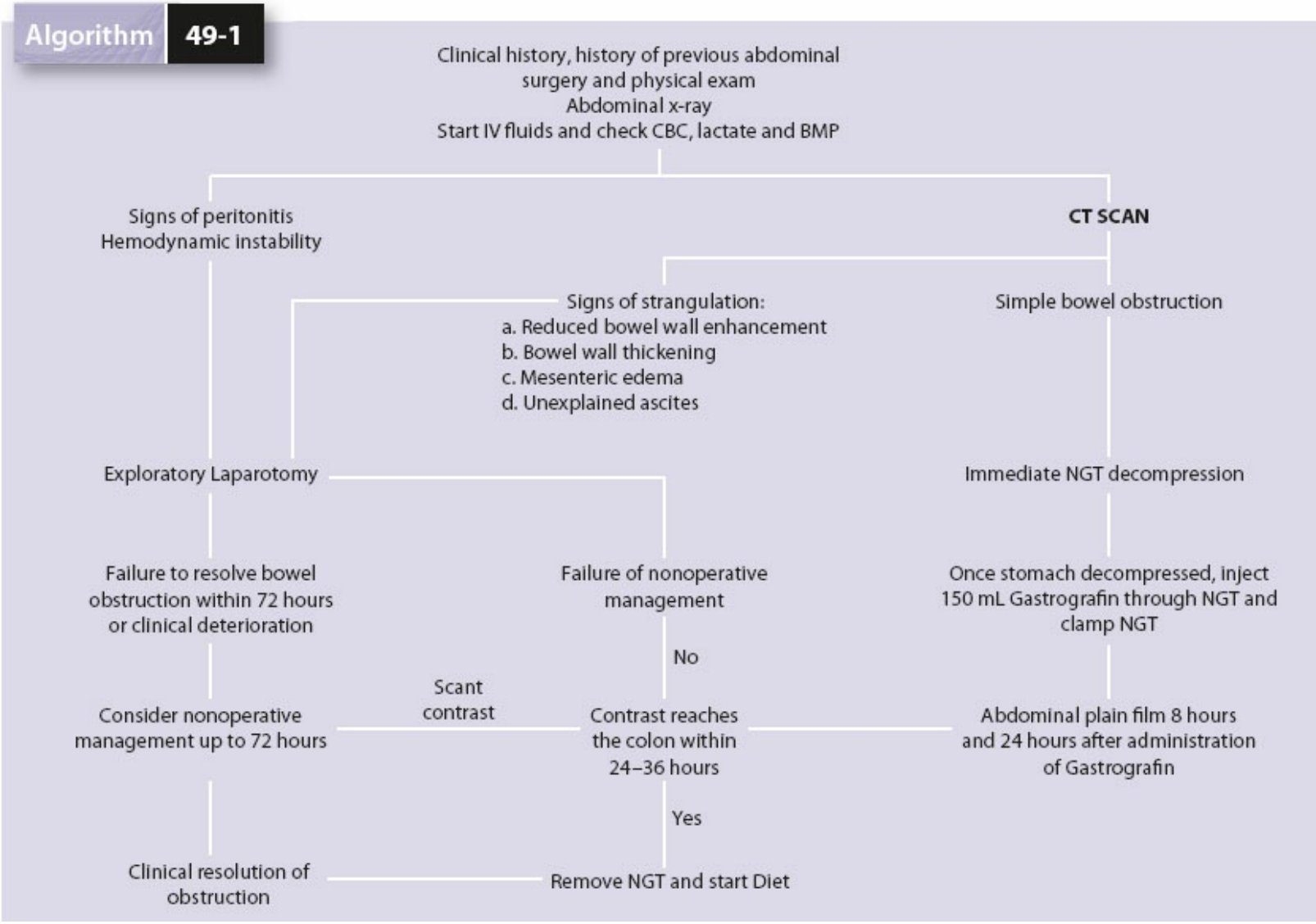

Algorithm 49-1. Algorithm for the management of adhesive small bowel obstruction.

The pathobiology of adhesion formation has been the subject of considerable investigation.[11] Histologic examination of chronic adhesions reveals foreign body reaction, usually to talc, starch, lint, intestinal content, or suture. Talc and starch are found less commonly now than previously, because of improvements in techniques of manufacture and sterilization of surgical gloves. Mesothelial cells are the presumed origin of tissue plasminogen activator (TPA). TPA binds fibrin and plasminogen, thereby preventing adhesion formation. In early studies, inflammatory cells, including mast cells,[77] were implicated in the process that produces adhesions. Recent studies[78,79] have emphasized the role of various cytokines in exacerbating or inhibiting adhesion formation in different animal models. Biologically active substances that might prove useful in preventing postoperative adhesions include transforming growth factor beta (TGF-beta) and vascular endothelial growth factor (VEGF), both of which may be targeted for inhibition without less fear of compromising the response to bacterial infection.[78,79]

Current strategies to prevent adhesions after a first laparotomy include targeting the fibrinolytic system, which enhances rapid healing and appears to minimize formation of peritoneal adhesions.[78] Attempts to minimize or prevent adhesion formation have resulted in development of hyaluronic acid–carboxymethylcellulose membrane

(Seprafilm, Genzyme, Cambridge, MA). This compound mechanically prevents adhesion formation by physically separating adjoining tissues. It is absorbed by the body in 7 days and thus is present only during the phase of fibrosis, and not as a persistent foreign body. Randomized trials have suggested that this compound prevents, minimizes severity, and decreases density and vascularity of adhesions.[78,80] Other trials and review of 17 RCT corroborate decreased incidence, extent, severity, density, and vascularity of adhesions but not total prevention of adhesions or reduction of the incidence of subsequent bowel obstruction,[81] and caution not be placed on anastomosis due to increased rate of anastomotic leak.[82] Seprafilm and similar barriers have been advocated for use in patients in whom a second abdominal procedure is planned or significant adhesions anticipated (e.g., Hartmann procedure, ileal pouch anal anastomosis with protecting ileostomy, pelvic surgery, gynecologic procedures, staged hepatic surgery and colon surgery) – though it has been proposed for all surgeries by the manufacturers. The largest randomized, single blind, controlled study on Seprafilm showed that the incidence of adhesive small bowel requiring reoperation was significantly lower for Seprafilm patient with absolute reduction rate of 1.6% and relative reduction rate of 47%.[83]

The Prevention of Postoperative Adhesion (POPA) study uses 2,000 icodextrin 4% solution before abdominal closure and follow-up upto 10 years showed that it is safe and reduces intra-abdominal adhesion formation and the risk of reobstruction (2.19% vs. 11.1%).[84] Small trials showed the potential use of hydrogen adhesion barrier spray[85] and lyophilized human peritoneal membrane.[86]

More important than pharmacologic approaches, however, are the efforts of the surgeon to pay meticulous attention to hemostasis and surgical technique, the avoidance of excessive tissue dissection, and careful search and removal of any extraneous material. The use of laparoscopic approaches, when feasible, should lower the likelihood of pathological adhesions as well.[87]

Early Postoperative Adhesions

Obstruction in the immediate period following abdominal surgery is uncommon but may occur in up to 1% of patients in the 4 weeks following laparotomy. Adhesions are responsible for approximately 90% of such cases and hernias for approximately 7%.[88] Intussusception, internal herniation, inflammation, abscess, intramural intestinal hematoma or technical errors may be responsible for the remainder of cases.[89–91] Most cases occur after surgery of the colon, especially abdominoperineal resections, or operations in the lower abdomen. It is rare for upper abdominal surgery to cause such obstructions. A common scenario is that a patient will undergo colectomy uneventfully, pass flatus and have bowel sounds by postoperative day 3. On the fourth postoperative day the patient suddenly becomes distended and uncomfortable, and stops passing flatus and stool. Patients with acutely evolving symptoms and signs represent complete obstruction and should be managed as such. In this latter setting, the mortality may be as high as 15% due to delays in recognition and operative intervention. The loss of bowel sounds after a short period of normal or hyperactive activity is worrisome for ischemia of the obstructed segment. The vast majority of such cases may be treated as partial

intestinal obstruction; nasogastric suction and intravenous fluids will help resolve symptoms within a few days (Algorithm 49-2). When the clinical course does not demand earlier intervention, a nonoperative approach may be tried for 10 to 14 days and will resolve the obstruction in over 75% of such cases.[88,90,92] It is recently noted that patients who experienced early postoperative adhesions may have a higher risk of developing adhesive SBO (26.5% vs. 7.5% at 5 years; $p < 0.001$).[91]

Bowel Obstruction after a Bariatric Procedure

The obesity epidemic sees the growth in the number of bariatric procedures which includes gastric banding, sleeve gastrectomy, gastric plication, roux-en-y gastric bypass, and biliopancreatic diversion with or without duodenal switch. Band slippage can occur in 15% to 20% of patients and typically presents with a history of upper abdominal symptoms of reflux, regurgitation, and dysphagia. Upper GI study is the preferred method of diagnosing band slippage showing the evidence of malposition of the band and proximal pouch dilatation with obstruction. The initial management is urgent band deflation using Huber needle and if this is unsuccessful or patient is acutely unwell, necrosis, abscess, or erosion must be considered which may require surgery. Intestinal obstruction occurs in 4.4% after roux-en-y gastric bypass. The etiology of obstruction includes internal hernia (53%), roux limb compression due to scarring (20%), adhesion (14%), stricture at gastrojejunal anastomosis, kinking of the alimentary limb, incisional hernia, and intestinal intussusception. The most common site of internal herniation is mesojejunal mesenteric window, followed by Petersen window and the mesocolic window.[93] It is paramount to differentiate bariatric from nonbariatric patients presenting with SBO since there are significant differences in their management. Nonoperative management was successful in 72% of non-postbariatric patients but surgery was performed in about 62% of postbariatric surgery patients with SBO. Also, the bariatric group is most likely to undergo laparoscopy (5% vs. 2%), abdominal wall reconstruction (38% vs. 9%) and is less likely to require colostomy (1% vs. 13%). The bariatric group underwent surgery sooner within an average of 24 hours compared to 3.3 days in non-postbariatric patients.[94]

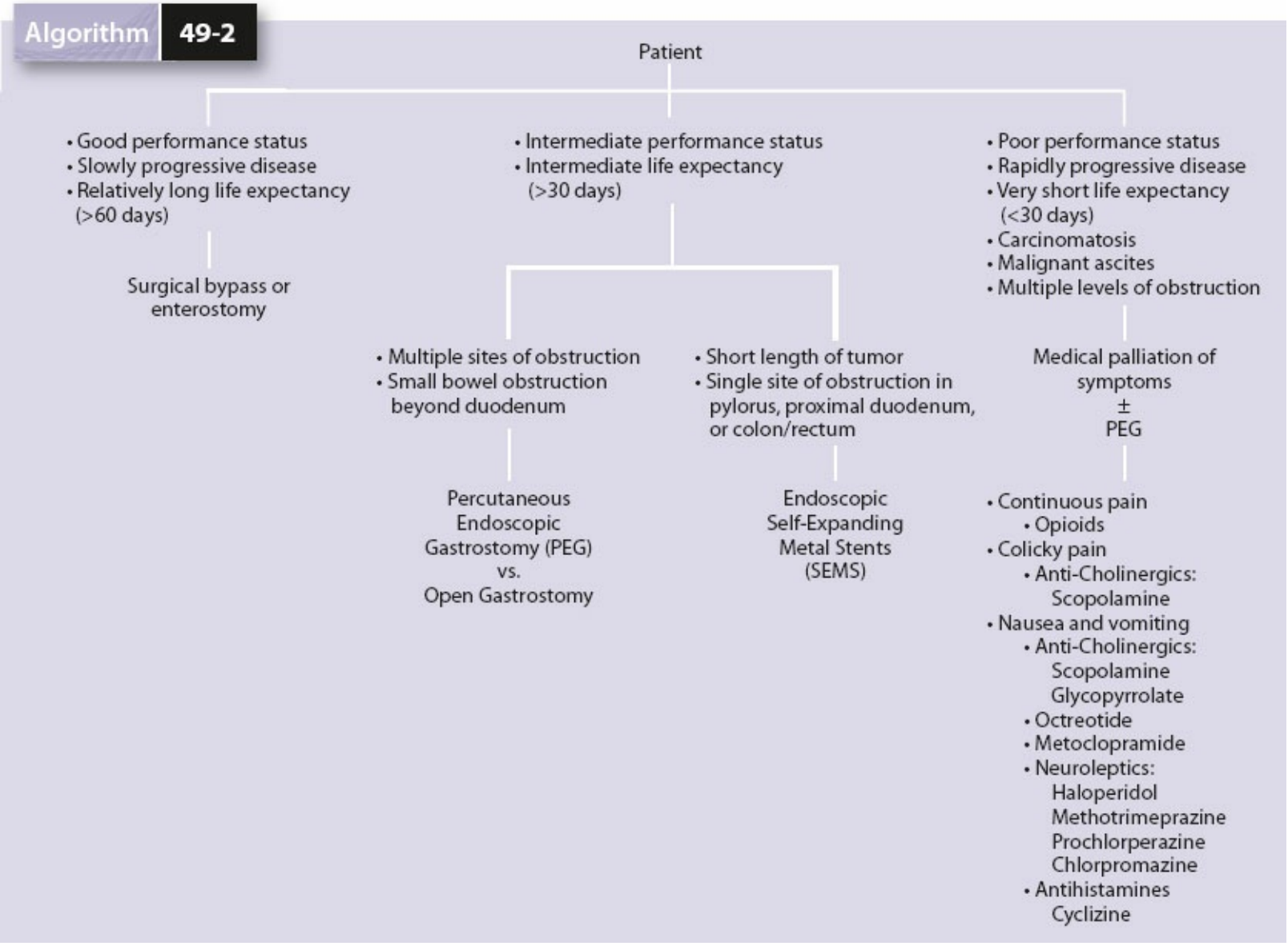

Algorithm 49-2. Approach to the management of malignant bowel obstruction.

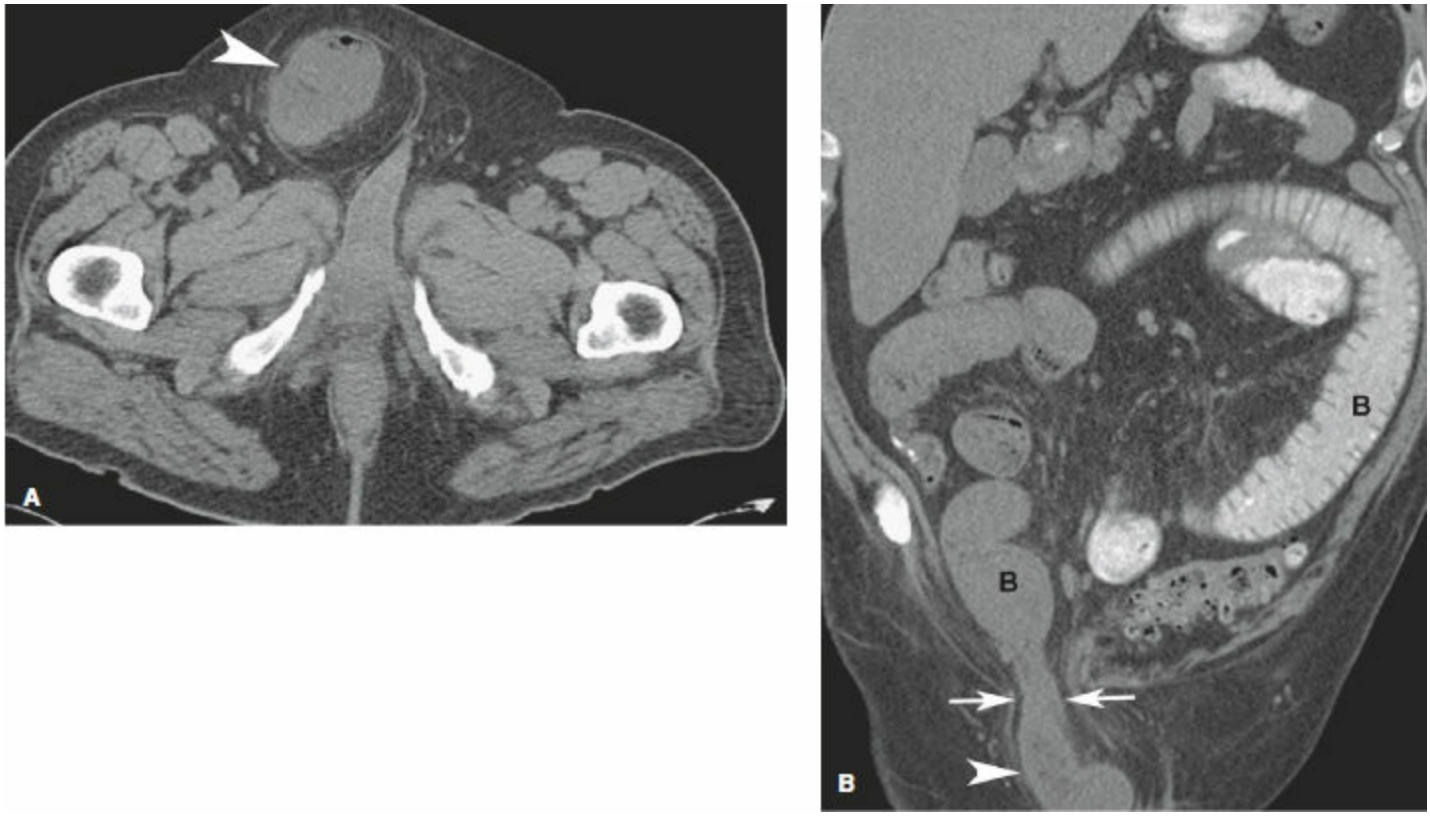

Figure 49-7. Computed tomography images of an inguinal hernia. Axial (**A**) and coronal (**B**) CT scan images showing incarcerated right inguinal hernia with air- and fluid-filled loop of small bowel (*arrowhead*) in the right inguinal canal (*arrow*) causing small bowel obstruction with dilated loops of proximal small bowel (**B**).

Hernia

Hernias of all types are second only to adhesions as the most frequent causes of obstruction in Western countries. External hernias such as inguinal (Fig. 49-7) or femoral hernias may present with the symptoms of obstruction and will not be diagnosed unless sought.[95] Femoral hernias are particularly prone to incarceration and bowel necrosis due to the small size of the hernia inlet.[95] Other hernias such as umbilical, incisional, paracolostomy, or lumbar hernias are obvious. Still others, such as internal hernias are usually diagnosed at laparotomy for obstruction. These include obturator hernias, paraduodenal hernias (Fig. 49-8), and hernias through the foramen of Winslow or mesenteries. When hernia has been identified as the cause of the obstruction, the patient is quickly resuscitated, given antibiotics, and taken to the operating room. The hernia is then reduced and the viability of the bowel assessed. If viable, the bowel is left alone; if not, it is resected. The hernia defect is then repaired. One important consideration is the Richter hernia (Fig. 49-9).[96] In this variant, only a portion of the wall of the bowel is incarcerated and thus incarceration and strangulation may not be associated with complete obstruction. These most frequently occur in association with femoral or inguinal hernias. Complete obstruction can occur if more than half of the bowel circumference is incarcerated.

For external (abdominal wall) hernias, it may be possible to perform *taxis,* that is, the manual reduction of an incarcerated/irreducible hernia. Reduction (taxis) of the hernia is usually successful. Occasionally taxis results in reduction of the contents of the hernia sac *en mass* (still obstructed), reduction of strangulated bowel resulting in generalized peritonitis, or reduction of an obstructed Richter hernia.[97–101] This is one reason for using circumspection in relying on taxis as a mode of treatment for incarcerated inguinal, femoral, and incisional hernias. In general, taxis should be followed expeditiously by operative repair.

Gallstone Ileus

As a result of intense inflammation surrounding a gallstone, a fistula may develop between the biliary tree and the small or large intestine. Most fistulae develop between the gallbladder fundus and duodenum. If the stone is greater than 2.5 cm in diameter, it can lodge in the narrowest portion of the terminal ileum, which is just proximal to the ileocecal valve. This complication is rare, accounting for less than 6 in 1,000 cases of cholelithiasis and no more than 3% of cases of intestinal obstruction. Typically, the patient is elderly female and presents with intermittent symptoms over several days, as the stone tumbles distally toward the ileum. The classic findings on plain radiographs include those of intestinal obstruction, a stone lying outside the right upper quadrant, and air in the biliary tree (Fig. 49-10). Treatment includes removal of the stone and resection of the obstructed segment only if there is evidence of tissue necrosis. The risk of a recurrent gallstone ileus is about 5% to 10%.[102,103] Such recurrences usually occur within 30 days of the initial episode and are usually due to stones in the small intestine that were missed at the original operation.

The difficult decisions in management of gallstone ileus focus on the fistula. The arguments in favor of disconnecting the fistula and removing the gallbladder have been the possibility of recurrence of gallstone ileus and the risk of cholangitis due to reflux of intestinal content into the biliary tree. When the latter operation is included, the mortality may be doubled as compared to simple removal of the gallstone. It is used selectively in good-risk patients. The long-term incidence of biliary tract infections has not been common enough to warrant the more aggressive approach at the initial operation. Some authors have advocated cholecystectomy at a second operation, especially if the patient is young and fit. The consensus is that cholecystectomy should not be performed at the initial operation for gallstone ileus, except in highly selected patients. A careful search of the entire intestine should be performed to exclude the possibility of additional large stones which can occur in up to 25% of patients.[102–104]

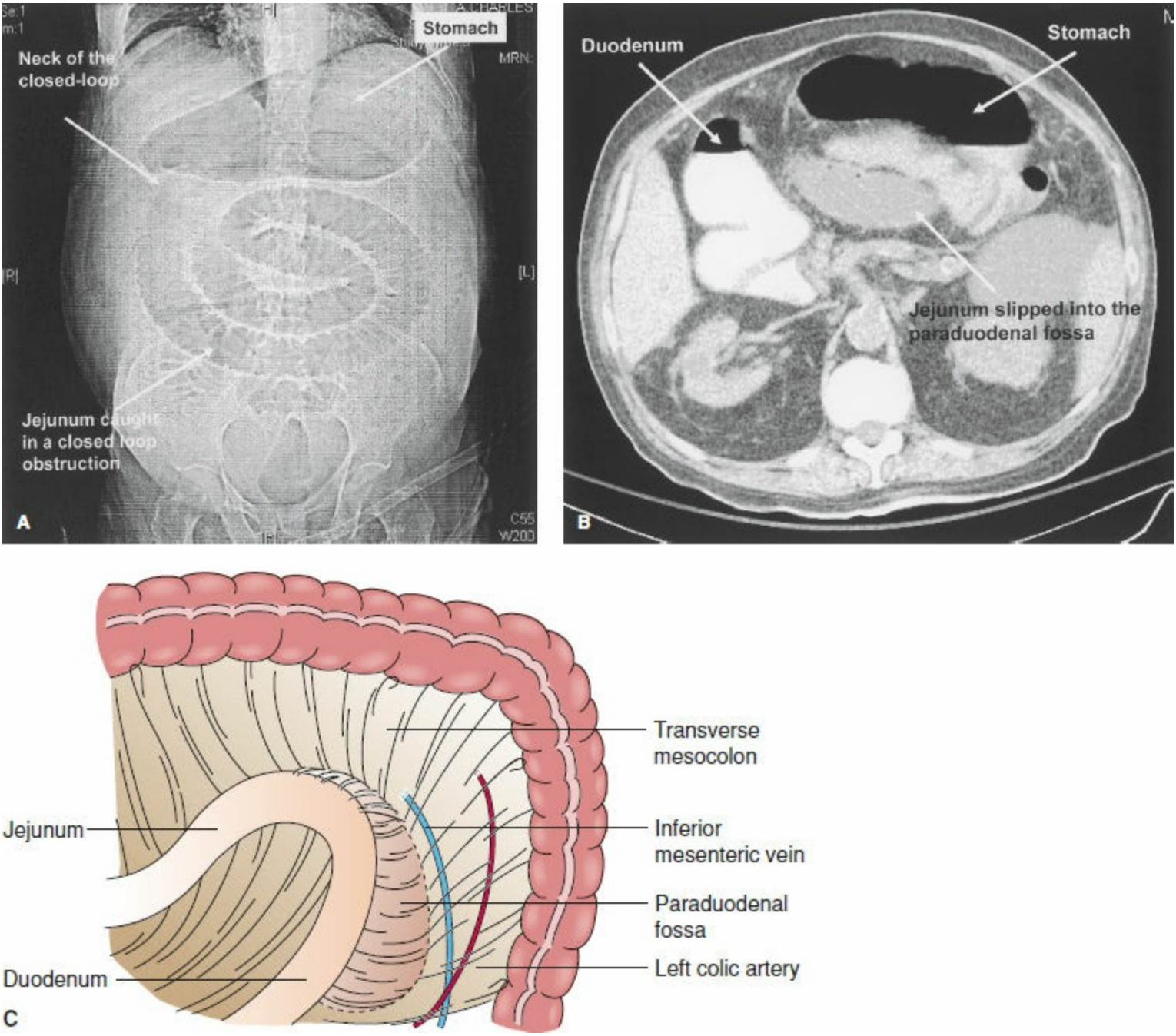

Figure 49-8. Paraduodenal hernia. **A:** Plain film of closed-loop obstruction with neck of the closed loop in the right upper abdomen. **B:** Computed tomography scan showing slippage of the jejunum behind the stomach, with dilatation and obstruction of the duodenum. **C:** Schematic diagram showing relationships of the paraduodenal fossa and transverse mesocolon.

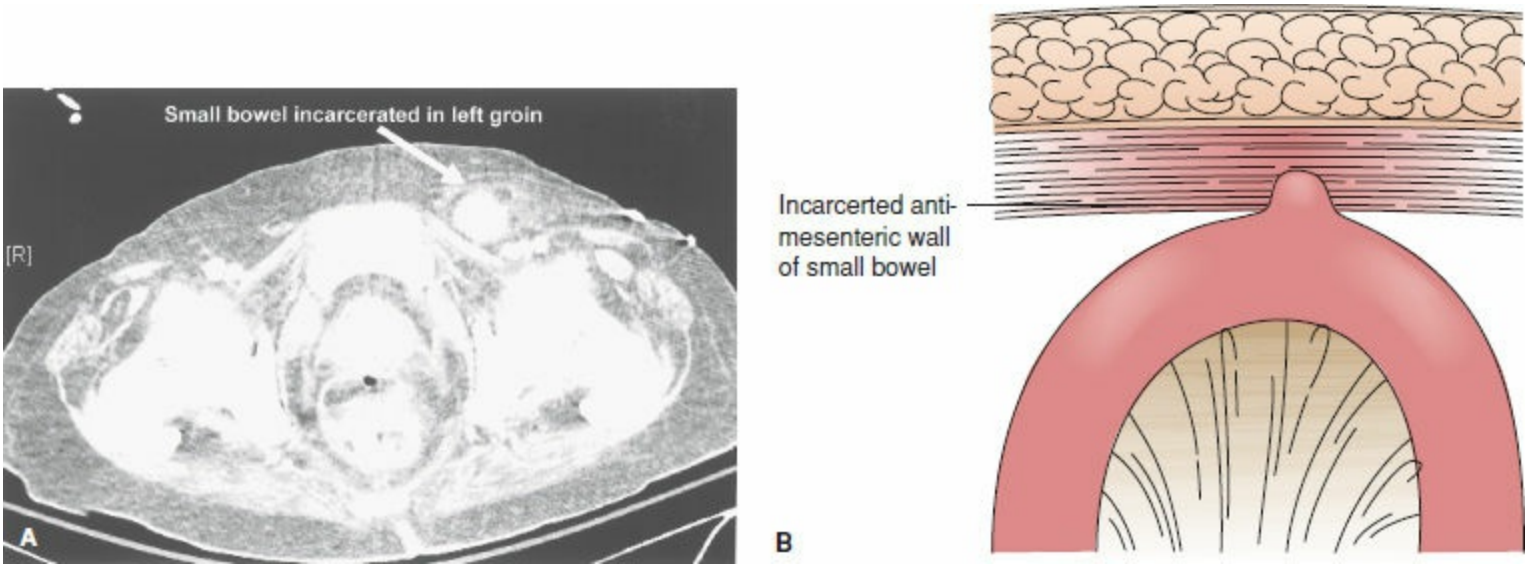

Figure 49-9. Richter hernia. **A:** Computed tomography scan showing contrast and air in the incarcerated segment within the left groin. **B:** Schematic diagram showing Richter hernia, in which the antimesenteric border (but not the whole wall) of the intestine is incarcerated.

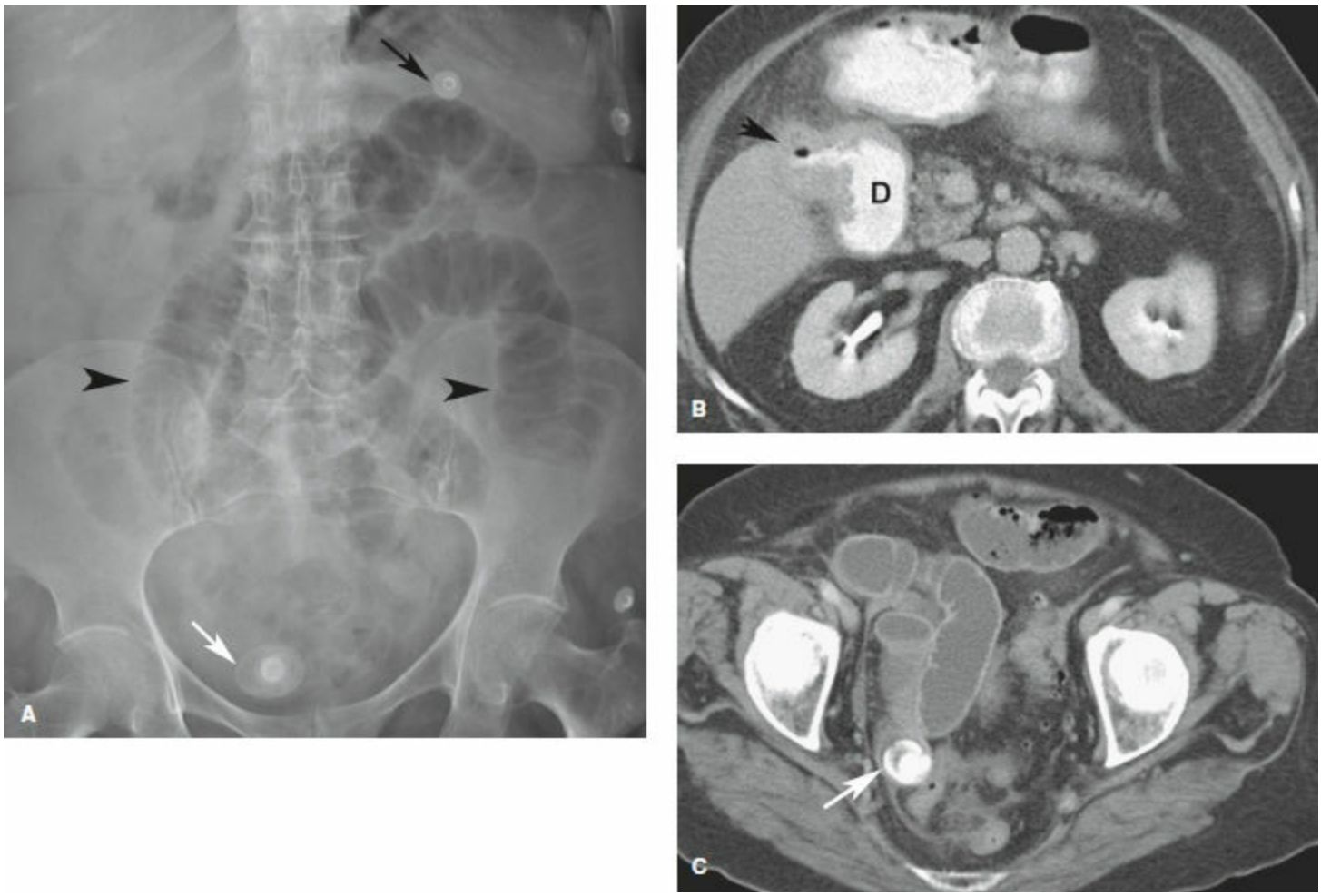

Figure 49-10. **A:** Plain radiograph of a patient with gallstone ileus, showing obstructed loops of small intestine (*black arrow*) in the abdomen and a gallstone (*white arrow*) in the pelvis (gallstone was initially misinterpreted as an EKG lead [*black arrow*]). **B:** Computed tomography (CT) scan showing a cholecystoduodenal fistula (*black arrow*) with air in the biliary tree (D, duodenum). **C:** CT scan showing gallstone (*white arrow*) in the distal ileum and fecalization of luminal content adjacent to the stone.

Intussusception

About 5% of intussusceptions occur in adults. An intussusception occurs when one segment of bowel telescopes into an adjacent segment, resulting in obstruction and ischemic injury to the intussuscepting segment (Fig. 49-11) and the obstruction may become complete, particularly if tissue inflammation and necrosis occur. Of adult cases, 90% are associated with pathologic processes.[105,106] Tumors, benign or malignant, act as the lead point of intussusception in more than 65% of adult cases. A significant proportion of cases have been reported to occur after abdominal surgery for lesions other than neoplasm. In cases not associated with neoplasm, Sarr et al.[106] reported that approximately 20% were related to the suture line, approximately 30% to adhesions, and approximately 60% to intestinal tubes. Intussusception related to long tubes can occur when the tube is withdrawn, but most frequently occurs with the tube in place. Perioperative intussusception frequently subsides without intervention.

Four types of intussusception are recognized: enteric (Fig. 49-12), ileocolic, ileocecal, and colonic. In the ileocolic form, the ileum telescopes into the colon past a fixed ileocecal valve. In the ileocecal form, the valve itself may be the lead point of the intussusception. Radiographic features of intussusception are not specific. Plain films reveal evidence of partial or complete obstruction. Occasionally, a sausage-shaped soft tissue density will be seen, outlined by two strips of air. Recently, in both pediatric and adult cases, it has been suggested that sonography may be useful in diagnosis. Nevertheless, the mainstays of diagnosis are contrast studies or CT scan. Because of the high incidence of tumors, surgery has generally been recommended. Reduction by hydrostatic pressure, which is the standard of care in pediatric cases, is not usually attempted in adults. Honjo et al. described preoperative reduction in 31.8% and 31.8% intraoperative reduction of adult intussusceptions. Preoperative reduction serves several functions including avoidance of emergency surgery, allowing radical surgery for cancer, reducing the extent of intestinal resection, and allows time for preoperative predation of the bowel. This may shift the paradigm in management of adult intussusception.[107] Clear indications for operation include long length and wide diameter of the intussusception, presence of a lead point, or evidence of bowel obstruction.[105] Recent studies have called into question the need to operate in all cases detected on sensitive imaging studies such as CT scan, arguing that a number of these patients can be safely managed without operation.[105] However, in the opinion of these authors, it is difficult to advise expectant management except in unusual circumstances.

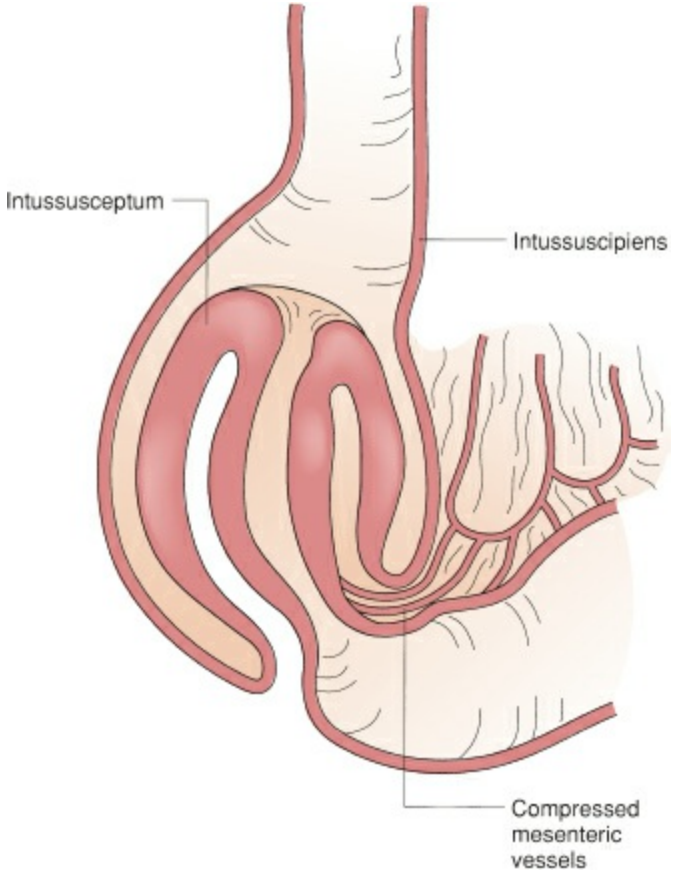

Figure 49-11. Anatomy of intussusception. The intussusceptum is the segment of bowel that invaginates into the intussuscipiens.

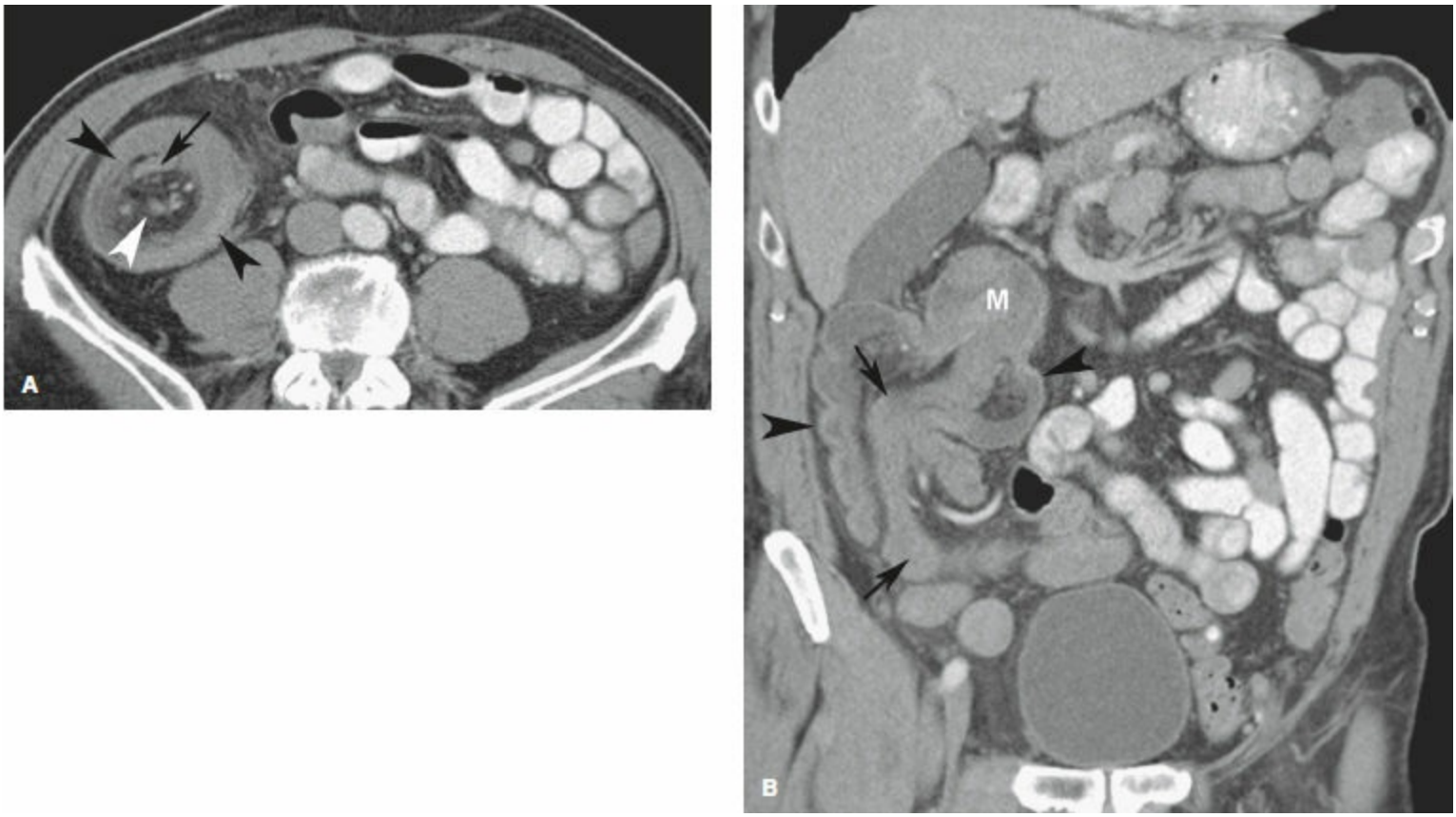

Figure 49-12. Axial (**A**) and coronal CT scan (**B**) images of an ileocolic intussusception secondary to colon carcinoma (M) as a lead point. Intussusceptum (*long arrows*) and intussuscipiens (*arrowhead*). Mesenteric vessels and fat (*white arrowhead*) accompany the intussusceptum.

Crohn Disease

Indications for surgery in Crohn disease are discussed elsewhere in this book. In this disease, obstruction occurs under two different sets of circumstances.[108] When the disease has flared acutely, the lumen may be narrowed by a reversible inflammatory process. The result is an open-loop obstruction that may respond, first to intravenous hydration and nasogastric decompression, and ultimately to therapy with corticosteroids or other anti-inflammatory regimens. Alternatively, obstruction may occur in the setting of a chronic stricture. Such strictures will not respond to conservative measures and, once diagnosed, operative therapy should not be delayed. One important clinical point is that about 7% of strictures in the colon, and an uncertain proportion of those in the small intestine, are malignant.[108] Extent of resection is thus based on intraoperative findings, that is, to margins beyond visibly diseased bowel and does not necessarily include enlarged lymph nodes in the mesentery. If there is suspicion for malignancy, a lymphadenectomy is performed.

A second clinical point is that Crohn-affected bowel may not be dilated proximal to the obstruction but can be complicated by a small perforation. Such a microperforation may not be large enough to be associated with free air on plain films. The patient may thus present with significant abdominal pain and tenderness. A CT scan is likely to be the most sensitive imaging modality for obtaining evidence that differentiates conditions that require immediate surgery (closed-loop obstruction and microperforation) from simple obstruction that would otherwise be observed. In the absence of clinical progression of symptoms and signs, however, extended conservative management is warranted before the patient is committed to surgery.

Malignant Obstruction

Obstruction can complicate malignancies of the small and large bowel in a number of settings. Studies have documented that 10% to 28% of patients with colorectal cancer and 20% to 50% of patients with ovarian cancer will present with a malignant bowel obstruction at some point during the course of their disease.[109] Most commonly, a primary lesion such as an adenocarcinoma or lymphoma will enlarge until the lumen of the intestine is blocked. The lesion then presents with symptoms and signs associated with the level of obstruction and are managed accordingly.

A second setting involves a patient who previously has undergone surgery for malignancy and now returns with evidence of bowel obstruction. The likelihood that the obstruction is due to recurrent disease is based on several factors, including the origin of the primary malignancy, the stage of the primary malignancy, and the designation of the original surgery as curative or palliative. Gastric and pancreatic carcinomas often present with or are subsequently complicated by peritoneal carcinomatosis and thus the subsequent obstruction is most likely due to malignancy. With respect to colon and rectal carcinomas, as many as 50% of cases presenting with obstruction after resection of the primary may be due to adhesions and not recurrent malignancy.[109,110] In addition, even if the obstruction is now due to unresectable disease, significant palliation can be obtained through bypass or enterostomy in up to 75% of patients (Fig. 49-13). However, the underlying diagnosis of cancer in this patient population mandates careful attention be paid to patient selection prior to any surgical intervention and risk factors for poor outcome (Table 49-4, Algorithm 49-2). In patients presenting with gastroduodenal and colorectal obstructing lesions who are not candidates for surgical bypass or enterostomy, endoscopic management options including percutaneous endoscopic gastrostomy (PEG) tube placement and self-expanding metallic stent (SEMS) placement, are available (Algorithm 49-2). These options have been associated with symptomatic relief in greater than 75% of patients.[109]

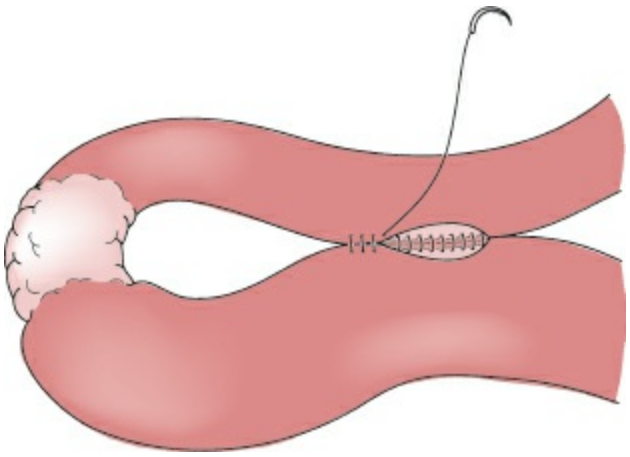

Figure 49-13. Significant palliation can be achieved in a patient with obstructing but unresectable malignancy. Enteroenterostomy is performed to bypass the obstructing segment.

Management of incurable malignant obstruction may require an approach that moves away from classical surgical teaching of nil by mouth, nasogastric tube, intravenous

fluids, and serial radiographs.[111] Patients with advanced malignant obstruction in the absence of a solitary or correctable obstructing lesion are generally managed without surgery (Algorithm 49-2). Patients are managed without a nasogastric tube if possible. They are encouraged to eat as soon as obstructive symptoms resolve using a low-fiber diet. Antiemetics and opioids via continuous subcutaneous infusions are used to manage nausea, vomiting, and colic, respectively. In addition, octreotide, a somatostatin analog, is used in palliation of refractory malignant intestinal obstruction by improving intestinal mucosal absorption, improving motility, reducing gastrointestinal hormone levels and intestinal secretions, and having a direct antineoplastic effect on the obstructing tumor.[112] This allows true palliative care outside a hospital setting saving patients the pain, discomfort, and complications of hospitalization and unproductive surgery.[111]

Volvulus

The term *volvulus* indicates that a loop of bowel is twisted more than 180 degrees about the axis of its mesentery. Volvulus has been reported for the cecum, transverse colon, splenic flexure, and sigmoid colon. A special variant of volvulus, complicating a condition known as *Chilaiditi syndrome,* can occur when redundant loops of the transverse colon slip between the liver and diaphragm and then undergo torsion.[113] Generally, the condition is asymptomatic, but when associated with volvulus must be relieved surgically.

Table 49-4 Results of Management of Malignant Obstructions: Risk Factors for Unfavorable Outcome

Advanced age (biologic/physiologic)
Poor performance status
Advanced stage of primary malignancy (previous treatments, availability of anticancer options, life expectancy)
Malnutrition/cachexia
Comorbidities
Absence of psychosocial support
Ascites (>100 cc associated with poor outcome)
Single vs. multiple sites of obstruction
Carcinomatosis (believed to respond poorly to surgical intervention)

The most common site for volvulus is the sigmoid colon, accounting for 65% of cases.[114] By definition, a volvulus is a form of closed-loop obstruction of the colon. Air is always present in the colon and rectum, and thus volvulus of any segment of the colon is associated with abdominal distention and, usually, severe abdominal pain. As shown in Figure 49-5, the most common radiographic feature is the "bent inner tube" appearance of the sigmoid, which is located in the upper abdomen. The preferred method of management involves endoscopic decompression. A rigid or flexible proctosigmoidoscope is advanced gently into the rectum until a rush of air and feces indicates that the loop has been untorsed. A rectal tube is then advanced well into the loop as a stent to prevent retorsion. Gangrene of the colon does not usually complicate the picture if the patient is seen and treated promptly. This conservative approach resolves the volvulus in 85% to 90% cases and elective resection or fixation of the redundant segment can then be planned. Following endoscopic decompression, recurrence of the volvulus is higher than 60%.[115] Thus, an operation to remove the sigmoid should be performed if the patient is fit for surgery.[116] However, a majority of these patients are elderly and infirm and approximately 15% have a history of psychiatric disorder. As a result, the patient may present with peritoneal findings, sepsis, and shock. In this setting, rapid resuscitation followed by urgent resection and colostomy is warranted. Other forms of volvulus generally cannot be detorsed without operation. Fixation of the torsed segment (e.g., via cecostomy or cecopexy) is generally a less satisfactory solution than resection of the involved segment and is not generally recommended.[114]

Radiation Enteritis

After asymptomatic periods lasting at least 10 years, chronic intestinal obstruction can result. Radiation injury elicits an underlying vasculitis and fibrosis that lead to chronic, recurring low-grade partial obstruction of the small intestine or stricturing and bleeding in the colon and rectum. Operation is indicated for incapacitating symptoms and obstruction not resolved by conservative management.[117] Recurrence of the original tumor as a cause of obstruction should be considered and excluded. However, the diffuse nature of the injury and pathologic responses can lead to massive resections that leave the patient with short-bowel syndrome. Attempts to suture scarred loops can also result in chronic inflammation and formation of interloop abscesses and fistulae. The incidence of suture line leak is high.[118] There are several experimental therapies used in the treatment and prevention of radiation enteritis which includes pentoxifylline–tocopherol combination, sulfasalazine, methylprednisolone, HBO, intraperitoneal octreotide, cysteine, triamcinolone, and amifostine.[119,120]

Role of Laparoscopy in Management of Small Bowel Obstruction

Open surgery is the preferred method in the management of strangulating SBO after failed conservative management but since the advent of laparoscopy for general abdominal surgery, a number of investigators have reported the feasibility of laparoscopic approaches to small and large bowel obstruction. Such approaches have been used, with varying degrees of success, to manage obstruction from a number of different etiologies (Table 49-5).[121–123] *Laparoscopic management of bowel obstruction* provides many potential benefits including quicker recovery of bowel function, shorter hospital stay, less postoperative pain, reduced recovery time and early return to full activity, and fewer postoperative complications including a decreased incidence of wound infection and pneumonia. Additionally, as suggested by both clinical and experimental studies in animal models, laparoscopy is associated with decrease in incidence, extent and severity of intra-abdominal adhesions compared with open surgery.[124,125] Thus laparoscopic management of bowel obstruction may result in a decreased lifetime risk for recurrent bowel obstruction. According to a systematic review and meta-analysis, laparoscopic adhesiolysis was associated with reduced overall complication rate with no significant difference in the occurrence of intraoperative injury to bowel and overall mortality.[126]

Table 49-5 Results for Outcome of Laparoscopic Management of Intestinal Obstruction: Favorable Attributes

Diaphragmatic (hiatal) hernia	Gallstone ileus
Inguinal hernia	Intussusception
Incisional hernia	Adenocarcinoma of colon
Femoral hernia	Diverticulitis
Spigelian hernia	Colitis (ishemic, radiation)
Internal hernia	Volvulus
Adhesions	Benign colon tumors
Chron disease	Periappendicular abscess
Small bowel tumor	Carcinomatosis
Meckel diverticula	Ogilvie syndrome
Ingested foreign body	Bezoar

Table prepared by William Peranteau, MD.

In adults, the most common etiology for which laparoscopic versus open surgical management of bowel obstruction has been evaluated is adhesive bowel obstruction.[123,127–136] Studies of laparoscopic lysis of adhesions for SBO indicate that it is feasible, with acceptable operative times, length of hospital stay, as well as conversion and complication rates (Table 49-6). Studies directly comparing laparoscopic to open surgical management of adhesive SBO highlight the benefits of the laparoscopic approach as indicated by statistically significant decreases in complication rates, time to return of bowel function, length of hospital stay, and even overall cost (Table 49-7).

Despite these benefits, laparoscopic management of bowel obstruction should be approached with caution and individualized to specific clinical situations.[137] Laparoscopy

is discouraged when the surgeon is uncomfortable with the technique or in patients presenting with peritonitis, hemodynamic instability, severe comorbid conditions, complete and distal obstruction, or when contraindications to pneumoperitoneum exist. Recent advancement and improvement in tools and skill in laparoscopy have paved the way for its increased use in the surgical management of SBO. Recently, consensus guidelines have been published emphasizing its role in selected group of patients.[138] Laparoscopically assisted lysis of adhesions may be attempted in case of first episode of SBO or anticipated single-band lesion. While it may be problematic to use a laparoscopic approach in managing obstruction in patients who have previously undergone extensive and open intra-abdominal procedures, it is safe to use a laparoscopic approach in managing obstruction in patients who have previously undergone laparoscopic procedures, especially focused procedures such as appendectomy and cholecystectomy.

Under these circumstances, success in using laparoscopy to confirm the diagnosis of obstruction is between 60% and 100%; its success in therapeutic resolution of the obstruction is lower, perhaps 40% to 80%. The predictive factors for a successful laparoscopic adhesiolysis are less than 2 previous laparotomies, nonmedian previous laparotomy, appendectomy as previous surgical treatment, unique band adhesion as phatogenetic mechanism of SBO, early laparoscopic management within 4 hours from onset of symptoms, no signs of peritonitis on physical examination, and experience of surgeon.[139] There should be a low threshold for open conversion. The usual reasons for converting to open adhesiolysis are inadequate laparoscopic control due to intestinal distention, extensive adhesions, iatrogenic perforations, bleeding, and resection of necrotic segments.[140] Operative technique plays a paramount role in the success of laparoscopic approach. In obtaining laparoscopic access, an open access (Hasson) technique, entry to the left upper quadrant and ultrasound-guided site entry were recommended.[49,138] Although recent studies suggest that laparoscopic approaches are safe, effective and beneficial, prospective randomized studies evaluating laparoscopic management of SBO are required to definitively document its benefits over the traditional open approaches. It is also important to point out the need for adhesion quantification in future research. Coccolini et al. proposed a peritoneal adhesion index ranging from 0 to 30, providing a more precise and standardized system for describing findings at operation.[141] Such standardization would enable integration of the results of different studies, permitting a better understanding of circumstances where treatments may be standardized and those where individualization is important.

Table 49-6 Outcomes and Complications of Laparoscopic Operations for Obstruction of the Small Intestine Due to Adhesions

Reference	Operative Time (min)	Conversion (%)[a]	Bowel Injury (%)	LOS (Days)	Reoperation (%)	Success (%)	Mortality (%)
Pekmezci et al.	99	6.7	6.7	4	0	100	0
Levard et al.	NR	40.9	8.4	4	4.5	95	2.2
Sato et al.	105	17.6	17.6	10.4	5.8	88	0
Suter et al.	NR	43	15.6	5.9	9	NR	2.4
Al-Mulhim et al.	58	32	NR	5	0	100	0
Chosidow et al.	71.7	16	3	5.03	NR	80	0
Strickland et al.	68	32.5	10	3.6	5	97	0
Leon et al.	108	35	7.5	2.9	17.5	81	0
Baily et al.	64	21.5	NR	3	10.8	NR	1.8
Navez et al.	77	40	9	6.6	2.9	85.3	2.9
Ibrahim et al.	NR	15	9.1	NR	3	NR	3
Overall	58–108	6.7–43	3–17.6	2.9–10.4	0–17.5	80–100	0–3

[a]Indications for conversion: unable to visualize obstruction site (22–49%), bowel necrosis or perforation (19–23%), neoplasm or suspicion of neoplasm (3–25%), iatrogenic perforation (14–19%), dense and numerous adhesions (14–50%), technical difficulties (6%), other (5%).
LOS, length of stay; NR, not recorded.
Adapted from Nagle A, Ujiki M, Denham W, et al. Laparoscopic adhesiolysis for small bowel obstruction. *Am J Surg* 2004; 187: 464–470.

Table 49-7 Outcomes, Complications, and Costs in Laparoscopic Management of Intestinal Obstruction Due to Adhesions

Reference	Conversion (%)		Complication (%)	Time to RBF (d)	LOS (Days)	Operative Time (min)	Cost ($)
Wullstein et al.	52[a]	Laparoscopic	Intraop: 29 *p = 0.156*[b] Postop: 19.2[c] *p = 0.032*	3.5 *p = 0.001*	11.3 *p <0.001*	103 *p >0.05*	NR
		Open	Intraop: 15[d] Postop: 40.4[e]	4.4	18.1	84	NR
Mancini et al.	17.2	Laparoscopic	19.2 *p = 0.008*	NR	6 *p = 0.0001*	NR	9,412 *p = 0.0003*
		Open	30.1	NR	9	NR	11,858

[a]Indications for conversion: need for resection (14.8%), extent of adhesions or problems in view (37%), uncertain viability of small bowel (22.2%), small bowel perforation (25.9%).
[b]Laparoscopic intraoperative complications: perforation (26.9%), hemorrhage (1.9%).
[c]Laparoscopic postoperative complications: pulmonary (1.9%), wound infection (5.8%), anastomotic leak (3.8%).
[d]Open intraoperative complications: perforation (13.5%), mesenteric injury (1.9%).
[e]Open postoperative complications: pulmonary (3.8%), cardiac (3.8%), DVT (1.9%), death (3.8%), wound infection (11.5%).
Table prepared by William Peranteau, MD.

7 Open exploratory laparotomy is the gold standard in treating unresolved SBO, but laparoscopic management should be considered in select group of patients. Types of intestinal obstruction that are more likely to lead to strangulation and the need for urgent/emergent operation include closed-loop obstructions, obstruction that occurs without a prior history of operation, and obstructions that occur after laparoscopic procedures.

ILEUS AND PSEUDO-OBSTRUCTION

Ileus

Etiologic Factors

8 An *ileus* or "eileos" (Greek for "twisting") reflects a loss of forward peristalsis and coordination of the motility of the different regions of the gastrointestinal tract causing a functional obstruction.[142] Clinically, bowel sounds, passage of flatus, and bowel movements have been used to signal the return of bowel function and coordination of peristalsis. Liquid contrast and radiolabeled marker studies suggest that effective duration of ileus varies in different regions of the alimentary tract.[143,144] A POI may last for 0 to 24 hours in the small intestine, 24 to 48 hours in the stomach, and 48 to 72 hours in the large bowel.[145,146] The type of surgery and the wide variety of endpoints used to measure gut recovery often decide the duration of ileus. There is no consensus as to which one is most clinically meaningful. Duration of ileus is therefore primarily dependent on the return of colonic motility and its coordination with other regions of the gastrointestinal tract. A typical period of ileus is thus self-limited and easily tolerated. Factors implicated in ileus (Table 49-6) are outlined below:

Neurohumoral Peptides. Increases in endogenous neuromuscular inhibitors of the bowel include norepinephrine, corticotropin-releasing hormone (CRH), nitric oxide, somastostatin, glucagon, gastric inhibitory peptide, opioids and other peptides such as calcitonin gene-related peptide, motilin, substance P, VIP_ and substance P, have all been established as inhibitory neurotransmitters in the intrinsic gut nervous system. Antagonists to VIP, substance P and inhibitors of NO synthesis improve postoperative bowel motility.[147,148] Calcitonin gene–related peptide inhibits postoperative gastric emptying and gastrointestinal transit.[149,150] The use of anticholinergic medications delays recovery of an ileus.[151]

One group of neurohumoral substances that are particularly important in this regard are the opioids, both synthetic and endogenous. Opioids are established neurotransmitters in central and peripheral nervous systems, and it is well established that their use delays gastric emptying and promotes nonpropulsive smooth muscle contraction with an increase in intraluminal pressure throughout the entire gastrointestinal tract.[152,153] Over the years, a series of experimental studies have indicated that recovery of ileus is accelerated during administration of specific antagonists to kappa or mu opioid receptors,[154,155] suggesting that endogenous opioid release modulates recovery from ileus.

Inflammation. A relatively recent series of experimental and clinical investigations have focused attention on the role of inflammatory cells and mediators of inflammation in the development of prolonged ileus. Surgical intervention results in elevated levels of interleukin-6 (IL-6), cyclooxygenase isoform COX-2, and inducible nitric oxide synthetase (iNOS), all mediators of inflammation from macrophages.[156,157] In experimental animals, focal manipulation of the bowel may result in a pan-enteric inflammation and ileus.[157] In

experimental animals and human subjects, activated macrophages have been found in the muscularis of the small bowel, as early as 3 hours after laparotomy.[158] Increased COX-2 expression leads to prostaglandin release. Jejeunal contractility appears to be impaired, an effect blocked in COX-2 knockout mice and by the administration of selective COX-2 inhibitors. In related studies both in experimental animals and human subjects, Kalff et al. found that NO synthesis is stimulated in activated macrophages in the muscular layer of the small intestine following surgical intervention. More recently, degranulation of mast cells has also been implicated in the pathogenesis of ileus after laparotomy. In this regard, it has been shown that surgical manipulation of intestines activates quiescent macrophages as well as mast cells, and that mast cell destabilizers can prevent mechanically induced intestinal inflammation and dysmotility.[159,160] Bowel wall edema from inflammation or intravenous fluid overload is another mechanism of impairment of GI motility.[161]

Table 49-8 Etiologies of Prolonged Ileus After Abdominal Operations

Neurogenic	Metabolic	Pharmacologic	Infectious
Spinal cord lesions or injury	Hypokalemia	Anticholinergics	Systemic sepsis
	Uremia	Opiates	Pneumonia
Retroperitoneal process hematoma, tumor	Ca^{++}, Mg^{++} imbalance	Autonomic blockers	Peritonitis
Ureteral colic	Hypothyroidism	Antihistamines	Herpes zoster
	Diabetic coma or ketoacidosis	Psychotropics	Tetanus
		Phenothiazines	Bacterial overgrowth (blind-loop)
		Haloperidol	
		Tricyclic antidepressants	
		Clonidine	
		Vincristine	

Inhibitory Neural Reflexes. Noxious spinal afferent signals are thought to increase inhibitory sympathetic activity in the gastrointestinal tract.[162] Blockade of spinal afferents with epidural local anesthetics or with topical capsaicin has been shown to accelerate resolution of ileus in experimental studies.[149,150] In clinical studies of patients undergoing complex abdominal operations through conventional laparotomy incisions, it appears that conventional intramuscular injections are less likely to be associated with prolonged ileus than strategies utilizing patient-controlled intravenous injection.[163,164] Moreover, utilization of epidural analgesia tends to decrease recovery times from ileus in this group of patients,[165–167] suggesting that autonomic pathways coursing through spinal cord may serve as control points for ileus. Recent studies also provide evidence that carbon monoxide, derived from the activity of heme oxygenase-2 in myenteric plexus of the intestine, may play a role in modulating smooth muscle activity and its regulation by enteric nervous system.[168–170]

Central responses have also been observed as a result of laparotomy[162] and have been linked to activation of afferent pathways in the vagus nerve and a general response of the

organism to stress and release of corticotrophin-releasing factor.[171] Very recently, the efferent pathways in the vagus have also been implicated as possible modulators or control points for the inflammatory response. A series of experimental studies[172,173] has suggested that the vagus participates in suppression of certain macrophage activities, leading to earlier resolution of intestinal ileus.[173] These observations offer the possibility of a multidimensional understanding of ileus, both in individuals who are recuperating normally and in those who have protracted ileus but no specific risk factors for it (e.g., undrained sepsis, overuse of narcotics, spinal cord injury, severe pelvic fractures, and retroperitoneal inflammation).

Diagnosis

It is important to distinguish between a normal *POI* and a *paralytic ileus.* The distinction is predominantly one of time since operation and based on circumstance. POI is less severe, self-limiting (lasts 2 to 3 days vs. 3 to 5 days) and is usually an indicator of colonic dysmotility rather than a paralytic ileus which represents inhibition of small bowel activity. A prolonged POI (PPOI) occurs with protracted signs or symptoms of abdominal distention, bloating, diffuse and persistent abdominal pain, nausea, vomiting, and inability to pass flatus or tolerate an oral diet.

It is also important to distinguish between a PPOI from a mechanical SBO. Clinically, the presence of intense colicky pain, feculent emesis, or rapidly progressing pain or distension is more suggestive of SBO than PPOI. Localized tenderness, fever, tachycardia, and peritoneal signs suggest bowel ischemia or perforation, necessitating emergent surgical intervention.[10]

A variety of clinical circumstances and laboratory tests may also increase suspicion for prolonged ileus and lessen concern for mechanical obstruction and associated complications. In addition to opiates, a number of medications have been associated with slow recovery of intestinal motor function (Table 49-8). Isolated metabolic disturbances such as ketoacidosis, hypomagnesemia, hypercalcemia, and hypokalemia can prolong ileus. Ileus can be caused and perpetuated by systemic inflammatory responses to sepsis, abscess, pneumonia, and pancreatitis.

9 When the patient's POI has extended beyond the expected period, plain films of the abdomen reveals gas in segments of both small and large bowel (Fig. 49-14). At this point, the patient may begin to experience some discomfort and distention, as swallowed air fills loops that do not have effective peristalsis. Bowel sounds may be present, if hypoactive. The differential diagnosis now includes the possibility of mechanical obstruction from early postoperative adhesions (see earlier). To differentiate early postoperative obstruction from ileus, contrast studies or CT scans are helpful. The latter may be useful if other abdominal pathology such as an abscess could be contributing to the clinical picture. *CT with oral contrast has a sensitivity and specificity of 90% to 100% in distinguishing ileus from a complete postoperative SBO.*[174] However, it is less reliable in distinguishing ileus from a partial SBO.[174] If the diagnosis is uncertain after CT, upper GI contrast studies (enteroclysis) with water-soluble radio-opaque contrast material (e.g.,

Gastrografin) are especially helpful in distinguishing ileus from partial SBO (which more closely mimics ileus than complete SBO) and in identifying the severity of partial obstruction.[174]

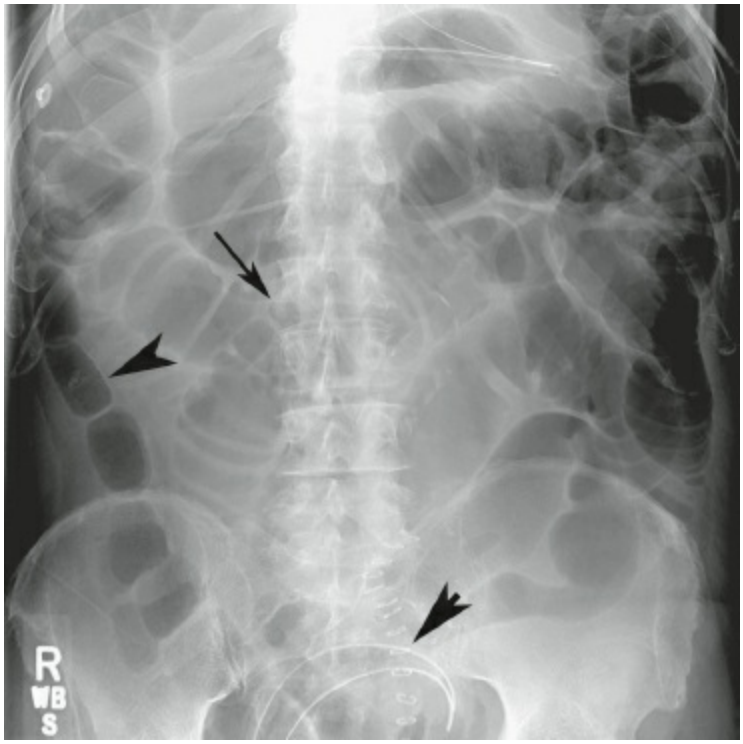

Figure 49-14. Plain supine abdominal radiograph of a patient with ileus. Air–fluid levels are present in the small intestine (*thin arrow*). Gas is seen in the colon (*thick arrowhead*). These findings are characteristic of, but not specific for, ileus. Surgical drains in the pelvis and skin staples (*short arrow*).

Management

10 A normal POI is usually self-limiting. Nevertheless, there are a number of interventions that are effective in reducing the duration of a normal postlaparotomy ileus (Table 49-9). Midthoracic epidurals with neuraxial local anesthetics has been shown to hasten the return of bowel function compared to systemic or epidural opioids.[165–167] Midthoracic local anesthetic epidurals block nociceptive afferent signals from the surgical site as well as sympathetic efferent outflow; this is useful for 48 to 72 hours postoperatively.

The goals in management in the normal period of postoperative ileus are to prevent uncomfortable distension, vomiting, and aspiration. Classic studies[6,10] indicate that flatus and the air accumulating during intestinal distension is derived largely from swallowing. Under normal circumstances, flatus is passed as early as 30 minutes after a "test bolus" of air is administered by tube into the stomach. Thus, passage of flatus is used, in reliable patients, as the index indicating coordination of all segments of the gastrointestinal tract and resolution of ileus.

For many years, the mainstay of therapy was the use of nasogastric suction to prevent accumulation of swallowed air and secreted fluids in an alimentary tract not yet coordinating flow distally. Subsequent studies have demonstrated that the putative

benefit does not compensate for risks of aspiration and discomfort of the tube. Thus, in routine abdominal cases such as colectomy, nasogastric tubes are used selectively[175,176] in patients who are felt to be at risk of complications of ileus, based on the surgeon's judgments about intraoperative findings or manipulations – prolonged handling and packing of the bowel, anticipation of intensive use of narcotics or other antikinetic agents, presence of sepsis or peritonitis, or extensive blood loss. Otherwise, a nasogastric tube is used for a short postoperative period or never placed, with the expectation that a small percentage of patients will require placement for symptoms.[176] In these patients, the patient is allowed nothing more than sips or ice chips until there is evidence (by listening for bowel sounds or the patient's report of "rumbles") that ileus is likely resolving. Intravenous fluids are necessary until the patient can be advanced to full intake of their requirements, usually after flatus is passed.

Table 49-9 Treatment for Postoperative Ileus

Treatment	Benefit	Drawback
Nasogastric tube	Possible relief of vomiting and bloating	Does not shorten duration of ileus May contribute to fever, atelectasis, and aspiration Discomfort
Early postoperative feeding	Stimulates reflex for propulsive bowel motility and enzyme secretion Stimulates immune system Reduces postoperative and posttraumatic infectious complications Reduces risk of anastomotic dehiscence, wound infection, pneumonia	Patients may not tolerate feeding
Opioid antagonists (Alvimopan)	Peripheral acting FDA approved to hasten postoperative ileus following partial large or small bowel resection with primary anastomosis	Possible cardiovascular or neoplastic risk Currently restricted to in-patient use only
Laparoscopic procedures	Earlier return of bowel function and discharge from hospital Minimal skin incision, minimal mechanical bowel manipulation	Not all patients and procedures are amenable to laparoscopic approach
Epidural anesthetics/ analgesics	Reduced duration of ileus vs. systemic opioid Increases splanchnic blood flow Anti-inflammatory	Risks associated with epidural catheter placement
Gum chewing	May shorten duration of ileus Simple and inexpensive	Limited data
Laxatives	May shorten duration of ileus Inexpensive	Limited data on efficacy
Nonsteroidal anti-inflammatory drugs (COX-2 inhibitors)	Decreases opioid needed for pain control May increase motility by acting as an anti-inflammatory	Possible increased risk of postoperative bleeding Other adverse effects

Adapted from Luckey A, Livingston E, Tache Y. Mechanisms and treatment of postoperative ileus. *Arch Surg*. 2003;138(2):206–214, Table 2.
Prepared by Zain Khalpey, MD.

In addition correctable conditions such as electrolyte disturbances or uremia are investigated and rectified. Mobilization has other benefits in reducing morbidity.[177,178] Early feeding is thought to stimulate gastrointestinal hormones, secretions and motility,

and coordinated propulsive activity. In addition early feeding may improve immune function, reduce[179] infectious and catabolic complications.[142,180] Despite the use of laxatives with prokinetic agents, no controlled trial exists to assess the possible beneficial effects of laxatives on POI.[142]

One treatment, gum chewing, has attracted attention as a simple and inexpensive method of accelerating return of bowel function. Mastication stimulates the cephalic vagal cholinergic pathways that increases gastrointestinal hormone secretion such as gastrin, pancreatic polypeptide, and neurotensin which affects gastrointestinal motility.[181,182] Since the initial publication of one small and underpowered study,[183] a number of prospective randomized trials have been conducted to test the hypothesis that gum chewing results in earlier passage of flatus and bowel movement in patients undergoing laparoscopic colectomy.[184,185] No conclusive evidence has been obtained to demonstrate a clear benefit of gum chewing, although subgroup analysis suggests some patients may benefit.[185] At the same time, prospective randomized studies continue to be performed, arguing one conclusion or the other.[186–190] According to one hypothesis sorbitol and other hexitols, the key gradients of "sugar-free" chewing gums may also play a role in the earlier recovery of POI.[191] A recent study[192] argued that nicotine gum might accelerate resolution of postoperative ileus through enhancement of vagal activation.

Salt and water disturbances in the body also may influence return of bowel function following laparotomy. In one study, patients undergoing colectomy received a restricted perioperative fluid resuscitation regimen or a standard, more liberal fluid resuscitation. The "restricted" group had a quicker passage of flatus and moved their bowels earlier, leading in part to shorter hospital stays.[193] Subsequent studies[194,195] have not uniformly suggested that recovery from ileus is faster with temperance in fluid resuscitation; or have indicated that there is a benefit from fluid restriction protocols but have not reported return of gastrointestinal function as an endpoint.[196] However, this benefit, as well as others, may be more clearly observed when fluid therapy is directed by physiologic assessments of volume status, such as esophageal Doppler monitoring of the great vessels and heart chambers.[197,198] A double-blind, randomized controlled clinical trial showed that Doppler-guided intraoperative fluid management decreases postoperative nausea, vomiting, ileus and wound infection.[199]

Experimental evidence of pharmacologic interventions specifically directed at abnormal surges of neurotransmitters or hormones that might prolong ileus have provided a useful insight into the pathophysiology of POI. Opioid antagonists, somatostatin analogs, sympatholytics, injection of local anesthetics into mesenteric nerve roots, or nonsteroidal anti-inflammatory agents, such as ketorolac, appear to promote faster recovery to normal myoelectric activity and intestinal transit times.[151,200,201] The peripherally acting, selective μ-opioid receptor antagonist alvimopan (Entereg™) has been reported to reduce GI recovery time and to facilitate hospital discharge for both open and laparoscopic colorectal surgery cases,[202] after gynecologic surgery,[203] after bowel resection, and after radical cystectomy.[204] Importantly, in one study, the effect of alvimopan accelerated recovery after open abdominal surgery as an independent influence in an accelerated recovery program[205] from colectomy.

Prokinetic agents such as metoclopramide, cisapride (presently not approved by U.S. Food and Drug Administration), and erythromycin have been evaluated for their efficacy in shortening the duration of POI. For ileus following upper gastrointestinal procedures (e.g., pancreaticoduodenectomy), such medications may be effective in promoting gastric emptying.[206–211] For general abdominal procedures involving the small intestine, colon, and retroperitoneal structures such as the aorta, there has been limited success in using such agents to shorten recovery times.[179] In multiple controlled studies, metoclopramide did not have significant impact on the duration of ileus.[212–214] In other studies, no benefit was observed when patients were given erythromycin. Promising results have been observed with cisapride and related agents,[179,206,208] which significantly reduced the duration of ileus. The results would depend on the route of its administration. However, this medication is no longer approved for use in the United States due to the occurrence of potentially fatal arrhythmias.[215] In a Cochrane review of fifteen systemically acting prokinetic drugs, the conclusion was that erythromycin has no effect and there are insufficient evidence to recommend cholecystokinin-like drugs, cisapride, dopamine antagonist, propranolol, or vasopressin. IV lidocaine and neostigmine might show a potential effect but more evidence is needed.[179] Mosapride, a selective 5-hydroxytryptamine 4 receptor agonist has been shown to reduce the duration of POI in animal and human studies.[216] Escin, a natural mixture of triterpene saponins extracted from dried seeds of horse chestnut (Aesculus hippocastanum or chinensis) also may shorten time to recovery of gastrointestinal motility.[217]

Along with pharmacologic measures, it should be emphasized that, in otherwise routine laparotomy or laparoscopy, gentle handling of tissues, meticulous attention to hemostasis, and applications of sound principles of wound management are likely to have the greatest impact on optimizing recovery from ileus and minimizing the incidence of prolonged ileus. Efforts to reduce incision size and time spent handling the intestines through the use of laparoscopic approaches clearly improves recovery from ileus in some if not all patients undergoing standardized intra-abdominal procedures such as appendectomy,[218] and colectomy.[219] Even in open procedures,[220] standardization of management and effective communication help expedite clinical fast-track pathways and facilitate earlier recovery of bowel function and discharge from hospital.[142,198,221] Currently proposed measures to minimize the prolongation of ileus are summarized in Table 49-10.

Table 49-10 Measures to Prevent Prolongation of Ileus

Minimization of trauma to tissues; using proper technique in the operating room with gentle handling of bowel during surgery
Minimal use of narcotics for analgesia, for any route of administration (intravenous, intramuscular, epidural)
Use of opioid antagonists (Alvimopan)
Generous use of midthoracic epidural anesthesia with local anesthetic use
Use of nonsteroidal anti-inflammatory (COX-2 inhibitors) agents for analgesia
Early feeding
Correction of any electrolyte or metabolic imbalances
Early recognition of septic complications (e.g., abdominal abscess, pneumonia, and central line sepsis) that may contribute to prolongation beyond the expected period for ileus

Colonic Pseudo-Obstruction (Ogilvie Syndrome)

Etiologic Factors

Acute pseudo-obstruction of the colon, also known as *Ogilvie syndrome,*[222] is a paralytic ileus of the large bowel, characterized by rapidly progressive abdominal distention, often painless.[223] Although the distention of the colon is not due to mechanical obstruction, the wall of the bowel, particularly that of the cecum, can become sufficiently distended so that its blood supply is compromised. Gangrene, perforation, peritonitis, and shock can follow. In 95% of the cases there are underlying diseases.[223,224] Less than 5% of the cases occur in the absence of other conditions.

Major risk factors for development of Ogilvie syndrome include traumatic injury (11%), infections such as pneumonia, sepsis (10%); obstetric/gynecologic conditions (10%); myocardial infarction and congestive heart failure (10%); abdominal and pelvic surgery (9%); neurologic conditions such as Parkinson disease, spinal cord injury, multiple sclerosis, and Alzheimer disease (9%); orthopedic procedures (7%); other medical conditions including metabolic imbalances, for example, hypokalemia, hypocalcemia, hypomagnesemia (32%); and other surgical conditions (12%).[222,224] Evidence suggests that Ogilvie syndrome is thought to be related, at least in part to sympathetic nervous overactivity or interference with sacral parasympathetic efferents, although there is little direct experimental evidence for this.[223] It is postulated that the distal colon becomes atonic on interruption of the S2 to S4 parasympathetic nerve fibers. Other theories about the pathophysiologic causes include autonomic dysfunction, reduced colonic ganglion cells, and loss of intrinsic nitric oxide activity but the cause remains unknown.[225]

Diagnosis

This syndrome is commonly encountered in patients hospitalized over 3 to 7 days, often in men more than 60 years of age. Primary manifestations variably include gastrointestinal symptoms such as nausea, vomiting, abdominal pain, constipation, and diarrhea.[223,224] Labored breathing, caused by abdominal distention, may be observed as part of the clinical picture. Other than distension, there are no characteristic physical or laboratory findings for this syndrome. On percussion the abdomen is resonant due to the presence of air in dilated segments of small intestine and colon. Sounds from the small intestine are present and may not be high pitched, as they are in intestinal obstruction.

Laboratory findings associated with this syndrome may include hypokalemia, hypocalcemia, hypomagnesemia, and hypophosphatemia, which are implicated as etiologic factors. Leukocytosis, elevation of sedimentation rate or c-reactive protein is also present if low-grade systemic inflammation is present or perforation is impending.

The diagnosis is usually apparent from plain film radiographs of the abdomen which may reveal air in the small bowel and distention of discrete segments of the colon (i.e., cecum or transverse colon often up to splenic flexure) or the entire abdominal colon. Haustral markings disappear with increasing distension. In doubtful cases and when bowel necrosis is not a significant worry, a hypaque contrast enema can establish the

nonmechanical nature of the dilatation. Alternatively, colonoscopy can be diagnostic as well as therapeutic. Features suggesting the complication of bowel ischemia may include localized tenderness, worsening leukocytosis, metabolic acidosis, evidence of sepsis, or a rapidly deteriorating clinical course.

It is important to differentiate this syndrome from toxic megacolon and mechanical obstruction before establishing a final diagnosis. Mechanical obstruction of the colon, occurring in volvulus or obturator obstructions from cancer or diverticular disease, presents with acute pain along with distension. In contrast, pseudo-obstruction is less often associated with acute pain and more likely to present with discomfort due to distention. However, lack of pain in postoperative patients on opiates or elderly patients cannot exclude mechanical obstruction. In plain x-rays, the pathognomonic signs of mechanical obstruction such as lack of gas in the distal colon or rectum, and air–fluid levels in small intestine on x-ray can also be seen in Ogilvie syndrome. CT scan is currently the standard method for identifying colon pseudo-obstruction and excluding other forms of obstruction.[223] Patients with toxic megacolon may manifest typically with symptoms such as fever, tachycardia, abdominal tenderness, bloody diarrhea or other manifestations of chronic inflammatory bowel disease along with "thumb printing" on the appearance of the abdomen on plain x-ray film in upright posture. Flexible sigmoidoscopy is contraindicated if toxic megacolon is thought to be likely, but it or contrast enemas[223] can be useful diagnostically and therapeutically if toxic megacolon is thought unlikely.

Management

Initial management includes resuscitation and correction of any underlying metabolic or electrolyte imbalances (Table 49-11). Patients should have physical examination and plain abdominal radiographs serially to correlate colonic diameters in order to determine which case needs colonoscopic decompression or surgery. If the patient is not very uncomfortable and the colonic distension is no greater than 12 cm, conservative treatment can be continued for 1 to 2 days. It may be helpful to place the patient in a prone position or at the knee chest position with hips held high, alternating right and left lateral decubitus position each hour. A nasogastric tube is helpful if the patient is vomiting and will prevent swallowed air from passing distally. When bowel ischemia is suspected, surgery is indicated. If bowel necrosis is found, the affected segment is resected and an ileostomy or colostomy should be performed. If the bowel is viable, a cecostomy is placed to vent the colon and prevent distention.

If, initially, the distention is painless and the patient shows no signs of toxicity or bowel ischemia, expectant management is successful in about 50% of cases.[223,226] The risk of spontaneous perforation is approximately 3%, with attendant mortality of 50%. In most patients acute colonic pseudo-obstruction usually resolves within 3 days.[223,227] If worsening and cecal diameter increases beyond 10 to 12 cm or if it persists for more than 48 hours, intervention is recommended. The duration of distention may be more important than the absolute size of the cecum with respect to spontaneous perforation. Colonoscopy should only be performed by experienced endoscopists. Endoscopic decompression is successful in 60% to 90% of cases, but the condition can recur in up to

40%. This rate of recurrence may be decreased by placement of a decompressive tube. Recurrence would require repeated colonoscopic decompression in approximately 40% of cases after initial successful decompression. The placement of a decompression with the aid of a guidewire at the time of colonoscopy may reduce the need for repeated colonoscopic decompression. Rectal tubes are ineffective as primary modalities in managing distention of the proximal colon. Such tubes may be useful in promoting passage of air and feces after colonoscopy but should not be used as a substitute for colonoscopic decompression. Percutaneous endoscopic left-sided colostomy (PEC), a minimally invasive technique, can be used to treat pseudo-obstruction provided these cases are carefully selected in the hands of a skilled endoscopist because of a high failure rate caused by infection.[228]

Table 49-11 Treatment for Pseudo-Obstruction

Treatment	Benefit
Nasogastric tube	Prevention of swallowed air from passing distally
Neostigmine	Increase motility through its parasympathomimetic action Premedication with colonoscopic decompression adding benefits
Erythromycin	Increases intestinal motility through motilin receptors in intestinal wall
Colonoscopic decompression	Prevention of complications such as perforation
Surgical interventions: total colectomy, Hartmann procedure, percutaneous endoscopic cecostomy	Required in case of refractory medical therapy

In anecdotal reports, prokinetic agents such as cisapride and erythromycin have been used to treat Ogilvie syndrome with some success. Erythromycin acts by binding to motilin receptors in the small intestine, causing intestinal smooth muscle contraction and perhaps better coordination with colonic motor function. Anecdotal reports have suggested the success of erythromycin treatment on either intravenous route for 3 days or oral route for 10 days.[229,230] However, the relative paucity of motilin receptors in colon smooth muscle may explain why erythromycin is only anecdotally effective in relieving colonic pseudo-obstruction. Successful resolution of pseudo-obstruction has been reported with sympatholytic agents or spinal sympathetic block. The efficacies of these modalities have not been systematically evaluated.[223,231]

Neostigmine, a parasympathomimmetic, is used in the treatment of acute colonic pseudo-obstruction. The decompression with this drug has been achieved in 80% to 100% with a recurrence rate of 5%.[223] Neostigmine may be a viable alternative to colonoscopy in pregnant women, provided mechanical obstruction is properly excluded. The administration of a polyerthylene glycol electrolyte balanced solution after initial

resolution of colonic dilation may reduce the recurrence rate with use of neostigmine.[232]

Neostigmine has expected cardiovascular side effects such as bradycardia, hypotension, and dizziness; and is excreted via the kidneys. The few relative contraindications to its use in treatment of acute colonic pseudo-obstruction are a baseline heart rate of less than 60 beats per minute or systolic blood pressure of less than 90 mm Hg; active bronchospasm requiring medication; a history of colon cancer or partial colonic resection; active gastrointestinal bleeding; pregnancy; or a serum creatinine concentration of more than 3 mg/dL (265 μmol/L). Other side effects would include mild to moderate crampy abdominal pain, excessive salivation and vomiting. Side effects such as increasing airway secretions and bronchospasm, can be reduced by concomitant use of glycopyrrolate without reduction of colonic response.[233,234] Ponec et al.[235] recommend use of neostigmine prior to colonoscopy, based on its easy administration, lower expense, and superior results in comparison to colonoscopy. Reported rates of response to treatment with neostigmine are 91% (single administration) and 100% (second administration) in a group of 21 randomized patients.[223,235] Colonoscopy is associated with morbidity of 3% and mortality of 1%. Further studies of this combination therapy are warranted. It should be emphasized however, that patients should undergo immediate exploration if they exhibit signs of clinical deterioration or bowel perforation (peritoneal signs on physical examination or free air on radiographs).

Surgery is reserved for patients not responding to medical and endoscopic management and for patients who develop signs of peritonitis or perforation. Percutaneous endoscopic cecostomy can also be performed if case conservative measures fail.[236] Cecostomy tubes are often poorly tolerated because of issues related to skin breakdown; in the authors opinion, this approach is advisable only when more extensive surgical procedures are considered too risky. Procedures such as total colectomy, ileostomy, and Hartmann procedure are taken into consideration in case of perforation.[223]

References

1. Treves F. *Intestinal Obstruction: Its varieties, with Their Pathology, Diagnosis, and Treatment.* Philadelphia, PA: H.C. Lea's Son and Co; 1884.
2. Ballantyne GH. The meaning of ileus. Its changing definition over three millennia. *Am J Surg* 1984;148(2):252–256.
3. Welch JP. History. In: *Bowel Obstruction: Differential Diagnosis and Clinical Management.* 1990, Philadelphia, PA: W.B. Saunders Co; 3–27.
4. Wangensteen OH, Paine JH. Treatment of acute intestinal obstruction by suction with a duodenal tube. *JAMA* 1933;101:1532.
5. Paine JR, Carlson HA, Wangensteen OH. Postoperative control of distension, nausea and vomiting; clinical study with reference to employment of narcotics, cathartics, and nasal catheter suction-siphinage. *JAMA* 1933;100(1910).
6. Wangensteen OH, Rea CE. The distension factor in simple intestinal obstruction: an experimental study with exclusion of swallowed air by cervical esophagostomy. *Surgery.* 1939;5(327).
7. Hartwell HJ, Hoguet JP. Experimental intestinal obstruction in dogs with special reference to the cause of death and the treatment by large amounts of normal saline solution. *JAMA* 1912;59(82).
8. Milamed DR, Hedley-Whyte J. Contributions of the surgical sciences to a reduction of the mortality rate in the United States for the period 1968 to 1988. *Ann Surg* 1994;219(1):94–102.
9. Wangensteen OH. *Intestinal Obstructions.* 3rd ed. Springfield: Charles C. Thomas; 1955.
10. Ellis H. *Intestinal Obstruction.* New York: Appleton Crofts; 1982:11–21.
11. Dayton MT, Dempsey DT, Larson GM, et al. New paradigms in the treatment of small bowel obstruction. *Curr Probl Surg* 2012;49(11):642–717.
12. Roscher R, Oettinger W, Beger HG. Bacterial microflora, endogenous endotoxin, and prostaglandins in small bowel obstruction. *Am J Surg* 1988;155(2):348–355.
13. Heneghan JB, Robinson JW, Menge H, et al. Intestinal obstruction in germ-free dogs. *Eur J Clin Invest* 1981;11(4):285–290.
14. Stark ME, Szurszewski JH. Role of nitric oxide in gastrointestinal and hepatic function and disease. *Gastroenterology* 1992;103(6):1928–1949.
15. Caplan MS, Hedlund E, Hill N, et al. The role of endogenous nitric oxide and platelet-activating factor in hypoxia-induced intestinal injury in rats. *Gastroenterology* 1994;106(2):346–352.
16. Barry MK, Aloisi JD, Pickering SP, et al. Nitric oxide modulates water and electrolyte transport in the ileum. *Ann Surg* 1994;219(4):382–388.
17. Kubes P. Nitric oxide modulates epithelial permeability in the feline small intestine. *Am J Physiol* 1992;262(6 Pt 1):G1138–G1142.

18. Shields R. The absorption and secretion of fluid and electrolytes by the obstructed bowel. *Br J Surg* 1965;52(10):774–779.
19. Wright HK, O'Brien JJ, Tilson MD. Water absorption in experimental closed segment obstruction of the ileum in man. *Am J Surg* 1971;121(1):96–99.
20. Sung DT, Williams LF Jr. Intestinal secretion after intravenous fluid infusion in small bowel obstruction. *Am J Surg* 1971;121(1):91–95.
21. Ruf W, Suehiro GT, Suehiro A, et al. Intestinal blood flow at various intraluminal pressures in the piglet with closed abdomen. *Ann Surg* 1980;191(2):157–163.
22. Ohman U. Studies on small intestinal obstruction. I. Intraluminal pressure in experimental low small bowel obstruction in the cat. *Acta Chir Scand* 1975;141(5):413–416.
23. Ohman U. The effects of luminal distension and obstruction on the intestinal circulation. In: Shepherd AP, Granger DN, eds. *Physiology of the Intestinal Circulation.* New York, NY: Raven Press; 1984:321.
24. Basson MD, Fielding LP, Bilchik AJ, et al. Does vasoactive intestinal polypeptide mediate the pathophysiology of bowel obstruction? *Am J Surg* 1989;157(1):109–115.
25. Nellgard P, Bojo L, Cassuto J. Importance of vasoactive intestinal peptide and somatostatin for fluid losses in small-bowel obstruction. *Scand J Gastroenterol* 1995;30(5):464–469.
26. Fevang J, Ovrebo K, Svanes K, et al. Endotoxin and cytokine release in strangulation obstruction and in partial occlusion of the mesenteric artery in pigs. *Eur Surg Res* 1999;31(1):26–38.
27. Fevang J, Ovrebo K, Ostgaard G, et al. Release of endothelin-1 in strangulation obstruction of the small bowel in pigs. *J Surg Res* 1998;79(1):77–84.
28. Fevang J, Ovreb⊘ K, Myking O, et al. Role of endothelin in the circulatory changes associated with small bowel strangulation obstruction in pigs: effects of the endothelin receptor antagonist bosentan. *J Surg Res* 2001;96(2):224–232.
29. Ozbek E, Ilbey YO, Cekmen M, et al. Bacterial translocation to kidney in rats with intestinal obstruction and the role of nitric oxide. *Arch Ital Urol Androl* 2009;81(1):56–58.
30. Palasthy Z, Kaszaki J, Lázár G, et al. Intestinal nitric oxide synthase activity changes during experimental colon obstruction. *Scand J Gastroenterol* 2006;41(8):910–918.
31. Enochsson L, Nylander G, Ohman U. Effects of intraluminal pressure on regional blood flow in obstructed and unobstructed small intestines in the rat. *Am J Surg* 1982;144(5):558–561.
32. Fondacaro J. Intestinal blood flow and motility. In: Shepherd AP, Granger DN, eds. *Physiology of the Intestinal Circulation.* New York, NY: Raven Press; 1984:107.
33. Frank JW, Sarr MG, Camilleri M. Use of gastroduodenal manometry to differentiate mechanical and functional intestinal obstruction: an analysis of clinical outcome. *Am J Gastroenterol* 1994;89(3):339–344.

34. Camilleri M. Jejunal manometry in distal subacute mechanical obstruction: significance of prolonged simultaneous contractions. *Gut* 1989;30(4):468–475.
35. Summers RW, Yanda R, Prihoda M, et al. Acute intestinal obstruction: an electromyographic study in dogs. *Gastroenterology* 1983;85(6):1301–1306.
36. Deloose E, Janssen P, Depoortere I, et al. The migrating motor complex: control mechanisms and its role in health and disease. *Nat Rev Gastroenterol Hepatol* 2012;9(5):271–285.
37. Eskelinen M, Ikonen J, Lipponen P. Contributions of history-taking, physical examination, and computer assistance to diagnosis of acute small-bowel obstruction. A prospective study of 1333 patients with acute abdominal pain. *Scand J Gastroenterol* 1994;29(8):715–721.
38. Taylor MR, Lalani N. Adult small bowel obstruction. *Acad Emerg Med* 2013;20(6):528–544.
39. Stewardson RH, Bombeck CT, yhus LM. Critical operative management of small bowel obstruction. *Ann Surg* 1978;187(2):189–193.
40. Sarr MG, Bulkley GB, Zuidema GD. Preoperative recognition of intestinal strangulation obstruction. Prospective evaluation of diagnostic capability. *Am J Surg* 1983;145(1):176–182.
41. Pain JA, Collier DS, Hanka R. Small bowel obstruction: computer-assisted prediction of strangulation at presentation. *Br J Surg* 1987;74(11):981–983.
42. Jancelewicz T, Vu LT, Shawo AE, et al. Predicting strangulated small bowel obstruction: an old problem revisited. *J Gastrointest Surg* 2009;13:93–99.
43. van Oudheusden TR, Aerts BA, de Hingh IH, et al. Challenges in diagnosing adhesive small bowel obstruction. *World J Gastroenterol* 2013;19(43):7489–7493.
44. Gollin G, Marks WH. Early detection of small intestinal ischemia by elevated circulating intestinal fatty acid binding protein (I-FABP). *Surg Forum* 1991;42 118–120.
45. Murray MJ, Barbose JJ, Cobb CF. Serum D(-)-lactate levels as a predictor of acute intestinal ischemia in a rat model. *J Surg Res* 1993;54(5):507–509.
46. Silen W, Hein MF, Goldman L. Strangulation obstruction of the small intestine. *Arch Surg* 1962;85:121–129.
47. Maglinte DD, Balthazar EJ, Kelvin FM, et al. The role of radiology in the diagnosis of small-bowel obstruction. *AJR Am J Roentgenol* 1997; 168(5):1171–1180.
48. Furukawa A, Yamasaki M, Furuichi K, et al. Helical CT in the diagnosis of small bowel obstruction. *Radiographics* 2001;21(2):341–355.
49. Di Saverio S, Coccolini F, Galati M, et al. Bologna guidelines for diagnosis and management of adhesive small bowel obstruction (ASBO): 2013 update of the evidence-based guidelines from the world society of emergency surgery ASBO working group. *World J Emerg Surg* 2013;8(1):42.
50. Branco BC, Chew MH, Eu KW. Systematic review and meta-analysis of the diagnostic

and therapeutic role of water-soluble contrast agent in adhesive small bowel obstruction. *Br J Surg* 2010;97(4):470–478.

51. Choi HK, Chu KW, Law WL. Therapeutic value of gastrografin in adhesive small bowel obstruction after unsuccessful conservative treatment: a prospective randomized trial. *Ann Surg.* 2002;236:1–6.
52. Abbas SM, Bissett IP, Parry BR. Meta-analysis of oral water-soluble contrast agent in the management of adhesive small bowel obstruction. *Br J Surg* 2007;94(4):404–411.
53. Assalia A, Schein M, Kopelman D, et al. Therapeutic effect of oral Gastrografin in adhesive, partial small-bowel obstruction: a prospective randomized trial. *Surgery* 1994;115(4):433–437.
54. Balthazar EJ, George W. Holmes lecture. CT of small-bowel obstruction. *AJR Am J Roentgenol* 1994;162(2):255–261.
55. Frager D, Medwid SW, Baer JW, et al. CT of small-bowel obstruction: value in establishing the diagnosis and determining the degree and cause. *AJR Am J Roentgenol* 1994;162(1):37–41.
56. Mallo RD, Salem L, Lalani T, et al. Computed tomography diagnosis of ischemia and complete obstruction in small bowel obstruction: a systematic review. *J Gastrointest Surg* 2005;9:690–694.
57. Barnett RE, Younga J, Harris B, et al. Accuracy of computed tomography in small bowel obstruction. *Am Surg* 2013;79(6):641–643.
58. Santillan CS. Computed tomography of small bowel obstruction. *Radiol Clin North Am* 2013;51(1):17–27.
59. Zalcman M, Sy M, Donckier V, et al. Helical CT signs in the diagnosis of intestinal ischemia in small-bowel obstruction. *AJR Am J Roentgenol* 2000;175(6):1601–1607.
60. Tresallet C, Lebreton N, Royer B, et al. Improving the management of acute adhesive small bowel obstruction with CT-scan and water-soluble contrast medium: a prospective study. *Dis Colon Rectum* 2009;52(11):1869–1876.
61. Ogata M, Imai S, Hosotani R, et al. Abdominal ultrasonography for the diagnosis of strangulation in small bowel obstruction. *Br J Surg* 1994;81(3):421–424.
62. Ogata M, Mateer JR, Condon RE. Prospective evaluation of abdominal sonography for the diagnosis of bowel obstruction. *Ann Surg* 1996;223:237–241.
63. Diaz JJ Jr, Bokhari F, Mowery NT, et al. Guidelines for management of small bowel obstruction. *J Trauma* 2008;64(6):1651–1664.
64. Brolin RE, Krasna MJ, Mast BA. Use of tubes and radiographs in the management of small bowel obstruction. *Ann Surg* 1987;206(2):126–133.
65. Fleshner PR, Siegman MG, Slater GI, et al. A prospective, randomized trial of short versus long tubes in adhesive small-bowel obstruction. *Am J Surg* 1995;170(4):366–370.
66. Chen XL, Ji F, Lin Q, et al. A prospective randomized trial of transnasal ileus tube vs nasogastric tube for adhesive small bowel obstruction. *World J Gastroenterol*

2012;18(16):1968–1974.
67. Fonseca AL, Schuster KM, Maung AA, et al. Routine nasogastric decompression in small bowel obstruction: is it really necessary? *Am Surg* 2013;79(4):422–428.
67a. Chen SC, Yen ZS, Lee CC, et al. Nonsurgical management of partial adhesive small-bowel obstruction with oral therapy: a randomized controlled trial. *CMAJ* 2005;173(10):1165–1169.
68. Fukami Y, Kurumiya Y, Mizuno K, et al. Clinical effect of hyperbaric oxygen therapy in adhesive postoperative small bowel obstruction. *Br J Surg* 2014;101(4):433–437.
69. Ambiru S, Furuyama N, Kimura F, et al. Effect of hyperbaric oxygen therapy on patients with adhesive intestinal obstruction associated with abdominal surgery who failed to respond to more than 7 days of conservative treatment. *Hepatogastroenterology* 2008;55(82–83):491–495.
70. Sykes PA, Boulter KH, Schofield PF. The microflora of the obstructed bowel. *Br J Surg* 1976;63:721–725.
71. Elmes ME, Howells CH, Lowe GH. Mucosal flora of the small intestine and the effect of pre-operative antibiotics. *J Clin Pathol* 1984;37:1272–1275.
72. Deitch EA. Simple intestinal obstruction causes bacterial translocation in man. *Arch Surg* 1989;124(6):699–701.
73. Cohn I Jr, Floyd CE, Dresden CF, et al. Strangulation obstruction in germfree animals. *Ann Surg* 1962;156:692–702.
74. Amundsen E, Gustafsson BE. Results of experimental intestinal strangulation obstruction in germfree rats. *J Exp Med* 1963;117:823–832.
75. Fevang BT, Fevang J, Lie SA, et al. Long-term prognosis after operation for adhesive small bowel obstruction. *Ann Surg* 2004;240:193–201.
76. Duron JJ, Silva NJ, du Montcel ST, et al. Adhesive postoperative small bowel obstruction: incidence and risk factors of recurrence after surgical treatment: a multicenter prospective study. *Ann Surg* 2006;244:750–757.
77. Liebman SM, Langer JC, Marshall JS, et al. Role of mast cells in peritoneal adhesion formation. *Am J Surg* 1993;165(1):127–130.
78. Attard JA, MacLean AR. Adhesive small bowel obstruction: epidemiology, biology and prevention. *Canad J Surg* 2007;50:291–300.
79. Cahill RA, Redmond HP. Cytokine orchestration in post-operative peritoneal adhesion formation. *World J Gastroenterol* 2008;14:4861–4866.
80. Beck DE. The role of Seprafilm bioresorbable membrane in adhesion prevention. *Eur J Surg Suppl* 1997;(577):49–55.
81. Vrijland WW, Tseng LN, Eijkman HJ, et al. Fewer intraperitoneal adhesions with use of hyaluronic acid-carboxymethylcellulose membrane: a randomized clinical trial. *Ann Surg* 2002;235(2):193–199.
82. Robb WB, Mariette C. Strategies in the prevention of the formation of postoperative adhesions in digestive surgery: A systematic review of the literature. *Dis Colon*

Rectum 2014;57(10):1228–1240.

83. Fazio VW, Cohen Z, Fleshman JW, et al. Reduction in adhesive small-bowel obstruction by Seprafilm adhesion barrier after intestinal resection. *Dis Colon Rectum* 2006;49(1):1–11.
84. Catena F, Ansaloni L, Di Saverio S, et al; World Society of Emergency Surgery. P.O.P.A. study: prevention of postoperative abdominal adhesions by icodextrin 4% solution after laparotomy for adhesive small bowel obstruction. A prospective randomized controlled trial. *J Gastrointest Surg* 2012;16(2):382–388.
85. Tjandra JJ, Chan MK. A sprayable hydrogel adhesion barrier facilitates closure of defunctioning loop ileostomy: a randomized trial. *Dis Colon Rectum* 2008;51(6):956–960.
86. Keller DS, Champagne BJ, Stein SL, et al. Pilot study evaluating the efficacy of AlloMEM for prevention of intraperitoneal adhesions and peritoneal regeneration after loop ileostomy. *Surg Endosc* 2013;27(10):3891–3896.
87. O'Leary DP, Coakley JB. The influence of suturing and sepsis on the development of postoperative peritoneal adhesions. *Ann R Coll Surg Engl* 1992;74(2):134–137.
88. Ellozy SH, Harris MT, Bauer JJ, et al. Early postoperative small-bowel obstruction: a prospective evaluation in 242 consecutive abdominal operations. *Dis Colon Rectum* 2002;45:1214–1217.
89. Stewart RM, Page CP, Brender J, et al. The incidence and risk of early postoperative small bowel obstruction. A cohort study. *Am J Surg* 1987;154(6):643–647.
90. Sajja SB, Schein M. Early postoperative small bowel obstruction. *Br J Surg* 2004;91:683–691.
91. Lee SY, Park KJ, Ryoo SB, et al. Early postoperative small bowel obstruction is an independent risk factor for subsequent adhesive small bowel obstruction in patients undergoing open colectomy. *World J Surg* 2014; 38(11):3007–3014.
92. Pickleman J, Lee RM. The management of patients with suspected early postoperative small bowel obstruction. *Ann Surg* 1989;210(2):216–219.
93. Hamdan K, Somers S, Chand M. Management of late postoperative complications of bariatric surgery. *Br J Surg* 2011;98(10):1345–1355.
94. Martin MJ, Beekley AC, Sebesta JA. Bowel obstruction in bariatric and nonbariatric patients: major differences in management strategies and outcome. *Surg Obes Relat Dis* 2011;7(3):263–269.
95. Ihedioha U, Alani A, Modak P, et al. Hernias are the most common cause of strangulation in patients presenting with small bowel obstruction. *Hernia* 2006;10:338–340.
96. Skandalakis PN, Zoras O, Skandalakis JE, et al. Richter hernia: Surgical anatomy and technique of repair. *Am Surg* 2006;72:180–184.
97. Ravikumar H, Babu S, Govindrajan M, et al. Reduction en-masse of inguinal hernia with strangulated obstruction. *Biomed Imaging Interv J* 2009;5(4):e14.

98. Wu SC, Wang CC, Sheen-Chen SM. Intestinal obstruction caused by intraoperative mass reduction of an incarcerated inguinal hernia–report of a case. *Int J Surg* 2008;6(6):e103–e105.
99. Magnus R. Late bowel obstruction due to kinking of the damaged loop following reduction of a strangulated hernia. *Br J Surg* 1965;52:121–122.
100. Gallagher WB, Segnitz RH. Intestinal obstruction due to incarcerated external hernia, with notes on non-operative reduction and interim elective herniorrhaphy. *Am J Surg* 1957;93(5):771–777.
101. Walsham WJ. Auto-reduction of hernia “en masse” as a cause of abdominal obstruction. *Br Med J* 1901;1(2099):691–692.
102. Reisner RM, Cohen JR. Gallstone ileus: a review of 1001 reported cases. *Am Surg* 1994;60(6):441–446.
103. Vagefi PA, Ferguson CM Hall JF. Recurrent gallstone ileus: third time is the charm. *Arch Surg* 2008;143:1118–1120.
104. Halabi WJ, Kang CY, Ketana N, et al. Surgery for gallstone ileus: a nationwide comparison of trends and outcomes. *Ann Surg* 2014;259(2):329–335.
105. Rea JD, Lockhart ME, Yarbrough DE, et al. Approach to management of intussusception in adults: a new paradigm in the computed tomography era. *Am Surg* 2007;73:1098–1105.
106. Sarr MG, Nagorney DM, McIlrath DC. Postoperative intussusception in the adult: a previously unrecognized entity? *Arch Surg* 1981;116(2):144–148.
107. Honjo H, Makio Mike, Hiroshi Kusanagi, et al. Adult intussusception: a retrospective review. *World J Surg* 2014;39:134–138.
108. Strong SA, Koltun WA, Hyman NH, et al; Standards Practice Task Force of The American Society of Colon and Rectal Surgeons. Practice parameters for the surgical management of Crohn’s disease. *Dis Colon Rectum* 2007;50:1735–1746.
109. Ripamonti CI, Easson AM, Gerdes H. Management of malignant bowel obstruction. *Eur J Cancer* 2008;44:1105–1115.
110. Soybel DI, Bliss DP Jr, Wells SA Jr. Colon and rectal carcinoma. *Curr Probl Cancer* 1987;11(5):257–356.
111. Glare PA, Dunwoodie D, Clark K, et al. Treatment of nausea and vomiting in terminally ill cancer patients. *Drugs* 2008;68:2575–2590.
112. Mystakidou K, Tsilika E, Kalaidopoulou O, et al. Comparison of octreotide administration vs conservative treatment in the management of inoperable bowel obstruction in patients with far advanced cancer: a randomized, double- blind, controlled clinical trial. *Anticancer Res* 2002;22:1187–1192.
113. Saber AA, Boros MJ. Chilaiditi’s syndrome: what should every surgeon know? *Am Surg* 2005;71:261–263.
114. Oren D, Atamanalp SS, Aydinli B, et al. An algorithm for the management of sigmoid colon volvulus and the safety of primary resection: experience with 827 cases. *Dis*

Colon Rectum 2007;50:489–497.

115. Wertkin MG, Aufses AH Jr. Management of volvulus of the colon. *Dis Colon Rectum* 1978;21(1):40–45.
116. Peoples JB, McCafferty JC, Scher KS. Operative therapy for sigmoid volvulus. identification of risk factors affecting outcome. *Dis Colon Rectum* 1990;33(8):643–646.
117. Regimbeau JM, Panis Y, Gouzi JL, et al; French University Association for Surgical Research. Operative and long term results after surgery for chronic radiation enteritis. *Am J Surg* 2001;182:237–242.
118. Meissner K. Late radiogenic small bowel damage: guidelines for the general surgeon. *Digestive Surg* 1999;16:169–174.
119. Harb AH, Abou Fadel C, Sharara AI. Radiation enteritis. *Curr Gastroenterol Rep* 2014;16(5):383.
120. Cetin E, Ozturk AS, Orhun H, et al. Role of triamcinolone in radiation enteritis management. *World J Gastroenterol* 2014;20(15):4341–4344.
121. Franklin ME, Gonzalez JJ Jr, Miter DB, et al. Laparoscopic diagnosis and treatment of intestinal obstruction. *Surg Endosc* 2004;18:26–30.
122. Kirshtein B, Roy-Shapira A, Lantsberg L, et al. Laparoscopic management of acute small bowel obstruction. *Surg Endosc* 2005;19:464–467.
123. Levard H, Boudet MJ, Msika S, et al; French Association for Surgical Research. Laparoscopic treatment of acute small bowel obstruction: a multicentre retrospective study. *ANZ J Surg* 2001;71:641–646.
124. Gutt CN, Oniu T, Schemmer P, et al. Fewer adhesions induced by laparoscopic surgery? *Surg Endosc* 2004;18:898–906.
125. Tittel A, Treutner KH, Titkova S, et al. Comparison of adhesion reformation after laparoscopic and conventional adhesiolysis in an animal model. *Langenbecks Arch Sur* 2001;386(2):141–145.
126. Li MZ, Lian L, Xiao LB, et al. Laparoscopic versus open adhesiolysis in patients with adhesive small bowel obstruction: a systematic review and meta-analysis. *Am J Surg* 2012;204(5):779–786.
127. Pekmezci S, Altinli E, Saribeyoglu K, et al. Enteroclysis-guided laparoscopic adhesiolysis in recurrent adhesive small bowel obstructions. *Surg Laparosc Endosc Percutan Tech* 2001;12:165–170.
128. Sato Y, Ido K, Kumagai M, et al. Laparoscopic adhesiolysis for recurrent small bowel obstruction: Long-term follow-up. *Gastrointest Endosc* 2001;54:476–479.
129. Suter M, Zermatten P, Halkic N, et al. Laparoscopic management of mechanical small bowel obstruction: are there predictors of success or failure? *Surg Endosc* 2000;14:478–483.
130. Al-Mulhim AA. Laparoscopic management of acute small bowel obstruction. Experience from a Saudi teaching hospital. *Surg Endosc* 2000;14:157–160.

131. Chosidow D, Johanet H, Montariol T, et al. Laparoscopy for acute small-bowel obstruction secondary to adhesions. *J Laparoendosc Adv Surg Tech A* 2000;10:155–159.
132. Strickland P, Lourie DJ, Suddleson EA, et al. Is laparoscopy safe and effective for treatment of acute small-bowel obstruction? *Surg Endosc* 1999;13:695–698.
133. Leon E, Metzger A, Tsiotos GG, et al. Laparoscopic management of small bowel obstruction: indications and outcomes. *J Gastrointest Surg* 1998;2:132–140.
134. Bailey IS, Rhodes M, O'Rourke N, et al. Laparoscopic management of acute small bowel obstruction. *Br J Surg* 1998;85:84–87.
135. Navez B, Arimont JM, Guiot P. Laparoscopic approach in acute small bowel obstruction. A review of 68 patients. *Hepatogastroenterology* 1998;45:2146–2150.
136. Ibrahim IM, Wolodiger F, Sussman B, et al. Laparoscopic management of acute small bowel obstruction. *Surg Endosc* 1996;10:1014–1015.
137. Ghosheh B, Salameh JR. Laparoscopic approach to acute small bowel obstruction: review of 1061 cases. *Surg Endosc* 2007;21:1945–1949.
138. Vettoretto N, Carrara A, Corradi A, et al. Laparoscopic adhesiolysis: consensus conference guidelines. *Colorectal Dis* 2012;14(5):e208–e215.
139. Farinella E, Cirocchi R, La Mura F, et al. Feasibility of laparoscopy for small bowel obstruction. *World J Emerg Surg* 2009;4:3.
140. Grafen FC, Neuhaus V, Schöb O, et al. Management of acute small bowel obstruction from intestinal adhesions: indications for laparoscopic surgery in a community teaching hospital. *Langenbecks Arch Surg* 2010;395(1):57–63.
141. Coccolini F, Ansaloni L, Manfredi R, et al. Peritoneal adhesion index (PAI): Proposal of a score for the "ignored iceberg" of medicine and surgery. *World J Emerg Surg* 2013;8(1):6.
142. Kehlet H. Postoperative ileus–an update on preventive techniques. *Nat Clin Pract Gastroenterol Hepatol* 2008;5:552–558.
143. Waldhausen JH, Shaffrey ME, Skenderis BS, et al. Gastrointestinal myoelectric and clinical patterns of recovery after laparotomy. *Ann Surg* 1990;211(6):777–784; discussion 785.
144. Condon RE, Cowles VE, Ferraz AA, et al. Human colonic smooth muscle electrical activity during and after recovery from postoperative ileus. *Am J Physiol* 1995;269(3 Pt 1):G408–G417.
145. Nadrowski L. Paralytic ileus: recent advances in pathophysiology and treatment. *Curr Surg* 1983;40(4):260–273.
146. Condon RE, Frantzides CT, Cowles VE, et al. Resolution of postoperative ileus in humans. *Ann Surg* 1986;203:574–581.
147. Espat NJ, Cheng G, Kelley MC, et al. Vasoactive intestinal peptide and substance P receptor antagonists improve postoperative ileus. *J Surg Res* 1995;58(6):719–723.
148. De Winter BY, Robberecht P, Boeckxstaens GE, et al. Role of VIP1/PACAP receptors

in postoperative ileus in rats. *Br J Pharmacol* 1998;124:1181–1186.
149. Zittel TT, Lloyd KC, Rothenhöfer I, et al. Calcitonin gene-related peptide and spinal afferents partly mediate postoperative colonic ileus in the rat. *Surgery* 1998;123(5):518–527.
150. Zittel TT, Reddy SN, Plourde V, et al. Role of spinal afferents and calcitonin gene-related peptide in the postoperative gastric ileus in anesthetized rats. *Ann Surg* 1994;219(1):79–87.
151. Frantzides CT, Cowles V, Salaymeh B, et al. Morphine effects on human colonic myoelectric activity in the postoperative period. *Am J Surg* 1992;163(1):144–148; discussion 144–148.
152. Thorn SE, Wattwil M, Lindberg G, et al. Systemic and central effects of morphine on gastroduodenal motility. *Acta Anaesthesiol Scand* 1996; 40(2):177–186.
153. Ferraz AA, Cowles VE, Condon RE, et al. Opioid and nonopioid analgesic drug effects on colon contractions in monkeys. *Dig Dis Sci* 1995; 40(7):1417–1419.
154. Kurz A, Sessler DI. Opioid-induced bowel dysfunction: pathophysiology and potential new therapies. *Drugs* 2003;63:649–671.
155. Riviere PJ, Pascaud X, Chevalier E, et al. Fedotozine reverses ileus induced by surgery or peritonitis: action at peripheral kappa-opioid receptors. *Gastroenterology* 1993;104(3):724–731.
156. Schwarz NT, Kalff JC, Türler A, et al. Prostanoid production via COX-2 as a causative mechanism of rodent postoperative ileus. *Gastroenterology* 2001;121:1354–1371.
157. Schwarz NT, Kalff JC, Türler A, et al. Selective jejunal manipulation causes postoperative pan-enteric inflammation and dysmotility. *Gastroenterology* 2004;126:159–169.
158. Kalff JC, Türler A, Schwarz NT, et al. Intra-abdominal activation of a local inflammatory response within the human muscularis externa during laparotomy. *Ann Surg* 2003;237(3):301–315.
159. de Jonge WJ, The FO, van der Coelen D, et al. Mast cell degranulation during abdominal surgery initiates postoperative ileus in mice. *Gastroenterology* 2004;127:535–545.
160. The FO, Bennink RJ, Ankum WM, et al. Intestinal handling-induced mast cell activation and inflammation in human postoperative ileus. *Gut* 2008;57:33–40.
161. Holte K, Kehlet H. Postoperative ileus: a preventable event. *Br J Surg* 2000;87(11):1480–1493.
162. Barquist E, Bonaz B, Martinez V, et al. Neuronal pathways involved in abdominal surgery-induced gastric ileus in rats. *Am J Physiol* 1996; 270:R888–R894.
163. Petros JG, Realica R, Ahmad S, et al. Patient-controlled analgesia and prolonged ileus after uncomplicated colectomy. *Am J Surg* 1995;170(4):371–374.
164. Stanley BK, Noble MJ, Gilliland C, et al. Comparison of patient-controlled analgesia versus intramuscular narcotics in resolution of postoperative ileus after radical

retropubic prostatectomy. *J Urol* 1993;150(5 Pt 1):1434–1436.

165. Block BM, Liu SS, Rowlingson AJ, et al. Efficacy of postoperative epidural analgesia: a meta-analysis. *J Am Med Assoc* 2003;290:2455–2463.
166. Moraca RJ, Sheldon DG, Thirlby R. The role of epidural anesthesia and analgesia in surgical practice. *Ann Surg* 2003;238:663–673.
167. Marret E, Remy C, Bonnet F; Postoperative Pain Forum Group. Meta-analysis of epidural analgesia versus parenteral opioid analgesia after colorectal surgery. *Br J Surg* 2007;94:665–673.
168. Napolitano LM. Carbon monoxide and ileus: inhaled gas to prevent retained gas? *Crit Care Med* 2005;33(6):1445–1446.
169. Moore BA, Overhaus M, Whitcomb J, et al. Brief inhalation of low-dose carbon monoxide protects rodents and swine from postoperative ileus. *Crit Care Med* 2005;33(6):1317–1326.
170. Korolkiewicz RP, Sein-Anand J, Ruczyn ski J, et al. The role and interactions of nitric oxide (NO), carbon monoxide (CO), and prostanoids in the pathogenesis of postoperative ileus in rats. *J Gastrointest Surg* 2004;8(3):346–357.
171. Taché Y, Bonaz Y. Corticotropin-releasing factor receptors and stress-related alterations of gut motor function. *J Clin Invest* 2007;117:33–40.
172. The FO, Boeckxstaens GE, Snoek SA, et al. Activation of the cholinergic anti-inflammatory pathway ameliorates postoperative ileus in mice. *Gastroenterology* 2007;133:1219–1228.
173. de Jonge WJ, van der Zanden EP, The FO, et al. Stimulation of the vagus nerve attenuates macrophage activation by activating the Jak2-STAT3 signaling pathway. *Nat Immunol* 2005;6:844–851.
174. Frager DH, Baer JW, Rothpearl A, et al. Distinction between postoperative ileus and mechanical small-bowel obstruction: value of CT compared with clinical and other radiographic findings. *AJR Am J Roentgenol* 1995; 164:891–894.
175. Sagar PM, Kruegener G, MacFie J. Nasogastric intubation and elective abdominal surgery. *Br J Surg* 1992;79(11):1127–1131.
176. Cheatham ML, Chapman WC, Key SP, et al. A meta-analysis of selective versus routine nasogastric decompression after elective laparotomy. *Ann Surg* 1995;221(5):469–476; discussion 476–478.
177. Waldhausen JH, Schirmer BD. The effect of ambulation on recovery from postoperative ileus. *Ann Surg* 1990;212(6):671–677.
178. Rao SS, Beaty J, Chamberlain M, et al. Effects of acute graded exercise on human colonic motility. *Am J Physiol* 1999;276(5 Pt 1):G1221–G1226.
179. Traut U, Brügger L, Kunz R, et al. Systemic prokinetic pharmacologic treatment for postoperative adynamic ileus following abdominal surgery in adults. *Cochrane Database Syst Rev* 2008;(1):CD004930.
180. Moore FA, Feliciano DV, Andrassy RJ, et al. Early enteral feeding, compared with

parenteral, reduces postoperative septic complications. The results of a meta-analysis. *Ann Surg* 1992;216(2):172–183.

181. Soffer EE, Adrian TE. Effect of meal composition and sham feeding on duodenojejunal motility in humans. *Dig Dis Sci* 1992;37(7):1009–1014.
182. Katschinski M, Dahmen G, Reinshagen M, et al. Cephalic stimulation of gastrointestinal secretory and motor responses in humans. *Gastroenterology* 1992;103(2):383–391.
183. Asao T, Kuwano H, Nakamura J, et al. Gum chewing enhances early recovery from postoperative ileus after laparoscopic colectomy. *J Am Coll Surg* 2002;195(1):30–32.
184. Matros E, Rocha F, Zinner M, et al. Does gum chewing ameliorate postoperative ileus? Results of a prospective, randomized, placebo-controlled trial. *J Am Coll Surg* 2006;202:773–778.
185. Purkayastha S, Tilney HS, Darzi AW, et al. Meta-analysis of randomized studies evaluating chewing gum to enhance postoperative recovery following colectomy. *Arch Surg* 2008;143:788–793.
186. Zaghiyan K, Felder S, Ovsepyan G, et al. A prospective randomized controlled trial of sugared chewing gum on gastrointestinal recovery after major colorectal surgery in patients managed with early enteral feeding. *Dis Colon Rectum* 2013;56(3):328–335.
187. Craciunas L, Sajid MS, Ahmed AS. Chewing gum in preventing postoperative ileus in women undergoing caesarean section: a systematic review and meta-analysis of randomised controlled trials. *BJOG* 2014;121(7):793–799; discussion 799.
188. Forrester DA, Doyle-Munoz J, McTigue T, et al. The efficacy of gum chewing in reducing postoperative ileus: a multisite randomized controlled trial. *J Wound Ostomy Continence Nurs* 2014;41(3):227–232.
189. Mohsenzadeh Ledari F, Barat S, Delavar MA, et al. Chewing sugar-free gum reduces ileus after cesarean section in nulliparous women: A randomized clinical trial. *Iran Red Crescent Med J* 2013;15(4):330–334.
190. Li S, Liu Y, Peng Q, et al. Chewing gum reduces postoperative ileus following abdominal surgery: a meta-analysis of 17 randomized controlled trials. *J Gastroenterol Hepatol* 2013;28(7):1122–1132.
191. Tandeter H. Hypothesis: hexitols in chewing gum may play a role in reducing postoperative ileus. *Med Hypotheses* 2009;72:39–40.
192. Wu Z, Boersema GS, Jeekel J, et al. Nicotine gum chewing: a novel strategy to shorten duration of postoperative ileus via vagus nerve activation. *Med Hypotheses* 2014;83(3):352–354.
193. Lobo DN, Bostock KA, Neal KR, et al. Effect of salt and water balance on recovery of gastrointestinal function after elective colonic resection: a randomised controlled trial. *Lancet* 2002;359(9320):1812–1818.
194. MacKay G, Fearon K, McConnachie A, et al. Randomized clinical trial of the effect of postoperative intravenous fluid restriction on recovery after elective colorectal

surgery. *Br J Surg* 2006;93:1469–1474.

195. Holte K, Foss NB, Andersen J, et al. Liberal or restrictive fluid administration in fast-track colonic surgery: a randomized, double-blind study. *Br J Anaesth* 2007;99:500–508.

196. Brandstrup B, T⊘nnesen H, Beier-Holgersen R, et al. Effects of intravenous fluid restriction on postoperative complications: comparison of two perioperative fluid regimens: a randomized assessor-blinded multicenter trial. *Ann Surg* 2003;238:641–648.

197. Wakeling HG, McFall MR, Jenkins CS, et al. Intraoperative oesophageal Doppler guided fluid management shortens postoperative hospital stay after major bowel surgery. *Br J Anaesth* 2005;95:634–642.

198. Abbas SM, Hill AG. Systematic review of the literature for the use of oesophageal Doppler monitor for fluid replacement in major abdominal surgery. *Anaesthesia* 2008;63:44–51.

199. Pillai P, McEleavy I, Gaughan M, et al. A double-blind randomized controlled clinical trial to assess the effect of Doppler optimized intraoperative fluid management on outcome following radical cystectomy. *J Urol* 2011; 186(6):2201–2206.

200. Cullen JJ, Eagon JC, Dozois EJ, et al. Treatment of acute postoperative ileus with octreotide. *Am J Surg* 1993;165(1):113–119; discussion 119–120.

201. Garcia-Caballero M, Vara-Thorbeck C. The evolution of postoperative ileus after laparoscopic cholecystectomy. A comparative study with conventional cholecystectomy and sympathetic blockade treatment. *Surg Endosc* 1993;7(5):416–419.

202. Kelley SR, Wolff BG, Lovely JK, et al. Fast-track pathway for minimally invasive colorectal surgery with and without alvimopan (Entereg)(TM): Which is more cost-effective? *Am Surg* 2013;79(6):630–633.

203. Fanning J, Valea FA. Perioperative bowel management for gynecologic surgery. *Am J Obstet Gynecol* 2011;205(4):309–314.

204. Lee CT, Chang SS, Kamat AM, et al. Alvimopan accelerates gastrointestinal recovery after radical cystectomy: a multicenter randomized placebo-controlled trial. *Eur Urol* 2014;66(2):265–272.

205. Vaughan-Shaw PG, Fecher IC, Harris S, et al. A meta-analysis of the effectiveness of the opioid receptor antagonist alvimopan in reducing hospital length of stay and time to GI recovery in patients enrolled in a standardized accelerated recovery program after abdominal surgery. *Dis Colon Rectum* 2012;55(5):611–620.

206. Hallerback B, Bergman B, Bong H, et al. Cisapride in the treatment of post-operative ileus. *Aliment Pharmacol Ther* 1991;5(5):503–511.

207. Davidson ED, Hersh T, Brinner RA, et al. The effects of metoclopramide on postoperative ileus. A randomized double-blind study. *Ann Surg* 1979;190(1):27–30.

208. Tollesson PO, Cassuto J, Rimbäck G, et al. Treatment of postoperative paralytic ileus

with cisapride. *Scand J Gastroenterol* 1991;26(5):477–482.

209. Smith AJ, Nissan A, Lanouette NM, et al. Prokinetic effect of erythromycin after colorectal surgery: randomized, placebo-controlled, double-blind study. *Dis Colon Rectum* 2000;43(3):333–337.
210. Yeo CJ, Barry MK, Sauter PK, et al. Erythromycin accelerates gastric emptying after pancreaticoduodenectomy. A prospective, randomized, placebo-controlled trial. *Ann Surg* 1993;218(3):229–237; discussion 237–238.
211. Bonacini M, Quiason S, Reynolds M, et al. Effect of intravenous erythromycin on postoperative ileus. *Am J Gastroenterol* 1993;88(2):208–211.
212. Jepsen S, Klaerke A, Nielsen PH, et al. Negative effect of metoclopramide in postoperative adynamic ileus. A prospective, randomized, double blind study. *Br J Surg* 1986;73(4):290–291.
213. Lykkegaard-Nielsen M, Madsen PV, Nielsen OV. Ceruletide vs. metoclopramide in postoperative intestinal paralysis. A double-blind clinical trial. *Dis Colon Rectum* 1984;27(5):288–289.
214. Cheape JD, Wexner SD, James K, et al. Does metoclopramide reduce the length of ileus after colorectal surgery? A prospective randomized trial. *Dis Colon Rectum* 1991;34(6):437–441.
215. Hennessy S, Leonard CE, Newcomb C, et al. Cisapride and ventricular arrhythmia. *Br J Clin Pharmacol* 2008;66(3):375–385.
216. Toyomasu Y, Mochiki E, Morita H, et al. Mosapride citrate improves postoperative ileus of patients with colectomy. *J Gastrointest Surg* 2011;15(8):1361–1367.
217. Xie Q, Zong X, Ge B, et al. Pilot postoperative ileus study of escin in cancer patients after colorectal surgery. *World J Surg* 2009;33(2):348–354.
218. Bennett J, Boddy A, Rhodes M. Choice of approach for appendicectomy: a meta-analysis of open versus laparoscopic appendicectomy. *Surg Laparosc Endosc Percutan Tech* 2007;17:245–255.
219. Abraham NS, Byrne CM, Young JM, et al. Meta-analysis of non-randomized comparative studies of the short-term outcomes of laparoscopic resection for colorectal cancer. *ANZ J Surg* 2007;77:508–516.
220. Basse L, Hjort Jakobsen D, Billesbølle P, et al. A clinical pathway to accelerate recovery after colonic resection. *Ann Surg* 2000;232(1):51–57.
221. Ludwig K, Enker WE, Delaney CP, et al. Gastrointestinal tract recovery in patients undergoing bowel resection: results of a randomized trial of alvimopan and placebo with a standardized accelerated postoperative care pathway. *Arch Surg* 2008;143:1098–1105.
222. Ogilvie WH. William Heneage Ogilvie 1887–1971. large-intestine colic due to sympathetic deprivation. A new clinical syndrome. *Dis Colon Rectum* 1987;30:984–987.
223. De Giorgio R, Knowles CH. Acute colonic pseudo-obstruction. *Br J Surg* 2009;96:229–

239.
224. Vanek VW, Al-Salti M. Acute pseudo-obstruction of the colon (Ogilvie's syndrome). An analysis of 400 cases. *Dis Colon Rectum* 1986;29(3):203–210.
225. De Giorgio R, Knowles CH. Acute colonic pseudo-obstruction. *Br J Surg* 2009;96(3):229–239.
226. Strodel WE, Nostrant TT, Eckhauser FE, et al. Therapeutic and diagnostic colonoscopy in nonobstructive colonic dilatation. *Ann Surg* 1983;197(4):416–421.
227. Sloyer AF, Panella VS, Demas BE, et al. Ogilvie's syndrome. Successful management without colonoscopy. *Dig Dis Sci* 1988;33(11):1391–1396.
228. Cowlam S, Watson C, Elltringham M, et al. Percutaneous endoscopic colostomy of the left side of the colon. *Gastrointest Endosc* 2007;65:1007–1014.
229. Armstrong DN, Ballantyne GH, Modlin IM. Erythromycin for reflex ileus in Ogilvie's syndrome. *Lancet* 1991;337:378.
230. Jiang DP, Li ZZ, Guan SY, et al. Treatment of pediatric Ogilvie's syndrome with low-dose erythromycin: a case report. *World J Gastroenterol* 2007; 13:2002–2003.
231. Lee JT, Taylor BM, Singleton BC. Epidural anesthesia for acute pseudo-obstruction of the colon (Ogilvie's syndrome). *Dis Colon Rectum* 1988; 31:686–691.
232. Sgouros SN, Vlachogiannakos J, Vassiliadis K, et al. Effect of polyethylene glycol electrolyte balanced solution on patients with acute colonic pseudo obstruction after resolution of colonic dilation: a prospective, randomized, placebo controlled trial. *Gut* 2006;55:638–642.
233. Korsten MA, Rosman AS, Ng A, et al. Infusion of neostigmine-glycopyrrolate for bowel evacuation in persons with spinal cord injury. *Am J Gastroenterol* 2005;100:1560–1565.
234. Child CS. Prevention of neostigmine-induced colonic activity. A comparison of atropine and glycopyrronium. *Anaesthesia* 1984;39(11):1083–1085.
235. Ponec RJ, Saunders MD, Kimmey MB. Neostigmine for the treatment of acute colonic pseudo-obstruction. *N Engl J Med* 1999;341(3):137–141.
236. Lynch CR, Jones RG, Hilden K, et al. Percutaneous endoscopic cecostomy in adults: a case series. *Gastrointest Endosc* 2006;64:279–282.

Chapter 50

Crohn Disease

Scott R. Steele and Eric K. Johnson

Key Points

1 Crohn's occurs anywhere along the gastrointestinal (GI) tract from mouth to anus and may present with one or more disease patterns – fistulizing, inflammatory, and fibrostenotic.

2 The indications for operating on Crohn disease involve managing complications of the disease, not cure.

3 Consider the patient's disease state and medical therapy for Crohn disease in the decision-making for surgery – this may require concomitant diversion in this patient population.

4 Whenever possible, preserve length of the small intestine and avoid extensive resections when not required.

5 Similar to ulcerative colitis, Crohn disease is associated with an increased long-term risk of developing colorectal cancer compared to the general population.

6 Asymptomatic Crohn disease (e.g., perianal fistula) does not necessarily require treatment.

7 Crohn disease is associated with a propensity for loose bowel movements and nonhealing wounds. Think of function first when treating perianal disease, and avoid overaggressive procedures on the sphincter that may alter continence.

INTRODUCTION

1 While many have heard the renowned account that Crohn disease derives its eponymous name more from the alphabetized listing of its authors (Crohn, Ginzburg, and Oppenheimer) in the 1932 *JAMA* publication "Regional ileitis: a pathological and clinical entity,"[1] some may not realize that it was a surgeon, Dr. A.A. Berg, who's patients and idea it was to evaluate the original 52 specimens.[2] Furthermore, the initial description of the condition was actually first made in 1769 by an Italian physician Giovanni Battista Morgagni – he of the anal columns, aortic sinus, and congenital diaphragmatic hernia fame.[3] Much has changed since then, and continues to evolve in the understanding and treatment of this idiopathic, ulcerogenic, inflammatory condition of the gastrointestinal (GI) tract. Therefore, where many students and physicians alike are quick to cite Crohn facts such as its ability to occur anywhere along the alimentary tract, has no "curative" operation, and is hallmarked by periods of flares and quiescent disease, what is often forgotten is that three-quarters or more of all patients will require at least one operation during their lifetime.[4] Therefore, not only must the problem at hand be addressed, but also the patient's future function should be carefully weighed when considering the proper therapeutic endeavor. Surgeons also need to be exceedingly aware of the indications, surgical options, and expected outcomes for patients with Crohn disease, as well as have a thorough understanding of the principles guiding both medical and surgical care to maximize outcomes. This chapter will review the pertinent information regarding the background, diagnostic evaluation, and treatment modalities for Crohn disease.

EPIDEMIOLOGY

Traditionally, Crohn disease is said to have a bimodal distribution with regard to age of onset, initially in the second and third decades, followed by a later, albeit smaller, peak in the sixth decade.[5] More recently, systematic reviews have found an annual incidence of Crohn disease ranging from 20.2 per 100,000 person-years in North America and 12.7 per 100,000 person-years in Europe to 5.0 person-years in Asia and the Middle East.[6] Even within regions, variations exist – the incidence in western Europe is almost twice that of eastern Europe, whereas the highest incidence of inflammatory bowel disease in the world is in the Faroe Islands. While data in developing countries remain relatively sparse, both the incidence and prevalence of Crohn disease are increasing in the United States and around the world. There is also an association with latitude, with increased incidences in higher latitude areas (i.e., Canada, Scandinavia, and Australia) compared to those closer to the equator. Males and females tend to be affected equally, though whites and certain ethnic groups such as those of Ashkenazi Jewish descent have higher overall rates.[7]

Although Crohn disease is not inherited through traditional Mendelian genetics, there does appear to be a familial predisposition. A positive family history in patients with Crohn disease occurs in 2% to 14%.[8] Closer examination reveals an approximate 5% age-adjusted lifetime risk of a first-degree relative of a Crohn disease proband developing IBD (up to 8% for those of Jewish ancestry).[9] On the other hand, the concordance rate for monozygotic twins ranges from 20% to 50%,[10] suggesting that genetics do play a role and that the disease is not entirely dependent on environmental and/or acquired factors. Furthermore, there does not appear to be a genetic concordance with regard to phenotypical manifestations (i.e., fibrostenotic, fistulizing, phelgmonous or extent of disease) among relatives.

ETIOLOGY

Despite tremendous progress in the overall understanding of the disease and advancements in the comprehension of the various phenotypical manifestations, the exact etiology of Crohn disease remains unknown. Most hypotheses suggest there involves interplay among the genetic makeup of the individual along with environmental, bacteriologic, immunologic, and epidemiologic factors that contribute to its development. Efforts in each of these areas continue in attempt to determine which are causative factors versus those that are simply associations.

Current theories revolve around the host–microbiome interaction, and the variable response that occurs along several pathways that may ultimately lead to the chronic inflammatory state seen in Crohn's.[11] In this model, intestinal microorganisms initiate an inappropriately regulated host immune response that results in a cascade of events ranging from altered permeability of the intestinal lumen to autoimmune "attacks" on several host organ systems.[12] The fecal and intestine mucosal bacterial make-up is also known to be altered in Crohn disease patients; however, it is unknown if this occurs as a result of the inflammatory process, or is itself a contributing factor to disease development.[13] Proteomic and metagenomic evaluation of commensal and altered GI microbiotia in Crohn patients indicates that there is an inappropriate pattern recognition with the microbiotia serving as the driver of the disease pathogenesis.[14]

Beginning in 1996, linkage studies of the human genome have helped with the discovery of several IBD genes that signify patients who are susceptible to Crohn disease development.[15] Most attention has revolved around the NOD2 (formerly CARD15) gene on chromosome 16, a region felt to be involved host interactions with bacterial lipopolysaccharide.[16] Genetic differences in the pattern-recognition proteins for which NOD2 codes may lead to an impaired sensing and handling of bacteria by the immune system, disrupting the tenuous balance of normal tolerance versus initiating an incorrect immune response. Since then, genome-wide association studies have provided insight that polymorphisms in genes such as the ATG16L1 and IRGM play a role in autophagy in Crohn patients. This process involves the regulation of cell development and differentiation, senescence, and ultimately the inflammatory system response to what the body deems is normal and abnormal.[17] In addition, other genes such as TLR4, HLA, and IRF5 are involved in the innate and adaptive immune system response seen in Crohn patients. Other causative immune factors have included overexpression and dysregulation of tumor necrosis factor, an imbalance between proinflammatory and anti-inflammatory cytokines, and an impaired mucosal susceptibility in sampling gut antigens.[18] Combined, these all contribute to regulatory mechanisms that may be altered and play a role in Crohn disease pathogenesis.

Infectious theories also continue to exist, [19] with specific organisms including *Mycobacterium avium* subspecies *paratuberculosis (*i.e.*,* Johne disease*), Campylobacter concisus,* adherent-invasive *Escherichia coli* (AIEC), and non-*H. pylori Helicobacter* species among the most common agents cited. Although the beneficial effects of antibiotics in the treatment of Crohn disease provide indirect evidence for a bacterial etiology, no distinct

organism has been identified to date. Similarly, several viruses have been postulated to have an association with Crohn disease, the most common being EBV, CMV, and measles. However, systematic reviews have found little evidence to support this notion.[20] Additionally, environmental factors are felt to play a role, highlighted by the well-established link to smoking with both an increased susceptibility and worsened clinical course. Finally, while patients with Crohn disease frequently have concomitant food intolerances, the role of dietary habits remains debatable.[21] Rather than a causative effect, it is felt that the microbiome in the human GI tract is heavily influenced by dietary intake, leading to a local environment ripe to foster susceptibility to Crohn disease.

DIAGNOSIS

As is well documented, Crohn disease falls under the umbrella of inflammatory bowel disease along with ulcerative colitis. In both conditions, there is no specific test at present to permit a definitive diagnosis; rather a combination of history and physical examination, laboratory, radiographic and endoscopic findings is utilized. This, in part, contributes to ~5% to 15% of patients with ulcerative colitis that will eventually be diagnosed with Crohn disease or patients who carry a diagnosis of indeterminate colitis.[22,23] Once diagnosed, Crohn patients are often categorized in several different manners, the most common of which involves either the site of disease or the patient's phenotypical manifestations (i.e., fibrostenotic, fistulizing, inflammatory). By location, the ileum (~60%) has the highest rate of disease incidence (Fig. 50-1). Localized inflammation in the ileocecal region occurs in ~45% of patients, whereas ~25% to 33% will have colonic involvement, 25% will have more proximal small bowel disease, and <10% will have upper GI or perianal disease. In general, patients with concomitant perianal disease tend to have a more severe clinical course,[24] and perianal disease in the setting of Crohn's may precede abdominal manifestations in up to 45%.[25]

When stratifying by disease pattern or phenotype, patients may have fibrostenotic (i.e., stricturing), fistulizing (i.e., penetrating), or inflammatory (i.e., phlegmonous) characteristics. Due to the heterogeneous nature of the disease, these manifestations may occur independently, concomitantly, or may even vary along the longitudinal course of the disease. Fibrostenotic patterns may occur in any location, though most commonly occur in the terminal ileal region, where patients present with obstructive-type symptoms such as nausea, vomiting, and decreased oral intake. Due to the recurrent chronic nature that results in progressive thickening of the bowel wall, medical management is typically unsuccessful and surgical intervention is required. Inflammatory disease may present with a wide range of symptoms such as abdominal pain, fever, and an abdominal mass and/or weight loss. Bowel movements may either be diarrhea or follow an obstructive pattern due to luminal narrowing or extrinsic compression from the phlegmon. Finally, penetrating or fistulizing disease also has a variable presentation. Patients may be completely asymptomatic, as in the case of many entero-enteral fistulas, present with anorectal abscesses and/or fistulas, or more commonly complain of symptoms mirroring involvement of the secondarily involved organ–recurrent urinary tract infections or pneumaturia, vaginal discharge, diarrhea, cutaneous feculent drainage, and/or hip/back pain from psoas involvement. While medical management continues to be a major component of each of the latter two patterns, surgery is often required for resolution of symptoms.

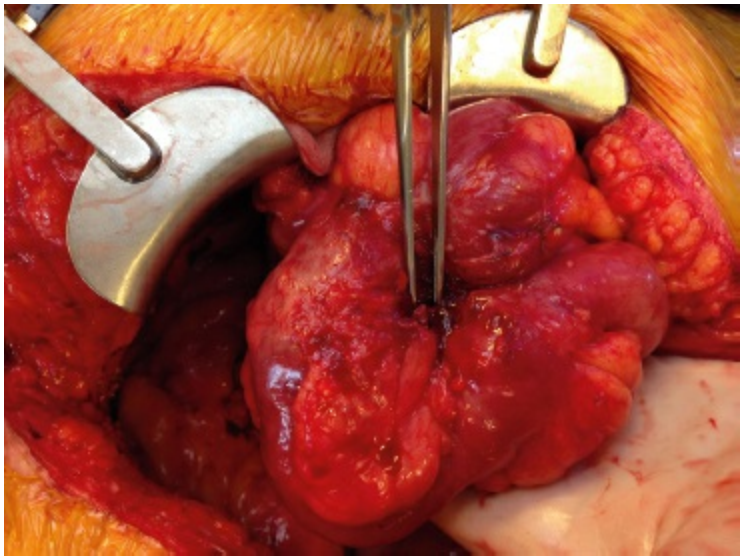

Figure 50-1. Terminal ileum with forceps pointing to intraloop chronic abscess cavity.

Clinical Evaluation

Small Bowel

The distribution of disease will in large part dictate the clinical presentation. The terminal ileum (along with the cecum) is the most commonly affected site, in addition to isolated more proximal small bowel disease. Patients with disease in this location will classically present with abdominal pain, fever, fatigue, nausea, and vomiting. The weight loss seen is a byproduct of both decreased oral intake as well as the malabsorptive process associated with Crohn's. When the disease is in the terminal ileum and ileocecal region, patients may present with a slow onset of right lower quadrant pain following meals, an abdominal mass, and (when the psoas is involved) pain with hip extension. Obstructive symptoms may also occur in patients with either fibrostenotic or acute inflammation (Fig. 50-2). Diarrhea tends to be nonbloody, though heme-positive stools may occur, and rarely gross blood is a manifestation from a small bowel source.

Colonic

Colonic involvement may occur in isolation in approximately one in four patients, though it is most often seen concomitantly in those with perianal (left-sided) or terminal ileal (cecal and ascending colon) disease.[26] Within the colon the distribution is somewhat variable, with approximately one-third of patients having total colonic involvement, 40% showing segmental disease, and left-sided only in up to 30%.[27] Regardless of the exact location within the large intestine, patients with colonic involvement may experience abdominal pain, and in some cases, malnutrition. Diarrhea is often of smaller volume and may be from several sources – malabsorptive (e.g., salt/water and bile acid malabsorption), infectious (e.g., CMV super-infection), or as a result from an entero-colonic fistula.[28,29] Unlike ulcerative colitis, rectal bleeding is not routine, and bowel movements are often nonbloody, except in those with moderate-to-severe Crohn colitis. In addition, similar to disease in the small bowel, patients can experience hip pain from fistulas, cramping and obstructive symptoms. Patients with chronic disease may also demonstrate pseudopolyps on endoscopic examination (Fig. 50-3).

Anorectal

Bissel[30] was the first to describe the anorectal component of Crohn, almost two years after the original description of the disease. Despite advances in the understanding of many features of Crohn disease, perianal complaints have been recognized as one of its most challenging aspects. Isolated perianal disease is the presenting symptom in ~5% to 15% of Crohn patients; though over the course of their lifetime, it is seen in 25% to 80%. The perianal area in Crohn patients has classically been felt to be a "window" into the abdomen, and perianal involvement is clearly more common in those with concomitant rectal or colonic disease.[31,32] In addition, active disease in the perineum is felt to act as a harbinger of an overall more virulent course.[33] The traditional anorectal complaints witnessed in non-Crohn patients are similar to those with the disease, including "standard" hemorrhoids, fissures, abscesses and fistulae. However, Crohn patients may

also manifest edematous (elephant ear) skin tags (Fig. 50-4), blue discoloration of the anus, and abscesses and fistulas that are often recurrent, multiple, and located well away from the anal verge. While fissures due to hypertonicity may be identified, more often Crohn fissures present as deep-seated, burrowing fissures – more like ulcers – and may be multiple, off the midline, extending in the muscle and associated with large skin tags. Finally, patients with long-standing Crohn's may develop anal stenosis or an anal stricture at the verge secondary to repeated bouts of chronic inflammation.

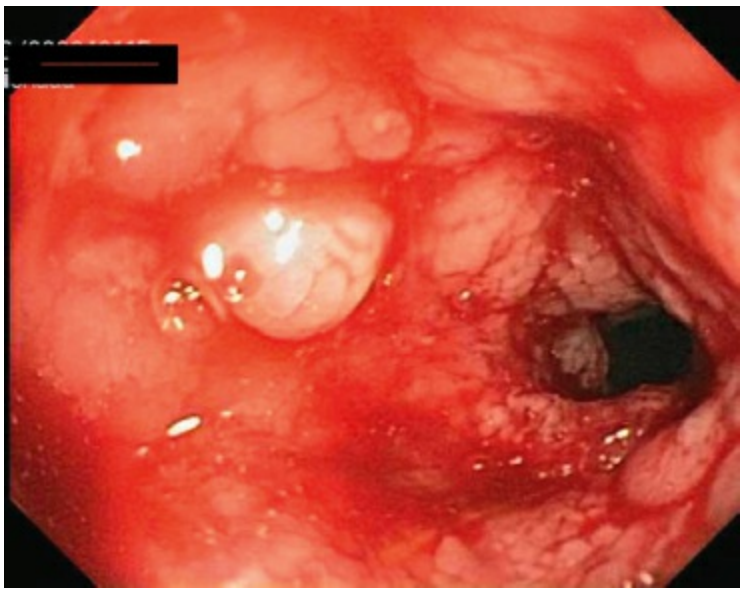

Figure 50-2. Endoscopic view of a terminal ileum stricture and active Crohn disease.

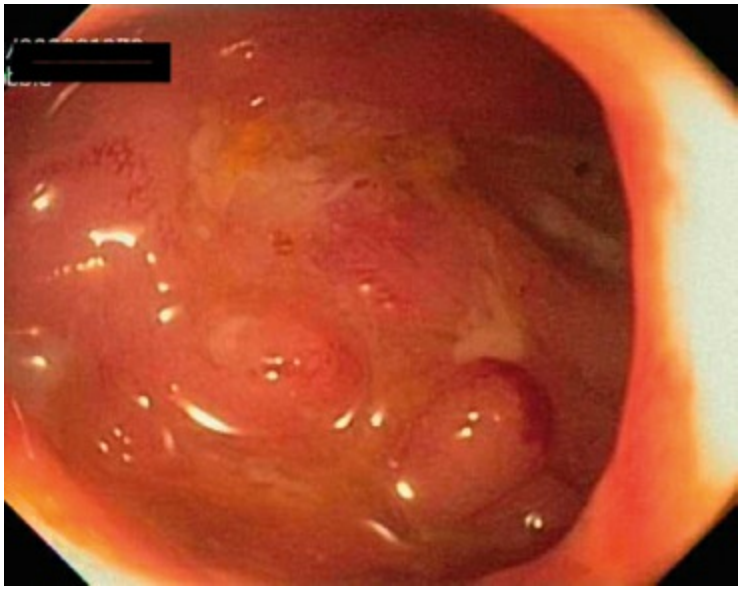

Figure 50-3. Endoscopic view of colonic pseudopolyps.



Figure 50-4. Anorectal Crohn disease. Large "elephant ear" skin tag.

Clinical evidence of perianal Crohn, as manifested by many of these features, is often deemed a hallmark of disease diagnosis, although occasionally a biopsy may be necessary. Due to local sepsis and perianal tenderness, patients may need to undergo an examination under anesthesia to fully identify the extent of the disease. Patients presenting with perianal findings consistent with Crohn disease should undergo a full alimentary tract evaluation, as previously stated, with endoscopic and radiologic evaluation. In addition, a thorough physical examination to identify any extraintestinal manifestations should be performed.

Upper Gastrointestinal Disease

Upper GI Crohn encompasses disease from the mouth through the jejunum. The incidence of upper tract involvement varies widely, with most studies reporting overall rates of $<5\%$. In patients with ileocolic disease, concomitant upper GI manifestations occur in 0.5% to 13%, yet up to 40% of patients will demonstrate early subclinical evidence of Crohn disease on radiologic and endoscopic evaluation.[34] Importantly, when patients have upper GI Crohn disease, they almost uniformly have concomitant disease of lower tract and should be evaluated to determine the extent of involvement. Upper tract disease is hallmarked by both obstructive symptoms and fistulas.[35] Patients typically present with abdominal pain, cramping, nausea, vomiting, or intolerance of oral intake leading to weight loss. While fistulas may be virtually to any site, the majority involving the proximal tract are gastrocolic or ileogastric in nature. Patients may be asymptomatic or present with diarrhea from high-output and colonic involvement. Crohn disease of the

esophagus is exceedingly rare, involving <0.5% of patients. Most patients will have inflammation or ulcers, though strictures and fistula have also been reported. As with other upper tract Crohn disease, extra-esophageal disease is nearly always present.[36]

Extra-Intestinal Disease

Similar to ulcerative colitis, patients with Crohn disease may have manifestations from the disease process that extend outside of the GI tract (Table 50-1). Extra-intestinal disease (EID) has been reported in ~6% to 47% of patients with inflammatory bowel disease, and has an increased concordance among siblings and first-degree relatives – suggesting a genetic component that has been linked to the major histocompatibility complex (MHC) on chromosome 6.[37,38] EID occurs secondary to the systemic inflammatory process associated with the underlying disease and affect a wide range of organ systems. While the GI tract may be the primary source, the dysfunction in immune regulation incites a pathologic response that may occur in nearly every location in the body simultaneous with, preceding, or following GI manifestations.[39] Overall, rheumatologic/joint problems (e.g., peripheral or sacroiliac arthritis, arthralgias) are the most common, occurring in up to one-third of patients. Other more frequent sites of involvement include the skin (Fig. 50-5), eyes, and hepatobiliary system; while the renal, pulmonary, nervous, and coagulation systems are typically involved to a lesser extent. It is important to distinguish between manifestations that parallel bowel disease activity (episcleritis, peripheral arthritis, and erythema nodosum) from those that do not (ankylosing spondylitis, pyoderma gangrenosum, and primary sclerosing cholangitis). Surgical intervention directed at the bowel may occasionally be required for recalcitrant EID that may appropriately go into remission following bowel resection.[40]

Table 50-1 Classification of Extra-intestinal Manifestations of Crohn Disease

Organ System	Extra-Intestinal Manifestations
Musculoskeletal	Arthralgias, peripheral arthritis, ankylosing spondylitis, sacroilitis
Ocular	Uveitis, iritis, episcleritis, conjunctivitis
Renal	Glomerulonephritis, amyloidosis
Skin/Mucocutaneous	Erythema nodosum, pyoderma gangrenosum, apthous ulcers
Blood	Thromboembolic disease, hemolytic anemia
Pulmonary	Bronchitis, pleuritis, tracheal stenosis
Hepatobiliary	Hepatitis, primary sclerosing cholangitis, pancreatitis, cirrhosis
Cardiac	Pericarditis, myocarditis
Neurologic	Demyelinating disease, neuritis

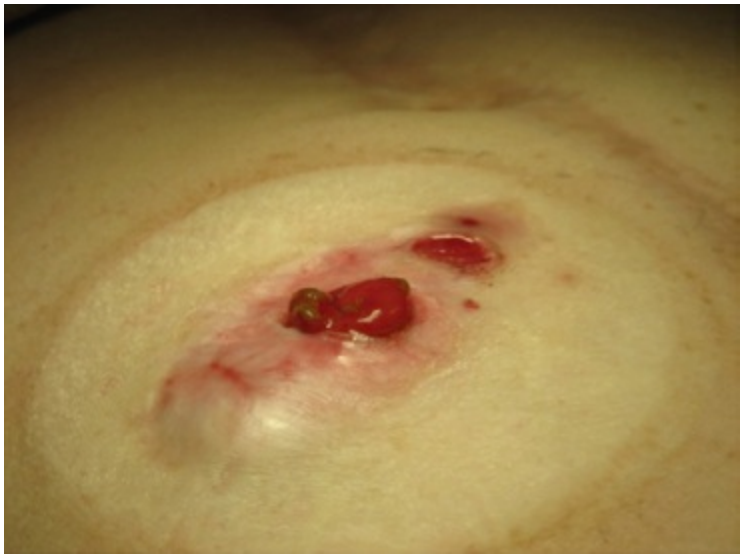

Figure 50-5. Peristomal pyoderma gangrenosum. (Courtesy of W. Brian Sweeney, MD.)

Radiology

Fluoroscopic Imaging

Radiologic work-up for Crohn patients is an invaluable part of the diagnostic evaluation. In addition to providing information on the acute process (i.e., abscess, phlegmon, fistula, stricture), diagnostic imaging is used to determine the extent of disease. Historically, contrast studies such as a barium enema have helped diagnose Crohn disease by identifying longitudinal and transverse linear ulcerations that create cobblestone and nodular patterns, skip lesions, fistulas, and strictures.[41] A small bowel follow-through has also been a long-standing modality utilized to evaluate for strictures, active disease (highlighted by ulceration, mucosal granularity, and loss of villous morphology), and fistulas (Fig. 50-6).

Computed Tomography

In many centers, computed tomography (CT) has now largely replaced the barium enema and small bowel follow-through, with the added ability to identify the extent of the disease and involvement of surrounding structures, manifested by segmental bowel thickening (Fig. 50-7), mesenteric fat stranding, and intra-abdominal fluid.[42] Additionally, CT is useful to identify secondarily involved organs or provide information that may be pertinent to preoperative planning, such as bladder or vaginal air indicating presence of a fistula, an adjacent psoas abscess in ileocecal disease, or ureteral obstruction that may require stenting. CT and magnetic resonance (MR) enterography provide improved detail of the mucosal surface and are especially useful in depicting fistulas and strictures, along with the added benefit of lower levels of radiation exposure. The latter is especially relevant considering the generally younger patient population, body habitus, and potential need for life-long repeat imaging associated with Crohn's.

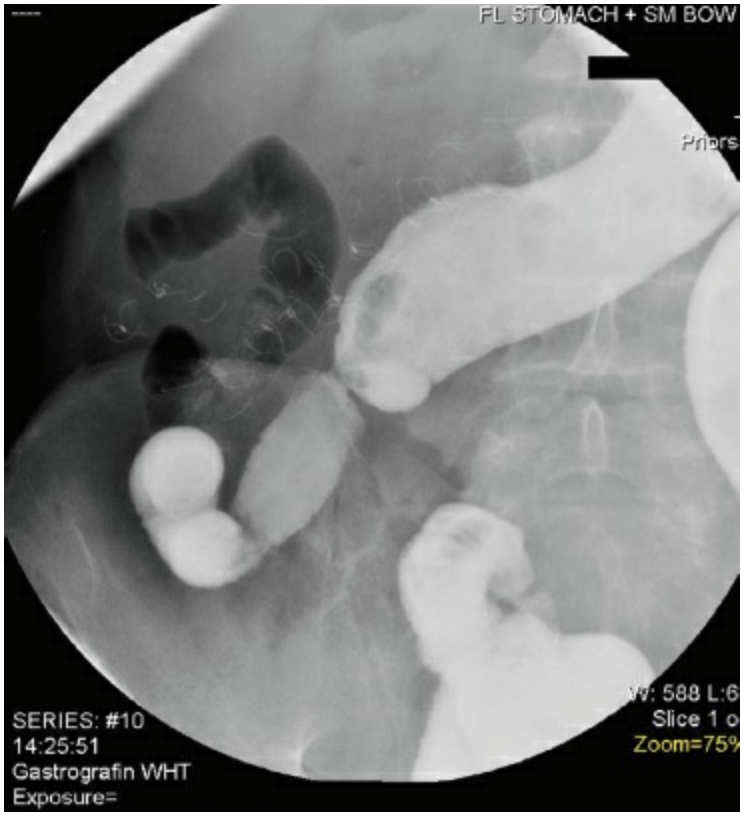

Figure 50-6. Small bowel follow-through demonstrating a tight stricture with proximal dilation.



Figure 50-7. Coronal cut of a CT demonstrating a jejunal stricture.

Magnetic Resonance Imaging

MR enterography in particular has been shown to be over 85% accurate in predicting stenosis (Fig. 50-8), abscess and fistula in preoperative planning, as well as changing the surgical strategy/approach in up to 10% of Crohn patients.[43] Furthermore, its sensitivity (85% to 90%), specificity (100%), and negative predictive value (77%) have made it ideal for detecting recurrent disease after surgery.[44,45]

MRI has also particularly been useful in the evaluation of complex perianal fistulas seen in Crohn patients, identifying secondary "hidden" tracts and occult abscesses that lend to higher failure rates if not addressed.[46] More recently, diffusion-weighted imaging and magnetization transfer imaging sequences have allowed bowel resolution previously not achievable to help identify disease, depict disease activity, and target interventions.[47]

PET Scan

Another modality typically not associated with inflammatory bowel disease, 18F-FDG positron emission tomography (PET) has been used for Crohn disease largely in academic and research centers to date.[48] While cost seems to be somewhat prohibitive, this emerging indication has the potential to (a) determine disease activity in a noninvasive manner, (b) provide information regarding subclinical disease, (c) deliver a qualitative measure of response to treatment, and (d) indicate disease activity that would otherwise be unobtainable by traditional methods.

Video Capsule Endoscopy

Finally, video capsule endoscopy uses wireless technology to capture continuous images of the upper GI tract mucosa. As up to 30% of patients will have disease limited to the small bowel, capsule endoscopy plays a unique role to determine disease presence and activity that are outside the reach of endoscopy and the limitations of traditional small bowel imaging. While the diagnostic yield may not be as high, it has been shown to be comparable to ileocolonoscopy and better than small bowel follow-through for the detection of small bowel inflammation.[49] Furthermore, negative predictive values range from 96% to 100%, essentially ruling out the diagnosis of Crohn's when the results are normal.[50] Of note, it is imperative to exclude the presence of moderate–severe strictures prior to its use, as their presence can result in bowel obstruction from the capsule becoming lodged at the point of stenosis (Fig. 50-9).

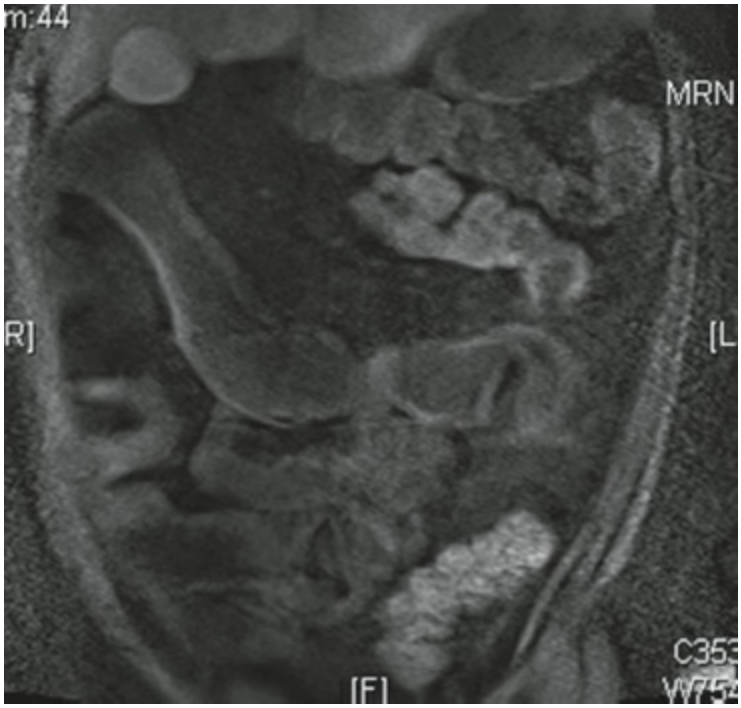

Figure 50-8. MR enterography demonstrating a small bowel stricture.

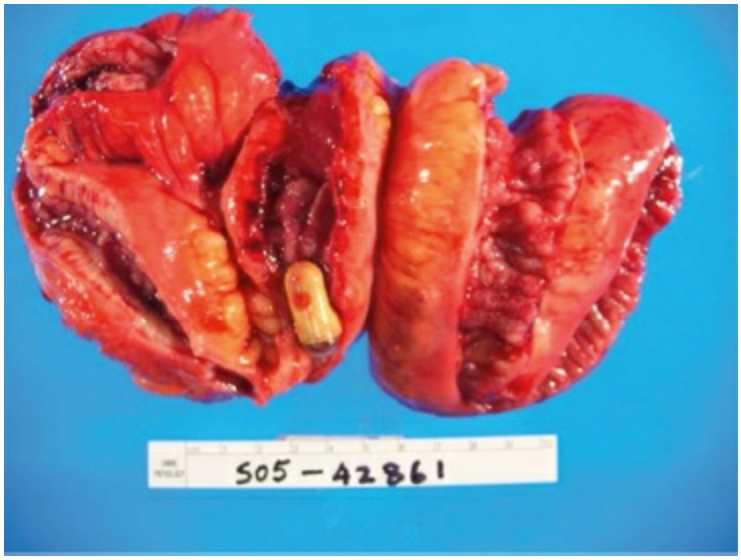

Figure 50-9. Video capsule endoscopy "pill" lodged in a Crohn stricture causing a bowel obstruction. (Courtesy of Justin A. Maykel, MD.)

Endoscopy

Whereas direct observation of the perianal area and anoscopy will identify disease such as skin tags, external fistula openings and fissures, endoscopy is needed to identify the extent and severity of the disease and perform biopsies to aid in diagnosis.[51] In the clinic, flexible or rigid sigmoidoscopy can be performed as adjuncts to the physical examination to evaluate the mid-to-upper rectum and sigmoid colon. However, endoscopic evaluation of the entire colon, including the terminal ileum, with colonoscopy along with appropriate biopsies is required in patients suspected of Crohn disease. Early changes seen in the mucosa include aphthous ulcerations, erosions, and serpiginous ulcers that occur in a skip-type pattern. As the full-thickness inflammatory cycle continues, these ulcerated areas become progressive, enlarge, and coalesce forming the cobblestone-type pattern. The presence of rectal sparing and terminal ileal disease may help differentiate Crohn disease from ulcerative colitis, although the latter may demonstrate similar characteristics due to medical therapy and backwash ileitis, respectively.[52] Finally, the presence of strictures or associated masses may indicate the need for surgical or therapeutic intervention.

Esophagogastroduodenoscopy (EGD) also plays a role for patients with suspected or known proximal disease and can identify ulcers, fistulas, and strictures that may be responsible for various upper GI symptoms (Fig. 50-10). In addition, EGD allows for therapeutic intervention such as dilation for those with gastric outlet obstruction.[53] Overall, both upper and lower endoscopies are relatively safe procedures with complications in IBD patients occurring in $<5\%$,[54] and generally consist of bleeding – though perforation remains a very small risk of every endoscopic procedure. Additionally, endoscopic evaluation provides an ability to track and quantify disease activity by use of the scoring systems such as the Crohn disease endoscopic index of severity (CDEIS) or Simple Endoscopic Score for Crohn disease (SES-CD).[55]

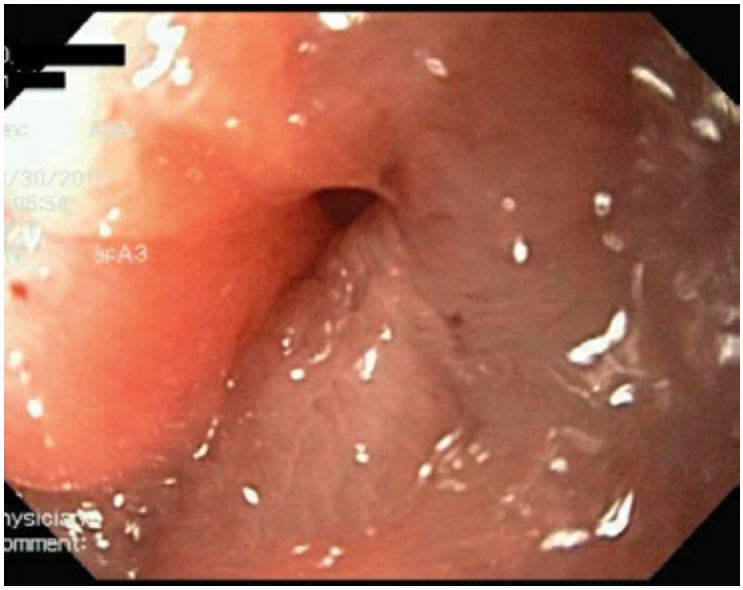

Figure 50-10. Endoscopic view of pyloric stenosis in a Crohn patient; this high-grade stenosis requires balloon dilation to pass the scope. (Courtesy of Mark Cumings, MD.)

Pathology

Classically, the presence of noncaseating granulomas on pathologic examination is pathognomonic of Crohn disease. However, in reality they are only found in 25% to 42% of patients, and may simply be a marker of more virulent disease.[56] In addition, long-standing ulcerative colitis patients may occasionally show granulomas on biopsy.[57] Furthermore, granulomas may be present but are not typically demonstrated on the specimens that are taken with routine depth endoscopic biopsies, rather only visible on resected full-thickness specimens. Other histologic evidence of Crohn disease includes architectural distortion of the crypts (size, shape, and symmetry) (Fig. 50-11), ulcerations, pseudopolyps (Fig. 50-12), and skip areas – some of which may also be found in ulcerative colitis. Other discriminating features of Crohn's include the potential for full-thickness involvement of the bowel wall, and the presence of "creeping fat," where the mesenteric fat extends over the serosal surface of the bowel wall – "creeping" over the normally distinct mesenteric/bowel wall interface. Furthermore, gross pathologic examination of Crohn specimens may range from acutely inflamed, edematous, hyperemic bowel to thickened, fibrotic, and "woody." Finally, the mesentery is classically thickened, with marked edema, friability and hypervascular in nature.

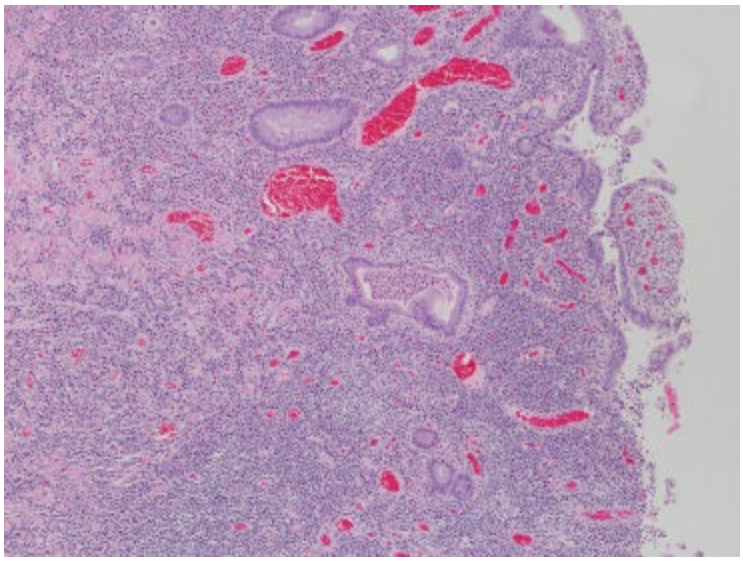

Figure 50-11. Active colitis with crypt abscess formation and atypical regenerative features consistent with chronic crypt-destructive colitis. (Courtesy of George Leonard, MD.)

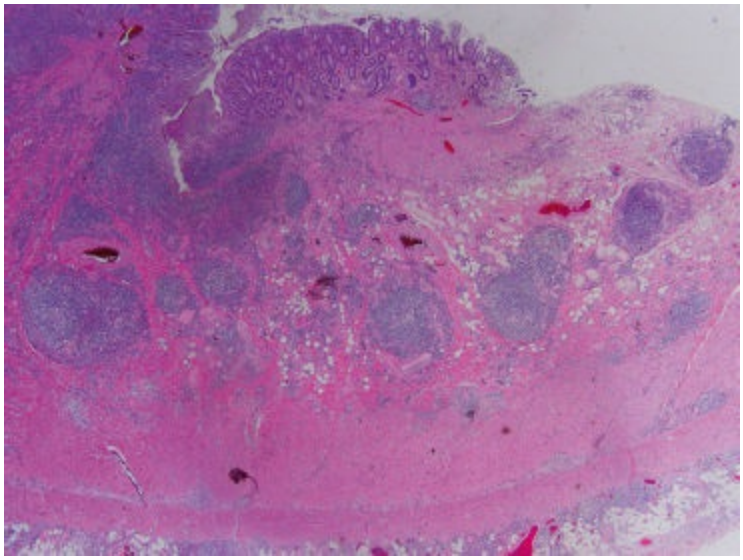

Figure 50-12. Full-thickness involvement of chronic inflammatory infiltrate from mucosa to serosa and pseudopolyp formation. (Courtesy of George Leonard, MD.)

Laboratory Analysis

No single laboratory examination will provide a definitive diagnosis of Crohn disease; yet, there are tests available to help discriminate between Crohn's and other processes. Routine serum profiles such as perinucelar antineutrophil cytoplasmic antibodies (p-ANCA) and anti-Saccharomyces cerevisiae antibodies (ASCA) have traditionally been used to help differentiate Crohn disease from ulcerative colitis. The former is a known marker associated with ulcerative colitis, whereas elevated levels of ASCA are associated with Crohn disease. Unfortunately, only 30% to 50% of Crohn patients will test positive for ASCA, and up to 10% of healthy individuals will also have elevated serum levels.[58]

C-reactive protein is a nonspecific marker for inflammation that has been useful in tracking disease activity and response to treatment. More recently, fecal biomarkers such as fecal calprotectin,[59] lactoferrin, and neopterin[60] are used to monitor intestinal inflammation, and have been shown to reliably correlate with disease activity and mucosal healing as measured endoscopically.[61] In addition they may play a role in helping to make a distinction between inflammatory bowel disease and functional bowel disorders, with reported sensitivities and specificities of ~80% to 85%.[62] While nonspecific, persistent elevations in fecal biomarkers have been shown also to correlate with higher levels of recurrence following surgical resection.[63]

DIFFERENTIAL DIAGNOSIS

The differential diagnosis in Crohn disease is wide and includes both benign and malignant processes (Table 50-2). While Crohn disease has certain traits that are more suggestive of its presence (e.g., noncontiguous multisite disease, fistulas, creeping fat), a variety of abdominal process may mimic Crohn's (Fig. 50-13). It is not an uncommon scenario for ileocolic Crohn's to be ultimately diagnosed from a clinical picture that may at first resemble acute appendicitis, right-sided diverticulitis, an infectious process, or a perforated malignancy. Radiologic studies may demonstrate similar patterns of bowel inflammation, laboratory examination often shows elevated CRP and/or white blood cell counts in each, and the patient demographics are routinely alike. When this occurs intraoperatively, a decision must then be made regarding whether or not to proceed with resection versus closure and medical management alone based on clinical findings. If a resection is performed, questions arise regarding the extent of resection such as whether or not to perform an ileocectomy versus appendectomy alone and what margins of resection are required for the situation at hand.

Table 50-2 Differential Diagnosis of Crohn Disease

- Ulcerative colitis
- *Clostridium difficile* infection
- Acute appendicitis
- Meckel diverticulitis
- Diverticulitis (diverticular-associated colitis)
- Infectious colitides (CMV, Yersinia, *E. coli,* Salmonella, etc.)
- Ischemic colitis
- Tuberculosis
- Radiation enteritis
- Behçet disease
- Malignancy
- Celiac sprue

When confronted with this situation in the operating room and Crohn's is suspected, traditional teaching recommends performing an appendectomy if the cecum is normal, or to withhold on resection and undergo medical treatment only. Yet, there are data to support performing an ileocolic resection at the time of surgery, with one series reporting almost half of patients required no further surgery as a result of their Crohn disease, compared to 92% of those undergoing appendectomy only (65% within the next 3 years).[64] Hence early ileocolonic resection may be in the patient's long-term best interests to avoid recurrent disease and repeated trips to the operating room.

When disease is isolated to the colon, the major differentiation involves distinguishing Crohn colitis from ulcerative colitis, though other infectious and inflammatory colitides remain in the differential. As previously noted, many of the same clinical and histopathologic traits are shared in both diseases, and contribute to the initial diagnostic dilemma, as well as those patients with indeterminate colitis or those that undergo a change in diagnosis from ulcerative colitis to Crohn's. Ultimately it is the entire

evaluation to include information taken from laboratory, pathologic, endoscopic, radiologic, and clinical examinations as outlined above that will help clarify the picture and aid in diagnosis.



Figure 50-13. "Creeping" fat on an ileal specimen.

TREATMENT

Medical Management

While an in-depth look regarding the medical management of Crohn disease is beyond the scope of this chapter, a few points are worth noting (Table 50-3). First, despite the spectrum of disease presentations, Crohn's remains one hallmarked by inflammation (i.e., abdominal pain) and diarrhea. As such, supportive care to include antidiarrheals and antimotility agents, along with a bland diet, are good first-line approaches to provide symptomatic control. It is important to exclude the concomitant presence of "super-infections" such as cytomegalovirus or *Clostridium difficile* infection, as antimotility medications may result in the onset of toxic megacolon and a rapidly progressive clinical deterioration. Yet, simple over-the-counter, readily available medications such as loperamide, diphenoxylate, and bismuth, along with prescription medications such as codeine and tincture of opium often provide tremendous relief to abdominal pain, cramping, and loose stools.

Crohn's has also been traditionally been called a "wasting disease," though increasing numbers of obese patients with Crohn's are observed. Despite this seeming paradox, nutritional support in both groups remains paramount. Ideally, preservation of oral feeding in any form is crucial for maintenance of the absorptive and protective mechanisms provided by the GI mucosal lumen villi and microvilli. However, when this is not possible, parenteral nutrition has become invaluable in preserving nutritional stores, aiding in maintenance of positive nitrogen balance, preventing weight loss and improving perioperative outcomes.[65] This must be weighed against the potential complications involved with intravenous routes to include infectious complications and thromboembolic events.

A tiered strategy for medical therapy is often utilized, taking into account the disease activity (flare *vs.* chronic), pattern (inflammatory *vs.* fistulizing *vs.* fibrotic) and location. Antibiotics and aminosalicylates are typically used in the induction and maintenance of remission, respectively, especially for those with mild-to-moderate disease. Antibiotics are also utilized for the treatment of an acute infection for both the abdominal and perianal locations, with metronidazole and fluoroquinolones among the most commonly used. In select cases, antibiotics can be given to patients with perianal disease including fistulas for maintenance of remission as well as decreasing pain. While the exact mechanism of action of antibiotics in Crohn disease is debated, by decreasing bacterial load and altering the bacterial milieu of the GI tract, disease activity is lessened.

Aminosalicylates (5-ASA) are traditionally used as first-line maintenance agents, and are generally well tolerated by patients. Depending on the predominant location of the disease, different moieties can be formulated to allow maximal drug concentration to be targeted at the appropriate site. 5-ASA compounds are not aspirin or nonsteroidal derivatives, though they do work to decrease proinflammatory mediators and function at the mucosal level with reduced systemic absorption. Similar to antibiotics, the mechanism of action in inflammatory bowel disease remains unclear, though levels of NF-KB, TNF,

and interleukin-1 have all been shown to decrease, as well as inhibiting both B- and T-cell function.[66] Additionally, they can be used in the perioperative period without increasing the risk of postoperative complications. Overall, this class of medications has been shown to prevent disease flares and minimize Crohn disease activity index for patients with mild disease, though the results have been inconsistent with questionable clinical benefit.[67] However, at most they have little downside and there is some data to suggest a decrease in disease recurrence following resection.

Steroids remain a mainstay in the treatment of Crohn disease for both the induction and maintenance of remission. They are especially useful in the setting of disease flares, where a "burst" followed by a weaning strategy may allow some of the more well-tolerated medications to be initiated as a maintenance regimen. Purported advantages to steroids include their low cost, ability to give via the intravenous, oral and rectal routes, and the relative speed and efficacy that they are able to help achieve quiescent disease. On the downside, ~14% to 45% of patients will ultimately have steroid recalcitrant disease, requiring either an escalation of medical therapy or surgical resection. Additionally, the wide range of potential complications of steroids ranging from adrenal suppression, insulin resistance, ocular disease, and osteopenia to psychosis, acne and weight gain, limits durable sustained use considerably. Budesonide is a synthetic corticosteroid that is taken orally or rectally, and the steroid effect is predominantly local due to a significant first-pass metabolism in the liver. While pooled analysis demonstrated inferior effects compared to systemic steroids, it has been shown to maintain rates of remission higher than placebo and comparable to prednisolone for those with mild disease.[68]

Table 50-3 Medical Treatment for Crohn Disease

Class of Medication	Examples	Role in Therapy
Steroids	Prednisone Prednisolone Methylprednisolone Budesonide[a]	Induction of remission
Immunomodulators	6-Mercaptopurine Methotrexate Azathioprine Tacrolimus Cyclosporine[b]	Maintenance of remission Induction in select cases
5-ASA	Sulfasalazine Pentasa Mesalamine Olsalazine	Maintenance of remission in mild cases
Biologics	Infliximab Adalimumab Certolizumab Natalizumab	Induction and maintenance of remission
Antibiotics	Metronidazole	Induction of remission Treatment of infection

[a]Budesonide is taken enterally and has only topical effect, no systemic effect.
[b]Cyclosporine can be used as rescue therapy/induction in refractory cases, but has not been supported by evidence in the treatment of Crohn disease.

The immunomodulator class of medications includes 6-mercaptopurine, azathioprine, methotrexate, tacrolimus, and cyclosporine. They work via different mechanisms of action, yet all serve a common purpose to alter the immune system in some capacity to blunt the patient's intrinsic response to what is considered "foreign" and to decrease inflammation. The first two (thiopurines) act via inhibition of purine synthesis, and must be monitored, as metabolites can lead to bone marrow suppression and hepatotoxicity. These drugs are useful for both the induction and maintenance of remission and particularly helpful in dose reduction and weaning patients off prednisone.[69] They also have a longer onset of action, and may take months until the full effect of the medication is witnessed. Methotrexate inhibits dihydrofolate reductase, also inhibiting purine and pyrimidine synthesis, and ultimately cytokine production. Its effects are better demonstrated with intramuscular or subcutaneous injection compared to oral, where both induction and remission rates are significantly worse.[70] Side effects range from blood dyscrasias and secondary malignancies to pneumonitis and hepatic fibrosis, and serial monitoring of liver function tests is recommended.

The comparatively new group of medications are the biologic agents such as infliximab, adalimumab, and certolizumab, which are monoclonal antibodies targeting tumor necrosis factor-α. They are also administered via subcutaneous or intravenous injection, with dosing intervals dependent on the patient response. Adalimumab is a fully human monoclonal antibody, and while still possible, provides the advantage of being less likely to develop drug antibodies than infliximab.[71] Together they are extremely useful in the induction of remission, and more and more are utilized as first-line therapy for moderate-to-severe disease (especially those with fistulizing disease), as well as in the maintenance of remission for medically refractory patients. Several large-scale multicenter randomized trials including CLASSIC I and II, CHARM, PRECiSE-1, and WELCOME have all demonstrated not only their collective efficacy, but also the ability to induce and maintain remission in patients who had previously lost response to one of the others.[72] They are not without reported significant side effects, however, including anaphylaxis, secondary malignancies, and opportunistic infections. Patients should be tested for latent tuberculosis prior to their administration to avoid resurgence. Additionally there is considerable debate in the literature as to their impact on perioperative complications and anastomotic leaks, with large center studies reporting contradictory results, and pooled analysis demonstrating a nonsignificant trend toward increased total complications (OR 1.72; 95% CI 0.93 to 3.19).[73] Despite this controversy, discretion may warrant consideration for diversion when these medications are used in the setting of higher-risk anastomoses.

Operative Management

Indications for Surgery

2 One of the basic tenets in the management of Crohn disease is that surgery is typically reserved either for failure of medical therapy (i.e., intractable disease or steroid dependency) or complications from the disease. Failure of medical management is still the most common reason for surgery in patients with Crohn disease, especially in colonic disease. Complications resulting in a potential need for operative intervention include fistula, abscess, obstruction (stricture), growth retardation, perforation, EID, bleeding, and malignancy. Of note, hemorrhage in Crohn disease tends to be a more rare event, and is more commonly seen in ulcerative colitis or diverticular disease. Each of these will be outlined in the following sections. Despite improvements in medical therapy, over 70% of all Crohn patients will require surgery at some point in their lives, with almost half of those undergoing one operation requiring additional procedures. Therefore, having a firm understanding of the general principles and technical specifics is important to surgeons who care for these patients.

General Principles

3 While Crohn disease can affect the entire GI tract from mouth to anus, certain overriding principles can help guide the planning and operative management. First, Crohn disease is a process marked by lifelong potential for recurrence; therefore, preservation of bowel when possible and consideration of future function are paramount concerns during the planning phase.[74] Next, the extent of resection required is dependent on multiple factors, including location and duration of disease, ability to exclude malignancy, and prior resections that may have resulted in shortened small bowel. In addition, as the stools tend to be loose, consideration must be given to rectal compliance and sphincter function during surgical planning to avoid a "perineal colostomy," whereby in-continuity management is preserved but the patient has no control. Furthermore, unlike ulcerative colitis, segmental resection for both small and large bowel is common with ileocolonic, colo-colonic, and rectal anastomoses all playing a role in avoiding a permanent stoma while maximizing functional bowel.[75] Crohn patients with pancolitis may undergo a total abdominal colectomy with ileorectal anastomosis (for those with rectal-sparing) or total proctocolectomy with end ileostomy.[76] Total proctocolectomy with ileal pouch-anal anastomosis is typically discouraged, and is normally the result of an initial misdiagnosis of ulcerative colitis.

4 Technical tips also come into play when planning for Crohn resections. For example, when performing a proctectomy, it is important to consider the potential for a delayed or nonhealed perineal wound. An intersphincteric dissection, which maximizes the amount of healthy muscle/tissue remaining, facilitates closure in attempt to avoid this complication. Some patients will require more extensive procedures such as flaps that utilize adjacent tissues (i.e., gracilis, bulbocavernosus), and may require plastic surgeon involvement.[77] In addition, as in the small bowel, length of resection margins does not influence the risk of relapse with segmental resections, and only grossly normal bowel is all that is required.[78]

Finally, diversion may be more commonly used due to both the presence of active disease as well as the potential negative healing effects of the Crohn medications.

ABDOMINAL FISTULAS

Intra-abdominal fistulas may arise from either the small or large bowel and affect nearly every adjacent structure. Similar to any fistula, it is important to determine the site of origin of the fistula, as this section of bowel will typically require a formal resection when symptomatic (Fig. 50-14). On the other hand, a section of bowel may simply be involved in the process secondarily as a "bystander," and the preferred treatment is to take the fistula down and primarily repair the site. It is important to ensure there is no significant active disease at the closure site, as this may predispose to healing problems and a subsequent leak. In this case, the preferred strategy would be to perform a segmental resection.[79] Transmural bowel inflammation and communication can also occur more commonly with the skin, bladder, or vagina. Once again, the bowel is the offending organ and should be resected, while ligation of the fistula and closure of the secondarily involved organ is adequate treatment. In certain cases, the inflammatory process is so intense, or there is a concern for concomitant malignancy, that the entire process should be resected en bloc. When an abscess is present, it is often preferable to percutaneously drain the abscess and ensure adequate medical therapy (that often includes biologics), prior to embarking on abdominal exploration.[80] Finally, asymptomatic entero-enteric or entero-colonic fistulas are often best left alone and treated medically, especially with the relative success of anti-TNF agents.[81]



Figure 50-14. Entero-enteric-colonic fistula.

OBSTRUCTION AND STRICTURE

Strictures in Crohn disease most commonly occur in the terminal ileum, but may arise anywhere along the GI tract (Fig. 50-15). Due to the transmural inflammation, it is not uncommon to have luminal narrowing within the bowel especially with repeated flares. However, the underlying pathophysiology may be from a phlegmonous/inflammatory process or secondary to the fibrostenotic pattern of disease. In the former, medical management may be successful, decreasing the inflammation and resolving the intrinsic or extrinsic "compression" on the bowel wall. On the other hand, patients with fibrotic strictures typically have little to no response to medical management (including anti-TNF agents) and most often require surgery.[82–84] Emerging evidence suggests early treatment of strictures with aggressive biologic therapy may aid in preventing the onset of fibrosis, especially in patients under 40, prior to the onset of the irreversible cascade of fibrosis where surgery becomes inevitable.[85]

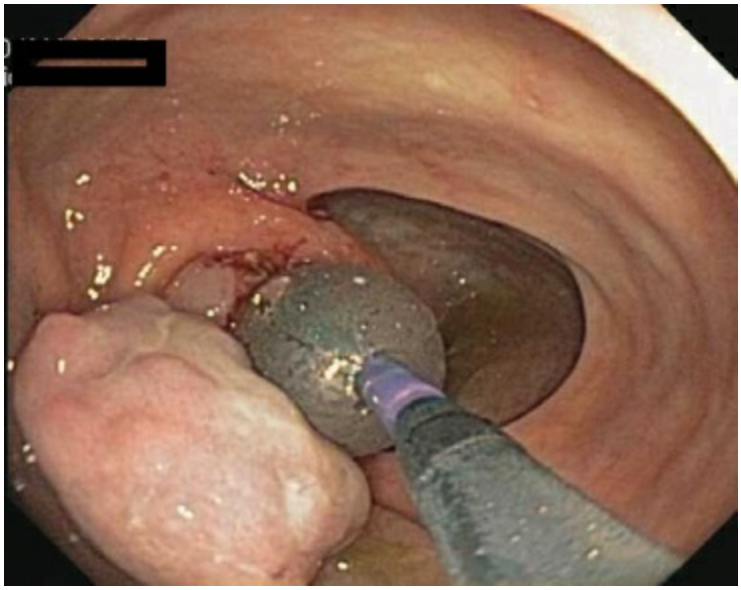

Figure 50-15. Endoscopic balloon passing through the ileocecal valve to dilate a stricture.

Strictures also differ somewhat based on their location. The rate of colonic strictures has been reported to be as high as 7% to 17%.[86] In general, these benign strictures are responsive to medical management as well as endoscopic dilation for moderate-to-high–grade stenosis. Complicating the situation, malignancy has been shown to be present in ~7% of all colonic strictures,[87] and Crohn disease carries an increased risk of colorectal cancer above the general population. Furthermore, it is very difficult to differentiate malignant from benign strictures on strictly clinical basis. Therefore all colonic strictures should undergo endoscopic evaluation and biopsy. If malignancy is detected (or the lesion appears worrisome and remains indeterminate on work-up), a standard oncologic resection should normally be performed. For those that are clearly benign and nonresponsive to medical management, endoscopic dilation has been shown to provide symptomatic relief. Technical success occurs in ~70% to 90%, and provides initial symptomatic resolution in over 80% of patients.[88] Unfortunately, most patients with

colonic strictures require repeated dilations. The procedure is generally safe, with hemorrhage and perforation occurring in <5%, and most often occur when balloon sizes over 25 mm are used. Although concomitant direct injection of the stricture with steroids or treatment with systemic steroids immediately after dilation have both demonstrated some success in case series, the true effect of this remains uncertain.

Strictures of the small bowel have been reported in 20% to 40% of Crohn patients.[89] Treatment typically consists of medical management, though depending on the severity, many patients will require intervention. Small bowel strictures are often amenable to dilation via double-balloon enteroscopy, especially in the 10- to 20-mm range, though perforation is a known risk.[90,91] Symptomatic relief occurs in ~75% to 90% following the first dilation, while approximately 30% to 40% will require repeated intervention over the next 3 years. For those with initial success, the cumulative dilation-free rate at 3 years is ~40% to 50%.[92] Overall complications occur in ~10% to 15% (<5% major complications), and include pain, fistula, fevers, bleeding, and perforation.[93] Despite this success, many will require operative intervention when symptoms fail to resolve, repeated bouts occur, or when a stricture is associated with a nonresolving inflammatory process, malnutrition, immunosuppression or fistula. Options then include strictureplasty (see below) or resection.

Strictureplasty preserves bowel length by avoiding resection altogether. The Heineke–Mikulicz method involves a longitudinal incision along the antimesenteric border of the bowel with a transverse closure, and is useful for shorter segments of bowel. Additional techniques include the Finney strictureplasty, classically used for longer strictures of 7 to 15 cm in length, where the diseased segment is opened longitudinally, the bowel is folded upon itself, and a full-thickness anastomosis is formed. In another method, an isoperistaltic strictureplasty is constructed such that the narrowed diseased portion of the bowel is anastomosed to the dilated segment of an adjacent loop in a side-to-side manner. Complications have been reported in 4% to 15% in large series, and include obstruction, bleeding, sepsis, perforation, and death.[94,95] Overall, 5-year recurrence rates for strictureplasty in jejunoileal and ileocolonic locations have been reported between 25% and 30%, including an ~3% site-specific recurrence. Similar to endoscopic dilation, malnutrition, presence of a phlegmon/perforation/fistula at the site, multiple strictures within a small segment, and suspicion of a malignancy are all contraindications to strictureplasty.[96]

Strictures at prior anastomotic sites may occur from recurrent disease or secondary to technical problems. They are often amenable to dilation,[97] yet they are often fibrotic in nature and nonresponsive, thus requiring resection for symptomatic strictures. To prevent this, evidence from systematic reviews and meta-analyses suggests that side-to-side stapled anastomoses in Crohn patients undergoing an ileocolonic resection have a decreased rate of postoperative complications (OR = 0.54), leak (OR = 0.45), recurrent (OR = 0.2), and reoperation (OR = 0.18) when compared to hand-sewn end-to-end anastomoses.[98,99]

MALIGNANCY

5 Historically, the risk of malignancy with Crohn disease was felt to be only slightly higher than the general population and significantly lower than the risk of patients with ulcerative colitis.[100] More recently, population-based data suggest that the cancer risk with long-standing Crohn's is ~4- to 20-fold above that of the average population, and equivalent to patients with ulcerative colitis. Known risk factors for malignancy include pancolitis (at least one-third) and a disease duration of >8 years.[101–103] Endoscopic surveillance strategies to detect malignancy have had to date mixed results.[104] Data from a large meta-analysis found that surveillance colonoscopy has not shown to effect survival in these patients, though lesions are typically detected earlier.[105,106]

The optimal surveillance strategy for patients with Crohn disease has not been determined. As such, most recommendations favor mimicking surveillance for ulcerative colitis in patients with Crohn colitis. In this algorithm, surveillance colonoscopy begins 8 years after disease onset for pancolitis and 15 years for patients with left-sided disease, and is repeated every 1 to 2 years. In addition, the American Society for GI Endoscopy, American College of Gastroenterology, and American Gastroenterological Association were unable to draw conclusions regarding the benefit or need to perform random surveillance biopsies.[107–109] Treatment for malignancy in the Crohn patient is similar to that of the general population, with resection following standard oncologic principles. As synchronous and metachronous lesions have been reported in up to 10%, consideration should be given to a subtotal colectomy with ileorectal anastomosis in the absence of rectal lesions.

While most evidence is from patients with ulcerative colitis, a polyp in a setting of colitis (nonadenoma dysplasia–associated lesion or mass-DALM) has traditionally felt to carry a significant risk of malignancy and is a strong indication for a formal resection.[101,110–113] While these nonadenoma-like DALMs should typically undergo a colectomy, more recent evidence suggests that complete endoscopic excision of an adenoma-like DALM (i.e., a sporadic adenoma occurring in a patient with colitis with or without active disease) may be safely undergo a surveillance protocol.[114] Low-grade dysplasia outside the setting of a nonadenoma-like DALM, and even in areas flat mucosa, warrants close follow-up, although the need for follow-up resection remains unproven.[101,113]

HEMORRHAGE

Patients with Crohn may complain of bloody stools, however, frank hemorrhage in Crohndisease is fairly uncommon. Possible sources include deep ulcerations, toxic colitis, an underlying mass, or concomitant diverticular bleed. Significant upper GI bleeding is also rare, and likely from a secondary source other than Crohn's (e.g., ulcer, varices, esophageal tear, malignancy). Similar to any other patient with a significant GI hemorrhage, patients require continued resuscitation, correction of any coagulopathy, and transfusion as indicated. Adjunctive measures such as intravascular vasopressin and infliximab have also been described,[115,116] though should not be considered first-line agents. Endoscopy is the most useful diagnostic and therapeutic maneuver for bleeding from either an upper or lower source. When endoscopy or medical therapy is unsuccessful or bleeding recurs, segmental resection is preferred when the source is localized in the large or small bowel. In the setting of unlocalized disease, every effort should be made to identify the source of bleeding, including upper and lower endoscopies, nuclear medicine scans, angiography, and small bowel evaluation (push endoscopy, video capsule endoscopy, or small bowel follow-through). However in the unstable or nonlocalizable lower source, a subtotal colectomy with end ileostomy may be required.[117] In the case of upper GI bleeding, the source may be localized and controlled with endoscopy or may require a resection or ligation as in patients without Crohn disease depending on the underlying pathology.

SPECIFIC CONSIDERATIONS

Gastroduodenal Disease

As stated, gastroduodenal disease occurs in 0.5% to 4% of all Crohn patients. The most common indications likely to require advanced or surgical intervention involve stricture/obstruction, fistula or bleeding. Isolated gastric disease is even more rare,[118] as the stomach will hardly ever be the sole source for the patient's complaints. It is important to exclude *H. pylori* infection, gastritis (NSAIDs), ulcers, and malignancy in the absence of disease elsewhere in the GI tract. Most patients will respond to medical management, especially with the anti–TNF-α therapy.[119] Gastric outlet obstruction at the level of the pylorus and first portion of the duodenum is often amenable to endoscopic balloon dilation, with avoidance of surgery in approximately half of patients.[120]

Duodenal strictures are more frequent with disease in this location, and case series have demonstrated successful amelioration of symptoms with endoscopic dilation.[121] More often, symptomatic duodenal strictures nonresponsive to medical therapy will be managed by strictureplasty, resection, or to a lesser extent, bypass (i.e., gastrojejujostomy). As previously noted, the type of strictureplasty will depend on the location, status of the surrounding tissues (i.e., ability to mobilize), and length of the stricture.[122] Fistulas typically arise from disease located more distally in the small bowel, and therefore require resection of the primary site with closure of the stomach or duodenum. Occasionally the upper tract is the original of the fistula and resection or bypass is required. With appropriate expertise, a laparoscopic approach has been associated with fewer complications and improved recovery. If bypass is performed, vagotomy is not needed; however, every effort should be made to avoid bypass if possible, as this is associated with worsening diarrhea and nutritional abnormalities.[123] For those cases where resection or closure of the duodenum is required, a jejunal serosal patch or Roux-en-Y duodenojejunostomy may help minimizing wound breakdown and recurrent fistulas.[124]

Small Bowel Disease

Most small bowel disease is amenable to surgical resection and primary anastomosis. As stated, strictureplasty is another option for those patients with short bowel, multiple sites of noncontiguous disease, and early recurrence – especially for those with noninflammatory patterns. Following resection, consideration should be given to the nutritional status of the patient, medications, and overall physiologic state, as diverting stoma may be required to minimize the incidence and consequences of an anastomotic leak. A minimally invasive approach, similar to other disease states, has been associated with improved short-term outcomes in Crohn patients including decreased morbidity, shorter length of stay, and reduced hospital charges for both primary and recurrent diseases.[125] In addition, despite some contradictory evidence, laparoscopy and open approaches appear to have similar long-term rates of disease recurrence.[126]

Bypass is rarely performed for small bowel disease. The rare case of a septic, obstructed patient with a large terminal ileum/ascending colon phlegmon involving the retroperitoneum that does not allow for safe mobilization or identification of the ureter and vascular anatomy may be one indication where bypass could still prove useful. These procedures have largely been abandoned as the underlying inflammatory process remains and has not been adequately addressed. Therefore, resection and strictureplasty continue to be the primary modalities to approach small bowel disease.

The mesentery in active Crohn disease always presents a particular challenge for surgeons. Due to its thick, edematous nature with increased neovascularization, adequate hemostasis is always a point of concern. Safe division in the era of open surgery involved techniques such as overlapping clamps with both mass and individual vessel suture ligation, where appropriate. Laparoscopic approaches typically rely on advanced vessel sealing devices for hemostasis, though they may be inadequate in the Crohn patient. Surgeons must then rely on other means such as placing an ENDOLOOP (Ethicon, Cincinnati, OH) on the major vessels or intracorporeal suturing. Crucial to whatever method is used is the notion to avoid mesenteric hematomas, as these may result in continued bleeding as well compromise the blood supply to the healthy remaining bowel.

Toxic Colitis

Toxic colitis may occur in Crohn patients similar to those with ulcerative colitis.[127] Following resuscitation and intravenous steroids or immunosuppressants, emergent surgical intervention is often required for those with recalcitrant disease, perforation, or a deteriorating clinical state. The operative procedure of choice is a subtotal colectomy with end-ileostomy. Debate exists as to the handling of the rectal stump, though options include a distal mucus fistula with remnant sigmoid, implantation into the subcutaneous space, or local reinforcement of the stump. Proctocolectomy should be avoided in this situation due to the prolonged operative time and increased risk of morbidity and mortality.

Table 50-4 Perioperative Complications of Bowel Resection in Crohn Patients*a*

Complication	Incidence
Bleeding	1–5%
Anastomotic leak	1.3–17%[b]
Anastomotic stricture	6–13%
Anastomotic recurrence of disease	15–39%
Bowel obstruction/ileus	5–23%
Abscess/intra-abdominal sepsis (excluding leak)	2.1–15%
Wound infection	10–33%
Thromboembolic	1.4–3.3%

[a]Risk factors: malnutrition, obesity, emergent surgery, immunosuppressant use, smoking, older age, open approach, stoma surgery.
[b]Depending on location and definition (clinical vs. radiologic).

Ileo-Anal Pouch

Ileo-anal pouch in the patient with Crohn disease most commonly occurs in the setting of an initial “mis”diagnosis of ulcerative colitis. More often to the point, the pouch is performed, and the patient will manifest Crohn disease at a later stage. While certain expert centers may advocate total proctocolectomy and ileal pouch construction for highly select patients with Crohn disease[128], in general, this is to be discouraged. Retrospective studies have reported 35% to 93% of patients will have Crohn’s-related complications such as pouchitis, abscesses, and pouch-anal fistulas, with another 10% requiring pouch excision or permanent diversion. Furthermore, roughly half of patients will experience urgency or continence issues. Of those patients with a functioning pouch, over half will continue to require medication to treat active Crohn disease[86,129,130] (Table 50-4).

6 A distinguishing characteristic of the surgical treatment for anorectal Crohn disease is to first consider whether or not they are symptomatic (see Algorithm 50-1). As a follow-on principle, aggressive intervention in the asymptomatic patient is unwarranted and potentially dangerous.

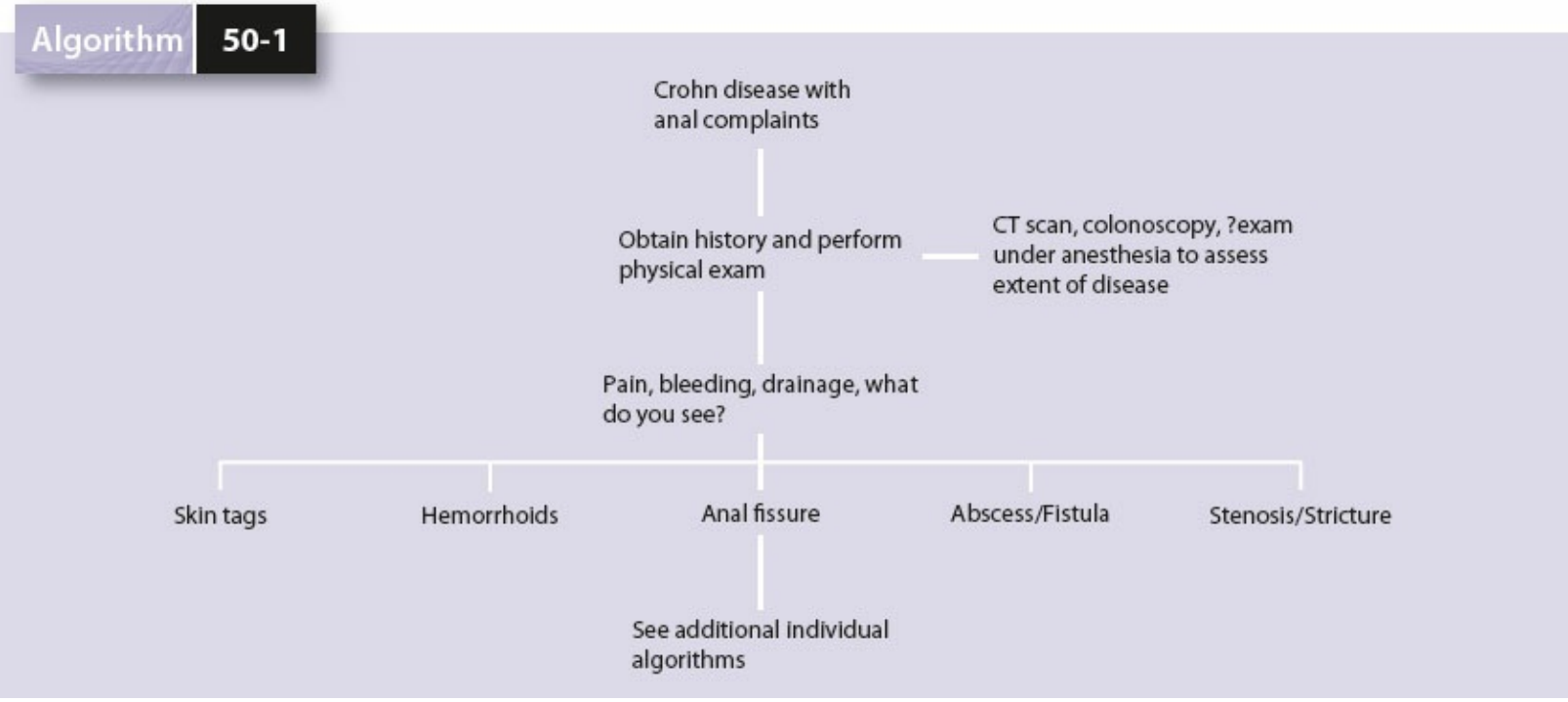

Algorithm 50-1. Crohn disease with anal complaints.

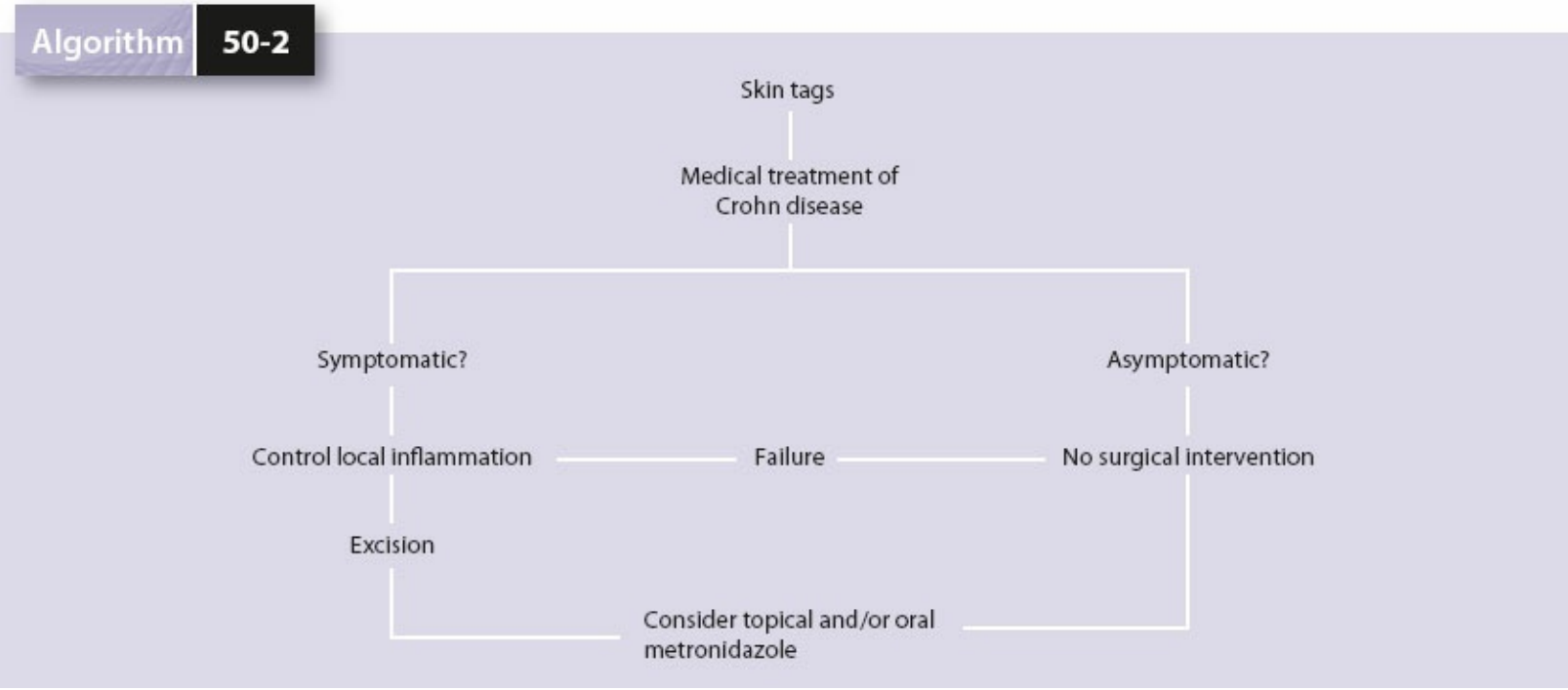

Algorithm 50-2. Anal skin tags in Crohn disease.

Specific Clinical Disease Processes

Anal Skin Tags and Hemorrhoids

7 Crohn patients often suffer from skin tags that appear as large, edematous, and blue colored (see Algorithms 50-2 and 50-3). Similarly, they may also suffer from internal and external hemorrhoids that may bleed, prolapsed, and cause difficulty with hygiene and irritation. It is important to keep in mind that Crohn patients have the propensity for poor healing, especially in the face of diarrhea. Patients should be counseled as to the risk of nonhealing wounds, continence problems, and mucus drainage.[131] Therefore, at least an initial attempt at conservative treatment with warm sitz baths and control of diarrhea is warranted. During this time, medical therapy toward Crohn should be also optimized, as active inflammation/proctitis will lead to increased morbidity. Should a conservative route fail, standard hemorrhoidectomy may be performed (in the absence of active proctitis). Topical metronidazole has been shown to improve posthemorrhoidectomy pain as well as improve healing, with very little downside.[132] Finally, although internal hemorrhoids may occur as in any other patient, they tend to be less symptomatic and often respond to conservative measures.

Anorectal Abscess/Fistula

Treatment of anorectal abscesses in the setting of Crohn is essentially no different than those of cryptoglandular origin – incision and drainage (see Algorithm 50-4). Crohn patients may have more extensive disease, and adjunct radiology testing may be useful, especially when the examination does not match the patient's symptoms. From a technical standpoint, it is important to place the incision as close to the anal verge as possible while still achieving adequate drainage, considering the possibility of fistula development.[133] Alternatively, a small pessar mushroom tipped catheter may be placed in the cavity, thus evacuating the abscess and allowing the cavity to close around the catheter, while allowing continued drainage.

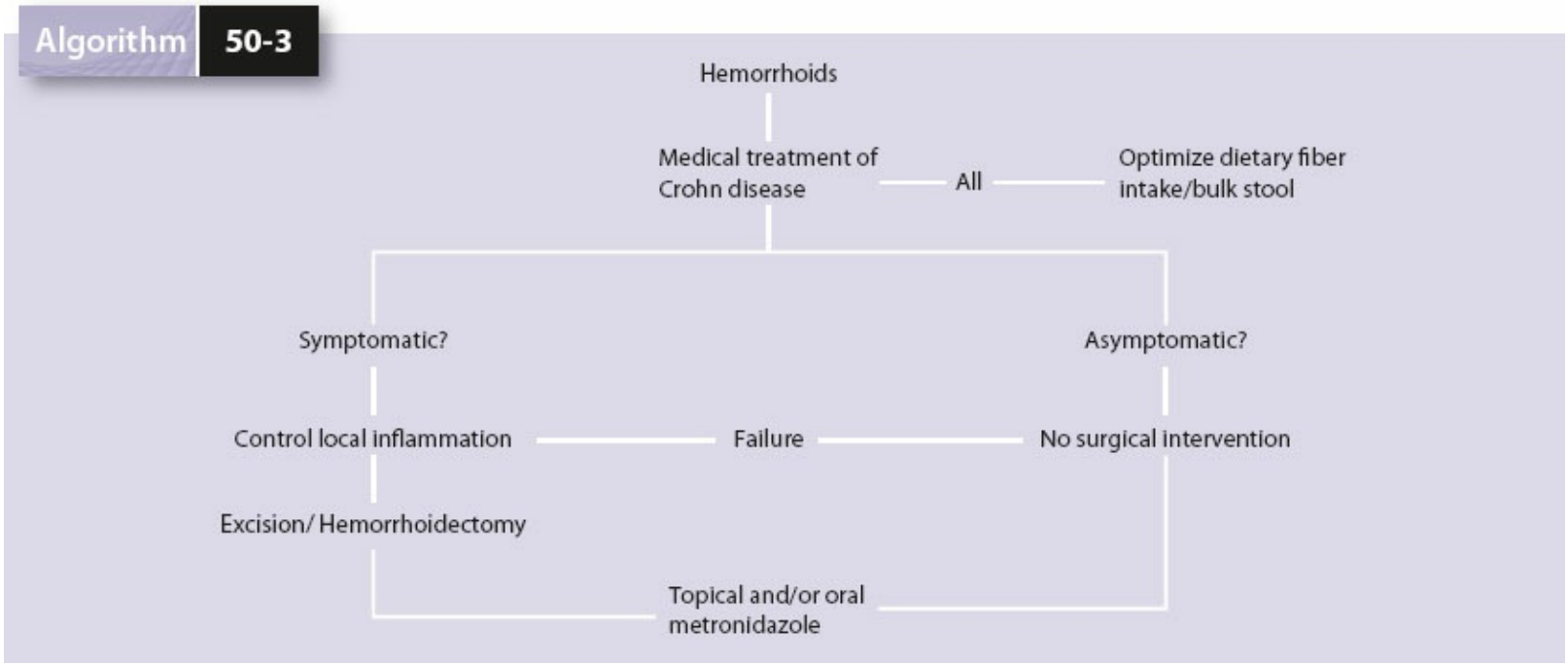

Algorithm 50-3. Hemorrhoids in Crohn disease.

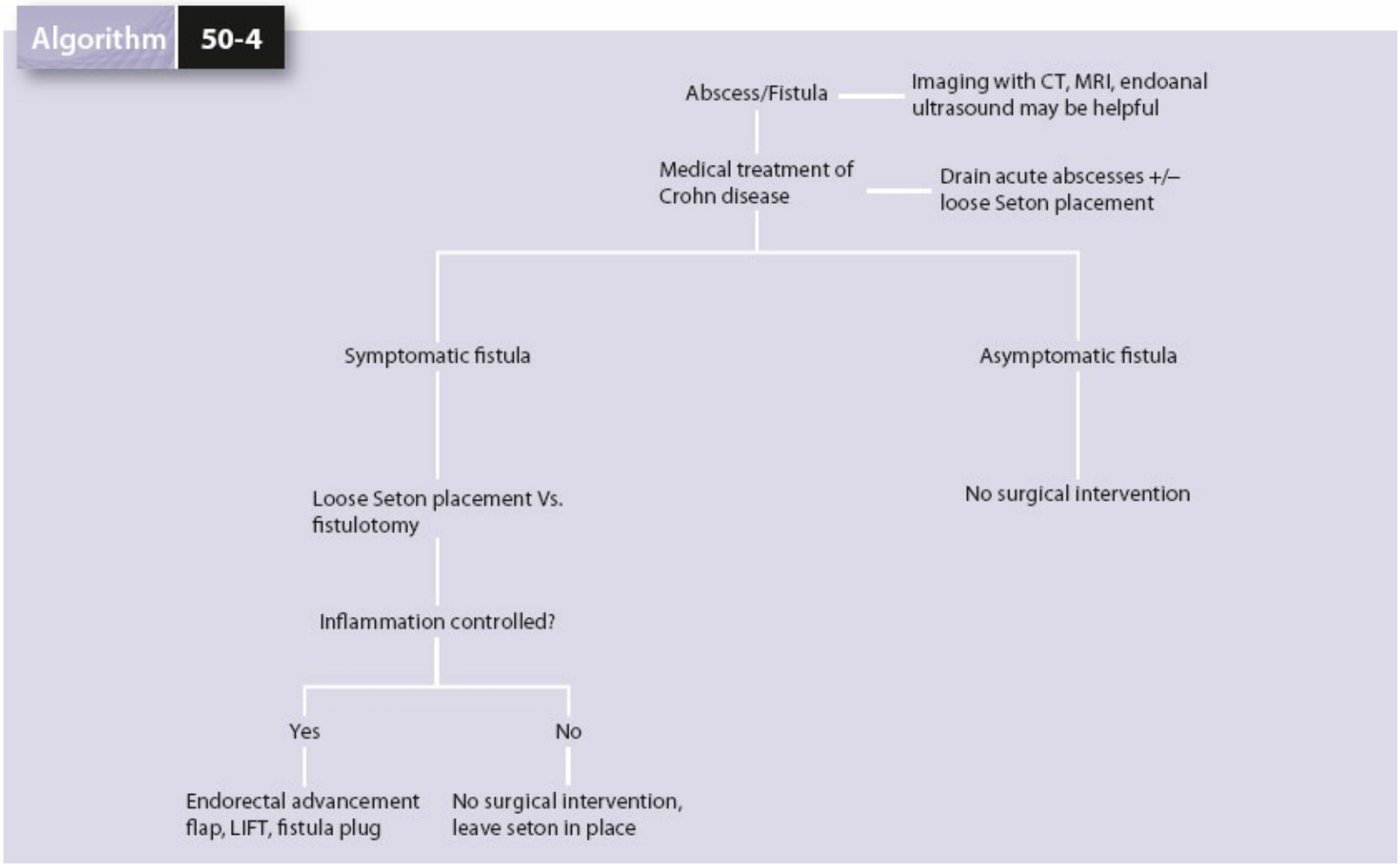

Algorithm 50-4. Anal abscess/fistula in Crohn disease.

Perianal fistulas are often deep, eroding through sphincter and occur in the setting of extensive scarring around the sphincter. Moreover, they can have high blind tracts, originate at levels well above the dentate line and are often found in conjunction with

active proctitis. Determining the anatomy of the tract is required, but attention should also be given to the presence or absence of proctitis, status of the sphincter, prior anal operations, and potential for chronic diarrhea (i.e., medically controlled or not). Aggressive fistulotomies must be avoided. Yet, low-lying fistulas in the absence of overt proctitis can often be treated safely with fistulotomy.[134] When the fistula is higher or more complex, endoanal advancement flaps, fistula plugs, or the LIFT procedure (ligation of the intersphincteric fistula tract) may all be performed with varying rates of success. Many patients with fistulous disease require chronic indwelling setons such as silastic vessel loops. Patients should be periodically reexamined both to ensure that there is adequate drainage, as well as to look for a potential malignant growth, with case reports of squamous cell and adenocarcinoma arising in a fistulous tract (Fig. 50-16). Unfortunately, fistulas and fistula procedures all vary in their outcomes, with healing rates ranging from 15% to 97% and morbidity rates 3% to 78%, making it difficult to accurately compare results. As such, consideration should be given for a diverting stoma for recurrent or complex fistulas. Finally, a small percentage of patients may require permanent diversion or even proctectomy.[135]

Rectovaginal/Anovaginal Fistula

Rectovaginal fistulas are particularly problematic in Crohn patients (Fig. 50-17). Because many of these fistulas are associated with a deeply erosive process and intense inflammation, extensive tracts and hidden associated abscesses may also be present. In addition, a rectovaginal fistula may originate from small bowel, thus limiting potential diagnostic methods such as the methylene blue enema. Many patients require diversion in this setting prior to any definitive repair to aid with control of proctitis and to optimize the conditions needed for successful healing. First-line options include use of the fistula plug, endorectal advancement flap, and LIFT procedure.[136] Due to the complexity of the wounds and need for healthy tissue interposition, muscle flaps (e.g., gracilis, bulbocavernosus) are especially useful, and may require a multidisciplinary team.

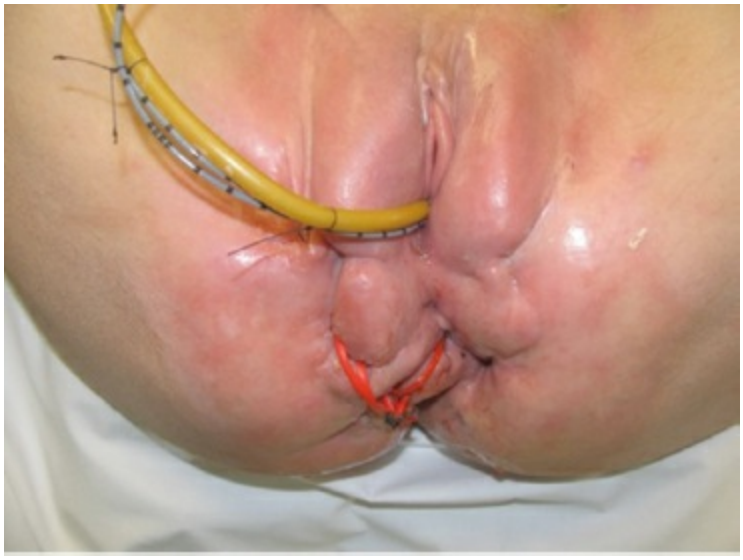

Figure 50-16. Adenocarcinoma arising out of a chronic fistula tract in a Crohn patient. (Courtesy of Howard Ross, MD.)



Figure 50-17. Rectovaginal fistula in a Crohn patient.

Anal Fissure

Patients with Crohn disease and anal fissures present a particular challenge. Decreasing the continence in any way may worsen an already difficult clinical situation, and limit the number of patients that may successfully undergo surgery (see Algorithm 50-5). Despite an appearance that is hallmarked by deep, burrowing, off the midline and sometimes multiple wounds (Fig. 50-18), many anal fissures are fortunately painless and require no intervention. Excessive pain should raise the suspicion for an underlying abscess and prompt an examination under anesthesia. Initial attempts at conservative therapy with topical metronidazole, smooth muscle relaxants and local anesthetics may be attempted to palliate symptoms and help with healing.[137] For particularly symptomatic fissures, botulinum toxin has also been used. In contrast, other authors have advocated a more aggressive surgical approach in Crohn patients, with one report citing 67% of patients who were treated surgically ultimately healed.[138] Yet, given the continence risks associated with surgery, medical management is the preferred initial therapy in patients with Crohn-related fissures. Surgical intervention should be reserved for those patients with minimal active anorectal inflammation who fail all reasonable conservative therapy, and still sphincter muscle division should be kept to a minimum.



Figure 50-18. Crohn fissure – notice the deep burrowing nature off the midline with signs of old fistula tracts.

Algorithm 50-5

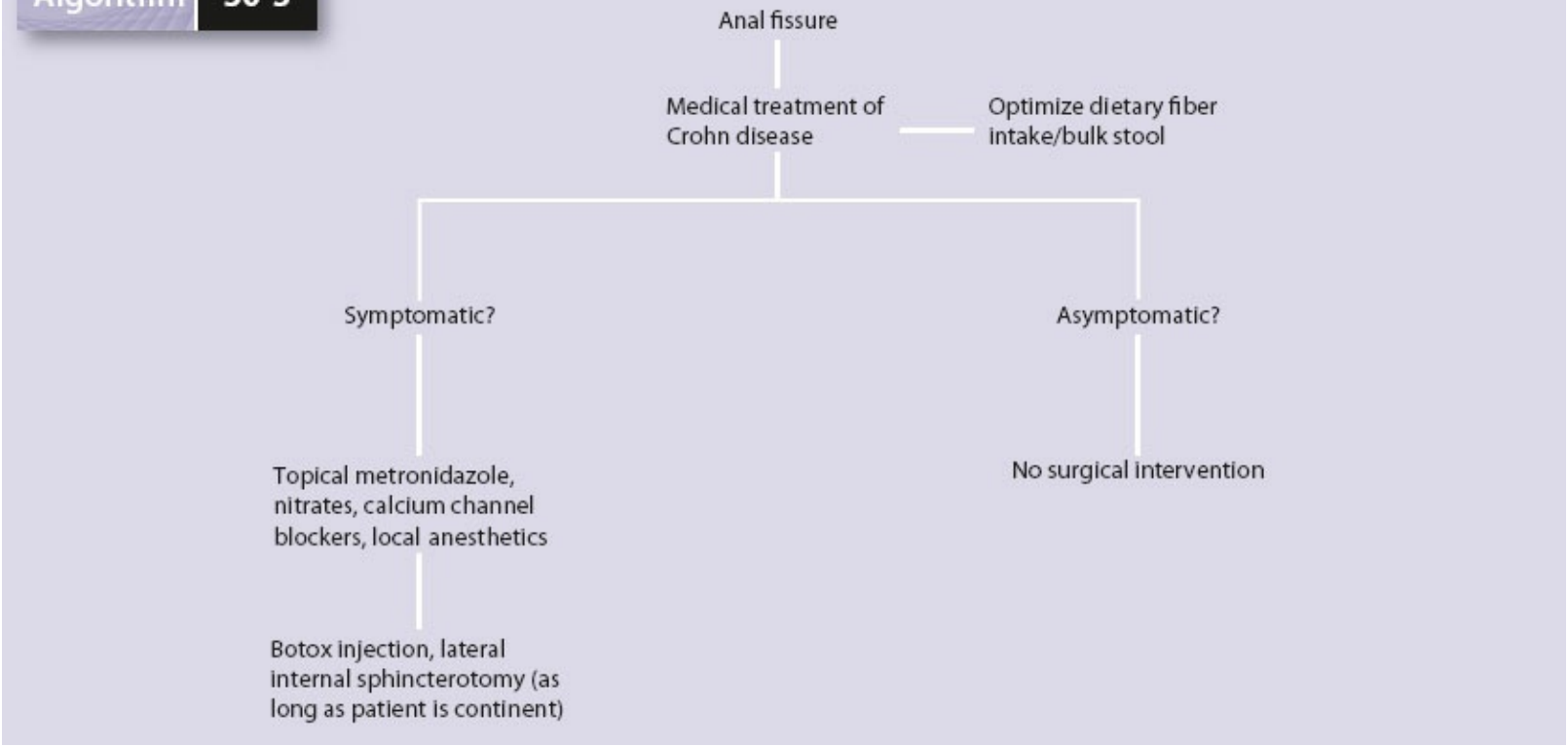

Algorithm 50-5. Anal fissure in Crohn disease.

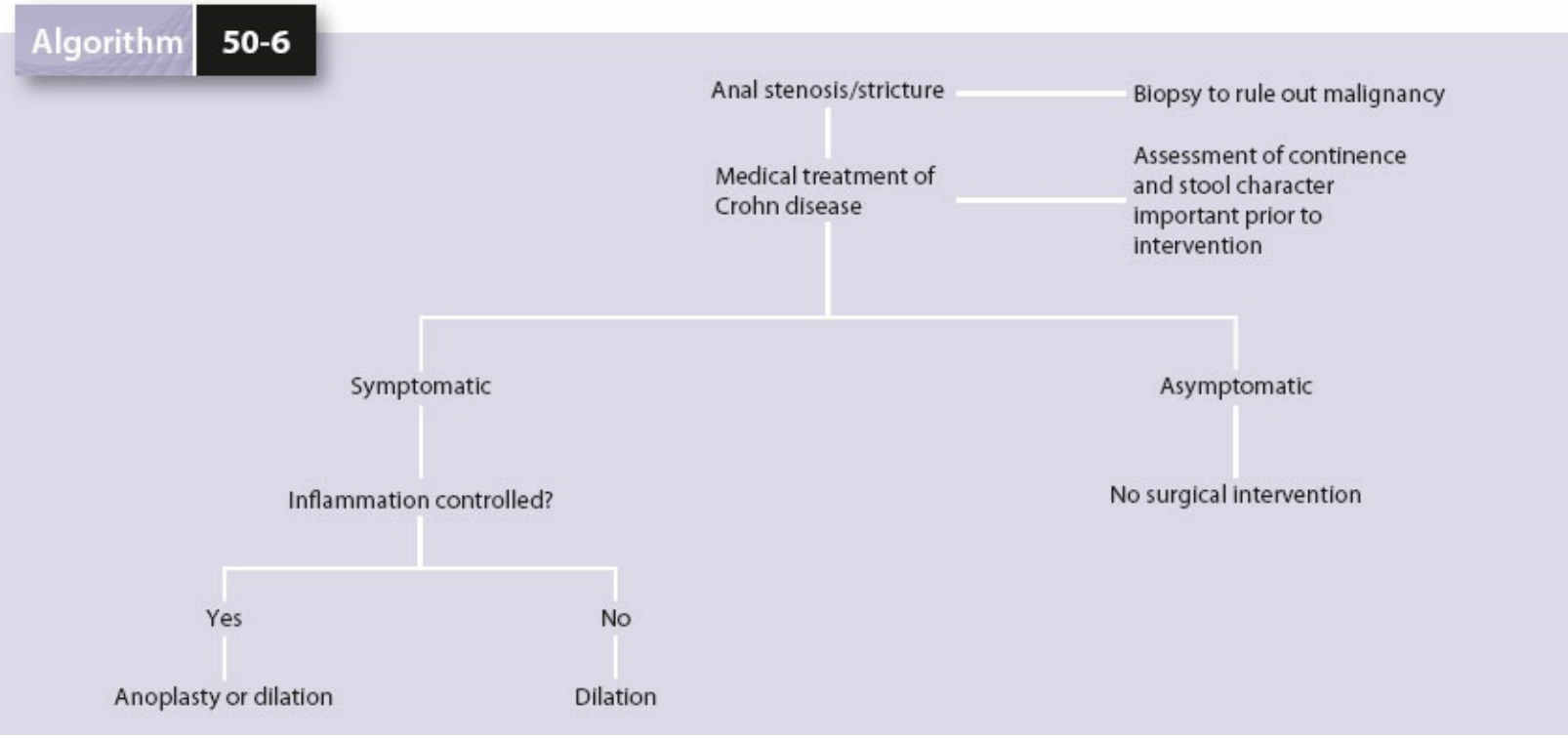

Algorithm 50-6. Anal stenosis/stricture and Crohn disease.

Anal Stenosis and Ulcer

Anal ulcers, stenosis, and strictures secondary to Crohn, while uncommon, can be extremely debilitating (see Algorithm 50-6). Single institutional series have demonstrated success rates of biologic agents in 18% to 60%.[139,140] Up to one-third of patients will have concomitant abscess or fistulas, and these should be appropriately drained. Due to the association of chronic inflammation with the development of malignancy, biopsy of any suspicious lesions should also be performed. For low-grade strictures, anal dilation has proven successful, though repeated session is the norm. Other options include steroid injection or biologics, balloon dilation, strictureplasty, flaps, and even proctectomy – depending on the severity and response to therapy.[141]

Anorectal Malignancy

Anorectal cancer may occur in any setting, including Crohn disease. Risk factors in patients with Crohn disease include the presence of chronic inflammation, long-standing open wounds, and use of immunosuppressant medication. Both squamous cell carcinoma (Marjolin ulcer), adenocarcinoma, and their variants may occur.[142] Patients (especially those with long-term indwelling setons) should be periodically examined to exclude the presence of malignancy. All suspicious lesions should undergo biopsy and any malignancy identified should undergo proper staging and treatment.

SUMMARY

Crohn disease remains a complex disease process with many different manifestations in the GI tract. Although advances in medical therapy continue to evolve and significantly alter the way patients are managed, surgeons still play a large role in both the medical and surgical therapies of the disease. Due to its recurring nature, surgeons must adhere to the principles of preventing and managing disease complications versus aiming for cure. By focusing on the maximization of functional outcomes, surgeons can optimize outcomes through a multimodality approach and minimize additional complications.

Financial Disclosure: No outside financial support or provision of supplies was solicited or received in connection with this work.

Disclosure and Proprietary Statement: This is an original work by the above authors. The opinions expressed are the authors' alone. They do not necessarily reflect the opinion of the United States Government, the US Department of Defense, or Madigan Army Medical Center.

References

1. Crohn BB, Ginzburg L, Oppenheimer GD. Regional ileitis: a pathologic and clinical entity. *JAMA* 1932;99(6):1323–1329.
2. Crohn BB, Ginzburg L, Oppenheimer GD. Landmark article Oct 15, 1932. Regional ileitis. A pathological and clinical entity. By Burril B. Crohn, Leon Ginzburg, and Gordon D. Oppenheimer. *JAMA* 1984; 251(1):73–79.
3. Zani A, Cozzi DA. Giovanni Battista Morgagni and his contribution to pediatric surgery. *J Pediatr Surg* 2008;43(4):729–733.
4. Whelan G, Farmer RG, Fazio VW, et al. Recurrence after surgery in Crohn's disease. Relationship to location of disease (clinical pattern) and surgical indication. *Gastroenterology* 1985;88(6):1826–1833.
5. Polito MJ, Childs B, Mellits ED, et al. Crohn's disease: influence of age at diagnosis on site and clinical type of disease. *Gastroenterology* 1996;111(3): 580–586.
6. Molodecky NA, Soon IS, Rabi DM, et al. Increasing incidence and prevalence of the inflammatory bowel diseases with time, based on systematic review. *Gastroenterology* 2012;142(1):46–54.
7. Loftus EV Jr, Silverstein MD, Sandborn WJ, et al. Crohn's disease in Olmsted County, Minnesota, 1940–1993: Incidence, prevalence, and survival. *Gastroenterology* 1998;114:1161–1168.
8. Halme L, Paavola-Sakki P, Turunen U, et al. Family and twin studies in inflammatory bowel disease. *World J Gastroenterol* 2006;12(23):3668–3672.
9. Yang H, McElree C, Roth MP, et al. Familial empirical risks for inflammatory bowel disease: differences between Jews and non-Jews. *Gut* 1993;34(4):517–524.
10. Halfvarson J, Bodin L, Tysk C, et al. Inflammatory bowel disease in a Swedish twin cohort: a long-term follow-up of concordance and clinical characteristics. *Gastroenterology* 2003;124(7):1767–1773.
11. Huttenhower C, Kostic AD, Xavier RJ. Inflammatory bowel disease as a model for translating the microbiome. *Immunity* 2014;40(6):843–854.
12. Reiff C, Kelly D. Inflammatory bowel disease, gut bacteria and probiotic therapy. *Int J Med Microbiol* 2010;300(1):25–33.
13. Macfarlane GT, Blackett KL, Nakayama T, et al. The gut microbiota in inflammatory bowel disease. *Curr Pharm Des* 2009;15(13):1528–1536.
14. Haag LM, Siegmund B. Exploring & exploiting our 'other self' - does the microbiota hold the key to the future therapy in Crohn's? *Best Pract Res Clin Gastroenterol* 2014;28(3):399–409.
15. Hugot JP, Laurent-Puig P, Gower-Rousseau C, et al. Mapping of a susceptibility locus for Crohn's disease on chromosome 16. *Nature* 1996;379:821–823.
16. Cho JH. The Nod2 gene in Crohn's disease: implications for future research into the genetics and immunology of Crohn's disease. *Inflamm Bowel Dis* 2001;7(3):271–275.

17. Műzes G, Tulassay Z, Sipos F. Interplay of autophagy and innate immunity in Crohn's disease: a key immunobiologic feature. *World J Gastroenterol* 2013;19(28):4447–4454.
18. Wallace KL, Zheng LB, Kanazawa Y, et al. Immunopathology of inflammatory bowel disease. *World J Gastroenterol* 2014;20(1):6–21.
19. Gilardoni LR, Paolicchi FA, Mundo SL. Bovine paratuberculosis: a review of the advantages and disadvantages of different diagnostic tests. *Rev Argent Microbiol* 2012;44(3):201–215.
20. Wagner J, Sim WH, Lee KJ, et al. Current knowledge and systematic review of viruses associated with Crohn's disease. *Rev Med Virol* 2013;23(3):145–171.
21. Cabré E, Domènech E. Impact of environmental and dietary factors on the course of inflammatory bowel disease. *World J Gastroenterol* 2012;18(29):3814–3822.
22. Yantiss RK, Odze RD. Diagnostic difficulties in inflammatory bowel disease pathology. *Histopathology* 2006;48(2):116–132.
23. Matsui T, Yao T, Sakurai T, et al. Clinical features and pattern of indeterminate colitis: Crohn's disease with ulcerative colitis-like clinical presentation. *J Gastroenterol* 2003;38(7):647–655.
24. Dias CC, Rodrigues PP, da Costa-Pereira A, et al. Clinical prognostic factors for disabling Crohn's disease: a systematic review and meta-analysis. *World J Gastroenterol* 2013;19(24):3866–3871.
25. Schwartz DA, Loftus EV Jr, Tremaine WJ, et al. The natural history of fistulizing Crohn's disease in Olmsted County, Minnesota. *Gastroenterology* 2002;122(4):875–880.
26. Farmer RG, Hawk WA, Turnbull RB Jr. Clinical patterns in Crohn's disease: a statistical study of 615 cases. *Gastroenterology* 1975;68(4 Pt 1):627–635.
27. Lapidus A, Bernell O, Hellers G, et al. Clinical course of colorectal Crohn's disease: a 35-year follow-up study of 507 patients. *Gastroenterology* 1998; 114(6):1151–1160.
28. Binder HJ. Mechanisms of diarrhea in inflammatory bowel diseases. *Ann N Y Acad Sci* 2009;1165:285–293.
29. Wenzl HH. Diarrhea in chronic inflammatory bowel diseases. *Gastroenterol Clin North Am* 2012;41(3):651–675.
30. Bissel AD. Localized chronic ulcerative ileitis. *Ann Surg* 1934;99:957–966.
31. McKee RF, Keenan RA. Perianal Crohn's disease–is it all bad news? *Dis Colon Rectum* 1996;39(2):136–142.
32. Homan WP, Tang C, Thorgjarnarson B. Anal lesions complicating Crohn disease. *Arch Surg* 1976;111(12):1333–1335.
33. Solomon MJ. Fistulae and abscesses in symptomatic perianal Crohn's disease. *Int J Colorectal Dis* 1996;11(5):222–226.
34. Isaacs KL. Upper gastrointestinal tract endoscopy in inflammatory bowel disease. *Gastrointest Endosc Clin N Am* 2002;12(3):451–462, vii.

35. Wagtmans MJ, van Hogezand RA, Griffioen G, et al. Crohn's disease of the upper gastrointestinal tract. *Neth J Med* 1997;50(2):S2–S7.
36. Decker GA, Loftus EV Jr, Pasha TM, et al. Crohn's disease of the esophagus: clinical features and outcomes. *Inflamm Bowel Dis* 2001;7(2):113–119.
37. Satsangi J, Grootscholten C, Holt H, et al. Clinical patterns of familial inflammatory bowel disease. *Gut* 1996;38(5):738–741.
38. Orchard TR, Thiyagaraja S, Welsh KI, et al. Clinical phenotype is related to HLA genotype in the peripheral arthropathies of inflammatory bowel disease. *Gastroenterology* 2000;118(2):274–278.
39. Rothfuss KS, Stange EF, Herrlinger KR. Extraintestinal manifestations and complications in inflammatory bowel diseases. *World J Gastroenterol* 2006; 12(30):4819–4831.
40. Rispo A, Musto D, Tramontano ML, et al. Surgery-induced remission of extraintestinal manifestations in inflammatory bowel diseases. *J Crohns Colitis* 2013;7(10):e504–e505.
41. Kelvin FM, Oddson TA, Rice RP, et al. Double contrast barium enema in Crohn's disease and ulcerative colitis. *AJR Am J Roentgenol* 1978;131(2):207–213.
42. Dambha F, Tanner J, Carroll N. Diagnostic imaging in Crohn's disease: what is the new gold standard? *Best Pract Res Clin Gastroenterol* 2014;28(3):421–436.
43. Spinelli A, Fiorino G, Bazzi P, et al. Preoperative magnetic resonance enterography in predicting findings and optimizing surgical approach in Crohn's disease. *J Gastrointest Surg* 2014;18(1):83–90.
44. Siddiki HA1, Fidler JL, Fletcher JG, et al. Prospective comparison of state-of-the-art MR enterography and CT enterography in small-bowel Crohn's disease. *AJR Am J Roentgenol* 2009;193(1):113–21.
45. Gallego Ojea JC, Echarri Piudo AI, Porta Vila A. [Crohn's disease: the usefulness of MR enterography in the detection of recurrence after surgery]. *Radiologia* 2011;53(6):552–559.
46. Vanbeckevoort D, Bielen D, Vanslembrouck R, et al. Magnetic resonance imaging of perianal fistulas. *Magn Reson Imaging Clin N Am* 2014;22(1):113–123.
47. Al-Hawary M, Zimmermann EM. A new look at Crohn's disease: novel imaging techniques. *Curr Opin Gastroenterol* 2012;28(4):334–340.
48. Shyn PB. 18F-FDG positron emission tomography: potential utility in the assessment of Crohn's disease. *Abdom Imaging* 2012;37(3):377–386.
49. Leighton JA, Gralnek IM, Cohen SA, et al. Capsule endoscopy is superior to small-bowel follow-through and equivalent to ileocolonoscopy in suspected Crohn's disease. *Clin Gastroenterol Hepatol* 2014;12(4):609–615.
50. Hall B, Holleran G, Costigan D, et al. Capsule endoscopy: High negative predictive value in the long term despite a low diagnostic yield in patients with suspected Crohn's disease. *United European Gastroenterol J* 2013; 1(6):461–466.

51. Carter D, Eliakim R. Current role of endoscopy in inflammatory bowel disease diagnosis and management. *Curr Opin Gastroenterol* 2014;30(4):370–377.
52. Joo M, Odze RD. Rectal sparing and skip lesions in ulcerative colitis: a comparative study of endoscopic and histologic findings in patients who underwent proctocolectomy. *Am J Surg Pathol* 2010;34(5):689–696
53. Kochhar R, Kochhar S. Endoscopic balloon dilation for benign gastric outlet obstruction in adults. *World J Gastrointest Endosc* 2010;2(1):29–35.
54. Ferreira J, Akbari M, Gashin L, et al. Prevalence and lifetime risk of endoscopy-related complications among patients with inflammatory bowel disease. *Clin Gastroenterol Hepatol* 2013;11(10):1288–1293.
55. Vucelic B. Inflammatory bowel diseases: controversies in the use of diagnostic procedures. *Dig Dis* 2009;27(3):269–277.
56. Morpurgo E, Petras R, Kimberling J, et al. Characterization and clinical behavior of Crohn's disease initially presenting predominantly as colitis. *Dis Colon Rectum* 2003;46(7):918–924.
57. Mahadeva U, Martin JP, Patel NK, et al. Granulomatous ulcerative colitis: a re-appraisal of the mucosal granuloma in the distinction of Crohn's disease from ulcerative colitis. *Histopathology* 2002;41(1):50–55.
58. Kim BG, Kim YS, Kim JS, et al. Diagnostic role of anti-Saccharomyces cerevisiae mannan antibodies combined with antineutrophil cytoplasmic antibodies in patients with inflammatory bowel disease. *Dis Colon Rectum* 2002;45(8):1062–1069.
59. Inoue K, Aomatsu T, Yoden A, et al. Usefulness of a novel and rapid assay system for fecal calprotectin in pediatric patients with inflammatory bowel diseases. *J Gastroenterol Hepatol* 2014;29(7):1406–1412.
60. Nancey S, Boschetti G, Moussata D, et al. Neopterin is a novel reliable fecal marker as accurate as calprotectin for predicting endoscopic disease activity in patients with inflammatory bowel diseases. *Inflamm Bowel Dis* 2013;19(5):1043–1052.
61. D'Haens G, Ferrante M, Vermeire S, et al. Fecal calprotectin is a surrogate marker for endoscopic lesions in inflammatory bowel disease. *Inflamm Bowel Dis* 2012;18(12):2218–2224.
62. Gisbert JP, McNicholl AG, Gomollon F. Questions and answers on the role of fecal lactoferrin as a biological marker in inflammatory bowel disease. *Inflamm Bowel Dis* 2009;15(11):1746–1754.
63. Abraham BP, Kane S. Fecal markers: calprotectin and lactoferrin. *Gastroenterol Clin North Am* 2012;41(2):483–495.
64. Weston LA, Roberts PL, Schoetz DJ, Jr., et al. Ileocolic resection for acute presentation of Crohn's disease of the ileum. *Dis Colon Rectum* 1996; 39(8):841–846.
65. Li G, Ren J, Wang G, et al. Preoperative exclusive enteral nutrition reduces the postoperative septic complications of fistulizing Crohn's disease. *Eur J Clin Nutr* 2014;68(4):441–446.

66. Caprilli R, Cesarini M, Angelucci E, et al. The long journey of salicylates in ulcerative colitis: The past and the future. *J Crohns Colitis* 2009;3(3):149–156.
67. Lim WC, Hanauer S. Aminosalicylates for induction of remission or response in Crohn's disease. *Cochrane Database Syst Rev* 2010;(12):CD008870.
68. Seow CH, Benchimol EI, Griffiths AM, et al. Budesonide for induction of remission in Crohn's disease. *Cochrane Database Syst Rev* 2008;(3):CD000296.
69. Prefontaine E, Macdonald JK, Sutherland LR. Azathioprine or 6-mercaptopurine for induction of remission in Crohn's disease. *Cochrane Database Syst Rev* 2010; (6):CD000545.
70. Alfadhli AA, McDonald JW, Feagan BG. Methotrexate for induction of remission in refractory Crohn's disease. *Cochrane Database Syst Rev* 2005;(1):CD003459.
71. Lapadula G, Marchesoni A, Armuzzi A, et al. Adalimumab in the treatment of immune-mediated diseases. *Int J Immunopathol Pharmacol* 2014; 27(1 suppl):33–48.
72. Scott FI, Osterman MT. Medical management of crohn disease. *Clin Colon Rectal Surg* 2013;26(2):67–74.
73. Kopylov U, Ben-Horin S, Zmora O, et al. Anti-tumor necrosis factor and postoperative complications in Crohn's disease: systematic review and meta-analysis. *Inflamm Bowel Dis* 2012;18(12):2404–2413.
74. Wolff BG. Resection margins in Crohn's disease. *Br J Surg* 2001;88(6):771–772.
75. Bernell O, Lapidus A, Hellers G. Recurrence after colectomy in Crohn's colitis. *Dis Colon Rectum* 2001;44(5):647–654.
76. Tekkis PP, Purkayastha S, Lanitis S, et al. A comparison of segmental vs subtotal/total colectomy for colonic Crohn's disease: a meta-analysis. *Colorectal Dis* 2006;8(2):82–90.
77. Scammell BE, Keighley MR. Delayed perineal wound healing after proctectomy for Crohn's colitis. *Br J Surg* 1986;73(2):150–152.
78. Raab Y, Bergstrom R, Ejerblad S, et al. Factors influencing recurrence in Crohn's disease. An analysis of a consecutive series of 353 patients treated with primary surgery. *Dis Colon Rectum* 1996;39(8):918–925.
79. Cellini C, Safar B, Fleshman J. Surgical management of pyogenic complications of Crohn's disease. *Inflamm Bowel Dis* 2010;16(3):512–517.
80. Sampietro GM, Casiraghi S, Foschi D. Perforating Crohn's disease: conservative and surgical treatment. *Dig Dis* 2013;31(2):218–221.
81. Poritz LS, Rowe WA, Koltun WA. Remicade does not abolish the need for surgery in fistulizing Crohn's disease. *Dis Colon Rectum* 2002;45(6):771–775.
82. Kawalec P, Mikrut A, Wiśniewska N, et al. Tumor necrosis factor-α antibodies (infliximab, adalimumab and certolizumab) in Crohn's disease: systematic review and meta-analysis. *Arch Med Sci* 2013;9(5):765–779.
83. Van Assche G, Geboes K, Rutgeerts P. Medical therapy for Crohn's disease strictures. *Inflamm Bowel Dis* 2004;10(1):55–60.

84. Bettenworth D, Rieder F. Medical therapy of stricturing Crohn's disease: what the gut can learn from other organs - a systematic review. *Fibrogenesis Tissue Repair* 2014;7(1):5.
85. Govani SM, Stidham RW, Higgins PD. How early to take arms against a sea of troubles? The case for aggressive early therapy in Crohn's disease to prevent fibrotic intestinal strictures. *J Crohns Colitis* 2013;7(11):923–927.
86. Brown CJ, Maclean AR, Cohen Z, et al. Crohn's disease and indeterminate colitis and the ileal pouch-anal anastomosis: outcomes and patterns of failure. *Dis Colon Rectum.*2005;48(8):1542–1549.
87. Yamazaki Y, Ribeiro MB, Sachar DB, et al. Malignant colorectal strictures in Crohn's disease. *Am J Gastroenterol* 1991;86(7):882–885.
88. Stienecker K, Gleichmann D, Neumayer U, et al. Long-term results of endoscopic balloon dilatation of lower gastrointestinal tract strictures in Crohn's disease: A prospective study. *World J Gastroenterol* 2009;15(21):2623–2627.
89. Swaminath A, Lichtiger S. Dilation of colonic strictures by intralesional injection of infliximab in patients with Crohn's colitis. *Inflamm Bowel Dis* 2008;14(2):213–216.
90. Despott EJ, Gupta A, Burling D, et al. Effective dilation of small-bowel strictures by double-balloon enteroscopy in patients with symptomatic Crohn's disease (with video). *Gastrointest Endosc* 2009;70(5):1030–1036.
91. Gill RS, Kaffes AJ. Small bowel stricture characterization and outcomes of dilatation by double-balloon enteroscopy: a single-centre experience. *Therap Adv Gastroenterol* 2014;7(3):108–114.
92. Hirai F, Beppu T, Takatsu N, et al. Long-term outcome of endoscopic balloon dilation for small bowel strictures in patients with Crohn's disease. *Dig Endosc* 2014;26(4):545–551.
93. Endo K, Takahashi S, Shiga H, et al. World J Short and long-term outcomes of endoscopic balloon dilatation for Crohn's disease strictures. *World J Gastroenterol* 2013;19(1):86–91.
94. Yamamoto T, Fazio VW, Tekkis PP. Safety and efficacy of strictureplasty for Crohn's disease: a systematic review and meta-analysis. *Dis Colon Rectum* 2007;50(11):1968–1986.
95. Campbell L, Ambe R, Weaver J, et al. Comparison of conventional and nonconventional strictureplasties in Crohn's disease: a systematic review and meta-analysis. *Dis Colon Rectum* 2012;55(6):714–726.
96. Hesham W, Kann BR. Strictureplasty. *Clin Colon Rectal Surg* 2013;26(2):80–83.
97. Chen M, Shen B. Comparable Short- and Long-term Outcomes of Colonoscopic Balloon Dilation of Crohn's Disease and Benign Non-Crohn's Disease Strictures. *Inflamm Bowel Dis* 2014;20(10):1739–1746.
98. He X, Chen Z, Huang J, et al. Stapled side-to-side anastomosis might be better than handsewn end-to-end anastomosis in ileocolic resection for Crohn's disease: a meta-

analysis. *Dig Dis Sci* 2014;59(7):1544–1551.

99. Simillis C, Purkayastha S, Yamamoto T, et al. A meta-analysis comparing conventional end-to-end anastomosis vs. other anastomotic configurations after resection in Crohn's disease. *Dis Colon Rectum* 2007;50(10):1674–1687.
100. Greenstein AJ, Sachar DB, Smith H, et al. Patterns of neoplasia in Crohn's disease and ulcerative colitis. *Cancer* 1980;46(2):403–407.
101. Jess T, Loftus EV Jr, Velayos FS, et al. Risk of intestinal cancer in inflammatory bowel disease: a population-based study from Olmsted county, Minnesota. *Gastroenterology* 2006;130(4):1039–1046.
102. Maykel JA, Hagerman G, Mellgren AF, et al. Crohn's colitis: the incidence of dysplasia and adenocarcinoma in surgical patients. *Dis Colon Rectum* 2006;49(7):950–957.
103. Friedman S, Rubin PH, Bodian C, et al. Screening and surveillance colonoscopy in chronic Crohn's colitis. *Gastroenterology* 2001;120(4):820–826.
104. Siegel CA, Sands BE. Risk factors for colorectal cancer in Crohn's colitis: a case-control study. *Inflamm Bowel Dis* 2006;12(6):491–496.
105. Shanahan F. Review article: colitis-associated cancer – time for new strategies. *Aliment Pharmacol Ther* 2003;18 suppl 2:6–9.
106. Collins PD, Mpofu C, Watson AJ, et al. Strategies for detecting colon cancer and/or dysplasia in patients with inflammatory bowel disease. *Cochrane Database Syst Rev* 2006;(2):CD000279.
107. Hanauer SB, Meyers S. Management of Crohn's disease in adults. *Am J Gastroenterol* 1997;92(4):559–566.
108. Farraye FA, Odze RD, Eaden J, et al; AGA Institute Medical Position Panel on Diagnosis and Management of Colorectal Neoplasia in Inflammatory Bowel Disease. AGA medical position statement on the diagnosis and management of colorectal neoplasia in inflammatory bowel disease. *Gastroenterology* 2010;138(2):738–745.
109. Leighton JA, Shen B, Baron TH, et al; Standards of Practice Committee, American Society for Gastrointestinal Endoscopy. ASGE guideline: endoscopy in the diagnosis and treatment of inflammatory bowel disease. *Gastrointest Endosc* 2006;63(4):558–565.
110. Cooper DJ, Weinstein MA, Korelitz BI. Complications of Crohn's disease predisposing to dysplasia and cancer of the intestinal tract: considerations of a surveillance program. *J Clin Gastroenterol* 1984;6(3):217–224.
111. Itzkowitz SH, Harpaz N. Diagnosis and management of dysplasia in patients with inflammatory bowel diseases. *Gastroenterology* 2004;126(6):1634–1648.
112. Greenson JK. Dysplasia in inflammatory bowel disease. *Semin Diagn Pathol* 2002;19(1):31–37.
113. Befrits R, Ljung T, Jaramillo E, et al. Low-grade dysplasia in extensive, long-standing inflammatory bowel disease: a follow-up study. *Dis Colon Rectum* 2002;45(5):615–

620.
114. Wanders LK, Dekker E, Pullens B, et al. Cancer risk after resection of polypoid dysplasia in patients with longstanding ulcerative colitis: a meta-analysis. *Clin Gastroenterol Hepatol* 2014;12(5):756–764.
115. Alla VM, Ojili V, Gorthi J, et al. Revisiting the past: intra-arterial vasopressin for severe gastrointestinal bleeding in Crohn's disease. *J Crohns Colitis* 2010;4(4):479–482.
116. Ando Y, Matsushita M, Kawamata S, et al. Infliximab for severe gastrointestinal bleeding in Crohn's disease. *Inflamm Bowel Dis* 2009;15(3):483–484.
117. Veroux M, Angriman I, Ruffolo C, et al. Severe gastrointestinal bleeding in Crohn's disease. *Ann Ital Chir* 2003;74(2):213–215; discussion 216.
118. Firth MG, Prather CM. Unusual gastric Crohn's disease treated with infliximab - a case report. *Am J Gastroenterol* 2002;97:S190.
119. Banerjee S, Peppercorn MA. Inflammatory bowel disease. Medical therapy of specific clinical presentations. *Gastroenterol Clin North Am* 2002;31:185–202
120. Rana SS, Bhasin DK, Chandail VS, et al. Endoscopic balloon dilatation without fluoroscopy for treating gastric outlet obstruction because of benign etiologies. *Surg Endosc* 2011;25(5):1579–1584.
121. Singh VV, Draganov P, Valentine J. Efficacy and safety of endoscopic balloon dilation of symptomatic upper and lower gastrointestinal Crohn's disease strictures. *J Clin Gastroenterol* 2005;39(4):284–290.
122. Tonelli F, Alemanno G, Bellucci F, et al. Symptomatic duodenal Crohn's disease: is strictureplasty the right choice? *J Crohns Colitis* 2013;7(10):791–796.
123. Shapiro M, Greenstein AJ, Byrn J, et al. Surgical management and outcomes of patients with duodenal Crohn's disease. *J Am Coll Surg* 2008;207(1):36–42.
124. Pettit S, Irving M. The operative management of fistulating Crohn's disease—experience with 100 consecutive cases. *Surg Gynecol Obstet* 1988;167:223–228.
125. Lesperance K, Martin M J, Lehmann R, et al. National trends and outcomes for the surgical therapy of ileocolonic Crohn's disease: a population-based analysis of laparoscopic vs. open approaches. *J Gastrointest Surg* 2009;13(7):1251–1259
126. Aarons CB. Laparoscopic surgery for Crohn disease: a brief review of the literature. *Clin Colon Rectal Surg* 2013;26(2):122–127.
127. Stewart D, Chao A, Kodner I, et al. Subtotal colectomy for toxic and fulminant colitis in the era of immunosuppressive therapy. *Colorectal Dis* 2009;11(2):184–190.
128. Joyce MR, Fazio VW. Can ileal pouch anal anastomosis be used in Crohn's disease? *Adv Surg* 2009;43:111–137.
129. Hartley JE, Fazio VW, Remzi FH, et al. Analysis of the outcome of ileal pouch-anal anastomosis in patients with Crohn's disease. *Dis Colon Rectum* 2004;47(11):1808–1815.
130. Braveman JM, Schoetz DJ Jr, Marcello PW, et al. The fate of the ileal pouch in

patients developing Crohn's disease. *Dis Colon Rectum* 2004;47(10):1613–1619.

131. Cracco N, Zinicola R. Is haemorrhoidectomy in inflammatory bowel disease harmful? An old dogma re-examined. *Colorectal Dis* 2014;16(7):516–519.
132. Nicholson TJ, Armstrong D. Topical metronidazole (10 percent) decreases posthemorrhoidectomy pain and improves healing. *Dis Colon Rectum* 2004;47(5):711–716.
133. Lewis RT, Bleier JI. Surgical treatment of anorectal Crohn disease. *Clin Colon Rectal Surg* 2013;26(2):90–99.
134. Sneider EB, Maykel JA. Anal abscess and fistula. *Gastroenterol Clin North Am* 2013;42(4):773–784.
135. Causey MW, Nelson D, Johnson EK, et al. An NSQIP evaluation of practice patterns and outcomes following surgery for anorectal abscess and fistula in patients with and without Crohn's disease. *Gastroenterol Rep (Oxf)* 2013;1(1):58–63.
136. Tozer PJ, Balmforth D, Kayani B, et al. Surgical management of rectovaginal fistula in a tertiary referral centre: many techniques are needed. *Colorectal Dis* 2013;15(7):871–877.
137. D'Ugo S, Franceschilli L, Cadeddu F, et al. Medical and surgical treatment of haemorrhoids and anal fissure in Crohn's disease: a critical appraisal. *BMC Gastroenterol* 2013;13:47.
138. Fleshner PR, Schoetz DJ Jr, Roberts PL, et al. Anal fissure in Crohn's disease: a plea for aggressive management. *Dis Colon Rectum* 1995;38(11):1137–1143.
139. Brochard C, Siproudhis L, Wallenhorst T, et al. Anorectal stricture in 102 patients with Crohn's disease: natural history in the era of biologics. *Aliment Pharmacol Ther* 2014;40(7):796–803.
140. Bouguen G, Trouilloud I, Siproudhis L, et al. Long-term outcome of non-fistulizing (ulcers, stricture) perianal Crohn's disease in patients treated with infliximab. *Aliment Pharmacol Ther* 2009;30(7):749–756.
141. Lawal TA, Frischer JS, Falcone RA, et al. The transanal approach with laparoscopy or laparotomy for the treatment of rectal strictures in Crohn's disease. *Laparoendosc Adv Surg Tech A* 2010;20(9):791–795.
142. Scharl M, Frei P, Frei SM, et al. Epithelial-to-mesenchymal transition in a fistula-associated anal adenocarcinoma in a patient with long-standing Crohn's disease. *Eur J Gastroenterol Hepatol* 2014;26(1):114–118.

Chapter 51

Small Bowel Tumors

Steven G. Leeds and James W. Fleshman

Key Points

1 The main types of primary small bowel tumors include adenoma, adenocarcinoma, neuroendocrine (carcinoid), lymphoma, and sarcoma (GIST). Surgical resection remains the treatment of choice for all except lymphoma (only needed for symptomatic lesions causing obstruction or bleeding).

2 There is a rising incidence of small bowel tumors, directly caused by a relative increase in the incidence of carcinoid tumors over adenocarcinoma of the small bowel. This trend is occurring globally.

3 Research is now focused on the molecular cause of the discrepancy between the number of small bowel and colorectal adenocarcinomas.

4 Size and location influence the symptoms caused by tumors within the small bowel. The majority of tumors found incidentally are asymptomatic.

5 Capsule endoscopy (CE) is helpful for diagnosis but lack of spatial orientation, inability to biopsy, and capsule retention causing obstruction limit its usefulness. Small bowel enteroscopy, device-assisted enteroscopy (DAE), or deep enteroscopy (DE), are excellent alternative modalities.

6 Even though small neuroendocrine tumors (NETs) can metastasize, the risk of metastasis correlates with the size of the primary tumor.

7 There are three common radiographic modalities used to diagnose small bowel tumors which include CT scan, MRI and CT, or MR enterography. NETs also benefit from octreotide scanning as a functional scan to detect metastasis.

8 Chromogranin A tends to be the most sensitive indicator of recurrence during surveillance of NET, and sensitivity and specificity depends on the functionality of the tumor.

9 Gastrointestinal stromal tumors (GISTs) arise from pacemaker cells (Interstitial cells of Cajal) of the small intestine and, based on mutations in the c-kit proto-oncogene region of the tyrosine kinase gene, respond to imitanib (tyrosine kinase inhibitor) monoclonal antibody. Surgical resection remains the only curative method of treatment.

10 Melanoma is the most common extraintestinal malignancy with predilection to metastasize to the small bowel.

INTRODUCTION

1 The small bowel can give rise to both malignant and benign neoplasms. It comprises about 75% of the entire length of the gastrointestinal tract and provides about 90% of its mucosal surface area, but surprisingly these neoplasms represent less than 5% of the cancer affecting the entire gastrointestinal tract.[1] Even so, small bowel cancer causes significant morbidity and mortality because of its potential to metastasize and to invade critical structures in the abdomen and retroperitoneum. The main types of malignancy include adenocarcinoma, neuroendocrine (carcinoid), lymphoma, and sarcoma (GIST). Several benign neoplasms such as lipomas, hamartomas, leiomyomas, and desmoid tumors are found in the small intestines. Recent large database queries have demonstrated that the most common malignancy is now carcinoid. Adenocarcinoma formerly was the most common, but the rising incidence of carcinoid tumors has recently surpassed it.[2,3] The relative inaccessibility of the small bowel endoscopically presents several difficulties in diagnosis, results in a delay in diagnosis, and yields advanced disease or metastatic disease at the time of treatment. There is some utility for upper endoscopy (EGD), but the progress in Pillcam endoscopy and small bowel enteroscopy has improved the ability to diagnose, and possibly treat, these neoplasms. Exploratory laparoscopy can also be utilized for diagnosis and in the treatment of these tumors. Once diagnosed, management varies based on the type of neoplasm. Metastatic tumors to the small bowel are rare, but direct invasion, and carcinomatosis tends to be the common presentation for nonprimary tumors. Operative treatment with extended resection is not possible with the small bowel like the extent of resection that can be performed in the colon. Now, treatment modalities and multidisciplinary approaches may offer improved survival.

EPIDEMIOLOGY

2 The American Cancer Society estimates that 6,900 new cases of small bowel cancer will be seen in 2015 with an estimated 1,100 deaths.[4] The incidences increased from the 2008 query estimating 6,110 new cases of small bowel cancer and about the same number of deaths, approximately 1,110.[5] These reports indicate a rising incidence of small bowel cancers, and are directly caused by the increasing incidence of carcinoid tumors of the small bowel.[2] This trend is occurring not only in the United States, but across the world. A recent review of cancer incidence showed a rising incidence of small bowel carcinoid tumors in England. The same rising incidence is demonstrated in the United States, along with a change in the distribution of the carcinoid tumors along the length of the small bowel.[3]

In the population below the age of 40, the incidence of small bowel neoplasms is low. The incidence for males and females is essentially the same. Sporadic, nonfamilial cancer occurs rarely in young patients.

PATHOGENESIS

With respect to the entire gastrointestinal tract, small bowel cancers are relatively rare. This raises the question as to why the region of the GI tract with the largest surface area has the lowest rate of cancer. Several factors have been identified as potential explanations; (1) the small bowel has liquid contents with an alkaline pH exposing the mucosa to a decrease in mechanical and chemical inflammation, (2) transit through the small bowel is rapid, thus shortening the time carcinogens are in contact with the mucosal surface, (3) there is a rapid turnover in epithelial cells in the mucosa outpacing the potential growth and development of neoplastic cells, (4) there is lower luminal bacterial load, particularly of anaerobes, which results in less total production of potential carcinogens, (5) the small bowel mucosa has an apparent enhanced ability to metabolize and/or detoxify certain dietary components or breakdown products that may be carcinogenic, and (6) the elaborate lymphoid tissue network surrounding the small bowel, and in particular, its ability to secrete immunoglobulin A, which might confer an increased immunologic-related tumor control.[1]

3 The discrepancy between the number of small bowel adenocarcinomas and colorectal adenocarcinomas has pushed the research to a molecular level. There is substantial effort toward identifying the pathways for the mutation resulting in these cancers. These pathways include K-ras, E-cadherin, β-catenin, and p-53. The largest study of small bowel adenocarcinomas, $n = 21$, analyzed a variety of genes known to be involved with tumor mutagenesis in nonhereditary and nonperiampullary small bowel adenocarcinomas. The outcomes showed that all tumors presented with the hMLH1 and hMSH2 (usually absent in mismatch repair defective inherited tumors) genes in the tumor nuclei. No APC gene mutations were detected. One specimen had a replication error (RER). β-Catenin was expressed in 17 specimens, 8 specimens had decreased or no expression of E-cadherin, and 5 specimens had overexpression of p-53.[6] This finding illustrates that the pathway to cancer that small bowel adenocarcinoma follows is different from the colorectal pathway.

PREDISPOSITION TO SMALL BOWEL CANCER

There are several predisposing risk factors for development of small bowel cancers. These include genetic and environmental factors.

Familial Adenomatous Polyposis

These patients have hundreds, and even thousands, of adenomas in their gastrointestinal tract, and have a 100% transformation rate to colorectal cancer if untreated. Interestingly, the leading cause of death for patients with familial adenomatous polyposis (FAP) is not the progression of colorectal cancer, due to the fact that most of the patients undergo a total colectomy. It is actually the malignant transformation of the periampullary adenoma to adenocarcinoma.[1]

Crohn Disease

Crohn disease is a significant risk factor to develop small bowel adenocarcinoma. The duration of disease, distal jejunal or ileal disease, early age of diagnosis, fistulizing-type disease, and male gender all contribute to a higher risk for development of small bowel adenocarcinoma.[7] The relative risk was reported as 33 (95% CI: 15.9 to 60.9).[8] The areas particularly susceptible are where longstanding inflammation has caused stricture formation. In these areas, the tumor tends to occur after at least 10 years of inflammation, and commonly contains signet-ring cell features similar to those found in colon cancer due to ulcerative colitis.

Celiac Disease

There is an increased risk for small bowel lymphomas as well as small bowel adenocarcinoma with those patients affected by celiac disease. Lymphomas tend to be both T-cell and non-Hodgkin lymphomas.[9]

Peutz–Jeghers Syndrome

This is an autosomal dominant syndrome characterized by hamartomatous polyps in the gastrointestinal tract and mucocutaneous melanin pigmentation. The increased risk of cancer is for breast, ovarian, testicular, pancreas, stomach, esophagus, and others. The mutation has been identified on the serine/threonine kinase 11 (STK 11) gene. Meta-analysis of Peutz–Jeghers syndrome indicated a relative risk for small bowel cancer of 520 when compared to the general population.[10]

Hereditary Nonpolyposis Colorectal Cancer

Hereditary nonpolyposis colorectal cancer (HNPCC) is an autosomal dominant gene that is associated with the mutation of mismatch repair genes. There is an increased risk to develop small bowel cancer with a relative risk of greater than 100 in carriers for the gene mutation.[11]

Other Familial Syndromes

Multiple endocrine neoplasia type 1 (MEN-1), von Hippal–Lindau syndrome, and neurofibromatosis type 1 all carry increased risk for developing neuroendocrine, or carcinoid tumors.[9]

Dietary and Lifestyle Predisposition

There are several indicators to the increased risk of developing small bowel cancer including cigarette smoking, increased BMI/obesity, red meat consumption, and alcohol consumption.[9]

CLINICAL PRESENTATION

4 The majority of these tumors, whether benign or malignant, are typically asymptomatic and are encountered incidentally. The biggest factor relating to the way small bowel tumors present is the size and location within the small bowel. Generally, tumors less than 4 cm are asymptomatic. This is even truer with benign lesions. The most common presenting symptoms are weight loss (30% to 50%), nausea, vomiting, anemia, and abdominal pain.[9] Late detection of asymptomatic malignant tumors results in metastases in about 50% of patients at the time of diagnosis.[12] Ulceration, perforation (in cases of lymphoma), obstruction, or bleeding are the most common presenting symptoms.[13] Intussusception or volvulus can occur rarely. NETs can present as functional syndromes, such as “carcinoid syndrome” with flushing, diarrhea, and tachycardia with late valvular dysfunction due to fibrotic scarring induced by serotonin (Table 51-1).

DIAGNOSIS

Examining the small bowel with accuracy is a difficult process. Upper and lower gastrointestinal endoscopy provides little information because of the limited access to the vast amount of mucosal surface. Colonoscopic intubation of the ileocecal valve is ideal but is not possible in about 5% to 10% of the patients.[14] Even with this intubation, only the most distal 25 cm of the terminal ileum can be surveyed. During upper endoscopy (EGD) the duodenum is visualized in the proximal portion typically leaving the distal duodenum and the rest of the small bowel unevaluated. In certain cases, and with maximal effort, the endoscope can be advanced beyond the ligament of Treitz. However, the risk of duodenal injury increases due to pressure in the curve of the duodenum. Nevertheless, both of these procedures are indicated to begin the workup. The entire small bowel needs to be evaluated for a source of the symptoms. Newer modalities have been developed to facilitate evaluation of the small bowel.

Table 51-1 Complications Resulting From Small Bowel Tumors

Complication	Details
Weight loss	30–50% of patients History and physical examination of the patient
Nausea/vomiting	Nonspecific finding
Obstruction	Include in differential for patients never undergoing an abdominal surgery Diagnosis made with radiographs or CT scan
Ulceration/bleeding	Commonly with lymphoma Mass can be seen on CT scan, but ulceration and bleeding found with capsule endoscopy or deep endoscopy
Perforation	Emergent surgical management May see free air on radiographs or CT scan
Metastasis	50% metastasis with incidence of malignant small bowel tumors at time of diagnosis

CAPSULE ENDOSCOPY

CE is an ingestible miniature camera that is capable of producing images throughout the small bowel to depict its entire mucosal lining. CE was introduced first in 2000. CE is used most commonly to evaluate the small bowel for a source of occult gastrointestinal bleed (OGIB).

Generally, CE is safe and widely used as a diagnostic test.[15] The only contraindications to its use are patients having swallowing disorders or bowel obstruction, with the possibility of capsule retention. There is a 2% capsule retention rate in most series.[16] Other limitations to CE are that it is time consuming; there is no biopsy potential, and no therapeutic capability.

A large meta-analysis completed by Triester et al.[17] demonstrated the incremental yield of CE over enteroscopy and small bowel barium radiography to be 35% and 59%, respectively. Although not statistically significant, the rate of identifying lesions was higher with CE. This is not surprising given CE's ability to evaluate more mucosal surface area than other modalities. Lewis et al. performed a meta-analysis of CE compared to small bowel barium swallow, EGD, colonoscopy, and small bowel enteroscopy. Detection rate for CE was 87% and missed lesion rate was 10%. The combination of the other 4 modalities yielded a 13% detection rate and missed lesion rate of 73%. Both large meta-analyses demonstrate the CE capability and superiority.[18]

There are several capsules in use around the world. For example, the Given M2A imaging CE (Given Imaging; Yokneam, Israel) is a pill-shaped capsule measuring 11 mm $\times$ 26 mm. Within the capsule, the contents consist of a light source, an imaging chip, a battery source, and a radio transmitter with an internal antenna. Its visual field is 140 degrees and is magnified 8 times. This capsule travels through most of the small bowel with peristalsis and is excreted in the feces. The camera is able to take two images every second and transmits image to an external recording device. The capsule has a battery life lasting between 6 and 8 hours. At the completion of the study there are 50,000 images. There is software available to help the interpreter evaluate for a suspected bleeding source. There is no consensus on preprocedural bowel preparation, but some advocate for bowel prep. Prokinetics may be beneficial because there is a 20% incomplete small bowel transit.[19]

SMALL BOWEL ENTEROSCOPY

The difficulty to evaluate the small bowel is based on its location and length. The scope needed to properly evaluate it is too long to have manual control of the tip. The bowel lies freely in the peritoneal cavity with essentially no fixation. Navigation with an endoscope has been traditionally difficult for this reason. Fixation points allow for proper evaluation of the foregut and colon in traditional endoscopy, but this is not the case for small bowel. DE utilizes a fixation point provided by the scope and the small bowel is brought to the viewing tip of the scope. Traditional endoscopy utilizes pushing the endoscope through the gastrointestinal tract which is impossible without external intraoperative manipulation of the bowel over the scope. Using this new method for evaluation has provided endoscopists with a steep learning curve and added length of time to complete the evaluation.

5 The disadvantages of CE are difficulty with orientation, inability to biopsy, possible obstruction, and capsule retention. Small bowel enteroscopy, DAE, or DE, are excellent alternative modalities.

DE allows the operator to obtain biopsies and to perform therapeutic interventions. There are three methods for DE available today.

Double-Ballon Enteroscopy

This technique was developed in 2001 by Hironi Yamamoto,[20] and introduced into Korea in 2004 where it found its way to the United States. This endoscope consists of a balloon at the tip of an endoscope that has a length of 140 cm. An overtube, also containing a balloon at the tip, fits over the scope to employ a push-and-pull technique.[21] This allows for examination of 240 to 360 cm. While the overtube balloon is inflated, the scope is advanced with its balloon deflated. The inflated overtube balloon will allow for a fixation point for the scope to maneuver through the small bowel. Once a significant advancement has occurred, the endoscope balloon is inflated, and the overtube balloon deflated. The overtube then slides along the endoscope to the end of the scope. The overtube balloon is reinflated to provide another fixation point as the endoscope balloon is taken down and advanced once more. This outlines the push technique as the endoscope is advanced with the overtube balloon inflated. The pull technique is when both balloons are inflated and the endoscopist pulls back on both. This will reset the ability to start the push technique again. This progression continues until the entire small bowel is evaluated.

The two most common enteroscope systems used have scope diameters of 8.5 mm and 9.3 mm with working channels of 2.2 mm and 2.8 mm. The working channels allow for the therapeutic and diagnostic options provided by these systems.

Double-balloon enteroscopy (DBE) is the most studied method to date and shows a diagnostic yield of 60% to 80% in patients with occult GI bleeding and other small bowel pathologies.[22] However, it may not be feasible in all patients and success rates vary from 16% to 86%.[20,23] This variation is due to differing patient populations across the world and the specific disease processes.

The main limitations to DBE are the invasive nature and prolonged duration of the procedure. The complication rate overall is reported as 0.8% but can be higher while performing therapeutic procedures such as electrocautery for a GI bleed, polypectomy, or dilation. The main complications are pancreatitis, ileus, and perforation.[24–26]

Single-Balloon Enteroscopy

This system was developed in 2007 and is similar to DBE, but the distinguishing trait is that this system lacks the endoscope balloon. There is still a balloon on the overtube used over the scope. Substituting in the endoscope balloon's place, the scope tip is hooked to hold the scope fixed to aid in the advancement of the overtube. Overall, the concept is the same as to fix a portion of the small bowel to allow for advancement of the endoscope.

The overtube is referred to as the splinting tube which has a hydrophilic coating that is activated with application of 30 mL of water. Radiopaque material is present at the tip to aid in the advancement with fluoroscopy.

Spiral Enteroscopy

Also in 2007, spiral enteroscopy (SE) was introduced which provides potential benefits with regard to shorter procedure time. A raised spiral on the exterior of the scope pulls the small bowel over the scope as it advances. This scope is 118 cm in length and has a diameter of 9.8 mm. The raised spiral grooves are 16 mm high. Clockwise rotation of the scope will advance the scope and counterclockwise rotation will withdraw the scope.

Studies for SE demonstrate shorter insertion depths with faster procedure times. There is variation in the insertion depth varying from 176 cm to 262 cm.[27,28] The complication rate is noted to be 0.3% with a perforation rate of 0.27%.[22] Overall, the device is simple to use with a learning curve of 5 cases.[22,29]

Exploratory Laparoscopy

The role of laparoscopy has improved the management of small bowel lesions over the last decades.[30,31] The advantages of DAE and imaging have been discussed at length, but the role for laparoscopic assessment of the peritoneal cavity for small bowel tumors plays a significant role in both diagnosis and treatment. Furthermore, the improvements in laparoscopy and surgeons abilities with a laparoscope have enabled minimally invasive management of small bowel tumors. Johnson et al.[32] evaluated all small bowel obstructions in a single institution requiring surgery. Successful completion of a laparoscopic approach was possible in 32% of patients (conversion to an open procedure was necessary in 40% of patients, with 20% of the conversions secondary to tumor. Small bowel was resected in 8% of the laparoscopic cases, 64% of the converted cases, and 41% of the case done completely open. Length of stay of patients with a purely laparoscopic approach was 7.7 days versus 11 days in the converted cases and 11.4 in the purely open cases.

There are distinct advantages to laparoscopy when the ability of the surgeon allows this approach. Direct visualization of the small bowel on the extraluminal side adds significant value to the management of small bowel tumors. Complete evaluation of the small bowel can be obtained laparoscopically by examining the entire small bowel in a systematic approach in order to visualize all aspects of the small bowel including the mesentery. In conjunction with endoluminal approaches, like small bowel enteroscopy, lesions can be located, biopsied, and if needed, resected.

The laparoscopic approach is limited by the extent of the disease process being investigated. Local spread of small bowel tumors will likely affect directly adjacent small bowel or other nearby organs. This invasion can make it impractical to proceed laparoscopically if one is to provide the patient with the best outcome. Also, most common tumors of the small bowel affect the mucosal surface only and extraluminal visual examination may be inadequate to identify the lesion. Exceptions to this would be utilizing small bowel enteroscopy to tattoo the lesion which can be easily seen from the extraluminal side. This would also facilitate a sound oncologic resection of the tumor. Hand-assisted laparoscopy is also helpful if palpation is essential and a small incision is desired.

A laparoscopic case should be converted to an open technique if conditions prevent oncologically sound technique in order to provide the patient with the best outcome.

MANAGEMENT

Benign

Adenomas are benign lesions that have malignant potential. This tends to follow the malignant degeneration seen in polyps of the large bowel, described in 1990,[33] and most commonly seen with periampullary tumors.[34] Interestingly, the distribution of adenomas tends to follow the small bowel's exposure to bile, making the most common location immediately distal to the papilla in the second portion of the duodenum and progressively decreases in the more distal intestine.[35]

Hamartomas are benign vascular tumors with a low malignant potential and usually associated with Peutz–Jeghers syndrome.[13] Lipomas are encountered as a single mass or as multiple and are usually encountered incidentally. Hemangiomas are rare benign tumors in the small bowel that present as GI bleeding.

The only reason for operative management of a benign small bowel lesion is to control symptoms. Mass effect causing intussusception or obstruction, hemorrhage, or a questioned presence of malignancy generates the need for local resection of the lesion. The diagnostic dilemma is the most common reason for resection of an incidentally found mass on contrast study or endoscopy. Hemangiomatous lesions can be resected or managed with angiographic embolization. The use of angiographic isolation and intraoperative angiographic methylene blue injection can be very helpful to guide resection of a bleeding field of small bowel angiomas.

Malignant

Discovery of small tumors is rare. Within the group of malignant tumors found in the small bowel, there are four main types. The most recent data from a single-institution tumor registry show that carcinoid tumors of the small bowel have surpassed the incidence for adenocarcinomas of the small bowel.[1] A total of 1,260 tumors were examined and their distribution throughout the small bowel was discussed. Carcinoid tumors (33%), adenocarcinomas (30%), lymphoma (16%), GIST (7%), and other cell types found (13%). The authors separated the different tumor types based on location within the small bowel, which changed the order of the most common tumors seen in each portion.

Neuroendocrine Tumors

NETs of the small bowel have increased in incidence significantly over the last 40 years, and mirror the overall increase in gastrointestinal NETs throughout the entire gastrointestinal tract. This is reflected in the recent SEER data ranking gastrointestinal NETs second, only behind colorectal cancer, as the most common cancer of the GI tract.[36] This has also been shown in Sweden[37] and in England.[3] NETs arise from a diffuse neuroendocrine system made up of secretory cells, called enterochromaffin cells, causing the propensity for these tumors to produce vasoactive substances. NETs, formerly known as carcinoid tumors, can be almost benign or very aggressive. Carcinoid syndrome was characterized in 1954 by Thorson et al. who associated the presence of the metastatic carcinoid tumor with the presence of some abnormal symptoms.[38] They related the increased production of serotonin causing systemic effects such as diarrhea, flushing, bronchospasm, cutaneous vasomotor symptoms, and cardiovascular dysfunction. Serotonin was actually extracted 1 year earlier from carcinoid tumors and labeled as the active ingredient in the symptoms.[39,40] Serotonin is derived from its precursor tryptophan, and when in circulation, it elicits particular symptoms. The liver will inactivate serotonin to make 5-hydroxyindoleacetic acid (5-HIAA) which is excreted by the kidney.[41]

Table 51-2 Pathologic Classification of Neuroendocrine Tumors

Pathologic Classification of Neuroendocrine Tumors		
Differentiation	**Grade**	**Criteria**
Well differentiated	Low (typical)	<2 mitoses/10 HPF and ≤2% Ki67 index
Intermediate (atypical)	2–20 mitoses/10 HPF or 3–20% Ki67 index	
Poorly differentiated	High	>20 mitoses/10 HPF or >20% Ki67 index

From Strosberg J. Neuroendocrine tumours of the small intestine. *Best Pract Res Clin Gastroenterol* 2012;26(6):755–773.

The presentation of NETs comes from two basic components of the tumor. First, the

tumor sizes can elicit effects such as obstructive symptoms or abdominal pain. Second, the hormonal secretion of the tumors can lead to symptoms, such as carcinoid syndrome. About 50% of NETs present in the ileum[1] and the majority of those are in the distal 60 cm of the ileum.[41] Most commonly these tumors metastasize to the liver, mesentery, and peritoneum.[42] The intraluminal effects of these tumors usually leads to the obstructive symptoms and the desmoplastic reaction of the small bowel mesentery produces the abdominal pain associated with the tumor burden.

6 Metastasis of small bowel NETs is related to primary tumor size. A literature review of 185 patients with small bowel NET showed an 85% nodal metastasis and 47% distant metastasis with tumors greater than 2 cm. With tumors between 1 and 1.9 cm, 70% had nodal metastasis and 19% had distant metastasis. With tumors less than 1 cm, there was 12% nodal metastasis and 5% distant metastasis.[43] Even though small NETs can metastasize, the risk of metastases does correlate with size of the primary tumor. This is influenced by the early invasion of bowel wall lymphatics and blockage of the lymphatics in the mesentery, forcing cells to flow retrograde into lymphatics along the bowel.

The mitotic rate and Ki-67 index are measured in order to provide the histologic grade of these tumors, which correlates closely with clinical behavior. These measurements categorize the tumors into one of three categories by grade; low, intermediate, and high. The 5-year survival rates are 79%, 74%, and 40%, respectively. Low and intermediate grade typically fall into the well-differentiated category and high grade is considered poorly differentiated (Table 51-2). Resection to maximally debulk the tumor, or maximize cytoreduction, is the only chance for cure in NETs.

A formal TNM staging classification has recently been instituted. This stratifies tumors into localized, locally advanced, and metastatic categories with associated 5-year survivals of 95%, 84%, and 51%, respectively (Table 51-3). Shortly after, in 2007, the American Joint Committee on Cancer adopted a TNM staging system proposed by the European Neuroendocrine Tumor Society (ENETS) specifically for tumors of the lower jejunum and ileum. This factored out the poorer prognosis of the tumors in other parts of the body such as the colon, rectum, and appendix[44] (Tables 51-4 and 51-5). Five-year survival rates were much different showing 100% for stage I and stage II cancers, 91% for stage III cancers, and 72% for stage IV cancers. Survival rates were slightly improved with presentation of another 270 NETs by Jann et al.[45]

7 Generally, diagnosis is made based on radiographic findings in conjunction with tumor markers. There are three common radiographic modalities used to diagnose these tumors, which include CT scan and MRI enterography and octreotide scanning.

Abdominal CT can help locate the primary tumor, but three-phase CT should be used for optimal evaluation of liver metastasis. The clinician should be mindful of the affinity of NETs to metastasize to the liver, especially in the setting of physical findings consistent with neuroendocrine peptide secretion. The arterial phase and the portal venous phase are typically the phases that maximize the ability to locate the metastatic lesions because NETs are typically rich in vascularity.[46] For the same reason, MRI can also be used to locate and evaluate metastatic lesions to the liver.

Table 51-3 5-Year Survival Rates by Carcinoid Location (1973–1997)*a*

Site	All Stages	Local Stage	Regional Stage	Distant Stage
Stomach	75.1%/55.3%	90.2%/69.6%	40.4%/27.2%	18.0%/9.0%
Small bowel	76.1%/54.6%	94.5%/70.4%	84.4%/64.1%	51.2%/32.4%
Appendix	76.3%/65.0%	95.6%/87.8%	80.0%/67.6%	37.5%/26.8%
Colon	69.5%/41.8%	94.1%/77.1%	72.5%/35.3%	27.8%/4.1%
Rectum	87.5%/77.8%	94.9%/86.2%	53.7%/42.1%	14.6%/13.1%

[a]Cancer-specific survival/relative overall survival.
Survival rates are all age-adjusted to standard 2000 population.
From Maggard M, O'Connell J. Updated population-based review of carcinoid tumors. *Ann Surg* 2004;240(1):117–122, with permission.

Table 51-4 Proposal for a TNM Classification for Endocrine Tumors of Lower Jejunum and Ileum

T-primary tumor	
TX	Primary tumor cannot be assessed
T0	No evidence of primary tumor
T1	Tumor invades mucosa or submucosa and size <1 cm
T2	Tumor invades muscularis propria or size >1 cm
T3	Tumor invades subserosa
T4	Tumor invades peritoneum/other organs
For any T, add (m) for multiple tumors	
N regional lymph nodes	
NX	Regional lymph nodes cannot be assessed
N0	No regional lymph node metastasis
N1	Regional lymph node metastasis
M	Distant metastasis
MX	Distant metastasis cannot be assessed
M0	No distant metastases
M1	Distant metastasis

Rindi G, Klöppel G, Couvelard A, et al. TNM staging of midgut and hindgut (neuro) endocrine tumors: a consensus proposal including a grading system. *Virchows Arch* 2007;451(4):757–762.

NETs often express somatostatin receptors rendering them detectable by imaging with radiolabeled forms of somatostatin called octreotide.[47] This was discovered during the refinement of the octreoscan, or SRS (somatostatin receptor scintigraphy). Five subtypes of somatostatin receptors have been identified and the somatostatin analogs from the octreotide scan bind with subtypes 2 and 5 which are present in 70% to 90% of NETs.[48] With the progression of diagnostic ability came the use of single-photon emission computed tomography (SPECT) to enhance the accuracy of differentiating areas of pathologic and physiologic uptake in the abdomen. This is a full-body scan that enables visualization of somatostatin uptake throughout the entire body.

Further use of radiolabeled markers has brought about advances in positron emission tomography with use of functional radiotracers for imaging. The advantages to this platform are the higher spatial resolution than the octreotide scanning. This also offers

advantages for detecting smaller lesions than other scanning methods. Octreotide, MBIG, and PIET scanning are used for follow-up of patients and staging of patients for distant disease when planning aggressive, multiorgan resections.

Making the diagnosis of small bowel NET is often late in its course and the chances of metastatic lesions being present are high because of this. However, surgical management is still an option for patients in cases of localized tumor burden and distant metastasis. Survival outcomes are better for those patients with stage I and stage II diseases, as previously discussed, and surgical excision of the primary tumor and local node metastasis is still the only curative therapy for these patients.[49] The primary focus in any instance with the presence of NET is to control the functional disorder associated with the tumor present, such as carcinoid syndrome. Several options are applicable to the tumor itself once any functional disorder is controlled and treated. These include close surveillance of indolent tumors, radiofrequency ablation (RFA) therapy for liver metastases, systemic therapy with somatostatin analogs or interferon, or cytotoxic or molecular targeted therapies. These are all options that can be used and have never been compared in a controlled comparison, making these therapies highly individualized.

Table 51-5 Disease Staging for Endocrine Tumors of Lower Jejunum and Ileum

Stage			
Disease Stages	T-Primary Tumor	N-Regional Nodes	M-Distant Metastasis
Stage I	T1	N0	M0
Stage IIA	T2	N0	M0
Stage IIB	T3	N0	M0
Stage IIIA	T4	N0	M0
Stage IIIB	Any T	N1	M0
Stage IV	Any T	Any N	M1

8 Chromogranins are glycoproteins that are stored in secretory vesicles within neuroendocrine tissue.[41] There are three distinct types named chromogranin A, B, and C. Chromogranin A tends to be the most sensitive indicator of a NET with varied sensitivity and specificity. For instance, false positives are noted in patients with atrophic gastritis, renal insufficiency, inflammatory bowel disease, and patients taking proton pump inhibitors.[50,51] Since chromogranin A has a low specificity, it is not used as a screening tumor marker for NETs, but can be used in those patients with an established diagnosis to assess disease progression and response to therapy in surgical resection.[41]

Surgical management with resection and the use of RFA still provides the best survival benefit for all patients with localized and advanced NET.[52,53] However, if needed, debulking procedures have been shown to be effective in improving symptoms[52] with greater than 90% resection. Planning for a two-step approach for radical resection to achieve complete resection has been shown to be effective.[54] With high tumor grades,

recurrence rates can be as high as 81%.[55] Transarterial chemoembolization (TACE) has been shown to be highly effective against nonresectable diffuse liver lesions to reduce symptoms.[53]

Medical management of NET includes a wide variety of agents including somatostatin analogs (octreotide) and peptide receptor radionucleotide therapy (PRRT), chemotherapeutic agents (doxorubicin–streptozotocin, dacarbazine, temozolomide, oxaliplatine, or interferon), monoclonal antibody therapy (bevacizumab), mTOR inhibitors (temsirolimus and everolimus), and multikinase inhibitors (sunitinuib, sorafenib, and pazopanib).

A combination of both medical and surgical management is outlined in Algorithm 51-1.

Since carcinoid can develop in all areas of the intestine, surveillance with endoscopy is important. Scanning with CT/MRI of the liver can guide reexploration and resection. Octreotide scanning, MBIG, or PET scanning can be helpful in controversial cases of possible metastases.

Small Bowel Adenocarcinoma

Small bowel adenocarcinomas represent the second-most common cancer of the small bowel with an incidence of 7.3 cases per million worldwide.[2,56,57] Small bowel adenocarcinoma, along with colorectal cancer, is more common in developed countries, and has higher incidence rates in North America and Western Europe.[58] Adenocarcinoma can be found throughout the entire small bowel, 56% is found in the duodenum.[2] Goodman et al. performed an examination of 26 population-based cancer registries to find that the overall age-adjusted incidence rates for small bowel adenocarcinoma favored men over women (7.7 to 5.1), and both men and women exhibited the same trend with regard to race. Black populations had an age-adjusted incidence rate of about twice the rate of white individuals, and the Hispanic population followed. The lowest incidence is in the Asian/Pacific Islander population.[59]

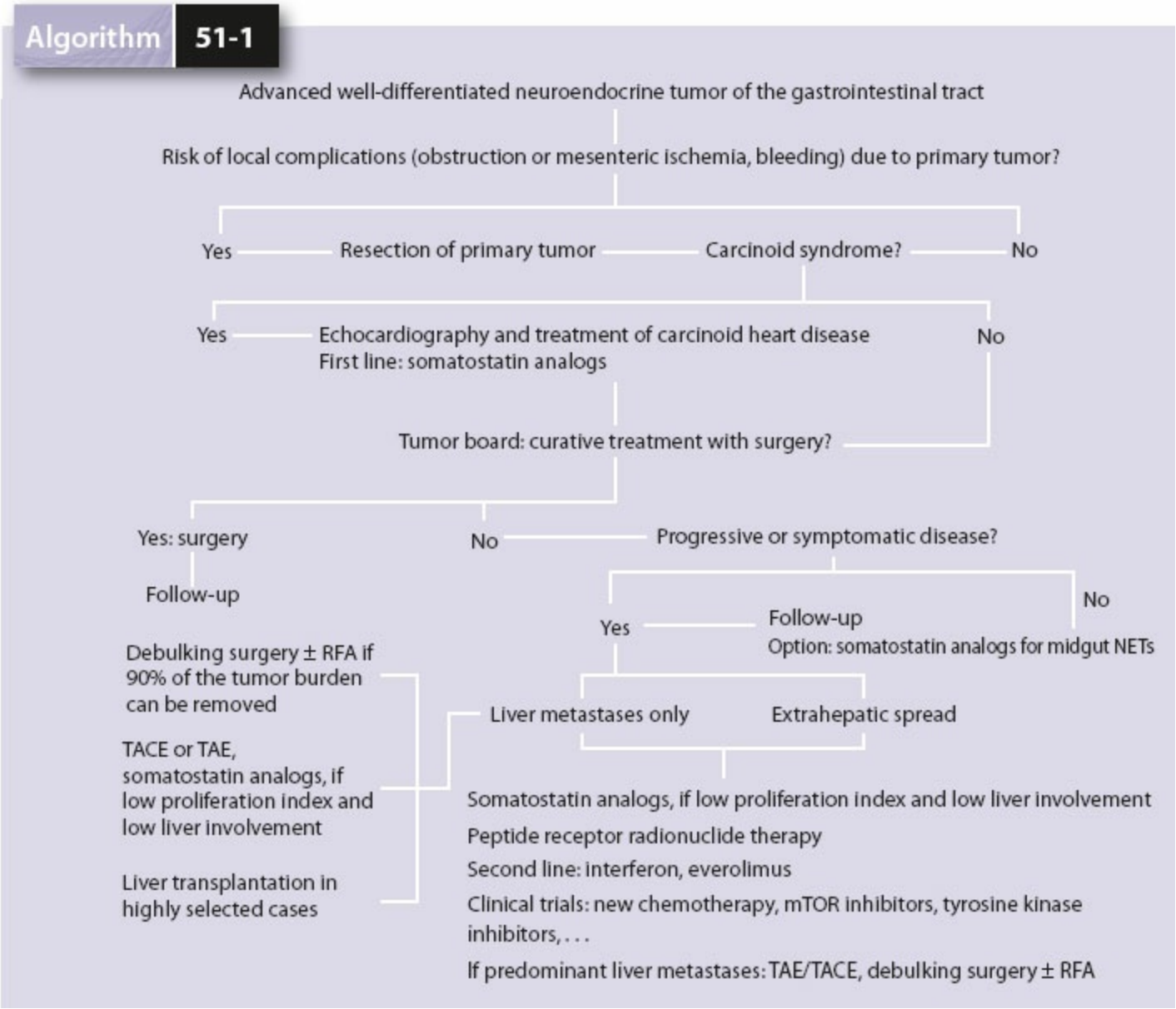

Algorithm 51-1. Management algorithm for patients with advanced neuroendocrine tumors (NETs) of the gastrointestinal tract. mTOR, mammalian target of rapamycin; PPI, proton pump inhibitor; RFA, radiofrequency ablation; TAE, transarterial embolization. (Walter T, Brixi-Benmansour H, Lombard-Bohas C, et al. New treatment strategies in advanced neuroendocrine tumours. *Dig Liver Dis* 2012;44(2):95–105.)

Presentation for small bowel adenocarcinoma is very nonspecific with the most common symptom on presentation being abdominal pain (45% to 76%).[57] Other common symptoms include nausea and vomiting, weight loss, fatigue and anemia, and GI bleeding.[60,61] Interestingly, with the indolent presentation of these cancers, patients can recall symptoms for long periods of time prior to diagnosis. Talamonti et al.[61] were able to identify a mean duration of symptoms at presentation at 10 months.

Simple laboratory testing can identify abnormalities that can indicate bleeding, and there are no specific tumor markers associated with a diagnosis of small bowel adenocarcinoma. Carcinoembryonic antigen (CEA) and carbohydrate antigen 19-9 (CA 19-9) are elevated in only about 30% to 40% of patients.[62] Radiologic and endoscopic modalities provide the best method for detecting small bowel adenocarcinoma. Unfortunately, these modalities can fail to make a diagnosis given the nonspecific nature

of the presenting symptoms.

Evaluation of the small bowel in order to make a diagnosis of small bowel adenocarcinoma can include upper GI swallow study with small bowel follow-through or enteroclysis. The major disadvantage to these modalities is the inability to assess extraluminal spread given the often late presentation. The use of CT and MR with enterography has drastically improved the ability to detect these cancers. The sensitivity rate for detecting small bowel tumors was 84.7% and a specificity of 96.9% when using CT enterography.[63] Using MR enterography (MRE) for detecting small bowel tumors has a sensitivity of 91% and a specificity of 95%.[64]

Endoscopic evaluation has been discussed elsewhere in this chapter, but EDG plays an important role in detecting small bowel adenocarcinomas because of the high rate of incidence in the duodenum.

The prognosis of small bowel adenocarcinoma varies. Prognosis is directly related to the tumor staging as it is the single most important prognostic indicator.[60] There are several factors that are related to the poor prognosis aside from advanced staging, including poor differentiation, positive margins after resection, duodenal location, male gender, elderly age, and black ethnicity.[57] Optimal diagnostic lymph node harvest at the time of surgery has been identified as requiring either 8 or 10 or more nodes for accurate assessment.[65,66] Patients can be staged (Table 51-6) and their disease-specific survival rates can be assessed based on the tumor site (Fig. 51-1) and change based on the number of lymph nodes examined (Fig. 51-2) and the number of positive lymph nodes (Fig. 51-3).

Table 51-6 Disease-Specific Survival According to Disease Stage, Total Number of Lymph Nodes Assessed, and Total Number of Positive Lymph Nodes

	% Cumulative 5-Year DSS		
No. of Lymph Nodes	Stage I	Stage II	Stage III
TLN			
0	70	44	
1–7	93	69	43
>7	95	83	56
PLN			
<3			58
>3			37
LNR[a]			
T1 (0.02–0.2)			63
T2 (0.21–0.5)			53
T3 (0.52–1)			30

[a]Stratified by tertiles.
DSS, disease-specific survival; TLN, total number of lymph nodes assessed; PLN, total number of positive lymph nodes; LNR, lymph node ratio.
Overman MJ, Hu CY, Wolff RA, et al. Prognostic value of lymph node evaluation in small bowel adenocarcinoma: Analysis of the surveillance, epidemiology, and end results database. *Cancer* 2010;116(23): 5374–5382.

Surgical management is the mainstay of therapy for small bowel adenocarcinoma with locoregional disease.[57] It has been known for almost 2 decades that resection of duodenal adenocarcinomas yields a 56% survival at 5 years with complete surgical resection and 0% survival at 5 years without resection.[67] Duodenal adenocarcinomas can be managed with pancreaticoduodenectomy or with segmental resection for the distal third and fourth portions for resectable tumors. Nodal involvement should prompt adjuvant therapy, but otherwise observation is sufficient (Algorithm 51-2). Jejunal and ileal adenocarcinomas should be managed with similar principles of segmental resection and regional lymph node dissection, with a right hemicolectomy for tumors involving the distal ileum.[57]

Medical management of small bowel adenocarcinoma consists of adjuvant therapy which is aimed toward controlling recurrence of adenocarcinoma at distant sites. Distant recurrence predominates over the high locoregional recurrence for duodenal adenocarcinomas.[57] Poultsides et al. recently showed in a series of 122 patients who had a pancreaticoduodenectomy for duodenal adenocarcinoma, the first site of recurrence was distant 59% of the time, locoregional 19% of the time, and both in 22% of the cases.[68] Adjuvant therapies involve 5-flourouracil/capecitabine, FOLFOX/CAPOX, FOLFIRI, or gemcitabine.

Lymphoma

There is an abundant amount of lymphoid tissue in the small bowel, especially in the terminal ileum. Lymphomas account for about 15% to 20% of small intestine neoplasms.[12] This mirrors the malignant transformation distribution patterns throughout the small intestine with regard to lymphoma. SEER database analysis from 1975 to 2003 shows a distribution of 60% to 65% in the ileum, followed by 20% to 25% in the jejunum, and 6% to 8% in the duodenum.[69] However, secondary lymphoma is much more common than primary lymphoma because the gastrointestinal tract is the most common site for extranodal disease.[13]

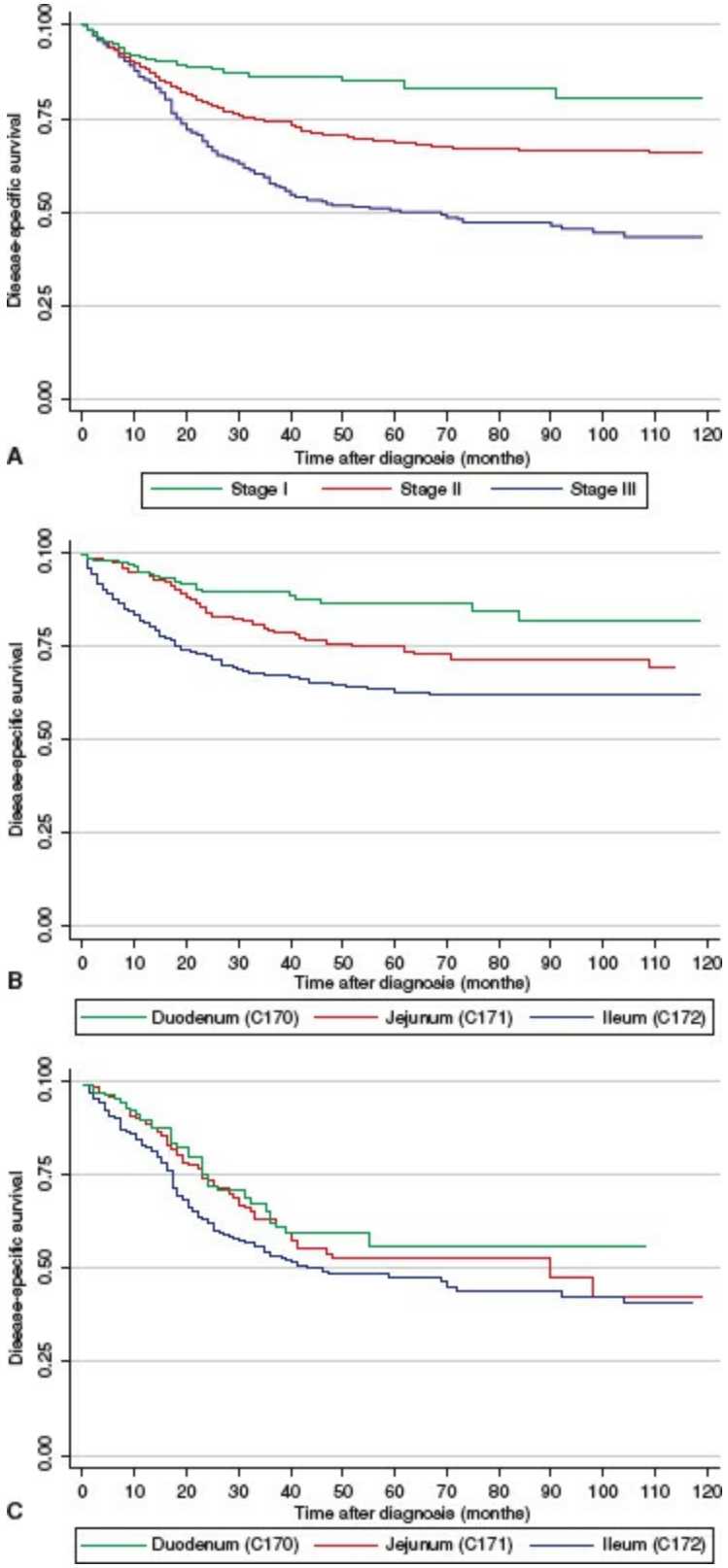

Figure 51-1. These Kaplan–Meier curves illustrate disease-specific survival stratified by (**A**) disease stage, (**B**) subsite in the small bowel for stage I and II diseases, and (**C**) subsite in the small bowel for stage III disease. Codes for the duodenum (C17.0), jejunum, (C17.1), and ileum (C17.2) are from the International Classification of Diseases for Oncology and Related Health Problems 10th Revision. (Overman MJ, Hu CY, Wolff RA, et al. Prognostic value of lymph node evaluation in small bowel adenocarcinoma: Analysis of the surveillance, epidemiology, and end results database. *Cancer* 2010;116(23):5374–5382.)

The typical clinical presentation of small bowel lymphoma is nausea, vomiting, abdominal pain, and weight loss. Severe symptoms, such as obstruction, intussusceptions,

or perforation are rare.[12]

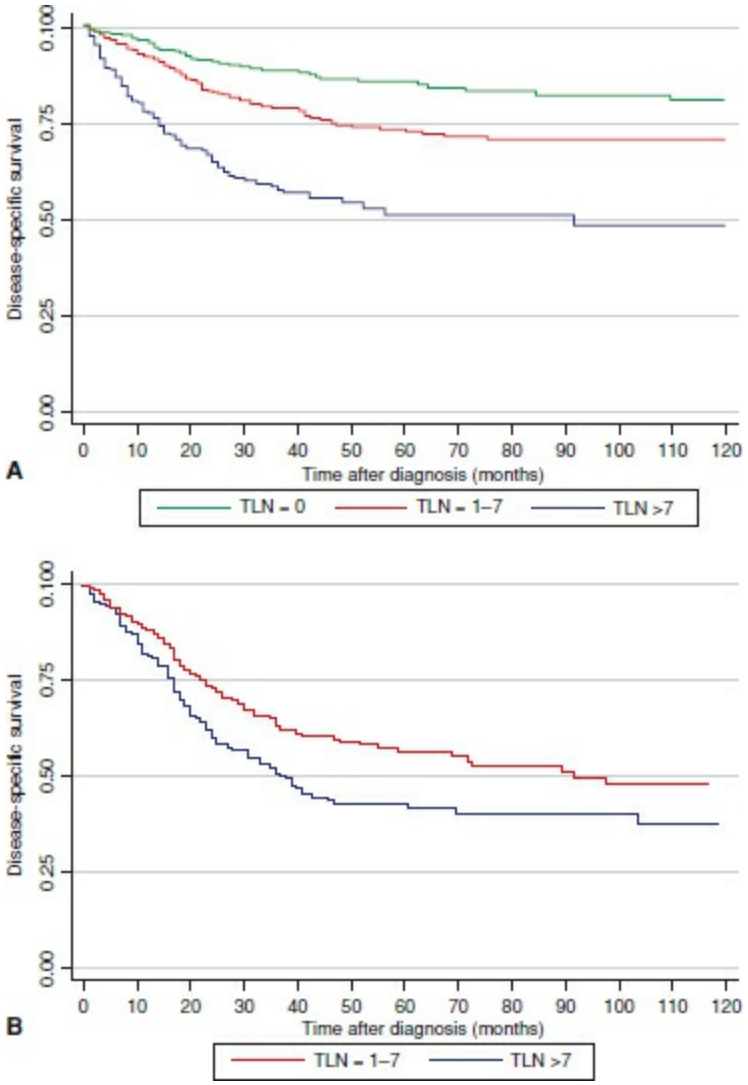

Figure 51-2. These Kaplan–Meier curves illustrate disease-specific survival stratified by (**A**) the total number of lymph nodes assessed (TLN) in patients with stage I and II diseases and (**B**) the TLNs assessed in patients with stage III disease. (Overman MJ, Hu CY, Wolff RA, et al. Prognostic value of lymph node evaluation in small bowel adenocarcinoma: Analysis of the surveillance, epidemiology, and end results database. *Cancer* 2010;116(23):5374–5382.)

Several types of lymphoma can occur in the small bowel. However, the most commonly encountered lymphoma is diffuse large B-cell lymphoma. Despite the incidence of lymphoma in the small intestine, surgery is typically not the method for management. These patients should undergo resection in situations of obstruction or bleeding, and should still receive chemotherapy.[12] Immunoproliferative small intestinal disease occurs in patients who are chronically immunosuppressed as a result of infection by *Helicobacter pylori* and *Campylobacter jejuni.* Antibiotic therapy for these bacteria usually results in regression of immunoproliferative small intestinal disease. Most of these patients relapse and will need radiation and chemotherapy with nutritional support.[70,71]

Gastrointestinal Stromal Tumor

9 GISTs are the most mesenchymal tumors of the small bowel. GISTs are found in the stomach (60% to 70%), small intestine (20% to 30%), and in the duodenum (4% to

5%).[72] GISTs are known to arise from the interstitial cells of Cajal, which are described as the gastrointestinal pacemakers.[73] Coincidentally, that same year GISTs were termed gastrointestinal pacemaker cell tumors, Hirota et al.[74] recognized the c-kit proto-oncogene which codes for a tyrosine kinase inhibitor, as the genetic mutation leading to GISTs. As a result, there has been a dramatic shift in the way GISTs are managed.

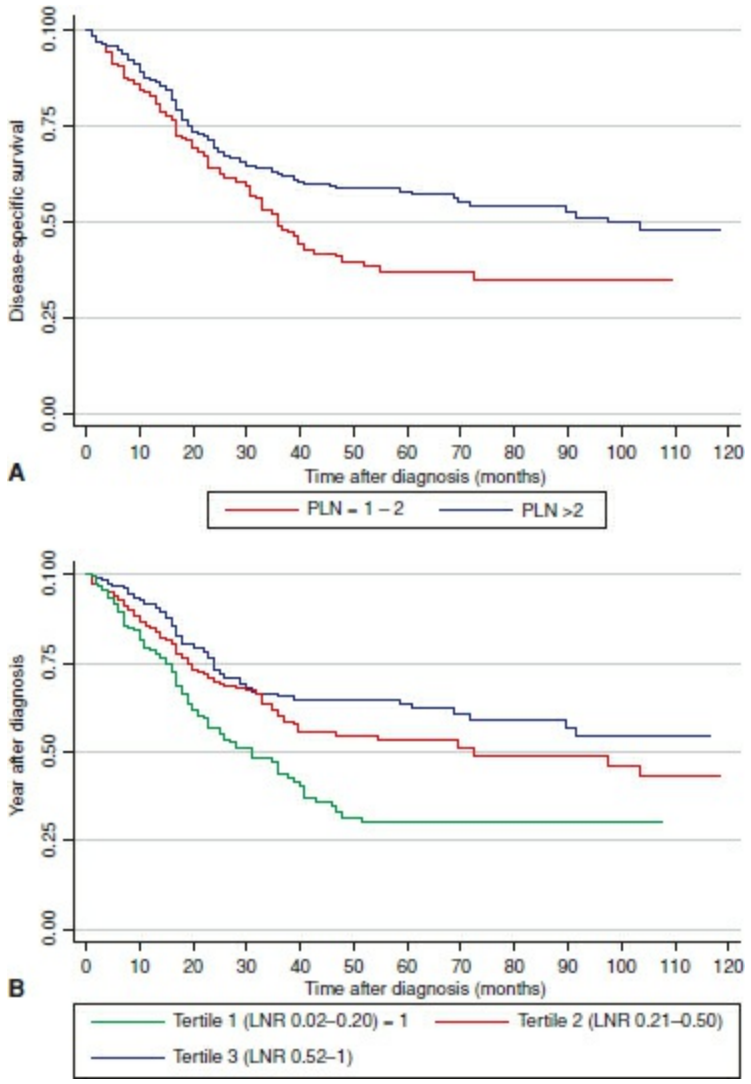

Figure 51-3. These Kaplan–Meier curves illustrate disease-specific survival stratified by (**A**) the number of positive lymph nodes (PLN) and (**B**) the lymph node ratio (LNR) in tertiles. (Overman MJ, Hu CY, Wolff RA, et al. Prognostic value of lymph node evaluation in small bowel adenocarcinoma: Analysis of the surveillance, epidemiology, and end results database. *Cancer* 2010;116(23):5374–5382.)

The diagnosis of small bowel GISTs is similar to that of other small bowel tumors; however, the GIST is unique with regard to the submucosal origin and its likelihood to grow in size away from the lumen of the small bowel. This also makes it difficult to make a diagnosis with intraluminal biopsy. A study by Bümming et al. in 2006 demonstrated that only one-third of diagnoses are made with biopsies, and that the most common method of detection was endoscopy and CT scan.[75] Most commonly, patients with GISTs present with vague abdominal symptoms, pain, GI bleeding from a mucosal erosion, or an abdominal mass.[76]

GISTs do not have the malignant pattern predicted in other types of cancers based on

histopathology alone. Several factors influence malignant behavior including tumor size, mitotic rate, tumor location, kinase mutational status, and occurrence of tumor rupture. Mitotic rate and tumor size are the most commonly acceptable indices for prognosis.[72]

Tumor size and location dictate the type of treatment. Complete surgical resection remains the only method for curative treatment, and simple negative margins are needed, as wide margins have not shown significant benefit.[72] Small segmental resection of the small bowel is adequate because GISTs rarely metastasize to lymph nodes. Lymph node dissection is not warranted. En bloc resection should be done for locally advanced GISTs.[72] Overall 5-year survival rate for patients with complete resection of GISTs is 50% to 65%.[72,76–78]

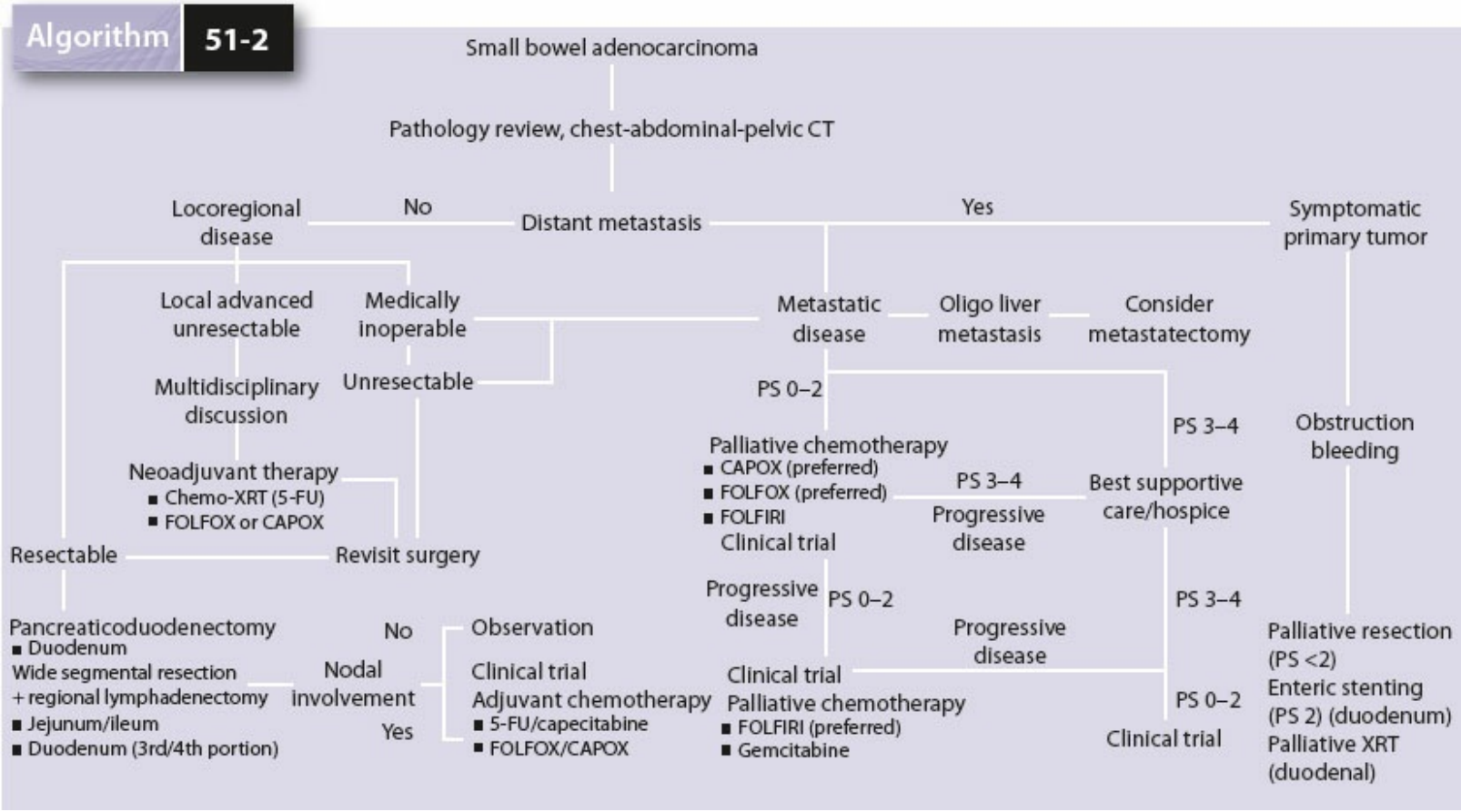

Algorithm 51-2. Algorithm showing the management of patients with small bowel adenocarcinomas. The treatment strategy depends on disease stage and involves en bloc resection for locoregional disease and systemic chemotherapy for metastatic disease. All current recommendations are based on case series, retrospective reviews or nonrandomized prospective trials because of an absence of any randomized data. 5-FU, 5-fluorouracil; CAPOX, capecitabine and oxaliplatin; FOLFIRI, 5-FU, leucovorin and irinotecan; FOLFOX, 5-FU, leucovorin and oxaliplatin; KRAS-WT, *KRAS* wild-type; PS, performance status; XRT, radiation therapy. (Elias D, Lefevre JH, Duvillard P, et al. Hepatic metastases from neuroendocrine tumors with a "thin slice" pathological examination: they are many more than you think. *Ann Surg* 2010;251(2):307–310.)

Patients have a defined risk for recurrence and may benefit from adjuvant therapy. The Modified NIH–Fletcher GIST Risk Assessment Criteria is presented in Table 51-7. Other risk assessment tools are available such as Armed Forces Institute of Pathology Classification and the Memorial Sloan-Kettering Cancer Center Prognostic Nomogram.

Adjuvant therapy utilizes imatinib (Gleevec). This drug is used in the treatment algorithms for patients with advanced or metastatic GIST or with resectable GIST. Algorithm 51-3A shows these algorithms. Imatinib is a competitive inhibitor for multiple tyrosine kinase inhibitors and was originally recommended for chronic myelogenous leukemia treatment. It became first-line treatment for GIST once it was recognized to disrupt the KIT oncogene in GISTs.[79] Shortly after that, imatinib was approved for use in unresectable or metastatic disease shown in Algorithm 51-3B.[80,81] A randomized prospective study was done in 2009 to evaluate imatinib for the use in adjuvant therapy, showing significant improvement in 5-year recurrence-free survival, 98% versus 83%, respectively, in the treatment group over placebo.[82] The NCCN guidelines in the management of GISTs provide a standard algorithm.[83]

Table 51-7 Modified NIH–Fletcher GIST Risk Assessment Criteria

Risk Category	Tumor Size (cm)	Mitotic Index (/50 HPF)	Primary Tumor Site
Very low risk	<2.0	≤5	Any
Low risk	2.1–5.0	≤5	Any
Intermediate risk	2.1–5.0	>5	Gastric
	<5.0	6–10	Any
	5.1–10.0	≤5	Gastric
High risk	Any	Any	Tumor rupture
	>10	Any	Any
	Any	>1G	Any
	>5.0	>5	Any
	2.1–5.0	>5	Nongastric
	5.1–10.0	≤5	Nongastric

GIST, gastrointestinal stromal tumor; HPF, high-power field.
Mullady DK, Tan BR. A multidisciplinary approach to the diagnosis and treatment of gastrointestinal stromal tumor. *J Clin Gastroenterol* 2013;47(7):578–585.

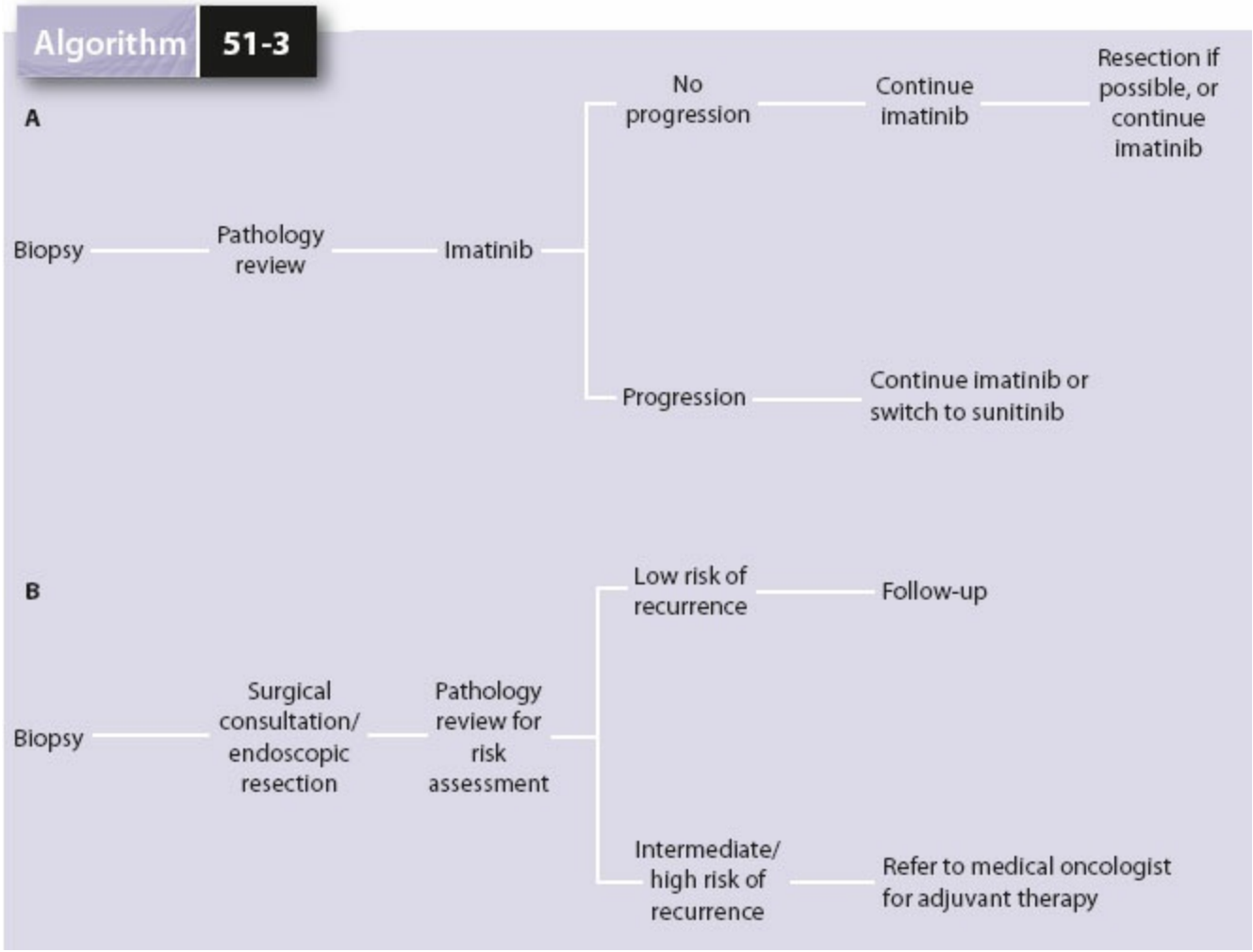

Algorithm 51-3. Treatment algorithms for patients with **(A)** advanced/metastatic GIST and **(B)** resectable GIST. GIST indicates gastrointestinal stromal tumor. (Mullady DK, Tan BR. A multidisciplinary approach to the diagnosis and treatment of gastrointestinal stromal tumor. *J Clin Gastroenterol* 2013;47(7):578–585.)

METASTATIC TUMORS TO THE SMALL BOWEL

10 Metastasis to the small bowel occurs in two different ways, either from distant spread or direct invasion from a nearby organ malignancy. The most common are from breast cancer and melanoma. Melanoma is the most common extraintestinal malignancy with predilection to metastasize to the small bowel (Fig. 51-4).[84] Patients with metastatic melanoma to the small bowel often present with other extraintestinal metastasis.[85] Primary tumors of intraperitoneal organs such as colon, ovary, uterus, and stomach metastasize to the small bowel.[84]

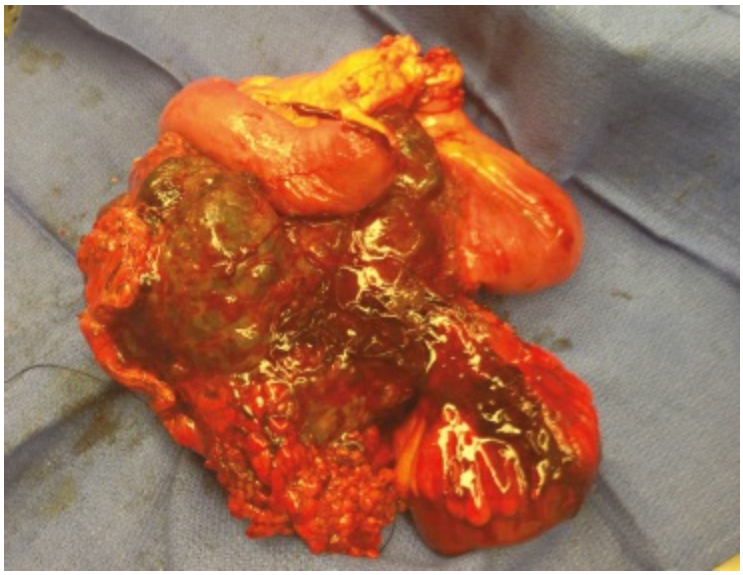

Figure 51-4. Metastatic melanoma to small bowel resecting en bloc.

Patients with small bowel metastasis are usually offered palliative systemic chemotherapy. Other palliative measures can be considered on a case-by-case basis including surgical resection, internal bypass, or usage of an endoscopically placed stent.[9]

References

1. Hatzaras I, Palesty JA, Abir F, et al. Small-bowel tumors: epidemiologic and clinical characteristics of 1260 cases from the connecticut tumor registry. *Arch Surg* 2007;142(3):229–235.
2. Bilimoria KY, Bentrem DJ, Wayne JD, et al. Small bowel cancer in the United States: changes in epidemiology, treatment, and survival over the last 20 years. *Ann Surg* 2009;249(1):63–71.
3. Ellis L, Shale MJ, Coleman MP. Carcinoid tumors of the gastrointestinal tract: trends in incidence in England since 1971. *Am J Gastroenterol* 2010; 105(12):2563–2569.
4. Jemal A, Siegel R, Xu J, et al. Cancer statistics, 2010. *CA Cancer J Clin* 2010; 60(5):277–300.
5. Jemal A, Siegel R, Ward E, et al. Cancer statistics, 2008. *CA Cancer J Clin* 2008; 58(2):71–96.
6. Wheeler JM, Warren BF, Mortensen NJ, et al. An insight into the genetic pathway of adenocarcinoma of the small intestine. *Gut* 2002;50(2):218–223.
7. Feldstein RC, Sood S, Katz S. Small bowel adenocarcinoma in Crohn's disease. *Inflamm Bowel Dis* 2008;14(8):1154–1157.
8. Canavan C, Abrams KR, Mayberry J. Meta-analysis: colorectal and small bowel cancer risk in patients with Crohn's disease. *Aliment Pharmacol Ther* 2006;23(8):1097–1104.
9. Reynolds I, Healy P, McNamara DA. Malignant tumours of the small intestine. *Surgeon* 2014;12(5), 263–270.
10. Giardiello FM, Brensinger JD, Tersmette AC, et al. Very high risk of cancer in familial Peutz–Jeghers syndrome. *Gastroenterology* 2000;119(6):1447–1453.
11. Vasen HF, Wijnen JT, Menko FH, et al. Cancer risk in families with hereditary nonpolyposis colorectal cancer diagnosed by mutation analysis. *Gastroenterology* 1996;110(4):1020–1027.
12. Cheung DY, Choi MG. Current advance in small bowel tumors. *Clin Endosc* 2011;44(1):13–21.
13. Williamson JM, Williamson RC. Small bowel tumors: pathology and management. *J Med Assoc Thai* 2014;97(1):126–137.
14. Lieberman DA, Faigel DO, Logan JR, et al. Assessment of the quality of colonoscopy reports: results from a multicenter consortium. *Gastrointest Endosc* 2009;69(3 Pt 2):645–653.
15. Hale MF, Sidhu R, McAlindon ME. Capsule endoscopy: current practice and future directions. *World J Gastroenterol* 2014;20(24):7752–7759.
16. Liao Z, Gao R, Xu C, et al. Indications and detection, completion, and retention rates of small-bowel capsule endoscopy: a systematic review. *Gastrointest Endosc* 2010;71(2):280–286.

17. Triester SL, Leighton JA, Leontiadis GI, et al. A meta-analysis of the yield of capsule endoscopy compared to other diagnostic modalities in patients with obscure gastrointestinal bleeding. *Am J Gastroenterol* 2005;100(11):2407–2418.
18. Lewis BS, Eisen GM, Friedman S. A pooled analysis to evaluate results of capsule endoscopy trials. *Endoscopy* 2005;37(10):960–965.
19. Sachdev MS, Ismail MK. Capsule endoscopy: a review. *South Med J* 2008; 101(4):407–414.
20. Yamamoto H, Sekine Y, Sato Y, et al. Total enteroscopy with a nonsurgical steerable double-balloon method. *Gastrointestinal Endoscopy* 2001;53(2):216–220.
21. Monkemuller K, Fry LC, Bellutti M, et al. Balloon-assisted enteroscopy: unifying double-balloon and single-balloon enteroscopy. *Endoscopy* 2008;40(6):537; author reply 539.
22. Riccioni ME, Bizzotto A, Cianci R. How can we compare apples and oranges? *Am J Gastroenterol* 2010;105(11):2504; author reply 2504–2505.
23. Ell C, May A. Mid-gastrointestinal bleeding: capsule endoscopy and push-and-pull enteroscopy give rise to a new medical term. *Endoscopy* 2006;38(1):73–75.
24. Heine GD, Hadithi M, Groenen MJ, et al. Double-balloon enteroscopy: indications, diagnostic yield, and complications in a series of 275 patients with suspected small-bowel disease. *Endoscopy* 2006;38(1):42–48.
25. May A, Nachbar L, Ell C. Double-balloon enteroscopy (push-and-pull enteroscopy) of the small bowel: feasibility and diagnostic and therapeutic yield in patients with suspected small bowel disease. *Gastrointest Endosc* 2005;62(1):62–70.
26. Mensink PB, Haringsma J, Kucharzik T, et al. Complications of double balloon enteroscopy: a multicenter survey. *Endoscopy* 2007;39(7):613–615.
27. Akerman PA, Agrawal D, Chen W, et al. Spiral enteroscopy: a novel method of enteroscopy by using the endo-ease discovery SB overtube and a pediatric colonoscope. *Gastrointest Endosc* 2009;69(2):327–332.
28. Buscaglia JM, Dunbar KB, Okolo PI 3rd, et al. The spiral enteroscopy training initiative: results of a prospective study evaluating the discovery SB overtube device during small bowel enteroscopy (with video). *Endoscopy* 2009;41(3):194–199.
29. Nagula S, Gaidos J, Draganov PV, et al. Retrograde spiral enteroscopy: feasibility, success, and safety in a series of 22 patients. *Gastrointest Endosc* 2011; 74(3):699–702.
30. Cunningham JD, Vine AJ, Karch L, et al. The role of laparoscopy in the management of intussusception in the Peutz–Jeghers syndrome: case report and review of the literature. *Surg Laparosc Endosc* 1998;8(1):17–20.
31. Canin-Endres J, Vine AJ, Karch L, et al. Laparoscopically assisted intestinal resection in 88 patients with Crohn's disease. *Surg Endosc* 1999;13(6):595–599.
32. Johnson KN, Chapital AB, Harold KL, et al. Laparoscopic management of acute small bowel obstruction: evaluating the need for resection. *J Trauma Acute Care Surg* 2012;72(1):25–30; discussion 30–1; quiz 317.

33. Sellner F. Investigations on the significance of the adenoma-carcinoma sequence in the small bowel. *Cancer* 1990;66(4):702–715.
34. Scott-Coombes DM, Williamson RC. Surgical treatment of primary duodenal carcinoma: a personal series. *Br J Surg* 1994;81(10):1472–1474.
35. Chow JS, Chen CC, Ahsan H, et al. A population-based study of the incidence of malignant small bowel tumours: SEER, 1973–1990. *Int J Epidemiol* 1996;25(4):722–728.
36. Yao JC, Hassan M, Phan A, et al. One hundred years after "carcinoid": epidemiology of and prognostic factors for neuroendocrine tumors in 35,825 cases in the United States. *J Clin Oncol* 2008;26(18):3063–3072.
37. Hemminki K, Li X. Incidence trends and risk factors of carcinoid tumors: a nationwide epidemiologic study from Sweden. *Cancer* 2001;92(8):2204–2210.
38. Thorson A, Biorck G, Bjorkman G, et al. Malignant carcinoid of the small intestine with metastases to the liver, valvular disease of the right side of the heart (pulmonary stenosis and tricuspid regurgitation without septal defects), peripheral vasomotor symptoms, bronchoconstriction, and an unusual type of cyanosis; a clinical and pathologic syndrome. *Am Heart J* 1954;47(5):795–817.
39. Lembeck, F. [Detection of 5-hydroxytryptamine in carcinoid metastases]. *Naunyn Schmiedebergs Arch Exp Pathol Pharmakol* 1954;221(1):50–66.
40. Erspamer V, Asero B. Identification of enteramine, the specific hormone of the enterochromaffin cell system, as 5-hydroxytryptamine. *Nature* 1952; 169(4306):800–801.
41. Strosberg J. Neuroendocrine tumours of the small intestine. *Best Pract Res Clin Gastroenterol* 2012;26(6):755–773.
42. Strosberg J, Gardner N, Kvols L. Survival and prognostic factor analysis of 146 metastatic neuroendocrine tumors of the mid-gut. *Neuroendocrinology* 2009;89(4):471–476.
43. Rorstad O, Klöppel G, Couvelard A, et al. Prognostic indicators for carcinoid neuroendocrine tumors of the gastrointestinal tract. *J Surg Oncol* 2005; 89(3):151–160.
44. Rindi G, Klöppel G, Couvelard A, et al. TNM staging of midgut and hindgut (neuro) endocrine tumors: a consensus proposal including a grading system. *Virchows Arch* 2007;451(4):757–762.
45. Jann H, Roll S, Couvelard A, et al. Neuroendocrine tumors of midgut and hindgut origin: tumor-node-metastasis classification determines clinical outcome. *Cancer* 2011;117(15):3332–3341.
46. Paulson EK, McDermott VG, Keogan MT, et al. Carcinoid metastases to the liver: role of triple-phase helical CT. *Radiology* 1998;206(1):143–150.
47. Krenning EP, Bakker WH, Kooij PP, et al. Somatostatin receptor scintigraphy with indium-111-DTPA-D-Phe-1-octreotide in man: metabolism, dosimetry and comparison

with iodine-123-Tyr-3-octreotide. *J Nucl Med* 1992;33(5):652–628.

48. Oberg K, Eriksson B. Nuclear medicine in the detection, staging and treatment of gastrointestinal carcinoid tumours. *Best Pract Res Clin Endocrinol Metab* 2005;19(2):265–276.
49. Walter T, Brixi-Benmansour H, Lombard-Bohas C, et al. New treatment strategies in advanced neuroendocrine tumours. *Dig Liver Dis* 2012;44(2):95–105.
50. Conlon JM. Granin-derived peptides as diagnostic and prognostic markers for endocrine tumors. *Regul Pept* 2010;165(1):5–11.
51. Sanduleanu S, De Bruïne A, Stridsberg M, et al. Serum chromogranin A as a screening test for gastric enterochromaffin-like cell hyperplasia during acid-suppressive therapy. *Eur J Clin Invest* 2001;31(9):802–811.
52. Gurusamy KS, Pamecha V, Sharma D, et al. Palliative cytoreductive surgery versus other palliative treatments in patients with unresectable liver metastases from gastro-entero-pancreatic neuroendocrine tumours. *Cochrane Database Syst Rev* 2009; (1):Cd007118.
53. Oberg K., Ferone D, Kaltsas G, et al. ENETS Consensus Guidelines for the Standards of Care in Neuroendocrine Tumors: biotherapy. *Neuroendocrinology* 2009;90(2):209–213.
54. Kianmanesh R, Sauvanet A, Hentic O, et al. Two-step surgery for synchronous bilobar liver metastases from digestive endocrine tumors: a safe approach for radical resection. *Ann Surg* 2008;247(4):659–665.
55. Elias D, Lefevre JH, Duvillard P, et al. Hepatic metastases from neuroendocrine tumors with a “thin slice” pathological examination: they are many more than you think. *Ann Surg* 2010;251(2):307–310.
56. Lu Y, Frobom R, Lagergren J. Incidence patterns of small bowel cancer in a population-based study in Sweden: increase in duodenal adenocarcinoma. *Cancer Epidemiol* 2012;36(3):e158–e163.
57. Raghav K, Overman MJ. Small bowel adenocarcinomas–existing evidence and evolving paradigms. *Nat Rev Clin Oncol* 2013;10(9):534–544.
58. Haselkorn T, Whittemore AS, Lilienfeld DE. Incidence of small bowel cancer in the United States and worldwide: geographic, temporal, and racial differences. *Cancer Causes Control* 2005;16(7):781–787.
59. Goodman MT, Matsuno RK, Shvetsov YB. Racial and ethnic variation in the incidence of small-bowel cancer subtypes in the United States, 1995–2008. *Dis Colon Rectum* 2013;56(4):441–8.
60. Halfdanarson TR, McWilliams RR, Donohue JH, et al. A single-institution experience with 491 cases of small bowel adenocarcinoma. *Am J Surg* 2010; 199(6):797–803.
61. Talamonti MS, Goetz LH, Rao S, et al. Primary cancers of the small bowel: analysis of prognostic factors and results of surgical management. *Arch Surg* 2002;137(5):564–570; discussion 570–571.

62. Zaanan A, Costes L, Gauthier M, et al. Chemotherapy of advanced small-bowel adenocarcinoma: a multicenter AGEO study. *Ann Oncol* 2010;21(9):1786–1793.
63. Van Weyenberg SJ, Meijerink MR, Jacobs MA, et al. MR enteroclysis in the diagnosis of small-bowel neoplasms. *Radiology* 2010;254(3):765–773.
64. Pilleul F, Penigaud M, Milot L, et al. Possible small-bowel neoplasms: contrast-enhanced and water-enhanced multidetector CT enteroclysis. *Radiology* 2006;241(3):796–801.
65. Nicholl MB, Ahuja V, Conway WC, et al. Small bowel adenocarcinoma: understaged and undertreated? *Ann Surg Oncol* 2010;17(10):2728–2732.
66. Overman MJ, Hu CY, Wolff RA, et al. Prognostic value of lymph node evaluation in small bowel adenocarcinoma: analysis of the surveillance, epidemiology, and end results database. *Cancer* 2010;116(23):5374–5382.
67. Barnes G Jr, Romero L, Hess KR, et al. Primary adenocarcinoma of the duodenum: management and survival in 67 patients. *Ann Surg Oncol* 1994;1(1):73–78.
68. Poultsides GA, et al. Duodenal adenocarcinoma: clinicopathologic analysis and implications for treatment. *Ann Surg Oncol* 2012;19(6):1928–1935.
69. Schottenfeld D, Beebe-Dimmer JL, Vigneau FD. The epidemiology and pathogenesis of neoplasia in the small intestine. *Ann Epidemiol* 2009;19(1):58–69.
70. Lecuit M, Lortholary O. Immunoproliferative small intestinal disease associated with Campylobacter jejuni. *Med Mal Infect* 2005;35 Suppl 2:S56–S58.
71. Nagashima R, Takeda H, Maeda K, et al. Regression of duodenal mucosa-associated lymphoid tissue lymphoma after eradication of Helicobacter pylori. *Gastroenterology* 1996;111(6):1674–1678.
72. Lai EC, Lau SH, Lau WY. Current management of gastrointestinal stromal tumors–a comprehensive review. *Int J Surg* 2012;10(7):334–340.
73. Kindblom LG, Remotti HE, Aldenborg F, et al. Gastrointestinal pacemaker cell tumor (GIPACT): gastrointestinal stromal tumors show phenotypic characteristics of the interstitial cells of Cajal. *Am J Pathol* 1998;152(5):1259–1269.
74. Hirota S, Isozaki K, Moriyama Y, et al. Gain-of-function mutations of c-kit in human gastrointestinal stromal tumors. *Science* 1998;279(5350):577–580.
75. Bümming P, Ahlman H, Andersson J, et al. Population-based study of the diagnosis and treatment of gastrointestinal stromal tumours. *Br J Surg* 2006;93(7):836–843.
76. DeMatteo RP, Lewis JJ, Leung D, et al. Two hundred gastrointestinal stromal tumors: recurrence patterns and prognostic factors for survival. *Ann Surg* 2000;231(1):51–58.
77. Nikfarjam M, Kimchi E, Shereef S, et al. Surgical outcomes of patients with gastrointestinal stromal tumors in the era of targeted drug therapy. *J Gastrointest Surg* 2008;12(11):2023–2031.
78. Krajinovic K, Germer CT, Agaimy A, et al. Outcome after resection of one hundred gastrointestinal stromal tumors. *Dig Surg* 2010;27(4):313–319.

79. Heinrich MC, Rubin BP, Longley BJ, et al. Biology and genetic aspects of gastrointestinal stromal tumors: KIT activation and cytogenetic alterations. *Hum Pathol* 2002;33(5):484–495.
80. van Oosterom AT, Judson I, Verweij J, et al. Safety and efficacy of imatinib (STI571) in metastatic gastrointestinal stromal tumours: a phase I study. *Lancet* 2001;358(9291):1421–1423.
81. Demetri GD, von Mehren M, Blanke CD, et al. Efficacy and safety of imatinib mesylate in advanced gastrointestinal stromal tumors. *N Engl J Med* 2002;347(7):472–480.
82. Dematteo RP, Ballman KV, Antonescu CR, et al. Adjuvant imatinib mesylate after resection of localised, primary gastrointestinal stromal tumour: a randomised, double-blind, placebo-controlled trial. *Lancet* 2009;373(9669):1097–1104.
83. Mullady DK, Tan BR. A multidisciplinary approach to the diagnosis and treatment of gastrointestinal stromal tumor. *J Clin Gastroenterol* 2013; 47(7):578–585.
84. Coco C, Rizzo G, Manno A, et al. Surgical treatment of small bowel neoplasms. *Eur Rev Med Pharmacol Sci* 2010;14(4):327–333.
85. Retsas S, Christofyllakis C. Melanoma involving the gastrointestinal tract. *Anticancer Res* 2001;21(2b):1503–1507.

SECTION G: PANCREAS

Chapter 52

Pancreas Anatomy and Physiology

Taylor S. Riall

Key Points

1 The pancreas is both an endocrine and exocrine organ.

2 The primary function of the exocrine pancreas is to synthesize and secrete enzymes necessary for digestion.

3 The primary function of the endocrine pancreas is regulation of body energy, primarily through control of carbohydrate metabolism. Pancreatic endocrine hormones also play a critical role in the complex regulation of pancreatic secretion and digestion.

4 Congenital anomalies of the pancreas largely result from failure of rotation or fusion of the ventral and dorsal pancreatic buds.

5 The pancreatic islets of Langerhans are composed of four major cell types – alpha (A), beta (B), delta (D), and pancreatic polypeptide (PP or F) cells which primarily secrete glucagon, insulin, somatostatin, and PP, respectively.

6 The different types of islet cells are not evenly distributed throughout the pancreas leading to a differential distribution of functional neuroendocrine tumors. In addition, resection of different parts of the pancreas has differing endocrine effects.

7 Pancreatic endocrine secretion also regulates pancreatic exocrine secretion. Insulin stimulates pancreatic exocrine secretion, amino acid transport, and synthesis of protein and enzymes, whereas glucagon acts in a counter-regulatory fashion, inhibiting the same processes.

8 Tests of pancreatic exocrine function include the secretin test, 24-hour fecal fat determination, dimethadione (DMO) test, the Lundh test meal, the triolein breath test, and the paraaminobenzoic acid (PABA) test. These tests help differentiate steatorrhea due to pancreatic insufficiency from other digestive disorders.

9 Exogenous administration of somatostatin inhibits the release of insulin, glucagon, growth hormone, and pancreatic polypeptide.

10 Knowledge of the relationship of the pancreas to surrounding structures including the stomach, duodenum, distal bile duct, hepatic arterial blood supply, splenic artery and vein, celiac axis, superior mesenteric artery and vein, portal vein, spleen, adrenal glands, colon and kidneys is critical in preventing injury to these structures during pancreatic surgery.

11 Resectability in pancreatic cancer in the absence of metastatic disease depends on the extent of involvement of the tumor with the major vascular structures including the superior mesenteric artery, superior mesenteric vein (SMV), portal vein, and celiac axis.

INTRODUCTION

1 The pancreas is a digestive organ with both exocrine and endocrine function. The exocrine pancreas constitutes 80% of the pancreatic mass and comprises acinar and ductal cells.

2 Acinar cells synthesize and secrete over 20 enzymes into the complex pancreatic ductal network, which then delivers them to the duodenum. The pancreatic secretions are alkaline and provide the optimal environment for the enzymes to carry out their digestive function in the small intestine.

3 The pancreatic endocrine cells are organized in discrete groups throughout the pancreas, called islets of Langerhans. The islets directly secrete hormones including insulin, glucagon, and somatostatin, directly into the blood stream in endo crine fashion. The primary function of the endocrine pancreas is regulation of body energy, primarily through control of carbohydrate metabolism. Pancreatic endocrine hormones also play a critical role in the complex regulation of pancreatic secretion and digestion.

The pancreas lies transversely in the retroperitoneum at the level of the second lumbar vertebrae. Understanding of the embryology of the pancreas is critical for recognizing rare congenital anomalies, understanding their significance, and treating them appropriately. In addition, when performing pancreatic and other upper abdominal operations, it is critical to understand the close relationship of the pancreas to adjacent organs (duodenum, stomach, spleen, transverse colon, bile duct, and left adrenal gland) and major vessels (celiac axis, superior mesenteric artery, superior mesenteric vein (SMV), splenic artery and vein, portal vein, inferior mesenteric vein, and vena cava). Knowledge of the normal pancreatic exocrine and endocrine physiology provides insight into the pathologic processes and subsequent treatments that can affect the normal function of the pancreas.

EMBRYOLOGY

Normal Pancreatic Embryology

The pancreas begins developing during the fifth week of gestation. Pancreatic development begins at the junction of the foregut and midgut as two endodermal pancreatic buds, the dorsal bud and the ventral bud. The dorsal and ventral buds comprise endoderm covered in splanchnic mesoderm. Both the acinar and islet cells differentiate from the endodermal cells found in the embryonic buds while the splanchnic mesoderm eventually develops into the dorsal and ventral mesentery.

The dorsal bud forms first and is larger. It ultimately forms much of the head, body, and tail of the pancreas. As the duodenum grows and rotates, the ventral bud rotates clockwise (Fig. 52-1) and fuses with the dorsal bud forming the uncinate process and inferior head of the pancreas. In the majority of cases, the duct in the ventral bud fuses with the duct in the dorsal bud to become the main pancreatic duct (duct of Wirsung), which drains the majority of the pancreas into the duodenum through the major papilla, or ampulla of Vater. The proximal duct of the dorsal bud forms the lesser or minor pancreatic duct (duct of Santorini) which drains into the duodenum through the minor papilla proximal to the ampulla of Vater.

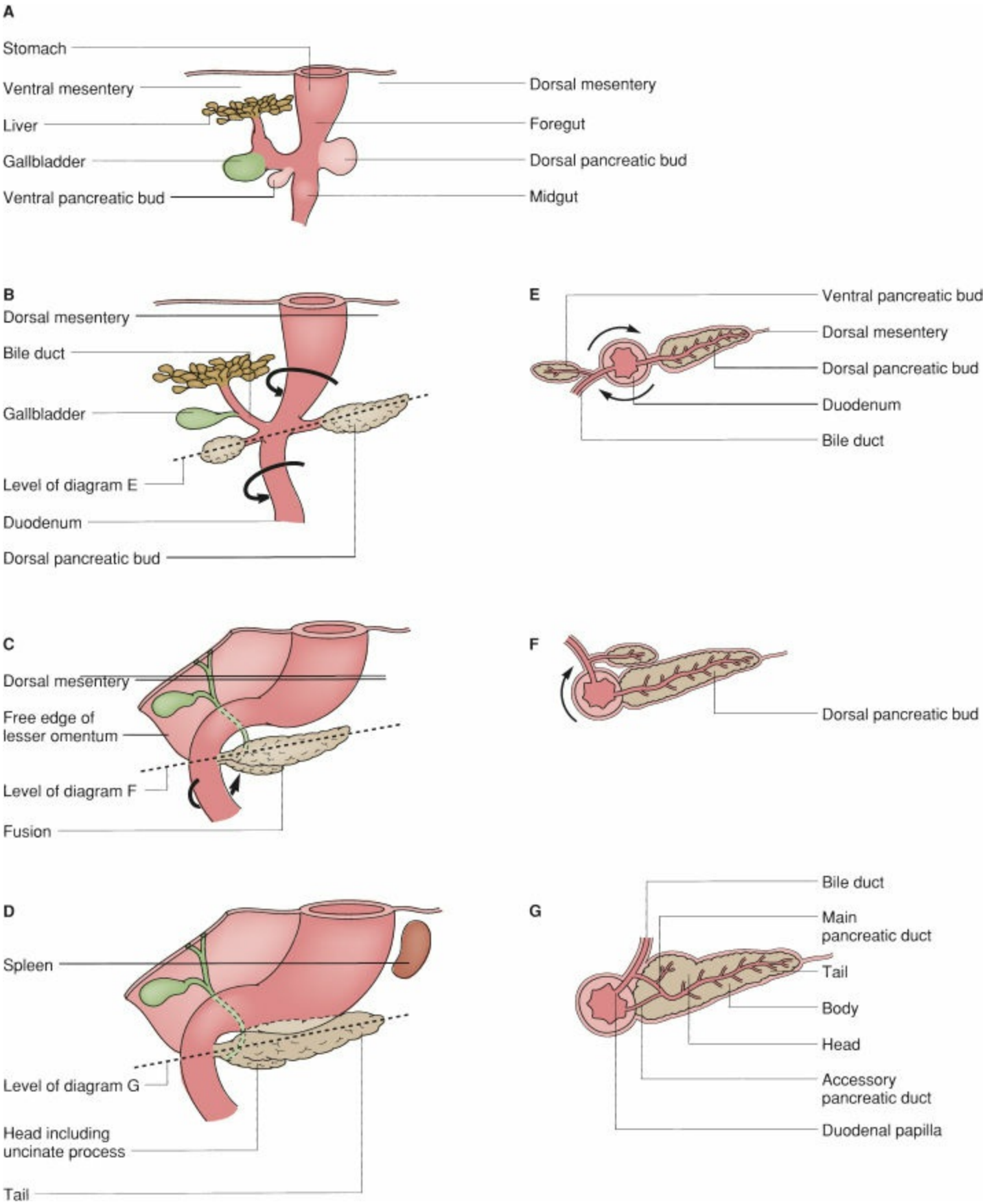

Figure 52-1. **A–D:** Schematic drawings of the successive stages in the development of the pancreas from the fifth through the eighth weeks. **E–G:** Diagrammatic transverse sections through the duodenum and the developing pancreas. Growth and rotations (*arrows*) of the duodenum bring the ventral pancreatic bud toward the dorsal bud and they subsequently fuse. The bile duct initially attaches to the ventral aspect of the duodenum and is carried around to the dorsal aspect as the duodenum rotates. The main pancreatic duct is formed by the union of the distal part of the dorsal pancreatic duct and the entire ventral pancreatic duct.

The endocrine function of the pancreas begins during gestation, whereas the exocrine function does not begin until after birth. The first glucagon-producing cells are seen in 3-week-old embryos and the first islets appear at approximately 10 weeks. During this early developmental period, predominantly glucagon-positive islet cells initially appear in the tail of the pancreas. Early glucagon-positive endocrine cells convert to nonepithelial cells and lose connection with the lumen and tight junctions. Subsequently, there is a major amplification of endocrine cell numbers, particularly B cells, which produce insulin.

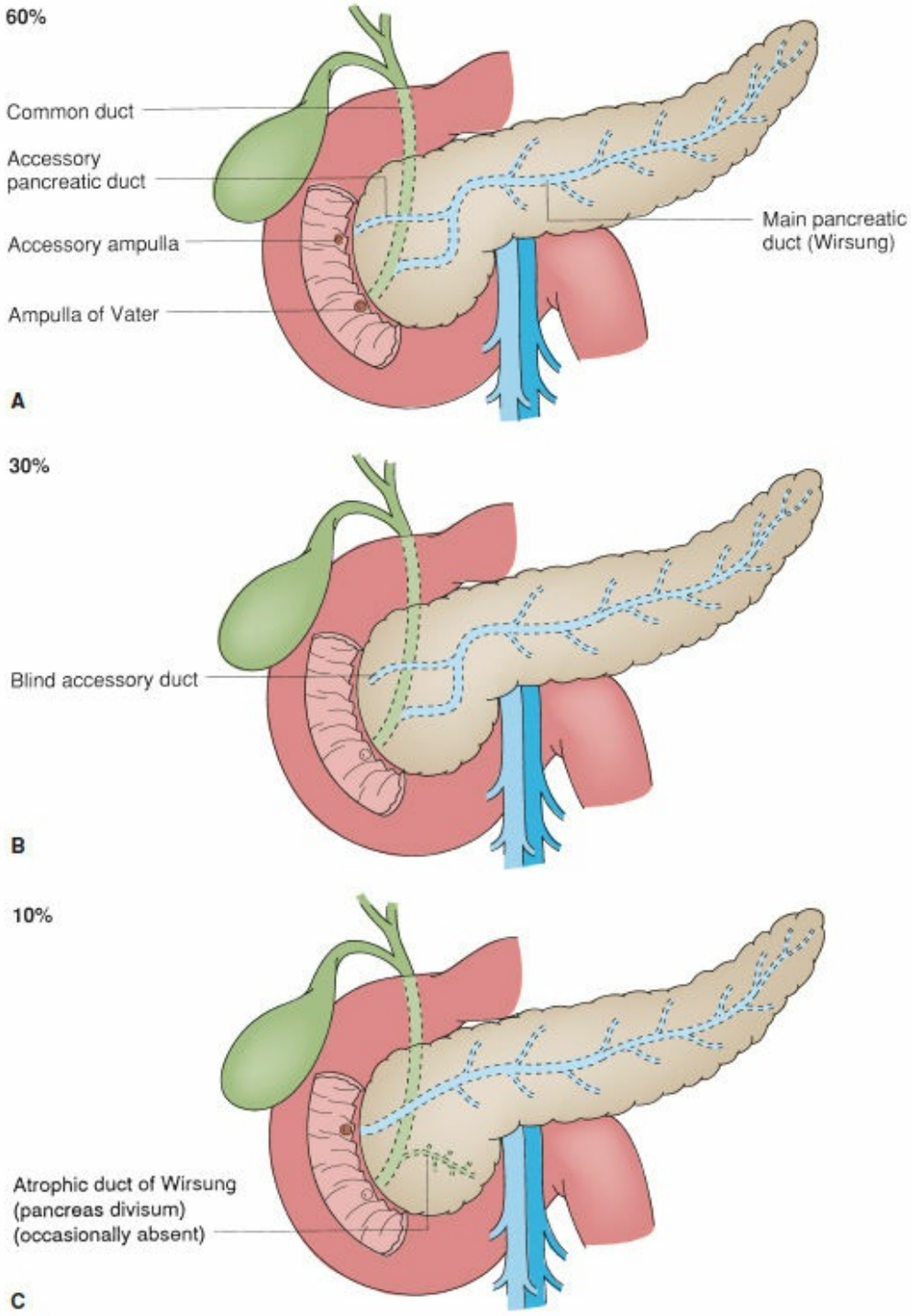
60%
Common duct
Accessory pancreatic duct
Accessory ampulla
Ampulla of Vater
Main pancreatic duct (Wirsung)
A
30%
Blind accessory duct
B
10%
Atrophic duct of Wirsung (pancreas divisum) (occasionally absent)
C

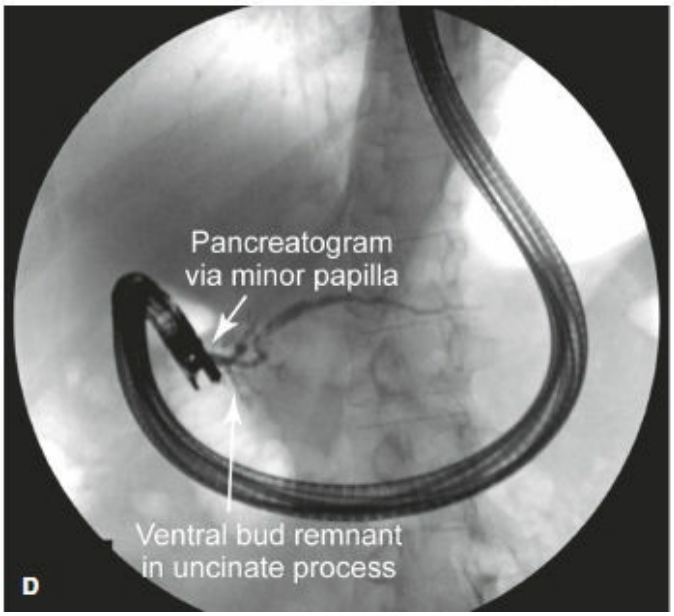
Pancreatogram via minor papilla
Ventral bud remnant in uncinate process
D

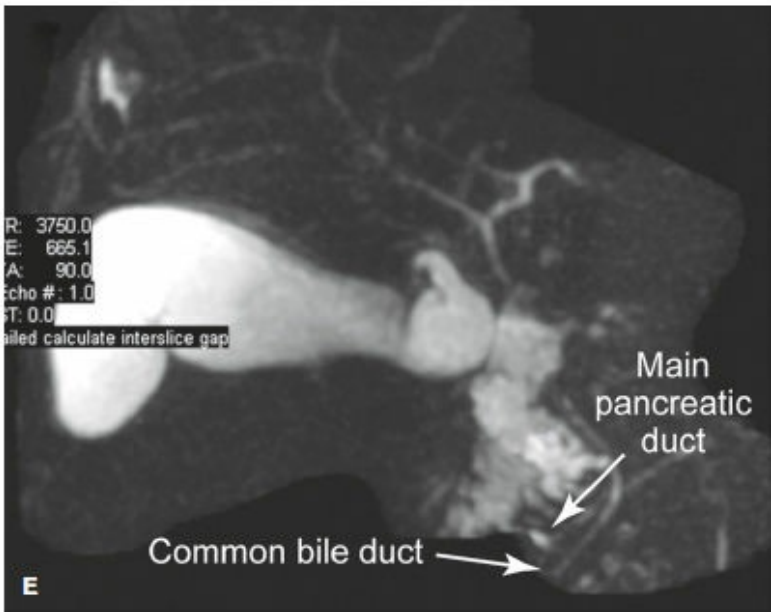
Main pancreatic duct
Common bile duct
E

Figure 52-2. Anatomic configuration of the intrapancreatic ductal system. **A:** The classic anatomy is present in 60% of cases, where the accessory duct drains into the minor papilla and the main duct drains into the ampulla of Vater. **B:** The accessory pancreatic duct is blind and does not drain into the duodenum in 30% of cases. **C:** A lack of communication between the two ducts, which occurs in 10% of cases, is referred to as *pancreas divisum*. When this occurs the main pancreatic duct drains into the duodenum through the minor papilla. **D:** Pancreaticogram obtained on ERCP through cannulation of the minor papilla in a patient with pancreas divisum; the main duct drains into the minor papilla. **E:** MRCP on the same patient. The main pancreatic duct drains into the minor papilla and the common bile duct drains into the ampulla of Vater.

Surgical Significance of Congenital Pancreatic Abnormalities

4 Abnormalities in the rotation and fusion of the pancreas during embryonic development can result in specific congenital anomalies that have surgical significance. In approximately 60% of people, rotation and fusion occur normally resulting in the classic anatomy seen in Figure 52-2A. The dorsal and ventral ducts fuse to form the main pancreatic duct which drains the majority of the pancreas into the ampulla of Vater. The lesser duct, formed from the proximal duct of the dorsal bud, drains into the duodenum at the minor papilla.

In approximately 30% of cases, the ventral and dorsal ducts fuse and drain normally into the duodenum at the ampulla of Vater. However, there is atrophy of the accessory or minor duct with a blind end and drainage into the duodenum (Fig. 52-2B). As this blind duct still communicates with the main pancreatic duct, this is of little to no clinical significance and most often found only at autopsy.

In 5% to 14% of cases, the fusion of the ventral and dorsal pancreatic ducts is incomplete (Fig. 52-2C–E).[1–3] As a result of the incomplete fusion, the majority of the pancreas is drained into the duodenum through the minor papilla. This is called pancreas divisum. Only the small remnant duct of the ventral bud drains the uncinate process into the duodenum via the ampulla of Vater. Whether or not pancreas divisum causes pancreatitis and abdominal pain is unclear.[1,4,5] It is often asymptomatic. However, mucosal stenosis at the minor papilla may lead to cystic dilatation of the dorsal duct resulting in pancreatitis and pain.[1,6–8] Pancreatitis or abdominal pain due to pancreas divisum is a diagnosis of exclusion, and other etiologies for the pancreatitis should be thoroughly investigated. If no other causes of pancreatitis are identified in the setting of abdominal pain, elevated amylase levels, and pancreas divisum, the anomaly is considered causative and an endoscopic or operative papillotomy of the minor papilla and accessory duct is indicated. Recurrent acute pancreatitis or chronic pancreatitis with chronic pain attributed to pancreas divisum is most often seen in young females.

Annular pancreas is a rare congenital anomaly of the pancreas first recognized in 1818. Early autopsy and surgical series estimate the incidence to be approximately 3 in 20,000.[9,10] However, with better imaging modalities such as computed tomography (CT), magnetic resonance cholangiopancreatography (MRCP), and endoscopy, the incidence is thought to be closer to 1 in 1,000.[11–13] Annular pancreas is thought to result from abnormal fusion of the ventral pancreatic bud to the duodenum, leading to improper rotation of the ventral bud around the duodenum.[14] This failure of rotation leads to a thin band of normal pancreatic parenchyma completely surrounding the second portion of the duodenum (Fig. 52-3A–C). This band is in continuity with the head of the pancreas and causes variable degrees of duodenal compression and stenosis. This abnormal ring of pancreatic tissue may contain a pancreatic duct. Therefore, the surgeon must be aware of this anomaly; if annular pancreas is incidentally encountered during an operation, it should not be divided. Division of the abnormal ring can result in pancreatic fistula or obstruction of pancreatic ductal drainage.

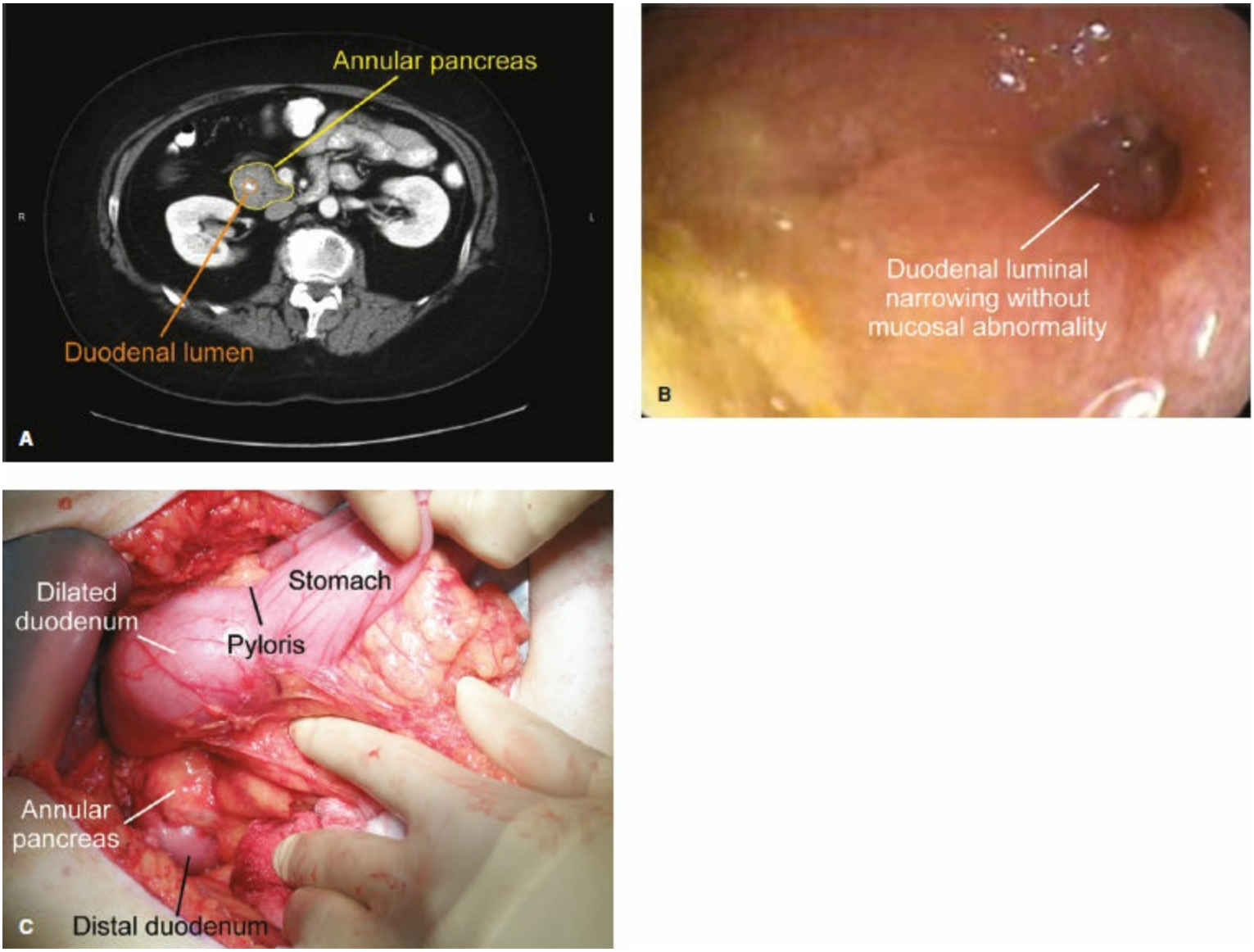

Figure 52-3. Annular pancreas. **A:** CT scan of a patient with annular pancreas. There is a ring of pancreatic tissue surrounding the duodenum, with a narrowed duodenal lumen. **B:** EGD image in the same patient. Note narrowing of the duodenal lumen with no mucosal lesion consistent with external compression by the annular pancreas. **C:** Intraoperative photo of an annular pancreas. Note the dilated duodenum after the pylorus, the ring of pancreatic tissue surrounding the duodenum just distal to the dilation, and the decompressed distal duodenum.

Annular pancreas can present at varying time points from in utero to adulthood.[13] When diagnosed in utero, the most common presentation is polyhydramnios due to duodenal obstruction. Newborns present most commonly with duodenal obstruction shortly after birth, as evidenced by low birth weight and feeding intolerance. In people who present in utero or in childhood, it is more commonly associated with other congenital anomalies including Down syndrome, cardiac anomalies, and other intestinal anomalies. Duodenal bypass (duodenoduodenostomy or gastrojejunostomy) is the treatment of choice in children.

Fifty percent of cases of annular pancreas occur in adults. Adults are less likely to present significant obstruction and less likely to require surgical intervention. If they do present with obstruction, treatment is similar to that in children. In adults, annular pancreas is more commonly associated with pancreas divisum and pancreatic neoplasia

than in children.[13] Heterotopic pancreas is pancreatic tissue outside the bounds of the normal pancreas without anatomic or vascular connections to the pancreas itself. Heterotopic pancreas occurs in 0.5% to 14% of autopsy series. The heterotopic pancreatic tissue is functional and can occur in a variety of sites including the stomach, duodenum, ileum, umbilicus, colon, appendix, gallbladder, and even within a Meckel diverticulum. This tissue is usually submucosal and uniformly contains acini and ducts. Up to one-third contains islet cells. Heterotopic pancreas is usually an incidental finding, but can present with ulceration, obstruction, or intussusception, in which case treatment is directed at the presenting symptoms and may require resection. In incidental and asymptomatic cases, no treatment is required. The heterotopic pancreas is susceptible to the same diseases as normal pancreas and can even undergo malignant transformation.[15,16]

EXOCRINE AND ENDOCRINE STRUCTURE

The exocrine structures of the pancreas account for 80% to 90% of the pancreatic mass while the endocrine structure accounts for approximately 2% of the pancreatic mass. The remainder of the pancreas comprises extracellular matrix, blood vessels, and major ductal structures.

Exocrine Structure

The exocrine structure of the pancreas is composed of two main components: the acinar cells and the ductal network. The acinar cells produce and secrete the enzymes and zymogens responsible for digestion. The acinar cells are pyramidal cells with an apex that faces the pancreatic ductal network. Approximately 20 to 40 acinar cells cluster together to form the functional unit called an acinus (Fig. 52-4A,B). Zymogen granules within the acinar cells contain the digestive enzymes for secretion into the ductal system. Located more centrally within the acinus, the centroacinar cell secretes alkaline fluid (pH 8.0) into the pancreatic ductal system. The acinus drains initially into small intercalated ducts, which join to form interlobular ducts that also secrete fluid and electrolytes (Fig. 52-4A). These interlobular ducts form secondary ducts that drain into the main pancreatic ductal system and eventually the duodenum at the ampulla of Vater.

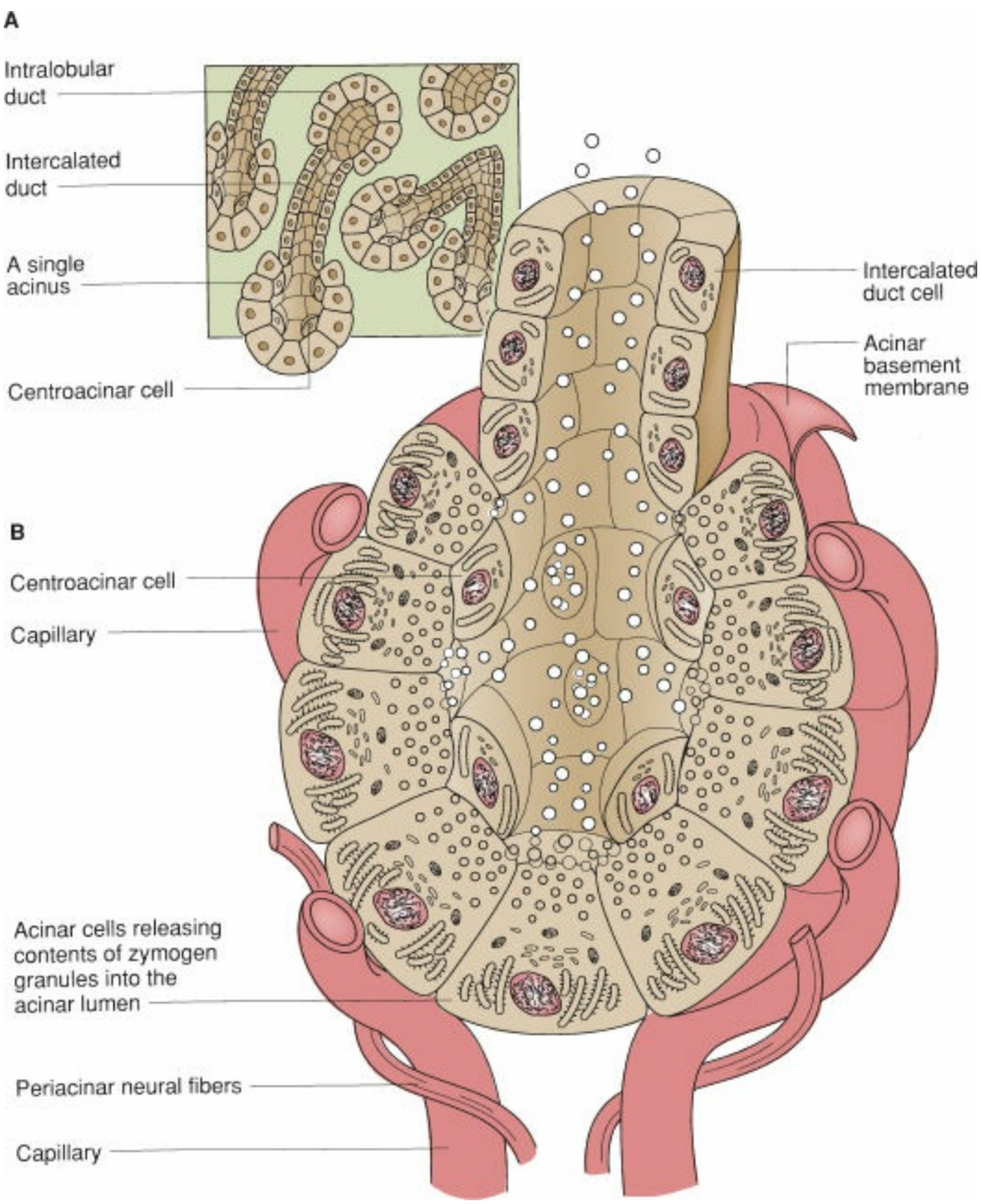

Figure 52-4. Histologic anatomy of the acinus. **A:** Low-magnification view of a portion of the pancreas. **B:** High-magnification view of a single acinus. The acinar cells, containing zymogen granules, are pyramidal cells with an apex that faces the pancreatic ductal network. Twenty to 40 acinar cells that cluster together to form the functional unit called an acinus. The centroacinar cell, also present within the acinus, functions to secrete fluid and electrolytes of the correct pH into the pancreatic ductal system. The acinus drains into small intercalated ducts, which join to form interlobular ducts that also secrete fluid and electrolytes. These interlobular ducts form secondary ducts that drain into the main pancreatic duct.

Endocrine Structure

5 The pancreatic islet cells are of neural crest origin and part of the family of amine precursor uptake and decarboxylation (APUD) cells. Each pancreatic islet is approximately 40 to 900 mm and contains an average of 3,000 cells. The islets are composed of four cell types. These cell types are differentially distributed both throughout the pancreas and within the islets. Table 52-1 describes the cell types, their hormonal products, and their location within the islet and the pancreas.

B (or beta) cells are located centrally within the islets. They constitute approximately 70% of the islet cell mass. The main secretory product of B cells is insulin, but they also excrete amylin and cholecystokinin. A (or alpha) cells and F cells are located peripherally within the islets and constitute 10% and 15% of the islet cell mass, respectively. Glucagon is secreted by A cells, which is the major counter-regulatory hormone to insulin in glucose homeostasis. F cells secrete pancreatic polypeptide. D cells are evenly distributed throughout the islet and constitute 5% of the islet cell mass.[17] They can be further divided into D cells which secrete somatostatin and D_2 cells which secrete vasoactive intestinal peptide (VIP). E (or epsilon cells) and C cells comprise $<1\%$ of the islet mass and secrete substance P and serotonin. They are of minimal clinical significance.

6 The distribution of endocrine cell types is not uniform throughout the pancreas. B and D cells are concentrated in the tail of the pancreas, whereas A cells (as well as C and E cells) are evenly distributed and F cells are concentrated in the pancreatic head and uncinate process. As such, resection of the pancreatic body and tail removes more of the insulin-producing cells and is more likely to cause endocrine insufficiency (diabetes). This distribution also has clinical relevance with regard to the location of endocrine neoplasms when they occur.

The islet cells have a rich blood supply supporting their endocrine role. The afferent arteriole enters the islet in an area of discontinuity in the non-B cells surrounding the periphery. The afferent arteriole then breaks into a capillary bed within the islet. Blood exits the islet through an efferent collecting venule. The hormones from the islet cells are secreted directly into this rich capillary network within the islet.

7 The most critical role of the pancreatic islet cells is the secretion of insulin and glucagon to maintain glucose homeostasis. Pancreatic endocrine secretion also regulates pancreatic exocrine secretion. Insulin stimulates pancreatic exocrine secretion, amino acid transport, and synthesis of protein and enzymes, whereas glucagon acts in a counter-regulatory fashion, inhibiting the same processes. The role of somatostatin is controversial. Somatostatin may have a direct inhibitory effect on pancreatic acinar cells, which possess somatostatin receptors. It may also act through an inhibitory effect on islet B cells.

PANCREATIC PHYSIOLOGY

Exocrine Function

The pancreas secretes 1.5 to 3 L of a pancreatic fluid daily. The enzymes and zymogens play a major role in the digestive activity of the gastrointestinal tract. Pancreatic fluid is alkaline (pH 7.6 to 9.0) and carries over 20 proteolytic enzymes and zymogens to the duodenum. The enzymes are released into the duodenum in their inactive state; the fluid serves to neutralize gastric acid and provides an optimal milieu for the function of these enzymes.

Pancreatic secretion is regulated via an intimate interaction of both hormonal and neural pathways that integrate the function of the pancreas, biliary tract, and small intestine. Vagal (parasympathetic) afferent and efferent pathways strongly affect pancreatic secretion. The secretion of enzyme-rich fluid is largely dependent on the vagal stimulation, whereas fluid and electrolyte secretion are more dependent on the direct hormonal effects of the secretin and cholecystokinin (CCK). Parasympathetic stimulation also causes the release of VIP, which also serves to stimulate secretin secretion.[18]

Table 52-1 Pancreatic Endocrine Cell Types

Cell Type	% Islet Cell Mass	Major Hormone Secreted	Location Within Islet	Location Within Pancreas	Associated Tumor Syndrome
A (alpha)	10%	Glucagon	Peripheral	Evenly distributed	Glucagonoma: necrolytic migratory erythema, diabetes, hypoaminoacidemia
B (beta)	70%	Insulin	Central	Body/Tail	Insulinoma: hypoglycemia and associated symptoms
D	5%[a]	Somatostatin	Evenly distributed	Body/Tail	Somatostatinoma: diabetes, gallstones, steatorrhea
D_2	5%[a]	Vasoactive intestinal peptide (VIP)	Evenly distributed	Body/Tail	VIPoma: high-volume secretory diarrhea, hypokalemia, metabolic acidosis, hypochlorhydria
F	15%	Pancreatic polypeptide	Peripheral	Head and uncinate process	Treatment directed at presenting symptoms
E C	<1%	Substance P, serotonin	Evenly distributed	Evenly distributed	None
G	Not present in normal physiologic state	Gastrin, ACTH-related peptides	Not applicable	Head, uncinate process, duodenum	Gastrinoma: acid hypersecretion, gastric/duodenal ulcers, diarrhea

[a]Combined D and D_2 mass.

Many neuropeptides also influence pancreatic secretion in an inhibitory fashion. These include somatostatin, pancreatic polypeptide, peptide YY, calcitonin gene–related peptides, neuropeptide Y, pancreastatin, enkephalin, glucagon, and galanin. While these neuropeptides are known to play a role in regulation of pancreatic secretion, the mechanisms of action and the intricate interplay between the neuropeptides is not fully understood.[18]

Bicarbonate Secretion

Bicarbonate is the most physiologically important ion secreted by the pancreas. Bicarbonate is formed from carbonic acid by the enzyme carbonic anhydrase. The secretion of water and electrolytes originates in the centroacinar and intercalated duct cells (Fig. 52-4). These cells secrete 20 mmol of bicarbonate per liter in the basal state and up to 150 mmol/L in the maximally stimulated state.[18] The bicarbonate secreted from the ductal cells is primarily derived from the plasma. Chloride efflux through the cystic fibrosis transmembrane conductance regulator (CFTR) leads to depolarization and bicarbonate entry through the sodium bicarbonate cotransporter.[18] As a result, chloride secretion varies inversely with bicarbonate secretion; the sum of these two anions balances the sodium and potassium cations and remaining constant and equal to that of the plasma.

Both secretin and VIP stimulate bicarbonate secretion by increasing intracellular cyclic AMP, which acts on the CFTR.[18] Gastric acid is the primary stimulus for release of secretin. Secretin is released from the duodenal mucosa in response to a duodenal lumen pH of less than 3.0 due to gastric acid.

The duodenum and jejunum release CCK in response to the presence of long-chain fatty acids, some essential amino acids (methionine, valine, phenylalanine, and tryptophan), and gastric acid. CCK is weak direct stimulator of bicarbonate secretion, but it acts as a neuromodulator and potentiates the stimulatory effects of secretin. Gastrin and acetylcholine are also weak stimulators of bicarbonate secretion.[19] Bicarbonate secretion is inhibited by atropine (vagal stimulation) and can be reduced by 50% after truncal vagotomy.[20] Islet cell peptides including somatostatin, pancreatic polypeptide, glucagon, galanin, and pancreastatin are thought to inhibit exocrine secretion.

Enzyme Secretion

Pancreatic enzymes originate in the acinar cells, which are highly compartmentalized. Proteins are synthesized in the rough endoplasmic reticulum, processed in the Golgi apparatus, and then targeted to the appropriate cell compartment (zymogen granules, lysosomes, etc.). The acinar cells secrete enzymes that fall into three major enzyme groups: amylolytic enzymes, lipolytic enzymes, and proteolytic enzymes. Amylolytic enzymes such as amylase hydrolyze starch to oligosaccharides and the disaccharide maltose. Lipolytic enzymes such as lipase, phospholipase A, and cholesterol esterase function work in conjunction with bile salts to digest fats and cholesterol. Proteolytic enzymes include endopeptidases (trypsin and chymotrypsin) and exopeptidases (carboxypeptidase). Endopeptidases act on the internal peptide bonds of proteins and polypeptides and exopeptidases act on the free carboxy- and amino-terminal ends of proteins. Proteolytic enzymes are secreted as inactive precursors. Enterokinase cleaves the lysine–isoleucine bond in trypsinogen to create the active enzyme trypsin. Trypsin then activates the other proteolytic enzyme precursors.[18]

The different pancreatic enzymes are not secreted in fixed ratios. They change in response to dietary alterations and stimuli such as gastric acid, hormones, and neuropeptides. When enzyme secretion is absent or impaired, malabsorption or incomplete digestion occurs, leading to fat and protein loss through the gastrointestinal tract. This is seen in patients with acute and chronic pancreatitis (who have destruction of the exocrine pancreas) and in patients who have undergone surgical resection of all or part of the pancreas. These patients often present with weight loss and steatorrhea secondary to malabsorption of nutrients. These signs and symptoms can be corrected by oral replacement of pancreatic enzymes with meals.

The nervous system initiates pancreatic enzyme secretion. This involves extrinsic innervation by the vagus nerve and subsequent innervation by the intrapancreatic cholinergic fibers. The neurotransmitters, acetylcholine and gastrin-releasing peptide activate calcium-dependent release of zymogen granules.[18] In addition, CCK is a predominant regulator of enzyme secretion, doing so through activation of specific membrane-bound receptors and calcium-dependent second messenger pathways. Secretin and VIP weakly stimulate acinar cell secretion directly, but also potentiate the effect of CCK on acinar cells (Fig. 52-5). Insulin is required locally and serves in a permissive role for secretin and CCK to promote exocrine secretion.[18]

Through the secretion of the three classes of enzymes, the pancreas regulates complete digestion of carbohydrates, fats, and proteins. Autodigestion of the pancreas by these proteolytic enzymes is prevented by packaging of proteases in an inactive precursor form and by the synthesis of protease inhibitors including pancreatic secretory trypsin inhibitor (PSTI), serine protease inhibitor, kazal type 1 (SPINK1), and protease serine 1 (PRSS1). These enzymes are found in the acinar cell and loss of these protective mechanisms can lead to activation, autodigestion, and acute pancreatitis. Mutations in the SPINK1 and PRSS1 genes are known to cause one of the aggressive familial forms of chronic pancreatitis, leading to recurrent episodes of pancreatitis, with associated exocrine and

endocrine insufficiency.[21,22]

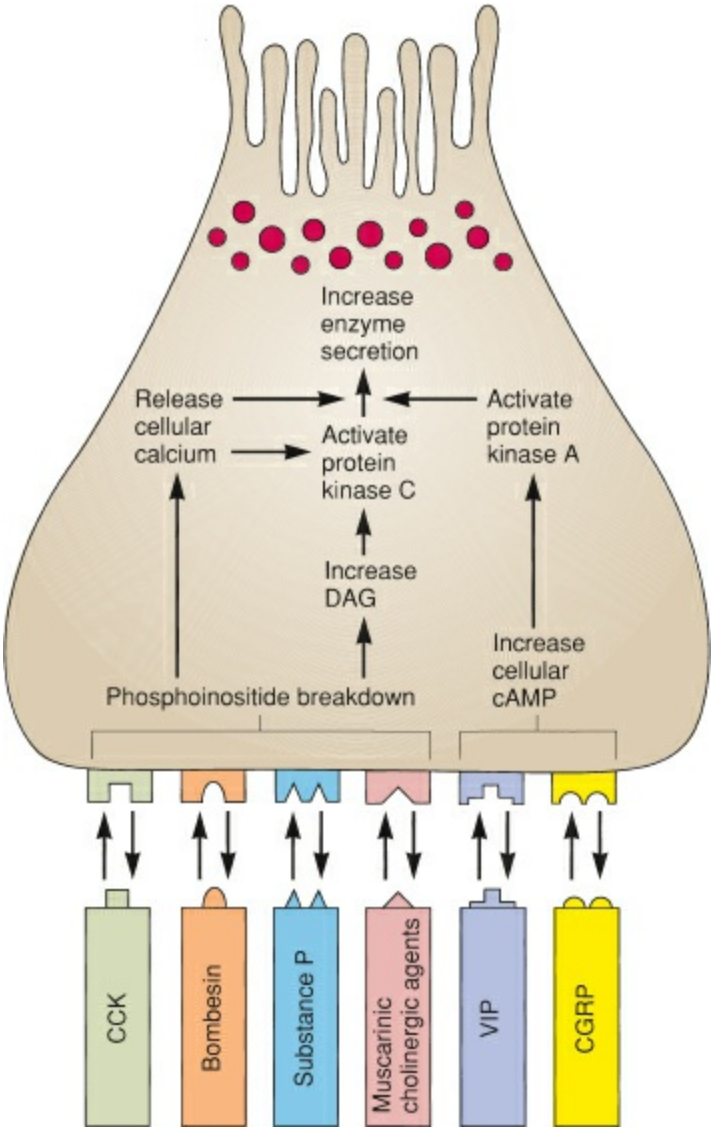

Figure 52-5. Schematic diagram of the acinar cell, demonstrating receptors for exocrine secretagogues and their intracellular bases of action. Six distinct classes of receptors are known, with principal ligands shown. CCK, cholecystokinin; VIP, vasoactive intestinal peptide; CRGP, calcitonin gene–related peptide; DAG, diacylglycerol.

Table 52-2 Characteristic Results of Secretin Testing: Volume, Bicarbonate Concentration, and Enzyme Secretion Changes in Pancreatic Disease Processes

Disorder	Pattern	Total Volume	Maximum Bicarbonate Secretion	Enzyme Secretion
End-stage pancreatitis	Total insufficiency	Decreased	Decreased	Decreased
Advanced pancreatic cancer	Total insufficiency	Decreased	Decreased	Decreased
Chronic pancreatitis	Qualitative insufficiency	Normal	Decreased	Normal
Pancreatic Cancer	Quantitative insufficiency	Decreased	Normal	Normal
Malnutrition[a]	Isolated enzyme deficiency	Normal	Normal	Decreased
Hemochromatosis, Zollinger–Ellison syndrome, cirrhosis	Hypersecretion	Increased	Normal	Normal

[a]Celiac disease, ulcerative colitis, and Crohn disease
Originally from Dreiling DA, Wolfson P. New insights into pancreatic disease revealed by the secretion test. In: Berk JE, ed. *Developments in Digestive Diseases*. Vol 2. Philadelphia, PA: Lea and Febiger; 1979:155.
Adapted from Table 53.3 in "Pancreatic Anatomy and Physiology" Chapter.

Tests of Pancreatic Exocrine Function

8 Several tests are useful in the assessment of pancreatic exocrine function. Such tests are useful in both diagnosing and determining the etiology of exocrine insufficiency (chronic pancreatitis, malnutrition, cancer, and Zollinger–Ellison syndrome) (Table 52-2). Steatorrhea from pancreatic exocrine dysfunction is the result of lipase deficiency and is usually not present until lipase secretion is reduced by 90%. The secretin test, the dimethadione test (DMO) and the Lundh test require duodenal intubation. The classic test of pancreatic exocrine function is the secretin test.[23] A patient fasts overnight. A double-lumen tube is then placed in the duodenum. Basal collections are performed for 20 minutes and analyzed for total volume, bicarbonate output, and enzyme secretion. An intravenous bolus of 2 units of secretin per kilogram is given and four collections every 20 minutes are analyzed for volume, bicarbonate levels, and enzyme levels.

Normal values for the standard secretin stimulation test are 2.0 mL of pancreatic fluid per kilogram per hour, bicarbonate concentration of 80 mmol/L, bicarbonate output of >10 mmol/L in 1 hour, and amylase secretion of 6 to 18 International Units/kg. The maximal bicarbonate concentration provides the greatest discrimination between normal subjects and patients with chronic pancreatitis.[24] The results of the secretin stimulation test for different pancreatic disease processes is shown in Table 52-2.

The pancreas metabolizes the anticonvulsant drug trimethadione to its metabolite, DMO. After placing a double-lumen tube in the duodenum, patients are given 0.45 g of trimethadione three times daily for 3 days. Secretin is given through the double-lumen tube to maximally stimulate pancreatic secretion. To measure pancreatic exocrine function, the duodenal output of DMO is analyzed.[25]

The Lundh test directly measures pancreatic enzyme secretion in response to a meal of carbohydrate, fat, and protein. A patient fasts overnight, then has a double-lumen duodenal tube placed. After basal duodenal fluid collection, patients are given a meal consisting of 18 g of corn oil, 15 g of casein, and 40 g of glucose in 300 mL of water. Duodenal fluid is collected every 30 minutes for 2 hours and analyzed for trypsin, amylase, and lipase. This test relies on endogenous secretin and CCK secretion and may be abnormal in diseases involving the intestinal mucosa.

N-benzoyl-1-tyrosyl paraaminobenzoic acid (BT-PABA) is cleaved by chymotrypsin to form paraaminobenzoic acid (PABA), which is then excreted in the urine. The PABA test is performed by administering 1 g of BT-PABA in 300 mL of water orally. Urine is then collected for 6 hours. Patients with chronic pancreatitis excrete less than 60% of the ingested dose of PT-PABA.

Suspected pancreatic exocrine dysfunction can also be confirmed giving patients a test meal and measuring serum levels of the islet cell hormone pancreatic polypeptide (PP). Basal and meal-stimulated levels of serum PP are reduced in severe chronic pancreatitis and after extensive pancreatic resection. After an overnight fast, a test meal of 20% protein, 40% fat, and 40% carbohydrate is ingested. The normal basal range of PP is 100 to 250 pg/mL. In severe chronic pancreatitis, the basal levels are often less than 50 pg/mL. The normal response to a meal is a rise in PP levels to 700 to 1,000 pg/mL for 2

to 3 hours after the meal. In severe disease, this response is decreased to less than 250 pg/mL. PP release depends on intact pancreatic innervation and can also be decreased after truncal vagotomy, antrectomy, or in the setting of diabetic autonomic neuropathy.

The triolein breath test is a noninvasive test of pancreatic exocrine insufficiency or malabsorption, but does not differentiate between the two.[26] 25 g of 14C-labeled corn oil (triglycerides) are given to the patient orally. The metabolite, 14C-carbon dioxide, can be measured in the breath 4 hours after administration. Patients with disorders of fat digestion or malabsorption exhale less than 3% of the dose per hour. The test can be repeated after pancreatic enzyme replacement. Patients with pancreatic insufficiency will achieve a normal rate of excretion of 14C-carbon dioxide, whereas patients with enteric disorders (malabsorption) show no improvement.

Many tests can help differentiate between steatorrhea caused by pancreatic exocrine insufficiency versus malabsorption (Table 52-3). The secretin test, the PABA test, and PP will be normal in intestinal malabsorption and abnormal in pancreatic insufficiency. The fecal fat test measures intraluminal digestion products. Fecal fat content is measured over a 24-hour time period. If the fecal fat is elevated to more than 20 g this indicates pancreatic insufficiency, whereas steatorrhea in the presence of low levels of fecal fat (<20 g) indicates intestinal dysfunction. A reduction of fecal fat can be used to demonstrate adequate replacement of pancreatic enzymes in patients with exocrine insufficiency. However, this test is time consuming and disliked by patients and pancreatic enzyme replacement is often titrated based on symptom relief if the clinical situation leads to a high index of suspicion for pancreatic exocrine insufficiency (i.e., long-standing chronic pancreatitis) or once the diagnosis of pancreatic insufficiency is made.

Table 52-3 Differential Diagnosis of Intestinal and Pancreatic Steatorrhea

Parameter	Intestinal Steatorrhea	Pancreatic Insufficiency
24-hr fecal fat	<20 g; soapy consistency	>20 g; only seepage
D-xylose	Abnormal (low)	Normal
Secretin test	Normal	Abnormal
Small bowel series	Abnormal	Normal
Small bowel biopsy	Abnormal	Normal
PABA test	Normal	Abnormal
PP response to meal	Normal	Abnormal
Vitamin B_{12} and folate	Abnormal (low)	Normal
Treatment with pancreatic enzymes	No change	Improvement

Serum amylase, lipase, and trypsinogen are not elevated in the physiologic state. As amylase is found in organs other than the pancreas (salivary glands, liver, small intestine, kidneys, and fallopian tubes), serum amylase levels may be elevated in both pancreatic and nonpancreatic diseases (Table 52-4). When pancreatic disease is suspected, the

measurement of serum amylase and lipase levels serve as a useful screening test. Assays for the isoenzymes of amylase can be performed, but are unreliable in determining whether the source of amylase is pancreatic or nonpancreatic and are not widely used. It has been shown that serum lipase is a more accurate biomarker of acute pancreatitis than serum amylase, with 19% of patients with acute pancreatitis having normal serum amylase levels, but only 3% having normal serum lipase levels.[27] Unlike amylase and lipase, serum trypsinogen is made only by the pancreas and may serve as a better marker for acute pancreatitis. Trypsinogen can also be measured in the urine and serves as a specific screening test for acute pancreatitis.[28,29] All three markers are cleared by the kidneys so in the setting of acute renal failure, all may be falsely elevated. These levels do not measure actual endocrine function, but are commonly used to diagnose acute pancreatitis and monitor its resolution.

In the case of acute pancreatitis, serum amylase and lipase levels are usually elevated and peak within 24 hours of the onset of symptoms. They return to normal within 2 to 4 days if the inflammation resolves. In cases of severe necrotizing pancreatitis, pancreatic ductal obstruction, and pseudocyst formation, amylase and lipase levels can remain elevated for much longer periods of time. In this case, elevated levels often reflect amylase-rich fluid within peripancreatic collections and not ongoing acute inflammation.

While amylase and lipase levels are elevated in over 85% of patients with acute pancreatitis, their elevation is far less common in chronic pancreatitis, where the exocrine function of the pancreas may be impaired. Amylase levels may be normal in patients with acute pancreatitis if there is a delay in their diagnosis or if their pancreatitis is related to hypertriglyceridemia, which can falsely decrease the serum amylase levels.[24]

Endocrine Function

The primary function of the endocrine pancreas is regulation of carbohydrate metabolism, primarily through regulation of insulin and glucagon secretion through a variety of feedback and regulatory mechanisms. Insulin promotes glucose transport into cells, inhibits glycogenolysis and fatty acid breakdown, and stimulates protein synthesis. Glucagon is the major counter-regulatory hormone to insulin. Glucagon secretion leads to elevated blood glucose levels through stimulation of glycogenolysis and gluconeogenesis.

Insulin Synthesis, Secretion, and Action

Insulin is a 56-amino-acid polypeptide with a molecular weight of 6 kD. It consists of two polypeptide chains (A and B) joined by two disulfide bridges. Insulin is synthesized by the B cells within the islets of Langerhans. Insulin is an anabolic hormone, promoting glucose transport into all cells except B cells, hepatocytes, and central nervous system cells. It also inhibits glycogenolysis and fatty acid breakdown but stimulates protein synthesis.

Table 52-4 Pancreatic and Nonpancreatic Causes of Hyperamylasemia

Pancreatic Diseases Causing Elevated Amylase Levels
Acute, uncomplicated pancreatitis
Pancreatic pseudocyst
Acute peripancreatic fluid collections
Pancreatic ascites
Pancreatic necrosis and/or abscess (infected pancreatic necrosis)
Pancreatic injury/trauma
Ductal obstruction in pancreatic cancer, pancreatic cystic neoplasms, or chronic pancreatitis
Nonpancreatic Diseases Causing Elevated Amylase Levels
Perforated duodenal ulcer
Duodenal ulcer penetrating pancreas
Small bowel obstruction
Ruptured ectopic pregnancy
Peritonitis
Salivary gland lesions (mumps, salivary duct stones, sialadenitis, iatrogenic ductal obstruction)
Other cancers (lung, esophagus, breast, ovarian)
Burns
Diabetic ketoacidosis
Renal insufficiency
Pregnancy

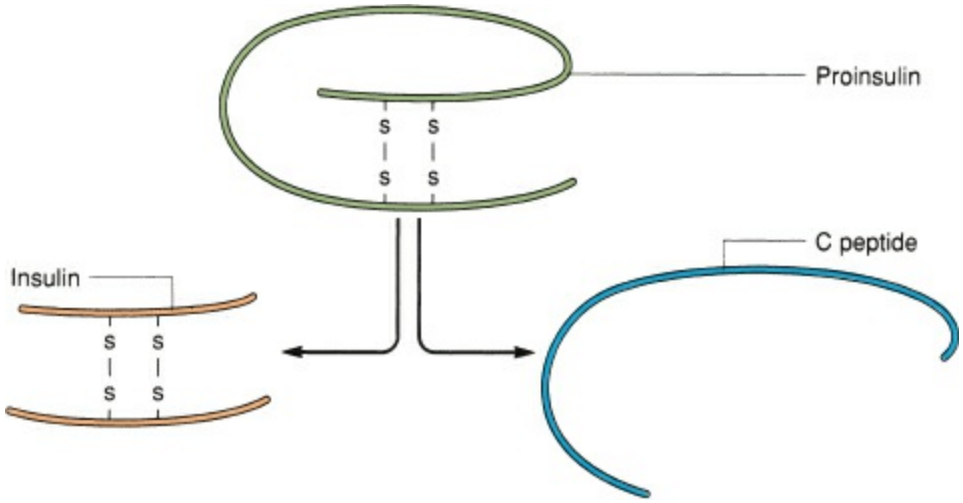

Figure 52-6. Synthesis of insulin. Proinsulin is synthesized by the endoplasmic reticulum and packaged within the secretory granules of the B cell. There it is cleaved into insulin and C peptide. Equimolar amounts of insulin and C peptide are secreted into the bloodstream.

The amino acid sequence varies among species, but the location of the disulfide bridges are highly conserved and are critical for its biologic activity. When pancreatic B cells are stimulated, proinsulin (precursor peptide to insulin) is synthesized in the endoplasmic reticulum and transported to the Golgi. In the Golgi, the proinsulin is packaged into granules where it is cleaved into insulin and the residual connecting peptide, C peptide (Fig. 52-6). The granules are then released directly into the bloodstream. Defects in the synthesis and cleavage of insulin can lead to rare forms of diabetes mellitus such as Wakayama syndrome and proinsulin syndrome.[30]

The secretion of insulin is tightly regulated by nutrient, neural, and hormonal factors. In response to glucose, the predominant nutrient regulator, insulin is secreted in two phases. The first phase is a short burst of stored insulin that lasts 4 to 6 minutes. This is followed by a sustained secretion of insulin, which requires active synthesis of the hormone within the islet cell. The B cell is sensitive to even small changes in glucose concentration and is maximally stimulated at concentrations of 400 to 500 mg/dL. Insulin is released in an oscillatory or pulsatile pattern controlled by an internal pacemaker which is present even in isolated islet cells.[31] Insulin has a short half-life of 7 to 10 minutes after secretion. Forty percent to 70% of insulin secreted into the portal venous system is metabolized by hepatocytes on the first pass through the liver. Excess insulin is then slowly metabolized by the liver, kidneys, and skeletal muscles. Insulin is not taken up by brain cells or red blood cells.

Insulin binds to a 300-kD glycoprotein cell surface receptor. Stimulation of the insulin receptor is dependent upon insulin concentration. Insulin resistance, present in type II diabetes, can be the result of decreased numbers of receptors or a decreased affinity for insulin. Glucose is actively transported across cell membranes throughout the body by glucose transporters. There are several classes of glucose transporters with varying affinities for glucose. The GLUT-2 transporter located on B cells has a low affinity for glucose. This results in low rates of transport at physiologic concentrations of glucose but an increased rate of transport at higher concentrations, with subsequent higher insulin

secretion rates.[32] The loss of B-cell GLUT-2 transporter can contribute to the development of diabetes mellitus.[33]

Through the enteroinsular axis, the release of enteric hormones in response to glucose potentiates insulin secretion. As such, orally administered glucose has a greater effect on insulin secretion than an equivalent amount of glucose administered intravenously. Gastric inhibitory polypeptide (GIP) is an important regulator of insulin secretion.[34] Additional gut peptides and hormones that stimulate insulin secretion include glucagon, glucagon-like peptide-1, and CCK, while somatostatin, amylin, and pancreastatin inhibit insulin secretion. Nutrients including certain amino acids (arginine, lysine, and leucine) and free fatty acids also regulate insulin secretion. Sulfonylurea compounds, which act independently of glucose concentration, also stimulate insulin secretion and are used in the treatment of type II diabetes, where the primary defect is peripheral insulin resistance and not insulin production or decreased islet-cell mass.

Parasympathetic and sympathetic innervation also influences B-cell activity. Both cholinergic and b-sympathetic fibers stimulate insulin secretion, whereas s-sympathetic fibers are inhibitory. A loss of pancreatic innervation in the setting of pancreatic transplantation can therefore result in changes in the pattern and quality of insulin secretion. There is a significant secretory reserve of insulin within the pancreas. Destruction or removal of 80% of the pancreatic islet cell mass is necessary before endocrine dysfunction becomes clinically apparent in the form of type I (insulin-dependent) diabetes.[35]

Glucagon Synthesis, Secretion, and Action

Glucagon, secreted by the islet A, is a single-chain, 29-amino-acid polypeptide with a molecular weight of 3.5 kD. Glucagon is the major catabolic hormone, elevating blood glucose levels through stimulation of glycogenolysis and gluconeogenesis in the liver. Like epinephrine, cortisol, and growth hormone, glucagon is considered a stress hormone because it increases metabolic fuel in the form of glucose during stress. Secretion of pancreatic glucagon is tightly controlled by neural, hormonal, and nutrient factors. Like insulin, glucose is the primary regulator, but the two hormones respond to glucose in reciprocal fashion. Glucose has a strong suppressive effect on glucagon secretion. The two hormones are counter-regulatory and function together to tightly control blood glucose levels. Excess glucagon can lead to hyperglycemia, whereas insufficient glucagon can lead to profound hypoglycemia. For this reason, the diabetes resulting from total pancreatectomy is very brittle and difficult to control due to the lack of endogenous glucagon to balance exogenously administered insulin.

Glucagon secretion is also stimulated by the amino acids arginine and alanine. Through paracrine effects within the islets, both insulin and somatostatin have a suppressive effect on glucagon secretion. The neural regulation of glucagon parallels that of insulin, with cholinergic fibers being strongly stimulatory, b-sympathetic fibers being weakly stimulatory, and a-sympathetic fibers being inhibitory. Dysfunctional A-cell secretion of glucagon may play a role in the elevation of blood sugar in diabetes.

Somatostatin Synthesis, Secretion, and Action

9 Somatostatin is a 14-amino-acid polypeptide weighing 1.6 kD. The role of endogenous somatostatin is unclear; it has not been proven to directly influence the secretion of other peptide hormones from islet cells. However, exogenous administration of somatostatin has been shown to inhibit the release of insulin, glucagon, growth hormone, and pancreatic polypeptide. Exogenous somatostatin administration has also been shown to inhibit gastric, pancreatic, and biliary secretion.

Both short- and long-acting synthetic peptides that mimic somatostatin pharmacologically have been developed. Somatostatin analogues are more potent inhibitors of growth hormone, glucagon, and insulin secretion than the natural hormone. They have been used to treat both exocrine and endocrine disorders of the pancreas. For example, in hormone-producing islet cell tumors which express somatostatin receptors, octreotide can effectively suppress the hormonal symptoms associated with the disease process and slow the progression of tumors.[36] There has been significant debate about the role of prophylactic somatostatin analogs in the prevention of pancreatic fistula formation after pancreatic surgery. A 2007 meta-analysis has shown that prophylactic octreotide reduces pancreatic fistula formation following elective pancreatic surgery[37] and a more recent randomized, controlled trial demonstrated that pasireotide given before surgery and for 7 days after surgery reduced the incidence of clinically significant postoperative fistulas, leaks, and abscesses.[38] A recent meta-analysis of pooled data from randomized trials failed to show any advantage of somatostatin analogs for accelerating fistula closure after pancreatic surgery.[39]

Pancreatic Polypeptide Synthesis, Secretion, and Action

Pancreatic polypeptide is a 36-amino-acid polypeptide secreted by the F cells of the pancreatic islet. The physiologic role of pancreatic polypeptide remains unclear. It has been shown to inhibit pancreatic exocrine secretion and gallbladder emptying. Cholinergic innervation predominantly regulates pancreatic polypeptide secretion. In diabetes and normal aging pancreatic polypeptide secretion is increased resulting in increased circulating pancreatic polypeptide levels.

Other Peptide Products

Other peptides are secreted within the pancreatic islet. These include neuropeptides such as VIP, galanin, amylin, pancreastatin, chromogranin A, and serotonin, which are believed to play a role in the regulation of islet cell secretion. Amylin, a 36-amino-acid polypeptide, is secreted by the B cells, but not in equimolar amounts to proinsulin. Amylin inhibits secretion of insulin and its uptake in the periphery. Amylin has been found to be deposited in the pancreas of patients with type II diabetes and has been implicated in the pathogenesis of the disease. Pancreastatin is another peptide found in large amounts in the pancreas. It is a derivative of chromogranin A, but its physiologic significance is unknown. Chromogranin A is produced by most neuroendocrine tumors and is a good marker for diagnosis and recurrence of pancreatic neuroendocrine tumors.

Tests of Pancreatic Endocrine Function

The most widely used tests of pancreatic endocrine function measure the body's ability to utilize glucose. The oral glucose tolerance test provides an indirect assessment of the insulin response to an oral glucose load; it measures the glucose profile and not the actual insulin response. After an overnight fast, two basal blood samples are drawn and glucose levels are analyzed. Patients are then given an oral glucose load of 40 g/m^2 over 10 minutes. Blood samples are then drawn every 30 minutes for 2 hours. The fasting glucose level should be less than 110 mg/dL. Fasting levels between 110 and 126 mg/dL are considered borderline, and fasting levels above 126 mg/dL are diagnostic of diabetes. The 2-hour glucose level should be below 140 mg/dL. Two-hour levels between 140 and 200 mg/dL are borderline, and 2-hour levels over 200 mg/dL are again diagnostic of diabetes mellitus. The test takes into account the gastrointestinal influences of glucose metabolism and can be affected by antecedent diet, drug use, exercise, and patient age.

The intravenous glucose tolerance test can be used to eliminate gastrointestinal influences on glucose metabolism. After basal glucose levels are obtained, this test is performed in similar fashion to the oral glucose tolerance test, except the glucose load is delivered as an intravenous bolus of 0.5 g/kg over 2 to 5 minutes. Blood is then drawn every 10 minutes for an hour. The disappearance of glucose per minute (K value) is calculated. A K value of 1.5 or higher is normal. The results are age adjusted, as the response to the intravenous glucose load decreases with age.

An insulinoma is a pancreatic neuroendocrine tumor that secretes insulin. The gold standard for diagnosis of insulinoma is the 72-hour monitored fast. This test documents Whipple triad of hypoglycemia, neuroglycopenic symptoms concurrent with hypoglycemia, and resolution of symptoms with administration of glucose. It also allows the clinic to rule out surreptitious administration of exogenous insulin. Within the B cell, proinsulin is cleaved into insulin and C-peptide prior to secretion. Therefore, both insulin and C-peptide levels can be measured in the blood stream and should be present in a 1:1 ratio. Surreptitious administration of exogenous insulin can be differentiated from insulinoma by the absence of C-peptide in the case of the exogenously administered insulin. Patients are fasted in a monitored setting. All nonessential medications are stopped and patients can only drink water, black, decaffeinated coffee, and diet sodas. Glucose and insulin levels as well as neuroglycopenic symptoms are closely monitored. The criteria for discontinuing the fast include serum glucose levels less than 45 mg/dL and the patient must be symptomatic. The 72-hour fast is highly sensitive for insulinoma and a patient rarely finishes this test without an unequivocal diagnosis. Urine should also be screened for the presence of sulfonylureas and other oral hypoglycemic medications.

The intravenous arginine test and tolbutamide response test are used to help in diagnosis of more rare hormone-secreting pancreatic neuroendocrine tumors. After an overnight fast, a patient is given a 30-minute intravenous infusion of 0.5 g/kg of arginine, which stimulates secretion of islet cell hormones. Blood samples are taken every 10 minutes and radioimmunoassays are performed for the hormone in question. This test is most useful for glucagon-secreting tumors and is not commonly used. Elevations of

plasma glucagon levels to over 400 pg/mL are diagnostic for glucagonoma.

Tolbutamide is a sulfonylurea that stimulates insulin secretion and secretion of other pancreatic endocrine hormones. After fasting overnight, blood samples are drawn and a patient is given 1 g of tolbutamide intravenously. Blood glucose is monitored for 1 hour and blood samples are drawn to determine levels of the hormone of interest. Sustained hypoglycemia with hypersecretion of insulin is diagnostic of insulinoma. Somatostatin levels more than twice as high as the normal values of the particular assay used are considered diagnostic of somatostatinoma.

PANCREATIC ANATOMY

The pancreas lies in the retroperitoneum at the level of the second lumbar vertebrae. It lies obliquely and transversely from its most caudal point at the duodenal C-loop on the right to its most cranial point in the splenic hilum on the left. The pancreas is composed of four anatomic parts: the head (including the uncinate process), the neck, the body, and the tail (Fig. 52-7).

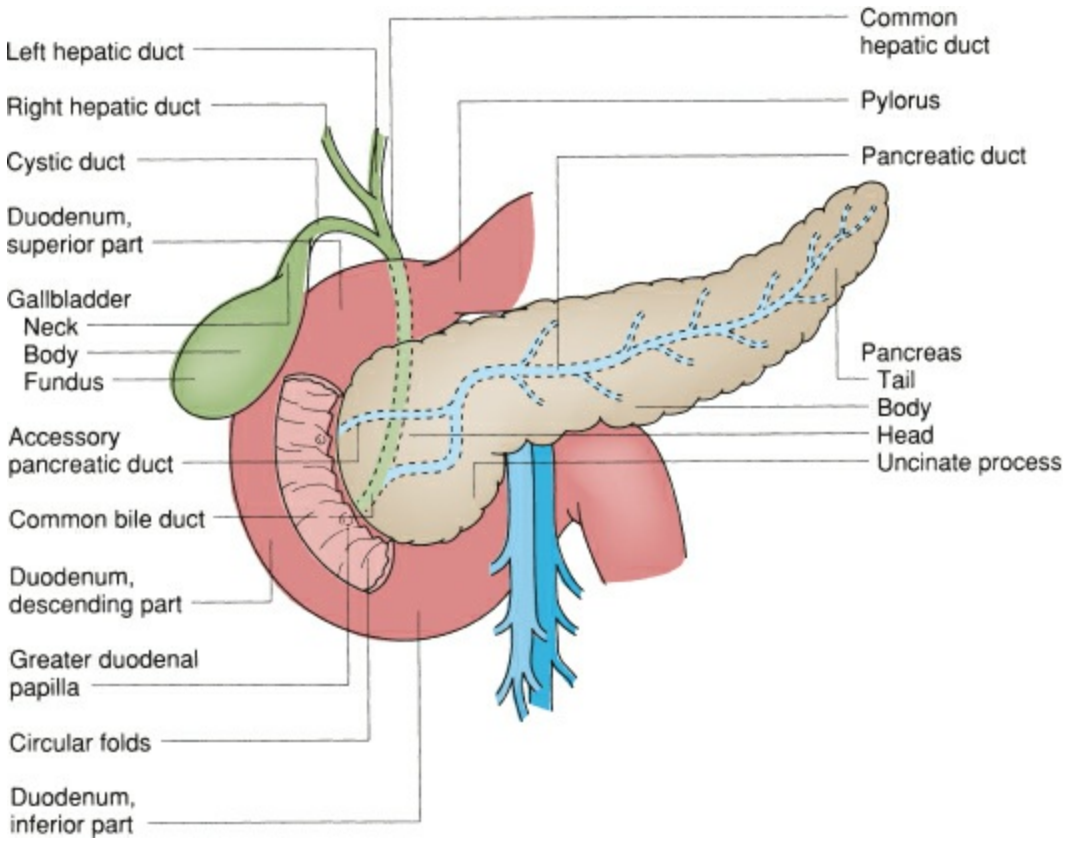

Figure 52-7. Normal pancreatic anatomy. The pancreatic head lies within the C-loop of the duodenum. The main pancreatic duct and common bile duct run through the head of the pancreas and drain into the duodenum at the ampulla of Vater. The superior mesenteric artery and vein lie posterior to the pancreatic neck.

Relationship to Adjacent Structures

The pancreatic head is further subdivided into the head and uncinate process. The head and uncinate process lie within the C-loop of the duodenum and include all the pancreatic parenchyma to the right of the superior mesenteric vessels. The pancreatic head is attached to the medial aspect of the descending and third portion of the duodenum and the two organs share a blood supply. The uncinate process projects from the inferior portion of the pancreatic head medially to the left, then posterior to the superior mesenteric vessels. The inferior vena cava, right renal artery and vein, and left renal vein lie posterior to the uncinate process and pancreatic head. The bile duct runs through the posterior and superior aspect of the pancreatic head, joining the pancreatic duct and draining into the duodenum medially at the ampulla of Vater (Fig. 52-7).

The pancreatic neck is the portion of pancreatic tissue that overlies the superior mesenteric artery and vein anteriorly. The anterior surface of the pancreatic neck lies directly posterior to the pylorus of the stomach. The body of the pancreas continues left from the pancreatic neck. The anterior surface of the pancreatic neck, body, and tail are covered with peritoneum and forms the floor of the omental bursa within the lesser sac. The stomach overlies the pancreatic body/lesser sac anteriorly. The posterior surface of the pancreatic body is not peritonealized and directly contacts the aorta, left adrenal gland, left kidney, and left renal artery and vein. The body of the pancreas is the portion overlying the second lumbar vertebrae. The tail of the pancreas begins anterior to the left kidney and extends superolaterally to the hilum of the spleen. The splenic artery and vein run along the posterior surface of the pancreas. The tail of the pancreas is in close proximity to the spleen and splenic flexure of the colon.

Pancreatic Ductal Anatomy

The main pancreatic duct, or duct of Wirsung, begins in the pancreatic tail. It most commonly runs within the posterior aspect of the pancreatic parenchyma, midway between the superior and inferior border of the gland. In the head of the pancreas, the pancreatic duct turns inferiorly at the genu of the pancreatic duct and joins the common bile duct, draining into the second portion of the duodenum at the ampulla of Vater. A common channel may exist between the common bile duct and main pancreatic duct and it varies in length across the population. At the level of the ampulla of Vater, the pancreatic duct is anterior and inferior to the common bile duct. At the ampulla of Vater, the sphincter of Oddi prevents reflux of duodenal contents into the bile duct and pancreatic duct. This sphincter of Oddi is controlled by a variety of neural and hormonal factors that regulate relaxation and constriction.

A normal main pancreatic duct is 2 to 4 mm in diameter and has a ductal pressure of approximately 15 to 30 mm Hg. This is higher than the pressure in the common bile duct (7 to 17 mm Hg) and serves to prevent reflux of bile into the pancreatic ductal system. There are over 20 side branches of the main pancreatic duct throughout the pancreas providing drainage of acinar units. The accessory pancreatic duct, or duct of Santorini, is more variable than the main pancreatic duct. It typically drains the uncinate process and inferior portion of the pancreatic head into the duodenum at the minor papilla, proximal to the ampulla of Vater.

Arterial Blood Supply

The pancreatic blood supply arises from the celiac axis and superior mesenteric artery. The celiac axis arises from the abdominal aorta and most commonly gives rise to the splenic artery, the left gastric artery, and the common hepatic artery (Fig. 52-8A). The splenic artery courses along the posterior surface of the pancreatic body and tail and gives rise to more than 10 branches which supply the pancreatic body and tail. The first branch of the splenic artery is the dorsal pancreatic artery; it arises close to the origin of the splenic artery and supplies blood to the proximal body. Further distally, the great pancreatic artery supplies the midportion of the body and the caudal pancreatic artery supplies the pancreatic tail.

The head of the pancreas is supplied by both the celiac and superior mesenteric artery (SMA). The gastroduodenal artery is the first branch off the common hepatic artery. Distal to the first portion of the duodenum, the gastroduodenal artery becomes the superior pancreaticoduodenal artery and divides into anterior and posterior branches. The SMA gives rise to the inferior pancreaticoduodenal artery, which also divides into anterior and posterior branches. The inferior and superior pancreaticoduodenal arcades form an extensive collateral network with the superior pancreaticoduodenal arcades, supplying both the duodenum and head of the pancreas. Anteriorly these arcades lie in the groove between the pancreas and duodenum. Posteriorly, they cross the common bile duct. The arterial blood supply of ampulla of Vater is from three pedicles off the superior and inferior pancreaticoduodenal arteries. The posterior pedicle, located at 11 o'clock, arises from the superior pancreaticoduodenal artery. The ventral commissural pedicle, located at 1 o'clock, arises from both arcades. Finally, the inferior pedicle at 6 o'clock arises from the anterior branch of the inferior pancreaticoduodenal artery. Near the head of the pancreas, branches arising from the splenic artery form collaterals with the inferior pancreaticoduodenal arcades.

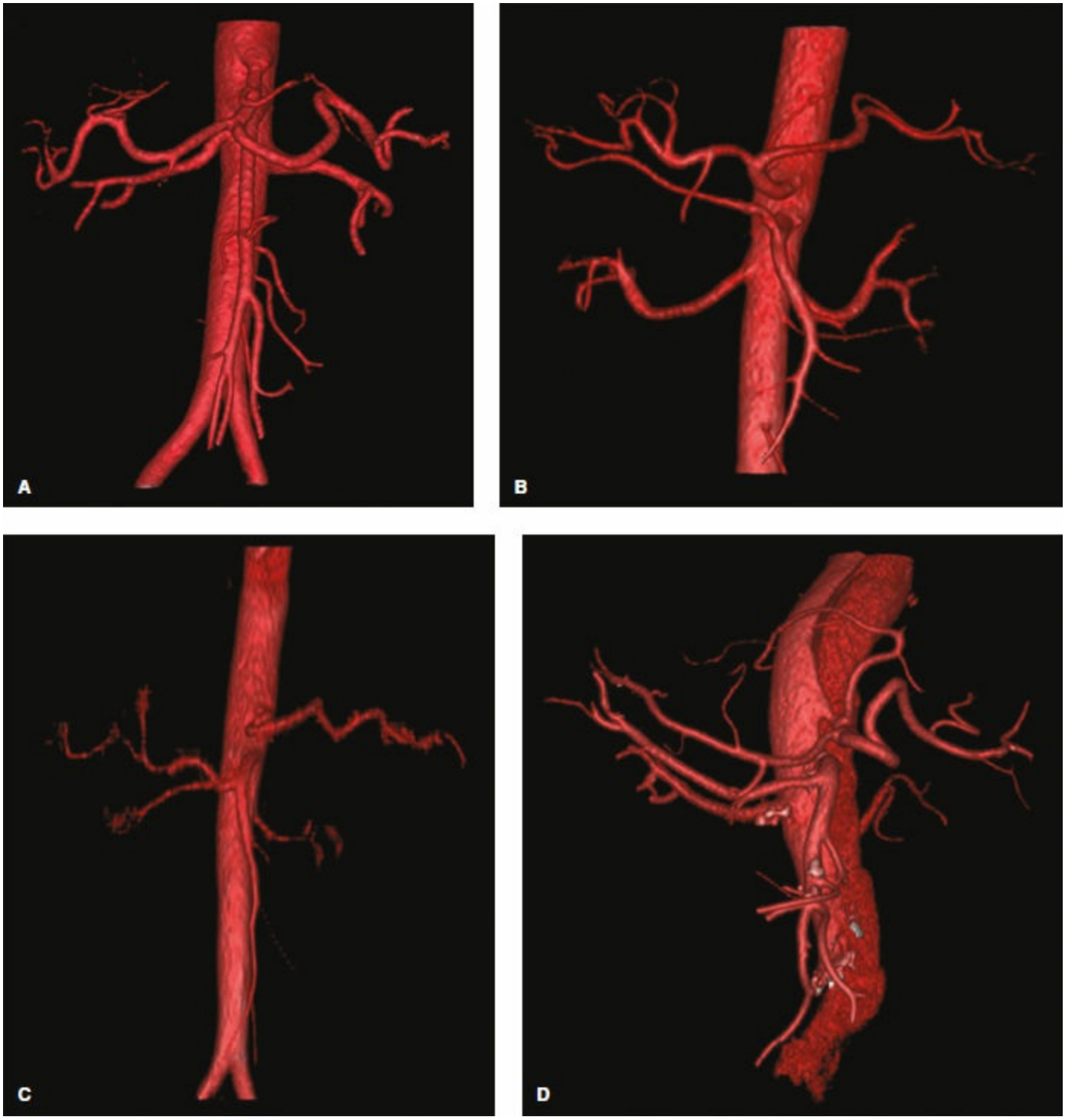

Figure 52-8. 3D CT reconstructions of (**A**) Normal arterial supply to the pancreas, (**B**) Replaced right hepatic artery arising from the superior mesenteric artery, (**C**) Replaced common hepatic artery arising from the superior mesenteric artery and (**D**) Replaced left hepatic artery arising from the splenic artery.

Variations or anomalies in the pancreatic and biliary blood supply are found in 20% to 30% of people. In most cases, all or part of the hepatic arterial blood supply does not arise from the celiac axis. As much of the pancreatic blood supply is derived from the hepatic arterial blood supply, these variations lead to variations in the pancreatic blood supply. In approximately 20% of patients, the replaced right hepatic artery arises from the superior mesenteric artery (Fig. 52-8B) in the retropancreatic position and traverses the upper edge of the uncinate process, then runs posterolateral to the portal vein. In this case, a pulse remains in the hepatoduodenal ligament and the gastroduodenal artery can

arise from the replaced right or the left hepatic artery. The right hepatic artery can also originate from the right gastric in 2% of cases or from the gastroduodenal artery in 6% of cases.

The entire hepatic arterial supply can be replaced, with the common hepatic artery originating from the SMA instead of the celiac axis (Fig. 52-8C). In this case, there is no hepatic arterial pulse medially in the hepatoduodenal ligament. The replaced common hepatic artery runs anterior to the portal vein, but posterior to the bile duct and gives rise to a gastroduodenal branch, which is also posterior to the bile duct. In approximately 10% of cases, the left hepatic artery can be aberrant, most commonly arising from the left gastric artery instead of the proper hepatic artery.

Venous Drainage

The venous drainage of the pancreas follows the arterial blood supply and is eventually returned to the portal circulation and delivered back to the liver. There are four main routes of venous drainage in the pancreas. In the pancreatic head the superior venous arcades drain either directly into the portal vein superiorly or laterally. The anterior and inferior pancreaticoduodenal arcades drain directly into the infrapancreatic SMV. There are rarely any anterior branches from the pancreatic head and neck into the superior mesenteric and portal veins. When they do occur, it is most commonly at the superior border of the pancreatic neck.

The body and tail of the pancreas has many venous tributaries that drain into the splenic vein, which joins the SMV posterior to the pancreatic neck forming the portal vein (PV). The three named tributaries of the splenic are the inferior pancreatic vein, the caudal pancreatic vein, and the great pancreatic vein. The inferior mesenteric vein (IMV) does not drain the pancreas, but joins the splenic vein posterior to the pancreatic body. The PV then drains the intestinal blood supply to the liver.

Lymphatic Drainage

Throughout the pancreas there is a rich periacinar network of lymphatic vessels which drain to five major nodal groups: superior, inferior, anterior, posterior, and splenic.[40] The superior nodal group runs along the superior border of the pancreas and celiac trunk. They drain the superior portion of the pancreatic head. The inferior nodal group along the inferior border of the head and body of the pancreas drain the inferior pancreatic head and uncinate process, eventually draining to the superior mesenteric and paraaortic lymph nodes. The anterior lymphatics drain to the prepyloric and infrapyloric nodes. The posterior lymph nodes include the distal common bile duct and ampullary lymphatics and drain directly into the paraaortic lymph nodes. Finally, the splenic lymph nodes drain the lymphatics of the pancreatic body and tail into the interceliomesenteric lymph nodes.

The Japanese Pancreas Society has classified the pancreatic lymphatic drainage into 18 lymph node stations (Table 52-5).[42] The greater and lesser curves of the stomach drain into lymph node stations 1 through 4. The anterior lymphatics described above drain into lymph node stations 5 and 6. The superior nodal group includes lymph node stations 7 through 9 along the left gastric artery, common hepatic artery, and celiac axis. The posterior lymph nodes include lymph node stations 12 (and all subdivisions) and 13, while the inferior nodal group comprises stations 14 through 17. The splenic lymph node group corresponds to Japanese lymph node stations 10 and 11.

Innervation

The innervation to the pancreas is derived from the vagus and thoracic splanchnic nerves as well as peptidergic neurons that secrete amines and peptides.[43] Parasympathetic and sympathetic fibers for ganglia along the celiac axis and superior mesenteric artery, which give rise to the pancreatic branches reach the pancreas by passing along the arteries from the celiac axis and superior mesenteric arteries. The parasympathetic nerves stimulate both exocrine and endocrine secretion, while the sympathetic fibers have a predominantly inhibitory effect (Fig. 52-9).[44] The peptidergic neurons secrete hormones including somatostatin, VIP, calcitonin gene–related peptide (CGRP), and galanin. While the peptidergic neurons influence exocrine and endocrine secretion, their precise physiologic role is unclear. The pancreas also has a rich network of afferent sensory fibers.

Table 52-5 Japanese Lymph Node Stations

Station Number	Name	Standard	Radical
3	Gastric lesser curve	No[a]	Yes[b]
4	Gastric greater curve	No[a]	Yes[b]
5	Superior pyloric	No[a]	Yes
6	Inferior pyloric	No[a]	Yes
8	Common hepatic artery	No	No
9	Celiac origin	No	Yes[c]
12	HEPATODUODENAL LIGAMENT		
12a2	Proper hepatic artery near GDA	No[d]	No[d]
12b2	Bile duct below cystic duct	Yes[e]	Yes[e]
12c	Around cystic duct	Yes	Yes
12p2	Retro portal vein below cystic duct	No[d]	No[d]
13	Posterior pancreaticoduodenal	Yes	Yes
14	SMA AND SMV NODES		
14a	Origin of SMA	No	No
14b	Right side of SMA	Yes[e]	Yes[e]
14c	Anterior SMA at middle colic	No	No
14d	Left side of SMA at first jejunal branch	No	No
14v	SMV nodes	Yes[e]	Yes[e]
16	AORTOCAVAL NODES		
16a2	Celiac to left renal vein	No	Yes[f]
16b1	Left renal vein to IMA	No	Yes
17	Anterior pancreaticoduodenal	Yes	Yes

[a]Unless a distal gastrectomy is performed as part of standard resection.
[b]Some of these nodes may accompany the distal gastrectomy specimen.
[c]Sampled only.
[d]Not formally resected.
[e]Some of these nodes may accompany the pancreaticoduodenectomy specimen.
[f]Some of these nodes, cephalad to the left renal vein, but not required to dissect the celiac axis origin.

With permission from Yeo CJ, Cameron JL, Lillemoe KD, et al. Pancreaticoduodenectomy with or without distal gastrectomy and extended retroperitoneal lymphadenectomy for periampullary adenocarcinoma, part 2: randomized controlled trial evaluating survival, morbidity, and mortality. *Ann Surg* 2002;236(3):355–366; discussion 366–358.[41]

SURGICAL SIGNIFICANCE OF PANCREATIC ANATOMY

10 Knowledge of the anatomy and anatomical variants can give clues to the diagnosis of pancreatic disease based on signs and symptoms. In addition, an understanding of the pancreatic anatomy in relation to adjacent structures is essential when performing operative procedures on the pancreas or surrounding structures including the duodenum, bile duct, and spleen.

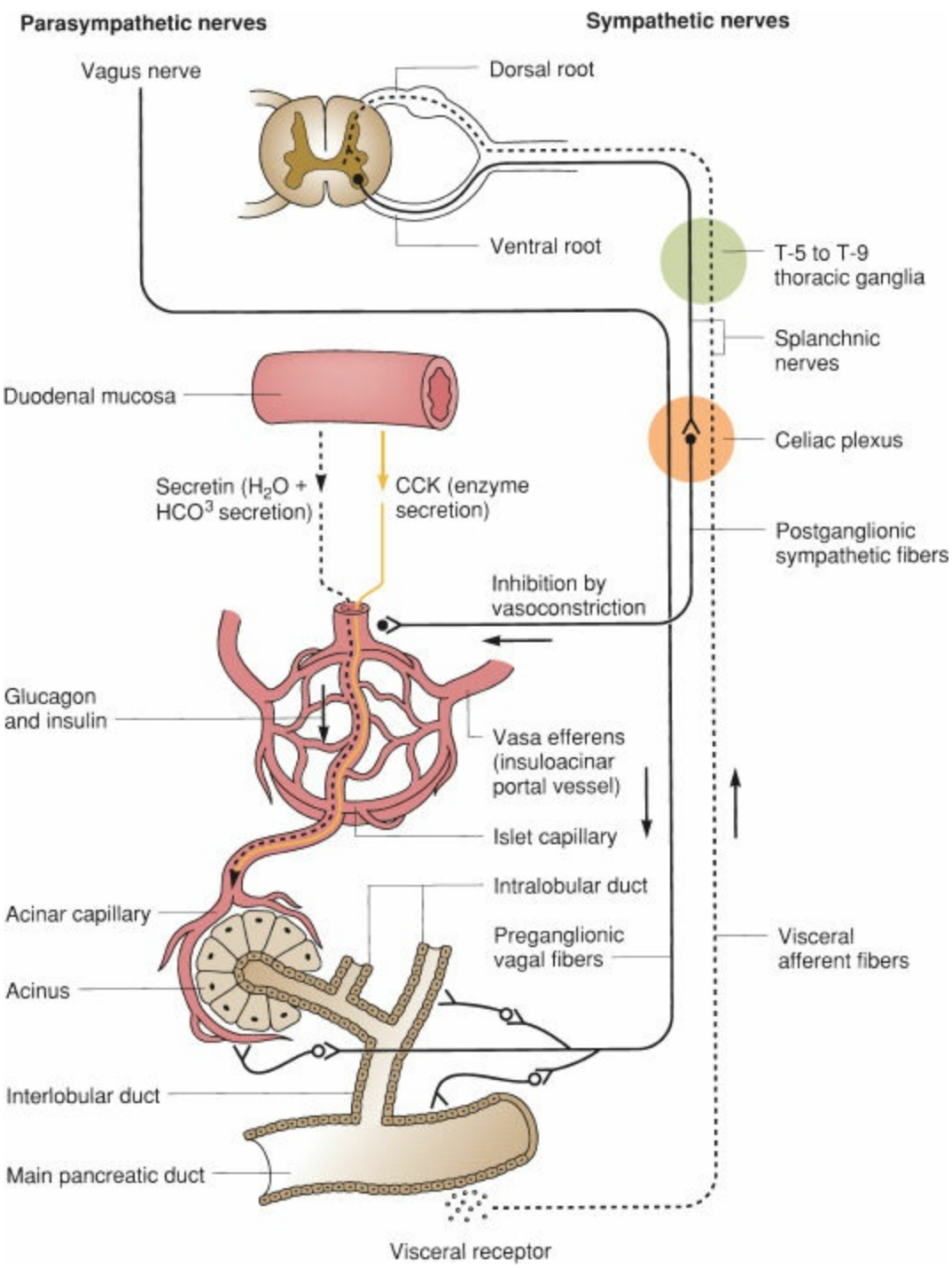

Figure 52-9. Schematic diagram of the neurohormonal control of the exocrine cells. Visceral receptors line the ductule system and carry the sensation of pain to the spinal cord. Sympathetic fibers first synapse in the celiac plexus after traveling through the thoracic ganglia and splanchnic nerves. Postganglionic fibers then synapse on intrapancreatic arterioles. Parasympathetic preganglionic fibers travel through the celiac plexus after leaving the vagus nerves and course with vessels and ducts to synapse on postganglionic fibers near acinar cells, islet cells, and smooth muscle cells of major ducts. Stimulation of these parasympathetic fibers results in an immediate release of pancreatic enzymes. Secretin and CCK first enter the pancreas through the capillary network of the islet cells, and then enter the separate capillary network of the acinar tissue through the insuloacinar portal vessels. Glucagon, somatostatin, pancreatic polypeptide, and insulin from the islets cells reach the acinar tissue immediately after release. In this way, the islet cells can influence the acinar tissue responses to CCK and secretin.

Pancreatic Anatomy and Pancreatic Cancer

Approximately, 75% of pancreatic adenocarcinomas occur in the pancreatic head at the genu of the pancreatic duct.[45] As a result, people who develop cancer in the head of the pancreas most commonly present with obstructive jaundice secondary to occlusion of the intrapancreatic bile duct by tumor, leading to earlier diagnosis. People with body and tail tumors present with abdominal pain and other vague abdominal symptoms, often leading to a delay in diagnosis. Nearly 85% of resected pancreatic tumors are in the head, neck, or uncinate process of the pancreas.[46]

Similarly, patients with cancer in the pancreatic head often have invasion of the adjacent duodenum. They may present with or develop signs and symptoms of duodenal or gastric outlet obstruction. In patients with unresectable disease, late gastric outlet obstruction in patients requiring gastrojejunostomy or duodenal stenting occurs in 10% to 20% of patients. A prospective, randomized trial demonstrated that the addition of prophylactic gastrojejunostomy in addition to hepaticojejunostomy significantly reduced gastric outlet obstruction in patients with unresectable disease undergoing open biliary bypass.[47] However, in the modern era, biliary stenting is so effective that operative hepaticojejunostomy for unresectable disease is rarely indicated. In the setting of isolated gastric outlet obstruction in unresectable disease, duodenal stenting is an option. When successful this can avoid surgery and its negative impact on the remaining quality of life. In a meta-analysis of trials comparing endoscopic stenting to gastrojejunostomy, stenting was associated with shorter time to oral intake and shorter length of stay, with similar complication rates, and decreased mortality.[48]

11 The ability to resect a pancreatic cancer depends on the presence or absence of metastatic disease and the extent of local vascular involvement. Pancreatic cancers are classified as resectable, borderline resectable, or unresectable (including locally advanced unresectable disease and metastatic disease). Table 52-6 shows the 2014 National Comprehensive Cancer Network definitions for resectable, borderline resectable, and unresectable disease.[49] Tumors are considered resectable if they have: (1) no distant metastases, (2) no radiographic evidence of SMV or PV distortion, and (3) clear fat planes around the celiac axis, hepatic artery, and SMA (Fig. 52-10A).

Table 52-6 Criteria for Resectability in Pancreatic Cancer

Resectability Status	Definition[49]
Resectable	No distant metastases No radiographic evidence or superior mesenteric vein (SMV) or portal vein (PV) distortion Clear fat planes around the superior mesenteric artery (SMA), hepatic artery, and celiac axis
Borderline Resectable	No distant metastases Venous involvement of the SMV or PV with distortion, narrowing, or occlusion of the vein with anatomic options for safe resection and reconstruction Gastroduodenal artery encasement up to the hepatic artery with short segment encasement or abutment of the hepatic artery without involvement of the celiac axis Tumor abutment of SMA <180 degrees the circumference of the vessel
Locally advanced/ unresectable	No distant metastases >180 degrees SMA involvement Invasion of the celiac axis Invasion or encasement of the aorta or inferior vena cava (IVC) Unreconstructable PV/SMV occlusion
Metastatic	Distant metastases (liver, lung, lymph nodes beyond the field of resection)

Tumors are considered borderline resectable if they have: (1) no distant metastases, (2) venous involvement of the SMV or PV with distortion or narrowing of the vein or occlusion of the vein with suitable vessel proximal and distal, allowing for safe resection and replacement, (3) gastroduodenal artery encasement up to the hepatic artery with either short segment encasement or direct abutment of the hepatic artery, without extension to the celiac axis, and (4) tumor abutment of the SMA not to exceed greater than 180 degrees of the circumference of the vessel wall (Fig. 52-10B).

Tumors are considered to be locally unresectable if there is: (1) no distant metastatic disease, (2) greater than 180 degrees SMA encasement, (3) any celiac axis abutment, (4) unreconstructable SMV/portal occlusion, (5) invasion or encasement of the aorta or inferior vena cava (IVC), and (6) nodal involvement outside the field of resection. Patients with any distant metastatic disease, most commonly to the liver or lymph nodes outside the field of resection, or the presence of peritoneal carcinomatosis are considered unresectable.

Pancreatic head cancers may also involve adjacent organs including the hepatic flexure of the colon, the gallbladder, or the stomach. If there are no distant metastases, resection of these organs *en bloc* is indicated. For cancers in the body and tail without distant metastasis, involvement of the splenic artery and/or vein does not preclude resection as these vessels are normally taken during the operation. However, involvement of the celiac axis or superior mesenteric artery precludes resection. Involvement of adjacent organs including the left kidney, left adrenal, spleen, and left colon can be resected if

involved with tumor and there is no distant disease.

Knowledge of the normal pancreatic blood supply is critical in order to perform an adequate cancer operation. As the duodenum and head of pancreas share a blood supply, it is necessary to remove these organs *en bloc* when performing an operation for carcinoma. While the duodenum can be preserved in resections performed for benign disease (duodenum-preserving pancreatic head resection), this is not the case in patients with cancer. Likewise, for cancers in the body and tail of the pancreas it is necessary to resect the spleen and its blood supply since it shares a blood supply with the tail of the pancreas. For benign diseases of the pancreatic tail, the spleen can be preserved.

There has been significant debate regarding the extent of lymph node dissection necessary in patients undergoing curative resection for pancreatic cancer. Table 52-5 shows the difference in extent of lymphadenectomy between the standard and radical procedure. The standard procedure includes the bile duct (station 12b2) and cystic duct lymph nodes (station 12c), the posterior (station 13) and anterior (station 17) pancreaticoduodenal lymph nodes, the SMV nodes (station 14v), and the nodes on the right side of the superior mesenteric artery (station 14b). Radical resection adds a distal gastrectomy (stations 3, 4, 5, and 6) and a retroperitoneal dissection extending from the right renal hilum to the left lateral border of the aorta horizontally with samples of celiac nodes, and from the portal vein to below the third portion of the duodenum vertically (lymph node stations 16a1, 16b2, and 9). In the United States, standard resection is most commonly performed.

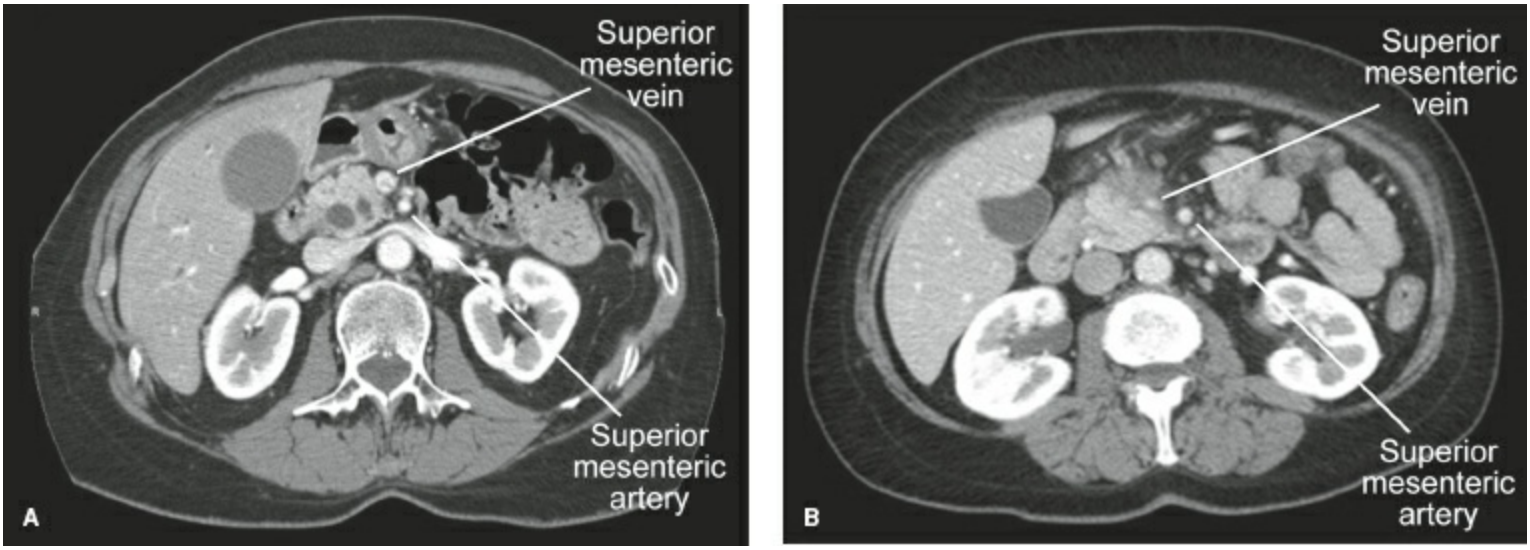

Figure 52-10. **A:** Resectable pancreatic head cancer. There is a clear plane between the tumor and both the superior mesenteric artery and superior mesenteric vein. **B:** Borderline resectable pancreatic cancer. Involvement of the superior mesenteric vein with distortion and narrowing; tumor abutment of the superior mesenteric artery less than 80 degrees of the circumference.

Awareness of the common anatomic variants in biliary and pancreatic arterial supply is necessary to prevent major vascular injury and damage to the hepatic blood supply during pancreatic resection. The gastroduodenal artery is the largest named artery taken during pancreaticoduodenectomy. In the case of a replaced right hepatic artery arising

from the superior mesenteric artery, the gastroduodenal artery can arise from this replaced vessel and enter the pancreas posterior to the bile duct. In addition, this replaced right hepatic artery courses to the liver lateral to the bile duct and can easily be injured during dissection of the pancreatic uncinate process off of the superior mesenteric vessels. A replaced right hepatic artery often supplies the entire right lobe of the liver causing significant hepatic ischemia if injured. In the case of a replaced right hepatic artery, there will still be a pulse medially in the hepatoduodenal ligament from the left hepatic artery, but this will supply only the left lobe of the liver.

In the case of a replaced common hepatic artery, the entire hepatic blood supply will be from the SMA. There will be no pulse medially in the hepatoduodenal ligament. The replaced vessel will again be posterior and lateral to the bile duct and at risk of injury if not correctly identified. Given the closer proximity of the replaced vessels to the pancreatic head and uncinate process, these replaced vessels may also be more prone to direct involvement by tumor. If injured or involved with tumor and resected, these often require reconstruction to restore adequate hepatic blood supply.

Due to the rich afferent sensory fiber network within the pancreas, abdominal pain and back pain are common presenting symptoms in patients with pancreatic cancer. As pancreatic cancer progresses, the nervous plexuses along the celiac axis in the retroperitoneum can be invaded by a tumor causing the characteristic intractable back pain. In this setting, celiac ganglion blockade (sympathectomy) or neurolysis using alcohol can provide significant pain relief by interrupting these somatic fibers. A celiac block can be performed endoscopically,[50] percutaneously, or intraoperatively. Endoscopic ultrasound (EUS)- or CT-guided celiac plexus neurolysis should be considered first-line therapy in patients with pain secondary to unresectable, locally advanced pancreatic cancer.[51] Celiac blockade has been shown to reduce pain in patients with unresectable pancreatic cancer undergoing operative bypass procedures for obstructive jaundice and duodenal obstruction.[52,53]

Pancreatic Anatomy and Pancreatitis

The intrapancreatic location of the distal common bile duct is critical to many pancreatic disease processes. Gallstone pancreatitis, the second most common cause of pancreatitis in the United States, is caused by gallstones passed into the common bile duct. These gallstones can obstruct the duct distally and lead to transient obstruction of the pancreatic duct with resulting reflux of pancreatic juice and bile into the pancreatic duct, causing pancreatitis.

In benign pancreatic diseases such as chronic pancreatitis, disease in the pancreatic head may cause benign biliary strictures and jaundice, whereas disease in the body and tail more often presents with abdominal pain. Pancreatic ductal anatomy and the presence or absence of ductal dilation dictate the choices for operative management. In the setting of a dilated pancreatic duct, drainage procedures may impact pancreatic pain and recurrent acute episodes. Conversely, in the setting of small duct disease, ablative therapy with resection (duodenum-preserving pancreatic head resection, pancreaticoduodenectomy, and distal pancreatectomy) is the treatment of choice when medical management fails.

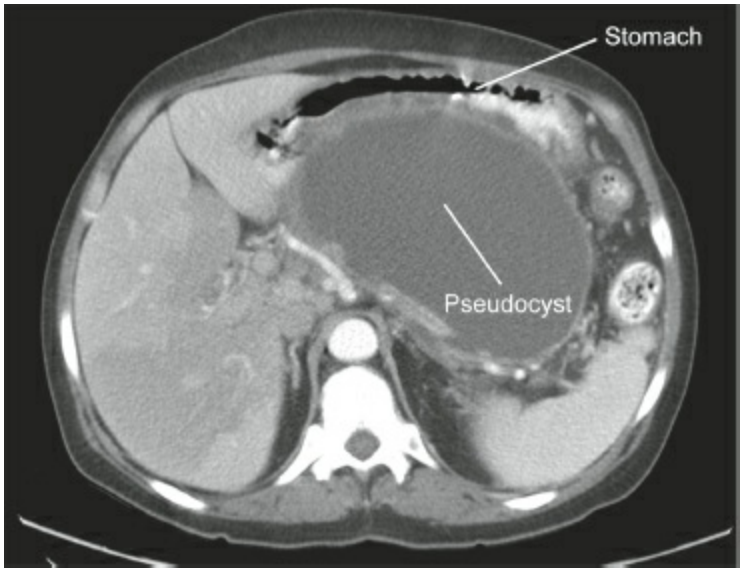

Figure 52-11. Large pancreatic pseudocyst in the lesser sac. The pseudocyst is compressing the stomach anteriorly.

In the setting of acute or chronic pancreatitis, ductal disruption can lead to the formation of a pancreatic pseudocyst. In many cases, these pseudocysts occur anterior to the pancreas in the lesser sac (Fig. 52-11). This often leads to early satiety and abdominal pain. When large pseudocysts abut the stomach, drainage can be achieved with endoscopic or operative cystgastrostomy.

Trauma and Pancreatic Injury

The pancreatic body lies anterior to the second lumbar vertebra deep in the retroperitoneum. In cases of blunt abdominal trauma, specifically deceleration injury, the pancreatic body is crushed against the second vertebral body and can be transected at this point. In trauma patients with elevated amylase and lipase levels, the trauma surgeon should be aware of this possibility and obtain cross-sectional pancreatic imaging to rule out ductal disruption. In the case of complete ductal disruption distal pancreatectomy or drainage of the pancreas into the intestine may be necessary.

Penetrating injury to the duodenum or pancreas often involves major vascular injury and in many cases is not survivable. In the case of injury to the IVC, the pancreas and duodenum must be mobilized out of the retroperitoneum (Kocher maneuver) in order to expose the vessels.

DIAGNOSTIC APPROACH TO PATIENTS WITH PANCREATIC DISEASE

Pancreatic Imaging (Studies of Pancreatic Structure)

If pancreatic disease is suspected, the pancreas can be imaged by several radiographic modalities including plain abdominal x-rays, upper gastrointestinal series, abdominal ultrasonography, CT MRCP, endoscopic retrograde cholangiopancreatography (ERCP), and EUS.

Abdominal Plain Films

Plain films of the abdomen may be useful in patients with acute and chronic pancreatitis. In patients with acute pancreatitis, the most common finding on plain film include a generalized ileus with air fluid levels, a localized ileus or “sentinel loop” of jejunum or duodenum in the area of the inflamed pancreas, or a cutoff of the colon due to distention of the transverse colon. In the setting of acute pancreatic fluid collections or pseudocysts, one may see an actual mass on plain film with displacement of the stomach or duodenum.[24] These findings are not sensitive or specific for acute pancreatitis, but in the setting of elevated amylase and lipase and associated abdominal symptoms can provide support for the diagnosis and an indication for more sensitive pancreatic imaging studies.

In the setting of chronic pancreatitis the most common finding on plain film is the presence of calcifications within the pancreas. These are most commonly seen at the level of the second lumbar vertebrae, where the pancreas lies in the retroperitoneum.

Upper Gastrointestinal Series

In the setting of a mass or mass effect on plain film, an upper gastrointestinal series can demonstrate displacement of the stomach or duodenum by a retroperitoneal mass. Displacement or narrowing of the duodenal C-loop suggests the presence of a pancreatic mass. However, the character of the mass (inflammatory, neoplastic, cystic, etc.) cannot be further defined on upper gastrointestinal series.[24] For this reason, upper gastrointestinal series has been largely replaced by ultrasound and other cross-sectional imaging modalities such as CT or MRCP.

Ultrasonography

Abdominal ultrasound can be useful in the setting of acute pancreatitis, chronic pancreatitis, pancreatic cystic lesions, pancreatic pseudocysts, and pancreatic cancer. In acute pancreatitis, the abdominal ultrasound may demonstrate gallstones, suggesting a potential etiology. In addition, the ultrasound can identify an enlarged pancreas, pancreatic edema and peripancreatic fluid collections consistent with the diagnosis of acute pancreatitis. Ultrasound can also identify pancreatic pseudocysts, cystic lesions, and other pancreatic masses.[24] Pancreatic pseudocysts usually appear as a smooth, round fluid collection without acoustic shadowing. A pancreatic cancer is more likely to distort the underlying pancreatic anatomy and appear as a localized, solid lesion on ultrasound, also without acoustic shadowing. Cystic neoplasms of the pancreas can have both solid and cystic components. They can be uniloculated or multiloculated and contain cysts of varying size. A large uniloculated neoplastic cyst is difficult to differentiate from a pancreatic pseudocyst.

Ultrasound examination can be limited by obesity, overlying bowel gas, recently performed barium contrast studies. Small masses or fluid collections can be easily missed. The presence of a mass on ultrasound is an indication for more extensive workup via CT or MRCP imaging.

Computed Tomography

Contrast enhanced, multidetector helical 3D CT is the most commonly performed study for the detection and characterization of pancreatic solid and cystic tumors. It is also useful in defining the pancreatic anatomy in the presence of chronic pancreatitis and identifying and following the complications of acute pancreatitis. CT is very sensitive for identifying pancreatic masses as small as 1 cm and can accurately distinguish solid from cystic lesions. The density of the lesion on CT can provide clues as to the diagnosis. Pancreatic adenocarcinomas are usually solid and hypodense, whereas pancreatic neuroendocrine tumors are vascular and appear hyperdense. Both pseudocysts and cystic lesions have components with fluid density.

CT is sensitive for the diagnosis of a malignant pancreatic adenocarcinoma. However, it is less sensitive and accurate in the diagnosis of cystic lesions. As CT scans are more commonly performed for a variety of indications, many cystic lesions are found incidentally. CT can be useful in identifying the characteristics associated with malignancy including tumor size greater than 3 cm, a dilated main pancreatic duct, and solid components within the cystic lesion.[54] However, significant controversy remains regarding observation versus resection of pancreatic cystic lesions.

Endoscopic Ultrasound

Compared to transabdominal ultrasound, EUS provides higher-resolution images of the pancreatic parenchyma and pancreatic duct. This procedure uses a transducer fixed to an endoscope that can be directed to the surface of the pancreas through the stomach or duodenum. EUS provides a useful adjunct to CT in the diagnosis of mucinous cystic lesions and malignancies. Pancreatic masses and cystic lesions can be well visualized on EUS, providing information about tumor size and invasion of major vascular structures. While more invasive than CT, EUS can provide useful additional information. EUS allows for fine-needle aspiration and/or biopsy, providing a tissue diagnosis, which is critical in the setting of planned neoadjuvant therapy for pancreatic adenocarcinoma. EUS can also provide information about pancreatic ductal anatomy without the risk of invasive ERCP, which can cause severe pancreatitis.

A list of 11 EUS criteria has been defined for the diagnosis of chronic pancreatitis. The ductal criteria include pancreatic duct stones, echogenic ductal walls, irregular ductal walls, pancreatic duct strictures, visible side branches, and ductal dilatation. The parenchyma criteria include echogenic strands, echogenic foci, calcifications, lobular contour, and pancreatic cysts. Recent studies have determined that three or more EUS criteria provides the best balance of sensitivity and specificity for histologic pancreatic fibrosis.[55]

Finally, in the setting of intractable pain in unresectable pancreatic cancer, chemical neurolysis of the celiac ganglion can be performed under EUS guidance. As with any endoscopic procedure, the risks include perforation of the stomach and/or duodenum.

Magnetic Resonance Cholangiopancreatography

MRCP is now being used more commonly as a noninvasive way to image both the biliary and pancreatic ducts. MRCP can provide excellent images and detect abnormalities of the common bile duct and main pancreatic duct, but it is more limited in its ability to detect abnormalities in the secondary ducts. This noninvasive imaging technique is very useful in high-risk patients and pregnant patients. It is also useful in diagnosis of persistent choledocholithiasis in the setting of gallstone pancreatitis. MRCP is most useful in settings where intervention such as biopsy or biliary drainage are unnecessary, thereby avoiding the risk of ERCP. MRCP can be a good modality for defining pancreatic ductal anatomy in patients with chronic pancreatitis and pancreatic pseudocysts to help plan operative management.

Endoscopic Retrograde Cholangiopancreatography

ERCP is the gold standard for providing information about pancreatic ductal anatomy. However, it is associated with significant complications and can often be avoided by using the previously described noninvasive tests. Five percent to 20% of patients develop clinical pancreatitis after ERCP and 25% to 75% have elevated amylase and lipase levels.[24] There is no way to prevent post-ERCP pancreatitis; however, high-pressure injection of the pancreatic duct is thought to contribute. Perforation of the gastrointestinal tract is a potential complication of ERCP.

ERCP is performed less commonly since much of the information can now be obtained with CT, MRCP, and/or EUS. However, it remains the procedure of choice when there is a high likelihood for the need of therapeutic intervention. For example, in patients with persistently elevated liver function tests in the setting of common duct stones ERCP is both diagnostic and therapeutic.

Pancreatic cancer is characterized by obstruction or stenosis of the pancreatic duct and or common bile duct (double-duct sign). ERCP remains the primary modality for palliation of obstructive jaundice with endostent placement. In chronic pancreatitis, the pancreatic duct may have irregularities including stenosis, dilation, sacculation, and ectasia. Pancreatic duct stones may be present within the pancreatic duct. Similar ductal changes can be observed immediately following acute attacks of pancreatitis. However, these abnormalities can be detected on MRCP or CT.

References

1. Klein SD, Affronti JP. Pancreas divisum, an evidence-based review: part II, patient selection and treatment. *Gastrointest Endosc* 2004;60(4):585–589.
2. Levy MJ, Geenen JE. Idiopathic acute recurrent pancreatitis. *Am J Gastroenterol* 2001;96(9):2540–2555.
3. Testoni PA. Aetiologies of recurrent acute pancreatitis: acute or chronic relapsing disease? *JOP* 2001;2(6):357–367.
4. Delhaye M, Engelholm L, Cremer M. Pancreas divisum: controversial clinical significance. *Dig Dis* 1988;6(1):30–39.
5. Delhaye M, Engelholm L, Cremer M. Pancreas divisum: congenital anatomic variant or anomaly? Contribution of endoscopic retrograde dorsal pancreatography. *Gastroenterology* 1985;89(5):951–958.
6. Cotton PB. Congenital anomaly of pancreas divisum as cause of obstructive pain and pancreatitis. *Gut* 1980;21(2):105–114.
7. Khalid A, Slivka A. Approach to idiopathic recurrent pancreatitis. *Gastrointest Endosc Clin N Am* 2003;13(4):695–716, x.
8. Manfredi R, Costamagna G, Brizi MG, et al. Pancreas divisum and “santorinicele”: diagnosis with dynamic MR cholangiopancreatography with secretin stimulation. *Radiology* 2000;217(2):403–408.
9. Ravitch MM, Woods AC, Jr. Annular pancreas. *Ann Surg* 1950;132(6):1116–1127.
10. Theodorides T. [Annular Pancreas]. *J Chir (Paris)* 1964;87:445–462.
11. Chevillotte G, Sahel J, Raillat A, et al. Annular pancreas. Report of one case associated with acute pancreatitis and diagnosed by endoscopic retrograde pancreatography. *Dig Dis Sci* 1984;29(1):75–77.
12. Glazer GM, Margulis AR. Annular pancreas: etiology and diagnosis using endoscopic retrograde cholangiopancreatography. *Radiology* 1979;133(2):303–306.
13. Zyromski NJ, Sandoval JA, Pitt HA, et al. Annular pancreas: dramatic differences between children and adults. *J Am Coll Surg* 2008;206(5):1019–1025; discussion 1025–1017.
14. Ikeda Y, Irving IM. Annular pancreas in a fetus and its three-dimensional reconstruction. *J Pediatr Surg* 1984;19(2):160–164.
15. Guillou L, Nordback P, Gerber C, et al. Ductal adenocarcinoma arising in a heterotopic pancreas situated in a hiatal hernia. *Arch Pathol Lab Med* 1994; 118(5):568–571.
16. Makhlouf HR, Almeida JL, Sobin LH. Carcinoma in jejunal pancreatic heterotopia. *Arch Pathol Lab Med* 1999;123(8):707–711.
17. Kleinman R, Gingerich R, Wong H, et al. Use of the Fab fragment for immunoneutralization of somatostatin in the isolated perfused human pancreas. *Am J Surg* 1994;167(1):114–119.

18. Greenberger N, Toskes P. Chapter 307. Acute and chronic pancreatitis (chapter). In: Fauci AS, Braunwald E, Kasper DL, et al., eds. *Harrison's Principles of Internal Medicine.* 17th ed: McGraw Hill: http://www.accessmedicine.com/content.aspx?aid=2875598. Accessed January 4, 2009.
19. Valenzuela JE, Weiner K, Saad C. Cholinergic stimulation of human pancreatic secretion. *Dig Dis Sci* 1986;31(6):615–619.
20. Konturek SJ, Becker HD, Thompson JC. Effect of vagotomy on hormones stimulating pancreatic secretion. *Arch Surg* 1974;108(5):704–708.
21. Oh HC, Kim MH, Choi KS, et al. Analysis of PRSS1 and SPINK1 mutations in Korean patients with idiopathic and familial pancreatitis. *Pancreas* 2008; 38(2), 180–183.
22. Masamune A, Kume K, Shimosegawa T. Differential roles of the SPINK1 gene mutations in alcoholic and nonalcoholic chronic pancreatitis. *J Gastroenterol* 2007;42 suppl 17:135–140.
23. Dreiling D, Wolfson P. *New Insights into Pancreatic Disease Revealed by the Secretin Test (chapter).* Vol 2. Philadelphia, PA: Lea and Febiger; 1979.
24. Toskes P, Greenberger N. Chapter 306. Approach to the patient with pancreatic disease (chapter). In: Fauci AS, Braunwald E, Kasper DL, et al., eds. *Harrison's Principles of Internal Medicine.* 17th ed: McGraw Hill: http:///www.accessmedicine.com/content.aspx?aID=2875521. Accessed January 4, 2009.
25. Noda A, Hayakawa T, Kondo T, et al. Clinical evaluation of pancreatic excretion test with dimethadione and oral BT-PABA test in chronic pancreatitis. *Dig Dis Sci* 1983;28(3):230–235.
26. Goff JS. Two-stage triolein breath test differentiates pancreatic insufficiency from other causes of malabsorption. *Gastroenterology* 1982;83(1 Pt 1):44–46.
27. Smith RC, Southwell-Keely J, Chesher D. Should serum pancreatic lipase replace serum amylase as a biomarker of acute pancreatitis? *ANZ J Surg* 2005; 75(6):399–404.
28. Kemppainen E, Hedstrom J, Puolakkainen P, et al. Increased serum trypsinogen 2 and trypsin 2-alpha 1 antitrypsin complex values identify endoscopic retrograde cholangiopancreatography induced pancreatitis with high accuracy. *Gut* 1997;41(5):690–695.
29. Kemppainen EA, Hedstrom JI, Puolakkainen PA, et al. Rapid measurement of urinary trypsinogen-2 as a screening test for acute pancreatitis. *N Engl J Med* 1997;336(25):1788–1793.
30. Nanjo K, Sanke T, Miyano M, et al. Diabetes due to secretion of a structurally abnormal insulin (insulin Wakayama). Clinical and functional characteristics of [LeuA3] insulin. *J Clin Invest* 1986;77(2):514–519.
31. Opara EC, Atwater I, Go VL. Characterization and control of pulsatile secretion of insulin and glucagon. *Pancreas* 1988;3(4):484–487.

32. Bell GI, Kayano T, Buse JB, et al. Molecular biology of mammalian glucose transporters. *Diabetes Care* 1990;13(3):198–208.
33. Orci L, Unger RH, Ravazzola M, et al. Reduced beta-cell glucose transporter in new onset diabetic BB rats. *J Clin Invest* 1990;86(5):1615–1622.
34. Ebert R, Creutzfeldt W. Gastrointestinal peptides and insulin secretion. *Diabetes Metab Rev* 1987;3(1):1–26.
35. Leahy JL, Bonner-Weir S, Weir GC. Abnormal glucose regulation of insulin secretion in models of reduced B-cell mass. *Diabetes* 1984;33(7):667–673.
36. Mulvihill S, Pappas TN, Passaro E Jr, et al. The use of somatostatin and its analogs in the treatment of surgical disorders. *Surgery* 1986;100(3):467–476.
37. Alghamdi AA, Jawas AM, Hart RS. Use of octreotide for the prevention of pancreatic fistula after elective pancreatic surgery: a systematic review and meta-analysis. *Can J Surg* 2007;50(6):459–466.
38. Allen PJ, Gonen M, Brennan MF, et al. Pasireotide for postoperative pancreatic fistula. *N Engl J Med* 2014;370(21):2014–2022.
39. Malleo G, Pulvirenti A, Marchegiani G, et al. Diagnosis and management of postoperative pancreatic fistula. *Langenbeck's Arch Surg.* 2014;399(7):801–810.
40. Cubilla AL, Fortner J, Fitzgerald PJ. Lymph node involvement in carcinoma of the head of the pancreas area. *Cancer* 1978;41(3):880–887.
41. Yeo CJ, Cameron JL, Lillemoe KD, et al. Pancreaticoduodenectomy with or without distal gastrectomy and extended retroperitoneal lymphadenectomy for periampullary adenocarcinoma, part 2: randomized controlled trial evaluating survival, morbidity, and mortality. *Ann Surg* 2002;236(3):355–366; discussion 366–358.
42. *Japanese Pancreas Society. Classification of Pancreatic Carcinoma, First English Edition*. Tokyo: Kanehara and Complany, Ltd.; 1996.
43. Ahren B, Taborsky GJ Jr, Porte D Jr. Neuropeptidergic versus cholinergic and adrenergic regulation of islet hormone secretion. *Diabetologia* 1986; 29(12):827–836.
44. Havel PJ, Taborsky GJ Jr. The contribution of the autonomic nervous system to changes of glucagon and insulin secretion during hypoglycemic stress. *Endocr Rev* 1989;10(3):332–350.
45. Yeo TP, Hruban RH, Leach SD, et al. Pancreatic cancer. *Curr Probl Cancer* 2002;26(4):176–275.
46. Sohn TA, Yeo CJ, Cameron JL, et al. Resected adenocarcinoma of the pancreas-616 patients: results, outcomes, and prognostic indicators. *J Gastrointest Surg* 2000;4(6):567–579.
47. Lillemoe KD, Cameron JL, Hardacre JM, et al. Is prophylactic gastrojejunostomy indicated for unresectable periampullary cancer? a prospective randomized trial. *Ann Surg* 1999;230(3):322–328; discussion 328–330.
48. Nagaraja V, Eslick GD, Cox MR. Endoscopic stenting versus operative gastrojejunostomy for malignant gastric outlet obstruction-a systematic review and

meta-analysis of randomized and non-randomized trials. *J Gastrointest Oncol* 2014;5(2):92–98.

49. National Comprehensive Cancer Network. *NCCN Clinical Practice Guidelines in Oncology*. Pancreatic Adenocarcinoma. Version I.2016. Available from: https://www.nccn.org/professionals/physician_gls/f_guidelines.asp. Accessed June 24, 2016.
50. Seicean A. Celiac plexus neurolysis in pancreatic cancer: the endoscopic ultrasound approach. *World J Gastroenterol* 2014;20(1):110–117.
51. Michaels AJ, Draganov PV. Endoscopic ultrasonography guided celiac plexus neurolysis and celiac plexus block in the management of pain due to pancreatic cancer and chronic pancreatitis. *World J Gastroenterol* 2007; 13(26):3575–3580.
52. Lillemoe KD, Cameron JL, Kaufman HS, et al. Chemical splanchnicectomy in patients with unresectable pancreatic cancer. A prospective randomized trial. *Ann Surg* 1993;217(5):447–455; discussion 456–447.
53. Gao L, Yang YJ, Xu HY, et al. A randomized clinical trial of nerve block to manage end-stage pancreatic cancerous pain. *Tumour Biol* 2014;35(3):2297–2301.
54. Tanaka M, Fernandez-del Castillo C, Adsay V, et al. International consensus guidelines 2012 for the management of IPMN and MCN of the pancreas. *Pancreatology* 2012;12(3):183–197.
55. Chong AK, Hawes RH, Hoffman BJ, et al. Diagnostic performance of EUS for chronic pancreatitis: a comparison with histopathology. *Gastrointest Endosc* 2007;65(6):808–814.

Chapter 53

Acute Pancreatitis

Jason S. Gold and Edward E. Whang

Key Points

1 In the United States, more than 75% of cases of acute pancreatitis are attributable to either gallstones or alcohol.

2 In general, a diagnosis of acute pancreatitis can be made with the presence of two of the following three features: (1) characteristic abdominal pain (acute onset of severe, persistent epigastric pain often radiating to the back); (2) serum lipase (or amylase) levels at least three times greater than the upper limit of normal; and (3) findings of acute pancreatitis on contrast-enhanced CT or MRI.

3 Approximately 80% of cases of acute pancreatitis are mild, associated with minimal systemic derangements, and generally resolve within 5 to 7 days, even with minimaltherapy.

4 Severe acute pancreatitis accounts for about 20% of cases and is defined as acute pancreatitis associated with one or more of the following: pancreatic necrosis, distant organ failure, and the development of local complications such as hemorrhage, abscess, or pseudocyst.

5 The mortality rate associated with severe acute pancreatitis ranges from 10% to 20%, with half of the deaths in the first 2 weeks as the result of SIRS-induced multisystem organ failure and the remaining occurring later as the result of pancreatic necrosis/infection.

6 The most important component of initial management of acute pancreatitis is fluid resuscitation.

7 Early ERCP in acute pancreatitis has been subjected to extensive study. Early ERCP with stone extraction and sphincterotomy clearly benefits the subset of patients with gallstone pancreatitis who have cholangitis.

8 Infection of pancreatic and peripancreatic necrosis complicates 30% to 70% of cases of acute necrotizing pancreatitis and most commonly becomes established during the second to third weeks after onset of disease.

9 Infected necrosis is suggested by clinical signs such as persistent fever, increasing leukocytosis, and imaging findings such as gas in peripancreatic collections. When the necessary, infected necrosis can be confirmed by CT-guided fine needle aspiration.

10 Invasive intervention is usually indicated in the presence of infected necrosis. In

contrast, sterile necrotic collections almost never require intervention in the acute phase of necrotizing pancreatitis.

11 Procedures for the treatment of infected necrosis are best performed when collections become walled off and demarcated from viable pancreatic tissue with at least partial liquefaction, which typically requires a delay of 4 to 6 weeks after disease onset.

12 Drainage alone is now the initial recommended intervention for infected pancreatic necrosis. This is most often accomplished through a percutaneous image-guided approach. When percutaneous drains are placed, preference should be given to a retroperitoneal approach. Drainage can also be accomplished through an endoscopic transluminal approach.

13 When required, débridement can often be performed through minimally invasive techniques.

14 Current well-accepted indications for intervention on pseudocysts and walled-off necrosis in the absence of infection include the presence of symptoms attributable to the collection such as intractable pain or obstruction of the stomach, duodenum or bile duct.

15 There are multiple treatment options available for the treatment of pancreatic pseudocysts and sterile walled-off necrosis, including percutaneous aspiration, percutaneous drainage, and internal drainage (performed transabdominally or endoscopically).

Acute pancreatitis is an acute inflammatory process of the pancreas with variable involvement of other regional tissues or remote organ systems.[1] In the United States, more than 250,000 patients are hospitalized annually with acute pancreatitis as the primary diagnosis. It is the principal cause of approximately 3,000 deaths per year and a contributing factor in an additional 2,500 deaths. The direct cost attributable to acute pancreatitis exceeds $2.5 billion per year in the United States.[2]

CLASSIFICATION AND DEFINITIONS

A useful system for defining and classifying acute pancreatitis and its complications was recently developed through an iterative process involving several national and international pancreas organizations.[3] This new system is a modification of widely accepted but outdated classification system originally derived from a multidisciplinary symposium held in 1992.[1] The clinically based definitions reached by consensus are shown in Table 53-1.

PATHOLOGY AND PATHOPHYSIOLOGY

The typical pathologic correlate of mild acute pancreatitis is *interstitial edematous pancreatitis,* in which the pancreatic parenchyma is edematous and infiltrated with inflammatory cells. Gross architectural features are preserved. In contrast, in *necrotizing pancreatitis* variable amounts of pancreatic parenchyma and peripancreatic fat have undergone tissue necrosis, with vascular inflammation and thrombosis being prominent features.

Studies using experimental models suggest that prototypical molecular and cellular derangements lead to pancreatic injury, regardless of the specific etiology or inciting event that triggers an episode of acute pancreatitis. Among the earliest of these derangements appears to be abnormal activation of proteolytic enzymes within pancreatic acinar cells.[4] Under normal conditions, trypsinogen and other digestive zymogens are stored in granules that are segregated from lysosomal enzymes (e.g., cathepsin B) and acid. Early in the course of acute pancreatitis, cytoplasmic vacuoles containing activated proteolytic enzymes appear. How the digestive enzymes are activated, and what role these vacuoles play has been the subject of much investigation. In the prevailing model, trypsinogen is believed to be activated to yield trypsin either by colocalization with the lysosomal hydrolase cathepsin B[5] or through autoactivation due to a moderately acidic pH[6]. It has been noted that the cytoplasmic vacuoles appearing in the acinar cell in experimental acute pancreatitis share expression of proteins with autophagosomes. Autophagosomes are vacuoles that degrade cellular components such as organelles in the process of autophagy. Highlighting the possible importance of autophagy in the development of pancreatitis, mice lacking expression of the autophagy-related gene *Atg5* in the pancreas fail to exhibit prototypical features of acute pancreatitis.[7]

CLASSIFICATION

Table 53-1 Terms Used in the Classification of Acute Pancreatitis

Term	Definition
Interstitial edematous pancreatitis	Acute inflammation and edema of the pancreas and peripancreatic tissues without necrosis
Necrotizing pancreatitis	Acute pancreatitis associated with necrosis of the pancreas or peripancreatic tissues
Acute peripancreatic fluid collection	Peripancreatic collection of simple fluid, not associated with an area of necrosis, occurring early in the course of acute pancreatitis and lacking a wall of granulation or fibrous tissue
Pseudocyst	Collection of fluid containing essentially no solid material enclosed by a wall of fibrous or granulation tissue, typically occurring more than 4 wks after onset of pancreatitis
Acute necrotic collection	A collection containing variable amounts of fluid and necrotic pancreas and/or peripancreatic tissue without a well formed encapsulating wall, typically occurring in the first 4 wks of an episode of necrotizing pancreatitis
Walled-off necrosis	An encapsulated collection of necrotic pancreas and/or peripancreatic tissue with variable amounts of fluid, usually occurring more than 4 wks after the onset of necrotizing pancreatitis

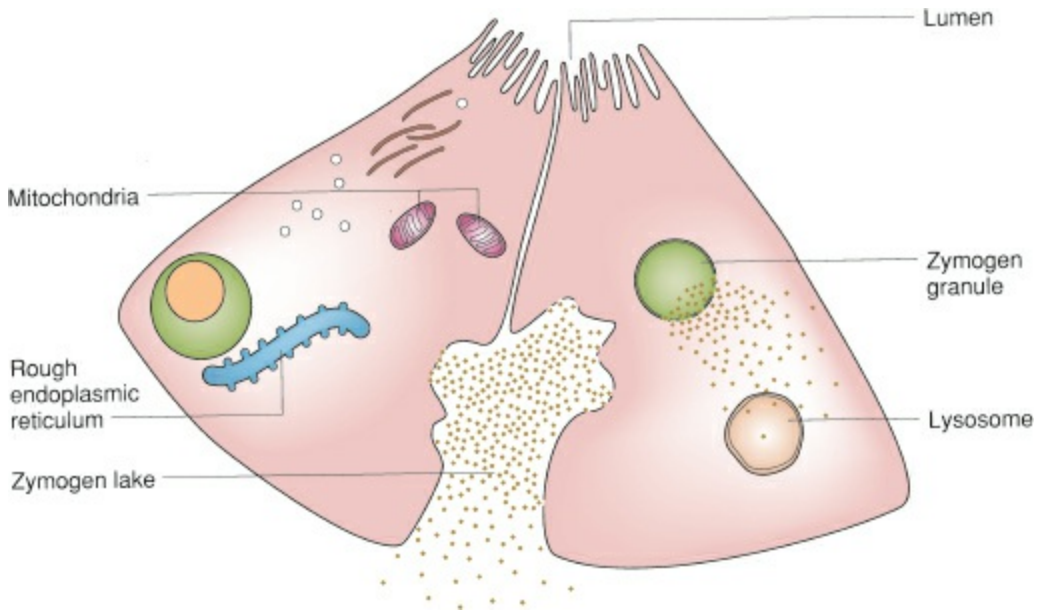

Figure 53-1. Schematic diagram depicting activation of proteolytic enzymes, possibly through colocalization of zymogen granules and lysosomes, and subsequent rupture of zymogen granules releasing the activated enzymes into the cytoplasm of the pancreatic acinar cell. The activated enzymes then undergo disordered basolateral discharge from the acinar cell into the pancreatic parenchyma.

Acinar cell injury induced by active trypsin allows it to be released into the pancreatic parenchyma (Fig. 53-1) where it activates more trypsin and other digestive enzymes (e.g., chymotrypsin, phospholipase, and elastase). Trypsin can also activate the

complement, kallikrein-kinin, coagulation, and fibrinolysis cascades within the pancreatic parenchyma. Activation of these enzymes is believed to initiate a vicious cycle in which activated enzymes cause cellular injury, an event that leads to the release of even more destructive enzymes. This cycle can overwhelm defense mechanisms that normally serve to limit the injurious consequences of premature trypsin activation within the pancreas (e.g., pancreatic secretory trypsin inhibitor–mediated inhibition of trypsin activity).

An inflammatory response is then generated in response to the initial acinar cell injury. This inflammatory response is marked by the infiltration of the pancreatic parenchyma with immune cells such as neutrophils, macrophages, monocytes, and lymphocytes and the release of a broad range of proinflammatory mediators such as tumor necrosis factor (TNF) α; interleukins (IL) 1β, 6, and 8; platelet-activating factor; chemokines (i.e., CXCL2 and CCL2); prostaglandins; and leukotrienes. The inflammatory response, to a large extent, determines the severity of pancreatitis, and the blockade of several components of the inflammatory response ameliorates the disease and reduces mortality in experimental models. The understanding of how the initial acinar cell injury provokes an inflammatory response is incomplete, but it appears that reactive oxygen species (ROS) and innate molecular pattern recognition (i.e., damage/danger-associated pattern molecules and toll-like receptors (TLRs) as well as the activation of transcription factors such as NF-κB play a role.[8]

The result of these events is pancreatic autodigestion, with injury to the vascular endothelium, interstitium, and acinar cells. Increases in vascular permeability lead to interstitial edema. Vasoconstriction, thrombosis, and capillary stasis can lead to ischemic (and perhaps ischemia–reperfusion) injury and the development of pancreatic necrosis. With severe pancreatic injury, the systemic inflammatory response syndrome (SIRS) and distant organ failure can occur. The systemic complications are believed to be mediated by digestive enzymes and inflammatory mediators released from the injured pancreas. For example, activated phospholipase A–induced digestion of lecithin (an important component of pulmonary surfactant) may play a role in pathogenesis of acute respiratory distress syndrome (ARDS) that occurs in the setting of acute pancreatitis. In addition, the circulatory and inflammatory effects induced by acute pancreatitis are postulated to impair intestinal epithelial barrier function, allowing for the translocation of bacteria from the intestinal lumen into the systemic circulation. This phenomenon has been demonstrated to occur in animal models and may account for the pathogenesis of pancreatic and peripancreatic infection that can complicate necrotizing pancreatitis.

ETIOLOGY

1 Although many etiologies of acute pancreatitis have been described, in the United States, more than 75% of cases are attributable to either gallstones or alcohol.

Gallstones

Gallstones cause approximately 35% of episodes of acute pancreatitis in the United States. In a mechanistic model proposed over a century ago, a gallstone lodged at the papilla of Vater occludes the ampullary orifice, leading to retrograde reflux of bile into the pancreatic duct through a common channel shared by the common bile duct and the pancreatic duct (Fig. 53-2). Although elements of this model have been challenged, the prevailing view is that transient or persistent obstruction of the ampullary orifice by a gallstone or edema induced by stone passage is the inciting factor in the pathogenesis of gallstone-induced pancreatitis. *Microlithiasis* refers to aggregates (<5 mm in diameter) of cholesterol monohydrate crystals or calcium bilirubinate granules detected as "sludge" within the gallbladder on ultrasonography or on examination of bile obtained during endoscopic retrograde cholangiopancreatography (ERCP). An etiologic role for microlithiasis in acute pancreatitis remains unproved; however, data derived from case-control studies suggest that cholecystectomy or endoscopic sphincterotomy can reduce the risk of recurrent acute pancreatitis in patients with microlithiasis.

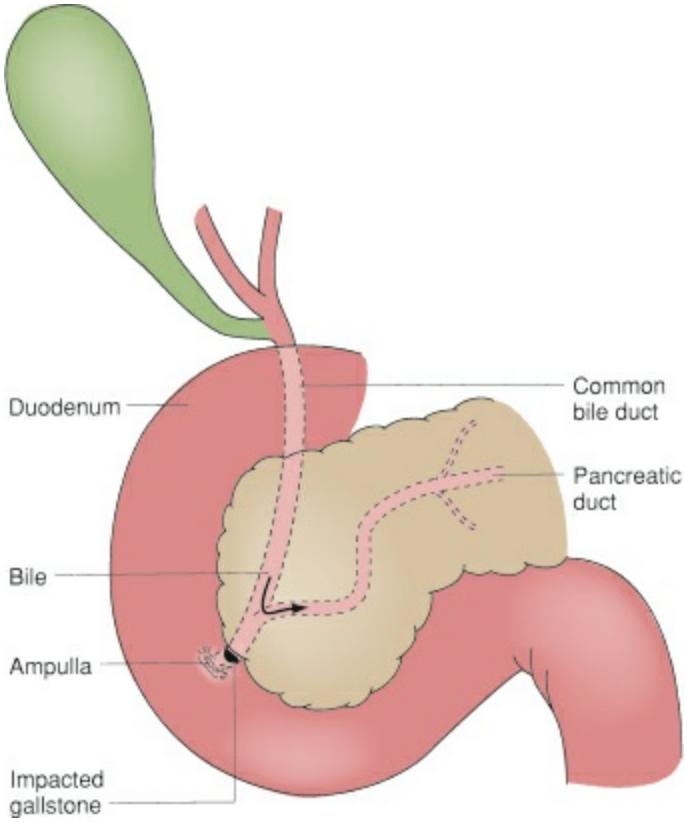

Figure 53-2. Illustration of the common channel concept. A gallstone lodged at the ampulla of Vater can cause reflux of bile into the pancreatic duct.

Alcohol

Ethanol causes approximately 40% of cases of acute pancreatitis in the United States. Most patients with alcohol-induced acute pancreatitis also have underlying chronic pancreatitis. Potential mechanisms by which alcohol-induced pancreatitis include sphincter of Oddi spasm, obstruction of small pancreatic ductules by proteinaceous plugs, alcohol-induced metabolic abnormalities (e.g., hyperlipidemia), and direct toxic effects induced by alcohol and its metabolites (e.g., acetaldehyde, acetate, and nonesterified fatty acids).

Other Etiologies

A wide range of other etiologies of acute pancreatitis have been identified (Table 53-2). Ongoing investigations are beginning to reveal specific gene abnormalities (e.g., mutations in cationic trypsinogen *PRSS1,* pancreatic secretory trypsin inhibitor *SPINK1,* and the cystic fibrosis transmembrane conductance regulator *CFTR*) that can be associated with pancreatitis. Patients for whom no etiology can be identified despite thorough evaluation are classified as having *idiopathic pancreatitis.*

Table 53-2 Etiology of Acute Pancreatitis

Gallstones
Ethanol
Iatrogenic causes ERCP Abdominal and nonabdominal operations Cardiopulmonary bypass
Trauma
Neoplasms (e.g., pancreatic cancer)
Pancreas divisum
Sphincter of Oddi spasm
Medications
Toxins Parathion Scorpion venom
Hyperlipidemia
Hypercalcemia
Infectious agents Viruses (e.g., mumps and Coxsackie B viruses; HIV) Bacteria (e.g., Salmonella and Shigella species; hemorrhagic Escherichia coli) Biliary parasites (e.g., Ascaris lumbricoides)
Genetic causes Cationic trypsinogen PRSS1 mutations Pancreatic secretory trypsin inhibitor SPINK1 mutations Cystic fibrosis transmembrane conductance regulator CFTR mutations
Autoimmune pancreatitis (lymphoplasmacytic sclerosing pancreatitis)
Vasculitis (e.g., systemic lupus erythematosus and polyarteritis nodosa)
Ischemia
Pregnancy
Endoscopic retrograde cholangiopancreatography (ERCP)

CLINICAL PRESENTATION

Abdominal pain, nausea, and vomiting are the most prevalent symptoms associated with acute pancreatitis. The pain is visceral in quality, is localized to the epigastrium, often radiates to the back, and may be alleviated with the patient leaning forward. Abdominal tenderness is the most prevalent sign of acute pancreatitis. Tachycardia and hypotension may result from intravascular hypovolemia. Low-grade fevers are common, but high-grade fevers are unusual in the absence of intra- or extrapancreatic infection. Jaundice may be evident in the presence of cholangitis (e.g., with gallstone-induced pancreatitis and persistent choledocholithiasis) or liver disease (alcohol-induced pancreatitis in a patient with cirrhosis). Evidence of retroperitoneal hemorrhage may be become apparent if blood dissects into the subcutaneous tissues of the flanks (Grey Turner sign), umbilicus (Cullen sign), or inguinal region (Fox sign); however, these findings are unusual. In approximately 20% of cases, acute pancreatitis is associated with SIRS, hemodynamic lability, and/or organ failure (particularly compromise of the cardiovascular, pulmonary, and renal systems) on presentation.

DIAGNOSIS

2 The differential diagnosis of acute pancreatitis includes other conditions causing acute upper abdominal pain, such as biliary colic and cholecystitis, acute mesenteric ischemia, small bowel obstruction, visceral perforation, and ruptured aortic aneurysm. Acute exacerbations of chronic pancreatitis can also be associated with clinical features resembling those of acute pancreatitis. In general, a diagnosis of acute pancreatitis can be made with the presence of two of the following three features: (1) characteristic abdominal pain (acute onset of severe, persistent epigastric pain often radiating to the back); (2) serum lipase (or amylase) levels at least three times greater than the upper limit of normal; and (3) findings of acute pancreatitis on contrast-enhanced computed tomography (CT) or magnetic resonance imaging (MRI).[9,10] Imaging tests should be used selectively, to rule out other diagnoses and for the indications discussed later. In cases of typical abdominal pain and confirmatory laboratory tests, imaging is usually not needed at the time of admission.

Laboratory Tests

With pancreatic injury, a variety of digestive enzymes escape from acinar cells and enter the systemic circulation. Of these enzymes, amylase is the most widely assayed to confirm the diagnosis of acute pancreatitis. Amylase levels rise within several hours after onset of symptoms and typically remain elevated for 3 to 5 days during uncomplicated episodes of mild acute pancreatitis. Because of the short serum half-life of amylase (10 hours), levels can normalize as soon as 24 hours after disease onset. The sensitivity of this test depends on what threshold value is used to define a positive result (90% sensitivity with a threshold value just above the normal range vs. 60% sensitivity with a threshold value at three times the upper limit of normal). Specificity (which also varies with the threshold values selected) is limited because a wide range of disorders can cause elevations in serum amylase concentration. Assays that detect increases in the serum concentration of amylase of pancreatic origin (P-isoamylase) alone are associated with greater specificity. Increased urinary amylase concentrations and amylase-to-creatinine clearance ratios occur with acute pancreatitis; however, these parameters offer no advantage over serum amylase concentrations, except in the evaluation of macroamylasemia (in which urinary amylase excretion is not increased despite elevations in serum amylase concentration).

Serum lipase concentrations increase with kinetics similar to those of amylase. It has a longer serum half-life than amylase, however, and may be useful for diagnosing acute pancreatitis late in the course of an episode (at which time serum amylase concentrations may have already normalized). Although lipase is more specific than amylase in the diagnosis of acute pancreatitis, note that lipase is produced at a range of nonpancreatic sites, including the intestine, liver, biliary tract, and stomach, and tongue.

The magnitude of the increases in amylase or lipase concentrations has no correlation with severity of pancreatitis. In general, the magnitude of increases in amylase concentrations tends to be greater in patients with gallstone pancreatitis than in those with alcohol-induced pancreatitis; however, this finding is unreliable in distinguishing between these two etiologies.

Imaging Tests

Findings on plain radiographs associated with acute pancreatitis are nonspecific and include ileus that may be generalized or localized to a segment of small intestine ("sentinel loop") or transverse colon ("colon cut-off sign"), psoas muscle margins that are obscured by retroperitoneal edema, an elevated hemidiaphragm, pleural effusions, and basilar atelectasis.

Ultrasonography may reveal a diffusely enlarged, hypoechoic pancreas. However, overlying bowel gas (particularly prominent with ileus) limits visualization of the pancreas in a large percentage of cases. Although ultrasonography has poor sensitivity in the diagnosis of acute pancreatitis, it plays an important role in the identification of the etiology of pancreatitis (e.g., the detection of gallstones).

CT scanning is the most important imaging test in the evaluation of acute pancreatitis. CT findings of mild acute pancreatitis include pancreatic enlargement and edema, effacement of the normal lobulated contour of the pancreas, and stranding of peripancreatic fat (Fig. 53-3). In addition, dynamic CT scanning performed after the bolus administration of intravenous contrast can demonstrate regions of pancreas that have poor or no perfusion, as seen with pancreatic necrosis (Fig. 53-4). Detection of necrosis plays an important role in assessment of disease severity, as discussed further later. CT can also characterize collections and other complications associated with acute pancreatitis.

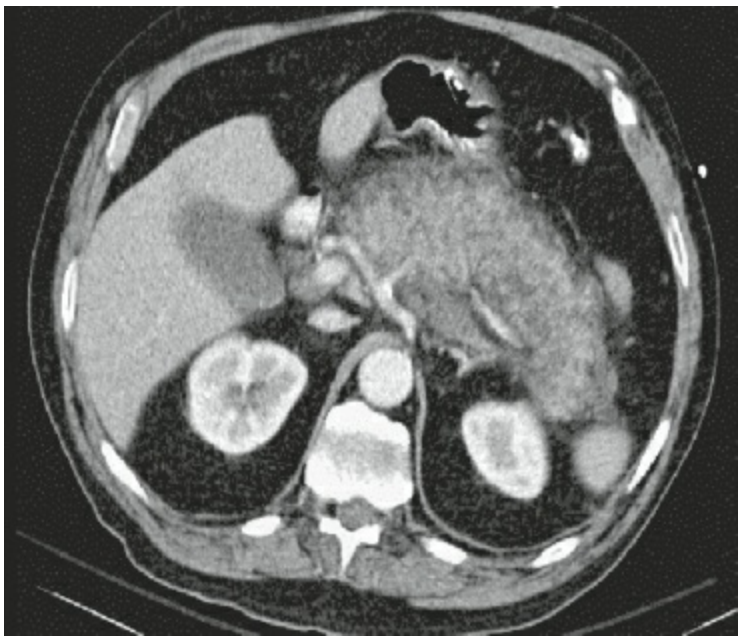

Figure 53-3. Computed tomography scan of acute interstitial pancreatitis.

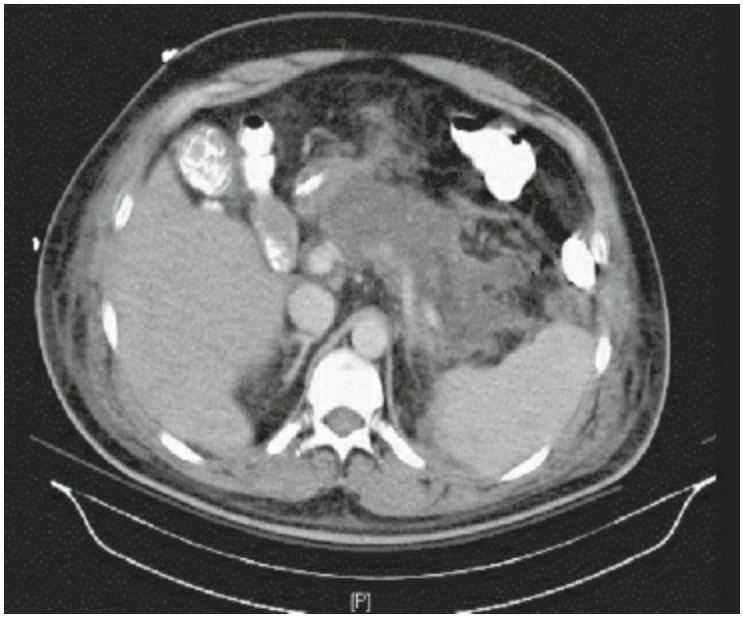

Figure 53-4. Computed tomography scan of acute necrotizing pancreatitis.

MRI and magnetic resonance cholangiopancreatography (MRCP) are being used with increasing frequency in patients with acute pancreatitis. These examinations have the potential to offer better definition of pancreatic and biliary ductal abnormalities than CT scanning, and they are applicable in patients for whom ionizing radiation or iodinated intravenous contrast agents used in CT scanning are contraindicated. MRI can suggest the presence of pancreatic necrosis even without the use of intravenous gadolinium. MRI also has the advantage of better characterizing collections associated with acute pancreatitis, in particular with respect to differentiating solid from liquid components. Disadvantages of MRI include high cost, limited availability, and the long duration of examinations.

ASSESSMENT OF DISEASE SEVERITY

3 Approximately 80% of cases of acute pancreatitis are mild, associated with minimal systemic derangements, and generally resolve within 5 to 7 days, even with minimal therapy. The mortality rate associated with mild acute pancreatitis is less than 1%.

4, **5** Approximately 20% of cases are associated with either organ failure or the development of local complications. The mortality rate for these patients ranges from approximately 10% to 20% in contemporary series.[11–14] One-half of deaths occur within the first 2 weeks after the onset of symptoms; these deaths are primarily the result of SIRS-induced multisystem organ failure. Most of the remaining deaths occur beyond 2 weeks after presentation and result from complications of pancreatic necrosis, especially infection.

Accurate prediction of severity early in the course of disease offers potential benefits in that complications can be anticipated and detected early through the use of intensive monitoring and frequent clinical assessment, and early and aggressive therapies can be instituted to attempt to prevent these complications. Several methods for assessing disease severity based on clinical parameters, serum markers, imaging, and scoring systems have been widely studied.

Revised Atlanta and Determinant-Based Classifications

An optimal system for the classification of severity of acute pancreatitis has not been universally accepted. Nevertheless, it is widely recognized that organ failure and local complications, particularly necrosis, are the two most important predictors of disease severity. While these two variables are often associated, they differ as to when in the course of disease they typically arise and the manner in which they contribute to disease severity. The early phase of acute pancreatitis (generally the first week after onset of symptoms) is characterized by the host response to the local pancreatic injury. Disease severity in the early phase is thus determined by organ failure resulting from the systemic inflammatory response. Organ failure can be immediately apparent on clinical presentation, and in fact, organ failure occurring in the early phase of disease is usually present on admission. In contrast, pancreatic necrosis, which occurs in 5% to 10% of cases of acute pancreatitis, may not be apparent on initial presentation and the extent of local complications can continue to evolve into the late phase of disease. Organ failure and death in the late phase are often determined by local complications, particularly infected necrosis.[3] While local complications can contribute to the mortality of patients with organ failure, there is also a subset of patients with pancreatic necrosis without organ failure who experience significant morbidity but have very low mortality.[13]

Two classification schemes based on organ failure and local complications have been proposed (Table 53-3).[3,13,15] While these classification schemes are quite useful and validated in predicting mortality,[11,14] their utility in predicting the course of disease on admission or within the first few days of hospitalization is limited by the fact that local complications and the resultant organ failure occurring in the late phase of the disease have not become apparent. Furthermore, a distinction is made between transient organ failure and persistent organ failure. This distinction cannot be made at the time of presentation. Similarly, the distinction between sterile necrosis and infected necrosis in the Determinant-Based Classification cannot be made with certainty until a patient with necrotizing pancreatitis shows signs of resolution.

Scoring Systems

The Ranson criteria, which is based on age, white blood cell count (WBC), glucose, serum lactate dehydrogenase (LDH), and serum aspartate aminotransferase (AST) all determined on admission as well as hematocrit drop, blood urea nitrogen (BUN), serum calcium, arterial partial pressure of oxygen (PaO_2), base deficit, and fluid requirement all determined after 48 hours, are easily tabulated, and the resulting scores are well correlated with morbidity and mortality rates.[16] The presence of three or more of these criteria is indicative of severe acute pancreatitis. Important limitations of the Ranson criteria are that the predictive score cannot be determined prior to 48 hours following admission and that it can only be used once. Furthermore, because these criteria were developed using a cohort of patients for whom alcohol was the predominant etiology of pancreatitis, their generalizability may be limited. A similar predictive scoring system developed in Glasgow using a cohort of patients for whom gallstones were the predominant etiology of pancreatitis is available.[17]

Acute Physiology and Chronic Health Evaluation (APACHE) II scores, which are based on patient age, indices of chronic health, and physiologic parameters, can be determined at any time after admission, can be updated continuously during the course of disease and may have greater predictive power than Ranson scores.[18] However, the complexity of calculating APACHE II (or related APACHE III) scores limits its application in routine clinical practice.

STAGING

Table 53-3 Criteria for Assessing Severity of Pancreatitis

Revised Atlanta Classification[3]
Mild acute pancreatitis ■ No organ failure AND ■ No local or systemic complications
Moderately severe acute pancreatitis ■ Transient organ failure without persistent organ failure AND/OR ■ Local or systemic complications
Severe acute pancreatitis ■ Persistent organ failure ■ Organ failure defined by cardiovascular failure (systolic blood pressure, <90 mm Hg and not fluid responsive), respiratory failure (PaO_2/FiO_2 ≤300), or renal failure (serum creatinine ≥1.9 mg/dL) ■ Transient organ failure resolves in <48 hrs, persistent organ failure lasts >48 hrs ■ Local complications include peripancreatic fluid collections and acute necrotic collections ■ Systemic complications are exacerbations of underlying comorbidities related to the acute pancreatitis
Determinant-Based Classification[13,15]
Mild acute pancreatitis ■ No (peri)pancreatic necrosis AND ■ No organ failure
Moderate acute pancreatitis ■ Sterile (peri)pancreatic necrosis AND/OR ■ Transient organ failure
Severe acute pancreatitis ■ Infected (peri)pancreatic necrosis OR ■ Persistent organ failure
Critical acute pancreatitis ■ Infected (peri)pancreatic necrosis AND ■ Persistent organ failure ■ Organ failure defined by cardiovascular failure (need for inotropic agent), respiratory failure (PaO_2/FiO_2 ≤300 mm Hg), or renal failure (creatinine ≥2.0 mg/dL) ■ Transient organ failure resolves in <48 hrs, persistent organ failure lasts ≥48 hrs

Recently another scoring system, the Bedside Index for Severity in Acute Pancreatitis (BISAP), based on five relatively straightforward parameters that are obtained within the first 24 hours of hospital admission, has been proposed. One point is assigned for the presence of each of the following: BUN >25 mg/dL, impaired mental status, SIRS, age >60 years, and the presence of a pleural effusion.[19] The BISAP has been validated and is comparable to the Ranson criteria[20,21] and the APACHE II Score[19,21,22] in its prediction of mortality.

Computed Tomography Scanning

The diagnostic application of CT scanning was discussed previously. Although not required for making a diagnosis on admission, a CT is often useful in patients who deteriorate or fail to improve. This technique is associated with greater than 90% sensitivity in the detection of pancreatic necrosis, a finding that is predictive of disease severity. Furthermore, CT scanning can also diagnose and characterize collections and can indicate infection (e.g., if air bubbles are present) in some cases. Because necrosis takes time to develop (in some patients up to 5 days), a contrast-enhanced CT scan obtained too early in the disease course (e.g., at the time of admission) does not have predictive value beyond clinical assessment (i.e., APACHE II or BISAP scoring).[23] In addition, concerns that early administration of iodinated intravenous contrast agents used in CT scanning may exacerbate pancreatic injury have been raised, although these agents have not been shown to cause or exacerbate pancreatitis in humans.[24]

Serum and Urinary Markers

C-reactive protein (CRP) is an easily assayed marker for which serum concentrations are well correlated with disease severity. However, CRP levels do not become significantly elevated until 48 hours after onset of disease; therefore, this marker is not useful for early prediction of disease severity. Lipopolysaccharide-binding protein (LBP), a class 1 acute-phase protein that binds and transfers bacterial lipopolysaccharide (LPS), has also been shown to correlate with disease severity but its elevation is similarly delayed. Serum concentrations of IL-6, IL-8, neutrophil elastase, angiopoietin-2, procalcitonin, and urinary concentrations of TAP (a product of trypsinogen activation) are also correlated with disease severity. Because these markers become elevated within 24 hours of disease onset, they may be relevant to early prediction strategies in the future. Currently, however, assays for these markers are not widely available.

MANAGEMENT

The goals of management for patients with acute pancreatitis are summarized below.

Correcting Pathophysiologic Derangements and Ameliorating Symptoms

6 The most important component of initial management is fluid resuscitation. In severe pancreatitis, third-space fluid losses can be large, with up to one-third of plasma volume being sequestered. The failure to appropriately resuscitate these patients is associated with increased morbidity and mortality. An indwelling urinary catheter should be placed, intravascular volume should be frequently assessed, and aggressive fluid and electrolyte replacement should be ensured. It should be noted, however, that adverse consequence of massive resuscitation can also complicate the course of patients with severe pancreatitis, and some recent studies have suggested an association between overresuscitation and increased complications and death. While the optimal fluid resuscitation strategy is not known, critically ill patients with pancreatitis should likely be aggressively and promptly resuscitated with lactated Ringer solution with the amount of fluid administered tailored individually based on signs of end- organ perfusion such as stabilization of blood pressure and heart rate and production of adequate urine output.[9,10,25]

Patients with potentially severe pancreatitis, as well as those for whom initial resuscitation fails, are best managed in a dedicated intensive care unit (ICU). Central venous monitoring may facilitate fluid management. Patients should be closely monitored for development of distant organ failure, particularly respiratory, cardiovascular, and renal failure, so that supportive management of these conditions (positive-pressure ventilation, administration of vasopressor agents, and hemodialysis, respectively) can be instituted without delay.

Abdominal pain is usually ameliorated with intravenous narcotics. In the past, morphine was avoided because of concerns that morphine-induced increases in sphincter of Oddi pressure might exacerbate an episode of pancreatitis. However, there is no clinical evidence that morphine can induce or exacerbate acute pancreatitis. Other analgesic agents commonly used in patients with acute pancreatitis include meperidine and fentanyl. Evacuation of gastric contents using a nasogastric tube should be instituted if vomiting is a prominent symptom; otherwise, it is unnecessary.

A fraction of patients with severe pancreatitis develop abdominal compartment syndrome (ACS). ACS is defined as a life-threatening sustained elevation of intra-abdominal pressure associated with new-onset organ failure or acute worsening of existing organ failure. ACS usually manifests with a tensely dilated abdomen, oliguria, and increased peak airway pressures. The diagnosis and treatment of ACS is discussed in more detail elsewhere in this book. In acute pancreatitis, ACS is associated with very severe disease, and approximately half of patients with ACS do not survive. ACS is treated by attempting to decrease intra-abdominal pressure. In some patients this can be accomplished by draining intra-abdominal collections and/or decompressing the bowel with nasogastric and rectal tubes. More than half of the patients with ACS in the setting of acute pancreatitis require a decompressive laparotomy.[9,26]

Minimizing Progression of Pancreatic Inflammation and Injury

Identification of strategies for interrupting the inflammatory cascades that induce pancreatic injury and distant organ failure is an area of active investigation. Currently, the only method used in routine clinical practice is bowel rest (nothing by mouth). The rationale underlying this approach is that avoidance of bolus oral nutrient intake may limit stimulation of pancreatic exocrine secretion induced by the presence of nutrients in the intestine, particularly the duodenum.

Patients with mild acute pancreatitis generally need no nutritional support, as their disease typically resolves within 1 week. In contrast, patients with severe pancreatitis usually have a more prolonged disease course and should begin to receive nutritional support as early as feasible. Although these patients traditionally have been administered total parenteral nutrition (TPN), accumulating evidence suggests that enteral nutrition is safe, is less costly, and may be associated with a lower complication rate than TPN.[27] Administration of enteral nutrition is also associated with the theoretical advantage of helping to maintain the integrity of the intestinal mucosal barrier, thus potentially limiting or preventing bacterial translocation. Enteral nutrients have typically been delivered to the jejunum through nasojejunal tubes to avoid stimulating pancreatic exocrine secretion, however, randomized controlled trials indicate that continuous feedings delivered through nasogastric tubes are equally safe and effective.[28,29] TPN is still required in many patients who do not tolerate enteral nutrition due to ileus.

Clinical trials of agents that inhibit activated pancreatic enzymes, inhibit pancreatic secretion, or interrupt the inflammatory cascade have yielded disappointing results. Meta-analyses of clinical trials of gabexate mesylate (a proteinase inhibitor), somatostatin, and octreotide suggest these agents have limited, if any, efficacy in improving outcomes in acute pancreatitis. A platelet-activating factor antagonist, lexipafant, showed promise in an initial study but not in a subsequent larger trial and is not currently recommended. Other adjuncts for which clinical trials have failed to demonstrate efficacy in limiting pancreatic injury in patients with acute pancreatitis include glucagon, anticholinergics, fresh frozen plasma, and peritoneal lavage.

Treating the Underlying Cause

7 This discussion is particularly relevant to patients with gallstone pancreatitis. There are both theoretical and experimental rationales to believe that removal of gallstones impacted at the ampulla of Vater early in the course of an episode of acute gallstone pancreatitis might limit disease severity. On the other hand, most gallstones that cause acute pancreatitis readily pass into the small intestine. The benefit of early ERCP in acute pancreatitis has been subjected to extensive study.[30] It has been shown that early ERCP with stone extraction and sphincterotomy clearly benefits the subset of patients with gallstone pancreatitis who have cholangitis.There also may be a benefit in patients with biliary obstruction who do not have cholangitis, although this is less clear. In patients, with cholangitis, ERCP should be performed urgently (within 24 hours). The timing of ERCP in patients with biliary obstruction is not clear (24 to 72 hours). It is reasonable to wait up to 48 hours for biliary obstruction to resolve. MRCP and endoscopic ultrasound (EUS) may be reasonable to screen for persistent choledocholithiasis in equivocal cases to prevent unnecessary intervention. In the absence of obstructive jaundice and/or cholangitis, early ERCP is associated with high complication rates but no apparent benefits and is therefore not recommended.

There is an approximately 18% incidence of recurrent pancreatitis or other gallstone-related complications during the 6-week period following an episode of gallstone pancreatitis in patients who do not undergo cholecystectomy.[31] Indeed, there is a substantial incidence of recurrent pancreatitis and gallstone-related complications in patients with biliary pancreatitis whose cholecystectomy is delayed even 2 weeks after hospital discharge.[32] Therefore, cholecystectomy should be performed during the same hospitalization for most patients with mild gallstone pancreatitis. This strategy does not increase operative complications, conversion to open procedures, or mortality.[31] In severe biliary pancreatitis, the risk of deferring surgery needs to be balanced against the risk of performing early surgery in patients who are debilitated and nutritionally compromised. Endoscopic sphincterotomy is another option, however, the high risk of recurrent gallstone-related complications and the higher mortality compared to cholecystectomy suggest that this strategy should be reserved for patients with severe comorbidities precluding safe surgery.[31,33]

Examples of other measures directed at correcting the underlying cause of pancreatitis include cessation of drugs known to cause pancreatitis and treatment of hypercalcemia or hyperlipidemia.

Preventing and Treating Complications

Complications of acute pancreatitis include pancreatic abscesses and infected necrosis, pseudocysts and walled-off necrosis, pancreatic ascites and fistulas, splenic vein thrombosis, and arterial pseudoaneurysms (Table 53-4). Infected necrosis as well as pseudocysts and sterile walled-off necrosis are discussed in detail below.

Infected Necrosis

8, **9** Infection of pancreatic and peripancreatic necrosis complicates 30% to 70% of cases of acute necrotizing pancreatitis and most commonly becomes established during the second to third weeks after onset of disease. Historical data suggest that mortality rates associated with untreated infected necrosis approach 100%. Infected necrosis is suggested by clinical signs such as persistent fever, increasing leukocytosis, and imaging findings such as gas in peripancreatic collections. When necessary, infected necrosis can be confirmed by cultures of aspirates of fluid or necrotic tissue obtained during CT-guided fine needle aspiration (FNA) or specimens collected during surgery. The concordance rate between bacteriologic results of FNA and those of surgical specimens is greater than 95%.[34] The peak occurrence of infected necrosis is between 2 and 4 weeks after presentation but it may occur at any time during the clinical course.

Table 53-4 Local Complications of Acute Pancreatitis

Necrosis
Infected necrosis
Pancreatic pseudocyst
Pancreatic ascites
Enteric or colonic fistula
Splenic vein thrombosis
Arterial pseudoaneurysm
Hemorrhage
Abdominal compartment syndrome

10 Invasive intervention is usually indicated in the presence of infected necrosis. In contrast, sterile necrotic collections almost never require intervention in the acute phase of necrotizing pancreatitis. As infected necrosis often consists of thick and tenacious materials, traditionally mechanical débridement via an open surgical approach was the primary treatment. Recently, less invasive approaches have been popularized. Minimally invasive approaches for the treatment of infected pancreatic necrosis are associated with fewer complications, however the mortality rate and the length of hospital stay appear to be predominantly determined by the disease process itself rather than the interventional approach. In centers with the appropriate expertise, most cases of infected pancreatic necrosis can now be managed using minimally invasive techniques.

11 Procedures for the treatment of infected necrosis are best performed when collections become walled-off and demarcated from viable pancreatic tissue with at least partial liquefaction, which typically requires a delay of 4 to 6 weeks after disease onset. This is especially true for débridement, as when it is performed too early, bleeding, incomplete removal of infected necrosis, resection of vital tissue, and loss of endocrine and exocrine function are more likely to ensue. Convincing evidence now supports delaying intervention whenever possible. Antibiotics can often be used to temporize the situation allowing necrotic collections to mature. A subset of patients may even be successfully treated with antibiotics alone. Patients with clinical deterioration and signs of sepsis despite the use of antibiotics who have clearly infected acute necrotic collections may require intervention within the first few weeks of acute pancreatitis.[9,10,35]

12 Drainage alone is the initial recommended intervention for infected pancreatic necrosis. This is most often accomplished through a percutaneous image-guided approach, which is technically feasible in the vast majority of cases. When percutaneous drains are placed, preference should be given to a retroperitoneal approach so that the drain tract can be used to perform video-assisted retroperitoneal débridement (VARD, see below). Drainage can also be accomplished through an endoscopic transluminal approach, particularly in the rare cases where a percutaneous approach is not feasible. Drainage alone can successfully treat infected necrosis in approximately 1/3 to 1/2 of cases.[9,10,35–38]

13 When required, débridement can often be performed through minimally invasive techniques. These techniques are reserved for patients without intra-abdominal catastrophes or other complications of acute pancreatitis mandating surgical exploration. VARD and direct endoscopic necrosectomy (DEN) are the two most widely utilized techniques for minimally invasive débridement.

VARD is usually accomplished through a retroperitoneal approach via flank incisions. The previously placed drain tracts are dilated to insert an operative nephroscope over a wire or to place laparoscopic ports that follow the drain tract into the retroperitoneum. Fluid that is encountered is suctioned and submitted for culture. Hydrodissection is used liberally. Gentle débridement of solid debris can be accomplished under direct vision through the entry site or under visualization with the videoscope. The goal of VARD is to facilitate drainage and not necessarily to perform a complete necrosectomy. Irrigation is usually continued postoperatively through surgically placed drains. In a multicenter randomized controlled trial, patients with infected pancreatic necrosis were randomized to undergo primary open necrosectomy or a step-up approach consisting of percutaneous or endoscopic drainage followed, in most cases (65%), by VARD. Open necrosectomy was rarely used when VARD could not be accomplished. Although mortality between the two groups did not differ, primary open necrosectomy was associated with a higher incidence of major complications and increased cost.[39]

DEN is performed via transmural puncture into a necrotic collection after insertion of an endoscopic. It is required that the collection abuts or is in close proximity to the stomach or duodenum. The collection can be visualized as a bulge in the wall of the

viscera or using EUS. The tract into the collection is then dilated and large bore stents are placed. Mechanical débridement can be performed with endoscopic instruments and/or irrigation. Nasocystic or percutaneous drains can be used to provide irrigation after the procedure. Typically, multiple sessions are necessary to completely débride the cavity. A small randomized controlled trial showed a decreased inflammatory response as well as decreased complications for patients undergoing endoscopic transgastric necrosectomy as opposed to VARD after failure of drainage for infected pancreatic necrosis.

Open necrosectomy may still be performed in the subset of patients not amenable to a minimally invasive approach or in centers without expertise in these techniques. For open necrosectomy, the abdomen is usually entered through a vertical midline or bilateral subcostal incision. The anterior surface of the pancreas can be exposed by dividing the gastrocolic ligament (greater omentum) and entering the lesser sac. If inflammatory changes have obliterated the lesser sac, an alternative route to the pancreas is achieved by dividing avascular portions of the transverse mesocolon. Clearly nonviable tissue should be débrided bluntly without attempting to perform anatomic resections. The débridement field is irrigated with several liters of sterile saline. There are several options for assuring that all necrotic tissue is removed after surgery. Traditionally, when the abdomen is closed, large-bore drains are placed, and postoperatively the drains are left in place at least 7 days and until the effluent becomes clear. This procedure is known as *necrosectomy with closed drainage.* Several authors prefer variants of this procedure in which either both gauze packing and drains are placed at the time of surgery and gradually withdrawn postoperatively (*necrosectomy with closed packing*) or where high-volume lavage of the lesser sac is performed through the drains placed at the time of surgery until the effluent becomes clear and the patient's clinical course improves (*necrosectomy with continuous lavage*). Other procedures including *necrosectomy with open packing,* where the retroperitoneum is marsupialized and the abdomen left open, and *necrosectomy with planned, staged relaparotomy,* in which the initial operation is followed by repeat laparotomies to change gauze packing or to perform additional débridement have fallen out of favor but may be necessary if necrosectomy is performed early in the course of disease before clear demarcation between necrotic and viable tissues has occurred. Modern mortality rates associated with necrosectomy performed for infected necrosis range from 10% to 20%.[40,41] On long-term follow-up, approximately 25% of survivors develop exocrine insufficiency, and 30% develop endocrine insufficiency. It should be noted that open necrosectomy is associated with better results in more recent series due to improvements in ICU care and implementation of delayed timing for surgery. The results of open necrosectomy in relation to VARD or DEN have not been directly compared after initial drainage. Although surgical débridement is clearly indicated for infected necrosis, its role in sterile necrosis has undergone evolution. In the past, early necrosectomy was recommended for patients with necrotizing pancreatitis, even in the absence of documented infection. The rationale for this approach was to prevent infection from developing and to remove the source of toxins and inflammatory mediators. Today, it is recommended that surgery should be avoided in patients without documentation of infected necrosis, based on favorable outcomes reported using this

conservative approach.[40,41] However, there remains a subset of patients with sterile necrosis who, despite prolonged supportive care, have persistent problems, including disabling pain, malaise, and gastric outlet obstruction who may benefit from interventions for sterile necrosis late in the course of disease.

Because of the high morbidity and mortality rates associated with infected necrosis, there has been much investigation into the use of antibiotics as prophylaxis against infection. Initial clinical trials failed to demonstrate a benefit of prophylactic antibiotics; however, these studies were flawed by the inclusion of patients with mild disease who were at low risk for developing infected necrosis and the use of antibiotics with poor penetration into the pancreas. Trials were published in the 1990s showing a significant reduction in the incidence of pancreatic infection among patients receiving antibiotic prophylaxis, and based on this evidence, the use of antibiotic prophylaxis in patients documented to have necrotizing pancreatitis has become a widespread practice. Several recent trials that failed to show a benefit for prophylactic antibiotics have now been published.[42,43] Similarly, recent meta-analyses of the available trials have failed to demonstrate a benefit for patients receiving prophylactic antibiotics.[44,45] Disadvantages of using prophylactic antibiotics include the risks of fungal superinfection and the selection of resistant organisms. Another strategy for prophylaxis against infection in patients with acute pancreatitis has been the administration of probiotic bacteria to reduce the load of pathogenic bacteria in the bowel; however, prospective evaluation has yielded disappointing results.[46]

An algorithm for the general management of acute pancreatitis and pancreatic necrosis is shown in Algorithm 53-1.

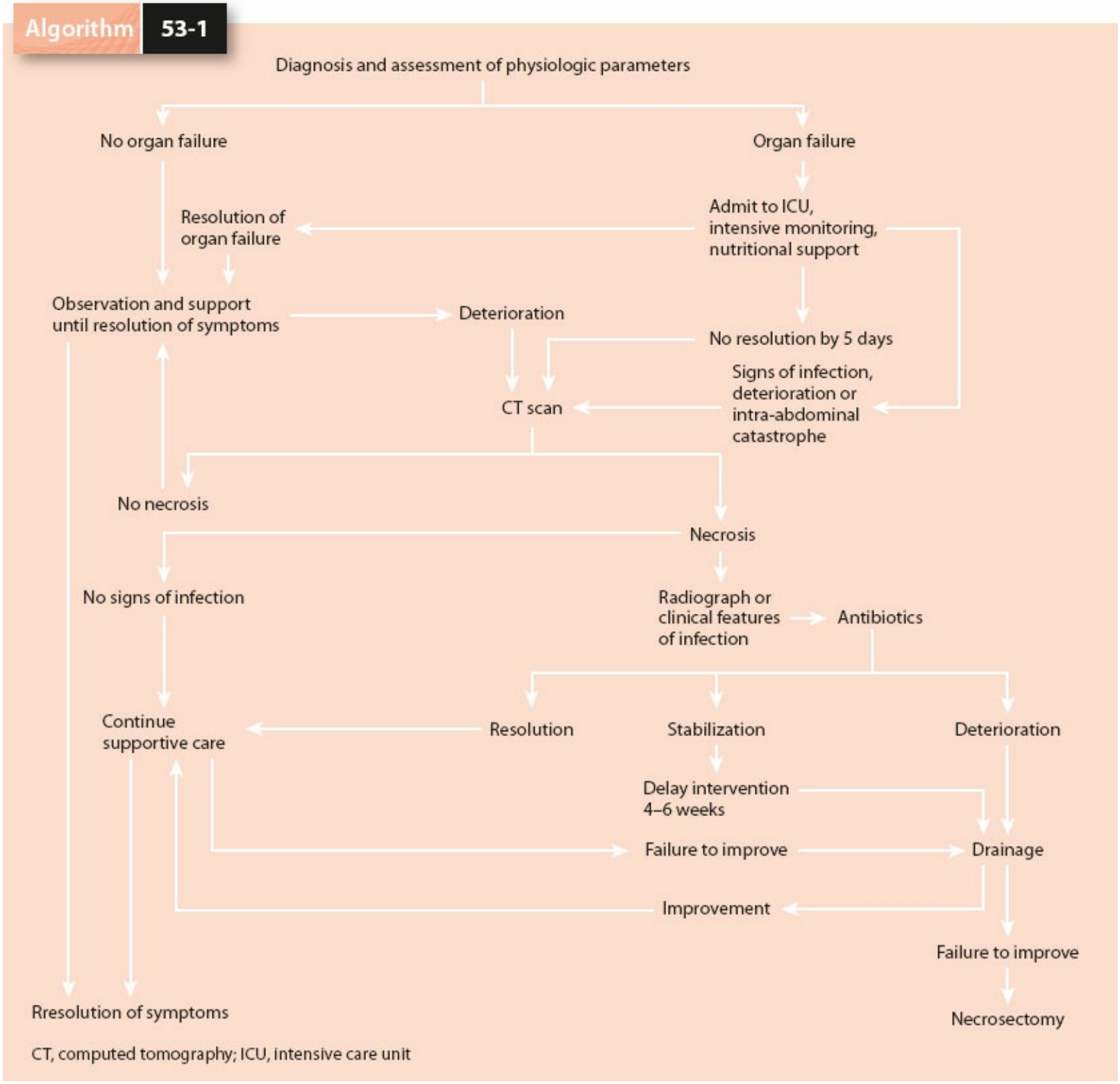

Algorithm 53-1. Algorithm for the management of acute pancreatitis.

Pseudocysts and Sterile Walled-Off Necrosis

Acute fluid collections develop in up to 30% to 50% of patients with acute pancreatitis. As most resolve spontaneously, no specific treatment directed at acute fluid collections is necessary in the absence of evidence that the fluid is infected. However, in up to 10% of patients with acute pancreatitis, these fluid collections progress to develop a wall of fibrous granulation tissue. Until recently, predominantly liquid collections with a well-formed wall appearing after an episode of acute pancreatitis were classified as

pseudocysts. It is now appreciated that many of the chronic collections seen after bouts of acute pancreatitis contain variable amounts of solid materials from the necrosis of pancreatic and peripancreatic tissues. In the new taxonomy, these collections are called walled-off necrosis. This distinction may better indicate how these collections should be treated, however, there is no distinction in the indication for intervention between pseudocysts and sterile walled-off necrosis.[35] The walls of these collections generally require at least 4 weeks from the onset of pancreatitis to mature. In contrast to true cysts, pseudocysts (and walled-off necrosis) do not have epithelium-lined walls.

Most pseudocysts and sterile walled-off necrosis are asymptomatic; however, they can cause upper abdominal pain, gastric outlet obstruction, and obstructive jaundice. Pseudocysts and walled-off necrosis can be diagnosed on ultrasonography or CT scanning (Figs. 53-5 and 53-6). It is important to distinguish cystic neoplasms of the pancreas from these lesions, as cystic neoplasms can be malignant or have malignant potential. Cystic lesions of the pancreas are being diagnosed with increasing frequency due to the routine use of CT and MRI scans. Cystic neoplams of the pancreas can usually be differentiated from pseudocysts and walled-off necrosis by the lack of evidence for antecedent pancreatitis or pancreatic trauma, or by the appearance on imaging studies. Pseudocysts are typically round, unilocular, and have a dense wall. In contrast, walled-off necrosis is typically heterogeneous with liquid and nonliquid density, with varying degrees of loculations, and is encapsulated by a well-defined wall. FNA, either by an image-guided percutaneous approach or an EUS-guided approach, can be used in cases where it is difficult to differentiate between pseudocysts or walled-off necrosis and cystic neoplasms. Pseudocysts and walled-off necrosis usually contain fluid with high amylase concentrations. In contrast, most neoplastic cysts do not communicate with the pancreatic duct and contain fluid with low amylase concentrations. These criteria, however, lack absolute predictive power.

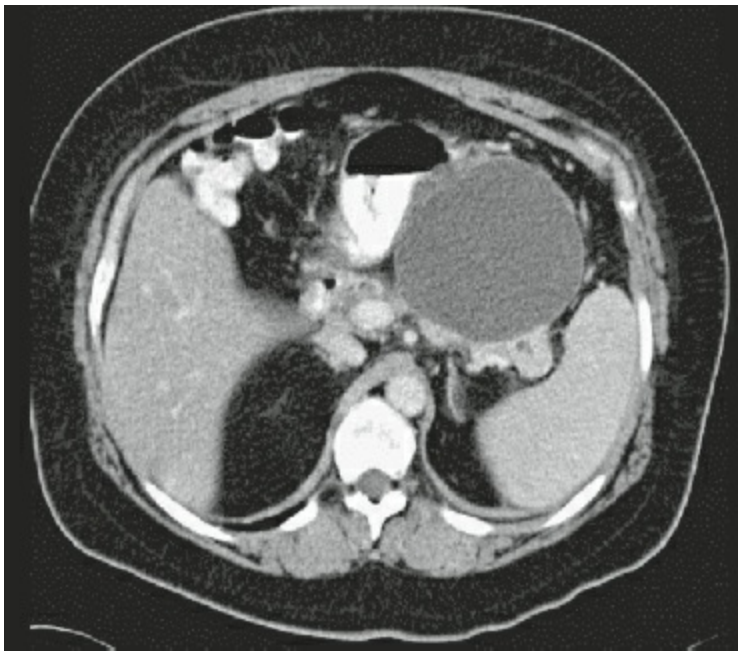

Figure 53-5. Computed tomography scan of pancreatic pseudocyst.

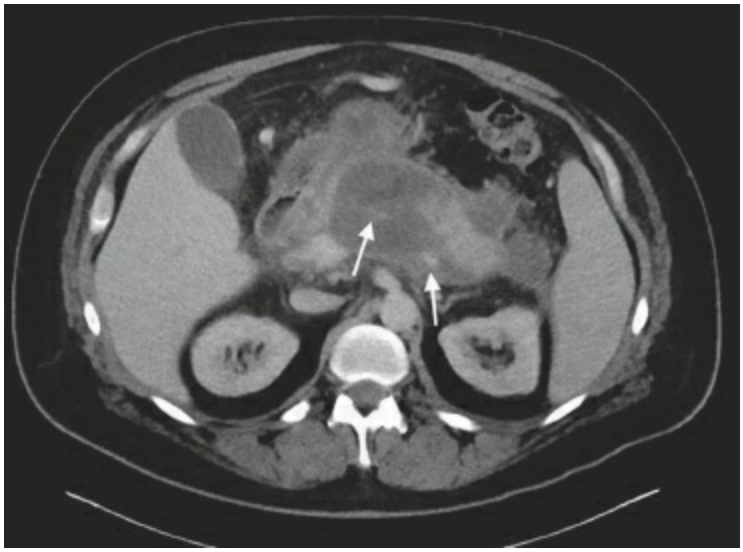

Figure 53-6. Computed tomography scan of walled-off necrosis. *Arrows* indicate the presence of solid material within the collection.

14 The management of pseudocysts and walled-off necrosis continues to evolve. In the past, surgical drainage of pseudocysts was recommended for all pseudocysts (even if asymptomatic) that persisted beyond a 6-week period of observation. This recommendation was based on a widely quoted report which suggested that pseudocysts that persist more than 6 weeks rarely resolve spontaneously and are associated with high complication rates.[47] However, subsequent reports suggest that the natural history of asymptomatic pseudocysts follows a more benign course, with most pseudocysts less than 6 cm in diameter resolving spontaneously without complications.[48,49] Even large, persistent collections may never cause symptoms or complications. Current well-accepted indications for intervention in the absence of infection include the presence of symptoms attributable to the collection such as intractable pain or obstruction of the stomach, duodenum, or bile duct.[9,10,35,50]

15 There are multiple treatment options available for the treatment of pancreatic pseudocysts and sterile walled-off necrosis, including percutaneous aspiration, percutaneous drainage, and internal drainage (performed transabdominally or endoscopically). The optimal indications for these procedures are not conclusively determined. Percutaneous aspiration alone is associated with high recurrence rates. Patients with chronic pancreatitis or pancreatic ductal abnormalities, particularly severe strictures or discontinuity of the pancreatic duct, have a high rate of failure with percutaneous drainage of pseudocysts. Percutaneous drainage alone should be avoided in these circumstances but may have a high rate of success in patients with normal ducts.[51] Endoscopic cystgastrostomy is an option for patients in whom the pseudocyst or walled-off necrosis is intimately adherent to the stomach or duodenum. This procedure is accomplished by transmural puncture of the pseudocyst, balloon dilation of the tract, and placement of a stent connecting the pseudocyst to the stomach. A small, single-center randomized controlled trial of surgical cystgastrostomy versus endoscopic cystgastrostomy (along with ERCP and stenting of pancreatic duct leaks or strictures) for pseudocysts showed equal efficacy along with decreased hospital stay and cost for the

endoscopic arm.[52] The treatment of symptomatic sterile walled-off necrosis can also be accomplished endoscopically (see description of DEN above). Due to the presence of necrotic debris within these collections, in contrast to pseudocyts, the need for multiple stents and/or multiple procedures, often with mechanical débridement, should be expected when walled-off necrosis is approached endoscopically. As of yet, high-quality data comparing the efficacy of surgical versus endoscopic treatment of symptomatic, sterile walled-off necrosis are lacking.

The most commonly performed surgical procedures used to treat pseudocysts and sterile walled-off necrosis include cystgastrostomy, cystoduodenostomy, and Roux-en-Y cystojejunostomy. Cystgastrostomy or cystoduodenostomy is applicable if a portion of the pseudocyst wall is adherent to the stomach or duodenum respectively allowing for the creation of an anastomosis. Otherwise, the cyst wall can be anastomosed to a Roux limb of jejunum. These procedures, which can be performed as open or laparoscopic operations, should be delayed until pseudocyst wall maturation occurs. Mortality rates associated with surgical drainage procedures average less than 5%, with pseudocyst recurrence rates averaging 10%.

References

1. Bradley EL 3rd. A clinically based classification system for acute pancreatitis. Summary of the International Symposium on Acute Pancreatitis, Atlanta, GA, September 11 through 13, 1992. *Arch Surg* 1993;128:586–590.
2. Peery AF, Dellon ES, Lund J, et al. Burden of gastrointestinal disease in the United States: 2012 update. *Gastroenterology* 2012;143:1179–1187.
3. Banks PA, Bollen TL, Dervenis C, et al. Classification of acute pancreatitis–2012: revision of the Atlanta classification and definitions by international consensus. *Gut* 2013;62:102–111.
4. Steer ML. Pathogenesis of acute pancreatitis. *Digestion* 1997;58 suppl 1:46–49.
5. Saluja AK, Donovan EA, Yamanaka K, et al. Cerulein-induced in vitro activation of trypsinogen in rat pancreatic acini is mediated by cathepsin B. *Gastroenterology* 1997;113:304–310.
6. Leach SD, Modlin IM, Scheele GA, et al. Intracellular activation of digestive zymogens in rat pancreatic acini. Stimulation by high doses of cholecystokinin. *J Clin Invest* 1991;87:362–366.
7. Hashimoto D, Ohmuraya M, Hirota M, et al. Involvement of autophagy in trypsinogen activation within the pancreatic acinar cells. *J Cell Biol* 2008; 181:1065–1072.
8. Gukovsky I, Li N, Todoric J, et al. Inflammation, autophagy, and obesity: common features in the pathogenesis of pancreatitis and pancreatic cancer. *Gastroenterology* 2013;144:1199–1209. e4.
9. Working Group IAP/APA Acute Pancreatitis Guidelines. IAP/APA evidence-based guidelines for the management of acute pancreatitis. *Pancreatology* 2013;13:e1–e15.
10. Tenner S, Baillie J, DeWitt J, et al. American College of Gastroenterology guideline: management of acute pancreatitis. *Am J Gastroenterol* 2013;108:1400–1415, 1416.
11. Nawaz H, Mounzer R, Yadav D, et al. Revised Atlanta and determinant-based classification: application in a prospective cohort of acute pancreatitis patients. *Am J Gastroenterol* 2013;108:1911–1917.
12. Petrov MS, Shanbhag S, Chakraborty M, et al. Organ failure and infection of pancreatic necrosis as determinants of mortality in patients with acute pancreatitis. *Gastroenterology* 2010;139:813–820.
13. Petrov MS, Windsor JA. Classification of the severity of acute pancreatitis: how many categories make sense? *Am J Gastroenterol* 2010;105:74–76.
14. Thandassery RB, Yadav TD, Dutta U, et al. Prospective validation of 4-category classification of acute pancreatitis severity. *Pancreas* 2013;42:392–396.
15. Dellinger EP, Forsmark CE, Layer P, et al. Determinant-based classification of acute pancreatitis severity: an international multidisciplinary consultation. *Ann Surg* 2012;256:875–880.
16. Ranson JH, Rifkind KM, Roses DF, et al. Prognostic signs and the role of operative

management in acute pancreatitis. *Surg Gynecol Obstet* 1974; 139:69–81.
17. Imrie CW, Benjamin IS, Ferguson JC, et al. A single-centre double-blind trial of Trasylol therapy in primary acute pancreatitis. *Br J Surg* 1978;65:337–341.
18. Larvin M, McMahon MJ. APACHE-II score for assessment and monitoring of acute pancreatitis. *Lancet* 1989;2:201–205.
19. Wu BU, Johannes RS, Sun X, et al. The early prediction of mortality in acute pancreatitis: a large population-based study. *Gut* 2008;57:1698–1703.
20. Cho YS, Kim HK, Jang EC, et al. Usefulness of the Bedside Index for severity in acute pancreatitis in the early prediction of severity and mortality in acute pancreatitis. *Pancreas* 2013;42:483–487.
21. Papachristou GI, Muddana V, Yadav D, et al. Comparison of BISAP, Ranson's, APACHE-II, and CTSI scores in predicting organ failure, complications, and mortality in acute pancreatitis. *Am J Gastroenterol* 2010;105:435–441.
22. Singh VK, Wu BU, Bollen TL, et al. A prospective evaluation of the bedside index for severity in acute pancreatitis score in assessing mortality and intermediate markers of severity in acute pancreatitis. *Am J Gastroenterol* 2009; 104:966–71.
23. Bollen TL, Singh VK, Maurer R, et al. A comparative evaluation of radiologic and clinical scoring systems in the early prediction of severity in acute pancreatitis. *Am J Gastroenterol* 2012;107:612–619.
24. Johnson CD, Stephens DH, Sarr MG. CT of acute pancreatitis: correlation between lack of contrast enhancement and pancreatic necrosis. *AJR Am J Roentgenol* 1991;156:93–95.
25. Fisher JM, Gardner TB. The "golden hours" of management in acute pancreatitis. *Am J Gastroenterol* 2012;107:1146–1150.
26. van Brunschot S, Schut AJ, Bouwense SA, et al. Abdominal compartment syndrome in acute pancreatitis: a systematic review. *Pancreas* 2014;43:665–674.
27. Marik PE, Zaloga GP. Meta-analysis of parenteral nutrition versus enteral nutrition in patients with acute pancreatitis. *BMJ* 2004;328:1407.
28. Eatock FC, Chong P, Menezes N, et al. A randomized study of early nasogastric versus nasojejunal feeding in severe acute pancreatitis. *Am J Gastroenterol* 2005;100:432–439.
29. Singh N, Sharma B, Sharma M, et al. Evaluation of early enteral feeding through nasogastric and nasojejunal tube in severe acute pancreatitis: a noninferiority randomized controlled trial. *Pancreas* 2012;41:153–159.
30. Tse F, Yuan Y. Early routine endoscopic retrograde cholangiopancreatography strategy versus early conservative management strategy in acute gallstone pancreatitis. *Cochrane Database Syst Rev* 2012;5:CD009779.
31. van Baal MC, Besselink MG, Bakker OJ, et al. Timing of cholecystectomy after mild biliary pancreatitis: a systematic review. *Ann Surg* 2012;255:860–866.
32. Ito K, Ito H, Whang EE. Timing of cholecystectomy for biliary pancreatitis: Do the

data support current guidelines? *J Gastrointest Surg* 2008;12(12):2164–2170.
33. McAlister VC, Davenport E, Renouf E. Cholecystectomy deferral in patients with endoscopic sphincterotomy. *Cochrane Database Syst Rev* 2007;(4):CD006233.
34. Gerzof SG, Banks PA, Robbins AH, et al. Early diagnosis of pancreatic infection by computed tomography-guided aspiration. *Gastroenterology* 1987;93:1315–1320.
35. Freeman ML, Werner J, van Santvoort HC, et al. Interventions for necrotizing pancreatitis: summary of a multidisciplinary consensus conference. *Pancreas* 2012;41:1176–1194.
36. Carter CR, McKay CJ, Imrie CW. Percutaneous necrosectomy and sinus tract endoscopy in the management of infected pancreatic necrosis: an initial experience. *Ann Surg* 2000;232:175–180.
37. Connor S, Alexakis N, Raraty MG, et al. Early and late complications after pancreatic necrosectomy. *Surgery* 2005;137:499–505.
38. Mouli VP, Sreenivas V, Garg PK. Efficacy of conservative treatment, without necrosectomy, for infected pancreatic necrosis: a systematic review and meta-analysis. *Gastroenterology* 2013;144:333–340.
39. van Santvoort HC, Besselink MG, Bakker OJ, et al. A step-up approach or open necrosectomy for necrotizing pancreatitis. *N Engl J Med* 2010;362:1491–1502.
40. Ashley SW, Perez A, Pierce EA, et al. Necrotizing pancreatitis: contemporary analysis of 99 consecutive cases. *Ann Surg* 2001;234:572–579.
41. Büchler MW, Gloor B, Müller CA, et al. Acute necrotizing pancreatitis: treatment strategy according to the status of infection. *Ann Surg* 2000;232:619–626.
42. Isenmann R, Runzi M, Kron M, et al. Prophylactic antibiotic treatment in patients with predicted severe acute pancreatitis: a placebo-controlled, double-blind trial. *Gastroenterology* 2004;126:997–1004.
43. Dellinger EP, Tellado JM, Soto NE, et al. Early antibiotic treatment for severe acute necrotizing pancreatitis: a randomized, double-blind, placebo-controlled study. *Ann Surg* 2007;245:674–683.
44. de Vries AC, Besselink MG, Buskens E, et al. Randomized controlled trials of antibiotic prophylaxis in severe acute pancreatitis: relationship between methodological quality and outcome. *Pancreatology* 2007;7:531–538.
45. Bai Y, Gao J, Zou DW, et al. Prophylactic antibiotics cannot reduce infected pancreatic necrosis and mortality in acute necrotizing pancreatitis: evidence from a meta-analysis of randomized controlled trials. *Am J Gastroenterol* 2008;103:104–110.
46. Besselink MG, van Santvoort HC, Buskens E, et al. Probiotic prophylaxis in predicted severe acute pancreatitis: a randomised, double-blind, placebo-controlled trial. *Lancet* 2008;371:651–659.
47. Bradley EL, Clements JL Jr., Gonzalez AC. The natural history of pancreatic pseudocysts: a unified concept of management. *Am J Surg* 1979;137:135–141.
48. Vitas GJ, Sarr MG. Selected management of pancreatic pseudocysts: operative versus

expectant management. *Surgery* 1992;111:123–130.

49. Yeo CJ, Bastidas JA, Lynch-Nyhan A, et al. The natural history of pancreatic pseudocysts documented by computed tomography. *Surg Gynecol Obstet* 1990;170:411–417.
50. Cannon JW, Callery MP, Vollmer CM Jr. Diagnosis and management of pancreatic pseudocysts: what is the evidence? *J Am Coll Surg* 2009;209:385–393.
51. Nealon WH, Bhutani M, Riall TS, et al. A unifying concept: pancreatic ductal anatomy both predicts and determines the major complications resulting from pancreatitis. *J Am Coll Surg* 2009;208:790–799.
52. Varadarajulu S, Bang JY, Sutton BS, et al. Equal efficacy of endoscopic and surgical cystogastrostomy for pancreatic pseudocyst drainage in a randomized trial. *Gastroenterology* 2013;145:583–590.

Chapter 54

Chronic Pancreatitis

Katherine A. Morgan and David B. Adams

Key Points

1. Chronic pancreatitis is heterogeneous in etiology with an increasingly recognized role of smoking and genetic factors.
2. The most common indication for intervention in chronic pancreatitis is severe, debilitating abdominal pain.
3. Medical and endoscopic therapies are frontline management of chronic pancreatitis, but are often unsuccessful.
4. Surgical intervention is aimed at achieving durable pain relief with least perioperative and long term morbidity.
5. Cutting edge therapies for chronic pancreatitis include total pancreatectomy with islet autotransplantation and minimally invasive techniques (laparoscopic and robotic).

INTRODUCTION

Chronic pancreatitis (CP) is an inflammatory disorder of the pancreas marked by fibrotic replacement of the pancreatic parenchyma. The clinical hallmark of disease is severe, debilitating, and recalcitrant abdominal pain, often associated with nutritional failure. CP typically results in progressive endocrine failure (type 3c diabetes mellitus)[1] and exocrine failure (malabsorption) in afflicted patients. Management of this challenging disorder is problematic due the complexities of disease pathogenesis, the clinical management of pain, and attendant impairments in patient quality of life.

EPIDEMIOLOGY

CP is a significant public health concern. Its prevalence and annual incidence are estimated at 0.2% to 0.6% and 7 to 10/100,000 respectively in the United States and Europe.[2] The economic impact is notable, with estimated annual healthcare expenditures for pancreatitis in the United States in 2004 were $3.7 billion.[3]

ETIOLOGY

The etiology of CP is heterogeneous and multifactorial. The M-ANNHEIM classification can be utilized to describe the (M) multiple risk factors for the development of pancreatitis including (A) alcohol consumption, (N) nicotine use, (N) nutrition, (H) hereditary factors, (E) efferent ductal obstruction, (I) immunologic factors, and (M) metabolic factors.[4]

Historically, alcohol use has been the most commonly implicated etiologic factor in CP in the Western world, classically comprising 60% to 90% of cases in observational studies in the 1970s to the 1990s.[5–7] More recent data from multiinstitutional prospective data, however, have demonstrated a lesser contributory role from alcohol, with association in approximately 45% of cases.[8] Dose and duration of alcohol consumption have been demonstrated to be contributory to CP development, although several more recent studies suggest that alcohol alone is not sufficient to cause CP. Byproducts from ethanol metabolism injure acinar cells and can activate pancreatic stellate cells (PSCs) to form extracellular matrix. Recent investigation suggests an association between pancreatitis and a locus on the X chromosome. A risk factor for alcoholic pancreatitis on the X chromosome may partially explain the higher incidence of alcoholic pancreatitis in men than in women, a difference that cannot be explained solely by alcohol consumption rate differences in men and women. In women, the high-risk allele acts as a recessive genetic disorder with consequent risk diminishment.[9]

1 Smoking has been determined as a significant risk factor in the development of CP. In the 1990s, a relationship between tobacco consumption and pancreatic calcifications was noted.[10] In addition, the synergistic effects of smoking and alcohol have been described.[11] More recently, a large multicenter epidemiologic study has shown that smoking is an independent risk factor for CP in a dose-dependent fashion.[8,12] In addition, tobacco use has been shown to be a strong risk factor for the progression of acute pancreatitis to CP, suggesting a role for smoking in pancreatic fibrogenesis.[13]

Genetic causes of CP have been increasingly recognized over the past couple of decades. In 1952, Comfort and Steinberg[14] described hereditary pancreatitis (HP) and in 1996, Whitcomb and colleagues delineated a mutation in the cationic trypsinogen gene PRSS1, which results in the inappropriate activation of trypsin and is responsible for HP.[15] HP is an autosomal dominant disorder with 80% penetrance, marked by recurrent acute pancreatitis beginning in early childhood, progression to CP in many, and a greatly (50×) increased risk of pancreatic cancer beginning in the fifth decade. Since, several other mutations in the PRSS1 gene have been identified. In addition, multiple other genetic foci have been implicated as contributing agents in CP as well, primarily related to the inappropriate activation of trypsin. Pancreas secretory trypsin inhibitor (serine protease inhibitor, kazal type 1, and SPINK1),[16] cystic fibrosis transmembrane conductance regulator gene (CFTR), chymotrypsinogen C (CTRC),[17] calcium-sensing receptor gene (CASR),[18] and gamma-glutamyltransferase 1 gene (GGT1)[19] have all been elucidated as conferring a susceptibility to CP development. Conversely the anionic trypsinogen gene PRSS2 may confer a protective advantage against the development of

pancreatitis.

Clearly, the etiology of pancreatitis is variable, complex, and incompletely understood.

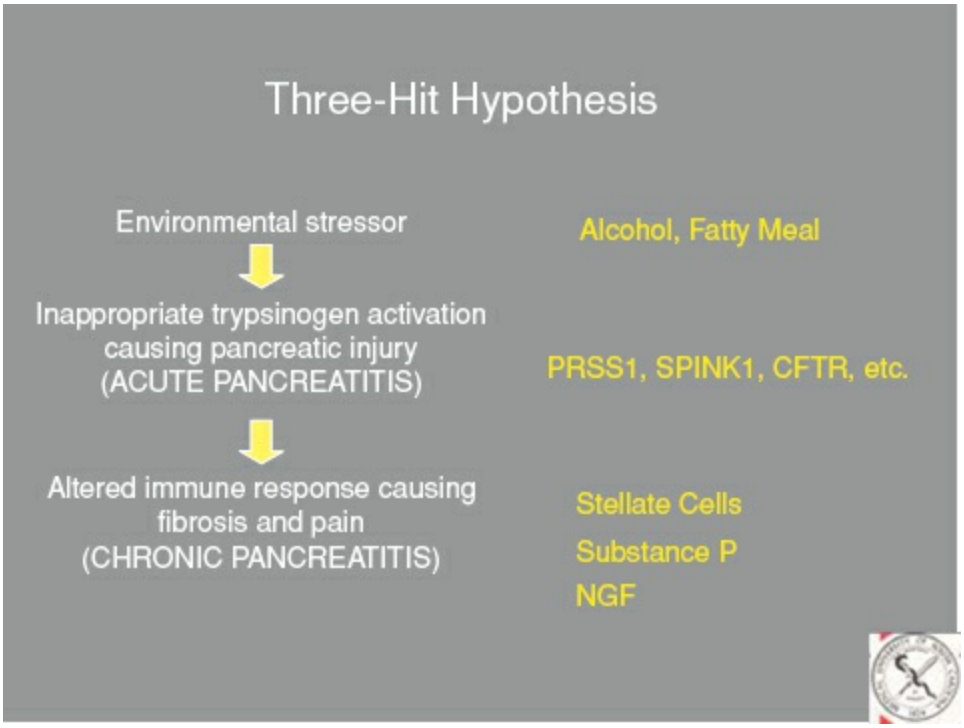

Figure 54-1. Three-hit hypothesis for pathophysiology of chronic pancreatitis. NGF, nerve growth factor. Adapted from Whitcomb DC. Genetic risk factors for pancreatic disorders. *Gastroenterology* 2013;144:1292–1302.

PATHOPHYSIOLOGY

The pathophysiology of CP is not well elucidated. A theory known as the "three-hit hypothesis" holds that (1) a stochastic event occurs resulting in (2) inappropriate trypsin activation causing acute pancreatitis. The patient then has (3) an unfavorable immunologic response to the inflammation resulting in fibrosis and CP (Fig. 54-1).[20] Environmental factors (e.g., alcohol and tobacco) are implicated as the inciting events to this cascade, with potential key modulating factors including genetics and the histologic milieu.

Insights into pathophysiology of pancreatitis have occurred through advances in cellular basic science. PSCs are causative in pancreatic fibrogenesis. PSCs are residents of the healthy pancreas that become activated by inflammatory cytokines during pancreatitis to become myofibroblast-like cells, producing extracellular matrix in the interstitial space.[21] In addition, several matrix metalloproteinases are implicated in altering extracellular matrix remodeling and collagen degradation, enhancing fibrogenesis and irreversibly altering the organ architecture to a diseased, fibrotic pancreas.[22]

The pathophysiology of the CP pain syndrome is not well delineated and is likely multifactorial. Classically, pancreatic ductal obstruction due to fibrosis and resulting in elevated intraductal pressures has been implicated as a primary cause for pain. Additionally, pancreatic capsular and parenchymal fibrosis resulting in intracapsular hypertension and ischemia, create a "pancreatic compartment syndrome," and has been theorized to result in pain. More recent theories have focused on peripancreatic neuropathy. On a histologic level, peripancreatic neuronal hypertrophy as well as infiltration of periaxonal tissue with inflammatory cells is evident.[23,24] Increased presence of the "pain neurotransmitters" is identified including calcitonin gene-related peptide and substance P, stimulated by nerve growth factor.[25] These changes in the peripancreatic neuronal milieu may result in peripheral and central neural sensitization and undoubtedly contribute to the CP pain syndrome. The pancreas has a uniquely villainous role in abdominal pain syndromes. No other visceral organ can match it in terms of pain severity. Neural remodeling precipitated by pancreas-synthesized tachykinins may lead to centralization of pain that is precipitated by extra pancreatic stimuli. The "phantom pancreatitis" pain that occurs after total pancreatectomy (TP) is related to centralization of pain pathways and is a reminder of the vast intersecting neuronal web of the pancreas and the foregut.

CLINICAL PRESENTATION

2 The primary presentation of CP is severe, intractable epigastric abdominal pain that radiates into the back. The classic pain is daily and constant with periods of exacerbation. Patients typically describe pancreatitis pain as if someone is slowing twisting a knife into the epigastrium and interscapular region. Patients often have associated gut dysfunction, with nausea, emesis, and difficulty tolerating a diet consistently, particularly during pain episodes. Pain and nausea are frequently precipitated by ingestion of a fatty meal or less commonly a high protein meal. Patients may develop endocrine failure (pancreatogenic diabetes, type 3c) and exocrine pancreatic insufficiency (EPI) over time. Less often, patients may present with an acute complication of CP such as biliary or duodenal obstruction, a pancreatic pseudocyst, pancreatic ascites, mesenteric venous thrombosis, or mesenteric arterial pseudoaneurysm (Table 54-1).

On physical examination, patients may generally appear malnourished and underweight. Abdominal tenderness in the epigastrum may be elicited. Significant laboratory values to be examined include chemistries to evaluate for dehydration and acidosis. A hepatic panel may reveal elevated alkaline phosphatase or direct bilirubin, indicating biliary obstruction, or hypoalbuminemia from chronic malnutrition. Serum amylase and lipase may be elevated or may be normal during pain exacerbations in advanced disease.

Table 54-1 Complications of Chronic Pancreatitis

Pain	90%
Pseudocyst	25–30%
Biliary stricture	10–15%
Mesenteric venous thrombosis	5–10%
Duodenal stricture	4–5%
Pseudoaneurysm	2–3%
Pancreatic adenocarcinoma	2–4%[a]
Extrapancreatic malignancy	10–15%

[a]Risk of pancreatic cancer is 2% after 10 years and 4% after 20 years with chronic pancreatitis.

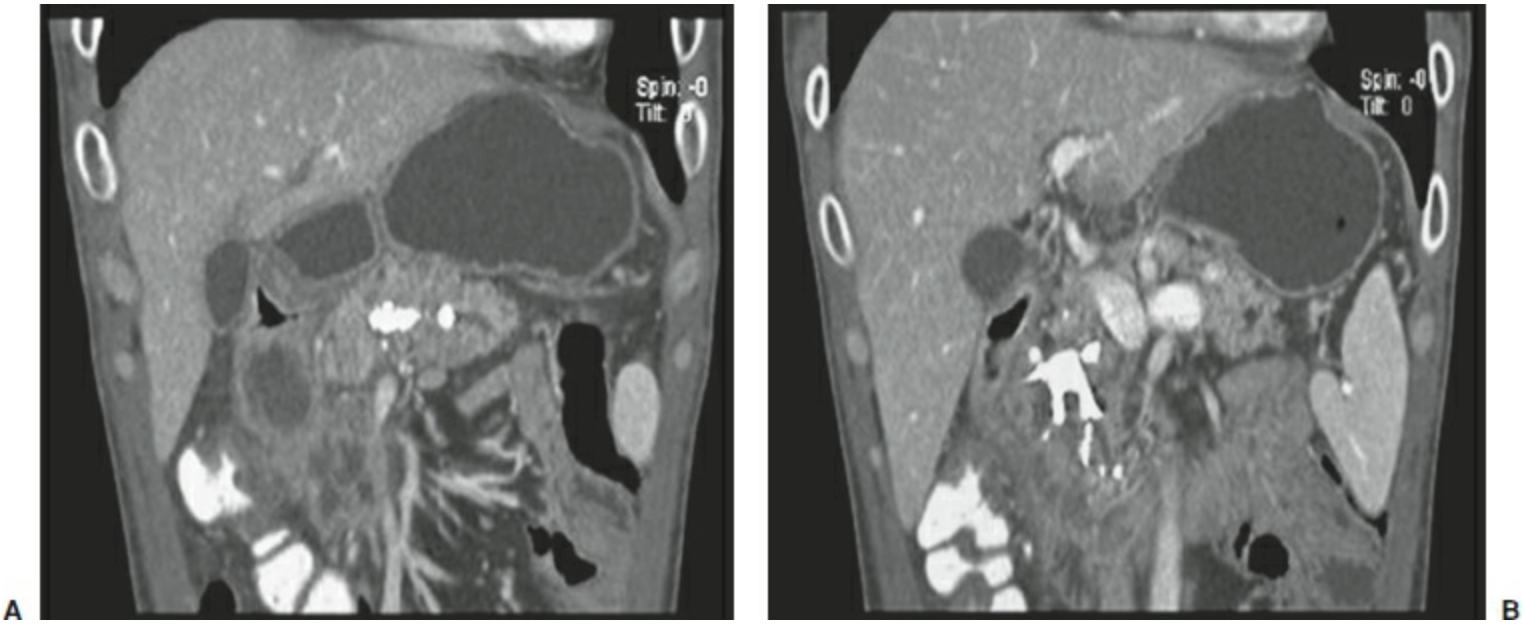

Figure 54-2. Contrasted CT scan in venous phase, coronal images showing (**A**), dilated main pancreatic duct with intraductal stones and (**B**), significant fibrotic disease burden in the head of the pancreas with intraparenchymal and intraductal calcifications.

RADIOGRAPHIC EVALUATION

Radiography is useful in both diagnosis and treatment planning in CP. The most relevant imaging modalities include contrast-enhanced computed tomography (CT), secretin-stimulated magnetic resonance imaging with cholangiopancreatography (MRCP), endoscopic retrograde cholangiopancreatography (ERCP), and endoscopic ultrasound (EUS).

Abdominal CT can show pancreatic parenchymal changes including edema, fibrosis, or atrophy. Pancreatic ductal dilation may be evident, as well as intraparenchymal and intraductal calcifications (Fig. 54-2). CT can also be helpful in recognizing intra-abdominal complications of pancreatitis such as biliary or duodenal obstruction, pancreatic pseudocysts or ascites, or thrombosis or pseudoaneurysms of the mesenteric vasculature. Similarly, MRCP can be very useful in showing parenchymal changes in enhancement and secretion (T1-weighted images) and ductal anatomy (T2-weighted images), particularly with the addition of secretin stimulation (Fig. 54-3). With the increased capabilities of MR technology over the past couple of decades, MR imaging has largely replaced ERCP for diagnostic imaging in CP. ERCP is the classic imaging modality for CP. The ERCP Cambridge classification system, derived from an international consensus, remains the gold standard of CP staging (Table 54-2).[26] In the modern era, ERCP is primarily utilized as a therapeutic modality. EUS is useful for evaluation of pancreatic parenchyma and ductal anatomy, while being less invasive than ERCP. EUS also has a grading system to objectify and document pancreatitis disease severity, although the modality still maintains interobserver variability (Table 54-3). With the addition of fine needle aspiration, EUS can be helpful in the differentiation of pancreatic neoplasms from CP.[27]

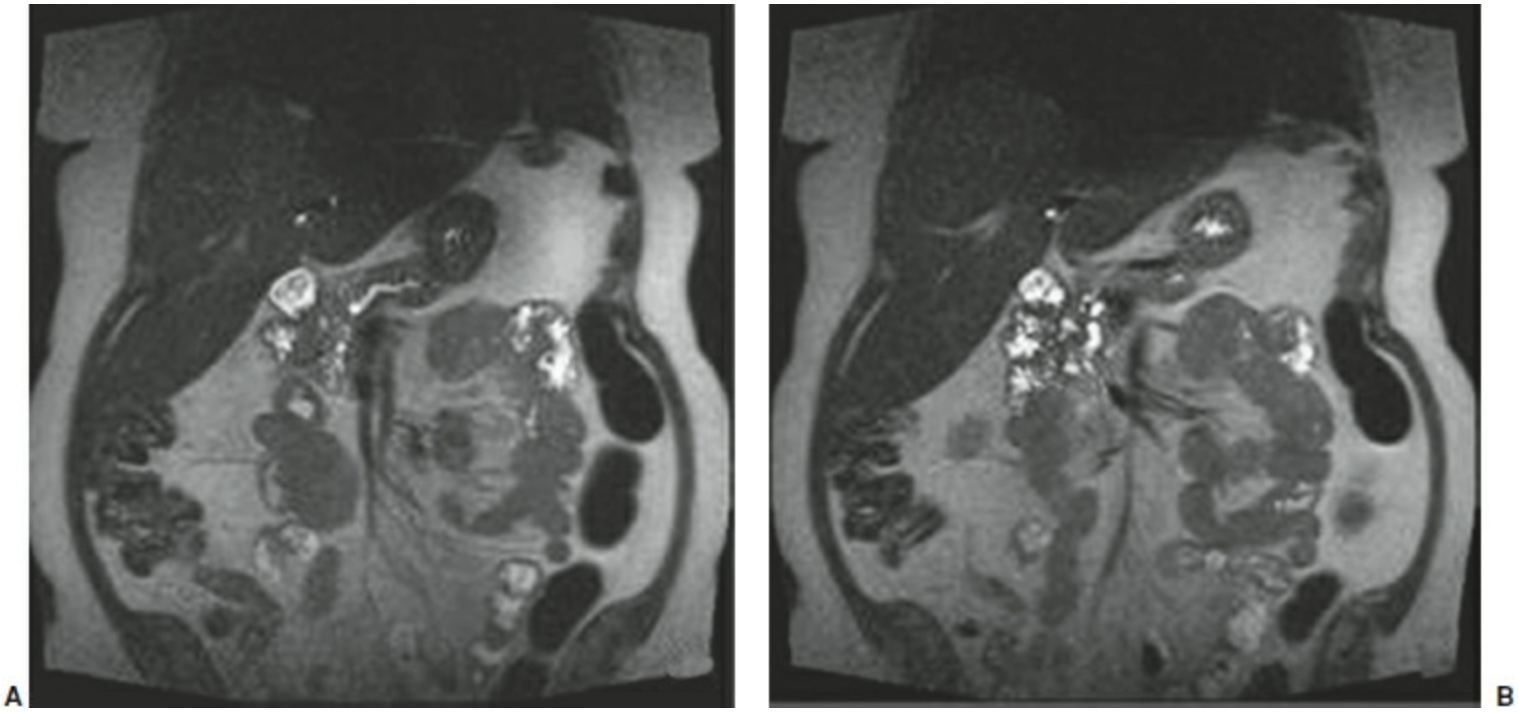

Figure 54-3. T2-weighted magnetic resonance imaging with secretin stimulation demonstrate a pathologically dilated pancreatic duct in the body of the pancreas (**A**), and cystic changes and dilated ducts in a fibrotic and inflammatory head of the pancreas (**B**).

Table 54-2 Cambridge Classification System for Chronic Pancreatitis by ERCP Imaging

Grade	Severity of Pancreatitis	ERCP Findings
1	Normal	Quality study, no abnormal features
2	Equivocal	Less than 3 abnormal branches
3	Mild	More than 3 abnormal branches
4	Moderate	Abnormal main duct and branches
5	Marked	As above with one or more of: Large cavities (>10 mm) Gross gland enlargement (>2× normal) Intraductal filling defects or calculi Duct obstruction, stricture or gross irregularity Contiguous organ invasion

ERCP, endoscopic retrograde cholangiopancreatography.
From Sarner M, Cotton PB. Classification of pancreatitis. *Gut* 1984;25: 756–759.

CONSIDERATIONS IN MANAGEMENT

3 Frontline management of CP includes risk factor modification, such as alcohol and tobacco cessation. Primary medical interventions entail pain management, including adjunctive behavioral therapy, and nutritional optimization, including pancreatic enzyme replacement.

Pancreatic enzymes are the mainstay of medical management of CP despite controversy about their efficacy. Enzyme replacement is presumed to improve pain by feedback inhibition of cholecystokinin (CCK) release from the duodenum, leading to decreased pancreatic exocrine secretions. A meta-analysis of six randomized, placebo-controlled trials did not reveal a significant benefit for supplemental pancreatic enzyme therapy for pain relief.[28] Antioxidant therapy has been proposed as a treatment for CP, based on the theory that antioxidants will reduce oxygen free radicals and ameliorate oxidative stress and pancreatic acinar cell injury. Prospective randomized trials have shown conflicting results in antioxidant therapy for CP.[29]

Table 54-3 EUS Criteria for Chronic Pancreatitis

Parenchymal Criteria	Normal (Low Probability)
Hyperechoic foci	0–2 criteria present
Hyperechoic strands	Indeterminate (Intermediate Probability)
Hyperechoic lobules, foci or areas	3–4 criteria present
Cyst	High Probability
Ductal Criteria	5–9 criteria present
Irregular duct contour	
Visible side branches	
Hyperechoic duct margin	
Dilated main duct	
Stone	

EUS, endoscopic ultrasound.
From Wallace MB, Hawes RH, Durkalski V, et al. The reliability of EUS for the diagnosis for chronic pancreatitis: interobserver agreement among experienced endosonographers. *Gastrointest Endosc* 2001;53:294–299.

Because CP pain is associated with extrapancreatic neuronal remodeling, neuromodulation with anticonvulsant or antidepressant medications similar to gabapentin have been utilized for CP pain management with limited success in patients with ongoing pancreatic inflammation.

Avoidance of narcotic analgesia in the management of CP pain is uniformly recommended. Analgesic management with nonsteroidal anti-inflammatory medication, acetaminophen, and tramadol is typically recommended. However, because the severity of pancreatic pain is so incapacitating, most patients who are evaluated for endoscopic or surgical management have been treated with narcotic analgesics and have developed physiologic narcotic dependence.

Behavioral therapy is a keystone of therapy in CP, particularly since many patients who are debilitated by CP are young and have previously been in good health. Behavioral

modification is effective in modulating pain perceptions in many chronic disorders. In addition, behavioral therapy is important in patients at risk for opioid misuse.[30]

Patients who have failed medical management, have continued debilitating pain or nutritional failure, and are physiologically fit are candidates for therapeutic interventions.

ENDOSCOPIC MANAGEMENT

ERCP is the primary endoscopic modality for therapy in CP. The principle goal with ERCP is to relieve any obstructive process. Potential maneuvers include sphincterotomy, stone extraction, stricture dilation, and stenting.

EUS can be utilized for endoscopic pseudocyst drainage procedures and for celiac plexus neurolysis. Percutaneous and endoscopic-guided celiac nerve blockade has been utilized to manage CP pain. Meta-analysis studies of EUS-guided celiac plexus blockade found short-term pain relief in about one-half of the subjects.[31]

In general, the endoscopic approach is undertaken prior to consideration of surgery, given the perceived advantages of lower morbidity with a less invasive approach. Two prospective, randomized, controlled trials have compared endoscopy and surgery in patients with obstructive CP. Dite and colleagues randomized 72 patients with CP, pancreatic duct obstruction and pain to endoscopic or surgical intervention. Endoscopic therapy consisted of ERCP with 52% undergoing sphincterotomy and stenting and 23% stone removal. Operative management was 20% drainage procedure and 80% resection. At 5-year follow-up, the surgical group had a greater proportion of patients that were pain free (34% vs. 15%).[32] In another study Cahen and colleagues from randomized 39 patients with dilated duct CP and pain to endoscopic or surgical management. Endoscopic treatment was ERCP with sphincterotomy and stenting, and operative therapy was a drainage procedure (longitudinal pancreaticojejunostomy). At 5-year follow-up, the surgical group had a greater proportion of patients that had pain relief (80% vs. 38%, $p = 0.001$), had larger improvements in quality of life, and underwent fewer procedures, despite equivalent morbidity, length of stay, and preserved pancreatic function.[33,34]

SURGICAL MANAGEMENT

4 Approximately two-thirds of patients with debilitating pain from CP fail medical and endoscopic managements and are candidates for consideration for operative therapy. The primary indication for surgical intervention in CP is intractable pain, and the goals of surgery are to effectively relieve pain while minimizing morbidity, including minimizing perioperative complications and preserving pancreatic parenchyma. As the underlying cause of CP pain is not well understood, operative decision-making can be difficult. The pancreatic anatomy is the primary determinant in surgical planning. Patients with a dilated (greater than 6 to 7 mm diameter) main pancreatic duct are assumed to have obstructive pathology and are candidates for a drainage-type procedure (lateral pancreaticojejunostomy, Frey procedure). In patients with a small-diameter main pancreatic duct, resection of fibrotic and poorly drained parenchyma is undertaken. Patients with head-predominant or tail-centered disease can undergo a directed partial resection. In patients with diffuse parenchymal involvement a TP with islet autotransplantation may be considered (Algorithm 54-1).

Parenchymal fibrosis associated with CP may involve adjacent organs and lead to complications requiring operative management. Other indications for surgical management of CP include terminal biliary stenosis, duodenal stenosis, gastric variceal hemorrhage due to splenic vein thrombosis, stenosis of the transverse colon, and symptomatic pancreatic pseudocysts. These complications are managed by a variety of bypass or resection procedures depending on the underlying pancreatic ductal disorder. Uncomplicated biliary stenosis is managed with biliary bypass with choledochoduodenostomy or Roux-en-Y hepaticojejunostomy.[35] When associated with an inflammatory mass in the head of the pancreas, pancreatic head resection may be indicated. When biliary stenosis is associated with CP and a pseudocyst in the region of the pancreatic head, pseudocyst drainage should be undertaken prior to performing biliary bypass as this may lead to resolution of the obstruction. Duodenal stenosis is usually associated with biliary stenosis and an inflammatory pancreatic head mass and is best managed with resection of the head of the pancreas.[36] When patient factors make resection unsafe, a double bypass is undertaken with gastrojejunostomy and biliary bypass. Gastric varices due to splenic vein occlusion are not an indication for operation unless associated with hemorrhage. When indicated for gastric variceal bleeding complications, splenectomy is indicated. Preoperative splenic artery embolization or balloon occlusion may diminish intraoperative blood loss when splenomegaly and fibrosis in the region of the pancreatic tail make operative control of the splenic artery problematic.[37] Fibrosing stenosis of the transverse colon, a rare complication of CP, is managed with colonic resection and anastomosis or colostomy, depending on the condition of the patient and the condition of the pancreas.[38] Pancreatic pseudocysts associated with CP and ductal obstruction are managed by addressing the underlying ductal disorder with resection or drainage procedures.[39]

Lateral Pancreaticojejunostomy

Retrograde pancreatic drainage for relapsing pancreatitis was described by Puestow and Gillesby in 1958.[40] A modification of this original drainage procedure that more closely resembles the modern-day technique of the lateral pancreaticojejunostomy (LPJ) was reported by Partington and Rochelle in 1960.[41] LPJ is the classic operation for pancreatic drainage and entails opening the pancreatic duct anteriorly along its length, medially to the level of the gastroduodenal artery and laterally into the tail. The opened pancreatic duct is then cleared of stones, including into the head, and anastomosed to a Roux-en-Y jejunal limb for drainage.

Procedure-specific complications of note include intraoperative hemorrhage (due to splenic vein or gastroduodenal artery injury), postoperative hemorrhage (often from the gastroduodenal artery), and anastomotic leak (seen in 10% of cases).

Multiple retrospective single-institution case series have been reported while evaluating outcomes with LPJ, with pain-relief rates of 48% to 91%.[42–49] Morbidity rates are low (20% on average) and endocrine and exocrine function is often preserved.[50] LPJ is an effective and safe procedure for pain relief in many patients with dilated duct pancreatitis. Recurrent pain does occur after LPJ, however, likely due to disease in the head of the pancreas. Intraductal stone disease in the head of the pancreas can be cleared with intraoperative pancreatoscopy and electrohydraulic lithotripsy, which has been shown to improve outcomes (reduced readmissions, increased pain-relief rates).[51] Alternatively, combining a localized head resection with LPJ can help to reduce recidivism.

Localized Pancreatic Head Resection with Lateral Pancreaticojejunostomy

In 1987, Frey and colleagues described a localized pancreatic head resection with a lateral pancreaticojejunostomy (LR-LPJ) with the goal of achieving pancreatic ductal drainage, resection of damaged and poorly drained parenchyma in the head of the pancreas, and preservation of the duodenum to minimize postoperative gastrointestinal dysfunction. The Frey procedure combines a classic longitudinal ductotomy of the neck, body and tail of the pancreas with unroofing of the pancreatic ducts in the head and uncinate process of the pancreas with a "coring" out of the overlying ductal tissue and preservation of the pancreas parenchyma along the posterior and lateral margin of the pancreas. Frey reported initially on 50 patients, describing a morbidity of 22% and a pain-relief rate of 84%.[52] His outcomes have been validated in modern series, both at his own institution and at others, with pain-relief rates of 62% to 88% and morbidity of 20% to 30% reported.[53–56]

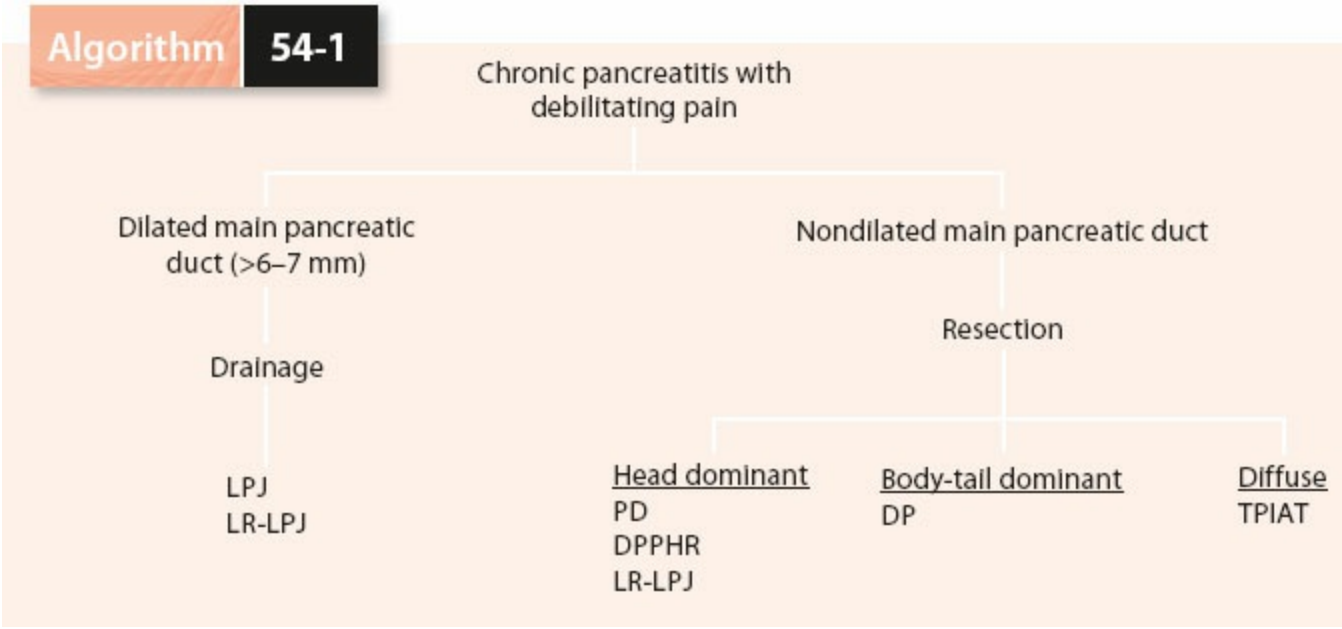

Algorithm 54-1. Algorithm for operative decision-making in chronic pancreatitis. LPJ, lateral pancreaticojejunostomy; LR-LPJ, local pancreatic head resection with lateral pancreaticojejunostomy; PD, pancreatoduodenectomy; DPPHR, duodenal-preserving pancreatic head resection; DP, distal pancreatectomy; TPIAT, total pancreatectomy with islet autotransplantation.

Pancreatic Head Resection

Pancreatoduodenectomy (PD) for CP was described as early as 1946 by Whipple.[57] In the modern era, PD is the operation of choice for patients with complicated CP and head-dominant disease. Patients may present with duodenal or biliary obstruction as well as obstructive pancreatopathy from an inflammatory mass in the head of the pancreas. Outcomes for PD include pain relief in 70% to 89% of patients, morbidity in 16% to 53%, and mortality in less than 5% in high-volume centers.[58–61]

The pylorus preserving pancreatoduodenectomy (PPPD) was popularized by Traverso and Longmire in 1978 in an effort to maintain the physiologic benefits of a functional pylorus.[62] PPPD has been well adopted into pancreas surgery although the purported nutritional advantages have not been evidenced.[63–67] Some authors, however, have reported improved professional rehabilitation[64] and improved quality of life after PPPD[66] as compared to classic PD.

Duodenal preserving pancreatic head resection (DPPHR) was developed by Beger and colleagues in the 1970s in an effort to decrease the morbidity of pancreatic head resection for CP. Pain relief is reported in 77% to 88% of patients, with professional rehabilitation rates of 63% to 69%. Morbidity and mortality are acceptable at 28.5% and 1%, respectively.[67–71] Multiple prospective randomized trials in comparing the various methods of pancreatic head resection in CP have been undertaken mostly in Germany over the past couple of decades, with no discernable advantage determined between them (Table 54-4).[71–76] A modification of the Beger procedure was described by the group in Berne in which the neck of the pancreas is left intact in its course over the portal vein thereby diminishing the risk of portal venotomy (Fig. 54-4).[77,78]

Distal Pancreatectomy

In patients with CP and disease localized to the body and tail of the pancreas or in patients with a main pancreatic duct stricture in the neck or body, distal pancreatectomy (DP) can be an effective means of pain relief. The majority of CP patients who are candidates for DP have severe inflammatory changes in the region of the splenic hilum, making concomitant splenectomy the most prudent course. Pain-relief rates of 57% to 84% are reported with occupational rehabilitation in 29% to 73%. Morbidity and mortality are reported in 15% to 32% and 2% to 2.2% of cases, respectively.[79–81] Postoperative pancreatic fistula after DP is the primary morbidity of this operation and appears to be related to patient-specific factors rather than operative technique.[82] DP appears to be applicable in approximately 9% to 25% of patients in larger series of patients undergoing surgery for CP.[49,83]

Total Pancreatectomy

TP for CP was performed as early as 1944 by Clagett at the Mayo Clinic. Perhaps tellingly, his patient died 10 weeks after surgery of a hypoglycemic event. TP can be an effective means of pain relief in patients with diffuse small-duct pancreatitis, patients who have failed lesser surgeries, and patients with hereditary pancreatitis. Excellent pain-relief rates of 72% to 100% have been described with TP, with morbidity rates of 22% to 54% and mortality 0 to 14%. There is a requisite brittle type 3c pancreatogenic diabetes that follows TP; however, with severe diabetic control problems in 15% to 75% of patients, and in one series, half of late postoperative deaths were due to hypoglycemia.[84,85] With TP, there is loss of not only insulin-producing beta cells but also loss of the alpha cells and other composite cells of the islet that produce hormones to maintain glucose homeostasis. As a result, patients may demonstrate an unpredictable response to exogenous insulin and importantly may develop hypoglycemic unawareness, which can be morbid.[86] Thus, TP is a good option for pain relief but the resultant diabetes is exceptionally morbid.

5 TP with islet autotransplantation (TPIAT) was described by Sutherland and colleagues at the University of Minnesota in 1978, with the goal of ameliorating the brittle diabetes after extensive pancreatectomy.[87] TPIAT has really only been performed with any regularity, however, over the past decade, and understanding of long-term outcomes is evolving. Pain-relief rates of 72% to 86% have been reported and patients have a significantly improved quality of life. Morbidity rates of 47% to 55% are reported, with 1.4% to 6% mortality, and insulin independence in 10% to 40% after islet transplant.[88–91] Insulin independence after TPIAT correlates with the number of islet equivalents per kilogram harvested[89,91] and transplanted islet function appears to be durable, with outcomes reported for more than 13 years.[92] TPIAT has been safely and effectively performed in children with hereditary pancreatitis, with insulin independence in 55%.[93] While this therapy holds promise, long-term outcomes data are currently lacking.

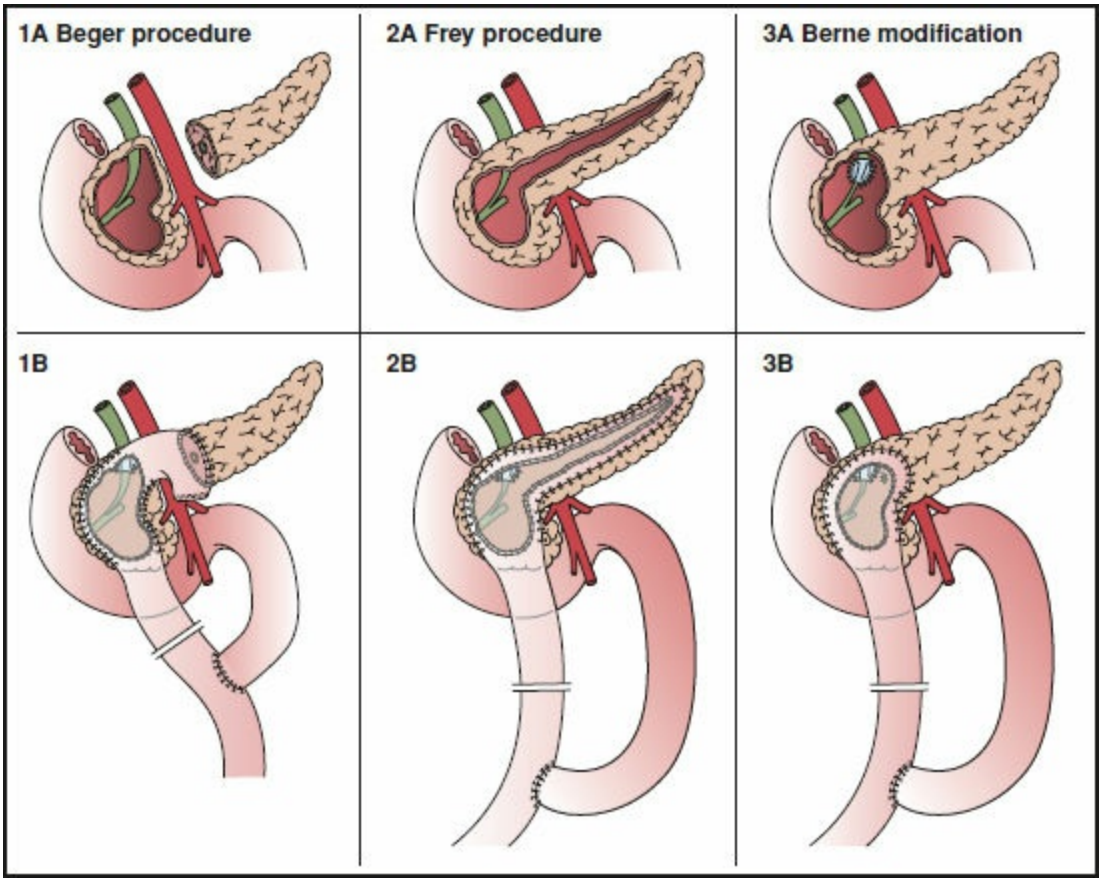

Figure 54-4. Schematic drawings of extent of resection (**A**), and method of reconstruction (**B**) for a Beger procedure (1), Frey procedure (2), and a Berne modification of the Beger procedure (3). Reproduced from Muller MW, Freiss H, Leitzbach S, et al. Perioperative and follow-up results after central pancreatic head resection (Berne technique) in a consecutive series of patients with chronic pancreatitis. *Am J Surg* 2008;196:364–372.

Table 54-4 Comparative Randomized Controlled Trials of Pancreatic Head Resection

Study	Comparison	N	Morbidity	Mortality	Pain Relief (%)
Klempa et al.[71]	PD	21	51	0	70
	DPPHR	22	54	5	82
Buchler et al.[72]	PPPD	20	20	0	67
	DPPHR	20	15	0	94
Farkas et al.[73]	PPPD	20	40	0	90
	DPPHR	20	0	0	85
Izbicki et al.[74]	DPPHR	20	20	0	95
	LRLPJ	22	9	0	89
Izbicki et al.[75]	LRLPJ	31	19	3	90
	PPPD	30	53	0	71
Strate et al.[76]	DPPHR	38	NR	NR	82
	LRLPJ	36	NR	NR	81

PD, pancreatoduodenectomy; DPPHR, duodenal-preserving pancreatic head resection; PPPD, pylorus-preserving pancreatic head resection; LRLPJ, local resection pancreatic head with longitudinal pancreaticojejunostomy.

Laparoscopic Surgery for Chronic Pancreatitis

Laparoscopy began in pancreas surgery with laparoscopic staging for pancreatic cancer. The development of endoscopic stapler technology in the mid-1990s allowed for pancreatic resections to be developed. In 1996, Gagner reported his experience with laparoscopic distal pancreatectomy.[94] Due to the recent epidemic of incidentally discovered low-grade pancreatic neoplasms, experience with laparoscopic DP has matured rapidly, and now it is currently the most commonly performed laparoscopic pancreatic resection. A large multicenter group reported on 667 distal pancreatectomies with 159 (24%) laparoscopic, and 14 (9%) were for CP. The authors reported lower blood loss, length of stay and morbidity with laparoscopy, and equivalent operative times and pancreatic fistula rates.[95] A recent meta-analysis of studies reporting experience with laparoscopic DP, including greater than 1,800 cases, showed similar advantages with laparoscopy, while maintaining quality.[96] While laparoscopic DP is arguably now the standard approach to resection of benign or low-grade neoplasms its wide application in patients with CP is still in evolution, as these cases are more technically challenging due to the distorted anatomy and loss of tissue planes in CP. Laparoscopic LPJ has been described by several authors and is technically feasible.[97] Success rate for the minimally invasive approach in this operation increases as the size of the pancreatic duct increases. The laparoscopic PD is being performed at many academic centers, mostly for malignant disease, but in a few with CP. The authors report reasonable operative times (median 357 to 368 minutes), blood loss (75 to 240 cc), morbidity (26.7% to 42%), and pancreatic fistula rates (6.7% to 18%).[98–100] The limitations of laparoscopic PD in CP are similar to those with laparoscopic DP, with the associated technical challenges of operating on a fibrotic gland.

CONCLUSIONS

CP is a complex disease, challenging in diagnosis and management. Notable recent progress has been made in understanding the underlying pathophysiology, including genetic causes and cellular and biochemical mechanisms, with much still to be learned. Surgery can be beneficial in many patients with debilitating pain from CP. Evolving surgical therapies, such as TPIAT and minimally invasive techniques, are promising.

References

1. Rickels MR, Bellin M, Toledo FG, et al. Detection, evaluation, and treatment of diabetes mellitus in chronic pancreatitis: recommendations from Pancreasfest 2012. *Pancreatology* 2013;13(4):336–342.
2. Levy P, Barthet M, Mollard BR, et al. Estimation of the prevalence and incidence of chronic pancreatitis and its complications. *Gastroenterol Clin Biol* 2006;30:838–844.
3. Everhart JE, Ruhl CE. Burden of digestive diseases in the United States Part III: liver, biliary tract, and pancreas. *Gastroenterology* 2009;136:1134–1144.
4. Schneider A, Lohr JM, Singer MV. The M-ANNHEIM classification of chronic pancreatitis: introduction of a unifying classification system based on a review of previous classifications of the disease. *J Gastroenterol* 2007;42:101–119.
5. Layer P, Yamamoto H, Kalthoff L, et al. The different courses of early and late onset idiopathic and alcoholic chronic pancreatitis. *Gastroenterology* 1994;107:1481–1487.
6. Dani R, Penna FJ, Nogueira CE. Etiology of chronic calcifying pancreatitis in Brazil: a report of 329 consecutive cases. *Int J Pancreatol* 1986;1:399–406.
7. Marks IN, Bank S, Louw JH. Chronic pancreatitis in the Western Cape. *Digestion* 1973;9:447–453.
8. Cote GA, Yadav D, Slivka A, et al. Alcohol and smoking as risk factors in an epidemiology study of patients with chronic pancreatitis. *Clin Gastroenterol Hepatol* 2011;9:266–273.
9. Whitcomb DC. Genetics of alcoholic and nonalcoholic pancreatitis. *Curr Opin Gastroenterol* 2012;28:501–506.
10. Cavallini G, Talamini G, Vaona B, et al. Effect of alcohol and smoking on pancreatic lithogenesis in the course of chronic pancreatitis. *Pancreas* 1994;9:42–46.
11. Maisonneuve P, Lowenfels AB, Mullhaupt B, et al. Cigarette smoking accelerates progression of alcoholic chronic pancreatitis. *Gut* 2005;54:510–514.
12. Yadav D, Hawes RH, Brand RE, et al. Alcohol consumption, cigarette smoking, and the risk of recurrent acute and chronic pancreatitis. *Arch Int Med* 2009;169:1035–1045.
13. Nojgaard C, Becker U, Matzen P, et al. Progression from acute to chronic pancreatitis: prognostic factors, mortality and natural cause. *Pancreas* 2011;40:1195–1200.
14. Comfort MW, Steinberg AG. Pedigree of a family with hereditary chronic relapsing pancreatitis. *Gastroenterology* 1952;21:54–63.
15. Whitcomb DC, Gorry MC, Preston RA, et al. Hereditary pancreatitis is caused by a mutation in the cationic trypsinogen gene. *Nat Genet* 1996;14:141–145.
16. Witt H, Luck W, Hennies HC, et al. Mutations in the gene encoding the serine protease inhibitor, Kazal type 1 are associated with chronic pancreatitis. *Nat Genet* 2000;25:213–216.

17. Szmola R, Sahin-Toth M. Chymotrypsin C promotes degradation of human cationic trypsin: identity with Rinderknecht's enzyme Y. *Proc Natl Acad Sci U S A* 2001;104:11227–11232.
18. Felderbauer P, Hoffman P, Einwachter H, et al. A novel mutation of the calcium sensing receptor gene is associated with chronic pancreatitis in a family with heterozygous SPINK1 mutations. *BMC Gastroenterol* 2003;3:34.
19. Brand H, Diergaarde B, O'Connell MR, et al. Variation in the gamma-glutamyltransferase 1 gene and risk of chronic pancreatitis. *Pancreas* 2011;40:1188–1194.
20. Whitcomb DC. Genetic risk factors for pancreatic disorders. *Gastroenterology* 2013;144:1292–1302.
21. Apte MV, Haber PS, Darby SJ, et al. Pancreatic stellate cells are activated by proinflammatory cytokines: implications for pancreatic fibrogenesis. *Gut* 1999;44:534–541.
22. Shek FW, Benyon RC, Walker FM, et al. Expression of transforming growth factor beta 1 by pancreatic stellate cells and its implications for matrix secretion and turnover in chronic pancreatitis. *Am J Pathol* 2002;160:1787–1798.
23. Bockman DE, Buchler M, Malfetheiner P, et al. Analysis of nerves in pancreatitis. *Gastroenterology* 1988;94:1459–1469.
24. Buchler M, Weihe E, Fries H, et al. Changes in peptidergic innervation in chronic pancreatitis. *Pancreas* 1992;7:183–192.
25. Michalski CW, Shi X, Reiser C, et al. Neurokinin-2 receptor levels correlate with intensity, frequency, and duration of pain in chronic pancreatitis. *Ann Surg* 2007;246:786–793.
26. Sarner M, Cotton PB. Classification of pancreatitis. *Gut* 1984;25:756–759.
27. Wallace MB, Hawes RH, Durkalski V, et al. The reliability of EUS for the diagnosis of chronic pancreatitis: interobserver agreement among experienced endosonographers. *Gastrointest Endosc* 2001;53:294–299.
28. Ferrone M, Raimondo M, Scolapio JS. Pancreatic enzyme pharmacotherapy. *Pharmacotherapy* 2007;27:910–920.
29. Siriwardena AK, Mason JM, Sheen AJ, et al. Antioxidant therapy does not reduce pain in patients with chronic pancreatitis: the ANTICIPATE study. *Gastroenterology* 2012;143(3):655–663.
30. Barth KS, Balliet W, Pelic CM, et al. Screening for current opioid misuse and associated risk factors among patients with chronic nonalcoholic pancreatitis pain. *Pain Med* 2014;15(8):1359–1364.
31. Kaufman M, Singh G, Das S, et al. Efficacy of endoscopic ultrasound-guided celiac plexus block and celiac plexus neurolysis for managing abdominal pain associated with chronic pancreatitis and pancreatic cancer. *J Clin Gastroenterol* 2010;44(2):127–134.

32. Dite P, Ruzicka M, Zboril V, et al. A prospective randomized trial comparing endoscopic and surgical therapy for chronic pancreatitis. *Endoscopy* 2003;35:553–558.
33. Cahen DL, Gouma DJ, Nio Y, et al. Endoscopic versus surgical drainage of the pancreatic duct in chronic pancreatitis. *NEJM* 2007;356:676–684.
34. Cahen DL, Gouma DJ, Laramee P, et al. Long-term outcomes of endoscopic vs. surgical drainage of the pancreatic duct in patients with chronic pancreatitis. *Gastroenterology* 2011;141:1690–1695.
35. Leppard WM, Shary TM, Adams DB, et al. Choledochoduodenostomy: is it really so bad? *J Gastrointest Surg* 2011;15:754–757.
36. Taylor SM, Adams DB, Anderson MC. Duodenal stricture: a complication of chronic fibrocalcific pancreatitis. *South Med J* 1991;84:338–341.
37. Adams DB, Mauterer DJ, Vujic IJ, et al. Preoperative control of splenic artery inflow in patients with splenic venous occlusion. *South Med J* 1990;83:1021–1024.
38. Adams DB, Davis BR, Anderson MC. Colonic complications of pancreatitis. *Am Surg* 1994 60:44–49.
39. Nealon WH, Walser E. Duct drainage alone is sufficient in the operative management of pancreatic pseudocyst in patients with chronic pancreatitis. *Ann Surg* 2003;237:614–620.
40. Puestow CB, Billesby WJ. Retrograde surgical drainage of pancreas for chronic relapsing pancreatitis. *Arch Surg* 1958;76:898–907.
41. Partington PF, Rochelle RE. Modified Puestow procedure for retrograde drainage of the pancreatic duct. *Ann Surg* 2001;233:793–800.
42. Nealon WH, Matin S. Analysis of surgical success in preventing recurrent acute exacerbations in chronic pancreatitis. *Ann Surg* 2001;233:793–800.
43. Greenlee HB, Prinz RA, Aranha GV. Longterm results of side to side pancreaticojejunostomy. *World J Surg* 1990;14:70–76.
44. Sato T, Miyashita E, Yamaguchi H, et al. The role of surgical treatment for chronic pancreatitis. *Ann Surg* 1986;203:266–271.
45. Bradley EL. Long term results of pancreaticojejunostomy in patients with chronic pancreatitis. *Am J Surg* 1987;153:207–213.
46. Holmberg JT, Isaksson G, Ihse I. Longterm results of pancreaticojejunostomy in chronic pancreatitis. *Surg Gynecol Obstet* 1985;160:339–346.
47. Sarles JC, Nacchiero M, Garani F, et al. Surgical treatment of chronic pancreatitis. Report of 134 cases treated by resection or drainage. *Am J Surg* 1982;144:317–321.
48. Adams DB, Ford MC, Anderson MC. Outcome after lateral pancreaticojejunostomy for chronic pancreatitis. *Ann Surg* 1994;219:481–489.
49. Schnelldorfer T, Lewin DN, Adams DB. Operative management of chronic pancreatitis: longterm results in 372 patients. *JACS* 2007;204:1039–1045.
50. Nealon WH, Thompson JC. Progressive loss of pancreatic function in chronic pancreatitis is delayed by main pancreatic duct decompression. a longitudinal

prospective analysis of the modified puestow procedure. *Ann Surg* 1993;217:458–468.
51. Rios G, Adams DB. Does intraoperative EHL improve outcome in the surgical management of chronic pancreatitis. *Am Surg* 2001;67:534–538.
52. Frey CF, Smith GJ. Description and rationale of a new operation for chronic pancreatitis. *Pancreas* 1987;2:701–707.
53. Frey CF, Amikura K. Local resection of the head of the pancreas combined with longitudinal pancreaticojejunostomy in the management of patients with chronic pancreatitis. *Ann Surg* 1994;220:492–504.
54. Keck T, Wellner UF, Riediger H, et al. Long term outcome after 92 duodenum preserving pancreatic head resections for chronic pancreatitis: comparison of Beger and Frey procedures. *J Gastrointest Surg* 2010;14:549–556.
55. Negi S, Singh A, Chaudhary A. Pain relief after Frey's procedure for chronic pancreatitis. *Br J Surg* 2010;97:187–195.
56. Pessaux P, Kianmanesh R, Regimbequ JM, et al. Frey Procedure in the Treatment of Chronic pancreatitis. *Pancreas* 2006;33:354–358.
57. Whipple AO. Radical surgery for certain cases of pancreatic fibrosis associated with calcareous deposits. *Ann Surg* 1946;124:991–1006.
58. Sakorafas GH, Farnell, MB, Nagorney DM, et al. Pancreatoduodenctomy for chronic pancreatitis: long term results in 105 patients. *Arch Surg* 2000;135:517–523.
59. Jimenez RE, Fernandez-Del Castillo C, Rattner DW, et al. Pylorus preserving pancreaticoduodenectomy in the treatment of chronic pancreatitis. *World J Surg* 2003;27:1211–1216.
60. Russell RC, Theis BA. Pancreatoduodenectomy in the treatment of chronic pancreatitis. *World J Surg* 2003;27:1203–1210.
61. Vickers SM, Chan C, Heslin MJ, et al. The role of pancreaticoduodenectomy in the treatment of severe chronic pancreatitis. *Am Surg* 1999;65:1108–1111.
62. Traverso LW, Longmire WP Jr. Preservation of the pylorus in pancreaticoduodenectomy. *Surg Gynecol Obstet* 1978;146:959–962.
63. Tran KT, Smeenk HG, van Eijck CH, et al. Pylorus preserving pancreaticoduodenectomy versus standard Whipple procedure: a prospective, randomized, multicenter analysis of 170 patients with pancreatic and periampullary tumors. *Ann Surg* 2004;240:738–745.
64. Seiler CA, Wagner M, Bachmann T, et al. Randomized clinical trial of pylorus-preserving duodenopancreatectomy versus classical Whipple resection—long term results. *Br J Surg* 2005;92:547–556.
65. Iqbal N, Lovegrove RE, Tilney HS, et al. A comparison of pancreaticoduodenectomy with pylorus preserving pancreaticoduodenectomy: a meta-analysis of 2822 patients. *EJSO* 2008;34:1237–1245.
66. Ohtsuka T, Yamaguchi K, Ohuchida J, et al. Comparison of quality of life after pylorus preserving pancreatoduodenectomy and Whipple resection.

Hepatogastroenterology 2003;50:846–850.

67. Beger HG, Krautzberger W, Bittner R, et al. Duodenum-preserving resection of the head of the pancreas in patients with severe chronic pancreatitis. *Surgery* 1985;97:467–475.
68. Beger HG, Buchler M, Bittner RR, et al. Duodenum-preserving resection of the head of the pancreas in severe chronic pancreatitis. Early and late results. *Ann Surg* 1989;209:273–278.
69. Beger HG, Schlosser W, Friess HM, et al. Duodenum preserving head resection in chronic pancreatitis changes the natural course of the disease: a single-center 26 year experience. *Ann Surg* 1999;230:512–519.
70. Buchler MW, Friess H, Bittner R, et al. Duodenum preserving pancreatic head resection: long term results. *J Gastrointest Surg* 1997;1:13–19.
71. Klempa I, Spatny M, Menzel J, et al. Pancreatic function and quality of life after resection of the head of the pancreas in chronic pancreatitis. a prospective, randomized comparative study after duodenum preserving resection of the head of the pancreas versus Whipple's operation. *Chirurg* 1995;66:350–359.
72. Buchler MW, Friess H, Muller MW, et al. Randomized trial of duodenum preserving pancreatic head resection versus pylorus preserving Whipple in chronic pancreatitis. *Am J Surg* 1995;169:65–69.
73. Farkas G, Leindler L, Daroczi M, et al. Prospective randomized comparison of organ preserving pancreatic head resection with pylorus preserving pancreaticoduodenectomy. *Langenbecks Arch Surg* 2006;391:338–342.
74. Izbicki JR, Bloechle C, Knoefel WT, et al. Duodenum preserving resection of the head of the pancreas in chronic pancreatitis: a prospective randomized trial. *Ann Surg* 1995;221:350–358.
75. Izbicki JR, Bloechle C, Broering DC, et al. Extended drainage versus resection in surgery for chronic pancreatitis: a prospective randomized trial comparing the longitudinal pancreaticojejunostomy combined with local pancreatic head excision with the pylorus preserving pancreatoduodenectomy. *Ann Surg* 1998;228:771–779.
76. Strate T, Taherpour Z, Bloechle C, et al. Long term follow up of a randomized trial comparing the Beger and Frey procedures for patients suffering from chronic pancreatitis. *Ann Surg* 2005;241:591–598.
77. Muller MW, Friess H, Leitzbach S, et al. Perioperative and follow up results after central pancreatic head resection in a consecutive series of patients with chronic pancreatitis. *Am J Surg* 2008;196:364–372.
78. Gloor B, Friess H, Uhl W, et al. A modified technique of the Beger and Frey procedure in patients with chronic pancreatitis. *Dig Surg* 2001;18:21–25.
79. Hutchins RR, Hart RS, Pacifico M, et al. Long term results of distal pancreatectomy for chronic pancreatitis in 90 patients. *Ann Surg* 2002;236:612–618.
80. Schoenberg MH, Schlosser W, Ruck W, et al. Distal pancreatectomy in chronic

pancreatitis. *Dig Surg* 1999;16:130–136.
81. Sakorafas GH, Sarr MG, Rowland CM, et al. Postobstructive chronic pancreatitis: results with distal resection. *Arch Surg* 2001;136:643–648.
82. Schnelldorfer T, Mauldin PD, Lewin DN, et al. Distal pancreatectomy for chronic pancreatitis: risk factors for postoperative pancreatic fistula. *J Gastrointest Surg* 2007;11:991–997.
83. Riediger H, Adam U, Fischer E, et al. Long-term outcome after resection for chronic pancreatitis in 224 patients. *J Gastrointest Surg* 2007;11:949–960.
84. Gruessner RW, Sutherland DE, Dunn DL, et al. Transplant options for patients undergoing total pancreatectomy for chronic pancreatitis. *JACS* 2004;198:559–567.
85. Dresler CM, Fortner JG, McDermott K, et al. Metabolic consequences of regional (total) pancreatectomy. 1991;214(2):131–140.
86. Rickles MR, Schutta MF, Markmann JF, et al. Beta cell function following human islet transplantation for type I diabetes. *Diabetes* 2005;54:100–106.
87. Sutherland DE, Matas AJ, Najarian JS. Pancreatic islet cell transplantation. *Surg Clin North Am* 1978;58:365–382.
88. Morgan K, Owczarski SM, Borckardt J, et al. Pain control and quality of life after pancreatectomy with islet autotransplantation for chronic pancreatitis. *J Gastrointest Surg* 2012;16:129–134.
89. Sutherland DE, Radosevich DM, Bellin MD, et al. Total pancreatectomy and islet autotransplantation for chronic pancreatitis. *JACS* 2012; 214:409–424.
90. Argo JL, Contreras JL, Wesley MM, et al. Pancreatic resection with islet cell autotransplant for the treatment of severe chronic pancreatitis. *Am Surg* 2008;74:530–536.
91. Rilo HR, Ahmad SA, D'Alessio D. Total pancreatectomy and autologous islet cell transplant as a means to treat severe chronic pancreatitis. *J Gastrointest Surg* 2003;7:978–989.
92. Robertson RP, Lanz KJ, Sutherland DE, et al. Prevention of diabetes for up to 13 years by autoislet transplantation after pancreatectomy for chronic pancreatitis. *Diabetes* 2001;50:47–53.
93. Chinnakotla S, Bellin MD, Schwartzenberg SJ, et al. Total pancreatectomy and islet autotransplantation in children for chronic pancreatitis: indication, surgical techniques, postoperative management, and long-term outcomes. *Ann Surg* 2014;97:1286–1291.
94. Gagner M, Pomp A, Herrera MF. Early experience with laparoscopic resections of islet cell tumors. *Surgery* 1996;120:1051–1054.
95. Kooby DA, Gillespie T, Bentrem D, et al. Left-sided pancreatectomy: a multicenter comparison of laparoscopic and open approaches. *Ann Surg* 2008;248:438–446.
96. Venkat R, Edil BH, Shulick RD, et al. Laparoscopic distal pancreatectomy is associated with significantly less overall morbidity compared to the open technique:

a systematic review and meta-analysis. *Ann Surg* 2012;255:1048–1059.

97. Tantia O, Jindal MK, Khanna S, et al. Laparoscopic lateral pancreaticojejunostomy: our experience of 17 cases. *Surg Endosc* 2004;18:1054–1057.
98. Palanivelu C, Rajan RS, Rangarajan M, et al. Evolution in techniques of laparoscopic pancreaticoduodenectomy. a decade long experience from a tertiary center. *J HBP Surg* 2009;16:731–740.
99. Kendrick ML, Cusati D. Total laparoscopic pancreaticoduodenectomy: feasibility and outcome in an early experience. *Arch Surg* 2010;145:19–23.
100. Asbun HJ, Stauffer JA. Laparoscopic vs open pancreaticoduodenectomy: overall outcomes and severity of complications using the Accordion Severity Grading System. *J Amer Coll Surg* 2012;215:810–819.

Chapter 55

Neoplasms of Exocrine Pancreas

Attila Nakeeb, Michael G. House, and Keith D. Lillemoe

Key Points

1 Recent evidence supports that pancreatic ductal adenocarcinoma arises from precursor lesions referred to as pancreatic intraepithelial neoplasia (PanIN) with progression from proliferative lesions without nuclear abnormality to carcinoma in situ, known as PanIN-3.

2 Intraductal papillary mucinous neoplasms (IPMNs) are intraductal mucin-producing tumors that range from benign adenomas to invasive carcinoma.

3 Contrast-enhanced computed tomography (CT) is the preferred noninvasive imaging test for the diagnosis and staging of pancreatic cancer.

4 Perioperative mortality rates following pancreatoduodenectomy have fallen to the range of 2% to 5% although perioperative complications occur in approximately 40% of patients.

5 Survival after pancreatoduodenectomy for pancreatic cancer is approximately 20% at 5 years with factors influencing survival including tumor size, margin status, and lymph node status.

6 Adjuvant chemotherapy is beneficial for patients following resection of pancreatic cancer.

7 Endoscopic palliation of patients with incurable pancreatic cancer located in the head may require biliary and duodenal stenting.

8 Patients found to be unresectable at laparotomy for head of pancreas cancer should be considered for biliary bypass, gastrojejunostomy, and chemical splanchnicectomy to palliate the symptoms of jaundice, duodenal obstruction, and pain, respectively.

INTRODUCTION

Pancreatic cancer is the fourth leading cause of cancer-related death in the United States and second only to colorectal cancer as a cause of gastrointestinal cancer-related death. The overall 5-year survival for patients with pancreatic cancer is 7%.[1] Surgical resection offers the only chance for long-term cure. Unfortunately, because of the late presentation, only 15% to 20% of patients are candidates for surgical intervention. Five-year survival after pancreaticoduodenectomy (PD) is about 25% to 30% for node-negative and 10% for node-positive disease.[2] The nonspecific symptoms associated with early pancreatic cancer, the inaccessibility of the pancreas to examination, the aggressiveness of the tumors, and the technical difficulties associated with pancreatic surgery make pancreatic cancer one of the most challenging diseases treated by surgeons and oncologists.

In recent years, significant advances have been made in our understanding of the pathogenesis and clinical management of pancreatic cancer. This chapter will review the epidemiology and risk factors associated with pancreatic cancer, discuss recent developments in the field of molecular genetics, and provide an update on the current clinical management of pancreatic cancer.

EPIDEMIOLOGY AND RISK FACTORS

In the United States, it is estimated that nearly 48,960 new cases of pancreatic cancer will be diagnosed with almost 40,560 people dying of the disease in 2015. Pancreatic cancer accounts for 3% of all cancers in the United States and is responsible for 7% of all cancer deaths. The incidence of pancreatic cancer in the United States is 12.4 per 100,000 populations. The lifetime risk for developing pancreatic cancer is 1.5%.[1] The incidence of pancreatic cancer has slowly been increasing, with an average increase of 0.8% per year over the last 10 years (Fig. 55-1). The risk for the development of pancreatic cancer is related to age, race, sex, tobacco use, diet, and specific genetic syndromes (Table 55-1). The incidence increases with advancing age. More than 80% of cases occur in persons between the ages of 60 and 80 years, and pancreatic cancer is rare in people younger than 40 years. The incidence and mortality rates for pancreatic cancer in African Americans of both sexes are higher than those in whites. The gender differences in pancreatic cancer have been equalizing during recent years. Pancreatic cancer is still more common in men than in women, but the incidence and mortality rates have increased in women while they have stabilized or slightly decreased in men.

Environmental and dietary factors have also been implicated as risk factors for the development of pancreatic cancer. The most consistently observed environmental risk for the development of pancreatic cancer is cigarette smoking. It has been estimated that cigarette smoking can increase the risk for pancreatic cancer between one and a half and five times. The mechanism is unknown, but carcinogens in cigarette smoke have been shown to produce pancreatic cancers in laboratory animals. In addition, autopsy studies have documented hyperplastic changes in pancreatic ductal cells with atypical nuclear patterns in smokers. Alcohol consumption does not seem to be a risk factor for pancreatic cancer despite conflicting past reports. Recent studies suggest that past studies linking pancreatic cancer to alcohol use may have been confounded by tobacco use. Similarly, coffee consumption and exposure to ionizing radiation have been shown not to be associated with an increased pancreatic cancer risk.

Several epidemiologic investigations have suggested that diet may play an important role in the development of pancreatic cancer. An apparent association has been noted between pancreatic cancer and an increased consumption of total calories, carbohydrate, cholesterol, meat, salt, dehydrated food, fried food, refined sugar, soy beans, and nitrosamines. The risks are unproven for the ingestion of fat, beta-carotene, and coffee. A protective effect has been reported for dietary fiber, vitamin C, fruits, and vegetables.[3]

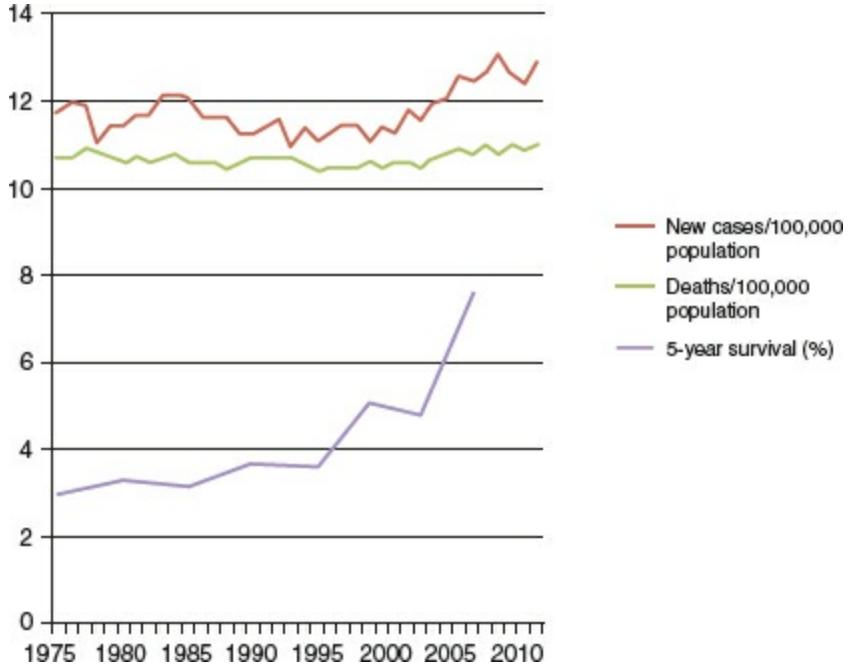

Figure 55-1. U.S. pancreatic cancer new cases, death rate, and 5-year survival. Adapted from EER Cancer Statistics Factsheets: Pancreas Cancer. National Cancer Institute. Bethesda, MD, http://seer.cancer.gov/statfacts/html/pancreas.html. Accessed March 10, 2016.

In addition to well-defined genetic syndromes, a number of common conditions have been thought to be etiologic factors in the development of pancreatic cancer. An apparent association between diabetes and pancreatic cancer has been suggested. Approximately 80% of patients diagnosed with pancreatic cancer have impaired glucose metabolism, impaired glucose tolerance, or diabetes mellitus. It is unclear if alterations in glucose tolerance/metabolism are a causative factor for pancreatic cancer or represent reaction to an enlarging malignancy in the pancreas. Among patients with newly diagnosed diabetes, 0.85% went on to be diagnosed with pancreatic cancer within 3 years.[4] Type II diabetes of at least 5 years duration has been shown to increase the risk of pancreatic cancer twofold.

The risk of pancreatic cancer has been shown to increase as body mass index increases. Examination of data from the Nurses' Health Study and the Health Professional's follow-up study show a 1.72 relative risk (95% CI 1.19–2.48) of pancreatic cancer in patients with a BMI >30 kg/m^2 as compared to individuals with a BMI <23 kg/m^2.

Chronic pancreatitis of any cause has been associated with a 25-year cumulative risk for the development of pancreatic cancer of approximately 4%. Other conditions for which a possible association with pancreatic cancer has been demonstrated include thyroid and other benign endocrine tumors, cystic fibrosis, and pernicious anemia.

Most cases of pancreatic cancer have no obvious predisposing factors. However, it is believed that between 5% and 10% of pancreatic cancers arise because of a familial predisposition. Six genetic syndromes have been associated with an increased risk for the development of pancreatic cancer (Table 55-2). These include hereditary nonpolyposis colon cancer, familial breast cancer associated with the *BRCA2* mutation, Peutz–Jeghers syndrome (PJS), ataxia–telangiectasia syndrome, familial atypical multiple mole–melanoma syndrome, and hereditary pancreatitis.

Table 55-1 Risk Factors for Pancreatic Cancer

	Increased Risk	Possible Risk	Unproved Risk
Demographic factors	Advancing age Male sex Black race	Geography	Socioeconomic status Migrant status
Host factors	Hereditary nonpolyposis colorectal cancer Familial breast cancer Peutz – Jeghers syndrome Ataxia – telangiectasia Familial atypical multiple-mole melanoma Hereditary pancreatitis		Peptic ulcer surgery
Environmental factors	Tobacco	Diet Occupation	Alcohol Coffee Radiation

Modified from Gold EB, Goldin SB. Epidemiology of and risk factors for pancreatic cancer. *Surg Oncol Clin North Am* 1998;7:67.

Table 55-2 Genetic Syndromes Associated with Hereditary Pancreatic Cancer

Syndrome	Mode of Inheritance	Gene	Fold Increase in Risk	Manifestation of Pancreatic Cancer
Peutz–Jeghers	AD	*STKII*	140×	Hamartomatous polyps of the gastrointestinal tract; mucocutaneous melanin macules
Hereditary pancreatitis	AD	*PRSSI*	60×	Recurrent episodes of severe pancreatitis starting at a young age
Familial pancreatic cancer	Unknown	Unknown	18×	At least one pair of first-degree relatives with pancreatic cancer
FAMMM	AD	p16	20×	Multiple nevi, atypical nevi, and melanomas
Familial breast cancer 2	AD	*BRCA2*	10×	Breast, ovarian, and pancreatic cancer
HNPCC	AD	*MSH2* *HLHI*	Unknown	Colonic, endometrial, and gastric cancers; mutator phenotype

AD, autosomal dominant; FAMMM, familial atypical multiple mole melanoma; HNPCC, hereditary nonpolyposis colorectal cancer.

MOLECULAR GENETICS

Invasive pancreatic ductal adenocarcinoma (PDAC) are genetically very complex, with wide-spread chromosome abnormalities, numerous losses and gains of large segments of DNA, and on average, more than 60 exomic alterations in each cancer.[5] PDAC harbors an average of 63 genome alterations, of which the majority are point mutations. Four key genes are frequently altered in PDAC: *KRAS, CDKN2A, TP53,* and *SMAD4* (Table 55-3). The most common gene alteration is in *KRAS* (Kirsten rat sarcoma viral oncogene homolog), where mutations occur in codons 12, 13, and 61. More than 90% of PDAC contain *KRAS* mutations. Point mutations of the K-*ras* oncogene impair the intrinsic guanosine triphosphatase activity of its gene product; the result is a protein that is constitutively active in signal transduction *and* activates various downstream signaling pathways, including the mitogen-activated protein kinase (MAPK) cascades. Ras proteins are involved in a variety of cellular functions, including proliferation, differentiation, and survival. Cyclin-dependent kinase inhibitor 2A gene (*CDKN2A*) is also inactivated in up to 90% of PDAC, due to intragenic mutations in association with allelic loss, homozygous deletion, or hypermethylation of the gene promoter. *CDKN2A* encodes a cyclin-dependent kinase inhibitor that controls G1–S transition in the cell cycle. Inactivation of *CDKN2A* leads to the loss of an important cell cycle checkpoint and therefore relatively unchecked proliferation. *TP53* is one of the most frequently mutated genes in many types of cancer, and is inactivated in about 75% of PDAC, mainly due to point mutations or small deletions. The *p53* gene product is a DNA-binding protein that acts as both a cell-cycle checkpoint and an inducer of apoptosis. Inactivation of the *p53* gene in pancreatic cancer leads to the loss of two important controls of cell growth: regulation of cellular proliferation and induction of cell death. *SMAD4* (*DPC4,* SMAD family member 4 gene). *SMAD4* encodes a transcription factor that mediates signaling of the transforming growth factor-β (TGF-β) superfamily. *SMAD4* is a tumor-suppressor gene that has been identified on chromosome 18q. This chromosome has been shown to be missing in nearly 90% of pancreatic cancers. The *SMAD4* gene is inactive in almost 50% of pancreatic carcinomas. The mutation appears to be a homozygous deletion in 30% of pancreatic cancers, and a point mutation in another 20% of tumors. *SMAD4* mutations are more specific than *p53* or *p16* mutations for pancreatic cancer.

Table 55-3 Genetic Alterations in Pancreatic Adenocarcinomas

Gene	Chromosome Locus	Frequency (%)
Oncogenes		
K-*ras*	12	90
Tumor suppressor genes		
CDKN2A	9p	95
p53	17p	50–75
SMAD4	18q	55
BRCA2	13q	7

Germline mutations in *BRCA2* and *CDKN2A,* and less frequently in *BRCA1, PALB2* and *ATM* have been identified in a small subset of patients with familial pancreatic cancer. The inactivation of *BRCA2,* which encodes a protein involved in DNA damage repair, is associated with a 3.5- to 10-fold increased risk of pancreatic cancer, as well as increased risk of breast and ovarian cancer. In addition, patients with Lynch syndrome (caused by germline mutation in one of the mismatch repair genes *MLH1, MSH2, MSH6,* or *PMS2*) and PJS (caused by germline mutation of the *STK11* gene) are at increased risk of pancreatic cancer. Approximately 4% of pancreatic cancers can be characterized by disorders of DNA mismatch–repair genes.[6]

PATHOLOGY

Tumors of the exocrine pancreas can be classified based on their cell of origin (Table 55-4). The most common neoplasms of the exocrine pancreas are ductal adenocarcinomas. Approximately 65% of pancreatic ductal cancers arise in the head, neck, or uncinate process of the pancreas; 15% originate in the body or the tail of the gland; and 20% diffusely involve the whole gland.

Solid Epithelial Tumors

Ductal Adenocarcinomas

Ductal adenocarcinomas account for more than 75% of all nonendocrine pancreatic cancers. Grossly, they are white–yellow, poorly defined, hard masses that often obstruct the distal common bile duct or main pancreatic duct. They are often associated with a desmoplastic reaction that causes fibrosis and chronic pancreatitis. Microscopically, they contain infiltrating glands of varying size and shape surrounded by dense, reactive fibrous tissue (Fig. 55-2). The epithelial cells sometimes form papillae and cribriform structures, and they frequently contain mucin. The nuclei of the cells can show marked pleomorphism, hyperchromasia, loss of polarity, and prominent nucleoli.

CLASSIFICATION

Table 55-4 Histologic Classification of 645 Cases of Primary Nonendocrine Cancer of the Pancreas

Classification	Number
Duct cell origin	572 (89%)
Duct cell adenocarcinoma	494
Giant cell carcinoma	28
Adenosquamous carcinoma	20
Microadenocarcinoma	16
Mucinous carcinoma	9
Mucinous cystadenocarcinoma	5
Acinar cell origin	8 (1%)
Acinar cell carcinoma	7
Cystadenoma	1
Uncertain histogenesis	61 (9%)
Pancreaticoblastoma	1
Papillary and cystic neoplasm	1
Mixed type – duct and islet cells	1
Unclassified	58
Connective tissue origin	4 (1%)

Bell RH. Neoplasms of the exocrine pancreas. In: Greenfield LJ, Mulholland MW, Oldham KT, eds. *Surgery: Scientific Principles and Practice*. 2nd ed. Philadelphia, PA: Lippincott–Raven; 1997:901, with permission.

Ductal adenocarcinomas tend to infiltrate into vascular, lymphatic, and perineural spaces. At the time of resection, most ductal carcinomas have already metastasized to regional lymph nodes. In addition to the lymph nodes, PDAC frequently metastasize to the liver (80%), peritoneum (60%), lungs and pleurae (50% to 70%), and adrenal glands (25%). They also can directly invade the duodenum, stomach, transverse mesocolon, colon, spleen, and adrenal glands.

1 The histologic examination of a pancreas resected for cancer frequently reveals the presence of precursor lesions in the pancreatic ducts and ductules adjacent to the cancer. This suggests that much like colon cancer, which arises from benign adenomas, pancreatic

cancer may also demonstrate progression to malignant from benign precursor lesions. These precursor lesions are referred to as pancreatic intraepithelial neoplasia (PanIN). Briefly, PanIN-1A and PanIN-1B are proliferative lesions without remarkable nuclear abnormality that have a flat and papillary architecture, respectively. PanIN-3 is associated with severe architectural and cytonuclear abnormalities, but invasion through the basement membrane is absent. The older term for PanIN-3 includes carcinoma in situ (CIS). PanIN-2 is an intermediate category between PanIN-1 and PanIN-3 and is associated with a moderate degree of architectural and cytonuclear abnormality.[7] Several lines of evidence suggest that PanINs are precursors of infiltrating pancreatic cancer: PanINs are often found in association with ductal adenocarcinomas, three-dimensional mapping techniques that demonstrated a stepwise transformation from mild dysplasia to severe dysplasia in pancreatic duct lesions, and PanINs demonstrate some of the same genetic changes seen in infiltrating adenocarcinomas, most notably activating point mutations in codon 12 of K-*ras* and mutations in the *p16* and *p53* tumor-suppressor genes.

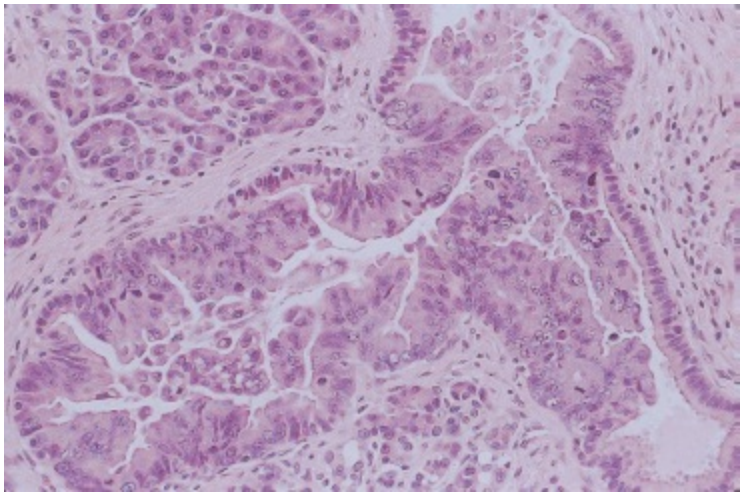

Figure 55-2. Microscopic appearance of ductal adenocarcinoma of the head of the pancreas demonstrating glands from an adenocarcinoma embedded in a fibrous matrix.

Adenosquamous Carcinomas

Adenosquamous carcinoma is a rare variant of ductal adenocarcinoma that shows both glandular and squamous differentiation. This variant appears to be more common in patients who have undergone previous chemoradiation therapy. The biologic behavior of adenosquamous carcinoma appears to be similar to that of ductal adenocarcinoma, with similar rates of perineural invasion, lymph node metastases, and dissemination.

Acinar Cell Carcinomas

Acinar cell carcinomas account for only 1% of pancreatic exocrine tumors. Acinar tumors are typically smooth, fleshy, lobulated, hemorrhagic, or necrotic. Histologically, they form acini, and the cells display an eosinophilic, granular cytoplasm. Immunohistochemical staining demonstrates expression of trypsin, lipase, chymotrypsin, or amylase. These tumors are more common in males with a male-to-female predominance of approximately 3:1. The age of diagnosis is usually in the fifth to seventh

decades. These tumors tend to be larger than ductal adenocarcinomas, often being larger than 10 cm. Although data are limited, it appears that patients with acinar cell carcinoma have a slightly better prognosis than patients with ductal carcinoma.[8] Therefore, surgical resection is the treatment of choice.

Giant Cell Carcinomas

Giant cell carcinomas account for less than 1% of nonendocrine pancreatic cancers. They tend to be large, with average diameters greater than 15 cm. Microscopically, they contain large, uninucleated or multinucleated tumor cells, many of which are pleomorphic. The nuclei contain prominent nucleoli and numerous mitotic figures. Giant cell carcinomas are associated with a poorer prognosis than ductal adenocarcinomas. There is a variant of giant cell carcinoma termed *giant cell carcinoma with osteoclast-like giant cells*. These lesions tend to be well circumscribed with nonpleomorphic giant cells and are less aggressive than standard giant cell carcinomas.

Pancreatoblastoma

Pancreatoblastomas occur primarily in children ages 1 to 15 years. Pancreatoblastomas contain both epithelial and mesenchymal elements. The epithelial component appears to arise from acinar cells. The tumors are typically larger than 10 cm and often contain areas of degeneration and hemorrhage. The prognosis appears to be more favorable than that for typical ductal adenocarcinoma if the tumor can be resected.

Cystic Epithelial Tumors

Cystic neoplasms also arise from the exocrine pancreas. Cystic neoplasms are less common than ductal adenocarcinomas, tend to occur in women, and are evenly distributed throughout the gland. Many pancreatic and peripancreatic cysts are actually benign inflammatory pseudocysts. It is important to identify cystic neoplasms because their management is very different from that of nonneoplastic cysts. With advancements in imaging technology, cystic lesions of the pancreas are being detected with increased frequency. With routine application of cross-sectional imaging to early diagnostic processes in medicine, pancreatic cysts are often detected incidentally.[9] Although many of these lesions are small and asymptomatic, they can have malignant potential. Therefore, the management of these patients is complex, and knowledge of pancreatic cyst natural history and predictors of neoplasia are important.

Serous Cystic Neoplasms

Serous cysts are epithelial neoplasms composed of uniform cuboidal glycogen-rich cells that usually form numerous small cysts containing serous fluid. Serous cystadenomas or microcystic adenomas are more common in women than in men (3:1 preponderance). These tumors can vary from a few centimeters to more than 10 cm in size. Twenty-five percent to 30% of patients are asymptomatic; however, most patients present with symptoms such as abdominal or epigastric pain, dyspepsia, nausea, or vomiting. Serous cystadenomas can be located anywhere in the pancreas – head, body, or tail – and usually do not communicate with the pancreatic ducts. Plain computed tomography (CT) shows a honeycomb pattern of microlacunae, with thin septa separating different segments. Serous cystic neoplasms can have a sunburst pattern of central calcification, which is seen in 10% to 30% of cases. Grossly, they appear as spongy, well-circumscribed, multiloculated cysts. Microscopically, they consist of a layer of simple cuboidal cells separated by dense fibrous bands. Most serous cystic neoplasms are benign, although malignant behavior has been reported rarely (<1% with metastases to the liver or peripancreatic lymph nodes). Symptomatic cysts or cysts that cannot be differentiated from other potentially malignant cysts should undergo surgical excision.

Mucinous Cystic Neoplasms

Mucinous cystic neoplasms (MCNs) are neoplasms composed of mucin-producing epithelial cells associated with an ovarian-type of stroma. These cysts usually do not communicate with the larger pancreatic ducts. MCNs are relatively uncommon but account for almost 30% of all cystic neoplasms. The mean age at diagnosis is between 40 and 50 years. MCNs are more common in women with a female-to-male ratio of 9:1. Most patients with MCNs present with vague abdominal symptoms that include epigastric pain or a sense of abdominal fullness. The majority (70% to 90%) of MCNs arises in the body or tail of the pancreas, and only a minority (10% to 30%) involves the head of the gland. Microscopically, the cysts are lined by tall columnar mucin-producing epithelium. These columnar cells have basal nuclei and abundant intracytoplasmic apical mucin and can

form flat sheets or papillae. The walls of the cysts contain a very distinctive "ovarian-type" stroma. This stroma is composed of densely packed spindle cells with sparse cytoplasm and uniform elongated nuclei. All MCNs are considered to be premalignant lesions and should be completely resected to prevent progression to malignancy.

Invasive mucinous cystadenocarcinomas are MCNs associated with an invasive carcinoma, whereas noninvasive mucinous neoplasms can be categorized into MCNs with low-grade dysplasia (adenoma), MCNs with moderate dysplasia (borderline) neoplasms, and MCNs with high-grade dysplasia (carcinoma in situ) based on the degree of architectural and cytologic atypia of the epithelial cells. In surgical series between 15% and 30% of all MCNs are associated with invasive carcinoma. Patients with mucinous cystadenocarcinomas tend to be 5 to 10 years older than patients with benign MCNs. The extent of invasive and in situ carcinomas in MCNs can be very focal. Therefore, a benign diagnosis cannot be established on biopsy alone and the lesions should be completely resected. The prognosis for patients with resected benign or borderline tumors is excellent. Patients with mucinous cystadenocarcinoma tend to do better than patients with ductal adenocarcinoma, with a 5-year survival of approximately 50%.

Intraductal Papillary-Mucinous Neoplasms

Intraductal papillary-mucinous neoplasms (IPMNs) are intraductal mucin-producing neoplasms with tall, columnar, mucin-containing epithelium with or without papillary projections. These neoplasms extensively involve the main pancreatic ducts and/or major side branches. In addition, IPMNs lack the ovarian stroma characteristic of MCNs. Similar to the well-defined adenoma–carcinoma sequence in PDAC (PanIN to invasive ductal carcinoma), IPMNs seem to follow a similar pattern progressing from IPMN with low-grade dysplasia to invasive carcinoma. Microscopically, they consist of papillary projections lined by columnar mucin-secreting cells. They show varying degrees of cellular atypia. The noninvasive IPMNs are graded on the basis of greatest degree of dysplasia and classified into low-grade, moderate-grade, and high-grade dysplasia or carcinoma in situ. Invasive IPMNs are either colloid or tubular, with the latter having a worse prognosis. The mean age of patients with invasive carcinoma is approximately 5 years older than patients with noninvasive IPMNs suggesting an approximately 5-year lag period for progression to malignancy. Further histologic subtyping of epithelial differentiation is based on the cell lineage, the morphology of the papillae, and the immunophenotype, and includes classification into intestinal, gastric, pancreaticobiliary, and oncocytic subtypes.

IPMNs are subclassified as main- and branch-duct types and as a mixed type that contains elements of both. Main-duct IPMN is characterized by involvement of the duct of Wirsung, which is dilated to more than 1 cm in diameter. Branch-duct IPMN originates in the side branches of the pancreatic ductal system and appears as a multilobular cystic lesion communicating with a nondilated main pancreatic duct. Typically, branch-duct IPMN occurs in the uncinate process–head of the gland, but it can also be seen in the neck and distal pancreas. If the main duct is dilated with synchronous involvement of the branch ducts, it is described as a mixed IPMN.

IPMNs are usually found in individuals in their 60s to 80s. Some patients may experience symptoms that include: abdominal pain, steatorrhea, weight loss, jaundice, diabetes, and chronic pancreatitis. A substantial number of these lesions are also detected as incidental findings on cross-sectional imaging studies performed for other indications. IPMNs appear to be more common in the head, neck, and uncinate process of the pancreas but can be found diffusely throughout the whole gland. CT scans will typically reveal a cystic mass in the head of the pancreas that appears to communicate with the pancreatic ductal system. On endoscopy, mucin can be seen oozing from the ampulla of Vater. Endoscopic retrograde cholangiopancreatography (ERCP) can be used to confirm that the cysts communicate with the pancreatic ducts.

MCNs are the main entity to consider in the differential diagnosis of IPMNs (Table 55-5). Two morphologic features distinguish IPMNs from MCNs: IPMNs communicate with ducts, mucinous cysts do not; IPMNs also lack an ovarian stroma that is present in mucinous cysts. In addition, mucinous cysts are usually seen in the tail of the pancreas and occur in middle-aged women, whereas IPMNs are found in the head of the pancreas and occur in older individuals of either sex.

As noted, IPMNs represent a continuum of disease from benign to malignant. In a large series of resected IPMNs from the Johns Hopkins Hospital,[10] the prognosis for the benign forms of the disease appears to be significantly better than for invasive IPMNs with 1-, 2-, and 5-year actuarial survivals of 97%, 94%, and 77%, respectively. Although invasive IPMNs are associated with disease progression and death, the prognosis remains markedly better than for invasive ductal carcinoma of the pancreas with survivals of 72%, 58%, and 43% at 1, 2, and 5 years, respectively. It is unclear if this fact is due to earlier presentation or differences in tumor biology.

Table 55-5 Comparison between Mucinous Cystic Neoplasm (MCN) and Intraductal Papillary Mucinous Neoplasm (IPMN)

	MCN	IPMN
Age (years)	40–50	60–80
Gender	More common in females	More common in males
Location	Body/tail	Head
Communicates with pancreatic duct	No	Yes
Mucin at ampulla	No	Yes
Ovarian like stroma	Yes	No

2 International consensus guidelines for the management of IPMNs have been developed.[11] CT or MRI with MRCP is recommended for imaging IPMNs. IPMNs are classified as having either “high-risk stigmata” or “worrisome features.” High-risk stigmata include obstructive jaundice in the setting of a cyst in the head of the pancreas, a main duct >10 mm, or a cyst with a solid enhancing component in the wall. Worrisome

features include cyst >3 cm, thickened enhanced cyst walls, nonenhanced mural nodules, main duct size between 5 and 9 mm, abrupt change in the MPD caliber with distal pancreatic atrophy, and lymphadenopathy. All cysts with "worrisome features" and cysts of >3 cm without "worrisome features" should undergo endoscopic ultrasonography (EUS), and all cysts with "high-risk stigmata" should be resected. If no "worrisome features" are present, no further initial work-up is recommended, although surveillance is still required (Algorithm 55-1).

The goal of surgical therapy for IPMNs should be a complete surgical resection yielding negative margins for all invasive and noninvasive disease. Unlike those patients with completely resected noninvasive MCNs (who are routinely cured), patients with completely resected noninvasive IPMNs should undergo careful follow-up and surveillance for the development of recurrent disease. Furthermore, patients with resected invasive IPMNs should also undergo careful follow-up and surveillance as they, too, remain at risk for the development of recurrent disease.

Solid-Pseudopapillary Tumor

Solid-pseudopapillary tumors (SPTs), also termed solid and cystic tumors, papillary cystic tumors, *Hamoudi tumors, and Frantz tumor* occur primarily in women in their third to fourth decades of life. Grossly, the masses range from 5 to 15 cm in diameter. Radiologically, they present as a well-demarcated heterogeneous mass with solid and cystic components, with a peripheral capsule which rarely shows calcification. EUS-guided fine needle aspiration (FNA) or core biopsy is often diagnostic, showing uniform cells forming microadenoid structures, branching, and papillary clusters with delicate fibrovascular cores. Most SPTs exhibit a benign behavior, and even the less than 20% that have vascular or perineural invasion, lymph node involvement or liver metastases can have a very indolent course. The overall 5-year survival is close to 97% in patients undergoing surgical resection.

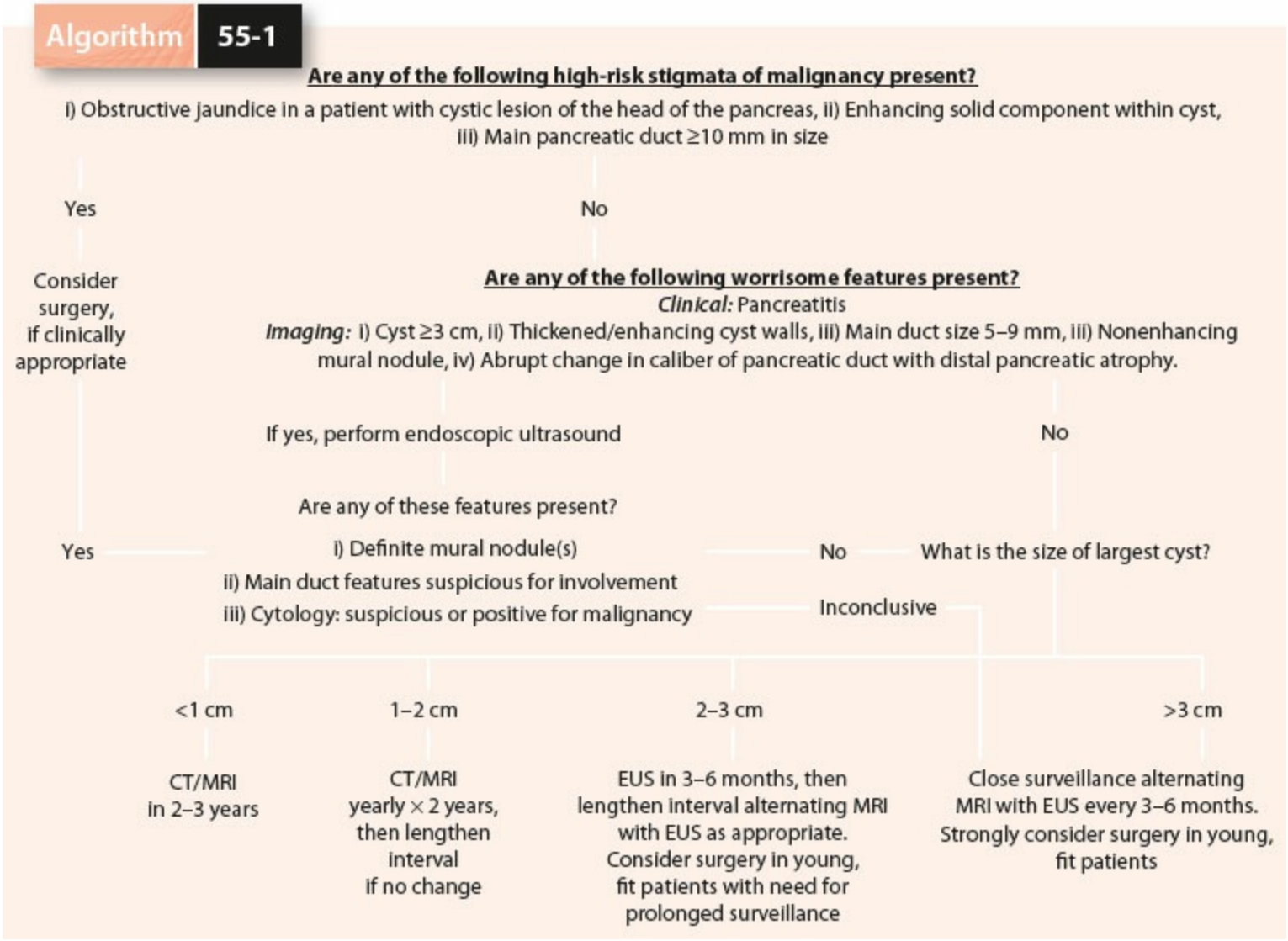

Algorithm 55-1. International consensus guidelines for the management of IPMNs. From Tanaka M, Fernandez-del Castillo C, Adsay V, et al. International consensus guidelines 2012 for the management of IPMN and MCN of the pancreas. *Pancreatology* 2012;12:183–197.

CLINICOPATHOLOGIC STAGING

Accurate pathologic staging of pancreatic cancer is important for providing prognostic information to patients and for comparing the results of various therapeutic trials. The American Joint Committee on Cancer (AJCC) staging for pancreatic cancer is shown in Table 55-6. This system, based on the TNM classification, takes into account the extent of the primary tumor (T), the presence or absence of regional lymph node involvement (N), and the presence or absence of distant metastatic disease (M).

DIAGNOSIS

Clinical Presentation

Many of the difficulties associated with the management of pancreatic cancer result from our inability to make the diagnosis at an early stage. The early symptoms of pancreatic cancer include anorexia, weight loss, abdominal discomfort, and nausea. Unfortunately, the nonspecific nature of these symptoms often leads to a delay in the diagnosis. Specific symptoms usually develop only after invasion or obstruction of nearby structures has occurred. Most pancreatic cancers arise in the head of the pancreas, and obstruction of the intrapancreatic portion of the common bile duct leads to progressive jaundice, acholic stools, darkening of the urine, and pruritus. Pain is a common symptom of pancreatic cancer. The pain usually starts as vague upper abdominal or back pain that is often ignored by the patient or attributed to some other cause. It is usually worse in the supine position and is often relieved by leaning forward. Pain may be caused by invasion of the tumor into the splanchnic plexus and retroperitoneum, and by obstruction of the pancreatic duct. Other digestive symptoms are also common in pancreatic cancer (Table 55-7).

Occasionally, pancreatic cancer may be discovered in an unusual manner. The onset of diabetes may be the first clinical feature in 10% to 15% of patients. An episode of acute pancreatitis may also be the initial presentation of pancreatic cancer if the tumor partially obstructs the pancreatic duct. It is important to consider a pancreatic cancer in patients presenting with acute pancreatitis, especially those without an obvious cause for their pancreatitis (alcohol or gallstones).

The most common physical finding at the initial presentation is jaundice (Table 55-8). Hepatomegaly and a palpable gallbladder may be present in some patients. In cases of advanced disease, cachexia, muscle wasting, or a nodular liver, consistent with metastatic disease, may be evident. Other physical findings in patients with disseminated cancer include left supraclavicular adenopathy (Virchow node), periumbilical adenopathy (Sister Mary Joseph node), and pelvic drop metastases (Blumer shelf). Ascites can be present in 15% of patients.

Table 55-6 American Joint Committee on Cancer Staging of Pancreatic Cancer, 7th Edition

Stage	T	N	M	5-Year Survival (%)
IA	T1	N0	M0	20–30
IB	T2	N0	M0	20–30
IIA	T3	N0	M0	10–25
IIB	T1, T2, T3	N1	M0	10–15
III	T4	Any N	M0	0–5
IV	Any T	Any N	M1	—

Tumor (T)

TX: Primary tumor cannot be assessed

T0: No evidence of primary tumor

Tis: Carcinoma in situ

T1: Tumor limited to the pancreas, 2 cm or less in greatest dimension

T2: Tumor limited to the pancreas, more than 2 cm in greatest dimension

T3: Tumor extends beyond the pancreas but without involvement of the celiac axis or the superior mesenteric artery

T4: Tumor involves the celiac axis or the superior mesenteric artery (unresectable primary tumor)

Regional Lymph Nodes (N)

NX: Regional lymph nodes cannot be assessed

N0: No regional lymph node metastasis

N1: Regional lymph node metastasis

Distant Metastasis (M)

MX: Distant metastasis cannot be assessed

M0: No distant metastasis

M1: Distant metastasis

Adapted from American Joint Committee on Cancer. Exocrine and Endocrine Pancreas. *AJCC Cancer Staging Manual*. 7th ed. New York, NY: Springer; 2010:241–246.

Table 55-7 Symptoms of Pancreatic Cancer

Symptom	Patients (%)
Head	
Weight loss	92
Jaundice	82
Pain	72
Anorexia	64
Dark urine	63
Light stools	62
Nausea	45
Vomiting	37
Weakness	35
Pruritus	24
Diarrhea	18
Melena	12
Constipation	11
Fever	11
Hematemesis	8
Body and Tail	
Weight loss	100
Pain	87
Weakness	43
Nausea	43
Vomiting	37
Anorexia	33
Constipation	27
Hematemesis	17
Melena	17
Jaundice	7
Fever	7
Diarrhea	3

Laboratory Studies

In patients with cancer of the head of the pancreas, laboratory studies usually reveal a significant increase in serum total bilirubin, alkaline phosphatase, and γ-glutamyl transferase indicating bile duct obstruction. The transaminases can also be elevated but usually not to the same extent as the alkaline phosphatase. In patients with localized cancer of the body and tail of the pancreas, laboratory values are frequently normal early in the course. Patients with pancreatic cancer may also demonstrate a normochromic anemia and hypoalbuminemia secondary to the nutritional consequences of the disease. In patients with jaundice, the prothrombin time can be abnormally prolonged. This usually is an indication of biliary obstruction, which prevents bile from entering the gastrointestinal tract and leads to malabsorption of fat-soluble vitamins and decreased hepatic production of vitamin K–dependent clotting factors. The prothrombin time can usually be normalized by the administration of parenteral vitamin K. Serum amylase and lipase levels are usually normal in patients with pancreatic cancer.

A wide variety of serum tumor markers have been proposed for use in the diagnosis and follow-up of patients with pancreatic cancer. The most extensively studied of these is CA 19–9, a Lewis blood group-related mucin glycoprotein. Approximately 5% of the population lacks the Lewis gene and therefore cannot produce CA 19–9. When a normal upper limit of 37 U/mL is used, the accuracy of the CA 19–9 level in identifying patients with pancreatic adenocarcinoma is only about 80%. When a higher cutoff value of more than 90 U/mL is used, the accuracy improves to 85%, and increasing the cutoff value to 200 U/mL increases the accuracy to 95%.[12] The combined use of CA 19–9 and ultrasonography, CT, or ERCP can improve the accuracy of the individual tests, so that the combined accuracy approaches 100% for the diagnosis of pancreatic cancer. Levels of CA 19–9 have also been correlated with prognosis and tumor recurrence. In general, higher CA 19–9 values before surgery indicate an increased size of the primary tumor and increased rate of unresectability. In addition, the CA 19–9 level has been used to monitor the results of neoadjuvant and adjuvant chemoradiation therapy in patients. Increasing CA 19–9 levels usually indicate recurrence or progression of disease, whereas stable or declining levels indicate a stable tumor burden, absence of recurrence on imaging studies, and an improved prognosis.

Table 55-8 Signs of Pancreatic Cancer

Sign	Patients (%)
Head	
Jaundice	87
Palpable liver	83
Palpable gallbladder	29
Tenderness	26
Ascites	14
Abdominal mass	13
Body and Tail	
Palpable liver	33
Tenderness	27
Abdominal mass	23
Ascites	20
Jaundice	13
Diarrhea	3

Radiologic Investigations

Radiologic imaging plays a crucial role in the diagnosis, staging, and follow-up of patients with pancreatic cancer. In addition to identifying the primary tumor, the goals of imaging include the assessment of local and regional invasion, evaluation of lymph nodes and vascular structures, identification of distant metastatic disease, and the determination of tumor resectability. Ultrasonography, computed tomography (CT), and magnetic resonance imaging (MRI) are all useful noninvasive tests in the patient suspected of having a pancreatic cancer.

Transabdominal ultrasonography (US) will reveal a pancreatic mass in 60% to 70% of patients with cancer. Pancreatic cancer typically appears as a hypoechoic mass on US. Ultrasonography may also demonstrate dilated intrahepatic and extrahepatic bile ducts, liver metastases, pancreatic masses, ascites, and enlarged peripancreatic lymph nodes. Because helical CT is just as sensitive as ultrasonography and provides more complete information about surrounding structures and the local and distant extent of the disease, transabdominal ultrasonography has been largely replaced by CT.

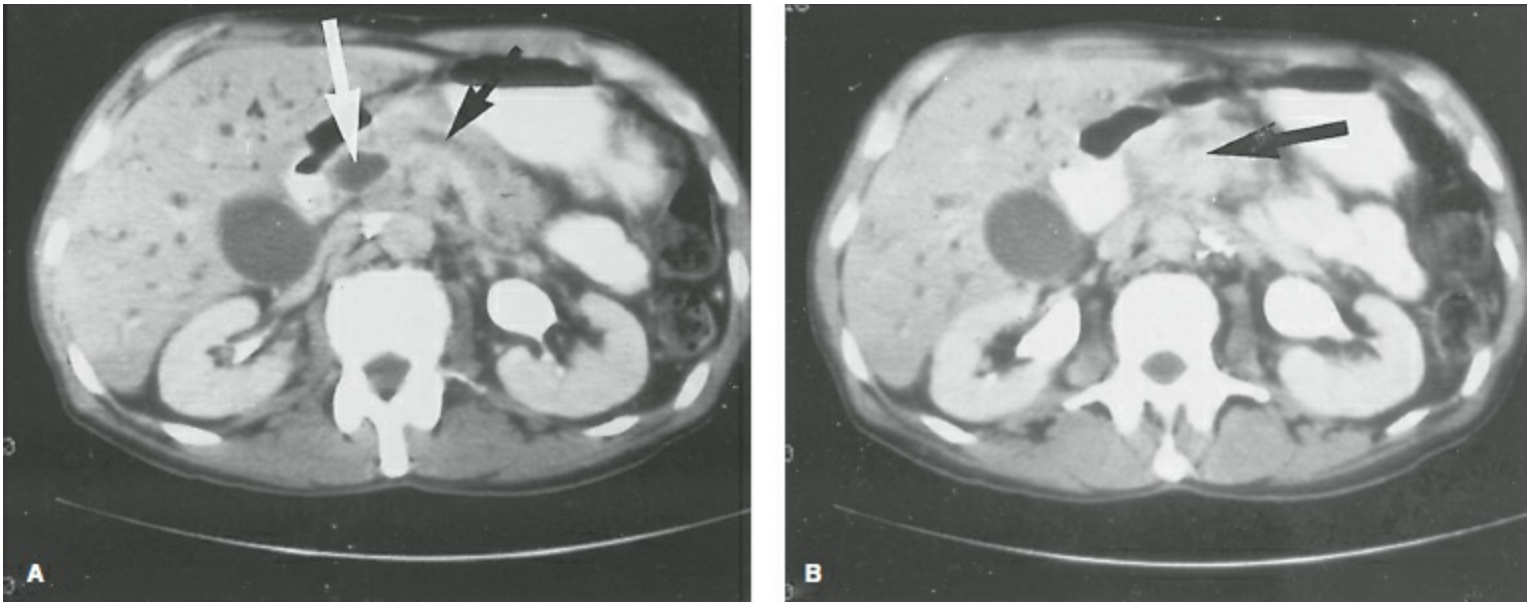

Figure 55-3. Computed tomogram of the abdomen of a patient with adenocarcinoma of the pancreas. **A:** The obstructed and dilated common bile duct (*light arrow*) and pancreatic duct (*dark arrow*) can be seen. In the adjacent cross section **B,** a large mass is present in the head of the pancreas (*arrow*).

3 Computed tomography (CT) scanning is currently the preferred noninvasive imaging test for the diagnosis of pancreatic cancer. Pancreas protocol CT should be performed with rapid injection of intravenous iodinated contrast. Slices should be reconstructed at less than or equal to 3 mm with overlap. At least two postcontrast acquisitions, in the late arterial (or parenchymal) and venous phases are useful to assess the arteries (celiac, common hepatic, peripancreatic, and superior mesenteric arteries) and veins (portal, splenic, and superior mesenteric veins). The parenchymal phase best shows the tumor as an ill-defined hypodense mass in the pancreatic parenchyma (Fig. 55-3), while the venous phase is best for detecting liver metastases. Neutral enteral contrast such as water should

be given, since this allows for better identification of the duodenal wall and results in artifact-free reformations. In many centers, no oral contrast is used. Coronal and sagittal reformations in both arterial and venous phases increase the sensitivity for determining local invasion. In addition to determining the primary tumor size, CT is used to evaluate invasion into local structures or metastatic disease.

In general, MRI offers no significant advantages over CT because of a low signal-to-noise ratio, motion artifacts, lack of bowel opacification, and low spatial resolution. MRI can be considered an alternative preoperative staging examination in patients with allergies to iodinated contrast agents and in patients with renal insufficiency. On MRI, a typical pancreatic adenocarcinoma appears hypointense on T1-weighted, unenhanced images, and has a variable appearance on T2-weighted sequences. The T2 signal of the tumor is often dependent on the amount of desmoplastic response associated with the tumor. On dynamic imaging following a gadolinium contrast injection, an adenocarcinoma enhances relatively less than the background pancreatic parenchyma in the early phase and then reveals progressive enhancement in the subsequent phases. Magnetic resonance imaging with MRCP is currently indicated for noninvasive diagnostic imaging to evaluate the biliary and pancreatic ducts and may be the optimal method to survey patients with IPMN and the pancreatic remnant after surgery.

Traditionally, the next step in the evaluation of the jaundiced patient has been cholangiography, either by the endoscopic or by the percutaneous route. If the endoscopic approach is used, the duodenum and ampulla can be visualized and biopsy specimens obtained if necessary. In addition, ERCP allows for direct imaging of the pancreatic duct. The sensitivity of ERCP for the diagnosis of pancreatic cancer approaches 90%. The finding of a long, irregular stricture in an otherwise normal pancreatic duct is highly suggestive of a pancreatic cancer (Fig. 55-4). Often, the pancreatic duct will be obstructed with no distal filling. Although ERCP is reliable in confirming the presence of a clinically suspected pancreatic cancer, it should not be used routinely. Diagnostic ERCP should be reserved for patients with presumed pancreatic cancer and obstructive jaundice in whom no mass is demonstrated on CT, symptomatic but nonjaundiced patients without an obvious pancreatic mass, and patients with chronic pancreatitis who develop jaundice.

EUS is a minimally invasive technique in which a high-frequency ultrasonographic probe is placed into the stomach and duodenum endoscopically and the pancreas is imaged. Tumors appear as hypoechoic areas in the pancreatic substance (Fig. 55-5). The strengths of EUS techniques for pancreatic cancer are the clarification of small lesions (<2 cm) when CT findings are questionable or negative, detection of malignant lymphadenopathy, detection of vascular involvement, and the ability to perform EUS-guided FNA for definitive diagnosis and staging. EUS is not effective in assessing metastatic disease to the liver. In patients for whom a tissue diagnosis is required (poor operative candidates or undergoing neoadjuvant therapy), EUS-guided FNA has been used to acquire tissue samples for cytologic analysis. This approach may avoid the risks of tumor seeding from percutaneous biopsy. The accuracy of EUS without FNA averages 85% for determining T-stage and 70% for determining N-stage diseases. The combination of EUS and FNA has a sensitivity of 93% and a specificity of 100% for T stage and an

accuracy of 88% for N stage.[13] At the time of diagnosis, only 10% of patients have tumors confined to the pancreas, 40% have locally advanced disease, and more than 50% have distant spread.

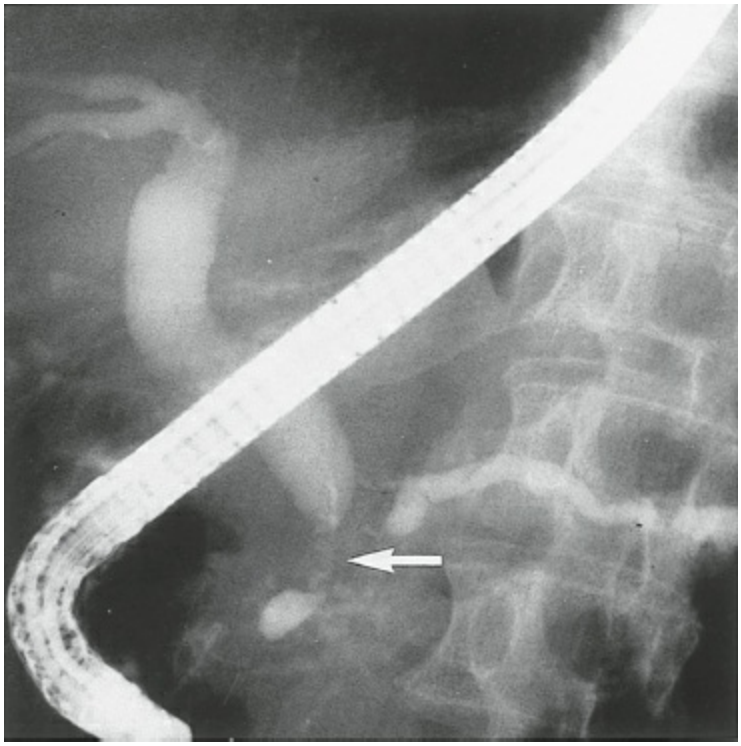

Figure 55-4. Endoscopic retrograde cholangiopancreatography in a patient with adenocarcinoma of the pancreas demonstrates a stricture of both the distal common bile duct and the pancreatic duct (*arrow*).

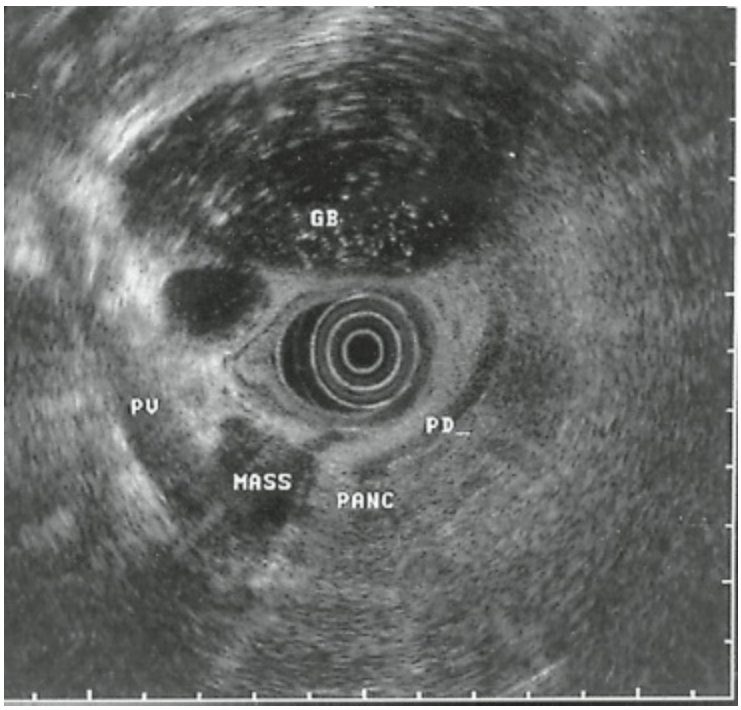

Figure 55-5. Endoscopic ultrasonogram of a 2.2-cm mass in the head of the pancreas. The transducer tip is located in the duodenum. The dilated common bile duct and gallbladder (GB) can be seen at the top of the image. The pancreatic duct (PD) is also dilated. The mass involves the portal vein (PV).

Percutaneous FNA of pancreatic masses is helpful in selected patients. The technique is

safe and generally reliable but is of limited use in patients in whom surgical exploration for attempted resection or palliation is planned. The reasons for not using FNA or percutaneous biopsy in potentially resectable lesions are twofold. First, even after repeated sampling, a negative result does not exclude malignancy; in fact, it is the smaller and likely more curable tumors that are likely to be missed by the needle. The second concern is the potential for seeding of the tumor, either along the needle tract or with intraperitoneal spread. Percutaneous biopsy is primarily indicated in patients with unresectable cancers based on preoperative staging to direct palliative chemoradiation therapy or in patients with cancer in the head of the pancreas in whom neoadjuvant protocols are being considered. Currently, however, EUS is the preferred technique when possible in either situation.

PREOPERATIVE STAGING

The goal of preoperative staging of pancreatic cancer is to determine the feasibility of surgery and the optimal treatment for each individual patient. Specific anatomy-based CT criteria can stratify patients into four distinct groups (Table 55-9): (1) Resectable, (2) Borderline, (3) Locally advanced, or (4) Metastatic. The extent of further staging to be performed depends on the individual patient and the surgeon's preference. Historically, patients with resectable CT criteria were offered operation as the first modality of therapy followed by adjuvant chemotherapy or chemoradiotherapy. Recent advances in the efficacy of systemic chemotherapy agents have further supported the hypothetical benefits of preoperative neoadjuvant chemotherapy even for resectable tumors. Patients with borderline or locally advanced pancreatic cancer based on CT criteria should receive preoperative chemotherapy or chemoradiotherapy. Ideally, patients in these high-risk categories of disease should be offered enrollment in clinical trials investigating novel treatment agents. Algorithm 55-2 outlines an algorithm for approaching patients with pancreatic cancer after complete staging and determination of resectability based on local vascular involvement according to CT findings.

STAGING LAPAROSCOPY

The use of diagnostic laparoscopy in pancreatic cancer remains controversial. Proponents believe that laparoscopy can identify a substantial number of unresectable patients with advanced disease and, therefore, should be uniformly applied to all patients with potentially resectable tumors.[14] On the other hand, opponents believe that the inherent cost of such a practice far outweighs the benefit to the small number of patients in whom diagnostic laparoscopy is useful. The liver and peritoneum are the most common sites of distant spread of pancreatic carcinoma. Once distant metastases have developed, survival is so limited that a conservative approach is usually indicated. Liver metastases larger than 1 cm in diameter can usually be detected by CT, but approximately 30% of these metastases are smaller and therefore may not be routinely detected. Moreover, peritoneal and omental metastases are usually only 1 to 2 mm in size and frequently can be detected only by direct visualization. With the recent improvements in CT imaging, the rate of unsuspected positive peritoneal findings approaches 10% to 15% for all patients. The percentage however varies with tumor location. Patients presenting with obstructive jaundice secondary to tumors in the head of the pancreas typically have only a 15% to 20% incidence of unexpected intraperitoneal metastasis after routine staging studies. In contrast, unexpected peritoneal metastasis is found in up to 50% of patients with cancer of the body and tail of the pancreas.[15]

Selective use of staging laparoscopy should be considered for patients at high risk of occult metastatic disease (Table 55-10). The information gained from preoperative staging provides the basis for planning therapy for each individual patient. If the results of preoperative staging with CT/MRI and laparoscopy show localized disease, resectability rates may approach 90% for tumors in the head of the pancreas.

Table 55-9 Preoperative Staging based on CT Findings

Metastatic Evidence of metastatic spread (typically to the liver, peritoneum, or lung)
Resectable No evidence of extrapancreatic disease Patent SMV/PV Normal tissue plane between tumor and the celiac, CHA, or the SMA.
Borderline resectable Patent SMV/PV, or short segment occlusion if reconstructable Evidence of tumor abutment (<180 degree or 50% vessel circumference) against celiac, CHA, or SMA
Locally advanced SMV/PV occlusion with no option for reconstruction Arterial encasement (>180 degree or 50% vessel circumference) of celiac, CHA, or SMA

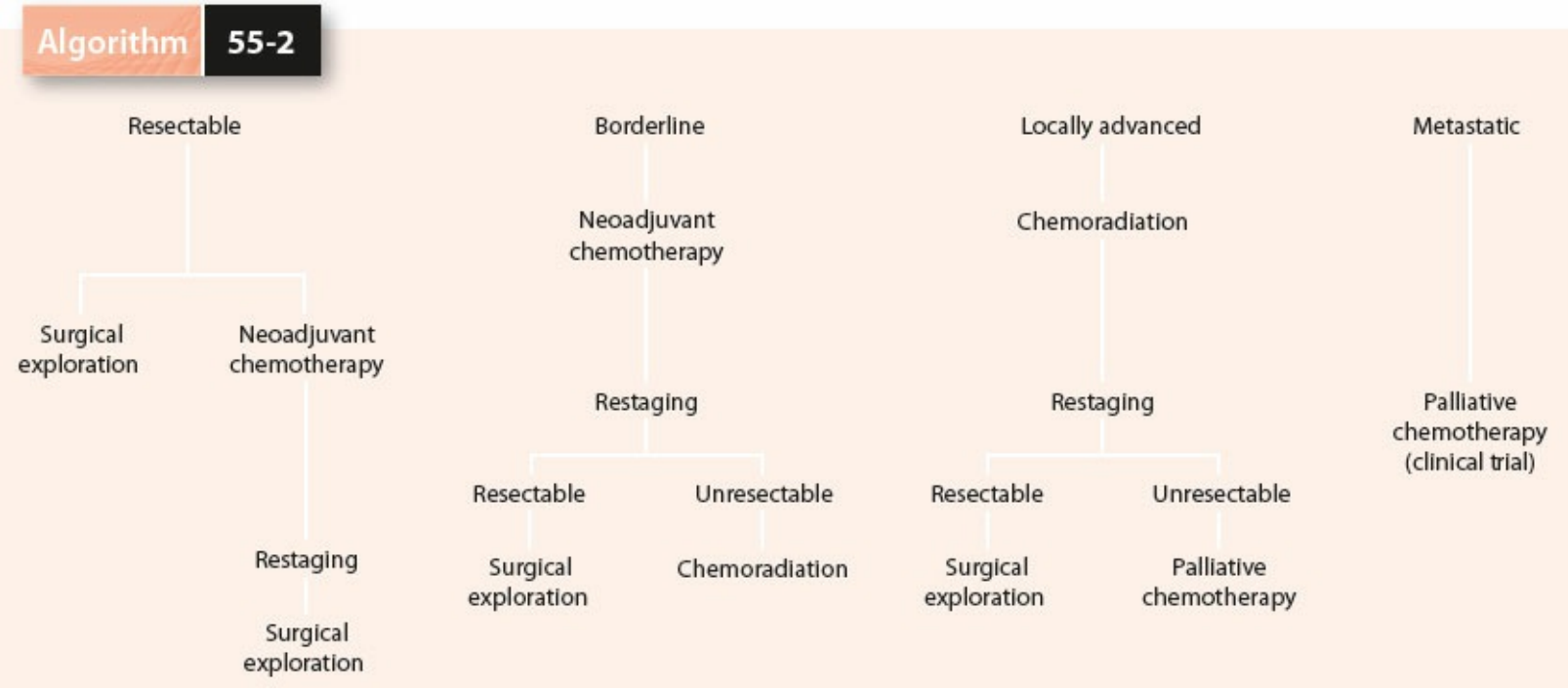

Algorithm 55-2. Management strategy based on CT criteria for resectability of pancreatic cancer.

RESECTION OF PANCREATIC CARCINOMA

Carcinoma of the Head, Neck, or Uncinate Process

In 1912, Kaush[16] reported the first successful resection of the duodenum and a portion of the pancreas for an ampullary cancer. In 1935, Whipple et al.[17] described a technique for radical excision of a periampullary carcinoma. The operation was originally performed in two stages. A cholecystogastrostomy to decompress the obstructed biliary tree and a gastrojejunostomy to relieve gastric outlet obstruction comprised the first stage. The second stage was performed several weeks later when the jaundice had resolved and the nutritional status had improved. During the second stage, an en bloc resection of the second portion of the duodenum and head of the pancreas was performed without reestablishing pancreatic–enteric continuity. Although earlier contributions had been made, the report by Whipple et al. began the modern-day approach to the treatment of pancreatic carcinoma.

Table 55-10 Signs of High Risk of Occult Metastatic Disease

Large primary tumors
Lesions in the neck, body, or tail of the pancreas
Equivocal radiographic findings suggestive of occult distant metastatic disease
Low-volume ascites
CT findings indicating possible carcinomatosis
Small hypodense regions in the hepatic parenchyma that suggest hepatic metastases that are not amenable to percutaneous biopsy
Subtle clinical and laboratory findings suggesting more advanced disease (e.g., marked hypoalbuminemia and/or weight loss, significant increases in CA19–9 level, and relatively severe pain requiring narcotic analgesia)

CT, computed tomography.

The operative management of pancreatic cancer consists of two phases: first, assessing tumor resectability and then, if the tumor is resectable, completing a PD and restoring gastrointestinal continuity. After the abdomen has been opened through an upper midline or bilateral subcostal incision, a careful search for tumor outside the limits of a pancreaticoduodenal resection should be carried out. The liver, omentum, and peritoneal surfaces are inspected and palpated, and suspect lesions are sampled and specimens submitted for frozen-section analysis. Next, regional lymph nodes are evaluated for tumor involvement. The presence of tumor in the periaortic lymph nodes of the celiac axis indicates that the tumor is beyond the limits of normal resection. However, the presence of tumor-bearing lymph nodes that normally would be incorporated within the resection specimen does not constitute a contraindication to resection.

Once distant metastases have been excluded, the primary tumor is assessed in regard to resectability. Local factors that preclude pancreaticoduodenal resection include

retroperitoneal extension of the tumor to involve the inferior vena cava or aorta or direct involvement or encasement of the superior mesenteric artery, hepatic artery, and celiac axis. Involvement of the superior mesenteric vein (SMV), or portal vein can be managed with venous resection and reconstruction in select cases. The technical aspects of determining local resectability begin with a Kocher maneuver and mobilization of the duodenum and head of the pancreas from the underlying inferior vena cava and aorta. Once the duodenum and head of the pancreas are mobilized sufficiently, the surgeon's hand can be placed under the duodenum and head of the pancreas to palpate the relationship of the tumor mass to the superior mesenteric artery. Inability of the surgeon to identify a plane of normal tissue between the mass and the arterial pulsation indicates direct tumor involvement of the superior mesenteric artery, and the possibility of complete tumor resection is eliminated.

The final step to determine resectability involves dissection of the superior mesenteric and portal veins to rule out tumor invasion. Identification of the portal vein can be simplified greatly if the common hepatic duct is divided and reflected early in the dissection. Once the hepatic duct has been divided, the posteriorly located portal vein can be identified easily. After the anterior surface of the portal vein is dissected posterior to the neck of the pancreas, the next step is to identify the SMV and dissect its anterior surface. This is done most easily by extending the Kocher maneuver past the second portion of the duodenum to include the third and fourth portions of the duodenum. During this extensive kocherization, the first structure that one encounters anterior to the third portion of the duodenum is the SMV. Alternatively the SMV may also be identified by tracing either the middle colic vein or the right gastroepiploic vein back to the SMV after entering the lesser sac thru the gastrocolic ligament. The anterior surface of the SMV then can be cleaned rapidly and dissected under direct vision by retracting the neck of the pancreas anteriorly. The dissection is continued until it connects to the portal vein dissection from above.

Most experienced pancreatic surgeons, at this point, proceed with a PD without obtaining a tissue diagnosis. The clinical presentation, results of preoperative CT and cholangiography, and operative findings of a palpable mass in the head of the pancreas surpass the ability of an intraoperative biopsy to define the diagnosis of malignancy.

Having excluded regional and distant metastases and demonstrated no tumor involvement in major vascular structures, the surgeon can proceed with PD with a high degree of certainty that the tumor is resectable. In the pylorus-preserving modification of PD, the duodenum is first mobilized and divided approximately 2 cm distal to the pylorus. If a classic Whipple procedure is to be performed, the stomach is divided to include approximately 40% to 50% of the stomach with the resected specimen. The gastroduodenal artery is exposed, ligated, and divided near its origin at the common hepatic artery. It is always important to confirm, before ligation, that the structure to be ligated is indeed the gastroduodenal artery and not a replaced right hepatic artery. Next, the neck of the pancreas is divided, with care taken to avoid injury to the underlying superior mesenteric and portal veins. The portal and superior mesenteric veins are then dissected from the uncinate process and head of the pancreas. At this point, the fourth

portion of the duodenum and the proximal jejunum are mobilized, with the proximal jejunum divided approximately 10 cm distal to the ligament of Treitz. The proximal jejunum and fourth portion of the duodenum are passed under the superior mesenteric vessels to the right, and the uncinate process is dissected from the superior mesenteric artery clearing all of the tissue along the right border of the artery. The course of the superior mesenteric artery should be clearly identified to avoid injury to this structure. At this point, the specimen consisting of the gallbladder and common bile duct; the head, neck, and uncinate process of the pancreas; the entire duodenum; and the proximal jejunum (and the distal stomach for a traditional Whipple procedure) is freed completely and removed from the operative field (Fig. 55-6). Margins should be inked to facilitate pathologic analysis of the specimen.

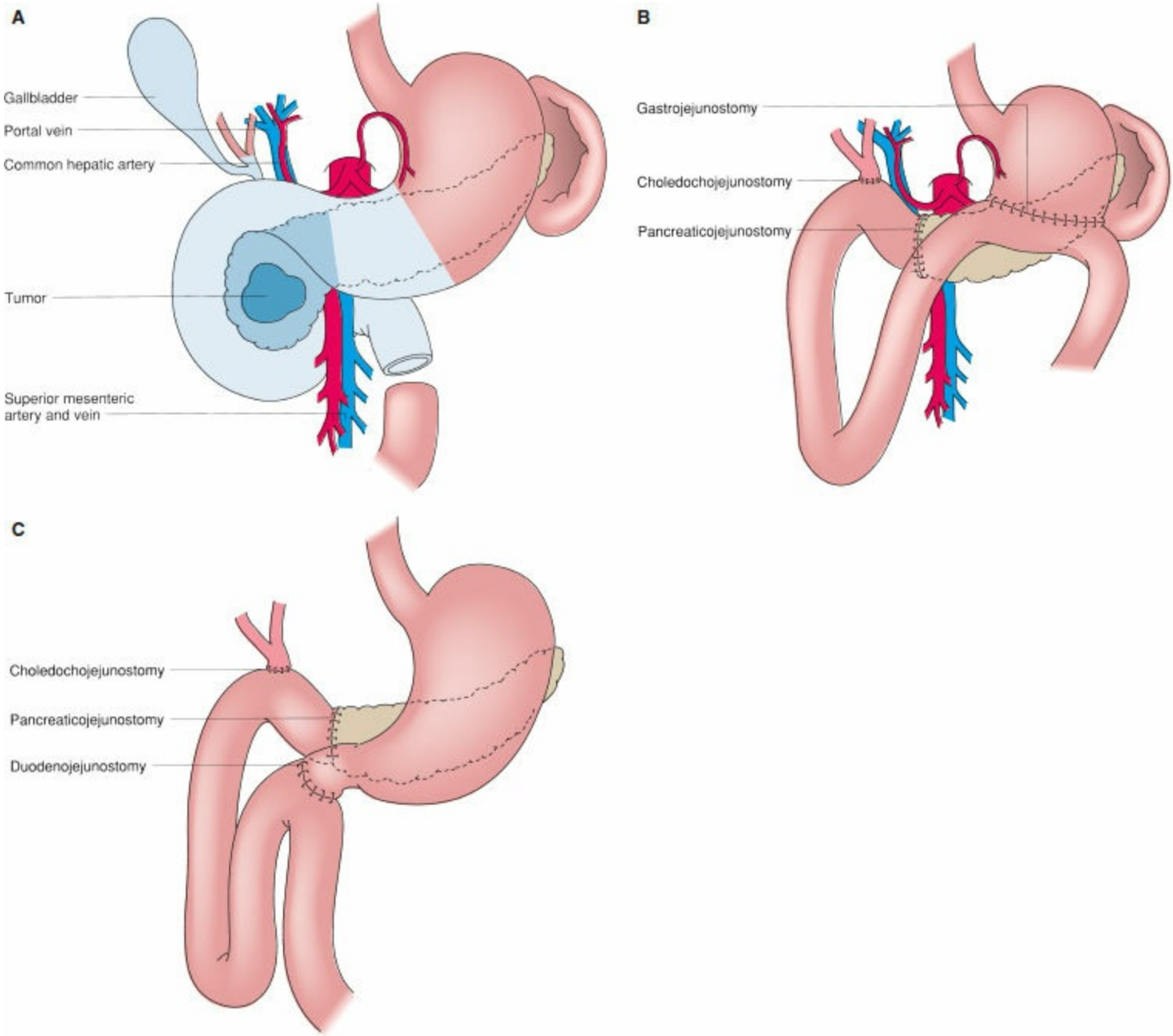

Figure 55-6. Pancreaticoduodenectomy. **A:** The tissue to be resected in a standard pancreaticoduodenectomy. **B:** Reconstruction after a standard pancreaticoduodenectomy. **C:** Reconstruction after the pylorus-sparing variation.

Table 55-11 Randomized Prospective Trials of Standard Versus Extended Lymphadenectomy for Pancreatic Cancer

Author	Year	Procedure	N	Op Time (Hours)	Morbidity (%)	Mortality (%)	3-Year Survival (%)
Pedrazzoli et al.[18]	1999	Standard	40	6.2	35	5	12
		Extended	41	6.6	45	5	6
Yeo et al.[19]	2002	Standard	146	5.9	29	4	36
		Extended	148	6.4	43	2	38
Farnell et al.[20]	2005	Standard	34	6.2	35	0	41
		Extended	31	7.6	45	2.6	25
Nimura et al.[21]	2012	Standard	51	7.0	12	0	29
		Extended	50	9	20	2	17
Jang et al.[22]	2014	Standard	83	5.9	32	0	25
		Extended	84	7.0	45	2.3	23

There are a number of techniques for restoring gastrointestinal continuity after a pancreaticoduodenal resection. Our preferred technique is to bring the end of the divided jejunum through the transverse mesocolon in a retrocolic fashion and perform an end-to-side pancreaticojejunostomy. The anastomosis is begun by placing a series of interrupted 3-0 silk sutures between the side of the jejunum and the posterior capsule of the end of the pancreas. A small enterotomy is then made in the jejunum to match the size of the pancreatic duct and an inner layer of interrupted 5-0 absorbable monofilament sutures are used to create a duct-to-mucosa anastomosis. Some surgeons prefer to stent this anastomosis with either a short indwelling pancreatic stent or an externalized pancreatic stent. The anastomosis is completed with an outer layer of 3-0 silk sutures placed between the anterior pancreatic capsule and the jejunum. An alternative to this duct-to-mucosa technique is to create an enterotomy approximately the same size as the pancreatic neck and to complete a running anastomosis circumferentially around the entire gland. This technique then allows invagination of the neck 1 to 2 cm into the lumen of the bowel by the outer anterior layer of the anastomosis. The biliary–enteric anastomosis is performed 10 cm distal to the pancreaticojejunostomy. An end-to-side hepaticojejunostomy is performed with a single interrupted layer of 4-0 absorbable synthetic suture material. No T tube or stent is generally necessary. Approximately 20 cm distal to the biliary–enteric anastomosis, an end-to-side duodenojejunostomy is performed in an antecolic manner with an inner continuous layer of 3-0 absorbable synthetic suture material and an outer interrupted layer of 3-0 silk. The final reconstruction is shown in Figure 55-6C.

Extent of Resection

Several technical aspects of PD remain controversial. These controversies include: (1) whether or not a radical lymph node dissection is necessary, (2) should a pylorus preserving or classic PD be performed, and (3) is there a role for laparoscopic pancreatic resections.

Several nonrandomized retrospective studies have advocated adding a radical

(extended) retroperitoneal lymph node dissection to PD in an attempt to improve survival. However, results from four randomized prospective trials (Table 55-11)[18–22] have shown extended lymph node dissections not to be beneficial. The prospective trial performed by Pedrazzoli et al.[18] suggested a survival advantage to extended retroperitoneal lymph node dissection in patients with positive lymph nodes. Eighty-one patients with pancreatic adenocarcinoma were randomized to either standard or radical lymphadenectomy over 3 years at six different institutions. While the two groups were similar with respect to preoperative parameters, operative morbidity, and overall survival, a subgroup analysis of the 48 patients with positive lymph nodes showed a statistically significant survival advantage for patients undergoing the extended lymph node dissection. However, the largest prospective randomized trial from the Johns Hopkins Hospital failed to demonstrate a survival advantage for a radical resection as compared with a classic PD.[19] Two hundred and ninety-four patients undergoing resection for periampullary adenocarcinoma were randomized between a standard resection (pylorus preserving PD with en bloc resection of the anterior and posterior pancreaticoduodenal lymph nodes, lower hepatoduodenal lymph nodes, and nodes along the right lateral aspect of the superior artery and vein) and a radical resection (standard resection plus distal gastrectomy and retroperitoneal lymph node dissection extending from the right renal hilum to the left lateral border of the aorta and from the portal vein to the inferior mesenteric artery). The groups did not differ with respect to age, gender, site of primary tumor, lymph node status, or margin status. There were no significant differences in 1-, 3-, or 5-year and median survival when comparing the standard and radical groups (Fig. 55-7). However, the radical group had a higher overall morbidity (43% vs. 29%) with significantly higher rates of delayed gastric emptying and pancreatic fistula in addition to a longer postoperative hospital stay.

In 1978, Traverso and Longmire[23] popularized the pylorus-preserving modification of the Whipple procedure. Preserving antral and pyloric function, the pylorus-preserving Whipple procedure reduces the incidence of troublesome postgastrectomy symptoms. A number of studies have documented that gastrointestinal function is better preserved in the pylorus-sparing modification than in the traditional operation. In addition, compared with the classic Whipple operation, the pylorus-preserving procedure is less time-consuming and technically easier to perform. Concerns exist in the use of the pylorus-preserving Whipple procedure for the management of periampullary tumors because of the possibility of compromising the already small proximal surgical margin of resection. This question has been addressed by a number of authors, and no difference appears to be found in survival among those patients treated with the pylorus-sparing Whipple procedure and those managed by the traditional Whipple resection.[24–26] Therefore, many pancreatic surgeons favor pylorus-preserving PD because it shortens the operative time, retains the entire stomach as a reservoir, and has a similar survival rate as compared with the classic PD.

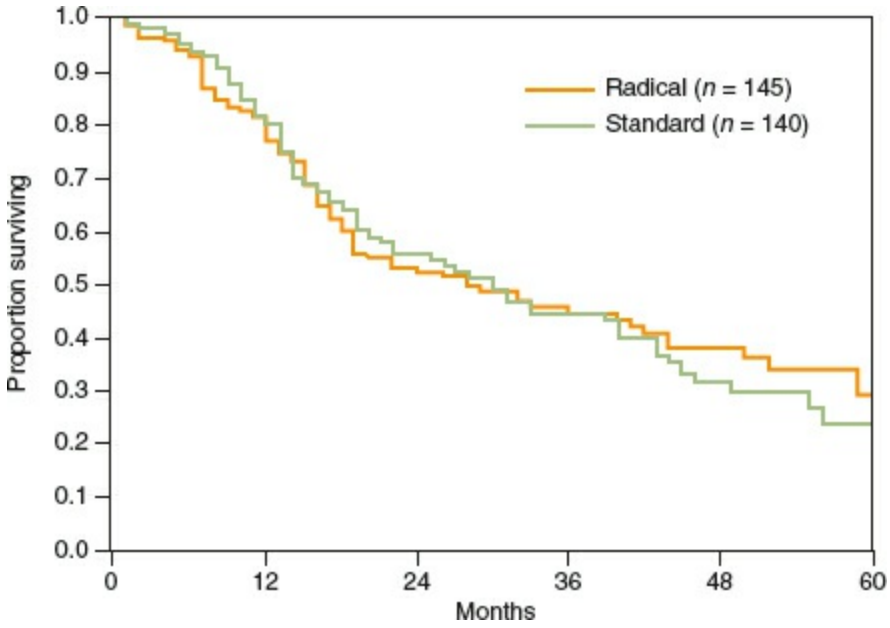

Figure 55-7. Actuarial survival for standard versus radical pancreaticoduodenectomy. From Yeo CJ, Cameron JL, Lillemoe KD, et al. Pancreaticoduodenectomy with or without distal gastrectomy and extended retroperitoneal lymphadenectomy for periampullary adenocarcinoma, part 2: randomized controlled trial evaluating survival, morbidity, and mortality. *Ann Surg* 2002;236:355–366; discussion 366–368, with permission.

In recent years, significant advances have been made in the application of minimally invasive techniques to the management of both benign and malignant pancreatic disorders. Initially, laparoscopic pancreatic surgery was limited to diagnostic staging in patients with pancreatic cancer prior to resection. More recently, minimally invasive techniques have been used to manage benign and malignant lesions of the pancreas. While laparoscopic distal pancreatic resections are being performed with increasing frequency,[27] the role of minimally invasive PD remains controversial. Laparoscopic or robotic PD is a technically demanding procedure due to the retroperitoneal location of the pancreas, its intimate association with surrounding gastrointestinal and major vascular structures, and the need for three separate anastomoses to complete the reconstruction. In addition, it is unclear whether an adequate cancer operation can be performed with respect to lymph node harvest and margin status in patients with malignancy. Currently, laparoscopic PD is only performed in a handful of specialized centers (Table 55-12). The procedures are performed as either robotic, pure laparoscopic, hand assisted, or as laparoscopic-assisted procedures with the resection being performed laparoscopically and the reconstruction being completed via a "mini" laparotomy or through a hand port.

Carcinoma of the Body and Tail

The surgical management of adenocarcinoma of the body and tail of the pancreas is much more limited than that of the head of the pancreas because of the extent of the disease usually present at the time of symptomatic presentation. Most patients are unable to undergo resection, based on findings of major vascular involvement on CT or peritoneal or liver metastases on laparoscopy. If an attempt at open exploration for possible cure is undertaken, the exploration should be started with a search for evidence of either metastatic disease to the liver or peritoneal implants. If this is not the case, the lesser sac is opened, and the SMV is identified as it passes under the neck of the pancreas. If this vessel is normal, and if the splenic vein does not appear to be obstructed preoperatively, a distal pancreatectomy with splenectomy is performed. The spleen is mobilized, as is the distal pancreas, and an en bloc resection of the structure, including the mass, is obtained. The resection should be extended as proximally as possible, with the transected pancreas simply oversewn. The tumor bed should be marked with the placement of clips for postoperative radiation therapy. If, as in most cases, the tumor cannot be resected, a tissue biopsy should be performed, in addition to a chemical splanchnicectomy with alcohol for pain management. In some cases, a prophylactic gastrojejunostomy may be indicated because of the potential for obstruction by tumor at the ligament of Treitz.

Postoperative Results

4 During the 1960s and 1970s, many centers reported operative mortality following PD in the range of 20% to 40%, with postoperative morbidity rates as high as 40% to 60%. During the last three decades, a dramatic decline in operative morbidity and mortality following PD has been reported at a number of centers, with operative mortality rates in the range of 2% to 3%.[33–35] The reasons behind this decline appear to be the following: (a) fewer, more experienced surgeons are performing the operation on a more frequent basis, (b) preoperative and postoperative care has improved, (c) anesthetic management has improved, and (d) large numbers of patients are being treated at high-volume centers.[36]

Although the operative mortality rates for pancreatic cancer have been reduced significantly, the complication rates approach 40% (Table 55-13). Pancreatic fistula remains the most frequent serious complication following PD, with an incidence ranging from 5% to 15%. In the past, the development of pancreatic fistula after PD was associated with mortality rates of 10% to 40%. Although the incidence of pancreatic fistula following PD remains stable, the overall associated mortality rate has diminished owing to improved management. Important supportive measures include careful maintenance of fluid and electrolyte balance, parenteral nutrition, and controlling the pancreatic leak with percutaneous or intraoperative drainage.

Table 55-12 Results for Minimally Invasive Pancreatoduodenectomy

Author	Year	N	Conv	Op Time (Minutes)	Mortality	Comp	Reop	LOS (Days)
Palanivelu et al.[28]	2007	42	0	370	0%	31%	NR	10.1
Kendrick and Cusati[29]	2010	65	4%	368	1.5%	40%	4.6%	7
Asbun and Stauffer[30]	2012	53	15%	541	5.7%	47%	3.8%	8.0
Chalikonda et al.[31]	2012	30	10%	476	3.0%	30%	10%	9.7
Zureikat et al.[32]	2013	132	8%	527	1.5%	62%	3.0%	10

Table 55-13 Complications After Pancreaticoduodenectomy

Common
Delayed gastric emptying
Pancreatic fistula
Intra-abdominal abscess
Hemorrhage
Wound infection
Metabolic
Diabetes
Pancreatic exocrine insufficiency
Uncommon
Fistula
Biliary
Duodenal
Gastric
Organ failure
Cardiac
Hepatic
Pulmonary
Renal
Pancreatitis
Marginal ulceration

From Yeo CJ, Cameron JL. Pancreatic cancer. *Curr Probl Surg* 1999;36: 61–152, with permission.

Long-Term Survival

5 Historically, 5-year survival rates for patients undergoing resection for adenocarcinoma of the head of the pancreas were reported to be in the range of 5%. However, recent studies have suggested an improved survival for patients following PD. In 2006, Winter et al.[37] reported on 1,175 patients who underwent operative resection for pancreatic adenocarcinoma. The actuarial 5-year survival for these patients was 18%, with a median survival of 18 months (Fig. 55.8). In this study, factors found to be important predictors of survival included tumor diameter (<3 cm), negative resection margin status, well/moderate tumor differentiation, and postoperative chemoradiation treatment. Patients who underwent resection with negative margins had a median survival of 20 months and a 5-year survival of 21%, whereas those with positive margins fared significantly worse, with a median survival of 14 months and a 5-year survival of 12%. The outcome was particularly favorable in the subgroup of patients with small tumors (<3 cm) who underwent margin-negative, node-negative resections; the median survival was 44 months and the 5-year survival was 43%.

6 At present, the general consensus of most surgeons treating patients with pancreatic carcinoma is that any future improvement in survival for this disease will involve improvements in systemic therapy. Despite advances in surgery and perioperative care that have resulted in markedly reduced postoperative mortality after pancreatoduodenectomy, the median survival for pancreatic cancer patients has changed minimally over the past two decades. Even with optimal surgical management, 5-year survival averages 15% to 20% for resectable disease and 3% for all stages combined. Approximately 85% of patients with resected pancreatic cancer will ultimately recur and die of their disease. These outcomes suggest that in most cases pancreatic cancer is a systemic disease at the time of diagnosis, making surgical resection alone inadequate therapy. The results of the most important randomized prospective trials of adjuvant therapy for pancreatic cancer are summarized in Table 55.14.

In 1985, the Gastrointestinal Tumor Study Group reported encouraging results from a prospective, randomized trial to evaluate the efficacy of adjuvant radiation and chemotherapy following curative resection for adenocarcinoma of the head of the pancreas.[38] Forty-three patients were randomized to either adjuvant therapy with radiation and 5-fluorouracil (5-FU) or no adjuvant therapy. The median survival for the 21 patients who received adjuvant therapy was 20 months, and three (14%) survived 5 years or longer. For the 22 patients who received no adjuvant therapy, the median survival was 11 months, and only 1 patient (4.5%) survived 5 years.

The randomized trial conducted by the European Organization for Research and Treatment of Cancer (EORTC),[39] sought to recapitulate the results of the GITSG study in 114 patients with pancreatic head lesions (observation, $n = 54$ and adjuvant treatment, $n = 60$). However, chemotherapy (5-FU) given during radiation was given as a continuous infusion (rather than via bolus) during each radiation sequence, depending on toxicity, for up to 5 days. No chemotherapy was given postchemoradiation. Fifty-six percent of patients received the intended chemotherapy dose during radiation. Patients in the chemoradiation arm had a median survival of 17.1 months versus 12.6 months in the observation arm ($p = 0.099$); 2- and 5-year overall survivals were 37% and 20%, respectively, for the experimental arm and 23% and 10%, respectively, for the control arm.

The ESPAC-1 trial published in 2004 analyzed 289 patients recruited from 53 hospitals in a 2×2 factorial design.[40] The four study groups included (1) surgery only ($n = 69$); (2) chemotherapy only ($n = 73$) consisting of 5-FU, 425 mg/m^2, and leucovorin, 20 mg/m^2, given daily for 5 days every 4 weeks for six cycles of treatment; (3) radiation therapy and 5-FU given ($n = 75$) according to the original GITSG method; and (4) both treatments ($n = 73$, chemoradiation followed by chemotherapy). The major study conclusions were that the 5-year overall survival comparisons between patients who received chemotherapy versus those that did not (21% vs. 8%, $p = 0.009$) and those that received radiation therapy versus those that did not (10% vs. 20%, $p = 0.05$). The authors concluded that adjuvant chemotherapy had a beneficial effect in resected

pancreatic cancer, whereas chemoradiation had a deleterious effect. A quality-of-life questionnaire showed no difference between those that received chemotherapy and those that did not, and those that received chemoradiation and those that did not. Thus, the survival benefit of adjuvant chemoradiation for pancreatic cancer patients remains unclear, and the optimal regimen has yet to be determined.

The RTOG 9704 trial, presented in abstract form in 2006,[41] contained 442 eligible patients who received adjuvant chemoradiation (5,040 cGy) given as continuous fractions with radiosensitizing doses of 5-FU. The comparisons were with the addition of either three cycles of 5-FU (one prechemoradiation, two postchemoradiation for 12 weeks) versus four cycles of gemcitabine (one prechemoradiation, three postchemoradiation). Although the study showed no overall difference in aggregate survival, when pancreatic head lesions only were considered (eliminating study results from resected lesions in the pancreatic body or tail), both median survival (16.7 vs. 18.8 months) and overall survival at 3 years (21% vs. 31%) favored the gemcitabine arm ($p = 0.047$). The study concluded that the addition of adjuvant gemcitabine to postoperative 5-FU chemoradiation was superior to the addition of 5-FU.

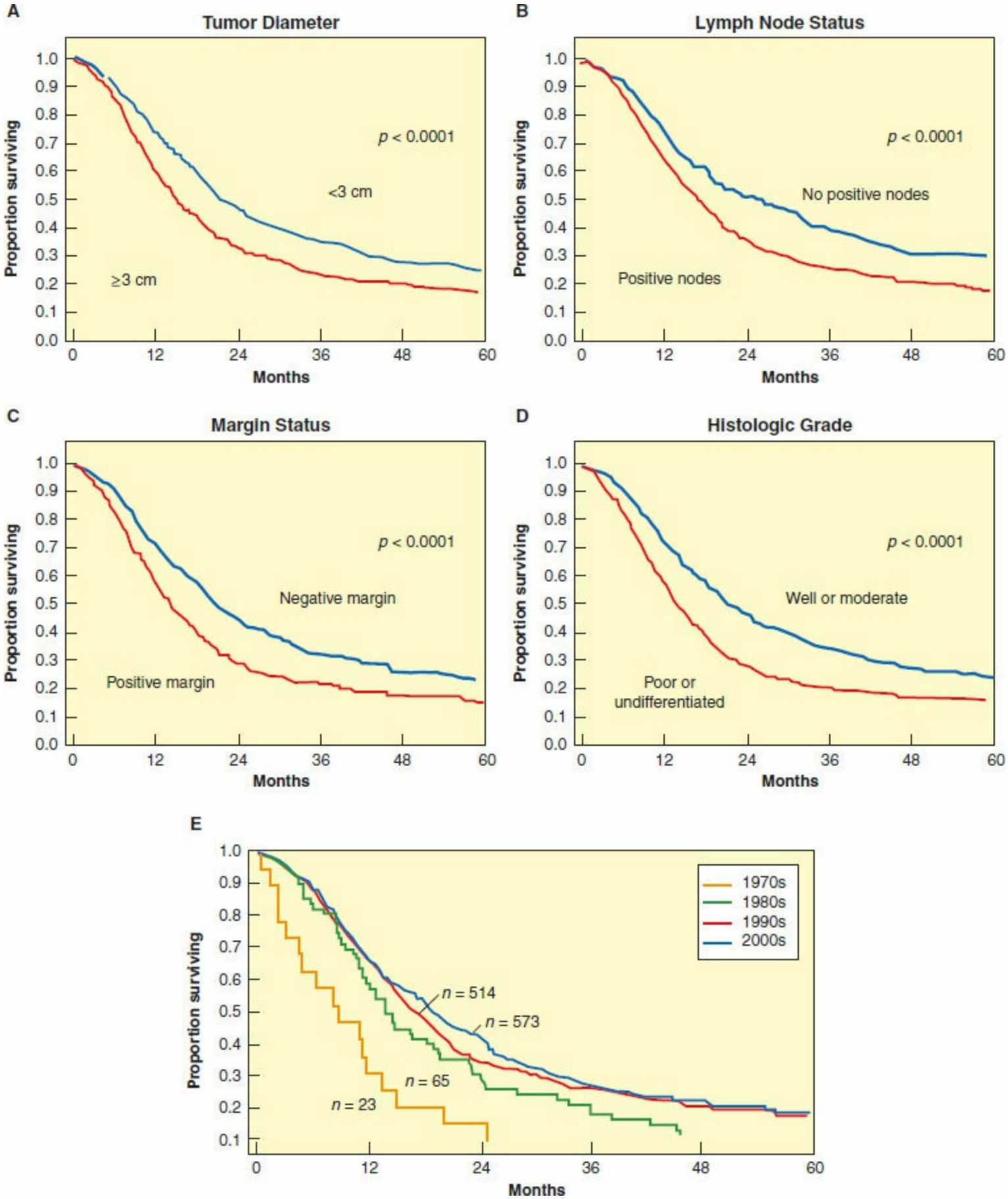

Figure 55-8. Survival of patients with pancreaticoduodenectomy based on tumor size **(A),** lymph node status **(B),** margin status **(C),** histologic grade **(D),** and historical context **(E)**. From Winter JM. Cameron JL. Campbell KA, et al. 1423 pancreaticoduodenectomies for pancreatic cancer: a single-institution experience. *J Gastrointest Surg* 2006; 10:1199–210, with permission.

Table 55-14 Randomized Prospective Trials of Adjuvant Therapy for Pancreatic Cancer

Study	Treatment Arm	Median Survival (Months)	2-Year Overall Survival (%)	5-Year Overall Survival (%)
GITSG[38]	Surg	11	18	0
	Surg, XRT, 5-FU	18	43	19
EORTC[39]	Surg	13	23	10
	Surg, XRT, 5-FU	17	37	20
ESPAC-1[40]	Surg	17	—	11
	Surg, 5-FU	20	40	21
	Surg, XRT, 5-FU	16	29	10
RTOG[41]	Surg, XRT, 5-FU	17	21 (3 y)	—
	Surg, XRT, Gemcitabine	19	31 (3 y)	—
CONKO[42]	Surg	20	42	12
	Surg, Gemcitabine	22	48	23

The CONKO-1 trial,[42] conducted in Germany and Austria, represented a randomization of 368 patients following R0 or R1 resection to either observation or an experimental arm of gemcitabine. After a median follow-up time of 53 months, the median disease-free survival was 13.9 months in the gemcitabine arm versus 6.9 months in the observation arm ($p < 0.001$). There was no difference in overall survival for the gemcitabine arm versus the control group – median survival was 22 versus 20 months. Although survival was not different, the authors concluded that postoperative gemcitabine significantly delayed the development of recurrent disease after complete resection of pancreatic cancer compared with observation alone and, thus, was supported as adjuvant therapy in resectable pancreatic cancer.

At present, many centers are utilizing preoperative neoadjuvant chemoradiation for the treatment of pancreatic cancer (Table 55-15). Neoadjuvant therapy offers several potential benefits including: (1) delivery of treatment to well-oxygenated tissue which enhances efficacy of chemoradiation, (2) downstaging can enhance ability to achieve a negative-margin resection and thereby reduce local recurrence, and (3) avoidance of surgery in patients with rapidly progressive disease. Neoadjuvant therapy can be completed without increasing the subsequent morbidity and mortality of surgical resection. The group from the M.D. Anderson Cancer Center reported on the multimodality treatment of 142 consecutive patients with localized adenocarcinoma of the pancreatic head.[43] A subset of 41 patients treated by preoperative chemoradiation and pancreatoduodenectomy were compared with 19 patients receiving pancreatoduodenectomy and postoperative adjuvant chemoradiation. Surgery was not delayed for any patient who received preoperative chemoradiation because of chemoradiation toxicity, but 24% of the eligible patients did not receive their intended postoperative chemoradiation because of delayed recovery following PD. The patients treated with rapid fractionation were reported to have a significantly shorter duration of

treatment (median, 62.5 days) than patients who received postoperative chemoradiation (median, 98.5 days). In early follow-up, no patient who received preoperative chemoradiation experienced a local recurrence, and peritoneal recurrence developed in only 10% of these patients. Local or regional recurrence developed in 21% of patients who received postoperative chemoradiation. The overall survival curves were similar for both cohorts.

Wolff et al.[46] examined 86 patients treated with weekly gemcitabine at a dose of 400 mg/m^2 and 30 Gy of radiation. Sixty-one patients ultimately underwent resection (71%). The median survival in the resected patients was 36 months which is significantly longer than those seen in regimens using 5-FU or paclitaxel as the radiation sensitizer. Analysis of the specimens revealed two pathologic complete responses and more than 50% nonviable tumor cells in 36 (59%). A gemcitabine-based regimen was also used in a multi-institutional study of 20 patients reported by Talamonti et al.[47] This group used full-dose gemcitabine and limited field radiation to 36 Gy (2.4 Gy/fraction). The authors described 14 patients as resectable and six as borderline resectable. Ultimately, all patients were explored and 17 resected (85%), again representing a very high rate of resectability. A single pathologic complete response was observed and, in 24% of tumors, greater than 90% of the tumor cells were felt to be nonviable. Also notable was the low incidence (6%) of margin positivity in this trial. The median survival in the resected patients was 26 months. Based on the results of these initial trials, gemcitabine-based neoadjuvant regimens remain of considerable interest.

Table 55-15 Selected Neoadjuvant Trials for Potentially Resectable Pancreatic Cancer

Author	Year	N	Regimen	Resected (%)	Median Survival (Months)
Spitz et al.[43]	1997	91	XRT, 5-FU	45	19
Hoffman et al.[44]	1998	53	XRT, 5-FU, Mitomycin C	45	16
Pisters et al.[45]	2002	37	XRT, Paclitaxel	54	19
Wolf et al.[46]	2002	86	XRT, Gemcitabine	73	36
Talamonti et al.[47]	2006	20	XRT, Gemcitabine	85	26
Evans et al.[48]	2008	86	XRT, Gemcitabine	74	34
Turrini et al.[49]	2009	102	XRT, 5-FU, Cisplatin	62	23

PALLIATION

7 Unfortunately, it has been the experience nationwide that only a minority of patients with carcinoma of the pancreas can undergo resection for possible cure at the time diagnosis is made. Therefore, the optimal palliation of symptoms to maximize quality of life is of primary importance in most patients with pancreatic cancer. Both operative and nonoperative options are available for the palliation of pancreatic cancer.

Jaundice

Obstructive jaundice is present in most patients who have pancreatic cancer. If left untreated, it can result in progressive liver dysfunction, hepatic failure, and early death. In addition, the pruritus associated with obstructive jaundice can be debilitating and usually does not respond to medication. When patients undergo exploration for possible cure and are found to have unresectable disease, a biliary bypass should be performed.

Traditionally, surgeons have performed either choledochojejunostomy or cholecystojejunostomy for the relief of malignant biliary obstruction. Both procedures are effective in relieving jaundice, but it appears that the rate of recurrent jaundice after cholecystojejunostomy is approximately 10%. Therefore, our preference for the palliation of obstructive jaundice is a hepaticojejunostomy or choledochojejunostomy reconstructed with a Roux-en-Y limb of jejunum. The surgical palliation of jaundice can be accomplished safely, with a mortality rate of less than 3% and an overall morbidity rate of 30% to 40%.[50] In recent years, nonoperative palliation has become available as an option for managing patients who are deemed unresectable by preop staging. Plastic or metal stents can be placed across the biliary obstruction by either an endoscopic or a percutaneous technique. For pancreatic cancer, the endoscopic approach is usually preferred. The overall morbidity rate for endoscopic stenting ranges up to 35%, but the rate of major procedure-related morbidity is less than 10%. Early complications include cholangitis, pancreatitis, and bile duct or duodenal perforation. The major late complications of stent placement are cholecystitis, duodenal perforation, and stent migration. Stent occlusion can result in episodes of cholangitis and recurrent jaundice. For most patients, an exchange of stents is required every 3 to 6 months. The newer metal stents appear to remain patent for longer periods.

Nonoperative palliation appears to be associated with lower complication rates, lower procedure-related mortality rates, and shorter initial periods of hospitalization in comparison with surgical palliation. However, the rate of recurrent jaundice is higher. No advantage with respect to long-term survival has been noted for either approach. Therefore, nonoperative palliation should be offered to patients with advanced disease or poor performance status. Surgical palliation should be considered for patients with an anticipated life expectancy of at least 6 months.

Duodenal Obstruction

At the time that pancreatic cancer is diagnosed, approximately one-third of patients have symptoms of nausea or vomiting. Although true mechanical obstruction of the duodenum seen by radiologic or endoscopic examination is much less frequent, duodenal obstruction develops in almost 20% of patients before they die as the disease progresses.[51] Duodenal obstruction can be caused in the C-loop by cancers of the head or at the ligament of Trietz by cancers of the body and tail. In patients with evidence of duodenal obstruction or impending obstruction, a gastrojejunostomy is indicated for palliation. This is typically performed as a retrocolic, isoperistaltic loop gastrojejunostomy with a loop of jejunum 20 to 30 cm distal to the ligament of Trietz.

In patients with unresectable pancreatic cancer who do not have symptoms of gastric outlet obstruction, whether or not to perform a prophylactic gastric bypass at the time of biliary bypass is a matter of debate. Surgeons who do not perform a prophylactic bypass feel that it needlessly increases the postoperative length of stay and can be associated with delayed gastric emptying and increased morbidity and mortality. However, data from a prospective, randomized trial of prophylactic gastrojejunostomy in patients with unresectable cancer do not support this view.[52] In this study, 44 patients were randomized to a gastrojejunostomy, and 43 did not undergo gastric bypass. No mortality occurred in either group. No difference was observed in either the complication rate or the postoperative length of stay (Table 55-16). However, late duodenal obstruction developed in 19% of the patients who did not undergo bypass. A recent multicenter prospective randomized controlled trial has confirmed these results.[53] Therefore, we believe that a prophylactic gastrojejunostomy should be performed in patients undergoing surgical palliation for unresectable pancreatic carcinoma.

Pain

Tumor-associated pain can be incapacitating in patients with unresectable pancreatic cancer. The postulated causes of tumor-associated pain are many and include tumor infiltration into the celiac plexus, increased parenchymal pressure caused by pancreatic duct obstruction, pancreatic inflammation, gallbladder distention resulting from biliary obstruction, and gastroduodenal obstruction. The management of pain in patients dying of carcinoma of the pancreas is one of the most important aspects of their care. The appropriate use of oral agents can be successful in most patients. Patients with significant pain should receive their medication on a regular schedule and not on an "as-needed" basis. The use of long-acting morphine derivative compounds appears to be best suited for such treatment. Percutaneous neurolytic block of the celiac axis, performed under either fluoroscopic or CT guidance, is also successful in the majority of patients at eliminating pain. Patients with unresectable cancer at the time of surgical exploration should receive a chemical splanchnicectomy, with 20 mL of 50% alcohol injected on either side of the aorta at the level of the celiac axis.[54]

Table 55-16 Prospective Randomized Trial of Prophylactic Gastrojejunostomy in Patients with Unresectable Periampullary Cancer

	Patients (No.)	Morbidity (%)	Mortality (%)	Postoperative Length of Stay (Days)	Late Gastric Outlet Obstruction (%)
Gastrojejunostomy	44	32	0	8.5	0
No gastrojejunostomy	43	33	0	8.0	19

Adapted from Lillemoe KD, Cameron JL, Hardacre JM, et al. Is prophylactic gastrojejunostomy indicated for unresectable periampullary cancer? *Ann Surg* 1999;230:322–330.

SUMMARY

8 The decision to perform nonoperative versus surgical palliation for pancreatic cancer is influenced by a number of factors, including the patient's symptoms, overall health status, predicted procedure-related morbidity and mortality, and projected survival. Surgical palliation can be completed with acceptable perioperative morbidity and mortality and postoperative length of stay. The avoidance of late complications of recurrent jaundice, duodenal obstruction, and disabling pain would strengthen the argument in favor of surgical palliation in those patients expected to survive 6 months or more. Nonoperative methods of palliation should be considered for patients in whom preoperative staging suggests distant metastatic disease or a locally unresectable tumor, patients who are not candidates for operative intervention, and those not expected to survive more than 3 months.

Radiation and Chemotherapy for Unresectable Pancreatic Carcinoma

Specific antitumor therapies in patients with advanced pancreatic carcinoma have been studied for years, with limited success. Trials evaluating the use of chemotherapy and radiation therapy both alone and in combination have shown a marginal improvement in survival, often with relatively high toxicity rates and some negative impact on quality of life. Recently gemcitabine, a deoxycytidine analog capable of inhibiting DNA replication and repair, has become increasingly popular. When gemcitabine was compared with bolus 5-FU in a randomized phase III trial, it was shown to confer a significant survival benefit in advanced pancreatic cancer, increasing median survival from 4.4 to 5.7 months and increasing 1-year survival from 2% to 18%, respectively.[55] A key end-point in this study was "clinical benefit response," based on reducing pain, improving performance status, and inducing weight gain, which was attained in 24% of patients receiving gemcitabine compared with 5% for those receiving 5-FU. In patients with metastatic pancreatic cancer that had progressed with 5-FU and then been treated with gemcitabine, the median survival (in 63 of 74 patients enrolled) was 3.9 months.[56] Seventeen patients (27%) attained a clinical benefit response with a median duration of 14 weeks. Gemcitabine is generally well tolerated with a low incidence of significant toxicity and therefore seems to be a reasonable choice for palliative therapy.

Long before gemcitabine was established as an option for adjuvant therapy, it was approved in the metastatic setting based on clinical benefit in patients who had symptomatic advanced disease.[55] Over the last two decades, several combinations of gemcitabine based chemotherapy have failed to improve outcome in patients with metastatic disease. Recently, both FOLFIRINOX (5-FU, leucovorin, irinotecan, and oxaliplatin) and nab-paclitaxel/gemcitabine were proven superior to gemcitabine alone in patients with metastatic pancreatic cancer leading to improvement in response rate (RR), progression-free survival (PFS) and OS.[57,58] Objective response rates have improved by nearly fivefold with these newer systemic regimens.

In addition to gemcitabine, other agents are currently being studied for a role in the palliation of patients with pancreatic adenocarcinoma. Examples of such agents are paclitaxel (Taxol), matrix metalloproteinase inhibitors (e.g., marimastat and perillyl alcohol), and inhibitors of angiogenesis, such as TNP-470. The results of such studies are eagerly awaited.

References

1. American Cancer Society. Cancer Facts & Figures 2015. *Atlanta: American Cancer Society;* 2015.
2. Sohn TA, Yeo CJ, Cameron JL, et al. Resected adenocarcinoma of the pancreas 616 patients: results, outcomes, and prognostic indicators. *J Gastrointest Surg* 2000;4:567–579.
3. Yeo CJ, Cameron JL. Pancreatic cancer. *Curr Probl Surg* 1999;36:61–152.
4. Chari ST, Leibson CL, Rabe KG, et al. Probability of pancreatic cancer following diabetes: a population based study. *Gastroenterology* 2005;129:504–511.
5. Takai E, Yachida S. Genomic alteration in pancreatic cancer and their relevance to therapy. *World J Gastrointest Oncol* 2015;7:250–258.
6. Brune KA, Kliein AP. Familial pancreatic cancer. In: Lowy Am, Leach SD, Philip PA, eds. *Pancreatic Cancer.* New York, NY: Springer Science + Buisness; 2008:65–79.
7. Brosens LA, Hackeng WM, Offerhaus GJ, et al. Pancreatic adenocarcinoma pathology: changing "landscape." *J Gastrointest Oncol* 2015;6:358–374.
8. Schmidt CM, Matos JM, Bentrem DJ, et al. Acinar cell carcinoma of the pancreas in the United States: prognostic factors and comparison to ductal adenocarcinoma. *J Gastrointest Surg* 2008;12:2078–2086.
9. Farrell JJ. Prevalence, diagnosis and management of pancreatic cystic neoplasms: current status and future directions. *Gut and Liver* 2015;9:571–589.
10. Sohn TA, Yeo CJ, Cameron JL, et al. Intraductal papillary mucinous neoplasms of the pancreas an updated experience. *Ann Surg.* 2004;239:788–797; discussion 797–799.
11. Tanaka M, Fernandez-del Castillo C, Adsay V, et al. International consensus guidelines 2012 for the management of IPMN and MCN of the pancreas. *Pancreatology* 2012;12:183–197.
12. Ritts RE, Pitt HA. CA 19–9 in pancreatic cancer. *Surg Oncol Clin North Am* 1998;7:93–101.
13. Dye CE, Waxman I. Endoscopic ultrasound. *Gastroenterol Clin North Am* 2002; 31:863–879.
14. Conlon KC, Dougherty E, Klimstra DS, et al. The value of minimal access surgery in the staging of patients with potentially resectable peripancreatic malignancy. *Ann Surg* 1996;223:134–140.
15. Barreiro CJ, Lillemoe KD, Koniaris LG, et al. Diagnostic laparoscopy for periampullary and pancreatic cancer: what is the true benefit? *J Gastrointest Surg* 2002;6:75–81.
16. Kausch W. Das Carcinom der papilla duodeni and seine radikale entfeinung. *Beitrage zur Klinische Chirurgie* 1912;78:439.
17. Whipple AO, Parsons WB, Mullins CR. Treatment of carcinoma of the ampulla of Vater. *Ann Surg* 1935;102:763–779.

18. Pedrazzoli S, DiCarlo V, Dionigi R, et al. Standard versus extended lymphadenectomy associated with pancreatoduodenectomy in the surgical treatment of adenocarcinoma of the head of the pancreas: a multicenter, prospective, randomized study. Lymphadenectomy Study Group. *Ann Surg* 1998;228:508–517.
19. Yeo CJ, Cameron JL, Lillemoe KD, et al. Pancreaticoduodenectomy with or without distal gastrectomy and extended retroperitoneal lymphadenectomy for periampullary adenocarcinoma, part 2: randomized controlled trial evaluating survival, morbidity, and mortality. *Ann Surg* 2002;236:355–366; discussion 366–368.
20. Farnell MB, Pearson RK, Sarr MG, et al. A prospective randomized trial comparing standard pancreatoduodenectomy with pancreatoduodenectomy with extended lymphadenectomy in resectable pancreatic head adenocarcinoma. *Surgery* 2005;138:618–630.
21. Nimura Y, Nagino M, Takao S, et al. Standard versus extended lymphadenectomy in radical pancreatoduodenectomy for ductal adenocarcinoma of the head of the pancreas: long-term results of a Japanese multicenter randomized controlled trial. *J Hepatobiliary Pancreat Sci* 2012;19:230–241.
22. Jang JY, Kang MJ, Heo JS, et al. A prospective randomized controlled study comparing outcomes of standard resection and extended resection, including dissection of the nerve plexus and various lymph nodes, in patients with pancreatic head cancer. *Ann Surg* 2014;259:656–664.
23. Traverso LW, Longmire WP Jr. Preservation of the pylorus in pancreaticoduodenectomy. *Surg Gynecol Obstet* 1978;146:959–962.
24. Kozuschek W, Reith HB, Waleczek H, et al. A comparison of long term results of the standard Whipple procedure and the pylorus preserving pancreatoduodenectomy. *J Am Coll Surg* 1994; 178:443–453.
25. Takada T, Yasuda H, Amano H, et al. Results of a pylorus-preserving pancreatoduodenectomy for pancreatic cancer: a comparison with results of the Whipple procedure. *Hepatogastroenterology* 1997;44:1536–1540.
26. Tran KT, Smeenk HG, van Eijck CH, et al. Pylorus-preserving pancreaticoduodenectomy versus standard Whipple procedure a prospective randomized multicenter analysis of 170 patients with pancreatic and periampullary tumors. *Ann Surg* 2004;240:738–745.
27. Kooby D, Gillespie T, Bentrem D, et al. Left-sided pancreatectomy: a multicenter comparison of laparoscopic and open approaches. *Ann Surg* 2008;248:438–446.
28. Palanivelu C, Jani K, Senthilnathan P, et al. Laparoscopic pancreaticoduodenectomy: technique and outcomes. *J Am Coll Surg* 2007;205:222–230.
29. Kendrick ML, Cusati D. Total laparoscopic pancreaticoduodenectomy: feasibility and outcome in an early experience. *Arch Surg* 2010;145:19–23.
30. Asbun HJ, Stauffer JA. Laparoscopic vs open pancreaticoduodenectomy: overall outcomes and severity of complications using the accordion severity grading system. *J Am Coll Surg* 2012;215:810–819.

31. Chalikonda S, Aguilar-Saavedra JR, Walsh RM. Laparoscopic robotic-assisted pancreaticoduodenectomy: a case-matched comparison with open resection. *Surg Endosc* 2012;26:2397–2402.
32. Zureikat AH, Moser AJ, Boone BA, et al. 250 Robotic pancreatic resections: safety and feasibility. *Ann Sur* 2013;258:554–562.
33. Yeo CJ, Cameron JL, Lillemoe KD, et al. Pancreaticoduodenectomy for cancer of the head of the pancreas: 201 patients. *Ann Surg* 1995;221:721–733.
34. Richter A, Neidergethmann M, Sturm JW, et al. Long-term results of partial pancreaticoduodenectomy for ductal adenocarcinoma of the pancreatic head: 25-year experience. *World J Surg* 2003;27:324–329.
35. Schmidt CM, Powell ES, Yiannoutsos CT, et al. Pancreaticoduodenectomy: a 20-year experience in 516 patients. *Arch Surg* 2004;139:718–725; discussion 725–727.
36. Sosa JA, Bowman HM, Gordon TA, et al. Importance of hospital volume in the overall management of pancreatic cancer. *Ann Surg* 1998;228:320–330.
37. Winter JM. Cameron JL. Campbell KA, et al. 1423 pancreaticoduodenectomies for pancreatic cancer: a single-institution experience. *J Gastrointest Surg* 2006;10:1199–1210.
38. Gastrointestinal Tumor Study Group. Further evidence of effective adjuvant combined radiation and chemotherapy following curative resection of pancreatic cancer. *Cancer* 1987;59:2006–2010.
39. Kinkenbijl JH, Jeekel J, Sahmoud T, et al. Adjuvant radiotherapy and 5-fluorouracil after curative resection of cancer of the pancreas and periampullar region. *Ann Surg* 1999;230:776–782; discussion 782–784.
40. Neoptolemos JP, Stocken DD, Freiss H, et al. A randomized trial of chemoradiotherapy and chemotherapy after resection of pancreatic cancer. *N Engl J Med* 2004;350:1200–1210.
41. Regine WF, Winter KW, Abrams R, et al. RTOG 9704 a phase III study of adjuvant pre and post chemoradiation (CRT) 5-FU vs. gemcitabine (G) for resected pancreatic adenocarcinoma. *J Clin Oncol* 2006;24:18S.
42. Oettle H, Post S, Neuhaus P, et al. Adjuvant chemotherapy with gemcitabine vs. observation in patients undergoing curative-intent resection of pancreatic cancer: a randomized controlled trial. *JAMA* 2007;297:267–277.
43. Spitz FR, Abbruzzese JL, Lee JE, et al. Preoperative and postoperative chemoradiation strategies in patients treated with pancreaticoduodenectomy for adenocarcinoma of the pancreas. *J Clin Oncol* 1997;15:928–937.
44. Hoffman JP, Lipsitz S, Pisansky T, et al. Phase II trial of preoperative radiation therapy and chemotherapy for patients with localized, resectable adenocarcinoma of the pancreas: an Eastern Cooperative Oncology Group Study. *J Clin Oncol* 1998;16:317–323.
45. Pisters PW, Wolff RA, Janjan NA, et al. Preoperative paclitaxel and concurrent rapid-

fractionation radiation for resectable pancreatic adenocarcinoma: toxicities, histologic response rates, and event-free outcome. *J Clin Oncol* 2002;20:2537–2544.

46. Wolff RA, Evans DB, Crane CH. Initial results of preoperative gemcitabine-based chemoradiation for resectable pancreatic Adenocarcinoma (abstract). *Proc Am Soc Clin Oncol* 2002;21:130a.
47. Talamonti MS, Small W Jr, Mulcahy MF, et al. A multi-institutional phase II trial of preoperative full-dose gemcitabine and concurrent radiation for patients with potentially resectable pancreatic carcinoma. *Ann Surg Oncol* 2006;13:150–158.
48. Evans DB, Varadhachary GR, Crane CH, et al. Preoperative gemcitabine-based chemoradiation for patients with resectable adenocarcinoma of the pancreatic head. *J Clin Oncol* 2008;26(21):3496–3502.
49. Turrini O, Viret F, Moureau-Zabotto L, et al. Neoadjuvant 5 fluorouracil-cisplatin chemoradiation effect on survival in patients with resectable pancreatic head adenocarcinoma: a ten-year single institution experience. *Oncology* 2009;76(6):413–419.
50. Sohn TA, Lillemoe KD, Cameron JL, et al. Surgical palliation of unresectable periampullary carcinoma in the 1990s. *J Am Coll Surg* 1999;188:658–666; discussion 666–659.
51. Sarr MG, Cameron JL. Surgical management of unresectable carcinoma of the pancreas. *Surgery* 1982; 91:123–133.
52. Lillemoe KD, Cameron JL, Hardacre JM, et al. Is prophylactic gastrojejunostomy indicated for unresectable periampullary cancer? *Ann Surg* 1999;230:322–328; discussion 328–330.
53. Van Heek NT, De Castro SM, van Eijck CH, et al. The need for a prophylactic gastrojejunostomy for unresectable periampullary cancer: a prospective randomized multicenter trial with special focus on assessment of quality of life. *Ann Surg* 2003;238:894–902; discussion 902–905.
54. Lillemoe KD, Cameron JL, Kaufman HS, et al. Chemical splanchnicectomy in patients with unresectable pancreatic cancer: a prospective randomized trial. *Ann Surg* 1993;217:447–455; discussion 456–457.
55. Burris HA 3rd, Moore MJ, Andersen J, et al. Improvements in survival and clinical benefit with gemcitabine as first-line therapy for patients with advanced pancreas cancer: a randomized trial. *J Clin Oncol* 1997;15(6):2403–2413.
56. Rothenberg ML, Moore MJ, Cripps MC, et al. A phase II trial of gemcitabine in patients with 5-FU refractory pancreas cancer. *Ann Oncol* 1996;7:347–353.
57. Conroy T, Desseigne F, Ychou M, et al. FOLFIRINOX versus gemcitabine for metastatic pancreatic cancer. *NEJM* 2011;364(19):1817–1825.
58. Von Hoff DD, Ervin T, Arena FP, et al. Increased survival in pancreatic cancer with nab-paclitaxel plus gemcitabine. *NEJM* 2013;369(18):1691–1703.

Chapter 56

Neoplasms of the Endocrine Pancreas

Harish Lavu, Jonathan R. Brody, and Charles J. Yeo

Key Points

1 Pancreatic endocrine neoplasms (PENs) originate from multipotential stem cells in pancreatic ductules. Therefore, use of the older terms *islet cell tumor* and *islet cell carcinoma* is now discouraged, in favor of the terms *pancreatic endocrine neoplasms* or *pancreatic endocrine tumors*.

2 PENs have traditionally been classified according to the size and the mitotic rate of the tumor into one of three categories: pancreatic endocrine microadenomas, well-differentiated PENs, and poorly differentiated or high-grade endocrine carcinomas.

3 The most recent World Health Organization classification uses the combination of a proliferative index (Ki-67) and mitotic rate to grade PENs while incorporating traditional TNM staging taking into account tumor size, peripancreatic invasion, and metastatic spread to lymph nodes/distant locations, which result in the classification of carcinoma.

4 The best initial imaging technique for a PEN is a high-quality multidetector computed tomography (CT) scan.

5 Endoscopic ultrasonography is particularly useful in localizing tumors in patients with gastrinoma and insulinoma.

6 Insulinomas may present with either neuroglycopenic symptoms (confusion, seizure, obtundation, and coma) or hypoglycemic-induced symptoms (palpitations, diaphoresis, and tachycardia).

7 Ninety percent of insulinomas are solitary, 90% are sporadic, and 90% are benign with their location evenly distributed throughout the pancreas.

8 Seventy-five percent of gastrinomas are sporadic (25% are associated with multiple endocrine neoplasia type 1 syndrome), and all should be considered to be of malignant potential.

9 Most gastrinomas are located in the *gastrinoma triangle* and may be intrapancreatic, within the wall of the duodenum, or in a peripancreatic lymph node, and in most cases local resection (enucleation) may be adequate therapy.

10 Glucagonomas usually present with a characteristic severe dermatitis (termed *necrolytic migratory erythema*) and are typically large and bulky and often with metastatic disease.

1 Pancreatic endocrine neoplasms (PENs) are rare tumors that account for 3% of pancreatic neoplasms and 7% of all neuroendocrine tumors.[1] Their incidence has increased nearly fivefold over the past 30 years, corresponding to the dramatic rise in the use of cross-sectional imaging in modern medicine. This has led to an increase in the rate of incidental diagnoses in asymptomatic patients.[2] First described by Nicholls in 1902 as a tumor arising from pancreatic islet cells, these "islet cell adenomas" were long thought to arise from the islets of Langerhans.[3] Recent investigations have revealed that PENs more likely originate from multipotential stem cells in pancreatic ductules.[4,5] This non–islet cell origin has been further demonstrated in tumors arising in patients with multiple endocrine neoplasia type1.[6] Therefore, use of the older terms *islet cell tumor* and *islet cell carcinoma* is now discouraged, in favor of the terms *pancreatic endocrine neoplasms* or *pancreatic endocrine tumors*.[7,8]

2 Traditionally, PENs were classified according to their size and the mitotic rate of the tumor. This system placed PENs into one of three categories: pancreatic endocrine microadenomas, well-differentiated PENs, and poorly differentiated or high-grade endocrine carcinomas. PENs are also differentiated by the presence (i.e., functional tumors) or absence (i.e., nonfunctional tumors) of a syndrome due to hormone production, with nonfunctional PENs (91%) being much more common than functional tumors (9%).[9,10] The production of certain hormones by the functional tumors and their resulting symptoms lead to well-described clinical syndromes, which are detailed later in this chapter.

PENs less than 0.5 cm in diameter are classified as pancreatic endocrine microadenomas. Oncologically, they are considered to be benign lesions. Their prevalence is estimated to be as high as 10% of the population in autopsy series.[11,12] Most pancreatic endocrine microadenomas are noted as incidental findings in pancreata resected for other indications and, by definition, produce no neoplastic syndromes (i.e., are nonfunctional). Functional PENs less than 0.5 cm are classified with well-differentiated PENs.

PENs measuring greater than 0.5 cm in diameter and having a low mitotic rate of less than 10 mitoses per 10 high-power fields are referred to as well-differentiated PENs. This group comprises the large majority of clinically relevant PENs. They are uncommon, with an estimated incidence of approximately 1 out of 100,000 people.[13,14] Although rare in children, cases have been described at all ages, and the peak incidence occurs between the ages of 40 and 60 years.[7] Overall distribution is equal between men and women with some differences in ratio among different functional types.

3 The classification of PENs has in the past been controversial, with no single dominant staging system in existence.[15] Multiple varying staging schemes (including those by the European Neuroendocrine Tumor Society (ENETS) and the American Joint Committee on Cancer (AJCC))[16,17] have been put forward, attempting to establish prognostic characteristics such as size, mitotic count, presence of necrosis, extrapancreatic invasion, vascular and perineural invasion, nuclear polymorphisms, and nodal involvement.[18–21] The most recent World Health Organization (WHO) classification attempts to standardize PEN grading by using a proliferation-based system together with classical histopathologic diagnostic criteria. This new classification takes into account the increasing importance of

the proliferative index Ki-67 as a prognostic marker for PENs. In this schema, PENs are graded into one of three categories based upon their Ki-67 proliferation index and mitotic rate. These include two categories of well-differentiated endocrine tumors and a third category of poorly differentiated endocrine carcinomas. In this system, the well-differentiated tumors include those which are grade 1 (Ki-67 <3%, <2 mitoses per 10 hpf) and grade 2 (Ki-67 3% to 20%, 2 to 20 mitoses per 10 hpf). Whereas, grade 3 (Ki-67 >20%, >20 mitoses per 10 hpf) tumors are considered poorly differentiated carcinomas.[22,23] By convention, the tumor is assigned the higher grade if the Ki-67 index and mitotic rate differ. Any local invasion beyond the pancreas or metastatic spread to lymph nodes or distant locations results in the classification of carcinoma (Table 56-1).

Table 56-1 WHO 2010 Classification of Well-Differentiated Pancreatic Endocrine Tumors

Grade	Mitotic Count/10 HPF	KI-67 Index (%)
G1	<2 per 10 HPF	<3
G2	2–20	3–20
G3	>20	>20
TNM	**Size (cm)**	**Muscularis Propria Invasion**
T1a	<1	–
T1b	1–2	–
T2	>2	+

HPF, high-power fields; WHO, World Health Organization.

Well-differentiated PENs can also be classified as functional or nonfunctional based on the presence or absence of an associated clinically recognizable syndrome (Table 56-2). These syndromes are the result of the secretion of biologically active hormones by the tumors and are confirmed by measurable elevations of the hormones in the blood. The most common functional PENs include insulinomas, gastrinomas, vasoactive intestinal polypeptide-omas (VIPomas), glucagonomas, and somatostatinomas. The incidence of these lesions ranges from 1 per 1 million for insulinomas to 1 per 40 million for somatostatinomas.[24] Even less common PENs secreting calcitonin,[25,26] parathyroid hormone–related protein,[27] growth hormone–releasing factor, and adrenocorticotropic hormone[28] have been reported. Nonfunctional PENs are classified as such due to their lack of an associated clinical syndrome. Some of the tumors in this group do secrete elevated amounts of hormones, including chromogranin A, which can be detected in either the serum or in surgical specimens using immunohistochemistry.[29] These secreted hormones either produce no clinical syndromes, as is seen with tumors that secrete pancreatic polypeptide,[30] or secrete hormones in subclinical amounts or inactive forms. Traditionally, functional PENs were reported to comprise the majority of PENs. As methods of detecting these lesions and patterns of presentation have evolved, due primarily to the widespread use of high-quality cross-sectional imaging, nonfunctional PENs now comprise the vast majority of surgically resected cases.[18,31]

The least common group of PENs is the poorly differentiated or high-grade endocrine carcinomas. These are aggressive tumors characterized by their high mitotic count and proliferation index (>20 mitotic figures per 10 high-powered fields, Ki-67 >20%).[23,32] These tumors primarily occur in adults and have a male predominance. Some have been reported to be functional, producing varied clinical syndromes (commonly gastrinoma, VIPoma, glucagonoma, and, less frequently, insulinoma). Prognosis is often poor, with the clinical course varying from a rapid decline to a more indolent, prolonged survival.

Table 56-2 Classification of Functional Pancreatic Endocrine Tumors

Tumor (Syndrome)	Clinical Features	Extrapancreatic Location	Malignancy Rate
Insulinoma	Hypoglycemia Anabolic state	Rare	10%
Gastrinoma (Zollinger–Ellison)	Peptic ulcer Diarrhea	Frequent	50%
VIPoma (Verner–Morrison; WDHA; pancreatic cholera)	Watery diarrhea Hypokalemia Achlorhydria/acidosis	10%	Most
Glucagonoma	Hyperglycemia Catabolic state Dermatitis	Rare	Most
Somatostatinoma	Hyperglycemia Steatorrhea Gallstones	Rare	Most

WDHA, watery diarrhea, hypokalemia, and either achlorhydria or acidosis.

MOLECULAR GENETICS

The majority of PENs are sporadic. Some of them, however, occur as part of inherited familial syndromes such as multiple endocrine neoplasia type 1 (MEN-1), von Hippel–Lindau (VHL) syndrome, neurofibromatosis (NF-1), and tuberous sclerosis (TSC) (see section below on genetic syndromes) (Table 56-3). Recent advances in high throughput DNA sequencing techniques have provided new insights into the genesis of PENs and possible reasons why certain tumors behave more aggressively than others as well as why tumors may respond more favorable to specific therapies (i.e., a more personalized approach to therapy of PENs).

Whole-Exome Sequencing of PENs

Specifically, in a 2011 landmark paper, Jiao et al. sequenced ~18,000 coding genes of 10 clinically well-characterized PENs.[33] Technically, this work dovetailed eloquently and aligned with the group's previous work of sequencing and analyzing multiple pancreatic ductal adenocarcinoma genomes.[34] Importantly, the investigators microdissected the samples in an effort to achieve a high purity and quality of DNA from neoplastic tissue. In the PENs cancer genomes compared to pancreatic ductal adenocarcinoma genomes a number of differences were discovered including >50% fewer mutations in PENs compared to pancreatic adenocarcinoma genomes; and commonly mutated genes such *KRAS* were not mutated in PENs (Table 56-4).[35] These genetic data support the notion that the chromosomal instability (CIN) and tumorigenesis process between these two pathologically distant pancreatic neoplasms are initiated by unique molecular and/or environmental events. The study went on to validate the common findings in the 10 PENs (labeled a discovery set) with an additional 58 PENs. Validating previous work and also underscoring the importance of the disruption in the chromatin-remodeling pathway in PENS, a majority of PENs harbored a tumor-specific inactivating mutation in *MEN-1*. Additional genes functionally important in a chromatin-remodeling complex, *DAXX* (death-domain–associated protein) and *ATRX* (alpha thalassemia/mental retardation syndrome X-linked), were frequently mutated in PENs as well. Correlating the clinical outcomes of these tumors, the study demonstrated that patients in this cohort with *MEN-1, DAXX,* and *ATRX* mutated tumors had unique outcomes compared to the other PENs. More recent work published in 2014, correlated *DAXX* and *ATRX* mutations, activation of alternative lengthening of telomeres, and global chromosomal alterations with pathologic features and outcome data.[36] Interestingly, this study identified that PENs harboring *DAXX* and *ATRX* mutations were more likely to have CIN and patients with this subtype of PENs had a reduction in survival.

Table 56-3 Familial Genetic Syndromes Associated with Pancreatic Endocrine Neoplasms (PENs)

Syndrome	Chromosomal Location	Gene Product	PEN Type
MEN-1	11q13	Menin	Gastrinoma Nonfunctional
VHL syndrome	3p25–26	VHL gene	Various
NF-1	17q11.2	Neurofibromin	Somatostatinomas

MEN-1, multiple endocrine neoplasia 1; NF, neurofibromatosis; VHL, von Hippel–Lindau.

This landmark sequencing work underscored the potential clinical importance of mutations in the mTOR pathway in a subset of PEN patients. As a reminder, the drug rapamycin targets mTOR, and thus, this finding should provide the framework in which we may stratify PEN patients for TOR inhibitor–based therapies (e.g., everolimus).[33] As this work demonstrated that mTOR dysregulation may be an important predictive

marker, others have shown that in a large panel of neuroendocrine tumors (195 of which only 19 where pancreatic) mTOR overexpression and/or its downstream-activated targets were associated with worse clinical outcomes (i.e., adverse prognostic markers).[37] This work provides another instance where a poor prognostic marker (for even development of disease) may serve counterintuitively as a positive predictive marker (for everolimus); an established biomarker, *BRCA2,* acts in a similar fashion.

Table 56-4 Portal Vein Sampling

Target Pathway	PDAC	PENs
Kras	>90%	0%
mTOR	<1%	~15%
TP53	>80%	<5%
DAXX/ATRX	0%	>40%
MEN1	0%	>40%

Examples of discovered "potental targeted" pathways/genes in pancreatic ductal adenocarcinoma (PDAC) compared to PENs. The percent roughly estimates the number of PDACs and PENs that would benefit from these potential targeted approaches.[35]

Genetic Links and Syndromes Related to PENs

Significant progress has been made in the genetic understanding of the MEN-1 syndrome in relation to PENs.[38] Chromosomal linkage studies have localized the genetic defect to the 11q13 locus, and studies of DNA markers have localized the MEN-1 gene between PYGM and D11S97. The gene contains 10 exons that code for a 610-amino-acid protein called menin, whose function is unknown, although it is classically labeled as a tumor suppressor gene. Some studies provide a possible explanation for loss of this gene in neuroendocrine tumors.[39] The menin protein is expressed in diverse tissues and is highly conserved evolutionarily. Menin is predominately a nuclear protein, which binds to JunD and may repress JunD-mediated transcription. Studies in patients with MEN-1 have shown allelic deletions at chromosome 11q13 in nearly 100% of parathyroid tumors, 85% of nongastrinoma islet cell tumors, and up to 40% of gastrinomas. In patients with sporadic tumors (without MEN-1), 11q13 deletions are seen in about 25%, 20%, and almost 50% of parathyroid tumors, nongastrinoma PENs, and gastrinomas, respectively. Recently it has been shown that a comprehensive genetic testing program for patients at risk for MEN-1 can identify patients harboring a MEN-1 mutation almost 10 years before the development of clinical signs or symptoms of disease.[40] Since MEN-1 loss has been detected in both the sporadic and the familial forms of PENs, the menin pathway is most likely involved in the overall pathogenesis of this disease, whether familial or sporadic in nature.[39]

Less frequently than MEN-1, PENs may be associated with VHL syndrome. VHL syndrome is another autosomal dominant inheritance disease that includes many clinical disorders[41] including retinal hemangioblastomas, cerebellar and medullary hemangioblastomas, and PENs. PENs are found in a small percentage of patients with VHL syndrome. A mutation in the VHL gene, a tumor suppressor located on chromosome 3p25–26, which regulates hypoxia-induced cell proliferation, is responsible. Although germline mutations with loss of heterozygosity (LOH) are associated with this disease, it has been proposed that other tumor suppressors most likely cooperate with VHL in order to form PENs. VHL-mutated PENs have been shown to have specific defects in angiogenesis and hypoxia-inducible factor pathways.[42]

NF-1 (von Recklinghausen disease) is an autosomal dominant disorder that produces a well-described clinical syndrome characterized by café-au-lait spots and neurofibromas. These patients may develop pancreatic somatostatinomas, often near the ampulla of Vater. The NF-1 gene is a tumor suppressor gene located on 17q11.2 that encodes for neurofibromin, a regulator of the mammalian target of rapamycin (mTOR) pathway. Loss of NF-1 results in mTOR activation and tumor development.[43,44]

Complementary Progression Modeling

Based on the data from the Marinoni study that attempted to molecularly subtype PENs,[36] a stepwise progression model of PENs were put forth: (1) initiation occurs (unknown mechanism); (2) DAXX/ATRX mutations induce transformation; (3) alternative lengthening of telomere (ALT)[45] activation and CIN; (4) clonal heterogeneity and a

selection of clones; and (5) metastases.[36] Complementary to this work, Zhang described a "double hit model" of PEN progression[35] wherein a first mutational hit (e.g., MEN1 or p53) can induce cell cycle progression, even under harsh tumor microenvironment conditions (low glucose). Then, the second hit (ATRX and mTOR) can cause cell growth and enhance cell invasion and metastatic potential,[35] even in the absence of cell–cell adhesion. These models highlight our recent and enhanced knowledge of the molecular etiology of PEN. However, future work will need to define the main initiating event that sets the stage for PEN transformation. Since *KRAS* activation appears to be unnecessary, other nonclassical genetic events (e.g., epigenetics and posttranscriptional gene regulation) should be surveyed as critical key events in this tumorigenesis process.

Molecular Targeting of PENs

In summary, PENs are becoming easier to characterize molecularly (and clinically) due to large scale sequencing efforts and a better understanding behind the molecular biologic aspects of these pancreatic tumors. Ongoing efforts to search for candidate genes and novel pathways that set the stage for CIN and initiation of tumorigenesis in these tumors will aid in unraveling the molecular etiology of this disease and perhaps even better druggable targets (see Table 56-4 for molecular pathways to target in PENs vs. pancreatic ductal adenocarcinoma). Still, the molecular characterization of these tumors have helped to pave the way for clinical trials targeting tyrosine kinases (e.g., sunitinib) and the mTOR pathways (e.g., everolimus). In fact, recent work explored targeting multiple points throughout the dysregulated pathway (PI3K/AKT/mTOR) in PENs by combining PI3K inhibitors with mTOR inhibitors and demonstrated that this combination may break initial and acquired drug resistance in PENs.[46] Future molecular interrogation of PENs combined with these types of preclinical targeting approaches should continue to move the field closer to a personalized approach to treating PENs with better targeted therapies.

PRESENTATION AND EVALUATION

There are three primary ways by which patients with PENs come to clinical attention: the incidental discovery of a mass in the pancreas during cross-sectional imaging, symptoms secondary to the mass effect of a lesion in the pancreas (i.e., obstructive jaundice or pain), and, as a consequence of the symptoms of a syndrome associated with a functional PEN. As mentioned previously, incidentally detected nonfunctional PENs currently comprise the majority of clinically relevant tumors. They are typically hypervascular on imaging studies such as computed tomography (CT) or magnetic resonance imaging (MRI). In the absence of any clinical syndrome, these lesions can be managed as any other incidental pancreatic lesion. Typically, the size of a PEN at discovery guides decision making between three standard options: serial observation, endoscopic ultrasound-guided biopsy, or definitive surgical resection. Size greater than 2 cm is a standard stratification measure, with lesions larger than this usually managed in a more aggressive fashion. If a nonfunctional PEN is suspected, baseline serum levels of chromogranin A and pancreatic polypeptide can be useful diagnostic markers prior to surgical resection. Chromogranin A is a 49-kDa protein contained within the neurosecretory vesicles of PENs, whose levels should be measured prior to surgical resection and are expected to significantly decline in the postoperative period with removal of the tumor burden. The chromogranin A levels can be tracked over time to document tumor recurrence, often before the lesions become visible on cross-sectional imaging studies.[47] Pancreatic polypeptide is secreted by the PP cells of the islets of Langerhans and can also be used to track patients with PENs, though its sensitivity (63%) is lower than that of chromogranin A.[48] Neuron-specific enolase is another tumor marker that is elevated in approximately 50% of PENs, most commonly in patients with pulmonary metastases.[49]

PENs presenting due to mass effect on surrounding structures resulting in jaundice, pain, or gastric outlet obstruction are uncommon. These lesions should be addressed as any other symptomatic pancreatic lesion with definitive surgical resection if clinically appropriate.

Patients presenting with symptoms from a functional PEN can be a diagnostic challenge. Three general principles apply to the diagnosis and treatment of patients with suspected functional neoplasms of the endocrine pancreas. One must first recognize the abnormal physiology or characteristic syndrome. Patients are often misdiagnosed or have their symptoms disregarded for years before an accurate diagnosis is reached. Characteristic clinical syndromes are well described for insulinoma, gastrinoma, VIPoma, and glucagonoma. The somatostatinoma syndrome is nonspecific, much more difficult to recognize, and exceedingly rare. Second is the detection of hormone elevations in the serum by radioimmunoassay. Such assays are readily available for measuring insulin, gastrin, vasoactive intestinal peptide (VIP), and glucagon. Assays for somatostatin, pancreatic polypeptide (PP), prostaglandins, and other hormonal markers are less commonly available but can be obtained from certain laboratories. The third step involves localizing and staging the tumor in preparation for possible operative

intervention (Algorithm 56-1).

LOCALIZATION AND STAGING

Computed Tomography

4 The initial imaging technique used to localize a PEN and stage the disease is high-quality multidetector three-dimensional CT.[50] The accuracy of CT in detecting primary PENs ranges from 64% to 82% and depends largely on the size of the tumor.[51,52] PENs are typically hyperdense (bright) on arterial phases of imaging. Lesions that are obvious during the early arterial phase can become isodense on later phases of imaging. Therefore, a multiphase approach is typically recommended.[53,54] CT is useful in assessing size and location of the primary tumor, proximity to visceral vessels, peripancreatic lymph node involvement, and the presence or absence of liver metastases (Fig. 56-1).

Magnetic Resonance Imaging

MRI is increasingly used in the detection of PENs, particularly small lesions. They are especially well visualized on T1- and T2-weighted images with fat suppression. MRI has the advantage of increased soft tissue contrast without the administration of intravenous contrast when compared to CT.[42] PENs characteristically have high signal intensity on T2-weighted images.[55] On dynamic contrast-enhanced T1-weighted images, the tumors show the same typical enhancement pattern as on CT scan. The sensitivity of MRI has been reported to be between 74% and 100%.[51,52]

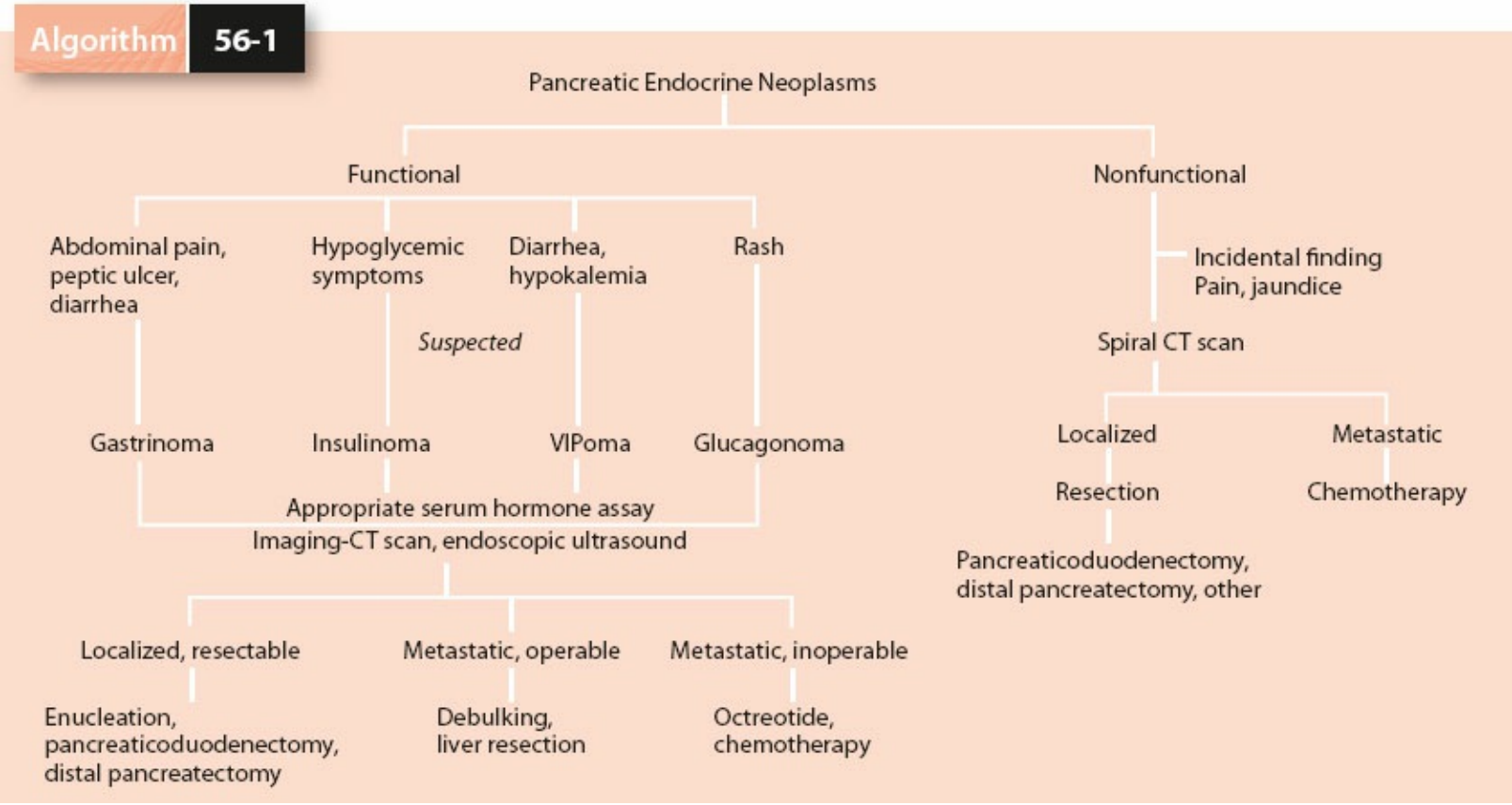

Algorithm 56-1. Diagnosis and management of pancreatic endocrine neoplasms.

Somatostatin Receptor Scintigraphy (Octreoscan)

Somatostatin receptor scintigraphy (SRS) also plays an important role in imaging patients with pancreatic endocrine tumors.[56–62] In this technique, the octapeptide analog of somatostatin (Octreotide) labeled with indium-111 is administered intravenously to patients in whom a PEN is suspected. Because neuroendocrine tumors often express large numbers of somatostatin receptors on their cell surfaces (Fig. 56-2), the tracer preferentially identifies tumors. The overall sensitivity of SRS has been reported to range from 74% to near 100% depending on the functional type of PEN.[63] There is a significant false-negative rate, indicating that negative SRS findings in patients with PENs should be viewed with caution. Nonfunctional tumors and insulinomas seem to be localized less frequently by SRS, while SRS performs well for gastrinoma, VIPoma, and glucagonoma. In addition, SRS appears to play a role in the evaluation of patients with metastatic pancreatic endocrine tumors, especially in identifying extrahepatic tumor spread. In a study by Frilling et al.,[62] 54% of patients with liver metastases had extrahepatic tumor spread detected by SRS that was not detected by alternate imaging techniques.

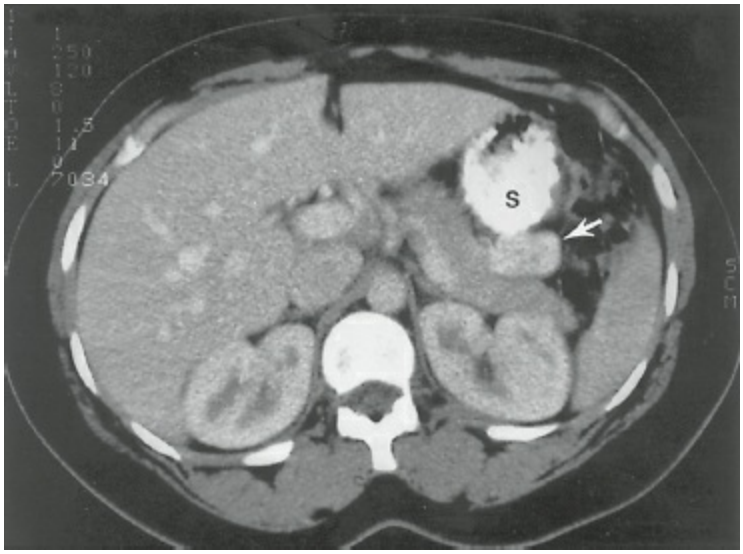

Figure 56-1. Computed tomography with oral and intravenous contrast in a patient with biochemical evidence of insulinoma. The neoplasm (*arrow*) is seen as a contrast-enhancing structure, 3 cm in diameter, in the tail of the pancreas posterior to the stomach (S). (From Yeo CJ. Islet cell tumors of the pancreas. In: Niederhuber JE, ed. *Current Therapy in Oncology*. St. Louis, MO: Mosby; 1993:272, with permission.)



Figure 56-2. Octreotide scan (*anterior view*) in a patient with a large endocrine tumor in the tail of the pancreas (large dark mass, upper right) and several hepatic metastases (upper left quadrant). A small amount of the tracer is seen in the bladder (lower midline).

Endoscopic Ultrasound

5 Endoscopic ultrasonography (EUS) has also shown utility in localizing PENs.[64–68] Rosch et al.[67] were able to localize 32 of 39 tumors (82%) correctly with EUS after CT had failed to locate the tumor (Fig. 56-3). In their experience, EUS was more sensitive than the combination of CT and visceral angiography. A more recent study by Proye et al.[69] evaluated preoperative EUS and SRS in 41 patients with insulinoma and gastrinoma. The sensitivity and positive predictive value of EUS were 77% and 94%, respectively, for pancreatic tumors; 40% and 100%, respectively, for duodenal gastrinomas; and 58% and 78%, respectively, for metastatic lymph nodes. These results indicate that EUS is best at detecting lesions in the head of the pancreas. It is less successful at evaluating the distal pancreas and the duodenal wall. Additionally, the procedure is operator dependent.[70] These results have been duplicated by others and have led some to suggest that EUS should serve as the initial localization procedure in patients with insulinoma and gastrinoma. Of note, the drawback to EUS is that it does not evaluate accurately for hepatic metastatic disease; rather, it is more sensitive than CT for imaging the duodenal wall, pancreatic parenchyma, and peripancreatic lymph nodes.

Intraoperative Ultrasound

Historically, the primary methods of localizing PENs intraoperatively have been visualization and palpation. With the advent of laparoscopic exploration for PENs, intraoperative ultrasound has been substituted for palpation. Results have been promising, with sensitivities reported between 75% and 90%.[71,72]

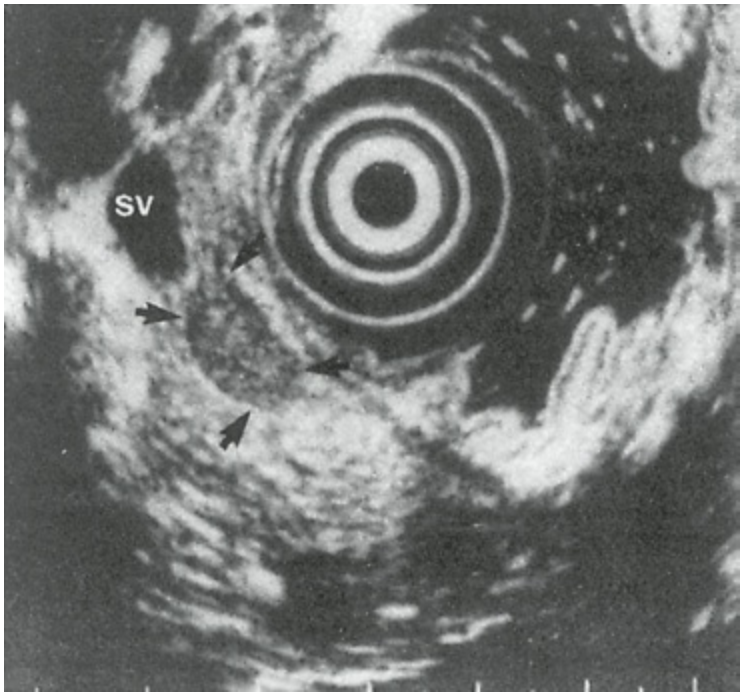

Figure 56-3. Endoscopic ultrasonographic image from a patient with an insulinoma (*arrows*) in the body of the pancreas. SV, splenic vein. (From Rosch T, Lightdale CJ, Botet JF, et al. Localization of pancreatic endocrine tumors by endoscopic ultrasonography. *N Engl J Med* 1992;326:1721–1726, with permission.)

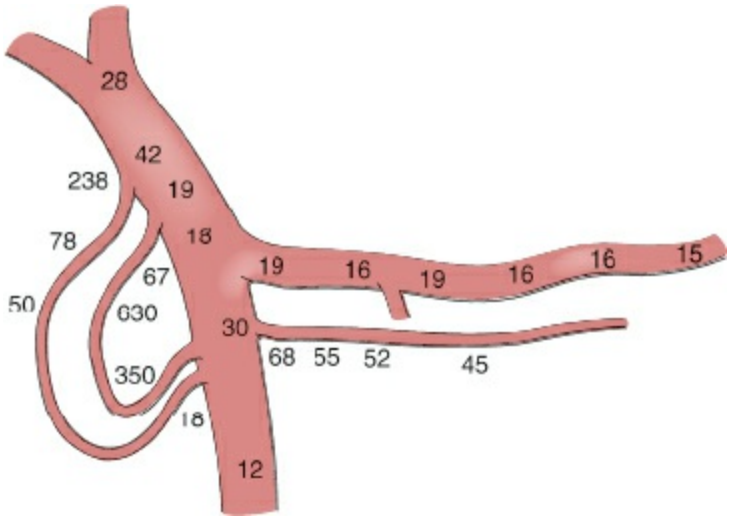

Figure 56-4. Schematic depiction of data from percutaneous transhepatic portal venous sampling (PTPVS) in a patient with an insulinoma. Insulin levels are given in microunits per milliliter. These data localize the neoplasm to the head of the pancreas. (Adapted from Norton JA, Sigel B, Baker AR, et al. Localization of an occult insulinoma by intraoperative ultrasonography. *Surgery* 1985;97:381–384.)

Venous Sampling

Percutaneous transhepatic portal venous sampling (PTPVS) and arterial stimulation with venous sampling (ASVS) are two techniques that are used exclusively for the diagnosis and localization of PENs. In a small number of cases, CT, MRI, SRS, and EUS are unsuccessful at localizing a PEN. When insulinoma or gastrinoma are suspected, PTPVS may help in localizing the occult neoplasm.[73–77] The technique involves placing a catheter percutaneously through the liver into the portal vein and then sequentially sampling for hormone levels in the splenic vein, superior mesenteric vein, and portal vein, thereby regionalizing the location of hormone production (Fig. 56-4). The overall accuracy of this test ranges from 70% to greater than 95% depending on the number of samples obtained, the persistence of autonomous hormone production by the tumor, and the careful handling and assaying of all samples. ASVS involves the selective visceral arterial injection of secretin or calcium with concurrent hepatic venous sampling for either gastrin or insulin.[78,79] Gastrinoma cells are known to respond to secretin by releasing gastrin,[80,81] and insulinoma cells are known to respond to calcium by releasing insulin. The provocative secretogogue is serially injected through an arterial catheter into at least three sites – the splenic, gastroduodenal, and inferior pancreaticoduodenal arteries. Samples are drawn from a hepatic vein catheter before and immediately after each injection. The arterial supply to the occult tumor can then be deduced based on which selective secretogogue injection is followed by a large increase in hepatic vein hormone concentration (Fig. 56-5). This technique, particularly when combined with intraoperative ultrasonography, results in a sensitivity of greater than 90%, essentially obviating the need for blind resection in unlocalized insulinomas.[71,82] Additionally, ASVS can differentiate the 5% of patients with nesidioblastosis from those with insulinoma.[83]

SURGICAL EXPLORATION

At the time of surgical exploration for PEN, a complete evaluation of the pancreas and peripancreatic regions is performed. The body and tail of the pancreas are exposed by dividing the gastrocolic ligament and entering the lesser sac. This portion of the pancreas can be partially elevated out of the retroperitoneum by dividing the inferior retroperitoneal attachments to the gland. After the second portion of the duodenum has been elevated out of the retroperitoneum by means of the Kocher maneuver, the pancreatic head and uncinate process are palpated bimanually. The liver is carefully assessed for evidence of metastatic disease. Potential extrapancreatic sites of tumor are evaluated in all cases, with particular attention paid to the duodenum, splenic hilum, small intestine and its mesentery, peripancreatic lymph nodes, and reproductive tract in women. The goals of surgical therapy for PENs include controlling the symptoms of hormone excess, safely resecting maximal tumor mass, and preserving maximal pancreatic parenchyma. Management strategies, including preoperative, intraoperative, and postoperative considerations, vary for the different types of endocrine neoplasms of the pancreas.

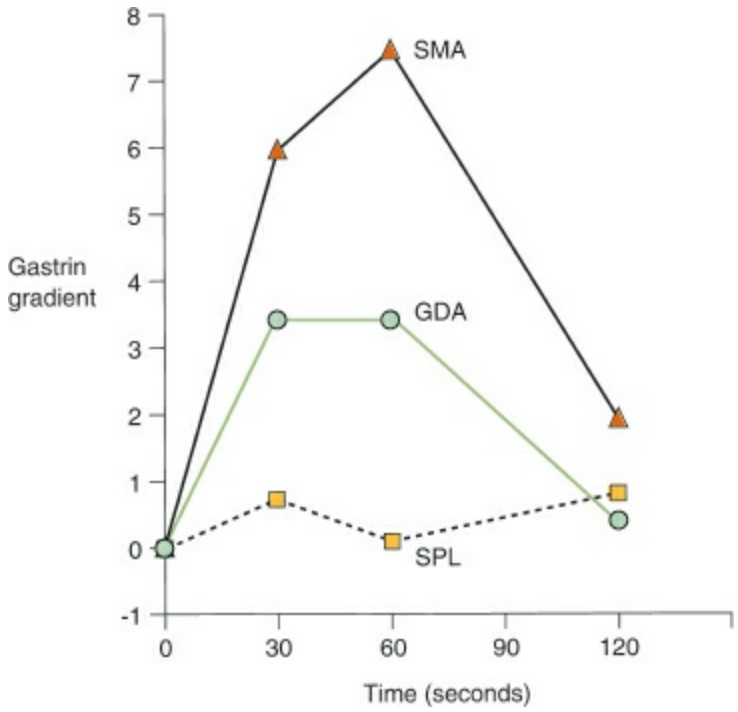

Figure 56-5. Graphic depiction of the results of arterial stimulation with venous sampling (ASVS) in a patient with gastrinoma. The rise in hepatic vein gastrin concentration (gastrin gradient) is plotted on the y-axis, and basal values are plotted on the x-axis: 1, 100% rise; 2, 200% rise; and so forth. A rise in the hepatic vein gastrin concentration observed after the injection of secretin into the superior mesenteric artery (SMA) and gastroduodenal artery (GDA) localizes the neoplasm to the head of the pancreas or duodenum. SPL, splenic artery. (Adapted from Thom AK, Norton JA, Doppman JL, et al. Prospective study of the use of intra-arterial secretin injection and portal venous sampling to localize duodenal gastrinomas. *Surgery* 1992;112:1002–1028; discussion 1008–1009.)

INSULINOMA

Insulinoma is the most common functional neoplasm of the endocrine pancreas (Table 56-5). The insulinoma syndrome is associated with the following features, known as Whipple triad[84]:

1. Symptoms of hypoglycemia during fasting
2. Documentation of hypoglycemia, with a serum glucose level typically below 50 mg/dL
3. Relief of hypoglycemic symptoms following administration of exogenous glucose

6 Autonomous insulin secretion in insulinomas leads to spontaneous hypoglycemia, with symptoms that can be classified into two groups (Table 56-5). Neuroglycopenic symptoms include confusion, seizure, obtundation, personality change, and coma. Hypoglycemia-induced symptoms, related to a surge in catecholamine levels, include palpitations, trembling, diaphoresis, and tachycardia. In most cases, patients consume carbohydrate-rich meals and snacks to relieve or prevent these symptoms.

Table 56-5 Insulinoma

Parameter	Description
Symptoms	Neuroglycopenia causes confusion, personality change, coma Catecholamine surge causes trembling, diaphoresis, tachycardia Anabolic state: weight gain
Diagnostic tests	Monitored fast Insulin-to-glucose ratio
Anatomic localization	Evenly distributed throughout pancreas

Whipple triad is not specific for insulinoma. The differential diagnosis of adult hypoglycemia is extensive and includes the following: reactive hypoglycemia, functional hypoglycemia associated with gastrectomy or gastroenterostomy, nonpancreatic tumors, pleural mesothelioma, sarcoma, adrenal carcinoma, hepatocellular carcinoma, carcinoid, hypopituitarism, chronic adrenal insufficiency, extensive hepatic insufficiency, and surreptitious self-administration of insulin or ingestion of oral hypoglycemic agents.

A common error made in evaluating a patient with suspected insulinoma is to begin with an oral glucose tolerance test. Instead, insulinoma is most reliably diagnosed by means of a monitored fast (via the withholding of exogenous glucose). During a monitored fast, blood is sampled for glucose and insulin determinations every 4 to 6 hours and when symptoms appear. Hypoglycemic symptoms typically occur when glucose levels are below 50 mg/dL, with concurrent serum insulin levels often exceeding 25 microunits/mL. Additional support for the diagnosis of insulinoma comes from the calculation of the insulin-to-glucose ratio at different times during the monitored fast. Normal persons have insulin-to-glucose ratios below 0.3, whereas patients with insulinoma typically demonstrate insulin-to-glucose ratios above 0.4 after a prolonged

fast. Other measurable β-cell products synthesized in excess in patients with insulinoma include C peptide and proinsulin. Elevated levels of both are typically found in the peripheral blood of patients with insulinoma.

The possibility of the surreptitious administration of insulin or oral hypoglycemic agents should be considered in all patients with suspected insulinoma. Levels of C peptide and proinsulin are not elevated in patients who self-administer insulin. Additionally, patients self-administering either bovine or porcine insulin may demonstrate anti-insulin antibodies in circulating blood. The ingestion of oral hypoglycemic agents, such as sulfonylureas, can be assessed by means of standard toxicologic screening.

7 Insulinomas are evenly distributed throughout the pancreas, with one-third found in the head and uncinate process, one-third in the body, and one-third in the tail of the gland.[85] Less than 3% are located outside the pancreas, with these lesions located in the peripancreatic area.[86] Ninety percent are found to be benign solitary adenomas amenable to surgical cure. Ninety percent of insulinomas are sporadic, with approximately 10% being associated with the MEN-1 syndrome. In patients with MEN-1, the possibility of multiple insulinomas must be considered, and recurrence rates are higher. In approximately 10% of patients, insulinoma is metastatic to the peripancreatic lymph nodes or liver, making the diagnosis of malignant insulinoma.

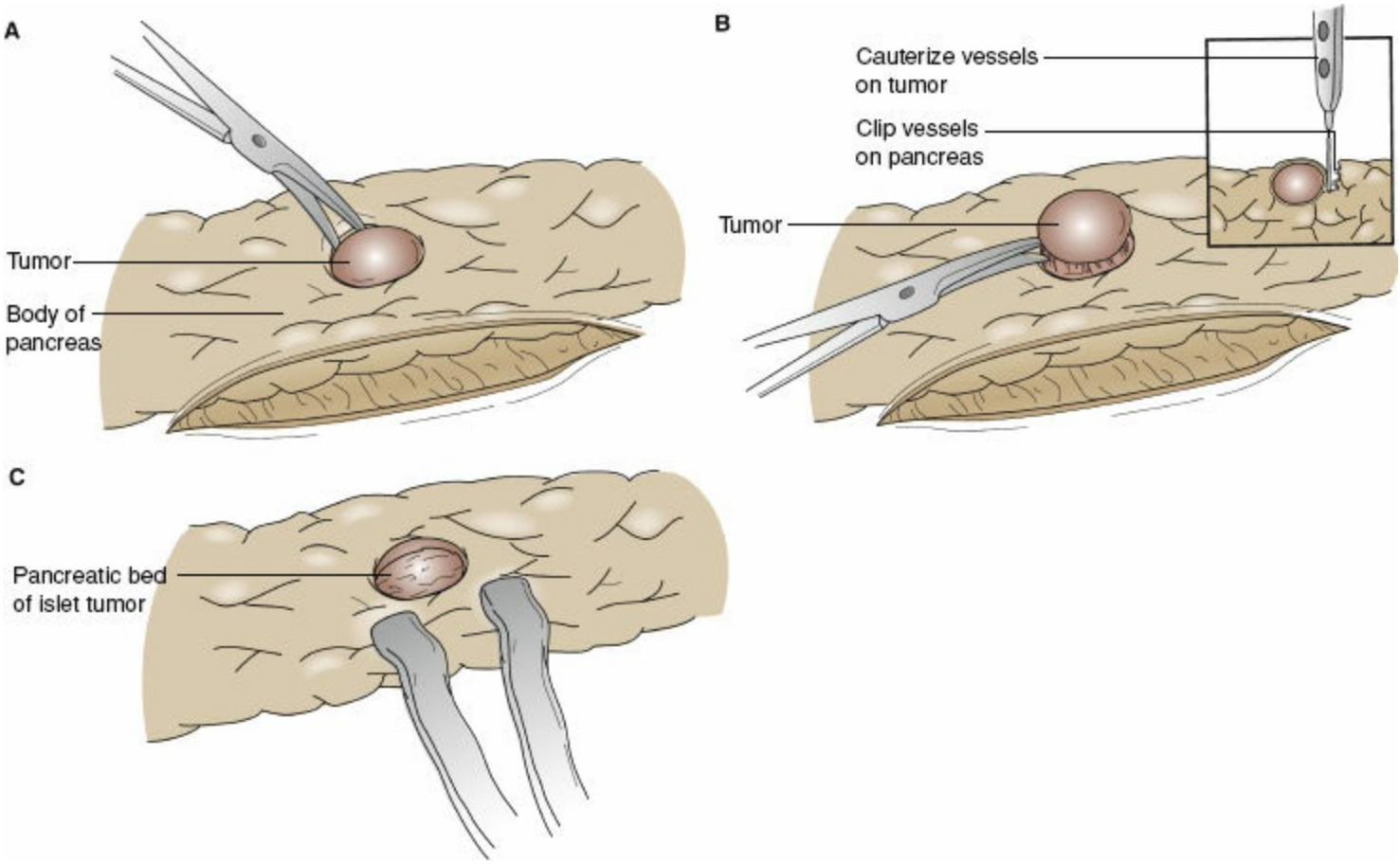

Figure 56-6. The technique for enucleating a benign pancreatic endocrine neoplasm with scissors (**A**) or electrocautery (**B**). **C:** After enucleation, the site of excision is drained.

After the diagnosis of insulinoma has been confirmed biochemically, the appropriate

localization and staging studies described earlier are performed (typically CT and EUS). Once the lesion has been localized,[87] patients undergo surgical exploration, where the pancreas is assessed not only by operative palpation but also by intraoperative ultrasonography. This allows for confirmation of preoperative localization and evaluates for the presence or absence of multiple primary tumors. Small, benign tumors that are not close to the main pancreatic duct can be removed by enucleation[88] (Fig. 56-6), regardless of their location in the gland. Larger tumors in the neck or proximal body may be resected via central pancreatectomy.[89–91] In the body and tail of the pancreas, insulinomas more than 2 cm in diameter and those close to the pancreatic duct are most commonly removed via distal pancreatectomy. Large lesions in the head or uncinate process of the gland may not be amenable to local resection and may occasionally require pancreaticoduodenectomy for complete excision.[92,93] Increasingly, experienced surgeons are utilizing a laparoscopic approach to these tumors. Both laparoscopic pancreatectomy and enucleation are now performed on a routine basis with excellent results.[94–98]

In rare instances, preoperative localization studies and intraoperative ultrasound fail to identify the tumor. Intraoperative biopsy of the pancreatic tail may help make the diagnosis of nesidioblastosis as the cause of hyperinsulism. Some authors have recommended a “blind” distal pancreatic resection to the level of the superior mesenteric vein (60% to 70% pancreatectomy), in the hope of excising an unidentified insulinoma in the body and tail. Others have suggested blind pancreaticoduodenectomy, because the thickness of the gland in this region makes it more likely to harbor an occult neoplasm. The favored approach at the current time is to defer any blind resection, close the patient without pancreatectomy, and perform postoperative selective arterial calcium stimulation with hepatic venous insulin sampling to allow for specific tumor localization and directed surgical excision at a second operation.[99]

Approximately 10% of insulinomas are malignant, presenting with lymph node or liver metastases. In the presence of hepatic metastases, resection of the primary tumor and accessible metastases should be considered if it can be performed safely.[100–102] Such tumor debulking can be helpful in reducing hypoglycemic symptoms and improving long-term survival. In patients with unresectable disease, medications such as diazoxide and octreotide can be used to reduce insulin secretion from the tumor, minimizing hypoglycemia. One promising new treatment is everolimus, an oral rapamycin analog that inhibits mammalian target of rapamycin (mTOR). In a pilot study of patients with refractory hypoglycemia due to metastatic insulinoma, everolimus resulted in improved glycemic control.[103] Dietary manipulations, including judicious spacing of carbohydrate-rich meals and the consumption of nighttime snacks, can also reduce the number of hypoglycemic episodes. Multiple chemotherapeutic regimens have been used including streptozocin, dacarbazine, doxorubicin, and 5-fluorouracil.[104–106] Combination chemotherapy has yielded the highest response rates but has not been shown to be curative.

GASTRINOMA (ZOLLINGER–ELLISON SYNDROME)

8 In 1955, Zollinger and Ellison described two patients with severe peptic ulcer disease and pancreatic endocrine tumors and postulated that an ulcerogenic agent originated from the pancreatic tumor.[107–109] It has been estimated that approximately 1 in 1,000 patients with primary duodenal ulcer disease and 2 in 100 patients with recurrent ulcer after ulcer surgery harbor gastrinomas.[110] Seventy-five percent of gastrinomas occur sporadically, and 25% are associated with the MEN-1 syndrome. Historically, the majority of gastrinomas were found to be malignant, with metastatic disease present at the time of initial workup. With increased awareness and screening for hypergastrinemia, the diagnosis of gastrinoma is made earlier and a higher percentage of patients present with benign and potentially curable neoplasms.[111]

Table 56-6 Gastrinoma

Parameter	Description
Symptoms	Peptic ulcer disease Diarrhea Esophagitis
Diagnostic tests	Serum gastrin measurement Gastric acid analysis (or pH testing) Secretin stimulation test
Anatomic localization	Duodenum and head of pancreas (gastrinoma triangle)

The clinical symptoms of patients with gastrinoma are a direct result of increased levels of circulating gastrin (Table 56-6). Abdominal pain and peptic ulceration of the upper gastrointestinal (UGI) tract are seen in up to 90% of patients. Diarrhea is seen in 50% of patients, with 10% having diarrhea as their only symptom. Esophageal symptoms or endoscopic abnormalities resulting from gastroesophageal reflux are seen in up to half of patients. The diagnosis of gastrinoma should be suspected in several clinical settings, including the initial diagnosis of peptic ulcer disease, recurrent ulcer after medical or surgical therapy, postbulbar ulcer, family history of ulcer disease, ulcer with diarrhea, prolonged undiagnosed diarrhea, MEN-1 kindred, nongastrinoma pancreatic endocrine tumors (high association of secondary hormone elevations), and prominent gastric rugal folds on UGI examination. Serum gastrin levels should be obtained in all of these settings.

In most patients with gastrinoma, the fasting serum gastrin level is greater than 200 pg/mL. Gastrin levels greater than 1,000 pg/mL in the setting of documented hyperacidity and ulcer disease are virtually pathognomonic for gastrinoma. Because hypergastrinemia can occur in other pathophysiologic states (Table 56-7), fasting hypergastrinemia alone is not sufficient for the diagnosis of gastrinoma. Gastric acid analysis (or at least gastric pH testing) is critical in differentiating between ulcerogenic (high levels of acid) and nonulcerogenic (low levels of acid) causes of hypergastrinemia. To obtain an accurate gastric acid analysis, patients must not be taking antisecretory

medications including histamine (H_2)-receptor antagonists or proton pump inhibitors (PPIs). The diagnosis of gastrinoma is supported by a basal acid output above 15 mEq/hr in nonoperated patients, a basal acid output exceeding 5 mEq/hr in patients with previous vagotomy or ulcer operations, or a ratio of basal acid output to maximal acid output exceeding 0.6.

Table 56-7 Disease States Associated With Hypergastrinemia

Nonulcerogenic causes (normal to low gastric acid secretion)
Atrophic gastritis
Pernicious anemia
Previous vagotomy
Renal failure
Short-gut syndrome
Ulcerogenic causes (excess gastric acid secretion)
Antral G-cell hyperplasia or hyperfunction
Gastric outlet obstruction
Retained excluded gastric antrum
Zollinger–Ellison syndrome

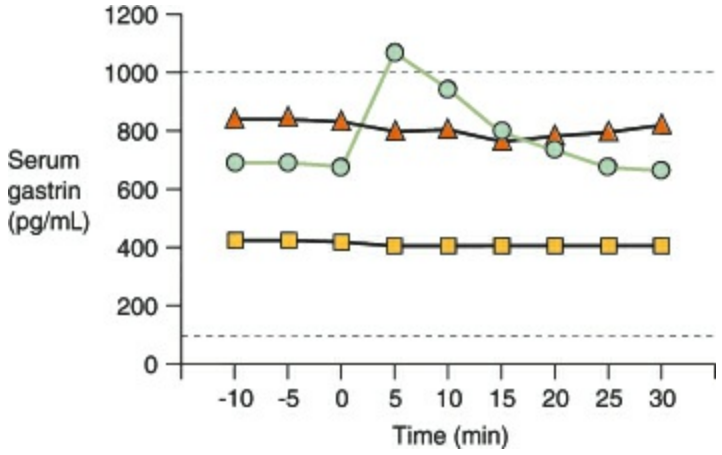

Figure 56-7. Results of intravenous secretin stimulation tests in patients with atrophic gastritis (*triangles*), gastric outlet obstruction (*squares*), and gastrinoma (*circles*). A positive test result, consistent with the presence of gastrinoma, is indicated by an increase over basal serum gastrin levels of at least 200 pg/mL. (Adapted from Wolfe MM, Jensen RT. Zollinger-Ellison syndrome: current concepts in diagnosis and management. *N Engl J Med* 1987;317:1200–1209.)

After documenting that hypergastrinemia and excessive acid secretion exist, provocative testing with secretin should be performed to differentiate between gastrinoma, antral G-cell hyperplasia or hyperfunction, and the other causes of ulcerogenic hypergastrinemia. This is achieved with a secretin stimulation test (Fig. 56-7). A baseline gastrin level is drawn. The patient is then stimulated with 2 units/kg of secretin as an intravenous bolus and subsequent gastrin samples are collected at 5-minute intervals for 30 minutes. An increase in the gastrin level by more than 200 pg/mL above the basal level supports the diagnosis of gastrinoma.

After the biochemical diagnosis of gastrinoma has been made, the gastric acid hypersecretion should be pharmacologically controlled. The PPIs are now considered the

drugs of choice for doing so.[112,113] The dose is adjusted to achieve a nonacidic pH during the hour immediately before the next dose of the drug. Typically, PPI doses needed for acid control exceed usual dosing levels. After the initiation of antisecretory therapy, all patients should undergo imaging studies to localize the primary tumor and to assess for metastatic disease.

If localization studies reveal unresectable hepatic metastases, the patient should undergo percutaneous or laparoscopic-directed liver biopsy to obtain a definitive histologic diagnosis. These patients should be maintained on long-term PPI therapy. Virtually all patients can be rendered achlorhydric with an appropriate dose of PPIs. Patients noncompliant with antisecretory therapy who experience complications related to their ulcer diathesis may require removal of the end organ (total gastrectomy) if tumor resection is not possible. However, total gastrectomy, once the operation of choice for gastrinoma, is now only rarely used.

9 If unresectable disease is not identified by staging studies, patients should be offered surgical exploration with curative intent. On exploration, the entire abdomen should be assessed for areas of extrapancreatic and extraduodenal gastrinomas. Most gastrinomas are found in the *gastrinoma triangle*[85,114] (Fig. 56-8), the area to the right of the superior mesenteric vessels, in the head of the pancreas or in the duodenal wall. Both intraoperative ultrasound and intraoperative upper endoscopy may be helpful in tumor localization. Transillumination of the duodenum may help identify small duodenal gastrinomas.[115,116] Well-encapsulated tumors less than 2 cm in size and distant from the pancreatic duct can be enucleated. Those situated deep in the parenchyma may require partial resection by pancreaticoduodenectomy or distal pancreatectomy. If no pancreatic tumor is identified, a longitudinal duodenotomy should be performed at the level of the second portion of the duodenum in search of duodenal microgastrinomas.[117,118] Small gastrinomas in the duodenal wall can be locally resected with primary closure of the duodenal defect. The routine use of duodenotomy increases the short- and long-term cure rates in patients with sporadic gastrinoma, because such a duodenotomy allows detection of more duodenal gastrinomas.[119] Duodenotomy did not impact the occurrence of hepatic metastases or disease-related mortality. In a small percentage of patients, gastrinoma is found only in peripancreatic lymph nodes, with these lymph nodes harboring the apparent primary tumor. Resection of these apparent lymph node primary gastrinomas has been associated with long-term eugastrinemia and biochemical cure in up to half of cases.[120] A review from the National Institutes of Health identified likely primary lymph node gastrinomas in 26 of 176 gastrinoma patients (14.7%), with 69% being eugastrinemic at a mean of 10 years after resection.[121]

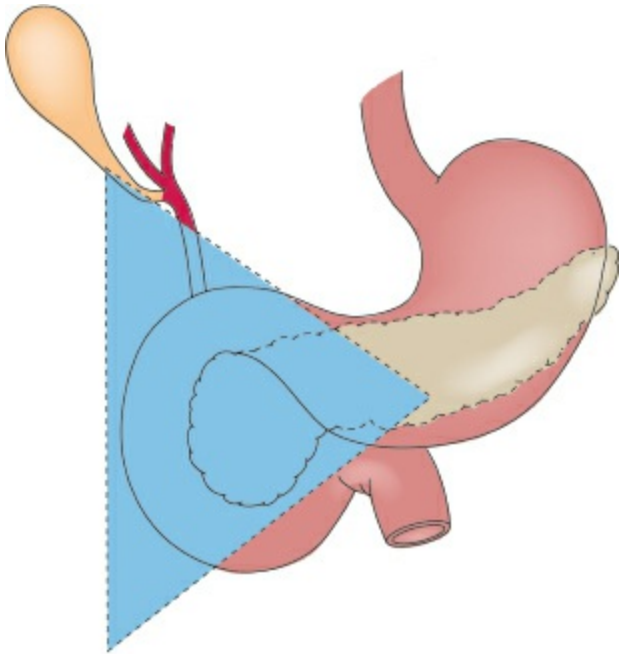

Figure 56-8. Most gastrinomas are found within the gastrinoma triangle.

Occasionally, preoperative localization studies may identify the tumor in the gastrinoma triangle, but at the time of exploration, the tumor is not demonstrable. Several surgical options are available at this point. First, a parietal cell vagotomy has been proposed as a way to reduce antisecretory drug dose requirements in patients on high-dose antisecretory drug therapy but without prior life-threatening complications.[122] However, this approach leaves behind potentially resectable gastrinoma and has lost favor as an option. A second option is total gastrectomy; however, the availability of PPIs has drastically reduced the need to perform this operation for gastrinoma. It may have a limited role in patients whose tumors cannot be localized, if they cannot or will not take their PPIs. Like parietal cell vagotomy, this leaves tumor behind. A third, controversial option in patients with localization to the gastrinoma triangle is blind pancreaticoduodenectomy. Some argue this should include distal gastrectomy, as duodenal gastrinomas may arise close to the pylorus and be left behind during a pylorus-preserving resection.

Patients with sporadic gastrinomas tend to fare better following resection than those with MEN-1. In a series of 151 patients reported by Norton et al.,[123] 123 had sporadic gastrinoma and 28 had MEN-1–associated gastrinoma. Of those with sporadic gastrinoma, 34% were free of disease 10 years following resection. None of the MEN-1 patients were free of disease at 10 years. A more recent review of 195 patients from the same institution demonstrated clear superiority of surgical intervention over other treatment strategies.[124] The rate of disease-related death was increased 23-fold in the group of patients treated without surgery. These data provide compelling evidence that patients with sporadic gastrinoma benefit from surgical exploration and complete tumor resection.

The management of gastrinoma in MEN-1 is not as clear. The surgical treatment of hypercalcemia caused by parathyroid hyperplasia should precede any surgery for hypergastrinemia in patients with MEN-1. In these patients, gastrin-secreting tumors are often multicentric and associated with lymph node metastases. Although some groups

have favored exploration only when MEN-1 gastrinoma tumors exceed 3 cm, it seems that earlier intervention may be warranted.[125,126] Unfortunately, more data from an appropriate clinical trial are needed to better define the timing of surgery for MEN-1 gastrinoma.

In the 1950s and 1960s, most gastrinomas were diagnosed late in the course of the disease, when the tumor burden was already significant. At that time, effective medical therapy did not exist, nor did sophisticated radiographic localization and staging techniques. Patients often suffered multiple ulcer complications, required total gastrectomy to control the ulcer diathesis, and typically succumbed to continued tumor growth following gastrectomy. Recent reviews of patients with surgically treated gastrinoma provide room for optimism.[127–130] Currently, up to 35% of patients who undergo resection with curative intent have been rendered eugastrinemic at follow-up. Cure rates approach 60% to 70% when the extent of disease allows a complete resection.

Most patients with incurable metastatic disease eventually die of tumor growth and dissemination. Multiple modalities have been used to treat such patients. Chemotherapy including streptozocin, 5-fluorouracil, and doxorubicin provides response rates of less than 50%.[131] Hormonal therapy with octreotide may relieve symptoms, reduce hypergastrinemia, and diminish hyperchlorhydria.[132,133] In patients with hepatic metastases, aggressive resection for debulking,[134–137] hepatic transplantation,[138] hepatic artery embolization, and interferon therapy have all been used, with variable results.

VIPOMA (VERNER–MORRISON SYNDROME)

Synonyms for VIPoma include WDHA syndrome (watery diarrhea, hypokalemia, and either achlorhydria or acidosis) and pancreatic cholera syndrome (Table 56-8). Verner and Morrison[139] characterized this secretory diarrheal syndrome in a 1958 report. Patients characteristically present with intermittent, severe, watery diarrhea averaging up to 5 L/d. Hypokalemia results from fecal loss of large amounts of potassium. Low serum potassium levels lead to lethargy, muscle weakness, and nausea. A metabolic acidosis may be present, due to loss of bicarbonate in the diarrhea. Half of the patients may have hyperglycemia or hypercalcemia, and cutaneous flushing can be observed in a minority. The diagnosis of VIPoma is made after other common causes of diarrhea have been excluded (Table 56-9)[140] and an elevated serum VIP level is documented.

Table 56-8 VIPoma

Parameter	Description
Symptoms	Watery diarrhea Weakness Lethargy Nausea
Diagnostic tests	Hypokalemia Achlorhydria Metabolic acidosis Serum VIP levels elevated
Anatomic localization	Most in body and tail of pancreas, with liver metastases

VIP, vasoactive intestinal peptide.

Table 56-9 Differential Diagnosis of Verner–Morrison Syndrome

Entity	Workup
Villous adenoma	Lower GI endoscopy
Laxative abuse	Stool examination for phenolphthalein
Celiac disease	Fecal fat measurement D-xylose tolerance test Small bowel biopsy
Parasitic and infectious diseases	Stool culture Ovum and parasite analysis *Clostridium difficile* toxin assay
Inflammatory bowel disease	Lower GI endoscopy Upper GI and small bowel series
Carcinoid syndrome	Urinary 5′-HIAA Upper GI and small bowel series Abdominal CT Serum serotonin measurement
Gastrinoma	Serum gastrin measurement Gastric acid analysis Secretin stimulation test

CT, computed tomography; GI, gastrointestinal; 5′-HIAA, 5′-hydroxyindoleacetic acid.

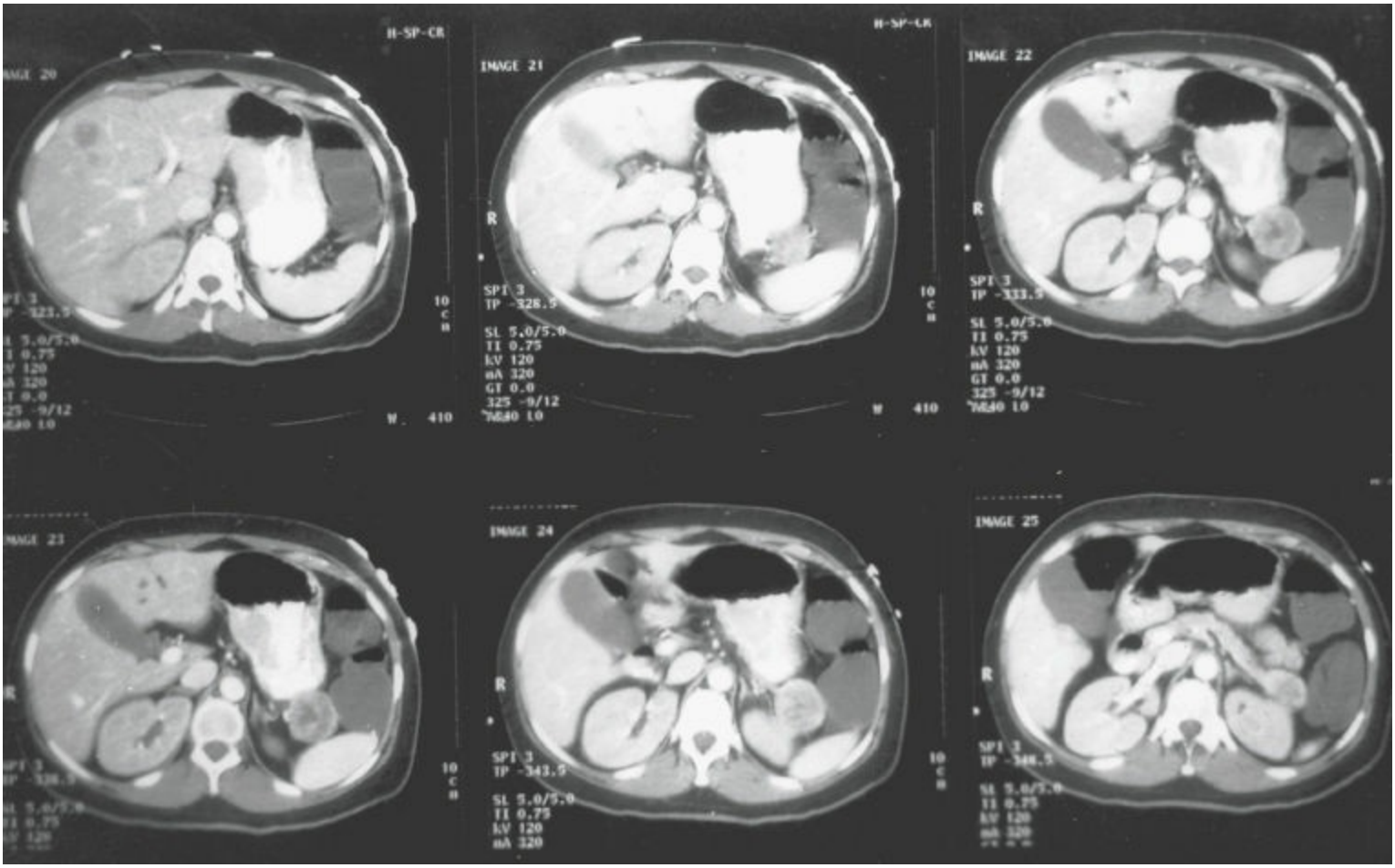

Figure 56-9. Several computed tomographic images from a patient with a primary vasoactive intestinal polypeptide-oma (VIPoma) in the tail of the pancreas. The tumor is nearly spherical. Its location is posterior to the stomach and adjacent to the spleen.

VIP secretion can be episodic, so repeated fasting levels should be measured if there is

a strong clinical suspicion. Preoperative tumor localization is critical, because 10% of patients may have extrapancreatic tumors located in the retroperitoneum or chest. Most tumors are located in the distal pancreas where they are amenable to resection via distal pancreatectomy (Fig. 56-9). In most cases, hepatic metastases accompany the primary tumor. Therapies directed at debulking these metastases such as resection or ablative strategies are appropriate.

Surgical excision is appropriate in nearly all patients with Verner–Morrison syndrome. Prior to surgery, fluid and electrolyte imbalances must be corrected. Octreotide can serve as a treatment adjunct, reducing the levels of circulating VIP, with a resultant decrease in the volume of diarrhea. Octreotide is also useful for symptom control in the setting of unresectable disease. Chemotherapy specific for this disease has not been well studied.

GLUCAGONOMA

10 The most common findings in the glucagonoma syndrome are severe dermatitis, mild diabetes, stomatitis, anemia, and weight loss (Table 56-10). The dermatitis manifests as a characteristic skin rash termed *necrolytic migratory erythema*. This rash exhibits cyclic migrations, and it has been theorized that the hypoaminoacidemia accompanying glucagonoma is the cause.

Table 56-10 Glucagonoma

Parameter	Description
Symptoms	Dermatitis manifested as necrolytic migratory erythema Stomatitis Catabolic state: weight loss
Diagnostic tests	Hyperglycemia Hypoproteinemia Serum glucagon measurement Serum amino acid profile
Anatomic localization	Most in body and tail of pancreas, with liver metastases

The diagnosis of glucagonoma is suggested by the clinical presentation and biopsy of the skin lesions but is secured by the documentation of high fasting levels of serum glucagon. Most glucagonomas are located in the body and tail of the gland. These tumors are typically large and bulky, and surgical resection requires distal pancreatectomy (Fig. 56-10). Metastases are found in most patients and safe debulking of these should be considered.[141] As in patients with VIPoma and insulinoma, octreotide can be useful in controlling the signs and symptoms (hyperglycemia and dermatitis) associated with incurable glucagonoma.

SOMATOSTATINOMA

The somatostatinoma syndrome is the least common of the five generally accepted functional pancreatic endocrine neoplasia syndromes, occurring in less than 1 in 40 million people. The clinical features are nonspecific including steatorrhea, diabetes, hypochlorhydria, and cholelithiasis (Table 56-11). Fasting plasma somatostatin levels of greater than 100 pg/mL can be used to confirm the diagnosis.

Most somatostatinomas are located in the pancreatic head or periampullary region.[142] Tumors are of variable size and are often easily localized. Metastatic disease may be present at the time of diagnosis. Safe resection of the primary tumor (often via pancreaticoduodenectomy) and careful debulking of hepatic metastases are indicated.

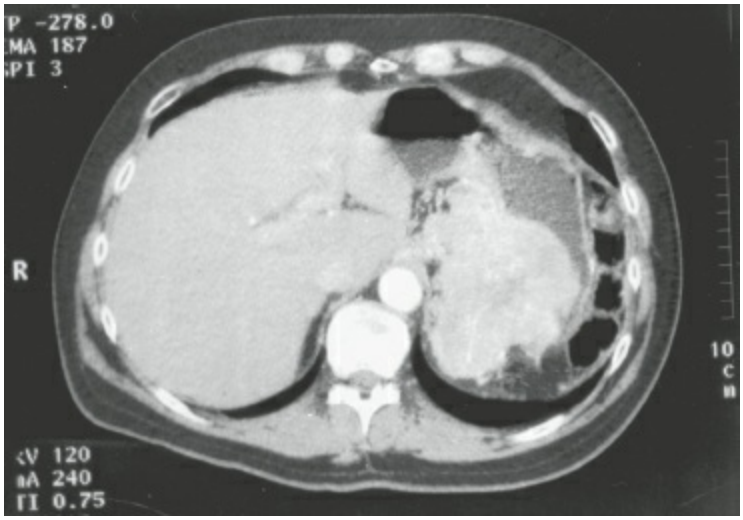

Figure 56-10. Computed tomography with oral and intravenous contrast in a patient with a glucagonoma. The large tumor appears to be posterior to the stomach and to the right of the aorta from the viewer's perspective.

Table 56-11 Somatostatinoma

Parameter	Description
Symptoms	Steatorrhea Right upper quadrant pain
Diagnostic tests	Hyperglycemia Hypochlorhydria Gallstones Serum somatostatin level
Anatomic localization	Most in head or uncinate process of pancreas; often periampullary

NONFUNCTIONAL PANCREATIC ENDOCRINE NEOPLASMS

Currently, the majority of patients with neoplasms of the endocrine pancreas have no defined clinical syndrome and no elevated functional hormone levels. Pancreatic PP and chromogranin A levels may be elevated, though neither is associated with a clinical syndrome. A study by Mutch et al.[143] determined a relationship between fasting plasma PP levels in patients with MEN-1 and the presence of radiographically detectable pancreatic endocrine tumor. A PP level that is more than three times the age-specific normal value is 95% sensitive and 88% specific for a PEN that can be imaged. The majority of patients with nonfunctional endocrine tumors are asymptomatic, however, those who present with symptoms will typically complain of abdominal pain, weight loss, or jaundice, caused by the space-occupying nature of the mass in the pancreas. Overall, nonfunctional tumors tend to grow more slowly and have a more indolent course than the highly lethal pancreatic ductal adenocarcinoma, yet the 5-year survival rate for PENs after resection remains only 65%, with a 10-year survival of 45%.[10]

Patients with operable disease should undergo formal surgical resection for potential cure via pancreaticoduodenectomy or distal pancreatectomy, depending on tumor location. Tumor enucleation, without formal resection may be appropriate for patients with small tumors (<2 cm), significant medical comorbidities, or those documented to have a low proliferative index (Ki-67). Patients with locally advanced disease involving the mesenteric vasculature may be candidates for radical mesenteric vascular resection (Fig. 56-11). With successful treatment, these patients can expect to enjoy a median survival in excess of 5 years.[144,145]

METASTATIC PANCREATIC ENDOCRINE TUMORS

At least one-third of patients with malignant PENs present with synchronous liver metastases at the time of diagnosis.[146] A subset of these patients remain asymptomatic and experience prolonged survival even without aggressive therapy.[104] However, overall 5-year survival with liver metastases is less than 50%.[147] PENs are one of the few tumors for which a survival advantage for surgical debulking has been shown.[135,146,148–150] In those selected patients where safe surgical resection of greater than 90% of the tumor burden can be achieved, 5-year survival rates of 60% to 75% have been reported.

Those with unresectable disease to the liver may be candidates for a variety of hepatic directed therapies for locoregional control and symptom palliation. These include hepatic artery embolization, radiofrequency/microwave ablation, and infusional chemotherapy.[151] Metastatic PENs have shown partial responses to chemotherapy. In 1992, the results of a trial conducted by the Eastern Cooperative Oncology Group (ECOG) were published.[104] In this study, 105 patients with advanced nonfunctional endocrine tumors were randomly assigned to one of three groups. The lowest response rate (30%) was seen in patients receiving chlorozotocin alone, an intermediate response rate (45%) was seen in patients receiving the combination of streptozotocin plus 5-fluorouracil, and the highest response rate (69%) was noted in patients receiving streptozotocin plus doxorubicin. The last regimen also showed significant survival advantage in comparison with the other two treatments. More recent attempts to replicate these results have been disappointing.[152]

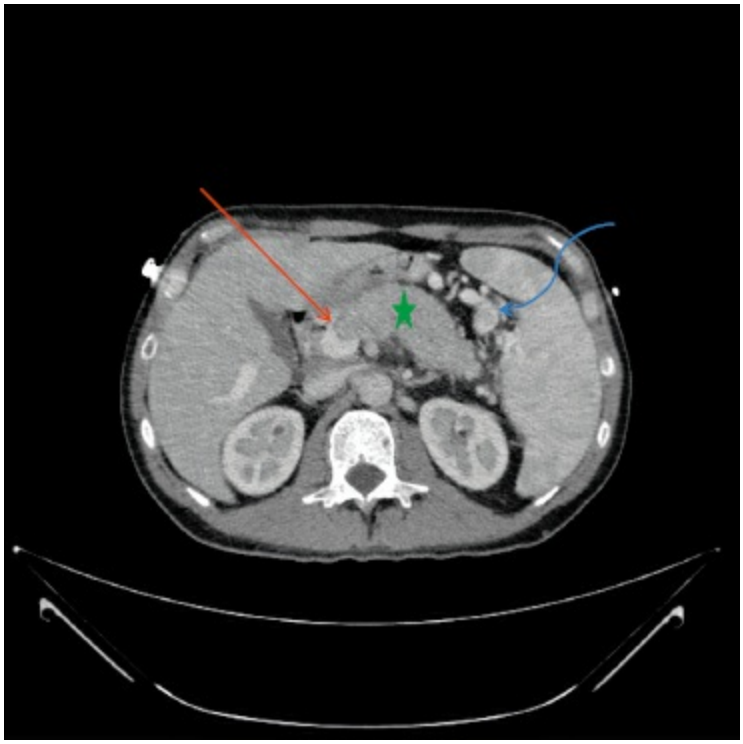

Figure 56-11. Computed tomography of a patient with a large PEN(*) replacing the pancreatic body and tail(*), with splenic vein occlusion, perigastric varices (*blue line*), and tumor thrombus (*red line*) growing into the portal vein. This patient underwent a distal pancreatectomy, splenectomy, and partial portal vein resection with tumor thrombectomy, with complete surgical extirpation of the malignancy.

Somatostatin analogs are another approach to treating metastatic PENs. Results are more favorable in tumors that have high-affinity receptors (gastrinomas, VIPomas, glucagonomas, and some nonfunctional tumors) as compared to insulinomas. Symptomatic improvement occurs in 60% to 90% of patients. However, an objective tumor response is seen in only 5% to 15% of patients, with stabilization of disease in 50% or more of patients.[153–155] In patients who fail to respond to traditional somatostatin analogs, such as octreotide and lanreotide, the novel multireceptor-targeted somatostatin analog pasireotide has shown the ability to offer symptom reduction, primarily because of its ability to bind to four of the five known somatostatin receptor subtypes.[156]

Two new targeted therapies have been approved for use in the setting of advanced metastatic PENs based upon the results of large multicenter phase 3 clinical trials. The first is the agent sunitinib malate (Sutent, Pfizer Inc.), an oral, small molecule, multitargeted tyrosine kinase inhibitor initially approved for the treatment of advanced renal cell carcinoma and refractory gastrointestinal stromal tumors. It has activity against VEGF and PDGF. In a large (171 patients) multinational, randomized, double-blind, placebo-controlled phase 3 trial in patients with advanced, well-differentiated PENs, patients receiving sunitinib had a median progression-free survival of 11.4 months compared with 5.5 months in the placebo group ($p < 0.001$).[157] The second agent everolimus, an oral inhibitor of the mammalian target of rapamycin (mTOR) was also tested in a large (410 patients) international, randomized, double blind, placebo-controlled phase 3 trial (RADIANT-3), in patients with advanced low- and intermediate-grade PEN. The median progression free survival of patients in the everolimus arm was 11 months compared to 4.6 months in the placebo arm ($p < 0.001$). Both of these oral agents have a favorable side-effect profile, and further studies to delineate their role in the treatment of PENs are currently underway.[158]

References

1. Lawrence B, Gustafsson BL, Chan A, et al. The epidemiology of gastroenteropancreatic neuroendocrine tumors. *Endocrinol Metab Clin North Am* 2011;40(1):1–18.
2. Yao JC, Hassan M, Phan A, et al. One hundred years after "carcinoid": epidemiology of and prognostic factors for neuroendocrine tumors in 35,825 cases in the United States. *J Clin Oncol* 2008;(18):3063–3072.
3. Nicholls AG. Simple adenoma of the pancreas arising from an island of Langerhans. *J Med Res* 1902;8:385–395.
4. Pour PM, Schmied B. The link between exocrine pancreatic cancer and the endocrine pancreas. *Int J Pancreatol* 1999;25(2):77–87.
5. Apel RL, Asa SL. Endocrine tumors of the pancreas. *Pathol Annu* 1995; 30:305–349.
6. Vortmeyer AO, Huang S, Lubensky I, et al. Non-islet origin of pancreatic islet cell tumors. *J Clin Endocrinol Metab* 2004;89(4):1934–1938.
7. Klimstra DS. Nonductal neoplasms of the pancreas. *Mod Pathol* 2007; 20(1):S94–S112.
8. Wick MR, Graeme-Cook FM. Pancreatic neuroendocrine neoplasms: a current summary of diagnostic, prognostic, and differential diagnostic information. *Am J Clin Pathol* 2001;115:S28–S45.
9. Halfdanarson TR, Rabe KG, Rubin J, et al. Pancreatic neuroendocrine tumors (PNETs): incidence, prognosis and recent trend toward improved survival. *Ann Oncol* 2008;19(10):1727–1733.
10. De Wilde RF, Edil BH, Hruban RH, et al. Well-differentiated pancreatic neuroendocrine tumors: from genetics to therapy. *Nat Rev Gastroenterol Hepatol* 2012;9(4):199–208.
11. Kimura W, Kuroda A, Morioka Y. Clinical pathology of endocrine tumors of the pancreas. Analysis of autopsy cases. *Dig Dis Sci* 1991;36(7):933–942.
12. Klimstra DS, Perren A, Oberg K, et al. Pancreatic endocrine tumors: non-functioning tumors and microadenomas. In: DeLellis RA, Lloyd RV, Heitz PU, et al., eds. *Pathology and Genetics of Tumours of Endocrine Organs.* Lyon, France: IARC Press; 2004:201–204.
13. Moldow RE, Connelly RR. Epidemiology of pancreatic cancer in Connecticut. *Gastroenterology* 1968;55:677–686.
14. Eriksson B, Oberg K. Neuroendocrine tumors of the pancreas. *Br J Surg* 2000;87:129–131.
15. Frankel WL. Update on pancreatic endocrine tumors. *Arch Pathol Lab Med* 2006;130(7):963–966.
16. Rindi G, de Herder WW, O'Toole D, et al. Consensus guidelines for the management of patients with digestive neuroendocrine tumors: why such guidelines and how we went about it. *Neuroendocrinology* 2006;84(3):155–157.

17. Strosberg JR, Cheema A, Weber JM, et al. Relapse-free survival in patients with nonmetastatic, surgically resected pancreatic neuroendocrine tumors: an analysis of the AJCC and ENETS staging classifications. *Ann Surg* 2012; 256(2):321–325.
18. Hochwald SN, Zee S, Conlon KC, et al. Prognostic factors in pancreatic endocrine neoplasms: an analysis of 136 cases with a proposal for low-grade and intermediate-grade groups. *J Clin Oncol* 2002;20(11):2633–2642.
19. Capella C, Heitz PU, Hafler H, et al. Revised classification of neuroendocrine tumours of the lung, pancreas and gut. *Virchows Arch* 1995;425(6):547–560.
20. La Rosa S, Sessa F, Capella C, et al. Prognostic criteria in nonfunctioning pancreatic endocrine tumours. *Virchows Arch* 1996;429(6):323–333.
21. Pelosi G, Bresaola E, Bogina G, et al. Endocrine tumors of the pancreas: Ki-67 immunoreactivity on paraffin sections is an independent predictor for malignancy: a comparative study with proliferating-cell nuclear antigen and progesterone receptor protein immunostaining, mitotic index, and other clinicopathologic variables. *Hum Pathol* 1996;27(11):1124–1134.
22. Boninsegna L, Panzuto F, Partelli S, et al. Malignant pancreatic neuroendocrine tumour: lymph node ratio and Ki-67 are predictors of recurrence after curative resections. *Eur J Cancer* 2012;48(11):1608–1615.
23. Kunz PL, Reidy-Lagunes D, Anthony LB, et al. Consensus guidelines for the management and treatment of neuroendocrine tumors. *Pancreas* 2013;42(4):557–577.
24. Goldin SB, Aston J, Wahi MM. Sporadically occurring functional pancreatic endocrine tumors: review of recent literature. *Curr Opin Oncol* 2008; 20(1):25–33.
25. McLeod MK, Vinik AI. Calcitonin immunoreactivity and hypercalcitoninemia in two patients with sporadic, nonfamilial, gastroenteropancreatic neuroendocrine tumors. *Surgery* 1992;111(5):484–488.
26. Howard JM, Gohara AF, Cardwell RJ. Malignant islet cell tumor of the pancreas associated with high plasma calcitonin and somatostatin levels. *Surgery* 1989;105(2 Pt 1):227–229.
27. Mao C, Carter P, Schaefer P, et al. Malignant islet cell tumor associated with hypercalcemia. *Surgery* 1995;117(1):37–40.
28. Aniszewski JP, Young WF Jr, Thompson GB, et al. Cushing syndrome due to ectopic adrenocorticotropic hormone secretion. *World J Surg* 2001;25(7):934–940.
29. Mukai K, Grotting JC, Greider MH, et al. Retrospective study of 77 pancreatic endocrine tumors using the immunoperoxidase method. *Am J Surg Pathol* 1982;6(5):387–399.
30. Tomita T, Kimmel JR, Friesen SR, et al. Pancreatic polypeptide in islet cell tumors. Morphologic and functional correlations. *Cancer* 1985;56(7):1649–1657.
31. Vagefi PA, Razo O, Deshpande V, et al. Evolving patterns in the detection and outcomes of pancreatic neuroendocrine neoplasms: the Massachusetts general hospital experience from 1977 to 2005. *Arch Surg* 2007;142(4):347–354.

32. Brodi C, Oberg K, Papotti M, et al. Pancreatic endocrine tumors: poorly differentiated endocrine carcinoma. In: DeLellis RA, Lloyd RV, Heitz PU, et al., eds. *Pathology and Genesis of Tumors of Endocrine Organs.* Lyon, France: IARC Press; 2004:207–208.
33. Jiao Y, Shi C, Edil BH, et al. DAXX/ATRX, MEN1, and mTOR pathway genes are frequently altered in pancreatic neuroendocrine tumors. *Science* 2011;331(6021):1199–203.
34. Jones S, Zhang X, Parsons DW, et al. Core signaling pathways in human pancreatic cancers revealed by global genomic analyses. *Science* 2008; 321(5897):1801–1806.
35. Zhang J, Francois R, Iyer R, et al. Current understanding of the molecular biology of pancreatic neuroendocrine tumors. *J Natl Cancer Inst* 2013; 105(14):1005–1017.
36. Marinoni I, Kurrer AS, Vassella E, et al. Loss of DAXX and ATRX are associated with chromosome instability and reduced survival of patients with pancreatic neuroendocrine tumors. *Gastroenterology* 2014;146(2):453–460.
37. Qian ZR, Ter-Minassian M, Chan JA, et al. Prognostic significance of MTOR pathway component expression in neuroendocrine tumors. *J Clin Oncol* 2013;31(27):3418–3425.
38. Marx S, Spiegel AM, Skarulis MC, et al. Multiple endocrine neoplasia type 1: clinical and genetic topics. *Ann Intern Med* 1998;129(6):484–494.
39. Toumpanakis CG, Caplin ME. Molecular genetics of gastroenteropancreatic neuroendocrine tumors. *Am J Gastroenterol* 2008;103(3):729–732.
40. Lairmore TC, Piersall LD, DeBenedetti MK, et al. Clinical genetic testing and early surgical intervention in patients with multiple endocrine neoplasia type 1 (MEN 1). *Ann Surg* 2004;239(5):637–645; discussion 645–647.
41. Halfdanarson TR, Rubin J, Farnell MB, et al. Pancreatic endocrine neoplasms: epidemiology and prognosis of pancreatic endocrine tumors. *Endocr Relat Cancer* 2008;15(2):409–427.
42. Speisky D, Duces A, Bièche I, et al. Molecular profiling of pancreatic neuroendocrine tumors in sporadic and Von Hippel-Lindau patients. *Clin Cancer Res* 2012;18(10):2838–2849.
43. Johannessen CM, Reczek EE, James MF, et al. The NF1 tumor suppressor critically regulates TSC2 and mTOR. *Proc Natl Acad Sci U S A* 2005;102(24):8573–8578.
44. Starker LF, Carling T. Molecular genetics of gastroenteropancreatic neuroendocrine tumors. *Curr Opin Oncol* 2009;21(1):29–33.
45. Heaphy CM, de Wilde RF, Jiao Y, et al. Altered telomeres in tumors with ATRX and DAXX mutations. *Science* 2011;333(6041):425.
46. Passacantilli I, Capurso G, Archibugi L, et al. Combined therapy with RAD001 e BEZ235 overcomes resistance of PET immortalized cell lines to mTOR inhibition. *Oncotarget* 2014;5(14):5381–5391.
47. Muniraj T, Vignesh S, Shetty S, et al. Pancreatic neuroendocrine tumors. *Dis Mon*

2013;59(1):5–19.
48. Panzuto F, Severi C, Cannizzaro R, et al. Utility of combined use of plasma levels of chromogranin A and pancreatic plypeptide in the diagnosis of gastrointestinal and pancreatic endocrine tumors. *J Endocrinol Invest* 2004;27(1):6–11.
49. Baudin E, Gigliotti A, Ducreux M, et al. Neuron-specific enolase and chromogranin A as markers of neuroendocrine tumours. *Br J Cancer* 1998;78(8):1102–1107.
50. Tamm EP, Kim EE, Ng CS. Imaging of neuroendocrine tumors. *Hematol Oncol Clin North Am* 2007;21(3):409–432; vii.
51. Ichikawa T, Peterson MS, Federle MP, et al. Islet cell tumor of the pancreas: biphasic CT versus MR imaging in tumor detection. *Radiology* 2000;216(1):163–171.
52. Vick C, Zech CJ, Hopfner S, et al. Imaging of neuroendocrine tumors of the pancreas. *Radiologe* 2003;43(4):293–300.
53. King AD, Ko GT, Yeung VT, et al. Dual phase spiral CT in the detection of small insulinomas of the pancreas. *Br J Radiol* 1998;71(841):20–23.
54. Van Hoe L, Gryspeerdt S, Marchal G, et al. Helical CT for the preoperative localization of islet cell tumors of the pancreas: value of arterial and parenchymal phase images. *AJR Am J Roentgenol* 1995;165(6):1437–1439.
55. Semelka RC, Cumming MJ, Shoenut JP, et al. Islet cell tumors: comparison of dynamic contrast-enhanced CT and MR imaging with dynamic gadolinium enhancement and fat suppression. *Radiology* 1993;186(3):799–802.
56. Termanini B, Gibril F, Reynolds JC, et al. Value of somatostatin receptor scintigraphy: a prospective study in gastrinoma of its effect on clinical management. *Gastroenterology* 1997;112(2):335–347.
57. Meko JB, Doherty GM, Siegel BA, et al. Evaluation of somatostatin-receptor scintigraphy for detecting neuroendocrine tumors. *Surgery* 1996;120(6):975–983; discussion 983–984.
58. Kisker O, Bartsch D, Weinel RJ, et al. The value of somatostatin-receptor scintigraphy in newly diagnosed endocrine gastroenteropancreatic tumors. *J Am Coll Surg* 1997;184(5):487–492.
59. Schirmer WJ, O'Dorisio TM, Schirmer TP, et al. Intraoperative localization of neuroendocrine tumors with 125I-TYR(3)-octreotide and a hand-held gamma-detecting probe. *Surgery* 1993;114(4):745–751; discussion 751–752.
60. Modlin IM, Tang LH. Approaches to the diagnosis of gut neuroendocrine tumors: the last word (today). *Gastroenterology* 1997;112(2):583–590.
61. Krausz Y, Bar-Ziv J, de Jong RB, et al. Somatostatin-receptor scintigraphy in the management of gastroenteropancreatic tumors. *Am J Gastroenterol* 1998;93(1):66–70.
62. Frilling A, Malago M, Martin H, et al. Use of somatostatin receptor scintigraphy to image extrahepatic metastases of neuroendocrine tumors. *Surgery* 1998;124(6):1000–1004.
63. Kwekkeboom DJ, Krenning EP. Somatostatin receptor imaging. *Semin Nucl Med*

2002;32(2):84–91.
64. Anderson MA, Carpenter S, Thompson NW, et al. Endoscopic ultrasound is highly accurate and directs management in patients with neuroendocrine tumors of the pancreas. *Am J Gastroenterol* 2000;95(9):2271–2277.
65. McLean AM, Fairclough PD. Endoscopic ultrasound in the localisation of pancreatic islet cell tumours. *Best Pract Res Clin Endocrinol Metab* 2005; 19(2):177–193.
66. Glover JR, Shorvon PJ, Lees WR. Endoscopic ultrasound for localisation of islet cell tumours. *Gut* 1992;33(1):108–110.
67. Rosch T, Lightdale CJ, Botet JF, et al. Localization of pancreatic endocrine tumors by endoscopic ultrasonography. *N Engl J Med* 1992;326(26):1721–1726.
68. Thompson NW, Czako PF, Fritts LL, et al. Role of endoscopic ultrasonography in the localization of insulinomas and gastrinomas. *Surgery* 1994; 116(6):1131–1138.
69. Proye C, Malvaux P, Pattou F, et al. Noninvasive imaging of insulinomas and gastrinomas with endoscopic ultrasonography and somatostatin receptor scintigraphy. *Surgery* 1998;124(6):1134–1143; discussion 1143–1144.
70. Mertz H, Gautam S. The learning curve for EUS-guided FNA of pancreatic cancer. *Gastrointest Endosc* 2004;59(1):33–37.
71. Grover AC, Skarulis M, Alexander HR, et al. A prospective evaluation of laparoscopic exploration with intraoperative ultrasound as a technique for localizing sporadic insulinomas. *Surgery* 2005;138(6):1003–1008; discussion 1008.
72. Zeiger MA, Shawker TH, Norton JA. Use of intraoperative ultrasonography to localize islet cell tumors. *World J Surg* 1993;17(4):448–454.
73. Norton JA, Shawker TH, Doppman JL, et al. Localization and surgical treatment of occult insulinomas. *Ann Surg* 1990;212(5):615–620.
74. Vinik AI, Moattari AR, Cho K, et al. Transhepatic portal vein catheterization for localization of sporadic and MEN gastrinomas: a ten-year experience. *Surgery* 1990;107(3):246–255.
75. Pedrazzoli S, Pasquali C, Miotto D, et al. Transhepatic portal sampling for preoperative localization of insulinomas. *Surg Gynecol Obstet* 1987; 165(2):101–106.
76. Vinik AI, Delbridge L, Moattari R, et al. Transhepatic portal vein catheterization for localization of insulinomas: a ten-year experience. *Surgery* 1991; 109(1):1–11; discussion 111.
77. Fraker DL, Norton JA. Localization and resection of insulinomas and gastrinomas. *JAMA* 1988;259(24):3601–3605.
78. Imamura M, Takahashi K, Adachi H, et al. Usefulness of selective arterial secretin injection test for localization of gastrinoma in the Zollinger-Ellison syndrome. *Ann Surg* 1987;205(3):230–239.
79. Rosato FE, Bonn J, Shapiro M, et al. Selective arterial stimulation of secretin in localization of gastrinomas. *Surg Gynecol Obstet* 1990;171(3):196–200.
80. Gower WR Jr, Buzogany JA Jr, Ellison EC, et al. Control of gastrin release in

cultured gastrinoma-derived G cells. *Surgery* 1988;104(2):424–430.
81. Chiba T, Yamatani T, Yamaguchi A, et al. Mechanism for increase of gastrin release by secretin in Zollinger-Ellison syndrome. *Gastroenterology* 1989;96(6):1439–1444.
82. Brown CK, Bartlett DL, Doppman JL, et al. Intraarterial calcium stimulation and intraoperative ultrasonography in the localization and resection of insulinomas. *Surgery* 1997;122(6):1189–1193; discussion 1193–1194.
83. Pereira PL, Roche AJ, Maier GW, et al. Insulinoma and islet cell hyperplasia: value of the calcium intraarterial stimulation test when findings of other preoperative studies are negative. *Radiology* 1998;206(3):703–709.
84. Whipple AO, Frantz VK. Adenoma of islet cells with hyperinsulinism: a review. *Ann Surg* 1935;101(6):1299–1335.
85. Howard TJ, Stabile BE, Zinner MJ, et al. Anatomic distribution of pancreatic endocrine tumors. *Am J Surg* 1990;159(2):258–264.
86. Ectors N. Pancreatic endocrine tumors: diagnostic pitfalls. *Hepatogastroenterology* 1999;46(26):679–690.
87. Richards ML, Gauger PG, Thompson NW, et al. Pitfalls in the surgical treatment of insulinoma. *Surgery* 2002;132(6):1040–1049; discussion 1049.
88. Menegaux F, Schmitt G, Mercadier M, et al. Pancreatic insulinomas. *Am J Surg* 1993;165(2):243–248.
89. Sauvanet A, Partensky C, Sastre B, et al. Medial pancreatectomy: a multi-institutional retrospective study of 53 patients by the French pancreas club. *Surgery* 2002;132(5):836–843.
90. Efron DT, Lillemoe KD, Cameron JL, et al. Central pancreatectomy with pancreaticogastrostomy for benign pancreatic pathology. *J Gastrointest Surg* 2004;8(5):532–538.
91. Goldstein MJ, Toman J, Chabot JA. Pancreaticogastrostomy: a novel application after central pancreatectomy. *J Am Coll Surg* 2004;198(6):871–876.
92. Udelsman R, Yeo CJ, Hruban RH, et al. Pancreaticoduodenectomy for selected pancreatic endocrine tumors. *Surg Gynecol Obstet* 1993;177(3):269–278.
93. Phan GQ, Yeo CJ, Cameron JL, et al. Pancreaticoduodenectomy for selected periampullary neuroendocrine tumors: fifty patients. *Surgery* 1997;122(6):989–996; discussion, 996–997.
94. Fernandez-Cruz L, Blanco L, Cosa R, et al. Is laparoscopic resection adequate in patients with neuroendocrine pancreatic tumors? *World J Surg* 2008;32(5):904–917.
95. Jaroszewski DE, Schlinkert RT, Thompson GB, et al. Laparoscopic localization and resection of insulinomas. *Arch Surg* 2004;139(3):270–274.
96. Iihara M, Kanbe M, Okamoto T, et al. Laparoscopic ultrasonography for resection of insulinomas. *Surgery* 2001;130(6):1086–1091.
97. Ayav A, Bresler L, Brunaud L, et al.; SFCL (Societe Francaise de Chirurgie Laparoscopique), AFCE (Association Francophone de Chirurgie Endocrinienne).

Laparoscopic approach for solitary insulinoma: a multicentre study. *Langenbecks Arch Surg* 2005;390(2):134–140.

98. Sweet MP, Izumisato Y, Way LW, et al. Laparoscopic enucleation of insulinomas. *Arch Surg* 2007;142(12):1202–1204; discussion 1205.
99. Thompson GB, Service FJ, van Heerden JA, et al. Reoperative insulinomas, 1927 to 1992: an institutional experience. *Surgery* 1993;114(6):1196–1204;discussion 1205–1206.
100. Carty SE, Jensen RT, Norton JA. Prospective study of aggressive resection of metastatic pancreatic endocrine tumors. *Surgery* 1992;112(6):1024–1031;discussion 1031–1032.
101. Modlin IM, Lewis JJ, Ahlman H, et al. Management of unresectable malignant endocrine tumors of the pancreas. *Surg Gynecol Obstet* 1993; 176(5):507–518.
102. McEntee GP, Nagorney DM, Kvols LK, et al. Cytoreductive hepatic surgery for neuroendocrine tumors. *Surgery* 1990;108(6):1091–1096.
103. Kulke MH, Bergsland EK, Yao JC. Glycemic control in patients with insulinoma treated with everolimus. *N Engl J Med* 2009;360(2):195–197.
104. Moertel CG, Lefkopoulo M, Lipsitz S, et al. Streptozocin-doxorubicin, streptozocin-fluorouracil or chlorozotocin in the treatment of advanced islet-cell carcinoma. *N Engl J Med* 1992;326(8):519–523.
105. Moertel CG, Hanley JA, Johnson LA. Streptozocin alone compared with streptozocin plus fluorouracil in the treatment of advanced islet-cell carcinoma. *N Engl J Med* 1980;303(21):1189–1194.
106. Altimari AF, Badrinath K, Reisel HJ, et al. DTIC therapy in patients with malignant intra-abdominal neuroendocrine tumors. *Surgery* 1987;102(6):1009–1017.
107. Zollinger RM, Ellison EH. Primary peptic ulcerations of the jejunum associated with islet cell tumors of the pancreas. *Ann Surg* 1955;142(4):709–723;discussion, 724–728.
108. Zollinger RM, Ellison EC, Fabri PJ, et al. Primary peptic ulcerations of the jejunum associated with islet cell tumors. Twenty-five-year appraisal. *Ann Surg* 1980;192(3):422–430.
109. Ellison EC, Johnson JA. The Zollinger-Ellison syndrome: a comprehensive review of historical, scientific, and clinical considerations. *Curr Probl Surg* 2009;46(1):13–106.
110. Wolfe MM, Jensen RT. Zollinger-Ellison syndrome. Current concepts in diagnosis and management. *N Engl J Med* 1987;317(19):1200–1209.
111. Andersen DK. Current diagnosis and management of Zollinger-Ellison syndrome. *Ann Surg* 1989;210(6):685–703.
112. Maton PN, Vinayek R, Frucht H, et al. Long-term efficacy and safety of omeprazole in patients with Zollinger-Ellison syndrome: a prospective study. *Gastroenterology* 1989;97(4):827–836.
113. Metz DC, Pisegna JR, Fishbeyn VA, et al. Currently used doses of omeprazole in Zollinger-Ellison syndrome are too high. *Gastroenterology* 1992; 103(5):1498–1508.

114. Stabile BE, Morrow DJ, Passaro E Jr. The gastrinoma triangle: operative implications. *Am J Surg* 1984;147(1):25–31.
115. Sugg SL, Norton JA, Fraker DL, et al. A prospective study of intraoperative methods to diagnose and resect duodenal gastrinomas. *Ann Surg* 1993; 218(2):138–144.
116. Frucht H, Norton JA, London JF, et al. Detection of duodenal gastrinomas by operative endoscopic transillumination. A prospective study. *Gastroenterology* 1990;99(6):1622–1627.
117. Farley DR, van Heerden JA, Grant CS, et al. Extrapancreatic gastrinomas. Surgical experience. *Arch Surg* 1994;129(5):506–511; discussion 511–512.
118. Chiarugi M, Pucciarelli M, Goletti O, et al. Outcome of surgical treatment for extrapancreatic gastrinomas. *Surg Gynecol Obstet* 1993;177(2):153–157.
119. Norton JA, Alexander HR, Fraker DL, et al. Does the use of routine duodenotomy (DUODX) affect rate of cure, development of liver metastases, or survival in patients with Zollinger-Ellison syndrome? *Ann Surg* 2004; 239(5):617–625; discussion 626.
120. Arnold WS, Fraker DL, Alexander HR, et al. Apparent lymph node primary gastrinoma. *Surgery* 1994;116(6):1123–1129; discussion 1129–1130.
121. Norton JA, Alexander HR, Fraker DL, et al. Possible primary lymph node gastrinoma: occurrence, natural history, and predictive factors: a prospective study. *Ann Surg* 2003;237(5):650–657; discussion 657–659.
122. Richardson CT, Peters MN, Feldman M, et al. Treatment of Zollinger-Ellison syndrome with exploratory laparotomy, proximal gastric vagotomy, and H2-receptor antagonists. A prospective study. *Gastroenterology* 1985; 89(2):357–367.
123. Norton JA, Fraker DL, Alexander HR, et al. Surgery to cure the Zollinger-Ellison syndrome. *N Engl J Med* 1999;341(9):635–644.
124. Norton JA, Jensen RT. Role of surgery in Zollinger-Ellison syndrome. *J Am Coll Surg* 2007;205(4 Suppl 1):S34–S37.
125. Cadiot G, Vuagnat A, Doukhan I, et al. Prognostic factors in patients with Zollinger-Ellison syndrome and multiple endocrine neoplasia type 1. Groupe d'etude des neoplasies endocriniennes multiples (GENEM and groupe de recherche et d'etude du syndrome de zollinger-ellison (GRESZE). *Gastroenterology* 1999;116(2):286–293.
126. Lowney JK, Frisella MM, Lairmore TC, et al. Pancreatic islet cell tumor metastasis in multiple endocrine neoplasia type 1: correlation with primary tumor size. *Surgery* 1998;124(6):1043–1048; discussion 1048–1049.
127. Norton JA, Doppman JL, Jensen RT. Curative resection in Zollinger-Ellison syndrome. Results of a 10-year prospective study. *Ann Surg* 1992; 215(1):8–18.
128. Fraker DL, Norton JA, Alexander HR, et al. Surgery in Zollinger-Ellison syndrome alters the natural history of gastrinoma. *Ann Surg* 1994;220(3):320–328; discussion 328–330.
129. Delcore R, Friesen SR. The place for curative surgical procedures in the treatment of sporadic and familial Zollinger-Ellison syndrome. *Curr Opin Gen Surg* 1994:69–76.

130. Zogakis TG, Gibril F, Libutti SK, et al. Management and outcome of patients with sporadic gastrinoma arising in the duodenum. *Ann Surg* 2003; 238(1):42–48.
131. von Schrenck T, Howard JM, Doppman JL, et al. Prospective study of chemotherapy in patients with metastatic gastrinoma. *Gastroenterology* 1988;94(6):1326–1334.
132. Mozell E, Woltering EA, O'Dorisio TM, et al. Effect of somatostatin analog on peptide release and tumor growth in the Zollinger-Ellison syndrome. *Surg Gynecol Obstet* 1990;170(6):476–484.
133. Mozell EJ, Cramer AJ, O'Dorisio TM, et al. Long-term efficacy of octreotide in the treatment of Zollinger-Ellison syndrome. *Arch Surg* 1992;127(9):1019–1024; discussion 1024–1026.
134. Elias D, Lasser P, Ducreux M, et al. Liver resection (and associated extrahepatic resections) for metastatic well-differentiated endocrine tumors: a 15-year single center prospective study. *Surgery* 2003;133(4):375–382.
135. Sarmiento JM, Heywood G, Rubin J, et al. Surgical treatment of neuroendocrine metastases to the liver: a plea for resection to increase survival. *J Am Coll Surg* 2003;197(1):29–37.
136. Sarmiento JM, Que FG, Grant CS, et al. Concurrent resections of pancreatic islet cell cancers with synchronous hepatic metastases: outcomes of an aggressive approach. *Surgery* 2002;132(6):976–982; discussion 982–983.
137. Norton JA, Kivlen M, Li M, et al. Morbidity and mortality of aggressive resection in patients with advanced neuroendocrine tumors. *Arch Surg* 2003;138(8):859–866.
138. Florman S, Toure B, Kim L, et al. Liver transplantation for neuroendocrine tumors. *J Gastrointest Surg* 2004;8(2):208–212.
139. Verner JV, Morrison AB. Islet cell tumor and a syndrome of refractory watery diarrhea and hypokalemia. *Am J Med* 1958;25(3):374–380.
140. Schiller LR. Chronic diarrhea. *Gastroenterology* 2004;127(1):287–293.
141. Chu QD, Al-kasspooles MF, Smith JL, et al. Is glucagonoma of the pancreas a curable disease? *Int J Pancreatol* 2001;29(3):155–162.
142. House MG, Yeo CJ, Schulick RD. Periampullary pancreatic somatostatinoma. *Ann Surg Oncol* 2002;9(9):869–874.
143. Mutch MG, Frisella MM, DeBenedetti MK, et al. Pancreatic polypeptide is a useful plasma marker for radiographically evident pancreatic islet cell tumors in patients with multiple endocrine neoplasia type 1. *Surgery* 1997;122(6):1012–1019; discussion 1019–1020.
144. Phan GQ, Yeo CJ, Hruban RH, et al. Surgical experience with pancreatic and peripancreatic neuroendocrine tumors: review of 125 patients. *J Gastrointest Surg* 1998;2(5):473–482.
145. Solorzano CC, Lee JE, Pisters PW, et al. Nonfunctioning islet cell carcinoma of the pancreas: survival results in a contemporary series of 163 patients. *Surgery* 2001;130(6):1078–1085.

146. House MG, Cameron JL, Lillemoe KD, et al. Differences in survival for patients with resectable versus unresectable metastases from pancreatic islet cell cancer. *J Gastrointest Surg* 2006;10(1):138–145.
147. Thompson GB, van Heerden JA, Grant CS, et al. Islet cell carcinomas of the pancreas: a twenty-year experience. *Surgery* 1988;104(6):1011–1017.
148. Chen H, Hardacre JM, Uzar A, et al. Isolated liver metastases from neuroendocrine tumors: does resection prolong survival? *J Am Coll Surg* 1998;187(1):88–92; discussion 92–93.
149. Chamberlain RS, Canes D, Brown KT, et al. Hepatic neuroendocrine metastases: does intervention alter outcomes? *J Am Coll Surg* 2000;190(4):432–445.
150. Touzios JG, Kiely JM, Pitt SC, et al. Neuroendocrine hepatic metastases: does aggressive management improve survival? *Ann Surg* 2005;241(5):776–783; discussion 783–785.
151. Toumpanakis C, Meyer T, Caplin ME. Cytotoxic treatment including embolization/chemoembolization for neuroendocrine tumours. *Best Pract Res Clin Endocrinol Metab* 2007;21(1):131–144.
152. Cheng PN, Saltz LB. Failure to confirm major objective antitumor activity for streptozocin and doxorubicin in the treatment of patients with advanced islet cell carcinoma. *Cancer* 1999;86(6):944–948.
153. Gorden P, Comi RJ, Maton PN, et al. NIH conference. Somatostatin and somatostatin analogue (SMS 201–995) in treatment of hormone-secreting tumors of the pituitary and gastrointestinal tract and non-neoplastic diseases of the gut. *Ann Intern Med* 1989;110(1):35–50.
154. Arnold R, Trautmann ME, Creutzfeldt W, et al. Somatostatin analogue octreotide and inhibition of tumour growth in metastatic endocrine gastroenteropancreatic tumours. *Gut* 1996;38(3):430–438.
155. Oberg K. Chemotherapy and biotherapy in the treatment of neuroendocrine tumours. *Ann Oncol* 2001;12(Suppl 2):S111–S114.
156. Kvols L, Wiedenmann K, Oberg K, et al. Safety and efficacy of pasireotide (SOM230) in patients with metastatic carcinoid tumors refractory or resistant to octreotide LAR: Results of a phase 2 study. *J Clin Oncol* 2006;24(18):4082.
157. Raymond E, Dahan L, Raoul JL, et al. Sunitinib malate for the treatment of pancreatic neuroendocrine tumors. *N Engl J Med* 2011;364(6):501–513.
158. Yao JC, Shah MH, Ito T, et al. Everolimus for advanced pancreatic neuroendocrine tumors. *N Engl J Med* 2011;364(6):514–523.

SECTION H: HEPATOBILIARY AND PORTAL VENOUS SYSTEM

Chapter 57

Hepatobiliary Anatomy

Trevor L. Nydam and Richard D. Schulick

Key Points

1 The most widely accepted nomenclature for liver anatomy is based on Couinaud's description of eight anatomic segments of the liver.

2 There are three major hepatic veins, with most patients having a right hepatic vein that joins the right anterior wall of the inferior vena cava (IVC) and middle and left hepatic veins that converge into a common trunk before joining the IVC.

3 Classic hepatic arterial anatomy exists in only approximately 50% of patients, with a replaced or accessory right hepatic artery arising from the superior mesenteric artery and a replaced or accessory left hepatic artery arising from the left gastric artery being the most common variants.

4 Callot triangle is bounded by the common hepatic duct on the left, the cystic duct inferiorly, and the cystic artery superiorly.

5 The blood supply of the common bile duct is segmental in nature and consists of branches from the cystic, hepatic, and gastroduodenal arteries, which meet to form collateral vessels that run in the 3 and 9 o'clock positions.

6 Multiphase computed tomography (CT) and magnetic resonance imaging (MRI) with intravenous contrast are commonly used to characterize hepatic lesions.

7 Magnetic resonance cholangiopancreatography (MRCP) is often used to view biliary anatomy as it involves no contrast agent and optimally can provide images that rival formal cholangiography.

8 Intraoperative ultrasonography is used routinely to assess the anatomy of the hepatic pedicles (portal vein, hepatic artery, and bile duct) and hepatic veins and to identify and characterize hepatic lesions within the parenchyma and their relationships within the eight anatomic segments.

9 The portal pedicles are invested with the Glisson capsule and have a very echogenic covering to them on ultrasound in contrast to hepatic vein branches.

10 The steps involved in major hepatectomy include optimal exposure, vascular inflow control, vascular outflow control, and parenchymal transection.

A precise knowledge of the anatomy of the liver and biliary tract and their relationship to associated blood vessels is essential for the performance of hepatobiliary surgery. Every

surgeon caring for a patient with a hepatobiliary problem should have a thorough understanding of the general anatomy and an absolute understanding of each individual patient's anatomy, because variations are common.

TOPOGRAPHIC ANATOMY

The normal adult liver is a large, wedge-shaped organ that occupies much of the right upper quadrant of the abdomen. Most of the liver bulk lays to the right of the midline where it molds to the undersurface of the right diaphragm, and where the lower border coincides with the right costal margin. The liver extends as a wedge to the left of the midline between the anterior surface of the stomach and the left dome of the diaphragm. The anterior surface of the liver is invested by visceral peritoneum that extends to the anterior abdominal wall in the midline from the ligamentum teres, or round ligament (the obliterated umbilical vessels), and by an obliquely oriented fusion of peritoneum known as the falciform ligament. Posteriorly, the investing peritoneum is contiguous with the peritoneum of the diaphragm and covers the liver, except for a *bare area* bounded by the *right and left triangular ligaments* (Fig. 57-1). The Glisson capsule is a thin, fibrous covering that envelops the liver deep to the peritoneum, sending fibrous septa into the hepatic parenchyma investing the portal structures.

Ordinarily, the liver can be separated from adjacent organs and structures by simply moving it or dividing loose areolar tissue (Fig. 57-2). Neoplastic or inflammatory conditions may obliterate these planes. Superiorly and anteriorly, the diaphragm or abdominal wall and liver may jointly be involved in a pathologic process. Posteriorly, the right adrenal gland or upper pole of the right kidney may involve or be involved by the liver. Inferiorly, the gallbladder, colon, duodenum, or periportal lymphatics may be involved. Cancers of the stomach or gastroesophageal junction may involve the left liver or vice versa.

MORPHOLOGIC AND FUNCTIONAL ANATOMY

The description and definition of the anatomic divisions of the liver have been revised and written about numerous times in the past 100 years.[1–8] At present, there is still confusion between the various hepatic anatomic nomenclatures in the English and French literature. Based only on morphologic criteria and surface anatomy, the liver can be divided into right and left halves by forming a plane through the gallbladder fossa (Cantlie line) and inferior vena cava (IVC) (Fig. 57-3). As will be shown later, this plane approximates the true division between the right and left halves using the more strict definition of a plane through the middle hepatic vein and IVC, but the middle hepatic vein is not obvious based solely on morphology and without ultrasound. Further subdivisions of the right half of the liver into a right anterior sector and a right posterior sector are not possible based only on surface anatomy. The left half of the liver can be further subdivided into a left medial section and left lateral section based on the umbilical fissure and falciform ligament. The caudate (tail-shaped) process of the liver is identified as lying posterior to the gastrohepatic ligament and emanating from a process of liver situated posterior to the main portal pedicle and anterior to the IVC.

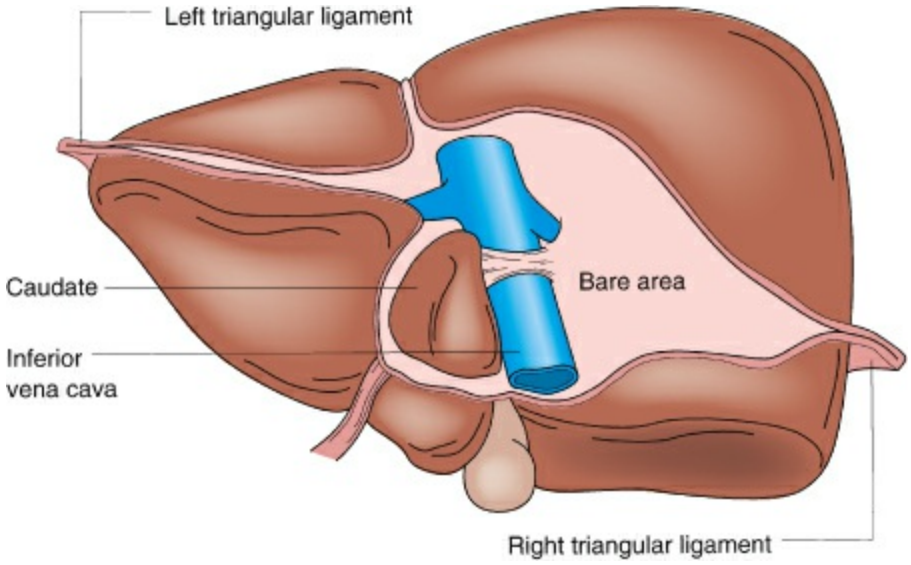

Figure 57-1. Posterior view of the liver, showing the level of peritoneal reflections.

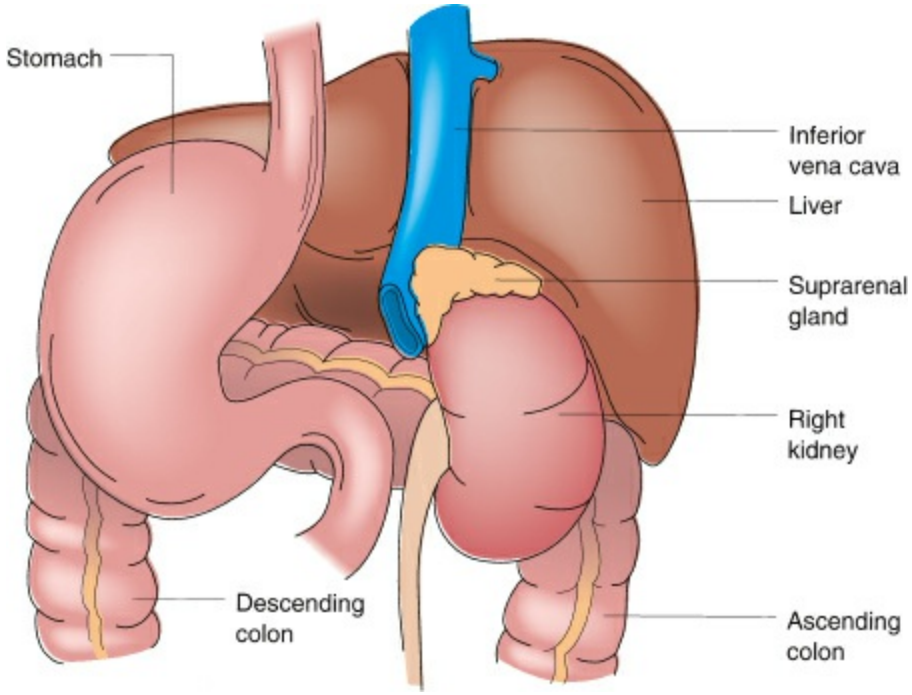

Figure 57-2. Posterior view of the liver, showing organs that produce impressions on its inferior surface.

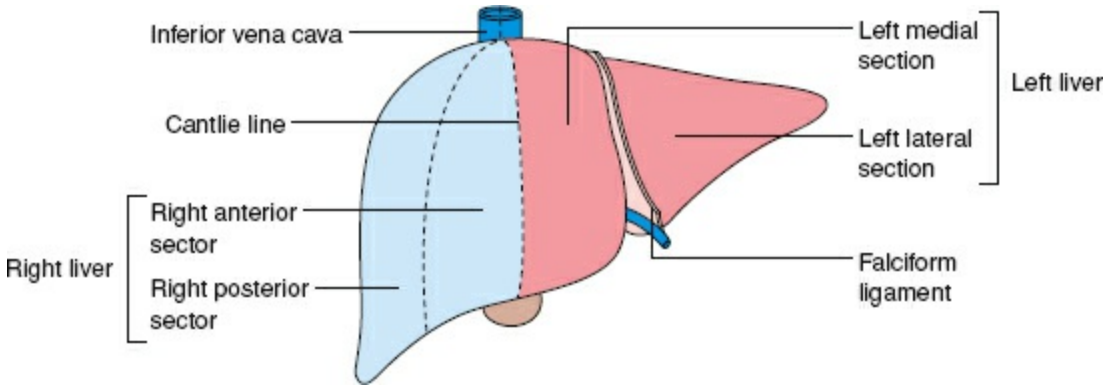

Figure 57-3. Anatomic division of the liver into right and left halves by a plane extending from the gallbladder fossa posteriorly to the inferior vena cava.

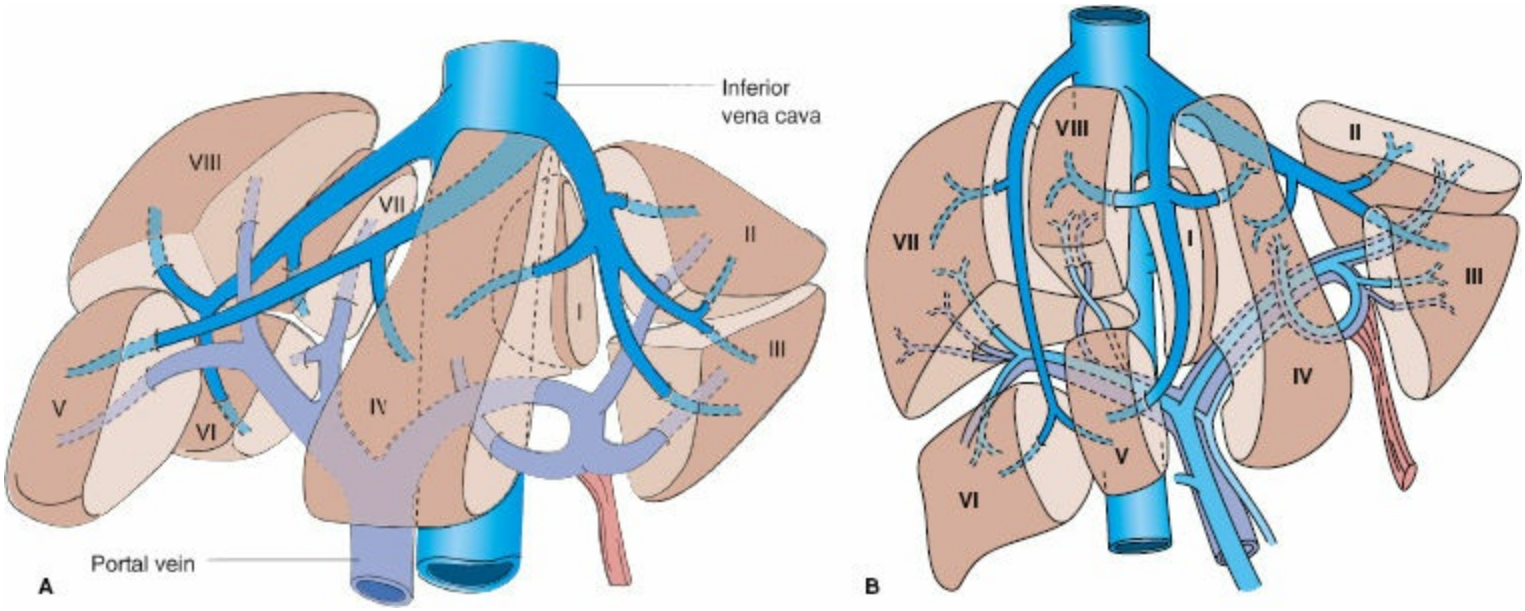

Figure 57-4. Functional divisions of the liver and liver segments according to Couinaud nomenclature with the liver in the natural position (**A**) and after it is mobilized (**B**).

1 The most widely accepted nomenclature is based on Couinaud's description of the discrete anatomic segments of the liver (Fig. 57-4).[6] The eight segments of a liver can be determined using surface anatomy and location of the three main hepatic veins, the portal pedicle bifurcation into right and left, and the umbilical fissure and falciform ligament. As described, the right and left halves of the liver are delineated by a plane through the middle hepatic vein and IVC. Segments II, III, and IV lie to the left of this plane and form the left half of the liver. Segments V, VI, VII, and VIII lie to the right of this plane and form the right half of the liver. Segment I, or the caudate process, is morphologically distinct from the two halves of the liver and emanates from a process of liver lying posterior to the portal pedicle and anterior to the IVC. Whereas the right and left halves of the liver derive blood supply from the corresponding right and left portal veins and hepatic arteries, segment I derives blood supply from both. Additionally, the right half of the liver has venous drainage primarily through the right and middle hepatic veins, and the left half of the liver primarily through the left and middle hepatic veins. Segment I, however, drains directly via small branches into the IVC. The left liver and especially the right liver usually have small accessory hepatic venous branches draining directly into the IVC. Occasionally on the right, the accessory branch is significant in size.

The right half of the liver can be further subdivided using a plane through the right hepatic vein and the IVC. Liver anterior to this plane forms the right anterior sector, and liver posterior to this plane forms the right posterior sector. The right anterior sector of the liver is composed of segment V (inferior to the portal bifurcation) and segment VIII (superior to the portal bifurcation). The right posterior sector of the liver is composed of segment VI (inferior to the portal bifurcation) and segment VII (superior to the portal bifurcation).

The left half of the liver can be further subdivided using a plane through the umbilical fissure and falciform ligament. Liver medial to this plane forms the left medial section of the liver or segment IV, and liver lateral to this plane forms the left lateral section of the

liver. The left medial section of the liver is sometimes divided into two halves, with IVa closer to the IVC and IVb farther. The left lateral section of the liver is further subdivided into segment II (which is superior) and segment III (which is inferior).

Hepatic Veins

2 Three major hepatic veins carry blood from the liver to the IVC. Most patients have a right hepatic vein that joins the right anterior wall of the IVC and middle and left hepatic veins that converge into a common trunk about 1 cm from the IVC that enters the left anterior wall of the IVC (Fig. 57-5). In some patients, the three main hepatic veins join the IVC via three distinct trunks. These hepatic veins usually lie within the hepatic parenchyma. Usually, a definable extraparenchymal segment of the hepatic veins, especially the right, can be dissected out before it empties into the IVC, which makes outflow control safer and easier. Usually, multiple accessory right hepatic veins empty from the right half of the liver directly into the IVC as it courses posterior to the liver (Fig. 57-6). On occasion, these accessory right hepatic veins are sizable and may even support venous outflow should the native right hepatic vein need to be taken. Additionally, sometimes an umbilical vein can be appreciated running to the falciform ligament between the middle and left hepatic veins and emptying into the terminal portion of the left hepatic vein.

Portal Veins

The superior mesenteric and splenic veins join posterior to the neck of the pancreas to form the main portal vein. It receives pyloric and coronary vein branches as it courses cephalad and obliquely to the right to form the most posterior structure within the hepatoduodenal ligament (portal triad). In the hilus of the liver, the main portal vein bifurcates into a short oblique right portal vein and a longer, more transverse, and more superficial left portal vein (Fig. 57-7). These branches then enter the parenchyma and become invested along with the other components of the portal triad by extensions of the Glisson capsule. Both the right and left portal veins give off small branches to dually supply segment I. The right portal vein usually enters the hepatic parenchyma immediately and is quick to divide into a right anterior portal vein supplying segments V and VIII and a right posterior portal vein supplying segments VI and VII. The left portal vein may remain near the surface of the left half of the liver in the hilar plate for a significant distance as it courses to the umbilical fissure to give off medial branches to segment IV and lateral branches to segments II and III.

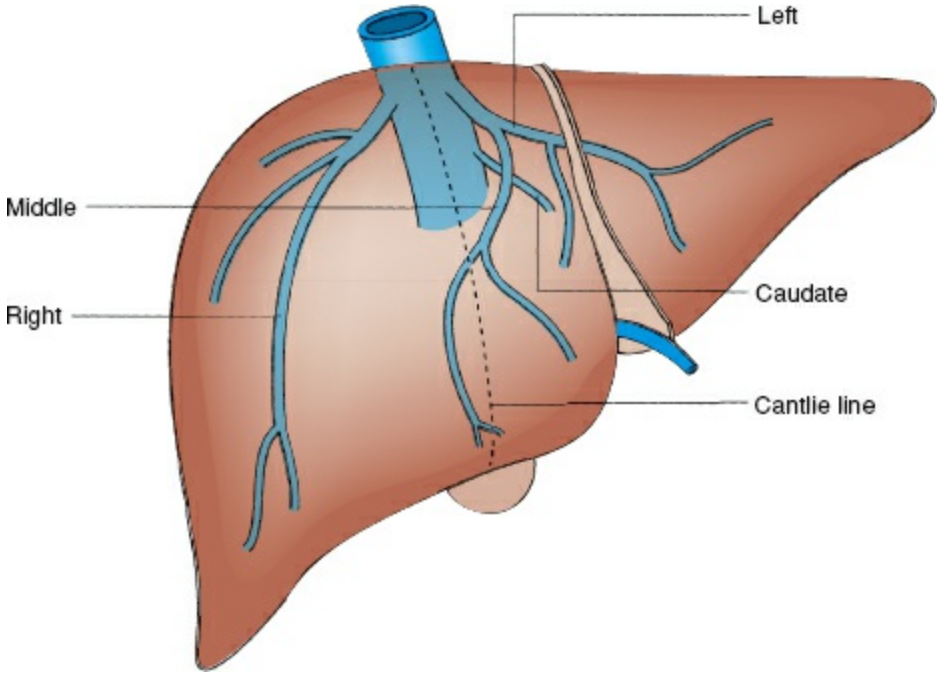

Figure 57-5. Three major hepatic veins drain the liver. The caudate segment of the liver usually drains directly into the inferior vena cava.

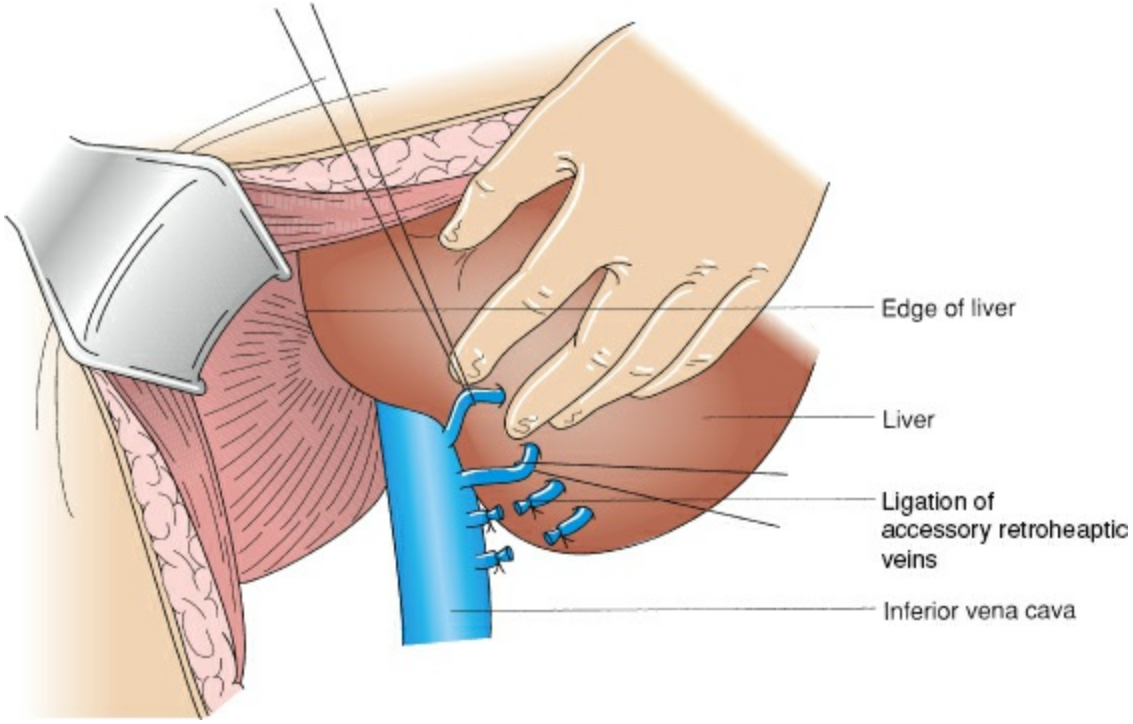

Figure 57-6. Retraction of right liver medially exposes small venous tributaries that drain the right liver directly into the retrohepatic vena cava. Several branches are ligated.

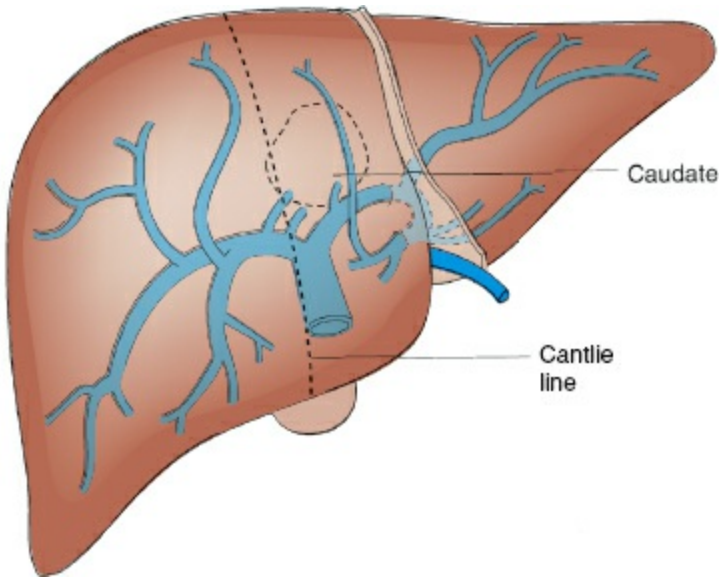

Figure 57-7. Intrahepatic divisions of the portal vein.

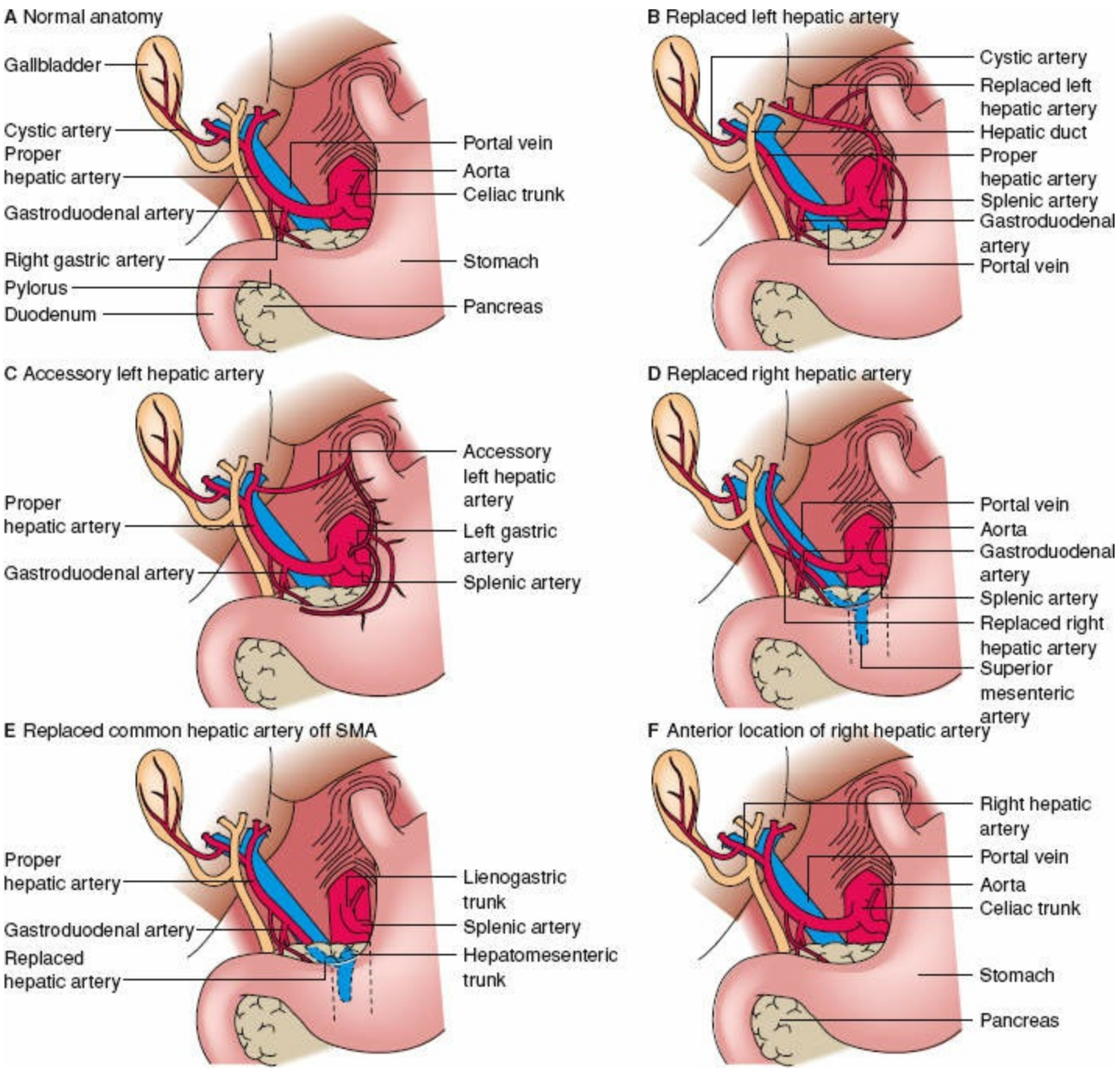

Figure 57-8. Variations in hepatic arterial anatomy.

Hepatic Arteries

3 There is much variability in the hepatic arterial supply to the liver. The most common anatomy is a common hepatic artery that arises from the celiac trunk and courses near the superior border of the neck of the pancreas. After the origins of the gastroduodenal, supraduodenal, and right gastric arteries, the proper hepatic artery courses in the left anterior aspect of the hepatoduodenal ligament in front of the portal vein and to the left of the common hepatic duct. The proper hepatic artery usually bifurcates into right and left hepatic arteries outside the liver. The anatomy of the hepatic artery is variable and should be familiar to surgeons operating in this area (Fig. 57-8). Approximately 45% of people have variant hepatic arterial anatomy.[9] The right hepatic artery usually courses posterior to the common hepatic duct but anterior to the right portal vein to supply the right liver. The left hepatic artery usually remains extrahepatic until near the base of the umbilical fissure, where it enters the liver to give off branches to segments II, III, and IV. Small branches from near the bifurcation of the proper hepatic artery also supply segment I. A middle hepatic artery branch may arise from either the right or left hepatic arteries after bifurcation. Although this anatomy is described as normal, it is found only in approximately 50% to 60% of patients. A replaced or accessory right hepatic artery may arise off of the superior mesenteric artery near its origin and course posteriorly or through the head of the pancreas to lie along the right posterior border of the hepatoduodenal ligament. A replaced or accessory left hepatic artery may arise off of the left gastric artery and course transversely toward the base of the umbilical fissure in the lesser omentum. In general, within the hepatic parenchyma, the hepatic arterial branches course closely with bile duct branches and fairly closely with portal venous branches, but not always, and anatomic variations should be suspected. The descriptions and frequency of hepatic arterial variants have been well characterized by Michels.[9]

Intrahepatic Biliary Tree

The right and left livers are respectively drained by the right and left hepatic ducts, whereas the caudate (segment I) is drained by several small ducts joining the confluence and the first several centimeters of both hepatic ducts. The intrahepatic ducts are tributaries of the corresponding hepatic ducts, which penetrate the liver invaginating the Glisson capsule at the hilus. Bile ducts are usually located above the corresponding portal branches, whereas hepatic arterial branches run inferiorly to the veins. The left hepatic duct directly drains the bile ducts to segments II, III, and IV, which constitute the left liver. The right hepatic duct drains the bile ducts from segments V, VI, VII, and VIII, which constitute the right liver. Usually, the bile ducts from segments V and VIII join to first form the anterior sectoral duct and the bile ducts from segments VI and VII join to first form the posterior sectoral duct prior to forming the right hepatic duct (Fig. 57-9).

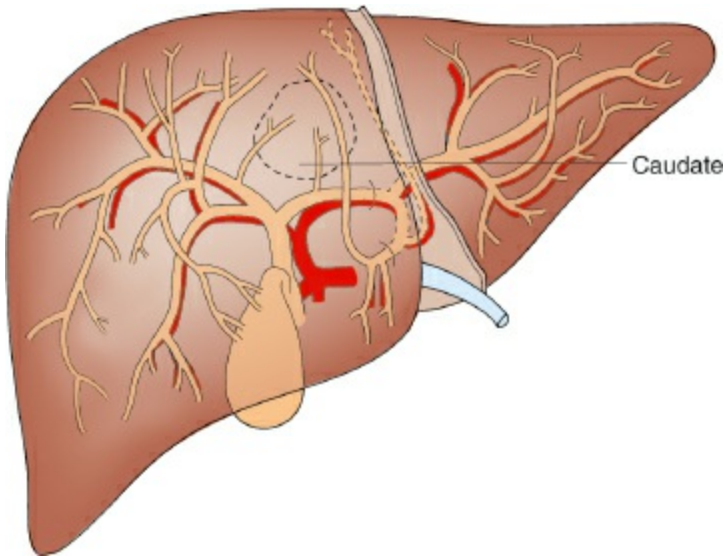

Figure 57-9. Intrahepatic divisions of the bile ducts and hepatic arteries.

Gallbladder

4 The gallbladder is a reservoir for bile located on the undersurface of the liver at the confluence of the right and left halves of the liver. It is separated from the hepatic parenchyma by a cystic plate, which is constituted of connective tissue applied to the Glisson capsule. The gallbladder may be deeply imbedded into the liver or occasionally presents on a mesenteric attachment, but usually lays in a gallbladder fossa. The gallbladder varies in size and consists of a fundus, a body, and an infundibulum. The tip of the fundus usually reaches the free edge of the liver and is closely applied to the cystic plate. The infundibulum of the gallbladder makes an angle with the body and may obscure the common hepatic duct, constituting a danger point during cholecystectomy. The cystic duct arises from the infundibulum of the gallbladder and extends to join the common hepatic duct. The lumen measures between 1 and 3 mm in diameter, and its length varies depending on the type of union with the common hepatic duct (Fig. 57-10). Callot triangle is bounded by the common hepatic duct on the left, the cystic duct inferiorly, and the cystic artery superiorly. Arterial blood reaches the gallbladder via the cystic artery, which usually originates from the right hepatic artery. Several known variations in the origin and course of the cystic artery are illustrated in Figure 57-11. The venous drainage of the gallbladder is directly into the liver parenchyma or into the common bile duct plexus.

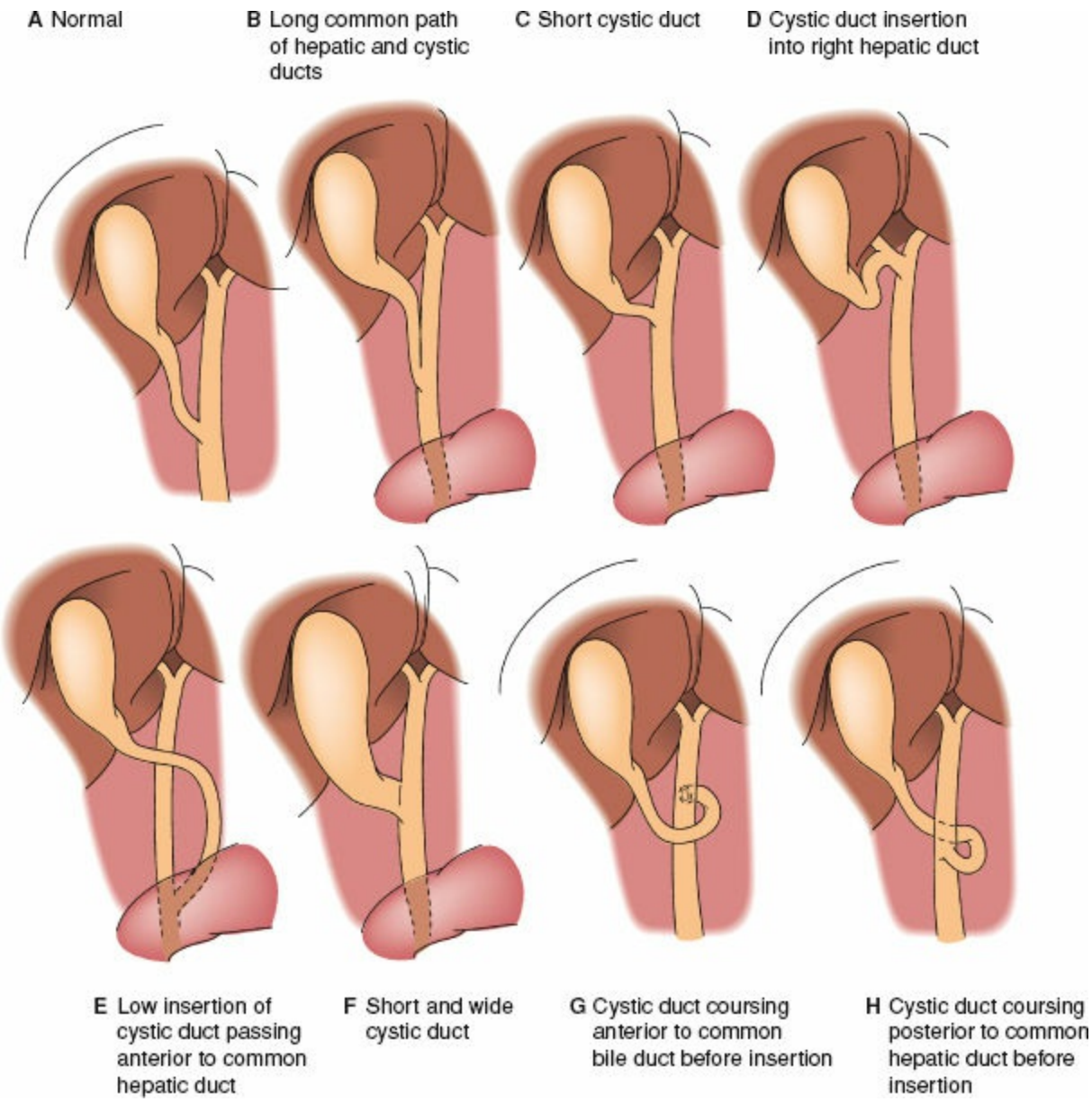

Figure 57-10. Variations in the junction of the cystic duct and common hepatic duct.

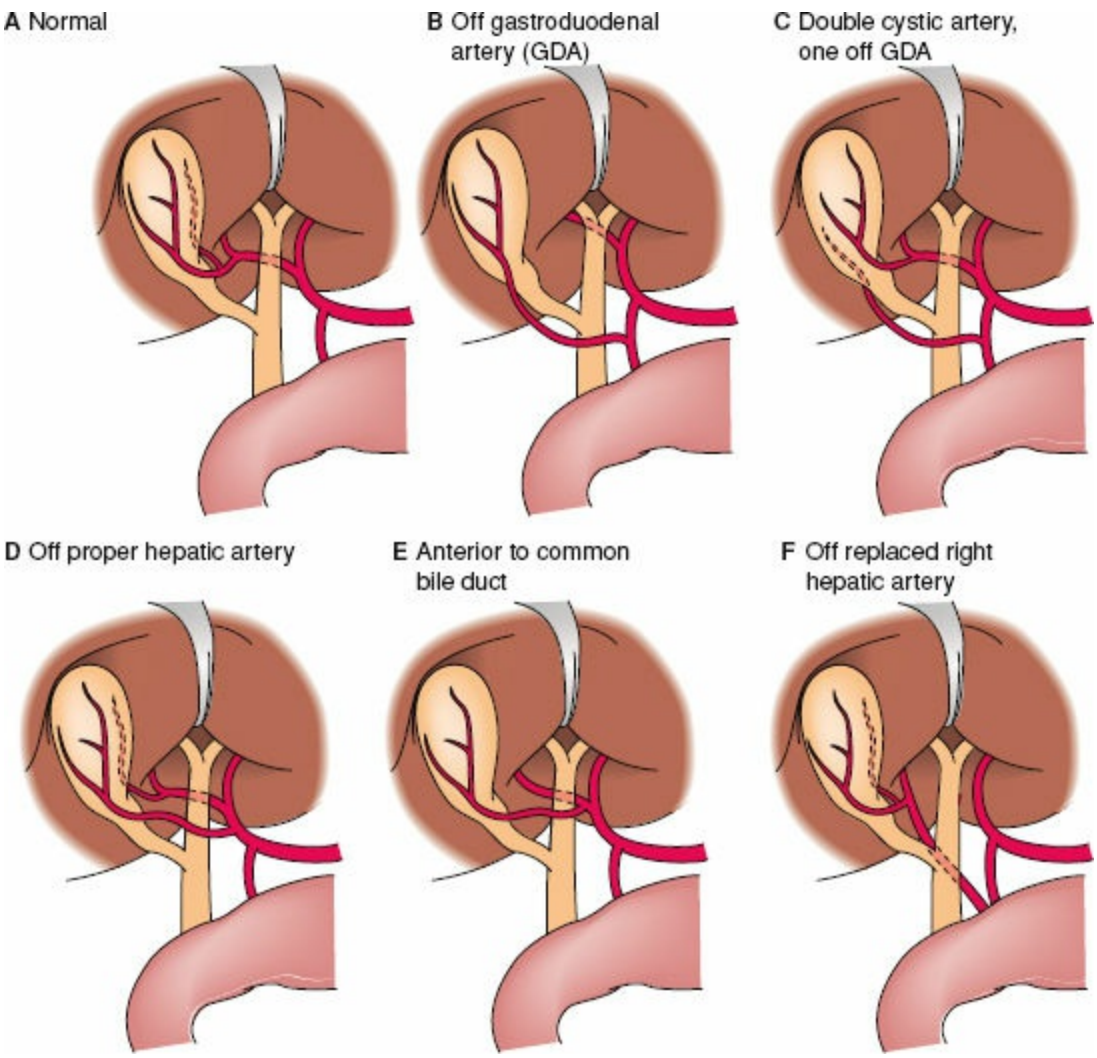

Figure 57-11. Variations of the cystic artery.

Common Bile Duct

The cystic and common hepatic ducts join to form the common bile duct. The common bile duct is approximately 8 to 10 cm in length and 0.4 to 0.8 cm in diameter. The common bile duct can be divided into three anatomic segments: supraduodenal, retroduodenal, and intrapancreatic (Fig. 57-12). The supraduodenal segment resides in the hepatoduodenal ligament lateral to the hepatic artery and anterior to the portal vein (Fig. 57-13). The course of the retroduodenal segment is posterior to the first portion of the duodenum, anterior to the IVC, and lateral to the portal vein. The pancreatic portion of the duct lies within a tunnel or groove on the posterior aspect of the pancreas. The common bile duct then enters the medial wall of the duodenum, courses tangentially through the submucosal layer for 1 to 2 cm, and terminates in the major papilla in the second portion of the duodenum (Fig. 57-12). The distal portion of the duct is encircled by smooth muscle that forms the sphincter of Oddi. The common bile duct usually joins the pancreatic duct to form a common channel before entering the duodenum at the ampulla of Vater. Some patients will have an accessory pancreatic duct emptying into the duodenum.

5 The blood supply of the common bile duct is segmental in nature and consists of branches from the cystic, hepatic, and gastroduodenal arteries. These meet to form collateral vessels that run in the 3 and 9 o'clock positions. The venous drainage forms a plexus on the anterior surface of the common bile duct that enters the portal system. The lymphatic drainage follows the course of the hepatic artery to the celiac nodes.

LIVER IMAGING

Computed Tomography

Computed tomography (CT) is widely available and quick and has become the main modality to initiate the assessment of hepatic processes. It also has the advantage of being able to quickly assess other organs within the abdominal cavity and chest. With the introduction of multidetector spiral CT, the resolution of hepatic lesions is quite good. This scanning technique allows total hepatic imaging in arterial, portal venous, and delayed phases after a rapid intravenous contrast bolus during a single breath hold by the patient (Fig. 57-14). In addition, three-dimensional reconstructions can be created to construct high-quality hepatic artery angiograms, portal venograms, and hepatic venograms. These reconstructions play a vital role in the selection of appropriate donors for live donor liver transplantation (Fig. 57-15). Drip infusion cholangiography with CT can provide distal intrahepatic duct cholangiograms that with the three-dimensional arteriograms and venograms are vital in planning donor hepatectomies and avoiding serious complications.

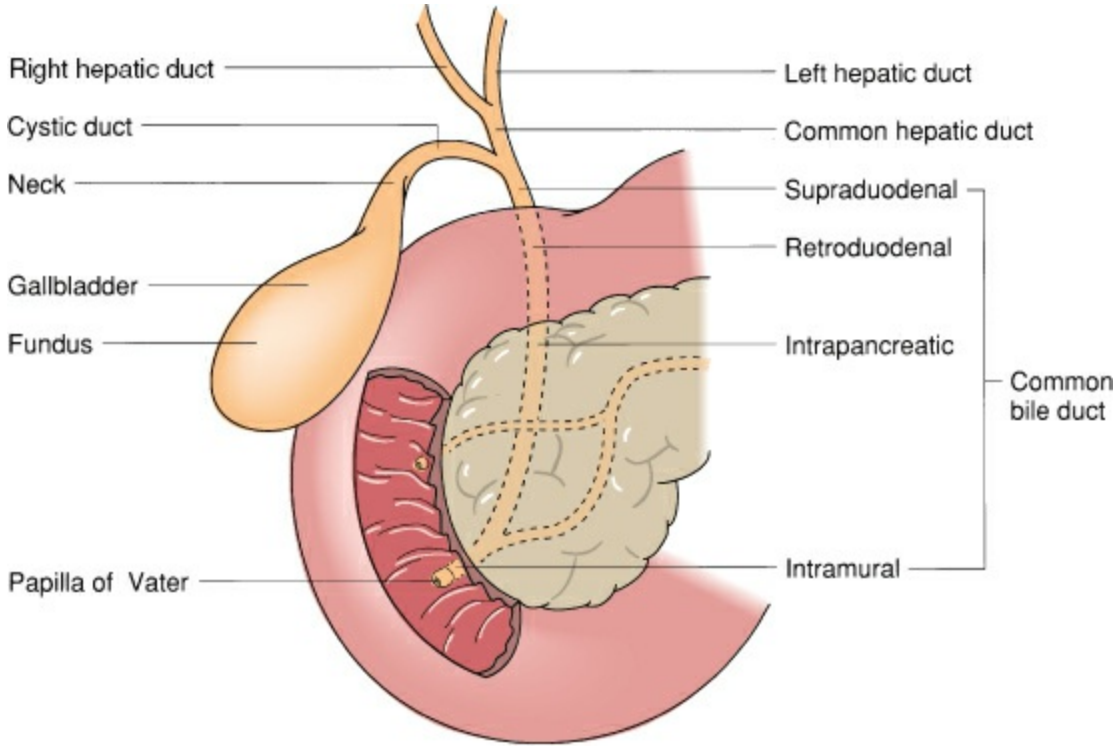

Figure 57-12. Anatomy of the extrahepatic biliary tree and pancreatic duct.

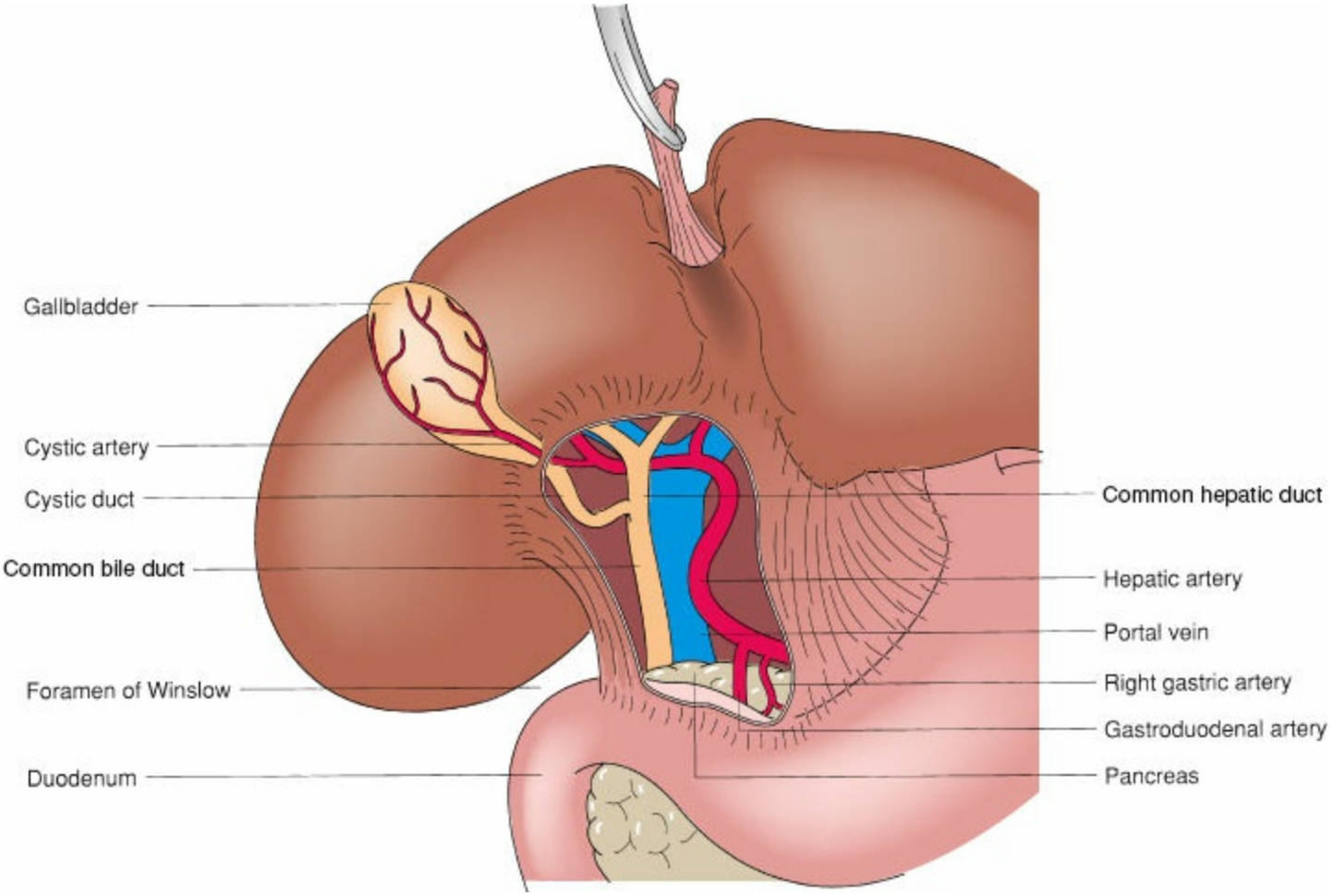

Figure 57-13. Relationship of structures within the hepatoduodenal ligament.

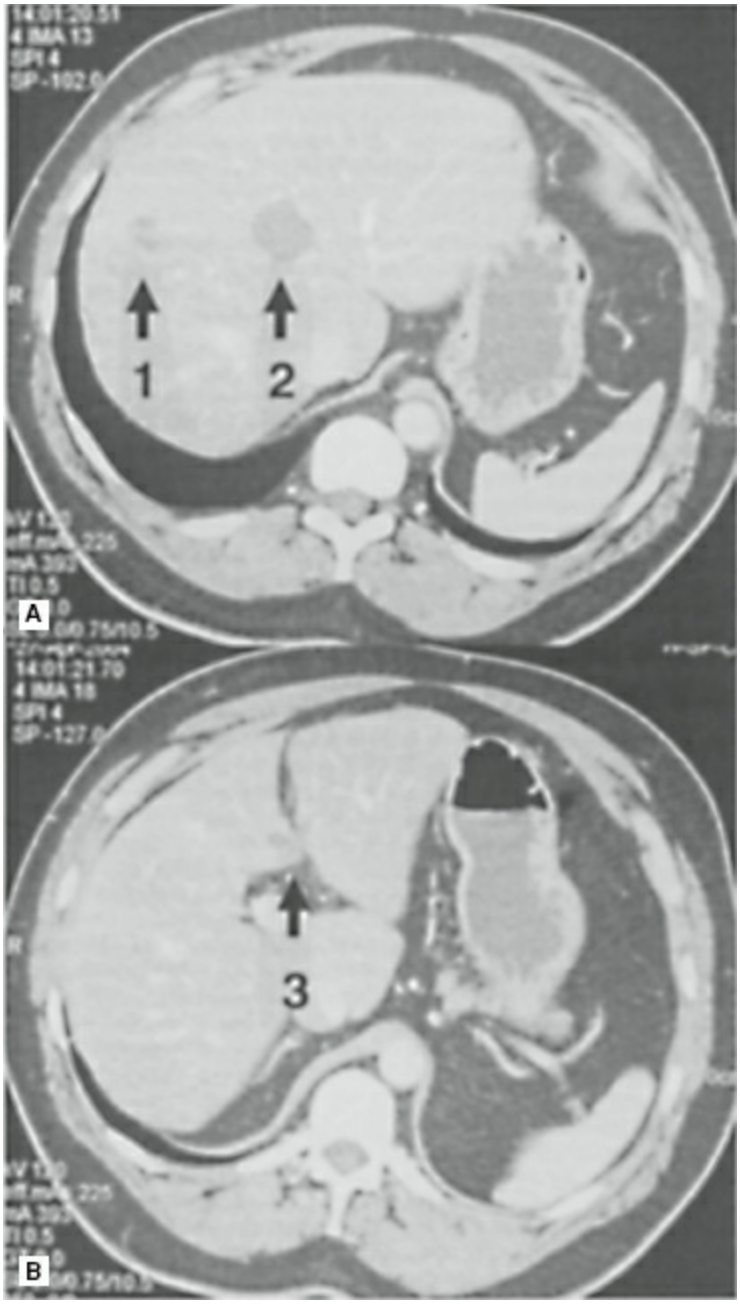

Figure 57-14. Portal venous phase of computed tomography (CT) scan from a patient with a history of colorectal cancer and three lesions in the liver. Lesion 1 in segment VIII is irregular and rim enhancing and was a colorectal cancer metastasis. Lesion 2 straddling segments IV and VIII has smooth borders, is not rim enhancing, and was found to be a cyst. Lesion 3 straddling segments IV and III across the umbilical fissure is irregular and rim enhancing and was a colorectal cancer metastasis.

Magnetic Resonance Imaging

6 Magnetic resonance imaging (MRI) of the liver with gadolinium as a contrast agent is commonly used to help further characterize hepatic lesions. Resolution of some lesions may be slightly better with MRI. Additionally, certain lesions, such as hemangiomas and cysts, can easily be identified based on MRI characteristics when the CT characteristics are indeterminate (Fig. 57-16). The disadvantages of MRI are its increased cost, increased amount of time to perform, inability to quickly screen other organs and body cavities within the same session, and wide variability in quality from one imaging center to another.

7 Magnetic resonance cholangiopancreatography (MRCP) is becoming more widely used to noninvasively view biliary anatomy (Fig. 57-17). The scans are heavily T2 weighted, which maximizes the signal from the biliary tree. No injection of contrast agent is needed, and under optimal conditions the resulting imaging can rival that of formal cholangiography. Three-dimensional reconstructions can be performed to view the biliary tree from multiple angles and can be helpful in distinguishing between stones, strictures, and neoplasms. Again, these reconstructions are vital to donor selection in live donor liver transplantation. Rarely is it necessary to proceed with endoscopic retrograde cholangiopancreatography (ERCP) to define the distal intrahepatic ductal anatomy.

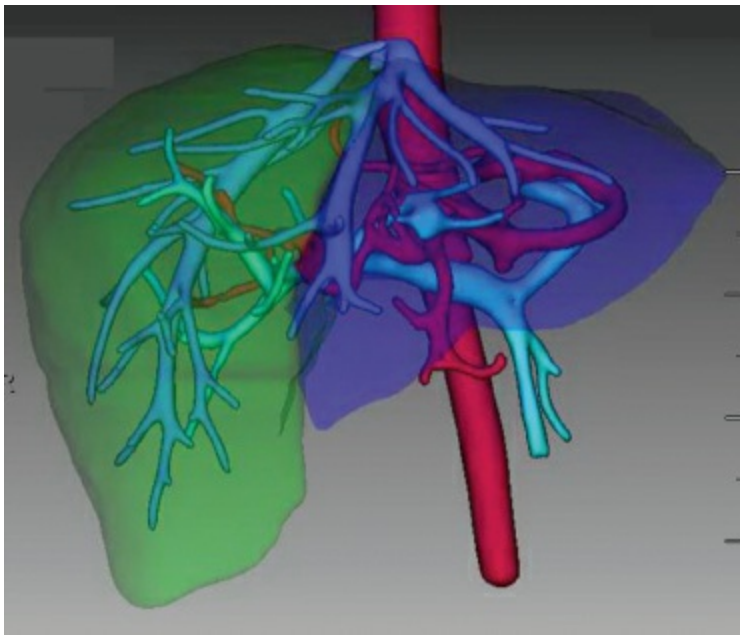

Figure 57-15. Three-dimensional reconstruction of the hepatic vasculature.

Ultrasonography

8 Hepatic ultrasonography can be applied transcutaneously or intraoperatively via open or laparoscopic surgery. It can be useful in identifying lesions within the hepatic parenchyma, to describe the consistency (i.e., fatty or cirrhotic) and identify dilation of the biliary tree and any abnormalities or stones within the gallbladder. In hepatobiliary surgical centers, intra operative ultrasonography is used routinely to assess the anatomy of the pedicles (portal vein, hepatic artery, and bile duct), the hepatic veins, and the hepatic parenchyma. It is useful both to further identify and characterize lesions within the hepatic parenchyma and to delineate their relationships within the eight anatomic segments of the liver. Additionally, it is often helpful to delineate proximity of lesions to major vascular structures and to survey for abnormal anatomy in planning a resection.

With ablation therapies more commonly employed, ultrasound has become indispensable in directing the use of radiofrequency ablation. This ablation therapy can be performed percutaneously, laparoscopically, and during open surgery.

9 Typically, intraoperative assessment of the liver involves examining the portal pedicles. The main portal pedicle is identified within the hepatoduodenal ligament. It is followed superiorly to the portal bifurcation into the main right and left pedicles. The portal pedicles are invested with the Glisson capsule and have a very echogenic covering to them in contrast to hepatic vein branches. The main right portal pedicle is followed toward the right where it gives off an anterior branch and a posterior branch (Fig. 57-18A). The right anterior branch gives off separate pedicles to segment V (caudad) and to segment VIII (cephalad). The right posterior branch gives off separate pedicles to segment VI (caudad) and to segment VII (cephalad). The main left pedicle is usually much longer and courses intact to the base of the umbilical fissure before branching into various segmental pedicles (Fig. 57-18B). At the base of the umbilical fissure, the main left pedicle courses anteriorly toward the round ligament and gives off a pedicle to segment IV medially and pedicles to segments II and III laterally. Next, if the falciform ligament has been divided, the hepatic veins can easily be visualized using intraoperative ultrasonography (Fig. 57-18C). As described previously, usually a larger right hepatic vein can be delineated and smaller left and middle hepatic veins joining into a common trunk before emptying into the IVC are seen. Commonly, an umbilical hepatic vein branch can be identified coursing between the middle and left hepatic veins and running under the falciform ligament. Not uncommonly, significant accessory right hepatic veins can be seen emptying from the posterior surface of the right liver directly into the IVC as it courses posterior to the liver. The identification of these accessory right hepatic veins is potentially important for both vascular control and preservation of outflow from the liver (in occasional cases where outflow of the remnant right liver can be supported by a very large accessory vein). Finally, the hepatic parenchyma is systematically scanned to identify lesions within the liver (Fig. 57-18). It is sometimes useful to adjust the ultrasound settings on a known lesion defined preoperatively to maximize the echogenicity in the hopes of identifying other occult lesions not identified preoperatively.

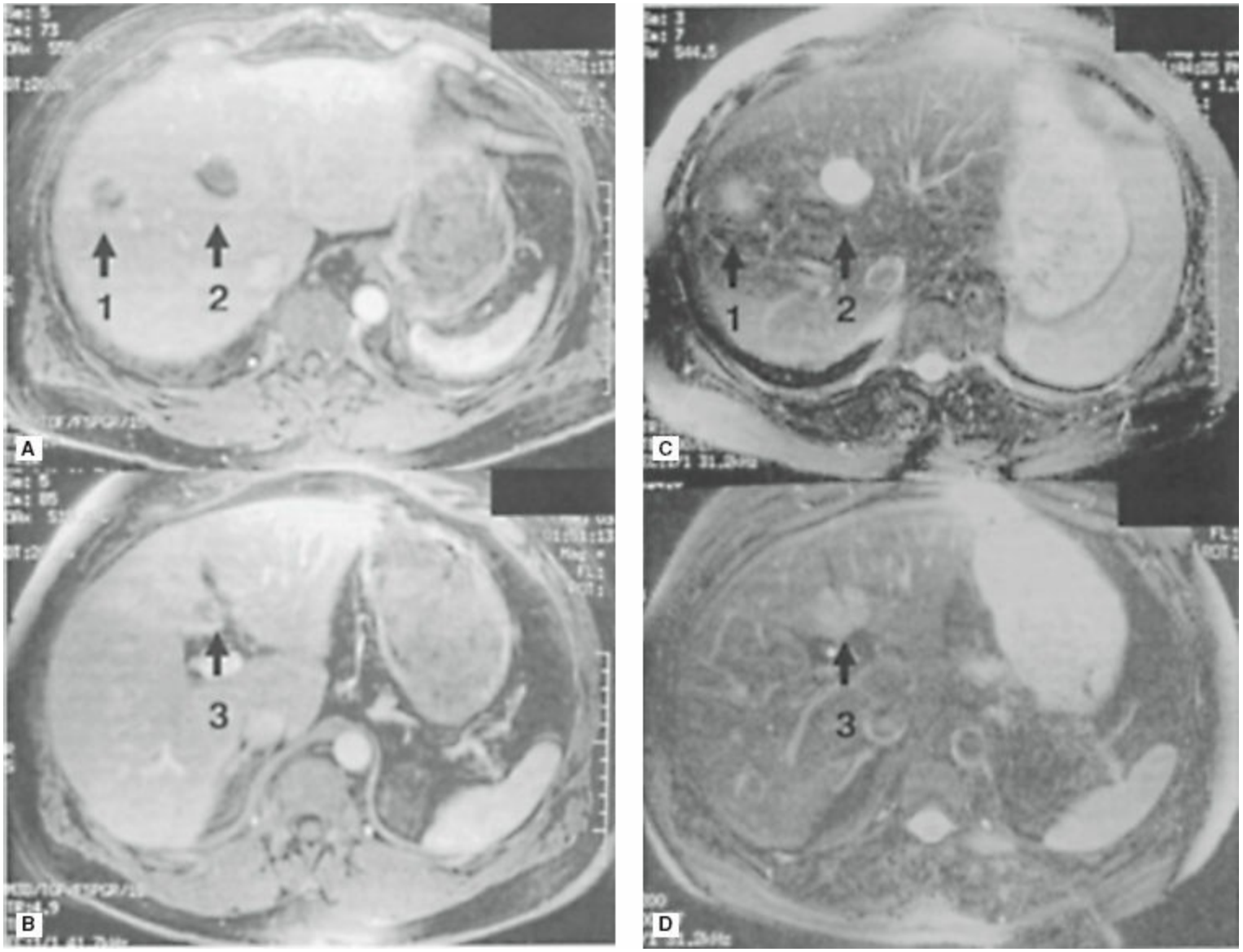

Figure 57-16. **A,B:** T1-weighted magnetic resonance imaging (MRI) with gadolinium from the same patient as in Figure 57-14 with history of colorectal cancer and three lesions in the liver. Lesion 1 in segment VIII is irregular and rim enhancing and was a colorectal cancer metastasis. Lesion 2 straddling segments IV and VIII has smooth borders, is not rim enhancing, and was found to be a cyst. Lesion 3 straddling segments IV and III across the umbilical fissure is irregular, rim enhancing, and was a colorectal cancer metastasis. **C,D:** T2-weighted MRI from the same patient with history of colorectal cancer and three lesions in liver. Lesion 1 in segment VIII is irregular and mildly bright and was a colorectal cancer metastasis. Lesion 2 straddling segments IV and VIII has smooth borders, is very bright, and was found to be a cyst. Lesion 3 straddling segments IV and III across the umbilical fissure is mildly bright and was a colorectal cancer metastasis. Colorectal metastases and many tumors are mildly bright on T2-weighted MRI, whereas cysts and hemangiomas are typically very bright.

Positron Emission Tomography

Positron emission tomography (PET), especially when combined with CT (PET-CT), has become a valuable tool in helping to select patients who will most benefit from aggressive liver resection. This technique is based on the increased metabolism of glucose in neoplastic tissues. A glucose analog, fluorodeoxyglucose, that is tagged with fluorine-18 is injected intravenously before scanning and is retained preferentially in metabolically active tumors over normal tissue. Sometimes PET scans will identify areas of occult disease within the liver, but more importantly, they can identify areas of extrahepatic occult disease previously unsuspected. When combined with a CT scanner within the same machine and the ability to fuse images, the areas of increased activity can be more precisely anatomically identified (Fig. 57-19).

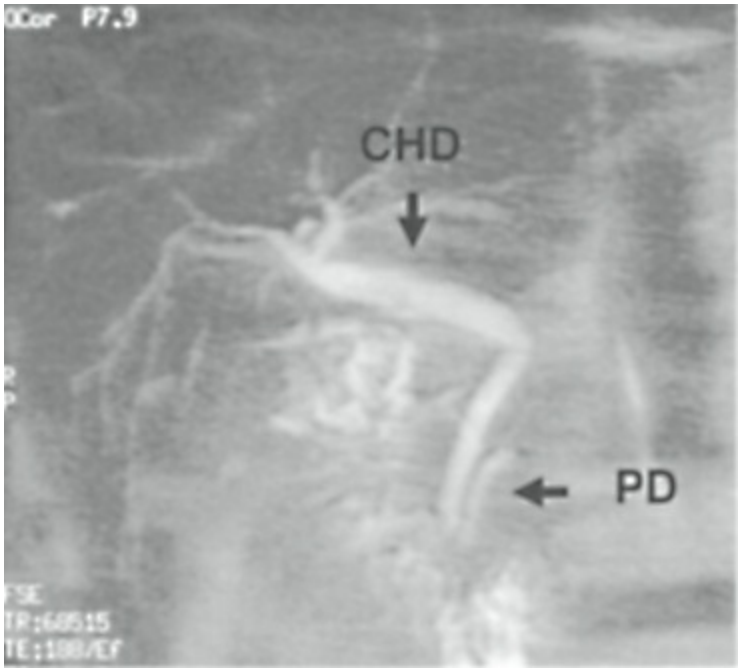

Figure 57-17. Magnetic resonance cholangiopancreatography (MRCP) of a patient after cholecystectomy with mild dilation of common hepatic duct (CHD). The pancreatic duct (PD) is also visible.

Correlation of Computed Tomographic Images with Segmental Anatomy

Preoperative CT remains the primary imaging modality used by most surgeons before hepatic resection. Figure 57-14 is provided to help correlate CT images to the segmental anatomy defined previously. The segments of the liver are defined using identifiable structures on the CT (Fig. 57-20).

PREOPERATIVE EVALUATION OF HEPATIC RESERVE

Whenever a surgical resection is planned, an important consideration is whether the remnant liver will be sufficient to regenerate and sustain the patient long term. In patients with relatively normal hepatic parenchyma (without active hepatitis, cirrhosis, or metabolic defects), up to 75% of the hepatic volume can be resected with good recovery as long as the remnant liver has adequate portal venous and hepatic arterial inflow, adequate hepatic venous outflow, and adequate biliary drainage. Many groups around the world have used various strategies to predict hepatic reserve (Tables 57-1 to 57-3). None of these tests or strategies has been demonstrated to clearly better predict outcome than another. Many centers in the United States rely simply on the Child–Pugh or MELD score and the prediction of adequate liver remnant volume after resection. In select circumstances, it may be of benefit to perform portal vein embolization to the right or left half (rare) of the liver in the hopes of obtaining compensatory hypertrophy of the other side before resection. This is especially useful when the predicted liver remnant after resection is small or if the patient has an underlying hepatic dysfunction that may not allow the remnant to fully regenerate and sustain the patient long term. To gain maximal growth of the left lateral section of the liver, some centers will also embolize the portal vein branches to segment IV in addition to the main right portal vein. The disadvantages of portal vein embolization include the need to wait 3 to 4 weeks before resection to allow the compensatory hypertrophy to occur and, for more central lesions, the need to commit to taking out one or the other side with an extended hepatectomy without the benefit of intraoperative evaluation.

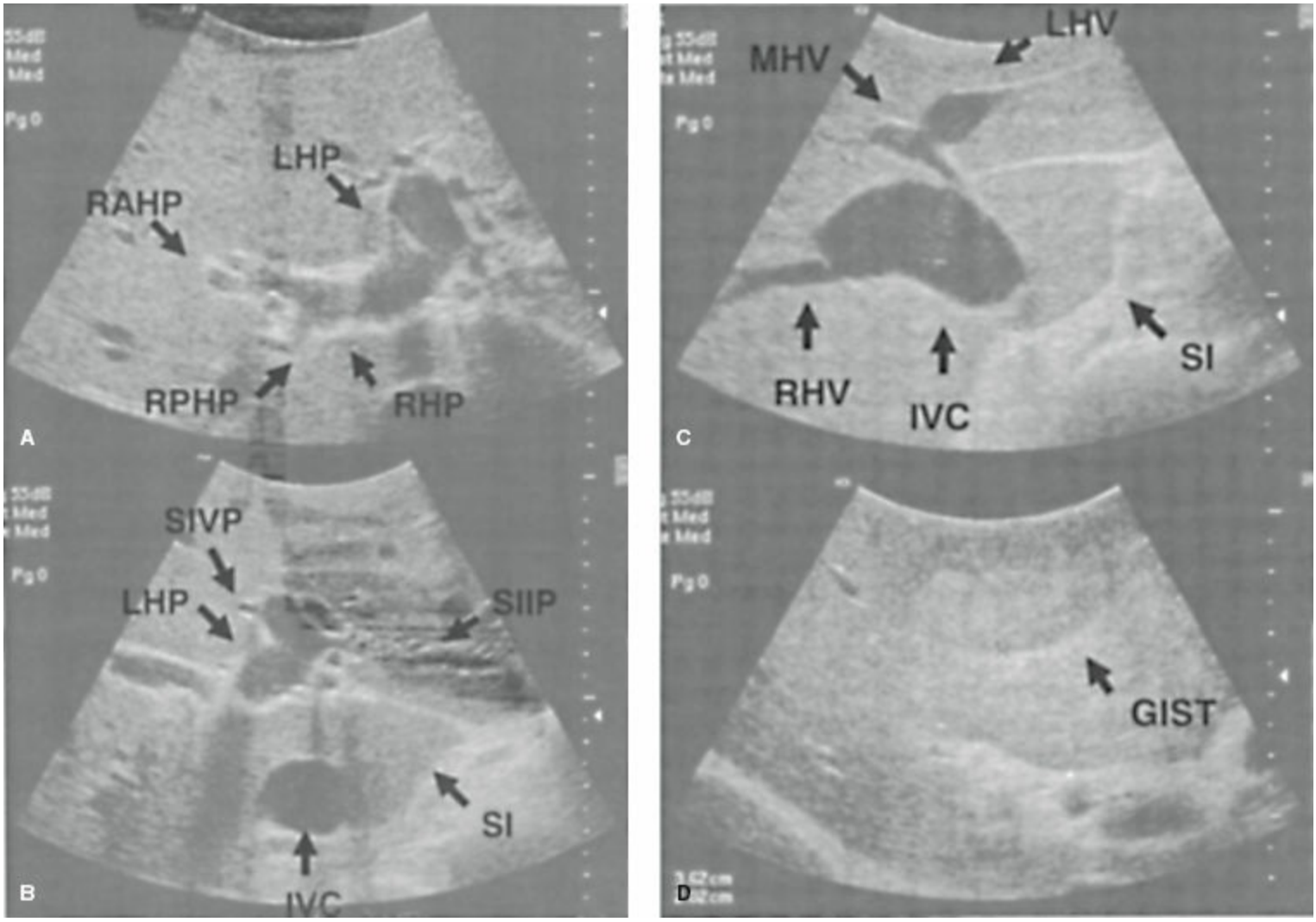

Figure 57-18. **A,B:** Intraoperative ultrasound images of liver demonstrating right hepatic pedicle (RHP), right anterior sector pedicle (RASP), right posterior sector pedicle (RPSP), left hepatic pedicle (LHP), segment II pedicle (SIIP), segment IV pedicle (SIVP), segment I (SI), and inferior vena cava (IVC). **C,D:** Intraoperative ultrasound images of liver demonstrating inferior vena cava (IVC), right hepatic vein (RHV), middle hepatic vein (MHV), left hepatic vein (LHV), segment I (SI), and a metastatic gastrointestinal stromal tumor lesion straddling segments IV and V of the liver.

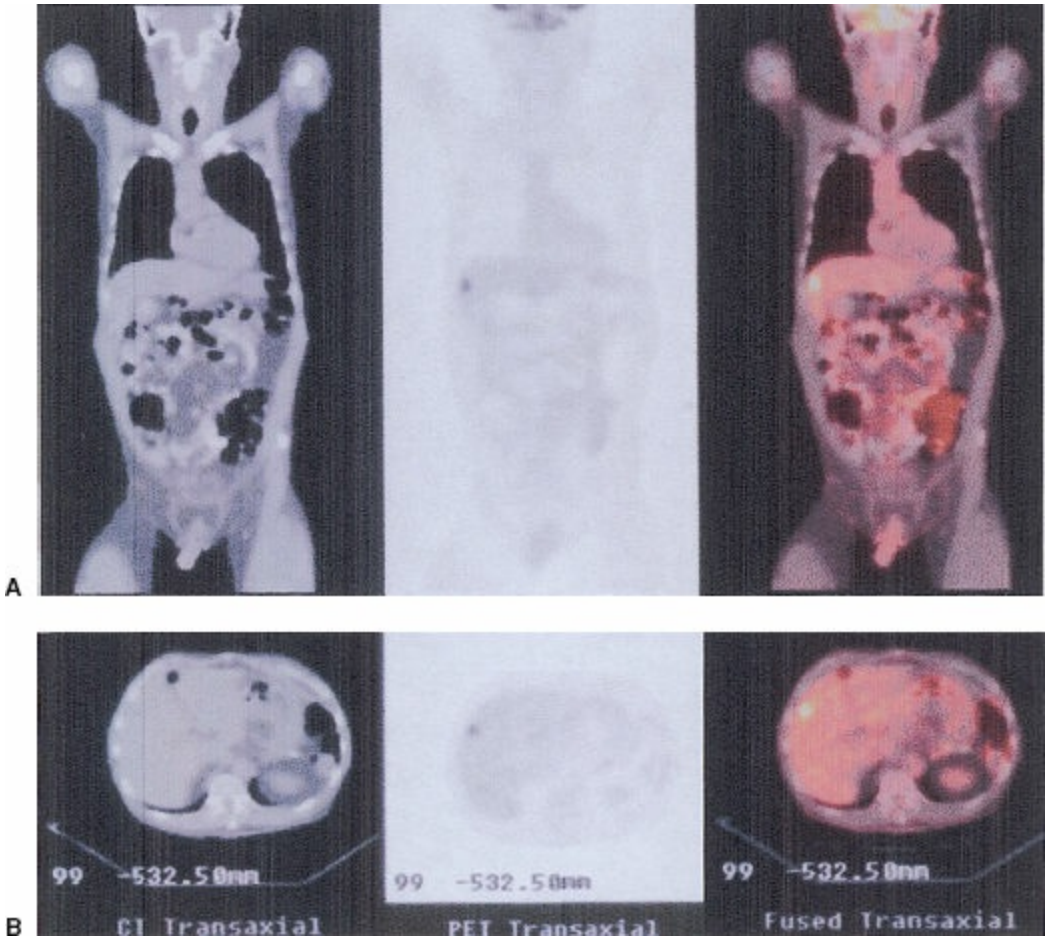

Figure 57-19. Positron emission tomography and computed tomography (PET-CT) scan images of patient in Figure 57-18B and C with solitary gastrointestinal stromal tumor metastasis straddling segments IV and V. Noncontrast CT images (**left**). PET images (**center**). Fusion images (**right**).

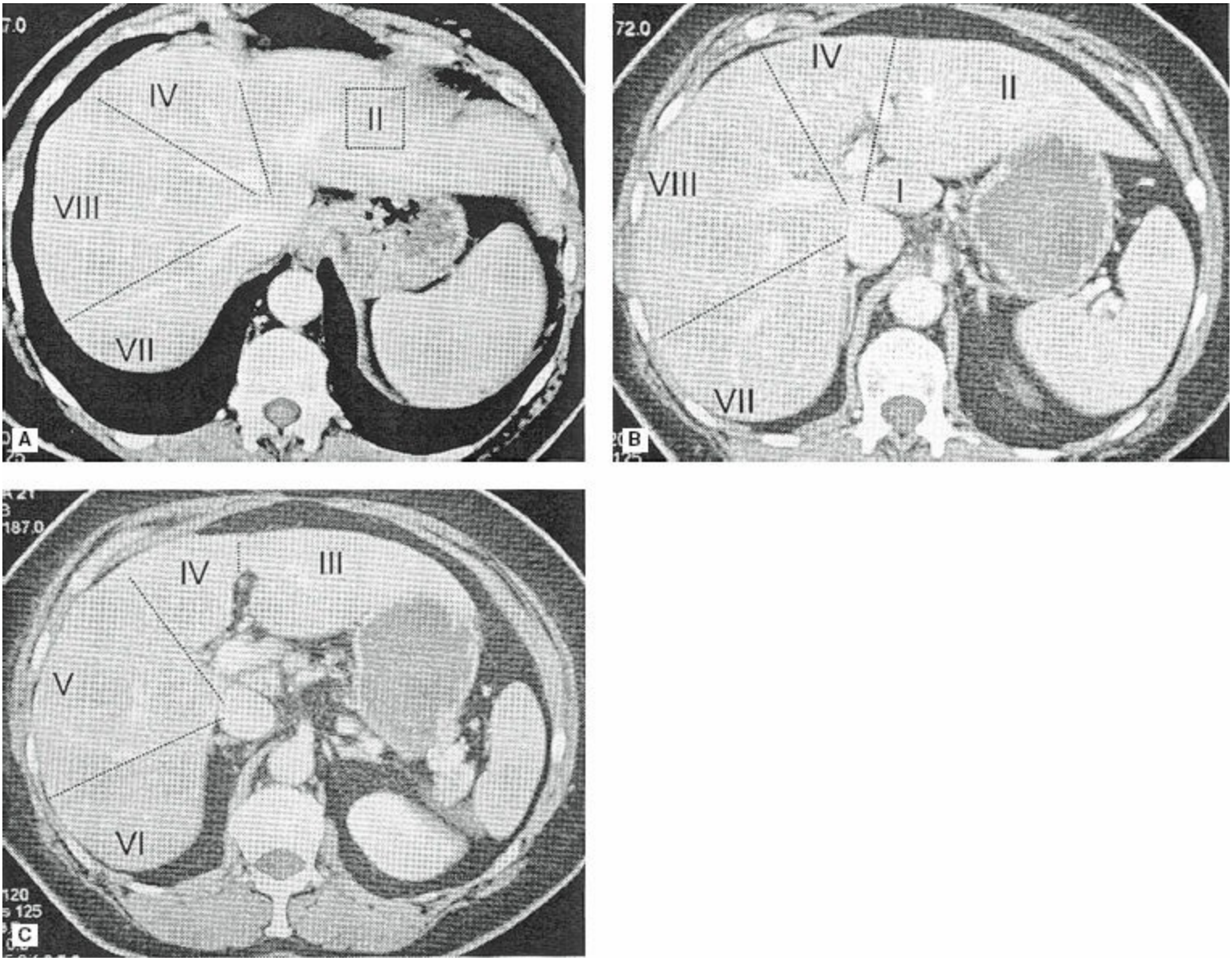

Figure 57-20. Computed tomography scan demonstrating segmental anatomy of the liver with cuts through the dome (**A**), just above the portal bifurcation (**B**), and below the portal bifurcation (**C**).

Table 57-1 Strategies to Predict Hepatic Reserve

- Child–Pugh score (Table 57-2) to assess synthetic ability (albumin, prothrombin time, and ascites), bile conjugation and excretory function (total bilirubin), and metabolic function (changes in mental status from ammonia retention)
- Model for End-Stage Liver Disease (MELD) score estimates 3-mo mortality in patients with chronic liver disease (Table 57-3)
- Clearance of galactose or organic anionic dyes, such as indocyanine green
- Tests of microsomal function such as caffeine clearance, lidocaine clearance, or aminopyrine breath tests
- Volumetric measurements of the liver and prediction of liver remnant after resection based on three-dimensional reconstructions from computed tomography and magnetic resonance imaging

ONCOLOGIC CONSIDERATIONS IN HEPATIC RESECTION

The decision of when and whether to operate is often just as important as the technical details of successfully removing a liver lesion(s) identified in a patient. It is very important to consider the likely diagnosis in making the decision of whether to operate. For example, a solitary liver lesion presenting in an elderly patient with a rising carcinoembryonic antigen (CEA) and a recent history of a resected colon cancer should be treated differently from a young woman with a solitary lesion with radiologic characteristics of a focal nodular hyperplasia lesion. It is important to consider the biology of the tumor within the patient. For example, a patient who represents with a solitary hepatic colorectal cancer metastasis 4 years after resection of the primary tumor will more likely benefit from hepatic resection than another patient who presents with eight synchronous lesions in the liver at the time of diagnosis of the primary tumor. It is important to consider whether the goal of resection is curative or palliative. For example, patients with neuroendocrine tumor metastases of the liver may be debulked of hepatic metastases, but they are rarely totally eradicated of disease. If the tumor is functional and difficult to control medically, then there may be a benefit to debulking. Even if the tumor is not functional, some evidence indicates that surgical debulking of liver metastases in carefully selected patients may benefit long-term survival. It is important to exclude other distant extrahepatic disease with a reasonable number of preoperative tests. For example, before performing hepatic resection for colorectal cancer metastases, it is often helpful to obtain a PET scan to exclude extrahepatic metastases. This will allow better selection of patients most likely to benefit from hepatic resection and will allow patients with previously unsuspected systemic disease to get systemic therapy sooner.

Table 57-2 Child–Pugh Classification

	1 Point	2 Points	3 Points
Bilirubin (mg/dL)	<2	2–3	>3
Albumin (g/dL)	>3.5	2.8–3.5	<2.8
Ascites	Absent	Moderate	Severe
Encephalopathy	Absent	Moderate	Severe
Prothrombin time Seconds prolonged INR	 <4 <1.7	 4–6 1.7–2.3	 >6 >2.3

INR, international normalized ratio.
Child-Pugh Class A: 5-6 points; Class B: 7-9 points; Class C: 10-15 points.

Table 57-3 MELD Score

MELD = 3.78 × ln[serum bilirubin (mg/dL)] + 11.2 × ln[INR] + 9.57 × ln[serum creatinine (mg/dL)]
40 or more—71.3% 3-month mortality
30–39—52.6% 3-month mortality
20–29—19.6% 3-month mortality
10–19—6.0% 3-month mortality
<9—1.9% 3-month mortality

Patient on renal replacement therapy (dialysis twice within the last week or >24 hours of CVVHD within the last week) will have a serum creatinine level of 4.0 mg/dL.

The comorbid status of the patient is also important. Extended hepatic resections with or without biliary reconstruction can exert a toll on even very fit patients. It is important to identify patients who may have difficulties with hepatic regeneration (e.g., those with a history of hepatitis, cirrhosis, or metabolic disorders). Patients with suspected cardiopulmonary disease should undergo appropriate preoperative evaluation and treatment before hepatic resection. Finally, other effective treatments and the optimal sequence of treatments should be considered. For example, in the treatment of hepatocellular carcinoma the possibilities include liver transplantation, liver resection, radiofrequency or microwave ablation, transarterial chemoembolization, and systemic chemotherapies. A patient with limited hepatocellular carcinoma and poor hepatic reserve due to chronic liver disease, cirrhosis, and portal hypertension is best treated with liver transplant, whereas a patient with normal liver parenchyma, minimal portal hypertension, and a resectable lesion may be best treated with liver resection. Additionally, some patients may best be treated with ablative techniques, especially if they have very small lesions that are easily approached percutaneously. Many patients are treated with a combination of these modalities. For example, most transplant centers will first treat hepatocellular carcinoma patients with chemoembolization to provide locoregional control while the patient is upgraded on the waiting list. Whether the patient is a candidate for liver transplantation or resection, this combination can give insight into the biology of the disease prior to definitive treatment.

INTRAOPERATIVE ASSESSMENT

Incisions for open hepatic resections usually involve a right subcostal incision. Significant exposure can be obtained with a trifurcated incision as shown in Figure 57-21. In the majority of cases, however, all that is needed is an extended right subcostal incision with a vertical extension to the base of the xiphoid. The xiphoid can be resected for better exposure. For bulky lesions on the left or if the left half of the liver extends significantly to the left upper quadrant, a left subcostal component can be added. In rare circumstances, especially for lesions high on the dome, an intercostal extension or even median sternotomy may improve exposure. This is especially true for lesions involving the hepatic vein and IVC confluences.

Several versions of self-retaining costal margin retractors or ringed retractors are available that provide good access to the subdiaphragmatic surface. For complete intraoperative ultrasonography and for major resections, complete mobilization of the involved side of the liver is required. The round ligament is divided and the falciform ligament divided. The right and/or left triangular ligaments are then divided to expose the bare areas of the liver. During exposure of the bare areas of the liver, care should be taken to avoid entering the right or left chest through the ligamentous portions of the diaphragm because this will cause excessive bellowing of the diaphragm and poor exposure until a chest tube is placed on that side or the hemithorax is “bubbled out” to remove the air and the diaphragm repaired. Additionally, the right and left phrenic veins are very superficial on the hemidiaphragm and can be injured. The right colon can be mobilized out of the field by dividing Gerota fascia over the right kidney and pulling the hepatic flexure inferiorly. To completely assess the caudate lobe, the overlying lesser omentum should be divided. Care should be taken to avoid inadvertently dividing a replaced or accessory left hepatic artery running in this space. After mobilization, a thorough bimanual examination should be performed and intraoperative ultrasonography used as previously described.

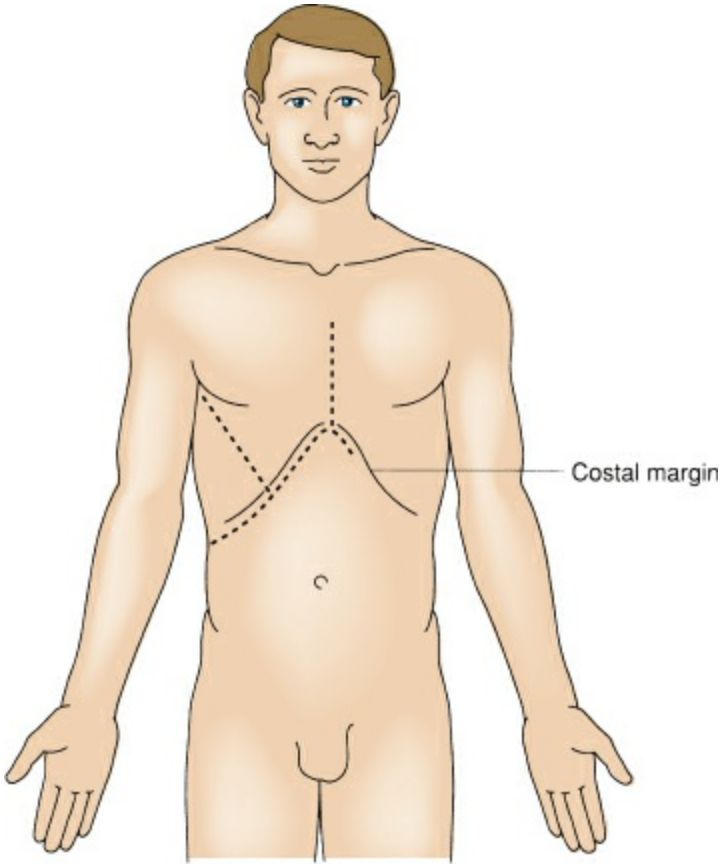

Figure 57-21. Incisions used for open hepatic resection.

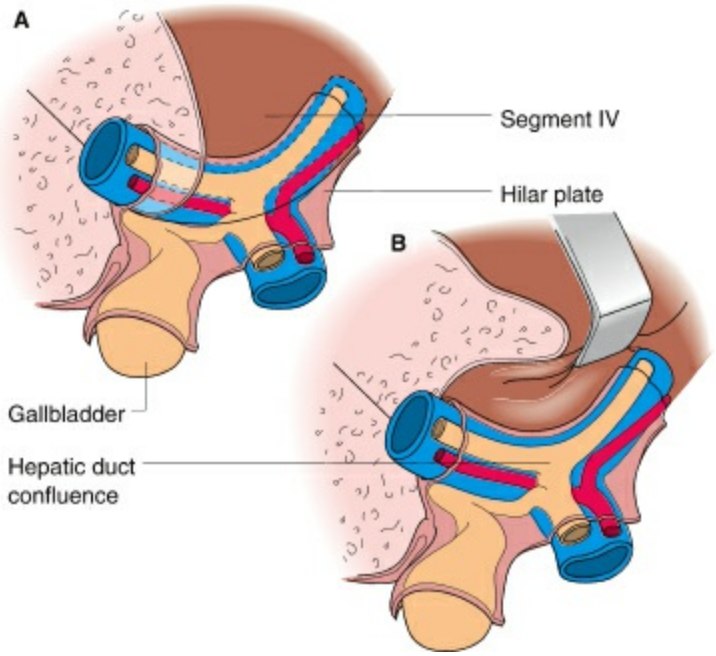

Figure 57-22. Lowering the hilar plate. **A:** The inferior border of segment IV overlies the hepatic duct confluence. **B:** Division of the connective tissue investment allows elevation of segment IV, which results in a "lower" hilar plate and surgical exposure to the hepatic duct confluence.

10 The porta hepatis is often dissected to identify the main bifurcations of the hepatic artery and portal vein and the confluence of the bile ducts. This allows individual ligation of the branches of these structures supplying one side of the liver while preserving the branches to the other side. Ligation of the hepatic artery and portal vein to one side also

allows the liver parenchyma to demarcate a line of resection between the right and left liver. Greater exposure of the superior aspect of the hepatic hilum and exposure of a high or intraparenchymal bifurcation of a portal triad structure may be aided by exposing the hilar plate (Fig. 57-22) and dividing the Glisson capsule at the most inferior border of segment IV. Inflow control to the liver can also be obtained by pedicle ligations in which small hepatotomies are made around the main right pedicle, main left pedicle, right anterior pedicle, or right posterior pedicle after identification with ultrasound (Fig. 57-23).[10] The pedicle of interest can be dissected out bluntly with a right angle or by palpation. The pedicle can then be clamped to confirm that it does indeed supply the area of liver of interest (i.e., right half, left half, right anterior section, or right posterior section). Once confirmed, the pedicle can be divided. Alternatively, the inflow pedicles can be divided as they are encountered while transecting hepatic parenchyma. With this technique, hemorrhage can be minimized by intermittent portal inflow occlusion, which is accomplished by gently clamping the main portal triad within the hepatoduodenal ligament ("Pringle maneuver").

Outflow control of the hepatic veins can be obtained before or after hepatic transection and should be decided on a case-by-case basis. When there is a significant extraparenchymal component to the hepatic vein(s), often it is easier to divide the hepatic vein(s) early and before parenchymal transection (but after inflow control) (Fig. 57-24). When the extraparenchymal component to the hepatic vein(s) is very short or absent and when the tumor margin is not near the junction of the hepatic vein(s) and IVC, it may be easier and safer to divide the hepatic vein(s) within the hepatic parenchyma after most of the parenchymal transection has been performed. The use of endoscopic vascular stapling devices has made the ligation of hepatic veins, whether extra- or intraparenchymally, much quicker and safer (Fig. 57-25).[10] It is often useful to keep the central venous pressure (CVP) of the patient low (<5 mm Hg) until after parenchymal transection as this will decrease bleeding from the IVC and hepatic vein branches.[11]

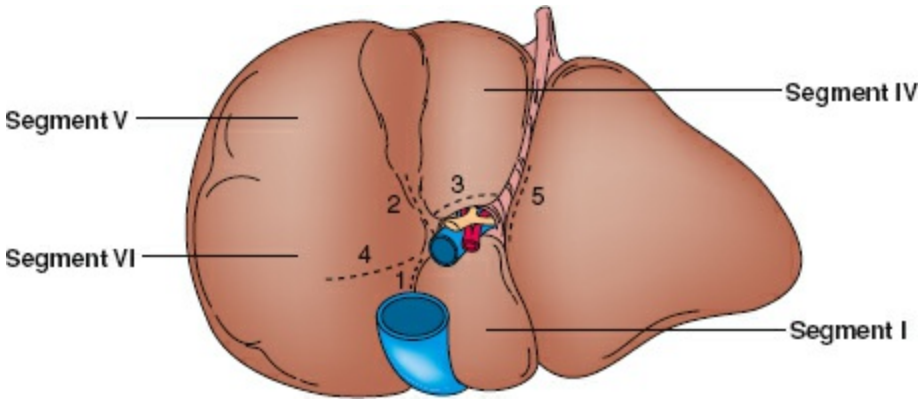

Figure 57-23. Hepatotomies to access pedicles for ligation: right hepatectomy, 1 and 2; left hepatectomy, 3 and 5; right anterior sectorectomy, 2 and 4; and right posterior sectorectomy, 1 and 4.

During live donor hepatectomy, a meticulous dissection of the portal triad is done isolating the main bifurcations of the hepatic artery, bile duct, and portal vein on the side that will be recovered. A cholecystectomy and trans-cystic intraoperative cholangiogram

is performed to confirm the biliary anatomy. Outflow control is obtained by dissection of the extrahepatic portion of the hepatic veins as previously described. After the graft hemiliver has been dissected off the IVC, the parenchyma is transected while ensuring continued inflow and outflow to both sides limiting any ischemia to the graft and remnant liver. The portal triad structures and the hepatic vein are divided and the graft is removed in coordination with the recipient operation.

Over the last decade there has been significant advances in minimally invasive liver resection. In large volume hepatobiliary centers with advanced laparoscopic skills both benign and malignant tumors in the peripheral segments (II to VI) are safely resected with good results. With more experience, formal hemihepatectomies are becoming more common. As with other laparoscopic operations, advantages include decreased postoperative pain, decreased length of stay, and earlier return to normal activity. A minimally invasive liver resection should proceed with the same indications and intraoperative steps employed in an open resection. The indications to resect benign tumors should not be broadened because an operation with potentially less associated morbidity can be offered to the patient. As with open resections, major minimally invasive liver resections include optimal exposure, vascular inflow and outflow control prior to parenchymal transection. Options for minimally invasive liver resection include a purely laparoscopic approach that does not employ the planned use of a hand port or mini-laparotomy incision. The specimen is removed through an extension of one of the laparoscopic port incisions or a small Pfannenstiel incision. The planned use of a hand port is an option for resections that require more manual control. Hybrid procedures that utilize the laparoscope to mobilize the liver and then proceed with a mini-laparotomy for the portal triad dissection and parenchymal are use by many for major resections. As centers gain more experience the trend is to perform more resections with the purely laparoscopic approach. Minimally invasive liver resection will progressively be used for more complex cases including live donor hepatectomies.

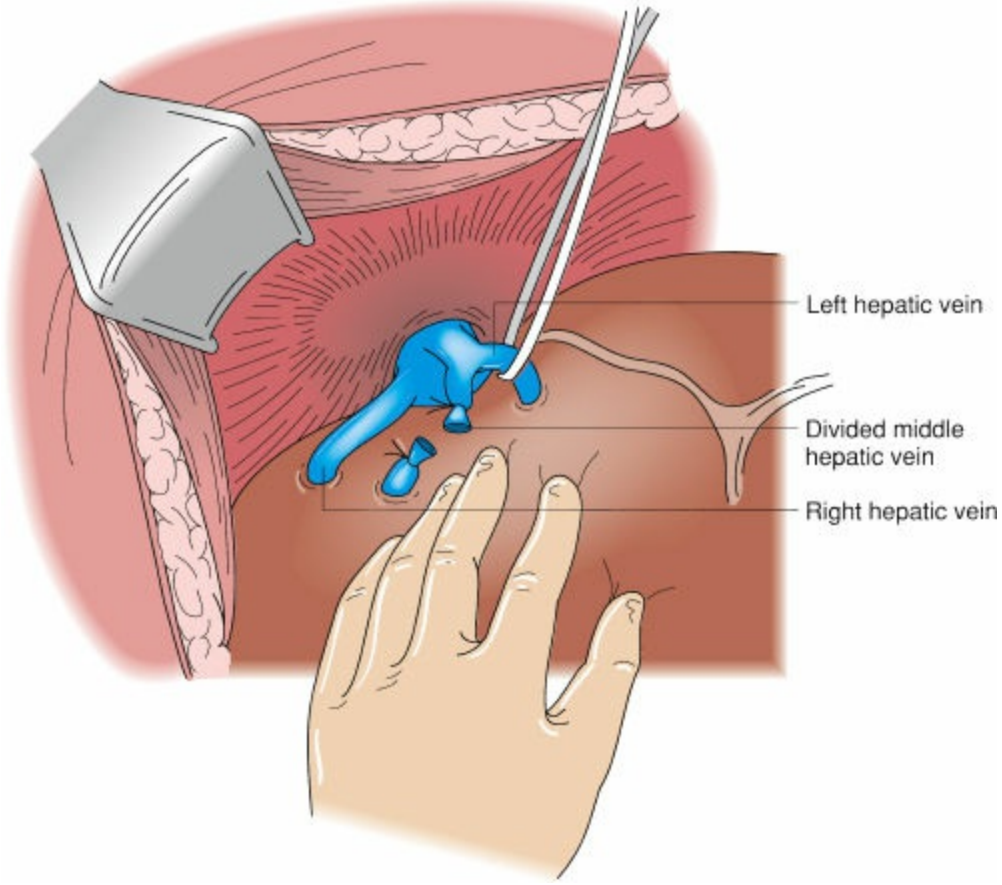

Figure 57-24. Caudal retraction of the left hepatic lobe with division of middle and left hepatic veins during left hepatic lobectomy. Often, the division of the middle and left hepatic veins is intraparenchymal.

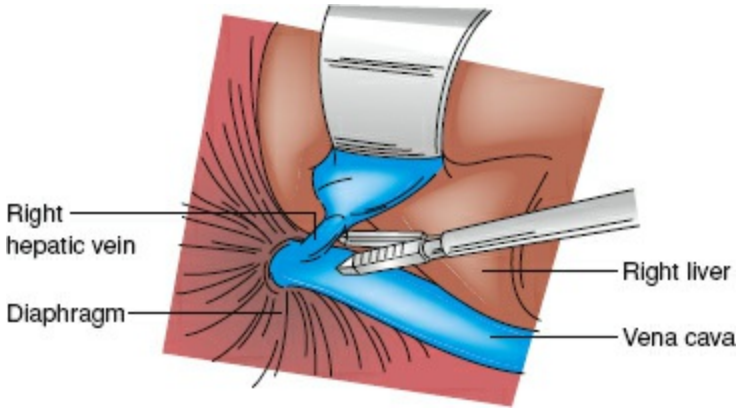

Figure 57-25. A vascular endoscopic stapling device is used to divide the right hepatic vein after the right side of the liver has been mobilized.

MAJOR HEPATECTOMIES

To develop a uniform nomenclature understood by all, the American and International Hepato-Pancreato-Biliary Associations (AHPBA and IHPBA) have adopted the Brisbane 2000 terminology of hepatic anatomy and resections. Right hepatectomy or right hemihepatectomy involves the resection of segments V through VIII. Left hepatectomy or hemihepatectomy involves the resection of segments II through IV. Either of these resections may or may not include resection of segment I, which should be stated. Extended right hepatectomy involves the resection of segments IV through VIII. Extended left hepatectomy involves the resection of segments II through V plus VIII. Again, either of these extended resections may or may not include resection of segment I, which should be stipulated.

Right anterior sectorectomy includes segments V and VIII. Right posterior sectorectomy includes segments VI and VII. Left medial sectionectomy removes segment IV. Left lateral sectionectomy includes segments II and III. A segmentectomy involves the resection of a single segment and a bisegmentectomy involves the resection of two contiguous segments.

The steps involved in each of these major hepatectomies include optimal exposure of the liver, vascular inflow control, vascular outflow control, and parenchymal transection. Vascular inflow control can be obtained by directly ligating the main right or left branches of the hepatic artery and portal vein in the hilum or by intermittent 10- to 20-minute intervals of a Pringle maneuver with 3 minutes in between to reestablish blood flow (or both). It is the authors' preference to encircle the hepatoduodenal ligament twice with a quarter-inch Penrose drain that is tightened and clamped for a Pringle maneuver. Pedicle ligation can also be performed, as described previously, or the pedicles can be controlled as they are encountered during parenchymal transection. It is the authors' preference to obtain vascular inflow by ligating the appropriate vessels in the hilum or by pedicle ligations and to supplement this with intermittent Pringle maneuvers, as necessary, during parenchymal transection. Often the Pringle maneuver is not required, but if bleeding from inflow vessels becomes significant, then it should be performed. Vascular outflow to the right or left liver can be obtained by exposing and ligating the hepatic veins, as previously described, or by ligating the vessels intraparenchymally during transection of the liver tissue. Parenchymal transection can be performed using a multitude of techniques including finger fracture, using a Kelly clamp to fracture, Cavitron Ultrasonic Surgical Aspirator (CUSA), harmonic scalpel, stapling devices, electrocautery devices with or without saline perfusion, high-pressure water jets, and radiofrequency planar arrays. The superiority of any one of these techniques has not been established, and all are used. With these techniques, individual blood vessels and bile ducts are cauterized, clipped, or sutured in rapid succession as they are encountered. Constant reevaluation of the direction of transection is important both to not injure vital structures to the remnant liver and to maintain a negative margin. After parenchymal transection and removal of the specimen, the raw surface of the liver is carefully inspected for bleeding and bile leakage, which can then be controlled by suture ligation

and the use of argon beam coagulation. The authors' preferences are to selectively use closed suction drains near resected liver surfaces to monitor and drain unrecognized postoperative bile leaks. Some centers have decreased the use of closed suction drains in favor of radiologic intervention when necessary, because they often clog or do not actually drain the fluid collections that form.

SEGMENTAL RESECTIONS

To maximize functional reserve, (multi)segmental or subsegmental (or nonanatomic) hepatectomies can be performed. For example, left lateral sectionectomy (segments II and III), central hepatectomy to remove the right anterior section (segments V and VIII) and left medial section (segment IV), right posterior sectionectomy (segments VI and VII), or caudate resection (segment I) are examples in which one, two, or three contiguous segments are removed to eradicate tumors within those regions of the liver. These resections are often done with intermittent Pringle maneuvers until the specific pedicles supplying these areas are controlled.

References

1. McIndoe AH, Counseller VX. A report on the bilaterality of the liver. *Arch Surg* 1927;15:589.
2. Hjörtsjö CH. The topography of the intrahepatic duct systems. *Acta Anat (Basel)* 1931;11:599–615.
3. Tung TT. La vascularixation veineuse du foie et ses applications aux resections hepatiques. *Thèse Hanoi* 1939.
4. Healy JE, Schroy PC. Anatomy of the biliary ducts within the human liver. Analysis of the prevailing pattern of branchings and the major variations of the biliary ducts. *AMA Arch Surg* 1953;66:599–616.
5. Goldsmith NA, Woodvurne RT. Surgical anatomy pertaining to liver resection. *Surg Gynecol Obstet* 1957;195:310–318.
6. Couinaud C. Le Foi: Etudes anatomogiques et chirurgicales. Paris: Masson; 1957.
7. Bismuth J, Houssin D, Castaing D. Major and minor segmentectomies–réglées–in liver surgery. *World J Surg* 1982;6:10–24.
8. Blumgart LH, Hann LE. Surgical and radiologic anatomy of the liver and biliary tract. In: Blumgart LH, Fong Y, eds. *Surgery of the Liver and Biliary Tract,* 3rd ed. New York, NY: WB Saunders; 2000.
9. Michels NA. Newer anatomy of the liver and its variant blood supply and collateral circulation. *Am J Surg* 1966;112:337.
10. Fong Y, Blumgart LH. Useful stapling techniques in liver surgery. *J Am Coll Surg* 1997;185:93–100.
11. Melendez JA, Arslan V, Fischer ME, et al. Perioperative outcomes of major hepatic resections under low central venous pressure anesthesia: blood loss, blood transfusion, and the risk of postoperative renal dysfunction. *J Am Coll Surg* 1998;187:620–625.

Chapter 58

Hepatic Infection and Acute Liver Failure

Andrew M. Cameron and Christine Durand

Key Points

1 Pyogenic abscess is increasing due to the rise of invasive procedures involving the liver, biliary tree, and pancreas.

2 The treatment for hydatid cysts is surgical resection after the introduction of antiparasitic medication.

3 Viral hepatitis due to hepatitis B and C represents a principal cause of chronic liver disease in the United States and worldwide, newer antiviral agents have made these diseases treatable or curable.

4 Liver transplant is the treatment of choice for decompensated cirrhosis or early hepatocellular cancer in a cirrhotic liver.

5 One-third of acute liver failure patients will die without a liver transplant. Results after liver transplant show greatly improved survival, though still inferior to that seen with transplantation for chronic disease.

PYOGENIC LIVER ABSCESS

Abscess in the liver due to bacteria is known as pyogenic abscess. Pyogenic liver abscess occurs relatively infrequently (incidence of 2.3 cases per 100,000 population) but still represents around 13% of abdominal abscesses. It most frequently occurs in the setting of bowel compromise in which spread to the liver is via the portal circulation or in the setting of direct spread from the biliary tree. Pyogenic abscess may also occur as a result of seeding in the setting of systemic infection.[1] Lastly, hepatic abscess is seen in liver transplant recipients and when observed suggests hepatic artery compromise (Fig. 58-1).

1 Over the past 20 years the increase in invasive procedures involving the liver, biliary tree, and pancreas has resulted in an increase in the rate of pyogenic abscess. Most pyogenic abscesses are solitary and polymicrobial and involve the right lobe of the liver. Individuals over 50 years of age, diabetics, liver transplant recipients, and those with malignancy are at the highest risk for pyogenic abscess.

Fever is the most frequent presenting symptom of pyogenic liver abscess, sometimes without other localizing signs. Right upper quadrant pain, chills, anorexia, weight loss, malaise, weakness, and jaundice are frequently present. Laboratory studies show elevated white blood cell count in most cases, though not always. Abnormal liver function tests, including elevated bilirubin or transaminases are seen in about half of the cases.[2,3]

Though a chest x-ray may reveal a right pleural effusion or elevated hemidiaphragm in 50% of cases, the radiographic test of choice is ultrasound (US) or CT scan. US will reveal abscess in 90% of cases and can guide drainage. CT is even more sensitive and will reveal small abscesses and differentiate these lesions from other pathology.[4]

Causative agents in hepatic abscess are gram-negative aerobes in two-thirds of patients, most commonly *Escherichia coli, Klebsiella pneumonia,* and Proteus species. Enterococci may also be present if the cause of the abscess is biliary; anaerobes may be isolated if the source is colonic. Streptococci species are frequently found as well. These microbes will be isolated from the lesion and the blood in most patients and it is helpful to draw blood cultures prior to the administration of antibiotics. Coverage should be broad and its duration is based on clinical response. A typical course is 14 days of IV antibiotics followed by oral medication for a total of 6 weeks.[5–7]

Percutaneous drainage is standard at this time and is almost always easily accomplished. A drainage catheter should be left in place until output is minimal, often around 7 days. If attempt at percutaneous drainage is complicated by ascites, multiple abscesses, transpleural approach, large size, or other consideration, an open approach may be required. Adequate drainage and prompt initiation of antibiotics are crucial, without which mortality rates are high. Other contributors to poor outcome include: multiple abscesses, non-Klebs pathogens, mixed bacterial and fungal abscesses, presence of respiratory symptoms, presence of malignancy, and large size (>5 cm).[8,9]

AMEBIC LIVER ABSCESS

Amebic liver abscesses are caused by *Entamoeba histolytica,* a protozoan. Systemic infection, or amebiasis, is most commonly asymptomatic, clinical manifestations include amebic dysentery and extraintestinal manifestations. Amebic liver abscess is the most common extraintestinal manifestation and is due to ascending portal infection. Amebiasis is most prevalent in tropical and subtropical regions with poor sanitation, as fecal–oral transmission is the most common route of infection. It is estimated that 40 to 50 million are infected each year worldwide, and in the United States the highest rates are seen in immigrants from endemic areas. Again, most infections are asymptomatic, but amebic dysentery, and pulmonary, cardiac, and brain involvement can occur, along with hepatic abscess.

Hepatic abscess occurs in only around 5% of cases of amebiasis. Men are affected 10 times more commonly than women, peak incidence is in the third, fourth, or fifth decade of life, and corticosteroid usage is a risk factor.[2,10] Ingested cysts pass through the stomach and reach the intestine. There the cyst wall is degraded and trophozoites are released. These infective particles multiply in the colonic lumen and then may enter mesenteric veins and eventually the liver. Amebic trophozoites there cause obstruction of venules, thrombosis and infarction of hepatic parenchyma, with resultant abscess formation (Fig. 58-2).

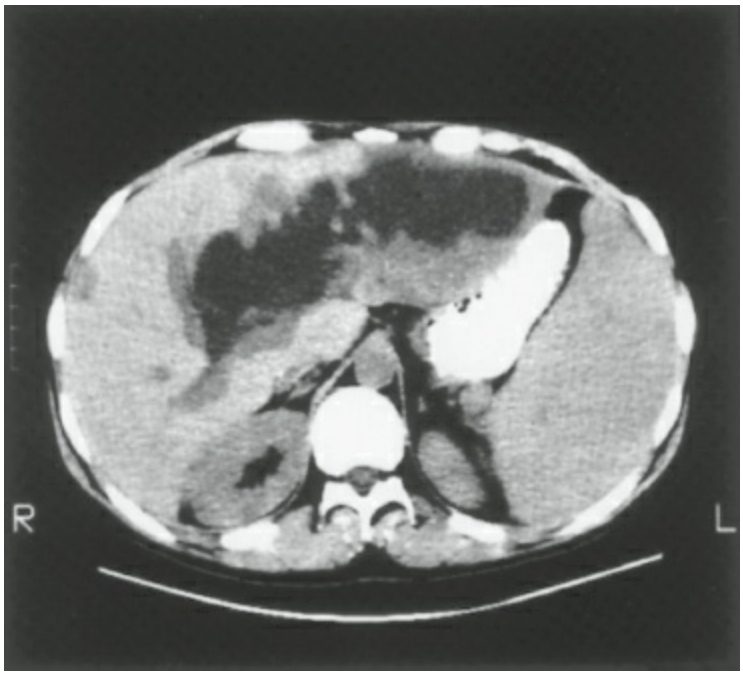

Figure 58-1. Computed tomogram of a pyogenic hepatic abscess in a liver transplant recipient with occlusion of the hepatic artery.

Amebic liver abscesses range in size from several millimeters to massive (Fig. 58-3). Clinical presentation is typically 8 to 20 weeks following return from endemic area and usually manifests as right upper quadrant pain and fever. Cough, sweating, malaise, weight loss, and hiccough may be present. Amebic abscesses are more common in the right lobe and tend to be singular. Lesions may show an enhancing rim and when drained

contained a dark, hemorrhagic, proteinaceous fluid often referred to as “anchovy paste” (Fig. 58-4). Abscesses have been described in the past as acute or chronic, and as benign or aggressive. Bacterial superinfection of amebic abscesses can occur and amebic abscesses can rupture into surrounding tissues or spaces, most frequently into the chest.[1,2,10–14] *E. histolytica* is not found in stool specimens of infected patients but diagnostic antibodies are present in the serum 7 to 10 days after the onset of symptoms in almost all patients.[15] Chest x-ray is frequently abnormal but CT scan is the diagnostic test of choice, often displaying the enhancing wall and a surrounding edema. MRI will likewise be diagnostic.[2,10,12]

Treatment is based on amebicidal drugs to eliminate liver organisms and a luminal agent to eliminate intraluminal cysts even if not seen in the stool given the low sensitivity of microscopy to identify organisms. Preferred tissue agents include metronidazole 500 to 750 mg three times a day for 7 to 10 days. Tinidazole 2 g orally for 5 days is an alternative treatment that is better tolerated. To eradicate intraluminal cysts, the following regimens can be used: paromomycin (25 to 30 mg/kg/day orally three times a day for 7 days), diiodohydroxyquin (650 mg orally three times a day for 20 days), or diloxanide furoate (500 mg orally three times daily for 10 days for adults). Metronidazole treats both intestinal and extraintestinal sites. Amebic abscesses can almost always be treated with medical therapy alone. Percutaneous drainage is considered in cases with poor response, when superinfection is suspected, or if there is risk of rupture. Open surgical drainage is almost never required and would be considered only in severe complicated cases.[2,10,13]

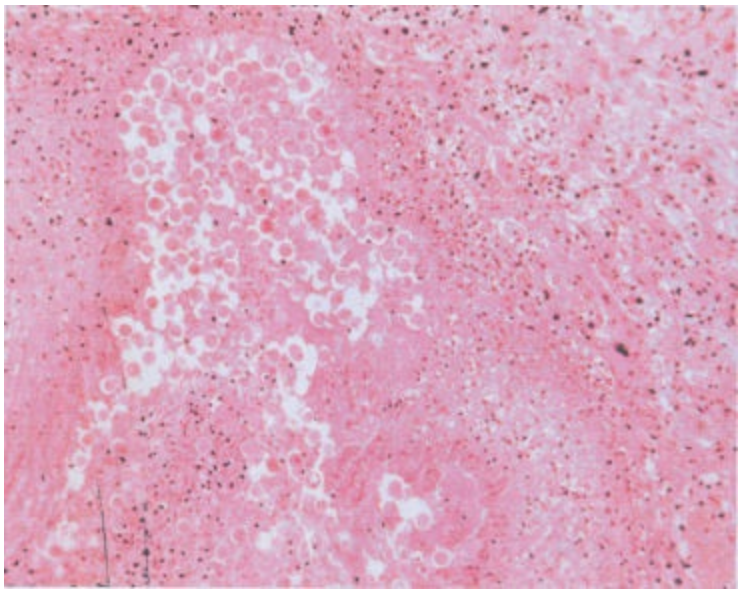

Figure 58-2. Amebic abscess of the liver. A photomicrograph of the margin of an amebic abscess shows fibroblastic proliferation surrounding the cavity and amebic trophozoites in the lumen. (Reproduced with permission from Rubin E, Farber JL. *Pathology*. 3rd ed. Philadelphia, PA: Lippincott Williams & Wilkins; 1999.)

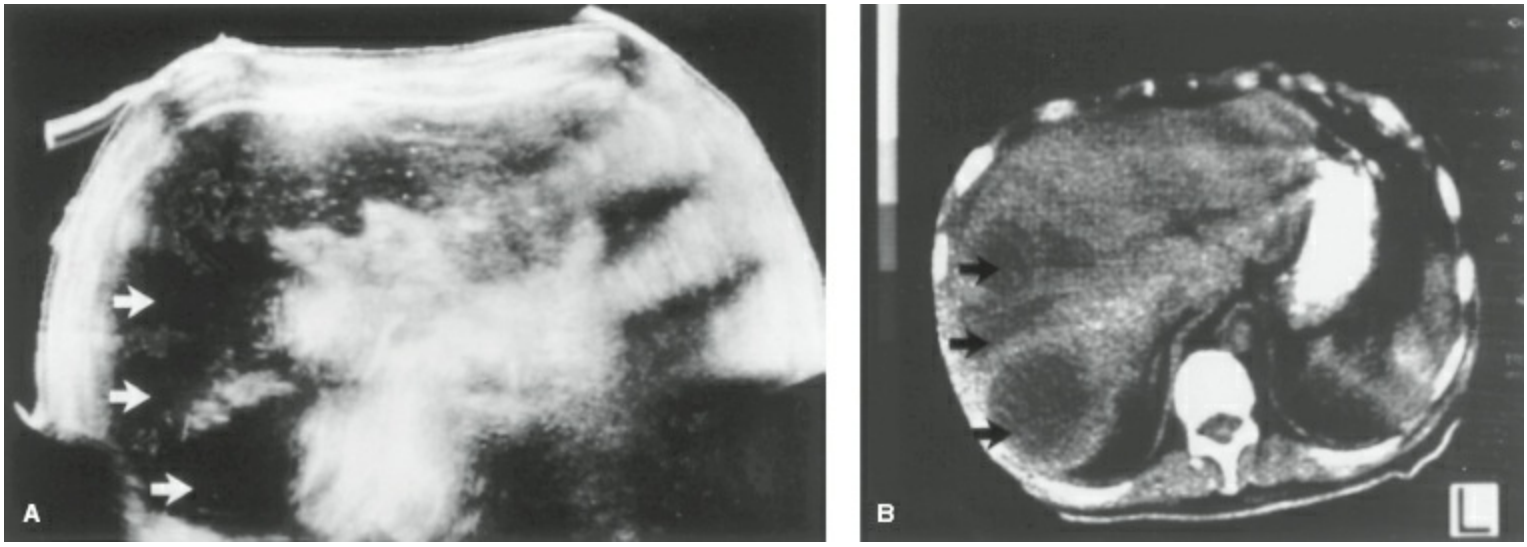

Figure 58-3. Sonogram **(A)** and computed tomogram **(B)** in a patient with multiple amebic abscesses (*arrows*).

ECHINOCOCCUS (HYDATID DISEASE)

Echinococcal infection, also called hydatid disease, is a parasitic disease due to echinococcal tapeworms including *Echinococcus granulosus* or *E. multilocularis* in humans. Echinococcus is endemic in the Mediterranean or other parts of the world in sheep rearing economies but is uncommon in the United States. The liver is most commonly affected by *E. granulosus*. Dogs are the definitive host and the life cycle of the organism is such that when the canine host ingests infected viscera (from sheep or cattle) scoleces released in the intestine develop into adult worms. Humans, an intermediate host, acquire echinococcal eggs by ingestion of contaminated foods or with infected animals. The echinococcal egg is digested in the duodenum and yields an embryo (oncospheres). Embryos invade the intestinal wall and reach the liver via the portal circulation. Surviving embryos lodge in the hepatic capillaries and develop into hydatid cysts. Though the liver is the most common location of hydatid cysts (50% to 75% of cases) the lungs can also be affected (25% of cases). *E. granulosus* and *E. vogeli* cause liver cysts while *E. multilocularis* is associated with alveolar disease.[12,16,17,18]



Figure 58-4. Amebic abscesses of the liver. The cut surface of the liver shows multiple abscesses containing "anchovy paste" material. (Reproduced with permission from Rubin E, Farber JL. *Pathology*. 3rd ed. Philadelphia, PA: Lippincott Williams & Wilkins; 1999.)

Liver involvement with echinococcal cyst can lead to venous obstruction, portal hypertension, sepsis, and cholangitis. Hydatid cysts are fluid filled, round, and contain three layers of host tissue: an outer 2- to 4-mm-thick fibrous pericyst composed of compressed and fibrotic liver tissue, a 2-mm-thick middle anuclear hyaline layer or ectocyst, and an internal germinal layer or endocyst derived from the parasites. As the cyst matures, invagination of the germinal layer leads to development of daughter cysts in the periphery (Fig. 58-5). Calcifications are frequently observed radiographically in both viable and nonviable cysts.[12,17,18]

Cysts may grow at an annual rate of around 1 to 3 cm/year. Enlarging cysts can cause symptoms of abdominal pain, biliary obstruction, and jaundice, or less commonly portal hypertension. Masses may be palpable clinically on examination. Involvement of the

biliary tree is variable. Biliary findings result due to communication between the pericyst and the bile ducts or due to rupture of the cyst into the biliary tree. Fistulous communication between the cyst and the biliary tract may result in superinfection of the cyst, cholangitis, and biliary obstruction. This bacterial contamination occurs in around 25% of cases. Occasionally, cysts may rupture into the peritoneal cavity causing abdominal pain and anaphylaxis. Multiple intra-abdominal cysts may develop due to intraperitoneal leakage. Hepatic hydatid cysts may perforate the diaphragm and lead to empyema, biliary-bronchial fistula, or pericardial collection.[19]

Laboratory tests may be normal or reveal biliary obstruction, and eosinophilia is frequently present. Serologic ELISA-based screening tests are associated with high false-positive and negative rates. Confirmatory electrophoresis when available has a higher accuracy rate. Hydatid cysts have a stereotypic appearance on radiographic studies. US imaging may show daughter cysts, a calcified rim, and the so-called water lily sign of the curved bands of the delaminated endocyst. CT scan shows a hypoattenuating lesion with daughter cysts (75%) and a calcified rim (50%). MRI often well displays daughter cysts, pericyst, and the "hydatid sand" of free scoleces. ERCP may be helpful in cases involving the biliary tree.[12,16]



Figure 58-5. A partly opened hepatic hydatid cyst. Brood capsule and daughter cysts are visible in the cavity. (Reproduced with permission from Kean BH, Sun T, Ellsworth RM. *Color Atlas/Text of Ophthalmic Parasitology*. New York: Igaku-Shoin; 1991:188.)

2 Open surgical resection is the treatment of choice for symptomatic or complicated hydatid cysts (Fig. 58-6). Surgical extirpation aims to remove the cyst intact without spillage of cyst contents. Alternatively, some have described aspiration of cyst contents prior to resection to minimize the result of any cyst spillage. After aspiration injection with ethyl alcohol or 20% sterile saline is undertaken to kill remaining scoleces. In cases where the aspirate is bilious and a communication with the biliary tree is thus suspected the cyst should be resected without alcohol injection to prevent the occurrence of

sclerosing cholangitis. Laparoscopic resection and percutaneous aspiration techniques have been reported, especially in conjunction with albendazole. Albendazole should be started 1 week prior to surgery and generally continued for at least 4 weeks postoperatively. It is poorly absorbed and should be given with a high-fat meal to increase bioavailability (15 mg/kg/day up to maximum of 400 mg twice daily). Mebendazole may be used as an alternative therapy but is less well absorbed. Postoperative morbidity and mortality are low following resection but not zero and recurrence after surgery is reported from 2% to 25%, and is associated with residual cysts or intraoperative spillage of cyst contents.[16–23]

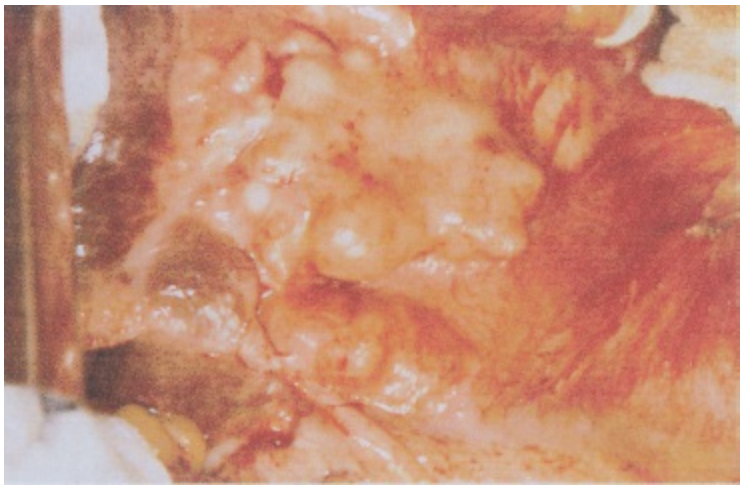

Figure 58-6. The external surface of the liver of a patient with echinococcosis before operation. (Reproduced with permission from Sun T. *Parasitic Disorders: Pathology, Diagnosis, and Management*. 2nd ed. Baltimore, MD: Lippincott Williams & Wilkins; 1999.)

SCHISTOSOMA

Schistosoma mansoni, S. japonicum, S. haematobium, and *S. mekongi* are species of trematode fluke that infect humans in endemic areas or visitors to these sites. Liver disease is especially severe with *S. mansoni, S. japonicum,* and *S. mekongi.* The life cycle of Schistosoma species alternates between sexual reproduction in humans and asexual multiplication in water snails. Cercariae enter the human host by penetrating the skin. An irritating maculopapular rash that lasts for several days is an early manifestation of infection. Schistosomes live in the intestinal lumen and eggs reach the liver via the portal circulation where they cause an inflammatory reaction.[17,18,24]

Infection in the liver is characterized by the presence of inflammatory granuloma surrounding schistosomal eggs. Acute schistosomiasis is seen typically in nonimmune visitors to endemic areas and presents as hepatomegaly and severe splenomegaly, often in children and adolescents. Severe cases with high egg infestation can lead to widespread hepatic necrosis and death. In contrast, chronic schistosomiasis is seen in young and middle-aged adults. It is usually asymptomatic until manifestations of portal hypertension declare themselves, such as variceal hemorrhage. Patients will typically present with hepatosplenomegaly, no ascites, and preserved synthetic function due to the presinusoidal nature of the condition. Hepatocellular carcinoma (HCC), colon cancer, and follicular lymphoma of the spleen have been reported in association with hepatic schistosomiasis.[12,17,18,25,26]

Diagnosis is typically made via the presence of schistosomal eggs in the stool (Kato–Katz smears), epidemiologic data, and biochemical or serologic findings. Typical laboratory features include eosinophilia and elevated alkaline phosphatase. Serum transaminases are typically normal. ELISA serum antibody tests are highly sensitive. Biopsy will show prominent granuloma formation and severe portal fibrosis (Fig. 58-7). Imaging studies are not typically useful in diagnosis of acute infection. In chronic cases US may show portal vein wall thickening. Hypertrophy of the left lobe, splenomegaly, and engorged venous collaterals may all be observed as well. CT may show fibrosis around portal vein branches as well presenting as low attenuation rings through the liver parenchyma.

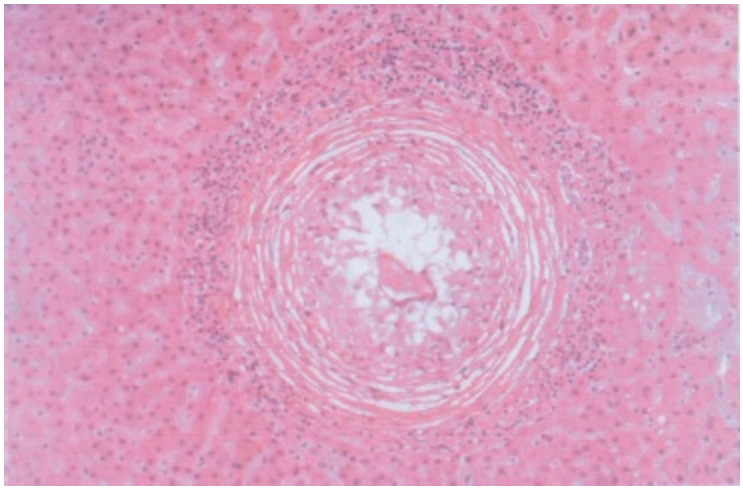

Figure 58-7. Hepatic schistosomiasis. A hepatic granuloma surrounds a degenerating egg of *Schistosoma mansoni*. (Reproduced with permission from Rubin E, Farber JL. *Pathology*. 3rd ed. Philadelphia, PA: Lippincott Williams & Wilkins; 1999.)

Preferred treatment of schistosomiasis is praziquantel, with cure efficacy around 90%. Treated patients should also undergo evaluation and management of any esophageal varices that may have developed.[17,18]

VIRAL HEPATITIDES

3 Viral hepatitis represents an important cause of chronic liver disease, cirrhosis, and hepatocellular cancer. Infection is pandemic in the United States and worldwide. Hepatitis C has become the most common indication for liver transplant in the United States and its recurrence has been the most common cause for graft loss after transplant. Liver transplant for hepatitis B has shown greatly improved results in recent years due to improved antiviral treatment. Hepatitis C is now following the same trajectory with the advent of effective antivirals.

The mechanism of liver injury is largely a host inflammatory response to virus. Table 58-1 summarizes current understanding of the characteristics of the five viruses most commonly associated with clinical hepatitis, their modes of transmission, and the consequences of infection.

GB Virus, formerly known as hepatitis G virus (HGV) does not appear to be deleterious to the liver. Other viral infections can produce acute hepatitis, particularly in immunocompromised hosts (e.g., Epstein–Barr virus, cytomegalovirus, herpes simplex virus, and varicella zoster virus). In some cases the hepatitis caused by these viruses in association with systemic symptoms can be severe and liver involvement may be the dominant manifestation of the patient's illness.

HEPATITIS A VIRUS

Molecular Structure

Hepatitis A virus (HAV) was identified in 1973[27] and belongs to the Picornaviridae family, genus Hepatovirus. Four distinct genotypes have been identified and all four genotypes belong to a single serotype.[28] HAV is a single-stranded RNA virus that is 27 nm in diameter and is nonenveloped. The viral genome is 7,474 nucleotides in length and is divided into 5- and 3-in untranslated regions and a single long open reading frame that encodes a 2,227 amino acid polypeptide. Upon processing this peptide yields four structural and seven nonstructural proteins.

Epidemiology/Risk Factors for Transmission

Hepatitis A has been long known (epidemic jaundice, catarrhal jaundice, campaign jaundice) and continues to occur worldwide. The incidence in the United States has declined with effective vaccination but remains around 1.2 per 100,000.[29]

The major mode of transmission is fecal–oral and it is more common in lower socioeconomic areas where sanitation is poor. Common risk factors in the United States are international travel, especially to Mexico or Central/South America; household contact with an infected family member; homosexual activity in men; ingestion of contaminated foods (shellfish, green onions, frozen strawberries) or waterborne outbreaks; children in daycare centers; and injection drug use.[30] Humans are the only host for HAV and the liver is the only affected tissue.

Clinical Features

Hepatitis A infection almost universally results in an acute, self-limited illness and can produce either icteric or anicteric syndromes (Fig. 58-8). The incubation period is 28 days. The anicteric prodrome lasts from 2 days to 3 weeks and typically consists of fatigue, malaise, nausea, vomiting, anorexia, fever, and right upper quadrant pain. The diagnosis may be missed in cases without jaundice. In cases where jaundice becomes manifest, it persists for 1 to 6 weeks. Transaminase levels are typically above 1,000 IU/mL, serum bilirubin above 10 mg/dL, and alkaline phosphatase values are elevated as well. Serum IgM antibodies are detected in 95% of patients and are the gold standard of diagnosis. IgG antibodies become elevated as jaundice subsides and may persist for years.

Table 58-1 Classification of Viral Hepatitis

The Viral Hepatitides					
Virus	**Hep A Picornavirus (RNA)**	**Hep B Hepadnavirus (DNA)**	**Hep C Flavivirus (RNA)**	**Hep D Viroid (RNA)**	**Hep E Calicivirus (RNA)**
Transmission Acute disease Evolution to chronic disease	Fecal–oral Common Never	Parenteral Common Infrequent in adults	Parenteral Uncommon Frequent (70%)	Parenteral Common Yes	Fecal–oral Yes Described in organ transplant recipients
New cases/year # Infected (US) Worldwide	180,000 — —	180,000 1,250,000 350,000,000	40,000 4,000,000 170,000,000	Unknown, found in approximately 5% of cases of HBV infection	300 Unknown, uncommon
Treatment	None	Lamivudine Adefovir Entecavir	Interferon + Ribavirin	Treatment of HBV	Mainly sanitary preventative
Prophylaxis	Vaccine and Ig	Vaccine and Ig	None	Vaccinate against HBV	In development
Fulminant failure	Rare	Yes	Never	With HBV, as coinfection or superinfection	Especially in pregnant women

HBV, hepatitis B virus; Hep, hepatitis; Ig, immunoglobulin.

HAV leads to fulminant liver failure in 0.01% to 0.35% of cases of acute HAV infection. This rare event mostly occurs in patients with underlying liver disease, especially chronic hepatitis C infection and less commonly hepatitis B infection or alcoholic liver disease. The risk of fulminant failure is also higher in people over 40 years of age, intravenous drug abusers, men who have sex with men, and in inhabitants of endemic areas.[31]

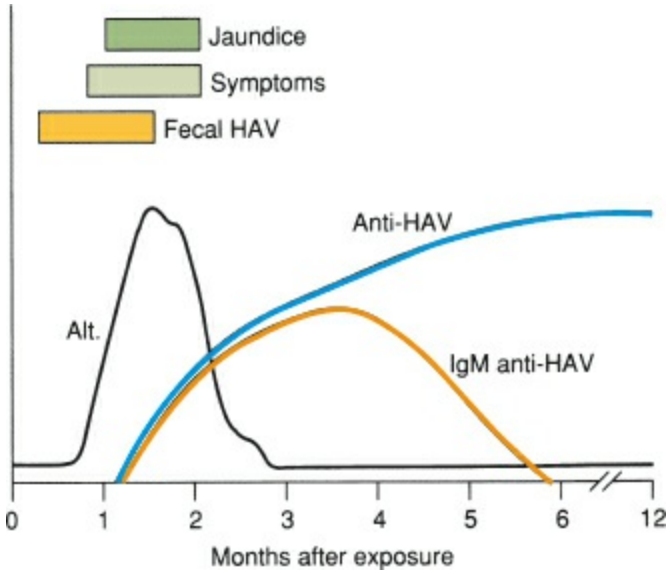

Figure 58-8. Clinical course of hepatitis A infection.

Treatment

Most patients with HAV infection recover with supportive care; approximately 20% require hospitalization in large outbreaks. Infection control measures such as hand washing and isolation should be a top priority to prevent spread of virus. Fecal shedding of virus occurs even prior to onset of symptoms and jaundice. Spontaneous recovery and survival even in cases of acute liver failure (ALF) may be as high as 50%. Liver transplantation is indicated in cases in which recovery seems unlikely. Recurrence of HAV in the allograft may be encountered and administration of immunoglobulin may be beneficial in such instances.[31,32]

A formalin-inactivated HAV vaccine is safe and effective in almost all recipients after two doses. Vaccination is recommended by the CDC for children 2 years of age or older in states or countries with high rates of infection (20 or more cases per year per 100,000 population) as well as in individuals at high risk such as persons infected with hepatitis B or C. Immune globulin administered within the first 14 days of exposure prevents disease in more than 85% of cases. Close contacts of patients with recent onset of the illness, people exposed to contaminated foods, and selected travelers to endemic areas benefit the most.[33]

HEPATITIS B VIRUS

Molecular Structure

Hepatitis B Virus (HBV) is a DNA virus that belongs to the hepadnavirus family. It is the smallest DNA virus with the ability to infect humans. HBV virions are 40 to 42 nm in diameter, with a double shell and an outer lipoprotein envelope. The viral nucleocapsid, or core, contains a 3.2-kb partially duplex DNA and a polymerase. Replication resembles that of retroviruses, in which the viral DNA polymerase acts as a reverse transcriptase. The HBV polymerase lacks proofreading activity. This is associated with an estimated 10^{5} to 10^{6} mutations per nucleotide per year and the resultant development of mutant forms of the virus.[34–36]

Epidemiology/Risk Factors for Transmission

It is estimated that over 350 million people worldwide are infected by HBV. In the developing world, perinatal infection is the most common mode of transmission. In the United States, transmission is primarily sexual as the virus is present in semen and vaginal fluids in addition to blood. Infection from intravenous drug use and occupational infections due to percutaneous exposure also occur. There are no known animal reservoirs or evidence that insects are involved in transmission of HBV. The hepatitis B virus replicates mainly in hepatocytes but is not itself cytotoxic. Liver injury is due to the resultant host immune response.

Clinical Features

The incubation period for HBV is 8 weeks. The presence of serum hepatitis B surface antigen (HBsAg) may precede jaundice. Acute infection is associated with detectable serum HBV DNA, hepatitis B early antigen (HBeAg), and IgM to hepatitis B core. HBeAg is a useful marker of viral replication except in patients with mutant viruses where it may be undetectable despite active replication (Fig. 58-9). In such cases detection of HBV DNA is diagnostic. Serum anti-HBc IgM becomes detectable with the onset of jaundice. In most patients, when HBV does not develop into chronic hepatitis, anti-HBc IgM becomes undetectable after 6 months. On occasion, however, it may persist for years after the acute infection or may recur as an amnestic phenomenon in reactivating chronic hepatitis B, thus limiting its usefulness as a marker of acute HBV infection.

Although HBV accounts for 40% of ALF in developing countries, it is estimated that the incidence in the United States is about 10%. Hepatitis B becomes fulminant in about 1% of acute infections. Women, elderly individuals, and those who sustain superinfection with another virus (such as HCV) seem to be at greater risk. Furthermore, the risk of ALF seems to be proportional to antibody titers of HBcAg and HBsAg. Some cases of ALF may be due to reactivation of HBV in patients with chronic infection. In cases of reactivation, reappearance of HBc IgM antibodies aids in the diagnosis. Spontaneous survival after HBV ALF is in the 25% range.[37,38]

Most patients with acute HBV infection in the Western world recover completely. Approximately 25% of these patients will develop jaundice but do not become HBV carriers. They will usually retain HBcAb and HBsAb markers with no detectable HBsAg or HBV DNA. Approximately 10% of Western adults with HBV infection do progress to become chronic carriers, as determined by the presence of HBsAg in serum for more than 6 months (Fig. 58-10). Most HBV carriers have a benign state with HBV DNA integrating into their native genome. The remainder of HBV carriers develop ongoing liver injury and usually have detectable HBeAg or HBV DNA and have free episomal HBV sequences in addition to the ones integrated into their native genomes.

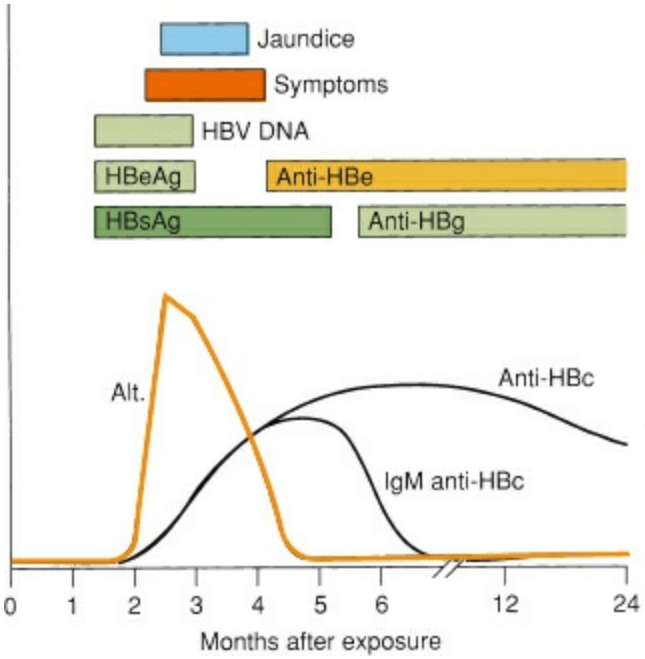

Figure 58-9. Clinical course of acute hepatitis B infection.

In Western Europe and North America the prevalence of chronic infection is less than 1% but ranges between 10% and 20% in endemic areas including southeast Asia, China, and sub-Saharan Africa. It is estimated that there 1 million deaths each year as a result of cirrhosis and HCC associated with chronic HBV worldwide.

Treatment

Primary prevention by means of vaccination constitutes the best treatment approach for HBV infection. Individuals at high risk include health care workers, visitors to highly endemic areas, men who have sex with men, sex workers, and intravenous drug users. The hepatitis B vaccine is given as a series of three intramuscular doses and has almost 100% efficacy among immunocompetent persons. Hepatitis B immune globulin has a reported efficacy of 90% in the prevention of newborn infections and approximately 75% in cases of needle sticks or sexual infections in people exposed to the virus with no prior immunity. It is administered as soon as possible after exposure together with the first dose of the hepatitis B vaccine series.

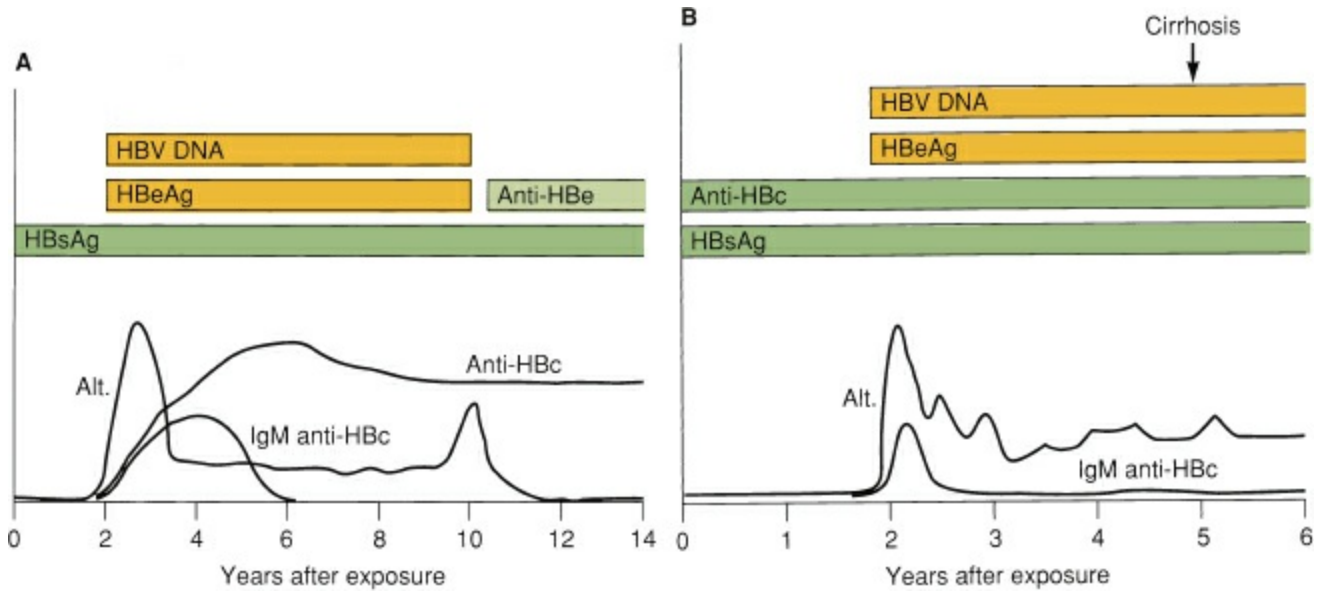

Figure 58-10. Clinical course of chronic hepatitis B. **A:** A benign chronic carrier has continued production of hepatitis B surface antigen but there is an absence of serum markers of viral replication. **B:** A pattern of continuing liver injury and serum markers of active viral replication.

Therapy is usually directed at HBeAg-positive cases that have an increased risk of cirrhosis and HCC. HBeAg-negative patients with high viral load may also benefit from treatment. Effectively controlled infection is determined by loss of HBsAg and absent viremia by PCR on antiviral treatment. The endpoint of treatment is loss of HBeAg and seroconversion to detectable HBeAb. In clinical trials about half of patients achieved this endpoint after 5 years of treatment but many patients will require a longer duration of therapy, in some cases, lifelong. Patients with chronic hepatitis B and cirrhosis or advanced fibrosis showed a reduction in the risk of HCC after continuous treatment with lamivudine.[35,39] Lamivudine is an orally effective antiviral agent that competitively inhibits the DNA polymerase. Its administration is associated with a more rapid seroconversion to HBeAg-positive status, a more rapid loss of HBeAg, improved aminotransferase levels, and a 3 to 4 log reduction in circulating levels of HBV DNA in the first 3 months of therapy. It is also associated with improved liver histologic findings in cases of chronic hepatitis.

Agents available to treat hepatitis B include interferon (IFN), lamivudine, entecavir,

adefovir, telbivudine, and tenofovir. The most widely used, well-tolerated, and effective agents include the nucleoside analogues lamivudine, entecavir, and tenofovir. Lamivudine is effective and low cost; its major limitation is the development of drug resistance. Entecavir and tenofovir are active against lamivudine-resistant variants and can be considered for first-line treatment in individuals if cost is not a limiting factor. Both lamivudine and tenofovir are active against human immunodeficiency virus (HIV), so these agents are preferred in individuals coinfected with HIV and HBV.

Liver transplantation is the treatment of choice in patients with hepatic failure. Recurrence of viral infection in the allograft can be as high as 80% in HBeAg-positive cases where no postoperative prophylaxis is administered. The combination of lamivudine and hepatitis B immune globulin posttransplantation reduced the reinfection rate to less than 10% and increased the 5-year survival rate to 80%.[35] Other posttransplant pharmacologic regimens are currently being examined.[40]

HEPATITIS C VIRUS

Molecular Structure

Hepatitis C virus (HCV) is a lipid enveloped, 9.4-kb, single-stranded RNA virus of the family Flaviviridae, genus Hepacivirus.[41] Six genotypes have been identified, which differ from one another by as much as 30% at the sequence level. Quasispecies within genotypes demonstrate further genetic heterogeneity and reflect the high rate of mutation seen in viral replication. Over 70% of US cases are due to genotype 1 virus.

Epidemiology/Risk Factors for Transmission

There are more than 185 million individuals infected with HCV worldwide, translating to a global prevalence of 2.8%. In the United States, there are an estimated 3.6 million HCV-infected individuals, approximately 1% of the population, but this is likely an underestimate as these estimates do not include high-risk homeless or incarcerated populations.[42,43]

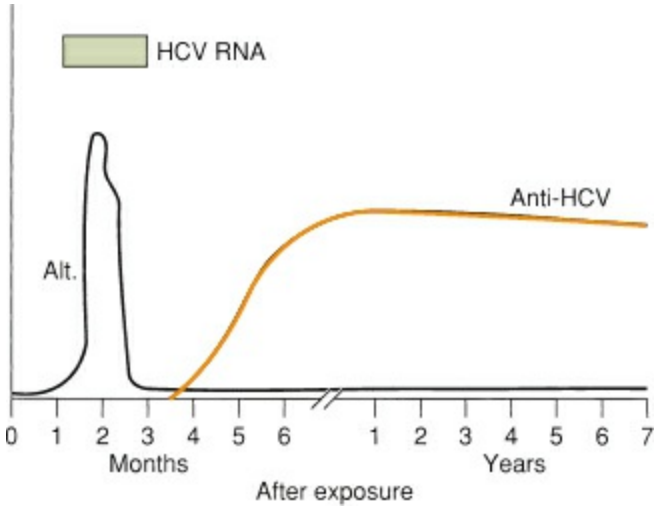

Figure 58-11. Clinical course in acute hepatitis C.

The most commonly identified risk factors are exposure to blood or blood products prior to 1992 and intravenous drug use. Other risk factors include intranasal drug use due to mucosal exposure to blood on drug paraphernalia, anal intercourse in men who have sex with men due to blood-mucosal exposure, occupational exposure, hemodialysis, tattooing, and perinatal transmission. In the United States, more than 80% of infections have been identified in adults born between 1945 and 1965.[41] Due to this observation, the CDC now recommends screening all individuals in this birth cohort irrespective of reported risk factors.

Clinical Features

The usual incubation period of HCV is 5 to 10 weeks. Most acutely infected patients are asymptomatic and therefore the infection goes unappreciated. Initial laboratory findings after infection include elevated ALT levels (500 to 1,000 IU/mL) and high HCV RNA titers (Fig. 58-11). HCV clearance is spontaneous in about 15% to 20% of individuals following primary infection. Hepatitis C infection by itself is almost never associated with ALF. Liver damage in the setting of chronic infection is due to host immune response rather than viral hepatotoxicity. Ongoing chronic hepatic injury leads to progressive fibrosis and cirrhosis which typically occurs over decades, in most cases undetected until the appearance of overt liver failure (Fig. 58-12). The incidence of hepatic decompensation (variceal hemorrhage, ascites, jaundice, encephalopathy) in the setting of cirrhosis is approximately 5% per year. Hepatitis C cirrhosis is strongly associated with the development of HCC. Extrahepatic manifestations of hepatitis C include membranoproliferative glomerulonephritis, cryoglobulinemia, diabetes, porphyria cutanea tarda, lichen planus, vitiligo, and non-Hodgkin lymphoma.[44]

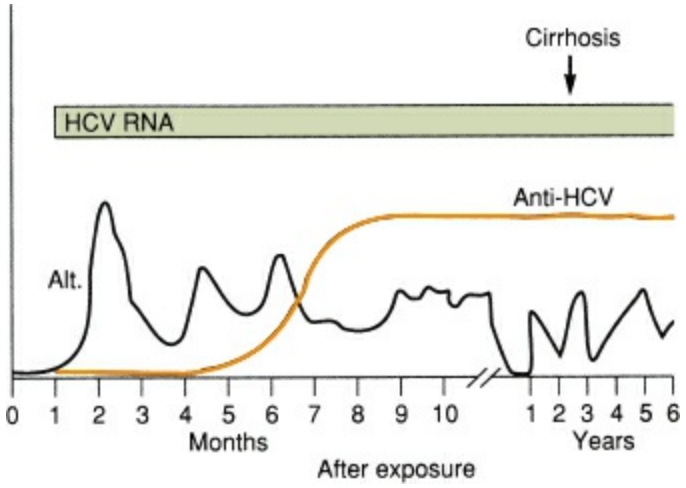

Figure 58-12. Clinical course in chronic hepatitis C.

The diagnosis of chronic hepatitis C is based on serologic demonstration of persistent HCV RNA and HCV antibodies. HCV RNA can be detected weeks earlier than antibodies, which typically appear 2 to 8 weeks after the initial infection.

Treatment

With the recent advent of highly effective, well-tolerated antiviral therapy, all individuals who develop hepatitis C should be offered treatment. The goal of treatment is a sustained virologic response or absence of HCV RNA in serum 3 to 6 months after stopping treatment. Therefore, unlike HBV, therapy in HCV is ideally curative.

In the past, the mainstay of therapy included IFN alpha combined with ribavirin (RBV) given for 48 weeks. This combination had poor tolerability and poor efficacy, with SVR rates for genotype 1 infections ranging from 35% to 45% depending on stage of disease and patient characteristics. In 2011, the first directly acting antivirals (DAAs) designed to specifically inhibit HCV proteins became available. Inhibitors of the HCV NS3A protease, boceprevir and telaprevir, were the first to be introduced but they still had to be given in combination with IFN and RBV. These first PI-based regimens increased SVR rates up to about 60% to 70%, but they compounded the toxicities of IFN and RBV, with high rates of serious adverse events including death. In 2013, more effective antivirals were introduced which allowed for IFN-free, ribavirin-free treatment regimens. With 12 to 24 weeks of treatment, DAA combinations have SVR rates between 95% and 100% and very few side effects. New antivirals include second-generation protease inhibitors nucleotide and nonnucleotide analog inhibitors of the HCV NS5B polymerase and inhibitors of the HCV NS5A replication complex. Over the next several years, many additional DAAs are expected to be approved. Determining the optimal combination for treatment will depend on factors such as genotype, comorbidities, and drug-drug interactions.

4 Transplantation is the treatment of choice in cases of irreversible decompensated cirrhosis due to HCV and in cases of HCC due to HCV. Thus, HCV has become the most common indication for liver transplantation in the United States and many countries worldwide. In many cases, treatment cannot completely reverse all hepatic damage from HCV and risk of HCC remains. Therefore, even if access to HCV diagnosis and effective treatment is optimal, the need for liver transplantation due to HCV is expected to continue for decades.

HEPATITIS D VIRUS

Molecular Structure

The hepatitis D virus (HDV), or delta agent, is an incomplete RNA virus that requires the presence of HBV for viral assembly and propagation. The only enzymatic activity of HDV is a ribozyme that cleaves circular RNA and makes it linear. The HDV genome is a 1,680 nucleotide, single-stranded circular RNA.[45] Eight genotypes have been proposed.[46] A single HDV antigen is encoded, it is a structural component of the virion, and a lipoprotein envelope is provided by HBV.

Epidemiology/Risk Factors for Transmission

HDV is found in approximately 5% of HBV carriers. Due to its dependence on HBV, HDV always occurs in association with HBV infection. Transmission is similar to that of HBV, via parenteral or sexual exposure to blood or body fluids. HDV hepatitis occurs only in HBsAg- positive patients.

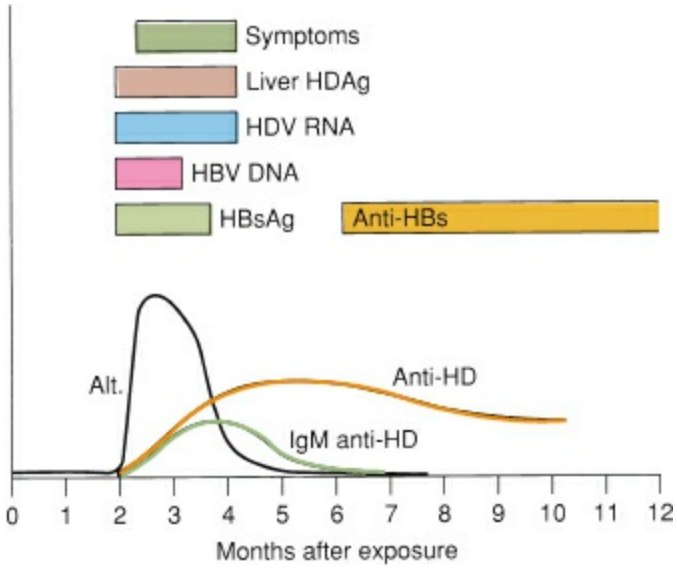

Figure 58-13. Synchronous infection with hepatitis B virus and hepatitis D virus.

Clinical Features

Acute infection is diagnosed by the presence of anti-HDV IgM. Anti-HBc IgM distinguishes coinfection from superinfection (Figs. 58-13 and 58-14). The diagnosis in patients with chronic liver disease is made by the presence of HBsAg and antibodies against HDV in the serum and confirmed by the presence of HDV antigen in the liver or HDV RNA in the serum (Fig. 58-15). ALF is seen with both coinfection (HDV and HBV simultaneously infects the host) and superinfection (HDV infects a host already infected with HBV). Superinfection seems to be associated with a higher mortality rate. Chronic HDV and HBV infection may coexist. Cirrhosis is observed in at least two-thirds of patients and occurs at a younger age than in patients infected with HBV alone.[47,48]

Treatment

Treatment and prevention of HDV are associated with that of hepatitis B, with which it always coexists. Vaccination for HBV is contributing to the decline in the incidence of HDV. Alpha IFN is the only currently available treatment for chronic HDV.

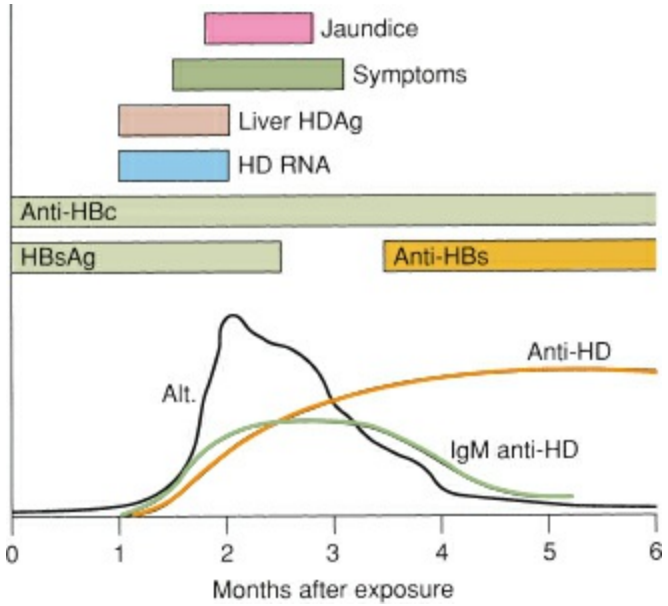

Figure 58-14. Superinfection of chronic hepatitis B carrier with hepatitis D.

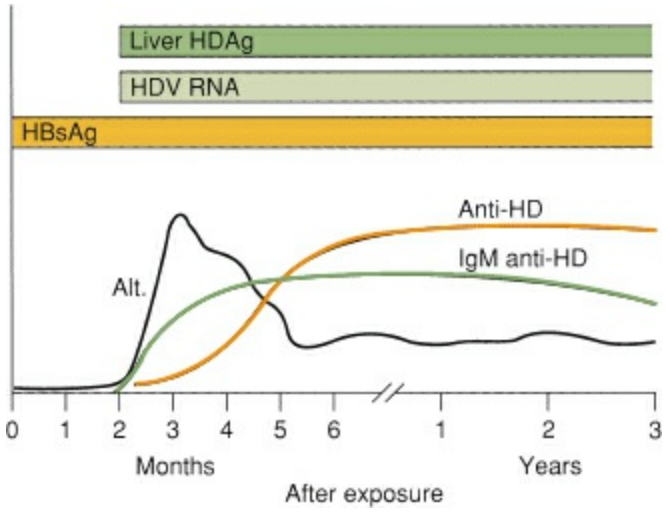

Figure 58-15. Clinical course of chronic hepatitis D infection.

HEPATITIS E VIRUS

Molecular Structure

Hepatitis E virus (HEV) is a nonenveloped single-stranded RNA virus. It is 30 nm in diameter and is most similar to other viruses of the Caliciviridae family. There are three large open reading frames, the first of which is 1,693 codons and codes for nonstructural proteins. The second is 660 codons and encodes structural proteins. The third is smaller and of undetermined function. There are thought to be four genotypes.[49]

Epidemiology/Risk Factors for Transmission

Hepatitis E is enterically transmitted and is epidemiologically similar to HAV. Infection has been prominently observed in Asia, Africa, the Middle East, and Central America. In addition, vertical transmission from mother to child has been documented and can be a source of perinatal morbidity and mortality.

Clinical Features

HEV generally causes a self-limited acute infection, although chronic infection has been described in organ transplant recipients. The incubation period usually lasts 3 to 8 weeks, and most individuals recover without chronic findings after a transient cholestatic episode (Fig. 58-16). However, young adults and women in late stages of pregnancy may develop fulminant cases of hepatitis E. Mortality from HEV is 0.5% to 4% in the general population but up to 20% in pregnant women.[50–52] Diagnosis is aided by detection of serum or fecal genomes during the acute phase. In addition, one can demonstrate anti-HEV IgM or IgG in follow-up.

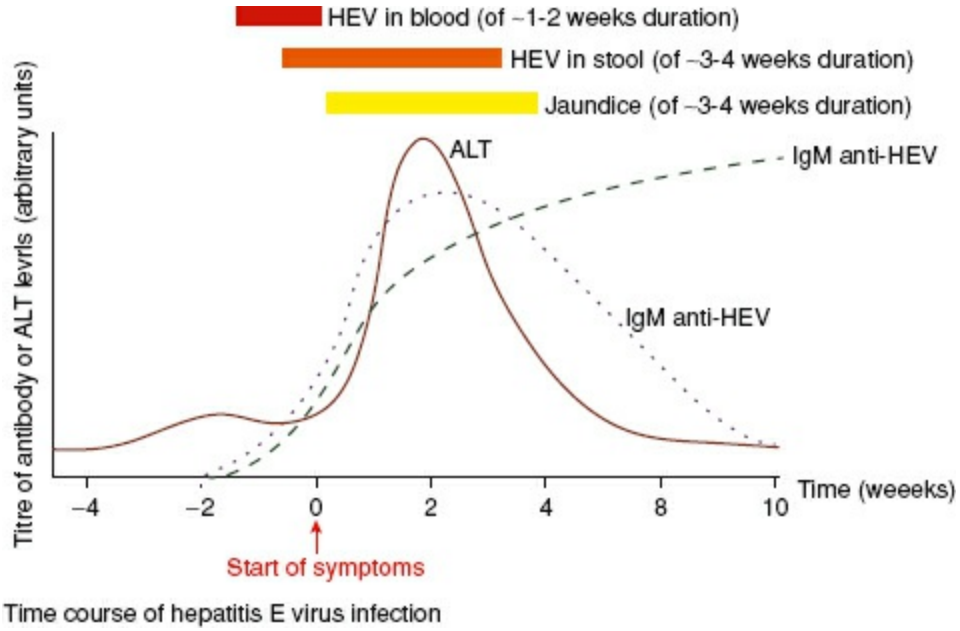

Figure 58-16. Clinical course of chronic hepatitis E infection. (Reproduced with permission from Expert Reviews in Molecular Medicine: (99)00129—5 h.htm; 6 December 1999.)

Treatment

Infection in most cases is self-limited; however, in immunosuppressed organ transplant patients HEV can cause persistent hepatitis and cirrhosis. There are no randomized controlled trials evaluating treatment options, but there are observational studies that report benefit with ribavirin treatment in organ transplant recipients.[53]

CYTOMEGALOVIRUS

Cytomegalovirus (CMV) is a member of the Beta-Herpesviridae family. It is usually associated with mild hepatitis but may occasionally cause ALF. Transmission can be intrauterine, perinatal, or postnatal; through intimate contact of infected fluids such as blood, saliva, or urine, or through transplanted organs. Infection is lifelong due to the latency of the virus and can be detected in up to 70% of individuals in US cities. Organ injury can occur as a result of primary infection or due to reactivation of latent infection. In the neonatal period congenital infection can be severe and fatal. In immunocompetent adults liver dysfunction tends to be found in association with CMV mononucleosis. In immunosuppressed adults, infection leads to liver dysfunction with jaundice and at times liver failure. Acalculous cholecystitis is another presentation.[31,54,55] CMV antigenemia and PCR to detect CMV DNA have made diagnosis rapid. Liver biopsy is important to establish the diagnosis of hepatitis. Pathologic examination shows inflammation and injury ranging from fatty changes to necrosis to fibrosis. Giant multinucleated cells and large nuclear inclusions can be encountered in hepatocytes and bile duct epithelial cells.[31,54,55]

First-line treatment is with ganciclovir or valganciclovir. Second-line agents for cases of resistant CMV include foscarnet, or cidofovir. Anti-CMV immune globulin can be used as an adjunct.[56]

EPSTEIN–BARR VIRUS

Epstein–Barr virus (EBV) is a DNA virus and member of the Herpesviridae family. Infection persists for life due to latency of the virus and it is usually transmitted by close personal or intimate contact via oral secretions. Some degree of liver involvement is encountered in almost all cases of primary EBV also known as mononucleosis. It is usually mild without major clinical manifestations and resolves spontaneously. The presence of jaundice may reflect either more severe hepatitis or an associated hemolytic anemia. Occasional cases of ALF have been reported in both the immunocompetent and immunocompromised population. Leukocytosis is usually present, with the presence of atypical lymphocytes being a hallmark. Detection of heterophile antibodies, or the "monospot test" is highly specific but somewhat insensitive with false-negative rates as high as 25% early in infection. If acute EBV is suspected and heterophile antibodies are not detected EBV-specific antibody testing can be used which are highly sensitive and specific. Treatment is supportive. Acyclovir has activity against EBV but clinical trials have not shown a clear benefit to use of acyclovir. Liver transplant has been reported in rare life-threatening situations.[54,56–58]

HERPES SIMPLEX VIRUS

The prevalence of antibodies to HSV-1 is around 75% in most populations and around 20% to HSV-2. Fulminant hepatitis is a rare complication of HSV infection; those at risk include the neonates, the immunocompromised, the malnourished, and the pregnant adults. Fulminant hepatitis is usually associated with multiorgan failure and is associated with a high mortality rate. Clinical features include high fever, anorexia with nausea, abdominal pain, leucopenia, and coagulopathy. Liver biopsy is important in establishing the diagnosis. Microscopic examination shows diffuse eosinophilic intranuclear inclusion bodies, multinucleated cells, widespread necrosis, and inflammation. Cowdry A-type intranuclear inclusions are typical. Confirmation is by PCR. Approved antivirals include acyclovir, famciclovir, and valacyclovir. Treatment with intravenous acyclovir should be initiated prior to confirmation of etiology given that progression of disease is extremely rapid and lethal. Liver transplantation can be considered even in cases of disseminated disease.[54–56]

VARICELLA ZOSTER VIRUS

Herpesvirus varicella (also called varicella zoster virus [VZV]) is usually associated with mild hepatitis but may occasionally cause ALF. Up to one-fourth of children with varicella (chickenpox) may exhibit temporary mild biochemical liver abnormalities. Reye syndrome may be encountered during the convalescence period especially in those who receive aspirin. In such cases mortality can be as high as 30%. Fulminant fatal hepatic failure is uncommon, but generally affects immunocompromised patients. Confirmation of the diagnosis can be achieved by isolation of the virus from affected tissues. Varicella zoster immune globin should be considered after exposure to the virus in immunocompromised or pregnant patients who lack immunity to VZV. Current therapies for VZV infection in immunocompetent and immunocompromised hosts include acyclovir, valacyclovir, and famciclovir. CDC guidelines should be followed for infection control.[31,54,56]

ACUTE LIVER FAILURE

Definition

ALF is an uncommon but serious condition with approximately 2,000 cases per year in the United States[59] and which carries a high mortality rate of 60% to 80%.[60] It is characterized by rapid deterioration of liver function as well as development of hepatic encephalopathy in an individual with no previous liver disease. Currently, emergency liver transplantation is the only therapeutic option available, and the King's College Criteria are widely accepted as the standard of guidance. ALF is responsible for about 5% of all liver related deaths and approximately 5% of all liver transplants are performed for this indication.[61]

The most widely accepted definition includes an international normalized ratio (INR) greater than 1.5 and any degree of mental alteration (encephalopathy) in a patient without pre-existing liver disease and with an illness of less than 26 weeks' duration. Patients with Wilson disease, vertically acquired hepatitis B, or autoimmune hepatitis can be considered to have ALF if the disease process has started within 26 weeks.[62] Although the literature suggests hyperacute (<7 days) and subacute (>21 days but <26 weeks) forms, they do not have prognostic significance except in the case of hyperacute failure due to acetaminophen toxicity which may carry a better prognosis.[63]

Diagnosis

A high index of suspicion is vital in early recognition of the disease process. Patients with evidence of moderate to severe hepatitis and any degree of encephalopathy require hospitalization since the process may proceed to death rapidly.[64] Likewise early transfer to an intensive care unit (ICU) setting in a liver transplant center is important (especially before the onset of grade III or IV encephalopathy) since worsening encephalopathy can potentially hamper transportation efforts due to concerns over increased intracranial pressure (ICP). Detailed history taking from accompanying persons including medications and herbal supplements taken and recent social history is essential. Stigmata of chronic liver disease should be assayed during the physical examination although jaundice may be a relatively late manifestation of the disease process. The initial recommended laboratory testing is listed in Table 58-2.[64] Lastly, transjugular liver biopsy can be considered as part of the initial workup to rule out neoplastic infiltration or HSV/herpes zoster virus (HZV) infection, although it is not always necessary, beneficial, or safe in all cases.[63]

Table 58-2 Management in Acute Liver Failure: Initial Laboratory Evaluations

Serum chemistries Sodium, potassium, chloride, bicarbonate, calcium, magnesium, phosphate, glucose, BUN, creatinine, amylase, lipase
Hepatic panel AST, ALT, alkaline phosphatase, total bilirubin, albumin
Prothrombin time/INR
Complete blood count
Arterial blood gas, lactate, ammonia
Toxicology screen
Viral hepatitis serologies Anti-HAV IgM, Hep B surface Ag, Anti-HBV core IgM, anti-HCV, anti-HEV IgM (if indicated)
Anti-VZV IgM, Anti-HSV IgM
Autoimmune markers ANA, ASMA, IgG levels, SPEP
Pregnancy test
Serum ceruloplasmin level and 24-hr urine copper collection (if Wilson disease is suspected)

Ag, antigen; ALT, alanine aminotransferase; ANA, antinuclear antibody; ASMA, anti–smooth muscle antibody; AST, aspartate aminotransferase; BUN, blood urea nitrogen; HAV, hepatitis A virus; HBV, hepatitis B virus; HCV, hepatitis C virus; HEV, hepatitis E virus; HSV, herpes simplex virus; IgM, immunoglobulin M; INR, international normalized ratio; SPEP, serum protein electrophoresis; VZV, varicella zoster virus.

Etiology

Etiology is important in ALF in that it may dictate administration of appropriate antidotes or to better anticipate prognosis and the potential need for liver transplantation.[65] Etiology seems to have geographic variation. In the United States, the most common reported cause of ALF is acetaminophen overdose (45% of cases), followed by unknown (15%), drug related (10%), hepatitis B virus (7%), autoimmune hepatitis (5%), and Wilson disease (2%).[66] In the United Kingdom, acetaminophen toxicity is reported in over 60% of cases, whereas in France, frequency of reported etiologies is viral due to hepatitis A and B (30%), acetaminophen (20%), other drug over dose (18%), and unknown (17%).[63,67]

Drug-induced Liver injury. Intrinsic hepatotoxins are usually dose dependent, while idiosyncratic responses are dose independent. Acetaminophen toxicity is dose dependent with serious injury seen with levels greater than 10 g/day but sometimes reported in cases with levels as low as 3 to 4 g/day range. Glutathione becomes depleted with excess free NAPQI (a toxic byproduct of acetaminophen) reacting with hepatocytes, causing liver injury.[65] In the presence of poor nutritional state or alcoholism, glutathione levels are chronically depleted further contributing to toxicity. Stevens–Johnson syndrome caused by phenytoin, amoxicillin-clavulanate, carbamazepine, or halothane, is a form of hypersensitivity idiosyncratic reaction, while isoniazid, valproate, and amiodarone mainly cause metabolic idiosyncratic reactions.

Viral Hepatitis. In those with HAV, ALF occurs around 0.5% of the time; age over 40 and other pre-existing liver disease represent increased risk. In those with HBV, ALF occurs in 1.5% of cases. ALF may occur due to new infection or reactivation of a chronic carrier state. HDV coinfection and HEV should be suspected in endemic areas. VZV, HSV, and CMV are other rare viral causes of ALF.[65]

Other. Acute Budd–Chiari syndrome, veno-occlusive disease, medications and herbs, and malignancies involving the liver (i.e., lymphoma, angiosarcoma) are less common causes of ALF.[64] Acute fatty liver of pregnancy (AFLP), and HELLP (Hemolysis, Elevated liver enzymes, Low platelets) are important diagnoses to be considered among pregnant women presenting with manifestations of ALF. AFLP occurs during the third trimester of pregnancy due to deficiencies in 3-hydroxyacyl-CoA dehydrogenase in both the mother and fetus with rapid deposition of triglycerides and free fatty acids into hepatocytes. HELLP also occurs in the third trimester or immediately postpartum. Autoimmune hepatitis (AIH) can present acutely with absence of autoimmune markers, where the diagnosis is made by exclusion and transjugular liver biopsy. In the fulminant form of Wilson disease, chelator treatment is ineffective and diagnosis is usually based on familial history of liver disease in a young adult with Coombs-negative hemolysis and low serum alkaline phosphatase or uric acid levels. Kayser–Fleischer rings are present in 50% of patients.[62] Diagnosis is usually confirmed by hepatic copper content greater than 250 μg/g in patients homozygous for Wilson disease, and the rate of urinary excretion may exceed 100 μg/24 hours.[68] Heat stroke, mushroom ingestion, EBV, and parvovirus B19 are rare causes of ALF.[63]

Clinical Features, Management, and Treatment

Acute liver injury in the absence of hepatic encephalopathy is a reversible entity unless an underlying chronic liver disease is present. Altered mental status accompanied by jaundice and elevated serum transaminases and prothrombin time is the hallmark of presentation. Rapid loss of liver mass can lead to multisystem organ failure and death.[64] Encephalopathy may be accompanied by myopathy and neuropathy, loss of vascular tone with hypotension, cardiac dysfunction, acute lung injury, gastrointestinal bleeding, pancreatitis, acute renal failure, and/or disseminated intravascular coagulopathy. Intracranial hypertension is recognized in 50% or greater of patients with stage IV coma. Therefore, neurocritical care with ability to respond to hemodynamic fluctuations becomes an important component of management. Other precepts are maintenance of normoxia, euglycemia, control of seizure, therapeutic hypothermia, osmotic therapy, and judicious hyperventilation.[69]

Initial management includes identification and treatment of infection, titration of intravascular volume expansion, and selection of fluids to minimize cerebral edema. Hypertonic saline may be considered to maintain serum sodium in the mildly hypernatremic range. Norepinephrine is the vasopressor of choice and early initiation of renal replacement therapy is important for tight control of intravascular volume. Mild reduction in blood CO_2 tension can also restore cerebral vasoreactivity and autoregulation.[69]

Advanced cerebral edema is associated with hyperventilation, hypertension, papillary abnormalities, decerebrate posturing, and ultimately uncal herniation and death. Arterial ammonia levels greater than 200 μg/dL may be correlated with herniation.[64] Although powered controlled trials are still needed to determine the role of intracranial pressure monitoring,[70] management should aim to keep the cerebral perfusion pressure (mean arterial pressure–intracranial pressure) over 50 mm Hg and the intracranial pressure below 25 mm Hg. Sustained pressures greater than these values for longer than 2 hours usually signifies irreversible brain damage.[64] Mannitol intravenous bolus doses of 0.5 to 1 g/kg are effective in decreasing cerebral edema by maintaining osmotic diuresis and can be repeated provided serum osmolarity does not exceed 320 mOsm/L.[62] Profound coagulopathy (INR >7) and/or planned invasive procedures warrant correction of coagulopathy with fresh frozen plasma (FFP) in combination with recombinant activate factor VII (rFVIIa).[62]

Liver Transplantation

Establishing the cause of ALF is an important determination of outcomes following liver transplantation, with the best results achieved with Wilson disease and the worst seen with idiosyncratic drug reactions. Overall survival rates following liver transplantation at 1 year are 20% below those seen for elective transplants performed for chronic disease but are similar to those achieved in patients with chronic disease who go to transplant from the ICU.[71]

5 Patients who are at high risk of progression to death should be identified and listed for transplantation in a timely fashion. Likewise, it is also crucial to identify patients who have become too sick to benefit from liver transplant. Relative contraindications to liver transplant include: sustained cerebral hypoperfusion (CPP <40 mm Hg) for longer than 2 hours, high doses of vasopressor, acute respiratory distress syndrome (ARDS) requiring high inspired FiO_2 and elevated PEEP.[69]

Life Support Systems

Various biologic and charcoal-based sorbent systems have been tested to date with no demonstrable clinical impact. Total plasma exchange has been studied retrospectively when used to stabilize patients until a transplant can be obtained or self-regeneration occurs.[63] Sorbent systems have shown transient detoxification with no long-term benefits at the expense of worsening coagulopathy. Porcine cell-based and hepatoblastoma-derived extracorporeal systems, the molecular adsorbents recirculating system (MARS),[72] and the Prometheus system[73] are available only for clinical trials and their future in the management of ALF remains uncertain.[62]

STAGING

Table 58-2 King's College Criteria of Poor Prognostic Indicators

Acetaminophen-induced ALF: Arterial pH <7.3 irrespective of coma grade *OR all of the following:* INR >6.5, creatinine >3.4 mg/dL (300 µmol/L), grade III/IV encephalopathy
Non-acetaminophen-induced ALF: INR >6.5 *OR any three of the following:* Age <10 or >40, drug toxicity or undetermined etiology, jaundice >7 days before encephalopathy, INR >3.5, bilirubin >17 mg/dL (300 µmol/L)

ALF, acute liver failure; INR, international normalized ratio.

Prognosis

Accurate prognosis in ALF is important to avoid unnecessary liver transplantation, and the traditionally accepted King's College Criteria are most commonly used for this purpose (Table 58-3). Of note is that the Model for End-Stage Liver Disease (MELD) system cannot be applied in ALF.[62]

ALF due to acetaminophen overdose, hepatitis A, shock liver, or pregnancy-related disease show a 50% or more transplant-free survival, while most other etiologies show only a 25% transplant free survival.[62] Other proposed but not widely accepted poor prognostic criteria include alpha fetoprotein levels, ratio of factor VIII and V levels, liver histology, and serum phosphate levels.

Recipients who underwent liver transplant for drug induced ALF in the United States from 1987 to 2006 were retrospectively studied and the most common drug groups were identified as acetaminophen, antituberculosis medicines, antiepileptics, and other antibiotics. Patients aged 7 years or younger with antiepileptic toxicity had the highest risk of death following liver transplantation compared to all other groups. Mechanical ventilation and elevated serum creatinine were identified as other predictors of poor survival after transplant.[74]

References

1. Kaplan GG, Gregson DB, Laupland KB. Population-based study of the epidemiology of and the risk factors for pyogenic liver abscess. *Clin Gastroenterol Hepatol* 2004;2:1032–1038.
2. Webb TH, Lillemoe KD, Pitt HA. Liver abscess. *Hosp Phys* 1989;25:46–59.
3. Rahimian J, Wilson T, Oram V, et al. Pyogenic liver abscess: recent trends in etiology and mortality. *Clin Infect Dis* 2004;39:1654–1659.
4. Hanbidge AE, Buckler PM, O'Malley ME, et al. From the RSNA refresher courses: imaging evaluation for acute pain in the right upper quadrant. *Radiographics* 2004;24:1117–1135.
5. Zibari GB, Maguire S, Aultman DF, et al. Pyogenic liver abscess. *Surg Infect (Larchmt)* 2000;1:15–21.
6. Lipsett PA, Huang CJ, Lillemoe KD, et al. Fungal hepatic abscesses: characterization and management. *J Gastrointest Surg* 1997;1:78–84.
7. Sharara AI, Rockey DC. Pyogenic liver abscess. *Curr Treat Options Gastroenterol* 2002;5:437–442.
8. Tan YM, Chung AY, Chow PK, et al. An appraisal of surgical and percutaneous drainage for pyogenic liver abscesses larger than 5 cm. *Ann Surg* 2005;241:485–490.
9. Yang CC, Yen CH, Ho MW, et al. Comparison of pyogenic liver abscess caused by non-Klebsiella pneumoniae and Klebsiella pneumoniae. *J Microbiol Immunol Infect* 2004;37:176–184.
10. Wells CD, Arguedas M. Amebic liver abscess. *South Med J* 2004;97:673–682.
11. Yang DM, Kim HN, Kang JH, et al. Complications of pyogenic hepatic abscess: computed tomography and clinical features. *J Comput Assist Tomogr* 2004;28:311–317.
12. Mortele KJ, Segatto E, Ros PR. The infected liver: radiologic-pathologic correlation. *Radiographics* 2004;24:937–955.
13. Lucey MR. Hepatic infection and acute hepatic failure. In: Greenfield LJ, Mulholland ML, Oldham KT, et al., eds. *Surgery: Scientific Principles and Practice.* 3rd ed. Philadelphia, PA: Lippincott Williams & Wilkins; 2001;943–958.
14. Lodhi S, Sarwari AR, Muzammil M, et al. Features distinguishing amoebic from pyogenic liver abscess: a review of 577 adult cases. *Trop Med Int Health* 2004;9:718–723.
15. Ahsan T, Jehangir MU, Mahmood T, et al. Amoebic versus pyogenic liver abscess. *J Pak Med Assoc* 2002;52:497–501.
16. Sayek I, Tirnaksiz MB, Dogan R. Cystic hydatid disease: current trends in diagnosis and management. *Surg Today* 2004;34:987–996.
17. DiazGranados CA, Duffus WA, Albrecht H. Parasitic diseases of the liver. In: Zakim D, Boyer TD, eds. *Hepatology. A Textbook of Liver Disease.* 4th ed. Philadelphia, PA:

WB Saunders; 2003:1073–1107.
18. Dunn MA. Parasitic diseases. In: Shiff ER, Sorrell MF, Maddrey WC, eds. *Schiff's Diseases of the Liver.* 8th ed. Philadelphia, PA: Lippincott Williams & Wilkins; 1999:1533–1548.
19. Kjossev KT, Losanoff JE. Classification of hydatid liver cysts. *J Gastroenterol Hepatol* 2005;20:352–359.
20. Bastid C, Ayela P, Sahel J. Percutaneous treatment of a complex hydatid cyst of the liver under sonographic control. Report of the first case. *Gastroenterol Clin Biol* 2005;29:191–192.
21. Chautems R, Buhler LH, Gold B, et al. Surgical management and long-term outcome of complicated liver hydatid cysts caused by Echinococcus granulosus. *Surgery* 2005;137:312–316.
22. Gollackner B, Längle F, Auer H, et al. Radical surgical therapy of abdominal cystic hydatid disease: factors of recurrence. *World J Surg* 2000;24:717–721.
23. Smego RA Jr, Sebanego P. Treatment options for hepatic cystic echinococcosis. *Int J Infect Dis* 2005;9:69–76.
24. Godyn JJ, Siderits R, Hazra A. Schistosoma mansoni in colon and liver. *Arch Pathol Lab Med* 2005;129:544–545.
25. Qiu DC, Hubbard AE, Zhong B, et al. A matched, case-control study of the association between Schistosoma japonicum and liver and colon cancers, in rural China. *Ann Trop Med Parasitol* 2005;99:47–52.
26. El-Zayadi AR. Curse of schistosomiasis on Egyptian liver. *World J Gastroenterol* 2004;10:1079–1081.
27. Feinstone SM, Kapikian AZ, Purceli RH. Hepatitis A: detection by immune electron microscopy of a virus like antigen associated with acute illness. *Science* 1973;182:1026.
28. Lemon SM, Jansen RW, Brown EA. Genetic, antigenic and biological differences between strains of hepatitis A virus. *Vaccine* 1992;10(suppl 1):S40–S44.
29. Wasley A, Samandari T, Bell BP. Incidence of hepatitis A in the United States in the era of vaccination. *JAMA* 2005;294:194–201.
30. Wheeler C, Vogt TM, Armstrong GL, et al. An outbreak of hepatitis A associated with green onions. *N Engl J Med* 2005;353:890–897.
31. Sanyal AJ, Stravitz RT. Acute liver failure. In: Zakim D, Boyer TD, eds. *Hepatology. A Textbook of Liver Disease.* 4th ed. Philadelphia, PA: WB Saunders; 2003:445–496.
32. Gane E, Sallie R, Saleh M, et al. Clinical recurrence of hepatitis A following liver transplantation for acute liver failure. *J Med Virol* 1995;45:35–39.
33. Craig AS, Schaffner W. Prevention of hepatitis A with the hepatitis A vaccine. *N Engl J Med* 2004;350:476–481.
34. Poland GA, Jacobson RM. Clinical practice: prevention of hepatitis B with the hepatitis B vaccine. *N Engl J Med* 2004;351:2832–2838.

35. Ganem D, Prince AM. Hepatitis B virus infection–natural history and clinical consequences. *N Engl J Med* 2004;350:1118–1129.
36. Wands JR. Prevention of hepatocellular carcinoma. *N Engl J Med* 2004;351:1567–1570.
37. Schiodt FV, Atillasoy E, Shakil AO, et al. Etiology and outcome for 295 patients with acute liver failure in the United States. *Liver Transpl Surg* 1999;5:29–34.
38. Lee WM. Hepatitis B virus infection. *N Engl J Med* 1997;337:1733–1745.
39. Liaw YF, Sung JJ, Chow WC, et al; Cirrhosis Asian Lamivudine Multicentre Study Group. Lamivudine for patients with chronic hepatitis B and advanced liver disease. *N Engl J Med* 2004;351:1521–1531.
40. Lai CL, Gane E, Liaw YF, et al. Telbivudine versus lamivudine in patients with chronic hepatitis B. *N Engl J Med* 2007;357:2576–2588.
41. Lauer GM, Walker BD. Hepatitis C virus infection. *N Engl J Med* 2001;345(1):41–52.
42. Denniston MM, Jiles RB, Drobeniuc J, et al. Chronic hepatitis C virus infection in the United States, National Health and Nutrition Examination Survey 2003 to 2010. *Ann Intern Med* 2014;160(5):293–300.
43. Armstrong GL, Wasley A, Simard EP, et al. The prevalence of hepatitis C virus infection in the United States, 1999 through 2002. *Ann Intern Med* 2006;144(10):705–714.
44. El-Serag HB, Hampel H, Yeh C, et al. Extrahepatic manifestations of hepatitis C among United States male veterans. *Hepatology* 2002;36:1439–1445.
45. Bichko V, Netter HJ, Wu TT, et al. Pathogenesis associated with replication of hepatitis delta virus. *Infect Agents Dis* 1994;3:94–97.
46. Le Gal F, Gault E, Ripault MP, et al. Eighth major clade for hepatitis delta virus. *Emerg Infect Dis* 2006;12:1447–1450.
47. Niro GA, Rosina F, Rizzetto M. Treatment of hepatitis D. *J Viral Hepat* 2005;12:2–9.
48. Kaymakoglu S, Karaca C, Demir K, et al. Alpha interferon and ribavirin combination therapy of chronic hepatitis D. *Antimicrob Agents Chemother* 2005;49:1135–1138.
49. Lu L, Li C, Hagedorn CH. Phylogenetic analysis of global hepatitis E virus sequences: genetic diversity, subtypes and zoonosis. *Rev Med Virol* 2006;16:5–36.
50. Centers for Disease Control (CDC). Enterically transmitted non-A, non-B hepatitis–East Africa. *MMWR Morb Mortal Wkly Rep* 1987;36:241–244.
51. Khuroo MS, Teli MR, Skidmore S, et al. Incidence and severity of viral hepatitis in pregnancy. *Am J Med* 1981;70:252–255.
52. Asher LV, Innis BL, Shrestha MP, et al. Virus-like particles in the liver of a patient with fulminant hepatitis and antibody to hepatitis E virus. *J Med Virol* 1990;31:229–233.
53. Brochot E, Choukroun G, Duverlie G. Ribavirin for chronic hepatitis E virus infection. *N Engl J Med* 2014;370(25):2446–2447.

54. Yousfi MM, Douglas DD, Rakela J. Other hepatitis viruses. In: Zakim D, Boyer TD, eds. *Hepatology. A Textbook of Liver Disease.* 4th ed. Philadelphia, PA: WB Saunders; 2003:1063–1072.
55. Schiff GM. Hepatitis caused by other viruses. In: Shiff ER, Sorrell MF, Maddrey WC, eds. *Schiff's Diseases of the Liver.* 8th ed. Philadelphia, PA: Lippincott Williams & Wilkins; 1999:869–877.
56. Hewlett G, Hallenberger S, Rubsamen-Waigmann H. Antivirals against DNA viruses (hepatitis B and the herpes viruses). *Curr Opin Pharmacol* 2004;4:453–464.
57. Hinedi TB, Koff RS. Cholestatic hepatitis induced by Epstein-Barr virus infection in an adult. *Dig Dis Sci* 2003;48:539–541.
58. Feranchak AP, Tyson RW, Narkewicz MR, et al. Fulminant Epstein-Barr viral hepatitis: orthotopic liver transplantation and review of the literature. *Liver Transpl Surg* 1998;4:469–476.
59. Hoofnagle JH, Carithers RL Jr, Shapiro C, et al. Fulminant hepatic failure: summary of a workshop. *Hepatology* 1995;21:240–252.
60. Mas A, Rodes J. Fulminant hepatic failure. *Lancet* 1997;349:1081–1085.
61. Akdogan M, Camci C, Gurakar A, et al. The effect of total plasma exchange on fulminant hepatic failure. *J Clin Apheresis* 2006;21:96–99.
62. Polson J, Lee WM. AASLD position paper: the management of acute liver failure. *Hepatology* 2005;41(5):1179–1197.
63. Ichai P, Samuel D. Etiology and prognosis of fulminant hepatitis in adults. *Liver Transpl* 2008;14:S67–S79.
64. Larson AM. Acute liver failure. *Dis Mon* 2008;54:458–485.
65. Sanyal AJ, Stravitz RT. Acute liver failure. In: Boyer TD, Wright TL, Manns MP, eds. *Zakim and Boyer's Hepatology: A Textbook of Liver Disease.* 5th ed. Philadelphia, PA: Saunders Elsevier; 2006:383–415.
66. Lee WM, Squires RH Jr, Nyberg SL, et al. Acute liver failure: summary of a workshop. *Hepatology* 2008;47:1401–1415.
67. Williams R, Wendon J. Indications for orthotopic liver transplantation in fulminant liver failure. *Hepatology* 1994;20:S5–S10.
68. Schilsky ML, Tavill AS. Wilson disease. In: Schiff ER, Sorrell MF, Maddrey WC, eds. *Schiff's Diseases of the Liver.* 9th ed. Philadelphia, PA: Lippincott Williams & Wilkins; 2003:1169–1186.
69. Kramer DJ, Canabal JM, Arasi LC. Application of intensive care medicine principles in the management of the acute liver failure patient. *Liver Transpl* 2008;14:S85–S89.
70. Raschke RA, Curry S, Rempe S, et al. Results of a protocol for the management of patients with fulminant liver failure. *Crit Care Med* 2008; 36(8):2244–2213.
71. O'Grady JG. Postoperative issues and outcome for acute liver failure. *Liver Transpl* 2008;14:S97–S101.
72. Heeman U, Treichel U, Loock J, et al. Stange albumin dialysis in cirrhosis with

superimposed acute liver injury. *J Hepatology* 2002;36(4 Pt 1):949–958.

73. Rifai K, Ernst T, Kretschmer U, et al. Prometheus (R)-a new extracorporeal system for the treatment of liver failure. *J Hepatol* 2003;39(6):984–990.
74. Mindikoglu AL, Magder LS, Regev A. Outcome of liver transplantation for drug induced acute liver failure in the United States: analysis of the United Network for Organ Sharing database. *Liver Transpl* 2009;15(7):719–729.

Chapter 59

Cirrhosis and Portal Hypertension

Michael R. Marvin, Robert M. Cannon, and Jean C. Emond

Key Points

1 Although the causes of cirrhosis and the morphologic and histologic changes seen in the liver overlap significantly, oxidative stress leading to chronic injury and inflammation appears to be a common theme.

2 The key mediator in alcohol-induced liver disease is acetaldehyde, which produces numerous deleterious effects on the liver.

3 Nonalcoholic fatty liver disease or nonalcoholic steatohepatitis (NASH) is characterized by infiltration of the liver with fat and is associated with obesity, hyperlipidemia, and noninsulin-dependent diabetes.

4 Viral hepatitis is the most common cause of cirrhosis worldwide, accounting for at least 50% of cases.

5 Budd–Chiari syndrome is a rare disease caused by mechanical obstruction of the hepatic veins owing to obstructing webs or membranes (most commonly in Asia and Africa) or thrombosis secondary to hypercoagulable states and neoplasms (most commonly in the West).

6 Hepatorenal syndrome is a complication of cirrhosis, usually associated with ascites, characterized by progressive renal failure in the absence of intrinsic renal disease.

7 Hepatic encephalopathy is a neuropsychiatric syndrome that occurs in the setting of hepatic disease and is characterized by variable alterations in mental status ranging from deficits detectable only by detailed psychometric tests to confusion, lethargy, and ultimately coma.

8 Portal hypertension is defined as a portal pressure above the normal range of 5 to 8 mm Hg and can be secondary to cirrhosis (hepatic), portal vein thrombosis (presinusoidal), or hepatic venous obstruction (postsinusoidal).

9 The Child–Turcotte–Pugh score is a scoring scale that incorporates clinical and laboratory data as a mean to assess the functional status of the liver, estimate hepatic reserve, and predict morbidity and mortality of liver disease. The model for end-stage liver disease (MELD) score is a highly reliable prognostic marker for cirrhosis, is calculated from standard laboratory tests, and has replaced the Child–Turcotte–Pugh score in liver transplant candidate stratification.

10 The use of the transjugular intrahepatic portosystemic shunt (TIPS) has become first-

line therapy for refractory or recurrent bleeding esophageal varices, with 6-month and 1-year patency rates and prevention of rebleeding in 92% and 82% of patients, respectively.

11 Although the surgical interventions for treatment of bleeding varices are divided into three main types – liver transplantation, shunt procedures, and devascularization procedures – the only definitive procedure in patients with cirrhosis is orthotopic liver transplant.

12 Spontaneous bacterial peritonitis is a potentially lethal complication of unknown etiology associated with portal hypertension with ascites that occurs in up to 10% of patients.

CIRRHOSIS

Background and Definition

Cirrhosis is the end result of multiple, varied, repeated, or chronic pathologic insults to the liver with subsequent repair that cause a derangement in the hepatic architecture; the primary histologic features are marked fibrosis, destruction of vascular and biliary elements, regeneration, and nodule formation (Fig. 59-1). In addition to progressive decrease of hepatic function, portal hypertension is the most prominent clinical manifestation associated with cirrhosis, but it is possible to have portal hypertension in the absence of cirrhosis. The continuum of cirrhosis to liver cancer and its devastating clinical consequences requires us to consider hepatocellular carcinoma (HCC) as a central complication of cirrhosis. Although the only definitive cure for cirrhosis remains liver transplantation, advances in the medical management of both the inciting factors of cirrhosis as well as its complications have led to remarkable improvements to both the quantity and quality of life in patients suffering from cirrhosis.

Pathophysiology

1 Cirrhosis is caused by a wide range of pathologic entities, including the viral hepatitides, alcohol, metabolic disorders, drug toxicity, and biliary obstruction, among others (Table 59-1). Triggered by the underlying cause, the liver is exposed to a broad range of pathologic injuries leading to hepatocyte death and the gradual loss of architectural integrity made permanent by the development of fibrosis. The capacity of the liver to regenerate is a distinct feature of the liver metaphorically represented in the Promethean myth, and the liver is able to absorb injury without structural alteration. However, the capacity of the liver to regenerate is finite, and understanding the deviation from successful regeneration with restoration of hepatocyte mass and normal architecture to the path leading to fibrogenesis and cirrhosis remains a central question in liver biology.[1,2] Significant progress in our understanding of the evolution of liver fibrosis, which ends with cirrhosis, has been gained in recent years.

The pathway from the injuring agent to fibrosis is of growing interest, and the central role of oxidative stress and chronic inflammation in many forms of liver injury has received growing attention. Oxidative stress and chronic inflammation appear to be the final common pathway in the development of cirrhosis. With ongoing inflammation, hepatocyte stress and death via apoptosis and necrosis lead to activation of hepatic stellate cells (HSCs), which appear to be the key mediator in the development of fibrosis.[3] Apoptotic bodies in particular appear to play a major role in the activation of HSCs as well as Kupffer cells, the resident macrophages of the liver.[4] Activation of these cells in turn leads to elaboration of proinflammatory and profibrogenic cytokines such as transforming growth factor beta 1 (TGF-β1) and platelet-derived growth factor (PDGF), creating a self-sustaining cycle.[5–10]

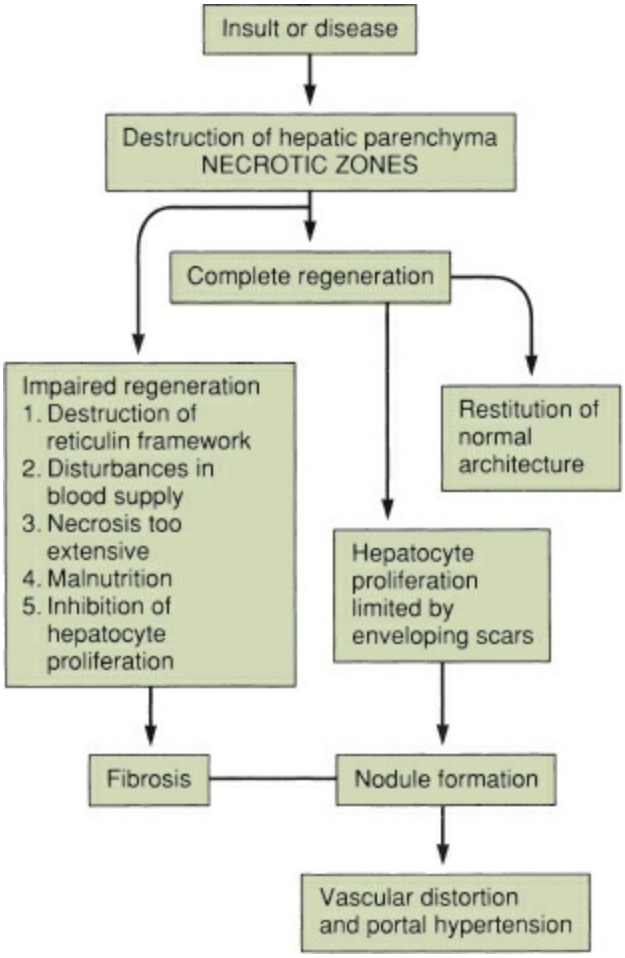

Figure 59-1. Evolution of cirrhosis. Fibrosis develops in nonregenerative necrotic areas, producing scars. The pattern of nodularity and scars reflects the type of response to injury (e.g., uniform vs. nonuniform necrosis) and the extent of injury.

Alcoholic liver disease has long been known to be associated with consequences of oxidative stress in the liver with failure of homeostatic mechanisms.[11] Obesity and metabolic syndrome, a major health problem in the United States, may produce hepatic injury and may potentiate the effects of viral injury.[12,13] In addition to direct oxidative stress, hepatocyte injury is mediated by a variety of mechanisms including proinflammatory cytokines[1] and failure of reparative or modulatory pathways.[14]

The failure of protective or reparatory mechanisms is also widely studied.[15] Over time, fibrosis is the inexorable consequence of ongoing hepatic injury. HSCs are located in the perisinusoidal space of Disse (Fig. 59-2).[16] In the normal liver, these cells are quiescent and are primarily responsible for the storage of vitamin A.[17] Injured hepatocytes release soluble factors that activate HSCs to differentiate into myofibroblastic HSCs, as evidenced by cellular enlargement and proliferation, an increase in rough endoplasmic reticulum, loss of vitamin A droplets, expression of actin filaments, and increased expression of "fibril-forming" collagen types I, III, and V.[18] They also express components of the extracellular matrix, including heparan sulfate, dermatan, chondroitin sulfate,[19] laminin,[20] and fibronectin.[21] Kupffer cells secrete TGF-β1, which appears to be critical for the activation of HSCs.[5,22] Both TGF-β and PDGF have been shown to enhance proliferation and fibrogenesis in animal models,[5,7,23] with TGF-β being the primary stimulator of collagen synthesis and fibrosis. Further evidence implicating TGF-β in the production of

hepatic fibrosis is the observation that levels of TGF-β are reduced by therapy with interferon-α in patients who are positive for hepatitis C. This reduction has been correlated with a regression of hepatic fibrosis.[24]

Table 59-1 Classification of Cirrhosis

Alcohol
Viral hepatitis
Biliary obstruction
Primary
Secondary
Veno-occlusive disease
Hemochromatosis
Wilson disease
Autoimmune
Syphilis
Drugs and toxins
α_1-Antitrypsin deficiency
Cystic fibrosis
Glycogen storage disease
Other metabolic diseases
Sarcoidosis
Copper
Small-bowel bypass
Idiopathic

In addition to the well-characterized effects of TGF-β1 and PDGF on activating HSCs, more recent research has demonstrated the central role of Hedgehog (Hh) in activation of HSCs and promotion of fibrosis.[25] Hh is a molecule involved in signaling pathways that help determine cell fate during embryogenesis. The Hh ligand binds to its cell surface receptor patched. Binding of Hh to patched releases another effector, named smoothened, from a chronic state of inactivation. Activation of smoothened leads to downstream activation of a number of proteins involved in nuclear transcription, thereby leading to changes in cell fate and differentiation.[25] In the liver, the two primary forms of Hh are Sonic Hedgehog (SHh) and Indian Hedgehog (IHh), which are expressed by hepatocytes, bile duct cells, and HSCs. In the healthy liver, quiescent HSCs and endothelial cells keep Hh inactive by production of inhibitory proteins. When the liver is injured, however, numerous cell types including hepatocytes, cholangiocytes, HSCs, progenitor cells, lymphocytes, duct cells, and endothelial cells produce elevated levels of Hh under the influence of cytokines such as PDGF and TGF-β.[25–30] Activation of the Hh pathway tends to be self-sustaining and resistant to negative feedback as long as the injury process continues.[31] It is this surge in Hh levels within the local hepatic milieu that signals quiescent HSCs to activate. The critical role of Hh signaling in HSC activation and fibrogenesis was recently demonstrated by Michelotti et al.,[32] who showed that deletion

of the Hh intermediary smoothened was sufficient to inhibit both HSC activation and fibrosis formation.

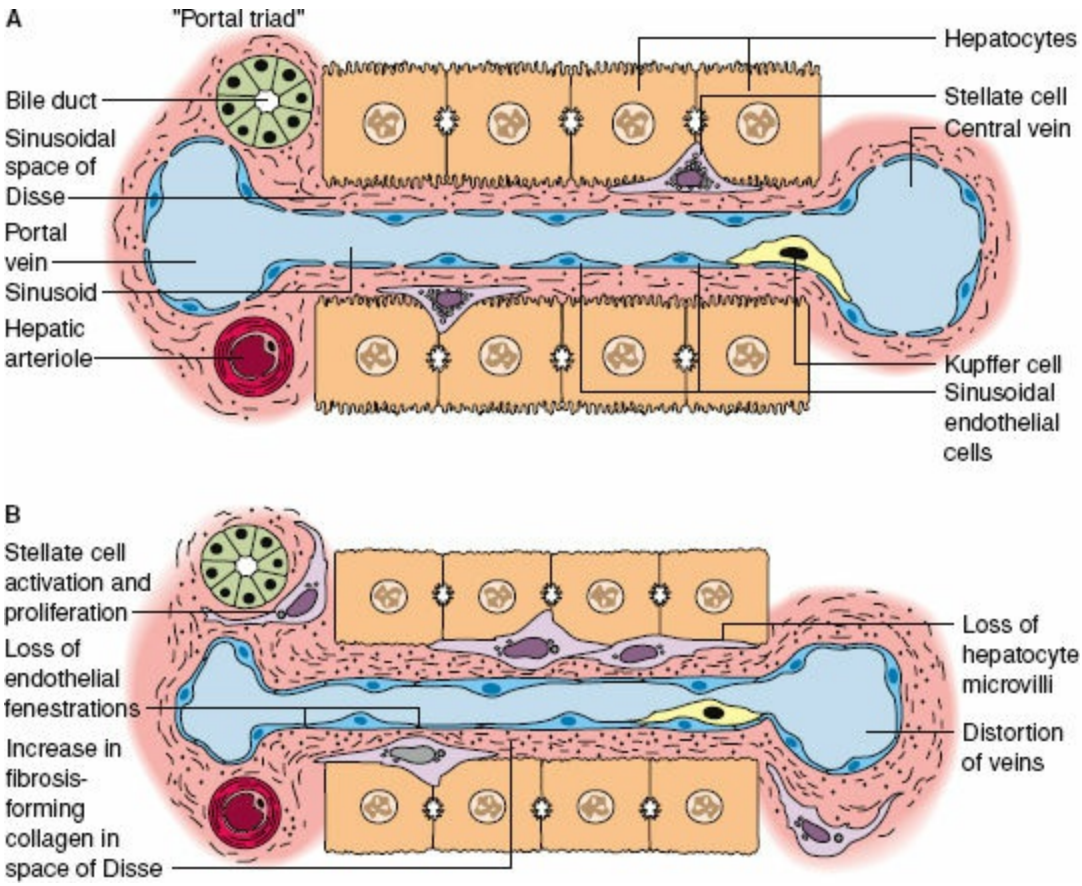

Figure 59-2. Matrix and cellular alterations in hepatic fibrosis. **A:** In normal liver, a modest amount of low-density matrix is present in the subendothelial space of Disse. **B:** In the fibrotic liver, the accumulation of fibril-forming matrix in this region leads to "capillarization" of the sinusoid and functional changes in all neighboring cell types.

Another interesting concept that has been gaining increasing recognition is the role of the gut microflora in the development of cirrhosis. Alcoholics, for example, are known to have a greater susceptibility to small intestinal bacterial overgrowth along with alterations in their gut microflora. This bacterial overgrowth and dysbiosis lead to increased levels of LPS, which reach the liver to stimulate Kupffer cells to produce proinflammatory cytokines. The end result is the generation of mitochondrial damage, reactive oxygen species, and ongoing hepatic inflammation.[33–35] A similar role for alterations in gut microflora has been demonstrated in nonalcoholic fatty liver disease (NAFLD).[36,37]

As a result of the activation of stellate cells and a subsequent enhancement in collagen and extracellular matrix synthesis, the space of Disse becomes thickened, so that "capillarization" develops and the normal fenestrated architecture of the sinusoidal endothelium is lost.[38] Obliteration of sinusoidal fenestrations may be the essential component of fibrosis-induced hepatocellular dysfunction in cirrhosis, preventing the normal flow of nutrients to hepatocytes and increasing vascular resistance.[39] In addition, production of endothelin-1, a potent vasoconstrictor, by endothelial or stellate cells can cause contraction of the myofilaments within the stellate cell, influencing blood flow to

injured areas and contributing to portal hypertension.[40] Initially, fibrosis may be reversible if the inciting agents are removed. With sustained injury, the process of fibrosis becomes irreversible and leads to cirrhosis. Growing attention has been given to approaches that might disconnect hepatic injury from the inexorable path of fibrosis.[41]

Among the most promising agents currently receiving the greatest attention in the treatment of fibrosis are the antioxidants.[4] The combination of N-acetylcysteine and metformin taken for 12 months has demonstrated reduction of fibrosis severity in patients with nonalcoholic steatohepatitis (NASH).[42] The glutathione donor S-adenosylmethionine (SAMe) has demonstrated improved mortality in alcoholic cirrhosis, and vitamin E has been shown to improve hepatic fibrosis in the setting of NAFLD.[4] While the results of studies utilizing these agents have had mixed results, ongoing investigations should establish their role in the treatment of fibrosis. Other studies have focused on utilization of inducible pluripotent stem cells and embryonic stem cells to replenish functional hepatocytes and restore liver function. Mesenchymal stem cells have been studied for their ability to reduce the profibrotic and proinflammatory milieus in the setting of hepatic damage. While these studies are in early stages, their potential is exciting.[43,44]

Classification Systems

Morphology

In 1977, the World Health Organization divided cirrhosis into three categories based on the morphologic characteristics of hepatic nodules (Fig. 59-3).[45]

Micronodular Pattern. Nodules are almost always less than 3 mm in diameter, are relatively uniform in size, are regularly distributed throughout the liver, and rarely contain portal tracts or efferent veins. Micronodular livers are usually of normal size or are mildly enlarged, and the fibrous septa vary in thickness. These changes reflect relatively early disease and are characteristic of a wide range of disease processes, including alcoholism, biliary obstruction, venous outflow obstruction, hemochromatosis, and Indian childhood cirrhosis.

Macronodular Pattern. In this category, nodules vary considerably in size and are larger than 3 mm in diameter, with some nodules measuring several centimeters. Portal structures and efferent veins are present but display architectural distortion. These livers are usually coarsely scarred with variably thick and thin septa and may be either normal or reduced in size. Two separate subcategories are recognized based on the nature of the fibrous septa. In the first category, characteristic of “posthepatitis” pathology and found in Wilson disease, fine, sometimes incomplete septa link portal tracts; these are difficult to see on gross inspection of the liver. The second is characteristic of “postnecrotic” disease, commonly found in patients with viral hepatitis, and is characterized by coarse, thick septa that are readily apparent on gross examination. Because of the relatively large size of the nodules relative to the size of biopsy specimens, diagnosis by biopsy may be difficult in macronodular cirrhosis.

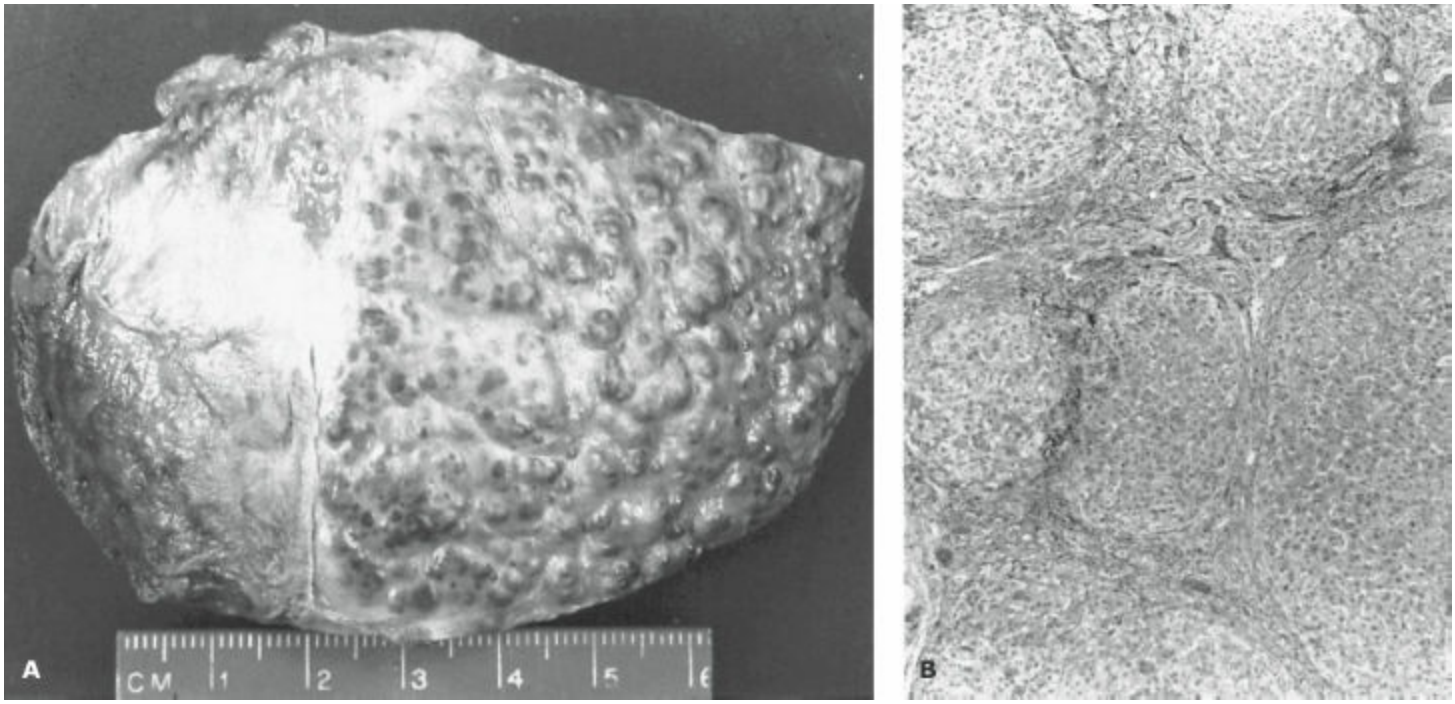

Figure 59-3. **A:** Small, shrunken liver and a fairly regular pattern of nodularity. This appearance is rather typical of end-stage cirrhosis, regardless of the cause. **B:** Photomicrograph of cirrhotic liver tissue, showing irregular nodules of regenerating hepatocytes surrounded by scar. Trichrome stain. (From Stal P, Broome U, Scheynius A, et al. Kupffer cell iron overload induces intercellular adhesion molecule-1 expression on hepatocytes in genetic hemochromatosis. *Hepatology* 1995;21:1308–1316.)

Mixed Pattern. This description is applied to livers in which both micronodules and macronodules are present in approximately equal proportions.

Etiology

Another commonly used method for classifying cirrhosis is by etiology. The causes of cirrhosis and the morphologic and histologic characteristics of the liver, however, overlap significantly. Oxidative stress leading to chronic injury and inflammation appears to be a common theme of these disorders, which leads to both scar formation and an increased risk of liver cancer.

Alcohol. The relationship between alcohol and liver disease has been well established. In 1849, Rokitansky, referring to the association of alcohol intake and liver disease, coined the term *Laennec cirrhosis.*[46] Consumption of at least 30 g of alcohol per day in women and 50 g of alcohol per day in men over at least 5 years is considered to the minimum threshold alcohol intake for cirrhosis to develop.[47] More than 50% of alcoholics with cirrhosis and two-thirds of patients with alcoholic hepatitis and cirrhosis die within 4 years of diagnosis.[48] Alcoholic cirrhosis is the second leading indication for liver transplantation overall, accounting for 40% of liver transplants in Europe and 25% in the United States.[49–51] Cirrhosis, however, develops in only 10% to 30% of heavy drinkers.[52] The reasons why cirrhosis develops in some alcoholics but not in others are not clear and may depend on a variety of factors, such as genetic predisposition, nutritional effects, concomitant drug use, and viral infection.

Alcoholic liver disease usually begins with a transition of normal architecture to fatty liver and alcoholic hepatitis, indicated histologically by the presence of megamitochondria, Mallory bodies (eosinophilic accumulations of intermediate filaments with cytokeratin proteins), inflammation and necrosis, and ultimately fibrosis (Fig. 59-4). Classically, the morphology of alcoholic cirrhosis is a micronodular pattern.

2 Although alcohol may directly activate stellate cells to produce collagen independently of inflammation and necrosis,[53] the key mediator in alcohol-induced liver disease is acetaldehyde, the product of alcohol metabolism by the enzyme alcohol dehydrogenase. Acetaldehyde (ADH) produces numerous deleterious effects on the liver, including the following: direct activation of stellate cells[54]; inhibition of DNA repair[55]; depletion of glutathione, which impairs mitochondrial function and the ability to handle free radical production; damage to microtubules, which causes protein and water sequestration[52]; and formation of reduced nicotinamide adenine dinucleotide (NADH), which opposes gluconeogenesis and inhibits fatty acid oxidation, so that steatosis and hyperlipidemia develop.[52] ADH is most active in the perivenular/centrilobular zone 3 of the hepatic lobule; as a result, relatively high concentrations of acetaldehyde are found in this area of the liver. In addition, zone 3 is hypoxic because of its distance from portal venous and hepatic arterial inflow. These two factors are presumably responsible for the characteristic initial perivenular location of alcohol-induced liver disease.

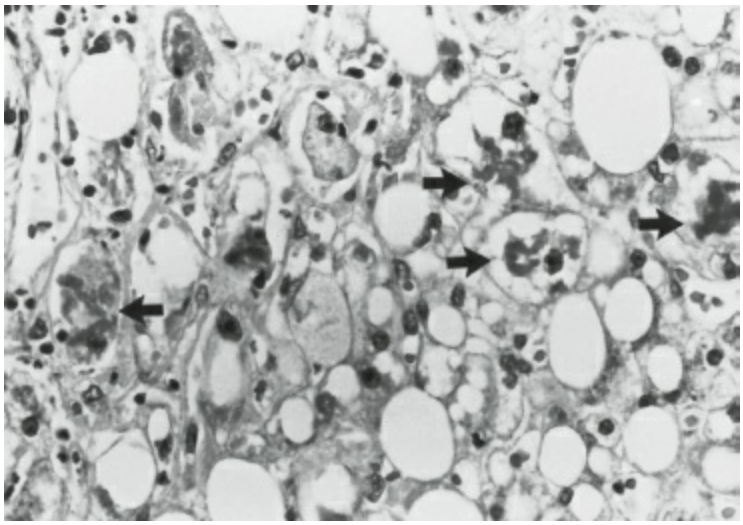

Figure 59-4. Alcoholic hepatitis. Mallory bodies (*arrows*) are evident within the swollen, clear cytoplasm of several hepatocytes. This hyaline material is chemotactic for leukocytes, many of which are seen within the field. Hematoxylin and eosin (H&E) stain × 470.

Other effects of ADH include induction of lipid peroxidation with subsequent loss of integrity of cell membranes, which causes the characteristic “ballooning degeneration” of alcohol-induced liver disease. In addition to its direct hepatic effects, ADH is now known to play a major role in the derangement of the gut–liver axis which plays a key role in alcohol-induced liver injury.[56] In the “leaky gut hypothesis,” ADH increases the permeability of the intestinal barrier,[57] allowing bacterial endotoxin (LPS) access to the liver via the portal circulation. Excess circulating endotoxin then activates Kupffer cells through interaction with Toll-like Receptor 4 (TLR4) to set off the inflammatory cascade

responsible for the development of alcoholic liver disease.[35] Necrosis and inflammation in the perivenular region activate the stellate cells in the space of Disse, so that fibrosis develops. With continued ingestion of alcohol and hepatic injury, expansion of the areas of fibrosis toward the periportal regions leads to bridging fibrosis and ultimately cirrhosis.

3 Nonalcoholic Fatty Liver Disease/Nonalcoholic Steatohepatitis. As noted earlier, this entity has become a major health problem in the United States and adds even further to the litany of health consequences of obesity. NASH, as this disease was previously called, is only one stage in the NAFLD process.[58] NAFLD is now the most common cause of chronic liver disease in the United States, affecting up to 30% to 46% of the population.[59,60] NASH-related cirrhosis is expected to surpass viral hepatitis as the leading indication for liver transplantation by 2025.[25] It is characterized by infiltration of the liver with fat, with or without inflammation (hepatitis), which shares pathologic features of alcohol-induced liver injury but occurs in patients who do not abuse alcohol. NAFLD is associated with obesity, hyperlipidemia, cardiovascular disease, and noninsulin-dependent diabetes, with 90% of NAFLD patients having at least one of these risk factors and 30% having three or more.[61] It now appears that most patients traditionally diagnosed with cryptogenic cirrhosis have NAFLD.[62] In addition to liver injury and cirrhosis, NAFLD is a major risk factor for primary liver cancer HCC and, in addition to hepatitis virus infection, accounts for the rapid rise in the incidence of HCC in Western countries.[63] More broadly considered, recent reports have identified obesity as a major risk factor for cancer deaths with a 4.5-fold increase of the relative risk for liver cancer in obese subjects.[64]

The current understanding of NAFLD and progression to NASH and cirrhosis involves a two-hit model, which is nicely explained in a review by Bohinc and Diehl.[25] In this model, insulin resistance leads to hepatic steatosis (the first hit), which sensitizes the hepatic parenchyma to environmental and extracellular insults (the second hit) leading to inflammation, necrosis, and fibrosis.[25] Dietary fructose has been identified as an important culprit in the development of hepatic steatosis by decreasing intracellular ATP and transforming to lipid in the absence of insulin.[65] Ongoing hepatic insults lead to activation of the inflammasome, a protein scaffold that results in the secretion of the inflammatory cytokines IL-1β and IL-18, further amplifying hepatic inflammation and injury. Inflammasome activation is increased by gut-derived bacterial endotoxin. This inflammation promotes increased Hh signaling and stellate cell activation with resultant fibrosis.[66]

Therapy for NASH centers on lifestyle modification, with a modest weight loss of 5% to 10% associated with significant histologic improvements in disease severity.[61] Now that the role of gut microflora is understood to play a major role in the pathogenesis of NASH and other liver diseases, the use of probiotics, most commonly lactobacilli and bifidobacteria, is being explored in the treatment of NASH. A recent meta-analysis of four randomized controlled trials demonstrated probiotics significantly decreased transaminases, total cholesterol, TNF-α, and insulin resistance.[67]

4 Hepatitis. Viral hepatitis is the most common cause of cirrhosis worldwide, accounting for at least 50% of cases. Hepatitis A, B, C, D, and E have all been proved to cause acute hepatitis, characterized histologically by lymphocytic parenchymal and portal inflammations, focal necrosis, ballooning degeneration, cholestasis, Kupffer cell and macrophage hypertrophy and hyperplasia, and lobular disarray. Only hepatitis B, C, and D have been shown to progress to chronic hepatitis, defined by persistent liver cell necrosis and inflammation lasting longer than 6 months. Chronic infection with hepatitis B virus (HBV) develops in fewer than 5% of patients who experience acute HBV infection. The development of cirrhosis in approximately 10% to 20% of chronically infected persons produces an overall rate of cirrhosis of approximately 1%. Hepatitis B remains a major public health problem in Asian countries and Africa, with up to 10% of the population showing evidence of chronic infection. The widespread use of antiviral medications effective against hepatitis B effectively suppresses viral replication to undetectable levels in up to 90% of patients, and may reverse fibrosis and even cirrhosis. Even with effective suppression of viral replication, however, HBV is not truly "cured" since the virus is incorporated into the host genome. This has important consequences as HCC can still develop in the noncirrhotic liver of HBV-infected patients.[68] In addition, public health strategies with systematic vaccination of newborns should substantially decrease the incidence of new infections.

In contrast, hepatitis C poses a much higher risk of chronic infection, and therapeutic strategies eradicate viral replication in a minority of patients. Of patients with hepatitis C virus (HCV), 90% become chronically infected, and chronic hepatitis develops in 60% of these patients. Among patients with chronic hepatitis, 30% progress to cirrhosis,[46] so that the incidence of cirrhosis in patients initially infected with hepatitis C is approximately 10%. Standard treatment for HCV was previously based on the combination of pegylated interferon and ribavirin, with sustained viral response (SVR) rates of up to 80% in patients with genotypes 2 and 3,[69] but results for the more common genotype 1 were only 40% to 50%, with the best reporting an SVR rate of 65%.[70] Compounding the limited efficacy of interferon-based therapy is the high rate of adverse events that prevents many patients from completing therapy.

The recent release of a new wave of oral antiviral therapies, termed direct-acting antivirals (DAAs), and allowing interferon-free regimens, however, has demonstrated more promising results (Table 59-2).

The fixed dose combination of 90-mg ledipasvir and 400-mg sofosbuvir is sold under the trade name Harvoni (Gilead Sciences) and is recommended as first-line therapy by the American Society for the Study of Liver Disease (AASLD) for the treatment of HCV genotypes 1a, 1b, and 4.[71] Ledipasvir is an inhibitor of the HCV protein NS5A, which limits viral replication. Sofosbuvir is a nucleotide inhibitor of the NS5B polymerase that terminates viral replication. In the ION-1 trial that leads to approval of the combination of these two agents for the treatment of HCV genotype 1, SVR rates of 97% to 99% were demonstrated after 12 weeks of therapy. No patients who received the 12-week regimen had adverse effects leading to early treatment discontinuation.[72] For treatment of genotype 4, the SYNERGY trial demonstrated an SVR rate of 95% by intention to treat

analysis following 12 weeks of ledipasvir/sofosbuvir therapy.[71] Ledipasvir/sofosbuvir is also recommended as first-line therapy for genotype 6. Sofosbuvir also has significant activity against genotypes 2 and 3 when combined with ribavirin, and genotypes 5 and 6 when combined with ribavirin and pegylated interferon.[71] Simeprevir is a novel NS3/4A protease inhibitor recommended as first-line therapy for HCV for genotypes 1a and 1b when used in combination with sofosbuvir. In the COSMOS trial, combination simeprevir/sofosbuvir for genotype 1 HCV demonstrated 95% SVR after 12 weeks of therapy in noncirrhotics, and 100% SVR after 24 weeks of therapy in cirrhotics.[73]

Table 59-2 Causes of Cholestasis

Extrahepatic
Common bile duct stones
Cancers
Pancreas
Ampulla of Vater
Bile duct
Cysts
Pancreatic
Choledochal
Infections
Parasites
Acquired immunodeficiency syndrome
Chronic pancreatitis
Bile duct strictures
Benign
Ischemic
Hodgkin disease
Biliary atresia
Intrahepatic
Primary biliary cirrhosis
Space-occupying lesions
Primary or metastatic hepatic tumors
Lymphoma
Amyloidosis
Vanishing bile duct syndrome
Allograft rejection
Graft versus host disease
Alagille syndrome
Idiopathic adult ductopenia
Primary sclerosing cholangitis
Hodgkin disease
Cystic fibrosis
Hepatocellular Cholestasis
Genetic
α-Antitrypsin deficiency
Benign recurrent intrahepatic cholestasis
Byler syndrome
Cholestasis of pregnancy
Abnormal bile acid synthesis
Porphyrias
Acquired
Viral hepatitis
Drugs
Alcoholic hepatitis
Bacterial infections
Total parenteral nutrition
Renal carcinoma
Hodgkin disease
Postoperative cholestasis

Another novel all-oral HCV regimen is the combination of ombitasvir, paritaprevir, ritonavir, and dasabuvir, marketed as the Viekira Pak (AbbVie). Ombitasvir inhibits NS5A, paritaprevir inhibits the NS3/4A protease, ritonavir is a CYP3A4 inhibitor without any HCV activity used to increase sensitivity to paritaprevir, and dasabuvir is a nonnucleotide NS5B polymerase inhibitor. The combination is recommended as first-line therapy for genotype 1a when used with weight-based ribavirin, genotype 1b (with ribavirin for cirrhotics), and genotype 4 (with ribavirin).[71] Against HCV genotype 1, SVR rates of 95.3% to 97% have been demonstrated.[74,75]

These results represent a revolution in the therapy of HCV that makes cure of HCV a possibility. In patients who respond to therapy, progression to cirrhosis is eliminated and

it is generally thought that HCC does not develop. In patients who do not respond to therapy, cirrhosis develops in approximately 40%, and HCC develops in 16% of these patients.[73]

Hepatitis D virus (HDV) is an RNA virus that requires the presence of HBV to be pathogenic. Superinfection of HBV-positive patients with HDV leads to a more rapid clinical course, with progression to cirrhosis in 70% to 80% of patients.[74] Among patients with compensated cirrhosis of viral origin, HCC developed in approximately 20% with HCV, 9% with HBV, and 41% with both HBV and HCV.[46] The progressive increase in hepatitis-infected individuals in the United States precedes an epidemic in HCC, which has been well documented and is expected to peak over the coming decade.[75]

Cholestasis. Cholestasis, defined as a decrease or absence of bile flow into the duodenum, may be caused by intrahepatic or extrahepatic biliary obstruction or defects in the ability of hepatocytes to excrete bile. Causes of cholestasis are presented in Table 59-2. Prolonged biliary obstruction leads to proliferation of bile ducts, formation of bile lakes caused by disruption of bile ducts, fibrosis, and ultimately secondary biliary cirrhosis as a result of the direct toxic effects of bile salts on hepatobiliary elements.

Immune or Inflammatory Cirrhosis. Although cholestasis is a generically toxic insult to the liver that can cause cirrhosis, several diseases that are characterized by cholestasis seem to be caused by underlying immune or inflammatory disorders affecting either small (primary biliary cirrhosis [PBC]) or large (primary sclerosing cholangitis [PSC]) bile ducts. PBC is a chronic, slowly progressive disease that most commonly affects middle-aged women; it is characterized by portal inflammation, destruction of intrahepatic bile ducts, and progression to cirrhosis. Approximately 95% of patients are women, and 95% of these women express antimitochondrial antibodies in serum.[76] The autoimmune inflammatory process damages both the bile ducts and, eventually, the hepatocytes as a result of leakage of bile acids into surrounding parenchyma.[77] Patients present with fatigue, jaundice, and pruritus, but as many as 60% of patients may be asymptomatic.[78] PBC progresses in the majority of patients; median survival times are approximately 10 to 15 years in asymptomatic patients and 7 years in symptomatic patients.[79,80] Poor prognostic factors include hyperbilirubinemia, advanced age, hepatosplenomegaly, and symptomatic disease.

Medical management of PBC is with the exogenous bile acid ursodeoxycholic acid (13 to 15 mg/kg/d). Complete response, as evidenced by normalization of liver enzymes without histologic progression, is seen in up to 30% of patients and can even lead to a normal life expectancy. Therapy for nonresponders includes immunosuppression with methotrexate, colchicine, or steroids, although the efficacy of these medications is in question.[81] Liver transplantation is ultimately required as the definitive treatment in most patients, and the parameters for liver transplantation and its timing are relatively predictable and have been well studied.[82]

PSC is a chronic, progressive cholestatic liver disease of unknown cause characterized by diffuse segmental intrahepatic or extrahepatic biliary ductular strictures with

associated fibrosis and inflammation. The disease has no cure and often leads to secondary biliary cirrhosis, portal hypertension, hepatic failure, and cholangiocarcinoma if hepatic transplantation is not performed. PSC is strongly associated with inflammatory bowel diseases, most commonly ulcerative colitis, and probably shares an underlying disturbance related to disturbed mucosal immunity of the gastrointestinal tract.[83] Approximately 70% of patients with PSC also have ulcerative colitis.[83] Conversely, approximately 5% of patients with ulcerative colitis have PSC, though subtler forms of the disease may be present but clinically asymptomatic. PSC is thought to be autoimmune in nature; elevated levels of autoantibodies and an increased expression of human leukocyte antigen (HLA) class II molecules on biliary epithelial cells have been observed.[84,85] Approximately two-thirds of patients are male and younger than 45 years of age at the time of diagnosis.[86] Patients with PSC may be completely asymptomatic (up to 44%) or have signs of advanced disease at the time of diagnosis.[83] Commonly, the diagnosis is made in symptomatic patients after endoscopic retrograde cholangiopancreatography (ERCP) has been performed to evaluate elevated liver enzymes, including alkaline phosphatase and γ-glutamyltransferase. Symptomatic patients have a waxing and waning course and may present with complaints of fatigue (75%), pruritus (25% to 70%), jaundice (30% to 69%), abdominal pain (16% to 37%), and weight loss (10% to 34%).[83] Complications secondary to progression to cirrhosis are less common and include ascites, variceal bleeding, and acute cholangitis.

The diagnosis of PSC is suggested by a history of inflammatory bowel disease in the setting of elevated liver enzymes and is established by cholangiography. The disease process may range from a single dominant stricture to, more commonly, diffuse multifocal sclerosis of the intrahepatic and extrahepatic bile ducts. Pathologically, bile ductular proliferation, periductal fibrosis and inflammation, ductopenia, and, less commonly, obliterative fibrous cholangitis may be present. PSC may be considered a premalignant condition. Like ulcerative colitis, PSC confers a significant risk of malignant transformation of the biliary mucosa, which is one of the considerations in considering patients for transplantation.[87] Cholangiocarcinoma develops in 1% to 2% of patients per year after the diagnosis of PSC, with an overall risk of up to 10%.[88] Screening for premalignant changes with ERCP and cytologic examination and serum testing of CA19-9 have been helpful, though both have limited specificity and sensitivity. Recently, it has been proposed that newer analysis methods of biliary material obtained at screening ERCP, including fluorescence in situ hybridization (FISH), may be used for chromosomal abnormalities associated with cancer with an increase in the sensitivity.[89]

There is no generally accepted medical therapy to treat PSC, so therapeutic efforts are directed toward complications of the disease. The major complications include biliary obstruction, cirrhosis, and cholangiocarcinoma. Dominant strictures, defined as stenosis less than 1.5 mm in the common bile duct or less than 1 mm in the hepatic duct, are readily treated endoscopically by means of dilation and/or stent placement.[90,91] Transplantation should be performed before cancer develops and, generally, the discovery of cancer has been considered an absolute contraindication to transplantation because of poor outcomes. Highly selected patients with localized tumors may be transplanted with

an acceptable survival rate with intensive preoperative therapy including radiation and chemotherapy, as proposed by Shaw and implemented on a larger scale by the Mayo group.[92]

Metabolic and Genetic Disorders. Some of these diseases are listed in Table 59-1. A description of all the metabolic disorders causing liver disease is beyond the scope of this chapter.

In hemochromatosis of the liver, an inborn error of metabolism causes an increased absorption of iron from the gastrointestinal tract. The pathophysiology of iron-induced hepatotoxicity is related to lipid peroxidation induced by iron in periportal regions of the liver. Activation of stellate cells by cytokines released from Kupffer cells that have phagocytosed necrotic hepatocytes injured by iron toxicity is also contributory.[93] Over time, the reaction progresses to bridging fibrosis and eventually to a mixed micronodular–macronodular cirrhosis. Treatment includes reduction of iron intake, repeated phlebotomy, and orthotopic liver transplantation.[94]

Wilson disease is an autosomal, recessively inherited disease caused by a deficiency in hepatocyte transport of copper into the bile. The disease is characterized biochemically by low serum ceruloplasmin levels and clinically by corneal pigmentation (Kayser–Fleischer rings), neuropsychiatric disease, and hepatic cirrhosis.[95] As copper accumulates in the liver, periportal inflammation develops that leads to piecemeal and lobular necroses, bridging fibrosis, and a mixed micronodular–macronodular cirrhosis. Treatment options include chelating agents, such as penicillamine, trientine, zinc salts, and orthotopic liver transplantation.

Venous Outflow Obstruction. Cirrhosis may also result from obstruction of the hepatic veins. Causes include chronic right-sided heart failure as a result of severe tricuspid regurgitation, constrictive pericarditis, and the Budd–Chiari syndrome (BCS).

Hepatic dysfunction secondary to passive vascular congestion in the setting of right-sided heart failure and increased right-sided heart pressures is caused by the transmission of increased pressure to the hepatic venous system. This increased pressure leads to sinusoidal congestion, perivenular atrophy, hemorrhagic necrosis, and distortion and enlargement of sinusoidal fenestrations.[96] Increased pressure also causes perisinusoidal edema that eventually exceeds the clearance capabilities of hepatic lymphatics, so that ascites develops.[97] Grossly, the liver is described as having a “nutmeg” appearance in which areas of hemorrhage are interspersed with relatively normal yellowish parenchyma.[97] Histologically, perivenular fibrosis progresses to bridging fibrosis that spares the portal regions. Portal sparing is characteristic of “cardiac cirrhosis.” In addition to causing ascites, chronic vascular congestion can lead to fibrosis in the space of Disse, which compromises nutrient delivery and contributes to portal hypertension and zone 3 hepatocellular injury.[98]

5 BCS is a rare disease caused by mechanical obstruction of the hepatic veins (Table 59-3). Obstruction may occur at the level of the terminal hepatic veins, the major hepatic veins, or the vena cava and may be caused by obstructing webs or membranes (most

commonly in Africa and Asia) or thrombosis secondary to hypercoagulable states and neoplasms (most commonly in the West).

The range of presentations is wide; some patients are completely asymptomatic, whereas acute hepatic failure or cirrhosis develops in others.[99] These variations in symptoms are related to the degree and rate of progression of hepatic outflow obstruction. Patients classically present with abdominal pain, hepatomegaly, and ascites. The diagnosis can be made by duplex Doppler ultrasonography, which has a sensitivity of 85% to 95%.[100] Identification of collateral vessels to subscapular or intercostal vessels on ultrasonography on ultrasound is a highly sensitive and specific finding.[101] Computed tomography (CT) and magnetic resonance imaging (MRI) offer optimal characterization of intrahepatic vascular anatomy and are currently used for the planning of complex interventions.[102] Medical management consists of anticoagulation and symptomatic management. Interventional radiologic procedures have now taken the forefront in management of BCS, in which accessible strictures may be treated with angioplasty or stenting. For patients unsuitable for reestablishment of hepatic venous outflow through the above means, transjugular intrahepatic portosystemic shunting (TIPS) is able to decompress both the inferior vena cava and the portal system.[101] In patients with fulminant BCS or in those who develop chronic decompensated cirrhosis, liver transplantation becomes an option.

Table 59-3 Etiology

Idiopathic
Hematologic disorders
Polycythemia vera
Paroxysmal nocturnal hemoglobinuria
Myeloproliferative disorders
Antithrombin III deficiency
Circulating lupus anticoagulants
Oral contraceptives
Pregnancy and postpartum
Tumors
Hepatocellular carcinoma
Renal cell carcinoma
Adrenal carcinoma
Leiomyosarcoma of the inferior vena cava
Vena caval webs
Infections
Amebic abscess
Aspergillosis
Hydatid cyst
Phlebitis
Trauma
Veno-occlusive disease

Diagnosis

Although cirrhosis can be asymptomatic for decades, significant information can be obtained by performing a thorough history and physical examination. A history of alcohol abuse, hepatitis, toxin or drug exposure, upper gastrointestinal bleeding, enlarging hemorrhoids, infections, and alteration in mental status suggests the possibility of liver disease. Physical findings associated with cirrhosis are listed in Table 59-4. In addition to these findings, fetor hepaticus, purpura and bruising, decreased body hair, and white nails are common.

Laboratory tests of liver function are indicated if liver disease is suggested by the history and physical examination. Although levels of bilirubin, aspartate aminotransferase, alanine aminotransferase, and alkaline phosphatase are elevated in hepatic disease, the increases are not specific for liver pathology, and levels may be normal even in the setting of significant disease. A very common finding in patients with cirrhosis is thrombocytopenia, caused by hypersplenism and portal hypertension. The platelet growth factor thrombopoietin, which is produced by the liver, has been shown to be decreased in patients with cirrhosis, and this deficit may contribute to the thrombocytopenia associated with hepatic disease.[103]

The definitive diagnosis of cirrhosis usually requires biopsy, either percutaneous or operative, or gross inspection during laparoscopy or laparotomy. Regardless of the method selected, it is crucial to obtain a large enough specimen to make the diagnosis. Current recommendations suggest that at least 11 portal tracts need to be assessed.[104] Several staging systems exist for the grading of fibrosis and cirrhosis, including the International Association for Study of the Liver (IASL), Batts–Ludwig, and Metavir systems. The AASLD recommends the Batts–Ludwig system as it gives a verbal diagnosis rather than numeric categories, and thus may be easier to interpret.[104]

Table 59-4 Physical Findings in Cirrhosis

Physical Findings	Incidence (%)
Palpable liver	96
Jaundice	68
Ascites	66
Spider angiomas	49
Dilated abdominal wall veins	47
Palpable spleen	46
Testicular atrophy	45
Palmar erythema	24
Noninfectious fever	22
Hepatic coma	18
Gynecomastia	15
Dupuytren contractures	5

Noninvasive methods to diagnose cirrhosis include ultrasonography, CT, and MRI,

which generally reveal an atrophic, nodular liver and an enlarged spleen. More recent work suggests that subtle changes in the hepatic veins may be early markers of cirrhosis.[102] Ultrasonographic criteria for cirrhosis include the demonstration of multiple nodular irregularities on the ventral liver surface that are clearly separate from the anterior abdominal wall. Parenchymal texture is altered in the setting of fibrosis, though this feature can be subtle. When these criteria are used, ultrasonography has been shown to have a sensitivity, specificity, and accuracy of approximately 90% in the diagnosis of cirrhosis.[105] Ultrasound-based transient elastography, a measure of liver stiffness, is playing an increasingly large role in the noninvasive assessment of fibrosis, with some studies demonstrating a 95% area under the receiver operating characteristic curve (AUROC) for diagnosing grade IV fibrosis (cirrhosis).[106]

More recently, several laboratory indexes have been found to correlate well with histologic grade of cirrhosis.[106,107] The NAFLD fibrosis score, for example, consists of age, BMI, diabetes, platelet count, albumin level, and AST/ALT ratio.[108] The AUROC of this scoring system in diagnosing stage 3 or greater fibrosis was 85% in a recent meta-analysis.[109] The Fibrotest (LabCorp) is a patented panel of biomarkers consisting of GGT, haptoglobin, bilirubin, apolipoprotein A1, and alpha-2-macroglobulin. The AUROC of Fibrotest for fibrosis greater than or equal to stage 2 has been shown to be up to 87%.[110] Indirect evidence of cirrhosis includes endoscopically discovered varices of the esophagus, and the presence of splenomegaly detected by CT or MRI.

Complications

Renal

Renal complications in cirrhosis are intrinsic to functional dysregulation of vascular tone throughout the body.[111] Several elements come into play and renal dysfunction is characterized by avid sodium retention despite normovolemia or hypervolemia, dilutional hyponatremia secondary to free water overload, ascites, and ultimately renal failure and the hepatorenal syndrome (HRS). The paradoxical arterial vasoconstriction of the renal arterial bed in the face of global fluid overload is critical to the pathophysiology of HRS.[112] Among the complications of cirrhosis, HRS confers the highest risk of mortality.[113] Although HRS is the most dramatic renal complication of liver failure, renal dysfunction in patients with advanced liver disease is generally multifactorial.[112] Renal insufficiency may develop in a patient with cirrhosis as a direct consequence of the underlying condition (i.e., PBC, amyloidosis), as a consequence of excessive diuretic use in the treatment of ascites and fluid overload, or as a secondary reaction to the release of cytokines or hormones by the liver that alter renal function.

DIAGNOSIS

Table 59-5 Differential Diagnosis of Acute Azotemia in Patients with Liver Disease

	Prerenal Azotemia	Hepatorenal Syndrome	Acute Renal Failure
Urinary sodium	<10 mEq/L	<10 mEq/L	>30 mEq/L
Urine/plasma creatinine ratio	>30:1	>30:1	<20:1
Urine osmolality	100 mOsm, or more than plasma osmolality	100 mOsm, or more than plasma osmolality	Equal to plasma osmolality
Urine sediment	Normal	Normal	Casts: cellular debris

Much progress has been made in the understanding of the pathophysiology of HRS focusing on the dysregulation of arterial tone in the end stages of liver disease. Empiric observations that support a functional or "secondary effect" theory include the lack of anatomic renal abnormalities in patients with cirrhosis-related renal dysfunction, the normal function of previously dysfunctional kidneys transplanted into otherwise healthy recipients, and resolution of renal abnormalities after successful hepatic transplantation. Recent clinical studies have defined the critical role of optimizing colloid balance in the patient with cirrhosis[114] and the exploration of regulators of renal blood flow such as terlipressin in counteracting the deranged vascular tone.[115]

Sodium Retention. Patients with cirrhosis who do not have ascites have relatively normal sodium-handling capabilities. Patients in whom ascites develops have a marked inability to excrete sodium. Because of this deficit, sodium intake in excess of renal

excretion contributes to fluid overload. Three potential mechanisms have been invoked to explain the cause of sodium retention and the development of ascites in cirrhotic patients. The first is the "underfill" theory, whereby portal hypertension causes an increase in pressure in the splanchnic circulation. Ascites occurs when hepatic lymph production exceeds lymphatic return, with subsequent contraction of the blood volume and renal sodium retention.[116] This theory was abandoned when it was shown that patients with cirrhosis were found to have increased, rather than decreased, plasma volume.[117] The second is the "overflow" theory, which suggests that the primary defect is inherent to the kidney. Abnormal renal retention of sodium leads to concomitant water retention, expansion of plasma volume, and subsequently edema and ascites.[117,118] The third and most currently accepted explanation is the "arterial vasodilation hypothesis," which suggests that the responsible defect lies within the vascular system, with arterial hypotension as the primary event. Arterial vasodilation in the splanchnic circulation leads to relative peripheral hypovolemia and activation of the renin–angiotensin–aldosterone and sympathetic nervous systems. The effects, in turn, are a release of antidiuretic hormone (arginine vasopressin), enhancement of sodium and water conservation, an increase in effective circulating volume, and edema and ascites.[119,120]

The cause of the splanchnic vasodilation is unclear. Some evidence suggests that nitric oxide may be the key mediator. Elevations in portal venous nitric oxide have been reported in both animal and human studies,[121,122] and inhibitors of nitric oxide production have been shown to reduce the activity of vasoconstrictor systems and enhance renal hemodynamics.[122] The exact role of nitric oxide activity in the pathophysiology of renal disease in cirrhosis remains to be determined. Other studies have demonstrated that extracellular fluid volume expansion precedes vasodilation,[123] and that pathologic activation of intrahepatic vascular sensors is the key mediator for the ensuing renal salt retention.[116]

Water Retention. Patients with cirrhosis and ascites may have a marked inability to handle free water. An increased production of antidiuretic hormone, decreased delivery of fluid to the diluting segments of the nephron, and reduced renal production of prostaglandins all may contribute.[117] Retention of water leads to dilutional hyponatremia (serum sodium 130 mEq/L), which can cause nausea, vomiting, lethargy, and seizures.[124]

6 Hepatorenal Syndrome. HRS is a complication of cirrhosis, most often with ascites, characterized by progressive renal failure in the absence of intrinsic renal disease. Renal dysfunction is thought to occur in up to 20% of patients hospitalized with cirrhosis and ascites.[125] In a large study of two major Spanish centers, HRS developed in 7.6% of patients admitted for the management of ascites.[126] Manifestations of the disease include progressive oliguria, with urine outputs of 400 to 800 mL/d, a rising serum creatinine level, increased cardiac output, and decreased arterial pressure. The disease process is highly variable and is associated with marked renal cortical vasoconstriction induced by activity of the renin–angiotensin–aldosterone and sympathetic nervous systems. In addition, the powerful endothelium-derived vasoconstrictor endothelin-1, combined with

decreased renal production of vasodilator prostaglandins, may play a role.

HRS may develop as a result of infection, use of nonsteroidal anti-inflammatory drugs, variceal hemorrhage, or excessive diuretic use in patients who were previously well compensated. The differentiation of HRS from acute renal failure is possible by the laboratory evaluation of urine and serum samples. HRS, however, is virtually indistinguishable by laboratory testing from prerenal azotemia. Both prerenal azotemia and HRS are characterized by extremely low sodium concentrations in the urine, high urine osmolality, high urine-to-plasma ratios of creatinine, and normal urinary sediment (Table 59-5). Criteria for the diagnosis of HRS are listed in Table 59-6.

DIAGNOSIS

Table 59-6 Diagnostic Criteria for Hepatorenal Syndrome[a]

Major Criteria
1. Low glomerular filtration rate, as indicated by serum creatinine >1.5 mg/dL or 24-hour creatinine clearance 40 mL/min
2. Absence of shock, ongoing bacterial infection, fluid losses, and current treatment with nephrotoxic drugs
3. No sustained improvement in renal function (decrease in serum creatinine to ≤1.5 mg/dL or increase in creatinine clearance to 340 mL/min) following diuretic withdrawal and expansion of plasma volume with 1.5 L of a plasma expander
4. Proteinuria <500 mg/d and no ultrasonographic evidence of obstructive uropathy or parenchymal renal disease
Additional Criteria
1. Urine volume <500 mL/d
2. Urine sodium <10 mEq/L
3. Urine osmolality greater than plasma osmolality
4. Urine red blood cells <50 per high-power field
5. Serum sodium concentration <130 mEq/L

[a]All major criteria must be present for the diagnosis of hepatorenal syndrome. Additional criteria are not necessary for the diagnosis but provide supportive evidence.
From Arroyo V, Ginés P, Gerbes A, et al. Definition and diagnostic criteria of refractory ascites and hepatorenal syndrome in cirrhosis. *Hepatology* 1996;23:164.

The treatment of ascites in patients with cirrhosis requires sodium and water restriction in addition to the use of diuretics. Excessive use of these treatment modalities may lead to increases in serum creatinine that can be difficult to distinguish from those of HRS. A failure to respond to cessation of diuretics and fluid challenge suggests HRS. If liver transplantation cannot be performed, patients with HRS usually die within months of the development of severe disease, defined as a serum creatinine level above 2 mg/dL.[113]

Management of HRS hinges on a three-pronged approach. First is treatment of the triggering event. The most common inciting factor is spontaneous bacterial peritonitis, followed by volume contraction (from multiple etiologies including gastrointestinal bleeding or the overzealous treatment of ascites). Over 70% of cases of acute HRS have been linked to bacterial infections.[127] The other two cornerstones of HRS treatment are vasoconstrictors and volume expansion with albumin. The vasopressin-analog terlipressin

is commonly used outside the United States. The oral vasopressor midodrine is commonly used in the United States, where terlipressin is not approved by the FDA. Others have examined norepinephrine as a substitute for terlipressin.[127] A meta-analysis of all randomized controlled trials of vasopressor use in the treatment of HRS has found a reduction in all-cause mortality when vasopressors are utilized.[128] Although advances in medical therapy have made the reversal of HRS possible in some patients, many will ultimately require liver transplantation in order to survive.

Pulmonary

Many pathologic processes in patients with cirrhosis affect pulmonary function. Some reflect an underlying condition that causes both hepatic and pulmonary diseases (i.e., cystic fibrosis, α_1-antitrypsin deficiency); others are primary pulmonary processes, such as interstitial lung disease, primary pulmonary hypertension (portopulmonary hypertension [POPH]), and obstructive airway disease. Three main pulmonary manifestations of cirrhosis are discussed here; one is related to increased intra-abdominal pressure secondary to ascites, one is caused by intrapulmonary shunting and is known as the hepatopulmonary syndrome (HPS), and the last is POPH.

The presence of copious ascitic fluid can lead to pulmonary dysfunction by compromising diaphragmatic excursion secondary to increases in intra-abdominal and intrapleural pressures. Ascites may also induce large pleural effusions known as hepatic hydrothorax because of the presence of lymphatic transdiaphragmatic communications between the abdomen and thorax.[129] These small diaphragmatic defects are typically found on the right side of the body. Effusions can compress the pulmonary parenchyma and impair gas exchange, so that ventilation–perfusion mismatch and hypoxemia develop. Patients present with worsening pulmonary symptoms in the setting of increasing abdominal girth. Pulmonary function testing reveals decreases in functional residual capacity and total lung capacity.[130] Marked improvement in pulmonary function results from medical management of ascites, large-volume paracentesis, and thoracentesis.[131,132] These interventions decrease the work of breathing and relieve symptoms. With control of ascites, even in the presence of pleural effusions, no other interventions may be necessary. For patients refractory to the above measures, second- and third-line strategies such as TIPS, indwelling pleural catheter placement, and pleurodesis have been described, although liver transplantation should be pursued in these patients for definitive management.[132]

HPS occurs in patients with mild to severe hepatic disease and in approximately 10% to 50% of patients with hepatic dysfunction.[133,134] Diagnostic criteria for HPS in patients with cirrhosis include PaO_2 <80 mm Hg or A–a gradient over 15 mm Hg in patients under 65 years old. The A–a gradient cutoff for patients over 65 is 20 mm Hg.[135] Other manifestations include platypnea (increased shortness of breath with movement from a supine to an erect position) and orthodeoxia (decreased oxygen tension on moving from a supine to an erect position). These two positional deficits in pulmonary function are related to the increased number of dilated capillaries in the basal areas of the lung; flow

is increased in these vessels while the subject is standing, so that shunting is increased. Physical findings include clubbing and cyanosis of the nail beds and spider angiomata.

Although the underlying cause of hypoxemia in these patients is right-to-left intrapulmonary shunting, ventilation–perfusion mismatch and impaired hypoxic vasoconstriction also play a role. Patients usually present with dyspnea and worsening hypoxemia without evidence of a primary pulmonary process. Initial diagnostic tools include pulse oximetry and arterial blood gas analysis. When significant hypoxemia is found, pulmonary function testing is useful to rule out obstructive or restrictive airway disease. A definitive diagnosis can be obtained by the use of contrast-enhanced echocardiography (bubble study) or technetium-macroaggregated albumin (MAA) scanning, which will confirm the presence of intrapulmonary vascular dilation.[136,137] Contrast echocardiography is the most sensitive test, whereby intrapulmonary vascular dilation is demonstrated by a late appearance of microbubbles in the left heart three to six cardiac cycles after injection.[138] MAA scanning is complementary to contrast echocardiography in the setting of coexisting intrinsic lung disease with severe hypoxemia, where MAA shunting of $>6\%$ suggests HPS as the major contributor to hypoxemia.[139] The only effective therapy for this disease is orthotopic liver transplantation, and those with HPS and with a PaO_2 <60 mm Hg receive extra priority at listing.[138]

POPH is defined as a mean pulmonary arterial pressure of greater than 25 mm Hg, pulmonary artery occlusion pressure <15 mm Hg, and pulmonary vascular resistance >240 dyn/s/cm^{-5} on right heart catheterization in the setting of documented portal hypertension.[135] It is a relatively rare ($<10\%$) complication of cirrhosis that, when severe, carries a substantial risk of mortality and is a relative contraindication to liver transplantation.[140,141] Screening of patients with cirrhosis by Doppler echocardiography will reveal evidence of elevated right heart pressures, which need to be confirmed by right heart catheterization. Although the high flow state of cirrhosis can elevate right-sided pressures, fixed obstruction of the pulmonary microcirculation is highly lethal and is not likely to improve with liver transplantation. The exact pathophysiology behind POPH is not known, but portal hypertension is a necessary component of the disease process. The hyperdynamic state in portal hypertension may be the main contributory factor, although the severity of POPH does not correlate with the severity of portal hypertension.[142] Treatment with prolonged intravenous infusion of prostaglandins has been shown to be effective in improving pulmonary hemodynamics but does not prolong survival.[141] The most commonly used drugs in POPH are oral endothelin receptor antagonists such as bosentan and ambrisentan. As stated above, severe POPH (mPAP >50 mm Hg) is an absolute contraindication to liver transplantation. For patients in whom medical therapy can maintain mPAP under 35 mm Hg and PVR under 400 dyn/s/cm^{-5}, priority listing for liver transplantation is available.[143]

Hepatic Encephalopathy

7 Etiology. Hepatic encephalopathy is a neuropsychiatric syndrome that occurs in the setting of hepatic disease. It is characterized by variable alterations in mental status,

ranging from deficits detectable only by detailed psychometric tests to confusion, lethargy, and ultimately frank coma. The disease may present in association with acute hepatic failure, as a consequence of progression of chronic liver disease, or after the creation of a surgical portosystemic shunt. Usually, a precipitating cause, such as an acute variceal hemorrhage or infection, can be found.

The causative agent in hepatic encephalopathy has been the subject of much debate. Most evidence implicates ammonia in the development of this condition. Ammonia is produced during the bacterial digestion of proteins in the gut, is absorbed into the portal circulation, and usually undergoes extensive degradation in the liver.[144] Most researchers believe that encephalopathy is caused by products, such as ammonia, derived from the gastrointestinal tract that are usually metabolized by the liver. These agents reach the peripheral circulation as a result of poor hepatic metabolism or through portosystemic shunts that may be physiologic or the result of surgical procedures. In patients with cirrhosis, in addition to the accumulation of ammonia in the blood, the permeability of the brain to ammonia appears to be increased.[145] Other suggested etiologic agents for hepatic encephalopathy include γ-aminobutyric acid (GABA), endogenous benzodiazepines,[146] branched-chain amino acids (BCAAs) (e.g., tryptophan),[147] neurotoxic short-chain fatty acids, mercaptans, phenols,[148] and endogenous opiates.[149]

The following observations suggest that ammonia is the key mediator in hepatic encephalopathy: (a) ammonia levels are increased in 80% to 90% of patients with the condition,[150] (b) factors that precipitate hepatic encephalopathy cause increases in ammonia levels, and (c) treatments that relieve hepatic encephalopathy lower ammonia levels.[151] Arguments against this hypothesis include the following: (a) levels of ammonia correlate poorly with the severity of hepatic encephalopathy, (b) high ammonia levels alone do not cause encephalopathy, (c) administration of ammonia to patients with cirrhosis but not hepatic encephalopathy does not cause encephalopathy, and (d) treatments that reduce ammonia levels also reduce the levels of other putative toxins.[151]

Clinical Features. A wide range of neurologic symptoms may occur in patients with hepatic dysfunction. Subtle deficits may include changes in personality, memory loss, alterations in sleep patterns, and minor decreases in intellectual function. Defects may be detectable only by detailed psychometric testing. If no known underlying liver disease is suspected, establishing the cause of an alteration in mental status may be difficult.

TREATMENT

Table 59-7 Treatment of Hepatic Encephalopathy

Identify precipitating factors
Disordered carbohydrate metabolism
Narcotics
Infection
Hypotension
Hypoxia
Excess exogenous protein
Gastrointestinal bleeding
Electrolyte abnormalities
Alkalosis
Supportive therapy
Eliminate dietary nitrogen
Purge gastrointestinal tract to remove blood and other nitrogenous compounds
Nonabsorbable antibiotics (neomycin or metronidazole)
Lactulose or lactitol
Dopamine receptor agonists
L-dopa and bromocriptine[a]
Branched-chain amino acid[b]
Temporary liver support
Orthotopic liver transplantation

[a]Arousal effect in selected patients may be secondary to enhanced renal function.
[b]High cost and equivocal benefits of intravenous amino acid mixtures make it difficult to justify routine use.

With progression of disease, asterixis, a rapid repetitive flexion–extension of the wrist that occurs in response to sustained extension of the forearm and fingers, may occur. In addition, stigmata of liver disease are usually evident, including fetor hepaticus and spider angiomas. The combination of asterixis, elevated ammonia levels, and altered mental status in a patient with known liver disease strongly suggests the diagnosis. Electroencephalographic changes are nonspecific and may occur in patients with a variety of other conditions.

Factors that commonly precipitate hepatic encephalopathy include impaired renal function, variceal hemorrhage, constipation, infection, excessive dietary protein, and drugs, especially benzodiazepines and barbiturates.

Treatment. Treatment options for hepatic encephalopathy include correction of the precipitating factors, alterations in diet, bowel cleansing, medications that reduce ammonia production and neutralize its effects, and medications to treat possible neurotransmitter and nutrient deficiencies.

A search for precipitating factors is imperative and includes cultures of urine, sputum, and ascitic fluid; determination of electrolyte abnormalities; screening for viral infection; assessment of overall volume status; drug history; and endoscopy (Table 59-7).

Therapy begins with a trial of volume expansion via intravenous hydration to relieve azotemia and reduce concentrations of toxic substances by dilution. The mainstays of treatment are directed at the removal of nitrogenous compounds from the gut. Most ammonia is produced within the small and large bowels by bacterial metabolism of dietary and endogenous protein. Orally administered cathartics and enemas are the best

methods to achieve bowel cleansing. While dietary restriction of protein intake was once a mainstay in the therapy of hepatic encephalopathy, the loss of skeletal muscle, which aids in breakdown of ammonia, is now recognized as an important contributor to hepatic encephalopathy. Current recommendations thus favor regular or increased protein diets along with medical therapy for hepatic encephalopathy. Since patients with cirrhosis often manifest a deficiency of BCAAs compare to aromatic amino acids (which worsen hepatic encephalopathy); supplementation with BCAAs has been shown to improve the rate of recovery from episodic hepatic encephalopathy.[152] L-carnitine supplementation has also been demonstrated to improve cognitive deficits and reduce ammonia levels.[153]

The cathartic of choice is lactulose, a nonabsorbable disaccharide that reaches the distal ileum and colon essentially unmetabolized. Many theories regarding the mechanism of action of lactulose have been proposed. Initially, the presumed mechanism of action was that on reaching the colon, lactulose is metabolized by colonic bacteria to acidic products that lower the pH of the colon. Lowering the pH inhibits the growth of ammonia- and urea-producing bacteria and promotes the growth of *Lactobacillus,* a bacterium with little proteolytic activity.[154] The validity of this theory has been questioned. It appears now that lactulose alters the metabolism of intestinal bacteria by providing carbohydrate, which enhances the bacterial uptake of ammonia.[155] Combined with the osmotic diarrhea caused by the cathartic activities of lactulose, this effect leads to an increased excretion of ammonia.

The dosage of lactulose, 45 to 90 g/d, is administered orally, divided into 3 or 4 doses. The dosage can be adjusted to produce two or three soft stools daily. Hourly doses of 30 to 45 mL can be used to induce more rapid improvement during the initial phase of therapy. Symptoms usually abate within 24 hours, but more than 48 hours may be required. Doses can be adjusted if side effects such as flatulence, diarrhea, and electrolyte abnormalities occur.

Nonabsorbable antibiotics have also been used to decrease the number and concentration of ammonia-forming bacteria in the gut. Most experience has accrued for neomycin and metronidazole. These antibiotics are active against gram-negative anaerobes such as *Bacteroides,* which are considered to be a major source of ammonia production.[156,157] The dosage of neomycin, 2 to 8 g/d, is divided into 4 doses and is continued for 4 to 10 days. Multiple double-blinded, randomized trials have determined the efficacy of antibiotics alone or in combination with lactulose. For acute hepatic encephalopathy, studies have shown that neomycin for 4 days is equally as effective as lactulose,[157] and metronidazole for 7 days is as effective as neomycin.[158] In addition, for chronic hepatic encephalopathy, neomycin for 10 days was equal to lactulose.[154]

Due to the risk of nephrotoxicity and irreversible ototoxicity, neomycin therapy has fallen out of favor.[159] Rifaximin, a minimally absorbed macrolide antibiotic, was approved by the FDA in 2013 for the maintenance therapy of hepatic encephalopathy and is now frequently used in an off-label fashion for acute episodes as well. In a recent randomized controlled trial, the addition of rifaximin to lactulose resulted in a higher proportion of patients experiencing complete reversal of hepatic encephalopathy (76% vs. 50.8%) and decreased mortality (23.1% vs. 49.1%) compared to lactulose and placebo.[160]

Thus, based on the most current evidence, the treatment of overt hepatic encephalopathy should consist of treatment of precipitating factors, followed by lactulose administration. Rifaximin should be added for patients without improvement in the first 24 hours. Following an episode of overt hepatic encephalopathy, maintenance therapy with lactulose and/or rifaximin should be administered indefinitely for secondary prophylaxis.[159]

PORTAL HYPERTENSION

8 Portal hypertension is defined as a portal vein pressure above the normal range of 5 to 8 mm Hg. Portal hypertension may also be defined by the hepatic vein–portal vein pressure gradient, which is greater than 5 mm Hg in portal hypertensive states.[161] Pressures in the portal venous system are usually measured indirectly via the wedged hepatic venous pressure utilizing a technique similar to that used to determine pulmonary capillary wedge pressure by pulmonary arterial (Swan–Ganz) catheterization.

Anatomy

The venous anatomy of the portal system is relatively constant, with the “usual” anatomy present in 98% of the population (Fig. 59-5). The portal vein is formed by the confluence of the superior mesenteric and splenic veins behind the neck of the pancreas. The inferior mesenteric vein most often joins the splenic vein before the portal vein is formed, but approximately one-third of the time the inferior mesenteric vein joins the superior mesenteric vein. The superior mesenteric vein may not be present, and the portal vein may be formed by multiple small branches from the mesenteric system that join the splenic vein.

Many branches of the portal venous system are affected when portal pressure rises. As pressure increases, blood flow decreases and the pressure in the portal system is transmitted to its branches. This transmission of pressure through branches of the portal system is beneficial in that it decreases overall portal pressure. It also is responsible for many of the complications of portal hypertension, however, because of the resulting dilation of venous tributaries.

The coronary or left gastric vein becomes highly significant in portal hypertension, by diverting portal blood to the veins of the lesser curve of the stomach and the esophagus, leading to the formation of varices. Other important collaterals include the inferior mesenteric vein, which connects with its rectal branches, which, when distended, form hemorrhoids; the umbilical vein in the ligamentum teres of the falciform ligament, which joins the left portal vein and causes abdominal wall veins around the paraumbilical plexus to dilate (caput medusae); the short gastric veins, branches of the splenic vein, which communicate with gastric veins and contribute to gastric varices; and the retroperitoneal veins of Retzius, which communicate with the gastrointestinal veins through the bare areas of the liver where no peritoneal layer separates the abdominal viscera from the retroperitoneum. The retroperitoneal collaterals can also form large splenorenal shunts that may decompress the portal system but are associated with severe encephalopathy.

Physiology

As in any vascular bed, portal hypertension is the product of blood flow and resistance. In nearly all cases, portal hypertension is caused by increased resistance to portal blood flow secondary to cirrhosis, portal vein thrombosis, or hepatic venous obstruction, though in rare instances, an arterioportal fistula may cause flow-related hypertension. Normally, the liver offers little resistance to portal flow because of the porous nature of the hepatic sinusoids and the capacity of the organ to expand. Moreover, the liver has limited control over portal blood flow; it is primarily a passive recipient of splanchnic flow, the primary regulation of which occurs at the level of the splanchnic arterioles.[162] As discussed earlier, the deposition of collagen in the space of Disse (capillarization), in addition to the contractile properties of stellate cells, causes an increased resistance to portal blood flow in cirrhosis. In addition, various cytokines and hormones contribute to elevated portal pressures by inducing splanchnic vasodilation and an increase in splanchnic flow.

The increased blood flow through collateral vessels and subsequently increased venous return cause the characteristic hemodynamic features of portal hypertension, which include an increase in cardiac output and total blood volume and a decrease in systemic vascular resistance.[163] Arteriovenous shunts within the liver, stomach, and small intestine contribute to the augmented venous return and decreased peripheral vascular resistance. Early in the course of portal hypertension, blood pressure may be normal, but with progression of disease, blood pressure usually falls.[164]

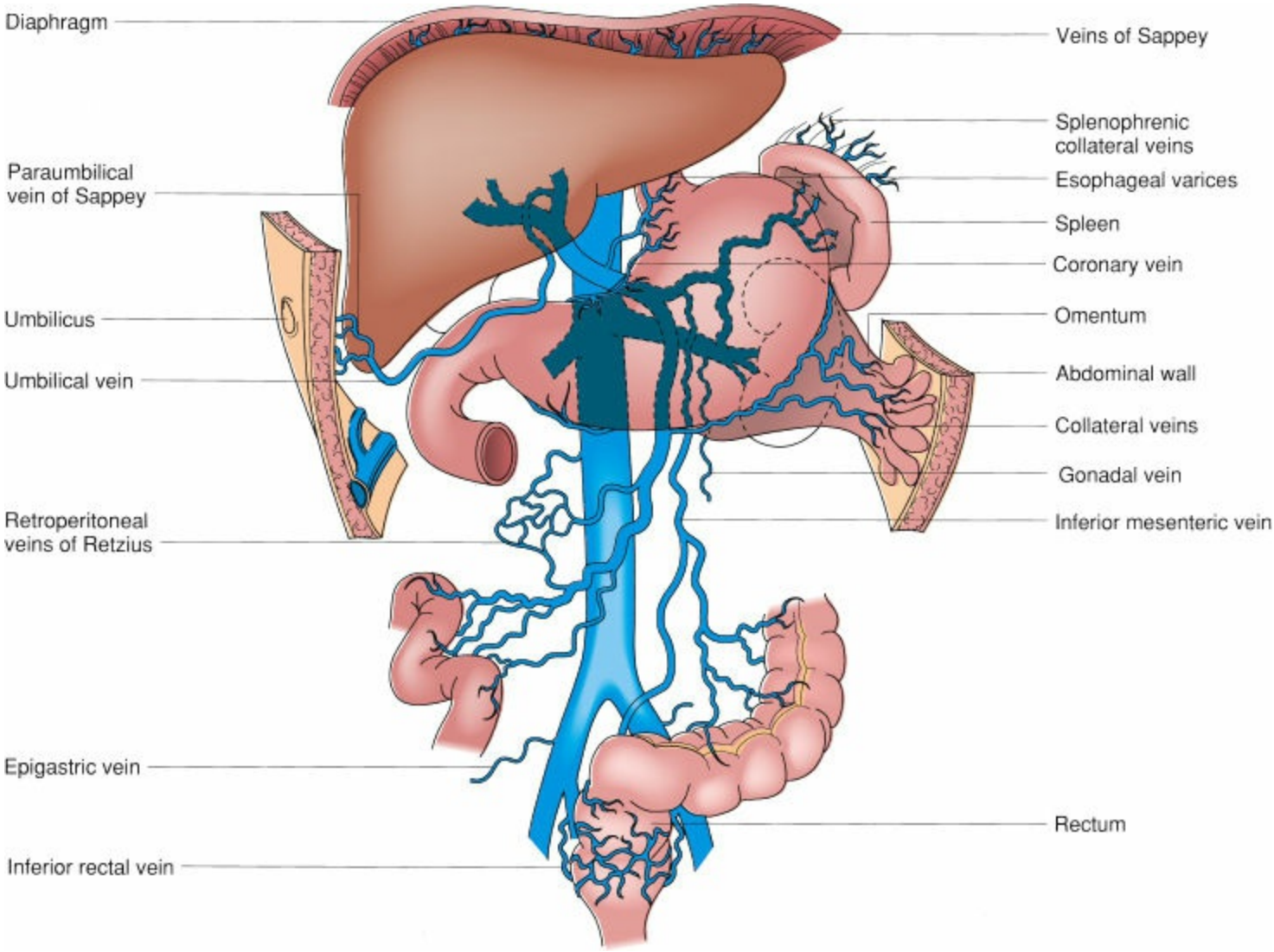

Figure 59-5. Potential venous collaterals that develop with portal hypertension. The veins of Sappey drain portal blood through the bare areas of the diaphragm and through paraumbilical vein collaterals to the umbilicus. The veins of Retzius form in the retroperitoneum and shunt portal blood from the bowel and other organs to the vena cava.

The portal venous concentration of nitric oxide, a potent vasodilator, has been shown to be elevated in patients with cirrhosis and portal hypertension.[165] In addition to nitric oxide, many other vasodilators are elevated in portal hypertension, including prostacyclin, endotoxin, and glucagon.[166]

Etiology

Many pathologic processes can cause portal hypertension (Table 59-8). These are usually classified as prehepatic, hepatic, or posthepatic (presinusoidal, sinusoidal, or postsinusoidal) conditions. As noted above, in prehepatic and posthepatic conditions, portal hypertension is the result of mechanical venous obstruction at the level of the portal or hepatic veins, respectively, whereas cirrhosis is the main cause of hepatic portal hypertension.

Budd–Chiari Syndrome and Veno-occlusive Disease

The BCS is caused by hepatic venous obstruction. The name of the syndrome is derived from two investigators, the first of whom (Budd)[167] described the classic presentation of abdominal pain, ascites, and hepatomegaly, and the second of whom (Chiari)[168] described the pathologic characteristics of the liver. The obstruction may occur at the level of the inferior vena cava, the hepatic veins, or the central veins within the liver itself and may be the result of congenital webs (most common in Africa and Asia), acute or chronic thrombosis (most common in the West), and malignancy. With occlusion of the hepatic veins, pressure increases in the central veins. As a result, centrilobular congestion, necrosis, and, with chronic disease, fibrosis and cirrhosis with portal hypertension develop.

In the West, the most common causes of this syndrome are hypercoagulable states associated with polycythemia vera, myeloproliferative disorders, paroxysmal nocturnal hemoglobinuria, and defects in the coagulation cascade, as in conditions associated with high estrogen levels (e.g., pregnancy, use of birth control pills).[169,170] Neoplasms may cause hepatic venous obstruction by direct invasion and occlusion of the vessels, or by establishment of a prothrombotic milieu secondary to the malignancy itself. In the East, the major causes of obstruction of the vena cava and hepatic veins are membranous webs that directly occlude the vessels. The etiology of vena cava webs is unknown. Veno-occlusive disease is characterized by obliterative endophlebitis of the intrahepatic veins (Table 59-3). Causes of veno-occlusive disease include medications, toxins, and pyrrolizidine alkaloids.

BCS may present with acute, subacute, or chronic symptoms and is often misdiagnosed. This is unfortunate, because early treatment will prevent the development of hepatic fibrosis, which can lead to end-stage liver disease. Nearly 50% of patients have had symptoms for more than 3 months.[171] Acute symptoms include hepatomegaly, right upper quadrant abdominal pain, nausea, vomiting, and ascites. In the chronic form of the disease, patients may present with the sequelae of cirrhosis and portal hypertension, including variceal bleeding, ascites, spontaneous bacterial peritonitis, fatigue, and encephalopathy. In the chronic form, the entire liver atrophies except for the caudate lobe, which may hypertrophy because its hepatic vein(s) enters the vena cava separately, so that venous outflow is not impeded.[100] The hypertrophy of the caudate lobe creates a longitudinal narrowing of the retrohepatic vena cava, which is surrounded by parenchyma, leading to secondary obstruction of the caval flow in the abdomen.

Table 59-8 Common Causes of Portal Hypertension

Disorders That Primarily Increase Resistance to Flow
Prehepatic
Congenital atresia
Extrinsic compression
Schistosomiasis
Portal, superior mesenteric, or splenic vein thrombosis
Hepatic
CHRONIC–CIRRHOTIC
Hepatitis B, C
α_1-Antitrypsin deficiency
Cryptogenic
Cystic fibrosis
Hemochromatosis
Nutritional (alcoholic)
Wilson disease
CHRONIC–NONCIRRHOTIC
Congenital hepatic fibrosis
Focal regenerative hyperplasia
Hepatic veno-occlusive disease
Idiopathic
Metastatic carcinoma
Sarcoidosis
Toxin and drug injuries
ACUTE DISEASE
Acute fatty liver
Alcoholic hepatitis
Fulminant hepatic failure
Posthepatic
Budd–Chiari syndrome
Chronic heart failure
Constrictive pericarditis
Vena cava webs
Disorders That Primarily Increase Flow
Hepatocellular carcinoma
Mesenteric arteriosclerotic or aneurysmal vascular disease
Osler–Weber–Rendu syndrome
Splenomegaly

Although the diagnosis can be made by ultrasonographic evaluation of the liver and its vasculature with a sensitivity of 85% to 95%,[169] cross-sectional imaging is essential for staging and planning therapy. Duplex scanning may reveal the location of the obstruction and characterize the flow within the vena cava and hepatic, portal, mesenteric, and splenic veins. Other common ultrasonographic findings consistent with BCS include lack of visualization of the hepatic veins, an enlarged caudate lobe with compressed inferior vena cava, enlarged intrahepatic collaterals, splenomegaly, and ascites.[101]. Thrombus within the hepatic veins or inferior vena cava may be directly visualized using contrast-enhanced magnetic resonance angiography (MRA).[172]

Because the vascular obstruction is usually well established at the time of presentation,

anticoagulation alone is rarely sufficient therapy for BCS. Although major open surgery has been favored in the past, including mesoatrial shunting,[173,174] and even liver transplantation,[175] minimally invasive approaches are now preferred.[176] The mainstay of therapy is mechanical decompression with a side-to-side portosystemic shunt, optimally achieved with a percutaneous portacaval shunt (see below). After shunt placement, the pressure on the vena cava by the caudate lobe is gradually relieved, leading to restoration of liver function.

A more direct solution, which is necessary in the face of complete caval obstruction, is the creation of a mesoatrial shunt, which was described by Cameron and Maddrey.[173] This radical procedure has been largely supplanted by percutaneous portacaval shunting (TIPS). The rates of postprocedural encephalopathy are usually not increased in patients with BCS, because they have anatomically healthy livers that recover fully if decompression is achieved early prior to the establishment of cirrhosis. In patients with end-stage liver disease, liver transplantation may be performed.[175] The 5-year survival rate for patients with good hepatic function before the shunt procedure is approximately 60%, with a 34% to 88% survival for patients after liver transplantation.[177] Postoperatively, patients are treated with long-term anticoagulation to prevent recurrent thrombosis.

As noted, minimally invasive treatment using TIPS may be first-line therapy, and it has supplanted surgical shunting in our practice.[178,179] Case reports and small series have suggested efficacy for this technique,[180] and a recent larger study has indicated 1- and 5-year survival rates of 93% and 74%, respectively.[181] Many patients develop shunt occlusion; however, further angiographic manipulation and long-term anticoagulation are required to maintain patency.

Portal Vein Thrombosis

Portal vein thrombosis is commonly associated with advanced cirrhosis, and may be the ominous portent of a HCC. Spontaneous portal vein thrombosis in the absence of cirrhosis is the cause of portal hypertension in fewer than 10% of adult patients but is the most common cause in children.[182,183] In contrast to patients with cirrhosis-induced portal hypertension, these patients have normal liver function and are not as susceptible to the development of complications such as encephalopathy. Causes of portal vein thrombosis include umbilical vein infection (the most common cause in children), coagulopathies (protein C and antithrombin III deficiency), hepatic malignancy, myeloproliferative disorders, inflammatory bowel disease, pancreatitis, trauma, and previous splenorenal shunt.[184] Most cases in adults are idiopathic.

The diagnosis can be made by sonography, which reveals an echogenic lesion in the lumen of the portal vein and an absence of portal venous flow on duplex examination.[185] With time, cavernous transformation of the portal vein may occur, in which channels develop within the clotted portal vein.[182] CT and MRI are also useful in establishing the diagnosis. Often, the initial manifestation of portal vein thrombosis is variceal bleeding in a noncirrhotic patient with normal liver function. Splenomegaly is another common finding.

The initial therapeutic option for the control of hemorrhage caused by portal vein thrombosis is esophageal variceal ligation. If unsuccessful, the distal splenorenal shunt has been the traditional surgical treatment for patients with isolated portal vein thrombosis. In patients whose intrahepatic portal vein is patent (most commonly children), however, a shunt created by placing an internal jugular vein graft between the superior mesenteric vein and the patent left portal vein within the parenchyma of the liver (Rex shunt) may be the optimal therapeutic procedure for reestablishing physiologic portal flow.[186] This is the most elegant solution for portal obstruction because the portal pressure is reduced by restoring blood flow to the liver, preventing chronic hepatic atrophy and dysfunction, which can occur in a patient with long-standing portal decompression. In fact, in our practice, the Rex shunt is the first-line treatment and we reserve splenorenal shunting for patients who have no remnant intrahepatic portal system to receive the shunted blood.

CLASSIFICATION

Table 59-9 Child–Turcotte Criteria for Hepatic Functional Reserve

Criterion	Class A	Class B	Class C
Encephalopathy	None	Minimal	Advanced
Ascites	None	Easily controlled	Poorly controlled
Bilirubin (mg/dL)	<2	2–3	>3
Albumin (g/gL)	>3.5	3–3.5	<3
Nutrition	Excellent	Good	Poor, "wasting"
Child–Turcotte–Pugh Grading of Severity of Liver Disease			
Score	**1**	**2**	**3**
Encephalopathy	None	1 or 2	3 or 4
Ascites	None	Mild	Moderate
Bilirubin (mg/dL)	1–2	2.1–3	≥3.1
Albumin (g/dL)	≥3.5	2.8–3.5	≤2.7
Prothrombin time (s)	1–4	4.1–6	≥6.1
or INR	<1.7	1.7–2.3	>2.3
Grade A, 5–6; grade B, 7–9; grade C, 10–15			

INR, international normalized ratio.
Adapted from Pugh RN, Murray-Lyon IM, Dawson JL, et al. Transection of the oesophagus for bleeding oesophageal varices. *Br J Surg* 1973;60(8):646–649, with permission.

Splenic Vein Thrombosis

Splenic vein thrombosis is most often caused by disorders of the pancreas, including acute and chronic pancreatitis, trauma, pancreatic malignancy, and pseudocysts. This association is related to the location of the splenic vein behind and close to the pancreas. Other causes include retroperitoneal masses, abscesses, and inflammatory bowel disease; the remaining cases are idiopathic. Gastric varices are present in approximately 80% of patients, and esophageal varices in 30% to 40%.[187] Isolated "sinistral" or left-sided portal hypertension occurs in the setting of normal liver function, and patients are readily cured

with splenectomy, although observation for asymptomatic patients is acceptable. The main indication for splenectomy is variceal hemorrhage.

Complications of Portal Hypertension

9 The most important complications of portal hypertension are gastrointestinal bleeding secondary to esophageal and gastric varices, ascites, and hepatic encephalopathy. The mortality risk associated with portal hypertension is primarily related to the functional status of the cirrhotic liver. Child introduced a scoring system of liver function for the purposes of assessing prognosis after portosystemic shunt surgery in patients with cirrhosis, which has been subsequently modified several times to the *Child–Turcotte–Pugh (CTP) score* (Table 59-9). These indices incorporate clinical and laboratory data as a means to assess the functional status of the liver, estimate hepatic reserve, and predict morbidity and mortality. They had been adopted by the United Network for Organ Sharing (UNOS) as a tool for stratifying pretransplant mortality risk for patients on the waiting list for liver transplantation.[188] Over the last decade, the use of these criteria in transplant has been replaced by the model for end-stage liver disease (MELD) score, which uses serum bilirubin, creatinine, and the international normalized ratio (INR) to produce a surprisingly robust prediction of 90-day mortality for patients with cirrhosis on the transplant list.[189] Though the CTP score produces a more complete assessment of the patient, its use of subjective clinical elements in the score made it unreliable as a verifiable element in assessment compliance with center behavior in national organ transplant policy.[190,191]

While the MELD score was initially developed for the prognosis of patients after TIPS, the CTP score has had long-standing use as a reliable predictor of mortality risk for shunt surgery and, by extension, mortality risk of patients with cirrhosis undergoing other types of abdominal surgery.[192,193] Patients with normal function, termed “Child A,” have adequate hepatic reserve and survival rates similar to those of noncirrhotic patients, whereas Child C patients have mortality rates in excess of 50% and may not tolerate any intervention short of hepatic transplantation.

Varices

One of the most life-threatening complications of portal hypertension is bleeding from esophageal varices. Esophageal varices are dilated veins found most commonly in the distal 5 cm of the esophagus. In the normal esophagus, a venous plexus is located in the submucosa; it becomes more superficially located to the lamina propria in the distal esophagus.[194–196] This more superficial location in the distal esophagus is consistent with the known increased occurrence of bleeding varices in that location. In addition, 5% to 33% of patients with portal hypertension have gastric varices.[197]

The pressure in the portal system is an important determinant of the likelihood for varices to develop. As noted earlier, portal pressure may be estimated from the hepatic vein wedge pressure, and the gradient between the wedge pressure and the free hepatic vein pressure is an indirect measure of the resistance across the liver. In general, varices do not develop in persons with hepatic vein–portal vein gradients below 12 mm Hg. Pressure gradients above 12 mm Hg are invariably present in patients with varices, but this pressure does not necessarily produce varices in all patients. Other, undetermined

factors must play a role. Gastroesophageal varices are present in 40% of patients with Child A cirrhosis, and in up to 85% of patients with Child C cirrhosis.[198] Varices may also be present in chronic liver disease without outright cirrhosis. For example, 16% of patients with chronic hepatitis C and bridging fibrosis have varices.[199]

In approximately 10% of all patients presenting with acute upper gastrointestinal bleeding, esophageal varices are the cause of bleeding. Rates of bleeding from varices vary among studies. In a study of the natural history of varices in which patients were prospectively followed for 6 years, esophageal varices developed in approximately 8% of patients with cirrhosis each year during the first 2 years of observation; the percentage increased to 30% by 6 years. Of the patients who had small varices detected at initial endoscopy, large varices developed in 25%.[200] Other studies show an incidence of varices of up to 90% for patients with cirrhosis.[201,202] Once varices are present, bleeding occurs in 25% to 35% of cases, with the highest risk occurring within the first year after diagnosis.[202,203] Patients with large varices are at the highest risk for an initial bleed. Spontaneous bleeding from varices ceases spontaneously in up to 40% of patients, although mortality and recurrent bleeding remain high.[198] Of patients who survive an episode of bleeding, 30% experience rebleeding within 6 weeks, and 70% at 1 year.[203,204] The correlation between severity of varices and derangement of hepatic function is inconstant, so mortality rates from bleeding varices range from 5% to 50%, with rates of 5%, less than 25%, and more than 50% for Child A, B, and C patients, respectively.[204]

The propensity for varices to bleed has been extensively studied. When combined with clinical data such as the presence of active alcohol consumption, certain endoscopic characteristics of varices have been correlated with initial episodes of bleeding (Table 59-10). These factors include variceal size, Child–Pugh class, and the presence of red wale markings (longitudinal dilated venules that resemble whip marks).[202] Direct and indirect measurements of portal pressure have been used to predict the likelihood of bleeding, with hemorrhage occurring only in patients with portal–hepatic venous gradients above 12 mm Hg.[205,206]

Table 59-10 Endoscopic Signs That Correlate with Risk for Variceal Rupture

Basic Color
White varices
Blue varices
Signs
Red color sign
Red wale marking
Cherry-red spot
Hematocystic spot
Diffuse redness
Form
Linear
Tortuous
Large

Adapted from Japanese Research Society for Portal Hypertension.

Table 59-11 Prevention/Treatment Options for Variceal Bleeding

Drug	Dose
Propranolol	10–20 mg bid titrated weekly to maximum of 160 mg bid
Nadolol	20 mg orally qd, titrated to reduction of HR by 20–25%, absolute HR of 55–60, symptoms
Isosorbide-5-mononitrate	20 mg orally tid
Vasopressin with nitroglycerin	0.4 U/min to maximum of 1.0 U/min, titrated to maintain SBP at approximately 100 mm Hg
Octreotide	50-mg bolus, followed by 50 mg/h for 5 d or until definitive treatment

HR, heart rate; SBP, systolic blood pressure.
Adapted from Rikkers LF. Variceal hemorrhage: surgical therapy. *Gastroenterol Clin North Am* 1993;22(4):821–842.

Diagnosis of Varices and Prevention of Initial Variceal Bleeding. Because of the severe consequences of variceal bleeding, methods to diagnose varices prior to bleeding and to prevent first (primary prophylaxis) and recurrent (secondary prophylaxis) episodes of bleeding have been developed. Esophagogastroduodenoscopy (EGD) is the gold standard for the diagnosis of gastroesophageal varices, and should be performed in all patients upon the initial diagnosis of cirrhosis. If no varices are present upon initial screening, an EGD should be repeated in 2 to 3 years for patients with compensated cirrhosis. If small (<5 mm) varices are present, EGD should be repeated in 1 to 2 years. Patients with decompensated cirrhosis should undergo yearly screening EGD based on current recommendations from the AASLD.[198] After varices are diagnosed, methods of primary and secondary bleeding prophylaxis include control of the underlying cause of cirrhosis (i.e., alcohol consumption) and pharmacologic and surgical interventions to lower portal pressure. The next section discusses methods of primary prophylaxis to prevent initial episodes of bleeding (Table 59-11).

Beta Blockade. The use of nonspecific β-adrenergic blockade has been studied extensively in randomized controlled trials of the primary prophylaxis of variceal bleeding. The mechanism of action of these drugs (propranolol, nadolol) involves effects of both β_1-adrenergic and β_2-adrenergic blockades, including decreased cardiac output and increased splanchnic arteriolar vasoconstriction as a result of the loss of opposing β_2-adrenergic dilation.[206,207] The combined effects decrease portal blood flow and subsequently portal pressure.

These drugs are effective in portal hypertension associated with prehepatic, intrahepatic, and posthepatic conditions,[208] regardless of whether ascites is present.[209] Not all patients respond to therapy, however. Two meta-analyses have evaluated seven randomized controlled trials comparing propranolol or nadolol with placebo in the prevention of initial variceal bleeding. Both analyses concluded that beta blockade is significantly correlated with a reduced incidence of bleeding.[210,211] A reduction of 40% was noted overall after all trial results were combined, with bleeding developing in approximately 16% of treated and 27% of untreated patients. The goal of therapy is to reduce the hepatic vein–portal vein gradient to below 12 mm Hg or to more than 20% below baseline.[212] Patients who meet these goals not only have a lower risk of variceal bleeding, but also of developing ascites, spontaneous bacterial peritonitis, and death.[213] In addition to reducing the number of first episodes of bleeding, beta blockade therapy has been shown to reduce mortality in most clinical trials.[214] A meta-analysis of these studies concluded that mortality from bleeding is reduced in patients with large varices.

Despite their known benefits, beta blockers are also associated with significant side effects that limit their universal application in patients with cirrhosis. There is no role for beta blockade to prevent formation of varices in patients who do not already have them, based on a large randomized study by Groszmann et al.[215] In this study, serious adverse events were significantly more common in patients undergoing timolol therapy compared to placebo. For patients with small (<5 mm) varices without high-risk features (decompensated cirrhosis, red wale markings), current guidelines from the AASLD state that beta blockers may be used, although convincing evidence of substantial benefits in this setting is lacking.[198]

Surgical Intervention. In the 1950s and 1960s, surgeons created prophylactic portosystemic shunts in an attempt to prevent variceal bleeding. These procedures were studied in a randomized controlled fashion and, although effective in preventing variceal bleeding, they caused an increased incidence of hepatic failure and encephalopathy and had no effect on overall survival.[216,217] These results provided clinical support for the notion that portal diversion accelerated the decline of liver function in patients with cirrhosis and they are no longer performed for this indication.

Endoscopic Sclerotherapy and Variceal Ligation. In the past, prophylactic sclerotherapy to prevent variceal bleeding was an accepted practice but technical challenges and esophageal and pulmonary complications have led to abandonment of endoscopic sclerotherapy (ES) for the primary prevention of variceal bleeding. Initial

investigations of the effectiveness of endoscopic variceal ligation (EVL) as a method of primary prophylaxis to prevent initial bleeding in high-risk patients with esophageal varices reported mixed results.[218,219] In one study, no statistically significant differences in the incidence of initial bleeding and mortality were found in a comparison of patients after variceal ligation with controls,[220] though subgroup analysis revealed a significant decrease in the incidence of initial bleeding for Child–Pugh class B patients.[219] Furthermore, there seems to be a significant prognostic divergence related to variceal size. As data have accumulated, consensus recommendations regarding prophylaxis have emerged as presented in recent practice guidelines from the AASLD. Briefly summarized, patients with cirrhosis with small, low-risk varices should be managed with beta-blocker prophylaxis. In those with medium or large varices with high-risk features (Child B or C, red wale markings), either EVL or beta blockade is acceptable primary prophylaxis. In the absence of the above high-risk features, beta blockade is preferred, with EVL reserved for those patients who have contraindications to, or are intolerant of beta blockers.[198]

Treatment of Esophageal Variceal Bleeding

Initial Management. Initial management of the patient with acute variceal bleeding includes the following: (a) establishment and maintenance of an airway; (b) hemodynamic monitoring; (c) placement of large-bore intravenous lines; (d) full laboratory investigation, including measurement of hemoglobin and hematocrit, coagulation profile, liver function tests, measurement of electrolytes, and assessment of renal function; (e) administration of blood products as needed, including packed red cells, platelets, and fresh frozen plasma; and (f) intensive care unit monitoring. Hemoglobin concentration should be maintained around 8 g/dL.[221,222] Transfusion to higher hemoglobin concentrations has been associated with higher portal pressure and worse outcomes. Furthermore, as gastrointestinal bleeding is associated with a high risk of subsequent spontaneous bacterial peritonitis in patients with cirrhosis, a 7-day course of antibiotics (typically a quinolone such as norfloxacin or ciprofloxacin) is also recommended as standard therapy for acute variceal bleeding.[223]

Pharmacologic Therapy. The administration of vasoactive medications can be commenced almost immediately after patient presentation if the history and physical findings suggest variceal bleeding. This practice decreases the rate of bleeding and enhances the endoscopic ability to visualize the site(s) of bleeding.

Vasopressin (antidiuretic hormone) has potent splanchnic vasoconstrictive properties that decrease portal venous and collateral flow and reduce portal pressure. In randomized prospective trials, as well as in a meta-analysis, continuous intravenous administration of vasopressin has proved to reduce variceal bleeding, an observation initially made in 1962.[224–226] When vasopressin was compared with placebo, bleeding stopped in an average of 52% of patients who received vasopressin and 18% of patients who received placebo. Rates of rebleeding as high as 45% were noted, however. Because of coronary vasoconstrictive effects, vasopressin is often used in combination with a vasodilator, such as nitroglycerin. The combination provides protection from adverse cardiac events and

increases the effectiveness of vasopressin by decreasing intrahepatic and collateral resistance.[227] A meta-analysis of three randomized controlled trials confirmed the increased effectiveness of vasopressin and nitroglycerin in comparison with vasopressin alone.[228]

Somatostatin and octreotide, its longer-acting eight-amino acid derivative, have been used extensively for the treatment of variceal bleeding. These agents decrease splanchnic blood flow indirectly by reducing the levels of other factors, such as glucagon, vasoactive intestinal peptide, and substance P, rather than by direct vasoconstriction.[229] The effects of somatostatin are limited to the splanchnic circulation, so that side effects are minimized.[230] A somatostatin and octreotide combination has proved to be as effective as vasopressin, sclerotherapy, and balloon tamponade in multiple studies.[231–233] Because of the lack of complications related to somatostatin therapy, octreotide is the initial drug of choice for the treatment of acute variceal hemorrhage. Dosing typically consists of a bolus of 50 μg followed by an infusion of 50 μg/hr, to be initiated as soon as variceal bleeding is suspected and continued for 3 to 5 days after the diagnosis has been verified.[198]

Endoscopic Interventions. Esophageal variceal ligation has become the principal approach to the initial control and ongoing treatment of variceal bleeding; it is performed at the bedside in acute bleeding and has replaced variceal sclerosis.

The technique of ligation (Fig. 59-6) includes placing an endoscope over a sheath (which allows multiple insertions and removal of the endoscope), suctioning of a varix into the lumen of a plastic channel, and then placing a rubber band around the tissue. The procedure is similar to the ligation of hemorrhoids. The tissue then sloughs in 1 to 3 days, leaving a shallow ulcer. Up to six bands can be placed at each session. Newer endoscopes allow for the placement of multiple bands without removal of the endoscope.

Success rates for variceal ligation range from 80% to 100%, in comparison with 77% to 94% for sclerotherapy, in controlled trials.[234] In patients with profuse bleeding, however, the type of endoscope used for variceal ligation may make visualization of the bleeding varices difficult leading some investigators to choose sclerotherapy in these patients, and use variceal ligation once bleeding is somewhat controlled.

Balloon Tamponade. The vast majority of patients (75% to 90%) with bleeding esophageal varices respond to endoscopic or pharmacologic therapy. For patients who fail these interventions, balloon tamponade (Fig. 59-7) is an alternative therapy with a high success rate in controlling bleeding. It entails the placement of a specialized nasogastric tube with two balloons that can be inflated separately and to different pressures to apply direct compression to the gastroesophageal junction and the esophagus. Once the mainstay in the initial management of variceal bleeding, use of these tubes is becoming a lost art, most suitable for initial stabilization of patients in a facility with limited availability of endoscopic or radiologic support. Because these tubes are difficult to use, and may cause fatal complications with esophageal injury, it remains important for surgeons and gastroenterologists with responsibility for managing gastrointestinal

bleeding to understand principles for safe use. The most commonly used tubes are the Sengstaken–Blakemore tube and the Minnesota tube. The former consists of a gastric balloon and an esophageal balloon with a sump port for gastric suctioning. The latter tube has an additional port above the esophageal balloon for the aspiration of saliva and other material from the esophagus and pharynx.

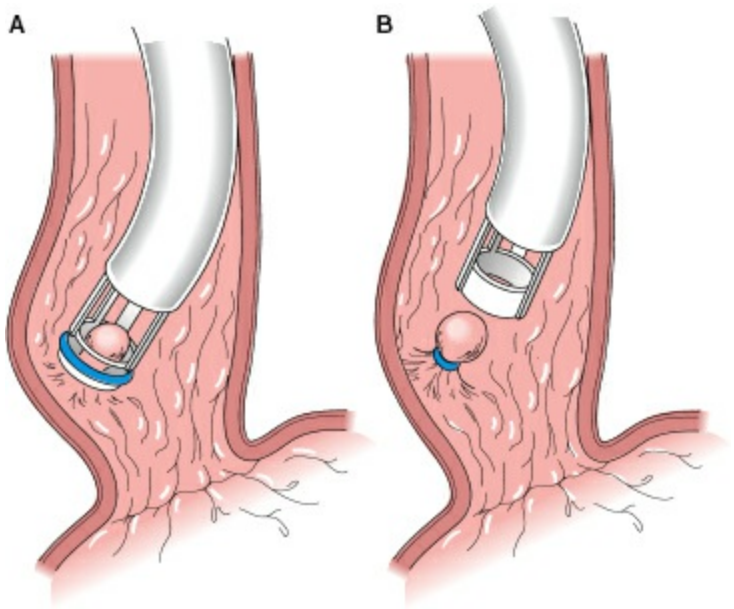

Figure 59-6. Endoscopic ligation of esophageal varices. The device used for ligation is based on the standard Barron-type ligator for the treatment of anal hemorrhoids. The esophageal varix is drawn up into the ligating device with suction (**A**), and the base of the varix is ligated with an O-ring (**B**). Up to six varices can be treated at a single session.

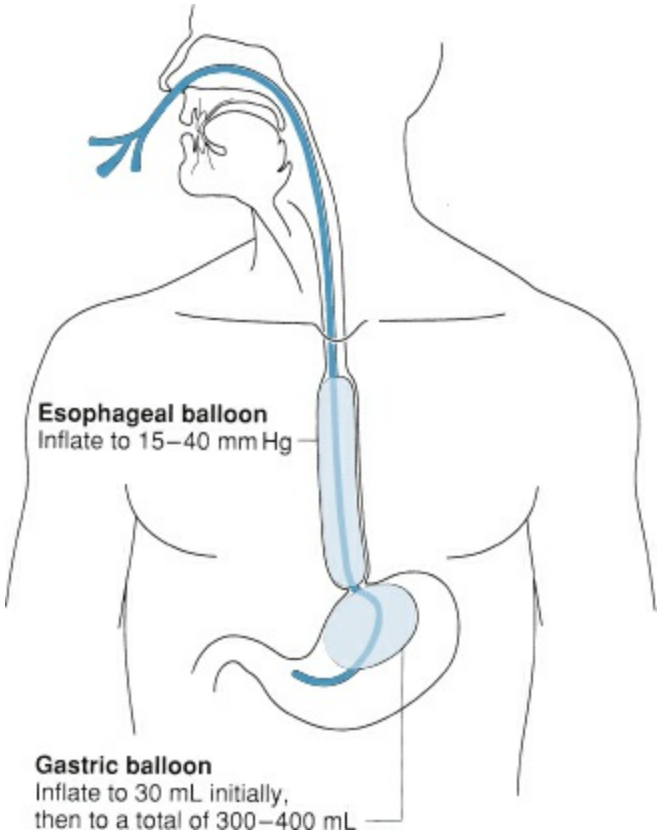

Figure 59-7. The Sengstaken–Blakemore tube is used to tamponade acutely bleeding gastroesophageal varices. The tube has three lumina—one to aspirate the stomach, another to inflate the gastric balloon, and a third to inflate the esophageal balloon. Patients treated with balloon tamponade should be in an intensive care unit, and endotracheal tubes should be placed in almost all to prevent aspiration.

Placement of these tubes begins with the establishment of a safe airway by endotracheal intubation. The tube is then passed through the nose and into the stomach. Radiographic confirmation that the tip of the tube is in the stomach is required before balloon inflation to prevent inadvertent intraesophageal inflation of the gastric balloon and resultant perforation. The gastric balloon is inflated with 200 mL of air and firmly pulled backward against the gastroesophageal junction to tamponade any proximal gastric bleeding. The esophageal balloon is then inflated to a pressure of 30 to 40 mm Hg, and the tube is secured to the patient by means of a facemask or helmet to ensure adequate stability of the tube and prevent inadvertent removal.

Because of the possible complications of balloon tamponade (e.g., aspiration, esophageal and gastric perforations, necrosis), which occur in 10% to 20% of patients, its use is restricted to approximately 24 hours. Success rates for cessation of bleeding are 70% to 80%, but more than half of all patients rebleed when the balloons are deflated. Although this method is highly effective in the initial control of bleeding, with an efficacy similar to that of pharmacologic agents, because of its transient effects it can be used only as a temporizing measure in anticipation of a more definitive procedure (e.g., TIPS, placement of a surgical shunt, or transplantation) and is used only after endoscopic and pharmacologic therapies have failed.

Transjugular Intrahepatic Portosystemic Shunt. In the 10% to 20% of patients who

continue to bleed or who have early rebleeding, a shunt procedure (to bypass the high-pressure hepatic vascular bed) may be indicated (Algorithm 59-1). The mortality rate associated with failure to control bleeding can be as high as 90%, and surgically created shunts in this setting are associated with a high morbidity and mortality rate.

10 The TIPS (Fig. 59-8) has become first-line treatment for bleeding esophageal varices when the aforementioned attempts fail.[235] Absolute contraindications to TIPS include congestive heart failure, uncontrolled sepsis, multiple hepatic cysts, severe pulmonary hypertension, and uncontrolled biliary obstruction. Relative contraindications include HCC, hepatic vein obstruction, severe coagulopathy or thrombocytopenia, and moderate pulmonary hypertension.[236] After ultrasonographic confirmation of patency of the portal vein, the procedure is performed in the interventional radiology suite, where a wire-guided stent (8 to 12 mm in diameter) is placed percutaneously into the jugular vein. The wire is then guided through the superior vena cava, right atrium, and inferior vena cava into a hepatic vein, after which the catheter traverses the hepatic parenchyma and joins the hepatic vein to a portal vein. This connection effectively creates a side-to-side portacaval shunt. Success rates in the cessation of variceal bleeding are as high as 90% to 100%, with an incidence of recurrent bleeding of approximately 10%.[237,238]

As discussed earlier, the ideal portosystemic shunt lowers the pressure in the portal system without critically reducing liver perfusion, which may cause hepatic dysfunction and may accelerate the progression of cirrhosis. It is possible to readily measure the portal pressure during TIPS, and many authors have proposed these measurements as a guide to optimal management of the TIPS to balance control of bleeding with hepatic perfusion. To control bleeding, the therapeutic goal is to reduce the hepatic–portal venous pressure gradient to below 12 mm Hg. TIPS reduces the portosystemic pressure gradient to a mean of approximately 9 to 15 mm Hg (average, 10 mm Hg) or to 40% to 62% below baseline.[239–241] A residual portal gradient less than 5 mm Hg has been associated with a deleterious impact on hepatic flow.[242] Earlier studies documented high mortality (40% to 60% at 6 to 7 weeks) despite the relative noninvasiveness of the procedure, reflecting the gravity of the clinical condition of most patients requiring this intervention. One potential cause of the high mortality is a delay in instituting TIPS until multiple unsuccessful attempts at sclerotherapy or banding have been made. Since well-validated instruments predict the survival of patients after TIPS, the procedure should be used with caution in patients with high MELD scores, though TIPS has been used successfully to bridge patients to transplantation.[243,244] The use of TIPS in massive variceal bleeding in a patient with a high MELD score who has contraindications to liver transplant should be regarded as a palliative intervention.

Algorithm 59-1

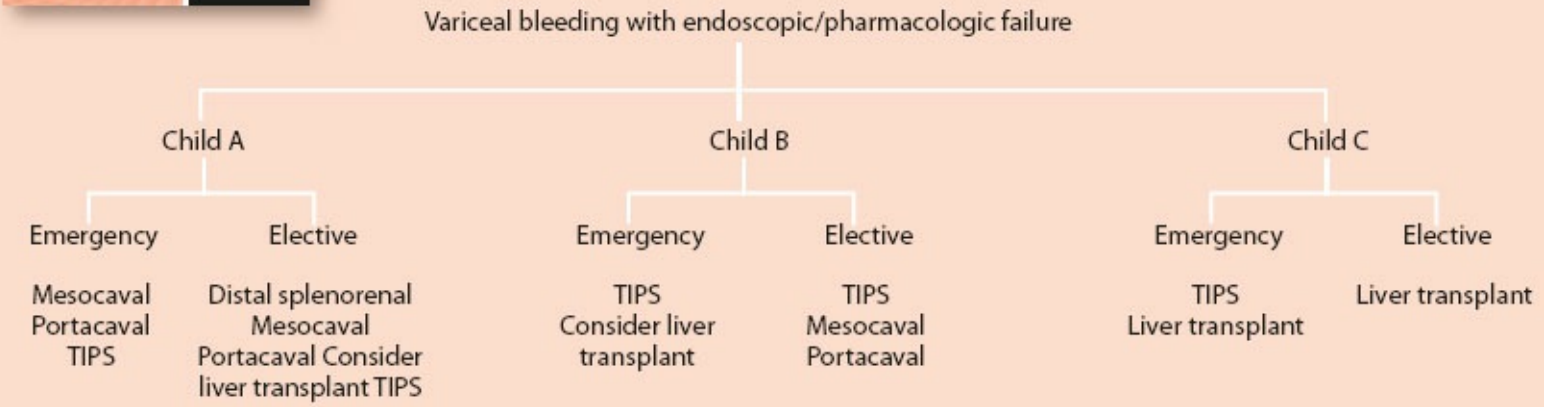

Algorithm 59-1. Suggested treatment options, in order of preference, for patients who fail medical management for variceal bleeding.

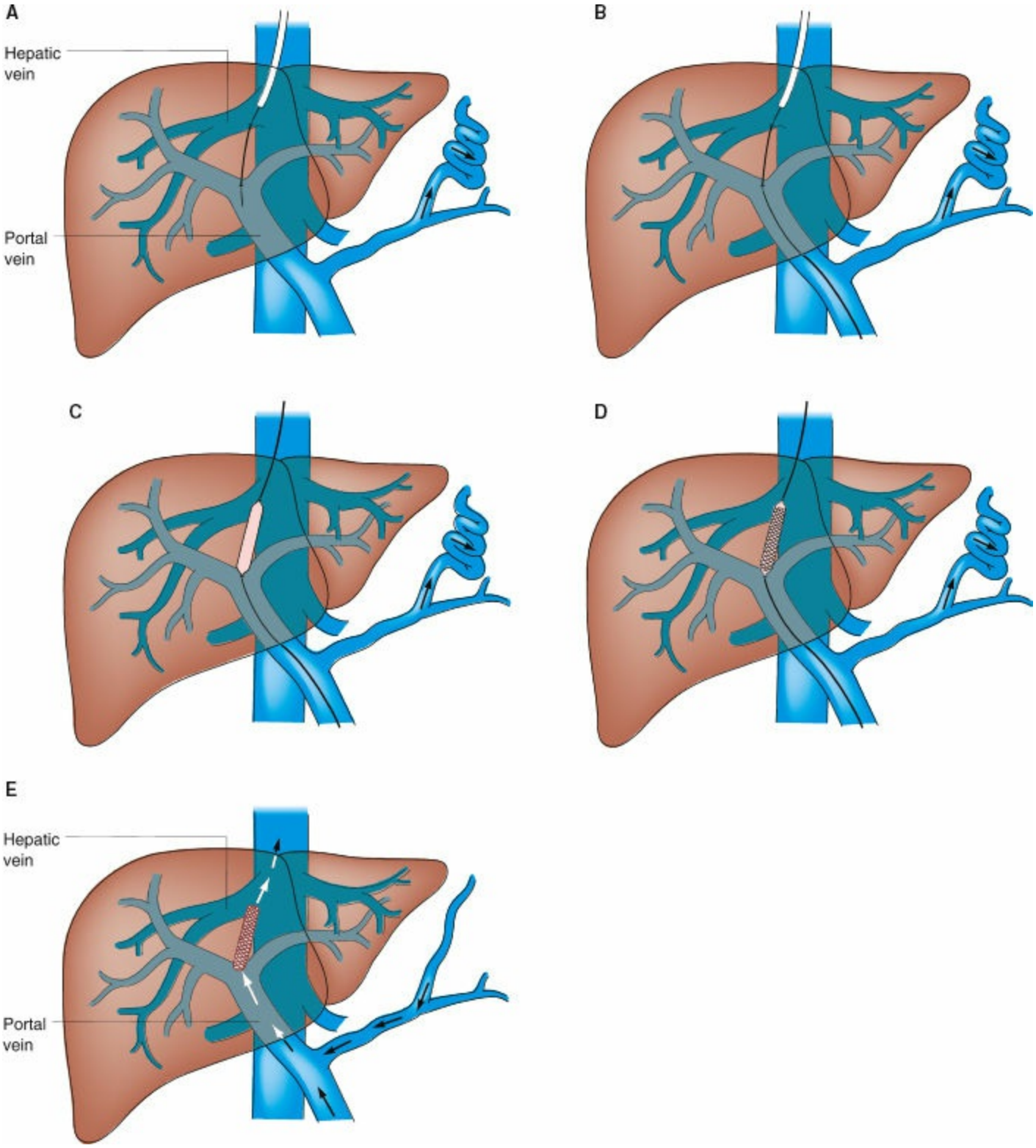

Figure 59-8. Schematic representation of the steps used to create a transjugular intrahepatic portosystemic shunt. **A:** A needle is directed from the IVC or hepatic veins into an intrahepatic portal venous branch. **B:** A guidewire is advanced into the portal venous system. **C:** The resulting tract is then balloon dilated. **D:** A stent is then placed into the dilated tract. **E:** Completed TIPS shunt. *Arrows* indicate direction of blood flow.

As with all portosystemic shunts, a significant complication of TIPS is the development of hepatic encephalopathy. The rate of hepatic encephalopathy following TIPS is 34%, compared to 19% following EVL for acute variceal bleeding, although the use of covered stents has reduced the rate of post-TIPS encephalopathy from when bare metal stents were used primarily.[245,246] Although in early series stenosis or occlusion of the stent

developed in up to 50% to 60% of patients in the first year, long-term patency can be maintained by ongoing surveillance of the shunt with redilatation, as needed. Shunt stenosis is managed angiographically with thrombolytic therapy, dilation, or replacement of the stent. The newest shunts are lined with polytetrafluoroethylene (PTFE) and have a much higher patency than the original permeable wallstents. Primary patency rates are 76% to 89% with shunt dysfunction occurring in only 15% of patients at 1 year.[236] Patients are usually followed at 3-month intervals by ultrasonography to assess the patency of the shunt. At 6 months of follow-up, 92% of patients had had no episodes of rebleeding, and 82% were free of hemorrhage at 1 year. It is safe to assert that the TIPS is now the standard procedure used to halt bleeding in patients who fail medical therapy. The ability to effectively decompress the portal circulation without open surgery in these critically ill patients has transformed clinical hepatology. Patients become medically stable and can be evaluated for transplantation electively. Patients with reversible liver disease (e.g., abstinent alcoholics) may recover fully without further intervention because the TIPS will slowly close as the liver heals.

Surgical Decompression

Background. Surgeons have been performing shunt procedures since the 1800s. The first was an end-to-side portacaval shunt with ligation of the distal portal vein, performed by Nicolai Eck (Eck fistula) in dogs. In 1945, Whipple[247] at the Columbia-Presbyterian Medical Center in New York performed this shunt for the first time for the indication of variceal bleeding. This group was also responsible for the development of the tube for the tamponade of bleeding esophageal varices, which adopted the name of Blakemore, as discussed previously.

11 Surgical interventions for the treatment of bleeding varices are divided into three main types: (a) liver transplantation, (b) shunt procedures, and (c) devascularization procedures. The only definitive procedure for the treatment of portal hypertension caused by cirrhosis is orthotopic liver transplantation, and the success of this option during the past two decades has revolutionized the treatment of portal hypertension and its complications in patients with end-stage liver disease. However, for the treatment of portal hypertension in patients without cirrhosis or in those whose liver function does not warrant a transplant (e.g., patients with portal vein thrombosis), decompressive surgically created shunts or devascularization procedures may be performed.

Shunts. Portosystemic shunts created operatively can be divided into three categories: (a) totally diverting (nonselective) shunts, (b) partially diverting shunts, and (c) selective shunts. Total shunts are created by completely bypassing the flow of blood away from the liver by joining the portal vein to the vena cava. Examples include the end-to-side portacaval shunt (Eck fistula) (Fig. 59-9) and the large-diameter (>10-mm) side-to-side portacaval (Fig. 59-10), mesocaval, and central splenorenal shunts. Because the pressure in the portal vein is much higher than that in the vena cava (or the renal vein), large side-to-side shunts divert all blood flow through the path of least resistance, so that flow in the portal vein is reversed, creating “hepatofugal” flow, out of the liver and decreasing

total hepatic perfusion. One of the causes of ascites in patients with portal hypertension is high pressure at the level of the hepatic sinusoids with protein-rich fluid leaking directly out of the swollen liver. The main difference between end-to-side and side-to-side shunts is that maintenance of high pressure with end-to-side shunts may worsen ascites, whereas side-to-side procedures effectively relieve this problem by reducing sinusoidal pressure. Complete portal blood flow diversion lowers portal pressure and is highly effective in the treatment of bleeding esophageal varices but, as noted earlier, may accelerate hepatic decompensation.

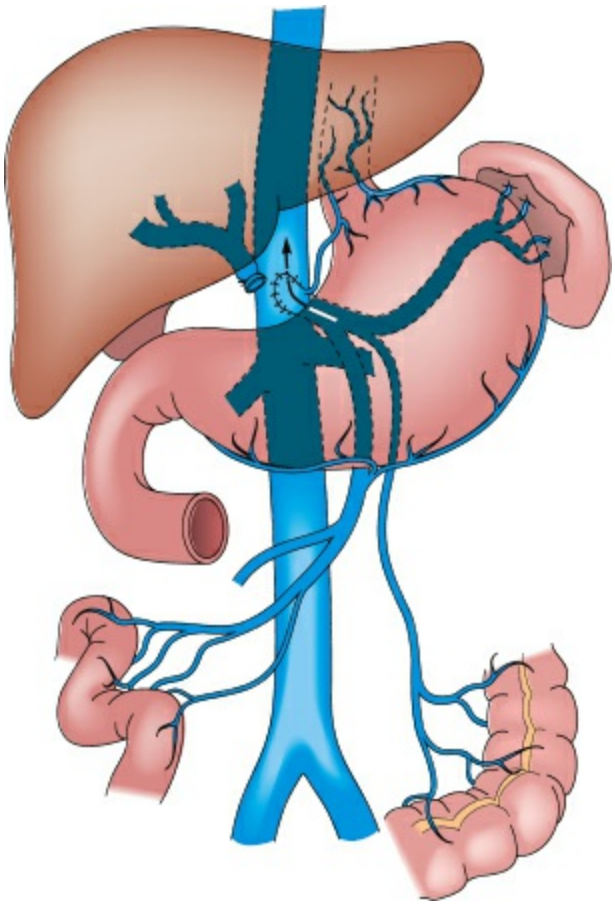

Figure 59-9. End-to-side portacaval shunt, also referred to as an Eck fistula. The portal vein is divided, the hepatic limb of the portal vein is ligated, and the splanchnic end of the portal vein is anastomosed end to side to the vena cava. All portal blood is necessarily diverted into the vena cava, and the hepatic limb of the portal vein cannot serve as an outflow tract.

The main complications of totally diverting shunts are a worsening of liver function and hepatic encephalopathy as a result of decreased flow through the liver and loss of hepatotropic factors from the mesenteric venous system. Another disadvantage of portacaval shunts is that the porta hepatis must be dissected, so that future surgical procedures in the area (e.g., liver transplantation) are more difficult.

Partially diverting shunts allow for the maintenance of hepatopetal flow while decompressing the high pressures in the portal system. The original shunts were larger than 10 mm in diameter and were able to create a gradient between the portal vein and vena cava that maintained some prograde hepatic flow. All these shunts, however, dilated over time and became complete shunts in that the portal vein to inferior vena cava

pressure gradient disappeared. The small-diameter (8-mm) side-to-side mesocaval (Fig. 59-11) and portacaval (Sarfeh) (Fig. 59-12) shunts are performed with an interposition graft made of either expanded PTFE or dacron. A significant component of the Sarfeh procedure is ligation of the coronary (left gastric), gastroepiploic, and other collateral veins. Bleeding from varices resolves in more than 90% of patients.[248,249] This smaller-diameter shunt has a higher resistance than the larger shunt, is synthetic and therefore does not dilate, can maintain hepatic perfusion, and is associated with a lower incidence of hepatic encephalopathy. With these shunts, portal pressure gradients can be reduced to the critical 12 mm Hg while hepatopetal flow is maintained in up to 80% to 90% of patients. In addition, the maintenance of mesenteric pressure at or relatively close to normal levels may prevent the hyperammonemia associated with total shunts. One relatively common complication is graft thrombosis, which occurs in up to 16% of patients.[249] Shunt thrombosis can usually be treated angiographically. Dissection at the porta hepatis leads to the formation of adhesions, which may compromise later liver transplantation.

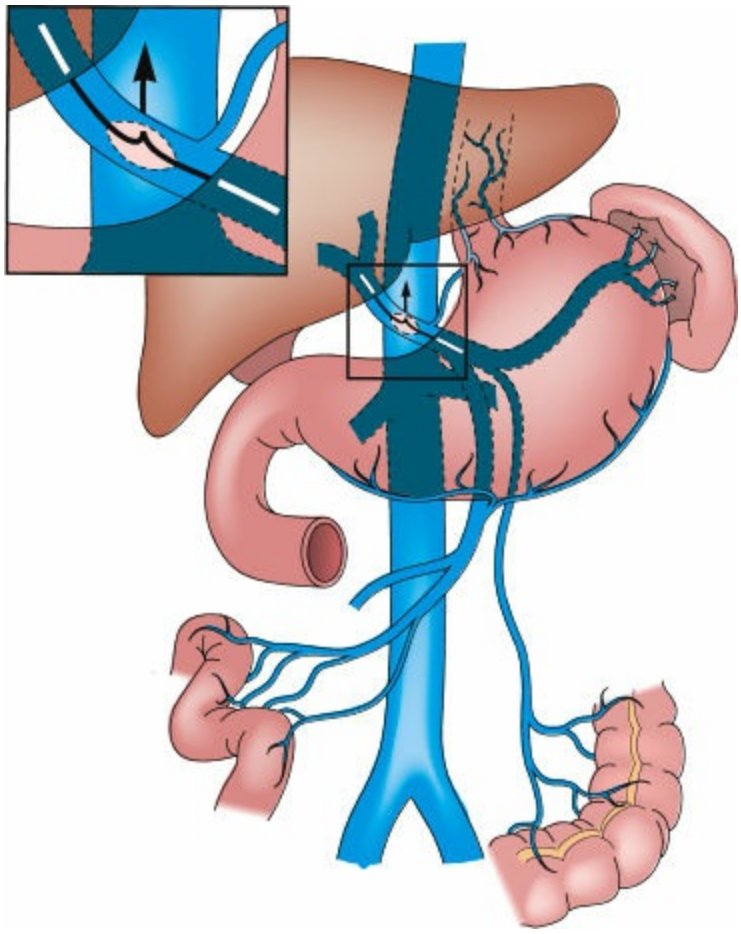

Figure 59-10. Side-to-side portacaval shunt. An anastomosis is made between the side of the portal vein and the side of the inferior vena cava. With a shunt of standard diameter, almost all splanchnic blood is diverted around the liver into the low-pressure vena cava. The hepatic limb of the portal vein serves as an outflow tract from the liver toward the low-pressure vena cava.

Selective shunts are designed to create two separate drainage systems within the portal venous network. A high pressure is maintained within the mesenteric system and a low

pressure is created in the esophagogastric system by shunting blood from the latter into the systemic circulation without decompressing the mesenteric network. The most traditional and most favored selective shunt is the distal splenorenal shunt (Fig. 59-13).[250] The distal splenorenal shunt selectively decompresses the gastroesophageal venous system through an anastomosis between the distal end of the splenic vein and the side of the renal vein. Decompression occurs through the short gastric veins, which are in continuity with the splenic vein. In addition, as in the small side-to-side shunts described earlier, collateral veins must be ligated.

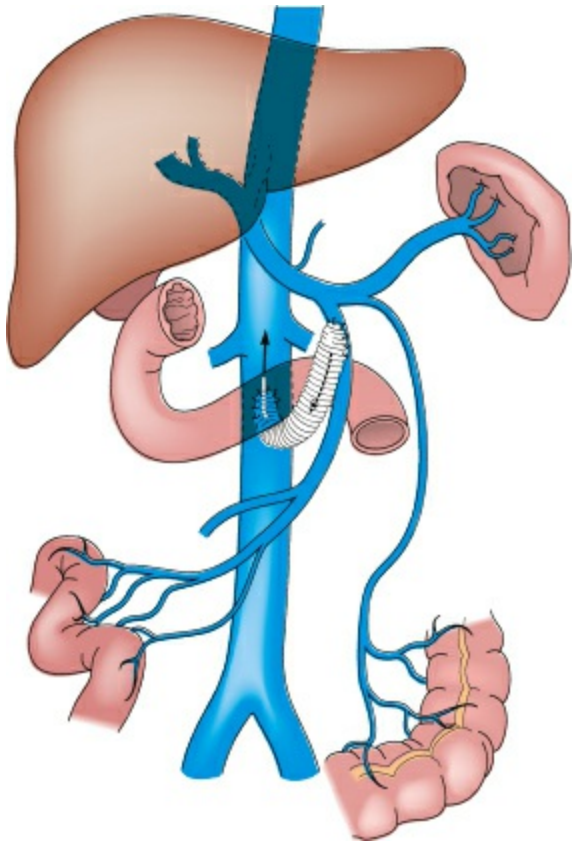

Figure 59-11. Interposition mesocaval shunt. A plastic prosthesis or an autogenous internal jugular vein is used for the shunt. One end is anastomosed to the inferior vena cava, and the other end is anastomosed to the trunk of the superior mesenteric vein. The shunt curves around the lower edge of the third portion of the duodenum and is sometimes called a C-shunt.

Advantages to this procedure are the following: (a) control of bleeding is excellent in more than 90% of patients, (b) no dissection of the porta hepatis is required, (c) hepatopetal flow is maintained, and (d) the incidence of encephalopathy (5% to 24%) and the risk of progressive liver failure are lower.[251] Experience with this shunt has revealed that most patients have hepatopetal flow, with 84% of alcoholic and 90% of nonalcoholic patients having prograde flow at 4 years after surgery.[252] Some loss of prograde portal flow does occur as a result of either portal vein thrombosis (approximately 10% of patients) or increased flow through collaterals located along the pancreas. This latter mechanism can be prevented by complete dissection of the splenic vein from the posterior aspect of the pancreas (splenopancreatic disconnection),[253] but this additional technique adds to the complexity of the operative procedure and to the incidence of complications.

The distal splenorenal shunt is relatively contraindicated in patients with significant ascites. Because no portal venous decompression occurs, ascites may increase after a distal splenorenal shunt is created. In addition, ligation of collateral vessels and lymphatics during the procedure contributes to increased portal pressures and subsequent increase in ascites. Patients with small splenic veins (<8 mm) have a relatively high incidence of shunt thrombosis.

Several trials comparing side-to-side total shunts with the distal splenorenal shunt found that they are equally effective (>90%) in stopping variceal hemorrhage.[254] The incidence of hepatic encephalopathy is lower after the distal splenorenal shunt, with rates of 36% and 15% for the total and selective shunts, respectively. Rates of rebleeding were similar and ranged from 0% to 30%, with no survival advantage for either procedure.

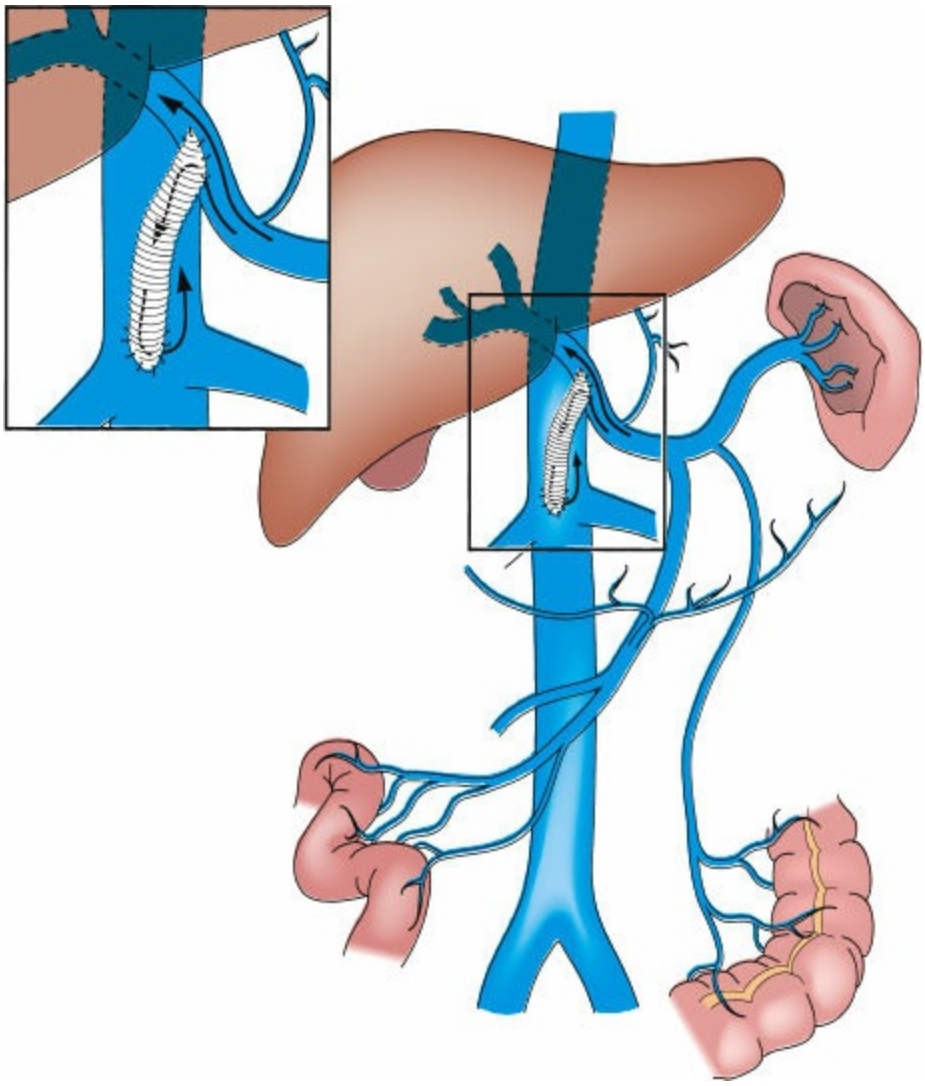

Figure 59-12. Small-diameter interposition portacaval Sarfeh shunt. A vascular prosthesis measuring 8 to 10 mm in diameter is interposed between the side of the vena cava and the side of the portal vein. The goal is to reduce portal pressure partially and thereby prevent variceal hemorrhage but still maintain sufficient pressure to permit the prograde flow of portal blood to the liver. This procedure is simpler to perform than that for the Warren shunt and theoretically avoids the problem of diversion of an increasing proportion of portal blood away from the liver over time, as occurs with the Warren shunt.

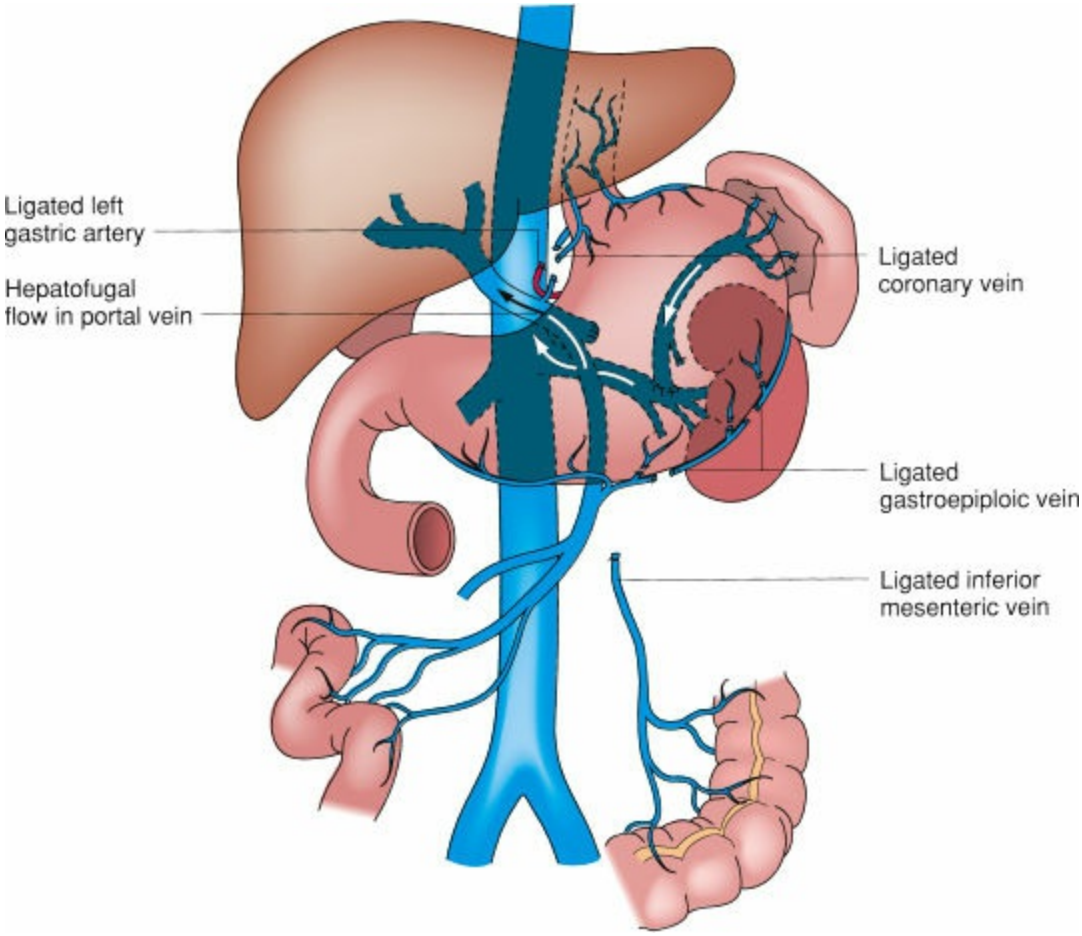

Figure 59-13. Distal splenorenal Warren shunt. The splenic vein is divided near its junction with the superior mesenteric vein. The distal end of the splenic vein is anastomosed to the renal vein. Varices are selectively decompressed through the stomach and short gastric veins into the splenic vein and then into the vena cava through the renal vein. Portal hypertension is maintained in the portal and superior mesenteric veins to provide enough pressure to drive portal blood through the diseased liver.

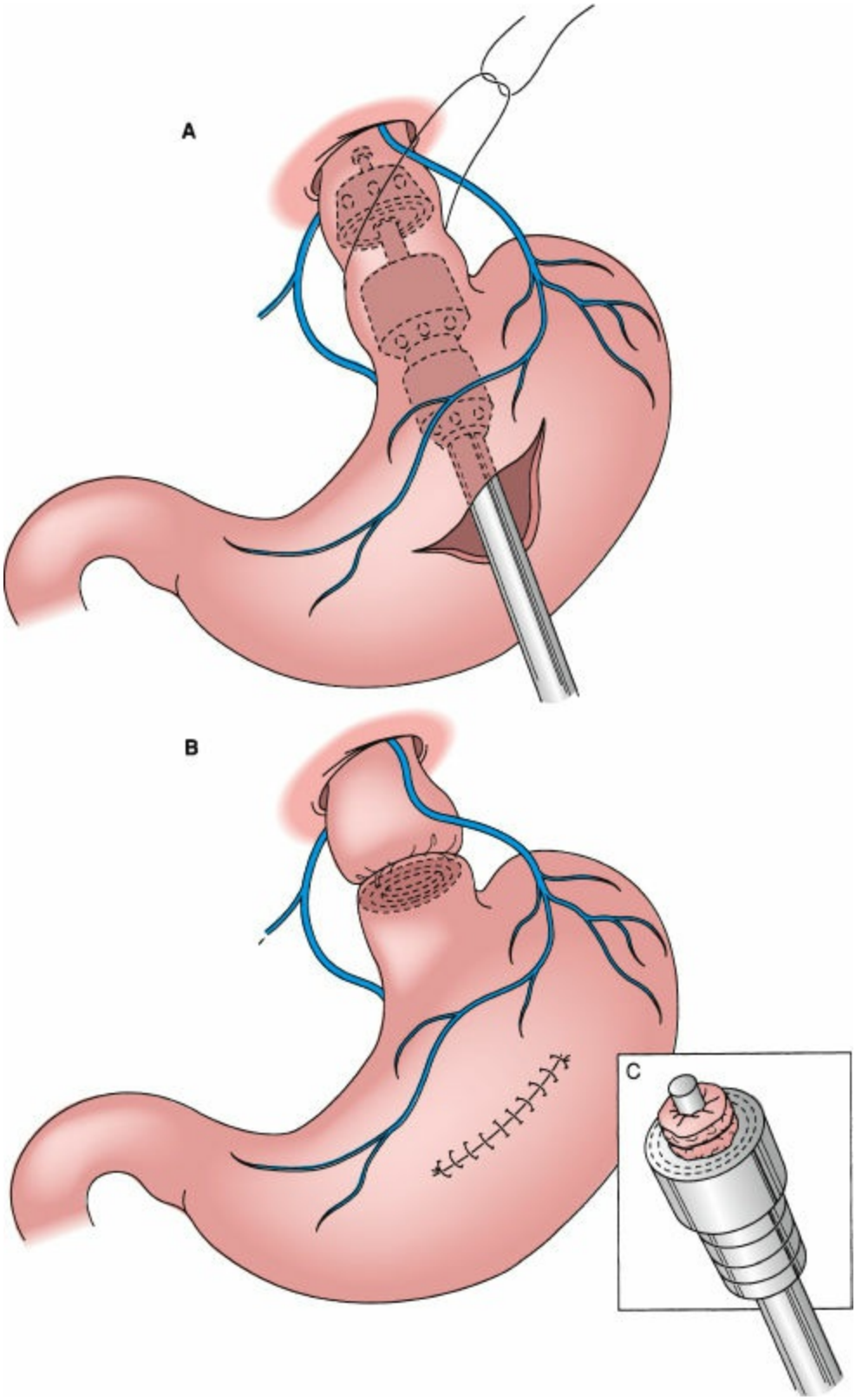

Figure 59-14. Transection and reanastomosis of the distal esophagus with the stapling device to control variceal hemorrhage. **A:** A stapling device is inserted through a small gastrotomy incision. **B:** When the device is fired, the esophagus is simultaneously transected and reanastomosed with staples. **C:** If the device fires correctly, a complete ring of esophageal tissue is excised.

Investigators have also used the side-to-side nonselective total shunt for the emergency treatment of bleeding varices. Bleeding stopped in more than 90% of patients with medical therapy alone, although bleeding often restarted shortly thereafter. Bleeding stopped in all patients after surgery, and 99% of patients were completely free of

episodes of rebleeding. The 5-year survival was approximately 80%, with the majority of deaths occurring during the first year after surgery as a result of progressive hepatic failure. Hepatic encephalopathy requiring recurrent intervention, including dietary restriction and lactulose or neomycin therapy, occurred in 8% of patients. These data support an aggressive, systematic approach to caring for these patients before, during, and after surgery, though most of these patients had alcoholic liver disease, which recovers rapidly with withdrawal of the alcohol.

Devascularization Procedures. Devascularization procedures are nonshunting techniques in which the venous drainage of the stomach and esophagus is disconnected from the liver and intestinal vessels. These procedures are relatively less technically demanding than shunting procedures and can be performed in patients with extensive portal thrombosis who preclude other options. They do not interfere with hepatopetal blood flow and therefore do not increase the incidence of hepatic encephalopathy.

The procedures range in complexity from simple esophageal transection and reanastomosis with an end-to-end anastomosis (EEA) stapler combined with ligation of the coronary vein (Fig. 59-14) to the Sugiura procedure (Fig. 59-15). The Sugiura procedure requires both abdominal and thoracic incisions, through which a splenectomy, devascularization of the proximal stomach and esophagus, transection of the esophagus with reanastomosis, and ligation of all gastroesophageal collaterals are performed.[255] The latter procedure can also be performed via a single abdominal incision.[256] Bleeding recurs in fewer than 5% of patients in Japan, but rates of rebleeding range from 10% to 54% in other countries.[257] Operative mortality rates range from 10% to 35% and outcomes are certainly related to the severity of liver disease. In our practice, these procedures are not used in patients with liver disease, but exclusively in patients with diffuse portomesenteric thrombosis, in whom decompressive shunts cannot be made.

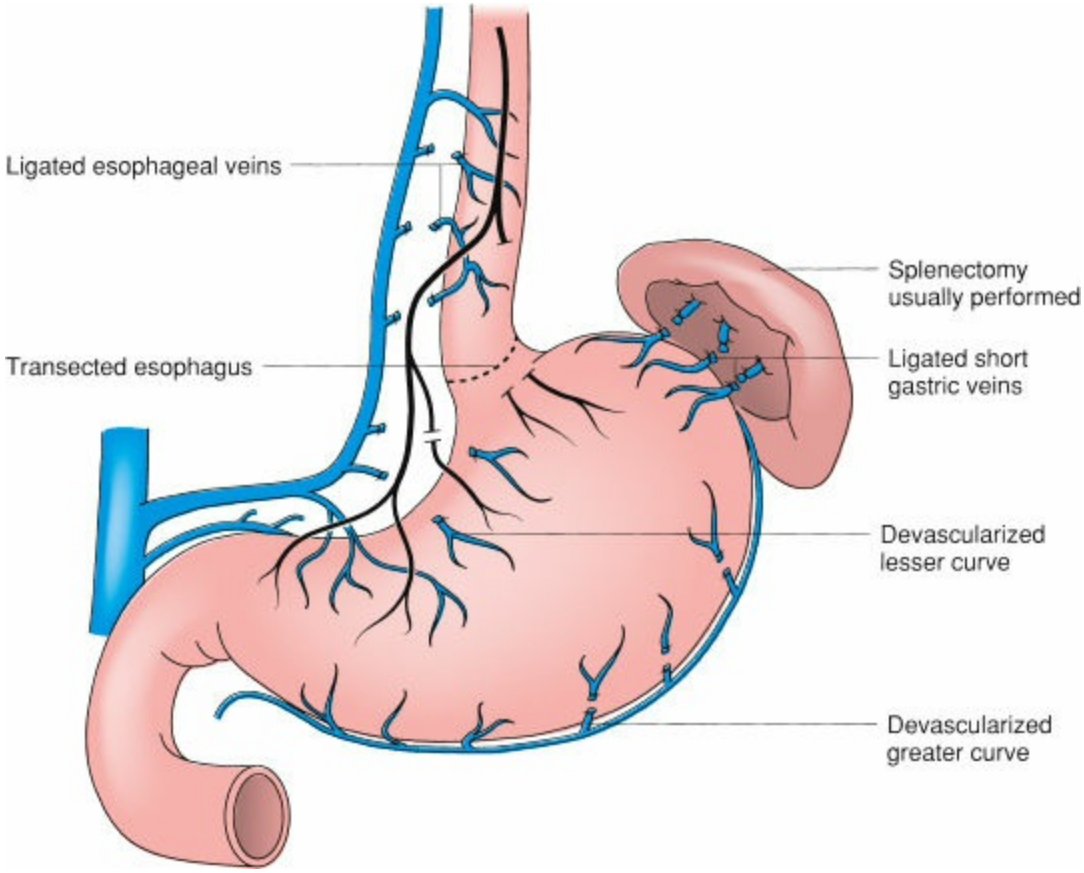

Figure 59-15. Sugiura esophageal transection and devascularization operation.

Hepatic Transplantation. Liver transplantation is the definitive therapy for portal hypertension and cirrhosis and the complications thereof, but is indicated for the overall management of end-stage liver disease and has no role in the control of acute variceal bleeding. When successful, transplantation treats both the underlying disease and any acute complication.

In conclusion, open surgical intervention short of liver transplantation for patients with cirrhosis and portal hypertension is becoming a rarity. With the advent of TIPS, the indications for surgically created shunts are dwindling. Although some studies have shown an increased need for reintervention in patients who have undergone TIPS for variceal bleeding, the overwhelming efficacy and safety of TIPS has essentially settled the issue and today, even in large liver centers, open portal decompressive procedures are rarely performed.

Current guidelines recommend nonselective beta blockade at the maximally tolerated dose for secondary prophylaxis, followed by serial EVL until all varices are obliterated. Patients should then undergo surveillance EGD every 6 to 12 months to evaluate for recurrent varices. TIPS should be reserved for Child A or B patients who bleed again despite combination medical and endoscopic therapy. Shunt surgery remains an option for good risk Child A patients. Those patients who are candidates should be referred to a transplant center for timely evaluation.[198]

Gastropathy and Gastric Varices. Approximately 10% of patients with esophageal varices also have gastric varices. Conversely, about 90% of patients with gastric varices

have esophageal varices.[197] Bleeding from gastric varices occurs in approximately 25% of affected patients and is usually more severe than bleeding from esophageal varices. Rebleeding occurs in up to 30% of patients after an initial bleed.[258] The same pharmacologic interventions used for esophageal varices are used to treat gastric varices. However, sclerotherapy and EVL have proven relatively ineffective for bleeding gastric varices, and endoscopic variceal obliteration with tissue adhesives such as N-butyl-cyanoacrylate or isobutyl-2-cyanoacrylate has shown better rates of initial hemorrhage control and prevention of recurrent bleeding. A large randomized controlled trial demonstrated better prevention of rebleeding following acute gastric variceal hemorrhage with N-butyl-cyanoacrylate compared to EVL.[259] Balloon tamponade may also be used as a temporizing measure while arrangements for definitive therapy are made. TIPS is the primary therapy for controlling gastric varices in patients who fail or cannot receive endoscopic therapy, with bleeding control rates of over 90% reported.[198] The distal splenorenal shunt is reserved for the rare patient who cannot receive TIPS.

Portal hypertensive gastropathy is a condition characterized by dilation of the venules and capillaries of the gastric mucosa without associated inflammation. The major complication of gastropathy is bleeding; gastropathy accounts for 4% to 38% of all episodes of acute bleeding in patients with cirrhosis.[260] TIPS may provide therapeutic decompression in this setting as well.

Ascites

One of the most important consequences of hepatic dysfunction in cirrhosis and portal hypertension is ascites. This development portends a significant worsening of the patient's condition, with markedly decreased survival rates. Ascites is defined as the accumulation of free fluid within the abdominal cavity (normally <150 mL). Causes of ascites are listed in Table 59-12. In cirrhosis, the fluid is derived from a combination of hepatic (high in protein) and splanchnic (low in protein) lymphs that cannot be absorbed as a result of the increased hydrostatic pressures within the liver and splanchnic systems secondary to cirrhosis and capillarization of the space of Disse.[261] Because of the loss of sinusoidal fenestrations and a subsequent decrease in their permeability, splanchnic lymph is more abundant than hepatic lymph in patients with advancing cirrhosis, so that the protein content of ascitic fluid is relatively low.[262] The main underlying pathophysiology in the development of ascites is renal sodium retention and associated water retention, which lead to fluid overload. Peripheral vasodilation and lower pressures are thought to be secondary to the dilator effects of nitric oxide, glucagon, and prostaglandins on nascent arteriovenous shunts present throughout the splanchnic vascular system, as well as in muscle, skin, and brain. The severity of liver disease is not uniformly correlated with the presence or absence of ascites.

DIAGNOSIS

Table 59-12 Differential Diagnosis of Ascites

Portal Hypertension
Cirrhosis and other intrahepatic diseases
Hepatic congestion
Congestive heart failure
Constrictive pericarditis
Inferior vena cava obstruction
Budd–Chiari syndrome
Portal vein occlusion
Hypoalbuminemia
Nephrotic syndrome
Protein-losing enteropathy
Malnutrition
Miscellaneous Disorders
Myxedema
Ovarian disease (Meigs syndrome, struma ovarii)
Peritoneal carcinomatosis
End-stage renal disease
Chylous ascites
Bile ascites
Urine ascites

From Sleisenger MH, Fordran JS. *Gastrointestinal Disease: Pathophysiology, Diagnosis and Management*. 4th ed. Philadelphia, PA: WB Saunders; 1989:433.

Clinical and Laboratory Features. Ascites may be present in patients with cirrhosis who have no other overt signs or symptoms. Patients may present with subtle signs of weight gain and an inability to fit into clothes. Physical examination reveals shifting dullness to percussion (1.5 L of ascitic fluid), fluid waves (10 L), and bulging flanks.[263] With progression of disease and massive ascites, respiratory status may be compromised secondary to increased intra-abdominal pressure and pleural effusions, which are often present and usually located on the right side. The progression may be slow or more rapid after an inciting event, such as a variceal bleed or infection.

Stigmata of poor liver function include peripheral muscle wasting, palmar erythema, spider angiomas, peripheral edema, a palpable liver, and caput medusae (dilated periumbilical veins). With progressive ascites and increased abdominal pressure, umbilical and inguinal hernias often develop and may be difficult to manage. Abdominal distention may be caused by gastrointestinal gas rather than ascites. Gas can be differentiated from fluid by eliciting hyperresonance to percussion, secondary to gas, as opposed to dullness with fluid. The most widely used test for the diagnosis of ascites is ultrasonography, which can also be helpful in determining the best location for therapeutic and diagnostic paracentesis.

Diagnostic Paracentesis. The differential diagnosis of ascites is presented in Table 59-12. Determination of the character of the ascitic fluid is helpful in establishing the diagnosis. Paracentesis may be performed in the midline, midway between the umbilicus and the pubic symphysis. The fluid from patients with cirrhosis is usually straw colored and clear; measurements of protein (usually <2 g/dL), quantitative cell counts, and

microbiologic culture and determination of pH, amylase, glucose, and albumin levels should be obtained. The serum-to-ascitic fluid albumin gradient (SAG) is calculated by subtracting the albumin concentration in ascites from the level found in serum. This gradient is helpful in determining the cause of ascites; high values (>1.1 g/dL) are generally associated with portal hypertension, whereas lower levels may be associated with other disorders, including malignancy.[264]

Treatment. Initial therapy is usually directed at control of renal sodium and water retention, with bed rest and dietary manipulation. The upright position exacerbates sodium retention as a result of venous pooling and relative hypovolemia. Up to 15% of patients respond to this therapy alone with a natriuresis. A low-sodium diet is a critical part of the management of patients with cirrhosis (1 to 2 g of sodium per day or 45 to 90 mEq/d). A major problem with a strict low-sodium diet is lack of palatability and poor compliance. Fluid restriction is also an essential component of therapy in patients in whom hyponatremia develops (sodium concentration <125 mEq/L), with only 1,000 to 1,500 mL of fluid allowed each day.

For the 85% to 95% of patients who do not respond to bed rest and fluid and salt restriction, the mainstay of treatment is diuresis (Table 59-13). The loop diuretic furosemide and the potassium-sparing diuretic spironolactone are the two most widely used agents, and they can be combined to minimize side effects and maximize effectiveness. A ratio of 40-mg furosemide to 100-mg spironolactone generally maintains potassium homeostasis. A diuresis of approximately 500 mL/d is the goal for patients with mild ascites and of up to 1 to 2 L/d for patients with both ascites and peripheral edema. More than 90% of patients respond to the combination of dietary manipulation and diuretics.[263,265]

Complications of the use of spironolactone include painful breast enlargement in males, hyperkalemia, and metabolic acidosis. Complications of the more potent furosemide include prerenal azotemia, which occurs in approximately 20% of patients as a result of excessive diuresis and hypovolemia.[274] Additional complications include hyponatremia and encephalopathy.

Large-volume paracentesis (removal of 4 to 6 L of ascitic fluid per day) and total paracentesis are techniques that can be used for patients with large amounts of fluid who are experiencing symptoms and are not responding to the aforementioned therapeutic endeavors. Patients requiring paracentesis usually have severe underlying liver disease and a 1-year survival rate of 25%.[266] The technique of paracentesis involves placing a catheter into the abdominal cavity, either in the lower midline or in one of the lower quadrants. Care is taken to enter lateral to the rectus muscle and avoid the inferior epigastric artery. More than 30 L of fluid can be removed by means of total paracentesis, with 6 to 10 g of albumin infused intravenously for each liter of ascitic fluid removed.[263,265,266] The albumin commonly is administered in the form of 25% albumin (12.5 g/50 mL). Controversy exists regarding the need for albumin replacement therapy in patients undergoing total paracentesis and repetitive large-volume paracentesis. Patients who have less than 5 L of ascitic fluid removed do not require albumin

replacement.[267]

Table 59-13 Treatment of Ascites

Bed rest
Sodium restriction 1–2 g/d (45–90 mEq/d)
Fluid restriction 1–1.5 L/d
Diuretics Spironolactone 50 mg PO q8h Maximum of 100 mg q6h Furosemide 40–370 mg/d
Antibiotics Cefotaxime 2 g IV q12h Ofloxacin 400 mg PO q12h Prophylaxis Norfloxacin 400 mg/d while hospitalized Ciprofloxacin 750 mg PO weekly Norfloxacin 400 mg/d for 6 mo Trimethoprim/sulfamethoxazole One double-strength tablet five times a week

The efficacy of paracentesis in the treatment of tense ascites has been studied extensively. Repetitive large-volume paracentesis has been shown to be as effective as diuretics in the treatment of moderate to severe ascites, with fewer systemic complications. A decreased length of hospital stay with no increase in the incidence of spontaneous bacterial peritonitis has been noted.[268] Paracentesis has become the therapy of choice for severe ascites.

Peritoneovenous shunts are surgically placed tubes that connect the peritoneal cavity with the superior vena cava via the internal jugular vein (Fig. 59-16). The two main types are the LeVeen shunt and the Denver shunt, both of which have a one-way valve that allows unidirectional movement of ascitic fluid from the peritoneal cavity into the systemic circulation. Although these shunts are effective in decreasing the volume of ascitic fluid, a significant number of major complications have been noted, including disseminated intravascular coagulation, heart failure, and sepsis,[266,269] and associated mortality rates are high (approximately 20%).[270] The shunt is occluded in approximately 50% of patients at 1 year, and no improvement in survival is noted.[266] The use of these shunts has drastically decreased with the development of the TIPS procedure. In addition to the use of TIPS, the placement of peritoneovenous shunts is now done percutaneously,

further increasing the safety of these procedures.

Surgically created portosystemic shunts have been used in the past for the treatment of ascites. Because of high morbidity and mortality rates, an increase in encephalopathy and progression to liver failure, and the addition of the TIPS procedure to treatment options, surgically created shunts are now used infrequently for this indication alone. As discussed earlier, the TIPS is a total nonselective shunt that decompresses the portal system and reduces pressure at the hepatic sinusoids, thereby eliminating the drive for the production of ascitic fluid. In a study evaluating the use of TIPS for the treatment of medically refractory ascites, the ascites resolved completely in almost 75% of patients, and a partial response was noted in an additional 20%.[271] In addition, renal function improved during the 6 months of follow-up. TIPS in this group of patients, however, was associated with an increase in the number of cases of encephalopathy. Although survival appears to be unaffected by a TIPS procedure when compared with large-volume paracentesis, TIPS may simplify the management of the patient while on the transplant waiting list.

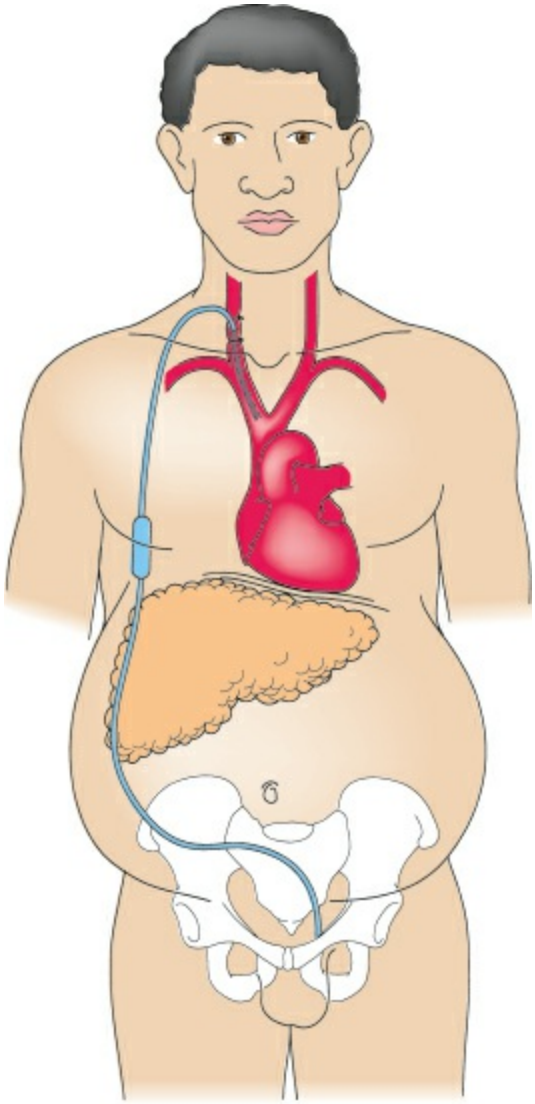

Figure 59-16. LeVeen peritoneovenous shunt used for routing ascitic fluid into the systemic circulation. The shunt consists of fenestrated tubing for insertion into the peritoneal cavity, a one-way valve, and a length of venous tubing for insertion into the superior vena cava.

12 Spontaneous bacterial peritonitis is a potentially lethal complication of portal hypertension with ascites that occurs in up to 10% of patients. The cause of spontaneous bacterial peritonitis is unknown. Antecedent gastrointestinal hemorrhage is common, and spontaneous bacterial peritonitis in this setting may be related to bacterial translocation from the gut. Deficits in immune function, both systemically and within the abdomen, including depressed[272] reticuloendothelial function,[273–275] low ascitic protein concentration, and deficient ascitic opsonic activity, may play a role. Patients often present with abdominal pain and fever, but 10% to 20% of cases are discovered on routine paracentesis.[276–278] In addition, patients may present with other signs not clearly related to spontaneous bacterial peritonitis, including worsening encephalopathy and deteriorating renal function. The diagnosis is easily made by examination of the ascitic fluid obtained by paracentesis. An elevated number of white blood cells (>250/mm3) are diagnostic. The vast majority of cases of spontaneous bacterial peritonitis are caused by a single organism, most commonly gram-negative enteric bacteria. Hematogenous spread may lead to infection with *Streptococcus pneumoniae* (Table 59-14). If more than one organism is present, the diagnosis of spontaneous bacterial peritonitis must be questioned, and a search for intra-abdominal disease (secondary peritonitis), such as a perforated viscus or diverticulitis, should be performed.

Table 59-14 Bacteriology of Spontaneous Bacterial Peritonitis

Organisms	Percentage of Total
Escherichia coli	40
Pneumococci	15
Streptococci	14
Klebsiella	7
Pseudomonas	3
Proteus	3
Staphylococci	3
Anaerobes	5
Other	20
Multiple isolates	10

Adapted from Targan S, Chow A, Gluze L. Role of anaerobic bacteria in spontaneous peritonitis of cirrhosis. *Am J Med* 1977;62:397.

The treatment of spontaneous bacterial peritonitis consists of supportive care and broad-spectrum antibiotics, most commonly cefotaxime, a third-generation cephalosporin. Protein replacement has been shown to significantly reduce mortality in patients with spontaneous bacterial peritonitis and is complementary to other interventions as established in the landmark publication from Barcelona.[279] Other antibiotics with proven efficacy include ofloxacin, a quinolone. This antibiotic has potent activity against gram-negative organisms and reaches high levels in ascitic fluid. For patients who are clinically stable and able to take oral medications, this is the drug of choice. Cure can be achieved in 75% to 90% of cases, but mortality rates are high, ranging from 20% to 40%.[280,281] The poor prognosis associated with spontaneous bacterial peritonitis warrants

consideration of liver transplantation.

Prophylactic oral or intravenous antibiotics are indicated for three distinct groups of patients with cirrhosis with ascites: (a) those with gastrointestinal hemorrhage, (b) those with low protein counts in the ascitic fluid (<10 to 15 g/L), and (c) those who have survived an episode of SBP.[282,283] The preferred antibiotics used in patients with hemorrhage are 7 days of either intravenous ceftriaxone or oral norfloxacin.[283] These antibiotics reduce the incidence of spontaneous bacterial peritonitis from approximately 15% to 20% to 3% to 9% and cause few side effects.[284–286] A meta-analysis evaluating the use of prophylactic antibiotics in patients with gastrointestinal hemorrhage confirmed the utility of prophylaxis, with an approximately 30% decrease in the incidence of infection, a 20% decrease in the incidence of spontaneous bacterial peritonitis and bacteremia, and a 10% improvement in overall survival.[287] In patients with low protein levels in the ascitic fluid, multiple regimens have proved effective in reducing the incidence of spontaneous bacterial peritonitis, from approximately 20% to less than 5%.[287–289]

Hernias and Ascites

Hernias of the anterior abdominal wall occur in up to 20% of patients with cirrhosis. The causes include increased intra-abdominal pressure and nutritional deficits, with muscular wasting and thinning of the fascia. If the hernias are left untreated, complications include incarceration, rupture, strangulation, and leakage. Patients with hernias and decompensated cirrhosis need to be evaluated for liver transplantation. In patients with stable liver function, hernias should be treated electively, with preoperative paracentesis to decrease intra-abdominal pressure. No increase in complication rates was noted in a study comparing the outcome of umbilical hernia repair in patients with and without ascites. A longer hospital stay and a significantly higher recurrence rate (73% vs. 14%) were noted, however, in the group of patients with ascites.[290–292] We favor the use of abdominal drains to remove the ascites until the incision is healed, thereby preventing ascites from leaking through the wound. Meticulous fluid management is essential during the postoperative period to prevent early reaccumulation of ascites.

In patients with severe ascites, TIPS should be performed before hernia repair to ensure a good result. Emergency repair of hernias complicated by skin breakdown with ascites leak or incarceration or strangulation is managed in a similar fashion with preoperative large-volume paracentesis, and aggressive control of ascites postoperatively.

References

1. Cataldegirmen G, Zeng S, Feirt N, et al. RAGE limits regeneration after massive liver injury by coordinated suppression of TNF-alpha and NF-kappaB. *J Exp Med* 2005;201:473–484.
2. Diehl AM, Chute J. Underlying potential: cellular and molecular determinants of adult liver repair. *J Clin Invest* 2013;123:1858–1860.
3. Friedman SL. Mechanisms of hepatic fibrogenesis. *Gastroenterology* 2008;134:1655–1669.
4. Czaja AJ. Hepatic inflammation and progressive liver fibrosis in chronic liver disease. *World J Gastroenterol* 2014;20:2515–2532.
5. Friedman SL, Arthur MJ. Activation of cultured rat hepatic lipocytes by Kupffer cell conditioned medium. Direct enhancement of matrix synthesis and stimulation of cell proliferation via induction of platelet-derived growth factor receptors. *J Clin Invest* 1989;84:1780–1785.
6. Czaja MJ, Weiner FR, Flanders KC, et al. In vitro and in vivo association of transforming growth factor-beta 1 with hepatic fibrosis. *J Cell Biol* 1989;108:2477–2482.
7. Matsuoka M, Pham NT, Tsukamoto H. Differential effects of interleukin-1 alpha, tumor necrosis factor alpha, and transforming growth factor beta 1 on cell proliferation and collagen formation by cultured fat-storing cells. *Liver* 1989;9:71–78.
8. Hayashi H, Sakai T. Biological significance of local TGF-beta activation in liver diseases. *Front Physiol* 2012;3:12.
9. Presser LD, McRae S, Waris G. Activation of TGF-beta1 promoter by hepatitis C virus-induced AP-1 and Sp1: role of TGF-beta1 in hepatic stellate cell activation and invasion. *PLoS One* 2013;8:e56367.
10. Bachem MG, Melchior R, Gressner AM. The role of thrombocytes in liver fibrogenesis: effects of platelet lysate and thrombocyte-derived growth factors on the mitogenic activity and glycosaminoglycan synthesis of cultured rat liver fat storing cells. *J Clin Chem Clin Biochem* 1989;27:555–565.
11. Albano E. New concepts in the pathogenesis of alcoholic liver disease. *Expert Rev Gastroenterol Hepatol* 2008;2:749–759.
12. Vuppalanchi R, Chalasani N. Nonalcoholic fatty liver disease and nonalcoholic steatohepatitis: selected practical issues in their evaluation and management. *Hepatology* 2009;49:306–317.
13. Rafiq N, Younossi ZM. Interaction of metabolic syndrome, nonalcoholic fatty liver disease and chronic hepatitis C. *Expert Rev Gastroenterol Hepatol* 2008;2:207–215.
14. Enomoto N, Ikejima K, Bradford BU, et al. Role of Kupffer cells and gut-derived endotoxins in alcoholic liver injury. *J Gastroenterol Hepatol* 2000;15(suppl):D20–D25.
15. Baskol G, Baskol M, Kocer D. Oxidative stress and antioxidant defenses in serum of patients with non-alcoholic steatohepatitis. *Clin Biochem* 2007;40:776–780.

16. Friedman SL, Roll FJ, Boyles J, et al. Hepatic lipocytes: the principal collagen-producing cells of normal rat liver. *Proc Natl Acad Sci U S A* 1985;82:8681–8685.
17. Wake K. “Sternzellen” in the liver: perisinusoidal cells with special reference to storage of vitamin A. *Am J Anat* 1971;132:429–462.
18. Takahara T, Kojima T, Miyabayashi C, et al. Collagen production in fat-storing cells after carbon tetrachloride intoxication in the rat. Immunoelectron microscopic observation of type I, type III collagens, and prolyl hydroxylase. *Lab Invest* 1988;59:509–521.
19. Gressner AM, Bachem MG. Cellular sources of noncollagenous matrix proteins: role of fat-storing cells in fibrogenesis. *Semin Liver Dis* 1990;10:30–46.
20. Loreal O, Levavasseur F, Rescan PY, et al. Differential expression of laminin chains in hepatic lipocytes. *FEBS Lett* 1991;290:9–12.
21. Ramadori G, Knittel T, Odenthal M, et al. Synthesis of cellular fibronectin by rat liver fat-storing (Ito) cells: regulation by cytokines. *Gastroenterology* 1992;103:1313–1321.
22. Li Y, Schwabe RF, DeVries-Seimon T, et al. Free cholesterol-loaded macrophages are an abundant source of tumor necrosis factor-alpha and interleukin-6: model of NF-kappaB- and map kinase-dependent inflammation in advanced atherosclerosis. *J Biol Chem* 2005;280:21763–21772.
23. Pinzani M, Gesualdo L, Sabbah GM, et al. Effects of platelet-derived growth factor and other polypeptide mitogens on DNA synthesis and growth of cultured rat liver fat-storing cells. *J Clin Invest* 1989;84:1786–1793.
24. Tsushima H, Kawata S, Tamura S, et al. Reduced plasma transforming growth factor-beta1 levels in patients with chronic hepatitis C after interferon-alpha therapy: association with regression of hepatic fibrosis. *J Hepatol* 1999;30:1–7.
25. Bohinc BN, Diehl AM. Mechanisms of disease progression in NASH: new paradigms. *Clin Liver Dis* 2012;16:549–565.
26. Sicklick JK, Li YX, Choi SS, et al. Role for hedgehog signaling in hepatic stellate cell activation and viability. *Lab Invest* 2005;85:1368–1380.
27. Witek RP, Yang L, Liu R, et al. Liver cell-derived microparticles activate hedgehog signaling and alter gene expression in hepatic endothelial cells. *Gastroenterology* 2009;136:320–330.
28. Jung Y, McCall SJ, Li YX, et al. Bile ductules and stromal cells express hedgehog ligands and/or hedgehog target genes in primary biliary cirrhosis. *Hepatology* 2007;45:1091–1096.
29. Rangwala F, Guy CD, Lu J, et al. Increased production of sonic hedgehog by ballooned hepatocytes. *J Pathol* 2011;224:401–410.
30. Sanchez A, Fabregat I. Growth factor- and cytokine-driven pathways governing liver stemness and differentiation. *World J Gastroenterol* 2010;16:5148–5161.
31. Omenetti A, Choi S, Michelotti G, et al. Hedgehog signaling in the liver. *J Hepatol* 2011;54:366–373.

32. Michelotti GA, Xie G, Swiderska M, et al. Smoothened is a master regulator of adult liver repair. *J Clin Invest* 2013;123:2380–2394.
33. Park BJ, Lee YJ, Lee HR. Chronic liver inflammation: clinical implications beyond alcoholic liver disease. *World J Gastroenterol* 2014;20:2168–2175.
34. Bode JC, Bode C, Heidelbach R, et al. Jejunal microflora in patients with chronic alcohol abuse. *Hepatogastroenterology* 1984;31:30–34.
35. Thurman RG II. Alcoholic liver injury involves activation of Kupffer cells by endotoxin. *Am J Physiol* 1998;275:G605–G611.
36. Goel A, Gupta M, Aggarwal R. Gut microbiota and liver disease. *J Gastroenterol Hepatol* 2014;29:1139–1148.
37. Abu-Shanab A, Quigley EM. The role of the gut microbiota in nonalcoholic fatty liver disease. *Nat Rev Gastroenterol Hepatol* 2010;7:691–701.
38. Schaffner F, Poper H. Capillarization of hepatic sinusoids in man. *Gastroenterology* 1963;44:239–242.
39. Reeves HL, Friedman SL. Activation of hepatic stellate cells–a key issue in liver fibrosis. *Front Biosci* 2002;7:d808–d826.
40. Oda M, Han JY, Yokomori H. Local regulators of hepatic sinusoidal microcirculation: recent advances. *Clin Hemorheol Microcirc* 2000;23:85–94.
41. DeLeve LD, Wang X, Kanel GC, et al. Prevention of hepatic fibrosis in a murine model of metabolic syndrome with nonalcoholic steatohepatitis. *Am J Pathol* 2008;173:993–1001.
42. de Oliveira CP, Stefano JT, de Siqueira ER, et al. Combination of N-acetylcysteine and metformin improves histological steatosis and fibrosis in patients with non-alcoholic steatohepatitis. *Hepatol Res* 2008;38:159–165.
43. Zhang Z, Wang FS. Stem cell therapies for liver failure and cirrhosis. *J Hepatol* 2013;59:183–185.
44. Schuppan D, Kim YO. Evolving therapies for liver fibrosis. *J Clin Invest* 2013;123:1887–1901.
45. Anthony PP, Ishak KG, Nayak NC, et al. The morphology of cirrhosis: definition, nomenclature, and classification. *Bull World Health Organ* 1977;55:521–540.
46. Chiaramonte M, Stroffolini T, Vian A, et al. Rate of incidence of hepatocellular carcinoma in patients with compensated viral cirrhosis. *Cancer* 1999;85:2132–2137.
47. Becker U, Deis A, Sorensen TI, et al. Prediction of risk of liver disease by alcohol intake, sex, and age: a prospective population study. *Hepatology* 1996;23:1025–1029.
48. Chedid A, Mendenhall CL, Gartside P, et al. Prognostic factors in alcoholic liver disease. VA Cooperative Study Group. *Am J Gastroenterol* 1991;86:210–216.
49. Singal AK, Guturu P, Hmoud B, et al. Evolving frequency and outcomes of liver transplantation based on etiology of liver disease. *Transplantation* 2013;95:755–760.
50. Burra P, Senzolo M, Adam R, et al. Liver transplantation for alcoholic liver disease in Europe: a study from the ELTR (European Liver Transplant Registry). *Am J*

Transplant 2010;10:138–148.
51. Singal AK, Chaha KS, Rasheed K, et al. Liver transplantation in alcoholic liver disease current status and controversies. *World J Gastroenterol* 2013;19:5953–5963.
52. Lieber CS. Medical disorders of alcoholism. *N Engl J Med* 1995;333:1058–1065.
53. Friedman SL. Seminars in medicine of the Beth Israel Hospital, Boston. The cellular basis of hepatic fibrosis. Mechanisms and treatment strategies. *N Engl J Med* 1993;328:1828–1835.
54. Moshage H, Casini A, Lieber CS. Acetaldehyde selectively stimulates collagen production in cultured rat liver fat-storing cells but not in hepatocytes. *Hepatology* 1990;12:511–518.
55. Lieber CS. *Medical and Nutritional Complications of Alcoholism: Mechanisms and Management*. New York, NY: Plenum; 1992.
56. Szabo G, Bala S. Alcoholic liver disease and the gut-liver axis. *World J Gastroenterol* 2010;16:1321–1329.
57. Rao RK. Acetaldehyde-induced increase in paracellular permeability in Caco-2 cell monolayer. *Alcohol Clin Exp Res* 1998;22:1724–1730.
58. Angulo P, Lindor KD. Non-alcoholic fatty liver disease. *J Gastroenterol Hepatol* 2002;17(suppl):S186–S190.
59. Clark JM. The epidemiology of nonalcoholic fatty liver disease in adults. *J Clin Gastroenterol* 2006;40(suppl 1):S5–S10.
60. Williams CD, Stengel J, Asike MI, et al. Prevalence of nonalcoholic fatty liver disease and nonalcoholic steatohepatitis among a largely middle-aged population utilizing ultrasound and liver biopsy: a prospective study. *Gastroenterology* 2011;140:124–131.
61. Schuppan D, Schattenberg JM. Non-alcoholic steatohepatitis: pathogenesis and novel therapeutic approaches. *J Gastroenterol Hepatol* 2013;28 (suppl 1):68–76.
62. Browning JD, Kumar KS, Saboorian MH, et al. Ethnic differences in the prevalence of cryptogenic cirrhosis. *Am J Gastroenterol* 2004;99:292–298.
63. Takamatsu S, Noguchi N, Kudoh A, et al. Influence of risk factors for metabolic syndrome and non-alcoholic fatty liver disease on the progression and prognosis of hepatocellular carcinoma. *Hepatogastroenterology* 2008;55:609–614.
64. Calle EE, Rodriguez C, Walker-Thurmond K, et al. Overweight, obesity, and mortality from cancer in a prospectively studied cohort of U.S. adults. *N Engl J Med* 2003;348:1625–1638.
65. Abdelmalek MF, Suzuki A, Guy C, et al. Increased fructose consumption is associated with fibrosis severity in patients with nonalcoholic fatty liver disease. *Hepatology* 2010;51:1961–1971.
66. Friedman SL. Liver fibrosis in 2012: convergent pathways that cause hepatic fibrosis in NASH. *Nat Rev Gastroenterol Hepatol* 2013;10:71–72.
67. Ma YY, Li L, Yu CH, et al. Effects of probiotics on nonalcoholic fatty liver disease: a meta-analysis. *World J Gastroenterol* 2013;19:6911–6918.

68. McMahon BJ. Chronic hepatitis B virus infection. *Med Clin North Am* 2014;98:39–54.
69. McHutchison JG, Lawitz EJ, Shiffman ML, et al. Peginterferon alfa-2b or alfa-2a with ribavirin for treatment of hepatitis C infection. *N Engl J Med* 2009;361:580–593.
70. Chou R, Hartung D, Rahman B, et al. Comparative effectiveness of antiviral treatment for hepatitis C virus infection in adults: a systematic review. *Ann Intern Med* 2013;158:114–123.
71. Sulkowski MS, Gardiner DF, Rodriguez-Torres M, et al. Daclatasvir plus sofosbuvir for previously treated or untreated chronic HCV infection. *N Engl J Med* 2014;370:211–221.
72. Kowdley KV, Lawitz E, Poordad F, et al. Phase 2b trial of interferon-free therapy for hepatitis C virus genotype 1. *N Engl J Med* 2014;370:222–232.
73. Shindo M, Ken A, Okuno T. Varying incidence of cirrhosis and hepatocellular carcinoma in patients with chronic hepatitis C responding differently to interferon therapy. *Cancer* 1999;85:1943–1950.
74. Szakacs JG, Szakacs JE. Progress in diagnosis of hepatitis and the cirrhotic liver. *Ann Clin Lab Sci* 1999;29:87–103.
75. El-Serag HB. Epidemiology of hepatocellular carcinoma in USA. *Hepatol Res* 2007;37(suppl 2):S88–S94.
76. Kaplan MM. Primary biliary cirrhosis. *N Engl J Med* 1996;335:1570–1580.
77. Portmann B, Popper H, Neuberger J, et al. Sequential and diagnostic features in primary biliary cirrhosis based on serial histologic study in 209 patients. *Gastroenterology* 1985;88:1777–1790.
78. Bhandari BM, Bayat H, Rothstein KD. Primary biliary cirrhosis. *Gastroenterol Clin North Am* 2011;40:373–386, viii.
79. Balasubramaniam K, Grambsch PM, Wiesner RH, et al. Diminished survival in asymptomatic primary biliary cirrhosis. A prospective study. *Gastroenterology* 1990;98:1567–1571.
80. Mahl TC, Shockcor W, Boyer JL. Primary biliary cirrhosis: survival of a large cohort of symptomatic and asymptomatic patients followed for 24 years. *J Hepatol* 1994;20:707–713.
81. Al-Harthy N, Kumagi T. Natural history and management of primary biliary cirrhosis. *Hepat Med* 2012;4:61–71.
82. Wiesner RH, Porayko MK, Dickson ER, et al. Selection and timing of liver transplantation in primary biliary cirrhosis and primary sclerosing cholangitis. *Hepatology* 1992;16:1290–1299.
83. Angulo P, Lindor KD. Primary sclerosing cholangitis. *Hepatology* 1999;30:325–332.
84. Angulo P, Peter JB, Gershwin ME, et al. Serum autoantibodies in patients with primary sclerosing cholangitis. *J Hepatol* 2000;32:182–187.
85. Liu JZ, Hov JR, Folseraas T, et al. Dense genotyping of immune-related disease regions identifies nine new risk loci for primary sclerosing cholangitis. *Nat Genet*

2013;45:670–675.
86. Zein CO. Primary sclerosing cholangitis. *Clin Liver Dis* 2013;17:211–227.
87. Bergquist A, Glaumann H, Persson B, et al. Risk factors and clinical presentation of hepatobiliary carcinoma in patients with primary sclerosing cholangitis: a case-control study. *Hepatology* 1998;27:311–316.
88. Bergquist A, Ekbom A, Olsson R, et al. Hepatic and extrahepatic malignancies in primary sclerosing cholangitis. *J Hepatol* 2002;36:321–327.
89. Barr Fritcher EG, Caudill JL, Blue JE, et al. Identification of malignant cytologic criteria in pancreatobiliary brushings with corresponding positive fluorescence in situ hybridization results. *Am J Clin Pathol* 2011;136:442–449.
90. Eaton JE, Talwalkar JA, Lazaridis KN, et al. Pathogenesis of primary sclerosing cholangitis and advances in diagnosis and management. *Gastroenterology* 2013;145:521–536.
91. Chapman R, Fevery J, Kalloo A, et al. Diagnosis and management of primary sclerosing cholangitis. *Hepatology* 2010;51:660–678.
92. De V I, Steers JL, Burch PA, et al. Prolonged disease-free survival after orthotopic liver transplantation plus adjuvant chemoirradiation for cholangiocarcinoma. *Liver Transpl* 2000;6:309–316.
93. Stal P, Broome U, Scheynius A, et al. Kupffer cell iron overload induces intercellular adhesion molecule-1 expression on hepatocytes in genetic hemochromatosis. *Hepatology* 1995;21:1308–1316.
94. Wheeler CJ, Kowdley KV. Hereditary hemochromatosis: a review of the genetics, mechanism, diagnosis, and treatment of iron overload. *Compr Ther* 2006;32:10–16.
95. Schilsky ML. Wilson's disease. In: Schiff ER, Sorrell M, Maddrey WC, eds. *Diseases of the Liver*. Philadelphia, PA: JB Lippincott; 1999:1091–1106.
96. Safran AP, Schaffner F. Chronic passive congestion of the liver in man. Electron microscopic study of cell atrophy and intralobular fibrosis. *Am J Pathol* 1967;50:447–463.
97. Dunn GD, Hayes P, Breen KJ, et al. The liver in congestive heart failure: a review. *Am J Med Sci* 1973;265:174–189.
98. Rosenberg P. The liver in circulatory failure. In: Schiff ER, Sorrell M, Maddrey WC, eds. *Diseases of the Liver*. Philadelphia, PA: JB Lippincott; 1999:1215–1227.
99. Tilanus HW. Budd–Chiari syndrome. *Br J Surg* 1995;82:1023–1030.
100. Gupta S, Barter S, Phillips GW, et al. Comparison of ultrasonography, computed tomography and 99mTc liver scan in diagnosis of Budd-Chiari syndrome. *Gut* 1987;28:242–247.
101. Ferral H, Behrens G, Lopera J. Budd-Chiari syndrome. *AJR Am J Roentgenol* 2012;199:737–745.
102. Zhang Y, Zhang XM, Prowda JC, et al. Changes in hepatic venous morphology with cirrhosis on MRI. *J Magn Reson Imaging* 2009;29:1085–1092.

103. Ishikawa T, Ichida T, Matsuda Y, et al. Reduced expression of thrombopoietin is involved in thrombocytopenia in human and rat liver cirrhosis. *J Gastroenterol Hepatol* 1998;13:907–913.
104. Rockey DC, Caldwell SH, Goodman ZD, et al. Liver biopsy. *Hepatology* 2009;49:1017–1044.
105. Simonovsky V. The diagnosis of cirrhosis by high resolution ultrasound of the liver surface. *Br J Radiol* 1999;72:29–34.
106. Kim MY, Jeong WK, Baik SK. Invasive and non-invasive diagnosis of cirrhosis and portal hypertension. *World J Gastroenterol* 2014;20:4300–4315.
107. Holmberg SD, Lu M, Rupp LB, et al. Noninvasive serum fibrosis markers for screening and staging chronic hepatitis C virus patients in a large US cohort. *Clin Infect Dis* 2013;57:240–246.
108. Angulo P, Hui JM, Marchesini G, et al. The NAFLD fibrosis score: a noninvasive system that identifies liver fibrosis in patients with NAFLD. *Hepatology* 2007;45:846–854.
109. Musso G, Gambino R, Cassader M, et al. Meta-analysis: natural history of non-alcoholic fatty liver disease (NAFLD) and diagnostic accuracy of non-invasive tests for liver disease severity. *Ann Med* 2011;43:617–649.
110. Imbert-Bismut F, Ratziu V, Pieroni L, et al. Biochemical markers of liver fibrosis in patients with hepatitis C virus infection: a prospective study. *Lancet* 2001;357:1069–1075.
111. Ohsuga M, Moreau R, Hartleb M, et al. Blunted systemic, splanchnic, and renal hemodynamic responses to atrial natriuretic peptide in rats with cirrhosis. *J Hepatol* 1994;20:91–96.
112. Angeli P, Merkel C. Pathogenesis and management of hepatorenal syndrome in patients with cirrhosis. *J Hepatol* 2008;48(suppl 1):S93–S103.
113. Gines A, Escorsell A, Gines P, et al. Incidence, predictive factors, and prognosis of the hepatorenal syndrome in cirrhosis with ascites. *Gastroenterology* 1993;105:229–236.
114. Martin-Llahí M, Pépin MN, Guevara M, et al. Terlipressin and albumin vs albumin in patients with cirrhosis and hepatorenal syndrome: a randomized study. *Gastroenterology* 2008;134:1352–1359.
115. Sharma P, Kumar A, Shrama BC, et al. An open label, pilot, randomized controlled trial of noradrenaline versus terlipressin in the treatment of type 1 hepatorenal syndrome and predictors of response. *Am J Gastroenterol* 2008;103:1689–1697.
116. Oliver JA, Verna EC. Afferent mechanisms of sodium retention in cirrhosis and hepatorenal syndrome. *Kidney Int* 2010;77:669–680.
117. Lieberman FL, Reynolds TB. Plasma volume in cirrhosis of the liver: its relation of portal hypertension, ascites, and renal failure. *J Clin Invest* 1967;46:1297–1308.
118. Levy M. Sodium retention and ascites formation in dogs with experimental portal

cirrhosis. *Am J Physiol* 1977;233:F572–F585.

119. Schrier RW, Arroyo V, Bernardi M, et al. Peripheral arterial vasodilation hypothesis: a proposal for the initiation of renal sodium and water retention in cirrhosis. *Hepatology* 1988;8:1151–1157.
120. P G. Renal Complications. In: Schiff ER, Sorrell M, Maddrey WC, eds. *Diseases of the Liver.* Philadelphia, PA: JB Lippincott; 1999:453–464.
121. Sarela AI, Mihaimeed FM, Batten JJ, et al. Hepatic and splanchnic nitric oxide activity in patients with cirrhosis. *Gut* 1999;44:749–753.
122. Martin PY, Gines P, Schrier RW. Nitric oxide as a mediator of hemodynamic abnormalities and sodium and water retention in cirrhosis. *N Engl J Med* 1998;339:533–541.
123. Levy M, Allotey JB. Temporal relationships between urinary salt retention and altered systemic hemodynamics in dogs with experimental cirrhosis. *J Lab Clin Med* 1978;92:560–569.
124. Sterns RH, Cappuccio JD, Silver SM, et al. Neurologic sequelae after treatment of severe hyponatremia: a multicenter perspective. *J Am Soc Nephrol* 1994;4:1522–1530.
125. Garcia-Tsao G, Parikh CR, Viola A. Acute kidney injury in cirrhosis. *Hepatology* 2008;48:2064–2077.
126. Montoliu S, Balleste B, Planas R, et al. Incidence and prognosis of different types of functional renal failure in cirrhotic patients with ascites. *Clin Gastroenterol Hepatol* 2010;8:616–622.
127. Wong F. Recent advances in our understanding of hepatorenal syndrome. *Nat Rev Gastroenterol Hepatol* 2012;9:382–391.
128. Gluud LL, Christensen K, Christensen E, et al. Systematic review of randomized trials on vasoconstrictor drugs for hepatorenal syndrome. *Hepatology* 2010;51:576–584.
129. Singer JA, Kaplan MM, Katz RL. Cirrhotic pleural effusion in the absence of ascites. *Gastroenterology* 1977;73:575–577.
130. Fitz G. Systemic complications of liver disease. In: Feldman M, ed. *Sleisenger and Fordtran's Gastrointestinal and Liver Disease.* Philadelphia, PA: Saunders; 1998:1340–1342.
131. Berkowitz KA, Butensky MS, Smith RL. Pulmonary function changes after large volume paracentesis. *Am J Gastroenterol* 1993;88:905–907.
132. Porcel JM. Management of refractory hepatic hydrothorax. *Curr Opin Pulm Med* 2014;20:352–357.
133. Hopkins WE, Waggoner AD, Barzilai B. Frequency and significance of intrapulmonary right-to-left shunting in end-stage hepatic disease. *Am J Cardiol* 1992;70:516–519.
134. Hourani JM, Bellamy PE, Tashkin DP, et al. Pulmonary dysfunction in advanced liver disease: frequent occurrence of an abnormal diffusing capacity. *Am J Med* 1991;90:693–700.

135. Rodriquez-Roisin R, Krowka MJ, Herve P, et al. Highlights of the ERS Task Force on pulmonary-hepatic vascular disorders (PHD). *J Hepatol* 2005;42:924–927.
136. Krowka MJ, Wiesner RH, Heimbach JK. Pulmonary contraindications, indications and MELD exceptions for liver transplantation: a contemporary view and look forward. *J Hepatol* 2013;59:367–374.
137. McAdams HP, Erasmus J, Crockett R, et al. The hepatopulmonary syndrome: radiologic findings in 10 patients. *AJR Am J Roentgenol* 1996;166:1379–1385.
138. Machicao VI, Balakrishnan M, Fallon MB. Pulmonary complications in chronic liver disease. *Hepatology* 2014;59:1627–1637.
139. Krowka MJ, Wiseman GA, Burnett OL, et al. Hepatopulmonary syndrome: a prospective study of relationships between severity of liver disease, PaO(2) response to 100% oxygen, and brain uptake after (99m)Tc MAA lung scanning. *Chest* 2000;118:615–624.
140. De Wolf AM, Begliomini B, Gasior TA, et al. Right ventricular function during orthotopic liver transplantation. *Anesth Analg* 1993;76:562–568.
141. Swanson KL, Wiesner RH, Nyberg SL, et al. Survival in portopulmonary hypertension: Mayo Clinic experience categorized by treatment subgroups. *Am J Transplant* 2008;8:2445–2453.
142. Kawut SM, Krowka MJ, Trotter JF, et al. Clinical risk factors for portopulmonary hypertension. *Hepatology* 2008;48:196–203.
143. Krowka MJ, Fallon MB, Mulligan DC, et al. Model for end-stage liver disease (MELD) exception for portopulmonary hypertension. *Liver Transpl* 2006;12:S114–S116.
144. Nomura F, Ohnishi K, Terabayashi H, et al. Effect of intrahepatic portal-systemic shunting on hepatic ammonia extraction in patients with cirrhosis. *Hepatology* 1994;20:1478–1481.
145. Lockwood AH, Yap EW, Wong WH. Cerebral ammonia metabolism in patients with severe liver disease and minimal hepatic encephalopathy. *J Cereb Blood Flow Metab* 1991;11:337–341.
146. Schafer DF, Jones EA. Hepatic encephalopathy and the gamma-aminobutyric-acid neurotransmitter system. *Lancet* 1982;1:18–20.
147. Mullen KD, Martin JV, Mendelson WB, et al. Could an endogenous benzodiazepine ligand contribute to hepatic encephalopathy? *Lancet* 1988;1:457–459.
148. Bengtsson F, Gage FH, Jeppson B, et al. Brain monoamine metabolism and behavior in portacaval-shunted rats. *Exp Neurol* 1985;90:21–35.
149. Zieve L, Doizaki WM, Zieve J. Synergism between mercaptans and ammonia or fatty acids in the production of coma: a possible role for mercaptans in the pathogenesis of hepatic coma. *J Lab Clin Med* 1974;83:16–28.
150. Yurdaydin C, Karavelioglu D, Onaran O, et al. Opioid receptor ligands in human hepatic encephalopathy. *J Hepatol* 1998;29:796–801.

151. Schenker S, Hoyumpa AM Jr. Pathophysiology of hepatic encephalopathy. *Hosp Pract (Off Ed)* 1984;19:99–103, 107–108, 110–114 passim.
152. Als-Nielsen B, Koretz RL, Kjaergard LL, et al. Branched-chain amino acids for hepatic encephalopathy. *Cochrane Database Syst Rev* 2003;(2):CD001939.
153. Malaguarnera M, Vacante M, Motta M, et al. Acetyl-L-carnitine improves cognitive functions in severe hepatic encephalopathy: a randomized and controlled clinical trial. *Metab Brain Dis* 2011;26:281–289.
154. Conn HO, Leevy CM, Vlahcevic ZR, et al. Comparison of lactulose and neomycin in the treatment of chronic portal-systemic encephalopathy. A double blind controlled trial. *Gastroenterology* 1977;72:573–583.
155. Mortensen PB. The effect of oral-administered lactulose on colonic nitrogen metabolism and excretion. *Hepatology* 1992;16:1350–1356.
156. Vince AJ, Burridge SM. Ammonia production by intestinal bacteria: the effects of lactose, lactulose and glucose. *J Med Microbiol* 1980;13:177–191.
157. Vince A, Zeegen R, Drinkwater JE, et al. The effect of lactulose on the faecal flora of patients with hepatic encephalopathy. *J Med Microbiol* 1974;7:163–168.
158. Morgan MH, Read AE, Speller DC. Treatment of hepatic encephalopathy with metronidazole. *Gut* 1982;23:1–7.
159. Leise MD, Poterucha JJ, Kamath PS, et al. Management of hepatic encephalopathy in the hospital. *Mayo Clin Proc* 2014;89:241–253.
160. Sharma BC, Sharma P, Lunia MK, et al. A randomized, double-blind, controlled trial comparing rifaximin plus lactulose with lactulose alone in treatment of overt hepatic encephalopathy. *Am J Gastroenterol* 2013;108:1458–1463.
161. Reynolds TB, Balfour DC Jr, Levinson DC, et al. Comparison of wedged hepatic vein pressure with portal vein pressure in human subjects with cirrhosis. *J Clin Invest* 1955;34:213–218.
162. Vorobioff J, Bredfeldt JE, Groszmann RJ. Increased blood flow through the portal system in cirrhotic rats. *Gastroenterology* 1984;87:1120–1126.
163. Moller S, Christensen E, Henriksen JH. Continuous blood pressure monitoring in cirrhosis. Relations to splanchnic and systemic haemodynamics. *J Hepatol* 1997;27:284–294.
164. Battista S, Bar F, Mengozzi G, et al. Hyperdynamic circulation in patients with cirrhosis: direct measurement of nitric oxide levels in hepatic and portal veins. *J Hepatol* 1997;26:75–80.
165. Jaffe DL, Chung RT, Friedman LS. Management of portal hypertension and its complications. *Med Clin North Am* 1996;80:1021–1034.
166. Gupta TK, Chen L, Groszmann RJ. Pathophysiology of portal hypertension. *Baillieres Clin Gastroenterol* 1997;11:203–219.
167. Budd BG. *On Diseases of the Liver.* London: John Churchill; 1845.
168. Chiari H. Uber die selbstandige phlebitis obliterans der hauptstamme der venae

hepaticae als todesursache. *Beitr Z Pathol Anat* 1899;26:1–18.

169. Gordon SC, Polson DJ, Shirkhoda A. Budd-Chiari syndrome complicating pre-eclampsia: diagnosis by magnetic resonance imaging. *J Clin Gastroenterol* 1991;13:460–462.
170. Valla D, Le MG, Poynard T, et al. Risk of hepatic vein thrombosis in relation to recent use of oral contraceptives. A case-control study. *Gastroenterology* 1986;90:807–811.
171. Mitchell MC, Boitnott JK, Kaufman S, et al. Budd-Chiari syndrome: etiology, diagnosis and management. *Medicine (Baltimore)* 1982;61:199–218.
172. Lin J, Chen XH, Zhou KR, et al. Budd-Chiari syndrome: diagnosis with three-dimensional contrast-enhanced magnetic resonance angiography. *World J Gastroenterol* 2003;9:2317–2321.
173. Cameron JL, Maddrey WC. Mesoatrial shunt: a new treatment for the Budd-Chiari syndrome. *Ann Surg* 1978;187:402–406.
174. Cameron JL, Herlong HF, Sanfey H, et al. The Budd-Chiari syndrome. Treatment by mesenteric-systemic venous shunts. *Ann Surg* 1983;198:335–346.
175. Halff G, Todo S, Tzakis AG, et al. Liver transplantation for the Budd-Chiari syndrome. *Ann Surg* 1990;211:43–49.
176. Cura M, Haskal Z, Lopera J. Diagnostic and interventional radiology for Budd-Chiari syndrome. *Radiographics* 2009;29:669–681.
177. Shaked A, Goldstein RM, Klintmalm GB, et al. Portosystemic shunt versus orthotopic liver transplantation for the Budd-Chiari syndrome. *Surg Gynecol Obstet* 1992;174:453–459.
178. Rautou PE, Moucari R, Escolano S, et al. Prognostic indices for Budd-Chiari syndrome: valid for clinical studies but insufficient for individual management. *Am J Gastroenterol* 2009;104:1140–1146.
179. Carnevale FC, Szejnfeld D, Moreira AM, et al. Long-term follow-up after successful transjugular intrahepatic portosystemic shunt placement in a pediatric patient with Budd-Chiari syndrome. *Cardiovasc Intervent Radiol* 2008;31:1244–1248.
180. Blum U, Rossle M, Haag K, et al. Budd-Chiari syndrome: technical, hemodynamic, and clinical results of treatment with transjugular intrahepatic portosystemic shunt. *Radiology* 1995;197:805–811.
181. Rossle M, Olschewski M, Siegerstetter V, et al. The Budd-Chiari syndrome: outcome after treatment with the transjugular intrahepatic portosystemic shunt. *Surgery* 2004;135:394–403.
182. Orozco H, Takahashi T, Mercado MA, et al. Surgical management of extrahepatic portal hypertension and variceal bleeding. *World J Surg* 1994;18:246–250.
183. Giouleme O, Theocharidou E. Management of portal hypertension in children with portal vein thrombosis. *J Pediatr Gastroenterol Nutr* 2013;57:419–425.
184. Cohen J, Edelman RR, Chopra S. Portal vein thrombosis: a review. *Am J Med*

1992;92:173–182.
185. Parvey HR, Raval B, Sandler CM. Portal vein thrombosis: imaging findings. *AJR Am J Roentgenol* 1994;162:77–81.
186. de Ville de GJ, Alberti D, Falchetti D, et al. Treatment of extrahepatic portal hypertension in children by mesenteric-to-left portal vein bypass: a new physiological procedure. *Eur J Surg* 1999;165:777–781.
187. Loftus JP, Nagorney DM, Ilstrup D, et al. Sinistral portal hypertension. Splenectomy or expectant management. *Ann Surg* 1993;217:35–40.
188. Brown RS Jr, Kumar KS, Russo MW, et al. Model for end-stage liver disease and Child-Turcotte-Pugh score as predictors of pretransplantation disease severity, posttransplantation outcome, and resource utilization in United Network for Organ Sharing status 2A patients. *Liver Transpl* 2002;8:278–284.
189. Forman LM, Lucey MR. Predicting the prognosis of chronic liver disease: an evolution from child to MELD. Mayo end-stage liver disease. *Hepatology* 2001;33:473–475.
190. Botta F, Giannini E, Romagnoli P, et al. MELD scoring system is useful for predicting prognosis in patients with liver cirrhosis and is correlated with residual liver function: a European study. *Gut* 2003;52:134–139.
191. Sheth M, Riggs M, Patel T. Utility of the Mayo end-stage liver disease (MELD) score in assessing prognosis of patients with alcoholic hepatitis. *BMC Gastroenterol* 2002;2:2.
192. Carbo J, Garcia-Samaniego J, Castellano G, et al. Liver cirrhosis and mortality by abdominal surgery. A study of risk factors. *Rev Esp Enferm Dig* 1998;90:105–112.
193. Mansour A, Watson W, Shayani V, et al. Abdominal operations in patients with cirrhosis: still a major surgical challenge. *Surgery* 1997;122:730–735.
194. Noda T. Angioarchitectural study of esophageal varices. With special reference to variceal rupture. *Virchows Arch A Pathol Anat Histopathol* 1984;404:381–392.
195. Kamath PS. Esophageal variceal bleeding: primary prophylaxis. *Clin Gastroenterol Hepatol* 2005;3:90–93.
196. Roberts LR, Kamath PS. Pathophysiology of variceal bleeding. *Gastrointest Endosc Clin N Am* 1999;9:167–174.
197. Sarin SK, Lahoti D, Saxena SP, et al. Prevalence, classification and natural history of gastric varices: a long-term follow-up study in 568 portal hypertension patients. *Hepatology* 1992;16:1343–1349.
198. Garcia-Tsao G, Sanyal AJ, Grace ND, et al. Prevention and management of gastroesophageal varices and variceal hemorrhage in cirrhosis. *Hepatology* 2007;46:922–938.
199. Sanyal AJ, Fontana RJ, Di Bisceglie AM, et al. The prevalence and risk factors associated with esophageal varices in subjects with hepatitis C and advanced fibrosis. *Gastrointest Endosc* 2006;64:855–864.

200. Cales P, Desmorat H, Vinel JP, et al. Incidence of large oesophageal varices in patients with cirrhosis: application to prophylaxis of first bleeding. *Gut* 1990;31:1298–1302.
201. North Italian Endoscopic Club for the Study and Treatment of Esophageal Varices. Prediction of the first variceal hemorrhage in patients with cirrhosis of the liver and esophageal varices. A prospective multicenter study. *N Engl J Med* 1988;319:983–989.
202. Graham DY, Smith JL. The course of patients after variceal hemorrhage. *Gastroenterology* 1981;80:800–809.
203. Polio J, Groszmann RJ. Hemodynamic factors involved in the development and rupture of esophageal varices: a pathophysiologic approach to treatment. *Semin Liver Dis* 1986;6:318–331.
204. Garcia-Tsao G, Groszmann RJ, Fisher RL, et al. Portal pressure, presence of gastroesophageal varices and variceal bleeding. *Hepatology* 1985;5:419–424.
205. Price HL, Cooperman LH, Warden JC. Control of the splanchnic circulation in man. Role of beta-adrenergic receptors. *Circ Res* 1967;21:333–340.
206. Braillon A, Moreau R, Hadengue A, et al. Hyperkinetic circulatory syndrome in patients with presinusoidal portal hypertension. Effect of propranolol. *J Hepatol* 1989;9:312–318.
207. Kiire CF. Controlled trial of propranolol to prevent recurrent variceal bleeding in patients with non-cirrhotic portal fibrosis. *BMJ* 1989;298:1363–1365.
208. Poynard T, Cales P, Pasta L, et al. Beta-adrenergic-antagonist drugs in the prevention of gastrointestinal bleeding in patients with cirrhosis and esophageal varices. An analysis of data and prognostic factors in 589 patients from four randomized clinical trials. Franco-Italian Multicenter Study Group. *N Engl J Med* 1991;324:1532–1538.
209. Feu F, Garcia-Pagan JC, Bosch J, et al. Relation between portal pressure response to pharmacotherapy and risk of recurrent variceal haemorrhage in patients with cirrhosis. *Lancet* 1995;346:1056–1059.
210. Andreani T, Poupon RE, Balkau BJ, et al. Preventive therapy of first gastrointestinal bleeding in patients with cirrhosis: results of a controlled trial comparing propranolol, endoscopic sclerotherapy and placebo. *Hepatology* 1990;12:1413–1419.
211. Ideo G, Bellati G, Fesce E, et al. Nadolol can prevent the first gastrointestinal bleeding in cirrhotics: a prospective, randomized study. *Hepatology* 1988;8:6–9.
212. Pascal JP, Cales P. Propranolol in the prevention of first upper gastrointestinal tract hemorrhage in patients with cirrhosis of the liver and esophageal varices. *N Engl J Med* 1987;317:856–861.
213. Abraldes JG, Tarantino I, Turnes J, et al. Hemodynamic response to pharmacological treatment of portal hypertension and long-term prognosis of cirrhosis. *Hepatology* 2003;37:902–908.
214. Prophylaxis of first hemorrhage from esophageal varices by sclerotherapy,

propranolol or both in cirrhotic patients: a randomized multicenter trial. The PROVA Study Group. *Hepatology* 1991;14:1016–1024.

215. Groszmann RJ, Garcia-Tsao G, Bosch J, et al. Beta-blockers to prevent gastroesophageal varices in patients with cirrhosis. *N Engl J Med* 2005; 353:2254–2261.
216. Grace ND, Muench H, Chalmers TC. The present status of shunts for portal hypertension in cirrhosis. *Gastroenterology* 1966;50:684–691.
217. D'Amico G, Pagliaro L, Bosch J. The treatment of portal hypertension: a meta-analytic review. *Hepatology* 1995;22:332–354.
218. Lo GH, Lai KH, Cheng JS, et al. Prophylactic banding ligation of high-risk esophageal varices in patients with cirrhosis: a prospective, randomized trial. *J Hepatol* 1999;31:451–456.
219. Svoboda P, Kantorova I, Ochmann J, et al. A prospective randomized controlled trial of sclerotherapy vs ligation in the prophylactic treatment of high-risk esophageal varices. *Surg Endosc* 1999;13:580–584.
220. Grace ND, Groszmann RJ, Garcia-Tsao G, et al. Portal hypertension and variceal bleeding: an AASLD single topic symposium. *Hepatology* 1998;28:868–880.
221. Castaneda B, Morales J, Lionetti R, et al. Effects of blood volume restitution following a portal hypertensive-related bleeding in anesthetized cirrhotic rats. *Hepatology* 2001;33:821–825.
222. de Franchis R. Evolving consensus in portal hypertension. Report of the Baveno IV consensus workshop on methodology of diagnosis and therapy in portal hypertension. *J Hepatol* 2005;43:167–176.
223. Rimola A, Garcia-Tsao G, Navasa M, et al. Diagnosis, treatment and prophylaxis of spontaneous bacterial peritonitis: a consensus document. International Ascites Club. *J Hepatol* 2000;32:142–153.
224. Fogel MR, Knauer CM, Andres LL, et al. Continuous intravenous vasopressin in active upper gastrointestinal bleeding. *Ann Intern Med* 1982;96:565–569.
225. Chojkier M, Groszmann RJ, Atterbury CE, et al. A controlled comparison of continuous intraarterial and intravenous infusions of vasopressin in hemorrhage from esophageal varices. *Gastroenterology* 1979;77:540–546.
226. Merigan TC Jr, Plotkin GR, Davidson CS. Effect of intravenously administered posterior pituitary extract on hemorrhage from bleeding esophageal varices. A controlled evaluation. *N Engl J Med* 1962;266:134–135.
227. Groszmann RJ, Kravetz D, Bosch J, et al. Nitroglycerin improves the hemodynamic response to vasopressin in portal hypertension. *Hepatology* 1982;2:757–762.
228. Tsai YT, Lay CS, Lai KH, et al. Controlled trial of vasopressin plus nitroglycerin vs. vasopressin alone in the treatment of bleeding esophageal varices. *Hepatology* 1986;6:406–409.
229. Bosch J, Kravetz D, Rodes J. Effects of somatostatin on hepatic and systemic

hemodynamics in patients with cirrhosis of the liver: comparison with vasopressin. *Gastroenterology* 1981;80:518–525.

230. Lee HY, Lee HJ, Lee SM, et al. A prospective randomized controlled clinical trial comparing the effects of somatostatin and vasopressin for control of acute variceal bleeding in the patients with liver cirrhosis. *Korean J Intern Med* 2003;18:161–166.
231. Burroughs AK, McCormick PA, Hughes MD, et al. Randomized, double-blind, placebo-controlled trial of somatostatin for variceal bleeding. Emergency control and prevention of early variceal rebleeding. *Gastroenterology* 1990;99:1388–1395.
232. Jaramillo JL, de la Mata M, Mino G, et al. Somatostatin versus Sengstaken balloon tamponade for primary haemostasia of bleeding esophageal varices. A randomized pilot study. *J Hepatol* 1991;12:100–105.
233. Burroughs AK, Hamilton G, Phillips A, et al. A comparison of sclerotherapy with staple transection of the esophagus for the emergency control of bleeding from esophageal varices. *N Engl J Med* 1989;321:857–862.
234. Young MF, Sanowski RA, Rasche R. Comparison and characterization of ulcerations induced by endoscopic ligation of esophageal varices versus endoscopic sclerotherapy. *Gastrointest Endosc* 1993;39:119–122.
235. Laberge JM, Ring EJ, Gordon RL, et al. Creation of transjugular intrahepatic portosystemic shunts with the wallstent endoprosthesis: results in 100 patients. *Radiology* 1993;187:413–420.
236. Corbett C, Mangat K, Olliff S, et al. The role of transjugular intrahepatic portosystemic stent-shunt (TIPSS) in the management of variceal hemorrhage. *Liver Int* 2012;32:1493–1504.
237. Sanyal AJ, Freedman AM, Luketic VA, et al. Transjugular intrahepatic portosystemic shunts for patients with active variceal hemorrhage unresponsive to sclerotherapy. *Gastroenterology* 1996;111:138–146.
238. Miller-Catchpole R. Diagnostic and therapeutic technology assessment. Transjugular intrahepatic portosystemic shunt (TIPS). *JAMA* 1995;273:1824–1830.
239. Patel NH, Chalasani N, Jindal RM. Current status of transjugular intrahepatic portosystemic shunts. *Postgrad Med J* 1998;74:716–720.
240. Kerlan RK Jr, Laberge JM, Gordon RL, et al. Transjugular intrahepatic portosystemic shunts: current status. *AJR Am J Roentgenol* 1995;164:1059–1066.
241. Radosevich PM, Laberge JM, Gordon RL. Current status and future possibilities of transjugular intrahepatic portosystemic shunts in the management of portal hypertension. *World J Surg* 1994;18:785–789.
242. Chung HH, Razavi MK, Sze DY, et al. Portosystemic pressure gradient during transjugular intrahepatic portosystemic shunt with Viatorr stent graft: what is the critical low threshold to avoid medically uncontrolled low pressure gradient related complications? *J Gastroenterol Hepatol* 2008;23:95–101.
243. Ryu RK, Durham JD, Krysl J, et al. Role of TIPS as a bridge to hepatic

transplantation in Budd-Chiari syndrome. *J Vasc Interv Radiol* 1999;10:799–805.
244. de Oliveira e Silva A, Cardoso ES, de Melo CR, et al. [Transjugular intrahepatic portosystemic shunts (TIPS) as a bridge for liver transplantation]. *Arq Gastroenterol* 1996;33:201–206.
245. Angermayr B, Cejna M, Koenig F, et al. Survival in patients undergoing transjugular intrahepatic portosystemic shunt: ePTFE-covered stentgrafts versus bare stents. *Hepatology* 2003;38:1043–1050.
246. Burroughs AK, Vangeli M. Transjugular intrahepatic portosystemic shunt versus endoscopic therapy: randomized trials for secondary prophylaxis of variceal bleeding: an updated meta-analysis. *Scand J Gastroenterol* 2002;37:249–252.
247. Whipple AO. The problem of portal hypertension in relation to the hepatosplenopathies. *Ann Surg* 1945;122:449–475.
248. Sarfeh IJ, Rypins EB. Partial versus total portacaval shunt in alcoholic cirrhosis. Results of a prospective, randomized clinical trial. *Ann Surg* 1994;219:353–361.
249. Rosemurgy AS, Goode SE, Zwiebel BR, et al. A prospective trial of transjugular intrahepatic portasystemic stent shunts versus small-diameter prosthetic H-graft portacaval shunts in the treatment of bleeding varices. *Ann Surg* 1996;224:378–384.
250. Hermann RE, Henderson JM, Vogt DP, et al. Fifty years of surgery for portal hypertension at the Cleveland Clinic Foundation. Lessons and prospects. *Ann Surg* 1995;221:459–466.
251. Orozco H, Mercado MA, Granados GJ, et al. Selective shunts for portal hypertension: current role of a 21-year experience. *Liver Transpl Surg* 1997;3:475–480.
252. Henderson JM, Warren WD, Millikan WJ, et al. Distal splenorenal shunt with splenopancreatic disconnection. A 4-year assessment. *Ann Surg* 1989;210:332–339.
253. Jin G, Rikkers LF. Cause and management of upper gastrointestinal bleeding after distal splenorenal shunt. *Surgery* 1992;112:719–725.
254. Orloff MJ, Orloff MS, Orloff SL, et al. Three decades of experience with emergency portacaval shunt for acutely bleeding esophageal varices in 400 unselected patients with cirrhosis of the liver. *J Am Coll Surg* 1995;180:257–272.
255. Sugiura M, Futagawa S. Esophageal transection with paraesophagogastric devascularizations (the Sugiura procedure) in the treatment of esophageal varices. *World J Surg* 1984;8:673–679.
256. Wexler MJ, Stein BL. Nonshunting operations for variceal hemorrhage. *Surg Clin North Am* 1990;70:425–448.
257. Cello JP, Crass R, Trunkey DD. Endoscopic sclerotherapy versus esophageal transection of Child's class C patients with variceal hemorrhage. Comparison with results of portacaval shunt: preliminary report. *Surgery* 1982;91:333–338.
258. Kim T, Shijo H, Kokawa H, et al. Risk factors for hemorrhage from gastric fundal varices. *Hepatology* 1997;25:307–312.
259. Tan PC, Hou MC, Lin HC, et al. A randomized trial of endoscopic treatment of acute

gastric variceal hemorrhage: n-butyl-2-cyanoacrylate injection versus band ligation. *Hepatology* 2006;43:690–697.

260. D'Amico G, Montalbano L, Traina M, et al. Natural history of congestive gastropathy in cirrhosis. The Liver Study Group of V. Cervello Hospital. *Gastroenterology* 1990;99:1558–1564.
261. Huet PM, Goresky CA, Villeneuve JP, et al. Assessment of liver microcirculation in human cirrhosis. *J Clin Invest* 1982;70:1234–1244.
262. Roberts LR, Kamath PS. Ascites and hepatorenal syndrome: pathophysiology and management. *Mayo Clin Proc* 1996;71:874–881.
263. Stanley MM, Ochi S, Lee KK, et al. Peritoneovenous shunting as compared with medical treatment in patients with alcoholic cirrhosis and massive ascites. Veterans Administration Cooperative Study on treatment of alcoholic cirrhosis with ascites. *N Engl J Med* 1989;321:1632–1638.
264. Marshall JB. Finding the cause of ascites. The importance of accurate fluid analysis. *Postgrad Med* 1988;83:189–190.
265. Bories P, Garcia CD, Michel H, et al. The treatment of refractory ascites by the LeVeen shunt. A multi-centre controlled trial (57 patients). *J Hepatol* 1986;3:212–218.
266. Aiza I, Perez GO, Schiff ER. Management of ascites in patients with chronic liver disease. *Am J Gastroenterol* 1994;89:1949–1956.
267. Gines P, Arroyo V, Quintero E, et al. Comparison of paracentesis and diuretics in the treatment of cirrhotics with tense ascites. Results of a randomized study. *Gastroenterology* 1987;93:234–241.
268. Sola R, Andreu M, Coll S, et al. Spontaneous bacterial peritonitis in cirrhotic patients treated using paracentesis or diuretics: results of a randomized study. *Hepatology* 1995;21:340–344.
269. Greig PD, Langer B, Blendis LM, et al. Complications after peritoneovenous shunting for ascites. *Am J Surg* 1980;139:125–131.
270. Ochs A, Rossle M, Haag K, et al. The transjugular intrahepatic portosystemic stent-shunt procedure for refractory ascites. *N Engl J Med* 1995; 332:1192–1197.
271. Sanyal AJ, Genning C, Reddy KR, et al. The North American Study for the treatment of refractory ascites. *Gastroenterology* 2003;124:634–641.
272. Runyon BA. Low-protein-concentration ascitic fluid is predisposed to spontaneous bacterial peritonitis. *Gastroenterology* 1986;91:1343–1346.
273. Rimola A, Soto R, Bory F, et al. Reticuloendothelial system phagocytic activity in cirrhosis and its relation to bacterial infections and prognosis. *Hepatology* 1984;4:53–58.
274. Runyon BA, Squier S, Borzio M. Translocation of gut bacteria in rats with cirrhosis to mesenteric lymph nodes partially explains the pathogenesis of spontaneous bacterial peritonitis. *J Hepatol* 1994;21:792–796.

275. Runyon BA, Morrissey RL, Hoefs JC, et al. Opsonic activity of human ascitic fluid: a potentially important protective mechanism against spontaneous bacterial peritonitis. *Hepatology* 1985;5:634–637.
276. Runyon BA. Early events in spontaneous bacterial peritonitis. *Gut* 2004; 53:782–784.
277. Guarner C, Runyon BA. Spontaneous bacterial peritonitis: pathogenesis, diagnosis, and management. *Gastroenterologist* 1995;3:311–328.
278. Hoefs JC, Runyon BA. Spontaneous bacterial peritonitis. *Dis Mon* 1985; 31:1–48.
279. Sort P, Navasa M, Arroyo V, et al. Effect of intravenous albumin on renal impairment and mortality in patients with cirrhosis and spontaneous bacterial peritonitis. *N Engl J Med* 1999;341:403–409.
280. Guarner C, Runyon BA, Heck M, et al. Effect of long-term trimethoprim-sulfamethoxazole prophylaxis on ascites formation, bacterial translocation, spontaneous bacterial peritonitis, and survival in cirrhotic rats. *Dig Dis Sci* 1999;44:1957–1962.
281. Runyon BA, Borzio M, Young S, et al. Effect of selective bowel decontamination with norfloxacin on spontaneous bacterial peritonitis, translocation, and survival in an animal model of cirrhosis. *Hepatology* 1995;21:1719–1724.
282. Runyon BA, McHutchison JG, Antillon MR, et al. Short-course versus long-course antibiotic treatment of spontaneous bacterial peritonitis. A randomized controlled study of 100 patients. *Gastroenterology* 1991;100:1737–1742.
283. Runyon BA. Introduction to the revised American Association for the study of liver diseases practice guideline management of adult patients with ascites due to cirrhosis 2012. *Hepatology* 2013;57:1651–1653.
284. Soriano G, Guarner C, Tomas A, et al. Norfloxacin prevents bacterial infection in cirrhotics with gastrointestinal hemorrhage. *Gastroenterology* 1992;103:1267–1272.
285. Lin HC. Antibiotic prophylaxis for the prevention of bacterial infections in cirrhotic patients with gastrointestinal hemorrhage. *Zhonghua Yi Xue Za Zhi (Taipei)* 2002;65:361–362.
286. Bernard B, Grange JD, Khac EN, et al. Antibiotic prophylaxis for the prevention of bacterial infections in cirrhotic patients with ascites: a meta-analysis. *Digestion* 1998;59(suppl 2):54–57.
287. Grange JD, Roulot D, Pelletier G, et al. Norfloxacin primary prophylaxis of bacterial infections in cirrhotic patients with ascites: a double-blind randomized trial. *J Hepatol* 1998;29:430–436.
288. Singh N, Gayowski T, Yu VL, et al. Trimethoprim-sulfamethoxazole for the prevention of spontaneous bacterial peritonitis in cirrhosis: a randomized trial. *Ann Intern Med* 1995;122:595–598.
289. Rolachon A, Cordier L, Bacq Y, et al. Ciprofloxacin and long-term prevention of spontaneous bacterial peritonitis: results of a prospective controlled trial. *Hepatology* 1995;22:1171–1174.

290. McKay A, Dixon E, Bathe O, et al. Umbilical hernia repair in the presence of cirrhosis and ascites: results of a survey and review of the literature. *Hernia* 2009;13:461–468.
291. Douard R, Lentschener C, Ozier Y, et al. Operative risks of digestive surgery in cirrhotic patients. *Gastroenterol Clin Biol* 2009;33:555–564.
292. Youssef YF, El GM. Mesh repair of non-complicated umbilical hernia in ascitic patients with liver cirrhosis. *J Egypt Soc Parasitol* 2007;37:1189–1197.

Chapter 60

Hepatic Neoplasms

Junichi Shindoh and Jean-Nicolas Vauthey

Key Points

1 Given the increasing complexity in the field of liver surgery, the surgical indications for hepatic neoplasms should be determined by a multidisciplinary team, including hepatobiliary surgeons, to optimize the treatment approach and adequate timing of surgery for patients who would benefit from hepatic resection.

2 Child–Turcotte–Pugh (CTP) classification describes the overall status of the hepatic functional reserve and the risk of treatment. Surgical resection is generally indicated for CTP class A or highly selected CTP class B patients, whereas CTP class C is a contraindication for hepatic resection.

3 Surgical therapy of benign hepatic neoplasms should be confined to symptomatic patients or those with a risk of malignant transformation (e.g., biliary cystadenoma, hepatic adenoma [HA]).

4 The choice of therapy for HCC should be individualized based on the tumor burden, degree of underlying liver disease, patient performance status, and overall possibility of side effects or complications balanced with acceptable clinical results.

5 Complete resection of colorectal liver metastases (CLM) is associated with an improved 5-year survival rate of up to 58%. Adequate assessment and preoperative management are essential in selecting patients with resectable or potentially resectable CLM.

6 For surgical planning, precise anatomic interpretation of the intrahepatic vascular structures is needed. Three-dimensional liver simulation techniques have recently been introduced which enable easy access to anatomic information and help with adequate surgical planning.

7 Portal vein embolization (PVE) is a safe and minimally invasive procedure to increase the size of the future liver remnant (FLR) and decrease the surgical risk of extended hepatectomies. Failure to respond to PVE is associated with postoperative hepatic insufficiency and mortality due to liver failure.

8 Adequate exposure of the surgical field and control of bleeding during hepatic parenchymal transection are basic requirements for safe liver surgery. Liver surgeons should be familiar with techniques for safe handling of the liver.

9 Laparoscopic liver resection has been recognized as a feasible and safe procedure for selected patients undergoing minor resections, and this approach has recently been

expanded to major hepatectomies. The indication for the laparoscopic approach should be determined by considering the technical feasibility, the surgeon's surgical skill, and the oncologic curability of the procedure.

INTRODUCTION

The management of hepatic neoplasms is an increasingly complex and multidisciplinary area of surgery. With advances in surgical technique and perioperative care, the safety of liver resection has dramatically improved over the decades and the mortality rate after major hepatectomy has recently been reported to be $<5\%$ at high-volume hepatobiliary centers.[1,2]

Liver resection and liver transplantation are widely accepted as curative surgical options for selected hepatic neoplasms. Surgical treatment for hepatic neoplasms requires the balancing of two conflicting factors, oncologic curability and surgical safety. The size of the future liver remnant (FLR) affects mortality and morbidity after liver resection, and the chance of cure is often linked to the extent of resection.[3,4] Therefore, the surgical indication should be determined based on the balance of surgical curability and extent of liver resection, especially for patients who have impaired hepatic functional due to underlying chronic liver disease. In this chapter, we review the basic principles of surgical management and appropriate surgical techniques for hepatic neoplasms.

PRIMARY ASSESSMENTS FOR TREATMENT SELECTION

Overview

When a hepatic neoplasm is found, the initial diagnostic steps should include (1) precise anatomic description of the hepatic lesion (size, number, location, and relation to intrahepatic vascular structures), (2) evaluation of the hepatic functional reserve in the underlying liver, and (3) assessment of the oncologic feature of the lesion in question.

The initial treatment is selected based on the information obtained from these primary assessments. When surgical management is considered, further workup is needed to determine or optimize the surgical indication through (1) detailed anatomic assessment and (2) systematic volumetry of FLR to stratify the risk of postoperative hepatic insufficiency and mortality from liver failure. If the estimated FLR is too small according to the hepatic functional reserve of an individual patient, portal vein embolization (PVE) or a two-stage approach[5,6] is considered in combination with local or systemic therapy, as appropriate.

1 Given the increasing complexity in this field of surgery, the surgical indication should be determined by a multidisciplinary team, including hepatobiliary surgeons. In the era of effective chemotherapy and various radiologic interventions, the surgical indication can change during the initial nonsurgical treatment even in patients with initially unresectable hepatic lesions. Because only surgical resection offers a chance of cure for patients with advanced hepatic malignancies, a multidisciplinary approach is important to identify patients who would benefit from surgery and to optimize overall treatment outcomes.

Screening for Underlying Liver Disease

Assessment of a patient with a new diagnosis of a hepatic neoplasm should begin with consideration of any underlying chronic liver disease. Viral hepatitis is the most common cause of chronic liver disease and primary liver cancer, affecting 240 million people with hepatitis B (HCB) and 130 to 150 million people with hepatitis C (HCV) worldwide – most of whom are unaware of their disease.[7] Thus, routine screening of viral hepatitis is mandatory for patients with hepatic neoplasms. The number of serology-negative patients with primary liver cancers is increasing, and alcoholic liver disease and nonalcoholic liver disease are the next leading causes of chronic liver disease. Both are characterized by histologic alterations, including steatosis, and each can lead to cirrhosis and primary liver cancer.[8,9] Careful history taking is important primarily to specify the risk of fatty liver disease, such as those due to obesity, alcohol abuse, diabetes mellitus, and metabolic syndrome. In addition, cholestatic liver disease is an important etiology for chronic liver disease because it is a common cause of decompensated cirrhosis requiring liver transplantation. Primary sclerosing cholangitis is a strong risk factor for cholangiocarcinoma and cases of end-stage primary sclerosing cholangitis are frequently complicated with malignant biliary stricture, which may be difficult to distinguish from benign biliary strictures. Finally, a history of systemic therapy for hepatic malignancy is an increasingly important factor in the era of effective chemotherapy. Several studies have confirmed that prolonged systemic therapy is associated with regimen-specific histopathologic injury of the liver[10–12] and decreased hepatic functional reserve.[12–15] Therefore, risk assessment of chemotherapy-induced liver injury is also necessary, especially for patients with colorectal liver metastases (CLM) for whom systemic treatment has been used.

Laboratory Tests

A comprehensive metabolic panel, a complete blood count, and measurement of coagulation parameters are essential for potential candidates for surgery. The basic functional status of the liver can be evaluated by serum albumin concentration, bilirubin concentration, and transaminase level. The renal function is also important because advanced liver disease is frequently compromised with renal dysfunction and impaired renal function is correlated with poor prognosis. Regarding the complete blood count, attention should be paid to platelet count. Thrombocytopenia is reportedly correlated with the degree of fibrosis in the underlying liver, and thrombocytopenia suggests the presence of hypersplenism and portal hypertension, which are associated with increased need for treatment. Among the coagulation parameters, prothrombin time is the most sensitive indicator of synthetic function of the liver. Because prothrombin time represents the activity of rapid-turnover proteins synthesized exclusively in the liver, prolonged prothrombin time indicates functional impairment of the liver in a real-time fashion.

Measurement of tumor markers specific to hepatic malignancies helps the diagnostic process for hepatic neoplasms. For hepatocellular carcinoma (HCC), serum alpha-fetoprotein (AFP) level, proportion of Lens-culinaris agglutinin-reactive fraction of AFP, and plasma des-gamma-carboxyprothrombin (DCP) level have been reported to be useful for both diagnosing and predicting surgical outcomes.[16] Recent studies have reported that these markers are also predictive for posttransplant recurrence of HCC.[17–19] For the other hepatic neoplasms, serum levels of carcinoembryonic antigen and CA19-9 are usually screened to evaluate the malignant potential of the lesions.

Stratification of Overall Status of the Hepatic Functional Reserve

2 For selection of treatment, the overall status of the hepatic functional reserve and the risk of treatment are stratified by the Child–Turcotte–Pugh (CTP) score, which is calculated using the presence of encephalopathy, presence of ascites, serum bilirubin concentration, serum albumin concentration, and prothrombin time (Table 60-1). The CTP score is now included in various treatment algorithms for hepatic neoplasms,[20–22] and liver resection is usually indicated for CTP class A patients or highly selected patients classified as CTP class B. The consensus is that CTP class C patients should not undergo surgical resection due to a high perioperative mortality rate.[21] In the field of liver transplantation, the Model for End-Stage Liver Disease (MELD) score has recently been used as a more sensitive parameter for transplant allocation because of its accuracy in predicting patient mortality on waiting lists.[23,24] Although its suitability and application for liver resection remains debatable,[25,26] the MELD score reportedly predicts posttransplant outcomes through optimizing transplant allocation.[27,28]

Table 60-1 Child–Turcotte–Pugh (CTP) Classification

	Points		
	1	2	3
Albumin (g/dL)	>3.5	2.8–3.5	<2.8
Bilirubin (mg/dL)	<2.0	2.0–3.0	>3.0
Prothrombin time			
Seconds	<4	4–6	>6
International normalized ratio (INR)	<1.7	1.7–2.3	>2.3
Ascites	None	Mild	Moderate to Severe
Encephalopathy	None	Grades I–II	Grades III–VI
CTP class A	5–6 points		
CTP class B	7–9 points		
CTP class C	10–15 points		

Imaging Studies

Adequate imaging is essential for diagnosis, staging, treatment planning, and evaluation of the response to chemotherapy of hepatic neoplasms. Computed tomography (CT) and magnetic resonance imaging (MRI) are the most common modalities used for diagnosing and evaluating patients with liver lesions. CT plays a central role in characterizing hepatic neoplasms because of its accessibility, practicality, low cost, and acceptable sensitivity and specificity. For diagnosis and adequate evaluation of tumor burden, dynamic contrast enhancement with a liver-specific protocol is necessary to characterize the vascularity and extension of the tumor. MRI combining gadolinium ethoxybenzyl diethylenetriamine pentaacetic acid (Gd-EOB-DTPA) delayed imaging and diffusion-weighted imaging provides the best performance for detecting and characterizing liver lesions, particularly those <10 mm in size.[29] Ultrasound is another important modality that is used both for preoperative diagnosis and postoperative follow-up. Although its sensitivity is inferior to CT and MRI, the advantages of ultrasound are that it is accessible and less invasive than the other diagnostic modalities. Contrast-enhanced ultrasound using the second-generation contrast medium perflubutane (Sonazoid) enables evaluation of vascularity and clear visualization of malignant lesions as areas lacking Kupffer cells. Furthermore, intraoperative application of this agent improves the diagnostic value of ultrasound and the curability of surgery.[30,31] ^{18}F-fluorodeoxyglucose positron emission topography (^{18}F-FDG-PET) may be a powerful adjunct to other liver imaging techniques in selected patients. Niekel et al.[32] reviewed 39 articles (3,391 patients) and showed that the estimated sensitivities to detecting CLM on a per-lesion basis for CT, MRI, and ^{18}F-FDG-PET were 74.4%, 80.3%, and 81.4%, respectively. In addition, the usefulness of ^{18}F-FDG-PET has been reported especially for detecting extrahepatic metastases or local recurrence.[33,34] However, increased sensitivity is usually associated with reduced specificity. Limitations of ^{18}F-FDG-PET include its limited availability, high cost, limited access to specialized techniques, and lack of expertise to interpret the results. Therefore, from a practical clinical perspective, CT, MRI, or both should be the first-line modalities for characterizing hepatic lesions and ^{18}F-FDG-PET can be used as the second-line modality for evaluating the metabolic features of the lesion or the presence of extrahepatic disease. Ultrasound should be used as a routine diagnostic tool throughout the perioperative period. It is mandatory for hepatobiliary surgeons to acquire expertise in ultrasonography.

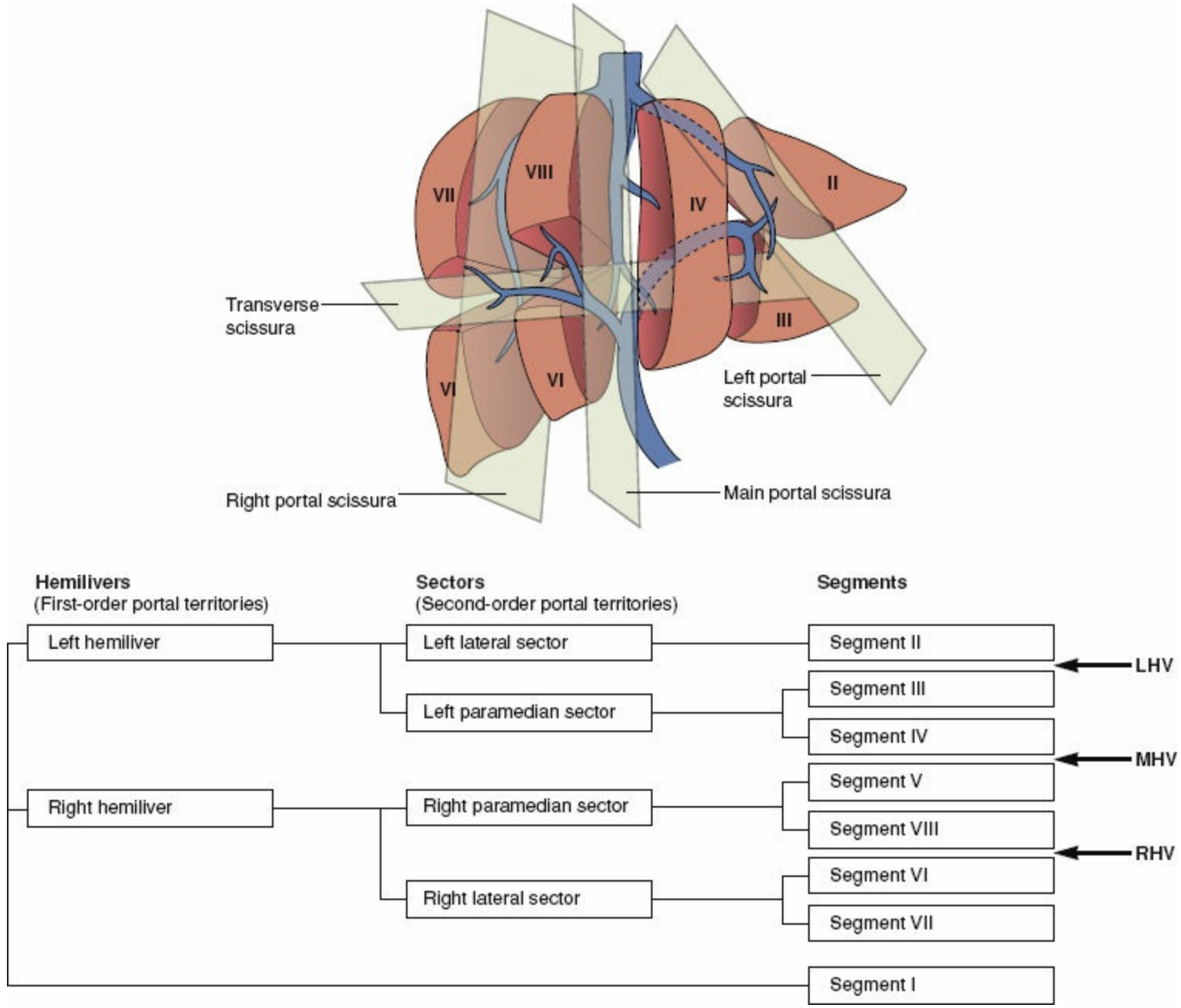

Figure 60-1. Couinaud segmental anatomy of the liver. In Couinaud theory, the liver is divided in to two hemilivers, four sectors, and eight segments according to the portal venous ramification pattern. Three major hepatic veins represent the position of intersectoral plane (called scissura). LHV, left hepatic vein; MHV, middle hepatic vein; RHV, right hepatic vein.

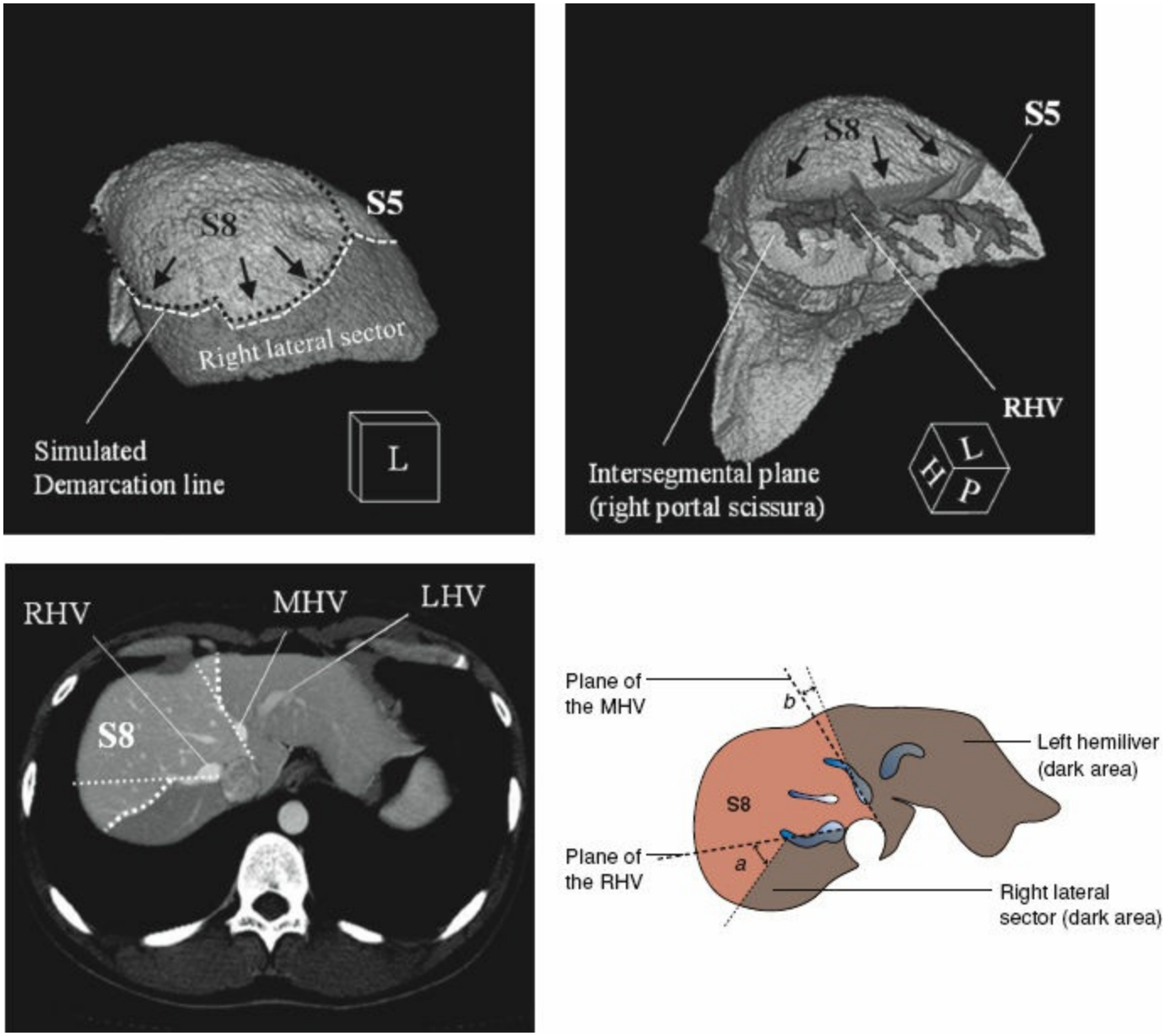

Figure 60-2. Three-dimensional shape of the intersegmental plane. **Top left:** Lateral view of the right hemiliver. The right lateral sector indicated by the dark-gray color and an interdigitated demarcation line is visible on the liver surface (*white dotted line*). Segment VIII (S8) protrudes dorsolaterally (*arrows*) relative to Segment V (S5). **Top right:** Dorsolateral view of the cut surface after a simulated right lateral sectorectomy. The right scissure exhibits a concave shape because of the protrusion of Segment VIII (H, head; L, left; P, posterior). Axial computed tomographic image (**bottom left**) and diagram (**bottom right**) illustrating that the intersegmental border between Segments VIII and VII is not compatible with the plane of the right hepatic vein. The posterolateral part of the right hepatic vein in Segment VIII is presented. (Adapted from Shindoh J, Mise Y, Satou S, et al. The intersegmental plane of the liver is not always flat–tricks for anatomical liver resection. *Ann Surg* 2010;251(5):917–922.)

In radiographic evaluation, the tumor location is described according to Couinaud anatomy for liver segments.[35] In Couinaud theory, the liver can be divided into two hemilivers, four sectors, and eight segments defined as the territories of the first-, second-, and third-order portal branches, respectively (Fig. 60-1). Because typical systematic surgical resection follows the segmental anatomy of the liver, the location of tumor should be defined based on accurate understanding of the segmental anatomy of the liver. "Segment" is defined as a territory of a portal branch and its actual three-dimensional

shape is not simple, despite depictions in many surgical textbooks.[36] For example, Segment VIII usually protrudes craniolaterally, overhanging the right hepatic vein (Fig. 60-2). Accordingly, a hepatic lesion located just to the cranial side or posterolateral side of the right hepatic vein is a Segment VIII tumor, which can be easily confirmed by tracking the nearest portal branches on CT images.

BENIGN HEPATIC NEOPLASMS

Cystic Lesions

Simple Cyst

The distinction between solid and cystic lesions is clinically important, as the vast majority of cystic lesions of the liver are benign in behavior. The majority of the incidentally diagnosed cystic lesions are simple cysts, which have no malignant potential and rarely become symptomatic. However, surgical treatment is considered for symptomatic giant cysts stretching the liver capsule or compressing the adjacent organs. Laparoscopic unroofing (Fig. 60-3) may be the ideal approach for these lesions, which has acceptably good outcomes and a negligible recurrence rate in experienced hands.[37]

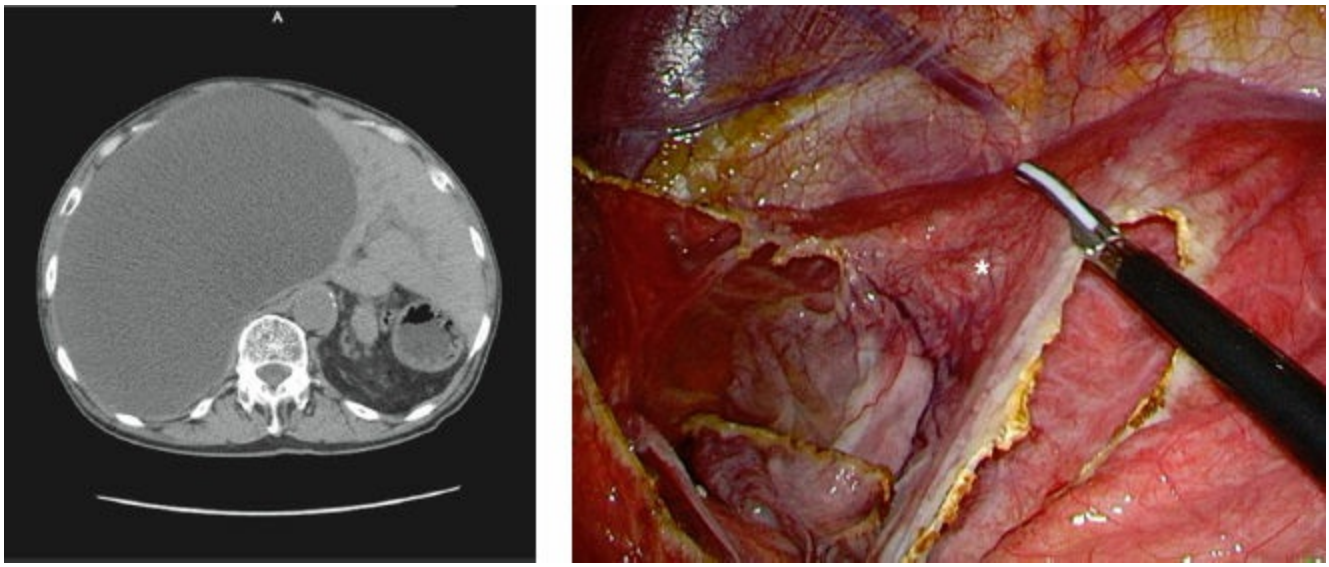

Figure 60-3. A huge hepatic cyst observed in the right hemiliver (**left**). Laparoscopic unroofing (**right**) was performed for this patient to relieve the abdominal pain associated with distension of the liver capsule. Cystic fluid was first suctioned and then the anterior wall of the cyst (*) was resected with an energy device. (Images courtesy to Dr. Yasuji Seyama.)

Polycystic Liver Disease

Polycystic liver disease (PLD) is a rare presentation of cystic liver lesions and can be difficult to manage.[38] Approximately 80% to 90% of PLD cases represent an autosomal dominant disease associated with polycystic kidney disease. In these patients, renal failure frequently occurs due to destruction of the kidney by multiple cysts. Although patients with PLD rarely develop hepatic failure regardless of the marked change in the distorted liver on imaging studies (Fig. 60-4), various symptoms caused by distention of the liver, stretching of the diaphragm, or compression of the adjacent organs require therapeutic intervention. Treatment for PLD should be performed in a stepwise fashion. Ultrasonically guided puncture of the cysts should be the first choice to decompress the distended cysts and drain the fluid. If percutaneous aspiration is not effective, the next option is laparoscopic fenestration of the cysts. Liver resection or transplantation should

be the final treatment option. A limited number of patients require liver transplantation due to the progressive destruction of liver parenchyma and hepatic dysfunction. However, liver transplantation for PLD is a challenging procedure due to severe adhesion and huge liver size, usually causes major bleeding, and requires a large amount of transfusions especially for patients with a history of multiple interventions or surgery for PLD. A recent report suggested that a history of open intervention is a strong risk factor for severe postoperative complications, longer hospital stay, and poor long-term outcomes after transplantation.[39] Therefore, a minimally invasive approach is preferable for disease-directed interventions for PLD as long as this approach is viable.



Figure 60-4. CT image of a patient with polycystic liver associated with autosomal dominant polycystic kidney disease. The liver is markedly distended due to destruction of the liver by multiple cysts and compensatory regeneration of hepatic parenchyma. However, the hepatic function is maintained with an albumin level of 2.8 g/dL, bilirubin level of 1.5 mg/dL, and INR of 1.12, with slight ascites and no evidence of encephalopathy (Child–Turcotte–Pugh class B).

Biliary Cystadenoma

3 Most hepatic cysts are asymptomatic, and surgical resection is indicated only for lesions for which there is concern for malignancy or malignant potential. Wall enhancement in contrast-enhanced CT, serrated or septated wall visualized by ultrasound, or rapid increase in size suggests malignant potential of a lesion. Biliary cystadenoma is the common cystic lesion with malignant potential, accounting for 5% of all cystic lesions in the liver.[40] These lesions arise from the biliary epithelium and typically present in middle-aged women. Because it is difficult to distinguish between cystadenoma and cystadenocarcinoma (Fig. 60-5) and because cystadenoma has a propensity toward local recurrence and malignant degeneration to cystadenocarcinoma,[41,42] surgical resection is indicated primarily when biliary cystadenoma is suspected.

Solid Lesions

Solid lesions should be handled with care because benign lesions are sometimes difficult to discriminate from malignant tumors.

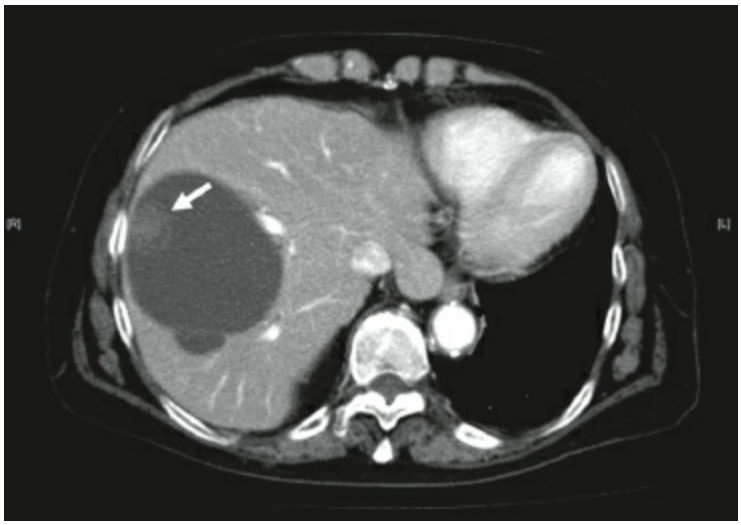

Figure 60-5. CT image of a cystadenocarcinoma. A multicystic lesion with an enhanced intracystic papillary component was observed (*arrow*).

Hemangioma

Hemangioma is the most common benign lesion observed in the liver; the estimated prevalence is 3% to 20%.[43] Most hemangiomas are identified in individuals aged 40 to 60 years and appear to be more common in women, with a female-to-male ratio of 2:1.[44] Grossly, hemangiomas are well-circumscribed and compressible lesions. Histopathologically, multiple blood vessels lined by endothelial cells are present.[45] The majority of hemangiomas are small asymptomatic lesions that can be managed nonsurgically. Spontaneous or traumatic rupture of hemangioma in exceptional cases has been reported, but the risk of rupture is considered very low. Therefore, the majority of these cases can be left untreated with regular follow-up imaging studies.

Accurate radiographic diagnosis of a hepatic hemangioma is important, as establishment of this diagnosis requires no additional intervention for the majority of patients. For diagnosis, a dynamic study is the most important for characterizing the hemodynamics in a lesion. Contrast-enhanced CT demonstrates a typical pattern of nodular enhancement from the periphery with central filling on delayed images (Fig. 60-6). Contrast-enhanced MRI also shows similar patterns in dynamic studies, and a very high intensity in T2-weighted images is suggestive of hemangioma. A diagnosis of hemangioma should be made based on these radiographic findings. Although biopsy is not absolutely contraindicated, a fatality from uncontrollable bleeding has been reported, so unnecessary biopsy should be avoided.[46]

Surgical resection is warranted in the setting of abdominal symptoms,[47–49] spontaneous rupture,[50] rapid growth of the lesion,[51] or coagulopathy due to Kasabach–Merritt syndrome. Elective surgical treatment is accomplished by either enucleation or formal hepatic resection. Enucleation is often easily performed because hemangiomas are

exophytic to some degree and a pseudocapsular plane can be developed efficiently. Hemangiomas typically have limited outflow and the internal pressure may be high. Early ligation of the feeding arteries, especially in patients with large hemangiomas, is a key point, as the size reduction caused by the decompression is technically beneficial for surgical manipulation and resection.

Focal Nodular Hyperplasia

Focal nodular hyperplasia (FNH) is the second most common benign neoplasm of the liver. A clinical and autopsy series estimated that FNH occurs in 4% to 8% of individuals, with a strong predilection for women aged 20 to 50 years.[43] Unlike the origin of hemangioma or hepatocellular adenoma, the origin of FNH is thought to be due to hyperplastic growth of normal hepatocytes with a malformed biliary draining system or a hyperplastic response to a pre-existing arteriovenous malformation. FNH does not contain a portal venous supply.

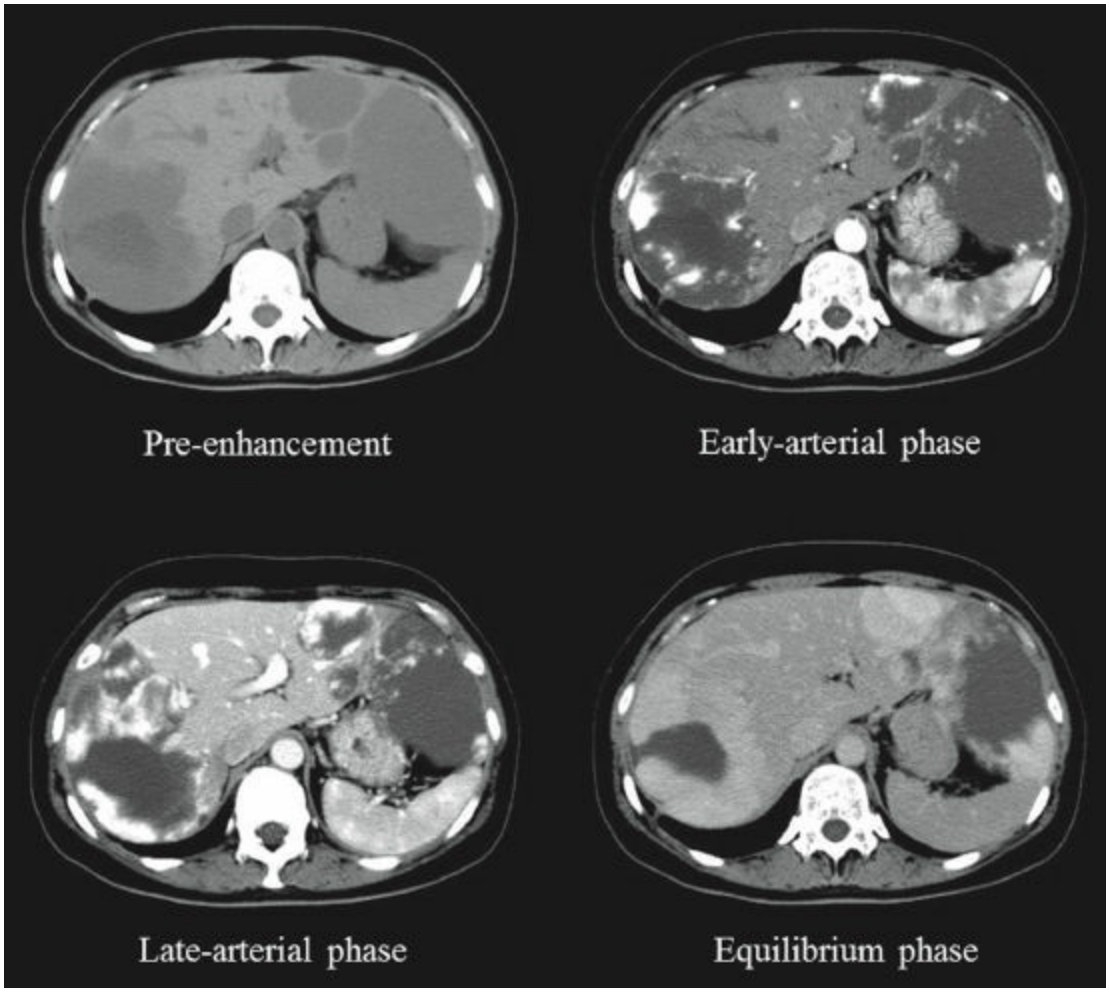

Figure 60-6. Nodular enhancement typically observed in hemangioma in dynamic CT. The mass is gradually enhanced from the peripheral part to the central part of the lesion.

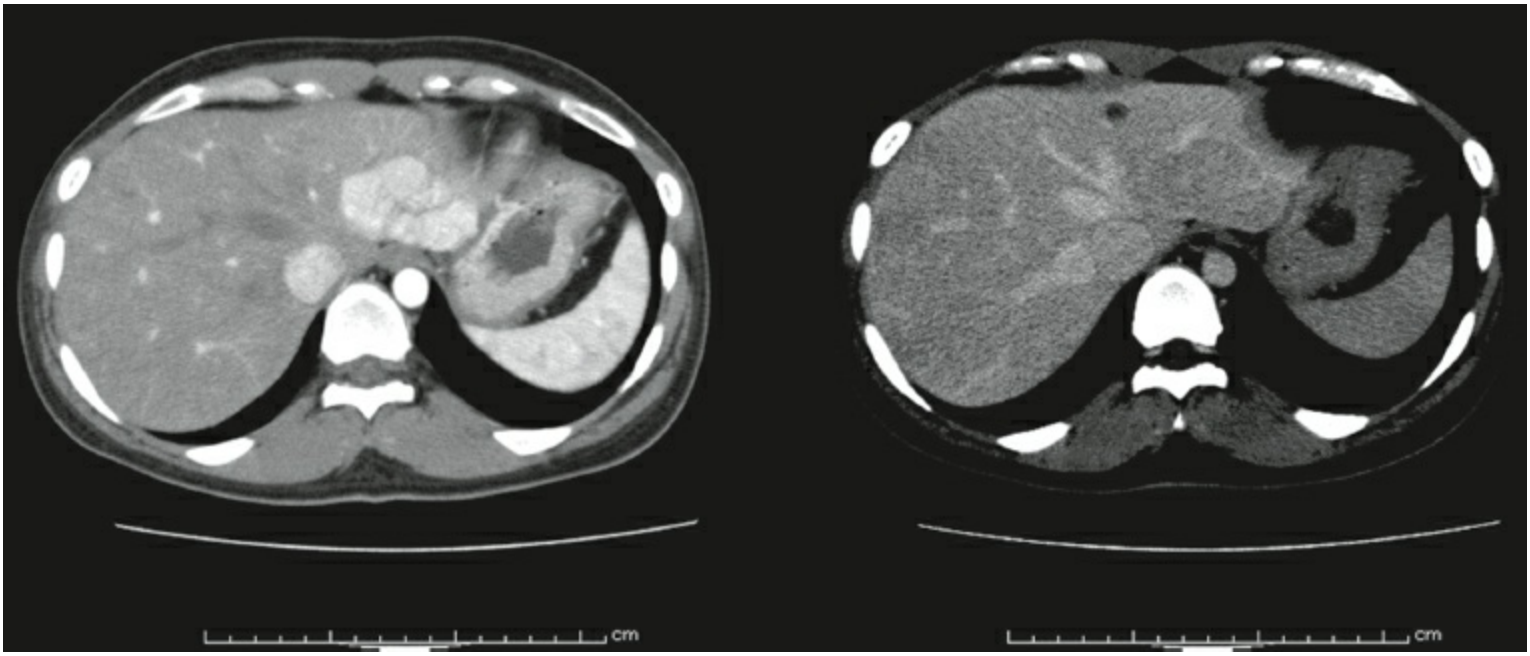

Figure 60-7. Typical dynamic CT image of focal nodular hyperplasia. The lesion is homogeneously enhanced in the arterial phase with central hypodensity area suggestive of a central scar (**left**). The mass becomes isodense in the portal phase (**right**).

In plain CT, the lesion is isoattenuated with normal liver and may exhibit the characteristic hypoattenuated central scar. With contrast in the arterial phase, FNHs enhance brightly and become again isoattenuated to adjacent parenchyma in the portal phase (Fig. 60-7). The central scar may enhance on delayed phases. MRI reveals a similar dynamic enhancement pattern: FNHs appear isointense on T1-weighted images and hyperintense on T2-weighted sequences. With gadolinium enhancement, the lesion is homogeneously enhanced in the arterial phase and the central scar becomes hypointense in the delayed phase.

The majority of FNHs is asymptomatic and found incidentally on abdominal imaging for other indications. Because of the benign nature of FNHs and the very low risk of spontaneous rupture, treatment should be reserved for patients with persistent symptoms not explained by another problem.

Hepatic Adenoma

Hepatic adenoma (HA) is a rare benign tumor with an estimated prevalence of approximately 1% on postmortem examinations.[52] Typically, HAs occur in women of child-bearing age who often have a history of long-term use of oral contraceptives. In the majority of the cases, HA lesions are solitary and asymptomatic. However, the presence of multiple nodules (typically >10 nodules) indicates a distinct entity called hepatic adenomatosis, which has a different implication for treatment.[53]

Adenomas are well-circumscribed lesions that contain sheets of hepatocytes without intervening biliary ductules or portal tracts. Conventionally, HA was considered to have variable imaging characteristics and was described as a heterogeneous hypervascular mass with areas of fat, hemorrhage, and necrosis on multiphase CT or MRI.[54] With the introduction of the new phenotype–genotype classification of HA, however, correlation

between the imaging characteristics and different subtypes has been reported.[55,56] HAs are grouped into 1 of 4 subtypes. HA-H (*HNF1A*-mutated hepatic adenoma) is the most frequently occurring one (35% to 40%), presenting steatosis and absence of inflammatory infiltrate or cytologic atypia. This subtype is frequently associated with somatic mutation of the *TCF1* (*HNF1A*) gene or heterozygous germline mutations of the *CYP1B1* gene. HA-B (β-catenin–mutated hepatic adenoma, 15% to 19%) is morphologically characterized by pseudoacinar formation and mild cytologic atypia. Steatosis is rare and inflammation is absent in this subtype. β-Catenin gene-activating mutations are frequently observed in this subtype. HA-I (inflammatory hepatic adenoma, 30% to 35%) exhibits pseudoportal tracts that lack veins and bile ducts and contain large, thick-walled arteries surrounded by fibroconnective tissue with variable ductular reaction and inflammation. The last subtype, HA-U (10%), is associated with gain-of-function mutations of the *IL6ST* gene. These HAs lack distinctive morphologic and molecular features.

Patients with HAs appear to have a risk of either rupture or malignant transformation (estimated risk of 4.2% to 4.5%[57,58]), which is different from the other benign lesions. The HA-B subtype has been found to be more frequently associated with the development of HCC.[59,60] For small lesions (<5 cm), some experts have recommended withdrawal of oral contraceptives in the expectation of tumor regression.[61,62] However, regression of HA upon cessation of oral contraceptives does not remove the risk of malignant transformation in women.[63] High-risk groups for malignant transformation include male patients, patients with a history of androgenic or anabolic steroid intake, and patients with glycogen storage disease.

The potential for malignant transformation and the risk of hemorrhage drive active surgical interventions for large HAs. Surgical resection is recommended for HAs >5 cm, those with intratumoral hemorrhage, and those that increase in size.[64–67] HAs are hypervascular tumors and are sometimes difficult to distinguish from HCC. Typically, HAs are represented by bright enhancement in the arterial phase and iso- to hypodensity in the portal phase (Fig. 60-8). With MRI, HAs are visualized as well-defined lesions with isointense or hyperintense features on T1- and T2-weighted images, depending on the fat content. Similar to dynamic CT, gadolinium enhancement shows marked enhancement in the arterial phase and isointensity in the portal phase.

PRIMARY HEPATIC MALIGNANCIES

Hepatocellular Carcinoma

Primary liver cancer is one of the most common solid tumors and the second-leading cause of cancer-related deaths worldwide.[68] Despite recent developments in preventing and treating viral hepatitis, nearly 750,000 deaths were reported in 2012 for patients with primary liver cancer. Among these cases, HCC is the most common type of hepatic malignancy. There is wide geographic variability in incidence, with the majority of the cases occurring in developing countries compared with developed countries. China alone accounts for more than half of the new cases of liver cancer; other high-incidence areas are sub-Saharan Africa, Japan, and Southeast Asia, where viral hepatitis or aflatoxin exposure is more endemic. In the United States, the incidence of HCC is increasing the second-fastest of all tumor types, probably due primarily to the HCV epidemic.[69] There is also global variation in the risk factors for HCC. HBV and HCV infections are the leading causes of HCC, accounting for 75% of the cases worldwide.[70] HBV infection is more common except in Japan, where HCV infection is the most common cause of HCC. Alcoholic liver disease accounts for a significant proportion of HCC in the Western countries. Aflatoxin exposure is also an important risk factor in China and sub-Saharan Africa.

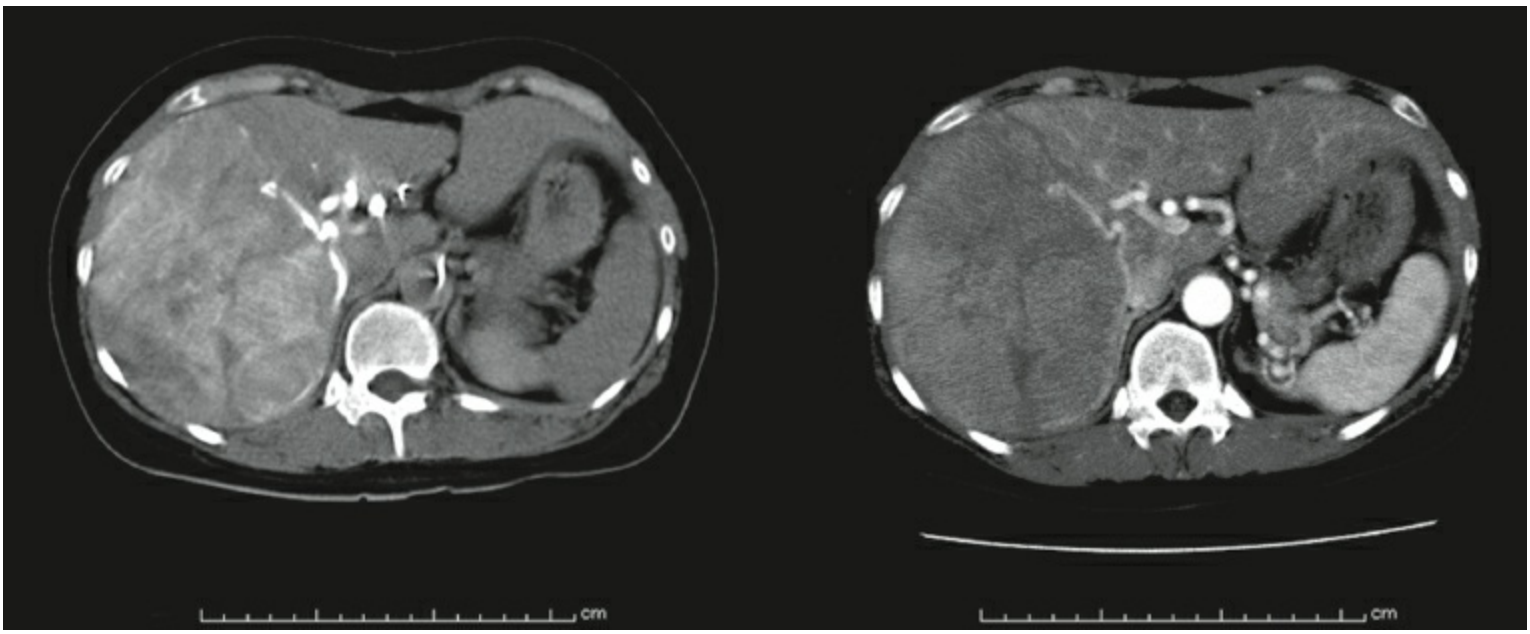

Figure 60-8. A huge hepatic adenoma found in a 31-year-old woman. Dynamic CT revealed early enhancement in the arterial phase **(left)** and iso- to hypodensity in the portal phase (**right**). This patient had no underlying liver disease and both serum alpha-fetoprotein level and plasma des-gamma-carboxyprothrombin level were within normal limits.

Screening measures for HCC have been assessed in various studies, which primarily focus on the roles of serum AFP level and ultrasound. The American Association for the Study of Liver Disease (AASLD) has created guidelines regarding the use of these screening techniques based on the best existing evidence.[20] The AASLD currently recommends serial hepatic ultrasonography and serum AFP measurement every 6 to 12

months for at-risk populations (e.g., any patient with cirrhosis). Similarly, the Japanese Society of Hepatology has recommended hepatic ultrasonography and serum AFP or plasma DCP measurement every 3 to 4 months and dynamic CT or MRI every 6 to 12 months for very-high-risk populations (e.g., those with HBV- or HCV-related cirrhosis), and hepatic ultrasonography and assessment for tumor markers every 6 months for high-risk populations (e.g., HBV- or HCV-related chronic hepatitis, or cirrhosis with other etiologies) with or without dynamic CT or MRI every 6 to 12 months, as appropriate.[71] A randomized controlled trial from China reported that the use of ultrasound and AFP enables early detection of HCC and lowers HCC-related mortality by 37% in patients with HBV infection.[72] Various nonrandomized studies have confirmed prognostic improvement through regular surveillance programs among patients at high risk of HCC.[73–75] Regarding the interval of screening, a recent meta-analysis revealed that surveillance every 6 months is significantly better than screening every 12 months for the early detection of HCC. Santi et al.[76] reported that 70% of newly diagnosed HCCs fell within the Milan criteria (solitary tumor ≤ 5 cm or ≤ 3 tumors with each tumor ≤ 3 cm)[77] when screening occurred at least every 6 months, while the proportion of HCCs that fell within the Milan criteria was 57% and the overall survival rate was inferior with surveillance every 6 to 12 months. When a suspected nodule is detected during regular screening, a contrast-enhanced three-phase CT or MRI is needed. Because HCCs are fed mainly by arterial flow, early enhancement and washout of contrast on the delayed phase of the scan are typical findings suggestive of HCC (Fig. 60-9). These enhancement characteristics increase the specificity of the scan to $>95\%$.[78]

4 The choice of therapy is individualized based on the tumor burden, degree of underlying liver disease, patient performance status, and overall possibility of side effects or complications balanced with acceptable results. The Barcelona Clinic Liver Cancer (BCLC) staging system[79] is widely used to stratify patients for specific therapies (Algorithm 60-1). However, the limitation of the BCLC algorithm is that it is fairly conservative with regard to the application of surgical therapy. Patients with larger solitary tumors are not considered surgical candidates despite growing experience with resection with acceptable outcomes in this group.[80,81] In the guidelines on liver cancer treatment proposed by the Japan Society of Hepatology,[22] surgical resection is indicated for CTP class A or class B patients with HCCs with up to three nodules irrespective of the size of each tumor, while liver transplantation is limited to CTP class C patients meeting the Milan criteria.

For HCC patients undergoing liver resection, strict assessment of the hepatic functional reserve is important because HCC usually develops in an injured liver and, accordingly, the maximum extent of resection must be estimated carefully. Functional investigations have been proposed to better evaluate the severity of chronic liver disease. Measurement of indocyanine green (ICG) retention rate at 15 minutes (ICG-R15) is the most frequently used test. For patients with obstructive jaundice or congenital intolerance to ICG, ^{99m}Tc-galactosyl human serum albumin (GSA) scintigraphy sensitively estimates the hepatic functional reserve. Algorithm 60-2 shows a decision tree used for surgical planning according to the individual hepatic functional reserve (Makuuchi criteria).[82] By strictly

following this algorithm, no mortality due to hepatic insufficiency was reported in the University of Tokyo series.[1]

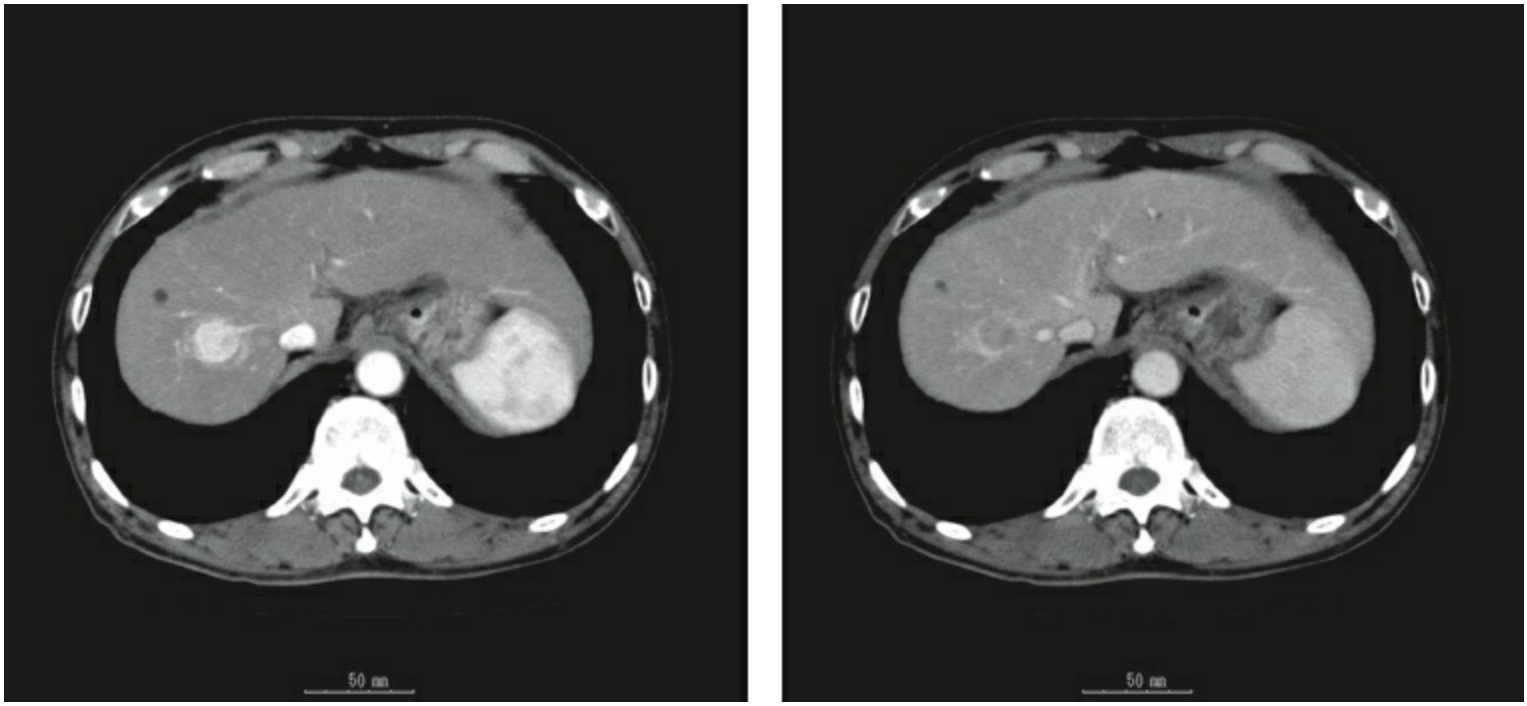

Figure 60-9. Typical enhancement pattern of HCC with early enhancement in the arterial phase (**left**) and washout in the portal phase (**right**).

Because HCC tends to spread via portal veins, anatomic resection of the tumor-bearing portal territory is a theoretically reasonable approach (Fig. 60-10). Although the efficacy of anatomic resection remains controversial, various studies have reported prognostic superiority of anatomic resection with an apparent lower local recurrence rate and a higher recurrence-free survival rate compared to nonanatomic limited resection of the liver.[83–85] Liver transplantation is another surgical approach with a theoretically higher chance of eradicating the tumor burden, especially for patients with severe hepatic dysfunction. Clinical outcomes of liver transplantation for HCC were initially poor in the early era. However, after the landmark study by Mazzaferro et al.,[77] good survival outcomes are expected in select HCC patients with tumors of limited size and a small number of nodules (Milan criteria). The selection criterion for transplantation used by Mazzaferro et al.[77] was a tumor diameter of ≤ 5 cm in patients with a single HCC or ≤ 3 cm in patients with 2 or 3 lesions. This criterion has since been extended with or without tumor markers or biopsy findings in several high-volume transplant centers (Table 60-2).[86–97]

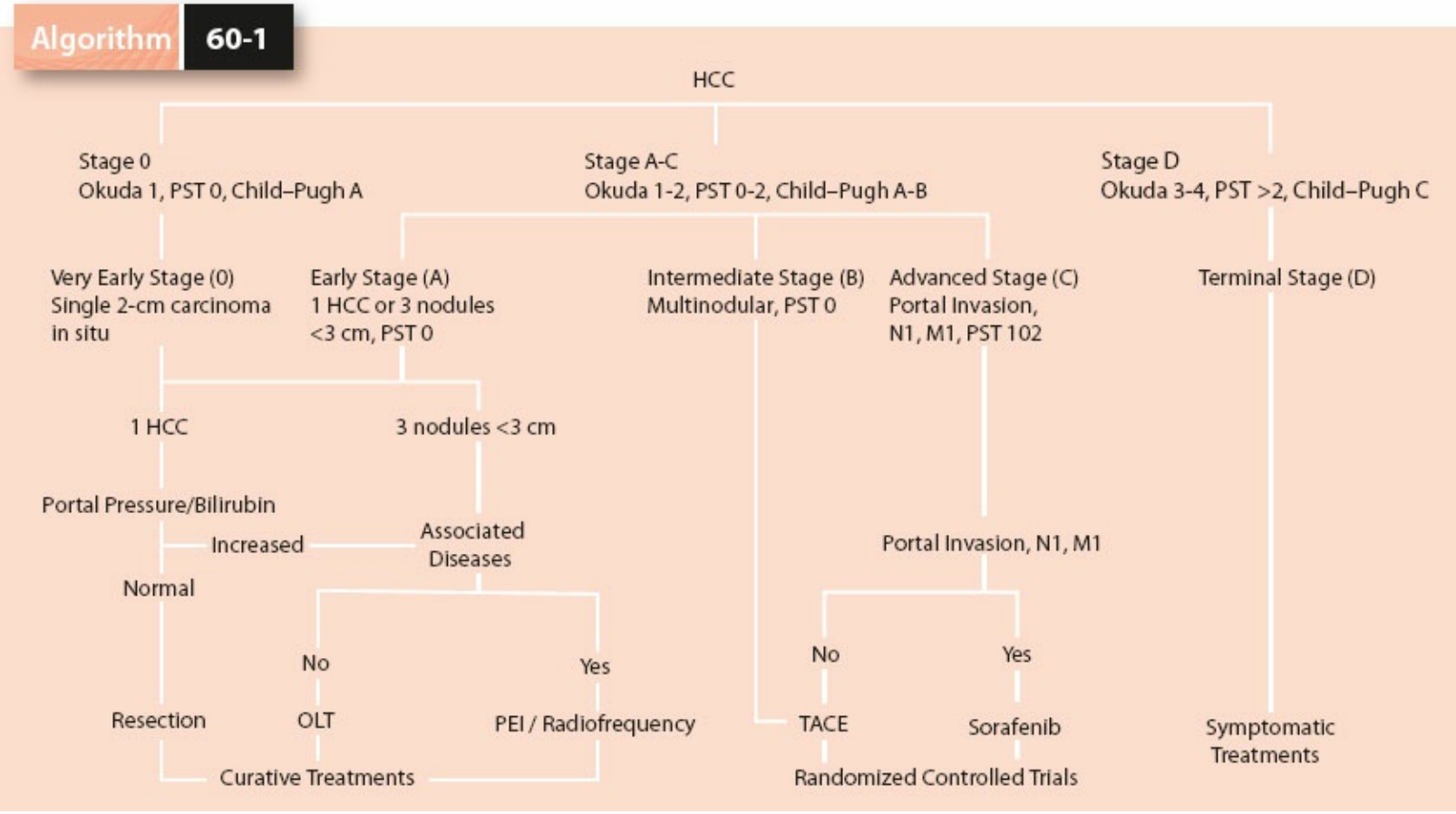

Algorithm 60-1. BCLC algorithm for treatment selection in patients with HCC. (Adapted from Llovet JM, Burroughs A, Bruix J. Hepatocellular carcinoma. *Lancet* 2003;362:1907–1917 with permission.)

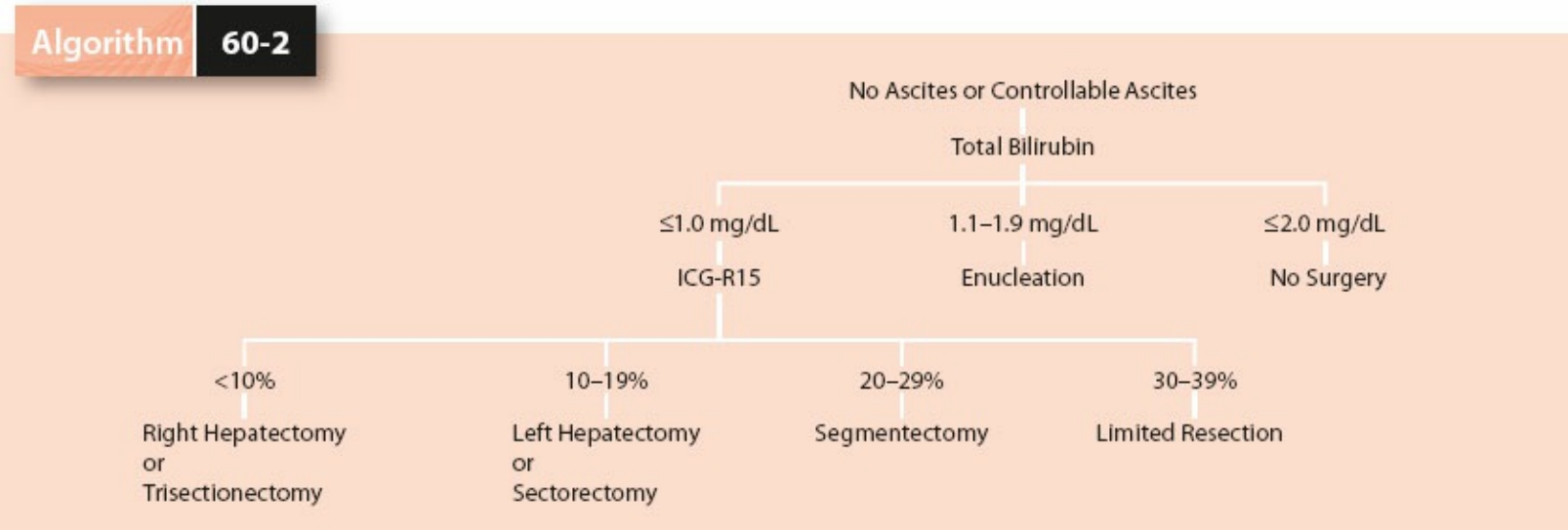

Algorithm 60-2. Treatment algorithm of patients with hepatocellular carcinoma (HCC) based on serum bilirubin level and indocyanine green retention rate at 15 minutes. (Adapted from Makuuchi Kosuge T, Takayama T, et al. Surgery for small liver cancers. *Semin Surg Oncol* 1993;9:298–304 with permission.)

Intrahepatic Cholangiocarcinoma

Intrahepatic cholangiocarcinoma (ICC) is a relatively uncommon disease, accounting for 5% to 30% of all primary liver malignancies.[98] In the United States, the age-adjusted incidence of ICC increased from 0.32 in 1975 to 0.85 per 100,000 population in 2000 and has yet to plateau.[99] The overall 5-year survival rate for patients with unresectable tumor is dismal: 5% to 10%. Because systemic therapy for ICC has not yet been established, surgical resection offers the only chance for cure. However, the overall 5-year survival rate after curative-intent surgery is disappointing at 20% to 35%.[100]

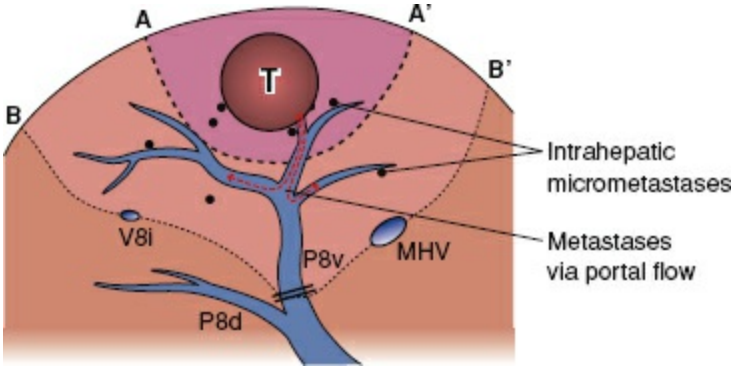

Figure 60-10. Theoretical concept of anatomic resection for HCC. This schema shows an example of resection for HCC located in the ventral part of Segment VIII. The *dashed line* A-A' indicates nonanatomic limited resection with adequate surgical margin and the *dotted line* B-B' represents anatomic resection of the ventral part of Segment VIII. Because the "tumor-bearing" portal territory is at high risk of harboring micrometastases scattered via portal veins (*arrows*), systematic removal of the corresponding portal region would offer a better chance of eradicating the cancer cells. With systematic removal of the territory of the ventral branch of Segment VIII, the tumor-bearing portal territory, which is at high risk of micrometastases, can be resected. T, tumor; P8v, ventral branch of Segment VIII portal pedicle; P8d, dorsal branch of Segment VIII portal pedicle; MHV, middle hepatic vein; V8i, intermediate vein for Segment VIII.

ICC is thought to derive from a common hepatic progenitor cell that may also give rise to HCC,[101] and combined hepatocellular-cholangiocarcinoma having histopathologic features of both HCC and ICC is sometimes observed. Risk factors for ICC have not yet been established, although chronic liver disease and cirrhosis are reportedly correlated with ICC. On dynamic imaging studies, ICC is not enhanced due to the hypovascular nature of this tumor type. However, various degrees of ring enhancement are observed surrounding the lesion, reflecting the fibrous connective tissue frequently observed around the tumor. In laboratory tests, elevated carcinoembryonic antigen or CA19-9 in primary solid liver lesion is suggestive of ICC.

A recent meta-analysis showed that factors associated with shorter overall survival included older patient age, larger tumor size, multiple tumors, lymph node metastasis, vascular invasion, and poor tumor differentiation. Because up to 30% of patients have lymph node metastases, routine lymphadenectomy is recommended,[102] although the survival benefit remains controversial.

METASTATIC LIVER TUMORS

Colorectal Liver Metastases

5 Colorectal cancer is the second-leading cause of cancer-related deaths in the United States. About 20% to 25% of colorectal cancer patients are found to have synchronous CLM,[103,104] and 35% to 55% develop CLM during the course of the disease.[105] The 5-year survival rate after curative resection of CLM has been reported to be up to 58%,[106–108] while the median survival duration for patients with CLM without any treatment is approximately 6 months.[104] Therefore, adequate assessment and preoperative management are important in selecting patients with resectable or potentially resectable CLM who are candidates for liver resection.

CLMs are classified as stage IV colorectal cancer. However, with recent advancements in chemotherapy and surgical management, the resectability of CLM has dramatically increased and long-term survival after resection of CLM has significantly improved.[109] The practical keys to the initial management of CLM include precise assessment of the extension of disease and the proper selection of the initial therapeutic options. Although surgical resection is potentially the most curative strategy for CLM, a multidisciplinary approach by surgeons, medical oncologists, radiologists, and pathologists is essential for selecting the patients who would benefit from surgery and to determine the optimal timing of surgery (Algorithm 60-3).[110]

Table 60-2 Published Results of Expanded Liver Transplant Eligibility Criteria for Hepatocellular Carcinoma

Authors (Year)	Eligibility Criteria	Overall Survival Rate (%)					
		Within Milan Criteria			Within Extended Criteria		
		1 yr	3 yrs	5 yrs	1 yr	3 yrs	5 yrs
Yao et al. (2001) ([96])	"UCSF criteria" No extrahepatic spread or macrovascular invasion Solitary tumor with diameter ≤6.5 cm, OR ≤3 nodules with maximum diameter ≤4.5 cm and total tumor diameter ≤8.0 cm	91	—	72	90	—	75
Ito et al. (2007) ([88])	"Kyoto criteria" No extrahepatic disease or macrovascular invasion ≤10 nodules with maximum diameter ≤5.0 cm, AND DCP ≤400 mAu/mL	—	—	72	—	—	87
Jonas et al. (2007) ([89])	No extrahepatic spread or macrovascular invasion Solitary nodule of any diameter, OR multiple nodules with individual diameter ≤6.0 cm and total tumor diameter ≤15.0 cm	—	75	—	—	68	—
Kwon et al. (2007) ([90])	No extrahepatic spread or macrovascular invasion Unlimited number of nodules if maximum diameter ≤5.0 cm AND AFP <400 ng/nL	—	—	>80	95	—	87
Sugawara et al. (2007) ([94])	"5–5 rules" No extrahepatic disease or macrovascular invasion Nodules ≤5 with maximum diameter ≤5.0 cm	92[a]	83[a]	81[a]	94[a]	86[a]	83[a]
Herrero et al. (2008) ([87])	"Clinica Universitaria de Navarra" No extrahepatic disease or macrovascular invasion Solitary nodule ≤6.0 cm, OR 2–3 nodules with maximum diameter ≤5.0 cm	88	73	66	88	72	68
Lee et al. (2008) ([91])	"Asan criteria" No extrahepatic disease or macrovascular invasion ≤6 nodules with maximum diameter ≤5.0 cm	—	—	76	—	—	76
Silva et al. (2008)([93])	No extrahepatic disease or macrovascular invasion ≤3 nodules with maximum diameter ≤5.0 cm and total tumor diameter ≤10.0 cm	82	68	69	92	79	69
Toso et al. (2008) ([95])	No extrahepatic disease or macrovascular invasion Total tumor volume <115 cm^3	—	—	82	—	—	80
Zheng et al. (2008) ([97])	"Hangzhou criteria" No extrahepatic disease or macrovascular invasion Total tumor diameter ≤8.0 cm OR total tumor diameter >8.0 cm, with grade I or II tumor on biopsy and AFP ≤400 ng/mL	94	78	78	93	71	71

Mazzaferro et al. (2009) ([92])	"Up-to-seven" No extrahepatic disease or macrovascular invasion Sum of number of nodules and diameter of largest nodule (in cm) ≤7	—	82 (MVI–) 77 (MVI+)	76 (MVI–) 72 (MVI+)	—	66 (MVI–) 60 (MVI+)	71 (MVI–) 47 (MVI+)
DuBay et al. (2011) ([86])	"Toronto criteria" No extrahepatic disease or macrovascular invasion Unrestricted tumor size or number No systemic symptoms Not poorly differentiated on biopsy (tumors beyond Milan criteria only)	—	—	72	—	—	70 79 (with biopsy)

MVI, microvascular invasion; UCSF, University of California San Francisco; AFP, alpha-fetoprotein; DCP, des-gamma-carboxyprothrombin.
[a]Updated data with personal communication.

In imaging evaluation, the choice of imaging technique for pretreatment assessment of CLM depends on the local expertise and the availability of imaging modalities. However, at least CT of the chest, abdomen (including three-phase liver protocol CT), and pelvis should be performed routinely to evaluate patients with CLM, with selective use of MRI and PET to further evaluate small hepatic nodules or extrahepatic disease.

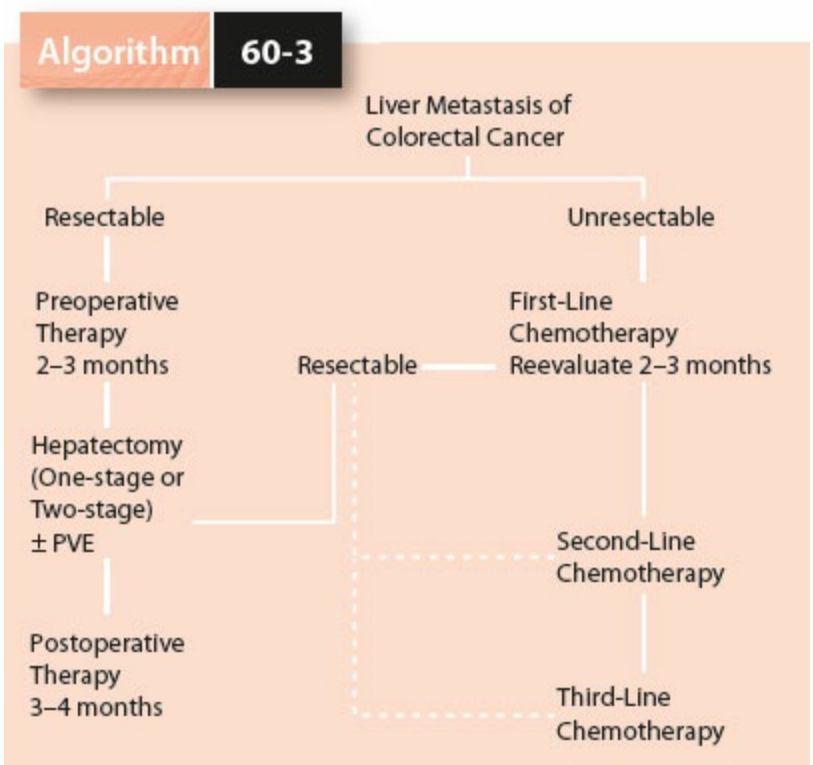

Algorithm 60-3. Multidisciplinary treatment approach for colorectal liver metastasis. (Adapted from Kopetz S, Vauthey JN. Perioperative chemotherapy for resectable hepatic metastases. *Lancet* 2008;371:964–965 with permission.)

The surgical indication for CLM should be considered from two standpoints: oncologic resectability and technical resectability. From an oncologic standpoint, complete resection of all viable disease is crucial if the patient is to derive the most benefit from surgery.

The presence of extrahepatic disease does not necessarily represent an absolute contraindication for surgery. Isolated lung metastases have reportedly been associated with a high 5-year survival rate (30% to 40%) when complete resection is feasible. Localized peritoneal disease correlates with an intermediate 5-year survival rate (15% to 30%), whereas para-aortic adenopathy and evidence of multiple sites of extrahepatic disease are rarely associated with favorable survival after resection of CLM (5-year survival rate $<15\%$).[111] These data suggest that patients harboring limited extrahepatic disease are amenable to surgical resection with a reasonable expectation for long-term control with adjuvant therapies.[112] However, when the extrahepatic disease is unresectable or uncontrollable with systemic chemotherapy, hepatic resection for CLM is contraindicated.

Another oncologically important factor in determining resectability is response to chemotherapy. With modern effective chemotherapy, disease progression during neoadjuvant systemic therapy is relatively rare. However, some patients present with tumor progression during preoperative systemic therapy. Growth of pre-existing intrahepatic metastases does not seem to be associated with poor outcomes. However, development of a new lesion is reportedly associated with a poor prognosis after resection of CLM.[113] Therefore, the oncologic behavior of the tumor during preoperative chemotherapy offers useful information to adequately stratify patients who would benefit from surgical resection.

From a technical standpoint, the resectability of CLM relies on anatomic considerations and underlying hepatic function. Because a safety limit for the extent of liver resection exists according to individual hepatic functional reserve, assessment of hepatic function and systematic volumetry of FLR are mandatory to estimate the risk of postoperative hepatic insufficiency and preoperative intervention to reduce the risk of surgery, as described later in this chapter. When the estimated FLR volume is smaller than the minimal FLR volume, to avoid postoperative hepatic insufficiency PVE or another approach, including two-stage resection, is considered.

Neuroendocrine Liver Metastases

Neuroendocrine tumors grow indolently and metastasize primarily to the liver. In the majority of the cases, these tumors are nonfunctioning and patients with a significant tumor burden can remain asymptomatic for years, while patients with minimal lesions can suffer various symptoms caused by excessive production of hormones by the tumor. Although the best treatment strategy has not yet been established, resection of functioning NETs reduces symptoms and prolongs survival. The survival rate of patients undergoing liver resection is relatively high, reaching 91% at 3 years[114] and 61% at 5 years,[115,116] even though the curative resection rate is relatively low. NETs are basically incurable in most advanced-stage cases. However, cytoreduction of $>90\%$ of the tumor volume is reportedly superior to other treatment options, such as transarterial embolization or systemic therapy.[117,118] To maximize the treatment outcomes, a multidisciplinary approach that includes surgery, transarterial embolization, systemic chemotherapy, and radiation is needed.

PREOPERATIVE SURGICAL MANAGEMENT

When surgical resection is selected as an initial treatment for hepatic malignancy, secondary assessments for surgical planning and preoperative management are required.

6 For surgical planning, precise anatomic interpretations of the intrahepatic vascular structures are needed. This step specifies the ramification pattern of each vascular structure based on the imaging studies and knowledge of anatomic variations.

Important variations in the portal venous system include its ramification patterns at the hepatic hilum. In approximately 80% of patients, the main portal vein bifurcates into the left and right portal branches at the hepatic hilum (bifurcation type). However, trifurcation into the left paramedian, right paramedian, and right lateral portal trunks at the hilum (10%) or early branching of the right lateral pedicle (10%) (trifurcation type) is frequently encountered in major hepatectomy. In addition, anomalies such as right-sided ligamentum teres (0.6% to 1.2%), lack of left portal trunk (0.9%), or lack of intrahepatic portal vein (<0.1%) are sometimes encountered. Because the portal ramification pattern defines the segmental anatomy of an individual liver, precise confirmation of the anatomy in the portal venous system is of primary importance.

As for the hepatic veins, attention should be paid to the drainage pattern of the right lateral sector (i.e., Segments VI + VII) because thick accessory right hepatic veins, such as the middle right hepatic vein or the inferior right hepatic vein,[119] are observed in nearly 70% of cases. Care must be taken when these veins are thick and drain a large portion of Segment VI or VII because ligation of these veins may cause congestion of the right lateral sector and because careless handling of the right hemiliver during mobilization may cause incidental injury of these veins, resulting in massive bleeding (Fig. 60-11).

Regarding the hepatic arteries, the presence or lack of a “replaced” or “accessory” hepatic artery is important. Typically, both right and left hepatic arteries are derived from the proper hepatic artery. However, there are two frequent variations in the ramification patterns of the left and right hepatic arteries: the left hepatic artery sometimes branches from the left gastric artery, running in the lesser omentum and feeding Segments II and III, and the right hepatic artery sometimes originates from the superior mesenteric artery, running behind the portal vein and reaching the right hemiliver on the right side of the hepatic hilum. When the total arterial supply for the left lateral section (Segments II + III) or right hemiliver comes from these aberrant arteries, these arteries are called “replaced” arteries, while they are called “accessory” arteries when the other arterial flow from the proper hepatic artery is also present. Because of the presence of a typical arterial route derived from the proper hepatic artery, accessory arteries can be ligated. In contrast, due to a lack of compensatory arterial supply from the proper hepatic artery, the replaced arteries should be preserved when the corresponding part of the liver is not resected. Therefore, preoperative review of the arterial anomalies in the early arterial phase in dynamic CT is essential, and a routine clamp test with Doppler ultrasound is needed before these aberrant arteries are ligated.

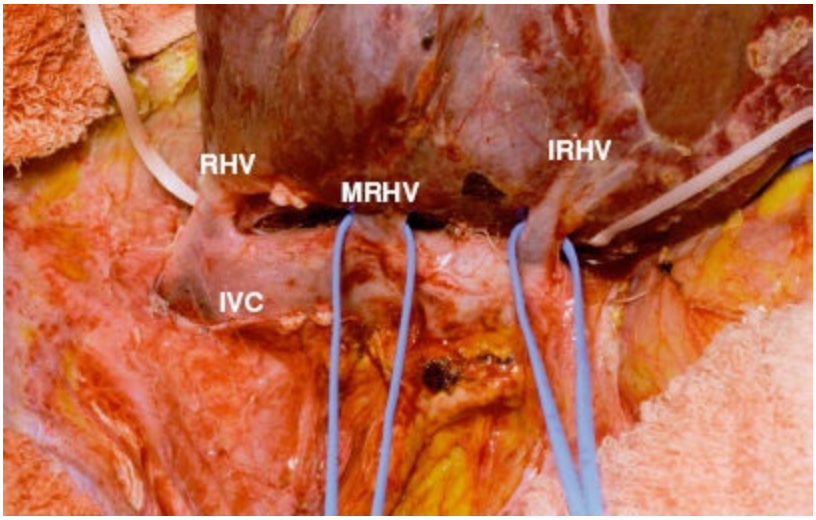

Figure 60-11. Multiple accessory right hepatic veins during liver mobilization. Intraoperative photo of the exposed right wall of the inferior vena cava during mobilization of the right lobe of the liver. IVC, inferior vena cava; RHV, right hepatic vein; MRHV, middle right hepatic vein; IRHV, inferior right hepatic vein. (Adapted from Shindoh J, Aoki T, Hasegawa K, et al. Donor hepatectomy using hanging maneuvers: Tokyo University experiences in 300 donors. *Hepatogastroenterology* 2012;59:1939–1943 with permission.)

Aside from the blood vessels, precise preoperative assessment of the biliary anatomy is difficult. There are considerable variations in the ramification pattern of the right-side biliary branches, while the anatomy of the left hepatic duct is rather simple and constant. Thus, right or extended right hepatectomy can be performed safely without any unnecessary injury to the biliary branches to be preserved. However, when left-side major hepatectomy is being performed, care should be paid not to injure the biliary branches for the right side. Magnetic resonance cholangiopancreatography may clarify the ramification pattern of the biliary tree. However, its imaging quality is not always satisfactory unless the intrahepatic bile duct is obstructed or dilated.

Based on this anatomic information and the tumor distribution, oncologically adequate types of resection can be planned and a safe vascular handling approach adopted. Conventionally, the quality of such meticulous anatomic assessments was highly dependent on the surgeon's knowledge or experience. However, with recent advancements in imaging modalities, three-dimensional reconstruction of CT images is easy and the three-dimensional liver simulation technique has provided ready access to the information on a patient's precise individual vascular anatomy (Fig. 60-12).[120]

Assessment of the Minimal Requirement of FLR and CT Volumetry

The functional reserve of the liver depends on the quality of the liver parenchyma. The volume of the FLR[4,14,121–123] and the regenerative capacity of the liver[124,125] are important predictors of postoperative morbidity and mortality after extended hepatectomy. The minimal requirement of the FLR volume is determined by the balance between the hepatic functional capacity per volume and the actual volume of the FLR. The ICG clearance test is widely used to measure the hepatic functional reserve and to determine an adequate extent of surgery, especially for patients with cirrhosis. The landmark criteria for the maximum extent of resection proposed by Makuuchi et al.[82] offer a simple algorithm to safely perform hepatic resection according to the ICG retention rate at 15 minutes (ICG-R15) (Algorithm 60-2), and the clinical relevance of this algorithm was validated in a large prospective cohort treated under the constant resection policy.[1] However, ICG-R15 has several limitations. First, it is used mainly to determine the extent of minor resection for patients with cirrhotic livers, and it does not offer a safety limit for major hepatectomy. Second, ICG-R15 is influenced by hepatic blood flow and measures performed after a meal, after exercise, or with patients with portosystemic shunts are not reliable. Third, because ICG is exclusively excreted in bile, the ICG test cannot be used for patients with obstructive jaundice or inherited hyperbilirubinemia. ^{99m}Tc-GSA, a scintigraphy agent that binds specifically to asialoglycoprotein receptors on hepatocytes, can be used to evaluate hepatic functional reserve. Because ^{99m}Tc-GSA scintigraphy is not influenced by the hepatic blood flow or biliary obstruction, it can be used to evaluate the hepatic functional reserve when the ICG clearance test is not appropriate.

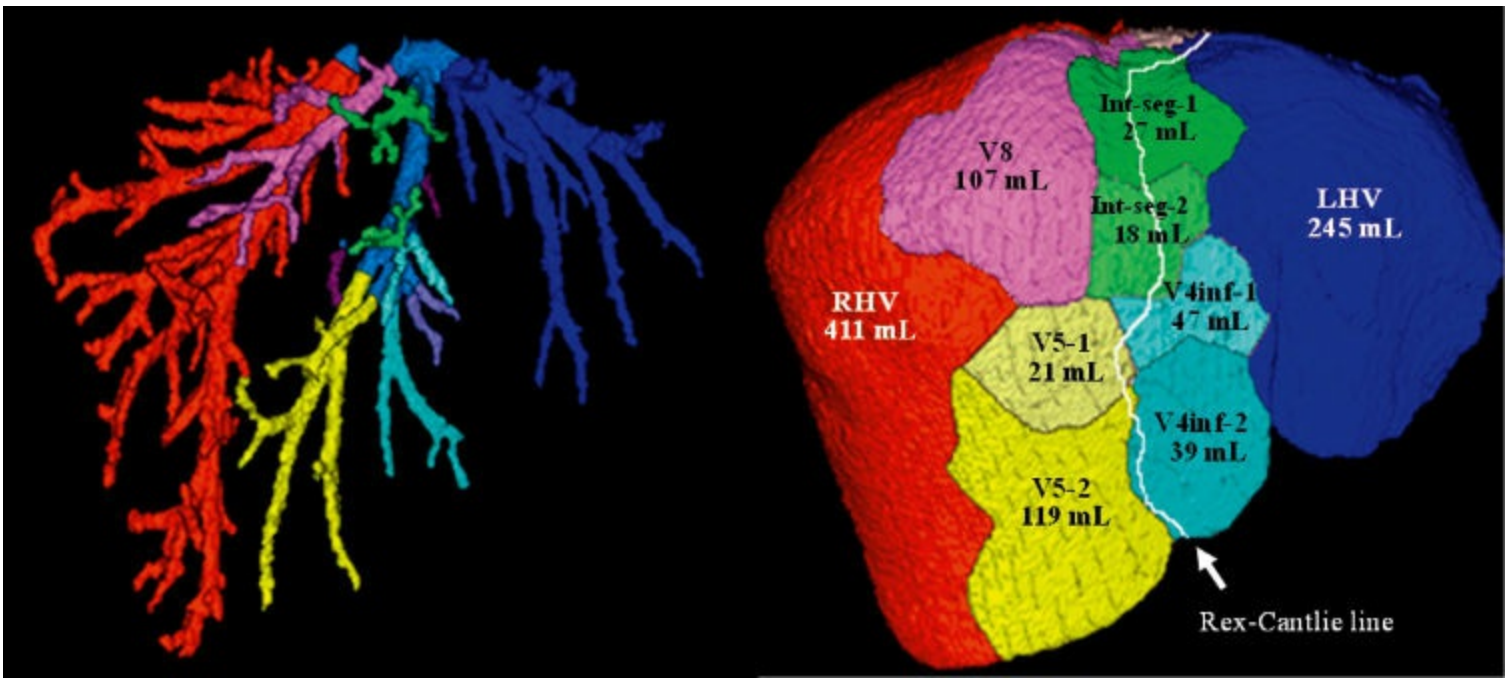

Figure 60-12. Three-dimensional evaluation of venous drainage areas. Three-dimensional volume assessment of venous drainage area predicts venous congestion area after deprivation of the corresponding hepatic venous branches or hepatic veins at surgery.

Evaluating the volume of the FLR is the most reliable approach to predicting outcome in patients who are candidates for major liver resection. Several methods have been described to evaluate the volume of the FLR. At The University of Texas MD Anderson Cancer Center, the standard liver volume (SLV) is estimated with a formula that relies on the linear correlation between the SLV and body surface area (BSA), as follows:

$$\text{SLV } (\text{cm}^3) = -794.41 + 1{,}267.28 \times \text{BSA } (\text{m}^2)$$

The standardized FLR (sFLR) is calculated as the ratio of the FLR volume divided by the SLV. In a series of 301 patients without chronic liver disease or hepatic injury who were undergoing extended right hepatectomy, an sFLR of $<20\%$ was a risk factor for postoperative liver insufficiency and 90-day postoperative mortality.[4] Patients with chemotherapy-induced liver injury require an sFLR of approximately 30% and those with cirrhosis require at least 40% residual volume.[13,14,121]

Of note, these volume criteria are based on the volume of the fully functioning hepatic parenchyma; in other words, the hepatic parenchyma with patent blood flow and intact biliary drainage. If combined resection of a hepatic vein is needed, the area with deprived venous drainage develops venous congestion and represents impaired hepatic function,[126,127] resulting in atrophy of the corresponding area.[128,129]

Portal Flow Modulation to Expand the Surgical Indication

7 PVE is a safe and minimally invasive procedure for inducing ipsilateral atrophy and compensatory contralateral hypertrophy of the FLR.[130–133] When the sFLR volume is considered insufficient according to the baseline status of the underlying liver, PVE is considered to expand the surgical indication and to improve the safety of major hepatectomy (Fig. 60-13).

Several studies have demonstrated the efficacy of PVE in terms of hepatic functional shift from the embolized liver to the FLR and reduced surgical risk. First, a dynamic functional shift from the embolized liver to the FLR after PVE was confirmed in three studies using the ICG excretion rate,[134] ^{99m}Tc-GSA scintigraphy,[135] or bile clearance.[136] All of those studies indicated that PVE produced a clear functional shift from the embolized liver to the nonembolized FLR with a concomitant increase in FLR volume. Another study showed that when a patient achieved sufficient growth of the FLR to meet the minimum criteria for FLR volume, the operative risk was significantly reduced compared to the risk for patients who did not meet the minimum FLR volume criteria after PVE.[4]

sFLR after PVE sensitively predicts the risk of postoperative hepatic insufficiency. However, recent studies have indicated that the regeneration capacity or speed of regeneration independently predicts short-term surgical outcomes in patients undergoing PVE for a small FLR. Ribero et al.[124] reported that the degree of hypertrophy in sFLR volume after PVE is significantly associated with surgical outcomes. A degree of hypertrophy $>5\%$ after PVE along with sFLR $>20\%$ predicted good postoperative outcomes with high specificity and sensitivity in patients with normal liver function. The kinetic growth rate (defined as the degree of hypertrophy at initial volume assessment divided by the number of weeks elapsed after PVE) sensitively predicts the risk of postoperative hepatic insufficiency. A kinetic growth rate $>2.0\%$/week is strongly associated with a low risk of postoperative morbidity and mortality irrespective of the sFLR volume.[125]

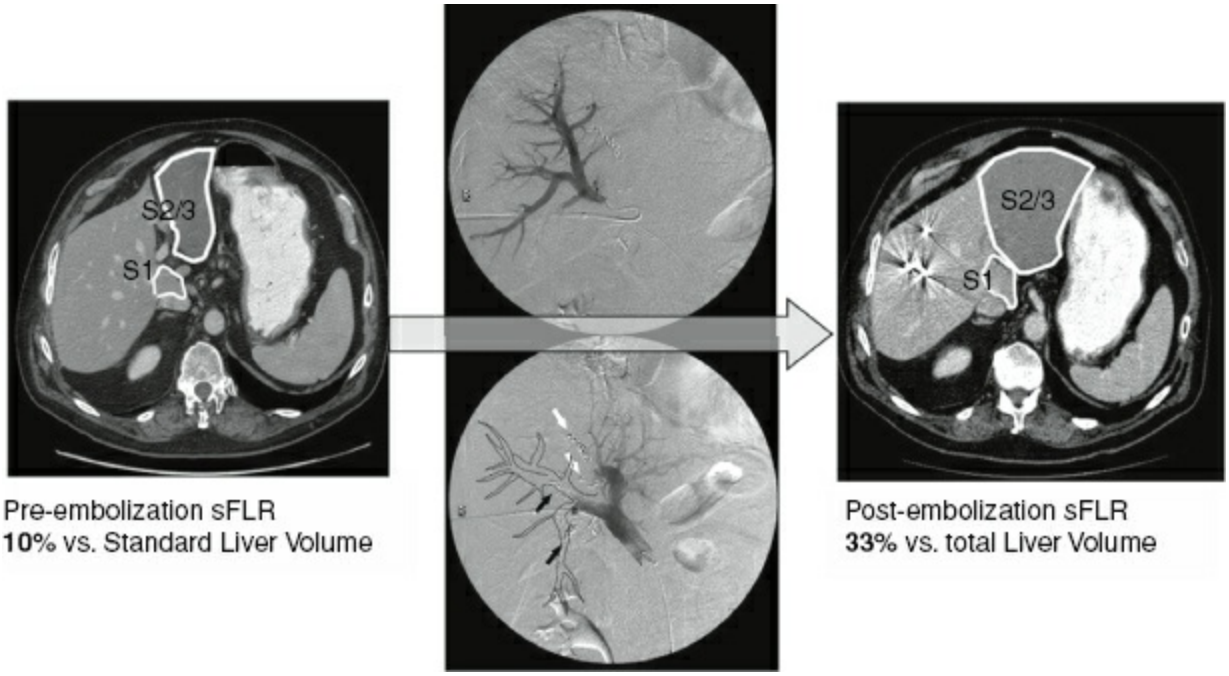

Figure 60-13. Example of right and segment IV portal vein embolization (PVE). Adequate hypertrophy of future liver remnant is observed from the standardized future liver remnant (sFLR) volume of 10% to 33% at 4 weeks after PVE.

Recently, a new short-interval, two-stage liver surgery technique was reported which consists of an initial open right portal vein ligation with in situ splitting of the liver parenchyma followed by reexploration for right trisectionectomy; this technique is called associating liver partition and portal vein ligation for staged hepatectomy (ALPPS).[137] The combination of portal vein ligation and in situ splitting of the liver to prevent cross-portal circulation between the lobes of the liver is believed to lead to profound hypertrophy of the FLR. However, preliminary data suggested a high incidence of major morbidity and inpatient mortality associated with this new procedure. The true efficacy of ALPPS in preventing postoperative hepatic insufficiency remains controversial and this procedure is still investigational.

SURGICAL TECHNIQUE

Exposure

8 Incision and exposure are key components of the quality of the exploration of the liver and the safety of hepatectomy. Various incisions – including the inverted-T (Mercedes) incision, bilateral subcostal (chevron) incision, right/left subcostal (Kocher/Kehr) incisions, J-shaped (Makuuchi) incision with or without thoracotomy, and inverted L-shaped (modified Makuuchi) incision (Fig. 60-14) – have been used to achieve these objectives. Recently evolved laparoscopic approaches may reduce the disadvantage of a large incision for hepatectomy. However, most hepatobiliary malignancies require complex surgical manipulations, including handling of the vena cava or major vessels just beneath the right atrium. Thus, hepatobiliary surgeons should be familiar with the traditional approaches for safe handling of the liver.

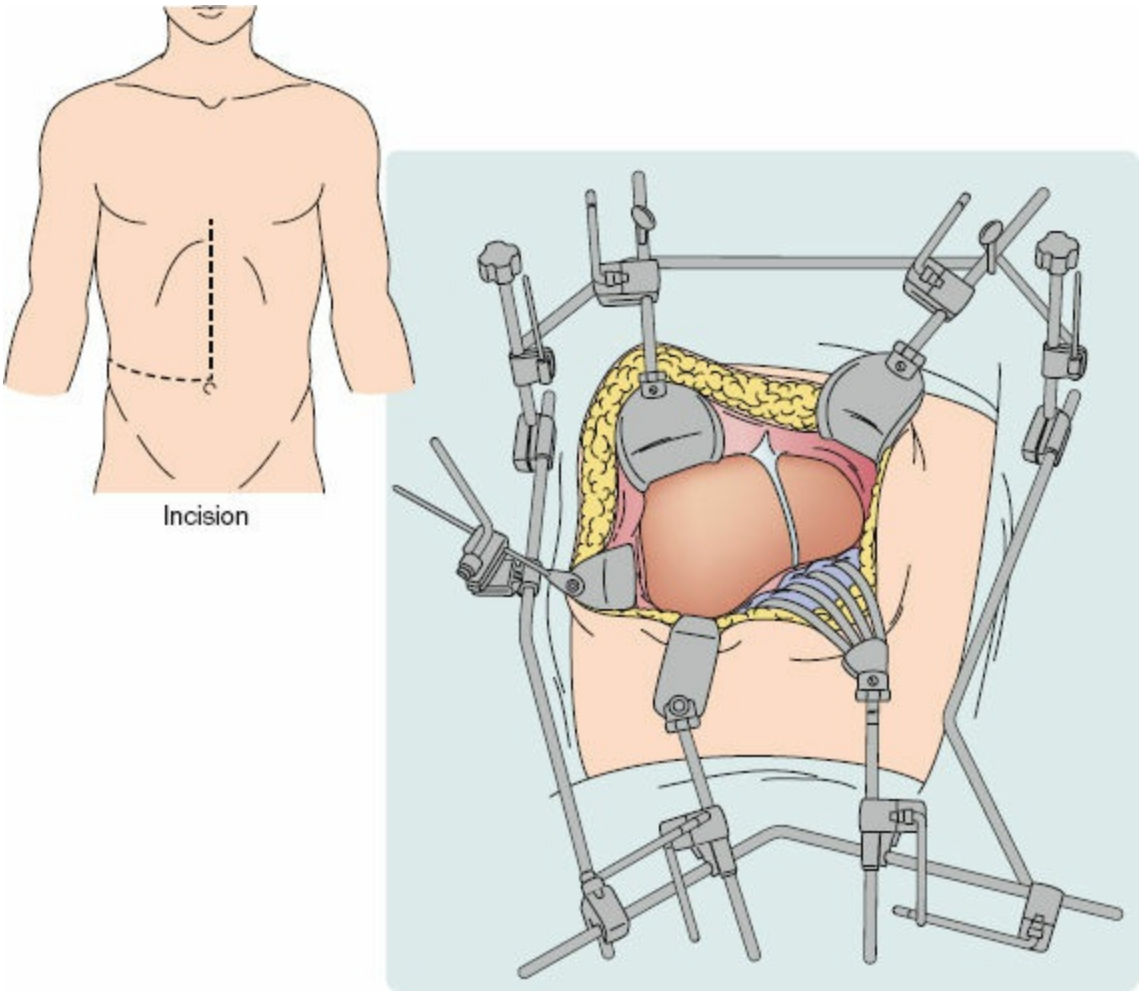

Figure 60-14. Inverted L-shaped incision and exposure. The inverted L-shaped (modified Makuuchi) incision. The incision begins cephalad to the xiphoid, extends to 1 cm above the umbilicus, and then extends laterally to the right. This incision achieves a superb en face view of critical structures, including the hepatocaval junction. (Adapted from Chang SB, Palavecino M, Wray CJ, et al. Modified Makuuchi incision for foregut procedures. *Arch Surg* 2010;145:281–284.)

Principles of Parenchymal Transection

The routine use of intraoperative ultrasonography has contributed to major improvements in liver resection techniques.[138] Intraoperative ultrasonography allows confirmation of the location of the tumors, the sites of intrahepatic anatomic structures, and the direction of transection. For anatomic resection of Couinaud segments, a segmental staining method with ultrasound guidance has been used to confirm the segmental border on the liver surface.

The key point in anatomic resection of the liver is exposure of the landmark vein on the cut surface of the liver. The three-dimensional shape of the intersegmental plane is not always flat and it varies considerably among individuals.[36,139] However, the specific landmark vein for each intersegmental plane of the liver is consistent. Because the actual shape of the intersegmental plane is difficult to recognize during parenchymal transection without a special staining technique such as the ICG fluorescent technique[140] or contrast medium for ultrasound,[141] the identification and exposure of the landmark vein on the cut surface of the liver is the only convincing technique that allows precise anatomic resection of the liver (Fig. 60-15).

For hepatic parenchymal transection, multiple techniques and devices are available to hepatobiliary surgeons, including clamps, staplers, jet cutters, ultrasonic aspirators (e.g., CUSA), saline-linked cautery (e.g., TissueLink), bipolar electrocoagulation devices, radiofrequency transection devices, harmonic scalpels, and microwave coagulators.[142–145]

Control of Bleeding

Inflow occlusion at the hepatic hilum (Pringle maneuver) is widely used to reduce blood loss during hepatic parenchymal transection. Intermittent inflow occlusion (15 minutes of clamping and 5 minutes of release) has been proven to be a safe procedure even for living-donor surgery for liver transplantation.[146,147] Under inflow occlusion, the amount of bleeding depends on the central venous pressure and the height of the manipulating point from the level of the inferior vena cava. Therefore, controlling central venous pressure by limiting the tidal volume and infusions in cooperation with anesthesiologists is important. In addition, adequate lifting of the hepatic parenchyma with the surgeon's left hand decreases back-bleeding during hepatic parenchymal transection.

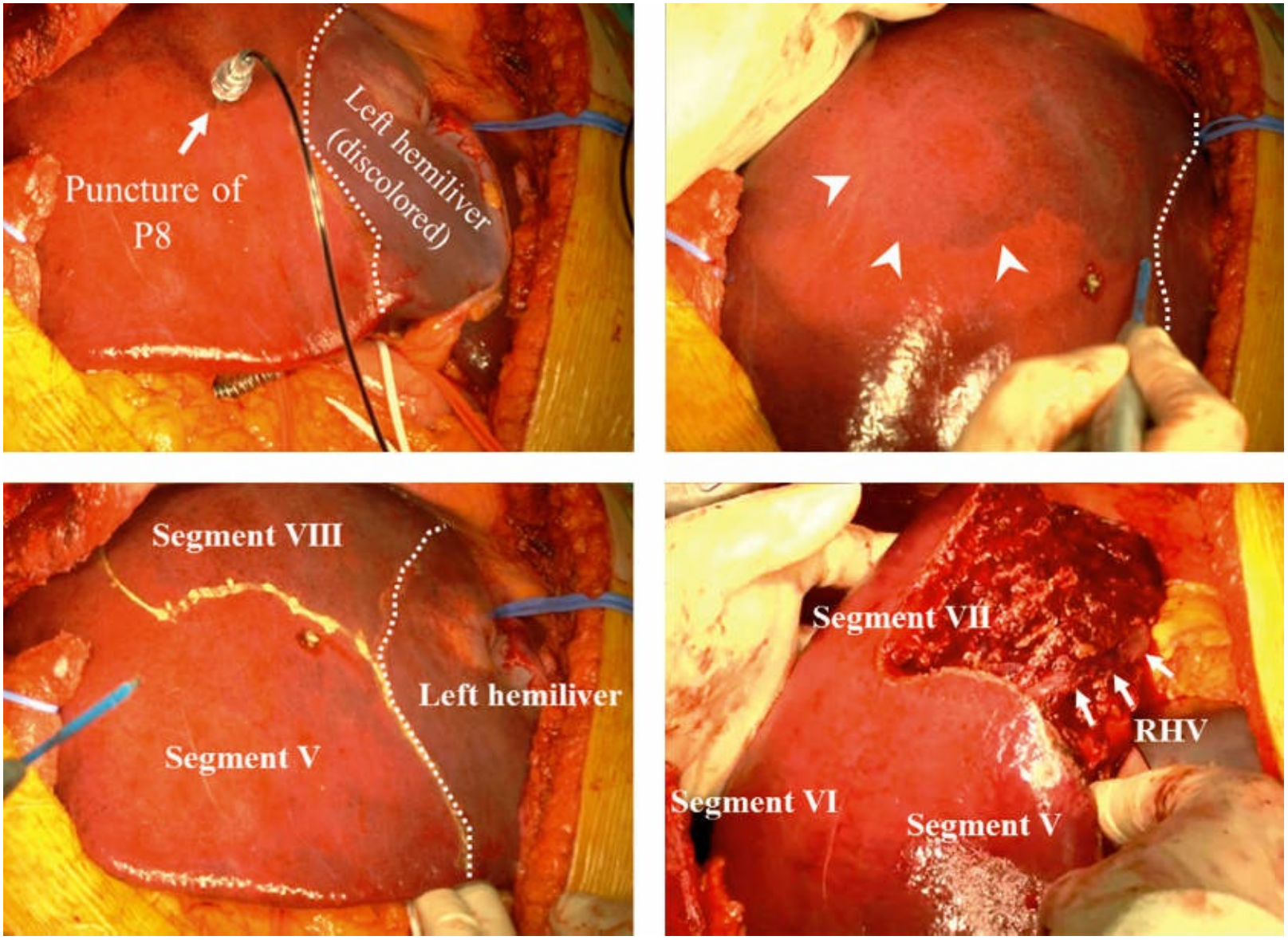

Figure 60-15. Anatomic resection of Segments I + II + III + IV + VIII. This patient was found to have a huge HCC generated in the left hemiliver on underlying steatohepatitis. Because the tumor also extended to Segments I and VIII, compressing the right hepatic vein and hepatic hilum, left trisectionectomy was considered to be the most optimal approach. However, due to impaired hepatic functional reserve (ICG-R15, 17%), the future liver remnant (i.e., right lateral sector) was considered too small (< 30% vs. standard liver volume). Therefore, Segment V was preserved with a staining technique. **Top left:** Puncture of Segment VIII portal pedicle under ultrasound guidance and injection of indigocarmine (*arrow*). **Top right:** Segment VIII was clearly stained on the surface of the liver (*arrowheads*). **Bottom left:** transection line for anatomic Segments I + II + III + IV + VIII resection was marked by cautery. **Bottom right:** completion of anatomic resection fully preserving Segments V, VI, and VII. The right hepatic vein is exposed on the cut surface of the liver (*arrows*).

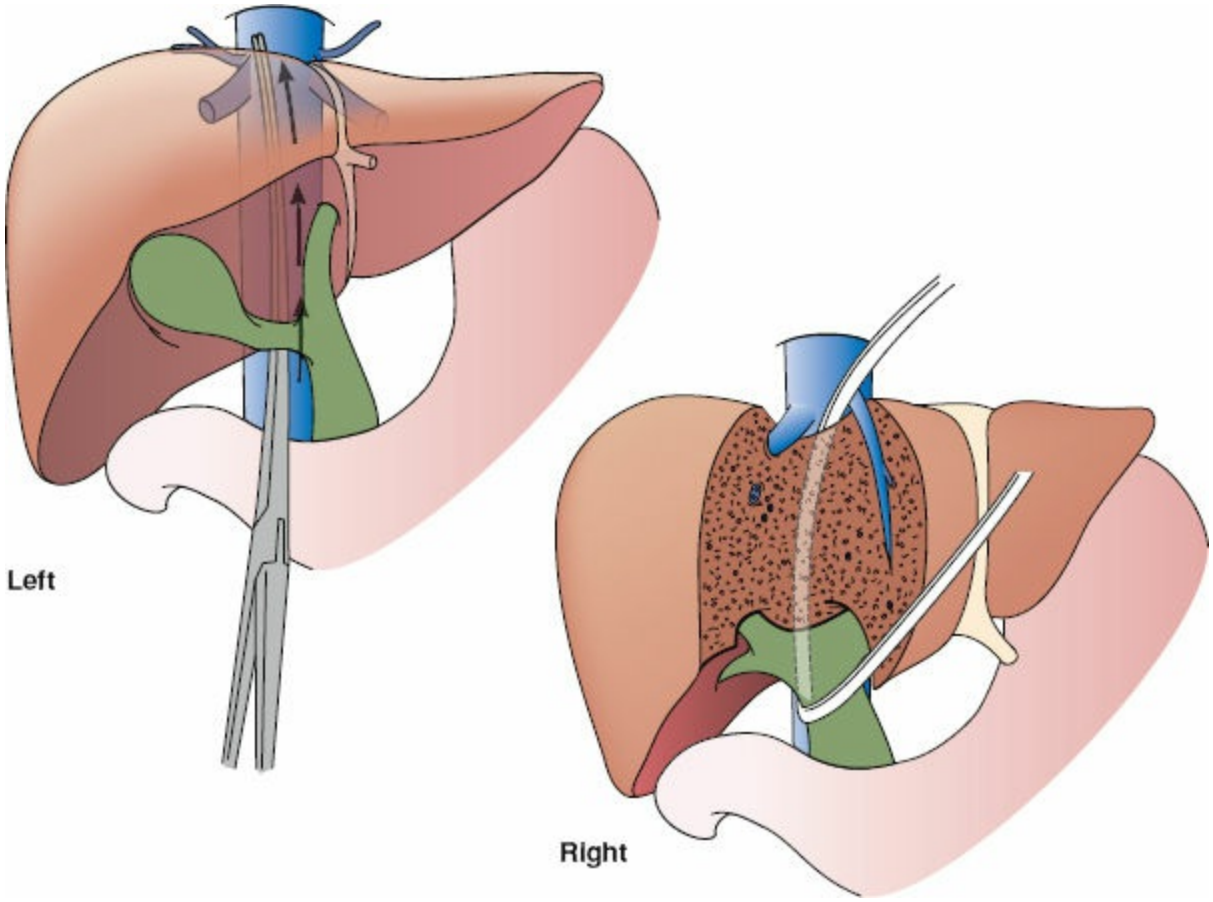

Figure 60-16. Retrohepatic dissection and hanging maneuver during anterior approach. **Left:** The avascular plane between the liver and the inferior vena cava is dissected and a tape is placed. **Right:** Traction of the tape during parenchymal transection allows adequate control of bleeding from the deeper transection plane of the liver. (Adapted from Donadon M, Abdalla EK and Vauthey JN. *J. Am Coll Surg* 2007;204:329–333.)

When conventional mobilization of the liver is difficult prior to parenchymal transection due to tumor invasion of the diaphragm on the right side of the liver, parenchymal transection needs to be preceded by mobilization of the right lobe (anterior approach). To control bleeding at the deeper part of the liver parenchyma in such cases, the hanging maneuver proposed by Belghiti et al.[148] is widely used. This maneuver involves dissecting the retrohepatic avascular space between the liver and the inferior vena cava and placing a tape for lifting the liver. By retracting the tape during parenchymal transection, squeezing pressure can be applied on the deep transection plane and may reduce bleeding (Fig. 60-16).

Bile Leak Test

Bile leak from the cut surface of the liver is a frequent major complication observed after liver resection and requires postoperative drainage according to the degree of leakage (Table 60-3).[149] Even though various intraoperative tests have been tried, bile leaks are still reported in up to 8% of patients who have undergone liver resection. Although it can be treated with adequate drainage, bile leak increases the risk of sepsis and hepatic insufficiency. One group recently assessed the efficacy of transcystic injection of air into the biliary system to test the patency of the biliary tract and to detect any air leak from the major ducts of the parenchymal transection surface (Fig. 60-17) and found that postoperative bile leak decreased from 10.8% to 1.0% ($p = 0.008$) with adequate use of a bile leak test after completion of hepatectomy.[150]

Staged Surgery

When the liver tumor burden is limited, including small tumors and anatomically favorably positioned bilateral metastases, a one-stage strategy involving one or more simultaneous partial hepatectomies in lobar hepatic resection is safe and effective.[151–156] In contrast, when extensive bilobar metastases are present, different surgical strategies are required.

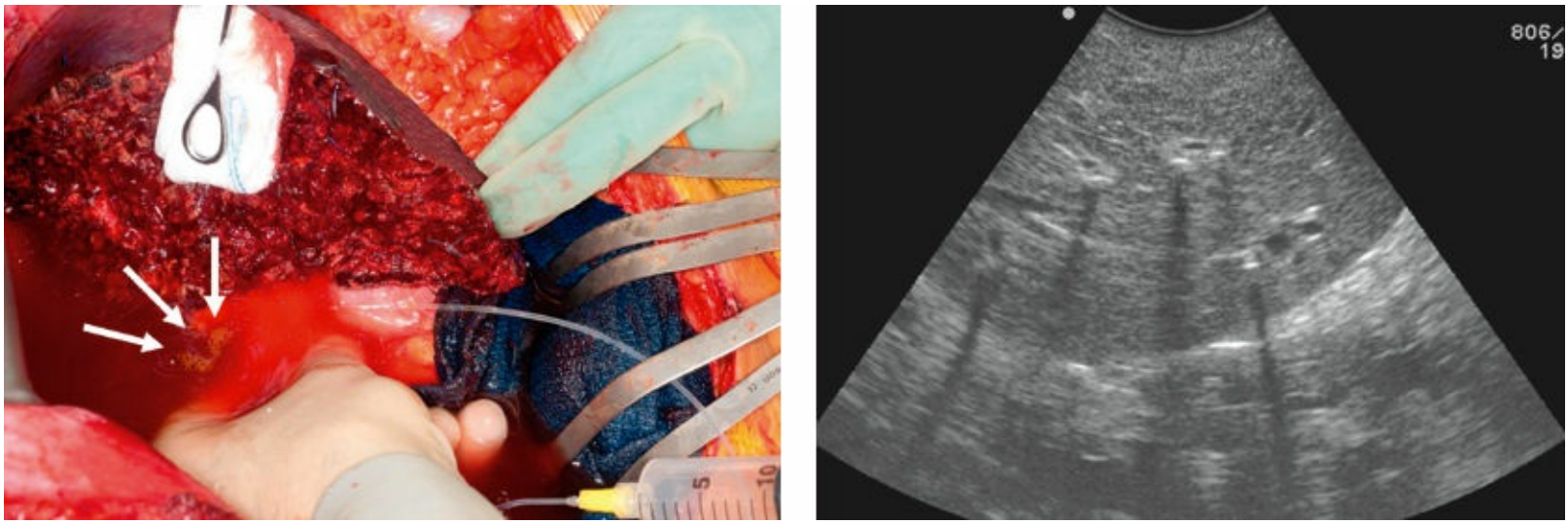

Figure 60-17. Air leak test for detection of bile leak. **Left:** With injection of air into the biliary tract, the point of bile leak can be sensitively detected as an air leak point (*arrows*). **Right:** Patency of the bile duct can be confirmed as pneumobilia on ultrasound image. (Adapted from Zimmitti G. Systematic use of an intraoperative air leak test at the time of major liver resection reduces the rate of postoperative biliary complications. *J Am Coll Surg* 217;1028–1037, with permission.)

Table 60-3 Definition and Grades of Bile Leak After Liver Resection by International Study Group of Liver Surgery (ISGLS)

Definition	Bile leakage is defined as fluid with an increased bilirubin concentration in the abdominal drain or in the intra-abdominal fluid on or after postoperative day 3, or as needed for radiologic intervention (i.e., interventional drainage) because of biliary collections or relaparotomy resulting from bile peritonitis. Increased bilirubin concentration in the drain or intra-abdominal fluid is defined as a bilirubin concentration at least three times greater than the serum bilirubin concentration measured at the same time.
Grade	
A	Bile leakage requiring no or little change in patients' clinical management
B	Bile leakage requiring a change in patients' clinical management (e.g., additional diagnostic or interventional procedures) but manageable without relaparotomy, or a grade A bile leakage lasting for >1 wk
C	Bile leakage requiring relaparotomy

Adapted from Koch M, Garden OJ, Padbury R, et al. Bile leakage after hepatobiliary and pancreatic surgery: a definition and grading of severity by the International Study Group of Liver Surgery. *Surgery* 149:680–8, 2011 with permission.

Two-stage liver resection is a reasonable approach for patients with advanced bilateral

CLM who responded to chemotherapy and in whom limited resection could clear the less affected side of the liver before a planned extended contralateral liver resection. Patients undergo first-stage limited resection of metastases in the left lobe that is followed by right PVE with or without Segment IV embolization to allow hypertrophy of the FLR. Then, extended right hepatectomy is completed after the sFLR meets the volume criteria. A previous study reported that 72.3% of the patients with planned two-stage liver resection completed the second-stage resection and the 5-year survival of these patients was 51% but 15% in the cases treated with chemotherapy alone.[157]

The ALPPS procedure is a similar approach in which right portal vein ligation and parenchymal transection at the time of first resection is performed instead of PVE. This procedure seems to offer rapid growth of the FLR compared with conventional PVE. However, because the safety of this new approach and the detailed techniques are still under investigation, clinical application should be limited to highly selected patients at high-volume hepatobiliary centers.

Laparoscopic Liver Resection

9 The laparoscopic approach for liver resection has evolved since the early 1990s[158–161] and its feasibility has since been established, especially for patients undergoing partial hepatectomy or left lateral segmentectomy.[162–165] Although this approach has benefits, including less postoperative pain, earlier recovery, and shorter length of hospital stay compared to the conventional open approach,[166–169] it requires experience with an open approach and advanced techniques in laparoscopic surgery. Because the liver is a large, heavy organ, mobilization and parenchymal transection require advanced skill in a limited surgical field. Recently, several centers have reported on the feasibility of the laparoscopic approach for major hepatectomy or graft procurement of living donors for liver transplantation; however, these complex laparoscopic procedures should not be approached by surgeons without significant laparoscopic liver surgery experience. In addition, for patients with hepatic malignancies, oncologic curability should be secured if the laparoscopic liver resection is adopted. Therefore, the indication for laparoscopic approach should be determined according to the technical feasibility, the surgeon's surgical skill, and the oncologic curability of the tumors.

Liver Transplantation

Liver transplantation is a reasonable approach with a theoretically higher chance of eradication of tumors, especially for patients with severe hepatic dysfunction. However, because of the negative impact of posttransplant immunosuppression on tumor recurrence or progression, liver transplantation was originally thought to be a contraindication for hepatic malignancy. More recent experience with liver transplantation for hepatoblastoma in children[170] or early-stage HCC[77] has led to cautious application of liver transplantation for hepatic malignancies. As we mentioned previously, several high-volume transplant centers have used their original expanded criteria for liver transplantation for HCC,[86–97,171] although these criteria have not yet been standardized and HCC meeting the Milan criteria remains a standard indication for liver transplantation.

Liver transplantation has also been used in selected patients with other hepatobiliary malignancies, such as NET,[172–174] epithelioid hemangioendothelioma,[175] colorectal cancer,[176] and hilar cholangiocarcinoma.[177,178] However, the clinical evidence remains limited and true efficacy over other nonsurgical treatments has not yet been proven.

SUMMARY

Despite recent advances in the nonsurgical treatment of hepatic neoplasms, surgical resection still plays a pivotal role. In the era of effective chemotherapy and interventional radiology, primary unresectable tumor can become resectable during the treatment course, especially for CLM. However, oncologic curability and surgical safety are, by nature, conflicting factors. Comprehensive assessment of the oncologic characteristics, the hepatic lesions, and the status of the underlying liver is essential for proper risk management and for selecting candidates with the greatest survival benefit from surgical resection.

References

1. Imamura H, Seyama Y, Kokudo N, et al. One thousand fifty-six hepatectomies without mortality in 8 years. *Arch Surg* 2003;138:1198–1206; discussion 1206.
2. Zimmitti G, Roses RE, Andreou A, et al. Greater complexity of liver surgery is not associated with an increased incidence of liver-related complications except for bile leak: an experience with 2,628 consecutive resections. *J Gastrointest Surg* 2013;17:57–64; discussion 64–55.
3. Jarnagin WR, Gonen M, Fong Y, et al. Improvement in perioperative outcome after hepatic resection: analysis of 1,803 consecutive cases over the past decade. *Ann Surg* 2002;236:397–406; discussion 406–397.
4. Kishi Y, Abdalla EK, Chun YS, et al. Three hundred and one consecutive extended right hepatectomies: evaluation of outcome based on systematic liver volumetry. *Ann Surg* 2009;250:540–548.
5. Adam R, Laurent A, Azoulay D, et al. Two-stage hepatectomy: A planned strategy to treat irresectable liver tumors. *Ann Surg* 2000;232:777–785.
6. Jaeck D, Bachellier P, Nakano H, et al. One or two-stage hepatectomy combined with portal vein embolization for initially nonresectable colorectal liver metastases. *Am J Surg* 2003;185:221–229.
7. World Health Organization. Hepatitis B and C fact sheets. 2014.
8. Yeh MM, Brunt EM. Pathologic features of fatty liver disease. *Gastroenterology* 2014;6(8):3303–3325.
9. White DL, Kanwal F, El-Serag HB. Association between nonalcoholic fatty liver disease and risk for hepatocellular cancer, based on systematic review. *Clin Gastroenterol Hepatol* 2012;10:1342–1359.e2.
10. Rubbia-Brandt L, Audard V, Sartoretti P, et al. Severe hepatic sinusoidal obstruction associated with oxaliplatin-based chemotherapy in patients with metastatic colorectal cancer. *Ann Oncol* 2004;15:460–466.
11. Vauthey JN, Pawlik TM, Ribero D, et al. Chemotherapy regimen predicts steatohepatitis and an increase in 90-day mortality after surgery for hepatic colorectal metastases. *J Clin Oncol* 2006;24:2065–2072.
12. Kishi Y, Zorzi D, Contreras CM, et al. Extended preoperative chemotherapy does not improve pathologic response and increases postoperative liver insufficiency after hepatic resection for colorectal liver metastases. *Ann Surg Oncol* 2010;17:2870–2876.
13. Azoulay D, Castaing D, Krissat J, et al. Percutaneous portal vein embolization increases the feasibility and safety of major liver resection for hepatocellular carcinoma in injured liver. *Ann Surg* 2000;232:665–672.
14. Shindoh J, Tzeng CW, Aloia TA, et al. Optimal future liver remnant in patients treated with extensive preoperative chemotherapy for colorectal liver metastases. *Ann Surg Oncol* 2013;20:2493–2500.
15. Takamoto T, Hashimoto T, Sano K, et al. Recovery of liver function after the

cessation of preoperative chemotherapy for colorectal liver metastasis. *Ann Surg Oncol* 2010;17:2747–2755.

16. Kiriyama S, Uchiyama K, Ueno M, et al. Triple positive tumor markers for hepatocellular carcinoma are useful predictors of poor survival. *Ann Surg* 2011;254:984–991.
17. Shindoh J, Sugawara Y, Nagata R, et al. Evaluation methods for pretransplant oncologic markers and their prognostic impacts in patient undergoing living donor liver transplantation for hepatocellular carcinoma. *Transpl Int* 2014;27:391–398.
18. Fujiki M, Takada Y, Ogura Y, et al. Significance of des-gamma-carboxy prothrombin in selection criteria for living donor liver transplantation for hepatocellular carcinoma. *Am J Transplant* 2009;9:2362–2371.
19. Vibert E, Azoulay D, Hoti E, et al. Progression of alphafetoprotein before liver transplantation for hepatocellular carcinoma in cirrhotic patients: a critical factor. *Am J Transplant* 2010;10:129–137.
20. Bruix J, Sherman M; Practice Guidelines Committee AAftSoLD. Management of hepatocellular carcinoma. *Hepatology* 2005;42:1208–1236.
21. Clavien PA, Petrowsky H, DeOliveira ML, et al. Strategies for safer liver surgery and partial liver transplantation. *N Engl J Med* 2007;356:1545–1559.
22. Kudo M. Hepatocellular carcinoma 2009 and beyond: from the surveillance to molecular targeted therapy. *Oncology* 2008;75(suppl 1):1–12.
23. Kamath PS, Wiesner RH, Malinchoc M, et al. A model to predict survival in patients with end-stage liver disease. *Hepatology* 2001;33:464–470.
24. Cejas NG, Villamil FG, Lendoire JC, et al. Improved waiting-list outcomes in Argentina after the adoption of a model for end-stage liver disease-based liver allocation policy. *Liver Transpl* 2013;19:711–720.
25. Schroeder RA, Marroquin CE, Bute BP, et al. Predictive indices of morbidity and mortality after liver resection. *Ann Surg* 2006;243:373–379.
26. Teh SH, Christein J, Donohue J, et al. Hepatic resection of hepatocellular carcinoma in patients with cirrhosis: Model of End-Stage Liver Disease (MELD) score predicts perioperative mortality. *J Gastrointest Surg* 2005;9:1207–1215; discussion 1215.
27. Nachmany I, Dvorchik I, Devera M, et al. A validated model for predicting outcome after liver transplantation: implications on transplanting the extremely sick. *Transpl Int* 2013;26:1108–1115.
28. Agopian VG, Petrowsky H, Kaldas FM, et al. The evolution of liver transplantation during 3 decades: analysis of 5347 consecutive liver transplants at a single center. *Ann Surg* 2013;258:409–421.
29. Koh DM, Collins DJ, Wallace T, et al. Combining diffusion-weighted MRI with Gd-EOB-DTPA-enhanced MRI improves the detection of colorectal liver metastases. *Br J Radiol* 2012;85:980–989.
30. Arita J, Takahashi M, Hata S, et al. Usefulness of contrast-enhanced intraoperative

ultrasound using Sonazoid in patients with hepatocellular carcinoma. *Ann Surg* 2011;254:992–999.

31. Itabashi T, Sasaki A, Otsuka K, et al. Potential value of sonazoid-enhanced intraoperative laparoscopic ultrasonography for liver assessment during laparoscopy-assisted colectomy. *Surg Today* 2014;44:696–701.
32. Niekel MC, Bipat S, Stoker J. Diagnostic imaging of colorectal liver metastases with CT, MR imaging, FDG PET, and/or FDG PET/CT: a meta-analysis of prospective studies including patients who have not previously undergone treatment. *Radiology* 2010;257:674–684.
33. Chen LB, Tong JL, Song HZ, et al. (18)F-DG PET/CT in detection of recurrence and metastasis of colorectal cancer. *World J Gastroenterol* 2007;13:5025–5029.
34. Truant S, Huglo D, Hebbar M, et al. Prospective evaluation of the impact of [18F]fluoro-2-deoxy-D-glucose positron emission tomography of resectable colorectal liver metastases. *Br J Surg* 2005;92:362–369.
35. Couinaud C. *Surgical Anatomy of the Liver Revised.* Paris, France: Couinaud; 1989.
36. Shindoh J, Mise Y, Satou S, et al. The intersegmental plane of the liver is not always flat–tricks for anatomical liver resection. *Ann Surg* 2010;251:917–922.
37. Gamblin TC, Holloway SE, Heckman JT, et al. Laparoscopic resection of benign hepatic cysts: a new standard. *J Am Coll Surg* 2008;207:731–736.
38. Vauthey JN, Maddern GJ, Blumgart LH. Adult polycystic disease of the liver. *Br J Surg* 1991;78:524–527.
39. Baber JT, Hiatt JR, Busuttil RW, et al. A 20-year experience with liver transplantation for polycystic liver disease: does previous palliative surgical intervention affect outcomes? *J Am Coll Surg* 2014;219(4):695–703.
40. Del Poggio P, Buonocore M. Cystic tumors of the liver: a practical approach. *World J Gastroenterol* 2008;14:3616–3620.
41. Devaney K, Goodman ZD, Ishak KG. Hepatobiliary cystadenoma and cystadenocarcinoma. A light microscopic and immunohistochemical study of 70 patients. *Am J Surg Pathol* 1994;18:1078–1091.
42. Wheeler DA, Edmondson HA. Cystadenoma with mesenchymal stroma (CMS) in the liver and bile ducts. A clinicopathologic study of 17 cases, 4 with malignant change. *Cancer* 1985;56:1434–1445.
43. Choi BY, Nguyen MH. The diagnosis and management of benign hepatic tumors. *J Clin Gastroenterol* 2005;39:401–412.
44. Gandolfi L, Leo P, Solmi L, et al. Natural history of hepatic haemangiomas: clinical and ultrasound study. *Gut* 1991;32:677–680.
45. Mergo PJ, Ros PR. Benign lesions of the liver. *Radiol Clin North Am* 1998;36:319–331.
46. Terriff BA, Gibney RG, Scudamore CH. Fatality from fine-needle aspiration biopsy of a hepatic hemangioma. *AJR Am J Roentgenol* 1990;154:203–204.

47. Erdogan D, Busch OR, van Delden OM, et al. Management of liver hemangiomas according to size and symptoms. *J Gastroenterol Hepatol* 2007;22:1953–1958.
48. Miura JT, Amini A, Schmocker R, et al. Surgical management of hepatic hemangiomas: a multi-institutional experience. *HPB (Oxford)* 2014;16(10):924–928.
49. Ozden I, Emre A, Alper A, et al. Long-term results of surgery for liver hemangiomas. *Arch Surg* 2000;135:978–981.
50. Corigliano N, Mercantini P, Amodio PM, et al. Hemoperitoneum from a spontaneous rupture of a giant hemangioma of the liver: report of a case. *Surg Today* 2003;33:459–463.
51. Mungovan JA, Cronan JJ, Vacarro J. Hepatic cavernous hemangiomas: lack of enlargement over time. *Radiology* 1994;191:111–113.
52. Karhunen PJ. Benign hepatic tumours and tumour like conditions in men. *J Clin Pathol* 1986;39:183–188.
53. Greaves WO, Bhattacharya B. Hepatic adenomatosis. *Arch Pathol Lab Med* 2008;132:1951–1955.
54. Grazioli L, Federle MP, Brancatelli G, et al. Hepatic adenomas: imaging and pathologic findings. *Radiographics* 2001;21:877–892; discussion 892–874.
55. Shanbhogue A, Shah SN, Zaheer A, et al. Hepatocellular adenomas: current update on genetics, taxonomy, and management. *J Comput Assist Tomogr* 2011;35:159–166.
56. Laumonier H, Bioulac-Sage P, Laurent C, et al. Hepatocellular adenomas: magnetic resonance imaging features as a function of molecular pathological classification. *Hepatology* 2008;48:808–818.
57. Farges O, Dokmak S. Malignant transformation of liver adenoma: an analysis of the literature. *Dig Surg* 2010;27:32–38.
58. Stoot JH, Coelen RJ, De Jong MC, et al. Malignant transformation of hepatocellular adenomas into hepatocellular carcinomas: a systematic review including more than 1600 adenoma cases. *HPB (Oxford)* 2010;12:509–522.
59. Zucman-Rossi J, Jeannot E, Nhieu JT, et al. Genotype-phenotype correlation in hepatocellular adenoma: new classification and relationship with HCC. *Hepatology* 2006;43:515–524.
60. Farges O, Ferreira N, Dokmak S, et al. Changing trends in malignant transformation of hepatocellular adenoma. *Gut* 2011;60:85–89.
61. van der Windt DJ, Kok NF, Hussain SM, et al. Case-orientated approach to the management of hepatocellular adenoma. *Br J Surg* 2006;93:1495–1502.
62. Charny CK, Jarnagin WR, Schwartz LH, et al. Management of 155 patients with benign liver tumours. *Br J Surg* 2001;88:808–813.
63. Gordon SC, Reddy KR, Livingstone AS, et al. Resolution of a contraceptive-steroid-induced hepatic adenoma with subsequent evolution into hepatocellular carcinoma. *Ann Intern Med* 1986;105:547–549.
64. van Aalten SM, Witjes CD, de Man RA, et al. Can a decision-making model be

justified in the management of hepatocellular adenoma? *Liver Int* 2012;32:28–37.
65. Dokmak S, Paradis V, Vilgrain V, et al. A single-center surgical experience of 122 patients with single and multiple hepatocellular adenomas. *Gastroenterology* 2009;137:1698–1705.
66. Deneve JL, Pawlik TM, Cunningham S, et al. Liver cell adenoma: a multicenter analysis of risk factors for rupture and malignancy. *Ann Surg Oncol* 2009;16:640–648.
67. Chun YS, House MG, Kaur H, et al. SSAT/AHPBA joint symposium on evaluation and treatment of benign liver lesions. *J Gastrointest Surg* 2013;17:636–644.
68. World Health Organization. World Cancer Report 2014. Lyon, France: The International Agency for Research on Cancer; 2014.
69. El-Serag HB, Davila JA, Petersen NJ, et al. The continuing increase in the incidence of hepatocellular carcinoma in the United States: an update. *Ann Intern Med* 2003;139:817–823.
70. Parkin DM, Bray F, Ferlay J, et al. Global cancer statistics, 2002. *CA Cancer J Clin* 2005;55:74–108.
71. Kudo M, Izumi N, Kokudo N, et al. Management of hepatocellular carcinoma in Japan: Consensus-Based Clinical Practice Guidelines proposed by the Japan Society of Hepatology (JSH) 2010 updated version. *Dig Dis* 2011;29:339–364.
72. Zhang BH, Yang BH, Tang ZY. Randomized controlled trial of screening for hepatocellular carcinoma. *J Cancer Res Clin Oncol* 2004;130:417–422.
73. Bolondi L, Sofia S, Siringo S, et al. Surveillance programme of cirrhotic patients for early diagnosis and treatment of hepatocellular carcinoma: a cost effectiveness analysis. *Gut* 2001;48:251–259.
74. Tanaka H, Nouso K, Kobashi H, et al. Surveillance of hepatocellular carcinoma in patients with hepatitis C virus infection may improve patient survival. *Liver Int* 2006;26:543–551.
75. Trevisani F, Cantarini MC, Labate AM, et al. Surveillance for hepatocellular carcinoma in elderly Italian patients with cirrhosis: effects on cancer staging and patient survival. *Am J Gastroenterol* 2004;99:1470–1476.
76. Santi V, Trevisani F, Gramenzi A, et al. Semiannual surveillance is superior to annual surveillance for the detection of early hepatocellular carcinoma and patient survival. *J Hepatol* 2010;53:291–297.
77. Mazzaferro V, Regalia E, Doci R, et al. Liver transplantation for the treatment of small hepatocellular carcinomas in patients with cirrhosis. *N Engl J Med* 1996;334:693–699.
78. Marrero JA, Hussain HK, Nghiem HV, et al. Improving the prediction of hepatocellular carcinoma in cirrhotic patients with an arterially-enhancing liver mass. *Liver Transpl* 2005;11:281–289.
79. Llovet JM, Bru C, Bruix J. Prognosis of hepatocellular carcinoma: the BCLC staging classification. *Semin Liver Dis* 1999;19:329–338.

80. Lim C, Mise Y, Sakamoto Y, et al. Above 5 cm, size does not matter anymore in patients with hepatocellular carcinoma. *World J Surg* 2014;38(11):2910–2918.
81. Shindoh J, Andreou A, Aloia TA, et al. Microvascular invasion does not predict long-term survival in hepatocellular carcinoma up to 2 cm: reappraisal of the staging system for solitary tumors. *Ann Surg Oncol* 2013;20:1223–1229.
82. Makuuchi M, Kosuge T, Takayama T, et al. Surgery for small liver cancers. *Semin Surg Oncol* 1993;9:298–304.
83. Hasegawa K, Kokudo N, Imamura H, et al. Prognostic impact of anatomic resection for hepatocellular carcinoma. *Ann Surg* 2005;242:252–259.
84. Shindoh J, Hasegawa K, Inoue Y, et al. Risk factors of post-operative recurrence and adequate surgical approach to improve long-term outcomes of hepatocellular carcinoma. *HPB (Oxford)* 2013;15:31–39.
85. Eguchi S, Kanematsu T, Arii S, et al. Comparison of the outcomes between an anatomical subsegmentectomy and a non-anatomical minor hepatectomy for single hepatocellular carcinomas based on a Japanese nationwide survey. *Surgery* 2008;143:469–475.
86. DuBay D, Sandroussi C, Sandhu L, et al. Liver transplantation for advanced hepatocellular carcinoma using poor tumor differentiation on biopsy as an exclusion criterion. *Ann Surg* 2011;253:166–172.
87. Herrero JI, Sangro B, Pardo F, et al. Liver transplantation in patients with hepatocellular carcinoma across Milan criteria. *Liver Transpl* 2008;14:272–278.
88. Ito T, Takada Y, Ueda M, et al. Expansion of selection criteria for patients with hepatocellular carcinoma in living donor liver transplantation. *Liver Transpl* 2007;13:1637–1644.
89. Jonas S, Mittler J, Pascher A, et al. Living donor liver transplantation of the right lobe for hepatocellular carcinoma in cirrhosis in a European center. *Liver Transpl* 2007;13:896–903.
90. Kwon CH, Kim DJ, Han YS, et al. HCC in living donor liver transplantation: can we expand the Milan criteria? *Dig Dis* 2007;25:313–319.
91. Lee SG, Hwang S, Moon DB, et al. Expanded indication criteria of living donor liver transplantation for hepatocellular carcinoma at one large-volume center. *Liver Transpl* 2008;14:935–945.
92. Mazzaferro V, Llovet JM, Miceli R, et al. Predicting survival after liver transplantation in patients with hepatocellular carcinoma beyond the Milan criteria: a retrospective, exploratory analysis. *Lancet Oncol* 2009;10:35–43.
93. Silva M, Moya A, Berenguer M, et al. Expanded criteria for liver transplantation in patients with cirrhosis and hepatocellular carcinoma. *Liver Transpl* 2008;14:1449–1460.
94. Sugawara Y, Tamura S, Makuuchi M. Living donor liver transplantation for hepatocellular carcinoma: Tokyo University series. *Dig Dis* 2007;25:310–312.

95. Toso C, Trotter J, Wei A, et al. Total tumor volume predicts risk of recurrence following liver transplantation in patients with hepatocellular carcinoma. *Liver Transpl* 2008;14:1107–1115.
96. Yao FY, Ferrell L, Bass NM, et al. Liver transplantation for hepatocellular carcinoma: expansion of the tumor size limits does not adversely impact survival. *Hepatology* 2001;33:1394–1403.
97. Zheng SS, Xu X, Wu J, et al. Liver transplantation for hepatocellular carcinoma: Hangzhou experiences. *Transplantation* 2008;85:1726–1732.
98. Kaczynski J, Hansson G, Wallerstedt S. Incidence, etiologic aspects and clinicopathologic features in intrahepatic cholangiocellular carcinoma–a study of 51 cases from a low-endemicity area. *Acta Oncol* 1998;37:77–83.
99. Shaib YH, Davila JA, McGlynn K, et al. Rising incidence of intrahepatic cholangiocarcinoma in the United States: a true increase? *J Hepatol* 2004; 40:472–477.
100. Mavros MN, Economopoulos KP, Alexiou VG, et al. Treatment and prognosis for patients with intrahepatic cholangiocarcinoma: systematic review and meta-analysis. *JAMA Surg* 2014;149(6):565–574.
101. Roskams T. Liver stem cells and their implication in hepatocellular and cholangiocarcinoma. *Oncogene* 2006;25:3818–3822.
102. de Jong MC, Nathan H, Sotiropoulos GC, et al. Intrahepatic cholangiocarcinoma: an international multi-institutional analysis of prognostic factors and lymph node assessment. *J Clin Oncol* 2011;29:3140–3145.
103. Almersjo O, Bengmark S, Hafstrom L. Liver metastases found by follow-up of patients operated on for colorectal cancer. *Cancer* 1976;37:1454–1457.
104. Bengmark S, Hafstrom L. The natural history of primary and secondary malignant tumors of the liver. I. The prognosis for patients with hepatic metastases from colonic and rectal carcinoma by laparotomy. *Cancer* 1969;23:198–202.
105. Pawlik TM, Choti MA. Surgical therapy for colorectal metastases to the liver. *J Gastrointest Surg* 2007;11:1057–1077.
106. Fong Y, Cohen AM, Fortner JG, et al. Liver resection for colorectal metastases. *J Clin Oncol* 1997;15:938–946.
107. Ito H, Are C, Gonen M, et al. Effect of postoperative morbidity on long-term survival after hepatic resection for metastatic colorectal cancer. *Ann Surg* 2008;247:994–1002.
108. Pawlik TM, Scoggins CR, Zorzi D, et al. Effect of surgical margin status on survival and site of recurrence after hepatic resection for colorectal metastases. *Ann Surg* 2005;241:715–722, discussion 722–714.
109. Kopetz S, Chang GJ, Overman MJ, et al. Improved survival in metastatic colorectal cancer is associated with adoption of hepatic resection and improved chemotherapy. *J Clin Oncol* 2009;27:3677–3683.
110. Kopetz S, Vauthey JN. Perioperative chemotherapy for resectable hepatic metastases.

Lancet 2008;371:963–965.

111. Chua TC, Saxena A, Liauw W, et al. Hepatectomy and resection of concomitant extrahepatic disease for colorectal liver metastases–a systematic review. *Eur J Cancer* 2012;48:1757–1765.
112. Adams RB, Aloia TA, Loyer E, et al. Selection for hepatic resection of colorectal liver metastases: expert consensus statement. *HPB (Oxford)* 2013; 15:91–103.
113. Nordlinger B, Sorbye H, Glimelius B, et al. Perioperative chemotherapy with FOLFOX4 and surgery versus surgery alone for resectable liver metastases from colorectal cancer (EORTC Intergroup trial 40983): a randomised controlled trial. *Lancet* 2008;371:1007–1016.
114. Jaeck D, Oussoultzoglou E, Bachellier P, et al. Hepatic metastases of gastroenteropancreatic neuroendocrine tumors: safe hepatic surgery. *World J Surg* 2001;25:689–692.
115. Andreou A, Brouquet A, Bharathy KG, et al. Liver resection for liver metastases from nondigestive endocrine cancer: Extrahepatic disease burden defines outcome. *Surgery* 2012;151(6):851–859.
116. Sarmiento JM, Heywood G, Rubin J, et al. Surgical treatment of neuroendocrine metastases to the liver: a plea for resection to increase survival. *J Am Coll Surg* 2003;197:29–37.
117. Clark GM, Sledge GW Jr, Osborne CK, et al. Survival from first recurrence: relative importance of prognostic factors in 1,015 breast cancer patients. *J Clin Oncol* 1987;5:55–61.
118. Madoff DC, Abdalla EK, Vauthey JN. Portal vein embolization in preparation for major hepatic resection: evolution of a new standard of care. *J Vasc Interv Radiol* 2005;16:779–790.
119. Makuuchi M, Hasegawa H, Yamazaki S, et al. The inferior right hepatic vein: ultrasonic demonstration. *Radiology* 1983;148:213–217.
120. Mise Y, Hasegawa K, Satou S, et al. Venous reconstruction based on virtual liver resection to avoid congestion in the liver remnant. *Br J Surg* 2011;98:1742–1751.
121. Kubota K, Makuuchi M, Kusaka K, et al. Measurement of liver volume and hepatic functional reserve as a guide to decision-making in resectional surgery for hepatic tumors. *Hepatology* 1997;26:1176–1181.
122. Zorzi D, Laurent A, Pawlik TM, et al. Chemotherapy-associated hepatotoxicity and surgery for colorectal liver metastases. *Br J Surg* 2007;94:274–286.
123. Azoulay D, Castaing D, Smail A, et al. Resection of nonresectable liver metastases from colorectal cancer after percutaneous portal vein embolization. *Ann Surg* 2000;231:480–486.
124. Ribero D, Abdalla EK, Madoff DC, et al. Portal vein embolization before major hepatectomy and its effects on regeneration, resectability and outcome. *Br J Surg* 2007;94:1386–1394.

125. Shindoh J, Truty MJ, Aloia TA, et al. Kinetic growth rate after portal vein embolization predicts posthepatectomy outcomes: toward zero liver-related mortality in patients with colorectal liver metastases and small future liver remnant. *J Am Coll Surg* 2013;216:201–209.
126. Kawaguchi Y, Ishizawa T, Miyata Y, et al. Portal uptake function in veno-occlusive regions evaluated by real-time fluorescent imaging using indocyanine green. *J Hepatol* 2013;58:247–253.
127. Hashimoto T, Miki K, Imamura H, et al. Sinusoidal perfusion in the veno-occlusive region of living liver donors evaluated by indocyanine green and near-infrared spectroscopy. *Liver Transpl* 2008;14:872–880.
128. Maema A, Imamura H, Takayama T, et al. Impaired volume regeneration of split livers with partial venous disruption: a latent problem in partial liver transplantation. *Transplantation* 2002;73:765–769.
129. Shindoh J, Satou S, Aoki T, et al. Hidden symmetry in asymmetric morphology: significance of Hjortsjo's anatomical model in liver surgery. *Hepatogastroenterology* 2012;59:519–525.
130. Abulkhir A, Limongelli P, Healey AJ, et al. Preoperative portal vein embolization for major liver resection: a meta-analysis. *Ann Surg* 2008;247:49–57.
131. Giraudo G, Greget M, Oussoultzoglou E, et al. Preoperative contralateral portal vein embolization before major hepatic resection is a safe and efficient procedure: a large single institution experience. *Surgery* 2008;143:476–482.
132. Mueller L, Hillert C, Moller L, et al. Major hepatectomy for colorectal metastases: is preoperative portal occlusion an oncological risk factor? *Ann Surg Oncol* 2008;15:1908–1917.
133. Shindoh J, Tzeng CW, Aloia TA, et al. Safety and efficacy of portal vein embolization before planned major or extended hepatectomy: an institutional experience of 358 patients. *J Gastrointest Surg* 2014;18:45–51.
134. Uesaka K, Nimura Y, Nagino M. Changes in hepatic lobar function after right portal vein embolization. An appraisal by biliary indocyanine green excretion. *Ann Surg* 1996;223:77–83.
135. Hirai I, Kimura W, Fuse A, et al. Evaluation of preoperative portal embolization for safe hepatectomy, with special reference to assessment of nonembolized lobe function with 99mTc-GSA SPECT scintigraphy. *Surgery* 2003;133:495–506.
136. Ijichi M, Makuuchi M, Imamura H, et al. Portal embolization relieves persistent jaundice after complete biliary drainage. *Surgery* 2001;130:116–118.
137. Schnitzbauer AA, Lang SA, Goessmann H, et al. Right portal vein ligation combined with in situ splitting induces rapid left lateral liver lobe hypertrophy enabling 2-staged extended right hepatic resection in small-for-size settings. *Ann Surg* 2012;255:405–414.
138. Makuuchi M, Hasegawa H, Yamazaki S. Ultrasonically guided subsegmentectomy.

Surg Gynecol Obstet 1985;161:346–350.

139. Ohashi I, Ina H, Okada Y, et al. Segmental anatomy of the liver under the right diaphragmatic dome: evaluation with axial CT. *Radiology* 1996;200:779–783.
140. Aoki T, Yasuda D, Shimizu Y, et al. Image-guided liver mapping using fluorescence navigation system with indocyanine green for anatomical hepatic resection. *World J Surg* 2008;32:1763–1767.
141. Shindoh J, Seyama Y, Umekita N. Three-dimensional staining of liver segments with an ultrasound contrast agent as an aid to anatomic liver resection. *J Am Coll Surg* 2012;215:e5–e10.
142. Aloia TA, Zorzi D, Abdalla EK, et al. Two-surgeon technique for hepatic parenchymal transection of the noncirrhotic liver using saline-linked cautery and ultrasonic dissection. *Ann Surg* 2005;242:172–177.
143. El Moghazy WM, Hedaya MS, Kaido T, et al. Two different methods for donor hepatic transection: cavitron ultrasonic surgical aspirator with bipolar cautery versus cavitron ultrasonic surgical aspirator with radiofrequency coagulator-A randomized controlled trial. *Liver Transpl* 2009;15:102–105.
144. Palavecino M, Kishi Y, Chun YS, et al. Two-surgeon technique of parenchymal transection contributes to reduced transfusion rate in patients undergoing major hepatectomy: analysis of 1,557 consecutive liver resections. *Surgery* 2010;147:40–48.
145. Takatsuki M, Eguchi S, Yamanouchi K, et al. Two-surgeon technique using saline-linked electric cautery and ultrasonic surgical aspirator in living donor hepatectomy: its safety and efficacy. *Am J Surg* 2009;197:e25–e27.
146. Imamura H, Takayama T, Sugawara Y, et al. Pringle's manoeuvre in living donors. *Lancet* 2002;360:2049–2050.
147. Torzilli G, Procopio F, Donadon M, et al. Safety of intermittent Pringle maneuver cumulative time exceeding 120 minutes in liver resection: a further step in favor of the "radical but conservative" policy. *Ann Surg* 2012;255:270–280.
148. Belghiti J, Guevara OA, Noun R, et al. Liver hanging maneuver: a safe approach to right hepatectomy without liver mobilization. *J Am Coll Surg* 2001;193:109–111.
149. Koch M, Garden OJ, Padbury R, et al. Bile leakage after hepatobiliary and pancreatic surgery: a definition and grading of severity by the International Study Group of Liver Surgery. *Surgery* 2011;149:680–688.
150. Zimmitti G, Vauthey JN, Shindoh J, et al. Systematic use of an intraoperative air leak test at the time of major liver resection reduces the rate of postoperative biliary complications. *J Am Coll Surg* 2013;217:1028–1037.
151. Rees M, Tekkis PP, Welsh FK, et al. Evaluation of long-term survival after hepatic resection for metastatic colorectal cancer: A multifactorial model of 929 patients. *Ann Surg* 2008;247:125–135.
152. Nordlinger B, Guiguet M, Vaillant JC, et al. Surgical resection of colorectal carcinoma metastases to the liver. A prognostic scoring system to improve case

selection, based on 1568 patients. Association Francaise de Chirurgie. *Cancer* 1996;77:1254–1262.

153. Fong Y, Fortner J, Sun RL, et al. Clinical score for predicting recurrence after hepatic resection for metastatic colorectal cancer: analysis of 1001 consecutive cases. *Ann Surg* 1999;230:309–318.
154. Wei AC, Greig PD, Grant D, et al. Survival after hepatic resection for colorectal metastases: a 10-year experience. *Ann Surg Oncol* 2006;13:668–676.
155. Kato T, Yasui K, Hirai T, et al. Therapeutic results for hepatic metastasis of colorectal cancer with special reference to effectiveness of hepatectomy: analysis of prognostic factors for 763 cases recorded at 18 institutions. *Dis Colon Rectum* 2003;46:S22–S31.
156. Scheele J, Altendorf-Hofmann A, Grube T, et al. [Resection of colorectal liver metastases. What prognostic factors determine patient selection?]. *Chirurg* 2001;72:547–560.
157. Brouquet A, Abdalla EK, Kopetz S, et al. High survival rate after two-stage resection of advanced colorectal liver metastases: response-based selection and complete resection define outcome. *J Clin Oncol* 2011;29:1083–1090.
158. Azagra JS, Goergen M, Gilbart E, et al. Laparoscopic anatomical (hepatic) left lateral segmentectomy-technical aspects. *Surg Endosc* 1996;10:758–761.
159. Croce E, Azzola M, Russo R, et al. Laparoscopic liver tumour resection with the argon beam. *Endosc Surg Allied Technol* 1994;2:186–188.
160. Kaneko H, Takagi S, Shiba T. Laparoscopic partial hepatectomy and left lateral segmentectomy: technique and results of a clinical series. *Surgery* 1996;120:468–475.
161. Rau HG, Meyer G, Cohnert TU, et al. Laparoscopic liver resection with the water-jet dissector. *Surg Endosc* 1995;9:1009–1012.
162. Buell JF, Thomas MT, Rudich S, et al. Experience with more than 500 minimally invasive hepatic procedures. *Ann Surg* 2008;248:475–486.
163. Koffron AJ, Auffenberg G, Kung R, et al. Evaluation of 300 minimally invasive liver resections at a single institution: less is more. *Ann Surg* 2007;246:385–392; discussion 392–384.
164. Nguyen KT, Laurent A, Dagher I, et al. Minimally invasive liver resection for metastatic colorectal cancer: a multi-institutional, international report of safety, feasibility, and early outcomes. *Ann Surg* 2009;250:842–848.
165. Nguyen KT, Gamblin TC, Geller DA. World review of laparoscopic liver resection-2,804 patients. *Ann Surg* 2009;250:831–841.
166. Cherqui D, Soubrane O, Husson E, et al. Laparoscopic living donor hepatectomy for liver transplantation in children. *Lancet* 2002;359:392–396.
167. Koffron AJ, Kung R, Baker T, et al. Laparoscopic-assisted right lobe donor hepatectomy. *Am J Transplant* 2006;6:2522–2525.
168. Suh KS, Yi NJ, Kim J, et al. Laparoscopic hepatectomy for a modified right graft in adult-to-adult living donor liver transplantation. *Transplant Proc* 2008;40:3529–3531.

169. Suh KS, Yi NJ, Kim T, et al. Laparoscopy-assisted donor right hepatectomy using a hand port system preserving the middle hepatic vein branches. *World J Surg* 2009;33:526–533.
170. Faraj W, Dar F, Marangoni G, et al. Liver transplantation for hepatoblastoma. *Liver Transpl* 2008;14:1614–1619.
171. Kaido T, Ogawa K, Mori A, et al. Usefulness of the Kyoto criteria as expanded selection criteria for liver transplantation for hepatocellular carcinoma. *Surgery* 2013;154:1053–1060.
172. Fan ST, Le Treut YP, Mazzaferro V, et al. Liver transplantation for neuroendocrine tumour liver metastases. *HPB (Oxford)* 2014;17(1):23–28.
173. Le Treut YP, Gregoire E, Klempnauer J, et al. Liver transplantation for neuroendocrine tumors in Europe-results and trends in patient selection: a 213-case European liver transplant registry study. *Ann Surg* 2013;257:807–815.
174. Mazzaferro V, Pulvirenti A, Coppa J. Neuroendocrine tumors metastatic to the liver: how to select patients for liver transplantation? *J Hepatol* 2007;47:460–466.
175. Grossman EJ, Millis JM. Liver transplantation for non-hepatocellular carcinoma malignancy: Indications, limitations, and analysis of the current literature. *Liver Transpl* 2010;16:930–942.
176. Hagness M, Foss A, Line PD, et al. Liver transplantation for nonresectable liver metastases from colorectal cancer. *Ann Surg* 2013;257:800–806.
177. Wu Y, Johlin FC, Rayhill SC, et al. Long-term, tumor-free survival after radiotherapy combining hepatectomy-Whipple en bloc and orthotopic liver transplantation for early-stage hilar cholangiocarcinoma. *Liver Transpl* 2008;14:279–286.
178. Schule S, Altendorf-Hofmann A, Utess F, et al. Liver transplantation for hilar cholangiocarcinoma–a single-centre experience. *Langenbecks Arch Surg* 2013;398:71–77.

Chapter 61

Calculous Biliary Disease

David A. Kooby, Joshua H. Winer, and Kenneth Cardona

Key Points

1 Gallstones are classified by their cholesterol content as either cholesterol (70% to 80%) or pigment (20% to 30%), with pigment stones further classified as black or brown.

2 Biliary sludge refers to a mixture of cholesterol crystals, calcium bilirubinate granules, and a mucin gel matrix and is thought to serve as the nidus for gallstone growth.

3 The pathogenesis of cholesterol gallstones is clearly multifactorial but essentially involves four factors: (a) cholesterol supersaturation in bile, (b) crystal nucleation, (c) gallbladder dysmotility, and (d) gallbladder absorption/secretion.

4 Prophylactic cholecystectomy is generally not indicated in patients with asymptomatic gallstones, because studies show that under 30% of patients will become symptomatic within 20 years and only 1% to 2% will develop gallstone-related complications, such as cholecystitis, per year.

5 Elective laparoscopic cholecystectomy is associated with a mortality rate of less than 0.3% and an overall complication rate of 10%, with less than 5% of patients requiring conversion to an open procedure.

6 Randomized trials have shown that laparoscopic cholecystectomy performed for acute cholecystitis (AC) during initial hospitalization can be performed safely resulting in a lower morbidity rate and shorter overall hospital stay when compared to delayed cholecystectomy during a separate admission.

7 Common bile duct (CBD) stones, similar to gallbladder stones, can have an asymptomatic course and pass spontaneously without clinical consequence. When symptomatic, the presentation of CBD stones can vary between mild biliary colic to fulminant sepsis from acute cholangitis, biliary pancreatitis, or hepatic abscesses.

8 ERCP with stone extraction is effective in removing stones in 85% to 95% of cases but is associated with postprocedural complications (pancreatitis and cholangitis) in 5% of cases.

9 Endoscopic cholangiography with sphincterotomy allows for the diagnosis of CBD stones in the vast majority of cases. The primary advantage of endoscopic retrograde cholangiopancreatography (ERCP) is that it allows for therapeutic intervention if stones are identified.

10 Acute cholangitis results from the combination of significant bacterial concentration in bile and increased biliary pressure associated with biliary obstruction.

INTRODUCTION

Cholelithiasis (gallbladder stone disease) is both a substantial healthcare problem and financial burden for the US healthcare system, with more than 20 million Americans afflicted, resulting in expenses of more than 6 billion dollars annually.[1] A recent report demonstrates that cholelithiasis and cholecystitis were the second most common gastrointestinal problems listed as the discharge diagnosis in 2009 with approximately 750,000 gallbladders removed.[2] Surgeons treating patients with gallstones and their associated conditions should have an understanding of biliary physiology and of the pathophysiology of gallstone formation. This chapter reviews the physiology and surgical management of calculous biliary disease.

BILIARY PHYSIOLOGY

An understanding of normal bile composition, synthesis, and metabolism is pertinent to the understanding of gallstone formation.

Bile Composition and Function

Healthy livers produce between 600 and 750 mL of bile per day. Normal bile is composed of bile acids (or salts, 61%), fatty acids (12%), cholesterol (9%), proteins (7%), phospholipids (3%), bilirubin (3%), and other substances (5%).[3] Bilirubin is the breakdown product of spent red blood cells and is conjugated with glucuronic acid prior to being excreted. Bile acid components can be further subclassified as primary bile acids and secondary bile acids. Primary bile acids (cholic and chenodeoxycholic acids) are synthesized in the liver and secondary bile acids (deoxycholic and lithocholic acids) represent primary bile acids that undergo deconjugation in the gut by bacteria. Cholesterol is produced primarily by the liver with little contribution from dietary sources, and is highly nonpolar and insoluble in water and thus in bile, as well. Phospholipids (95% phosphatidylcholine in healthy individuals) are synthesized in the liver in conjunction with bile salt synthesis. Percentages of biliary phospholipid and cholesterol vary with underlying liver disease.

Bile facilitates the intestinal absorption of lipids, fat-soluble vitamins and various drugs, and promotes excretion of certain organic solids, such as bilirubin and cholesterol. Bile acids solubilize lipids and facilitate their absorption and excretion through emulsification of dietary fats. More recent evidence shows that bile acids regulate their own synthesis, perform various endocrine and autocrine functions, and serve as ligands for various nuclear receptors involved in carbohydrate, triglyceride, and sterol metabolism.[4] Bile acids also interact with cell surface receptors involved in glucose and lipid metabolism, energy consumption, and immune response.[5]

The potency of bile is increased through the process of concentration (5 to 10×) within the gallbladder, as electrolytes, water, and calcium are reabsorbed (Table 61-1). Sodium chloride channels actively transport salt across the epithelium efficiently[6] and water follows passively in response to the resultant osmotic force. Calcium absorption is less efficient, resulting in a net increase in calcium percentage in stored bile. As gallbladder bile becomes concentrated, the capacity of bile to solubilize cholesterol lessens. Solubility of the micellar fraction is increased; however, solubility of phospholipid–cholesterol vesicles is reduced. It is the vesicular fraction of vesicular cholesterol combined with the increased concentration of calcium in the gallbladder lumen that promotes development of cholesterol crystals and subsequent gallstones.

Table 61-1 Composition of Hepatic and Gallbladder Bile

Characteristic	Hepatic	Gallbladder
Sodium (mEq/L)	160	270
Potassium (mEq/L)	5	10
Chloride (mEq/L)	90	15
Bicarbonate (mEq/L)	45	10
Calcium (mEq/L)	4	25
Magnesium (mEq/L)	2	—
Bilirubin (mEq/L)	1.5	15
Protein (mEq/L)	150	—
Bile acids (mEq/L)	50	150
Phospholipids (mEq/L)	8	40
Cholesterol (mEq/L)	4	18
Total solids (mEq/L)	—	125
pH	7.8	7.2

Enterohepatic Circulation

Bile acids travel in the bile through the liver, biliary tree, intestines, and the portal venous circulation to return to the liver, thereby recovering 95% of bile acids, with the other 5% passing in stool. Hepatocytes secrete bile acids through a rate-limiting, ATP-dependent process via a bile salt export pump. Approximately 600 to 750 mL of bile is produced daily. Hormones, such as secretin, cholecystokinin (CCK), and gastrin increase bile flow primarily by promoting active secretion of chloride-rich fluid in the bile ducts.

Gallbladder Function

The main functions of the gallbladder are to concentrate and store bile during the fasting state and deliver bile into the duodenum when needed. Bile reenters the distal bile duct and is secreted into the duodenum in response to a meal. The gallbladder mucosa is unique in that it has the greatest absorptive capacity per unit of any structure in the body, but the gallbladder itself has a limited storage capacity of approximately 50 mL; thus the bile it can store is made more effective through the process of concentration.

The gallbladder's mucosa secretes mucous glycoproteins and hydrogen ions. Mucous glycoproteins are actively secreted from the mucosal glands in the gallbladder neck and cystic duct. The resultant mucous barrier protects the gallbladder epithelium from the detergent effect of concentrated bile salts. The transport of hydrogen ions by the gallbladder epithelium leads to a decrease in bile pH through an active sodium-exchange mechanism. Acidification of bile in the gallbladder promotes calcium solubility, thereby preventing its precipitation as calcium salts and subsequent gallstone formation. The gallbladder's normal acidification process lowers the pH of hepatic bile from 7.5 to 7.8 down to 7.1 to 7.3.[7]

Biliary Motility

Gallbladder filling is facilitated through tonic contraction of the ampullary sphincter, which maintains a constant pressure in the common bile duct (CBD) (10 to 15 mm Hg). There are periods of gallbladder filling flanked by brief periods of partial emptying (10% to 15% of its volume) of concentrated bile. These emptying periods are coordinated with each passage of chyme through the duodenum via the migrating myoelectric complex (MMC) and the hormone motilin. Following a meal, the release of stored bile from the gallbladder requires coordination of both gallbladder contraction and sphincter of Oddi relaxation. CCK is released from the duodenal mucosa in response to a meal, and this hormone serves as a major stimulus for gallbladder contraction. Following a meal, the gallbladder releases 50% to 70% of its contents within 30 to 40 minutes. Gallbladder refilling then occurs gradually over the next 60 to 90 minutes. Many other hormonal and neural pathways are also necessary for the coordinated action of the gallbladder and sphincter of Oddi. Dysmotility of the gallbladder increases the time bile dwells in the gallbladder, and along with calcium precipitation, plays a central role in the pathogenesis of gallstones.[8]

Sphincter of Oddi

The human sphincter of Oddi is a complex structure that is functionally independent from the duodenal musculature. Endoscopic manometric studies demonstrate that the sphincter of Oddi creates a high-pressure zone between the bile duct and the duodenum, which regulates the flow of bile and pancreatic juice into the duodenum while preventing regurgitation of duodenal contents into the biliary tract. Through this action, a higher luminal pressure is maintained in the biliary tract than in the duodenal lumen.

Both neural and hormonal factors influence the sphincter of Oddi. In humans, sphincter of Oddi pressure and phasic wave activity diminish in response to CCK. Thus, sphincter pressure relaxes after a meal, allowing the passive flow of bile into the duodenum. During fasting, high-pressure phasic contractions of the sphincter of Oddi persist through all phases of the MMC. Results of animal studies demonstrate that sphincter of Oddi phasic waves do vary with the MMC, permitting partial gallbladder emptying and increasing bile flow during phase III of the MMC; a mechanism which may serve to limit accumulation of biliary crystals during fasting.[9] Neurally mediated reflexes link the sphincter of Oddi with the gallbladder and stomach to coordinate the flow of bile and pancreatic juice into the duodenum. The cholecystosphincter of Oddi reflex allows the sphincter to relax as the gallbladder contracts. Similarly, antral distention causes both gallbladder contraction and sphincter relaxation.

GALLSTONES

Ten to 20% of adults in the United States will be affected by gallstones during their lifetime.[10] The vast majority of people with gallstone will have asymptomatic disease diagnosed incidentally via imaging (ultrasound [US], computed tomography [CT], or magnetic resonance imaging [MRI]) for other health problems. It is estimated that 2% to 3% per year of those with known gallstones will develop symptoms[11] and 1% to 2% will develop more complex problems such as cholecystitis, pancreatitis, or cholangitis annually.[12] Gallstones represent a failure to maintain certain biliary solutes, primarily cholesterol and calcium salts, in a solubilized state, and can form in the gallbladder and less commonly in the bile ducts.

Gallstone Formation

1, 2 The gallbladder fills with hepatic bile during tonic contraction of the ampullary sphincter. Following a meal, the duodenum releases the gut peptide CCK, which stimulates gallbladder emptying. Fifty to 70% of the gallbladder contents are forced into the duodenum and then refilling gradually happens within the next 60 to 90 minutes.[13] The combination of hepatic bile acidification and concentration in the gallbladder, by 5 to 10-fold, enhance calcium solubility; however, the secretion of mucous glycoproteins to protect the mucosa from bile salts serves as a nidus for cholesterol stone formation. An important biliary precipitate in gallstone pathogenesis is biliary "sludge," which refers to a mixture of cholesterol crystals, calcium bilirubinate granules, and a mucin gel matrix. Biliary sludge has been observed clinically in prolonged fasting states or with the use of long-term total parenteral nutrition (TPN). Both of these conditions are also associated with gallstone formation. The finding of macromolecular complexes of mucin and bilirubin, similar to biliary sludge in the central core of most cholesterol gallstones, suggests that sludge may serve as the nidus for gallstone formation.



Figure 61-1. **A:** Cholesterol gallstones. **B:** Black pigment gallstones. **C:** Brown pigment gallstones.

Gallstone Types

3 Gallstones are classified by their cholesterol content as either cholesterol or pigment stones. Pigment stones are further classified as either black or brown (Fig. 61-1). In most American populations, 70% to 80% of gallstones are cholesterol stones and the others are black pigment stones.

Cholesterol Gallstones

Pure cholesterol gallstones are uncommon, as most have a core of calcium salts (90%). The pathogenesis of cholesterol gallstones involves four key factors: (a) cholesterol supersaturation in bile, (b) crystal nucleation, (c) gallbladder dysmotility, and (d) gallbladder absorption/secretion.

Cholesterol Supersaturation. The key to maintaining cholesterol in solution is the formation of micelles, a bile salt–phospholipid–cholesterol complex, and cholesterol–phospholipid vesicles (Fig. 61-2). Present theory suggests that in states of excess cholesterol production, these large vesicles may exceed their capability to transport cholesterol and crystal precipitation may occur. Cholesterol solubility depends on the relative concentration of cholesterol, bile salts, and phospholipid. By plotting the percentages of each component on triangular coordinates, the micellar zone in which cholesterol is completely soluble can be demonstrated (Fig. 61-3). In the area above the curve, bile is supersaturated with cholesterol and precipitation of cholesterol crystals can occur.

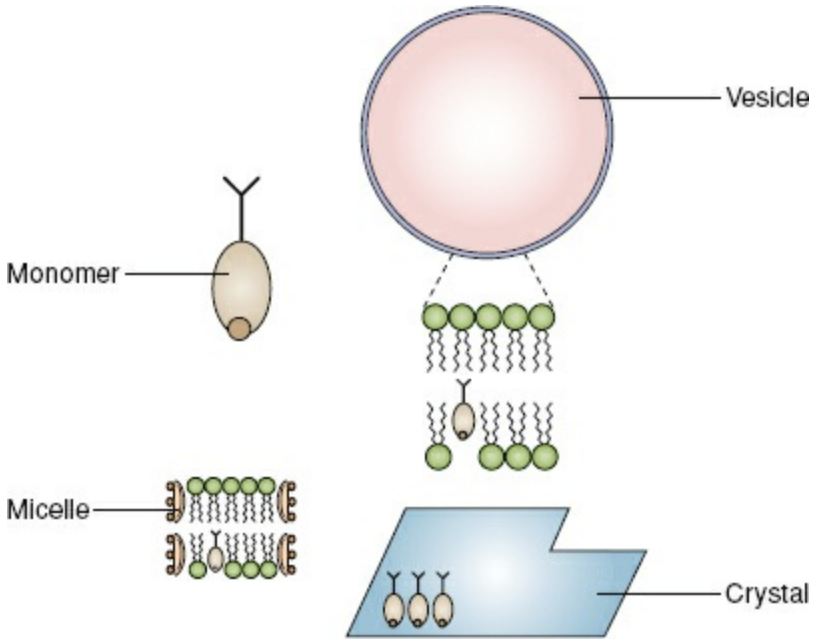

Figure 61-2. Phases of cholesterol in bile.

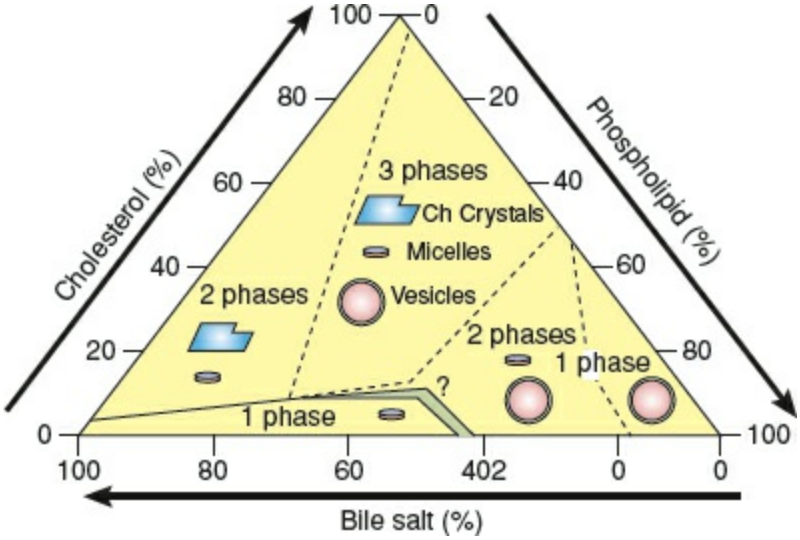

Figure 61-3. Equilibrium phase diagram for bile salt–lecithin–cholesterol–water at a concentration of 10% solids, 90% water. The monomeric phase is not depicted as a phase because it exists at the same concentration throughout. The one-phase zone contains only micelles. Several other zones exist, but only the two on the left above the one-phase zone apply to human gallbladder bile, and both contain cholesterol monohydrate crystals at equilibrium.

Cholesterol Crystallization. Cholesterol supersaturation does not always result in stone formation. As bile is concentrated in the gallbladder, a net transfer of phospholipids and cholesterol from vesicles to micelles occurs. The phospholipids are transferred more efficiently than cholesterol, leading to cholesterol enrichment in the vesicles. These cholesterol-rich vesicles aggregate to form large multilamellar liquid vesicles that then precipitate cholesterol monohydrate crystals. Several pronucleating factors including mucin glycoproteins, immunoglobulins, and transferrin accelerate the precipitation of cholesterol in bile.

Gallbladder Motility. For gallstones to cause clinical symptoms, they must obtain a size sufficient to produce mechanical injury to the gallbladder or obstruction of the biliary tree. Growth of stones may occur in two ways: (a) progressive enlargement of individual crystals or stones by deposition of additional insoluble precipitate at the bile–stone interface, or (b) fusion of individual crystals or stones to form a larger conglomerate. Poor gallbladder motility increases the dwell time of bile in the gallbladder, further promoting stone formation. Clinical conditions associated with reduced gallbladder motility include prolonged fasting, long-term TPN administration, surgical vagotomy, diabetes mellitus, and supratherapeutic levels of somatostatin resulting from either somatostatin-producing tumors or in patients receiving long-term somatostatin therapy.

Gallbladder Absorption/Secretion. Alterations in sodium, chloride, bicarbonate, and water absorption may alter the milieu for cholesterol saturation and crystal formation as well as for calcium precipitation.[14]

Pigment Gallstones

Pigment gallstones are classified as either brown or black pigment stones.

Brown Pigment Stones. These stones are composed of calcium bilirubinate, fatty acid soaps (calcium palmitate and calcium stearate), cholesterol, and mucinous glycoproteins (products of bacterial biofilms). They are earthy in texture and are typically found in the intrahepatic and extrahepatic bile ducts (as opposed to the gallbladder) in states of increased bile duct stasis, such as sclerosing cholangitis, congenital biliary cystic disease, chronic biliary strictures, chronic pancreatitis, duodenal diverticula, and infections with bacteria or biliary parasites. East Asian populations are particularly at risk of brown stone formation due to susceptibility to *oriental cholangiohepatitis* (recurrent pyogenic cholangitis). In this condition, bacteria produce a biofilm rich in glucuronidase, which hydrolyses conjugated bilirubin to free bilirubin. Free bilirubin precipitates when mixed with calcium.

In these settings, bacteria-producing slime and bacteria containing the enzyme glucuronidase cause enzymatic hydrolysis of soluble conjugated bilirubin glucuronide to form free bilirubin, which then precipitates with calcium leading to stone formation.

Black Pigment Stones. These stones form primarily in the gallbladder in sterile bile and are associated with advanced age, chronic hemolysis, alcoholism, cirrhosis, pancreatitis, and total parenteral nutrition, and are typically tarry. These stones are usually not associated with infected bile and are located almost exclusively in the gallbladder.

INDICATIONS FOR CHOLECYSTECTOMY

Asymptomatic Patients

4 Given that the large majority of individuals with gallstones are asymptomatic and have no associated complications, most patients can be managed expectantly without surgical intervention. Prophylactic cholecystectomy may, however, be indicated in certain circumstances (Table 61-2). Patients who have a higher risk of cancer in the setting of gallbladder disease, such as Native Americans, presence of large gallstones (>2.5 cm), or calcification of gallbladder wall ("porcelain gallbladder") are commonly offered prophylactic cholecystectomy. Patients who are more likely to have recurrent symptoms or complications secondary to gallstone disease may also undergo prophylactic cholecystectomy; examples of these conditions include hereditary spherocytosis, sickle cell disease, other hemoglobinopathies, the bariatric patients, and pediatric patients. Finally, some clinicians argue that organ transplant patients with gallstones should undergo pretransplant prophylactic cholecystectomy given the possible higher risk of developing complicated gallstone disease due to chronic immunosuppression.

Patients with asymptomatic gallstones who are not offered a cholecystectomy, or choose not to undergo an operation, can be managed with other therapies. In patients with small gallstones (<5 mm) oral dissolution therapy with bile salts may be utilized.[22] Ursodeoxycholic acid (ursodiol) appears to work by dissolving cholesterol crystals and decreasing hepatic secretion of biliary cholesterol thereby decreasing the number of stones. It is also thought that this would decrease the number of colic attacks. Unfortunately, the majority of stones recur (>50% at 5 years) and in a prospective randomized study of 177 patients from the Netherlands, a country that has a long waiting list for elective biliary procedures, ursodiol did not decrease the number of attacks nor gallstone-related complications during the waiting period for cholecystectomy.[23]

Table 61-2 Indications for Prophylactic Cholecystectomy

Pediatric gallstones
Congenital hemolytic anemia
Gallstones >2.5 cm in diameter
Calcified (porcelain) gallbladder (risk of cancer ~5–6%[15–17])
Bariatric surgery (controversial)[18,19]
Long common channel of bile and pancreatic ducts[20,21]
No access to medical care

Table 61-3 Natural History of Gallstones

Degree of Symptoms	Symptoms Requiring Cholecystectomy	Complications of Gallstones
Asymptomatic	1–2%/yr	1–2%/yr
Mild symptoms	6–8%/yr	1–3%/yr
Symptomatic	5–30%/yr	7/yr

An additional therapy, although not commonly employed, is extracorporeal shock wave lithotripsy (ESWL). This therapy uses energy ("shock") waves, produced by different methods depending on the generator technology, to dissolve stones. ESWL can dissolve small calculi or decrease the size of larger calculi and make them potentially extractable by endoscopic or percutaneous techniques, if in the CBD or distal cystic duct, or dissolvable by oral therapy if present in the gallbladder. It is a relatively safe procedure with rare complications, including: hematoma (biliary or otherwise), bowel perforation, and necrotizing pancreatitis.[24]

Symptomatic Patients

It is estimated that 2% to 3% per year of those with known gallstones will develop symptoms[11] and 1% to 2% will develop more complex problems (such as cholecystitis, pancreatitis, or cholangitis) annually (Table 61-3).[12] Those who develop symptoms will most often have biliary colic, or right upper quadrant (RUQ) pain, which will often recur. Biliary colic will often last for several hours after onset before subsiding. Biliary colic develops secondary to intermittent impaction of gallstones at the gallbladder neck as the gallbladder contracts in order to deliver its contents into the CBD. In more than 50% of patients it occurs following a fatty meal. Biliary colic can be associated with belching, bloating, and even nausea or emesis. Over time this intermittent obstruction leads to increased tension in the gallbladder wall and more chronic pain and inflammation known as chronic cholecystitis.

COMPLICATED GALLSTONE-RELATED DISEASE

Complicated gallstone-related disease (acute cholecystitis [AC], choledocholithiasis, and associated consequences of gallstone pancreatitis or cholangitis) will occur in 0.3% to 3% of patients per year.[25] These complications increase the morbidity and potential mortality of patients with gallstones.

Acute Cholecystitis

AC develops when a gallstone(s) lodges in the gallbladder neck (infundibulum) obstructing bile flow into the CBD. This obstruction leads to biliary stasis, gallbladder wall edema, venous obstruction, and in extreme cases, eventual arterial obstruction causing necrosis of the gallbladder wall. Its course can range from mild pain with fevers to frank sepsis secondary to perforation or development of emphysematous/gangrenous cholecystitis. Clinically, patients present in a similar manner to those with biliary colic; however the pain is constant, unrelenting, and often associated with fevers, tachycardia, and a leukocytosis. The diagnosis is typically made with a thorough history and physical examination, in which the patient may present with midepigastric or RUQ pain, as well as, localized peritoneal irritation. *Murphy's sign,* which is defined by cessation of inspiration secondary to pain, due to the presence of an inflamed gallbladder during deep abdominal palpation at the midclavicular line of the RUQ, is pathognomonic for AC.

Imaging and Diagnosis

A variety of imaging tests can be used when evaluating the patient with AC, each of which have different strengths and weaknesses, and serve as an adjunct to a thorough history and physical examination.

Ultrasound (US) uses oscillating sound waves to measure differences in tissue densities and interfaces between liquids and solids and is the backbone of imaging for gallstone disease (Fig. 61-4). The primary advantages of US are that it is readily available, quickly performed, and avoids ionizing radiation. The main disadvantage is that it is user-dependent, and technique and experience are therefore quite important.[26] AC can be diagnosed by various US criteria, with the higher number of criteria met on US examination, the more likely for cholecystitis to be present. These criteria include gallbladder wall thickening >5 mm, pericholecystic fluid, gallstones, and a positive sonographic *Murphy sign* characterized by pain and cessation of inspiration when the probe is pressed over the gallbladder. A 2012 meta-analysis by Kiewiet et al.[27] which included 26 studies with 2,847 patients, evaluated the role of US as a tool to diagnose AC, and reported a sensitivity of 81% and specificity of 83% with the comparison being against surgical pathologic findings in the majority of patients.

HIDA scan (biliary scintigraphy) first came into use in the late 1970s.[28] The injectable radioactive dye (derivatives of technetium and iminodiacetic acid) used is preferentially taken up by the liver and excreted into the bile and should fill both the CBD and gallbladder if there is free flow through the entire biliary system. A HIDA scan is considered positive for AC if there is lack of visualization of the gallbladder due to cystic duct occlusion from gallstones which does not allow the radioactive tracer to enter the gallbladder (Fig. 61-5). The overall sensitivity for AC of a HIDA scan is 95% to 98% with a specificity of >90%.[27,28] A false-positive HIDA scan can occur in various situations, including consumption of a recent meal (the gallbladder is contracted due to CCK), prolonged fasting (the gallbladder has concentrated thick bile which acts as a mechanical obstruction to entrance of the tracer), chronic cholecystitis, or the presence of underlying

hepatobiliary disease.

Limitations of HIDA scans are that it is not always readily available, especially after hours, and require exposure to ionizing radiation; thus, most clinicians will begin with US and then use HIDA to clarify equivocal US results. Several studies have looked at the utility of adding HIDA to US in the case of diagnostic dilemma, but the combined modalities do not appear to add sensitivity or specificity for detection of AC, although they may provide additional morphologic information.[29–31]

CT scans are typically less helpful for diagnosing uncomplicated gallstone disease, as most gallstones (85%) are not radiopaque. CT scans are limited in their ability of evaluating the CBD and identifying an obstruction of the cystic duct, which is a prerequisite for the diagnosis of AC.[26,32–34] They have been shown to be less sensitive and specific than US.[32] CT scans can be helpful, however, in evaluating patients for complications of AC (Fig. 61-4). Gangrenous cholecystitis, which is the most common AC complication, occurs in up to 38% of patients with AC. Gallbladder perforation and abscess formation can be seen in up to 8% to 12% of AC cases. A CT scan can detect a defect in the gallbladder wall in 53% of patients with early perforation whereas US cannot easily delineate a mural defect, unless large, although both will likely help detect the resulting abscess formation (Fig. 61-6).

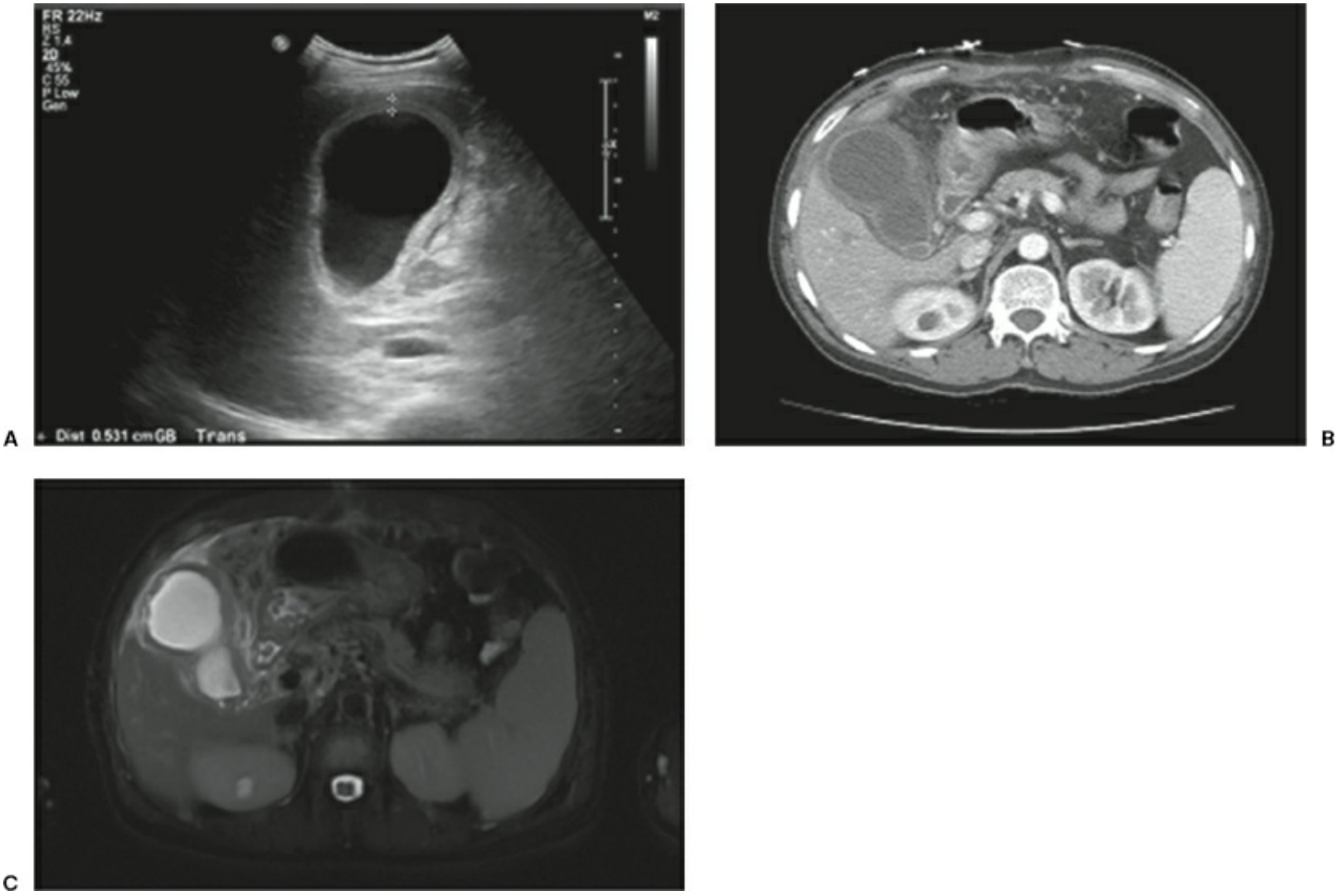

Figure 61-4. Classic acute cholecystitis seen on US (**A**) with luminal distention, gallbladder wall thickening >5 mm, and pericholecystic fluid; CT scan (**B**) demonstrates similar findings of wall thickening and pericholecystic stranding; MRI T2 fat-saturated sequence (**C**) demonstrates gallbladder wall edema and pericholecystic fluid, as well as small stones in the gallbladder neck. (Image courtesy of Aarti Sekhar, MD and David Schuster, MD, Emory University Department of Radiology.)

MRI has only been evaluated in small studies in the setting of AC. Its sensitivity and specificity are similar to that of US (approximately 80% to 85% for both). MRI is useful for evaluation of the biliary tree and to assess for the presence of choledocholithiasis; however, it can overestimate the presence of gallbladder wall inflammation (Fig. 61-4). Advancements in MRI protocols employing unique tracers that are taken up and excreted in the biliary tree similar to iminodiacetic acid compounds, such as Eovist, are currently under investigation.[35] Ultimately, the current cost and availability of MRI machines make it of limited use for the diagnosis of AC.

Treatment

The treatment of AC can consist of medical or surgical therapies and the correct treatment modality will depend on the individual clinical scenario. The medical treatment of AC involves nothing *per os,* parenteral hydration, and antibiotics until the patient's clinical examination improves and pain resolves. The diet is then slowly advanced and the patient

is kept on a low-fat diet until cholecystectomy is performed. Despite symptom resolution, the patient should undergo an *interval* cholecystectomy, as the likelihood of a second biliary-related complication is high. Surgical therapy consists of either a laparoscopic or open cholecystectomy, or placement of a cholecystostomy tube in combination with medical therapy.

5 Cholecystectomy. Cholecystectomy is considered standard therapy for patients with symptomatic gallstones and AC. With regard to the surgical treatment of AC, the discussion in the literature has been the timing of the cholecystectomy – early versus delayed. Early cholecystectomy removes the pathologic source, usually within the first 72 hours of presentation. Certain clinicians advocate for delayed cholecystectomy to allow the acute inflammatory response to resolve potentially making the surgery safer with fewer complications and morbidity, such as bile duct injuries, bleeding, and conversion from laparoscopic to open procedure.

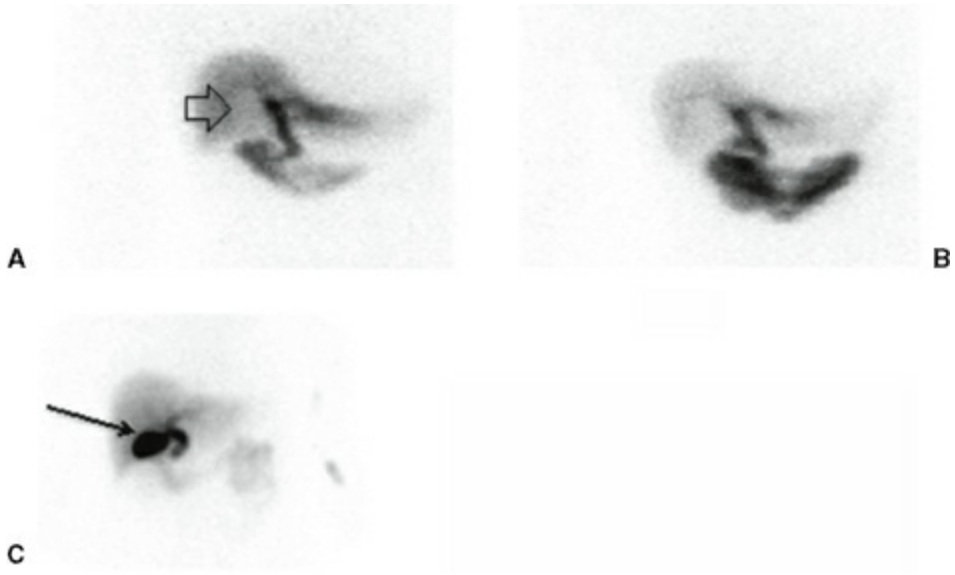

Figure 61-5. HIDA scan (**A**) demonstrating positive result with uptake of tracer within liver and excretion through the common bile duct with filling of the duodenum, but absence of filling of gallbladder (*arrowhead*) even on delayed postmorphine imaging (**B**), confirming cystic duct occlusion. Final panel (**C**), shows normal filling of gallbladder (*arrow*), or a negative result. (Image courtesy of Aarti Sekhar, MD and David Schuster, MD, Emory University Department of Radiology.)

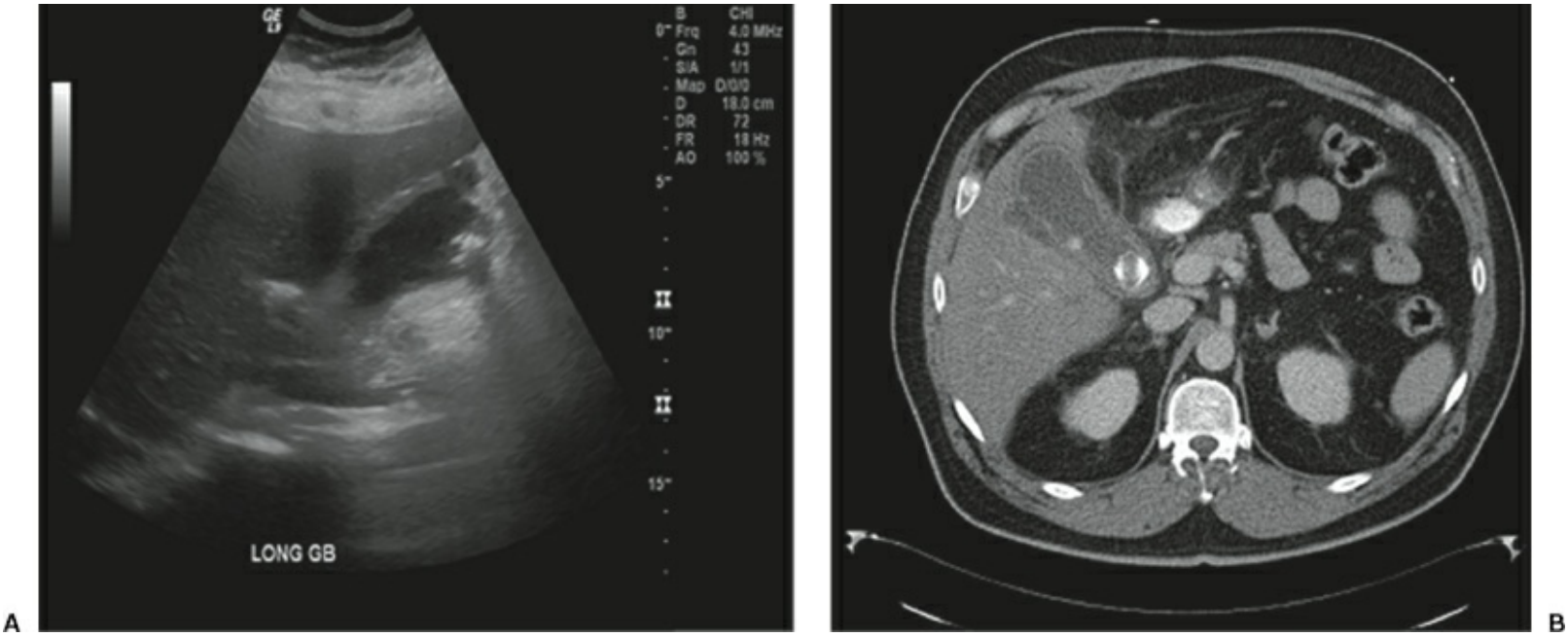

Figure 61-6. Examples from two patients with focal perforations of the gallbladder wall seen on US (**A**) and CT scan (**B**). Large perforations are visible with either modality, but CT is more sensitive for detecting smaller perforations. (Image courtesy of Aarti Sekhar, MD and David Schuster, MD, Emory University Department of Radiology.)

6 A 2006 meta-analysis showed no significant differences in patient outcomes between early and delayed surgeries with respect to bile duct injuries, bleeding complications, laparoscopic-to-open conversion, postoperative infection, and patient death.[36] It was noted that over 23% of delayed patients presented with complications requiring emergent cholecystectomy. Furthermore, total hospital stay, including the index admission and subsequent admissions for biliary complications and later cholecystectomy, was significantly shorter for early cholecystectomy, leading to a decreased cost to the patient and system.

Early has also been somewhat of a misnomer, as traditionally this early approach has consisted of performing a cholecystectomy within 72 hours of the onset of symptoms. A Cochrane review in 2006,[37] which included 6 randomized trials with 488 patients, compared early (within 7 days of presentation) to late (>6 weeks after initial treatment) cholecystectomy and found similar results to the above meta-analysis with no increase in terms of complications and outcomes. Multiple studies demonstrate that *early* should be within the index admission and the 72-hour limit is not as much a steadfast rule given improved skills of surgeons with laparoscopic surgery and the understanding that surgery delayed to a different admission could potentially lead to worse complications.

A recent study from Italy seems to confirm these data. Patients (n = 316) were enrolled in a prospective study[38] to assess the benefit of immediate cholecystectomy during the index admission or delayed surgery after at least 4 weeks. As with the other studies, the complication profiles were no different between the two groups; however, the subgroup analysis within the early intervention group showed that immediate surgery on admission or early surgery within 48 hours was associated with shorter operative time, similar conversion and complication rates, and shorter hospital stay. Within the delayed group, 26% required rehospitalization and 37% required urgent reevaluation

prior to planned surgery.

Percutaneous Cholecystostomy. In the otherwise healthy patient with AC, laparoscopic cholecystectomy should be considered the therapy of choice during the index hospitalization. However, in the elderly patient with poor performance status, multiple comorbidities, or for the extremely ill patient in the intensive care unit, the underlying medical status may impact increased perioperative risk and therefore preclude surgical intervention. Percutaneous cholecystostomy (PC) may be employed as a bridge or final therapy in such patients. This procedure was first described in the 1980s by Radder et al.[39] and involves the placement of a percutaneous transhepatic drain into the gallbladder (Fig. 61-7). The transhepatic approach has remained the method of choice to reduce intraperitoneal bile leak in case of tube dislodgement. Use of this approach has grown over 500% since 1994, along with the field of interventional radiology.[40] Typically, rapid patient improvement is seen following decompression in combination with antibiotics tailored to bacterial isolates. In most patients, an interval cholecystectomy will be performed 6 weeks or more after the drain is placed. Removing the drain alone is usually not sufficient, as the cystic duct obstruction is typically still present. If Bile is draining from the catheter, then it may be possible to remove the catheter after 6 weeks without removing the gallbladder in patients with questionable fitness for surgery.

Acalculous Cholecystitis

Acute acalculous cholecystitis (AAC) represents 12% of all cases of AC with the incidence being significantly higher in intensive care unit patients.[41] AAC is associated with increased bile stasis and therefore decreased gallbladder emptying, which typically occurs in the setting of severe illness with multiple contributing mediators, such as the inflammatory response, total parenteral nutrition, and high-dose narcotics. The diagnosis of ACC requires a high index of clinical suspicion, as patients are often critically ill and unable to communicate symptoms. The potential consequences of late diagnosis are considerable, with gallbladder ischemia and progression to gangrene and eventual perforation resulting in a mortality rate of up to 30%.[42] Diagnosis may be made using bedside ultrasonography following similar criteria as used for acute calculous cholecystitis, with the exception of lack of calculi. The sensitivity of US in this setting ranges from 50% to 100% with a specificity of 90% to 94%. HIDA scan with morphine amplification can be used to increase bile secretory pressure and allow bile to reflux through a contracted gallbladder neck, thereby decreasing false-positive rates, providing sensitivity rates of 67% to 100% and specificity rates of 69% to 100%.[41]

US remains the initial test of choice, as it is relatively inexpensive, and may be performed at the bedside in the ICU. However, a negative US in a patient with a high clinical suspicion for AAC may benefit from a HIDA scan to improve diagnostic yield.[43] Treatment of AAC is either a cholecystectomy in the stable patient or more likely, PC tube placement in the critically ill, unstable patient.

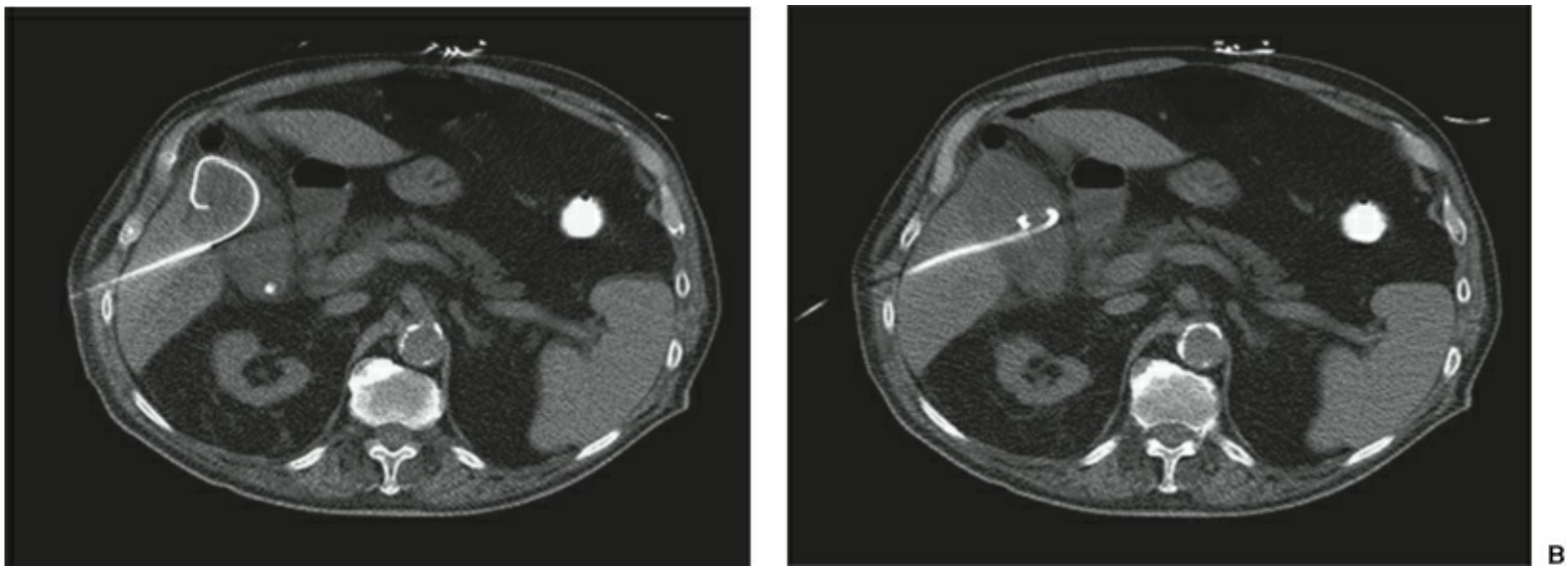

Figure 61-7. CT guided placement of a 10-French cholecystostomy tube for acute cholecystitis in a nonoperative patient. Note transhepatic (across the liver) placement. These tubes may be placed using US or CT guidance. (Image courtesy of Aarti Sekhar, MD and David Schuster, MD, Emory University Department of Radiology.)

Chronic Cholecystitis

In most patients (>90%), gallstones are the causative factor of chronic cholecystitis and lead to recurrent episodes of cystic duct obstruction manifesting as recurrent biliary colic. These recurrent attacks can lead to scarring and a nonfunctioning, noncontracting gallbladder. A patient with chronic cholecystitis present similarly to those with symptomatic cholelithiasis (i.e., biliary colic) and it is often difficult to distinguish between the two conditions. Diagnosis is accomplished with a US documenting gallstones in the setting of recurrent episodes of RUQ abdominal pain. Patients may exhibit atypical symptoms or a clinician may desire confirmation of a causal relationship to the calculi seen on US, and a HIDA scan may be useful in this situation.[28] The treatment for chronic cholecystitis is cholecystectomy.

Gallstone Pancreatitis

Gallstone pancreatitis develops as a result of choledocholithiasis (gallstones that have migrated into the CBD). Stone impaction at the distal CBD near the Ampulla of Vater, where the CBD and pancreatic duct join, may interfere with the flow of exocrine pancreatic secretions resulting in reflux into the pancreatic duct with subsequent autolysis secondary to release of digestive enzymes. It is the second most common cause of pancreatitis after alcohol abuse. The clinical diagnosis of pancreatitis is made by the constellation of upper abdominal pain, serum amylase or lipase >3 times the upper level of normal, and/or imaging studies demonstrating acute inflammation of the pancreas, although imaging is not generally required.[44]

Treatment for pancreatitis is dependent on the severity of the local and systemic response and beyond the scope of this chapter. However, the underlying cause, the lodged stone, must be addressed. Recent guidelines from the International Association of Pancreatology (IAP),[44] suggest that the majority of stones will pass by themselves, and only if there is evidence of cholangitis (see below under *cholangitis*) should endoscopic retrograde cholangiopancreatography (ERCP) be performed for stone extraction. Regardless of the need for stone extraction, the gallbladder should be removed to prevent further episodes of pancreatitis.

The timing of the cholecystectomy in the setting of gallstone pancreatitis is controversial. It was previously thought that given the acute inflammation, the risk of injury to the CBD or other structures was too high for immediate surgery and an interval cholecystectomy (4 to 8 weeks from the initial admission) was indicated. Evidence now supports early intervention with cholecystectomy being performed during the index admission.[45,46]

CHOLECYSTECTOMY

Historical Perspectives

Laparoscopic cholecystectomy is the most common gastrointestinal surgical procedure performed in the United States, with more than 750,000 procedures performed yearly. Carl Langenbuch was the first to describe the open cholecystectomy in Germany in 1882. A century later, laparoscopic cholecystectomy was introduced and has since become the preferred method for removal of the gallbladder with over 90% of elective procedures and 70% of urgent cholecystectomies being performed laparoscopically.[25]

True contraindications to the laparoscopic approach to cholecystectomy, include (i) patient inability to tolerate pneumoperitoneum, (ii) bleeding diatheses, and (iii) decompensated cirrhosis, given the risk of fracturing of the liver and bleeding.[22] Patients at higher risk for complications following the laparoscopic approach are those with AC, morbid obesity, previous upper abdominal surgery, and well-compensated cirrhosis.

Technique

The procedure traditionally is performed using four ports. The abdomen is typically entered near the umbilicus and the abdomen is insufflated to 15 mm Hg. Three further operating ports are placed under direct visualization: two 5-mm ports in the RUQ subcostally in a position to grasp the fundus of the gallbladder and retract it cephalad and another in a position to grasp the infundibulum (often in the anterior axillary and midclavicular lines, respectively), and a third 5-mm trocar or 10/12-mm trocar is placed in the subxiphoid/midepigastric region (Fig. 61-8).

The fundus and infundibulum are grasped to retract the gallbladder cephalad exposing the cystic duct and the triangle of Calot (defined by the liver edge, cystic duct, and common hepatic duct), which holds the cystic artery (Fig. 61-8). The dissection of the lymphatic and fatty tissue within the triangle should allow for visualization of two distinct structures entering the gallbladder (the cystic artery and cystic duct) creating what is known as the *critical view*. The cystic duct and artery are fully encircled and individually controlled with two surgical clips placed toward the porta hepatis and one toward the gallbladder and then divided. The peritoneum surrounding the gallbladder is then incised, and using the two 5-mm RUQ ports, the gallbladder is maximally retracted in order to develop the adventitial plane between the gallbladder and Glisson capsule (Fig. 61-9). The gallbladder is then removed off the liver from the infundibulum toward the fundus. Hemostasis within the gallbladder fossa is assured and the gallbladder is extracted through the umbilical port, which may need to be enlarged in the setting of significant calculi, within an impermeable plastic bag, which decreases the risk of infection at the site of removal. This is especially true if the gallbladder is acutely inflamed, gangrenous, or perforated as the risk of infection at the extraction site is increased.

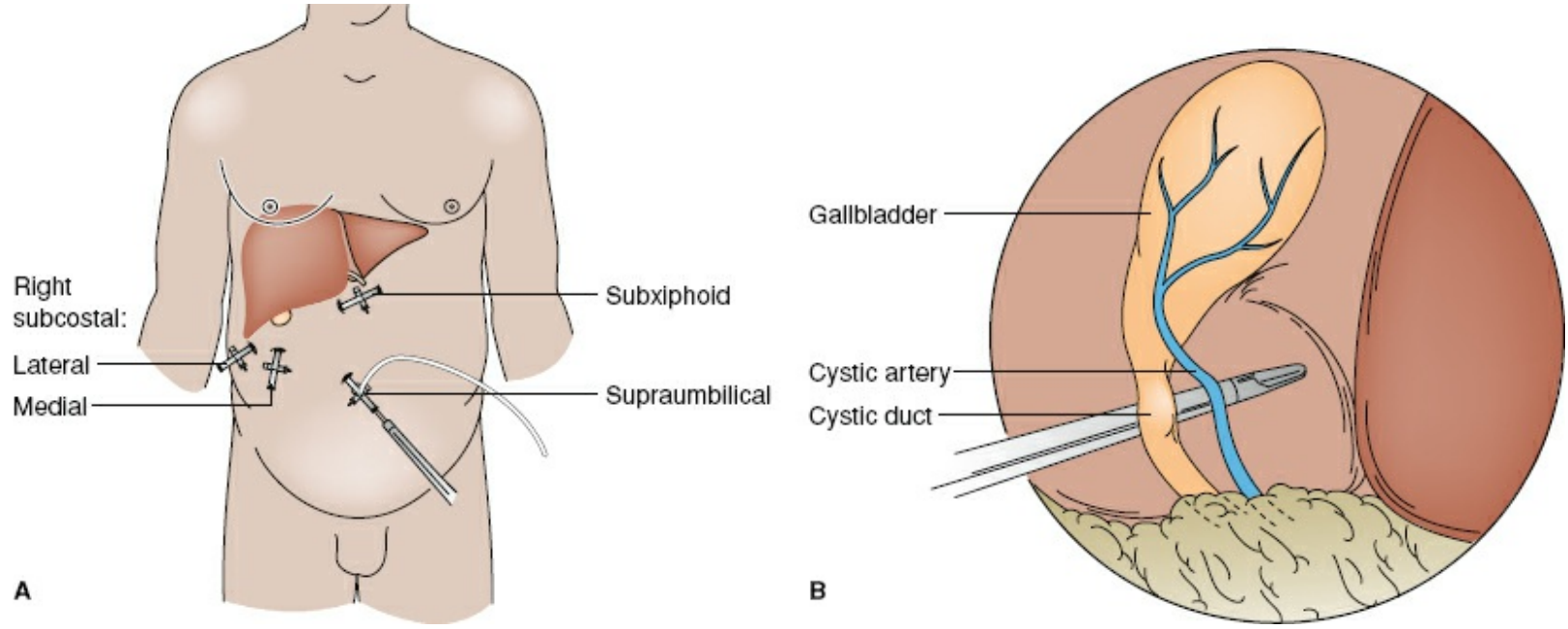

Figure 61-8. **A:** Trocar placement for laparoscopic cholecystectomy. The laparoscope is placed through a 10-mm port just above the umbilicus. Additional ports are placed in the epigastrium, subcostally in the midclavicular, and near the anterior axillary lines. **B:** The "critical view" of safety. The triangle of Calot is dissected free of all tissue except for the cystic duct and artery, and the base of the liver bed is exposed. When this view is achieved, the two structures entering the gallbladder can only be the cystic duct and artery. Visualization of the common bile duct is not necessary.

If the anatomy is unclear, a cholangiogram may be useful and can be performed laparoscopically via access of the gallbladder infundibulum or proximal cystic duct. A cholangiogram is performed by ligating the cystic duct or gallbladder proximally and incising the anterior surface of the gallbladder infundibulum or proximal cystic duct for placement of a cholangiocatheter. At this point, a radio-opaque contrast agent is injected, and under fluoroscopy the biliary ductal anatomy is defined. Newer techniques of fluorescent-assisted cholangiogram using systemically injected near-infrared dyes, such as indocyanine green or methylene blue, may assist in identification of the critical structures without requiring intraoperative catheter placement or ionizing radiation exposure making the procedure less technically demanding.[47]

Laparoscopic cholecystectomy in the elective setting for symptomatic cholelithiasis, or as an interval operation in the setting of AC, can often be performed in the outpatient setting. Factors that may influence admission include starting the operation later in the day, uncontrolled pain or nausea, and longer operative time (greater than 1 hour).[48]

Other Approaches

As practitioners and patients have become more exposed and familiar with the laparoscopic treatment of various surgical conditions, desire for even more minimally invasive, and to a certain degree cosmetic approach has increased. This led to the development of the single-incision approach to laparoscopic cholecystectomy (SILS). This is performed by placing a multiport access device through the umbilicus and inserting various instruments through the single port in order to dissect the critical structures and the gallbladder. The safety of SILS in elective cholecystectomies has been proven in various clinical trials.[49,50] The proponents of SILS espouse the cosmetic appeal, although this metric was not supported in a Cochrane review.[50] Detractors point to the increased operative time and increased hernia rates.[51]

Robotic SILS was developed to improve upon the limitations of standard SILS (reduced visualization and limited traction). The intuitive computer software assists in triangulation of the arms through the single umbilical port and due to proprietary port design (Fig. 61-10), the issue of instrument interference is decreased. This approach, however, may significantly increase the overall cost to the patient and healthcare system with no proven benefit to date in terms of outcomes when compared to conventional laparoscopy. Nonetheless, given the new technology it is still early in the experience and further studies are required to truly determine the niche, if any, for robotic and SILS cholecystectomies.[52–54]

Open cholecystectomy has been relegated to a relative rare operation since the introduction and wide spread acceptance of laparoscopic surgery. The open technique is still employed in certain clinical settings, such as (i) the need for a potential second procedure, like concurrent CBD procedure, (ii) known complicated anatomy, or (iii) need for conversion from a laparoscopic procedure to an open procedure due to inability to identify anatomy or unexpected findings in approximately 10% to 15% of planned operations.[55] Open cholecystectomy can be performed through either an upper midline or right subcostal (Kocher) incision. Unlike laparoscopic cholecystectomy, dissection often begins at the fundus and proceeds in a retrograde, dome-down fashion toward Calot triangle with identification of the cystic artery and duct at the gallbladder neck.

Serious complications of laparoscopic or open cholecystectomy are rare and the associated mortality rate is $<0.3\%$. The most severe complication of cholecystectomy is a biliary tract injury. The incidence of bile duct injury following laparoscopic cholecystectomy is between 0.3% and 0.6% (vs. 0.2% and 0.3%, historically for open surgery). Major vascular injuries, especially to the right hepatic artery, may occur in association with biliary injuries due to their close anatomic relationship. Otherwise, vascular injuries to hepatic vessels and other major causes of bleeding are rare.

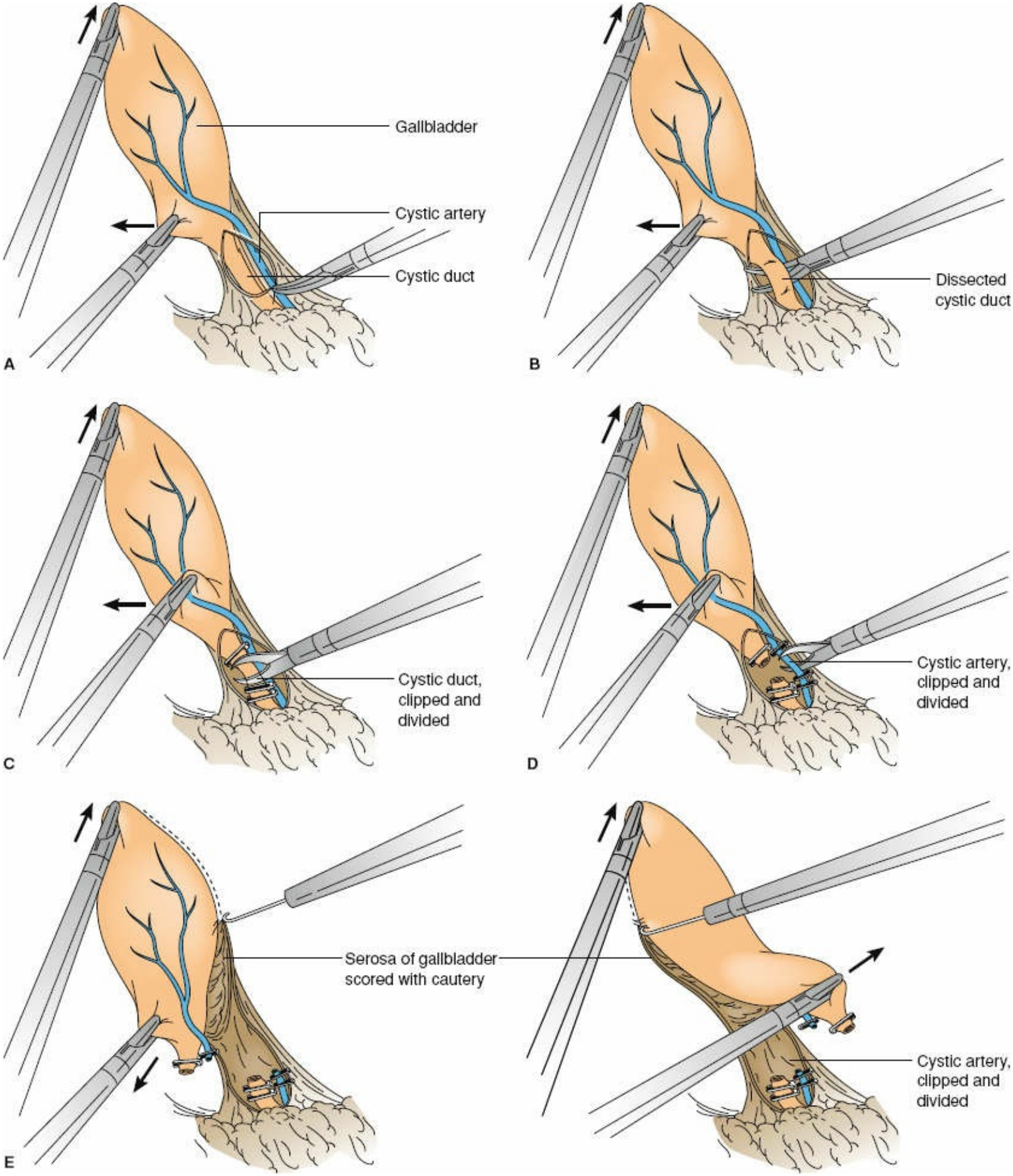

Figure 61-9. **A:** The peritoneum overlying the cystic duct–gallbladder junction is opened with blunt dissection. **B:** The cystic duct is isolated. **C:** The cystic duct is clipped proximal and distal and divided with the hook scissors. **D:** The cystic artery is dissected, clipped, and divided. **E:** The gallbladder is dissected from the liver by scoring the serosa with electrocautery.

Spillage of stones into the peritoneal cavity during laparoscopic cholecystectomy occurs in 5% to 40% of cases. Intra-abdominal abscess, subcutaneous abscess, and fistulization of stones through the abdominal wall have all been described and therefore every attempt should be made to remove spilled stones. Large stones or massive spills should be removed as best possible to prevent delayed complications, but mandatory laparotomy does not appear necessary.[56]

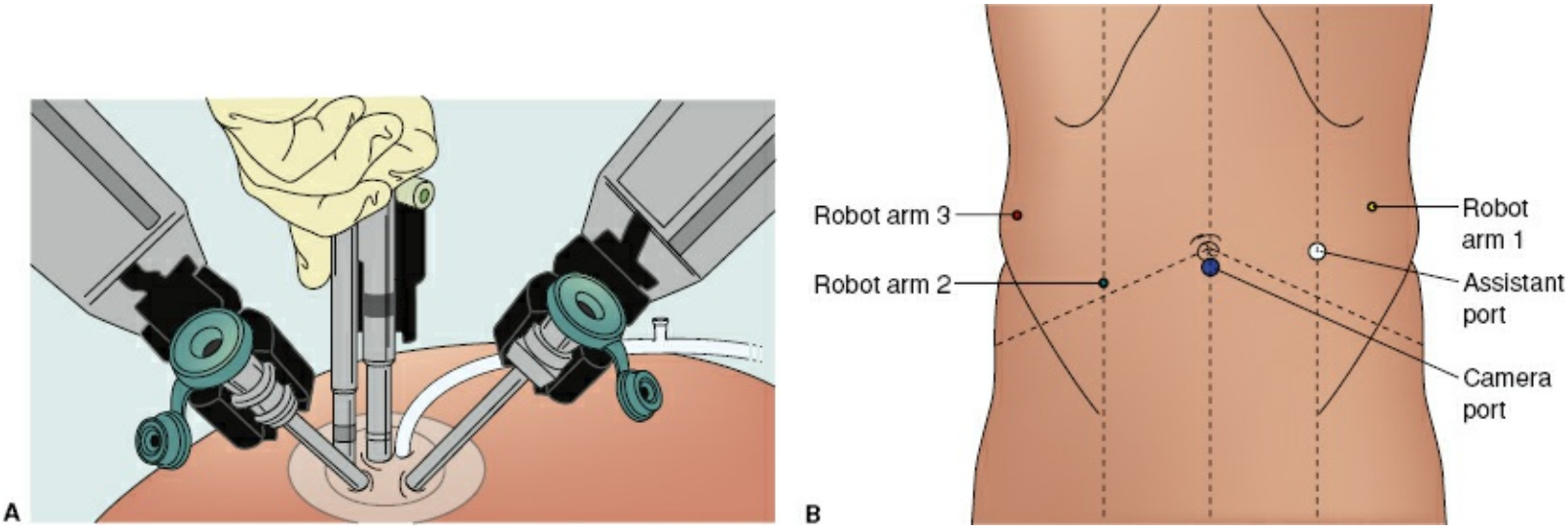

Figure 61-10. (**A**) Single port robotic (umbilical placement) and (**B**) conventional port positioning for robotic cholecystectomy: red, green, and yellow = robot arms (arms 1, 2, and 3, respectively); blue = camera port; white = assistant port if needed.

Special Considerations

Gallbladder Cancer

A gallbladder containing an unsuspected cancer is removed in 0.2% to 3% of all laparoscopic cholecystectomies.[57] If cancer is suspected preoperatively (30% of cases), the gallbladder should be extracted in an impermeable bag to reduce the risk of seeding the peritoneum and/or port sites. If a gallbladder cancer is discovered, additional hepatic resection may be required and appropriate referral to a hepatobiliary specialist is indicated. Of note, severe AC may present in a similar manner on imaging as a gallbladder cancer and complicate management decisions as to whether an upfront en-bloc resection should be performed (Fig. 61-11).

Cholecystoenteric Fistulae

Fistulization occurs in approximately 1% to 2% of all patients undergoing a cholecystectomy. The most common site of fistulization is to the duodenum and colon.[58] A fistula develops secondary to decompression of the gallbladder into the adjacent bowel loop during an episode of AC. Complications of a cholecystoenteric fistula are rare, but a large gallstone may pass into the bowel and cause a mechanical bowel obstruction, usually distally in areas of narrow caliber, such as the ileocolic valve or sigmoid colon. This obstruction is known as a *gallstone ileus*. If this complication occurs, the initial management involves removal of the gallstone through an enterotomy with possible bowel resection. Decision to proceed with removal of the biliary-enteric fistula and cholecystectomy at the time of operation rests on surgical judgment, taking patient fitness and degree of tissue inflammation into account.[59] Staging the operative repair of the fistula and cholecystectomy to a later date should be considered. An association between the presence of a cholecystoenteric fistula and gallbladder cancer has been suggested, therefore a certain degree of clinical suspicion for cancer is warranted in this scenario.

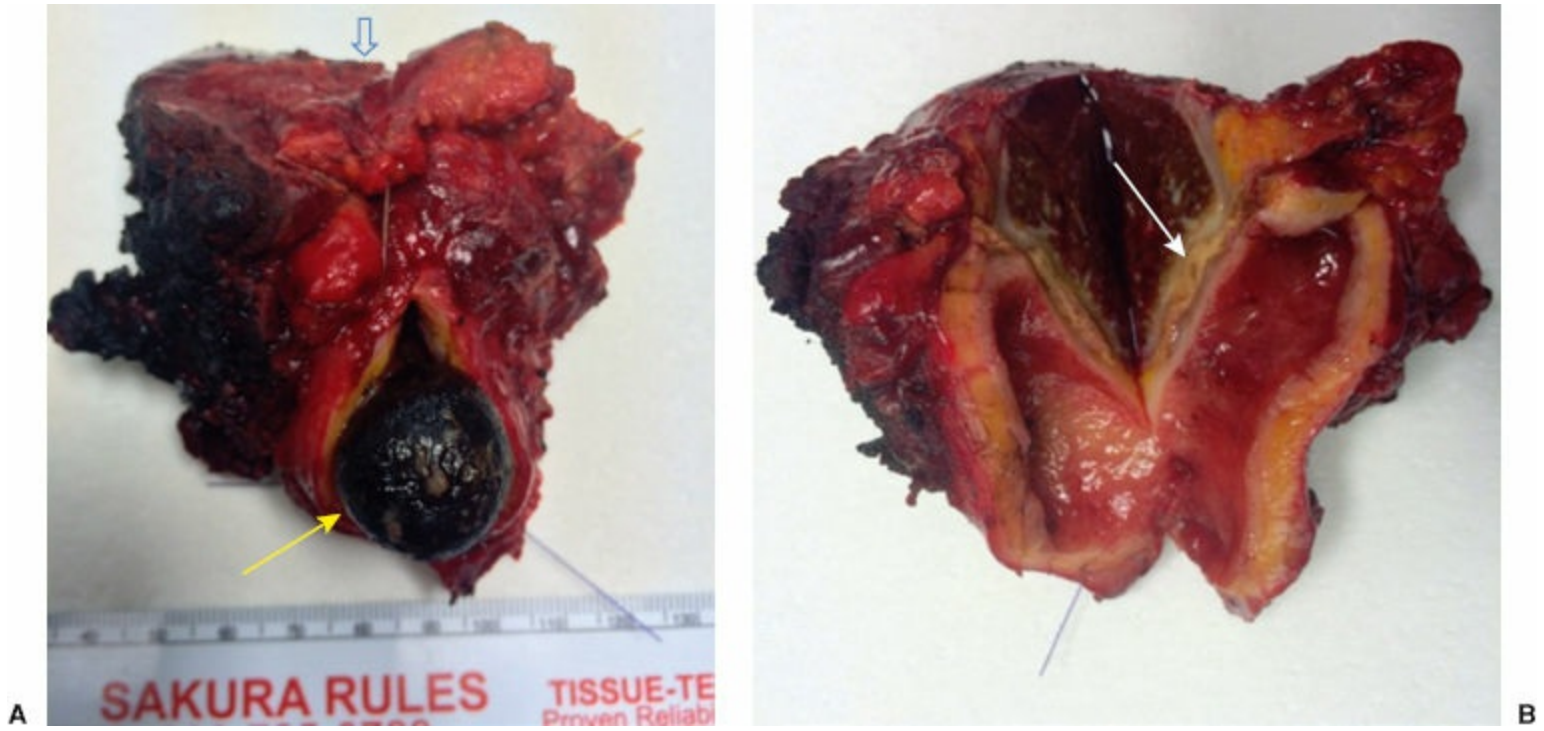

Figure 61-11. En bloc cholecystectomy and segment 4b/5 liver resection (*blue arrow head*) for concern of gallbladder carcinoma. **A:** Final pathology demonstrated acute on chronic cholecystitis secondary to presences of large pigmented gallstone (*yellow arrow*). **B:** There is evidence of perforation into segment 4 of liver with resulting abscess and fibrosis (*white arrow*) mimicking a gallbladder cancer on imaging.

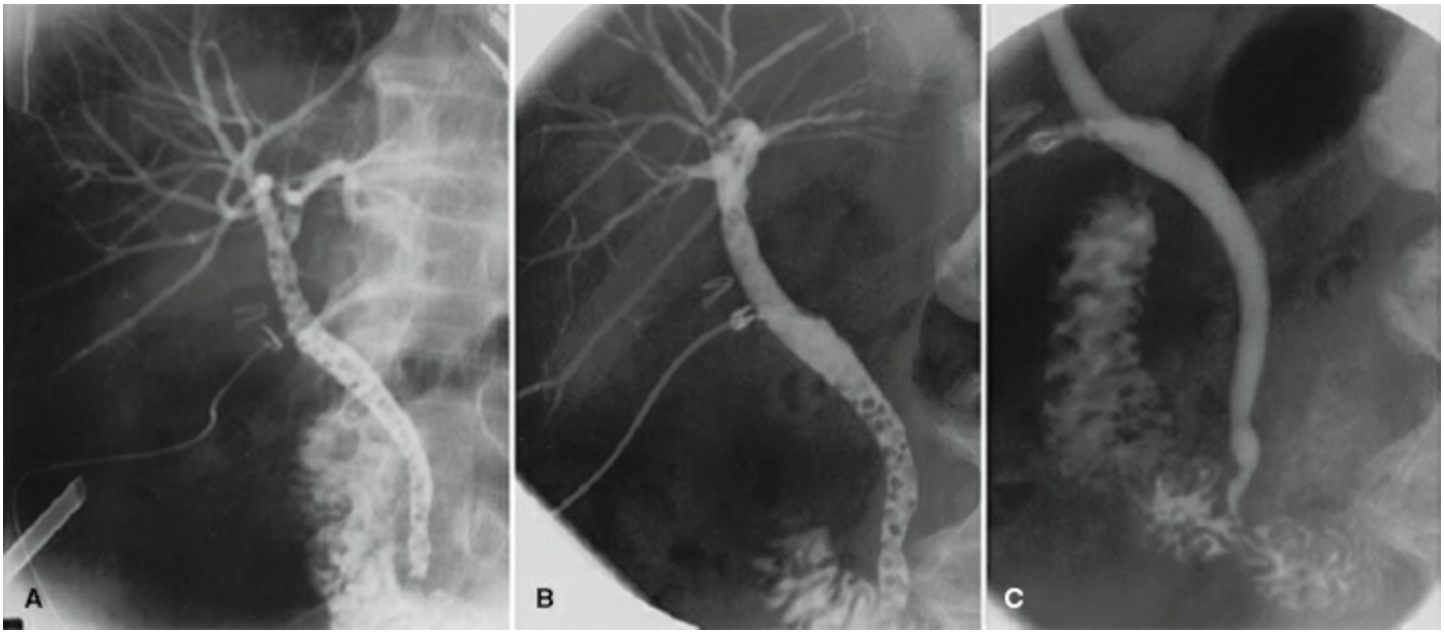

Figure 61-12. Operative cholangiography showing calculi filling the common bile duct and common hepatic duct (**A**). These calculi are still present at 48 hours (**B**) but have passed at 6 weeks (**C**). (Adapted from Collins C, Maguire D, Ireland A, et al. A prospective study of common bile duct calculi in patients undergoing laparoscopic cholecystectomy: natural history of choledocholithiasis revisited. *Ann Surg* 2004;239(1):28–33.)

Cholecystitis During Pregnancy

After appendicitis, biliary disease is the second most common gastrointestinal ailment requiring surgical consideration during pregnancy.[60] The development of biliary disease

in pregnancy appears to be secondary to the hormonal changes that occur during pregnancy which both increase the cholesterol secretion in bile and decrease bile acid secretion and gallbladder contractility. Gallstones develop in up to 3% of pregnant women with gallbladder sludge seen in up to 30% of cases. Medical therapy alone is associated with a failure rate that varies depending on the trimester of pregnancy (92% for first trimester, 69% for second trimester, and 44% for third trimester).[61] Fetal demise unfortunately occurs in 12% of nonoperatively treated woman with AC, and is significantly higher in women who develop gallstone pancreatitis. The risk of miscarriage after an operative intervention for AC is between 2.2% and 5.6%.[62] There are no prospective studies evaluating cholecystectomy during pregnancy, but evidence-based guidelines suggest that laparoscopic surgery is safe in any trimester, although trocar positioning may need to be adjusted.[63]

CHOLEDOCHOLITHIASIS

Overview

Choledocholithiasis, defined as the presence of stones in the extrahepatic biliary tree, is a routine, yet to a certain degree diagnostic and therapeutically challenging, gastrointestinal illness encountered by the practicing general surgeon. The last few decades have seen considerable advancements in both the diagnostic modalities and treatment approaches available in the management of choledocholithiasis or as more commonly referred to CBD stones. In this section, we will discuss the clinical presentation and management of CBD stones.

Classification and Etiology

CBD stones are typically classified as primary or secondary stones. Primary CBD stones originate within the bile duct and are more commonly seen in patients from Southeast Asian countries. Primary CBD stones can also develop in conditions associated with bile stasis, such as: (i) benign biliary strictures, (ii) bile duct cysts (choledochal cysts), or (iii) sphincter of Oddi dysfunction. These stones are characteristically pigmented stones, which form *de novo* as a result of bactericidal action on calcium bilirubinate, thus producing a soft brown-pigmented stone.[64,65]

Secondary stones originate from the gallbladder and migrate into the bile duct. They are the most common type of CBD stone accounting for approximately 85% of CBD stones seen in the United States and Western countries. The majority (75%) of these stones are cholesterol stones with only a minority being black-pigmented stones.[66,67] It is estimated that approximately 10% to 15% of patients with symptomatic gallstones will have CBD stones and the vast majority of patients with secondary CBD stones will have gallstones.[68,69]

Clinical Presentation

7 CBD stones, similar to gallbladder stones, can have an asymptomatic course and pass spontaneously into the duodenum without clinical consequence.[69] The exact incidence and frequency in which this occurs is unknown. In nonjaundiced patients with nondilated bile ducts on US, the incidence of CBD stones at the time of cholecystectomy is approximately 5% with one-third of these patients passing the stone(s) spontaneously (Fig. 61-12).

When symptomatic, the presentation of CBD stones can vary between mild biliary colic to fulminant sepsis from acute cholangitis, biliary pancreatitis, or hepatic abscesses. Biliary colic is the most common presentation and it is characterized by intermittent RUQ abdominal pain due to the increased pressure that develops within the obstructed bile duct. These episodes can also be associated with jaundice and in the absence of a superimposed bile infection this process can occur sporadically over time as the stone intermittently obstructs the flow of bile, resulting in development of acute ascending cholangitis. Biliary pancreatitis is the second most common presentation of CBD stone disease.

Predictors of Common Bile Duct Stones

There is no single biochemical or radiologic test that accurately predicts the presence of CBD stones. Numerous studies have assessed the predictive value of serum liver biochemical tests (total bilirubin, alkaline phosphatase, Y-glutamyl transpeptidase, alanine aminotransferase, and aspartate aminotransferase) and the utility of transabdominal US in predicting the diagnosis of CBD stones. Although liver biochemical tests have a strong negative predictive value of 97%, they only have a positive predictive value of 15% to 50% when they are abnormal in patients with suspected CBD stones.[70,71] Transabdominal US is a valuable test in diagnosing gallbladder stones however, its utility in detecting CBD stones is poor with a sensitivity of 22% to 55%.[72] Therefore, a thorough history and physical examination, in conjunction with the appropriate biochemical and imaging studies, are required when clinical suspicion for CBD stones exists.

Table 61-4 A Proposed Strategy to Assign Risk of Choledocholithiasis in Patients with Symptomatic Cholelithiasis Based on Clinical Predictors

Predictors of choledocholithiasis	
Very strong	
CBD stone on transabdominal US	
Clinical ascending cholangitis	
Bilirubin >4 mg/dL	
Strong	
Dilated CBD on US (>6 mm with gallbladder in situ)	
Bilirubin level 1.8–4 mg/dL	
Moderate	
Abnormal liver biochemical test other than bilirubin	
Age older than 55 yrs	
Clinical gallstone pancreatitis	
Assigning a likelihood of choledocholithiasis based on clinical predictors	
Presence of any very strong predictor	High
Presence of both strong predictors	High
No predictors present	Low
All other patients	Intermediate

CBD, Common bile duct.
Adapted from Maple JT, Ben-Menachem T, Anderson MA, et al. The role of endoscopy in the evaluation of suspected choledocholithiasis. Gastrointest Endosc, 2010. 71(1): p. 1–9.

Numerous prognostic nomograms, formulas, and algorithms have been developed to assist the clinician in establishing the diagnosis of CBD stones.[72] The American Society for Gastrointestinal Endoscopy proposed a risk-stratification scheme based on common predictive factors previously identified (Table 61-4).[72] Using this scheme, patients can be categorized into low (<10%), intermediate (10% to 50%), or high (>50%) probability of

choledocholithiasis. This scheme has subsequently been validated in a large multi-institutional series of patients with suspected choledocholithiasis.[73]

Diagnostic Studies

Biochemical Liver Profile

Serum chemistry analysis of liver enzymes (AST and ALT) as well as total bilirubin and alkaline phosphatase levels are routinely performed in patients being evaluated for calculous biliary pathology. Elevated total bilirubin (>4 mg/dL) and alkaline phosphatase levels have typically been correlated with the presence of CBD stones. In addition, elevated gamma-glutamyltransferase levels, although not routinely obtained, has been correlated with the presence of CBD stones with a sensitivity of 85%.

Ultrasonography

Transabdominal US (Fig. 61-13A) plays a critical role in the diagnosis of gallbladder stones and has the advantages of being noninvasive, widely available, and inexpensive. Unfortunately, studies have shown that US is limited in its ability to reliably detect CBD stones (sensitivity of 15% to 30%); primarily due to its inability to adequately assess the distal CBD because of overlying bowel in this region. The value of US in the assessment of CBD stones is in its ability to detect a dilated CBD. A normal CBD diameter is 3 to 6 mm although a mild increase in CBD diameter with increasing age can be seen.[74] A CBD diameter ≥8 mm is considered abnormal and suggestive of CBD stones in a jaundiced patient with gallstones. The sensitivity in detecting a dilated CBD on US is 77% to 87% with a negative predictive value of 95% when a normal CBD is seen.[71] It is important to note that CBD stones can still be present in the absence of a dilated CBD.

Endoscopic ultrasound (EUS) is a semi-invasive procedure that can assess for distal CBD stones with a sensitivity and specificity of 88% to 94% and 94% to 95%, respectively.[75,76] EUS is superior to other invasive diagnostic studies in its ability to detect small (<5 mm) CBD stones and is associated with an extremely low complication rate (0.1% to 0.3%).[77] Certain treatment algorithms are recommending an EUS-first approach prior to ERCP in patients at intermediate risk of CBD stones, when the diagnosis of choledocholithiasis is unclear, or in patients with severe gallstone pancreatitis. If no stones are seen on EUS, an ERCP can be avoided. Use of this approach will depend on the local expertise and availability of this technology and the increased clinical and financial costs must be taken into consideration.

Laparoscopic intraoperative US using a high-frequency (7.5- to 10- MHz) probe allows for successful evaluation of the CBD in 88% to 100% of cases with a sensitivity of detecting CBD stones of 71% to 100%.[78] In addition, laparoscopic US, similar to EUS, allows for the adequate evaluation of the distal bile duct for stones. It is important to note that all types of US modalities are limited by the inability to provide a therapeutic intervention.

Computed Tomography

Overall helical CT (Fig. 61-13B) has shown a slighter better sensitivity (65% to 88%) and specificity (73% to 97%) rate in detecting CBD stones when compared to transabdominal US. This comes at an increased cost to the healthcare system and potentially unnecessary

radiation exposure. The utility in CT is its ability to assess for other conditions that may have similar presenting symptoms as CBD stones. CT cholangiography has not been widely adopted across centers and therefore is still in evolution.

Magnetic Resonance Imaging

Magnetic resonance cholangiopancreatography (MRCP) has proven to be a useful adjunct in the diagnosis of CBD stones (Fig. 61-13C). MRCP has the advantage of being noninvasive and providing detailed biliary anatomy. This comes at an increased cost as well as an inability to provide any therapeutic intervention. The accuracy of detecting CBD stones with MRCP is between 93% and 100% and it has a sensitivity of 85% to 92% and specificity of 97%.[79,80] Recent data suggest that MRCP may not be that sensitive in detecting small CBD stones, as evidenced by a sensitivity of 33% to 70% in patients with CBD stones <6 mm.[81] Selective use of MRCP in patients at low and intermediate risk of CBD stones can identify patients who may benefit from an endoscopic or intraoperative bile duct exploration.

Cholangiography

8 The gold standard in the diagnosis of CBD stones has been direct cholangiography. This traditionally has been accomplished by invasive methods such as ERCP, percutaneous transhepatic cholangiography (PTC), and intraoperative cholangiography (IOC).

ERCP is currently the most routinely used invasive method in the assessment of patients with presumed CBD stones (Fig. 61-13D). ERCP typically involves an endoscopic sphincterotomy followed by catheter access of the biliary tree for cholangiogram. ERCP sensitivity has been reported to be between 89% and 93% with a specificity of 100%.[82,83] The primary advantage of ERCP is that it allows for therapeutic intervention if stones are identified. However, since ERCP is an invasive procedure it is associated with increased morbidity. Complications that can develop after ERCP are pancreatitis (1.3% to 6.7%), ascending biliary infection (0.6% to 5%), hemorrhage (0.3% to 2%), and perforation (0.1% to 1.1%).[72] Due to its invasiveness and associated complications, ERCP should be reserved for those patients at high risk of having CBD stones.

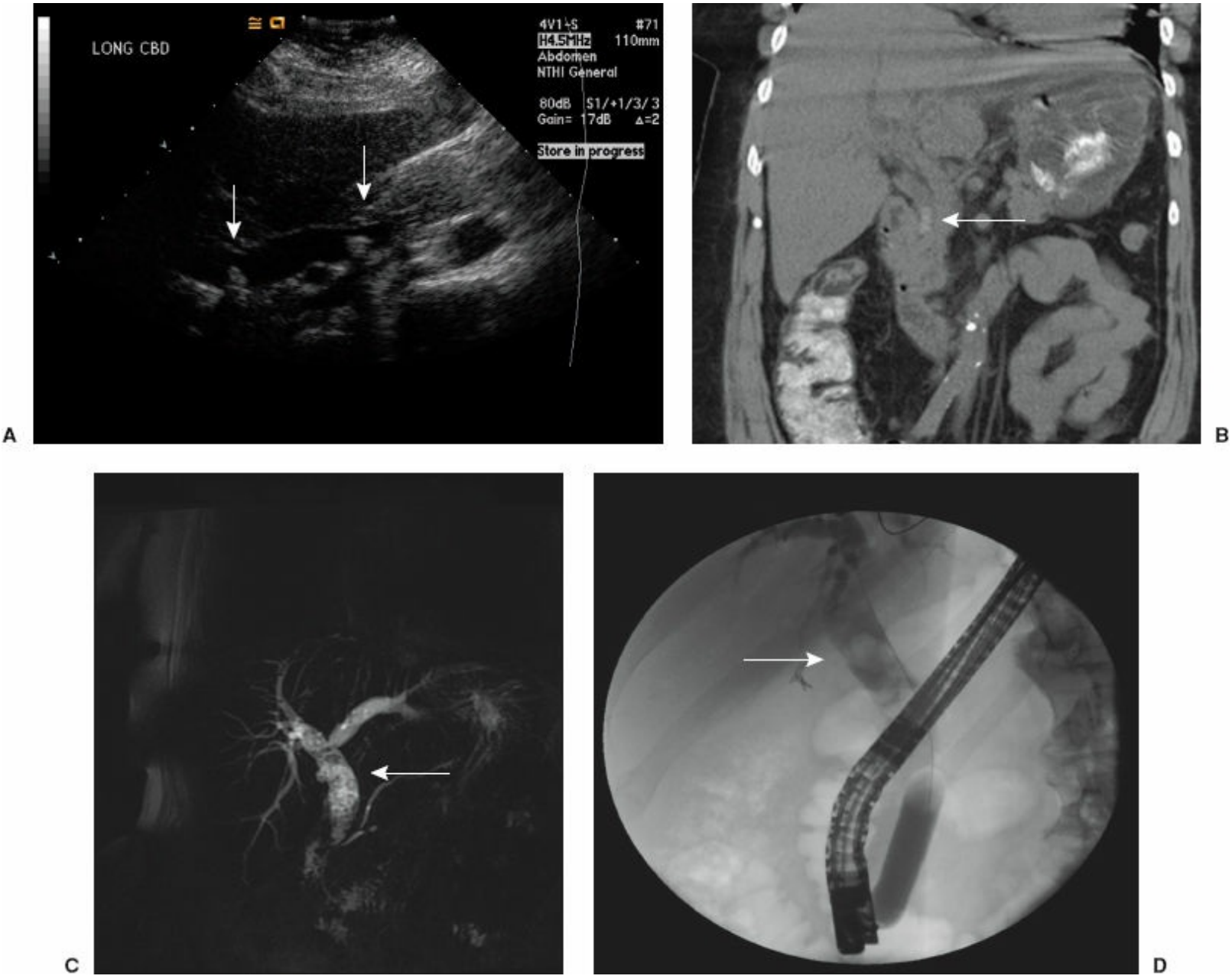

Figure 61-13. CBD stones are identified (*white arrow*) on ultrasonography (**A**), computed tomography (**B**), MRCP (**C**), and ERCP (**D**).

PTC is comparable to ERCP in terms of success rate (>90% with dilated intrahepatic bile ducts) and complication rate (~5%); however, it is typically used in cases in which ERCP was unsuccessful or aberrant gastroduodenal anatomy is present.

IOC, which can be accomplished laparoscopically or open, is primarily performed as adjunct to cholecystectomy (Fig. 61-12). IOC has an overall success rate for detecting CBD stones of >95% with a sensitivity and specificity of 59% to 100% and 93% to 100%, respectively.[72] To improve upon its accuracy, adequate filling of the intrahepatic bile ducts as well as flow of contrast into the duodenum should be identified and appropriately documented. CBD stones identified on IOC can then be addressed immediately with a laparoscopic or open CBD exploration or postoperatively via ERCP (discussed further below). Traditionally, the three primary purposes of performing an IOC were to define biliary ductal anatomy, identify CBD stones, and serve as an educational tool. There is still considerable debate on whether or not IOC, more

specifically laparoscopic IOC, should be performed routinely versus selectively during laparoscopic cholecystectomy.[84] Advocates argue that asymptomatic CBD stones can be identified and biliary injuries prevented by performing routine IOC. Proponents of selective IOC argue that patients should be risk-stratified and only those patients at considerable risk should undergo IOC.

Management

Before the laparoscopic era, IOC was routinely performed and identification of CBD stones was managed immediately with open CBD exploration and T-tube biliary drainage. In the current era, patients should be appropriately risk-stratified by a thorough history and physical examination with appropriate biochemical liver profile and imaging adjuncts to assess for possible CBD stones. As described above, there are many diagnostic options available to the practicing surgeon to assess for CBD stones and once the diagnosis of CBD stones is established, many options, from a therapeutic standpoint, are also available to the treating surgeon. These options include (i) endoscopic, (ii) percutaneous, (iii) laparoscopic, and (iv) open approaches or a combination of any of these techniques.

The choice of the best diagnostic test and ultimate therapeutic intervention is dictated in great part by the local expertise of the radiologist, gastroenterologist, interventional radiologist, and surgeon at the treating institution (Algorithm 61-1). Hence, no single standardized approach to the diagnosis and management of CBD stones has been established. Nonetheless, patients at low to intermediate risk of CBD stones can be evaluated by less invasive diagnostic methods preoperatively (MRCP or EUS) or intraoperatively with IOC. Patients at high risk of stones should undergo preoperative ERCP. The clinical scenario in which the CBD stones present, asymptomatic (incidental stone) versus symptomatic (cholangitis, biliary pancreatitis, or jaundice), must be put into context and incorporated into the treatment decision plan.

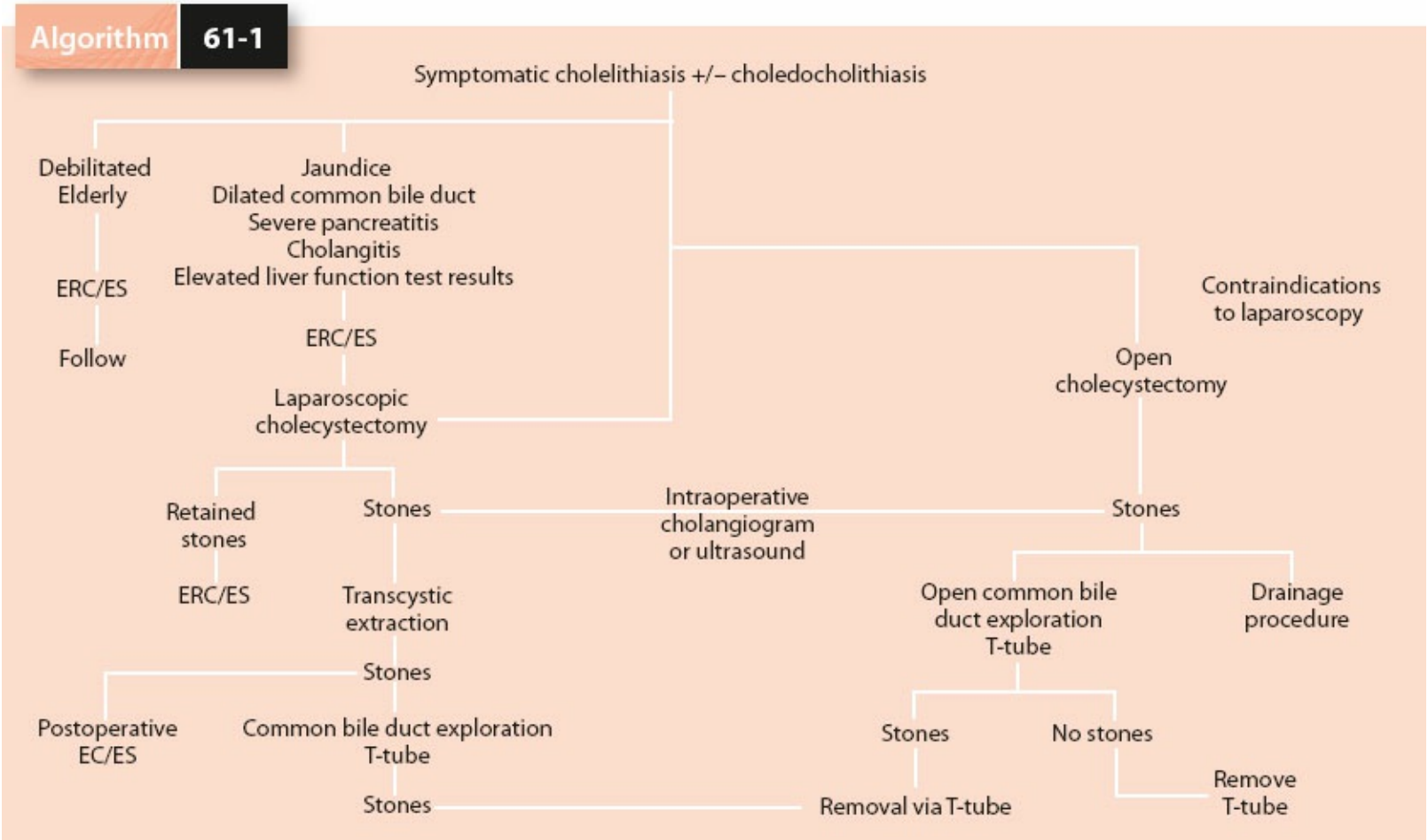

Algorithm 61-1. Algorithm for the management of common bile duct stones.

Endoscopic Approach

9 ERCP with endoscopic sphincterotomy allows for the diagnosis and treatment of CBD stones. ERCP with stone extraction is effective in removing stones in 85% to 95% of cases. Stone extraction is typically accomplished with either a balloon catheter or stone basket. Additional techniques, such as mechanical lithotripsy, extracorporeal shock-wave lithotripsy, or intracorporeal lithotripsy with laser or electrohydraulic probes have been used to manage large stones (>15 mm), multiple stones, hard stones, and/or intrahepatic stones.

Circumstances in which ERCP with sphincterotomy should be considered as the initial therapeutic intervention are (i) acute cholangitis secondary to distal CBD stone, (ii) gallstone pancreatitis with biliary obstruction, (iii) in frail medically unfit patients, and (iv) in patients who require cholecystectomy whom are found to be at high risk or have CBD stones. Additionally, it is recommended that preoperative ERCP be undertaken if expertise in laparoscopic CBD exploration is not available. Preoperative ERCP will allow the treating clinician to identify circumstances (i.e., large stones, impacted stones, duodenal diverticula, aberrant gastroduodenal anatomy, or bile duct stricture) in which the patient may not be amendable to endoscopic stone extraction and thus would require either percutaneous or surgical biliary drainage depending on the available expertise at the treating institution.

An alternative approach for patients at low or intermediate risk of CBD stones would be to perform an IOC at the time of cholecystectomy with plans to perform an ERCP either intraoperatively or postoperatively, if indicated. In the latter situation, this would require another anesthetic intervention and the surgeon runs the risk that complete bile duct clearance is not achieved endoscopically and additional procedures would be required.

Percutaneous Approach

From a therapeutic standpoint, simple percutaneous biliary drainage for decompression of an obstructed biliary tree can be performed safely and efficiently with minimal difficulty. However, percutaneous transhepatic CBD stone removal is more labor intensive and normally requires multiple sessions after initial access of the biliary tree. Maturation (at least 7 days) of the transhepatic fistula from the skin to the bile duct is required prior to attempting percutaneous stone extraction with either balloon catheter or stone basket. In addition, various procedures, such as mechanical lithotripsy, electrohydraulic lithotripsy, and extracorporeal shock-wave lithotripsy can then be performed via a percutaneous route once a mature transhepatic fistula has been established.

Laparoscopic Approach

Concomitant laparoscopic common bile duct exploration (LCBDE) at the time of laparoscopic cholecystectomy is a method that allows for the complete management of secondary CDB stones and gallstones in one setting. The main advantage of this approach is that all of the calculous biliary pathology is addressed with one intervention and under one anesthetic procedure. Studies have shown that the success rate of this concomitant

approach is approximately 94% to 97%, which is similar to outcomes seen with endoscopic clearance.[85,86] The morbidity of a LCBDE (7%) compares favorably to ERCP. However, LCBDE has yet to gain widespread use, due in great part to the lack of adaptation and expertise across institutions. LCBDE is ideal for patients with CBD stones incidentally identified at the time of IOC or those suspected to be at high risk of having CBD stones. LCBDE can be performed via a transcystic, transcholecystic, or choledochotomy technique. Cystic and CBD diameter and stone size, location, and number need to be considered when determining the appropriate LCBDE technique.

Laparoscopic transcystic CBDE is the preferred technique and allows for the extraction of small (<1 cm) CBD stones if the diameter and quality of the cystic duct allows. A tortuous or low-inserting cystic duct, large (>1 cm) stones, and/or common hepatic or intrahepatic stones are relative contraindications to this technique. This technique avoids the need for a choledochotomy and thus potential need for a T-tube. The transcystic approach involves placement of a guide wire into the CBD through the cystic ductotomy made for the IOC. With the guide wire in place, a cholangiocatheter can be advanced into the CBD, which is then saline irrigated in attempt to flush small stones out of the bile duct under fluoroscopic guidance. An adjunct to this maneuver is to dilate the major papilla with a Fogarty balloon catheter and/or administer intravenous glucagon prior to flushing the CBD in order to facilitate the passage of stones. A 3-mm choledochoscope can be passed into the CBD for direct visualization and stone extraction can be accomplished with the use of a basket. An adjunct to this technique is to dilate the cystic duct prior to stone extraction. These techniques can also be applied to the transcholecystic approach, which involves making an incision in the body of the gallbladder. At the completion of either of these approaches, the cystic duct can be easily closed as it is typically done during laparoscopic cholecystectomy, and biliary drainage with a T-tube is not necessary.

An alternative laparoscopic approach is to perform a laparoscopic choledochotomy. The advantage to this approach is that multiple stones, larger stones (>1 cm), or common hepatic or intrahepatic stones can be removed. In this approach, an anterior longitudinal incision on the CBD below the cystic duct is made to allow for adequate access but also to avoid unwanted injury to the arterial supply of the bile duct. Similar techniques of CBDE, discussed previously, can then be undertaken to clear the CBD of stones. The disadvantage of this approach is that advanced laparoscopic biliary skills are required and conventionally, the choledochotomy is closed over a T-tube. The potential benefits of leaving a T-tube is that it allows for the postoperative decompression of the biliary tree, potentially minimizes bile strictures, and allows for access to the biliary tree postoperatively in case of retained stones[87]; this approach has been associated with a higher morbidity rate when compared to the transcystic approach. The increased complication rate is primarily attributed to the placement of the T-tube, and is due to (i) bile leakage, (ii) wound issues at T-tube insertion site, (iii) dislodgement or displacement of T-tube leading to biliary obstruction, and (iv) persistent biliary fistula.[88] Alternative biliary drainage approaches, such as intrabiliary stenting, endoscopic nasobiliary drainage, percutaneous transhepatic biliary drainage, C-tube, and J-tube drainage via the cystic duct after laparoscopic choledochotomy, have been investigated and have shown

promising results.[87] Moreover, recent data suggest that routine biliary drainage with a T-tube is not indicated and primary closure of the CBD is superior to drainage with a T-tube in regard to postoperative complications and biliary-specific complications.[87]

Open Approach

In the previous era of open cholecystectomies, open CBD exploration was routinely performed and was the standard treatment for CBD stones. It was associated with a low morbidity rate and low stone retention rate (1% to 3%). In the current era of advanced endoscopic, percutaneous, and laparoscopic approaches, open CBD exploration is infrequently performed. However, when other approaches fail, open CBD exploration may be necessary. This technique starts with a wide Kocher maneuver to allow for exposure and palpation of the entire bile duct. The choledochotomy is similar to the one made laparoscopically and the methods of stone extraction are also similar with the added benefit that digital manipulation is possible. A 12-French T-tube is usually placed and secured with interrupted sutures (4-0 absorbable sutures). Completion cholangiography is mandatory to assess for CBD clearance and for leakage around the T-tube. The T-tube is left to gravity bag until postoperative days 3 to 7 when a T-tube cholangiogram is performed and if no obstruction is present the tube can be clamped and eventually pulled after 4 to 6 weeks once the tract has matured. If retained stones are identified, the biliary tree can be accessed percutaneously via the T-tube, once the tract has matured, and the stones can be removed.

Certain patients with impacted stones at the ampulla or with primary bile duct stones, history of recurrent stones, intrahepatic stones, or a benign distal bile duct stricture may require an open biliary drainage procedure, such as a transduodenal sphincteroplasty or choledochoduodenostomy or Roux-en-Y biliary bypass (i.e., choledochojejunostomy or hepaticojejunostomy) as definitive therapy. The advantage of a choledochoduodenostomy is that endoscopic access to the bile duct is maintained, however if a side-to-side choledochoduodenostomy is performed, the patient is at risk for developing a *sump syndrome* (obstruction of the distal limb of the bile duct with food debris leading to possible obstruction of the anastomosis, cholangitis, and/or pancreatitis). This syndrome is avoided with a Roux-en-Y biliary bypass, however at the cost of losing access to the bile duct endoscopically.

ETIOLOGY OF ACUTE CHOLANGITIS

Table 61-5 Etiologies of Acute Cholangitis

Noniatrogenic
Benign Conditions
Choledocholithiasis
Primary
Secondary
Pancreatitis (chronic/acute), including pancreatic pseudocyst
Papillary stenosis
Mirizzi syndrome
Choledochal cysts and Caroli disease
Biliary strictures
Ischemia
Primary sclerosing cholangitis
Recurrent choledocholithiasis
Recurrent cholangitis
Other inflammatory conditions
Malignancies
Pancreatic cancer
Cholangiocarcinoma
Duodenal/ampullary cancer
Primary tumor or metastasis to liver, gallbladder, or porta hepatis
Iatrogenic
Obstructed biliary endoprosthesis
Iatrogenic biliary stricture
Direct surgical trauma
Ischemia-induced stricture
Anastomotic stricture (bilibiliary/bilienteric anastomosis)

Adapted from *Cameron: Current Surgical Therapy*. 11th ed. 2014.

Specific Conditions

Acute Cholangitis

10 Acute cholangitis can be a morbid condition and thus prompt recognition and initiation of treatment is paramount. Acute cholangitis is defined by bacterial infection of an obstructed biliary ductal system. Table 61-5 lists the various causes of cholangitis. The most common cause for cholangitis is choledocholithiasis; however, malignant strictures that have required endoscopic or percutaneous manipulation are becoming a routine cause of acute cholangitis at tertiary referral centers. The spectrum of clinical severity can range from a mild self-limited course to a more severe potentially life-threatening disease characterized by fulminant sepsis with multiorgan dysfunction. The classic triad of RUQ pain, fever, and jaundice, known as Charcot triad, commonly defines the clinical presentation of cholangitis. Development of septic shock and mental status changes in this setting is known as Reynolds pentad.

Acute cholangitis is a clinical diagnosis supported by laboratory and radiographic studies. Elevated bilirubin, alkaline phosphatase, and transaminase levels in conjunction with a leukocytosis are commonly present. Radiographic studies will confirm the presence of an abnormal dilated biliary ductal system.

The management of cholangitis should follow three principles: (1) vigorous resuscitation and hemodynamic support, (2) broad-spectrum antibiotics, and (3) relief of biliary obstruction (Algorithm 61-2).[89] The majority (80%) of patients who present with acute cholangitis will improve with fluid resuscitation and administration of antibiotics, and therefore CBDE with biliary decompression can be performed in a more elective and stable environment. Emergent biliary decompression will be required in 20% of patients who do not respond clinically within 12 to 24 hours of initiation of medical management or in patients who present with a toxic clinical picture. Biliary decompression can be achieved either endoscopically or percutaneously. In patients with a perihilar obstruction, strictured biliary-enteric anastomosis, or nonfunctioning percutaneous biliary drainage catheters are best managed via the percutaneous route. If the obstruction is within the distal biliary tree then endoscopic biliary drainage is recommended. This can be accomplished by endoscopic biliary CBDE and stone extraction or by simple biliary decompression with placement of a plastic biliary stent in unstable patients. In the setting in which either percutaneous or endoscopic drainage is not possible or available, then surgical CBD exploration and biliary drainage with a T-tube is indicated.

Intrahepatic Stones

Intrahepatic stones, or hepatolithiasis, are a form of primary CBD stones that are infrequently encountered in Western countries and are primarily prevalent in Southeast Asian countries. Intrahepatic stones are defined as stones present above the confluence of the left and right hepatic ducts. These stones are primarily brown pigment stones that contain more cholesterol, and less bile acids and bilirubin than extrahepatic stones. The Japanese have classified intrahepatic stones, as *type I* for patients with intrahepatic stones only, *type IE* for patients with intra- and extrahepatic bile duct stones, *type L* for left-sided

intrahepatic duct stones, *type R* for right-sided intrahepatic duct stones, and *type C* for caudate stones. *Type I* stones account for approximately 45% to 50% of intrahepatic stones identified in Asian countries,[90] however in Italy *type I* stones account for approximately 75% of intrahepatic stones.[91] Intrahepatic stones typically occur in the setting of chronic biliary stasis secondary to processes, such as (i) choledochal cysts, (ii) biliary strictures, and (iii) biliary parasites. Interestingly, the majority (70%) of patients with intrahepatic stones do not have concomitant gallbladder stones.

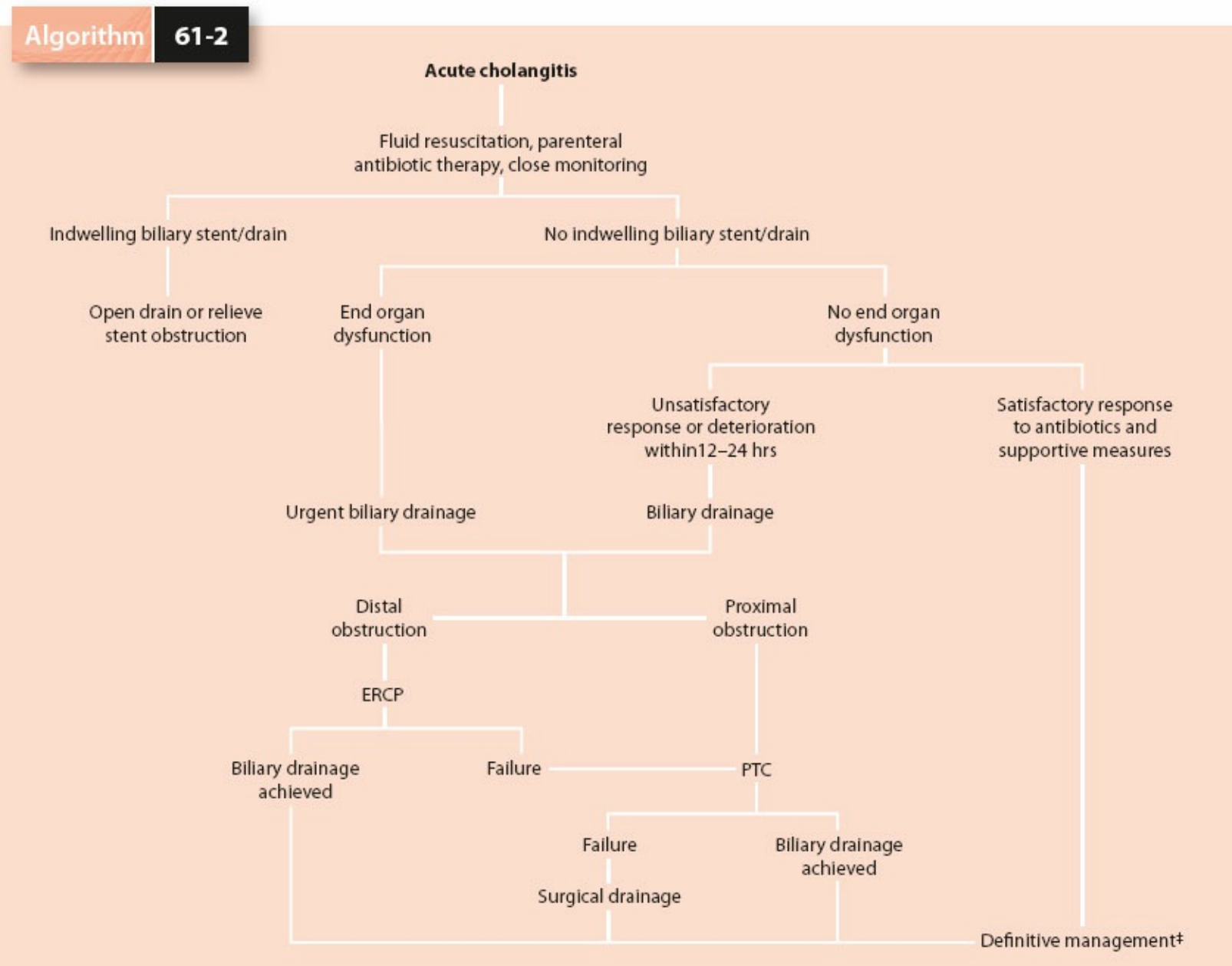

Algorithm 61-2. Management of acute cholangitis. (Adapted from *Cameron: Current Surgical Therapy.* 11th ed. 2014.)

Intrahepatic stones typically present with RUQ or epigastric abdominal pain associated with jaundice and fever. The previously discussed diagnostic modalities (US, CT, MRCP, and endoscopic and percutaneous cholangiogram) have similar advantages and disadvantages when evaluating patients with intrahepatic stones. Ultimately, an endoscopic or percutaneous cholangiogram will be required for complete evaluation. The percutaneous transhepatic approach with placement of biliary drainage catheters is

preferred since it allows for direct access to the intrahepatic bile ducts for subsequent therapeutic interventions. With advancements in percutaneous transhepatic techniques, intrahepatic stones can be managed nonsurgically in many cases using similar endoscopic techniques of stone extraction or stone lithotripsy mentioned previously; however, surgery also plays a critical role in the management of intrahepatic stones. If the intrahepatic stone disease is isolated to a single segment or lobe of liver and is associated with significant parenchymal atrophy or biliary strictures, then hepatic resection of this portion of liver should be considered. If stones occur in the setting of a stricture at the biliary confluence, then a Roux-en-Y hepaticojejunostomy may be warranted.

References

1. Shaffer EA. Epidemiology and risk factors for gallstone disease: has the paradigm changed in the 21st century? *Curr Gastroenterol Rep* 2005;7:132–140.
2. Peery AF, Dellon ES, Lund J, et al. Burden of gastrointestinal disease in the United States: 2012 update. *Gastroenterology* 2012;143:1179–1187 e1–e3.
3. TZ K, A M, A P. *Proteomics of Human Body Fluids.* New Jersey: Humana Press; 2007.
4. Kuipers F, Bloks VW, Groen AK. Beyond intestinal soap–bile acids in metabolic control. *Nat Rev Endocrinol* 2014;10:488–498.
5. Wang H, Chen J, Hollister K, et al. Endogenous bile acids are ligands for the nuclear receptor FXR/BAR. *Mol Cell* 1999;3:543–53.
6. Graewin SJ, Kiely JM, Lu D, et al. Leptin regulates gallbladder genes related to gallstone pathogenesis in leptin-deficient mice. *J Am Coll Surg* 2008;206:503–510.
7. Shiffman ML, Sugerman HJ, Moore EW. Human gallbladder mucosal function. Effect of concentration and acidification of bile on cholesterol and calcium solubility. *Gastroenterology* 1990;99:1452–1459.
8. Doty JE, Pitt HA, Kuchenbecker SL, et al. Impaired gallbladder emptying before gallstone formation in the prairie dog. *Gastroenterology* 1983;85:168–174.
9. Behar J, Corazziari E, Guelrud M, et al. Functional gallbladder and sphincter of Oddi disorders. *Gastroenterology* 2006;130:1498–1509.
10. Stinton LM, Shaffer EA. Epidemiology of gallbladder disease: cholelithiasis and cancer. *Gut liver* 2012;6:172–187.
11. Ransohoff DF, Gracie WA, Wolfenson LB, et al. Prophylactic cholecystectomy or expectant management for silent gallstones. A decision analysis to assess survival. *Ann Intern Med* 1983;99:199–204.
12. Thistle JL, Cleary PA, Lachin JM, et al. The natural history of cholelithiasis: the National Cooperative Gallstone Study. *Ann Intern Med* 1984;101:171–175.
13. Fidler JL, Knudsen JM, Collins DA, et al. Prospective assessment of dynamic CT and MR cholangiography in functional biliary pain. *AJR Am J Roentgenol* 2013;201:W271–W282.
14. Cai JS, Chen JH. The mechanism of enterohepatic circulation in the formation of gallstone disease. *J Membr Biol* 2014;247:1067–1082.
15. Stephen AE, Berger DL. Carcinoma in the porcelain gallbladder: a relationship revisited. *Surgery* 2001;129:699–703.
16. Towfigh S, McFadden DW, Cortina GR, et al. Porcelain gallbladder is not associated with gallbladder carcinoma. *Am Surg* 2001;67:7–10.
17. Schnelldorfer T. Porcelain gallbladder: a benign process or concern for malignancy? *J Gastrointest Surg* 2013;17:1161–1168.
18. Tsirline VB, Keilani ZM, El Djouzi S, et al. How frequently and when do patients undergo cholecystectomy after bariatric surgery? *Surg Obes Relat Dis* 2014;10:313–

321.
19. Shiffman ML, Sugerman HJ, Kellum JM, et al. Gallstone formation after rapid weight loss: a prospective study in patients undergoing gastric bypass surgery for treatment of morbid obesity. *Am J Gastroenterol* 1991;86:1000–1005.
20. Kamisawa T, Funata N, Hayashi Y, et al. Pathologic changes in the non-carcinomatous epithelium of the gallbladder in patients with a relatively long common channel. *Gastrointest Endosc* 2004;60:56–60.
21. Roukounakis N, Manolakopoulos S, Tzourmakliotis D, et al. Biliary tract malignancy and abnormal pancreaticobiliary junction in a Western population. *J Gastroenterol Hepatol* 2007;22:1949–1952.
22. Abraham S, Rivero HG, Erlikh IV, et al. Surgical and nonsurgical management of gallstones. *Am Fam Phys* 2014;89:795–802.
23. Venneman NG, Besselink MG, Keulemans YC, et al. Ursodeoxycholic acid exerts no beneficial effect in patients with symptomatic gallstones awaiting cholecystectomy. *Hepatology* 2006;43:1276–1283.
24. Tandan M, Reddy DN. Extracorporeal shock wave lithotripsy for pancreatic and large common bile duct stones. *World J Gastroenterol* 2011;17:4365–4371.
25. Duncan CB, Riall TS. Evidence-based current surgical practice: calculous gallbladder disease. *J Gastrointest Surg* 2012;16:2011–2025.
26. Yarmish GM, Smith MP, Rosen MP, et al. ACR appropriateness criteria right upper quadrant pain. *J Am Coll Radiol* 2014;11:316–322.
27. Kiewiet JJ, Leeuwenburgh MM, Bipat S, et al. A systematic review and meta-analysis of diagnostic performance of imaging in acute cholecystitis. *Radiology* 2012;264:708–720.
28. Ziessman HA. Hepatobiliary scintigraphy in 2014. *J Nucl Med* 2014;55:967–975.
29. Kalimi R, Gecelter GR, Caplin D, et al. Diagnosis of acute cholecystitis: sensitivity of sonography, cholescintigraphy, and combined sonography-cholescintigraphy. *J Am Coll Surg* 2001;193:609–613.
30. Blaivas M. Ultrasound in the detection of venous thromboembolism. *Crit Care Med* 2007;35:S224–S234.
31. Kaoutzanis C, Davies E, Leichtle SW, et al. Abdominal ultrasound versus hepato-imino diacetic acid scan in diagnosing acute cholecystitis–what is the real benefit? *J Surg Res* 2014;188:44–52.
32. Shakespear JS, Shaaban AM, Rezvani M. CT findings of acute cholecystitis and its complications. *AJR Am J Roentgenol* 2010;194:1523–1529.
33. Paulson EK. Acute cholecystitis: CT findings. *Semin Ultrasound CT MR* 2000;21:56–63.
34. Bennett GL, Balthazar EJ. Ultrasound and CT evaluation of emergent gallbladder pathology. *Radiol Clin North Am* 2003;41:1203–1216.
35. Choi IY, Cha SH, Yeom SK, et al. Diagnosis of acute cholecystitis: value of contrast agent in the gallbladder and cystic duct on Gd-EOB-DTPA enhanced MR

cholangiography. *Clin Imag* 2014;38:174–178.
36. Lau H, Lo CY, Patil NG, et al. Early versus delayed-interval laparoscopic cholecystectomy for acute cholecystitis: a metaanalysis. *Surg Endosc* 2006; 20:82–87.
37. Gurusamy KS, Davidson C, Gluud C, et al. Early versus delayed laparoscopic cholecystectomy for people with acute cholecystitis. *Cochrane Database Syst Rev* 2013;6:CD005440.
38. Degrate L, Ciravegna AL, Luperto M, et al. Acute cholecystitis: the golden 72-h period is not a strict limit to perform early cholecystectomy. Results from 316 consecutive patients. *Langenbecks Arch Surg* 2013;398:1129–1136.
39. Radder RW. Ultrasonically guided percutaneous catheter drainage for gallbladder empyema. *Diagn Imaging* 1980;49:330–333.
40. Duszak R Jr, Behrman SW. National trends in percutaneous cholecystostomy between 1994 and 2009: perspectives from Medicare provider claims. *J Am Coll Radiol* 2012;9:474–479.
41. Barie PS, Eachempati SR. Acute acalculous cholecystitis. *Gastroenterol Clin North Am* 2010;39:343–357, x.
42. Barie PS, Fischer E. Acute acalculous cholecystitis. *J Am Coll Surg* 1995;180:232–244.
43. Mariat G, Mahul P, Prev t N, et al. Contribution of ultrasonography and cholescintigraphy to the diagnosis of acute acalculous cholecystitis in intensive care unit patients. *Intens Care Med* 2000;26:1658–1663.
44. Working Group IAP/APA Acute Pancreatitis Guidlines. IAP/APA evidence-based guidelines for the management of acute pancreatitis. *Pancreatology* 2013;13:e1–e15.
45. Johnstone M, Marriott P, Royle TJ, et al. The impact of timing of cholecystectomy following gallstone pancreatitis. *Surgeon* 2014;12:134–140.
46. Mador BD, Panton ON, Hameed SM. Early versus delayed cholecystectomy following endoscopic sphincterotomy for mild biliary pancreatitis. *Surg Endosc* 2014;28(12):3337–3342.
47. Osayi SN, Wendling MR, Drosdeck JM, et al. Near-infrared fluorescent cholangiography facilitates identification of biliary anatomy during laparoscopic cholecystectomy. *Surg Endosc* 2014;29(2):368–375.
48. Giger UF, Michel JM, Opitz I, et al. Risk factors for perioperative complications in patients undergoing laparoscopic cholecystectomy: analysis of 22,953 consecutive cases from the Swiss Association of Laparoscopic and Thoracoscopic Surgery database. *J Am Coll Surg* 2006;203:723–728.
49. Qiu J, Yuan H, Chen S, et al. Single-port versus conventional multiport laparoscopic cholecystectomy: a meta-analysis of randomized controlled trials and nonrandomized studies. *J Laparoendosc Adv Surg Tech A* 2013;23:815–831.
50. Gurusamy KS, Vaughan J, Rossi M, et al. Fewer-than-four ports versus four ports for laparoscopic cholecystectomy. *Coch Database Syst Rev* 2014;2:CD007109.
51. Alptekin H, Yilmaz H, Acar F, et al. Incisional hernia rate may increase after single-

port cholecystectomy. *J Laparoendosc Adv Surg Tech A* 2012;22:731–737.
52. Pietrabissa A, Sbrana F, Morelli L, et al. Overcoming the challenges of single-incision cholecystectomy with robotic single-site technology. *Arch Surg* 2012; 147:709–714.
53. Romero-Talamas H, Kroh M. Cholecystectomy by using a surgical robotic system. *J Hepatobiliary Pancreat Sci* 2014;21:11–17.
54. Breitenstein S, Nocito A, Puhan M, et al. Robotic-assisted versus laparoscopic cholecystectomy: outcome and cost analyses of a case-matched control study. *Ann Surg* 2008;247:987–993.
55. Gurusamy KS, Davidson BR. Surgical treatment of gallstones. *Gastroenterol Clin North Am* 2010;39:229–244, viii.
56. MacFadyen BV Jr, Vecchio R, Ricardo AE, et al. Bile duct injury after laparoscopic cholecystectomy. The United States experience. *Surg Endosc* 1998;12:315–321.
57. Cavallaro A, Piccolo G, Di Vita M, et al. Managing the incidentally detected gallbladder cancer: Algorithms and controversies. *Int J Surg* 2014;12(suppl 2):S108–S119.
58. Costi R, Randone B, Violi V, et al. Cholecystocolonic fistula: facts and myths. A review of the 231 published cases. *J Hepatobiliary Pancreat Surg* 2009; 16:8–18.
59. Zaliekas J, Munson JL. Complications of gallstones: the Mirizzi syndrome, gallstone ileus, gallstone pancreatitis, complications of “lost” gallstones. *Surg Clin North Am* 2008;88:1345–1368, x.
60. Knab LM, Boller AM, Mahvi DM. Cholecystitis. *Surg Clin North Am* 2014; 94:455–470.
61. Sucandy I, Tellagorry J, Kolff JW. Minimally invasive surgical management of acute cholecystitis during pregnancy: what are the recommendations? *Am Surg* 2013;79:E251–E252.
62. Gilo NB, Amini D, Landy HJ. Appendicitis and cholecystitis in pregnancy. *Clin Obstetr Gynecol* 2009;52:586–596.
63. Pearl J, Price R, Richardson W, et al; Society of American Gastrointestinal Endoscopic S. Guidelines for diagnosis, treatment, and use of laparoscopy for surgical problems during pregnancy. *Surg Endosc* 2011;25:3479–3492.
64. Cetta FM. Bile infection documented as initial event in the pathogenesis of brown pigment biliary stones. *Hepatology* 1986;6:482–489.
65. Kaufman HS, Magnuson TH, Lillemoe KD, et al. The role of bacteria in gallbladder and common duct stone formation. *Ann Surg* 1989;209:584–591; discussion 91–92.
66. Conte D, Fraquelli M, Giunta M, et al. Gallstones and liver disease: an overview. *J Gastrointestin Liver Dis* 2011;20:9–11.
67. Reshetnyak VI. Concept of the pathogenesis and treatment of cholelithiasis. *World J Hepatol* 2012;4:18–34.
68. Lacaine F, Corlette MB, Bismuth H. Preoperative evaluation of the risk of common bile duct stones. *Arch Surg* 1980;115:1114–1116.
69. Collins C, Maguire D, Ireland A, et al. A prospective study of common bile duct

calculi in patients undergoing laparoscopic cholecystectomy: natural history of choledocholithiasis revisited. *Ann Surg* 2004;239:28–33.

70. Barkun AN, Barkun JS, Fried GM, et al. Useful predictors of bile duct stones in patients undergoing laparoscopic cholecystectomy. McGill Gallstone Treatment Group. *Ann Surg* 1994;220:32–39.
71. Onken JE, Brazer SR, Eisen GM, et al. Predicting the presence of choledocholithiasis in patients with symptomatic cholelithiasis. *Am J Gastroenterol* 1996;91:762–767.
72. Maple JT, Ben-Menachem T, Anderson MA, et al. The role of endoscopy in the evaluation of suspected choledocholithiasis. *Gastrointestin Endosc* 2010;71:1–9.
73. Rubin MI, Thosani NC, Tanikella R, et al. Endoscopic retrograde cholangiopancreatography for suspected choledocholithiasis: testing the current guidelines. *Dig Liver Dis* 2013;45:744–749.
74. Bachar GN, Cohen M, Belenky A, et al. Effect of aging on the adult extrahepatic bile duct: a sonographic study. *J Ultrasound Med* 2003;22:879–882; quiz 83–85.
75. Tse F, Liu L, Barkun AN, et al. EUS: a meta-analysis of test performance in suspected choledocholithiasis. *Gastrointestin Endosc* 2008;67:235–244.
76. Garrow D, Miller S, Sinha D, et al. Endoscopic ultrasound: a meta-analysis of test performance in suspected biliary obstruction. *Clin Gastroenterol Hepatol* 2007;5:616–623.
77. Bournet B, Migueres I, Delacroix M, et al. Early morbidity of endoscopic ultrasound: 13 years' experience at a referral center. *Endoscopy* 2006;38:349–354.
78. Machi J. Intraoperative and laparoscopic ultrasound. *Surg Oncol Clin North Am* 1999;8:205–226.
79. Romagnuolo J, Bardou M, Rahme E, et al. Magnetic resonance cholangiopancreatography: a meta-analysis of test performance in suspected biliary disease. *Ann Int Med* 2003;139:547–557.
80. Verma D, Kapadia A, Eisen GM, et al. EUS vs MRCP for detection of choledocholithiasis. *Gastrointestin Endosc* 2006;64:248–254.
81. Boraschi P, Neri E, Braccini G, et al. Choledocolithiasis: diagnostic accuracy of MR cholangiopancreatography. Three-year experience. *Magn Reson Imaging* 1999;17:1245–1253.
82. Prat F, Amouyal G, Amouyal P, et al. Prospective controlled study of endoscopic ultrasonography and endoscopic retrograde cholangiography in patients with suspected common-bileduct lithiasis. *Lancet* 1996;347:75–79.
83. Tseng LJ, Jao YT, Mo LR, et al. Over-the-wire US catheter probe as an adjunct to ERCP in the detection of choledocholithiasis. *Gastrointestin Endoscopy* 2001;54:720–723.
84. Orenstein SB, Marks JM, Hardacre JM. Technical aspects of bile duct evaluation and exploration. *Surg Clin North Am* 2014;94:281–296.
85. Koc B, Karahan S, Adas G, et al. Comparison of laparoscopic common bile duct

exploration and endoscopic retrograde cholangiopancreatography plus laparoscopic cholecystectomy for choledocholithiasis: a prospective randomized study. *Am J Surg* 2013;206:457–463.

86. Paganini AM, Lezoche E. Follow-up of 161 unselected consecutive patients treated laparoscopically for common bile duct stones. *Surg Endosc* 1998;12:23–29.
87. Yin Z, Xu K, Sun J, et al. Is the end of the T-tube drainage era in laparoscopic choledochotomy for common bile duct stones is coming? A systematic review and meta-analysis. *Ann Surg* 2013;257:54–66.
88. Wills VL, Gibson K, Karihaloot C, et al. Complications of biliary T-tubes after choledochotomy. *ANZ J Surg* 2002;72:177–180.
89. William R. J. *Blumgart's Surgery of the Liver, Biliary Tract, and Pancreas.* 5th ed. Philadelphia, PA: Elsevier Inc; 2013.
90. Liu CL, Fan ST, Wong J. Primary biliary stones: diagnosis and management. *World J Surg* 1998;22:1162–1166.
91. Vetrone G, Ercolani G, Grazi GL, et al. Surgical therapy for hepatolithiasis: a Western experience. *J Am Coll Surg* 2006;202:306–312.

Chapter 62

Biliary Injuries and Strictures and Sclerosing Cholangitis

Chad G. Ball and Keith D. Lillemoe

Key Points

1 Most bile duct injuries or strictures currently occur in association with laparoscopic cholecystectomy, with an overall incidence of 0.3% to 0.7%.

2 Recognition of a bile duct injury during laparoscopic cholecystectomy is uncommon (< 30% of cases), but if recognized, repair as either an end-to-end duct-to-duct anastomosis in very selected cases or hepaticojejunostomy should be performed.

3 Cholangiography, usually performed by a percutaneous transhepatic route, should be performed in all cases to define the proximal biliary anatomy needed for reconstruction and to allow placement of biliary catheters to control the ongoing bile leak.

4 Patients with biliary injuries most commonly present in the early postoperative course, usually with bile leakage. Despite recognition of an ongoing bile leak, urgent return to the operating room should be avoided.

5 The repair of a bile duct injury recognized in the postoperative period requires a hepaticojejunostomy in almost all cases and should be performed with transanastomotic biliary stents.

6 A successful result following repair of a bile duct injury can be expected in 80% to 90% of patients. Return to a normal quality of life is also expected. In the modern era, death associated with either bile duct injury or the operative repair is uncommon, occurring in less than 2% of patients.

7 Percutaneous or balloon dilatation of biliary strictures can lead to successful outcomes in selective patients, although the long-term results generally favor surgical reconstruction.

8 Primary sclerosing cholangitis is an autoimmune disease characterized by intrahepatic and extrahepatic inflammatory strictures of the bile ducts. Patients are at risk for the development of cholangiocarcinoma and/or end-stage liver disease. There is no known specific effective medical therapy for primary sclerosing cholangitis. Primary sclerosing cholangitis has become one of the most common indications for liver transplantation.

9 Bile duct strictures associated with alcoholic chronic pancreatitis are best managed by

biliary bypass.

Biliary injuries and strictures are among the most difficult challenges that a surgeon faces. Although numerous technologic developments have facilitated diagnosis and management, bile duct injuries and strictures remain a significant clinical problem. If they go unrecognized or are managed improperly, life-threatening early complications such as sepsis and multisystem organ failure or late implications of biliary cirrhosis, portal hypertension, and cholangitis can develop. To avoid these complications, virtually every patient with a bile duct stricture should undergo evaluation and treatment with the goal of relieving the obstruction to bile flow and its associated hepatic injury. Finally, the occurrence of a major bile duct injury during an elective cholecystectomy remains one of the most common indications for charges of medical practice in the United States.

Benign bile duct strictures can have numerous causes (Table 62-1). Most biliary strictures occur after primary operations on the gallbladder or biliary tree. With the introduction of laparoscopic cholecystectomy, bile duct injuries and associated strictures have been seen with increased frequency. Operative injury to the bile ducts can also occur during nonbiliary operations on the gallbladder or biliary tree or as a result of external penetrating or blunt abdominal trauma. Inflammatory conditions and fibrosis caused by chronic pancreatitis, gallstones in the gallbladder or the bile duct, stenosis of the sphincter of Oddi, or biliary tract infections can also cause benign bile duct strictures. Finally, primary sclerosing cholangitis, a rare disease of unknown cause, can result in multiple strictures of the intrahepatic and extrahepatic bile ducts. This chapter focuses primarily on postoperative bile duct strictures and primary sclerosing cholangitis.

POSTOPERATIVE BILE DUCT STRICTURES

Pathogenesis

1 Most benign bile duct strictures result from operations in or near the right upper quadrant. More than 80% of strictures occur after injury to the bile ducts during cholecystectomy. The exact incidence of bile duct injury is unknown because many cases may go unreported in the literature. Data suggest that the incidence of bile duct injury during open cholecystectomy is 1 in 500 to 1,000 cases. The incidence of bile duct injury during laparoscopic cholecystectomy is clearly higher. Although a wide range in the incidence of injury can be found in reported series, the most accurate data most likely come from surveys encompassing thousands of patients. These reports reflect the results from a large number of surgeons in both community and teaching hospitals. The results of such series suggest an incidence of bile duct injury during laparoscopic cholecystectomy ranging from 0.3% to 0.7%.[1] Furthermore, the incidence of bile duct injury associated with laparoscopic cholecystectomy does not appear to have diminished in more recent surveys, suggesting that the previously observed increase is not simply the result of a learning curve associated with the laparoscopic technique. Finally, due to the high frequency of laparoscopic cholecystectomy, it is estimated that one in every two or three surgeons will create a bile duct injury during his or her career.

Table 62-1 Causes of Benign Bile Duct Strictures

Postoperative Strictures
Injury at Primary Biliary Operations
Laparoscopic cholecystectomy
Open cholecystectomy
Common bile duct exploration
Injury at Other Operative Procedures
Gastrectomy
Hepatic resection
Portacaval shunt
Stricture of a biliary-enteric anastomosis
Blunt or penetrating trauma
Strictures Caused by Inflammatory Conditions
Chronic pancreatitis
Cholelithiasis and choledocholithiasis
Primary sclerosing cholangitis
Stenosis of the sphincter of Oddi
Duodenal ulcer
Crohn disease
Viral infections
Toxic drugs

A number of factors are associated with bile duct injury during either open or laparoscopic cholecystectomy, including acute or chronic inflammation, inadequate exposure, patient obesity, and failure to identify structures before clamping, ligating, or dividing them. More specific causes of bile duct injury also exist. Bleeding from the cystic or hepatic arteries can lead to bile duct injury during attempts to gain hemostasis. The generous application of Ligaclips at either open or laparoscopic cholecystectomy to hilar areas not well visualized can result in placing a clip on or across a bile duct, with resultant injury (Fig. 62-1). Failure to recognize congenital anatomic anomalies of the bile ducts, such as insertion of the right hepatic duct into the cystic duct or a long common wall between the cystic duct and the common bile duct, can also lead to injury (Fig. 62-2). It should also be noted that a significant discussion has ensued regarding the optimal timing of performing a laparoscopic cholecystectomy in the setting of acute inflammation of the gallbladder. Although 30-day postoperative morbidity and mortality rates may remain independent of timing, it is clear that patients who undergo laparoscopic cholecystectomy beyond 24 hours are more likely to require an open procedure, and sustain significantly longer postoperative and overall lengths of hospital admission (and therefore cost).[2]

A number of technical factors are associated with laparoscopic cholecystectomy that can also increase the risk of bile duct injury compared with the open procedure. These factors include the use of an end-viewing laparoscope, which alters the surgeon's perspective of the operative field. The issue of visual alignment and perspective has become even more topical with the proliferation of single incision laparoscopic cholecystectomy which is known to be associated with a higher rate of common bile duct injury than the traditional 4-incision laparoscopic technique utilizing an angled scope.[3] Excessive cephalad retraction of the gallbladder fundus can cause the cystic duct and common bile duct to become aligned in the same plane. This distortion often results in the classic laparoscopic injury, in which the common bile duct is mistaken for the cystic duct and clipped and divided (Fig. 62-3).[4] The role of intraoperative cholangiography (IOC) in preventing bile duct injury during laparoscopic cholecystectomy is controversial. Individual series have failed to demonstrate that either performing routine or selective IOC affects the incidence of bile duct injury. Although an initial retrospective nationwide cohort analysis of Medicare patients undergoing laparoscopic cholecystectomy between 1992 and 1999 demonstrated that common bile duct injuries occurred in 0.39% of patients in which IOC was performed versus 0.58% in patients not undergoing IOC (unadjusted relative risk, 1.49; 95% confidence interval 1.42–1.57),[5] a more recent Medicare-based study (2000 to 2009) analyzing over 92,000 patients undergoing cholecystectomy identified no statistically significant association between IOC and common bile duct injury.[6] The authors therefore concluded that IOC is not effective as a preventive strategy against common duct injury during cholecystectomy.[6] Furthermore, the proper interpretation of IOC can minimize the extent of injury. Nevertheless, only 27% of surgeons in the United States perform IOC routinely.[7] Finally, ample evidence exists to support the conclusion that the experience of the surgeon in performing laparoscopic cholecystectomy can be correlated with the risk of bile duct injury.

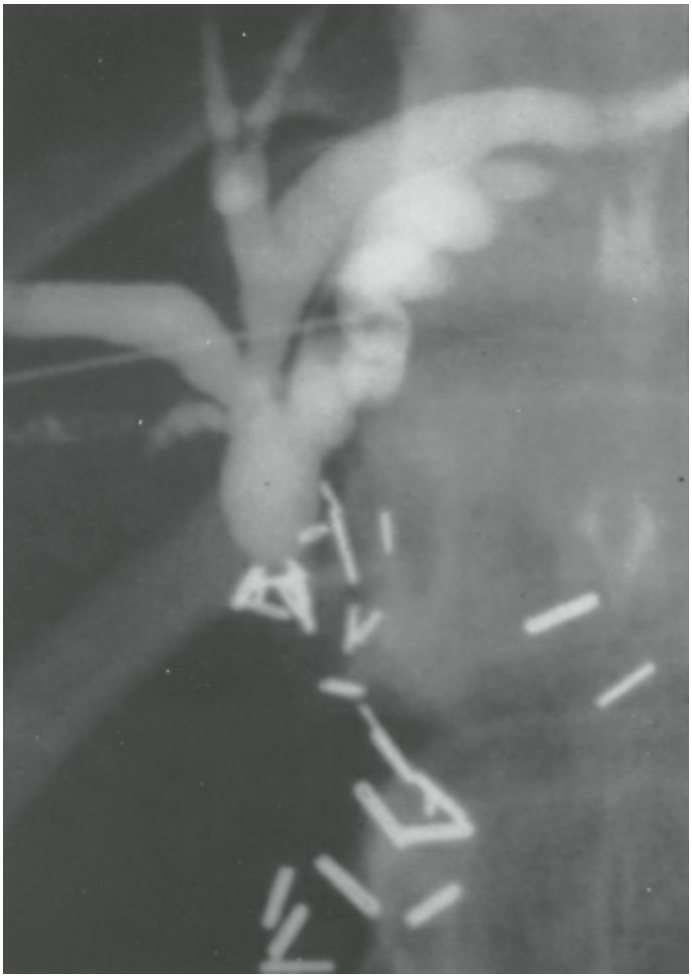

Figure 62-1. Percutaneous transhepatic cholangiogram in a patient with a bile duct stricture secondary to iatrogenic injury during cholecystectomy. Numerous surgical clips can be seen in the area of the stricture. (Reproduced with permission from Lillemoe KD, Pitt HA, Cameron JL. Postoperative bile duct strictures. *Surg Clin North Am* 1990;70:1356–1380.)

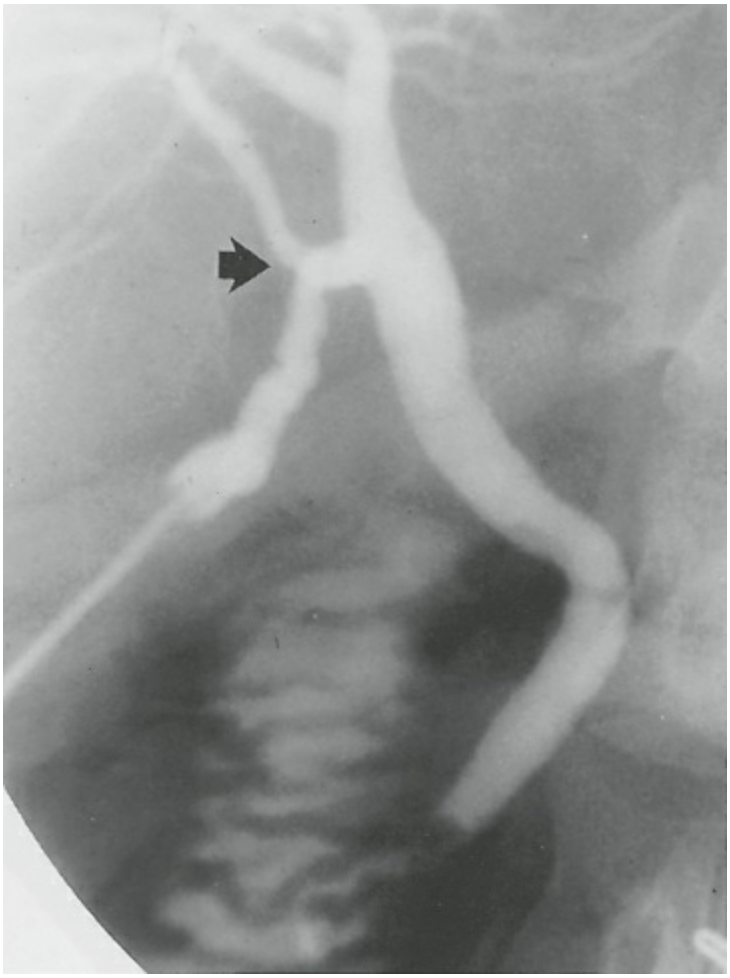

Figure 62-2. Operative cholangiogram demonstrating a right lobe segmental bile duct entering the cystic duct (*arrow*). Division of the cystic duct proximal to this insertion can result in a bile leak or obstruction of bile flow from a significant segment of the liver.

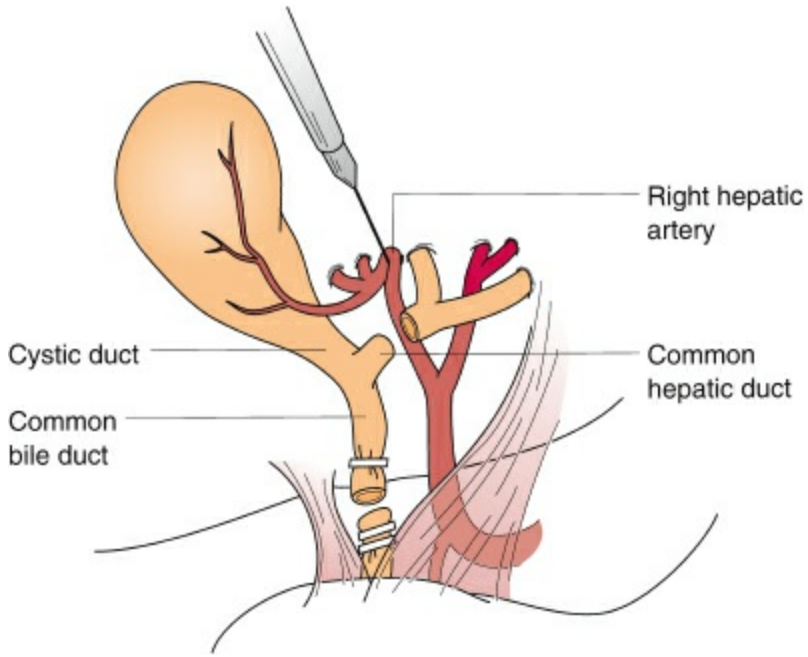

Figure 62-3. Classic laparoscopic bile duct injury. The common bile duct is mistaken for the cystic duct and transected. A variable extent of the extrahepatic biliary tree is resected with the gallbladder. The right hepatic artery, in background, is also often injured.

In recent years, there has been a growing understanding of surgeon cognitive factors associated with bile duct injury during laparoscopic cholecystectomy. An analysis examining 252 biliary injuries during laparoscopic cholecystectomy using human error factor and cognitive science techniques found that 97% of injuries were caused by visual-perceptual illusion or inadequate visualization.[8] Further work from the same group has determined a major explanation for the surgeon's frequent inability to recognize bile duct injury. These bile duct injuries appear to be associated with confirmation bias, which is a propensity to seek cues to confirm a belief and to discount cues that might discount the belief. Although cognitive factors are important for the understanding of the psychological issues associated with bile duct injuries, surgeons must continue to have the appropriate corrective mechanisms in place to minimize the chance of these injuries, including knowledge of anatomy, typical mechanisms of injury, and an appropriate level of suspicion and logic. An example of such a corrective mechanism occurs within the operative technique of laparoscopic cholecystectomy, which defines the "critical view of safety," and therefore helps prevent misidentification and injury of the major bile ducts.[9] This anatomical-based safety concept can be further developed by including the orientation and relative positions of the multiple structure of interest within adjacent regional anatomy (hepatic artery, sulcus of Rouvier, umbilical fissure, and common bile duct).

The importance of ischemia of the bile duct in the formation of postoperative strictures has been emphasized. Injury to the hepatic artery at the time of biliary injury during laparoscopic cholecystectomy has been recognized at an increased incidence, as high as 50%, when investigated at the time of presentation.[10] The true impact of an arterial injury however, remains debated. It is clear that the most common site of vasculobiliary injury is the right hepatic artery.[11] Damage to this vessel can lead to a higher injury level on the bile duct than the gross observed mechanical injury. Vasculobiliary injuries may also have specific effects on the arteries (pseudoaneurysm with delayed hemorrhage), bile ducts (necrosis, stenosis, cholangitis) and/or liver (necrosis, atrophy) over variable lengths of time.[11] Finally, concurrent hepatic artery and portal vein injuries can have catastrophic effects on the liver, including rapid necrosis. A more clinically common cause of ischemia can be unnecessary dissection around the bile duct during cholecystectomy or bile duct anastomosis, which can divide or injure the major arteries of the bile duct that run in the 3-o'clock and 9-o'clock positions.

Another important factor contributing to the formation of biliary strictures is the intense connective tissue response with fibrosis and scarring that can occur after bile duct injury. Experimental studies of bile duct ligation in a canine model have demonstrated immediate and sustained elevation of bile duct pressure and progressive increase in bile duct diameter. Histologic changes at 1 month after ligation have shown that the bile duct wall is thickened, with a reduction of mucosal folds and loss of surface microvilli, associated with a well-defined epithelial degeneration. Biochemical analysis of connective tissue response to ligation showed that collagen synthesis and prolene hydroxylase activity is increased within 2 weeks in the obstructed bile duct and is sustained throughout the period of observation. Finally, a marked local inflammatory response can

develop in the adjacent tissue in association with bile leakage, which occurs with many bile duct injuries. This inflammation can be further intensified in the face of infection. This inflammation results in fibrosis and scarring in the periductal tissue, further contributing to stricture formation. These factors can be of major importance in bile duct injuries during laparoscopic cholecystectomy, which are frequently associated with bile leaks.

After cholecystectomy and common bile duct exploration, the two most common operations associated with bile duct injury are gastrectomy and hepatic resection. The most common situation resulting in bile duct injury during gastrectomy involves dissection of the pyloric region and the first portion of the duodenum in the face of inflammation from peptic ulcer disease. The injury occurs during mobilization of the duodenum either for creation of a Billroth I gastroduodenostomy or for closure of the duodenal stump. Biliary injury during liver resection is most likely to occur during dissection of the hepatic hilum.

In addition to iatrogenic bile duct injury occurring during cholecystectomy or other operations, bile duct strictures can also occur at biliary anastomoses. Such strictures can occur at a biliary-enteric anastomosis performed for reconstruction after resection for benign or malignant disease of the pancreaticobiliary system, or after end-to-end bile duct anastomosis performed for hepatic transplantation (even in the context of chronic immunosuppressive therapy) or for repair of traumatic injury. Ischemia of the anastomosis caused by excessive skeletonization of the duct in preparation for the anastomosis is an important factor in many such strictures.

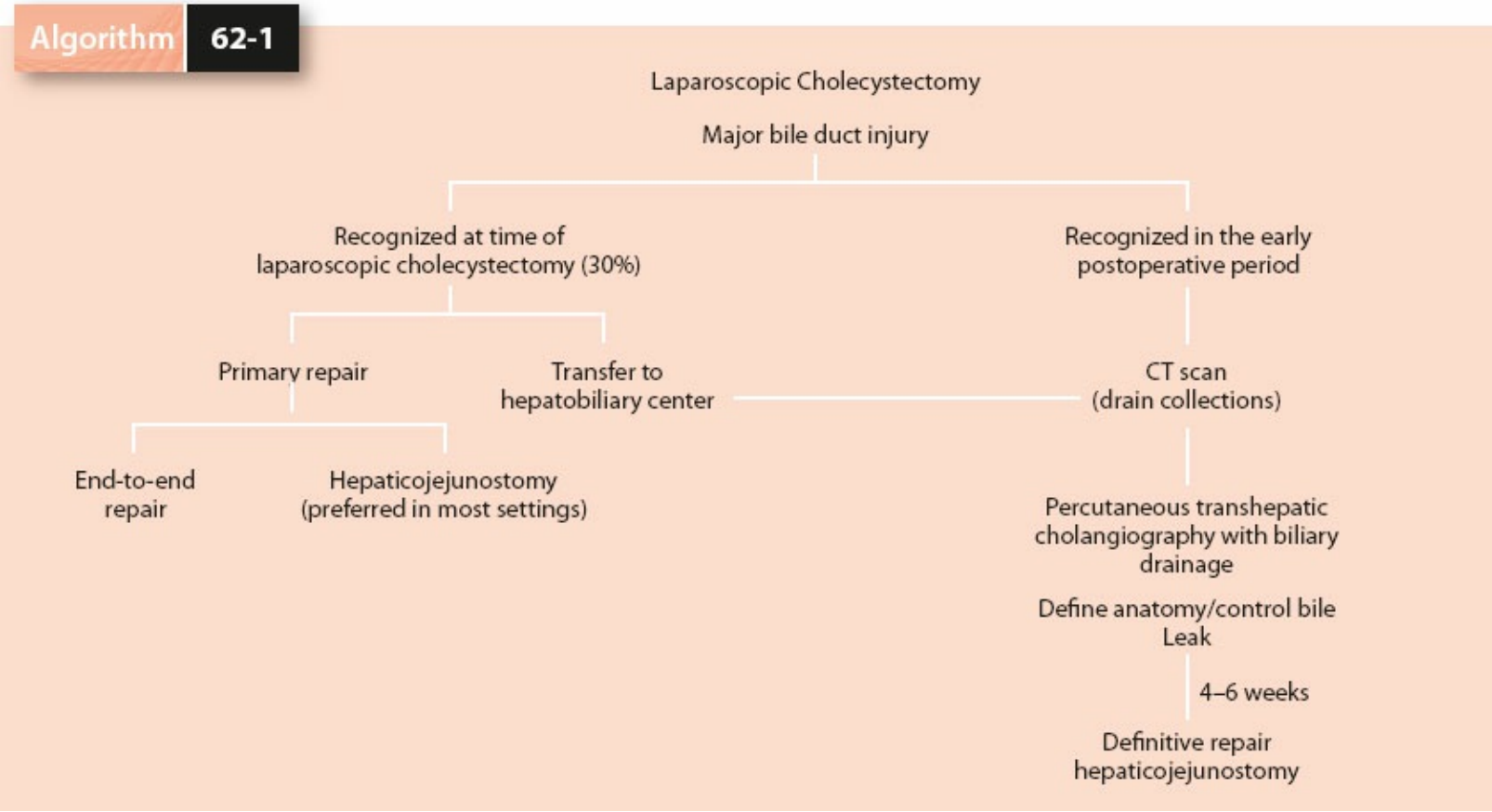

Algorithm 62-1. Algorithm for diagnosis and management of bile duct injury associated with laparoscopic cholecystectomy.

Unfortunately, the recurrence of bile duct strictures after an initial attempt at repair is not uncommon and can also account for a number of anastomotic strictures.[12,13] A number of other factors have been evaluated in patients who have a recurrent bile duct stricture, including the location of the stricture, the length of follow-up, the influence of previous operations, the type of operation performed, the type of sutures used, and the use and duration of postoperative stenting.[14] Previous attempts at repair, performance of a procedure other than choledochojejunostomy or hepaticojejunostomy, and stricture location higher in the biliary tree appear to be associated with a higher incidence of recurrent stricture. Finally, long-term follow-up of a bile duct anastomosis is important because strictures can develop years after the original anastomosis.

Clinical Presentation

2 Most patients with biliary injuries present early after their initial operation (Algorithm 62-1). After open cholecystectomy, only approximately 10% of postoperative strictures are actually suspected within the first week, but nearly 70% are diagnosed within the first 6 months, and more than 80% are diagnosed within 1 year of surgery. In series reporting bile duct injuries during laparoscopic cholecystectomy, the injury is usually recognized either during the procedure (25% to 30%) or, more commonly, in the early postoperative period.

Patients suspected of having a postoperative bile duct injury within days to weeks of initial operation usually present in one of two ways. One presentation is the progressive elevation of liver function test results, particularly total bilirubin and alkaline phosphatase levels. These changes can often be seen as early as the second or third postoperative day. The second mode of early presentation is with leakage of bile from the injured bile duct. This presentation appears to occur most often in patients presenting with bile duct injuries after laparoscopic cholecystectomy. Bilious drainage from operatively placed drains or through the wound after cholecystectomy is abnormal and represents some form of biliary injury. In patients without drains (including patients in whom the drains have been removed), the bile can leak freely into the peritoneal cavity or it can loculate as a collection. Free accumulation of bile into the peritoneal cavity results in either biliary ascites or bile peritonitis. Similarly, a loculated bile collection can result in sterile biloma (Fig. 62-4) or in an infected subhepatic or subdiaphragmatic abscess.

Patients with postoperative bile duct strictures who present months to years after the initial operation frequently have evidence of cholangitis. The episodes of cholangitis are often mild and respond to antibiotic therapy. Repetitive episodes usually occur before the definitive diagnosis. Less commonly, patients may present with painless jaundice and no evidence of sepsis. Finally, patients with markedly delayed diagnoses may present with advanced biliary cirrhosis and its complications.

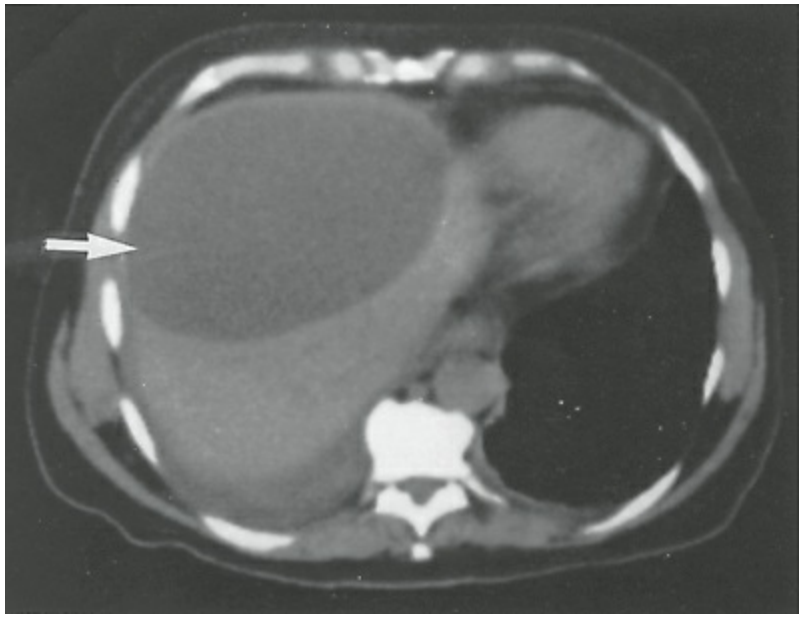

Figure 62-4. Large bile duct collection (biloma; *arrow*) occurring after bile duct injury. (Reproduced with permission from Lillemoe KD, Pitt HA, Cameron JL. Postoperative bile duct strictures. *Surg Clin North Am* 1990;70:1355–1380.)

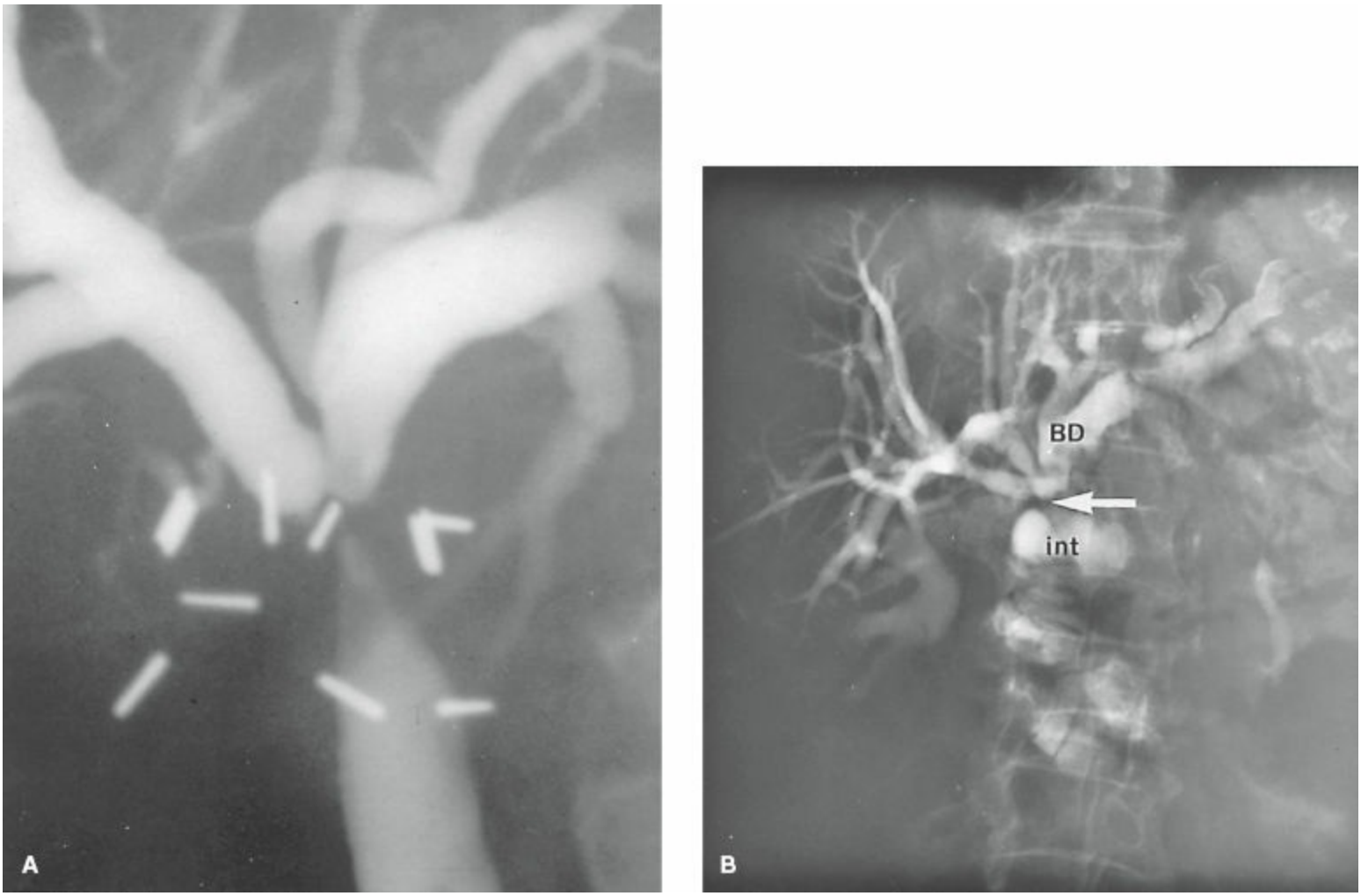

Figure 62-5. **A:** Percutaneous transhepatic cholangiogram demonstrating bile duct stricture at hepatic duct bifurcation with proximal duct dilatation. **B:** Percutaneous transhepatic cholangiogram demonstrating stricture (*arrow*) at a hepaticojejunostomy anastomosis. BD, bile duct; int, intestine.

Laboratory Investigation

Liver function tests usually show evidence of cholestasis. In patients with bile leakage, the bilirubin can be normal or minimally elevated because of absorption from the peritoneal cavity. When elevated, serum bilirubin usually ranges from 2 to 6 mg/dL, unless secondary biliary cirrhosis has developed. Serum alkaline phosphatase is usually elevated. Serum aminotransferase levels can be normal or minimally elevated except during episodes of cholangitis. If advanced liver disease exists, hepatic synthetic function can be impaired, with lowered serum albumin and a prolongation of prothrombin time. Serum electrolytes and complete blood count are typically normal unless there is associated biliary sepsis.

Radiologic Examination

The imaging techniques of abdominal ultrasound and computed tomography (CT) play an important initial role in the evaluation of patients with benign postoperative biliary strictures. In patients who present in the early postoperative period with evidence of a bile leak or biliary sepsis, these studies are useful to rule out the presence of intra-abdominal collections that might require drainage (Fig. 62-4). CT and ultrasound are also important in the initial evaluation of the patient presenting with a bile duct stricture months to years after initial operation. Both studies can confirm biliary obstruction by demonstrating a dilated biliary tree. CT is especially useful in identifying the level of obstruction of the extrahepatic bile duct.

In patients suspected of having early postoperative bile duct injury, a radionucleotide biliary scan can confirm bile leakage. In patients with postoperative external bile fistula, injection of water-soluble contrast media through the drainage tract (sinography) can often define the site of leakage and the anatomy of the biliary tree.

3 The "gold standard" for evaluation of patients with bile duct strictures is cholangiography. Percutaneous transhepatic cholangiography (PTC) is usually more valuable than endoscopic retrograde cholangiography (ERC) in patients with major bile duct injuries following laparoscopic cholecystectomy. PTC is more useful in that as it defines the anatomy of the proximal biliary tree that is to be used in the surgical reconstruction (Fig. 62-5). Furthermore, PTC can be followed by placement of percutaneous transhepatic catheters, which can be useful in decompressing the biliary system both to treat or prevent cholangitis and to control an ongoing bile leak. These catheters can also be of assistance in surgical reconstruction and provide access to the biliary tree for nonoperative dilation. ERC is less useful than PTC in major bile duct transections during laparoscopic cholecystectomy because the discontinuity of the extrahepatic bile duct usually prevents adequate filling of the proximal biliary tree (Fig. 62-6). Often, ERC can demonstrate a normal-sized distal bile duct up to the site of the stricture without visualization of the proximal biliary system (Fig. 62-7). This finding is frequently the case in patients with injury during laparoscopic cholecystectomy, when the distal bile duct is often clipped and divided. The development of magnetic resonance cholangiopancreatography (MRCP) has provided a noninvasive technique that provides excellent delineation of the biliary anatomy. The quality of these images has led some surgeons to advocate this technique as the initial step in the evaluation of patients with suspected bile duct injuries and may eliminate the need for a diagnostic ERC in many patients. MRCP is especially worth considering if the referral surgeon has a low pretest probability of utilizing transhepatic stents for subsequent reconstructive purposes.

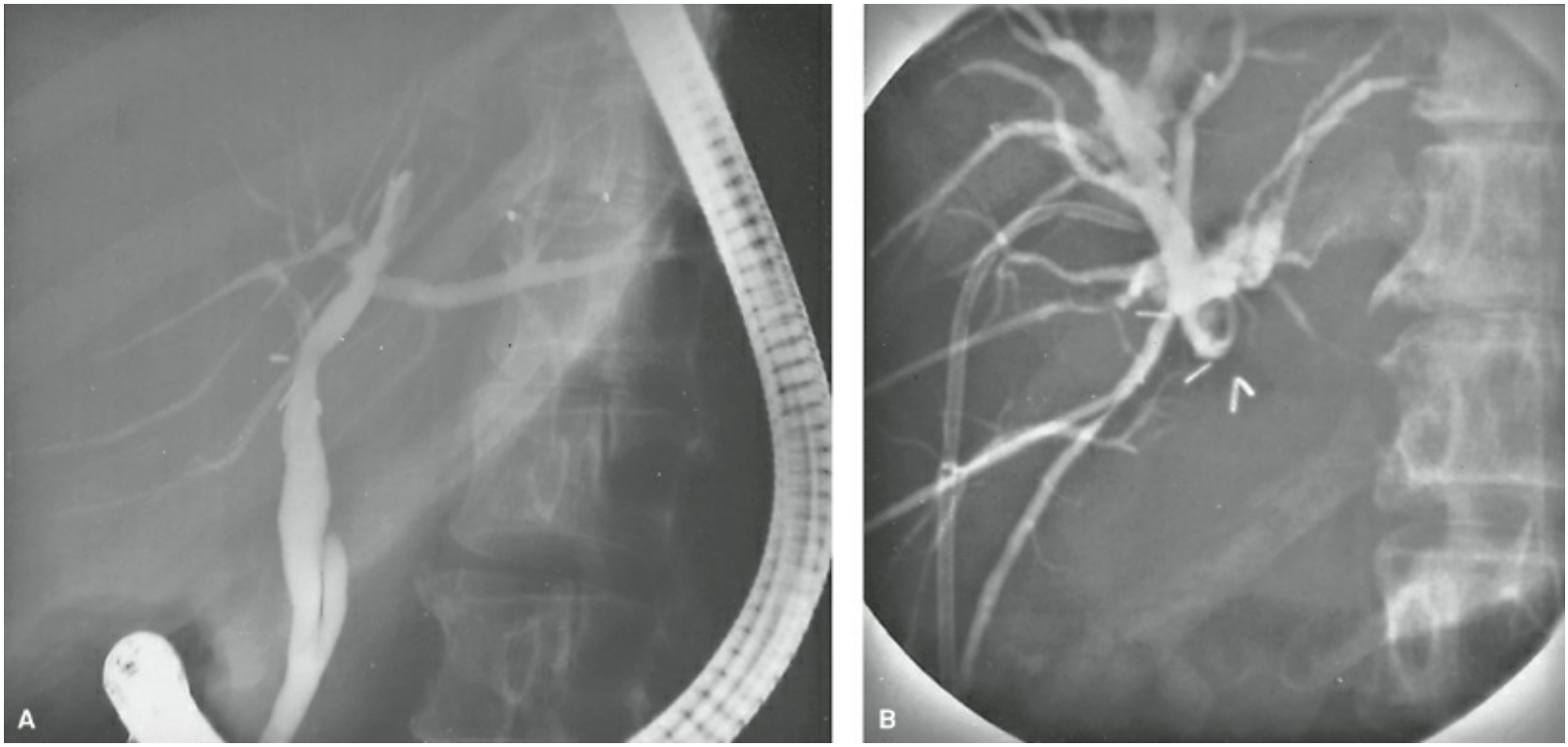

Figure 62-6. **A:** Endoscopic retrograde cholangiogram showing a relatively normal biliary tree in a patient with a postoperative bile collection (see Fig. 62-5). **B:** Percutaneous transhepatic cholangiogram of the same patient, showing entire right hepatic posterior lobe segment obstructed as the result of ligation of the segmental duct. The patient had an unrecognized anatomic variant similar to that shown in Figure 62-2.

Preoperative Management

4 The preoperative management of a patient with a postoperative bile duct stricture depends primarily on the timing of the presentation. Patients presenting in the early postoperative period can be septic with either cholangitis or intra-abdominal bile collections. Sepsis must be controlled first with broad-spectrum parenteral antibiotics, percutaneous biliary drainage, and percutaneous or operative drainage of biliary leaks. Once sepsis is controlled, there is no hurry in proceeding with surgical reconstruction of the bile duct stricture. The combination of proximal biliary decompression and external drainage allows most biliary fistulas to be controlled or even to close. The patient can then be discharged home to allow several weeks to elapse for resolution of the inflammation in the periportal region and recovery of overall health.

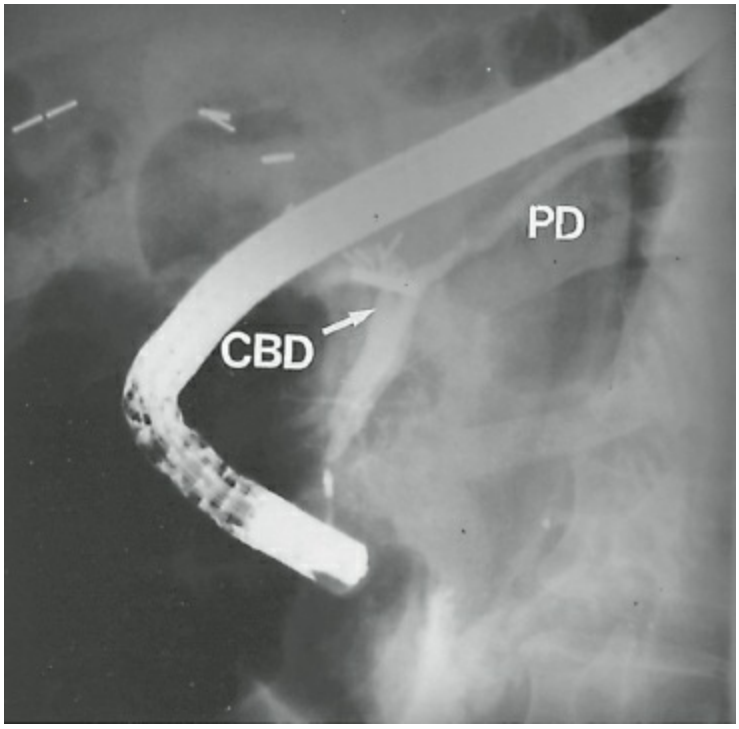

Figure 62-7. Endoscopic retrograde pancreaticocholangiogram showing filling of a normal pancreatic duct (PD). The common bile duct (CBD), however, does not fill beyond the large clip that appears to be placed across the duct. (Reproduced with permission from Lillemoe KD, Pitt HA, Cameron JL. Postoperative bile duct strictures. *Surg Clin North Am* 1990;70:1355–1380.)

The management of a suspected bile duct injury after laparoscopic cholecystectomy presenting with a bile leak deserves special mention. Often, when bile leakage is suspected, the surgeon believes that urgent surgical exploration is necessary. Unfortunately, at laparotomy, the marked inflammation associated with bile spillage and the small decompressed biliary tree that appears retracted high into the porta hepatis make recognition of the injury and repair virtually impossible. In such cases, every attempt should be made to define the biliary anatomy by preoperative cholangiography (PTC or MRCP) and to control the bile leak with percutaneous biliary drainage. In many cases, early operative intervention is not required because the bile collections or ascites can either be drained percutaneously or simply is absorbed from the peritoneal cavity.

Delayed reconstruction, aided by percutaneous biliary catheters, then allows optimal surgical results.[14]

In patients who present with a biliary stricture remote from the initial operation, symptoms of cholangitis can necessitate urgent cholangiography and biliary decompression. Biliary drainage is best accomplished by the transhepatic method, although successful endoscopic stent placement can also be accomplished. Parenteral antibiotics and biliary drainage should be continued until sepsis is controlled. In patients who present with jaundice but without cholangitis, cholangiography should be performed to define the anatomy. Preoperative biliary decompression in patients without cholangitis has not been demonstrated to improve outcome.

Surgical Management

The goal of operative management of bile duct stricture is the establishment of bile flow into the proximal gastrointestinal tract in a manner that prevents cholangitis, sludge or stone formation, restricture, and biliary cirrhosis. This goal is best accomplished with a tension-free anastomosis between healthy tissues. A number of surgical alternatives exist for primary repair of bile duct strictures, including end-to-end repair, Roux-en-Y hepaticojejunostomy or choledochojejunostomy, choledochoduodenostomy, and mucosal grafting. The choice of repair depends on a number of factors, including the extent and location of the strictures, the experience of the surgeon, and the timing of the repair.

Immediate Repair of Intraoperative Bile Duct Injury

In many cases, initial proper management of bile duct injury recognized at the time of cholecystectomy can avoid the development of a bile duct stricture. Unfortunately, recognition of a bile duct injury is uncommon during either open or laparoscopic cholecystectomy. If bile leakage is observed or atypical anatomy is encountered during laparoscopic cholecystectomy, early conversion to an open technique and prompt cholangiography are imperative. If a segmental or accessory duct less than 3 mm has been injured and cholangiography demonstrates segmental or subsegmental drainage of the injured ductal system, simple ligation of the injured duct is adequate. If the injured duct is 4 mm or larger, however, it is likely to drain multiple hepatic segments or the entire right or left lobe and thus requires operative repair.

If the injury involves the common hepatic duct or the common bile duct, repair should also be carried out at the time of injury. The aims of any repair should be to maintain ductal length and not to sacrifice tissue, as well as to affect a repair that will not result in postoperative bile leakage. To accomplish these goals, all repairs at the time of initial operation should involve some sort of external drainage. If the injured segment of the bile duct is short (<1 cm) and the two ends can be opposed without tension, an end-to-end anastomosis can be performed with placement of a T-tube through a separate choledochotomy either above or below the anastomosis (Fig. 62-8A). Generous mobilization of the duodenum out of the retroperitoneum (Kocher maneuver) can be useful to help approximate the injured ends of the bile duct. An end-to-end repair, however, should be avoided if the ductal injury is near the hepatic duct bifurcation. It must also be remembered that in the nontransplantation setting, the patient does not have the benefit of a lower stricture rate due to chronic immunosuppression.

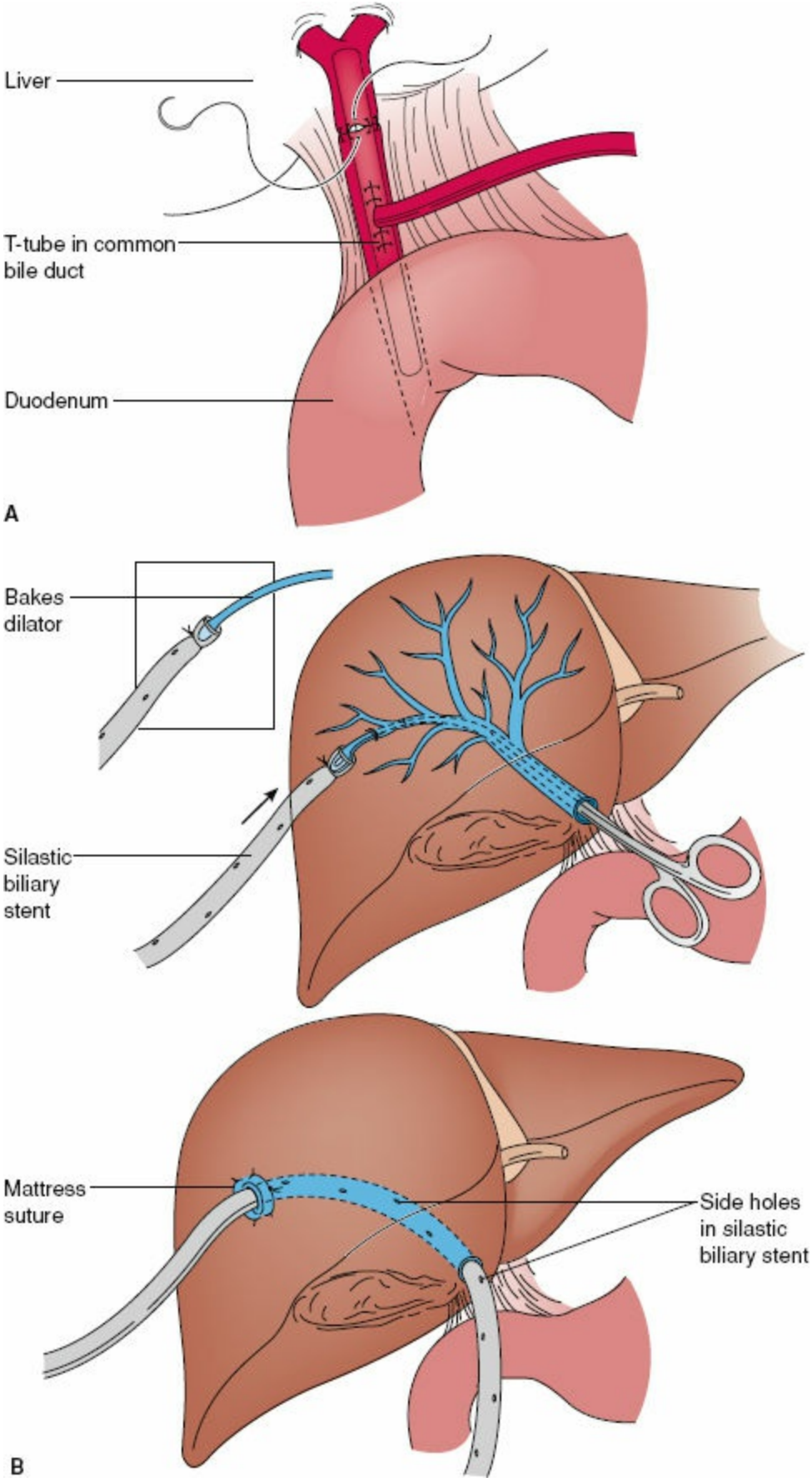

Figure 62-8. All biliary anastomoses performed for the reconstruction of acute bile duct injury should have external drainage. **A:** If the injured segment of bile duct is short (<1 cm) and the two ends can be opposed without tension, an end-to-end anastomosis can be performed with placement of a T-tube through a separate choledochotomy either above or below the anastomosis. The T-tube should not be brought out directly through the anastomosis. **B:** With more proximal injuries or if the segment of injured bile duct is greater than 1 cm, an end-to-end bile duct anastomosis should be avoided and a Roux-en-Y hepaticojejunostomy should be constructed. A transanastomotic stent can be placed

retrograde through the transected duct and exited to the hepatic parenchyma to allow postoperative external drainage.

5 For proximal injuries or if the injured segment of the bile duct is greater than 1 cm in length, an end-to-end bile duct anastomosis should be avoided because of the excessive tension that usually exists in these situations. In these circumstances, the distal bile duct should be oversewn, and the proximal bile duct should be debrided of injured tissue and anastomosed in an end-to-side fashion to a Roux-en-Y jejunal limb. The use of a Roux-en-Y jejunal limb is preferable to anastomosis to the duodenum because, in the latter case, an anastomotic leak results in a duodenal fistula. A transanastomotic Silastic stent can be placed retrograde through the transected duct and exiting the hepatic parenchyma (Fig. 62-8B) to allow for postoperative external drainage.

Unfortunately, most bile duct injuries during laparoscopic cholecystectomy occur in the hands of surgeons who are not experienced in performing complex biliary reconstruction. In such settings, the surgeon should consider *not* repairing the injury and not risk further worsening the situation. The biliary tree should be drained via a retrograde catheter to facilitate cholangiography, but the bile duct should not be ligated. More specifically, ligation of the proximal bile duct most often leads to stump necrosis, subsequent bile leakage and a more challenging reconstruction due to proximal migration of the injury itself.[15] The subhepatic space should be well drained to control the biliary leak. Prompt transfer to a tertiary hepatobiliary center should then be made.

The long-term results of immediate repair of common bile duct injuries are uncertain. Most injuries occur away from major centers, and therefore, even the successes are unlikely to be reported in the literature. In a Swedish report, early primary repair with end-to-end anastomosis resulted in good outcomes in only 22% of patients. Anastomotic leak requiring reoperation occurred in 32% of patients, and late stricture occurred in another 37% of patients. In patients undergoing immediate repair with a biliary-enteric anastomosis, good results were seen in 54% of patients, with strictures occurring in only 12% of patients. Similar poor late results were observed in another series in which 29 of 36 patients with primary end-to-end repair had postoperative strictures within 4 years.

Elective Repair of Bile Duct Injuries and Established Strictures

Several principles are associated with successful repair of a biliary injury or stricture: exposure of healthy proximal bile ducts that provide drainage of the entire liver; preparation of a suitable segment of intestine that can be brought to the area of the stricture without tension, most frequently a Roux-en-Y jejunal limb; and creation of a direct biliary-enteric mucosal-to-mucosal anastomosis. A number of alternatives for elective repair of bile duct strictures exist. The choice of procedure is dictated by the location of the stricture, the history of previous unsuccessful attempts at repair, and the surgeon's personal preference. Simple excision of a bile duct stricture and end-to-end bile duct anastomosis or repair of the damaged duct can rarely be accomplished because of the invariable loss of duct length as a result of fibrosis associated with the injury. Similarly, anastomosis of the proximal bile duct to the duodenum as a choledochoduodenostomy is not suitable for most postcholecystectomy strictures because an adequate length of bile

duct for creating a tension-free anastomosis to the duodenum usually cannot be obtained. Thus, in almost all cases, hepaticojejunostomy constructed to a Roux-en-Y limb of jejunum is the preferred procedure.

Many surgeons believe that a transanastomotic stent is helpful in almost all cases. In the early postoperative period, a stent is used to decompress the biliary tree and provide access for cholangiography. If the injury involves the common bile duct or the common hepatic duct at least 2 cm distal to the hepatic duct bifurcation, and adequate proximal bile duct mucosa can be defined, the use of long-term biliary stents is not necessary. In these situations, the preoperatively placed percutaneous transhepatic catheter or operatively placed T-tube is used to decompress the biliary-enteric anastomosis for 4 to 6 weeks after surgery. When adequate proximal bile duct is not available for a good mucosa-to-mucosa anastomosis, long-term stenting of the biliary-enteric anastomosis with a Silastic transhepatic stent is recommended. For strictures involving the hepatic duct bifurcation, both the right and left main hepatic ducts should be individually stented.

An operative technique for biliary reconstruction with transhepatic stents using the preoperatively placed percutaneous transhepatic catheters begins with dissection of the porta hepatis, which usually involves separating adhesions of the duodenum and hepatic flexure of the colon to the Glisson capsule and gallbladder fossa.[16] Identification of the proximal biliary segment can be difficult and can be aided by the presence of the transhepatic biliary catheter. This is particularly true for bile duct transections that will retract high into the porta. If a primary duct stricture exists, the bile duct is then divided at the lowest extent of the stricture and dissected proximally. A segment of the strictured duct should be resected and submitted for pathologic examination. The distal duct is then oversewn, and the bile duct proximal to the stricture is carefully dissected circumferentially in a cephalad direction for a distance not to exceed 5 mm. Excessive dissection should be avoided to prevent vascular compromise of this segment of duct, which will be used for the anastomosis. After mobilization and division of the bile duct, the biliary catheters protrude through the proximal end (Fig. 62-9A). A radiologic guide wire is then placed through these catheters. The preoperatively placed catheter can then be exchanged over the wire for a properly sized Silastic stent. These stents are 70 cm long and range from 12 French to 22 French. Multiple side holes are present along 40% of the length of the stent. These side holes are left to reside within the intrahepatic biliary tree and the portion of the Roux-en-Y jejunal limb used for the biliary anastomosis. The end of the stent without the side holes exits through the hepatic parenchyma and is brought out through a stab wound in the upper anterior abdomen. After stent placement, a Roux-en-Y jejunal limb is prepared, and the anastomosis is then performed as an end-to-side hepaticojejunostomy (Fig. 62-9B–D).

The importance of the hilar (epicholedochal) arterial plexus in cases of proximal bile duct injuries is also worth mention. More specifically, performing a “high” hepaticojejunostomy reconstruction to an intact proximal hilar bridge between the right and left hepatic ducts utilizes robust crossing arterial anatomy and is believed by many surgeons to minimize the risk of subsequent biliary stenosis.

An alternative technique has been described for management of bile duct strictures

involving the bifurcation and one or both of the hepatic ducts in which a side-to-side anastomosis of the left hepatic duct to the Roux-en-Y limb is constructed. A long opening along the anterior surface of the left hepatic duct is anastomosed to the side of the Roux-en-Y limb. Because it is possible to dissect the anterior surface of the left hepatic duct high up into the hepatic parenchyma, this procedure permits anastomosis to normal mucosa, even though there can be fibrosis and stricture at the bifurcation of the ducts and in the distal portion of the hepatic duct. This technique can avoid the need for postoperative stenting.

Surgical Outcome

Morbidity and Mortality

Repairs of bile duct strictures are performed primarily in major medical centers by experienced surgeons, yet these operations are still associated with significant morbidity and mortality. In 1982, a review of 38 series published since 1900 that included more than 7,643 procedures performed on 5,586 patients reported an overall operative mortality rate of 8.3%.[17] More recently the incidence of operative mortality has decreased markedly with improved technology and a multidisciplinary approach, as well as improved surgical experience. A recent series of 200 consecutive patients managed at the Johns Hopkins Hospital reported three deaths in patients who did not undergo an attempt at repair who were referred with sepsis secondary to an uncontrolled biliary leak, for a mortality rate of 1.5%. Definitive surgical reconstruction was performed in 175 patients with a perioperative mortality of only 1.7%.[18] In this series the timing of repair, the mode of presentation, previous attempts of repair, and the level of injury did not influence outcome. Chronic liver disease can be an important factor for operative mortality and morbidity with advanced biliary cirrhosis and portal hypertension leading to mortality rates approaching 30%. Fortunately in the modern era, such advanced disease is uncommon. In most series postoperative morbidity rates are in the range of 20% to 40%. In the recent Hopkins series, complications occurred in 41% of patients. Most of the complications were minor and could be managed with either interventional radiology techniques or conservative management. No patient required reoperation for postoperative complications. The median length of stay in this series was 8 days.

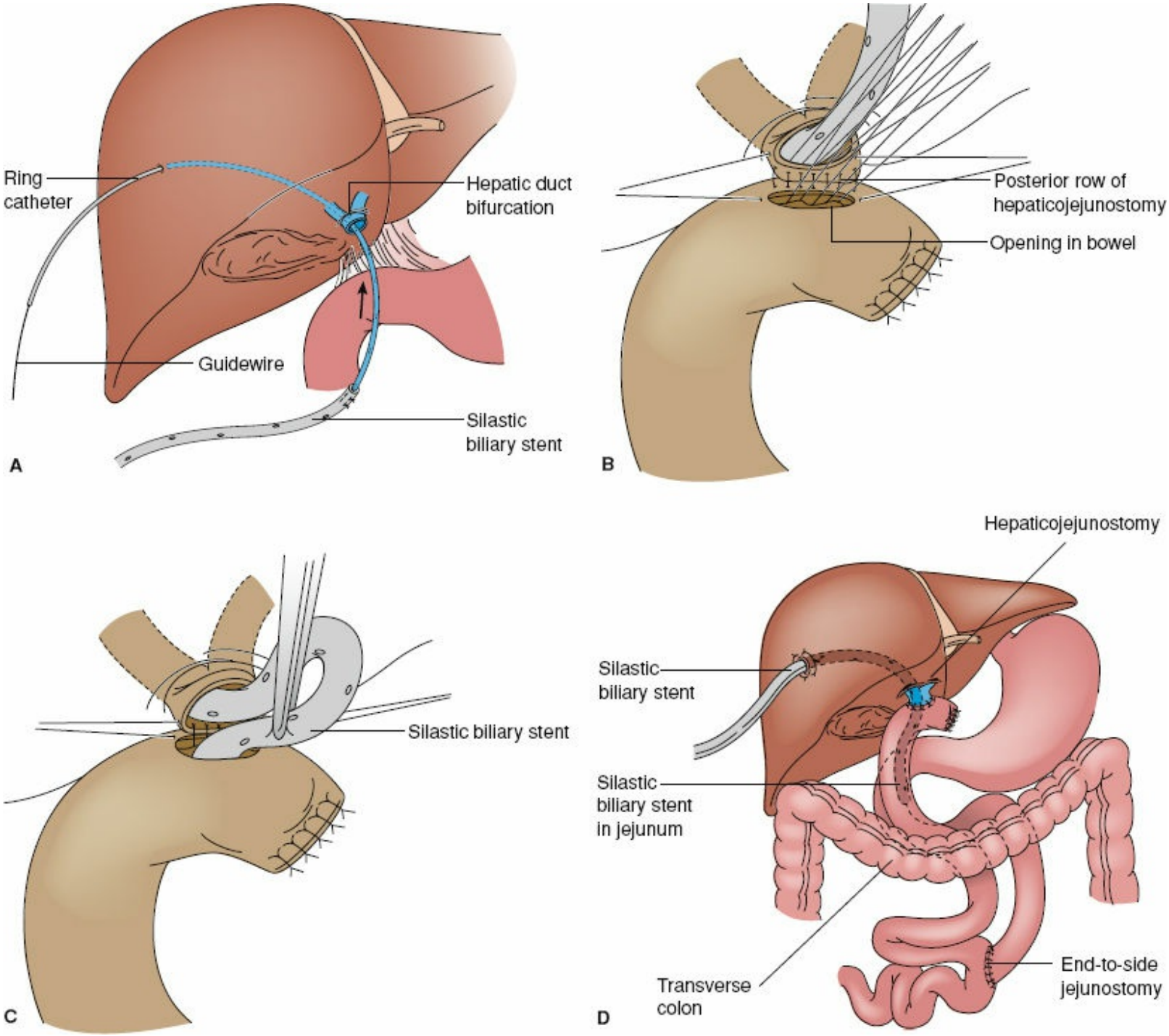

Figure 62-9. Technique of biliary reconstruction. **A:** A Silastic stent is sutured to the preoperatively placed transhepatic catheter, which protrudes through the transected hepatic duct and through the catheter tract in the hepatic parenchyma. **B:** A Roux-en-Y jejunal loop is then anastomosed to the hepatic duct and (**C**) the Silastic stent is placed through the anastomosis. **D:** A completed Roux-en-Y hepaticojejunostomy with a transanastomotic stent.

Long-Term Results

6 Historically, excellent long-term results were achieved in 70% to 90% of patients who underwent repair of bile duct strictures (Table 62-2). The definition of satisfactory results in most series requires that patients have no symptoms, jaundice, or cholangitis. Length of follow-up is important in analyzing final results because recurrent strictures can occur up to 20 years after the initial procedure (Fig. 62-10).[12,13] Approximately two-thirds of restrictures are evident within 2 years, and 90% are seen within 7 years. The percentage

of patients with good results is inversely related to the number of previous repairs. Other factors that favor a good outcome include young age at the time of stricture repair, use of a Roux-en-Y biliary-enteric anastomosis, absence of infection and hepatic fibrosis, and use of transhepatic stents.

Table 62-2 Results of Surgical Management of Bile Duct Strictures

Investigators	Patients	Success (%)	Follow-Up (mo)
Pitt et al., 1982[12]	66	86	60
Pelligrini et al., 1984[13]	60	78	102
Genest, 1986	105	82	60
Innes, 1988	22	95	72
Pain, 1988	163	72	133
Pitt et al., 1989[19]	25	88	57
David et al., 1993[20]	35	83	50
Lillemoe et al., 2000[21]	142	91	58
Walsh et al., 2007[22]	144	89	67
Pitt et al., 2013[23]	104	88	

As illustrated earlier, in the era before laparoscopic cholecystectomy, excellent long-term results were obtainable in tertiary care centers specializing in the management of these problems. Questions had arisen as to whether the excellent results of bile duct strictures after open cholecystectomy could be directly transferred to patients sustaining laparoscopic bile duct injuries. Some researchers had suggested that the mechanism of bile duct injury during laparoscopic cholecystectomy, the complex nature of many of these injuries, and the frequent association of significant inflammation and fibrosis secondary to sustained, unrecognized bile leakage might result in poor long-term results. Furthermore, the high percentage of these patients who have undergone unsuccessful operations, often performed by the primary laparoscopic surgeon, might also lead to a poor long-term outcome. Evidence for the latter hypothesis was provided by a review of the records of 85 patients who underwent a total of 112 biliary repairs.[24] Four factors determined the success or failure of treatment in this series. These factors included performance of preoperative cholangiography, the choice of surgical repair, details of the operative repair, and experience of the surgeon performing the repair. The importance of preoperative delineation of anatomy was clear, in that 96% of procedures in which cholangiograms were not obtained before repair were unsuccessful, and 69% of repairs were not successful when the cholangiographic data were incomplete. When cholangiographic data were complete, the initial repair was successful in 84% of patients. The type of repair was also of significance in influencing outcome. A primary end-to-end ductal repair over a T-tube was unsuccessful in all patients in whom a complete transection of the bile duct had taken place, whereas 63% of Roux-en-Y hepaticojejunostomies were successful. Attempts at repair by the primary surgeon were

successful only in 17% of cases, and in no case was a secondary repair by the primary surgeon successful. In those cases in which the first repair was performed by a tertiary care biliary surgeon, a 94% success rate was obtained.

The outcome of management of 142 patients with major bile duct injuries treated during the 1990s has been reported.[21] Laparoscopic cholecystectomy was the initial operation in 75% of these patients, and 41% had undergone a previous attempt or attempts at surgical repair before referral. In this series with a median follow-up of 58 months (range, 11 to 119 months), a successful outcome was obtained in 91% of patients. In this series the level of injury, clinical presentation, history of prior repair, and length of biliary stenting did not influence outcome. Comparable results have been reported from other high-volume hepatobiliary centers.[22,25] These results suggest that surgical reconstruction of major bile duct injuries after laparoscopic cholecystectomy can still result in excellent long-term results.

Table 62-3 Results of Transhepatic Balloon Dilation of Bile Duct Strictures

Investigators	Patients	Success (%)	Follow-Up (mo)
Mueller et al., 1986[32]	61	70	36
Williams, 1987	64	78	28
Moore, 1987	18	83	33
Pitt et al.,1989[19]	20	55	59
Citron et al., 1991	28	93	38
Misra et al., 2004[33]	51	58	76
Pitt et al., 2013[23]	70	50	

Despite the overall success of biliary reconstruction, there is a small subset of patients with major bile duct injuries in whom standard repair techniques appear to be inadequate. Factors, such as delay in diagnosis, complex injuries above the hepatic confluence, associated vasculobiliary injuries, and liver atrophy can all negatively affect the outcomes of standard reconstruction. In this select population excellent results have been observed with major hepatectomy.[26] A classic example of this scenario would be a patient who has sustained a right posterior sectoral bile duct injury, and subsequent hepatic atrophy with associated recurrent cholangitits. These patients typically benefit most from a right posterior hepatic sectionectomy, as opposed to an attempt at a challenging hepaticojejunostomy reconstruction to a small duct within an abnormal liver. Finally, in rare cases with failure of all standard surgical techniques of reconstruction with resultant end-stage liver disease, liver transplantation may offer the opportunity for survival.[27] Interestingly, many of these extreme injuries are caused during open cholecystectomy and therefore, trauma caused by migration from the cystic plate into the hilar plate itself.[11]

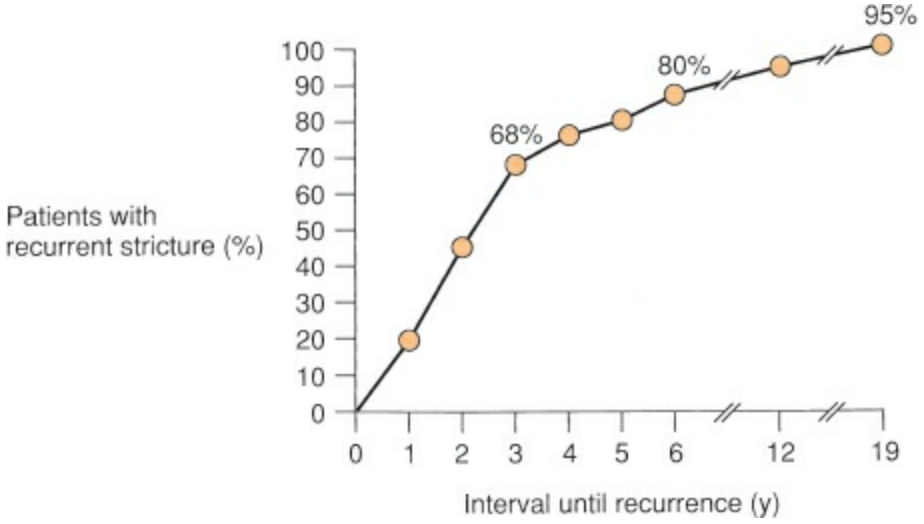

Figure 62-10. The cumulative percentage of recurrent strictures with respect to the time from the initial repair until the next repair. (Adapted from Pitt HA, Miyamoto T, Parapatis SK, et al. Factors influencing outcome in patients with postoperative biliary strictures. *Am J Surg* 1982;144:14–21.)

Although large series from tertiary referral centers have reported excellent long-term results, the overall impact of bile duct injuries on society is significant in terms of health care costs, disability, and even mortality. In an analysis of patients undergoing laparoscopic cholecystectomy from the U.S. Medicare database, Flum et al. demonstrated that the adjusted hazard ratio for death during the follow-up period was significantly higher (2.79, 95% confidence level 2.71–2.88) for patients with a bile duct injury than in those patients without a bile duct injury.[28] The hazard increased with advancing age and comorbidities and decreased with the experience of the repairing surgeon. The adjusted hazard of death during follow-up was 11% greater if the repairing surgeon was the same as the injuring surgeon. These data certainly further support the referral of most patients with bile duct injuries to centers with greater experience in the management of the injuries.

Finally, although the overall success of the surgical management of laparoscopic bile duct injuries associated with laparoscopic cholecystectomy is excellent, there is an impression that patients may have an impaired quality of life even after successful repair of their bile duct injury. Quality-of-life assessments after laparoscopic cholecystectomy bile duct injury have been addressed in several recent reports.[29,30] These results have generally reported either comparable or mildly diminished quality of life compared with matched controls. Interestingly, in one study, patients who reported pursuing a law suit following their injury had significantly worse quality-of-life scores in all domains when compared to those who did not entertain legal action.[29] The most recent study, which spanned a 23-year period (169 month median follow-up), evaluated 62 patients who had generally undergone a Roux-en-Y hepaticojejunostomy (86%) reconstruction, confirmed that mental health concerns were more common place than physical or general health issues following bile duct injuries. While most patients displayed an eventual return to their physical baseline, psychological quality of life was much more difficult to correct over time.[31]

Nonoperative Management

Operative management of bile duct strictures is technically difficult and continues to be associated with significant postoperative morbidity and mortality. Moreover, in all series, recurrent strictures develop in a proportion of patients. These factors, in addition to technical advances in the fields of therapeutic radiology and endoscopy, have led to the development of nonoperative techniques for management of bile duct strictures. The optimal method for management using these techniques is dependent on the presence and anatomy of biliary-enteric continuity.

Percutaneous Balloon Dilation

The management of benign bile duct strictures using the percutaneous transhepatic route is indicated primarily in patients with a failed prior biliary-enteric anastomosis to a jejunal limb. The procedure in many cases can be performed with a combination of local anesthesia and intravenous sedation. In this technique, access to the proximal biliary tree is gained and the stricture is traversed with a guide wire under fluoroscopic guidance. At this point, the stricture is dilated using angioplasty-type balloon catheters, chosen on the basis of the location of the stricture and the diameter of the normal duct (Fig. 62-11). After the procedure, a transhepatic stent is left in place across the stricture to allow access to the biliary tree for follow-up cholangiography, repeat dilation, and maintenance of a lumen during the healing process. In most series, numerous dilations are required.

The results from a number of series have been encouraging (Table 62-3). In a multicenter review of bile duct strictures treated in the open cholecystectomy era, 3-year follow-up showed a 67% patency rate for anastomotic and a 76% patency rate for iatrogenic primary bile duct strictures, yielding an overall 70% success rate.[32] A report of 51 patients with bile duct strictures after laparoscopic cholecystectomy managed with percutaneous dilation showed a success rate of 58% with a mean follow-up of 76 months.[33]

Complications of balloon dilation are frequent. Cholangitis, hemobilia, and bile leaks can occur in up to 20% of patients. Bleeding, usually from the hepatic parenchyma, has been reported, with transfusions often necessary. Sepsis due to cholangitis can occur despite antibiotic prophylaxis. Sepsis and significant bleeding seldom occur in patients dilated by a T-tube tract, suggesting that much of the morbidity is the result of traversing the hepatic parenchyma by the large percutaneously placed catheters.

Endoscopic Balloon Dilation

Endoscopic balloon dilation is often considered technically possible only in patients with primary bile duct strictures or with strictures at a prior primary end-to-end repair or choledochoduodenal anastomosis. With the advent of double-balloon enteroscopy however, more patients are now able to undergo endoscopic retrograde cholangiopancreatography (ERCP) following preceding hepaticojejunostomies, as well as a myriad of bariatric procedures. In select cases, laparoscopic assisted ERCP is also possible. This technique begins with ERC and endoscopic sphincterotomy. The stricture is traversed retrograde with an atraumatic guide wire, and sequential balloon dilation is used. Reevaluation with cholangiography is performed every 3 to 6 months. Redilation is performed as necessary. In most cases, an endoprosthesis is left in place after dilation for at least 12 months.

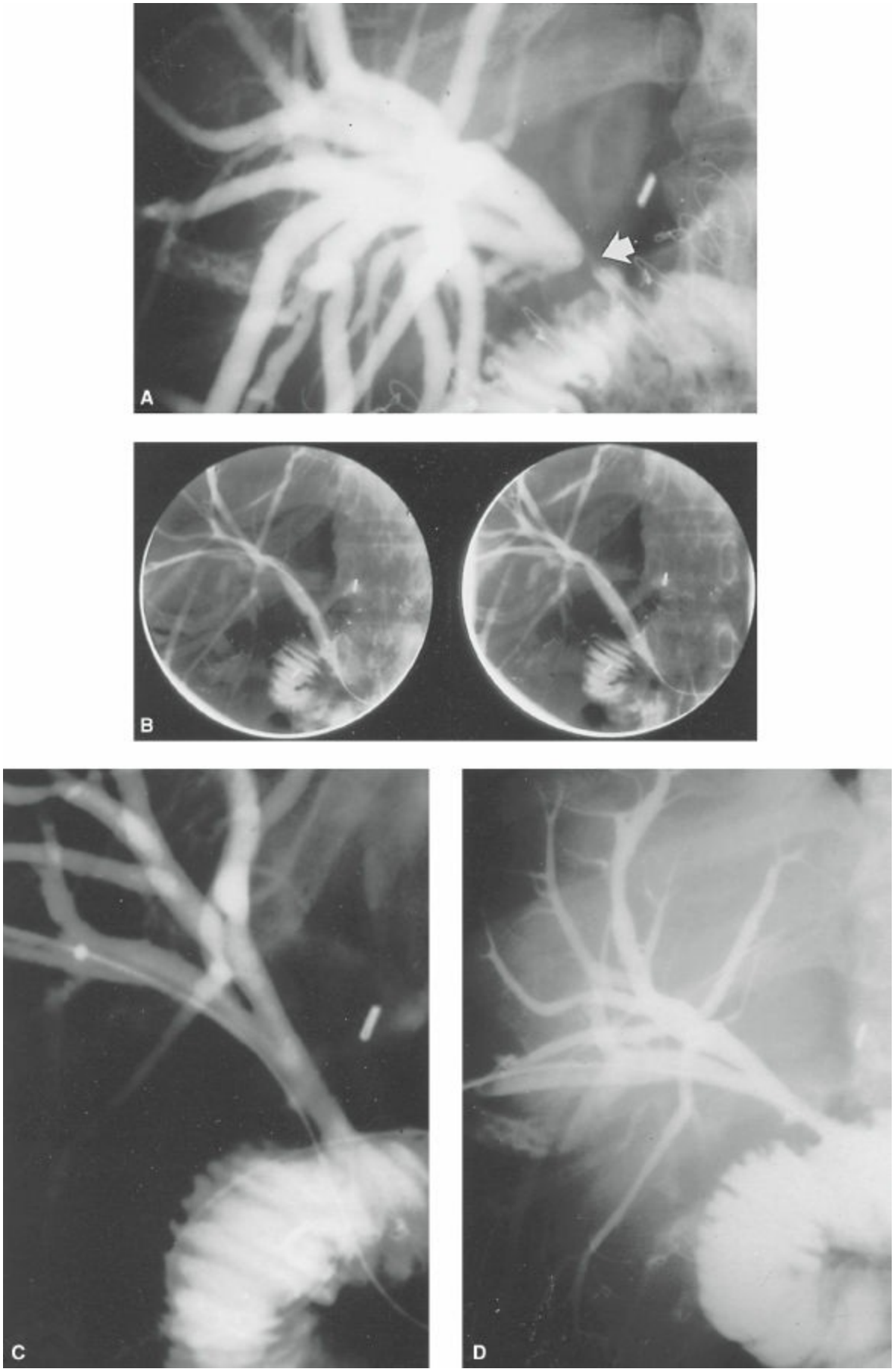

Figure 62-11. **A:** Transhepatic cholangiogram demonstrating stricture (*arrow*) at a previous choledochojejunostomy. **B:** Progressive dilation of the strictured anastomosis with an angioplasty balloon catheter. **C:** Postdilation stenting of the anastomotic stricture for prolonged periods. **D:** Subsequent cholangiogram demonstrating resolution of the anastomotic stricture. (Reproduced with permission from Pitt HA, Kaufman SL, Coleman J, et al. Benign postoperative biliary strictures: operate or dilate? *Ann Surg* 1989;210:417–425; discussion 426–427.)

7 The reported experience with endoscopic dilation of benign bile duct strictures is shown in Table 62-4. The largest experience comes from the group in The Netherlands who recently reported their experience in 110 patients.[34] The mean number of stents placed was two, the mean duration of stenting was 11 months, and stent-related complications occurred in 33% of patients with one death. Twenty percent of patients were eventually referred for surgery. The overall reported success rate was 74% with a mean follow-up of 7.6 years. A similar experience was reported in the United States.[35] In this series, 18 of 25 strictures were postoperative. Strictures were located at the cystic duct junction in 17 patients and in the distal bile duct in the remaining eight patients. Of 25 patients, 22 (88%) had significant clinical benefit from the therapy. Only two complications occurred in this series – one case each of pancreatitis and cholangitis.

Comparative Data

Comparison of results of nonoperative dilation with those of surgery has been difficult. Few centers have significant experience with both operative and nonoperative management. Furthermore, the definition of a successful procedure, the reporting of complications, and the length of follow-up has not been consistent in the literature. There are no prospective randomized studies to compare these techniques; however, three retrospective comparative studies exist. In the first study, a retrospective review of the results at the Johns Hopkins Hospital between 1979 and 1987 compared percutaneous balloon dilation and surgery in 43 patients with benign postoperative bile duct strictures.[19] Twenty-five patients underwent surgical repair with Roux-en-Y hepaticojejunostomy with postoperative transhepatic stenting for a mean of 13 ± 1.3 months. Twenty patients had percutaneous balloon dilation, a mean of 3.9 times, and were stented transhepatically for a mean of 13.3 ± 2 months. Three patients were managed with both surgery and balloon dilation. The two groups were similar with respect to multiple parameters that might have influenced outcome, including age, sex, associated medical problems, and presentation with either obstructive jaundice or biliary fistulas. No patients died after any of the procedures. Procedure-related morbidity occurred in 20% of surgical patients and in 35% of the patients undergoing balloon dilation. For both groups, a successful outcome was defined as no evidence of cholangitis or jaundice requiring another procedure more than 12 months from the onset of treatment. A failed treatment was defined as the need for crossover to the other treatment modality, either operation or dilation, or late death from liver failure, biliary sepsis, or portal hypertension. A successful repair was achieved in 89% of the surgical patients and in only 52% of the balloon dilation patients (Fig. 62-12). The overall late mortality rate in this series was 10%. One late death occurred in the surgical group, whereas three late deaths followed balloon dilation (4% vs. 15%, respectively). No deaths, however, were attributed to liver failure, biliary sepsis, or portal hypertension associated with the bile duct stricture.

Table 62-4 Results of Endoscopic Balloon Dilatation of Bile Duct Strictures

Investigators	Patients	Success (%)	Follow-Up (mo)
Foutsch, 1985	9	55	6
Geenen et al., 1989[35]	25	88	48
David et al., 1993[20]	46	83	48
De Reuver et al., 2007[34]	110	74	91
Pitt et al., 2013[23]	115	76	

To define further the relative benefits of the two procedures, total hospital stay and total procedural costs were determined. As expected, initial hospitalization was longer for surgery than for balloon dilation. When rehospitalization for further dilation,

complications, or recurrences was considered, total hospital stay did not differ significantly between the two groups. Cost data paralleled hospitalization data and did not differ significantly between the groups. Thus, the authors concluded that until properly designed, randomized, prospective, controlled trials can be performed, surgical repair for benign postoperative strictures appears to be associated with fewer problems and a greater success rate.

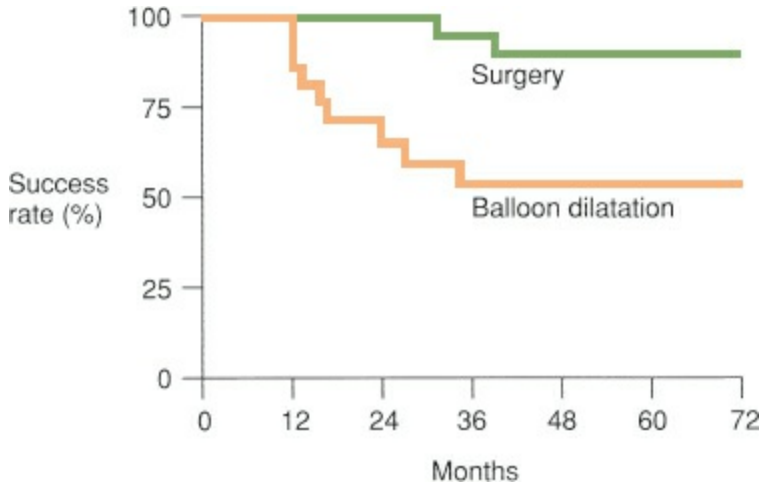

Figure 62-12. Actuarial success rates over 72 months for surgery (89%) and balloon dilation (52%). The difference is statistically significant ($p < 0.01$). (Adapted from Pitt HA, Kaufman SL, Coleman J, et al. Benign postoperative biliary strictures: operate or dilate? *Ann Surg* 1989;210:417–425; discussion 426–427.)

In the second comparative study, the group from The Netherlands compared endoscopic versus surgical treatment of benign bile duct strictures.[21] Thirty-five patients were treated surgically, and 66 were treated by endoscopic stenting. Patient characteristics, initial injury, previous repairs, and the level of obstruction were comparable in both groups. Surgical therapy consisted of Roux-en-Y hepaticojejunostomy, and endoscopic therapy consisted of placement of an endoprosthesis with trimonthly elective exchange for 1 year. Successful stent placement was accomplished in 94% of patients managed endoscopically. Six of the 66 endoscopic patients, however, underwent surgical reconstruction either for failed stent placement or for other reasons. Early complications occurred more frequently in the surgically treated group (26% vs. 8%; $p < 0.03$). However, the only procedure-related death occurred in a patient in whom severe pancreatitis developed after endoscopic stent placement. Late complications, which included primarily episodes of cholangitis, occurred only in the endoscopic group (27%). The overall complication rates, therefore, were similar at 26% for surgical patients and 35% for endoscopic patients. The mean follow-up and definition of success were similar to those in the aforementioned study. After surgery, excellent results were observed in 83% of patients, with a recurrent stricture developing in six patients at a mean of 40 months after the initial operation. After endoscopic stenting, excellent results were observed in 72% of patients, with restricture developing in 18% of patients at a mean of 3 months after stent removal. The investigators concluded that endoscopic stenting should be considered for the initial attempt at definitive management in suitable patients in the hope of avoiding

reoperation.

The final and most recent comparative study describing 528 patients over 18 years has confirmed a number of interesting observations.[23] More specifically, patients with all types of bile duct injuries were most commonly treated by endoscopists (40%), followed by surgeons (36%) and interventional radiologists (24%). Success rates however were higher for surgery (88%) compared to either endoscopy (76%) or interventional radiology (50%). This observation was accomplished with an overall morbidity amongst the surgical cohort of 24% with no 90-day mortality. Not surprisingly, outcomes also improved dramatically over time amongst all approaches. Although the reason for this progress is clearly multifactorial, issues such as improved selection of patients for each approach, increased experience in reconstruction at the surgeon level (and therefore, fewer surgeons performing repairs overall), and perhaps pursuit of more proximal biliary-enteric anastamoses and/or more selective use of transhepatic stents may each play a role. Taken as a whole, this modern analysis of bile duct injuries confirms the importance of ensuring significant clinician experience with this complication, a multidisciplinary team comprised of HPB surgeons, interventional endoscopists and interventional radiologists, and thoughtful selection of a given patient for the appropriate therapeutic option with the highest chance of long-term success.

Table 62-5 Diseases Associated with Primary Sclerosing Cholangitis

Disease	Frequency (%)
Ulcerative colitis	40–60
Pancreatitis	12–25
Diabetes mellitus	5–10
Retroperitoneal fibrosis	Rare
Riedel thyroiditis	Rare
Crohn disease	Rare
Histiocytosis X	Rare
Sicca complex	Rare
Rheumatoid arthritis	Rare
Hypertrophic osteoarthropathy	Rare
Sarcoidosis	Rare
Angioimmunoblastic lymphadenopathy	Rare
Acquired immunodeficiency syndrome	Rare

PRIMARY SCLEROSING CHOLANGITIS

Primary sclerosing cholangitis is an idiopathic disease characterized by intrahepatic and extrahepatic inflammatory strictures of the bile ducts that cannot be attributed to other specific causes. The cause of primary sclerosing cholangitis is unknown. Many experts consider primary sclerosing cholangitis to be an autoimmune reaction because it is associated with other autoimmune diseases, such as ulcerative colitis, retroperitoneal fibrosis, and Riedel thyroiditis (Table 62-5). It is likely that a number of causes, including viral or bacterial infections, toxic drug reactions, and congenital anomalies, can all result in the same end-stage injury that is recognized as primary sclerosing cholangitis.

The usual clinical presentation of patients with primary sclerosing cholangitis involves intermittent jaundice, which begins insidiously in the fourth or fifth decade of life. Right upper quadrant pain, pruritus, fever, weight loss, and fatigue can also occur. The disease is characterized by cyclic remissions and exacerbations. Despite the nomenclature, acute cholangitis is uncommon without previous biliary manipulation or surgery. The diagnosis is suggested by clinical presentation associated with cholestatic liver function test abnormalities. The levels of bilirubin often fluctuate with respect to the remissions and exacerbations of the disease and the extent of hepatic injury. Alkaline phosphatase is usually elevated out of proportion to the serum bilirubin, and is a more persistent finding. The diagnosis, however, usually is confirmed by cholangiography, which reveals multiple dilatations and strictures (beading) of the intrahepatic and extrahepatic bile ducts (Fig. 62-13). MRCP has become the preferred procedure as it is noninvasive. ERC, however, remains an important tool for both diagnostic and therapeutic procedures. An important distinction must be made as cholangiocarcinoma must be considered in the differential diagnosis of a dominant stricture. Furthermore, cholangiocarcinoma may develop after presentation in up to 30% of patients with primary sclerosing cholangitis. Therefore, endoscopic brushings and biopsies are frequently required. The disease should be followed closely by cholangiography and liver biopsy to provide appropriate management before the development of biliary cirrhosis.

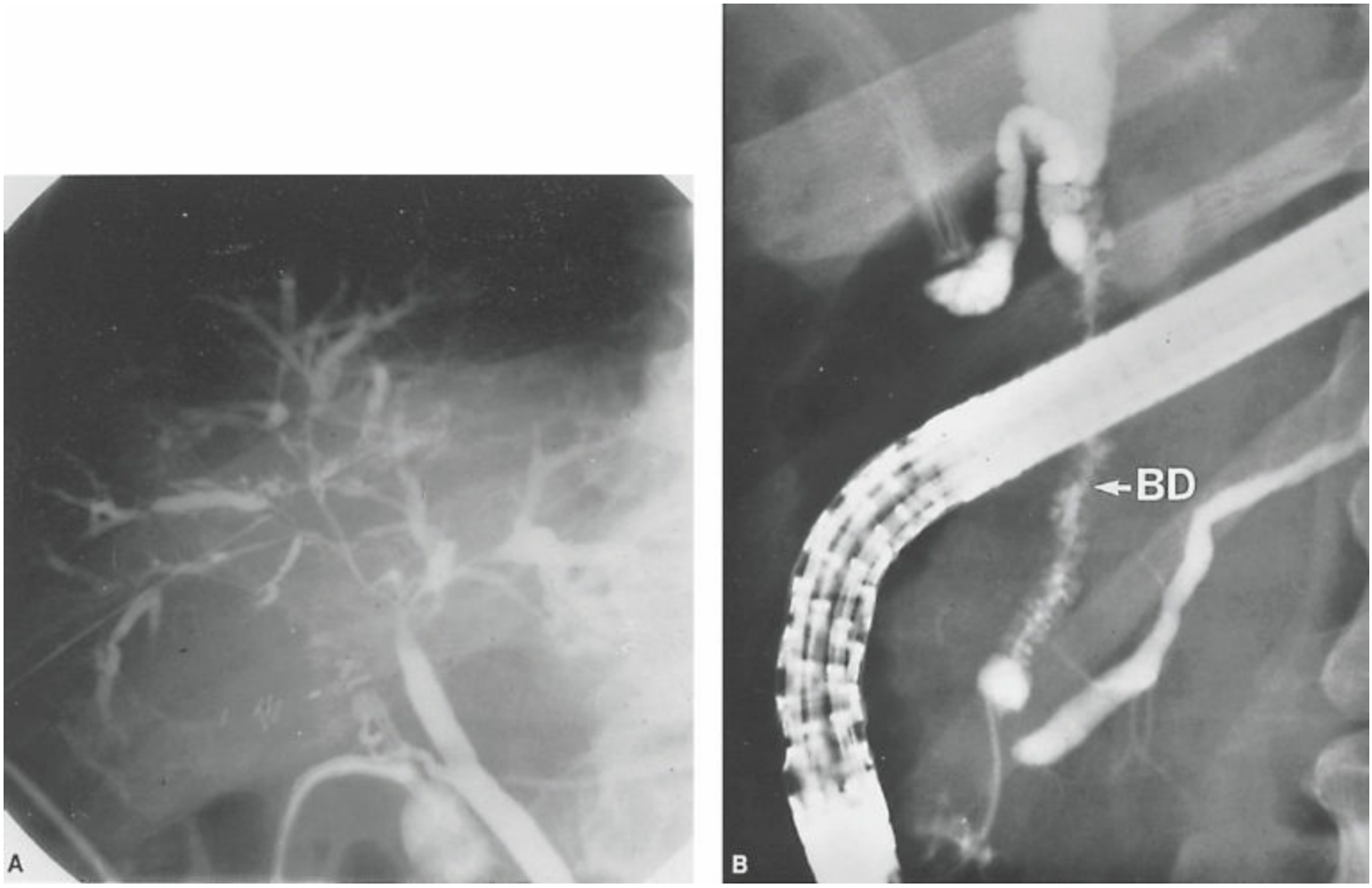

Figure 62-13. **A:** Cholangiogram of a patient with primary sclerosing cholangitis. Multiple irregular strictures and dilatation (beading) of intrahepatic bile ducts can be seen. **B:** Endoscopic retrograde cholangiogram showing extensive involvement of extrahepatic bile duct (BD) with primary sclerosing cholangitis. (B reproduced with permission from Lillemoe KD, Pitt HA, Cameron JL. Primary sclerosing cholangitis. *Surg Clin North Am* 1990;70:1390.)

No known specific medical therapy is effective for primary sclerosing cholangitis. The most encouraging results, from a prospective, randomized, placebo-controlled trial, suggest that ursodeoxycholic acid significantly improves serum liver function tests and liver histologic appearance. Unfortunately, there were no significant differences in clinical outcome between the two groups at up to 6 years of follow-up.[36] Nonoperative dilation therapy by the endoscopic route has been used for dominant strictures with favorable results.[37]

8 An aggressive surgical approach is advocated for selected symptomatic patients with primary sclerosing cholangitis because of the lack of effective medical therapy. One surgical approach, in patients with a dominant stricture at the hepatic duct bifurcation, uses resection of the bifurcation and long-term transhepatic stenting with Silastic stents. This mode of therapy was recently reported in 77 patients with resection of the hepatic duct bifurcation, with hepatic lobectomy performed in another four patients.[38] The perioperative complication rate was 39% and 30-day mortality was 3.9%. Bilirubin improved and 57% of patients had no primary sclerosing cholangitis–related readmissions. At median follow-up of 10.5 years, the 5- and 10-year survival rates were 76.4% and 52.7%, respectively. Cholangiocarcinoma did not develop in any patients and

only seven required liver transplant. Over the same period, liver transplant was performed in 49 patients with cirrhosis with a 10-year survival of 57%.

The role of biliary surgery in primary sclerosing cholangitis, however, has decreased considerably with the growing success of liver transplantation. Primary sclerosing cholangitis has become one of the most common indications for liver transplantation in the United States, with 5-year actuarial survival and graft survival rates of 85% and 72%, respectively.[39] Liver transplantation should be considered before the disease is too advanced. The development of a poor quality of life as a result of disabling fatigue, intractable pruritus, severe muscle wasting, and chronic or recurrent bacterial cholangitis or persistent elevations in serum bilirubin are primary indications for referral for liver transplantation.

Preoperative recognition of cholangiocarcinoma is extremely important in this population in that the development of this complication significantly worsens the result after liver transplantation. The presence of known malignancy results in patients being refused transplantation. The microscopic identification of intrahepatic cholangiocarcinoma in the absence of lymph node involvement, often demonstrated in the explanted liver specimen, however, does not usually portend a poor prognosis. Although it can be extremely difficult to confidently confirm or refute the presence of cholangiocarcinoma in this setting, both MRCP and more recently SpyGlass cholangioscopy during ERCP can be extremely helpful. SpyGlass cholangioscopy in particular provides the advantage of direct visualization of the biliary mucosa/lesion, as well as an opportunity for biopsy.

Patients with primary sclerosing cholangitis have a significantly higher rate of development of nonanastomotic biliary strictures after liver transplantation, with histologic features on posttransplantation biopsy consistent with recurrence of the disease. Other causes of stricture, such as hepatic artery thrombosis, preservation-related ischemia, cytomegalovirus infection, and chronic ductopenic rejection, can cause similar lesions. Recurrent primary sclerosing cholangitis usually does not have an aggressive course.

Resection of the hepatic duct bifurcation and long-term transanastomotic stenting in selected patients can preclude or delay the need for hepatic transplantation. Moreover, this operation does not eliminate or influence the results of hepatic transplantation. Resection of the hepatic bifurcation and long-term transhepatic stenting can be recommended for selected patients with primary sclerosing cholangitis with severe strictures at or distal to the hepatic duct bifurcation but without established biliary cirrhosis. In patients with biliary cirrhosis, hepatic transplantation is recommended.

BILE DUCT STRICTURES SECONDARY TO CHRONIC PANCREATITIS

9 Chronic pancreatitis is an uncommon cause of benign bile duct strictures, resulting in less than 10% of such cases. Transient partial obstruction of the distal common bile duct caused by inflammation and edema frequently occurs in patients with acute pancreatitis. With chronic pancreatitis, however, the clinical problem is distal bile duct obstruction caused by inflammation and parenchymal fibrosis of the gland. These strictures classically involve the entire intrapancreatic segment of the common bile duct and are associated with dilatation of the entire proximal biliary tree (Fig. 62-14). In most cases, the cause of the chronic pancreatitis is alcoholism. Often, advanced disease is present in that the incidence of pancreatic calcification, diabetes, and malabsorption is increased at the time of presentation with jaundice compared with patients with chronic pancreatitis without jaundice. Common bile duct strictures have been reported to occur in 3% to 29% of patients with chronic alcoholic pancreatitis. In a review of a number of clinical series, the overall incidence of common bile duct strictures in patients with chronic pancreatitis was 5.7%.[40] The exact incidence of common bile duct strictures is not known, however, because cholangiography is not routinely performed in patients with chronic pancreatitis.

The clinical presentation of patients with common bile duct strictures secondary to chronic pancreatitis is variable. Some patients have no symptoms, with the diagnosis of bile duct strictures suggested only by abnormal liver function test results. The serum alkaline phosphatase appears to be the most sensitive laboratory finding and is elevated in more than 80% of patients. Abdominal pain with or without jaundice is another common presentation. In some cases, the abdominal pain can be difficult to distinguish from the pain associated with chronic pancreatitis. Failure to recognize and address a bile duct stricture, however, can lead to ultimate failure of operative procedures performed for chronic pain in patients with chronic pancreatitis. Finally, the development of jaundice in patients with chronic pancreatitis must be differentiated from underlying periampullary malignancy.

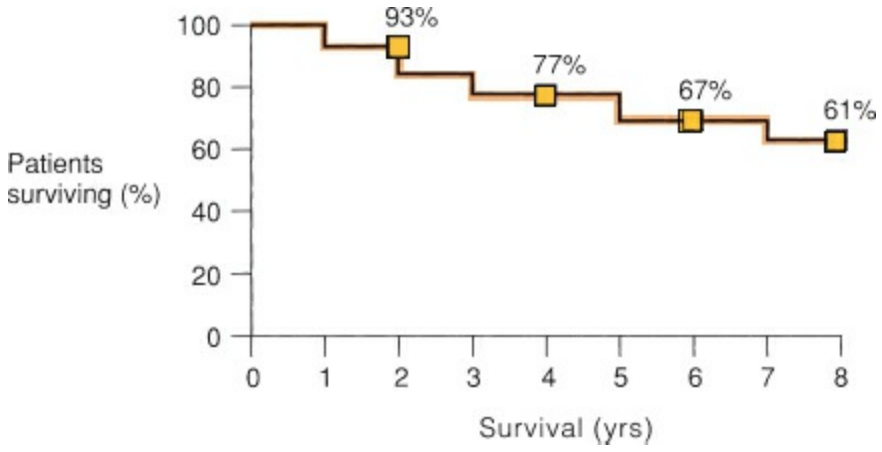

Figure 62-14. Actuarial survival rates among 31 noncirrhotic patients with primary sclerosing cholangitis who underwent resection of the hepatic bifurcation and long-term transhepatic stenting. (Reproduced with permission from Lillemoe KD, Pitt HA, Cameron JL. Primary sclerosing cholangitis. *Surg Clin North Am* 1990;70:1381–1402.)

The definitive evaluation of patients with a bile duct stricture caused by chronic pancreatitis is cholangiography. Either MRCP or ERCP is the preferred diagnostic procedure as they both can demonstrate both biliary and pancreatic ductal anatomy, which is essential in optimal surgical management of chronic pancreatitis. ERCP with stenting allows decompression of the obstructed biliary tree if necessary for cholangitis or severe jaundice. A long (usually 2- to 4-cm), smooth, gradual tapering of the common bile duct is most compatible with a benign stricture due to chronic pancreatitis (Fig. 62-15).

The indications for surgical management of common bile duct strictures due to chronic pancreatitis are clear in patients with significant pain, jaundice, or cholangitis. Controversy exists, however, concerning the necessity of biliary decompression in patients with an asymptomatic elevation of serum alkaline phosphatase. In general, biliary bypass is indicated because changes from obstructive biliary cirrhosis have been observed in liver biopsy specimens obtained from patients with long-standing, functionally significant biliary obstruction due to chronic pancreatitis.[41,42] Some clinicians may also consider biliary dilatation and temporary intraluminal stenting in this setting using either endoscopic (preferred) or percutaneous approaches.

Choledochoduodenostomy and Roux-en-Y choledochojejunostomy are acceptable methods of biliary bypass in patients with bile duct strictures caused by chronic pancreatitis. Choledochoduodenostomy is preferred by many surgeons because it does not divert bile from the duodenum, is technically easier to perform, and leaves the jejunum intact for any associated procedures required for decompression of an obstructed gastrointestinal tract or pancreatic duct. Finally, in patients in whom periampullary malignancy cannot be completely ruled out by the clinical course or imaging studies, or in patients with significant chronic pain thought secondary to proximal pancreatic duct disease, pancreaticoduodenectomy offers an excellent treatment option. The results of surgical management of distal bile duct structures due to chronic pancreatitis are usually excellent, with a low rate of perioperative complications and excellent long-term results.

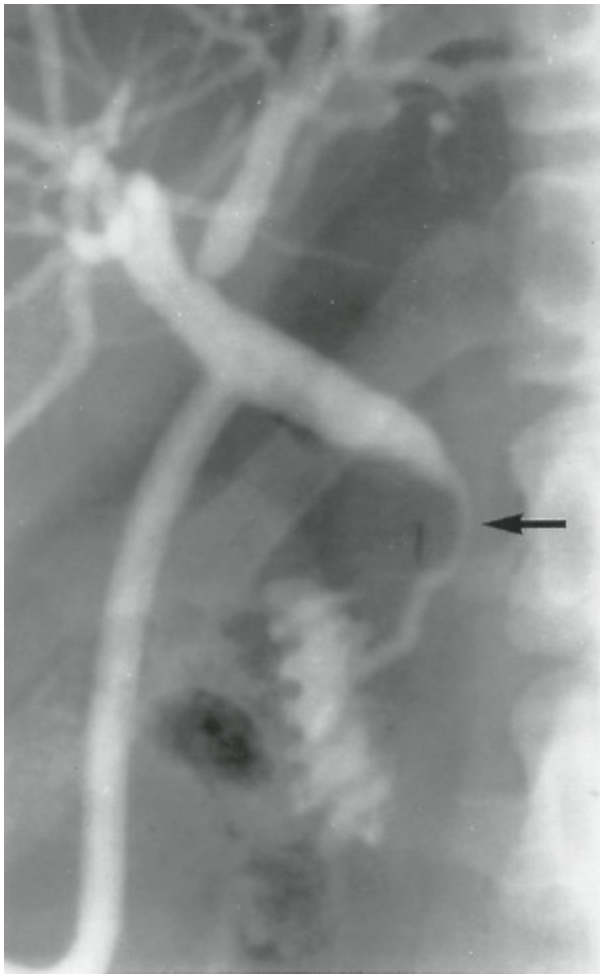

Figure 62-15. Cholangiogram of a patient with a long distal common bile duct stricture (*arrow*) caused by chronic pancreatitis.

Transduodenal sphincteroplasty is not recommended for the management of common bile duct strictures caused by chronic pancreatitis because the stricture is too long to be managed adequately by this technique. Similarly, endoscopic sphincterotomy has no role in the management of biliary obstruction due to chronic pancreatitis. Limited experience has been reported with balloon dilation of distal bile duct strictures secondary to pancreatitis, with little long-term follow-up.

Over the last decade another variant of chronic pancreatitis has been recognized as a cause of distal bile duct stricture – autoimmune pancreatitis.[43] This process is characterized by a lymphoplasmacytic infiltrate and is associated with secretion of large amounts of immunoglobulin (Ig) 4. The condition can mimic pancreatic cancer and is diagnosed by characteristic imaging studies and elevation of serum Ig4 levels. Treatment is with corticosteroids with surgical resection or bypass reserved for unresponsive cases or when a diagnostic dilemma remains. Although Ig4 serology is highly sensitive (90%), cases where equipoise remains can also undergo an initial empiric test of corticosteroids to assist in achieving the diagnosis and potentially provide concurrent therapy.

MISCELLANEOUS CAUSES OF BILE DUCT STRICTURES

Benign strictures of the bile duct can result from the chronic inflammation associated with gallstones in either the gallbladder or common bile duct. This cause of bile duct strictures is uncommon and is a rare complication of gallstone disease. Bile duct strictures caused by cholelithiasis are usually associated with a narrowing at the level of the common hepatic duct caused by a stone impacted in the infundibulum of the gallbladder. The narrowing can be caused by two means. First, simple compression can occur from a large stone lying adjacent to the common hepatic duct (Mirizzi type A). Second, chronic or acute inflammation arising from the gallbladder or cystic duct can extend to the contiguous bile duct, resulting in stricture formation (Mirizzi type B, C, or D). The biliary obstruction associated with either of these conditions is known as *Mirizzi syndrome* and culminates in Mirizzi type E disease which occurs in any case of bilioenteric fistula.[44]

The clinical presentation of a bile duct stricture caused by cholelithiasis is often associated with acute cholecystitis and hyperbilirubinemia. In some long-standing cases, these findings exist in the face of chronic gallbladder symptoms. If hyperbilirubinemia is present and urgent cholecystectomy is not indicated, ERCP or PTC can help to delineate the preoperative biliary anatomy. Most cases that are associated with acute cholecystitis, however, are recognized at the time of cholecystectomy and operative cholangiography. When the duct compression is associated with acute inflammation, the common hepatic duct almost always returns to normal after the offending stone has been removed by cholecystectomy and the inflammatory process has resolved. Care must be taken during the dissection to avoid creation of a defect in the common hepatic duct. Rarely, after the acute episode has resolved, a well-established stricture presents months to years after the acute episode. In such cases, management by Roux-en-Y hepaticojejunostomy is appropriate.

Strictures due to choledocholithiasis are also rare. The presumed mechanism is erosion of the epithelium of the distal duct, creating inflammation with subsequent fibrosis and stricture. Because of the anatomic tapering of the common bile duct, nearly all stones are entrapped in the intrapancreatic portion of the duct and are often difficult to remove by the supraduodenal route.

Excessive intraoperative manipulation at the time of bile duct exploration with forceps, scoops, and catheters can often create additional trauma to an already friable distal duct. After the stone has been removed, the distal bile duct should be gently sized with a soft rubber catheter to be sure that no stricture exists. If a stricture persists after stone removal, it may not be recognized until the time of postoperative T-tube cholangiography. If recognized in the postoperative period, time should be allowed for resolution of inflammation before considering stricture repair. If a distal bile duct stricture does persist, a biliary-enteric anastomosis with either Roux-en-Y choledochojejunostomy or a choledochoduodenostomy is indicated. If the proximal duct is adequately dilated (>2 cm in diameter) to allow a large choledochoduodenal anastomosis, this procedure is usually preferable because of its technical ease and excellent results.

Stenosis of the sphincter of Oddi, or papillitis, is a benign intrinsic obstruction of the outlet of the common bile duct, usually associated with inflammation, fibrosis, or muscular hypertrophy. Sphincter stenosis can result in any of three clinical conditions: (a) common bile duct obstruction due to fibrotic stenosis of the papilla, (b) recurrent pancreatitis, or (c) recurrent right upper quadrant pain without jaundice or pancreatitis. The pathogenesis of the inflammation of sphincter stenosis is unclear. In many cases, it is thought to result from the trauma of the passage of multiple small stones from the common duct through the ampulla. This trauma results in inflammation, scarring, and stricture formation. Many patients with papillary stenosis have no gallstones. Other potential mechanisms include primary sphincter motility disorders and congenital anomalies. The clinical presentation is usually either jaundice or cholangitis. In some cases, an impacted common bile duct stone may be present. The diagnosis can be supported with either PTC or ERC. This condition can be managed by sphincterotomy performed either endoscopically or operatively. If a cholecystectomy was performed previously, endoscopic papillotomy is the initial procedure of choice.

Cholangiohepatitis is an unusual infection of the biliary tree frequently associated with *Clonorchis sinensis* and other parasites. These infections are most commonly seen in natives of Asia. Most patients present with recurrent episodes of cholangitis. Cholangiography can demonstrate multiple strictures of both the intrahepatic and extrahepatic biliary tree, with the bile ducts filled with sludge and stones (Fig. 62-16). Surgical management consists of cholecystectomy and improved biliary drainage with either Roux-en-Y choledochojejunostomy or choledochoduodenostomy. Access to the biliary tree for postoperative management of intrahepatic stones or sludge should be maintained with either transhepatic biliary stents or a choledochojejunocutaneous or subcutaneous fistula. No specific medical management is available for this condition.

Finally, rare causes of benign intrahepatic and extrahepatic bile duct strictures have been reported secondary to intrahepatic arterial infusion of 5-fluorouracil used in the treatment of hepatic metastases of colorectal carcinoma. The clinical picture closely resembles primary sclerosing cholangitis but usually can be managed by simple discontinuation of infusion and, in some cases, percutaneous transhepatic drainage. Surgery should be reserved for patients with persistent evidence of biliary obstruction. A similar cholangiographic appearance has been reported in patients with acquired immunodeficiency syndrome. The pathogenesis of this injury is believed to be viral and related to cytomegalovirus infection. No experience in the surgical management of this condition has been reported.

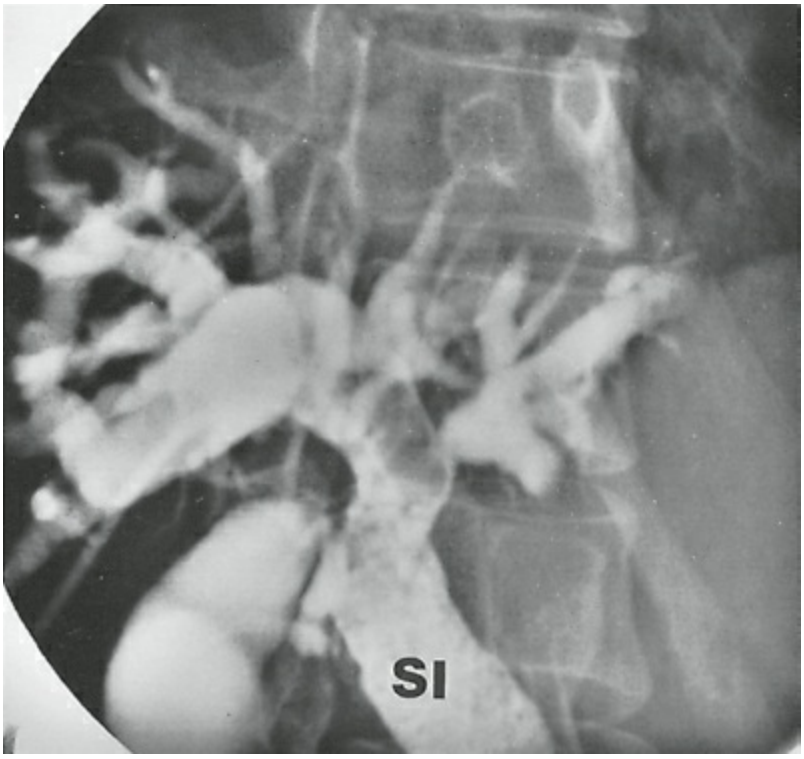

Figure 62-16. Cholangiogram of a patient with cholangiohepatitis with diffuse bile duct dilatation. The biliary tree is filled with sludge (Sl) and stones.

References

1. Hall JG, Pappas TN. Current management of biliary strictures. *J Gastrointest Surg* 2004;8:1098–1110.
2. Brooks KR, Scarborough JE, Vaslef SN, et al. No need to wait: an analysis of the timing of cholecystectomy during admission for acute cholecystitis using the American College of Surgeons National Surgical Quality Improvement Program database. *J Trauma Acute Care Surg* 2012;74:167–173; 173–174.
3. Joseph M, Phillips MR, Farrell TM, et al. Single incision laparoscopic cholecystectomy is asscoaited with a higher bile duct injury rate: a review and word of caution. *Ann Surg* 2012;256:1–6.
4. Branum G, Schmitt C, Baillie J, et al. Management of major biliary complications after laparoscopic cholecystectomy. *Ann Surg* 1993;217:532–540; discussion 540–541.
5. Flum DR, Dellinger EP, Cheadle A, et al. Intraoperative cholangiography and risk of common bile duct injury during laparoscopic cholecystectomy. *JAMA* 2003;289:1639–1644.
6. Sheffield KM, Riall TS, Kuo YF, et al. Association between cholecystectomy with vs without intraoperative cholangiography and risk of common duct injury. *JAMA* 2013;310:812.
7. Massaruch NN, Devlin A, Elrod JA, et al. Surgeon knowledge, behavior and opinions regarding intraoperative cholangiography. *J Am Coll Surg* 2008; 207:821–820.
8. Way LW, Stewart L, Gantert W, et al. Causes and prevention of laparoscopic bile duct injuries: analysis of 252 cases from a human factors and cognitive psychology perspective. *Ann Surg* 2003;273:460–469.
9. Strasberg SM, Hertl M, Soper NJ. An analysis of the problem of biliary injury during laparoscopic cholecystectomy. *J Am Coll Surg* 1995;180:101–125.
10. Alves A, Farges O, Nicolet J, et al. Incidence and consequence of an hepatic artery injury in patients with postcholecystectomy bile duct strictures. *Ann Surg* 2003;230:93–96.
11. Strasberg SM, Helton WS. An analytical review of vasculobiliary injury in laparoscopic and open cholecystectomy. *HPB(Oxford)* 2011;13:1–14.
12. Pitt HA, Miyamoto T, Parapatis SK, et al. Factors influencing outcome in patients with postoperative biliary strictures. *Am J Surg* 1982;144:14–21.
13. Pellegrini CA, Thomas MJ, Way LW. Recurrent biliary stricture: patterns of recurrent and outcome of surgical therapy. *Am J Surg* 1984;147:175–180.
14. Lillemoe KD, Martin SA, Cameron JL, et al. Major bile duct injuries during laparoscopic cholecystectomy: follow-up after combined surgical and radiologic management. *Ann Surg* 1977;225:459–471.
15. Mercado MA, Chan C, Jacinto JC, et al. Voluntary and involuntary ligature of the bile duct in iatrogenic injuries: a nonadvisable approach. *J Gastrointest Surg* 2008;12:1029–1032.

16. Lillemoe KD. Treatment of laparoscopic bile duct injuries. *Curr Tech Gen Surg* 1997;6:1.
17. Warren KW, Christophi C, Armendari ZR. The evolution and current perspectives of the treatment of benign bile duct strictures: a review. *Surg Gastroenterol* 1982;1:141.
18. Sicklick JK, Camp MS, Lillemoe KD, et al. Surgical management of bile duct injuries sustained during laparoscopic cholecystectomy: perioperative results in 200 patients. *Ann Surg* 2005;241:786–792; discussion 793–795.
19. Pitt HA, Kaufman SL, Coleman J, et al. Benign postoperative biliary strictures: operate or dilate? *Ann Surg* 1989;210:417–425; discussion 426–427.
20. David PHP, Tanka AKF, Rauws EAJ, et al. Benign biliary strictures: surgery or endoscopy? *Ann Surg* 1993;217:237.
21. Lillemoe KD, Melton GB, Cameron JL, et al. Postoperative bile duct strictures: management and outcome in the 1990s. *Ann Surg* 2000;232:430–441.
22. Walsh RM, Henderson JM, Voglt DP, et al. Long-term outcome of biliary reconstruction for bile duct injuries from laparoscopic cholecystectomies. *Surgery* 2007;142:450–456; discussion 456–457.
23. Pitt HA, Sherman S, Johnson MS, et al. Improved outcomes of bile duct injuries in the 21st century. *Ann surg*2013;258:490–499.
24. Stewart L, Way LW. Bile duct injuries during laparoscopic cholecystectomy. *Arch Surg* 1995;130:1123–1128; discussion 1129.
25. Murr MM, Gigot JI, Nagorney DM, et al. Long-term results of biliary reconstruction after laparoscopic bile duct injuries. *Arch Surg* 1999;134:604–609; discussion 609–610.
26. Laurent A, Sanvanet A, Farges O, et al. Major hepatectomy for the treatment of complex bile duct injury. *Ann Surg* 2008;248:77–83.
27. de Santibanes E, Ardilles V, Gadano A, et al. Liver transplantation: the last measure in the treatment of bile duct injuries. *World J Surg* 2008;32:1714–1721.
28. Flum DR, Cheadle A, Prela C, et al. Bild duct injury during cholecystectomy and survival in Medicare beneficiaries. *JAMA* 2003;290:2168–2173.
29. Melton GB, Lillemoe KD, Cameron JL, et al. Major bile duct injuries associated with laparoscopic cholecystectomy: effect on quality of life. *Ann Surg* 2002;235:888–895.
30. Horgan AM, Hoti E, Winter DC, et al. Quality of life after iatrogenic bile duct injury: a case control study. *Ann Surg* 2009;249:292–295.
31. Ejaz A, Spolverato G, Kim Y, et al. Long-term health-related quality of life after iatrogenic bile duct injury repair. *J Am Coll Surg* 2014;219:923–932 e10.
32. Mueller PR, van Sonnenberg E, Ferrucci JT Jr, et al. Biliary stricture dilatation: multicenter review of clinical management in 73 patients. *Radiology* 1986;160:17–22.
33. Misra S, Melton GB, Geschwind JF, et al. Percutaneous management of bile duct strictures and injuries associated with laparoscopic cholecystectomy: a decade of experience. *J Am Coll Surg* 2004;198:218–226.

34. de Reuver P, Rauws EA, Vermenlen M, et al. Endoscopic treatment of post-surgical bile duct injuries: long term outcomes and predictors of success. *Gut* 2007;56:1599–1605.
35. Geenen DJ, Geenen JE, Hogan WJ, et al. Endoscopic therapy for benign bile duct strictures. *Gastrointest Endosc* 1989;35:367–371.
36. Lindor KD. Ursodiol for primary sclerosing cholangitis. Mayo Primary Sclerosing Cholangitis-Ursodeoxycholic Acid Study Group. *N Engl J Med* 1997;336:691–695.
37. Gluck M, Cantone NR, Brandabur JJ, et al. A 20-year experience with endoscopic therapy for primary sclerosing cholangitis. *J Clin Gastroenterol* 2008;42:1032–1039.
38. Pawlik TM, Olbrecht VA, Pitt HA, et al. Primary sclerosing cholangitis: role of extrahepatic biliary resection. *J Am Coll Surg* 2008;206:822–830; discussion 830–832.
39. Gross JA, Shackelton CR, Farmer DG, et al. Orthotopic liver transplantation for primary sclerosing cholangitis: a 12-year single center experience. *Ann Surg* 1997;225:472–481; discussion 481–483.
40. Stahl TJ, Allen MO, Ansel M, et al. Partial biliary obstruction caused by chronic pancreatitis: an appraisal of indications for surgical biliary drainage. *Ann Surg* 1988;207:26–32.
41. Warshaw AL, Schapiro RH, Ferrucci JT Jr, et al. Persistent obstructive jaundice, cholangitis, and biliary cirrhosis due to common bile duct stenosis in chronic pancreatitis. *Gastroenterology* 1976;70:562–567.
42. Afroudakis A, Kaplowitz N. Liver histopathology in chronic bile duct stenosis due to chronic alcoholic pancreatitis. *Hepatology* 1981;1:65–72.
43. Chari ST, Smyrk TC, Levy MJ, et al. Diagnosis of autoimmune pancreatitis: the Mayo Clinic experience. *Clin Gastro Hepta* 2006;4:1010–1016; quiz 934.
44. Beltran MA. Mirizzi syndrome: history, current knowledge and proposal of a simplified classification. *World J Gastroenterol* 2012;18:4639–4650.

Chapter 63

Biliary Neoplasms

Kaitlyn J. Kelly, Yuman Fong, and Sharon Weber

Key Points

1 Surgery remains the only curative option for biliary malignancies.

2 Gallbladder cancer is a rare malignancy with a dismal prognosis because of its insidious onset, propensity for local invasion, and rapid disease progression.

3 The association of gallstones with carcinoma is probably related to chronic inflammation.

4 Patients with choledochal cysts have an increased risk of carcinoma developing anywhere in the biliary tree, but the incidence is highest in the gallbladder.

5 The only curative option in patients with gallbladder cancer is complete surgical resection.

6 Nonoperative palliative biliary decompression can be accomplished with percutaneous or endoscopic stenting, depending on the level of obstruction.

INTRODUCTION

1 Tumors arising in the gallbladder and biliary tree are rare, with approximately 10,650 cases per year in the United States and 140,000 per year worldwide.[1,2] These tumors are often asymptomatic until late in the course of the disease. Consequently, these tumors commonly present in an advanced, often unresectable stage. Surgery remains the only curative option for biliary malignancies. Complete resection of biliary neoplasms, however, often requires radical resections and complex biliary reconstructions that are only routinely safe at specialized, high-volume centers. Surgery also offers potential for effective palliation of these cancers, including biliary bypasses for jaundiced patients with unresectable tumors. Both the late diagnosis and the complex operative techniques required for potentially curative resection contribute to the challenge of these cases. In addition, there are no proven effective options for adjuvant treatment. This chapter reviews the incidence, diagnosis, and therapy of these malignancies as well as the outcomes of treatment.

GALLBLADDER CARCINOMA

2 Gallbladder cancer is a rare malignancy with a dismal prognosis because of its insidious onset, propensity for local invasion, and rapid disease progression. Overall, most series report a 5-year survival of less than 5%.

Incidence

Gallbladder cancer is the most common biliary tract malignancy, but there are only 6,000 to 7,000 new cases diagnosed nationally each year. Attesting to the rarity of this lesion, after routine screening of abdominal ultrasounds in asymptomatic patients in Japan, only 19 out of 194,767 patients (0.01%) were found to have gallbladder cancer.[3] This tumor occurs more frequently in women (female:male ratio = 3:1), and peak incidence is in the seventh decade.[4] There is a tremendously increased risk of gallbladder cancer, in particular indigenous populations, including Mapuche Indians in South America (12.3 cases/100,000 males and 27.3/100,000 females, and Native Americans in New Mexico (8.9 cases/100,000 people).[5,6]

The increased risk of gallbladder cancer with cholelithiasis is well established; 70% to 90% of all patients with carcinoma also have gallstones. However, less than 0.5% of patients with gallstones are found to have gallbladder cancer.[5] In recent series of patients undergoing elective cholecystectomy for gallstones, gallbladder cancer is found incidentally in $<0.5\%$ of patients.[7] The association of gallstones with carcinoma is probably related to chronic inflammation. Larger stones (>3 cm) are associated with a 10-fold increased risk of cancer.[6,8]

3 The association of gallbladder cancer with gallstone disease has led some investigators to question whether all patients with gallstones should undergo cholecystectomy. The argument against this approach is that the use of cholecystectomy only for symptomatic patients, thus leaving the gallbladder in place in patients with asymptomatic gallstones, has not led to an increase in the prevalence of gallbladder cancer over time. Also, epidemiologic studies have found that the 20-year risk of developing cancer in patients with gallstones is less than 0.5% for the overall population and 1.5% for high-risk groups.[5] Thus, routine cholecystectomy for asymptomatic gallstones because of concern for gallbladder cancer does not appear to be warranted.

In the past, the finding of a calcified gallbladder wall, called “porcelain gallbladder” (Fig. 63-1), was associated with a high risk of cancer, in some series ranging from 25% to 60%.[9] Thus, the recommendation was for all patients with porcelain gallbladder to undergo open cholecystectomy, even if asymptomatic. Recent series evaluating this issue, however, suggest that the risk of gallbladder cancer in patients with porcelain gallbladder has likely been greatly overestimated. In fact, although patients with limited areas of calcification of the wall may have a higher incidence of gallbladder cancer (7%), patients with diffuse calcification of the gallbladder wall, the classic presentation for porcelain gallbladder, do not appear to have an increased risk of gallbladder cancer.[10,11]

4 Patients with choledochal cysts have an increased risk of carcinoma developing anywhere in the biliary tree, but the incidence is highest in the gallbladder. This risk increases with age. Therefore, cholecystectomy is recommended for all patients with choledochal cysts at the time of diagnosis.

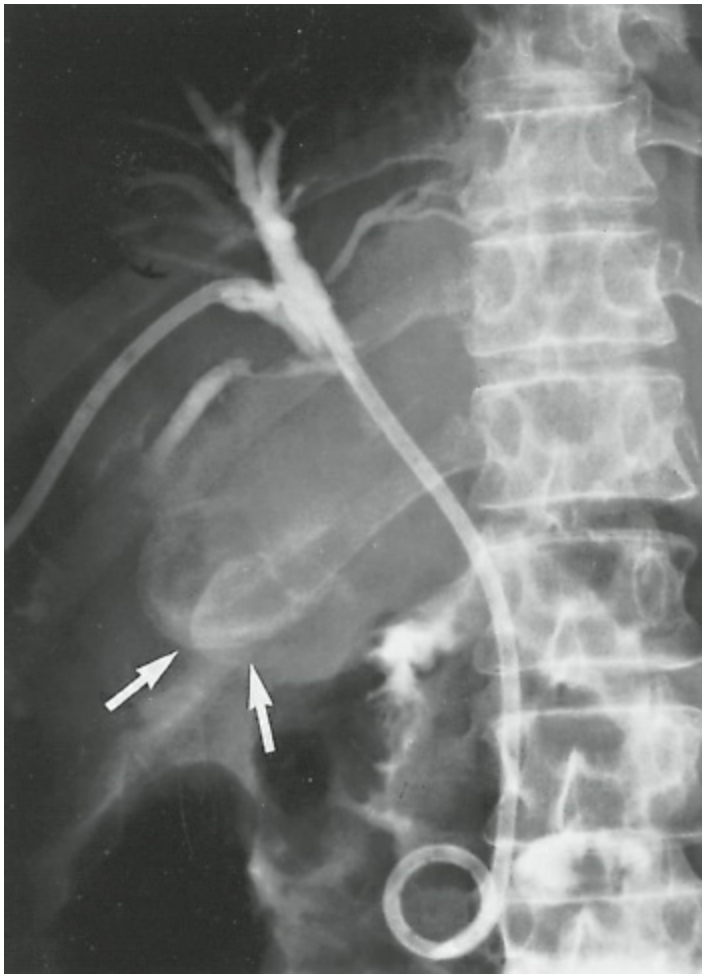

Figure 63-1. Unresectable gallbladder cancer demonstrating palliative transhepatic percutaneous stent placed to relieve jaundice. Porcelain gallbladder is present (*arrows*).

Pathology and Staging

More than 80% of gallbladder cancers are adenocarcinomas; there are several histologic subtypes, including papillary, nodular, and tubular. Papillary tumors, which grow predominantly into the gallbladder lumen, have an improved prognosis compared with the other subtypes.[12] Poor prognostic signs in gallbladder cancer include grade, and vascular invasion.[12,13] The most important prognostic factor may be lymph node status, although 5-year survivors with nodal involvement have been documented.[14,15] Less than 5% of cases are squamous cell carcinomas, with the remaining 10% being anaplastic lesions.

Gallbladder cancer spreads via the lymphatic and venous drainage. Because of drainage of the cholecystic veins directly into the adjacent liver, these tumors often involve hepatic parenchyma, most often portions of segments IV and V. Lymphatic spread is first to the cystic duct (Calot) node, then to pericholedochal and hilar nodes, and finally to peripancreatic, duodenal, periportal, celiac, and superior mesenteric artery nodes. Nodal disease in the porta hepatis often causes common bile duct (CBD) obstruction and resultant jaundice, which is the first clinical symptom in 30% of patients. Jaundice may also be caused by tumors arising in the infundibulum, which may spread directly to the cystic duct and common hepatic duct. Although peritoneal metastases are frequent, distant extraperitoneal metastases are not.

Limited information exists regarding the genetic changes in gallbladder cancer. Recently reported gene abnormalities associated with gallbladder cancer include p53, K-ras, CDKN2 (9p21), FGFR, and PI3 kinase pathway aberrations.[16–20] The finding that patients with an anomalous pancreaticobiliary junction have a greater frequency of K-ras mutations has led investigators to believe that reflux of pancreatic enzymes into the biliary tree may contribute to the development of cancer.[16] Because of our limited knowledge of the sequence of molecular changes, there are no known detectors of early disease or of risk assessment. Clearly, this is an area that needs improvement, particularly in endemic areas.

The American Joint Committee on Cancer's (AJCC) seventh edition of its tumor, node, metastasis (TNM) staging system (Table 63-1) reflects prognostic characteristics of tumor depth, regional nodal disease, and distant spread. The gallbladder differs histologically from the rest of the gastrointestinal tract in that it lacks a muscularis mucosa and submucosa. The gallbladder wall is composed of (a) a single layer of columnar cells, the mucosa, and lamina propria; (b) a fibromuscular layer; (c) a perimuscular, subserosal layer containing lymphatics and neurovascular structures; and (d) a serosal surface, except where the gallbladder is embedded in the liver. Because lymphatics are present in the subserosal layer only, tumors invading less than the full thickness of the muscular layer have minimal risk of nodal spread. Thus, disease invading into, but not through, the muscular layer of the gallbladder is T1b disease (stage I), whereas invasion into the perimuscular connective tissue is T2 (stage II). Stage III disease includes tumors that have perforated the serosa or have directly invaded the liver or other surrounding structures (T3), which are clearly more advanced but still potentially resectable. Tumors that invade

the main portal vein, hepatic artery, or two or more extrahepatic organs/structures are classified as T4 (stage IVA) and are typically unresectable. Lymph node metastasis to regional, periportal nodes are N1 whereas those to more distant nodes outside of what would be included in a standard resection (celiac, periaortic, and superior mesenteric nodes) are N2. N1 nodal metastasis is classified as stage IIIB and N2 as stage IVB. In line with other pancreaticobiliary malignancies, the stage III grouping refers to locally advanced disease and stage IV indicates metastatic disease.

Clinical Findings and Diagnosis

Most patients are found to have gallbladder cancer during workup or treatment of cholelithiasis or choledocholithiasis. In patients with symptoms, abdominal pain consistent with biliary colic or acute cholecystitis is most common. Patients also present with jaundice, weight loss, anorexia, or an increase in abdominal girth secondary to ascites. Physical findings may include right upper quadrant tenderness or a palpable mass, hepatomegaly, and ascites. Laboratory investigation, if abnormal, is most often consistent with biliary obstruction. Because of its nonspecific presentation and the lack of reliable screening tests, gallbladder cancer is not diagnosed preoperatively in more than half the cases.

Imaging evaluation often reveals a thickened gallbladder wall or a mass within or replacing the gallbladder on ultrasound examination. Because polyps, asymmetric wall thickening from cholecystitis (especially xanthogranulomatous type), and carcinoma can have an echogenicity similar to the gallbladder wall, these lesions are often difficult to distinguish. This is even more difficult when inflammation is present from gallstones. At times, ultrasound can visualize invasion of the liver, adjacent adenopathy, and a dilated biliary tree. The ability of ultrasound to differentiate benign from neoplastic disease is enhanced using endoscopic ultrasound, and may be more specific than computed tomography (CT) or magnetic resonance imaging (MRI).[21–23]

A dynamic contrast-enhanced CT scan may identify a gallbladder mass or invasion into the liver parenchyma or adjacent organs. The classic finding in a patient with gallbladder cancer is asymmetric thickening of the gallbladder wall. Staging of gallbladder carcinoma using CT, however, is limited by poor sensitivity in identifying nodal spread.[24]

In patients who are jaundiced, direct cholangiography may be useful to delineate the extent of biliary involvement as well as to palliate symptoms of biliary obstruction. A mid–bile duct obstruction not caused by gallstones is gallbladder cancer until proved otherwise (Fig. 63-2). More recently, with improvements in MRI technology, diffusion-weighted imaging and magnetic resonance cholangiopancreatography (MRCP) have evolved into a single, noninvasive imaging modality that allows complete assessment of biliary, vascular, hepatic parenchymal, and nodal involvement, as well as involvement of adjacent organs (Fig. 63-3).[25–27]

STAGING

Table 63-1 American Joint Committee on Cancer, 7th Edition, Staging System for Gallbladder Carcinoma

Stage	Tumor	Nodes	Metastasis
0	Tis	N0	M0
I	T1	N0	M0
II	T2	N0	M0
IIIA	T3	N0	M0
IIIB	T1–3	N1	M0
IVA	T4	N0–1	M0
IVB	Any T	N2	M0
	Any T	Any N	M1

Definition of TNM	
Primary Tumor (T)	
TX	Primary tumor cannot be assessed
T0	No evidence of primary tumor
Tis	Carcinoma in situ
T1	Tumor invades lamina propria or muscular layer
T1a	Tumor invades lamina propria
T1b	Tumor invades muscular layer
T2	Tumor invades perimuscular connective tissue; no extension beyond serosa or into liver
T3	Tumor perforates the serosa (visceral peritoneum) and/or directly invades the liver and/or one other adjacent organ or structure, such as the stomach, duodenum, colon, pancreas, omentum, or extrahepatic bile ducts
T4	Tumor invades main portal vein or hepatic artery or invades two or more extrahepatic organs or structures
Regional Lymph Nodes (N)	
NX	Regional lymph nodes cannot be assessed
N0	No regional lymph node metastases
N1	Nodes confined to the hepatic hilus (including nodes along the common bile duct, hepatic artery, portal vein, and cystic duct
N2	Metastases to celiac, periduodenal, peripancreatic, and/or superior mesenteric artery lymph nodes
Distant Metastasis (M)	
M0	No distant metastasis
M1	Distant metastasis

Used with the permission of the American Joint Committee on Cancer (AJCC), Chicago, Illinois. The original source for this material is the AJCC Cancer Staging Manual, Seventh Edition (2010) published by Springer Science and Business Media LLC, www.springer.com

In patients who present with incidentally discovered gallbladder cancer following cholecystectomy, staging should be performed with high-quality CT or MRI of the chest, abdomen, and pelvis. There is no clear role for PET/CT in this setting.[28]

Surgery

5 It is clear that the only curative option in patients with gallbladder cancer is complete surgical resection. It is essential for optimal patient care that patients with gallbladder cancer be recognized before laparoscopic cholecystectomy is performed, because of the risk of bile spillage, with its potential for subsequent carcinomatosis.[29]

Role of Staging Laparoscopy

Because a large percentage of patients with gallbladder cancer are found to have occult, unresectable disease at the time of surgical exploration, several authors have investigated the use of initial staging laparoscopy for this disease.[30–33] Because gallbladder cancer has such a propensity to spread intra-abdominally, this tumor is ideal for detection of intra-abdominal metastases with laparoscopy. This is demonstrated by the fact that up to 50% of patients are found to have unresectable disease at the time of laparoscopy.[34,35] Patients who are found to have unresectable disease at laparoscopy can begin other forms of systemic therapy earlier and may undergo the procedure as an outpatient. Particularly because patients with unresectable disease have a median survival of only 6 months, the impact on quality of life, including decreased length of stay in the hospital, cannot be overemphasized.



Figure 63-2. Endoscopic retrograde cholangiopancreatogram obtained from a patient with gallbladder cancer. Mid–bile duct obstruction (*arrow*) is caused by direct extension of tumor to the cystic and common hepatic duct.

Cholecystectomy With or Without Partial Hepatectomy

Gallbladder cancer, if not completely surgically removed, results in rapid local progression and death. In a collected review of 5,836 patients with gallbladder cancer, the overall mean survival was between 2 and 5 months, whereas the 5-year survival was 4%.[5] The 5-year survival of patients undergoing resection with curative intent was 17%. Of the 2,115 patients with unresectable disease, only a single survivor was found at 5 years. Although surgical resection represents the treatment of choice and the only potentially curative therapy available, resection is possible in only 25% of patients at presentation because of the advanced nature of the disease.[5]

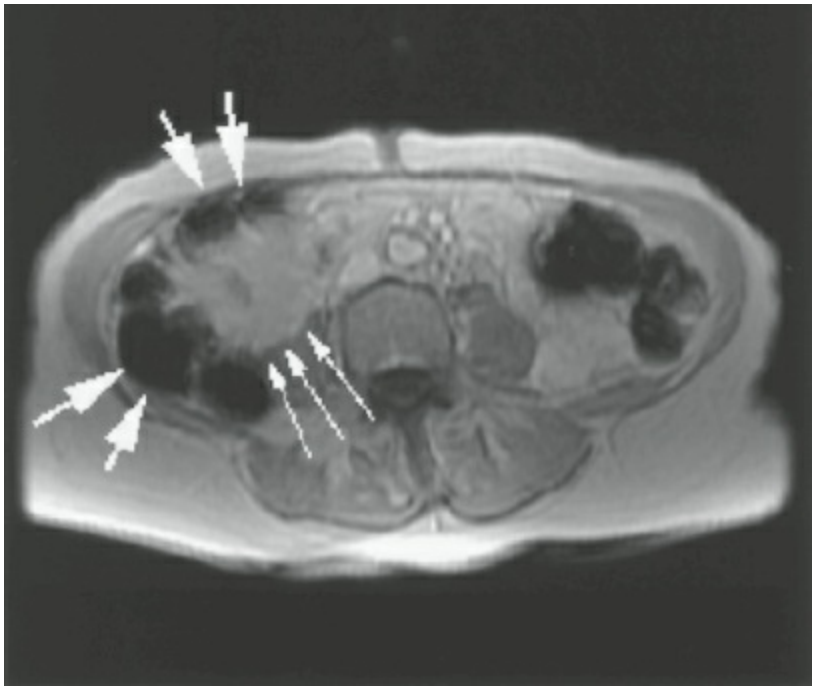

Figure 63-3. T1-weighted magnetic resonance imaging scan of a patient with gallbladder cancer (*small arrows*) with extension into the duodenum and the hepatic flexure of colon (*large arrows*).

There is little doubt that the results of treatment, as well as the scope of operation, are related to depth of tumor penetration (Table 63-2). For tumors limited to the muscular layer of the gallbladder (T1), there is near-universal agreement that simple cholecystectomy is adequate.[15,36–38] T1 tumors have not yet invaded the subserosal layer, which contains lymphatics, and therefore lymphadenectomy is not required. Attesting to the fact that early gallbladder carcinoma is completely curable, simple cholecystectomy has resulted in 90% to 100% survival when early cancer is an incidental finding after elective cholecystectomy.[15,47]

RESULTS

Table 63-2 Five-Year Survival After Resection for Gallbladder Cancer

Author	T1 or T2 Tumors		T3 or T4 Tumors	
	Simple Cholecystectomy (%)	Radical Cholecystectomy or Segmental Resection (%)	Simple Cholecystectomy (%)	Radical Cholecystectomy or Segmental Resection (%)
Wanebo et al.[39]	33	—	3	13
Ouchi et al.[38]	57	100	0	23
Nakamura et al.[40]	—	100	—	15
Donohue et al.[36]	—	—	0	29
Shirai et al.[15]	—	72	—	37
Fong et al.[41]	—	58 (T2)	—	25
Wakai et al.[42]	100[a] (10-year survival, T1b only)	75[a] (10-year survival, T1b only)	—	—
Kai et al.[43]	25	60 (T2)	—	—
Jensen et al.[44]	29	42	—	—
Mayo et al.[45]	16	53	8	11

[a]No significant difference.

Table 63-3 Results After Radical Resection for Gallbladder Cancer

Author	Number Resected	Mortality (%)	5-year Survival (%)
Nakamura et al.[40]	15	0	25
Donohue et al.[36]	42	2	33
Ogura et al.[37]	1,686	5	51
Shirai et al.[15]	40	0	65
Bartlett et al.[14] Fong et al.[41]	102	4	58
Taner et al.[46]	131	2	13
Kai et al.[43]	90	2	40
Jensen et al.[44]	443	—	42
Mayo et al.[45]	202	2	—

Difficulty can arise at the time of surgery in evaluating polypoid lesions of the gallbladder as either benign or early gallbladder cancer. Although it appears that frozen section diagnosis is fairly reliable in distinguishing whether lesions are malignant or benign (95% accurate), the accuracy in correctly assessing depth of invasion is only 70%.[47] Thus, it may be difficult at the time of surgery to determine the extent of resection. Because of this, pursuing a more aggressive resection if the depth of invasion is in doubt is important for adequate tumor clearance.

The extent of surgical resection for T2 or greater tumors is controversial, with recommendations ranging from simple cholecystectomy to radical excision, including hepatectomy. For advanced local disease, some groups have advocated radical resections, including hepatectomy and pancreatectomy. Whereas it is clear that major hepatic resection can be performed safely with a mortality less than 5% (Table 63-3) it has not been universally accepted that more aggressive resections, such as combined hepatectomy

and pancreaticoduodenectomy, improve survival.[14,15,36,37,40,48]

To understand the rationale for extensive resections, it is also important to understand the pattern of spread of gallbladder cancer. Direct extension to the adjacent liver parenchyma often occurs first, followed by adjacent organ involvement, including duodenum, colon, and stomach (Fig. 63-2). Lymphatic spread of gallbladder cancer is routine, often involving nodes in the porta hepatis, peripancreatic region, celiac axis, and the aortocaval nodal basins. There is currently no consensus on the extent of lymphadenectomy that is appropriate for gallbladder cancer. Extensive lymphadenectomy including para-aortic nodes is advocated in the East, but is not universally accepted. Recently, a technique of intraoperative nodal staging was proposed that entails sampling the highest peripancreatic lymph node for frozen section. This is the lymph node situated between the N1 and N2 nodal stations at the junction of the bile duct and the superior border of the head of the pancreas (Fig. 63-4). Metastatic disease to this node has been shown to be a poor prognostic factor.[49]

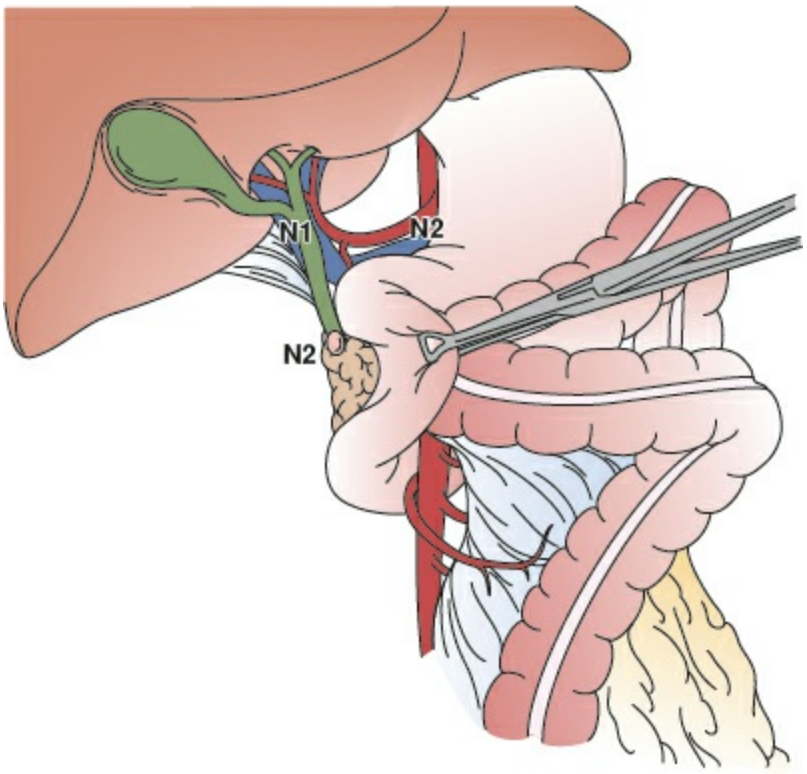

Figure 63-4. Illustration of the highest peripancreatic lymph node.

Because the gallbladder is not surrounded by serosa where it is attached to the liver in the gallbladder fossa, even T2 tumors (full-thickness invasion of the muscular layer into the perimuscular connective tissue, no extension beyond serosa or into liver) can invade the normal plane of dissection in the gallbladder fossa during simple cholecystectomy. Therefore, T2 tumors cannot be completely removed with cholecystectomy alone, and a radical cholecystectomy, with resection of a 1- to 2-cm rim of normal liver around the gallbladder fossa, is the minimal resection that is required. Many authors, however, have found that segmental resection of segments IVb and V of the liver, which abut the gallbladder fossa, results in a more anatomically controlled dissection with less blood

loss.[50] An additional part of the definitive surgical treatment is regional lymphadenectomy, because about half the patients with T2 tumors are found to have nodal spread after resection.[14] Dissection of lymph nodes should include all tissues from the bifurcation of the hepatic ducts to the distal CBD. Proponents of this approach advocate liver resection on the basis that it is the only way to obtain an adequate margin on the hepatic side of the gallbladder and resection of the regional nodes allows the best chance for complete tumor clearance. For all of these reasons, simple cholecystectomy is inadequate for T2 or greater tumors. When larger anatomic hepatic resections have been performed in patients with T2 tumors, it has increased the 5-year survival from 25% to 40% after simple cholecystectomy to 70% to 100% after radical resection.[14,36–38,39,43,44,51,52]

For T3 and T4 lesions, there is a high likelihood of intraperitoneal and hematogenous spread and significant morbidity from the radical procedures that are often necessary for excision of local disease. Recent series, however, support an aggressive approach to resection of these large tumors, particularly if no indication of nodal involvement is found (Table 63-3). For T3 and resectable T4 tumors, a minimal resection includes segments IVb and V, and in many cases an extended right hepatectomy (segments IV, V, VI, VII, and VIII) may be necessary to obtain complete resection. With aggressive resection, long-term survival can be achieved even for patients with these more advanced tumors.[14,15,36,37,40,53]

Surgical exploration should be performed for all patients without medical contraindications. If a T1 tumor is suspected, a cholecystectomy and biopsy of regional nodes should be performed after thorough examination of the abdominal cavity for any signs of tumor dissemination. The pathology and depth of penetration should be confirmed by frozen section, and the procedure terminated if a T1 tumor with negative margins is confirmed. For T2 lesions, either a radical cholecystectomy (wedge resection of the hepatic bed) or a segment IVb and V resection with lymphadenectomy should be performed.[14] For T3 lesions, a segment IVb and V resection or extended right hepatectomy is performed. Finally, for T4 lesions, a more radical excision of the liver, such as extended right hepatectomy, usually must be performed for adequate tumor clearance.

Tumor location may be important in determining the extent of resection. If the tumor arises in the gallbladder infundibulum, the CBD is often involved with tumor, either by direct extension or external invasion of the hepatoduodenal ligament. In this case, an extended liver resection and removal of a portion of the CBD should be performed. Reconstruction is then performed by Roux-en-Y hepaticojejunostomy. Tumor arising in the fundus of the gallbladder, however, can be treated with limited hepatic resection without excision of the CBD. Complete regional lymphadenectomy should be performed, skeletonizing the CBD, hepatic artery, and portal vein. Short-term postoperative outcomes following resection of gallbladder cancer have remained relatively stable over time, with postoperative morbidity occurring in 30% to 40% of patients, and mortality occurring in $<5\%$ (Table 63-4).

Incidentally or Laparoscopically Discovered Gallbladder Cancer

Gallbladder cancer is often discovered during pathologic examination after cholecystectomy for presumed benign disease. Because of the popularization of laparoscopic cholecystectomy in the past decade, an increasing number of patients with gallbladder cancer are found incidentally. Patients with T1b or greater tumors and no signs of distant disease should be offered exploration and further resection to eradicate all diseases. In a series of 135 patients who underwent reexploration following laparoscopic cholecystectomy, 61% of all and 36% of those with T1b primary tumors were found to have residual disease.[54] In this study, survival following reresection of residual locoregional disease was extremely poor and was not different from that of patients with metastatic disease. Improved survival has been demonstrated following reresection to achieve negative margins, however, especially in patients with T2 or T3 disease.[51,55,56] While laparoscopic port-site recurrence has been reported, it is associated with peritoneal-based disease. Port-site excision at the time of reexploration is no longer recommended as recent data have shown that it is not associated with decreased recurrence or improved survival.[57,58]

Reresection after recent cholecystectomy is often technically challenging. Postoperative inflammation in the right upper quadrant often hinders distinction of tumor from normal tissue. Bile spillage at the time of the initial operation may result in carcinomatosis.[59] Determination of ductal or nodal involvement by tumor is always difficult at the time of reoperation. In addition, postoperative fibrosis often encases the right hepatic artery, which crosses behind the bile duct in most patients. Because of this, during a second operation for incidentally discovered gallbladder cancer, an extended right hepatectomy along with excision of the extrahepatic biliary tree and portal lymphadenectomy is often necessary. This resection allows adequate exposure for lymphadenectomy and greater confidence of a negative margin on the bile duct, and also permits biliary reconstruction to only one side of the liver. The disadvantage is that a large portion of normal liver parenchyma is sacrificed, and consequently, transient postoperative liver dysfunction is common. Although it may be more difficult to curatively resect disease in patients with incidentally discovered gallbladder cancer after laparoscopic cholecystectomy, there is no difference in overall survival between patients with incidentally discovered gallbladder cancer who are submitted to curative resection and those patients who undergo initial curative resection.[50]

When a patient presents with T1a gallbladder cancer discovered after simple cholecystectomy, the pathology should be reviewed to determine if the entire gallbladder has been removed and if the cystic duct margin is clear of tumor. If the cystic duct margin is positive, the patient requires bile duct excision. If all margins are negative, no further therapy is warranted. If the tumor is proved to be T1b or greater, complete staging should be performed. In the absence of metastatic disease, patients should be counseled regarding reexcision to attempt complete resection, chemotherapy with or without radiation, or observation. Patients with a known or suspected early gallbladder carcinoma should be referred to an experienced center where curative-intent resection can be performed at the initial operation.

Adjuvant Therapy

Adjuvant therapy for gallbladder cancer remains a controversial and unproved consideration and is rarely utilized.[45] Very few randomized trials have been completed, and the conclusions that can be drawn from them are limited given the small sample sizes. Given the relative rarity of these malignancies in the United States, large-scale, randomized trials are feasible only in the context of a multi-institutional or cooperative group setting.

In 2002, a randomized phase III trial of adjuvant chemotherapy with 5-fluorouracil and mitomycin C versus surgery alone for patients with pancreaticobiliary malignancies having resection found that in the subset of patients with gallbladder cancer ($n = 112$), the 5-year survival rate was significantly better in the adjuvant group (26%) versus the control group (14%).[60] Similarly, the 5-year disease-free survival rate was 20.3% versus 11.6%, clearly favoring the adjuvant therapy group. A recent review of the SEER database also reported an association between adjuvant chemoradiation therapy and improved survival in patients with locoregionally advanced disease.[61] This finding prompted a multi center phase II trial of adjuvant capecitabine and gemcitabine followed by concurrent capecitabine and radiation therapy for patients with resected gallbladder cancer or extra hepatic cholagiocarcinoma. The results of this study were published in 2015 and showed promising findings of 65% two-year survival.[62] These studies suggest that patients with gallbladder cancer with high risk for recurrence (T2 or greater, node-positive, or margin-positive) should be considered for adjuvant treatment with systemic chemotherapy or chemoradiation.

Table 63-4 Complications Postoperative Morbidity Following Resection of Gallbladder Cancer Over Time in the United States[56]

Postoperative Morbidity	1991–1995 ($n = 681$)	1996–1999 ($n = 543$)	2000–2002 ($n = 833$)	2003–2005 ($n = 898$)	Total ($n = 2955$)
Overall	[a]249 (37)	191 (35)	244 (29)	285 (32)	969 (33)
Infection	30 (4)	23 (4)	27 (3)	37 (4)	117 (4)
Percutaenous Drain	33 (5)	25 (5)	45 (5)	56 (6)	159 (5)
Hemorrhage	17 (3)	17 (3)	21 (3)	28 (3)	83 (3)
30 Day Mortality	23 (3)	26 (5)	31 (4)	44 (5)	124 (4)

[a]Results are reported as *n* (%).

Prognosis

The 5-year survival rate for all patients with gallbladder cancer is less than 5% in most series, with a median survival of 6 months. This is primarily because most patients present with unresectable disease. Of those patients undergoing resection, survival is dependent on depth of penetration and nodal status. Nearly 100% survival is reported after simple cholecystectomy for T1a disease, whereas patients with T2 and T3 tumors without nodal disease have a 5-year survival greater than 50%.[14,15,40,52] Node positivity is an ominous finding, with few series reporting 5-year survivors.

Follow-up after Resection for Gallbladder Cancer

The most common sites of recurrence after resection of gallbladder cancer include carcinomatosis, intrahepatic metastases, or nodal recurrence in the retroperitoneum. For most tumors, local recurrence is found synchronously with diffuse intra-abdominal spread. Therefore, surgical treatment of recurrence has little potential for cure. The main goal of surgery after recurrence of resected gallbladder cancer is to provide palliation of symptoms such as pruritus or cholangitis associated with jaundice, or bowel obstruction associated with carcinomatosis. When jaundice or cholangitis is the presenting symptom of possible recurrence, a nonsurgical palliative approach using percutaneous transhepatic cholangiogram (PTC) and stenting is usually favored unless a benign postsurgical stricture is suspected. Because of the rapid growth of tumor in patients with recurrence, the hospitalization and recovery time from a surgical bypass is usually not justified for recurrences resulting in biliary obstruction.

The routine follow-up of a patient after resection of gallbladder cancer includes office visits every 3 months with physical examination and measurement of liver function tests, and cross-sectional imaging every 3 to 6 months for the first 2 years. In patients who remain free of disease at 2 years, follow-up should be continued on an individualized basis. Although CA19-9 may be elevated in patients with gallbladder cancer, the sensitivity and specificity are poor and, thus, should not be used for screening patients for recurrence.[63] If recurrence is identified, systemic therapy with gemcitabine and cisplatin should be considered as it has been shown to prolong survival in the setting of metastatic disease.[64] For patients who cannot tolerate this regimen, alternatives include single-agent gemcitabine or gemcitabine plus capecitabine.[65]

Issues for the Future

Clearly, improving our ability to recognize early gallbladder cancer in high-risk geographic areas would have an important impact on outcome in these patients. This will likely require implementation of screening programs in high-risk areas, which could result in prophylactic cholecystectomy.[66] Additionally, standardization of minimum pathologic assessment of gallbladder specimens in high-risk areas is important to allow for accurate diagnosis, staging, and treatment of patients.

Further studies on characterization of molecular aberrations in gallbladder cancer by next generation sequencing and other technologies may lead to the discovery of targetable mutations and lead to the development of novel therapies. Additionally, there is a theoretical role for neoadjuvant therapy for patients with locoregionally advanced gallbladder cancer given their poor prognosis following surgery. Clinical trials in this area are needed.

BILE DUCT CARCINOMA

Bile duct carcinomas may arise within the liver (intrahepatic cholangiocarcinoma [ICC] or peripheral cholangiocarcinoma), at the liver hilum (hilar cholangiocarcinoma or Klatskin tumor), or in the extrahepatic bile duct (extrahepatic cholangiocarcioma [ECC]). While all arise from the biliary epithelium, the location of these tumors affects prognosis as well as the potential for curative resection.

Resection of biliary neoplasms, particularly hilar cholangiocarcinoma, often requires radical resections and complex biliary reconstructions that should be performed only at high-volume, experienced centers. There is also a role for surgery in palliation for these cancers by providing biliary bypass for jaundiced patients with unresectable tumors. Because disease is often diagnosed late in the course and because complex operative techniques are required for potentially curative resection, these tumors represent one of the greatest challenges for definitive treatment. Adding to this is that there are no proven effective options for adjuvant therapy.

INCIDENCE

The incidence of ICC in the United States is approximately 0.7/100,000 with a similar mortality. During the last 30 years, it appears that both the incidence and mortality in the United States are increasing.[64] The overall incidence of hilar cholangiocarcinoma, the most common type, is 1.0/100,000 per year in the United States, although rates are higher in other geographic regions such as Israel and Japan.[68] Recent population studies have noted a trend toward a relative increased incidence of ICC compared to ECC.[4,69,70] Using the Surveillance, Epidemiology and End Results-Medicare databases, Welzel et al.[70] noted HCV infection, chronic nonalcoholic liver disease and obesity, and smoking being associated only with ICC and not ECC, possibly explaining the divergent trends in incidence. Cholangiocarcinomas arise slightly more often in males, with a male-to-female ratio of 1.3:1 and an average age of 50 to 70 years.

Known risk factors for cholangiocarcinoma include primary sclerosing cholangitis, ulcerative colitis, choledochal cysts, and biliary tract infection, either with *Clonorchis* or in chronic typhoid carriers.[71] Some industrial chemicals (e.g., nitrosamines, dioxin, asbestos, and polychlorinated biphenyls) have also been implicated in the pathogenesis of cholangiocarcinoma. Although there has been some suggestion of an increased risk of cholangiocarcinoma arising after transduodenal sphincteroplasty,[72] it is difficult to determine if this is caused by the surgical intervention or the underlying disease leading to sphincteroplasty.

Pathology and Staging

More than 90% of these bile duct cancers are adenocarcinomas. They are morphologically described as nodular, which is the most common, scirrhous, diffusely infiltrating, or papillary. Histologic subtypes include acinar, ductular, trabecular, alveolar, and papillary. Papillary tumors have an improved outcome. Much less common types of bile duct tumors include cystadenocarcinomas, hemangioendotheliomas, and mucoepidermoid carcinomas.

STAGING

Table 63-5 American Joint Committee on Cancer, 7th Edition, Staging System for Perihilar Bile Duct Carcinoma

Stage	Tumor	Nodes	Metastasis
0	Tis	N0	M0
I	T1	N0	M0
II	T2a–b	N0	M0
IIIA	T3	N0	M0
IIIB	T1–3	N1	M0
IVA	T4	N0–1	M0
IVB	Any T	N1–2	M0
	Any T	Any N	M1

Definition of TNM	
Primary Tumor (T)	
TX	Primary tumor cannot be assessed
T0	No evidence of primary tumor
Tis	Carcinoma in situ
T1	Tumor confined to bile duct, with extension up to the muscle layer or fibrous tissue
T2a	Tumor invades beyond the wall of the bile duct to surrounding adipose tissue
T2b	Tumor invades adjacent hepatic parenchyma
T3	Tumor invades unilateral branches of the portal vein or hepatic artery
T4	Tumor invades main portal vein or its branches bilaterally; or the common hepatic artery; or the second-order biliary radicals bilaterally; or unilateral second-order biliary radicals with contralateral portal vein or hepatic artery involvement.
Regional Lymph Nodes (N)	
NX	Regional lymph nodes cannot be assessed
N0	No regional lymph node metastasis
N1	Regional lymph node metastasis (including nodes along the cystic duct, common bile duct, hepatic artery, and portal vein)
N2	Metastasis to periaortic pericaval, superior mesenteric artery, and/or celiac artery lymph nodes
Distant Metastasis (M)	
M0	No distant metastasis (no pathologic M0; use clinical M to complete stage group)
M1	Distant metastasis

Used with the permission of the American Joint Committee on Cancer (AJCC), Chicago, Illinois. The original source for this material is the AJCC Cancer Staging Manual, Seventh Edition (2010) published by Springer Science and Business Media LLC, www.springer.com

In patients with ICC, negative prognostic signs include vascular invasion, multiple tumors, and lymph node metastases, but not tumor size.[73] These tumors can be sclerotic, masslike, or cystic lesions.

Historically, ECCs have been classified according to their location in the upper (60%), middle (15% to 20%), or lower third (15% to 20%) of the bile duct. Middle-third lesions arise between the cystic duct and the superior border of the duodenum. Lower-third lesions are found below the superior border of the duodenum but above the ampulla. The

problem with this classification is that the anatomic landmarks are somewhat arbitrary and not clinically useful. Most mid–bile duct malignant obstructions are caused by gallbladder cancer. A more useful classification is to divide these lesions into upper-half or lower-half tumors, based on the location of the cystic duct as it enters the common duct (in the case of normal anatomy). The usefulness of this classification scheme is that it allows the surgeon to delineate whether a hepatic or pancreatic resection will be required for clearance of tumor. The AJCC TNM staging system (seventh edition) for bile duct cancers is described in Tables 63-5 and 63-6.

Other staging systems have been created that attempt to incorporate clinically important indicators of resectability for hilar cholangiocarcinoma that are defined preoperatively, including hepatic lobe atrophy or portal vein involvement.[74] With the increasing acceptance of major hepatic resection for these tumors, this preoperative staging system attempts to define whether there is ipsilateral involvement alone, because tumors with bilateral extension past the primary biliary radicles are not resectable.

STAGING

Table 63-6 American Joint Committee on Cancer, 7th Edition, Staging System for Distal Bile Duct Carcinoma

Stage	Tumor	Nodes	Metastasis
0	Tis	N0	M0
IA	T1	N0	M0
IB	T2	N0	M0
IIA	T3	N0	M0
IIB	T1–3	N1	M0
III	T4	Any N	M0
IV	Any T	Any N	M1

Definition of TNM	
Primary Tumor (T)	
TX	Primary tumor cannot be assessed
T0	No evidence of primary tumor
Tis	Carcinoma in situ
T1	Tumor confined to bile duct histologically
T2	Tumor invades beyond the wall of the bile duct
T3	Tumor invades gallbladder, pancreas, duodenum, or other adjacent organs without involvement of the celiac axis or the superior mesenteric artery
T4	Tumor involves the celiac axis or the superior mesenteric artery
Regional Lymph Nodes (N)	
NX	Regional lymph nodes cannot be assessed
N0	No regional lymph node metastasis
N1	Regional lymph node metastasis
Distant Metastasis (M)	
M0	No distant metastasis (no pathologic M0; use clinical M to complete stage group)
M1	Distant metastasis

Used with the permission of the American Joint Committee on Cancer (AJCC), Chicago, Illinois. The original source for this material is the AJCC Cancer Staging Manual, Seventh Edition (2010) published by Springer Science and Business Media LLC, www.springer.com

Clinical Findings and Diagnosis

The presentation of patients with cholangiocarcinoma is variable. Patients with hilar or extrahepatic tumors most commonly present with painless jaundice. Symptoms of mild right upper quadrant pain, pruritus, anorexia, malaise, and weight loss may also be reported. Cholangitis is the presenting symptom in 10% to 30% of patients. Some patients, particularly those with ICC may be asymptomatic and have their tumors discovered incidentally or on evaluation for elevations of alkaline phosphatase and gamma-glutamyl transferase. Many of these patients will present to the surgeon with a biopsy showing adenocarcinoma without a known primary tumor. The standard evaluation in these patients should include tumor markers to rule out an elevated carcinoembryonic antigen (CEA) or α-fetoprotein (AFP); upper and lower endoscopy to evaluate for a gastrointestinal source; CT scan to assess for a primary tumor in the gastrointestinal tract or pancreas; and, in women, a mammogram. If no site of primary disease is found, in most patients, the diagnosis is ICC.

Various imaging tests are available to assess patients with cholangiocarcinoma. Abdominal ultrasound is noninvasive, easily available, and inexpensive, and thus is commonly used as a first imaging modality. It can establish the level of biliary obstruction and rule out other etiologies, such as choledocholithiasis. On CT, cholangiocarcinomas most often appear as hypodense masses with irregular margins on precontrast phase images, with peripheral rim enhancement on arterial phase, followed by progressive hyperattenuation on venous and delayed phases.[75] Intrahepatic lesions often exhibit associated capsular retraction and segmental/lobar atrophy and ductal dilatation. Hilar and proximal extrahepatic lesions demonstrate dilated intrahepatic biliary ducts with a normal, collapsed gallbladder, and, depending on the level of the tumor, a nondilated or partially dilated extrahepatic biliary tree (Fig. 63-5). While conventional CT is useful for assessment for extrahepatic, metastatic disease and perihilar adenopathy, high-resolution CT and/or MRI are required for accurate assessment of the tumor and for determination of respectability (Figs. 63-6 and 63-7).[75] Portal vein patency can be determined with ultrasound, CT, or MRI. Particularly for hilar tumors, signs of hepatic lobar atrophy should be carefully sought, because this indicates ipsilateral portal vein involvement by tumor. MRCP offers the potential of evaluating parenchymal, vascular, biliary, and nodal involvement with a single noninvasive examination.[25,27,76]

In most centers, direct cholangiography is used to evaluate the extent of biliary involvement and provide palliation for jaundice. Endoscopic retrograde cholangiopancreatography (ERCP) has little role to play in high biliary obstruction because opacification of the proximal biliary tree is difficult. ERCP, however, can be effectively used to image more distal lesions. At the time cholangiography is performed, some authors advocate the routine preoperative placement of biliary drainage catheters to aid in intraoperative identification of the bile ducts.[77,78] Others have found a higher incidence of infectious complications and mortality, and a longer hospital stay, after preoperative placement of biliary drainage catheters.[79–81] The difficulty in making the decision regarding preoperative stenting is that many patients are severely symptomatic

because of jaundice and pruritus and require palliation, thus if the operation is delayed, many patients require palliation.

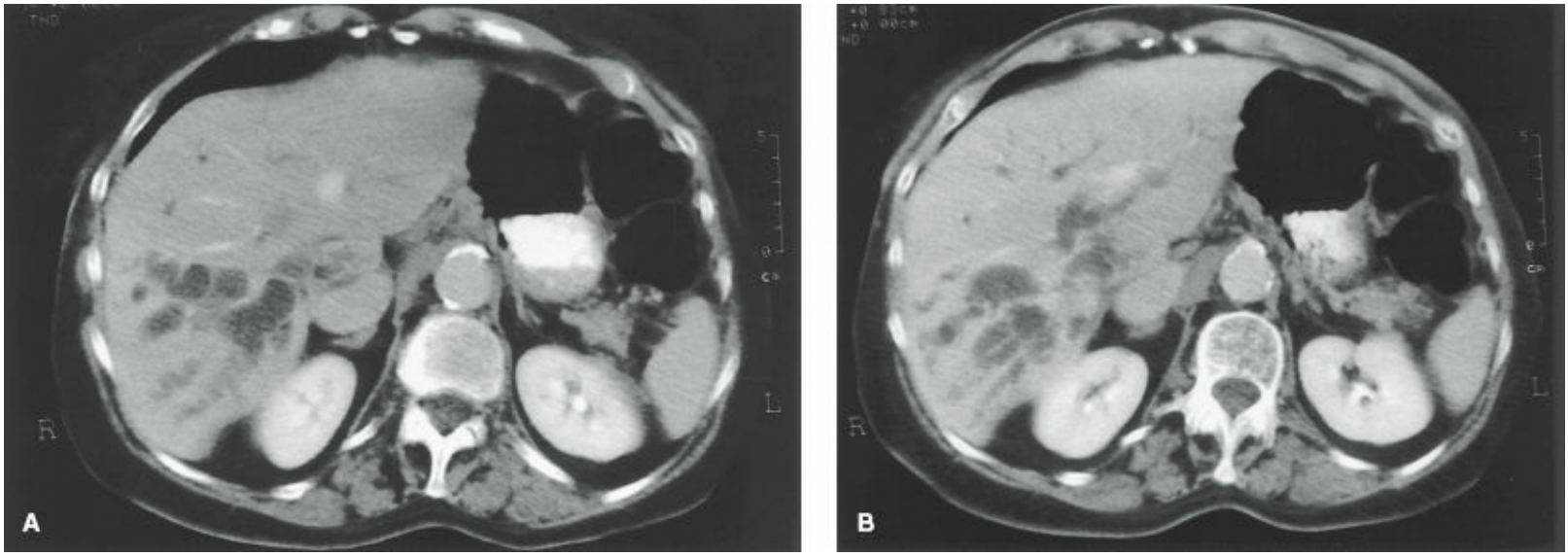

Figure 63-5. Computed tomography scan in a patient with hilar cholangiocarcinoma, demonstrating dilated intrahepatic ducts in the right lobe but inability to directly visualize tumor.

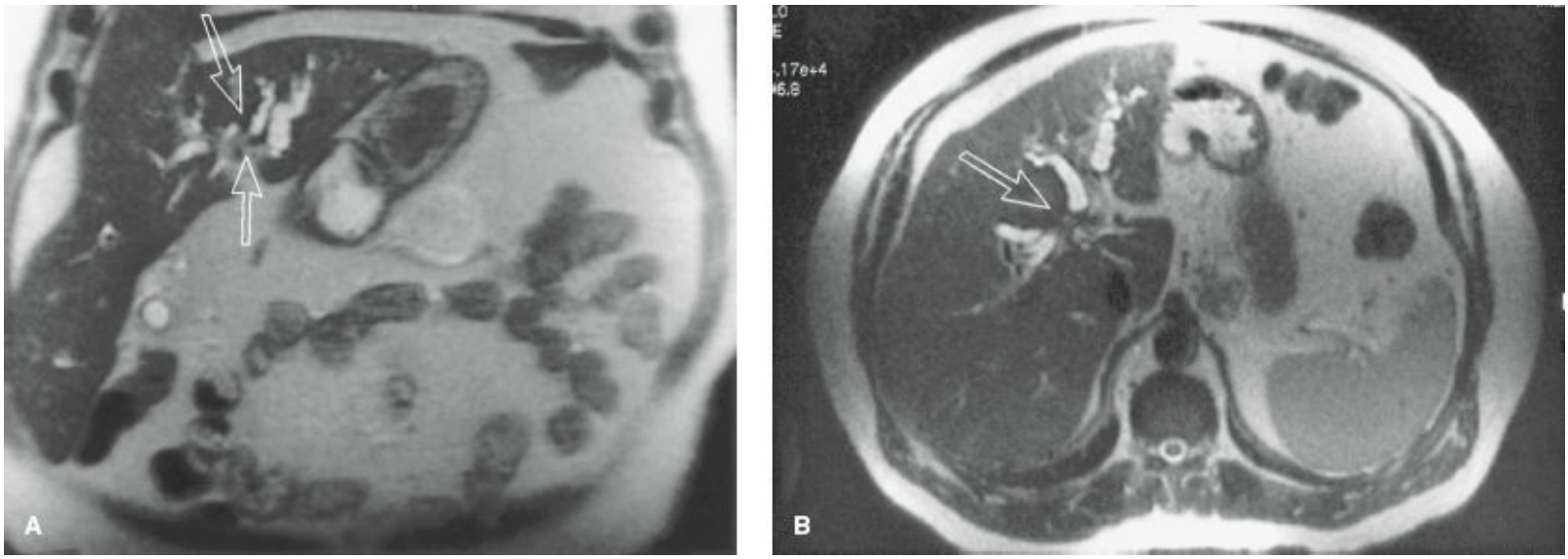

Figure 63-6. Coronal (**A**) and axial (**B**) magnetic resonance imaging in a patient with hilar cholangiocarcinoma. Dilated intrahepatic ducts are present with a soft tissue density consistent with tumor (*arrows*).

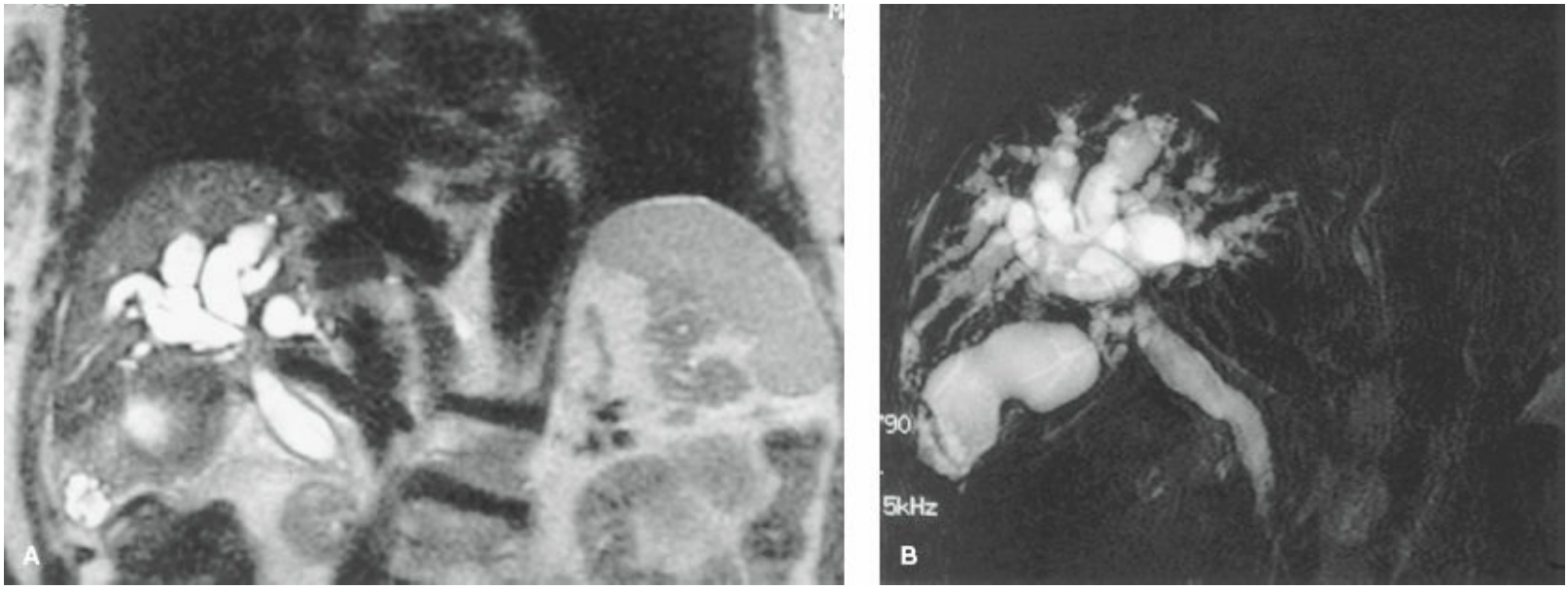

Figure 63-7. Coronal (**A**) magnetic resonance imaging and magnetic resonance cholangiopancreatography (**B**) in a patient with hilar cholangiocarcinoma, demonstrating dilated intrahepatic ducts narrowing at the area of obstruction.

In many cases, it is difficult to obtain pathologic confirmation of cholangiocarcinoma except in very advanced cases, even with the use of biliary brushings and cytology obtained at the time of direct cholangiography. In most cases, patients are offered surgical therapy based on clinical suspicion and radiographic appearance. In patients with ICC, cross-sectional imaging with CT scan is usually sufficient. Tumors may be masslike or may have cystic areas.

Surgery

Untreated, most patients with bile duct cancers die within a year of diagnosis.[81,82] Surgical excision is the treatment of choice, with no other potentially curative therapy available. The immediate causes of death are most commonly hepatic failure or cholangitis related to tumor growth and inadequate drainage of the biliary tree.[83] Therefore, the goals of surgery are complete removal of tumor with R0 margins while leaving a sufficient liver remnant, and establishing adequate biliary drainage. Patients with ICC require additional consideration. Those patients with multifocal and especially bilobar intrahepatic tumors, even if technically resectable with negative margins and adequate remnant liver, should not be considered for resection. These patients have very poor prognosis indicating that bilobar hepatic spread represents hematogenous metastasis.[84] What remains controversial is whether peritumoral satellite lesions also represent metastatic disease. Because this is unknown and surgery is the only potentially curative therapy for these patients, satellite lesions are not currently considered a contraindication to resection.

Hilar cholangiocarcinoma is often unresectable due to local factors. These include invasion of the main portal vein or both the right and left portal veins and hepatic arteries and tumor extension into second-order biliary radicals of both right and left hepatic lobes. By contrast, tumors extending into second- or third-order biliary radicles on one side of the liver without vascular involvement can be resected for cure. It has become clear over the last three decades that curative treatment for patients with tumors of the hilum or those involving the upper half of the bile duct depends on aggressive excision that often requires a major liver resection. Until as recently as one decade ago, treatment of hilar cholangiocarcinomas was associated with mortality as high as 30%.[85–89] Recently, major improvements in the safety of these operations have been demonstrated, and resection of hilar tumors now results in mortality of less than 10%, even when liver resections are required.[85,86,88,90]

Role of Staging Laparoscopy

Because of the potential morbidity of a laparotomy that has no therapeutic benefit, staging laparoscopy has been advocated to save patients from unnecessary laparotomy. In patients with hilar cholangiocarcinoma, up to 25% will benefit from staging laparoscopy because of detection of occult extrahepatic disease.[33,34] Laparoscopy is a very sensitive means to detect peritoneal metastases or additional intrahepatic disease through the use of laparoscopic ultrasound but is less sensitive in detecting nodal metastases or locally invasive tumors.

Partial Hepatectomy With or Without Bile Duct Resection

The extent of hepatectomy required for resection of cholangiocarcinoma is dependent on the tumor location in relation to the portal inflow and venous outflow of the liver. Intraoperative ultrasound is a useful adjunct for assessment of tumor extent and for small satellite lesions that may not be apparent on cross-sectional imaging.

Small ICCs may be removed by segmentectomy or sectorectomy, but these tumors are often large and require extended right or left hepatectomy. For hilar and proximal hepatic duct lesions, complete resection usually requires combined biliary and hepatic resection with or without major vascular reconstruction. Additionally, caudate resection is often required because of direct extension into caudate biliary radicles or parenchyma.[74,89,91] Resection of the extrahepatic bile duct with Roux-en-Y hepaticojejunostomy to the remnant duct is required in these cases. Intraoperative assessment of the bile duct resection margin should be performed if additional duct can potentially be taken. If not, assessment on permanent sectioning is sufficient.

Lymphadenectomy

Regional lymphadenectomy is essential for accurate staging of cholangiocarcinoma, and may be important for locoregional disease control, but has historically been underperformed for intrahepatic and hilar tumors.[73,92] Recent data have shown that lymph node metastases are present in 30% to 40% of patients.[73,92–94] Regional lymph nodes include those along the porta hepatis, the hepatoduodenal ligament, the hepatic artery for essentially all patients. In addition, for those with primary tumors of the right hemiliver, retropancreatic nodes should be removed. For those with primary tumors of the left hemiliver, perigastric lesser curve nodes (levels 1, 3, and 5) should be removed.[95] As is true for gallbladder cancer, there is currently no consensus on the minimum number of lymph nodes needed for accurate staging of cholangiocarcinoma.

Pancreaticoduodenectomy

For cholangiocarcinoma of the lower half of the extrahepatic bile duct, pancreaticoduodenectomy is requiring for complete tumor extirpation. The proximal bile duct margin should be assessed by frozen section to ensure tumor clearance. Regional lymphadenectomy is inherent in this procedure.

Liver Transplantation for Hilar CC and the Mayo Protocol

Orthotopic liver transplantation (OLT) was thought to hold promise for patients with hilar CC, because of the ability to achieve adequate margins by complete hepatectomy. Unfortunately, when used as a single treatment modality, results have been poor. Three- and 5-year survival rates have been reported at 25% to 30%.[96–98] Because of this poor outcome, the Mayo Clinic developed a protocol combining neoadjuvant therapy with liver transplant, based on a strategy initially developed by the University of Nebraska. This protocol uses high-dose neoadjuvant 5-fluorouracil and brachytherapy followed by liver transplantation.[99,100] Inclusion criteria include (i) locally advanced unresectable disease with either positive intraluminal brush cytology, positive intraluminal biopsy, or CA19-9 $\geq$100 in the setting of a radiographic malignant stricture; (ii) primary sclerosing cholangitis with resectable disease; and (iii) absence of medical contraindications for OLT. Since 2003, biliary aneuploidy as demonstrated by digital image analysis (DIA)(77) and fluorescent in situ hybridization have been considered equivalent to cytology.[101] Exclusion criteria include (i) extrahepatic disease including regional lymph node

involvement; (ii) uncontrolled infection; (iii) prior attempt at resection; (iv) prior treatment with radiation or chemotherapy; and (v) previous malignancy within 5 years. In this protocol, patients receive external beam radiotherapy to a target dose of 4,500 cGy with concomitant fluorouracil (5-FU). Following this, transcatheter iridium-192 brachytherapy with a target dose of 2,000 to 3,000 cGy is administered. Thereafter, patients receive oral capecitabine as tolerated until transplantation. It is important that, prior to transplantation, patients undergo a staging laparotomy, at which time biopsy of perihilar lymph nodes as well as any lymph nodes or nodules suspicious for tumor is performed. Only patients with negative staging operations remain eligible for transplantation.[99]

Table 63-7 Results after Resection for Hilar Cholangiocarcinoma

Author	N	Percent Resected	Postoperative Mortality (%)	5-Yr Survival (%)	Survival (Months)	
					Mean	Median
Cameron et al.[76]	96	55	2	8		18
Hadjis et al.[88]	131	21	7	12	25	
Altaee et al.[84]	70	21		19		12
Baer et al.[85]	48	44	4	23	34	
McMasters et al.[102]	91	44	0	26		22
Klempnauer et al.[103]	151		10	28		24
Nagino et al.[104]	173	80	10	26		
Nakeeb et al.[105]	72	57		34		
Jarnagin et al.[106]	225	71	10	27		35
Rea et al.[98]	46		9	26		28
Jang et al.[107]	48		0	48		
Konstadoulakis et al.[108]	73	81	7	35		
Yubin et al.[109]	115	100	2	22		40

Patients eligible for OLT under this protocol have locally advanced tumors but no pathologic nodal disease. The prolonged course of neoadjuvant therapy, staging laparotomy, and time on the OLT waiting list provides an opportunity to exclude patients demonstrating disease progression. This highly rigorous selection bias in favor of patients with biologically favorable disease is reflected in the early outcomes published from the Mayo group. In a recent review of 71 patients enrolled in this transplant protocol, only 38 underwent transplantation (38%). These patients were compared to 26 patients (of 54 explored, 48%) who underwent successful resection. When compared to those undergoing resection (some with node-positive disease), patients undergoing transplantation were younger ($p < 0.001$) and more likely to have inflammatory bowel disease ($p < 0.03$) and PSC ($p < 0.001$). It is important that only 58% of patients had histologically proven cancer. In these highly disparate groups, 5-year survival was 82% after transplantation (38 patients) compared to 21% after resection of 26 patients ($p = 0.022$).[97] There were

also fewer recurrences in the transplant patients (13% vs. 27%), and recurrences became apparent later after transplantation than after resection (mean 40 months vs. 21 months). Direct comparisons are difficult with this study given the differences between groups.

At present, OLT cannot be considered a standard form of therapy for hilar cholangiocarcinoma for patients with resectable disease, but it does offer a potential option for patients with underlying PSC or those with unresectable tumors who fit the rigorous inclusion and exclusion criteria of the protocol.

Prognosis After Resection

Results of major studies on resection of hilar cholangiocarcinoma are summarized in Table 63-7. In patients amenable to curative resection, the median survival is 35 months with a 5-year survival rate of 10% to 30%.[79,87,88,96,100,110] Surgical resection provides both improved survival and improved quality of life. The greatest risk factors for recurrence include the presence of positive margins, and node-positive tumors.[111]

In patients with ICC, expected 3-year survival rates as high as 60% have been reported, with 5-year survival rates of 30% to 45%.[35,111,112] Patients with unresectable disease have a median survival of 12 months.[35,113] Thus, completely resected ICC appears to have an improved prognosis over proximal (hilar) cholangiocarcinoma. Patients with cholangiocarcinomas arising in the distal bile duct have both an increased resectability rate and improved prognosis over those with hilar cholangiocarcinomas.[90] Patients with resectable distal bile duct cancer have a 5-year survival rate of 30% to 50%, with a decreased survival if nodes are involved with tumor.[114,115]

Unresectable Cholangiocarcinoma

6 For patients with unresectable hilar cholangiocarcinomas, significant improvement in quality of life can be achieved with surgical bypass. Palliative bypass can be performed in several ways. A partial excision of the left lateral segment and biliary-enteric anastomosis to the left hepatic duct (Longmire procedure) was used commonly in the past, but more recently surgical techniques have become less complicated and do not require hepatic parenchymal transection. One technique involves biliary decompression through the left duct, approached through the round ligament, a segment III bypass (Fig. 63-8). Opening the bridge of tissue just beneath the ligamentum teres allows access to the duct. In this position, a long anastomosis can be performed from the segment III duct to a jejunal limb because of the horizontal course of the duct in this location. Although less commonly used, the right hepatic duct can be approached at the base of the gallbladder fossa. This is technically more difficult and results in a higher rate of late bypass failure.[116]

Nonoperative palliative biliary decompression can be accomplished with percutaneous or endoscopic stenting, depending on the level of obstruction. Proximal lesions are usually approached percutaneously with placement of expandable stents or drainage catheters (Fig. 63-9). Internal stents result in fewer electrolyte abnormalities and improvement in patient comfort, although morbidity and mortality occurs in up to 30% of patients and stent occlusion is common.[117–119] There is a significant risk of cholangitis with external and internal drainage, occurring in more than 90% of patients with metallic

expandable internal stents in one series.[118] Bleeding and bile leaks are also frequent complications. More recent techniques (e.g., photodynamic therapy) have been used to palliate patients with biliary obstruction and may hold some promise for the future.[120]

Because patients with unresectable disease have a short median survival, those whose disease is clearly unresectable on preoperative imaging should undergo percutaneous internal or external drainage. In patients who undergo exploratory surgery and whose disease is found to be unresectable, surgical bypass offers fewer episodes of cholangitis, with an improved quality of life. In some series, surgical bypass for patients with unresectable disease is the only biliary drainage procedure ever required by the patient.

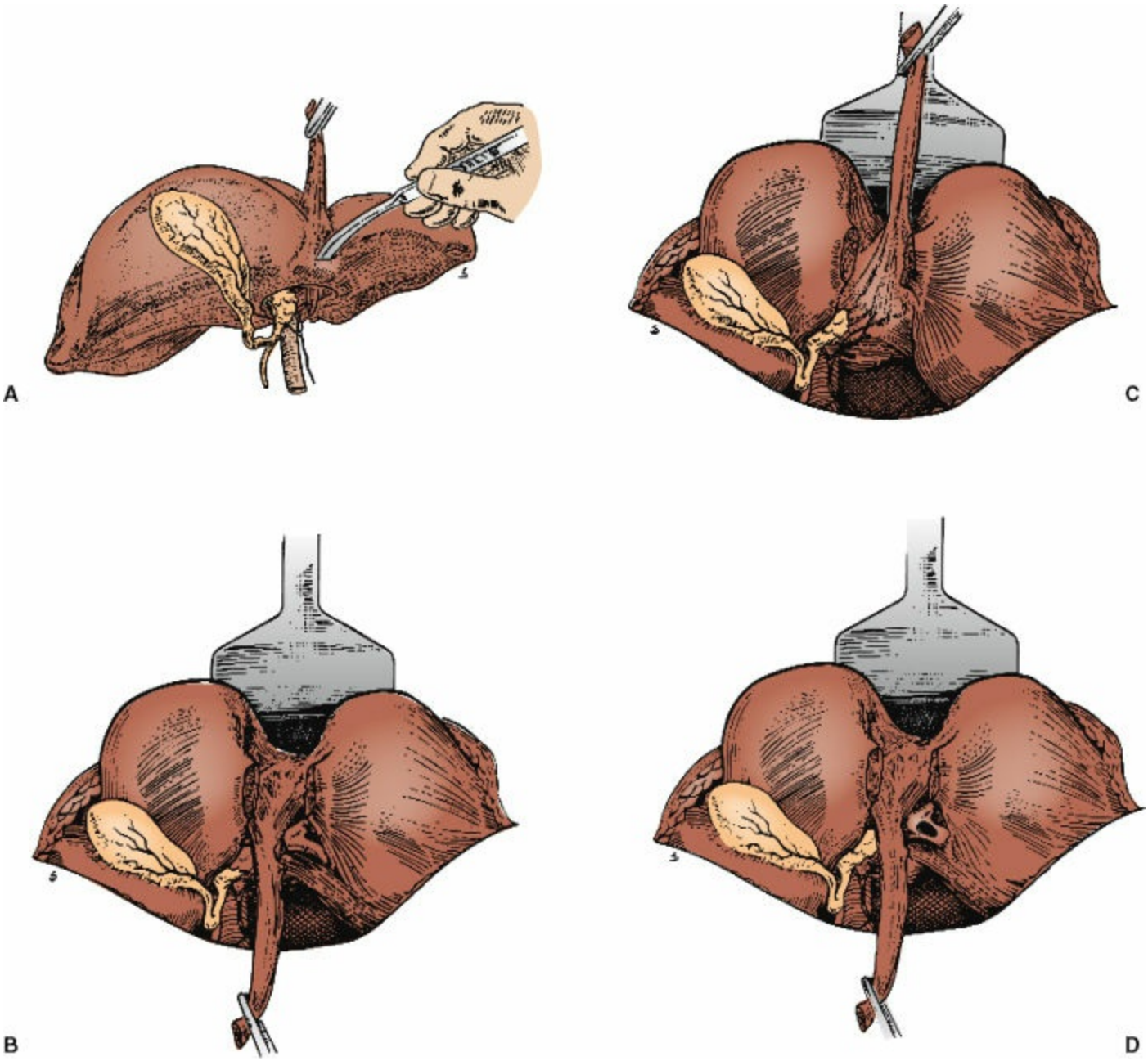

Figure 63-8. Surgical approach to segment III duct. **A:** The bridge of tissue present at the base of the liver is divided. **B:** The ligamentum teres is held superiorly to expose the tissue overlying the segment III duct. **C:** The segment III duct is exposed. **D:** The duct is opened in preparation for anastomosis with a Roux-en-Y jejunal limb. (Courtesy of Dr. L. H. Blumgart.)

In patients with unresectable distal cholangiocarcinomas, palliation can be achieved with surgical bypass, percutaneous biliary drains, or ERCP-placed stents. The simplest and most effective way to relieve jaundice is usually with an ERCP stent. Although surgical bypass offers improved patency and fewer episodes of cholangitis, the morbidity of the procedure is not warranted in patients with these aggressive tumors.

Adjuvant Therapy

To date, no chemotherapeutic regimen has consistently shown activity against cholangiocarcinoma. Many of the issues that pertain to chemotherapy trials in gallbladder cancer are directly relevant to the interpretation of trials for cholangiocarcinomas. Studies performed to date have typically been small, single-institution trials, including patients with both gallbladder and bile duct cancers.[121]

Although 5-fluorouracil (5-FU)–based chemotherapy is often offered to patients with unresectable disease, the likelihood of response is less than 10%. Capecitabine as a single agent may have some modest activity in cholangiocarcinomas.[122] When capecitabine was used in combination with gemcitabine in a recent prospective study, overall survival was 14 months.[65] Gemcitabine and cisplatin combination therapy has also been tested in phase II studies of patients with advanced biliary tract carcinoma.[123,124] Results of these studies demonstrated response rates of 27% to 34.5%, and overall survival of 9.7 to 11 months. The use of mitomycin C and doxorubicin (Adriamycin), in combination with 5-FU, has resulted in combined response rates of less than 30%, with higher toxicity than 5-FU alone.[125]

With the exception of extrahepatic disease, there is no clear role for adjuvant chemotherapy in the treatment of cholangiocarcinoma. The previously mentioned phase II trial from 2015 showed a promising 2 year survival for patients with extra hepatic cholangiocarinoma treated with adjuvant capecitabine/gemcitabine and concurrent capecitabine and radiation therapy.[62] Aside from this study, however, previous data suggested no difference in overall survival (36% vs. 42%, $p = 0.6$) or loco regional recurrence (38% vs. 37%, $p = 0.13$) in patients who underwent R0 resection alone versus those with high loco regional recurrence risk who received adjuvant chemoradiation therapy.[126] Similar to the recommendations for gallbladder cancer, patients with extra hepatic cholangiocarcinoma who undergo R0 or R1 resection should be considered for adjuvant capecitabine/gemcitabine and concurrent capecitabine and radiation therapy.

In cases of unresectable cholangiocarcinoma, the use of external beam radiation therapy has been explored.[91,127–130] To date, no study has clearly demonstrated efficacy for this modality. Anecdotal reports of long-term survivors after external beam radiotherapy show that some individuals may benefit from such treatment, but this must be weighed against the potential complications (e.g., duodenal or bile duct stenosis and duodenitis). The most encouraging results involve use of intraoperative or interstitial radiation.[127,128,130,131] Our current practice is to use combined interstitial radiation and external beam radiation in unresectable cases after palliative bypass. In patients whose disease is resected and have node- or margin-positive disease, systemic therapy with gemcitabine or 5-FU, or 5-FU–based chemoradiation, or enrollment in a clinical trial should be strongly encouraged.

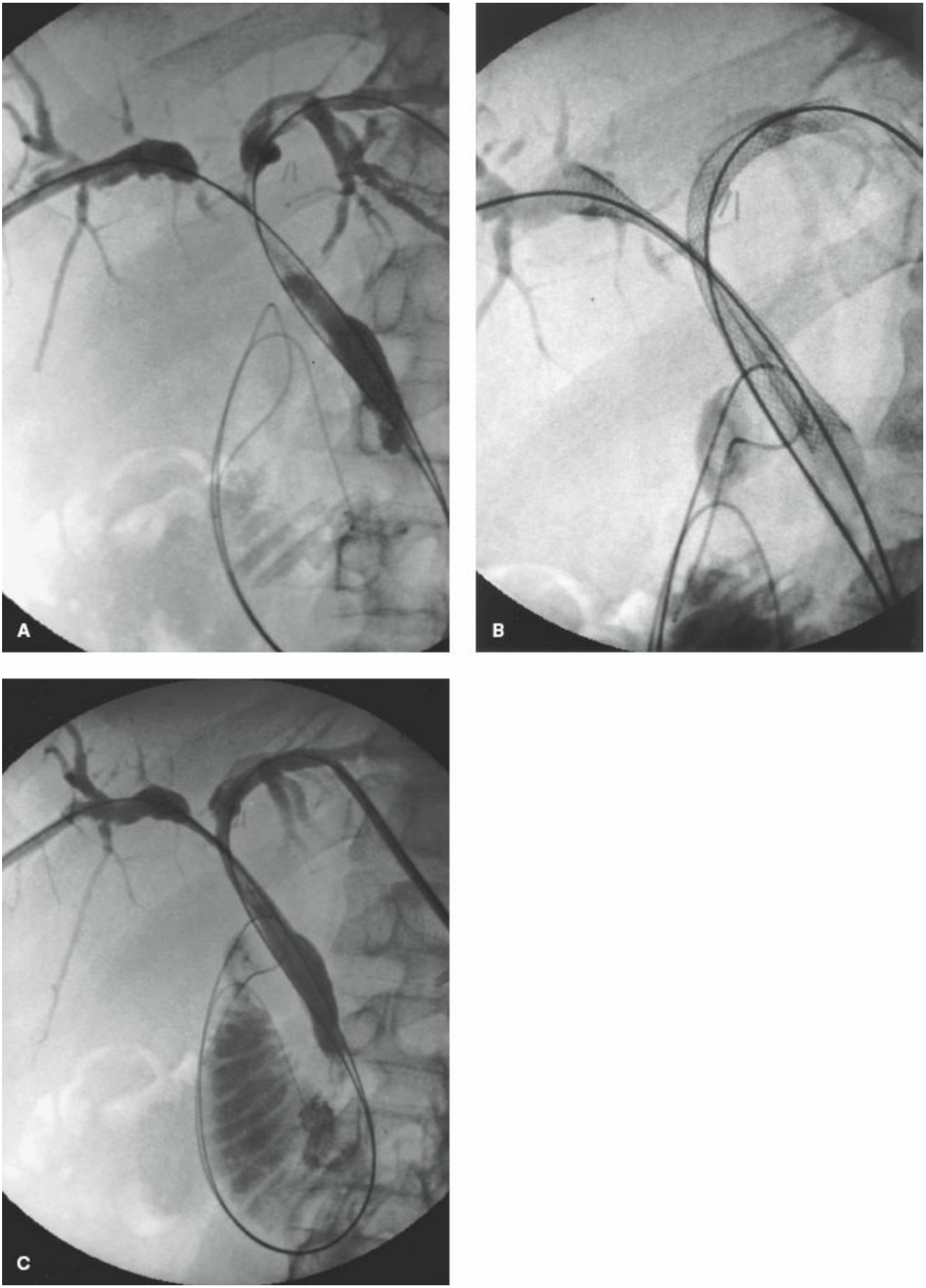

Figure 63-9. **A:** Percutaneous transhepatic cholangiogram in a patient with hilar cholangiocarcinoma, demonstrating biliary obstruction at the confluence. The patient has previously had placement of internal/external stents for biliary drainage. **B:** Film demonstrates appearance of wall stents after deployment into the left and right biliary ducts. **C:** After stenting, the cholangiogram demonstrates adequate biliary drainage, with contrast filling the duodenum.

Follow-up After Resection of Cholangiocarcinoma

Recurrence following resection of ICC is within the liver in 60% of patients. While data are lacking, there is some evidence to suggest that there is a role for reresection in highly selected patients. The most likely site of recurrence after resection of hilar cholangiocarcinoma is locally within the bile duct, regional lymph nodes, or liver. Therapy for recurrence is palliative. Surgical reexcision is usually impossible because of the challenging anatomic location and the radical procedures that are required for resection of the primary tumor. The main symptoms of recurrence that demand palliation are pruritus or cholangitis associated with jaundice. For biliary drainage to relieve jaundice or cholangitis, either surgical drainage or drainage by PTC can be effective. Endoscopic drainage has little role in the relief of jaundice in patients who have had Roux-en-Y biliary reconstruction. For limited recurrences, intraluminal brachytherapy or external beam radiotherapy may improve palliation and, potentially, survival.[132]

Routine follow-up consists of office visits every 3 months with physical examination and measurement of liver function tests. Although a rising alkaline phosphatase level is a reliable indicator of evolving biliary obstruction, patients recovering from liver resection and biliary obstruction can have persistent elevations of alkaline phosphatase. Up to 10% of patients with biliary surgical reconstruction, however, may develop a benign anastomotic stricture. Most patients with recurrence or a benign stricture will present with jaundice or cholangitis. Surveillance cross-sectional imaging is recommended every 3 to 6 months for the first 2 years following resection and should be individualized thereafter.

Issues for the Future

Further studies are needed to develop effective adjuvant, and potentially neoadjuvant, therapies for cholangiocarcinoma. Continued assessment of novel drugs and radiosensitizers, and biologic agents is warranted. A better understanding of the molecular pathogenesis and genetics of bile duct cancers may lead to new therapeutic strategies and possibly preventive strategies for high-risk populations.

BENIGN GALLBLADDER NEOPLASMS

Incidence

Benign tumors of the biliary tract are rare, but have been reported more frequently as imaging modalities (e.g., ultrasound and CT scan) have come into widespread and frequent use. In patients undergoing cholecystectomy, the reported incidence of benign gallbladder tumors is less than 3%.

Pathology

Polyps and Pseudotumors

Benign gallbladder tumors are most frequently polyps or polypoid lesions. The incidence of polyps in asymptomatic patients is about 5%.[3] Cholesterol polyps (cholesterolosis), accounting for half of all gallbladder polypoid lesions, result from epithelium-covered, cholesterol-laden macrophages in the lamina propria.[133] These lesions are likely a result of an error in cholesterol metabolism. They extend from the mucosa on a narrow stalk, grossly appearing as yellow spots on the mucosal surface. Nearly all are multiple, and most are less than 10 mm in size.[133,134] When a polyp is pedunculated, it is benign in most cases; alternatively, sessile "polyps" are more often malignant (Fig. 63-10). Inflammatory polyps result from chronic inflammation and extend by a narrow vascularized stalk into the gallbladder lumen. None of these lesions are considered premalignant, although isolated cases of cholesterolosis associated with in situ carcinoma have been reported.[135]

Adenomas

Gallbladder adenomas are found infrequently. They may be tubular or papillary, both arising from the epithelial layer of the gallbladder. Multiple papillary adenomas, or papillomas, are called *papillomatosis*. A direct association between benign adenoma, adenoma containing carcinoma in situ, and invasive carcinoma has been demonstrated; thus these lesions are considered premalignant.[136] Malignant transformation, however, has only rarely been reported, primarily from large adenomas. In one series, all benign adenomas were less than 12 mm in diameter, whereas the adenomas with cancerous foci were greater than 12 mm.[135]



Figure 63-10. T2-weighted magnetic resonance imaging scan showing a sessile polyp within the gallbladder (*arrow*) that was malignant on histologic examination.

Adenomyomatosis

Adenomyomatosis of the gallbladder is characterized by localized or diffuse hyperplastic extensions of the mucosa into, and often beyond, a hypertrophied gallbladder muscular layer. Hyperplasia occurs at outpouchings of the mucosa of the gallbladder through the wall (Rokitansky–Aschoff sinuses) and through the crypts of Luschka. This can result in focal thickening of the gallbladder wall, resembling gallbladder adenocarcinoma. The etiology is unknown. This lesion may be premalignant, because cases of adenocarcinoma arising in or near adenomyomatosis have been reported, but this relationship is unclear.[127,138]

Other Benign Gallbladder Tumors

Other benign lesions include tumors arising from the tissue of the gallbladder wall, such as leiomyomas, lipomas, hemangiomas, granular cell tumors, and heterotopic tissue, including gastric, pancreatic, or intestinal epithelium.

Clinical Findings

Patients with benign gallbladder tumors typically present with symptoms consistent with choledocholithiasis, including right upper quadrant pain, fatty food intolerance, and nausea. Many benign gallbladder lesions are also discovered incidentally after elective cholecystectomy. Therefore, symptoms caused by benign lesions are difficult to separate from those caused by gallstones. Most lesions, however, are asymptomatic and are discovered incidentally during imaging for other abdominal conditions.

Diagnosis

Diagnosis of benign gallbladder polyps is usually made when an ultrasound study is obtained to evaluate a patient for symptoms consistent with gallstones. On ultrasound, a filling defect that does not change with position is likely a polyp or carcinoma and not a gallstone. Cholesterol polyps are typically small, submucosal, multiple, and hyperechoic on ultrasound because of their high cholesterol content. Other than this typical appearance and the fact that malignant polyps are usually more than 1 cm in size, it is difficult to differentiate benign from malignant polyps.

Both intravenous contrast-enhanced and unenhanced CT may be important in distinguishing benign from malignant polyps. In a recent series examining 31 polypoid lesions of the gallbladder, contrast-enhanced CT detected all of the lesions. Benign polyps were not visualized with unenhanced CT, unlike neoplastic tumors, thus improving the ability to distinguish these lesions when both enhanced and unenhanced CT scans were obtained.[9] Endoscopic ultrasound has also been used to image these lesions, and may be more accurate than transabdominal ultrasound in differentiating benign from malignant tumors.[22]

Treatment

Large polyps, greater than 10 mm, have the greatest malignant potential.[9,133,134] Without the evidence of invasion or metastatic disease, however, no radiologic test can reliably differentiate benign from malignant lesions. Therefore, if large (>1 cm) polyps are present, even in asymptomatic patients without stones, cholecystectomy is warranted.[139] Additionally, resection is recommended for smaller pedunculated lesions with evidence of a vascularized stalk. Small pedunculated lesions with the gross characteristics of a benign cholesterol polyp may be observed and resected only if symptomatic. Although these lesions have routinely been followed with ultrasound, a recent prospective study suggested that polyps smaller than 1 cm do not progress to carcinoma.[140] Cholecystectomy, however, is still considered the standard of care if there is any increase in size.

BENIGN BILE DUCT NEOPLASMS

Incidence

Benign bile duct tumors, at times clinically resembling hilar cholangiocarcinoma, are less common, occurring in less than 1% of patients.[4]

Pathology

Attesting to the rarity of these lesions, only two cases of benign extrahepatic bile duct disease occurred in 4,200 biliary tract operations in one institution.[141] The most common benign tumors of the extrahepatic biliary tree arise from the glandular epithelium lining the ducts; about two-thirds of benign tumors are polyps, adenomatous papilloma, or bile duct adenomas. Most are found in the periampullary region, but they can be distributed throughout the entire biliary tree (Fig. 63-11). Multiple papillomas also have been reported throughout the intrahepatic and extrahepatic biliary tree, termed *multiple biliary papillomatosis*. Although local recurrence and progression to death from obstructive jaundice and cholangitis occur frequently in these rare cases, these tumors have little, if any, malignant potential. Other benign tumors (e.g., cystadenoma, granular cell myoblastoma, leiomyoma, and heterotopic tissue) have also been reported.

One condition that deserves consideration is the case of "malignant masquerade," an inflammatory, fibrotic lesion clinically resembling hilar cholangiocarcinoma, but pathologically consisting only of extensive fibrosis and inflammatory cells without evidence of dysplasia or preneoplastic change.[142–144] In patients being considered for palliative treatment alone with presumed hilar cholangiocarcinoma, it is essential to obtain a tissue diagnosis. It is inappropriate to treat benign lesions by percutaneous stenting because of the excellent outcome after resection of these lesions.

Clinical Findings

Biliary obstruction, with resultant jaundice or cholangitis, is frequently the presenting symptom in patients with benign bile duct tumors. Symptoms may also include epigastric pain or nausea. Because these tumors are indolent, symptoms may be intermittent or gradually progressive.

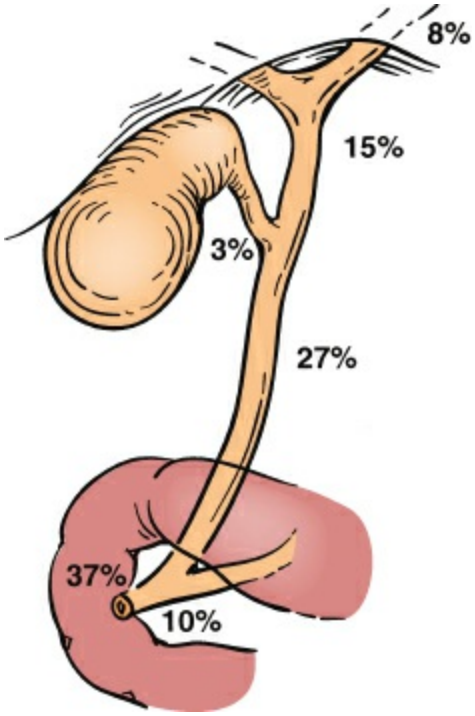

Figure 63-11. Distribution of papillomas and adenomas of the biliary tree. The ampulla and common bile duct are the most frequent sites.

Diagnosis

Because of the presence of jaundice, benign bile duct tumors are usually initially evaluated with ultrasound. Many patients then undergo ERCP or PTC and CT scan. A diagnosis of malignant masquerade should be suspected in patients with mass lesions that resemble hilar cholangiocarcinomas, but without lobar atrophy or portal vein involvement.

Treatment

Resection and reconstruction are performed to relieve jaundice and cholangitis. The preferred reconstruction is a Roux-en-Y choledochojejunostomy to decrease the risk of postoperative biliary stricture or recurrent cholangitis.

References

1. Siegel R, Ma J, Zou Z, et al. Cancer statistics, 2014. *CA Cancer J Clin* 2014; 64(1):9–29.
2. Wistuba II, Gazdar AF. Gallbladder cancer: lessons from a rare tumour. *Nat Rev Cancer* 2004;4(9):695–706.
3. Okamoto M, Okamoto H, Kitahara F, et al. Ultrasonographic evidence of association of polyps and stones with gallbladder cancer. *Am J Gastroenterol* 1999;94(2):446–450.
4. Diehl AK. Epidemiology of gallbladder cancer: a synthesis of recent data. *J Natl Cancer Inst* 1980;65(6):1209–1214.
5. Piehler JM, Crichlow RW. Primary carcinoma of the gallbladder. *Surg Gynecol Obstet* 1978;147(6):929–942.
6. Hundal R, Shaffer EA. Gallbladder cancer: epidemiology and outcome. *Clin Epidemiol* 2014;6:99–109.
7. Pitt SC, Jin LX, Hall BL, et al. Incidental gallbladder cancer at cholecystectomy: when should the surgeon be suspicious? *Ann Surg* 2014;260(1):128–133.
8. Diehl AK. Gallstone size and the risk of gallbladder cancer. *JAMA* 1983; 250(17):2323–2326.
9. Shinkai H, Kimura W, Muto T. Surgical indications for small polypoid lesions of the gallbladder. *Am J Surg* 1998;175(2):114–117.
10. Stephen AE, Berger DL. Carcinoma in the porcelain gallbladder: a relationship revisited. *Surgery* 2001;129(6):699–703.
11. Towfigh S, McFadden DW, Cortina GR, et al. Porcelain gallbladder is not associated with gallbladder carcinoma. *Am Surg* 2001;67(1):7–10.
12. Henson DE, Albores-Saavedra J, Corle D. Carcinoma of the gallbladder. Histologic types, stage of disease, grade, and survival rates. *Cancer* 1992;70(6):1493–1497.
13. Yamamoto M, Nakajo S, Tahara E. Carcinoma of the gallbladder: the correlation between histogenesis and prognosis. *Virchows Arch A Pathol Anat Histopathol* 1989;414(2):83–90.
14. Bartlett DL, Fong Y, Fortner JG, et al. Long-term results after resection for gallbladder cancer. Implications for staging and management. *Ann Surg* 1996;224(5):639–646.
15. Shirai Y, Yoshida K, Tsukada K, et al. Radical surgery for gallbladder carcinoma. Long-term results. *Ann Surg* 1992;216(5):565–568.
16. Matsubara T, Sakurai Y, Sasayama Y, et al. K-ras point mutations in cancerous and noncancerous biliary epithelium in patients with pancreaticobiliary maljunction. *Cancer* 1996;77(8 suppl):1752–1757.
17. Wistuba II, Albores-Saavedra J. Genetic abnormalities involved in the pathogenesis of gallbladder carcinoma. *J Hepatobiliary Pancreat Surg* 1999;6(3):237–244.
18. Wistuba II, Sugio K, Hung J, et al. Allele-specific mutations involved in the

pathogenesis of endemic gallbladder carcinoma in Chile. *Cancer Res* 1995;55(12):2511–2515.

19. Javle M, Rashid A, Churi C, et al. Molecular characterization of gallbladder cancer using somatic mutation profiling. *Hum Pathol* 2014;45(4):701–708.
20. Jiao Y, Pawlik TM, Anders RA, et al. Exome sequencing identifies frequent inactivating mutations in BAP1, ARID1A and PBRM1 in intrahepatic cholangiocarcinomas. *Nat Genet* 2013;45(12):1470–1473.
21. Mizuguchi M, Kudo S, Fukahori T, et al. Endoscopic ultrasonography for demonstrating loss of multiple-layer pattern of the thickened gallbladder wall in the preoperative diagnosis of gallbladder cancer. *Eur Radiol* 1997;7(8):1323–1327.
22. Sugiyama M, Xie XY, Atomi Y, et al. Differential diagnosis of small polypoid lesions of the gallbladder: the value of endoscopic ultrasonography. *Ann Surg* 1999;229(4):498–504.
23. Bang SH, Lee JY, Woo H, et al. Differentiating between adenomyomatosis and gallbladder cancer: revisiting a comparative study of high-resolution ultrasound, multidetector CT, and MR imaging. *Korean J Radiol* 2014;15(2):226–234.
24. Ohtani T, Shirai Y, Tsukada K, et al. Spread of gallbladder carcinoma: CT evaluation with pathologic correlation. *Abdom Imaging* 1996;21(3):195–201.
25. Demachi H, Matsui O, Hoshiba K, et al. Dynamic MRI using a surface coil in chronic cholecystitis and gallbladder carcinoma: radiologic and histopathologic correlation. *J Comput Assist Tomogr* 1997;21(4):643–651.
26. Kang TW, Kim SH, Park HJ, et al. Differentiating xanthogranulomatous cholecystitis from wall-thickening type of gallbladder cancer: added value of diffusion-weighted MRI. *Clin Radiol* 2013;68(10):992–1001.
27. Schwartz LH, Coakley FV, Sun Y, et al. Neoplastic pancreaticobiliary duct obstruction: evaluation with breath-hold MR cholangiopancreatography. *AJR Am J Roentgenol* 1998;170(6):1491–1495.
28. Corvera CU, Blumgart LH, Akhurst T, et al. 18F-fluorodeoxyglucose positron emission tomography influences management decisions in patients with biliary cancer. *J Am Coll Surg* 2008;206(1):57–65.
29. Fong Y, Brennan MF, Turnbull A, et al. Gallbladder cancer discovered during laparoscopic surgery. Potential for iatrogenic tumor dissemination. *Arch Surg* 1993;128(9):1054–1056.
30. Barbot DJ, Marks JH, Feld RI, et al. Improved staging of liver tumors using laparoscopic intraoperative ultrasound. *J Surg Oncol* 1997;64(1):63–67.
31. Bhargava DK, Sarin S, Verma K, et al. Laparoscopy in carcinoma of the gallbladder. *Gastrointest Endosc* 1983;29(1):21–22.
32. Dagnini G, Marin G, Patella M, et al. Laparoscopy in the diagnosis of primary carcinoma of the gallbladder. A study of 98 cases. *Gastrointest Endosc* 1984;30(5):289–291.

33. Weber SM, DeMatteo RP, Fong Y, et al. Staging laparoscopy in patients with extrahepatic biliary carcinoma. Analysis of 100 patients. *Ann Surg* 2002;235(3):392–399.
34. Vollmer CM, Drebin JA, Middleton WD, et al. Utility of staging laparoscopy in subsets of peripancreatic and biliary malignancies. *Ann Surg* 2002;235(1):1–7.
35. Weber SM, Jarnagin WR, Klimstra D, et al. Intrahepatic cholangiocarcinoma: resectability, recurrence pattern, and outcomes. *J Am Coll Surg* 2001; 193(4):384–391.
36. Donohue JH, Nagorney DM, Grant CS, et al. Carcinoma of the gallbladder. Does radical resection improve outcome? *Arch Surg* 1990;125(2):237–241.
37. Ogura Y, Mizumoto R, Isaji S, et al. Radical operations for carcinoma of the gallbladder: present status in Japan. *World J Surg* 1991;15(3):337–343.
38. Ouchi K, Owada Y, Matsuno S, et al. Prognostic factors in the surgical treatment of gallbladder carcinoma. *Surgery* 1987;101(6):731–737.
39. Wanebo HJ, Castle WN, Fechner RE. Is carcinoma of the gallbladder a curable lesion? *Ann Surg* 1982;195(5):624–631.
40. Nakamura S, Sakaguchi S, Suzuki S, et al. Aggressive surgery for carcinoma of the gallbladder. *Surgery* 1989;106(3):467–473.
41. Fong Y, Jarnagin W, Blumgart LH. Gallbladder cancer: comparison of patients presenting initially for definitive operation with those presenting after prior noncurative intervention. *Ann Surg* 2000;232(4):557–569.
42. Wakai T, Shirai Y, Yokoyama N, et al. Early gallbladder carcinoma does not warrant radical resection. *Br J Surg* 2001;88(5):675–678.
43. Kai M, Chijiiwa K, Ohuchida J, et al. A curative resection improves the postoperative survival rate even in patients with advanced gallbladder carcinoma. *J Gastrointest Surg* 2007;11(8):1025–1032.
44. Jensen EH, Abraham A, Habermann EB, et al. A critical analysis of the surgical management of early-stage gallbladder cancer in the United States. *J Gastrointest Surg* 2009;13(4):722–727.
45. Mayo SC, Shore AD, Nathan H, et al. National trends in the management and survival of surgically managed gallbladder adenocarcinoma over 15 years: a population-based analysis. *J Gastrointest Surg* 2010;14(10):1578–1591.
46. Taner CB, Nagorney DM, Donohue JH. Surgical treatment of gallbladder cancer. *J Gastrointest Surg* 2004;8(1):83–89.
47. Yamaguchi K, Chijiiwa K, Saiki S, et al. Reliability of frozen section diagnosis of gallbladder tumor for detecting carcinoma and depth of its invasion. *J Surg Oncol* 1997;65(2):132–136.
48. Yamaguchi K, Tsuneyoshi M. Subclinical gallbladder carcinoma. *Am J Surg* 1992;163(4):382–386.
49. Kelly KJ, Dukleska K, Kuk D, et al. Prognostic significance of the highest

peripancreatic lymph node in biliary tract adenocarcinoma. *Ann Surg Oncol* 2014;21(3):979–985.

50. Billingsley KG, Jarnagin WR, Fong Y, et al. Segment-oriented hepatic resection in the management of malignant neoplasms of the liver. *J Am Coll Surg* 1998;187(5):471–481.
51. Shih SP, Schulick RD, Cameron JL, et al. Gallbladder cancer: the role of laparoscopy and radical resection. *Ann Surg* 2007;245(6):893–901.
52. Shirai Y, Yoshida K, Tsukada K, et al. Inapparent carcinoma of the gallbladder. An appraisal of a radical second operation after simple cholecystectomy. *Ann Surg* 1992;215(4):326–331.
53. Chijiiwa K, Tanaka M. Carcinoma of the gallbladder: an appraisal of surgical resection. *Surgery* 1994;115(6):751–756.
54. Butte JM, Kingham TP, Gonen M, et al. Residual disease predicts outcomes after definitive resection for incidental gallbladder cancer. *J Am Coll Surg* 2014;219(3):416–429.
55. Dixon E, Vollmer CM Jr, Sahajpal A, et al. An aggressive surgical approach leads to improved survival in patients with gallbladder cancer: a 12-year study at a North American Center. *Ann Surg* 2005;241(3):385–394.
56. Fuks D, Regimbeau JM, Le Treut YP, et al. Incidental gallbladder cancer by the AFC-GBC-2009 Study Group. *World J Surg* 2011;35(8):1887–1897.
57. Fuks D, Regimbeau JM, Pessaux P, et al. Is port-site resection necessary in the surgical management of gallbladder cancer? *J Visc Surg* 2013;150(4):277–284.
58. Maker AV, Butte JM, Oxenberg J, et al. Is port site resection necessary in the surgical management of gallbladder cancer? *Ann Surg Oncol* 2012;19(2):409–417.
59. Weiland ST, Mahvi DM, Niederhuber JE, et al. Should suspected early gallbladder cancer be treated laparoscopically? *J Gastrointest Surg* 2002;6(1):50–56; discussion 56–57.
60. Takada T, Amano H, Yasuda H, et al. Is postoperative adjuvant chemotherapy useful for gallbladder carcinoma? A phase III multicenter prospective randomized controlled trial in patients with resected pancreaticobiliary carcinoma. *Cancer* 2002;95(8):1685–1695.
61. Wang SJ, Lemieux A, Kalpathy-Cramer J, et al. Nomogram for predicting the benefit of adjuvant chemoradiotherapy for resected gallbladder cancer. *J Clin Oncol* 2011;29(35):4627–4632.
62. Ben-Josef E, Guthrie KA, El-Khoueiry AB, et al. SWOG 0809: a phase II intergroup trial of adjuvant capecitabine and gencitabine followed by radiotherapy and concurrent capecitabine in extra hepatic cholangiocarcinoma and gallbladder carcinoma. *J Clin Oncol* 2015;33(24):2617–2622.
63. Kim HJ, Kim MH, Myung SJ, et al. A new strategy for the application of CA19-9 in the differentiation of pancreaticobiliary cancer: analysis using a receiver operating

characteristic curve. *Am J Gastroenterol* 1999;94(7):1941–1946.

64. Knox JJ, Hedley D, Oza A, et al. Combining gemcitabine and capecitabine in patients with advanced biliary cancer: a phase II trial. *J Clin Oncol* 2005;23(10):2332–2338.
65. Iyer RV, Gibbs J, Kuvshinoff B, et al. A phase II study of gemcitabine and capecitabine in advanced cholangiocarcinoma and carcinoma of the gallbladder: a single-institution prospective study. *Ann Surg Oncol* 2007;14(11):3202–3209.
66. Lazcano-Ponce EC, Miquel JF, Munoz N, et al. Epidemiology and molecular pathology of gallbladder cancer. *CA Cancer J Clin* 2001;51(6):349–364.
67. Patel T. Increasing incidence and mortality of primary intrahepatic cholangiocarcinoma in the United States. *Hepatology* 2001;33(6):1353–1357.
68. Pitt HA, Dooley WC, Yeo CJ, et al. Malignancies of the biliary tree. *Curr Probl Surg* 1995;32(1):1–90.
69. Endo I, Gonen M, Yopp AC, et al. Intrahepatic cholangiocarcinoma: rising frequency, improved survival, and determinants of outcome after resection. *Ann Surg* 2008;248(1):84–96.
70. Welzel TM, Mellemkjaer L, Gloria G, et al. Risk factors for intrahepatic cholangiocarcinoma in a low-risk population: a nationwide case-control study. *Int J Cancer* 2007;120(3):638–641.
71. de Groen PC, Gores GJ, LaRusso NF, et al. Biliary tract cancers. *N Engl J Med* 1999;341(18):1368–1378.
72. Hakamada K, Sasaki M, Endoh M, et al. Late development of bile duct cancer after sphincteroplasty: a ten- to twenty-two-year follow-up study. *Surgery* 1997;121(5):488–492.
73. Nathan H, Pawlik TM, Wolfgang CL, et al. Trends in survival after surgery for cholangiocarcinoma: a 30-year population-based SEER database analysis. *J Gastrointest Surg* 2007;11(11):1488–1496; discussion 1496–1497.
74. Burke EC, Jarnagin WR, Hochwald SN, et al. Hilar Cholangiocarcinoma: patterns of spread, the importance of hepatic resection for curative operation, and a presurgical clinical staging system. *Ann Surg* 1998;228(3):385–394.
75. Aloia TA, Charnsangavej C, Faria S, et al. High-resolution computed tomography accurately predicts resectability in hilar cholangiocarcinoma. *Am J Surg* 2007;193(6):702–706.
76. Soto JA, Barish MA, Yucel EK, et al. Magnetic resonance cholangiography: comparison with endoscopic retrograde cholangiopancreatography. *Gastroenterology* 1996;110(2):589–597.
77. Cameron JL, Pitt HA, Zinner MJ, et al. Management of proximal cholangiocarcinomas by surgical resection and radiotherapy. *Am J Surg* 1990;159(1):91–97; discussion 97–98.
78. Nakayama T, Ikeda A, Okuda K. Percutaneous transhepatic drainage of the biliary tract: technique and results in 104 cases. *Gastroenterology* 1978;74(3):554–559.

79. Hochwald SN, Burke EC, Jarnagin WR, et al. Association of preoperative biliary stenting with increased postoperative infectious complications in proximal cholangiocarcinoma. *Arch Surg* 1999;134(3):261–266.
80. McPherson GA, Benjamin IS, Hodgson HJ, et al. Pre-operative percutaneous transhepatic biliary drainage: the results of a controlled trial. *Br J Surg* 1984;71(5):371–375.
81. Pitt HA, Gomes AS, Lois JF, et al. Does preoperative percutaneous biliary drainage reduce operative risk or increase hospital cost? *Ann Surg* 1985; 201(5):545–553.
82. Okuda K, Kubo Y, Okazaki N, et al. Clinical aspects of intrahepatic bile duct carcinoma including hilar carcinoma: a study of 57 autopsy-proven cases. *Cancer* 1977;39(1):232–246.
83. Ottow RT, August DA, Sugarbaker PH. Treatment of proximal biliary tract carcinoma: an overview of techniques and results. *Surgery* 1985; 97(3):251–262.
84. El Rassi ZE, Partensky C, Scoazec JY, et al. Peripheral cholangiocarcinoma: presentation, diagnosis, pathology and management. *Eur J Surg Oncol* 1999;25(4):375–380.
85. Altaee MY, Johnson PJ, Farrant JM, et al. Etiologic and clinical characteristics of peripheral and hilar cholangiocarcinoma. *Cancer* 1991;68(9):2051–2055.
86. Baer HU, Stain SC, Dennison AR, et al. Improvements in survival by aggressive resections of hilar cholangiocarcinoma. *Ann Surg* 1993;217(1):20–27.
87. Bengmark S, Ekberg H, Evander A, et al. Major liver resection for hilar cholangiocarcinoma. *Ann Surg* 1988;207(2):120–125.
88. Bismuth H, Nakache R, Diamond T. Management strategies in resection for hilar cholangiocarcinoma. *Ann Surg* 1992;215(1):31–38.
89. Hadjis NS, Blenkharn JI, Alexander N, et al. Outcome of radical surgery in hilar cholangiocarcinoma. *Surgery* 1990;107(6):597–604.
90. Nagorney DM, Donohue JH, Farnell MB, et al. Outcomes after curative resections of cholangiocarcinoma. *Arch Surg* 1993;128(8):871–877; discussion 877–879.
91. Cameron JL, Broe P, Zuidema GD. Proximal bile duct tumors: surgical management with silastic transhepatic biliary stents. *Ann Surg* 1982;196(4):412–419.
92. Ito K, Ito H, Allen PJ, et al. Adequate lymph node assessment for extrahepatic bile duct adenocarcinoma. *Ann Surg* 2010;251(4):675–681.
93. de Jong MC, Nathan H, Sotiropoulos GC, et al. Intrahepatic cholangiocarcinoma: an international multi-institutional analysis of prognostic factors and lymph node assessment. *J Clin Oncol* 2011;29(23):3140–3145.
94. Ribero D, Pinna AD, Guglielmi A, et al. Surgical approach for long-term survival of patients with intrahepatic cholangiocarcinoma: a multi-institutional analysis of 434 patients. *Arch Surg* 2012;147(12):1107–1113.
95. Edge SB, American Joint Committee on Cancer. *AJCC Cancer Staging Manual.* 7th ed. New York, NY: Springer; 2010.

96. Brandsaeter B, Isoniemi H, Broome U, et al. Liver transplantation for primary sclerosing cholangitis; predictors and consequences of hepatobiliary malignancy. *J Hepatol* 2004;40(5):815–822.
97. Meyer CG, Penn I, James L. Liver transplantation for cholangiocarcinoma: results in 207 patients. *Transplantation* 2000;69(8):1633–1637.
98. Robles R, Figueras J, Turrion VS, et al. Spanish experience in liver transplantation for hilar and peripheral cholangiocarcinoma. *Ann Surg* 2004; 239(2):265–271.
99. Rea DJ, Munoz-Juarez M, Farnell MB, et al. Major hepatic resection for hilar cholangiocarcinoma: analysis of 46 patients. *Arch Surg* 2004;139(5):514–523; discussion 523–525.
100. Sudan D, DeRoover A, Chinnakotla S, et al. Radiochemotherapy and transplantation allow long-term survival for nonresectable hilar cholangiocarcinoma. *Am J Transplant* 2002;2(8):774–779.
101. Kipp BR, Stadheim LM, Halling SA, et al. A comparison of routine cytology and fluorescence in situ hybridization for the detection of malignant bile duct strictures. *Am J Gastroenterol* 2004;99(9):1675–1681.
102. McMasters KM, Tuttle TM, Leach SD, et al. Neoadjuvant chemoradiation for extrahepatic cholangiocarcinoma. *Am J Surg* 1997;174(6):605–608.
103. Klempnauer J, Ridder GJ, von Wasielewski R, et al. Resectional surgery of hilar cholangiocarcinoma: a multivariate analysis of prognostic factors. *J Clin Oncol* 1997;15(3):947–954.
104. Nagino M, Nimura Y, Kamiya J, et al. Segmental liver resections for hilar cholangiocarcinoma. *Hepatogastroenterology* 1998;45(19):7–13.
105. Nakeeb A, Tran KQ, Black MJ, et al. Improved survival in resected biliary malignancies. *Surgery* 2002;132(4):555–563.
106. Jarnagin WR, Fong Y, DeMatteo RP, et al. Staging, resectability, and outcome in 225 patients with hilar cholangiocarcinoma. *Ann Surg* 2000; 234(4):507–517.
107. Jang JY, Kim SW, Park DJ, et al. Actual long-term outcome of extrahepatic bile duct cancer after surgical resection. *Ann Surg* 2005;241(1):77–84.
108. Konstadoulakis MM, Roayaie S, Gomatos IP, et al. Aggressive surgical resection for hilar cholangiocarcinoma: is it justified? Audit of a single center's experience. *Am J Surg* 2008;196(2):160–169.
109. Yubin L, Chihua F, Zhixiang J, et al. Surgical management and prognostic factors of hilar cholangiocarcinoma: experience with 115 cases in China. *Ann Surg Oncol* 2008;15(8):2113–2119.
110. Blumgart LH, Hadjis NS, Benjamin IS, et al. Surgical approaches to cholangiocarcinoma at confluence of hepatic ducts. *Lancet* 1984;1(8368):66–70.
111. Reding R, Buard JL, Lebeau G, et al. Surgical management of 552 carcinomas of the extrahepatic bile ducts (gallbladder and periampullary tumors excluded). Results of the French Surgical Association Survey. *Ann Surg* 1991;213(3):236–241.

112. Lieser MJ, Barry MK, Rowland C, et al. Surgical management of intrahepatic cholangiocarcinoma: a 31-year experience. *J Hepatobiliary Pancreat Surg* 1998;5(1):41–47.
113. Berdah SV, Delpero JR, Garcia S, et al. A western surgical experience of peripheral cholangiocarcinoma. *Br J Surg* 1996;83(11):1517–1521.
114. Fong Y, Blumgart LH, Lin E, et al. Outcome of treatment for distal bile duct cancer. *Br J Surg* 1996;83(12):1712–1715.
115. Nakeeb A, Pitt HA, Sohn TA, et al. Cholangiocarcinoma. A spectrum of intrahepatic, perihilar, and distal tumors. *Ann Surg* 1996;224(4):463–473; discussion 473–475.
116. Jarnagin WR, Burke E, Powers C, et al. Intrahepatic biliary enteric bypass provides effective palliation in selected patients with malignant obstruction at the hepatic duct confluence. *Am J Surg* 1998;175(6):453–460.
117. Glattli A, Stain SC, Baer HU, et al. Unresectable malignant biliary obstruction: treatment by self-expandable biliary endoprostheses. *HPB Surg* 1993;6(3):175–184.
118. Kuvshinoff BW, Armstrong JG, Fong Y, et al. Palliation of irresectable hilar cholangiocarcinoma with biliary drainage and radiotherapy. *Br J Surg* 1995;82(11):1522–1525.
119. Lee BH, Choe DH, Lee JH, et al. Metallic stents in malignant biliary obstruction: prospective long-term clinical results. *AJR Am J Roentgenol* 1997;168(3):741–745.
120. Rumalla A, Baron TH, Wang KK, et al. Endoscopic application of photodynamic therapy for cholangiocarcinoma. *Gastrointest Endosc* 2001;53(4):500–504.
121. Yee K, Sheppard BC, Domreis J, et al. Cancers of the gallbladder and biliary ducts. *Oncology (Williston Park)* 2002;16(7):939–946, 949; discussion 949–950, 952–953, 956–957.
122. Stemmler J, Heinemann V, Schalhorn A. Capecitabine as second-line treatment for metastatic cholangiocarcinoma: a report of two cases. *Onkologie* 2002;25(2):182–184.
123. Meyerhardt JA, Zhu AX, Stuart K, et al. Phase-II study of gemcitabine and cisplatin in patients with metastatic biliary and gallbladder cancer. *Dig Dis Sci* 2008;53(2):564–570.
124. Thongprasert S, Napapan S, Charoentum C, et al. Phase II study of gemcitabine and cisplatin as first-line chemotherapy in inoperable biliary tract carcinoma. *Ann Oncol* 2005;16(2):279–281.
125. Oberfield RA, Rossi RL. The role of chemotherapy in the treatment of bile duct cancer. *World J Surg* 1988;12(1):105–108.
126. Borghero Y, Crane CH, Szklaruk J, et al. Extrahepatic bile duct adenocarcinoma: patients at high risk for local recurrence treated with surgery and adjuvant chemoradiation have an equivalent overall survival to patients with standard-risk treated with surgery alone. *Ann Surg Oncol* 2008;15(11):3147–3156.
127. Fletcher MS, Brinkley D, Dawson JL, et al. Treatment of high bileduct carcinoma by internal radiotherapy with iridium-192 wire. *Lancet* 1981; 2(8239):172–174.

128. Iwasaki Y, Ohto M, Todoroki T, et al. Treatment of carcinoma of the biliary system. *Surg Gynecol Obstet* 1977;144(2):219–224.
129. Kopelson G, Gunderson LL. Primary and adjuvant radiation therapy in gallbladder and extrahepatic biliary tract carcinoma. *J Clin Gastroenterol* 1983;5(1):43–50.
130. Ikeda H, Kuroda C, Uchida H, et al. [Intraluminal irradiation with iridium-192 wires for extrahepatic bile duct carcinoma–a preliminary report (author's transl)]. *Nihon Igaku Hoshasen Gakkai Zasshi* 1979; 39(12):1356–1358.
131. Todoroki T, Iwasaki Y, Okamura T, et al. Intraoperative radiotherapy for advanced carcinoma of the biliary system. *Cancer* 1980;46(10):2179–2184.
132. Shiina T, Mikuriya S, Uno T, et al. Radiotherapy of cholangiocarcinoma: the roles for primary and adjuvant therapies. *Cancer Chemother Pharmacol* 1992;31(suppl):S115–S118.
133. Koga A, Watanabe K, Fukuyama T, et al. Diagnosis and operative indications for polypoid lesions of the gallbladder. *Arch Surg* 1988;123(1):26–29.
134. Furukawa H, Kosuge T, Shimada K, et al. Small polypoid lesions of the gallbladder: differential diagnosis and surgical indications by helical computed tomography. *Arch Surg* 1998;133(7):735–739.
135. Akiyama T, Sahara H, Seto K, et al. Gallbladder cancer associated with cholesterosis. *J Gastroenterol* 1996;31(3):470–474.
136. Kozuka S, Tsubone N, Yasui A, et al. Relation of adenoma to carcinoma in the gallbladder. *Cancer* 1982;50(10):2226–2234.
137. Aldridge MC, Gruffaz F, Castaing D, et al. Adenomyomatosis of the gallbladder. A premalignant lesion? *Surgery* 1991;109(1):107–110.
138. Kurihara K, Mizuseki K, Ninomiya T, et al. Carcinoma of the gall-bladder arising in adenomyomatosis. *Acta Pathol Jpn* 1993;43(1–2):82–85.
139. Aldridge MC, Bismuth H. Gallbladder cancer: the polyp-cancer sequence. *Br J Surg* 1990;77(4):363–364.
140. Csendes A, Burgos AM, Csendes P, et al. Late follow-up of polypoid lesions of the gallbladder smaller than 10 mm. *Ann Surg* 2001;234(5):657–660.
141. Farris KB, Faust BF. Granular cell tumors of biliary ducts. Report of two cases and review of the literature. *Arch Pathol Lab Med* 1979;103(10):510–512.
142. Hadjis NS, Collier NA, Blumgart LH. Malignant masquerade at the hilum of the liver. *Br J Surg* 1985;72(8):659–661.
143. Standfield NJ, Salisbury JR, Howard ER. Benign nontraumatic inflammatory strictures of the extrahepatic biliary system. *Br J Surg* 1989;76(8):849–852.
144. Verbeek PC, van Leeuwen DJ, de Wit LT, et al. Benign fibrosing disease at the hepatic confluence mimicking Klatskin tumors. *Surgery* 1992;112(5):866–871.

SECTION I: COLON AND RECTUM

Chapter 64

Colon and Rectal Anatomy and Physiology

Sandy H. Fang and Elizabeth C. Wick

Key Points

1 The mesorectum is invested by the fascia propria of the rectum.

2 The ileocolic branch of the superior mesenteric artery supplies the right colon and part of the transverse colon.

3 The inferior mesenteric artery supplies part of the transverse colon, sigmoid colon, and rectum.

4 The inguinal lymph nodes drain the lymphatics from the anal canal below the dentate line.

5 The colon has 10^{13} bacteria, which promote mucosal immunity, help digest complex nutrients, and protect against pathogenic organisms.

6 Alterations in the colonic flora have been associated with inflammatory bowel disease and colorectal cancer.

7 Constipation is one of the most common conditions treated by physicians, but only rarely is it due to colonic inertia.

8 During postoperative ileus, the stomach recovers after 1 to 2 days, the small bowel after 1 day, and the colon after 3 days.

9 Thoracic epidural use after colorectal surgery can shorten postoperative ileus.

10 Sacral nerve stimulation is a newer and effective treatment for fecal incontinence.

INTRODUCTION

While the complex coordination of stool through the colon, rectum, and anus is the main function of the colon, it also plays a role in the complex digestion and absorption of carbohydrate and protein residue, creates a balanced environment for bacteria, and lubricates stool for transit. Understanding the anatomy and physiology of the colon, rectum, and anus is important to treating the pathology associated with it.

EMBRYOLOGY OF THE COLON AND RECTUM

The primitive gut is derived from endoderm and begins to form during the third to fourth week of gestation. It is divided into three segments: foregut, midgut, and hindgut. Embryologically, the colon is derived from the midgut, which is supplied by the superior mesenteric artery, and the hindgut, which is supplied by the inferior mesenteric artery.[1] The midgut gives rise to the small intestine distal to the ampulla of Vater, the cecum and appendix, the ascending colon, and the right half to two-thirds of the transverse colon. During the sixth gestational week, the midgut herniates from the abdominal cavity into the extraembryonic coelom, undergoes a 270-degree counterclockwise rotation around the superior mesenteric artery, and then returns to the abdominal cavity at 10 weeks' gestation. The hindgut gives rise to the distal one-third of the transverse colon, descending and sigmoid colon, rectum, and upper portion of the anal canal. The terminal end of the hindgut is the endoderm-lined pouch termed the *cloaca.* During development, the cloaca is partitioned by the urorectal septum into the rectum and upper anal canal and urogenital sinus. Ultimately, the distal anal canal arises from canalization of the ectoderm. The pectineal or dentate line marks the junction between tissue derived from endoderm and ectoderm in the anal canal.

ANATOMY OF THE COLON AND RECTUM

The colon begins in the right lower quadrant of the abdomen as the cecum. The ileum enters the colon at the posteromedial aspect at the ileocecal valve.[1] Characteristics unique to the colon are (a) taeniae coli, (b) haustra, and (c) appendices epiploicae, located on the antimesenteric surface of the colon. There are three taeniae (anterior, posterior medial, and posterior lateral), which are condensations of the outer longitudinal muscle layer in the colon. They are named according to their attachments: taenia mesocolica (attached to the mesocolon), taenia omentalis (attached to the greater omentum), taenia libera (no attachments). The taeniae originate at the base of the appendix, course along the length of the colon, and then converge at the rectosigmoid junction.

On average, the colon is 150 cm long. The taenia are one-sixth shorter than the colon and are believed to be responsible for pockets of the colon wall called sacculations or haustra.[1] The epiploicae appendices are fat appendages seen on the colonic serosa.

The colon consists of five layers: mucosa, submucosa, circular muscle layer, longitudinal muscle layer, and serosa (Fig. 64-1). Microscopically, the colonic mucosa is a columnar epithelium marked by crypts and goblet cells. Unlike the small intestine, the columnar epithelium of the colon and rectum does not have villi. The submucosa is the strongest layer of bowel and contains Meissner plexus. The myenteric plexus of Auerbach is on the external surface of the circular muscle layer. The outer longitudinal muscles form the taeniae coli. Finally the serosa is not present in the lower portions of the rectum.

The colon begins in the right lower quadrant with the cecum. The cecum extends approximately 6 to 8 cm below the ileocecal valve (where the terminal ileum enters the posteromedial aspect of the cecum) (Fig. 64-2). The angulation between the ileum and cecum via the superior and inferior ileocecal ligaments is important in maintaining competence against reflux at the ileocecal junction.[2] The cecum is the widest portion of the colon (7.5 to 8.5 cm in diameter), has the thinnest wall, and is entirely enveloped by peritoneum. The appendix originates from the lowest portion of the cecum and can be readily identified by following the converging taeniae. In 85% to 95% of people, the appendix lies posterior to the cecum, lateral and in line to the terminal ileum, but the position can vary, with the most frequent variants being retrocecal (toward the psoas muscle), pelvic, and retroileal.[3] During colonoscopy, visualization of the appendiceal orifice and ileocecal valve are the landmarks required in a complete colonic examination. From the cecum, the right colon ascends to the hepatic flexure (approximately 15 cm). The hepatic flexure is anterior to the inferior pole of the right kidney and overlies the second portion of the duodenum. The hepatic flexure is marked by medial, anterior, and downward angulation of the colon. When the right colon and mesentery are mobilized during a colectomy, care must be taken to avoid injury to the underlying duodenum. Only the anterior surface of the right colon is invested with peritoneum; laterally, the white line of Toldt marks the extent of the peritoneal covering and serves as an important landmark during surgical mobilization of the colon.

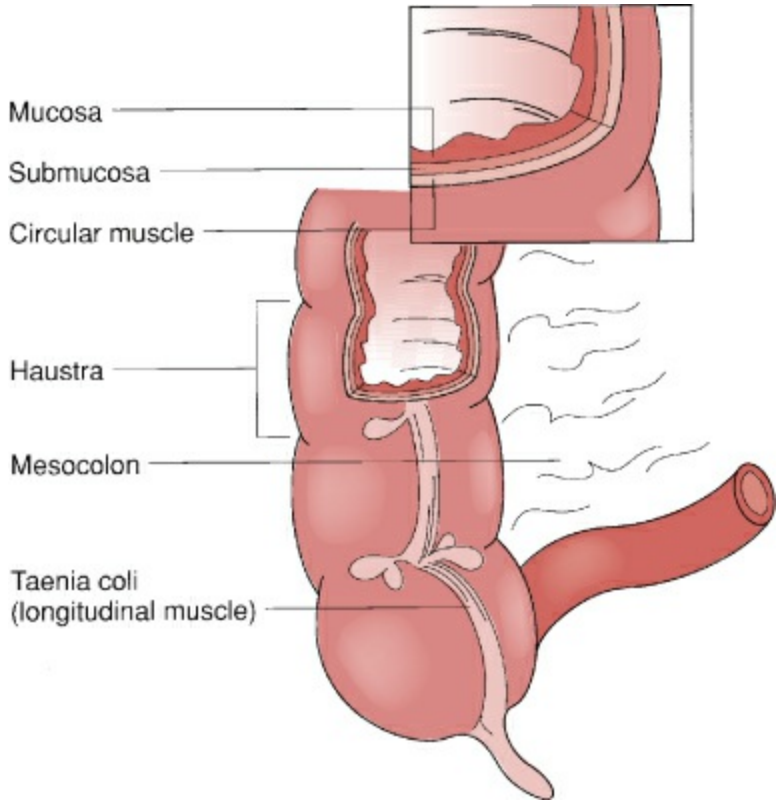

Figure 64-1. Layers of the colonic wall.

The transverse colon stretches from the hepatic flexure to the splenic flexure and is the longest segment of colon (between 30 cm and 60 cm). The transverse colon is suspended by the transverse mesocolon and is completely intraperitoneal. It is the most mobile portion of the colon and may descend to the level of the iliac crests or deep into the pelvis. The greater omentum descends from the greater curve of the stomach in front of the transverse colon and then ascends to attach to the transverse colon on its anterosuperior edge. To mobilize the transverse colon or enter the lesser sac, the fusion plane of the omentum to the transverse colon must be dissected. The splenic flexure is situated high in the left upper quadrant, more cephalad than the hepatic flexure, and lies anterior to the mid-left kidney and abuts the lower pole of the spleen. There are attachments from the colon to the diaphragm at the level of the 10th and 11th ribs and spleen (phrenocolic and splenocolic ligaments), and these must be carefully divided during mobilization of the splenic flexure to avoid splenic injury.

The descending colon is approximately 25 cm long and courses from the splenic flexure to its junction with the sigmoid colon at the pelvic brim. It lies anterior to the left kidney and, like the right colon, the anterior, lateral, and medial portions of the descending colon are covered by peritoneum.

The sigmoid colon extends from the pelvic brim to the sacral promontory, where it continues as the rectum and generally measures 15 to 50 cm in length. It is completely invested by peritoneum. The rectosigmoid junction is marked by the convergence of the colonic taenia. The sigmoid colon is extremely mobile and has a generous mesentery that extends along the pelvic brim from the iliac fossa across the sacroiliac joint to the second or third sacral segment. Because of its mobile mesentery, the sigmoid colon can twist and cause an obstruction, termed *sigmoid volvulus*. The left ureter runs in the intersigmoid

fossa, which is at the base of the mesosigmoid. When a high ligation of the inferior mesenteric artery is performed during a cancer operation or the sigmoid colon is being mobilized along the white line of Toldt, the left ureter should be identified to avoid inadvertent injury. Preoperative placement of urinary stents can be useful for locating the ureter intraoperatively in complex, reoperative pelvic surgery.

1 At the sacral promontory, the colon becomes the rectum. The outer layer of the rectal wall is composed of the longitudinal muscle, where the three teniae splay. The rectum measures 12 to 15 cm in length. It proceeds posterior and caudal along the curvature of the sacrum and coccyx, passing through the levator ani muscles, at which point it turns abruptly caudal and posteriorly at the anorectal ring, becoming the anal canal. Anterior to the rectum are the uterine cervix and posterior vaginal wall in women, and the bladder and prostate in men. Posteriorly, the rectum occupies the sacral concavity where the median sacral vessels, presacral veins, and sacral nerves run, all of which are invested in the presacral fascia. The rectum is marked by three curves. The upper and lower curves are convex and to the right, while the middle is convex and to the left. Within the lumen, these correspond to the valves of Houston, which separate the lower third, middle third, and upper third of the rectum – important landmarks when the location of a rectal abnormality is established endoscopically (the lower rectal valve is at 7 to 8 cm from the anal verge, middle rectal valve at 9 to 11 cm, and upper rectal valve at 12 to 13 cm).[4] The valves do not contain all layers of the bowel wall and thus biopsy at this location carries minimal risk of perforation. The middle valve of Houston is the internal landmark corresponding to the anterior peritoneal reflection. The anterior and lateral surfaces of the upper third of the rectum are intraperitoneal, whereas only the anterior surface of the middle third of the rectum is intraperitoneal in location. The lower third of the rectum is entirely extraperitoneal. The mesorectum is the term used to describe the areolar tissue surrounding the rectum that contains nerves, lymphatics, and terminal branches of the superior hemorrhoidal branch of the inferior mesenteric artery. Although it invests the rectum circumferentially, the mesorectum is most prominent posterior to the rectum. It is invested by the fascia propria of the rectum, a continuation of the parietal endopelvic fascia (Fig. 64-3). The fascia propria (investing fascia) includes the distal two-thirds of the posterior rectum and the distal one-third of the anterior rectum, where it is no longer intraperitoneal. A total mesorectal excision entails removal of the entire rectum without violating the fascia propria of the rectum. This is accomplished by mobilizing the rectum using the plane between the fascia propria of the rectum and the presacral fascia. Anterior to the investing fascia (fascia propria) is a delicate layer of connective tissue known as Denonvilliers fascia, which separates the rectum from its anterior structures. Waldeyer fascia (rectosacral fascia) is the presacral fascia that is an extension of the parietal pelvic fascia from the periosteum of sacral segment four to the posterior wall of the rectum. It contains branches of the sacral splanchnic nerves. Below Waldeyer fascia is the supralevator or retrorectal space.

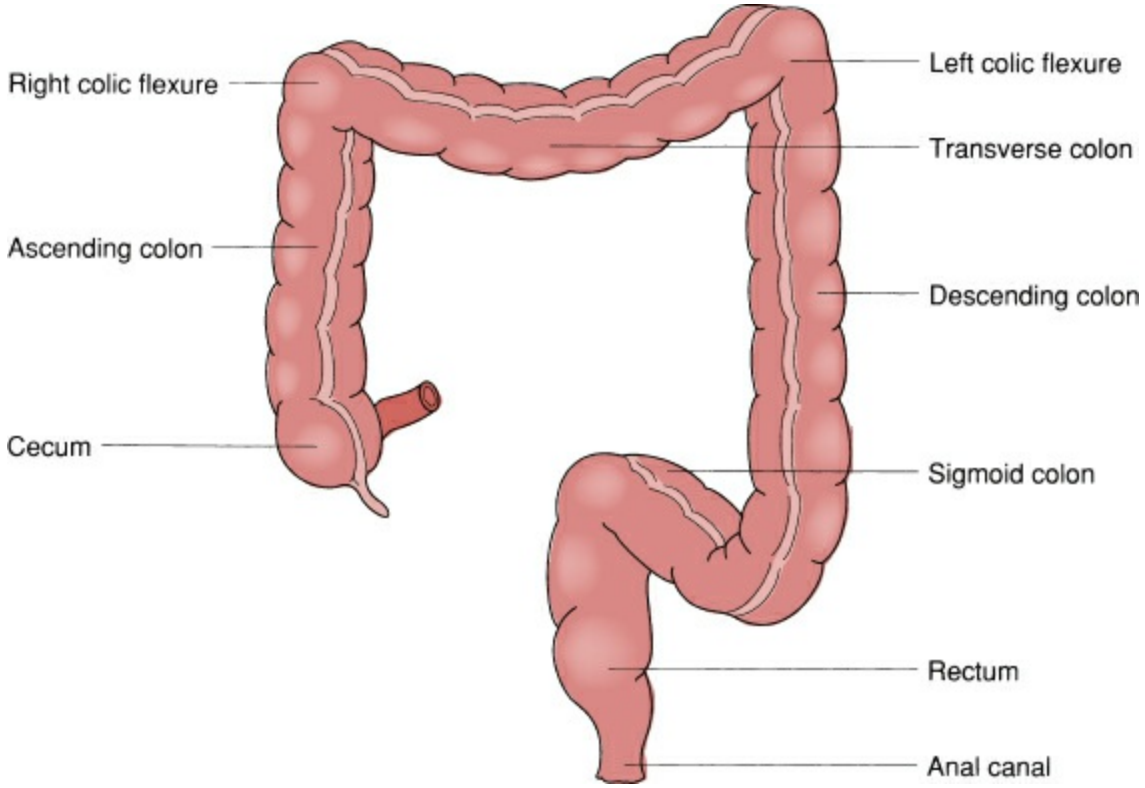

Figure 64-2. General anatomic components of the colon.

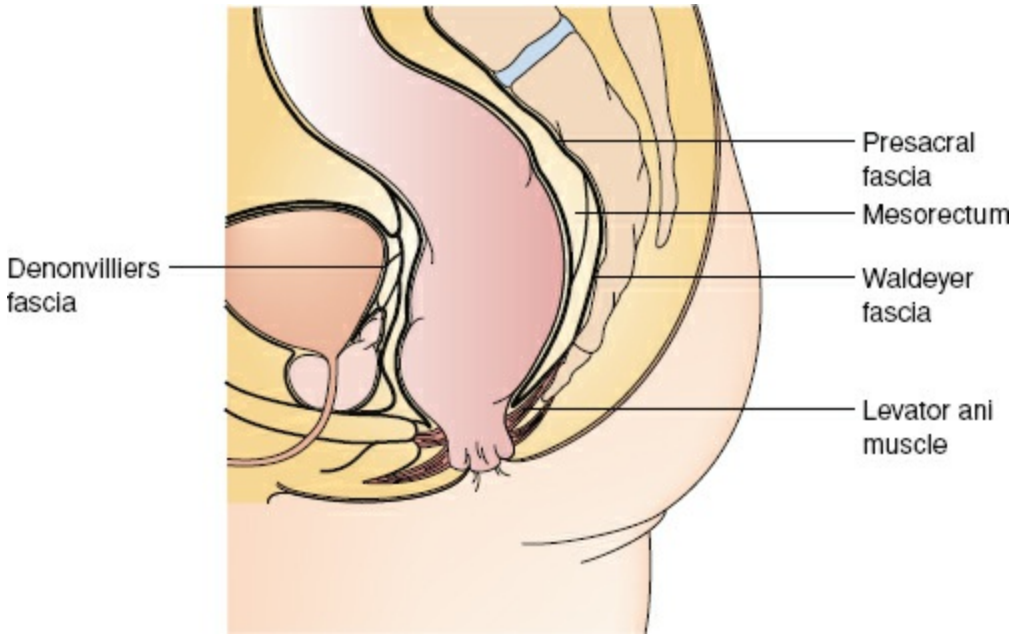

Figure 64-3. Fascial relationships of the pelvis.

The surgical anal canal begins at the anorectal ring or levator ani muscles and extends to the anal verge. It measures 2 to 4 cm and is usually longer in men than in women. The internal anal sphincter (continuation of the circular smooth muscle of the rectum) and the external anal sphincter (continuation of the puborectalis muscle) encircle the anal canal and control fecal continence. The internal anal sphincter relies on autonomic innervation, while the external anal sphincter uses somatic innervation. The median length and thickness of the female anterior external sphincter is 11 and 13 mm and thus a small tear sustained during vaginal delivery may cause fecal incontinence.[5] There are three layers of

the external sphincter – subcutaneous (traversed by the conjoined longitudinal muscle with some fiber attachments to the skin), superficial (connective tissue attaches posteriorly, forming the anococcygeal ligament), and deep (continues with the puborectalis muscle). Between the internal and external anal sphincters, the longitudinal muscle of the rectum joins fibers of the levator ani and puborectalis muscles to form the conjoined longitudinal muscle. The dentate line marks the transition between the columnar epithelium of the intestine and the squamous epithelium of the anal canal. The transition between these two epithelia is called the anal transitional zone. The Columns of Morgagni are the 6 to 14 longitudinal folds located at the dentate line. Small pockets between these columns called anal crypts contain anal glands, which may become obstructed with foreign material to cause an infection. Below the dentate line is the anoderm, which extends to the anal verge and does not contain accessory skin structures, such as hair, sebaceous and sweat glands. The autonomic nervous system innervates proximal to the dentate line and the somatic nervous system supplies the anoderm and distally.

Pelvic Floor

The perineal body is the tendinous insertion of the external anal sphincter, bulbocavernosus, and superficial and deep transverse perineal muscles. It supports the perineum and separates the vagina from the anus.

Three striated muscles that attach to the pubic bone make up the pelvic floor or levator ani muscles: iliococcygeus, pubococcygeus, and puborectalis. The pelvic floor muscles are supplied by branches from the third sacral nerve, while the external anal sphincter is supplied by nerve fibers traveling with the pudendal nerve on the levators undersurface.

The puborectalis originates from the back of the symphysis pubis and forms a U-shaped sling as it joins the opposite muscle posteriorly. The iliococygeus muscle arises from the ischial spine and posterior part of the obturator fascia and travels inferiorly, posteriorly, and medially to insert into the last two segments for the sacrum and coccyx. The pubococcygeus muscle arises from the anterior half of the obturator fascia and the posterior pubis. Its fibers are directed backward, downward, and medially, where they decussate with fibers of the opposite side. The decussation is called the anococcygeal raphe.

Anorectal Spaces

The perianal space surrounds the anal canal superficially and contains the external hemorrhoidal plexus. The ischioanal space extends laterally and goes superiorly to the levator ani from the skin on the perineum. The levator ani and external sphincter muscles form the medial boundary, while the lateral wall is formed by the obturator fascia. The superficial postanal space connects the perianal spaces with each other posteriorly below the anococcygeal ligament, while the deep postanal space lies above the anococcygeal ligament. The ischioanal and perianal spaces make the ischioanal fossa. The deep postanal and ischiorectal spaces form a horseshoe configuration that may be involved in a horseshoe abscess. Below the perianal space between the sphincter muscles is the intersphincteric space. The submucosal space contains the internal hemorrhoidal plexus and lies between the internal anal sphincter and the mucosa distal to the dentate line. Proximally, it becomes the submucosa of the rectum. Above the levator complex is the supralevator space, which extends superiorly to the peritoneum at the rectosacral fascia. The retrorectal space extends above the rectosacral fascia and lies between the upper two-thirds of the rectum and sacrum.

Arterial Blood Supply

2 3 The arterial blood supply to the colon, rectum, and anus is highly variable. The following summarizes the general courses of the arterial blood supply. The superior mesenteric artery arises from the aorta, runs posterior to the pancreas, and passes anterior to the third portion of the duodenum (Fig. 64-4). In addition to supplying the small bowel through jejunal and ileal branches, the superior mesenteric artery gives rise to the ileocolic, right colic, and middle colic branches that supply the cecum, ascending colon, and proximal transverse colon. The right colic arterial anatomy is particularly variable and can be absent or arise from the ileocolic or the superior mesenteric artery. The middle colic artery has a right branch that supplies the hepatic flexure and the right portion of the transverse colon, while the left branch supplies the left portion of the transverse colon. The inferior mesenteric artery arises from the anterior surface of the aorta, typically 3 to 4 cm above the aortic bifurcation, and supplies the distal transverse colon, descending colon, sigmoid colon, and upper rectum. The inferior mesenteric artery gives rise to the left colic artery and sigmoidal branches, then continues in the sigmoid mesentery, and after crossing the left iliac vessels, is renamed the superior rectal/hemorrhoidal artery. The inferior mesenteric artery may also function as an important collateral vessel to the lower extremities during instances of distal aortic occlusion. The superior hemorrhoidal artery descends behind the rectum and splits into right and left branches in the mesorectum. It is the main blood supply of the rectum. The middle and inferior rectal/hemorrhoidal arteries arise from either the internal pudendal arteries or the hypogastric arteries and supply the distal two-thirds of the rectum. The presence of the middle rectal artery, in particular, can be variable. A series of arterial arcades along the mesenteric border of the entire colon, known as the marginal *artery of Drummond,* connect the superior mesenteric and inferior mesenteric arterial systems. The marginal artery may be attenuated or absent at the distal transverse colon/splenic flexure, the delineation between the midgut and hindgut, and thus ischemic colitis most commonly affects this region. The *arc of Riolan* (“meandering mesenteric artery”) is a short loop connecting the left branch of the middle colic artery and the trunk of the inferior mesenteric artery. The inferior rectal/hemorrhoidal arteries traverse the ischioanal fossa and supply the anal canal and external anal sphincter muscles.

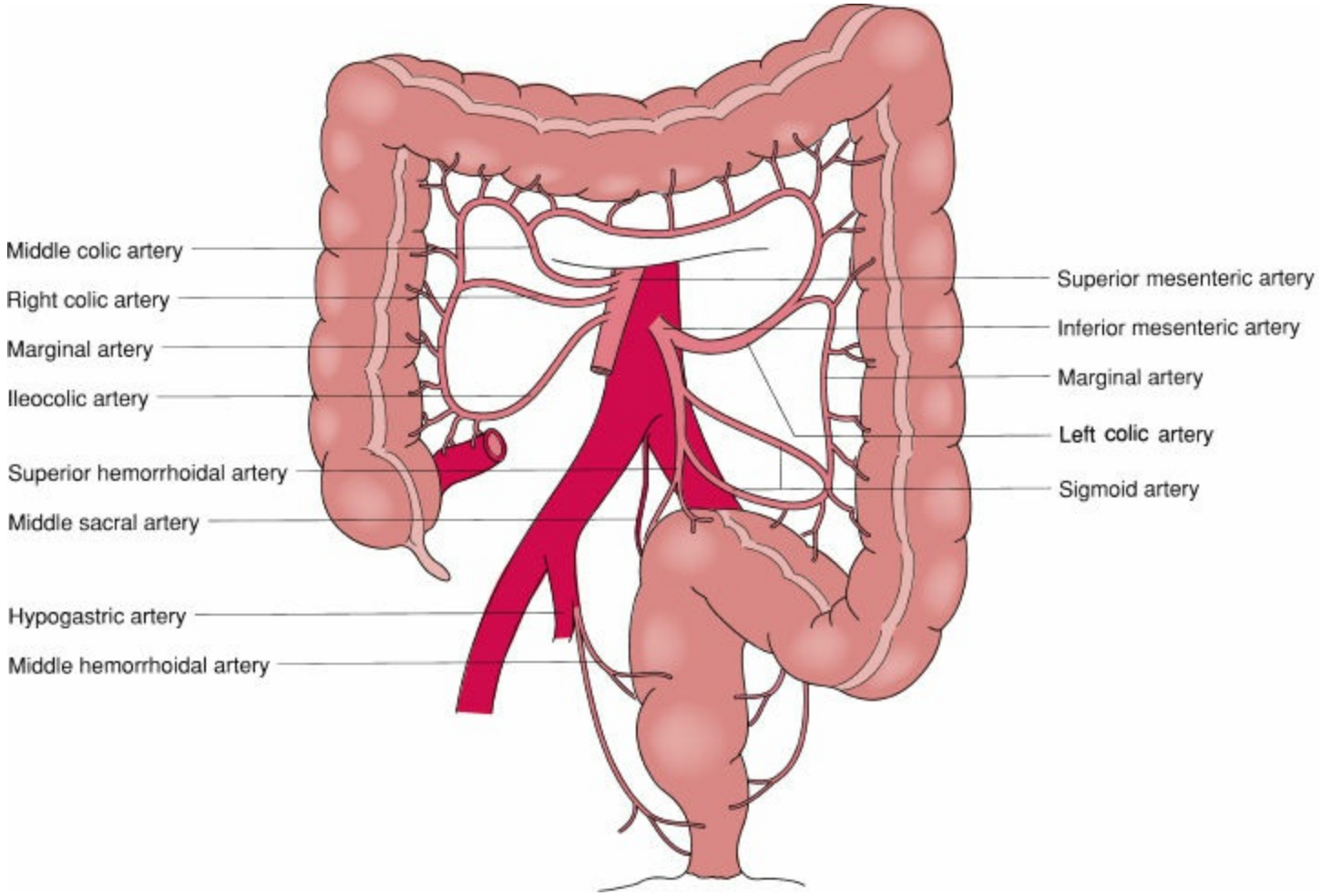

Figure 64-4. Arterial blood supply of the colon.

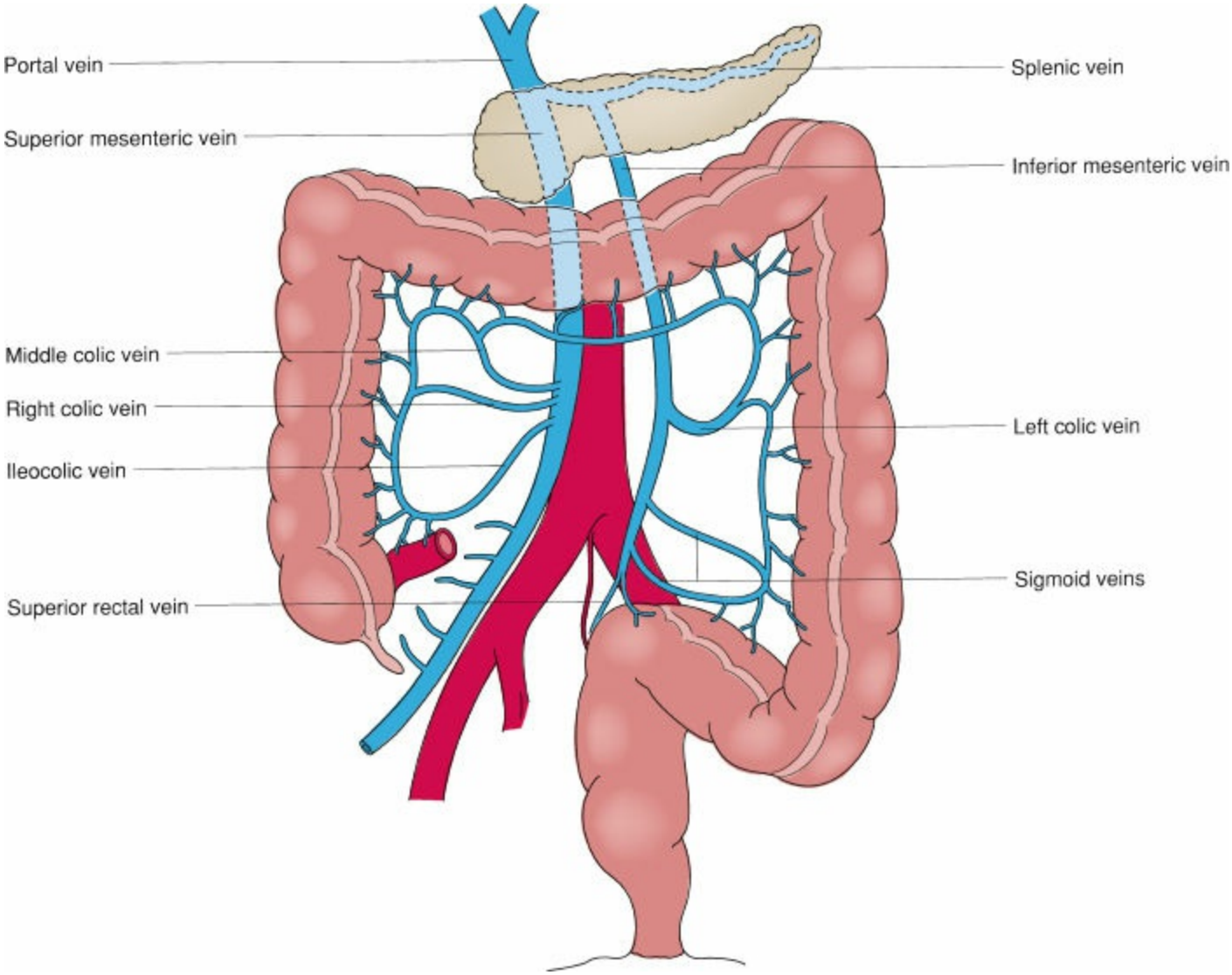

Figure 64-5. Venous drainage of the colon by the portal vein.

VENOUS DRAINAGE

The veins that drain the large intestine bear the same terminology and follow a course similar to that of their corresponding arteries (Fig. 64-5). The veins from the right colon and transverse colon, along with the veins draining the small intestine, drain into the superior mesenteric vein. The superior mesenteric vein runs slightly anterior to and to the right of the superior mesenteric artery. The superior mesenteric vein courses beneath the neck of the pancreas, where it joins with the splenic vein to form the portal vein. The inferior mesenteric vein is a continuation of the superior rectal vein and drains blood from the left colon, sigmoid colon, rectum, and superior anal canal. The inferior mesenteric vein follows a course of its own, starting at the left colic artery, and ascends over the psoas muscle in a retroperitoneal plane. The vein courses under the body of the pancreas to drain into the splenic vein. During an anterior resection of the rectum, division of the inferior mesenteric vein at the inferior border of the pancreas can provide additional mobility of the left colon to facilitate a coloanal anastomosis. The superior hemorrhoidal (rectal) veins drain blood from the rectum and upper part of the anal canal, where the internal hemorrhoidal plexus is situated, into the portal system via the inferior mesenteric vein. The middle hemorrhoidal (rectal) veins drain the lower part of the rectum and upper part of the anal canal into the systemic circulation via the internal iliac veins. The inferior hemorrhoidal (rectal) veins drain blood from the lower rectum and anal canal, where the external hemorrhoidal plexus is located, via the internal pudendal veins into the systemic venous circulation via the internal iliac veins. In the setting of portal hypertension, the superior, middle, and inferior hemorrhoidal veins interact to shunt venous blood from the portal system into the systemic circulation.

LYMPHATIC DRAINAGE

4 Lymphatic drainage generally follows the arterial blood supply of the colon and rectum. In the anal canal, lesions above the dentate line drain into the inferior mesenteric lymph nodes. Lesions below the dentate line drain into the internal iliac lymph nodes but can also drain into the inferior mesenteric lymph nodes.

Neural Components

The colon possesses extrinsic and intrinsic (enteric) neuronal systems. The extrinsic system consists of sympathetic and parasympathetic nerves that inhibit or stimulate colonic peristalsis, respectively. The sympathetic innervation to the right colon originates from the lower thoracic segments of the spinal cord and travels in the thoracic splanchnic nerves to the celiac and superior mesenteric plexuses. Postganglionic fibers emerge from here and course along the superior mesenteric artery and its branches to the right side of the colon. The parasympathetic nerves originate from the right vagus nerve and travel along with the sympathetic nerves to the right side of the colon. The left side of the colon and the rectum receive sympathetic fibers that arise from L1 through L3 segments of the spinal cord. This passes through the ganglionated sympathetic chains and leaves as a lumbar sympathetic nerve to join the preaortic plexus. It extends along the inferior mesenteric artery as the mesenteric plexus and then becomes the presacral nerve or superior hypogastric plexus. These hypogastric nerves are identified at the sacral promontory 1 cm lateral to the midline. The key zones of sympathetic nerve damage are during ligation of the inferior mesenteric artery and during initial posterior rectal mobilization adjacent to the hypogastric nerves. The parasympathetic supply to the left side of the colon and the rectum comes from S2 through S4 spinal cord segments. The sacral nerve fibers become the nervi erigentes, which join the pelvic plexus at the pelvic side walls. To prevent injury during full mobilization of the rectum, the lateral ligament should be cut close to the rectal side wall. Both the sympathetic and parasympathetic nervous systems play a role in erection, in that damage to the parasympathetics can lead to erectile dysfunction, while retrograde ejaculation can occur with damage to sympathetic nerve injury.

The intrinsic, or enteric, nervous system consists of two groups of plexuses that are identified by their location within the colon wall. This system can function independently of the central nervous system and controls motility and exocrine and endocrine functions of the gut, and is involved in intestinal immune regulation and inflammatory responses. The Meissner plexus is located in the submucosa between the muscularis mucosae and the circular muscle of the muscularis propria and is important in secretory control. The myenteric plexus, also known as the *Auerbach plexus,* is located between the inner circular muscle and outer longitudinal muscle layers of the colon and primarily controls intestinal motility.[4]

The internal anal sphincter is supplied by the sympathetic and parasympathetic nerves that supply the lower rectum. The parasympathetic nerves are inhibitory. The external sphincter is supplied by the inferior rectal branch of the internal pudendal nerve and the perineal branch of S4. Sensation of the anal canal is from the inferior rectal nerve, a branch of the pudendal nerve.

PHYSIOLOGY

The colon's function is to absorb, store, digest carbohydrate and protein residues, and secrete mucus.

Absorption

The colon absorbs water, sodium, and chloride and secretes potassium and bicarbonate. The physiologic control of colonic water and electrolyte transport requires careful integration of neural, endocrine, and paracrine components. Although colonic epithelium does not actively absorb glucose or amino acids as the small-intestinal epithelium does, the colon does absorb short-chain fatty acids and vitamins that are produced by bacterial breakdown of nonabsorbed carbohydrates and amino acids. These short-chain fatty acids, which include acetate, butyrate, and propionate, are absorbed in a concentration-dependent fashion. They are a major (70% of colonic mucosal energy) energy substrate for colonic epithelial cells and represent the major fecal anions.[6]

Approximately 1,500 mL of ileal effluent reaches the cecum in a 24-hour period, 90% of which is reabsorbed in the colon; 100 to 150 mL of water remains in stool. The colon has a tremendous capacity that allows it to absorb as much as 5 to 6 L of water within a 24-hour period. When colonic capacity is exceeded, diarrhea results.[7] Normally formed feces consist of 70% water and 30% solid material. Almost half of the solid material is made up of bacteria and the other half is composed of undigested food material and desquamated epithelium. Water absorption in the colon is a passive process that depends primarily on the osmotic gradient established by the active transport of sodium across the colonic epithelium. The composition of ileal effluent and luminal flow rates also play an important role in water absorption. Upsetting the balance of these three factors results in diarrhea. The absorptive capacity is not the same throughout each segment of the colon. Salt and water absorption is greatest in the right colon. Patients undergoing a right hemicolectomy should therefore be counseled preoperatively that they may experience loose bowel movements in the early postoperative period. Patients should also be reassured that this will resolve with time as the remaining colon adapts.

Sodium absorption by the colonic epithelium is an active cellular transport process similar to that seen in small-intestinal and renal epithelial cells.[8] Initially, sodium absorption involves the passive movement of sodium across the apical membrane into the mucosal cell down an electrochemical gradient. To maintain an adequate electrochemical gradient, intracellular sodium is removed from the cell into the interstitial space in exchange for potassium at the basolateral membrane. This is an energy-dependent process that is controlled by Na^+-K^+-adenosine triphosphatase (ATPase). Mineralocorticoids (predominantly aldosterone) and glucocorticoids accelerate sodium absorption and potassium excretion in the colon by increasing Na^+-K^+-ATPase activity.[9] Potassium movement into the colonic lumen is primarily a passive process that depends on the electrochemical gradient generated by the active transport of sodium across colonic epithelial cells. Chloride absorption in the colon is generally thought to be an energy-independent process that is associated with reciprocal exchange for bicarbonate at the luminal border of the mucosal cell.[10] Patients with a ureterosigmoidoscopy may develop hyperchloremia and secrete excessive amounts of bicarbonate.

Twenty percent of urea synthesized by the liver is metabolized mainly in the colon. This is converted into 200 to 300 mL of ammonia each day, of which most is absorbed by

passive coupled diffusion with bicarbonate and forms ammonia and carbon dioxide. Ammonia is also derived from dietary nitrogen, epithelial cells, and bacterial debris. Mucus is produced by goblet cells and secreted into the lumen via stimulation of the pelvic nerves.

Colonic Flora

5 The bacterial flora of the colon is established soon after birth and depends in large part on dietary and environmental factors. The colon is populated by approximately 10^{13} commensal bacteria.[10] The vast majority of the normal colonic flora consists of anaerobic bacteria, with *Bacteroides* species being most prevalent, particularly *B. fragilis*.[11] Aerobic colonic bacteria are mainly coliforms and enterococci, with *Escherichia coli* being the most predominant coliform. The colonic flora is important for (a) digestion and absorption of complex macromolecules, (b) protecting the colon against invasion by noncommensal bacteria, and (c) development of mucosal immunity. Fermentation of carbohydrates generates short-chain fatty acids, including acetic acid, propionic acid, and butyrate, which is the primary nutrient for the colonic mucosa. Colonic bacteria also produce certain vitamins, such as vitamin K and B_{12}, which are absorbed by the host. The enterohepatic circulation of bilirubin and bile acids depends on bacterial enzymes produced by fecal flora. The degradation of bile pigments by colonic bacteria gives stool its characteristic brown color. Colonic bacteria also play an important role in preventing infection by controlling the growth of potentially pathogenic bacteria such as *Clostridium difficile*.

6 Host and colonic flora have a mutualistic relationship; however, disturbances of this coexistence can lead to human disease.[12] Changes in diet and use of antibiotics can dramatically alter the microbiome. Dysregulation of the flora has been implicated in the pathogenesis of inflammatory bowel disease, obesity and, to a lesser extent, colorectal cancer. Increasingly, dysregulation has also been linked to nongastrointestinal diseases including autism and other neurologic conditions. In animal studies, mice with certain immune deficiencies that make them prone to colitis fail to develop colitis when raised under germ-free conditions. Analysis of the microbiota of patients with inflammatory bowel disease revealed markedly different flora compositions in ulcerative colitis, Crohn disease, and healthy control patients. Similarly, certain genetically altered mice with a propensity to develop colorectal cancer fail to develop tumors in germ-free conditions. Although studies of human flora and colorectal cancer are limited, preliminary studies have raised interest in modulating the colonic flora as a way to treat and/or prevent colitis and other diseases of the colon.

Colonic Motility

Motor activity varies greatly throughout the colon. There are two patterns of colonic motility: segmental contractions, which are single or clustered contractions, and propagated activity, which is either high-amplitude (>100 mm Hg) propagated contractions (HAPCs) or low-amplitude (<60 mm Hg) propagated contractions (LAPCs). *Segmental contractions* are intermittent contractions of the longitudinal and circular muscles that result in the segmented appearance of the colon.[13] These contractions propel luminal contents in a back-and-forth pattern over short distances, slowing aboral transit and allowing for water reabsorption.[14] *Propagated activity* consists of strong, propulsive contractions of the smooth muscle that involve a long segment of colon.[15] The LAPCs move luminal contents forward at a rate of 0.5 to 1.0 cm/s and typically last for 20 to 30 seconds.[13] HAPCs occur three to four times per day, primarily after awakening, exercise, and after meals.

The orderly progression of colonic luminal contents from cecum to anus requires the coordination of smooth muscle contractions. Calcium-dependent cyclic depolarization and repolarization of the colonic smooth muscle cell membrane generates a basic electrical pattern of slow-wave activity. This activity allows each smooth muscle cell to control its own contraction and to couple with adjacent smooth muscle cells.[16] The extrinsic (autonomic) and intrinsic (enteric) neuronal systems also interact to influence colonic motility.

Defecation

As the fecal mass enters the rectum, the internal anal sphincter relaxes, while the external anal sphincter contracts to maintain continence. Distention of the rectum in this setting is the primary stimulus for defecation to begin. At this point, the urge to defecate may be suppressed by conscious contraction of the external anal sphincter. Receptive relaxation of the rectal ampulla accommodates the fecal mass and the urge to defecate passes unless the volume of feces is extremely large or the sphincter mechanism is impaired. If the subject voluntarily accedes to the urge to defecate, a Valsalva maneuver occurs, which increases the intra-abdominal pressure to overcome the resistance of the external anal sphincter. Relaxation of the pelvic muscles causes the pelvic floor to descend and the anorectal angle to straighten. Conscious inhibition of the external anal sphincter then allows passage of the feces. On completion, the pelvic floor returns to its resting position and the anal sphincter muscles return to their resting activity, closing the anal canal. Under normal circumstances, this process occurs once every 24 hours; however, the interval between bowel movements may vary between 8 and 12 hours and 2 to 3 days in normal subjects.

The frequency of defecation is influenced by multiple environmental and dietary factors. The gastrorectal reflex occurs as postprandial defecation. An increase in rectal tone results in increased pressure from the fecal mass on the rectal wall, providing heightened sensation.

Anal Continence

There are varying degrees of anal continence, with a spectrum from complete control to complete lack of control. Maintaining continence is complex, as both voluntary and involuntary mechanisms play a role in anal continence. The most important mechanisms involve the internal anal sphincter, which contributes 52% to 85% of the pressure generated to maintain continence.[17,18] The rest of the contribution to the anal basal pressure includes the following: 30% from the external anal sphincter and 15% from the hemorrhoidal cushions. The internal sphincter is supplied by dual extrinsic innervation: sympathetic outflow (S5) via the hypogastric nerve provides motor supply and inhibition by parasympathetic outflow (S1–S3). The external sphincter nerve supply is dependent on the pudendal nerve (S2–S4) and maintains tonic activity at rest. When stool enters the rectum, the contents of the rectum are sampled by sensors in the anal canal to determine whether the contents are solid, liquid, or gas. By discriminating between the consistency of the stool, the pelvic floor and sphincter muscles are able to coordinate a complex mechanism through angulation of the pelvic floor and contraction of the anal sphincter muscles. Other mechanisms contributing to continence include stool consistency and volume. Modification of the stool consistency to more solid and less voluminous stool may allow a patient to recapture fecal control. Reservoir function of the rectum consists of lateral angulations of the sigmoid colon and the valves of Houston as a mechanical barrier to slow the progression of stool.

DISORDERS OF COLONIC MOTILITY AND ANAL CONTINENCE

Constipation

7 Constipation is common and may affect up to 15% of people, but only a portion of affected individuals seek medical help.[19] Colorectal surgeons, gastroenterologists, gynecologists, and family medicine physicians are frequently called upon to treat constipation.[20] To evaluate constipation, the clinician must ask focused questions about bowel function. Constipation can mean infrequent bowel movements, straining, or hard stools. The Rome criteria were developed to help standardize the diagnosis (Table 64-1). Constipation can be caused by lifestyle choices, side effects of medications taken for other reasons, medical conditions (such as hypothyroidism), structural abnormalities of the colon, pelvic floor dysfunction, and colonic inertia (Table 64-2). Evaluation of the constipated patients includes a thorough history, a physical examination including a rectal examination, and evaluation for sources of pelvic floor dysfunction such as rectocele. Colonoscopy may be necessary to eliminate a structural bowel obstruction as the cause of constipation.

DIAGNOSIS

Table 64-1 Rome III Criteria for the Diagnosis of Constipation

Two or more of the following:
Straining in >25% of bowel movements
Incomplete evacuation of the rectum in >25% of bowel movements
Hard stool consistency in >25% of bowel movements
Three or fewer bowel movements weekly
Manual maneuvers in >25% of bowel movements
Sensation of anorectal obstruction in >25% of bowel movements
Do not meet the criteria for irritable bowel syndrome
Loose stools rarely present without the use of laxatives

From Longstreth GF, Thompson WG, Chey WD, et al. Functional bowel disorders. *Gastroenterology* 2006;130(5):1480–1491.

ETIOLOGY

Table 64-2 Causes of Constipation

Lifestyle
Inadequate fluid intake
Inadequate fiber intake
Inactivity
Laxative abuse
Medications
Anticholinergics
Antidepressants
Antihypertensive medications
Iron
Narcotics
Medical Conditions
Spinal cord dysfunction
Multiple sclerosis
Diabetes mellitus
Hypothyroidism
Uremia
Hypercalcemia
Electrolyte abnormality
Depression
Anorexia
Sexual abuse
Colon Abnormality
Cancer
Crohn disease
Chagas disease
Irradiation
Pelvic Floor Dysfunction
Nonrelaxing puborectalis
Anal stenosis
Rectocele

From Longstreth GF, Thompson WG, Chey WD, et al. Functional bowel disorders. *Gastroenterology* 2006;130(5):1480–1491.

After eliminating medication-related or metabolic causes of constipation and in the absence of systemic symptoms, it may be practical to initiate medical therapy before proceeding with radiologic testing for rare conditions such as colonic dysmotility or pelvic floor dysfunction. The goal of first-line medical therapy is to increase stool bulk and physical activity. Fiber intake should be increased to 20 to 30 g/d. To achieve this recommended daily amount, fiber supplementation with either psyllium or methylcellulose is frequently required. At least eight glasses of water should be ingested daily. Fiber and water intake increases stool bulk, and bulky bowel movements stimulate colonic motility. If fiber, water, and exercise do not relieve constipation, then laxatives

should be added to the regimen. Laxatives can be divided into different categories by mechanism of action (Table 64-3). Osmotic laxatives are usually the first-line treatment for severe constipation. Long-term use of laxatives, which irritate the colon, should be avoided, however, because they can actually impair colon function. Melanosis coli, a dark discoloration of the colonic mucosa seen on colonoscopy, is a sign of frequent laxative use.

Table 64-3 Laxatives

Bulking Agents (Soluble Fiber)
Psyllium (Konsyl, Metamucil)
Methylcellulose (Citrucel)
Calcium polycarbophil (FiberCon)
Colonic Stimulants/Irritants
Senna (Senokot and Peri-Colace)
Cascara
Bisacodyl (Dulcolax)
Stool Softeners
Mineral oil
Docusate sodium (Colace)
Osmotic Laxatives
Lactulose
Polyethylene glycol (MiraLAX)
Sodium phosphate (Fleets Phosphosoda)
Magnesium hydroxide (milk of magnesia)

Some patients whose constipation does not respond to standard medical therapy will be found to have slow-transit constipation or pelvic floor dysfunction, both of which require radiologic studies for diagnosis. The most common technique for evaluating colonic transit is a Sitz marker study (Fig. 64-6). To complete this test, all laxatives must be stopped 48 hours before the study. On day 0, a set number of radiopaque markers are ingested; an abdominal radiograph is obtained on day 1 to document that the markers were ingested and have passed through the small bowel into the colon, and again on day 5 to determine if the markers have been expelled. Normally, on day 5, more than 80% of the markers should be evacuated. If more than 20% of the markers remain and they are either clustered in the right colon or evenly distributed throughout the colon, the patient has slow-transit constipation. Outlet obstruction is suggested by clustering of the markers in the sigmoid or rectum. Outlet dysfunction can be further evaluated with defecography, a fluoroscopic study of defecation. Slow-transit constipation is best treated with surgery, and obstructed defecation with biofeedback therapy.

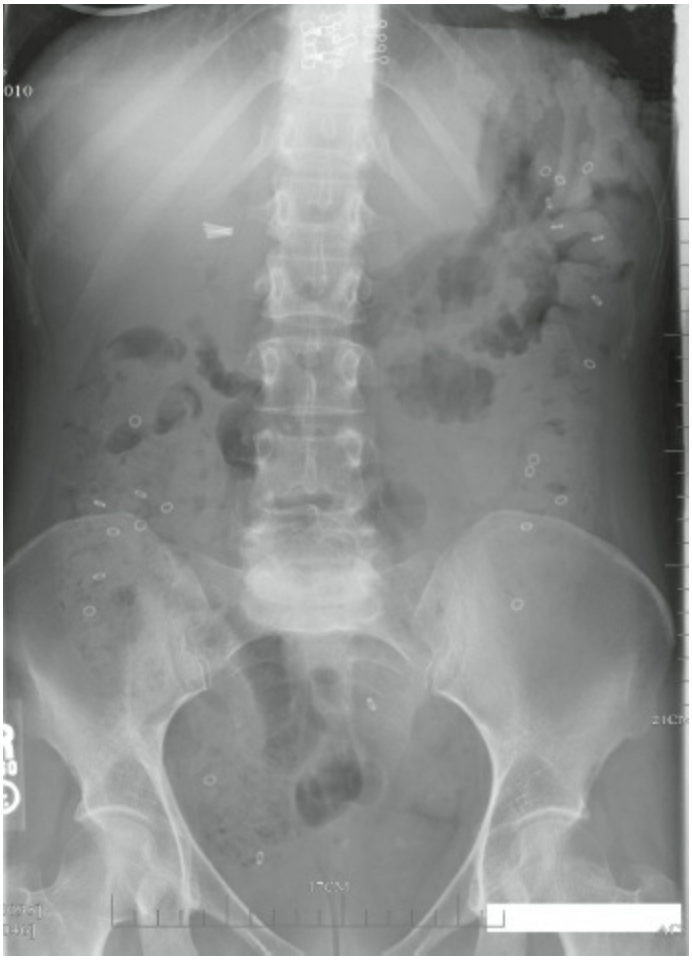

Figure 64-6. Sitz marker study demonstrating colonic inertia.

Postoperative Ileus

8 9 Postoperative ileus is transient impairment of bowel function after an operation. It is most common in patients after intra-abdominal surgical procedures, particularly colonic operations. Clinically, postoperative ileus is manifested by abdominal distention and delayed passage of flatus and, less frequently, by nausea and vomiting. After an abdominal operation, the colon usually takes 3 to 5 days to recover, whereas the stomach and small bowel resume normal motor function more rapidly (1 to 2 days and 1 day, respectively).[21] In a recent multicenter study, the average length of hospital stay after bowel resection was 6.6 days, with 11.5% of patients requiring a nasogastric tube for ileus.[22] Postoperative ileus is multifactorial. Surgical and anesthetic technique, narcotic use, inactivity, and postoperative infectious complications all have been implicated in prolonged ileus. Bowel manipulation has also been suggested to contribute to the development of ileus.[22] The observation that postoperative ileus is shorter after minimally invasive surgery adds credence to this theory.[23] Use of the anesthetic agent halothane, as well as opioid analgesics, can prolong postoperative ileus.[21] After surgery, systemically administered morphine, in addition to binding to μ-opioid receptors in the central nervous system and promoting analgesia, binds to peripheral μ-opioid receptors in the colon and causes nonpropulsive electrical activity that can prolong ileus.[24] Given this, recent research has focused on strategies to minimize the use of perioperative narcotics with the goal of preventing or minimizing postoperative ileus. One of the most promising strategies is the use of a thoracic epidural for postoperative analgesia. In addition to delivering analgesia with minimal narcotics, thoracic epidural blocks promote parasympathetic activity by blunting sympathetic inhibition of the gut, thereby promoting gut motility. The greatest benefit is seen with epidural infusions of local anesthetic (lidocaine or bupivacaine), as compared to narcotics.[21] Other benefits of using thoracic epidurals in the postoperative period are improved mental acuity and overall better pain control as compared to traditional narcotic-based regiments, both of which promote early mobility, particularly in elderly patients.[25] Alvimopan, an oral medication that blocks the μ-opioid receptors in the gastrointestinal tract, is the most studied medication to prevent postoperative ileus. A phase III multicenter study of patients who had a bowel resection or hysterectomy found that alvimopan (12 mg before surgery, then twice a day until discharge) decreased hospital stay by 18 hours as compared to placebo, in narcotic naïve patients.[26] As understanding of gut neurophysiology continues to improve, it is anticipated that more narcotic sparing pain regimens will be available for the management of postoperative pain.

Enhanced recovery protocols are increasingly gaining traction in the United States. Initially called Fast Track Surgery by Wilmore and Kehlet,[27] and later Enhanced Recovery After Surgery (ERAS), they focus on incorporating evidence-based treatments into clinical pathways with a particular emphasis on multimodal pain management and avoidance of narcotics.[28] General principles of enhanced recovery protocols include preoperative education, avoidance of preoperative fasting and postoperative nasogastric tubes, early introduction of enteral feeding, avoidance of parenteral narcotic analgesia.[29] The

enhanced recovery protocols accelerate surgical recovery and are associated with reductions in length of hospital stay and decreased 30 postoperative morbidity including infectious complications and postoperative ileus.[30–33] In order to implement protocols and maintain high levels of compliance, enhanced recovery requires a multidisciplinary team approach with surgeons, anesthesia providers, nurses and care coordinators collaborating for both the implementation and sustaining of the protocol. Patient engagement and preoperative expectation setting is essential. Most successful programs have developed enhanced recovery focused educational materials and report marked increase in patient satisfaction postprotocol implementation.

Irritable Bowel Syndrome

Irritable bowel syndrome is defined as abdominal pain that is not associated with an anatomic abnormality and may or may not be associated with alterations in bowel habits. The causes of this disorder are uncertain. Emotional stress and psychiatric illness have been implicated in the pathogenesis of the disorder and may exacerbate symptoms.[34] Physiologic abnormalities have also been demonstrated, as has abnormal colonic motility in response to an ingested meal.[35] Altered myoelectric activity and abnormal gut hormone secretion have also been cited as potential causes.

Because no one, clear cause of irritable bowel syndrome has been demonstrated, no specific treatment regimen has been defined for this disorder. Most patients have asymptomatic periods interrupted by intervals of symptoms. The approach to treatment begins with an evaluation of the factors associated with irritable bowel syndrome. Diagnosis and treatment of an underlying psychiatric problem may resolve the patient's symptoms. A detailed dietary history should also be taken, and factors that contribute to constipation or diarrhea should be adjusted appropriately. If these management strategies are not successful, gradually introducing anticholinergic medications may be helpful. Anticholinergic agents can reduce the rate of myoelectric activity and decrease tonic contractions in the colon, thereby relieving the cramping and bloating that many patients experience. Low doses of tricyclic antidepressants, including imipramine, amitriptyline, and nortriptyline, often decrease or eliminate abdominal symptoms. Constipation is known to be one major side effect of these agents, which may be helpful in patients with irritable bowel syndrome and underlying diarrhea, but a problem in patients with pre-existing constipation. The myriad treatment options described for irritable bowel syndrome underscores the poor understanding of this clinical entity.

Colonic Pseudo-obstruction

Colonic pseudo-obstruction, also known as *Ogilvie syndrome,* is massive dilation of the colon without an actual mechanical obstruction. In 1948, Ogilvie described two patients with colonic pseudo-obstruction from malignant infiltration of the celiac plexus that he postulated led to sympathetic inhibition.[36] In the intestine, stimulation of the sympathetic nervous system decreases intestinal motility, whereas activation of the parasympathetic nervous system promotes contractility. Colonic pseudo-obstruction results from an imbalance in the autonomic nervous system of the gastrointestinal tract. Various metabolic conditions, pharmacologic agents, and traumatic factors can alter the balance of the intestinal autonomic nervous system and have been associated with colonic pseudo-obstruction.[37] The most frequent presenting symptoms are abdominal pain and nausea and vomiting. On physical examination, the abdomen is distended and tympanic and may be mildly tender when palpated. Marked colonic distention present on an abdominal radiograph is the hallmark of the condition (Fig. 64-7). Fever and leukocytosis are rare and should raise the concern for perforation.[38] First-line management of colonic pseudo-obstruction is conservative and consists of nasogastric decompression, cessation of oral feedings, correction of fluid and electrolyte imbalances, and avoidance of narcotics and anticholinergics. If abdominal radiographs do not show gas throughout the colon, an abdominal computed tomography scan or a Gastrografin enema should be considered to rule out a mechanical obstruction. With conservative measures, colonic pseudo-obstruction resolves in more than 75% of cases. When the pseudo-obstruction persists for more than 6 days and/or the diameter of the cecum on abdominal radiograph is greater than 12 cm, the risk for cecal perforation increases.[38,39]

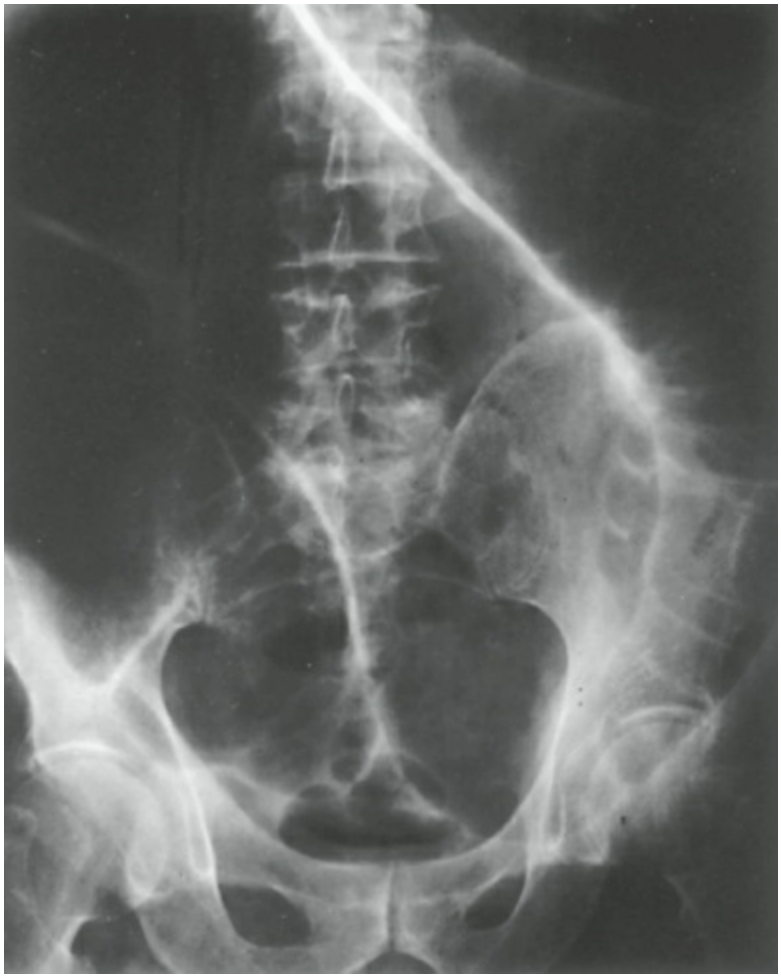

Figure 64-7. Pseudo-obstruction of the colon (Ogilvie syndrome).

Colonic pseudo-obstruction is most commonly seen in elderly patients who may have other significant medical conditions, so when free perforation occurs, it can be associated with significant morbidity and mortality (up to 40% in one study).[40] In patients whose pseudo-obstruction is not responding to conservative therapy but who have no signs of peritonitis, 2.5 mg of neostigmine given intravenously over 2 to 3 minutes has been found to decompress the colon promptly in nearly all patients.[41,42] Neostigmine is a reversible acetylcholinesterase inhibitor that stimulates the intestinal parasympathetic receptors, promoting colonic motility.[43] In a randomized controlled study, the pseudo-obstruction resolved promptly in 10 of 11 patients.[41] If neostigmine fails to decompress the colon, another alternative is decompressive colonoscopy. In one series, 69% of patients had resolution of their pseudo-obstruction after colonoscopy to remove air.[43] Surgery is reserved for patients with obvious peritoneal signs or whose pseudo-obstruction has not improved after all forms of nonsurgical therapy. In such patients, when the possibility of cecal perforation is high, a cecostomy can be considered.

Anal Incontinence

Anal incontinence is defined as the inability to control the passage of gas, liquid, or solid stool. Obstetric trauma from vaginal deliveries is the most common cause of fecal incontinence in adult women.[1] Occult sphincter injury is reported in 25% to 35% of women on endoanal ultrasound after delivery. Vaginal deliveries that require forceps/vacuum-assistance and/or episiotomies are associated with increased risk of subsequent fecal incontinence. Others include aging, anorectal surgery, inflammatory bowel disease, infectious proctitis, anal or rectal neoplasm, congenital malformations (e.g., spina bifida, imperforate anus, myelomeningocele), traumatic injury, sequelae of radiation, underlying neurologic disorders (diabetes, multiple sclerosis, pudendal neuropathy and fecal impaction).

Workup consists of obtaining a history focusing on the above etiologic factors, evaluation and optimization of underlying medical conditions, documentation of bowel habits, and further characterization of the incontinence. It is important to establish if other pelvic floor disorders are present as well by eliciting symptoms of rectal and pelvic organ prolapse, as well as urinary incontinence. The most common scoring system to quantitate fecal incontinence is the Cleveland Clinic Florida Fecal Incontinence Score (CCF-FIS) (Table 64-4).[44,45] Physical examination should note anal sphincter tone, as well as associated scars from prior anorectal surgery or vaginal delivery. Physiologic studies to assess incontinence complement the history and physical examination and include anorectal manometry for evaluation of anal sphincter function, and endoscopic ultrasound for detection of occult sphincter defects. Other diagnostic studies to consider, based on symptoms include defecography (to evaluate for pelvic organ prolapse), and colonoscopy (to diagnose occult malignancy or inflammatory bowel disease).

Table 64-4 Cleveland Clinic Incontinence Score

	Never	Rarely	Sometimes	Usually	Always
Incontinence for solid stool	0	1	2	3	4
Incontinence for liquid stool	0	1	2	3	4
Incontinence for gas	0	1	2	3	4
Alteration in lifestyle	0	1	2	3	4
Need to wear a pad or plug	0	1	2	3	4

Never = 0
Rarely ≤1/month
Sometimes <1/week, >1/month
Usually ≤1/day, >1/week
Always ≥1/day
0 = perfect
20 = complete incontinence

Initial management is conservative and consists of medication to optimize bowel and biofeedback to ensure that the anal muscles are squeezing appropriately. A trial with bulking agents, such as fiber and constipating agents is effective for many patients with loose stools and incontinence; bulky, soft stools are easiest for the anal sphincter muscles

to retain. For patients with incontinence related to fecal impaction, a laxative regimen including enemas and scheduled disimpactions can improve control. Biofeedback is a form of physical therapy that retrains muscle (external sphincter and pelvic floor muscles) and facilitates anal-neuro feedback for discrimination of rectal sensations. Biofeedback has been shown to improve fecal incontinence in 50% to 86% of patients.[46–49] Because it is safe, inexpensive, and effective, biofeedback should be offered to all patients who do not respond to medical therapy.

10 The most common surgical interventions are overlapping sphincteroplasty, injectable agents, sacral nerve stimulation (SNS), and colostomy. Traditionally, overlapping sphincteroplasty has been the standard of care for patients with fecal incontinence and a sphincter defect on imaging studies. Short-term success rates have been as high as 70%; however, long-term functional outcomes are poor.[50–55] A newer option, injectable agents augment the anal cushions and are used for mild to moderate degrees of passive fecal incontinence. Different biomaterials have been used but the most common is SOLESTA (hyaluronic acid/dextranomer) (Salix Pharmaceuticals, Inc). Complications are minor and self-limiting and include proctalgia and/or pain at the injection site, local bruising and inflammatory reaction. Efficacy data are sparse but one large randomized controlled trial demonstrated improvement in continence for half the patients treated with SOLESTA.[56] The FDA-approved SNS for treatment of fecal incontinence in 2011. It is a two-stage procedure, in which there is a trial period, involving percutaneous implantation of an electrode into S3. If there is a $>50\%$ improvement in symptoms, the patient proceeds to the second stage which involves placement of a permanent stimulator. Between 50% and 92% success rates have been reported with an improvement of $\geq 50\%$ reduction in the number of incontinent episodes per week compared to baseline. Perfect continence has been achieved in 40% of subjects.[57–68] Since SNS was approved, it has largely replaced overlapping sphincteroplasty as the first line treatment. Finally, colostomy is a last resort in patients in whom all other treatment modalities have failed.

SUMMARY

The colon, rectum, anus all help coordinate very complicated functions. Understanding their physiology is important in the management of their associated pathology.

References

1. Gordon PH, Nivatvongs S, ed. *Principles and Practice of Surgery for the Colon, Rectum, and Anus.* 3rd ed. New York, NY: Informa Healthcare USA, Inc; 2007.
2. Kumar D, Phillips SF. The contribution of external ligamentous attachments to function of the ileocecal junction. *Dis Colon Rectum* 1987;30:410–416.
3. Wakeley CP. The Position of the vermiform appendix as ascertained by an analysis of 10,000 cases. *J Anat* 1933;67:277–283.
4. Jorge JM, ed. *Anatomy and Embryology of the Colon, Rectum, and Anus.* New York, NY: Springer; 2007.
5. Morren GL, Beets-Tan RG, van Engelshoven JM. Anatomy of the anal canal and perianal structures as defined by phased-array magnetic resonance imaging. *Br J Surg* 2001;88:1506–1512.
6. Latella G, Caprilli R. Metabolism of large bowel mucosa in health and disease. *Int J Colorectal Dis* 1991;6:127–132.
7. Szmulowicz UM, Hull TL. Colonic physiology. *The ASCRS Textbook of Colon and Rectal Surgery.* New York, NY:Springer;2011.
8. Grady GF, Duhamel RC, Moore EW. Active transport of sodium by human colon in vitro. *Gastroenterology* 1970;59:583–588.
9. Giller J, Phillips SF. Electrolyte absorption and secretion in the human colon. *Am J Digest Dis* 1972;17:1003–1011.
10. Hooper LV, Gordon JI. Commensal host-bacterial relationships in the gut. *Science* 2001;292:1115–1118.
11. Ilseung Cho, Blaser MJ. The Human Microbiome: at the interface of health and disease. *Nat Rev Genet* 2012;13(4):260–270.
12. Rescigno M. The pathogenic role of intestinal flora in IBD and colon cancer. *Curr Drug Targets* 2008;9:395–403.
13. Ritchie JA. Movement of segmental constrictions in the human colon. *Gut* 1971;12:350–355.
14. Husebye, E. The patterns of small bowel motility: physiology and implications in organic disease and functional disorders. *Neurogastroenterology and Motility* 1999;11(3):141–161.
15. Hertz AF. The passage of food along the human alimentary canal. *Guys Hosp Rep* 1907;61:389–427.
16. Daniel EE. Symposium on colonic function. Electrophysiology of the colon. *Gut* 1975;16:298–306.
17. Cali RL, Blatchford GJ, Perry RE, et al. Normal variation in anorectal manometry. *Dis Colon Rectum* 1992;35:1161–1164.
18. Frenckner B, Euler CV. Influence of pudendal block on the function of the anal sphincters. *Gut* 1975;16:482–489.

19. Higgins PD, Johanson JF. Epidemiology of constipation in North America: a systematic review. *Am J Gastroenterol* 2004;99:750–759.
20. Bharucha AE. Constipation. *Best Pract Res Clin Gastroenterol* 2007;21:709–731.
21. Maron DJ, Fry RD. New therapies in the treatment of postoperative ileus after gastrointestinal surgery. *Am J Ther* 2008;15:59–65.
22. Delaney CP, Wolff BG, Viscusi ER, et al. Alvimopan, for postoperative ileus following bowel resection: a pooled analysis of phase III studies. *Ann Surg* 2007;245:355–363.
23. Bohm B, Milsom JW, Fazio VW. Postoperative intestinal motility following conventional and laparoscopic intestinal surgery. *Arch Surg* 1995;130:415–419.
24. Frantzides CT, Cowles V, Salaymeh B, et al. Morphine effects on human colonic myoelectric activity in the postoperative period. *Am J Surg* 1992; 163:144–148; discussion 8–9.
25. Mann C, Pouzeratte Y, Boccara G, et al. Comparison of intravenous or epidural patient-controlled analgesia in the elderly after major abdominal surgery. *Anesthesiology* 2000;92:433–441.
26. Wolff BG, Michelassi F, Gerkin TM, et al. Alvimopan, a novel, peripherally acting mu opioid antagonist: results of a multicenter, randomized, double-blind, placebo-controlled, phase III trial of major abdominal surgery and postoperative ileus. *Ann Surg* 2004;240:728–734; discussion 34–35.
27. Wilmore DW, Kehlet H. Management of patients in fast track surgery. *BMJ* 2001;322:473–476.
28. Ljungqvist O. ERAS-enhanced recovery after surgery: moving evidence-based perioperative care to practice. *JPEN J Parenter Enteral Nutr* 2014;38:559–566.
29. Lubowski DZ. Enhanced recovery after surgery and laparoscopic colorectal surgery: where to now? *ANZ J Surg* 2014;84:500–501.
30. Geltzeiler CB, Rotramel A, Wilson C, et al. Prospective study of colorectal enhanced recovery after surgery in a community hospital. *JAMA Surg* 2014; 149(9):955–961.
31. Bagnall NM, Malietzis G, Kennedy RH, et al. A systematic review of enhanced recovery care after colorectal surgery in elderly patients. *Colorectal Dis* 2014;16(12):947–956.
32. Chambers D, Paton F, Wilson P, et al. An overview and methodological assessment of systematic reviews and meta-analyses of enhanced recovery programmes in colorectal surgery. *BMJ Open* 2014;4:e005014.
33. Greco M, Capretti G, Beretta L, et al. Enhanced recovery program in colorectal surgery: a meta-analysis of randomized controlled trials. *World J Surg* 2014; 38:1531–1541.
34. Walker EA, Roy-Byrne PP, Katon WJ. Irritable bowel syndrome and psychiatric illness. *Am J Psychiatry* 1990;147:565–572.
35. Munakata J, Naliboff B, Harraf F, et al. Repetitive sigmoid stimulation induces rectal hyperalgesia in patients with irritable bowel syndrome. *Gastroenterology*

1997;112:55–63.
36. Ogilvie H. Large-intestine colic due to sympathetic deprivation. *Br Med J* 1948;2:671.
37. Saunders MD, Cappell MS. Endoscopic management of acute colonic pseudo-obstruction. *Endoscopy* 2005;37:760–763.
38. Vanek VW, Al-Salti M. Acute pseudo-obstruction of the colon (Ogilvie's syndrome). An analysis of 400 cases. *Dis Colon Rectum* 1986;29:203–210.
39. Johnson CD, Rice RP, Kelvin FM, et al. The radiologic evaluation of gross cecal distension: emphasis on cecal ileus. *AJR Am J Roentgenol* 1985;145:1211–1217.
40. Nanni G, Garbini A, Luchetti P, et al. Ogilvie's syndrome (acute colonic pseudo-obstruction): review of the literature (October 1948 to March 1980) and report of four additional cases. *Dis Colon Rectum* 1982;25:157–166.
41. Ponec RJ, Saunders MD, Kimmey MB. Neostigmine for the treatment of acute colonic pseudo-obstruction. *N Engl J Med* 1999;341:137–141.
42. Trevisani GT, Hyman NH, Church JM. Neostigmine: safe and effective treatment for acute colonic pseudo-obstruction. *Dis Colon Rectum* 2000; 43:599–603.
43. Saunders MD, Kimmey MB. Systematic review: acute colonic pseudo-obstruction. *Aliment Pharmacol Ther* 2005;22:917–925.
44. Rockwood TH, Church JM, Fleshman JW, et al. Patient and surgeon ranking of the severity of symptoms associated with fecal incontinence: the fecal incontinence severity index. *Dis Colon Rectum* 1999;42:1525–1532.
45. Jorge JM, Wexner SD. Etiology and management of fecal incontinence. *Dis Colon Rectum* 1993;36:77–97.
46. Byrne CM, Solomon MJ, Young JM, et al. Biofeedback for fecal incontinence: short-term outcomes of 513 consecutive patients and predictors of successful treatment. *Dis Colon Rectum* 2007;50:417–427.
47. Keck JO, Staniunas RJ, Coller JA, et al. Biofeedback training is useful in fecal incontinence but disappointing in constipation. *Dis Colon Rectum* 1994;37:1271–1276.
48. Bartlett L, Sloots K, Nowak M, et al. Biofeedback for fecal incontinence: a randomized study comparing exercise regimens. *Dis Colon Rectum* 2011;54:846–856.
49. Schwandner T, Konig IR, Heimerl T, et al. Triple target treatment (3T) is more effective than biofeedback alone for anal incontinence: the 3T-AI study. *Dis Colon Rectum* 2010;53:1007–1016.
50. Barisic GI, Krivokapic ZV, Markovic VA, et al. Outcome of overlapping anal sphincter repair after 3 months and after a mean of 80 months. *Int J Colorectal Dis* 2006;21:52–56.
51. Demirbas S, Atay V, Sucullu I, et al. Overlapping repair in patients with anal sphincter injury. *Med Princ Pract* 2008;17:56–60.
52. Evans C, Davis K, Kumar D. Overlapping anal sphincter repair and anterior levatorplasty: effect of patient's age and duration of follow-up. *Int J Colorectal Dis* 2006;21:795–801.

53. Fleshman JW, Peters WR, Shemesh EI, et al. Anal sphincter reconstruction: anterior overlapping muscle repair. *Dis Colon Rectum* 1991;34:739–743.
54. Jesudason SR, Mathai V, Gladwin G, et al. Functional outcome of overlapping sphincter repair for anal incontinence. *Trop Gastroenterol* 1999;20:189–190.
55. Lamblin G, Bouvier P, Damon H, et al. Long-term outcome after overlapping anterior anal sphincter repair for fecal incontinence. *Int J Colorectal Dis* 2014;29(11):1377–1383.
56. Graf W, Mellgren A, Matzel KE, et al. Efficacy of dextranomer in stabilised hyaluronic acid for treatment of faecal incontinence: a randomised, sham-controlled trial. *Lancet* 2011;377:997–1003.
57. Altomare DF, Ratto C, Ganio E, et al. Long-term outcome of sacral nerve stimulation for fecal incontinence. *Dis Colon Rectum* 2009;52:11–17.
58. Boyle DJ, Murphy J, Gooneratne ML, et al. Efficacy of sacral nerve stimulation for the treatment of fecal incontinence. *Dis Colon Rectum* 2011;54:1271–1278.
59. Damon H, Barth X, Roman S, et al. Sacral nerve stimulation for fecal incontinence improves symptoms, quality of life and patients' satisfaction: results of a monocentric series of 119 patients. *Int J Colorectal Dis* 2013;28:227–233.
60. Devroede G, Giese C, Wexner SD, et al. Quality of life is markedly improved in patients with fecal incontinence after sacral nerve stimulation. *Female Pelvic Med Reconstr Surg* 2012;18:103–112.
61. George AT, Kalmar K, Panarese A, et al. Long-term outcomes of sacral nerve stimulation for fecal incontinence. *Dis Colon Rectum* 2012;55:302–306.
62. Lim JT, Hastie IA, Hiscock RJ, et al. Sacral nerve stimulation for fecal incontinence: long-term outcomes. *Dis Colon Rectum* 2011;54:969–674.
63. Maeda Y, Lundby L, Buntzen S, et al. Outcome of sacral nerve stimulation for fecal incontinence at 5 years. *Ann Surg* 2014;259:1126–1131.
64. Mellgren A, Wexner SD, Coller JA, et al. Long-term efficacy and safety of sacral nerve stimulation for fecal incontinence. *Dis Colon Rectum* 2011; 54:1065–1075.
65. Michelsen HB, Thompson-Fawcett M, Lundby L, et al. Six years of experience with sacral nerve stimulation for fecal incontinence. *Dis Colon Rectum* 2010; 53:414–421.
66. Takano S, Boutros M, Wexner SD. Sacral nerve stimulation for fecal incontinence. *Dis Colon Rectum* 2013;56:384.
67. Wexner SD, Coller JA, Devroede G, et al. Sacral nerve stimulation for fecal incontinence: results of a 120-patient prospective multicenter study. *Ann Surg* 2010;251:441–449.
68. Wexner SD, Hull T, Edden Y, et al. Infection rates in a large investigational trial of sacral nerve stimulation for fecal incontinence. *J Gastrointest Surg* 2010; 14:1081–1089.

Chapter 65

Acute Gastrointestinal Hemorrhage

Jason S. Mizell and Richard H. Turnage

Key Points

1 Upper gastrointestinal (UGI) hemorrhage accounts for about 80% of cases of acute GI blood loss.

2 The most common cause of acute UGI hemorrhage is peptic ulcer disease and the most common cause of acute lower gastrointestinal (LGI) hemorrhage is diverticulosis.

3 Upper GI bleeding typically presents with hematemesis (the vomiting of blood) or melena (the passage of black, tarry stool), whereas lower GI bleeding typically causes hematochezia (the passage of fresh blood from the rectum).

4 Most patients (about 80%) suffering from GI hemorrhage will stop bleeding spontaneously. Those who do not stop or those who rebleed are at particularly high risk to suffer an in-hospital complication, require operative control of their hemorrhage, or die.

5 Esophagogastroduodenoscopy (EDG) is the initial diagnostic study of choice for patients suspected of bleeding from the esophagus, stomach or duodenum and colonoscopy is the procedure of choice for evaluating patients with a suspected lower GI hemorrhage.

6 Nonsteroidal anti-inflammatory drugs are an important risk factor for the development of GI hemorrhage in general and gastroduodenal ulcer formation in particular.

7 Treatment of patients bleeding from gastroduodenal ulcer is intravenous proton pump inhibitor and endoscopic thermocoagulation or mechanical ligation or clipping of the bleeding vessel.

8 In general, a patient bleeding from esophageal varices should undergo urgent pharmacologic therapy with intravenous octreotide and endoscopic banding of the bleeding varices.

9 Lower GI hemorrhage due to diverticulosis is generally managed nonoperatively due to a low risk of persistent or recurrent bleeding.

1 Acute gastrointestinal (GI) hemorrhage is categorized as upper or lower depending upon the location of the bleeding relative to the ligament of Treitz. Upper GI (UGI) hemorrhage (i.e., bleeding from the esophagus, stomach, or duodenum) accounts for

about 80% of cases of acute GI blood loss, with most of the remainder coming from the colon. The small intestine is the site of hemorrhage in about 1% to 5% of cases.[1,2] Although it may be decreasing,[3] the incidence of UGI bleeding is estimated to be about 37 to 150 episodes per 100,000 individuals depending upon the population sampled,[4] whereas the incidence of lower GI (LGI) bleeding is about 20 cases per 100,000 individuals.[5] Overall, GI hemorrhage accounts for roughly 300,000 hospitalizations and 30,000 deaths annually in the United States.[6]

2 The differential diagnosis of overt UGI and LGI hemorrhage and the relative frequency of the most common causes of GI bleeding are shown in Tables 65-1 and 65-2 and Figure 65-1A,B, respectively. Although the incidence varies by age, overall the most common causes of acute UGI hemorrhage are peptic ulcer disease (31% to 58%), gastritis and mucosal erosions (9% to 30%), and gastroesophageal varices (3% to 23%)[1,4] whereas diverticulosis (24% to 47%), all forms of colitis (6% to 26%), neoplasms (9% to 17%), and angiodysplasia (2% to 12%) account for most instances of lower GI hemorrhage.[1,5,7–10]

PATIENT CHARACTERISTICS

Patients who suffer significant GI hemorrhage are more commonly older (average age approximately 60 to 70 years)[1,4]) and male compared with individuals without GI bleeding. Furthermore, these individuals are more likely to use alcohol, tobacco, aspirin, nonsteroidal anti-inflammatory drugs (NSAIDs), and anticoagulants.[1,11] Predictors of risk for acute GI bleeding are shown in Table 65-3.

Coexisting chronic illnesses are common in patients suffering either a UGI or LGI hemorrhage. Various studies have suggested a correlation between GI bleeding and correlates of poor health such as the use of multiple medications, reduced levels of physical activity, and inability to complete basic self-care tasks.[11] Cardiovascular,[11] hepatic, and renal disease[12] are particular risk factors for acute GI bleeding. The presence of these chronic illnesses, as well as chronic obstructive pulmonary disease and cirrhosis, also greatly increase the risk of rebleeding after endoscopic control.[13] Tobacco is also associated with higher rates of significant GI hemorrhage. A prospective cohort study of 5,888 men and women found that the multivariate-adjusted hazard ratio for subjects who smoked more than half a pack per day was 2.14 (95% CI = 1.22, 3.75) for UGI bleeding.[11]

Certain medications increase the risk of GI hemorrhage. Many studies have related the use of NSAIDs and aspirin to significant GI bleeding. The risk is particularly elevated for UGI bleeding but NSAIDs increase the risk of LGI hemorrhage as well. In Vreeburg's review of 951 patients with UGI hemorrhage, 41% used NSAIDs or aspirin. Van Leerdam reported that more than half of the patients bleeding from ulcers were actively taking NSAIDs or ASA.[14] Mellemkjaer et al.[15] found that the observed to expected ratio of UGI hemorrhage in a cohort of 156,138 users of NSAIDs was 4.1 (95% CI = 3.8, 4.5). Other medications known to increase the risk of GI hemorrhage include corticosteroids, spironolactone,[16] and the selective serotonin reuptake inhibitors (SSRIs).[17,18]

The use of anticoagulants is also an important risk factor for acute GI bleeding. Coumadin is a particularly common cause. Kaplan found the age- and sex-adjusted hazard ratio for GI bleeding in patients taking oral anticoagulants was 2.59 (95% CI = 1.71, 3.93).[11] Vreeburg et al.[4] reported that 17% of their patients with UGI hemorrhage were taking coumadin and the international normal ratio (INR) was greater than 4 in more than half of these patients. Because coumadin metabolism can be affected by so many interfering substances, inadvertent coumadin toxicity is a common problem, often presenting with GI hemorrhage. Antiplatelet agents such as clopidogrel and ticlopidine are also associated with an increased risk of GI hemorrhage.[19]

Table 65-1 Differential Diagnosis of Acute Upper Gastrointestinal Hemorrhage by Anatomic Site

Esophagus

- Esophagitis
  - Reflux
  - Infectious (fungal, viral)
- Esophageal varices
- Neoplasms

Stomach

- Peptic ulcer disease
  - Gastric ulcer
- Gastroesophageal varices
  - Portal gastropathy
- Gastric antral vascular ectasia (watermelon stomach)
- Dieulafoy ulcer
- Arteriovenous malformation
- Neoplasms
  - GI stromal tumors (leiomyoma, leiomyosarcoma)
  - Lymphoma
  - Adenocarcinoma
  - Carcinoid tumors
- Mallory–Weiss Tear
- Stress gastritis

Duodenum

- Peptic ulcer disease
  - Duodenal ulcer
- Arteriovenous malformation
- Neoplasms
  - Lymphoma
  - GI stromal tumors
  - Duodenal adenocarcinoma
  - Pancreatic adenocarcinoma
  - Carcinoid tumors
- Dieulafoy ulcers
- Aortoduodenal fistula
- Diverticula

Hepatopancreatic-biliary

- Hemobilia
- Pancreatitis-induced pseudoaneurysm

CLINICAL PRESENTATION

3 The presentation of GI bleeding can range from mild asymptomatic bleeding to overt GI bleeding. UGI bleeding typically presents with hematemesis (the vomiting of blood) or melena, whereas LGI bleeding typically presents with hematochezia. Melena is a black, tarry stool resulting from the degradation of blood by enteric bacteria. It may occur with the loss of as little as 50 to 200 mL of blood.[20,21] Bleeding from the small intestine or right colon may also appear black if it has remained in the GI tract for more than 12 to 14 hours.[22] Hematochezia is the passage of bright red blood, maroon-colored blood, or blood clots from the rectum. However, massive UGI hemorrhage can cause hematochezia in as many as 11% of patients, but this is typically associated with hemodynamic instability.[23] Patients with acute GI bleeding may present with the hemodynamic consequences of hemorrhage including light-headedness, dizziness, orthostatic syncope or near syncope, shortness of breath, or palpitations from tachycardia.

Table 65-2 Differential Diagnosis of Acute Lower Gastrointestinal Hemorrhage by Anatomic Site

Small Intestine	Colon and Rectum
NSAID-induced ulcers	Diverticulosis
Diverticula	Colitis
Meckel diverticula	Crohns disease
Pseudodiverticula	Ulcerative colitis
Neoplasms	Radiation colitis
Lymphoma	Infectious colitis
GI stromal tumors	Ischemic colitis
Adenocarcinoma	Neoplasms
Carcinoid tumor	Adenocarcinoma
Inflammation	GI stromal tumors
Crohn disease	Lymphoma
Radiation enteritis	Carcinoid tumors
Ischemic enteritis	Arteriovenous malformation
Infectious enteritis	Iatrogenic
Arteriovenous malformations	Polypectomy sites
Aortoenteric fistula	Benign rectal diseases
	Hemorrhoids
	Rectal ulcers

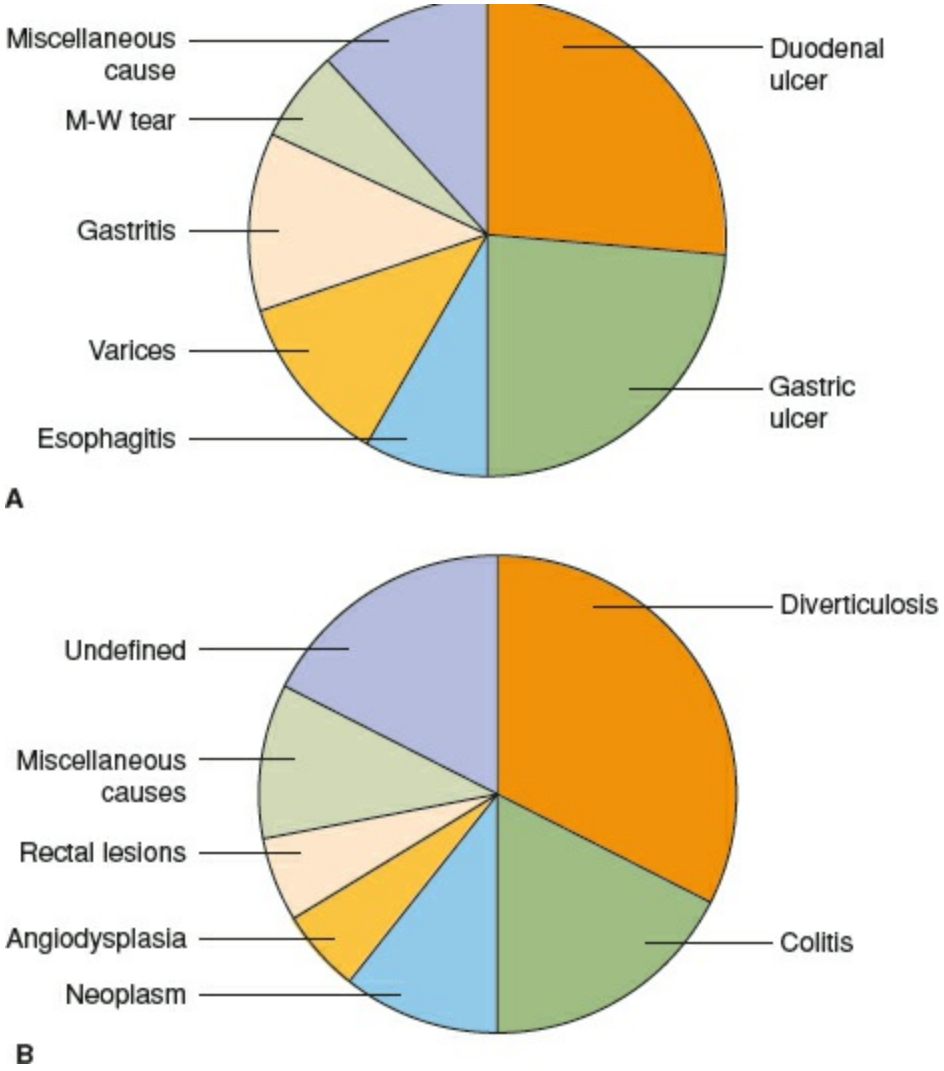

Figure 65-1. **A:** The relative frequency of the most common causes of upper gastrointestinal hemorrhage in the United States. These data represent the percentage of patients with each of these causes of UGI hemorrhage for 482 patients in a survey of the members of the American College of Gastroenterology published by Peura et al.[1] in 1997. These data are very similar to that reported by Vreeburg in a multi-institutional study of 951 patients sustaining a UGI hemorrhage in the hospitals in and surrounding Amsterdam.[4] **B:** The relative frequency of the most common causes of lower gastrointestinal hemorrhage. These data, reported by Lingenfelser and Ell[5] are the percentage of patients with each of these causes of lower GI hemorrhage in 912 patients collected in five studies from Europe, the Orient, and the United States[1,7–10]

The medical history and physical examination provide important clues of the etiology of the patient's hemorrhage and the potential risk to the patient's life. The occurrence of melena after several days of worsening epigastric or upper abdominal pain suggests peptic ulcer disease; whereas hematemesis or melena following vomiting or retching strongly suggests a Mallory–Weiss tear. Massive, painless UGI hemorrhage in a patient with cirrhosis suggests bleeding from gastroesophageal varices, although other etiologies including peptic ulcer disease or a Mallory–Weiss tear must also be considered. The medical history should elicit the presence of risk factors for GI hemorrhage alluded to in the previous paragraphs and in Table 65-3 .

A systematic physical examination will document the magnitude of bleeding and the patient's ability to compensate. Massive hemorrhage is associated with signs and

symptoms of hypovolemic shock, including cool, clammy, mottled skin, tachycardia, tachypnea, flat jugular veins, oliguria, and perhaps hypotension. These responses may be altered by advanced age, concomitant medical problems, and particular medications. Physical examination should also document evidence of cirrhosis and portal hypertension (i.e., ascites, spider angiomas, hepatosplenomegaly, palmar erythema, and large hemorrhoidal veins). A rectal examination may demonstrate bright red blood or melena. The clinical scenario alone will usually not localize the location of the bleeding, so other diagnostic studies are often required to identify the cause and site of bleeding.

PROGNOSTIC FACTORS

4 Most patients (approximately 80%) suffering from GI hemorrhage will stop bleeding spontaneously. Those who do not stop or those who rebleed are at particularly high risk to suffer an in-hospital complication, require operative control of their hemorrhage, or die. Several classification systems have been developed to separate patients with low risk of complications from those with a high risk of complications due to acute UGI and LGI hemorrhage. These systems have also been used to stratify those patients who may be safely managed as an outpatient from those requiring in-hospital care.[24] The BLEED classification system addresses both UGI and LGI hemorrhage and consists of the following parameters: ongoing bleeding, low systolic blood pressure, elevated prothrombin time, erratic mental status, and unstable comorbid disease. Patients with at least one BLEED criterion are more likely to suffer in-hospital complications from UGI bleeding (31% vs. 4%) or LGI bleeding (38% vs. 12%) than are patients with no criteria.[25]

Table 65-3 Characteristics of Individuals at an Increased Risk of Developing Acute Gastrointestinal Bleeding

Increased Age
Male sex
Unmarried (vs. married)
Perceived fair or poor health status
Cardiovascular disease
Diabetes mellitus
Renal disease
Difficulty with activities of daily living
Low level of physical activity
Increased numbers of medications
Oral anticoagulant use

From Kaplan RC, Heckbert SR, Koepsell TD, et al. Risk factors for hospitalized gastrointestinal bleeding among older persons. Cardiovascular Health Study Investigators. *J Am Geriatr Soc* 2001;49:126–133.

Table 65-4 Rockall Risk Scoring System and Rates of Rebleeding and Mortality

Variable	Score								
	0			1		2		3	
Age	<60 yrs			60–79 yrs		≥80 yrs			
Shock	"No shock" Systolic blood pressure ≥100 Heart rate <100			"Tachycardia" Systolic blood pressure ≥100 Heart rate ≥100		"Hypotension" Systolic blood pressure <100			
Comorbidity	None			None		Cardiac failure Ischemic heart disease Any major comorbidity		Renal failure Liver failure Disseminated malignancy	
Diagnosis	Mallory–Weiss tear No lesion identified No stigmata of recent hemorrhage			All other diagnosis		Malignancy of the upper GI tract			
Major stigmata of recent hemorrhage	None or dark spot only					Blood in upper GI tract Adherent clot Visible or spurting vessel			
Score	0	1	2	3	4	5	6	7	8+
Percent mortality	0	0	0.2	2.9	5.3	10.8	17.3	27	41

From Rockall TA, Logan RF, Devlin HB, et al. Risk assessment after acute upper gastrointestinal haemorrhage. *Gut* 1996;38:316–321.

Prognostic systems for UGI hemorrhage have been more widely adopted than those for LGI hemorrhage. One widely used system is the Rockall score for assessing the risk of death and rebleeding in patients with UGI hemorrhage (Table 65-4). Using this model, Rockall et al. found that rebleeding occurred in less than 5% of patients and mortality was virtually zero (0% to 0.2%) in patients with scores of 0 to 2. In contrast, a fourth to nearly one-half of patients with a Rockall score of 5 to 8+ rebled; the mortality rate for these patients was 11% to 41%. In this study, rebleeding significantly affected the likelihood of death, particularly for patients with intermediate scores of 3 or 4 and 5 to 7 in which there was a three- to fivefold increase in mortality rates.[26]

The Rockall classification has been widely accepted as accurate and importantly has been externally validated.[27–30] However, the full classification scheme requires endoscopic assessment. An alternative scoring system – the Glasgow–Blatchford bleeding score (GBS) – is based on clear and readily available clinical and laboratory indices without the need for endoscopy Table 65-5. It was designed to predict need for clinical intervention due to UGI hemorrhage. This scoring system has been subjected to multi-institutional trials and found to be at least as effective as and possibly more accurate than the Rockall system.[31,32] These authors suggested that patients with a score of 0 can be safely managed as outpatients.

Conversely, patients with LGI bleeding typically present with less hemodynamic instability. Factors that is indicative of a severe lower GIB thus necessitating more urgent intervention include:

- Heart rate >100/min
- Initial systolic blood pressure 115 mm Hg or less
- History of syncope

- Nontender abdominal examination
- Bleeding per rectum during the first 4 hours of evaluation
- History of aspirin use
- Charlson Comorbidity Index score of more than 2.[33]

INITIAL EVALUATION AND RESUSCITATION

Upon presentation, two large-bore intravenous lines should be placed in peripheral veins and intravascular volume resuscitation begun with an isotonic saline solution. Most patients stop bleeding spontaneously, and crystalloid volume resuscitation is all that is required. Blood is drawn for type and crossmatch, complete blood count with platelet count, electrolyte measurement, liver function tests, and coagulation profiles. It is important to emphasize that on presentation, the hematocrit or hemoglobin level may not accurately reflect the magnitude of acute blood loss. Estimates of the severity of hemorrhage must be based on clinical parameters.

The massively bleeding patient should receive packed red blood cells (RBCs) to restore intravascular volume and oxygen-carrying capacity. The decision to transfuse blood or blood products depends on the individual needs of the patient and the cause of the bleeding. The risks of the blood products (i.e., infection and allergic reactions) must be weighed against the risks of withholding transfusion (i.e., anemia, decreased oxygen-carrying capacity, coagulopathy). In general, blood products are used early in the management of patients with limited cardiac and pulmonary reserve (who are unable to withstand or compensate for an acute reduction in their systemic oxygen delivery) and those with lesions that are at particular high risk for continued or recurrent hemorrhage (e.g., gastroesophageal varices).

Careful hemodynamic monitoring of these potentially critically ill patients is vital to successful management. There are no clear recommendations, but it seems reasonable for those patients who are actively bleeding and those who have recently sustained significant hemorrhage to be admitted to an intensive care unit for close monitoring of hemodynamic parameters and evidence of continued or recurring hemorrhage. The presence of significant underlying illnesses, such as cardiac, renal, hepatic, or pulmonary insufficiency, may necessitate noninvasive monitoring or invasive cardiac monitoring with central venous and arterial catheters. The information gained from these devices allows cardiac performance to be optimized during intravascular volume replacement. The placement of a urinary catheter and frequent monitoring of heart rate, blood pressure, urine output, and mental status are the minimum necessary to monitor patients who have suffered GI hemorrhage. The importance of prompt, adequate resuscitation and diligent observation cannot be overemphasized as the cornerstone for managing these potentially mortally ill patients.

Table 65-5 Glasgow–Blatchford Bleeding Score (GBS)

	Score Value
Blood Urea (mmol/L)	
<6.5	0
6.5–7.9	2
8.0–9·9	3
10.0–25.0	4
>25.0	6
Hemoglobin for Men (g/L)	
≥130	0
120–129	1
100–119	3
<100	6
Hemoglobin for Women (g/L)	
≥120	0
100–119	1
<100	6

	Score Value
Systolic Blood Pressure (mm Hg)	
100–109	1
90–99	2
<90	3
Other Markers	
Pulse <100	0
Pulse ≥100/min	1
Presentation with melena	1
Presentation with syncope	2
Hepatic disease[a]	2
Cardiac failure[b]	2
Absence of melena, syncope, hepatic disease or cardiac disease	0

[a]Known history, or clinical and laboratory evidence, of chronic or acute liver disease.
[b]Known history, or clinical and echocardiographic evidence, of cardiac failure.
Adapted from Stanley AJ, Ashley D, Dalton HR, et al. Outpatient management of patients with low-risk upper-gastrointestinal haemorrhage: multicentre validation and prospective evaluation. *Lancet* 2009;373:42–47.

DIAGNOSTIC APPROACH

5 After the restoration of circulating blood volume, the next step is to identify the source of bleeding so that definitive therapy may be instituted. If the patient presents with hematemesis, localization of the bleeding to the esophagus, stomach, or duodenum is relatively straightforward and esophagogastroduodenoscopy (EGD) should be performed promptly to identify the source of bleeding. When blood or coffee-ground guaiac-positive material is present in the gastric aspirate, EGD will likely define the site of bleeding. Bright red blood per rectum strongly suggests a lower GI source of bleeding unless the patient is hemodynamically unstable in which case the hemorrhage may originate from a source proximal to the ligament of Treitz. A general algorithm for evaluating patients with acute UGI and LGI hemorrhage is presented in Algorithm 65-1.

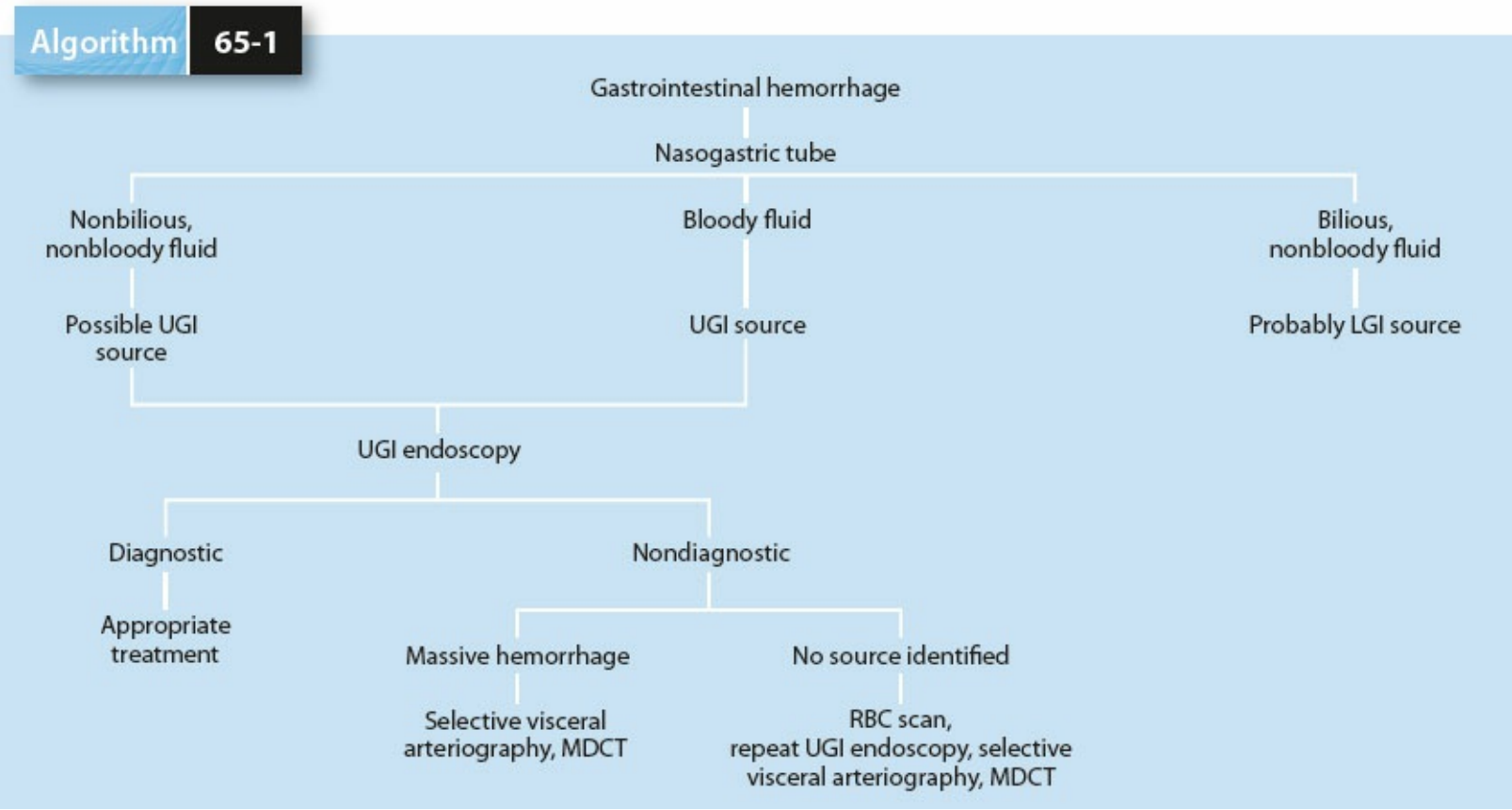

Algorithm 65-1. Diagnostic steps in the evaluation of gastrointestinal hemorrhage.

Table 65-6 Predictors of Persistent or Recurrent Bleeding in Patients with Nonvariceal UGI Hemorrhage

	Range of Odds Ratios for Increased Risk
Clinical Factors	
Age >65 yrs	1.3
>70 yrs	2.30
Shock (systolic blood pressure <100 mm Hg)	1.2–3.65
Health status (ASA Class 1 vs. 2–5)	1.94–7.63
Comorbid illness	1.6–7.63
Erratic mental status	3.21 (95% CI: 1.53, 6.74)
Ongoing bleeding	3.14 (95% CI: 2.40–4.12)
Laboratory Factors	
Initial hemoglobin <10 gm/dL or hematocrit <0.30	0.8–2.99
Coagulopathy (prolonged partial thromboplastin time)	1.96 (95% CI: 1.46, 2.64)
Presentation of Bleeding	
Melena	1.6 (95% CI: 1.1, 2.4)
Red blood on rectal examination	3.76 (95% CI: 2.26, 6.26)
Blood in gastric aspirate or stomach	1.1–11.5
Hematemesis	1.2–5.7
Endoscopic Factors	
Active bleeding on endoscopy	2.5–6.48
Endoscopic high-risk stigmata	1.91–4.81
Clot	1.72–1.9
Ulcer size ≥2 cm	2.29–3.54
Diagnosis of gastric or duodenal ulcer	2.7 (95% CI: 1.2, 4.9)
Ulcer location	
High on lesser curvature	2.79
Superior wall of duodenal bulb	13.9
Posterior wall of duodenal bulb	9.2

ASA, American Society of Anesthesiologists.
From Barkun A, Bardou M, Marshall JK, et al.. Consensus recommendations for managing patients with nonvariceal upper gastrointestinal bleeding. *Ann Intern Med* 2003;139:843–857.

Gastric Aspiration

Recent studies have called into question the routine placement of nasogastric tubes (NGTs) in all patients with suspected GI bleeding. In patients with hematemesis, gastric aspiration is not necessary to obtain a diagnosis of a UGI bleed. However, it can provide useful information regarding the rate of hemorrhage. Knowing the degree to which a patient is bleeding may help guide clinical decision making, such as the need to initiate octreotide, transfuse blood emergently, urgently perform an EGD, or determine whether or not ICU monitoring is necessary.[34]

In the absence of hematemesis, aspiration of gastric fluid after the placement of a NGT may be used to distinguish between a UGI and LGI source of bleeding. Two studies with more than 700 patients found that the presence of blood in the gastric aspirate was a good indicator of a UGI source; however, its absence was unreliable in predicting the presence or absence of a UGI source.[35,36] In one study of 220 patients with UGI sources of bleeding, the sensitivity, specificity, and accuracy of the nasogastric aspirate was 42% (95% confidence interval [CI] = 32, 51%), 91% (95% CI = 83, 95%), and 66% (95% CI = 59, 72%), respectively.[36] While a clear aspirate does not rule out a UGI source of bleeding, aspiration of blood confirms it. Additionally, placing an NGT may help remove blood from the gastric lumen to improve visualization once the EGD is performed. However, NGT placement can be associated with pain, aspiration, and pneumothorax.[37] Additionally, other less invasive methods may indicate a UGI source (black stool, BUN/creatinine ratio >30, and age younger than 50 years). Due to these factors, NGT placement prior to EGD should not be routine but instead individualized to each patient.

Endoscopy

Esophagogastroduodenoscopy

EGD will identify the site of bleeding in about 95% of cases of UGI bleeding and is the initial diagnostic study for patients suspected of bleeding from the esophagus, stomach, or duodenum.[38] The sensitivity of the procedure is significantly enhanced when performed within the first 24 hours of presentation.[4] A systematic review of the literature found that early endoscopy (i.e., performed within 24 hours of admission) was associated with a decreased transfusion requirement and decreased length of stay.[39] A prospective, randomized trial found that early endoscopy allowed the triaging of 46% of patients to outpatient care without any adverse effects.[40] Previous consensus guidelines and several cohort studies have related various endoscopic stigmata of recent or active hemorrhage to a heightened risk of rebleeding or continued bleeding.[41–44] Laine and Peterson[41] analyzed data from 37 prospective trials in which patients with bleeding ulcers did not receive endoscopic therapy; they found that the rate of further bleeding was less than 5% for those patients with a clean ulcer base and increased to 10% for patients with a flat spot, 22% for those with an adherent clot, 43% for those with a nonbleeding visible vessel, and 55% for those with active bleeding. Endoscopic features predictive of persistent or recurrent bleeding and mortality are shown in Tables 65-6, 65-7, and 65-8. In addition to these ulcer-specific factors, endoscopy allows identification of lesions with a high risk of continued hemorrhage and mortality (i.e., gastroesophageal varices), and those with a low risk (e.g., Mallory–Weiss tears). The efficacy of endoscopy-based modalities to control UGI hemorrhage is discussed in subsequent sections.

Colonoscopy

Although the efficacy of colonoscopy in determining the cause of occult GI bleeding is undisputed, historically its role in the evaluation of patients with acute LGI bleeding was less well agreed upon. Recently however, newer studies have established it as the procedure of choice for patients with suspected LGI bleeding despite its limitations.[45–48] Colonic lavage with a polyethylene glycol solution can be used to clear the lumen of clot and stool providing adequate visualization of the mucosa,[49] but others have reported good visualization of the mucosa even in the absence of mechanical bowel preparation.[50]

Studies have shown a diagnosis is made in 74% to 100% of patients with an LGI bleed undergoing colonoscopy, and a pool analysis of six recent studies found a composite yield of 91% for colonoscopy.[47,48,51,52] A meta-analysis examined the role of colonoscopy as the primary diagnostic modality for patients with acute lower GI bleeding and found that 69% (range 48% to 90%) of urgent colonoscopies identified a source or a presumptive source of bleeding.[53] Even in the setting of unprepped bowel, urgent colonoscopy has been shown to identify bleeding colon and distal ileal lesions in 82 of 85 patients (97%).[50] Stigmata of recent hemorrhage for LGI bleeding are similar to those of UGI lesions and include an actively bleeding site, a nonbleeding visible vessel, and an adherent clot; these findings have been associated with continued hemorrhage and therefore the need for urgent colectomy.[7,54] Jensen et al.[45] reported that 25% to 50% of

patients with *any* of these three factors continued to bleed or rebled and ultimately required urgent colectomy. Others have found colonoscopy to be less accurate in the diagnosis of LGI bleeding, for example, Al Qahtani et al.[55] reported a series of 136 patients in which colonoscopy identified only 45% of the sources of bleeding.

Enteroscopy

For those patients who present with hematochezia in whom the initial EGD and colonoscopy is nondiagnostic, repeating these studies before evaluating the small intestine is warranted given the very small frequency in which the bleeding originates from the small intestine (1%). Repeating the EGD and colonoscopy when the patient is better resuscitated will often detect lesions such as ulcers or vascular ectasias that were obscured by blood at the initial endoscopy or the vasoconstriction of the GI mucosa that accompanies hemorrhagic shock.

Endoscopy of the small bowel with an enteroscope or a pediatric colonoscope will allow inspection of the proximal 60 cm of the jejunum[56] and the use of a long videoenteroscope may allow visualization of 100 to 150 cm of intestine beyond the ligament of Treitz.[57] Jensen et al.[58] in an experience with more than 200 patients with obscure sources of GI bleeding reported success in identifying the etiology in 79% of instances using enteroscopy. In their experience, vascular ectasias and postbulbar ulcers were the most common causes of obscure GI bleeding.

Table 65-7 Predictors of Mortality in Patients with Nonvariceal UGI Hemorrhage

	Range of Odds Ratios for Increased Risk
Clinical Factors	
Age 60–69 yrs	3.5 (95% CI: 1.5, 4.7)
≥70 yrs	4.5–12.7
>80 yrs	5.7 (95% CI: 2.9, 10.2)
Shock (systolic blood pressure <100 mm Hg)	1.18–6.4
Health status (ASA class 1 vs. 2–5)	2.6–9.52
Comorbid illness	1.19–12.1
Continued or rebleeding	5.29–76.23
Sepsis	5.4 (95% CI: 1.5, 19.6)
Presentation of bleeding	
Red blood on rectal examination	2.95 (95% CI: 1.29, 6.76)
Blood in gastric aspirate or stomach	0.43–18.9
Hematemesis	2.0 (95% CI: 1.1, 3.5)
Onset of bleeding while hospitalized for other causes	2.77 (95% CI: 1.64, 4.66)
Laboratory Factors	
Elevated blood urea nitrogen level	5.5–18
Elevated serum creatinine level	14.8 (95% CI: 2.6, 83.5)
Elevated serum aminotransferase levels	4.2–20.2

ASA, American Society of Anesthesiologists.
From Barkun A, Bardou M, Marshall JK, et al.. Consensus recommendations for managing patients with nonvariceal upper gastrointestinal bleeding. *Ann Intern Med* 2003;139:843–857.

Intraoperative enteroscopy using a combination of push enteroscopes *per os* and *per rectum* or via enterotomy can allow examination of the entire small bowel. While the endoscopist manipulates the scope, the surgeon manually advances the bowel over the endoscope. After the bowel is telescoped onto the endoscope it is slowly withdrawn while the endoscopist examines the mucosal lumen and the surgeon watches the transilluminated bowel wall. While this technique can be effective, it is limited by its invasive nature.[59]

Double Balloon Enteroscopy

This technique utilizes a long enteroscope and a long overtube. Both the overtube and the enteroscope have balloons at the end. When the balloon of the enteroscope is inflated it "grabs" the mucosal surface and allows advancement of the overtube whose balloon is deflated. The overtube balloon is then inflated while the enteroscope balloon is deflated. The enteroscope is then advanced while the inflated overtube balloon grips the mucosa. Using these alternate inflation–deflation cycles, long distance advancement of the enteroscope has been achieved.[2] In one U.S. multicenter study, the average distance achieved was 360 cm with a diagnosis made in 43% of cases.[60] In some cases lesions may be seen that are missed by other techniques.[61]

Wireless Capsule Endoscopy

Imaging of the small intestine is also possible with wireless capsule endoscopy (CE) which consists of a battery, light source, imaging-capturing system, and transmitter. This capsule endoscope is 11 × 30 mm and is moved solely by peristalsis. This system captures and sends usually two images per second (newer versions can send more frames per second) for about 8 hours to an ultra–high-frequency band radiotelemetry unit worn by the patient. In 85% of cases, the capsule reaches the cecum within this time frame.[62] The location of the capsule is suggested by the strength of the signal. Several studies have shown high diagnostic yields using this technique and found it to be at least equivalent to and in some studies superior to double balloon enteroscopy in patients with obscure GI bleeding.[63] It has also been shown to have a higher diagnostic yield with comparable outcomes when compared to angiography.[64] The main risk of CE is capsule retention. One difficulty with CE is the very large amount of data to be reviewed. For an 8-hour study, 50,000 to 60,000 images are generated, which takes approximately 40 to 60 minutes to review.

Selective Visceral Arteriography

Selective visceral arteriography is primarily useful in patients with UGI or LGI bleeding in whom endoscopy cannot be performed or has been unsuccessful in determining the site of ongoing, rapid hemorrhage. Successful angiographic identification of the source of bleeding occurs in 27% to 86% of instances and depends primarily upon the presence of active arterial bleeding at the time of the study (Fig. 65-2).[55,65] The extravasation of contrast may be detected if the patient is bleeding at rates greater than 0.5 to 1 mL/min[66]; this correlates clinically with the requirement for continuous volume infusion to maintain hemodynamic stability. Pennoyer et al.,[67] however, were unable to identify any clinical parameters (including tachycardia, numbers of transfusions, or orthostatic hypotension) that could increase the diagnostic yield of selective angiography, including scintigraphy demonstrating ongoing bleeding. However, a study by Hammond et al.[68] found an early (within 2 minutes) positive scintigraphy has a 60% positive predictive value for a positive angiogram. Additionally, it has been shown that a positive scintigram increases the likelihood of a positive angiogram from 22% to 53%.[69] Several groups have used heparin, vasodilators, or thrombolytics to improve the diagnostic yield of arteriography in patients with nondiagnostic studies.[70,71] Mernagh et al.[72] found that the administration of heparin intravenously for 24 hours increased the diagnostic yield of visceral angiography from 33% (6 of 18) to 67% (12 of 18). Others have found that the intra-arterial infusion of a vasodilator, heparin, and/or urokinase (a thrombolytic) failed to identify the source of bleeding in 5 of 7 patients.[73] It should be noted that these provocative techniques are not commonly employed.

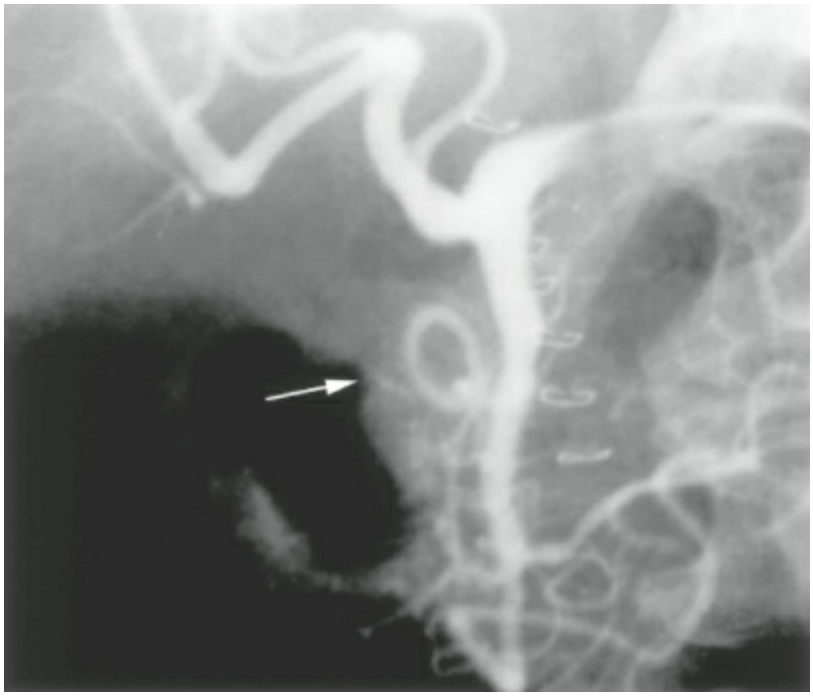

Figure 65-2. Selective celiac arteriography with injection into the common hepatic artery in a patient bleeding from a duodenal diverticulum. Extravasation of contrast from a branch of the gastroduodenal artery can be seen (*arrow*).

One major advantage of visceral arteriography is its therapeutic potential. Transcatheter embolization of bleeding vessels was first reported in the early 1970s.[74,75]

Modern instruments allow superselective catheterization of terminal vessels allowing satisfactory embolization with less risk for ischemic complications. Further discussion of therapeutic use can be found below.

Abdominal Scintigraphy

Abdominal scintigraphy with ^{99m}technetium (Tc)-labeled RBCs lacks the spatial resolution and diagnostic precision of angiography and endoscopy; however, it is of most value in detecting intermittently bleeding lesions, those with very low rates of hemorrhage such as vascular malformations, and in evaluation of LGI bleeding due to the lower sensitivity of endoscopy within the LGI tract as compared to the UGI tract. Abdominal scintigraphy utilizing ^{99m}Tc-RBCs has been shown to be the most sensitive examination due to its ability to detect bleeding rates as low as 0.04 to 0.1 mL/min.[76,77] In a review of seven retrospective studies with nearly 400 patients, the median diagnostic accuracy of scintigraphy was 82% (range, 52% to 95%). However, in this review, ^{99m}Tc-RBCs was incorrect in 5% to 48% of instances (median 18%).[65] Suzman et al.[78] summarized 20 retrospective studies containing 804 positive studies and reported a false-positive rate of 19%. The large variation in these studies results from differences in scan timing, technical skills, and expertise. Additionally, precise localization of the site of bleeding may be complicated by the rapid distribution of isotope throughout the intestine by peristalsis or by accumulation in the right colon.[79] More recent techniques of cine scintigraphy may improve the diagnostic accuracy (Fig. 65-3).[80] One area where radionuclide scanning has a clear role is in the diagnosis of Meckel diverticulum. ^{99}Tc-pertechnate is secreted by ectopic gastric mucosa in Meckel diverticula.[81] This study should be considered early in the evaluation of young individuals with LGI bleeding.

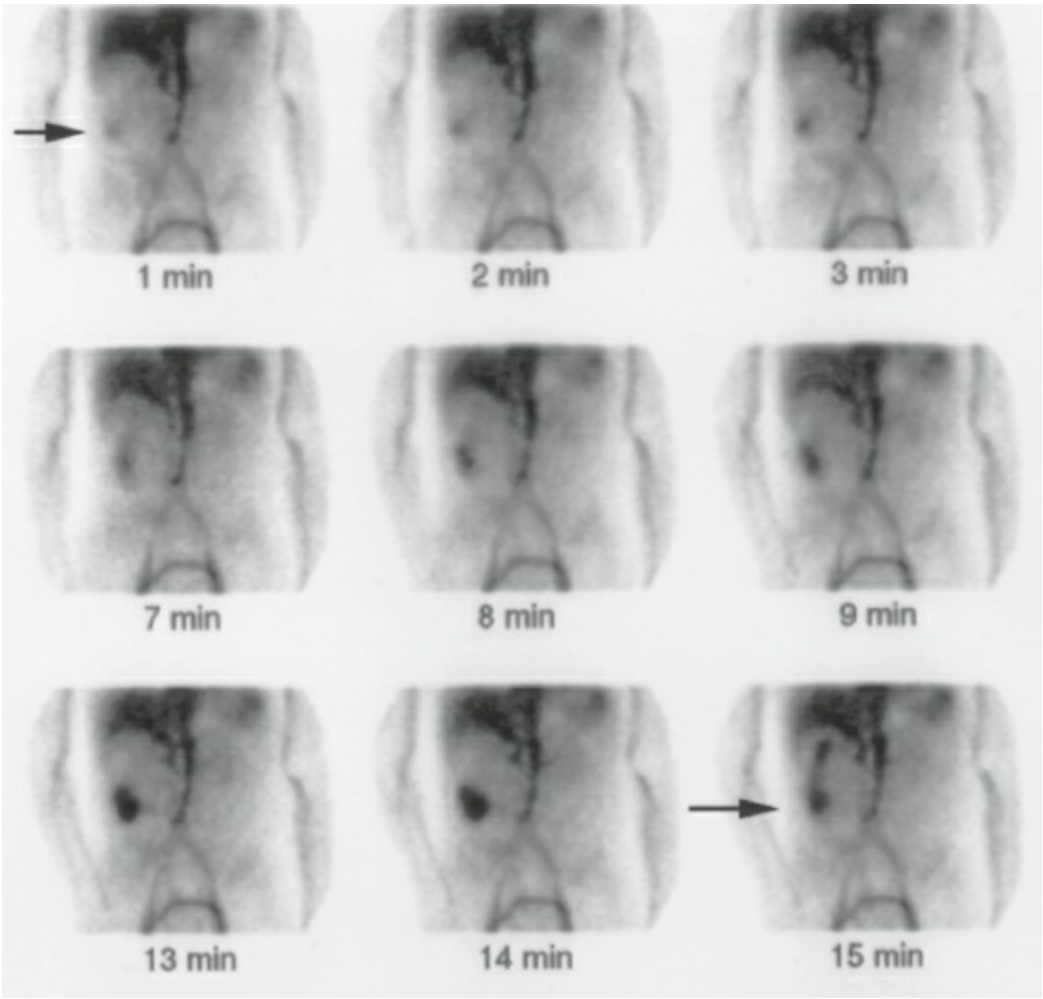

Figure 65-3. Cine-^{99}Tc erythrocyte scintigraphy showing extravasation of isotope in the right colon. Only a small portion of the image set is shown. *Arrows* point to accumulation of isotope in right colon. Bleeding was due to delayed hemorrhage following endoscopic polypectomy.

CT Scanning

CT scanning has been used to detect GI bleeding using a variety of specialized techniques.[82–84] Multidetector-row helical computed tomography (MDCT) is establishing itself as a rapid, noninvasive, and accurate diagnostic method in acute GIB. In arterial phase MDCT, active GI bleeding is defined as active contrast extravasation with a focal area of high attenuation within the bowel lumen.[85] Yoon et al.[86] presented the first prospective study evaluating the accuracy of MDCT and found an overall sensitivity of 90.9% for the detection of acute GI bleeding and specificity of 99%. Additional studies have supported its use.[87,88] Limitation of MDCTs are radiation dose, contrast allergies, contrast nephropathy, and it being a purely diagnostic rather than therapeutic modality. However, it is fast, accurate, widely available, reproducible, noninvasive, and a positive study can subsequently guide interventionalists to directly perform time-saving super-selective angiograms of the bleeding site.[85] In the future this may continue to become a more available and useful technique.

COMMON CAUSES OF GI HEMORRHAGE AND TREATMENT

Upper GI Hemorrhage

Peptic Ulcer Disease

Peptic ulcer disease is the most common cause of acute UGI hemorrhage, accounting for nearly 40% of cases in most series although this proportion may be decreasing.[89] About 15% to 20% of patients with peptic ulcer disease experience bleeding during the course of their disease and as many as 20% of these patients will have bleeding as the initial manifestation. Hemorrhage is the principal cause of death from peptic ulcer disease and has replaced intractable pain as the most frequent indication for surgery. Complications of peptic ulcer disease occur more commonly in older patients who often have coexisting medical problems, which profoundly influence their risk of morbidity and mortality.

Duodenal ulcers occur slightly more frequently than gastric ulcers. Penetration of the ulcer through the posterior wall of the duodenal bulb is associated with erosion into the gastroduodenal artery or one of its branches, resulting in brisk hemorrhage. Patients may present with hematemesis of bright red blood and clots or with melena alone. Between 80% and 90% of patients stop bleeding spontaneously during the initial stages of therapy with volume resuscitation.

In general, patients with gastric ulcers tend to be older and have coexisting medical problems that increase morbidity and mortality compared with duodenal ulcers. Bleeding may occur from any site in the stomach, although ulcers occurring at the incisura are most common. At this site, involvement of the branches of the left gastric artery may result in brisk, if not torrential, hemorrhage. The clinical presentation of patients bleeding from gastric ulcers is similar to that of duodenal ulcers, with hematemesis, melena, and hematochezia.

6 An important risk factor for the development of GI hemorrhage and gastroduodenal ulcer formation is the use of NSAIDs. NSAID use has been associated with a continuum of mucosal injury ranging from small acute mucosal hemorrhages to large chronic ulcers. It has been estimated that 10% to 15% of regular NSAID users have chronic gastric ulcers.[90] Symptoms correlate poorly with the degree of mucosal injury since as many as 20% of ulcers penetrating the muscularis are asymptomatic.[91] Case control and cohort studies have suggested that NSAIDs are associated with a relative risk of GI hemorrhage and ulceration ranging from about 2 to 9.1.[92] Ketorolac, in particular, has been associated with a high risk of GI bleeding (relative risk approaches 25).[93] The risk of NSAID-associated complications is highest in patients with a history of UGI bleeding, the elderly, those patients taking oral anticoagulants,[94] or corticosteroids. Patients with a prior history of peptic ulcer disease also appear to be at increased risk of NSAID-associated GI hemorrhage and tend to have a significantly worse outcome when compared to individuals not using NSAIDs.[95]

The tremendous frequency with which NSAIDs are used by the elderly underscores the magnitude of this problem. Individuals with a history of NSAID-induced hemorrhage may benefit from the prostaglandin E_1 analog, misoprostol, which has been shown to prevent

NSAID-induced gastric erosions and ulcers.[96] Histamine (H_2)-receptor blockers (ranitidine and cimetidine) are effective in preventing NSAID-induced duodenal ulcers, but appear to have little effect on the occurrence of gastric lesions.[91,97] Proton pump inhibitors (PPIs) have also been shown to be protective in patients on NSAIDs, with greater efficacy than H_2 blockers.[98] NSAIDs are also associated with lower GI bleeding, including lesions not generally considered related to NSAID-induced ulcers such as diverticulosis.[99,100] Selective COX-2 inhibitors have been marketed as being safer than nonselective NSAIDs, although some of these have been withdrawn from the U.S. market for other safety concerns. It appears that these selective inhibitors cause fewer UGI problems overall than traditional NSAIDs, the main benefit being fewer uncomplicated ulcers. Various studies have shown no decrease in complicated events, including clinically significant bleeding episodes.[101,102] However, in a Cochrane systematic review of the GI safety of COX-2 inhibitors, COX-2 inhibitors produced significantly fewer gastroduodenal ulcers (relative risk, 0.26; 95% CI = 0.23–0.30) and ulcer complications (relative risk, 0.39; 95% CI = 0.31–0.50), as well as fewer withdrawals caused by GI symptoms when compared to nonselective NSAIDs.[103]

Medical Treatment

7 Once bleeding from the UGI tract is confirmed, treatment with a PPI should be initiated. Acute use of a PPI has been shown in several studies to decrease rebleeding.[43,104–107] Although the Scottish Intercollegiate Guidelines Network (SIGN) recommended withholding PPI therapy until after endoscopy,[108,109] in our opinion the balance of evidence would suggest no harm and perhaps a benefit from early PPI use. An 80-mg intravenous bolus of omeprazole or pantoprazole followed by an infusion at 8 mg/hr produces the most reliable acid suppression.[110] All patients should be tested for *Helicobacter pylori* (*H. pylori*) infection and treated if found. Treatment of the infection significantly reduces the recurrence of hemorrhage when compared to no treatment or chronic antisecretory treatment alone.[111] Interestingly *H. pylori* infection may be less common in patients with bleeding ulcers than in those with nonbleeding ulcers.[112]

Endoscopic Treatment

The endoscopic appearance of a bleeding ulcer has important prognostic and therefore therapeutic implications, as alluded to in Tables 65-6 and 65-7. A modification of the system employed by Forrest et al.[113] is shown in Table 65-8. In this system, category I findings are indicative of active bleeding while category II findings provide evidence of recent hemorrhage. In general, only actively bleeding ulcers (i.e., Forrest category I lesions) are treated endoscopically.

Table 65-8 Forrest Classification of Endoscopic Appearance of Bleeding Ulcers

Ia	Spurting bleeding
Ib	Nonspurting, active bleeding
IIa	Visible vessel
IIb	Nonbleeding ulcer with overlying clot
IIc	Ulcer with hematin-covered (black) base
III	Clean ulcer base

From Yamaguchi T, Yoshikawa K. Enhanced CT for initial localization of active lower gastrointestinal bleeding. *Abdom Imaging* 2003;28:634–636.

A variety of endoscopic techniques are available to arrest hemorrhage from bleeding ulcers. The precise method of treatment is less important than the correct selection of patients and the experience of the endoscopist. Examples of methods typically include mechanical, thermal, or injection.

Mechanical ligation of bleeding vessels can be achieved with endoscopic ligation (banding), endoscopic clipping, or endoloop ligation.[114–116] Of these three methods, endoscopic clipping is the method most commonly employed for bleeding ulcers.

Heater probes and monopolar and bipolar electrocoagulation probes can also effectively control UGI hemorrhage. Monopolar probes apply high-frequency electrical current to the tissue, resulting in localized heating to 100°C and sealing of the bleeding vessel by coagulation necrosis of the surrounding tissue and vessel wall. Multipolar electrocoagulation (bicap) probes consist of three equally spaced pairs of bipolar microelectrodes. This orientation of electrodes allows coagulation of tissue from tangential approaches and eliminates some of the disadvantages of the monopolar probe, such as the unpredictable depth of thermal injury, adherence of tissue, and clot dislodgement. Direct thermal coagulation of a bleeding point can also be produced by applying a heater probe, consisting of an aluminum tip coated with Teflon. The tip is rapidly heated to 250°C by an inner coil. The tip can be irrigated with a water jet to prevent accumulation of debris and clot. Heat conducted from the probe produces tissue coagulation to a depth of 1 to 5 mm.

Injection of epinephrine to induce vasoconstriction has been used successfully to control acutely bleeding ulcers, particularly as an adjunct to electrocautery or mechanical hemostasis with clips. A meta-analysis of 15 studies concluded that injection alone was inferior to either clips alone, or clips plus injection.[117] This study showed no difference between clips and thermocoagulation.

Although not commonly employed, the injection of sclerosants has been well described as a method of treating esophageal varices and has been used for controlling nonvariceal bleeding. Sodium morrhuate and ethanolamine oleate are most commonly used to treat esophageal varices, whereas ethanol and polidocanol are most commonly used for nonvariceal sites. These agents act by thrombosing bleeding vessels and causing necrosis and subsequent fibrosis of surrounding tissue. Clinical experience with sclerosants has been similar to that obtained with electrocoagulation. In one large multicenter study of 332 actively bleeding patients or patients with stigmata of recent hemorrhage who underwent injection of 98% alcohol around the lesions, less than 1% continued to bleed, 6% rebled, and only 3% required emergency operative intervention.[118]

A meta-analysis of 25 randomized trials of endoscopic therapy for bleeding ulcers concluded that endoscopic treatment methods have a beneficial effect on survival by reducing the rate of recurrent hemorrhage. This analysis suggested that endoscopic therapy results in a relative reduction of 69% in recurrent bleeding, 62% in emergent surgery, and 30% in mortality rate, with the greatest benefit seen in actively bleeding ulcers and ulcers with nonbleeding visible vessels.[119] The effectiveness of early aggressive endoscopic diagnosis and treatment is further supported by a report of 562 patients bleeding from a variety of causes of whom only 2.5% required emergency operations to control hemorrhage.[120] Several other more recent studies have confirmed the critical role of endoscopy and control of UGI hemorrhage.[43,121,122] For most patients with evidence of persistent bleeding, a second attempt at endoscopic hemostasis should be attempted because this can provide up to 75% of patients with durable hemostasis. Exceptions may include patients with ulcers greater than 2 cm in diameter and those who have hypotension associated with a rebleeding episode, since such patients may be at an increased risk for failure of repeat endoscopic hemostasis.[104,121,123]

Operative Treatment

The successful use of endoscopic therapies has relegated operative procedures to a rescue role for those cases in which endoscopy is unsuccessful in arresting hemorrhage. Numerous studies have attempted to identify those patients at greatest risk of continued or recurrent bleeding. Of the many factors examined, those associated with the highest risk of rebleeding included patients in hypovolemic shock during the initial endoscopy, ulcers greater than 2 cm in diameter, and endoscopic stigmata of recent or ongoing hemorrhage (Forrest type I and II lesions).[123] Many studies have demonstrated the ability of endoscopy to identify those patients at greatest risk of rebleeding. In one review, the presence of active bleeding was associated with a 90% to 100% chance of continued or recurrent hemorrhage. A nonbleeding visible vessel had a 40% to 50% chance, adherent clot 20% to 30%, oozing without visible vessel 10%, flat spot 5% to 10%, and clean-based ulcer 1% to 2%.[124] Even in those patients who rebleed following initial endoscopic therapy, two-thirds may be successfully retreated endoscopically thus avoiding operative intervention.[90] Factors that must be considered in decisions regarding the timing of operative intervention include the magnitude of the initial (or recurrent) hemorrhage, the physiologic ability of the patient to withstand continued or recurrent hemorrhage, and the likelihood of recurrent or continued hemorrhage. It is generally accepted that elderly patients and those with significant concurrent medical problems should undergo operative intervention earlier during the course of the hemorrhage since these individuals will poorly tolerate continued bleeding, recurrent hypotension, and repeated transfusions.

The type of operation depends on the pathology encountered. For bleeding gastric ulcers, the operation of choice depends on the patient's condition and location of the ulcer. For favorably located ulcers, excision of the ulcer with closure of the gastrotomy will suffice. If the ulcer is unfavorably located, for example, near the gastroesophageal junction, simple oversewing of the vessel through the base of the ulcer may adequately control bleeding.[125] If a gastric ulcer is left in situ, follow-up endoscopy is necessary 4 to

8 weeks later to either confirm healing or obtain tissue to rule out malignancy. Extensive gastric resections such as antrectomy, subtotal or total gastrectomy are generally not performed in these unstable patients.

For patients bleeding from duodenal ulcers, the type of surgery performed has changed since the development of PPIs and treatment of *H. pylori*. Formerly, truncal vagotomy, pyloroplasty, and oversewing of the bleeding vessel were the most widely used operation. However, the trend is now more toward direct ligation of the bleeding vessel through the duodenotomy.[126] When performed, ligation should incorporate the gastroduodenal artery proximal and distal to the ulcer as well as the transverse pancreatic artery. Despite the above noted trend, a recent study has shown vagotomy and drainage may be superior to simple oversewing of the vessel.[127]

Angiographic Embolization

Of late, much has been written about the use of transcatheter embolization for peptic ulcer disease. In general, angiographic embolization is used after failure of endoscopic treatment in patients who cannot or will not undergo surgery. One large review (including nonulcer UGI indications) showed a high technical success rate (i.e., localization of bleeding and deployment of the embolic agent) but a clinical success rate of only 51%.[128] Other reviews have shown higher success rates ranging from 69% to 100% technical success rate and 63% to 97% clinical success rate.[129] Significant ischemic complications can occur however. While this technique has utility in select patients, it should not be considered as a first-line treatment option for bleeding peptic ulcers, but may have a role as a safe alternative to surgery for ulcers refractory to endoscopic treatment.

Stress Gastritis

Although studies in the 1960s and 1970s demonstrated acute erosions of the gastric mucosa in as many as 60% to 100% of critically ill patients, the incidence has markedly decreased over the past four decades. Factors postulated to have been important in this phenomenon include (1) the widespread use of prophylactic gastric alkalinization; (2) improvements in the ability to detect and treat sepsis; (3) improvements in the ability to monitor and correct hemodynamic instability; and (4) the ability to provide adequate nutritional support of critically ill patients.

In general, stress gastritis is characterized by the appearance of multiple superficial gastric ulcerations within 12 to 14 hours of an acute injury. These lesions, initially localized to the fundus and body of the stomach, later involve the entire gastric surface. Patients at greatest risk include those with sepsis, major burns, severe trauma, and critically ill patients with a coagulopathy and respiratory insufficiency.[130] In this setting, the disease appears to represent the gastric component of the multiorgan failure syndrome.

The pathogenesis of this disease is discussed in detail in Chapter 45. The primary defect is in the protective processes that maintain the integrity of the gastric mucosal barrier. Although some gastric acid secretion is required for the development of stress gastritis, it is clear that the hypersecretion of acid is not the cause of mucosal injury. Altered gastric mucosal blood flow and impaired clearance of hydrogen ions from the mucosa appear to be of particular importance; therefore, the best method of prevention of stress gastritis is to prevent gastric ischemia and acid injury. Stress gastritis should be differentiated from the deep, often solitary ulcerations occurring in patients with severe central nervous system lesions (Cushing ulcers).

Generally hemorrhage is the only symptom that patients with stress gastritis experience. Overt bleeding is often heralded by the appearance of flecks of blood in the gastric aspirate. The superficial nature of the lesions makes perforation unlikely.

Prophylactic therapy is directed toward preventing hemorrhage, primarily by neutralizing gastric acid, augmenting mucosal defenses, and removing or preventing physiologic stress. The gastric pH should be maintained between 3.5 and 4.5.[131] Antacids, H_2-receptor antagonists, PPIs, and sucralfate have all been used to prevent stress gastritis. Alkalinization of the gastric contents is associated with oral and fecal flora colonization of the stomach and has raised concerns about an increased risk of nosocomial pneumonia. This concern prompted the use of sucralfate as a preferred prophylactic agent for some time instead of antacids or cimetidine.[132] However, a prospective, randomized trial of 1,200 critically ill patients receiving either ranitidine or sucralfate for stress ulcer prophylaxis found that those patients receiving ranitidine had a lower bleeding rate (1.7%) than the sucralfate group (3.8%) but there was no difference in mortality or incidence of ventilator-assisted pneumonia.[133] Since that time, studies have shown PPIs to be a safe and effective method of stress prophylaxis, but the number of studies with high-quality data is still lacking.

The success of these prophylactic measures has led to a dearth of recent experience in

managing patients bleeding from stress gastritis. Based on early reports, attention to blood replacement, intravascular volume restoration, and correction of coagulation defects are associated with the cessation of hemorrhage in nearly 80% of cases and as such are the principal means of initial treatment. A variety of nonoperative techniques have been employed with variable success in arresting hemorrhage from stress gastritis including endoscopic and embolization techniques and the selective catheterization of the left gastric artery with continuous infusion of vasopressin.[134]

Based on these same early experiences, very few patients bleeding from erosive gastritis require operative intervention to arrest hemorrhage. A variety of surgical treatment options have been reported including vagotomy and pyloroplasty with oversewing of bleeding sites, vagotomy and hemigastrectomy, total gastrectomy, and gastric devascularization. The dilemma facing the surgeon is that these critically ill patients poorly tolerate extensive procedures, yet lesser operations often fail to control hemorrhage. Regardless of the operation performed, mortality risk depends on the underlying illness, particularly in the presence of multiple organ failure. Mortality rates between 30% and 60% are commonly quoted, with as many as one-fourth of the deaths resulting from continued hemorrhage. Rebleeding rates ranging from 25% to 61% have been reported. The combination of vagotomy, hemigastrectomy, and oversewing of bleeding points has been touted as more successful in these patients; however, rebleeding rates of 11% to 44% and operative mortality rates ranging from 33% to 63% have been associated with this procedure.[135] More extensive operations, such as near total gastrectomy or total gastrectomy are associated with significant mortality although they successfully stop hemorrhage.

Gastroesophageal Varices

Cirrhosis is a leading cause of death in the United States and variceal hemorrhage is a common mode of death for these patients. About 30% of people with cirrhosis develop gastroesophageal varices; of these individuals, about 30% bleed as a result of the varices, usually within 1 to 2 years of diagnosis. Gastroesophageal varices are a significant cause of UGI hemorrhage, accounting for about 20% of such cases. Patients with bleeding gastroesophageal varices tend to have much higher rebleeding rates, transfusion requirements, lengths of hospitalization, and risk of death than do patients bleeding from nonvariceal causes.[120,136]

Although the basic tenets of resuscitation for massive variceal hemorrhage are similar to those for any cause of massive bleeding, intravenous volume resuscitation should be particularly judicious. The hyperaldosteronemic state of cirrhosis promotes sodium and water retention with aggravation of ascites and peripheral edema. Accurate blood replacement is imperative since overtransfusion may worsen portal hypertension and exacerbate hemorrhage. Invasive cardiac monitoring with Swan–Ganz catheterization may be particularly useful for guiding volume replacement. Coagulation deficits should be aggressively corrected by administering fresh frozen plasma. Thrombocytopenia, secondary to hypersplenism or dilution, should be treated promptly with pooled platelet transfusions. Sedatives are best avoided or used sparingly because cirrhosis impairs the liver's ability to metabolize many of these drugs. Adequate prophylaxis for delirium tremens should be administered to alcoholics.

As with other sources of UGI hemorrhage, early endoscopy is imperative for successful diagnosis and therapy.[137] The identification of varices alone is not adequate to incriminate them as the source of the hemorrhage since up to half of patients with cirrhosis bleed from a source other than varices. Furthermore, endoscopy may identify factors associated with a heightened risk of variceal hemorrhage such as the size and number of varices and the presence of red, blue, or other colored spots on the varix. The presence of gastric and duodenal varices and portal hypertensive changes in the gastric mucosa (portal gastropathy) will influence therapeutic decisions and prognosis.

Although vasopressin has commonly been used in the management of variceal hemorrhage, its use has been limited due to the potent vasoconstrictive properties causing cardiac and peripheral ischemia, arrhythmias, hypertension, and bowel ischemia. More recent reports suggest the superiority of somatostatin or its synthetic analog, octreotide. It is thought that octreotide causes splanchnic arteriolar vasoconstriction and reduces variceal and azygous vein flow with limited direct effects on portal pressure.[138] Meta-analyses have shown that the infusion of somatostatin is more effective and safer than vasopressin in the pharmacologic control of variceal hemorrhage.[139,140] Other studies have shown that somatostatin or octreotide can improve the results of sclerotherapy or endoscopic variceal ligation.[141,142] Although neither somatostatin nor vasopressin plus nitroglycerin definitively treat the bleeding esophageal varices, these modalities may provide initial control of hemorrhage, reducing transfusion requirements and providing time for resuscitation before definitive treatment.

Another temporizing method used for massively bleeding patients is balloon tamponade using a Sengstaken–Blakemore tube or a Minnesota tube. These devices consist of a gastric tube with esophageal and gastric balloons. In the case of a Minnesota tube, a proximal esophageal lumen allows for the aspiration of swallowed secretions. Inflation of the gastric (and if required esophageal) balloons tamponade the bleeding varices, controlling hemorrhage in more than 80% of cases. Hemorrhage recurs in 25% to 50% of patients upon deflation of the balloons, thus limiting this technique to a temporizing role.[143] The greatest value of these tubes is for arresting massive hemorrhage that has been unresponsive to other measures, allowing time for resuscitation and angiographic definition of the portal system before definitive treatment.

When used inappropriately, these tubes can be associated with significant morbidity and mortality. Complications occur in 4% to 9% of patients with the most frequent being aspiration pneumonitis. Measures to prevent pulmonary complications include endotracheal intubation before tube insertion and the placement of an esophageal tube to remove swallowed salivary secretions. Other significant complications include esophageal rupture or necrosis and airway occlusion during the attempted removal of an incompletely deflated gastric balloon. Because of the availability of endoscopy, these tubes are rarely used today.

8 Endoscopic sclerotherapy, endoscopic clipping or endoscopic variceal ligation (banding) have become the most widely used modalities for the initial definitive control of bleeding esophageal varices. Several studies have confirmed that these techniques arrest acute variceal hemorrhage in 90% to 95% of patients. In general, a patient bleeding from esophageal varices should undergo urgent pharmacologic therapy and banding of the varices at the time of the first emergency endoscopy. Sclerotherapy can be used if ligation is technically difficult.[137] A single endoscopic treatment controls variceal bleeding in more than 70% of patients, and a second treatment increases the rate of control from 90% to 95%. Continued or recurrent hemorrhage after endoscopic treatment often requires emergency portal decompression either with transjugular intrahepatic portosystemic shunting (TIPS) or rarely surgery.[144–146] Following an initial episode of variceal hemorrhage several options are available for the prevention of further hemorrhage. These options, as well as the operative management of bleeding esophageal varices are discussed in detail in Chapter 59.

Mallory–Weiss Tears

The Mallory–Weiss syndrome is acute UGI hemorrhage that occurs after retching or vomiting. Mallory and Weiss described the laceration of the gastric cardia and postulated that violent emesis against an unrelaxed cardia was the mechanism of injury. They were able to produce similar mucosal tears in cadavers by forcing gastric contents against an occluded gastroesophageal junction.[147] The typical patient is an alcoholic who begins to retch and vomit after an alcohol binge although this syndrome may also be found in nonalcoholics with bouts of emesis. Initially the vomitus consists of gastric contents without blood and subsequently the patient develops hematemesis and/or melena. Overall, these lesions account for about 5% to 10% of patients with UGI bleeding.[120,136,148]

The initial management of these patients is similar to that of patients bleeding from other sources of UGI hemorrhage and includes volume resuscitation, gastric lavage, and decompression. Most patients with Mallory–Weiss tears stop bleeding spontaneously, either before treatment or after these early measures. Once bleeding has stopped, rebleeding is rare.

In patients who continue to bleed despite these maneuvers, nonoperative and operative therapeutic options are available. Nonoperative management, consisting of endoscopic electrocoagulation, banding or injection therapy, has been successfully applied to these lesions.[149] In cases not amenable to endoscopic therapy, operative management consists of oversewing the laceration through an anterior longitudinal gastrotomy in the middle third of the stomach.

LOWER GI HEMORRHAGE

Although the passage of maroon or bright red blood per rectum may occur in the presence of a massive UGI hemorrhage, this finding most commonly indicates a source distal to the ligament of Treitz. The absence of blood in bilious nasogastric lavage further supports a distal location of hemorrhage. Although numerous potential causes of LGI hemorrhage are possible (Table 65-2), colonic diverticulosis and colitis are by far the most common. Small bowel sources and other colonic pathology such as colon cancer are relatively unusual causes of acute GI hemorrhage.

Diagnostic Approach

The most important question to answer when presented with a patient with LGI hemorrhage is not, “What is bleeding?” but rather, “Where is the bleeding?” The common causes of colonic hemorrhage are mucosal in nature, not palpable, and not visible from the serosal surface of the bowel. Therefore, it is imperative that the surgeon makes every effort to localize the source of bleeding preoperatively since it is usually impossible to locate intraoperatively. If the surgeon waits to attempt localization until it is clear that surgical treatment will be required it may be too late. Colonoscopy, tagged RBC scanning and/or angiography should be obtained as early as possible after presentation.

After determination that the bleeding is likely from an LGI source, it is important to first exclude anorectal causes of hemorrhage, such as hemorrhoidal bleeding. At this point, colonoscopy is usually performed as it can rule out anorectal causes of bleeding, but also help determine non-anorectal causes of hemorrhage. In the authors’ experience, despite studies showing high value, colonoscopy in an actively bleeding patient with an unprepped colon is seldom therapeutic. However, it can be of significant diagnostic benefit. It is usually fairly easy to determine when bleeding is from a neoplasm, and noting the location helps guide the surgeon in decision making. Conversely in AVMs and diverticular bleeding, locating the actual source of bleeding is often unsuccessful due to the presence of blood and stool. However, noting the extent of blood in the colon can be helpful to guide future surgical decision making. For example, if blood is only noted in the sigmoid colon and rectum, this suggests bleeding is from a distal source and a sigmoid colectomy may suffice if bleeding persists. Alternatively if blood is noted throughout the entire colon, the location of the bleed is unclear and a total colectomy may be necessary. The terminal ileum should be intubated as well. While a small amount of blood can reflux into the terminal ileum, if an extensive amount of blood is noted then a small bowel source should be considered and the surgeon should be hesitant about performing a total colectomy if bleeding persists.

Alternatively, a tagged RBC scan can be obtained as soon as practical, or in occasional cases of massive hemorrhage, conventional angiography or MDCT. If the tagged RBC scan localizes a bleeding site, the patient is then sent for angiography to attempt to embolize the bleeding vessel. If the tagged RBC scan does not demonstrate bleeding, then it is probable that bleeding has stopped. One may then proceed to colonoscopy after adequate mechanical bowel preparation.

If the bleeding is rapid enough to warrant emergency surgery, bleeding can usually be demonstrated by tagged RBC scan, MDCT, or angiography. It should be the very rare patient who will need to proceed to surgery for LGI hemorrhage with failed preoperative localization. In these cases a careful search for small bowel bleeding sources, possibly including intraoperative small bowel endoscopy, should be performed.

Colonic Diverticulosis

9 In Western society, the prevalence of colonic diverticula increases with age such that about 60% of people in their seventh decade of life are affected and the incidence increases roughly 1% per year. Only about 20% of patients with diverticulosis have symptoms attributable to these lesions and less than 5% experience hemorrhage.[150] Hemorrhage from diverticular disease is most often massive, associated with hematochezia, and accompanied by varying degrees of hemorrhagic shock. Classically, patients present with a sudden occurrence of mild lower abdominal discomfort, rectal urgency, and the subsequent passage of a large bloody stool. Because the colon can contain large volumes of blood, neither the volume nor the frequency of bloody stools is a reliable guide to the rate of hemorrhage. Despite the massive nature of hemorrhage, most patients with diverticular disease stop bleeding spontaneously. Most series report bleeding ceases spontaneously in 80% of cases, although up to 25% to 50% can rebleed. Of those who rebled, less than one-fourth required surgery.[151]

Bleeding associated with diverticular disease comes from a perforated vasa recta located at the neck or apex of a diverticulum. The vasa recta penetrates the colonic wall from the serosa to the submucosa through obliquely oriented connective tissue septa. Protrusion of colonic mucosa through this connective tissue plane causes apposition of the diverticulum and the vasa recta (Fig. 65-4). Ulceration of the mucosa within the neck of the diverticulum and disruption of the arterial wall produces hemorrhage into the lumen of the bowel. Although diverticular disease is more prevalent in the left colon, right-sided lesions account for half or more episodes of bleeding.[151,152] Risk factors for rebleeding are hypertension, NSAID use, coagulopathy, renal failure, ischemic heart disease, and cluster type diverticula.[153,154]

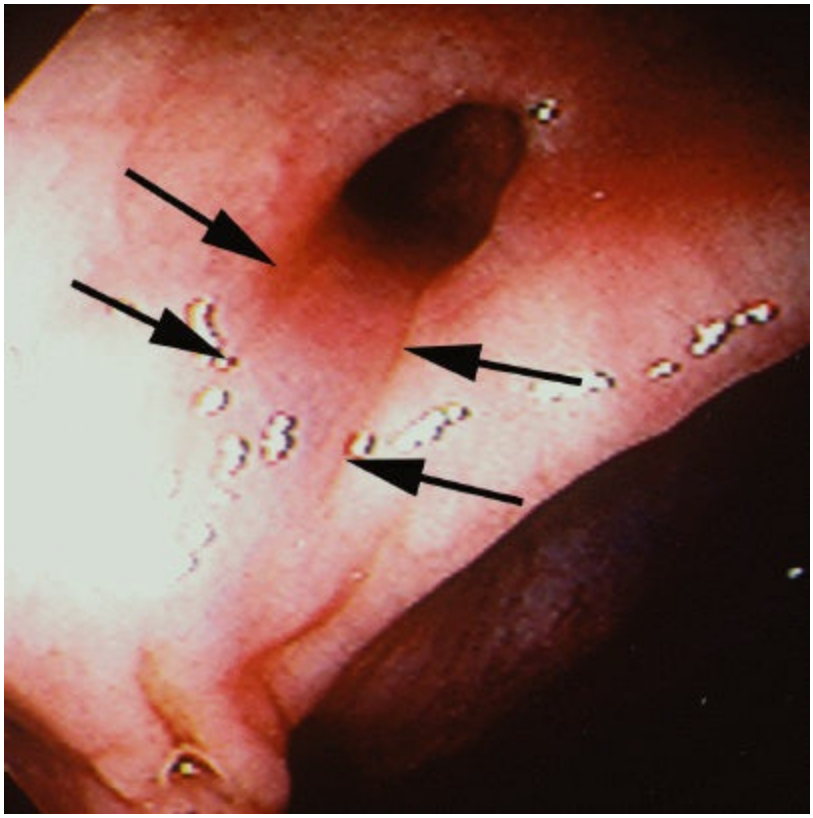

Figure 65-4. Colonoscopic view of a colonic diverticulum. A vasum rectum is seen entering the diverticulum and forming one of the walls.

The massive nature of the bleeding caused by colonic diverticula limits the diagnostic usefulness of colonoscopy. Rarely is a bleeding vessel seen within a diverticulum and the presence of blood or clot within a diverticulum is of no diagnostic benefit. Selective mesenteric arteriography may demonstrate the luminal extravasation of contrast; however, in one study of patients bleeding from diverticulosis, angiographic localization was effective in less than 20% of patients.[155] Failure to visualize a bleeding point is usually due to cessation of active bleeding at the time of angiography.

Given the relatively low risk of recurrent hemorrhage, patients who stop bleeding should be treated expectantly. About 10% of patients bleeding from colonic diverticula continue to bleed and ultimately require operative intervention. Embolization of bleeding vessels in the colon has been reported to be safe and effective in the majority of patients; however there is a definite risk of ischemic complications.[156,157] The rapid nature of the hemorrhage and the difficulty in defining the site of bleeding through the endoscope can limit endoscopic attempts at control of diverticular hemorrhage, especially in patients with large volume rapid bleeding.

If the site of bleeding can be localized, patients who continue to bleed from diverticular disease should undergo resection of the colon segment that contains the site of bleeding. Even after successful localization of a bleeding source, the least operation that can usually be contemplated is a hemicolectomy or wide segmental colectomy. Segmental colon resection has been associated with rebleeding rates of only 0% to 15% and mortality rates of 0% to 13%. Tagged RBC scanning, while sensitive, cannot always pinpoint a bleeding site with great accuracy. Although angiography usually gives more precise localization,

correlation between the vascular pattern and the anatomic location is sufficiently imprecise to warrant at least a segmental resection. Finally, measurement with colonoscopy is notoriously misleading with even experienced endoscopists making mistakes about the precise site of a lesion. If the location is unable to be localized and the blood appears confined to the colon, a total abdominal colectomy should be performed as most studies show rebleeding rates of 0%, and “blind” segmental colectomy has been shown to have a rebleeding rate of up to 75%.[65] However, the surgeon and patient should be aware of a failure rate even after total abdominal colectomy as the small bowel could potentially be the source. There are few worse sights for the surgeon than blood coming from an ileostomy after a blind total abdominal colectomy for bleeding.

Although a total colectomy, often with end ileostomy, for nonlocalized ongoing colonic hemorrhage may occasionally be necessary, it should be performed only after exhaustive attempts to localize the site of bleeding. Total colectomy is associated with greater perioperative morbidity rates than segmental resection and postoperative volume losses from ileostomies or diarrhea may present a significant problem to elderly patients.

Colonic Angiodysplasia

Sometimes called vascular ectasias or arteriovenous malformations, these lesions are believed to arise from the age-related degeneration of previously normal intestinal submucosal veins and overlying mucosal capillaries. Angiodysplasia is located most frequently in the cecum and ascending colon, although it may be found more distally in 20% to 30% of cases. Multiple lesions may be present in as many as 40% to 75% of all cases.[158] Microscopically, angiodysplasia consists of dilated, thin-walled vessels that appear to be ectatic veins and venules localized within the submucosa. A dilated submucosal vein is often found and occasionally an enlarged artery. Angiodysplasia is generally thought to be an acquired lesion associated with aging, but the exact etiology is unknown.

The prevalence of colonic angiodysplasia in the general population appears to be less than 1%.[159] These lesions may present with hematochezia, melena, occult blood loss, or iron-deficiency anemia. Bleeding lesions are most commonly found in the right colon. As compared to diverticular bleeding, episodes of hemorrhage from vascular ectasias are usually less severe, and are somewhat more likely to recur. After the initial episode of hemorrhage, the majority of patients will stop bleeding spontaneously.[160]

Vascular ectasias may be diagnosed by either colonoscopy or by selective mesenteric angiography. Colonoscopy has been reported to have a sensitivity of 80% in demonstrating vascular ectasias.[161] However, colonoscopic diagnosis of these lesions in actively bleeding patients may be confounded by the presence of other incidental lesions including traumatic and suction artifacts produced during the examination. In addition, after significant bleeding and hypovolemia, the shunting of blood flow away from the intestinal mucosa may obscure these lesions in inadequately resuscitated patients. When vascular ectasias are located, colonoscopy can be used effectively to treat vascular ectasias either by coagulation or possibly injection of sclerosants.[162,163]

Selective mesenteric angiography may also demonstrate these lesions and compliment colonoscopy, particularly in patients who are massively bleeding or in whom colonoscopy was unrevealing or incomplete. Characteristic angiographic findings include a densely opacified and slowly emptying, dilated, tortuous vein (found in 90% of patients), a vascular tuft (seen in 66% to 75% of patients), and an early-filling vein (usually a segmental vein in the cecum or right colon, although at times, it may be the ileocolic vein).

The natural history of these lesions was revealed by the clinical course of 101 patients with colonic vascular ectasias.[161] Of the 15 asymptomatic individuals without a history of bleeding, none bled during a period of follow-up to 68 months (mean, 23 months). For 31 patients with overt bleeding or anemia who were treated only with blood transfusion, the rebleeding rates at 1 and 3 years were 26% and 46%, respectively. This study suggests that the risk of bleeding for incidentally discovered lesions is minimal and empiric therapy is not warranted. However, the risk of recurrent hemorrhage for most symptomatic patients is substantial and may increase with time.

Medical treatment of vascular ectasias has been used although there is currently no

proven effective medical therapy. Hormone treatment using high-dose estrogens and progesterone has been used since the 1950s but convincing proof of efficacy is lacking. Indeed, most evidence would suggest no antibleeding effect of hormonal treatment.[164] More recently the antiangiogenic drug thalidomide, hormones, and octreotide have been suggested as treatment options but data are lacking.[165–167]

Endoscopic therapy has, however, proved to be more effective. Nonrandomized investigations with vascular ectasias managed with monopolar electrocoagulation, endoscopic injection sclerotherapy, contact probes, and lasers have been published with good results. All methods appear to be effective for treating bleeding vascular ectasias and all are associated with procedure-related morbidity rates of 2% to 10%. Perforation has been reported in all of these experiences with rates of 2% to 3%.

Patients bleeding from vascular ectasias in whom endoscopic hemostatic methods are unsuccessful or unavailable can be treated with resection of the colon following preoperative localization of the bleeding site. For the usual patient bleeding from a vascular ectasia in the cecum or ascending colon, a right colectomy with ileotransverse colostomy is the treatment of choice. The value of preoperative localization of the bleeding site cannot be overstated, and every effort should be made to determine the site of hemorrhage prior to laparotomy.

Ischemic Colitis

Ischemic colitis is a common cause of LGI hemorrhage especially in the elderly. Bleeding is a common presenting manifestation of ischemic colitis occurring in approximately one-half to three-fourths of patients but is usually not massive.[168,169] Although ischemic colitis may occur with occlusion of a major artery (such as ligation of the inferior mesenteric artery during abdominal aortic aneurysm repair), in most cases it results from impaired local microvascular perfusion of the colonic wall. It occurs most commonly in the elderly who often have significant medical comorbidities. Renal failure requiring hemodialysis, hypertension, cardiovascular disease, vasoactive medications, and a variety of other risk factors have been associated with the disease.[170] In many cases a specific initiating event cannot be identified. Any segment of the colon may be involved. Profound ischemia may lead to full-thickness necrosis, peritonitis, and perforation. Lesser degrees of ischemia may result in vague mild to moderate abdominal pain (helping differentiate it from diverticulosis), diarrhea, and mild to moderate bleeding. Life-threatening hemorrhage is uncommon.

Ischemic colitis can be diagnosed with colonoscopy in which case the mucosa may vary from edematous to hemorrhagic and necrotic. Rarely is angiography helpful in these cases as it rarely demonstrates major vessel occlusion.[169] Most patients will recover uneventfully with supportive care alone. When operative management is required it is often necessitated by peritonitis or other signs of full-thickness necrosis. In these critically ill patients the mortality rate is relatively high due to the critical nature of these patients' pre-existing comorbid conditions.

UNUSUAL CAUSES OF ACUTE GASTROINTESTINAL HEMORRHAGE

As outlined in Tables 65-1 and 65-2, a wide variety of other pathologic processes may present with acute GI hemorrhage. Although these lesions generally comprise a relatively small percentage of the total number of cases of overt GI hemorrhage, they can present vexing problems to the clinician faced with a bleeding patient in whom the usual etiologies have been excluded. There are a number of case reports in the literature of extremely rare causes of GI bleeding that will not be discussed here. The following lesions occur commonly enough that clinicians are likely to encounter them in their practice.

Dieulafoy Vascular Malformation

Dieulafoy vascular malformation is an unusual cause of recurrent hematemesis, in which bleeding originates from an unusually large (1- to 3-mm diameter) artery running through the gastric submucosa for variable distances. Erosion of the gastric mucosa overlying the vessel results in necrosis of the arterial wall and brisk hemorrhage. The size of the mucosal defect is usually small (2 to 5 mm) and without evidence of chronic inflammation. These lesions may rarely occur in other anatomic locations of these lesions such as the colon.[171–173]

Painless hematemesis and melena are typical. Recurrent bleeding with spontaneous cessation is also common. In a collective review of 101 cases, the mean age of the patients was 52 years, and the lesion occurred twice as frequently in men as women. There was no significant association with alcohol abuse or antecedent symptoms.[174]

The diagnosis is most frequently made endoscopically by demonstrating arterial bleeding from a pinpoint mucosal defect. Occasionally, a small arterial vessel may be seen protruding from the gastric mucosa. Characteristically, the lesions are located within 6 cm of the esophagogastric junction along the lesser curvature although they may occur in other sites as well.

Most patients can be managed endoscopically by injection of epinephrine, sclerotherapy, banding, clipping or coagulation.[175,176] A subset of patients will require retreatment or surgical excision for control of hemorrhage. After cessation of hemorrhage few patients rebleed from these lesions even when treated only be endoscopic methods.[177]

Gastric Antral Vascular Ectasia

Sometimes abbreviated as GAVE syndrome, this entity is also known as “Watermelon Stomach” because of its characteristic endoscopic appearance. Longitudinal erosions are seen in the antrum radiating from the pylorus. It usually causes chronic blood loss and not acute hemorrhage. The etiology is not known but there is a prominent association with connective tissue disorders. It can usually be treated by endoscopic argon coagulation but occasionally antrectomy is necessary.[178]

Angiodysplasia of the Stomach and Small Intestine

Angiodysplastic lesions may occur throughout the GI tract. Similar to colonic lesions, they appear as minute, flat, or slightly raised red lesions with round or stellate shapes. The margins are characteristically sharp with a pale mucosal halo surrounding the lesion. The lesions are frequently multiple and are found most commonly in the stomach and duodenum, although esophageal and small intestinal involvement has also been described.

In general, these lesions may be diagnosed by endoscopy, although their minute size and sessile nature may complicate their detection. The lesions may also be readily mistaken for submucosal hemorrhage associated with acute gastritis or trauma artifact from an NGT or the endoscope. The lesions may also be demonstrated arteriographically since they have many of the features described for colonic vascular ectasia.

Endoscopic injections of sclerosants, electrocoagulation, and laser photocoagulation have all been used to treat gastroduodenal angiodysplasia with good results. The multiplicity of lesions often necessitates several courses of therapy to eliminate recurring hemorrhage. Surgical resection of the gastric or intestinal wall containing the lesion as well as oversewing of the bleeding lesion have been reported to successfully control hemorrhage.

Aortoenteric Fistula

Although communication between the aorta and the intestine may occur as a result of aneurysmal disease or infectious aortitis (*primary aortoenteric fistula*), most of those encountered currently are due to the erosion of an aortic vascular prosthesis through the wall of the distal duodenum (*secondary aortoenteric fistula*). The incidence of aortoenteric fistula following aortic reconstructive surgery is about 1% with most of these fistulas arising from the proximal graft anastomosis. Secondary aortoenteric fistulas are believed to develop after prolonged contact of a prosthetic graft with a fixed segment of intestine. Ultimately erosion of the graft through the bowel wall results in a low-grade infection around the graft; involvement of the infection with the suture line leads to dehiscence of the anastomosis and massive hemorrhage.

The interval between aortic reconstructive surgery and the onset of GI hemorrhage may range from a few days to many years; the median interval is about 3 years.[179] Most patients have an initial episode of GI bleeding (i.e., herald bleed) that is followed in hours, days, or weeks by catastrophic hemorrhage. Patients may also complain of back or abdominal pain and less commonly have fever or signs of sepsis from infection of the graft.

The diagnosis of an aortoenteric fistula must be considered in any patient with an aortic prosthesis or an abdominal aortic aneurysm who presents with GI hemorrhage. Endoscopy should be urgently performed following resuscitation to disclose evidence of an aortoenteric fistula or another cause of bleeding (e.g., peptic ulcer disease with stigmata of recent hemorrhage). If endoscopy fails to demonstrate an aortoenteric fistula or another convincing source of bleeding and the patient is not massively bleeding, computed tomography may be helpful in detecting perigraft infection or other evidence of an aortoenteric fistula. In patients who are actively bleeding, exploratory laparotomy with exposure of the proximal graft should be undertaken. Identification of an aortoenteric fistula or erosion requires resection of the graft with extra-anatomical bypass and repair of the duodenal wall, or aortic reconstruction using a variety of techniques such as aortic reconstruction with popliteal vein or human allografts.[180] The operative management of aortoduodenal fistulas is considered in greater detail in Chapter 96.

Meckel Diverticulum

Bleeding from a Meckel diverticulum is a common cause of lower GI hemorrhage in children but is rare in older adults. Meckel diverticula are present in approximately 2% of the population. The lifetime risk of a complication from a Meckel diverticulum is about 4%.[181] About 25% of patients with symptomatic Meckel diverticula present with hemorrhage.[182] In a series of 17 patients who bled from Meckel diverticula, 11 experienced frank hemorrhage while 6 had chronic occult blood loss. The incidence of GI hemorrhage is greatest in the first decade of life and steadily decreases from that point. In one series, no patient older than 40 years of age, and only one patient older than 31 years, bled from a Meckel diverticulum,[182] although it has been reported in the very elderly.[183] The pathogenesis of this bleeding involves the occurrence of ectopic gastric mucosa with peptic ulceration of adjacent bowel wall. Although these lesions may be demonstrated by enteroclysis, abdominal scintigraphy following the intravenous injection of ^{99}technetium-pertechnetate demonstrates the ectopic gastric mucosa within the diverticulum, suggesting the correct diagnosis. Treatment consists of resecting the diverticulum with adjacent bowel. Diverticulectomy alone will be associated with persistence of the ulcer and the possibility of recurrent hemorrhage.

Small Intestinal Diverticulum

Diverticular disease of the small intestine is another uncommon cause of either UGI hemorrhage (duodenal) or LGI hemorrhage (jejunoileal diverticula).[184] The pathogenesis is similar to that of colonic diverticula with erosion of a vasa recta through the diverticular wall and the acute onset of massive hemorrhage. Depending on the location of the diverticulum, patients may present with either hematemesis, melena, or hematochezia. Hemorrhage from this source can be a vexing diagnostic problem because jejunoileal lesions are beyond the reach of the gastroscope and bleeding from duodenal diverticula may be difficult to discern. Mesenteric angiography or intraoperative enteroscopy may localize the site of hemorrhage in actively bleeding patients. Segmental resection of the involved intestine is the treatment of choice.

Hemorrhage Following Endoscopic Procedures

Significant hemorrhage can occur following endoscopic biopsy, sphincterotomy, and other traumatic procedures. Fortunately these complications are uncommon. Colonoscopy may rarely cause clinically significant bleeding (0.1% to 0.2%).[185] Biopsy of lesions increase the risk up to 10-fold. Usually this is minor and self-limited and may occur up to 12 days after the procedure.[186] The bleeding site can be confirmed by tagged red cell scanning, arteriography, or colonoscopy. Arteriography and colonoscopy can be used therapeutically as described previously. Endoscopically placed bands such as those used for esophageal varices, have also been reported to be successful in arresting hemorrhage.[98] Surgical treatment is rarely required.

Hemorrhage following endoscopic biliary sphincterotomy occurs in approximately 2% of patients.[187] Mild immediate bleeding is common and is usually self-limited. Late hemorrhage usually occurs within 48 hours of the procedure but can occur many days after sphincterotomy.[188] More severe hemorrhage can usually be controlled by epinephrine injection,[188] making the need for operative treatment uncommon.

References

1. Peura DA, Lanza FL, Gostout CJ, et al. The American College of Gastroenterology Bleeding Registry: preliminary findings. *Am J Gastroenterol* 1997;92:924–928.
2. Raju GS, Gerson L, Das A, et al. American Gastroenterological Association (AGA) Institute technical review on obscure gastrointestinal bleeding. *Gastroenterology* 2007;133:1697–1717.
3. Laine L, Yang H, Chang SC, et al. Trends for incidence of hospitalization and death due to GI complications in the United States from 2001 to 2009. *Am J Gastroenterol* 2012;107:1190–1195.
4. Vreeburg EM, Snel P, de Bruijne JW, et al. Acute upper gastrointestinal bleeding in the Amsterdam area: incidence, diagnosis, and clinical outcome. *Am J Gastroenterol* 1997;92:236–243.
5. Lingenfelser T, Ell C. Lower intestinal bleeding. *Best Pract Res Clin Gastroenterol* 2001;15:135–153.
6. Cappell MS, Friedel D. Initial management of acute upper gastrointestinal bleeding: from initial evaluation up to gastrointestinal endoscopy. *Med Clin North Am* 2008;92:491–509, xi.
7. Richter JM, Christensen MR, Kaplan LM, et al. Effectiveness of current technology in the diagnosis and management of lower gastrointestinal hemorrhage. *Gastrointest Endosc* 1995;41:93–98.
8. Bramley PN, Masson JW, McKnight G, et al. The role of an open-access bleeding unit in the management of colonic haemorrhage. A 2-year prospective study. *Scand J Gastroenterol* 1996;31:764–769.
9. Longstreth GF. Epidemiology and outcome of patients hospitalized with acute lower gastrointestinal hemorrhage: a population-based study. *Am J Gastroenterol* 1997;92:419–424.
10. Kok KY, Kum CK, Goh PM. Colonoscopic evaluation of severe hematochezia in an Oriental population. *Endoscopy* 1998;30:675–680.
11. Kaplan RC, Heckbert SR, Koepsell TD, et al. Risk factors for hospitalized gastrointestinal bleeding among older persons. Cardiovascular Health Study Investigators. *J Am Geriatr Soc* 2001;49:126–133.
12. Fiaccadori E, Maggiore U, Clima B, et al. Incidence, risk factors, and prognosis of gastrointestinal hemorrhage complicating acute renal failure. *Kidney Int* 2001;59:1510–1519.
13. Cheng HC, Chuang SA, Kao YH, et al. Increased risk of rebleeding of peptic ulcer bleeding in patients with comorbid illness receiving omeprazole infusion. *Hepato Gastroenterol* 2003;50:2270–2273.
14. van Leerdam ME, Vreeburg EM, Rauws EA, et al. Acute upper GI bleeding: did anything change? Time trend analysis of incidence and outcome of acute upper GI bleeding between 1993/1994 and 2000. *Am J Gastroenterol* 2003;98:1494–1499.

15. Mellemkjaer L, Blot WJ, Sorensen HT, et al. Upper gastrointestinal bleeding among users of NSAIDs: a population-based cohort study in Denmark. *Br J Clin Pharmacol* 2002;53:173–181.
16. Verhamme K, Mosis G, Dieleman J, et al. Spironolactone and risk of upper gastrointestinal events: population based case-control study. *BMJ* 2006; 333:330.
17. Dalton SO, Johansen C, Mellemkjaer L, et al. Use of selective serotonin reuptake inhibitors and risk of upper gastrointestinal tract bleeding: a population-based cohort study. *Arch Intern Med* 2003;163:59–64.
18. Masclee GM, Valkhoff VE, Coloma PM, et al. Risk of upper gastrointestinal bleeding from different drug combinations. *Gastroenterology* 2014;147:784–792.e9.
19. Garcia Rodriguez LA, Lin KJ, Hernandez-Diaz S, et al. Risk of upper gastrointestinal bleeding with low-dose acetylsalicylic acid alone and in combination with clopidogrel and other medications. *Circulation* 2011;123:1108–1115.
20. Daniel WA, Egan S. The quantity of blood required to produce a tarry stool. *JAMA* 1939;113:2232.
21. Schiff L, Stevens RJ, Shapiro N, et al. Observations on the oral administration of citrated blood in man. II. The effect on the stools. *Am J Med Sci* 1942;203:409–412.
22. Hilsman JH. The color of blood-containing feces following the instillation of citrated blood at various levels of the small intestine. *Gastroenterology* 1999;15:131–134.
23. Barnert J, Messmann H. Management of lower gastrointestinal tract bleeding. *Best Pract Res Clin Gastroenterol* 2008;22:295–312.
24. Longstreth GF, Feitelberg SP. Outpatient care of selected patients with acute non-variceal upper gastrointestinal haemorrhage. *Lancet* 1995;345:108–111.
25. Kollef MH, O'Brien JD, Zuckerman GR, et al. BLEED: a classification tool to predict outcomes in patients with acute upper and lower gastrointestinal hemorrhage. *Crit Care Med* 1997;25:1125–1132.
26. Rockall TA, Logan RF, Devlin HB, et al. Risk assessment after acute upper gastrointestinal haemorrhage. *Gut* 1996;38:316–321.
27. Sanders DS, Carter MJ, Goodchap RJ, et al. Prospective validation of the Rockall risk scoring system for upper GI hemorrhage in subgroups of patients with varices and peptic ulcers. *Am J Gastroenterol* 2002;97:630–635.
28. Rockall TA, Logan RF, Devlin HB, et al. Selection of patients for early discharge or outpatient care after acute upper gastrointestinal haemorrhage. National audit of acute upper gastrointestinal haemorrhage. *Lancet* 1996; 347:1138–1140.
29. Camellini L, Merighi A, Pagnini C, et al. Comparison of three different risk scoring systems in non-variceal upper gastrointestinal bleeding. *Dig Liver Dis* 2004;36:271–277.
30. Vreeburg EM, Terwee CB, Snel P, et al. Validation of the Rockall risk scoring system in upper gastrointestinal bleeding. *Gut* 1999;44:331–335.
31. Stanley AJ, Ashley D, Dalton HR, et al. Outpatient management of patients with low-

risk upper-gastrointestinal haemorrhage: multicentre validation and prospective evaluation. *Lancet* 2009;373:42–47.

32. Stanley AJ, Dalton HR, Blatchford O, et al. Multicentre comparison of the Glasgow Blatchford and Rockall scores in the prediction of clinical end-points after upper gastrointestinal haemorrhage. *Aliment Pharmacol Ther* 2011;34:470–475.
33. Strate LL, Orav EJ, Syngal S. Early predictors of severity in acute lower intestinal tract bleeding. *Arch Int Med* 2003;163:838–843.
34. Anderson RS, Witting MD. Nasogastric aspiration: a useful tool in some patients with gastrointestinal bleeding. *Ann Emerg Med* 2010;55:364–365.
35. Aljebreen AM, Fallone CA, Barkun AN. Nasogastric aspirate predicts high-risk endoscopic lesions in patients with acute upper-GI bleeding. *Gastrointest Endosc* 2004;59:172–178.
36. Witting MD, Magder L, Heins AE, et al. Usefulness and validity of diagnostic nasogastric aspiration in patients without hematemesis. *Ann Emerg Med* 2004;43:525–532.
37. Pitera A, Sarko J. Just say no: gastric aspiration and lavage rarely provide benefit. *Ann Emerg Med* 2010;55:365–366.
38. Chung YF, Wong WK, Soo KC. Diagnostic failures in endoscopy for acute upper gastrointestinal haemorrhage. *Br J Surg* 2000;87:614–617.
39. Spiegel BM, Vakil NB, Ofman JJ. Endoscopy for acute nonvariceal upper gastrointestinal tract hemorrhage: is sooner better? A systematic review. *Arch Intern Med* 2001;161:1393–1404.
40. Lee JG, Turnipseed S, Romano PS, et al. Endoscopy-based triage significantly reduces hospitalization rates and costs of treating upper GI bleeding: a randomized controlled trial. *Gastrointest Endosc* 1999;50:755–761.
41. Laine L, Peterson WL. Bleeding peptic ulcer. *N Engl J Med* 1994;331:717–727.
42. Villanueva C, Balanzo J, Espinos JC, et al. Prediction of therapeutic failure in patients with bleeding peptic ulcer treated with endoscopic injection. *Dig Dis Sci* 1993;38:2062–2070.
43. Barkun A, Bardou M, Marshall JK, et al.. Consensus recommendations for managing patients with nonvariceal upper gastrointestinal bleeding. *Ann Intern Med* 2003;139:843–857.
44. Chung IK, Kim EJ, Lee MS, et al. Endoscopic factors predisposing to rebleeding following endoscopic hemostasis in bleeding peptic ulcers. *Endoscopy* 2001;33:969–975.
45. Jensen DM, Machicado GA, Jutabha R, et al. Urgent colonoscopy for the diagnosis and treatment of severe diverticular hemorrhage. *N Eng J Med* 2000;342:78–82.
46. Davila RE, Rajan E, Adler DG, et al. ASGE guideline: the role of endoscopy in the patient with lower-GI bleeding. *Gastrointest Endosc* 2005;62:656–660.
47. Green BT, Rockey DC, Portwood G, et al. Urgent colonoscopy for evaluation and

management of acute lower gastrointestinal hemorrhage: a randomized controlled trial. *Am J Gastroenterol* 2005;100:2395–2402.

48. Lhewa DY, Strate LL. Pros and cons of colonoscopy in management of acute lower gastrointestinal bleeding. *World J Gastroenterol* 2012;18:1185–1190.
49. Elta GH. Urgent colonoscopy for acute lower-GI bleeding. *Gastrointest Endosc* 2004;59:402–408.
50. Chaudhry V, Hyser MJ, Gracias VH, et al. Colonoscopy: the initial test for acute lower gastrointestinal bleeding. *Am Surg* 1998;64:723–728.
51. Strate LL, Naumann CR. The role of colonoscopy and radiological procedures in the management of acute lower intestinal bleeding. *Clin Gastroenterol Hepatol* 2010;8:333–343.
52. Angtuaco TL, Reddy SK, Drapkin S, et al. The utility of urgent colonoscopy in the evaluation of acute lower gastrointestinal tract bleeding: a 2-year experience from a single center. *Am J Gastroenterol* 2001;96:1782–1785.
53. Zuckerman GR, Prakash C. Acute lower intestinal bleeding. Part II: etiology, therapy, and outcomes. *Gastrointest Endosc* 1999;49:228–238.
54. Foutch PG. Diverticular bleeding: are nonsteroidal anti-inflammatory drugs risk factors for hemorrhage and can colonoscopy predict outcome for patients? *Am J Gastroenterol* 1995;90:1779–1784.
55. Al Qahtani AR, Satin R, Stern J, et al. Investigative modalities for massive lower gastrointestinal bleeding. *World J Surg* 2002;26:620–625.
56. Rossini FP, Pennazio M. Small-bowel endoscopy. *Endoscopy* 2000;32:138–145.
57. Kovacs TO, Jensen DM. Recent advances in the endoscopic diagnosis and therapy of upper gastrointestinal, small intestinal, and colonic bleeding. *Med Clin North Am* 2002;86:1319–1356.
58. Jensen DM, Kovacs TO, Jutabha R. Gastrointestinal bleeding (GIB) of obscure origin in an era of managed care and push enteroscopy. *Gastrointest Endosc* 1997;45:AB92.
59. Jakobs R, Hartmann D, Benz C, et al. Diagnosis of obscure gastrointestinal bleeding by intra-operative enteroscopy in 81 consecutive patients. *World J Gastroenterol* 2006;12:313–316.
60. Mehdizadeh S, Ross A, Gerson L, et al. What is the learning curve associated with double-balloon enteroscopy? Technical details and early experience in 6 U.S. tertiary care centers. *Gastrointest Endosc* 2006;64:740–750.
61. Ross A, Mehdizadeh S, Tokar J, et al. Double balloon enteroscopy detects small bowel mass lesions missed by capsule endoscopy. *Dig Dis Sci* 2008;53:2140–2143.
62. Swain P, Fritscher-Ravens A. Role of video endoscopy in managing small bowel disease. *Gut* 2004;53:1866–1875.
63. Teshima CW, Kuipers EJ, van Zanten SV, et al. Double balloon enteroscopy and capsule endoscopy for obscure gastrointestinal bleeding: an updated metaanalysis. *J Gastroenterol Hepatol* 2011;26:796–801.

64. Leung WK, Ho SS, Suen BY, et al. Capsule endoscopy or angiography in patients with acute overt obscure gastrointestinal bleeding: a prospective randomized study with long-term follow-up. *Am J Gastroenterol* 2012; 107:1370–1376.
65. Vernava AM III, Moore BA, Longo WE, et al. Lower gastrointestinal bleeding. *Dis Colon Rectum* 1997;40:846–858.
66. Nusbaum M, Baum S. Radiographic demonstration of unknown sites of GI bleeding. *Surg Forum* 1963;14:374–375.
67. Pennoyer WP, Vignati PV, Cohen JL. Mesenteric angiography for lower gastrointestinal hemorrhage: are there predictors for a positive study? *Dis Colon Rectum* 1997;40:1014–1018.
68. Hammond KL, Beck DE, Hicks TC, et al. Implications of negative technetium 99m-labeled red blood cell scintigraphy in patients presenting with lower gastrointestinal bleeding. *Am J Surg* 2007;193:404–408.
69. Gunderman R, Leef J, Ong K, et al. Scintigraphic screening prior to visceral arteriography in acute lower gastrointestinal bleeding. *J Nucl Med* 1998; 39:1081–1083.
70. Ryan JM, Key SM, Dumbleton SA, et al. Nonlocalized lower gastrointestinal bleeding: provocative bleeding studies with intraarterial tPA, heparin, and tolazoline. *J Vasc Interv Radiol* 2001;12:1273–1277.
71. Kim CY, Suhocki PV, Miller Jr MJ, et al. Provocative mesenteric angiography for lower gastrointestinal hemorrhage: results from a single-institution study. *J Vasc Interv Radiol* 2010;21:477–483.
72. Mernagh JR, O'Donovan N, Somers S, et al. Use of heparin in the investigation of obscure gastrointestinal bleeding. *Can Assoc Radiol J* 2001; 52:232–235.
73. Bloomfeld RS, Smith TP, Schneider AM, et al. Provocative angiography in patients with gastrointestinal hemorrhage of obscure origin. *Am J Gastroenterol* 2000;95:2807–2812.
74. Rosch J, Dotter CT, Brown MJ. Selective arterial embolization. A new method for control of acute gastrointestinal bleeding. *Radiology* 1972; 102:303–306.
75. Bookstein JJ, Chlosta EM, Foley D, et al. Transcatheter hemostasis of gastrointestinal bleeding using modified autogenous clot. *Radiology* 1974; 113:277–285.
76. Smith R, Copely DJ, Bolen FH. 99m-Tc-RBC scintigraphy: correlation of gastrointestinal bleeding rates with scintigraphic findings. *AJR Am J Roentgenol* 1987;148:869–874.
77. Thorne DA, Datz FL, Remley K, et al. Bleeding rates necessary for detecting acute gastrointestinal bleeding with technetium-99m-labeled red blood cells in an experimental model. *J Nucl Med* 1987;28:514–520.
78. Suzman MS, Talmor M, Jennis R, et al. Accurate localization and surgical management of active lower gastrointestinal hemorrhage with technetium-labeled erythrocyte scintigraphy. *Ann Surg* 1996;224:29–36.

79. Beck DE, Margolin DA, Whitlow CB, et al. Evaluation and management of gastrointestinal bleeding. *Ochsner J* 2007;7:107–113.
80. Maurer AH, Rodman MS, Vitti RA, et al. Gastrointestinal bleeding: improved localization with cine scintigraphy. *Radiology* 1992;185:187–192.
81. Singh PR, Russell CD, Dubovsky EV, et al. Technique of scanning for Meckel diverticulum. *Clin Nucl Med* 1978;3:188–192.
82. Yamaguchi T, Yoshikawa K. Enhanced CT for initial localization of active lower gastrointestinal bleeding. *Abdom Imaging* 2003;28:634–636.
83. Ernst O, Bulois P, Saint-Drenant S, et al. Helical CT in acute lower gastrointestinal bleeding. *Eur Radiol* 2003;13:114–117.
84. Tew K, Davies RP, Jadun CK, et al. MDCT of acute lower gastrointestinal bleeding. *AJR Am J Roentgenol* 2004;182:427–430.
85. Jaeckle T, Stuber G, Hoffmann M, et al. Acute gastrointestinal bleeding: value of MDCT. *Abdom Imaging* 2008;33:285–293.
86. Yoon W, Jeong YY, Shin SS, et al. Acute massive gastrointestinal bleeding: detection and localization with arterial phase multi-detector row helical CT. *Radiology* 2006;239:160–167.
87. Scheffel H, Pfammatter T, Wildi S, et al. Acute gastrointestinal bleeding: detection of source and etiology with multi-detector-row CT. *Eur Radiol* 2007;17:1555–1565.
88. Jaeckle T, Stuber G, Hoffmann M, et al. Detection and localization of acute upper and lower gastrointestinal (GI) bleeding with arterial phase multi-detector row helical CT. *Eur Radiol* 2008;18:1406–1413.
89. Boonpongmanee S, Fleischer DE, Pezzullo JC, et al. The frequency of peptic ulcer as a cause of upper-GI bleeding is exaggerated. *Gastrointest Endosc* 2004;59:788–794.
90. Hirschowitz BI, Lanas A. NSAID association with gastrointestinal bleeding and peptic ulcer. *Agents Actions Suppl* 1991;35:93–101.
91. Ehsanullah RS, Page MC, Tildesley G, et al. Prevention of gastroduodenal damage induced by non-steroidal anti-inflammatory drugs: controlled trial of ranitidine. *BMJ* 1988;297:1017–1021.
92. Strom BL, Taragin MI, Carson JL. Gastrointestinal bleeding from the nonsteroidal anti-inflammatory drugs. *Agents Actions Suppl* 1990;29:27–38.
93. Laporte JR, Ibanez L, Vidal X, et al. Upper gastrointestinal bleeding associated with the use of NSAIDs: newer versus older agents. *Drug Safety* 2004; 27:411–420.
94. Shorr RI, Ray WA, Daugherty JR, et al. Concurrent use of nonsteroidal anti-inflammatory drugs and oral anticoagulants places elderly persons at high risk for hemorrhagic peptic ulcer disease. *Arch Intern Med* 1993;153:1665–1670.
95. Klein WA, Krevsky B, Klepper L, et al. Nonsteroidal antiinflammatory drugs and upper gastrointestinal hemorrhage in an urban hospital. *Dig Dis Sci* 1993;38:2049–2055.
96. Lanza FL, Fakouhi D, Rubin A, et al. A double-blind placebo-controlled comparison of

the efficacy and safety of 50, 100, and 200 micrograms of misoprostol QID in the prevention of ibuprofen-induced gastric and duodenal mucosal lesions and symptoms. *Am J Gastroenterol* 1989;84:633–636.

97. Robinson MG, Griffin JW Jr, Bowers J, et al. Effect of ranitidine on gastroduodenal mucosal damage induced by nonsteroidal antiinflammatory drugs. *Dig Dis Sci* 1989;34:424–428.
98. Pfaffenbach B, Adamek RJ, Wegener M. Endoscopic band ligation for treatment of post-polypectomy bleeding. *Z Gastroenterol* 1996;34:241–242.
99. Wilcox CM, Alexander LN, Cotsonis GA, et al. Nonsteroidal antiinflammatory drugs are associated with both upper and lower gastrointestinal bleeding. *Dig Dis Sci* 1997;42:990–997.
100. Holt S, Rigoglioso V, Sidhu M, et al. Nonsteroidal antiinflammatory drugs and lower gastrointestinal bleeding. *Dig Dis Sci* 1993;38:1619–1623.
101. Laine L, Curtis SP, Cryer B, et al. Assessment of upper gastrointestinal safety of etoricoxib and diclofenac in patients with osteoarthritis and rheumatoid arthritis in the Multinational Etoricoxib and Diclofenac Arthritis Long-term (MEDAL) programme: a randomised comparison. *Lancet* 2007;369:465–473.
102. Laine L, Curtis SP, Langman M, et al. Lower gastrointestinal events in a double-blind trial of the cyclo-oxygenase-2 selective inhibitor etoricoxib and the traditional nonsteroidal anti-inflammatory drug diclofenac. *Gastroenterology* 2008;135:1517–1525.
103. Rostom A, Muir K, Dubé C, et al. Gastrointestinal safety of cyclooxygenase-2 inhibitors: a Cochrane Collaboration systematic review. *Clin Gastroenterol Hepatol* 2007;5:818–828. e5.
104. Barkun A, Sabbah S, Enns R, et al. The Canadian Registry on Nonvariceal Upper Gastrointestinal Bleeding and Endoscopy (RUGBE): endoscopic hemostasis and proton pump inhibition are associated with improved outcomes in a real-life setting. *Am J Gastroenterol* 2004;99:1238–1246.
105. Lau JY, Leung WK, Wu JC, et al. Omeprazole before endoscopy in patients with gastrointestinal bleeding. *N Engl J Med* 2007;356:1631–1640.
106. Chan FK. Proton-pump inhibitors in peptic ulcer disease. *Lancet* 2008;372:1198–1200.
107. Leontiadis GI, Sharma VK, Howden CW. Proton pump inhibitor therapy for peptic ulcer bleeding: Cochrane collaboration meta-analysis of randomized controlled trials. *Mayo Clin Proc* 2007;82:286–296.
108. Management of Acute Upper and Lower Gastrointestinal Bleeding: A National Clinical Guideline. http://wwwsignacuk/pdf/sign105pdf2009
109. Palmer K, Nairn M. Management of acute gastrointestinal blood loss: summary of SIGN guidelines. *BMJ* 2008;337:a1832.
110. Dore MP, Graham DY. Ulcers and gastritis. *Endoscopy* 2004;36:42–47.
111. Vergara M, Casellas F, Saperas E, et al. Helicobacter pylori eradication prevents

recurrence from peptic ulcer haemorrhage. *Eur J Gastroenterol Hepatol* 2000;12:733–737.

112. Pilotto A, Leandro G, Di Mario F, et al. Role of Helicobacter pylori infection on upper gastrointestinal bleeding in the elderly: a case-control study. *Dig Dis Sci* 1997;42:586–591.
113. Forrest JA, Finlayson ND, Shearman DJ. Endoscopy in gastrointestinal bleeding. *Lancet* 1974;2:394–397.
114. Raju GS, Gajula L. Endoclips for GI endoscopy. *Gastrointest Endosc* 2004; 59:267–279.
115. Naga MI, Okasha HH, Foda AR, et al. Detachable endoloop vs. elastic band ligation for bleeding esophageal varices. *Gastrointest Endosc* 2004; 59:804–809.
116. Cappell MS, Friedel D. Acute nonvariceal upper gastrointestinal bleeding: endoscopic diagnosis and therapy. *Med Clin North Am* 2008;92:511-viii.
117. Sung JJ, Tsoi KK, Lai LH, et al. Endoscopic clipping versus injection and thermocoagulation in the treatment of non-variceal upper gastrointestinal bleeding: a meta-analysis. *Gut* 2007;56:1364–1373.
118. Asaki S. *Endoscopic Haemostasis by Local Absolute Alcohol Injection for UGI Tract Bleeding: a Multicentre Study. Endoscopic Surgery.* New York, NY: Elsevier; 1999:105.
119. Sacks HS, Chalmers TC, Blum AL, et al. Endoscopic hemostasis. An effective therapy for bleeding peptic ulcers. *JAMA* 1990;264:494–499.
120. Sugawa C, Steffes CP, Nakamura R, et al. Upper GI bleeding in an urban hospital. Etiology, recurrence, and prognosis. *Ann Surg* 1990;212:521–526.
121. Adler DG, Leighton JA, Davila RE, et al. ASGE guideline: the role of endoscopy in acute non-variceal upper-GI hemorrhage. *Gastrointest Endosc* 2004;60:497–504.
122. Loren A. Endoscopic therapy for acute nonvariceal upper gastrointestinal hemorrhage: a meta-analysis. *Gastroenterology* 1992;102:139–148.
123. Lau JY, Sung JJ, Lam YH, et al. Endoscopic retreatment compared with surgery in patients with recurrent bleeding after initial endoscopic control of bleeding ulcers. *N Engl J Med* 1999;340:751–756.
124. Gupta PK, Fleischer DE. Nonvariceal upper gastrointestinal bleeding. *Med Clin North Am* 1993;77:973–992.
125. Teenan RP, Murray WR. Late outcome of undersewing alone for gastric ulcer haemorrhage. *Br J Surg* 1990;77:811–812.
126. Reuben BC, Stoddard G, Glasgow R, et al. Trends and predictors for vagotomy when performing oversew of acute bleeding duodenal ulcer in the United States. *J Gastrointest Surg* 2007;11:22–28.
127. Schroder VT, Pappas TN, Vaslef SN, et al. Vagotomy/drainage is superior to local oversew in patients who require emergency surgery for bleeding peptic ulcers. *Ann Surg* 2014;259:1111–1118.
128. Poultsides GA, Kim CJ, Orlando R III, et al. Angiographic embolization for gastroduodenal hemorrhage: safety, efficacy, and predictors of outcome. *Arch Surg*

2008;143:457–461.
129. Loffroy R, Rao P, Ota S, et al. Embolization of acute nonvariceal upper gastrointestinal hemorrhage resistant to endoscopic treatment: results and predictors of recurrent bleeding. *Cardiovasc Interv Radiol* 2010;33:1088–1100.
130. Cook DJ, Fuller HD, Guyatt GH, et al. Risk factors for gastrointestinal bleeding in critically ill patients. Canadian Critical Care Trials Group. *N Engl J Med* 1994;330:377–381.
131. Stollman N, Metz DC. Pathophysiology and prophylaxis of stress ulcer in intensive care unit patients. *J Crit Care* 2005;20:35–45.
132. Driks MR, Craven DE, Celli BR, et al. Nosocomial pneumonia in intubated patients given sucralfate as compared with antacids or histamine type 2 blockers. The role of gastric colonization. *N Engl J Med* 1987;317:1376–1382.
133. Cook D, Guyatt G, Marshall J, et al. A comparison of sucralfate and ranitidine for the prevention of upper gastrointestinal bleeding in patients requiring mechanical ventilation. Canadian Critical Care Trials Group. *N Engl J Med* 1998;338:791–797.
134. Athanasoulis CA. Therapeutic applications of angiography (first of two parts). *N Engl J Med* 1980;302:1117–1125.
135. Robert A, Kauffman G. Stress ulcers, erosions, and gastric mucosal injury. In: Sleisinger M, Fordtran J, eds. *Gastrointestinal Disease: Pathophysiology, Diagnosis, Management.* 4th ed. Philadelphia, PA: Saunders; 1989:772–792.
136. Wilcox CM, Clark WS. Causes and outcome of upper and lower gastrointestinal bleeding: the Grady Hospital experience. *South Med J* 1999;92:44–50.
137. de Franchis R. Revising consensus in portal hypertension: report of the Baveno V consensus workshop on methodology of diagnosis and therapy in portal hypertension. *J Hepatol* 2010;53:762–768.
138. Jenkins SA, Baxter JN, Critchley M, et al. Randomised trial of octreotide for long term management of cirrhosis after variceal haemorrhage. *BMJ* 1997;315:1338–1341.
139. Imperiale TF, Teran JC, McCullough AJ. A meta-analysis of somatostatin versus vasopressin in the management of acute esophageal variceal hemorrhage. *Gastroenterology* 1995;109:1289–1294.
140. Burroughs AK. Octreotide in variceal bleeding. *Gut* 1994;35:S23–S27.
141. Avgerinos A, Nevens F, Raptis S, et al. Early administration of somatostatin and efficacy of sclerotherapy in acute oesophageal variceal bleeds: the European Acute Bleeding Oesophageal Variceal Episodes (ABOVE) randomised trial. *Lancet* 1997;350:1495–1499.
142. Besson I, Ingrand P, Person B, et al. Sclerotherapy with or without octreotide for acute variceal bleeding. *N Engl J Med* 1995;333:555–560.
143. Hermann RE, Traul D. Experience with the Sengstaken-Blakemore tube for bleeding esophageal varices. *Surg Gynecol Obstet* 1970;130:879–885.
144. Monescillo A, Martinez-Lagares F, Ruiz-del-Arbol L, et al. Influence of portal

hypertension and its early decompression by TIPS placement on the outcome of variceal bleeding. *Hepatology* 2004;40:793–801.

145. Orloff MJ, Orloff MS, Orloff SL, et al. Three decades of experience with emergency portacaval shunt for acutely bleeding esophageal varices in 400 unselected patients with cirrhosis of the liver. *J Am Coll Surg* 1995; 180:257–272.
146. Papatheodoridis GV, Goulis J, Leandro G, et al. Transjugular intrahepatic portosystemic shunt compared with endoscopic treatment for prevention of variceal rebleeding: A meta analysis. *Hepatology* 1999;30:612–622.
147. Mallory GK, Weiss S. Hemorrhages from lacerations of the cardiac orifice of the stomach due to vomiting. *Am J Med Sci* 1929;178:506–515.
148. Silverstein FE, Gilbert DA, Tedesco FJ, et al. The national ASGE survey on upper gastrointestinal bleeding. II. Clinical prognostic factors. *Gastrointest Endosc* 1981;27:80–93.
149. Park CH, Min SW, Sohn YH, et al. A prospective, randomized trial of endoscopic band ligation vs. epinephrine injection for actively bleeding Mallory-Weiss syndrome. *Gastrointest Endosc* 2004;60:22–27.
150. McGuire HH Jr, Haynes BW Jr. Massive hemorrhage for diverticulosis of the colon: guidelines for therapy based on bleeding patterns observed in fifty cases. *Ann Surg* 1972;175:847–855.
151. McGuire HH Jr. Bleeding colonic diverticula. A reappraisal of natural history and management. *Ann Surg* 1994;220:653–656.
152. Casarella WJ, Kanter IE, Seaman WB. Right-sided colonic diverticula as a cause of acute rectal hemorrhage. *N Engl J Med* 1972;286:450–453.
153. Niikura R, Nagata N, Yamada A, et al. Recurrence of colonic diverticular bleeding and associated risk factors. *Colorectal Dis* 2012;14:302–305.
154. Okamoto T, Watabe H, Yamada A, et al. The association between arteriosclerosis related diseases and diverticular bleeding. *Int J Colorectal Dis* 2012;27:1161–1166.
155. Boley SJ, DiBiase A, Brandt LJ, et al. Lower intestinal bleeding in the elderly. *Am J Surg* 1979;137:57–64.
156. Kuo WT, Lee DE, Saad WE, et al. Superselective microcoil embolization for the treatment of lower gastrointestinal hemorrhage. *J Vasc Interv Radiol* 2003;14:1503–1509.
157. Gady JS, Reynolds H, Blum A. Selective arterial embolization for control of lower gastrointestinal bleeding: recommendations for a clinical management pathway. *Curr Surg* 2003;60:344–347.
158. Foutch PG. Angiodysplasia of the gastrointestinal tract. *Am J Gastroenterol* 1993;88:807–818.
159. Foutch PG, Rex DK, Lieberman DA. Prevalence and natural history of colonic angiodysplasia among healthy asymptomatic people. *Am J Gastroenterol* 1995;90:564–567.

160. Sharma R, Gorbien MJ. Angiodysplasia and lower gastrointestinal tract bleeding in elderly patients. *Arch Intern Med* 1995;155:807–812.
161. Richter JM, Hedberg SE, Athanasoulis CA, et al. Angiodysplasia. Clinical presentation and colonoscopic diagnosis. *Dig Dis Sci* 1984;29:481–485.
162. Gupta N, Longo WE, Vernava AM. Angiodysplasia of the lower gastrointestinal tract: an entity readily diagnosed by colonoscopy and primarily managed nonoperatively. *Dis Colon Rectum* 1995;38:979–982.
163. Bemvenuti GA, Julich MM. Ethanolamine injection for sclerotherapy of angiodysplasia of the colon. *Endoscopy* 1998;30:564–569.
164. Junquera F, Feu F, Papo M, et al. A multicenter, randomized, clinical trial of hormonal therapy in the prevention of rebleeding from gastrointestinal angiodysplasia. *Gastroenterology* 2001;121:1073–1079.
165. Bauditz J, Lochs H. Angiogenesis and vascular malformations: antiangiogenic drugs for treatment of gastrointestinal bleeding. *World J Gastroenterol* 2007;13:5979–5984.
166. Dabak V, Kuriakose P, Kamboj G, et al. A pilot study of thalidomide in recurrent GI bleeding due to angiodysplasias. *Dig Dis Sci* 2008;53:1632–1635.
167. Szilagyi A, Ghali MP. Pharmacological therapy of vascular malformations of the gastrointestinal tract. *Can J Gastroenterol* 2006;20:171.
168. Medina C, Vilaseca J, Videla S, et al. Outcome of patients with ischemic colitis: review of fifty-three cases. *Dis Colon Rectum* 2004;47:180–184.
169. Scharff JR, Longo WE, Vartanian SM, et al. Ischemic colitis: spectrum of disease and outcome. *Surgery* 2003;134:624–629.
170. Green BT, Tendler DA. Ischemic colitis: a clinical review. *South Med J* 2005; 98:217–222.
171. Chaer RA, Helton WS. Dieulafoy's disease. *J Am Coll Surg* 2003;196:290–296.
172. Lee YT, Walmsley RS, Leong RW, et al. Dieulafoy's lesion. *Gastrointest Endosc* 2003;58:236–243.
173. Gimeno-Garcia AZ, Parra-Blanco A, Nicolas-Perez D, et al. Management of colonic Dieulafoy lesions with endoscopic mechanical techniques: report of two cases. *Dis Colon Rectum* 2004;47:1539–1543.
174. Veldhuyzen van Zanten SJ, Bartelsman JF, Schipper ME, et al. Recurrent massive haematemesis from Dieulafoy vascular malformations–a review of 101 cases. *Gut* 1986;27:213–222.
175. Park CH, Sohn YH, Lee WS, et al. The usefulness of endoscopic hemoclipping for bleeding Dieulafoy lesions. *Endoscopy* 2003;35:388–392.
176. Cheng CL, Liu NJ, Lee CS, et al. Endoscopic management of Dieulafoy lesions in acute nonvariceal upper gastrointestinal bleeding. *Dig Dis Sci* 2004;49:1139–1144.
177. Romaozinho JM, Pontes JM, Lerias C, et al. Dieulafoy's lesion: management and long-term outcome. *Endoscopy* 2004;36:416–420.
178. Novitsky YW, Kercher KW, Czerniach DR, et al. Watermelon stomach:

pathophysiology, diagnosis, and management. *J Gastrointest Surg* 2003;7:652–661.

179. Nagy SW, Marshall JB. Aortoenteric fistulas. Recognizing a potentially catastrophic cause of gastrointestinal bleeding. *Postgrad Med* 1921;93:211–212.
180. Ali AT, Modrall JG, Hocking J, et al. Long-term results of the treatment of aortic graft infection by in situ replacement with femoral popliteal vein grafts. *J Vasc Surg* 2009;50:30–39.
181. Yahchouchy EK, Marano AF, Etienne JC, et al. Meckel's diverticulum. *J Am Coll Surg* 2001;192:658–662.
182. Mackey WC, Dineen P. A fifty year experience with Meckel's diverticulum. *Surg Gynecol Obstet* 1983;156:56–64.
183. Lichtstein DM, Herskowitz B. Massive gastrointestinal bleeding from Meckel's diverticulum in a 91-year-old man. *South Med J* 1998;91:753–754.
184. El-Haddawi F, Civil ID. Acquired jejuno-ileal diverticular disease: a diagnostic and management challenge. *ANZ J Surg* 2003;73:584–589.
185. Rabeneck L, Paszat LF, Hilsden RJ, et al. Bleeding and perforation after outpatient colonoscopy and their risk factors in usual clinical practice. *Gastroenterology* 2008;135:1899–1906.
186. Gibbs DH, Opelka FG, Beck DE, et al. Postpolypectomy colonic hemorrhage. *Dis Colon Rectum* 1996;39:806–810.
187. Halme L, Doepel M, von Numers H, et al. Complications of diagnostic and therapeutic ERCP. *Ann Chir Gynaecol* 1999;88:127–131.
188. Vasconez C, Llach J, Bordas JM, et al. Injection treatment of hemorrhage induced by endoscopic sphincterotomy. *Endoscopy* 1998;30:37–39.

Chapter 66

Ulcerative Colitis

Dorin T. Colibaseanu and David W. Larson

Key Points

1 Ulcerative colitis is a form of inflammatory bowel disease (IBD) largely limited to the mucosa and submucosa of the colon and rectum. This process is continuous, beginning at the rectum, and extending proximally for a variable distance.

2 The acute indications for surgical intervention are fulminant disease, toxic megacolon, and bleeding. Failures of medical management, dysplasia, or cancer are indications for elective surgery.

3 The intestinal manifestations of ulcerative colitis (UC) are cured by removal of the colon and rectum.

4 Current surgical options depend on the acuity of presentation of the disease; minimally invasive methods should be employed when clinically indicated and technically feasible.

5 Proctocolectomy with ileal pouch-anal anastomosis (IPAA) provides patients with a continent reservoir; a Brooke ileostomy is available for those patients who do not qualify for a pouch construction.

6 Although perioperative and late complications after ileal pouch-anal reconstruction are not uncommon, the vast majority of patients enjoy a high quality of life after surgery.

INTRODUCTION

1 Ulcerative colitis (UC) and Crohn disease (CD) affect more than 1.4 million people in the United States. Together these two diseases have many common characteristics, yet they are two distinct entities.[1] UC is a nonspecific and idiopathic inflammatory bowel disease (IBD) of unknown etiology that primarily affects the mucosa and submucosa of the colon and rectum. It is characterized by recurring episodes of inflammation. While medical treatment remains the mainstay of UC management, it does not represent a cure.

EPIDEMIOLOGY

Determining the exact incidence of UC is difficult because mild cases might never be reported, and the disease itself is uncommon. In North America, the reported incidence varies between 2.2 and 19.2 cases per 100,000 person-years.[1–5] Global incidence and prevalence of UC tends to be the highest along northern latitudes, and lower in Asia and the Middle East.[5–8] Over time, the incidence of IBD has increased globally, especially the last 20 years.[9,10]

Etiology and Risk Factors

Development of UC is likely due to the interaction of multiple genes, and environmental factors. It is more common in Jewish and Caucasian populations, and infrequent in black and Hispanic populations.[11,12]

Genetics

Both environmental and genetic risk factors have been implicated in the development of UC; however, the exact pathogenesis has not been fully elucidated. Up to 20% of the patients with IBD are part of families with other afflicted members. It is recognized that there is a non-Mendelian genetic predisposition to developing UC. Monozygotic twin concordance rate for UC varies between 10% and 19%, and it increases over time.[13–15] The offspring of parents with UC can have a risk of developing UC as high as 33%.[16] Genetic concordance in CD is higher than in UC, and more than 100 loci have been associated with increased risk for developing IBD (Table 66-1).[17–21] Major histocompatibility complex HLA-DR2 is associated with UC, and there are at least 15 distinct loci that are associated with risk of developing UC.[22–25]

Environmental Factors

There remains a bimodal distribution of UC, which typically develops between 15 and 40 years of age and then in a smaller subgroup later in life between 50 and 80 years (Fig. 66-1).[26] UC appears to be slightly more common in men.[27,28]

Table 66-1 Genes Commonly Implicated in Ulcerative Colitis and Crohn Disease

UC	Crohn's	UC and Crohn's
IL22	NOD2	JAK2
IL22	IRGM	IL12B/p40
IL10	ATG16L1	STAT3
ECM1	IBD5/5q31	IL23R
IFNg	5p13/PTGER4	Nkx2.3
ARPC2	ICOSLG	3p21/MST1
OTUD3	LRRK2	CCNY
PLA2G2E	ITLN1	CDKAL4
	CCR6	TNFRSF6B
	PTPN2	IL18RAP
	TNFSF15(TL1A)	PCMG1
	DLG5	
	NLRP3	
	OCTN1	
	ZNF365	
	10q21	

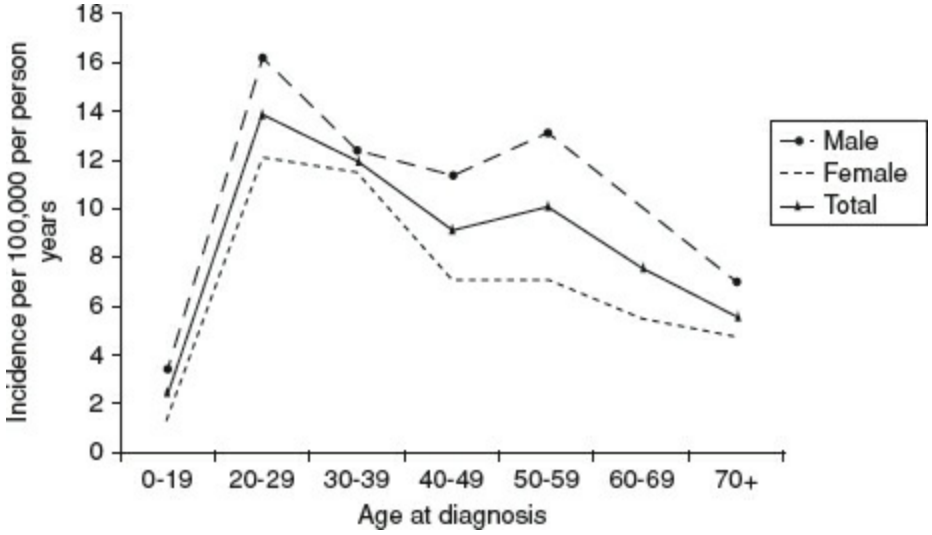

Figure 66-1. Age-specific incidence of UC in Midwestern US population. (Adapted from Loftus CG, Loftus EV Jr, Harmsen WS, et al. Update on the incidence and prevalence of Crohn's disease and ulcerative colitis in Olmsted County, Minnesota, 1940–2000. *Inflamm Bowel Dis* 2007;13:254–261.)

Diet rich in saturated fats, and refined sugar has been associated with higher incidence of UC. Physical activity however, is not strongly associated to incidence of UC.[29–31] Smoking appears to have a protective effect for UC; conversely former smokers have an increased risk of UC compared to those who never smoked.[32–34] The apparent protective effect of smoking extends to some of the extraintestinal manifestations of UC, in particular primary sclerosing cholangitis (PSC) and occurrence of pouchitis.[35,36] Interestingly, an appendectomy also has a protective effect from developing UC, though the mechanism is essentially unknown. Large, retrospective studies have shown a protective effect of 55% to 70%,[37–41] especially if the findings at the operation were consistent with appendicitis or lymphadenitis.[39] The mechanistic theories proposed for this interesting finding include the notion that as the body's immune system responds to the inflammatory process of appendicitis, it adapts such that the inappropriate inflammatory process that defines UC never occurs. The environmental risks for development of CD and UC have some similarities but the diseases are in essence distinct entities (Table 66-2).

CLINICAL FEATURES

UC symptoms parallel the degree of the disease. Typically, UC affects the rectum, extending proximally in a continuous fashion, and can involve the entire colon. Most commonly the distal colon is involved for various length, however, approximately 20% of the time, patients present with pancolitis.[42] The classic symptoms of UC are diarrhea, and rectal bleeding. Additional symptoms include tenesmus, urgency, and colicky abdominal pain.[43] Persistent pain is uncommon, and often can represent severe disease with inflammation extending to the serosa.[44] The sensation of constipation and incomplete evacuation can occur if there is severe rectosigmoid inflammation and spasm. As the disease progresses, systemic symptoms of fever, anorexia, weight loss, and malaise ensue. Severity of disease can be calculated using the Mayo Severity Index Calculator (Table 66-3).[45] Other calculators exist.

Extraintestinal Disease

Hepatobiliary

Approximately 3% to 5% of UC patients develop PSC. Generally, the patients are asymptomatic, though as the disease progresses liver enzyme elevation, pruritus, fatigue, chills, and right upper quadrant pain can develop. The risk of acquiring PSC is independent of colonic UC activity, and the risk persists after proctocolectomy. In addition, PSC is an independent risk factor for developing dysplasia/cancer in patients with UC.[46]

Ophthalmologic

Greater than 3% of patients with UC can develop iritis, episcleritis, or uveitis. Episcleritis severity can parallel GI symptoms, but uveitis does not match GI disease activity. Though uveitis is less common, the disease is more severe, and if not promptly treated can result in blindness. Topical steroids and infliximab have successfully been used in treating UC uveitis.[47]

Table 66-2 Clinicopathologic Features of Ulcerative Colitis vs. Crohn's

Common Clinicopathologic Characteristics of IBD		
Manifestation	**UC**	**CD**
Bleeding	Common	Rare
Crypt abscesses	Common	Rare
Rectal involvement	Common	Rare
Small bowel involvement	Rare	Common
Transmural inflammation	Rare	Common
Bowel wall fissures	Rare	Common
Fibrosis	Rare	Common
Fistulas	Rare	Common
Perianal disease	Rare	Common
Ulcers	Rare	Common
Coblestoning	None	Common
Pattern of involvement	Continuous, distal to proximal, mucosal	Skip lesions, transmural

Table 66-3 The Mayo Severity Index

Stool Frequency (Total number of stools/day) (3-day average)
0 = Normal number of stools for this patient
1 = 1–2 stools/day more than normal for this patient
2 = 3–4 stools/day more than normal for this patient
3 = >5 stools/day more than normal for this patient
Rectal Bleeding (3-day average)
0 = No blood seen
1 = Streaks of blood with <50% of stools
2 = Obvious blood seen with >50% of stools
3 = Blood alone passed
Physician's Global Assessment (PGA)
0 = Normal
1 = Mild disease
2 = Moderate disease
3 = Severe disease
Finding of Flexible Proctosigmoidoscopy
0 = Normal or inactive disease
1 = Mild disease (erythema, decreased vascular pattern, mild friability)
2 = Moderate disease (marked erythema, absent vascular pattern, friability, erosions)
3 = Severe disease (spontaneous bleeding, ulceration)

Cutaneous

Manifestations of UC can include erythema nodosum and pyoderma gangrenosum (Fig. 66-2). Erythema nodosum generally follows the disease progress of the GI symptoms, occurring in up to 4% of patients with UC.[48] These violet subcutaneous nodules can be treated with topical steroids, though most commonly, systemic treatment of GI symptoms will also help with erythema nodosum. While pyoderma gangrenosum occurs less frequently than erythema nodosum, its treatment is more difficult as the disease course of pyoderma gangrenosum does not always parallel UC activity. Infliximab has shown some promise in treating pyoderma gangrenosum.[49]

Musculoskeletal

These conditions are responsible for the most frequent extraintestinal complaints. Sacroileitis and ankylosing spondylitis are associated with UC flairs, and remissions. Carriers of HLA-B27 are especially prone to ankylosing spondylitis. Successful treatment of sacroiliatis with NSAIDs does not preclude progression of spondylitis. Methotrexate has also been successfully used, and there are increasing data of successful use of anti-TNF agents.[50]

DIAGNOSIS

Physical examination is often unrevealing, though generalized pain is often an indicator of severe disease. A triad of tachycardia, fever, and leukocytosis are indicators for systemic toxicity and should alert the clinician of impending need of surgical intervention. Vague discomfort, and perianal irritation are common findings due to bowel movement frequency.

Imaging

Conventional x-rays can be useful in the rare cases of obstruction and/or perforation. The use of contrast studies allow for the identification of signs of severe inflammation with loss of haustral markings, although they have largely been replaced by more modern imaging modalities. Figure 66-3 shows distended colon with loss of haustral markings, concerning for toxic megacolon.

Abdominal computed tomography with oral and/or rectal contrast and CT enterography protocols are the modern imaging techniques of choice and provide additional information regarding the severity of disease. The presence of fistulas, phlegmon, mass, or abscess is an indication of a disease process other than UC as these findings may in fact represent other diagnoses such as Crohn, diverticulitis, and cancer.

MRI has the advantage of limiting ionizing radiation exposure, benefiting the young especially, and those that potentially may require multiple imaging studies over the years. Additionally, MRI has the capability of improved soft tissue differentiation. Particularly in the last decade, developments in MRI hardware and software has made this imaging modality an especially valuable tool in diagnosing and following patients with UC (Fig. 66-4).[51]



Figure 66-2. **A:** Erythema nodosum. **B:** Pyoderma gangrenosum. (Reproduced with permission from Goodheart HP. *A Photoguide of Common Skin Disorders: Diagnosis and Management*. Baltimore, MD: Lippincott Williams & Wilkins; 1999.)

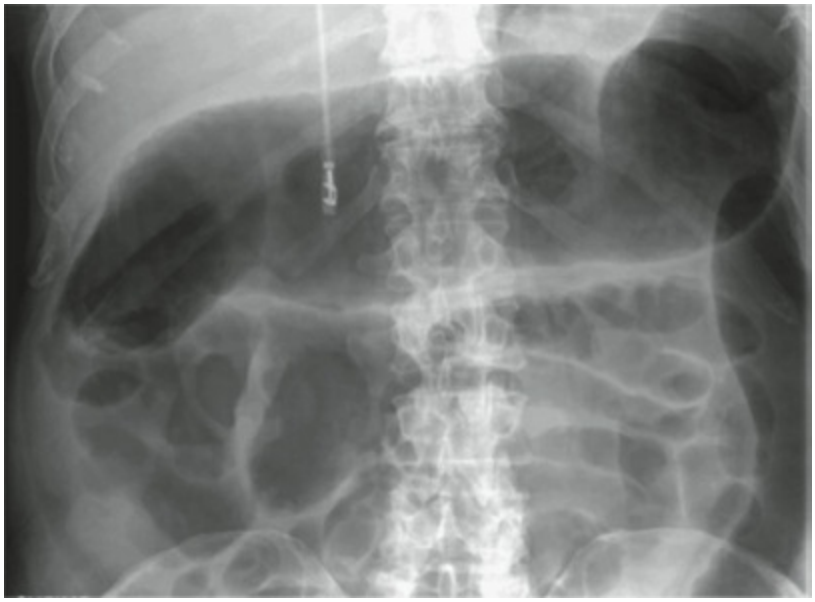

Figure 66-3. Abdominal x-ray of Megacolon Beck DE, Roberts PL, Saclarides TJ, et al. *ASCRS*. New York, NY: Springer; 2011.

Ultrasound and nuclear medicine may provide complementary information in addition to CT and MRI but are currently used less commonly and are utilized only for specific situations.

Endoscopy

Endoscopic evaluation is the most useful tool in diagnosing UC. Often the first step is a flexible sigmoidoscopy or rigid proctoscopy especially in cases of acute flare, when a full colonoscopy may pose a significant risk of perforation. The macroscopic appearance of the colon through the endoscopy can often differentiate between UC and CD. Biopsies are taken, in addition to stool samples to rule out bacterial pathogens and ova/parasites.

Pathology

Macroscopic Appearance

UC always starts in the rectum and progresses proximally (Fig. 66-5). Although UC is a mucosal and submucosal disease, in the acute setting of severe disease, the colon wall can be inflamed transmurally, mimicking CD.

The mucosa is involved in a confluent manner, and unlike CD, fibrosis and strictures are uncommon (Table 66-2). Most importantly, the presence of stricturing disease in UC represents the potential for malignancy, which must be excluded. Superficial fissures are common, as are pseudopolyps. On occasion, the rectum can appear to be spared, especially if topical medication has been used through enema or suppository.

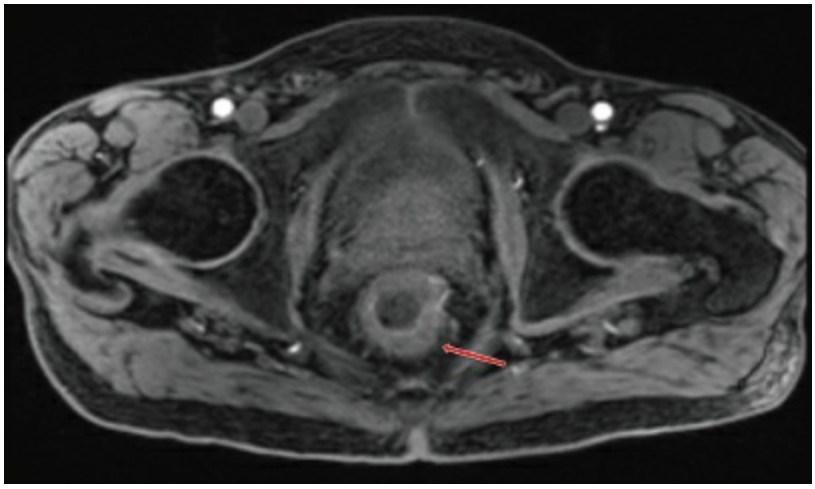

Figure 66-4. MRI demonstration of active UC with rectal wall thickening, increased vascularity, and inner layer hyperenhancement. Courtesy of Dr. William Reed.

Microscopic Appearance

UC is an inflammatory process, thus neutrophil infiltration is common, and crypt abscesses form, which then coalesce to form ulcers (Table 66-2). Goblet cell mucin depletion and crypt distortion are common in UC. In long-standing UC, special attention must be given to the presence of dysplastic lesions, though these can be difficult to identify in cases of acute inflammation.

Differential Diagnosis

Bloody diarrhea can be a symptom of an infectious process. It is important to rule out pathogenic bacteria, parasites, and viruses. *Clostridium difficile* should specifically be excluded. Other infectious agents include Salmonella, *Escherichia coli* (0157:H7 strain), Camphylobacter, and Entamoeba.

In nearly 10% of the cases, it is impossible to definitively classify the colitis. Over time, a portion of these indeterminate colitis cases will separate as either Crohn's or UC. However some will remain as indeterminate, especially if the serology assessment is inconclusive (for both ASCA and p-ANCA).[52]

MANAGEMENT

Medical Management

Corticosteroids

Corticosteroids are frequently used as the primary rescue medication in treatment of acute flares of UC. Corticosteroid efficacy in inducing remission approaches 70%.[53,54] Lack of improvement or disease progression with corticosteroid treatment is followed by biologic agent treatment (as a secondary rescue medication) or surgery.[55] Overall, the use of corticosteroids is decreasing, largely due to the increase in the number and treatment effectiveness of the biologic agents available. Corticosteroids should not be used for maintenance of remission due to their side-effect profile. Topical corticosteroids such as budesonide or rectal preparations can be effective and have a reduced side-effect profile. However, these medications are not typically used in the acute setting. The side-effect profile of systemic corticosteroids includes osteoporosis, diabetes, glaucoma, and infections, among others. Long-term use of corticosteroids is associated with an increase in mortality.[56]

Aminosalicylic Acid Compounds (5-ASA)

These compounds are most commonly used as first line medications in treating mild UC, and can be used in maintenance of remission. Concomitant use of oral and rectal preparation is effective in maintenance of UC remission.[57] Noncompliance with 5-ASA maintenance therapy is associated with a fivefold increase in disease recurrence.[58,59] Cases of nephrotoxicity have been reported with use of 5-ASA, though these cases are rare. Folate must be supplemented with treatment of 5-ASA as its absorption is impaired by 5-ASA.

Immunomodulators (Nonbiologic)

Cyclosporine can be used as an effective first-line or second-line rescue medication (e.g., after failed corticosteroid treatment) and is currently used at a limited number of centers. It is most commonly used as first-line treatment, and serves as an option for those patients recalcitrant to corticosteroid treatment.[60] Close monitoring of cyclosporine levels is necessary. Cyclosporine toxicity profile includes hypertension, renal failure, and infections.[61]

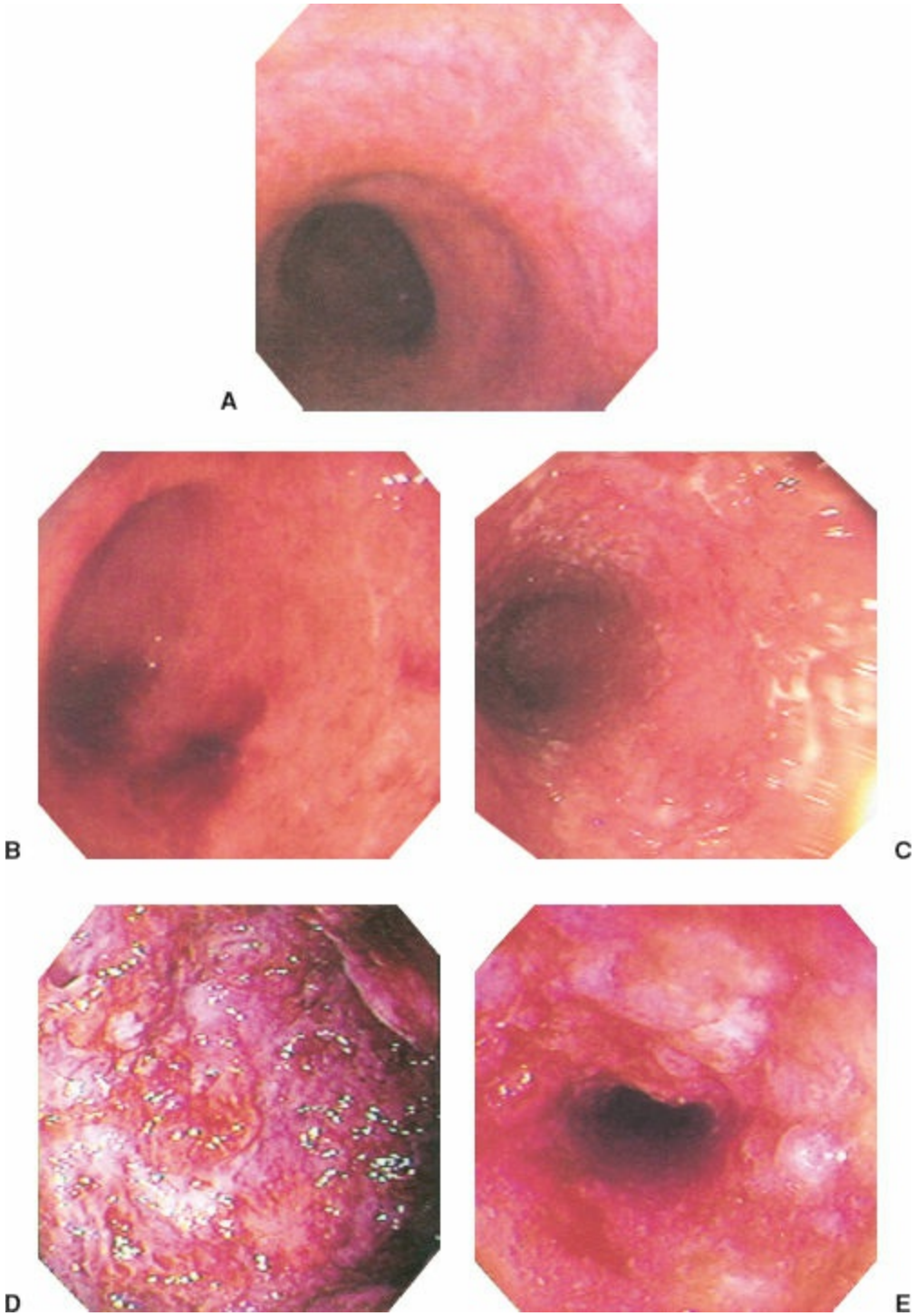

Figure 66-5. UC endoscopic findings with **A:** Loss of normal vascular pattern. **B:** Contact bleeding. **C:** Granularity. **D:** Ulceration and friability. **E:** Colonic stricture. (Reproduced with permission from Corman ML. *Colon and Rectal Surgery*, 5th ed. Philadelphia, PA: Lippincott Williams & Wilkins; 2005.)

Mercaptopurine (6-MP). 6-MP and its prodrug azathioprine are thiopurine analogs and have been used extensively in the treatment of UC. They are superior to 5-ASA treatment alone and are often clinically used in combination with either 5-ASA or anti-TNF drugs in treating IBD.[62] Skin cancers and lymphoma have been reported with thiopurine.[63] Severe infections have been reported with use of these medications.[64] Liver enzyme elevations, pancreatitis, and cholestasis have also been seen, and the most commonly reported side effects are headaches, hypersensitivity, and abdominal pain.

Methotrexate. This medication is rarely used in UC, more commonly used in CD, although its side-effect profile makes its use difficult even in CD. Hepatotoxicity bone marrow suppression and central nervous system side effects limit the use of this medication.[65]

Biologic Immunomodulator Agents

Infliximab is the first anti-TNF medication that was used in treatment of CD in 1988, then shortly after became FDA approved for use in UC. Infliximab is chimeric mouse–human monoclonal antibody. Infliximab has been found to successfully induce remission in over 60% of the UC patients treated in the ACT 1 and 2 trials.[66] Extended follow-up of the patients in the trial found that 15% of patients who initially responded to infliximab subsequently had to discontinue therapy due to side effects or loss of efficacy.[67] Approximately 9% of patients continued to be treated with infliximab for 3 years. Adalimumab, certolizumab, and golimumab were then added to the list of the anti-TNF agents, a list that is continually growing. Both infliximab and golimumab have been efficacious in inducing and maintaining remission in UC patients.[66,68,69] Among the biologic agents' side-effect profile, infection remains a persistent concern.[70,71] The data regarding malignancy risk with anti-TNF agents are mixed; there appears to be an increased risk of lymphoma.[72]

SURGERY

Indications of Surgical Intervention

2 Approximately 20% to 30% of patients that develop UC will ultimately need an operation.[73,74] Indications for surgery include fulminant colitis, toxic megacolon, uncontrolled bleeding, neoplasia, recalcitrance to medical management, unrelenting extraintestinal manifestations, and development of significant side effects of the treatment medications.

Toxic Megacolon

This is a life-threatening, surgical emergency. Toxic megacolon (Fig. 66-3) is not specific to UC; it can occur in cases of infectious collidities (*C. difficile,* Shigella, Salmonella, etc.), or ischemic colitis. Patients present with systemic toxicity, heralded by high fever, tachycardia, severe abdominal pain, leukocytosis or leukopenia, and a distended, thickened colon. Immediate, aggressive resuscitation and broad-spectrum antibiotics should be started, and all opiates, and antidiarrheal agents should be ceased. An infectious cause should immediately be ruled out as treatment for UC includes corticosteroids, treatment which would be detrimental to the management of infectious colidities. Toxic megacolon is seen most often in new cases of UC, but acute exacerbations of chronic UC can also lead to toxic megacolon. Nonoperative treatment can be attempted, however, any signs of instability, worsening of the clinical condition, or lack of improvement within 3 to 5 days should be followed by prompt operative treatment. In one study, nearly half of all patients with UC treated nonoperatively subsequently required surgery, most under urgent or emergent circumstances.[75] In the contemporary era of biologic options, failure can occur in up to 30% in the short term (within 30 days), and it is unclear in the long term how many of these patients will need a colectomy, and under what clinical circumstances.[76]

Fulminant Colitis

Patients presenting with tachycardia, fever, and surgical tenderness need aggressive resuscitation. Intravenous steroids should be started promptly, and the patients should be offered surgical treatment immediately if their condition deteriorates. In general terms, patients should improve within 3 to 5 days on medical therapy. Early surgical intervention has shown a clear decrease in the mortality rate in patients failing medical therapy.[77,78]

Uncontrolled Bleeding

Less than 5% of the patients affected with UC have life-threatening bleeding. In this rare circumstance an abdominal colectomy is necessary. These cases represent approximately 10% of the emergent colectomies performed in UC.[79]

Carcinoma/Dysplasia

Stage for stage, cancer in the setting of UC has the same prognosis, however, cancer is often detected at a later stage in UC. Nearly 20% of the patients with colorectal carcinoma in the setting of UC are unresectable at the time of diagnosis.[80,81] The highest risk of colorectal cancer (CRC) is seen in those UC patients with a long history of pancolitis, a risk that accrues after 8 to 10 years of UC. The absolute risk of CRC development is less than 8% after 30 years of UC.[82] Patients with over 8 years of UC, particularly with extensive colitis, should undergo colonoscopy yearly, or every 2 years.[83] It is often difficult to identify dysplasia in inflamed colon, and thus at the time of colonoscopy, random biopsies are obtained in addition to sampling any polyps, adenomas, or dysplasia-associated mass or lesions (DALM). Undetected synchronous cancer can coexist in areas of low- and high-grade dysplasia.[84] Thus, high-grade dysplasia, nonadenoma-like DALMs, and multifocal dysplasia are indications for proctocolectomy, though there is ongoing research in this area.

Recalcitrance to Medical Treatment

Some patients do not respond fully to medical treatment, and either have persistent symptoms despite maximal medical treatment, or respond only to corticosteroids, and are thus subject to the side effects of long-term corticosteroid treatment.

Extracolonic Manifestations

3 Proctocolectomy can help with some of the extracolonic manifestations, though PSC, pyoderma gangrenosum, and ankylosing spondylitis specifically do not respond to surgery. Proctocolectomy has shown to help with erythema nodosum, and small/large joints arthralgia, though the role of colectomy is not completely defined in the treatment of extraintestinal manifestations of UC.[85]

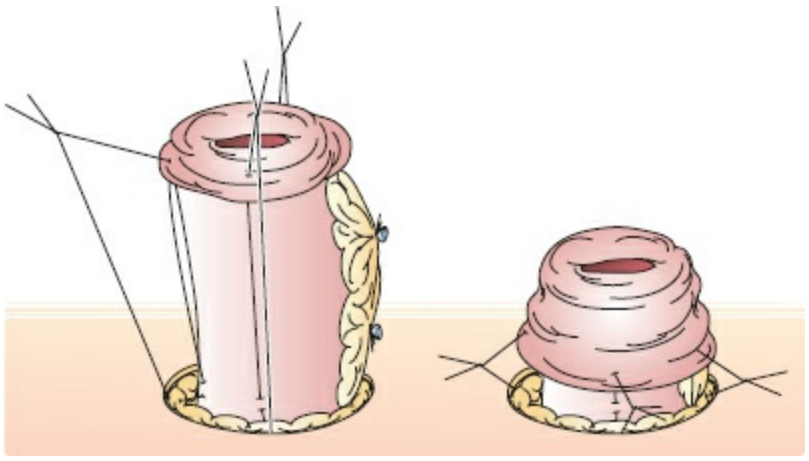

Figure 66-6. Brooking ileostomy.

Surgical Management

Unlike CD, proctocolectomy is curative for gastrointestinal UC. As the disease begins in the rectum and involves the colon proximally for a variable distance, ultimately proctectomy should be performed for definitive treatment of UC.

Multiple surgical options are available, with treatment dependent on the urgency of presentation, and general condition of the patient. Currently, in emergency conditions, the operation of choice is a subtotal colectomy with preservation of the rectum, and a Brooke ileostomy (Fig. 66-6). Resection of the rectum in the emergent setting should be avoided if possible, to both to allow continent reconstruction at a later time and to avoid a perineal dissection in suboptimal conditions. Mobilizing the rectum unnecessarily in emergent conditions disrupts the presacral planes, and will make later reconstruction more difficult. In addition, the ureters and pelvic nerves are put at risk. Additional consideration should be given to the level of ileal transection proximally, keeping in mind that a later ileal pouch reconstruction is dependent on the ileocolic arterial arcade, and thus all efforts should be made to keep this vascular network intact.

Abdominal Colectomy with a Brooke Ileostomy

The location of stoma should be marked preoperatively with the help of an enterostomal therapist if at all possible. Managing a poorly placed stoma is a major source of frustration for the patient postoperatively. Additionally, appropriately training and educating the patient preoperatively with regard to the care of their stoma is critical to their postoperative progress.

4 A minimally invasive approach should be attempted if the patient is stable and the surgeon is sufficiently comfortable with the operation.[86,87] A systematic technique should be employed, and with sufficient training and experience excellent outcomes can be achieved.[88]

The operation is started in the lithotomy position. If there is a concern regarding visualization of the ureters, it is recommended that ureteral stents be placed. Though they do not reduce the rate of ureter injury, they do help identify an injury immediately, and facilitate prompt repair.[89] The colon is mobilized in a lateral to medial fashion most commonly (Figs. 66-7 and 66-8), and unless there is concern of dysplasia/neoplasia, the vessels (ileocolic, middle colic, and inferior mesenteric artery branches) can be transected distally, facilitating safer mobilization. Particular attention should be paid to the splenic flexure, as a splenic tear will unnecessarily complicate the operation.

Once the colon has been completely mobilized and the vessels have been divided, the distal ileum can be transected. Particular attention must be paid to the integrity of the ileocolic vessel arcade, as the subsequent ileal pouch construction is largely dependent on these vessels. The colon can then be extracted through the ileostomy site, or through either a low vertical midline or a Pfannenstiel incision. The terminal ileum can then be extracorporialized and a Brooke ileostomy can be constructed (Fig. 66-6). It is critical to make sure that the small bowel mesentery is not twisted before “brooking” the ileostomy.

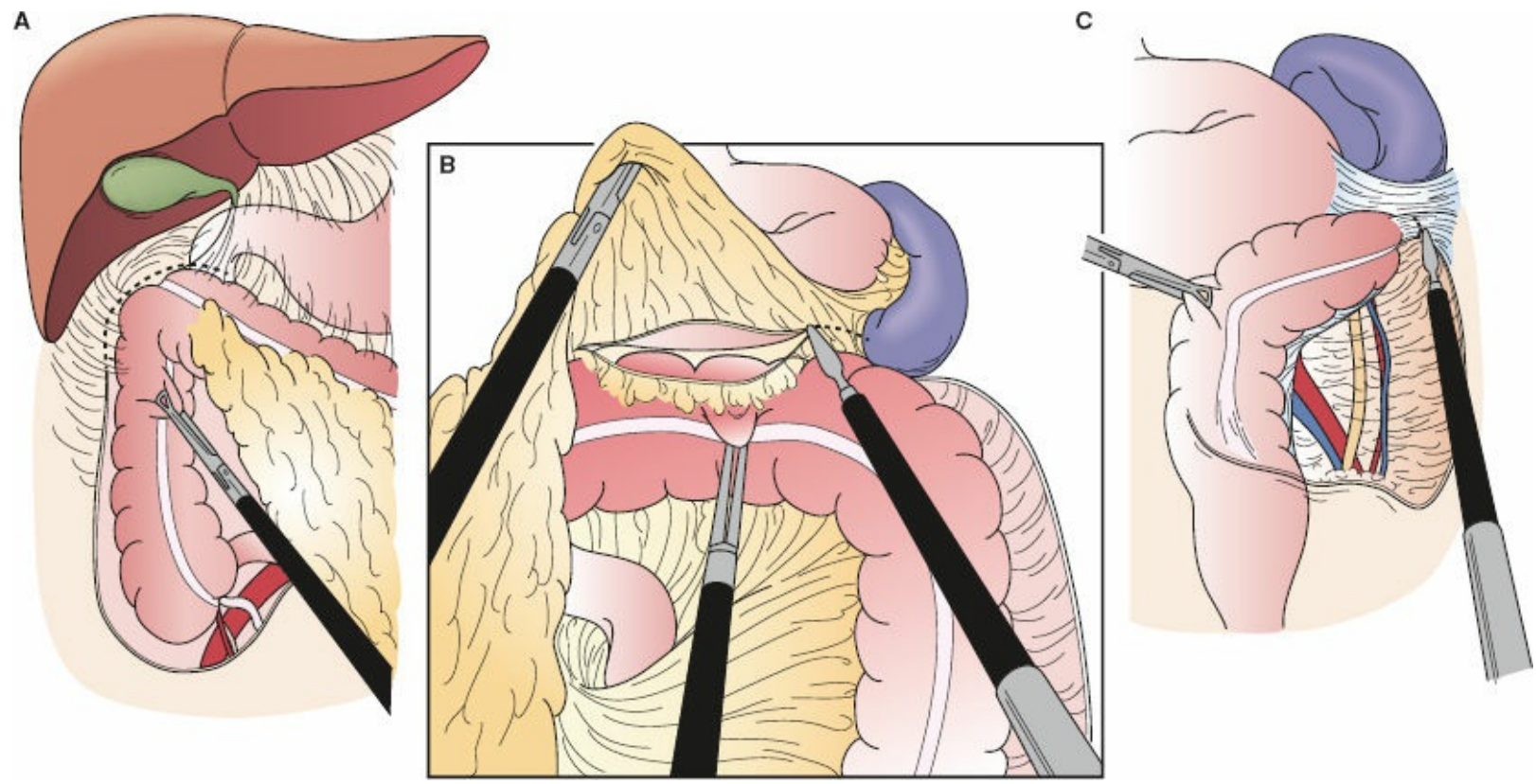

Figure 66-7. Colon mobilization. **A:** right colon. **B:** transverse colon. **C:** left colon.

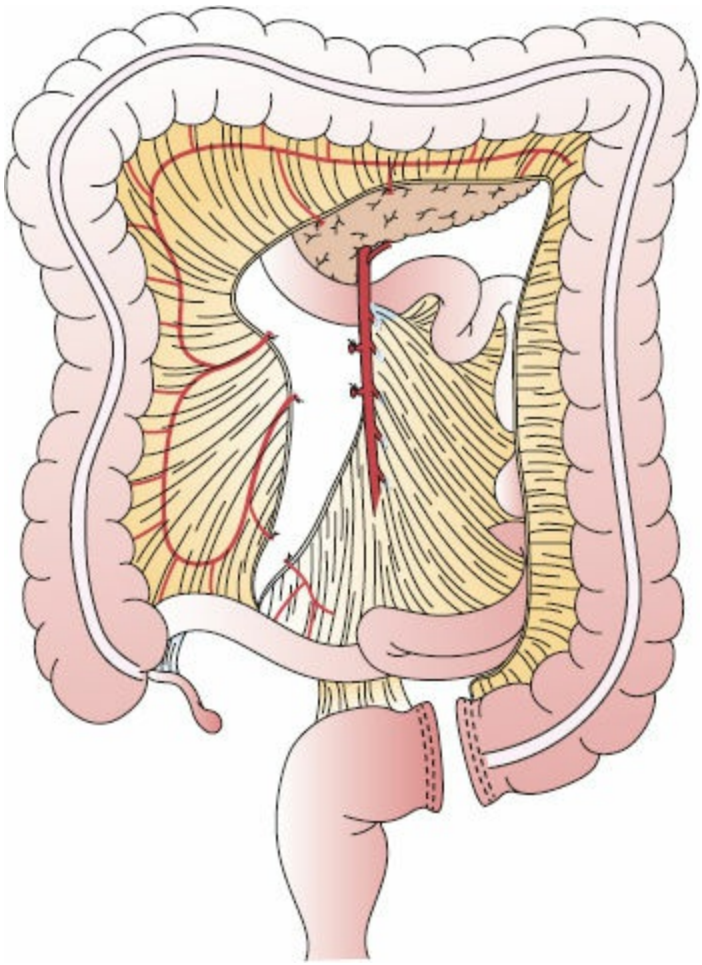

Figure 66-8. Mobilized colon with vessels divided, and stapled at the rectum. This specimen is ready for extraction; the ileum can be transected intracorporeally, or after specimen is extracorporealized.

Proctocolectomy with Brooke Ileostomy

Abdominal colectomy is performed as above. In cases of rectal dysplasia or cancer, a total mesorectal excision is necessary. Patient is placed in Trendelenburg position and all bowel is displaced in the upper abdomen. The sigmoid and rectum are placed on tension, and any adhesions are freed. If the uterus and ovaries prevent visualization or adequate dissection, they are affixed in place by passing a 0-Prolene stitch through the abdominal wall, through the uterus, and back through the abdominal wall. Retracting the uterus anteriorly will help with visualization and dissection in the plane posterior to the vagina. The rectal mobilization is commenced by placing the rectum on cephalad and anterior traction. The peritoneum on the right of the rectum, medial to the ureters and the pelvic nerves is incised. This embryologic plane is followed cephalad just posterior to superior rectal artery along its course, tracing it proximally to the inferior mesenteric artery (IMA). Careful dissection just posterior to the IMA pedicle toward the left pelvic sidewall will reveal the left ureter; its location is almost always higher than expected. Lateral (on the left) to the ureter, the gonadal vessels are found. The ureter is retroperitoneal, and as such all efforts should be made to avoid incising the retroperitoneum, and instead, it is safer if this embryologic layer is left undisturbed. Following this shiny layer superiorly, one can easily carry the dissection cephalad until the IMA is identified and skeletonized. In the absence of neoplasia, it is unnecessary to perform a high (proximal) ligation of the IMA, though by doing so, one simplifies the dissection. Once the IMA (or the left colic artery) is identified and skeletonized, it can be divided with the appropriate instrument, after making sure that both ureters are well out of the field.

Carrying the pelvic dissection distally, the pelvic nerves and the ureters should be clearly identified and protected. Meticulous dissection can be done relatively bloodlessly. During anterior dissection of the rectum, all effort should be made to continue the dissection posterior (on the rectum side) of the Denovilliers fascia, specifically in men, to avoid sexual dysfunction. Similarly, during posterior mobilization of the rectum particular attention should be given to identifying the presacral fascia, as dissection posterior to this layer puts at risk the presacral vessels which can result in troublesome and sometimes life-threatening bleeding. Once the dissection is carried out to the pelvic floor circumferentially, a clamp can be placed on the proposed transection site, and the distance from the anal verge can be assessed by a simple digital rectal examination. If the distance is appropriate then the perineal dissection can follow. The patient is placed in Trendelenburg position, with both feet raised to afford exposure to the perineum. The dissection plane starts in the intersphincteric plane. This dissection leaves the external sphincter in situ, and can be incorporated in closing the perineal incision, which decreases the complication rate. This intersphincteric plane is followed proximally and circumferentially with particular attention anteriorly, to avoid injury to the vagina in women and urethra in men. Once the intra-abdominal plane is reached, this part of the dissection is done.

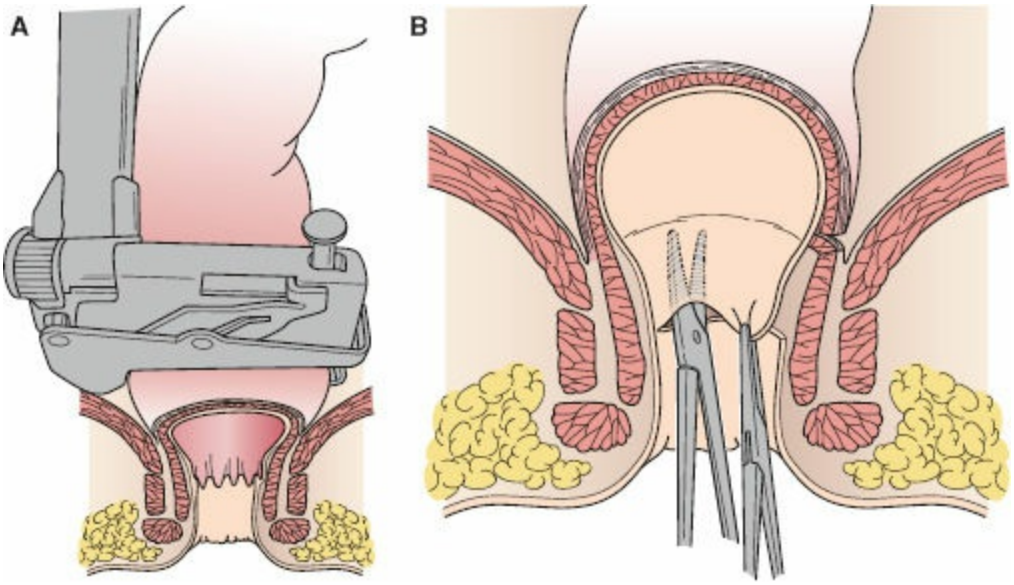

Figure 66-9. Distal rectal transection, (**A**) stapled above the dentate line, or (**B**) a mucosectomy in preparation for a hand-sewn anastomosis.

Proctocolectomy with Ileal Pouch-Anal Anastomosis (IPAA)

5 The colectomy and rectal mobilization are performed as above, however, once one reaches the pelvic floor the rectum is transected approximately 1 cm above the anorectal ring with the stapler (Fig. 66-9A). This rectal cuff will allow for better function, but will require surveillance as it is at risk for cuffitis, and neoplasia. Alternatively, a mucosectomy can be done (Fig. 66-9B) with a subsequent hand-sewn IPAA anastomosis, though this is mostly done in cases of distal neoplasia, and poorer function is observed.

Once the proctectomy is finished, a pouch is fashioned from the terminal ileum. Multiple configurations are possible; the J-pouch configuration is the most popular in the United States (Fig. 66-10). This is constructed by first aligning the terminal ileum into a J-configuration. It is necessary for the apex of the pouch (the end connection of the pouch to the anus) to reach the rectal cuff or anus. Usually, if the apex can be stretched without tension beyond the symphysis pubis, the pouch should reach the anastomosis site without undue tension. Multiple maneuvers can be done to "lengthen" the reach of the pouch, and are beyond the scope of this discussion. The pouch is usually between 10 and 20 cm in length, and ultimately optimizing reach has some effect on how long the pouch is. Once the apex location is decided on, the two limbs of the ileum are aligned with interrupted suture. An enterotomy is made at the apex of the pouch, and a stapler is used to fashion a common channel between the two limbs of ileum. The pouch can then be attached by using an EEA stapler device (placing the anvil in the J-pouch, and firing pin through the rectal pouch), or by performing a hand-sewn anastomosis (Fig. 66-11).

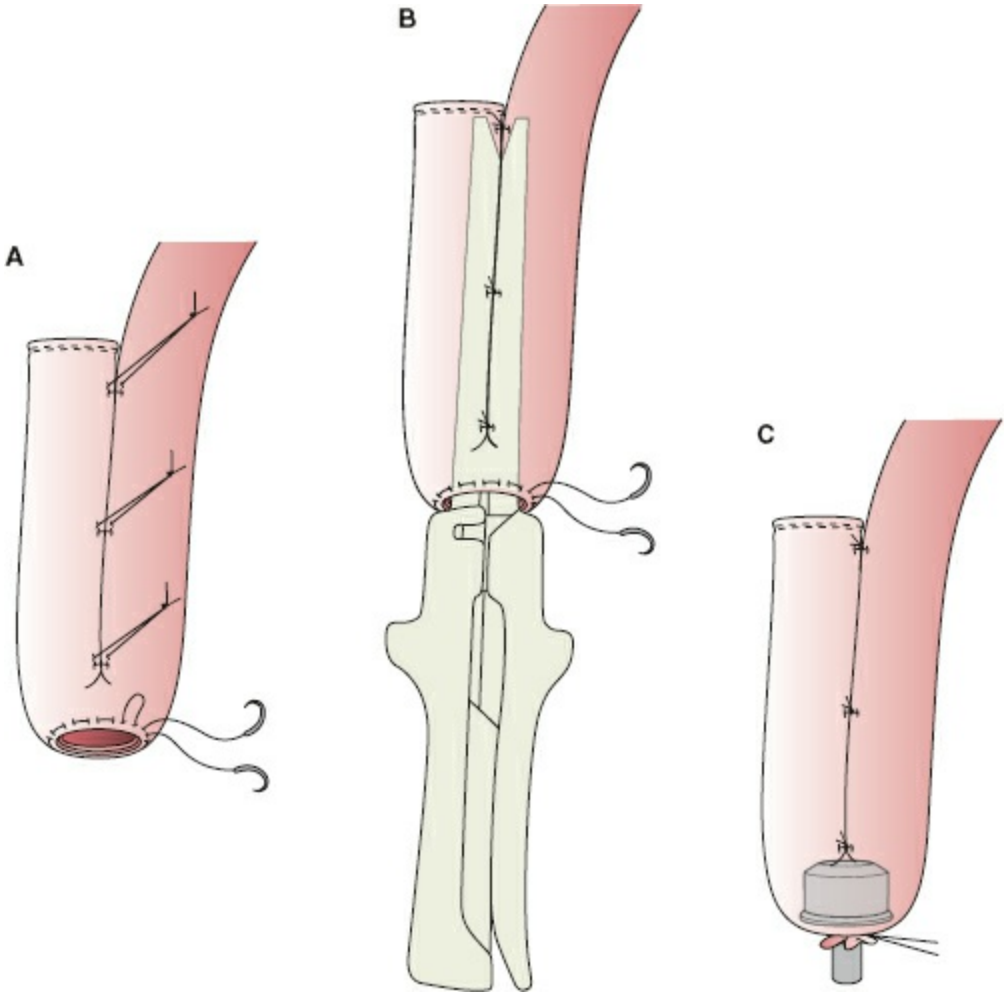

Figure 66-10. IPAA construction and anastomosis. (**A**) terminal ileum alignment for (**B**) common channel creation. **C:** EEA anvil attachment at the apex of the pouch.

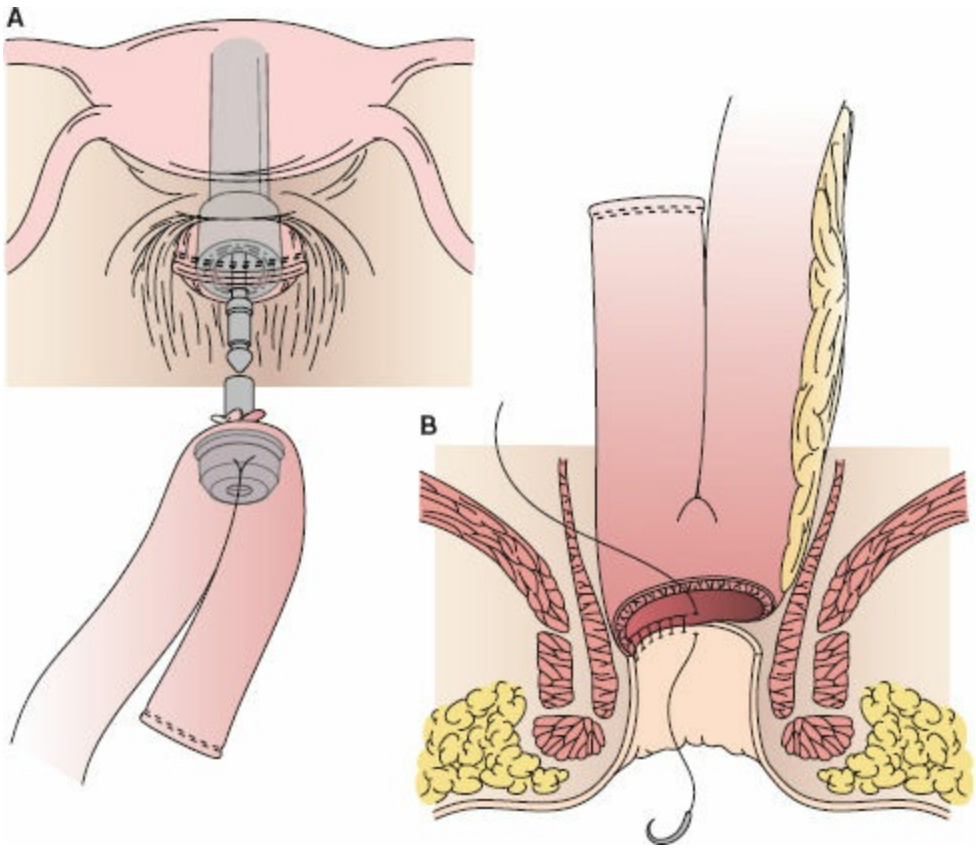

Figure 66-11. Anastomosis of the J-Pouch with (**A**) stapled anastomosis and (**B**) hand-sewn anastomosis.

IPAA-Postoperative Complications

6 The majority of patients who have an IPAA report high quality of life. Small bowel obstruction occur in up to 20% of patients, most commonly managed nonoperatively.[90] The J-pouch is at risk for postoperative abscess, fistula, and pelvic sepsis, which can occur anytime after the pouch formation. Immediate intervention with drainage and antibiotic treatment to control the infection is key, as prolonged infection puts the pouch at risk.[91,92]

Pouchitis is a nonspecific inflammation of the pouch that occurs in up to 40% of the patients.[93] This is the most common complication after IPAA. Pouchitis is treated initially with oral antibiotics. If pouchitis does not resolve, pouch evaluation using endoscopy is undertaken, with pouch mucosa biopsy, and further evaluations can include testing for infections, such as *C. difficile*. Other medications that have shown to help treat pouchitis are corticosteroids, budesonide, 5-aminosalicylic acid, and allopurinol.[94]

Corticosteroid use does not preclude IPAA construction, though a slightly higher rate of anastomotic leaks is observed, thus, usage of a diverting ileostomy should be considered in this patient population.[95] The effect of preoperative use of anti-TNF agents is not clear and limited to nonrandomized studies.

Routine surveillance of the pouch for dysplasia is not essential, however, surveillance of the rectal cuff or transitional zone is necessary (both stapled and hand-sewn anastomoses). The incidence of carcinoma in the rectal remnant/anal transition zone is rare but reported.[96]

Proctocolectomy with Koch Pouch

This is the second continent option (in addition to IPAA). Only a few centers worldwide perform this procedure, and the technique is beyond the scope of this chapter.

In summary, UC is an inflammatory bowel condition influenced by both genetic and environmental factors. Its treatment includes increasingly sophisticated medical and surgical treatment regimens. An individualized, multidisciplinary treatment approach should be employed for each patient, at an institution that has the experience and volume to provide the most current and appropriate treatment.

References

1. Loftus EV Jr. Clinical epidemiology of inflammatory bowel disease: incidence, prevalence, and environmental influences. *Gastroenterology* 2004;126:1504–1517.
2. Stonnington CM, Phillips SF, Zinsmeister AR, et al. Prognosis of chronic ulcerative colitis in a community. *Gut* 1987;28:1261–1266.
3. Stowe SP, Redmond SR, Stormont JM, et al. An epidemiologic study of inflammatory bowel disease in Rochester, New York. Hospital incidence. *Gastroenterology* 1990;98:104–110.
4. Bernstein CN, Blanchard JF, Rawsthorne P, et al. Epidemiology of Crohn's disease and ulcerative colitis in a central Canadian province: a population-based study. *Am J Epidemiol* 1999;149:916–924.
5. Molodecky NA, Soon IS, Rabi DM, et al. Increasing incidence and prevalence of the inflammatory bowel diseases with time, based on systematic review. *Gastroenterology* 2012;142:46–54.e42; quiz e30.
6. Shivananda S, Lennard-Jones J, Logan R, et al. Incidence of inflammatory bowel disease across Europe: is there a difference between north and south? Results of the European Collaborative Study on Inflammatory Bowel Disease (EC-IBD). *Gut* 1996;39:690–697.
7. Sood A, Midha V. Epidemiology of inflammatory bowel disease in Asia. *Indian J Gastroenterol* 2007;26:285–289.
8. Kappelman MD, Rifas-Shiman SL, Kleinman K, et al. The prevalence and geographic distribution of Crohn's disease and ulcerative colitis in the United States. *Clin Gastroenterol Hepatol* 2007;5:1424–1429.
9. Loftus EV Jr, Schoenfeld P, Sandborn WJ. The epidemiology and natural history of Crohn's disease in population-based patient cohorts from North America: a systematic review. *Aliment Pharmacol Ther* 2002;16:51–60.
10. Munkholm P, Langholz E, Nielsen OH, et al. Incidence and prevalence of Crohn's disease in the county of Copenhagen, 1962–87: a sixfold increase in incidence. *Scand J Gastroenterol* 1992;27:609–614.
11. Calkins BM, Lilienfeld AM, Garland CF, et al. Trends in incidence rates of ulcerative colitis and Crohn's disease. *Dig Dis Sci* 1984;29:913–920.
12. Mayberry JF, Judd D, Smart H, et al. Crohn's disease in Jewish people–an epidemiological study in south-east Wales. *Digestion* 1986;35:237–240.
13. Orholm M, Binder V, Sorensen TI, et al. Concordance of inflammatory bowel disease among Danish twins. Results of a nationwide study. *Scand J Gastroenterol* 2000;35:1075–1081.
14. Halfvarson J, Bodin L, Tysk C, et al. Inflammatory bowel disease in a Swedish twin cohort: a long-term follow-up of concordance and clinical characteristics. *Gastroenterology* 2003;124:1767–1773.
15. Watts DA, Satsangi J. The genetic jigsaw of inflammatory bowel disease. *Gut*

2002;50(suppl 3):III31–36.
16. Laharie D, Debeugny S, Peeters M, et al. Inflammatory bowel disease in spouses and their offspring. *Gastroenterology* 2001;120:816–839.
17. Cuthbert AP, Fisher SA, Mirza MM, et al. The contribution of NOD2 gene mutations to the risk and site of disease in inflammatory bowel disease. *Gastroenterology* 2002;122:867–874.
18. Fisher SA, Tremelling M, Anderson CA, et al. Genetic determinants of ulcerative colitis include the ECM1 locus and five loci implicated in Crohn's disease. *Nat Genet* 2008;40:710–712.
19. Franke A, Balschun T, Sina C, et al. Genome-wide association study for ulcerative colitis identifies risk loci at 7q22 and 22q13 (IL17REL). *Nat Genet* 2010;42:292–294.
20. Rioux JD, Silverberg MS, Daly MJ, et al. Genomewide search in Canadian families with inflammatory bowel disease reveals two novel susceptibility loci. *Am J Hum Genet* 2000;66:1863–1870.
21. Glocker EO, Kotlarz D, Boztug K, et al. Inflammatory bowel disease and mutations affecting the interleukin-10 receptor. *N Engl J Med* 2009;361:2033–2045.
22. Toyoda H, Wang SJ, Yang HY, et al. Distinct associations of HLA class II genes with inflammatory bowel disease. *Gastroenterology* 1993;104:741–748.
23. Okada Y, Yamazaki K, Umeno J, et al. HLA-Cw*1202-B*5201-DRB1*1502 haplotype increases risk for ulcerative colitis but reduces risk for Crohn's disease. *Gastroenterology* 2011;141:864–871.e1–5.
24. Duerr RH, Taylor KD, Brant SR, et al. A genome-wide association study identifies IL23R as an inflammatory bowel disease gene. *Science* 2006;314:1461–1463.
25. Silverberg MS, Cho JH, Rioux JD, et al. Ulcerative colitis-risk loci on chromosomes 1p36 and 12q15 found by genome-wide association study. *Nat Genet* 2009;41:216–220.
26. Loftus CG, Loftus EV Jr, Harmsen WS, et al. Update on the incidence and prevalence of Crohn's disease and ulcerative colitis in Olmsted County, Minnesota, 1940–2000. *Inflamm Bowel Dis* 2007;13:254–261.
27. Ekbom A, Helmick C, Zack M, et al. The epidemiology of inflammatory bowel disease: a large, population-based study in Sweden. *Gastroenterology* 1991;100:350–358.
28. Loftus EV Jr, Silverstein MD, Sandborn WJ, et al. Ulcerative colitis in Olmsted County, Minnesota, 1940–1993: incidence, prevalence, and survival. *Gut* 2000;46:336–343.
29. Geerling BJ, Dagnelie PC, Badart-Smook A, et al. Diet as a risk factor for the development of ulcerative colitis. *Am J Gastroenterol* 2000;95:1008–1013.
30. Jowett SL, Seal CJ, Pearce MS, et al. Influence of dietary factors on the clinical course of ulcerative colitis: a prospective cohort study. *Gut* 2004;53:1479–1484.
31. Khalili H, Ananthakrishnan AN, Konijeti GG, et al. Physical activity and risk of

inflammatory bowel disease: prospective study from the Nurses' Health Study cohorts. *BMJ* 2013;347:f6633.

32. Boyko EJ, Koepsell TD, Perera DR, et al. Risk of ulcerative colitis among former and current cigarette smokers. *N Engl J Med* 1987;316:707–710.
33. Mahid SS, Minor KS, Soto RE, et al. Smoking and inflammatory bowel disease: a meta-analysis. *Mayo Clin Proc* 2006;81:1462–1471.
34. Calkins BM. A meta-analysis of the role of smoking in inflammatory bowel disease. *Dig Dis Sci* 1989;34:1841–1854.
35. Loftus EV Jr, Sandborn WJ, Tremaine WJ, et al. Primary sclerosing cholangitis is associated with nonsmoking: a case-control study. *Gastroenterology* 1996;110:1496–1502.
36. van Erpecum KJ, Smits SJ, van de Meeberg PC, et al. Risk of primary sclerosing cholangitis is associated with nonsmoking behavior. *Gastroenterology* 1996;110:1503–1506.
37. Frisch M, Biggar RJ: Appendectomy and protection against ulcerative colitis. *N Engl J Med* 2001;345:222–223; author reply 223–224.
38. Frisch M, Johansen C, Mellemkjaer L, et al. Appendectomy and subsequent risk of inflammatory bowel diseases. *Surgery* 2001;130:36–43.
39. Andersson RE, Olaison G, Tysk C, et al. Appendectomy and protection against ulcerative colitis. *N Engl J Med* 2001;344:808–814.
40. Rutgeerts P, D'Haens G, Hiele M, et al. Appendectomy protects against ulcerative colitis. *Gastroenterology* 1994;106:1251–1253.
41. Sandler RS. Appendicectomy and ulcerative colitis. *Lancet* 1998;352:1797–1798.
42. Holtmann MH, Galle PR. Current concept of pathophysiological understanding and natural course of ulcerative colitis. *Langenbecks Arch Surg* 2004;389:341–349.
43. Silverberg MS, Satsangi J, Ahmad T, et al. Toward an integrated clinical, molecular and serological classification of inflammatory bowel disease: report of a Working Party of the 2005 Montreal World Congress of Gastroenterology. *Can J Gastroenterol* 2005;19(suppl A):5A–36A.
44. Sands BE. From symptom to diagnosis: clinical distinctions among various forms of intestinal inflammation. *Gastroenterology* 2004;126:1518–1532.
45. Schroeder KW, Tremaine WJ, Ilstrup DM. Coated oral 5-aminosalicylic acid therapy for mildly to moderately active ulcerative colitis. a randomized study. *N Engl J Med* 1987;317:1625–1629.
46. Shetty K, Rybicki L, Brzezinski A, et al. The risk for cancer or dysplasia in ulcerative colitis patients with primary sclerosing cholangitis. *Am J Gastroenterol* 1999;94:1643–1649.
47. Suhler EB, Smith JR, Wertheim MS, et al. A prospective trial of infliximab therapy for refractory uveitis: preliminary safety and efficacy outcomes. *Arch Ophthalmol* 2005;123:903–912.

48. Farhi D, Cosnes J, Zizi N, et al. Significance of erythema nodosum and pyoderma gangrenosum in inflammatory bowel diseases: a cohort study of 2402 patients. *Med (Baltimore)* 2008;87:281–293.
49. Agarwal A, Andrews JM. Systematic review: IBD-associated pyoderma gangrenosum in the biologic era, the response to therapy. *Aliment Pharmacol Ther* 2013;38:563–572.
50. Generini S, Giacomelli R, Fedi R, et al. Infliximab in spondyloarthropathy associated with Crohn's disease: an open study on the efficacy of inducing and maintaining remission of musculoskeletal and gut manifestations. *Ann Rheum Dis* 2004;63:1664–1669.
51. Gee MS, Harisinghani MG. MRI in patients with inflammatory bowel disease. *J Magn Reson Imaging* 2011;33:527–534.
52. Geboes K, De Hertogh G. Indeterminate colitis. *Inflamm Bowel Dis* 2003;9:324–331.
53. Faubion WA Jr, Loftus EV Jr, Harmsen WS, et al. The natural history of corticosteroid therapy for inflammatory bowel disease: a population-based study. *Gastroenterology* 2001;121:255–260.
54. Rutgeerts P, Lofberg R, Malchow H, et al. A comparison of budesonide with prednisolone for active Crohn's disease. *N Engl J Med* 1994;331:842–845.
55. Travis SP: Predicting outcome in severe ulcerative colitis. *Dig Liver Dis* 2004;36:448–449.
56. Lichtenstein GR, Feagan BG, Cohen RD, et al. Serious infections and mortality in association with therapies for Crohn's disease: TREAT registry. *Clin Gastroenterol Hepatol* 2006;4:621–630.
57. d'Albasio G, Pacini F, Camarri E, et al. Combined therapy with 5-aminosalicylic acid tablets and enemas for maintaining remission in ulcerative colitis: a randomized double-blind study. *Am J Gastroenterol* 1997;92:1143–1147.
58. Higgins PD, Rubin DT, Kaulback K, et al. Systematic review: impact of non-adherence to 5-aminosalicylic acid products on the frequency and cost of ulcerative colitis flares. *Aliment Pharmacol Ther* 2009;29:247–257.
59. Kane S, Huo D, Aikens J, et al. Medication nonadherence and the outcomes of patients with quiescent ulcerative colitis. *Am J Med* 2003;114:39–43.
60. Lichtiger S. Cyclosporine therapy in inflammatory bowel disease: open-label experience. *Mt Sinai J Med* 1990;57:315–319.
61. Rayner CK, McCormack G, Emmanuel AV, et al. Long-term results of low-dose intravenous ciclosporin for acute severe ulcerative colitis. *Aliment Pharmacol Ther* 2003;18:303–308.
62. D'Haens G, Baert F, van Assche G, et al. Early combined immunosuppression or conventional management in patients with newly diagnosed Crohn's disease: an open randomised trial. *Lancet* 2008;371:660–667.
63. Mason M, Siegel CA. Do inflammatory bowel disease therapies cause cancer? *Inflamm*

Bowel Dis 2013;19:1306–1321.

64. George J, Present DH, Pou R, et al. The long-term outcome of ulcerative colitis treated with 6-mercaptopurine. *Am J Gastroenterol* 1996;91:1711–1714.
65. Laharie D, Seneschal J, Schaeverbeke T, et al. Assessment of liver fibrosis with transient elastography and FibroTest in patients treated with methotrexate for chronic inflammatory diseases: a case-control study. *J Hepatol* 2010;53:1035–1040.
66. Rutgeerts P, Sandborn WJ, Feagan BG, et al. Infliximab for induction and maintenance therapy for ulcerative colitis. *N Engl J Med* 2005;353:2462–2476.
67. Reinisch W, Sandborn WJ, Rutgeerts P, et al. Long-term infliximab maintenance therapy for ulcerative colitis: the ACT-1 and -2 extension studies. *Inflamm Bowel Dis* 2012;18:201–211.
68. Sokol H, Seksik P, Carrat F, et al. Usefulness of co-treatment with immunomodulators in patients with inflammatory bowel disease treated with scheduled infliximab maintenance therapy. *Gut* 2010;59:1363–1368.
69. Ford AC, Sandborn WJ, Khan KJ, et al. Efficacy of biological therapies in inflammatory bowel disease: systematic review and meta-analysis. *Am J Gastroenterol* 2011;106:644–659, quiz 660.
70. Crum NF, Lederman ER, Wallace MR. Infections associated with tumor necrosis factor-alpha antagonists. *Med (Baltimore)* 2005;84:291–302.
71. Wallis RS, Broder MS, Wong JY, et al. Granulomatous infectious diseases associated with tumor necrosis factor antagonists. *Clin Infect Dis* 2004;38:1261–1265.
72. Mariette X, Tubach F, Bagheri H, et al. Lymphoma in patients treated with anti-TNF: results of the 3-year prospective French RATIO registry. *Ann Rheum Dis* 2010;69:400–408.
73. Langholz E, Munkholm P, Davidsen M, et al. Colorectal cancer risk and mortality in patients with ulcerative colitis. *Gastroenterology* 1992;103:1444–1451.
74. Allison J, Herrinton LJ, Liu L, et al. Natural history of severe ulcerative colitis in a community-based health plan. *Clin Gastroenterol Hepatol* 2008;6:999–1003.
75. Grant CS, Dozois RR. Toxic megacolon: ultimate fate of patients after successful medical management. *Am J Surg* 1984;147:106–110.
76. Jarnerot G, Hertervig E, Friis-Liby I, et al. Infliximab as rescue therapy in severe to moderately severe ulcerative colitis: a randomized, placebo-controlled study. *Gastroenterology* 2005;128:1805–1811.
77. Albrechtsen D, Bergan A, Nygaard K, et al. Urgent surgery for ulcerative colitis: early colectomy in 132 patients. *World J Surg* 1981;5:607–615.
78. Hawley PR. Emergency surgery for ulcerative colitis. *World J Surg* 1988; 12:169–173.
79. Robert JH, Sachar DB, Aufses AH Jr, et al. Management of severe hemorrhage in ulcerative colitis. *Am J Surg* 1990;159:550–555.
80. van Heerden JA, Beart RW Jr. Carcinoma of the colon and rectum complicating chronic ulcerative colitis. *Dis Colon Rectum* 1980;23:155–159.

81. Lavery IC, Chiulli RA, Jagelman DG, et al. Survival with carcinoma arising in mucosal ulcerative colitis. *Ann Surg* 1982;195:508–512.
82. Rutter MD, Saunders BP, Wilkinson KH, et al. Thirty-year analysis of a colonoscopic surveillance program for neoplasia in ulcerative colitis. *Gastroenterology* 2006;130:1030–1038.
83. Itzkowitz SH, Present DH, Crohn's and Colitis Foundation of America Colon Cancer in IBD Study Group. Consensus conference: colorectal cancer screening and surveillance in inflammatory bowel disease. *Inflamm Bowel Dis* 2005;11:314–321.
84. Murphy J, Kalkbrenner KA, Pemberton JH, et al. Dysplasia in ulcerative colitis as a predictor of unsuspected synchronous colorectal cancer. *Dis Colon Rectum* 2014;57:993–998.
85. Goudet P, Dozois RR, Kelly KA, et al. Characteristics and evolution of extraintestinal manifestations associated with ulcerative colitis after proctocolectomy. *Dig Surg* 2001;18:51–55.
86. Holubar SD, Larson DW, Dozois EJ, et al. Minimally invasive subtotal colectomy and ileal pouch-anal anastomosis for fulminant ulcerative colitis: a reasonable approach? *Dis Colon Rectum* 2009;52:187–192.
87. Holubar SD, Privitera A, Cima RR, et al. Minimally invasive total proctocolectomy with Brooke ileostomy for ulcerative colitis. *Inflamm Bowel Dis* 2009;15:1337–1342.
88. Boller AM, Larson DW. Laparoscopic restorative proctocolectomy for ulcerative colitis. *J Gastrointest Surg* 2007;11:3–7.
89. Rosenstein DI, Alsikafi NF. Diagnosis and classification of urethral injuries. *Urol Clin North Am* 2006;33:73–85, vi-vii.
90. MacLean AR, Cohen Z, MacRae HM, et al. Risk of small bowel obstruction after the ileal pouch–anal anastomosis. *Ann Surg* 2002;235:200–206.
91. Scott NA, Dozois RR, Beart RW Jr, et al. Postoperative intra-abdominal and pelvic sepsis complicating ileal pouch–anal anastomosis. *Int J Colorectal Dis* 1988;3:149–152.
92. Heuschen UA, Allemeyer EH, Hinz U, et al. Outcome after septic complications in J-pouch procedures. *Br J Surg* 2002;89:194–200.
93. Hahnloser D, Pemberton JH, Wolff BG, et al. Results at up to 20 years after ileal pouch–anal anastomosis for chronic ulcerative colitis. *Br J Surg* 2007;94:333–340.
94. Holubar SD, Cima RR, Sandborn WJ, et al. Treatment and prevention of pouchitis after ileal pouch–anal anastomosis for chronic ulcerative colitis. *Cochrane Database Syst Rev* 2010:CD001176.
95. Lake JP, Firoozmand E, Kang JC, et al. Effect of high-dose steroids on anastomotic complications after proctocolectomy with ileal pouch–anal anastomosis. *J Gastrointest Surg* 2004;8:547–551.
96. Branco BC, Sachar DB, Heimann TM, et al. Adenocarcinoma following ileal pouch–anal anastomosis for ulcerative colitis: review of 26 cases. *Inflamm Bowel Dis* 2009;15:295–299.

Chapter 67

Colonic Polyps and Polyposis Syndromes

Robert S. Bresalier and C. Richard Boland

Key Points

1 Colorectal neoplasia develops through multistep carcinogenesis that involves the gradual accumulation of genetic and epigenetic alterations in the genome. This process usually requires the presence of some forms of genomic or epigenetic instability, and neoplasms may require several decades to evolve from their earliest stages to fully advanced disease.

2 Genetic and familial factors play an important role in the genesis of both the sporadic (common) and syndromic forms of colorectal neoplasia, such as familial adenomatous polyposis and Lynch syndrome.

3 Colorectal carcinoma usually evolves gradually from colorectal adenomas in clinically identifiable stages; removal of adenomas reduces the incidence of colorectal carcinoma.

4 The genetic bases of familial adenomatous polyposis and Lynch syndrome (previously called hereditary nonpolyposis colorectal cancer) have been identified, which facilitate the early identification and diagnosis of affected individuals.

5 A wide range of clinical heterogeneity is present in the familial colorectal cancer syndromes, and attenuated forms of familial adenomatous polyposis and Lynch syndrome can be subtle and a challenge to the clinician.

COLORECTAL POLYPS

The gastrointestinal tract accounts for more neoplastic disease than any other organ system in the body. In North America, neoplasms of the colon and rectum have attracted the greatest interest because of their relatively high incidence, and because appropriate intervention can dramatically modify the morbidity and mortality associated with them. The adenoma is the most common precursor of colorectal cancer, and early removal of adenomatous polyps can interrupt the natural history of the disease and prevent death.

Colorectal cancers can develop through one of at least three molecular pathways, and each variety appears to have some unique clinical and pathologic features.[1–3] The adenoma–carcinoma sequence is virtually canonical at this time and describes the common pathway taken by neoplasms that have "chromosomal instability." It has subsequently been proposed that "serrated" polyps, especially those in the right colon, may be precursors of colon cancers with the microsatellite instability (MSI) phenotype. It is becoming increasingly important to understand the clinical behavior of colorectal neoplasms in the context of the genetic and molecular bases of these lesions.

Classification of Colorectal Polyps

The term polyp (from the Greek *polypous,* "morbid excrescence") refers to a macroscopic protrusion of the colonic mucosa into the bowel lumen. This can result from abnormal growth of the mucosa or from a submucosal process that causes the mucosa to protrude into the lumen. Mucosal polyps can be sessile, protruding directly from the colonic wall, or pedunculated, extending from the mucosa through a fibrovascular stalk.

Mucosal polyps in the colon can be categorized as neoplastic, with malignant potential, and nonneoplastic, with no malignant potential (Table 67-1). Neoplastic polyps include benign adenomatous polyps that may evolve to carcinoma, adenomatous polyps that contain foci of intramucosal carcinoma (carcinoma in situ), and adenomatous polyps in which carcinoma has penetrated the muscularis mucosae (invasive carcinoma). A serrated polyp (sessile serrated adenoma [SSA] and traditional serrated adenoma [TSA]) appears to originate in a manner unique from typical adenomas, but is also a premalignant lesion. Instead of evolving through the traditional multistep pathway, SSAs in the proximal colon appear to evolve through a pathway that involves both *BRAF* mutation and progressive methylation of DNA that result in the silencing of multiple genes. The fine details of this pathway remain to be elucidated. Sometimes a polyp is found in which carcinoma has completely obliterated the adenomatous tissue from which it arose (polypoid carcinoma).

Nonneoplastic mucosal polyps include hyperplastic polyps (HPs) (a form of serrated polyp which does not directly progress to cancer), juvenile polyps, Peutz–Jeghers hamartomas, and a variety of inflammatory polyps, including those associated with inflammatory bowel disease. Any submucosal lesion can expand to push the mucosa into the bowel lumen and thus appear as a polypoid lesion. Examples include lipomas, leiomyomas, colitis cystica profunda, pneumatosis cystoides intestinalis, lymphoid aggregates, primary or secondary lymphomas, carcinoid tumors, and other metastatic neoplasms.

Neoplastic Mucosal Polyps

Most colorectal cancers arise in pre-existing adenomatous polyps. Neoplastic mucosal epithelium evolves through a series of progressive, cumulative molecular and cellular steps that lead to altered proliferation, cellular accumulation, and glandular disarray. In some instances, the polyp also achieves the ability to invade and metastasize through the adenoma-to-carcinoma sequence.

Several lines of evidence support the assumption that colorectal adenocarcinomas arise from adenomatous polyps. The descriptive epidemiology of colonic adenomas parallels that of carcinomas, but the benign lesions occur earlier. Adenomas are rare in geographic regions with a low prevalence of colon cancer, and the distribution of adenomas in the colon parallels that of carcinomas. Adenomas often occur in anatomic proximity to colon cancers, and cancer risk is proportional to the number of adenomas present synchronously or metachronously in a patient. Cancer is often present in polyps removed endoscopically or surgically, and the risk for cancer is proportional to the degree of dysplasia or atypia in the polyp. Conversely, histologically evident residual adenomatous tissue may be

found surrounding carcinomas. Most important, results from several studies indicate that the systematic removal of adenomatous polyps during screening sigmoidoscopy or surveillance colonoscopy decreases the risk for the development of colorectal cancers and death from this disease.

Table 67-1 Classification of Colorectal Polyps

Mucosal Polyps
Neoplastic
Benign
Adenomatous polyps
Tubular adenoma
Tubulovillous adenoma
Villous adenoma
Sessile serrated adenoma or polyp
Traditional serrated adenoma
Malignant
Carcinoma in situ
Invasive carcinoma
Polypoid carcinoma
Nonneoplastic
Hyperplastic polyps
Juvenile polyps
Peutz–Jeghers polyps
Inflammatory polyps
Normal epithelium
Submucosal Polyps
Lipomas
Leiomyomas
Colitis cystica profunda
Pneumatosis cystoides intestinalis
Lymphoid aggregates
Lymphoma (primary or secondary)
Carcinoids
Metastatic neoplasms

Pathogenesis

Molecular Biology

1 Genetic changes that lead to the development of adenomas (and carcinomas) can be loosely organized into three broad categories: alterations in proto-oncogenes, loss of tumor-suppressor gene activity, and abnormalities of genes involved in DNA repair (Fig. 67-1).[1–3] Several different mechanisms are involved in altering these genes. Typically, oncogenes become overactive by mutation, rearrangement, or amplification. Tumor-suppressor genes become inactivated by mutation or deletion, or silenced through promoter methylation. Tumor-suppressor genes require inactivation of both copies of alleles, making this process more complex. It is now clear, however, that the development of adenoma and carcinoma is always associated with the progressive accumulation of genetic changes, and this process is termed multistep carcinogenesis.[1–4]

In familial adenomatous polyposis (FAP), Lynch syndrome (previously called hereditary nonpolyposis colorectal cancer [HNPCC]), and other familial syndromes, the first genetic alteration is inherited in the germline, and therefore present in every cell. Environmental factors or "accidents" occurring in the DNA from faulty replication or DNA damage are then required for the additional genetic mutations, termed somatic mutations, as the process moves toward cancer. The clinical phenotype for the inherited predispositions to gastrointestinal cancer is initially normal. The germline mutation provides the first alteration or "hit," which greatly increases the likelihood of neoplasia and that the disease will occur at a younger age. FAP and Lynch syndrome account for about 3% to 4% of all colorectal cancers, but it is estimated that as many as 30% of colorectal cancers occur in the context of a positive family history, which is probably mediated by numerous subtle differences in DNA sequence (called single nucleotide polymorphisms, or SNPs) that exert small changes in risk.

"Sporadic" polyps and cancers are associated with multiple somatic mutations, all of which are caused by spontaneous decay of DNA, exogenous insults, or are accidents that occur during the replication of DNA. The occurrence of most cases of colorectal cancer has been attributed to the high frequency of cancer in the colon and rectum compared to other organs is a consequence of the number of stem cell divisions that occurs in human colon. To some degree, the occurrence of colorectal cancer is often a matter of "bad luck."[5]

Destabilization of the genome is a prerequisite to carcinogenesis. This most commonly involves chromosomal instability, which is manifested as widespread chromosomal deletions, duplications, and rearrangements that produce aneuploidy. Alternatively, increased rates of mutations, often in tandemly repeated DNA sequences known as microsatellites (i.e., microsatellite instability or MSI) or a form of epigenetic instability called the CpG island methylator phenotype (CIMP), in which genes are inappropriately silenced by promoter methylation[1–3] are mechanisms that can lead to progressive multistep carcinogenesis. Genomic (or epigenetic) instability generates a large number of random alterations, which are often silent or lead to the extinction of the cell. However, occasional genetic alterations enhance growth and survival, and the successive

accumulation of those changes will eventually facilitate the evolution of a neoplastic cell.

Cellular proto-oncogenes are a group of evolutionarily conserved genes that play a role in signal transduction and the normal regulation of cell growth. They function by being turned on when growth is stimulated and then turned off when sufficient growth has been achieved. Inappropriate activation of these genes, usually through mutation that activates the protein or rearrangement of the promoter sequences, leads to unregulated growth-regulatory signaling and excessive cellular proliferation. The prototypical oncogene in CRC is in *KRAS,* and mutations in this gene are progressively more frequent in larger, more advanced adenomatous polyps. The tumor-suppressor gene *APC* on chromosome 5q is critical to the evolution of the colorectal adenoma. Allelic losses of chromosome 5q occur early during carcinogenesis in the colon, and this is frequently the initial step in the evolution of colorectal neoplasia. *APC* acts as the "gatekeeper" of colonic epithelial proliferation, and inactivation of this gene will lead to net cellular proliferation and initiation of neoplasia in the colon. The protein produced by the *APC* gene plays a central role in regulating the intracellular concentrations of the transcription factor, β-catenin. *β-catenin* is highly expressed in cells at the base of the colonic crypt, where it stimulates proliferation. As the cell commits to terminal differentiation, the *APC* gene is expressed, which downregulates β-catenin by phosphorylation of the protein, targeting it for degradation.

Inactivating alterations in the *p53* tumor-suppressor gene are a critical step in the transition from adenoma to carcinoma, as the p53 protein normally prevents cells with damaged DNA from progressing from the G1 to the S phase in the cell cycle. Alterations in *APC, p53,* and *KRAS* are the most common alterations in most CRCs. However, a subset of about 15% of CRCs are "hypermutated" and have a different signature pattern of somatic mutations.[6]

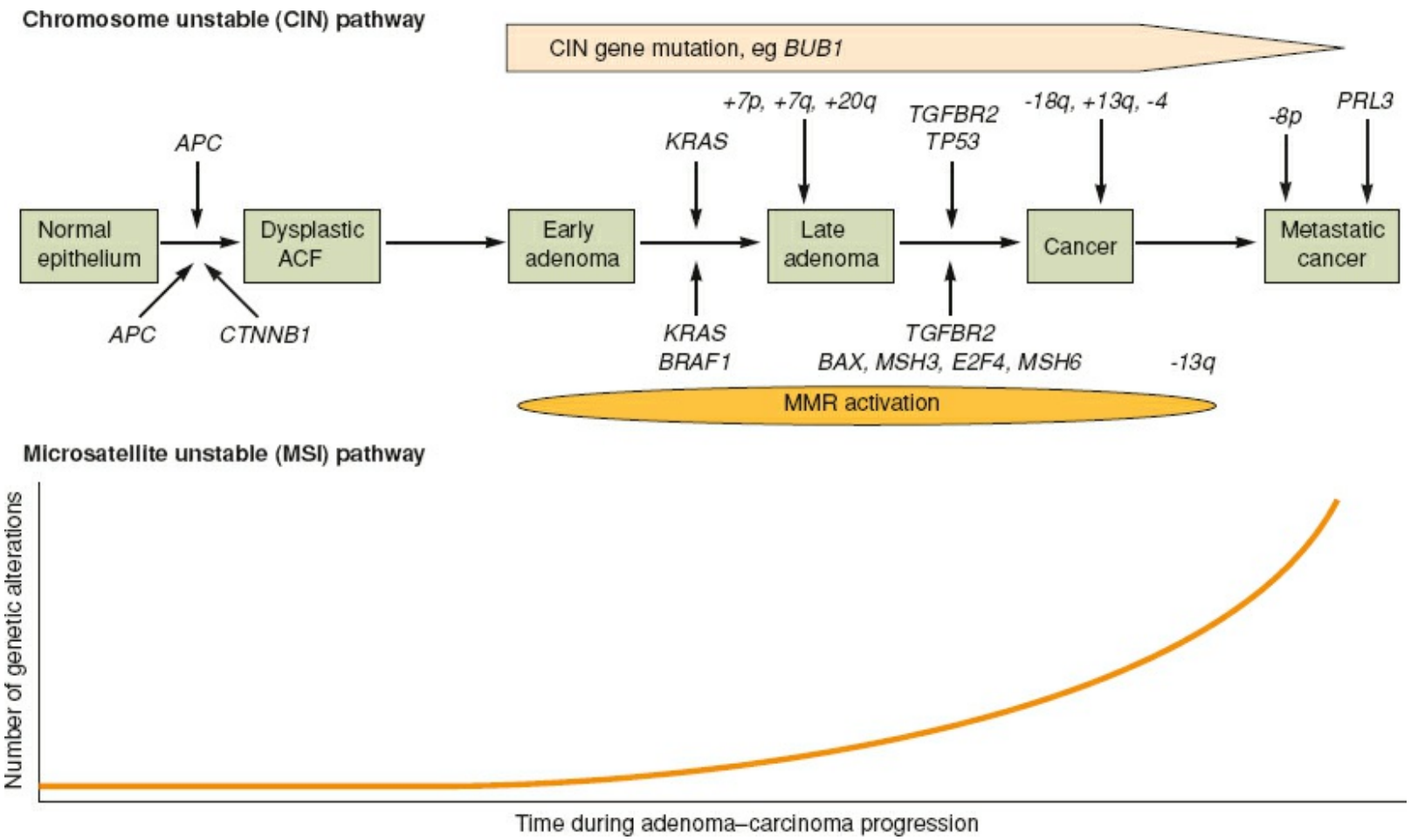

Figure 67-1. Proposed sequence of molecular genetic events in the evolution of colon cancer. Carcinomas arise from an accumulation of events whose sequence has been defined for two of the carcinogenesis pathways. As illustrated here, tumors progress through the adenoma-to-carcinoma sequence along pathways marked by chromosomal instability (CIN) or microsatellite instability (MSI). At least one more pathway, characterized by promoter methylation of tumor-suppressor genes, serrated polyps, and cancers with variable degrees of microsatellite instability, is incompletely understood, and not shown here. ACF, aberrant crypt focus; TGF, transforming growth factor. (After Grady WM. Genomic instability and colon cancer. *Cancer Metastasis Rev* 2004;23:11; Grady WM, Carethers JM. Genomic and epigenetic instabilility in colorectal cancer progression. *Gastroenterology* 2008;135:1079–1099.)

The major form of hypermutation occurs when the DNA mismatch repair (MMR) system is inactivated. Germline mutations in the DNA MMR genes *MSH2, MLH1, MSH6,* and *PMS2* cause Lynch syndrome, which historically was called HNPCC.[7] In the hereditary CRC syndromes, germline mutations inactivate one copy of the gene, and the other allele is inactivated by a "somatic" genetic event that occurs locally in an individual colonic epithelial cell. Loss of DNA MMR results in a diffuse mutational signature in the tumor called microsatellite instability, or MSI. This defect leads to the mutational inactivation of several key genes important for maintaining normal cellular behavior. The *transforming growth factor-β receptor II* (*TGF-βRII*) gene, for example, is mutated in 85% of MSI colorectal cancers. This inactivates the receptor, renders the cell unresponsive to TGF-β, and permits it to escape normal growth regulation. The MSI multistep carcinogenesis pathway to tumor development is seen in about 15% of all colorectal cancers,[8] and progression from adenoma to carcinoma occurs in a shorter time period than occurs in the chromosomal instability pathway seen in most colorectal cancers,

which is thought to require 10 to 20 years. MSI colorectal neoplasms appear to account for two clinical observations. First, the MSI pathway may account for the occurrence of cancers 1 or 2 years after a negative colonoscopy (“interval cancers”). Second, it may account for the relatively small number of adenomatous polyps found with MSI, since they may evolve into cancer in a shorter timeframe than usually occurs.

Histopathology and Malignant Potential

Adenomatous polyps are characterized according to their physical features, size, glandular structure, and degree of dysplasia, which all have important implications for clinical management. Polyps may be sessile, with a broad-based attachment to the colonic wall, or pedunculated, attached to the colonic wall by way of a fibrovascular stalk (Fig. 67-2). Whether a polyp is sessile or pedunculated previously determines whether the endoscopist can remove the polyp completely by snare polypectomy. Newer endoscopic techniques such as endomucosal resection (EMR) and endomucosal dissection (ESD) have now allowed for resection of most sessile polyps. Diminutive polyps that measure 5 mm or less in diameter are not likely to contain high-grade dysplasia or invasive carcinoma. Malignant potential increases with polyp size in all histologic groups of adenoma.

Adenomas are classified histologically according to their glandular structure. Aberrant (dysplastic) crypts and microadenomas may be the earliest lesions detected in the flat mucosa of patients at risk. These enlarge and progress to macroscopic adenomatous polyps. Tubular adenomas are characterized by a complex network of branching adenomatous glands, whereas villous adenomas contain fronds or folds of mucosa that have overgrown their underlying stroma and project toward the colonic lumen (Fig. 67-3). Often, both histologic types coexist in a mixed tubulovillous adenoma.

All conventional adenomas, by definition, consist of dysplastic mucosa. The term dysplasia refers to abnormalities in crypt architecture (such as irregular branching or crowded “back-to-back” glands) and cytologic detail (enlarged, pleomorphic, and hyperchromatic nuclei with multiple mitoses and pseudostratification; Fig. 67-4). Dysplasia may be mild, moderate, or severe, depending on the degree to which these characteristics are present. Severe, or high-grade, dysplasia represents carcinoma in situ when the basement membrane has not been invaded. Extension into the lamina propria denotes intramucosal carcinoma. Invasion into the muscularis mucosae defines invasive carcinoma and the malignant polyp. The degree of dysplasia usually correlates with polyp size and the extent of villous architecture. Occasionally, nonmalignant adenomatous mucosa can be displaced below the muscularis mucosae, probably due to trauma associated with colonic motility. This must be distinguished from malignant invasion and is termed pseudoinvasion.

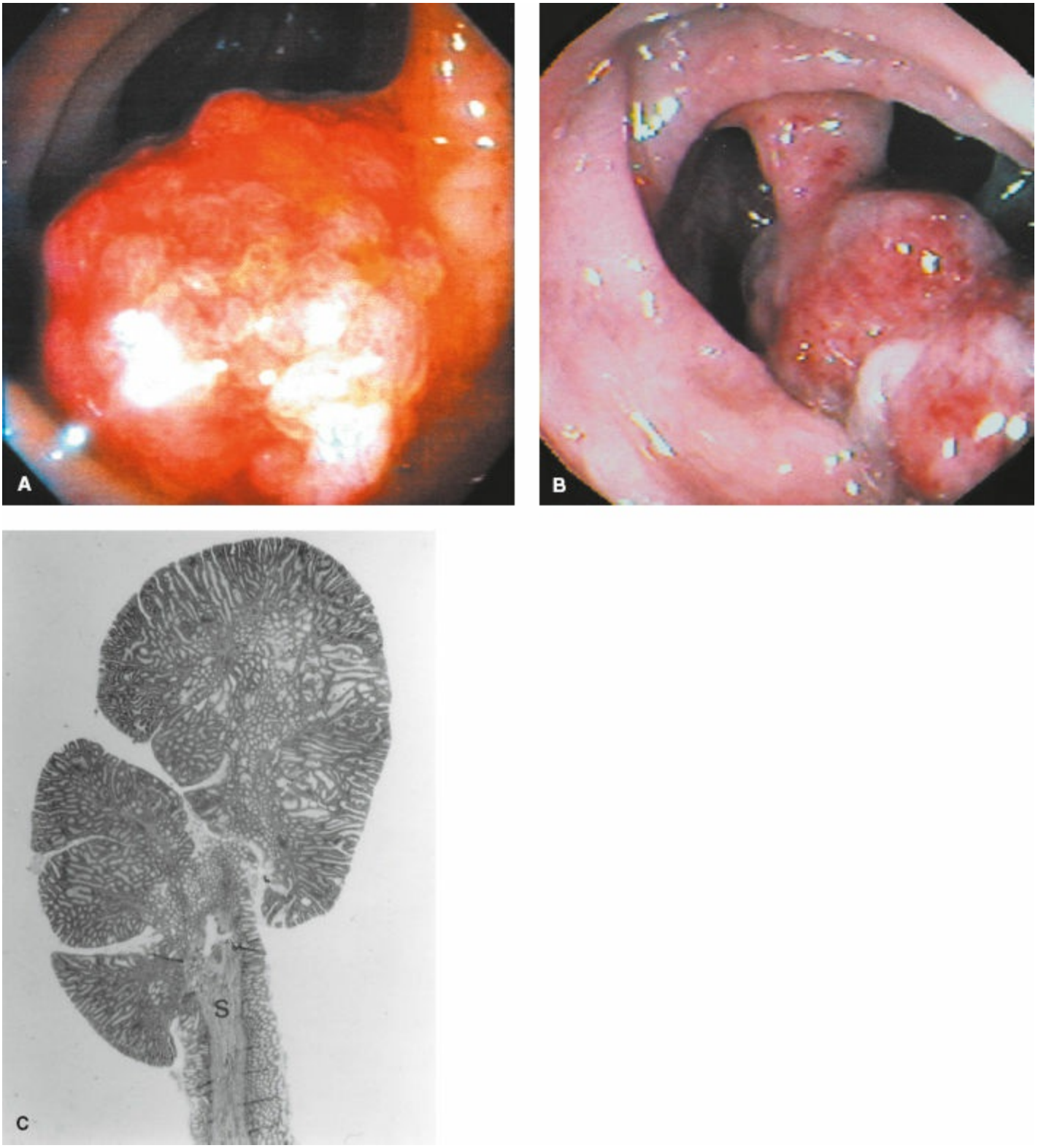

Figure 67-2. Mucosal polyps of the colon may be sessile, protruding directly from the colonic wall, or pedunculated, extending from the mucosa through a fibrovascular stalk. **A:** Large sessile polyp seen at colonoscopy. The polyp has a broad-based attachment to the mucosa. **B:** Pedunculated polyp seen at colonoscopy. The polyp is attached to the mucosa through a distinct stalk. **C:** Low-power photomicrograph of a pedunculated polyp (a tubular adenoma) cut in cross section to demonstrate its fibrovascular stalk (*S*).

It is now recognized that some serrated polyps (characterized by a "saw-tooth" pattern of colonic crypts) may be precursors to carcinoma.[9] HPs are typically small (diminutive polyps <5 mm) and are usually located in the distal colon and rectum. These are the most common type of serrated polyps (30% to 40% of all polyps and 80% to 90% of

serrated polyps), and do not appear to have direct malignant potential. SSAs are distinct from conventional adenomas with respect to histology and molecular biology, and are typically nondysplastic. SSAs are characterized by distorted crypt bases and crypt dilation (Fig. 67-5) and by migration of the proliferative zone to the side of the crypt. SSAs are associated with *BRAF* mutations and CIMP, which can lead to epigenetic silencing of MMR genes such as *MLH1,* resulting in MSI. SSAs are typically right-sided, often flat (Fig. 67-5A), and may be covered by a so-called "mucous cap" (Fig. 67-5B). TSAs are the least common form of serrated lesion. They have villiform features and are typically protuberant or pedunculated left-sided lesions which contain areas of dysplasia. TSAs commonly have *KRAS* mutations and may give rise to microsatellite stable cancers. Serrated polyposis syndrome is a syndrome characterized by multiple serrated polyps (Fig. 67-5D).[9–11] These polyps are most often SSAs, but HPs and TSAs may also occur in this setting. The exact genetic defect and actual risk of malignancy associated with this syndrome are unknown.

Even though nearly all adenocarcinomas of the colon and rectum arise in adenomatous polyps, not all polyps evolve into carcinoma; in fact, most do not. The malignant potential of adenomatous polyps is related to polyp size and the histologic characteristics. Large polyps and those with predominantly villous architecture are more likely to contain coincident carcinoma (Fig. 67-6). These features are interdependent, however, because large polyps are more likely to be villous and dysplastic. Adenomas that measure 0.5 cm or less are most often tubular adenomas and rarely contain severe dysplasia or carcinoma ($<0.5\%$ in autopsy series). Likewise, only 1% to 2% of adenomatous polyps smaller than 1 cm contain carcinoma, but autopsy studies suggest that as many as 40% of adenomas greater than 2 cm contain cancer. Data derived from the examination of colonoscopic polypectomy specimens indicate similar trends but suggest a lower incidence of cancer-containing polyps.

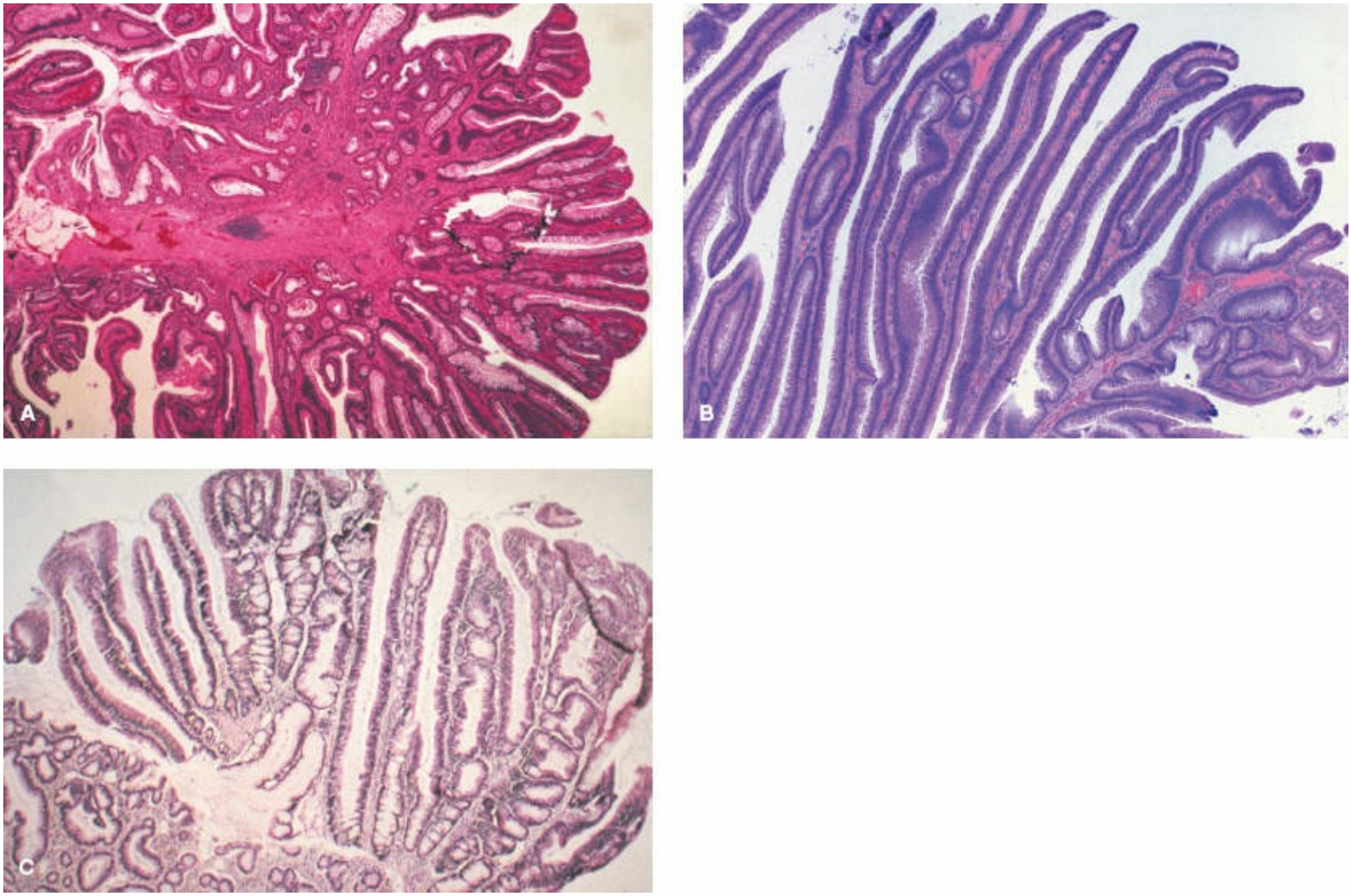

Figure 67-3. Histology of adenomatous polyps. **A:** Tubular adenomas are characterized by a complex network of branching adenomatous glands (see also C). **B:** Villous adenomas consist of glands that extend straight down from the surface to the base as fingerlike projections; this pattern may be suggested by the gross appearance of these polyps. **C:** Tubulovillous adenoma.

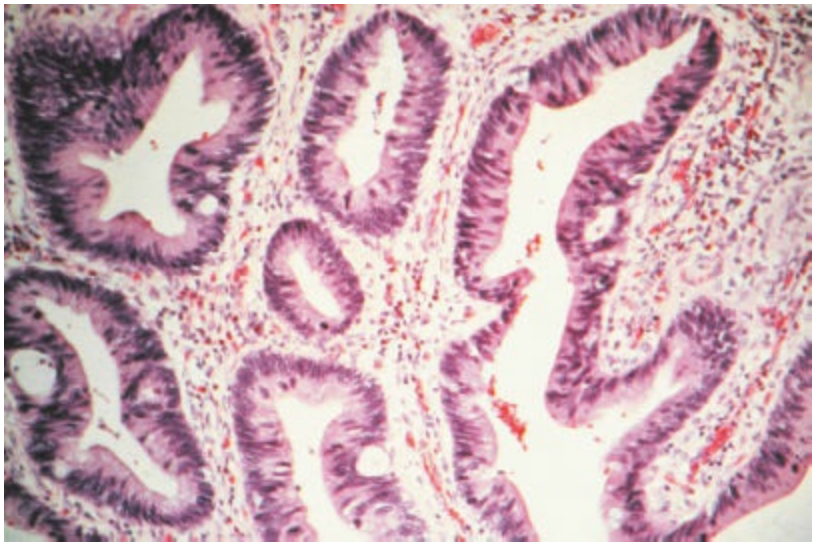

Figure 67-4. Moderate dysplasia. Dysplastic mucosa is characterized by crowded, irregular glands and cells with enlarged, hyperchromatic nuclei of varied size and shape that do not line up uniformly on the basement membrane (pseudopalisading). Adenomas are composed of dysplastic mucosa in which the degree of atypia may vary. These changes precede the development of invasive carcinoma.

Epidemiology

Prevalence

The descriptive epidemiology of adenomatous polyps of the colon and rectum parallels that of colorectal carcinoma with relation to geographic distribution, age, prevalence, and genetic susceptibility. Like colorectal cancer, adenomas are common in Western countries such as the United States, but their prevalence traditionally has been low in parts of Asia (notably India), South America, and sub-Saharan Africa. Epidemiologic patterns for both adenomas and carcinomas are shifting with the acquisition of a “Western” lifestyle in many areas, particularly in Korea, Japan, and parts of Southeast Asia. Estimates of adenoma prevalence in the United States vary depending on the mode of data collection. Data from older studies were collected from autopsies and sometimes grouped all polyps together, whereas more recent studies have examined adenoma prevalence in the context of endoscopic screening. Studies using colonoscopy previously suggested an adenoma prevalence in patients without symptoms who are older than 50 years that ranges between 20% and 40%. More recent data from colonoscopies, where quality measures such as optimized cleansing preparations and withdrawal times have been employed, suggest adenoma detection rates (ADRs) which may exceed 50%.[12] Based on autopsy studies, one-half to two-thirds of people older than 65 years have colonic adenomas. Adenoma prevalence increases with age in all populations. Age-associated prevalence rates suggest that adenomas precede carcinomas in a given population by at least 5 to 10 years; it may be much longer, as polyps do not produce symptoms and, unlike cancers, dating the onset can only be estimated. Advancing age also correlates with multiplicity of polyps, polyp size, and higher degrees of dysplasia. In addition, 30% to 50% of patients with one adenoma have a synchronous adenoma elsewhere in the colon.[13]

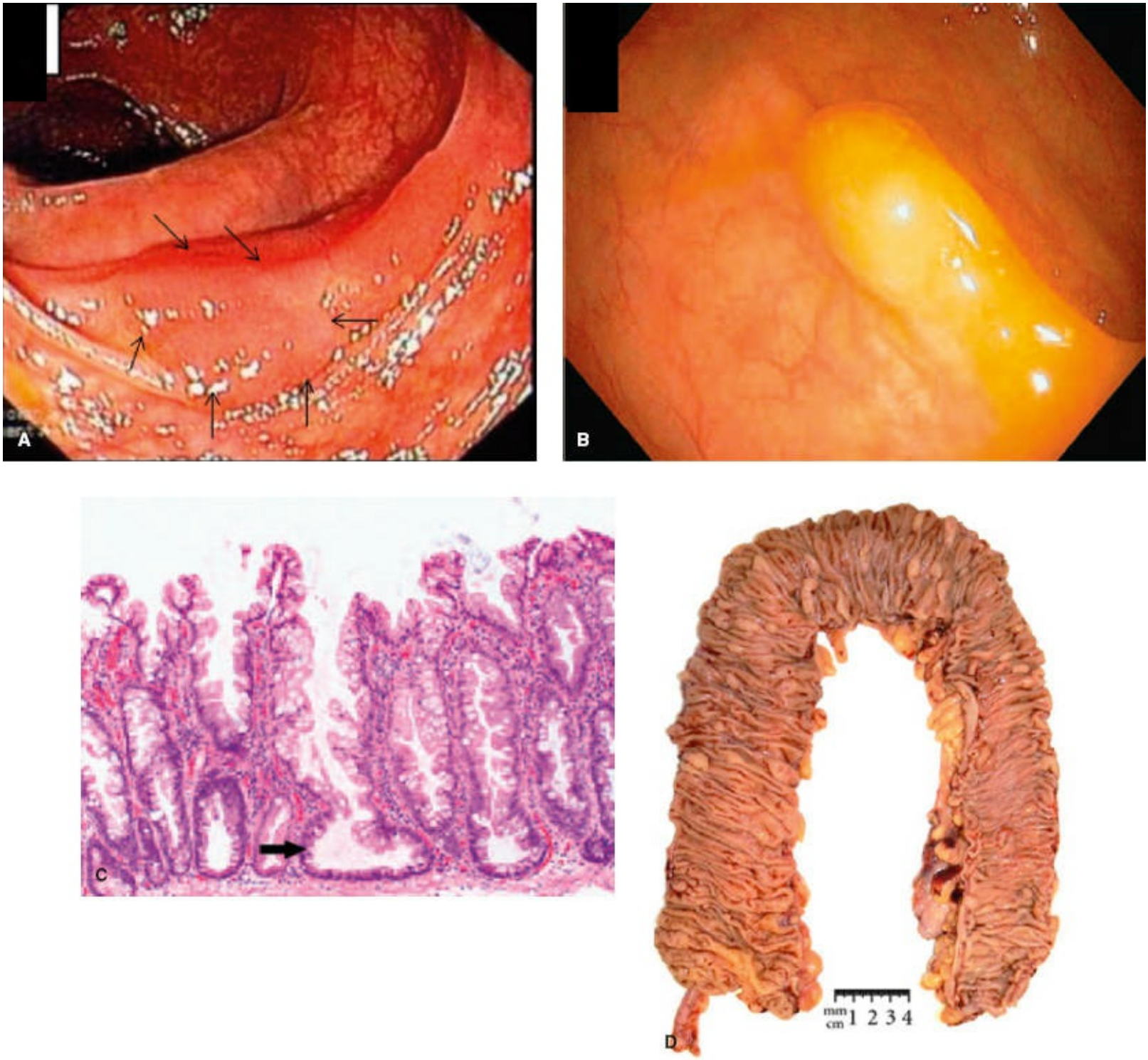

Figure 67-5. Sessile serrated adenomas are often flat lesions located in the right colon (**A**). They may be obscured by "mucous caps" (**B**). Histologically they are characterized by a serrated surface epithelium, distorted crypt bases (**C**) and crypt dilation. Serrated polyposis syndrome presents with multiple serrated polyps (**D**).

Heredity

2 Heredity plays a role not only in FAP and Lynch syndrome but also in the development of sporadic adenomas. Sporadic (nonsyndromic) adenomatous polyps and colon cancers represent more than 95% of colorectal neoplasms. Clinical studies, including case-control and prospective analyses, indicate a two- to threefold increased risk for colon cancer among first-degree relatives of patients with a history of colonic adenoma or carcinoma. The relative risk increases when there are more affected relatives and when adenomas

and carcinomas occur in young relatives. The impact of family history becomes prognostically insignificant in patients whose polyps are discovered after age 60. In most families, it is not possible to separate the impact of commonly shared genes from the impact of shared environmental exposures.

Anatomic Distribution

Autopsy series and colonoscopic examination of patients who do not have symptoms previously suggested that although adenomas are uniformly distributed throughout the colon, the distribution of clinically important larger adenomas is more similar to that of carcinomas, with a left-sided predominance. There appears to have been a "migration" over the past few decades, toward right-sided lesions in Western countries; 75% to 90% of SSAs are right sided, as are about 90% of sporadic CRCs with MSI.

Natural History

3 Adenomas are common in people older than 50 years, and although most carcinomas arise in adenomatous polyps, relatively few adenomas progress to carcinoma. Little precise information is available on what proportion of adenomas evolves to carcinomas. In Norway, an example of a high-risk Western population, it has been estimated that colorectal adenomas are present in 29% of the population older than 35 years. The conversion rate from adenoma to carcinoma in this group (based on cancer incidence from multiple tumor registries) has been calculated to be 0.25% per year. In other words, the risk that a colorectal cancer will develop in a polyp-bearing person within 10 years is 2.5%. The annual conversion rates to invasive cancer for people with adenomas larger than 1 cm, villous components, and severe dysplasia have been estimated to be 3%, 17%, and 37%, respectively, based on these inferences. Data from a national colonoscopy database in Germany suggested that the annual transition rates from advanced adenoma (adenomas $\geq$1 cm, tubulovillous or villous adenomas, adenomas with high-grade dysplasia) to cancer is comparable among women and men, but strongly increases with age.[14] Projected annual transition rates from advanced adenoma to cancer increased from 2.6% in age group 55 to 59 years to 5.1% in age group 80 and older among men, for example. These estimated rates in older age groups are in line with previous estimates derived from small case series but are considerably lower for younger age groups.

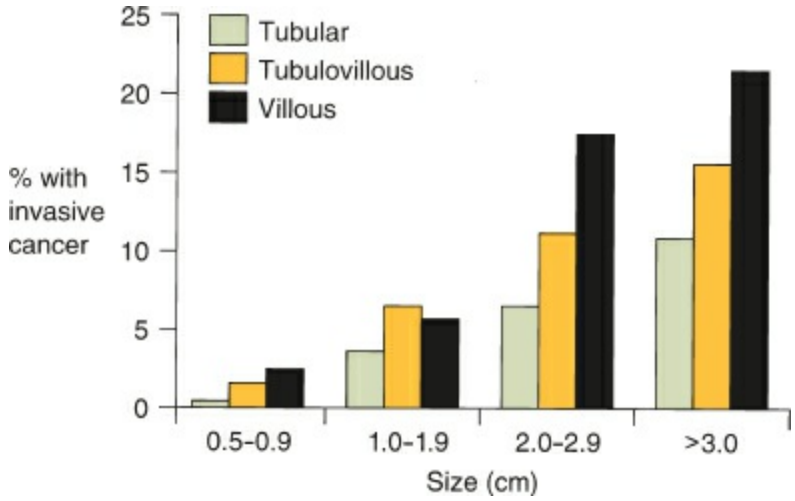

Figure 67-6. The relation of adenoma size and histology to malignant potential based on an analysis of 7,000 endoscopically removed polyps. The incidence of polyp-associated carcinoma determined from examination of polypectomy specimens is lower than that derived from early autopsy studies. (Data derived from Shinya H, Wolff WI. Morphology, anatomic distribution, and cancer potential of colonic polyps. *Ann Surg* 1979;1990:675.)

Both longitudinal follow-up of a small number of people with unresected adenomas and studies of age distribution provide indirect evidence that the evolution from adenoma to carcinoma takes at least 5 to 10 years. Age prevalence data from the National Polyp Study (NPS), for example, suggest that it may take as long as 5 to 10 years for normal-appearing mucosa to develop into a macroscopically visible adenomatous polyp, and an additional 3 to 5 years for invasive carcinoma to develop, in most instances. Case-control studies also support that the development of adenomas in the colon and the evolution to carcinoma occur slowly. Several studies, including the NPS, have estimated that the significant protective effect of screening endoscopy may last at least 10 years.[15] The risk and rate of progression of SSAs is not as well documented. It has been postulated that the evolution of SSAs to invasive carcinoma may take place in a shorter period of time than the conventional adenoma to carcinoma sequence, but this remains to be firmly established.

Associated Disease States

A number of clinical situations have been associated with a greater than average risk for adenoma development, but the evidence in most cases is tenuous. Although adenomas and carcinomas develop frequently in patients who have undergone urinary diversion by way of ureterosigmoidoscopy, this is largely of historical interest. Nonetheless, patients who have undergone this procedure require periodic colonoscopic surveillance for adenoma and carcinoma development. An increased prevalence of colonic adenomas and carcinomas has been reported in patients with acromegaly, and patients with elevated gastrin levels have been reported to be at increased risk for colorectal neoplasia. Alleged associations between colorectal adenomas and a history of prior cholecystectomy, atherosclerosis, acrochordons (skin tags), and HPs remain unproven.

Clinical Features

Adenomatous polyps of the colon and rectum are highly prevalent in Western societies, but most patients with colonic adenomas do not have symptoms directly referable to these lesions. Overt bleeding manifesting as hematochezia may occur with larger polyps, which may be evident when the polyps are located distally in the rectum. Adenomas typically lose less than 1 mL of blood daily unless they are 2 cm or larger in size. Although colorectal polyps are the most common lesions detected in patients without symptoms undergoing colonoscopy because of the presence of fecal occult blood, the polyps are probably not responsible for the bleeding. Very large colonic polyps may be associated with obstructive symptoms, such as lower abdominal cramping or alterations in bowel habits, but this is unusual. Secretory diarrhea with accompanying hypokalemia and hypochlorhydria has been associated with very large villous adenomas of the distal colon and rectum. This is a rare syndrome, and the search for secretagogues such as vasoactive intestinal polypeptide or prostaglandins in patients with polyps and diarrhea, is infrequently productive.

Adenomas Associated with Lynch Syndrome and Its Variants

Lynch syndrome is a disease of autosomal dominant inheritance in which cancers arise in discrete adenomas, but polyposis (i.e., dozens or hundreds of polyps) does not occur. Lynch syndrome patients can get adenomas, HPs, and sessile serrated polyps (SSPs), but adenoma is the lesion that leads to cancer. The loss of DNA MMR activity usually occurs after the appearance of a small adenoma, and typically occurs after the adenoma is 8 mm or greater in diameter.[16] The mean cumulative number (plus 2 standard deviations) of adenomas in mutation carriers undergoing annual screening colonoscopy is 3 by age 30 and 6 by age 50.[17] However, there are outliers with larger numbers. Currently, the diagnosis of Lynch syndrome is made by finding a germline mutation in the DNA MMR gene, not by clinical criteria.[18] The frequency of Lynch syndrome in the general population is difficult to determine, but Lynch syndrome accounts for about 3% to 4% of all colorectal cancer cases; this suggests that Lynch syndrome may occur in about 2 to 5 per 1,000 of the population.

Turcot syndrome is a term of historical significance, in which there is a concurrence of primary brain tumors and multiple colorectal adenomas or cancer in young people. With the advent of accurate genetic characterization, these families may be categorized as either FAP or Lynch syndrome, as brain tumors are an occasional complication of both diseases, more often a medulloblastoma in FAP, and glioblastomas in Lynch syndrome.[19]

Diagnosis

Most colorectal adenomas are asymptomatic and often are detected in the setting of an evaluation for unrelated colonic symptoms or occult blood in the stool. Similarly, adenomatous polyps frequently are detected when patients without symptoms are screened for colorectal neoplasia. Nevertheless, data strongly suggest that the detection and removal of adenomatous polyps are important in reducing colorectal cancer–related mortality.

In 2008, a joint guideline on screening and surveillance for early detection of colorectal cancer and adenomatous polyps was issued by the American Cancer Society (ACS), the U.S. Multi-Society Task Force on Colorectal Cancer (USMTF), and the American College of Radiology (ACR).[20] This update of previous guidelines is notable in that it grouped screening tests into those that primarily detect cancer (annual fecal occult blood tests [FOBTs] including those that are guaiac-based or immunochemical, and stool DNA tests, interval not specified) and those that can detect early cancer and adenomatous polyps (flexible sigmoidoscopy every 5 years, colonoscopy every 10 years, double-contrast barium enema every 5 years, or computed tomography [CT] colonography every 5 years). In November 2008, the U.S. Preventative Services Task Force (USPSTF) also issued updated guidelines (Table 67-2).[21] Based on a targeted evidence-based review and a decision-analytic modeling analysis, the USPSTF recommended screening of average-risk individuals age 50 to 75 years with high-sensitivity FOBTs annually, sigmoidoscopy every 5 years plus FOBTs every 3 years, or colonoscopy every 10 years. Notably, the USPSTF indicated that while the benefits of screening outweigh the potential harms for 50 to 75 year olds, the likelihood that detection and early intervention will yield a mortality benefit declines after age 75 because of the long average time between adenoma development and cancer diagnosis. Routine screening was therefore not recommended for adults aged 76 to 85 years, and screening was not recommended at all in adults older than 85. These guidelines also indicated that for all populations there is insufficient evidence to assess the benefits and harms of screening with CT colonography or fecal DNA testing.

The American College of Gastroenterology (ACG) Guidelines for Colorectal Cancer Screening also grouped options into cancer prevention tests (colonoscopy every 10 years, flexible sigmoidoscopy every 5 to 10 years, and CT colonography every 5 years) and cancer detection tests (annual FOBT with fecal immunochemical tests [FITs], fecal DNA testing every 3 years).[22] Colonoscopy is considered the preferred choice overall. The ACG also recommends that screening in African Americans should begin at age 45 instead of age 50 for average-risk individuals, and that CT colonography replace double-contrast barium enema as a radiologic option. The “European guidelines for quality assurance in colorectal cancer screening and diagnosis” is a 386-page document authored by 90 authors from 32 countries which provides an evidence-based review of existing data on CRC screening which stresses quality measures and cost effectiveness.[23] Numerous international CRC screening programs have been initiated as evidence grows for an impact of CRC screening on mortality.[24]

Fecal Occult Blood Tests

Screening studies from both Europe and the United States indicate that a polyp is detected in about 30% of patients without symptoms who are 50 years of age or older and undergo colonoscopy for follow-up of a positive fecal occult blood test result. Blood loss from polyps is related to polyp size, and positive fecal occult blood test results are related to polyp size and proximity to the rectum. In one study where rehydrated Hemoccult slides were used (rehydration results in greater sensitivity but also increases the number of false-positive findings), only 15% of polyps smaller than 1 cm were associated with a positive Hemoccult test result, whereas 80% of polyps larger than 2 cm were associated with a positive result. In another study, standard testing with Hemoccult cards detected 17% of adenomas smaller than 1 cm and 42% of adenomas larger than 1 cm. A prospective randomized study of fecal occult blood tests in which rehydrated Hemoccult cards were used indicated that annual testing reduces colorectal cancer–related deaths by 33% through 18 years of follow-up.[25] This study, in addition to two European trials, has also demonstrated a 15% to 21% reduction in colon cancer–related death from biennial fecal occult blood testing.[26] Thus, unless one rigorously performs the fecal occult blood test on an annual basis, the reduction in colorectal cancer mortality will be disappointing.

Methods that may decrease the false-positive FOBT rates while maintaining or increasing sensitivity currently are being refined and compared for efficiency with Hemoccult-type slide tests. FITs are designed to detect human globin and are not affected by diet or drugs. A variety of FITs are now available worldwide and FIT is likely to replace guaiac-based FOBTs. FITs have good performance characteristics compared with standard heme-based FOBT tests, and may have superior sensitivity and specificity for detecting colonic neoplasms.[27–29] Issues which remain to be resolved regarding FIT include the optimal number of samples to be tested, requirements for storage and shipping (effect of temperature), and the relative benefit of quantitative (specific amount of hemoglobin per gram of stool) versus qualitative (i.e., positive or negative) reporting, and the optimal "cut-off" for a positive test. The quantitative immunochemical FOBT has been shown to have very good sensitivity and specificity for detection of clinically significant neoplasia in studies of asymptomatic and symptomatic patients, but test performance in prospective screening programs has been less well studied. Recent studies suggest the effectiveness of FIT for programmatic screening for colorectal cancer, but adenoma detection remains much lower than that of carcinoma.[29] FITs have now been included as the preferred form of FOBT in screening guidelines.

CLASSIFICATION

Table 67-2 Guidelines for Screening Average-Risk Individuals for Colorectal Cancer

Screening Tool	U.S. Preventive Services Task Force[a]	American Cancer Society, U.S. Multi-Society Task Force, American College of Radiology Joint Guidelines[b]
High-sensitivity FOBT (guaiac based or immunochemical)	Recommended annually as an option	Recommended annually as an option
Flexible sigmoidoscopy + high-sensitivity FOBT q3y	Recommended q5y as an option	Recommended q5y as an option
Colonoscopy	Recommended q10y as an option	Recommended q10y as an option
Double-contrast barium enema	Not recommended as an option	Recommended q5y
Computed tomography colonography	Not recommended as an option	Recommended q5y
Stool DNA testing	Not recommended	Recommended (interval uncertain)

[a]U.S. Preventive Services Task Force. Screening for colorectal cancer: US Preventative Services Task Force recommendation statement. *Ann Int Med* 2008;149:627–637. The U.S. Preventative Services Task Force recommends screening for adults age 50 to 75 years. Screening for adults age 76 to 85 is not routinely recommended, and for adults older than 85 years screening is not recommended.
[b]Levin B, Lieberman DA, McFarland B, et al. Screening and surveillance for the early detection of colorectal cancer and adenomatous polyps 2008: a joint guideline from the American Cancer Society, the US Multi-Society Task Force on Colorectal Cancer, and the American College of Radiology. *CA Cancer J Clin* 2008;58:130–160. Testing options are divided into those that detect adenomatous polyps and cancer (flexible sigmoidoscopy, colonoscopy, double-contrast barium enema, computed tomography colonography) and those that primarily detect cancer (FOBT, stool DNA testing).
FOBT, fecal occult blood test.

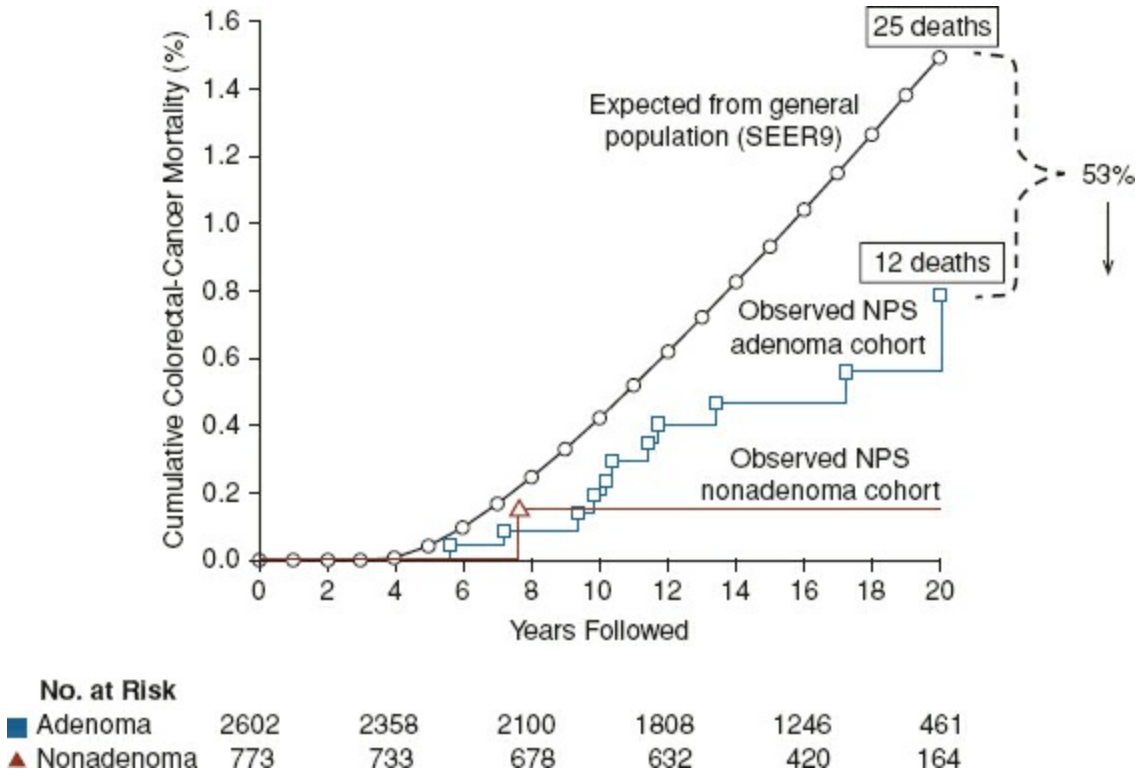

Figure 67-7. CRC mortality in the National Polyp Study for adenoma and nonadenoma patients with comparison with the US incidence-based mortality rates over up to 20 years The number of subjects at risk per years followed is given for the adenoma (*blue line*) and nonadenoma (*red line*) cohorts. The cumulative incidence-based mortality for the average risk US Population is taken from SEER data (*black line*). Among patients who had adenomas removed during participation in the study, after a median of 15.8 years, there was a 53% reduction in colorectal cancer mortality compared to expected deaths from colorectal cancer in the general population. (Modified from Zauber AG, Winawer SJ, O'Brien MJ, et al. Colonoscopic polypectomy and long-term prevention of colorectal-cancer deaths. *N Engl J Med* 2012;366:687–696.)

Results from the NPS strongly indicate that the removal of index polyps detected by fecal occult blood testing and other methods, together with subsequent colonoscopic

surveillance, results in a very substantial reduction in colorectal cancer mortality. A recent update of this trial with median follow-up of 15.8 years indicated that colonoscopic polypectomy is associated with a 53% reduction in mortality from CRC compared with the expected incidence-based mortality from CRC in the general population (Fig. 67-7).[15]

Sigmoidoscopy

The benefit of sigmoidoscopy in interrupting the adenoma-to-carcinoma sequence is suggested by a number of studies. Three prospective randomized trials have now shown that programmatic screening with flexible sigmoidoscopy can have an impact on CRC-related incidence and mortality, mostly related to the detection and removal of adenomas.[30–32] The UK Flexible Sigmoidoscopy Screening Trial is a randomized trial which tested the hypothesis that a single flexible sigmoidoscopy screening offered at approximately age 60 years can lower the incidence and mortality of CRC.[30] In per protocol analyses, the incidence of CRC was reduced by 33% and mortality by 43% (23% and 31%, respectively, based on intention to treat analysis), and the incidence of cancer of the rectum and sigmoid was reduced by 50%. The Prostate, Lung, Colorectal and Ovarian Cancer Screening Trial (PLCO) enrolled 154,900 subjects aged 55 to 74 in a prospective randomized trial that compared flexible sigmoidoscopy with repeat screening at 3 or 5 years to a usual-care control group.[31] Flexible sigmoidoscopy reduced CRC incidence by 21% with a benefit observed in both the proximal and distal colon, and reduced overall mortality by 26% (intention-to-treat analyses). Mortality from distal CRC (distal to the splenic flexure) was reduced by 50%, while mortality from proximal CRC was unaffected. The Italian Randomized Controlled Trial (SCORE) demonstrated that once-only sigmoidoscopy significantly reduced CRC incidence by 18% and mortality by 22% (not significant) in intention-to-treat analyses, and by 31% and 38%, respectively in per-protocol analyses (both significant).[32] These results have resulted in once in a lifetime flexible sigmoidoscopy being included as an option in the UK National Health Service Bowel Cancer Screening Programme; FOBT is the other option.

Colonoscopy, Barium Enema, Computed Tomography Colonography, and Stool DNA Testing

Colonoscopy may be the most effective tool to screen for colorectal neoplasia (and especially adenomas), but data from prospective randomized trials are lacking. The NPS of polypectomy and surveillance strongly suggested a reduction in colorectal cancer mortality as a result of removing adenomatous polyps compared to historic reference populations. A Canadian population-based study compared the risk of developing colorectal cancer after a negative colonoscopy in all Ontario residents with a history of a complete negative colonoscopy with controls consisting of the Ontario population without a history of colonoscopy.[33] In the negative colonoscopy cohort, the relative risk of distal colorectal cancer was significantly lower than the control group in each of the 14 years of follow-up, while the relative risk for proximal colorectal cancer was significantly lower mainly during the last 7 years of follow-up. A second Canadian case-control study demonstrated that complete colonoscopy was also associated with fewer deaths from left-

sided colorectal cancer, but not from right-sided cancer. Several other population-based analyses and analyses of individual screening programs in the United States, Canada, and Europe also suggest that increased use of colonoscopy is associated with mortality reduction from CRC, but this reduction varies by the site of the cancer.[34–38] A large case-control study using SEER-Medicare data demonstrated that colonoscopy was associated with a 60% decreased risk of CRC-related death, but the association was stronger for distal (OR 0.24; 95% CI: 0.21 to 0.27) than proximal (OR 0.58; 95% CI: 0.53 to 0.64) CRC, consistent with European and Canadian studies.[38] These reports suggest that either proximal lesions are not detected as reliably as distal ones at colonoscopy, that the lesions grow at different rates based upon location in the colon, or both.

These findings are of interest in light of arguments that colonoscopy is preferable to sigmoidoscopy, because there may be a substantial incidence of proximal colonic cancers and advanced adenomas beyond the reach of the sigmoidoscope. Some of these individuals may not have distal findings on sigmoidoscopy that would trigger a subsequent colonoscopy. Two trials[39,40] suggested that approximately 50% of individuals with advanced proximal neoplasms (adenoma >1 cm; adenoma with villous features or dysplasia; cancer) have no distal neoplasms. Fewer than 2% of those who did not have distal neoplasms, however, had an advanced proximal lesion. A decision analysis commissioned by the USPSTF supports colonoscopy every 10 years as a screening option measured in life-years gained, and the joint guidelines authored by the ACS, USMTF, and ACR recommend colonoscopy as a means of preventing colorectal cancer through adenoma detection and removal.

High-contrast endoscopy using dye or stain solutions combined with colonoscopy (chromoendoscopy) or high-resolution optical methods (e.g., narrow-band imaging and laser confocal endoscopy) have been suggested as a means of identifying lesions in high-risk groups, or as an adjunct to colonoscopy where flat lesions (so-called “flat adenomas”) are suspected. Recent evidence suggests that flat or depressed neoplasms are more common than previously appreciated and carry a high relative risk of containing in situ or invasive carcinoma.[41]

Air-contrast barium enema (ACBE) has been included as an option in a variety of screening guidelines, but has for the most part been supplanted by other methods due to its poor sensitivity for detecting small polyps. CT colonography, or “virtual” colonoscopy, involves the use of helical CT to generate high-resolution images of the abdomen and pelvis. CT colonography has the potential advantage of being a rapid and safe method of providing full structural evaluation of the entire colon. Two trials provide evidence that CT colonography may be a valid alternative for primary colon cancer screening. The National CT Colonography Trial[42] directed by the American College of Radiology Imaging Network (ACRIN) was a multicenter study that employed CT colonography and same-day colonoscopy using a standard matching protocol in 2,600 asymptomatic individuals. Per patient sensitivity of CT colonography for adenomas greater than 10 mm was 90% with a negative predictive value of 99%. A second trial[43] compared CT colonography and optical colonoscopy in parallel screening cohorts and demonstrated similar rates of detection of advanced neoplasia in both groups. Several key issues need to be addressed as the use of

CT colonography becomes more widespread, principal among which is determination of the acceptable size cut-off of a lesion detected by CT colonography that will necessitate a follow-up colonoscopy.

A great deal of knowledge has been accumulated recently about genetic alterations that occur during colon carcinogenesis, as discussed earlier. A molecular approach to colorectal cancer screening is therefore attractive since it targets biologic changes that are fundamental to the neoplastic process. Fecal DNA testing relies on the detection of genetic alterations in DNA shed into the stool from neoplastic lesions. Recent prospective data using a multimarker panel which includes both stool DNA testing and FIT showed >90% sensitivity for detecting colorectal cancer, but suboptimal performance for detecting high-risk adenomas. The sensitivity for detection of advanced adenoma with the combined stool DNA marker/FIT panel was 42.4%. FIT alone detected only 23.8% of advanced adenomas.[29] Based on these data, the FDA has approved the combined panel for screening for colorectal neoplasia.

Management of Adenomas

Index Polypectomy

Once detected, adenomas should be completely removed, preferably by endoscopic snare polypectomy (Fig. 67-8). Polypectomy is relatively safe and easily performed when adenomas are small or pedunculated. Newer techniques such as EMR and ESD have made it possible to remove even large sessile lesions (Fig. 67-9). Large sessile villous adenomas (>2 cm), especially those with high-grade dysplasia have a great potential for malignant degeneration. If such lesions cannot be completely removed by snare polypectomy or EMR, and when there is uncertainty about the polypectomy margin in the case of pathologically advanced lesions, segmental surgical resection may be necessary. Diminutive polyps, on the other hand, carry little malignant potential. If they are too small for snare polypectomy, ablation with a hot biopsy forceps is a reasonable approach. Because 30% to 50% of patients with one adenoma have a synchronous adenoma elsewhere in the colon, the entire colon should be "cleared" by colonoscopy in polyp-bearing patients.

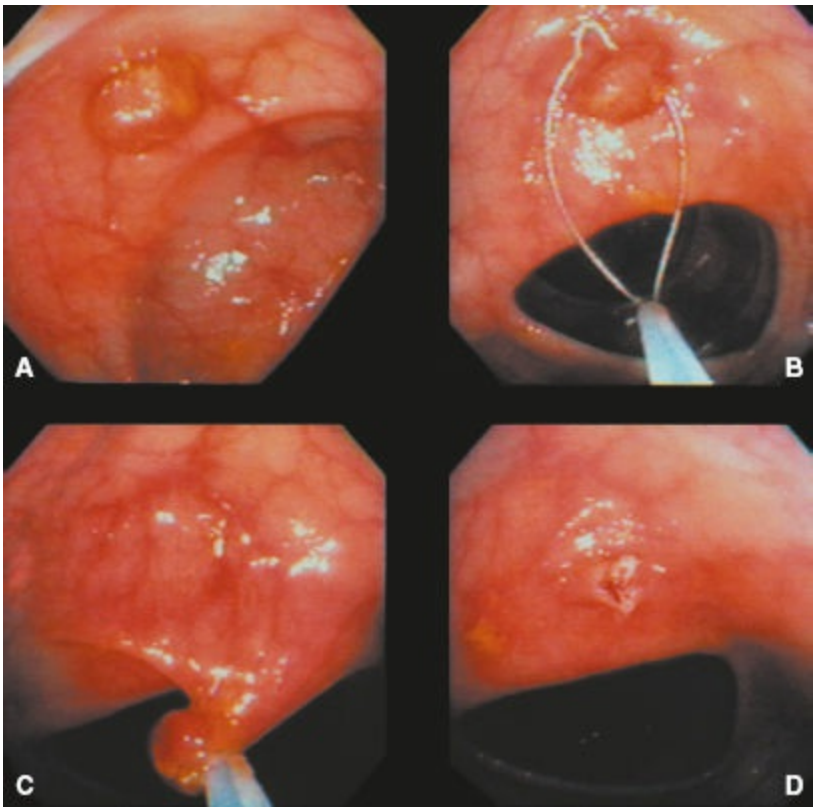

Figure 67-8. Endoscopic snare polypectomy. **A:** A small colonic polyp. **B:** The polypectomy snare is placed around the polyp. **C:** The snare is closed around the base of the polyp, and the head of the polyp is gently pulled away from the wall and into the lumen. Current is applied to cut the stalk and cauterize the site. **D:** The site after completion of polypectomy.

Quality Measures

As the number of colonoscopies (and colonoscopists) increases, quality assurance measures will need to be adopted. One measure of quality assurance relates to adequate visualization of the colonic mucosa. ADR is defined by the percentage of screening or

surveillance colonoscopies of average risk with at least one adenoma and is the most commonly used quality measure in practice. Benchmarks for adequate ADRs have been suggested as at least 15% for women and 25% for men (20% overall). The ADR is considered by the ASGE/ACG Task Force on Quality in Endoscopy to be the best neoplasia-related indicator of quality performance for screening colonoscopy. The ADR has been demonstrated to be an independent predictor of the risk of interval colorectal cancer after screening colonoscopy.[44–46] Endoscopist characteristics derived from administrative data are associated with the development of postcolonoscopy colorectal cancer, and have potential use as quality indicators. Other quality measures include the quality of bowel preparation and completeness of polyp resection. The incomplete resection rate in the Complete Adenoma Resection (CARE) study was 10.1% overall, and varied broadly among endoscopists.

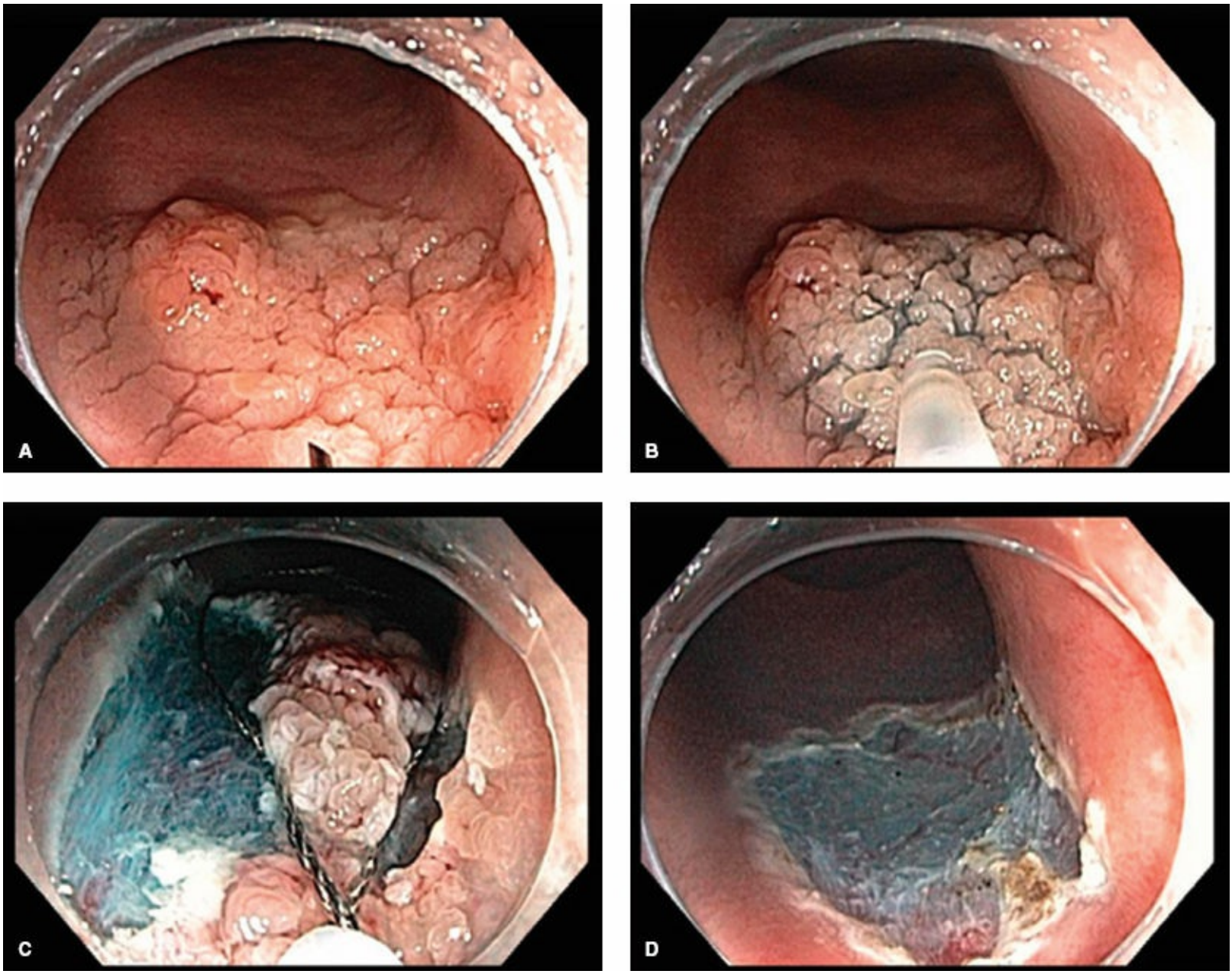

Figure 67-9. Endomucosal resection (EMR) of a large sessile polyp. **A:** Large sessile adenoma seen at colonoscopy. **B:** Saline-containing indigo carmine dye is injected into the mucosa to lift the polyp. **C:** The polyp is resected piecemeal using a polypectomy snare. **D:** Completed EMR.

Follow-Up

Much of our current practice has come from information gained through the NPS, first organized in 1978. Additional metachronous adenomas are likely to develop in patients who have had adenomas removed. Colonoscopic surveillance studies have provided estimates of the frequency and time course of recurrence in these patients. Data from the NPS suggested a recurrence rate of 32% to 42% by 3 years after index polypectomy. A prospective colonoscopic analysis also demonstrated a cumulative recurrence rate at 3 years of 42%. Most adenomas detected at this 3-year interval were small tubular adenomas. Age above 60 years, multiple adenomas at index polypectomy and large size of the index adenoma predicted polyp recurrence in the NPS, but only multiplicity predicted recurrence of polyps with advanced pathologic features (i.e., >1 cm, high-grade dysplasia, or invasive cancer) at follow-up. The 3-year recurrence rate in patients with a known history of adenoma (42%) was higher than the incidence rate of adenoma appearance de novo during this period in patients who had no adenomas detected on index colonoscopy (16%).[22]

The high recurrence rate of adenomas after index polypectomy supports the use of postpolypectomy surveillance in patients with known histories of adenoma. Colonoscopy is the preferred means of follow-up in these patients. ACBEs are inadequate for surveillance examinations; they miss a substantial number of large lesions and most small polyps. Barium enema has been supplanted by the use of CT colonography, as discussed earlier. Colonoscopy is the most accurate means of evaluating the colonic mucosa, and most importantly, allows biopsy and removal of polyps.

Several studies, including data from the NPS, indicate that surveillance intervals for colonoscopy should be tailored to risk of recurrence. One recent study examined the relative risk for advanced neoplasia within 5.5 years of a baseline colonoscopy.[47] There was a strong association between the results of baseline-screening colonoscopy and the rate of serious incident lesions during surveillance. This study confirmed that patients with one or two small tubular adenomas represent a low-risk group compared with other patients with colorectal neoplasia.

Table 67-3 lists the 2012 updated Multi-Society Task Force on Colorectal Cancer guidelines for screening, surveillance, and early detection of colorectal adenomas and cancer for individuals at increased risk or at high risk of disease. This group represents the American Gastroenterological Association Institute, the American Society for Gastrointestinal Endoscopy, and the American College of Gastroenterology. A clinical decision tool based on these guidelines was also published in 2014.[48] These guidelines suggest that those whose index lesion consists of one or two small tubular adenomas with low-grade dysplasia should have a follow-up colonoscopy no sooner than 5 to 10 years after the initial polypectomy. The precise timing within this interval should be based on clinical factors (prior findings, family history, patient and physician preferences). In those with a large (>1 cm) adenoma, multiple (3 to 10) adenomas, or adenomas with high-grade dysplasia or villous change, colonoscopy should be repeated within 3 years after the initial polypectomy. Although the risk for recurrence of advanced adenomas at this follow-up interval is greater in patients with high-risk adenomas than those with low-risk

adenomas, the incremental risk is small.[49] If the examination is normal or shows only one or two small tubular adenomas with low-grade dysplasia, then the interval for the subsequent examination should be 5 years. Patients with more than 10 adenomas on a single examination should have a follow-up colonoscopy less than 3 years after the initial polypectomy and the presence of an underlying familial polyposis syndrome should be considered. Patients with sessile adenomas that are removed piecemeal should have follow-up colonoscopy in 2 to 6 months to verify complete removal. Guidelines for follow-up of serrated polyps are currently similar to those of conventional adenomas (3 years for lesions $\geq$10 mm, or with dysplasia for TSAs; 5 years for lesions in the proximal colon and without dysplasia; and 1 year for serrated polyposis syndrome).

Table 67-3 Guidelines for the Surveillance of Adenomas in People at Increased or High Risk for Colorectal Cancer

Risk Category	Age to Begin Surveillance	Recommendation	Comment
Increased Risk: Patients with History of Adenomas at Prior Colonoscopy			
Patients with one or two small tubular adenomas with low-grade dysplasia	5–10 yrs after initial polypectomy	Colonoscopy	Precise timing based on clinical factors, patient and physician preferences
Patients with 3–10 adenomas or one adenoma >1 cm or any adenoma with villous features or high-grade dysplasia	3 yrs after initial polypectomy	Colonoscopy	If follow-up examination is normal or shows one or two small tubular adenomas, subsequent examination at 5 yrs
Patients with >10 adenomas on a single examination	<3 yrs after initial polypectomy	Colonoscopy	Consider familial CRC syndrome
Patients with sessile adenomas that are removed piecemeal	2–6 mo to verify complete removal	Colonoscopy	Surveillance individualized based on endoscopist's judgment
Increased Risk: Patients with Family History			
CRC or adenomatous polyps in a first-degree relative before age 60 yrs or in two or more first-degree relatives at any age	Age 40 or 10 yrs before the youngest case in the immediate family	Colonoscopy	Every 5 yrs
Either CRC or adenomatous polyps in a first-degree relative age ≥60 yrs or in two second-degree relatives with CRC	Age 40 yrs	Screening options at intervals recommended for average-risk individuals	Screening should begin at an earlier age, but individuals may be screened with any recommended form of testing
High Risk			
Genetic diagnosis of FAP or suspected FAP without genetic testing evidence	Age 10–12 yrs	Annual FSIG to determine if the individual is expressing the genetic abnormality and counseling to consider genetic testing	If the genetic test is positive, colectomy should be planned
Genetic or clinical diagnosis of Lynch syndrome, or individuals at increased risk of Lynch syndrome	Age 20–25 yrs or 10 yrs before the youngest case in the immediate family	Colonoscopy every 1–2 yrs and counseling to consider genetic testing for inherited DNA MMR	Genetic testing for Lynch syndrome should be offered to first-degree relatives of persons with a known gene mutation. It should also be offered when the family mutation is not known but one of the first three of the modified Bethesda criteria is present.

CRC, colorectal cancer; FAP, familial adenomatous polyposis; FSIG, flexible sigmoidoscopy; MMR, mismatch repair.
Derived from Levin B, Lieberman DA, McFarland B, et al. Screening and surveillance for the early detection of colorectal cancer and adenomatous polyps 2008: a joint guideline from the American Cancer Society, the Multi-Society Task Force on Colorectal Cancer and the American College of Radiology. *CA Cancer J Clin* 2008;58:130–160; Lieberman DA, Rex DK, Winawer SJ et. al. Guidelines for colonoscopy surveillance after screening polypectomy: a consensus update by the US Multi-Society Task Force on Colorectal Cancer. *Gastroenterology* 2012;143:844–857.

Management of Malignant Polyps

Endoscopic polypectomy is adequate treatment for an adenomatous polyp–containing cancer if it can be demonstrated that the cancer is confined to the head of the polyp (i.e., carcinoma in situ or intramucosal carcinoma; Fig. 67-10). The adequacy of simple polypectomy has been controversial in cases in which malignant cells have invaded the polyp stalk (Fig. 67-11), but most studies indicate that polypectomy is adequate treatment provided that a margin of more than 2 mm is present, the cancer is not poorly differentiated, and no vascular or lymphatic invasion is noted. The presence of cancer at or near the margin is significantly associated with an adverse outcome, even in the absence of other unfavorable parameters. On the other hand, in the absence of unfavorable histology and with a negative margin, the incidence of residual cancer is low (<1%). These criteria are more difficult to assess in sessile polyps. If an adequate margin cannot be demonstrated or negative histologic parameters are present, surgery is recommended to treat the possibility of residual neoplasia or regional lymph node metastases.

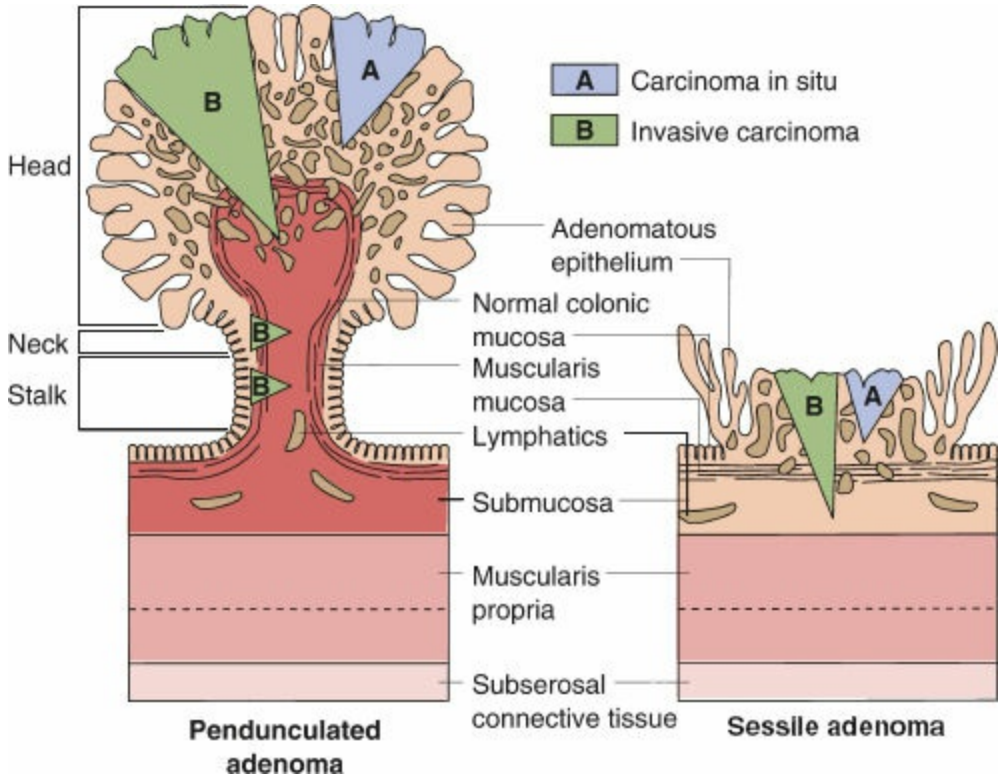

Figure 67-10. Diagram representation of cancer-containing polyps. Pedunculated adenoma is described on the left and a sessile adenoma on the right. In carcinoma in situ, malignant cells are confined to the mucosa. These lesions are adequately treated by endoscopic polypectomy. Polypectomy is adequate treatment for invasive carcinoma only if the margin is sufficient (2 mm), the carcinoma is not poorly differentiated, and no evidence of venous or lymphatic invasion is found. (After Haggitt RC, Glotzbach RE, Soffen EE, et al. Prognostic factors in colorectal carcinomas arising in adenomas: implications for lesions removed by endoscopic polypectomy. *Gastroenterology* 1985;89:328.)

Primary Prevention of Adenoma Recurrence

Primary prevention relates to the ability of identifying genetic, environmental, and biologic factors that cause cancer, and to mitigate their outcomes. Laboratory, clinical, and epidemiologic evidence suggests that the regular use of nonsteroidal anti-inflammatory drugs (NSAIDs), including aspirin, is associated with a substantially decreased risk for the development of colorectal cancer. Four published trials have demonstrated a reduction in adenoma recurrence in chemoprevention trials involving aspirin.[50,51] Given the biologic plausibility, preclinical in vitro and animal data, and data on adenoma regression in patients with FAP, three large randomized trials, which studied over 6,000 patients in total, were undertaken to examine the effect of cyclooxygenase-2 (COX-2)–selective inhibitors on new adenoma formation in individuals with a history of sporadic adenomas. All of these trials demonstrated a highly significant reduction in new adenoma formation in those taking a COX-2–selective inhibitor (celecoxib or rofecoxib) compared to placebo over 3 years. In the Adenoma Prevention with Celecoxib (APC) trial,[52] the use of celecoxib was associated with a dose-dependent 33% to 45% reduction in the development of new adenomas by 3 years, with a 57% to 66% reduction in the number of patients developing advanced adenomas. Unfortunately, adverse thrombotic cardiovascular events were associated with COX-2 inhibition in two of these trials. Recent data suggest that increased cardiovascular risk may be associated with most NSAIDs, and not just COX-2 inhibitors.

Other agents currently undergoing study for chemoprevention of colorectal neoplasia include the ornithine decarboxylase inhibitor difluoromethylornithine (DFMO), the bile acid ursodiol, the 3-hydroxy-3-methylglutaryl-coenzyme A (HMG-CoA) reductase inhibitors such as pravastatin and lovastatin, epidermal growth factor receptor (EGFR) inhibitors, and matrix metalloproteinase (MMP) inhibitors. The combination of DFMO and the NSAID sulindac were studied in a randomized placebo-controlled trial to assess their efficacy in preventing sporadic adenoma recurrence in 375 subjects. The use of this regimen was associated with a 70% reduction in new adenomas at 3 years compared to placebo.[53] Larger studies are underway to confirm this result and to fully assess toxicity of this combination. A population-based case-control study of individuals with colorectal cancer and matched controls demonstrated a 47% relative reduction of colorectal cancer associated with statin use, but further investigation is needed to assess the overall benefits of this group of agents.

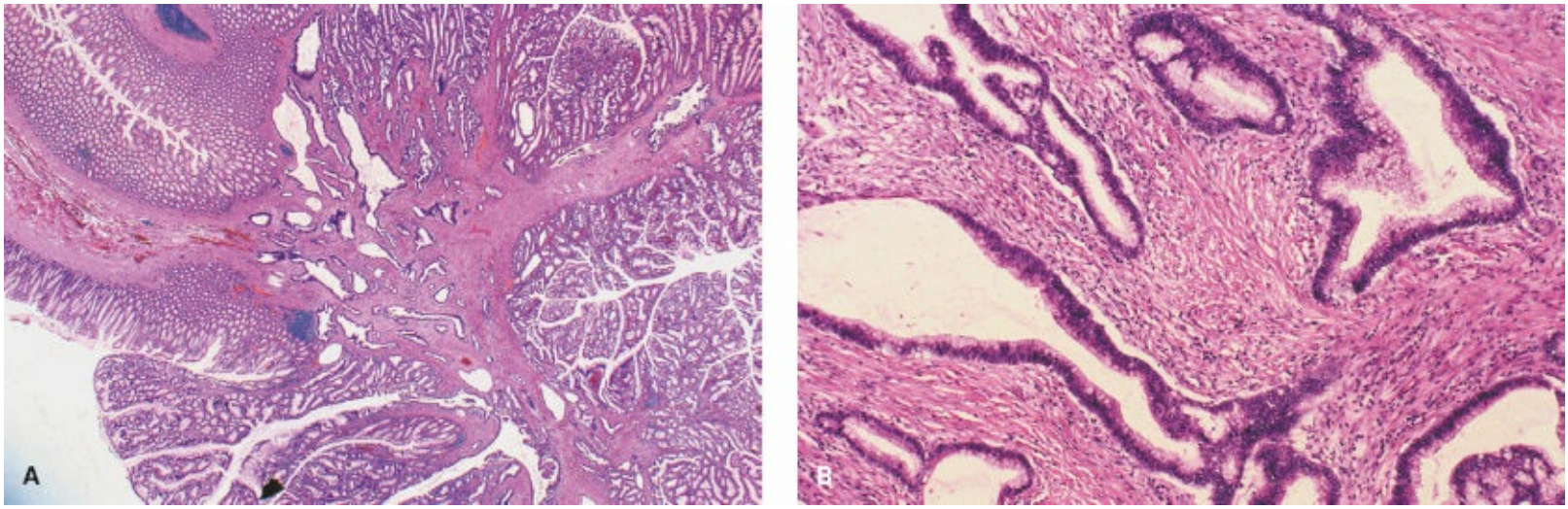

Figure 67-11. Invasive carcinoma in the stalk of an adenomatous polyp. **A:** Low-power view. Malignant glands can be seen invading fibrovascular stalk. **B:** High-power magnification of malignant glands in stalk. Nuclei are large, hyperpigmented, and crowded.

Supplemental calcium reduces proliferative activity in the mucosa of experimental animals and patients at high risk for the development of colorectal cancer. A large body of observational and laboratory studies suggests a role for dietary calcium supplementation in chemoprevention. A prospective, double-blind, placebo-controlled trial showed that supplemental calcium (3,000 mg of calcium carbonate per day, equivalent to 1,200 mg of elemental calcium) reduced the incidence and number of recurrent adenomas in subjects with a recent history of such lesions. The protective effect of calcium supplementation on the risk of colorectal adenoma recurrence extended up to 5 years after cessation of active treatment, even in the absence of continued supplementation.[54] Analysis of serum vitamin D status in subjects suggested that calcium supplementation and vitamin D status appear to act together to reduce the risk of adenoma recurrence. A prospective trial designed to assess the individual effects of calcium and vitamin D and the combination on adenoma recurrence, however, failed to demonstrate an effect of any of these agents.

"Essential" fatty acids are required for biologic processes, but cannot be synthesized by humans and must therefore be obtained from dietary sources. The main polyunsaturated fatty acids (PUFAs) docosahexaenoic acid (*DHA,* $22{:}6^{\Delta 4,7,10,13,16,19}$) and eicosapentaenoic acid (*EPA,* $20{:}5^{\Delta 5,8,11,14,17}$) are considered "essential" and are obtained predominantly from cold water oily fish such as mackerel and salmon. A randomized trial in subjects with FAP demonstrated that an enteric-coated formulation of EPA has chemopreventive efficacy in reducing rectal polyp burden to a degree similar to that previously observed with selective COX-2 inhibitors.[55] The role for N-3 PUFAs in "sporadic" colorectal adenoma prevention is currently being evaluated.

Trials of supplemental dietary fiber, as well as antioxidant vitamins such as β-carotene and vitamins C and E, have not convincingly demonstrated any effect on adenoma recurrence.

OTHER MUCOSAL SUBMUCOSAL POLYPS

Hyperplastic Polyps

HPs are small, usually sessile lesions most frequently encountered in the distal colon and rectum (Fig. 67-12A). Although grossly indistinguishable from small adenomas, they carry no significant potential for malignant degeneration particularly when located in the distal colon or rectum. However, HPs must be distinguished from SSAs, which carry significant malignant potential. Macroscopically, HPs are almost always less than 1 cm in size, and most are in the distal colon. In fact, when HPs are found proximal to the rectosigmoid region, one must consider the possibility that this is actually an SSA. Microscopically, HPs are characterized by a saw-toothed epithelial pattern representing micropapillary luminal infoldings of columnar absorptive cells and mature, frequently hyperdistended goblet cells (Fig. 67-12B). Elongation and subsequent infolding of the epithelium may be caused by an expanded, but otherwise normally located, replication zone in the crypt. The cytologic atypia characteristic of adenomatous polyps is not seen in these lesions.

HPs are common age-related lesions found in about one-third of the population older than 50 years. Although they often coexist with adenomas in polyp-bearing patients, no convincing evidence has been found that HPs *per se* are harbingers of adenoma development. Because HPs are asymptomatic and carry no malignant potential, no specific treatment is required for these lesions. If an HP is the only lesion detected on index-flexible sigmoidoscopy or colonoscopy, no further evaluation is indicated.

Sessile Serrated Adenomas

SSAs or SSPs – the terms are essentially interchangeable – are distinct from conventional adenomas with respect to histology and molecular biology, and are typically nondysplastic in appearance (Fig. 67-5), but may contain areas of dysplasia or intramucosal carcinoma. They are characterized by the serrated appearance of the surface epithelium (common to all serrated lesions), distorted crypt bases and crypt dilation, and by migration of the proliferative zone to the side of the crypt. SSAs represent 3% to 22% of serrated lesions and 75% to 90% of SSAs are right-sided.[9] They are often flat (>90%), and may be covered by a so-called "mucous cap." These features often make endoscopic detection difficult, emphasizing the importance of high-quality endoscopy including an excellent bowel preparation and adequate withdrawal times to yield high polyp detection rates. These polyps are thought to be the precursors of sporadic (non-Lynch syndrome) colorectal cancers with MSI, which are overwhelmingly found in the proximal colon.

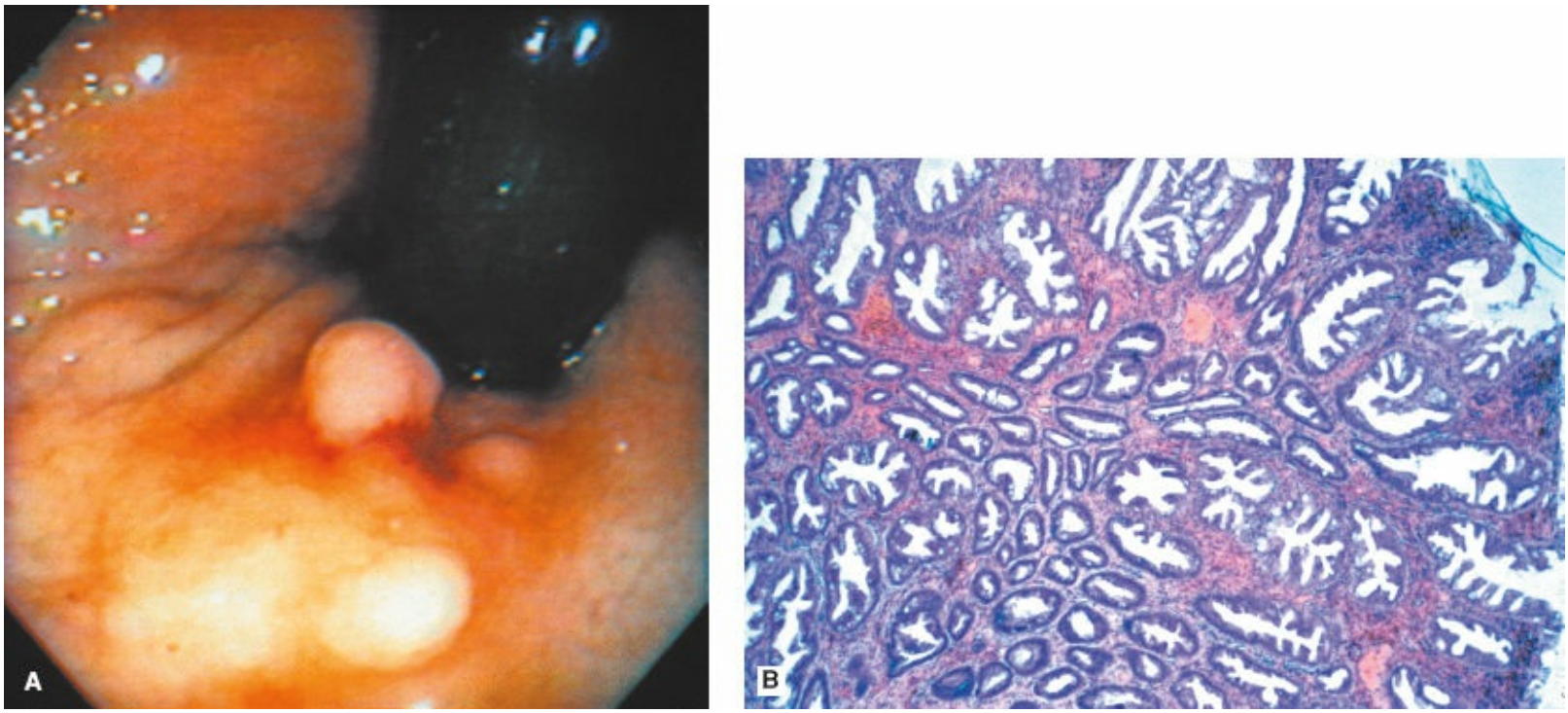

Figure 67-12. Hyperplastic polyps. **A:** Several diminutive hyperplastic polyps seen in the rectum during flexible sigmoidoscopy. **B:** Photomicrograph of a hyperplastic polyp, characterized by elongated glands with papillary infoldings that have a typical serrated epithelial pattern.

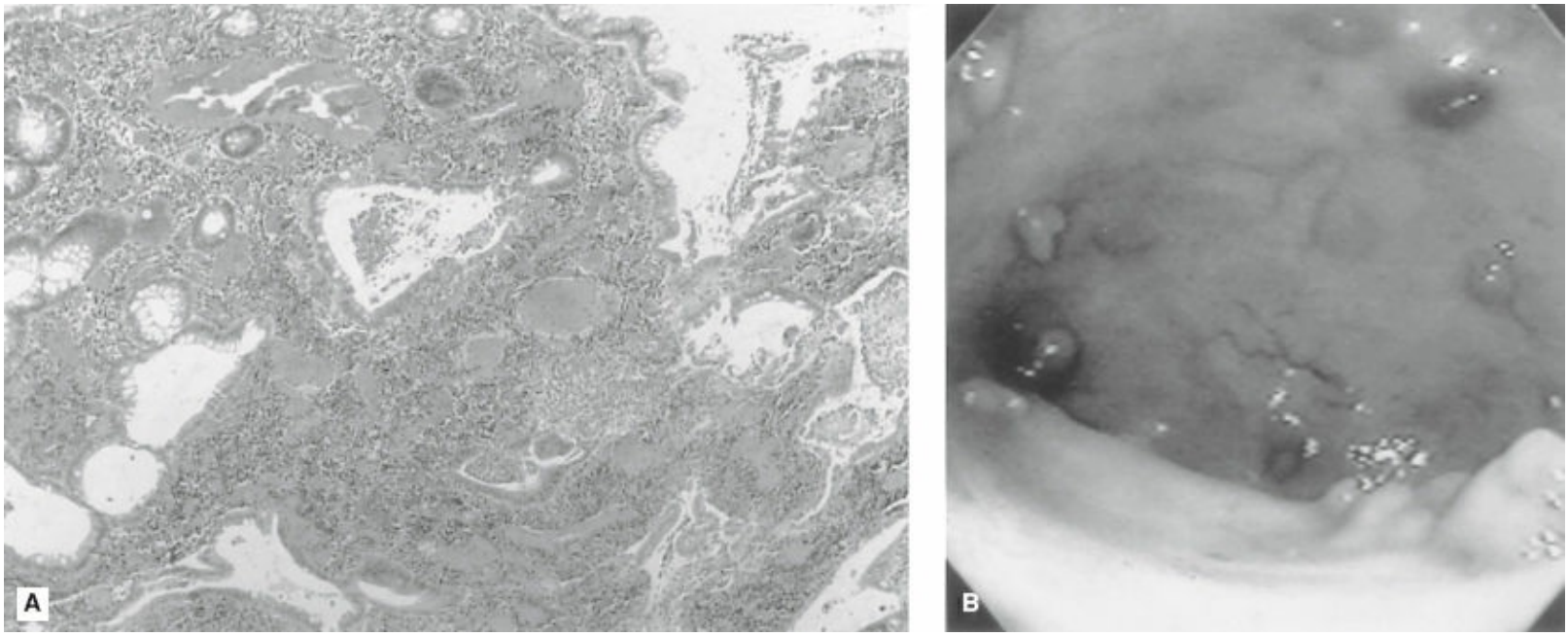

Figure 67-13. Inflammatory polyps. **A:** Severe mucosal inflammation with infiltrates and granulation tissue shown here microscopically can appear clinically with a polypoid configuration. **B:** Resolution of inflammation can leave exuberant polyps covered by normal epithelium, which are called pseudopolyps, a misnomer. These are truly polyps, but are not neoplastic.

Juvenile Polyps

Juvenile polyps can occur sporadically or as part of a juvenile polyposis syndrome (JPS). These mucosal polyps consist of dilated cystic mucus-filled glands and abundant lamina propria with an inflammatory infiltrate. Seventy-five percent of these occur in children younger than 10 years of age, often appearing as single pedunculated cherry-red polyps with a smooth surface and contour. The exact prevalence of such lesions has not been determined, but they are thought to be acquired lesions detectable in about 2% of children. Juvenile polyps often present with hematochezia because they are highly vascularized lesions. Rectal prolapse and auto-amputation may occur with distal lesions, whereas intussusception may be precipitated by proximal juvenile polyps, particularly in the context of familial syndromes. Individually, these polyps have no malignant potential, but symptomatic polyps should be removed to prevent further complications. Juvenile polyposis, on the other hand, is associated with an increased risk for the early development of cancer.

Inflammatory Polyps

Inflammatory mucosal polyps are common in the setting of idiopathic inflammatory bowel disease. Marked inflammation and ulceration coexist with granulation tissue in a distorted mucosal architecture that appears polypoid because of confluent areas of ulceration, leaving behind islands of intact epithelium (Fig. 67-13A). Subsequent healing leads to the appearance of polypoid, nonneoplastic excrescences covered by normal colonic epithelium, and are called “pseudopolyps,” in spite of the fact that they are truly polypoid excrescences (Fig. 67-13B). They need not be removed and are important largely because they make it difficult to recognize subtle, early neoplastic lesions in these high-risk patients. Severe chronic inflammation of any kind, including a variety of infectious diseases (tuberculosis, amebiasis, schistosomiasis, and amebic colitis), may result in inflammatory polyps that resemble those found in idiopathic inflammatory bowel disease.

Submucosal Polyps

Submucosal masses can expand to push the colonic mucosa into the bowel lumen and thus appear as polypoid lesions. Many submucosal lesions (e.g., lipomas, leiomyomas) are clinically asymptomatic and must be differentiated from neoplastic lesions. Others are malignant lesions that require early detection, such as lymphomas and metastatic tumors. Many submucosal lesions are not detected on endoscopic mucosal biopsy because standard biopsy forceps do not reach beyond the mucosa. If a submucosal lesion is suspected, multiple biopsy specimens of the same site sometimes provide tissue for diagnosis.

Lipomas are benign fatty tumors that occur throughout the gastrointestinal tract but are most commonly found in the cecum near the ileocecal valve (Fig. 67-14). They appear endoscopically as soft, smooth polyps that are pliable and deformable. The overlying mucosa is intact but may be light yellow in appearance. These are benign lesions that have little clinical significance and are more commonly seen in obese patients.

Isolated *lymphoid nodules* consisting of benign lymphoid tissue may appear as sessile smooth polyps of various sizes, with a predilection for the distal colon and rectum. These are usually asymptomatic. Diffuse nodular lymphoid hyperplasia also occurs in children as an incidental finding. The nodules must be distinguished from primary or secondary lymphoma of the large intestine, which may present as mucosal nodularity resembling the pseudopolyposis of inflammatory bowel disease or even a familial polyposis syndrome (Fig. 67-15). Flow cytometry of the lymphocytes in the lesion will be helpful; benign polyposis is polyclonal, whereas lymphomas are monoclonal and may overexpress cyclin D.

Pneumatosis cystoides intestinalis consists of multiple air-filled cysts within the submucosa. This may be an incidental finding in patients with chronic obstructive pulmonary disease, scleroderma, or an asymptomatic pneumoperitoneum secondary to recent surgery or instrumentation, in which air or colonic gas diffuses into the cysts. These sometimes resolve with administration of oxygen. A far more virulent form of pneumatosis is associated with fulminant mucosal inflammation, ischemia, or necrotizing enterocolitis in children. These cysts are thought to result from mucosal invasion by gas-producing bacteria.

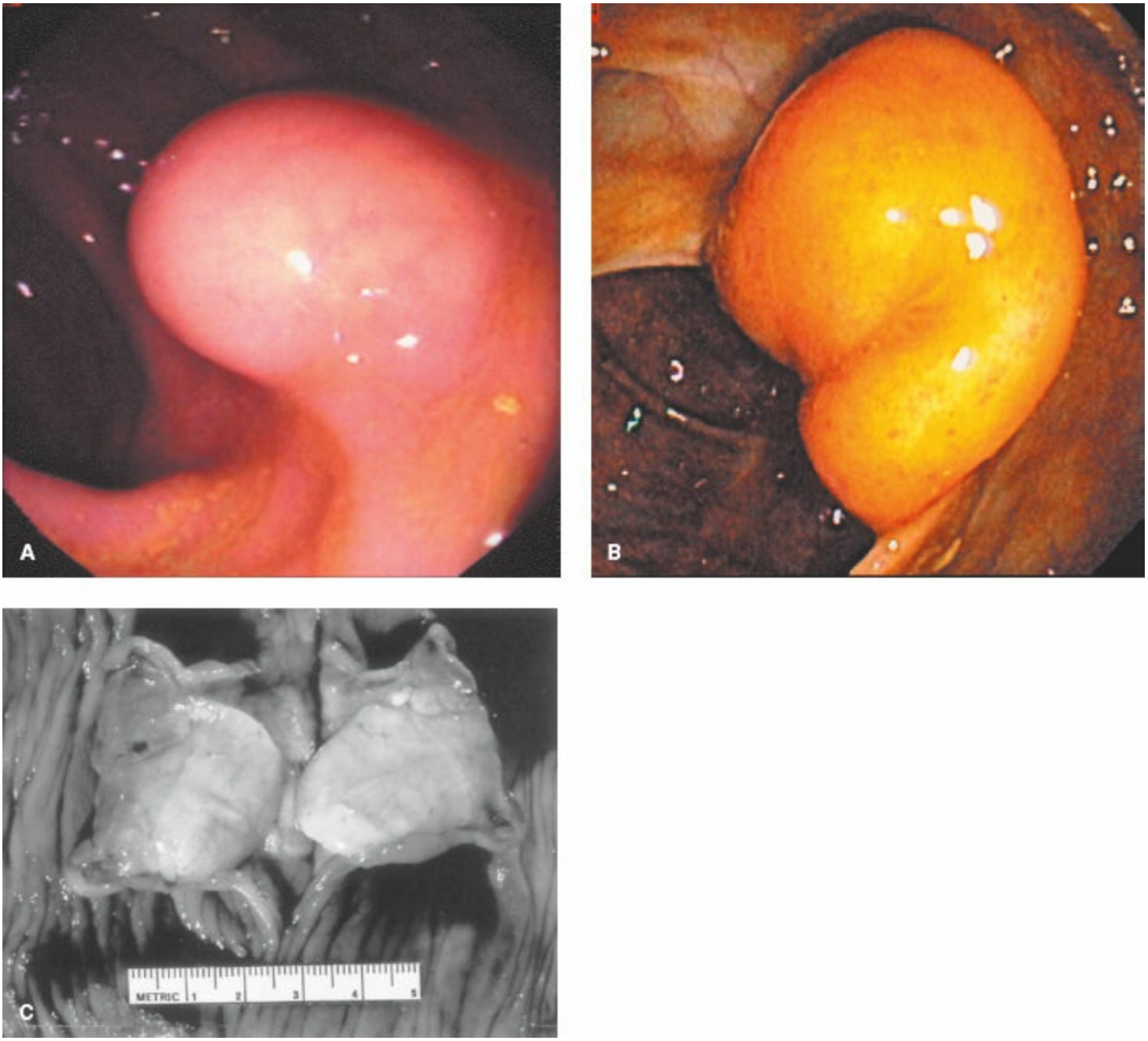

Figure 67-14. Submucosal lipomas. **A:** Lipoma seen at colonoscopy. Submucosal fatty tissue causes the mucosa to protrude into the lumen; such protrusion appears as a polyp. Overlying mucosa is smooth. **B:** Lipomatous infiltration of ileocecal valve seen at colonoscopy. **C:** Colectomy specimen showing a large submucosal lipoma cut in cross section.

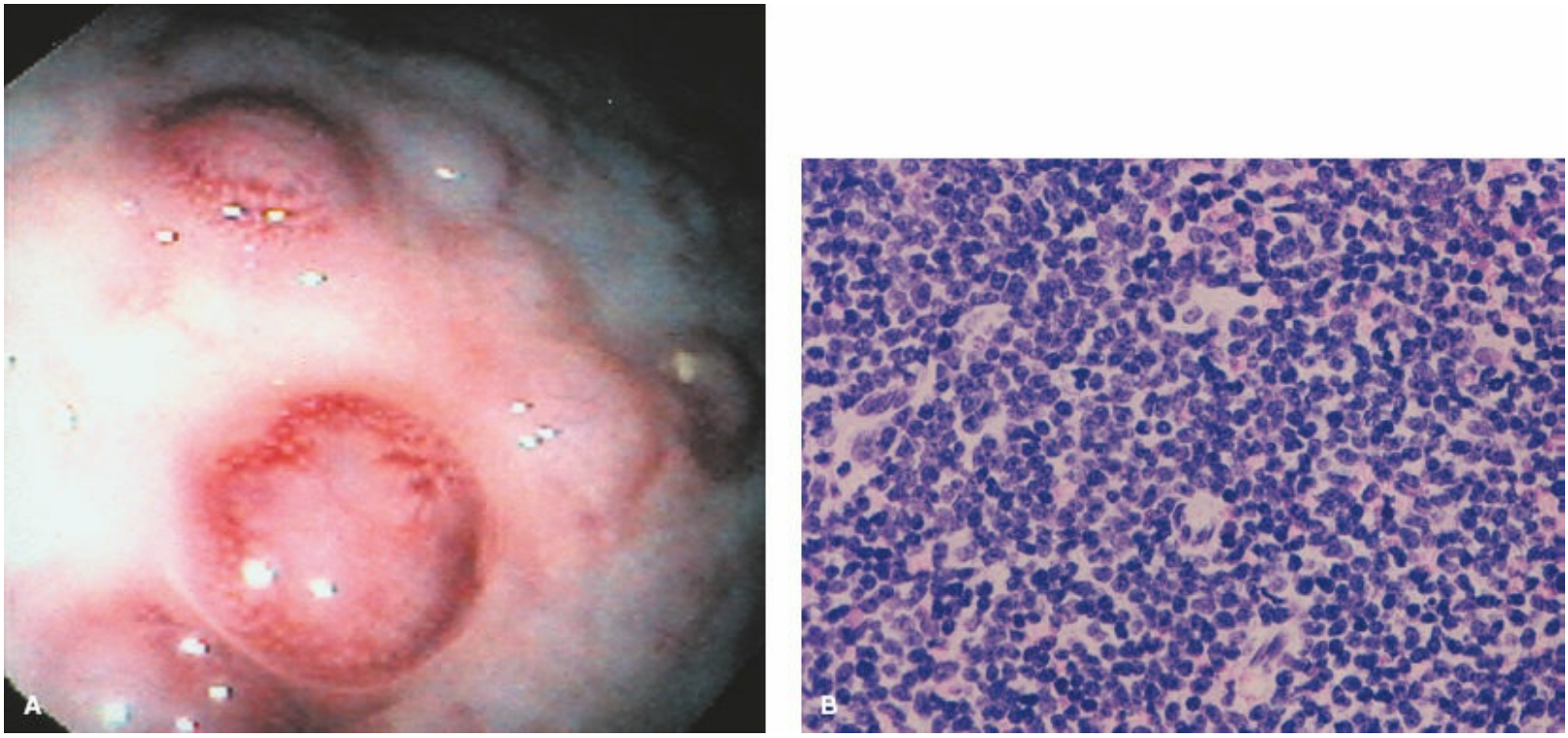

Figure 67-15. Lymphomatous polyposis of the colon. **A:** Colonoscopic view of B-cell lymphoma presenting as multiple colonic polyps. **B:** Histology of lymphoma is one of the polyps.

Colitis cystica profunda is a rare condition in which the intestinal wall is thickened by submucosal mucus-filled cysts of various sizes and an accumulation of fibroblasts in the lamina propria. It can present as an ulcerating or mass lesion in the rectosigmoid in association with the solitary rectal ulcer syndrome. Although the pathogenesis of this condition is unknown, it may result from the downward displacement of colonic glands during trauma or chronic inflammation followed by healing. The appearance of aberrant submucosal glandular epithelium and acellular mucous lakes must be distinguished from a colloid or mucinous carcinoma, because this lesion has no malignant potential.

Carcinoid tumors of the rectum appear as isolated, small, yellow-gray submucosal nodules. These are often incidental findings during sigmoidoscopy. Most are smaller than 1 cm, have little malignant potential, and are amenable to local excision. Lesions larger than 2 cm are more likely to be malignant but seldom give rise to metastases. These lesions should be treated aggressively with complete excision. Rectal carcinoid tumors are usually asymptomatic but may present with hematochezia. They are not associated with the carcinoid syndrome. Carcinoid tumors in the proximal colon may be locally invasive or metastasize to the liver, liberating vasoactive peptides into the systemic circulation and producing the carcinoid syndrome.

Other lesions that can present as submucosal polyps include metastatic tumors, such as malignant melanoma, and benign lesions, such as leiomyomas, fibromas, lymphangiomas, hemangiomas, and endometriosis.

GASTROINTESTINAL POLYPOSIS SYNDROMES

Gastrointestinal polyposis indicates the presence of a systemic process that promotes the development of multiple polyps throughout the gastrointestinal tract. In some instances, the polyps are located predominantly in the colon; however, in others, polyps may be found in the stomach, small intestine, colon, and rectum. The classification of the polyposis syndromes has traditionally been based on the histologic characteristics of the polyps, but gradually an awareness of the genetic basis for the most important of these syndromes has permitted more precise diagnosis and rational approaches to treatment.

Familial Adenomatous Polyposis

4 FAP is an autosomal dominant, genetic disease characterized by the development of multiple adenomatous polyps throughout the colon and rectum (Fig. 67-16). The polyps first appear in adolescence, with the median age of onset being about 16 years. The number of polyps in each patient is variable, and they increase in number and size with advancing age. The genetic basis for this disease is an inactivating germline mutation in the *APC* gene. In part, the age of onset, number of polyps, and age at which cancer develops are determined by the location of the mutation in the *APC* gene (Fig. 67-17). Some mutations (located in the middle of the gene) predispose to a very large number of adenomas (>5,000), and other mutations in the first three exons to a smaller number (<100). Additional factors not related to the mutation on the *APC* gene, some genetic and some environmental, also modify the clinical characteristics of the disease.[56]

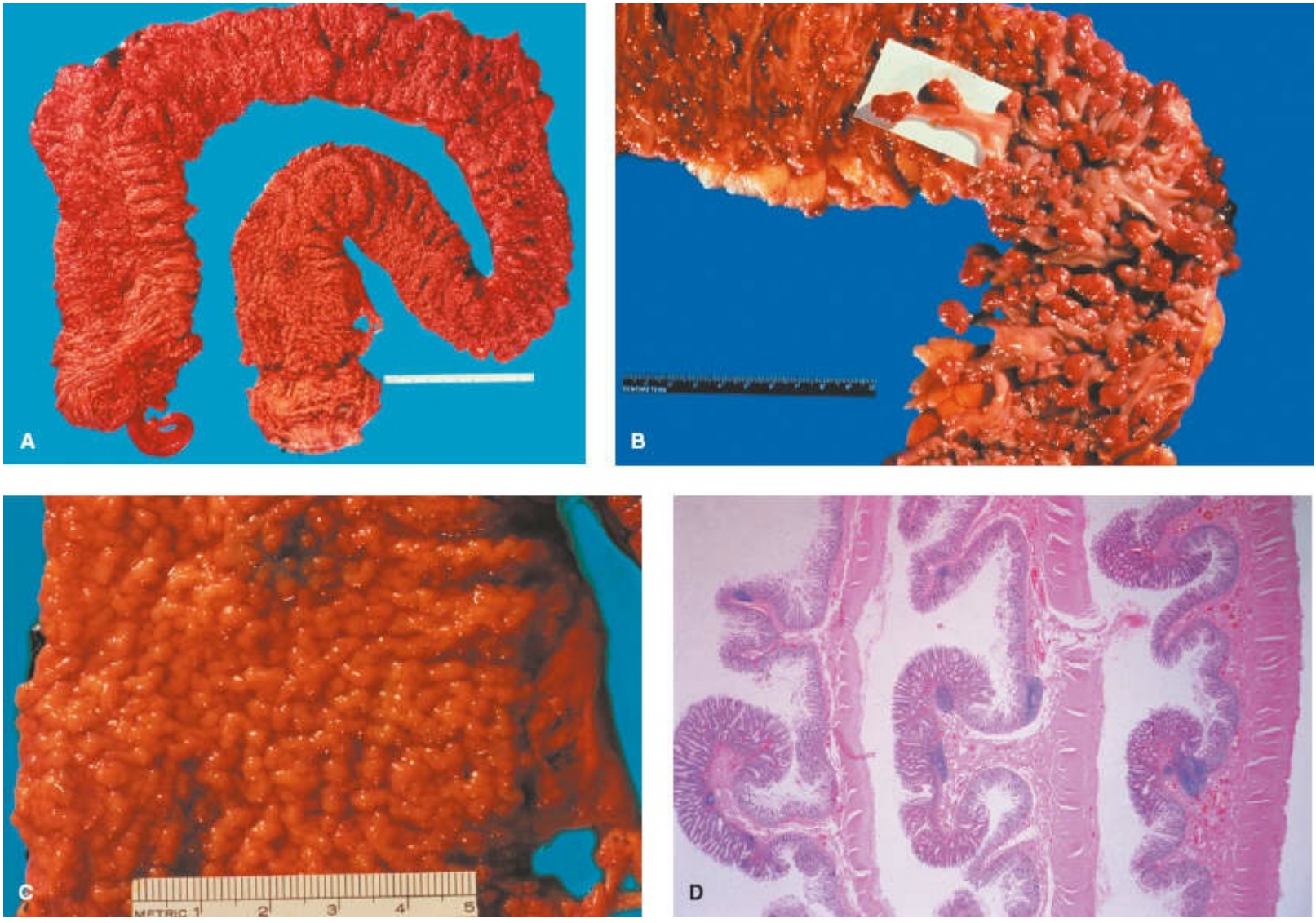

Figure 67-16. Familial adenomatous polyposis (FAP). **A:** Gross specimen of a resected colon from a patient with FAP. **B:** Sessile and pedunculated adenomatous polyps in the colon of a patient with FAP. **C:** Close-up view of a profuse type of FAP, in which the mucosa is carpeted with innumerable polyps. **D:** Photomicrograph demonstrating profuse FAP with both sessile and pedunculated adenomatous polyps.

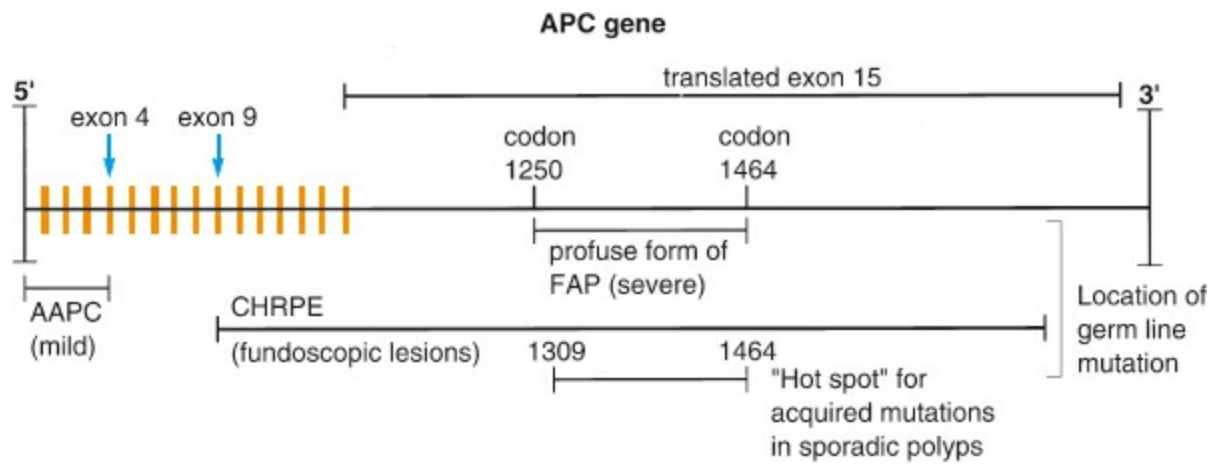

Figure 67-17. This scheme of the *APC* (adenomatous polyposis coli) gene illustrates the genotype–phenotype correlations. Most mutations of *APC* result in premature stop codons; therefore, the site of the mutation usually indicates the relative length of the mutant protein product. Mutations at the 5′ end of the gene produce "attenuated" FAP, a milder form of the disease. The retinal lesions (congenital hypertrophy of retinal pigmented epithelium [CHRPE]) occur when the mutations are between exons 9 and 15. The portion of the *APC* gene that binds to other cytoskeletal elements in the cell is represented at the 3′ end of the 15th exon. Mutations in a hot spot immediately downstream from the β-catenin–binding site (between codons 1250 and 1464) result in a more virulent, profuse form of familial adenomatous polyposis. This site is also the location of most of the acquired mutations in sporadic colorectal neoplasms.

Gastrointestinal Features

Polyps in the stomach and small intestine develop in about 90% of patients with FAP. The gastric polyps consist of fundic gland polyps, which are not premalignant lesions. These may appear to be dysplastic, but in the Western world (North America and Europe), gastric cancer is rare. Gastric cancer is a considerable diagnostic problem in FAP in Japan and Korea, however.

Small-intestinal neoplasia is not rare in FAP and principally occurs in the periampullary region of the duodenum. Duodenal adenomatous polyps, which typically appear later than the colonic lesions, may be multiple but tend not to carpet the proximal small intestine. The ampulla of Vater is a particular target for neoplastic development. With time, carcinoma develops in 5% to 10% of these patients, so that duodenal surveillance is required. Spigelman has developed a classification system that can be used to determine optimal surveillance for duodenal neoplasia, which is based on the number, size, and histologic features of the duodenal polyps (Table 67-4). Adenomas and carcinomas occur in the jejunum and ileum, but these are rare, and routine screening of the small intestine is not recommended. Polyps in the terminal ileum may represent lymphoid aggregates rather than adenomas and should be biopsied for diagnostic purposes.

Classically, it has been stated that the natural history of FAP is for cancer to develop at a median age in the mid-40s. As mentioned, the development of cancer is variable and is based in part on the location of the germline mutation in the *APC* gene. Colon cancer is rather unusual before 30 years of age, and cancer may not develop in patients with the attenuated form of FAP until they are in their 50s or 60s. Cancer occurring in the teenage years has been reported as a result of a patient who had both FAP and Lynch syndrome. Thus, the treatment of these patients relies increasingly on a genetic characterization of

the disease.

Extraintestinal Features

Traditionally, patients with manifestations of FAP together with extraintestinal manifestations were considered to have Gardner syndrome. It is now appreciated that families with FAP all have extraintestinal manifestations and that no distinction can be made between families with Gardner syndrome and those with FAP. FAP is characterized by osteomas of the mandible, skull, and long bones and a variety of other benign soft tissue tumors, such as fibromas, lipomas (Fig. 67-18), and sebaceous cysts, which should not be confused with the sebaceous adenomas and carcinomas seen in the Muir–Torre syndrome variant of Lynch syndrome. Osteomas are commonly found in the skull and may be multiple. Some of these lesions have been reported to regress and later reappear. Osteomas may also be found in the mandible, and radiographs of the mouth may reveal impacted or supernumerary teeth. Congenital hypertrophy of the retinal pigmented epithelium (CHRPE) is present in some families with FAP, depending on the location of the mutation in the *APC* gene. CHRPE lesions may be seen in 5% of the general population but are small and usually single. Multiple, bilateral, and large CHRPE lesions strongly suggest FAP. It will require a slit-lamp examination and knowledgeable ophthalmologist to make this diagnosis with confidence, as these are not readily seen in an office ophthalmoscopic examination.

Table 67-4 Spigelman Classification for Management of Duodenal Adenomas in Individuals with FAP

	Points		
	1	2	3
A. Duodenal Disease Grading			
Polyp number	1–4	5–20	>20
Polyp size (mm)	1–4	5–20	>20
Histology	Tubular adenoma	Tubulovillous	Villous
Dysplasia	Mild	Moderate	Severe
B. Recommended Upper GI Surveillance in FAP			
Spigelman stage	Interval to EGD		
Stage 0 (0 points)	5 yrs		
Stage I (1–4 points)	5 yrs		
Stage II (5–6 points)	3 yrs		
Stage III (7–8 points)	1–2 yrs		
Stage IV (9–12 points)	EUS or surgery		

EGD, esophagogastroduodenoscopy; EUS, endoscopic ultrasound; FAP, familial adenomatous polyposis; GI, gastrointestinal.

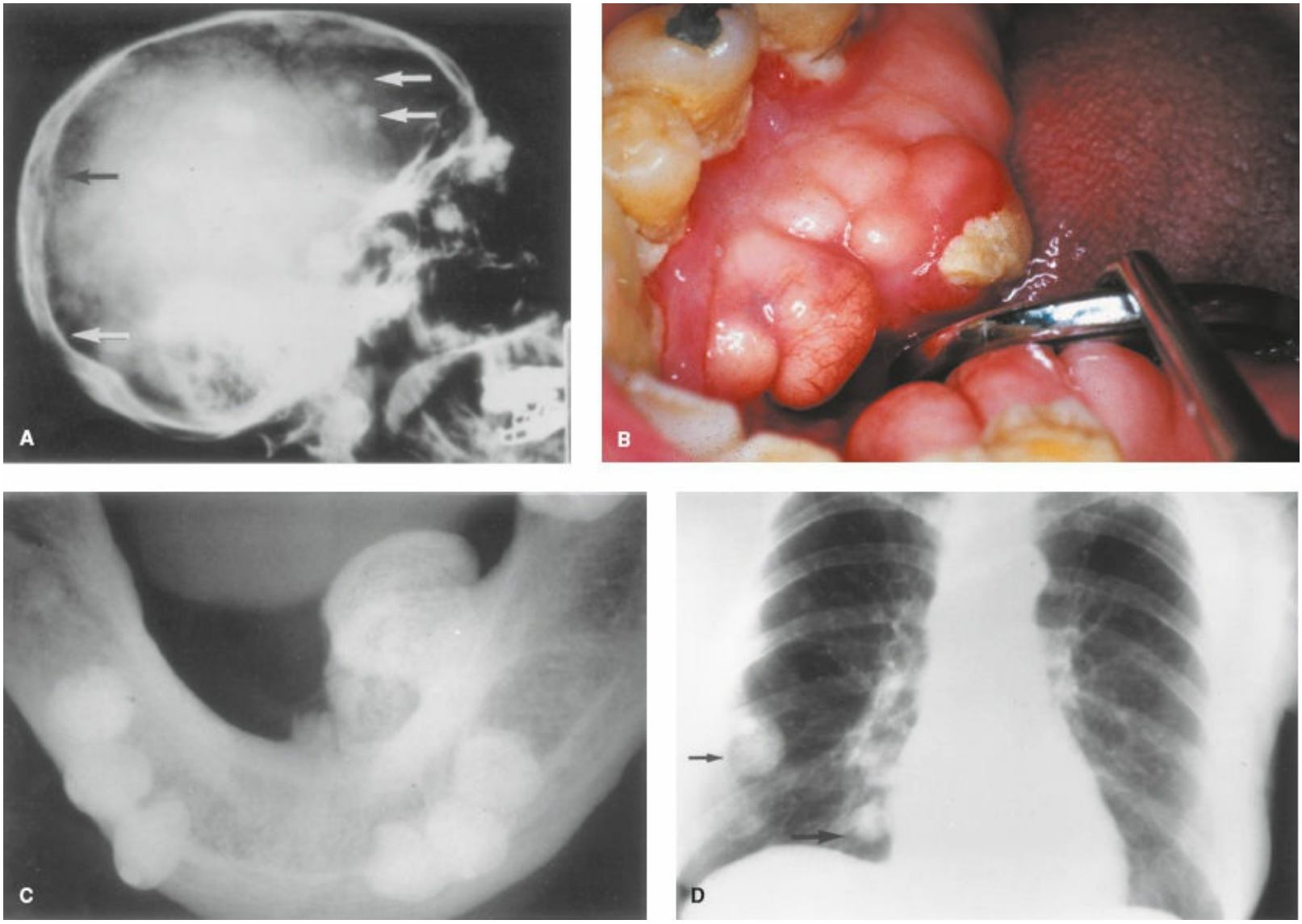

Figure 67-18. Extraintestinal manifestations of familial adenomatous polyposis (FAP). **A:** Skull film demonstrating osteomas of the calvarium (*arrows*). **B:** Photograph of the mandible demonstrating protuberant mandibular osteomas. **C:** Mandibular radiograph demonstrating a large osteoma of the mandible. **D:** Chest radiograph demonstrating multiple fibromas (*arrows*) in a patient with FAP.

Malignant tumors in the colon are considered to be nearly inevitable in FAP patients, and they may occur occasionally in the duodenum or (less commonly) elsewhere in the gastrointestinal tract. Patients with FAP are also at increased risk for brain tumors, thyroid tumors, adrenal tumors, and malignant tumors of the hepatobiliary tree. Medulloblastomas are a rare complication of FAP, but the risk for this tumor is increased 99-fold in FAP families.

Desmoid Tumors

Desmoid tumors are currently the major cause of mortality and morbidity in FAP (after colorectal cancer) and develop in 10% to 15% of such patients, often as a complication of laparotomy, but sometimes spontaneously. These are benign but aggressive tumors of mesenteric fibroblasts that can encase and obstruct the gastrointestinal tract, arteries, veins, or ureters. They frequently occur in the abdominal wall. In some instances, desmoid tumors can virtually fill the abdominal cavity, and can be lethal. Desmoids are

readily visualized on CT of the abdomen, and surgical management of these should be avoided unless they are superficially located. These are more common in women and in those with a positive family history of desmoid tumors.

Genetic Basis of FAP

FAP occurs when a germline mutation in the *APC* gene inactivates the function of the *APC* protein. In most instances, the genetic lesion creates a premature stop codon in the *APC* gene, which in turn leads, to nonsense-mediated decay of the mRNA or the translation of a truncated, nonfunctional *APC* protein. Germline deletions of *APC* also cause FAP. The *APC* gene encodes a large protein (311 kd) that binds to other intracellular proteins – most importantly, the catenins. The *APC* gene encodes 2,843 codons (one for each amino acid) and is broken into 15 translated exons. The structure of the *APC* gene is unique in that the 15th exon makes up about 75% of the coding sequence of the gene. Because it is unusually large, this long, open reading frame is a large target for mutations. This genetic vulnerability probably accounts for the fact that about 25% of mutations in the *APC* occur de novo, in which neither parent carries the mutation, and there is no prior family history of FAP.

The location of the germline mutation is of some clinical significance (Fig. 67-19). For example, mutations that occur at the 5′ end of the gene, particularly in the first three exons, result in a clinically mild or "attenuated" form of FAP, in which the number of polyps is smaller and the onset of disease occurs about 10 years later, with cancer developing in the sixth or seventh decade. This occurs because the *APC* gene has an internal ribosomal reentry site downstream of the mutation, which permits the cell to bypass and ignore the premature stop codon. To complicate the situation, family members with the same mutation may have variable manifestations of the disease. Indeed, some members who inherit this mutation have few polyps and no cancer, yet can pass an increased risk for cancer to their progeny.

In contrast, mutations that occur in the "mutation cluster region" of the 15th exon, in a segment between codons 1,250 and 1,464, are associated with a particularly virulent form of the disease, in which the number of polyps is greater than 5,000 and the average age for the development of colorectal cancer is significantly earlier (median age, 34 years). Also, mutations at the extreme 3′ end of the gene may be associated with a milder phenotype, with fewer polyps and later onset of cancer. In families who have FAP with CHRPE lesions, the mutations are usually in exons 9 through 15 and only rarely in families whose mutations are in the first 8 exons. Thus, knowledge of the location of the germline mutation can be useful in predicting the clinical manifestations and guide therapy.

Diagnosis

The clinical diagnosis of FAP is usually obvious clinically, but the availability of a genetic diagnosis has changed the approach to this disease. Currently, optimal practice is to obtain a germline diagnosis in an individual who is definitely affected, in order to characterize and counsel the family. A mutation in *APC* can be found in most (90%) of

these individuals using commercially available diagnostic laboratories. This will assist in the early and definitive identification of family members who carry the disease-causing mutation and will alleviate anxiety for those who do not. The risk to inherit the mutated gene from an affected parent is 50%, and there is no gender preference. A genetic diagnosis is particularly useful in the attenuated forms of FAP, where the diagnosis is not obvious, and this can help select those family members who need additional surveillance and reassure those who do not. Family members who have the *APC* mutation should begin endoscopic surveillance from their early teens at yearly intervals.[57]

About 25% of patients have FAP that is not present in either parent. This can represent the autosomal recessive form of the disease (*MutYH*-associated polyposis; see later), misattribution of paternity, or phenotypic variation in which a parent actually has a milder form of the disease.

Genetic testing is an essential part of the clinical management of the hereditary cancer, but it can be a challenge. The genetic results are sometimes ambiguous and difficult for the physician to interpret. Additionally, some patients mistake the germline test as a test for cancer. Issues of guilt and denial are prominent in genetic disorders. It is strongly recommended that physicians enlist the involvement of genetic counselors when performing genetic testing and counseling in such patients. The federal "Genetic Information and Non-Discrimination Act" (GINA) protects asymptomatic patients carrying a germline mutation for a serious disease from discrimination in the workplace or with health insurance.

Management

Surgery is the only reasonable management option in FAP, and the clinical decision involves the selection and timing of the operation. The diagnosis of FAP is often made in adolescence, but the development of cancer may not be anticipated for 20 to 30 years after the first polyp appears, depending on the location of the mutation in the *APC* gene. When a child is found to have a germline mutation in *APC,* sigmoidoscopy should begin in the early teenage years, particularly if the mutation is in the "mutation cluster region" or the family's phenotype is known to be associated with thousands of polyps. Ideally, one would like a patient to reach adulthood prior to the colectomy, as the pelvis is larger and the individual is better able to cope with the disease psychologically.

The safest surgical approach is a total proctocolectomy with an ileoanal J-pouch anastomosis. No rectal mucosa should be left behind, since it is at risk for the development of neoplasia. Even with careful endoscopic surveillance of the rectal segment, invasive carcinomas may develop.

The fact that small adenomatous polyps of the rectum can spontaneously regress visibly after a subtotal colectomy and ileorectal anastomosis underscores the reversible nature of the benign adenoma. Additionally, it has been found that adenomas can regress in FAP in response to treatment with sulindac. Several reports have confirmed that even large numbers of polyps regress in patients on 150 to 200 mg of sulindac twice per day. Unfortunately, the polyps reappear when the drug is stopped, and cancer may develop despite treatment with sulindac. Medical treatment is therefore not a safe or reliable first-

line treatment for FAP. Furthermore, such treatment may create the illusion of false assurance of preventing cancer. Sulindac is not effective in the management of upper gastrointestinal tract neoplasia.

Management of Extracolonic Disease. In addition to the risks for colorectal neoplasia, patients with FAP are at risk for the development of osteomas, lipomas, fibromas, and a variety of other lesions. Although these mesenchymal tumors can degenerate into sarcomas, this is a sufficiently rare event that prophylactic surveillance and surgery are not indicated. Likewise, CHRPE lesions do not require treatment. Gastric carcinoma is distinctly uncommon in North American populations where the lifetime risk for gastric cancer in FAP is 0.5%. The bigger problem is that the gastric polyps may look ominous endoscopically and dysplastic pathologically, and one should be reluctant to perform a gastrectomy on a person who has already had a colectomy. Caution is advised when following large gastric polyps in FAP.

The two major management issues after removal of the colon and rectum are periampullary neoplasia and desmoid tumors. One or more adenomas are found in the duodenum in 90% of patients with FAP, usually close to the ampulla of Vater. These lesions should be excised for biopsy and destroyed by electrocautery, laser, or other ablative approaches. Subsequent examination of the upper gastrointestinal tract is guided by the Spigelman criteria (Table 67-4). Complex neoplasms, including adenomas with varying degrees of dysplasia, may require individualized management, including the use of biliary stents while extensive ablative therapy of the periampullary region is performed. Surgical approaches may be required for advanced neoplasms (i.e., carcinoma in situ or invasive carcinoma), but therapeutic endoscopy remains the first option. Duodenotomy with local surgical excision is an option for some of these lesions; occasionally, a Whipple procedure is required for invasive lesions in this region, with low mortality, but considerable morbidity.[58]

Desmoid tumors are aggressive benign tumors of fibroblasts that can cause multiple clinical complications; they are a significant cause of morbidity and mortality in FAP. They typically grow slowly and can surround or compress vascular structures, nerves, or the abdominal viscera. They are more common in women and may be hormonally responsive, so estrogen administration (oral contraceptives or hormone replacement therapy) should be avoided in these patients. Surgical management is generally avoided unless simple local excision of an abdominal wall lesion is possible, and postoperative recurrences are common. Radiotherapy has been used to control the growth of some of these but is generally reserved for superficial lesions. No medical approach to this disease has been uniformly successful. A combination of sulindac plus tamoxifen may be tried for intra-abdominal tumors and has been successful in some patients. Cytotoxic chemotherapy with doxorubicin was successful in a patient whose tumor was refractory to other treatment. Anecdotally, some of these lesions may have *c-kit* mutations and are responsive to imatinib (Gleevec).

Familial Adenomatous Polyposis Variants

5 A number of names, especially *Gardner syndrome,* have been attached to variations of FAP to emphasize the presence of particular extracolonic findings. As mentioned, Gardner syndrome is the same entity as FAP. A few families with prominent sebaceous cysts were historically said to have Oldfield syndrome, and families with brain tumors were said to have Turcot syndrome. All these syndromes represent the variable expression of germline mutations in the *APC* gene and are largely of historical interest. The current mode of classifying FAP families is based on the *APC* gene mutation.

MutYH-Associated Polyposis or MAP

An autosomal recessive form of polyposis has been linked to inheritance of germline mutations in the base excision repair gene *MutYH,* a DNA glycolase.[59–61] MAP should be considered when multiple adenomatous polyps occur in siblings or in a person who has no vertical family history of polyposis and there is no detectable germline mutation in the *APC* gene. These patients have a relatively mild (attenuated) form of adenomatous polyposis, typically develop 20 to 500 adenomas, and the polyposis is frequently detected in patients 35 to 65 years old. These patients are at very high risk for colorectal cancer, and the disease may present with cancer. The extraintestinal manifestations of FAP, such as duodenal adenomas or CHRPE lesions, occasionally occur but are less common in MAP than FAP. The pathogenesis of this disease is that the germline mutations in *MutYH* permit an excess number of acquired mutations in the *APC* gene (and other genes) to occur in the colon; these mutations are typically G:C → T:A transversions, which is a consequence of losing the DNA base excision repair system. More than 1.3% of the Caucasian population carries a single copy of the MutYH alleles Y179C, G396D, and E480X (previously designated Y165C, G382D, and E466X, respectively, but changed due to renumbering of the coding sequence), and these carriers have a slight increase in colon cancer risk. The Y179C variant has less enzymatic activity than G396D mutation; therefore, homozygotes with Y179C have the most severe phenotype, followed by those with one Y179D and some other mutation, followed by other mutations, which explain the phenotypic heterogeneity in this disease.[62] Many reference laboratories test for the three commonest *MutYH* mutations on DNA sent from patients with a diagnosis of FAP if there is no detectable germline mutation (or deletion) in *APC*. This strategy is only rational when dealing with European-based mutations. For non-European populations in which this diagnosis is being considered, it is necessary to have the entire *MutYH* gene sequenced. MAP patients can sometimes be managed with frequent colonoscopy when the phenotype is mild, but a colectomy or proctocolectomy may be indicated depending upon the size and distribution of the adenomas, or in patients who choose not to comply with regular colonoscopic surveillance.

Peutz–Jeghers Syndrome

Peutz–Jeghers syndrome is an autosomal dominant familial syndrome associated with multiple gastrointestinal polyps and characteristic skin pigmentation. The gene

responsible for this disease encodes a serine/threonine kinase called *LKB1* or *STK11* (Table 67-5); carriers of the gene are highly predisposed to a number of early-onset cancers.

Gastrointestinal Features. The gastrointestinal polyps in Peutz–Jeghers syndrome are nonneoplastic hamartomas consisting of a supportive framework of smooth muscle tissue covered by somewhat hyperplastic epithelium (Fig. 67-20). These are histologically distinct from juvenile polyps and show no inflammatory cell infiltrate. Polyps may be found in the stomach, small intestine, or colon, and in each instance they have a distinctive appearance. Peutz–Jeghers polyps can usually be identified as such by the pathologist, and the characteristic cutaneous pigmentation makes this syndrome readily recognizable.

Table 67-5 Genetic Alterations in Colonic Polyposis Syndromes

Polyposis Syndrome	Chromosome	Gene
Familial adenomatous polyposis (FAP)	5q21	*APC*
MutYH-associated polyposis (MAP)	1p35	*MutYH* (recessive)
Peutz–Jeghers syndrome	19p13.3	LKB1/STK11
Juvenile polyposis coli	18q21.1	SMAD4/MADH4
Juvenile polyposis coli	10q22.3	BMPR1A
Juvenile polyposis coli	9q34.11	ENG (endoglin)
Bannayan–Riley–Ruvalcaba syndrome	10q23	PTEN
Cowden disease	10q23	PTEN
Hereditary mixed polyposis (one family)	15q13.3	GREM1

Skin Lesions. The cutaneous manifestations of Peutz–Jeghers syndrome may be found early in life and consist of dark, macular lesions on the mouth (both on the skin and in the buccal mucosa), nose, lips, hands, feet, genitalia, and anus. These lesions tend to become less obvious by the time of puberty. Unlike ordinary freckles, the cutaneous lesions of Peutz–Jeghers syndrome are present from birth. Moreover, ordinary freckles typically do not extend beyond the vermilion border of the lips, nor is the buccal mucosa involved, as it is in Peutz–Jeghers syndrome.

Clinical Complications. The principal complication of Peutz–Jeghers syndrome is intestinal obstruction, which may develop in infancy or childhood. This complication is most prominent in the small intestine because of its narrower diameter. Gastrointestinal bleeding may also be seen in this disease.

Cancer in the small intestine or colon can occur in Peutz–Jeghers syndrome; however, this is an uncommon complication.[63] It is thought that neoplasia may arise from foci of

adenomatous epithelium found in some Peutz–Jeghers polyps. The risk for cancer is such that prophylactic surgery is not recommended.

Patients with Peutz–Jeghers syndrome are at increased risk for cancers within and outside the gastrointestinal tract. Cancer developed in about half of the patients in one large study at a median age of about 50 years. At risk are the stomach, small intestine, colorectum, gonads, breasts, pancreas, and biliary tree. Ovarian cysts and sex cord tumors are seen in 5% to 12% of female patients, and boys are at risk for endocrinologically active Sertoli cell testicular tumors that may produce feminizing features before puberty. No internal organ is individually at sufficiently high risk for cancer that a specific screening regimen or prophylactic surgery is indicated. The clinician should be aware of these risks, however, and should be particularly alert to gonadal tumors (which are otherwise rare) and breast cancer (for which screening should start at an early age and bilateral disease should be suspected).

Management. The management of Peutz–Jeghers syndrome is limited to the removal of polyps; endoscopic techniques should be used when possible. Surgery may be required for intussusception caused by small-intestinal polyps. The risk for neoplastic development should be kept in mind, but these patients are not candidates for prophylactic removal of any section of the gastrointestinal tract. As mentioned earlier, gonadal neoplasms and breast cancer are potential complications that may require surgery.

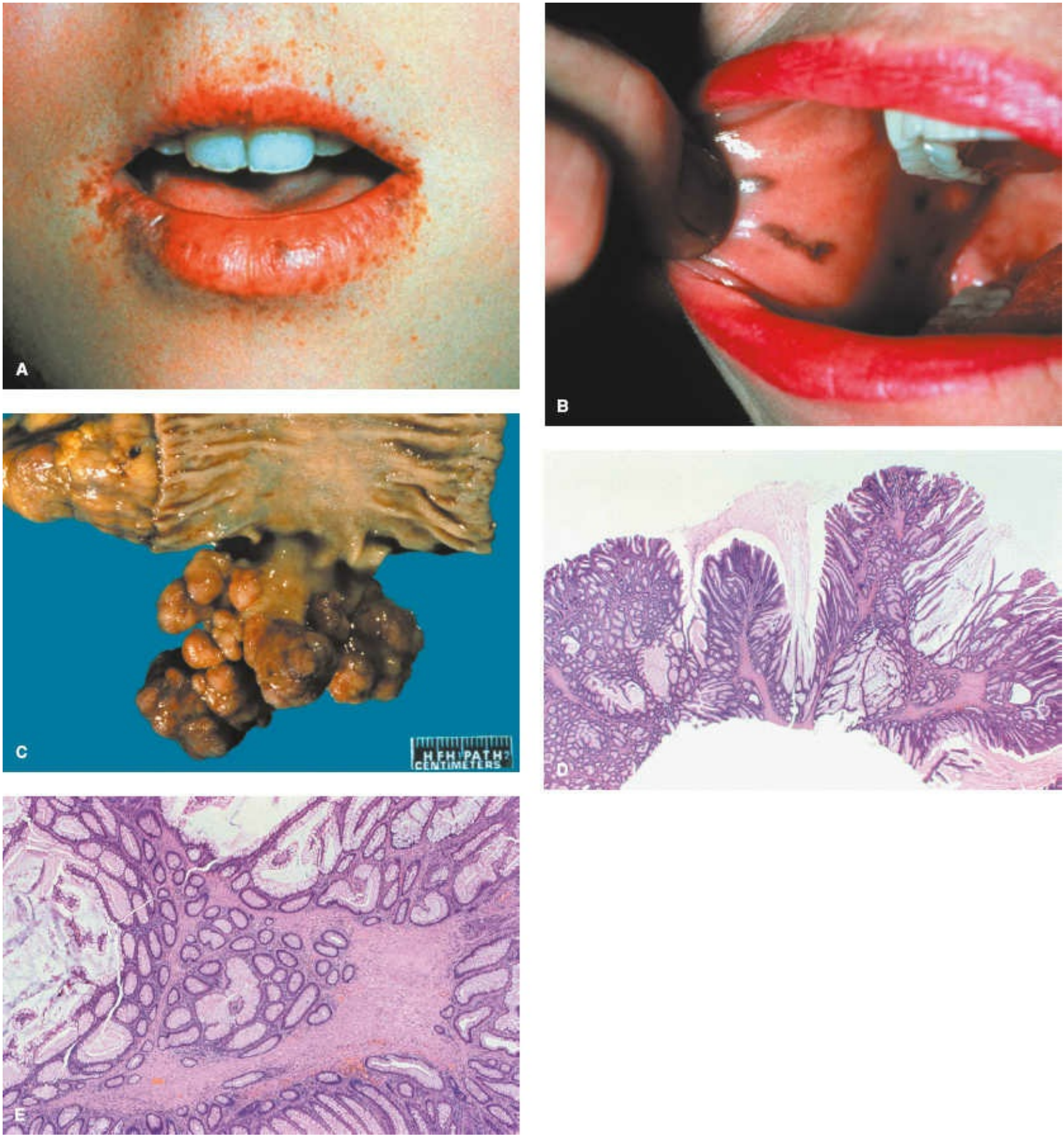

Figure 67-19. Peutz–Jeghers syndrome. **A:** Perioral hyperpigmentation. **B:** Hyperpigmented buccal mucosa. **C:** Gross specimen of a Peutz–Jeghers polyp illustrating a large multilobular lesion. **D:** Low-power photomicrograph of a Peutz–Jeghers polyp of the colon revealing smooth muscle stroma covered by nonneoplastic colonic epithelium. **E:** Photomicrograph of the Peutz–Jeghers polyp at higher power indicates that the stroma contains arborizing bands of smooth muscle.

Juvenile Polyposis

Juvenile polyps are pathologically characteristic lesions that can be solitary or part of a polyposis syndrome. Juvenile polyps are most commonly solitary lesions found in the rectum during childhood. The lesions may be large and are made up of an edematous, mildly inflamed lamina propria covered by normal colonic epithelium (Fig. 67-17). If multiple polyps are found, a familial JPS should be suspected. Three different syndromic presentations have been reported; it is not known, however, whether these are truly distinctive syndromes. They may consist of JPS limited to the colon, JPS throughout the gastrointestinal tract, and JPS limited to the stomach. The genetic basis of this syndrome is not completely understood, but germline mutations in the *SMAD4* (also called the *MADH4* gene) and *BMPR1A* genes each account for about 20% of JPS cases in which the genetic cause can be found.[64,65] Both these genes are involved in the TGF-β signaling pathway. Also, there are rare cases of patients who have both JPS and hereditary hemorrhagic telangiectasia; these patients typically have mutations in the *SMAD4* gene. Although alterations in the *PTEN* gene were reportedly linked to JPS, germline mutations in this gene are only found in the rare Bannayan–Riley–Ruvalcaba variant, a childhood disorder characterized by macrocephaly, intestinal hamartomatous polyps, and unique pigmented macules of the penis.[66] Other characteristics include ocular abnormalities, delayed motor development, lipid storage myopathy, and Hashimoto disease. This disorder shares features with Cowden syndrome, which is also caused by *PTEN* mutations.[67]

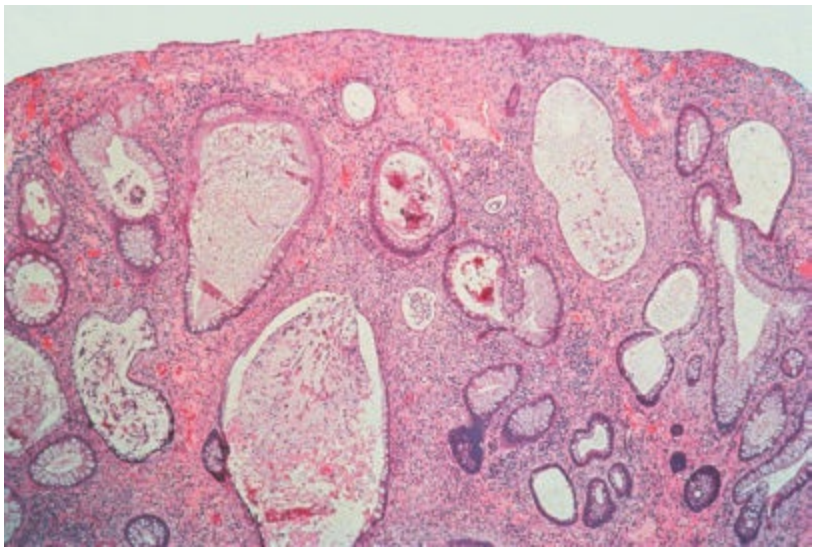

Figure 67-20. Photomicrograph of a juvenile polyp reveals an attenuated surface epithelium overlying an edematous lamina propria with fluid- and mucus-filled cystic structures.

The manifestations of JPS can vary but are usually limited to bleeding, intussusception, obstruction, and the passage of autoamputated lesions. In some children, a life-threatening protein-losing enteropathy may develop that requires surgical resection of the affected segment of intestine. Patients with familial juvenile polyposis are at increased risk for the development of colorectal cancer and require careful surveillance.

Other Familial Polyposis Syndromes

A variety of other rare syndromes may give rise to multiple gastrointestinal polyps. Cowden syndrome consists of multiple gastrointestinal hamartomas and may be complicated by multiple lesions of the face that arise from follicular epithelium and are pathologically trichilemmomas.[68] This disease is most often linked to germline mutations in the *PTEN* gene. The diagnosis of Cowden syndrome should be considered for patients with multiple trichilemmomas. Gastrointestinal polyps, which are usually asymptomatic, may develop in these patients. The polyps may include hamartomas, HPs, and ganglioneuromas of the colon. Glycogenic acanthosis of the esophagus may also occur and usually is found incidentally as multiple, diminutive, flat polyps of the esophagus. These patients have an increase in the estimated lifetime risks for the development of breast cancer (85%), thyroid cancer (35%), endometrial cancer (28%), colorectal cancer (9%), kidney cancer (34%), and melanoma (6%).[69] Cowden syndrome patients should be in the care of someone knowledgeable with these risks. Germline mutations of the *PTEN* gene can be identified in most families with Cowden syndrome.[70]

Other diseases, such as neurofibromatosis (von Recklinghausen syndrome) and the basal cell nevus syndrome, may be associated with multiple gastrointestinal polyps; however, symptomatic complications of these polyps are uncommon.

NONFAMILIAL GASTROINTESTINAL POLYPOSIS SYNDROMES

Multiple gastrointestinal polyps are occasionally seen in nonfamilial syndromes. The Cronkhite–Canada syndrome is an acquired, nonfamilial syndrome characterized by cutaneous lesions (Fig. 67-21), chronic diarrhea, protein-losing enteropathy, and gastrointestinal polyps. The enteropathy may produce progressive inanition and dehydration that can result in death. The diarrhea is attributable to diffuse mucosal injury of the small intestine but may be complicated by bacterial overgrowth. Gastrointestinal polyps are present in most patients and occur in the stomach, small intestine, colon, and rectum. These polyps are pathologically similar to juvenile retention-type polyps. The lamina propria is edematous and contains an inflammatory infiltrate. As has been reported in juvenile polyps, the lesions in this syndrome may contain adenomatous epithelium, and occasionally carcinomas have complicated this disease, but this is not a usual feature of the disease. A variety of medical and surgical measures have been used as treatment, and primary attention should be drawn to the treatment of the diarrhea and maintenance of the nutritional status. The cutaneous lesions consist of onycholysis, alopecia, and hyperpigmentation. Multiple therapeutic approaches have been tried, including broad-spectrum antibiotics, steroids, antihistamines, and extended bowel rest with parenteral nutritional support. Each approach has had occasional success, but none is uniformly effective. The disease is more common in Asia than in North America or Europe. Curiously, the cutaneous features may resolve despite persistence of the gastrointestinal polyps.



Figure 67-21. Cronkhite–Canada syndrome. Onycholysis and hyperpigmentation are characteristic cutaneous manifestations of Cronkhite–Canada syndrome, a nonfamilial, poorly understood, and acquired condition in which multiple juvenile, inflammatory-type gastrointestinal polyps and characteristic cutaneous features are found.

Other acquired lesions that may present with multiple gastrointestinal polyps include inflammatory pseudopolyps in the setting of inflammatory bowel disease, lymphoma, pneumatosis cystoides intestinalis, and multiple lipomas or HPs. None of these syndromes

requires specific surgical treatment.

References

1. Grady WM, Carethers JM. Genomic and Epigenetic instability in colorectal cancer pathogenesis. *Gastroenterology* 2008;135:1079–1099.
2. Pritchard CC, Grady WM. Colorectal cancer molecular biology moves into clinical practice. *Gut* 2011;60:116–129.
3. Grady WM, Markowitz SD. The molecular pathogenesis of colorectal cancer and its potential application to colorectal cancer screening. *Dig Dis Sci* 2015;60(3):762–772.
4. Hanahan D, Weinberg RA. Hallmarks of cancer: the next generation. *Cell* 2011;144:646–674.
5. Tomasetti C, Vogelstein B. Cancer etiology. Variation in cancer risk among tissues can be explained by the number of stem cell divisions. *Science* 2015; 347:78–81.
6. The Cancer Genome Atlas Network. Comprehensive molecular characterization of human colon and rectal cancer. *Nature* 2012;487:330–337.
7. Boland CR. Evolution of the nomenclature for the hereditary colorectal cancer syndromes. *Fam Cancer* 2005;4:211–218.
8. Umar A, Boland CR, Terdiman JP, et al. Revised Bethesda guidelines for hereditary nonpolyposis colorectal cancer (Lynch syndrome) and microsatellite instability. *J Natl Cancer Inst* 2004;96:261–268.
9. Crockett SD, Snover DC, Ahnen DJ, et al. Sessile serrated adenomas:an evidence-based guide to management. *Clin Gastroenterol Hepatol* 2015;13:11–26.
10. Rosty C, Buchanan DD, Walsh MD, et al. Phenotype and polyp landscape in serrated polyposis syndrome: a series of 100 patients from genetics clinics. *Am J Surg Pathol* 2012;36:876–882.
11. Snover D, Ahnen D, Burt R, et al. Serrated polyps of the colon and rectum and serrated (hyperplastic) polyposis. In: Bozman F, Carniro FM, Hruban R, et al., eds. *WHO Classification of Tumours of the Digestive System.* 4th ed. Berlin: Springer-Verlag, 2010.
12. Raju GS, Vadyal V, Slack R, et al. Adenoma detection rate in patients undergoing a comprehensive colonoscopy screening. *Cancer Med* 2013;2:391–402.
13. Winawer SJ, Zauber AG, Gerdes H, et al. Risk of colorectal cancer in the families of patients with adenomatous polyps. National Polyp Study Workgroup. *N Engl J Med* 1996;334:82–87.
14. Brenner H, Hoffmeister M, Stegmaier C, et al. Risk of progression of advanced adenomas to colorectal cancer by age and sex: estimates based on 840,149 screening colonoscopies. *Gut* 2009;56:1585–1589.
15. Zauber AG, Winawer SJ, O'Brien MJ, et al. Colonoscopic polypectomy and long-term prevention of colorectal cancer deaths. *N Engl J Med* 2012; 366:687–696.
16. Yurgulun MB, Goel A, Hornick JL, et al. Microsatellite instability and DNA mismatch repair protein deficiency in Lynch syndrome colorectal polyps. *Cancer Prev Res(Phila)* 2012;5:574–582.

17. Edelstein DL, Axilbund J, Baxter M, et al. Rapid development of colorectal neoplasia in patients with Lynch syndrome. *Clin Gastroenterol Hepatol* 2011; 9:340–343.
18. Boland CR, Lynch HT. The history of Lynch syndrome. *Fam Cancer* 2013; 12:145–157.
19. Hamilton SR, Liu B, Parsons RE, et al. The molecular basis of Turcot's syndrome. *N Engl J Med* 1995;332:839–847.
20. Levin B, Lieberman DA, Mcfarland B, et al. Screening and surveillance for the early detection of colorectal cancer and adenomatous polyps, 2008: a joint guideline from the American Cancer Society, the US Multi-Society Task Force on Colorectal Cancer, and the American College of Radiology. *CA Cancer J Clin* 2008;58:130–160.
21. U.S. Preventative Services Task Force. Screening for colorectal cancer: U.S. Preventative Services Task Force recommendation statement. *Ann Int Med* 2008;149:627–637.
22. Rex DK, Johnson DA, Anderson HC, et al. American College of Gastroenterology guidelines for colorectal cancer screening 2008. *Am J Gastroenterol* 2009;104:739–750.
23. Segnan N, Patrick J, von Karsa L (eds). European guidelines for quality assurance in colorectal screening and diagnosis. Luxembourg: International Agency for Research on Cancer; 2010;1–386.
24. Swan S, Siddiqui AA, Meyers RE. International colorectal cancer screening programs: population contact strategies., testing methods and screening rates. *Pract Gastroenterol* 2012;20–29.
25. Mandel JS, Bond JH, Church TR, et al. Reducing mortality from colorectal cancer by screening for fecal occult blood. Minnesota Colon Cancer Control Study. *N Engl J Med* 1993;328:1365–1371.
26. Mandel JS. Screening of patients at average risk for colon cancer. *Med Clin North Am* 2005;89:43–59.
27. Haug UH, Hundt S, Brenner H. Quantitative immunochemical fecal occult blood testing for colorectal adenoma detection: evaluation in the target population of screening and comparison with qualitative tests. *Am J Gastroenterol* 2010;105:682–690.
28. De Wijkerslooth TR, Stoop EM, Bossuyt PM, et al. Immunochemical fecal occult blood testing is equally sensitive for proximal and distal advanced neoplasia. *Am J Gastroenterol* 2012;107:1570–1578.
29. Imperiale TF, Ransohoff DF, Itzkowitz SH, et al. Multitarget stool DNA testing for colorectal cancer screening. *N Engl J Med* 2014;371:187–188.
30. Atkin W, Edwards R, Kralj-Hans I, et al. Once-only sigmoidoscopy screening in the prevention of colorectal cancer :a multicenter randomized controlled trial. *Lancet* 2010;375:1624–1633.
31. Schoen RE, Pinsky PF, Weissfeld JL, et al. Colorectal incidence and mortality with

screening flexible sigmoidoscopy. *N Engl J Med* 2012;366:2345–2357.
32. Segnan N, Armoroli P, Bonelli L, et al. Once-only sigmoidoscopy in colorectal cancer screening: follow up findings of the Italian randomized controlled trial–SCORE. *J Natl Cancer Inst* 2011;103:1310–1322.
33. Lakoff J, Paszat LF, Saskin R, et al. Risk of developing proximal versus distal colorectal cancer after a negative colonoscopy: a population based study. *Clin Gastroenterol Hepatol* 2008;6:1117–1121.
34. Baxter NN, Goldwasser MA, Paszat LF, et al. Association of colonoscopy and death from colorectal cancer. *Ann Int Med* 2009;150:1–8.
35. Rabeneck L, Paszat LF, Saskin R, et al. Association between colonoscopy rates and colorectal cancer mortality. *Am J Gastroenterol* 2010;105:1627–1632.
36. Brenner H, Hoffmeister M, Volker A, et al. Protection from right-and left-sided colorectal neoplasms after colonoscopy: population-based study. *J Natl Cancer Inst* 2010;102:89–95.
37. Stock C, Knudsen AB, Lansdorp-Vogelaar L, et al. Colorectal cancer mortality prevented by use and attributable to colonoscopy. *Gastrointestuinal Endosc* 2011;73:435–443.
38. Singh H, Nugent Z, Demers AA, et al. The reduction in colorectal cancer mortality after colonoscopy varies by site of cancer. *Gastroenterology* 2010;139:1128–1137.
39. Imperiale TF, Wagner DR, Lin CY, et al. Risk of advanced proximal neoplasms in asymptomatic adults according to the distal colorectal findings. *N Engl J Med* 2000;343:169–174.
40. Lieberman DA, Weiss DG, Bond JH, et al. Use of colonoscopy to screen asymptomatic adults for colorectal cancer. Veterans Affairs Cooperative Study Group 380. *N Engl J Med* 2000;343:162–168.
41. Soetikno RM, Kaltenbach T, Rouse RV, et al. Prevalence of nonpolypoid (flat and depressed) colorectal neoplasms in asymptomatic and symptomatic adults. *JAMA* 2008;299:1027–1035.
42. Johnson DJ, Chen M-H, Toledano AY, et al. Accuracy of CT colonography for detection of large adenomas and cancer. *N Engl J Med* 2008;359:1207–1217.
43. Kim D, Pickhardt PJ, Taylor AJ, et al. CT colonography versus colonoscopy for the detection of advanced neoplasia. *N Engl J Med* 2007;357:1403–1412.
44. Patel S, Ahnen DJ. Prevention of interval colorectal cancers: what every clinician needs to know. *Clin Gastroenterol Hepatol* 2013;12:7–15.
45. Kaminski MF, Regula J, Krazewska E, et al. Quality indicators for colonoscopy and the risk of interval cancer. *N Engl J Med* 2010;362:1995–1803.
46. Baxter NN, Sutradhar R, Forbes SS, et al. Analysis of administrative data finds endoscopist quality measures associated with postcolonoscopy colorectal cancer. *Gastroenterology* 2011;140:65–72.
47. Lieberman DA, Weiss DG, Harford WV, et al. Five year colon surveillance after

screening colonoscopy. *Gastroenterology* 2007;133:1077–1085.
48. Lieberman DA. Colon polyp surveillance: clinical decision tool. *Gastroenterology* 2014;146:305–306.
49. Laiyemo AO, Murphy G, Albert PS, et al. Postpolypectomy colonoscopy surveillance guidelines: predictive accuracy for advanced adenomas at 4 years. *Ann Int Med* 2008;148:419–426.
50. Logan RF, Grainge MJ, Shepherd VC, et al. Aspirin and folic acid for prevention of recurrent colorectal adenomas. *Gastroenterology* 2008;134:29–38.
51. Baron JA, Cole BF, Sandler RS, et al. A randomized trial of aspirin to prevent colorectal adenomas. *N Engl J Med* 2003;348:891–899.
52. Bertagnolli MM, Eagle CJ, Zauber AG, et al. Celecoxib for the prevention of sporadic colorectal adenomas. *N Engl J Med* 2006;355:873–884.
53. Meyskins FL, McLaren CE, Pelot D, et al. Difluoromethylornithine plus sulindac for the prevention of sporadic colorectal adenomas: a randomized placebo-controlled, double-blind trial. *Cancer Prev Res* 2008;1:9–11.
54. Grau M, Baron JA, Sandler RS, et al. Prolonged effect of calcium supplementation on risk of colorectal adenomas in a randomized trial. *J Natl Cancer Inst* 2007;99:129–136.
55. West N, Phillips RK, Hutchinson JM, et al. Eicosapentaenoic acid reduces rectal polyp number and size in familial adenomatous polyposis. *Gut* 2010; 59:918–925.
56. Giardiello FM, Krush AJ, Petersen GM, et al. Phenotypic variability of familial adenomatous polyposis in 11 unrelated families with identical APC gene mutation. *Gastroenterology* 1994;106:1542–1547.
57. Vasen HF, Moslein G, Alonso A, et al. Guidelines for the clinical management of familial adenomatous polyposis. *Gut* 2008;57:704–713.
58. Skipworth JR, Morkane C, Raptis DA, et al. Pancreaticoduodenectomy for advanced duodenal and ampullary adenomatosis in familial adenomatous polyposis. *HBP (Oxford)* 201;13:342–349.
59. Sieber OM, Lipton L, Crabtree M, et al. Multiple colorectal adenomas, classic adenomatous polyposis, and germ-line mutations in MYH. *N Engl J Med* 2003;348:791–799.
60. Vogt S, Jones N, Christian D, et al. Expanded extracolonic tumor spectrum in MUTYH-associated polyposis. *Gastroenterology* 2009;137:1976–1985.
61. Wang L, Baudhuin LM, Boardman LA, et al. MYH mutations in patients with attenuated and classic polyposis and with young-onset colorectal cancer without polyps. *Gastroenterology* 2004;127:9–16.
62. Jones N, Vogt S, Nielsen M, et al. Increased colorectal cancer incidence in obligate carriers of heterozygous mutations in MUTYH. *Gastroenterology* 2009;137:489–494.
63. Bresalier RS. Management of high-risk colonoscopy patients. *Gastrointest Endos Clin N Am.* 2010;20:629–640.

64. Howe JR, Sayed MG, Ahmed AF, et al. The prevalence of MADH4 and BMPR1A mutations in juvenile polyposis and absence of BMPR2, BMPR1B, and ACVR1 mutations. *J Med Genet* 2004;41:484–491.
65. Howe JR, Shellnut J, Wagner B, et al. Common deletion of SMAD4 in juvenile polyposis is a mutational hotspot. *Am J Hum Genet* 2002;70:1357–1362.
66. Marsh DJ, Coulon V, Lunetta KL, et al. Mutation spectrum and genotype-phenotype analyses in Cowden disease and Bannayan-Zonana syndrome, two hamartoma syndromes with germline PTEN mutation. *Hum Mol Genet* 1998;7:507–515.
67. Chi SG, Kim HJ, Park BJ, et al. Mutational abrogation of the PTEN/MMAC1 gene in gastrointestinal polyps in patients with Cowden disease. *Gastroenterology* 1998;115:1084–1089.
68. Marra G, Armelao F, Vecchio FM, et al. Cowden's disease with extensive gastrointestinal polyposis. *J Clin Gastroenterol* 1994;18:42–47.
69. Tan MH, Mester JL, Ngeow J, et al. Lifetime cancer risks in individuals with germline PTEN mutations. *Clin Cancer Res* 2012;18:400–407.
70. Eng C. PTEN: one gene, many syndromes. *Hum Mutat* 2003;22:183–198.

Chapter 68

Colorectal Cancer

Julio Garcia-Aguilar

Key Points

1. Incidence and overall mortality for colorectal cancer (CRC) are decreasing, most likely due to increased screening. Risk-factor modification and improved therapy also likely contribute to this trend.
2. Our greater understanding of the molecular biology of CRC may provide a means of identifying disease biomarkers and developing more targeted therapies.
3. Advances in imaging techniques have improved risk stratification via more accurate baseline tumor staging and treatment selection.
4. Improved risk stratification and neoadjuvant therapy have enabled physicians to eliminate some therapeutic components in some patients' treatment regimens.
5. Use of laparoscopic and robotic surgical techniques in combination with enhanced recovery programs has accelerated patient recovery, reduced length of hospital stay, and reduced postoperative complications.
6. While long-term survival for patients with stage IV disease remains low, median survival for these patients has improved significantly in recent years, probably due to more effective chemotherapy and more aggressive surgery.
7. Multidisciplinary treatment involving surgical oncologists, medical oncologists, radiation oncologists, as well as liver surgeons, gastroenterologists, and stoma therapists improves outcomes and quality of life in patients with CRC.

Colorectal cancer kills tens of thousands of people every year in the United States. If diagnosed at an early stage, however, it is one of the most curable malignancies. Identification of populations at risk and screening of asymptomatic patients are therefore crucial imperatives. This chapter provides a comprehensive overview of the disease, including epidemiology, risk factors, molecular characteristics, progression, staging, screening, diagnosis, and treatment.

EPIDEMIOLOGY

1 Colorectal cancer (CRC) is the third most common malignancy and the second most common cause of cancer death in the United States. It is estimated that in 2015, a total of 132,700 people were diagnosed with CRC in the United States, and 49,700 died from the disease.[1] Approximately 1 in 20 Americans will be diagnosed with CRC in their lifetime. Death from CRC could be reduced significantly by applying current knowledge about screening, early diagnosis, and treatment standards. The incidence and mortality rates for CRC have been decreasing for the last three decades, but the decreases have accelerated since 2001 (Fig. 68-1). Between 2007 and 2011, the incidence of CRC decreased at a rate of 3.6% for both genders, and mortality at a rate of 2.6% in males and 3% in females. The declines in incidence and mortality have been attributed to the detection and removal of precancerous polyps as a result of CRC screening programs, changing patterns in CRC risk factors, and improvements in treatment.

The incidence and mortality rates for CRC increase with age. The median age at colon cancer diagnosis is 69 years in men and 74 years in women; for rectal cancer, 63 in men and 65 in women. More than 90% of CRCs are diagnosed in patients 50 years or older. Both the incidence and mortality for CRC are 30% to 40% higher in men than in women. The reasons for these differences are not completely understood but probably reflect an interaction between risk factors and hormonal differences. There are also gender differences in the distribution of CRC, with a higher proportion of proximal tumors in women.

There are great disparities in CRC incidence and mortality between ethnic and racial groups. Both are highest for African Americans and lowest for Asians/Pacific Islanders, but the differences in mortality are proportionally larger compared to the differences in incidence. The decline in mortality for CRC that began in the 1980s did not start affecting African Americans until the 1990s. These differences are attributed to disparities in access to screening and care. The decline in CRC-related mortality among African Americans has also accelerated in recent years.[2]

CRC is the third most common cancer in men and the second most common cancer in women worldwide, with an estimated 1.4 million new cases diagnosed in 2012 (Fig. 68-2). It is responsible for 8% of cancer deaths worldwide. The age-standardized incidence of CRC varies significantly in different countries. It is highest in North America, New Zealand, Australia and Western Europe and lowest in India and many African countries. While the incidence is decreasing in some developed countries (United States) and stabilizing in others (France, Australia), it is increasing in Asia (Japan) and the Middle East (Kuwait), Eastern European countries (Czech Republic, Slovakia, Slovenia), and some Southern European countries (Spain). The increase in incidence has been attributed to changes in risk factors, such as the Westernization of diets, obesity, and smoking. However, despite the increase in incidence, mortality for CRC is decreasing in many countries, most likely because of improvements in both screening and treatment.[2]

RISK FACTORS

There are numerous factors associated with the risk of CRC (Table 68-1).[3] Some are behavioral, and potentially modifiable. Others are genetic or hereditary, and therefore nonmodifiable. Information about individual risk factors can be used to reduce incidence and mortality through behavior modification and screening programs.[4] Except for the relatively uncommon hereditary syndromes with known patterns of inheritance, the relative contribution of inherited and environmental factors to the development of CRC is controversial. Analysis of cohorts of twins from Scandinavian countries suggests a significant but relatively minor contribution of hereditary factors to the development of sporadic CRC; the environment seems to play a larger role in the development of sporadic cancers.[5]

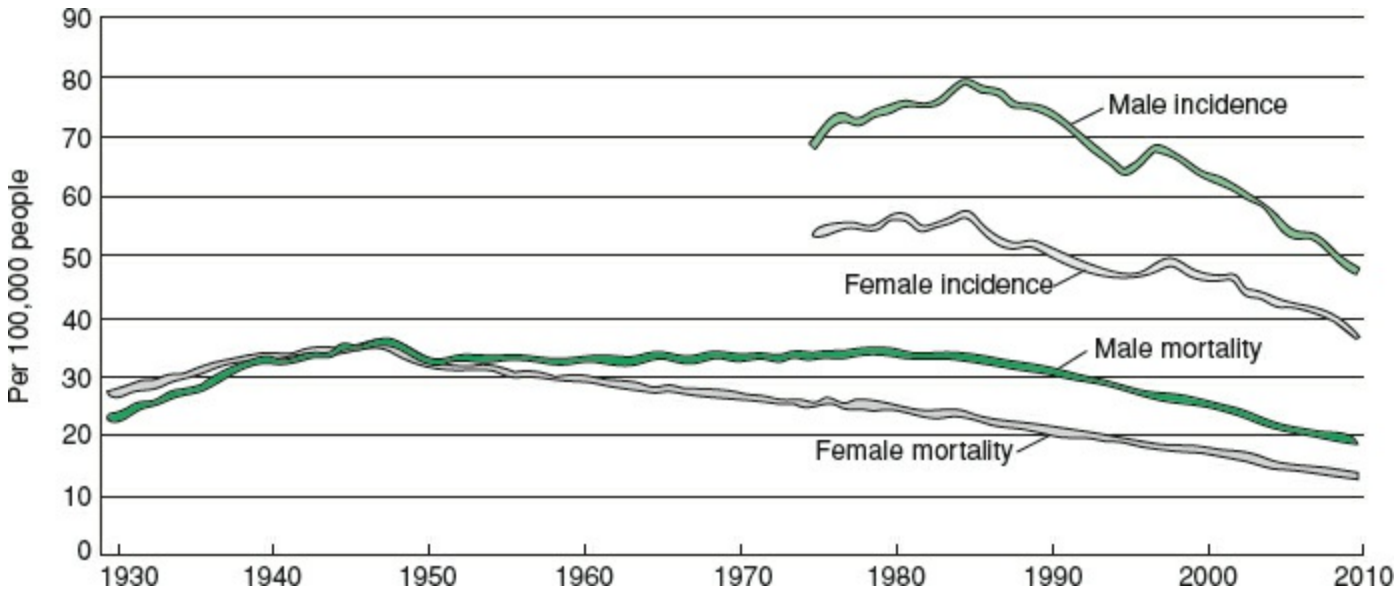

Figure 68-1. Trends in Colorectal Cancer Incidence and Death Rates by Sex, USA, 1930–2010. (From The American Cancer Society, Colorectal Cancer Facts and Figures 2014–2016.)

The list of behavioral or modifiable factors includes obesity, physical inactivity, smoking, diet, and alcohol intake.[6] Obesity is associated with increased risk of developing CRC in both men and women.[7,8] Abdominal obesity, measured as waist size, seems to be more important than excess weight, particularly in men. Being overweight increases the risk of CRC, independent of the level of physical activity. The most physically active people have a 25% lower risk of developing CRC, compared to the least active people. Both recreational and occupational physical activity reduces CRC risk, and sedentary people who become physically active later in life do reduce their CRC risk.[9] The geographical differences in the incidence of CRC, and the change in incidence in migrant populations, suggest that diet is probably an important risk factor.[10] The risk of CRC has been associated with a high consumption of red or processed meats.[11,12] On the other hand, the risk of CRC is inversely correlated with the intake of fiber and whole grains, fruits and vegetable, dairy products and calcium, vitamin D, and folates.[6] Alcohol consumption is causally associated with the development of CRC, and the effect seems to

be dose-dependent. The risk seems to be higher for men than for women. There is no difference in the effect with regard to the type of alcohol.[13] Smoking increases the incidence and mortality from CRC, and in particular, rectal cancer.[14,15]

Table 68-1 Factors Associated with Risk of Developing Colorectal Cancer

Factors That Increase Risk
Behavioral, Modifiable
Heavy EtOH use (2–4 drinks/day)
Obesity
Red or processed meats
Smoking
Physical inactivity
Hereditary, Nonmodifiable
Hereditary Polyposis and Nonpolyposis Syndromes
Family History
First-degree relative with CRC
Multiple relatives with CRC
Relative diagnosed with CRC before age 45
Medical History
Inflammatory bowel disease (Crohn disease, ulcerative colitis)
Diabetes
Factors That Decrease Risk
Physical activity
Dairy
Fruit and vegetable
Dietary fiber
Vitamin D and folates

Three-quarters of CRCs occur in people who do not have any particular predisposing factors, and who are therefore considered to be at average risk. The remaining 25% of patients have hereditary risk factors that predispose them to the development of CRC: either a well-defined hereditary CRC syndrome (5%) or a close relative who has been diagnosed with the disease (20%). People with a first-degree relative with CRC have between a 1.9 and 4.4 relative risk of developing CRC, compared to the average population. The risk is higher when the affected relative was diagnosed at an early age, or when several relatives have been affected.[16,17] CRC survivors have four times the lifetime risk of developing a new (metachronous) CRC, compared with people at average risk. The estimated mean annual incidence of metachronous CRC is 0.3%, with a cumulative incidence of 3.1% at 10 years.[18] A personal history of adenomatous colorectal polyps also increases the risk of CRC, in particular for patients with larger or multiple

polyps and an early age at diagnosis.[19]

Patients with chronic inflammatory bowel disease, both ulcerative colitis and Crohn disease, are at increased risk of developing CRC.[20,21] The risk increases with the duration of the disease. It is estimated that, after 10 years of disease, the risk of developing CRC increases by around 1% each year. Thus, it is estimated that patients with 30 years of inflammatory bowel disease have an 18% risk of developing CRC. The risk is higher for patients diagnosed with inflammatory bowel disease at an early age, and with disease extending proximal to the splenic flexure. However, the incidence of CRC in patients with ulcerative colitis seems to be decreasing. A recent meta-analysis of population-based cohort studies reported a 1.7 increased risk of CRC among inflammatory bowel disease patients, compared to the general population, after adjusting for age, gender, and duration of disease.[22] These changes are probably due to more effective treatments and the efficacy of surveillance programs.[23]

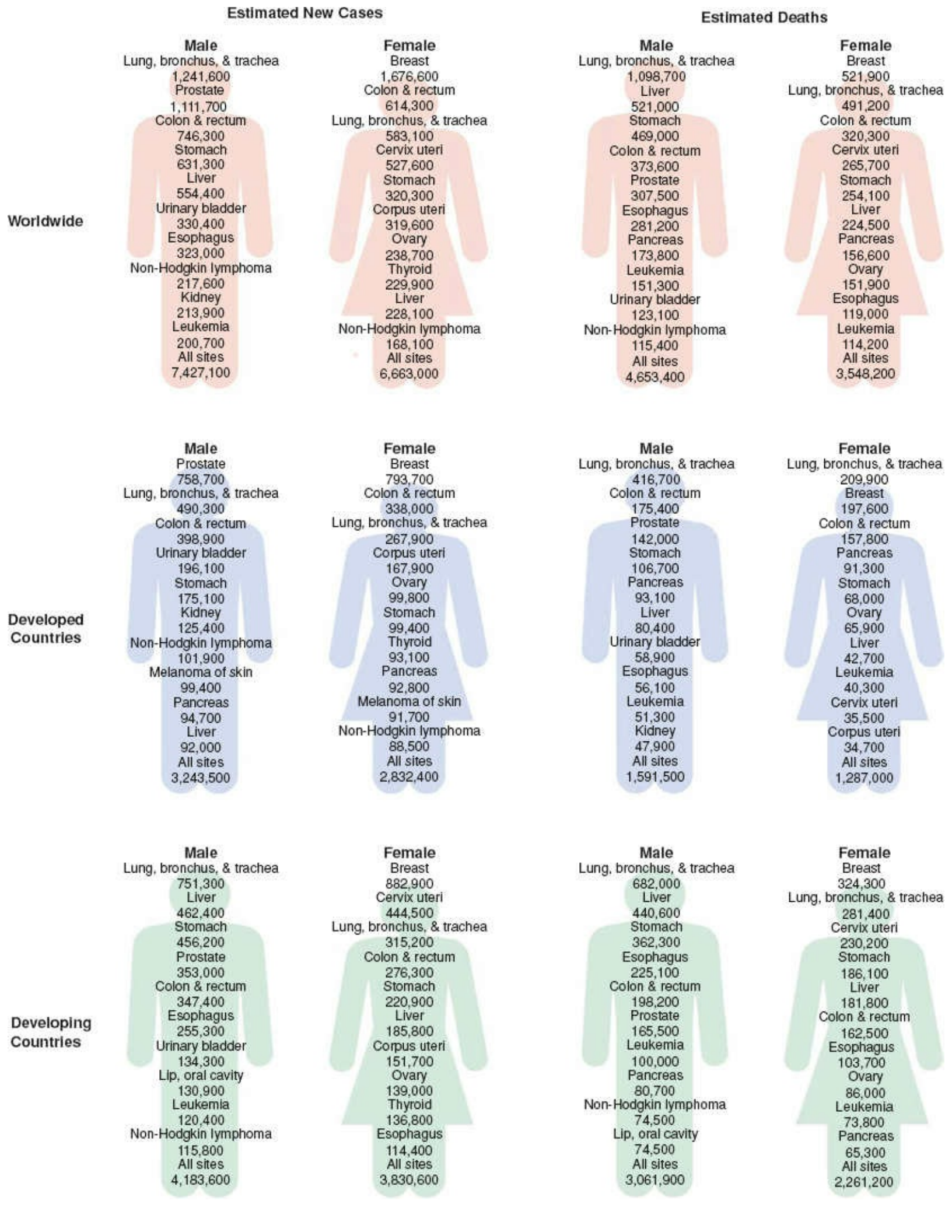
Estimated New Cases
Estimated Deaths
Worldwide
Male
Lung, bronchus, & trachea
1,241,600
Prostate
1,111,700
Colon & rectum
746,300
Stomach
631,300
Liver
554,400
Urinary bladder
330,400
Esophagus
323,000
Non-Hodgkin lymphoma
217,600
Kidney
213,900
Leukemia
200,700
All sites
7,427,100
Female
Breast
1,676,600
Colon & rectum
614,300
Lung, bronchus, & trachea
583,100
Cervix uteri
527,600
Stomach
320,300
Corpus uteri
319,600
Ovary
238,700
Thyroid
229,900
Liver
228,100
Non-Hodgkin lymphoma
168,100
All sites
6,663,000
Male
Lung, bronchus, & trachea
1,098,700
Liver
521,000
Stomach
469,000
Colon & rectum
373,600
Prostate
307,500
Esophagus
281,200
Pancreas
173,800
Leukemia
151,300
Urinary bladder
123,100
Non-Hodgkin lymphoma
115,400
All sites
4,653,400
Female
Breast
521,900
Lung, bronchus, & trachea
491,200
Colon & rectum
320,300
Cervix uteri
265,700
Stomach
254,100
Liver
224,500
Pancreas
156,600
Ovary
151,900
Esophagus
119,000
Leukemia
114,200
All sites
3,548,200
Developed Countries
Male
Prostate
758,700
Lung, bronchus, & trachea
490,300
Colon & rectum
398,900
Urinary bladder
196,100
Stomach
175,100
Kidney
125,400
Non-Hodgkin lymphoma
101,900
Melanoma of skin
99,400
Pancreas
94,700
Liver
92,000
All sites
3,243,500
Female
Breast
793,700
Colon & rectum
338,000
Lung, bronchus, & trachea
267,900
Corpus uteri
167,900
Ovary
99,800
Stomach
99,400
Thyroid
93,100
Pancreas
92,800
Melanoma of skin
91,700
Non-Hodgkin lymphoma
88,500
All sites
2,832,400
Male
Lung, bronchus, & trachea
416,700
Colon & rectum
175,400
Prostate
142,000
Stomach
106,700
Pancreas
93,100
Liver
80,400
Urinary bladder
58,900
Esophagus
56,100
Leukemia
51,300
Kidney
47,900
All sites
1,591,500
Female
Lung, bronchus, & trachea
209,900
Breast
197,600
Colon & rectum
157,800
Pancreas
91,300
Stomach
68,000
Ovary
65,900
Liver
42,700
Leukemia
40,300
Cervix uteri
35,500
Corpus uteri
34,700
All sites
1,287,000
Developing Countries
Male
Lung, bronchus, & trachea
751,300
Liver
462,400
Stomach
456,200
Prostate
353,000
Colon & rectum
347,400
Esophagus
255,300
Urinary bladder
134,300
Lip, oral cavity
130,900
Leukemia
120,400
Non-Hodgkin lymphoma
115,800
All sites
4,183,600
Female
Breast
882,900
Cervix uteri
444,500
Lung, bronchus, & trachea
315,200
Colon & rectum
276,300
Stomach
220,900
Liver
185,800
Corpus uteri
151,700
Ovary
139,000
Thyroid
136,800
Esophagus
114,400
All sites
3,830,600
Male
Lung, bronchus, & trachea
682,000
Liver
440,600
Stomach
362,300
Esophagus
225,100
Colon & rectum
198,200
Prostate
165,500
Leukemia
100,000
Pancreas
80,700
Non-Hodgkin lymphoma
74,500
Lip, oral cavity
74,500
All sites
3,061,900
Female
Breast
324,300
Lung, bronchus, & trachea
281,400
Cervix uteri
230,200
Stomach
186,100
Liver
181,800
Colon & rectum
162,500
Esophagus
103,700
Ovary
86,000
Leukemia
73,800
Pancreas
65,300
All sites
2,261,200

Figure 68-2. Estimated New Cancer Cases and Deaths Worldwide for Leading Cancer Sites by Sex and Level of Economic Development, 2012 (excluding nonmelanoma skin cancers). (From Torre LA, Bray F, Siegel RL, et al. Global Cancer Statistics, 2012. *CA Cancer J Clin* 2015;65:87–108.)

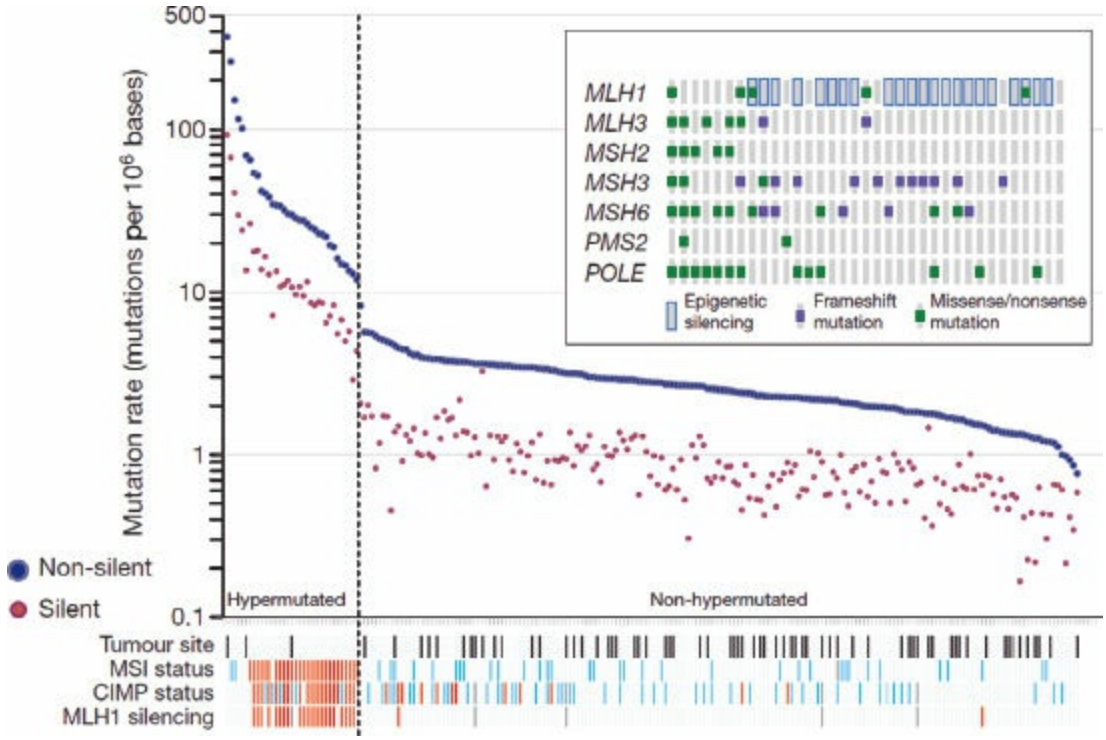

Figure 68-3. Mutation frequency across 224 human colorectal cancer samples from The Cancer Genome Atlas. Note the clear separation of hypermutated (median of 728 nonsilent mutations per tumor) and nonhypermutated (median of 58 nonsilent mutations). Red, MSI high, CIMP high, or MLH1 silenced; light blue, MSI low, or CIMP low; black, rectum; white, colon; gray, no data. (From Comprehensive Molecular Characterization of Human Colon and Rectal Cancer. The Cancer Genome Atlas Network. *Nature* 2012;487(7407):330–337.)

Patients with type II diabetes have a higher risk of developing CRC compared to the nondiabetic individual, even when adjusting for factors such as obesity and sedentary lifestyle.[24] In addition, CRC survival rates are lower for diabetic patients compared to nondiabetic patients.[25] The relationship between diabetes and CRC seems to be stronger for men than for women.

MOLECULAR CHARACTERISTICS

2 The traditional model of CRC tumor development is often represented as a linear and sequential progression from normal epithelium to small adenoma, to large adenoma, to invasive carcinoma, and finally to metastatic disease.[26] This so-called adenoma–carcinoma sequence has been deemed the result of the progressive accumulation of alterations in the genome. This model has shaped our understanding of key genetic alterations that result in colorectal tumorigenesis, and has had an enormous clinical impact by highlighting the importance of screening and surveillance. Whole genome analysis with high-throughput technologies has added new information that is broadening our understanding of colorectal carcinogenesis. Every CRC has a multitude of distinct genetic alterations that perturb a number of molecular pathways. This genetic heterogeneity ultimately has a bearing on the speed of growth, local invasiveness, metastatic potential, and response to therapy. As our understanding of these molecular changes improves, we anticipate that we will be able to provide better screening and prognostic tools, and discover new tumor-specific therapies.

The most comprehensive molecular analysis of CRC to date has been conducted by The Cancer Genome Atlas Consortium.[27] They have used state of the art technology to elucidate the mutational spectrum, the chromosomal and sub-chromosomal changes, the epigenetic regulation and transcriptional alterations in a large number of CRCs. A key finding that has helped frame our molecular understanding of CRC is the wide variation in the number of somatic mutations present in most tumors. According to the number of mutations, CRC can be effectively classified as hypermutated, harboring a median of 728 nonsilent mutations per tumor, and nonhypermutated, with a median of 58 nonsilent mutations (Fig. 68-3). Nonhypermutated tumors comprise 84% of CRCs, and are characterized by chromosomal instability (CIN). CIN is the result of missegregation of chromatids in tumor cells, resulting in gains and losses of entire chromosomes or chromosomal segments; manifesting as aneuploidy and copy number alterations (CNA).[28] Common patterns of aneuploidy and CNAs in nonhypermutated CRC include amplifications in chromosome arms 1q, 7p and q, 8q, 13q, 17q, and 20p/q, and deletions in 8p, 14q, 15q, 17p, and 18p/q. Some of these CNAs could account for the loss of important tumor suppressors such as TP53 (on 17p), DCC, and SMAD4 (on 18q), and the amplification of oncogenes such as ERBB2 (on 17q). In short, CIN in nonhypermutated tumors can activate critical oncogenes, and inactivate tumor suppressors that contribute to the acquisition of tumorigenic traits.

The hypermutated tumors, representing 16% of all CRCs, are deficient in the mismatch-repair (MMR) mechanisms controlling the correction of errors that occur during DNA replication. The end result of MMR deficiency is a form of genetic instability characterized by the accumulation of mutations throughout the genome, primarily in repetitive sequences known as microsatellites; this is known as microsatellite instability (MSI).[29] The mutational burden ultimately provides these MSI tumors with their malignant potential. Unlike CIN tumors, MSI tumors generally remain diploid or near-diploid. They are less likely to have KRAS, TP53, SMAD4 mutations, and more likely to

have BRAF and TGFBR2 mutations (Fig. 68-4). MSI can arise from either the germline inactivating mutations or the epigenetic silencing of one of several MMR genes (MLH1, MLH3, MSH2, MSH3, and MSH6). Research into the mechanisms of epigenetic silencing of MSI tumors has helped elucidate the CpG Island Methylator Phenotype (CIMP), whereby the methylation of CpG sequences in the promoter region of MMR genes (most commonly MLH1) leads to their transcriptional silencing.

The classification of CRC according to the type of genomic instability is clinically relevant. MSI tumors tend to be preferentially right sided, have a solid or cribriform histologic pattern, contain large number of tumor-infiltrating lymphocytes, are less responsive to fluoropyrimidine, and in general carry a better prognosis, compared to CIN tumors.

The genomic instability that characterizes CRC is associated with alterations in a number of key pathways; among others, the WNT, MAPK, PI3K, TGF-β and p53 pathways (Fig. 68-5). The WNT signaling pathway contributes to the tightly regulated homeostasis of intestinal epithelial crypts, and its alteration is considered an initiating event in colorectal carcinogenesis. The WNT signaling pathway is altered in greater than 90% of both hypermutated and nonhypermutated CRCs. The most prevalent alteration leading to dysregulation of the WNT pathway occurs through biallelic inactivation of the tumor suppressor adenomatous polyposis coli (APC) gene.[30] Patients with familial adenomatous polyposis (FAP) have a germline mutation in one allele of the APC gene, and their risk of developing CRC is virtually 100%. The WNT pathway is also commonly altered as a result of stabilizing mutations of the CTNNB1 gene coding for β-catenin, a protein normally targeted for degradation by APC. The accumulation of β-catenin as a result of APC loss or stabilizing CTNNB1 mutations leads to its translocation to the nucleus, where it interacts with transcription factors of the TCF/LCF family, turning them into transcriptional activators. The end result is an increase in the transcription of genes that are normally important for stem cell renewal and differentiation but, when inappropriately expressed at high levels, can cause cancer.

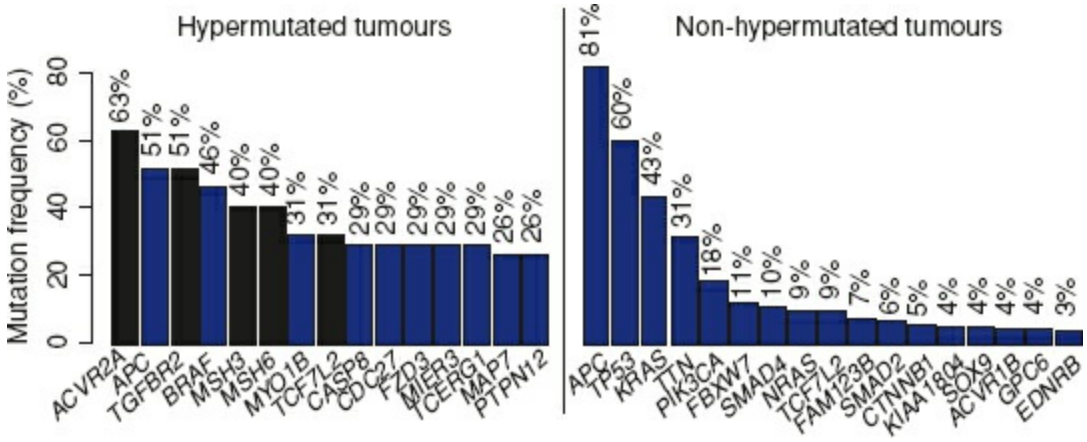

Figure 68-4. Most significantly mutated genes in hypermutated and nonhypermutated tumors. Blue bars represent genes identified using the MutSig algorithm, and black bars represent genes identified by manual examination of sequence data. (From Comprehensive Molecular Characterization of Human Colon and Rectal Cancer. The Cancer Genome Atlas Network. *Nature* 2012;487(7407):330–337.)

Mutational inactivation of the TGF-β pathway, important in regulating cell growth arrest and apoptosis, is a common event in CRC.[31] In the majority of hypermutated tumors, the TGF-β gene is inactivated by a frameshift mutation in a polyadenine repeat within the coding sequence. It can also be inactivated by point mutation in the kinase domain. Downstream effectors of this pathway such as the transcription factor SMAD4, and associated proteins SMAD2 and SMAD3, are also inactivated by mutation or homozygous deletion of chromosomal segment 18q. Another member of this pathway, deleted in CRC (DCC), is also commonly inactivated by deletion of chromosome 18q.

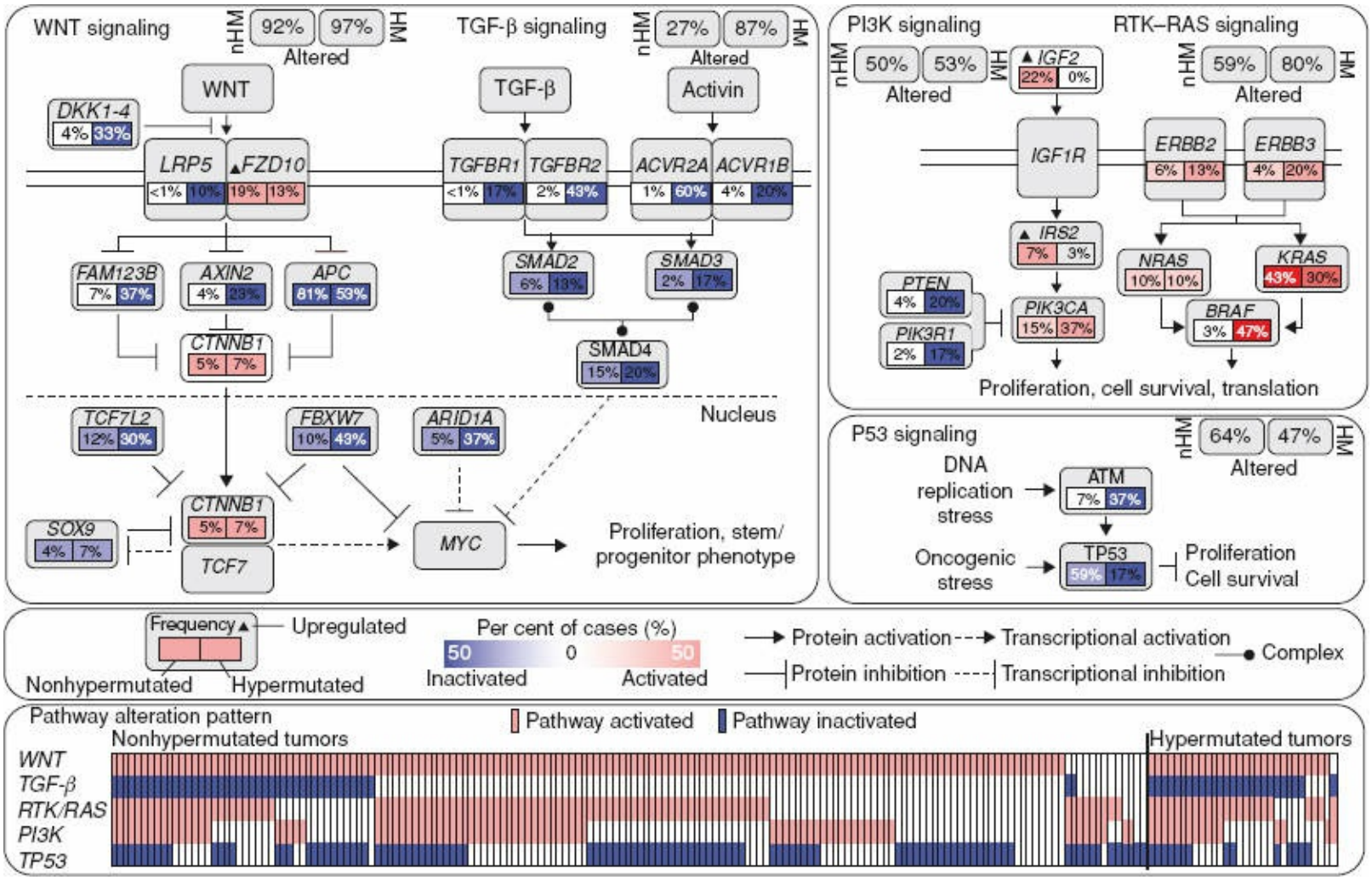

Figure 68-5. Frequency of genetic changes leading to deregulation of recognized signaling pathways in CRC. Alterations are defined as somatic mutations, homozygous deletions, high-level focal amplifications, and in some cases, significant up- or downregulation of gene expression. Red/blue denote activation/inactivation, respectively. Bottom panel shows alterations across samples in five main pathways (WNT, TGF-B, RTK/KRAS, PI3K, TP53, if at least one gene in the pathway is altered). nHM, nonhypermutated; HM, hypermutated. (From Comprehensive Molecular Characterization of Human Colon and Rectal Cancer. The Cancer Genome Atlas Network. *Nature* 2012;487(7407):330–337.)

A common theme of the WNT and TGF-β signaling pathways is the increased activity of c-Myc, a regulator gene that codes for a multifunctional transcription factor which plays a role in cell cycle progression, apoptosis, and cellular transformation. c-Myc seems to play a central role in colorectal carcinogenesis.[32]

The TP53 gene is a member of a pathway of regulators of cell cycle arrest and cell

death in response to a variety of genotoxic stresses. Mutations in the TP53 tumor suppressor gene occur in more than half of nonhypermutated CRCs. In most tumors, both alleles of the gene are inactivated by a combination of a mutation in one allele, and loss of the second allele by deletion of the chromosomal segment 17p. Loss of the TP53 tumor suppressor gene is generally considered an early event that plays a role in the transition from adenoma to invasive carcinoma.[33] In hypermutated tumors, the TP53 pathway may be attenuated by mutations in other genes, such as the proapoptotic BAX.

The MAPK pathway consists of a cascade of tightly coordinate kinases that work together to regulate cell division and proliferation. KRAS, a protooncogene that becomes constitutively activated by mutation, resulting in uncontrolled cell proliferation, is mutated in 37% of CRC. Interestingly, a number of studies from model organisms reveal that KRAS mutation by itself is not sufficient to initiate tumorigenesis; in order to have oncogenic potential it requires a previous APC mutation. The MAPK pathway is the molecular pathway that has successfully been therapeutically targeted in CRC. Inhibition of this pathway using antibodies against the epidermal growth factor receptor (EGFR) reduces progression in wild-type KRAS/NRAS metastatic CRC.[34] Activating mutations of BRAF, also an effector member of the MAPK pathway downstream of KRAS, are seen in 13% of CRC. The BRAF mutation, found almost exclusively in hypermutated tumors, has been associated with poor prognosis.

The PI3K/AKT/mTOR signaling pathway, with important roles in cell proliferation and apoptosis, is abnormally activated in nearly half of all CRCs. Moreover, in the TCGA cohort, PI3K and RAS pathways are simultaneously affected by mutations in one-third of all CRCs, suggesting that simultaneous inhibition of both pathways may be required to achieve a therapeutic effect.[35]

The characterization of genome-level alterations in CRC has led to the identification of new sub-classifications that share marked similarities across genomic structure, gene and protein expression, and even the activity of the tumor microenvironment.[36–39] While these sub-classifications continue to be resolved and studied, they have shown potential to prognosticate tumor behavior and oncologic outcomes.[40]

The advances in genomic characterizations have revealed CRC to be a heterogeneous and complex disease. While the patterns of genomic instability and alterations of signaling pathways are aligned with specific phenotypic tumor characteristics, many tumors do not fit cleanly into any single category. Rather, they may host elements of genomic instability and dysregulated signaling pathways that may not be well characterized yet.

HISTOPATHOLOGY AND PROGRESSION

CRC is an adenocarcinoma arising from the epithelial lining of the large bowel. Some CRCs may develop de novo, but most result from malignant transformation of adenomatous polyps. In the past, only tubular and villous adenomas were considered to develop into invasive adenocarcinomas. However, recent evidence suggests that serrated polyps can also develop into CRCs. Polyps arise from normal mucosa, and gradually increase in size. Some polyp characteristics – size larger than 1 cm, tubulovillous or villous histology, multiple occurrences – are associated with a high risk of malignant transformation. Most screening programs are designed to recognize the presence of polyps, or early malignant change in polyps or the surrounding mucosa.

HISTOPATHOLOGIC TYPES OF COLORECTAL CANCER

Table 68-2 Colorectal Cancer: Histopathologic Types

Carcinomas
Adenocarcinoma
Medullary carcinoma
Mucinous adenocarcinoma (greater than 50% mucine content)
Signet ring cell carcinoma (greater than 50% signet ring cells)
Neuroendocrine adenocarcinoma
Squamous cell carcinoma
Adenosquamous carcinoma
Small cell carcinoma
Undifferentiated carcinoma
Other Tumors
Carcinoid
Lymphoma
Sarcomas

The majority of CRCs are typically adenocarcinomas that form glandular structures resembling the normal colonic epithelium. However, there are several histologic types of adenocarcinoma (Table 68-2). Colorectal adenocarcinomas are assigned to one of four histologic grades according to their histologic resemblance to the normal colonic epithelium (Table 68-3). The histologic grade is associated with oncologic outcome independent of other risk factors, including tumor staging.

CRC is locally invasive, potentially spreading through the full thickness of the bowel wall into adjacent tissues. From the primary site, CRC often extends to the regional lymph nodes and to other organs. CRC can metastasize to almost any organ, but the most common sites are the liver and lungs. Approximately 20% to 34% of patients have metastases at the time of diagnosis, and another 30% of those initially treated with curative intent will subsequently develop distant metastases. Other sites of distant

metastasis are the brain and bones, but these are unusual in the absence of liver metastases. Patients may also develop peritoneal spread, with the formation of malignant ascites. The risk of nodal metastasis increases with the depth of tumor invasion into the bowel wall, and the risk of distant metastasis is higher for patients with nodal metastasis.

STAGING AND PROGNOSIS

The anatomical extent or stage of the tumor at the time of diagnosis is a key factor in deciding upon treatment and defining prognosis in patients with CRC. The tumor–node–metastasis (TNM) classification developed by the UICC/AJCC is firmly established as the preferred staging system (Table 68-4). It classifies CRC according to the extent of the primary tumor (T), the involvement of the regional lymph nodes (N), and the presence or absence of distant metastasis (M). The TNM classification is important for both clinical and pathologic staging. Most colon cancers, and many rectal cancers, are staged after surgery and pathologic examination of the surgical specimen (pTNM). Many rectal cancer patients, and a small but growing number of colon cancer patients, do not receive surgery as the initial therapy, which makes clinical TNM (cTNM) staging based on medical history, physical examination, endoscopy, and imaging, increasingly important. As tumors experience a variable degree of regression with preoperative chemotherapy and/or radiation, it is important that patients receiving neoadjuvant therapy are assigned an accurate cTNM stage before starting treatment. For patients who have received neoadjuvant therapy, a modified pathologic staging is generated after surgical resection, annotated by the prefix y (ypTNM). The 7th edition of the AJCC Cancer Staging Manual incorporates a four-tier tumor regression grading (TRG) system for patients receiving neoadjuvant therapy. In this grading system TRG 0 represents Complete Response, no viable tumor cells or complete pathologic response (pCR); TRG 1, Moderate Response; TRG 2, Minimal Response; and TRG 3, Poor Response. Tumor regression seems to correlate closely with prognosis and long-term oncologic outcome.[41]

HISTOLOGIC GRADE

Table 68-3 Histologic Grading

G1	Well differentiated
G2	Moderately differentiated
G3	Poorly differentiated
G4	Undifferentiated
GX	Grade cannot be assessed

The AJCC staging system is updated periodically in response to newly acquired clinical data and understanding of the biology of the tumor. The 7th edition of the AJCC Cancer Staging Manual, for all cancers diagnosed after January 1, 2010, was updated based on observed survival outcomes obtained from the National Cancer Institute's Surveillance, Epidemiology, and End Results (SEER) program.[42] Relative survival in CRC patients decreases according to the depth of tumor penetration into the bowel wall and number of lymph nodes involved, but the presence of distant metastasis is the single most important predictor of survival in these patients (Table 68-4). Other tumor and treatment-related prognostic factors, in addition to the TNM stage, are listed in Table 68-5.

Quantitative parameters of lymph node evaluation – number of positive lymph nodes,

total number of lymph nodes examined, and lymph node ratio – have prognostic implications in CRC. The number of nodes involved by tumor is included in the N category of the TNM system. The current staging system recommends examining a minimum of 12 lymph nodes for adequate staging.[42] The total number of lymph nodes retrieved is lower in rectal cancer patients treated with preoperative chemotherapy and radiation, but the minimal number of nodes required for adequate staging in these patients is unknown. The total number of nodes examined has an important impact on outcome in patients with colon and rectal cancer; in patients with all T and N combinations, the probability of survival increases linearly with the number of lymph nodes examined. The lymph node ratio, defined as the number of positive lymph nodes divided by the total number of retrieved nodes, has also been considered an independent predictor of survival.[43,44] However, the results have not been extensively validated and the lymph node ratio is not currently included in staging. Irregular tumor deposits in the mesocolon or mesorectum without surrounding lymph node tissue, are considered peritumoral tumor deposits; they are not counted as lymph nodes but are classified as N1c, and contribute to stage III.[42] These are considered to represent large vessel or perineural invasion. The significance of micrometastasis detected by immunohistochemistry (usually with anticytokeratin antibodies) in H&E negative nodes of patients with stage II disease is controversial. Although some studies have reported an association between micrometastasis, increased recurrence and reduced survival, the detection of micrometastasis has not been incorporated into clinical practice, and at the present time should be considered investigational.[45,46]

The location of the tumor also provides prognostic information. In general, tumors located in the right colon have better prognosis compared with tumors located in the left or transverse colon. This may be attributed, in part, to the higher proportion of MSI tumors in the right side of the colon. In patients with rectal cancer, tumors located in the distal rectum have worse prognosis compared to tumors located in the upper rectum.

The quality of the surgery and the completeness of tumor resection also provide important prognostic information. The distance of tumor to the circumferential resection margin (CRM) – defined as the surgically dissected nonperitonealized surface of the specimen – provides important prognostic information in both colon and rectal cancers. The presence of tumor at the CRM, because of advanced stage or inadequate resection, is associated with a high rate of recurrence and decreased probability of survival. In rectal cancer patients, the CRM is defined as positive if the tumor, either by direct tumor extension or positive lymph node, is equal to or less than 1 mm from the resection margin.

The AJCC has established codes for completeness of the resection, which should be reported for each procedure.[42] A resection is defined as R0 when the entire tumor is resected and the margins are histologically negative; R1 when the margins are grossly uninvolved but histologically positive; and R2 when the tumor is not completely resected, and there is gross residual tumor at the primary site, regional lymph nodes, or metastatic sites.

Other factors associated with worse outcomes include elevated CEA levels before

surgery, high histologic grade, signet ring cell and small cell histopathologic type, lymphatic and blood vessel invasion, and perineural invasion.[47–52] Vascular invasion is considered a sign of aggressive behavior in CRC, and has been associated with a higher risk of disease progression and poor prognosis. Capillary invasion is often associated with lymphatic invasion, and these are commonly designated as lymphovascular invasion. Large vessel invasion, detectable on magnetic resonance imaging (MRI), is now reported separately.

While the TNM staging system provides important prognostic information, it is inadequate for individual prognostication. Outcomes for individual patients within each tumor stage are variable. Recently, nomograms using a number of clinical and pathologic characteristics have been designed to improve prediction and survival beyond TNM staging in patients with colon or rectal cancer, particularly in the setting of stage II tumors (Fig. 68-6).[53] In addition to providing prognostic information, nomograms may potentially guide clinical decisions, such as the use of adjuvant chemotherapy or the regularity of surveillance. However, nomograms have not become part of the treatment strategy.

A number of molecular markers such as MSI, 18q loss of heterozygosity, TP53, p21, among others, have been associated with prognosis in CRC patients. But none of these are routinely incorporated into clinical practice. Somatic RAS mutations have been associated with lack of response to anti–EGFR targeted therapies, and clinical guidelines worldwide now recommend testing for both KRAS and NRAS mutations if anti-EGFR therapy is contemplated in patients with stage IV disease.[54] In addition, when a KRAS or NRAS mutation is not found, some recommend V600E BRAF testing because the data suggest that those tumors are also unresponsive to anti-EGFR therapy. However, these mutations have not been incorporated into the staging system.

Based on recent advances in the molecular characterization of CRC, a number of multigene molecular signatures have been designed as prognosticators of recurrence and outcomes. The Onco*type* DX Colon Cancer Assay, developed by Genomic Health, Inc. (Redwood City, CA, USA) is an assay based on the expression of 12 genes that play roles in cell-cycle and stromal responses.[55,56] The assay was designed and validated using formalin-fixed, paraffin-embedded tissue samples from patients enrolled in the Cancer and Leukemia Group B (CALGB) 9581 cohort.[57,58] The predictive model provides a score predicting 3-year recurrence risk in stage II colon cancers, and appears most effective in MMR-proficient T3 tumors. Another commercially available tool is ColoPrint, developed by Agendia (Amsterdam, The Netherlands). With a similar premise, this tool is an 18-gene signature found to be predictive of distant metastasis in stage II colon cancers.[59,60] ColDx, developed by Almac (Craigavon, UK) is a microarray-based tool that uses 634 probes to identify patients with stage II colon cancer at high risk of recurrence.[61] While these molecular signatures seem to determine risk of recurrence independent of other well-established risk factors, they have not been fully incorporated into clinical practice.

Table 68-4 Clinical and Pathologic Staging[4]

Definitions	
Primary Tumor (T)	
TX	Primary tumor cannot be assessed
T0	No evidence of primary tumor
Tis	Carcinoma in situ: intraepithelial or invasion of lamina propria[1]
T1	Tumor invades submucosa
T2	Tumor invades muscularis propria
T3	Tumor invades through muscularis propria into pericolorectal tissues
T4a	Tumor penetrates to the surface of the visceral peritoneum[2]
T4b	Tumor directly invades or is adherent to other structures[2,3]
Regional Lymph Nodes (N)	
Nx	Regional lymph nodes cannot be assessed
N0	No regional lymph node metastases
N1	Metastases in 1–3 regional lymph nodes
N1a	Metastases in one regional lymph node
N1b	Metastases in 2–3 regional lymph nodes
N1c	Tumor deposit(s) in the subserosa, mesentery or nonperotinealized pericolic or perirectal tissues without regional lymph node metastasis
N2	Metastases in 4 or more regional lymph nodes
N2a	Metastases in 4–6 regional lymph nodes
N2b	Metastases in 7 or more regional lymph nodes
Distant Metastases (M)	
M0	No distant metastases
M1	Distant metastases
M1a	Metastasis confined to one organ or site (e.g., liver, lungs, ovary, and nonregional lymph node)
M1b	Metastases in more than one organ/site or the peritoneum

Anatomic Stage/Prognostic Factors

Stage	T	N	M	DUKES[a]	MAC[a]
0	Tis	N0	M0	—	—
I	T1	N0	M0	A	A
	T2	N0	M0	A	B
IIA	T3	N0	M0	B	B2
IIB	T4a	N0	M0	B	B2
IIC	T4b	N0	M0	B	B3
IIIA	T1–T2	N1/N1c	M0	C	C1
	T1	N2a	M0	C	C1
IIIB	T3–T4a	N1/N1c	M0	C	C2
	T2–T3	N2a	M0	C	C1/C2
	T1–T2	N2b	M0	C	C1
IIIC	T4a	N2a	M0	C	C2
	T3–T4a	N2b	M0	C	C2
	T4b	N1-N2	M0	C	C3
IVA	Any T	Any N	M1a	—	—
IVB	Any T	Any N	M1b	—	—

Note: cTNM is the clinical classification, pTNM is the pathologic classification. The y prefix is used for those cancers that are classified after neoadjuvant pretreatment (e.g., ypTNM). Patients who have a pathologic complete response are ypT0N0cM0 that may be similar to Stage group 0 or I. The prefix r is to be used for those cancers that have recurred after disease-free interval (rTNM). (From American Joint Committee on Cancer. *Colon and Rectum Cancer Staging, 7th ed*. http://cancerstaging.org/references-tools/quickreferences/documents/colonmedium.pdf.)

[a]DUKES B is a composite of better (T3N0M0) and worse (T4N0M0) prognostic groups, as is DUKES C (any T N1M0 and any T N2 M0). MAC is modified Astler-Coller Classification.

Table 68-5 Colorectal Cancer Prognostic Factors

Prognostic Factors
TNM stage
Total number of nodes examined
Tumor location
Circumferential resection margin
Preoperative CEA levels
Histologic grade
Histopathologic type
Lymphovascular invasion
Perineural invasion
Microsatellite instability
Tumor regression grade (in tumors treated with neoadjuvant therapy)
KRAS mutation

SCREENING AND PREVENTION

The slow development of CRC from a benign polyp to an invasive cancer provides a window of opportunity for the detection and removal of premalignant adenomatous polyps and early-stage cancers. Removal of adenomatous polyps reduces the incidence of cancer, and the diagnosis of CRC at earlier stages reduces mortality.[62,63] A number of prospective studies have proven that screening for colorectal polyps and cancer using a variety of methods reduces CRC mortality, and the reduction in mortality persists long-term after screening.[64–66] There is good evidence that screening has contributed significantly to the drop in CRC mortality rates from a peak a few decades ago. Screening for CRC is cost-effective, in terms of the quality-adjusted life-years gained, compared to nonscreening. In the United States, screening for CRC is recommended for men and women over age 50, but compliance remains suboptimal because more than one-third of Americans report not having participated in a screening program.

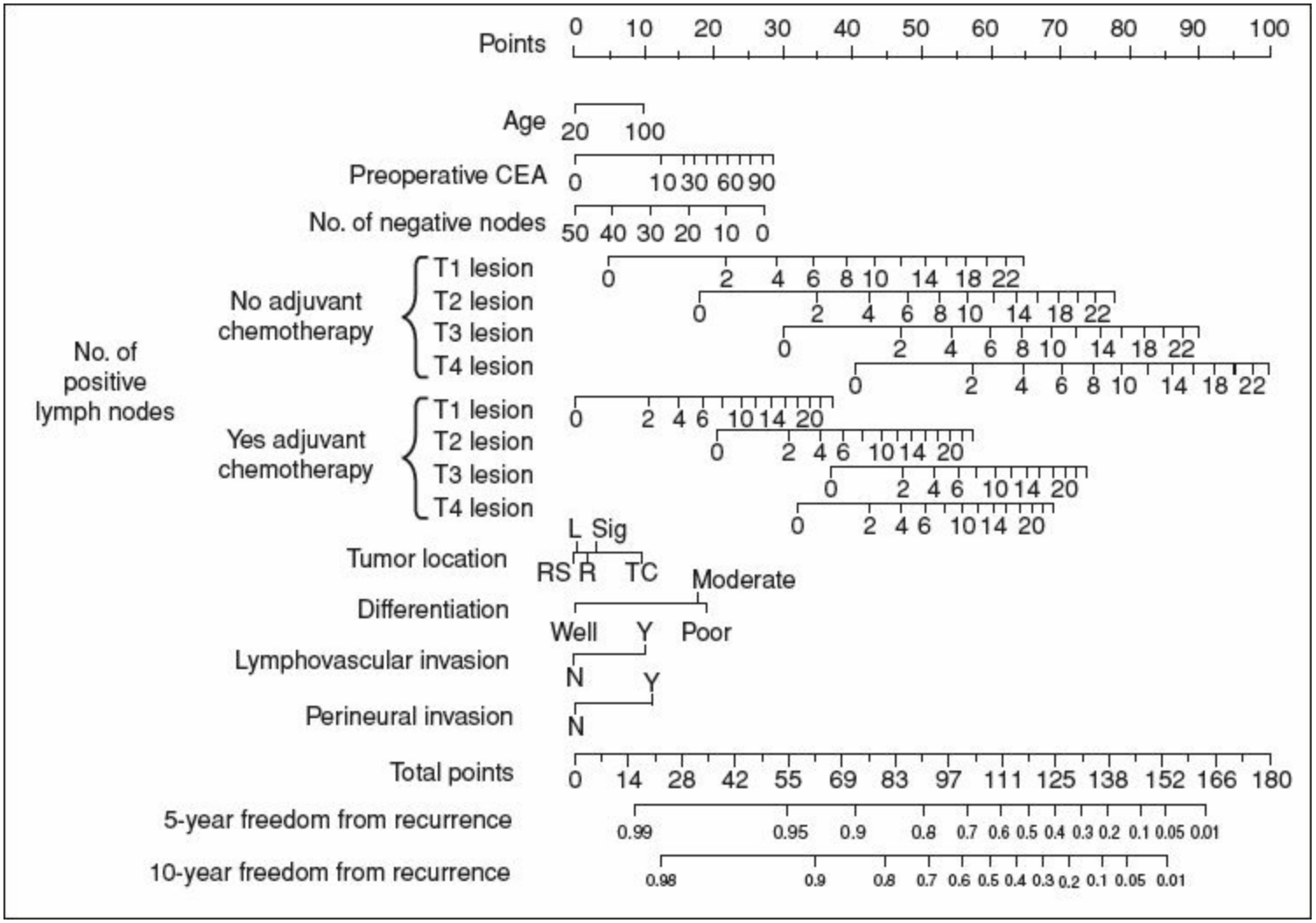

Figure 68-6. Nomogram to predict 5-year and 10-year recurrence-free survival in colon cancer. Used by drawing a straight line up to the Points axis to determine how many points toward recurrence the patient should receive. Sum of the points received from each prognostic variable is then located along the total points axis. Then drawing a line down from the total Points axis to the 5-year or 10-year freedom from recurrence axes provides the patient's specific risk. RS, rectosigmoid colon; L, left colon; R, right colon; Sig, sigmoid colon; TC, transverse colon. (From Weiser et al. 2008, *J Clin Oncol* 26:380–385.)

Table 68-6 Tools for Colorectal Cancer Screening

a. Fecal tests. Detect primarily cancer
   Guaiac-based fecal occult blood test (gFOBT)
   Fecal immunochemical test (FIT)
   Stool DNA test (sDNA)
b. Structural examinations. Detect polyps and colorectal cancer
   Flexible sigmoidoscopy (FSIG)
   Optical-colonoscopy (OC)
   Double–contrast barium enema (DCBE)
   Computed tomography colonoscopy (CTC)

Screening Tests

Numerous screening methods for CRC have been used over the years (Tables 68-6 and 68-7). These fall into one of two categories: stool tests, which detect the presence of blood or altered DNA in the stool; and structural tests, which identify polyps and cancers. Efficacy in detecting CRC, cost-effectiveness as a screening tool, supporting evidence, and patient acceptability vary for each of these tests.[67–69]

Stool Tests

CRCs and polyps bleed more than the normal mucosa, and detecting occult blood in the stool is the basis of the most widely used screening tests. Blood is detected by searching the stool for hemoglobin using chemical or immunologic methods; patients found to have blood in the stool should then undergo colonoscopy. The original fecal occult blood tests (FOBTs) relied on guaiac-based detection of the pseudoperoxidase activity of hemoglobin. However, as pseudoperoxidase activity is not specific to human hemoglobin, foods such as red meat can produce false positives. Medications such as aspirin and nonsteroidal anti-inflammatory drugs can also cause a false-positive reaction. Other foods, in particular those rich in vitamin C, can cause false-negative results and should also be avoided before a test. Thus, for improved accuracy, a special diet and avoidance of these drugs should be followed for 2 to 3 days before FOBT. As most tumors bleed slowly and intermittently, the sensitivity of this test remains low. Rehydration of the test cards increases sensitivity, at the cost of reducing specificity. The sensitivity of the test increases with the number of samples tested; testing two samples per stool on three consecutive bowel movements is recommended. Several prospective, randomized trials have demonstrated that screening by FOBT, followed by total colonic evaluation with colonoscopy in individuals with a positive test, reduces mortality from CRC.[70–72]

Fecal immunochemical tests (FITs) rely on antibodies that are specific to human hemoglobin, and the analysis of samples by automated quantification methods. FITs are as sensitive as the guaiac-based tests, but more specific in detecting human hemoglobin in stool. They therefore avoid the false-negative results in the presence of vitamin C, and the false positives obtained in guaiac-based testing from red meats. The test does not require dietary modification beforehand, and the handling of the specimens is less demanding. As with any fecal test, a positive result with FIT requires a complete colonoscopic examination. Several studies have demonstrated that FIT has better screening performance, compared to FOBT.[73,74] As an additional consideration, FIT may be more easily implemented as a screening regimen, compared with sole usage of colonoscopy.[75] Based on this evidence, a number of countries have introduced screening programs utilizing these tools.

Detection of altered DNA from exfoliated tumor cells has been investigated as a screening test for CRC for years. Similar to the detection of hemoglobin, detection of altered DNA triggers patient referral for colonoscopy. Large, prospective studies of this test show fair sensitivity in detecting CRC and low sensitivity in detecting large adenomas, compared with colonoscopy.[76,77] A more recent study using new stabilizing

buffers, more discriminating markers, and more sensitive analytical methods, has shown that stool DNA testing is more sensitive than FIT in detecting CRC and advanced precancerous lesions. However, the specificity of stool DNA testing was found to be inferior to FIT, with roughly 10% of the screened individuals having a false-positive result.[78] There are concerns that a positive stool DNA test and negative colonoscopy may lead to additional and unnecessary work-up for malignancy. Therefore, screening guidelines of the U.S. Preventive Services Task Force do not currently recommend the fecal DNA test as a screening option.

Structural Tests

Two-thirds of CRCs and polyps are located in the sigmoid colon and rectum, and can be reached with a 60-cm flexible sigmoidoscope. The presence of adenomatous polyps in the rectosigmoid colon increases the probability of finding additional polyps or cancers in more proximal segments of the large bowel. If an adenomatous polyp is found during flexible sigmoidoscopy, the patient should undergo a complete colonoscopy. Flexible sigmoidoscopy is safe, fast, requires minimal preparation, and can be performed in an office-based setting, as conscious sedation is not needed. The risk of perforation with flexible sigmoidoscopy is approximately 1 in 20,000, but the lack of sedation can occasionally be associated with discomfort, deterring some patients from undergoing future examinations. The effectiveness of flexible sigmoidoscopy as a screening modality requires examination to at least 40 cm from the anal verge, and the ability of the endoscopist to biopsy-suspected adenomas. The main limitation of flexible sigmoidoscopy is that it does not examine the entire colon. However, as distal tubular adenomas are often indicative of proximal advanced neoplasia, the efficacy of flexible sigmoidoscopy is greatest when patients with distal adenomas are subsequently referred for colonoscopy. Due to differences in the distribution of colorectal neoplasia in patients of different age, gender, and racial groups, the efficacy of flexible sigmoidoscopy may vary. Several case-control studies have demonstrated that screening by sigmoidoscopy reduces mortality from CRC by two-thirds in the setting of tumors located within reach of the sigmoidoscope.[79,80] More recently, several prospective studies have demonstrated that screening with flexible sigmoidoscopy reduced CRC incidence and mortality by approximately 25%.[81–83] The reduction in incidence occurs in both the proximal and distal colon, while the reduction in mortality applies mainly to tumors in the distal colon. The optimal interval between tests is still controversial. In some studies, flexible sigmoidoscopy was performed every 3 to 5 years. At least two prospective trials demonstrated a reduction in CRC incidence and mortality with only one flexible sigmoidoscopy screening between 55 and 64 years of age.[83,84]

Although the evidence for combining FOBT and flexible sigmoidoscopy is weak, some studies have shown that the combination of these two screening methods is more effective in detecting colorectal neoplasia than each method used individually.[85] The combined approach has a theoretical advantage of detecting lesions located throughout the colon, but its impact on mortality from CRC is unknown. In the United States, annual FOBT combined with flexible sigmoidoscopy every 5 years is a common screening

method for the average-risk population.

Colonoscopy is considered the most accurate test for the early diagnosis and prevention of CRC. It allows direct visualization of the mucosa of the entire colon and rectum, simultaneously allowing the biopsy or removal of suspicious lesions. Colonoscopy is also used to evaluate patients who have tested positive on other screening tests. However, colonoscopy is inconvenient, requires dietary modification and bowel preparation beforehand, is usually performed under conscious sedation, and carries a risk of complications of 1–2 per 1,000. Colonoscopy is also more expensive compared to other screening methods. Overall, patient acceptability of colonoscopy seems to be higher compared to other invasive screening methods, and it is now the most commonly used screening method in the United States. There is indirect evidence from microsimulation and case-control studies that colonoscopy reduces mortality.[86] However, randomized controlled trials proving that screening with colonoscopy reduces CRC mortality are lacking. Comparative studies show that colonoscopy is more effective in detecting advanced colonic neoplasia, in both men and women, than a single FOBT combined with sigmoidoscopy. Colonoscopy is more likely to detect preneoplastic polyps, but just as likely to detect invasive CRC as FITs. In addition, colonoscopy provides the protective benefit of screening the proximal colon.[87] For average-risk individuals colonoscopy screening should start at 50 years of age and be repeated every 10 years.

Table 68-7 Screening and Surveillance for Colorectal Cancer According to Risk[7]

Risk Category	Age to Begin	Recommendation	Comment
Average Risk			
	50	Annual FOB test plus flexible sigmoidoscopy every 5 years Colonoscopy every 10 years Double-contrast barium enema every 5 years CT colonography every 5 years	If positive, colonoscopy is indicated. Screening is recommended up to 75 years of age
Increased Risk – Patients with History of Polyps at Prior Colonoscopy			
Patients with small rectal hyperplastic polyps	—	Colonoscopy or other screening options at intervals recommended for average-risk individuals	An exception is patients with a hyperplastic polyposis syndrome. They are at increased risk for adenomas and colorectal cancer and need to be identified for more intensive follow-up
Patients with 1 or 2 small tubular adenomas with low grade dysplasia	5–10 years after the initial polypectomy	Colonoscopy	The precise timing within this interval should be based on other clinical factors (such as prior colonoscopy findings, family history, and the preferences of the patient and judgment of the physician)
Patients with 3–10 adenomas, 1 adenoma ≥1 cm, or any adenoma with villous features or high-grade dysplasia	3 years after the initial polypectomy	Colonoscopy	Adenomas must have been completely removed. If the follow-up colonoscopy is normal or shows only 1 or 2 small tubular adenomas with low-grade dysplasia, then the interval for the subsequent examination should be 5 years
Patients with ≥10 adenomas on a single examination	3 years after the initial polypectomy	Colonoscopy	Consider the possibility of an underlying familial syndrome

Patients with sessile adenomas that are removed piecemeal	2–6 months to verify complete removal	Colonoscopy	Once complete removal has been established, subsequent surveillance needs to be individualized based on the endoscopist's judgment. Completeness of removal should be based on both endoscopic and pathologic assessments
Increased Risk – Patients with Colorectal Cancer			
Patients with colon and rectal cancer should undergo high-quality perioperative clearing	3–6 months after cancer resection, if no unresectable metastases are found during surgery; alternatively, colonoscopy can be performed intraoperatively	Colonoscopy	In the case of nonobstructing tumors, this can be done by preoperative colonoscopy. In the case of obstructing colon cancers, CTC with intravenous contrast or DCBE can be used to detect neoplasms in the proximal colon
Patients undergoing curative resection for colon or rectal cancer	1 year after the resection (or 1 year following the performance of the colonoscopy that was performed to clear the colon of synchronous disease)	Colonoscopy	This colonoscopy at 1 year is in addition to the perioperative colonoscopy for synchronous tumors. If the examination performed at 1 year is normal, then the interval before the next subsequent examination should be 3 years. If that colonoscopy is normal, then the interval before the next subsequent examination should be 5 years. Following the examination at 1 year, the intervals before subsequent examinations may be shortened if there is evidence of HNPCC or if adenoma findings warrant earlier colonoscopy. Periodic examination of the rectum for the purpose of identifying local recurrence, usually performed at 3-to 6-month intervals for the first 2 or 3 years, may be considered after low anterior resection of rectal cancer

Increased Risk – Patients with a Family History			
Either colorectal cancer or adenomatous polyps in a first-degree relative before age 60 years or in 2 or more first-degree relatives at any age	Age 40 years, or 10 years before the youngest case in the immediate family	Colonoscopy	Every 5 years
Either colorectal cancer or adenomatous polyps in a first-degree relative age 60 or older or in 2 second-degree relatives with colorectal cancer	Age 40 years. Screening options at intervals recommended for average-risk individuals	Screening options at intervals recommended for average-risk individuals	Screening should be at an earlier age, but individuals may choose to be screened with any recommended form of testing
High Risk			
Genetic diagnosis of FAP or suspected FAP without genetic testing evidence	Age 10–12 years	Annual FSIG to determine if the individual is expressing the genetic abnormality and counseling to consider genetic testing	If the genetic test is positive, colectomy should be considered
Genetic or clinical diagnosis of HNPCC or individuals at increased risk of HNPCC	Age 20–25 years, or 10 years before the youngest case in the immediate family	Colonoscopy every 1–2 years and counseling to consider genetic testing	Genetic testing for HNPCC should be offered to first-degree relatives of persons with a known inherited MMR gene mutation. It should also be offered when the family mutation is not already known, but 1 of the first 3 of the modified Bethesda criteria is present
Inflammatory bowel disease, chronic ulcerative colitis, and Crohn colitis	Cancer risk begins to be significant 8 years after the onset of pancolitis or 12–15 years after the onset of left-sided colitis	Colonoscopy with biopsies for dysplasia	Every 1–2 years; these patients are best referred to a center with experience in the surveillance and management of inflammatory bowel disease

CRC, colorectal cancer; CSPY, colonoscopy; CTC, computed tomographic colonography; DCBE, double-contrast barium enema; FAP, familial adenomatous polyposis; FSIG, flexible sigmoidoscopy; HNPCC, hereditary nonpolyposis colon cancer; MMR, mismatch repair.

Double-contrast barium enema can detect most of the clinically important lesions in the colon but, as with colonoscopy, its effectiveness as a screening test for CRC is based only on indirect evidence. Similar to colonoscopy, it requires dietary modification and mechanical bowel preparation, and is associated with patient discomfort. In addition, a positive test mandates a colonoscopy. While double-contrast barium enema every 5 years should provide the same degree of protection as the other screening strategies, it is rarely used as a primary screening method today. Its clinical role as a screening tool at this time is primarily for visualization of the colon in patients who cannot undergo a complete colonoscopy.

Computed tomography colonography (CTC), also referred to as virtual colonoscopy, involves thin-section, multidetector, helical CT, and three-dimensional viewing for interpretation.[88] CTC identifies 90% of cancers or adenomas measuring more than 10 mm in diameter in asymptomatic individuals 50 years of age or older.[89] It is more sensitive than other screening methods, but can miss flat lesions and polyps smaller than 10 mm in diameter. CTC obviates some of the drawbacks of colonoscopy, such as the need for sedation and recovery time, but also has downstream consequences: it delivers a dose of

radiation that may become substantial with repeated examinations, and detects incidental extra-colonic findings that may trigger expensive, and sometimes unnecessary diagnostic investigations. Furthermore, it requires standard bowel preparation and gaseous distension of the colon. New methods of tagging and subtracting residual stool may obviate the routine need for mechanical bowel preparation. Finally, patients with lesions found on CTC still require full visualization of the colon by colonoscopy. CTC is now considered an acceptable screening alternative for average-risk individuals, starting at 50 years of age; the interval between such examinations remains uncertain, although a 5-year interval has been suggested, based on computer simulation models.[90]

Risk Categories

Patients with symptoms of CRC should undergo the appropriate diagnostic studies; they are not candidates for screening. Screening recommendations for the general population are based on individual risk assessment. Based on the past medical history and family history of CRC or polyps, individuals are assigned to one of three risk categories, with different screening recommendations (Table 68-7).[91]

Average Risk

People at average risk for the development of CRC (asymptomatic men and women without risk factors, over 50 years of age in the United States and 60 in the United Kingdom) could undergo yearly FOBT, combined with flexible sigmoidoscopy every 5 years. People with a positive FOBT or a polyp identified by flexible sigmoidoscopy should undergo entire colon and rectum examination by colonoscopy. Double-contrast barium enema every 5 years, or colonoscopy every 10 years, is an accepted screening alternative in the average-risk population. CTC every 5 years is also an option. Digital rectal examination (DRE) should be performed at the time of sigmoidoscopy or colonoscopy in all individuals.

Increased Risk

Family History. Individuals with a first-degree relative (parent, sibling, or child) with CRC or adenomatous polyps diagnosed before 60 years of age should start screening with colonoscopy at 40 years of age or 10 years younger than the earliest diagnosis in their family, whichever comes first. The test should be repeated every 5 years. Individuals with one first-degree relative with CRC or adenomatous polyp diagnosed at 60 years of age or older, or with two or more second-degree relatives (grandparent, grandchild, aunt, uncle, niece, nephew, half-sibling) with CRC or adenomatous polyps at any age, should undergo screening as average-risk individuals – but starting at 40 years of age. Patients with one second-degree relative or one or more third-degree relatives (first cousin) affected are considered to be at average risk.

History of Polyps at Previous Colonoscopy. Patients undergoing endoscopic excision of a small (<1 cm) adenomatous polyp should have the entire colon examined at the time of the polypectomy. Colonoscopy should be repeated 5 years later. If the test is negative, they should then follow the screening recommendations for average risk.[92]

Patients with more than three adenomas, adenomas with villous features or high-grade dysplasia, or a large adenomatous polyp (>1 cm) who have the entire colon examined at the time of polypectomy, should undergo complete colonoscopy 3 years later – and, if normal, every 5 years thereafter.

A complete colonic examination should be carried out before surgery in any patient undergoing a planned curative resection for CRC. The colonoscopy should be repeated at 1 year to exclude metachronous lesions. If the examination at 1 year is normal, it should be repeated after 3 years, and every 5 years thereafter if the previous one was normal.

Patients with Colorectal Cancer. Patients with colon and rectal cancer should undergo high-quality perioperative clearing of polyps with colonoscopy 3 to 6 months after resection, if not performed before surgery. Surveillance after curative resection is described in detail in Surveillance after Curative Resection for Colon and Rectal Cancer section.

High Risk

This category includes individuals from families diagnosed with hereditary forms of CRC.

Familial Adenomatous Polyposis. Once the diagnosis of FAP is established, the patient should undergo colectomy, or a yearly colonoscopy until colectomy. Upper gastrointestinal endoscopy should be performed every 1 to 2 years. Siblings and children of a patient with FAP should start surveillance by flexible sigmoidoscopy at puberty.

MYH-Associated Polyposis. Depending on the individual, age of presentation, and number and size of polyps, the patient may be advised to undergo a prophylactic colectomy or yearly colonoscopy beginning at 25 years of age. Upper gastrointestinal surveillance should be performed following the guidelines for patients with FAP.

Lynch Syndrome. Individuals from families fitting the Amsterdam criteria for HNPCC should have a colonoscopy at 21 years of age, then every 2 years until 40 years of age, and yearly thereafter. Genetic counseling and testing should be considered.

At-risk members of families with hereditary cancer syndromes should be informed about the benefits and limitations of genetic counseling and genetic testing.

Consequences of Screening

The full spectrum of clinical consequences of screening, other than the prevention of deaths from CRC, is difficult to predict because every screening strategy initiates a cascade of events, each one with uncertain probability. The rate of false-positive tests, the number of colonoscopies performed, the complications of the screening and diagnostic tests, and the number of patients who may require surveillance as a consequence of screening, are complex factors that arise at different times over several decades. However, cost-effectiveness analysis in the United States has demonstrated that screening for CRC in average-risk patients, according to the strategies outlined above, compares favorably with other healthcare interventions such as mammography or treatment of mild hypertension.[93,94] It is important to understand that screening does not completely eliminate the risk of CRC. Up to 9% of CRCs are diagnosed within 6 to 36 months after a screening colonoscopy.[95,96] These interval cancers tend to be preferentially located in the proximal colon. This may be related to failure to reach the proximal colon, residual stool obscuring the view in the proximal colon, or different characteristics of the proximal lesions that makes them more difficult to detect or remove.

Implementation of Guidelines

The general population has limited awareness of the risks of CRC or its symptoms; as a result the number of individuals participating in screening programs has been low. The dissemination of information to patients is an essential part of the screening program. Primary care physicians have a responsibility to inform their patients about their risk of CRC, the benefits of screening and different screening strategies, and to set up a system for implementing these guidelines.[94,97,98] Through such efforts, the proportion of adults 50 to 75 years of age having colonoscopy has increased steadily in the last decade: from 19.1% in 2000 to 55% in 2010.[3]

DIAGNOSIS

While the proportion of CRCs diagnosed through screening is increasing, most are still diagnosed after patients become symptomatic. CRC can cause a myriad of symptoms, many of which are nonspecific and highly prevalent among healthy individuals. Therefore, the diagnosis of colorectal carcinoma often requires a high index of suspicion.

Symptoms and Signs

The most common symptoms in patients with CRC are abdominal pain, change in bowel habits, rectal bleeding, anemia, anorexia, and weight loss. The clinical manifestations of CRC differ depending on the location and stage of the tumor.

Abdominal pain is nonspecific; it may be localized to any quadrant of the abdomen, or may be diffuse. When the pain is persistent and colicky, it is more likely to represent obstructive symptoms resulting from a left-sided lesion. More localized tenderness with signs of localized peritonitis indicates local invasion of the adjacent peritoneum or perforation. It can be difficult to distinguish the pain associated with diverticular disease from that due to a carcinoma in the sigmoid or descending colon. Patients with diverticular disease may also have an underlying carcinoma. Abdominal pain may occasionally be related to extensive metastatic disease in the liver or retroperitoneal lymph nodes. Rectal cancer can also cause perineal discomfort and is often associated with tenesmus, the sensation of incomplete defecation. A locally advanced rectal cancer can also cause sacral or sciatic pain.

An unexplained change in bowel habits lasting more than 2 weeks requires investigation for CRC. Constipation associated with colicky abdominal pain is a common manifestation of partially obstructing tumors. Abdominal pain, constipation, and abdominal distension suggest a complete colonic obstruction, which is more common in tumors located in the sigmoid colon and rectum. Some patients with sigmoid or rectal cancer may also complain of diarrhea, which may sometimes be bloody.

Bleeding from tumors in the sigmoid colon and rectum is often wrongly attributed to hemorrhoids or other benign anal conditions. However, blood from hemorrhoids is usually bright red and is accompanied by anal discomfort; the bleeding is intermittent and splashes the toilet pan. Anal fissure is also a common cause of rectal bleeding; the blood is often bright, occurring after defecation, and is typically associated with sharp anal pain triggered by defecation. Painless defecation with rectal blood that is darker in color and mixed in with stool is more likely to be secondary to an underlying carcinoma. Rectal bleeding, particularly when associated with tenesmus, requires a thorough diagnostic investigation to exclude an underlying rectal tumor.

The development of nonspecific anemia of unknown origin is a common manifestation in patients with a carcinoma in the proximal colon. Patients with unexplained microcytic anemia should be examined initially with colonoscopy. Anorexia and weight loss frequently accompany CRC, and are often associated with advanced disease. The differential diagnosis in these patients is a gastric carcinoma, but when investigations are negative it is important to exclude a large-bowel malignancy. As the bowel lumen is larger and the stools overall looser in the proximal colon, obstructive symptoms are uncommon; therefore, patients with tumors proximal to the splenic flexure often present with advanced disease.

It should be remembered that the presence of colon cancer can also be identified incidentally during investigations for other pathologies such as gallstones, gynecologic, or urinary conditions. A complete family history, with emphasis on past history of CRC or

polyps, is essential to diagnose some hereditary cancer syndromes. A family history of endometrial, gastric, urologic, or other HNPCC-associated cancers is also important because it may help in diagnosing Lynch II syndrome.

The evaluation of patients suspected of CRC requires a complete physical examination. Features that should arouse suspicion of malignancy include pallor, palpable abdominal mass, and a palpable mass on DRE. Hepatomegaly indicates advanced disease with extensive liver metastases, and consequently a very poor prognosis. A hard mass in the pouch of Douglas felt on DRE may indicate peritoneal carcinomatosis. Other signs of an underlying CRC include pneumaturia, ischiorectal or perineal abscesses, or even deep venous thrombosis.

The differential diagnosis of CRC includes diverticulitis, irritable bowel syndrome, inflammatory bowel disease, ischemic colitis, and benign anorectal conditions such as hemorrhoids or rectal mucosal prolapse.

Diagnostic Evaluation

Patients with symptoms suggesting CRC should have a colonoscopy to evaluate the entire colon (Fig. 68-7). The examination should be complete, as up to 4% of patients with CRC have synchronous cancers and many more have colorectal polyps.[99,100] Up to one-third of these synchronous cancers are in locations requiring a different surgical resection, further emphasizing the importance of complete colonoscopy. As many patients undergo minimally invasive surgery today, the endoscopist should mark the vicinity of the tumor with India ink to help locate the lesion intraoperatively. CT colonography and DCBE are less effective in investigating patients with symptoms suggestive of CRC, but they are useful in patients with partially obstructive tumors, in whom colonoscopy cannot be completed. In patients with obstructive lesions, the proximal colon can be examined either by preoperative imaging studies such as PET-CT, or intraoperatively by direct palpation of the colon. In any case, patients with a complete colonoscopy before surgery should have a surveillance colonoscopy 6 months after surgery.

Assessment of the extent of disease at the time of diagnosis is important because clinical stage, particularly in rectal cancer, dictates treatment decisions. A CT scan of the chest, abdomen, and pelvis with intravenous and oral contrast is important in order to locate the tumor, detect mesenteric nodes, and exclude liver metastasis and gross peritoneal carcinomatosis (Fig. 68-7). In addition, preoperative imaging helps the surgeon plan the resection. In patients with iodine allergy, and in patients with undetermined lesions on CT, a PET-CT or and abdominal or pelvic MRI may provide additional information.

Laboratory evaluation includes complete blood cell count, coagulation parameters, and chemistry panel. Preoperative CEA should be measured because it provides prognostic information, and can be useful during patient surveillance.

TREATMENT

Surgery is the primary treatment for CRC, but for many patients surgery is not the initial form of treatment and some do not require surgery at all. Treatment is different for colon than for rectal cancer, and depends also on the clinical stage of the tumor. Treatment decisions must also take into account the patient's performance status, comorbidities, hereditary CRC predisposition, as well as desires and expectations.

Preoperative Preparation

All patients undergoing surgery for colon and rectal cancer require similar preoperative preparation aimed at optimizing the technical success of the procedure and avoiding perioperative complications. Surgical site infection (SSI) is the most common complication after colon and rectal cancer resection, occurring in 4% to 26% of cases.[101,102] In addition to causing patient suffering, SSIs lengthen hospital stay and increase costs.[103] The institutional rate of SSI after colorectal surgery is now an important quality metric for several benchmarking programs. A number of federal and state-wide initiatives aimed at improving surgical care recommend implementing measures to reduce the rate of SSI and other complications in patients undergoing elective colorectal surgery.[104,105]

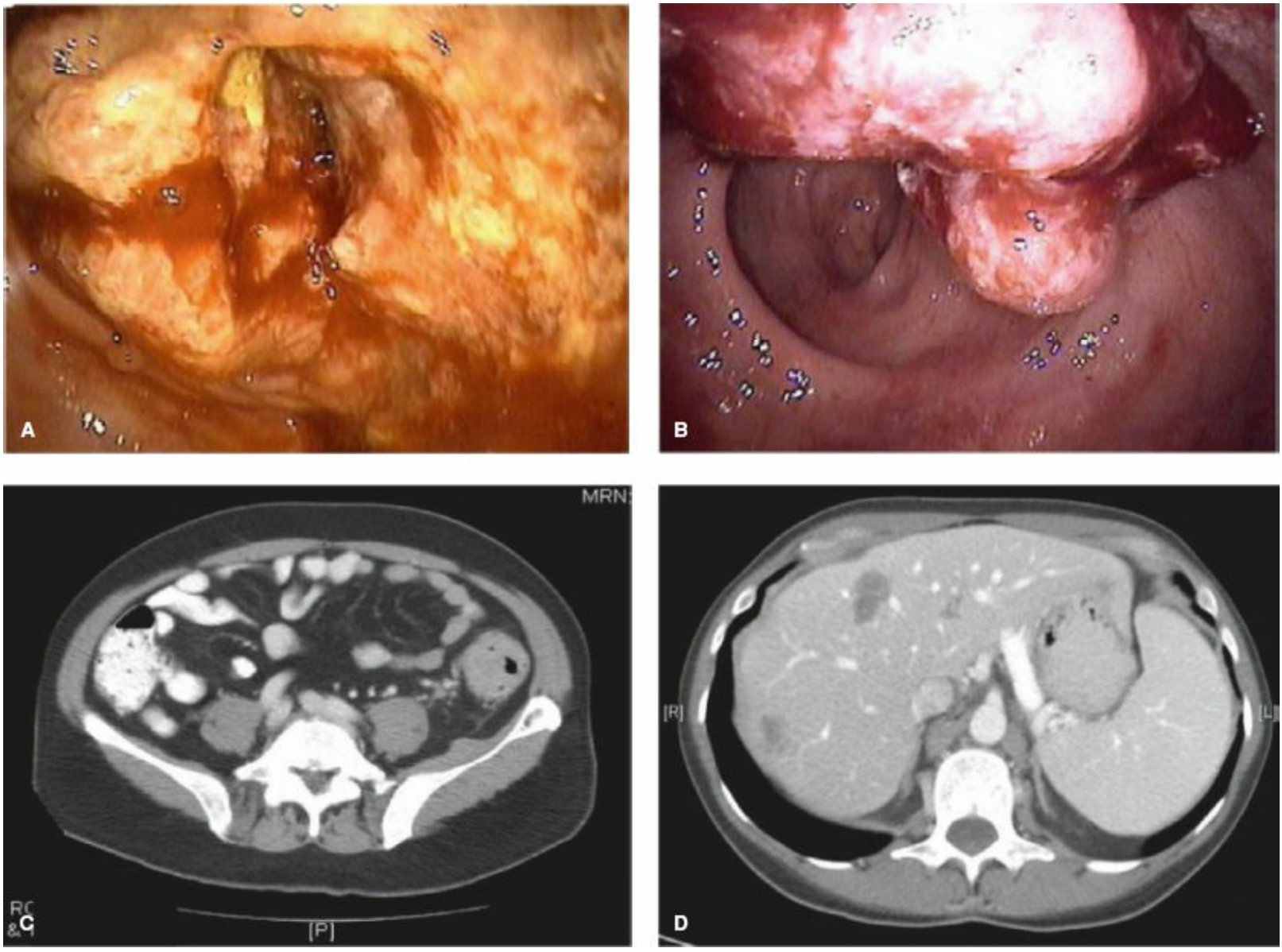

Figure 68-7. Staging modalities for colorectal cancer. **A:** Obstructing colon cancer at colonoscopy. **B:** Polypoid colonic tumor at colonoscopy. **C:** Cecal circumferential tumor with regional lymphadenopathies. **D:** Liver metastases of colorectal origin.

The colon has the largest concentration of bacteria in the human body. A gram of feces

contains 10^{11} polymicrobial bacteria, mostly gram negatives and anaerobes.[106] Oral mechanical bowel preparation using polyethylene glycol to reduce the bacterial load and risk of intraoperative fecal spillage has been considered an axiom in colon and rectal surgery. However a number of prospective trials have failed to demonstrate benefit from mechanical bowel cleansing in preventing SSIs.[107,108] These results were confirmed by a Cochrane systematic review of 5,805 patients; the authors concluded that there is no statistically significant evidence that patients benefit from mechanical bowel preparation or the use of rectal enemas.[109] Another recent systematic review by the Agency for Health Care Research and Quality reached similar conclusions. Oral mechanical bowel preparation appeared to be protective, compared to no preparation, for peritonitis or intra-abdominal abscess, but the evidence was weak. The study could not draw any conclusion on potential harms, such as dehydration and electrolyte imbalances, related to use of oral mechanical bowel preparation.[110] Despite the lack of solid data, many surgeons still recommend oral mechanical bowel preparation because manipulation and suturing is easier with a clean colon.

High-quality evidence indicates that antibiotics covering aerobic and anaerobic bacteria, delivered orally or intravenously (or both) prior to elective colorectal surgery, reduce the risk of postoperative surgical wound infection by as much as 66%.[111] Oral antibiotics, neomycin- and erythromycin-based, are delivered the day before surgery, in combination with the oral mechanical bowel preparation. For patients without penicillin allergy, a second-generation cephalosporin (cefotetan or cefoxitin) is administered intravenously within 30 minutes of the surgical incision, with re-dosing during the procedure as required according to the half-life of the drug and the duration of surgery. For penicillin-allergic patients, metronidazole or clindamycin combined with either ciprofloxacin or gentamicin is acceptable, as are aztreonam and fluoroquinolones.[112] Ertapenem, a long-acting carbapenem active against gram negatives and anaerobes, is an accepted alternative to second-generation cephalosporins for prophylaxis in CRC. Ertapenem has a long life and does not require re-dosing in prolonged procedures, but has been associated with increasing risk of *Clostridium difficile* infection.[113] Other measures that prevent SSI include tight glucose control in diabetic patients, smoking cessation, clipping rather than shaving the skin of the abdominal wall, and maintaining normothermia and adequate oxygenation during anesthesia.[114]

Patients undergoing surgery for CRC are also at risk of deep venous thrombosis and pulmonary embolism, and should have thromboembolic prophylaxis with unfractionated heparin or low-molecular-weight heparin during the peri- and postoperative periods.[115]

As the incidence of CRC increases with age, many patients have cardiovascular or respiratory conditions requiring medical clearance before surgery. While technical advances have made CRC operations safer, optimal outcomes require special effort to ensure that the patient's overall health is optimal at the time of surgery. Many CRC patients have other comorbid conditions such as diabetes, hypertension, and coronary artery disease requiring medical evaluation before undergoing surgery. Comorbidities can impact decision-making and affect short- and long-term outcomes. Patient clinical and performance status should be optimized to reduce the risk of perioperative complications.

Fertility options should be discussed with all individuals of child-bearing potential.

Patients who may require a stoma should be seen before surgery by an enterostomal therapist. Adequate marking of the site improves outcomes for patients requiring a stoma. Preoperative teaching shortens the time patients require to become proficient managing the stoma, and reduces hospital stay.[116]

The Enhanced Recovery After Surgery (ERAS) protocols were introduced in open colorectal surgery in the 1990s, with the aim of speeding patient recovery, improving patient outcomes and satisfaction, shortening hospitalization, and reducing healthcare costs.[117] ERAS protocols span the entire perioperative period, and attempt to minimize surgical stress and postoperative ileus through patient education, preoperative hydration and carbohydrate loading, goal-directed intraoperative fluid management, narcotic sparing for intraoperative and postoperative pain control, and early mobilization and oral feeding in the postoperative period. A number of prospective trials have indicated that the implementation of ERAS protocols reduces length of hospital stay, compared to conventional recovery in patients undergoing open or minimally invasive surgery for CRC.[118,119] A recent systematic review and a meta-analysis confirmed that ERAS protocols resulted in a shorter length of stay and a reduction in overall complications, with no difference in mortality and surgical complications.[120,121] Similar results have recently been reported from an international registry.[122]

Principles of Surgical Treatment

The goal for any curative-intent surgery is to remove the tumor-bearing segment of the bowel with adequate margins, along with en bloc excision of the mesentery containing the feeding vessels and regional lymph nodes. The location of the primary tumor determines lymphatic drainage and dictates the extent of the resection. Lymphatic capillaries are primarily located in the submucosal and subserosal layers of the bowel wall. The lymphatic flow in the colon is primarily circumferential, with longitudinal spread along the bowel wall thought to be less than 1 cm in each direction. Therefore, a 5-cm margin of normal bowel on either side of the primary tumor is considered sufficient to avoid anastomotic recurrence. The length of the terminal ileum resected in patients with rectal cancer does not influence the risk of anastomotic recurrence. In the rectum, where the longitudinal lymphatic flow is primarily upward, cancer cells rarely spread distally along the bowel wall farther than 1 cm from the macroscopic distal end of the tumor. Consequently, a 2-cm margin of normal bowel distal to the tumor, or even less in patients treated with neoadjuvant therapy, is considered appropriate to an oncologically safe resection.[123]

The lymphatic channels in the bowel wall drain to the regional nodes, which are classified in different groups according to their proximity to the bowel and its blood supply (Fig. 68-8). The “epicolic” nodes are located in the bowel wall under the peritoneum, usually close to the epiploic appendices. The “paracolic” lymph nodes are located along the marginal vessels. Next, the “intermediate” nodes are positioned in the middle of the mesentery. Finally, the “central” or “apical” lymph nodes are located close to the root of the mesentery, near the origin of the named vessels. While CRC generally spreads sequentially from the paracolic to the central or apical lymph nodes, nodal metastases skipping one of the groups are common.[124]

The extent of the mesenteric resection is determined by the need to remove all the lymph nodes draining the corresponding segment of bowel, including the central lymph nodes located at the origin of the named feeding blood vessels. As most tumors are located between two named vascular pedicles, both of these should be resected at their origin. When suspected of being involved by tumor, the central nodes should be marked on the specimen, as they have negative prognostic information. Other lymph nodes located away from the feeding vessels and suspected of tumor involvement during surgery, should be removed and analyzed, because in some patients the lymphatic drainage does not follow an orderly pattern.[125,126] If residual metastatic lymph nodes remain after sampling, the resection should be considered incomplete.

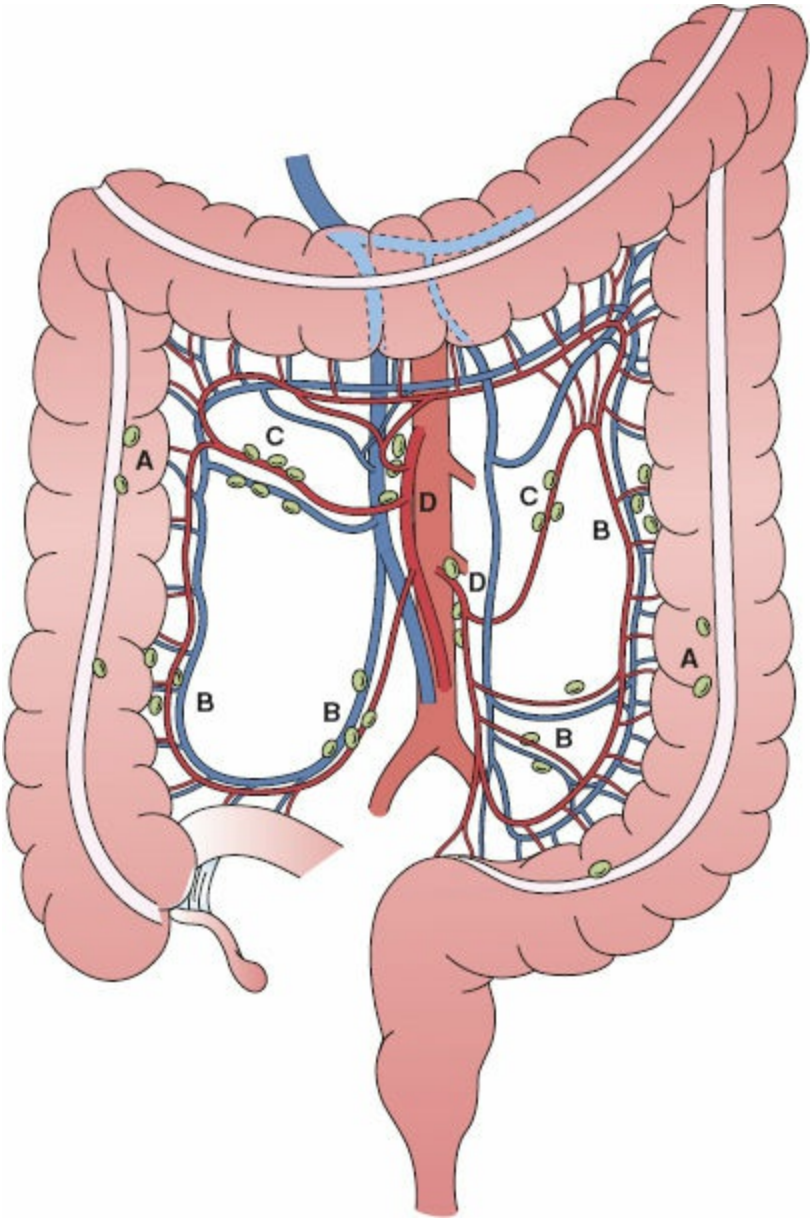

Figure 68-8. Anatomy of the colon. **A:** Epicolic lymph nodes. **B:** Paracolic lymph nodes. **C:** Intermediate lymph nodes. **D:** Apical-central lymph nodes.

While achieving safe oncologic margins and adequate lymphadenectomy are the main considerations when performing a surgical resection for CRC, ensuring an adequate blood supply to the bowel ends, and maintaining tension-free anastomosis, are also important in order to avoid anastomotic complications.

Locally advanced tumors attached to other organs should be removed en bloc with contiguously involved structures. As it is impossible to distinguish clinically or radiographically between inflammatory adhesions and tumor infiltration, it is preferable to perform an en bloc resection of any organ attached to the primary tumor, rather than spilling cancer cells by separating structures infiltrated by tumor. Intraoperative tumor perforation has negative prognostic implications. It is important to report the completeness of the resection (R0, R1, or R2), combining clinical and pathologic information, to determine risk of locoregional recurrence and long-term prognosis.

The concept of the no-touch technique, with initial control of the vascular supply before manipulation of the tumor to avoid releasing cancer cells into the blood stream, has not

been shown to be associated with improved outcomes.[127] However, early vascular control with medial-to-lateral dissection of the mesentery, before mobilization of the colon, is the preferred approach during minimally invasive colorectal surgery, because it helps identify all vascular and retroperitoneal structures.

Proper surgical technique is crucial in achieving optimal results in CRC patients. The removal of the rectum along with its mesorectal envelope, using sharp dissection along normal anatomical planes – an operation called total mesorectal excision, or TME – is associated with a reduced risk of local tumor recurrence.[128,129] Application of the same surgical principles to colon cancer, including the removal of all the lymph node–bearing mesentery to the origin of the named blood vessels – an operation called complete mesocolic excision or CME – is also associated with a lower rate of local tumor recurrence in colon cancer patients.[130] Differences in expertise and surgical technique probably explain surgeon and institutional differences in outcomes among patients treated for CRC. A recent study from Denmark has shown that CME surgery is associated with better disease-free survival than conventional cancer resection for patients with stage I to III colon adenocarcinoma.[131]

TREATMENT OF LOCALIZED COLON CANCER

Malignant Colonic Polyps

The identification of a focus of invasive carcinoma in a polyp removed by snare excision during colonoscopy represents a surgical dilemma. These types of polyps are often referred to as “malignant polyps,” to distinguish them from lesions that are almost exclusively invasive adenocarcinoma with exophytic or polypoid morphology. Malignant polyps are encountered more often because tumors are diagnosed at an earlier stage, as a result of screening programs. Although there are some lymphatic channels in the lamina propria, tumors superficial to the muscularis mucosa (also known as intramucosal carcinoma, carcinoma in situ, or Tis) are considered to carry no risk of lymph node metastasis. When the malignant cells penetrate beyond the muscularis mucosa they can access the lymphatic channels of the submucosa and metastasize to the regional lymph nodes. This risk of nodal metastasis depends on the morphology of the polyp, the depth of the invasive component, the presence of unfavorable histologic features (grade 3 or 4, angiolymphatic invasion, perineural invasion) and the margin of resection.[132] Imaging studies are usually of no help in these patients, except to exclude distant metastases (which are uncommon). In pedunculated polyps with focus of invasive cancer located in the head, neck, or stalk of the polyp, with favorable histologic features, resected with negative margins, the risk of nodal metastasis is small (Fig. 68-9). In these circumstances additional surgery is considered unnecessary, as the risk of surgery may outweigh the risk of residual tumor in the bowel wall or nodal metastasis. On the other hand, patients with pedunculated polyps with focus of invasive adenocarcinoma reaching the base of the polyp, sessile polyps with focus of invasive adenocarcinoma, the presence of adenocarcinoma at the resection margin, and malignant polyps with unfavorable histologic features, are at risk of regional nodal metastasis, and should be offered surgical resection.[133,134] Other factors such as the location of the polyp in the colon or rectum,[135] the patient’s comorbidities and performance status, and the patient’s desires, should be taken into consideration. Therefore, a final decision should only be made after full review of the pathology reports, and disclosure to the patient of the risks and benefits of each approach.

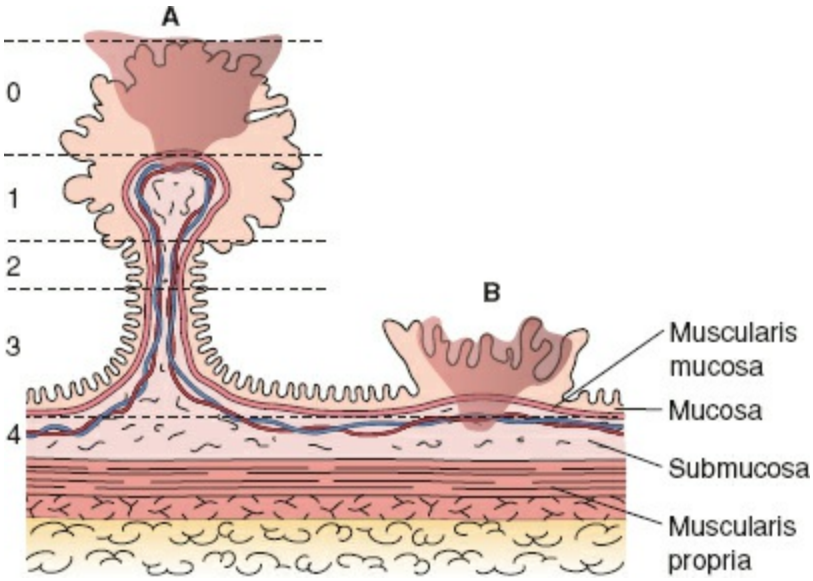

Figure 68-9. Malignant polyp. Haggitt levels of invasion. Level 0, Noninvasive, severe dysplasia; Level 1, Invading through muscularis mucosa but limited to the head of pedunculated polyp; Level 2, Invading the neck of pedunculated polyp; Level 3, Invading the stalk of pedunculated polyp; Level 4, Invading into submucosa of the bowel wall below the stalk of a pedunculated polyp. All sessile polyps.

Surgery for Localized Colon Cancer

Patients with biopsy-proven adenocarcinoma of the colon without evidence of distant metastasis, and without contraindications to major surgery, should be treated with surgical resection. The extent of a colon cancer resection is dictated by the location of the primary tumor. Tumors in the cecum and ascending colon require a right hemicolectomy that implies division of the ileocolic, right colic, and sometimes the right branch of the middle colic vessels (Fig. 68-10). The portion of the omentum attached to the removed segment of colon should be resected en bloc with the colon and mesentery. Tumors located at the hepatic flexure and in the right side of the transverse colon require an extended right colectomy that, in addition to the ileocolic and right colic vessels, requires division of the middle colic vessels at their origin (Fig. 68-10). Tumors in the mid portion of the transverse colon can be treated with an extended right colectomy, or a transverse colectomy. A transverse colectomy involves division of the middle colic vessels only, but often requires mobilization of both the hepatic and splenic flexure to ensure a tension-free anastomosis (Fig. 68-10). Tumors located in the distal transverse colon, splenic flexure, and proximal descending colon can be treated with a left hemicolectomy, which requires division of the left branch of the middle colic and left colic artery at its branch point from the inferior mesenteric artery (Fig. 68-10). Locally advanced tumors located in the transverse colon can metastasize to the regional lymph nodes located along the greater omentum and gastroepiploic arcades, leading some surgeons to recommend removal of the omentum with the gastroepiploic arcade. In these patients, an omentectomy with division of the gastroepiploic vessels at their origin may be necessary for complete nodal control.[136] However, the benefit of such an extended lymphadenectomy is debated. Sigmoid tumors require sigmoid colectomy, which includes the superior rectal artery and its takeoff from the inferior mesenteric artery (Fig. 68-10).

Patients with synchronous tumors, which occur in up to 5.3% of patients with CRC, should be investigated for hereditary CRC syndromes or other predisposing conditions. Patients with sporadic synchronous cancers can be treated with separate resections, or an extended resection incorporating both lesions, depending on the location of the primaries.[137] When performing a segmental resection, it is important to preserve the blood supply to the intermediate segment of colon in order to avoid ischemia, which can lead to perioperative complications. Synchronous tumors in patients with HNPCC, or other risk factors such as inflammatory bowel disease, are indications for a subtotal or total colectomy.

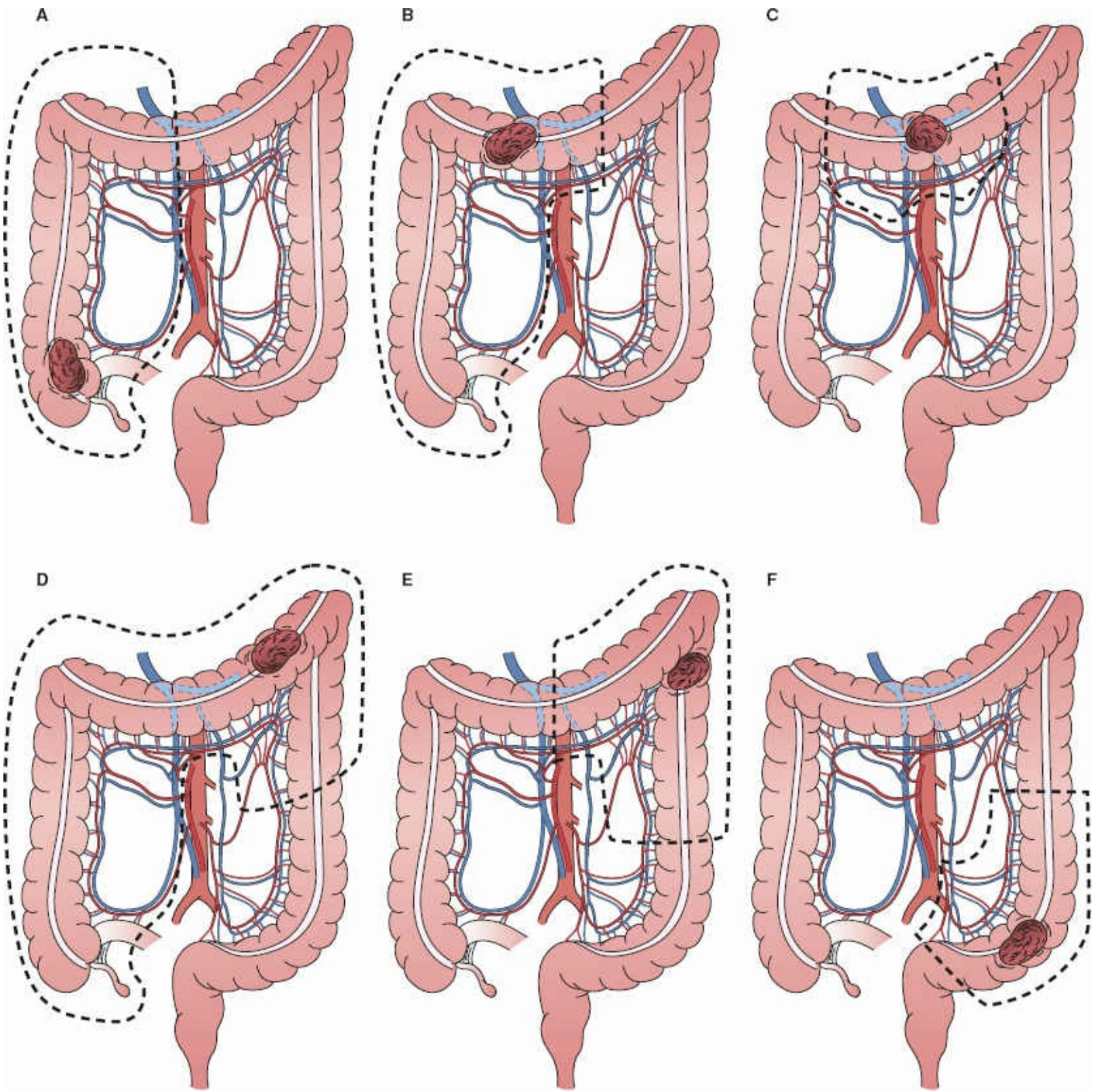

Figure 68-10. Segmental colonic resections. **A:** Right colectomy. **B:** Extended right colectomy to transverse colon. **C:** Transversectomy. **D:** Right colectomy extended to splenic flexure. **E:** Left colectomy. **F:** Sigmoidectomy.

A number of well-conducted prospective trials have proved that laparoscopic colectomy for cancer is associated with short-term benefits and equivalent long-term oncologic outcomes, compared with the traditional open surgical approach (Table 68-8). Patients treated laparoscopically have less postoperative pain, earlier return of bowel function, shorter hospital stay, and a decreased rate of complications. However, laparoscopic surgery is technically challenging and has a long learning curve. Laparoscopy may be

particularly difficult in patients with multiple adhesions from previous surgery, in obese patients, and in patients with locally advanced disease. Late conversion from laparoscopic to open surgery (also known as reactive conversion) is associated with higher complication rates compared to open surgery, while early or preemptive conversion is associated with complication rates similar to open surgery.[138]

Laparoscopic colectomy is typically performed using a number of ports, usually 3 to 5, and a specimen extraction site. Additional expertise allows minimally invasive surgery to use fewer ports, smaller instruments, and shorter incisions. This trend has resulted in the single port laparoscopic surgery (SPLS) for the treatment of colon and rectal cancers. The operation is performed through a small port located at the specimen extraction site. The camera and the operating ports are all positioned through the SPLS device. A recent systematic review of 38 case series, including 565 patients operated by SPLS, suggested that the procedure is feasible but technically challenging. Evidence regarding its safety was limited.[139]

Table 68-8 Open versus Laparoscopic Colon Resections, Results of the Most Representative Series

Open/Laparoscopic	COST[8,9] (2004–2007)	COLOR (2005–2009)[10,11]	CLASICC[12–15] (2005–2007–2010–2013)	Leung[16] (2004)	ALCCAS[17] (2008)
Patients	863	1,248	794 (413 colon)	403	594
Operative time (min)	95/150 $p < 0.001$	115/145 $p < 0.001$	135/185	189/144 $p < 0.001$	107/158 $p \leq 0.001$
Blood loss	NR	175/100 $p < 0.001$	NR	238/169 $p = 0.06$	100/100 $p = 0.17$
Length of incision (cm)	18/6 $p < 0.001$	NR	22.8/7	NR	20.6/8 $p < 0.001$
Conversion (%)	21	17	25	23.2	14.6
First bowel movement	NR	4.6/3.6 $p < 0.001$	6/5	4.6/4 $p = 0.03$	4.9/4.4 $p = 0.011$
LN removed (mean/median)	12/12 (median)	10/10 (median)	13.5/12 (mean)	12.1/11.1 $p = 0.18$	13/13 (mean) $p = 0.156$
Overall morbidity (%)	20/21 $p = 0.64$	20/21 $p = 0.88$	26/26 p = n/s	22/19 p = n/s	45.3/37.8 $p = 0.062$
30-day mortality (%)	1/<1 $p = 0.4$	2/1	5/4	2.4/0.6 $p = 0.97$	1.4/0.7 $p = 0.488$
Hospital stay (days)	6/5 $p < 0.001$	9.3/8.2 $p < 0.001$	10/8	8.7/8.2 $p < 0.001$	10.6/9.5 $p = 0.068$
Reoperation rate	<2/<2 $p = 1$	5/7 $p = 0.13$	NR	2.9/3.5	4.4/5.4 $p = 0.543$
5 Years – DFS	68.4/69.2 $p = 0.94$	68/66.5 $p = 0.7$	64/57.6 $p = 0.399$	78.3/75.3 $p = 0.45$	71.2/72.7 $p = 0.7$
5 Years – OS	74.6/76.4 $p = 0.93$	74.2/73.8 $p = 0.45$	62.7/55.7 $p = 0.253$	79.9/76.1 $p = 0.61$	76/77 $p = 0.64$

The authors compared results of patients included in this review with those of a group

of 3,526 patients treated with conventional laparoscopic colectomy and included in a Cochrane Review. They found that, in spite of lower BMI and smaller tumors, SPLS did not result in less postoperative pain or shorter hospital stay, compared to conventional laparoscopic surgery.[139]

The introduction of robotic platforms, which enhance the visualization and dexterity of the surgeon, has added a new dimension to minimally invasive colon cancer surgery. The evidence accumulated so far indicates that robotic colon resection is associated with lower conversion rates, similar short-term outcomes, and higher costs, compared to conventional laparoscopic colon resection.[140]

Postoperative Adjuvant Therapy for Localized Colon Cancer

Many patients with what appears to be localized colon cancer at the time of diagnosis develop recurrence after a curative-intent surgery. These recurrences are attributed to micrometastases that are already present, but clinically undetectable, at the time of diagnosis. Postoperative adjuvant chemotherapy aims to improve survival by eradicating micrometastatic disease. Numerous chemotherapeutic agents are now considered for adjuvant therapy, mostly based on their efficacy as observed in the setting of metastatic colon cancer. However, the mainstays of adjuvant therapy following resection of localized colon cancer remain fluoropyrimidines (5-fluorouracil [5-FU] and capecitabine) and oxaliplatin.

5-FU, a member of the family of antimetabolites, is a pyrimidine analog that works by irreversible inhibition of thymidylate synthase (TS), the rate-limiting enzyme in pyrimidine nucleotide synthesis, and by incorporation of its metabolites into RNA and DNA. 5-FU can only be delivered intravenously and is commonly administered with leucovorin, a reduced folate that is thought to stabilize fluorouracil's interaction with the enzyme TS. Capecitabine is an oral prodrug of fluorouracil that is absorbed intact through the gastrointestinal mucosa and undergoes enzymatic conversion to fluorouracil. Response rates to fluoropyrimidine, as first-line therapy alone for metastatic CRC, are only around 10% to 20%. Neutropenia, stomatitis and diarrhea are the most common side effects of 5-FU. The toxicity profile for capecitabine is similar to 5-FU, with hand-foot syndrome being more frequent. Oxaliplatin produces cytotoxic effects by forming both inter- and intra-strand cross links leading to disruption of DNA replication and apoptosis. As a single agent, oxaliplatin has limited effect in CRC; but in combination it enhances the cytotoxic effect of fluoropyrimidines, possibly through downregulation of TS. The most relevant side effect of oxaliplatin is a progressive and often irreversible peripheral neuropathy. Other chemotherapy agents commonly used in patients with metastatic CRC have not shown proven benefit in the adjuvant setting.

The use of adjuvant therapy for stage III colon cancer was first shown to provide measurable benefit in the National Cancer Institute (NCI) Cooperative Intergroup trial INT-0035. Patients who received 5-FU and levamisole for 1 year after surgical resection had a 33% risk-reduction in death or recurrence, compared to those who underwent surgery alone.[141,142] Since then, we have come to recognize that levamisole is overall an inactive agent; therapeutic combinations have evolved and have been tested rigorously.[143] A number of multi-institutional prospective, randomized trials have demonstrated a survival advantage with postoperative chemotherapy in selected patients after curative-intent surgery, compared to surgery alone. Pooled analyses of these trials have reported an approximately 30% reduction in recurrence, and 26% improvement in survival, in patients with stage III colon cancers treated with 6 months of postoperative fluoropyrimidine-based chemotherapy.[144,145] More recently, the landmark MOSAIC (Multicenter International Study of oxaliplatin, fluorouracil, and leucovorin in the Adjuvant Treatment of Colon Cancer) trial, which randomized 2,246 stage II/III colon cancer patients to 5-FU/leucovorin with or without oxaliplatin, reported an additional

20% reduction in recurrence and 5% improvement in 5-year disease-free survival (73.3% vs. 67.4%; $p = 0.003$) in patients treated with 5-FU/leucovorin plus oxaliplatin, compared to 5-FU/leucovorin alone.[146,147] Based on these results, the current recommendation for patients with stage III colon cancer following curative-intent surgery consists of 6 months of 5-FU/leucovorin and oxaliplatin (FOLFOX), or capecitabine and oxaliplatin (CAPEOX).

Several studies have proven that the addition of irinotecan – a topoisomerase I inhibitor that is effective in metastatic CRC – to standard fluoropyrimidines is not superior to fluorouracil/leucovorin combinations alone in stage III colon cancers.[148] Similarly, bevacizumab (anti–VEGF-A) and cetuximab (anti-EGFR), two biologic agents that have shown efficacy in metastatic disease, do not improve survival, compared to FOLFOX alone.[149–151] Therefore, at the present time there is no role for irinotecan, bevacizumab, or cetuximab in the adjuvant treatment of CRC.

The use of adjuvant chemotherapy after curative resection for stage II CRC has been controversial for more than a decade. Three prospective, randomized trials have addressed the subject using 5-FU–based regimens,[142,152,153] all of them failing to show a clear benefit of adjuvant treatment over observation alone. The addition of oxaliplatin to the adjuvant regimen does not seem to improve the results of pyrimidine-based regimens for stage II. Most of the evidence for adjuvant treatment in stage II CRC comes from pooled analyses, in which stage II and III CRC patients, undergoing different chemotherapy regimens and controls, are analyzed. The most influential one, including 37 trials and 11 meta-analyses, found a significant improvement in DFS for 5% to 10%, favoring adjuvant chemotherapy; nevertheless, no difference in OS was observed.[154] Therefore, postoperative adjuvant chemotherapy is still not routinely recommended after curative resection for stage II CRC. However, there is evidence that some node-negative patients at high risk for recurrence may benefit from postoperative adjuvant chemotherapy. Determining which patients are at high risk has most commonly included consideration of features such as tumor perforation, T4 category tumors, poorly differentiated histology, lymphovascular or perineural invasion, and patients with fewer than 12 nodes in the surgical specimen (who are considered inadequately staged).[155] At the present time, the use of adjuvant therapy for stage II disease ought to be weighed carefully by a multidisciplinary team, with adequate counseling of the patient. As mentioned earlier, some predictive nomograms may help stratify risk in patients with stage II disease, enabling us to more effectively select those more likely to benefit from adjuvant therapy; however, these tools have not been widely incorporated into clinical practice.

The search for molecular prognosticators aimed at stratifying stage II patients according to the risk of relapse, is an active area of research. MMR deficiency has been associated with an improved prognosis, but a decreased benefit from fluoropyrimidine-based adjuvant therapies, in patients with stage II disease.[156] Because of this, MMR testing is recommended for patients with stage II disease. Current guidelines recommend no use of single-agent fluoropyrimidine treatment for patients with stage II tumors exhibiting MSI or MMR deficiency. The multi-gene molecular signatures discussed

previously were developed, in large part, to stratify risk in patients with stage II CRC, and to identify those most likely to benefit from adjuvant chemotherapy. While initial results are promising, there is insufficient evidence to recommend their use in selecting adjuvant therapy for patients with stage II CRC.

TREATMENT OF LOCALIZED RECTAL CANCER

The treatment of rectal cancer presents different challenges, but also different opportunities, compared to colon cancer. Given the location of the rectum within the narrow bony pelvis surrounded by the urogenital organs, large blood vessels, and autonomic nerves, and its proximity to the anal sphincters, rectal cancer surgery is technically challenging, potentially associated with perioperative complications, and often followed by loss of urinary, sexual, and bowel function that permanently impairs quality of life. In addition, rectal cancer has been associated with a higher rate of local recurrence after curative-intent surgery, compared to colon cancer. But the extraperitoneal location of most of the rectum and its proximity to the anal orifice make it accessible to explorations (DRE, endorectal ultrasound [ERUS]) and interventions (external beam radiation therapy, brachytherapy, and local excision [LE]) not currently available for colon cancer.

The selection of the best treatment option for each rectal cancer patient is a complex process and requires consideration of the clinical tumor stage, location of the tumor within the rectum, the impact of treatment upon anorectal and genitourinary function, and the consequences for the patient in terms of prognosis and quality of life. Some rectal cancers can be treated with LE. Others require a transabdominal resection (TAR) of the rectum, with or without sphincter preservation. Finally, many rectal cancer patients require chemotherapy and radiation to reduce the risk of local recurrence and distant metastasis.

Anatomy of the Rectum

The rectum represents the distal portion of the large bowel, extending from the rectosigmoid junction – the area where the tenia coli (characteristic of the sigmoid colon) splay and become the longitudinal muscular layer of the rectum – to the anorectal ring, a palpable anatomical landmark that corresponds to the imprint of the puborectalis muscle on the bowel wall. The anal canal extends from the anorectal ring to the anal verge, the palpable groove between the distal edge of the internal sphincter and the subcutaneous portion of the external sphincter (Fig. 68-11). For practical purposes and standardization, the rectum is defined in terms of distance in centimeters from the anal verge. The distance of a tumor from the anal verge is best measured using a rigid proctoscope, which allows the simultaneous visualization of the anal verge and the centimeter marks on the outside of the scope. In European countries, tumors with the distal edge located within the last 15 cm of the large bowel are considered rectal cancers; in the United States, the limit is 12 cm. The location of tumor in relation to the peritoneal reflection and the promontory, and its distance from the anal verge, can also be determined by MRI, in particular sagittal views.

The mesorectum is the visceral mesentery of the rectum containing the terminal branches of the superior rectal vessels and the rectum's lymphatic drainage. The upper portion of the rectum is located above the anterior peritoneal reflection; it is covered with peritoneum in the front and on both sides, and has a posterior mesorectum attached to the concavity of the sacrum, which is a continuation of the mesentery of the sigmoid colon. Below the peritoneal reflection the rectum is completely extraperitoneal and fully surrounded by the mesorectum. The mesorectum is covered by a thin, glistening membrane called the mesorectal fascia (MRF). Posteriorly, the mesorectum is separated from the presacral fascia by an avascular plane of loose areolar tissue that is the natural plane of dissection during a radical proctectomy. Anteriorly, the mesorectum is separated from the urogenital organs by a remnant of the fusion of two layers of the embryologic peritoneal cul-de-sac known as Denonvilliers fascia – an important anatomical landmark in rectal cancer surgery. Below the peritoneal reflection, the lateral ligaments connect the mesorectum to the pelvic sidewall. The mesorectum tapers off distally as the rectum funnels toward the anorectal ring, where the longitudinal layer of the muscularis propria becomes the internal anal sphincter.

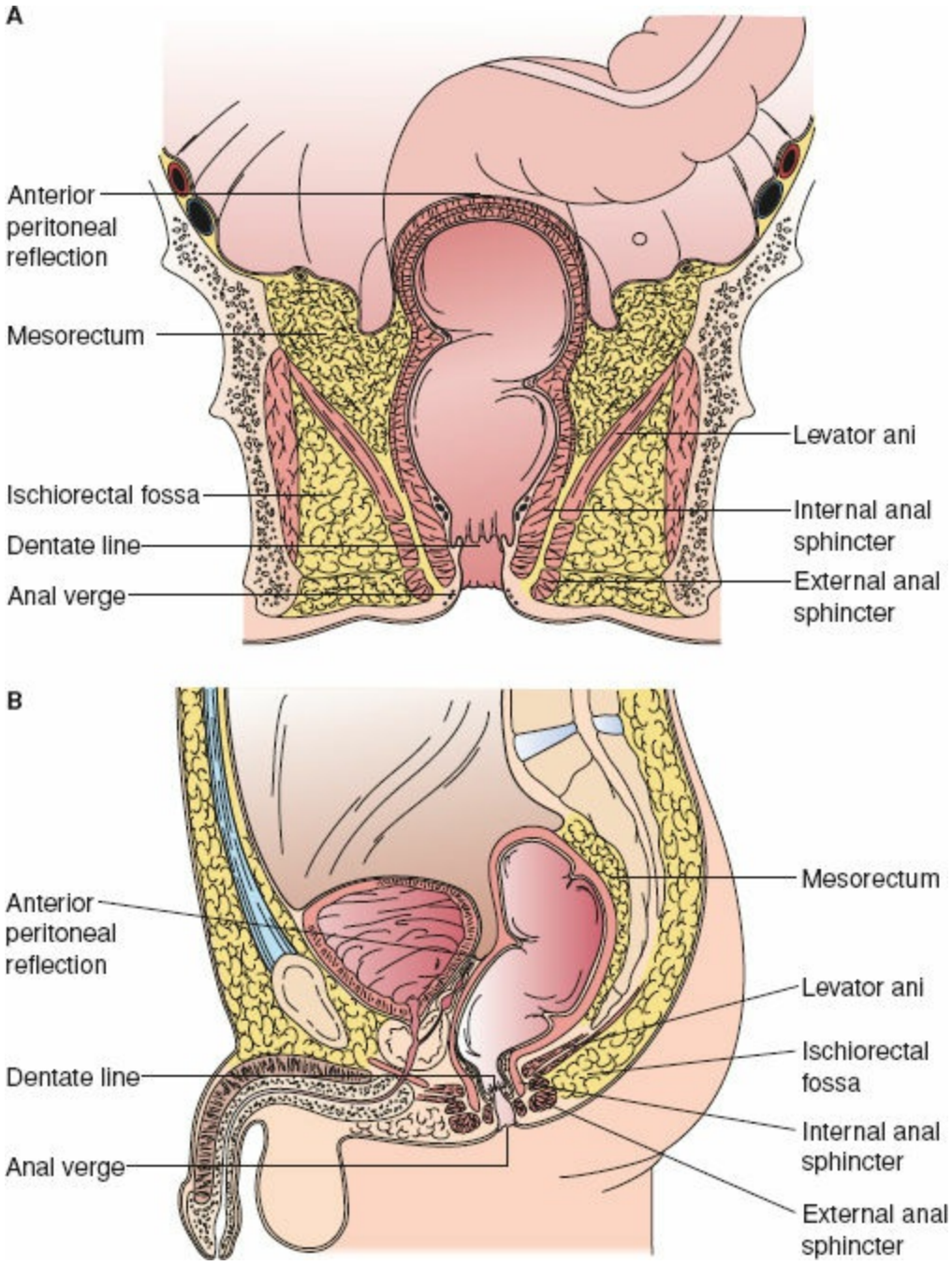

Figure 68-11. Anatomy of the rectum. **A:** Coronal pelvis. **B:** Sagittal pelvis.

The blood supply of the rectum comes primarily from the superior rectal artery, which is the terminal branch of the inferior mesenteric artery after it gives off the left colic artery. The superior rectal vein has a parallel course to its homonymous artery, and joins the left colic vein to form the inferior mesenteric vein draining into the splenic vein. The lower portion of the rectum and the anal canal also receive blood supply from the internal iliac vessels through the middle rectal artery, an inconsistent branch of the inferior vesical artery; the inferior rectal artery is a branch of the pudendal artery. The middle and inferior rectal vessels anastomose with the upper rectal vessels, supplying enough blood to the entire rectum. As in other locations, the middle and inferior rectal veins follow the course of the homonymous arteries, draining into systemic circulation through the internal iliac veins.

The anatomy of the autonomic pelvic nerve system is very important when operating in

the rectum, because of its proximity to the plane of dissection during different parts of the operation. Damage to these nerves can result in urinary and/or sexual dysfunction. The hypogastric plexus, located in front of the aorta, contains predominantly preganglionic sympathetic fibers originating from the lumbar sympathetic trunk. The fibers of the hypogastric plexus converge at the level of the aortic bifurcation into well-defined hypogastric nerves, which course laterally and anteriorly over the internal iliac vessels toward the lateral pelvic sidewall. There they join the splanchnic pelvic nerves, containing primarily postganglionic parasympathetic fibers from the anterior rami of S2, S3, and S4, to form the pelvic plexus. Branches of the pelvic plexus provide innervation to the distal ureter, the vas deferens, the seminal vesicles, urinary bladder, and prostate. Branches of the pelvic plexus also provide innervation to the distal rectum, passing through the lateral rectal ligaments, or lateral stalks. Finally, distal to the lateral rectal ligaments, the distal pelvic plexus forms the urogenital neurovascular bundles that pass close to the posterolateral aspect of the seminal vesicles or the vagina, extending toward the apex of the prostate and the neck of the bladder.

Clinical Staging of Rectal Cancer

The preoperative evaluation of the rectal cancer patient follows the same principles as that of the colon cancer patient, but the wider spectrum of therapeutic options for rectal cancer patients requires accurate information about the location and stage of the tumor. The clinical stage is important in making treatment decisions, such as the intent of the treatment (palliative or curative), the need for neoadjuvant therapy, or even the extent of the surgery (LE vs. TME).

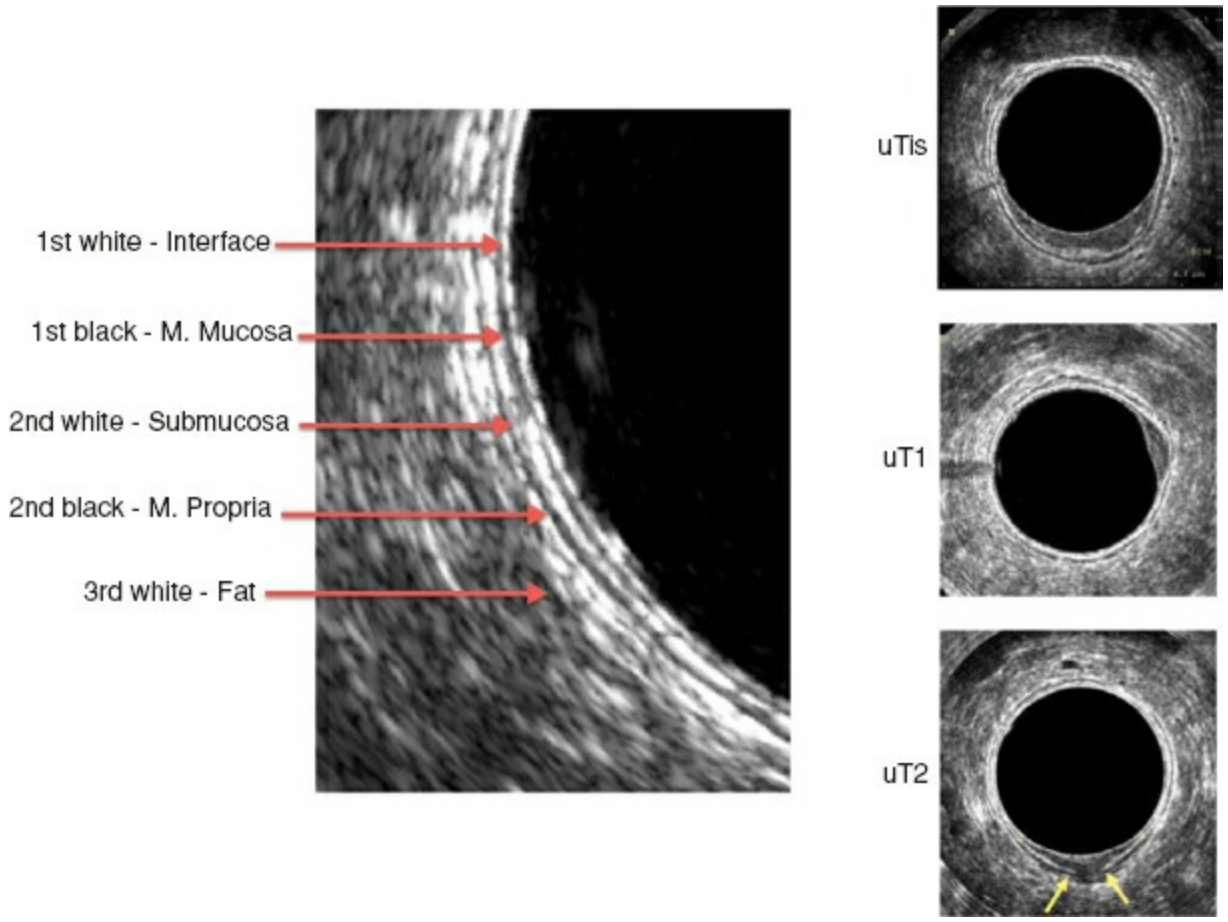

Figure 68-12. Endorectal ultrasound. Role in rectal cancer staging.

Patients with rectal cancer should undergo a complete colonoscopy because synchronous polyps are present in up to 30% of patients, and synchronous cancers in up to 5.3% of patients. They also require a CT scan of the chest, abdomen, and pelvis to exclude distant metastasis, which is present in 20% of patients at the time of diagnosis.

The preoperative locoregional staging of rectal cancer follows the clinical TNM system, based on depth of tumor penetration in the rectal wall and the presence of regional lymph nodes. However, the preoperative assessment of rectal cancer goes beyond determination of clinical tumor stage; it includes the distance of tumor from the anal verge, its relationship to the sphincter complex and the levator muscles, the proximity of tumor to the MRF, and the presence of extramural venous invasion (EMVI). This information is essential in planning treatment and surgery. Gross morphologic features such as size, morphology, and ulceration have been associated with prognosis. However, when stratified by stage, these characteristics have not appeared to contribute independently to

oncologic outcomes, and therefore they are not incorporated into treatment decisions.

3 DRE and proctoscopy provide the surgeon with the first direct impression of the tumor. Tumor mobility on DRE provides a gross estimation of the tumor depth of invasion. There is a four-category clinical classification of rectal tumors, based on mobility on DRE, which supposedly corresponds to the four T categories of the TNM system. However, the correlation between the clinical and pathologic T classifications is not very accurate, and varies significantly with the experience of the examiner. In general, DRE is able to distinguish between mobile tumors, most likely limited to the bowel wall, and tethered or fixed tumors, likely penetrating beyond the bowel wall. However, DRE fails to identify more than 50% of pathologically proven involved nodes.[157] Finally, only very distal tumors are within reach of the examining finger. Therefore, pretreatment clinical staging requires imaging studies; namely, ERUS, multidetector CT (MDCT) scan, and MRI.

Ultrasound with an endorectal rotating probe is the imaging modality that best depicts the different layers of the bowel wall, and it is most useful for staging early rectal cancer (Fig. 68-12).[158] But ERUS has a relatively short focal range, and cannot depict important anatomical structures such as the MRF. MDCT scans provide accurate images of the rectum, adjacent pelvic structures, and even the MRF, but have lower tissue resolution compared to MRI. A CT scan of the chest, abdomen, and pelvis should be performed in every rectal cancer patient to exclude distant metastases. MRI with a surface phased-array coil has become the preferred imaging modality for locoregional staging of rectal cancer. Using various sequences and multiple planes, MRI provides high-tissue resolution and excellent anatomical depiction of the rectum, the mesorectum, the MRF, the levator muscles, and other pelvic structures, relative to tumor location (Fig. 68-13).[159] The addition of new contrast agents and advanced functional sequences such as diffusion-weighted imaging (DWI) and dynamic contrast enhancement (DCE) permit the quantification of tumor biologic processes such as microcirculation, vascular permeability, and tissue cellularity. While still experimental, these images are potentially useful for early assessment of rectal cancer response to neoadjuvant therapy.[160,161]

Comparative studies suggest that ERUS is at least as accurate as MRI and more accurate than CT scan in assessing the depth of tumor penetration in the bowel wall. The accurate detection of involved mesorectal lymph nodes remains a challenge for all three techniques, however. Two meta-analyses of a number of case series assessing the accuracy of these three techniques reported a wide range of sensitivities and specificities for each, reflecting not only differences in technology, but also wide variation in the criteria used to define malignant lymph nodes.[162,163] However, the older studies included in these analyses were conducted before MRI techniques for rectal cancer staging were fully developed. At this time, MRI with a rectal cancer protocol provides the most useful information in a majority of rectal cancer patients, and has great utility for surgical planning, while ERUS is most useful for staging early-stage tumors.

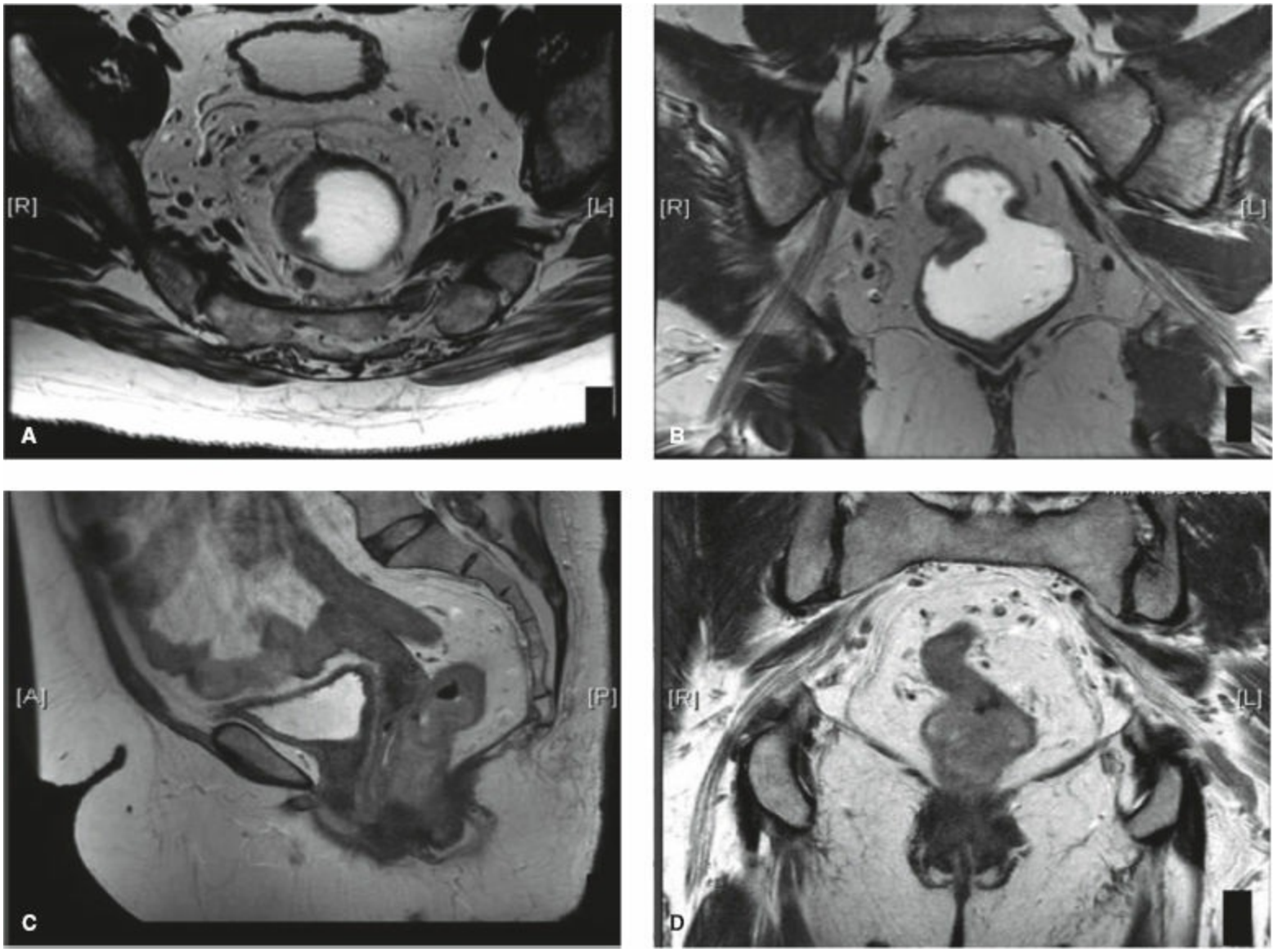

Figure 68-13. Magnetic resonance imaging. Role in rectal cancer staging.

Tumor distance from the MRF – the CRM when performing TME surgery – has prognostic implications for local recurrence and patient survival, and has become one of the most important parameters in the preoperative evaluation of rectal cancer patients.[164] MRI is the most accurate imaging modality in determining the distance of the tumor to the MRF, and predicting CRM involvement. The MERCURY trial, a prospective observational study assessing the accuracy of MRI in predicting a curative resection in rectal cancer, reported 92% specificity in predicting a negative CRM.[165] Other important tumor features accurately assessed by MRI, and associated with patient outcomes, are extramural spread, EMVI, involvement of the peritoneal reflection, and distance of tumor from the levator muscle and sphincter complex.[166,167] Using information on these parameters for patients registered to the MERCURY trial, clinicians are able to stratify rectal cancer patients with good prognosis (e.g., clear CRM, no evidence of EMVI, T2 or T3 <5 mm and not involving the intersphincteric plane) with a 3% LR rate and an 85% 5-year DFS after treatment with surgery alone.[168] In European and Scandinavian countries, the information gained from imaging, rather than clinical TNM staging, is used to determine treatment in patients with rectal cancer.[169]

4 Tumor response to neoadjuvant therapy has prognostic value, and re-staging after neoadjuvant therapy is becoming increasingly important in reassessing treatment options and planning the surgical procedure. Some patients with a clinical complete response are now offered alternatives to rectal resection, such as “wait-and-see,” in the context of clinical trials.[170,171] However, endoscopy and DRE tend to underestimate tumor response to CRT.[172] Morphologic imaging modalities such as ERUS and CT provide a rough estimate of tumor regression, but cannot reliably distinguish post-treatment edema, fibrosis, and necrosis from residual tumor.[173] Similarly, MRI assessment of tumor response based on the reduction of signal intensity relative to pre-treatment images, that occurs when tumor is replaced by fibrosis, correlates poorly with pCR.[174] Functional studies such as FDG-PET with or without simultaneous CT, are valuable in assessing partial tumor response, but are not sensitive enough to identify pCR.[175] MRI dynamic sequences such as DWI and DCE, which provide an estimate of tissue perfusion and cellularity, are currently under investigation in assessing rectal cancer response to CRT.[176]

Local Excision for Early-Stage Rectal Cancer

Selected patients with stage I rectal cancer, those with tumors localized to the bowel wall (T1 or T2) and without involvement of the mesorectal nodes (N0), can be hypothetically cured with a LE of the portion of the rectal wall containing the tumor. This operation spares most of the mortality, morbidity, and bowel, urinary and sexual dysfunction associated with TME. However, the success of LE requires meticulous patient selection. With LE, the mesorectum is not inspected for pathologic nodal staging. Therefore, LE should only be offered to patients with a low risk of nodal metastasis. The selection criteria for LE include: tumor size smaller than 3 cm, involving less than 30% of the circumference of the rectum, mobile on DRE, localized to the submucosa on ERUS, without evidence of metastatic lymph nodes on ERUS and CT or MRI, and no high-risk histologic features (i.e., grade 3 or 4, lymphovascular or perineural invasion).[177]

In the past, only tumors located in the distal rectum could be treated with conventional transanal excision (TAE), and LE was recommended only for tumors located within 8 cm from the anal verge. With the use of endoscopic instrumentation and large operating proctoscopes (TEM™, Richard Wolf Medical Instruments Corp., Vernon Hills, IL; TEO™, Karl Stortz Corp., El Segundo, CA) or single-port devices (TAMIS, Trans-Anal Minimally Invasive Surgery), LE can now be easily performed for tumors located in the mid and upper rectum. However, the benefit of LE is more significant for very distal tumors that otherwise would require a low anastomosis or a permanent stoma. The real benefit of LE for tumors located in the upper rectum is a matter of debate.

Independent of the approach, a full-thickness excision of the portion of the bowel wall involved by tumor, with a 1-cm negative margin is required to avoid local recurrence (Fig. 68-14). The final decision regarding the suitability of LE is made after the pathologic evaluation of the surgical specimen. If the resection margins are positive, depth of invasion is beyond the submucosa (T stage ≥ 2), or the histology reveals high-risk features (grade 3 or 4, lymphovascular or perineural invasion), the patient should be offered immediate salvage TME.

Even in patients with tumors meeting all selection criteria, LE is associated with a higher rate of LR compared to TME. The recurrence rates for T1 tumors treated with LE have been described as up to 23%.[178–180] While some patients who develop LR after a failed LE are candidates for salvage TME, only half of these patients are ultimately cured of their tumors. Recurrences after LE generally present as more advanced tumors, often requiring extended pelvic dissections.[181,182] The oncologic outcome for these patients is worse than those treated originally with TME; this reinforces the importance of patient selection for this strategy.

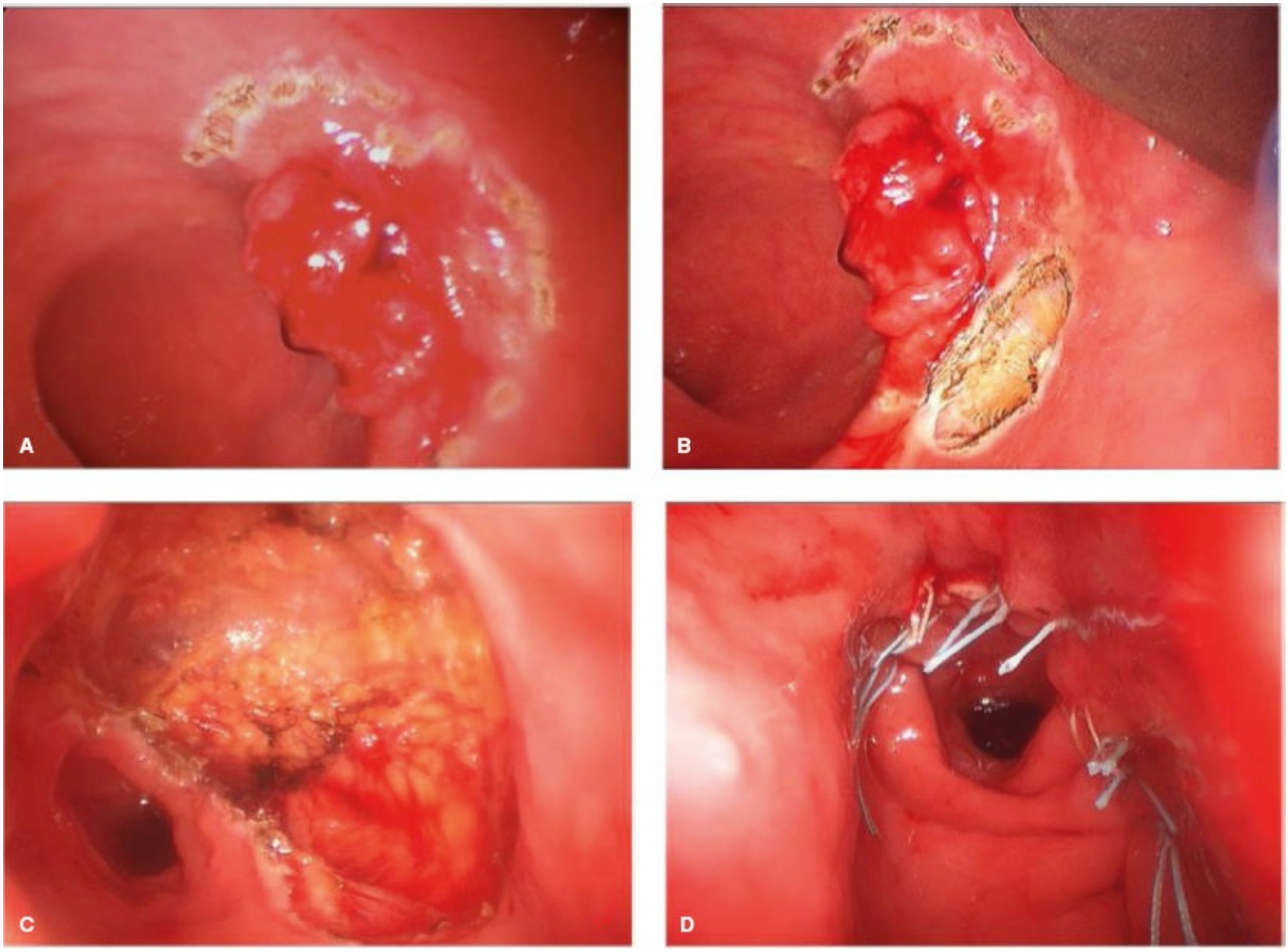

Figure 68-14. Local excision of early rectal cancer. **A:** Marking resection margins. **B:** Incision up to mesorectal fascia. **C:** Resection lodge. **D:** Defect closed with interrupted absorbable sutures.

A number of retrospective case series have compared the results of LE versus radical surgery (RS) for patients with early-stage rectal cancer. A cohort study from the National Cancer Database (NCDB) reported a 12.5% LR rate for LE, versus 6.9% for T1 tumors treated with RS ($p < 0.001$). Five-year overall survival was 77.4% for LE versus 81.7% for RS ($p = 0.09$).[183] Other series have reported similar results.[184] However, comparisons between LE and RS are limited by selection bias, since patients having LE tend to be older, have more comorbid conditions, and lower-lying tumors; whereas patients having RS tend to be younger and healthier with higher-lying – but usually larger – tumors.

A recent systematic review of one small randomized trial and 12 observational studies, including a total of 2,855 patients with T1N0M0 rectal cancer treated by LE (TAE/TEM-TEO) versus RS, showed that LE was associated with lower perioperative mortality (relative risk 0.31, 95% CI 0.14–0.71), major postoperative complications (relative risk 0.20, 95% CI 0.10–0.41), and need for a permanent stoma (relative risk 0.17, 95% 0.09–0.30). The LR rate was higher for patients treated with LE, and overall survival significantly lower, compared to patients treated with RS. The relative risk of dying after

LE was 1.46 (95% CI 1.19–1.77), which corresponds to 72 more deaths per 1,000 patients at 5 years. Meta-regression showed that the difference in overall survival observed between groups could be explained by the higher use of LE for tumors located in the lower third of the rectum, which is associated with worse prognosis. Survival was similar between groups when only tumors located in the distal rectum were included in the analysis.[185]

A number of studies have compared the outcomes of different techniques – conventional transanal excision, TEMS, TEO, and TAMIS – for LE of rectal cancer, with most comparisons limited to conventional TAE and TEMS. A recent meta-analysis of 6 retrospective case series including 927 procedures, reported that TEMS was associated with less specimen fragmentation, less positive resection margins, and lower LR rates. No difference was observed in complication rate.[186]

In summary, the literature suggests that LE may be an alternative to TME for patients with small, distal T1N0 rectal cancers, without high-risk histologic features, that would otherwise require a CAA or an APE. Transanal endoscopic techniques may be superior to conventional transanal excision. Patients considering LE should be informed about the potential gains in improved quality of life, but also about the higher risk of LR and the need for salvage surgery.

Patients with T2N0 tumors are not candidates for treatment by LE alone, independent of tumor histologic features. The rate of LR for these patients when treated with LE alone ranges from 13% to 47%, significantly higher compared to similar stage tumors treated with TAR. Five-year overall survival is also significantly lower for patients with T2N0 tumors treated with LE (65% to 67.6%) compared to TAR (76.7% to 81%).[183,187] A recent survey of the NCDB found that patients with T2N0 tumors treated with LE alone had a higher hazard ratio for death compared to similar patients treated with TAR (1.535, 95% CI 1.283–1.835).[188] Similar results have been reported in an independent cohort from the SEER database.[189] Based on this evidence, LE alone cannot be recommended as an alternative to RS for patients with T2N0 tumor treated with curative intent.

Radiation therapy has been used to reduce the rate of LR in patients with T2N0 rectal cancer treated with LE. A number of retrospective case series have reported 15% to 21% LR rates and 66% to 76.1% 5-year survival rates with LE followed by radiation or chemoradiation for T2N0 tumors.[190–193] The CALGB 8984 trial investigated the role of LE followed by 5-FU-based adjuvant chemoradiation for patients with T2N0 cancers, reporting a 66% (95% CI, 51% to 84%) overall survival and 64% (95% CI, 51% to 80%) DFS.[194] The trial compared the survival curves of patients with similar stage tumors treated with TME, concluding that LE and postoperative chemoradiation may be an alternative for patients with T2N0 tumors. However, 32% of the patients initially accrued for this trial were ultimately excluded from analysis due to tumor size, inaccurate staging, surgical specimen fragmentation, high-grade histologic features, or involved resection margins. Therefore, the conclusion is applicable only for properly staged early rectal cancers penetrating only into the muscularis propria (pT2), with full-thickness excision negative resection margins, and no high-risk histologic features.

The results of several retrospective studies have suggested that chemoradiation before

LE reduces the risk of recurrence to rates similar to those observed in similar stage patients treated with TME alone.[195,196] However, these studies are limited by small sample size, variable clinical staging criteria and imaging modalities, and the use of different CRT regimens. A retrospective study using the SEER database showed that patients who had undergone neoadjuvant CRT and LE had equivalent oncologic outcomes compared to patients who had a major resection.[189] One prospective trial found that patients with ERUS-staged T2N0 rectal cancer treated with neoadjuvant CRT had similar recurrence and survival rates when randomized to LE or RS. More than one in four patients in the RS arm required a permanent colostomy, and a similar number required a temporary ileostomy.[197] The ACOSOG Z6014 trial, a single arm study investigating the use of 5-FU and oxaliplatin-based neoadjuvant CRT and LE in T2N0 tumors, recently reported a complete pathologic response in 44% of patients.[198] Only 2 (3%) patients had developed recurrence after 4 years of follow-up. The 3-year DFS was 87%, with a 3-year OS of 90%. At the end of the follow-up 70 of 72 patients treated with this approach had organ preservation.[199] In summary, the optimal treatment of T2N0 rectal cancer is TME; LE alone is not an alternative to radical resection in patients treated with curative intent. Postoperative CRT may be an alternative to TME in a patient with a distal clinical stage T1N0 cancer who is unexpectedly found to have a T2 tumor after LE and is interested in preserving the rectum. Neoadjuvant CRT followed by LE may be an alternative for patients with very distal T2N0 tumors interested in organ preservation, who otherwise would require a permanent colostomy.

LE and other forms of local therapy, such as endocavitary radiation, brachytherapy, or electrofulguration, have been used for palliation in patients who have more advanced tumors or are unfit for a major surgical procedure.

Transabdominal Resection for Rectal Cancer

Patient preparation for rectal cancer surgery is similar to that for colon cancer surgery. Stoma marking is particularly important in these patients, as many will require a temporary or permanent stoma. In addition to discuss fertility options with all individuals of child-bearing potential, female patients receiving neoadjuvant radiation who are interested in preserving fertility should consult their gynecologist regarding the possibility of ovarian transposition. Mechanical bowel preparation, antibiotic and thromboembolic prophylaxis are similar to those described for colon cancer patients. Many surgeons recommend a rectal washout immediately before surgery to eliminate exfoliated cancer cells that could potentially implant in the anastomosis and cause LR. In fact, a recent meta-analysis with 5,012 patients found that this practice is associated with a lower incidence of LR.[200] On the operative table, the patient should be placed in lithotomy with the legs in stirrups to provide the surgeon with simultaneous access to the abdomen and perineum. It is important to avoid pressure on the bony prominences, which might cause peroneal nerve compression. Patients requiring prolonged Trendelenburg position during surgery are at risk of compartment syndrome, in particular obese patients and those with peripheral vascular disease. These patients require monitoring of the peripheral pulses, and position changes, to prevent compartment ischemia.

Principles of Total Mesorectal Excision

The principle of rectal cancer treatment is the eradication of the primary tumor and its lymphatic drainage by en bloc removal of the rectum and the mesorectum, following well-defined anatomical planes. This operation, known as total mesorectal excision, or TME, requires dissection under direct vision along the areolar tissue plane situated between the MRF and the presacral fascia (Fig. 68-15). A sharp dissection along this plane is associated with a higher probability of achieving a negative CRM, lower risk of bleeding from inadvertent tearing of the presacral veins, and reduced risk of injuring the hypogastric nerves.[128]

Adequate lymphadenectomy requires division of the lymphovascular pedicle at the origin of the superior rectal vessels, caudal to the branching of the left colic artery from the inferior mesenteric artery (usually defined as low tie). In patients with clinically suspicious nodes at the origin of the inferior mesenteric artery, the lymphovascular control should be extended proximally by dividing the inferior mesenteric artery close to the origin (high tie). In both cases the sigmoidal branches are included in the surgical specimen; therefore, the proximal division of the bowel should ideally be performed at the junction of the descending and the sigmoid colon, incorporating most of the sigmoid colon in the surgical specimen.[201] As distal tumor extension along the rectal wall is limited, a distal margin of 2 cm of normal bowel wall is considered adequate for most tumors. However, distal spread in the mesorectum may extend farther than intramural spread. Not infrequently, mesorectal deposits are found 3 to 4 cm distal to the lower edge of the tumor. Therefore, for tumors of the upper rectum, the mesorectal excision should be extended to 5 cm distal to the lower edge of the tumor. In these patients the

mesorectum should be divided perpendicular to the axis of the rectum. As some of the distal mesorectum is left in the pelvis along with the distal rectal stump, this operation is known as tumor-specific TME (TSME), to distinguish it from the TME performed with dissection carried to the pelvic floor, the rectum divided distal to the end of the mesorectum, and the entire mesorectum included in the surgical specimen.[123]

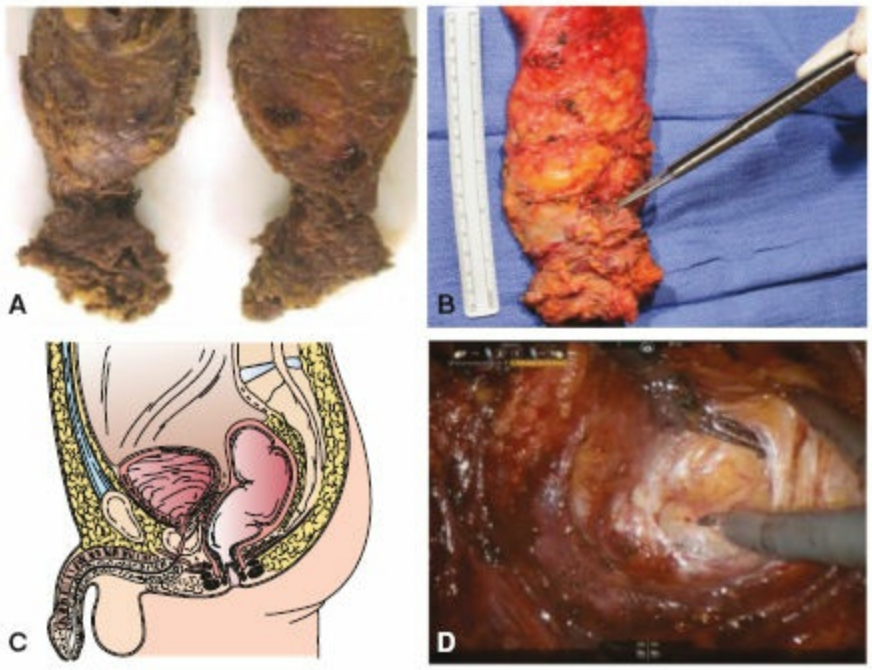

Figure 68-15. Total mesorectal excision. **A:** APR specimen. **B:** ELAPE specimen. **C:** Planes of dissection for TME. **D:** Robotic TME.

Sphincter Saving Procedures

A TSME or a TME is compatible with sphincter preservation by anastomosing the divided end of the descending or the sigmoid colon to the rectal stump. This operation is known as a low anterior resection or LAR (Fig. 68-16). In this operation the rectum is divided distal to the tumor using a stapling device that simultaneously staples and divides the rectum, leaving a short rectal stump. The anastomosis is completed with a circular stapler that brings together the end of the colon to the rectal stump. The re-establishment of the large bowel's continuity by suturing the colon to the anal canal, working through the anus, is known as coloanal anastomosis or CAA (Fig. 68-17). The connection of the colon to the rectum or anal canal can be performed by an end-to-end or a side-to-end connection, or with the creation of a J-pouch reservoir (Fig. 68-18). A tension-free, well-vascularized low colorectal or coloanal anastomosis requires a complete mobilization of the entire left colon with take-down of the splenic flexure, including division of the inferior mesenteric vein close to the ligament of Treitz. The blood supply to the entire left colon is based on the left branch of the middle colic vessels through the marginal artery.

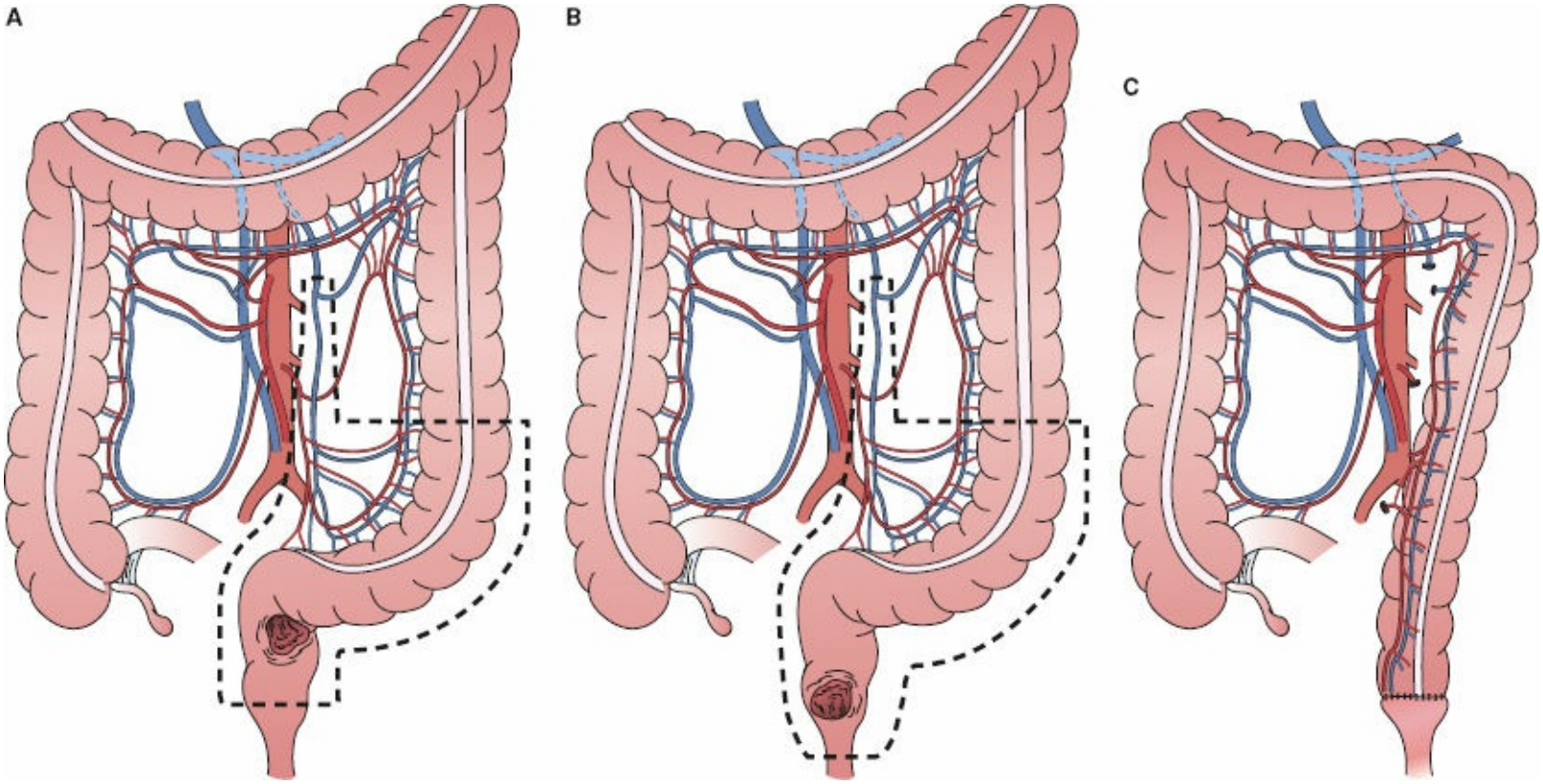

Figure 68-16. **A:** Low anterior resection, section in the distal third of the rectum, candidate for colorectal anastomosis. **B:** Low anterior resection, section above the sphincteric complex, candidate for coloanal anastomosis. **C:** Colorectal anastomosis.

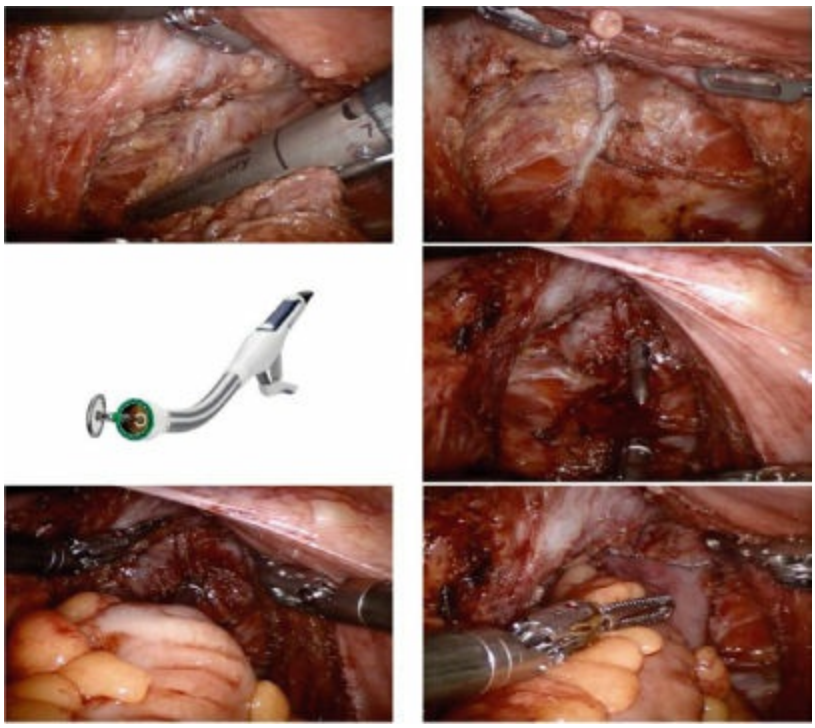

Figure 68-17. Double stapling technique for low colorectal end-to-end anastomosis.

Many patients undergoing a sphincter-saving procedure report high bowel frequency, urgency, soiling, and inability to defer defecation for 15 minutes.[202] This constellation of symptoms is commonly known as low anterior resection syndrome (LARS).[203] The frequency and severity of these symptoms is variable and depends, to some degree, on

the location of the tumor and the anastomosis, the patient's prior bowel function, and the use of neoadjuvant or adjuvant therapy.[204] Pelvic irradiation, before or after surgery, increases significantly the risk of bowel dysfunction.[205,206] The anatomical and physiologic factors that contribute to LARS are not completely understood. Anal sphincter pressures are not different in patients with or without LARS. What appears to be different is an exaggerated anal sphincter relaxation to even small volumes of stool within the neorectum.[207] Surgeons have tried to overcome this low capacitance of the neorectum – which results from an end-to-end anastomosis – by creating a colonic reservoir: either a colonic J-pouch, or a side-to-end anastomosis. A number of studies have compared the functional outcomes after straight end-to-end anastomosis and a colonic J-pouch. A systematic review of reconstructive techniques after LAR identified 9 trials that randomized a total of 473 rectal cancer patients to either colonic J-pouch or straight end-to-end anastomosis, reporting that short-term bowel function was better for J-pouch compared to straight anastomosis.[208] Frequency and urgency were less prevalent in patients with a colonic J-pouch, but the rate of fecal incontinence was similar in both groups. The only two trials that followed patients for more than 118 months found minimal or no long-term differences between groups. Although the methodology of these studies was very heterogeneous, they do indicate that a colonic J-pouch is associated with a short-term improvement in frequency and urgency, but no apparent long-term benefit, compared to end-to-end anastomosis. The same systematic review found no differences in anastomotic leak rate, or other complications, between groups. Of note, almost one-third of patients with colonic J-pouches often complained of long-term difficulty emptying the rectum, requiring use of laxatives or suppositories.[209,210] These symptoms are more prevalent when larger pouches are created; therefore, pouch size should be limited to 5 to 6 cm.[211,212]

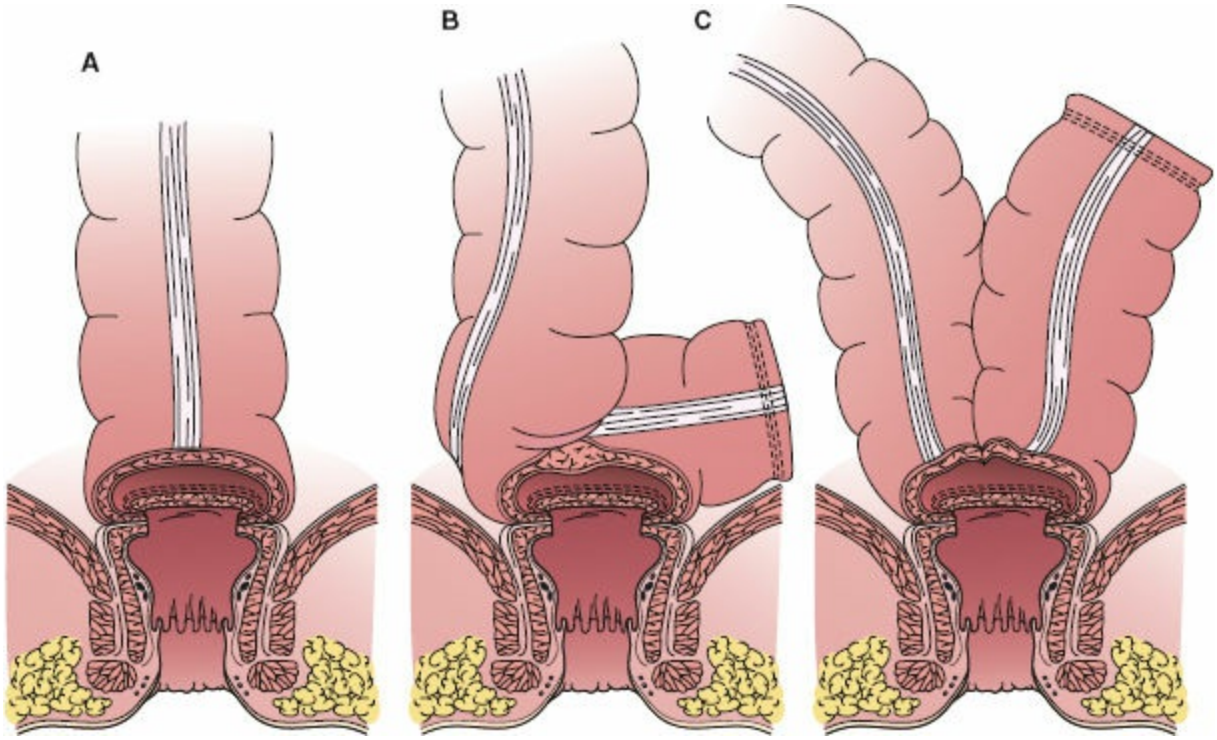

Figure 68-18. Reconstructive options after LAR. **A:** End-to-end anastomosis. **B:** End-to-side anastomosis. **C:** J-pouch anastomosis.

The side-to-end anastomosis (created by inserting the anvil of a circular stapler 3 to 4 cm from the end of the mobilized descending colon) can also potentially increase the reservoir capacity of the anastomosis. It has similar functional results, but is easier to construct than the colonic J-pouch; although it, too, is associated with defecatory problems.[213] The creation of a transverse coloplasty proximal to an end-to-end anastomosis is another option used to increase the capacity of the neorectum, but is associated with a higher anastomotic leak rate.[208]

In summary, colonic reservoirs are associated with a temporary improvement in bowel frequency and urgency, but have the risk of long-term defecatory problems. In general, the author prefers an end-to-end anastomosis using the larger descending colon, rather than the sigmoid colon, for creation of the neorectum.

The integrity of the anastomosis should be tested intraoperatively with a pneumatic test, or by endoscopy, with distension of the bowel while submerging the anastomosis in water. Air leaks thus detected may be treated with suture repair, re-do of the anastomosis, and/or the creation of a proximal diverting stoma. Testing the integrity of the anastomosis during surgery has been associated with a lower risk of clinical postoperative anastomotic leak.[214]

Low colorectal and coloanal anastomoses have a risk of leakage ranging from 3% to 34%, depending on the patient population, the use of neoadjuvant radiation, the distance of the anastomosis from the anal verge, and the surgical technique.[215,216] An anastomotic leak can cause pelvic sepsis, which may not only preclude sphincter preservation, but has also been associated with an increased risk of local recurrence and poorer survival[217] (although more recent data have questioned this association).[218,219] To prevent these possible complications, a diverting stoma is recommended for patients having a TME, and

for patients receiving neoadjuvant radiation.[220] Diverting stomas do not prevent complications, but mitigate the consequences of a leak and reduce the need for urgent reoperation in patients developing a leak.[221,222] A loop ileostomy is preferred over a transverse loop colostomy because it is easier to create and close.[223] However, loop ileostomies are associated with postoperative dehydration and electrolyte abnormalities requiring hospital readmission.[224] Prevention of these complications requires adequate patient education and training about stoma management.

Abdominoperineal Excision

For many cancers located in the distal rectum, particularly those infiltrating the levator muscles or the anal sphincter, an oncologically safe circumferential and/or distal resection margin is not compatible with sphincter preservation. In these patients an R0 resection requires a TME with en bloc excision of the levator muscles and the anal canal, and the creation of a permanent end colostomy. This operation is known as abdominoperineal excision of the rectum or APE (Fig. 68-19). As the name indicates, the APE has two parts: an abdominal part and a perineal part. During the abdominal part, the proximal lymphovascular control, division of the colon, and dissection along the mesorectal plane are similar to those in LAR, except that the mesorectal dissection should stop at the upper level of the levators, to avoid disturbing the portion of the rectum resting on the levator muscles. During the perineal part, the anal canal with the sphincter complex and the levator muscles are dissected off the ischiorectal fat, all the way to the apex of the ischiorectal fossa. The levators are divided close to their insertion in the white line near the obturator internus and coccygeus muscles. The levator muscles are left attached to the rectum, and the resulting surgical specimen has a cylindrical appearance; therefore, this procedure is called cylindrical APE or extralevator APE (ELAPE) (Fig. 68-20).[225] However, some surgeons question the need to entirely remove both levator muscles in every rectal cancer patient, and recommend removing only the portion of the levators required to clear the tumor. This operation has been called the standard APE or SAPE.[226] The choice between an ELAPE and SAPE is controversial. The potential oncologic benefit of larger tissue removal needs to be weighed against the increased morbidity potentially associated with a larger perineal defect, particularly in patients treated with neoadjuvant therapy.[227] A recent meta-analysis with 949 patients from one randomized trial, one prospective case-control study, and six retrospective case series, indicated that ELAPE is associated with lower intraoperative rectal perforation, lower positive CRM, and lower risk of local recurrence, but with similar complication rates, compared to SAPE.[228] At the present time, the hypothetical benefit of the ELAPE over the SAPE has not been proven conclusively. It is possible that both techniques – the total or the tumor-specific excision of the levator muscles – may be equivalent as long as an R0 resection, with an intact rectal specimen, is achieved.

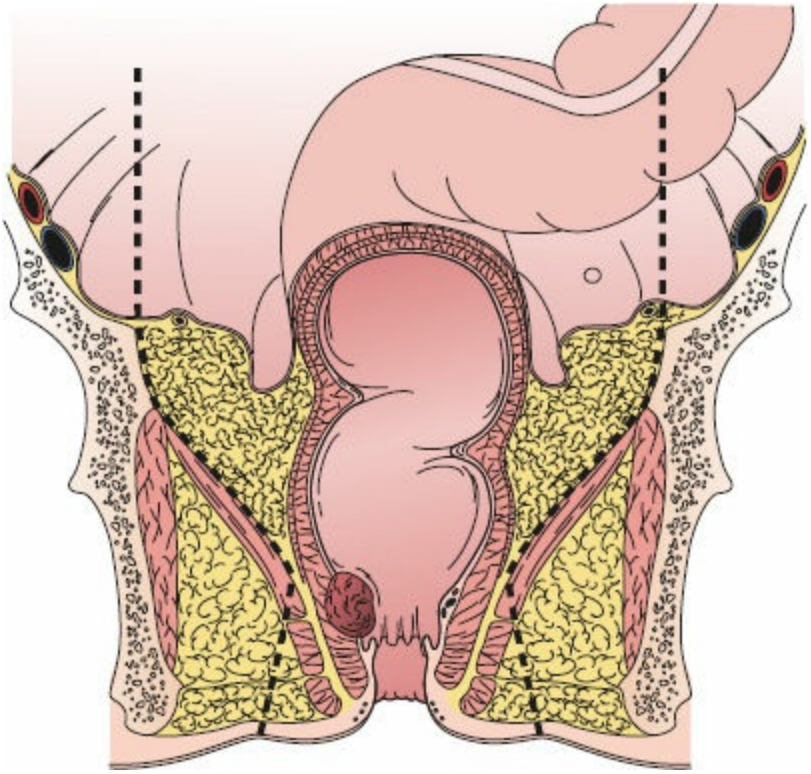

Figure 68-19. Abdominoperineal excision of the rectum (APE).

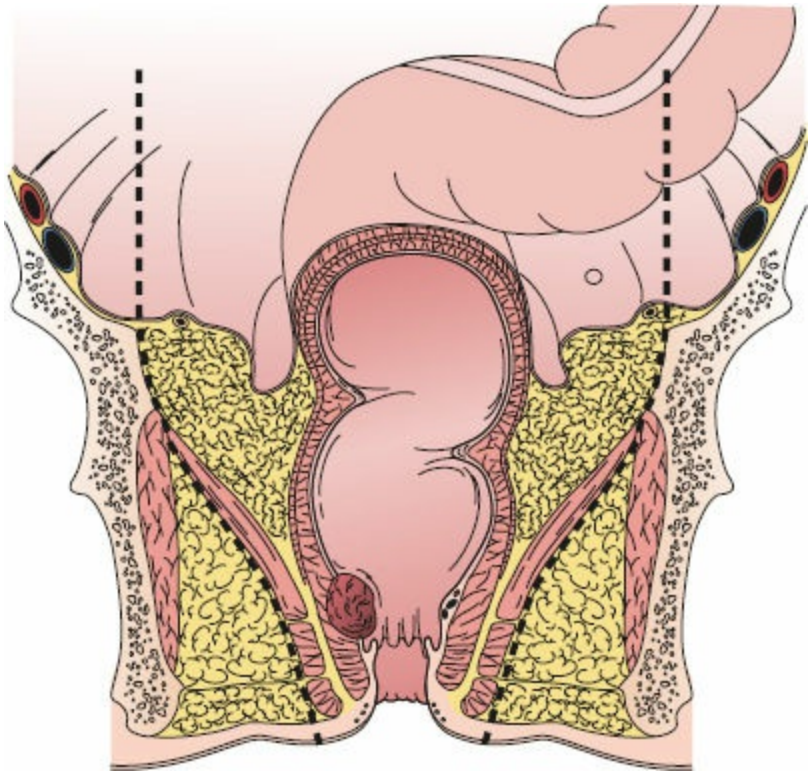

Figure 68-20. Cylindrical APE.

Many surgeons will perform both parts of the APE operation with the patient in modified lithotomy, also known as the Lloyd–Davis position. It provides relatively good access to the perineum and allows two teams to work simultaneously – one in the abdomen, and one in the perineum. Others perform the abdominal part in the supine position, and the perineal part with the patient prone over a hip roll and padding of the bony prominences. The prone position, also known as jackknife position, provides better

exposure of the perineum, and facilitates assistance and teaching. It requires turning the patient, which takes time, and does not allow a two-team approach. Results seem to be similar with both approaches, and the selection is based on the surgeon's preferences.[229]

Minimally Invasive Surgery for Rectal Cancer

5 Open surgery for rectal cancer requires long abdominal incisions. An APE can be performed though a midline infraumbilical or low transverse incision. Most sphincter-preserving procedures (SSPs) require a long midline incision, extending from the epigastrium to the symphysis of the pubis, in order to permit access to the entire left side of the large bowel from the splenic flexure to the lower rectum. These abdominal incisions are a source of patient discomfort, and short- and long-term morbidity. The goal of minimally invasive surgery in rectal cancer is to reduce the size of the abdominal incision, thus expediting recovery, without compromising the completeness of the mesorectal excision or the oncologic outcomes. However, the adoption of minimally invasive surgery for rectal cancer has been slow due to the difficulty of working in the relatively deep and narrow pelvic space using long, rigid, nonarticulated laparoscopic instruments. According to a number of retrospective case series and small randomized controlled trials, laparoscopic TME is associated with less postoperative pain, less surgical morbidity, and shorter length of hospital stay, but equivalent completion of the mesorectal excision, CRM positivity, and even LR, compared to open TME.[230–232] While these studies have shown that laparoscopic TME is feasible, less than 20% of all rectal cancer operations are performed laparoscopically in the United States.[233]

Three large multi-institutional prospective, randomized trials have compared open and laparoscopic TME for rectal cancer (Table 68-9).[234–236] A fourth prospective study conducted in the United States, the ACOSOG Z6051, has completed accrual, but the results are not available yet. The combined experience of these trials indicates that laparoscopic TME results in longer operative time, less blood loss, faster bowel recovery, and shorter hospital stay compared to open TME. Operative mortality and intraoperative and postoperative complications were not different between groups. The proportions of patients having an SSP, a complete mesorectal excision, or a positive CRM were not different between groups, nor was the number of lymph nodes retrieved. However, conversion and positive CRM rates in the laparoscopic arms varied widely between different studies. These differences could be explained by trial design, inclusion criteria, randomization, and use of neoadjuvant therapy. Only the CLASICC and COREAN trials have reported 3-year oncologic outcomes. LR, distant metastasis (DM) and survival were not different between groups. However, these results should be interpreted with caution, because the CLASICC trial was not specifically powered to detect differences between treatment groups in rectal cancer patients, and the COREAN trial allowed a 15% difference as the noninferiority margin. Therefore, while these studies justify the use of laparoscopy in rectal cancer, it is prudent to wait for the final results of the larger COLOR II and ACOSOG Z6051 trials before endorsing laparoscopy as the preferred surgical approach to LARC.

Table 68-9 Open versus Laparoscopic Rectal Resections: Results of the Most Representative Series

Open/Laparoscopic	CLASICC[12–15] (2005–2007–2010–2013)	COLOR II[18,19] (2013)	COREAN[20,21] (2010–2014)
n	381	1,103	340
Rectal cancer included	All	T1–3 (>2 mm from endopelvic fascia) Upper-mid-low	Mid-low cT3Nx
Neoadjuvant CRT (%)	0	34/32	100/100
Operative time (min)	135/180[a]	188/240 $p < 0.001$	197/224.9 $p = 0.001$
Blood loss (mL)	NR	400/200 $p < 0.001$	217.5/200 $p = 0.006$
TME (%)	67/79	67/60 $p = 0.120$	100/100
APR (%)	27/25	23/29	14.1/11.2 $p = 0.708$
Conversion	34	17	1.2
Positive CRM (%)	14/16 $p = 0.8$	10/10 $p = 0.850$	4.1/2.9 $p = 0.770$
Lymph nodes (*n*)	13.5/12	14/13 $p = 0.085$	18/17 $p = 0.085$
First bowel movement (days)	6/5	3/2 $p < 0.001$	5.12/4.02 $p < 0.001$
Hospital stay (days)	13/10	9/8 $p = 0.036$	9/8 0.056
Morbidity (%)	13/14	37/40 $p = 0.42$	23.5/21.1 $p = 0.603$
Local recurrence	10.1/9.7 $p = 0.96$	5/5[a,c]	4.9/2.6 $p = 0.42$
Systemic recurrence	18.6/16.4 $p = 0.74$	20.1/19.1[a,c]	17/15 $p = 0.42$
DFS (%)	52.1/53.2 $p = 0.953$[a]	70.8/74.8[a,c]	72.5/79.2[b]
OS (%)	52.9/60.3 $p = 0.132$[a]	83.6/86.7[a,c]	90.4/91.7[b]

[a]3-year survival.
[b]5-year survival.
[c]Difference <5% calculated for noninferiority.

Many surgeons currently perform a hybrid approach consisting of the laparoscopic lymphovascular control and colon mobilization, and the open mesorectal dissection and anastomosis through a lower abdominal transverse incision. The hybrid approach is aimed at facilitating the most technically challenging portion of the operation: the dissection of the distal rectum and the creation of the anastomosis. With this approach the size of the abdominal wall incision is smaller compared with a totally open procedure, but larger than with a totally laparoscopic procedure. Although there is some evidence of short-term advantages to this approach compared to open surgery,[237] long-term benefits compared to

the totally open or laparoscopic approaches are unknown.

The robotic platform (da Vinci®) was introduced to the surgical armamentarium to facilitate the minimally invasive approach to procedures such as prostatectomy, hysterectomy, and TME, which require optimal visualization and dexterity in the narrow pelvic space. The experience accumulated thus far – based on retrospective institutional case series – suggests that robotic TME is equivalent to laparoscopic TME in terms of completeness of the mesorectal excision, CRM positivity, and short-term oncologic outcomes. Conversion rates appear to be lower compared to laparoscopic TME, but hospital charges are higher.[238] A prospective, randomized study comparing laparoscopic and robotic TME – the Robotic Versus Laparoscopic Resection for Rectal Cancer (ROLARR) trial – has completed accrual, but the results are not available yet.[239] However, as laparoscopy has not become standard in LARC, it is likely that the controversy regarding the benefit of robotic TME will continue for years.

The transanal–transabdominal proctectomy, or down-to-up TME, is a transanal, minimally invasive approach for the dissection of the distal rectum in patients with a narrow pelvis.[240,241] With this approach, lymphovascular control, the entire colonic mobilization, and dissection of the upper rectum are performed using conventional transabdominal laparoscopy. The dissection of the distal rectum is performed through the anus, using either conventional transanal equipment for very distal tumors, or endoscopic equipment (TEMS, TEO, TAMIS) for higher tumors. The rectal wall is incised circumferentially, distal to the tumor, and the MRF is identified. The lumen of the colon is closed with a purse-string suture to avoid contamination. The dissection is carried cephalad in the proper plane until the abdominal field is reached. The specimen is then removed, and the anastomosis performed through the anus. This approach is particularly useful for patients with very distal rectal cancers treated with chemoradiation therapy, in which the surgeon has no anatomical cues about where to transect the rectum in order to achieve a negative distal margin. The transanal approach allows the surgeon to choose precisely the point for transecting the rectum while visualizing the distal edge of the tumor. The benefit of the down-to-up approach for higher rectal cancers that could be treated with a conventional transabdominal dissection and a double-stapled anastomosis are uncertain.

Adjuvant Chemoradiation for Locally Advanced Rectal Cancer

Several randomized, controlled trials conducted in the pre-TME era demonstrated that radiation therapy (RT) given before or after surgery reduced the rate of LR, compared to surgery alone.[242–244] However, the relevance of these trials was later questioned, because surgery was not standardized and the LR rates reported in the control arms – approximately 25% – were considered too high compared to that of patients treated in later years with surgery alone according to TME principles.[129] The efficacy of RT in the setting of quality TME surgical resection was investigated in the Dutch Colorectal Cancer Group trial, which randomized 1,861 patients with resectable disease to TME alone or short-course RT (SCRT) (5Gy a day × 5 days, for a total dose of 25Gy), followed by TME within 2 to 7 days. The study showed that SCRT reduced the rate of LR in resectable rectal cancer treated by TME, compared to TME alone; however, SCRT did not provide a significant survival benefit.[245] This trial proved that preoperative RT decreases the rate of LR in LARC patients treated with TME surgery.

The benefit of combining chemotherapy with RT was proven by several randomized trials that compared postoperative RT combined with 5-FU, administered as a bolus or as continuous venous infusion (CVI), to postoperative RT alone, in patients with pathologic stage II and III rectal cancer.[246,247] The results proved that combined 5-FU and radiation was more effective than radiation alone in reducing the risk of LR, and that CVI 5-FU was associated with lower toxicity compared to bolus 5-FU.

The European Organization for Research and Treatment of Cancer (EORTC) protocol 22921 was developed to assess the effect of adding CT to preoperative RT, and the subsequent value of postoperative CT in rectal cancer patients.[248] At the 5-year mark, LR was significantly lower in all three arms receiving any CT (pre- or postoperative) compared to preoperative RT alone, indicating a benefit of CT in reducing the risk of LR, regardless of when it was administered. The addition of CT to RT did not impact survival. Additional work by the Federation Francophone de la Cancerologie Digestive corroborated these findings.[249] These studies showed that, similar to what was found using postoperative radiation, adding CT to preoperative RT also reduced the rate of LR, compared to preoperative RT alone.

The German Rectal Cancer Group (CAO/ARO/AIO 94) compared preoperative versus postoperative CRT in 823 patients with clinical T3–4/N+ rectal cancer.[250] RT in this trial consisted of 50.4 Gy in 25 fractions with bolus 5-FU as a radiosensitizer. In the preoperative treatment group, surgery was performed 6 weeks after completion of CRT. Both groups had surgery according to TME principles, and received postoperative adjuvant CT. The preoperative CRT group had less toxicity and lower 5-year LR rates compared to the postoperative CRT group (6% vs. 13%). This study found no differences in the rates of DR, DSS, or OS. The NSABP R-03 study also compared the use of preoperative versus postoperative 5-FU/LV, using 45 Gy in 25 fractions in T3/4, N+ patients, to evaluate differences in DFS, LR, or OS.[251] Despite stopping the study early due to limited accrual, the R-03 study reported better DFS in the preoperative CRT group, compared to the postoperative group, with a near-significant difference ($p = 0.065$) in

OS and no difference in LR. The results of these two trials established preoperative CRT as the preferred treatment for LARC in both Europe and the United States.

More recently, it has been shown that capecitabine is noninferior to infusional 5-FU as a radiosensitizer for LARC, in both the NSABP R-04 trial and the German Cancer Research Center multi-center trial.[252,253] Several large, prospective trials have failed to prove that the addition of oxaliplatin to a fluoropyrimidine (5-FU or capecitabine) is superior to fluoropyrimidine alone as a radiosensitizer in patients with LARC.[252,254–256] In fact, patients receiving the oxaliplatin plus a fluoropyrimidine had a greater rate of adverse events, with similar or lower tumor response rates. Therefore, based on the current evidence, oxaliplatin is not recommended as a radiosensitizer to a fluoropyrimidine in patients with LARC.

In addition to the standard hypofractionation (180 to 200 cGy a fraction) commonly delivered during the standard CRT, radiation therapy is also frequently delivered as short course (SCRT) using fewer, larger fractions (5 Gy daily fractions for 5 consecutive days and a total dose of 25 Gy). In these patients, surgery is performed within 7 days of completion of the radiation. Both schemes are biologically equivalent in eradicating cancer cells, but SCRT has the potential benefits of shorter duration of treatment, more efficient utilization of resources, and reduced cost compared to CRT. However, higher dose per fraction increases the risk of delayed toxicity, and tumor regression is lower with SCRT. Two prospective, randomized trials comparing SCRT with CRT have reported equivalent local tumor control with both regimens, and the selection between CRT and SCRT is based on doctor and patient preferences.[257,258] In general, CRT is preferred in the setting of large tumors that may benefit from maximal tumor regression before surgery.

Current guidelines recommend CRT with the aim of reducing the risk of LR for all patients with stage II and III rectal cancer. However, the risk of LR is variable depending on the distance of the tumor from the anal verge, the risk being lower for tumors located in the upper rectum compared to those in the lower rectum. It is possible that some patients with high rectal cancers, specifically those with T3N0 tumors and a clear CRM, may not actually benefit from preoperative radiation but may simply be exposed to radiation-associated toxicity. A current trial in the United States seeks to address this question by comparing the outcomes of rectal cancer patients treated with neoadjuvant chemotherapy, with or without radiation, before TME.[259]

Adjuvant Chemotherapy for Locally Advanced Rectal Cancer

In the past, LR was the dominant problem in patients with LARC, but in the modern era more patients develop distant metastasis than LR. Consequently, patients with LARC treated with neoadjuvant CRT and TME are recommended for postoperative adjuvant chemotherapy, with the aim of reducing distant metastasis and improving survival. However, the data supporting this recommendation are limited, and based heavily on experience using adjuvant therapy for resected colon cancers. The QUASAR study discussed above showed that adjuvant chemotherapy has a modest effect in lowering recurrence and improving survival in stage II/III CRCs following curative-intent surgery.[153] However, the cohort was not powered to demonstrate differences in the 29% of rectal cancer patients who were accrued, and the association with better outcomes stems from subset analysis. In contrast, the 10-year update of the EORTC 22921 trial showed no difference in OS or DFS with the addition of 5-FU–based postoperative chemotherapy in rectal cancer patients treated with preoperative RT or CRT and TME.[260] However, these results have been criticized because the proportion of patients receiving the full dose of postoperative adjuvant chemotherapy was only 43%, thus underestimating the therapeutic effect. A meta-analysis of 21 controlled trials in patients receiving potentially curative surgery, including a total of 4,854 patients randomized to surgery plus fluoropyrimidine-based postoperative chemotherapy, and 4,367 patients to surgery and observation, has shown a significant reduction in the risk of death (17%) (HR = 0.83, CI: 0.76–0.91) and a reduction in the risk of DR (25%) (HR = 0.75, CI: 0.68–0.83) among patients undergoing adjuvant chemotherapy, compared to those undergoing observation.[261] Available data were insufficient to investigate the effect of adjuvant chemotherapy separately in different TNM stages. These data support the use of postoperative chemotherapy after curative-intent surgery in patients with rectal cancer. Similar to colon cancer patients, patients with LARC treated with CRT and TME are recommended to receive 5-FU or capecitabine plus oxaliplatin-based adjuvant chemotherapy. The length of adjuvant treatment in rectal cancer is shorter compared to colon cancer (4 months vs. 6 months), given the use of sensitizing 5-FU or capecitabine during CRT.

A common criticism about the use of postoperative adjuvant chemotherapy after curative surgery in patients with rectal cancer is low treatment compliance. In some series, up to 27% of eligible patients never start treatment, and more than 50% require dose reductions or treatment interruptions or delays.[248,256] This is particularly relevant, as a systematic review of 10 studies – including more than 15,000 patients – evaluated the effect of timing on the efficacy of postoperative adjuvant therapy, demonstrating that each 4-week delay in treatment correlated with a 14% decrease in OS.[262] The low compliance with postoperative adjuvant chemotherapy has been attributed to postoperative complications, slow recovery after surgery, delays due to closure of the temporary ileostomy, or simply patient refusal. Delivering systemic chemotherapy before surgery has the potential advantage of increasing treatment compliance, potentially enhancing the efficacy of CT in preventing DM, and ultimately improving survival. In

addition, it increases response of the primary tumor, and shortens the time to temporary ileostomy reversal. A number of studies have shown that compliance with systemic chemotherapy is higher when it is delivered before CRT and TME, compared with conventional postoperative adjuvant chemotherapy in patients LARC patients who are candidates for curative surgery.[263–265] Although solid data from large prospective studies are still lacking, in the most recent edition of the NCCN guidelines neoadjuvant chemotherapy before CRT and TME is contemplated as an option in the treatment of LARC patients.

Outcomes of Multimodality Treatment in Patients with Locally Advanced Rectal Cancer

Perioperative mortality in patients undergoing multimodality therapy, including total mesorectal excision for LARC, ranges from 1% to 3.5%, and between 23% and 48% of patients develop perioperative complications.[250,266,267] Sepsis is the most common complication after rectal cancer surgery. A recent systematic review of the literature, including 53 prospective cohort studies and 45 randomized trials, found a 2% postoperative death rate, 7% rate of surgical wound infection, 11% rate of anastomotic leakage, and a 12% rate of pelvic sepsis.[267] In addition to pelvic sepsis, perineal wound dehiscence is the most common complication after APE. In a large systematic review of 32 studies, the rate of perineal wound complication was 15.3% for patients treated with surgery alone, and 32% in those treated with surgery and RT.[227] Many of these patients also had pelvic sepsis. The proportion of patients with perineal complication was similar for those who had ELAP: 14.8% for surgery alone and 37.6% for surgery and radiation. The rate of perineal hernia was also similar for patients treated with SAPE and ELAPE: 1.8% versus 2%. Other common postoperative complications include urinary retention, pneumonia, and thromboembolic disease.

Surgery for rectal cancer, particularly when combined with CRT or SCRT, has iatrogenic long-term consequences including urinary, sexual, and bowel dysfunction. Up to 39% of patients develop urinary complications, 45% sexual dysfunction, and even a larger proportion, bowel dysfunction.[268,269] A recent population-based study found a 26% rate of moderate bowel problems, 17% urinary dysfunction, and 25% severe problems with sexual function among patients treated for rectal cancer. Patients with a stoma were more likely to have difficulty with body image and sexual activity compared to patients with no stoma. Less than 30% of rectal cancer patients reported perfect health; rectal cancer patients were more likely to report problems, compared to patients with colon cancer. A follow-up study of the Dutch TME trial recently reported that these treatment-related symptoms persist 14 years after treatment; they reported increased sexual dysfunction, and a small decrease in overall functioning, as measured by a variety of quality of life questionnaires distributed to the general population.[270]

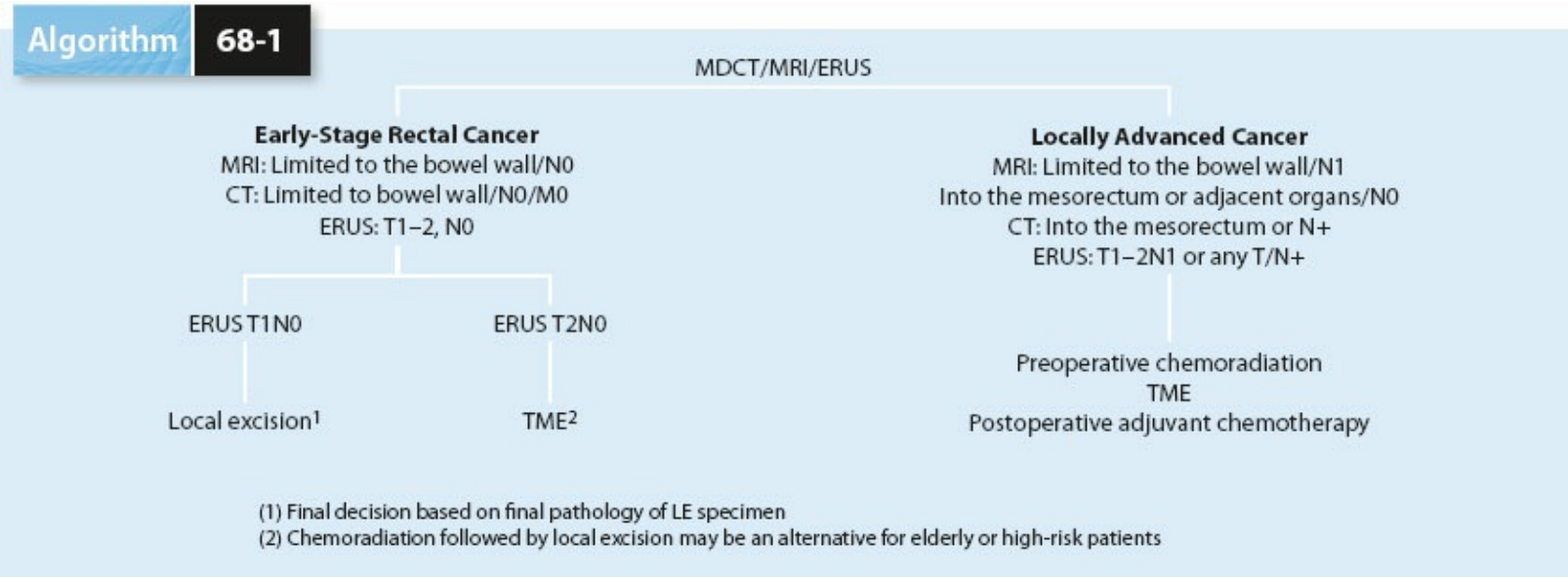

Algorithm 68-1. Approach to rectal cancer according to clinical staging.

Contemporary cohorts of stage II/III rectal cancer treated with neoadjuvant CRT, TME, and postoperative chemotherapy have mostly reported 5-year LR rates between 5% and 10%, 5-year DFS of around 60%, and 5-year OS around 70%.

Treatment Selection in Patients with Localized Rectal Cancer

Unlike patients with localized colon cancer, who all require oncologic resection as the initial form of therapy, patients with rectal cancer have multiple treatment options. The selection among different options depends primarily on the clinical stage of the tumor, as determined by DRE, proctoscopy, and imaging studies, on the distance of tumor from the anal verge, and on patient performance status and expectations.

The standard treatment for patients with stage I rectal cancer (T1N0 or T2N0) is TME, but LE has increasingly been chosen as a reasonable and acceptable alternative for patients with distal T1N0 tumors. CRT and LE may also be considered as an alternative to TME in patients with T2N0 tumors interested in sphincter preservation, in whom a TME would require a permanent colostomy.

More advanced tumors – those penetrating beyond the muscularis propria (T3–4, any N) and/or involving the regional lymph nodes (any T, N+), and without evidence of distance metastasis – have several treatment options. In the United States and many other countries, where decisions regarding the treatment of rectal cancer are based on clinical TNM staging, patients with locally advanced disease are treated with 5-FU or capecitabine-based CRT, followed by TME, with consideration given to FOLFOX prior to CRT as an acceptable option (Algorithm 68-1).

In Europe and Scandinavia, where rectal cancer patients are stratified into different risk categories based on MRI features, patients are recommended for different treatment approaches according to their individual risk category (Algorithm 68-2). The MRI-based risk stratification system uses a number of features, such as the proximity of the primary tumor to the MRF, the depth of tumor penetration into the mesorectum, the presence of large venous invasion, and the presence of metastatic lymph nodes.[168] Based on these features, they have developed a three-tier classification scheme that includes low risk (the good), intermediate risk (the bad), and high risk (the ugly); each group with a different risk of relapse, and therefore requiring different treatment strategies.[169,271] The low-risk group is recommended TME alone. The intermediate group is recommended SCRT followed by TME, while the high-risk group is recommended neoadjuvant CRT followed by TME. This treatment approach, guided by MRI risk categorization, is based mainly on results of prospective observational studies conducted in institutions with significant expertise in rectal cancer, but has not yet been tested in prospective, randomized trials.

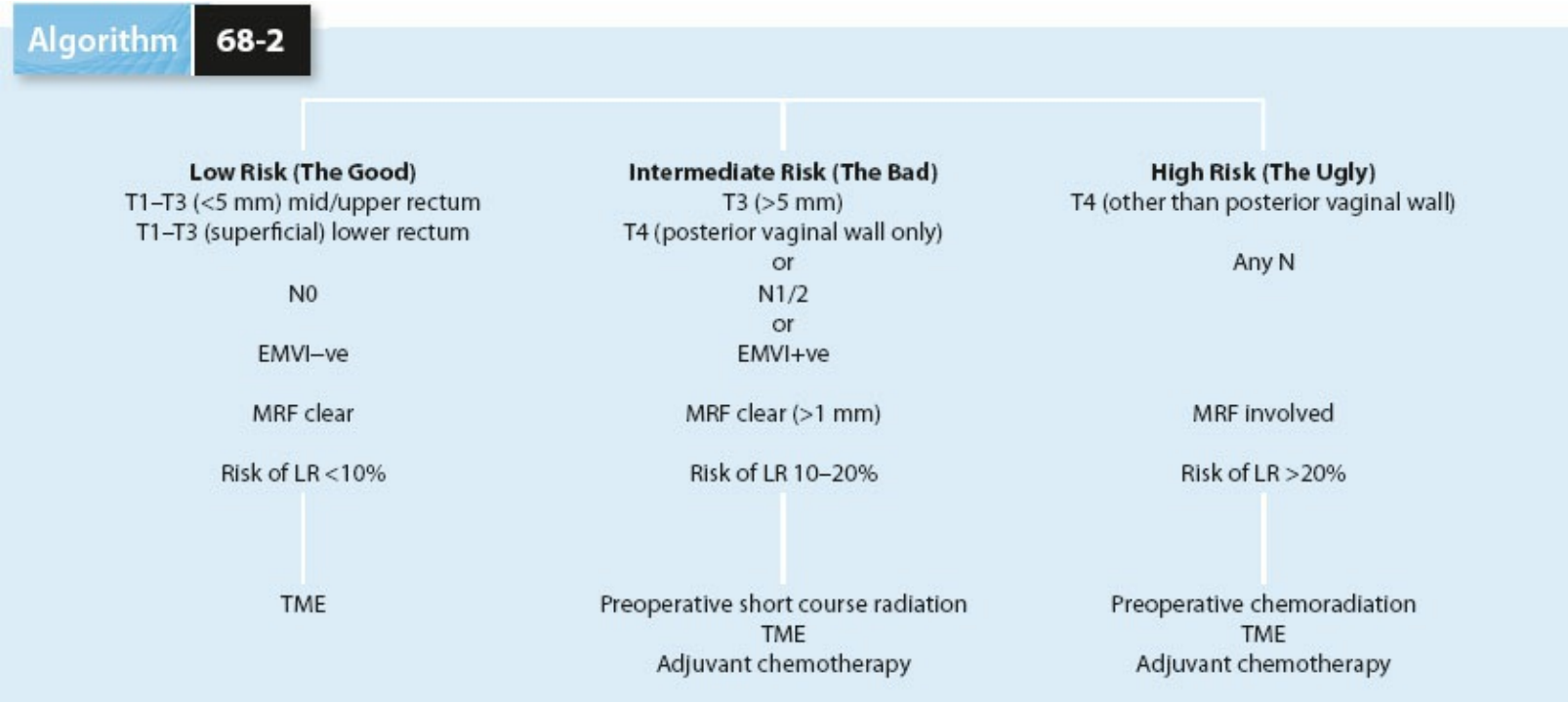

Algorithm 68-2. Approach to locally advanced rectal cancer based on a three-tier risk stratification system ("the good, the bad, and the ugly").

For patients requiring a TME, the decision between an APE and an SSP depends on the relationship of the tumor with the anal sphincter and the levator muscle. In general, an APE is required when the tumor directly involves these structures, or is so close to the sphincter that resection with a negative resection margin will result in a loss of sphincter function. In borderline cases, baseline anal sphincter and bowel function, as well as patient wishes and desires should be taken into consideration. The patient should be counseled about LR rates and expected long-term surgical outcomes.

TUMOR-RELATED EMERGENCIES

Between 15% and 30% of all CRC patients present as surgical emergencies, obstruction (78%) being the most common presentation, followed by perforation (10%) and bleeding (4%).[272–274] Chronic bleeding leading to severe anemia is common, particularly in right-sided tumors; but acute hemorrhage requiring surgical or endovascular intervention is infrequent. Obstruction is the presenting symptom in more than 15% of patients diagnosed with CRC, and CRC is responsible for more than 50% of all cases of acute colonic obstruction.[275] Rectal cancers seldom present as an emergency (5.9%); this is much more likely with colon cancers (21.7%),[273] most of which are in the left colon where the feces are solid, the lumen is smaller, and tumors are more likely to be annular. Large bowel obstruction may be secondary to other conditions such as diverticular disease and volvulus, which are the differential diagnosis of CRC.

The obstructed bowel undergoes significant changes in motility, secretion, and blood flow, which are responsible for the clinical manifestations. Proximal to the obstructed segment, particularly in left-sided obstructions, the colon develops mass action contractions, which cause colic pain. Persistent obstruction and progressive distension lead to colonic hypomotility. Colonic obstruction causes progressive abdominal distension as a result of the accumulation of gas (mostly nitrogen from swallowed air), increased fluid secretion, and hyperproliferation of anaerobic bacteria. The accumulation of fluid in the distended colon can lead to dehydration. Progressive distension in the presence of a competent ileocecal valve results in a closed-loop obstruction. The increase in intraluminal pressure can compromise the mucosal blood flow and lead to irreversible ischemia. Tension in the wall of the distended bowel increases in proportion to the fourth power of the radius; the risk of ischemia and subsequent perforation is therefore high, particularly in the cecum, the segment of colon with the largest diameter.[276] The risk of perforation is related not only to the caliber of the colon, but also to the onset of obstruction (higher risk when acute) and the duration of the obstruction. Mucosal ischemia has been implicated as the cause of a nonspecific form of colitis that, in some patients, develops proximal to the site of obstruction. The presence of ischemia, which can only be diagnosed at the time of surgery, should influence the extent of resection.

Acute colonic obstruction manifests as abdominal discomfort or frank pain (depending on the onset of the obstruction), reduction or complete cessation of the passage of flatus and feces, and progressive abdominal distension. Abdominal tenderness, particularly if associated with fever and leukocytosis, requires immediate evaluation to exclude perforation or ischemia. DRE reveals an empty rectum in most patients with large bowel obstruction.

Colonic obstruction must be distinguished from pseudo-obstruction. While the symptoms are similar, colonic pseudo-obstruction often presents in a specific clinical setting (patient immobilization, use of opioids, electrolyte imbalance), is still associated with passage of small amounts of stool and flatus, and is not associated with tenderness.[277] However, definitive diagnosis often requires specific radiologic tests, such as a water-soluble contrast enema or CT.

A plain abdominal film demonstrates colonic distension, with air-fluid levels, and a cut-off at the site of obstruction. The absence of small bowel distension indicates a competent ileocecal valve, with an increased risk of cecal perforation. The presence of gas in the small bowel and rectum raises the possibility of ileus or colonic pseudo-obstruction, but radiologic findings can be misleading. The presence of intramural gas indicates advanced ischemia. A chest radiograph should always be obtained to exclude the presence of pneumoperitoneum.

A water-soluble contrast enema may help to determine the degree and level of obstruction. The flow of contrast to the cecum and the absence of mucosal abnormalities suggest pseudo-obstruction. The osmotic effect of the water-soluble contrast material may have a therapeutic effect in decompressing the colon in these patients.[278] The mucosal detail at the site of obstruction may help to define the cause of obstruction. However, endoscopy is a better alternative to contrast enema when confirming the presence of cancer. CT of the chest, abdomen, and pelvis often locates the transition point between the distended bowel above the obstruction and the collapsed bowel distal to that point. It also helps define the cause of the obstruction and, if malignant obstruction is confirmed, it is useful in staging the tumor.[279]

When compared with elective surgery, patients requiring emergency surgery have more advanced disease. Even when stratified by stage, however, survival is worse for patients undergoing emergency surgery.[273,280] Also, an R1 resection is 10 times more likely for patients receiving emergency surgery.[281]

Patients presenting with obstructing CRC have higher operative mortality and morbidity and a poorer long-term prognosis than patients undergoing elective resection.[274,282] Perioperative mortality is three times higher in surgery performed for obstruction, compared with elective surgery.[274] Cardiopulmonary complications and abdominal sepsis are the major causes of in-hospital mortality and morbidity. The aim of surgery is therefore to minimize morbidity while obtaining functional results similar to those obtained for patients undergoing elective resection.

Patients with colonic obstruction are often dehydrated, and require preoperative fluid resuscitation and correction of electrolyte imbalances before surgery. A urinary catheter facilitates fluid management. Unstable patients should be monitored appropriately in the intensive care unit. A nasogastric tube prevents accumulation of swallowed air. Given the large fecal load proximal to the point of obstruction, antibiotic prophylaxis with a second-generation cephalosporin or a combination of an aminoglycoside and metronidazole should be given at the time of surgery.

The surgical management depends on the location of the obstruction. Lesions proximal to the splenic flexure are commonly treated by an extended right hemicolectomy, with primary anastomosis between the terminal ileum and the nonobstructed colon distal to the lesion. This is a single procedure that removes the entire segment of distended and potentially ischemic bowel, and eliminates the risk of leaving a synchronous tumor in the obstructed colon. Some of these patients develop mild diarrhea, which is usually temporary.

The management of a lesion located distal to the splenic flexure is more controversial.

The earlier described three-stage procedure is rarely used today (1 – Diverting colostomy, 2 – Tumor resection and anastomosis, 3 – Colostomy closure). A safe choice is the two-stage procedure, with initial resection of the segment containing the tumor, closure of the rectal stump as a Hartmann pouch, and construction of an end colostomy, followed by bowel anastomosis at a later date. However, the cumulative mortality and morbidity of both procedures is significant, and at least 30% of patients are left with a permanent colostomy.[283] In most tertiary centers, this operation is now limited to situations in which a primary anastomosis is contraindicated (e.g., extensive peritoneal contamination and/or severe sepsis).

The goal of surgery today is to relieve the obstruction and treat the cancer in a single operative procedure. Options include: (1) self-expanding metallic stents (SEMS) as a bridge to elective segmental colon resection, (2) subtotal colectomy and ileorectal anastomosis, (3) segmental colon resection, intraoperative colonic lavage, and primary anastomosis.

The rationale for the use of SEMS is temporary relief of the obstruction, avoiding the morbidity associated with an emergency operation, allowing medical stabilization, full staging work-up, one-stage surgery with primary anastomosis, and a minimally invasive approach. Most of the experience with this method comes from retrospective case-series studies; the success in relieving the obstruction ranges from 40% to 100%.[284] SEMS also has associated complications, such as re-obstruction (12%), migration (11%), and perforation (4.5%).[284]

Several randomized, controlled trials comparing SEMS with emergency surgery have been published, with conflicting results.[285–289] Overall, the clinical success rate of relieving obstruction with SEMS ranges from 40% to 97%. It is important to recognize that the overall complication rate across these trials is variable (8.3% to 35%) and a recent prospective trial conducted in the Netherlands was stopped prematurely, due to an increased number of colonic perforations in the SEMS arm.[289] Perforation from the use of stents may result in a shorter DFS.[290]

A subtotal colectomy with ileorectal anastomosis is a quick operation in which nondistended bowel is used for the anastomosis. This procedure minimizes the risk of fecal spillage, eliminates the risk of missing a synchronous tumor in the obstructed portion of the colon, and facilitates surveillance. The disadvantages, however, include a higher incidence of bowel obstruction after ileorectal anastomosis and the development of postoperative diarrhea, which may become incapacitating in elderly patients.[291]

A segmental resection with intraoperative colonic lavage and primary anastomosis avoids the risk of postoperative diarrhea, but carries a risk of fecal spillage and missing synchronous tumor. In addition, it requires using previously obstructed bowel for the construction of the anastomosis. Surgical tradition has condemned the performance of an anastomosis in an unprepared colon. Experience accumulated from the management of patients with civilian colon trauma has demonstrated that, under specific circumstances, a primary anastomosis can be performed safely in an unprepared colon, provided the bowel appears healthy and there is no extensive soiling in the peritoneal cavity. This experience has been transferred to the treatment of malignant colonic obstruction. Therefore, a

segmental resection with colonic lavage and primary anastomosis is a viable option, as long as the colon is not ischemic and there is in no spillage during the operation. The use of a temporary diverting ileostomy may be necessary, but when the safety of a primary anastomosis is questionable, a staged procedure with a segmental resection, a Hartmann pouch, and an end colostomy, may be preferable.[292]

SURVEILLANCE AFTER CURATIVE RESECTION FOR COLON AND RECTAL CANCER

Of the almost 1 million patients diagnosed with CRC worldwide every year, two-thirds have curative intent surgery, but ultimately one-third of them will develop recurrence of disease or a second colorectal primary. Most recurrences arise within 3 years of the initial treatment, and almost all arise within 5 years. Recurrences are usually diagnosed at an advanced stage and have an ominous prognosis. Surveillance regimens aim to identify recurrences before they become symptomatic, and while they are still potentially resectable.[293,294] Several meta-analyses of prospective, randomized trials comparing intensive or minimal surveillance after curative resection in patients with stage I to III CRC suggest that recurrences were diagnosed earlier and surgical salvage was more likely in patients undergoing intensive surveillance.[293,295] The survival benefit can only be partly attributed to the improved ability to resect recurrences; other elements such as increased psychological support, behavior modifications, and better treatment of comorbid conditions that accompany intensive surveillance regimens are also thought to contribute to improved survival. Based on this evidence, cancer organizations have established guidelines for surveillance after curative resection of CRC. All of them include a combination of regular history and physical examination, determination of CEA level, endoscopy, and imaging of the chest, abdomen, and pelvis (Table 68-10). Some clinicians recommend surveillance for stage II/III disease, while others also include stage I. In the future, surveillance will be risk-adapted, targeting patients more likely to benefit from intensive surveillance based on clinical and molecular prognostic factors. Despite these recommendations, a recent population-based cohort study of 57 patients concluded that 70% were diagnosed between scheduled examinations.[294]

TREATMENT OF STAGE IV COLON AND RECTAL CANCER

Between 20% and 34% of all CRC patients have metastasis at the time of diagnosis; these are known as synchronous metastases. Another one-third of patients will develop metastasis sometime after undergoing treatment of the primary disease; this is known as metachronous metastasis. Synchronous metastases are usually more extensive and, in general, carry a worse prognosis compared to metachronous metastases.

The liver is the most common site of CRC metastasis, and liver metastasis is the most common cause of cancer death in patients with CRC. Autopsy studies have revealed that 50% of patients dying from CRC have liver metastasis and, in one-third of them, the liver is the only site of metastatic disease.[296] Some patients with liver-only metastatic disease are resectable at the time of diagnosis. Others are not resectable, due to the involvement of critical structures by large volume of metastatic disease. The treatment of stage IV CRC patients is complex, and requires consideration of the number of organs involved, the number and size of the metastasis, the location, the symptoms related to the primary in the colon or rectum, whether the tumor is resectable or not, and the patient's performance status. Treatment decisions should be made after discussion in a multidisciplinary tumor board.[297] A simplified algorithm for the treatment of patients with stage IV CRC is presented in Algorithm 68-3. The discussion is centered on patients with liver metastasis, but these principles are equally applicable to patients with lung metastasis. Surgery is the only curative treatment for patients with colorectal metastasis. Other forms of local therapy, such as ablation, may improve survival. Most patients with metastatic disease benefit from systemic chemotherapy, either as adjuvant treatment to surgery or as the sole form of treatment.

Table 68-10 Comparison of Surveillance Options After Curative Resection[a]

	History and Physical	CEA	Colonoscopy	Imaging	Additional Notes
US Multi-Society Task Force (2006)[22]	q3–6 months for first 2–3 years	—	At 1 year, if normal then next in 3 years, if normal then next in 5 years	—	When complete perioperative colonic evaluation not performed (e.g. obstructing cancer), intraoperative colonoscopy or at 3–6 months post-op
NCCN (2013)[23]	q3–6 months (years 1, 2); q6 months (years 3–5)	q3–6 months (years 1, 2); q6 months (years 3–5)	At 1 year, if normal then next in 3 years, then q5	CT q1 year (3 years)	If preoperative colonoscopy not performed, should be done at 3–6 months post-op
ESMO (2010)[24]	q3–6 months (years 1–3), q6–12 months (years 4, 5)	q3–6 months (years 1–3), q6–12 months (years 4, 5)	At 1 year, then q3–5 years	CT C/A q6–12 months (3 years); CEUS can substitute for CT Abd	Contrast-enhanced U/S can substitute for CT abdomen
NICE (2014)[25]	—	At least q6 months (3 years)	At 1 year, then q5 years	CT C/A/P twice in first 3 years	
ASCO (2013)[26]	q3–6 months (5 years)	q3–6 months (5 years)	At 1 year, then q5 years	CT C/A/P q1 year (3 years)	If preoperative colonoscopy not performed, should be done after adjuvant therapy (before 1 year)
JSCCR (2010)[27]	q3 months (years 1–3), q6 months (years 4, 5)	q3 months (years 1–3), q6 months (years 4, 5)	At 1 year, then at 3 years	CT C/A q5 months (years 1–3), then q1 year (years 4, 5)	

[a]Summary estimation of published guidelines. Please refer to primary sources cited for more specific algorithms and details. Reinvestigation and complete staging is recommended for any signs suspicious for recurrence.

Algorithm 68-3

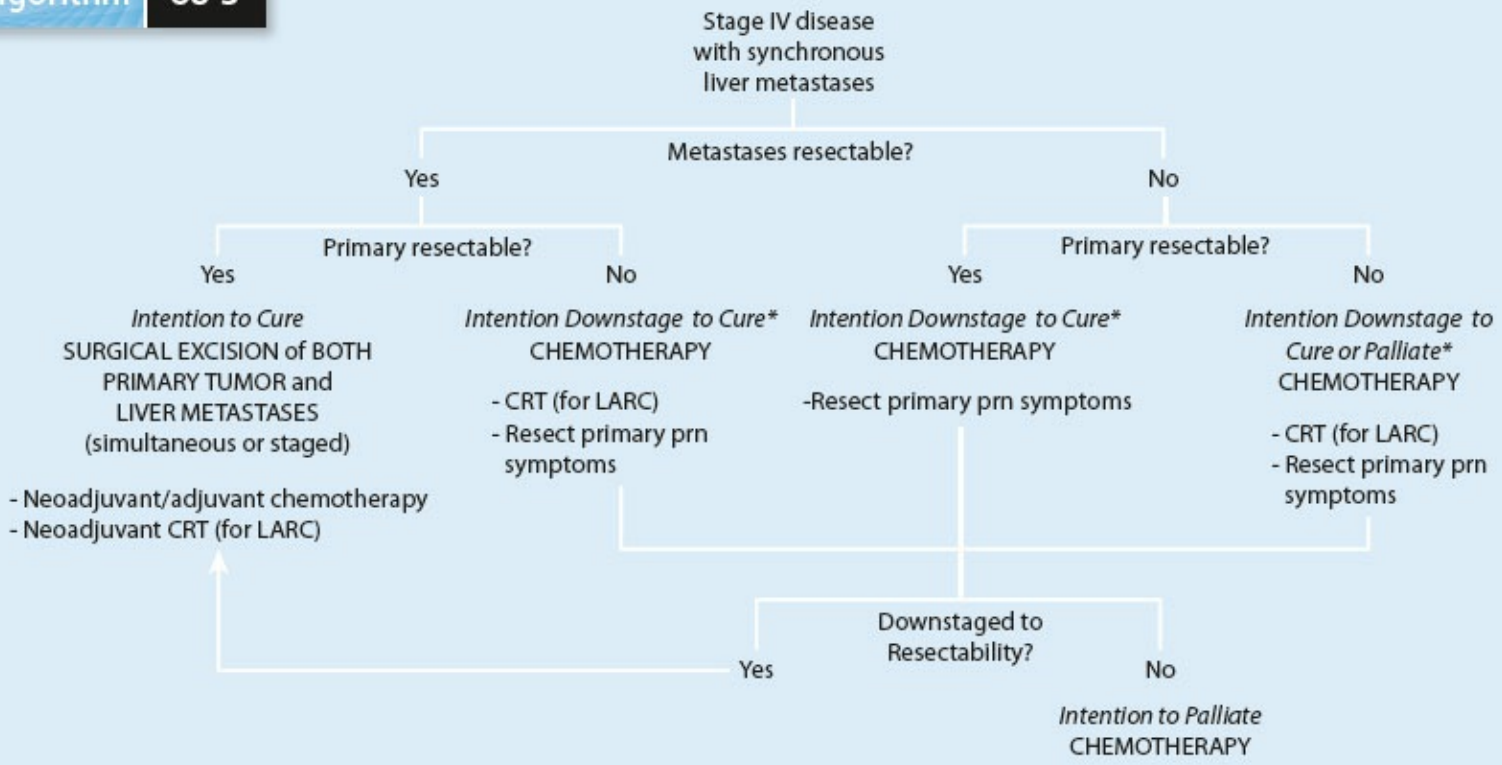

*Adjunctive treatments including stents, radiofrequency ablation, HIPEC, etc, may have a role
ESMO 2014 guidelines recommend expanded RAS wild-type (KRAS, NRAS) as criterion for use of EGFR inhibitors
LARC - locally advanced rectal cancer; CRT - chemoradiation therapy

Algorithm 68-3. Stage IV rectal cancer treatment algorithm.

Treatment of the Primary Tumor in Stage IV CRC

In the past, all patients presenting with synchronous metastasis were recommended to have resection of the primary tumor, to avoid complications such as obstruction or perforation during treatment of the metastatic disease. However, recent data suggest that patients with unresectable metastasis and an asymptomatic primary are unlikely to develop complications related to the primary tumor that require surgical intervention while the patient is receiving systemic chemotherapy. Currently, primary tumor resection is recommended for patients undergoing curative-intent resection of all metastatic disease, or for patients with unresectable metastasis and a symptomatic primary tumor. The treatment of patients with asymptomatic primary tumor and unresectable metastasis is controversial. The benefit of avoiding complications related to tumor progression should be balanced against the mortality and morbidity associated with a noncurative resection, and the delay in starting systemic chemotherapy.

Observational studies and secondary analysis of prospective trials have reported an association between primary tumor resection and improved survival. A recent meta-analysis found a difference of 6.4 months in survival in patients undergoing resection.[298] However, these studies are limited by strong patient selection bias and outdated chemotherapy regimens. Patients undergoing resection are more likely to have liver-only disease, single metastasis, and tumors located in the colon. Rectal cancer patients are less likely to undergo primary tumor resection compared to patients with colon cancer, probably due to the higher complexity of rectal surgery, the possibility of using palliative CRT, and the fear of a colostomy.

Resection of asymptomatic tumors in stage IV disease has not consistently shown improvements in survival, nor does it necessarily reduce the risk of complications.[299] A recent analysis of the SEER database revealed that the proportion of patients with stage IV CRC undergoing primary tumor resection has been progressively decreasing in the last decade.[300] Despite this decrease in primary tumor resection, relative survival has been increasing during the same period of time. The improvement in survival has coincided with the introduction of more effective chemotherapy agents. However, the relative contribution of the declining rate of primary resection and the more active chemotherapeutic agents is unknown. These data lend support to current guidelines that do not recommend primary tumor resection in asymptomatic patients with unresectable metastasis.[177,301] In the SEER data analysis, more than half of the patients with stage IV CRC, diagnosed in 2009, had resection of the primary tumor, suggesting that current treatment practice lags behind evidence-based treatment guidelines.

Surgical Treatment of Colorectal Metastasis

Overall, only 6% of CRC patients with liver metastasis survive beyond 5 years, but in patients with resectable liver metastasis the reported 5-year survival rate ranges from 25% to 40%. Patients with a single, isolated liver metastasis have 5-year overall survival rates as high as 71%. Liver metastases are considered resectable with curative intent if all disease can be removed, with negative resection margin, while preserving adequate liver reserve. Incomplete resection or tumor debulking is not recommended, because it is associated with morbidity without impacting survival. The size of the metastasis is not a contraindication for surgery. When a curative liver resection may potentially result in insufficient liver remnant, portal vein embolization of the involved liver lobe is recommended to induce hypertrophy of the contralateral lobe of the liver. Repeated resection of recurrent liver metastasis is feasible, but the probability of survival decreases with each subsequent resection.

The role of nonsurgical liver-directed therapy for the treatment of liver-only or liver-dominant metastatic disease is controversial. Tumor ablation is indicated in patients who are amenable to local therapy, but are not candidates for surgical resection due to comorbidities. It can also be combined with surgery in patients with mixed resectable and unresectable lesions due to their anatomical location or insufficient liver remnant.[302] Other liver-directed therapies for which there is no consensus regarding efficacy are liver-directed chemotherapy using a hepatic artery infusion pump, transarterial hepatic chemoembolization/radioembolization, and liver-directed radiation.

Colorectal lung metastasis can also be surgically removed following the same principles outlined for liver metastasis. Resection must be complete, based on the anatomic location of the disease, and with maintenance of adequate respiratory function. Resection of both liver and lung metastasis is feasible in selected cases, but resection in the presence of nonhepatic extra-pulmonary disease should be reserved for carefully selected patients. Ablation and radiation are also options for patients with nonresectable lung metastasis.[301]

Chemotherapy for Metastatic Disease

Principles of Chemotherapy

6 A number of antineoplastic agents such 5-FU or capecitabine, oxaliplatin, and irinotecan, and new biologic agents, such as bevacizumab, ziv-aflibercept, cetuximab, panitumumab, and regorafenib, are currently used in combination or as single agents in patients with metastatic CRC. The putative mechanism of action and the toxicity profile of each drug are presented in Table 68-11. The choice of the treatment regimen is based on the goals of therapy, the type and time of previous therapy, and the toxicity profile of the constituent drugs.[177,301] The chemotherapy regimens commonly used as first-line therapy in patients appropriate for intensive therapy include: FOLFOX (5-FU/LV/oxaliplatin), FOLFIRI (5-FU/LV/irinotecan), CapeOx (capecitabine/oxaliplatin), infusional 5-FU/LV, capecitabine as a single agent, or FOLFIRINOX (5-FU/LV/oxaliplatin/irinotecan). Cetuximab or bevacizumab can be added to first-line therapy in patients with KRAS/NRAS wild-type CRC, and other combinations such as FOLFOXIRI with bevacizumab have shown promising results.[303,304] The role of maintenance therapy after first-line therapy, and treatment after progression of metastatic disease on first-line therapy, is beyond the scope of this chapter. Median survival of patients with unresectable metastatic CRC, which previously rarely exceeded 12 months, now exceeds 30 months when these agents are used. Increasing evidence suggests that the selection of chemotherapeutic agents will continue to be guided by molecular and genomic characterizations. Early reports have indicated that combined therapy with BRAF and EGFR inhibitors may be effective in treating BRAF V600E metastatic CRCs specifically.[305]

Adjuvant Chemotherapy in Resectable Disease

The majority of patients who undergo resection for CRC liver metastasis ultimately relapse in the liver. It is theorized that the addition of systemic therapy provides treatment of occult micrometastatic disease, reducing the risk of relapse. A number of randomized controlled trials have found a modest improvement in RFS, but not in OS, with chemotherapy delivered before or after liver resection, compared with resection alone. The optimal timing of chemotherapy remains unknown.[306] The potential advantages of preoperative therapy include earlier treatment of micrometastatic disease, evaluation of tumor responsiveness, and the possibility of avoiding resection in patients with tumor progression during therapy. The main disadvantages of preoperative chemotherapy are the progression of nonresponsive tumors that become unresectable during systemic chemotherapy, and the increase in perioperative morbidity due to chemotherapy-induced liver toxicity. The EORTC Intergroup Trial – the only randomized trial evaluating the role of perioperative FOLFOX (3 months before and 3 months after liver surgery) in the management of resectable liver metastases – demonstrated an absolute increase of 7.3% in 3-year progression-free survival in the combined treatment group, compared with the resection-alone group.[307,308] This trial demonstrated an increased rate of postoperative complications in the chemotherapy group (25%)

compared with surgery-alone (16%), specifically showing a doubling in biliary fistula and hepatic failure rates. The study concluded that perioperative chemotherapy may improve cancer-specific outcomes, but at the cost of increased rates of postoperative complications, including liver dysfunction. Long-term follow-up has revealed the same benefit in progression-free survival, but no difference in OS with the addition of perioperative chemotherapy. The chemotherapy regimens used in the adjuvant setting are the same as those used in first-line therapy. However, bevacizumab can be added as long as it is discontinued at least 6 to 8 weeks before surgery and not re-started for 8 weeks after surgery, because it interferes with wound healing.[309] Cetuximab and panitumumab have been added to first-line regimens in patients with KRAS/NRAS wild type, but the benefits have been inconsistent. In fact, recent data suggest these could even be detrimental; therefore, they are not recommended at this time.[310]

Table 68-11 Main Chemotherapeutic Agents

Agents	Mechanism	Common Side Effects
5-FU	Pyrimidine analog, thymidylate synthase (TS) inhibitor	Hematologic: thrombocytopenia. GI: mucositis. Hepatic steatosis (yellow liver). Photosensitivity
Folinic acid (leucovorin)	Enhances 5-FU effects and contributes to TS inhibition	—
Irinotecan	Topoisomerase I inhibitor	Hematologic: myelosuppression. GI: diarrhea. Hepatic steatosis.
Capecitabine	Pro-drug of 5-FU	GI: mucositis
Oxaliplatin	Platinum-based agent, DNA cross-linking	Peripheral neuropathy GI: sinusoidal congestion (blue liver)
Cetuximab/ panitumumab	Anti-EGFR monoclonal antibody (for use with KRAS wild-type tumors only)	Acneiform skin rash
Bevacizumab	Anti-VEGF monoclonal antibody	Compromised wound healing

Chemotherapy in Borderline Resectable Disease

A few patients present with liver-only metastases that are not amenable to a complete resection, due to close proximity to essential anatomical structures. Systemic chemotherapy in this setting aims to convert an unresectable patient to resectable status. The duration of treatment in these patients is important. There is a need to balance the minimum time required to achieve a response that will make the patient resectable, while avoiding hepatotoxicity from the chemotherapeutic agents. Both FOLFOX and FOLFIRI increase resectability in 12.5% to 40% of patients initially considered unresectable. A study has shown that adding irinotecan to FOLFOX (FOLFIRINOX) in patients with initially unresectable metastasis increased the resection rate compared to FOLFOX alone.[311] Adding EGFR inhibitors to FOLFOX or FOLFIRI increased the resectability rate in patients with wild-type KRAS/NRAS tumors and initially unresectable liver metastasis.[312,313] Angiogenesis inhibitors combined with FOLFIRI modestly increase

resectability of initially unresectable liver metastasis compared to FOLFIRI alone, but have no effect when combined with oxaliplatin-containing regimens.[314,315] To limit FOLFOX- and FOLFIRI-associated toxicity, patients receiving systemic chemotherapy to increase resectability should be evaluated for response every 2 months, and undergo surgery as soon as they become resectable.

Treatment of Peritoneal Carcinomatosis

Most patients with peritoneal carcinomatosis have widespread metastatic disease, and are treated with systemic chemotherapy. The treatment of patients with the peritoneum as the only site of metastasis is controversial.[316,317] Complete cytoreductive surgery (CRS), with removal of all visible abdominal and pelvic disease, and hyperthermic intraperitoneal chemotherapy (HIPEC) are now commonly used in patients with peritoneum-only metastatic CRC. The most commonly used drug for intraperitoneal chemotherapy is mitomycin C, which is minimally active against CRC. As experimental data do not support any biologic benefit from the hyperthermia component, the role of HIPEC has been questioned. Oxaliplatin, irinotecan, doxorubicin, paclitaxel, and carboplatin have also been tested. Comparative studies have not shown a conclusive advantage of mitomycin C over oxaliplatin.[318] This aggressive treatment is associated with significant mortality (0.9% to 5%) and morbidity (12% to 52%), with the most common complications being surgical site infection, hematologic toxicity, and intestinal fistula. Many single institution case series have reported improved survival in patients treated with CRS and HIPEC followed by systemic chemotherapy, compared to systemic chemotherapy alone. A recent review of 19 studies conducted from 1999 to 2009 reported a median survival of 33 months for patients treated with CRS and HIPEC versus 12.5 months for patients undergoing palliative surgery and/or systemic chemotherapy.[319] These studies have been criticized because of strong patient selection bias favoring peritoneum-only disease in the CRS/HIPEC group, an undefined role for palliative treatment, and suboptimal chemotherapy in the nonsurgical group. The only prospective trial published so far randomized patients to 5-FU/LV with palliative surgery versus CRS, HIPEC, and postoperative 5-FU/LV. OS was 12.6 months in the standard arm versus 22.2 months in the HIPEC group.[320] This study has been criticized because it also included patients with pseudomyxoma peritonei of appendiceal origin, and because it was conducted before most of the drugs currently used in metastatic disease were available. In spite of this criticism, CRS and HIPEC are commonly performed regimens for patients with peritoneum-only colorectal metastasis.[321]

The selection criteria for this complex and potentially morbid treatment are not well defined. The most important prognostic factors in patients undergoing CRS and HIPEC are the Peritoneal Cancer Index (PCI), a grading of tumor burden at the time of surgery, and the completeness of cytoreduction (CC) score. Unfortunately, the determinants of these scores are only available at the time of abdominal exploration during surgery. Therefore, they have not been useful in selecting those patients more likely to benefit from CRS and HIPEC. Recently, a Peritoneal Surface Disease Severity Score (PSDSS) that includes patient symptoms, extent of peritoneal dissemination, and primary tumor

histology has been developed to stratify patients at the time of diagnosis, without the need of an operation.[322] The PSDSS score system has been found to be an independent prognostic factor in multivariate analysis, not only for patients undergoing CRS and HIPEC, but also for patients treated with systemic chemotherapy. This score may help eliminate selection bias in future comparisons of different treatments, in patients with peritoneum-only metastatic CRC.

TREATMENT OF LOCALLY RECURRENT CRC

LR after curative-intent surgery is defined as a relapse of tumor in the surgical field of the initial procedure, including the anastomosis, regional nodes, surgical scars, and drain tracts.[323] While most patients with LR also have distant metastasis, a few have isolated LR. A complete surgical resection is the only curative option for patients with isolated locally recurrent CRC, but is associated with considerable morbidity and mortality.[324] In spite of this criticism, CRS plus HIPEC is commonly performed for patients with peritoneum-only colorectal metastasis.

The risk of LR is higher for rectal cancer compared to colon cancer, for advanced stage tumors (T4), for tumors with high-risk histologic features (lymphovascular and perineural invasion, grade III or IV, signet ring cell histology), perforating or obstructing tumors, and patients with close or involved CRM. Most local recurrences present within 3 years after the primary surgery, but LR tends to occur later in patients treated with CRT and surgery, compared to those treated with surgery alone. In the Dutch TME trial, 10% of LRs occurred more than 3 years after surgery in patients treated with TME, versus 31% in patients treated with preoperative RT and TME.[325]

While some LRs are detected though surveillance, while asymptomatic, most are diagnosed after they become symptomatic. Symptoms of local recurrence include bowel obstruction, abdominal distension, rectal or vaginal bleeding, and urinary problems.[326] Pelvic pain is common, and is a predictor of reduced long-term survival.[327] A common manifestation in patients who have had abdominoperineal resection (APR) is a nonhealing perineal wound. Whenever symptoms suggestive of recurrence arise, a detailed history and complete physical examination must be done. This includes DRE in patients who have undergone sphincter-preserving surgery, and a pelvic examination in females. If recurrent tumor is identified, endoscopy and imaging studies will help assess extent of disease and surgical risk. A complete colonoscopy should be performed if possible. Intraluminal recurrences are easily diagnosed with endoscopy and biopsy. Cystoscopy is required for patients who present with urogenital symptoms, as these strongly indicate tumoral invasion of the ureters and bladder.[328] CEA is routinely measured during follow-up surveillance after primary rectal cancer resection. Elevation of this tumor marker is frequently the first sign of recurrence[329]; however, elevated CEA is present in only about 50% of patients. Patients with elevated CEA should undergo further work-up with imaging studies.

A CT scan of the chest, abdomen, and pelvis is the primary imaging modality used in these patients, and it is especially helpful in identifying metastases in the liver, lung, and peritoneum, and evaluating regional adenopathy.[330] MRI is more accurate than CT in detecting and staging pelvic LR[331]; although it has been ineffective when added to routine follow-up in detecting ERUS it may be useful in diagnosing LR after LE of distal rectal cancer.[332] Positron emission tomography (PET) using the glucose analog fluorodeoxyglucose (FDG), particularly when combined with a CT scan, is helpful in distinguishing between postsurgical changes and tumor recurrence. In a recent meta-analysis comparing FDG-PET, FDG-PET/CT, CT, and MRI in the detection of recurrent

CRC in patients with high suspicion of recurrent disease, based on symptoms or elevated CEA, FDG-PET and FDG-PET/CT performed more accurately than CT scan.[333] PET/CT also demonstrated greater accuracy than MRI in identification of lymph node recurrence in a lesion levels analysis.[334] Overall accuracy of FDG-PET/CT is slightly higher than FDG-PET: 92.3% (94% sensitivity, 77.2% specificity) versus 89% (90.3% sensitivity, 80% specificity).[335] However, lesions measuring less than 1 cm in diameter are more difficult to detect with PET scanning, as are mucinous tumors, due to poor FDG uptake. Finally, FDG-PET cannot be used to detect or evaluate LR if there is residual inflammation of the tumor bed secondary to chronic leaks. Regardless of the imaging studies used to help diagnose LR, histologic confirmation is imperative. Anastomotic recurrences should be biopsied endoscopically; extraluminal recurrences can usually be biopsied percutaneously, under radiologic (CT) guidance.

7 The treatment of locally recurrent CRC should be discussed in a multidisciplinary setting, since it often involves colorectal surgical oncologists, radiation oncologists, medical oncologists, and other specialists. Patients with multifocal LR should be treated with systemic chemotherapy, as in metastatic disease. Only patients with localized LR and good performance status are candidates for surgical resection. Even these patients may benefit from additional systemic chemotherapy or chemoradiation, if they did not receive it at the time of treatment of the primary tumor.[336] Some patients with recurrent rectal cancer treated initially with standard doses of radiation (50.4 Gy in 180 cGy fractions, or biologically equivalent total dose), can be re-irradiated to the gross tumor volume using small fractions (180 to 200 cGy), with or without sensitizing chemotherapy.[336] Re-irradiation seems to increase the possibility of an R0 resection in patients with resectable disease, or provides good palliation in unresectable patients. Following preoperative chemotherapy and/or radiotherapy, re-staging should be done to exclude interim development of distant metastasis and to ascertain the extent of the LR.

Surgery is the only curative option for patients with locally recurrent rectal cancer. Without treatment, median survival is typically 6 to 7 months[337]; systemic chemotherapy can prolong survival, similar to patients with systemic recurrence. Only patients with good performance status, with recurrences that, based on anatomical location, are amenable to an R0 resection, should be considered surgical candidates. A resection with gross positive margins (R2) should not be attempted, because it provides no oncologic advantage to the patient and is associated with significant morbidity. Patients found to have microscopic positive margins (R1) may benefit from intraoperative radiation. However, this modality is only available at some institutions, and requires preoperative planning. Therefore, the treatment of locally recurrent CRC should be limited to institutions with appropriate expertise and equipment.

Only about one-third of patients with isolated locally recurrent CRC are candidates for surgical salvage with curative intent. In the Intergroup Study 0114, which investigated several chemotherapy regimens in patients with locally advanced rectal cancer, only 159 (35%) of the 448 patients with single-site first recurrences in the liver, lung, or pelvis had curative-intent surgery.[326] The proportion of patients undergoing resection was similar

for liver, lung, or local recurrences. OS differed significantly between the resected and nonresected groups, with 5-year OS of 27% and 6%, respectively ($p < 0.001$). The 5-year DFS was in the range of 30% for patients undergoing resection of tumors in solitary sites of the liver or lung, and 20% for those undergoing resection of LRs. Retrospective case series from institutions with experience in the treatment of locally recurrent CRC report 5-year survival rates close to 35% for patients with R0 resections, compared to 21% for patients with R1 resections.

Palliation is an important aspect of the treatment of patients with unresectable LR. Bowel obstruction often requires palliative surgery, stomas, endoluminal stents, or percutaneous gastrostomy tubes. Urinary obstruction is common, requiring stents or percutaneous nephrostomies. Pain is a common symptom in these patients, often requiring the assistance of pain specialists and specialists in palliative care.

References

1. Siegel RL, Miller KD, Jemal A. Cancer statistics, 2015. *CA Cancer J Clin* 2015;65(1):5–29.
2. American Cancer Society. *Global Cancer facts & Figures.* 3rd ed. Available at www.cancer.org. 2015.
3. American Cancer Society. *Colorectal cancer Facts & Figures 2014–2016.* Atlanta; 2014.
4. Chan AT, Giovannucci EL. Primary prevention of colorectal cancer. *Gastroenterology* 2010;138(6):2029–2043.e10.
5. Lichtenstein P, Holm NV, Verkasalo PK, et al. Environmental and heritable factors in the causation of cancer–analyses of cohorts of twins from Sweden, Denmark, and Finland. *N Engl J Med* 2000;343(2):78–85.
6. Song M, Garrett WS, Chan AT. Nutrients, foods, and colorectal cancer prevention. *Gastroenterology* 2015;148(6):1244–60.e16.
7. Larsson SC, Wolk A. Obesity and colon and rectal cancer risk: a meta-analysis of prospective studies. *Am J Clin Nutr* 2007;86(3):556–565.
8. Bardou M, Barkun AN, Martel M. Obesity and colorectal cancer. *Gut* 2013;62(6):933–947.
9. Boyle T, Keegel T, Bull F, et al. Physical activity and risks of proximal and distal colon cancers: a systematic review and meta-analysis. *J Natl Cancer Inst* 2012;104(20):1548–1561.
10. Monroe KR, Hankin JH, Pike MC, et al. Correlation of dietary intake and colorectal cancer incidence among Mexican-American migrants: the multiethnic cohort study. *Nutr Cancer* 2003;45(2):133–147.
11. Kim E, Coelho D, Blachier F. Review of the association between meat consumption and risk of colorectal cancer. *Nutr Res* 2013;33(12):983–994.
12. Bastide NM, Chenni F, Audebert M, et al. A central role for heme iron in colon carcinogenesis associated with red meat intake. *Cancer Res* 2015;75(5):870–879.
13. Roswall N, Weiderpass E. Alcohol as a risk factor for cancer: existing evidence in a global perspective. *J Prev Med Public Health* 2015;48(1):1–9.
14. Liang PS, Chen TY, Giovannucci E. Cigarette smoking and colorectal cancer incidence and mortality: systematic review and meta-analysis. *Int J Cancer* 2009;124(10):2406–2415.
15. Parajuli R, Bjerkaas E, Tverdal A, et al. Cigarette smoking and colorectal cancer mortality among 602,242 Norwegian males and females. *Clin Epidemiol* 2014;6:137–145.
16. Butterworth AS, Higgins JP, Pharoah P. Relative and absolute risk of colorectal cancer for individuals with a family history: a meta-analysis. *Eur J Cancer* 2006;42(2):216–227.

17. Henrikson NB, Webber EM, Goddard KA, et al. Family history and the natural history of colorectal cancer: systematic review. *Genet Med* 2015;17(9):702–712.
18. Mulder SA, Kranse R, Damhuis RA, et al. The incidence and risk factors of metachronous colorectal cancer: an indication for follow-up. *Dis Colon Rectum* 2012;55(5):522–531.
19. Martinez ME, Baron JA, Lieberman DA, et al. A pooled analysis of advanced colorectal neoplasia diagnoses after colonoscopic polypectomy. *Gastroenterology* 2009;136(3):832–841.
20. Eaden JA, Abrams KR, Mayberry JF. The risk of colorectal cancer in ulcerative colitis: a meta-analysis. *Gut* 2001;48(4):526–535.
21. Jess T, Gamborg M, Matzen P, et al. Increased risk of intestinal cancer in Crohn's disease: a meta-analysis of population-based cohort studies. *Am J Gastroenterol* 2005;100(12):2724–2729.
22. Lutgens MW, van Oijen MG, van der Heijden GJ, et al. Declining risk of colorectal cancer in inflammatory bowel disease: an updated meta-analysis of population-based cohort studies. *Inflamm Bowel Dis* 2013;19(4):789–799.
23. Andersen NN, Jess T. Has the risk of colorectal cancer in inflammatory bowel disease decreased? *World J Gastroenterol* 2013;19(43):7561–7568.
24. Peeters PJ, Bazelier MT, Leufkens HG, et al. The risk of colorectal cancer in patients with type 2 diabetes: associations with treatment stage and obesity. *Diabetes Care* 2015;38(3):495–502.
25. Mills KT, Bellows CF, Hoffman AE, et al. Diabetes mellitus and colorectal cancer prognosis: a meta-analysis. *Dis Colon Rectum* 2013;56(11):1304–1319.
26. Fearon ER, Vogelstein B. A genetic model for colorectal tumorigenesis. *Cell* 1990;61(1):759–767.
27. Cancer Genome Atlas Network. Comprehensive molecular characterization of human colon and rectal cancer. *Nature* 2012;487(7407):330–337.
28. Negrini S, Gorgoulis VG, Halazonetis TD. Genomic instability–an evolving hallmark of cancer. *Nat Rev Mol Cell Biol* 2010;11(3):220–228.
29. Vilar E, Gruber SB. Microsatellite instability in colorectal cancer—the stable evidence. *Nat Rev Clin Oncol* 2010;7(3):153–162.
30. Nathke I. Cytoskeleton out of the cupboard: colon cancer and cytoskeletal changes induced by loss of APC. *Nat Rev Cancer* 2006;6(12):967–974.
31. Tenesa A, Dunlop MG. New insights into the aetiology of colorectal cancer from genome-wide association studies. *Nat Rev Genet* 2009;10(6):353–358.
32. Ben-David E, Bester AC, Shifman S, et al. Transcriptional dynamics in colorectal carcinogenesis: new insights into the role of c-Myc and miR17 in benign to cancer transformation. *Cancer Res* 2014;74(19):5532–5540.
33. Naccarati A, Polakova V, Pardini B, et al. Mutations and polymorphisms in TP53 gene–an overview on the role in colorectal cancer. *Mutagenesis* 2012;27(2):211–218.

34. Segelov E, Chan D, Shapiro J, et al. The role of biological therapy in metastatic colorectal cancer after first-line treatment: a meta-analysis of randomised trials. *Br J Cancer* 2014;111(6):1122–1131.
35. Francipane MG, Lagasse E. mTOR pathway in colorectal cancer: an update. *Oncotarget* 2014;5(1):49–66.
36. Sadanandam A, Lyssiotis CA, Homicsko K, et al. A colorectal cancer classification system that associates cellular phenotype and responses to therapy. *Nat Med* 2013;19(5):619–625.
37. Marisa L, de Reynies A, Duval A, et al. Gene expression classification of colon cancer into molecular subtypes: characterization, validation, and prognostic value. *PLoS Med* 2013;10(5):e1001453.
38. Zhang B, Wang J, Wang X, et al. Proteogenomic characterization of human colon and rectal cancer. *Nature* 2014;513(7518):382–387.
39. Isella C, Terrasi A, Bellomo SE, et al. Stromal contribution to the colorectal cancer transcriptome. *Nat Genet* 2015;47(4):312–319.
40. Calon A, Lonardo E, Berenguer-Llergo A, et al. Stromal gene expression defines poor-prognosis subtypes in colorectal cancer. *Nat Genet* 2015; 47(4):320–329.
41. Mace AG, Pai RK, Stocchi L, et al. American Joint Committee on Cancer and College of American Pathologists regression grade: a new prognostic factor in rectal cancer. *Dis Colon Rectum* 2015;58(1):32–44.
42. Edge S BD, Compton CC, et al. *AJCC Cancer Staging Manual.* 7th ed. New York, NY: Springer; 2010.
43. Costi R, Beggi F, Reggiani V, et al. Lymph node ratio improves TNM and Astler-Coller's assessment of colorectal cancer prognosis: an analysis of 761 node positive cases. *J Gastrointest Surg* 2014;18(10):1824–1836.
44. Ozawa T, Ishihara S, Nishikawa T, et al. Prognostic significance of the lymph node ratio in stage IV colorectal cancer patients who have undergone curative resection. *Ann Surg Oncol* 2014;22(5):1513–1519.
45. Sloothaak DA, Sahami S, van der Zaag-Loonen HJ, et al. The prognostic value of micrometastases and isolated tumour cells in histologically negative lymph nodes of patients with colorectal cancer: a systematic review and meta-analysis. *Eur J Surg Oncol* 2014;40(3):263–269.
46. Mescoli C, Albertoni L, Pucciarelli S, et al. Isolated tumor cells in regional lymph nodes as relapse predictors in stage I and II colorectal cancer. *J Clin Oncol* 2012;30(9):965–971.
47. Liebig C, Ayala G, Wilks J, et al. Perineural invasion is an independent predictor of outcome in colorectal cancer. *J Clin Oncol* 2009;27(31):5131–5137.
48. Takagawa R, Fujii S, Ohta M, et al. Preoperative serum carcinoembryonic antigen level as a predictive factor of recurrence after curative resection of colorectal cancer. *Ann Surg Oncol* 2008;15(12):3433–3439.

49. Sun LC, Chu KS, Cheng SC, et al. Preoperative serum carcinoembryonic antigen, albumin and age are supplementary to UICC staging systems in predicting survival for colorectal cancer patients undergoing surgical treatment. *BMC Cancer* 2009;9:288.
50. Ueno H, Shirouzu K, Eishi Y, et al. Characterization of perineural invasion as a component of colorectal cancer staging. *Am J Surg Pathol* 2013;37(10):1542–1549.
51. Betge J, Pollheimer MJ, Lindtner RA, et al. Intramural and extramural vascular invasion in colorectal cancer: prognostic significance and quality of pathology reporting. *Cancer* 2012;118(3):628–638.
52. Betge J, Kornprat P, Pollheimer MJ, et al. Tumor budding is an independent predictor of outcome in AJCC/UICC stage II colorectal cancer. *Ann Surg Oncol* 2012;19(12):3706–3712.
53. Weiser MR, Landmann RG, Kattan MW, et al. Individualized prediction of colon cancer recurrence using a nomogram. *J Clin Oncol* 2008;26(3):380–385.
54. Wong NA, Gonzalez D, Salto-Tellez M, et al. RAS testing of colorectal carcinoma—a guidance document from the Association of Clinical Pathologists Molecular Pathology and Diagnostics Group. *J Clin Pathol* 2014;67(9):751–757.
55. O'Connell MJ, Lavery I, Yothers G, et al. Relationship between tumor gene expression and recurrence in four independent studies of patients with stage II/III colon cancer treated with surgery alone or surgery plus adjuvant fluorouracil plus leucovorin. *J Clin Oncol* 2010;28(25):3937–3944.
56. Gray RG, Quirke P, Handley K, et al. Validation study of a quantitative multigene reverse transcriptase-polymerase chain reaction assay for assessment of recurrence risk in patients with stage II colon cancer. *J Clin Oncol* 2011;29(35):4611–4619.
57. Yothers G, O'Connell MJ, Lee M, et al. Validation of the 12-gene colon cancer recurrence score in NSABP C-07 as a predictor of recurrence in patients with stage II and III colon cancer treated with fluorouracil and leucovorin (FU/LV) and FU/LV plus oxaliplatin. *J Clin Oncol* 2013; 31(36):4512–4519.
58. Venook AP, Niedzwiecki D, Lopatin M, et al. Biologic determinants of tumor recurrence in stage II colon cancer: validation study of the 12-gene recurrence score in cancer and leukemia group B (CALGB) 9581. *J Clin Oncol* 2013;31(14):1775–1781.
59. Salazar R, Roepman P, Capella G, et al. Gene expression signature to improve prognosis prediction of stage II and III colorectal cancer. *J Clin Oncol* 2011;29(1):17–24.
60. Kopetz S, Tabernero J, Rosenberg R, et al. Genomic classifier ColoPrint predicts recurrence in stage II colorectal cancer patients more accurately than clinical factors. *Oncologist* 2015;20(2):127–133.
61. Kennedy RD, Bylesjo M, Kerr P, et al. Development and independent validation of a prognostic assay for stage II colon cancer using formalin-fixed paraffin-embedded tissue. *J Clin Oncol* 2011;29(35):4620–4626.

62. Winawer SJ, Zauber A, Ho MN, et al. Prevention of colorectal cancer by colonoscopic polypectomy. The National Polyp Study Workgroup. *N Eng J Med* 1993;329(27):1977–1981.
63. Lieberman DA. Clinical practice. Screening for colorectal cancer. *N Eng J Med* 2009;361(12):1179–1187.
64. Zauber AG, Winawer SJ, O'Brien MJ, et al. Colonoscopic polypectomy and long-term prevention of colorectal-cancer deaths. *N Eng J Med* 2012;366(8):687–696.
65. Shaukat A, Mongin SJ, Geisser MS, et al. Long-term mortality after screening for colorectal cancer. *N Eng J Med* 2013;369(12):1106–1114.
66. Loberg M, Kalager M, Holme O, et al. Long-term colorectal-cancer mortality after adenoma removal. *N Eng J Med* 2014;371(9):799–807.
67. Whitlock EP, Lin J, Liles E, et al. *U.S. Preventive Services Task Force Evidence Syntheses, formerly Systematic Evidence Reviews. Screening for Colorectal Cancer: An Updated Systematic Review.* Rockville, MD: Agency for Healthcare Research and Quality (US); 2008.
68. Whitlock EP, Lin JS, Liles E, et al. Screening for colorectal cancer: a targeted, updated systematic review for the U.S. Preventive Services Task Force. *Ann Intern Med* 2008;149(9):638–658.
69. Lansdorp-Vogelaar I, Knudsen AB, Brenner H. Cost-effectiveness of colorectal cancer screening. *Epidemiol Rev* 2011;33(1):88–100.
70. Mandel JS, Bond JH, Church TR, et al. Reducing mortality from colorectal cancer by screening for fecal occult blood. Minnesota Colon Cancer Control Study. *N Eng J Med* 1993;328(19):1365–1371.
71. Jorgensen OD, Kronborg O, Fenger C. A randomised study of screening for colorectal cancer using faecal occult blood testing: results after 13 years and seven biennial screening rounds. *Gut* 2002;50(1):29–32.
72. Lindholm E, Brevinge H, Haglind E. Survival benefit in a randomized clinical trial of faecal occult blood screening for colorectal cancer. *Br J Surg* 2008;95(8):1029–1036.
73. Brenner H, Tao S. Superior diagnostic performance of faecal immunochemical tests for haemoglobin in a head-to-head comparison with guaiac based faecal occult blood test among 2235 participants of screening colonoscopy. *Eur J Cancer.* 2013;49(14):3049–3054.
74. Hol L, van Leerdam ME, van Ballegooijen M, et al. Screening for colorectal cancer: randomised trial comparing guaiac-based and immunochemical faecal occult blood testing and flexible sigmoidoscopy. *Gut* 2010;59(1):62–68.
75. Quintero E, Castells A, Bujanda L, et al. Colonoscopy versus fecal immunochemical testing in colorectal-cancer screening. *N Eng J Med* 2012; 366(8):697–706.
76. Ahlquist DA, Sargent DJ, Loprinzi CL, et al. Stool DNA and occult blood testing for screen detection of colorectal neoplasia. *Ann Intern Med* 2008;149(7):441–450, w81.
77. Lidgard GP, Domanico MJ, Bruinsma JJ, et al. Clinical performance of an automated

stool DNA assay for detection of colorectal neoplasia. *Clin Gastroenterol Hepatol* 2013;11(10):1313–1318.

78. Imperiale TF RD, Itzkowitz SH, Levin TR, et al. Multitarget stool DNA testing for colorectal-cancer screening. *N Engl J Med* 2014;370(14):1287–1297.
79. Selby JV, Friedman GD, Quesenberry CP Jr, et al. A case-control study of screening sigmoidoscopy and mortality from colorectal cancer. *N Eng J Med* 1992;326(10):653–657.
80. Newcomb PA, Norfleet RG, Storer BE, et al. Screening sigmoidoscopy and colorectal cancer mortality. *J Natl Cancer Inst* 1992;84(20):1572–1575.
81. Schoen RE, Pinsky PF, Weissfeld JL, et al. PLCO Project Team. Colorectal-cancer incidence and mortality with screening flexible sigmoidoscopy. *N Engl J Med* 2012;355(25):2345–2357.
82. Holme Ø, L⊘berg M, Kalager M, et al. Effect of flexible sigmoidoscopy screening on colorectal cancer incidence and mortality: a randomized clinical trial. *JAMA* 2014;312(6):606–615.
83. Segnan N, Armaroli P, Bonelli L, et al. Once-only sigmoidoscopy in colorectal cancer screening: follow-up findings of the Italian Randomized Controlled Trial–SCORE. *J Natl Cancer Inst* 2011;103(17):1310–1322.
84. Atkin WS, Edwards R, Kralj-Hans I, et al. UK Flexible Sigmoidoscopy Trial Investigators. Once-only flexible sigmoidoscopy screening in prevention of colorectal cancer: a multicentre randomised controlled trial. *Lancet* 2010;375(9726):1624–1633.
85. Segnan N, Senore C, Andreoni B, et al. Randomized trial of different screening strategies for colorectal cancer: patient response and detection rates. *J Natl Cancer Inst* 2005;97(5):347–357.
86. Rutter CM, Savarino JE. An evidence-based microsimulation model for colorectal cancer: validation and application. *Cancer Epidemiol Biomarkers Prev* 2010;19(8):1992–2002.
87. Sharaf RN, Ladabaum U. Comparative effectiveness and cost-effectiveness of screening colonoscopy vs. sigmoidoscopy and alternative strategies. *Am J Gastroenterol* 2013;108(1):120–132.
88. de Haan MC, Pickhardt PJ, Stoker J. CT colonography: accuracy, acceptance, safety and position in organised population screening. *Gut* 2015;64(2):342–350.
89. Johnson CD, Chen MH, Toledano AY, et al. Accuracy of CT colonography for detection of large adenomas and cancers. *N Eng J Med* 2008;359(12):1207–1217.
90. Burt RW, Cannon JA, David DS, et al. colorectal cancer screening. *J Natl Compr Cancer Netw* 2013;11(12):1538–1575.
91. Levin B, Lieberman DA, McFarland B, et al. Screening and surveillance for the early detection of colorectal cancer and adenomatous polyps, 2008: a joint guideline from the American Cancer Society, the US Multi-Society Task Force on Colorectal Cancer, and the American College of Radiology. *Gastroenterology* 2008;134(5):1570–1595.

92. Winawer SJ, Zauber AG, Fletcher RH, et al. Guidelines for colonoscopy surveillance after polypectomy: a consensus update by the US Multi-Society Task Force on Colorectal Cancer and the American Cancer Society. *Gastroenterology* 2006;130(6):1872–1885.
93. Pignone M, Saha S, Hoerger T, et al. Cost-effectiveness analyses of colorectal cancer screening: a systematic review for the U.S. Preventive Services Task Force. *Ann Intern Med* 2002;137(2):96–104.
94. Maciosek MV, Coffield AB, Edwards NM, et al. Priorities among effective clinical preventive services: results of a systematic review and analysis. *Am J Prevent Med* 2006;31(1):52–61.
95. Singh S, Singh PP, Murad MH, et al. Prevalence, risk factors, and outcomes of interval colorectal cancers: a systematic review and meta-analysis. *Am J Gastroenterol* 2014;109(9):1375–1389.
96. Samadder NJ, Curtin K, Tuohy TM, et al. Increased risk of colorectal neoplasia among family members of patients with colorectal cancer: a population-based study in Utah. *Gastroenterology* 2014;147(4):814–821.e5.
97. Lairson DR, Dicarlo M, Deshmuk AA, et al. Cost-effectiveness of a standard intervention versus a navigated intervention on colorectal cancer screening use in primary care. *Cancer* 2014;120(7):1042–1049.
98. Gupta S, Halm EA, Rockey DC, et al. Comparative effectiveness of fecal immunochemical test outreach, colonoscopy outreach, and usual care for boosting colorectal cancer screening among the underserved: a randomized clinical trial. *JAMA Intern Med* 2013;173(18):1725–1732.
99. Mulder SA, Kranse R, Damhuis RA, et al. Prevalence and prognosis of synchronous colorectal cancer: a Dutch population-based study. *Cancer Epidemiol* 2011;35(5):442–447.
100. Latournerie M, Jooste V, Cottet V, et al. Epidemiology and prognosis of synchronous colorectal cancers. *Br J Surg* 2008;95(12):1528–1533.
101. Eagye KJ, Nicolau DP. Deep and organ/space infections in patients undergoing elective colorectal surgery: incidence and impact on hospital length of stay and costs. *Am J Surg* 2009;198(3):359–367.
102. Cima R, Dankbar E, Lovely J, et al. Colorectal surgery surgical site infection reduction program: a national surgical quality improvement program–driven multidisciplinary single-institution experience. *J Am Coll Surg* 2013;216(1):23–33.
103. Urban JA. Cost analysis of surgical site infections. *Surg Infect (Larchmt)* 2006;7(Suppl 1):S19–S22.
104. American College of Surgeons. American College of Surgeons National Surgical Quality Improvement Program® (ACS NSQIP®). https://www.facs.org/quality-programs/acs-nsqip.
105. Cataife G, Weinberg DA, Wong HH, et al. The effect of Surgical Care Improvement

Project (SCIP) compliance on surgical site infections (SSI). *Med Care* 2014;52(2 Suppl 1):S66–S73.

106. Stephen AM, Cummings JH. The microbial contribution to human faecal mass. *J Med Microbiol* 1980;13(1):45–56.
107. Contant CM, Hop WC, van't Sant HP, et al. Mechanical bowel preparation for elective colorectal surgery: a multicentre randomised trial. *Lancet* 2007;370(9605):2112–2117.
108. Jung B, Pahlman L, Nystrom PO, et al. Multicentre randomized clinical trial of mechanical bowel preparation in elective colonic resection. *Br J Surg* 2007;94(6):689–695.
109. Guenaga KF, Matos D, Wille-Jorgensen P. Mechanical bowel preparation for elective colorectal surgery. *Cochrane Database Syst Rev* 2011(9):Cd001544.
110. Dahabreh IJ, Steele DW, Shah N, et al. AHRQ Comparative Effectiveness Reviews. *Oral Mechanical Bowel Preparation for Colorectal Surgery*. Rockville, MD: Agency for Healthcare Research and Quality (US); 2014.
111. Nelson RL, Gladman E, Barbateskovic M. Antimicrobial prophylaxis for colorectal surgery. *Cochrane Database Syst Rev* 2014;5:Cd001181.
112. Bratzler DW, Dellinger EP, Olsen KM, et al. Clinical practice guidelines for antimicrobial prophylaxis in surgery. *Am J Health Syst Pharm* 2013;70(3):195–283.
113. Itani KM, Wilson SE, Awad SS, et al. Ertapenem versus cefotetan prophylaxis in elective colorectal surgery. *N Eng J Med* 2006;355(25):2640–2651.
114. Poggio JL. Perioperative strategies to prevent surgical-site infection. *Clin Colon Rectal Surg* 2013;26(3):168–173.
115. Kakkos SK, Caprini JA, Geroulakos G, et al. Combined intermittent pneumatic leg compression and pharmacological prophylaxis for prevention of venous thromboembolism in high-risk patients. *Cochrane Database Syst Rev* 2008(4):Cd005258.
116. Danielsen AK, Burcharth J, Rosenberg J. Patient education has a positive effect in patients with a stoma: a systematic review. *Colorectal Dis* 2013;15(6):e276–e283.
117. Bardram L, Funch-Jensen P, Jensen P, et al. Recovery after laparoscopic colonic surgery with epidural analgesia, and early oral nutrition and mobilisation. *Lancet* 1995;345(8952):763–764.
118. Serclova Z, Dytrych P, Marvan J, et al. Fast-track in open intestinal surgery: prospective randomized study (Clinical Trials Gov Identifier no. NCT00123456). *Clin Nutr* 2009;28(6):618–624.
119. Yang D, He W, Zhang S, et al. Fast-track surgery improves postoperative clinical recovery and immunity after elective surgery for colorectal carcinoma: randomized controlled clinical trial. *World J Surg* 2012;36(8):1874–1880.
120. Zhuang CL, Ye XZ, Zhang XD, et al. Enhanced recovery after surgery programs versus traditional care for colorectal surgery: a meta-analysis of randomized

controlled trials. *Dis Colon Rectum* 2013;56(5):667–678.
121. Spanjersberg WR, Reurings J, Keus F, et al. Fast track surgery versus conventional recovery strategies for colorectal surgery. *Cochrane Database Syst Rev* 2011(2):Cd007635.
122. ERAS Compliance Group. The impact of enhanced recovery protocol compliance on elective colorectal cancer resection: results from an international registry. *Ann Surg* 2015;261(6):1153–1159.
123. Monson JR, Weiser MR, Buie WD, et al. Standards Practice Task Force of the American Society of Colon and Rectal Surgeons. Practice parameters for the management of rectal cancer (revised). *Dis Colon Rectum* 2013;56(5):535–550.
124. Shiozawa M, Akaike M, Yamada R, et al. Clinicopathological features of skip metastasis in colorectal cancer. *Hepatogastroenterology* 2007; 54(73):81–84.
125. Toyota S, Ohta H, Anazawa S. Rationale for extent of lymph node dissection for right colon cancer. *Dis Colon Rectum* 1995;38(7):705–711.
126. Saha S, Johnston G, Korant A, et al. Aberrant drainage of sentinel lymph nodes in colon cancer and its impact on staging and extent of operation. *Am J Surg* 2013;205(3):302–305; discussion 5–6.
127. Wiggers T, Jeekel J, Arends JW, et al. No-touch isolation technique in colon cancer: a controlled prospective trial. *Br J Surg* 1988;75(5):409–415.
128. Heald RJ. The 'Holy Plane' of rectal surgery. *J Royal Soc Med* 1988;81(9):503–508.
129. MacFarlane JK, Ryall RD, Heald RJ. Mesorectal excision for rectal cancer. *Lancet* 1993;341(8843):457–460.
130. Hohenberger W, Weber K, Matzel K, et al. Standardized surgery for colonic cancer: complete mesocolic excision and central ligation–technical notes and outcome. *Colorectal Dis* 2009;11(4):354–364; discussion 64–65.
131. Bertelsen CA, Neuenschwander AU, Jansen JE, et al. Disease-free survival after complete mesocolic excision compared with conventional colon cancer surgery: a retrospective, population-based study. *Lancet Oncol* 2015;16(2):161–168.
132. Nivatvongs S. Surgical management of malignant colorectal polyps. *Surg Clin North Am* 2002;82(5):959–966.
133. Haggitt RC, Glotzbach RE, Soffer EE, et al. Prognostic factors in colorectal carcinomas arising in adenomas: implications for lesions removed by endoscopic polypectomy. *Gastroenterology* 1985;89(2):328–336.
134. Butte JM, Tang P, Gonen M, et al. Rate of residual disease after complete endoscopic resection of malignant colonic polyp. *Dis Colon Rectum* 2012;55(2):122–127.
135. Okabe S, Shia J, Nash G, et al. Lymph node metastasis in T1 adenocarcinoma of the colon and rectum. *J Gastrointest Surg* 2004;8(8):1032–1039; discussion 9–40.
136. Kessler H, Hohenberger W. Extended lymphadenectomy in colon cancer is crucial. *World J Surg* 2013;37(8):1789–1798.
137. Nosho K, Kure S, Irahara N, et al. A prospective cohort study shows unique

epigenetic, genetic, and prognostic features of synchronous colorectal cancers. *Gastroenterology* 2009;137(5):1609–1620.e1–3.

138. Yang C, Wexner SD, Safar B, et al. Conversion in laparoscopic surgery: does intraoperative complication influence outcome? *Surg Endosc* 2009;23(11):2454–2458.
139. Fung AK, Aly EH. Systematic review of single-incision laparoscopic colonic surgery. *Br J Surg* 2012;99(10):1353–1364.
140. Kim CW, Kim CH, Baik SH. Outcomes of robotic-assisted colorectal surgery compared with laparoscopic and open surgery: a systematic review. *J Gastrointest Surg* 2014;18(4):816–830.
141. Laurie JA, Moertel C, Fleming TR, et al. Surgical adjuvant therapy of large bowel carcinoma: an evaluation of levamisole and the combination of levamisole and fluorouracil. *J Clin Oncol* 1989;7:1447–1456.
142. Moertel CG, Fleming TR, Macdonald JS, et al. Intergroup study of fluorouracil plus levamisole as adjuvant therapy for stage II/Dukes' B2 colon cancer. *J Clin Oncol* 1995;13(12):2936–2943.
143. Porschen R, Bermann A, Loffler T, et al. Fluorouracil plus leucovorin as effective adjuvant chemotherapy in curatively resected stage III colon cancer: results of the trial adjCCA-01. *J Clin Oncol* 2001;19(6):1787–1794.
144. Mamounas E, Wieand S, Wolmark N, et al. Comparative efficacy of adjuvant chemotherapy in patients with Dukes' B versus Dukes' C colon cancer: results from four National Surgical Adjuvant Breast and Bowel Project adjuvant studies (C-01, C-02, C-03, and C-04). *J Clin Oncol* 1999;17(5):1349–1355.
145. Sargent DJ, Goldberg RM, Jacobson SD, et al. A pooled analysis of adjuvant chemotherapy for resected colon cancer in elderly patients. *N Eng J Med* 2001;345(15):1091–1097.
146. Andre T, Boni C, Mounedi-Boudiaf L, et al. Oxaliplatin, fluorouracil, and leucovorin as adjuvant treatment for colon cancer. *N Eng J Med* 2004;350:2343–2351.
147. Andre T, Boni C, Navarro M, et al. Improved overall survival with oxaliplatin, fluorouracil, and leucovorin as adjuvant treatment in stage II or III colon cancer in the MOSAIC trial. *J Clin Oncol* 2009;27(19):3109–3116.
148. Van Cutsem E, Labianca R, Bodoky G, et al. Randomized phase III trial comparing biweekly infusional fluorouracil/leucovorin alone or with irinotecan in the adjuvant treatment of Stage III colon cancer: PETACC-3. *J Clin Oncol* 2009;27:3117–3125.
149. Allegra CJ, Yothers G, O'Connell MJ, et al. Bevacizumab in stage II-III colon cancer: 5-year update of the National Surgical Adjuvant Breast and Bowel Project C-08 trial. *J Clin Oncol* 2013;31(3):359–364.
150. de Gramont A, Van Cutsem E, Schmoll HJ, et al. Bevacizumab plus oxaliplatin-based chemotherapy as adjuvant treatment for colon cancer (AVANT): a phase 3 randomised controlled trial. *Lancet Oncol* 2012; 13(12):1225–1233.
151. Alberts SR SD, Nair S, Mahoney MR, et al. Effect of oxaliplatin, fluorouracil, and

leucovorin with or without cetuximab on survival among patients with resected stage III colon cancer: a randomized trial. *JAMA* 2012;307(13):1383–1393.

152. Schippinger W, Samonigg H, Schaberl-Moser R, et al. A prospective randomised phase III trial of adjuvant chemotherapy with 5-fluorouracil and leucovorin in patients with stage II colon cancer. *Br J Cancer* 2007; 97(8):1021–1027.
153. Gray R, Barnwell J, McConkey C, et al. Adjuvant chemotherapy versus observation in patients with colorectal cancer: a randomised study. *Lancet* 2007;370(9604):2020–2029.
154. Figueredo A, Charette ML, Maroun J, et al. Adjuvant therapy for stage II colon cancer: a systematic review from the Cancer Care Ontario Program in evidence-based care's gastrointestinal cancer disease site group. *J Clin Oncol* 2004;22(16):3395–3407.
155. Marshall JL. Risk assessment in Stage II colorectal cancer. *Oncology (Williston Park, NY)* 2010;24(1 Suppl 1):9–13.
156. Ribic CM SD, Moore MJ, Thibodeau SN, et al. Tumor microsatellite-instability status as a predictor of benefit from fluorouracil-based adjuvant chemotherapy for colon cancer. *N Eng J Med* 2003;349(3):247–257.
157. Nicholls RJ, Mason AY, Morson BC, et al. The clinical staging of rectal cancer. *Br J Surg* 1982;69(7):404–409.
158. Garcia-Aguilar J, Pollack J, Lee SH, et al. Accuracy of endorectal ultrasonography in preoperative staging of rectal tumors. *Dis Colon Rectum* 2002;45(1):10–15.
159. Beets-Tan RG, Lambregts DM, Maas M, et al. Magnetic resonance imaging for the clinical management of rectal cancer patients: recommendations from the 2012 European Society of Gastrointestinal and Abdominal Radiology (ESGAR) consensus meeting. *Eur Radiol* 2013;23(9):2522–2531.
160. Heijnen LA, Lambregts DM, Martens MH, et al. Performance of gadofosveset-enhanced MRI for staging rectal cancer nodes: can the initial promising results be reproduced? *Eur Radiol* 2014;24(2):371–379.
161. Hotker AM, Garcia-Aguilar J, Gollub MJ. Multiparametric MRI of rectal cancer in the assessment of response to therapy: a systematic review. *Dis Colon Rectum* 2014;57(6):790–799.
162. Kwok H, Bissett IP, Hill GL. Preoperative staging of rectal cancer. *Int J Colorectal Dis* 2000;15(1):9–20.
163. Bipat S, Glas AS, Slors FJ, et al. Rectal cancer: local staging and assessment of lymph node involvement with endoluminal US, CT, and MR imaging–a meta-analysis. *Radiology* 2004;232(3):773–783.
164. Nagtegaal ID, Quirke P. What is the role for the circumferential margin in the modern treatment of rectal cancer? *J Clin Oncol* 2008;26(2):303–312.
165. MERCURY Study Group. Diagnostic accuracy of preoperative magnetic resonance imaging in predicting curative resection of rectal cancer: prospective observational study. *BMJ* 2006;333(7572):779.

166. Brown G, Radcliffe AG, Newcombe RG, et al. Preoperative assessment of prognostic factors in rectal cancer using high-resolution magnetic resonance imaging. *Br J Surg* 2003;90(3):355–364.
167. Taylor FG, Quirke P, Heald RJ, et al. Preoperative magnetic resonance imaging assessment of circumferential resection margin predicts disease-free survival and local recurrence: 5-year follow-up results of the MERCURY study. *J Clin Oncol* 2014;32(1):34–43.
168. Taylor FG, Quirke P, Heald RJ, et al. Preoperative high-resolution magnetic resonance imaging can identify good prognosis stage I, II, and III rectal cancer best managed by surgery alone: a prospective, multicenter, European study. *Ann Surg* 2011;253(4):711–719.
169. Blomqvist L, Glimelius B. The 'good', the 'bad', and the 'ugly' rectal cancers. *Acta Oncol* 2008;47(1):5–8.
170. Habr-Gama A, Perez RO, Nadalin W, et al. Operative versus nonoperative treatment for stage 0 distal rectal cancer following chemoradiation therapy: long-term results. *Ann Surg* 2004;240(4):711–717; discussion 7–8.
171. Maas M, Beets-Tan RG, Lambregts DM, et al. Wait-and-see policy for clinical complete responders after chemoradiation for rectal cancer. *J Clin Oncol* 2011;29(35):4633–4640.
172. Guillem JG CD, Shia J, Moore HG, et al. Clinical examination following preoperative chemoradiation for rectal cancer is not a reliable surrogate end point. *J Clin Oncol* 2005;23(15):3475–3479.
173. Pastor C SJ, Sola J, Baixauli J, et al. Accuracy of endoscopic ultrasound to assess tumor response after neoadjuvant treatment in rectal cancer: can we trust the findings? *Dis Colon Rectum* 2011;54(9):1141–1146.
174. Allen SD, Padhani AR, Dzik-Jurasz AS, et al. Rectal carcinoma: MRI with histologic correlation before and after chemoradiation therapy. *AJR Am J Roentgenol* 2007;188(2):442–451.
175. Guillem JG, Ruby JA, Leibold T, et al. Neither FDG-PET nor CT is able to distinguish between a pathological complete response and an incomplete response after neoadjuvant chemoradiation in locally advanced rectal cancer: a prospective study. *Ann Surg* 2012;(2):289–295.
176. Gollub MJ, Gultekin DH, Akin O, et al. Dynamic contrast enhanced-MRI for the detection of pathological complete response to neoadjuvant chemotherapy for locally advanced rectal cancer. *Eur Radiol* 2012;22:821–831.
177. National Comprehensive Cancer Network. *NCCN Clinical Practice Guidelines in Oncology - Rectal Cancer.* Available at www.nccn.org. 2015 [cited February 2015].
178. Garcia-Aguilar J, Mellgren A, Sirivongs P, et al. Local excision of rectal cancer without adjuvant therapy: a word of caution. *Ann Surg* 2000; 231(3):345–351.
179. Paty PB, Nash GM, Baron P, et al. Long-term results of local excision for rectal

cancer. *Ann Surg* 2002;236(4):522–529; discussion 9–30.

180. Madbouly KM, Remzi FH, Erkek BA, et al. Recurrence after transanal excision of T1 rectal cancer: should we be concerned? *Dis Colon Rectum* 2005;48(4):711–719; discussion 9–21.
181. Weiser MR, Landmann RG, Wong WD, et al. Surgical salvage of recurrent rectal cancer after transanal excision. *Dis Colon Rectum* 2005;48(6):1169–1175.
182. Friel CM, Cromwell JW, Marra C, et al. Salvage radical surgery after failed local excision for early rectal cancer. *Dis Colon Rectum* 2002;45(7):875–879.
183. You YN, Baxter NN, Stewart A, et al. Is the increasing rate of local excision for stage I rectal cancer in the United States justified? a nationwide cohort study from the National Cancer Database. *Ann Surg* 2007;245(5):726–733.
184. Peng J, Chen W, Sheng W, et al. Oncological outcome of T1 rectal cancer undergoing standard resection and local excision. *Colorectal Dis* 2011;13(2):e14–e19.
185. Kidane B, Chadi SA, Kanters S, et al. Local resection compared with radical resection in the treatment of T1N0M0 rectal adenocarcinoma: a systematic review and meta-analysis. *Dis Colon Rectum* 2015;58(1):122–140.
186. Clancy C, Burke JP, Albert MR, et al. Transanal endoscopic microsurgery versus standard transanal excision for the removal of rectal neoplasms: A systematic review and meta-analysis. *Dis Colon Rectum* 2015;58(2):254–261.
187. Mellgren A, Sirivongs P, Rothenberger DA, et al. Is local excision adequate therapy for early rectal cancer? *Dis Colon Rectum* 2000;43(8):1064–1071; discussion 71–74.
188. Stitzenberg KB, Sanoff HK, Penn DC, et al. Practice patterns and long-term survival for early-stage rectal cancer. *J Clin Oncol* 2013;31(34):4276–4282.
189. Bhangu A, Brown G, Nicholls RJ, et al. Survival outcome of local excision versus radical resection of colon or rectal carcinoma: a surveillance, epidemiology, and end results (seer) population-based study. *Ann Surg* 2013;258(4):563–571.
190. Minsky BD, Enker WE, Cohen AM, et al. Local excision and postoperative radiation therapy for rectal cancer. *Am J Clin Oncol* 1994;17(5):411–416.
191. Chakravarti A, Compton CC, Shellito PC, et al. Long-term follow-up of patients with rectal cancer managed by local excision with and without adjuvant irradiation. *Ann Surg* 1999;230(1):49–54.
192. Bouvet M, Milas M, Giacco GG, et al. Predictors of recurrence after local excision and postoperative chemoradiation therapy of adenocarcinoma of the rectum. *Ann Surg Oncol* 1999;6(1):26–32.
193. Benson R, Wong CS, Cummings BJ, et al. Local excision and postoperative radiotherapy for distal rectal cancer. *Int J Radiat Oncol Biol Phys* 2001;50(5):1309–1316.
194. Greenberg JA, Shibata D, Herndon JE, 2nd, et al. Local excision of distal rectal cancer: an update of cancer and leukemia group B 8984. *Dis Colon Rectum* 2008;51(8):1185–1191; discussion 91–94.

195. Kim CJ, Yeatman TJ, Coppola D, et al. Local excision of T2 and T3 rectal cancers after downstaging chemoradiation. *Ann Surg* 2001;234(3):352–358; discussion 8–9.
196. Nair RM, Siegel EM, Chen DT, et al. Long-term results of transanal excision after neoadjuvant chemoradiation for T2 and T3 adenocarcinomas of the rectum. *J Gastrointest Surg* 2008;12(10):1797–1805; discussion 805–806.
197. Lezoche E, Baldarelli M, Lezoche G, et al. Randomized clinical trial of endoluminal locoregional resection versus laparoscopic total mesorectal excision for T2 rectal cancer after neoadjuvant therapy. *Br J Surg* 2012;99(9):1211–1218.
198. Garcia-Aguilar J, Shi Q, Thomas CR Jr, et al. A phase II trial of neoadjuvant chemoradiation and local excision for T2N0 rectal cancer: preliminary results of the ACOSOG Z6041 trial. *Ann Surg Oncol* 2012;19(2):384–391.
199. Garcia-Aguilar J, Renfro LA, Chow, OS, et al. Organ preservation for clinical T2N0 distal rectal cancer using neoadjuvant chemoradiotherapy and local excision (ACOSOG Z6041): results of an open-label, single-arm, multi-institutional, phase 2 trial. *Lancet Oncol* 2015;15(15):1537–1546.
200. Rondelli F, Trastulli S, Cirocchi R, et al. Rectal washout and local recurrence in rectal resection for cancer: a meta-analysis. *Colorectal Dis* 2012;14(11):1313–1321.
201. Lange MM, Buunen M, van de Velde CJ, et al. Level of arterial ligation in rectal cancer surgery: low tie preferred over high tie. A review. *Dis Colon Rectum* 2008;51(7):1139–1145.
202. Zotti P, Del Bianco P, Serpentini S, et al. Validity and reliability of the MSKCC Bowel Function instrument in a sample of Italian rectal cancer patients. *Eur J Surg Oncol* 2011;37(7):589–596.
203. Emmertsen KJ, Laurberg S. Low anterior resection syndrome score: development and validation of a symptom-based scoring system for bowel dysfunction after low anterior resection for rectal cancer. *Ann Surg* 2012;255(5):922–928.
204. Emmertsen KJ, Laurberg S. Bowel dysfunction after treatment for rectal cancer. *Acta Oncol* 2008;47(6):994–1003.
205. Lundby L, Krogh K, Jensen VJ, et al. Long-term anorectal dysfunction after postoperative radiotherapy for rectal cancer. *Dis Colon Rectum* 2005;48(7):1343–1349; discussion 9–52; author reply 52.
206. Chen TY, Wiltink LM, Nout RA, et al. Bowel function 14 years after preoperative short-course radiotherapy and total mesorectal excision for rectal cancer: Report of a multicenter randomized trial. *Clin Colorectal Cancer* 2014;14(2):106–114.
207. Lewis WG, Martin IG, Williamson ME, et al. Why do some patients experience poor functional results after anterior resection of the rectum for carcinoma? *Dis Colon Rectum* 1995;38(3):259–263.
208. Brown CJ, Fenech DS, McLeod RS. Reconstructive techniques after rectal resection for rectal cancer. *Cochrane Database Syst Rev* 2008(2):Cd006040.
209. Parc R, Tiret E, Frileux P, et al. Resection and colo-anal anastomosis with colonic

reservoir for rectal carcinoma. *Br J Surg* 1986;73(2):139–141.

210. Seow-Choen F, Goh HS. Prospective randomized trial comparing J colonic pouch-anal anastomosis and straight coloanal reconstruction. *Br J Surg* 1995;82(5):608–610.
211. Hida J, Yasutomi M, Fujimoto K, et al. Functional outcome after low anterior resection with low anastomosis for rectal cancer using the colonic J-pouch. Prospective randomized study for determination of optimum pouch size. *Dis Colon Rectum* 1996;39(9):986–991.
212. Lazorthes F, Gamagami R, Chiotasso P, et al. Prospective, randomized study comparing clinical results between small and large colonic J-pouch following coloanal anastomosis. *Dis Colon Rectum* 1997;40(12):1409–1413.
213. Machado M, Nygren J, Goldman S, et al. Functional and physiologic assessment of the colonic reservoir or side-to-end anastomosis after low anterior resection for rectal cancer: a two-year follow-up. *Dis Colon Rectum* 2005;48(1):29–36.
214. Daams F, Wu Z, Lahaye MJ, et al. Prediction and diagnosis of colorectal anastomotic leakage: a systematic review of literature. *World J Gastrointest Surg* 2014;6(2):14–26.
215. Jones OM, John SK, Horseman N, et al. Low anastomotic leak rate after colorectal surgery: a single-centre study. *Colorectal Dis* 2007;9(8):740–744.
216. Eberl T, Jagoditsch M, Klingler A, et al. Risk factors for anastomotic leakage after resection for rectal cancer. *Am J Surg* 2008;196(4):592–598.
217. McArdle CS, McMillan DC, Hole DJ. Impact of anastomotic leakage on long-term survival of patients undergoing curative resection for colorectal cancer. *Br J Surg* 2005;92(9):1150–1154.
218. den Dulk M, Marijnen CA, Collette L, et al. Multicentre analysis of oncological and survival outcomes following anastomotic leakage after rectal cancer surgery. *Br J Surg* 2009;96(9):1066–1075.
219. Smith JD, Paty PB, Guillem JG, et al. Anastomotic leak is not associated with oncologic outcome in patients undergoing low anterior resection for rectal cancer. *Ann Surg* 2012;256(6):1034–1038.
220. Matthiessen P, Hallbook O, Andersson M, et al. Risk factors for anastomotic leakage after anterior resection of the rectum. *Colorectal Dis* 2004; 6(6):462–469.
221. Tan WS, Tang CL, Shi L, et al. Meta-analysis of defunctioning stomas in low anterior resection for rectal cancer. *Br J Surg* 2009;96(5):462–472.
222. Machado M, Hallbook O, Goldman S, et al. Defunctioning stoma in low anterior resection with colonic pouch for rectal cancer: a comparison between two hospitals with a different policy. *Dis Colon Rectum* 2002; 45(7):940–945.
223. Rondelli F, Reboldi P, Rulli A, et al. Loop ileostomy versus loop colostomy for fecal diversion after colorectal or coloanal anastomosis: a meta-analysis. *Int J Colorect Dis* 2009;24(5):479–488.
224. Chun LJ, Haigh PI, Tam MS, et al. Defunctioning loop ileostomy for pelvic anastomoses: predictors of morbidity and nonclosure. *Dis Colon Rectum*

2012;55(2):167–174.
225. Marr R, Birbeck K, Garvican J, et al. The modern abdominoperineal excision: the next challenge after total mesorectal excision. *Ann Surg* 2005;242(1):74–82.
226. Perdawood SK, Lund T. Extralevator versus standard abdominoperineal excision for rectal cancer. *Tech Coloproctol* 2014;19(3):145–152.
227. Musters GD, Buskens CJ, Bemelman WA, et al. Perineal wound healing after abdominoperineal resection for rectal cancer: a systematic review and meta-analysis. *Dis Colon Rectum* 2014;57(9):1129–1139.
228. Yu HC, Peng H, He XS, et al. Comparison of short- and long-term outcomes after extralevator abdominoperineal excision and standard abdominoperineal excision for rectal cancer: a systematic review and meta-analysis. *Int J Colorect Dis* 2014;29(2):183–191.
229. de Campos-Lobato LF, Stocchi L, Dietz DW, et al. Prone or lithotomy positioning during an abdominoperineal resection for rectal cancer results in comparable oncologic outcomes. *Dis Colon Rectum* 2011;54(8):939–946.
230. Lujan J, Valero G, Hernandez Q, et al. Randomized clinical trial comparing laparoscopic and open surgery in patients with rectal cancer. *Br J Surg* 2009;96(9):982–989.
231. Ng KH, Ng DC, Cheung HY, et al. Laparoscopic resection for rectal cancers: lessons learned from 579 cases. *Ann Surg* 2009;249(1):82–86.
232. Greenblatt DY, Rajamanickam V, Pugely AJ, et al. Short-term outcomes after laparoscopic-assisted proctectomy for rectal cancer: results from the ACS NSQIP. *J Am Coll Surg* 2011;212(5):844–854.
233. Yeo H, Niland J, Milne D, et al. Incidence of minimally invasive colorectal cancer surgery at National Comprehensive Cancer Network centers. *J Natl Cancer Inst* 2015;107(1):362.
234. Jayne DG, Thorpe HC, Copeland J, et al. Five-year follow-up of the Medical Research Council CLASICC trial of laparoscopically assisted versus open surgery for colorectal cancer. *Br J Surg* 2010;97(11):1638–1645.
235. Jeong SY, Park JW, Nam BH, et al. Open versus laparoscopic surgery for mid-rectal or low-rectal cancer after neoadjuvant chemoradiotherapy (COREAN trial): survival outcomes of an open-label, non-inferiority, randomised controlled trial. *Lancet Oncol* 2014;15(7):767–774.
236. van der Pas MH, Haglind E, Cuesta MA, et al. Laparoscopic versus open surgery for rectal cancer (COLOR II): short-term outcomes of a randomised, phase 3 trial. *Lancet Oncol* 2013;14(3):210–218.
237. Vithiananthan S, Cooper Z, Betten K, et al. Hybrid laparoscopic flexure takedown and open procedure for rectal resection is associated with significantly shorter length of stay than equivalent open resection. *Dis Colon Rectum* 2001;44(7):927–935.
238. Xiong B, Ma L, Zhang C, et al. Robotic versus laparoscopic total mesorectal excision

for rectal cancer: a meta-analysis. *J Surg Res* 2014;188(2):404–414.

239. Collinson FJ, Jayne DG, Pigazzi A, et al. An international, multicentre, prospective, randomised, controlled, unblinded, parallel-group trial of robotic-assisted versus standard laparoscopic surgery for the curative treatment of rectal cancer. *Int J Colorect Dis* 2012;27(2):233–241.
240. de Lacy AM, Rattner DW, Adelsdorfer C, et al. Transanal natural orifice transluminal endoscopic surgery (NOTES) rectal resection: "down-to-up" total mesorectal excision (TME)–short-term outcomes in the first 20 cases. *Surg Endosc* 2013;27(9):3165–3172.
241. Rouanet P, Mourregot A, Azar CC, et al. Transanal endoscopic proctectomy: an innovative procedure for difficult resection of rectal tumors in men with narrow pelvis. *Dis Colon Rectum* 2013;56(4):408–415.
242. Prolongation of the disease-free interval in surgically treated rectal carcinoma. Gastrointestinal Tumor Study Group. *N Eng J Med* 1985;312(23):1465–1472.
243. Fisher B, Wolmark N, Rockette H, et al. Postoperative adjuvant chemotherapy or radiation therapy for rectal cancer: results from NSABP protocol R-01. *J Natl Cancer Inst* 1988;80:21–29.
244. Gerard A, Buyse M, Nordlinger B, et al. Preoperative radiotherapy as adjuvant treatment in rectal cancer: final results of a randomized study of the European Organization for Research and Treatment of Cancer (EORTC). *Ann Surg* 1988;208:606–614.
245. Kapiteijn E, Marijnen CA, Nagtegaal ID, et al. Preoperative radiotherapy combined with total mesorectal excision for resectable rectal cancer. *N Eng J Med* 2001;345(9):638–646.
246. O'Connell MJ, Martenson JA, Wieand HS, et al. Improving adjuvant therapy for rectal cancer by combining protracted-infusion fluorouracil with radiation therapy after curative surgery. *N Eng J Med* 1994;331(8):502–507.
247. Smalley SR, Benedetti JK, Williamson SK, et al. Phase III trial of fluorouracil-based chemotherapy regimens plus radiotherapy in postoperative adjuvant rectal cancer: GI INT 0144. *J Clin Oncol* 2006;24(22):3542–3547.
248. Bosset JF, Collette L, Calais G, et al. Chemotherapy with preoperative radiotherapy in rectal cancer. *N Eng J Med* 2006;355(11):1114–1123.
249. Gerard JP, Conroy T, Bonnetain F, et al. Preoperative radiotherapy with or without concurrent fluorouracil and leucovorin in T3–4 rectal cancers: results of FFCD 9203. *J Clin Oncol* 2006;24(28):4620–4625.
250. Sauer R, Becker H, Hohenberger W, et al. Preoperative versus postoperative chemoradiotherapy for rectal cancer. *N Eng J Med* 2004;351(17):1731–1740.
251. Roh MS, Colangelo LH, O'Connell MJ, et al. Preoperative multimodality therapy improves disease-free survival in patients with carcinoma of the rectum: NSABP R-03. *J Clin Oncol* 2009;27(31):5124–5130.
252. O'Connell MJ, Colangelo LH, Beart RW, et al. Capecitabine and oxaliplatin in the

preoperative multimodality treatment of rectal cancer: surgical end points from National Surgical Adjuvant Breast and Bowel Project trial R-04. *J Clin Oncol* 2014;32(18):1927–1934.

253. Hofheinz RD, Wenz F, Post S, et al. Chemoradiotherapy with capecitabine versus fluorouracil for locally advanced rectal cancer: a randomised, multicentre, non-inferiority, phase 3 trial. *Lancet Oncol* 2012;13(6):579–588.
254. Gerard JP, Azria D, Gourgou-Bourgade S, et al. Comparison of two neoadjuvant chemoradiotherapy regimens for locally advanced rectal cancer: results of the phase III trial ACCORD 12/0405-Prodige 2. *J Clin Oncol* 2010;28(10):1638–1644.
255. Aschele C, Cionini L, Lonardi S, et al. Primary tumor response to preoperative chemoradiation with or without oxaliplatin in locally advanced rectal cancer: pathologic results of the STAR-01 randomized phase III trial. *J Clin Oncol* 2011;29(20):2773–2780.
256. Rodel C, Liersch T, Becker H, et al. Preoperative chemoradiotherapy and postoperative chemotherapy with fluorouracil and oxaliplatin versus fluorouracil alone in locally advanced rectal cancer: initial results of the German CAO/ARO/AIO-04 randomised phase 3 trial. *Lancet Oncol* 2012;13(7):679–687.
257. Bujko K, Nowacki MP, Nasierowska-Guttmejer A, et al. Long-term results of a randomized trial comparing preoperative short-course radiotherapy with preoperative conventionally fractionated chemoradiation for rectal cancer. *Br J Surg* 2006;93(10):1215–1223.
258. Ngan SY, Burmeister B, Fisher RJ, et al. Randomized trial of short-course radiotherapy versus long-course chemoradiation comparing rates of local recurrence in patients with T3 rectal cancer: Trans-Tasman Radiation Oncology Group trial 01.04. *J Clin Oncol* 2012;30(31):3827–3833.
259. Schrag D, Chemotherapy alone or chemotherapy plus radiation therapy in treating patients with locally advanced rectal cancer undergoing surgery. [cited 3/18/2015]; available from http://clinicaltrials.gov/show/NCT01515787.
260. Bosset JF, Calais G, Mineur L, et al. Fluorouracil-based adjuvant chemotherapy after preoperative chemoradiotherapy in rectal cancer: long-term results of the EORTC 22921 randomised study. *Lancet Oncol* 2014; 15(2):184–190.
261. Petersen SH, Harling H, Kirkeby LT, et al. Postoperative adjuvant chemotherapy in rectal cancer operated for cure. *Cochrane Database Syst Rev* 2012;3:CD004078.
262. Biagi JJ, Raphael M, Mackillop WJ, et al. Association between time to initiation of adjuvant chemotherapy and survival in colorectal cancer: a systemic review and meta-analysis. *JAMA* 2011;305(22):2335–2342.
263. Chau I, Brown G, Cunningham D, et al. Neoadjuvant capecitabine and oxaliplatin followed by synchronous chemoradiation and total mesorectal excision in magnetic resonance imaging-defined poor-risk rectal cancer. *J Clin Oncol* 2006;24(4):668–674.
264. Fernandez-Martos C, Pericay C, Aparicio J, et al. Phase II, randomized study of concomitant chemoradiotherapy followed by surgery and adjuvant capecitabine plus

oxaliplatin (CAPOX) compared with induction CAPOX followed by concomitant chemoradiotherapy and surgery in magnetic resonance imaging-defined, locally advanced rectal cancer: Grupo cancer de recto 3 study. *J Clin Oncol* 2010;28(5):859–865.

265. Cercek A, Goodman KA, Hajj C, et al. Neoadjuvant chemotherapy first, followed by chemoradiation and then surgery, in the management of locally advanced rectal cancer. *J Natl Compr Cancer Netw* 2014; 12(4):513–519.
266. Marijnen CA, Kapiteijn E, van de Velde CJ, et al. Acute side effects and complications after short-term preoperative radiotherapy combined with total mesorectal excision in primary rectal cancer: report of a multicenter randomized trial. *J Clin Oncol* 2002;20(3):817–825.
267. Paun BC, Cassie S, MacLean AR, et al. Postoperative complications following surgery for rectal cancer. *Ann Surg* 2010;251(5):807–818.
268. Peeters KC, van de Velde CJ, Leer JW, et al. Late side effects of short-course preoperative radiotherapy combined with total mesorectal excision for rectal cancer: increased bowel dysfunction in irradiated patients–a Dutch colorectal cancer group study. *J Clin Oncol* 2005;23(25):6199–6206.
269. Hendren SK, O'Connor BI, Liu M, et al. Prevalence of male and female sexual dysfunction is high following surgery for rectal cancer. *Ann Surg* 2005;242(2):212–223.
270. Wiltink LM, Chen TY, Nout RA, et al. Health-related quality of life 14 years after preoperative short-term radiotherapy and total mesorectal excision for rectal cancer: report of a multicenter randomised trial. *Eur J Cancer* 2014;50(14):2390–2398.
271. Smith N, Brown G. Preoperative staging of rectal cancer. *Acta Oncol* 2008;47(1):20–31.
272. Scott NA, Jeacock J, Kingston RD. Risk factors in patients presenting as an emergency with colorectal cancer. *Br J Surg* 1995;82(3):321–323.
273. Wong SK, Jalaludin BB, Morgan MJ, et al. Tumor pathology and long-term survival in emergency colorectal cancer. *Dis Colon Rectum* 2008;51(2):223–230.
274. McArdle CS, Hole DJ. Emergency presentation of colorectal cancer is associated with poor 5-year survival. *Br J Surg* 2004;91(5):605–609.
275. Yeo HL, Lee SW. Colorectal emergencies: review and controversies in the management of large bowel obstruction. *J Gastrointest Surg* 2013; 17(11):2007–2012.
276. Lopez-Kostner F, Hool GR, Lavery IC. Management and causes of acute large-bowel obstruction. *Surg Clin North Am* 1997;77(6):1265–1290.
277. Batke M, Cappell MS. Adynamic ileus and acute colonic pseudo-obstruction. *Med Clin North Am* 2008;92(3):649–670, ix.
278. Dachman AH. What are the indications for use of water-soluble contrast agent enemas in colon distension? *AJR Am J Roentgenol* 1996;166(4):988.
279. Maddu KK, Mittal P, Arepalli CD, et al. Colorectal emergencies and related

complications: a comprehensive imaging review–noninfectious and noninflammatory emergencies of colon. *AJR American J Roentgenol* 2014;203(6):1217–1229.

280. Bass G, Fleming C, Conneely J, et al. Emergency first presentation of colorectal cancer predicts significantly poorer outcomes: a review of 356 consecutive Irish patients. *Dis Colon Rectum* 2009;52(4):678–684.
281. Metcalfe MS, Norwood MG, Miller AS, et al. Unreasonable expectations in emergency colorectal cancer surgery. *Colorectal Dis* 2005;7(3):275–278.
282. Tekkis PP, Kinsman R, Thompson MR, et al. The Association of Coloproctology of Great Britain and Ireland study of large bowel obstruction caused by colorectal cancer. *Ann Surg* 2004;240(1):76–81.
283. Deans GT, Krukowski ZH, Irwin ST. Malignant obstruction of the left colon. *Br J Surg* 1994;81(9):1270–1276.
284. Watt AM, Faragher IG, Griffin TT, et al. Self-expanding metallic stents for relieving malignant colorectal obstruction: a systematic review. *Ann Surg* 2007;246(1):24–30.
285. Cheung HY, Chung CC, Tsang WW, et al. Endolaparoscopic approach vs conventional open surgery in the treatment of obstructing left-sided colon cancer: a randomized controlled trial. *Arch Surg* 2009;144(12):1127–1132.
286. Alcantara M, Serra-Aracil X, Falco J, et al. Prospective, controlled, randomized study of intraoperative colonic lavage versus stent placement in obstructive left-sided colonic cancer. *World J Surg* 2011;35(8):1904–1910.
287. Pirlet IA, Slim K, Kwiatkowski F, et al. Emergency preoperative stenting versus surgery for acute left-sided malignant colonic obstruction: a multicenter randomized controlled trial. *Surg Endosc* 2011;25(6):1814–1821.
288. Ghazal AH, El-Shazly WG, Bessa SS, et al. Colonic endolumenal stenting devices and elective surgery versus emergency subtotal/total colectomy in the management of malignant obstructed left colon carcinoma. *J Gastrointest Surg* 2013;17(6):1123–1129.
289. van Hooft JE, Bemelman WA, Oldenburg B, et al. Colonic stenting versus emergency surgery for acute left-sided malignant colonic obstruction: a multicentre randomised trial. *Lancet Oncol* 2011;12(4):344–352.
290. Sloothaak DA, van den Berg MW, Dijkgraaf MG, et al. Oncological outcome of malignant colonic obstruction in the Dutch Stent-In 2 trial. *Br J Surg* 2014;101(13):1751–1757.
291. SCOTIA Study Group. Single-stage treatment for malignant left-sided colonic obstruction: a prospective randomized clinical trial comparing subtotal colectomy with segmental resection following intraoperative irrigation. *Br J Surg* 1995;82(12):1622–1627.
292. Sasaki K, Kazama S, Sunami E, et al. One-stage segmental colectomy and primary anastomosis after intraoperative colonic irrigation and total colonoscopy for patients with obstruction due to left-sided colorectal cancer. *Dis Colon Rectum* 2012;55(1):72–78.

293. Tjandra JJ, Chan MK. Follow-up after curative resection of colorectal cancer: a meta-analysis. *Dis Colon Rectum* 2007;50(11):1783–1799.
294. Baca B, Beart RW Jr, Etzioni DA. Surveillance after colorectal cancer resection: a systematic review. *Dis Colon Rectum* 2011;54(8):1036–1048.
295. Jeffery M, Hickey BE, Hider PN. Follow-up strategies for patients treated for non-metastatic colorectal cancer. *Cochrane Database Syst Rev* 2007(1):Cd002200.
296. Welch JP, Donaldson GA. The clinical correlation of an autopsy study of recurrent colorectal cancer. *Ann Surg* 1979;189(4):496–502.
297. Siriwardena AK, Mason JM, Mullamitha S, et al. Management of colorectal cancer presenting with synchronous liver metastases. *Nat Rev Clin Oncol* 2014;11(8):446–459.
298. Clancy C, Burke JP, Barry M, et al. A meta-analysis to determine the effect of primary tumor resection for stage IV colorectal cancer with unresectable metastases on patient survival. *Ann Surg Oncol* 2014;21(12):3900–3908.
299. Cirocchi R, Trastulli S, Abraha I, et al. Non-resection versus resection for an asymptomatic primary tumour in patients with unresectable stage IV colorectal cancer. *Cochrane Database Syst Rev* 2012;8:Cd008997.
300. Hu CY, Bailey CE, You YN, et al. Time trend analysis of primary tumor resection for stage IV colorectal cancer: less surgery, improved survival. *JAMA Surg* 2015;150(3):245–251.
301. National Comprehensive Cancer Network. NCCN Clinical Practice Guidelines in Oncology – colon cancer. Available at www.nccn.org. 2015.
302. Wong SL, Mangu PB, Choti MA, et al. American Society of Clinical Oncology 2009: clinical evidence review on radiofrequency ablation of hepatic metastases from colorectal cancer. *J Clin Oncol* 2010;28(3):493–508.
303. Loupakis F, Cremolini C, Masi G, et al. Initial therapy with FOLFOXIRI and bevacizumab for metastatic colorectal cancer. *N Eng J Med* 2014; 371(17):1609–1618.
304. Jones C, Taylor MA, McWilliams B. The role of cetuximab as first-line treatment of colorectal liver metastases. *HPB (Oxford)* 2013;15(1):11–17.
305. Yaeger R, Cercek A, O'Reilly EM, et al. Pilot trial of combined BRAF and EGFR inhibition in BRAF-mutant metastatic colorectal cancer patients. *Clin Cancer Res* 2015;21(6):1313–1320.
306. Araujo R, Gonen M, Allen P, et al. Comparison between perioperative and postoperative chemotherapy after potentially curative hepatic resection for metastatic colorectal cancer. *Ann Surg Oncol* 2013;20(13):4312–4321.
307. Nordlinger B, Sorbye H, Glimelius B, et al. Perioperative chemotherapy with FOLFOX4 and surgery versus surgery alone for resectable liver metastases from colorectal cancer (EORTC Intergroup trial 40983): a randomised controlled trial. *Lancet* 2008;371(9617):1007–1016.

308. Nordlinger B, Sorbye H, Glimelius B, et al. Perioperative FOLFOX4 chemotherapy and surgery versus surgery alone for resectable liver metastases from colorectal cancer (EORTC 40983): long-term results of a randomised, controlled, phase 3 trial. *Lancet Oncol* 2013;14(12):1208–1215.
309. Scappaticci FA, Fehrenbacher L, Cartwright T, et al. Surgical wound healing complications in metastatic colorectal cancer patients treated with bevacizumab. *J Surg Oncol* 2005;91(3):173–180.
310. Primrose J, Falk S, Finch-Jones M, et al. Systemic chemotherapy with or without cetuximab in patients with resectable colorectal liver metastasis: the New EPOC randomised controlled trial. *Lancet Oncol* 2014; 15(6):601–611.
311. Ychou M, Rivoire M, Thezenas S, et al. A randomized phase II trial of three intensified chemotherapy regimens in first-line treatment of colorectal cancer patients with initially unresectable or not optimally resectable liver metastases. The METHEP trial. *Ann Surg Oncol* 2013;20(13):4289–4297.
312. Bokemeyer C, Bondarenko I, Makhson A, et al. Fluorouracil, leucovorin, and oxaliplatin with and without cetuximab in the first-line treatment of metastatic colorectal cancer. *J Clin Oncol* 2009;27:663–671.
313. Van Cutsem E, Kohne CH, Hitre E, et al. Cetuximab and chemotherapy as initial treatment for metastatic colorectal cancer. *N Eng J Med* 2009;360:1408–1417.
314. Fuchs CS, Marshall J, Mitchell E, et al. Randomized, controlled trial of irinotecan plus infusional, bolus, or oral fluoropyrimidines in first-line treatment of metastatic colorectal cancer: results from the BICC-C Study. *J Clin Oncol* 2007;25(30):4779–4786.
315. Saltz LB, Clarke S, Diaz-Rubio E, et al. Bevacizumab in combination with oxaliplatin-based chemotherapy as first-line therapy in metastatic colorectal cancer: a randomized phase III study. *J Clin Oncol* 2008;26:2013–2019.
316. Cercek A, Saltz L. Factors dictating outcomes in patients with colorectal cancer and peritoneal carcinomatosis: selection, resection, or convection? *J Clin Oncol* 2012;30(3):226–228.
317. Franko J, Shi Q, Goldman CD, et al. Treatment of colorectal peritoneal carcinomatosis with systemic chemotherapy: a pooled analysis of North Central Cancer Treatment Group phase III trials N9741 and N9841. *J Clin Oncol* 2012;30(3):263–267.
318. Hompes D, D'Hoore A, Wolthuis A, et al. The use of oxaliplatin or mitomycin C in HIPEC treatment for peritoneal carcinomatosis from colorectal cancer: a comparative study. *J Surg Oncol* 2014;109(6):527–532.
319. Chua TC, Esquivel J, Pelz JO, et al. Summary of current therapeutic options for peritoneal metastases from colorectal cancer. *J Surg Oncol* 2013;107(6):566–573.
320. Verwaal VJ, Bruin S, Boot H, et al. 8-year follow-up of randomized trial: cytoreduction and hyperthermic intraperitoneal chemotherapy versus systemic chemotherapy in patients with peritoneal carcinomatosis of colorectal cancer. *Ann*

Surg Oncol 2008;15:2426–2432.

321. Cao C, Yan TD, Black D, et al. A systematic review and meta-analysis of cytoreductive surgery with perioperative intraperitoneal chemotherapy for peritoneal carcinomatosis of colorectal origin. *Ann Surg Oncol* 2009;16(8):2152–2165.
322. Pelz JO, Stojadinovic A, Nissan A, et al. Evaluation of a peritoneal surface disease severity score in patients with colon cancer with peritoneal carcinomatosis. *J Surg Oncol* 2009;99(1):9–15.
323. Abulafi AM, Williams NS. Local recurrence of colorectal cancer: the problem, mechanisms, management and adjuvant therapy. *Br J Surg* 1994; 81(1):7–19.
324. Bozzetti F, Bertario L, Rossetti C, et al. Surgical treatment of locally recurrent rectal carcinoma. *Dis Colon Rectum* 1997;40(12):1421–1424.
325. van Gijn W, Marijnen CA, Nagtegaal ID, et al. Preoperative radiotherapy combined with total mesorectal excision for resectable rectal cancer: 12-year follow-up of the multicentre, randomised controlled TME trial. *Lancet Oncol* 2011;12(6):575–582.
326. Tepper JE, O'Connell M, Hollis D, et al. Analysis of surgical salvage after failure of primary therapy in rectal cancer: results from Intergroup Study 0114. *J Clin Oncol* 2003;21(19):3623–3628.
327. Hashiguchi Y, Sekine T, Sakamoto H, et al. Intraoperative irradiation after surgery for locally recurrent rectal cancer. *Dis Colon Rectum* 1999;42(7):886–893; discussion 93–95.
328. Balbay MD, Slaton JW, Trane N, et al. Rationale for bladder-sparing surgery in patients with locally advanced colorectal carcinoma. *Cancer* 1999;86(11):2212–2216.
329. Tan E, Gouvas N, Nicholls RJ, et al. Diagnostic precision of carcinoembryonic antigen in the detection of recurrence of colorectal cancer. *Surg Oncol* 2009;18(1):15–24.
330. Chau I, Allen MJ, Cunningham D, et al. The value of routine serum carcino-embryonic antigen measurement and computed tomography in the surveillance of patients after adjuvant chemotherapy for colorectal cancer. *J Clin Oncol* 2004;22(8):1420–1429.
331. Lambregts DM, Cappendijk VC, Maas M, et al. Value of MRI and diffusion-weighted MRI for the diagnosis of locally recurrent rectal cancer. *Eur Radiol* 2011;21(6):1250–1258.
332. de Anda EH, Lee SH, Finne CO, et al. Endorectal ultrasound in the follow-up of rectal cancer patients treated by local excision or radical surgery. *Dis Colon Rectum* 2004;47(6):818–824.
333. Maas M, Rutten IJ, Nelemans PJ, et al. What is the most accurate whole-body imaging modality for assessment of local and distant recurrent disease in colorectal cancer? A meta-analysis: imaging for recurrent colorectal cancer. *Eur J Nucl Med Mol Imaging* 2011;38(8):1560–1571.
334. Schmidt GP, Baur-Melnyk A, Haug A, et al. Whole-body MRI at 1.5 T and 3 T compared with FDG-PET-CT for the detection of tumour recurrence in patients with

colorectal cancer. *Eur Radiol* 2009;19(6):1366–1378.

335. Lu YY, Chen JH, Chien CR, et al. Use of FDG-PET or PET/CT to detect recurrent colorectal cancer in patients with elevated CEA: a systematic review and meta-analysis. *Int J Colorectal Dis* 2013;28(8):1039–1047.

336. Vermaas M, Nuyttens JJ, Ferenschild FT, et al. Reirradiation, surgery and IORT for recurrent rectal cancer in previously irradiated patients. *Radiother Oncol* 2008;87(3):357–360.

337. Garcia-Aguilar J, Cromwell JW, Marra C, et al. Treatment of locally recurrent rectal cancer. *Dis Colon Rectum* 2001;44(12):1743–1748.

Chapter 69

Diverticular Disease

Lauren A. Kosinski, Kirk Ludwig, and Mary F. Otterson

Key Points

1 Diverticulosis and its complications are common in Western societies.
2 Sigmoid and left colon involvement predominate in non-Asian industrialized nations; the rectum is spared.
3 Lack of dietary fiber, colonic anatomy, and disordered colonic motility are likely contributors to the development of diverticulosis.
4 New data suggest that uncomplicated diverticulitis may be an inflammatory rather than an infectious process.
5 Computed tomography (CT) imaging markedly improves diagnostic accuracy and treatment planning.
6 Early, judicious use of contrast enema studies or colonoscopy can safely help distinguish diverticular stricture from cancer.
7 Antibiotic therapy, bowel rest, and percutaneous drainage of diverticular abscesses can often convert surgical emergencies into elective operations.
8 Bowel resection with primary anastomosis and temporary, diverting loop stoma is favored in acute cases when possible; single-stage operations are preferred for elective cases.
9 Early enthusiasm for emergency laparoscopic washout and repair of diverticular perforations has not been supported by prospective, randomized trials.
10 Criteria for elective colon resection for diverticulitis are evolving and trending toward more restrictive indications.

Diverticular disease (DD) is one of the most common problems treated by surgeons, and management strategies have evolved significantly in the last 15 years. A short time ago, virtually all cases of acute diverticulitis were treated as surgical emergencies. Patients routinely underwent staged procedures and were taken to the operating room for sigmoid colectomy and temporary end-colostomy within hours of admission. Surgical and radiologic innovations have introduced less invasive options for managing even complex disease. Surgery, when necessary, is often performed electively or semi-electively.

Key among recent major shifts in the diagnosis and management of DD are (a) strategies for converting diverticular surgical emergencies into single-stage, elective

operations with avoidance of a colostomy; (b) utilization of computed tomography (CT) imaging for diagnosis and CT-guided percutaneous drainage of diverticular abscesses; (c) reconsideration of indications for elective surgery; and (d) emergence of laparoscopic surgical techniques as state-of-the-art approaches for DD. Fear that younger patients with diverticulitis or older patients with a single episode of diverticulitis were at increased risk of perforated diverticulitis and colostomy construction has been allayed by data that show no increased risk. These data and recognition that even elective resection for DD may have higher complication and colostomy rates than elective colon cancer resections[1] have fueled concern that the cure might be worse than the disease and are shaping more stringent guidelines for elective resection.

CLASSIFICATION

1 Diverticulosis refers to the presence, whether symptomatic or asymptomatic, of colonic diverticula. In common medical usage, this refers to the presence of pseudodiverticula in which mucosa and submucosa have herniated through the circular layer of the muscularis propria, a very common acquired condition in Western societies. True diverticula are rare. DD refers to the broad range of symptoms and findings associated with diverticulosis and includes diverticulitis, an inflammatory and often infectious process. Inflammation can be acute or chronic. Acute inflammation can present with a pericolonic phlegmon, colon perforation leading to focal abscess formation, or generalized purulent or fecal peritonitis. Acute and chronic inflammation can result in fistula formation between the involved bowel segment and the bladder, vagina, or skin. With chronic or recurrent inflammation, scarring of the involved segment can cause bowel wall thickening, dysmotility, and stricture, which may present as altered bowel habit or even frank obstruction.

ANATOMY

2 Colonic diverticula are pulsion diverticula that occur in predictable sites on the bowel wall. Likewise, the pattern of segmental involvement of the colon and its progression are predictable. The sigmoid colon is at highest risk and is affected in 95% of patients. Involvement is isolated to the sigmoid colon in 30% to 60% of cases. Total colonic involvement occurs in 7% to 10% of cases.[2] The rectum is almost always spared. This segmental pattern of involvement is not observed in Asia, where 70% of pseudodiverticula are isolated to the right colon and cecum. The reason for this discrepancy is not known. Right colon pseudodiverticula are more likely to be solitary and tend to originate near the ileocecal valve.[3,4] When true colonic diverticula develop, they are also more likely to be right sided; however, they are still much less common than pseudodiverticula of the right colon.

INCIDENCE

Diverticulosis is rare in nonindustrialized, less affluent societies. The French surgeon Alexis Littre is credited with first describing diverticulosis in 1700, but it was not until the mid-1800s that there were reports in the medical literature about the disease process and its treatment.[5] The prevalence of diverticulosis increased after the industrial revolution and through this century. Even before 1940, it was recognized infrequently; retrospective reviews of colon radiographs and pathologic specimens record an incidence of 5% to 10%.[6] An incidence of 46% in people 51 years of age and older was reported by Hughes from postmortem studies in 200 cadavers (Table 69-1).[7] Incidence as a function of gender varies by study, some studies citing an increased incidence among men and others finding a higher incidence among women. It may be that the spectrum of complications and the age at which they develop are gender specific. The majority of people with diverticulosis remain asymptomatic; only 15% to 30% will go on to develop symptomatic disease.[8] Of these, only 30% will require operative treatment.[9] In the United States in 1998, 2.2 million cases of DD were treated at an estimated cost of $2 billion.[10] In 2005, DD was the primary diagnosis in 307,000 hospital discharges and accounted for 1.6 million inpatient days of care.[11]

Table 69-1 Incidence of Diverticulosis in Western Society

Age	≤25 Yrs	≤45 Yrs	>60 Yrs	>80 Yrs
Incidence	1–2%	33%	40%	60%

ETIOLOGY

3 Neither the etiology of diverticulosis nor factors causing progression to symptomatic disease have been rigorously defined, but lack of dietary fiber, colonic dysmotility, and colonic structural abnormalities and age-related changes have all been implicated. There may be an association between irritable bowel syndrome (IBS) and diverticulitis, the microbiome may be a mediator in diverticular inflammation, and idiopathic inflammation may also contribute to the DD spectrum.

Structural/Anatomic Factors

In the colon, the outer, longitudinal layer of the muscularis propria is condensed in three longitudinal bands called the taeniae coli. One of these runs along the mesenteric aspect of the colon; the other two are antimesenteric in location (Fig. 69-1). Mesenteric blood vessels encircle the colon and penetrate the circular muscle in the intertaenial areas between the mesenteric taenia and the two antimesenteric taeniae. Pseudodiverticula develop at areas where these vessels pass through muscle.[12] Postmortem studies of the colon wall showed thinning of the circular muscle associated with early diverticula. Gaps in the circular muscle were observed with larger diverticula.[7]

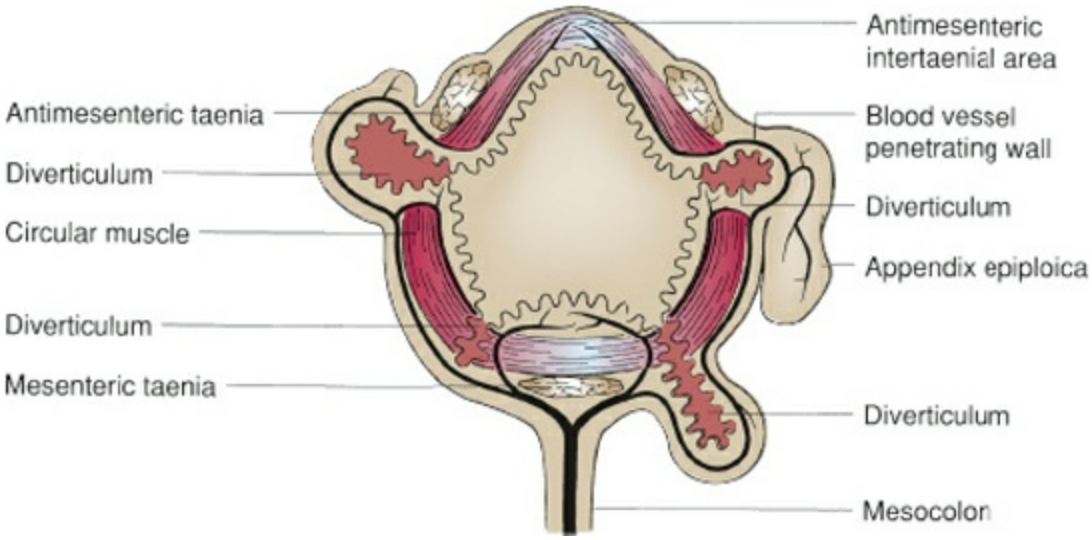

Figure 69-1. Cross section of the colon illustrating the relation of diverticula to the blood vessels penetrating the circular muscle layer, the taeniae, and the appendices epiploicae.

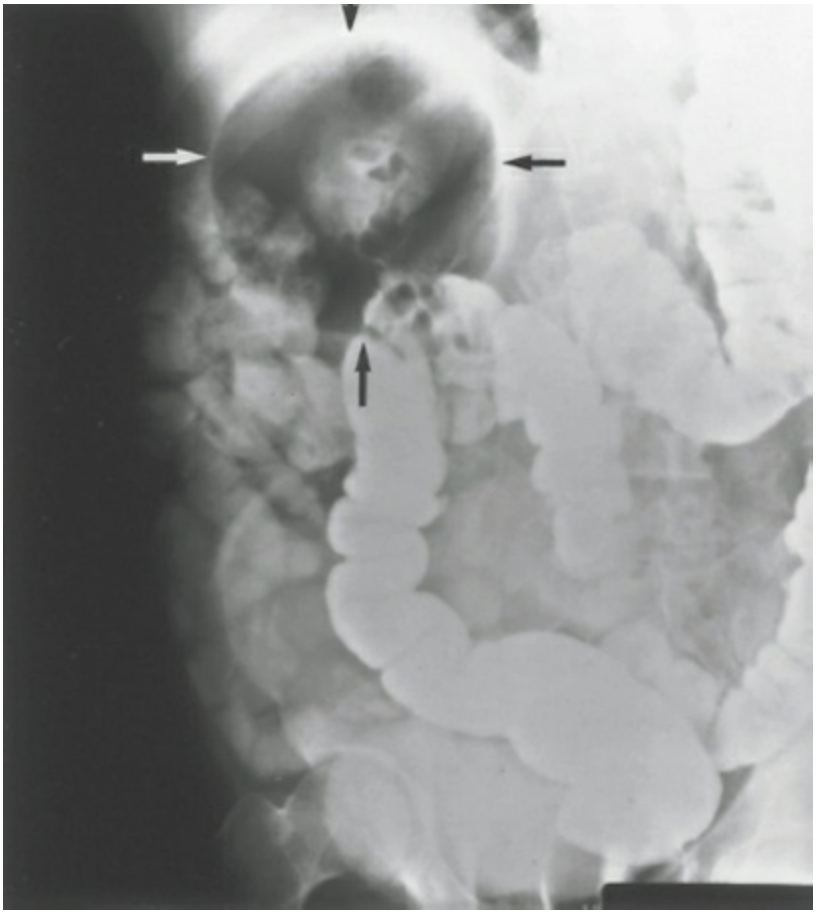

Figure 69-2. Postevacuation film of barium enema, demonstrating a giant colonic diverticulum (*arrows*) partially filled with barium. (Reproduced with permission from McNutt R, Schmitt D, Schulte W. Giant colonic diverticula. *Dis Colon* 1988;31:625.)

In contrast to typical pseudodiverticula, giant colonic diverticula almost always arise from the antimesenteric border of the colon. They are assumed to be a complication of ordinary colonic diverticulosis, possibly developing after inflammatory narrowing of the neck of a pseudodiverticulum causes a ball-valve mechanism that entraps gas in the diverticulum, causing it to enlarge (Fig. 69-2).[13]

The observation of colonic diverticula in young patients with connective tissue disorders such as Marfan disease and Ehlers–Danlos syndrome raises the question of whether connective tissue genetic derangements play a role in diverticulosis development.[14,15] Ordinary senescent connective tissue change may be a factor as well. Cross-linkage of collagen fibrils in the colon wall increases with age, rising markedly after age 40, and appears to decrease compliance of the colon wall. In comparison with age-matched controls, this cross-linkage is exaggerated in patients with diverticulosis.[16]

Thickening of the colon wall in diverticulosis was originally attributed to muscle hypertrophy.[12,17] This was disproven by histologic studies, but increased elastin deposition in the taeniae coli of patients with uncomplicated diverticulosis has been shown. The taeniae are shortened as a result, causing the circular muscle to be accordioned in the two intertaenial zones, the same areas where pseudodiverticula more commonly form.[18] The functional significance of this is not known, but it has been speculated that muscle contractions may be stronger in these areas.

Motility Factors

Four unusual colonic motility patterns have been observed in the setting of diverticulosis: segmentation, high-pressure waves, slow-wave motility pattern, and disorganized propulsive activity.

Segmentation

Painter et al.[19] used cineradiography and manometry to study colonic motility and reported that when simultaneous haustral contractions occur in the same segment of colon, high pressure is generated in the intervening bowel, causing ballooning of the colon wall and distention of diverticula (Fig. 69-3).

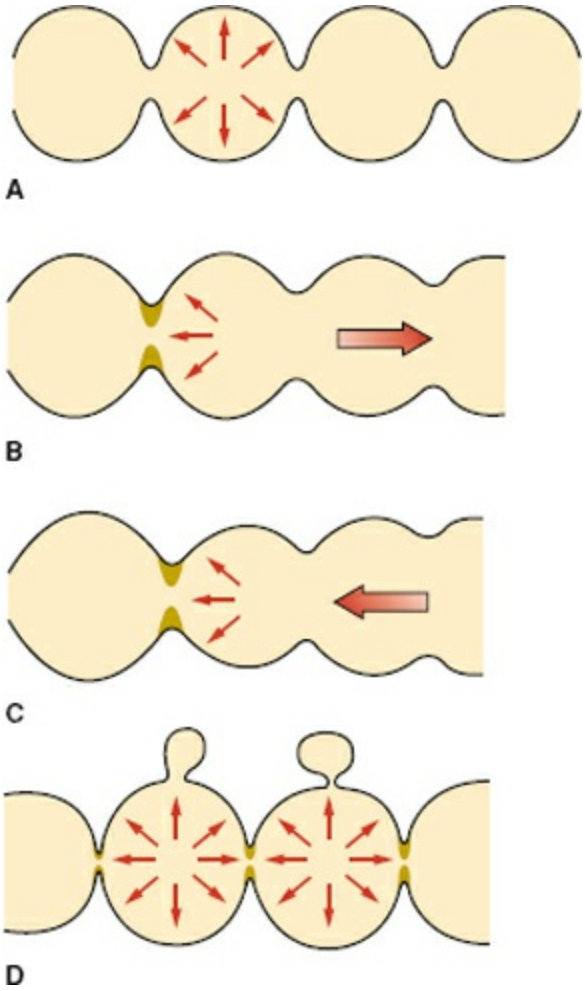

Figure 69-3. The role of segmentation in colonic physiology. **A:** Interhaustral ring contraction ("segmentation") leads to increased luminal pressure when there is simultaneous segment wall contraction. **B:** Relaxation of an interhaustral ring allows passage of colon contents from the high-pressure segment to a neighboring low-pressure segment. **C:** Resistance to colon content flow can be imposed by interhaustral ring contraction that functions as a baffle. Resultant interruption of flow can also significantly increase luminal pressure in that segment. **D:** Diverticula always arise from the segment wall between interhaustral rings and never at the rings.

High-Pressure Waves

High-pressure waves are independent of normal peristalsis and have an amplitude of 10 mm Hg in normal patients but have higher amplitude (up to 90 mm Hg) and longer

duration in patients with diverticulosis.[20]

Slow-Wave Motility Pattern

The normal slow-wave pattern in the colon is altered in DD.[21,22]

Disorganized Propulsive Activity

High-amplitude propulsive contractions occurred more frequently and were more likely to be disorganized in patients with DD than normal subjects. Retropulsive contractions occurred more frequently in segments of colon with diverticulosis.[23]

Diet

Decreased dietary fiber is the most consistent factor associated with the high incidence of diverticulosis in Western populations. Painter and Burkitt first elucidated this connection after noting the striking disparity in incidence between British society and sub-Saharan populations. They measured colon transit time and stool weights in over 1,000 individuals in the United Kingdom and sub-Saharan Africa. The rise in the incidence of DD coincident with the rise in refined food products in diets in the West was also noted.[24] Painter and Burkitt[25] also reported improvement of DD symptoms in patients who increased dietary fiber and recrudescence of symptoms once fiber intake decreased again. There is now a rising incidence of diverticulosis among previously low-risk populations in concert with changes to a Western-style diet as a consequence of economic development or immigration. Japanese immigrants to the United States acquire diverticulosis risk comparable to other Westerners, although the right-sided predominance of diverticulosis seen among Asians persists.[5,26] The exact protective mechanism of stool bulk is not understood. Evidence that contradicts the role of low-fiber diet or constipation as contributing factors to DD is provided by a study of 2813 patients enrolled in a vitamin D and colon polyp colonoscopy study. Five hundred and thirty-nine patients aged 45 to 75 who had the incidental colonoscopic finding of diverticulosis without antecedent history of it were compared to 1569 controls. The control group had a higher self-reported history of less frequent or lumpy stools, and there was no difference in dietary fiber intake. However, inaccuracies of bowel and diet habit self-reports, the evaluation of individuals with asymptomatic diverticulosis versus symptomatic DD, and the imperfect sensitivity of colonoscopy for detection of diverticulosis should be considered in the interpretation of these findings.[27]

While the focus on dietary fiber has emphasized insoluble fiber, soluble fiber may also be of value. Soluble fiber is processed by intestinal flora, which may in turn affect diverticulosis.[26,28] Finally, despite the long-held admonition to avoid eating nuts and seeds, there is no evidence to support this recommendation.[29]

Other Factors

Other neurologic and chemical mediators of colonic motility may play a role in pseudodiverticula genesis. Vasoactive intestinal peptide levels are increased in the bowel wall of patients with diverticulosis.[30] Age-related vagal attrition has been postulated to contribute to colonic smooth muscle dysmotility.[31] Alterations of serotonin expression and function are noted after resolution of acute diverticulitis and may contribute to lasting symptoms.[32]

Emerging Concepts

Two observations have focused interest in the possibility of a primary inflammatory etiology of diverticulitis. One is that a subset of patients with uncomplicated diverticulitis are unresponsive to antibiotic therapy as would be expected in the case of a smoldering, focal bowel-wall infection due to diverticular sepsis or microperforation (see below). The other is that anti-inflammatory medications appear to reduce flares of diverticulitis in some patients. Shifts in the microbiome have also been detected in other lower gastrointestinal system disorders including colon cancer and IBD.[33–36] Subtle peridiverticular inflammatory changes have been noted in some patients with asymptomatic DD.[37] Whether diverticulosis results from or causes inflammation and whether progression to diverticulitis likewise results from or causes inflammation is an open question. Similar questions have existed regarding an interrelation between IBS and DD. A longitudinal study of administrative and clinical data from the Veterans' Association found the hazard ratio for developing IBS after an episode of diverticulitis was 4.7 compared to controls even though the study group of older males (mean age 62 years) is generally a lower risk group for IBS.[38] Whether these "new IBS" cases should actually be regarded as segmental diverticulitis that could be managed by resection as opposed to a pan-colonic phenomenon has not been demonstrated.

Pathogenesis of Diverticulitis

4 The process by which a subset of people with diverticulosis develop diverticulitis has yet to be explained. Overwhelming inflammatory changes that develop with perforation or other complications of diverticulitis likely obscure subtle histologic details that might explain the pathogenesis of the disease. Traditionally, it has been postulated that mechanical obstruction by food or fecal material of a diverticulum leads to bacterial proliferation, gas, and toxin production in the occluded diverticulum, causing diverticulitis. However, the largely extracolonic manifestations of diverticulitis (phlegmon, abscess, and free perforation) suggest micro- or macroperforation as the inciting event, possibly as a kind of diverticular "blow-out" secondary to segmentation-type contractions or high-pressure waves. In recent years (and perhaps with the rising number of patients undergoing screening colonoscopy), peridiverticular inflammation has been identified, often in asymptomatic patients. Diverticulitis-associated colitis is of unrecognized clinical significance, partly because so many patients with these findings are asymptomatic and partly because the findings are not uniformly evident in patients requiring surgical therapy for diverticulitis. It has been suggested that low-grade inflammation could alter bowel motility and thereby contribute to diverticular perforation risk. Endoscopists are cautioned to avoid confusing diverticulitis-associated colitis with inflammatory bowel disease. Probiotics and nonsteroidal anti-inflammatory medications are being explored as potentially protective agents.[26,39,40]

Diagnosis

Noninflammatory Diverticular Disease

Most patients with diverticulosis noted on barium study, colonoscopy, or abdominal CT scan are asymptomatic. In patients who have vague, crampy, left lower quadrant pain in the absence of fever, leukocytosis, or CT findings of focal inflammation, other causes of pain must also be considered. Additional symptoms reported may include nausea, flatulence, bloating, and change of bowel habit. The differential diagnosis includes colonic adenocarcinoma, constipation, inflammatory bowel disease, and IBS. There are no peritoneal signs on examination, the rectal examination is unrevealing, and proctoscopy shows no inflammation. Postinflammatory neurogenic alteration has been postulated as a cause of visceral hypersensitivity.[41–43] Nonspecific, mild mucosal inflammation and muscle spasm may also contribute. There is considerable overlap with IBS. In addition to high-fiber modification of the diet and bulk-forming agents such as psyllium or flaxseed, anticholinergics, analgesics, and antibiotics can be prescribed to manage symptoms.

Hemorrhagic Diverticular Disease. Like bleeding from colonic angiodysplasia, diverticular hemorrhage is classically asymptomatic until presentation with lower gastrointestinal hemorrhage that can be massive. This differs from hemorrhage from inflammatory bowel disease or ischemic colitis where there are typically symptoms before bleeding begins. A foregut source of bleeding must be excluded by nasoenteric recovery of bilious, nonbloody aspirate or upper endoscopy. Likewise, an anorectal source of bleeding must be excluded by examination. Localization of lower gastrointestinal hemorrhage of any cause is necessary to help guide appropriate colon resection should that be required. Although most cases of diverticular hemorrhage are self-limited, recurrence or failure of bleeding to stop spontaneously determines the need for resection. Colonoscopy, tagged red blood cell scan, or, if bleeding is brisk enough, angiography is used to localize bleeding (Fig. 69-4).

Giant Colonic Diverticula. Symptoms and signs of giant colonic diverticula may be noninflammatory (pain, bloating, nausea, vomiting, diarrhea, abdominal tenderness and mass) or inflammatory, resulting from perforation (pain, leukocytosis, fever, localized or generalized peritonitis).[13]

Inflammatory Diverticular Disease

The constellation of inflammatory signs and symptoms corresponds to the spectrum of inflammatory complications of DD. The Hinchey classification[44] categorized the severity of acute diverticulitis and has been modified to reflect refinements of diagnosis enabled by improved CT scan quality (Table 69-2).[45] The modified classification also includes manifestations of chronic inflammation such as fistula formation and stricture/obstruction.

Symptoms of acute diverticulitis include steady, left lower-quadrant abdominal pain; fever; change in bowel habits (constipation or diarrhea); anorexia; nausea; vomiting;

bloating; and urinary tract symptoms such as urinary frequency or retention. Examination will reveal left lower-quadrant tenderness that may be appreciable only with deep palpation in stage 0 inflammation. In stage I or II inflammation, focal peritoneal signs in the left lower quadrant are likely, and there may be a tender mass. Digital rectal examination may also reveal pelvic tenderness or a tender mass in the cul-de-sac. Generalized peritoneal signs would be expected for stage III or IV inflammation. Dehydration with earlier stages or evolving sepsis with later stages may cause tachycardia and hypotension. Leukocytosis is more likely with advancing stage of inflammation. The differential diagnosis includes perforated colon cancer, acute appendicitis, perforated peptic ulcer, acute ischemic colitis, pancreatitis, and flare of Crohn disease or ulcerative colitis. Normal serum amylase and lipase help exclude a diagnosis of pancreatitis. Imaging studies and endoscopy help to distinguish diverticulitis from the other diagnoses. However, active inflammation or contained perforation may limit the utility of rectal contrast CT, barium enema studies, and endoscopy in the acute setting. Distinguishing perforated colon cancer from DD can be especially challenging, even in the operating room.

Diverticular fistula formation represents internal drainage of an abscess (or external drainage in the case of colocutaneous fistulas). Approximately half of diverticular fistulas are colovesical fistulas. Women with colovesical or colovaginal fistulas have usually had a hysterectomy.[46,47] Urinary tract infection symptoms, pneumaturia, and fecaluria are common complaints. Recurrent urinary tract infection in elderly men should raise concern for the presence of a colovesical fistula, which is often secondary to DD. Passage of feces or flatus from the vagina is a characteristic symptom of a colovaginal fistula. Colocutaneous fistulas are a rare complication of DD.

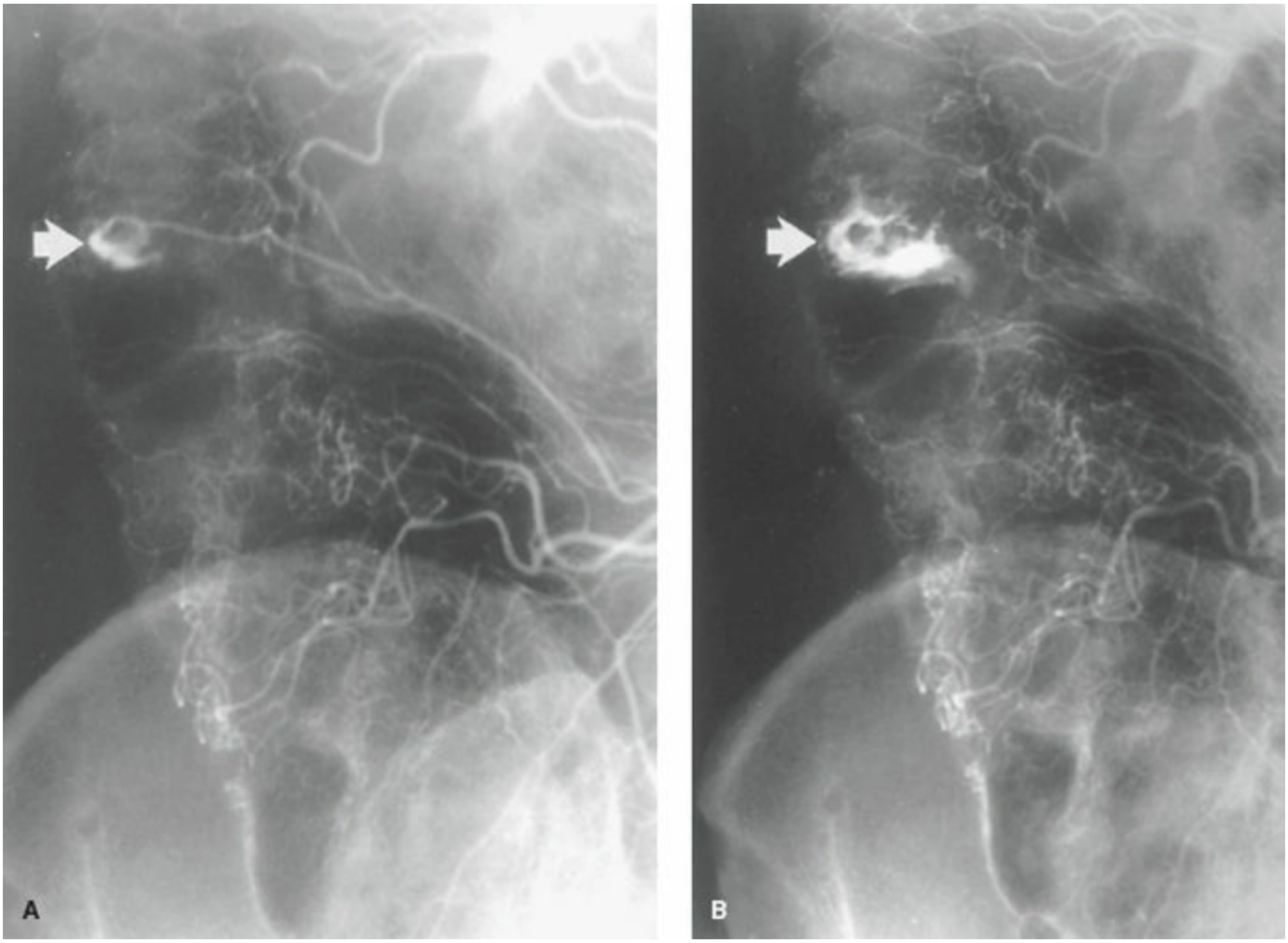

Figure 69-4. Superior mesenteric arteriogram from a patient with bleeding from a right colon diverticulum. **A:** Early radiograph with contrast material outlining the diverticulum (*arrow*). **B:** Late radiograph demonstrating overflow of contrast material into the colonic lumen(*arrow*).

Thirteen percent of large-bowel obstructions are due to DD. The concurrent incidence of colon carcinoma in 7% of patients with symptomatic sigmoid DD confounds diagnosis and treatment.[48] CT scan is not as reliable for distinguishing these diagnoses as colonoscopy or contrast enema studies.

Right-sided diverticulitis frequently is confused with appendicitis, and misdiagnosis is common. The duration of symptoms is usually longer than appendicitis. Patients are usually older than those with appendicitis (late 30s or 40s) but younger than patients with typical left-sided diverticulosis (over 50 years of age).[49,50]

CLASSIFICATION

Table 69-2 Modified Hinchey Classification

Hinchey Classification	Modified Hinchey Classification	Comments
	0 Mild clinical diverticulitis	Left lower quadrant pain, elevated white blood cells, fever, no confirmation by imaging or surgery
I Pericolic abscess or phlegmon	Ia Confined pericolic inflammation – phlegmon	
II Pelvic, intra-abdominal, or retroperitoneal abscess	II Pelvic, distant intra-abdominal, or retroperitoneal abscess	
III Generalized purulent peritonitis	III Generalized purulent peritonitis	No open communication with bowel lumen
IV Generalized fecal peritonitis	IV Fecal peritonitis fistula colovesical/colovaginal/coloenteric/colocutaneous	Free perforation, open communication with bowel lumen
Obstruction	Large- and/or small-bowel obstruction	

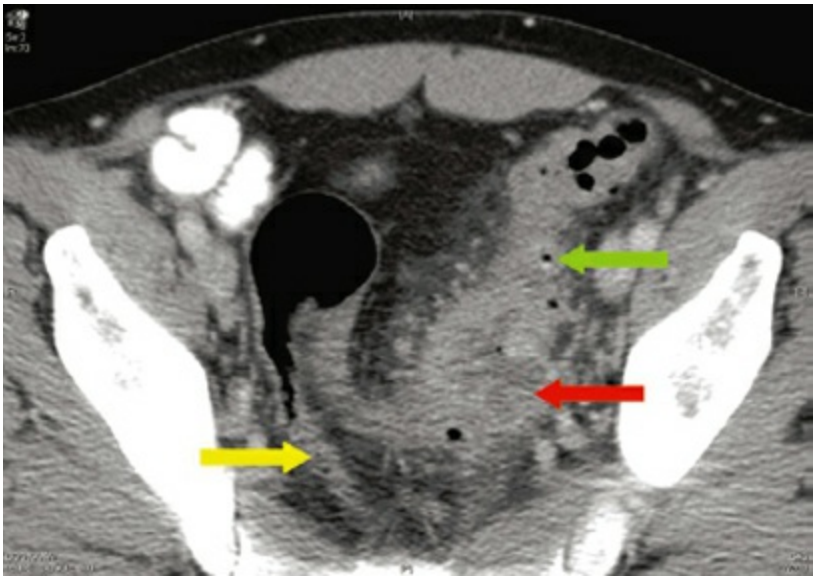

Figure 69-5. Sigmoid diverticulitis with pericolic abscess(*arrows*).

Imaging and Diagnostic Studies for Diverticular Disease

Plain Radiographs. While seldom useful in the diagnosis of uncomplicated diverticulitis, a three-way abdominal series that includes an upright chest radiograph, an abdominal flat plate, and a left lateral decubitus view is useful for demonstrating free air. An ileus pattern or soft tissue mass may also be detected.[51,52]

5 Computed Tomography Scan. CT scanning has revolutionized the diagnosis of acute diverticulitis and, sometimes, by way of percutaneous abscess drainage, its treatment. The accuracy of CT scans in the acute setting is central to the trend toward converting what formerly were surgical emergencies into elective, often single-stage operations. Intravenous and water-soluble oral and rectal enteric contrast should be administered. Water-soluble contrast is used to avoid barium peritonitis that may result if barium leaks from a perforated diverticulum into the peritoneal cavity.

A CT scan can reveal the presence and extent of diverticulosis, but its real strength is characterizing extracolonic inflammatory change. Signs of inflammation include colon wall thickening, pericolic fat stranding, or phlegmon formation. Pericolic abscess size and location can be detected (Fig. 69-5). Perforation is evidenced by free air; contained perforation may be identified by loculated extraluminal pericolic air. CT more accurately demonstrates diverticular abscesses and severity of inflammation than contrast enema studies.[53] Air in the bladder or contrast in the vagina may indicate the presence of a fistula (Fig. 69-6).

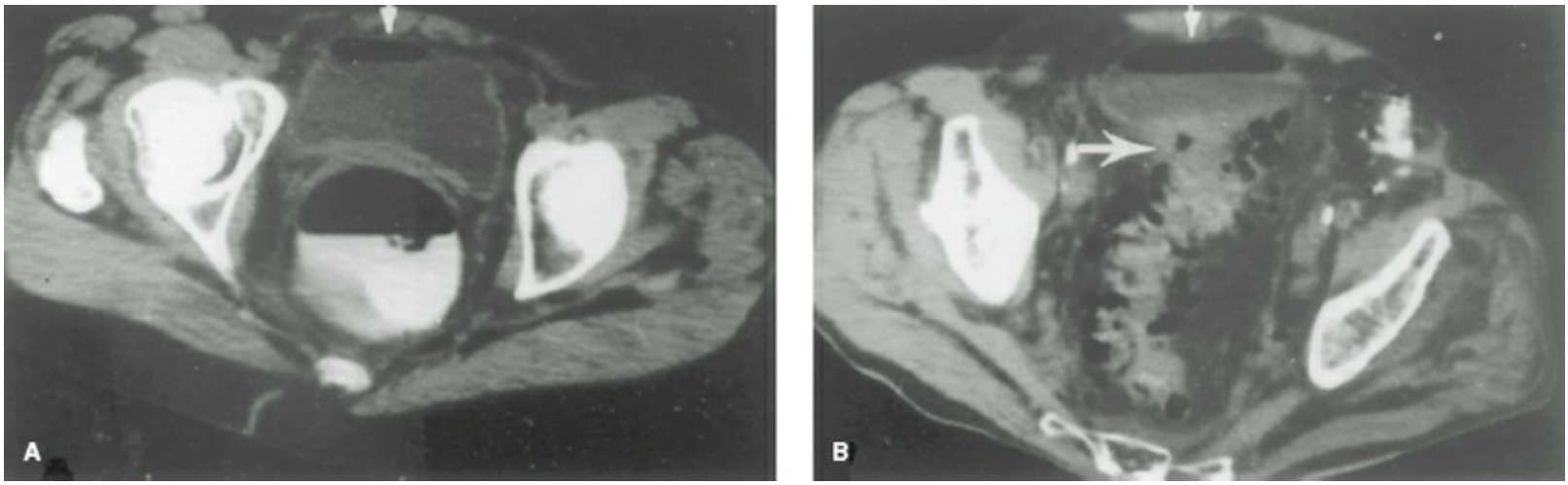

Figure 69-6. **A:** Computed tomography scan demonstrating air in the urinary bladder (*arrow*) in the presence of a colovesical fistula secondary to diverticulitis. **B:** Air in the urinary bladder (*small arrow*) in association with a paravesical inflammatory mass (*large arrow*). (Reproduced with permission from Sarr MG, Fishman EK, Goldman SM. Enterovesical fistula. *Surg Gynecol Obstet*1987;164(1):41–48.)

Rao et al.[54] reported a misdiagnosis rate of up to 67% for diverticulitis in patients with abdominal pain managed without CT imaging. An alternate diagnosis is suggested by CT scan in 45% to 58% of cases when diverticulitis is not found, including small-bowel obstruction, acute cholecystitis, appendicitis, gynecologic disease, and primary epiploic appengitis.[55] Correct preoperative diagnosis of right-sided diverticulitis has also been enhanced by CT scanning.

Not only is CT useful for improving diagnostic accuracy, but also findings can predict failure of medical management or risk of secondary complications following medical management.

Ambrosetti et al. reported on 423 patients with acute diverticulitis on CT scan, categorizing them as having either moderate disease or severe disease. Criteria for moderate disease included localized wall thickening or inflammation of pericolic fat (modified Hinchey stage Ia; see Table 69-2). Severe disease included the presence of extraluminal air or contrast (contained perforation) or abscess (modified Hinchey stages Ib and II). Of the 42 patients who failed nonoperative management, 32 had severe disease. Twenty percent of those patients who were initially successfully managed nonoperatively developed secondary complications such as fistulas (median follow-up 46 months). They concluded that the presence of severe disease at the index episode

predicted failure of nonoperative management and that there is a high risk of secondary complications after initial nonoperative management.[56]

Ultrasound. Abdominal ultrasound has been emphasized in the European literature and is attractive as a strategy for limiting radiation exposure. However, its diagnostic limitations (user dependence, interference from overlying bowel gas, and decreased accuracy in obese patients) have precluded its widespread adoption in the United States. In skilled hands, it may have a role in image-guided percutaneous drainage of abscesses.[57]

Contrast Enema Study (Barium Enema). Contrast enemas have been the "gold standard" test for the presence and anatomic distribution of diverticula (Fig. 69-7). For reasons cited earlier, CT scan has supplanted contrast enemas in the acute setting. However, they are better than CT for helping distinguish colon cancer from diverticular obstruction, and contrast can also traverse narrowed areas of the colon impassable by an endoscope. While caution must be used in the acute setting to avoid perforation, these studies can be performed safely. Caveats are that contrast must be administered gently, water-soluble contrast should be used, and a single contrast study is performed in unprepared bowel to avoid the increased risk of perforation and fecal contamination with the administration of air. In chronic DD, the contrast enema can demonstrate stricture, angulation, and segmentation-type contractions. It can also be useful for the evaluation of fistulas.

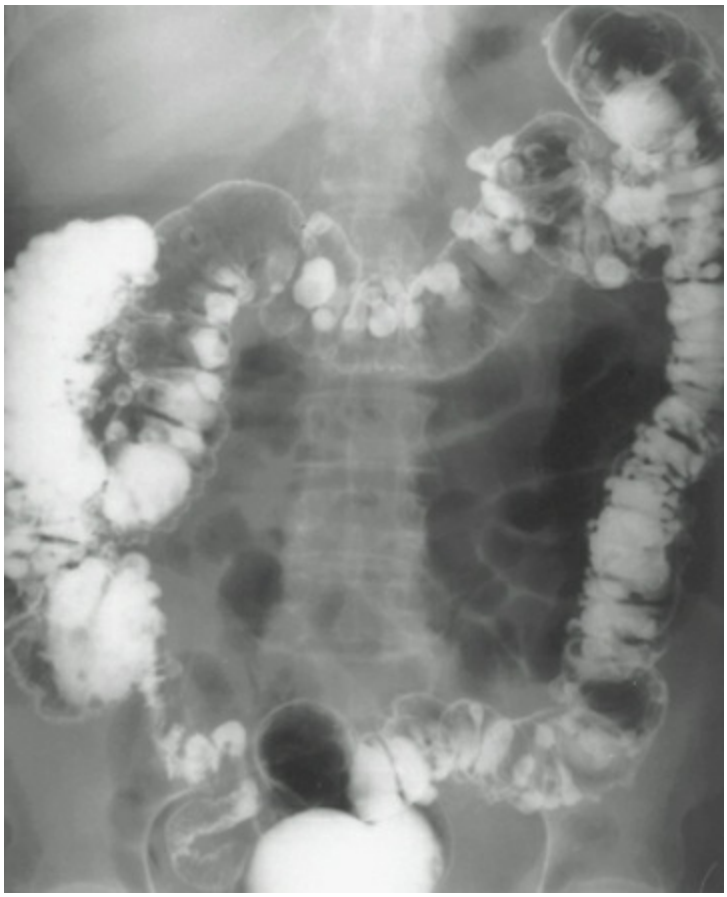

Figure 69-7. Barium enema showing multiple diverticula of the colon.

6 Endoscopy. Like contrast enema studies, colonoscopy or flexible sigmoidoscopy can be used judiciously in the acute setting. It is particularly helpful in distinguishing malignancy from DD and can therefore help guide early management of acute presentations when malignancy as the cause of symptoms is being considered.

Cystoscopy. Cystoscopy can help diagnose colovesical fistulas. Although the fistula tract is usually difficult to see, focal hyperemia and inflammation may be noted. Symptoms of a colovesical fistula and air in the uninstrumented bladder on CT scan are usually sufficient for diagnosis.

TREATMENT

Symptomatic Diverticulosis

Fiber supplements and increased dietary fiber (goal 25 to 30 g/d) constitute the cornerstone of symptomatic diverticulosis treatment once diverticular stricture has been ruled out as the cause of symptoms. Stricture is an indication for elective segmental colectomy, typically a sigmoid colectomy to remove the area of stricture and the most dense region of diverticula.

Hemorrhagic Diverticular Disease

Diverticular hemorrhage stops spontaneously in more than 90% of patients; of these, 75% will not bleed again.[58] Patients who have a second episode of diverticular hemorrhage should undergo hemicolectomy of the involved portion of colon[59] after localizing the site of hemorrhage endoscopically with a tagged red blood cell scan or with angiography, because these patients are likely to bleed again. If the site of bleeding cannot be determined definitively as left or right sided, a subtotal colectomy is the procedure of choice.[60]

Diverticulitis

7 The treatment of diverticulitis typically parallels the Hinchey classification (Algorithm 69-1)[44]:

- Stage I, confined pericolic abscess: antibiotics and bowel rest
- Stage II, pelvic or retroperitoneal abscess: percutaneous abscess drainage
- Stage III, purulent peritonitis: resuscitation and urgent operation
- Stage IV, feculent peritonitis: resuscitation and urgent operation

Stage I diverticulitis is mild when patients can tolerate a diet, have no systemic symptoms (no fever, tachycardia, hypotension), and have no substantial peritoneal signs. The CT scan shows either minor pericolic fat stranding or wall thickening in the presence of diverticulosis. Outpatient management is usually appropriate for these patients. Broad-spectrum oral antibiotics are prescribed for 7 to 10 days, and patients start a clear liquid diet, advancing to a solid diet as symptoms resolve. If this is a first episode of presumed diverticulitis, an elective confirmatory study with either barium enema or colonoscopy is planned after inflammation has subsided. Progression of symptoms on this regimen warrants hospital admission and repeat CT scan may be necessary. The vast majority (70% to 100%) of patients with uncomplicated diverticulitis will recover without operative intervention. Although nearly a third will relapse, long-term fiber supplementation appears to reduce this risk.[61]

Severe stage I inflammation is indicated by intolerance of diet, possible nausea and vomiting, fever, chills, and peritoneal signs on examination, which are often focal. The CT scan may show a phlegmon or contained pericolic abscess. These patients are admitted to the hospital for parenteral broad-spectrum antibiotics. They are placed on bowel rest, intravenous fluids are administered, and if nausea and vomiting are major symptoms, a nasogastric tube may be placed. Analgesia is provided but limited to enable evaluation of symptom progression. In addition, since narcotics are known to cause strong, nonpropulsive sigmoid colon contractions, their use in patients with diverticulitis should be minimized. Small (<2 cm) pericolic abscesses may resolve with intravenous antibiotics; larger contained abscesses will likely require percutaneous drainage with CT (or possibly ultrasound) guidance.[61,62] If a smaller abscess is treated initially with antibiotics only but symptoms fail to improve, percutaneous drainage should be considered. Progression of symptoms despite percutaneous drainage of an abscess usually indicates the need for surgery. Historically, 10% to 25% of patients requiring hospitalization for treatment of diverticulitis will not improve or will worsen with medical management alone; overall, 30% of hospitalized patients will require an operation. Those patients who recover from an initial episode of complicated diverticulitis (contained perforation or abscess) should be considered for single-stage, elective segmental colectomy after the resolution of acute inflammation.[63] As will be discussed further, minimally invasive surgical techniques are increasingly being used with good outcomes in these patients.

Patients who fail nonoperative management of diverticulitis or who present with

purulent or feculent peritonitis require operative treatment. The goal of surgery in these patients – especially if they are toxic, developing multisystem organ failure, or hemodynamically unstable – is to resect the perforation and make a stoma. This defines a Hartmann procedure, in which the offending segment of colon is resected, a proximal stoma is constructed, and the distal colon and/or rectum are closed and left in the pelvis. The distal remaining segment of colon and rectum is referred to as a Hartmann pouch. This approach was favored for many years because it is quick and simple and there is no chance of anastomotic leak. However, 30% to 50% of patients treated in this way never undergo reversal of the stoma, and when they do, the complication rate is high (major complications in 5% to 25%, anastomotic leak in 2% to 30%).[64,65]

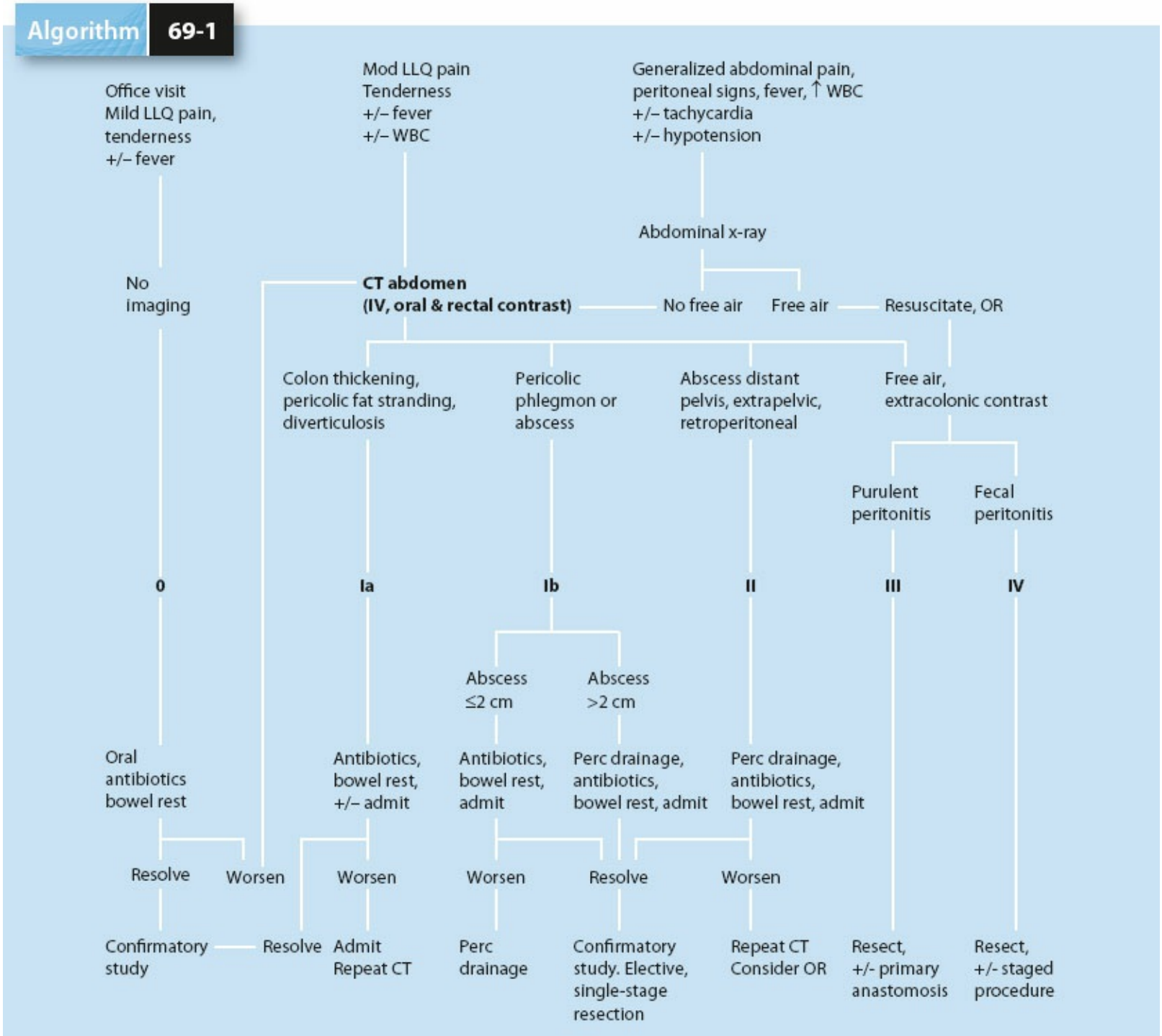

Algorithm 69-1. Diverticulitis Treatment based on Modified Hinchey Score (0–IV).

Despite these problems, this is still the procedure of choice in unstable patients. However, in the more stable patient who requires an urgent operation because of generalized diverticular peritonitis on presentation or failure of nonoperative management, the goal should be resection with primary anastomosis and creation of a diverting stoma, usually a loop ileostomy. The anastomotic leak rate in patients with free diverticular perforation who undergo a single-stage operation acutely is 13%.[66] While diverting ileostomy or colostomy upstream from a primary anastomosis does not prevent an anastomotic leak, it lessens the consequences of a leak by diverting the fecal stream from the area, preventing potentially devastating gross fecal soilage through the defect.

Obstruction

Complete obstruction from DD is unusual. Partial obstruction resulting from edema, spasm, and inflammation is more common. The differential diagnosis includes cancer and inflammatory bowel disease. Medical treatment and elective resection are usually successful. Rarely is the placement of a colonic stent necessary, but it may be used to allow for bowel preparation before a single-stage resection with primary anastomosis. A diverting stoma may be necessary to relieve obstruction and enable completion of the workup and treatment before definitive resection. If perforation has resulted from obstruction, even when the distinction between obstructive cancer and diverticular obstruction cannot be made, the perforated segment should be resected and diverting end-colostomy performed. If this is a right-sided process in a relatively stable patient, primary anastomosis and diverting loop ileostomy can be considered.

Fistula

The presence of a fistula usually obviates the need for an emergency operation because the abscess has in effect spontaneously drained internally. A single-stage operation should be planned. The bladder side of a colovesical fistula is usually disrupted bluntly at the time of colon resection. No repair of the bladder is needed unless there is a visibly patent opening at the transected fistula tract site. A urinary drainage catheter is left in place for 7 to 10 days after surgery.[46] A cystogram can be done to verify closure of the tract opening and can facilitate discharge without an indwelling catheter following laparoscopic resection, which is often earlier than after open procedures. It is not necessary to leave a pelvic drain at the time of resection. Likewise, fistula tract openings to the vaginal cuff do not require closure. At most, omentum can be draped into the pelvis to separate the fresh colorectal anastomosis from the opening on the vagina.

Giant Colonic Diverticulum

Treatment is surgical resection of the involved segment of colon. Planned electively, a single-stage operation is indicated. Once perforated, the decision process parallels common diverticulitis, preference being given to resection with primary anastomosis and diverting loop stoma in the stable patient.

MANAGEMENT

Operative Strategies

8 The most important advance in the surgical management of DD besides trying to convert staged, emergency operations into elective, single-stage operations is the introduction of minimally invasive surgical techniques. No matter what the approach, certain challenges face the surgeon operating for DD. Inflammation distorts the anatomic planes. Dense fibrosis and adhesions impede sharp dissection and make it difficult to get good traction and countertraction that enable dissection. Inflammatory adhesions interfere with visualization and sometimes even palpation of anatomic structures.

Key concepts apply to both laparoscopic and open procedures. The goal is not to remove every diverticulum but rather to resect the area of inflammation or complication. The proximal resection line should be at soft, pliable bowel. The distal resection line must be at the top of the rectum demarcated by splaying of the bunched longitudinal muscle fibers (taenia coli) into the continuous longitudinal, outer layer of the rectal muscularis propria. The point of transection is almost never below the anterior pelvic peritoneal reflection. The splenic flexure should almost always be mobilized to facilitate creation of a tension-free colorectal anastomosis. The anastomotic site itself must be free from diverticula, which can be difficult in the patient with dense, pandiverticulosis. Manual, pinch dissection (or “finger fracture”) techniques are used to separate structures and divide areas of fibrosis and thick adhesions. Dissection commences away from the focus of inflammation, usually proximal to it. The left ureter should be identified as early as possible and before transecting major vessels or the colon. In the setting of severe inflammation in the left lower quadrant or pelvis, it can be very helpful to mobilize and divide the proximal bowel as an initial operative maneuver. Likewise, when dense inflammation makes the standard, lateral-to-medial mobilization of the sigmoid difficult, a medial-to-lateral approach can sometimes provide access to less inflamed tissues. While typically not needed, when a preoperative CT scan shows dense inflammation in proximity to the left ureter, placement of ureteral stents can help with ureteral identification and protection during dissection. Whether using open or laparoscopic techniques, an elective operation should be deferred for 4 to 6 weeks after the last episode of inflammation so that acute inflammatory changes do not interfere with either the dissection or the construction of a safe colorectal anastomosis.[67]

There is growing experience with laparoscopic resection of even complicated DD. A meta-analysis comparing laparoscopic to open diverticulitis resections concluded that the laparoscopic patients had lower infection rates (overall and wound); decreased pulmonary, gastrointestinal, and cardiovascular complications; and a shorter time to recovery of bowel function and hospital discharge. Although studies in the meta-analysis included acute and chronic indications for surgery and complicated as well as uncomplicated diverticulitis in both groups, the authors cautioned that the retrospective nature of the reviewed studies introduced selection bias.[68] When laparoscopic resections for DD are performed early (2 to 16 days after hospital admission), the conversion rates

are higher than when surgery is delayed (more than 6 weeks).[69] Hand-assisted minimally invasive operations may offer significant benefit compared to pure laparoscopic surgery for DD, showing lower conversion rates, shorter operative times, and no compromise of the speedy recovery associated with fully laparoscopic operations.[70]

Elective Surgery

Several observations form the basis of recommendations for elective resection following episodes of diverticulitis. Forty percent of diverticulitis patients admitted to the hospital will develop a complication, 23% following a single episode and 58% following two episodes. Thirty to 45% of patients hospitalized for diverticulitis will have another flare, usually within 5 years (90%). Among patients hospitalized a second time, only 10% remain symptom-free.[71–73] Mortality doubles with a second flare. The classic indications for elective resection include two or more episodes of documented diverticulitis, a single episode of complicated diverticulitis (modified Hinchey stage Ib or II), one documented episode in an immunocompromised patient, one documented episode in a young patient (40 to 50 years old), and an inability to exclude cancer as the cause of the signs and symptoms.

9 Practice parameters outlined by the American Society of Colon and Rectal Surgeons note that most patients who present with complicated diverticulitis do so at their first episode, so operating on patients with uncomplicated episodes of diverticulitis may not reduce the risk of emergency surgery and mortality. “The age and medical condition of the patient, the frequency and severity of the attack(s), and whether there are persistent symptoms after the acute episode” may be better determinants of recommendation for elective resection.[61] Complications develop often enough after successful medical management of complicated diverticulitis to warrant recommending elective resection.[56] Kaiser et al.[45] reported that 41% of patients treated with percutaneous drainage of a diverticular abscess will later develop severe sepsis.

It has been noted that the incidence of DD has steadily increased among young people, from 12% in 1969[74] to 20% in 1998[75] to 54% in a study of young and obese American patients in 2006.[76] Traditionally, elective colon resection was recommended for young people (age younger than 50 years) after one documented episode of uncomplicated diverticulitis. This recommendation was based on the belief that DD is more virulent in young patients. However, data are conflicting in this regard. There have been reports of young patients increased risk of complicated disease at presentation, increased frequency of recurrences (in the same time period as older patients, not as a function of longevity), and higher risk of needing emergency surgery and colostomy. Recommendation for elective resection following a single episode of uncomplicated diverticulitis in patients younger than 50 years of age was motivated by an interest in avoiding a colostomy and avoiding major morbidity and mortality. In view of conflicting data and adoption of technical strategies for avoiding end-colostomies in all patients, Nelson et al. have suggested following the same guidelines that are used for older patients.[63,77–83]

10 Immunocompromised patients are more likely to fail medical management and must be watched closely since the manifestations of failure may be more subtle than in immunocompetent patients. Transplant patients, those on steroids or chemotherapy, diabetics, and dialysis patients are at risk. Elective resection in anticipation of transplant is also considered in some patients with DD. Interestingly, human immunodeficiency virus (HIV)-positive patients with normal CD4 counts appear to behave as if they were

immunologically normal with respect to the incidence of diverticulitis and its clinical course. Since HIV infection has principally been an illness of younger people, most studies of diverticulitis have not included a large number of HIV-positive patients.[84] That may change as longevity improves with current antiretroviral regimens.

SUMMARY

DD is common and includes a spectrum of presentations and anatomic locations, favoring the left colon in Western societies. The etiology is likely multifactorial, with a low-residue diet being a common factor. The CT scan has dramatically improved diagnostic accuracy and helped with treatment planning. Treatment often parallels the Hinchey stage, particularly the modified Hinchey classification. Surgical treatment has evolved to favor medical management and image-guided percutaneous drainage of abscesses when feasible to convert surgical emergency–staged procedures into either single-stage procedures or procedures with primary anastomosis and diverting loop stoma. The distinction of complicated DD and colon cancer can be difficult, but early contrast enema studies or colonoscopy can be safely performed and are the most helpful diagnostic procedures in this setting. The indications for elective resection following successful medical management of DD are being reconsidered, and it is becoming clear that elective sigmoid resection for DD should be offered to avoid recurrent symptoms, not primarily to avoid free perforation and the need for an emergent colostomy. Minimally invasive surgery is state of the art, and the hand-assisted techniques are particularly useful for elective DD resections.

References

1. Van Arendonk KJ, Tymitz KM, Gearhart SL, et al. Outcomes and costs of elective surgery for diverticular disease: a comparison with other diseases requiring colectomy. *JAMA Surg* 2013;148(4):316–321.
2. Feingold D, Steele SR, Lee S, et al. Practice parameters for the treatment of sigmoid diverticulitis. *Dis Colon Rectum* 2014;57(3):284–294
3. Nakada I, Ubukata H, Goto Y, et al. Diverticular disease of the colon at a regional general hospital in Japan. *Dis Colon Rectum* 1995;38(7):755–759.
4. Sugihara K. Diverticular disease of the colon in Japan. *Ann Acad Med Singapore.* 1987;16(3):504–508.
5. Martel J, Raskin JB. History, incidence, and epidemiology of diverticulosis. *J Clin Gastroenterol* 2008;42(10):1125–1127.
6. Spriggs EI, Marxer OA. An address on intestinal diverticula. *Br Med J* 1926;1:130–134.
7. Hughes LE. Postmortem survey of diverticular disease of the colon. I. Diverticulosis and diverticulitis. *Gut* 1969;10(5):336–344.
8. Horner JL. Natural history of diverticulosis of the colon. *Am J Dig Dis* 1958;3(5):343–350.
9. Minardi AJ Jr, Johnson LW, Sehon JK, et al. Diverticulitis in the young patient. *Am Surg* 2001;67(5):458–461.
10. Sandler RS, Everhart JE, Donowitz M, et al. The burden of selected digestive diseases in the United States. *Gastroenterology* 2002;122(5):1500–1511.
11. De Frances CJ, Cullen KA, Kozak LJ. National Hospital Discharge Survey: 2005 annual summary with detailed diagnosis and procedure data. *Vital Health Stat 13* 2007;29(165):1–209.
12. Slack WW. The anatomy, pathology, and some clinical features of diverticulitis of the colon. *Br J Surg* 1962;50:185–190.
13. Gallagher JJ, Welch JP. Giant diverticular of the sigmoid colon: a review of differential diagnosis and operative management. *Arch Surg* 1979;114(9):1079–1083.
14. Beighton PH, Murdoch JL, Votteler T. Gastrointestinal complications of the Ehlers-Danlos syndrome. *Gut* 1969;10(12):1004–1008.
15. Cook JM. Spontaneous perforation of the colon: report of two cases in a family exhibiting Marfan's stigmata. *Ohio State Med J* 1968;64:73.
16. Wess L, Eastwood MA, Wess TJ, et al. Cross linking of collagen is increased in colonic diverticulosis. *Gut* 1995;37(1):91–94.
17. Morson BC. The muscle abnormality in diverticular disease of the colon. *Proc R Soc Med* 1963;56:798–800.
18. Whiteway J, Morson BC. Elastosis in diverticular disease of the sigmoid colon. *Gut* 1985;26(3):258–266.

19. Painter NS, Truelove SC, Ardran GM, et al. Segmentation and the localization of intraluminal pressures in the human colon, with special reference to the pathogenesis of colonic diverticula. *Gastroenterology* 1965;49:169–177.
20. Painter NS. The aetiology of diverticulosis of the colon with special reference to the action of certain drugs on the behaviour of the colon. *Ann R Coll Surg Engl* 1964;34:98–119.
21. Taylor I, Duthie HL. Bran tablets and diverticular disease. *Br Med J* 1976;1(6016):988–990.
22. Snape WJ Jr, Carlson GM, Matarazzo SA, et al. Evidence that abnormal myoelectrical activity produces colonic motor dysfunction in the irritable bowel syndrome. *Gastroenterology* 1977;72(3):383–387.
23. Bassotti G, Battaglia E, Spinozzi F, et al. Twenty-four hour recordings of colonic motility in patients with diverticular disease: evidence for abnormal motility and propulsive activity. *Dis Colon Rectum* 2001;44(12):1814–1820.
24. Painter NS, Burkitt DP. Diverticular disease of the colon: a deficiency disease of Western civilization. *Br Med J* 1971;2(5759):450–454.
25. Painter NS, Burkitt DP. Diverticular disease of the colon, a 20th century problem. *Clin Gastroenterol* 1975;4(1):3–21.
26. Korzenik JR. Diverticulitis: new frontiers for an old country: risk factors and pathogenesis. *J Clin Gastroenterol* 2008;42(10):1128–1129.
27. Peery AF, Sandler RS, Ahnen DJ, et al. Constipation and a low-fiber diet are not associated with diverticulosis. *Clin Gastroenterol Hepatol* 2013;11(12):1622–1627.
28. Korzenik JR. Case closed? Diverticulitis: epidemiology and fiber. *J Clin Gastroenterol* 2006;40(suppl 3):S112–S116.
29. Strate LL, Liu YL, Syngal S, et al. Nut, corn, and popcorn consumption and the incidence of diverticular disease. *JAMA* 2008;300(8):907–914.
30. Milner P, Crowe R, Kamm MA, et al. Vasoactive intestinal polypeptide levels in sigmoid colon in idiopathic constipation and diverticular disease. *Gastroenterology* 1990;99(3):666–675.
31. Yun AJ, Bazar KA, Lee PY. A new mechanism for diverticular diseases: aging-related vagal withdrawal. *Med Hypotheses* 2005;64(2):252–255.
32. Costedio MM, Coates MD, Danielson AB, et al. Serotonin signaling in diverticular disease. *J Gastrointest Surg* 2008;12(8):1439–1445.
33. Floch MH. A hypothesis: is diverticulitis a type of inflammatory bowel disease?*J Clin Gastroenterol* 2006;40(suppl 3):S121–S125.
34. Daniels L, Philipszoon LE, Boermeester MA. A hypothesis: Important role for gut microbiota in the etiopathogenesis of diverticular disease. *Dis Colon Rectum* 2014;57(4):539–543.
35. Strate LL, Modi R, Cohen E, et al. Diverticular disease as a chronic illness: evolving epidemiologic and clinical insights. *Am J Gastroenterol* 2012;107(10):1486–1893.

36. Hall JF. The microbiome and diverticulitis: a new target for medical therapy?*Dis Colon Rectum* 2014;57(4):544–545.
37. Ghorai S, Ulbright TM, Rex DK. Endoscopic findings of diverticular inflammation in colonoscopy patients without clinical acute diverticulitis: prevalence and endoscopic spectrum. *Am J Gastroenterol* 2003;98(4):802–806.
38. Cohen E, Fuller G, Bolus R, et al. Increased Risk for Irritable Bowel Syndrome After Acute Diverticulitis. *Clin Gastroenterol Hepatol* 2013;11(12):1614–1619.
39. Floch MH, Bina I. The natural history of diverticulitis: fact and theory. *J Clin Gastroenterol* 2004;38(5 suppl):S2–S7.
40. West AB. The pathology of diverticulitis. *J Clin Gastroenterol* 2008; 42(10):1137–1138.
41. Simpson J, Scholefield JH, Spiller RC. Origin of symptoms in diverticular disease. *Br J Surg* 2003;90(8):899–908.
42. Stead RH. Nerve remodelling during intestinal inflammation. *Ann N Y Acad Sci* 1992;664:443–455.
43. Brewer DB, Thompson H, Haynes IG, et al. Axonal damage in Crohn's disease is frequent, but non-specific. *J Pathol* 1990;161(4):301–311.
44. Hinchey EJ, Schaal PG, Richards GK. Treatment of perforated diverticular disease of the colon. *Adv Surg* 1978;12:85–109.
45. Kaiser AM, Jiang JK, Lake JP, et al. The management of complicated diverticulitis and the role of computed tomography. *Am J Gastroenterol* 2005;100(4):910–917.
46. Woods RJ, Lavery IC, Fazio VW, et al. Internal fistulas in diverticular disease. *Dis Colon Rectum* 1988;31(8):591–596.
47. Grissom R, Snyder TE. Colovaginal fistula secondary to diverticular disease. *Dis Colon Rectum* 1991;34(11):1043–1049.
48. Chintapalli KN, Esola CC, Chopra S, et al. Pericolic mesenteric lymph nodes: an aid in distinguishing diverticulitis from cancer of the colon. *AJR Am J Roentgenol* 1997;169(5):1253–1255.
49. Graham SM, Ballantyne GH. Cecal diverticulitis. A review of the American experience. *Dis Colon Rectum* 1987;30(10):821–826.
50. Gouge TH, Coppa GF, Eng K, et al. Management of diverticulitis of the ascending colon. 10 years' experience. *Am J Surg* 1983;145(3):387–391.
51. Hayward MW, Hayward C, Ennis WP, et al. A pilot evaluation of radiography of the acute abdomen. *Clin Radiol* 1984;35(4):289–291.
52. Field S, Guy PJ, Upsdell SM, et al. The erect abdominal radiograph in the acute abdomen: should its routine use be abandoned? *Br Med J (Clin Res Ed)* 1985;290(6486):1934–1936.
53. Ambrosetti P, Jenny A, Becker C, et al. Acute left colonic diverticulitis–compared performance of computed tomography and water-soluble contrast enema: prospective evaluation of 420 patients. *Dis Colon Rectum* 2000;43(10):1363–1367.

54. Rao PM, Rhea JT, Novelline RA, et al. Helical CT with only colonic contrast material for diagnosing diverticulitis: prospective evaluation of 150 patients. *AJR Am J Roentgenol* 1998;170(6):1445–1449.
55. Rao PM, Rhea JT, Novelline RA. Helical CT of appendicitis and diverticulitis. *Radiol Clin North Am* 1999;37(5):895–910.
56. Ambrosetti P, Grossholz M, Becker C, et al. Computed tomography in acute left colonic diverticulitis. *Br J Surg* 1997;84(4):532–534.
57. Sudakoff GS, Lundeen SJ, Otterson MF. Transrectal and transvaginal sonographic intervention of infected pelvic fluid collections: a complete approach. *Ultrasound Q* 2005;21(3):175–185.
58. Lewis M. Bleeding colonic diverticula. *J Clin Gastroenterol* 2008;42(10):1156–1158.
59. McGuire HH Jr. Bleeding colonic diverticula. A reappraisal of natural history and management. *Ann Surg* 1994;220(5):653–656.
60. Drapanas T, Pennington DG, Kappelman M, et al. Emergency subtotal colectomy: preferred approach to management of massively bleeding diverticular disease. *Ann Surg* 1973;177(5):519–526.
61. Rafferty J, Shellito P, Hyman NH, et al. Practice parameters for sigmoid diverticulitis. *Dis Colon Rectum* 2006;49(7):939–944.
62. Ambrosetti P, Chautems R, Soravia C, et al. Long-term outcome of mesocolic and pelvic diverticular abscesses of the left colon: a prospective study of 73 cases. *Dis Colon Rectum* 2005;48(4):787–791.
63. Chautems RC, Ambrosetti P, Ludwig A, et al. Long-term follow-up after first acute episode of sigmoid diverticulitis: is surgery mandatory?: a prospective study of 118 patients. *Dis Colon Rectum* 2002;45(7):962–966.
64. Aydin HN, Remzi FH, Tekkis PP, et al. Hartmann's reversal is associated with high postoperative adverse events. *Dis Colon Rectum* 2005;48(11):2117–2126.
65. Constantinides VA, Heriot A, Remzi F, et al. Operative strategies for diverticular peritonitis: a decision analysis between primary resection and anastomosis versus Hartmann's procedures. *Ann Surg* 2007;245(1):94–103.
66. Salem L, Flum DR. Primary anastomosis or Hartmann's procedure for patients with diverticular peritonitis? A systematic review. *Dis Colon Rectum* 2004;47(11):1953–1964.
67. Reissfelder C, Buhr HJ, Ritz JP. What is the optimal time of surgical intervention after an acute attack of sigmoid diverticulitis: early or late elective laparoscopic resection? *Dis Colon Rectum* 2006;49(12):1842–1848.
68. Purkayastha S, Constantinides VA, Tekkis PP, et al. Laparoscopic vs. open surgery for diverticular disease: a meta-analysis of nonrandomized studies. *Dis Colon Rectum* 2006;49(4):446–463.
69. Zingg U, Pasternak I, Guertler L, et al. Early vs. delayed elective laparoscopic-assisted colectomy in sigmoid diverticulitis: timing of surgery in relation to the acute

attack. *Dis Colon Rectum* 2007;50(11):1911–1917.

70. Lee SW, Yoo J, Dujovny N, et al. Laparoscopic vs. hand-assisted laparoscopic sigmoidectomy for diverticulitis. *Dis Colon Rectum* 2006;49(4):464–469.
71. Parks TG. Natural history of diverticular disease of the colon. *Clin Gastroenterol* 1975;4(1):53–69.
72. Farmakis N, Tudor RG, Keighley MR. The 5-year natural history of complicated diverticular disease. *Br J Surg* 1994;81(5):733–735.
73. Makela J, Vuolio S, Kiviniemi H, et al. Natural history of diverticular disease: when to operate? *Dis Colon Rectum* 1998;41(12):1523–1528.
74. Parks TG. Natural history of diverticular disease of the colon. A review of 521 cases. *Br Med J* 1969;4(5684):639–642.
75. Makela J, Kiviniemi H, Laitinen S. Prevalence of perforated sigmoid diverticulitis is increasing. *Dis Colon Rectum* 2002;45(7):955–961.
76. Zaidi E, Daly B. CT and clinical features of acute diverticulitis in an urban U.S. population: rising frequency in young, obese adults. *AJR Am J Roentgenol* 2006;187(3):689–694.
77. Pautrat K, Bretagnol F, Huten N, et al. Acute diverticulitis in very young patients: a frequent surgical management. *Dis Colon Rectum* 2007;50(4):472–477.
78. Nelson RS, Velasco A, Mukesh BN. Management of diverticulitis in younger patients. *Dis Colon Rectum* 2006;49(9):1341–1345.
79. Spivak H, Weinrauch S, Harvey JC, et al. Acute colonic diverticulitis in the young. *Dis Colon Rectum* 1997;40(5):570–574.
80. Guzzo J, Hyman N. Diverticulitis in young patients: is resection after a single attack always warranted? *Dis Colon Rectum* 2004;47(7):1187–1190; discussion 1190–1191.
81. Vignati PV, Welch JP, Cohen JL. Long-term management of diverticulitis in young patients. *Dis Colon Rectum* 1995;38(6):627–629.
82. Anaya DA, Flum DR. Risk of emergency colectomy and colostomy in patients with diverticular disease. *Arch Surg* 2005;140(7):681–685.
83. West SD, Robinson EK, Delu AN, et al. Diverticulitis in the younger patient. *Am J Surg* 2003;186(6):743–746.
84. Sachar DB. Diverticulitis in immunosuppressed patients. *J Clin Gastroenterol* 2008;42(10):1154–1155.

Chapter 70

Anorectal Disorders

David J. Maron and Steven D. Wexner

Key Points

1 The most common manifestation of internal hemorrhoids is painless, bright red rectal bleeding associated with bowel movements. A high-fiber diet supplemented with bulk-forming agents may reduce symptoms of hemorrhoids and is ideal for first- and second-degree hemorrhoids.

2 Rubber band ligation is suitable for symptomatic first- and second- and some third-degree internal hemorrhoids that do not respond to bulk-forming agents.

3 Hemorrhoidectomy is required in only a few patients with symptomatic hemorrhoids. It should be considered when conservative therapy has failed, or when hemorrhoids are complicated by associated pathology such as ulceration, fissures, fistulas, large hypertrophied anal papillae, or extensive skin tags.

4 Anal fissure is an ischemic ulcer in the lower portion of the anal canal; its treatment, both medical and surgical, involves relaxing the internal anal sphincter.

5 Anal fistula is a chronic form of perianal abscess, spontaneously or surgically drained, in which the tract persists, with an internal opening at the dentate line and an external opening on the perianal skin.

6 Rectal prolapse results from intussusception that extends beyond the anal verge. Fit patients are best treated with transabdominal rectopexy. Patients with significant medical comorbidities are best treated using a perineal approach.

7 Anal condylomata acuminata are caused by human papillomavirus, as are anal intraepithelial neoplasia and anal cancers.

8 Palpable lesions of the anal canal are not hemorrhoids and may be cancers; examination under anesthesia and biopsy allow for correct diagnosis.

ANATOMY AND PHYSIOLOGY

A detailed understanding of the anatomy and physiology of the rectum and anus is critical to accurate diagnosis and management of anorectal disorders.

The Rectum

The rectum begins at the level of the sacral promontory and measures approximately 15 cm in length. It descends along the curvature of the sacrum and passes through the levator ani muscles, where it becomes the anal canal. Although the rectum develops from the hindgut in conjunction with the sigmoid and left colon, it differs from the colon in that the outer muscular layer is continuous, characterized by the merging of the three taenia bands. The rectum has three lateral curves whose infoldings form submucosal folds in the lumen, known as the valves of Houston. Because of these curves, the rectum may gain 5 cm in length when straightened during resection.

The posterior aspect of the rectum lacks peritoneum and is directly adherent to the mesorectum. Anteriorly, the upper two-thirds of the rectum are covered by peritoneum; the lower third has no peritoneal covering. The level of the anterior peritoneal reflection (also referred to as the pouch of Douglas) is variable, but is usually 7 to 9 cm from the anal verge in men and 5 to 7 cm in women. The mesorectum is covered with a thin layer of investing fascia (fascia propria), which is distinct from the fascia overlying the sacrum. It is in this plane between these two fascial layers that a “total mesorectal excision” for rectal cancer is performed. The endopelvic fascia that covers the sacrum posterior to the rectum is also referred to as Waldeyer fascia; anteriorly, Denonvilliers fascia lies between the rectum and the vagina in females and the seminal vesicles in males (Fig. 70-1).[1]

The Anal Canal and Sphincters

The anal canal is the terminal portion of the intestinal tract, and extends from the rectum for approximately 4 cm through the pelvic floor musculature to the hair-bearing skin of the anal margin. The circular smooth muscle layer of the rectum continues distally and thickens to form the internal anal sphincter (IAS), which extends to approximately 1.5 cm below the dentate line. The internal sphincter is surrounded by a continuous sheet of striated muscle of the pelvic floor, which is comprised of three distinct muscles – the puborectalis muscle, the levator ani muscle, and the external anal sphincter (Fig. 70-2). These muscles are critical both in the maintenance of continence and in defecation. The levator ani muscle is a broad, thin, funnel-shaped muscle that forms the floor of the pelvic cavity (Figs. 70-3 and 70-4). The puborectalis muscle originates on the posterior aspect of the pubic bones and forms a u-shaped sling around the anal canal that helps to maintain an acute angle between the rectum and anus. The external sphincter is an elliptical-shaped muscle that extends from the coccyx (anococcygeal ligament) around the internal sphincter. The external sphincter extends slightly caudad to the IAS, thereby forming the intersphincteric groove at the anal verge. The superficial fibers of the external anal sphincter insert into the skin of the anal verge as the corrugator cutis ani. The perineal body lies at the central portion of the perineum where the external sphincter, bulbospongiosus, and transverse perineal muscles meet and separates the anus from the vagina.

The lining of the anal canal contains different types of epithelium at different levels. At the anal verge, the skin becomes anoderm, a squamous lining without hair. Approximately 2 cm from the anal verge, the dentate line appears as a comb-like line due to folds in the mucosa. These folds are named the columns of Morgagni, and typically contain a small pocket or crypt at the inferior end. The mucosa at this level is a mixture of squamous, transitional, and columnar epithelium; this is referred to as the anal transition zone. The mucosa of the upper anal canal is lined by columnar epithelium. The internal hemorrhoidal plexus lies deep to the mucosa within the anal canal.

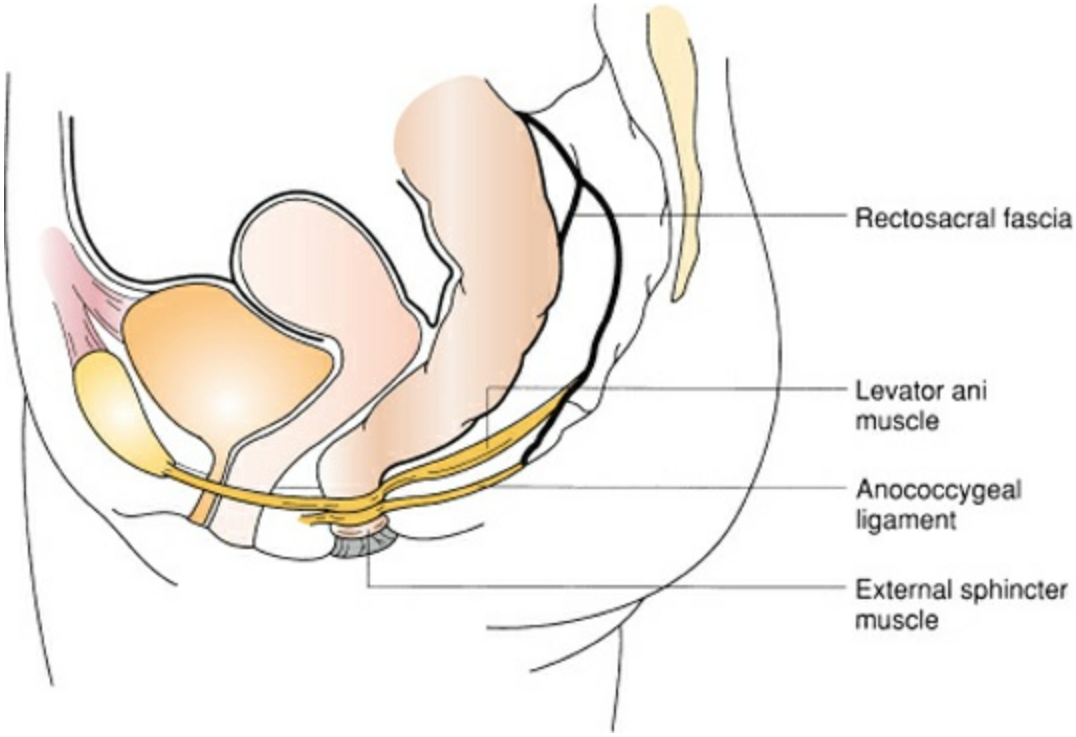

Figure 70-1. Fascial attachments of the rectum.

Understanding the various types of epithelium within the anal canal is important for the diagnosis of both benign and malignant conditions of the anus. The histology of tumors of the anal canal is critical to understanding the typical behavior and management of the disease. Squamous cell lesions that arise at the anal margin are often treated as skin cancers (wide excision), whereas those arising within the anal canal are treated with chemoradiation. Adenocarcinomas of the anal canal typically arise from the upper anus and are treated similar to adenocarcinomas of the distal rectum. Fistulas of the anal canal typically originate from the crypts at the dentate line, however fistulas associated with Crohn's disease will often arise from the columnar epithelium of the upper anal canal, and those associated with hidradenitis will originate from the mucosa or skin below the dentate line.

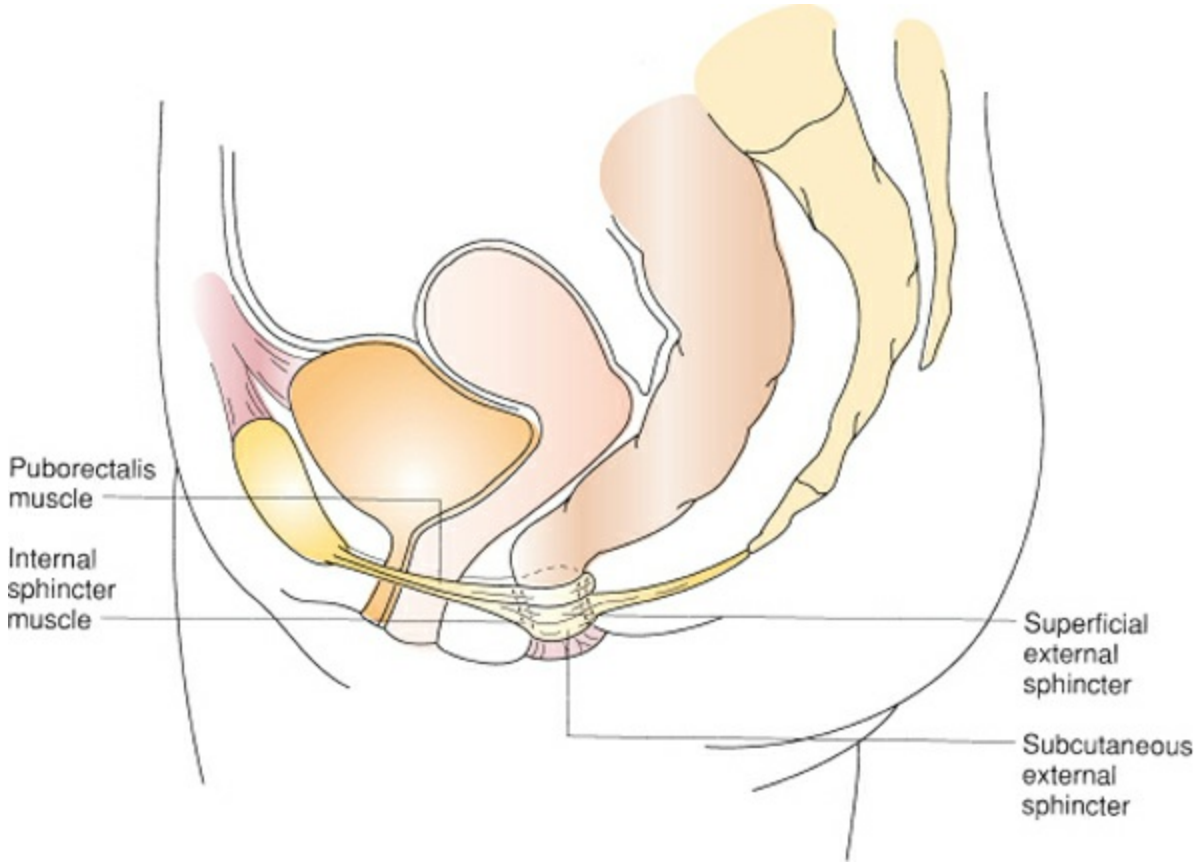

Figure 70-2. Arrangement of the external sphincter muscles.

The rectum and anus receive abundant blood supply from the superior, middle, and inferior rectal arteries (Fig. 70-5). The superior rectal (hemorrhoidal) artery starts as the terminal branch of the inferior mesenteric artery, descending posterior to the rectum where it bifurcates to supply the rectum and upper anal canal. The middle rectal arteries arise from the internal pudendal or inferior gluteal arteries (branches of the internal iliac artery). The inferior rectal arteries also arise from the internal pudendal arteries (in Alcock canal) and traverse the ischioanal fossa to supply the anal sphincters and anal canal. There are multiple communications among these three vessels.

The venous drainage of the anus is via both the portal and system venous systems (Fig. 70-6). The superior rectal vein drains the rectum and upper anal canal into the portal venous system through the inferior mesenteric vein. The middle and inferior rectal veins drain into the systemic venous system via the internal iliac veins. Because of the rich communication between these veins, patients with portal hypertension may develop porto-systemic shunts resulting in bleeding rectal varices.

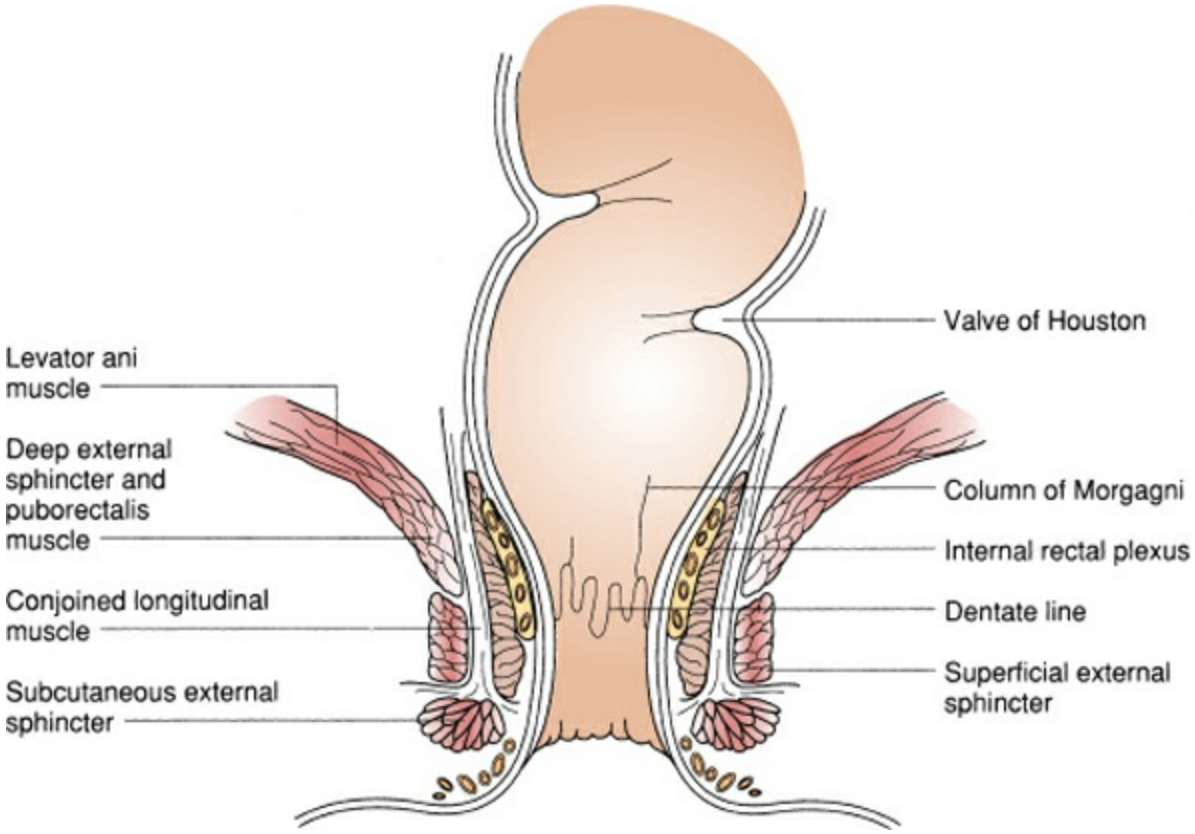

Figure 70-3. Anatomy of the anal canal.

Lymphatic drainage of the rectum and anus mirrors the arterial supply (Figs. 70-7 and 70-8). Drainage from the upper and middle rectum flows to the inferior mesenteric lymph nodes. The lower rectum and upper anal canal may drain to the inferior mesenteric nodes, or may drain laterally to the internal iliac nodes. Lymph from the anus below the level of the dentate line typically drains to the inguinal lymph nodes, however drainage may also occur to the inferior mesenteric and internal iliac nodes. Clinically this drainage pattern is important in patients with squamous cell cancers of the anus, as palpation of enlarged inguinal lymph nodes may signify metastatic disease.

The rectum and urogenital organs are supplied by a vast network of both sympathetic and parasympathetic nerves (Fig. 70-9). The sympathetic nerves branch from the sympathetic trunk from the first three segments of the lumbar spinal cord and synapse at the preaortic plexus. Some postsynaptic nerves innervate the upper rectum, while others travel distally to form the hypogastric plexus, which extends laterally along the rectum to form the pelvis plexus. The parasympathetic nerves (nervi erigentes) originate from the second, third, and fourth sacral nerve roots. These nerves then join the sympathetic nerves in the pelvic plexus to supply both the lower rectum and urogenital organs. This plexus lies within the lateral attachments of the rectum and along Denonvillers fascia.

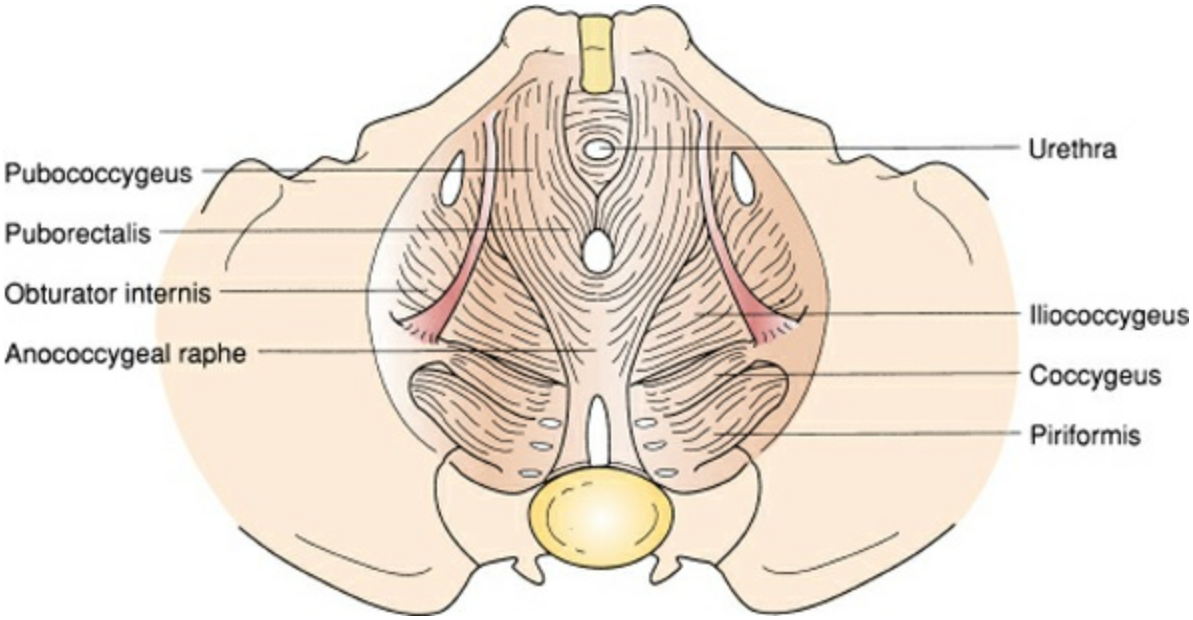

Figure 70-4. Muscles of the pelvic floor.

Preservation of both the hypogastric and pelvic plexuses during proctectomy is essential in maintaining normal sexual function.[2] In men, parasympathetic innervation is responsible for erection, while a complex interaction between sympathetic, parasympathetic, and somatic pathways produces ejaculation. Injury to the nervi erigentes may result in impotence, while injury to the hypogastric sympathetic trunks may cause retrograde ejaculation. Injury to the pelvic nerves may also lead to bladder dysfunction. In women, dysfunction following nerve injury is less well understood, however some patients do report dyspareunia and decreased lubrication during intercourse following pelvic surgery.

The IAS receives both sympathetic and parasympathetic nerves, and maintains tonic contraction at rest. The external anal sphincter is innervated by the inferior rectal branch of the pudendal nerve and perineal branch of the fourth sacral nerve. The inferior rectal nerve also carries sensory information from the anal canal. The majority of sensory nerve endings within the anal canal are located distal to the dentate line, however patients may sense painful stimuli up to 1.5 cm proximal to this area. Clinically this anatomy is relevant, as external hemorrhoids (below the dentate line) are sensitive to touch, while internal hemorrhoids (above the dentate line) may often be manipulated (banding, etc.) without the need for anesthesia. In addition, sensory receptors within the anal canal allow the discrimination between solid or liquid stool and flatus.

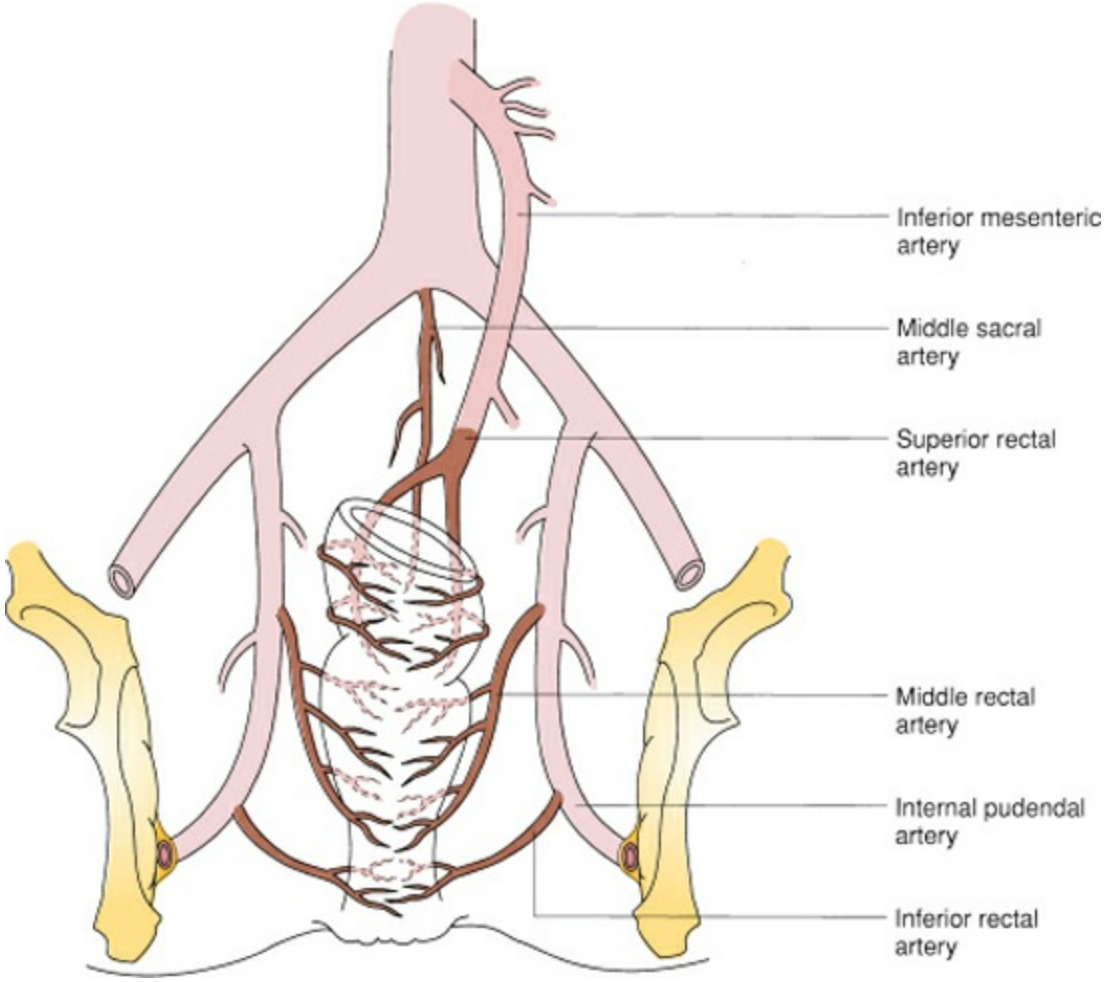

Figure 70-5. Arterial supply of the rectum and anal canal.

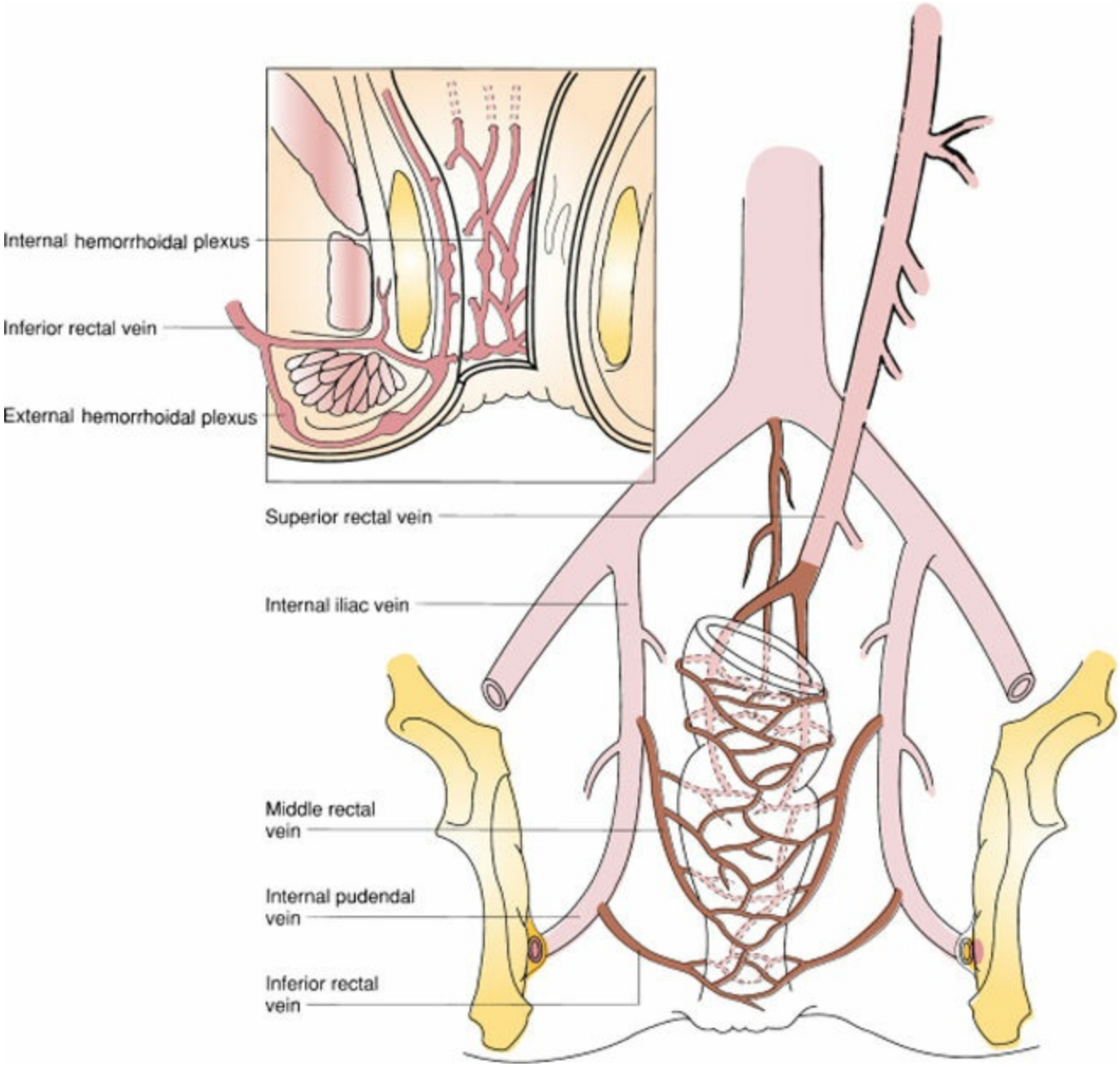

Figure 70-6. Venous drainage of the rectum and anal canal.

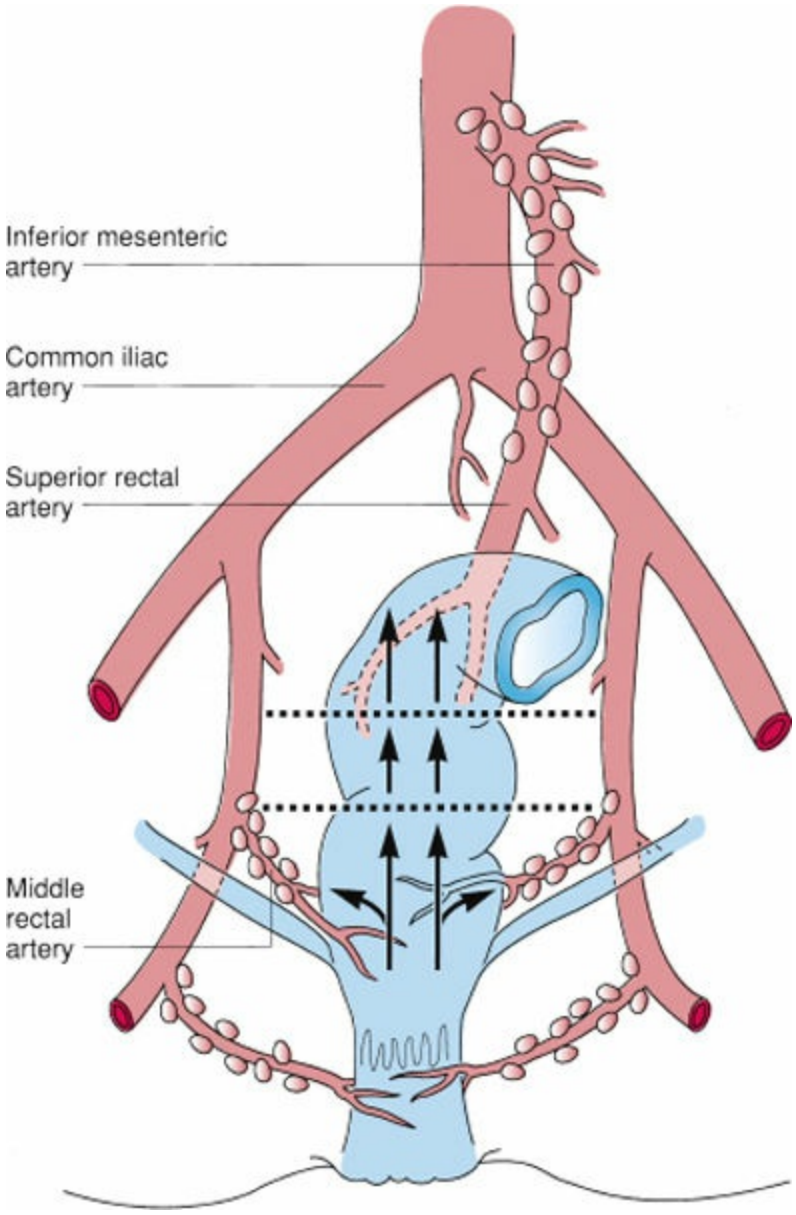

Figure 70-7. Lymphatic drainage of the rectum.

Physiology

The principal function of the anus is the maintenance of continence and regulation of defecation. The physiology of the defecation and maintenance of continence are complex, and involve both voluntary and involuntary muscular activities. Continence is also affected by the compliance and tone of the rectum, the consistency and volume of the stool, the sensation of the anorectum, and the muscular activity of the pelvic floor muscles. The hemorrhoidal plexus may also contribute to continence by acting as a "cushion" to keep the anus closed. Alterations of any of these mechanisms of continence may result in impaired continence.

The primary function of the rectum is to act as a reservoir for stool until it is a socially acceptable time and place for evacuation. When stool enters the rectum from the colon and the rectum becomes distended, receptors within the puborectal muscle initiate the rectoanal inhibitory reflex. This distension leads to simultaneous relaxation of the IAS and contraction of the external anal sphincter, allowing the stool to descend toward the anal canal. This sphincter response allows for "sampling," or determination by the sensory epithelium of the anal canal as to whether the distension is from gas or stool. If defecation is deferred, the musculature of the rectum relaxes, thereby decreasing the pressure within the rectum; this is referred to as accommodation.

Continence is maintained by the fact that the pressure within the anal canal is higher than the pressure within the rectum. This high-pressure zone (between 40 and 70 mm Hg) within the anal canal is primarily accounted for by the IAS, however the external sphincter and puborectal muscle contribute as well. Autonomic innervation keeps the internal sphincter under tonic contraction and cannot be altered by voluntary control. Contraction of the external anal sphincter will often more than double the intra-anal pressure, however this muscle can typically be contracted voluntarily for only 40- to 60-second periods. The angle between the anus and rectum also may aid in the maintenance of continence by creating a flap valve and preventing stool from entering the anus. This anteroposterior angle is maintained by the contraction of the sling-shaped pubrectalis muscle.

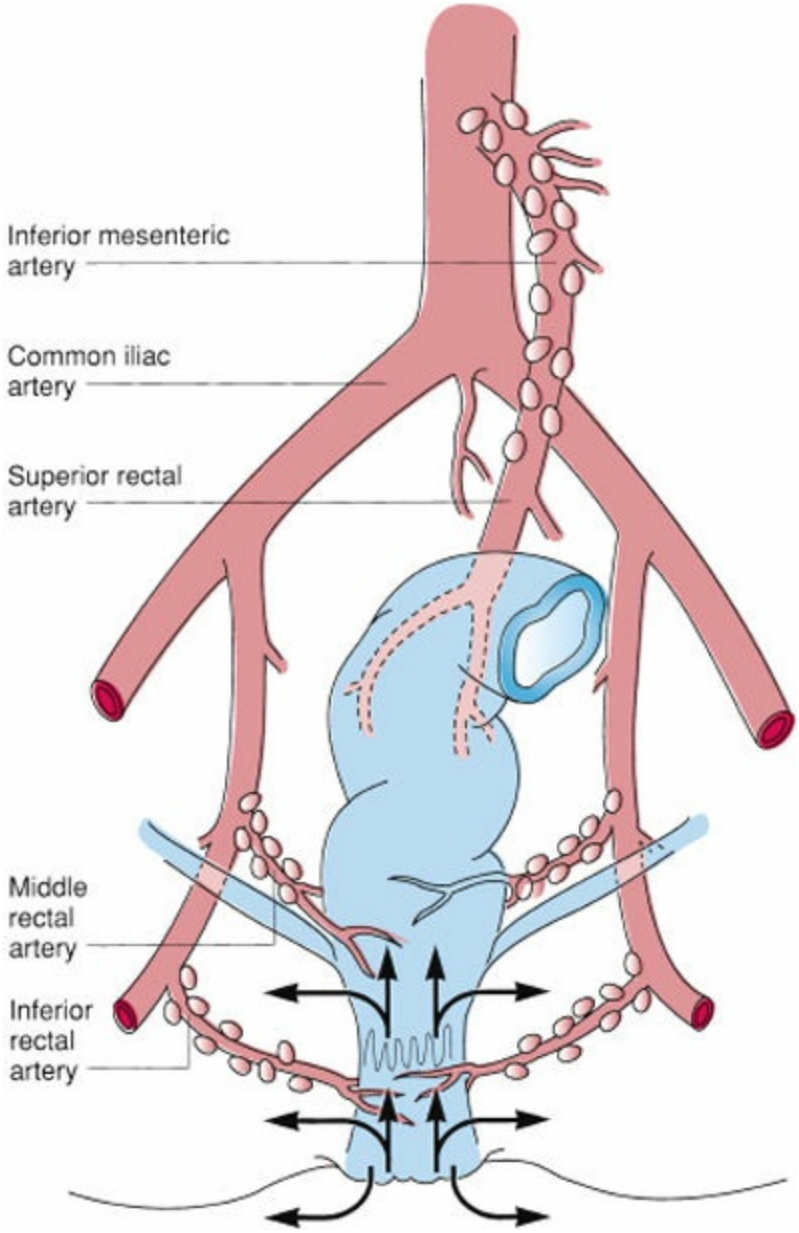

Figure 70-8. Lymphatic drainage of the anal canal.

Defecation involves both voluntary and involuntary mechanisms. If the call to defecate is answered, either the sitting or squatting position is assumed, thereby helping to straighten the anorectal angle. Straining by increasing the intra-abdominal pressure leads to a reflex relaxation of the puborectal muscle which further opens the anorectal angle and shortens the anal canal. Both the internal and external anal sphincters relax, the pelvic floor descends, and a funneling occurs, allowing the rectal contents to be expelled. After completion of rectal evacuation, a "closing reflex" occurs, where transient contraction of the external anal sphincter and puborectalis help to restore tonic contracture of the IAS (Fig. 70-10).

Diagnostic Evaluation of the Anus

Accurate diagnosis of anorectal disorders requires a detailed history and physical examination, and may include both anatomical and functional testing. Underlying illness or mediation use may present with symptoms in the anal area, and it is important to know about travel history and sexual activity. The most common presenting symptoms of anorectal disease are pain, bleeding, discharge, and change in bowel habits.

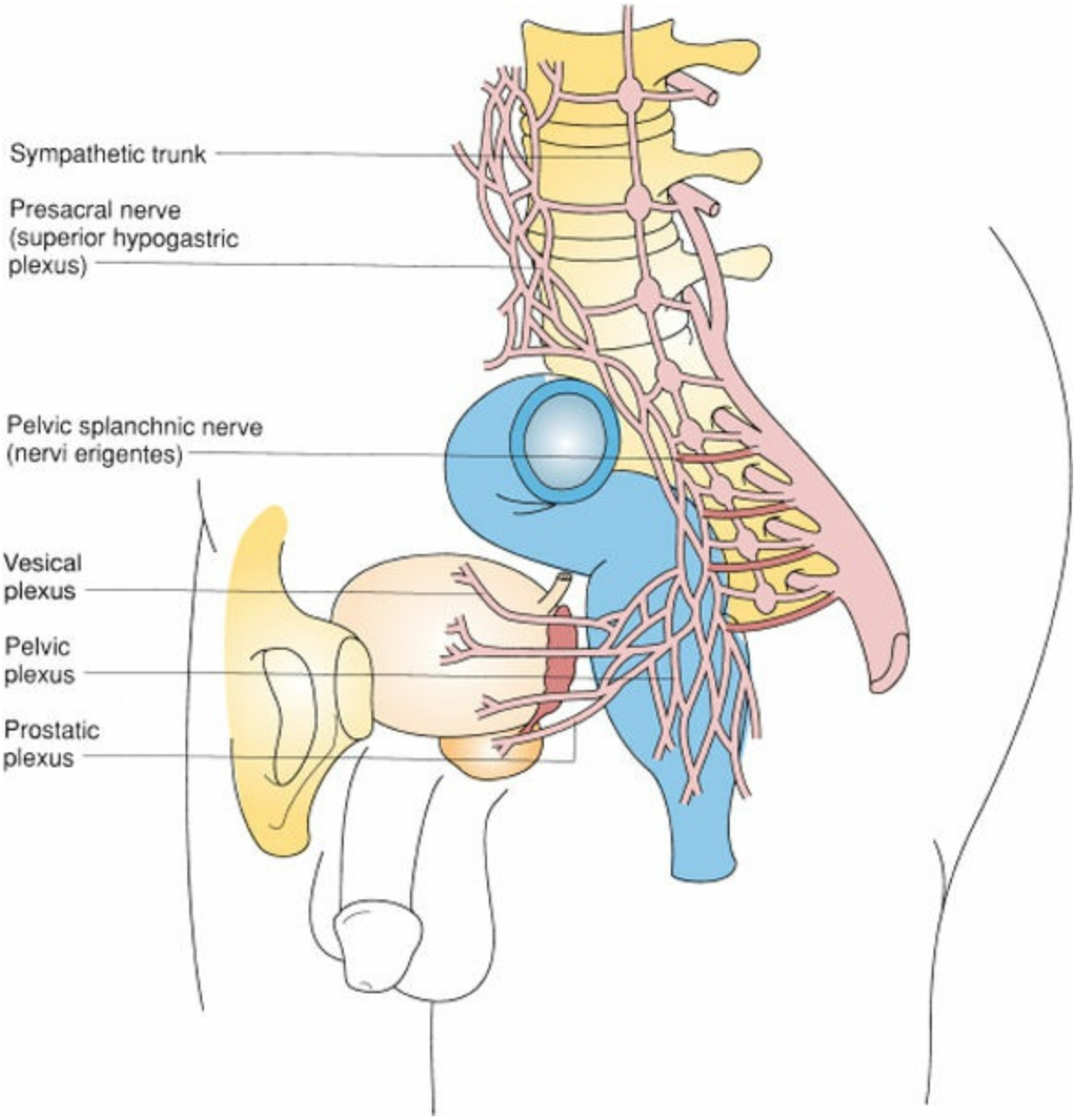

Figure 70-9. Sympathetic and parasympathetic nerve supply of the rectum.

Bleeding may be seen as the result of an anal condition, or may represent bleeding from a more proximal source in the gastrointestinal system. Obtaining a history of the type and frequency of bleeding may help in making the diagnosis. Bleeding that is bright red and is not mixed with the stool may indicate an anal source, while blood in the form of clots or melena is more indicative of a colonic source. Even in patients with rectal bleeding in whom an anal disorder is found, it is important to consider colonoscopic evaluation of the colon to exclude other sources, particularly in patients who are at increased risk for cancer.

Anal pain associated with swelling that may or may not be related to defecation may be indicative of a thrombosed external hemorrhoid or an abscess. Pain that occurs during or immediately after defecation is often secondary to an anal fissure. Episodic pain (unrelated to bowel movements) that lasts for a short duration may be due to a condition known as proctalgia fugax or levator ani syndrome.

Physical examination of the anus should include a visual inspection of the perianal area as well as a digital examination (Table 70-1). Patients can be examined in either the left lateral decubitus or prone jack-knife position. Simple explanation and reassurance about the planned examination helps to ensure cooperation of the patient and minimize discomfort. Inspection of the anus may demonstrate skin tags or external hemorrhoids, fissures, scars, or excoriation of the skin. Straining during inspection may help to demonstrate rectal prolapse or perineal descent. Digital examination with a well-lubricated gloved index finger will give information including the tone of the anal sphincters as well identification of any rectal masses.

More detailed evaluation of the anus includes anoscopy, rigid or flexible proctosigmoidoscopy, and ultrasonography, as well as physiologic tests such as anal manometry, electromyography, pudendal nerve assessment, and defecography. Use of these tests for specific conditions will be discussed later in the chapter.

BENIGN ANORECTAL DISEASE

Hemorrhoids

Hemorrhoids are cushions of vascular tissue found in the anal canal found from birth. Histologically, this tissue contains vascular structures whose walls do not contain muscle, and are therefore considered sinusoids instead of veins. The number and location of hemorrhoids may vary, however most commonly there are three pillars located in the left lateral, right anterior, and right posterior quadrants.

The term “hemorrhoids” typically refers to clinical situations where these vascular cushions are abnormal and cause symptoms. External hemorrhoids are defined by their location distal to the dentate line and are covered with squamous epithelium. Although these may swell and make anal hygiene difficult, they may also cause pain secondary to formation of clot within the sinusoid (thrombosed external hemorrhoids). Internal hemorrhoids are located proximal to the dentate line and are covered by transitional epithelium. As there are no somatic nerve endings here, internal hemorrhoids do not cause pain, but may present with bleeding or downward displacement of the cushion during defecation (referred to as prolapse). Hemorrhoids are classified according to the degree of prolapse (Table 70-2).

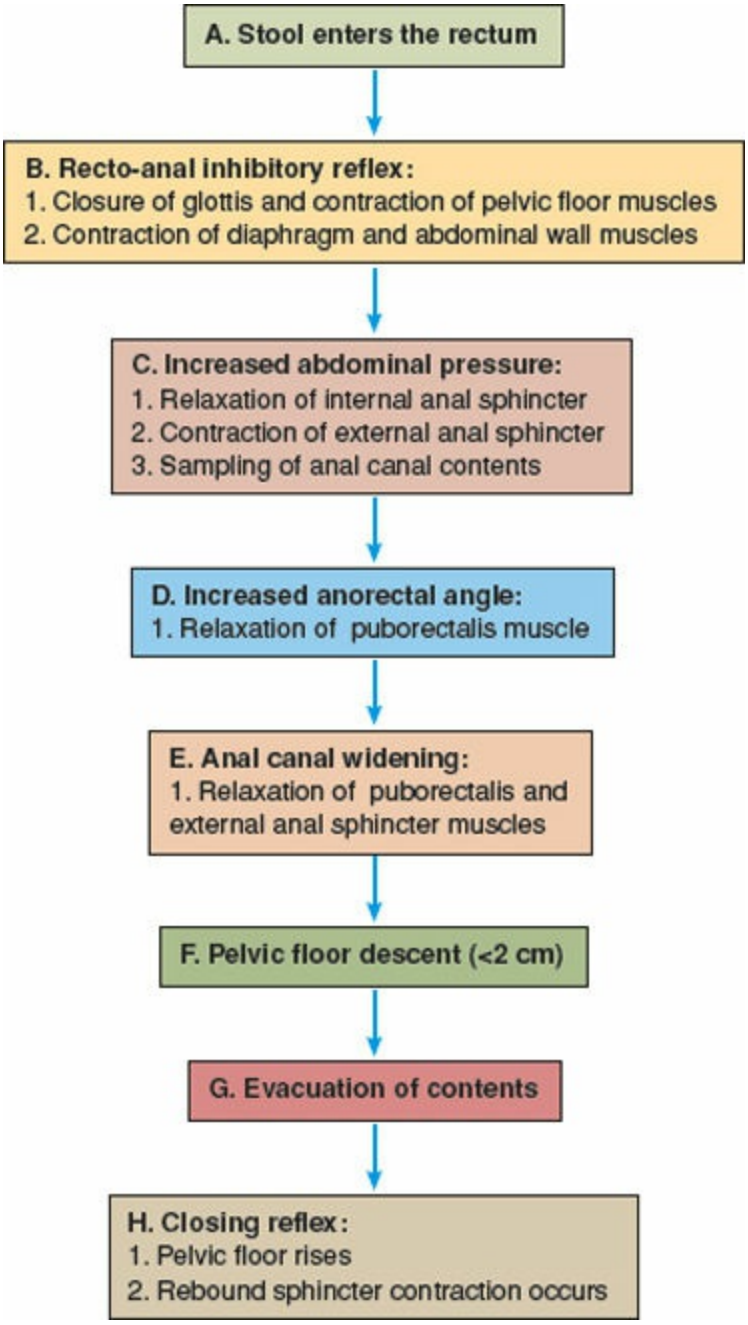

Figure 70-10. Mechanics of defecation.

Clinical Manifestations

1 Although patients may present with complaints of "hemorrhoids," many of the symptoms of pain, itching, burning, and swelling may not be related to hemorrhoidal disease, instead being due to anal fissure, prolapsed anal papilla, or pruritus ani. The most common symptoms of internal hemorrhoids are bleeding with bowel movements and prolapse of tissue with defecation. Patients will often describe blood dripping into the bowl and staining the toilet water bright red. After passing a firm stool or a forceful straining, bleeding may continue with bowel movements for several days and then resolve for a variable length of time. It is rare that hemorrhoidal bleeding is severe enough to result in anemia. Patients may also complain of a sensation of incomplete evacuation of the rectum, and in chronic cases of prolapse may complain of mucous drainage or incontinence.

Physical examination should include inspection both at rest and during straining, digital rectal examination, and anoscopy. Evaluation may be performed in either the left lateral or prone jack-knife position. Inspection will help to exclude other pathology, including anal fissure, external opening of an anal fistula, and perianal excoriation, as well as to evaluate for the presence of skin tags, external hemorrhoids, and prolapse. Internal hemorrhoids are soft and cannot be reliable diagnosed with the examining finger, however digital rectal examination may help to rule out a low rectal or anal neoplasm. If prolapse is present, it is possible to reduce the hemorrhoidal tissue during the examination. Anoscopy provides definitive examination of the anal canal, however this should be avoided in patients with anal pain due to fissure or abscess. While anoscopy may provide the diagnosis of hemorrhoids or other intra-anal pathology, patients presenting with rectal bleeding should also undergo assessment of the large intestine. In young patients, a flexible sigmoidoscopy may be sufficient, however in patients over the age of 50, those with significant risk factors for polyps or malignancy, or patients with inflammatory bowel disease, a colonoscopy should be performed.

Table 70-1 The Complete Digital Rectal Examination

Preparation
Enema
Left lateral decubitus position
Lighting, gloves, lubrication, anoscope
Visualization
Retract the buttocks
Inspect for:
Soiling
Excoriation or abrasion
Scarring
Patulous anus, deformity or flattening of folds
Fissure
External fistula opening
Anal wink reflex
Prolapse through anus with strain
External hemorrhoids
Palpation
Slow insertion of gloved, lubricated finger
Pain with examination
Palpable sphincter defect
Perineal body scarring
Anal stenosis
Relaxed or increased tone
Prostate abnormalities (men) or anterior rectocele (women)
Gross blood present
Muscle function: squeeze
Adequate
Accessory muscle use
Strain
Adequate
Puborectalis relaxation
Prolapsing tissue
Other organ prolapse

Table 70-2 Hemorrhoids Classification

Degree	Description
First	Hemorrhoids bleed but do not prolapse
Second	Hemorrhoids prolapse on straining but reduce spontaneously
Third	Hemorrhoids prolapse and require manual reduction
Fourth	Prolapsed hemorrhoids cannot be manually reduced

Treatment

Depending on the severity of the symptoms and the grade of the hemorrhoids, patients may be treated through nonoperative measures, office-based procedures, or operative therapy.

Nonoperative Management

As constipation and excessive straining during defecation are often the underlying causes of hemorrhoids, symptoms can be reduced or eliminated in many patients by altering their dietary intake and lifestyle. This goal is often achieved in patients with grade 1 or 2 hemorrhoids by increasing fluid and fiber in the diet, increasing physical exercise, and adding supplemental fiber. Fiber helps to add moisture to the stool to decrease constipation, and the addition of fiber has been shown in a double-blind, placebo controlled trial to be effective in reducing hemorrhoidal bleeding.[3] Warm sitz baths, suppositories, and topical creams or ointments may also help to alleviate symptoms, however they often do not provide a long-term solution.

2 In patients with first-, second-, or third-degree internal hemorrhoids with no symptomatic external disease who fail conservative therapy, office-based therapies such as rubber band ligation, sclerotherapy, or photocoagulation may be an option. Rubber band ligation can be performed through an anoscope in the office without the use of anesthesia. The band is placed around the hemorrhoid above the dentate line, causing localized ischemia of the intervening tissue (Fig. 70-11). More than one hemorrhoid may be banded at one time, however multiple synchronous bands may lead to increased pain. A portion of the hemorrhoid and the rubber band are passed during defecation 48 to 72 hours following application. Fibrosis that occurs at the site of the banding causes fixation of the remaining hemorrhoidal tissue, which helps to prevent further prolapse and bleeding. Relief of symptoms may be achieved in up to 80% of patients who undergo banding, however recurrence rates as high as 30% have been reported.[4] Complications of hemorrhoidal banding include severe pain requiring removal of the band, increased bleeding, and thrombosis of the hemorrhoids. Severe perianal sepsis is a rare complication, and should be suspected in any patient who develops worsening pain, fever, or the inability to void.

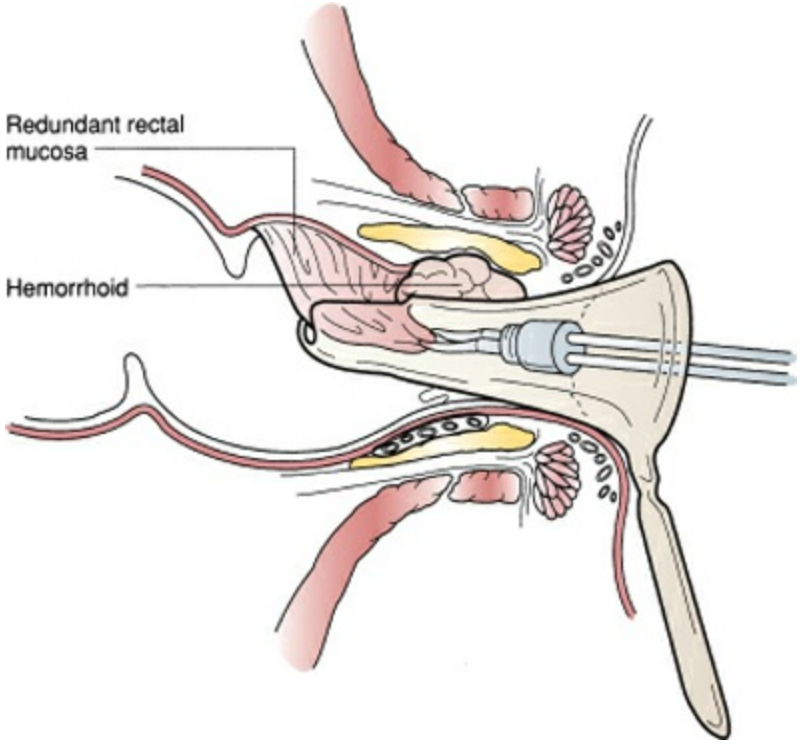

Figure 70-11. Rubber band ligation of an internal hemorrhoid.

Sclerotherapy involves the injection of a sclerosing agent into the submucosa that leads to fibrosis of the surrounding tissue. Many different injection agents have been described, however phenol is most commonly used. Injection is performed through an anoscope, and may be an option for symptomatic hemorrhoids that are too small to band. It is important not to inject the sclerosant directly into the hemorrhoids or thrombosis may ensue. Infrared photocoagulation causes thrombosis and tissue destruction within the anal canal. The probe is applied just proximal to the internal hemorrhoids through an anoscope. Results with both sclerotherapy and photocoagulation are varied and tend to be temporary only.

Operative Treatment

3 Excisional hemorrhoidectomy should be considered in patients who fail conservative or office-based procedures, who have combined internal and external hemorrhoids, who have hemorrhoids that require manual reduction (grade 3), or who have associated pathology such as ulceration, fissures, or fistulas. Hemorrhoidectomy is typically an outpatient procedure, and in most cases local or regional (spinal) anesthesia may be used, however general anesthesia may also be employed. The patient is placed in the prone jack-knife position with the buttocks taped apart. An elliptical incision is made, beginning on the anoderm to remove any external component of the hemorrhoid, and is continued to the base of the hemorrhoid above the dentate line (Fig. 70-12). It is critical to preserve the underlying IAS muscle, as damage to the IAS may lead to postoperative incontinence. One, two, or three hemorrhoidal bundles may be excised at once, however it is also critical to ensure that normal anoderm is left between the excision sites; failure to preserve this anoderm may lead to postoperative anal stenosis. The dissection may be undertaken with the use of a scalpel, scissors, electrocautery, or controlled electrical

energy such as ultrasonic shears or a bipolar vessel sealing device. The wound may be left open or, more commonly, may be closed with absorbable suture.

Excisional hemorrhoidectomy is superior to office-based therapies in achieving complete remission of hemorrhoidal symptoms, however complications including stenosis and hemorrhage are more common.[5] Patients who undergo hemorrhoidectomy are also less likely to require multiple treatments. Surgical treatment of hemorrhoids can unfortunately also result in significant postoperative pain, and patients often require narcotic pain medication and may require up to 2 to 4 weeks to recover.

Stapled hemorrhoidopexy, while initially described as a treatment of mucosal prolapse, is also an option for prolapsing and bleeding hemorrhoids. Also known as the Procedure for Prolapse and Hemorrhoids (or PPH), this technique involves the removal of a circumferential sleeve of mucosa and submucosa of the distal rectum and anus. A circular stapler creates an anastomosis which elevates the anal canal and fixes the anal cushions into their normal anatomic positions. Because the resection is performed above the level of the dentate line, this technique is advantageous as it may result in less postoperative pain. It has no effect on external hemorrhoids, and therefore its use is somewhat limited.

Stapled hemorrhoidopexy is begun by placing a purse string suture in the mucosa and submucosa approximately 4 cm above the dentate line, incorporating all the redundant tissue circumferentially (Fig. 70-13). Correct placement of this suture is critical to prevent placement of the stapler too close to the dentate line, which can result in chronic pain. The anvil of a specialized circular stapler is then passed above the purse string, and the suture is used to pull the mucosa and submucosa into the stapler head. The stapler is then fired, which excises the sleeve of tissue and creates the anastomosis.

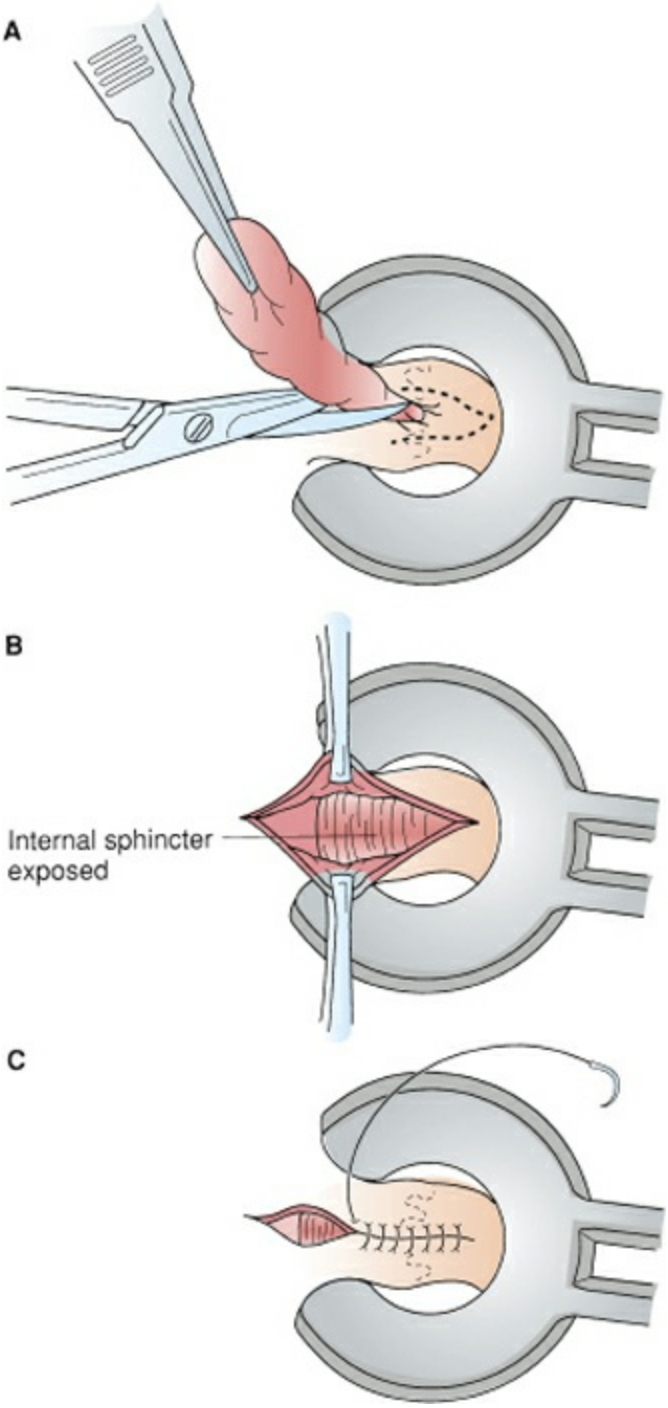

Figure 70-12. Technique of internal closed hemorrhoidectomy. **A:** Exposure of hemorrhoid with elliptic excision starting at perianal skin and extending to anorectal ring. **B:** Submucosal hemorrhoidal plexus dissected from the internal sphincter, anoderm, and mucosa. **C:** Wound closed with a running suture.

A meta-analysis of prospective randomized studies demonstrated that when compared with excisional hemorrhoidectomy, stapled hemorrhoidopexy offers some short-term benefits including less postoperative pain and earlier return to normal activity.[6] In long-term follow-up, however, stapled hemorrhoidopexy has been associated with a higher rate of recurrent symptoms. Although PPH has been associated with several unique complications (rectovaginal fistula, staple line bleeding, and chronic pain), the overall rates of postoperative complications did not differ between the procedures.

Doppler-guided transanal hemorrhoid devascularization involves suture ligation of each hemorrhoidal column with resection of the hemorrhoid. A specific anoscope that includes

a Doppler probe is used to identify the signal of the vessel feeding each hemorrhoidal column, typically above or just at the top of the column. Once the vessel is identified, it is then ligated with a suture and the Doppler probe is again used to confirm the disappearance of the signal. Typically the hemorrhoidal column is then also oversewn with this suture. The purported benefit of this procedure is that because the ligation occurs above the dentate line, postoperative pain should be significantly lower than with an excisional hemorrhoidectomy. Long-term results with this procedure are limited, however some authors have reported effectiveness in 90%.[7]

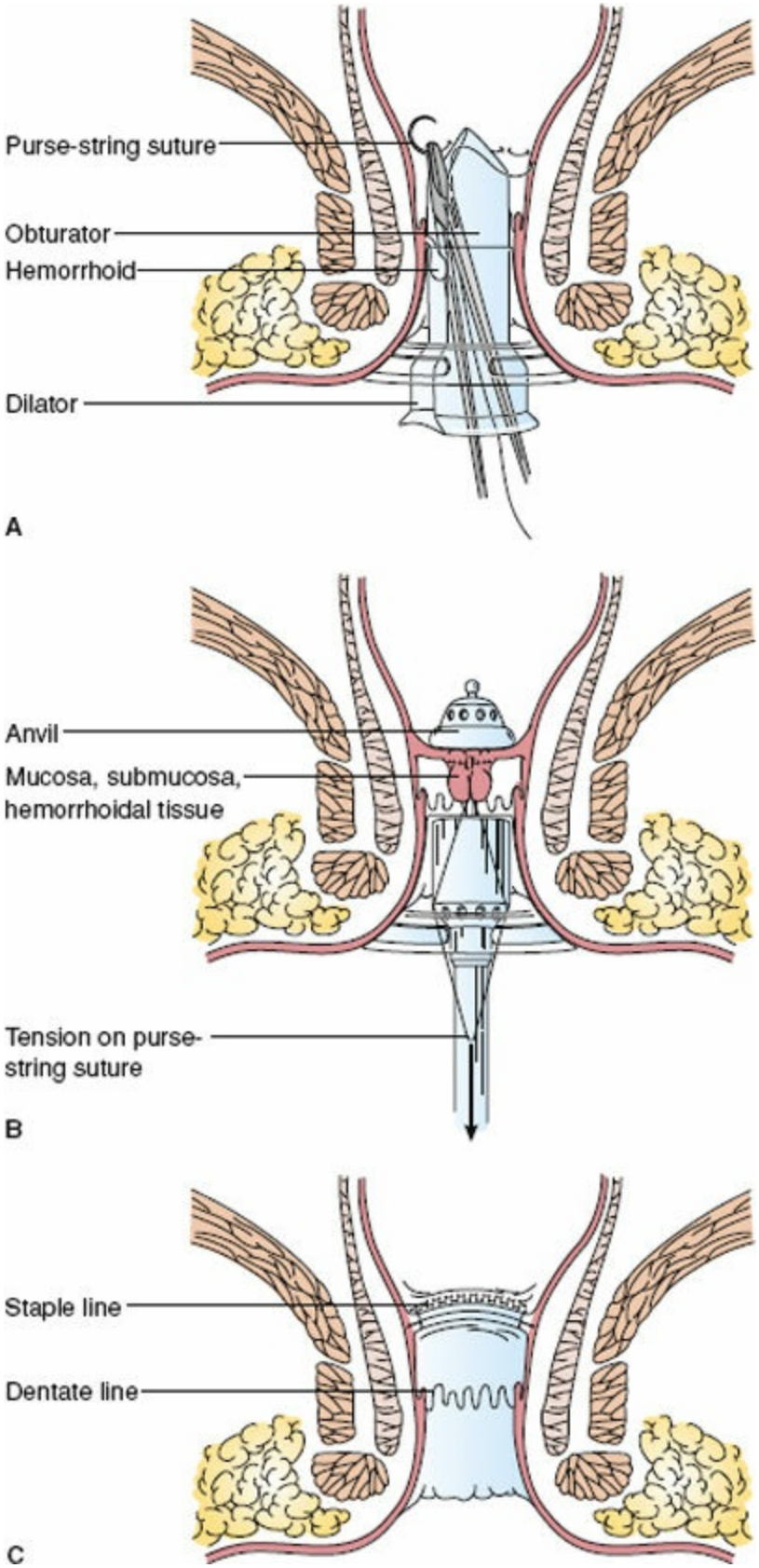

Figure 70-13. Stapled circular hemorrhoidectomy or procedure for prolapsing hemorrhoids. **A:** A purse-string suture is placed in the rectal mucosa proximal to hemorrhoids. **B:** The stapler anvil is placed proximal to the purse string, and the purse string is tied down to draw hemorrhoidal tissue into the staple line. **C:** The stapler is fired and removed, excising a sleeve of distal rectal tissue and creating a stapled anastomosis.

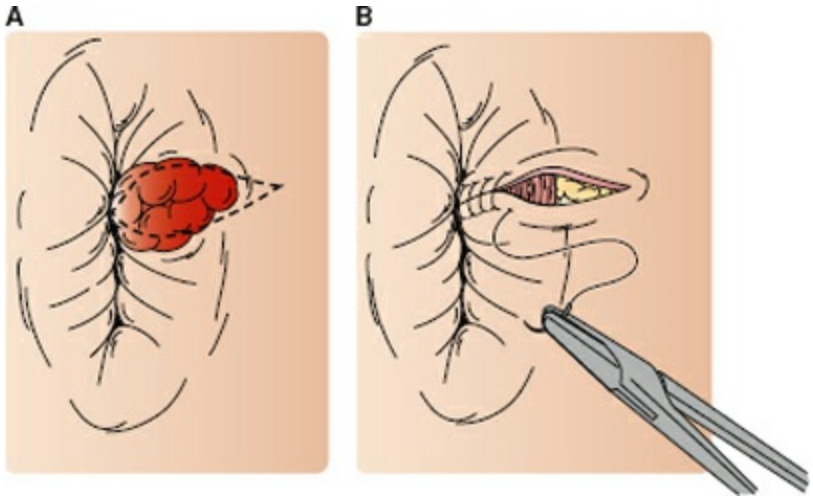

Figure 70-14. **A, B:** Excision of the entire thrombosed hemorrhoid.

Special Hemorrhoid Situations

Thrombosed External Hemorrhoids. Thrombosed external hemorrhoids are a relatively common complication of hemorrhoidal disease. The exact etiology is unknown, however their presence is often associated with physical exertion or straining (heavy exercise, moving or lifting furniture) or a bout of severe constipation. Patients typically present with a painful, tender mass in the perianal area. Frequently, the thrombosis will lead to necrosis of the overlying skin and patients will complain of bleeding that is independent of bowel movements.

The management of thrombosed external hemorrhoids depends on when in the course of the disease the patient presents. The pain associated with this condition typically peaks within 48 hours and normally begins to subside after 4 days. If left untreated, the clot in the thrombosed vessels will dissolve within several weeks. Following resolution, large thrombosed hemorrhoids may remain as skin tags.

Because this condition is self-limiting, management is typically conservative and includes pain control with a mild analgesic, warm sitz baths, and a bulk-producing agent (usually psyllium fiber). If the patient presents within the first 48 hours, the procedure of choice is excision of the entire thrombosed hemorrhoid (Fig. 70-14). This procedure may be performed in the office or emergency room with the use of a local anesthetic. Using scissors, the thrombosed hemorrhoid is excised with the underlying vein; it is important to excise the entire thrombus in order to prevent recurrence. The skin edges are then reapproximated with the use of an absorbable suture or may be left open.

Incarcerated Hemorrhoids. Rarely, patients will present with prolapsed fourth-degree hemorrhoids which have become incarcerated. While internal hemorrhoids do not typically cause pain, patients with incarcerated hemorrhoids often have severe pain and may develop urinary retention. Edematous prolapsed hemorrhoids are seen, often in combination with large external components as well. Traditionally this condition has been treated with an urgent or emergent hemorrhoidectomy, however there is concern that leaving inadequate anoderm between the excision sites may lead to postoperative stenosis. Instead, patients may be treated with oral or intravenous pain medications and

stool softeners, allowing the edema to resolve and the prolapse to reduce. These patients should then be offered an elective hemorrhoidectomy to prevent recurrence.

Anal Fissure

5 Anal fissure is an ulcer-like tear in the mucosal lining of the anal canal distal to the dentate line. Although more commonly found in younger patients, fissures can occur at any age and equally afflict male and females. Fissures can be classified as acute or chronic, and as primary or secondary. Primary anal fissures are almost always located in the posterior or anterior midline, and are not associated with any underlying disease. Secondary fissures may occur in a lateral position, and should alert the clinician to the possibility of Crohn's disease, HIV infection, tuberculosis, syphilis, or a hematologic malignancy. Anal fissures that have been present for longer than 6 weeks duration are arbitrarily classified as chronic.

The exact etiology is not known, however several mechanisms are thought to lead to the development of anal fissure. Trauma to the anal canal appears to be the initiating factor, most commonly as the result of passage of hard stool, as a low fiber diet seems to be associated with the development of anal fissure.[8] Fissure may also occur following prolonged bouts of diarrhea, or following childbirth, most likely the result of forces from the fetus on the anal canal.

Hypertonicity of the IAS with resultant ischemia has also been implicated in development of chronic anal fissure. Ninety percent of fissures are found in the posterior midline of the anal canal, where Doppler flow studies and cadaver vascular injections have demonstrated relatively low perfusion. Studies have shown that when compared with normal subjects, patients with chronic anal fissure have higher resting pressure of the IAS. If the pressure within the anal sphincter approaches or exceeds the intra-arterial pressure of the inferior rectal artery, this may lead to relative ischemia and the development of an ischemic ulcer. This theory is strengthened by the fact that reduction of anal pressure following sphincterotomy improves blood flow to the anal canal, thereby promoting healing of the fissure.[9]

Clinical Manifestations

Anal fissure typically presents with pain during defecation and rectal bleeding. Patients often describe the pain as knifelike or as a tearing sensation, which may persist for several hours or longer after bowel movements. Rectal bleeding is typically bright red, and is separate from the stool and often seen only after wiping. Constipation is a common complaint of patients with anal fissure, and is frequently both a precipitating event and a result of patients' fear of a painful bowel movement.

The diagnosis of anal fissure can be made on physical examination by gently spreading the buttocks apart to visualize the anal verge. Fissures will appear as a longitudinal or oval-shaped tear and may be associated with a sentinel pile, a protruding skin tag at the distal end of the fissure. Fibers of the IAS may be visible in chronic anal fissures. Once a diagnosis of fissure has been made, digital examination or anoscopy adds little other than increased pain for the patient, and should therefore be avoided.

Management

Medical Management. Symptomatic relief of anal pain from fissures may be obtained by warm sitz baths two to three times per day. Topical anesthetics or anti-inflammatory ointments may also be of benefit. The majority of patients with acute anal fissure will respond to conservative measures including sitz baths and the addition of a bulking agent such as psyllium fiber. Acute anal fissures often heal within 6 weeks, although the recurrence rate approaches 20%.[10]

As anal fissure is associated with hypertonicity of the anal sphincter, medical therapy is directed as decreasing resting anal pressures. Nitric oxide is a potent neurotransmitter that induces relaxation of the IAS. Application of 0.2% nitroglycerin ointment twice daily has been shown to induce healing in as many as 85% of patients,[11] however, patient compliance is often low due to nitrate-induced headache. Calcium-channel blockers have also been shown to reduce anal pressures. Topical diltiazem or nifedipine has been shown to have healing rates equivalent or superior to nitroglycerin[12] without the associated side effects. Unfortunately, recurrence rates with all of these therapies approach 50% in many series.

Botulinum toxin is an endopeptidase that blocks acetylcholine release at the neuromuscular junction, resulting in temporary paralysis of skeletal muscle. Although its exact mechanism of action in smooth muscle is not understood, injection of the toxin also results in relaxation of the IAS. The technique, dose, and success rates have widely varied in the literature, however some authors have reported success in 60% to 80% of patients. The most common side effect is temporary anal incontinence, typically only to flatus. The use of botulinum toxin may be an option in patients who have failed topical treatment, but who may be at a high risk of complications from surgery.

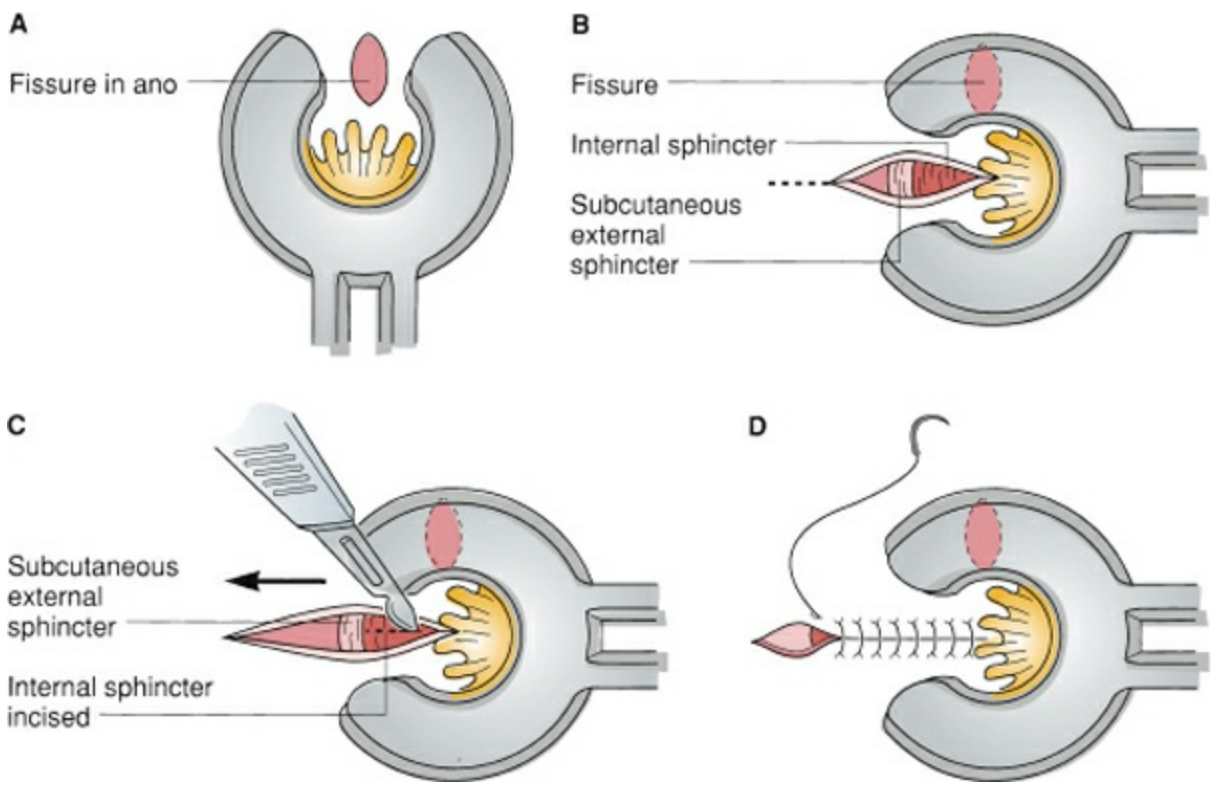

Figure 70-15. Lateral internal sphincterotomy (open method). **A:** The fissure in the midline is left alone. **B:** With a speculum used to expose the left lateral quadrant, an incision is made through the subcutaneous tissue to expose both the subcutaneous external sphincter and the internal sphincter. **C:** The internal sphincter is incised to its full thickness; care is taken not to cut the external sphincter. **D:** The wound is closed.

Surgical Management. In patients with chronic or recurrent fissures that fail to heal with medical management, surgical intervention is warranted. The most commonly performed procedure is the lateral internal sphincterotomy, which is an outpatient procedure that may be performed under local, spinal, or general anesthesia. When performed in an open fashion, an incision is made overlying the anal sphincter complex in the lateral position away from the fissure (Fig. 70-15). The internal sphincter is identified, and a portion of the muscle is cut typically extending cephalad to the level of the apex of the fissure. The wound is then closed with an absorbable suture. The procedure can also be performed in a closed fashion, where the scalpel is inserted into the intersphincteric groove, turned horizontally, and used to cut the internal sphincter as the anal canal is stretched open with a speculum. Healing rates following sphincterotomy range from 90% to 100%, however, impairment of continence following the procedure has been reported to be as high as 47%.[13]

In patients who are at high risk of experiencing postoperative incontinence, an alternative approach may be the use of an advancement flap. This procedure involves excision of the fissure, surrounding scar tissue, and any skin tags. A variety of flap configurations including V-Y, Y-V, house, and others have been employed to help close the defect. Healing rates following fissurectomy and advancement flap are comparable to those following sphincterotomy.

Anorectal Abscess

The vast majority of anorectal abscesses result from infection of the glands that empty into the anal crypts within the anal canal at the level of the dentate line. Other causes of anorectal abscess include inflammatory bowel disease, trauma including iatrogenic (usually gynecologic or surgical) trauma, infections such as tuberculosis and actinomycosis, and malignancy. Since these glands lie within the intersphincteric space, blockage of a duct results first in an intersphincteric abscess which can then spread to the surrounding spaces (Fig. 70-16). The most commonly encountered anorectal abscess occurs in the perianal area, followed in frequency by ischioanal, intersphincteric, and supralevator (Fig. 70-17).

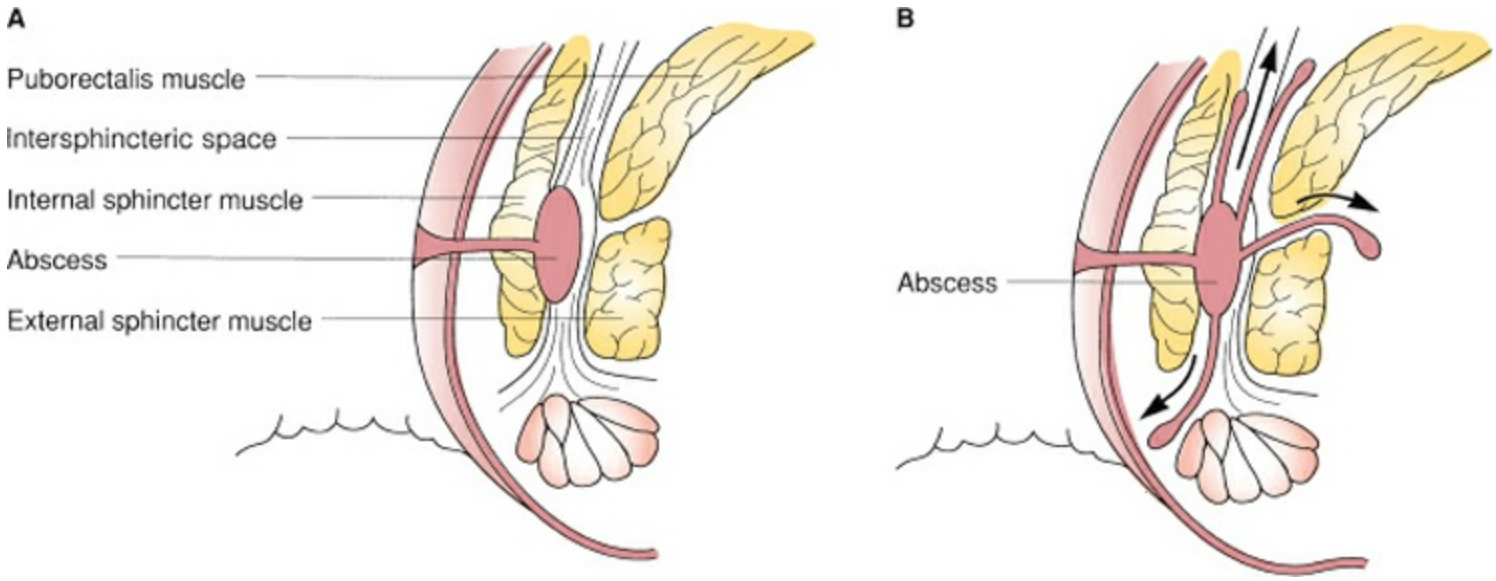

Figure 70-16. Pathways of infection start in the intersphincteric space (**A**) and then spread to perianal spaces, forming perianal abscesses (**B**).

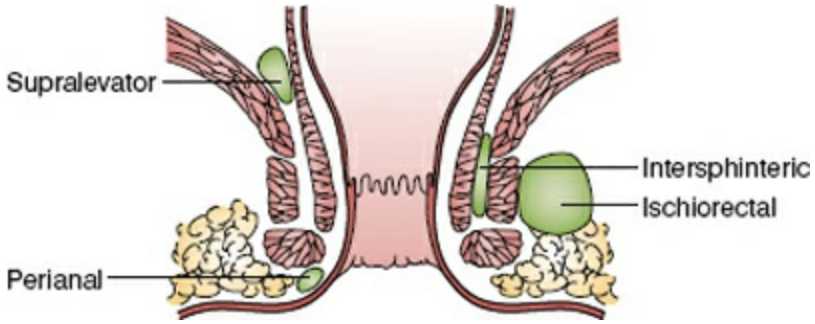

Figure 70-17. Classification of anorectal abscess.

Clinical Manifestations

Most patients with anal abscess present with pain. In patients with perianal or ischioanal abscesses, pain may be accompanied by swelling and erythema. Conversely, patients with supralevator abscess are less likely to present with swelling and may have accompanying fever. Patients with severe rectal pain may also develop urinary retention.

Management

Treatment of anorectal abscesses requires incision and drainage; antibiotics alone are ineffective and may allow the suppurative process to progress to a more complicated abscess. The use of antibiotics in conjunction with drainage may be considered in the patient with concomitant cellulitis or in immunocompromised patients.

Most patients with perianal abscesses can be treated in an outpatient setting under local anesthesia. An elliptical or cruciate incision is made over the most tender area or area of fluctuance, and the skin edges are trimmed to prevent early closure of the wound, and all loculations are drained. Routine culture of the drainage is not recommended. Packing is also not necessary; rather, patients are instructed to soak the area in warm water and simply keep the wound covered with gauze.

Patients with superficial ischioanal abscesses may be treated in a similar fashion, however patients with deeper or more complex abscesses typically require an examination under anesthesia with drainage in the operating room. Less commonly, patients may present with bilateral ischioanal abscess, a condition referred to as a horseshoe abscess. These infections typically begin in the deep postanal space, which spread to both ischioanal areas. Treatment requires that the deep postanal space be drained, which is accomplished by making a longitudinal incision in the skin between the tip of the coccyx and the anus and exposing the anococcygeal ligament. The ligament is then divided and the deep postanal space drained; counter incisions are then made overlying the ischioanal areas as well.

Patients with intersphincteric abscess often present with severe anorectal pain, however no indurated or fluctuant area is evident. These patients also typically require an examination under anesthesia. In the operating room, an intersphincteric abscess can be diagnosed by palpation of a protrusion into the anal canal or aspiration of purulent fluid from the intersphincteric space. Drainage is performed by dividing a portion of the internal sphincter muscle along the length of the abscess cavity.

Supralevator abscesses are less common and can often be difficult to diagnose. Because the location of the abscess is adjacent to the abdominal cavity, patients may present with abdominal or pelvic pain. Digital examination may demonstrate induration or a tender mass located in the distal rectum above the level of the anorectal ring. The etiology of a supralevator abscess dictates its management. These abscesses may result as an extension of an intersphincteric abscess, extension of an ischioanal abscess, or may result from an intra-abdominal abscess from perforated diverticulitis, appendicitis, or Crohn’s disease. Supralevator abscess secondary to extension from an ischioanal abscess should be drained through the ischioanal area. Supralevator abscess secondary to extension from an intersphincteric abscess should be drained into the rectum, as drainage through the ischioanal area may result in a complex suprasphincteric fistula. Percutaneous drainage may be an option in patients with supralevator abscess secondary to an intra-abdominal source.

Rarely, anorectal abscess can result in necrotizing infection and death, a condition referred to as Fournier gangrene. This situation may result from a delay in diagnosis and management of an anorectal abscess, infection with a highly virulent organism, or may be due to patient factors such as diabetes or compromised immune function. The infection

superficially spreads around the perineum, causing necrosis of the skin and underlying muscle and fascia. Treatment includes empiric broad-spectrum intravenous antibiotics and prompt surgical debridement of the necrotic tissue until healthy tissue is encountered.

Anal Fistula

6 A fistula is generally defined as an abnormal communication between two epithelialized surfaces. Anal fistula (or fistula-in-ano) represents a communication between the anorectal canal and the perianal skin as the result from spontaneous or surgical drainage of an anorectal abscess. The incidence of fistulas following abscess drainage ranges from 5% to 83% in the medical literature, but is generally thought to occur in one-quarter to one-third of patients.[14] Anal fistulas may also occur in up to 30% of patients with Crohn's disease.

Classification

Treatment of anal fistulas is in part dictated by the type of fistula. Fistulas are classified by their relation to the anal sphincter complex (Fig. 70-18).[15] The most common type is the intersphincteric fistula, followed by transsphincteric, suprasphincteric, and extrasphincteric (Box 70-1).

Clinical Manifestations

The majority of patients with anal fistula have a history of previous anorectal abscess which either spontaneously drained or were surgically incised. Recurrence of anorectal abscess in the same location often indicates the presence of an underlying fistula. Patients complain of drainage, intermittent swelling, pain with defecation, and occasional bleeding. Physical examination often demonstrates an external opening on the perianal skin with granulation tissue. Drainage of fecal, purulent, or serosanguinous drainage may be evident or can be elicited with digital rectal examination or compression of the fistula tract.

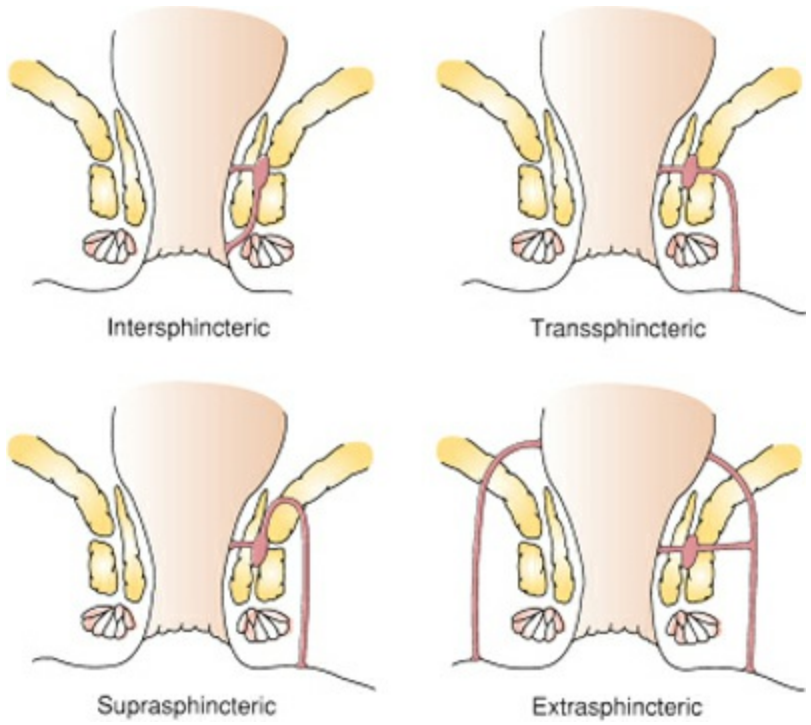

Figure 70-18. The four main anatomic types of fistula.

Box 70-1 Classification of Anal Fistulas

Intersphincteric Fistula. The tract of the fistula lies within the intersphincteric space and the external opening lies close to the anal verge. These fistulas are the most common, and typically result following a perianal abscess.

Transsphincteric Fistula. The fistula tract begins in the intersphincteric space and then traverses through a portion of the external sphincter muscle. The external opening typically lies over the ischioanal fossa.

Suprasphincteric Fistula. The fistula tract begins in the intersphincteric space and then passes upward above the external sphincter and then perforates the levator ani muscles to drain through the ischioanal fossa.

Extrasphincteric Fistula. The fistula tract begins in the distal rectum rather than the anal canal and perforates the levator ani muscles to drain through the ischioanal fossa. These fistulas are rare and develop typically from Crohn's disease or rectal trauma.

Hidradenitis suppurativa may present in a similar fashion to anal fistula, with multiple openings on the perianal skin with surrounding induration. Unlike anal fistulas, however, any tracks associated with hidradenitis are superficial and do not communicate with the anal canal. A pilonidal sinus with perianal extension may also mimic an anal fistula, but in this situation the tract moves superiorly, away from the anal canal. Much less commonly actinomycosis can mimic a complex fistula.

Examination under anesthesia is recommended in order to treat any undrained abscess and to identify the internal opening. Flexible sigmoidoscopy may also be performed to evaluate for concomitant inflammatory bowel disease or malignancy. Under anoscopic guidance, a fistula probe can be inserted into the external opening through the fistula tract to determine the location of the internal opening. Goodsall rule states that if an imaginary line is drawn transversely across the anus, an external fistula opening seen posterior to this line will originate from an internal opening in the posterior midline, whereas an opening anterior to this line will originate from the closest anal crypt (Fig. 70-19).

Locating the internal opening is not always possible with a fistula probe, and in this situation other diagnostic maneuvers may be necessary. Injection of the external opening with hydrogen peroxide either with or without the use of endoanal ultrasound may help identify smaller fistulas. For patients with multiple or complex fistulas, fistulography with a water soluble contrast and fluoroscopy has been described, although the use of magnetic resonance imaging has largely replaced this.

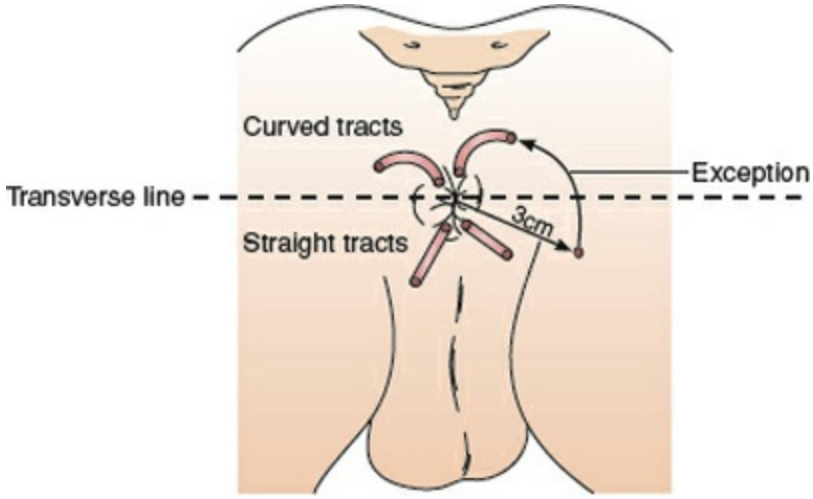

Figure 70-19. Goodsall's rule for anal fistula.

Management

Options in the surgical treatment of an anal fistula include fistulotomy, cutting seton, fibrin glue, collagen plug, ligation of the intersphincteric fistula tract (LIFT), and advancement flaps. Specific treatment is dictated by the path of the fistula and the amount of sphincter complex that is involved in the tract. Any division of the sphincter muscle during treatment of a fistula carries with it a risk of impaired continence. Patients at higher risk of incontinence include those with pre-existing impaired continence (elderly patients and women with a history of episiotomy) and patients with chronically loose stools (colitis and Crohn's disease). The location of the fistula is also important; the sphincter complex is shorter anteriorly in women, and division of muscle here is particularly risky.

Simple submucosal, intersphincteric, and low transsphincteric fistulas may be managed with fistulotomy with very low risk of postoperative incontinence. Under regional or general anesthesia, the patient is placed in the prone jack-knife position. A fistula probe is inserted from the external opening to identify the internal opening at the dentate line. If there is no significant muscle overlying the probe, the tissue is incised and any granulation tissue is curetted. The wound is left open to heal by secondary intention, or the wound may be marsupialized by suturing the wound edges to the tract.

Fistulas that involve a significant portion of the sphincter muscle (high transsphincteric and suprasphincteric fistulas) are better managed in a staged fashion with the use of a seton. A seton is a suture or vessel loop that is passed through the fistula tract and is tied to itself to form a ring between the internal and external openings. The purpose of this is to facilitate drainage of the fistula and promote wound contracture. Setons may be used as a bridge to a more definitive procedure, or may be used in a "cutting" fashion. A cutting seton is tightened at regular intervals, gradually cutting through the sphincter muscle. In theory, this leads to fibrosis of the sphincter muscle rather than a retracted defect. This may be continued until the fistula has completely resolved, or a staged fistulotomy may be performed to divide the remaining sphincter muscle.

In an effort to minimize postoperative incontinence, fibrin glue and collagen plugs have been used in the treatment of anal fistulas. The mere existence of this plethora of

therapeutic alternatives attests to the lack of satisfactory efficacy with all of them. Fibrin glue is made of a combination of fibrinogen, thrombin, and calcium. Injection of this into the fistula tract is thought to induce clot formation and promote the growth of collagen to close the fistula. Short-term success rates have been reported as high as 70%, however late recurrences despite initial healing are common.[16] Fistula plugs made of porcine submucosal collagen inserted into the fistula tract are intended to provide a scaffold for the growth of fibroblasts to heal the fistula. Long-term healing with fistula plugs has also been disappointing, with success rates of only 30%,[17] however, success rates may be higher in long fistula tracts.

LIFT is a surgical technique that avoids division of the sphincter complex. With the patient in the prone jack-knife position, a probe is passed through the fistula tract. An incision is then made in the intersphincteric groove directly overlying the probe, and plane between the two muscles is dissected. The fistula tract is then divided and ligated between the internal and external sphincter muscles. Success with this procedure has been reported as high as 88%.[18] If the LIFT procedure fails, the fistula often recurs in the intersphincteric plane, thereby allowing treatment with a fistulotomy.

The use of endorectal advancement flaps has been advocated for high transsphincteric and suprasphincteric fistulas, fistulas associated with inflammatory bowel disease, fistulas in patients who have failed other treatments, and anterior fistulas in female patients. In this procedure, the fistula tract is either cored out or curetted, and the internal opening is identified and excised. A full-thickness flap of rectal mucosa and submucosa is raised and advanced, typically 1 cm below the level of the internal opening. It is important to maintain adequate blood supply by creating a flap, the base of which is twice the width of the apex. Successful healing following an endorectal advancement flap has been reported in as high as 90% of patients, although much lower in patients with Crohn's disease and/or receiving steroids.[19]

Anal Fistula Associated with Crohn's Disease

Treatment of anal fistulas in patients with Crohn's disease can be particularly challenging. Surgical treatment of these fistulas is associated with poor wound healing and the risk of sphincter injury. Medical treatment of the underlying Crohn's disease is therefore extremely important in improving the chance of fistula healing. Antibiotics such as ciprofloxacin and metronidazole have been shown useful; 8 weeks of oral metronidazole has reportedly eliminated drainage, erythema, and induration in up to 80% of patients.[20] Treatment with azathioprine and methotrexate have been shown to have little impact on fistula healing. Infliximab, a monoclonal antibody against tumor necrosis factor-α, has been shown to be effective in Crohn's anal fistulas. Treatment with infliximab alone has been shown to reduce the number of draining fistulas by half in 62% of Patients with Crohn's disease (compared with only 26% of patients treated with placebo).[21] When combined with surgical intervention, fistulas in patients treated with infliximab may heal faster than those treated with surgery alone.[22]

Surgical intervention in patients with Crohn's anal fistulas should be conservative and limited initially to adequate drainage with liberal use of draining setons. Although

fistulotomy for subcutaneous fistulas may be considered, active Crohn's disease within the rectum is associated with poor outcomes. Due to the high likelihood of recurrence or the development of additional fistulas, any division of the sphincter muscle should be avoided. Once any infection has been drained and the underlying Crohn's disease has been optimally controlled with medication, repair with either an endorectal advancement flap or LIFT may be an option. In rare cases of Crohn's anal fistulas, fecal diversion with a stoma or proctectomy may be warranted.

Rectovaginal Fistula

A rectovaginal fistula is a communication between the anterior wall of the anal canal or rectum and the posterior wall of the vagina. Obstetrical injury is the most frequent cause of acquired rectovaginal fistulas, however trauma, infection, and radiation may also result in their development (Table 70-3). Rectovaginal fistulas can be classified according to their location (Fig. 70-20). In low fistulas, the rectal opening is at or below the dentate line; in high fistulas, the vaginal opening is at or near the cervix. A second classification system is based on the location, size, and cause of the fistula (Table 70-4).

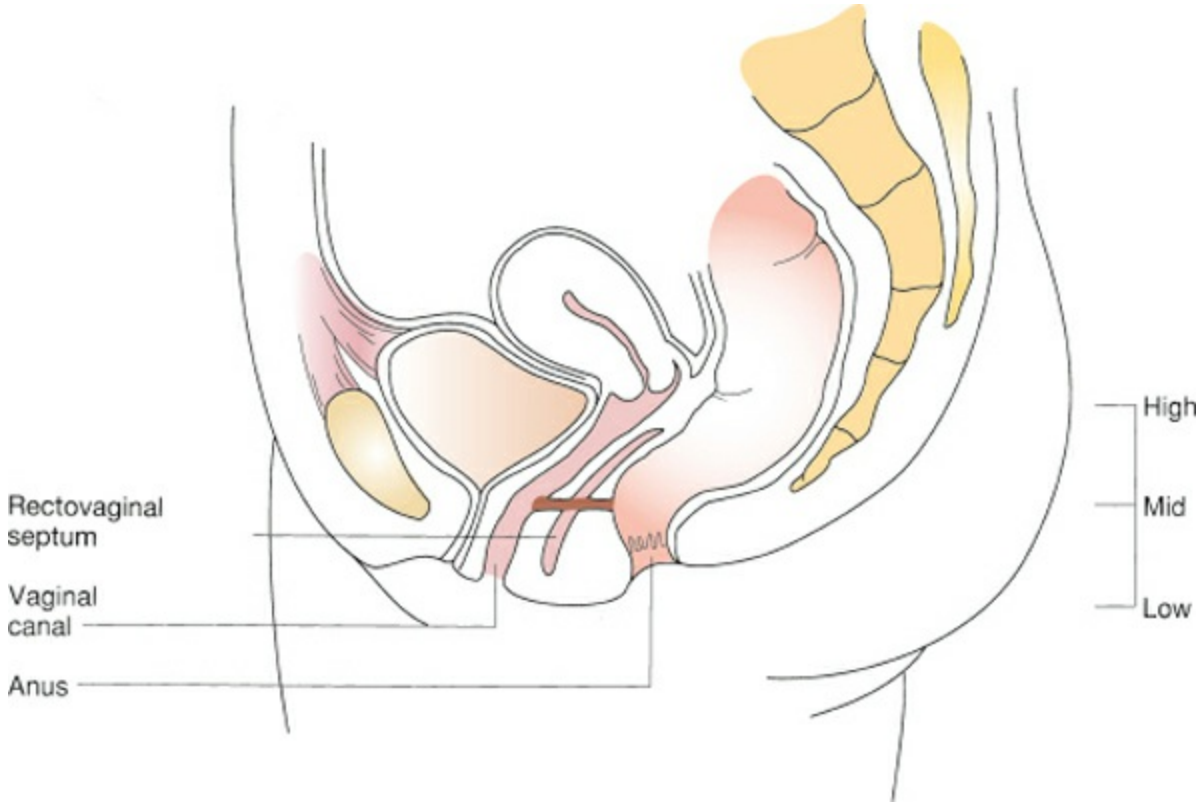

Figure 70-20. Rectovaginal fistula classified by location. Fistulas are low when located at or just cephalad to the dentate line, high when near the cervix, and mid when located in between.

ETIOLOGY

Table 70-3 Causes of Rectovaginal Fistula

Congenital maldevelopment
Trauma
Obstetric
Operative
Blunt and penetrating injury
Foreign body
Infection of anal canal or vaginal septum
Pelvic irradiation
Neoplasm

Clinical Manifestations

The clinical presentation of a rectovaginal fistula depends on the size and location of the fistula. In patients with small or low fistulas, the most common symptom is the passage of flatus from the vagina. Patients with large fistulas may complain of vaginal discharge with fecal odor, passage of flatus or stool from the vagina, recurrent urinary tract infections, or painful vaginitis.

Diagnosis is typically made on physical examination. Digital rectal examination or bimanual examination of rectum and vaginal may demonstrate the defect. Anoscopy may be helpful in visualizing the opening in low fistulas, while proctoscopy or flexible sigmoidoscopy may be required in mid or high fistulas. If a rectovaginal fistula is suspected clinically but no defect can be visualized, a methylene blue rectal enema may be administered following vaginal tampon insertion. Staining on the tampon is suggestive of a fistula. A contrast rectal enema under fluoroscopy may be needed in more complex cases to identify the fistula.

CLASSIFICATION

Table 70-4 Classification System Based on the Location, Size, and Cause of Rectovaginal Fistula

Characteristic	Simple	Complex
Location	Low to midvaginal septum	High vaginal septum
Size	2.5 cm or less in diameter	2.5 cm or more in diameter
Cause	Traumatic or infectious cause	Inflammatory bowel disease irradiation, neoplastic cause

Management

Spontaneous healing of rectovaginal fistulas may occur in some small fistulas that are secondary to obstetrical trauma. In these patients, it is important to wait 3 to 6 months before considering surgical repair, as this will allow resolution of any inflammation. Nonoperative healing is much less likely to occur in patients with fistulas secondary to inflammatory bowel disease or radiation. In patients with small fistulas and minimal symptoms, medical treatment with bulk agents such as fiber may be sufficient in controlling symptoms.

Treatment of low rectovaginal or anovaginal fistulas may be accomplished by endorectal advancement flap, vaginal advancement flap, or perineal procedures. Advancement flap is typically the initial procedure in patients without symptoms of incontinence. Most colorectal surgeons prefer to perform an advancement flap transanally rather than vaginally as the repair is to the high-pressure side. After the fistula site in the rectum is excised and closed, a rectal flap consisting of mucosa, submucosa, and a portion of the internal sphincter muscle is advanced to cover the opening in the rectal wall (Fig. 70-21). The opening in the vagina may be left open to drain. Success rates of endorectal advancement flaps for simple low rectovaginal fistulas are as high as 83%.[23]

If a low rectovaginal fistula is associated with incontinence secondary to a defect in the anal sphincter, repair with an overlapping sphincter repair has been shown to have good results. Using this technique, an incision is made over the perineal body, and the plane between the rectum and vagina is developed. The cut ends of the anal sphincter are identified and mobilized. The fistula tract is excised and closed, and the ends of the sphincter muscle are reapproximated in an overlapping fashion. Patients with no evidence of sphincter defect who have failed endorectal advancement flap may be candidates for closure with an interposition graft. This involves closure of the fistula and placement of well-vascularized tissue between the rectum and vagina. The bulbocavernosus muscle (Martius flap) and gracilis muscle are the most commonly used muscle flaps. These latter procedures are usually performed after a stoma has been created. The stoma is closed after healing has been documented by both rectal and vaginal contrast studies and examination under anesthesia.

Rectovaginal fistulas located higher in rectum often require a transabdominal repair. Simple fistulas with healthy surrounding tissue may sometimes be repaired by mobilization of the rectovaginal septum, division of the fistula, and layered closure of the rectal defect. Most cases, particularly larger fistulas and/or fistulas associated with Crohn's disease or radiation, will require resection of the rectum to below the site of the fistula as a low anterior resection with coloanal anastomosis. It may be useful in these cases to also place healthy tissue such as omentum or muscle between the rectum and vagina to prevent recurrent fistula. While patients with simple rectovaginal fistulas do not typically require fecal diversion, those with complex fistulas will often require creation of a colostomy in conjunction with surgical repair. Elderly patients or patients with severe Crohn disease may be better served by a permanent colostomy.

Pilonidal Disease

Pilonidal disease refers to a subcutaneous infection occurring in the midline of the sacrococcygeal area, the gluteal cleft. Pilonidal disease typically presents in young patients, occurs more frequently in men than women, and is more prevalent in hirsute individuals. The exact etiology of pilonidal disease is unknown, however it is believed to be related to hair. Pilonidal abscess or sinuses develop either from an infection within hair follicles in the area, or from a foreign-body reaction to hairs that become embedded in the skin.

Diagnosis

The presenting symptoms in many patients with *pilonidal abscess* are pain, swelling, and erythema near the top of the gluteal cleft. A *pilonidal sinus* occurs following spontaneous or surgical drainage of a pilonidal abscess, and present as a nonhealing wound or chronic drainage from the area. Early in the development, patients may complain of pain while sitting, and may have only mild cellulitis. A painful fluctuant mass can often easily be seen in patients with acute abscess. Chronic pilonidal sinuses can be visualized in the intergluteal fold. The majority of these tracts run cephalad, however occasionally a tract may run toward the anus; in these patients, it is important to differentiate pilonidal disease from hidradenitis suppurativa and anal fistula. Careful examination can demonstrate an opening or openings in the midline referred to as “pits,” and likely represent either ruptured hair follicles or the site at which a hair shaft penetrates the skin.

Treatment

Incision and drainage is the treatment of choice for an acute pilonidal abscess. This can typically be done in the office with the use of local anesthesia, although rarely may require drainage in the operating room. A longitudinal or elliptical incision is made over the abscess, and any hair within the cavity is removed. Patients are instructed to clean the wound regularly and to cover the wound. Packing is not necessary. Antibiotics are not indicated, unless there is significant associated cellulitis.

Chronic pilonidal sinuses have been treated in numerous ways, however no one specific treatment has proved completely satisfactory. Nonoperative treatments that have been suggested include shaving or laser hair removal of the area surrounding the sinus until healing has occurred, although the efficacy of this strategy is unknown. The most common surgical treatments include wide local excision, excision with flap closure, or specialized procedures such as the Bascom procedure.

Wide local excision incorporates removal of the pilonidal sinus, any associated pits, as well as some normal surrounding tissue. The wound may be left open to heal by secondary intention, or may be primarily closed. Patients whose wounds are left open often require intensive wound care with wet-to-dry dressings and gentle debridement of devitalized tissue and exudates, and complete healing may take several months. In an effort to reduce wound healing times, the edges of the wound may be “marsupialized” by suturing the wound edges to the base. As the pilonidal sinus may be chronically infected,

postoperative infection is a concern in patients with primary closure. In a randomized trial, patients who underwent primary closure had significantly higher rates of postoperative infection and recurrence when compared with those patients whose wounds were left open.[24]

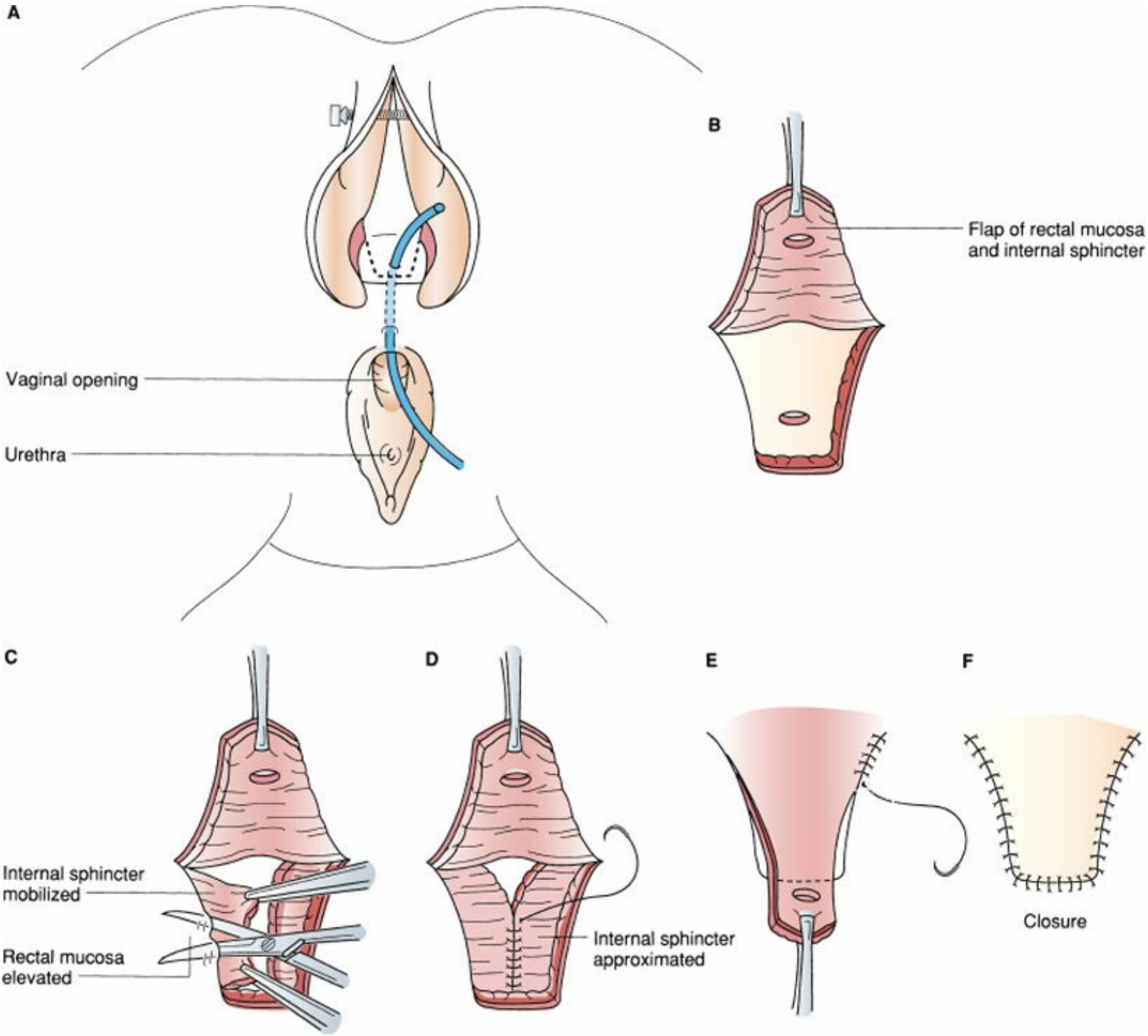

Figure 70-21. Endorectal advancement of anorectal flap. **A:** Exposure is gained by an anal speculum, and the fistula is identified. Outline of endorectal flap, extending proximally to 7 cm from the anal verge. **B:** The full-thickness flap is created to include the internal sphincter muscle. **C:** Lateral mobilization is made on each side in the submucosal plane. **D:** Anorectal wall on each side is approximated. **E** and **F:** The endorectal flap is pulled down to cover the wound and sutured. The fistula is excised. The aperture in the vagina is not sutured but is left open for drainage.

As excision often leads to a large defect, numerous flap closures have been described

for pilonidal disease. These include a rhomboid rotational flap, gluteus maximus rotational flap, z-plasty, and an advancement flap of skin and gluteal fat (Karydakis flap).[25] Excellent results have been reported from specialty centers using these approaches.

The Bascom procedure is based on the premise of removing the pilonidal disease while avoiding excision of large areas of normal tissue. This involves making a vertical incision at least 1 cm off the midline overlying the chronic cavity, without excising the walls of the cavity. The sinus tracts leading to the midline pits are probed and curetted to remove any granulation tissue. The midline pits are then excised and closed, while the lateral incision is left to close by secondary intention. Excellent results have been reported with this procedure,[26] however, no trials comparing this to other techniques have been published.

Rectal Prolapse

4 Rectal prolapse (procidentia) is a relatively uncommon condition in which there is a full-thickness protrusion of the rectum through the anal canal. A related condition is rectal intussusception, which is where the rectum telescopes into itself but not through the anus. Rectal prolapse is significantly more common in females than in males, and many patients have a long standing history of straining and constipation. Association with other pelvic floor conditions such as urinary incontinence, voiding disorders, and cystoceles is common. Prolapse is also more commonly found in patients with dementia, mental retardation, and schizophrenia.

Pathophysiology

The exact cause of rectal prolapse is not known, however it likely represents chronic progression of intussusception. As the rectum or rectosigmoid infolds onto itself, it progressively pulls the rectal wall away from its attachments to the sacrum and pelvic sidewall. With persistent straining, the bowel continues to intussuscept, eventually leading the entire wall of the rectum to evert through the anal opening. Studies of anorectal function in patients with rectal prolapse demonstrate that these patients often have impaired resting and voluntary squeeze pressures in the anal sphincter, decreased rectal capacity, impaired continence, and inadequate puborectalis relaxation during defecation. Incontinence is likely secondary to chronic mechanical stretching of the sphincters from the prolapse, stretch injury to the pudendal nerves, and loss of normal sensation of the anal canal. Several anatomic abnormalities are typically seen in patients with chronic rectal prolapse (Table 70-5), however, it is unclear whether these are factors that lead to prolapse or whether they are caused by the condition.

ETIOLOGY

Table 70-5 Anatomic Abnormalities in Rectal Prolapse

- Abnormally deep rectovaginal or rectovesical pouch
- Lax and atonic musculature of the pelvic floor
- Lack of normal fixation of the rectum and an elongated mesorectum
- Unusually redundant sigmoid colon
- Lax and atonic anal sphincter

Solitary rectal ulcer syndrome (SRUS) is a rare condition that is also likely related to intussusception of the rectum. The straining from constipation can lead to an ulcer in the anterior rectal wall from repeated mucosal trauma. In severe cases, SRUS may lead to gastrointestinal hemorrhage and chronic pain. Biopsies of these ulcers often demonstrate mucosal glands displaced within the submucosa, which may lead to the misdiagnosis of carcinoma.

Evaluation

The diagnosis of rectal prolapse is clinically made on the basis of the history and physical

examination. Patients typically present complaining of a mass with defecation that may or may not spontaneously reduce. Prolapse is often associated with fecal or mucous soilage and pelvic discomfort; pain is not typically present. Digital rectal examination often demonstrates a patulous anus with decreased sphincter tone. Full-thickness rectal prolapse will appear as concentric rectal rings protruding through the anus (Fig. 70-22). It is important to differentiate full-thickness prolapse from prolapsed hemorrhoids or mucosal prolapse, which will appear as radial folds. If the prolapse is not obvious, it is best demonstrated by asking the patient to strain while seated on a commode. Anoscopy or proctoscopy will often show mildly inflamed mucosa or ulceration. Patients should be evaluated with a colonoscopy to evaluate for bleeding and to rule out a mass, which can rarely serve as the lead point of intussusception. For those patients with chronic constipation, a colonic transit study may help to determine whether colonic resection may be necessary. Anal manometry is not typically useful other than to document baseline function. When intussusception is suspected but cannot be visualized, defecography may be helpful and may demonstrate other related conditions such as enterocele or puborectalis dyssynergy. Patients with other pelvic floor complaints require further evaluation by urogynecology.

Management

Surgical intervention is the gold standard for treating full-thickness rectal prolapse, however nonoperative management with treatment of the constipation and pelvic floor strengthening exercises has been described in patients who are poor surgical candidates. While the objective is to resolve the prolapse, repair may also help to improve or restore fecal continence and correct functional constipation. Several different operations have been described for rectal prolapse, either from an abdominal or perineal approach. The benefit of a perineal approach is that it can be performed under regional anesthesia and generally is less painful that an abdominal approach. The perineal procedures may be ideal for older patients or those individuals who may not tolerate general anesthesia or major abdominal surgery. The trade-off is that the recurrence rates of a perineal approach are generally higher (up to 38%) than an abdominal approach (less than 12%).[27] Perineal repair of rectal prolapse includes the Altemeier perineal rectosigmoidectomy and Delorme plication. Abdominal approaches include rectopexy, with or without concomitant sigmoid colon resection.



Figure 70-22. Full-thickness rectal prolapse will appear as concentric rectal rings protruding through the anus.

Perineal rectosigmoidectomy (Altemeier procedure) is a transanal surgery in which the prolapsed rectum and redundant sigmoid colon are excised through the rectum. The procedure is typically performed in the prone jack-knife position and can be performed under general or spinal anesthesia (Fig. 70-23). The rectum and sigmoid colon are resected and a low anastomosis is performed just proximal to the dentate line. Ideally a levator muscle imbrication and a colonic j-pouch are performed prior to a stapled or hand-sewn anastomosis. The former maneuver may help improve continence while the latter adjunct may help decrease bowel frequency. Without these steps, loss of the compliant rectum combined with low resting anal sphincter pressures often results in incontinence, soiling, and urgency. Major long-term complications include recurrence, fecal urgency, tenesmus, and anastomotic stricture. Overall results vary, but there is some data to suggest that among the perineal approaches, the Altemeier procedure has the lowest recurrence rates and best functional outcomes.[28]

The Delorme procedure is also typically performed in the prone position, and is useful in patients whose rectum does not prolapse more than 5 cm. This procedure involves stripping the mucosa of the prolapsed rectum from the muscularis propria, followed by plication of the muscularis propria and reanastomosis of the mucosal ring (Fig. 70-24). This procedure may also be combined with levatoroplasty or sphincter repair in an effort to improve functional outcomes. This technique has a high recurrence rate but has very low associated morbidity, and may therefore be useful in frail, older patients.

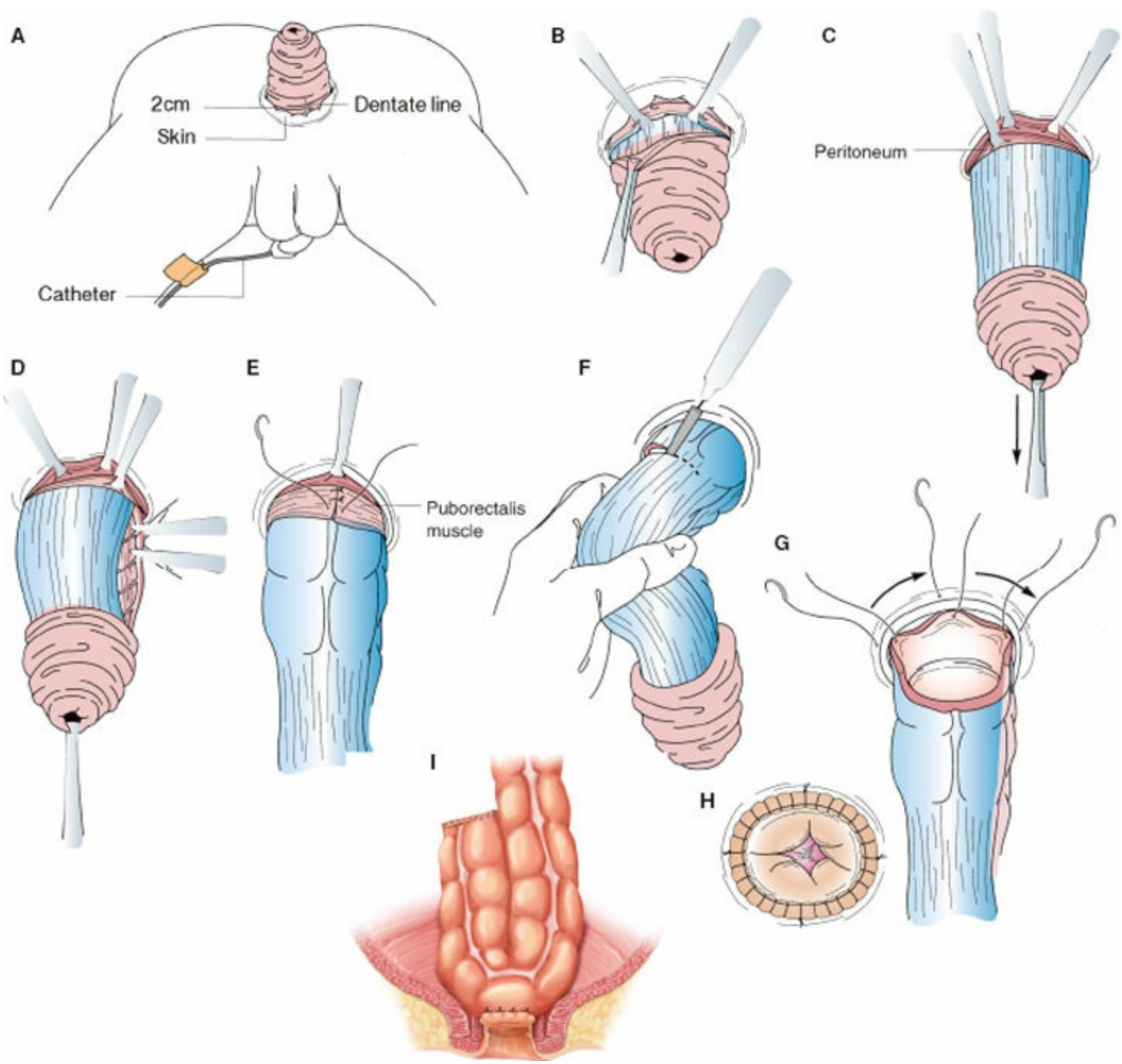

Figure 70-23. Perineal rectosigmoidectomy. The patient is placed in the prone jack knife position with both legs in gynecologic stirrups. **A** and **B:** A circular incision is made on the prolapsed rectum 2 cm proximal to the dentate line. **C:** The peritoneal attachment is dissected from the anterior rectal wall, thus opening into the peritoneal cavity. **D:** The mesorectum or mesosigmoid is clamped and divided laterally and posteriorly. **E:** This is followed by approximation of the puborectalis. **F:** The anterior wall of the protruding rectum is cut 1 cm distal to the anal verge. **G:** Stay sutures of 2-0 synthetic absorbable material are placed in four quadrants. **H:** Anastomosis with interrupted stitches; **I:** Colonic J pouch.

Transabdominal rectopexy involves a thorough mobilization of the rectum to the level of the pelvic floor musculature, followed by fixation of the mesorectum to the presacral fascia below the sacral promontory (Fig. 70-25). Fixation may be performed through a laparotomy or Pfannenstiel incision, or with a minimally invasive approach (laparoscopic or robotic assisted). Fixation of the rectum can be accomplished with suture, tacks, or the placement of a mesh (posterior to the rectum or as a supportive sling around the rectum). In patients with a history of chronic constipation and evidence of slow transit on colonic

transit studies, rectopexy may be combined with resection of the sigmoid colon. In these cases, the anastomosis should be performed above the level of the rectopexy to reduce the risk of anastomotic complications. Recurrence rates following rectopexy are generally lower than 10%, and many patients will have improvement in fecal continence. While division of the “lateral stalks” during resection rectopexy seems to reduce recurrence rates, it may exacerbate constipation.

One multicenter cohort study of 643 patients who underwent an abdominal repair of rectal prolapse demonstrated pooled 5- and 10-year recurrence rates of 7% and 29%, respectively.[29] No difference was identified based on the degree of mobilization or resection. In addition, similar recurrence rates were seen in patients who underwent suture rectopexy and mesh rectopexy, and in patients who underwent open or laparoscopic repairs. Another abdominal approach, ventral rectopexy, has also been recently popularized for the treatment of rectal intussusception and prolapse. This procedure involves mobilization of the anterior rectum, with no or minimal posterior dissection, followed by anterior mesh placement and sacral fixation. This technique was devised in an effort to spare patients from the risk of autonomic complications associated with complete rectal mobilization. Published recurrence rates are similar to those for other abdominal approaches. The abdominal operations can be performed as open, laparoscopic, or robotic procedures.

Fecal Incontinence

Fecal incontinence is an embarrassing and socially devastating condition that affects up to 18% of the population and up to 50% of nursing home residents.[30] Incontinence may be as severe as the involuntary passage of solid stool, but also includes patients who are unable to control the passage of flatus and those who suffer from chronic leakage that requires the use of pads. It is important to understand that fecal incontinence is not a diagnosis, but a symptom of which there are multiple potential causes.

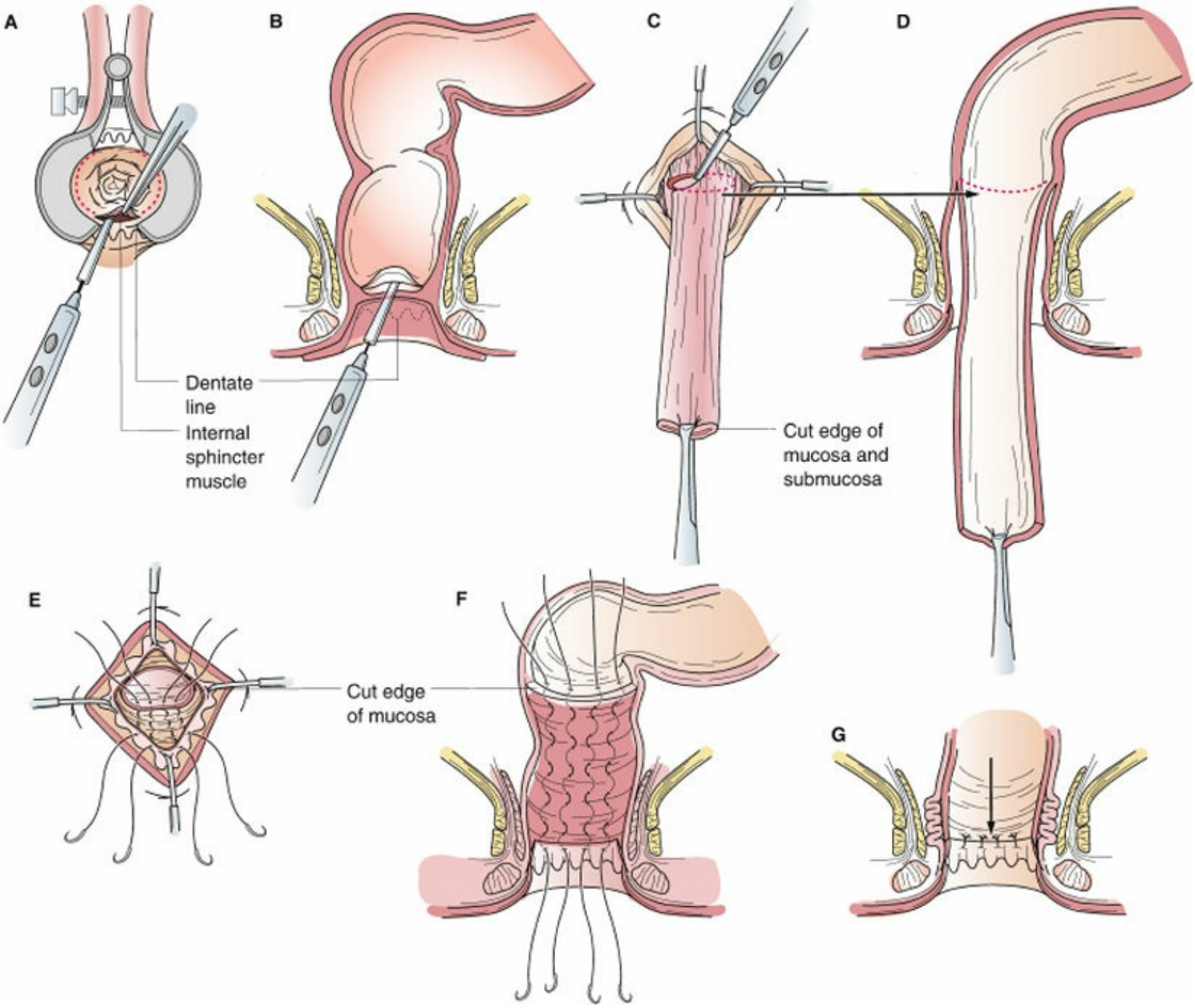

Figure 70-24. Modified Delorme procedure. Patient is placed in the prone position. **A** and **B:** With a Pratt speculum used for exposure, a circumferential incision is made 1 cm proximal to the dentate line. The submucosa is dissected from the underlying internal sphincter. At the level of the anorectal ring, the Pratt speculum is replaced by Lonestar (r) retractors placed at a right angle to the dentate line. **C** and **D:** Proximal to the anorectal ring, the dissection continues in the mucosal plane until the mucosa resists being pulled down. The mucosal tube is then cut. **E** and **F:** With 2-0 synthetic absorbable sutures, the mucosa at the upper cut end is brought down to the mucosa at the lower cut end, taking along the denuded anorectal wall. Eight such sutures are placed all around. **G:** At completion of the anastomosis, the anorectum is plicated.

Anal continence requires a complex integration of function between the anal sphincters and pelvic floor (see Physiology), but is also dependent on the volume and consistency of the stool, the compliance of the rectum, and normal neurologic function. It is for this reason that a large volume of diarrheal stool entering the rectum may overcome anal continence, even in a healthy patient. Other disease states such as inflammatory bowel

disease and radiation proctitis, as well as central nervous system pathologies such as spinal cord injury may also produce incontinence. Incontinence is far more common in female patients, although obstetrical tears of the anal sphincter may not present as incontinence for two or more decades following the injury. Injury to the pelvic floor muscles and pudendal nerves may also result following childbirth. Damage to the sphincter complex can result from surgical intervention (fistulotomy or internal sphincterotomy), trauma, or chronic stretching as seen in rectal prolapse.

Evaluation

A thorough history is important, as it will frequently lead the physician to the potential underlying causes of the incontinence. Obstetrical and surgical history should be noted, as well as any change in bowel consistency. It is helpful to quantify the frequency and degree of fecal incontinence with the use of a validated incontinence scoring system.[31] Symptoms of other pelvic floor conditions including urinary incontinence, and rectal prolapse should also be elicited. Physical examination should include inspection of the perianal skin for scars from previous surgery or obstetrical injury, excoriation from chronic soiling, or large prolapsing hemorrhoids. Digital examination can provide a gross assessment of both resting tone and squeeze effort.

In addition to the history and physical examination, several tests of anorectal anatomy and physiology can be done to investigate the cause of incontinence. Endoanal ultrasonography can provide a circumferential anatomic image of the anal canal, including visualization of the internal and external sphincters and any defects in these. Anorectal manometry may help to establish a baseline of resting and squeeze pressures, and may help to identify decreased rectal compliance. Electromyography of the pelvic floor with evaluation of pudendal nerve terminal motor latency may help to identify a neurologic cause of incontinence. Defecography may aid in operative planning by identifying previously unrecognized disorders such as rectocele or intussusception. The evaluation of a patient with fecal incontinence must also include an assessment of the impact of the symptoms on the patient's quality of life. This is important because the need for intervention is often based on the patient's desires rather than a threat to his or her health.

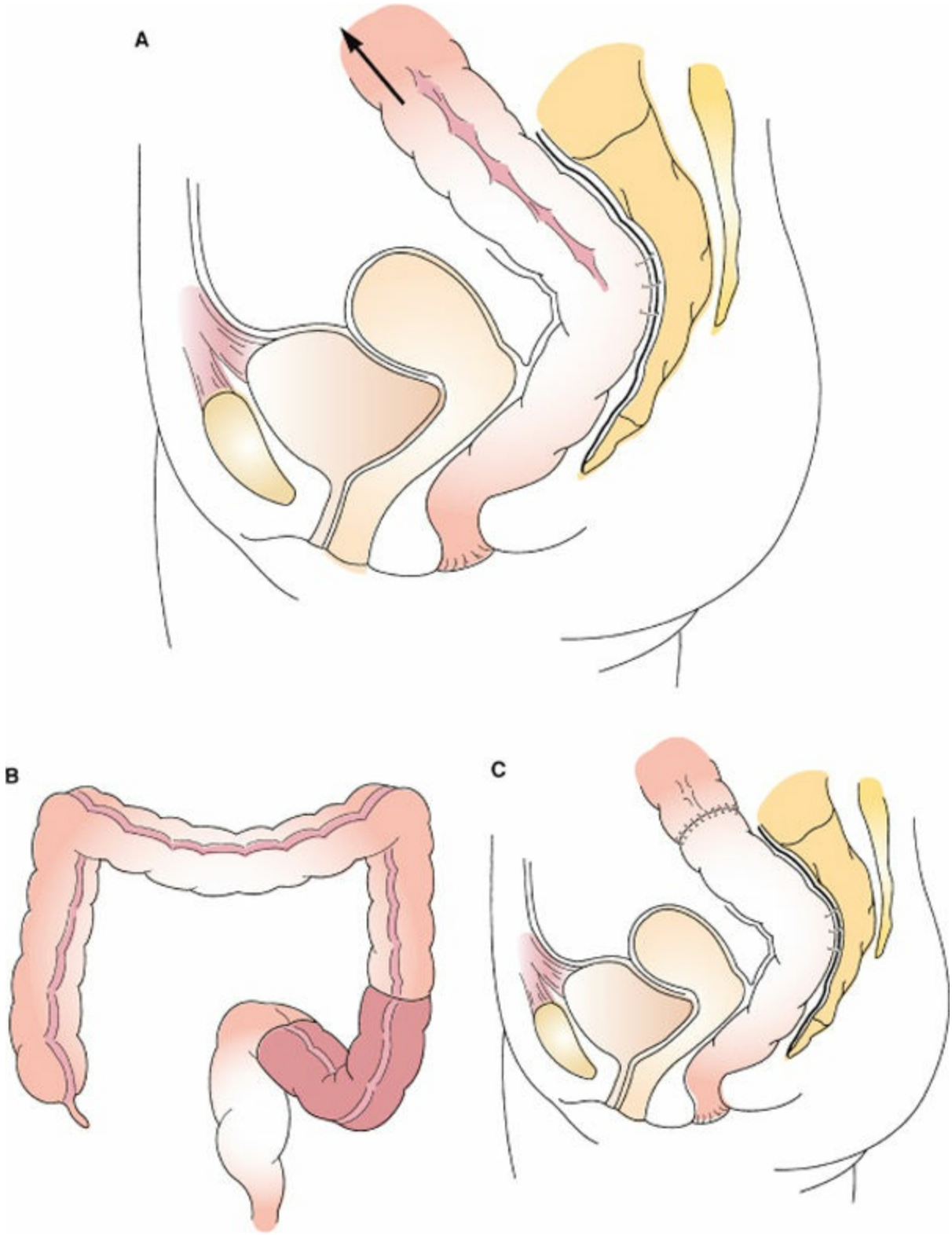

Figure 70-25. Transabdominal rectopexy. After full mobilization of the rectum (**A**,**B**), the endorectal fascia and peritoneum on each side is sutured to presacral fascia, below the promontory of the sacrum (C).

Management

Patients with chronic diarrhea, neurologic conditions, or systemic illnesses are best treated medically. This treatment is generally directed at regulation of bowel habits, with the goal of decreasing the frequency of bowel movements. The addition of a fiber supplement adds bulk to the stool and absorbs fluid, creating a more solid stool that is easier to sense and to control. Constipating agents such as loperamide, diphenoxylate

atropine, codeine, and bile acid binders may help to make stool harder and less frequent, thereby making it easier for the patient to control. In an effort to decrease leakage, some patients may benefit from the use of regular enemas to maintain an empty rectum.

Biofeedback is a pelvic floor retraining physical therapy program that can be very helpful in the treatment of patients with disorders of the pelvic floor. This "retraining" aims to provide increased strength to the sphincters, sensation of the anorectum, and coordination of the pelvic floor. Biofeedback typically employs the use of a pressure-sensitive probe placed into the anal canal to monitor the strength and coordination of the anal sphincter and pelvic floor musculature. The data from the probe are then transmitted to a monitor, where the patient is able to watch the manometric tracings. Through a series of coached exercises and visual feedback, improvements can be made in pelvic muscle control, threshold of sensation within the rectum, and overall control of defecation. Several studies have demonstrated the effectiveness of biofeedback in improving continence, with success rates ranging from 50% to 90%,[32] however, results are often dependent on the quality of the therapist and the motivation of the patient.

Other options for patients with less severe fecal incontinence include radiofrequency treatment and the injection of biocompatible bulking agents into the anal canal. The Secca™ procedure involves the use of radiofrequency delivered to the anal sphincter, which results in tissue remodeling.[33,34] Several case series have demonstrated the efficacy of this procedure, with more than half of patients treated reporting improvement in their symptoms.[35] Injection of a bulking agent (silicone or carbon-coated microbeads) into the anal submucosal or intersphincteric space may help to increase resting pressures by augmenting the anal cushions or restoring anal symmetry.

Operative management of anal incontinence is reserved for patients with frequent symptoms that have significant impact on a patient's quality of life. For patients with incontinence resulting from obstetrical injury or previous anorectal surgery and evidence of an external anal sphincter defect on imaging, overlapping sphincteroplasty is an option. With the patient in the prone position, a curved incision parallel to the anus is made over the perineal body. The two ends of the sphincter muscle are identified and are mobilized laterally. In order to recreate the complete circle of the anal sphincter, the ends of the muscle are sutured in an overlapping fashion (Fig. 70-26). Short-term outcomes following sphincteroplasty are quite good, with up to 85% of patients reporting improvement, however, many patients report deterioration of function over time.[36]

The artificial bowel sphincter (ABS) involves the placement of a cuff around the anal canal that generates external pressure to maintain tonic closure. This inflatable cuff is attached to a pressure-regulating reservoir placed in the retropubic space, and a control pump which is implanted into the labium majoris or scrotum (Fig. 70-27). When the patient feels the urge to defecate, the cuff is deflated for several minutes, thereby opening the anal canal to allow passage of stool. The complication rate of this procedure is quite high, with reports of explantation or revision of the device in almost half of all patients due to infection or malfunction, however the majority of patients with a functioning device report marked improvement in continence.[37] Although the ABS is no longer commercially available, the magnetic anal sphincter, now in trials in the USA, may

allow for the significant benefits of the ABS without the very high rates of infection, extrusion, and explantation.

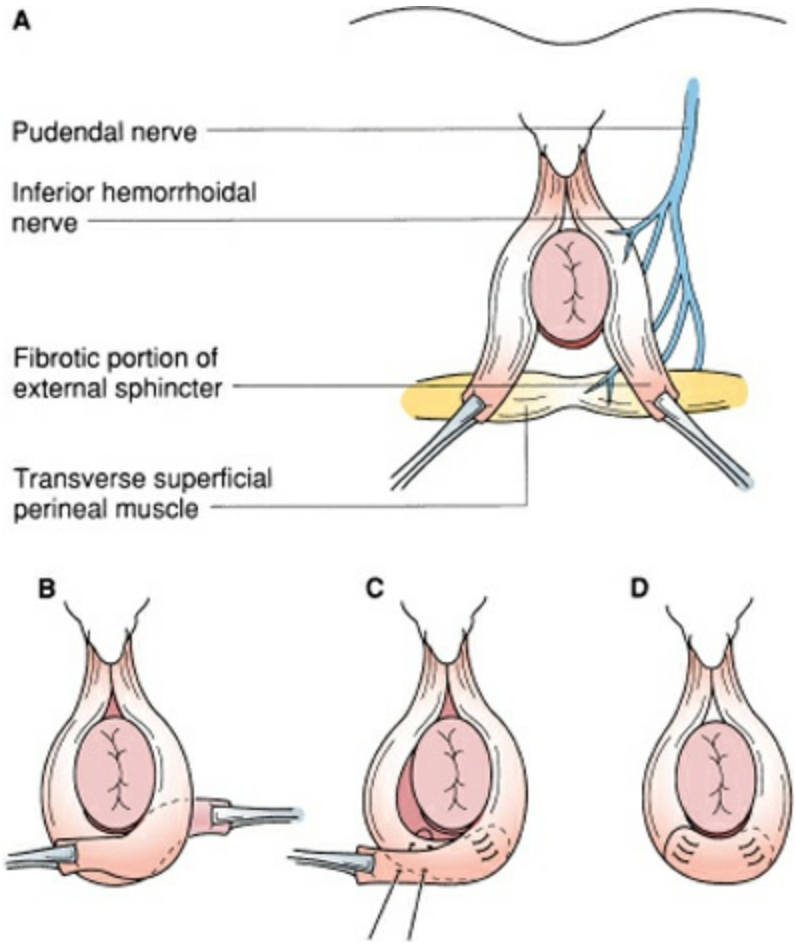

Figure 70-26. Overlapping sphincteroplasty. **A.** An anterior curvilinear incision is made over the perineal body, the scar is divided, and the edges of the external sphincter are grasped with Allis clamps. **B.** The external sphincter is dissected until the edges can be overlapped for several centimeters. **C** and **D.** An overlapping repair is performed with four mattress sutures.

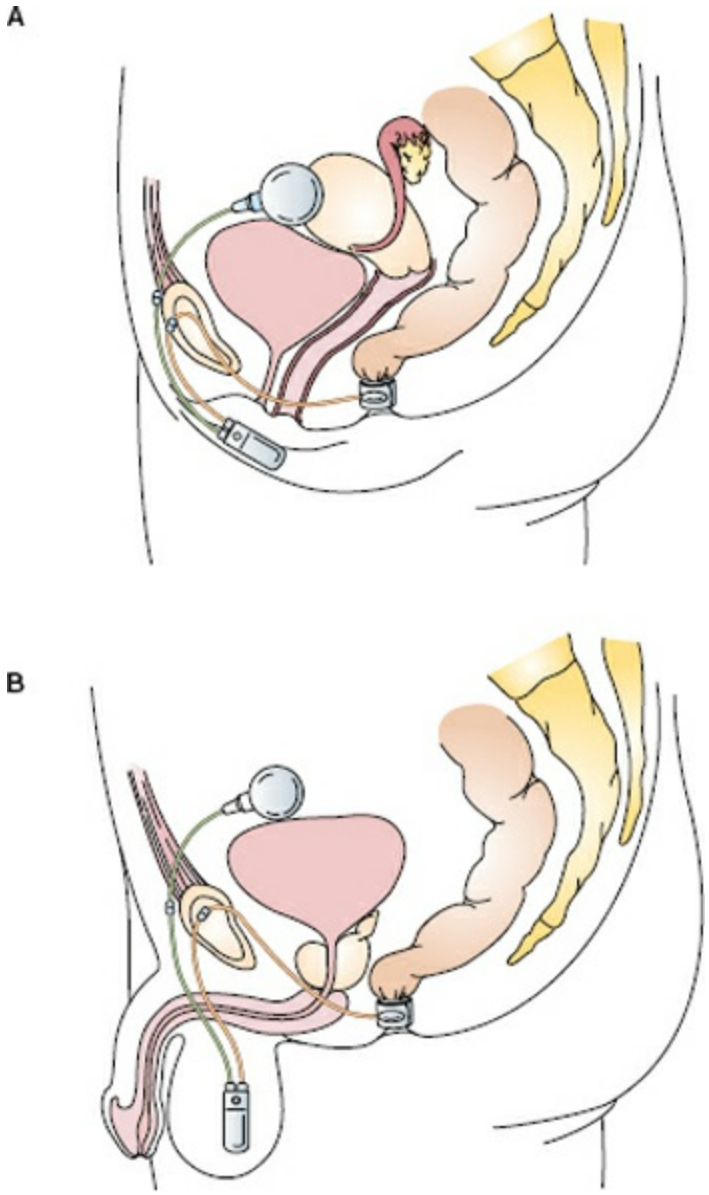

Figure 70-27. Implanted silicone neosphincter. **A:** Female. **B:** Male.

Sacral nerve stimulation (SNS) involves the percutaneous placement of an electrode into the foramen of the sacral vertebrae, most commonly S3. SNS was initially used to treat urinary incontinence, however it was noted that patients with combined incontinence had improvement in fecal continence as well; the exact mechanism of action is unknown. Following lead placement under fluoroscopy, the patient undergoes a 2-week test period to assess the effect of stimulation. If continence is significantly improved, a permanent stimulator is implanted subcutaneously at a second operation. Durable 5-year results have been reported, with 89% of patients reporting improvement and 36% reporting full continence.[38] SNS may be offered to patients both with and without evidence of sphincter defects. Tibial nerve stimulation has also been shown to lead to improvement in anal continence, however this therapy is currently not approved for use in the United States.[39]

In patients with severe incontinence for whom alternative methods have failed, creation of a sigmoid colostomy may improve quality of life and allow them to resume normal daily activities.

Sexually Transmitted Diseases of the Anorectum

The annual incidence of sexually transmitted diseases is approximately 15 million cases in the United States. As anal erotic practices have increased, the incidence of sexually transmitted diseases of the anus and rectum has also increased. These are typically the result of anal receptive intercourse, but in some instances represent contiguous spread from genital infections.

Gonorrhea

Gonorrhea is caused by the gram-negative intracellular diplococcus *Neisseria gonorrhoeae,* with an incubation period that ranges from 3 days to 2 weeks. Symptomatic anorectal gonococcal infection results in pruritus or tenesmus, accompanied by a mucoid and sometimes bloody rectal discharge. Left untreated, a more advanced systemic infection can occur resulting in such conditions as endocarditis, pericarditis, and a unilateral migratory gonococcal arthritis of large joints.

Anorectal gonorrhea results in a thick yellow mucopurulent discharge from the anus. This purulent material is often able to be expressed from the anal crypts and can be visualized directly by applying gentle external pressure while viewing the distal anorectum through an anoscope. Sigmoidoscopy may reveal a proctitis extending to no more than about 10 cm from the anal verge. Although these findings may be mistaken for an ulcerative or nonspecific proctitis, abscesses, fistulae, and ulcers are not typical. Diagnosis is confirmed by culture on a Thayer–Martin medium plate incubated in a carbon dioxide environment.

Due to the increasing prevalence of penicillinase-producing *N. gonorrhoeae,* penicillin G is no longer recommended. First-line treatment is a single intramuscular injection of 250 mg of ceftriaxone. Alternative treatments that have been proposed include single oral dose of 500 mg of cefixime or a single oral dose of a fluoroquinolone. Because of the high rate of concomitant infection with Chlamydia, patients should be given appropriate treatment for Chlamydia as well. Sexual partners from the past 60 days should also be treated.

Chlamydia/Lymphogranuloma Venereum

Chlamydia trachomatis is the most common sexually transmitted bacterial infection worldwide. In the United States, male homosexuals account for the majority of rectal Chlamydial infections. With 15 known serotypes, anorectal Chlamydia infection can cause proctitis (serotypes D-K) or lymphogranuloma venereum (LGV) (serotypes L1–L3). Transmission of disease is through anoreceptive intercourse, with an incubation period ranging from 5 days to 2 weeks; secondary involvement can also occur as a late manifestation of genital infection.

Symptoms of non-LGV anorectal infection include rectal pain, tenesmus, and fever, although a substantial number of infected patients will be asymptomatic. Examination reveals enlarged matted inguinal lymph nodes and proctosigmoidoscopy shows an erythematous rectal mucosa without frank ulcerations. Patients with LGV also complain of pain, fever, and tenesmus but often have a slight mucopurulent discharge and

hematochezia. The inguinal lymph nodes in LGV are often more enlarged as they fuse into a large indurated mass with overlying erythema. Evaluation of the rectal mucosa reveals a more severe granular proctitis with mucosal friability and frank ulceration. Left untreated, the disease may progress to fistulae, abscesses, and late rectal strictures. In this setting, LGV may be confused for perianal Crohn's disease, however the marked inguinal lymphadenopathy may help distinguish LGV from Crohn's.

Treatment of Chlamydia infection is with a single oral dose of azithromycin (1 g) or doxycycline (100 mg) twice a day for 7 days. Alternative therapy includes erythromycin or a fluoroquinolone. Treatment of LGV is a 21-day course of either erythromycin or doxycycline. Sexual partners also require treatment to prevent reinfection.

Herpes Simplex Virus

Herpes is the most prevalent sexually transmitted disease in the United States where it is estimated that 20% of the general population are affected. The majority of anorectal herpes infections are caused by HSV-2 with only about 10% being caused by HSV-1. Transmission is through autoinoculation or direct contact with an infected individual who is shedding the virus, and the clinical infection may begin 4 to 21 days following anoreceptive intercourse. Patients present with small red vesicles which may be clustered or scattered in the perianal skin, anal canal or perineum, are extremely painful to touch. Proctoscopy reveals friable mucosa, ulceration, and the mucopurulent discharge. These findings will be limited to the distal 10 cm on proctoscopy. Tender inguinal adenopathy occurs in up to 50% of patients with HSV proctitis. Recurrent attacks are generally milder and shorter in duration.

Diagnosis is made on clinical examination, finding multinucleated giant cells with intranuclear inclusion bodies on Pap smear, a positive Tzank preparation or a positive culture. As the acute infection is self-limited, treatment includes warm sitz baths and oral analgesics. The use of antiviral medications has been shown to shorten the length of symptoms, but does not affect recurrence rates. Acyclovir (400 mg five times/day for 10 days) is most commonly used for initial infection. Recurrent attacks may be treated with acyclovir (200 mg five times/day) or valacyclovir (500 mg twice/day). Suppressive antiviral therapy may be considered in patients who have more than five attacks per year.

Condyloma Acuminata

7 Anal condylomata acuminate or "warts" are caused by the human papilloma virus (HPV). HPV is a papovirus, and more than 80 subtypes of HPV have been identified. Serotypes 6 and 11 are most commonly associated with the benign, exophytic condylomata of the anogenital region. Serotypes 16 and 18 have been associated with more aggressive lesions that can progress to invasive squamous cell cancers.

The primary mode of transmission of anogenital HPV is sexual intercourse. Inoculation of the anal epithelium allows entry of the HPV into the basal cell layers. As these cells proliferate viral replication occurs in the nucleus. The basal cells then migrate toward the surface and infective particles are released in the form of visible warts. Mature infectious particles are found in the surface layers of these lesions.

Condyloma acuminata are easily recognized as epithelialized cauliflower-like projections. They may be flat, raised, sessile or pedunculated, and range in size from millimeters to a large fungating lesions known as giant condyloma acuminatum (Buschke–Lowenstein). They may be in clusters or grow to cover the perineum and anal canal in a "carpet-like" fashion. The warts may be asymptomatic or may cause pruritus, bleeding, or discharge. Anoscopy is important in evaluating for lesions within the anal canal.

The goal of treatment is removal of all gross disease while minimizing morbidity, although this does not ensure eradication of infection. Tangential excision, cryotherapy, or fulguration of small lesions with local anesthesia can be performed as an office procedure with little discomfort to the patient. Larger lesions are treated by excision in the operating room, while electrodessication is performed of any remaining smaller condyloma.

Topical agents such as podofilox and imiquimod can be applied by the patient, but neither is approved for use in the anal canal. Imiquimod is an immune response modifier that increases local production of interferon. Complete response can be expected in 50% of patients treated with imiquimod, with 11% of patients experiencing a recurrence. It can be used as initial treatment with electrodessication reserved for those who have incomplete response, or following destructive treatment and epithelial healing to treat remaining or recurrent disease.[40]

Anal Intraepithelial Neoplasia

The role of HPV in the development of cervical cancer in females has been clearly established, however its significance in the development of anal cancer is not as well defined. Serotypes 16 and 18 have a higher propensity to initiate the development of carcinoma, and have a predilection for the less stable epithelium of the upper anal canal transition zone rather than the modified skin of the lower anal canal anoderm. They may, however, be identified in the anal skin margin as well.

The incidence of anal cancer in HIV-positive homosexual males is estimated to be 38 times that of the general population and twice the risk in HIV-negative homosexual males.[41] HPV infection has been reported in 93% of HIV-positive homosexual males compared with 60% of HIV-negative homosexual males.[42] Anal intraepithelial neoplasia (AIN), a precursor to the development of anal cancer, also has a markedly increased incidence in HIV-positive individuals. It is felt that as HIV disease has become a chronic, manageable condition, patients are living long enough to progress from AIN to anal cancer. Some have therefore recommended screening and surveillance programs similar to those for cervical cancer.

Anal cytology has been described as a screening tool to detect abnormal cells in high-risk patients. Those who are found to have abnormal Papanicolaou smears undergo high-resolution anoscopy with acetowhitening and staining with Lugol solution and biopsy of any suspicious lesions. Options for treatment include local destruction (cryotherapy or fulguration), excision, or observation.

AIN is graded on the degree of dysplasia. Low-grade AIN (grade I) rarely undergoes

malignant transformation, and can be observed or ablated if symptomatic. High-grade AIN (grades II and III) is believed to be the premalignant counterpart of anal squamous cell cancer, however the incidence and predictability of the progression of AIN to invasive cancer is unclear. Some authors recommend aggressive destruction or excision of any high-grade lesions, however there is currently no evidence that removal of high-grade AIN results in a reduction of the risk of anal cancer. Others have therefore instead recommended that AIN be observed unless there are gross visible lesions or ulcerations present.

HIV and AIDS

Surgery for anorectal diseases is the most common indication for surgery in HIV-infected patients and in 5% of patients their anorectal complaint is the presenting symptom of their HIV infection. Several studies demonstrated poor wound healing and increased morbidity in the surgical treatment of anorectal disease in AIDS patients. Delayed or failed wound healing has been associated with presence of AIDS, absolute leukocyte count, and CD4 count.

Anal fissures that occur in the HIV-positive patient must be distinguished from idiopathic AIDS-related anal ulcers and ulcerating sexually transmitted diseases such as HSV or syphilis. Anal fissures in this patient population are indistinguishable from those in the general population and their treatment is similar – initial conservative management with surgery for treatment failures. Treatment of fissure in HIV-positive patients also includes controlling diarrhea when possible and encouraging abstinence from anoreceptive intercourse.

With the increasing use of highly active antiretroviral therapy (HAART), the incidence of AIDS-related anorectal ulcers has decreased markedly, however they are still found in patients with low CD4 counts. AIDS-related ulcers typically occur more proximal in the anal canal (frequently above the dentate line), are broad based with deep ulceration with destruction sphincter planes, and may demonstrate mucosal bridging. Surgical debridement allows for adequate drainage of feculent or purulent material trapped in the ulcer and removes necrotic debris. The area should also be biopsied to rule out malignancy. Intralesional injection with steroids has also been described to decrease pain, however it has not been demonstrated to affect healing. Perianal suppurative diseases are common conditions in AIDS patients. Abscesses should be drained using small incisions, and judicious use of draining setons will help lessen recurrent sepsis. The abscess should also be cultured and broad-spectrum antibiotics should be given.

Kaposi sarcoma, which is associated with the herpesvirus HHV-8, is one of the more common malignancies in AIDS patients. Found more commonly in patients with low CD4 counts, its incidence has decreased in the era of HAART therapy. Kaposi sarcoma may occur in the colon or rectum, but may also be found in the anal canal and perianal skin. Most patients are asymptomatic, however bleeding or obstruction may rarely occur. Treatment is directed at improving the patient's CD4 count, however radiation and chemotherapy have also been employed.

Symptomatic cytomegalovirus (CMV) infection may also occur in profoundly

immunocompromised AIDS patients. CMV can cause proctocolitis that presents with diarrhea, fever, and abdominal pain. Examination of the mucosa of the rectum demonstrated sharply demarcated hallow ulcers with fibrinous exudate. Biopsies that demonstrate “owl’s eye” inclusion bodies are diagnostic. Treatment is with antiviral medications and initiation of HAART therapy.

NEOPLASTIC ANORECTAL DISEASE

Neoplasms of the anal region are relatively rare, and include both benign and malignant tumors. Important in the diagnosis and management of these conditions is defining the location of the tumor with reference to landmarks such as the dentate line and anal verge because treatment of tumors of the anal canal is often significantly different from treatment of tumors of the anal margin. The American Joint Commission on Cancer has developed standardized terminology and has recognized the anal verge as the line dividing between the anal canal and anal margin. Although it may be difficult to determine the exact location of large, bulky tumors that encompass both the anal canal and anal verge, the location of most tumors of the anal margin can be determined with inspection alone.

Anal Margin Tumors

Bowen Disease (High-Grade AIN)

Although AIN is more common in HIV-positive individuals, high-grade AIN may develop in the perianal skin of HIV-negative patients. Also referred to as Bowen disease, these lesions tend to grow slowly, and are more prevalent in older women and immunosuppressed patients.[43] While perianal Bowen disease is often asymptomatic, patients may present with burning or pruritus. Changes seen on examination may range from thickened erythematous skin to discrete scaly or crusted plaques, often making it difficult to differentiate from other disorders such as psoriasis or eczema. Biopsy of any atypical anal lesions is mandatory (Fig. 70-28).

While wide local excision has traditionally been the treatment of choice for Bowen disease, the understanding that the disease is likely related to HPV infection has changed the treatment paradigm. Excision should be performed in any patient with intractable itching or burning, those with an atypical lesion or a lesion than 3 cm, or when biopsy demonstrates invasive squamous cell cancer. Mapping of the perianal skin with circumferential biopsies will often show residual disease, and evidence that this practice improves patient outcomes is lacking. As in patients with HIV and AIN, the role of high-resolution anoscopy with staining of the perianal skin remains controversial. Although Bowen disease is a premalignant condition, the rate of malignant transformation in the HIV-negative population is likely lower than in HIV-positive patients with high-grade AIN. Patients with asymptomatic disease may therefore be closely observed, with target biopsy of any suspicious areas.

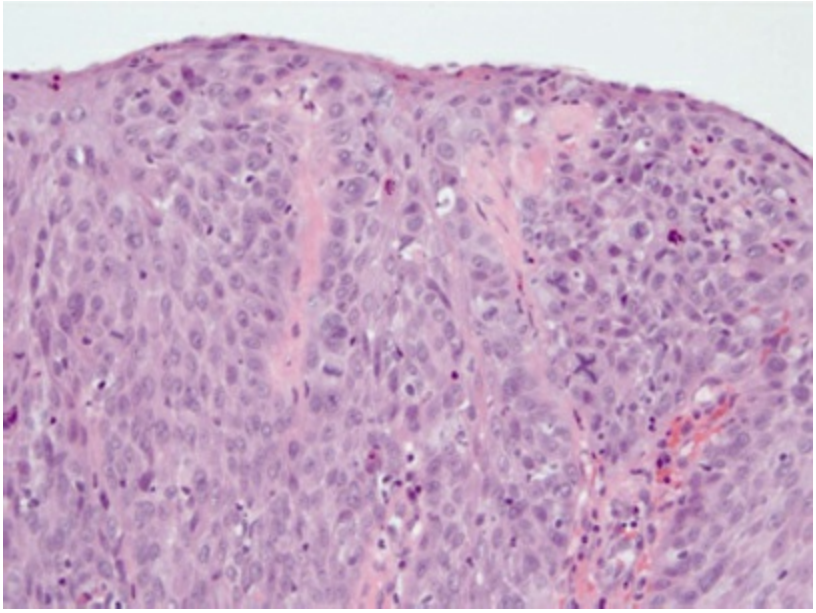

Figure 70-28. Biopsy of any atypical anal lesion. With permission from Bejarano PA, Boutros M, Berho M. Anal Squamous Intraepithelial Neoplasia. *Gastroenterol Clin North Am* 2013;42(4):893–912.

Squamous Cell Carcinoma

8 Squamous cell carcinomas (SCCs) located at the anal margin are similar to those that develop elsewhere in skin. The disease afflicts men and women at an equal rate and tends

to present in the seventh decade of life. Patients often present with a mass, pruritus, rectal pain, or bleeding, and the gross appearance is typically a mass with central ulceration and rolled, everted edges. While symptoms may mimic other conditions such as fistula, hemorrhoids, or chronic pruritus, any chronic unhealed or indurated ulceration in the perianal area should be biopsied (Fig. 70-29). Due to its location, the diagnosis of perianal squamous cell cancer is often delayed, with more than 50% of cases diagnosed more than 24 months after the onset of symptoms.[44]

Treatment of superficial squamous cell cancer of the anal margin that does not invade muscle is local excision with a 1-cm margin. Radiation or chemoradiation should be considered for large tumors invading the sphincter and/or radical resection with abdominoperineal resection is another option, however this procedure has been associated with high failure rates from local recurrence, inguinal lymph node metastasis, and distant metastasis.[45] The prognosis for patients with T1 tumors (those <2 cm) is excellent, with 5-year survival rates approaching 100%. Five-year survival of patients with larger tumors is variable, depending on the type of treatment.



Figure 70-29. Chronic unhealed or indurated ulceration in the perianal area. Courtesy of Dr. Scott Steele.

Paget Disease

Paget disease is an intraepithelial adenocarcinoma of the perianal skin. While this disease was initially described in the breast, it may also occur in the axilla and anogenital region. The exact origin of Paget cells is unknown, however authors have hypothesized that they arise from apocrine or sweat glands, or are metastatic from an underlying adenocarcinoma. Perianal Paget disease begins as a benign in situ neoplasm but may eventually become invasive as an adenocarcinoma.

Paget disease is rare disease, and occurs most commonly in elderly patients. The typical appearance is an erythematous, sometimes sharply demarcated rash that may ooze or scale. Paget disease must be differentiated from other dermatologic conditions such as

eczema, lichen sclerosis, and hyperkeratosis; these conditions tend to present in a circumferential pattern, whereas Paget disease tends to be unilateral. The diagnosis is made by biopsy, which demonstrates the presence of periodic acid–Schiff positive Paget cells (Fig. 70-30). Patients with Paget disease should also undergo a colonoscopy, as synchronous visceral carcinomas have been found in up to 50% of patients.[46]

The treatment of perianal Paget disease in the absence of invasive carcinoma is wide local excision. Because the disease may extend beyond the grossly visible margin, mapping biopsies at least 1 cm from the edge of the lesion in all four quadrants is recommended. Small lesions may be resected with the wound left open, however if extensive resection is required, reconstruction may be performed with advancement or rotational flaps.[47]

Patients with perianal Paget disease and concomitant rectal adenocarcinoma should undergo abdominoperineal resection, whereas those with anal cancer should be treated with chemotherapy and radiation. Patients with invasive Paget disease should undergo APR, however the prognosis is quite poor as the majority of patients have distant metastases at the time of diagnosis.[48] The pattern of metastasis is similar to that of adenocarcinomas of the distal rectum.

Basal Cell Carcinoma

Basal cell carcinomas of the perianal skin are rare. Similar to basal cell cancers of the skin elsewhere on the body, these tumors typically appear as an ulcer with irregular and raised edges. This condition is more common in men than women, and one-third of patients have basal cell cancers on other cutaneous sites.[49] Treatment is wide local excision followed by close surveillance, as recurrence is not uncommon.

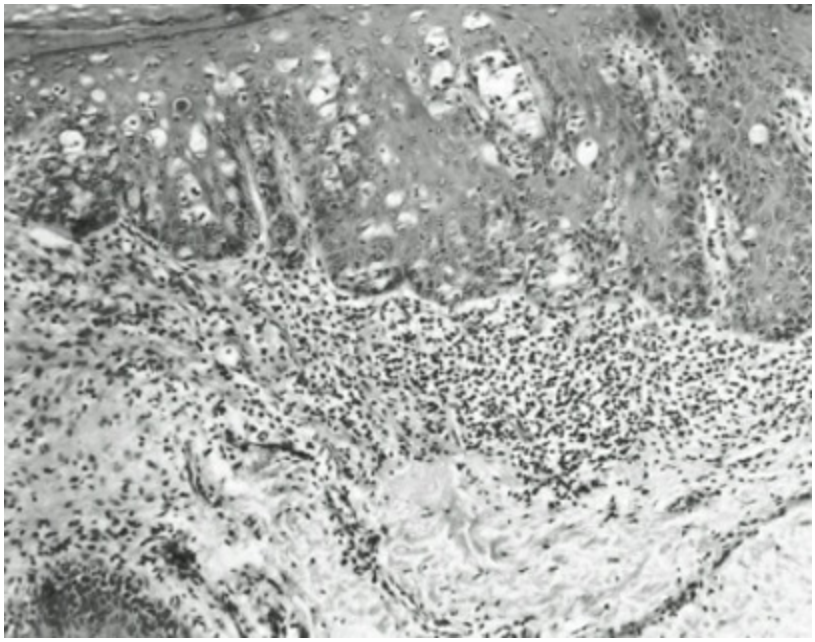

Figure 70-30. Perianal Paget disease. Paget cells are above the basal layer.

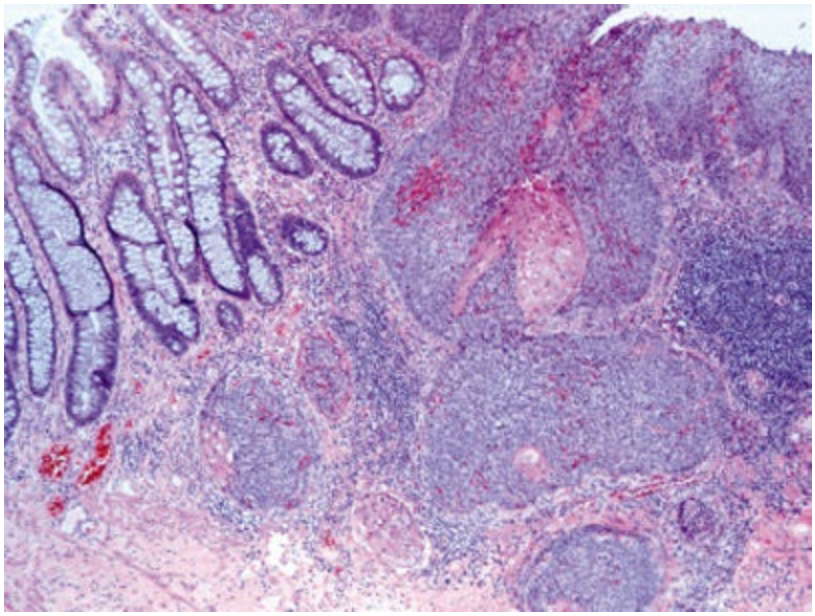

Figure 70-31. Epidermoid cancer of the anal canal. Courtesy of Dr. Mariana Berho.

Anal Canal Tumors

Epidermoid or Squamous Cell Carcinoma

Cancers that arise within the anal canal differ in treatment and prognosis from tumors that occur in the perianal skin. Epidermoid cancer of the anal canal has various microscopic appearances, including squamous cell (large cell keratinizing), transitional zone (large cell nonkeratinizing), basaloid, or mucoepidermoid epithelium (Fig. 70-31). The term cloacogenic carcinoma has also been used for basaloid and transitional carcinomas. The clinical presentation, treatment, and prognosis are similar among the different forms of epidermoid carcinomas.

Patients with anal canal tumors typically present with bleeding and pruritus. As with anal margin tumors, these symptoms are often initially misdiagnosed as hemorrhoids or fissure. Digital examination of the anal canal will often demonstrate an indurated mass. Anoscopy allows for visualization of the tumor and biopsy to confirm the diagnosis. Physical examination should also include palpation of the inguinal region to evaluate for enlarged lymph nodes. Although there is no association between epidermoid anal cancer and colorectal cancer, most clinicians recommend a colonoscopy to evaluate the colon and rectum.

Staging of squamous cell cancer of the anal canal is based on the size of the primary tumor and evidence of lymph node and distant metastases and is detailed in Table 70-6. Although endoanal ultrasound may demonstrate the depth of invasion and enlarged perirectal lymph nodes, these variables are not part of the TNM staging system. Enlarged or suspicious groin lymph nodes should be biopsied, either by excision or fine-needle aspiration. Computed tomography of the abdomen and pelvis is indicated to detect for distant metastatic disease. PET scanning is not typically done as part of the initial staging, however it may be useful in assessing persistent or recurrent disease after treatment. HIV testing should be considered in those patients who are at higher risk.

Prior to 1975, the treatment of anal canal squamous cell cancer included surgery alone or radiation therapy alone. Early-stage lesions were treated by local excision while patients with more advanced tumors underwent abdominoperineal resection. Local recurrence rates approached 50% and 5-year survival was 40% to 70%.[50] Nigro et al. treated patients with preoperative chemotherapy and radiation prior to APR in an effort to decrease recurrence rates and discovered that the majority of these tumors had completely regressed at the time of surgery. This finding led them to recommend treatment with chemoradiation alone with surgery reserved for patients with residual disease, commonly referred to as the Nigro Protocol. This regimen includes external beam radiation to the primary carcinoma as well as the pelvic and inguinal lymph nodes, combined with intravenous 5-fluorouracil and mitomycin C. A typical modified Nigro regimen is summarized in Table 70-7. Since the initial report, multiple studies have confirmed these results, including two randomized trials.[51,52]

Patients who are treated with chemoradiation should be followed closely to detect any evidence of recurrence. This includes physical examination and anoscopy with biopsy of any suspicious areas. In patients with persistent or recurrent disease, abdominoperineal

resection is recommended. Studies of patients who underwent salvage APR show better survival in recurrent rather than persistent disease, with a 57% 5-year survival rate.[53] Inguinal node metastasis at initial presentation prior to treatment with chemoradiation is also associated with poor outcome after APR for treatment failure.[54] It is important to consider that perineal wound complication rates are high in patients who undergo APR for recurrent anal cancer after treatment with chemoradiation,[55] and reconstruction with a rectus abdominis myocutaneous flap should be considered. Radical groin dissection may also be considered in patients with symptomatic inguinal disease after chemoradiation.

Adenocarcinoma

Anal canal adenocarcinomas are relatively rare, accounting for less than 10% of all anal carcinomas.[56] Their presentation is similar to squamous cell cancers of the anal canal, with pain, bleeding, pruritus, and a palpable mass, although these tumors tend to have a more aggressive natural history than SCC. These tumors tend to present in the seventh decade of life and occur equally in males and females.[57]

Adenocarcinomas of the anal canal are classified according to their cell of origin. Rectal-type adenocarcinomas arise from the transitional zone in the upper anal canal and are indistinguishable from adenocarcinoma of the distal rectum. These tumors are treated in a similar manner as rectal cancer, with chemoradiation followed by abdominoperineal resection; local excision may be an option in small, early stage tumors that do not invade the anal sphincter complex. Anal gland-type adenocarcinomas arise from the mucin-secreting goblet cells that line the glands within the anal canal. These tumors may develop in an extramucosal manner without involvement of the anal canal epithelium. There have also been reports of mucinous adenocarcinoma developing in the setting of a chronic anal fistula, although the likely origin of these tumors is also the goblet cells within the anal glands. Anal gland-type adenocarcinomas have a lower response rate to chemoradiation than SCC of the anal canal, and these tumors are therefore best treated with combined chemoradiation and abdominoperineal resection.

Melanoma

Melanoma occurs most commonly in the skin and eyes, but can also develop from the transitional epithelium within the anal canal or the anoderm at the anal verge. This tumor is more common in females than in males and is relatively rare, accounting for less than 1% of all anal malignancies. Symptoms are typically pain, pruritus, and bleeding. Most lesions are pigmented, and may frequently be incorrectly diagnosed as a thrombosed hemorrhoid. Some anal melanomas may not contain pigment and can be difficult to differentiate from SCC.

Anal canal melanomas spread submucosally into the rectum, but do not typically invade other organs. Lymphatic spread to mesenteric lymph nodes is present in up to 35% of patients at the time of diagnosis,[58] and hematogenous spread to distant sites is common as well. Melanomas of the anal canal do not respond to chemotherapy or radiation, making surgery the only chance for cure. Options include wide local excision or abdominoperineal resection, however the prognosis is extremely poor, with 5-year

survival rates of less than 30%.[59] While APR may help to reduce local recurrence, survival rates do not differ from wide local excision and most authors therefore advocate for local excision to avoid the morbidity of a permanent colostomy.[60]

STAGING AND CLASSIFICATION

Table 70-6 American Joint Committee on Cancer Staging Classification for Squamous Cell Carcinoma of the Anal Canal

Primary Tumor (T)	
Tx:	Primary tumor cannot be assessed
T0:	No evidence of primary tumor
Tis:	Carcinoma in situ
T1:	Tumor 2 cm or less in greatest dimension
T2:	Tumor more than 2 cm but not more than 5 cm in greatest dimension
T3:	Tumor more than 5 cm in greatest dimension
T4:	Tumor of any size invades adjacent organ(s), e.g., vagina, urethra, bladder (involvement of sphincter muscle alone is not classified as T4)
Regional Lymph Nodes (N)	
Nx:	Regional lymph nodes cannot be assessed
N0:	No regional lymph node metastasis
N1:	Metastasis in perirectal lymph node(s)
N2:	Metastasis in unilateral internal iliac and/or inguinal lymph nodes
N3:	Metastasis in perirectal and inguinal lymph nodes and/or bilateral internal iliac and/or inguinal lymph nodes
Distant Metastasis (M)	
Mx:	Distant metastasis cannot be assessed
M0:	No distant metastasis
M1:	Distant metastasis
Stage Grouping	
Stage 0	Tis, N0, M0
Stage I	T1, N0, M0
Stage II	T2, N0, M0
	T3, N0, M0
Stage IIIA	T1, N1, M0
	T2, N1, M0
	T3, N1, M0
	T4, N0, M0
Stage IIIB	T4, N1, M0
	Any T, N2, M0
	Any T, N3, M0
Stage IV	Any T, Any N, M

Used with the permission of the American Joint Committee on Cancer (AJCC), Chicago, Illinois. The original source for this material is the AJCC Cancer Staging Manual, Seventh Edition (2010) published by Springer Science and Business Media LLC, www.springer.com

Table 70-7 Modified Nigro Regimen for Squamous Cell Carcinoma of the Anal Canal

Treatment	Dose	Schedule
External radiation	50 Gy, to the primary carcinoma and 35–45 Gy to pelvic inguinal nodes	Start day 1 (2 Gy/d, 5 d/wk for 5 wk)
Systemic chemotherapy	Fluorouracil, 1,000 mg/m^2/24 h as a continuous infusion for 4 d	Start day 1; repeat 4-d infusion starting day 28
Mitomycin C	10–15 mg/m^2 as intravenous bolus	Day 1 only

References

1. Lindsey I, Guy RJ, Warren BF, et al. Anatomy of Denonvilliers' fascia and pelvic nerves, impotence, and implications for the colorectal surgeon. *Br J Surg* 2000;87(10):1288–1299.
2. Church JM, Raudkivi PJ, Hill GL. The surgical anatomy of the rectum–a review with particular relevance to the hazards of rectal mobilisation. *Int J Colorectal Dis* 1987;2(3):158–166.
3. Alonso-Coello P, Mills E, Heels-Ansdell D, et al. Fiber for the treatment of hemorrhoids complications: a systematic review and meta-analysis. *Am J Gastroenterol* 2006;101(1):181–188.
4. Iyer VS, Shrier I, Gordon PH. Long-term outcome of rubber band ligation for symptomatic primary and recurrent internal hemorrhoids. *Dis Colon Rectum* 2004;47(8):1364–1370.
5. Shanmugam V, Thaha MA, Rabindranath KS, et al. Systematic review of randomized trials comparing rubber band ligation with excisional haemorrhoidectomy. *Br J Surg* 2005;92(12):1481–1487.
6. Shao WJ, Li GC, Zhang ZH, et al. Systematic review and meta-analysis of randomized controlled trials comparing stapled haemorrhoidopexy with conventional haemorrhoidectomy. *Br J Surg* 2008;95(2):147–160.
7. Ratto C, Donisi L, Parello A, et al. Evaluation of transanal hemorrhoidal dearterialization as a minimally invasive therapeutic approach to hemorrhoids. *Dis Colon Rectum* 2010;53(5):803–811.
8. Jensen SL. Diet and other risk factors for fissure-in-ano. Prospective case control study. *Dis Colon Rectum* 1988;31(10):770–773.
9. Schouten WR, Briel JW, Auwerda JJ. Relationship between anal pressure and anodermal blood flow. The vascular pathogenesis of anal fissures. *Dis Colon Rectum* 1994;37(7):664–669.
10. Hananel N, Gordon PH. Re-examination of clinical manifestations and response to therapy of fissure-in-ano. *Dis Colon Rectum* 1997;40(2):229–233.
11. Lund JN, Scholefield JH. Glyceryl trinitrate is an effective treatment for anal fissure. *Dis Colon Rectum* 1997;40(4):468–470.
12. Ezri T, Susmallian S. Topical nifedipine vs. topical glyceryl trinitrate for treatment of chronic anal fissure. *Dis Colon Rectum* 2003;46(6):805–808.
13. Nelson R. A systematic review of medical therapy for anal fissure. *Dis Colon Rectum* 2004;47(4):422–431.
14. Sözener U, Gedik E, Kessaf Aslar A, et al. Does adjuvant antibiotic treatment after drainage of anorectal abscess prevent development of anal fistulas? A randomized, placebo-controlled, double-blind, multicenter study. *Dis Colon Rectum* 2011;54(8):923–929.
15. Parks AG, Gordon PH, Hardcastle JD. A classification of fistula-in-ano. *Br J Surg*

1976;63(1):1–12.
16. Cintron JR, Park JJ, Orsay CP, et al. Repair of fistulas-in-ano using fibrin adhesive: long-term follow-up. *Dis Colon Rectum* 2000;43(7):944–949; discussion 949–950.
17. van Koperen PJ, Bemelman WA, Gerhards MF, et al. The anal fistula plug treatment compared with the mucosal advancement flap for cryptoglandular high transsphincteric perianal fistula: a double-blinded multicenter randomized trial. *Dis Colon Rectum* 2011;54(4):387–393.
18. Lewis R, Lunniss PJ, Hammond TM. Novel biological strategies in the management of anal fistula. *Colorectal Dis* 2012;14(12):1445–1455.
19. Sonoda T, Hull T, Piedmonte MR, et al. Outcomes of primary repair of anorectal and rectovaginal fistulas using the endorectal advancement flap. *Dis Colon Rectum* 2002;45(12):1622–1628.
20. Jakobovits J, Schuster MM. Metronidazole therapy for Crohn's disease and associated fistulae. *Am J Gastroenterol* 1984;79(7):533–540.
21. Present DH, Rutgeerts P, Targan S, et al. Infliximab for the treatment of fistulas in patients with Crohn's disease. *N Engl J Med* 1999;340(18):1398–1405.
22. Gaertner WB, Decanini A, Mellgren A, et al. Does infliximab infusion impact results of operative treatment for Crohn's perianal fistulas? *Dis Colon Rectum* 2007;50(11):1754–1760.
23. Lowry AC, Thorson AG, Rothenberger DA, et al. Repair of simple rectovaginal fistulas. Influence of previous repairs. *Dis Colon Rectum* 1988;31(9):676–678.
24. Fuzun, M., Bakir H, Soylu M, et al. Which technique for treatment of pilonidal sinus–open or closed? *Dis Colon Rectum* 1994;37(11):1148–1150.
25. Bessa SS. Results of the lateral advancing flap operation (modified Karydakis procedure) for the management of pilonidal sinus disease. *Dis Colon Rectum* 2007;50(11):1935–1940.
26. Senapati A, Cripps NP, Thompson MR. Bascom's operation in the day-surgical management of symptomatic pilonidal sinus. *Br J Surg* 2000;87(8):1067–1070.
27. Madiba TE, Baig MK, Wexner SD. Surgical management of rectal prolapse. *Arch Surg* 2005;140(1):63–73.
28. Agachan F, Reissman P, Pfeifer J, et al. Comparison of three perineal procedures for the treatment of rectal prolapse. *South Med J* 1997;90(9):925–932.
29. Raftopoulos Y, Senagore AJ, Di Giuro G, et al. Recurrence rates after abdominal surgery for complete rectal prolapse: a multicenter pooled analysis of 643 individual patient data. *Dis Colon Rectum* 2005;48(6):1200–1206.
30. Brown HW, Wexner SD, Segall MM, et al. Accidental bowel leakage in the mature women's health study: prevalence and predictors. *Int J Clin Pract* 2012;66(11):1101–1108.
31. Jorge JM, Wexner SD. Etiology and management of fecal incontinence. *Dis Colon Rectum* 1993;36(1):77–97.

32. Hayden DM, Weiss EG. Fecal incontinence: etiology, evaluation, and treatment. *Clin Colon Rectal Surg* 2011;24(1):64–70.
33. Berho M, Wexner SD, Botero-Anug AM, et al. Histopathologic advantages of compression ring anastomosis healing as compared with stapled anastomosis in a porcine model: a blinded comparative study. *Dis Colon Rectum* 2014;57(4):506–513.
34. Frascio M1, Mandolfino F, Imperatore M, et al. The SECCA procedure for faecal incontinence: a review. *Colorectal Dis* 2014;16(3):167–172.
35. Takahashi-Monroy T, Morales M, Garcia-Osogobio S, et al. SECCA procedure for the treatment of fecal incontinence: results of five-year follow-up. *Dis Colon Rectum* 2008;51(3):355–359.
36. Bravo Gutierrez A, Madoff RD, Lowry AC, et al. Long-term results of anterior sphincteroplasty. *Dis Colon Rectum* 2004;47(5):727–731; discussion 731–732.
37. Wong MT, Meurette G, Wyart V, et al. The artificial bowel sphincter: a single institution experience over a decade. *Ann Surg* 2011;254(6):951–956.
38. Hull T, Giese C, Wexner SD, et al. Long-term durability of sacral nerve stimulation therapy for chronic fecal incontinence. *Dis Colon Rectum* 2013;56(2):234–245.
39. Knowles CH, Horrocks EJ, Bremner SA, et al; CONFIDeNT study group. Percutaneous tibial nerve stimulation versus sham electrical stimulation for the treatment of faecal incontinence in adults (CONFIDeNT): a double-blind, multicentre, pragmatic, parallel-group, randomised controlled trial. *Lancet* 2015;386(10004):1640–1648.
40. Viazis N, Vlachogiannakos J, Vasiliadis K, et al. Earlier eradication of intra-anal warts with argon plasma coagulator combined with imiquimod cream compared with argon plasma coagulator alone: a prospective, randomized trial. *Dis Colon Rectum* 2007;50(12):2173–2179.
41. Frisch M, Biggar RJ, Goedert JJ. Human papillomavirus-associated cancers in patients with human immunodeficiency virus infection and acquired immunodeficiency syndrome. *J Natl Cancer Inst* 2000;92(18):1500–1510.
42. Trombetta LJ, Place RJ. Giant condyloma acuminatum of the anorectum: trends in epidemiology and management: report of a case and review of the literature. *Dis Colon Rectum* 2001;44(12):1878–1886.
43. Sarmiento JM, Wolff BG, Burgart LJ, et al. Perianal Bowen's disease: associated tumors, human papillomavirus, surgery, and other controversies. *Dis Colon Rectum* 1997;40(8):912–918.
44. Möller C, Saksela E. Cancer of the anus and anal canal. *Acta Chir Scand* 1970;136(4):340–348.
45. Fuchshuber PR, Rodriguez-Bigas M, Weber T, et al. Anal canal and perianal epidermoid cancers. *J Am Coll Surg* 1997;185(5):494–505.
46. Beck DE. Paget's disease and Bowen's disease of the anus. *Semin Colon Rectal Surg* 1995;6:143–149.
47. Hassan I, Horgan AF, Nivatvongs S. V-Y island flaps for repair of large perianal

defects. *Am J Surg* 2001;181(4):363–365.

48. Skinner PP, Ogunbiyi OA, Scholefield JH, et al. Skin appendage involvement in anal intraepithelial neoplasia. *Br J Surg* 1997;84(5):675–678.
49. Paterson CA, Young-Fadok TM, Dozois RR. Basal cell carcinoma of the perianal region: 20-year experience. *Dis Colon Rectum* 1999;42(9):1200–1202.
50. Rousseau DL Jr, Petrelli NJ, Kahlenberg MS. Overview of anal cancer for the surgeon. *Surg Oncol Clin N Am* 2004;13(2):249–262.
51. Epidermoid anal cancer: results from the UKCCCR randomised trial of radiotherapy alone versus radiotherapy, 5-fluorouracil, and mitomycin. UKCCCR Anal Cancer Trial Working Party. UK Co-ordinating Committee on Cancer Research. *Lancet* 1996;348(9034):1049–1054.
52. Bartelink H, Roelofsen F, Eschwege F, et al. Concomitant radiotherapy and chemotherapy is superior to radiotherapy alone in the treatment of locally advanced anal cancer: results of a phase III randomized trial of the European Organization for Research and Treatment of Cancer Radiotherapy and Gastrointestinal Cooperative Groups. *J Clin Oncol* 1997;15(5):2040-2049.
53. Mariani P, Ghanneme A, De la Rochefordière A, et al. Abdominoperineal resection for anal cancer. *Dis Colon Rectum* 2008;51(10):1495–1501.
54. Nguyen WD, Mitchell KM, Beck DE. Risk factors associated with requiring a stoma for the management of anal cancer. *Dis Colon Rectum* 2004;47(6):843–846.
55. Christian CK, Kwaan MR, Betensky RA, et al. Risk factors for perineal wound complications following abdominoperineal resection. *Dis Colon Rectum* 2005;48(1):43–48.
56. Tarazi R, Nelson RL. Adenocarcinoma of the anus. *Semin Colon Rectal Surg* 1995;6:169–173.
57. Beal KP, Wong D, Guillem JG, et al. Primary adenocarcinoma of the anus treated with combined modality therapy. *Dis Colon Rectum* 2003;46(10):1320–1324.
58. Weyandt GH, Eggert AO, Houf M, et al. Anorectal melanoma: surgical management guidelines according to tumour thickness. *Br J Cancer* 2003; 89(11):2019–2022.
59. Bullard KM, Tuttle TM, Rothenberger DA, et al. Surgical therapy for anorectal melanoma. *J Am Coll Surg* 2003;196(2):206–211.
60. Pessaux P, Pocard M, Elias D, et al. Surgical management of primary anorectal melanoma. *Br J Surg* 2004;91(9):1183–1187.

Chapter 71

Diseases of Appendix

Edward A. Levine and Nathan Mowery

Key Points

1 The anatomy of the appendix tells the story of the epidemiology of appendicitis and can serve as a road map for its intra-abdominal location.

2 Despite advances in diagnostic tests, appendicitis remains a clinical diagnosis.

3 When indicated helical CT with IV contrast is the test of choice when imaging is indicated in patients with suspected appendicitis.

4 In selected patients with acute, uncomplicated appendicitis, antibiotic treatment is an appropriate alternative to appendectomy.

5 The decision to perform an interval appendectomy following successful nonoperative management with antibiotics and percutaneous drainage remains controversial.

6 Laparoscopic appendectomy confers many benefits over open appendectomy, and should be strongly considered as the preferred approach where surgical expertise is appropriate and equipment is available and affordable.

7 Outpatient appendectomy should be considered in cases of uncomplicated appendicitis.

8 Appendiceal cancer represents approximately 1% of colon malignancies.

9 Appendiceal cancer typically presents as unexpected finding on final pathology after appendectomy for presumed acute appendicitis.

10 Cytoreductive surgery and hyperthermic intraperitoneal chemotherapy (HIPEC) is a standard approach for appendiceal cancer with peritoneal dissemination.

APPENDICITIS

The first description of appendicitis in the literature was by Lorenz Heister in 1711.[1] He described a perforated appendix with associated abscess in the autopsy report of a prisoner. Unfortunately, autopsy was the most common operation done for appendicitis until 1827, when a French surgeon, Francois Melier, suggested removing the appendix during episodes of right lower-quadrant pain.[1] It was not until advances in anesthesia and antisepsis developed in the late 1800s that appendectomy became more common.

Perhaps the most famous case of appendicitis is that of King Edward VII, the first son of Queen Victoria. After a prolonged period waiting to inherit the crown from his mother, Edward, was set to become King of England. Less than 2 weeks before the coronation, the future king developed abdominal discomfort. A staff of physicians attended to Edward including two prominent British surgeons, Lord Joseph Lister and Sir Frederic Treves. They observed right lower-quadrant swelling, tenderness, and fever in the future king. The medical staff was unanimous in recommending an operation, but Edward was hesitant on the eve of his coronation. It fell to Lister to persuade Edward that an urgent operation was necessary. Westminster Abbey not only hosted coronations but also funerals of British royalty. Edward responded to his medical staff, “I must keep faith with my people and go to the [Westminster] Abbey for the coronation.” Edward was adamant, and after hearing him repeat “I must go to the Abbey,” Treves replied, “Then, Sir, you will go as a corpse.”

Edward finally consented to surgery, and on June 24, 1902, Treves operated on Edward at Buckingham Palace. He opened a large periappendiceal abscess, evacuated pus, and left two large drains in place. He did not remove the appendix. The wound was packed open and the entire procedure took approximately 40 minutes. Edward recovered successfully and underwent coronation approximately 7 weeks after surgery. He served as king for the remaining eight years of his life without ever undergoing an interval appendectomy.

ANATOMY

1 The anatomy of the appendix tells the story of the epidemiology of appendicitis. Embryologically, the appendix is part of the cecum from which it originates where the three tenia coli coalesce on the cecum. Not surprisingly, the appendix resembles the cecum histologically and includes circular and longitudinal muscle layers. In addition, the appendix contains an abundance of lymph follicles in the submucosa, numbering approximately 200. The highest number of lymph follicles occurs in the 10- to 20-year-old age group, with a decline in number after age 30; lymph follicles are typically absent after age 60.

The appendix arises from the cecum approximately 2.5 cm below the ileocecal valve. It varies in length from complete agenesis to more than 30 cm, but it is usually 5 to 10 cm in length. The mean width is 0.5 to 1.0 cm. The various positions of the appendix are conveniently categorized into the following locations: paracolic (the appendix lies in the right paracolic gutter lateral to the cecum), retrocecal (the appendix lies posterior to the cecum and may be partially or totally extraperitoneal), preileal (the appendix is anterior to the terminal ileum), postileal (the appendix is posterior to the ileum), promontoric (the tip of the appendix lies in the vicinity of the sacral promontory), pelvic (the tip of the appendix lies in or toward the pelvis), and subcecal (the appendix lies inferior to the cecum). Wakeley[2] performed a postmortem analysis of 10,000 cases and described the frequency of the location of the appendix as follows: retrocecal, 65.3%; pelvic, 31%; subcecal, 2.3%; preileal, 1%; and right paracolic and postileal, 0.4%. In essence, the appendix may lie in multiple locations, essentially at virtually any position in a clockwise rotation from the base of the cecum. The clinician must appreciate that the anatomic location of the appendix determines the presentation of symptoms and signs during an episode of appendicitis.

PATHOPHYSIOLOGY

Wangensteen and Dennis[3] demonstrated experimentally that luminal obstruction leads to the development of acute appendicitis. The appendix has a small luminal diameter in relation to its length. Conventional wisdom holds that this configuration predisposes the appendix to closed-loop obstruction and subsequent inflammation. Specifically, proximal obstruction (by any number of initiating factors) leads to ongoing mucous secretion of the appendiceal mucosa distal to the obstruction into a closed lumen with elevation of intraluminal pressure. Rapid distention of the appendix ensues because of its small luminal capacity and intraluminal pressures can reach 50 to 65 mm Hg. Distension of the appendix stimulates visceral afferent pain fibers, producing a somewhat vague and diffuse periumbilical pain. Distention of the appendix often causes reflex nausea and/or vomiting with a progressive increase in the severity of the visceral pain.

As luminal pressure increases, venous pressure is exceeded and mucosal ischemia develops. Once luminal pressure exceeds 85 mm Hg, thrombosis of the venules that drain the appendix occurs and, in the setting of continued arteriolar inflow, vascular congestion and engorgement of the appendix become manifest. With vascular congestion, the appendiceal mucosa becomes hypoxic and begins to ulcerate, resulting in compromise of the mucosal barrier, and leading to invasion of the appendiceal wall by intraluminal bacteria. This sets in motion an inflammatory process that leads to mucosal disruption followed by serosal involvement and finally inflammation of the nearby parietal peritoneum, resulting in the characteristic shift in location of pain to the right lower quadrant along with localized tenderness. If unimpeded, luminal pressure rises to a level that induces venous infarction, full-thickness necrosis, and perforation. The length of time required for the disease to progress to gangrene and perforation is highly variable. One study demonstrated a mean duration of abdominal pain of 46.2 hours in patients with gangrene and 70.9 hours for perforation.[4]

Fecal stasis and fecaliths are the most common cause of appendiceal obstruction, followed by lymphoid hyperplasia, vegetable matter and fruit seeds, inspissated barium from previous radiographic studies, intestinal worms (especially ascarids), and tumors (such as carcinoid). It is important to note that the offending agent causing obstruction is only found in 50% of the cases. Accordingly, it is fair to state that luminal obstruction appears to account for many cases of appendicitis, but the cause for a substantial number of cases remains elusive.

DIAGNOSIS OF ACUTE APPENDICITIS

Despite knowing about the disease process for over 300 years, identifying which patients have it still poses a significant challenge today. In the United States, approximately 11 of 10,000 people will develop acute appendicitis over their lifetime, with the typical age of onset between the ages of 11 and 19 years.[5] Appendicitis is a common problem; there are more than 300,000 hospital discharges for appendicitis in the United States per year. Due to its frequent epidemiology it is often thought of as a straightforward diagnosis, but this is rarely the case. Diagnostic errors are common, with overdiagnosis leading to negative appendectomies, and with delays in diagnosis leading to perforations. The misdiagnosis of appendicitis has significant economic ramifications; in a nationwide study of administrative data, a negative appendectomy rate of 15% resulted in more than $740 million in hospital charges.[6] On the other end of the spectrum, delay or error in diagnosis of acute appendicitis is now one of the most frequent allegations of medical malpractice that are leveled against general surgeons, emergency medicine physicians, and primary care physicians.

As with any patient presenting with abdominal pain the evaluation should begin with a thorough history and physical examination. In certain populations, appendicitis remains one of the disease processes cared for by surgeons that can be diagnosed with a careful history and physical examination alone, sparing the patient the cost and discomfort of imaging. Published guidelines note that the combination of clinical and laboratory findings of characteristic abdominal pain, localized tenderness, and laboratory evidence of inflammation will identify most patients with suspected appendicitis.[7] Other diagnostic strategies may include radiologic imaging or the use of scoring systems with or without computer support. Ultimately, the “gold standard” for a positive diagnosis is the histopathologic confirmation of appendicitis, although standard criteria are lacking.

HISTORY AND PHYSICAL EXAMINATION

2 Despite advances in diagnostic tests, appendicitis remains a clinical diagnosis. Clinical symptoms elicited by the history may include fever, nausea, vomiting, anorexia, migration of pain to the right lower quadrant, and aggravation of pain by movement. Physical examination may reveal signs of peritoneal irritation in the right lower quadrant or diffusely. Rectal examination may reveal tenderness. There is evidence that the order that the symptoms present in is often diagnostic. Authors have suggested that pain usually comes before nausea or fever and if the order is reversed then the diagnosis is not appendicitis. Furthermore, there are a variety of named signs that may be associated with appendicitis depending upon the location of the inflamed appendix (Table 71-1). The signs and symptoms are common and nonspecific; each individual sign and symptom is only weakly predictive of appendicitis.[8] Furthermore, the differential diagnosis for right lower-quadrant abdominal pain is wide and varies with age and gender. When signs and symptoms were compared between children and adults, they were similarly predictive of appendicitis, with the exception of right lower-quadrant pain which had a much higher likelihood ratio in adults than in children.[9,10] Another limitation of relying on clinical findings alone is that elicitation of physical signs is subjective; multiple studies have demonstrated poor interrater reliability between trainees and attending physicians, as well as between subspecialists.[11,12] However, when used in combination with laboratory values, the diagnostic utility of clinical findings increases significantly.

LABORATORY VALUES

Laboratory values that have been associated with acute appendicitis include leukocytosis, left shift, and elevated markers of inflammation such as C-reactive protein (CRP) and erythrocyte sedimentation rate.[8,10] As with the clinical symptoms and signs, each individual laboratory test value is only weakly discriminatory and predictive of acute appendicitis.[8] However, combinations of clinical findings and laboratory values or combinations of multiple laboratory values are more accurate and predictive.[8] A meta-analysis revealed that the greatest discriminators and predictors of acute appendicitis included a history of migration of pain, clinical findings of peritoneal irritation, and laboratory values reflecting an inflammatory response (i.e., CRP).[8]

Table 71-1 Named Clinical Signs Associated With Appendicitis

Dunphy sign	Increased right lower-quadrant pain with coughing
Obturator sign	Increased pain with flexion and internal rotation of the hip
Psoas sign	Increased pain with passive extension of the right hip (can be elicited with the patient lying on the left side)
Rovsing sign	Increased right lower-quadrant pain during palpation in the left lower quadrant

Table 71-2 Alvarado or MANTRELS Scoring System

	Variable	Value
Symptoms	Migration Anorexia Nausea–vomiting	1 1 1
Signs	Tenderness in right lower quadrant Rebound of pain Elevation of temperature (>37.3°C)	2 1 1
Laboratory	Leukocytosis (WBC <10,000/uL) Shift to the left (>75% neutrophils)	2 1
Total Score		10

There have been numerous studies evaluating other potential serum and urinary markers of appendicitis, including but not limited to inflammatory cytokines such as serum interleukin-6, interleukin-8, and tumor necrosis factor alpha; serum neutrophil proteins such as lactoferrin and calprotectin; and urinary markers such as leucine-rich α-2-glycoprotein. None of these have been shown to be superior to traditional markers of inflammation in a prospective trial.

There are several clinical scoring systems that have been used in the diagnosis of acute appendicitis. The most common is the Alvarado scoring system published in 1986, also referred to as MANTRELS based on the mnemonic for remembering the combination of

eight signs and symptoms (Table 71-2).[13] The score ranges from 0 to 10; a patient with a score of 5 or 6 is typically observed, whereas a patient with a score of 7 or greater should undergo operation.[13] Since then, there have been several studies evaluating the diagnostic accuracy of the Alvarado score, as well as modified versions of the Alvarado score such as the Pediatric Appendicitis Score,[14] and other scores such as the Kharbanda[15] and Lintula[16] scores. In general, these clinical scoring systems have better predictive ability than individual symptoms or signs alone. However, these scoring systems do not have sufficient discriminatory or predictive ability to routinely be used alone to diagnose appendicitis. They have been used to determine the need for further radiologic studies[17] or as a guide for dictating clinical management.[18]

RADIOLOGIC IMAGING

At one time, surgical clinical acumen was graded on the ability to diagnose appendicitis on physical examination, but currently, more and more patients are diagnosed using imaging studies. Population-based analyses of regional administrative data in the 1980s and 1990s demonstrated a significant increase in the use of ultrasound (US) and computed tomography (CT). One would hope that this increase in imaging would lead to a decrease in the number of ruptured or negative appendectomies, but that is not the case.[19,20] On one hand, imaging may be helpful in the evaluation of patients with abdominal pain for excluding other diagnoses or for preventing unnecessary operations.[19] On the other hand, imaging could potentially delay operative intervention, and in the case of CT, radiologic imaging exposes patients to the risks of ionizing radiation. Ultrasonography does not expose patients to ionizing radiation but is more operator dependent. In a meta-analysis of US and CT in children and adults, both US and CT were highly specific (93% to 95%) in children and adults, whereas CT was more sensitive than US.[21]

3 The Surgical Infection Society and Infectious Disease Society of America guidelines recommend helical CT with IV contrast as the test of choice when imaging is indicated in patients with suspected appendicitis. There is moderate supporting evidence for this from well-designed but nonrandomized trials.[7,22] A recent meta-analysis evaluated the effect of CT on negative appendectomies, rates of perforation, and time to surgery in patients with acute right lower-quadrant pain.[23] The meta-analysis concluded that preoperative CT resulted in a reduced rate of negative appendectomies but an increase in time to surgery, although there was no increase in rate of perforation. There are some data to support the use of noncontrast CT of the abdomen in adults. The test had reasonably high sensitivity and specificity for clinical decision making (93% and 96%, respectively).[24]

There have been only a few randomized trials evaluating different strategies incorporating radiologic imaging on clinical outcomes. Only one trial found a difference in accuracy. Lee and colleagues compared a strategy of mandatory or selective CT scanning in patients with suspected appendicitis and less than 72 hours of symptoms. They found there were fewer negative appendectomies and perforations in the group undergoing mandatory scans.[25] Another trial reported that CT scanning changed management in only 26% of patients.[26]

Clearly, CT can be useful for cases without clear indications for surgery.

IDENTIFYING PERFORATED APPENDICITIS PREOPERATIVELY

Distinguishing whether or not a patient is likely to have perforated or nonperforated appendicitis preoperatively may be helpful in terms of counseling the patient about alternatives for management (i.e., early vs. delayed appendectomy), risk for complications, and the expected postoperative course. A recent meta-analysis identified four studies that presented data for perforated appendicitis. Based on these studies, high values of laboratory markers of inflammation such as a WBC and granulocyte count and the CRP level were relatively strong predictors of perforated appendicitis, whereas low values were relatively strong predictors of not having perforated appendicitis.[8] A combination of clinical finding and laboratory values can help identify ruptured appendicitis preoperatively by developing a scoring system for children based on five variables, including components of history, physical examination, laboratory values, and CT findings.[27] When the scoring system was applied to the study patient population, it increased the specificity of the pediatric surgeon's preoperative assessment from 83% to 98%.[27]

FUTURE DIRECTIONS IN DIAGNOSIS

Research is ongoing to identify accurate, efficient, and cost-effective methods of diagnosis. Advances have included using molecular techniques for profiling gene and protein expression to identify novel markers for appendicitis.[28–30] Imaging alternatives to CT scans such as bedside surgeon-performed US,[31] magnetic resonance imaging,[32] or low-radiation CT scanning[33] are being investigated in terms of their diagnostic accuracy and their potential to reduce exposure to radiation. Another avenue of investigation is the use of machine learning and advanced statistical models for informing decision making.[34] As advances in technology and diagnostic strategies are made, any improvements in accuracy must be balanced against the proven utility of bedside clinical evaluation as well as costs and potential harms.



Figure 71-1. Acute suppurative appendicitis.

MANAGEMENT

Background for Nonoperative Management for Acute Uncomplicated Appendicitis

Appendectomy for acute appendicitis is one of the most common surgical procedures performed worldwide (Fig. 71-1). In the United States, appendectomy incurs considerable indirect costs resulting from time lost from work, school, or usual activities after the procedure.[35] The individual lifetime risk of appendicitis is 8.6% for men and 6.7% for women.[36] Uncomplicated acute appendicitis is considered almost universally to be an indication for an appendectomy. In 1894, open appendectomy was accepted as the treatment standard, because it saved lives, and since that time, the dictum that surgical removal of the appendix is necessary has been largely unchallenged.[37] All surgeons are taught that appendicitis untreated will march on and eventually perforate which puts the patient's recovery in question. Thus, early surgical exploration and appendectomy is advocated for source control. However, appendectomy for nonperforated appendicitis is not without associated harm. The long-term risk of small bowel obstruction is estimated at 1.3% at 30 years after appendectomy.[38] In addition, the "negative" appendectomy rate ranges from 10% to 20%, and remains unchanged despite the widespread use of CT.[39–41]

Meanwhile, nonoperative management with antibiotics has been established as the treatment for various intra-abdominal infections such as uncomplicated diverticulitis, salpingitis, and neonatal enterocolitis.[42] It is surprising that nonoperative management of uncomplicated acute appendicitis remains largely unexplored despite evidence that it often resolves, either spontaneously or with antibiotic therapy, and has been shown by limited studies to have outcomes equivalent to those of appendectomy.[43,44] Accordingly, it may be reasonable to call into question the assumptions and "evidence" that have supported routine appendectomy for this condition.

Spontaneous resolution of appendiceal inflammation does occur, although its frequency is unknown. Presumably, increasing intraluminal pressure dislodges the obstructing material back into the cecum, thereby relieving the distention and inflammatory process. Evidence of previous inflammation may be recognized subsequently as a fibrotic, kinked, or adhesed appendix when viewed at a future operation. In 1 series of 1,000 patients with appendicitis, 9% reported having had a similar clinical illness in the past and 4% reported more than one previous attack.[45]

Widespread CT scan utilization for the diagnosis of appendicitis has resulted in a significant increase in the number of CT scans performed annually.[46] This has led to several interesting observations regarding the possibility of spontaneous resolution of appendicitis from several centers. Inclusion of a CT scan result in the Alvarado score has been shown to increase the rate of appendectomy. When classified as having a low likelihood of appendicitis (Alvarado score ≤ 4), patients who underwent a CT scan had an appendectomy rate of 48%.[46] In contrast, those with an Alvarado score ≤ 4 who did not undergo a CT scan had an appendectomy rate of only 12% suggesting that some percentage of the population resolved spontaneously.

Decadt and colleagues made a comparable observation for those patients who presented with nonspecific abdominal pain.[47] The investigators used diagnostic laparoscopy instead of CT scan in the management of patients with nonspecific abdominal pain. Patients were randomized to either (1) diagnostic laparoscopy or (2) nonoperative management (with operative intervention if peritonitis developed). The appendectomy rate was 39% for those randomized to diagnostic laparoscopy and 13% for those managed nonoperatively. These indirect findings and evidence are suggestive that uncomplicated, acute appendicitis may be initially managed nonoperatively.

Nonoperative Management of Acute Appendicitis

To date, there have been few randomized studies of nonoperative versus operative therapy for acute appendicitis, and none have been conducted in the United States. Several reports have appeared in the literature over the last half decade describing nonoperative management of acute, uncomplicated appendicitis.[18,48–50]

The trial that has received the most attention was conducted in Sweden.[48] All patients older than 18 years with presumed appendicitis diagnosed by the physician based on clinical history, laboratory tests, US, CT, and physical examination were included. A total of 369 consecutive patients were randomized to antibiotic treatment or surgery. Study patients received intravenous (IV) antibiotics (cefotaxime 1 g twice and metronidazole 1.5 g once) for at least 24 hours. During this time patients received IV fluids with no oral intake. Patients whose clinical status had improved the following morning were discharged to continue with oral antibiotics (ciprofloxacin 500 mg twice per day and metronidazole 400 mg 3 times per day) for a total of 10 days. In patients whose clinical condition had not improved, IV treatment was prolonged.

There were 202 patients in the study group (antibiotics) and 167 patients in the control group (appendectomy). In the study group, 106 (52.5%) completed the intended antibiotic treatment, and 154 (92.2%) in the control group underwent an appendectomy. Of 108 patients who initially improved without surgery, 15 (13.9%) had recurrent appendicitis at a median follow-up time of 1 year. One-third of recurrences appeared within 10 days following discharge from the hospital. Of the 15 patients with recurrence, 12 had surgery (4 patients had gangrenous or perforated appendicitis and 1 patient underwent ileocecal resection) and 3 had a second round of antibiotic treatment with success.

Efficacy in the study group according to intention to treat was 48.0% (97 of 202). Eleven of 119 (9.2%) patients who primarily received antibiotics had an appendectomy owing to clinical progression. The preoperative characteristics of these patients were similar to those of the patients who fulfilled the antibiotic treatment. Of 250 surgically explored patients, 223 (89.2%) had appendicitis. Primary treatment efficacy was 90.8% for antibiotic therapy compared to 89.2% for surgical exploration analyzed per protocol. Major complications and total hospital cost for the primary admission were both lower in the antibiotic treatment group. This study shows that nonoperative management is an option in properly selected patients.

One of the largest retrospective series reporting nonoperative management of appendicitis comes from Japan.[51] Shindoh and colleagues reviewed their institutional experience with nonoperative management of appendicitis; in this report 367 patients met inclusion criteria (right lower-quadrant pain, WBC $>9{,}000$ or CRP >1.0 mg/dL). The authors describe the following three study groups: (1) initial operation or appendectomy, (2) nonoperative group, and (3) initial nonoperative group converted to surgery (failure). In the nonoperative groups, patients received antibiotics and were evaluated 24 hours later. If the physical examination or laboratory parameters worsened, surgical management was considered. In this cohort, 143 (39%) underwent initial operation

(group 1), whereas 224 (61%) were managed with initial antibiotic therapy. In the initial nonoperative group, 91 patients did not respond to antibiotics and underwent appendectomy. Factors predictive of failure included CRP (odds ratio [OR] 5.5, 95% CI: 1.94 to 17.29) and the presence of an appendicolith (OR 4.7, 95% CI: 1.15 to 24.46). Of note, in this study recurrence of appendicitis was observed in 4.7% of patients initially managed nonoperatively.

One of the inherent difficulties and biases in conducting a well-planned randomized clinical trial, centers on pathologic confirmation of appendicitis. On one hand, for those patients with "suspected" appendicitis who receive antibiotics only, treatment successes may cause one to consider the underlying diagnosis ("is it really appendicitis?"). On the other hand, the number of patients who undergo a negative appendectomy is not zero and exposure of these patients to surgical risks and complications is a valid concern. The report by Hansson and colleagues demonstrated a threefold increased rate of complications in the appendectomy group when compared to the nonoperative, antibiotic only group.[48]

4 The data presented are suggestive that in selected patients with acute, uncomplicated appendicitis, antibiotic treatment seems to be an appropriate alternative to appendectomy. Multivariate analysis of patient characteristics failed to demonstrate any logistic model for inclusion or rejection of patients for the specified treatments. A few of these studies have found that presence of the fecaliths is predictive of failure. Further studies are needed to create informed multivariate models that adjust for all of the important clinical covariates. Therefore, most patients older than 18 years without obvious signs of intra-abdominal perforation can be offered antibiotic treatment as first-line therapy. Clinical progression and surgical judgment may then determine whether there is a real need for surgical exploration. The benefit would be a significantly reduced frequency of major complications related to surgery, and potentially reduced costs.

Management of Complicated Appendicitis

Of the 11 of 10,000 people in the United States who will develop acute appendicitis over their lifetime,[5] an estimated 2% to 6% of patients will present with an appendiceal mass, either in the form of an inflammatory phlegmon or abscess.[52] The optimal management of these cases remains controversial. There is no consensus in the surgical literature on whether to proceed immediately with appendectomy or initial nonoperative management in this setting of complicated appendicitis. Another dilemma in the management of appendicitis initially managed conservatively with antibiotics is whether or not to perform an appendectomy at a later date (interval appendectomy). The data are disparate regarding actual recurrence rates of appendicitis following nonoperative management, but they are commonly reported between 5% and 20%.[53–55] In addition to recurrent appendicitis, a clinical concern in older patients who present with a cecal phlegmon is malignancy. In these cases, interval appendectomy allows the correct pathologic diagnosis to be made.[56] The effect of these management decisions on duration of hospital stay, number of interventions, healthcare costs, and overall patient satisfaction must be considered.

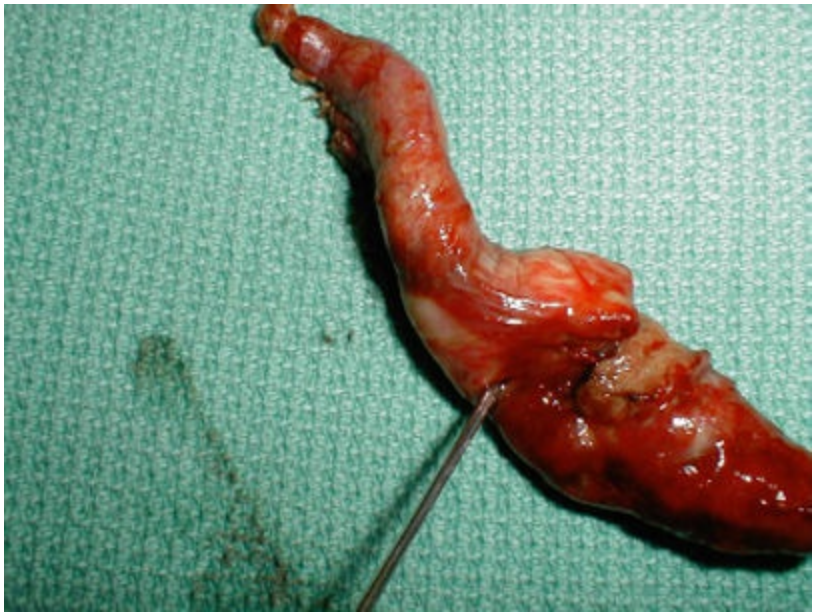

Figure 71-2. Perforated appendicitis.

Appendiceal Abscess

Appendiceal abscess is commonly associated with delayed presentation, fever, leukocytosis, and a palpable mass in the right lower quadrant (Fig. 71-2). The diagnosis is confirmed with CT or US. Management of these patients remains controversial. The traditional nonsurgical approach consists of percutaneous drainage and IV antibiotics, with or without interval appendectomy. Others suggest immediate appendectomy and surgical drainage of the abscess. The evidence supporting both approaches is weak, as most studies are retrospective and often combine patients with appendiceal abscess and phlegmon into a single cohort called "appendiceal mass." Several meta-analyses have been performed to try to identify differences between the two treatment strategies. Andersson and Petzold performed a meta-analysis on 19 retrospective studies from 1969 to 2005. The limitation of this study is the lack of uniform definition of appendiceal abscess and phlegmon. Nevertheless, the meta-analysis revealed that nonsurgical treatment failed in 7.6% of patients (CI: 3.2 to 12.0). Immediate appendectomy is associated with a higher morbidity with an OR of 3.3 (CI: 1.9 to 5.6). Based on these findings, the authors recommended nonsurgical management of patients with appendiceal abscess.[53] Similar conclusions were reached by Simillis and colleagues, who performed a meta-analysis of 16 retrospective studies and 1 nonrandomized prospective study from 1969 to 2007, comparing immediate appendectomy (725 patients) versus nonsurgical treatment (847 patients).[57] Immediate appendectomy is associated with greater incidence of ileus or bowel obstruction, abdominal or pelvic abscess, and wound infection compared to nonsurgical treatment. There was no difference in the overall duration of hospitalization, but the immediate appendectomy group required more reoperations. The higher rate of complications associated with immediate appendectomy has been attributed to greater inflammatory response to surgery in the setting of infection, as well as the technical difficulty with inflamed tissue. Most of the studies analyzed in these meta-analyses utilized open appendectomy techniques. The potential disadvantages of early operation may be mitigated by the laparoscopic techniques. Laparoscopic appendectomy results in less local inflammation due to better visualization and instrumentation.[58]

St. Peter and colleagues conducted a prospective randomized trial comparing immediate laparoscopic appendectomy to nonsurgical treatment in 40 pediatric patients presenting with appendiceal abscess.[59] Immediate laparoscopic appendectomy tends toward longer operative time (61 minutes vs. 42 minutes) compared with interval laparoscopic appendectomy performed at 10 weeks from initial presentation. The immediate appendectomy group had fewer healthcare visits and few CT scans. However, there was no difference in recurrent abscess rate, total length of hospitalization, or total charges. They concluded that immediate laparoscopic appendectomy is as safe as nonsurgical management. The safety of immediate laparoscopic appendectomy for appendiceal abscess is supported by several other retrospective or uncontrolled studies.[60–63] The infectious complications of immediate appendectomy can be reduced by improved laparoscopic techniques, such as use of extraction bag, endostaplers rather than

endoloops, and limited irrigation to avoid bacterial contamination.[64,65]

Appendiceal Phlegmon

The management of acute appendicitis complicated by an appendiceal phlegmon typically involves 1 of 3 treatment strategies (Fig. 71-3). The first, and most commonly accepted, is initial treatment with broad spectrum antibiotics and IV fluids until the acute inflammation subsides; appendectomy is then performed on an interval basis. Another strategy involves appendectomy upon initial presentation. Finally, following resolution of the acute inflammation with broad spectrum antibiotics, the patient is managed expectantly without interval appendectomy. Prospective data comparing these strategies are sparse, with most systematic reviews drawing heavily upon retrospective data.

At present, there is no agreed upon approach for the management of an appendiceal phlegmon. A recently published survey of a group of general surgeons in England found that 75% still favor interval appendectomy following resolution of symptoms.[66] Proponents for interval appendectomy state that removing the appendix is a technically easier operation once the acute inflammation subsides, potentially avoiding inadvertent injury to adjacent loops of involved bowel, as well as extended resection of the cecum or ascending colon.[56] Although the risk of recurrent appendicitis remains small after successful nonoperative treatment of an appendiceal phlegmon, proponents of interval appendectomy state that the risk of interval appendectomy is also small and eliminates the possibility of recurrent appendicitis.[54] In a recent systematic review published by Hall and colleagues, 127 children were managed without planned interval appendectomy.[67] The incidence of recurrent appendicitis ranged from 0% to 42% in the three studies included in the review, with an overall risk of 20.5% (95% CI: 14.3 to 28.4).

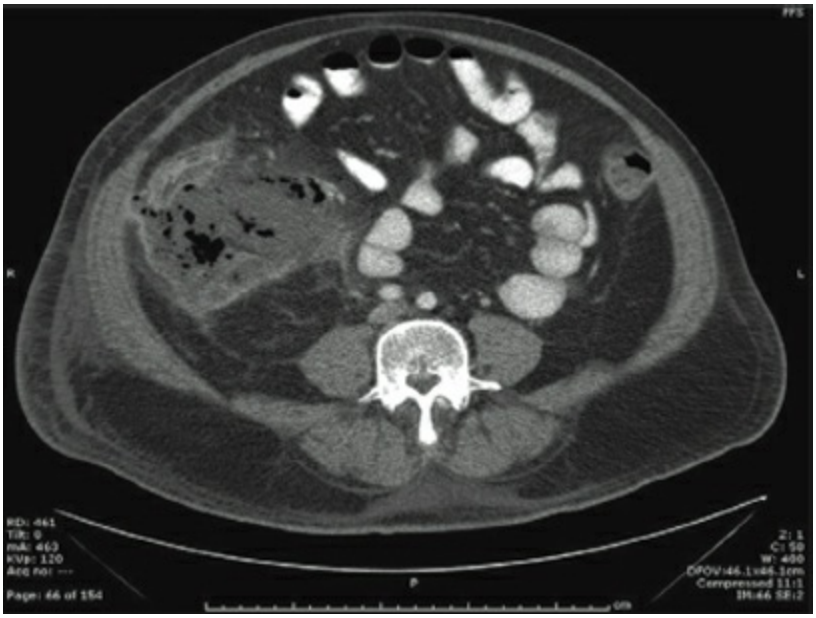

Figure 71-3. Perforated appendicitis with associated abscess.

The complication rates following interval appendectomy were also published in this review, with an overall incidence of 3.4% (95% CI: 2.2 to 5.1). The authors concluded that the likelihood of recurrent appendicitis, as well as the risk of complication after interval appendectomy, are both sufficiently low that the decision to proceed with

interval appendectomy is typically based on clinical criteria.

Interval Appendectomy

Interval appendectomy provides a tissue diagnosis when diagnostic uncertainty exists. This is particularly important in adults because the differential diagnosis of an inflammatory mass in the right lower quadrant can be quite extensive, with neoplastic etiologies of particular concern. In a systematic review and meta-analysis, 2,771 included patients were initially treated nonoperatively for an appendiceal phlegmon or abscess.[53] On follow-up, 31 patients were found to have a malignant diagnosis. In patients younger than 40 years with an appendiceal mass, only 4 were found to have a malignant diagnosis on follow-up: 2 children had carcinoid of the appendix, a 26-year-old woman presented with an ovarian malignancy, and a 25–year-old man presented with metastatic gastric cancer. The overall estimate of a malignant diagnosis was 1.2% (95% CI: 0.6% to 1.7%), with an incidence of 0.2% (95% CI: 0.0% to 0.05%) in children. Inflammatory bowel disease was established as a diagnosis during follow-up in 0.7% of patients (95% CI: 0.2% to 11.9%), with a higher incidence again seen in adults. Although primarily retrospective, these data underscore the need for follow-up, either with CT scan or colonoscopy, after successful treatment of an appendiceal phlegmon in adults.[53]

The presence of an appendicolith associated with an appendiceal phlegmon deserves special mention, as its presence has been used as a guide to proceed with interval appendectomy following successful nonoperative management. A retrospective cohort study reviewed the outcomes of 96 pediatric patients with appendicitis who presented with either an inflammatory mass or phlegmon, and were initially managed nonoperatively by the staff surgeon.[68] Six patients who failed initial nonoperative management underwent appendectomy and were excluded. Forty-one patients were scheduled for elective appendectomy by their surgeon and were also excluded from analysis. The remaining patients were included in the study and their outcomes over a 2-year period were reported. Of these, 37% had an appendicolith and 63% did not. The overall recurrence rate for appendicitis was 42%; in patients with an appendicolith, the recurrence rate was 72% compared to 26% in patients without an appendicolith (relative risk of 2.8 in patients with an appendicolith). The authors concluded that the presence of an appendicolith predicts failure of nonoperative management of periappendiceal phlegmon or abscess. It is important to note that the overall recurrence rate of appendicitis in this study is higher than what is typically reported elsewhere in the literature, and this may influence the true effect of an appendicolith on failure of nonoperative management.

Unfortunately, there are no data from a randomized, prospective trial evaluating whether or not the presence of an appendicolith is predictive of failure of initial nonoperative management of ruptured appendicitis with phlegmon or abscess. As such, any conclusions from this study should be viewed as hypothesis-generating for a future randomized controlled trial.

In deciding whether or not to proceed with routine interval appendectomy following successful nonoperative management of an appendiceal phlegmon or abscess, the effect of cost must also be considered.[69] Even with a high probability of recurrent appendicitis

(assumed to be 40%), financial analysis does not favor elective interval appendectomy.

A more robust randomized trial looking at the return to normal activity examined 131 total patients enrolled: 64 receiving initial appendectomy, and 67 were assigned to interval appendectomy.[70] In the primary appendectomy group, time to normal activity was 13.8 versus 19.4 days in the interval appendectomy group ($P < 0.001$). Of note, the relative risk of any adverse event associated with interval appendectomy was 1.86; specific outcomes measured included intra-abdominal abscess, small-bowel obstruction, unplanned readmission, and recurrent appendicitis, and these were all seen with higher frequency in the interval appendectomy group. The authors conclude that early appendectomy significantly reduced the time away from normal activity and showed a significantly lower adverse event rate.

5 The optimal management strategy of an appendiceal phlegmon or abscess remains elusive as most recommendations are based on retrospective data, but recent randomized trials in children indicate that early appendectomy results in faster return to normal activity with favorable complication rates when compared to interval appendectomy.[70] Performing an interval appendectomy following successful nonoperative management with antibiotics and percutaneous drainage, as needed, has yet to be evaluated in a randomized trial. Higher-quality evidence from prospective, randomized trials will help surgeons decide whether or not interval appendectomy in the setting of an appendicolith is appropriate.

SURGICAL OPTIONS FOR ACUTE APPENDICITIS

Laparoscopic versus Open Appendectomy

The open appendectomy was initially described by McBurney in 1894, and has remained relatively unchanged since its introduction. In 1983, Semm described a laparoscopic approach for removing the appendix, advocating the advantages of laparoscopic surgery for one of the most frequently performed surgical procedures.[71] Since open appendectomy also typically involves a small incision, short hospital stay, rapid return to normal activity, and low postoperative morbidity, demonstrating clear superiority of one approach over the other has been elusive. Although many randomized control trials comparing open versus laparoscopic appendectomy have been performed, many contain methodologic flaws, including inadequate allocation concealment, lack of reporting of randomization method, failure of adequate blinding, lack of analysis by intention-to-treat, and incomplete follow-up data.[72] That being said, these randomized trials, as well as systematic reviews and meta-analyses of these studies, have provided a great deal of insight into the specific benefits and drawbacks of each approach. In deciding between a laparoscopic and open approach, specific issues that must be considered include learning curve, operative time, associated morbidity, cost, pain, cosmesis, hospital length of stay, and time to return to normal activity. Unfortunately, measures vary across studies and conclusions have been inconsistent.

A large retrospective review of prospectively acquired data, compared outcomes of laparoscopic versus open appendectomy in 222 hospitals participating in the American College of Surgeons National Surgical Quality Improvement Program (ACS NSQIP) was conducted by Ingraham and colleagues.[73] The analysis of 30-day outcomes following laparoscopic and open appendectomy showed overall morbidity, serious morbidity, surgical site infection, and serious morbidity or mortality to be higher in patients undergoing open appendectomy, although these complications were generally low in both groups. A Cochrane review of 67 trials comparing laparoscopic and open appendectomy was updated in 2010.[74] Of these studies, the vast majority (56) were conducted in adults. Outcomes assessed by the included trials most frequently included operating time, complication rates, hospital stay, pain, and return to normal activity.

6 Although a variety of complications were evaluated, due to inconsistencies in the definition and reporting of these complications, the authors only examined two specific complications in their analysis: wound infection and intra-abdominal abscess. Following laparoscopic appendectomy, wound infections were approximately one-half as likely when compared to open appendectomy (OR 0.43; 95% CI: 0.34 to 0.54). Conversely, laparoscopic appendectomy was associated with a nearly threefold increase in the likelihood of intra-abdominal abscess when compared to an open technique (OR 1.77; 95% CI: 1.14 to 2.76). Operative time was 10 minutes longer for laparoscopic appendectomy (95% CI: 6 to 15), but this difference has been decreasing in recently published trials. Laparoscopic appendectomy was also associated with lower postoperative pain, shorter hospital stay (1.1 days), and faster return to normal activity

(5 days), although these results are highly heterogeneous and further study is warranted. Hospital and operational costs are higher with laparoscopic appendectomy, but again, these results are strongly heterogeneous. The authors concluded that laparoscopic appendectomy confers many benefits over open appendectomy, and should be strongly considered as the preferred approach where surgical expertise is appropriate and equipment is available and affordable.

The question of whether or not appendectomy should be performed via an open or laparoscopic technique has been inherently difficult to answer because both approaches offer similar advantages, namely, a small incision, low incidence of complications, a short hospital stay, and rapid return to normal activity. Newer studies would favor laparoscopic approaches but the answer is still not definitive. Ultimately the surgical approach remains up to the surgeon. Well-trained surgeons should be facile in both approaches should the need arise.

Single-Incision (Single-Port) Laparoscopic (SILS) Appendectomy

In the evolving era of "scarless surgery," SILS has been utilized for appendectomy. A single-incision laparoscopic-assisted appendectomy for acute appendicitis was first reported in adult patients in 1992.[75] Soon thereafter, this surgical approach began to be reported in children, with the first reports utilizing a single umbilical incision with a laparoscopic-assisted appendectomy, in which the appendectomy was performed after exteriorization through the umbilical incision.[76] Since then, several techniques under the auspices of SILS have been utilized including natural orifice transluminal endoscopic surgery and many variations of single-incision techniques.[77–80] The touted advantages of the SILS approach to appendectomy are similar to general laparoscopy compared to open operations, including less pain, faster recovery, and better cosmesis. However, critics countered these with concerns about increased costs, longer operation times, and higher complication rates.[81]

In adult studies comparing SILS with conventional three-port laparoscopic appendectomy, advantages in cosmetic outcomes were at the cost of longer operation times and substantial early postoperative pain.[82] SILS is even more popular in children without significant data that show a benefit. Oltmann and colleagues[83] reported that SILS with appendectomy is feasible and safe in the pediatric population. Although operating times were longer than the conventional three-port laparoscopic appendectomy, the authors suggested these should improve with better instrumentation and experience. St. Peter and colleagues[84] reported on the only randomized control trial comparing SILS-assisted appendectomy to conventional three-port laparoscopic appendectomy in 160 children with nonperforated acute appendicitis. Utilizing an extracorporeal appendectomy, there was a nonsignificant difference in wound infection rates of 3.3% for SILS patients compared to 1.7% for conventional laparoscopy. Although there was a statistically significant difference in operative time between the two approaches, the SILS technique was only 5.4 minutes longer (29.8 ± 11.6 vs. 35.2 ± 14.5 minutes). The investigators suggested that the difference was not clinically relevant and both techniques had comparable outcomes.

Operative Approach in Complicated Appendicitis

Clinical evidence that supports the laparoscopic approach for complicated (perforated or intra-abdominal abscess) appendicitis remains controversial. The concern over greater incidence of intra-abdominal abscess following the laparoscopic approach was reported in some studies[85–87] but not supported by others.[88,89] Due to the increased morbidity associated with complicated disease, some surgeons have opted for an initial nonoperative approach.[70,84,90] Using nonoperative treatment for complicated appendicitis followed by interval appendectomy obviates the need to manage the inflammatory environment in the acute stage. Such a strategy has been shown to be successful in treating most of the cases of complicated appendicitis with shorter hospitalization, lower charges, and lower morbidity.[91,92]

Outpatient Appendectomy

Traditionally, patients are hospitalized for 24 hours after laparoscopic appendectomy. As we move toward laparoscopic appendectomy becoming a new standard, the question has arisen if this surgery can be done as an outpatient operation. Although this strategy has been advanced in many elective abdominal procedures – laparoscopic cholecystectomy,[93] gastric bypass,[94] and incisional hernia repair,[95] for example – surgeons remain hesitant to discharge patients on the day of emergency surgery, particularly one with an infectious etiology. As recently as 2004, the average length of stay for laparoscopic appendectomy was 2.06 days.[96]

Most protocols in the literature describe discharge after a set of criteria has been reached. Utilizing these protocols it has been shown that discharge can occur as soon as 171 minutes after completion of the surgery.[97] This is true regardless of the time of day the surgery was completed. In the largest published adult series, 55% of the patients were discharged between the hours of 6 PM and 6 AM.[97] Other studies confirm that a protocol for outpatient appendectomy can be successful for early same day discharge.[98,99] In a study of 179 children 158 were targeted for same day discharge. Twenty-one patients were excluded due to findings of perforated or gangrenous appendicitis. One hundred and twenty six (80%) were discharged the same day as surgery with exceptions being made for social issues (too late at night or families unwilling to leave).[100]

The studies to date, have been unable to show a difference in morbidity in the groups when comparing immediate discharge to patients who are admitted.[96,97,99,101] In the largest of the studies on the topic postoperative complications occurred in 2.4% of outpatients and 11.7% per cent of inpatients ($P = 0.16$). Complications included superficial wound infections, urinary retention, urinary tract infection, intra-abdominal bleeding, pneumonia, and infected hematoma. Based upon the data, the authors concluded that outpatient laparoscopic appendectomy can be performed safely in selected patients.[98]

7 Certainly from an economic standpoint, an argument could be made for this transition to outpatient surgery for uncomplicated appendicitis. Length of stay following laparoscopic appendectomy for uncomplicated appendicitis ranges from 1.6 days to 2.1 days.[102] If an outpatient protocol were applied universally, it could result in annual healthcare savings of $920 million. Even a more conservative estimate done in Canada comparing outpatient appendectomies to same day discharges showed a cost saving of $323 Canadian dollars per patient.[99]

APPENDICEAL NEOPLASMS

8, **9** Approximately 1% of all appendectomy specimens will contain a neoplasm.[103] The most common tumors are carcinoid, benign mucoceles, and mucinous carcinoma. Rare tumors of the appendix include adenoma, adenocarcinoid, lymphoma, and GI stromal tumors. Appendiceal cancer is a rare disease, yet its incidence in the reported literature varies depending on the histologic types included in the classification of appendiceal malignancies. Historic evidence suggests that appendiceal primaries are diagnosed in approximately 1% of all appendectomy specimens.[103–105] In a SEER database retrospective analysis that excluded low-grade carcinoid tumors, the annual age-adjusted incidence of appendiceal primaries was 0.12 cases per 1,000,000 of population. Appendiceal adenocarcinoma represented 66.5% of these patients.[106] Extrapolating from the SEER data, the annual incidence of the appendiceal adenocarcinoma in the country should be around 300 to 400 cases, although estimates up to 2,000 cases annually in the United States have been made. This incidence approximates the estimate that the appendix represents approximately 1% of the mucosal surface of the colon, with 137,000 cases of colorectal carcinoma in the United States encountered annually.[107] The rate of appendiceal neoplasms seems to be increasing.

There are no reliable early symptoms of appendiceal cancer, which, in part, explains why the majority of these patients are diagnosed incidentally during surgical exploration or late when peritoneal or systemic dissemination has already occurred. The rarity of appendiceal neoplasms makes screening programs unrealistic, and they are found by colonoscopy in $<10\%$ of cases.[108]

The treatment of appendiceal neoplasms depends upon type, stage, and medical comorbidities; not all appendiceal tumors demand the same therapy, operative or otherwise. Interestingly, appendiceal adenocarcinomas are associated with secondary tumors in up to 35% of patients, most often involving other areas of the GI tract.[109]

Mucoceles

Mucoceles of the appendix refer to a distended mucin-filled organ, which can be due to either benign (cystadenoma) or malignant (cystadenocarcioma) disease (Fig. 71-4). Such mucoceles are due to an obstructed appendiceal lumen, leading to a large mucin-filled structure, often with calcification in the wall. Such lesions can be readily diagnosed by CT scans, and are often incidental findings. A simple appendectomy is curative for benign cystadenomas. Resection should be done with great care so as not to rupture the lesion, which can lead to dissemination. With rupture, whether of a histologically benign or even more commonly with a malignant cystadenocarcinoma, peritoneal tumor implantation can occur, leading to mucinous ascites, and a condition known as pseudomyxoma peritonei (PMP, see below). The presence of epithelial cells in the mucin extruded from the mucocele at the time of rupture greatly increases the likelihood of recurrence. Due to the potential for malignancy, and possible sequellae of rupture (spontaneous or iatrogenic), appendectomy should be performed in otherwise healthy patients.

Appendiceal Adenocarcinoma

Appendiceal adenocarcinoma typically presents either with symptoms suggestive of appendicitis or symptoms related to peritoneal dissemination. CT or MRI imaging is preferred and PET imaging is of little value in these cases.[110–113] Appendiceal adenocarcinoma represents an unusual neoplasm, which has several variants. Mucinous appendiceal carcinoma is the most common, with colonic type or the signet-ring variant being less common, and associated with poorer outcomes.[114] Appendiceal carcinomas are now more common than carcinoid (neuroendocrine) tumors. The appendiceal carcinomas are further subdivided into low- and high-grade lesions.[115,116] Low-grade lesions (sometimes also known as disseminated peritoneal mucinous tumors) have more than double the long-term survival rate of high-grade lesions. Signet-ring cells are associated with a poorer prognosis. For known high-grade appendiceal carcinoma without peritoneal or distant metastasis, a right colectomy is appropriate surgical therapy. Those found to have nodal metastases should be considered for systemic chemotherapy, with regimens used for colon carcinoma.

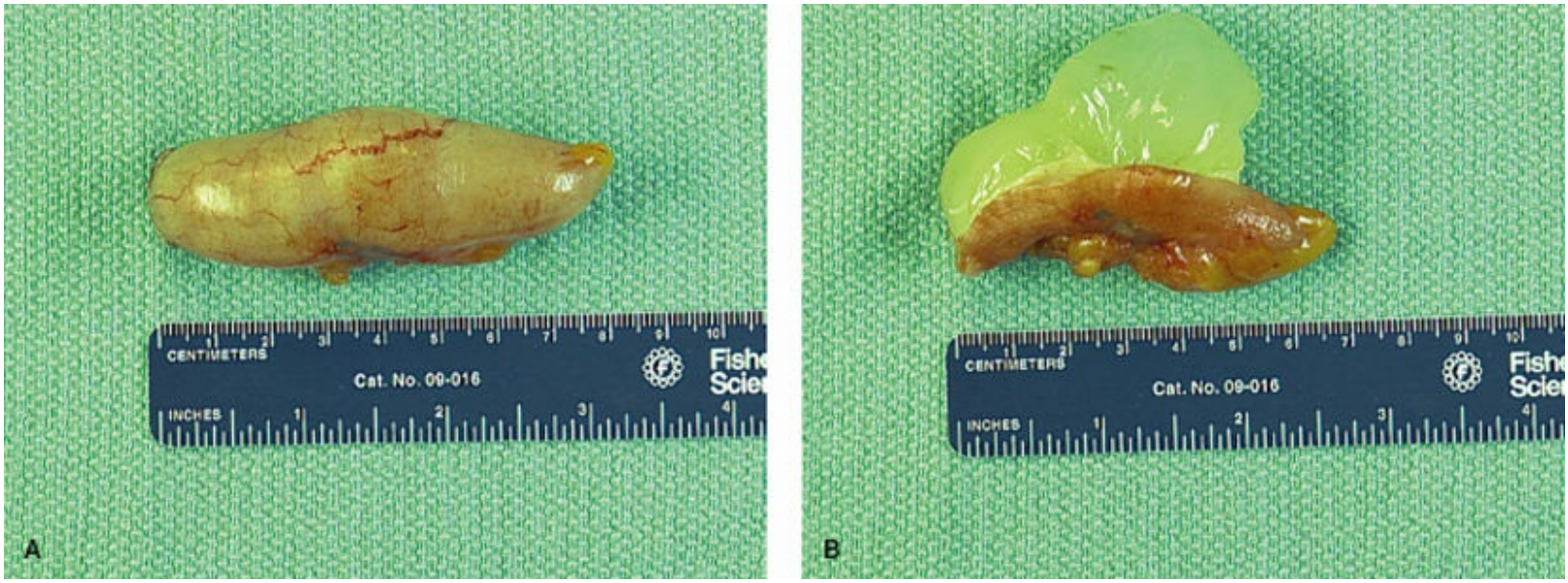

Figure 71-4. **A:** Mucocele. **B:** Mucocele (opened).

In patients with appendiceal carcinoma, peritoneal dissemination is frequently found at presentation (50% of high-grade and 20% of low-grade lesions),[114] and begins with tumor-induced obstruction of the appendiceal lumen. The obstruction in the face of continued mucin production eventually leads to perforation, and subsequent dissemination of mucous-producing epithelial cells throughout the peritoneal cavity. The pattern of spread is clearly related to the grade of disease. Low-grade mucin-producing lesions are associated with implantation, and spread along the peritoneal surfaces with distant or lymphatic metastases in less than 10% of cases. A typical pattern of peritoneal disseminations begins in the right lower quadrant of the abdomen followed by the pelvis, right upper quadrant, then diffusely throughout the peritoneal spaces. This is distinguished from high-grade lesions, which have more substantial risks of nodal and systemic metastasis, resulting in poorer prognosis. In addition, approximately 7% of the

low-grade lesions have lymph-node involvement, and another 16% will dedifferentiate into higher-grade lesions during the course of the disease.[117,118]

The rarity of the disease has unique implications in diagnosis, classification, terminology, and treatment. Therefore, several misconceptions are still prevalent among clinicians. First, due to the fact that the majority of PMP cases occur in association with appendiceal primaries the term “pseudomyxoma peritonei” has been used as synonym with the variant of appendiceal-induced peritoneal surface disease associated with excessive production of mucin. Although most PMP is indeed from appendiceal neoplasms, the term is descriptive and can be applied to any primary (including ovarian, colon, or even pancreatic mucinous) cancer that has the ability to produce mucinous ascites.[119] Consequently, the term PMP would be better used as a clinical sign rather as a distinct disease. Second, not all mucinous appendiceal tumors are associated with long-term survival. Factors such as histologic grade, tumor biology of the primary lesion,[120] age, functional status of the patient, and extent of disease at the time of diagnosis determine the prognosis of these patients. Third, not every appendiceal primary is associated with mucin production or ascites. Many patients present with peritoneal disease that has no phenotypic difference from any other gastrointestinal malignancy with peritoneal dissemination (Fig. 71-5).

10 The management of patients with peritoneal surface disease from appendiceal neoplasms is still a matter of debate. These patients have been traditionally treated with debulking procedures or systemic chemotherapy alone.[119,121,122] Right colectomy does not seem to convey a survival advantage in patients with peritoneal dissemination.[123] Though low-grade appendiceal tumors treated with limited debulking procedures can provide some patients with prolonged survival, more than 90% of these patients will inevitably develop local recurrence and death from bowel obstruction.[121] To deal with the problem of postdebulking residual microscopic disease, a variety of “adjuvant” therapies have been evaluated. Intraperitoneal photodynamic therapy, radiation (with 32P), and chemotherapy instillation have been tried and largely abandoned. In 1980, hyperthermic intraperitoneal perfusion was described by Spratt.[123] Sugarbaker subsequently published his early experience in combining cytoreduction with heated intraperitoneal chemotherapy.[124,125] This combined approach of aggressive cytoreduction combined with HIPEC has since been more thoroughly evaluated at many centers.[126] HIPEC is now considered a standard of care in the treatment of peritoneal dissemination from appendiceal cancer (Fig. 71-6).

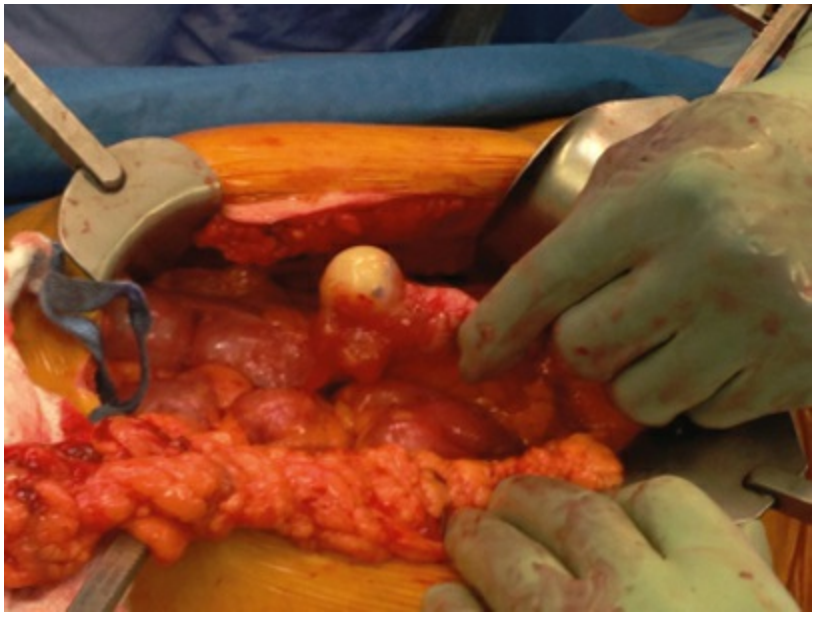

Figure 71-5. Mucinous appendiceal neoplasm with pseudomyxoma peritonei.



Figure 71-6. Completed perfusion circuit (closed abdomen technique), with dual inflow and outflow cannulas.

Most experienced centers approach to peritoneal dissemination from appendiceal tumors has been aggressive cytoreduction surgery, with the goal of removal of all gross disease if feasible. Selection criteria should include a resectable primary lesion, resectable peritoneal disease, freedom from extra-abdominal disease, and good performance status. The resection typically entails peritonectomy procedures, omentectomy and potentially multivisceral resection (if the peritoneal disease cannot be stripped from the organ). The cytoreductive phase is followed by hyperthermic intraperitoneal chemotherapy (HIPEC), see figure. Mitomycin is the standard agent used in the perfusate, with perfusions running for 30 to 120 minutes depending upon the center. This is typically administered with mild hyperthermia (40 to 43°C), as elevated temperatures are associated with enhanced antineoplastic effect in vivo, and help maintain normothermia after cytoreduction. After completion of the HIPEC, the patient is definitively closed. If complete cytoreduction is

achieved, at an initial procedure, if the disease recurs, selected patients may undergo repeat exploration and perfusion as dictated by their performance status and symptoms.[127] Patient selection and the demands of cytoreduction have significant learning curves and are best not performed by the occasional operator.[128,129] Patients with low-grade disease who undergo complete cytoreduction and HIPEC have 10-year survival rates in the 70% to 80% range.[129–131] These cytoreductive procedures can be formidable procedures, and have been associated with considerable morbidity, however more recent experience from major centers suggests improvements and complication rates which are in keeping with those expected for major procedures on patients with disseminated malignancy.[128,129,132,133]

Systemic chemotherapy for peritoneal surface disease from low-grade appendiceal neoplasms is largely ineffective. This is due to both the inability of systemically delivered drugs to reach effective intraperitoneal concentrations, and the slow-growth kinetics of the malignant cells. A phase II study in advanced unresectable low-grade appendiceal primaries, with concurrent mitomycin C and capecitabine, showed a “response” in 38% of the patients in the form of either stabilization or radiologic reduction in the volume of disease.[134] For high-grade lesions it seems that systemic chemotherapy improves progression-free survival, even after a HIPEC with complete cytoreduction.[135,136] Chemotherapy with FOLFOX, in the preoperative setting for high-grade appendiceal mucinous lesions, was found to have progression of disease in 50% of the patients, and significant tumor response observed in 29% of cases.[137] In addition, several groups have evaluated a number of alternative treatment modalities including photodynamic therapy,[138] and external beam radiation therapy.[119] None of these treatments have significantly altered the clinical course of these patients.

Carcinoids

Approximately one-third of all appendiceal neoplasms are carcinoids, which are tumors of neuroendocrine/neural crest origin. Of all carcinoid tumors within the GI tract, approximately half arise within the appendix. Carcinoid tumors of the appendix are usually found incidentally on pathologic examination of the inflamed appendix. Most appendiceal carcinoids are <2 cm in size and arise in or near the tip, thus they rarely cause obstruction. These tumors have a characteristic firm yellow appearance, and when advanced, may be associated with a surrounding desmoplastic reaction. Approximately 25% of cases present with nodal metastases and 10% with distant metastases.[139–141] Tumor markers (such as CEA, chromogranin, or urinary hyroxyindole acetic acid) may be useful for following up carcinoid cases, and should be obtained prior to resection.

In regard to treatment and prognosis, the key feature is the size of the tumor. Most carcinoids are small and those <1 cm in diameter, are adequately treated by simple appendectomy. Lesions between 1 and 2 cm have a 7.5% risk of nodal disease and a 4% risk of distant metastasis, while those larger than 2 cm have a 33% risk of nodal disease, and a 12% risk of distant metastasis.[142] For lesions 2 cm in size or greater, a right hemicolectomy is indicated, principally for the attendant lymphadenectomy.[142] For lesions between 1 and 2 cm, right colectomy is considered for high-grade malignant lesions with a high mitotic index, mesoappendiceal invasion, lymphovascular invasion, tumors located at the base of the appendix with positive margins, and goblet cell adenocarcinoid tumors.[143] Overall survival at 5 years approaches 100% for node-negative lesions <3 cm, 85% for node-positive lesions and 30% for metastatic lesions.[144] Appendiceal carcinoids are associated with liver metastases, and in these cases the carcinoid syndrome may be present. The number and location of liver lesions, as well as the associated symptoms, dictates treatment in these cases.[142,144]

Carcinoid syndrome is typically treated with somatostatin analogs as well as systemic chemotherapy. There is a role for debulking of metastases, which may result in improved quality of life and overall survival for those with the paraneoplastic carcinoid syndrome.

References

1. Major RH. *Classic Descriptions of Disease.* 3rd ed. Springfield, IL: Charles C. Thomas; 1945.
2. Wakeley CP. The position of the vermiform appendix as ascertained by an analysis of 10,000 cases. *J Anat* 1933;67(Pt 2):277–283.
3. Wangensteen OH, Dennis C. Experimental proof of the obstructive origin of appendicitis in man. *Ann Surg* 1939;110(4):629–647.
4. Bennion RS, Thompson JE, Baron EJ, et al. Gangrenous and perforated appendicitis with peritonitis: treatment and bacteriology. *Clin Ther* 1990; 12(suppl C):31–44.
5. Buckius MT, McGrath B, Monk J, et al. Changing epidemiology of acute appendicitis in the United States: study period 1993–2008. *J Surg Res* 2012;175(2):185–190.
6. Flum DR, Koepsell T. The clinical and economic correlates of misdiagnosed appendicitis: nationwide analysis. *Arch Surg* 2002;137(7):799–804; discussion 804.
7. Solomkin JS, Mazuski JE, Bradley JS, et al. Diagnosis and management of complicated intra-abdominal infection in adults and children: guidelines by the Surgical Infection Society and the Infectious Diseases Society of America. *Surg Infect (Larchmt).* 2010;11(1):79–109.
8. Andersson RE. Meta-analysis of the clinical and laboratory diagnosis of appendicitis. *Br J Surg* 2004;91(1):28–37.
9. Wagner JM, McKinney WP, Carpenter JL. Does this patient have appendicitis? *JAMA* 1996;276(19):1589–1594.
10. Bundy DG, Byerley JS, Liles EA, et al. Does this child have appendicitis? *JAMA* 2007;298(4):438–451.
11. Yen K, Karpas A, Pinkerton HJ, et al. Interexaminer reliability in physical examination of pediatric patients with abdominal pain. *Arch Pediatr Adolesc Med* 2005;159(4):373–376.
12. Kharbanda AB, Fishman SJ, Bachur RG. Comparison of pediatric emergency physicians' and surgeons' evaluation and diagnosis of appendicitis. *Acad Emerg Med* 2008;15(2):119–125.
13. Alvarado A. A practical score for the early diagnosis of acute appendicitis. *Ann Emerg Med* 1986;15(5):557–564.
14. Samuel M. Pediatric appendicitis score. *J Pediatr Surg* 2002;37(6):877–881.
15. Kharbanda AB, Taylor GA, Fishman SJ, et al. A clinical decision rule to identify children at low risk for appendicitis. *Pediatrics* 2005;116(3):709–716.
16. Lintula H, Kokki H, Pulkkinen J, et al. Diagnostic score in acute appendicitis. Validation of a diagnostic score (Lintula score) for adults with suspected appendicitis. *Langenbeck's Arch Surg* 2010;395(5):495–500.
17. Rezak A, Abbas HM, Ajemian MS, et al. Decreased use of computed tomography with a modified clinical scoring system in diagnosis of pediatric acute appendicitis. *Arch*

Surg 2011;146(1):64–67.
18. Farahnak M, Talaei-Khoei M, Gorouhi F, et al. The Alvarado score and antibiotics therapy as a corporate protocol versus conventional clinical management: randomized controlled pilot study of approach to acute appendicitis. *Am J Emerg Med* 2007;25(7):850–852.
19. Flum DR, McClure TD, Morris A, et al. Misdiagnosis of appendicitis and the use of diagnostic imaging. *J Am Coll Surg* 2005;201(6):933–939.
20. Flum DR, Morris A, Koepsell T, et al. Has misdiagnosis of appendicitis decreased over time? A population-based analysis. *JAMA* 2001;286(14):1748–1753.
21. Doria AS, Moineddin R, Kellenberger CJ, et al. US or CT for diagnosis of appendicitis in children and adults? A meta-analysis. *Radiology* 2006; 241(1):83–94.
22. Solomkin JS. Evaluating evidence and grading recommendations: the SIS/IDSA guidelines for the treatment of complicated intra-abdominal infections. *Surg Infect* 2010;11(3):269–274.
23. Krajewski S, Brown J, Phang PT, et al. Impact of computed tomography of the abdomen on clinical outcomes in patients with acute right lower quadrant pain: a meta-analysis. *Can J Surg* 2011;54(1):43–53.
24. Hlibczuk V, Dattaro JA, Jin Z, et al. Diagnostic accuracy of noncontrast computed tomography for appendicitis in adults: a systematic review. *Ann Emerg Med* 2010;55(1):51–59 e51.
25. Lee CC, Golub R, Singer AJ, et al. Routine versus selective abdominal computed tomography scan in the evaluation of right lower quadrant pain: a randomized controlled trial. *Acad Emerg Med* 2007;14(2):117–122.
26. Walker S, Haun W, Clark J, et al. The value of limited computed tomography with rectal contrast in the diagnosis of acute appendicitis. *Am J Surg* 2000;180(6):450–454; discussion 454–455.
27. Williams RF, Blakely ML, Fischer PE, et al. Diagnosing ruptured appendicitis preoperatively in pediatric patients. *J Am Coll Surg* 2009;208(5):819–825; discussion 826–818.
28. Kentsis A, Lin YY, Kurek K, et al. Discovery and validation of urine markers of acute pediatric appendicitis using high-accuracy mass spectrometry. *Ann Emerg Med* 2010;55(1):62–70 e64.
29. Muenzer JT, Jaffe DM, Schwulst SJ, et al. Evidence for a novel blood RNA diagnostic for pediatric appendicitis: the riboleukogram. *Pediatr Emerg Care* 2010;26(5):333–338.
30. Murphy CG, Glickman JN, Tomczak K, et al. Acute appendicitis is characterized by a uniform and highly selective pattern of inflammatory gene expression. *Mucosal Immunol* 2008;1(4):297–308.
31. Burford JM, Dassinger MS, Smith SD. Surgeon-performed ultrasound as a diagnostic tool in appendicitis. *J Pediatr Surg* 2011;46(6):1115–1120.

32. Leeuwenburgh MM, Lameris W, van Randen A, et al. Optimizing imaging in suspected appendicitis (OPTIMAP-study): a multicenter diagnostic accuracy study of MRI in patients with suspected acute appendicitis. Study Protocol. *BMC Emerg Med.* 2010;10:19.
33. Kim SY, Lee KH, Kim K, et al. Acute appendicitis in young adults: low- versus standard-radiation-dose contrast-enhanced abdominal CT for diagnosis. *Radiology* 2011;260(2):437–445.
34. Hsieh CH, Lu RH, Lee NH, et al. Novel solutions for an old disease: diagnosis of acute appendicitis with random forest, support vector machines, and artificial neural networks. *Surgery* 2011;149(1):87–93.
35. DeFrances CJ, Podgornik MN. *2004 National hospital discharge survey*. *Adv Data* 2006; (371):1–19.
36. Addiss DG, Shaffer N, Fowler BS, et al. The epidemiology of appendicitis and appendectomy in the United States. *Am J Epidemiol* 1990;132(5):910–925.
37. McBurney C. IV. The incision made in the abdominal wall in cases of appendicitis, with a description of a new method of operating. *Ann Surg* 1894;20(1):38–43.
38. Tingstedt B, Johansson J, Nehez L, et al. Late abdominal complaints after appendectomy–readmissions during long-term follow-up. *Dig Surg* 2004;21(1):23–27.
39. Coursey CA, Nelson RC, Patel MB, et al. Making the diagnosis of acute appendicitis: do more preoperative CT scans mean fewer negative appendectomies? A 10-year study. *Radiology* 2010;254(2):460–468.
40. Rao PM, Rhea JT, Rattner DW, et al. Introduction of appendiceal CT: impact on negative appendectomy and appendiceal perforation rates. *Ann Surg* 1999;229(3):344–349.
41. Simpson J, Samaraweera AP, Sara RK, et al. Acute appendicitis–a benign disease? *Ann R Coll Surg Engl* 2008;90(4):313–316.
42. Mason RJ. Surgery for appendicitis: is it necessary? *Surg Infect* 2008;9(4):481–488.
43. Eriksson S, Granstrom L. Randomized controlled trial of appendicectomy versus antibiotic therapy for acute appendicitis. *Br J Surg* 1995;82(2):166–169.
44. Winn RD, Laura S, Douglas C, et al. Protocol-based approach to suspected appendicitis, incorporating the Alvarado score and outpatient antibiotics. *ANZ J Surg* 2004;74(5):324–329.
45. Lewis FR, Holcroft JW, Boey J, et al. Appendicitis. A critical review of diagnosis and treatment in 1,000 cases. *Arch Surg* 1975;110(5):677–684.
46. Petrosyan M, Estrada J, Chan S, et al. CT scan in patients with suspected appendicitis: clinical implications for the acute care surgeon. *Eur Surg Res* 2008;40(2):211–219.
47. Decadt B, Sussman L, Lewis MP, et al. Randomized clinical trial of early laparoscopy in the management of acute non-specific abdominal pain. *Br J Surg* 1999;86(11):1383–1386.

48. Hansson J, Korner U, Khorram-Manesh A, et al. Randomized clinical trial of antibiotic therapy versus appendicectomy as primary treatment of acute appendicitis in unselected patients. *Br J Surg* 2009;96(5):473–481.
49. Malik AA, Bari SU. Conservative management of acute appendicitis. *J Gastrointest Surg* 2009;13(5):966–970.
50. Styrud J, Eriksson S, Nilsson I, et al. Appendectomy versus antibiotic treatment in acute appendicitis. A prospective multicenter randomized controlled trial. *World J Surg* 2006;30(6):1033–1037.
51. Shindoh J, Niwa H, Kawai K, et al. Predictive factors for negative outcomes in initial non-operative management of suspected appendicitis. *J Gastrointest Surg* 2010;14(2):309–314.
52. Deakin DE, Ahmed I. Interval appendicectomy after resolution of adult inflammatory appendix mass–is it necessary? *Surgeon* 2007;5(1):45–50.
53. Andersson RE, Petzold MG. Nonsurgical treatment of appendiceal abscess or phlegmon: a systematic review and meta-analysis. *Ann Surg* 2007;246(5):741–748.
54. Puapong D, Lee SL, Haigh PI, et al. Routine interval appendectomy in children is not indicated. *J Pediatr Surg* 2007;42(9):1500–1503.
55. Tekin A, Kurtoglu HC, Can I, et al. Routine interval appendectomy is unnecessary after conservative treatment of appendiceal mass. *Colorectal Dis* 2008;10(5):465–468.
56. Lugo JZ, Avgerinos DV, Lefkowitz AJ, et al. Can interval appendectomy be justified following conservative treatment of perforated acute appendicitis? *J Surg Res* 2010;164(1):91–94.
57. Simillis C, Symeonides P, Shorthouse AJ, et al. A meta-analysis comparing conservative treatment versus acute appendectomy for complicated appendicitis (abscess or phlegmon). *Surgery* 2010;147(6):818–829.
58. Schietroma M, Piccione F, Carlei F, et al. Peritonitis from perforated appendicitis: stress response after laparoscopic or open treatment. *Am Surg* 2012;78(5):582–590.
59. St Peter SD, Aguayo P, Fraser JD, et al. Initial laparoscopic appendectomy versus initial nonoperative management and interval appendectomy for perforated appendicitis with abscess: a prospective, randomized trial. *J Pediatr Surg* 2010;45(1):236–240.
60. Goh BK, Chui CH, Yap TL, et al. Is early laparoscopic appendectomy feasible in children with acute appendicitis presenting with an appendiceal mass? A prospective study. *J Pediatr Surg* 2005;40(7):1134–1137.
61. Kang KJ, Lim TJ, Kim YS. Laparoscopic appendectomy is feasible for the complicated appendicitis. *Surg Laparosc Endosc Percutan Tech* 2000;10(6):364–367.
62. Senapathi PS, Bhattacharya D, Ammori BJ. Early laparoscopic appendectomy for appendicular mass. *Surg Endosc* 2002;16(12):1783–1785.
63. Yau KK, Siu WT, Tang CN, et al. Laparoscopic versus open appendectomy for complicated appendicitis. *J Am Coll Surg* 2007;205(1):60–65.

64. Cash C, Frazee R. Improvements in laparoscopic treatment for complicated appendicitis. *J Laparoendosc Adv Surg Tech A* 2012;22(6):581–583.
65. Gupta R, Sample C, Bamehriz F, et al. Infectious complications following laparoscopic appendectomy. *Can J Surg* 2006;49(6):397–400.
66. Ahmed I, Deakin D, Parsons SL. Appendix mass: do we know how to treat it? *Ann R Coll Surg Engl* 2005;87(3):191–195.
67. Hall NJ, Jones CE, Eaton S, et al. Is interval appendicectomy justified after successful nonoperative treatment of an appendix mass in children? A systematic review. *J Pediatr Surg* 2011;46(4):767–771.
68. Ein SH, Langer JC, Daneman A. Nonoperative management of pediatric ruptured appendix with inflammatory mass or abscess: presence of an appendicolith predicts recurrent appendicitis. *J Pediatr Surg* 2005;40(10):1612–1615.
69. Raval MV, Lautz T, Reynolds M, et al. Dollars and sense of interval appendectomy in children: a cost analysis. *J Pediatr Surg* 2010;45(9):1817–1825.
70. Blakely ML, Williams R, Dassinger MS, et al. Early vs interval appendectomy for children with perforated appendicitis. *Arch Surg* 2011; 146(6):660–665.
71. Semm K. Endoscopic appendectomy. *Endoscopy* 1983;15(2):59–64.
72. Meeks DW, Kao LS. Controversies in appendicitis. *Surg Infect* 2008; 9(6):553–558.
73. Ingraham AM, Cohen ME, Bilimoria KY, et al. Comparison of outcomes after laparoscopic versus open appendectomy for acute appendicitis at 222 ACS NSQIP hospitals. *Surgery* 2010;148(4):625–635; discussion 635–627.
74. Sauerland S, Jaschinski T, Neugebauer EA. Laparoscopic versus open surgery for suspected appendicitis. *Cochrane Database Syst Rev* 2010(10):CD001546.
75. Pelosi MA, Pelosi MA 3rd. Laparoscopic appendectomy using a single umbilical puncture (minilaparoscopy). *J Reprod Med* 1992;37(7):588–594.
76. Valla J, Ordorica-Flores RM, Steyaert H, et al. Umbilical one-puncture laparoscopic-assisted appendectomy in children. *Surg Endosc* 1999; 13(1):83–85.
77. Garey CL, Laituri CA, Ostlie DJ, et al. A review of single site minimally invasive surgery in infants and children. *Pediatr Surg Int* 2010;26(5):451–456.
78. Muensterer OJ, Puga Nougues C, Adibe OO, et al. Appendectomy using single-incision pediatric endosurgery for acute and perforated appendicitis. *Surg Endosc* 2010;24(12):3201–3204.
79. Ponsky TA, Diluciano J, Chwals W, et al. Early experience with single-port laparoscopic surgery in children. *J Laparoendosc Adv Surg Tech A* 2009;19(4):551–553.
80. Tam YH, Lee KH, Sihoe JD, et al. Initial experience in children using conventional laparoscopic instruments in single-incision laparoscopic surgery. *J Pediatr Surg* 2010;45(12):2381–2385.
81. Sesia SB, Haecker FM, Kubiak R, et al. Laparoscopy-assisted single-port appendectomy in children: is the postoperative infectious complication rate different?

J Laparoendosc Adv Surg Tech A 2010;20(10):867–871.
82. Vidal O, Valentini M, Ginesta C, et al. Laparoendoscopic single-site surgery appendectomy. *Surg Endosc* 2010;24(3):686–691.
83. Oltmann SC, Garcia NM, Ventura B, et al. Single-incision laparoscopic surgery: feasibility for pediatric appendectomies. *J Pediatr Surg* 2010; 45(6):1208–1212.
84. St Peter SD, Adibe OO, Juang D, et al. Single incision versus standard 3-port laparoscopic appendectomy: a prospective randomized trial. *Ann Surg* 2011;254(4):586–590.
85. Horwitz JR, Custer MD, May BH, et al. Should laparoscopic appendectomy be avoided for complicated appendicitis in children? *J Pediatr Surg* 1997;32(11):1601–1603.
86. Krisher SL, Browne A, Dibbins A, et al. Intra-abdominal abscess after laparoscopic appendectomy for perforated appendicitis. *Arch Surg* 2001; 136(4):438–441.
87. Tang E, Ortega AE, Anthone GJ, et al. Intraabdominal abscesses following laparoscopic and open appendectomies. *Surg Endosc* 1996;10(3):327–328.
88. Canty TG Sr, Collins D, Losasso B, et al. Laparoscopic appendectomy for simple and perforated appendicitis in children: the procedure of choice? *J Pediatr Surg* 2000;35(11):1582–1585.
89. Meguerditchian AN, Prasil P, Cloutier R, et al. Laparoscopic appendectomy in children: a favorable alternative in simple and complicated appendicitis. *J Pediatr Surg* 2002;37(5):695–698.
90. Oliak D, Yamini D, Udani VM, et al. Nonoperative management of perforated appendicitis without periappendiceal mass. *Am J Surg* 2000;179(3):177–181.
91. Bufo AJ, Shah RS, Li MH, et al. Interval appendectomy for perforated appendicitis in children. *J Laparoendosc Adv Surg Tech A* 1998;8(4):209–214.
92. Kogut KA, Blakely ML, Schropp KP, et al. The association of elevated percent bands on admission with failure and complications of interval appendectomy. *J Pediatr Surg* 2001;36(1):165–168.
93. Gurusamy KS, Junnarkar S, Farouk M, et al. Day-case versus overnight stay in laparoscopic cholecystectomy. *Cochrane Database Syst Rev* 2008(1):CD006798.
94. Sasse KC, Ganser JH, Kozar MD, et al. Outpatient weight loss surgery: initiating a gastric bypass and gastric banding ambulatory weight loss surgery center. *JSLS* 2009;13(1):50–55.
95. Moreno-Egea A, Cartagena J, Vicente JP, et al. Laparoscopic incisional hernia repair as a day surgery procedure: audit of 127 consecutive cases in a university hospital. *Surg Laparosc Endosc Percutan Tech* 2008;18(3):267–271.
96. Guller U, Hervey S, Purves H, et al. Laparoscopic versus open appendectomy: outcomes comparison based on a large administrative database. *Ann Surg* 2004;239(1):43–52.
97. Frazee RC, Abernathy SW, Davis M, et al. Outpatient laparoscopic appendectomy

should be the standard of care for uncomplicated appendicitis. *J Trauma Acute Care Surg* 2014;76(1):79–82; discussion 82–73.

98. Cash CL, Frazee RC, Smith RW, et al. Outpatient laparoscopic appendectomy for acute appendicitis. *Am Surg* 2012;78(2):213–215.
99. Dubois L, Vogt KN, Davies W, et al. Impact of an outpatient appendectomy protocol on clinical outcomes and cost: a case-control study. *J Am Coll Surg* 2010;211(6):731–737.
100. Alkhoury F, Burnweit C, Malvezzi L, et al. A prospective study of safety and satisfaction with same-day discharge after laparoscopic appendectomy for acute appendicitis. *J Pediatr Surg* 2012;47(2):313–316.
101. Jain A, Mercado PD, Grafton KP, et al. Outpatient laparoscopic appendectomy. *Surg Endosc* 1995;9(4):424–425.
102. Worni M, Ostbye T, Gandhi M, et al. Laparoscopic appendectomy outcomes on the weekend and during the week are no different: a national study of 151,774 patients. *World J Surg* 2012;36(7):1527–1533.
103. Collins DC. 71,000 human appendix specimens. A final report, summarizing forty years' study. *Am J Proctol* 1963;14:265–281.
104. McCusker ME, Cote TR, Clegg LX, et al. Primary malignant neoplasms of the appendix: a population-based study from the surveillance, epidemiology and end-results program, 1973–1998. *Cancer* 2002;94(12):3307–3312.
105. Connor SJ, Hanna GB, Frizelle FA. Appendiceal tumors: retrospective clinicopathologic analysis of appendiceal tumors from 7970 appendectomies. *Dis Colon Rectum* 1998;41:75–80.
106. Votanopoulos KI, Shen P, Stewart JH, et al. Current status and future directions in appendiceal cancer with peritoneal dissemination. *Surg Oncol Clin N Am* 2012;21(4):599–609
107. Siegel R, Ma J, Zou Z, et al. Cancer statistics, 2014. *CA Cancer J Clin* 2014; 64:9–29.
108. Trivedi AN, Levine EA, Mishra G. Adenocarcinoma of the appendix is rarely detected by colonoscopy. *J Gastrointest Surg* 2009;13(4):668–675.
109. Cortina R, McCormick J, Kolm P, et al. Management and prognosis of adenocarcinoma of the appendix. *Dis Colon Rectum* 1995;38:848–852.
110. Low RN, Barone RM, Gurney JM, et al. Mucinous appendiceal neoplasms: preoperative MR staging and classification compared with surgical and histopathologic findings. *AJR Am J Roentgenol* 2008;190(3):656–665.
111. Stewart JH, Shen P, Russell GB, et al. Appendiceal neoplasms with peritoneal dissemination: outcomes after cytoreductive surgery and intraperitoneal hyperthermic chemotherapy. *Ann Surg Oncol* 2006;13(5):624–634.
112. Rohani P, Scotti SD, Shen P, et al. Use of FDG-PET imaging for patients with disseminated cancer of the appendix. *Am Surg* 2010;76(12):1338–1344.
113. Votanopoulos KI, Russell G, Randle RW, et al. Peritoneal surface disease (PSD) from

appendiceal cancer treated with cytoreductive surgery (CRS) and hyperthermic intraperitoneal chemotherapy (HIPEC): overview of 481 cases. *Ann Surg Oncol* 2014.

114. Turaga KK, Pappas SG, Gamblin T. Importance of histologic subtype in the staging of appendiceal tumors.*Ann Surg Oncol* 2012;19:1379–1385.
115. Bradley RF, Stewart JH, Russell GB, et al. Pseudomyxoma peritonei of appendiceal origin: a clinicopathologic analysis of 101 patients uniformly treated at a single institution, with literature review. *Am J Surg Pathol* 2006; 30(5):551–559.
116. Ronnett BM, Zahn CM, Kurman RJ, et al. Disseminated peritoneal adenomucinosis and peritoneal mucinous carcinomatosis. A clinicopathologic analysis of 109 cases with emphasis on distinguishing pathologic features, site of origin, prognosis, and relationship to "pseudomyxoma peritonei". *Am J Surg Pathol* 1995;19(12):1390–1408.
117. Foster JM, Gupta PK, Carreau JH, et al. Right hemicolectomy is not routinely indicated in pseudomyxoma peritonei. *Am Surg* 2012;78(2):171–177.
118. Chua TC, Al-Zahrani A, Saxena A, et al. Secondary cytoreduction and perioperative intraperitoneal chemotherapy after initial debulking of pseudomyxoma peritonei: a study of timing and the impact of malignant dedifferentiation. *J Am Coll Surg* 2010;211(4):526–535.
119. Gough DB, Donohue JH, Schutt AJ, et al. Pseudomyxoma peritonei. Long-term patient survival with an aggressive regional approach. *Ann Surg* 1994; 219(2):112–119.
120. Levine EA, Blazer DG 3rd, Kim MK, et al. Gene expression profiling of peritoneal metastases from appendiceal and colon cancer demonstrates unique biologic signatures and predicts patient outcomes. *J Am Coll Surg* 2012; 214(4):599–606; discussion 606–607.
121. Miner TJ, Shia J, Jaques DP, et al. Long-term survival following treatment of pseudomyxoma peritonei: an analysis of surgical therapy. *Ann Surg* 2005; 241(2):300–308.
122. Shapiro JF, Chase JL, Wolff RA, et al. Modern systemic chemotherapy in surgically unresectableneoplasms of appendiceal origin: a single-institution experience. *Cancer* 2010;116:316–322.
123. Spratt J, Adcock M, Miskovin M, et al. Clinical delivey system for intraperitoneal hyperthermic chemotherapy. *Cancer Res* 1980;40:256–260.
124. Sugarbaker PH, Landy D, Pascal R. Intraperitoneal chemotherapy for peritoneal carcinomatosis from colonic or appendiceal cystadenocarcinoma: rationale and results of treatment. *Prog Clin Biol Res* 1990;354B:141–170.
125. Sugarbaker PH, Kern K, Lack E. Malignant pseudomyxoma peritonei of colonic origin. Natural history and presentation of a curative approach to treatment. *Dis Colon Rectum* 1987;30(10):772–779.
126. Chua TC, Moran BJ, Sugarbaker PH, et al. Early- and long-term outcome data of patients with pseudomyxoma peritonei from appendiceal origin treated by a strategy

of cytoreductive surgery and hyperthermic intraperitoneal chemotherapy. *J Clin Oncol* 2012;30(20):2449–2456.

127. Votanopoulos KI, Ihemelandu C, Shen P, et al. Outcomes of repeat cytoreductive surgery with hyperthermic intraperitoneal chemotherapy for the treatment of peritoneal surface malignancy. *J Am Coll Surg.* 2012; 215(3):412–417.
128. Kusamura S, Baratti D, Deraco M. Multidimensional analysis of the learning curve for cytoreductive surgery and hyperthermic intraperitoneal chemotherapy in peritoneal surface malignancies. *Ann Surg* 2012;255(2)348–356.
129. Levine EA, Stewart JH, Shen P, et al. Cytoreductive surgery and intraperitoneal hyperthermic chemotherapy for peritoneal surface malignancy: experience with 1,000 patients. *J Am Coll Surg* 2014;518:573–587.
130. Stewart JH, Shen P, Russell GB, et al. Appendiceal neoplasms with peritoneal dissemination: outcomes after cytoreductive surgery and intraperitoneal hyperthermic chemotherapy. *Ann Surg Oncol* 2006;13:1–11.
131. Esquivel J, Sugarbaker PH. Clinical presentation of the pseudomyxoma syndrome. *Br J Surg* 2000;87:1414–1418.
132. Chua TC, Yan TD, Saxena A, et al. Should the treatment of peritoneal carcinomatosis by cytoreductive surgery and hyperthermic intraperitoneal chemotherapy still be regarded as a highly morbid procedure? *Ann Surg* 2009;249:900–907.
133. Jafari MD, Halabi WJ, Stamos MJ, et al. Surgical outcomes of hyperthermic intraperitoneal chemotherapy, analysis of American College of Surgeons Quality Improvement Program. *JAMA Surg* 2014;149(2):170–175.
134. Farquharson AL, Pranesh N, Witham G, et al. A phase II study evaluating the use of concurrent mitomycin C and capecitabine in patients with advanced unresectable pseudomyxoma peritonei. *Br J Cancer* 2008; 99(4):591–596.
135. Blackham AU, Swett K, Eng C, et al. Perioperative systemic chemotherapy for appendiceal mucinous carcinoma peritonei treated with cytoreductive surgery and hyperthermic intraperitoneal chemotherapy. *J Surg Oncol* 2014; 109:740–745.
136. Lieu CH, Lambert LA, Wolff RA, et al. Systemic chemotherapy and surgical cytoreduction for poorly differentiated and signet ring cell adenocarcinomas of the appendix. *Ann Oncol* 2012;23(3):652–658.
137. Sugarbaker PH, Bijelic L, Chang D, et al. Neoadjuvant FOLFOX chemotherapy in 34 consecutive patients with mucinous peritoneal carcinomatosis of appendiceal origin. *J Surg Oncol* 2010;102(6):576–581.
138. Sindelar WF, DeLaney TF, Tochner Z, et al. Technique of photodynamic therapy for disseminated intraperitoneal malignant neoplasms. Phase I study. *Arch Surg* 1991;126(3):318–324.
139. Mullen JT, Savarese, D. Carcinoid tumors of the appendix: a population-based study. *J Surg Oncol* 2011;104:41–44.
140. Rorstad O. Prognostic indicators for carcinoid neuroendocrine tumors of the

gastrointestinal tract. *J Surg Oncol* 2005;89:151–160.

141. Landry CS, Woodall C, Scoggins CR, et al. Analysis of 900 appendiceal carcinoid tumors for a proposed predictive staging system. *Arch Surg* 2008;143(7):664–670; discussion 670.
142. Moertel CG, Weiland LH, Nagorney DM, et al. Carcinoid tumor of the appendix: treatment and prognosis. *N Engl J Med* 1987;317:1699.
143. Goede AC, Caplin ME, Winslet MC. Carcinoid tumour of the appendix. *Br J Surg* 2003;90:1317–1322.
144. Sandor A, Modlin IM. A retrospective analysis of 1570 appendiceal carcinoids. *Am J Gastroenterol* 1998;93:422–428.

SECTION J: HERNIA AND SPLEEN

Chapter 72

Abdominal Wall Hernias

Robert J. Fitzgibbons, Jr., Thomas H. Quinn, and Devi Mukkai Krishnamurty

Key Points

1 Surgeons have traditionally been taught the anatomy of the abdominal wall from an outside to inside perspective. However, with the increasing use of intra-abdominal or preperitoneal approaches to abdominal wall reconstruction, a better understanding of the anatomy from the inside to the outside perspective is important.

2 Major risk factors for the development of an abdominal wall hernias include chronic obstructive pulmonary disease, smoking, high intra-abdominal pressure, collagen vascular disease, thoracic or abdominal aortic aneurysm, peritoneal dialysis, matrix metalloproteinase (MMP) abnormalities, and an increased type I: type III collagen ratio.

3 Inguinal hernias constitute approximately 75% of abdominal wall hernias, with femoral hernia accounting for 5%. Femoral hernias are more common in women, but a woman with a groin hernia is still five times more likely to have an inguinal hernia (usually indirect) than a femoral. Incisional, umbilical, and epigastric hernias account for 15%, and miscellaneous hernias make up the other 5%.

4 The literature dealing with groin hernia in women is insufficient making management decisions difficult.

5 Watchful waiting is an acceptable alternative to routine repair for male inguinal hernia patients with minimal symptoms. This does not apply to females because of the higher risk of a hernia accident. Patients in the watchful waiting group should be aware of the likelihood long-term crossover into treatment group.

6 The performance of a “tension-free” inguinal hernia repair dramatically reduces the risk of recurrent hernia to a rate generally reported to be less than 2%.

7 The frequency of at least some long-term groin pain after inguinal herniorrhaphy is approximately 10% at 1 year with moderate to severe pain in 1% to 2%.

8 Abdominal wall dynamics are better addressed with muscles re-approximated, contributing to improved quality of life and patient satisfaction.

9 Abdominal wall reconstruction and component separation are useful tools in the armamentarium of the hernia surgeon.

10 Historical recurrence rates of 30% to 40% following ventral hernia repair have been dramatically reduced by modern tension-free repairs.

One of the most frequently performed operations by general surgeons worldwide is the repair of an abdominal wall hernia. According to the National Institute of Diabetes and Digestive and Kidney Diseases (NIDDK), in the years 2009–2010, abdominal wall hernias were responsible for 3.6 million ambulatory care visits, 380,000 hospitalizations, and 1,322 deaths in the United States.[1] In the past, most training programs relegated the repair of abdominal hernias to the junior members of the surgical team with little regard for results.[2] However, in the modern era of heightened emphasis on accountability to our patients, this is changing rapidly. Interest by the academic community in the science behind hernia repair as well as an explosion in device development by industry has resulted in significant changes in many surgeons' practices. In this chapter, we have provided a detailed description of the abdominal wall anatomy, an understanding of which is key in the success of a hernia repair. We have then described the different treatment options with their available evidence and have included some of the newer developments in the field of hernia surgery.

ANATOMY OF THE ABDOMINAL WALL AND GROIN

1 Surgeons have traditionally been taught the anatomy of the abdominal wall from an outside to inside perspective. However, with the increasing use of intra-abdominal or preperitoneal approaches to abdominal wall reconstruction, a better understanding of the anatomy from the inside to the outside perspective is important. The anatomy of the abdominal wall and the inguinal region are presented, first from the viewpoint of the surgeon using open techniques and subsequently from the perspective of the surgeon utilizing the laparoscope. Anatomic terms for which synonyms and eponyms are commonly used are listed in Table 72-1. Specific anatomic nomenclature can now be found in *Terminologia Anatomica,* the successor to *Nomina Anatomica.*

The abdominal wall spans the gap between the lower ribs and the pelvis; the lowest ribs, pelvic brim, and lumbar spine comprise its only skeletal support. The muscular and aponeurotic structures that provide much of the integrity of the wall must not only compress and contain abdominal viscera but also contribute to the support and movement of the spine and pelvis.

The sheets of relatively thin muscles and aponeuroses that make up the abdominal wall would, individually, seem to predispose to visceral eventration. However, the laminar layout of these sheets over most of the wall precludes this in most cases. The most common sites of hernia formation are found between laminations, where only peritoneum and fascia are found between the viscera and skin. These weak areas are most important to the hernia surgeon and are described in detail in the subsequent sections dealing with the anterior and posterolateral abdominal wall and the inguinal region.

Anterior Abdominal Wall

Superficial Fascia, Vessels, and Nerves

The anterior abdominal wall does not consist solely of muscle and aponeurosis; it can also be the repository for copious amounts of adipose tissue (panniculus adiposus) in its superficial fascial layer, often called *Camper fascia*. This layer, which is continuous inferiorly with the outer layer of fascia covering the perineum and genitalia, also contains the dartos muscle fibers of the scrotum. The major blood vessels of the superficial fatty layer are the superficial epigastric vessels and superficial circumflex iliac vessels, which are tributaries of the femoral vessels. The superficial fascia is also replete with lymphatic vessels that drain into the inguinal lymph nodes inferior to the umbilicus. The lymphatic structures cross the inguinal ligament, so that they are potentially placed in the surgical field during open herniorrhaphy.

Table 72-1 Anatomic Terms with Common Synonyms and Eponyms

Fascial Structures/Spaces
Fatty layer of superficial fascia; panniculus adiposus; Camper fascia
Investing fascia of external abdominal oblique; fascia innominata
Membranous layer of superficial fascia; Scarpa fascia
Retroinguinal space; space of Bogros
Retropubic space; space of Retzius
Ligamentous Structures
Iliopectineal ligament; iliopectineal arch
Iliopubic tract; Thompson ligament (band)
Inguinal ligament; Poupart ligament
Lacunar ligament; Gimbernat ligament
Pectineal ligament; Cooper ligament
Aponeurosis-Derived Structures
Arcuate line; semicircular line; linea semicirculars; line of Douglas
Falx inguinalis (often incorrectly referred to as *conjoined tendon*)
Reflected inguinal ligament; reflex ligament; Colles ligament
Semilunar line; linea semilunaris

A second fascial layer in the superficial abdominal wall is the deep fascia of Scarpa. Although most commonly considered a distinct anatomic layer, Scarpa fascia actually consists of compressed fibrous components of the superficial fascia.[3] The deeper fibrous tissue of the superficial fascia forms the fundiform ligament of the penis (suspensory ligament of the female clitoris), continues onto the penis and scrotum, and ultimately fuses with the superficial fascia of the perineum.

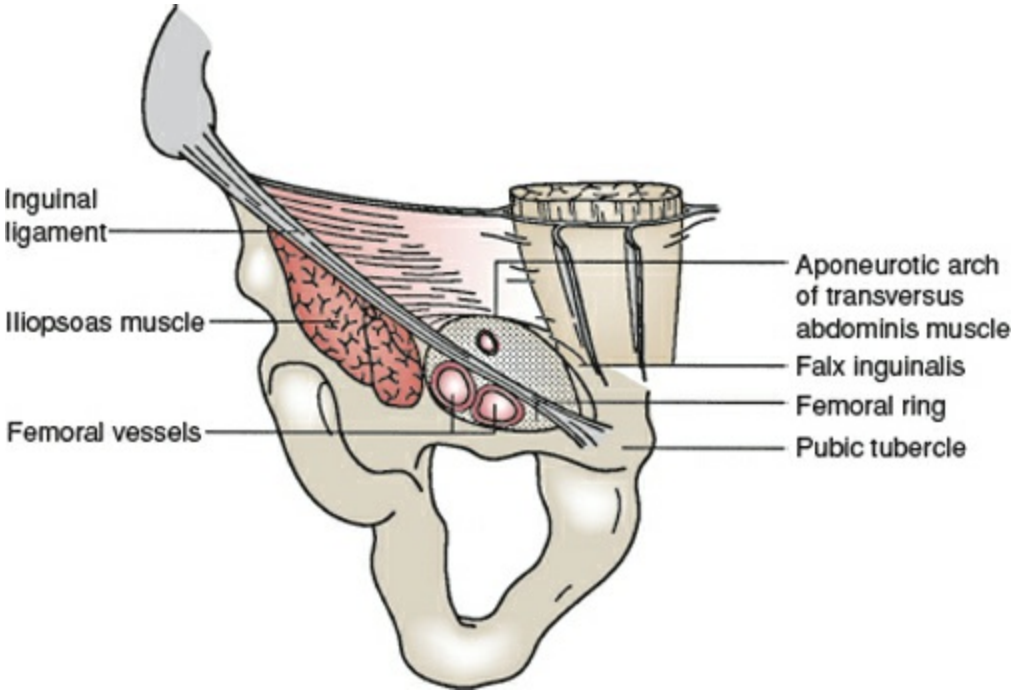

Figure 72-1. The myopectineal orifice. Superior to the inguinal ligament, this area includes the inguinal (Hesselbach) triangle. Inferior to the ligament, the orifice transmits the iliopsoas muscle, the femoral nerve and vessels, and the femoral canal and sheath. (Reproduced with permission from Wantz GE. *Atlas of Hernia Surgery.* New York, NY: Raven Press; 1991:4.)

The superficial fascia also fuses with the layer of fascia (fascia innominata) investing the external abdominal oblique muscle. This fascia is bound inferiorly to the inguinal ligament and pubis before continuing onto the thigh, where it blends with the fascia lata to seal the space beneath and inferior to the inguinal ligament, which is the inferior portion of the myopectineal orifice (Fig. 72-1). This portion of the inguinal region includes the Hesselbach (inguinal) triangle superiorly and therefore constitutes the weakest aspect of the groin.

The skin of the anterior abdominal wall is segmentally innervated in the familiar dermatome pattern. The nerve branches to this area are derived from the anterior and lateral cutaneous branches of the ventral rami of the 7th to 12th intercostal nerves and from the ventral rami of the first and second lumbar nerves. Disruption of one of these nerves is rarely noted by the postoperative patient because the dermatome fields overlap significantly. The anterior and lateral cutaneous branches reach the subcutaneous layer by coursing between the flat lateral muscles and by piercing the sheath of the rectus abdominis.

Anterior Musculature and Ligaments

The division of the wall into anterior and posterior segments is somewhat artificial because the anterior muscles, with the exception of the rectus abdominis, arise posteriorly and also form part of the posterior wall.

The three muscles of the lateral aspect of the anterior abdominal wall (Fig. 72-2) are composed of a variable amount of muscle with a large aponeurosis. The aponeurosis is the tendon of insertion for the lateral muscles, and it also forms the sheath of the rectus

abdominis. The midline decussation of the three aponeuroses forms the linea alba. Fibrous tissue layers are of great importance to the hernia surgeon because of their ability to support sutures. *Fascia* and *aponeurosis* are terms commonly used to describe these fibrous structures, but are often confused and used interchangeably. In this chapter, an aponeurosis is defined as the non–muscle-fiber-containing portion of a muscle usually present at insertion points. Muscle fibers are said to "give way" to the corresponding aponeurosis. Fascia, on the other hand, is the fibrous tissue that lines or envelops muscles.

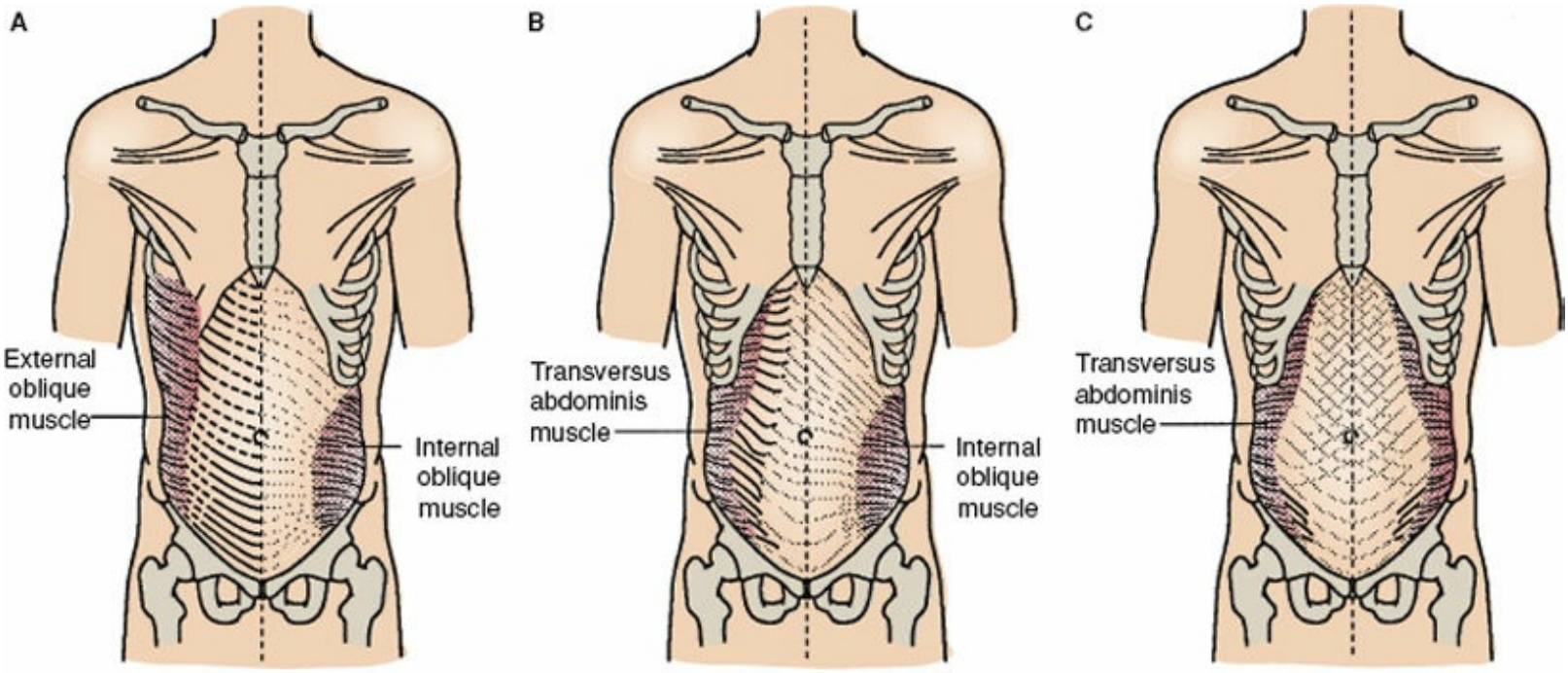

Figure 72-2. Pattern of crossing of the aponeurotic fascicles of the abdominal wall musculature. **A:** Fascicles from the right external oblique and anterior lamina of the left internal oblique. **B:** Fascicles from the right transversus abdominis and posterior lamina of the left internal oblique. **C:** Fascicles between the right and left transversus abdominis muscles.

External Abdominal Oblique Muscle and Associated Ligaments

The external abdominal oblique muscle (Figs. 72-2 and 72-3A,B) is the most superficial of the three lateral abdominal muscles. The external abdominal oblique arises from the posterior aspects of the lower eight ribs and interdigitates with both the serratus anterior and the latissimus dorsi at its origin. The direction of the muscle fibers varies from nearly horizontal in its upper portion to oblique in the middle and lower portions. The mostly horizontal fibers, which originate posteriorly, insert onto the anterior portion of the iliac crest. The obliquely arranged anteroinferior fibers of insertion fold on themselves to form the inguinal ligament. The remaining portion of the aponeurosis inserts into the linea alba after contributing to the anterior portion of the rectus abdominis sheath. Some fibers cross the linea alba to reinforce further the anterior rectus sheath of the opposite side.

The more medial fibers of the aponeurosis of the external oblique divide into a medial and a lateral crus to form the external or superficial inguinal ring. The spermatic cord (or round ligament) and branches of the ilioinguinal and genitofemoral nerves pass through this opening. The *inguinal ligament* (Fig. 72-4) is worthy of special consideration because of its important role as both a landmark and an integral component of many groin hernia

repairs. The inguinal ligament is formed by obliquely oriented anteroinferior aponeurotic fibers of the external abdominal oblique. The ligament is formed when the aponeurosis folds beneath itself. Its lateral attachment is to the anterior superior iliac crest; its medial insertion is primarily on the pubic tubercle.

The medial insertion of the inguinal ligament in most persons is dual. One portion runs along the superior surface of the pubic tubercle and symphysis to form (or at least reinforce) the superior pubic ligament. The other portion is fan shaped and spans the distance between the inguinal ligament proper and the pectineal line of the pubis. This fan-shaped portion of the ligament is called the *lacunar ligament* (Fig. 72-4). It blends laterally with the pectineal (Cooper) ligament.

Internal Abdominal Oblique Muscle and Aponeurosis

The middle layer of the lateral abdominal group is the internal abdominal oblique muscle (Figs. 72-2 and 72-3B,C). This muscle primarily arises from the iliac fascia along the iliac crest and forms a band of iliac fascia fused with the inguinal ligament. The uppermost fibers course obliquely toward the distal ends of the lower three or four ("floating") ribs. The muscle fibers of the internal oblique fan out following the shape of the iliac crest so that the lowermost fibers are directed inferiorly. These fibers arch over the round ligament, or spermatic cord. Some of the lower muscle bundles in the male join fibers of the transversus abdominis to form the cremaster muscle. The aponeurosis of the internal oblique (Fig. 72-5A) above the level of the umbilicus splits to envelop the rectus abdominis, re-forming in the midline to join and interweave with the fibers of the linea alba. Below the level of the umbilicus (Fig. 72-5B), the aponeurosis does not split but rather runs anterior to the rectus muscle, continues medially as a single sheet, joins the anterior rectus sheath, and finally contributes to the linea alba. The aponeurotic portion of the internal oblique is widest at the level of the umbilicus.

Transversus Abdominis Muscle and Aponeurosis

The transversus abdominis muscle (Figs. 72-2 and 72-3C) arises from the fascia along the iliac crest and inguinal ligament and from the lower six costal cartilages and ribs, where it interdigitates with the lateral diaphragmatic fibers. The muscle bundles of the transversus abdominis for the most part run horizontally. The lower medial fibers, however, may continue in a more inferomedial course toward the site of insertion on the crest and pecten of the pubis.

The aponeurosis of the transversus abdominis joins the posterior lamina of the internal abdominal oblique, forming above the umbilicus a portion of the posterior rectus sheath. Below the umbilicus, the transversus abdominis aponeurosis is a component of the anterior rectus sheath. The gradual termination of aponeurotic tissue on the posterior aspect of the rectus abdominis forms the arcuate line (of Douglas) (Fig. 72-6). The medial aponeurotic fibers of the transversus abdominis insert on the pecten pubis and the crest of the pubis to form the falx inguinalis. These fibers infrequently are joined by a portion of the internal oblique aponeurosis; only then is a true conjoined tendon formed.[4]

The arch formed by the termination of the aponeurotic fibers of the transversus

abdominis is called the *aponeurotic arch* (Fig. 72-6). The area beneath the arch varies. A high arch may be a predisposing factor in direct inguinal hernia. Contraction of the transversus abdominis causes the arch to move down toward the inguinal ligament in a kind of shutter mechanism, which reinforces the weakest area of the groin when intra-abdominal pressure is raised.

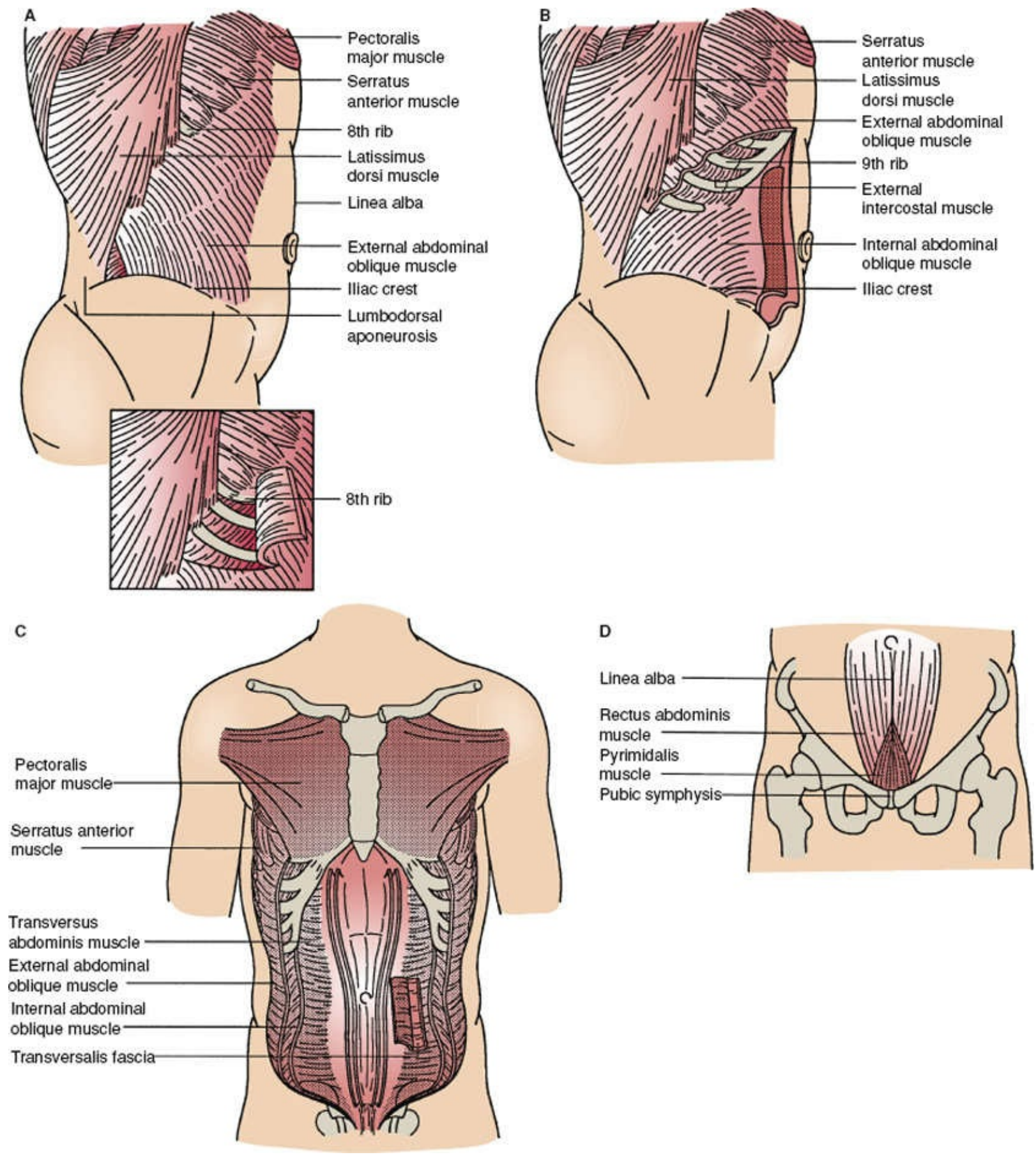

Figure 72-3. **A:** External oblique muscle and aponeurosis. **B:** Internal oblique muscle and aponeurosis. **C:** Transversus abdominis muscle and aponeurosis. **D:** Lower rectus abdominis and pyramidalis muscle. The linea alba is formed by the intermeshed fibers of the aponeuroses of the lateral muscle layers; it is tensed by the pyramidalis, which inserts into it.

Rectus Abdominis

The rectus abdominis (Figs. 72-3D and 72-5) forms the central and anchoring muscle mass of the anterior abdomen. The rectus muscle arises from the fifth to the seventh costal cartilages and inserts on the pubic symphysis and pubic crest. Each rectus muscle is segmented by tendinous intersections at the levels of the xiphoid process and the umbilicus and at a point midway between these two. The principal blood supply reaches the muscle from the superior and inferior epigastric arteries (Fig. 72-5), which anastomose just superior to the umbilicus. Other vessels are anterior branches of the intercostal arteries; these reach the muscle by entering the lateral aspect of the rectus sheath. The innervation of the muscle is from the 7th to the 12th intercostal nerves, which laterally pierce the aponeurotic sheath of the muscle. The lateral edge of the muscle is demarcated by a slight depression in the aponeurotic fibers coursing toward the muscle; this depression is the *semilunar line*.

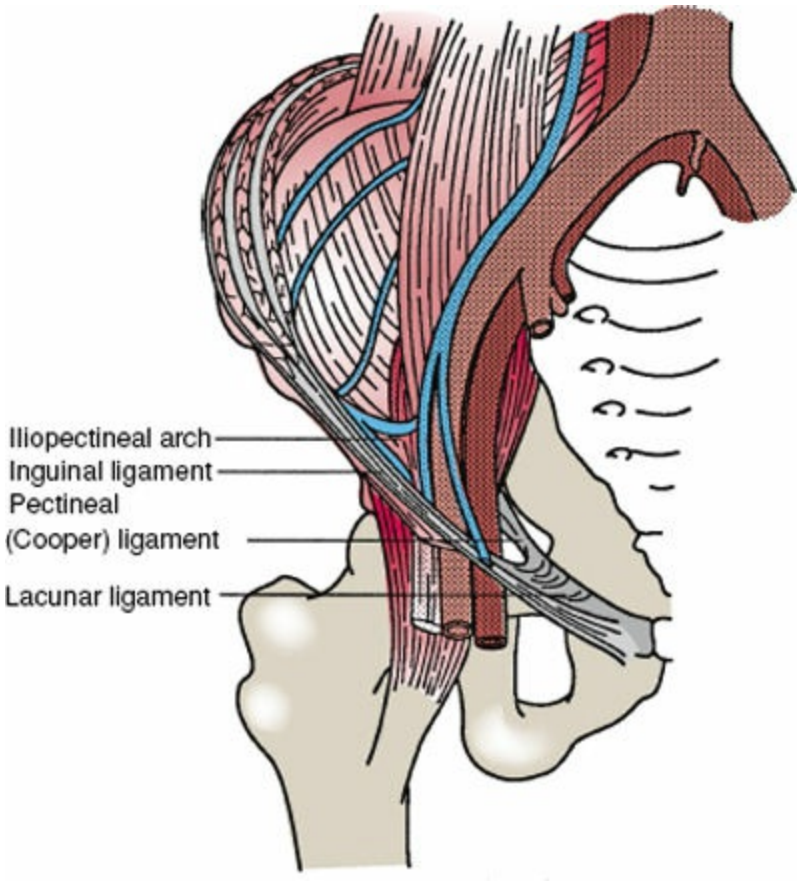

Figure 72-4. Ligamentous structures of the inguinal region. The iliopubic tract is not seen in this view because it is obscured by the inguinal ligament. The lacunar ligament is the expanded medial end of the inguinal ligament; on the pecten pubis, it blends with the inguinal (Cooper) ligament.

The small pyramidalis muscle (Fig. 72-3D) accompanies the rectus abdominis at its origin in a minority of people. The pyramidalis arises from the pubic symphysis. It lies within the rectus sheath and tapers to attach to the linea alba, the conjunction of the two rectus sheaths and the major site of insertion of three aponeuroses from all three lateral muscle layers.

Rectus Sheath

Although the components of the rectus sheath individually have been discussed in relation to the three lateral abdominal muscles, it should also be considered as a distinct entity. Three features of the rectus muscle and its sheath can be observed even topographically in well-muscled or very thin subjects:

1. The semilunar line is a slight depression in the aponeurotic fibers corresponding to the lateral edge of the rectus muscle. It marks the site of initial lateral insertion of the aponeurotic tendons of the lateral abdominal muscles.
2. The tendinous inscriptions divide each muscle into three parts.[5] These are the basis of the expression "six pack," popularized by bodybuilders.
3. The linea alba is the midline confluence of the aponeuroses of the rectus muscles and also the internal and external oblique muscles.

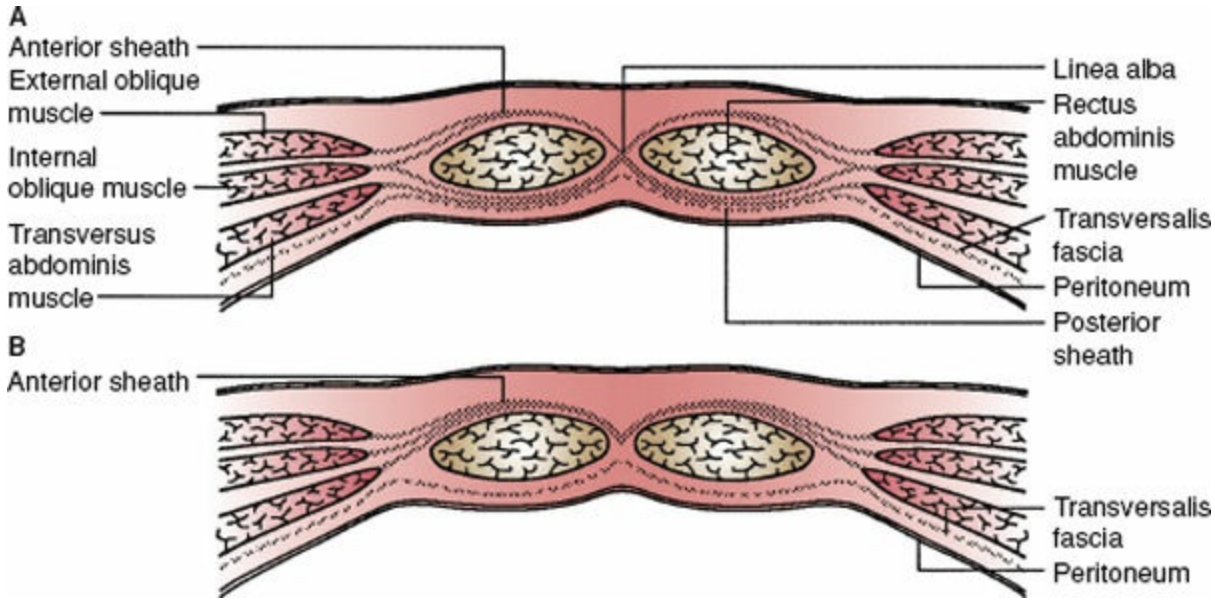

Figure 72-5. **A:** Immediately superior to the umbilicus, the rectus sheath consists of anterior and posterior components. The anterior sheath is composed of the aponeuroses of the external and internal abdominal oblique muscles, and the posterior sheath consists of the posterior aponeurotic lamina of the internal oblique and the aponeurosis of the transversus abdominis muscle. **B:** The rectus sheath inferior to the arcuate line (of Douglas) consists of an anterior portion made up of fibers from all aponeurotic layers; the posterior portion at this point comprises only transversalis fascia covered internally by peritoneum.

The composition of the rectus sheath varies depending on the level sampled. The anterior sheath superior to the umbilicus is composed of the aponeurosis of the external abdominal oblique and the anterior lamina of the internal abdominal oblique. The transversalis aponeurosis does not participate in the formation of the anterior sheath at this level. At a variable level inferior to the umbilicus, the anterior sheath is a composite of all the aponeurotic layers.

The posterior sheath of the rectus muscle superior to the umbilicus is a lamination of the posterior lamina of the aponeurosis of the internal abdominal oblique and the transversus abdominis aponeurosis. The external abdominal oblique does not participate in the formation of the posterior portion of the rectus sheath. At a highly variable site

inferior to the umbilicus, all the aponeurotic tendons pass anteriorly to form the anterior rectus sheath. The fibers of the posterior sheath are seen to attenuate gradually. The aponeurotic fibers do not end abruptly at the arcuate line. This transfer of connective tissue away from the posterior rectus sheath causes the arcuate line (of Douglas) to form on the posterior surface of the muscle (Fig. 72-6). The tissue covering the deep surface of the rectus muscle inferior to the arcuate line is primarily the transversalis fascia.

Some have questioned this traditional scheme of rectus sheath composition, contending that each of the aponeurotic layers superior to the umbilicus is actually bifid, with both contributing to the anterior and posterior sheaths.[6] The fibers of the posterior sheath are seen to attenuate gradually. The concept of rectus sheath composition favored by most is shown in Figure 72-7.[7]

Innervation and Blood Supply of the Anterior Abdominal Wall

The innervation of the anterior wall muscles is multiple. The lower intercostal and upper lumbar nerves (T7 to T12, L1, L2) contribute most of the innervation to the lateral muscles, the rectus abdominis, and the overlying skin. The nerves pass anteriorly in a plane between the internal abdominal oblique and the transversus abdominis, eventually piercing the lateral aspect of the rectus sheath to innervate the muscle therein. The external oblique muscle receives branches of the intercostal nerves, which penetrate the internal oblique. The anterior ends of the nerves form part of the cutaneous innervation of the abdominal wall. The first lumbar nerve divides into the ilioinguinal and iliohypogastric nerves. These may divide within the psoas major muscle or between the internal oblique and transversus abdominis muscles. The ilioinguinal nerve may communicate with the iliohypogastric nerve before innervating the internal oblique. The ilioinguinal nerve then passes through the external inguinal ring to run with the spermatic cord, whereas the iliohypogastric nerve pierces the external oblique to innervate the skin above the pubis. The cremaster muscle fibers, which are derived from the internal oblique muscle, are innervated by the genitofemoral nerve (L1, L2).

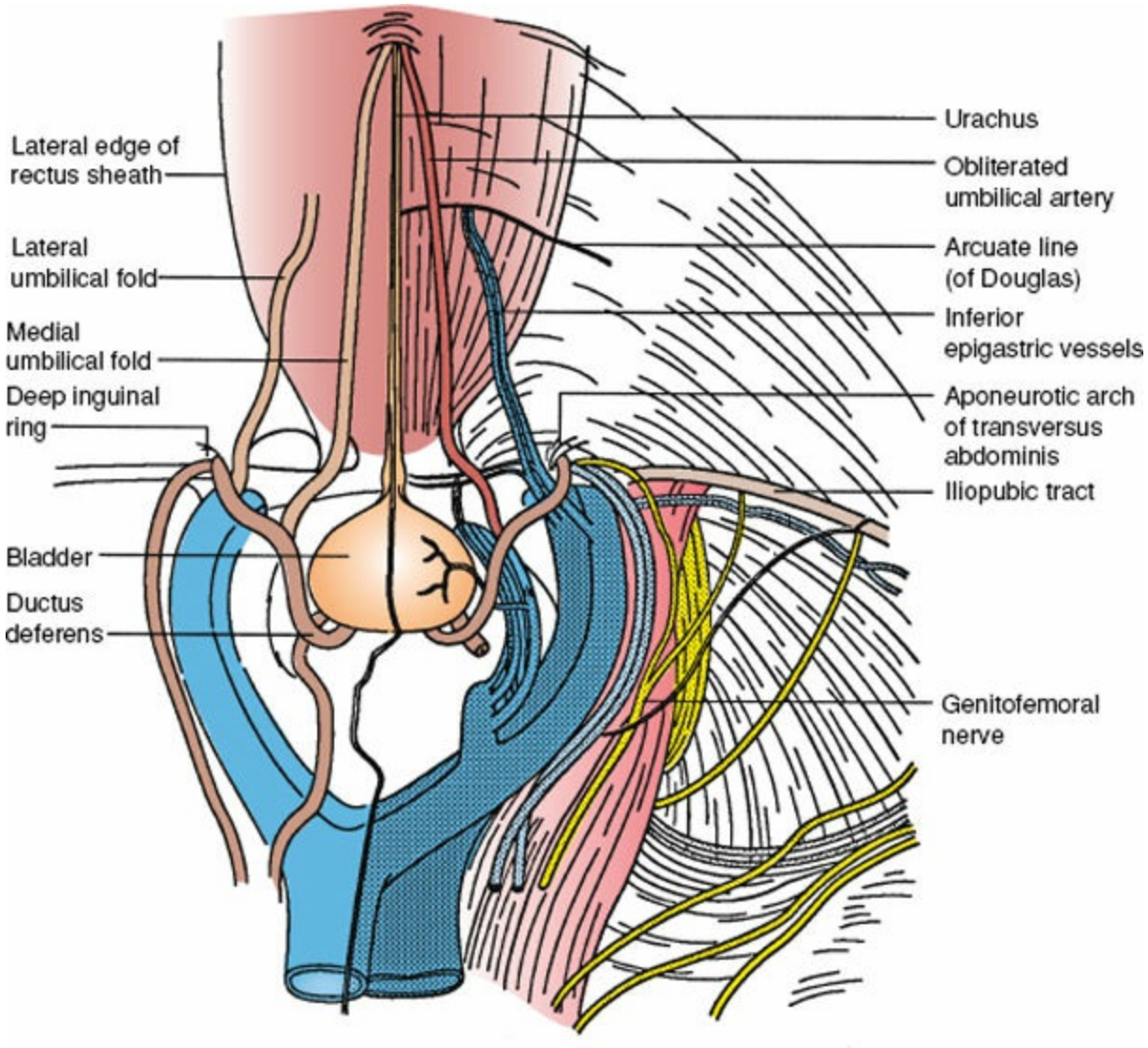

Figure 72-6. The deep inguinal region, pelvis, and anterior abdominal wall from the viewpoint of a surgeon using a laparoscopic technique. The anterior wall folds upward approximately at the iliopubic tract in this illustration.

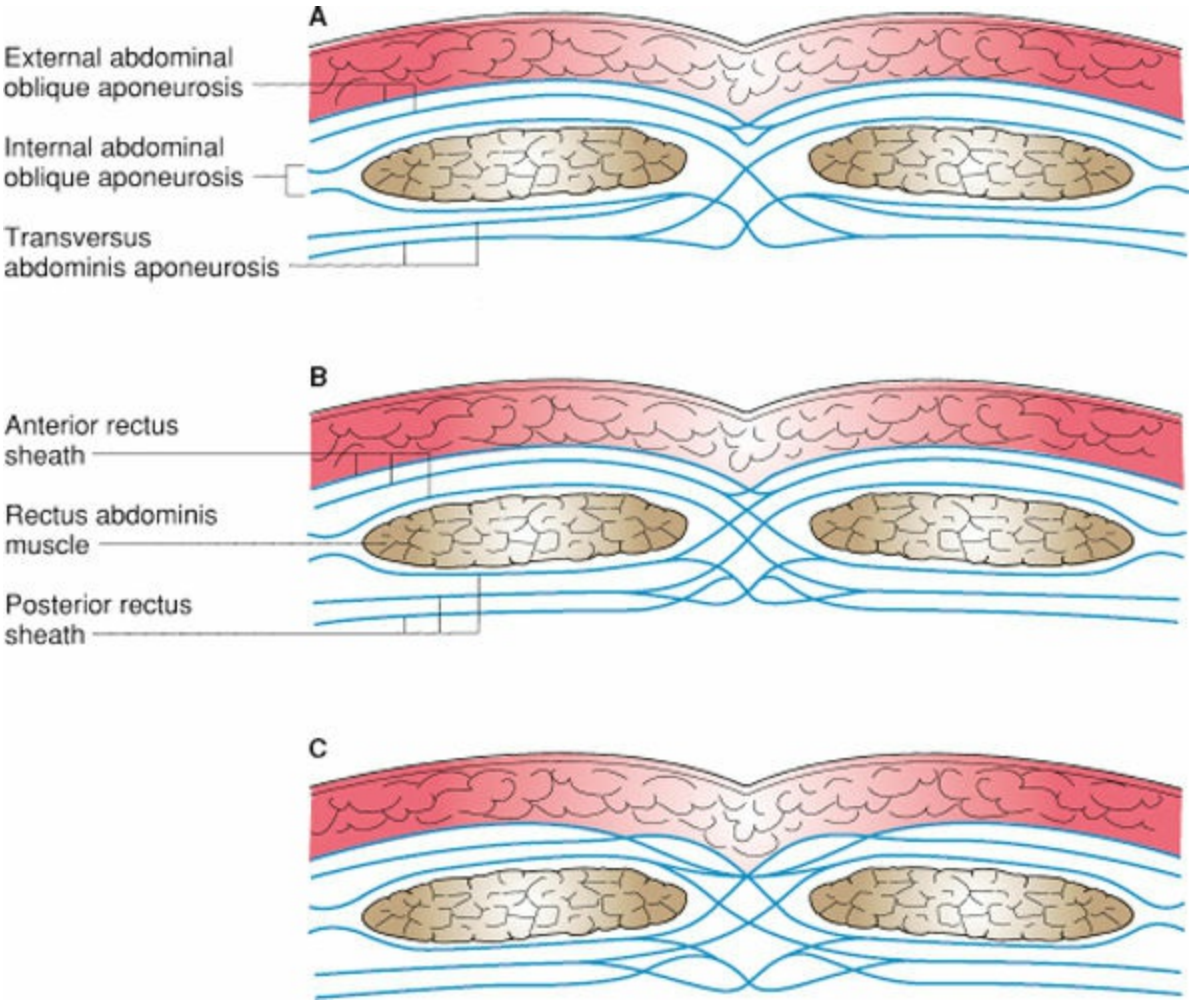

Figure 72-7. Patterns of midline decussation of the aponeuroses. **A:** Single anterior and posterior lines of decussation. **B:** Single anterior and triple posterior lines of decussation. **C:** Triple anterior and posterior lines of decussation.

The blood supply of the lateral muscles of the anterior wall is primarily from the lower three or four intercostal arteries, the deep circumflex iliac artery, and the lumbar arteries. The rectus abdominis has a complicated blood supply derived from the superior epigastric artery (a terminal branch of the internal thoracic, or internal mammary, artery), the inferior epigastric artery (a branch of the external iliac artery), and the lower intercostal arteries. The latter arteries enter the sides of the muscle after traveling between the oblique muscles. The superior and inferior epigastric arteries enter the rectus sheath and anastomose near the umbilicus.

Posterolateral (Lumbar) Abdominal Wall

The posterolateral or lumbar portion of the abdominal wall (Fig. 72-8) is often overlooked in discussions of abdominal hernia, perhaps because of the much more common occurrence of groin and femoral hernias. The configuration of the muscle layers in the lumbar area also predisposes to hernia formation. For the purposes of this discussion, the lumbar portion of the abdominal wall is defined as the area bounded superiorly by the 12th rib, inferiorly by the iliac crest, and medially by the erector spinae group. Eight muscles arrayed in three layers constitute the posterolateral or lumbar portion of the abdominal wall.

The most superficial layer is composed of the external abdo-minal oblique muscle, which arises from the posteroinferior portion of the lower ribs and inserts in part along the posterior iliac crest. Closely associated with the external oblique in this area is the latissimus dorsi, which arises from the posterior iliac crest, the spinous processes of the sacrum and lumbar vertebrae, and the lumbodorsal fascia. The muscle courses obliquely toward its insertion on the medial aspect of the intertubercular groove of the humerus. The triangular space formed by the two muscles just described and the iliac crest is called the *inferior lumbar (Petit) triangle* (Fig. 72-8A).

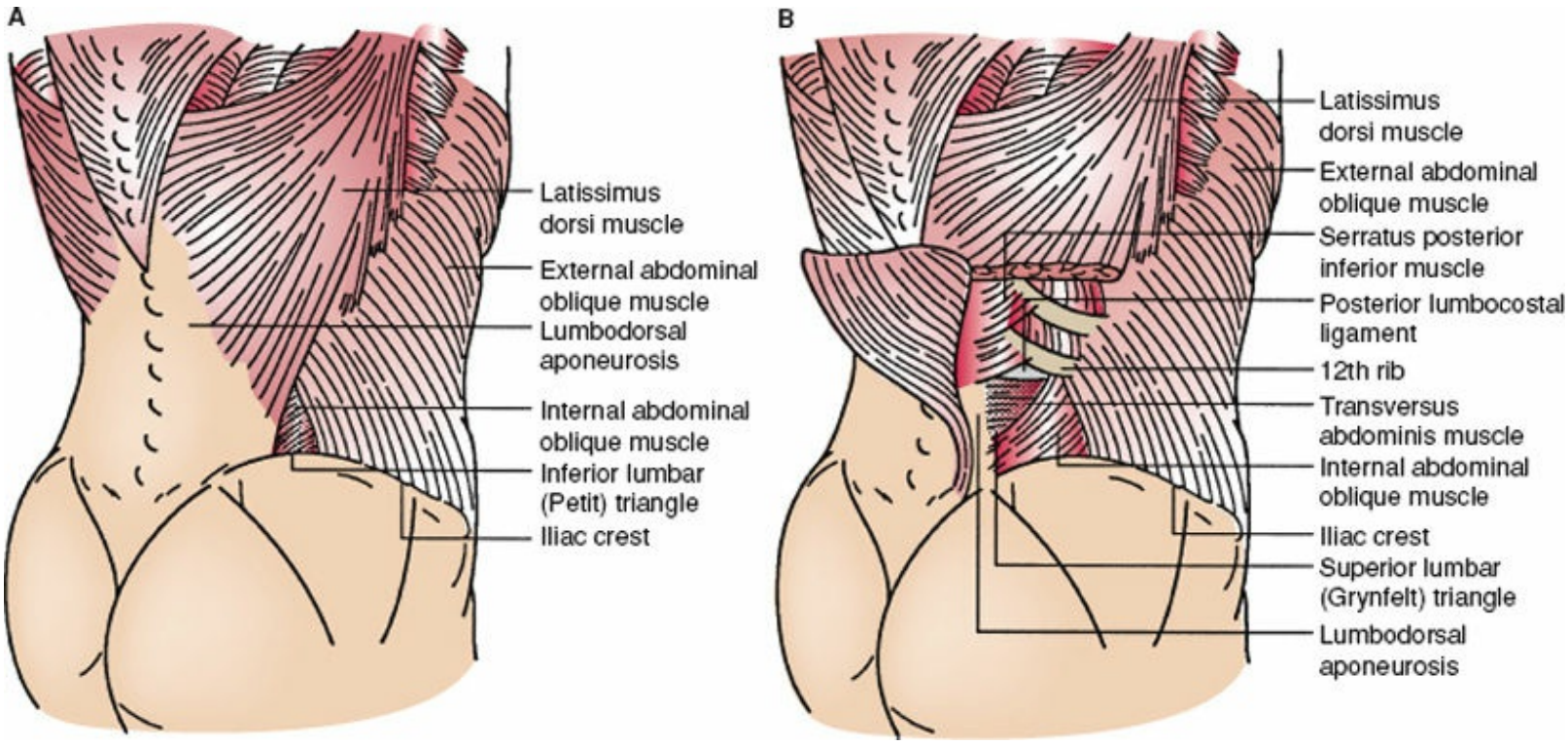

Figure 72-8. The lumbar abdominal wall with the inferior lumbar triangle (**A**) and the superior lumbar triangle (**B**).

The middle layer of lumbar abdominal muscles consists of the erector spinae, the internal abdominal oblique, and the extremely thin insignificant serratus posterior inferior. The erector spinae forms a significant portion of the abdominal wall in the lumbar region, with fibers extending nearly the length of the spinal column. The internal abdominal oblique muscle forms the remainder of the layer. The serratus posterior inferior arises from the lumbodorsal fascia and inserts on the lower four ribs. The middle

layer of lumbar muscle is associated with the superior lumbar triangle, a more common site of hernia than the inferior lumbar triangle described previously. The superior triangle (Fig. 72-8B) is formed superiorly by the 12th rib, the serratus posterior inferior, and the superior lumbocostal ligament; inferiorly by the upper border of the internal abdominal oblique; and medially by the erector spinae.

The deep layer of the lumbar abdominal wall includes three muscles: the quadratus lumborum, the psoas major, and the transversus abdominis. The quadratus lumborum primarily arises from the posterior iliac crest and inserts on the 12th rib. The psoas major arises from vertebrae T12 through L5 and passes beneath the inguinal ligament to insert on the lesser trochanter of the femur.

Deep Inguinal Region

Laparoscopic View

Deep Aspect of the Anterior Abdominal Wall, Peritoneal Folds, and Associated Structures. If one creates a space in the abdominal cavity by distending it with gas, an excellent view of the anterior wall can be obtained. The umbilical peritoneal folds (Fig. 72-9) in most subjects are very prominent and provide easily identified landmarks. The folds (ligaments) primarily exist because the peritoneum covers underlying structures.

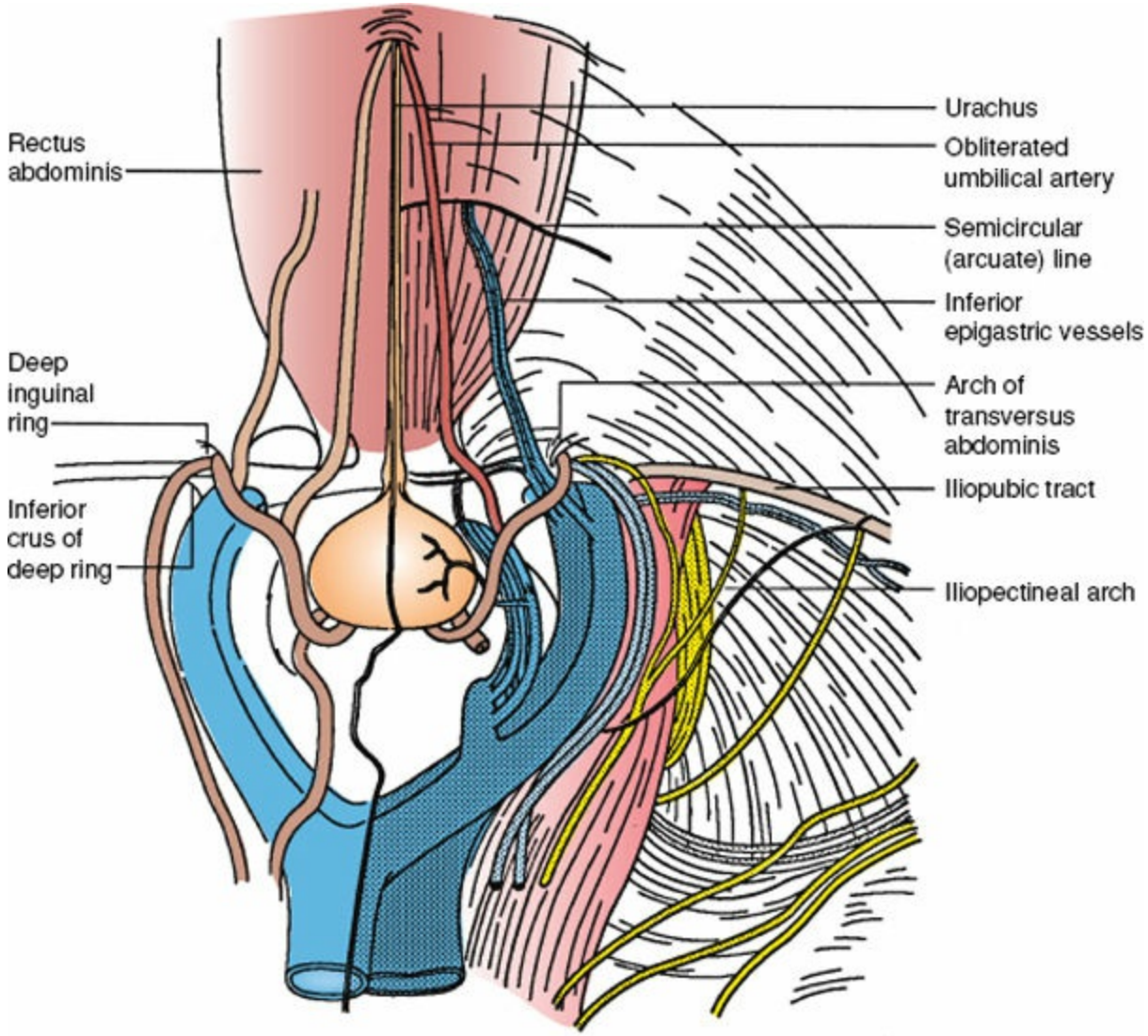

Figure 72-9. The deep inguinal region and the anterior abdominal wall seen from within the abdomen. The urachus, the obliterated portion of the umbilical artery, and the inferior epigastric vessels are covered by peritoneal folds, respectively called the median, medial, and lateral umbilical folds.

The single median umbilical fold extends from the umbilicus to the urinary bladder and covers the urachus, the fibrous remnant of the fetal allantois. The urachus may be patent for a short distance in adults or may open into the umbilical scar in newborns. The medial umbilical fold is formed by the underlying obliterated portion of the fetal umbilical artery. This normally cordlike structure, like the urachus, may be patent for a portion of its length. Indeed, the proximal, patent portion of the artery normally supplies the

superior vesicular arteries to the bladder. The lateral fold covers the inferior epigastric arteries as they course toward the posterior rectus sheath, which they enter approximately at the level of the arcuate line.

Between the median and the medial ligaments, a depression is usually found that is called the *supravesical fossa.* This is the site of hernias of the same name. The fossa formed between the medial and lateral ligaments is the medial fossa; this is the site of direct inguinal hernias. The lateral fossa is less well delineated than the others. The medial border of the fossa is formed by the lateral umbilical ligament and the rectus abdominis. This fossa does not have a lateral border; rather, the concavity slowly attenuates. The deep inguinal ring is located in the lateral fossa and therefore is the site of the congenital or indirect inguinal hernia.

Transversalis Fascia

The transversalis fascia (endoabdominal fascia) is perhaps the most commonly misunderstood structure in the literature devoted to groin hernia. Confusion results because surgeons may actually be referring to very different anatomic structures when discussing various hernia repairs; however, each may use the same anatomic term or eponym. Indeed, perhaps the biggest reservation among surgeons intent on performing a Shouldice repair is a precise definition of what is being sewn to what.

The transversalis fascia proper is a continuous sheet that extends throughout the extraperitoneal space. The term *transversalis fascia* is generally defined as the deep or endoabdominal fascia covering the internal surface of the transversus abdominis, the iliacus, the psoas muscles, and the obturator internus and portions of the periosteum. One variant of this convention is the use of terms specific to the muscle covered by the fascia (e.g., iliac fascia).

Most authors feel that only one layer of transversalis fascia exists, whereas others maintain that the transversalis fascia comprises two layers, or laminae.[8] The posterior lamina is a layer of fibrous connective tissue that widely varies in density and continuity and is interspersed with adipose tissue, as seen in Figure 72-10. This layer is often referred to simply as the *preperitoneal fascia.* The anterior lamina is more uniform and is adherent to the deep surface of the transversus abdominis and the rectus abdominis. The posterior lamina is contained within the preperitoneal space, which is defined as the space between the peritoneum and the anterior lamina of the transversalis fascia. The inferior epigastric vessels are enclosed by, or interspersed with, the adipose tissue and the fibrous tissue of the posterior lamina of the transversalis fascia. The vessels are in contact anteriorly with the anterior lamina of the transversalis fascia as they course upward to enter the rectus abdominis sheath.

Transversalis Fascia Derivatives

The transversalis fascia analogs or derivatives are the iliopectineal arch, iliopubic tract, and crura of the deep inguinal ring. The superior and inferior crura form a transversalis fascia sling, a structure shaped like a “monk’s hood,” around the deep inguinal ring (Fig. 72-9). The transversalis fascia also contributes the internal spermatic fascia to the

spermatic cord at this point. This “sling” has functional significance; when the transversus abdominis contracts, the crura of the ring are pulled upward and laterally, which results in a valvular action that helps to prevent the indirect formation of a hernia.

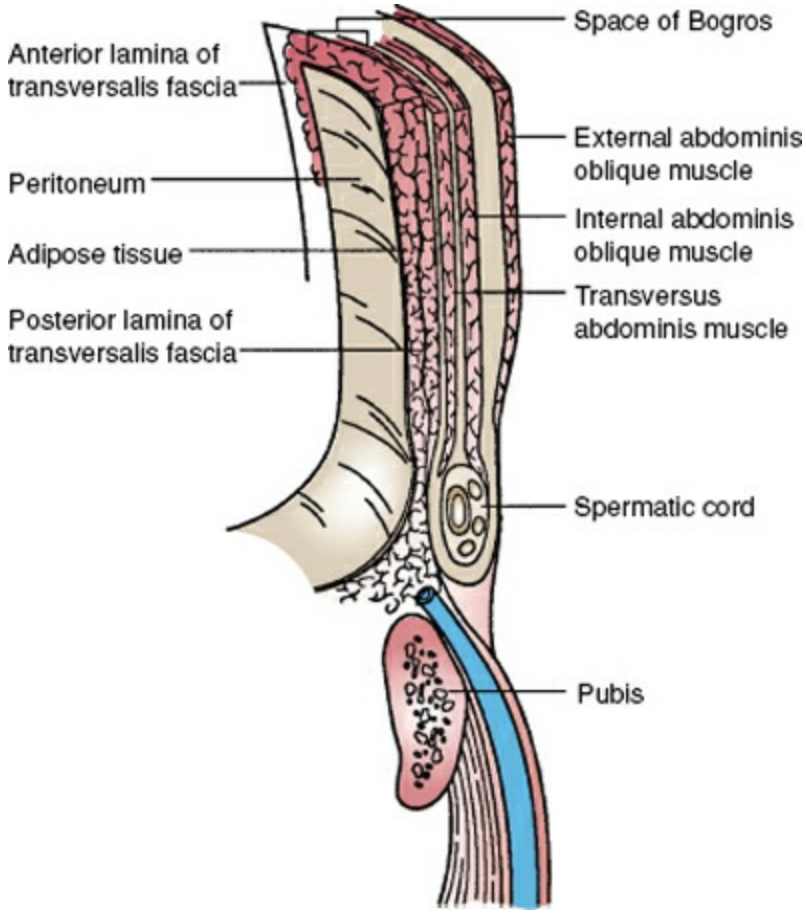

Figure 72-10. A parasagittal section through the layers of the anterior abdominal wall and groin. Observe that the transversalis fascia is depicted as a bilaminar structure.

The iliopubic tract (Figs. 72-9 and 72-11) has become an increasingly important landmark for surgeons as the use of laparoscopic technology has increased.[9,10] The iliopubic tract is the thickened band of transversalis fascia formed at the zone of transition between the deep surfaces of the iliac and transversus abdominis muscles. The structure courses parallel to the more superficially located inguinal ligament, is attached to the iliac crest laterally, and inserts on the pubic tubercle medially. The tract forms along its course a portion of the inferior crus of the deep inguinal ring and then contributes to the anterior and medial walls of the femoral sheath. The tract fuses with the inguinal ligament to form a component of the inferior wall of the inguinal canal. At its insertion on the pubic tubercle, it curves backward slightly to blend with the Cooper pectineal ligament. The pectineal ligament is actually a condensation of periosteum and is not a true analog of the transversalis fascia, but it is reinforced by fibers from the iliopubic tract and inguinal ligament.

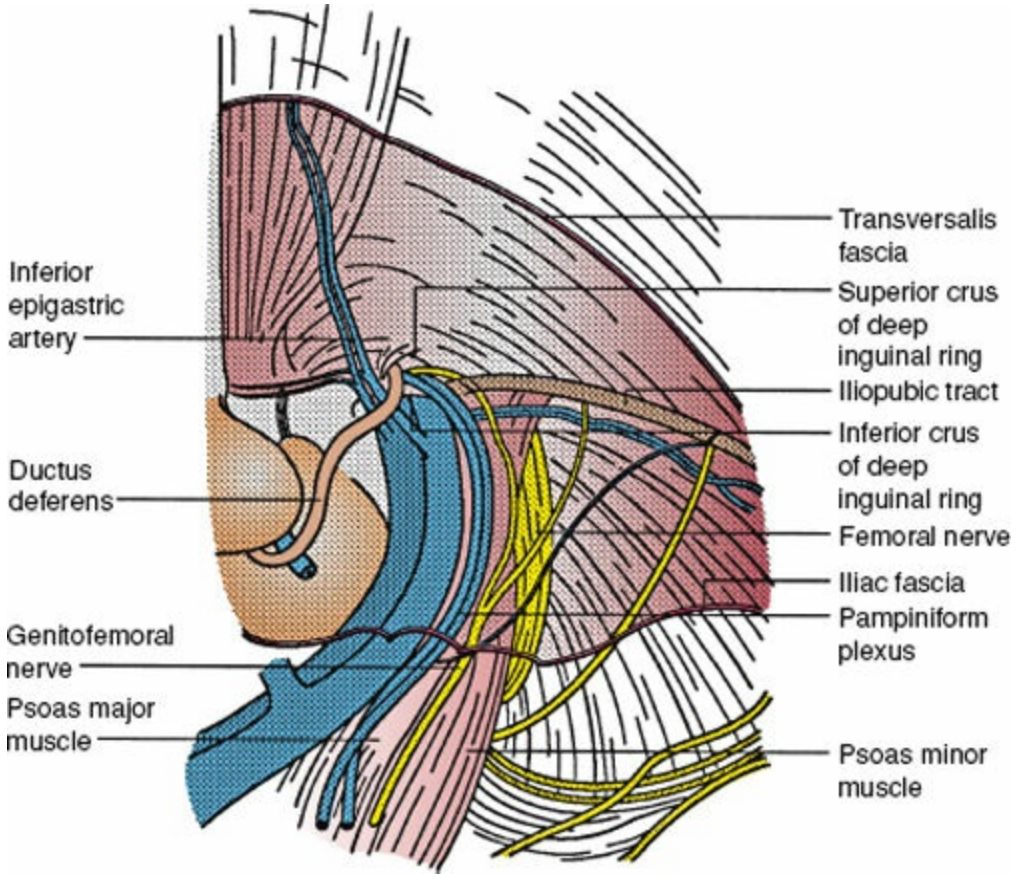

Figure 72-11. A schematic representation of the deep inguinal region. The iliopubic tract is shown as a thickening of the transversalis fascia, inferior to which many of the branches of the lumbar plexus exit the pelvis.

The iliopubic tract contains not only fibrous connective tissue but also some elastic fibers.[11] In one series, the iliopubic tract was a substantial structure, suitable for use in hernia repairs, in 42% of the specimens examined. The tract, whether substantial or not, can be used as a readily identified landmark.

The iliopubic tract has particular significance because of its importance as a landmark to the laparoscopic surgeon. Many of the branches of the lumbar plexus run inferior to the tract, and damage to these nerves may be the result of aggressive dissection or the placement of tacks or staples to affix a prosthesis below this structure. The tract is not obviously visible in every patient from a laparoscopic view, but its location should always be immediately known to the surgeon because of its constant relationship to the other landmarks in this area.

The iliopectineal arch (Fig. 72-9) is also a condensation of the transversalis fascia. The iliopectineal arch commences at the medial border of the iliacus muscle, where it is continuous with the iliac fascia, itself a portion of the transversalis (endoabdominal) fascia. The arch separates the vascular compartment containing the femoral vessels from the neuromuscular compartment containing the iliopsoas muscle, femoral nerve, and lateral femoral cutaneous nerve. The iliopectineal arch also contributes to the proximal portion of the femoral sheath, thereby joining the iliopubic tract in the formation of the femoral sheath.

Femoral Sheath, Canal, and Ring

The femoral sheath (Fig. 72-12) is primarily composed of extensions of the transversalis fascia. The sheath is best understood in terms of the structures contained within. As the external iliac artery and vein pass beneath the inguinal ligament to become the femoral vessels, they are covered anteriorly by the transversalis fascia proper. This fascial layer is posteriorly and laterally joined by portions of the iliopsoas fascia, which themselves are continuations of the transversalis fascia. At the inguinal ligament, the iliopsoas fascia forms the iliopectineal arch. This arch divides the vascular compartment (lacuna vasorum), containing the femoral vessels, from the muscular portion (lacuna musculorum), which contains the iliopsoas muscle, femoral nerve, and lateral femoral cutaneous nerve. The vascular lacuna is further divided by septa into compartments for the vessels and the femoral branch of the genitofemoral nerve.

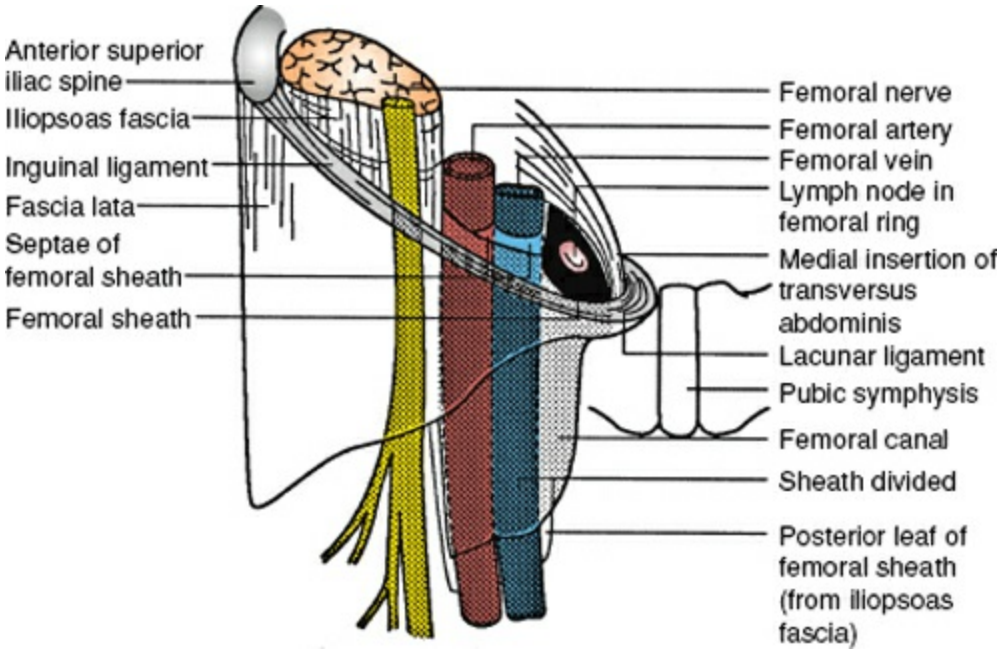

Figure 72-12. Schematic view of the femoral sheath, ring, and canal. The transversalis fascia forms the anterior portion of the sheath, and the iliopsoas fascia forms the posterior portion. Septae separate the vessels from each other and the vein from the femoral canal. The femoral ring contains a lymph node. The ring is formed medially by the aponeurosis of the transversus abdominis aponeurosis, anteriorly by the inguinal ligament, posteriorly by the pubic bone, and laterally by the femoral sheath.

The medial border of the femoral sheath follows the transversus abdominis aponeurosis to its insertion just lateral to that of the lacunar ligament and extends inferiorly to fuse eventually with the medial septum and adventitia of the femoral vein. The resultant cone-shaped cul-de-sac is the femoral canal. The canal normally contains only wisps of connective tissue and small lymphatic nodes. The wider proximal part of the canal, the femoral ring, contains a large node, which is often referred to as the *Cloquet node*.

The femoral ring is the extraperitoneal opening of the canal. The boundaries of the ring are formed medially by the curved edge of the transversus abdominis aponeurosis, not the lacunar ligament, which inserts more medially.[12] Laterally, the ring is bounded by the connective tissue septum and the adventitia that is interposed between it and the femoral vein. The anterior boundary is the inguinal ligament; posteriorly, the ring is reinforced by

the iliopubic tract and iliopectineal ligament. The canal is not in direct communication with the pelvic cavity. The transversalis fascia is not a component of the roof of the canal because it is diverted at this point to form the femoral sheath. This weakened area is therefore quite prone to hernia formation, especially in female subjects.

Inguinal (Hesselbach) Triangle

The inguinal triangle is the site of direct inguinal hernias. This triangle is most often described from the anterior aspect (Fig. 72-13), in which case the inguinal ligament forms the base of the triangle, the rectus abdominis forms the medial border, and the inferior epigastric vessels form the superolateral border. The triangle as originally described by Hesselbach had the pectineal ligament as its base. The latter description is quite useful to the surgeon viewing the abdomen from within because the inguinal ligament cannot be seen from this viewpoint. When the inguinal triangle is transilluminated, the thinness and translucency of the area of abdominal wall within the triangle underscores its importance in hernia development and repair. In the most translucent area, little or no muscle is present. Only the peritoneum and the transversalis fascia cover the triangle here. The aponeurotic arch of the transversus abdominis crosses the triangle just below the apex in most people. A high aponeurotic arch affords less reinforcement to the triangle and may therefore predispose a person to the formation of a direct inguinal hernia.

Components of the Spermatic Cord

The spermatic cord (Figs. 72-11 and 72-14) is closely associated with the deep inguinal ring. The spermatic cord is most appropriately described at this point because the deep ring itself is formed by derivatives of transversalis fascia, as is the innermost covering layer of the spermatic cord, the internal spermatic fascia. The middle covering layer is called the *cremasteric fascia* and contains the cremasteric muscle bundles; both are derived from the internal abdominal oblique muscle and fascia. The outermost covering of the spermatic cord is the external spermatic fascia, which is continuous with the investing fascia of the external abdominal oblique muscle.

The tunica vaginalis is initially a component of the cord, but normally it atrophies and closes early in neonatal life. This structure is an evagination of peritoneum. The testicle descends retroperitoneally in fetal life and is merely in contact with the posterior aspect of the tunica. An indirect congenital hernia enters the patent tunica vaginalis.

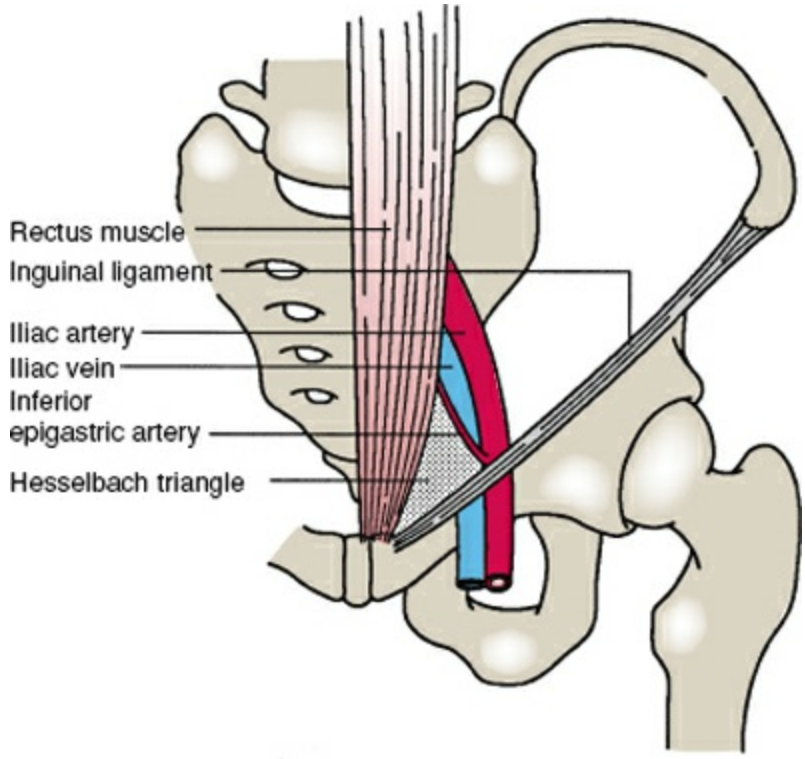

Figure 72-13. The inguinal (Hesselbach) triangle.

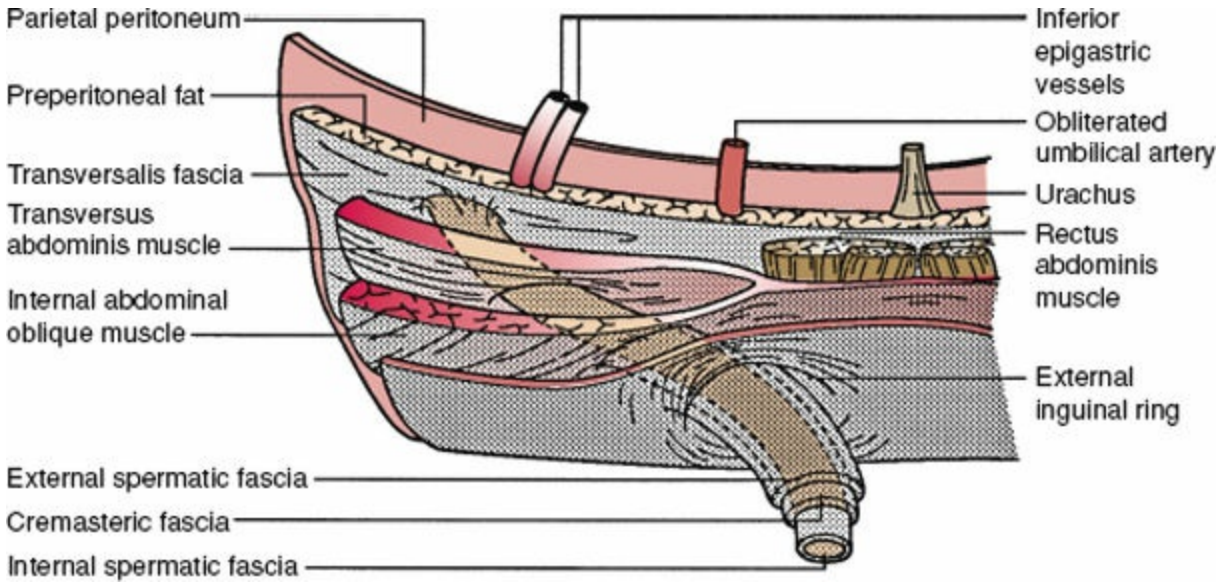

Figure 72-14. The component layers covering the contents of the spermatic cord.

The cord structures enclosed by the coverings described earlier are the ductus (vas) deferens, the pampiniform venous plexus, the testicular artery, and the genital branch of the genitofemoral nerve, a branch of the lumbar plexus (Figs. 72-9, 72-11, and 72-15).

Branches of the Lumbar Plexus

The nerves crossing the iliac fossa are some of the most variable in the body. This variability may be the cause of frequent intraoperative injury to the fragile nerves. The lumbar plexus is formed by roots from the 12th thoracic nerve and the first through fourth lumbar nerves. Cutaneous territories innervated by branches of the lumbar plexus are seen in Figure 72-15A. The five terminal branches commonly encountered in

laparoscopic herniorrhaphy can be discerned in many people as they course across the iliacus muscle covered by peritoneum and the iliac fascia (a portion of the transversalis–endopelvic fascia). The nerves form within or deep to the psoas major muscle (Fig. 72-15B), often ramifying with other nerves within or close to the muscle. The nerve branches initially lie within the so-called triangle of pain,[13] bordered medially by the psoas muscle, anteriorly and inferiorly by the iliopubic tract, and laterally by the iliac crest. With the exception of the genital branch of the genitofemoral nerve, the branches of the lumbar plexus destined for the thigh run beneath the iliopubic tract.

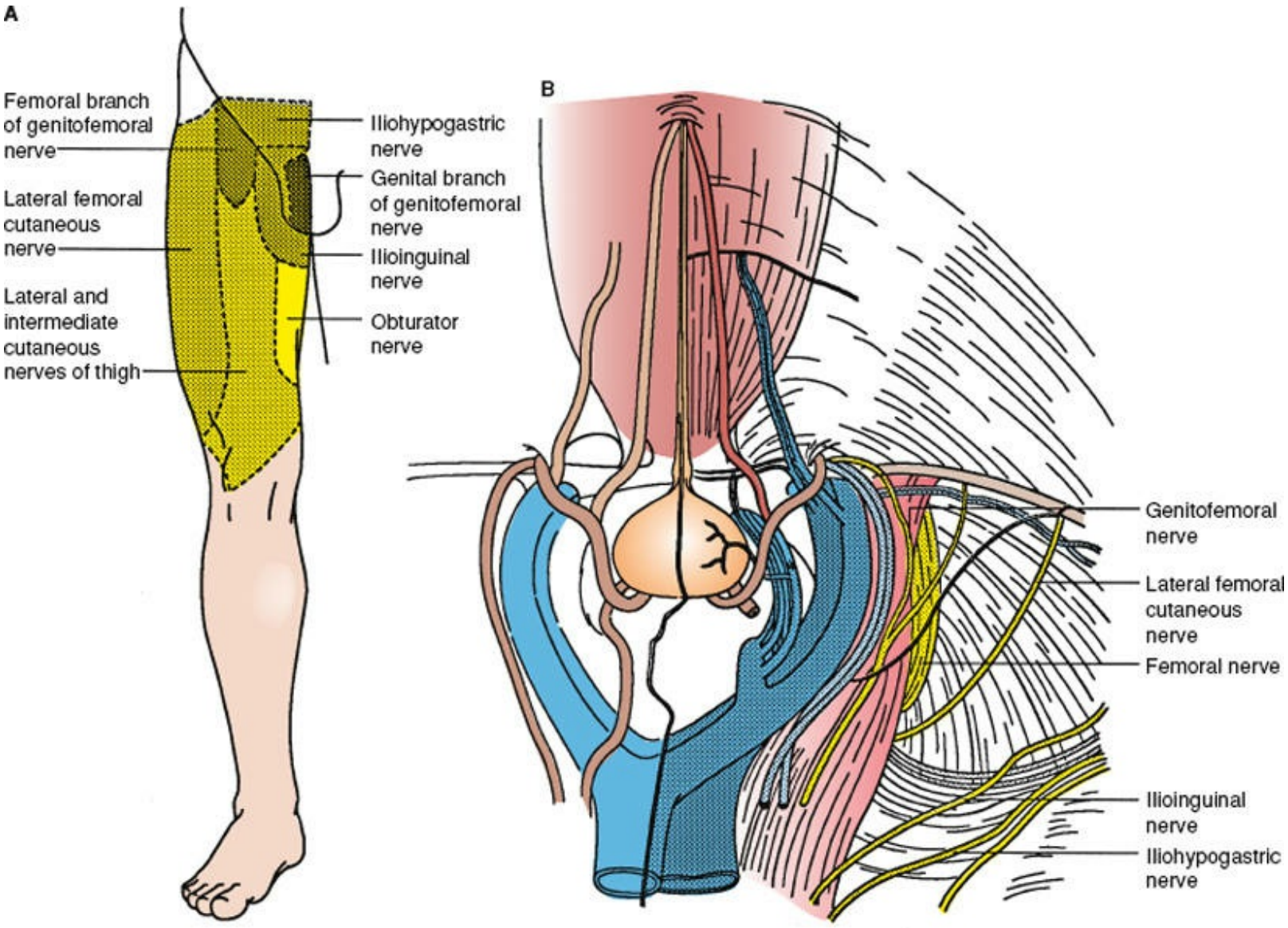

Figure 72-15. **A:** The cutaneous territories innervated by several branches of the lumbar plexus. **B:** Some of the branches of the lumbar plexus seen from within the abdomen.

The most anterior of the nerves encountered, the genitofemoral nerve, is also the most variable. This nerve may occur as a single trunk lying deep to the peritoneum and fascia on the anterior surface of the psoas muscle. The nerve may also divide into its component genital and femoral branches within the muscle. The genital branch travels with the spermatic cord, entering at the deep inguinal ring; it ultimately innervates the cremaster muscle and the lateral scrotum. The femoral branch of the nerve innervates the skin of

the proximal mid-thigh.

The lumbar plexus branch encountered immediately deep to the lateral aspect of the psoas muscle is the large femoral nerve. Although not routinely encountered during laparoscopy, the femoral nerve has been injured in some cases.[14] The lateral femoral cutaneous nerve crosses the iliac fossa under the iliac fascia to run deep to the iliopubic tract and the inguinal ligament, which it pierces to enter the thigh.

The iliohypogastric nerve typically arises with the ilioinguinal by a common trunk from the first lumbar nerve. They may exchange fibers within the muscle, but they usually diverge immediately to form individual nerves. The iliohypogastric nerve crosses the iliac fossa just inferior to the kidney and pierces the transversus abdominis. The subsequent course of the nerve carries it between the transversus and the internal abdominal oblique until it pierces the aponeuroses of both obliques just above the external inguinal ring.

The ilioinguinal nerve normally crosses the iliac fossa just inferior to the iliohypogastric nerve. In its typical further course, the nerve pierces the transversus abdominis and internal abdominal oblique above the iliac crest and eventually enters the inguinal canal. The nerve may run more diagonally through the iliac fossa and then pierce the iliopubic tract to reach the inguinal canal.[15] This path “can obviously render the nerve more vulnerable to iatrogenic injury.”

Vasculature of the Abdominal Wall and Deep Inguinal Region

The vasculature of the deep inguinal region and anterior abdominal wall has been analyzed by surgeons for well over 100 years. The importance and variability of these vessels have been underscored by the ominous mnemonics used to refer to them – "crown of death" (*corona mortis*) and "triangle of doom." The primary blood supply to the deep anterior wall is from the inferior epigastric artery. This artery is a branch of the external iliac artery. In many cases, an artery called the "aberrant" obturator artery arises from the inferior epigastric, which joins the "normal" obturator artery and thereby forms a circle – the corona mortis – before entering the obturator foramen. Injury to the circle, usually sustained while the surgeon is working in the area of the Cooper ligament, causes copious bleeding. Recent studies have indicated that aberrant obturator vessels are present in between 60% and 90% of the whole pelves studied.[16,17]

The veins in this area are also prone to injury because many, especially the iliopubic veins and obturator veins and their tributaries, may be much larger than their accompanying arteries. One network of veins in the area is situated on the inferior deep surface of the rectus muscles. The veins of this network, which anastomose with the pubic branches discussed earlier, have been called the *rectusial veins*.[18]

The vessels in the vascular compartment of the deep inguinal region are the external iliac artery and vein. They arise within a triangular area bordered laterally by the gonadal vessels and medially by the ductus deferens. The primary continuations of the external iliac vessels are the femoral artery and vein. The inferior epigastric artery is a branch of the external iliac. The obturator artery may arise from either of these arteries as a replacement or accessory to the obturator branch of the internal iliac artery.

A final vessel to consider in this review is the deep circumflex iliac artery (Fig. 72-10). The origin of this artery is extremely variable, but its course is predictable along the iliopubic tract. It pierces the transversalis fascia and runs along the iliac fossa to anastomose eventually with a deep lumbar artery. Because the deep circumflex artery runs along the iliopubic tract, it can inadvertently be stapled or otherwise injured during laparoscopic herniorrhaphy.

Pelvic Floor and Obturator Muscles

The pelvic musculature normally affords remarkable support to the structures within the true pelvis. Although a myoaponeurotic hammock-like sheet forms the pelvic diaphragm, obturator muscles and membrane, and urogenital diaphragm, herniation of fat or viscera through or around any of these layers occurs. The potential for hernia formation is increased because of the openings through which many structures exit or enter the pelvis.

The Latin term *obturator* is translated as "stopper for a bottle." The aptly named obturator internus, along with its membrane and the obturator externus, closes off nearly all the large obturator foramen. The small superolateral aperture through which the obturator vessels and nerve pass is the site where obturator hernias form. The obturator internus arises from the deep surface of parts of all three pelvic bones. The muscle fibers converge on a tendon, which leaves the pelvis through the lesser sciatic foramen to insert on the greater trochanter. The dense internal obturator fascia covers the muscle and is thickened to form the arcuate ligament, from which the levator ani muscles (the pelvic diaphragm) are in part suspended. The obturator internus fascia splits to enclose the pudendal vessels in the pudendal canal. The external obturator muscle arises from the pelvic bones surrounding the obturator foramen and from the anterior portion of the obturator membrane. The external obturator muscle is supplied by the obturator nerve and vessels.

The component muscles of the bowl-shaped pelvic diaphragm, the pubococcygeus, iliococcygeus, and puborectalis, along with the coccygeus form the floor of the pelvis. The pubococcygeus arises from the posterior aspect of the pubis and the thickened portion of the internal obturator fascia, called the *tendinous arch* (Fig. 72-16), that spans the distance between the pubis and ischial spine. The puborectalis, the midportion of the diaphragm, arises from the pubis and loops around the rectum as the puborectal sling. The iliococcygeus is suspended at its origin from the tendinous arch and inserts on the coccyx. The coccygeus muscle completes the diaphragm posteriorly, arising from the ischial spine and inserting on the sides of the coccyx.

The area remaining between the sacrum and the greater sciatic foramen is filled for the most part by the piriformis muscle. The piriformis arises from the anterior surface of the second through fourth sacral vertebrae and the sacrotuberous ligament. This muscle exits the pelvis through the greater sciatic foramen, which is thereby divided into suprapiriform and infrapiriform portions (Figs. 72-16 and 72-17). The superior gluteal nerves and vessels pass through the suprapiriform foramen, whereas the inferior gluteal nerves and vessels in company with the sciatic nerve pass through the infrapiriform foramen.

The most pronounced deficit in the pelvic diaphragm is situated anteriorly, where an aperture must allow the urogenital structures to pass out of the pelvis. This area is reinforced by the urogenital diaphragm, a structure primarily consisting of the superficial and deep transverse perineal muscles. The deep transverse perineal muscle is enclosed by a weak superior fascia and a sturdier inferior perineal fascia. The urogenital diaphragm recently has been shown to be more funnel shaped than sandwichlike, as previously

depicted in many atlases. The urogenital diaphragm exists only in humans because the human pelvic outlet faces inferiorly, unlike that of quadrupeds.

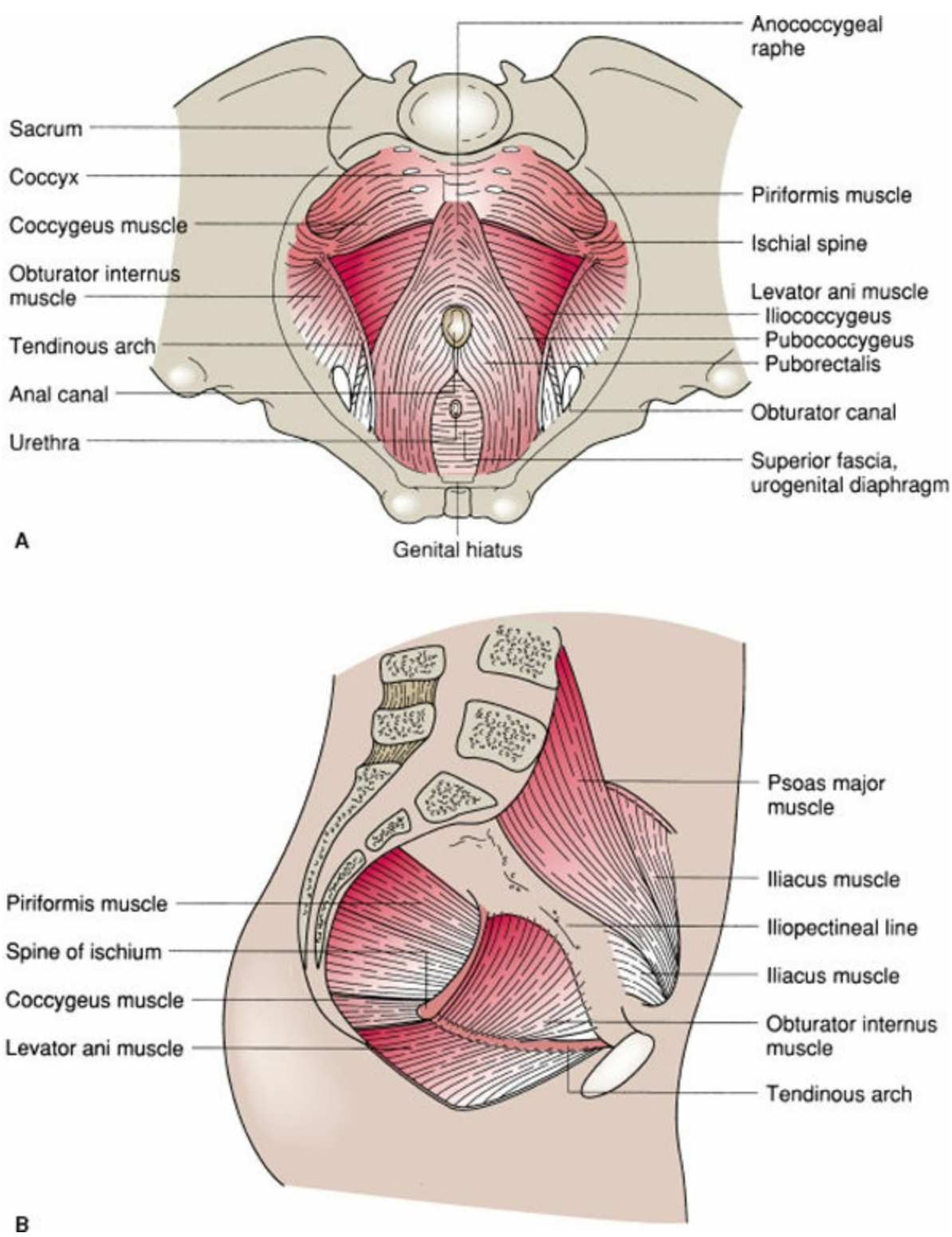

Figure 72-16. **A:** The pelvic diaphragm (levator ani and the piriformis) and the urogenital diaphragm viewed from within the pelvis. **B:** Hemisection of the pelvis revealing the levator ani, piriformis, obturator internus, and psoas muscles.

WHY DO HUMAN BEINGS DEVELOP ABDOMINAL WALL HERNIAS?

2 The most common hernias develop at sites where the abdominal wall has natural openings such as the internal inguinal ring, the umbilicus, and the esophageal hiatus. Previous surgical entry sites (incisional hernia) are also common areas where hernias develop. Factors that increase the pressure in the abdominal cavity, such as obesity, heavy lifting, coughing with chronic lung disease, straining during a bowel movement or urination (prostatism), chronic lung disease, and ascites, have traditionally been considered important in the etiology, especially at these natural openings. Developmental phenomena also play a role. For example, in the evolution from a quadruped to a biped, the unprotected groin is more vulnerable to changes in intra-abdominal pressure, predisposing to inguinal herniation. Major risk factors for the development of an abdominal wall hernias include chronic obstructive pulmonary disease, smoking, high intra-abdominal pressure, collagen vascular disease, thoracic or abdominal aortic aneurysm, peritoneal dialysis, matrix metalloproteinase (MMP) abnormalities, and an increased type I: type III collagen ratio.

The role of heavy lifting, especially a single strenuous event, is an unsettled question and has considerable medical–legal ramifications. There is minimal evidence that vigorous abdominal wall activity is an independent risk factor for abdominal wall hernia development despite the overwhelming opinion to the contrary in the lay literature.[19–21] In a systematic review of existing evidence performed by Svendsen and colleagues, regarding the effects of occupational and mechanical exposures in relation to inguinal hernias, a causal relationship could not be established between specific mechanical insults and occurrence of inguinal hernia, hernia recurrence, and persistent pain after inguinal hernia repair.[22,23] According to the results of another register-based male cohort study in Denmark, increasing cumulative exposure to daily lifting activities and prolonged standing or walking at work was associated with an increased risk of having an indirect inguinal hernia repair.[22,23] The authors hypothesized that patent processus vaginalis may be more susceptible to changes in intra-abdominal pressures, whereas in a direct hernia, other mechanisms may be involved in connective tissue degradation and weakening of the transversalis fascia. Still, the role of mechanical activity in the development of abdominal wall hernia is not completely clear, and further research is needed to determine if inguinal hernias can be prevented and if the postoperative prognosis can be improved by reducing occupational mechanical exposures.

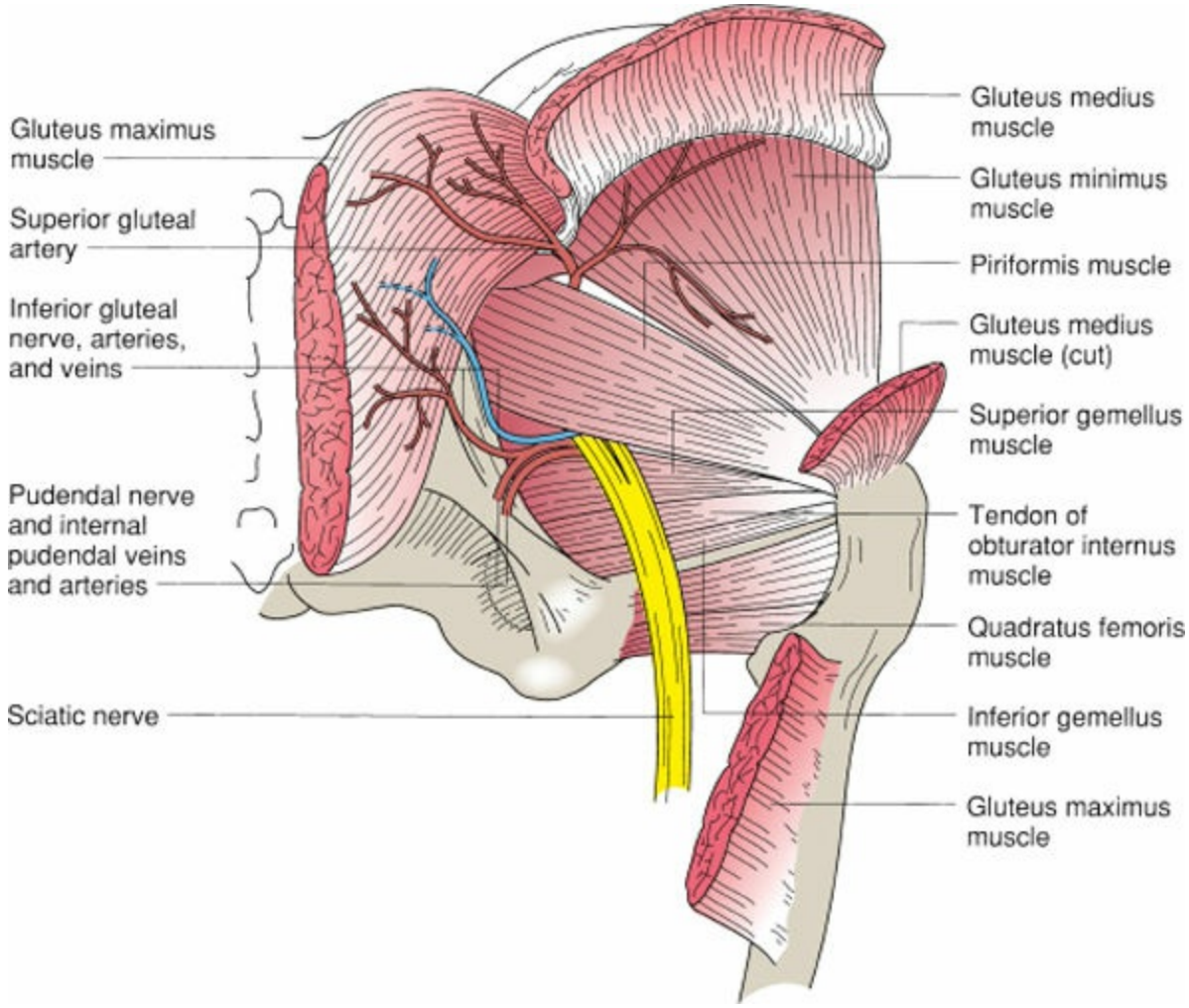

Figure 72-17. The gluteal muscles and lateral rotators of the hip. External relations of the sciatic foramen are also evident.

Familial predisposition and the role of connective tissue diseases in hernia development have received considerable attention in recent years. Particularly important for inguinal hernia is a family history as it has been reported to increase the risk up to 8 times.[24,25] Various connective tissue disorders, such as osteogenesis imperfecta, Marfan syndrome, Ehlers–Danlos syndrome, and congenital hip dislocation, are associated with hernias. Imbalances in collagen, the basic building block of the abdominal wall, are believed to contribute to hernia disease. While type I collagen confers predominantly tensile strength, type III collagen consists of thinner fibers and is regarded as a temporary matrix during tissue remodeling. A decreased ratio of type I to type III collagens can be detected in fascial and skin specimens obtained from patients with hernias. A similar phenomenon was discovered by Cannon and Read in smokers when they performed biopsies of the rectus sheaths from adult smokers with inguinal hernias and coined the term “metastatic emphysema.”[26] The investigators also demonstrated significantly greater levels of circulating serum elastolytic activity in patients who smoke.

Aside from primary defects in collagen synthesis, the imbalances in collagen in patients with hernia can be attributed to altered extracellular matrix (ECM) which is maintained in a dynamic balance of synthesis and degradation by a complex set of enzymes. MMPs,[27] which are a group of 23 structurally related zinc-dependent enzymes, protease with

collagenolytic activity and have a pivotal role in the integrity and composition of the ECM.

The association between MMP overexpression and abdominal wall hernia was initially demonstrated by Bellon and colleagues, who studied the expression of MMP-1 and MMP-2 in the transversalis fascia of patients with direct and indirect inguinal hernia. Since then, several studies have been conducted, aiming at elucidating the role of MMPs in the development of primary and recurrent abdominal wall hernias. For this purpose, MMP levels in fascia, skin, hernia sac, and blood specimens of patients with inguinal, incisional, and recurrent abdominal wall hernias have been measured. The expression of MMP mRNA in cultured fibroblasts has also been investigated to evaluate cell–cell and cell–matrix interactive mechanisms as causative factors for abnormal MMP production. In addition to this, in-vitro studies have been performed to study the effect of different mesh materials on MMP expression on cultured fibroblasts; in one such study, polypropylene has been shown to induce less MMP2 expression than polygalactin. The function of MMPs is further regulated by a variety of endogenous regulators, the most important ones are known as tissue inhibitors of MMPs (TIMPs).[28–30] Studies have shown that an imbalance between MMP and TIMP activity may have a role pathogenesis of abdominal wall hernias.[31]

Despite the increasing knowledge regarding MMPs in incisional and inguinal hernia, the exact role of MMPs in the pathogenesis of hernia formation remains unclear. Most studies are small and not completely controlled; and there is a remarkable heterogeneity among studies concerning the characteristics of the study populations, the examined tissue specimens, and the biochemical assays used. In addition to MMP and TIMPs, factors that have been implicated in hernia development include deficiency of the elastic fiber system of the transversalis fascia, decreased tropoelastin and lysyl oxidase-like 1 synthesis, elastase overexpression and TGF-beta1 overexpression. It remains unclear whether these alterations in hernia patients are a part of the “cause or effect” phenomenon. Another interesting area of research are drug classes that can suppress MMP expression (e.g., tetracyclines, especially doxycycline, aspirin, statins, and thiazolidinediones) and understanding their role in hernia prevention and treatment.[32]

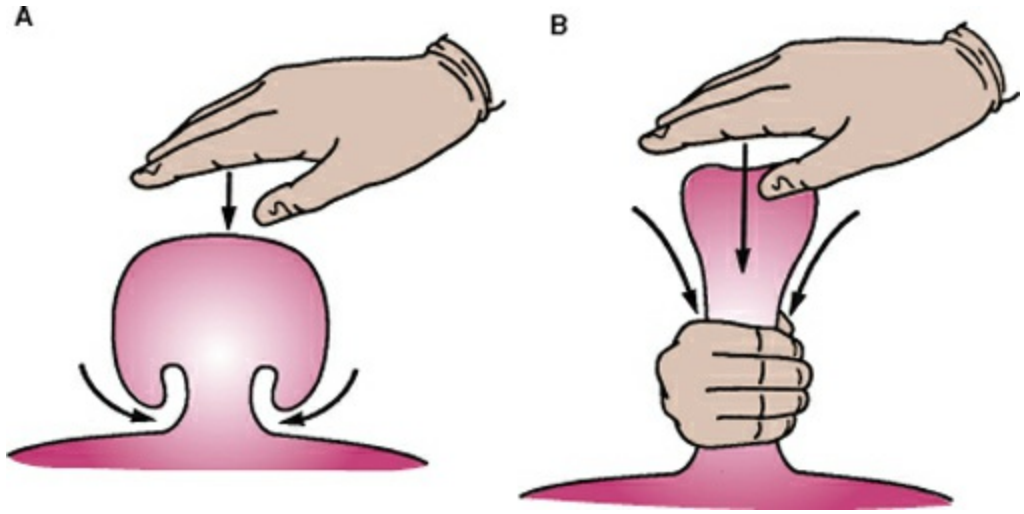

Figure 72-18. Reduction of a hernia by taxis. **A:** Applying pressure on the hernia directly occludes the neck. **B:** Elongating the neck of the hernia while applying pressure allows reduction.

COMPLICATIONS OF HERNIAS

Hernia Accident

For years, surgeons have been taught that all hernias should be repaired at diagnosis to prevent a hernia accident, which is defined as a bowel obstruction or incarceration with strangulation, because of the perception that patients presenting with these complications have an unacceptable increase in mortality. This thinking, however, has not stood up when tested in randomized controlled trials. For example, for men with asymptomatic inguinal hernias, randomized controlled trials have shown that a strategy of watchful waiting is safe.[33]

Incarceration

Incarcerated means “trapped” or “imprisoned.” Clinically, an incarcerated hernia is an irreducible hernia. An incarceration is not in and of itself a surgical emergency. Many hernias are chronically incarcerated due to adhesions of contents (e.g., omentum, bowel, ovary, etc.) to the hernia sac. The hernia itself is not necessarily tense to palpation, and the overlying skin appears normal. Normal bowel sounds may be heard within the hernia. It is important to differentiate an incarcerated hernia from a hydrocele of the cord. One can get above the hydrocele with the examining fingers. One cannot get above a hernia, however, as it communicates with the abdominal cavity. Hydroceles will transilluminate clearly, but a hernia will not.

An acutely incarcerated, painful hernia must be managed carefully. An attempt at reduction is reasonable unless there are signs of strangulation, which is not always obvious by clinical examination. Immediate surgical exploration is the safest approach when the diagnosis is not clear. The advantage of reduction followed by elective repair is that edematous tissue associated with an acute incarceration can return to normal, which presumably will translate into a better repair with less chance of infection.[34] If an attempt at reduction seems reasonable, the patient is sedated and placed in bed. The Trendelenburg position should facilitate reduction of a groin hernia. An attempt should be made at the initial examination to reduce the hernia. The maneuver of taxis entails grasping the neck of the hernia with the fingers of one hand and then applying intermittent pressure on the most distal part of the hernia with the other hand. Taxis has the effect of elongating the neck of the hernia so that the contents of the hernia may be guided through this area back into the abdominal cavity with a rocking movement. Mere pressure on the most distal part of the hernia causes bulging of the hernial sac around the neck, which can occlude the neck and prevent it from being reduced (Fig. 72-18). The maneuver of taxis should not be performed with excessive pressure or too vigorously. If the hernia is strangulated, gangrenous bowel might be reduced into the abdomen or perforated in the process. One or two gentle attempts should be made at taxis. If they are unsuccessful, this procedure should be abandoned. Rarely, the hernia together with its peritoneal sac and constricting neck may be reduced into the abdomen (reduction en masse). The patient would then have persistent obstruction after reduction of the hernia.

Intestinal Obstruction

One hundred years ago, the most common cause of intestinal obstruction was a hernia. At the present time, hernia is third, after adhesive obstructions and cancer. Hernia is an important cause of obstruction that is not infrequently missed on clinical examination. When a patient with an intestinal obstruction is examined, great emphasis should be placed on adequate exposure of the entire abdominal wall and groin area (from nipples to knees). Proper lighting is essential because previous scars can fade with time and become barely perceptible. The patient with intestinal obstruction as a result of a hernia will have a tense hernia that is irreducible. The abdomen itself will be distended, and high-pitched bowel sounds with frequent rushes will be heard. If the process continues to the complication of strangulation, these signs will disappear. Unlike adhesive small-bowel obstructions, partial small-bowel obstructions secondary to hernia are rare. Most patients will have had vomiting and obstipation.

A plain roentgenogram of the abdomen will reveal the signs of an intestinal obstruction – dilated loops of bowel with air–fluid levels and no bowel gas distal to the obstruction. Frequently on a plain roentgenogram, one can see bowel shadows in the region of the hernia. A lateral view is often useful to demonstrate this feature more clearly. Contrast studies are not usually necessary in this instance. Computed tomography (CT) reliably demonstrates the hernia with characteristic features of obstruction and should be considered if the clinical diagnosis is not certain (Fig. 72-19) because a distal intestinal obstruction secondary to another cause (e.g., adhesions) may result in significant distention of a coincidental nonobstructing hernia of the abdominal wall. Should the examiner focus attention exclusively on the hernia, the real cause of the obstruction may be missed when the hernia is repaired.



Figure 72-19. Computed tomogram showing a left-sided inguinal hernia.

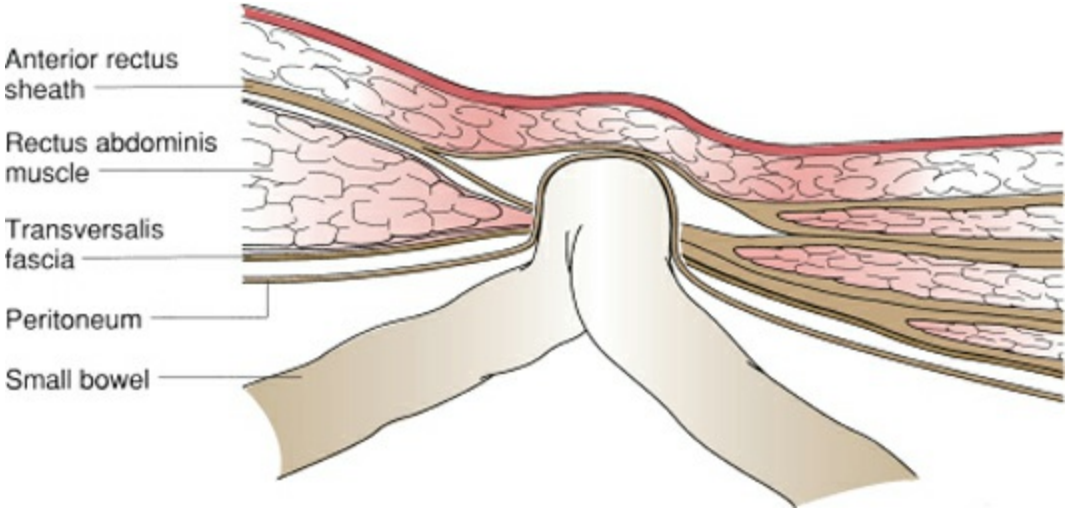

Figure 72-20. Richter hernia. Part of the bowel wall herniates through the defect in the abdominal wall.

The next steps in management include resuscitation followed by urgent surgery. At surgery, an approach directly over the hernia is used. In all patients, the entire gastrointestinal tract must be assessed to eliminate causes of obstruction other than the hernia itself. This is done before the hernia is repaired. The bowel, if viable, is reduced into the abdomen. If difficulty is encountered in reducing the hernia, the neck of the hernia can be widened. In the case of an inguinal hernia, division of the neck with or without ligation and division of the inferior epigastric vessels is safe, and the hernia contents can be reduced into the abdomen. In the case of a femoral hernia, the inguinal ligament can be split anteriorly and the hernia contents reduced into the abdomen. If the bowel is nonviable, then a bowel resection can be performed with anastomosis. The hernia is then repaired.

Strangulation

Strangulation of a hernia is a serious and life-threatening condition in which the hernia contents become ischemic and nonviable. The pathogenesis of this condition involves intra-abdominal contents within the hernia sac. Straining may push more contents into the sac, and the tense sac then causes pressure at the neck. This pressure initially produces venous congestion, resulting in edema. Eventually, the pressure is so great that the arterial supply is obstructed and the contents become gangrenous.

When intestine is involved, in addition to having an irreducible hernia and intestinal obstruction, the patient is toxic, dehydrated, and febrile. Examination of the abdomen reveals the signs of an intestinal obstruction, with distention and increased bowel sounds. Absolute constipation and vomiting are other manifestations. The hernia itself is tense, irreducible, and very tender, and the overlying skin may be discolored with a reddish or bluish tinge. No bowel sounds are heard within the hernia itself. The patient commonly manifests a leukocytosis with a predominance of polymorphonuclear leukocytes. Blood gases may reveal metabolic acidosis.

Management of these patients requires urgent attention to detail. No attempt should be made to reduce the hernia. Rapid resuscitation should commence immediately, with nasogastric suction and replacement of fluids and electrolytes. The patient should be given antibiotics. Once the patient is resuscitated, urgent surgery commences to expose the hernia, open the sac, and assess the viability of the bowel. More bowel can be pulled into the hernia so that viable bowel can be transected and the gangrenous portion removed. An end-to-end anastomosis should be performed and the bowel then reduced into the abdominal cavity. The hernia is then repaired.

Richter Hernia

August Gottlieb Richter in 1785 described a hernia type that bears his name in which the antimesenteric border of the intestine protrudes into the hernia sac without involving the entire circumference of the intestine so that intestinal obstruction does not occur (Fig. 72-20). The most common site is the femoral ring (36% to 88%), followed by the inguinal canal (12% to 36%), and an abdominal wall incision (4% to 25%). Miscellaneous locations include umbilical, obturator, supravesical, Spigelian, triangle of Petit, sacral foramen, Morgagni, internal, and diaphragmatic.[35] The routine use of laparoscopy by general surgeons has resulted in an increased incidence at trocar sites such that most surgeons will repair the fascia for trocar sleeves greater than 5 mm. The surgical treatment is to expose the herniated bowel by opening the sac. The neck of the sac is enlarged to allow delivery of the bowel into the wound. Any areas of gangrene are excised and the bowel wall reconstituted. The hernia is then repaired.

Prosthetic Materials

The development of a wide variety of materials for abdominal wall reconstruction makes it possible to individualize the selection of prostheses so that they can be used in almost all clinical situations. Currently available prosthetic materials can be divided into synthetic or biologic depending on their source. The synthetic prostheses can be further classified as noncomposite heavyweight plastic, noncomposite heavyweight membrane, noncomposite lightweight plastic, composite, and coated prosthesis. Although surgeons use the term mesh to refer to all varieties of hernia prostheses, this is inaccurate as only prostheses that have large grossly visible interstices should be termed meshes. Microporous material such as expanded polytetrafluoroethylene (ePTFE) have no visible interstices, do not promote ingrowth as with the mesh prosthesis, and act more like a membrane. In the absence of infection, synthetic material is preferred to biologic prostheses. The materials that have the longest track record for routine use in hernia surgery include polyester, polypropylene, either monofilament (Marlex, Prolene) or polyfilament (Surgipro); Dacron (Mersilene); and ePTFE (Gore-Tex). Synthetic materials such as polypropylene or polyester work by inciting an intense fibroplastic response to form a strong scar plate interface. Because of this response, they should not be used adjacent to the viscera because of the propensity of these materials to erode into intra-abdominal organs, most commonly intestine, resulting in fistulization. The weight of the polypropylene or polyester meshes, as well as the size of the pores, is a controversial issue currently. As an example, a 7.5- × 15-cm polypropylene mesh (Prolene, Ethicon, Inc.) contains about 80 g/m^2 of polypropylene, while a polypropylene–poliglecaprone-25 (Monocryl) lightweight mesh of the same size (UltraPro, Ethicon, Inc.) contains less than 30 g/m^2. One of the ways of reducing the amount of nonabsorbable material in a mesh is to increase the size of the pores. Many authorities believe that the inflammatory response incited by the small-pore, heavyweight plastic meshes can lead to chronic pain; a sensation of being able to feel the mesh; increased stiffness of the abdominal wall with loss of compliance; and shrinkage, which can lead to recurrence. There is increasing

evidence that decreasing the density of polypropylene and increasing the size of the pores reduces this foreign body response, resulting in less long-term pain than normal mesh with a similar recurrence rate.[36–39] Recently, there have been reports of "burst mesh" or central mesh failures with the use of lightweight mesh in the repair of large ventral hernias and thus, one should exercise caution while employing them in repair of massive hernias.[40]

Table 72-2 Classification and Examples of Prosthetic Materials Currently Available for Hernia Repair

Noncomposite						
Heavyweight Plastic	**Heavyweight Membrane**	**Lightweight Plastic**	**Composite**	**Coated**	**Absorbable**	**Biologic**
Ethicon Prolene™ Mesh (PPL)	Gore Soft Tissue Patch™ (ePTFE)	Ethicon Ultrapro™ (PPL + poliglecaprone 25)	Bard Composix™ EX & LP (Polypropylene + ePTFE)	Atrium c-Qur™ (PPL + Omega-3-fatty acid)	Phasix™ Mesh (Poly-4-Hydroxybutyrate P4HB)	Alloderm™ (Cadaveric Human skin)
Dacron™ Polyester mesh	Gore Mycromesh™ (ePTFE)	Atrium Prolite ultra™	Bard Ventralex™ (PPL + ePTFE + PPL tail)	Symbotex™ Composite Mesh Covidien monofilament polyester (PET) A bioabsorbable collagen film	TIGR™ Mesh	Strattice™ Porcine acellular dermal matrix
Prolene hernia system (PHS)™ Ethicon (PPL)	GoreTex™ (ePTFE)	Parietex™ Lightweight (Polyester)	Bard Kugel™ Hernia Patch (PPL + ePTFE + PPL ring)	Gore DualMesh™ Plus (ePTFE + silver + chlorhexidine)	BioA™ Mesh	Surgisis™ Porcine submucosa
Ethicon Prolene™ soft Mesh (PPL)	Gore Infinit™ mesh (knitted PTFE)		Ethicon Physiomesh™ Flexible Composite Mesh	Bard Sepramesh™ (PPL + hydrogel barrier)	VICRYL™ (polyglactin 910) Woven Mesh	AlloMax™ Human collagen matrix
PROLENE™ 3D Patch PPL Mesh	Bard Dulex™ mesh			VENTRALIGHT™ ST Mesh Lightweight PPL + hydrogel barrier		Permacol Porcine dermal matrix
Covidien Surgipro™ Flat Sheet Mesh (PPL)				Ethicon Proceed™ (PPL + PDS + ORC)		PeriGuard™ Bovine pericardium with glutaraldehyde
Marlex™ (PPL)				Covidien Parietene™ (PPL + hydrophilic collagen) Covidien Parietex™ (POL + hydrophilic collagen) Bard Ventrio™ ST patch (PPL + hydrogel barrier) Parietex™ Optimized Composite (PCOx) Mesh (Polyester + Collagen)		Veritas™ Bovine pericardium FlexHD™ Human allograft skin SurgiMend™ Fetal bovine dermal collagen

When contact of mesh with viscera cannot be avoided, either a nonmesh material such as ePTFE alone or a dual-layered prosthesis with a standard plastic mesh on the side facing the abdominal wall and ePTFE facing the viscera should be used. Because ePTFE heals by encapsulation rather than incorporation as with the mesh prostheses, it does not have the propensity to erode or fistulize which makes it suitable for use adjacent to abdominal viscera. This lack of incorporation has a downside in terms of increased susceptibility of ePTFE to infection, and when these do get infected, they almost always have to be removed. On the other hand, the incorporated mesh materials such as polypropylene can commonly be salvaged when infected. To address this issue, manufacturers have developed temporary or biodegradable adhesion barrier materials to coat the mesh on the side facing the viscera to prevent adhesions without the need for ePTFE (Table 72-2). The injured peritoneum forms a mesothelial layer as quickly as 5 to 7 days with the adhesion barrier products being degraded over the course of an average

of 30 (range 28 to 240) days.[41] Neither the adhesion barriers nor ePTFE can completely eliminate adhesions. Patients who undergo laparotomy after either type of prosthesis has been placed intra-abdominally are routinely found to have significant adhesions to the device. However, these adhesions tend to be filmy and easily taken down. It remains to be seen if the long-term performance of coated prostheses compares to ePTFE with its long track record.

The role of biologic tissue matrix in ventral hernia repair has evolved over the last few years. These materials are derived from human, porcine, or fetal bovine skin; porcine small intestine submucosa; and bovine pericardium and are processed to remove hair, cells, and cell components as well as other antigens present in the matrix, leaving only the highly organized collagen architecture with the surrounding extracellular ground tissue.[32] The matrix acts as a scaffold to allow native tissue and neovascularization to infiltrate the healing wound and promote strong tissue in-growth that limits contraction. These properties, theoretically, lead to increased resistance to infection. Some biologics undergo further processing to increase the crosslinking between collagen fibers and to decrease susceptibility to degradation by collagenase. In general, these materials possess the physical and mechanical characteristics of a clinically acceptable surgical mesh in that have sufficient mechanical strength to withstand the physiologic and anatomic stresses of the abdominal wall.[42–44]

Because of the properties mentioned above, it is felt by some surgeons that the best indication for biologic prostheses is in contaminated wounds, where a synthetic prosthesis may be contraindicated. They are not useful in grossly infected wounds presumably because of the high collagenase content present, which destroys them. It should be noted that none of the biologic prostheses are regulated by the U.S. Food and Drug Administration (FDA) as a medical device and are typically approved under a 510 (K) approval process which is primarily based on safety. These materials were introduced into clinical practice and used in contaminated fields without prior FDA approval or clearance for this indication.[45] Another major argument against them is their expense, as they generally cost 20 to 30 times that of the plastic prostheses. The majority of evidence for the use of biologic prostheses for hernia repair is based on retrospective studies and mostly in clean procedures. Pooled results from 635 patients treated with three different biologic materials have revealed a recurrence rate of up to 18% to 30% at 2 years with biologic prostheses.[43,45] Retrospective study with long-term follow-up (>5 years) with the use of porcine acellular dermal matrix for repair of incisional hernias *at risk for infection* showed a recurrence rate of 20% and 53% when used as an onlay or intraperitoneal sublay technique compared to 80% when used as a bridge in either inlay or sublay position, with particularly high recurrence rates seen in contaminated (71%) and grossly infected (100%) wounds.[46] Although these materials allow a single stage repair of hernias in a contaminated field, with no or little need for mesh removal in case of subsequent wound infection, the high rate of recurrence with the use of biologics, especially in contaminated fields, remains a concern.

A major factor in the popularity of biologic materials for hernia repair is reluctance among many surgeons regarding the use of synthetic mesh in clean-contaminated and

contaminated fields, although currently available evidence does not support this view. A retrospective review evaluating lightweight polypropylene mesh placed in a sublay position, in clean-contaminated and contaminated cases revealed a 14% surgical site infection rate (7.1% for clean-contaminated and 34% for contaminated cases) and a 7% recurrence rate at a mean follow-up of 10 months.[47] Results from this and other similar experiences challenge the surgical dictum contraindicated in a contaminated surgical field. Even when infectious complications occur, synthetic macroporous mesh materials can often be salvaged without the need for removal.

Another interesting area of research is development of novel materials which integrate the desirable qualities of both biologic and synthetic mesh materials. Examples of such materials include Phasix® mesh (Davol, Warwick RI) which is a long-term resorbable mesh composed of monofilament poly-4-hydroxybutyrate, TIGR Matrix Surgical Mesh® (Novus Scientific) which is composed of fast and slow degrading synthetic reabsorbable fibers (Glycolide, lactide and trimethylene carbonate). These materials are gradually reabsorbed by the body in a predictable fashion. Preclinical in vivo and in vitro studies have shown favorable results with these materials, and further clinical evaluation with these materials is currently underway.[48] Fast absorbable prostheses such as polyglactin are not durable and almost never result in long-term correction of an abdominal wall defect but are sometimes useful as a temporary substitute when a nonabsorbable prosthesis is contraindicated (i.e., a grossly infected wound).

GROIN HERNIAS

Groin hernias are described as inguinal and femoral, the inguinal hernias being further subdivided into direct and indirect hernias (some authorities refer to these as medial and lateral hernias, respectively). Groin hernias may be primary or recurrent. An indirect hernia occurs as a protrusion of abdominal contents through the internal ring, lateral to the inferior epigastric vessels, into the inguinal canal. Indirect inguinal hernias (lateral hernias) are situated within the spermatic cord and therefore may extend into the scrotum. In female patients, the hernia follows the round ligament and may present as a swelling in the labium. A direct hernia (medial hernia) is a protrusion through the triangle of Hesselbach medial to the inferior epigastric vessels. These hernias develop through an area where the endoabdominal fascia is not protected by overlying muscle. Direct hernias do not usually involve the cord, as they tend to protrude forward. However, they occasionally track alongside the cord down the entire length of the inguinal canal and even enter the scrotum. For this reason, the only absolute distinction between a direct and an indirect hernia is the relationship to the inferior epigastric vessels. Inguinal hernias are more common in men (with a 15% lifetime risk among men aged >25 years) with a male to female age-adjusted ratio of 7.5:1.[49] A femoral hernia protrudes through the femoral canal, which is bordered by the inguinal ligament superiorly, the pubic ramus medially and inferiorly, and the femoral vein laterally. This hernia presents below the inguinal ligament (Fig. 72-21). In a sliding hernia, part of the sac is formed by the viscera, on the left side the sigmoid colon or bladder, and on the right side the cecum or bladder (Fig. 72-22).

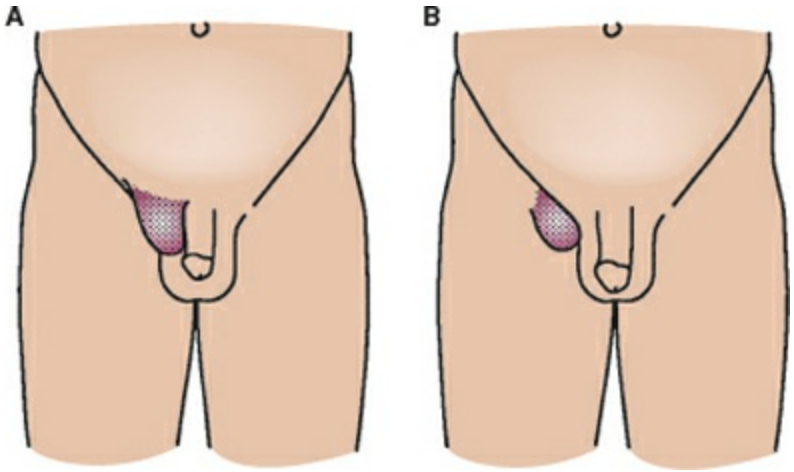

Figure 72-21. **A:** Inguinal hernia. This presents above the inguinal ligament and extends below it. **B:** Femoral hernia. This presents below the inguinal ligament.

Epidemiology

1. Inguinal hernias occur in persons of all ages, from the neonate to the elderly. Inguinal hernias constitute approximately 75% of abdominal wall hernias, with femoral hernia accounting for 5%. Femoral hernias are more common in women, but a woman with a groin hernia is still five times more likely to have an inguinal hernia (usually indirect) than a femoral. Incisional, umbilical, and epigastric hernias account for 15% and miscellaneous hernias make up the other 5%. The lifetime risk of developing a groin hernia is approximately 25% in males and 5% in females. Inguinal hernias are more common on the right than the left and are 10 times more likely in males than in females.[50] Indirect inguinal hernias are twice as common as direct hernias. The reported prevalence of inguinal hernia in the general population varies widely in the literature primarily due to a lack of a consistent reporting mechanism; for example, questionnaire versus actual physical examination. The most reliable data use hernia repair as a surrogate for the prevalence.[51] For example, in a study using the Danish Hospital registry, the country's population of 5,639,885 people was studied. There were 46,717 groin hernia repairs reported between 2005 and 2010 making it possible to estimate prevalence for various age groups as shown in (Fig. 72-23).

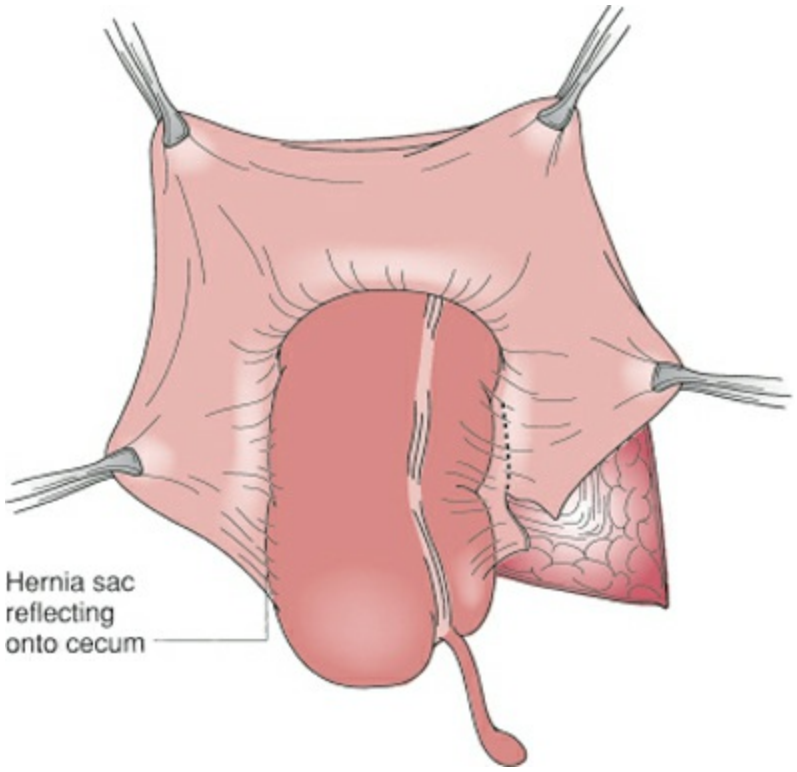

Figure 72-22. Sliding hernia (right indirect inguinal).

2. The figure confirms a bimodal incidence pattern peaking at the extremes of life with an initial peak at 0 to 5 years followed by a second peak at 70 to 80 years.[51] Right-sided inguinal hernias are more common than left. In men, indirect inguinal hernias outnumber direct by about 2:1, with femoral hernias making up a much smaller proportion. The literature dealing with groin hernia in women is insufficient making

management decisions difficult. For females, indirect inguinal hernias are the most common which are five times more common than femoral hernias, with direct hernias occurring rarely. Overall, femoral hernias account for fewer than 10% of all groin hernias and the prevalence is higher in females than in males. Femoral hernias are especially dangerous as 40% of all femoral hernias present as emergencies, with incarceration or strangulation and need emergency repair which is associated with high mortality. A study from the Swedish Hernia Registry analyzing 90,648 inguinal hernia operations (83,753 males, 6,895 females) between 1992 and 2003 revealed a higher percentage of emergency operations in women (16.9%) than in men (5%).[52] Femoral recurrences are particularly common in women in whom the diagnosis at the time of the primary repair was a direct inguinal hernia, strongly suggesting a missed femoral hernia at the original procedure since direct hernias are very rare in women. Femoral hernias are also more common in older patients and in those who have previously undergone inguinal hernia repair. Risk factors for the development of an inguinal hernia are listed in Table 72-3.

Classification

The primary purpose of a classification system for any disease is to stratify for severity so that reasonable comparisons can be made between various treatment strategies.[53] However, with the multiplicity of operative techniques and approaches for repair of groin hernias, no one classification system has been accepted by all practitioners. The reason why it is so difficult to develop a classification system that all surgeons can agree on is that in the final analysis, the physical examination represents an important component and no one has been able to eliminate its subjectivity. The European Hernia Society, Nyhus, Gilbert, Schumpelick, Harkins, Casten, Halverson and McVay, Lichtenstein, Bendavid, Stoppa, Alexandre, and Zollinger have developed groin hernia classification systems. The European Hernia Society classification is a simple system using three variables, location (M = medial, L = lateral, and F = femoral) and size of the defect (1 [≤1 finger], 2 [1 to 2 fingers], and 3 [≥3 fingers]) and status (P = primary, R = recurrent, and X = unknown) (Table 72-4).[54] This system and the Nyhus system, which is detailed in Table 72-5, are widely used by hernia surgeons.

Table 72-3 Risk Factors for the Development of an Inguinal Hernia

Male sex
Increased age
COPD
Smoking
Low body mass index
High intra-abdominal pressure
Collagen vascular disease
History of abdominal aortic aneurysm
History of thoracic aortic aneurysm
Patent processus vaginalis
History of an open appendectomy
Peritoneal dialysis
Family history

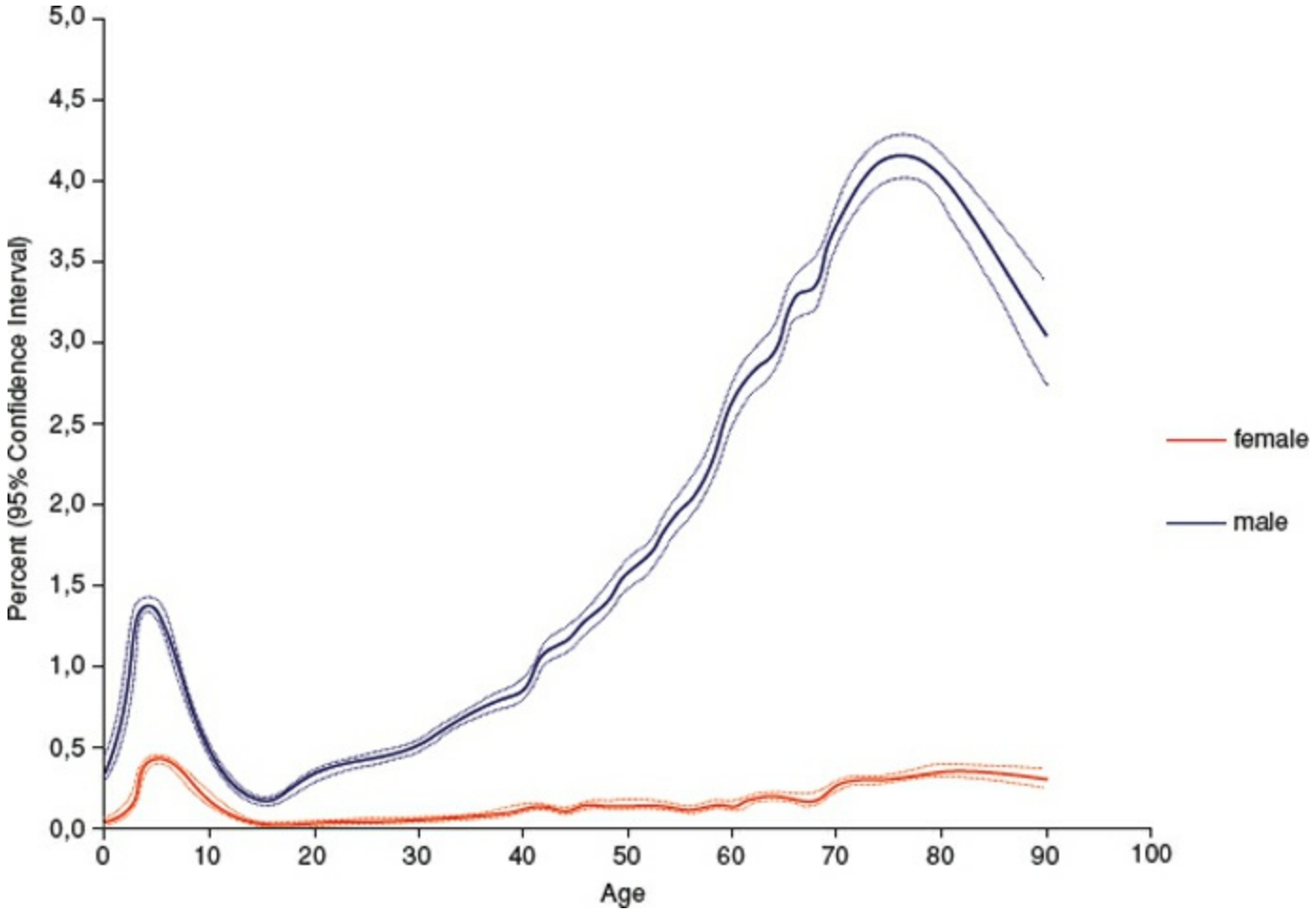

Figure 72-23. Prevalence of combined inguinal and femoral hernia repair (i.e., all groin hernias), stratified by age and gender. The results indicate the percentage of persons at a given age in the population who were operated for a groin hernia during the study period. Example: 4.19% CI 4.04% to 4.34% of all males aged 75 to 80 years in Denmark were operated for a groin hernia at least once during the study period. From Burcharth J, Pedersen M, Bisgaard T, et al. Nationwide prevalence of groin hernia repair. *PLoS One* 2013;8(1):e54367, with permission.

Clinical Diagnosis

Groin hernias present with a swelling that has a cough impulse. With indirect hernias, the swelling may extend down into the scrotum. The swelling reduces when the patient lies down. Sometimes, the hernia does not reduce easily and the patient has to reduce it manually. Applying pressure over the midinguinal point (midway between the anterior superior iliac spine and the pubic tubercle and just above the inguinal ligament) with the fingertip will control an indirect hernia and prevent it from protruding when the patient strains. A direct hernia will not be controlled with this maneuver. Similarly, if the scrotum is invaginated with the index finger and the tip of the finger is placed through the external inguinal ring into the canal, and the patient is then asked to strain, an indirect hernia will push against the fingertip, whereas a direct hernia will push against the pulp of the finger. It should be noted that the accuracy of this clinical assessment is questioned by many authorities. A femoral hernia presents as a swelling below the inguinal ligament and just lateral to the pubic tubercle (Fig. 72-21).

Table 72-4 EHS Classification of Groin Hernias

EHS Groin Hernia	Primary (P)			Recurrent (R)	
	0	1	2	3	x
Lateral (L)					
Medial (M)					
Femoral (F)					

Table 72-5 Nyhus Classification of Groin Hernias

Type	Description
I	Indirect hernia Normal-sized internal ring Typically in infants, children, small adults
II	Indirect hernia Dilated internal ring Posterior wall intact Inferior epigastric vessels not displaced Does not extend to the scrotum
III	Posterior wall defect
IIIA	Direct hernia Size not taken into account
IIIB	Indirect hernia Dilated internal ring encroaching on Hesselbach triangle (massive scrotal, sliding, or pantaloon type)
IIIC	Femoral hernia
IV	Recurrent hernia
IVA	Direct
IVB	Indirect
IVC	Femoral
IVD	Combined

Table 72-6 Differential Diagnosis of a Groin Hernia

Hydrocele
Encysted hydrocele of the cord
Varicocele
Epididymo-orchitis
Torsion of the testis
Undescended testis
Ectopic testis
Testicular tumor
Pseudohernia
Femoral artery aneurysm
Saphena varix
Lipoma of spermatic cord
Inguinal lymphadenopathy
Psoas abscess
Cutaneous lesions (e.g., sebaceous cyst and skin tumor)

Differential Diagnosis

The clinical presentation of a groin hernia, especially when large, is frequently obvious to the examiner. Smaller hernias and recurrent hernias can be confused with a number of different conditions that can be mistaken for a hernia (Table 72-6).

A hydrocele extending into the scrotum or an encysted hydrocele of the cord can involve the groin area. The distinguishing features are that the examining hand can get above a hydrocele but not above a hernia and that a hydrocele transilluminates very clearly. A varicocele does not transilluminate, has the characteristic feel of a "bag of worms," and is more tube-like in conformation. Lesions of the testicle may sometimes mimic a hernia, particularly in inflammatory conditions, such as epididymo-orchitis. The distinguishing features are intense pain extending down into the scrotum. The testicle itself is enlarged and tender, as is the epididymis. On rectal examination, the seminal vesicles are tender. This condition may be bilateral. Torsion of the testicle is distinguished by the fact that the testicle is absent from the scrotum and the swelling in the groin feels firm. A sonogram reveals a solid mass in the testicle, which has been pulled up because of the torsion. Testicular tumors, if large enough, may extend up to the groin area, but they have a solid feel and sonography can distinguish them.

Pseudohernia is a condition that occurs in patients with denervation of the abdominal wall musculature (e.g., after polio). The abdominal wall muscles bulge forward on straining and have the appearance of a hernia. An aneurysm of the femoral artery may present as a groin swelling but with an expansile impulse and sometimes a bruit. If thrombosis develops in the aneurysm, pulsation may be lost. In this instance, the aneurysm becomes tender. Femoral aneurysms move from side to side but not up and down. A saphena varix usually presents below the inguinal ligament and represents a varicosity of one of the branches of the long saphenous vein as it emerges from the hiatus. It is particularly common in pregnancy. Like a hernia, the varix has a cough impulse and becomes more prominent when the patient is standing. Compression over the femoral hiatus obliterates this lesion. The varix is sometimes associated with varicose veins farther down the lower limb. The overlying skin has an associated bluish discoloration. A lipoma within the spermatic cord is a very common condition and, from anatomic studies and surgical dissection, is now regarded as a hernia of the extraperitoneal fat.[55] If found at surgery, the lipoma is removed to avoid a persistent bulge in the inguinal region despite a successful hernia repair.

Enlargement of inguinal lymph nodes may also be mistaken for herniation. Inflammatory nodes are usually tender; metastatic lymphadenopathy is usually not tender. If inguinal lymph nodes are replaced by metastasis, a primary lesion should be looked for in the skin in any part of the lower limb. The perineum and anal canal should also be examined. Lymphadenopathy can also be caused by lymphoma, and groin nodes may be the only site. Lymphadenopathy characteristically appears as a well-circumscribed mass below the inguinal ligament that one can get above with the examining hand. Lymph nodes are solid on ultrasonography, and for this reason, it may be difficult to differentiate nodes from a femoral hernia containing omentum.

Surgical Indications

5 Historically, surgeons have recommended repair of inguinal hernias at diagnosis unless specific contraindications are present. This recommendation is based on the presumption that the morbidity and mortality associated with a bowel obstruction and/or strangulation is greater than the risks of operation. This concept was challenged for asymptomatic or minimally symptomatic patients based on two randomized controlled trials comparing a strategy of watchful waiting to routine repair for male inguinal hernia patients with minimal symptoms. In 2006, Fitzgibbons and colleagues randomized 724 patients to watchful waiting versus tension-free hernia repair from five North American Centers and found no difference in quality of life at 2 years and an acceptably low rate of hernia accidents (1.8 per 1,000 patient-years) in the watchful waiting group.[56] Similar results were determined in the other trial conducted in the United Kingdom.[57] It should be noted that long-term follow-up from these randomized controlled trials have demonstrated a crossover rate of up to 70% by 10 years for patients in the watchful waiting group, with crossover being much higher for patients older than 65 years of age.[58] The most common reason for crossover was increasing pain. Despite the high crossover rate, only 2.5% of the patients in the watchful waiting group developed incarceration for which they underwent surgery with no mortality. In summary, watchful waiting is a safe strategy for asymptomatic or minimally symptomatic hernias. However, patients who opt for this strategy should be informed that it is safe to delay surgery for several years, but increasing symptoms will more than likely make them choose to have their hernia repaired over the next 10 years.

An alternative to surgical repair is a mechanical device known as a truss which consists of a belt with a pad that is applied to the groin after spontaneous or manual reduction of a hernia and has been used for centuries. It serves to maintain reduction and possibly prevents enlargement of the hernia. There are insufficient studies to determine how effective trusses actually are and whether they are as good as surgery for the control of symptoms. Most patients find them cumbersome to use and difficult to keep clean. With prolonged usage, atrophy of the spermatic cord has been reported and eventual surgical repair is made more difficult due to fibrosis of the tissues. However, some patients do achieve symptomatic relief.

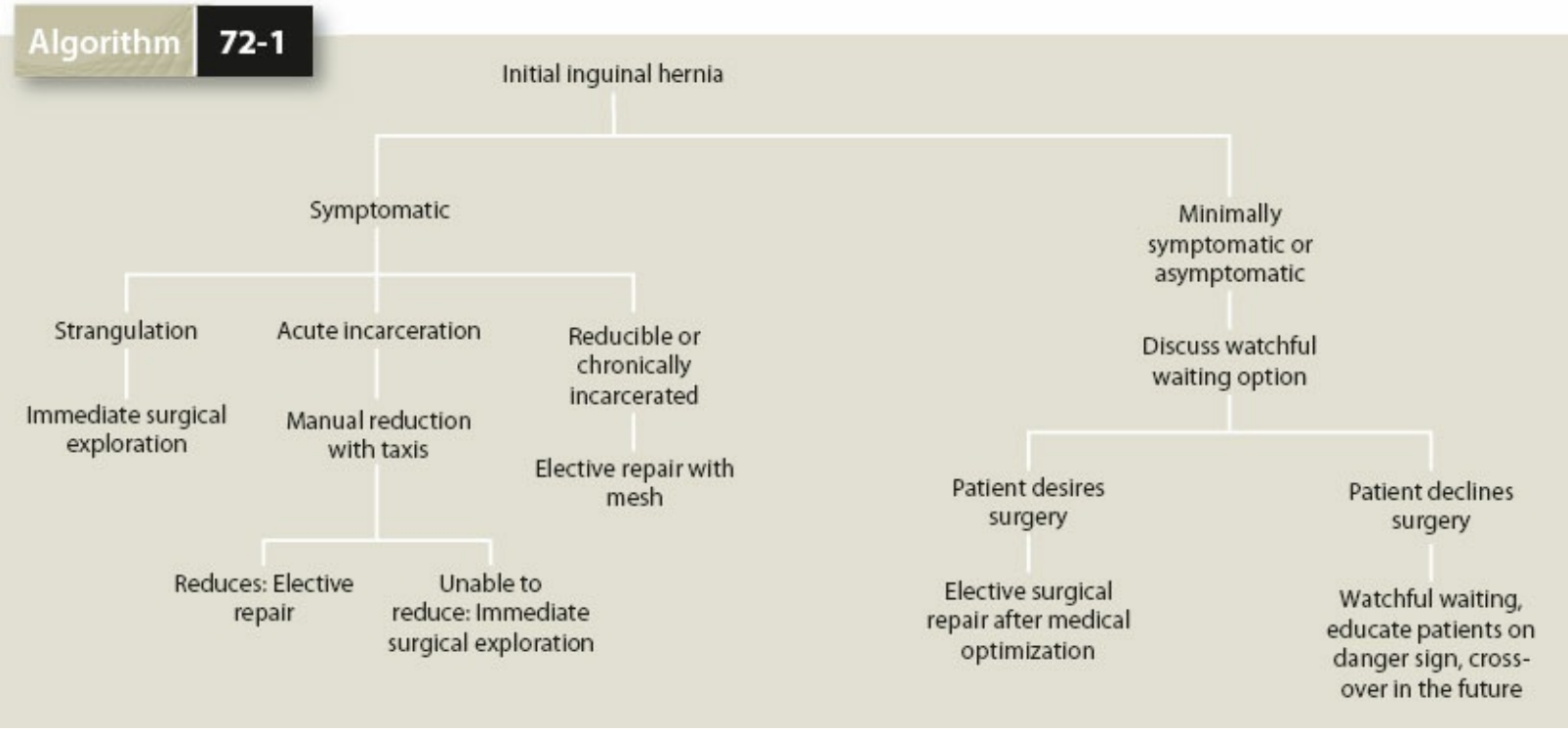

Algorithm 72-1. Management of initial inguinal hernia.

Preoperative Considerations

Most elective groin hernias can be repaired on outpatient basis. Local anesthesia is sufficient for most cases of open inguinal hernia repairs with or without supplemental intravenous sedation. Its greatest advantage is the virtual elimination of urinary retention when compared to regional or general anesthesia.[59] General anesthesia is an acceptable alternative and is preferred by many surgeons. Indeed, epidemiologic information from databases primarily in Europe disclose that local anesthesia is used in only about 10%.[60] Regional anesthesia has the highest incidence of cardiovascular complications and should be avoided.[61] Laparoscopic hernia repairs require general anesthesia and can only be performed in patients who can safely tolerate general anesthesia and a pneumoperitoneum. Antibiotic prophylaxis has not been shown to be of any value except in patients at high risk for infection.[62] Nevertheless, it is routinely used in the United States because of medicolegal considerations when placing prosthesis.

Surgical Treatment of Groin Hernias

6 Four developments in the latter half of the 20th century significantly decreased morbidity and favorably influenced the recurrence rate to the currently accepted level of less than 2%: (a) the routine use of prosthetic materials, (b) the widespread acceptance of the "tension-free" concept, (c) the realization that the preperitoneal space can be used for hernia repair, and (d) therapeutic laparoscopy (Algorithms 72-1 and 72-2). These concepts are discussed in this section; the treatment strategies are divided between an open approach in the conventional anterior space and a preperitoneal approach, either open or laparoscopic.

Open Approach

The simplest Nyhus type I indirect inguinal hernias, which include most inguinal hernias in children, are adequately treated by obliteration of the congenital patent processus vaginalis alone. Since the inguinal floor is otherwise normal, reconstruction is not required. Classically, the hernia sac is dissected from the cord structures, ligated, and removed at its origin at the internal ring, the so-called high ligation of the sac, thus the term *herniotomy*. The skin incision starts at the pubic tubercle and is extended laterally. The external oblique aponeurosis is opened in the line of its fibers through the external ring and the lower leaf is freed from the spermatic cord. The spermatic cord is freed from the floor of the inguinal canal and the pubic tubercle. Mobilization of the cord structures is completed by means of blunt dissection, and a Penrose drain is placed around them so that they can be retracted during the procedure.

The genital branch of the genitofemoral nerve and the spermatic vessels are included with the cord. The ilioinguinal and iliohypogastric nerves are usually preserved. The cremasteric fibers are separated, and the hernia sac is dissected from the cord structures to a point proximal to the internal ring. Ligation can be performed at this point (high ligation), followed by division of the neck of the sac. Prior to this, the sac can be opened to allow a digital examination of the abdominal cavity and femoral ring. Alternatively, the sac may be simply inverted. The proponents of not opening the sac feel that with this method the patient experiences less pain because the highly innervated peritoneum has not been violated.

The terms *herniorrhaphy* or *hernioplasty* are used when a procedure to reconstruct the inguinal floor is added. For indirect hernias, the sac is first dealt with in an identical manner as for a herniotomy. The only exception is large indirect inguinal scrotal hernias where complete removal of the sac might result in too high of an incidence of cord and testicular complications because of the extensive dissection required to completely separate them from the cord. Most authorities believe that these large sacs are best transected at the midpoint of the canal, and the distal sac is left in situ. Direct hernia sacs are almost never removed but instead are dissected from surrounding structures and reduced into the preperitoneal space. Dividing the transversalis fascia circumferentially at the neck (base) of the sac will aid in this reduction in some cases. The defect may be closed primarily at this point to maintain the reduction while a formal repair is being

performed. The latter is considered a matter of convenience and adds nothing to the strength of the final outcome. The area of weakness in the posterior wall is then reinforced with the patient's own tissues.



Algorithm 72-2. Management of recurrent inguinal hernia.

The next step is to reconstruct the inguinal floor. There are two ways to do this. The first is a tissue repair, so named because only the patient's native tissue is used without foreign prosthetic material. The second is the tension-free repair (TFR). This implies the use of a prosthesis to repair the weakened inguinal floor, eliminating the need to reapproximate tissues that were not in apposition naturally. Edoardo Bassini (1844–1924) is considered the father of modern inguinal hernia surgery because in the latter part of the 19th century he introduced the first tissue repair based on solid anatomic principles, which became the "gold standard" for inguinal hernia repair for most of the 20th century. His scientific approach led to the development of several distinct steps essential for the procedure (Table 72-7). Before Bassini's achievements, elective herniorrhaphy was almost never recommended because the results were so bad.

Table 72-7 Essential Steps for the Inguinal Hernia Repair

1. Complete division of the external oblique aponeurosis and the transversalis fascia
2. Differentiation between indirect and direct defects
3. Isolation of the spermatic cord
4. Ligation and removal of the sac at the deep inguinal ring flush with the peritoneum
5. Oblique reconstruction of the inguinal canal with an anterior and posterior wall and an internal and external ring

Today, there are at least 70 named tissue repairs described in the literature.[63] Most are relatively minor modifications of the Bassini, Shouldice, and McVay repairs and therefore, for the purposes of this chapter, only these will be presented. In the Bassini repair, the transversus abdominis aponeurosis together with the transversalis fascia is sutured to the shelving edge of the inguinal ligament with nonabsorbable interrupted sutures (Fig. 72-24). In the Shouldice repair, the transversalis fascia is divided from the internal ring to the pubic tubercle. The musculofascial elements laterally are then sutured to different levels of the inferior flap of the external oblique aponeurosis with four rows of running sutures (Fig. 72-25). Although the suture material originally used for this repair was stainless steel wire, other nonabsorbable materials, such as Prolene, are now used. The McVay repair (Fig. 72-26) addresses both inguinal and femoral hernias. The central attenuated portion of the inguinal floor is excised. The Cooper ligament must be clearly identified. The inguinal floor is then repaired by approximating the transversus abdominis aponeurosis and transversalis fascia to the Cooper ligament between the pubic tubercle and the femoral vein. A so-called transition stitch is then necessary between the transversalis fascia, Cooper ligament, and inguinal ligament to bring the repair above the femoral vessels. The repair is then continued laterally along the inguinal ligament.

A relaxing incision is necessary for repairs of large indirect hernias and whenever the McVay repair is used. Failure to make a relaxing incision has been implicated in a greater incidence of recurrence. The relaxing incision is made in the anterior rectus sheath in a vertical direction and is extended 3 to 4 cm above the pubis to a level opposite the internal ring (Fig. 72-26). The resulting defect in the sheath is protected posteriorly by the body of the rectus muscle, which prevents herniation at that site.

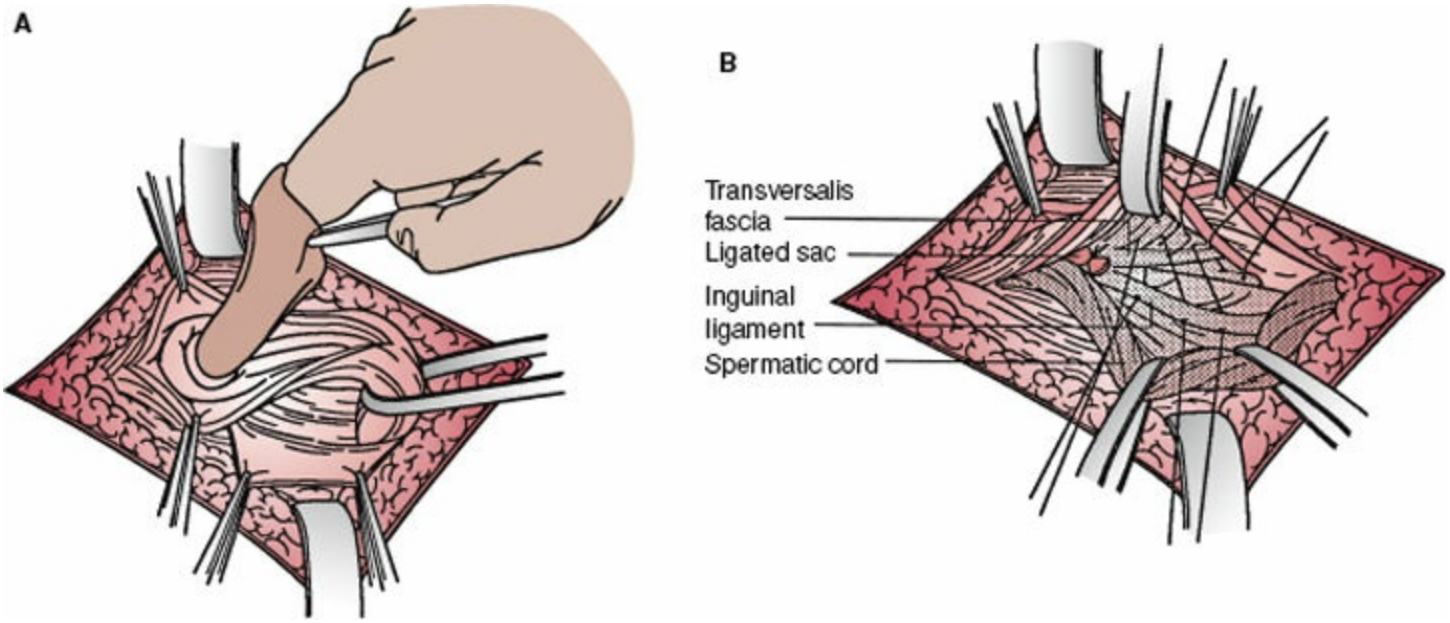

Figure 72-24. Bassini repair.

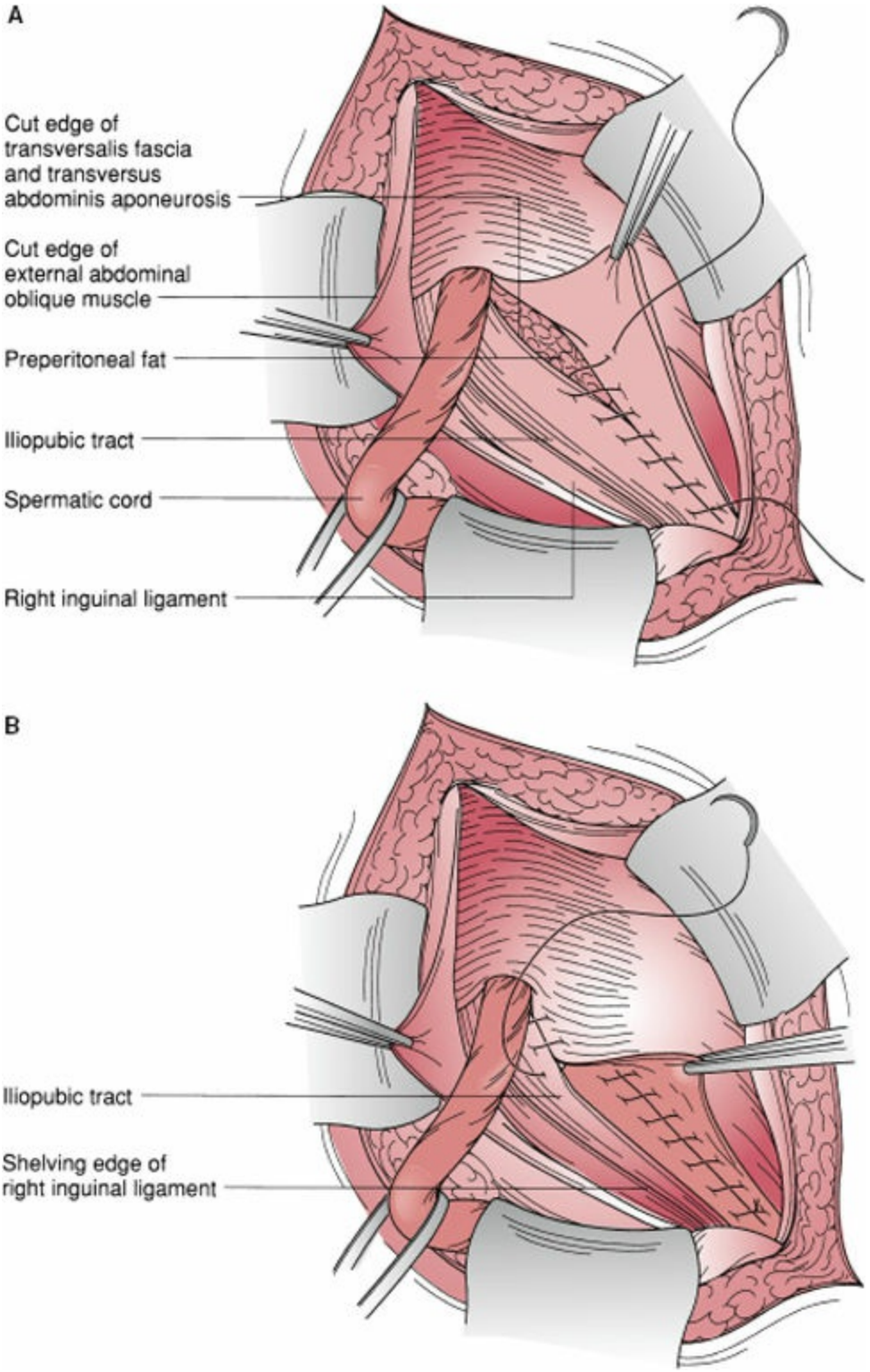

Figure 72-25. Shouldice repair.

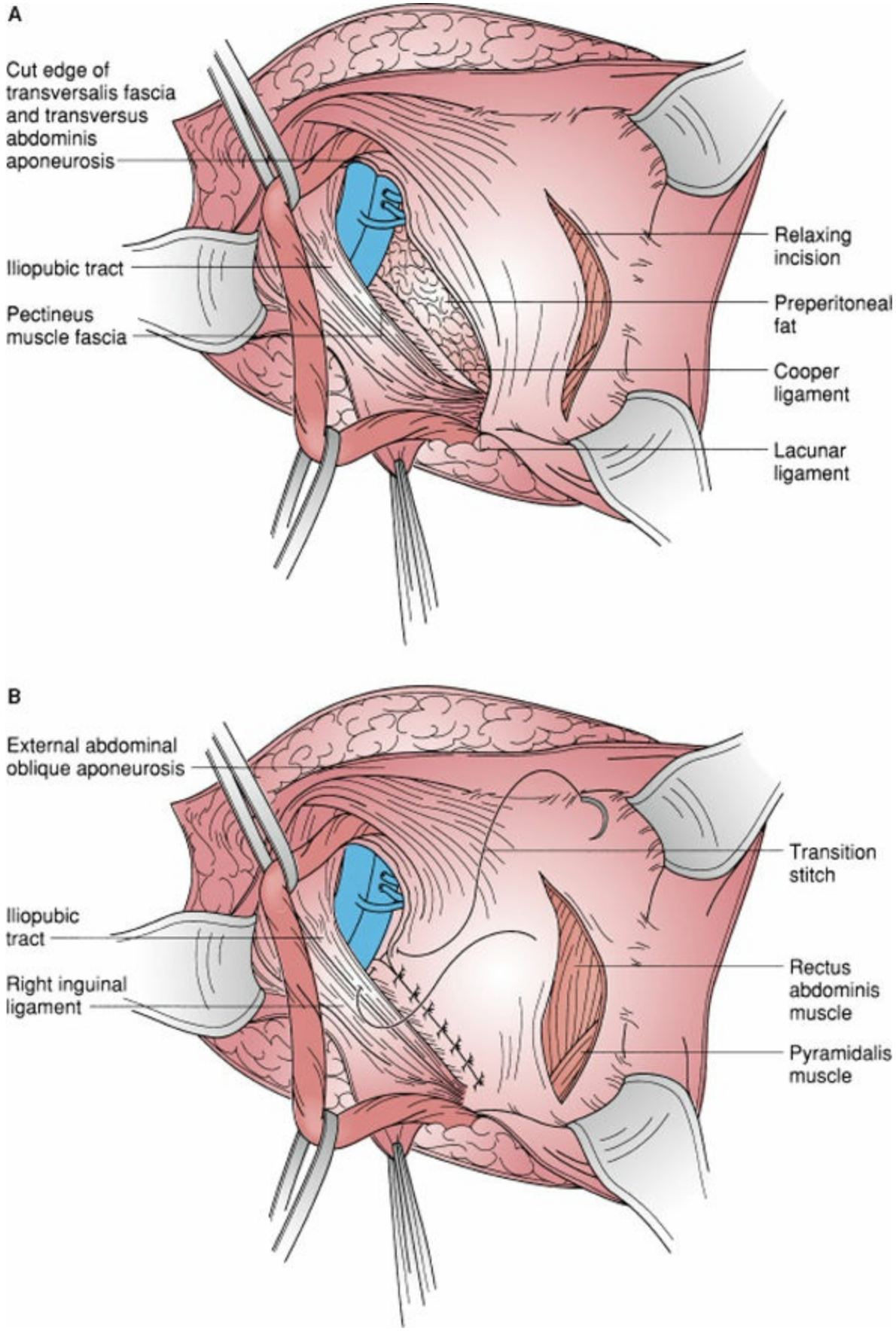

Figure 72-26. McVay (Cooper ligament) repair.

As population-based studies began to supplant personal series, it became obvious that the recurrence rate for tissue repairs with the exception of the Shouldice repair approached 10% to 15% in the general surgical practice.[64] In the 1990s, widespread adoption of the routine use of prosthesis (usually a mesh material) as popularized by

Lichtenstein has resulted in the near elimination of the Bassini approach in the United States with recurrence rates decreasing by 50% to 75%.[65] The Lichtenstein operation or open mesh herniorrhaphy, which is considered the "gold standard" operation for inguinal hernias with a recurrence rate of 1% to 1.6% (Fig. 72-27).[66] The initial dissection is identical to the tissue repairs described. Once the sac has been dealt with, a 15 × 11-cm sheet of polypropylene mesh is used, the medial end of which is rounded to the shape of the medial corner of the inguinal canal. This medial end is sutured to the anterior rectus sheath 2 cm medial to the pubic tubercle. In deference to nerve entrapment, most surgeons now use an absorbable suture, something considered heresy in the past. The same suture is then continued laterally in a running locking fashion securing the inferior edge of the prosthesis to either side of the pubic tubercle and the shelving edge of the inguinal ligament. The periosteum of the bone is avoided to prevent osteitis pubis. The suture is continued to attach the lower edge of the prosthesis to the shelving edge of the inguinal ligament up to a point just lateral to the internal ring. If a femoral hernia is present, the posterior surface of the mesh is sutured to the Cooper ligament after the inferior edge has been attached to the inguinal ligament. Alternatively, the inferior edge of the prosthesis is sewn directly to Cooper ligament medially and then transitioned to the inguinal ligament over the femoral vessels. Both techniques close the femoral canal. A slit is cut in the lateral end of the mesh to produce a narrow (one-third width) tail below and a wider (two-thirds width) tail above. The spermatic cord is positioned between the two tails. The wider tail is placed over the narrow one and a so-called shutter valve stitch placed just lateral to the cord including the inferior surface of the superior tail, the inferior surface of the inferior tail, and the inguinal ligament. The tails are then tucked under the external oblique aponeurosis to the level of the anterior superior iliac spine. The external oblique aponeurosis is closed to re-create the external ring. The wound is closed in layers.

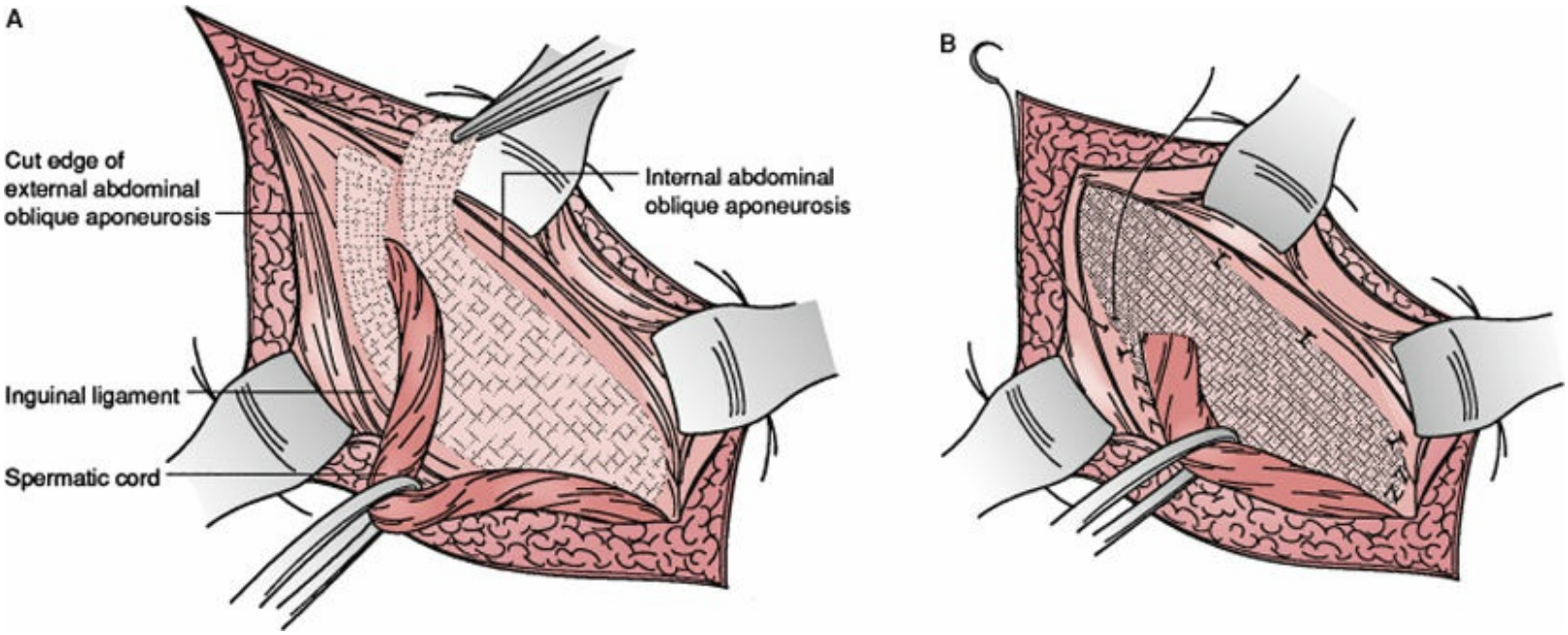

Figure 72-27. The Lichtenstein hernioplasty, showing placement of the mesh.

A popular modification of the Lichtenstein operation has been termed the plug-and-patch repair. As the name implies, a plug usually constructed from polypropylene is inserted in the defect and secured with interrupted sutures to either the internal ring (for an indirect hernia) or the neck of the defect (for a direct hernia). The patch is then placed over the plug to cover the inguinal floor as in the Lichtenstein. One might argue that this operation is nothing more than a Lichtenstein on top of a plug, and in fact the term "plugstenstein" has been used to describe it. However, the difference with a plug-and-patch repair is that only one or two sutures – or, sometimes, no sutures – are used to secure the flat prosthesis to the underlying inguinal floor. This results in an operation that is fast and very easy to teach. However, based on trials comparing the plug and patch to the Lichtenstein technique, no benefit with respect to recurrence rate and/or chronic pain has been demonstrated.[62]

Preperitoneal Approach

The preperitoneal space is situated between the transversalis fascia and the peritoneum. The final common denominator in all groin hernias is failure of the transversalis fascia to retain the intra-abdominal contents. Repairs performed in this space make the distinction between direct, indirect, and femoral irrelevant because the repair is accomplished behind the defective transversalis fascia, addressing the entire myopectineal orifice.

For a conventional, open operation, the preperitoneal space can be entered via a lower midline incision or a transverse incision placed slightly higher than usual. The rectus muscle is retracted medially and the preperitoneal space entered. A large prosthesis is used that extends far beyond the margins of the myopectineal orifice and envelops the visceral sac. The mesh is held in place by intra-abdominal pressure, which pushes outward toward the undersurface of the transversalis fascia. If the hernial sac is large, it is amputated or inverted beneath a purse-string suture to smooth the external surface of the visceral sac. The distal peritoneal sac is left in place, undissected, and attached to the cord. With a sliding indirect hernia, the sac is easily dissected away from the cord. Proponents of this technique feel that polyester is better suited than other prostheses because of its pliability. For a bilateral repair, one large chevron-shaped mesh can be used for both sides. One disadvantage of this technique is the need for a larger incision and substantial amount of dissection and the associated pain. Laparoscopic hernia repairs avoid the disadvantages of a large incision while providing the advantages of preperitoneal repair.

Several newer, less invasive preperitoneal techniques have been developed to place a mesh in the preperitoneal space. For example, in the Kugel procedure, a small incision is made over the deep inguinal ring and the preperitoneal space is developed bluntly followed by the use of a prosthesis with an incorporated reinforcing ring. This ring can be deformed to allow the prosthesis to be introduced into the preperitoneal space and then the ring causes it to spring back to its original shape, providing wide overlap of the myopectineal orifice.[67] The procedure works well in experienced hands but because it is partially blind, considerable training is required. In addition, in earlier designs, the peripheral memory recoil ring was made of polyethylene terephthalate which had a

tendency to fracture over time occasionally resulting in injury to nearby viscera.[68] Another approach is to take advantage of both the preperitoneal space and the conventional anterior space using a bilayered prosthesis in which a cylinder of prosthetic material connects the two layers through the hernia defect or the internal ring.[69] One such prosthetic is the Prolene Hernia System (PHS) where both an onlay and sublay mesh is placed. Trials comparing PHS to the Lichtenstein technique have not shown any difference with respect to recurrence rate and chronic pain.[62] The objection to this system is that both the conventional anterior and the preperitoneal spaces are dissected making the repair of a recurrence more difficult.

Laparoscopic Approach

The terminology to describe a laparoscopic inguinal herniorrhaphy can be confusing. A laparoscopic preperitoneal hernia repair, in which a laparoscopy is performed and the preperitoneal space is entered with a second incision in the peritoneum, is called a *transabdominal preperitoneal repair,* or TAPP repair. An inguinal hernia repair in which prosthetic material is placed intraperitoneally over the defect under laparoscopic guidance is referred to as an *intraperitoneal onlay mesh repair,* or IPOM repair. The third general type of laparoscopic approach is the *totally extraperitoneal laparoscopic repair,* or TEP repair. Laparoscopy, by definition, implies that the peritoneal cavity has been entered. To refer to this technique as *extraperitoneal* therefore represents a contradiction in terms. However, because a laparoscope and related instruments are used, it is fitting to discuss the extraperitoneal approach along with the other laparoscopic inguinal herniorrhaphies.

The TAPP and the TEP laparoscopic inguinal herniorrhaphies are the most popular. Both are modeled after the conventional preperitoneal operations. The major difference is that the preperitoneal space is entered through three trocar sites rather than through a large conventional incision. The ensuing radical dissection of the preperitoneal space with placement of a large prosthesis is similar to the conventional preperitoneal operation.

Laparoscopic Versus Conventional Herniorrhaphy. Randomized controlled trials as well as a meta-analysis of pooled data from these trials have shown that on average, patients undergoing laparoscopic herniorrhaphy have less pain initially than open, tension-free herniorrhaphy and return to normal activities sooner with a lower incidence of wound infection and hematoma and less chronic pain/numbness.[61,70] The difference is even greater when the comparison is made to nonprosthetic repairs. For recurrent hernias after conventional open repair, laparoscopic inguinal hernia repair results in lesser postoperative pain and faster convalescence. However, the potential advantages of laparoscopic hernia repair must be interpreted in light of the disadvantages, which include significantly longer operative time and complications related to the laparoscopy such as bowel perforation or major vascular injury, potential adhesive complications at sites where the peritoneum has been breached or prosthetic material has been placed, the need for a general anesthetic, and increased cost because of the expensive equipment. On the other hand, the conventional operation can be performed under local anesthesia on an

outpatient basis, with minimal risk of intra-abdominal injury, and the cost is less. A long steep learning curve exists for laparoscopic hernia repairs, especially TEP, and an unacceptably high recurrence rate may be seen when this procedure is performed by inexperienced surgeons without appropriate training and mentoring. A recent meta-analysis including 27 randomized trials as well as an additional cohort study revealed a statistically significant higher risk of recurrence of primary hernias after laparoscopic repair as compared with open repair. The clinical significance of this is questioned because the absolute numbers were not impressive, that is, reoperation rates in the cohort study, 4.1% versus 2.1%.[71,72] The operation is particularly difficult if a previous operation has been done in the preperitoneal space (e.g., the index hernia repair or a prostatectomy) because of scaring with significant risk for bladder or vascular injury. Despite the expected advantages, the choice between laparoscopy and other techniques still depends on local expertise availability. Only dedicated centers are able to routinely offer laparoscopy for a recurrent inguinal hernia.

Patient and Procedure Selection. Assuming equivalence for recurrence and complication rates between laparoscopic and open tension-free hernia repair for a given surgeon, all adult patients with inguinal hernias who are candidates for general anesthesia can be considered candidates for laparoscopic inguinal hernia repair. Certain hernia types, such as those that are recurrent, bilateral, or otherwise complicated, are particularly suited for the laparoscopic approach.[73,74] In addition, women may be better served with a laparoscopic operation because the femoral space is addressed, which should eliminate the excessive incidence of femoral recurrence observed with conventional operations such as the Lichtenstein.[52] Contraindications to laparoscopic inguinal hernia repairs include intra-abdominal infection and coagulopathy. Relative contraindications for laparoscopic inguinal hernia repair include intra-abdominal adhesions from previous surgery, ascites, or previous retropubic space surgery, because of the increased risk for bladder injury. Severe underlying medical illness is also a relative contraindication because of the added risk of general anesthesia and these patients are better suited for a conventional operation under local anesthesia. An incarcerated sliding scrotal hernia is a relative contraindication, especially when it involves the sigmoid colon, because of the high risk for perforation during the dissection.

Operative Techniques

Transabdominal Preperitoneal Repair. The procedure is begun with a thorough diagnostic laparoscopy done through an umbilical cannula to rule out unrelated pathology and carefully inspect both myopectineal orifices. Two additional cannulas are placed just lateral to the rectus sheath on either side of the umbilicus (Fig. 72-28). For a unilateral hernia, a transverse incision is begun at the lateral side of the medial umbilical ligament and extended to open its lateral leaf to the anterior superior iliac spine. If the medial umbilical ligament appears to compromise exposure, it can be divided. Electrocautery is used to minimize bleeding from the remnants of the embryologic umbilical artery. A radical dissection of the preperitoneal space is then performed with mostly blunt

dissection and generous use of electrocautery, as bleeding in this area is particularly troublesome if it interferes with illumination. The ipsilateral and contralateral pubic tubercles, inferior epigastric vessels, Cooper ligament, and iliopubic tract are identified (Fig. 72-29). The cord structures are mobilized, and the peritoneal flap is dissected several centimeters proximal to the bifurcation of the vas deferens and the internal spermatic vessels. Recurrences have been attributed to inadequate mobilization of the peritoneal flap, which does not allow the prosthesis to lie flat in this area. If small, an indirect sac is mobilized away from the cord structures and reduced. If large, the sac is divided at a convenient point distal to the internal ring and only the proximal portion is mobilized. A direct sac readily reduces during the preperitoneal dissection. An easily visible layer of fatty tissue separates the thinned out transversalis fascia lining the defect and the peritoneum.

A large piece of polypropylene mesh (at least 14 × 11 cm) is placed in the preperitoneal space to cover the contralateral pubic tubercle medially and extending onto the anterior abdominal wall superiorly at least 2 cm above the hernia defect, to the anterior superior iliac spine laterally, and over the Cooper ligament inferiorly. Most surgeons prefer to fasten the prosthesis with staples, tacks, or glue, but there is increasing evidence that fixation is not necessary when a large prosthesis is used that widely overlaps the entire myopectineal orifice. Staples or tacks are never placed below the iliopubic tract when lateral to the internal spermatic vessel because of the danger of damage to the important nerves in this area. The last step is to cover the prosthesis by closing the peritoneum with sutures, tacks, staples, or glue.[75] The goal is to isolate the prosthesis from the abdominal viscera rather than to always achieve precise approximation of the peritoneal edges. This is because gaps can form if the peritoneum is closed under tension allowing bowel to migrate into the preperitoneal space. A better option is to secure the inferior peritoneal flap to the transversalis fascia above the prosthesis and leave the superior flap alone.

For bilateral inguinal hernias, the same peritoneal incision and preperitoneal dissections are used. The symphysis pubis is completely exposed so that both preperitoneal dissections communicate with each other. This exposure allows the placement of one large prosthesis (at least 25 × 8 cm) that essentially covers the entire lower pelvis. By not incising the peritoneum between the two medial umbilical ligaments, one avoids the theoretical complication of dividing a patent urachus.

Totally Extraperitoneal Repair. An incision is made at the umbilicus, as if one were planning to perform open laparoscopy. The rectus sheath is opened on one side and the rectus muscle is retracted laterally. Blunt dissection is then begun in the space between the rectus muscle and the posterior rectus sheath. Once the space is large enough, two additional cannulas are placed in the midline, one approximately 5 cm above the symphysis pubis and the other midway between the umbilicus and the symphysis pubis. The dissection of the preperitoneal space is completed under direct vision. The rest of the operation is identical to the TAPP procedure described previously except that peritoneal closure is not necessary. Popular alternatives are to use a water- or air-filled balloon

dissector to perform the preperitoneal dissection and to place the two accessory cannulas on either side of the umbilicus, as in the TAPP procedure, instead of in the midline.

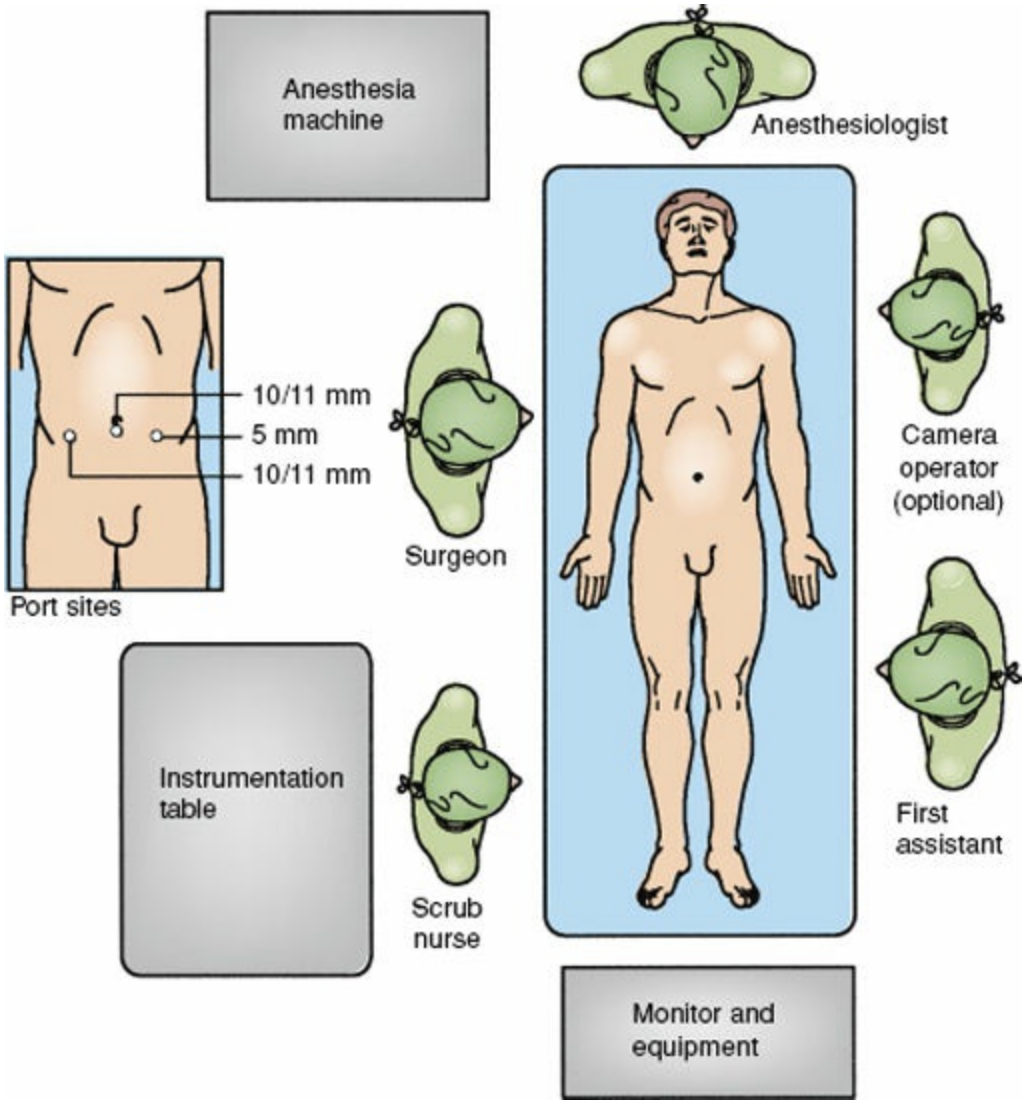

Figure 72-28. Typical operative setup and cannula site selection for a transabdominal preperitoneal (TAPP) laparoscopic inguinal herniorrhaphy.

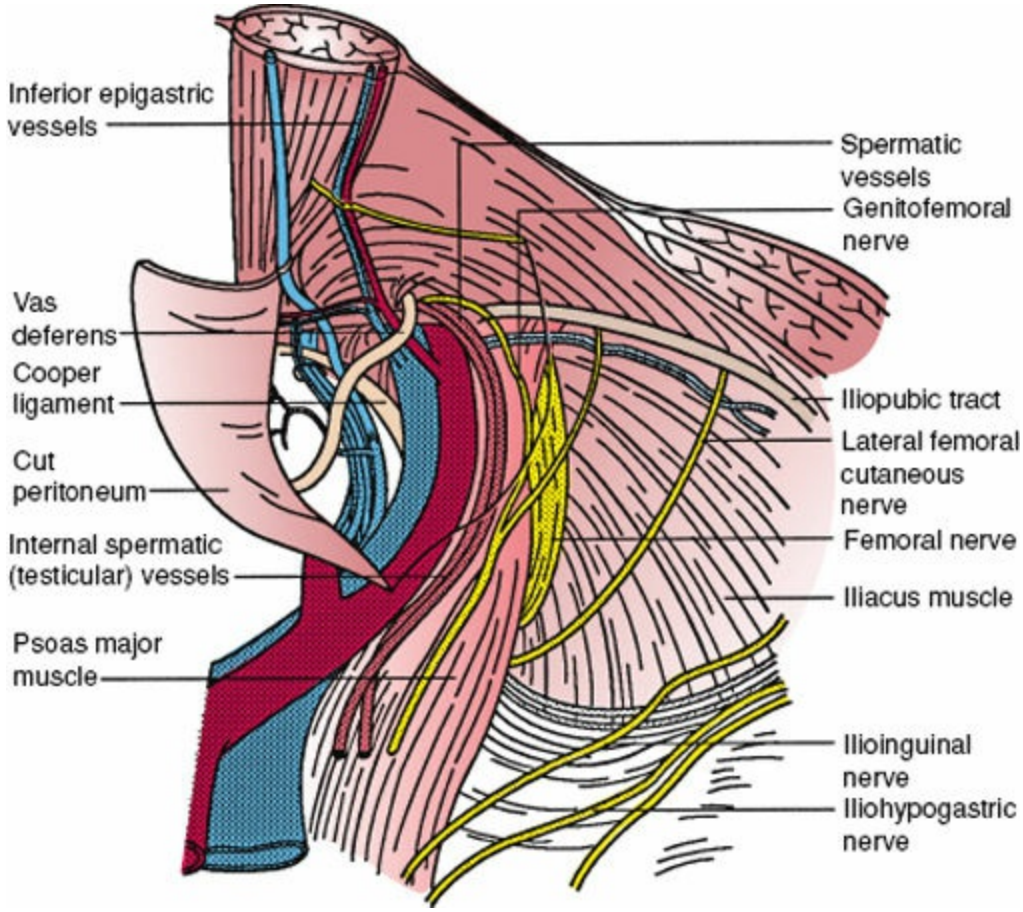

Figure 72-29. Important structures that must be identified after a preperitoneal dissection: inferior epigastric vessels, Cooper ligament, spermatic vessels, vas deferens, iliopubic tract, genitofemoral nerve, femoral nerve, lateral femoral cutaneous nerve, ilioinguinal nerve, iliacus muscle, and psoas major muscle.

The presumed advantages of the TEP procedure are that the inherent complications of entering the peritoneal cavity, such as intra-abdominal organ injury or postoperative bowel obstruction secondary to adhesions or trocar site herniation, are avoided. However, the operative space is limited, and considerable experience is required to become familiar with the anatomy from this perspective. In addition, it is not yet clear whether inadvertent breaches in the peritoneal cavity that are difficult to visualize because of the direction of the optics might negate the potential benefits of this approach.

Intraperitoneal Onlay Mesh Repair. The TAPP and the TEP herniorrhaphies are better considered minimal access procedures rather than minimally invasive because of the extensive dissection required in the preperitoneal space. The IPOM procedure was developed to be a truly minimally invasive operation. By placing the prosthesis one layer deep to the preperitoneal space directly onto the peritoneum, one can eliminate the need for a radical preperitoneal dissection. Initial laparoscopy and accessory cannula placement are the same as in the TAPP procedure. A large piece of prosthetic material is introduced into the peritoneal cavity and secured in place with staples, tacks, or sutures. An attempt is made to use the same landmarks described previously for the TAPP procedure. The main concern is development of the complications of intraperitoneal placement of a prosthesis in contact with intra-abdominal organs. The procedure is regaining some popularity because of the development of the adhesion barrier prosthetics for ventral

hernia repair.

Special Considerations: Pediatric Hernias

Given the high incidence of indirect inguinal hernias due to a patent processus vaginalis in pediatric patients, hernia repairs are completed using a high ligation technique. Concerns exist with the use of mesh in adolescents with respect to effect on fertility, long-term groin pain, and infection risk.[76,77] Postpubertal males have a similar anatomy to the adult population with a larger inguinal ring diameter and variations on transverse fascia defects. It is unclear as to which age/size does a child become an adult with respect to principles of hernia repair. Longitudinal studies comparing different hernia repair techniques in adolescents are needed before we can determine optimal treatment for adolescents especially those with weak inguinal floors and direct hernias.

Femoral Hernias

Femoral hernias are much rarer and account for 2% to 4% of groin hernia repairs and can present a challenge to even the most experienced surgeon. As such, femoral hernias are more common in women and often present with an acute episode of incarceration, intestinal obstruction, or strangulation, so that emergency surgery is necessary. It can be difficult to reduce the hernia at surgery, and it is not uncommon to have to divide the inguinal ligament to obtain greater freedom to perform this reduction. Femoral hernias can be repaired from a lower approach, in which a vertical incision is made over the femoral triangle in the upper thigh. The hernia is approached from below the inguinal ligament and reduced, and then the defect is closed by suturing the inguinal ligament to the Cooper ligament from below. An alternative is to insert a rolled plug of mesh into the defect and suture the periphery to the inguinal ligament and Cooper ligament.[66] The repair can also be carried out from above via an inguinal approach, as in the McVay repair. The posterior floor of the inguinal canal is dissected out, and the Cooper ligament is repaired after the hernia has been reduced. A third type of femoral hernia repair is the preperitoneal repair. Access to the preperitoneal space is gained through an abdominal incision or laparoscopy. A recent study based on the Swedish national register revealed that preperitoneal mesh techniques (both laparoscopic and open) are a better choice for women with femoral hernias.[78] As effective as the Lichtenstein operation is for men, it may not be the best choice for woman. This is because the Lichtenstein operation, unless modified, only addresses an inguinal hernia and not a femoral hernia. On the other hand, the preperitoneal herniorrhaphies result in coverage of the entire myopectineal orifice and thus both femoral and inguinal hernias are treated. Indeed, in the Swedish study a much higher femoral recurrence rate was observed in women compared to men especially after the repair of a direct inguinal hernia. This is significant because direct hernias are almost unheard of in women providing strong evidence that the femoral hernia was actually missed at the index operation.[52]

SPORTS HERNIA/ATHLETIC PUBALGIA

The term *sports hernia* is confusing because, by definition, these patients do not actually have a hernia but rather a weakness of the posterior inguinal floor. This condition has received considerable attention in the lay press because of its prevalence in high-profile athletes involved in sports who require rapid changes in direction of the hip area such as soccer, football, basketball, track and field, tennis, and hockey. Alteration in the complex balance that must be maintained between the lower abdominal muscles and the leg adductor muscles and tendons, all revolving around the area of the pubic bone, is the final common denominator for many of the conditions that cause groin pain in up to 5% of athletes (Fig. 72-30).[79] The first step in approaching these patients is to make sure that one is not dealing with a cause outside of the groin with referred pain, such as lumbosacral radiculopathic pain, prostatitis, hip disease, and a gastrointestinal cause. The differential diagnosis is listed in Table 72-8.

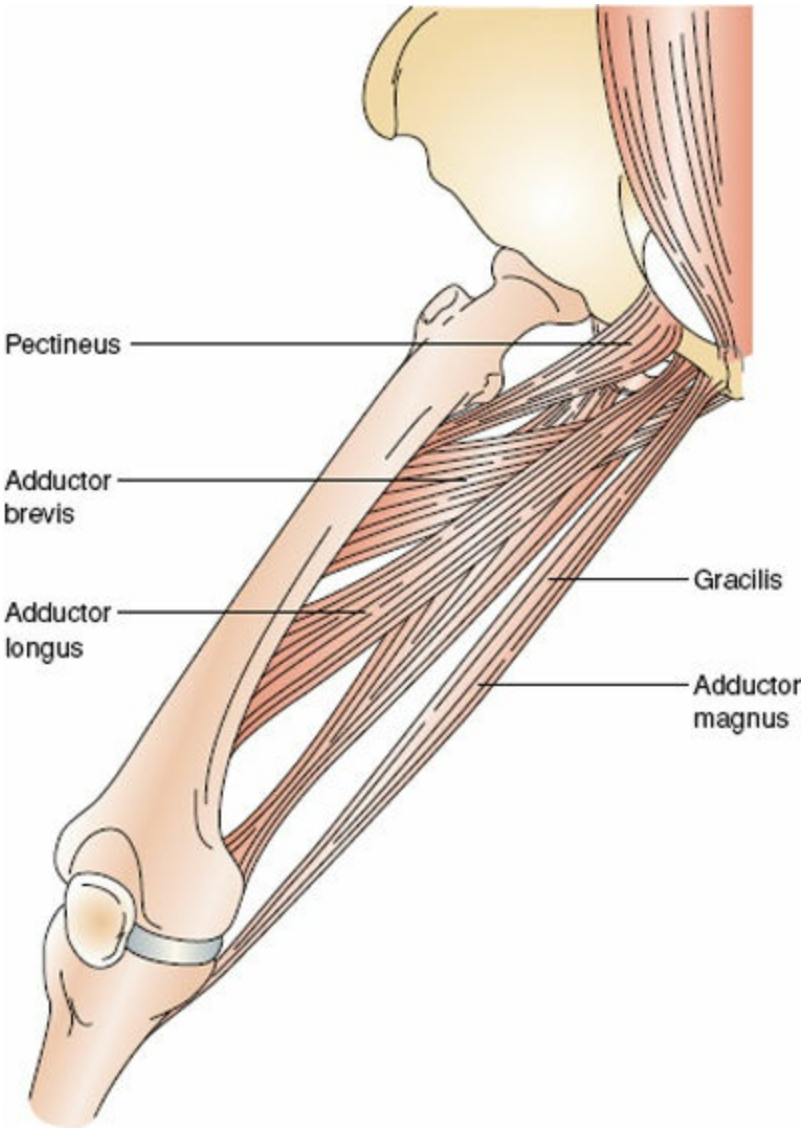

Figure 72-30. Complicated arrangement of muscle pulling in different directions that attach to the pubic bone.

DIAGNOSIS

Table 72-8 Conditions Other Than a Hernia Associated With Groin Pain

- Nerve entrapment
- Adductor tenoperiostitis
- Pelvic stress fractures
- Osteitis pubis
- Symphysis syndrome
- Gilmore groin (groin disruption)
- Iliopsoas bursitis
- Tendinopathies
- Posterior inguinal wall insufficiency or avulsion fractures
- Synovitis
- Osteoarthritis
- Legg–Calvé–Perthes disease
- Slipped femoral capital epiphysis
- Osteochondritis dissecans or avascular necrosis of the femoral head
- Acetabular labral tears
- Prostatitis
- Epididymitis
- Nephrolithiasis
- Urinary tract infection
- Lymphadenitis

Some authorities prefer to refer to this condition as "athletic pubalgia," as this conveys the concept that the physical examination is inconclusive and the cause of groin pain is unclear. Imaging may be performed by ultrasound, but cross-sectional imaging (CT or magnetic resonance imaging [MRI]) is the most useful diagnostic modality in the absence of a highly experienced ultrasonographer.[80] Compared to CT, MRI provides excellent overall anatomic detail especially with the development of fast imaging scanners that will allow dynamic imaging (i.e., performed during straining) with or without the addition of intraperitoneal contrast agents.

The initial treatment is conservative with forced inactivity, elastic immobilization bandages, ice/massage, nonsteroidal anti-inflammatory analgesics, and occasional steroids (systemic and/or local). Surgery is a last resort. Although lacking clear-cut anatomic justification, a mesh hernia repair similar to either an anterior Lichtenstein or a TEP laparoscopic operation is the most popular procedure, sometimes combined with a variety of muscle reattachment procedures and tenotomies. The best results are obtained with a multidisciplinary approach including a surgeon, an orthopedist, a physical therapist, and a sports medicine physician. Not surprisingly, the results are variable given the lack of objective criteria to recommend operation but can be gratifying in some in this motivated group of patients.

Complications of Inguinal Hernia Repair

Complications Related to the Patient

Urinary Retention. The most common predisposing factor for urinary retention after a hernia repair is the use of general or regional anesthesia.[59] Meta-analyses of randomized controlled trials comparing various hernia techniques performed under general anesthesia have not shown a difference in urinary retention rates.[81–84] Predisposing factors for urinary retention include overhydration with intravenous fluid during surgery, use of opioid analgesics, older age, prostatic symptoms, and prolonged operative time.[85,86] Intermittent catheterization or temporary placement of an indwelling urinary catheter is usually adequate therapy. Prophylactic and therapeutic use of alpha adrenergic blockers including prazosin and tamsulosin have been shown in some studies as an effective strategy to prevent postoperative urinary retention.[87,88]

Ileus. Ileus can be seen with either the conventional or the laparoscopic procedure but is more common with the latter. Treatment is symptomatic, and spontaneous resolution is the rule. Nasogastric decompression is occasionally needed.

Complications Related to the Herniorrhaphy

Recurrence. A lower risk for recurrence with the use of prosthetic material for the repair of an inguinal hernia has been clearly proven by meta-analysis.[89] Recurrence rates of 2% or less are now routinely reported from specialty centers performing either laparoscopic or conventional TFRs. Although the recurrence rate for hernia repairs is less than 1% at the Shouldice Clinic, others have not been able to duplicate this outstanding record with this or any of the other nonprosthetic repairs.[90] Complications during the first month after surgery; operation for recurrence; and sutured repairs without mesh, with either anterior or preperitoneal techniques, are associated with an increased recurrence rate. A laparoscopic approach is also considered a risk for recurrence because of its higher potential for technical failure, especially in the less experienced. This was felt to be the most likely reason for a higher recurrence rate at 2 years in a Veterans Affairs study for the laparoscopic approach (10%) compared to an open TFR (4% for the Lichtenstein repair).[91]

A consistent definition of a recurrent hernia does not exist because of the difficulty in differentiating a lipoma of the cord, a seroma, or an expansile bulge of the internal oblique muscle from a true hernia recurrence. It may be that reoperation rates as a surrogate provides the most accurate data.[92] From a clinical standpoint, a hernia should not be classified recurrent unless there is a visible bulge or there is unequivocal evidence of a hernia by an imaging modality such as ultrasound, CT, or MRI. This is especially important for patients who present with pain after their hernia repair because their pain is likely due to a preoperative condition other than the hernia or a postinguinal herniorrhaphy pain syndrome which might be exacerbated by further groin surgery. Femoral recurrences are seen after a Lichtenstein repair because the femoral canal is not routinely closed with the classic technique.[52]

The general principle for managing recurrent hernias depends on the original repair. The logical approach is to perform the herniorrhaphy in the space that has not been dissected. If the patient had a previous conventional repair, then a preperitoneal repair is best chosen. On the other hand, if the index operation was a preperitoneal one, then a repair that is performed in the conventional inguinal space is best. The dissection of the preperitoneal space after a failed herniorrhaphy has been performed is particularly challenging, with significant risk for vascular, neurologic, and bladder injury.

7 Postherniorrhaphy Groin Pain. Now that the recurrence rate has been brought down to a minimum using modern hernioplasty techniques, chronic postoperative groin pain syndromes (persisting >3 to 6 months post surgery) have emerged as the biggest issue facing inguinal hernia surgeons (Algorithm 72-3). Poobalan and colleagues published a critical review of inguinal herniorrhaphy studies between 1987 and 2000.[93] The frequency of at least some long-term groin pain was as high as 53% at 1 year (range, 0% to 53%). On average, moderate or severe postherniorrhaphy groin pain probably occurs in about 10% of patients. Several factors have been suggested to be related to the development and intensity of postherniorrhaphy including psychological status, presence of preoperative pain at surgical site, nerve injury, intraoperative nerve handling, surgical technique (open vs. laparoscopic), and acute postoperative pain. Risk prediction model for persistent postoperative pain–based preoperative, intraoperative, and postoperative factors can be helpful in predicting which patients will be more likely to suffer from postherniorraphy pain.[76]

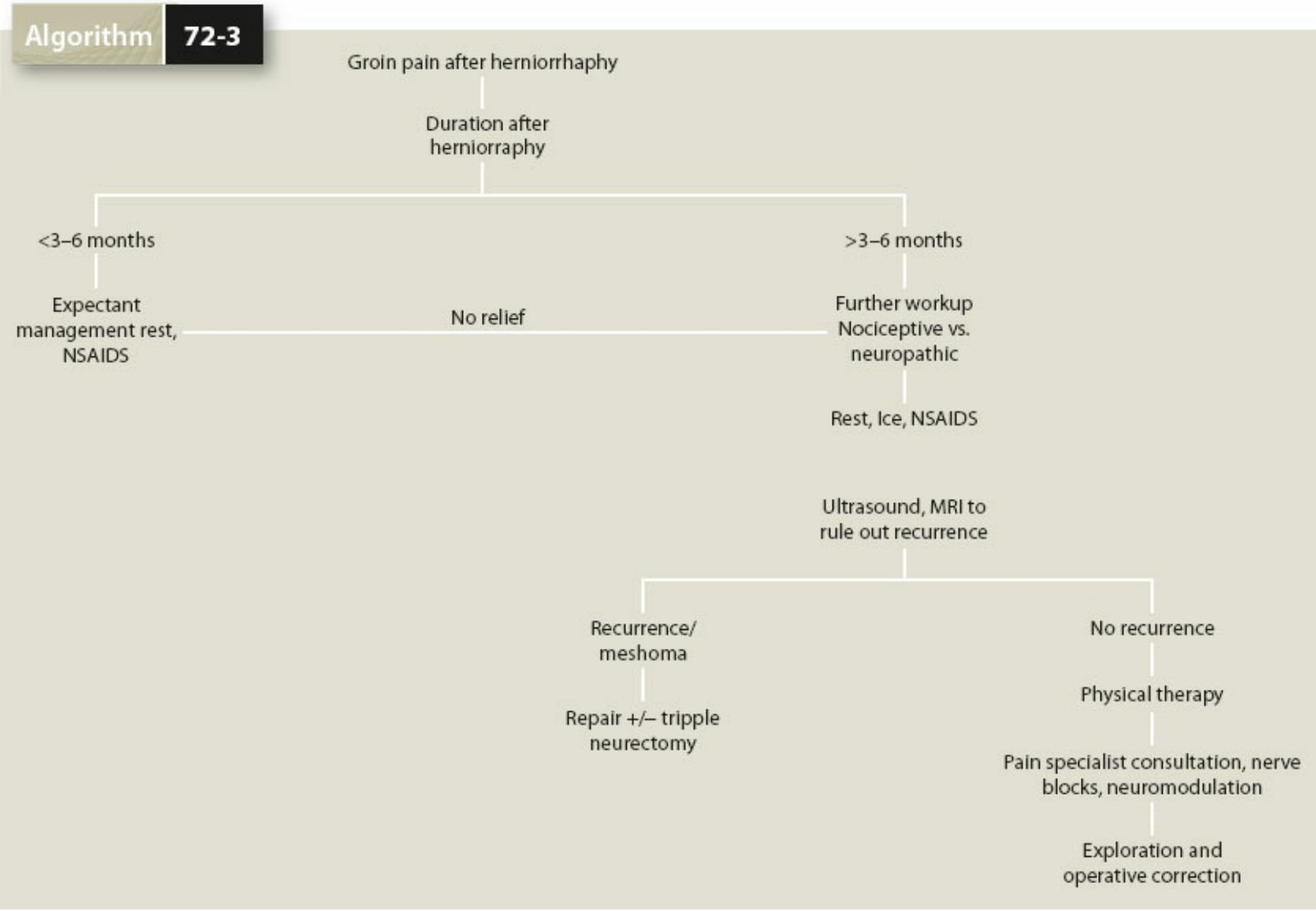

Algorithm 72-3. Management of groin pain after herniorraphy.

Perhaps the most important single determination for the chronic postherniorrhaphy pain patient is to decide whether the pain is the same or different from that which brought the hernia to the attention of the physician in the first place. There are a variety of conditions that cause groin pain (Table 72-8). CT, ultrasonography, herniography, laparoscopy, and MRI all have their place in the evaluation of these patients. MRI is perhaps the most beneficial because of its ability to differentiate between muscle tear, osteitis pubis, bursitis, and stress fracture. Strain of the adductor muscle complex (adductor longus, brevis, magnus, and gracilis muscles) is commonly overlooked in this group.

True postherniorrhaphy groin pain should be divided into two types: (a) nociceptive pain, which is caused by tissue damage, is further subdivided into somatic and visceral pain, and (b) neuropathic pain due to direct nerve damage. Somatic pain is the most common and is usually caused by damage to ligaments, tendons, and muscles. Visceral pain refers to that which is related to a specific visceral function such as urination or ejaculation (see dysejaculation syndrome, later). Neuropathic pain is much less common but is important to recognize because surgical treatment is possible if the cause is incorporation of a nerve in staples or suture material. The nerves that are usually

involved are the ilioinguinal nerve, the iliohypogastric nerve, both the genital and femoral branches of the genitofemoral nerve, and the lateral cutaneous nerve of the thigh. The former two are especially prone to injury during a conventional herniorrhaphy, whereas the latter are most likely damaged during laparoscopy. A femoral nerve injury is extremely rare and is usually the result of a gross technical misadventure. Pain and/or paraesthesia in their distribution characterize patients' symptoms for the more common nerves. There is significant overlap of these nerves, and therefore, it is commonly difficult to sort out exactly which nerve is damaged. Both nociceptive and neuropathic pain is best treated initially with reassurance and conservative treatment with anti-inflammatory medications and local nerve blocks because these will frequently resolve spontaneously. An exception is the patient who complains of severe pain immediately (i.e., in the recovery room). This patient may be best served by immediate re-exploration before scar tissue develops. When groin exploration is required, triple neurectomy and neuroma excision, adhesiolysis, and foreign body removal (i.e., mesh or suture) are options for treatment. The patients reoperated for persistent pain after hernia surgery often experience a reduction in pain, but a small percentage of patients experience no relief or even worsening of their symptoms.[94] Given the heterogeneity of the problem, further well designed studies are necessary to identify patient population that may benefit the most from surgical intervention.

Cord and Testicles

Infertility. Infertility caused by inguinal hernia surgery is a recognized complication. The cause of infertility can be related to either the vas deferens or the testicle. The incidence of injury to the vas deferens during inguinal herniorrhaphy has been estimated at 0.3% for adults and between 0.8% and 2% for children.[95] Injury to the testicle, which eventually leads to atrophy, is estimated to occur in about 0.5% for primary hernia repairs but increases 10-fold to 5% for recurrent repairs. Injuries to the vas deferens that may present as an obstruction include division, ligation, clipping, stapling, electrocauterization, devascularization, and scarification. In addition, there is evidence that there is a small subset of patients whose inflammatory response to mesh is so severe that vasal obstruction results.[96] In addition to obstruction, traction injuries during normal cord mobilization may damage the muscular layer of the vas deferens, which then interferes with rapid sperm transfer during ejaculation.[97] Sperm antibodies may develop as a result of extravasation of sperm at an injury site, which is why a unilateral injury can also result in infertility. The role of mesh in the causation of infertility has been implicated by some small case series and case reports. Ironically, one of the major arguments for the routine use of mesh in inguinal hernia surgery is to preserve fertility. The theory is that by decreasing the generally accepted recurrence rate in the general population from 10% to 15% seen with Bassini and its variants to less than 5% with the mesh tension-free approach, reoperative surgery, with its heavy toll of testicular loss, is avoided.[98]

Ischemic Orchitis. Damage to the blood supply of the testicle can cause ischemic orchitis

and testicular atrophy.[97] Ischemic orchitis occurs in about 1% of primary hernioplasties but is much more common with operations performed for recurrent hernias.[99] It manifests as postoperative inflammation of the testicle developing within 1 to 2 days after surgery. The patient has a painfully enlarged testicle that is hard in consistency and associated with low-grade fever. Pain is severe and may last several weeks. Ischemic orchitis is caused by thrombosis of the veins draining the testicle after extensive dissection of the spermatic cord. It is generally accepted that the incidence can be decreased by division of large inguinal–scrotal sacs leaving the distal sac open in situ rather than excising it.[100] The majority of patients with testicular swelling as an immediate complication of herniorrhaphy recover without testicular atrophy. In one report, testicular atrophy developed in 19 patients among 52,583 primary inguinal hernia repairs (0.036%) and 33 patients among 7,169 recurrent inguinal hernia repairs (0.46%).[101] A substantial number of patients who develop testicular atrophy after inguinal herniorrhaphy have no history of a testicular problem at the time of the index operation. The management of a patient with ischemic orchitis is usually conservative with elevation and anti-inflammatory medication. Antibiotics and steroids have been used but their value is unproved.

Miscellaneous. Hydroceles occasionally develop after inguinal herniorrhaphy, but the cause is not known and therefore a preventative measure is not possible. The urologic literature suggests that the practice of leaving the distal aspect of an indirect inguinal sac in situ rather than removing it should be incriminated, but this is not accepted by most experienced hernia surgeons. The treatment is the same as for any other hydrocele. Testicular descent is a complication felt to be related to complete division of the cremasteric muscle, but the occurrence is variable. The cord structures lose their tethering effect, allowing the testicle to descend into the most dependent portion of the scrotum. Due to the elasticity of the scrotum, with time, gravity causes the scrotum to elongate. Patients complain their testicle “drops into the toilet” and can be quite unhappy. Few hernia surgeons now routinely completely divide the cremasteric muscle, so it is hoped that this will become a rare phenomenon. The dysejaculation syndrome is characterized by searing, burning, painful sensations throughout the groin around the time of ejaculation. The incidence is approximately 0.04%.[100]

Wound Infection. This is a surprisingly rare complication of groin herniorrhaphy ($<5\%$) and the reason for the “protected” status, especially when compared to prosthetic ventral herniorrhaphy, is not known.[101] Most cases of necrotizing fascitis following inguinal hernia repair have been associated with either strangulated bowel or appendicitis in the hernial sac. Necrotizing fasciitis has only previously been reported in a few cases following elective hernia repair. Other factors leading to infection are pre-existing infection or ulceration of the skin over the hernia, obesity, incarcerated or obstructed bowel within the hernia, and perforation of the bowel at the time of hernia repair. Untreated seromas can become secondarily infected. It is not always necessary to remove the mesh prosthesis in the presence of infection. A trial of local wound care after opening of the incision and debridement is warranted.

Seromas. Seromas are common with extensive flap dissection in large hernias and with the use of synthetic mesh in laparoscopic hernia repairs and are possibly related to the size of the mesh used. The fluid eventually resorbs spontaneously. Aspiration is performed for symptomatic relief only. Strategies to prevent and manage seromas are largely based on empiricism and personal opinion, as objective data are nearly absent.

Bleeding. Hemorrhage can occur from the cremasteric, internal spermatic, or inferior epigastric vessels. Conservative treatment with reassurance is preferred for a stable hematoma. Evacuation is rarely required. Injuries to the deep circumflex artery, the corona mortis, or the external iliac vessels may result in a large retroperitoneal hematoma.

Prosthetic Complications. Shrinkage of polypropylene and other meshes should be considered by surgeons when performing prosthetic repairs. The decrease in size is felt to be due to scarification of the recipient's tissue. Intestinal obstruction or fistulization is possible by erosion, especially if there is physical contact between intestine and the prosthesis. Rejection because of an allergic response is possible but extremely rare. What patients cite as "rejection" of the mesh is usually the result of infection. Local erosion into the cord structures has also been reported.[102]

Complications Related to Laparoscopy

Vascular Injury. These are for the most part related to access. The most serious injuries occur to vessels that reside in the retroperitoneum. For all laparoscopic procedures, the risk for major vascular injury that requires operative intervention is 0.9 per 1,000 cases.[103] The vessels most at risk are the distal aorta, common iliac arteries and veins, and inferior vena cava and the inferior epigastric vessels. Injuries to the renal vessels have also been reported. These vessels are fixed and may be penetrated even if the safety mechanisms of the needle or trocar are working properly. The mesenteric and omental vessels are also at risk, especially in the presence of adhesions. The epigastric arteries may be injured with secondary cannula placement.

The insufflation needle is the most common cause of vascular injury but may be self-limiting; on the other hand, injuries caused by a trocar are usually more obvious and catastrophic. The mortality associated with retroperitoneal injury secondary to trocar insertion ranges from 9% to 36%, even with rapid identification and repair. When retroperitoneal trocar injury is suspected, immediate conventional laparotomy is almost always indicated. Most abdominal wall vascular complications occur during the placement of secondary cannulas. Usually, pressure can be applied to bleeding at the trocar site with the cannula. Occasionally, suture ligation is required, which has been simplified by the development of disposable "exit devices" designed to facilitate the placement of fascial sutures. Most of these complications can be avoided by placing the secondary trocars under direct vision.

Gas Embolism. This is caused by intravascular insufflation.[104] It is an uncommon complication, unique to the needle insufflation technique. Careful attention to tests

confirming proper peritoneal needle placement will keep the incidence of this complication low.

Visceral Injury. Visceral injuries are uncommon, occurring in 1.8 per 1,000 cases of all laparoscopic procedures, but they have a mortality rate of 5%.[103] The most common means of injury is the insufflation needle. Simple repair laparoscopically is usually possible as most are self-limiting. If the injury is caused by a trocar, formal repair of the injury will be needed. The injury can be repaired laparoscopically if the skill of the laparoscopic surgeon is sufficient. Otherwise, laparotomy is mandatory. Quite often, these injuries go unnoticed at the time of insult, so that visceral injury is the most common cause of late morbidity and mortality associated with laparoscopic access. Patients typically present with peritonitis and sepsis 2 days to 1 week after surgery.

Bladder Injury. Bladder injury can be the result of a laparoscopic misadventure or can be directly related to the herniorrhaphy. Laparoscopic peritoneal access can result in a bladder perforation, usually the result of failure to decompress a distended bladder. Less commonly, injury is associated with a congenital bladder abnormality. Bladder injury has not been reported with the open access technique. Injury to the bladder can also occur during secondary suprapubic trocar placement during the course of an operation. When bladder injury occurs, it is usually obvious. After Veress needle insertion, urine is withdrawn into the syringe, or blood and gas are noticed in the urine if the patient is catheterized. In questionable cases, methylene blue dye may be instilled into the bladder to look for leakage. Bladder injury recognized during laparoscopy should be repaired laparoscopically provided the experience of the surgeon is sufficient. This should be followed by bladder drainage for 7 to 10 days.

Bladder injury may present in a delayed fashion with hematuria and lower abdominal discomfort. A retrograde cystogram usually confirms the diagnosis. Small defects may be managed with postoperative decompression via an indwelling catheter for urinary drainage, while larger defects necessitate repair. The bladder is especially prone to injury during preperitoneal herniorrhaphies or when the preperitoneal space has previously been dissected (e.g., previous preperitoneal hernia repair or prostatectomy).[105]

Bowel Obstruction. This problem plagued the developmental stages of laparoscopic inguinal herniorrhaphy for two reasons. First, the importance of closing trocar sites at the fascial level if greater than 5 mm was not appreciated, resulting in the occasional patient with an incarcerated or strangulated ventral hernia at the trocar site, leading to the clinical presentation of a bowel obstruction. There are now several different types of reusable and disposable appliances designed to facilitate trocar site fascial closure, which should minimize the incidence of these hernias. The second is inadequate peritoneal closure over the prosthesis, which allows bowel to migrate into the preperitoneal space, also resulting in intestinal obstruction. Steps taken to avoid tension at the peritoneal closure site (see TAPP technique section) have decreased this problem. Theoretically, the TEP procedure eliminates the possibility of this complication because the abdomen is not entered. However, inadvertent breaches of the peritoneum during a TEP herniorrhaphy

are common, especially in patients with thin peritoneum or those who have scar tissue associated with previous lower abdominal surgery. These peritoneal lacerations can be difficult to recognize because they are not in the visual field of the limited working space, and indeed, intestinal obstruction has been reported.[106]

Diaphragmatic Dysfunction. Phrenic nerve palsy has been reported with a variety of laparoscopic procedures; it is usually transient but has been known to require a short period of mechanical ventilation. Stretching during the pneumoperitoneum probably causes this complication.

Hypercapnia. This is the result of inadequate compensatory ventilation given the fact that, in the vast majority of laparoscopic procedures, carbon dioxide is used as the insufflating agent.

Table 72-9 Classification of Ventral Abdominal Wall Hernias

Incisional
Umbilical and paraumbilical
Epigastric
Parastomal
Less common variations
Spigelian hernias
Interparietal hernia
Richter hernia
Miscellaneous

VENTRAL ABDOMINAL WALL HERNIAS

Repair of ventral abdominal wall hernia is one of the most common procedures performed by a general surgeon. Ventral hernias comprise a diverse group of hernias and are best divided into their various subtypes when discussing surgical management because the natural history as well as results of operations varies depending on the specific hernia. Table 72-9 uses the common terminology familiar to all surgeons for classifying abdominal wall hernias. Table 72-10 is a classification system published by Zollinger that expands upon Table 72-9 by further subdividing ventral hernias based on etiology.[107] An expert panel of European Hernia Society proposed a grid classification system of incisional hernias in based on localization, size, recurrences, and symptoms (Table 72-11)[108,109] and the Ventral Hernia Working Group (VHWG)[110] (Table 72-12) has proposed a grading system for ventral hernias based on risk of post-operative surgical site occurrences.

Table 72-10 Zollinger Classification of Ventral Abdominal Wall Hernias

Congenital
Omphalocele
Gastroschisis
Umbilical (infant)
Acquired
Midline
Diastasis recti
Epigastric
Umbilical
Adult, acquired, paraumbilical
Median
Supravesical
Anterior, posterior lateral
Paramedian
Spigelian
Interparietal
Incisional
Midline
Paramedian
Transverse
Special operative sites
Traumatic
Penetrating, auto-penetrating
Blunt
Focal, minimal injury
Moderate injury
Extensive force or shear
Destructive

Table 72-11 European Hernia Society (EHS) Classification of Incisional Hernia

Midline	Subxyphoid	M1
	Epigastric	M2
	Umbilical	M3
	Infraumbilical	M4
	Suprapubic	M5
Lateral	Subcostal	L1
	Flank	L2
	Iliac	L3
	Lumbar	L4
Recurrent incisional hernia	Yes	No
Length (cm)		Width (cm)
Width		W1
<4 cm		W2
4–10 cm		W3
>10 cm		

UMBILICAL AND PERIUMBILICAL HERNIAS

Umbilical and periumbilical hernias are usually congenital, caused by arrest of the normal spontaneous closure of the umbilical ring through which umbilical blood vessels pass in the developing fetus, which results in a defect in the fascia covered by skin. In infants, the fascial defect varies in size but is most commonly 1 to 2 cm. A large proportion of pediatric umbilical hernias heal spontaneously, and 80% of them close by the time the patient is 2 years old. This is the only abdominal wall defect genetically programmed to close. Persistent umbilical hernias require surgery. In older patients, the onset is usually sudden and the defect is relatively small. There are several syndromes associated with umbilical hernias such as mucopolysaccharide storage diseases, Beckwith–Wiedemann syndrome, and Down syndrome. Predisposing factors for the development of umbilical hernias in adults are multiple pregnancies, obesity, cirrhosis with ascites, and large abdominal tumors, all of which cause an increase in intra-abdominal pressure.[111] Male gender is also a risk factor with the peak incidence of repair at about age 60 years.[112] The differential diagnosis includes the varicosities that extend radially from the umbilicus in persons with portal hypertension, the so-called caput medusae (Fig. 72-31). The varicosities have a bluish discoloration and fill when the patient is straining. A metastatic deposit of intra-abdominal cancer at the umbilicus may mimic umbilical herniation. Cancer cells reach this area via lymphatics in the falciform ligament. Metastasis presents as a hard nodule, and biopsy is diagnostic. Other periumbilical masses that can be confused with an umbilical hernia include umbilical granulomas, omphalomesenteric duct remnant cysts, and urachal cysts.



Figure 72-31. Caput medusae. Large periumbilical collaterals in a patient with portal hypertension.

The management of umbilical hernias is nonoperative in children up to the age of 2 or 3 years because spontaneous closure is the rule. In those who require surgery, adults or children, the repair depends on the size of the hernia. An infraumbilical semilunar incision is made and the hernia identified. There may or may not be a true peritoneal sac, as smaller hernias usually consist of preperitoneal fat only. If a sac is present, it can be opened and the contents reduced into the abdomen. Alternatively, the hernia can be dissected circumferentially to the fascial opening and reduced without entering the peritoneal cavity. The dissection can be continued beneath the fascia creating a preperitoneal space for the placement of a prosthesis, if needed. Several techniques can be used to close the fascial defect. In 1901, James Mayo described the classic overlapping, vest-over-pants (double-breasting or waistcoat) technique, which bears the name of his clinic, in which the upper edge of the linea alba overlaps the lower edge (Fig. 72-32).[113] The operation is losing popularity now because it is generally not consistent with the tension-free concept popular in hernia surgery today.[114] It requires more dissection than other procedures to create the flaps and is therefore more painful. Simple suture herniorrhaphy is the easiest procedure but has the highest recurrence rate (especially with high body mass index [BMI] and smoking), and therefore should be used only for small defects. For larger hernias, particularly in adults, the preperitoneal space can be exploited by bluntly dissecting the peritoneum from the undersurface of the posterior rectus sheath for enough distance to be able to place an appropriate prosthesis. If the peritoneum is not entered, a mesh prosthesis is preferred, which is placed in the preperitoneal space and then the fascial edges closed if the defect is small enough.

Otherwise, a bridging technique can be used with the fascial edges sewn to the underlying mesh. If the peritoneal cavity is entered, then a composite prosthesis (e.g., ePTFE + polypropylene) or a mesh prosthesis with an adhesion barrier (see prosthetic materials section) can be placed intraperitoneally with the adhesion barrier facing the viscera. A laparoscopic approach for umbilical hernias is a good option for recurrent hernias or hernias with defects larger than 3 cm and, in retrospective reviews, has been shown to decrease operative times and result in faster recovery to normal activities. The technical details are similar to those of a laparoscopic incisional hernia repair (see incisional hernia section).

Table 72-12 Ventral Hernia Working Group (VHWG) Classification of Incisional Hernia

Grade 1	Grade 2 Comorbid	Grade 3 Potentially Contaminated	Grade 4 Infected
Low risk of complications No history of wound infections	Smoker Obese Diabetic Immunosuppressed COPD	Previous wound infection Stoma present Violation of gastrointestinal tract	Infected mesh Septic dehisence

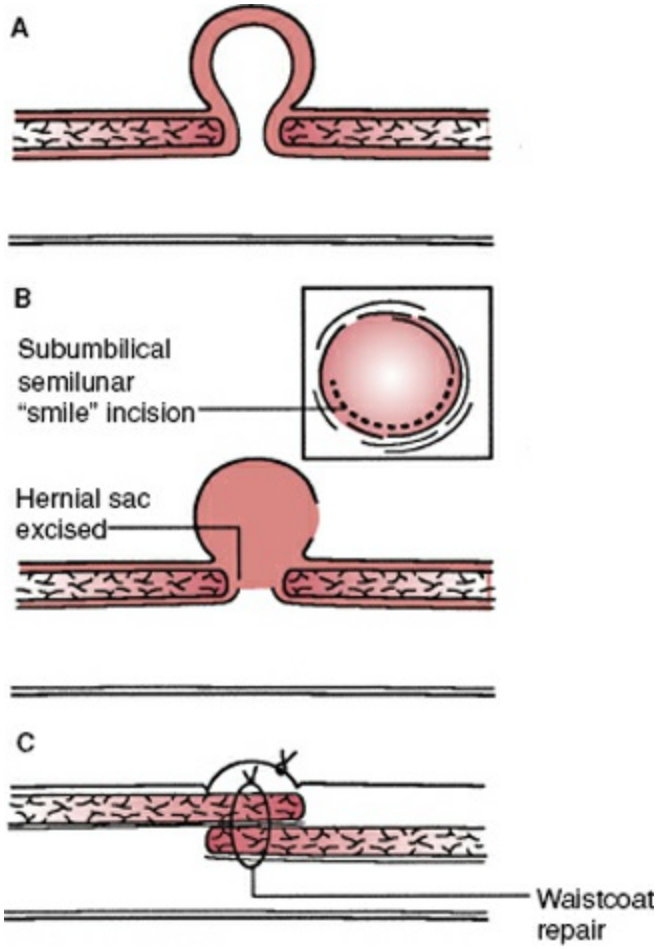

Figure 72-32. Mayo repair of an umbilical hernia. **A:** Diagram of longitudinal section through the hernia. **B:** Subumbilical "smile" incision. The hernial sac is excised. **C:** Waistcoat type of closure.

EPIGASTRIC HERNIAS

Epigastric hernias occur through a defect in the linea alba. In the majority of patients, only a single decussation of the fibers of the linea alba is present rather than the usual triple decussation (Fig. 72-7). The incidence of epigastric herniation reported varies from less than 1% to as high as 5%. Epigastric hernias are more common in woman than men with a peak incidence of repair around age 40 years.[112] About 50% of them are asymptomatic. Most are less than 1 cm and contain only incarcerated preperitoneal fat without a peritoneal sac. For this reason, epigastric hernias commonly cannot be visualized with laparoscopy. Patients complain of a painful nodule in the upper midline. Repair by reduction of the preperitoneal fat and simple closure of the defect is curative. These hernias are prone to recur, with rates as high as 10%, which has led many surgeons to routinely include a prosthetic underlay just as in umbilical or incisional hernias.

Left untreated, an epigastric hernia can become large enough for a peritoneal sac to form, into which the intra-abdominal contents can protrude. The sac is usually wide, and serious complications are not common. About 20% are multiple, and this needs to be ascertained prior to operation if all the defects are to be addressed, because after anesthesia induction, they can be difficult to identify.

In *diastasis recti,* the two rectus muscles are separated widely. The area of the linea alba is stretched and protrudes like a fin. The condition almost never produces complications and therefore surgical correction is not routinely recommended. However, many patients find the defect unsightly and request treatment. They should be cautioned that many insurance companies consider this a cosmetic defect and will not reimburse. Surgery involves removal of a strip of the weakened linea alba and reapproximation. An alternative is a mesh repair done laparoscopically.

INCISIONAL HERNIAS

Incisional hernias occur as a complication of prior surgery. These hernias can follow any type of abdominal surgery, regardless of the type of incision. More than 2 million laparotomies are performed yearly in the United States, and the reported incidence of incisional hernia varies between 2% and 20%[115] and is one of the most common reasons for reoperation.[109] The highest incidence is with midline incisions (10.5%) and transverse incisions (7.5%), but hernias are well documented following paramedian incisions as well (2.5%).[116] The cumulative incidence of incisional hernias is linear, as they can present after considerable delay following the index operation. Poor surgical technique, rough handling of tissues, use of rapidly degraded absorbable suture materials, closure of the abdomen under tension, and infection of the wound are technical causes of incisional hernias. Morbid obesity, cigarette smoking, pulmonary disease, debilitation from cancer, chemotherapy, the use of steroids, hypoalbuminemia, and other pre-existing comorbid conditions are patient factors that have been incriminated. Patients with an aortic aneurysm or a proven defect in collagen metabolism also exhibit an increased incidence of incisional hernias.[117] Read and Yoder in a retrospective review found that 17% of incisional hernias are incarcerated or strangulated at presentation.[118] The consequences of unrepaired enlarging symptomatic hernias include loss of abdominal domain; significant biomechanical alterations that affect posture; compromise of activities of daily living, including lifting and straining; and poor cosmetics. Most of the published literature on treatment options addresses midline defects. The management of nonmidline incisional hernias (i.e., subcostal, transverse, or gridiron incisions) to some extent must be extrapolated.[119]

At least some ventral hernias can be prevented by proper abdominal closure after a laparotomy. Monofilament slowly absorbable or nonabsorbable sutures should be placed in the aponeurosis only 5 to 8 mm from the wound edge, not to include muscle, 4 to 5 mm apart in a single layer. Studies have shown that nonabsorbable sutures result in a lower incidence of incisional herniation but at the cost of increased wound pain and chronic suture sinuses when they become infected.[106] These suture sinuses tend to be multiple and take years to eradicate by probing the sinus tracks and removing deep sutures. The development of better monofilament absorbable sutures has caused most surgeons to use a slowly absorbable monofilament suture.[107] Using small needles is recommended to avoid including excessive amounts of tissue. By measuring the suture remnants in relationship to the total length of the suture, one can calculate a suture length to wound length ratio which should never be less than 4.[120]

Another common practice after laparotomy is to prescribe abdominal binders. Although most surgeons prescribe abdominal binders following laparotomy, there is no evidence that these devices decrease pain; improve respiratory function; or prevent incisional hernias, seroma formation, or wound complications. The use of a binder may provide some comfort in the immediate postoperative period to some patients and may be recommended for this purpose only.[121,122]

Massive Hernia

Although there is no consistent definition as to what constitutes a massive hernia, this term applies to abdominal wall hernias with a large portion of the abdominal contents situated within the sac and to hernias that are said to have “loss of domain” because the contents of the hernia exceed the capacity of the abdominal cavity. Many of these hernias are associated with morbid obesity, skin ulcerations, enterocutaneous fistulae, diverting stomas, and distortion of the abdominal wall from multiple prior attempts to repair them. Several physiologic changes such as alteration of ventillatory equilibrium and impairment of venous return results from long-standing massive hernias. Forced reduction of the hernia with replacement of contents into the abdominal cavity can increase intra-abdominal pressure considerably, resulting in respiratory insufficiency and cardiovascular compromise.[123] In extreme cases, it is impossible to return the contents to the abdomen and repair the hernia defect without resection of intra-abdominal contents, such as colectomy with omentectomy. Repair of massive ventral hernias with loss of domain is technically challenging and is associated with high morbidity, mortality, and recurrence rates. A good understanding of the abdominal wall anatomy and the nature of fascial defects is essential prior to repairing these ventral hernias. Complications of repair are common and include respiratory compromise, abdominal compartment syndrome, skin flap necrosis, and wound infection, in addition to the usual surgical complications. Therefore, repair should not be recommended unless there are overwhelming indications such as disabling symptoms, bowel obstruction or strangulation, or extensive skin ulceration caused by the hernia. These patients might best be seen in centers with special interest in this area where teams have been assembled to treat complex abdominal wall pathologies.[124]

Preoperative Preparation

The key to successful management of ventral hernia is good preoperative work-up. Many of these patients have had multiple prior surgeries including previous attempts at hernia repair and it is important for the surgeon to obtain and review all the previous operative reports and evaluate the nature of previous surgeries, incision types, and closure techniques. Smoking and obesity are major contributors to failure of ventral hernia repair. At our institution, we require 4 weeks of smoking cessation prior to elective ventral hernia repair. Morbidly obese patients are at increased risk for wound infection and dehiscence and should be managed in a multidisciplinary setting with the bariatric surgery team, and sometimes a staged approach may be needed with weight loss surgery initially with temporary repair of ventral hernia followed by definitive repair once the patient achieves maximal weight loss and has fewer comorbidities. Management of chronic wounds and infections (both local and distant), smoking cessation, optimization of cardiopulmonary and nutritional status, and control of blood sugars in diabetic patients is recommended prior to surgery also optimize the chances of a successful repair. Imaging studies in the form of CT scan of the abdomen and pelvis, although not routinely indicated, may be helpful for preoperative planning in patients with large or complex ventral hernias, posttraumatic hernias, morbid obesity, and special cases such as lumbar hernias. Functional cine MRI is a new technology that can be used to find postoperative adhesions.[125] A mechanical bowel preparation may be used in patients with complex ventral hernias. On the day of surgery, special attention must be paid to the administration of thromboembolism prophylaxis and preoperative antibiotics. An iodophor skin barrier may be used to decrease mesh contact with the skin. In the operating room, sharp debridement of devitalized or infected tissues is recommended and sometimes a staged approach for hernia repair is necessary. Prior to abdominal wall closure, attention should be paid to ventilator mechanics as rising peak and plateau pressures can be early signs of abdominal compartment syndrome.

Progressive Preoperative Pneumoperitoneum

Progressive preoperative pneumoperitoneum (PPP), which was first described for repair of giant incisional hernias, was described by Goni Moreno in 1940 and is a useful technique in these patients to expand the abdominal cavity by stretching the abdominal wall and the diaphragm.[29,123,126,127] The maneuver involves injecting room air (or CO_2) via a needle or implantable catheter every 1 to 3 days to tolerance (development of shoulder pain, difficulty breathing, or subcutaneous emphysema). This can be performed by patients and families as outpatient, but some surgeons prefer to use pressure monitoring, keeping it less than 15 mm Hg. Although theoretically attractive, pneumoperitoneum is not always successful. The injected gas sometimes preferentially enters the hernia sac and distends it with minimal effect on the abdominal cavity. In addition, pneumoperitoneum has been shown to diminish lower extremity venous return. This could translate into a higher risk of thromboembolic complications.

PPP has been more commonly applied in Europe and South America with good results

for large ventral hernias. In a recent study, safety and feasibility of this approach were shown in 16 patients.[123] Of these 16 patients, 7 still required an additional procedure such as ileocecectomy or lateral relaxing incision on the rectus sheath to achieve abdominal wall closure. In another small series consisting of 9 patients, PPP was sufficient to reduce the visceral contents, permitting a retrorectus repair in 80% of these patients.[128] Of 9 patients, 1 patient with diabetes mellitus developed an abdominal wall abscess requiring drainage in the postoperative period. Many surgeons in North America are skeptical about the approach, questioning how one ensures that the air injected stays in the peritoneal cavity and does not leak into the hernia sac, enlarging it further. Also of concern is the possibility of infection and the cost, especially if in-hospital monitoring is needed.

Tissue Expansion

Tissue expanders can also be used when either skin or the myofascial elements of the abdominal wall are deficient.[129] They are implanted subcutaneously or subfascially and are gradually inflated until the desired amount of extra tissue is obtained. The limitation of the technique is the delay in definitive repair while the expansion is going on and the considerable amount of pain that patients complain of. The intra-abdominal placement of tissue expanders has also been described to address the issue of loss of domain, but this is primarily confined to the pediatric literature.

Visceral Resection

In certain circumstances, resection of intra-abdominal viscera is necessary to avoid causing increase in intra-abdominal pressure. Options include total omentectomy, subtotal colectomy, and removal of retroperitoneal fat.

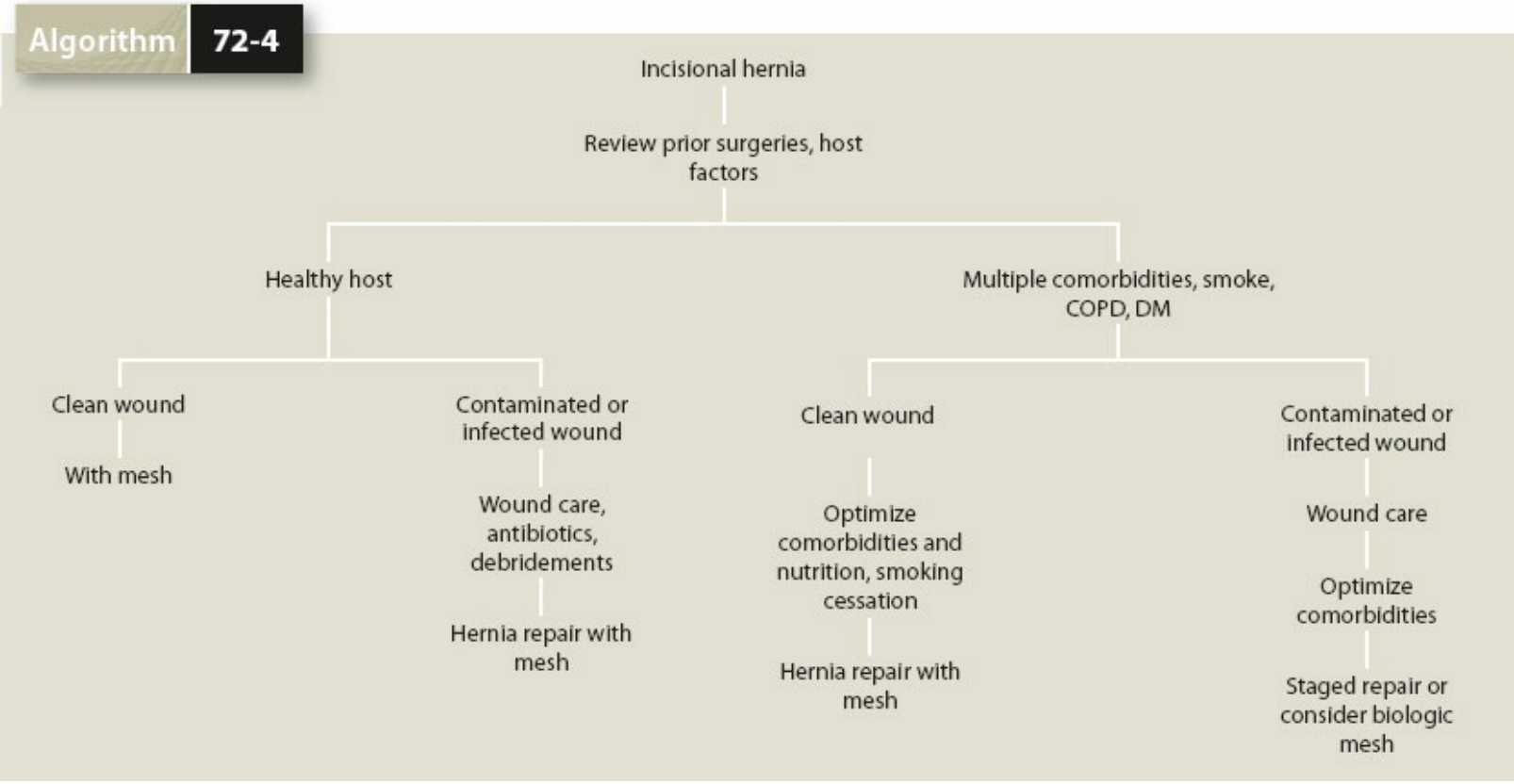

Algorithm 72-4. Management of incisional hernia.

Treatment of Ventral Hernias

General Principles

8 As described above, the abdominal wall is a complex unit and plays an important role in respiration, defecation, micturition, movement of the trunk, and protection of intra-abdominal organs (Algorithm 72-4). It has been shown that health-related quality of life improves after ventral incisional hernia repair, presumably related to improved abdominal wall function.[130] Many experts believe that reapproximation of rectus muscles in the midline restores functional abdominal wall anatomy and is recommended if it can be performed without excessive tension.

Nonprosthetic Repairs

Traditionally, the repair of an incisional hernia depended on the size of the hernia. If the defect was solitary and 3 cm or less, primary closure with nonabsorbable suture material was recommended. This concept is now questioned after the publication of a landmark prospective randomized trial by Luijendijk and colleagues from the Netherlands in the year 2000 and updated in 2004 comparing a prosthetic repair versus primary suture.[131,132] These investigators found a 50% reduction in the recurrence rate when a prosthesis was used, and this even applied to small hernias (<10 cm^2). For this reason, a simple, nonprosthetic technique should be reserved for only the smallest hernias in patients without risk factors for further recurrence.

Component Separation

9 Abdominal wall reconstruction and component separation are useful tools in the armamentarium of the hernia surgeon. The main types of component separation techniques currently used are described below.

Anterior Component Separation. A more complex nonprosthetic repair is the component separation technique popularized in the early 1990s by Ramirez and colleagues which is based on lateral fasciotomies that allow sliding of the muscular fascia layers toward the midline providing coverage for large midline abdominal wall defects.[133] Originally, it was proposed as a tissue repair for patients with contaminated wounds to avoid use of prosthesis, but several modifications have been described since the original description. In this technique, the skin and subcutaneous fat are dissected free from the anterior sheath of the rectus abdominis muscle and the aponeurosis of the external oblique muscle. The aponeurosis of the external oblique muscle is transected longitudinally just lateral to the lateral side of the rectus sheath (Fig. 72-33). It is important to extend the incision inferiorly up to the inguinal ligament and superiorly onto the chest wall at least 5 to 7 cm cranial to the costal margin especially for defects close to the xiphoid. The external oblique muscle is separated from the internal oblique muscle, as far laterally as possible in a relatively avascular plane, beyond the area of skin undermining toward the midaxillary line. This step is safe because the neurovascular bundle (comprising the intercostal nerves and vessels) lies deep to the internal oblique

muscle. The result is that the internal oblique muscle and the rectus abdominis slide medially for about 7 to 10 cm. When necessary, 2 to 4 cm of additional length can be gained by performing a posterior rectus release, separating the posterior rectus sheath from the rectus abdominal muscle. This step may be difficult in patients who have scarring from previous surgical procedures. Care must be taken not to damage the neurovascular bundle that runs between the internal oblique and transversus abdominis muscle to enter the rectus sheath posterolaterally. After advancement of the rectus complex toward the midline, the fascial closure is performed followed by layered closure of the subcutaneous tissues and skin with drains. Several modifications to the original technique have been described. The technique can also be used as an adjuvant to the prosthetic repairs described next.

Posterior Component Separation. This technique is an extension of the posterior rectus release (Fig. 72-34).[134] Once the lateral aspect of the posterior rectus space has been developed, the posterior rectus sheath is incised just medial to the neurovascular bundles penetrating the rectus muscle so that they are not damaged (Fig. 72-35). This procedure should start cranial to the umbilicus which will then expose the underlying transversus abdominis muscle which is then incised along its medial edge: starting this dissection caudal to the umbilicus will lead to more difficulty getting into the appropriate plane because the transversus abdominis muscle has no muscle fibers in this region This step allows entrance into plane between transversalis fascia/peritoneum and the transversus abdominis muscle (Fig. 72-36).

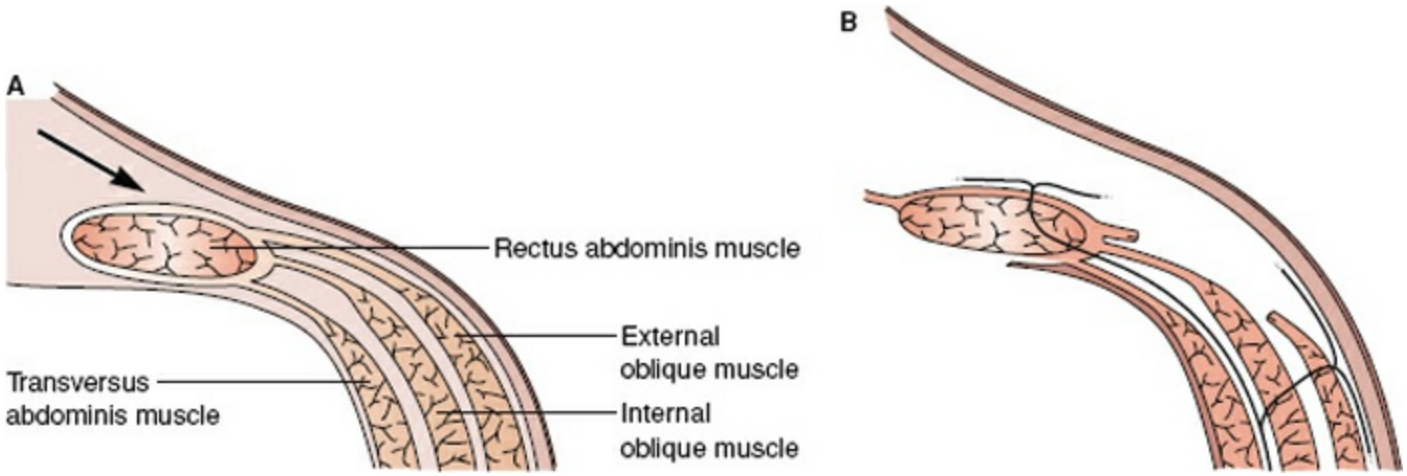

Figure 72-33. Component separation technique.

The dissection can then be extended laterally to the psoas muscle. The dissection plane can be extended cephalad to the diaphragm by dissecting dorsal to the sternum, sweeping the peritoneum/transversalis fascia off the diaphragm. Inferiorly, the dissection can be extended into the space of Retzius to expose the symphysis pubis and Cooper ligament. This dissection results not only in the creation of a large retromuscular space beyond the linea semilunaris but also allows for significant medial advancement of the posterior rectus sheaths which are then closed in the midline followed by placement of mesh in retromuscular plane and fixation with transabdominal sutures and possibly bone anchors.

The anterior sheaths can then be reapproximated in the midline because the transverse abdominus release allows further medialization of the anterior sheaths or the gap can be bridged with mesh. This technique is an important addition in the armamentarium of surgeons dealing with complex abdominal wall problems and has been shown to have favorable perioperative morbidity and acceptable recurrence rates compared to anterior component separation.[121] The technique is particularly suited for addressing recurrent hernias after a prior anterior component separation but probably should not be used simultaneously in combination with a concurrent anterior component separation. However, posterior component separation is technically difficult because the transversalis fascia/peritoneum complex posteriorly can be extremely thin, tearing easily. In order to isolate the viscera from the prosthetic which will eventually be placed, these tears must be repaired. If this is not possible, one of the adhesion barrier prostheses should be used. A much easier dissection can be accomplished by not dividing the transversus abdominis muscle while continuing laterally in the plane between the transversus abdominis muscle and the internal oblique muscle.[135] But, this theoretically should denervate the muscle because the intercostal nerves travel to the rectus muscle in this plane (see anatomy section). This remains a controversial issue because another component separation technique known as the Memphis modification completely detaches the rectus muscle out of its bed after an external oblique release leaving only the cranial and caudal attachments intact in a manner similar to a tram flap.[136] This technique allows for a completely tension-free reapproximation of the rectus muscles in the midline. Because the authors do not report an excessive rate of either rectus atrophy or abdominal wall dysfunction, one must assume that the nerve supply accompanying the inferior and superior epigastric vessels is sufficient. In addition, this technique is probably best suited for patients who are not hernia formers but require medialization of the fascial gap after trauma.

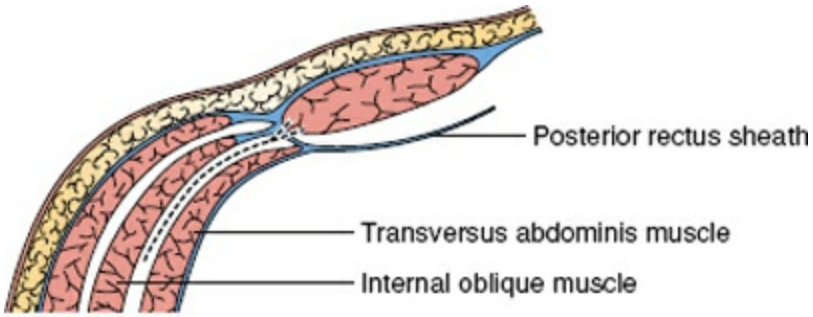

Figure 72-34. The retromuscular space is developed by incising the posterior rectus sheath and dissecting the rectus abdominis muscle from the underlying rectus sheath.

Endoscopic Component Separation. This technique was developed to lessen the degree of abdominal dissection and potentially address the wound complications associated with open component separation with the use of a balloon dissector and laparoscopic instruments. The technique involves making 2- to 4-cm incisions just below the costal margin in anterior axillary line (lateral to the attachment of the external oblique aponeurosis on the rectus sheath). The space between the external and internal oblique

muscles is dissected and under camera guidance, dissector balloon is inflated which further aids blunt dissection in this layer. The external oblique aponeurosis is then divided. A Balloon dissector can be used in the subcutaneous space as well. This technique can be followed by either open or laparoscopic hernia repair.[137,138] One potential limitation might be the adequacy of the myofascial advancements using this technique. Proponents of this technique claim reduction in postoperative stay by about 50% and a distinct advantage in the setting of stomas, but it remains to be seen if it is effective in the long term (Fig. 72-32).

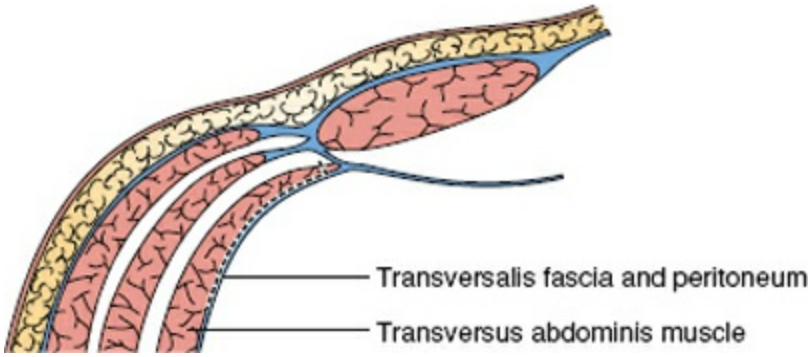

Figure 72-35. The posterior rectus sheath is incised about 0.5 to 1 cm medial to the anterior/posterior rectus sheath junction to expose the underlying transversus abdominis muscle. Note the perforator nerves that are preserved during retromuscular dissection and subsequent posterior component release.

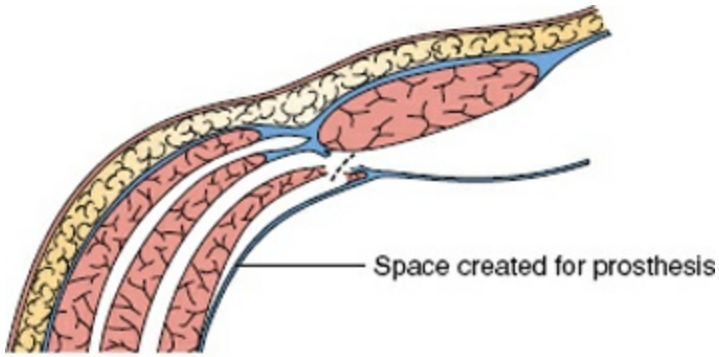

Figure 72-36. Division of the posterior rectus fascia just medial to the linea semilunaris and perforator nerves followed by division/release of the transversus abdominis muscle along its entire medial edge.

Prosthetic Repairs

The concept of prosthetic use is not new as it was proposed by Usher and colleagues in 1958 for hernia repair using a polypropylene mesh.[139] Over the ensuing years, lessons have been learnt: (a) the use of absorbable mesh leads to a high relapse rate, (b) repetition of a previously inadequate technique frequently fails, (c) a simple inlay technique that bridges the defect has a high failure rate, (d) reinforcement of the entire scar is advisable irrespective of operative findings, and (e) the success of a mesh repair depends on the extent of overlap or underlap.[140]

Numerous techniques for prosthetic incisional hernia repair have been described, which is not surprising since there are so many variables. For example, there are five potential spaces to place the prosthesis (Figs. 72-3 and 72-37).

Because of the number of different repairs, it is not practical to describe each one in detail. However, most of them represent a variation of one of the general classes described.

Onlay Prosthetic Technique. The basis of this procedure is to place a prosthesis over any of a wide variety of simple repairs. Although it has some proponents, many surgeons feel that this technique offers little advantage over the simple repair that the prosthesis overlies. This may be explained by Pascal's law which states that pressure exerted on an enclosed fluid acts equally in all directions. In an onlay technique, this results in lifting forces against the mesh.[141]

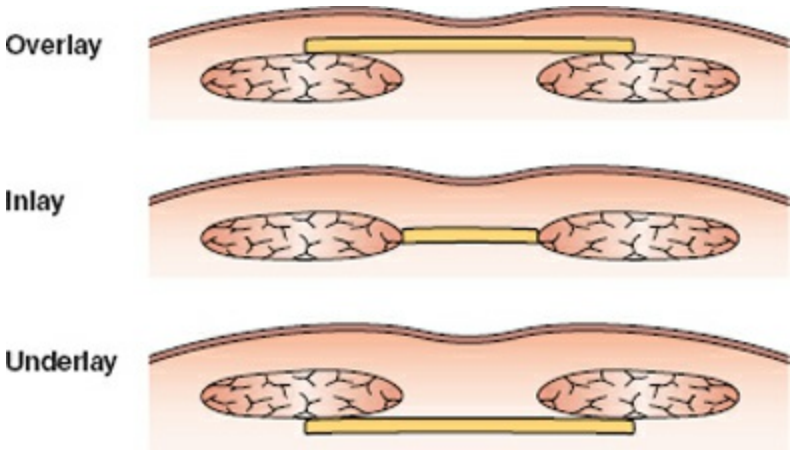

Figure 72-37. Potential spaces in the abdominal wall to place prosthetic material: onlay or on top of the anterior abdominal fascia; under the anterior fascia but in front of the muscle (if the mesh bridges that space, it would be an inlay technique); retrorectus space or the underlay technique below the muscle but above the posterior fascia; preperitoneal (important when below the arcuate line); intraperitoneal.

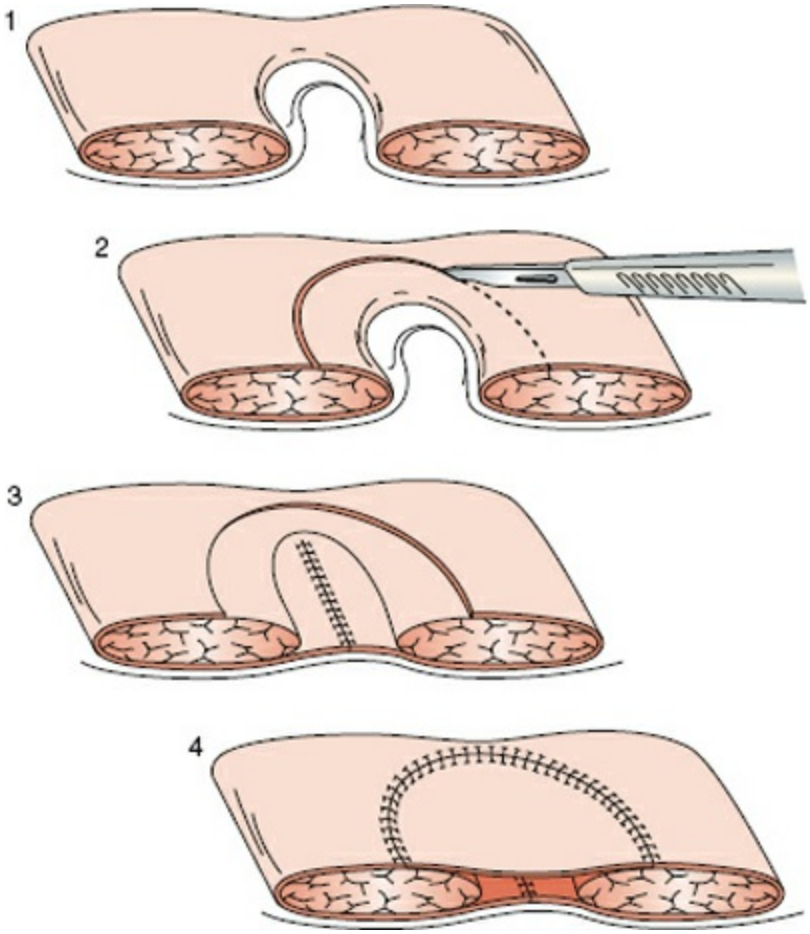

Figure 72-38. **1:** Hernia defect with bulging sac. **2:** Anterior fascia is incised longitudinally on either side of the defect. **3:** The anterior fascia is then rotated medially, in effect lengthening the posterior sheath to allow primary closure, isolating the abdominal contents from the anterior fascia. **4:** Prosthetic material is used to bridge the anterior fascia.

Prosthetic Bridging Technique. A prosthetic bridging repair became popular in the 1990s in keeping with the tension-free concept for inguinal herniorrhaphy. The basic principle underlying this technique is that for a prosthetic repair to be effective, the defect should be bridged. Although this repair is theoretically attractive, it has not been nearly as successful for incisional hernias as for inguinal hernias. The recurrence rate is especially high in obese patients. It is not recommended but may be the last resort if the defect is so large that abdominal wall closure cannot be obtained even with sophisticated techniques such as component separation. One modification technique used for massive abdominal hernias is known as medialization which consists of closure of the abdominal wall with ePTFE followed by scheduled serial visits to the operating room to tighten the prosthesis by removing a strip in the middle and suturing the edges together. This technique allows definitive abdominal wall closure after a mean six serial visits.[142]

Combined Fascia and Mesh Closure. This group of repairs combines features of the component separation technique (described below) with the tension-free concept. By incising the anterior fascia and rotating the medial edge toward the midline in continuity with the posterior fascia, the posterior fascia is effectively lengthened (Fig. 72-38). The posterior fascia is closed primarily, but the anterior fascia is bridged with a prosthesis.

Sublay Prosthetic Technique. The sublay prosthetic repair, sometimes referred to as the

retromuscular approach, is characterized by the placement of a large prosthesis in the space between the abdominal muscles and the peritoneum (Fig. 72-17). It was popularized by Rives, Velamenta, Stoppa, and Wantz and is particularly suitable for large and multiply recurrent hernias when most of the abdominal wall must be reconstructed.[124,143,144] It is considered the most effective conventional incisional hernia repair and therefore the one against which other procedures must be measured. Its major disadvantage is its need for wide undermining of the abdominal layers with the potential risk of devascularization of the abdominal wall or the creation of a large seroma, which later leads to infection. Suction drains are used by most surgeons, although the literature does not unequivocally support their use.[145]



Figure 72-39. Perforating blood vessels supplying the rectus muscle.

The procedure is begun by excising the previous scar and dissecting the peritoneal sac of the hernia to the level of the fascia. Occasionally, the sac does not have to be opened and the procedure can be performed totally extraperitoneal. More commonly, the sac is thin and easily disrupted, making entrance into the peritoneal cavity inevitable. The posterior rectus sheath is opened on each edge of the hernia defect and dissected away from the undersurface of the recti to the lateral edge of the rectus sheath, with care being taken to prevent damage to the perforating blood vessels at the lateral side of the sheath (Fig. 72-39). The posterior rectus sheaths are then approximated to each other primarily (unless the peritoneum has not been opened). During this part of the procedure, flaps must be created by dissecting the skin and subcutaneous tissue off the underlying fascia laterally until enough tension is relieved to allow primary closure of the anterior rectus sheath. It is sometimes necessary to add component separation to further decrease the tension. A large mesh prosthesis (combined with ePTFE or an adhesion barrier if the approximation of the posterior rectus sheath is inadequate) is then placed in this space outside the repaired posterior sheath but beneath the recti. The mesh is secured in this position with several sutures directly to the posterior rectus sheath. An alternative is to use a suture passer to pass the two tails of a suture placed on the lateral side of a prosthesis through the lateral edge of the rectus sheath through separate fascia openings.

The suture is then tied in the subcutaneous tissue resulting in a secure anchoring of the prosthesis in the abdominal wall. If the subcutaneous tissue dissection from the anterior rectus sheath has not been too extensive, the sutures cannot be retrieved in the subcutaneous tissue and therefore the suture passer is pushed through the entire thickness of the subcutaneous tissue and then through a small stab incision in the skin. The suture is tied and the knot allowed to retract back into the subcutaneous tissue and the skin is approximated over it. The procedure is completed by reapproximating the anterior rectus sheaths, thus bringing the rectus muscles back to their normal configuration. The best long-term results are obtained when the anterior fascia can be closed bringing the muscles back together because of an improvement in abdominal wall mechanics. However, it is sometimes impossible to achieve this and the gap must be bridged with a prosthesis (Fig. 72-40).

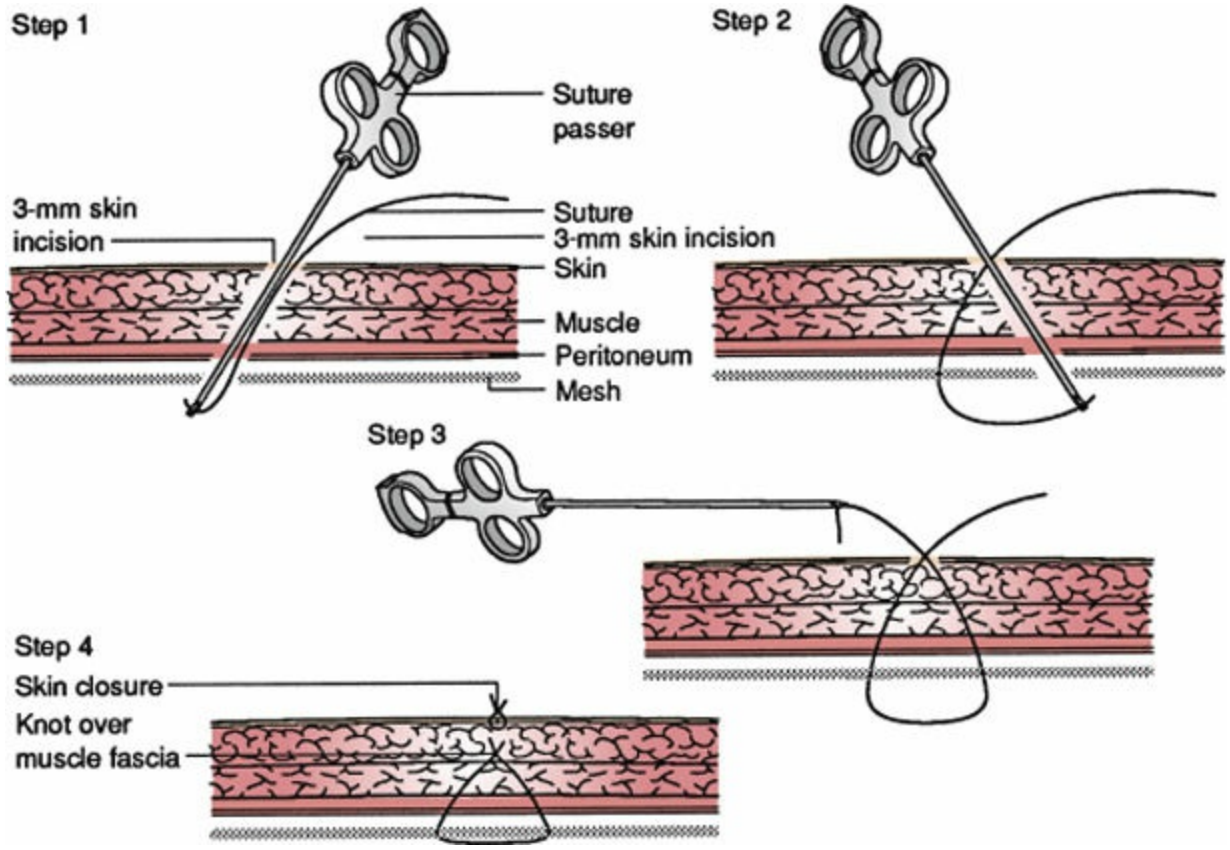

Figure 72-40. Fixation of prosthesis to the peritoneal surface of the abdominal wall with the use of a suture passer. Step 1: The suture passer device with a heavy nonabsorbable suture is passed through a 3-mm stab incision in the skin at an oblique angle. The device and suture traverse the entire abdominal wall and then the prosthesis. Once the peritoneal cavity is entered, the suture is released and the passer is withdrawn back into the subcutaneous tissue. Step 2: The device is redirected at a different angle through the abdominal wall and prosthesis and the suture is grasped. Step 3: The suture is pulled out of the abdominal cavity so that the two free ends are extracorporeal. Step 4: The suture is tied with the knot resting on the fascia. The skin is then closed.

Role of Flaps and Grafts

The use of flaps and grafts is usually reserved for patients in whom a conventional component separation repair with a retromuscular prosthesis is not possible. Free fascia

lata grafts, autodermal grafts, and pedicled or free vascularized flaps have been reported, but are reserved for the most complex abdominal wall reconstructions.

Laparoscopic Ventral Hernia Repair. This operation was developed in the 1990s as a natural extension as surgeons became trained in the laparoscopic method for many commonly performed abdominal procedures. The greatest value of laparoscopic surgery is that reapproximation of abdominal muscles can be performed and the "gold standard" sublay technique can be replicated by the intra-abdominal placement of a submuscular prosthesis, eliminating the need for the extensive abdominal wall dissection implicit in the conventional operation.[53] ePTFE has a long track record of safety with contact with intra-abdominal viscera, and the development of the adhesion barrier–coated mesh prosthesis has made intra-abdominal placement more attractive. Laparoscopic surgery provides several advantages including decreased blood loss, lower wound infection rates, decreased hospital stay, and patient preference.[125,146] Improvements in wound complications and recurrence rates have not been consistently demonstrated. Seromas are more commonly seen with laparoscopic repair but these mostly resolve uneventfully without needing additional intervention. Certain absolute contraindications to laparoscopic ventral hernia repairs exist including patients with hemodynamic instability and bowel compromise.

Entrance to the abdominal cavity followed by adhesiolysis can be problematic for a surgeon performing a laparoscopic ventral hernia repair and devastating complications are possible, which is the Achilles heel of this operation. This is because patients with incisional hernias by definition have had previous abdominal surgery and the midline is commonly not usable for initial access because of a previous incision in the area. The surgeon must make an educated guess as to the least likely place for significant adhesions as well as be familiar with alternative access techniques away from the midline. Unrecognized visceral injury can be the consequence if extreme care about entrance and adhesiolysis is not maintained. These injuries commonly go undetected until the patient develops signs of septic shock because it is difficult to differentiate peritoneal signs from ordinary postoperative pain. This accounts for the significant mortality with this complication. Surgeons performing laparoscopic ventral hernia repairs must have the good judgment to abandon the procedure in the face of a hostile abdomen. Left or right upper quadrant, subcostally, is generally a safe access site for the initial port.[125]

Once the abdomen has been safely entered and the adhesiolysis completed, the abdominal contents are reduced from the hernia defect under direct laparoscopic guidance. The number and location of the sites of cannula placement vary depending on the size and location of the hernia. Once all the hernia defects are identified, the operating surgeon must make a decision to either continue the procedure laparoscopically or convert to an open operation. In our opinion, multiple "swiss cheese defects" are the best indication for a laparoscopic repair. On the other hand, if there are only one or two defects with wide separation of the muscles, the laparoscopic repair is not as effective for two reasons: (a) the prosthesis will tend to balloon out through this defect, simulating a recurrence even though the hernia is technically repaired, and (b) abdominal wall dynamics are addressed more effectively if the muscles can be reapproximated. The

muscles can commonly be approximated using a suture passer/trocar site closing device similar to that demonstrated in Figure 72-40. Our group favors conversion to an open, conventional operation in situations where it is not possible to reapproximate the muscles, but this philosophy is not shared by all. Even in the event of conversion, laparoscopy can be used as a useful adjunct to perform initial adhesiolysis and to examine the closure at the end of the repair to ensure approximation of fascial edges and rule out any inadvertent injury to intra-abdominal organs from the repair.

If laparoscopic hernia repair is planned, after initial adhesiolysis and examination of the defect, the prosthesis is prepared by placing absorbable sutures extracorporeally around its circumference with long tails extending from the nonadhesion barrier side. It is then rolled up and introduced through the largest cannula. After it is unrolled, a suture passer is introduced into the abdomen to grasp each of the suture tails through a single stab incision but separate musculofascial openings in array, which corresponds to the previously placed prosthesis sutures (Fig. 72-40). The sutures can be tied extracorporeally and the knot allowed to retract back into the subcutaneous tissue of the stab incisions. The skin is then closed over them. It is important that the prosthesis be positioned onto the peritoneum so that it widely overlaps the hernia defect (4 to 6 cm, at least). The prosthesis is further secured to the anterior abdominal wall with staples, tacks, or sutures using the suture passer technique.

Table 72-13 European Hernia Society (EHS) Classification of Parastomal Hernias

EHS Classification Grid for Parastomal Hernia		Small <5 cm	Large >5 cm
Concomitant incisional hernia	No		
	Yes	Primary	Recurrent

PARASTOMAL HERNIAS

Parastomal hernia is an incisional hernia related to the presence of an ostomy which can have significant effects on the patients' quality of life, physical and psychological well being, and health care resources.[147] The incidence of parastomal hernia varies with the type of the stoma (1.8% to 28% for ileostomy and 4% to 48% for colostomies).[148,149] Studies designed with very careful follow-up suggest that a paracolostomy hernia develops in more than 50% of patients followed for longer than 5 years with most occurring in the first 2 years. The true incidence of parastomal hernias has been difficult to quantify given the lack of uniform definition of what constitutes a hernia, variable follow-ups, and inadequacy of physical examination to diagnose early occurrences.[150] Poor site selection or technical errors, such as making the fascial opening too large, excessive splitting and stretching of muscle fibers, epigastric nerve denervation, placing a stoma in an incision, or emergency rather than elective creation of stoma, account for some of these hernias. Placing a stoma lateral to the rectus sheath is widely touted as a cause, but this is now being challenged. Obesity, malnutrition, advanced age, collagen abnormalities, postoperative sepsis, abdominal distention, constipation, obstructive uropathy, steroid use, and chronic lung disease also contribute. Other techniques for stomal construction, such as extraperitoneal tunneling, stapled ostomy, and prophylactic mesh reinforcement for permanent colostomies especially in the posterior sublay position have been suggested, but their role in prevention of parastomal hernias is uncertain given the lack of randomized controlled trials and good quality evidence. A classification system for parastomal hernias has been recommended based on the size and presence of a concomitant incisional hernia by the European Hernia Society (Table 72-13) which will help standardize the definition of parastomal hernias for future studies.[151]

Fortunately, patients tolerate these hernias well. Most of the parastomal hernias are asymptomatic and therefore can be treated conservatively. Fewer than 20% of patients with parastomal hernias have a complication that mandates repair, and life-threatening complications, such as bowel obstruction or strangulation, are rare. Routine repair is therefore not recommended. Table 72-14 lists possible indications. The three general types of stomal hernia repair are fascial repair, stomal relocation, and prosthetic repair, which can be performed either laparoscopically or open. Fascial repair involves a local exploration around the stoma site, with primary closure of the defect. This approach is associated with up to 75% recurrence rate[152] and should be considered of historical interest only. Stomal relocation[150] is usually indicated in patients with other stomal problems, such as skin excoriation or suboptimal stomal construction. The major drawbacks of stomal relocation are the fact that a laparotomy is required, which in and of itself causes more morbidity than some of the other techniques, and that it exposes the patient to the risk of three new incisional hernias at (a) the old stoma site, (b) the laparotomy incision site, and (c) the new stoma site with reported recurrence rates ranging from 24% to 86%.

Table 72-14 Indications for Repair of a Parastomal Hernia

Absolute
Obstruction
Incarceration with strangulation
Relative
Incarceration
Prolapse
Stenosis
Intractable dermatitis
Difficulty with appliance management
Large size
Cosmesis
Pain

Whenever possible, a prosthetic repair should be considered as this appears to be the most effective, although few randomized trials have been performed to unequivocally prove this. Options for the location of mesh placement in parastomal hernia repair are as follows:

1. Onlay with the mesh placed anterior to the anterior rectus aponeurosis. A hockey stick incision is usually performed outside the boundaries of the patient's appliance (Fig. 72-41). The skin and subcutaneous tissue are then undermined to identify the fascial defect, which is closed primarily and reinforced with a prosthetic onlay. The problem with this approach is that the undermining of subcutaneous tissue leads to seroma formation, which sometimes goes on to infection. Recurrence rates of up to 26% have been reported with this technique with a mesh removal rate up to 23%.[153]
2. Inlay with the mesh placed to bridge the defect and sutured to the fascial edges. This alternative has, in multiple series, been shown to have the highest chance of recurrence and suffers from the seroma problem, as with the onlay.
3. Sublay with the mesh placed dorsal to the rectus muscle and anterior to the posterior rectus sheath or mesh placement between posterior rectus sheath and peritoneum has been described in small case series. Posterior component separation with retromuscular mesh positioning is a technique that has been described in patients with complex parastomal hernias which uses mesh to reinforce all "at risk" areas for recurrence.[154]
4. Intraperitoneal inlay mesh (IPOM). An intra-abdominal prosthetic repair eliminates the need for the abdominal wall dissection and is therefore becoming increasingly popular. It also enlists the mechanical advantage of placing the prosthesis on the peritoneal side of the abdominal wall.[155] The intra-abdominal approach is particularly suited for laparoscopy, and several techniques have been described.[156] This can be performed in two ways. (1) The Sugarbaker technique which involves securing the mesh over the entire fascial defect circumferentially except laterally where the bowel exits to create a mesh flap valve around the stoma. This decreases the amount of contact with the stoma, decreasing the chances of infection. (2)The Keyhole technique where a 2- to 3-cm cutout is made in the mesh for the ostomy while widely covering the defect. This

can be tricky as too small of an opening can obstruct the enterostomy while too large of an opening can result in recurrence.

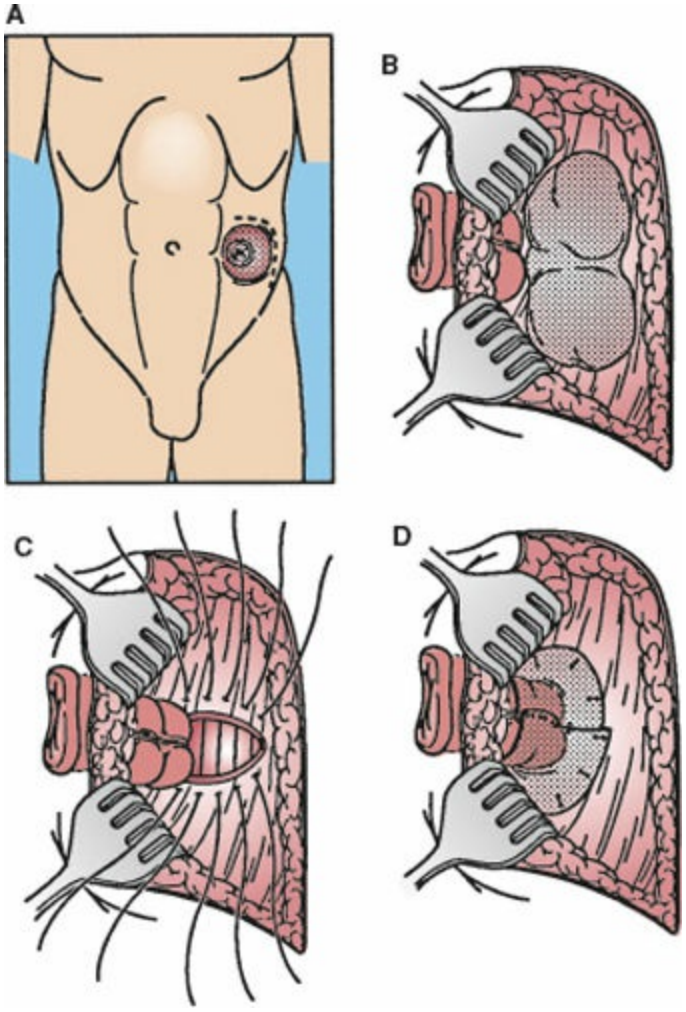

Figure 72-41. Repair of a parastomal hernia. **A:** Incision around hernia. **B:** Hernial sac is identified, the contents are reduced, and the peritoneum is closed. **C:** The edges of the fascial defect are reapproximated. **D:** The fascial repair is reinforced with polypropylene mesh, which is wrapped around the subcutaneous portion of the colon and sutured in place.

5. Laparoscopic repair of parastomal hernia. Laparoscopic repair of parastomal hernias has the advantage of avoiding a large incision while providing superior view of the defect and allowing for intraperitoneal mesh placement.[157] Currently descried techniques of laparoscopic repair include: (1) modified Sugarbaker technique, (2) Keyhole technique, and (3) Sandwich technique which combines both these approaches. Reported recurrence rates range from 0% to 47% with infection rates up to 16%, conversion rates range from 0% to 15% and 10% rate of mesh explantation. The most common mesh used for laparoscopic repair is ePTFE which is inert and more resistant to adhesions and erosion compared to standard mesh.

Prophylactic Mesh Placement

Recent randomized controlled trials and a recent meta-analysis have shown that prophylactic implantation of both biologic and synthetic mesh in a preperitoneal or sublay position for both ileostomies and colostomies is safe and effective and may be associated with some of these studies showing a decreased incidence (15% vs. 52%) of parastomal herniation.[158,159] Synthetic meshes are cost effective without added morbidity or mortality. These studies have had limitations such as small sample size, heterogeneous population, and variable follow-up. Prospective multicenter randomized controlled study comparing standard stoma creation to re-enforcement with porcine acellular dermal matrix showed similar incidence of parastomal hernia at 24 months in both groups. Further large scale randomized controlled trial with follow-up are necessary to identify specific group of patients in whom re-enforcement is essential and cost effective and to study long-term effects of this approach.[159]

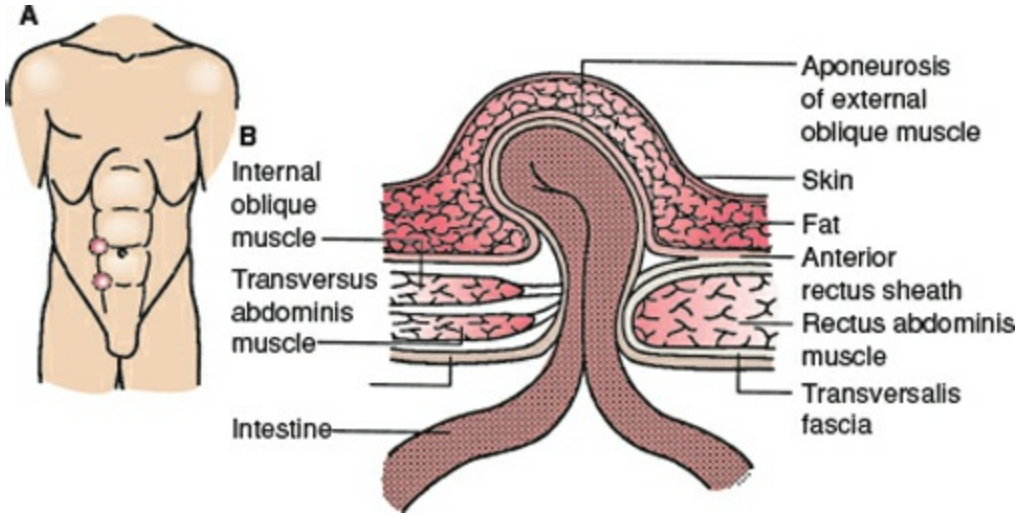

Figure 72-42. Spigelian hernia. **A:** Usual site of occurrence. **B:** Transverse section of abdominal wall showing site of defect.

UNUSUAL HERNIAS

Spigelian Hernia

A Flemish anatomist, Adriaan van der Spieghel, first described the semilunar line, which is the lower limit of the posterior rectus sheath. Also called the spontaneous lateral ventral hernia, a Spigelian hernia protrudes through an area of weakness just lateral to the rectus sheath and just below this line (Fig. 72-42). The hernia is usually interparietal, rarely penetrating the external oblique fascia, and therefore can be difficult to appreciate. Most of the time, this hernia appears below the arcuate line. This is an unusual hernia; only 744 cases have been described in the literature. The usual presentation is lower abdominal swelling just lateral to the border of the rectus muscle. Spigelian hernias often occur in elderly female patients. They are usually small, about 1 to 2 cm in diameter, although large hernias up to 14 cm in diameter have been described. Omentum and small or large bowel may enter the sac. Incarceration and strangulation are common complications of this hernia. Because the hernia is deep to the external oblique fascia, the clinical presentation may not be obvious. Pain and tenderness may be the only signs. Plain roentgenograms may show a bowel shadow in this area, and CT can demonstrate the defect well. Treatment is operative repair. A transverse incision is centered over the mass. The external oblique aponeurosis is split to reveal the protrusion. If a large sac is present, it is divided and sutured. The aponeurotic defect is triangular, with its base at or near the lateral border of the rectus muscle. The defect is closed by joining the separated transversus and internal oblique layers. Another option is a laparoscopic repair, done using an intra-abdominal or preperitoneal approach. Recurrence is uncommon.

Table 72-15 Types of Lumbar Hernia

Type	Description
Superior lumbar hernia of Grynfeltt	Occurs through a space between the latissimus dorsi, the serratus posterior inferior, and the posterior border of the internal oblique muscle
Inferior lumbar hernia of Petit	Occurs through a defect in the space bounded by the latissimus dorsi posteriorly, the iliac crest inferiorly, and the posterior border of the external oblique anteriorly
Secondary lumbar hernia	Develops as a result of trauma, mostly surgical (e.g., renal surgery), or infection; lumbar hernias were encountered relatively frequently in the past in cases of spinal tuberculosis with paraspinal abscesses

Lumbar Hernia

The lumbar region is the area bounded inferiorly by the iliac crest and superiorly by the 12th rib, posteriorly by the erector spinae group of muscles, and anteriorly by the edge of the external oblique muscle as it extends from the 12th rib to the iliac crest. The three varieties of lumbar hernia are described in Table 72-15. These hernias require repair if they are large, and because of the size of the defect, synthetic mesh is used. For the inferior lumbar hernia, a rotation flap of fascia lata can be used (Fig. 72-43).

Obturator Hernia

This hernia is the result of abdominal contents protruding through the obturator canal in the pelvis. This canal is the opening in the superior part of the obturator membrane covering the foramen formed by the union of the pubic bone and ischium, through which the obturator nerve, artery, and vein pass from the pelvic cavity into the thigh. A recent history of profound asthenia and weight loss is not unusual, which is most likely due to the loss of the protective fat in the obturator canal.[160] This may account for the fact that women, more often than men, are afflicted with this hernia because their broader pelvis results in a larger obturator canal. The diagnosis of an obturator hernia is difficult because it is rare and physical examination is rarely helpful because the associated mass is concealed beneath the adductor muscles of the thigh. The main symptom is intermittent pain. During repair, the defect is approached transperitoneally; the hernia is reduced and mesh placed over the defect. Depending on the expertise of the responsible surgeon, either a conventional open or laparoscopic operation is reasonable.

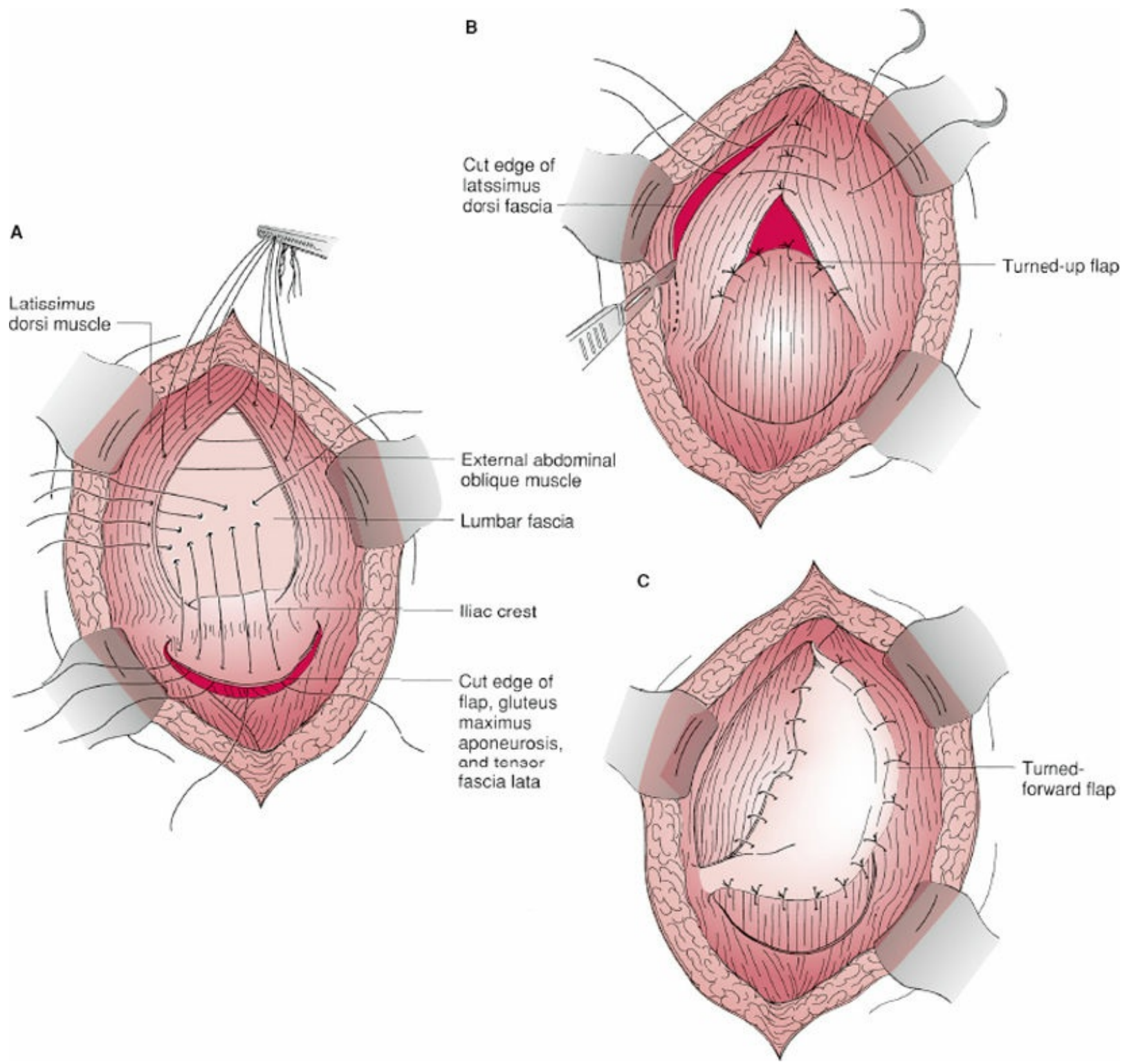

Figure 72-43. Technique of repair of inferior lumbar hernia.

Sciatic Hernia

A sciatic hernia is a protrusion of a peritoneal sac through the major or minor sciatic foramen (Fig. 72-44). These very rare hernias present with a swelling on the buttock. The sciatic nerve may be involved. A ureter can become obstructed if it is included with the herniated tissues. The treatment of these hernias is surgical. Both transperitoneal and transgluteal approaches have been described. A combination of the two is sometimes used. The defect usually requires a prosthetic mesh repair.

Supravesical Hernia

This hernia is anterior to the urinary bladder and forms when the integrity of the transversus abdominis muscle and the transversalis fascia fail, both of which insert into the Cooper ligament. The preperitoneal space is continuous with the retropubic space of Retzius, and the hernial sac protrudes into this area. The sac of the hernia is directed laterally, emerges at the lateral border of the rectus muscle, and presents in the inguinal, femoral, or obturator region. It can also be associated with an inguinal, femoral, or obturator hernia. Treatment of this hernia depends on recognizing it at the time of groin exploration and reinforcing the defect.

A second variety of these hernias is known as an internal supravesical hernia. They are classified according to whether they cross in front of, beside, or behind the bladder (Fig. 72-45). Bowel symptoms predominate in patients with these hernias, and urinary tract symptoms develop in up to 30%. The treatment is surgical, and a transperitoneal approach is used through a low midline incision. The hernias can usually be reduced without difficulty. The neck of the sac should be divided and closed.

Interparietal Hernia

This hernia is one in which the hernial sac lies between the layers of the abdominal wall. It may be either *preperitoneal* (between the peritoneum and the transversalis fascia) or *interstitial* (between the muscle layers of the abdominal wall). The majority are inguinal, in which case they are designated *inguinal interstitial* hernias. An *inguinal crural* hernia occurs when the sac passes behind the inguinal ligament in the region of the femoral ring.

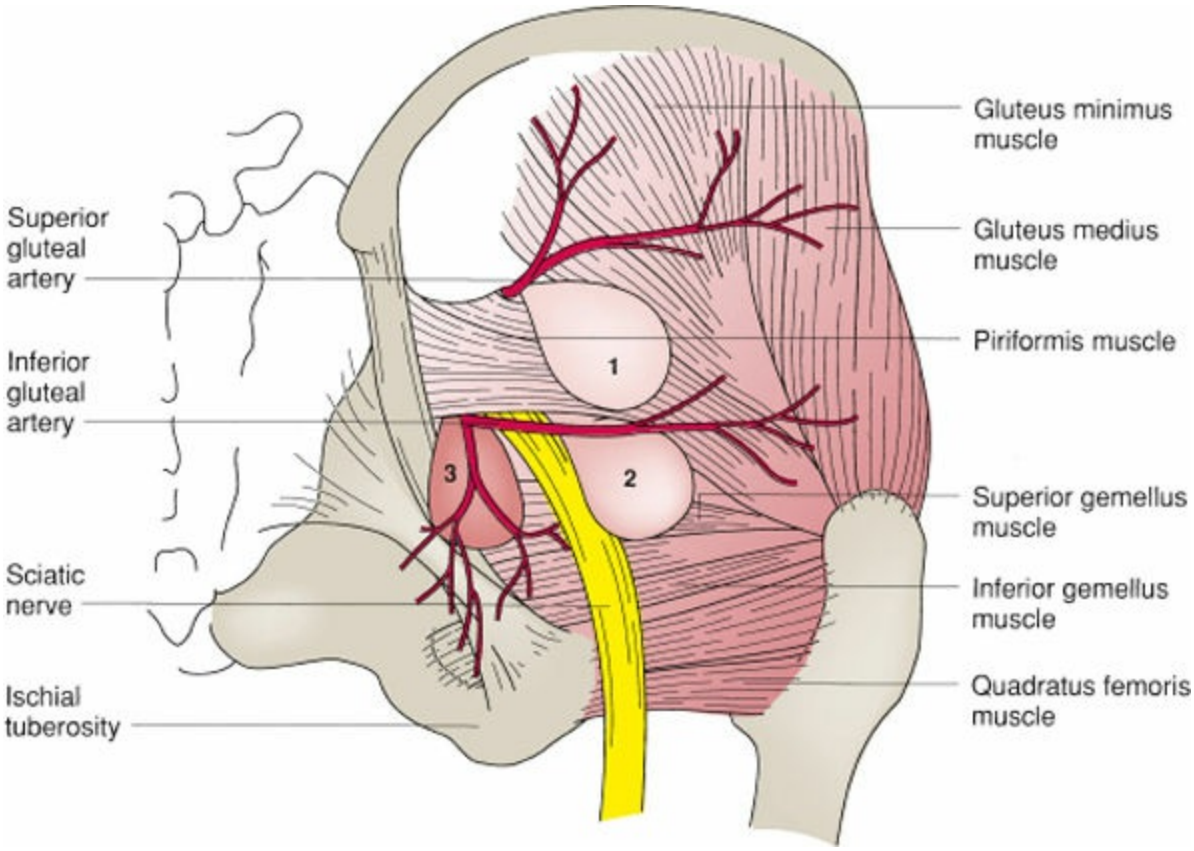

Figure 72-44. Sciatic hernia. **1:** Suprapiriform. **2:** Infrapiriform. **3:** Subspinous.

The cause of these hernias appears to be related to congenital abnormalities; they have been associated with failure of the testis to descend, congenital pouches, and other abnormalities, such as absence of the cremaster and absence of the external abdominal ring.

The diagnosis of these hernias is difficult because no swelling of the abdominal wall is obvious unless the hernia is large. Pain is commonly the only symptom, and it is not unusual for patients to present with intestinal obstruction secondary to incarceration. CT, ultrasonography, and laparoscopy can be helpful in making the diagnosis. Not infrequently, the correct diagnosis is made only at operation. The defect is repaired according to the principles described for inguinal and incisional hernias.

Flank Hernia

Relaxation of lateral abdominal wall is an underrecognized consequence of the lateral flank incision which leads to a lateral bulge, mostly without an associated fascial defect, usually in patients who have undergone urologic, vascular, or neurosurgical procedures which result in transection of the intercostal nerves and resulting atrophy. In majority of these cases, patients mainly complain of asymmetric appearance, but sometimes they can have discomfort associated with organs getting trapped in the bulge and both these problems can hugely impact patients' quality of life.

Littre Hernia

Littre hernia is a groin hernia containing a Meckel diverticulum. These hernias sometimes also contain the appendix. If the diverticulum is symptomatic or strangulated, then it is mandatory to resect it at the time of the hernia repair.

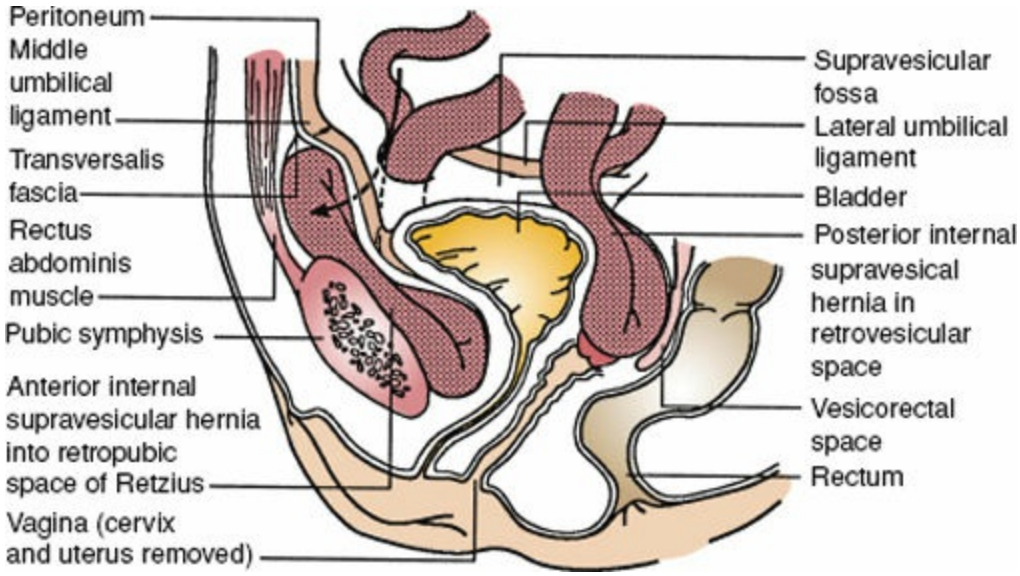

Figure 72-45. Internal supravesical hernias.

Perineal Hernia

These hernias are more common in older female patients and are related to a lax pelvic floor. They are termed *anterior* or *posterior* according to their relationship to the transverse perineal muscle. The anterior hernias usually present as a swelling in the labium or lateral vaginal wall. The posterior hernias present between the rectum and the ischial tuberosity. Surgical repair requires a transperitoneal approach, and, if the opening is large, a prosthetic mesh repair is required.

Perivascular Hernia

These hernias present through defects between the inguinal ligament and the iliopubic bone. They are known by various eponyms according to their position. The hernia protruding through a defect in the lacunar ligament is *Laugier hernia.* The hernia protruding through the pectineal fascia is *Cloquet hernia.* The hernia extending anterior to the femoral vessels but behind the inguinal ligament is *Velpeau hernia.* The hernia behind the vessels is *Serafini hernia.* Lateral to the femoral artery are two hernias, the anterior one being *Hesselbach hernia* and the more posterior one *Partridge hernia* (Fig. 72-46).

Complications of Ventral Hernia Repair

The complications of abdominal wall hernia repair are not infrequent, and their incidence depends on the size and type of hernia defect, the type of prostheses used, and the repair technique employed. The complications of hernia repair can be categorized according to whether they are related to the patient, or the operative technique and are listed in Table 72-16. Except for the complications unique to laparoscopy, complications occur at similar rates in both laparoscopic and conventional procedures.

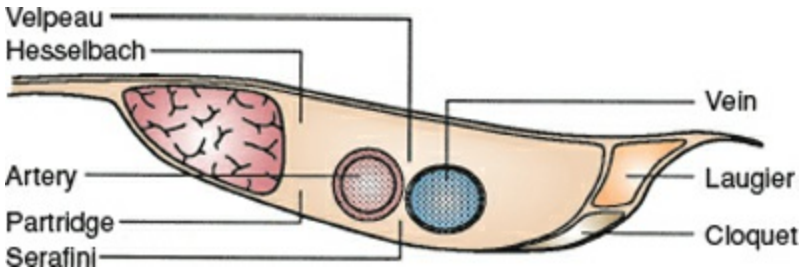

Figure 72-46. Perivascular hernias and their eponyms.

Complications Related to Patients

Ileus. Ileus can be seen with either the conventional or the laparoscopic procedure but is more common with the latter. Treatment is symptomatic, and spontaneous resolution is the rule. Nasogastric decompression is occasionally needed.

10 Recurrence. Several factors contribute to the poor results obtained in repairing incisional hernias. These include pre-existing comorbid conditions, including debilitation from cancer, morbid obesity, the use of steroids, and chemotherapy. Lateral detachment of the mesh and inadequate mesh fixation caused by mesh distraction is another important cause of recurrence and is more commonly seen in the inlay techniques.[91,115] Historical recurrence rates of 30% to 40% following ventral hernia repair have been dramatically reduced by modern TFRs.

Table 72-16 Complications of Herniorrhaphy

Related to Laparoscopy	Related to Hemiorrhaphy
Vascular injury	Recurrence
Intra-abdominal	Neurologic
Retroperitoneal	Iliohypogastric
Abdominal wall	Ilioinguinal
Gas embolism	Genitofemoral
Visceral injury	Lateral cutaneous
Bowel perforation	Cord and testicular problems
Bladder perforation	Wound infection
Trocar site complications	Seroma
Hematoma	Hydrocele
Hernia	Hematoma
Wound infection	Wound
Keloid	Scrotal
Bowel obstruction	Retroperitoneal
Trocar or peritoneal closure site hernia	Osteitis pubis
Adhesions	Prosthetic complications
Diaphragmatic dysfunction	Contraction
Hypercapnia	Erosion
Related to Patient	Infection
Urinary infection	Rejection
Ileus	Pain
Nausea and vomiting	
Aspiration pneumonia	
Cardiovascular and respiratory insufficiency	

Surgical Site Occurrences. Surgical site occurrences include superficial, deep, and organ space surgical site infections (SSIs) and wound dehiscence. The incidence of surgical site infection for incisional hernia is in the range of 10% to 15%, and is probably related to wound ischemia due to the required flap dissection. Other factors leading to infection are pre-existing infection or ulceration of the skin over the hernia, obesity, incarcerated or obstructed bowel within the hernia, and perforation of the bowel at the time of hernia repair. Risk models developed for predicting SSI risk include the Ventral Hernia Risk Score (VHRS) and the Hernia Wound Risk Assessment Tool (HW-RAT) using preoperative patient characteristics, operative factors, and wound characteristics which identify patients at increased risk for surgical site occurrences and can be used to guide clinical decisions and patient counseling (Table 72-17; Fig. 72-47).[161,162]

Seromas. Seromas are common with extensive flap dissection in large ventral hernias and with the use of synthetic mesh in laparoscopic hernia repairs and are possibly related to the size of the mesh used. The fluid eventually resorbs spontaneously. Aspiration is performed for symptomatic relief only.

Bleeding. Bleeding and postoperative hematomas are common complications of hernia

repair. Adequate hemostasis should be ensured especially if large flaps are raised to prevent this complication. Hematomas, like seromas, tend to get infected and should be monitored closely.

Prosthetic Complications. Shrinkage of polypropylene and other meshes should be considered by surgeons when performing prosthetic repairs. Sufficient overlap anticipating a 20% contracture is accepted by most. The decrease in size is felt to be due to scarification of the recipient's tissue. Intestinal obstruction or fistulization is possible by erosion, especially if there is physical contact between intestine and the prosthesis. Intra-abdominal placement of a mesh prosthesis should be avoided in favor of ePTFE or perhaps a biologic prosthesis whenever possible. Rejection because of an allergic response is possible but extremely rare.

Complications Related to Laparoscopy

These complications have been described above and include gas embolism, visceral injury, bladder injury, bowel obstruction, diaphragmatic dysfunction, and hypercapnia.

Table 72-17 HW RAT Breakdown of Risk Factors for Wound Complications

Risk Grouping	Risk Factors	Risk Score
Mild risk factors (+1)	Diabetes	1
	COPD	1
	Class I obesity	1
	45–64 yrs old	1
	Intra-abdominal procedure	1
Intermediate risk factors (+2)	Smoking	2
	ASA physical status >2	2
	Panniculectomy	2
	Clean-contaminated wound	2
	Partially dependent functional status	2
	Low albumin	2
	<45 yrs of age	2
	Operative time 43–71 (min)	2
Moderate risk factors (+3)	Totally dependent functional status	3
	Inpatient operation	3
	Class III obesity	3
	Component separation	3
Severe risk factors (+4 or more)	Contaminated wound	4
	Operative time (71–117 min)	4
	Dirty/infected wound	5
	Operative time (>118 min)	6

HW-RAT	Risk Score	Number of Patients (%)	Incidence of SSO (%)
1	0–10	16,097 (59.6%)	538(3.3%)
2	11–13	5,784 (21.4%)	536 (9.3%)
3	14–16	2,861 (12.3%)	472(14.2%)
4	17–19	998 (21.7%)	217(21.7%)
5	>19	812 (3.0%)	215 (26.5%)

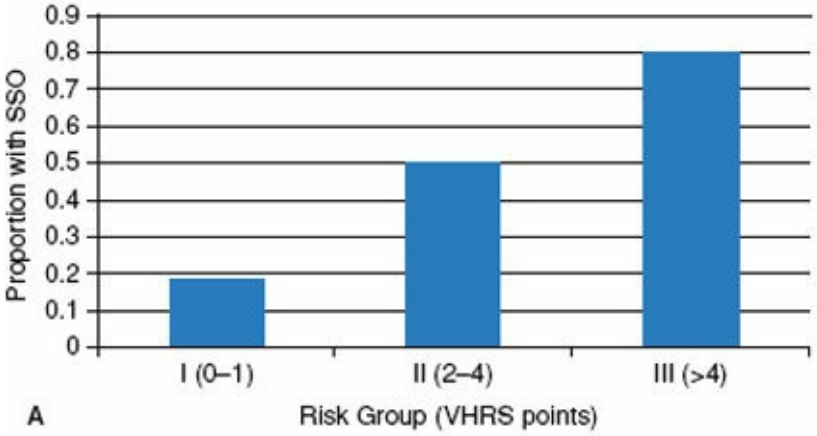

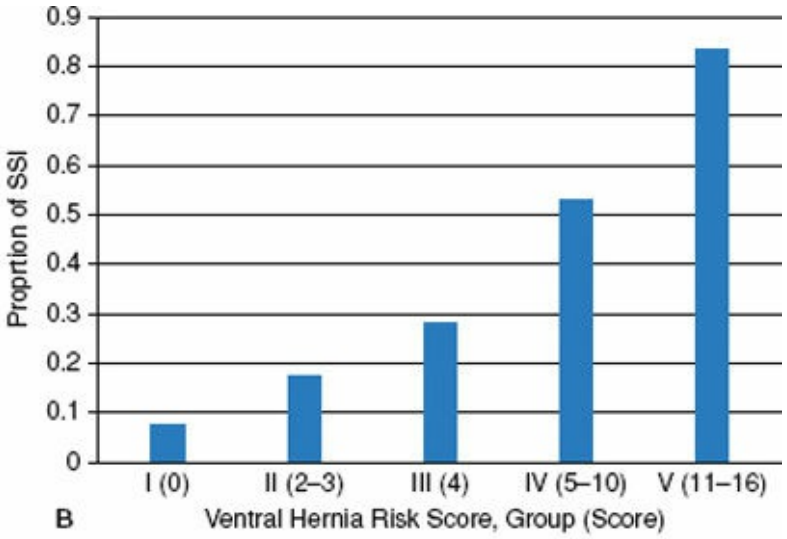

	VHRS for SSO	VHRS for SSI
OR	Points	Points
Mesh implant	2	—
Concomitant hernia repair	2	2
Skin flaps created	2	2
ASA score ≥3	—	2
BMI ≥40	—	3
Wound class 4	9	7

Figure 72-47. **A,B:** Ventral Hernia Risk Score (VHRS) for surgical site occurrence and surgical site infection.

References

1. *Digestive Disease Statistics for the United States [Internet].* 2013. Available from: www.digestive.niddk.nih.gov. Accessed September 27, 2016.
2. Robson AJ, Wallace CG, Sharma AK, et al. Effects of training and supervision on recurrence rate after inguinal hernia repair. *Br J Surg* 2004;91(6):774–777.
3. Hollingshead HW. The abdominal wall and inguinal region. *Anatomy for Surgeons.* Vol. 2. New York, NY: Paul B. Hoeber;1961:224.
4. Condon RE. Reassessment of groin anatomy during the evolution of preperitoneal hernia repair. *Am J Surg* 1996;172(1):5–8.
5. Milloy FJ, Anson BJ, Mcafee DK. The rectus abdominis muscle and the epigastric arteries. *Surg Gynecol Obstet* 1960;110:293–302.
6. Askar OM. Surgical anatomy of the aponeurotic expansions of the anterior abdominal wall. *Ann R Coll Surg Engl* 1977;59(4):313–321.
7. Cooper A. *The Anatomy and Surgical Treatment of Abdominal Hernia.* 1804.
8. Skandalakis PN, Zoras O, Skandalakis JE, et al. Transversalis, endoabdominal, endothoracic fascia: who's who? *Am Surg* 2006;72(1):16–18.
9. Teoh LS, Hingston G, Al-Ali S, et al. The iliopubic tract: an important anatomical landmark in surgery. *J Anat* 1999;194(Pt 1):137–141.
10. Quinn TH, Ryberg A, Annibali R, et al. Anatomy of the anterior abdominal wall and deep inguinal region from the laparoscopic surgeon's perspective. In: Lansafame RJ, ed. *Prevention and Management of Complications in Minimally Invasive Surgery.* New York, NY: Igaku Shoin; 1996:197.
11. Marks SC Jr, Gilroy AM, Page DW. The clinical anatomy of laparoscopic inguinal hernia repair. *Singapore Med J* 1996;37(5):519–521.
12. Anson BJ, Morgan EH, McVay CB. Surgical anatomy of the inguinal region based upon a study of 500 body-halves. *Surg Gynecol Obstet* 1960;111:707–725.
13. Annibali R., Quinn TH, Fitzgibbons RJ Jr. Anatomy of the inguinal region from the laparoscopic perspective: critical areas for laparoscopic hernia repair. In: Bendavid R, ed. *Prostheses and Abdominal Wall Hernias.* Austin, TX: Landes; 1994:82.
14. Annibali R, Quinn TH, Fitzgibbons RJ Jr. Avoiding nerve injury during laparoscopic hernia repair: critical areas for staple placement. In: Arregui ME, Nagan RF, eds. *Inguinal Hernia: Advances or Controversies?* Oxford, Great Britain: Radcliffe Medical; 1994:41.
15. Brick WG, Colborn GL, Gadacz TR, et al. Crucial anatomic lessons for laparoscopic herniorrhaphy. *Am Surg* 1995;61(2):172–177.
16. Gilroy AM, Hermey DC, DiBenedetto LM, et al. Variability of the obturator vessels. *Clin Anat* 1997;10(5):328–332.
17. Missankov AA, Asvat R, Maoba KI. Variations of the pubic vascular anastomoses in

black South Africans. *Acta Anat (Basel)* 1996;155(3):212–214.
18. Bendavid R. The space of Bogros and the deep inguinal venous circulation. *Surg Gynecol Obstet* 1992;174(5):355–358.
19. Sanjay P, Woodward A. Single strenuous event: does it predispose to inguinal herniation? *Hernia* 2007;11(6):493–496.
20. Read RC. Why do human beings develop groin hernias? In: Fitzgibbons RJ, Greenburg AG, eds. *Nyhus and Condon's Hernia.* 5th ed. Philadelphia, PA: Lippincott Williams & Wilkins; 2002:219–227.
21. Weber A, Garteiz D, Valencia S. Epidemiology of inguinal hernia: a useful aid for adequate surgical decisions. In: Bendavid R, Abrahamson J, Arregui M, et al., eds. *Abdominal Wall Hernia.* New York, NY: Springer; 2001.
22. Svendsen SW, Frost P, Vad MV, et al. Risk and prognosis of inguinal hernia in relation to occupational mechanical exposures–a systematic review of the epidemiologic evidence. *Scand J Work Environ Health* 2013; 39(1):5–26.
23. Vad MV, Frost P, Bay-Nielsen M, et al. Impact of occupational mechanical exposures on risk of lateral and medial inguinal hernia requiring surgical repair. *Occup Environ Med* 2012;69(11):802–809.
24. Lau H, Fang C, Yuen WK, et al. Risk factors for inguinal hernia in adult males: a case-control study. *Surgery* 2007;141(2):262–266.
25. Burcharth J, Pommergaard HC, Rosenberg J. The inheritance of groin hernia: a systematic review. *Hernia* 2013;17(2):183–189.
26. Cannon DJ, Read RC. Metastatic emphysema: a mechanism for acquiring inguinal herniation. *Ann Surg* 1981;194(3):270–278.
27. Jansen PL, Mertens Pr Pr, Klinge U, et al. The biology of hernia formation. *Surgery* 2004;136(1):1–4.
28. Bellon JM, Bajo A, Ga-Honduvilla N, et al. Fibroblasts from the transversalis fascia of young patients with direct inguinal hernias show constitutive MMP-2 overexpression. *Ann Surg* 2001;233(2):287–291.
29. Klinge U, Zheng H, Si ZY, et al. Synthesis of type I and III collagen, expression of fibronectin and matrix metalloproteinases-1 and -13 in hernial sac of patients with inguinal hernia. *Int J Surg Investig* 1999;1(3):219–227.
30. Smigielski J, Brocki M, Kuzdak K, et al. Serum MMP 2 and TIMP 2 in patients with inguinal hernias. *Eur J Clin Invest* 2011;41(6):584–588.
31. Antoniou GA, Tentes IK, Antoniou SA, et al. Matrix metalloproteinase imbalance in inguinal hernia formation. *J Invest Surg* 2011;24(4):145–150.
32. Tharappel JC, Bower CE, Whittington Harris J, et al. Doxycycline administration improves fascial interface in hernia repair. *J Surg Res* 2014; 190(2):692–698.
33. Turaga K, Fitzgibbons RJ Jr, Puri V. Inguinal hernias: should we repair? *Surg Clin North Am* 2008;88(1):127, 138, ix.
34. Harissis HV, Douitsis E, Fatouros M. Incarcerated hernia: to reduce or not to reduce?

Hernia 2009;13(3):263–266.

35. Boughey JC, Nottingham JM, Walls AC. Richter's hernia in the laparoscopic era: four case reports and review of the literature. *Surg Laparosc Endosc Percutan Tech* 2003;13(1):55–58.
36. Currie A, Andrew H, Tonsi A, et al. Lightweight versus heavyweight mesh in laparoscopic inguinal hernia repair: a meta-analysis. *Surg Endosc* 2012; 26(8):2126–2133.
37. Bringman S, Wollert S, Osterberg J, et al. Three-year results of a randomized clinical trial of lightweight or standard polypropylene mesh in Lichtenstein repair of primary inguinal hernia. *Br J Surg* 2006;93(9):1056–1059.
38. Cobb WS, Kercher KW, Heniford BT. The argument for lightweight polypropylene mesh in hernia repair. *Surg Innov* 2005;12(1):63–69.
39. Conze J, Kingsnorth AN, Flament JB, et al. Randomized clinical trial comparing lightweight composite mesh with polyester or polypropylene mesh for incisional hernia repair. *Br J Surg* 2005;92(12):1488–1493.
40. Petro CC, Nahabet EH, Criss CN, et al. Central failures of lightweight monofilament polyester mesh causing hernia recurrence: a cautionary note. *Hernia* 2015;19(1):155–159.
41. Deeken CR, Faucher KM, Matthews BD. A review of the composition, characteristics, and effectiveness of barrier mesh prostheses utilized for laparoscopic ventral hernia repair. *Surg Endosc* 2012;26(2):566–575.
42. Bachman S, Ramshaw B. Prosthetic material in ventral hernia repair: how do I choose? *Surg Clin North Am* 2008;88(1):101, 112, ix.
43. Primus FE, Harris HW. A critical review of biologic mesh use in ventral hernia repairs under contaminated conditions. *Hernia* 2013;17(1):21–30.
44. Rosen MJ. Biologic mesh for abdominal wall reconstruction: a critical appraisal. *Am Surg* 2010;76(1):1–6.
45. Rohrich RJ. Current concepts in the use of acellular dermal matrices in surgery. *Plast Reconstr Surg* 2012;130(5 Suppl 2):1S–3S.
46. Abdelfatah MM, Rostambeigi N, Podgaetz E, et al. Long-term outcomes (>5-year follow-up) with porcine acellular dermal matrix (Permacol) in incisional hernias at risk for infection. *Hernia* 2015;19(1):135–140.
47. Carbonell AM, Criss CN, Cobb WS, et al. Outcomes of synthetic mesh in contaminated ventral hernia repairs. *J Am Coll Surg* 2013;217(6):991–998.
48. Deeken CR, Matthews BD. Characterization of the mechanical strength, resorption properties, and histologic characteristics of a fully absorbable material (poly-4-hydroxybutyrate-PHASIX Mesh) in a porcine model of hernia repair. *ISRN Surg* 2013;2013:238067.
49. Ruhl CE, Everhart JE. Risk factors for inguinal hernia among adults in the US population. *Am J Epidemiol* 2007;165(10):1154–1161.

50. Nilsson E, Kald A, Anderberg B, et al. Hernia surgery in a defined population: a prospective three year audit. *Eur J Surg* 1997;163(11):823–829.
51. Burcharth J, Pedersen M, Bisgaard T, et al. Nationwide prevalence of groin hernia repair. *PLoS One* 2013;8(1):e54367.
52. Koch A, Edwards A, Haapaniemi S, et al. Prospective evaluation of 6895 groin hernia repairs in women. *Br J Surg* 2005;92(12):1553–1558.
53. Prasaud P, Cemaj S, Fitzgibbons RJ. Basic features of groin hernia and its repair. In: Yeo CJ, Dempsey DT, Klein AS, eds. *Shakelford's Surgery of the Alimentary Tract.* 6th ed. Philadelphia, PA: Saunders; 2006.
54. Miserez M, Alexandre JH, Campanelli G, et al. The European Hernia Society groin hernia classification: simple and easy to remember. *Hernia* 2007;11(2):113–116.
55. Nasr AO, Tormey S, Walsh TN. Lipoma of the cord and round ligament: an overlooked diagnosis? *Hernia* 2005;9(3):245–247.
56. Fitzgibbons RJ Jr, Giobbie-Hurder A, Gibbs JO, et al. Watchful waiting vs. repair of inguinal hernia in minimally symptomatic men: a randomized clinical trial. *JAMA* 2006;295(3):285–292.
57. O'Dwyer PJ, Norrie J, Alani A, et al. Observation or operation for patients with an asymptomatic inguinal hernia: a randomized clinical trial. *Ann Surg* 2006;244(2):167–173.
58. Fitzgibbons RJ Jr, Ramanan B, Arya S, et al. Long-term results of a randomized controlled trial of a nonoperative strategy (watchful waiting) for men with minimally symptomatic inguinal hernias. *Ann Surg* 2013;258(3):508–515.
59. van Veen RN, Mahabier C, Dawson I, et al. Spinal or local anesthesia in lichtenstein hernia repair: a randomized controlled trial. *Ann Surg* 2008;247(3):428–433.
60. Kehlet H, Aasvang E. Groin hernia repair: Anesthesia. *World J Surg* 2005; 29(8):1058–1061.
61. Simons MP, Aufenacker T, Bay-Nielsen M, et al. European Hernia Society guidelines on the treatment of inguinal hernia in adult patients. *Hernia* 2009 Aug;13(4):343–403.
62. Miserez M, Peeters E, Aufenacker T, et al. Update with level 1 studies of the European Hernia Society guidelines on the treatment of inguinal hernia in adult patients. *Hernia* 2014;18(2):151–163.
63. Amid PK. Groin hernia repair: open techniques. *World J Surg* 2005;29(8):1046–1051.
64. Rubenstein RS, Beck S, Lohr KN, et al. *Conceptualization and Measurement of Physiologic Health for Adults. Surgical Conditions.* Santa Monica, CA: RAND Corporation; 1983. Report No.: vol 15.
65. Scott NW, McCormack K, Graham P, et al. Open mesh versus non-mesh for repair of femoral and inguinal hernia. *Cochrane Database Syst Rev* 2002;(4):CD002197.
66. Amid PK, Shulman AG, Lichtenstein IL. Open "tension-free" repair of inguinal hernias: the Lichtenstein technique. *Eur J Surg* 1996;162(6):447–453.

67. Kugel RD. Minimally invasive, nonlaparoscopic, preperitoneal, and sutureless, inguinal herniorrhaphy. *Am J Surg* 1999;178(4):298–302.
68. Wiegering A, Schlegel N, Isbert C, et al. Lessons and challenges during a 5-year follow-up of 21 Composix Kugel implantations. *Hernia* 2013; 17(4):435–443.
69. Gilbert AI, Young J, Graham MF, et al. Combined anterior and posterior inguinal hernia repair: intermediate recurrence rates with three groups of surgeons. *Hernia* 2004;8(3):203–207.
70. Treadwell J, Tipton K, Oyesanmi O, Sun F, Schoelles K. Surgical Options for Inguinal Hernia: Comparative Effectiveness Review. Comparative Effectiveness Review No. 70. (Prepared by the ECRI Institute Evidence-based Practice Center under Contract No. 290-2007-10063.) AHRQ Publication No. 12-EHC091-EF. Rockville, MD: Agency for Healthcare Research and Quality. August 2012. Available from: www.effectivehealthcare.ahrq.gov/reports/final.cfm
71. El-Dhuwaib Y, Corless D, Emmett C, et al. Laparoscopic versus open repair of inguinal hernia: a longitudinal cohort study. *Surg Endosc* 2013; 27(3):936–945.
72. O'Reilly EA, Burke JP, O'Connell PR. A meta-analysis of surgical morbidity and recurrence after laparoscopic and open repair of primary unilateral inguinal hernia. *Ann Surg* 2012;255(5):846–853.
73. EU Hernia Trialists Collaboration. Laparoscopic compared with open methods of groin hernia repair: systematic review of randomized controlled trials. *Br J Surg* 2000;87(7):860–867.
74. Bisgaard T, Bay-Nielsen M, Kehlet H. Re-recurrence after operation for recurrent inguinal hernia. A nationwide 8-year follow-up study on the role of type of repair. *Ann Surg* 2008;247(4):707–711.
75. Kaul A, Hutfless S, Le H, et al. Staple versus fibrin glue fixation in laparoscopic total extraperitoneal repair of inguinal hernia: a systematic review and meta-analysis. *Surg Endosc* 2012;26(5):1269–1278.
76. Aasvang EK, Kehlet H. Chronic pain after childhood groin hernia repair. *J Pediatr Surg* 2007;42(8):1403–1408.
77. Tekatli H, Schouten N, van Dalen T, et al. Mechanism, assessment, and incidence of male infertility after inguinal hernia surgery: a review of the preclinical and clinical literature. *Am J Surg* 2012;204(4):503–509.
78. Dahlstrand U, Wollert S, Nordin P, et al. Emergency femoral hernia repair: a study based on a national register. *Ann Surg* 2009;249(4):672–676.
79. Taylor DC. Abdominal musculature abnormalities as a cause of groin pain in athletes. *Am J Sports Med* 1991;19(4):421.
80. van den Berg JC, de Valois JC, Go PM, et al. Radiological anatomy of the groin region. *Eur Radiol* 2000;10(4):661–670.
81. Jensen P, Mikkelsen T, Kehlet H. Postherniorrhaphy urinary retention–effect of local, regional, and general anesthesia: a review. *Reg Anesth Pain Med* 2002;27(6):612–617.

82. Goldman G, Leviav A, Mazor A, et al. Alpha-adrenergic blocker for posthernioplasty urinary retention. Prevention and treatment. *Arch Surg* 1988; 123(1):35–36.
83. Koch CA, Grinberg GG, Farley DR. Incidence and risk factors for urinary retention after endoscopic hernia repair. *Am J Surg* 2006;191(3):381–385.
84. Haskell DL, Sunshine B, Heifetz CJ. A study of bladder catheterization with inguinal hernia operations. *Arch Surg* 1974;109(3):378–380.
85. Hudak KE, Frelich MJ, Rettenmaier CR, et al. Surgery duration predicts urinary retention after inguinal herniorrhaphy: a single institution review. *Surg Endosc* 2015;29(11):3246–3250.
86. Patel JA, Kaufman AS, Howard RS, et al. Risk factors for urinary retention after laparoscopic inguinal hernia repairs. *Surg Endosc* 2015;29(11):3140–3145.
87. Mohammadi-Fallah M, Hamedanchi S, Tayyebi-Azar A. Preventive effect of tamsulosin on postoperative urinary retention. *Korean J Urol* 2012; 53(6):419–423.
88. Gonullu NN, Dulger M, Utkan NZ, et al. Prevention of postherniorrhaphy urinary retention with prazosin. *Ann Surg* 1999;65(1):55–58.
89. EU Hernia Trialists Collaboration. Repair of groin hernia with synthetic mesh: meta-analysis of randomized controlled trials. *Ann Surg* 2002; 235(3):322–332.
90. Bendavid R. The Shouldice technique: a canon in hernia repair. *Can J Surg* 1997;40(3):199, 205, 207.
91. Neumayer L, Giobbie-Hurder A, Jonasson O, et al. Open mesh versus laparoscopic mesh repair of inguinal hernia. *N Engl J Med* 2004;350(18):1819–1827.
92. Kald A, Nilsson E, Anderberg B, et al. Reoperation as surrogate endpoint in hernia surgery. A three-year follow-up of 1565 herniorrhaphies. *Eur J Surg* 1998;164(1):45–50.
93. Poobalan AS, Bruce J, Smith WC, et al. A review of chronic pain after inguinal herniorrhaphy. *Clin J Pain* 2003;19(1):48–54.
94. Magnusson N, Gunnarsson U, Nordin P, et al. Reoperation for persistent pain after groin hernia surgery: a population-based study. *Hernia* 2015; 19(1):45–51.
95. Sheynkin YR, Hendin BN, Schlegel PN, et al. Microsurgical repair of iatrogenic injury to the vas deferens. *J Urol* 1998;159(1):139–141.
96. Shin D, Lipshultz LI, Goldstein M, et al. Herniorrhaphy with polypropylene mesh causing inguinal vasal obstruction: a preventable cause of obstructive azoospermia. *Ann Surg* 2005;241(4):553–558.
97. Ceylan H, Karakok M, Guldur E, et al. Temporary stretch of the testicular pedicle may damage the vas deferens and the testis. *J Pediatr Surg* 2003; 38(10):1530–1533.
98. Fitzgibbons RJ Jr. Can we be sure polypropylene mesh causes infertility? *Ann Surg* 2005;241(4):559–561.
99. Wantz GE. Testicular atrophy and chronic residual neuralgia as risks of inguinal hernioplasty. *Surg Clin North Am* 1993;73(3):571–581.
100. Bendavid R. Complications of groin hernia surgery. *Surg Clin North Am*

1998;78(6):1089–1103.
101. Sanchez-Manuel FJ, Lozano-Garcia J, Seco-Gil JL. Antibiotic prophylaxis for hernia repair. *Cochrane Database Syst Rev* 2007;(3):CD003769.
102. Silich RC, McSherry CK. Spermatic granuloma. An uncommon complication of the tension-free hernia repair. *Surg Endosc* 1996;10(5):537–539.
103. Ahmad G, Duffy JM, Phillips K, et al. Laparoscopic entry techniques. *Cochrane Database Syst Rev* 2008;(2):CD006583.
104. Mirski MA, Lele AV, Fitzsimmons L, et al. Diagnosis and treatment of vascular air embolism. *Anesthesiology* 2007;106(1):164–177.
105. Leibl BJ, Schmedt CG, Kraft K, et al. Recurrence after endoscopic transperitoneal hernia repair (TAPP): causes, reparative techniques, and results of the reoperation. *J Am Coll Surg* 2000;190(6):651–655.
106. Rink J, Ali A. Intestinal obstruction after totally extraperitoneal laparoscopic inguinal hernia repair. *JSLS* 2004;8(1):89–92.
107. Zollinger RMJ. Classification of ventral and groin hernias. In: Fitzgibbons RJ, Greenburg AG, eds. *Nyhus and Condon's Hernia.* 5th ed. Philadelphia, PA: Lippincott Williams & Wilkins; 2002:71.
108. Korenkov M, Paul A, Sauerland S, et al. Classification and surgical treatment of incisional hernia. Results of an experts' meeting. *Langenbecks Arch Surg* 2001;386(1):65–73.
109. Muysoms FE, Miserez M, Berrevoet F, et al. Classification of primary and incisional abdominal wall hernias. *Hernia* 2009;13(4):407–414.
110. Ventral Hernia Working Group, Breuing K, Butler CE, et al. Incisional ventral hernias: review of the literature and recommendations regarding the grading and technique of repair. *Surgery* 2010;148(3):544–558.
111. Brandt ML. Pediatric hernias. *Surg Clin North Am* 2008;88(1):27, 43, vii–viii.
112. Burcharth J, Pedersen MS, Pommergaard HC, et al. The prevalence of umbilical and epigastric hernia repair: a nationwide epidemiologic study. *Hernia* 2015;19(5):815–819.
113. Mayo WJ VI. An operation for the radical cure of umbilical hernia. *Ann Surg* 1901;34(2):276–280.
114. Lau H, Patil NG. Umbilical hernia in adults. *Surg Endosc* 2003;17(12):2016–2020.
115. Shell DH 4th, de la Torre J, Andrades P, et al. Open repair of ventral incisional hernias. *Surg Clin North Am* 2008;88(1):61, 83, viii.
116. Carlson MA, Ludwig KA, Condon RE. Ventral hernia and other complications of 1,000 midline incisions. *South Med J* 1995;88(4):450–453.
117. Franz MG. The biology of hernia formation. *Surg Clin North Am* 2008; 88(1):1, 15, vii.
118. Read RC, Yoder G. Recent trends in the management of incisional herniation. *Arch Surg* 1989;124(4):485–458.

119. Moreno-Egea A, Carrillo A, Aguayo JL. Midline versus nonmidline laparoscopic incisional hernioplasty: a comparative study. *Surg Endosc* 2008; 22(3):744–749.
120. Israelsson LA, Millbourn D. Prevention of incisional hernias: how to close a midline incision. *Surg Clin North Am* 2013;93(5):1027–1040.
121. Christoffersen MW, Olsen BH, Rosenberg J, et al. Randomized Clinical Trial on the postoperative use of an abdominal binder after laparoscopic umbilical and epigastric hernia repair. *Hernia* 2015;19(1):147–153.
122. Bouvier A, Rat P, Drissi-Chbihi F, et al. Abdominal binders after laparotomy: review of the literature and French survey of policies. *Hernia* 2014; 18(4):501–506.
123. Mayagoitia JC, Suarez D, Arenas JC, et al. Preoperative progressive pneumoperitoneum in patients with abdominal-wall hernias. *Hernia* 2006;10(3):213–217.
124. Flament JB, Palot JP, Burde A. Treatment of major incisional hernias. *Probl Gen Surg* 1995;12(1):151–158.
125. Bittner R, Bingener-Casey J, Dietz U, et al. Guidelines for laparoscopic treatment of ventral and incisional abdominal wall hernias (International Endohernia Society (IEHS)-part 1. *Surg Endosc* 2014;28(1):2–29.
126. Moreno IG. Chronic eventrations and large hernias; preoperative treatment by progressive pneumoperitomeum; original procedure. *Surgery* 1947; 22(6):945–953.
127. Toniato A, Pagetta C, Bernante P, et al. Incisional hernia treatment with progressive pneumoperitoneum and retromuscular prosthetic hernioplasty. *Langenbecks Arch Surg* 2002;387(5–6):246–248.
128. Dumont F, Fuks D, Verhaeghe P, et al. Progressive pneumoperitoneum increases the length of abdominal muscles. *Hernia* 2009;13(2):183–187.
129. Bikhchandani J, Fitzgibbons RJ Jr. Repair of giant ventral hernias. *Adv Surg* 2013;47:1–27.
130. Mussack T, Ladurner R, Vogel T, et al. Health-related quality-of-life changes after laparoscopic and open incisional hernia repair: a matched pair analysis. *Surg Endosc* 2006;20(3):410–413.
131. Luijendijk RW, Hop WC, van den Tol MP, et al. A comparison of suture repair with mesh repair for incisional hernia. *N Engl J Med* 2000;343(6):392–398.
132. Burger JW, Luijendijk RW, Hop WC, et al. Long-term follow-up of a randomized controlled trial of suture versus mesh repair of incisional hernia. *Ann Surg* 2004;240(4):578, 583; discussion 583–585.
133. Ramirez OM, Ruas E, Dellon AL. “Components separation” method for closure of abdominal-wall defects: an anatomic and clinical study. *Plast Reconstr Surg* 1990;86(3):519–526.
134. Novitsky YW, Elliott HL, Orenstein SB, et al. Transversus abdominis muscle release: a novel approach to posterior component separation during complex abdominal wall reconstruction. *Am J Surg* 2012;204(5):709–716.

135. Carbonell AM, Cobb WS, Chen SM. Posterior components separation during retromuscular hernia repair. *Hernia* 2008;12(4):359–362.
136. DiCocco JM, Fabian TC, Emmett KP, et al. Components separation for abdominal wall reconstruction: the Memphis modification. *Surgery* 2012; 151(1):118–125.
137. Azoury SC, Dhanasopon AP, Hui X, et al. A single institutional comparison of endoscopic and open abdominal component separation. *Surg Endosc* 2014;28(12):3349–3358.
138. Rosen MJ, Jin J, McGee MF, et al. Laparoscopic component separation in the single-stage treatment of infected abdominal wall prosthetic removal. *Hernia* 2007;11(5):435–440.
139. Usher FC, Ochsner J, Tuttle LL Jr. Use of marlex mesh in the repair of incisional hernias. *Am Surg* 1958;24(12):969–974.
140. Klinge U, Conze J, Krones CJ, et al. Incisional hernia: open techniques. *World J Surg* 2005;29(8):1066–1072.
141. Alexander AM, Scott DJ. Laparoscopic ventral hernia repair. *Surg Clin North Am* 2013;93(5):1091–1110.
142. Lipman J, Medalie D, Rosen MJ. Staged repair of massive incisional hernias with loss of abdominal domain: a novel approach. *Am J Surg* 2008;195(1):84–88.
143. Temudom T, Siadati M, Sarr MG. Repair of complex giant or recurrent ventral hernias by using tension-free intraparietal prosthetic mesh (Stoppa technique): lessons learned from our initial experience (fifty patients). *Surgery* 1996;120(4):738, 743; discussion 743–744.
144. Wantz GE. Incisional hernioplasty with Mersilene. *Surg Gynecol Obstet* 1991;172(2):129–137.
145. Gurusamy KS, Samraj K. Wound drains after incisional hernia repair. *Cochrane Database Syst Rev* 2007;(1):CD005570.
146. Bingener J, Buck L, Richards M, et al. Long-term outcomes in laparoscopic vs open ventral hernia repair. *Arch Surg* 2007;142(6):562–567.
147. Kald A, Juul KN, Hjortsvang H, et al. Quality of life is impaired in patients with peristomal bulging of a sigmoid colostomy. *Scand J Gastroenterol* 2008;43(5):627–633.
148. Carne PW, Robertson GM, Frizelle FA. Parastomal hernia. *Br J Surg* 2003; 90(7):784–793.
149. Hansson BM, Slater NJ, van der Velden AS, et al. Surgical techniques for parastomal hernia repair: a systematic review of the literature. *Ann Surg* 2012;255(4):685–695.
150. Rubin MS, Schoetz DJ Jr, Matthews JB. Parastomal hernia. Is stoma relocation superior to fascial repair? *Arch Surg* 1994;129(4):413, 418; discussion 418–419.
151. Smietanski M, Szczepkowski M, Alexandre JA, et al. European Hernia Society classification of parastomal hernias. *Hernia* 2014;18(1):1–6.
152. Allen-Mersh TG, Thomson JP. Surgical treatment of colostomy complications. *Br J*

Surg 1988;75(5):416–418.

153. Hotouras A, Murphy J, Thaha M, et al. The persistent challenge of parastomal herniation: a review of the literature and future developments. *Colorectal Dis* 2013;15(5):e202–e214.
154. Raigani S, Criss CN, Petro CC, et al. Single-center experience with parastomal hernia repair using retromuscular mesh placement. *J Gastrointest Surg* 2014;18(9):1673–1637.
155. Sugarbaker PH. Peritoneal approach to prosthetic mesh repair of paraostomy hernias. *Ann Surg* 1985;201(3):344–346.
156. Virzi G, Scaravilli F, Ragazzi S, et al. Laparoscopic paracolostomy hernia mesh repair. *Surg Laparosc Endosc Percutan Tech* 2007;17(6):548–550.
157. Shah NR, Craft RO, Harold KL. Parastomal hernia repair. *Surg Clin North Am* 2013;93(5):1185–1198.
158. Wijeyekoon SP, Gurusamy K, El-Gendy K, et al. Prevention of parastomal herniation with biologic/composite prosthetic mesh: a systematic review and meta-analysis of randomized controlled trials. *J Am Coll Surg* 2010; 211(5):637–645.
159. Fleshman JW, Beck DE, Hyman N, et al. A prospective, multicenter, randomized, controlled study of non-cross-linked porcine acellular dermal matrix fascial sublay for parastomal reinforcement in patients undergoing surgery for permanent abdominal wall ostomies. *Dis Colon Rectum* 2014; 57(5):623–631.
160. Salameh JR. Primary and unusual abdominal wall hernias. *Surg Clin North Am* 2008;88(1):45, 60, viii.
161. Fischer JP, Wink JD, Tuggle CT, et al. Wound risk assessment in ventral hernia repair: generation and internal validation of a risk stratification system using the ACS-NSQIP. *Hernia* 2015;19(1):103–111.
162. Berger RL, Li LT, Hicks SC, et al. Development and validation of a risk-stratification score for surgical site occurrence and surgical site infection after open ventral hernia repair. *J Am Coll Surg* 2013;217(6):974–982.

Chapter 73

The Spleen

Giorgos C. Karakousis and Douglas L. Fraker

Key Points

1. The spleen relates to the diaphragm both superiorly and laterally, and it generally spans the 9th, 10th, and 11th ribs along the left mid to posterior axillary line.
2. Accessory spleens are small nodules of splenic tissue that are completely separate from the main body of the spleen. Accessory spleens are important in disease processes in which a complete removal of all splenic tissue is mandatory for long-term cure such as certain autoimmune disorders.
3. The primary hematologic function of the spleen is removal of senescent erythrocytes or remodeling of abnormal red blood cells, and the recycling of iron by splenic macrophages.
4. The immunologic function of the spleen is to generate an immune response to antigens that are identified and cleared from the blood system.
5. The spleen is the most common intra-abdominal organ injured by blunt trauma in the United States.
6. The pathophysiology of immune thrombocytopenic purpura (ITP) is development of an IgG antibody to a platelet antigen. For patients who have failed medical therapy, an elective splenectomy may be recommended.
7. Hypersplenism is a physical enlargement of the spleen that can occur because of neoplastic disorders, hematopoietic disorders of the bone marrow, and metabolic or storage disorders. In neoplastic disorders, the spleen is infiltrated and enlarged by leukemia or lymphoma cells.
8. The types of organisms that account for infection are typically encapsulated organisms (most commonly *Streptococcus pneumonia*).

The spleen has been a mysterious organ throughout surgical and medical history with a clear understanding and appreciation of its function only emerging in the latter half of the 20th century. The reasons for this paucity of knowledge on the spleen are multifactorial. The spleen has no obvious function that can be discerned from its anatomical structures or features; there are no clear relationships of gross pathology of the spleen to many of the diseases for which it is important; and, even in present time, it is difficult to obtain a biopsy of the spleen, thereby limiting the amount of tissue available for pathologic study.

The diseases (other than trauma) in which the spleen has importance are generally of a hematologic or immunologic nature. Understanding of the normal physiology and subsequent pathophysiology of the spleen is important for surgical decision-making regarding when to recommend splenectomy and whether a partial splenectomy is possible. The only surgical procedure applied for the treatment of splenic disorders for the majority of history was splenectomy. Current variations on that procedure include laparoscopic splenectomy, partial splenectomy, and other spleen-preserving procedures. The history of surgery for the spleen, its anatomy and physiology, and the relevant disease processes as well as operative techniques are reviewed.

HISTORY

The spleen has had a colorful history based on the function ascribed to this organ by many of the prominent scientists throughout the ages (Table 73-1).1[1] Even the origin of the English term “spleen” is unclear. It is felt to come from the Greek “splen” which may have been derived from the Greek word “splancknon,” meaning a viscus, or the Greek word “spaw,” which means to draw.[2] The dark purple red color led ancients to believe that the spleen may draw spoiled or bad parts of the blood to itself which predates one of the major roles of the spleen as a filtration device for senescent red blood cells. In ancient Greece, the spleen was felt to be the source of black bile that was one of the four cardinal humors related to melancholy.[2] However, ancient authors wrote in the Talmud that the spleen was the seat for laughter and removal of the spleen would limit mirth in that person.[2] It was felt that the spleen was a source of discomfort sometimes felt as “a stitch in the side” for athletes and that by removal or ablation of the spleen an individual would run faster. Reports of the earliest procedures on the spleen indicate that runners in ancient Greece may have had their spleens ablated in an effort to improve their performance. This hypothesis was studied in an experimental model almost 2000 years later in 1922 at Johns Hopkins University, in which splenectomized mice versus control mice were evaluated for their ability to run a race and the splenectomized mice were reported to be faster.[2]

During the Renaissance, scientists began to question the various roles ascribed to splenic function. Paracelsus rejected the black bile theory and questioned whether the spleen had any meaningful role at all in the early 16th century. One of his students named Zaccarella reportedly performed the first splenectomy in the year 1549 in Palermo, Italy, removing the large spleen of a 24-year-old woman successfully.[2] This organ was reportedly displayed in the town square after this landmark but unsubstantiated procedure. Versalius during that same era performed splenectomy in mice and other animals and determined that the spleen was not essential to life as there was no clear difference following removal. Around this time in 1581, Viard performed what is felt to be perhaps the first splenic-preserving procedures, removing a portion of the spleen in two patients in which the organ had prolapsed through an abdominal wound. The first authenticated splenectomy was performed in Germany in 1826 by Carl Frederick Quitterbaum in a patient with secondary hypersplenism due to cirrhosis. This high-risk patient succumbed 6 hours after the procedure. The first successful operation in which the patient survived was performed by Jules Pean in France in 1865 for a large splenic cyst. This patient was operated on for what was thought to be an ovarian cystic mass, but it was found to be arising from the inferior portion of the spleen and required splenectomy for removal and the patient survived. In this early period of splenic surgery, there was much pessimism due to the high operative mortality rate primarily from hemorrhage. A collective series published in 1877 reported 50 splenectomies with a 70% overall mortality rate. By 1900, Bessel-Hagen reported 360 splenectomies with a 40% mortality rate. An in-depth discussion of the spleen in literature, art, and history was recently published by Morgenstern.[3]

Table 73-1 Historical Milestones in Surgery of the Spleen

1549	First reported splenectomy by Zaccarella in Italy
1826	First documented splenectomy by Quitterbaum in Germany
1865	First successful splenectomy by Paen in France
1892	First trauma splenectomy by Reigner in Germany
1911	Elective splenectomy for autoimmune hemolytic anemia
1916	Elective splenectomy for immune thrombocytopenia purpura
1952	First report of overwhelming postsplenectomy sepsis
1962	First report of splenic salvage procedure for trauma
1991	Laparoscopic splenectomy

The 20th century brought technical advances in terms of hemostasis and blood transfusion as well as an understanding of the pathophysiology of splenic function.[4] The spleen was identified as the site of red cell destruction in autoimmune hemolytic anemia by Micheli in 1911. Paul Kaznelson, who was a Czech medical student, postulated that the removal of the spleen in patients with idiopathic thrombocytopenic purpura would be of benefit and, in 1916, he reported the successful treatment of a patient with that disease with splenectomy. Throughout the 20th century, as the understanding the pathophysiology of hematologic and immune disorders associated with the spleen increased, it became clearer the roles for splenectomy that are pertinent to modern-day practice.

EMBRYOLOGY AND ANATOMY

1 The spleen develops from the mesoderm as an outpouching from the mesogastrium during the 5th week of gestation[4–6] with the natural rotation of the gut during subsequent development placing the spleen in its typical position in the left upper quadrant of the abdomen (Fig. 73-1). In that location, the spleen relates to the diaphragm both superiorly and laterally, and it generally spans the 9th, 10th, and 11th ribs along the left mid to posterior axillary line. The ventral surface of the spleen relates to the greater curvature of the stomach and the tail of the pancreas. The tail of the pancreas touches the splenic capsule in 30% of cases and is 1 cm away in 70% of cases. The inferior pole relates to the left kidney posteriorly and the splenic flexure of the colon anteriorly.

The normal size of the spleen is approximately 13 × 7 × 4 cm.[5] The typical weight of a spleen in a young adult is felt to be 150 to 200 g and this decreases to approximately 100 g in the elderly population (Fig. 73-2).[7,8] It is felt that the spleen must double in size to the range of 300 to 400 g to project below the costal margin to allow palpation of the spleen tip on abdominal examination in a patient undergoing deep inspiration.[9] The weight assigned to the spleen in defining massive splenomegaly has been arbitrarily set at 1,500 g or 10 times the average adult splenic weight. There can be a significant cleft in the capsule of the spleen that may be confused with splenic disruption on CT scan obtained for trauma.

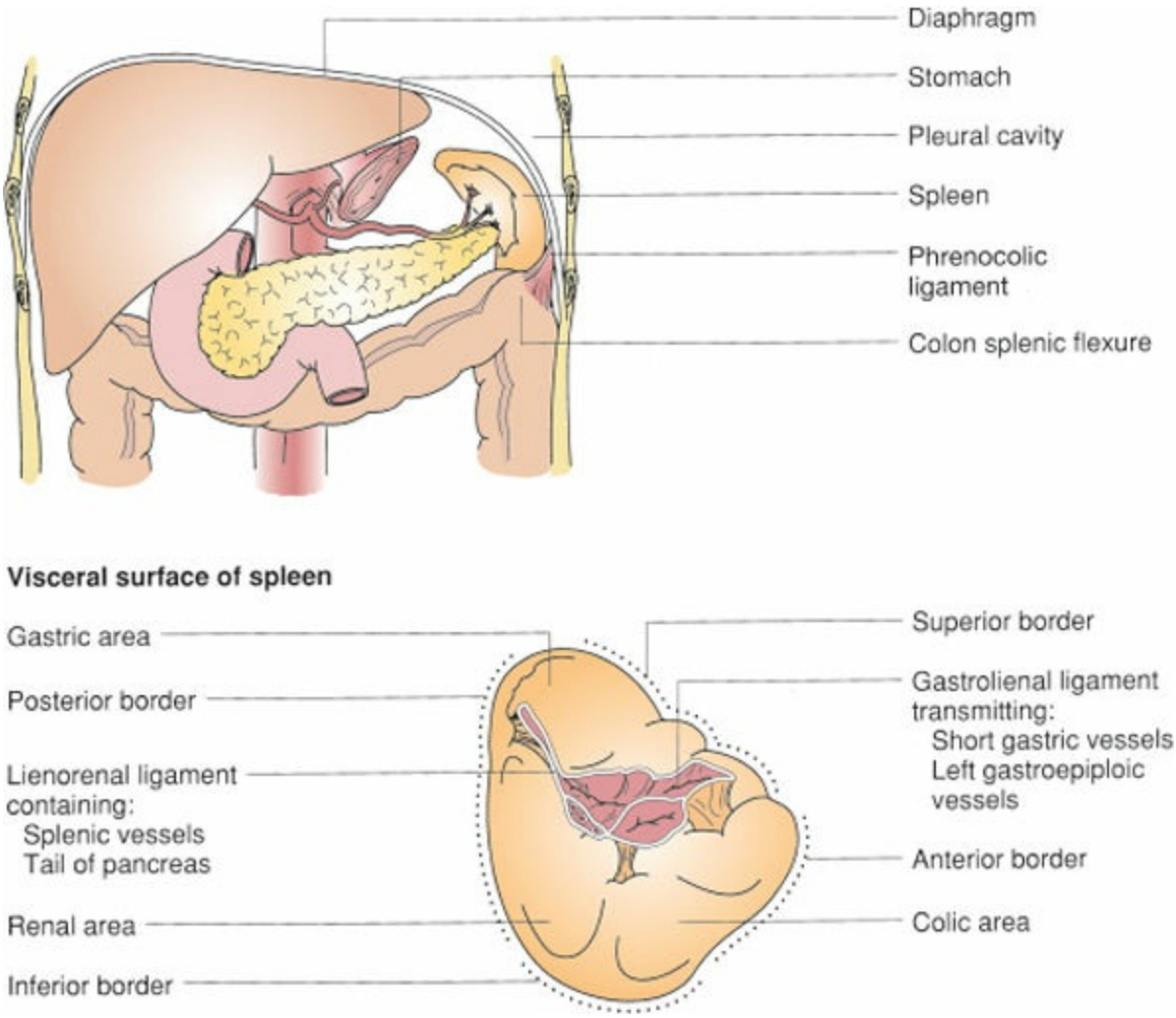

Figure 73-1. Anatomic relation of the spleen to the liver, diaphragm, pancreas, colon, and kidney. The stomach is sectioned to illustrate the anatomic relation in situ.

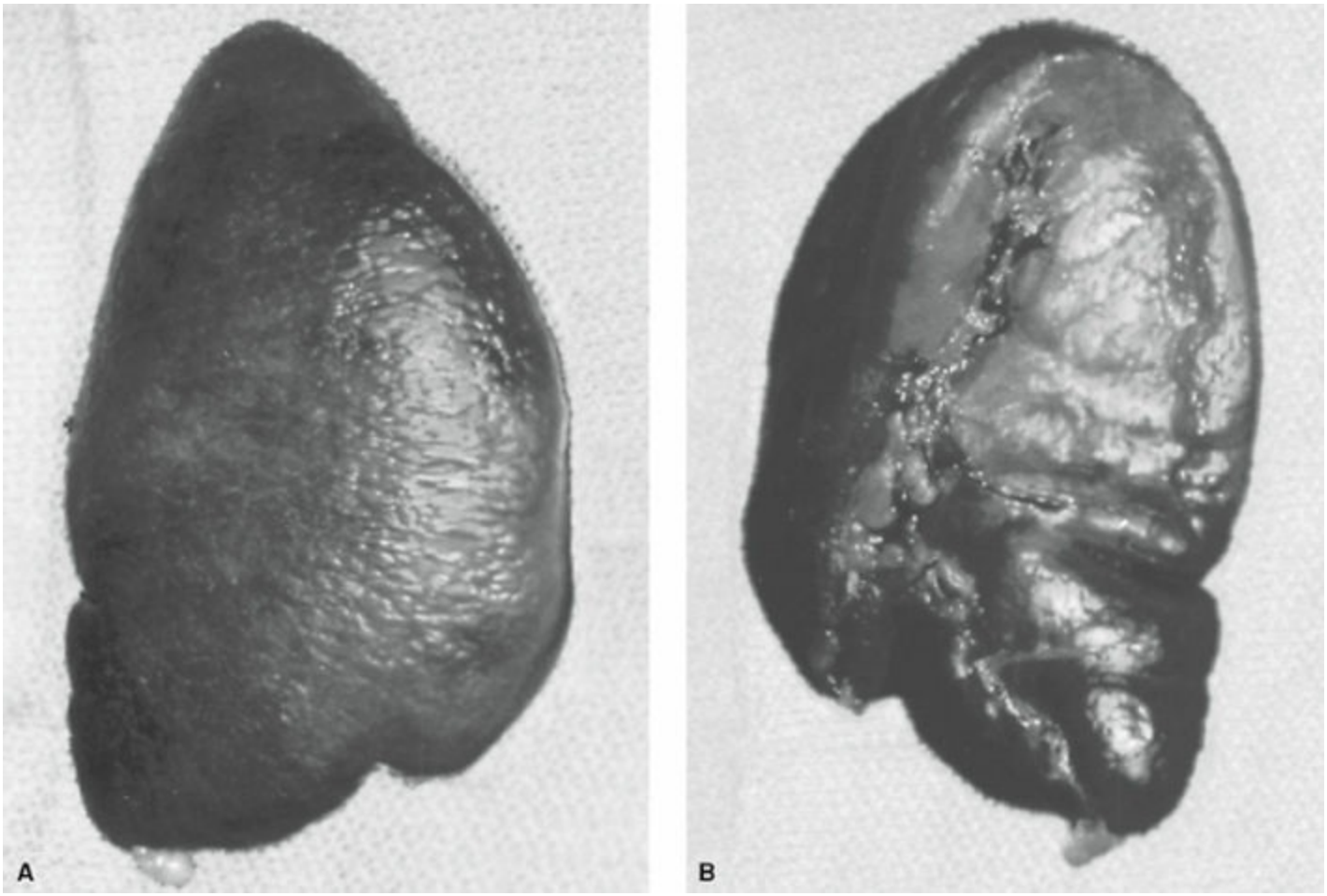

Figure 73-2. **A:** The lateral or diaphragmatic surface of the spleen, showing the lobulated edge and the glistening capsule. **B:** The hilar surface of the spleen, showing the ligatures on the cephalad short gastric vessels and the caudal hilar vessels.

The vascular anatomy of the spleen is rather straightforward.[10] The splenic artery is one of the three major trunks along with the left gastric artery and common hepatic artery branching off from the celiac axis (Fig. 73-3). This artery has a characteristic appearance on celiac arteriograms as a serpentine artery with loops extending both superiorly and inferiorly. There are several small pancreatic branches that supply blood to the body and tail of the pancreas along the lengths of this vessel. The first major splenic branch occurs approximately 2 to 3 cm from the hilum and it is called the superior polar artery. The main artery then divides into anywhere between three and five segmental branches that enter along the trabeculae of the spleen. Additional blood supply to the spleen comes from the left gastroepiploic artery via the short gastric vessels. When the spleen is massively enlarged, it may have direct vessels that are parasitized from the omentum, diaphragm, or the mesentery of the splenic flexure of the colon. The splenic artery generally travels outside the parenchyma of the pancreas just at the superior border although loops that go inferiorly may be completely covered by the posterior surface of the pancreas whereas superior loops may be well away from the pancreatic surface. It is these more cranially located curves that are the optimal place to provide a ligature for control of the splenic artery during procedures in which there is significant thrombocytopenia or for enlarged spleens. These are generally areas that have few

pancreatic branches and avoid proximity to the splenic vein that occurs when the artery loops inferiorly.

The splenic vein is formed by segmental venous branches that leave the trabeculae and coalesce into the main splenic vein in the hilum of the spleen (Fig. 73-3). The splenic vein is intimately associated with the posterior surface of the tail and body of the pancreas to its junction with the superior mesenteric vein forming the portal vein. The inferior mesenteric vein may join the splenic vein directly at several areas along its course or may come together right at the junction of the superior mesenteric vein. There are again several pancreatic branches that directly enter this splenic vein. The blood flow to the spleen in the typical adult is estimated to be 200 to 300 mL/min or approximately 5% of the cardiac output.[10]

The lymph node drainage generally follows the vasculature. The primary lymph nodes are located in the hilum of the spleen and also along the splenic artery at the superior border of the pancreas and along the short gastric vessels.

There are several ligaments that maintain the spleen in its fixed position in the left upper quadrant (Fig. 73-4).[6] Three of these ligaments are virtually always present (except in the condition of the “wandering spleen”)[11] and two may be present to variable extents, depending on the individual patient and the disease process. The first ligament that is constant is the splenogastric ligament that is a left-sided superior extension of the greater omentum along the proximal greater curvature of the stomach. Within this area supplied by the left gastroepiploic vessels are short gastric vessels that branch to the upper pole of the spleen and often provide the upper two-thirds of the spleen with alternative blood supply. The second and very important ligament is the splenorenal ligament that runs parallel to the posterolateral border of the spleen and attaches this to the superior pole of Gerota fascia developing the left kidney. This ligament is divided when mobilizing the spleen during splenectomy and allows reflection of the spleen with or without tail of the pancreas medially. The splenocolic ligament is short and may be avascular or have small blood vessels that go from the inferior tip of the spleen to the splenic flexure of the colon. This may be divided by cautery or may have vessels that need controlled with ties or clips during mobilization of the splenic flexure of the colon.

Two ligaments that are variably present are the spleno- omental attachments and the splenophrenic attachments (Fig. 73-4). The free part of the greater omentum may have variable association with the splenic capsule along the inferior pole. There are often small vessels that may be controlled by electrocautery. This attachment may be absent or may be quite extensive over the lower pole of the spleen. It is this attachment to the omentum that often leads to disruption of the capsule along this inferior pole causing bleeding in other abdominal procedures and may even eventually result in splenectomy for control with an inadvertent injury. Before exerting inferior traction on the omentum during any procedure, the extent of attachments to the lower pole of the spleen should be investigated and, if present, should be divided prior to more vigorous mobilization. There may be direct ligaments connecting the spleen to the diaphragm identified as splenophrenic ligaments. These typically are present to a greater degree when the spleen is diseased or enlarged. They may be avascular or may have branches of vessels

parasitized from the diaphragm blood supply especially with large spleens.

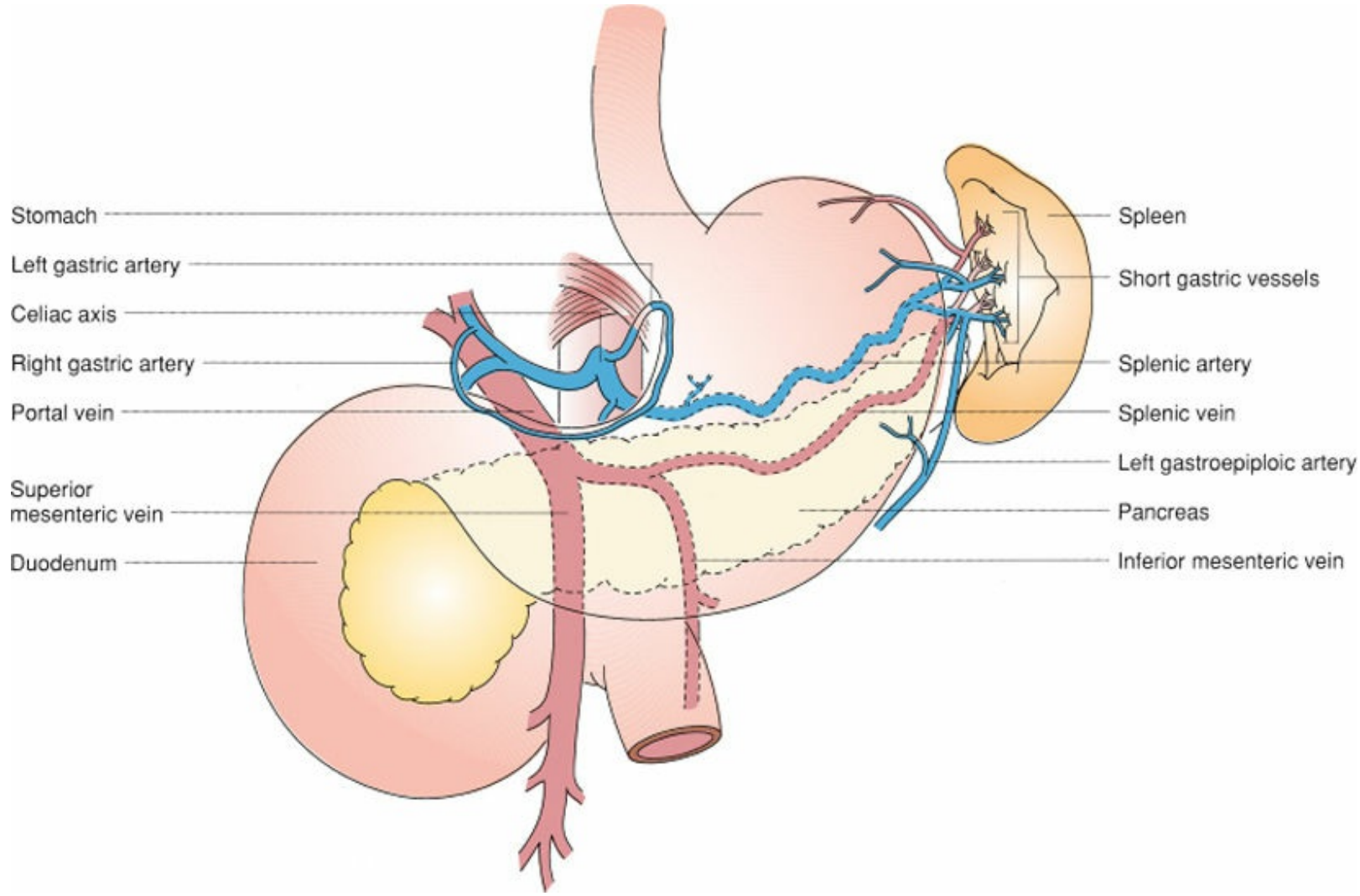

Figure 73-3. The arterial blood flow to the spleen is derived from the splenic artery, the left gastroepiploic artery, and the short gastric arteries (vasa brevia). The venous drainage into this portal vein is also shown.

The anatomy of the spleen itself is segmental being fed by arteries and drained by veins that leave via the trabecula.[12] The trabeculae are fibrous bands that attach to the splenic capsule. The parenchyma of the spleen in between these trabeculae is divided into a small area of white pulp surrounding the arteries, a marginal zone, and the larger predominant area of red pulp that comprises 75% of the splenic parenchyma.[13,14] The capsule of the spleen is quite thin as it is only a few cells layers thick. This consists of a single layer of mesothelium and several layers of fibroelastic tissue. In other mammals but not humans, there may be variable amounts of smooth muscle in the capsule. This smooth muscle would allow contraction and mobilization of the circulating blood cells that are stored in the spleen.[15] The trabecular arteries that enter the spleen as continuation of the segmental arterial branches then give off perpendicular branches to form the central arteries (Fig. 73-5). Surrounding these central arteries is the periarterial lymphatic sheath that is composed of T lymphocytes as well as follicles with B cells at various stages of development. During the antigenic stimulation, this area greatly expands with more mature and secondary follicles. The marginal zone is the borderline between the white

pulp and the red pulp and contains a mixture of lymphatics and macrophages. The structure of the red pulp is made up of splenic cords with an intervening area called splenic sinuses. The splenic cords, also known as the cords of Billroth, are a meshwork of fibroblasts and a large number of mature macrophages. The splenic sinuses are an interconnective meshwork of fairly random red cell spaces that are thin walled and generally filled with large numbers of erythrocytes.[14]

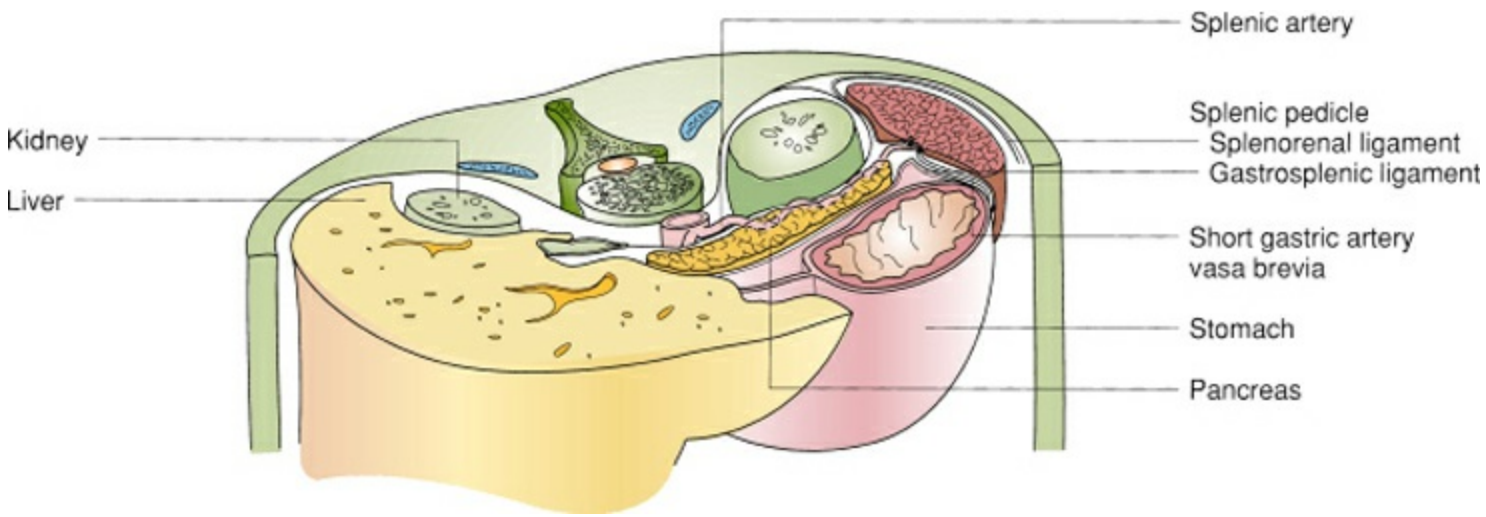

Figure 73-4. The relations of the spleen to the abdominal and retroperitoneal viscera are seen in a cross section of the left-facing torso.

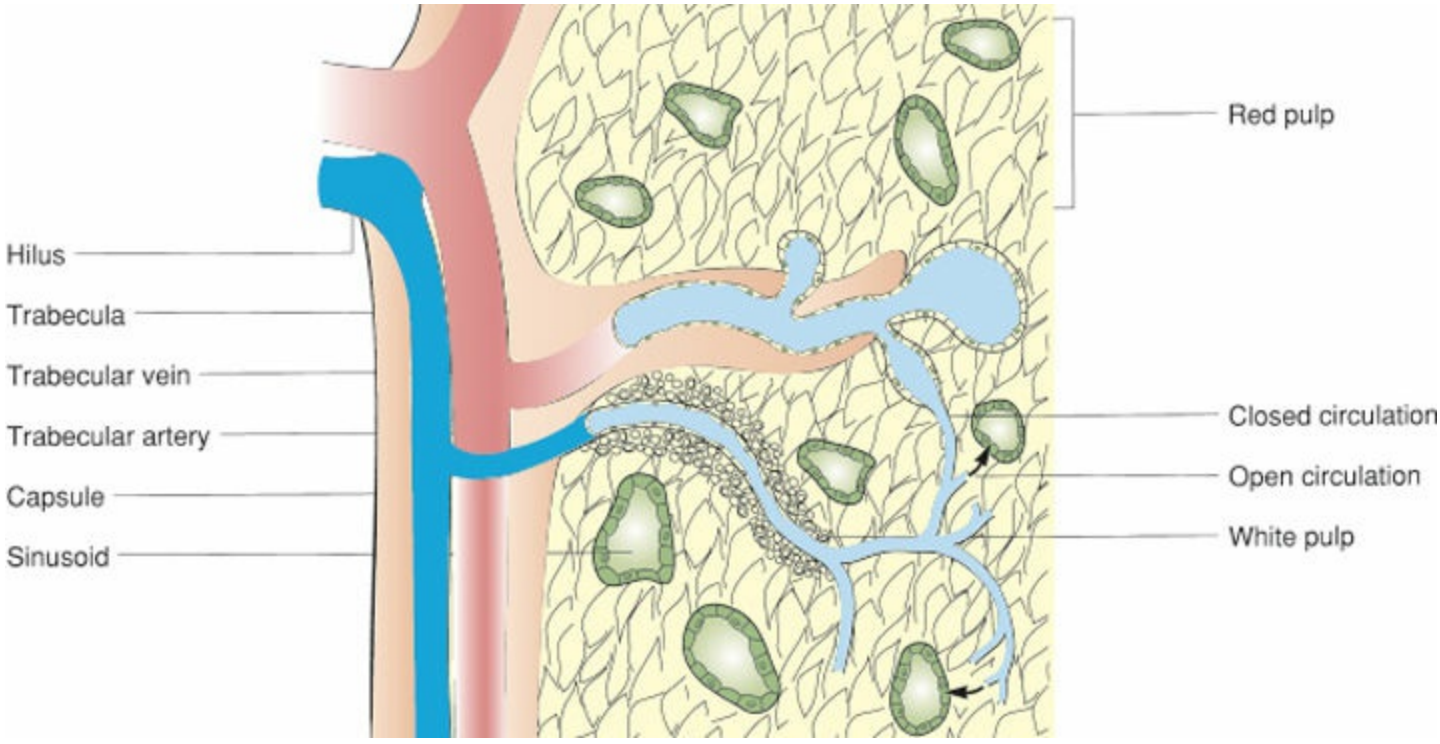

Figure 73-5. The splenic microanatomy is shown with depictions of both the open and closed circulations.

Studies on blood flow show two alternative routes to the spleen being fast flow and slow flow.[16] A small proportion of the blood goes through the splenic arteries and returns rapidly to the splenic veins. This fast flow pattern consists of a greater predominance of plasma and few erythrocytes because of streaming and accounts for only 10% of flow. A

particularly large portion of the erythrocytes that enter the spleen travel through the highly fenestrated meshwork in the red pulp as part of the filtration process of the spleen. This slow path or slow flow comprises up to 90% of the splenic blood flow and relates to the role of the spleen in clearly senescent erythrocytes.

2 Accessory spleens are small nodules of splenic tissue that are completely separate from the main body of the spleen. They typically range in size from 0.5 cm up to 3–4 cm. The reported incidence of accessory spleens ranges between 10% and 20%. The most common location for these small nodules of splenic tissue is in the splenic hilum, the omentum most commonly between the stomach and transverse colon but also within the greater omentum, and the small bowel mesentery. However, they can occur virtually anywhere in the abdomen including the retroperitoneum behind the spleen and in the pelvis. Accessory spleens are important in disease processes in which a complete removal of all splenic tissue is mandatory for long-term cure such as certain autoimmune disorders. A preoperative nuclear medicine spleen scan may also be helpful in some circumstances to identify sources of residual splenic tissue,[17] particularly when present in less common locations.

PHYSIOLOGY

The major functions of the spleen can be divided into two general categories of hematologic functions and immunologic functions (Table 73-2).[14] For hematologic functions, the spleen primarily is an organ related to the destruction or clearance of the circulating blood cell elements as a normal physiologic mechanism. This physiologic filtration function is increased in disease states that produce hypersplenism. The spleen may play a minor role in hematopoiesis and storage of blood cells that can be mobilized for the circulation with the predominantly stored cell being platelets predominantly platelets. In terms of the immunologic functions, the spleen relates to the vascular system in many of the same ways that lymph nodes relate to the lymphatic system. The white pulp and marginal zones are most important for the immunologic functions, whereas the red pulp is primarily related to the hematologic functions. However, the macrophages that line the cords or fill the cords in the red pulp are clearly also important for immunosurveillance for intravascular pathogens.

Table 73-2 Normal Functions of the Spleen

Hematologic
Culling or destruction of senescent erythrocytes
Pitting or removal of cytoplasm inclusive in erythrocytes
Reservoir for platelets and granulocytes
Hematopoiesis – as fetus or in conditions with bone marrow destruction
Immunologic
Filtration and trapping of circulatory antigens
Lymphocyte stimulation and proliferation
Antibody production in germinal follicles
Production of opsonin-tuftsin and properdin
Opsonins: tuftsin and properdin

3 The primary hematologic function of the spleen is removal of senescent erythrocytes or remodeling of abnormal red blood cells with various deformities and the recycling of iron by splenic macrophages.[14] The average life span of a normal erythrocyte measured on clearance studies in humans is estimated to be approximately 120 days.[18] It is also estimated that the spleen destroys approximately 100 billion erythrocytes daily in the red pulp. The process of removal or phagocytosis of erythrocytes or other blood cells is called culling. The blood flow patterns of the spleen lead to a hemoconcentrated erythrocyte-laden fluid that enters the sinuses of the red pulp. Here a slow flow through the sinusoid network with adjacent macrophage filled cords leads to the environment in which erythrocytes may become trapped and then phagocytized by the macrophages. The precise mechanism by which senescent red cells are identified for destruction in normal physiology is unclear. One hypothesis would be that over the course of the life span of an

erythrocyte, there is loss of either membrane elements or total membrane material such that the red cells become less compliant and therefore become trapped in the mesh of the sinusoids. A second hypothesis is that specific cell surface marker molecules may become either more exposed or less available to allow identification of senescent cells targeted for destruction. Pathologic destruction of red cells occurs in diseases such as hereditary spherocytosis or elliptocytosis in which genetic defect creates abnormal red cell pliability limiting its passage through the red pulp. Similarly, in sickle cell anemia, the genetic defect in the hemoglobin alters red cell shape and creates destruction with clogging of the sinusoids. A second pathologic mechanism in which destruction of red cells is increased is in disease processes in which there is an increase in red pulp volume, a condition known as hypersplenism.

The second physiologic process involving circulating erythrocytes is remodeling or pitting that is partial removal of the cell membrane typically associated with the cytoplasmic inclusions. Erythrocytes with a remnant of the cell nucleus remaining pass more slowly through the splenic red pulp because of their larger size.[14] The nuclear remnant may be trapped passing through a small space in the spleen and this solid particle that does not allow deformation gets pinched off in the process of pitting. Intracytoplasmic inclusions include Howell–Jolly bodies that are nuclear remnants, Heinz bodies that are denatured hemoglobin, and Pappenheimer bodies that are iron granules.

The destruction of the other circulating cellular elements of the blood (platelets and leukocytes) is more in the realm of pathophysiology of the spleen than normal physiologic function. The disease processes in which these cells are removed are related to either autoantibodies to cell surface elements or hypersplenism. If either platelets or white blood cells become coated with antibodies, the Fc portion of the immunoglobulin will interact with the Fc receptors on the macrophages in the splenic cords leading to phagocytosis of these cell types. With splenic enlargement from various causes of hypersplenism, a similar process of destruction may occur even without any autoantibodies or defects in the cells just because of an increase in splenic mass.

The spleen serves as a potential source for hematopoiesis of all cell types during gestation. In normal humans, there is felt to be very little if any production of red cells, granulocytes, or platelets, which is not the case in other mammals. In the white pulp of the spleen, there are germinal centers with amplification and production of reactive lymphocytes. The cords of the spleen are filled with macrophages and throughout normal adult life there may be production of lymphocytes and macrophages in the spleen. In certain disease states, the spleen may develop the capacity for erythropoiesis and myelopoiesis. The best example is agnogenic myeloid metaplasia (AMM), discussed in more detail later. In this disease, the bone marrow is replaced with fibrotic scar and a portion of the hematopoietic function of the marrow is taken over by the spleen that is typically quite enlarged.

The final hematologic function of the spleen may be as a reservoir of circulating cellular elements.[15] In humans, the only significant cell type that is stored in the spleen is platelets and it is estimated that 30% of all platelets may reside in the spleen. This

function may be more important than other mammals particularly those with significant smooth muscle lining the capsule of the spleen that allows contracture with expulsion of large numbers of stored cells as a physiologic response to injury.

4 The immunologic function of the spleen is primarily to generate an immune response to antigens that are identified and cleared from the blood system. Either opsonized antigens or specific encapsulated microorganisms are important examples of target antigens trapped by the spleen. The spleen is an ideal environment for generation of either a cellular or humoral immune response. There are all of the necessary cells types for stimulation of the immune response including phagocytic cells, dendritic cells, T cells, and B cells that may form general follicles to generate specific antibody responses. These interactions primarily occur in the marginal zone in the white pulp that may become quite enlarged and hypertrophied during antigen stimulation. These cellular components and the structure of the germinal follicles are essentially identical to those found in lymph node tissue that becomes enlarged in a similar way with antigenic stimulation via microbes or antigens in the lymphatic system.

The spleen is also involved in nonspecific immune responses. It is the site of synthesis of both properdin and tuftsin that are opsonins. Tuftsin is a small peptide that binds to the surface of granulocytes and promotes phagocytic function by these cells.[19] Properdin can initiate the alternate pathway of complement activation that may be important in destruction of abnormal cells or bacteria that are antibody bound. The spleen is not the only source of these nonspecific immune-enhancing proteins and therefore splenectomy may lead to only a modest alteration in this function.

PATHOPHYSIOLOGY

There are characteristic responses that share many common features under the broad category of hyposplenism and hypersplenism. These features highlight the normal physiologic functions of the spleen and provide guidelines and influence clinical decision-making when managing patients after splenectomy or in deciding which patients should undergo splenectomy.

Hyposplenism

By far, the most common cause of hyposplenism is surgical removal.[20] Other explanations would be an unusual situation of a congenitally small or absent spleen or acquired destruction of splenic tissue as occurs in sickle cell anemia or celiac disease. The diagnosis can be verified by 99Tc-labeled spleen scan or pitted red blood cell count. Pathophysiologic consequences of hyposplenism or the changes seen after a splenectomy are predictable from the known functions of the spleen. There are hematologic changes in the circulating cells that can be predicted from the splenic functions of culling, pitting, and as a reservoir for platelets (Table 73-3). There are changes in the immunologic responses that are important primarily in infants or young children, which can lead to the problem of overwhelming postsplenectomy sepsis. There are a variety of other causes for hyposplenism listed in Table 73-4.

Table 73-3 Hematologic Changes Postsplenectomy/Hyposplenic Condition

1. Erythrocytes
Howell–Jolly bodies (nuclear fragments)
Heinz bodies (hemoglobin deposits)
Pappenheimer bodies (iron deposits)
Target cells
Spur cells (acanthocytes)
2. Platelets
Transient thrombocytosis
3. Leukxocytes
Transient leukocytosis
Persistent lymphocytosis
Persistent monocytosis

The changes in circulating blood cells after splenectomy in cases of hyposplenism affect the erythrocytes, leukocytes, and platelets. Over time, the intracytoplasmic inclusions in the red cells that are normally cleared by the spleen accumulate resulting in presence of Howell–Jolly bodies, Heinz bodies, and Pappenheimer bodies as well as target cells with excess red blood cell membrane and occasionally increase in the circulating nucleated red blood cells or reticulocytes. As the spleen is the organ of storage for a large proportion of the platelets, a splenectomy often results in thrombocytosis with platelet counts postsplenectomy ranging between 500,000 and up to one million in some cases. This increased platelet count tends to be transient and may be a reflection of the fact that the spleen while being a storage organ for platelets may not be a primary area of platelet destruction after the typical half-life of 10 days. The immediate response after a splenectomy in white cells is leukocytosis again reflecting storage of a large proportion of white cells in the spleen.[21] As with the thrombocytosis, this effect is transient but there may be long-term increases in the proportion of circulating lymphocytes and monocytes after the splenectomy. Preserving even a small amount of spleen can preserve splenic

function in clearing senescent blood cells.[22]

Clinical sequelae of hyposplenism or following splenectomy are discussed in more detail at the end of this chapter.

Hypersplenism

Hypersplenism is increased splenic function that is manifested clinically by the decrease in one or more of the circulating blood elements. The specific criteria for hypersplenism are: (1) documented anemia, thrombocytopenia, or leukopenia; (2) normal compensatory response by the bone marrow to correct the cytopenia; and (3) correction of this cytopenia by splenectomy. Some definitions of hypersplenism may also include the criteria for splenomegaly. This more restrictive definition would not necessarily incorporate, however, diseases or disorders related to abnormalities in circulating blood cells such as immune thrombocytopenic purpura (ITP) or autoimmune hemolytic anemia. The second approach to categorizing hypersplenism is to classify the disorders on the basis of whether the primary abnormality is in the circulating blood cells versus in the spleen itself (Table 73-5). For either situation, the pathophysiology is that the spleen is the site of destruction for one or more circulating blood elements. In cases of significantly enlarged spleen, additional symptoms relate to mass effect from the spleen on adjacent organs. The most important symptom is early satiety and weight loss as the stomach is compressed between the liver and the enlarged spleen. There are a variety of causes of hypersplenism that are typically neoplastic but may be related to primary blood cell dysfunction or abnormalities or other condition such as portal hypertension due to cirrhosis or splenic vein thrombosis. Hypersplenism is the most important indication for elective isolated splenectomy[21] to reverse the cytopenia and often to relieve compressive symptoms from splenomegaly.

Table 73-4 Causes/Disorders Associated with Hyposplenism

Splenectomy
Sickle cell anemia
Congenital asplenia (autosomal recessive disorder)
Autoimmune disorders (e.g., glomerulonephritis and SLE)
Celiac disease/inflammatory bowel disease
Tumor or cystic replacement of spleen
Amyloidosis
Splenic vascular accident
Radiation

SLE, systemic lupus erythematosus.

Table 73-5 Causes of Hypersplenism

I. Primary diseases of blood cells; normal spleen
   A. Congenital
      i. Erythrocyte abnormalities
         a. Hereditary spherocytosis
         b. Hereditary elliptocytosis
         c. Glucose 6 phosphate dehydrogenase deficiency
         d. Pyruvate kinase deficiency
      ii. Hemoglobin abnormalities
         a. Thalassemia major
         b. Sickle cell anemia (eventually results in splenic infarction and hyposplenism)
      iii. Platelet abnormalities
         a. Wiskott–Aldrich syndrome
   B. Acquired
      i. Autoimmune hemolytic anemia
      ii. Autoimmune neutropenia – Felty syndrome
      iii. Immune thrombocytopenia purpura
      iv. Thrombotic thrombocytopenia purpura

II. Primary disorders of the spleen
   A. Neoplastic
      i. Hairy cell leukemia
      ii. Chronic lymphocytic leukemia
      iii. Chronic myelogenous leukemia
      iv. Non-Hodgkin lymphoma
   B. Cellular infiltrative (hematopoiesis)
      i. Agnogenic myeloid metaplasia
      ii. Mastocytosis
      iii. Chediak–Higashi
   C. Metabolic infiltration
      i. Gaucher disease
      ii. Sarcoidosis
   D. Vascular
      i. Splenic vein thrombosis
      ii. Portal vein hypertension (cirrhosis)

SURGICAL TREATMENT FOR DISEASES RELATING TO THE SPLEEN

Until fairly recently, the only pertinent operation to discuss in relationship to disease involving the spleen was open splenectomy. Appreciation of the increased risk of infection in inpatients who are asplenic or hyposplenic in the late 1960s and the early 1970s led to two new surgical procedures. First, there was an interest in splenic preservation in cases of trauma with procedures including splenorrhaphy and other types of ways to save damaged spleen. Second, procedures to do partial splenectomy were developed primarily for elective surgery in which hypersplenisim existed but a complete splenectomy was not necessary and there were advantages to partial splenectomy. The most recent change in surgery of the spleen relates to the explosion in the minimally invasive surgery that has happened over the past 25 years.[23] The spleen is very susceptible to a laparoscopic excision and recent reports have utilized laparoscopic splenectomy for virtually all indications including to remove massive spleens. Despite its increasing utilization in most major centers, though, laparoscopic splenectomy still appears to constitute only a minority of the splenectomy procedures performed nationally.

Indications for Splenectomy

To better describe and understand operative indications in surgery of the spleen, one could categorize splenectomy or procedures of the spleen into eight general areas:

1. *Trauma* or injury to the spleen.
2. *Autoimmune/erythrocyte disorders.* In this category of disease, there are specific cytopenias related to antibodies targeting platelets, erythrocytes, or neutrophils with the second category of diseases related to intrinsic structural changes within the erythrocyte. For these disorders, total splenectomy is typically indicated for cure.
3. *Hypersplenism* results in decreased circulating blood cells often including all subtypes of platelets and red blood cells. Hypersplenism may be related to neoplastic infiltration of the spleen or infiltration with lipids and other stored products that lead to massive spleen. Hypersplenism may cause symptoms due to the splenic size.
4. *Incidental splenectomy.* The spleen may be removed as part of a standard operation to remove the distal pancreas most commonly, and also for proximal gastric cancers due to the direct or nodal involvement. Other enlarged tumors of the left upper quadrant and retroperitoneum such as sarcoma and adrenal tumor, and left-sided renal cell cancers, may require splenectomy because of association of these tumors with the spleen or its vessels.
5. *Iatrogenic splenectomy.* This is a category that may be underreported but includes splenectomy or splenic preservation procedures due to inadvertent injury to the spleen during surgery for other reasons within the general abdominal cavity or, specifically, the left upper quadrant.
6. *Diagnostic procedures.* This category of splenectomy includes cases when the spleen is removed primarily to make a clinical diagnosis when none is available.[24] A subcategory of this would be staging laparotomy for Hodgkin disease that is rapidly becoming more of a historical footnote as the treatment of this lymphoma now rarely requires splenectomy.
7. *Vascular abnormalities.* Splenectomy for vascular events or abnormalities includes patients with splenic vein thrombosis or less commonly splenic artery aneurysms.
8. *Miscellaneous procedures.* This would include treatment of simple and neoplastic cysts, echinococcal cysts of the spleen, and treatment of the symptomatic “wandering spleen,” a congenital anomaly.

An estimated 22,000 splenectomies are performed annually in the United States.[25] Two recent reports have been published describing 10-year experiences for all splenectomies done in their respective institutions. The first report is the combined series of 1,280 splenectomies over a 10-year interval from the Barnes Hospital in St. Louis and the Brigham and Women’s Hospital in Boston.[24] The second report is a single institution over the identical time period from Vanderbilt University.[26] In the Barnes/Brigham series, there were 1,280 splenectomies, and in the Vanderbilt series there were 896 splenectomies (see Table 73-6). One can see that dependent on the type of institution and referral patterns, the indications for splenectomy vary to some degree. In the Vanderbilt

series, the majority of splenectomies are done for trauma, which account for 41.5% of all operations done in that institution. In the Barnes/Brigham & Women's series, the most common indication was incidental splenectomy in which the spleen was removed as part of an excision of another organ, typically large tumor somewhere in the left upper quadrant of the abdomen. The second most frequent indication for splenectomy was staging laparotomy for Hodgkin disease. This is likely to be different in the ensuing decade as both treatment indications and diagnostic techniques have significantly eliminated this practice after 1990. These differences highlight that indications for splenectomy can vary dramatically among centers, in part related to trauma volume at the centers and cancer case referrals. It also should be noted that if one eliminates the traumatic, incidental, and staging procedures, the most common indication in both series relates to autoimmune or erythrocyte disorder.

Table 73-6 Indications for Splenectomy in Two Large Series From Academic Medical Centers

	Barnes/Brigham & Women's[28]	Vanderbilt[29]
N	1,280	896
Dates	1986–1995	1986–1995
Trauma	167 (13.0%)	372 (41.5%)
Autoimmune/erythrocyte disorders	219 (17.1%)	140 (15.6%)
Hyperplasia	99 (7.7%)	138 (15.4%)
Incidental	336 (26.3%)	110 (12.3%)
Iatrogenic	NA	33 (8.1%)
Diagnostic unknown	122 (9.5%)	18 (2.0%)
Diagnostic staging for Hodgkin disease	258 (20.2%)	NA
Vascular	74 (5.8%)	21 (2.3%)
Miscellaneous	5 (0.4%)	24 (2.7%)

Table 73-7 Grading of Splenic Injuries

Grade	Laceration	Hamartoma
I	<1 cm in depth	Subcapsular <10% of surface
II	1 to 3 cm in depth not involving a trabecular vessel	Subcapsular 10–50% of surface area or 5 cm in diameter
III	>3 cm depth or any depth involving a trabecular vessel	Subcapsular >50% of surface area or intraparenchymal
IV	Segmental or hilar vessel involvement	
V	Shattered spleen or hilar vessel disruption	

The details of the indications for splenectomy in each of these categories are discussed. The specific indications for splenectomy (whether total or partial), the alternative treatments that are available, and the results from surgical removal of the spleen are also

reviewed.

Trauma of the Spleen

5 The spleen is the most common intra-abdominal organ injured by blunt trauma in the United States and in many institutions splenectomy remains the most common operative procedure performed on the spleen.[27] The history of splenic surgery mirrors the history of surgery for trauma. In the ancient medical literature, there have been reports of resection of portions of the spleen that had herniated through a flank wound.[28] The first documented splenectomy for penetrating trauma occurred in San Francisco by a British naval surgeon named O'Brien in 1816 when a spleen protruded out the side of a knife wound.[12] In the late 19th century, Theodor Billroth observed during an autopsy of a patient who died of head trauma 5 days earlier that there was minimal blood in the peritoneum from the fracture of the splenic capsule and predicted that these injuries might be managed operatively. Although in the earlier part of the 20th century, splenic trauma was uniformly managed by a complete splenectomy, Dr. Campos Christo of Brazil reported partial splenectomy and splenic salvage for both penetrating and blunt trauma in 1962 (Table 73-1).[4] This initial report, combined with the ability to obtain repeated cross-sectional imaging and with the understanding of splenic function, has led to the current management guidelines of nonoperative management for lower-grade splenic injuries and operative management centered around splenic preservation when possible.[29]

The most common modes of blunt injuries leading to splenic rupture are motor vehicle accidents as well as bicycle accidents in which upper abdominal trauma may occur. The signs and symptoms of isolated splenic injury include tenderness in the left upper quadrant of the abdomen. Attention must be directed towards the lower lateral left ribs; focal tenderness over ribs 9 through 11 in that region should raise suspicion of possible splenic injury. Approximately 20% of cases of rib fracture can be demonstrated on radiographs. Patients may have referred pain to the left shoulder (Kehr sign) particularly when placed in the Trendelenburg position with palpation of the upper abdomen. The spleen itself is rarely palpable but when a left upper quadrant mass is palpable, it likely represents a contained hematoma or a subcapsular hematoma (Ballance sign). Depending on the severity of the injury, patients may have no hemodynamic instability or may be in frank hypovolemic shock. The grading system for splenic trauma is summarized in Table 73-7.

The diagnostic studies associated with splenic rupture would potentially include a decrease in hematocrit and hemoglobin although initial assessment before volume resuscitation may show normal levels. After a short period of time there is often a leukocytosis in the range of 15,000 to 20,000. Plain abdominal x-ray films, in addition to possibly showing left rib fractures, may show displacement or a corrugated appearance along the greater curvature of the stomach due to a hematoma infiltrating the gastrosplenic ligament (Fig. 73-6). Peritoneal lavage will reveal the presence of blood in the abdomen. The most important current tool for diagnosis particularly in patients who are hemodynamic stable enough to be managed conservatively is the CT scan. Contrast CT scan will show the splenic contour and will also show the amount of extrasplenic blood (Fig. 73-7).[30]

Overall blunt injuries comprise the majority of splenic trauma, but the spleen is susceptible to penetrating trauma in the retroperitoneum, lower thoracic penetrating trauma, or upper abdominal penetrating trauma. A 15-year state review of splenic trauma in Pennsylvania reported 10,652 (92%) blunt injuries and 893 (8%) penetrating.[29] The management and diagnosis of penetrating injuries trauma of the thorax and upper abdomen are less of a diagnostic dilemma as a majority of these patients undergo abdominal exploration because of associated injuries. In some series, there are additional injuries in 90% to 100% of patients with penetrating trauma to the spleen and 40% to 60% associated injuries in cases of blunt trauma.



Figure 73-6. Abdominal film in a patient with a splenic rupture from blunt trauma with a perisplenic hematoma displacing the greater curvature of the stomach medially. The scalloped appearance is indicative of blood in the gastrosplenic ligament (radiograph courtesy of Dr. C. William Schwab).

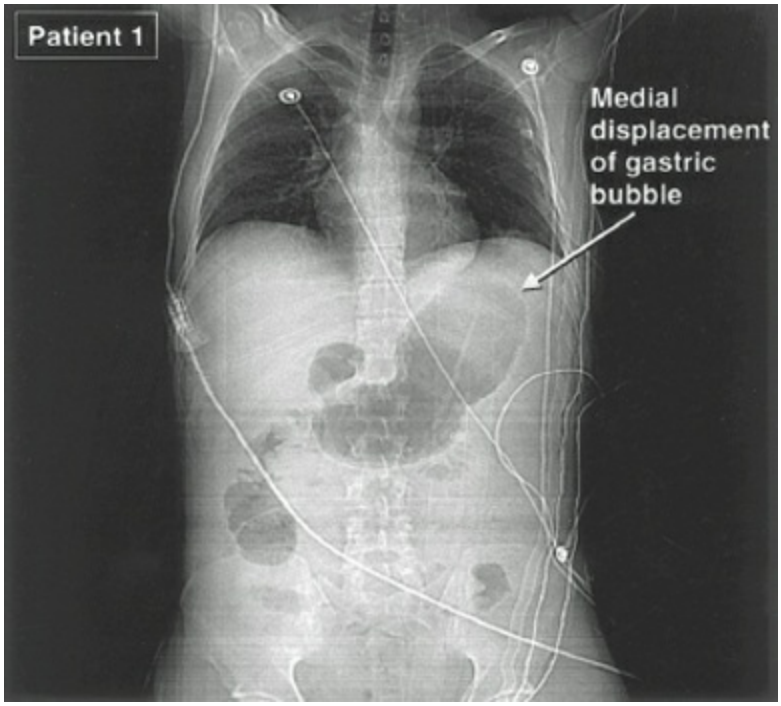

Figure 73-7. A contrast CT scan on a patient with splenic rupture near the hilum. There is considerable blood in the perisplenic fossa as well as free blood in the peritoneal cavity around the liver (radiograph courtesy of Dr. C. William Schwab).

Management of splenic injuries historically has been a laparotomy with splenectomy. Since Christo introduced the ability to do either partial splenectomy or splenorrhaphy, there has been an increased trend with surgical procedures to try to repair or preserve part, if not all, of the spleen. The current trend in management is a nonoperative approach with observation in serial CT scans.[31] The presence of peritonitis, associated injuries requiring surgery, overall injury severity, evidence of hypovolemic shock with ongoing bleeding, and the patient's age are the primary factors that are taken into consideration while deciding on nonoperative versus operative management of blunt splenic injuries.[29] If patients have diffuse peritonitis or if patients have hypotension related to hypovolemic shock, urgent laparotomy is indicated (Fig. 73-8). There have been increasing reports of splenectomy successfully performed laparoscopically for blunt splenic trauma[32]; however, a minimally invasive approach is typically used very selectively in this setting, given the frequent hemodynamic instability and concurrent injuries that may be better addressed via laparotomy. For patients who are hemodynamically stable and do not have other injuries that require surgical management, the recommendation is to attempt nonoperative observation of these patients.

The standard nonoperative management protocol would include very close observation in an intensive care unit or a similar monitored environment. Patients would have serial abdominal examinations as well as serial hemoglobin and hematocrit assessments. Any change in status in which patients remain otherwise relatively stable would be evaluated with a follow-up CT scan to see if there is progressive or ongoing bleeding demonstrated by increased hemoperitoneum or expansion of splenic hematoma. A recent report noted that routine follow-up CT scans did not alter management in patients treated nonoperatively.[33] Only patients with changes in hemodynamic parameters had a change

in management. With this conservative management, the majority of patients would avoid laparotomy for isolated splenic blunt trauma.[34] If patients are older, have associated injuries, or have ongoing blood loss, a laparotomy is appropriate for blunt splenic trauma.[28,35] Again, the nature of the splenic injury is graded relative to the degree of damage to the splenic parenchyma and the proximity to the splenic hilum and major blood vessels (Table 73-7). The principles of operative management would include stopping ongoing hemorrhage while preserving the maximal amount of viable splenic parenchyma. Nonviable or devascularized tissue must be debrided.[36] Partial splenectomy has been popularized on the basis of the concept of segmental blood supply via the trabecular arteries. A variety of approaches can be taken to more minor peripheral splenic trauma including primary repair or mesh repair (Fig. 73-9). Utilization of multiple material that are available for hemostasis including microfibrillar collagen, thrombins of gelfoam, or fibrin glue sealants have been utilized to obtain control of splenic hemorrhage. The argon beam coagulator is a very useful instrument for capsular tear or evulsions. Of note, all of these techniques that have been applied to patients with blunt trauma can be similarly applied to patients who have inadvertent trauma to the spleen during operations for other reasons (surgeries involving dissection of the splenic flexure of the colon or the left kidney, adrenal gland, or stomach).

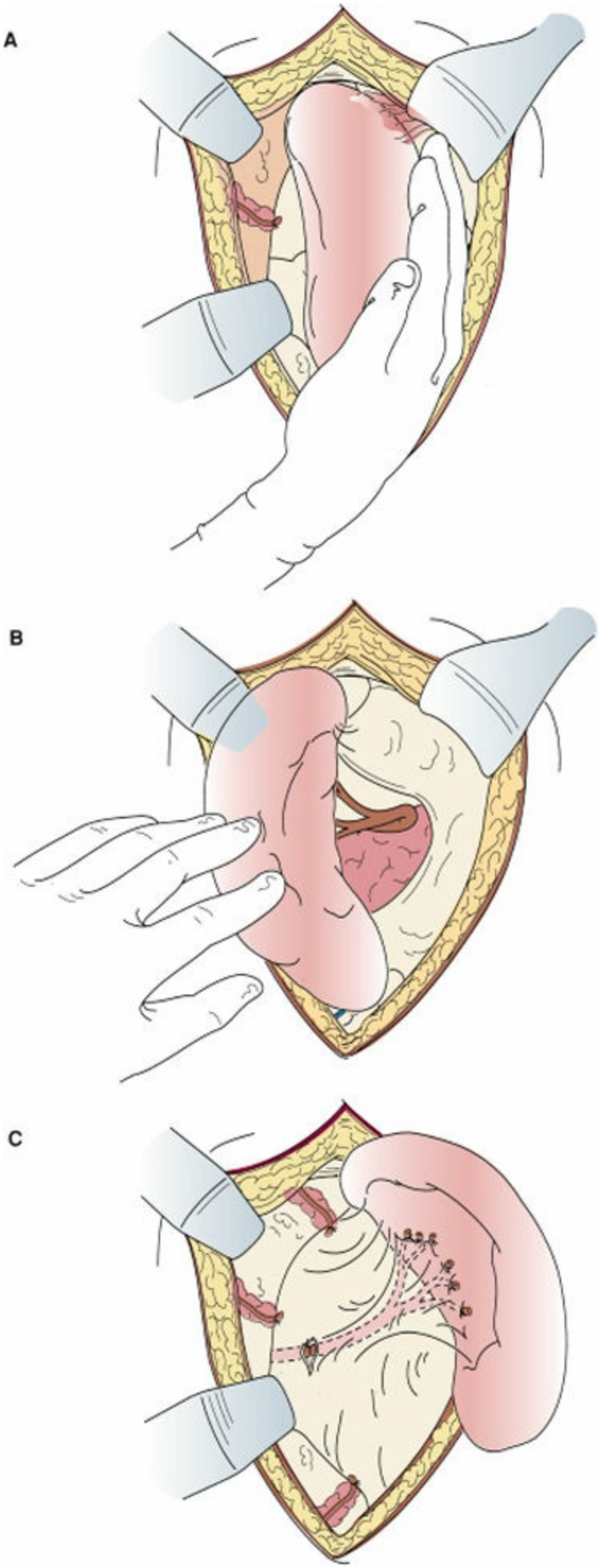

Figure 73-8. **A,B:** Rapid mobilization of a bleeding spleen can be accomplished in most patients by blunt dissection of the lateral attachments. **C:** The splenic hilum can then be quickly controlled.

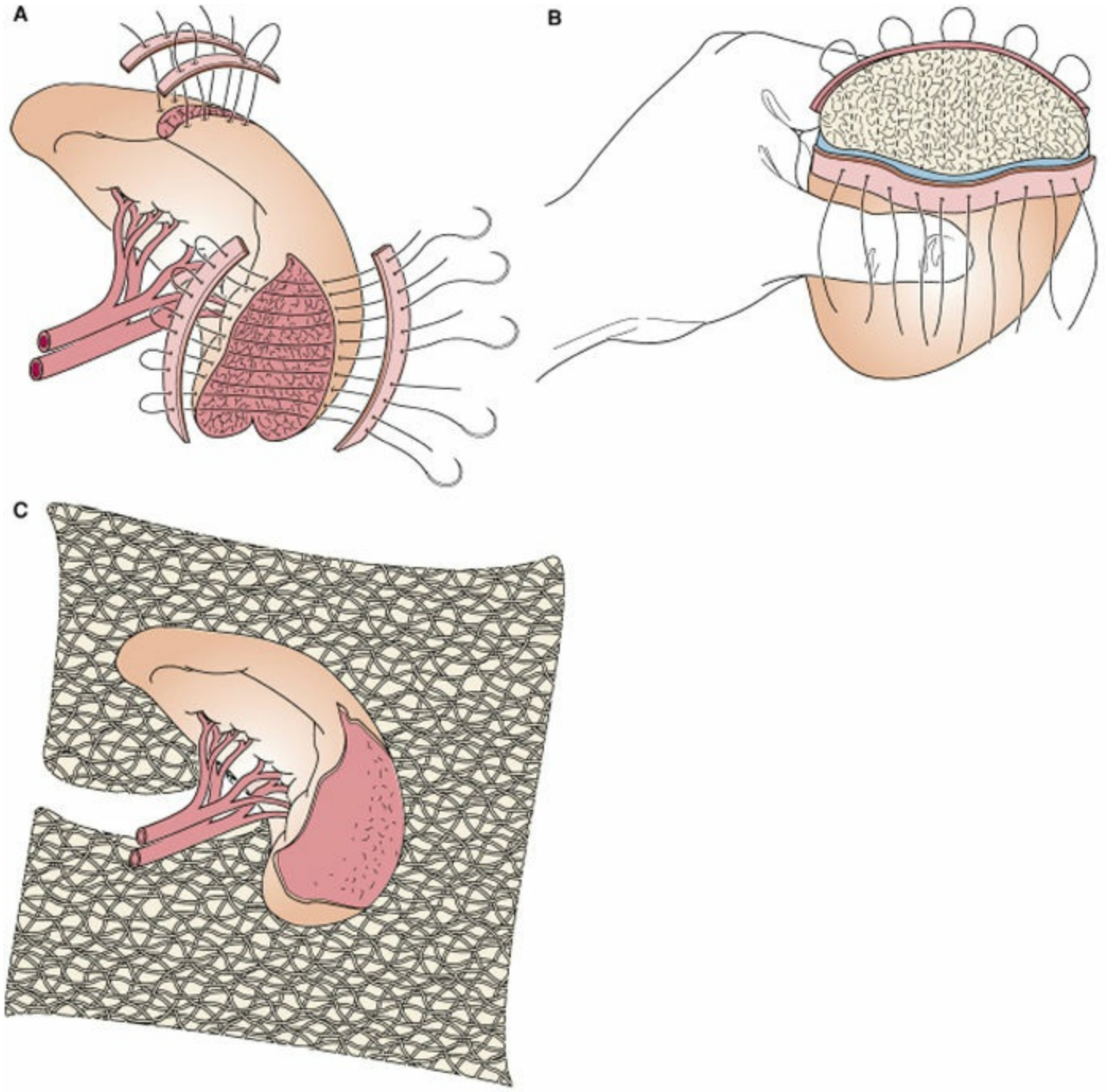

Figure 73-9. **A:** Techniques to suture superficial splenic lacerations. **B:** Technique to control bleeding after hemisplenectomy. The sutures can be interlocked. **C:** Polyglycolic acid mesh sheets or mesh bags can be applied to spleens that have had the capsule stripped away.

Over the past decade, this trend towards non-surgical management has expanded, with increasing success rates noted with conservative management. A recent study of more than 625 patients with blunt trauma over the past decade compared with the prior decade showed that there was an increase in initial nonoperative management from 61% to 85%.[37] The success rate of nonoperative management increased as well from 77% to 96% and the splenic salvage rate from 57% to 88%.[37] This may be partly due to a decreased distribution of more severe splenic injuries and partly the result of an increasing trend toward the use of embolization of splenic arteries as part of the nonoperative management of blunt trauma. A recent systematic review of 16,490 patients with blunt

splenic trauma reported that for severe splenic trauma, nonoperative management was associated with a decreased mortality rate as compared with operative management (4.8% vs. 13.5%).[38] However, the higher mortality rate observed in the group managed operatively appeared could be explained by the presence of other concurrent injuries in that group. The authors concluded that, while nonoperative management remains the recommended approach by the American Association for the Surgery of Trauma for grade I and II injuries, the data for managing more severe splenic injuries are very heterogeneous with multiple potential confounders, making it more difficult to interpret.

Since its introduction in the early 1992 as a potential maneuver to improve the nonoperative management of blunt splenic injury, embolization with either coils or gelfoam of either proximal or distal splenic vessels has had increased utilization,[39] extending into the management of selected grade 3 or 4 injuries. In the study comparing the outcome of blunt trauma over the past two decades, the use of embolization increased from 2.7% to 22.6%.[37] The majority of studies provide similar data that the overall success rate for nonoperative management with splenic artery embolization is improved and could decrease the use of blood products.[40] There have been some recent studies stating that this may be overutilized and a report of a failure rate of 27% in patients with embolization failed and needed surgical exploration.[41] Again, these comparative studies are not matched in terms of severity of injury or even the techniques used for the splenic artery embolization.

One corollary with the nonoperative management of blunt splenic trauma is the risk of delayed rupture. Standard guidelines of conservative management are that patients should have stable hemoglobin for 36 to 48 hours and have resolution of abdominal pain prior to discharge. The delayed rupture rate in a large series of more than 1,900 patients showed that 27 patients were readmitted for splenectomy within 180 days of discharge,[42] a delayed rupture rate of 1.4%. The median time from injury to readmission for splenectomy was 8 days with the range of 3 to 146 days. Similar results were obtained in an institutional study of 450 patients with nonoperative management of blunt splenic injury. In this group, 4% failed with eventual splenectomy due to delayed rupture.[43] Both studies stress that with the increased use of nonoperative management, the potential risks of delayed rupture require very specific discharge instructions to patients regarding reonset of acute abdominal pain with other signs and symptoms of hypotension requiring emergent transportation to the nearest emergency room or hospital facility.

Another area of splenic trauma is atraumatic splenic rupture. This can be considered more spontaneous rupture and it occurs primarily with enlargement of the spleen with malignant disorders either primary or secondary metastases, infectious disease, or inflammatory diseases, or technical disorders such as pregnancy or peripartum rupture. In a large series of more than 900 patients with atraumatic spontaneous rupture of the spleen, only 6.4% had no pathologic or mechanical causes that were identified.[44]

Autoimmune/Erythrocyte Disorders

There are two categories of disease in which abnormalities do not originate in terms of the histology, pathology, or size of the spleen but rather are due to either autoimmune phenomenon or intrinsic diseases within circulating cells that lead to their destruction. The most common and obvious example of this is ITP in which antibodies to platelet antigens lead to destruction of platelets and thrombocytopenia with the spleen being the primary source of platelet elimination. Related diseases affecting erythrocytes and neutrophils with specific antibodies and splenic elimination occur to lesser degrees.

A second category of disease is not an autoimmune phenomenon but rather an intrinsic cellular defect that leads to a shortened half-life of this specific blood cell within the circulation primarily to elimination within the spleen. As discussed in the physiology section given earlier, a normal role of the spleen is to eliminate senescent erythrocytes and the anatomic structures of splenic circulation are well suited to that task. If erythrocytes are altered in terms of their structure, this may lead to more rapid elimination. In other diseases, genetic differences in the hemoglobin may result in splenic changes particularly in the setting of hypoxia that occurs within the splenic sinusoids. The most obvious example of this would be sickle cell anemia. A final example is an alteration in the cellular adhesion molecule that leads to increased interaction and thrombocytopenia in the Wiskott–Aldrich syndrome.

Immune Thrombocytopenic Purpura

ITP is often a diagnosis of exclusion once all other causes such as drug-induced thrombocytopenia or evidence of bone marrow failure are eliminated.[45] ITP is a disease characterized by autoimmune destruction of platelets with clinical manifestations of thrombocytopenia manifest by susceptibility to easy or excess bleeding.[46] ITP may be classified into an acute form and a chronic form. Acute ITP generally occurs in children younger than 8 years following an upper respiratory viral illness. The majority of children with acute ITP will have spontaneous remissions, whereas only a small minority of adults who develop ITP have remission and most go on to develop chronic ITP. This disease is usually self-limited and requires surgical intervention only in the case of intracranial bleeding. Chronic ITP accounts for the vast majority of cases considered for splenectomy. Similar to autoimmune hemolytic anemia, this disease may be idiopathic or may be secondary to a lymphoproliferative disorder, connective tissue disorder such as systemic lupus erythematosus, or drug or bacterial exposure. The average age at diagnosis is in the fourth decade of life and it affects women more commonly than men. As HIV was identified in the mid-1980s, it was noted that patients with acquired immunodeficiency syndrome (AIDS) were developing disease virtually identical to ITP.[47] AIDS patients with newly diagnosed ITP and risk factors for HIV should undergo screening.

6 The pathophysiology of ITP is development of an IgG antibody to a platelet antigen. This is felt to be most commonly directed against the fibrinogen receptor (glycoprotein IIb/IIIa and IR/IX).[48] The spleen plays a predominant role in this disease as it may be the

site of initial antibody production.[49] It is almost certainly the site of continued antibody production, and in the majority of patients the spleen is the primary site of platelet destruction. Since the targeted antigen is an intravascular cell, and since the spleen stores large numbers of platelets, it is felt that the initial reaction to the platelet cell antigen may occur in the spleen. Studies on antibody levels have indicated that overall IgG production in spleens from patients with ITP is markedly increased over individuals with normal spleens. Similarly, following splenectomy the amount of IgG antibody is somewhat decreased. The spleen is also the predominant site of platelet destruction. As noted earlier, the macrophages located in the cords of Billroth have receptors for the Fc portion of the IgG and will bind and phagocytize the antibody-coated platelets. A second more recently described component of the pathophysiology is an inappropriately decreased level of production of thrombopoietin for that level of thrombocytopenia. Cloning of the thrombopoietin receptor or the megakaryocytes has led to several new agents that can alter this aspect of the pathophysiology of ITP.[50,51]

To be considered to have ITP, the platelet count has to at least be $<100{,}000$, but typically patients do not become symptomatic unless platelet counts are $<50{,}000$. Platelet counts in this disorder may drop to very low levels, well below 10,000 on occasion. Assays are now available to identify the IgG antiglobulin on the platelet surface verifying the disease, but over one third of the patients have no clear identification of antiplatelet antibodies. Bone marrow analysis shows an increased megakaryocytes production as compensatory mechanism to the thrombocytopenia. In this disorder, there is often no splenomegaly and the spleen may be somewhat smaller than typical. Only 2% of patients with ITP have palpable spleens. For this reason, there is virtually no leukopenia or anemia associated with ITP due to hypersplenism. There may be anemia secondary to chronic blood loss. The risk of a fatal hemorrhage in patients with ITP overall is 0.0162 and 0.0389 cases/patient year and predicted 5-year mortality rates are 2.2% for patients <40 years of age and 47.8% for patients older than 60 years.[52]

The treatment of ITP includes standard measures to treat any ongoing bleeding, medical therapies designed to increase platelet count, and splenectomy. First-line medical therapy options include platelet transfusion, corticosteroids, gamma-immunoglobulin, and the recently approved Rho (d) immunoglobulin.[53] Platelet transfusions should be discouraged unless patients are actively bleeding as platelets will become rapidly coated with IgG and will be sequestered and destroyed in the spleen. High-dose corticosteroids produce an initial response in the majority of patients but this is unfortunately not sustained. Approximately 75% of the patients will have an increase in platelet count that is significant within 24 hours of starting high-dose steroids.[54] However, only 15% to 25% of patients will have a sustained remission with chronic ITP following steroid therapy. A second aspect of initial medical treatment for chronic ITP has been administration of intravenous IgG immunoglobulin. This treatment takes only between 3 and 5 days to show an effect and generally does not put patients into complete remission. The mechanism of action of immune gamma globulin is felt to be saturation of the Fc receptors on the splenic macrophages.[55] The administered gamma globulin may coat red

cells and they may provide a competitive interference such that platelet destruction is decreased. A new available drug is the recently approved Rho (d) immunoglobulin that specifically targets the Fc receptors.

In patients who have not achieved a sustained remission with medical therapy, which is the majority of patient with chronic ITP, an elective splenectomy is recommended. A large series analyzed 135 case series between 1966 and 2004[56] and reported results in terms of normalization of platelet counts, predictive features evaluating which patients would likely achieve complete response following splenectomy, and reported complications of the procedure including morbidity and mortality (Table 73-8). Among the case series analyzed reporting only on adults (1,731 patients), the complete response upon splenectomy was noted to be 66% (median follow-up of 29 months). Response rates tended to be higher among children, and when cases series evaluating adults and children (2,463 patients) were included in analysis, the complete response rate was noted to be 72% (median follow-up 23 months).[56] Among cases series that included a multivariate analyses in the systematic review, age (younger) was associated with an increased likelihood of response to splenectomy. Response to prior medical therapy was not found as an independent predictor in those studies, and site of platelet sequestration also was variably reported among the case series evaluated with regard to its predictive role on response to splenectomy. A proportion of patients with initial response to splenectomy (15% to 20%) develops relapse with long-term follow-up. One cause for a failed splenectomy for ITP would be residual splenic tissue most commonly in the form of a missed accessory spleen but also in the form of splenosis.[17] While earlier reports expressed concerns of laparoscopy splenectomy demonstrating a high number of failure rates secondary to residual splenic tissue,[57] more recent studies suggest similar efficacy of the laparoscopic and open approaches in the management of patients with ITP.[58]

Several new agents have recently been developed or been applied to the treatment of ITP. There were initially several studies with rituximab, which is a chimeric humanized monoclonal antibody directing CD20 against B cells.[59–61] It was primarily developed to treat lymphoma but it has been used in autoimmune disorders and has been tried in phase 2 studies for chronic splenectomy failure ITP. Response rates have been somewhat sporadic between 25% and 50%. Two new drugs binding the thrombopoietin receptor on megakaryocytes have recently been approved for second-line treatment of chronic ITP: the recombinant peptide romiplostim and eltrombopag, a thrombopoeitin nonpeptide mimetic.[62] Again, it was realized that there is decreased thrombopoietin production for the degree of thrombocytopenia seen in ITP. Romiplostim, which is a fusion protein agonist for thrombopoietin receptor administered by subcutaneous injection, led to response rates of 49% versus 2% for placebo with an overall clinical response rate of 83%.[48,63] An oral nonpeptide thrombopoietin receptor agonist, eltrombopag, showed response rates of 79% versus 28% in a placebo controlled trial.[64] Several other newer agents including AKR-501 (thrombopoietin nonpeptide mimetic), and fostamatinib disodium, a spleen tyrosine kinase inhibitor are under clinical investigation.[62] The role of these and other agents in the armamentaria against treatment of ITP will only likely increase in scope in the future. Future studies will define the role of these new

compounds and may decrease the incidence and need for splenectomy.

Thrombotic Thrombocytopenia Purpura

Thrombotic thrombocytopenia purpura, or Moschcowitz syndrome, is a poorly understood much more virulent syndrome than ITP in which thrombocytopenic purpura is only one manifestation. This disease is characterized by widespread occlusion of arterials and capillaries by hyalin membranes that are composed of a combination of platelets and fibrinogen. The classic pentad of symptoms reflects various organ injuries with this microvascular process. This includes thrombocytopenic purpura, with microvascular disease in the skin, neurologic manifestations due to microvascular disease in the central nervous system, renal failure or hematuria due to microvascular disease in the kidney, microvascular hemolytic anemia due to destruction of red cells traveling to damaged small vessels, and fever. The precise etiology is unknown but may be related to an autoimmune response to small vessel endothelial cell antigen.

Table 73-8 Results From 135 Combined Case Series Evaluating Splenectomy for ITP

Cure Rate		
% of patients with normalized platelet counts		
All reports	68.9%	3,506/5,086
Adult series only	66.0%	1,731/2,623
Adult pediatric combined	72.1	1,785/2,468
% of patients with normalized platelet counts	67.2%	779/1,159
With 5-year follow-up		
Complications		
Perioperative mortality		
Total	0.81%	51/6,256
Laparotomy	0.96%	48/4,955
Laparoscopy	0.23%	3/1,301
Perioperative complications		
Total	12.0%	406/3,386
Laparotomy	12.9%	318/2,465
Laparoscopy	9.6%	88/921

Adapted from Kojouri K, Vesely SK, Terrell DR, et al. Splenectomy for adult patients with idiopathic thrombocytopenic purpura: A systematic review to assess long-term platelet count responses, prediction of response, and surgical complications. *Blood* 2004;104(9):2623–2634.

The therapeutic options for this disease include administration of fresh frozen plasma and/or plasmapheresis, high-dose corticosteroids, and antiplatelet drugs.[65] The benefits seen with plasmapheresis would indicate that there is a toxic substance that is contributing to the etiology of this disorder circulating in the plasma, whereas the benefit of administration of fresh frozen plasma would indicate lack of some necessary substance that has yet to be identified. High-dose corticosteroids also lead to some benefit. Aspirin

and dipyridamole block platelet agglutination. A combination of these therapies now leads to a significant improvement of symptoms in 70% of patients. For patients failing to respond or patients who relapse, a splenectomy has been performed with some success.[66,67] The majority of the long-term survivors with thrombotic thombocytopenic purpura (TTP) have undergone splenectomy, implying that this organ has some major role in the pathophysiology of this disease.[68] The precise mechanism of splenic contribution is unclear. Mortality rates in the past have been as high as 90% to 95% for this disorder but are improving with aggressive treatment plans and a better understanding and diagnosis of this disorder.

Autoimmune Hemolytic Anemia

Autoimmune hemolytic anemia or acquired hemolytic anemia results from antibodies produced to red cell membrane proteins that lead to red cell destruction. This disease is more common in women than in men with the ratio of 2:1, and it typically presents after the age of 50 years. Patients present with acute symptoms consisting of anemia, jaundice, and occasional fever. The spleen is enlarged in approximately half of the patients. Laboratory diagnosis shows a positive direct Coomb test indicating antibody coating the erythrocytes. There is also significant reticulocytosis and increased indirect bilirubin in the serum.

The disease is considered to be either idiopathic in 40% to 50% of the cases in which no identified drug or infectious cause is identified or secondary to infection or drug. Of the secondary cases, the most common infections are mycoplasmal pneumonia, viral infections, infectious mononucleosis, and AIDS, and it can also occur with neoplastic diseases such as leukemia and lymphoma. The major drugs that cause secondary autoimmune hemolytic anemia are penicillin, quinidine, hydralazine, and methyldopa.

A second way that autoimmune hemolytic anemia is categorized is by either cold antibodies or warm antibodies. Warm antibodies are predominantly IgG, whereas cold antibodies are predominantly IgM. This distinction is quite important when considering splenectomy as a treatment. The spleen contains macrophages that bind the Fc portion of IgG. For this reason, in patients with warm antibody hemolytic anemia, the spleen is the primary source of destruction of the red cells by the red pulp macrophages. However, since the spleen does not contain receptors to bind IgM or the cold antibodies, there is no destruction of the red cells in this form of hemolytic anemia. Rather, IgM either causes complement fixation with destruction of red cells in the liver predominantly, or there is agglutination of red cells in peripheral circulation such as the distal extremities leading to peripheral red cell destruction with clinical manifestations similar to Raynaud phenomenon. Splenectomy for patients with cold antibody or IgM hemolytic anemia is not effective.

The treatment of autoimmune hemolytic anemia initially consists of supportive therapy such as blood transfusions. For patients who have disease secondary to an acute infection such as a mycoplasm pneumonia, the disease may be self-limited. For drug-induced hemolytic anemia, the offending agent is removed as quickly as possible. The initial form of treatment is typically high-dose corticosteroids that cause a beneficial response in 75%

of the patients. If patients again have drug-induced disease and the offending agent is removed or the acute infection resolves, this may lead to long-term resolution. In idiopathic autoimmune hemolytic anemia, only 25% of patients have sustained remission from steroid use. In patients who have relapse after steroid therapy or who are ineligible for steroid therapy and have warm antibodies, a splenectomy has a high likelihood of benefit. Eighty percent of patients show a good response in correcting the anemia by splenectomy.[69] This is felt to be almost certainly related to removal of the site of destruction of the erythrocytes but also may be due to a decrease in production of source of antibodies.

Autoimmune Neutropenia (Felty Syndrome)

Approximately 1% of patients with chronic rheumatoid arthritis will develop splenomegaly and neutropenia. This triad of rheumatoid arthritis, neutropenia, and splenomegaly is known as Felty syndrome.[70] High levels of IgG have been identified on the surface of neutrophils with evidence of increased production of granulocytes in the bone marrow. Pathologic analysis of spleens removed in patients with Felty syndrome show a significant but proportional increase in the white pulp of the spleen as opposed to other conditions of splenomegaly.[71] Microscopically, there is evidence of excess accumulation of neutrophils in both the T cell zone and the white pulp, as well as the cords and sinuses of the red pulp.

Patients with this disease will have recurrent infections due to neutropenia as well as dysfunction of the available neutrophils that are coated with antineutrophil IgG. Recurrent infections, as well as chronic leg ulcers, are the predominant symptoms. Symptomatic patients should undergo splenectomy and the vast majority of patients will have resolution of their neutropenia within 2 to 3 days.[72] Even patients who do not have a significant increase in neutrophil count should get some benefit because of improved neutrophil function.[73]

Hereditary Spherocytosis

Hereditary spherocytosis, also known as congenital hemolytic jaundice or familial hemolytic anemia, is an autosomal dominant disease that is the most common of the congenital hemolytic anemias affecting 1 in 5,000 individuals.[74] There are a variety of genetic defects in this syndrome that primarily affect spectrin and ankyrin that alter the binding of the cytoskeleton to the erythrocyte cellular membrane causing decreased cellular plasticity with membrane loss.[75] The normal shape of the erythrocyte is changed from the biconcave disc into a sphere and the decreased membrane-to-volume cell ratio causes a lack of deformability that impacts the passage of erythrocytes through channels of the splenic red pulp. Because of this delay in cell transit, there is ATP deprivation resulting in increased cellular destruction. The condition is more frequent in Caucasians and in African Americans and is usually noted in the childhood or adolescent ages. Since it is an autosomal dominant inheritance, patients may be screened and diagnosed at quite an early age.

The diagnosis is primarily made by evaluation of the red cell smear showing a large

number of spherocytes. Spherocytes may also appear during autoimmune hemolytic anemias but in hereditary spherocytosis the Coombs test is negative and an osmotic fragility test may be performed which is diagnostic. Also, contributing to the diagnosis is a positive family history.

Patients with hereditary spherocytosis have mild to moderate anemia, splenomegaly, and jaundice. The patients may have intermittent flares of disease that cause significant increased rates of hemolysis causing jaundice. Between 30% and 60% of patients have been reported to have pigmented gallstones due to the breakdown of hemoglobin.[74]

The treatment for hereditary spherocytosis is splenectomy that is indicated in virtually all patients.[76] This treatment does not remove the spherocytes but it relieves all symptoms.[77] The major question involving management of these patients is the timing of splenectomy. Because of the increased incidence of overwhelming postsplenectomy sepsis in very young children, it is usually recommended that patients wait until after the age of at least 4 if not 6 years prior to splenectomy. For younger patients who are very symptomatic and require splenectomy, partial splenectomies have been reported to be beneficial in relieving the abdominal symptoms as well as the anemia and may be a useful alternative procedure until patients reach an age in which total splenectomy is safer.[78] Patients with partial splenectomies had regrowth of tissue but with short term did not have recurrent anemia.[69] Patients should be assessed at the time of scheduling a splenectomy for the presence of gallstones and a laparoscopic cholecystectomy should be performed if stones are identified.

Hereditary Elliptocytosis

Hereditary elliptocytosis is a disease that is related to hereditary spherocytosis although not as severe. For patients who are symptomatic, virtually all of the same comments regarding pathophysiology and treatment can be made about hereditary elliptocytosis as for hereditary spherocytosis. This disease is also inherited in an autosomal dominant pattern and the defect is felt to be present in spectrin. The predominant abnormality changes spectrin such that it exists as a dimer instead of tetramer that is the normal structure. This change leads to an alteration in membrane plasticity that creates cells that are more elliptically shaped instead of a biconcave disc.

The signs and symptoms caused in this disease are much more mild than hereditary spherocytosis in that only 10% of patients have clinical manifestations of anemia, splenomegaly, and in some cases jaundice. The treatment recommendation for symptomatic patients is splenectomy again, which may be performed with laparoscopic techniques and also cholecystectomy if gallstones are present.

Hereditary Nonspherocytic Hemolytic Anemia

There is a heterogeneous group of rare hemolytic anemias caused by inherited defects primarily enzymes involved in glycolysis. It is felt that these genetic defects may decrease cellular energy production leading to increased red cell destruction as these cells pass through the relatively hypoxic environment of the red pulp of the spleen. The most common subtypes in this group of hemolytic anemias are pyruvate kinase deficiency and

glucose 6-phosphate dehydrogenase (G6PD) deficiency. Patients present with anemia, jaundice, increased reticulocytes, and possibly cholelithiasis. The diagnosis can be facilitated in that the shape of the cell does not show typically spherocytes and there is normal osmotic fragility.

The primary treatment for these diseases is blood transfusion. In G6PD deficiency, splenectomy is not felt to be beneficial whereas it may reverse some of the symptoms associated with pyruvate kinase deficiency.

Thalassemia

Thalassemia is an autosomal dominant disease with a variety of structural defects in one of the globin chains. The disease is categorized as these are alpha, beta, gamma, or delta thalassemia, depending on which of the globin chains is defective. The vast majority of patients in North America have beta thalassemia. Thalassemia major, otherwise known as Mediterranean anemia or Cooley anemia, is a homozygous expression of this genetic defect. Thalassemia minor is a heterozygous expression and these patients are only mildly symptomatic and are carriers for the more severe form of the disease.

The pathophysiology of thalassemia major or beta thalassemia is the lack of production of normal beta-chain hemoglobin leading to a surplus of alpha-chain hemoglobin in adult patients. These excess globin chains precipitate in the cytoplasm and attach to the inner surfaces of cytoplasmic membrane leading to poor passage of these cells through the splenic sinusoids. This intracellular inclusion then leads to increased destruction and over time causes significant splenomegaly due to this increased clearance of red cells.

The diagnosis is made by identifying microcytic hypochromic anemia with target cells and an increase in reticulocytes on the peripheral smear. Protein electrophoresis will show very low levels of hemoglobin A with predominant amounts of the fetal hemoglobin or hemoglobin F. The clinical symptom of alpha-thalassemia major is severe anemia within the first year of life. Decreased growth rate, enlargement of the head, splenomegaly, and hepatomegaly are the typical clinical findings.[79]

The primary treatment for thalassemia major is frequent transfusions combined with iron chelation therapy. Some patients may develop significant splenomegaly due to overload or hypertrophy from excess trapping of red cells.[80] Patients may be referred for splenectomy for symptomatic splenomegaly or for patients with massive and frequent transfusion requirements. One report suggested that episodes of transfusion are decreased from 18 per year down to 4 per year after splenectomy. In general, if there are symptoms of massive splenomegaly, these will be resolved with splenectomy as well. As with other hematologic disorders in children, there has been a recent trend toward partial splenectomy particularly in children younger than 4 to 5 years.[81] This will result in symptomatic improvement in between 1 and 2 years with recurrent disease due to hypertrophy of the residual splenic remnant.[82]

Although splenectomy may be beneficial in terms of the transfusion requirements and local symptoms, the typical mode of death with this disease is myocardial failure due to hemosiderin accumulation. Splenectomy does not alter this cardiac problem to any great extent. In fact, recent data suggest that splenectomy in thalassemia patients increases

vascular complications.

Sickle Cell Anemia

Sickle cell anemia is a hereditary hemolytic anemia that is due to a genetic alteration of a single amino acid substitution in the beta chain. This results in a change from glutamic acid to valine in the sixth amino acid position of the beta chain of hemoglobin molecule. Because of this substitution, patients who are homozygous for sickle cell defect have a characteristic stiffening or sickling of the red blood cells when they become hypoxic.[83] This change in red cell shape leads to blockage in hypoxic areas such as the red pulp of the spleen. There can occasionally be sequestration crises in which a portion of the blood volume gets actively trapped or sequestered to the spleen during the sickle cell crisis. This pattern of red cell shape change in relatively hypoxic areas can lead to tissue infarction with bone pain, hematuria, abdominal pain, and priapism.

The incidence of this disease, which almost exclusively occurs in the black population, is approximately 0.5% for homozygous disease, with approximately 8% of African Americans being carriers for the sickle cell trait. Patients who have a combination of a sickle cell allele as well as a beta thalassemia allele manifest a similar disease process.

The clinical signs of the disease usually present during the second 6 months of life as in early infancy the patient is asymptomatic due to the presence of fetal hemoglobin. The patients may have acute crises with abdominal pain and bone pain in conjunction with significant anemia. During acute crises of splenic sequestration, there may be massive enlargement of the spleen with an urgent decompressive splenectomy required. Patients who do not need splenectomy for splenic sequestration may be followed as this disease goes through a natural progression of ischemic necrosis of large areas of the spleen with eventual hyposplenism with a shrunken organ by early adolescence. Splenectomy is reserved for the very young patients who have massive splenomegaly in sequestration crises early in life.

Wiskott–Aldrich Syndrome

Wiskott–Aldrich syndrome is an X-linked disease characterized by thrombocytopenia, combined B- and T-cell deficiency, eczema, and a propensity to develop other malignancies. The genetic defect in this disease is felt to be related to an abnormal adhesion molecule affecting immune cell interaction as well as platelet adhesion. Thrombocytopenia is the major problem with this rare disease and most patients present with manifestations of poor clotting, bloody diarrhea, epistaxis, and petechiae at a young age. The platelet counts typically range between 20,000 and 40,000 and the platelets that are present are dysfunctional being small sized, 25% to 50% of normal platelet volume. In this disease, the spleen sequesters platelets and partially degrades them releasing "microplatelets" back into the circulation.[84]

Splenectomy in the Wiskott–Aldrich syndrome was initially avoided as there was a very problematic postoperative course characterized by severe and fatal infections due to the underlying immunodeficiency combined with the potential for overwhelming postsplenectomy infection. However, splenectomy does increase the number, size, and

function of platelets and can lead to amelioration of the bleeding problems in very symptomatic patients.[84] The combination of splenectomy with antibiotic suppression particularly in younger patients may be beneficial. The optimal treatment of Wiskott–Aldrich syndrome is an human leukocyte antigen (HLA) match sibling bone marrow transplantation.[85] However, splenectomy with antibiotics results in better survival than unmatched bone marrow transplantation. Patients who do not undergo bone marrow transplantation or splenectomy typically do not survive past the age of 5 years. The pathology of spleens removed for Wiskott–Aldrich syndrome shows a near complete depletion of white pump supporting the clinical immune deficiency seen in this syndrome.[86]

Hypersplenisim

7 Hypersplenism is a physical enlargement of the spleen that can be broadly categorized as the neoplastic disorders, hematopoietic disorders of the bone marrow, and metabolic or storage disorders. In neoplastic disorders, the spleen is infiltrative and large typically by leukemic or lymphoma cells. This often happens in the mid or late course of a person's disease but can be associated with isolated splenomegaly in which the splenectomy is performed not only to treat hypersplenism, but also to make the definitive diagnosis (see Diagnostic Splenectomy section below). Hypersplenism can be associated with diseases of hematopoiesis related to myeloid metaplasia in which the bone marrow is infiltrated with fibrotic material and the spleen becomes a site of secondary non–bone marrow hematopoiesis. Enlargement can lead to symptoms of hypersplenism due to the massive size of the spleen and often the benefits of extramedullary hematopoiesis are outweighed by the sites of circulating blood cell destruction in this enlarged spleen. Secondary hyperplenism can also occur when there is deposition of lipid within the spleen such as in Gaucher disease leading to enlargement that can cause pancytopenia. Each of these categories of secondary hypersplenism is associated with pancytopenia and mass effect of the spleen causing early satiety and weight loss. These disorders typically lead to spleen size more than 1,500 g and can produce spleens that essentially fill the entire left side of the abdomen.

Chronic Lymphocytic Leukemia

Chronic lymphocytic leukemia (CLL) is the most common of all chronic leukemias. It predominantly affects males more than females with 2:1 predominance and has a peak incidence in the sixth decade of life or older. This indolent disease presents with fatigue, lymphadenopathy, hepatosplenomegaly, and eventually anemia and thrombocytopenia. The disease progression may occur over a 5- to 10-year period.



Figure 73-10. A massively enlarged, 2.2-kg spleen from a patient with chronic lymphocytic leukemia. Superficial areas of infarction are indicated by thin arrows and splenic infarction by the thick arrow.

Patients by definition in stage II or greater CLL will have splenomegaly and anemia and thrombocytopenia secondary to hypersplenism. Splenomegaly often reaches very large sizes and patients may have symptoms secondary to the compressive effects of the large spleen on the stomach with early satiety and pain (Fig. 73-10). Treatment of early stage disease is either observation or treatment with nontoxic doses of alkylating agents such as chlorambucil or cyclophosphamide. There are many treatment options for higher-risk patients, including fludarabine, cyclophosphamide (Cytoxan), rituximab in varied combination, and other chemotherapeutic agents. Many patients will eventually develop hypersplenism and splenomegaly. One strategy that has been employed in particular for patients who are nonoperative candidates is splenic radiation.[87] The splenic radiation has decreased the size of the spleen improving symptoms due to mass effect, but it may have complications of further thrombocytopenia and leukopenia.

Splenectomy is a highly successful treatment for both the pressure effects due to splenomegaly and the cytopenias.[88,89] Reports of 85% resolution of thrombocytopenia and 100% resolution of anemia have been published.[90] The negative feature of splenectomy in this patient population is that they are typically elderly and are typically debilitated from having gone through years of having CLL and potentially prior chemotherapy treatment. In one series in which a prospective comparison was made between splenectomy and fludarabine for later stage CLL, there was a 9% perioperative mortality in the splenectomy group primarily due to sepsis in this patient population.[91]

However, in this same study, there were highly significant improvements in thrombocytopenia and anemia. The patients who are younger and have larger spleen sizes tend to do better. In this comparative study of patients with Rai stage IV CLL, the 2-year actuarial survival rate was 51% in the splenectomy arm and a 28% survival rate in the fludarabine arm.[91] At present, splenectomy is recommended for patients who have failed medical therapy and have anemia with transfusion requirements or thrombocytopenia with bleeding or compressive symptoms such as splenomegaly.

Chronic Myelogenous Leukemia

Chronic myelogenous leukemia (CML) is a leukemia with the cell of origin, a primitive hematopoietic cell. This primordial cell can differentiate into myeloid cell lines, erythroid cell lines, platelet cell lines, and possibly B lymphoid and T lymphoid cells. CML occurs preferentially in men to women at a 1.5:1 ratio, and like CLL typically occurs in the sixth decade of life or older. This disease varies from CLL in that it invariably progresses from a chronic stage to an accelerated and blastic stage whereas CLL remains more indolent. The initial chronic phase may last anywhere between 1 and 5 years and is characterized by splenomegaly, constitutional symptoms of fatigue, abdominal fullness, and weight loss.[92] The accelerated phase is apparent with 15% of circulating cells being more immature blast cells and then within 3 to 6 months this generally converts to the terminal blast phase in which the blastic cells fill the bone marrow and the circulating blood at $>30\%$ of leukocytes and may cause destruction of other organs. Death due to infection or bleeding invariably results after the blast crisis begins.

The diagnosis of CML is made by the leukocytosis with myeloid differentiation and presence of granulocytes filling the bone marrow space. Ninety percent of patients have the classic Philadelphia chromosome that is a reciprocal translation between chromosomes 9 and 22. On the basis of randomized trials, there is no benefit in terms of delaying the accelerated and blast phases of the disease by doing a splenectomy during the chronic phase of the disease. Certain select patients who have significant hypersplenism or splenomegaly may benefit with symptomatic improvement during the chronic phase.[93,94]

A recent study from MD Anderson reports their experience of splenectomy during the accelerated or blast phase of disease.[95] Patients were referred for this procedure with symptoms of splenomegaly in 42% of cases, thrombocytopenia in 30% of cases, to potentially improve administration of chemotherapy by reducing the hypersplenism in 19% of cases, and because of symptoms with both hypersplenism and thrombocytopenia in 9% of cases. The perioperative mortality rate in this series of 53 patients was 1.9% with one patient death. There was universal benefit of symptoms related to splenomegaly and there was a marked improvement of platelet count and requirement for platelet transfusions in patients with preoperative thrombocytopenia. The median 6-month transfusion requirements decreased from 21 down to 1, combining both platelet and red cell transfusions. The median postsplenectomy survival was 19 months for patients in the accelerated phase and 6.5 months for patients in the blastic phase of their disease. This report concludes that for select patients who have severe transfusion requirements and/or

severe symptoms of splenomegaly, there is objective benefit with relatively low morbidity in patients with this later stage of CML.

Non-Hodgkin Lymphoma

Non-Hodgkin lymphoma is the most common cause of lymphoma outnumbering Hodgkin disease by a ratio of almost 6:1 in the United States. Non-Hodgkin lymphoma is a much more heterogeneous disease with a large range of histologic cell types defined by morphology and immunohistochemistry studies to differentiate subgroups of the disease. The clinical course of these different subgroups correlates with these microscopic findings. In general, diffuse or infiltrative non-Hodgkin lymphoma tends to have a worse prognosis than nodular NHL. The diffuse high-grade type occurs most commonly in the younger patient population (age <35 years) or the very elderly. More aggressive non-Hodgkin lymphomas tend to be T-cell lymphomas with the low grade tending to be B cell. Non-Hodgkin lymphoma as opposed to Hodgkin disease occurs at presentation in approximately one-third of cases in extranodal sites while two-thirds are limited to lymphadenopathy.[96,97] In general, the disease is more diffuse at the time of presentation mandating treatment by combination chemotherapy. It is for this reason that the staging laparotomy classically using Hodgkin disease (see below) is not applicable in NHL.

In patients dying of NHL, up to 80% of patients will have significant splenic involvement with splenomegaly due to lymphatic infiltration.[98,99] As is true with other infiltrative neoplastic diseases, symptoms of pancytopenia and splenomegaly are common in patients with NHL. Patients who are operative candidates have significant benefit with up to 80% of patients having decreased transfusion requirements and the majority of patients having relief of gastric oppression and pain symptoms due to splenomegaly.[100] In terms of the response of the pancytopenias, it is somewhat dependent on the bone marrow reserve that may have been heavily pretreated with prior chemotherapy and/or radiation therapy. There is no differential test to identify adequate marrow reserve and the only assessment in that situation is whether a patient has a response following splenectomy.

Hairy Cell Leukemia

Hairy cell leukemia is a low-grade lymphoproliferative disorder with characteristic “hairy cells” due to irregular filament projections from the cell surface that give an appearance of hair under light microscopy.[101] This leukemia is a B-lymphocyte tumor that infiltrates the bone marrow and spleen with almost no peripheral lymphadenopathy. There may and may not be enlargement of the liver. The disease is much more common in males than in females by a fourfold difference and the onset of disease is typically in the fifth or sixth decade of life.

The initial symptoms most commonly relate to enlargement of the spleen either by direct effects of splenomegaly or by pancytopenia due to hypersplenism (Fig. 73-11).[102] Patients may have early satiety or upper quadrant pain with a large palpable spleen infiltrated with leukemic cells. The enlarged spleen often causes symptoms related to anemia with a transfusion requirement, bleeding due to thrombocytopenia, and frequent

infections due to leukopenia. In the past, hairy cell leukemia was described as the "surgical leukemia" as splenectomy was recommended as the primary treatment since virtually all patients would have resolution of their symptoms of splenomegaly and splenectomy was considered the standard of care.[103] However, the vast majority of patients relapsed, some as early as 6 to 12 months later, and only 40% to 50% of patients received long-term benefit from the cytopenias due to bone marrow replacement with hairy cell infiltrates.

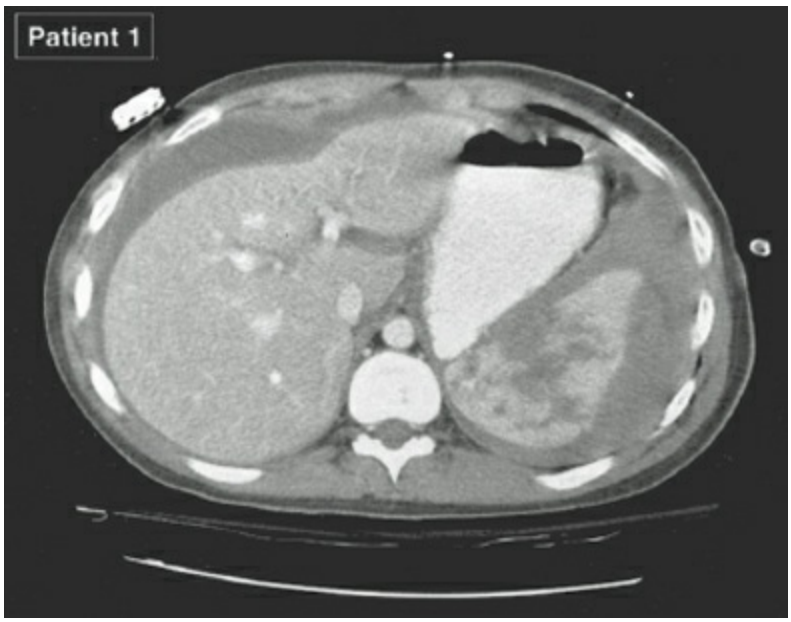

Figure 73-11. Spleen from a patient with hairy cell leukemia. Note the whitened anterior edge of the spleen and the white "sugar-coating" spots on the surface.

In 1984, medical therapy initially with recombinant alpha-interferon led to improved responses.[104] Newer trials with purine analogs such as pentostatin (2-doxycoformycin) and 2-chlorodoxydenosine provided a beneficial nonsurgical therapy.[105] A randomized trial comparing pentostatin with α-interferon showed a complete response rate of 78% with pentostatin versus 11% with α-interferon and this has now become a first-line therapy.[106] The 10-year survival rate for pentostatin is 96% and 100% for cladribine.[107] Five percent to 10% of patients who are resistant to medical therapy may be offered splenectomy as a salvage therapy.

Myelodysplastic Syndrome

AMM or myelodysplastic syndrome (MDS) with myeloid metaplasia is a poorly understood disorder characterized by a fibrotic replacement of the bone marrow compartment with extramedullary hematopoiesis and massive splenomegaly.[108] The pathophysiology of the disease is poorly understood but includes a nonclonal proliferation of fibroblasts making a dense fibrous stroma that fills the marrow space and contributes to hepatosplenomegaly and lymphadenopathy. This fibrous proliferation may be under control of secreted growth factors such as transformin growth factor beta.[109] Other myeloproliferative diseases include polycythemia vera and essential or idiopathic thrombocytosis.

The clinical symptoms and features of MDS relate to anemia and splenomegaly via direct mass effects or hypersplenism.[110] Patients tend to be in the fifth decade of life or older. They present with constitutional symptoms, including weight loss, fatigue, as well as abdominal fullness and discomfort due to splenomegaly. There may be pain from splenic infarctions. Patients may present with bleeding due to thrombocytopenia. Hepatomegaly is present in 50% to 75% of patients and splenomegaly is present in virtually all patients. The massively enlarged spleens in MDS are often some of the largest spleens by weight in most clinical series.

The combination of massive splenomegaly with increased blood flow via the enlarged spleen and hepatomegaly with fibrosis leading to relative portal hypertension creates a unique situation in which some of the clinical symptoms may be similar to portal hypertension from other cause as patients may present with varices and ascites. The diagnosis is made by evaluation of peripheral blood smear that shows immature red blood cells with poikilocytes and tear-shaped cells. There can be either thrombocytopenia or thrombocytosis with platelet counts of greater than one million. Similarly, there may be leukopenia or there may be elevated white blood cell counts similar to CML. Bone marrow biopsy often produces a dry tap due to the fibrotic replacement of the marrows.

Treatment is generally targeted to palliate the symptoms that are present.[110] Anemia and thrombocytopenia can be treated with transfusions. There is some role for alkylating agents and steroids, and in patients with thrombocytosis, hydroxyurea is of benefit.[111] Splenectomy is indicated for relief of significant symptoms of hypersplenism or splenomegaly.[112] Hypersplenism is manifested by anemia and thrombocytopenia with increasing transfusion requirements of bleeding. The patients who have significant pain and early satiety with massively enlarged spleens may benefit by removal of the mass effect. Finally, MDS is a unique situation in which splenectomy may treat portal hypertension as it can increase blood flow through a fibrotic and enlarged liver decreasing variceal bleeding and possibly ascites.[113]

The Mayo Clinic has updated the use of splenectomy over the past three decades for patients with myelofibrosis.[114] A total of 314 patients have been treated overall with 91 patients treated during the last 10 years. The primary indications for surgery were mechanical symptoms of compression due to massive splenomegaly in 49%, severe anemia in 25%, portal hypertension in 15%, and thrombocytopenia in 11%. Meaningful improvement in symptoms was observed in 30% to 50% of patients, but the overall complication rate was 28% and there were 6.7% perioperative deaths.[114] Furthermore, there is no clear impact on overall patient survival or disease course or the intramedullary manifestations of myeloid metaplasia after splenectomy. A recent study of 89 patients from Duke University who underwent splenectomy for myeloid neoplasms similarly demonstrated significant morbidity and mortality rates in this cohort of patients (38% and 18%, respectively), with MDS/myeloproliferative neoplasm, anemia, hypoalbuminemia, and abnormal white blood cell count associated with decreased patient survival rate.[115] Given these results, one would have to take into consideration all factors, including severity of symptoms and comorbidities, before recommending splenectomy for this hematologic disorder.

Recent treatment strategies have been employed in MDS in the past 10 years. One is antiangiogenic therapy and the other is immunosuppressive treatment.[110] It was recently identified that there was an increase in neovascularity of the bone marrow in patients with MDS and vascular endothelial cell growth factor appears to play a prominent role in pathophysiology. Specific antiangiogenic therapy to block vascular endothelial growth factor (VEGF), including the recently reported trial of thalidomide, led to independence from needing transfusions in a subgroup of patients with MDS. Interest in immunosuppressive therapy in MDS occurred because the subset of these patients with refractory anemia has autoimmune pathophysiology. Young patients or patients with HLA-DR 15 appear to have autoimmune etiology and have responded to immunosuppressive therapy. A new treatment includes JAk2 inhibitors (ruxolitinib); in one study, JAK2 V617F mutation was identified in 63% of patients and independently predicted progression to large splenomegaly.[116] Stem cell transplant is considered for appropriately selected patients with primary myelofibrosis deemed to have high-risk disease as predicted by the Dynamic International Prognostic Scoring System-plus or with particular genetic mutational status.[117] This scoring system takes into account factors that carry prognostic significance, including age >65 years, leukocyte count >25,000/μL, hemoglobin <10 g/dL, circulating blast cells ≥1%, and presence of constitutional symptoms.[118]

Metastatic Disease to the Spleen

The incidence of splenic metastases in autopsy studies of patients coming to malignancy ranges between 2.3% and 7.1%.[119] It is rare that splenic metastatic lesions are isolated disease. This commonly occurs in colon cancer and ovarian cancer. In patients who have multiple areas of intra-abdominal malignancies, the most common histologies are breast, lung, colorectal, ovarian, and melanoma. There can rarely be isolated metastasis that may be excised for an increase in disease free survival rate particularly for colorectal cancer and melanoma.[120] Techniques to differentiate benign from malignant processes would include fine needle aspiration biopsy, magnetic resonance imaging (MRI) with gadolinium looking at enhancement patterns, and microbubble control to report using ultrasound techniques.[121]

Metabolic or Infiltrative Diseases

Gaucher disease is an autosomal recessive disorder with a deficiency in the lysosomal hydrolase, β-glucosidase, which is encoded by chromosome 1. Gaucher disease is the most common lysosomal storage disease. β-Glucosidase typically degrades sphingolipids like glucocerebroside. There is a marked increased incidence of this disorder in Ashkenazi Jews. There are three types of this disease. Type I, the adult form, comprises 99% of cases and is the one in which splenectomy over the past was useful. The defect in the acid β-glucosidase causes an accumulation of undegraded glycolipids that are taken up by the reticuloendothelial cells and result in infiltration of the spleen, liver, and bone marrow. The most common symptoms with this disease relate to hypersplenism as well as direct effects on massive splenomegaly. Thrombocytopenia with bleeding problems and anemia

causing fatigue are the most common effects of hypersplenism. Patients also may have such massive spleens that they have early satiety and weight loss due to gastric compression.

The diagnosis can be confirmed by the measurement of acid β-glucosidase activity in peripheral white blood cells or cultured fibroblasts. With the cloning of the gene, patients can be screened by molecular techniques to identify carriers. Prenatal diagnosis is also available by amniocentesis.

In the past, treatment has included supportive care with platelet transfusions as well as erythrocyte transfusions. Splenectomy was frequently performed for advanced cases and in this disease a significant experience with partial splenectomy was developed in the early 1990s.[122–124] The goals of the subtotal splenectomy are partially to prevent the complications of overwhelming postsplenectomy sepsis and partially to protect the lipid and bone marrow by leaving a residual splenic fragment for continued deposition of lipid. In this disease, the techniques having worked out to safely perform partial splenectomy leaving a small residual upper pole fragment vascularized from the short gastric vessels.

Recently, it has been established that enzyme replacement with purified placental acid β-glucosidase is safe with good efficacy. Patients are given between 30 and 60 units/kg of enzyme intravenously every other week and the symptoms and signs are typically reversed. A recombinant β-glucosidase (alglucerase) is now available for therapy and the role of splenectomy has been largely displaced by this medical management.

INCIDENTAL SPLENECTOMY

In a large series evaluating reasons for splenectomy from the combined series from Barnes Hospital and Brigham & Women's Hospital, the single most common indication (26% of cases) for removing the spleen identified was an incidental procedure.[24] This would be categorized as an operation primarily for an adjacent organ or tumor in which the spleen needs to also be removed. The actual primary treatments of those various disease entities in adjacent organs are subjects of multiple other chapters within this textbook, but a few comments should be made regarding the reasons for splenectomy and whether it is always appropriate.

The one common indication for an incidental splenectomy to remove tumors is during removal of the distal pancreas. For decades, the standard procedure when a distal pancreatectomy was performed was a splenectomy. The reason for splenectomy is that the splenic vein is intimately associated with the undersurface of the pancreas and has many direct branches to the pancreatic parenchyma. The splenic artery generally is superior to the pancreatic border and could be preserved but because of removal of the splenic vein and for completeness of the resection, an en bloc resection of the distal pancreas and spleen is typically performed. Because of the interest in splenic preservation due to the incidence of postsplenectomy infection, two different approaches have been employed to remove the distal pancreas without removing the spleen. The more technically challenging operation is a distal pancreatectomy with preservation of the splenic artery and vein. This can be performed only if there is a relatively small amount of invasive tumor or for benign neoplasia in which the splenic vein can be tediously dissected away from the pancreatic tissue tying multiple side branches and then dividing the pancreatic parenchyma leaving the splenic vessel intact. The second spleen preserving distal pancreatectomy involves ligation of the splenic artery and vein but preservation of short gastric vessels and utilizing those vessels as collateral inflow and outflow to maintain splenic viability. A recent report demonstrated no increased risks of preoperative complications or morbidity with this approach.[125] Removal of the distal pancreas with splenic preservation has also been recently reported as a laparoscopic procedure as well.[126] For patients with tumors that mandate removal of the lymph nodes of the splenic hilum or with direct association of the tumor with splenic parenchyma, certainly it is more appropriate to do an operation based on neoplastic principles and perform a distal pancreatectomy/splenectomy. In other indications, if the anatomy is appropriate and the completeness of tumor resection is not compromised, splenic preservation is certainly possible.

Additional procedures in which it is quite common to perform a splenectomy include proximal gastric cancers. The importance of complete nodal dissection in terms of long-term results in gastric resections has been debated for several decades. A report from Japan noted that in 20% of proximal gastric cancers there was positive splenic hilum nodes identified as level X lymph nodes.[127] These authors emphasize the need to perform associated splenectomy with grossly positive nodal disease in the splenic hilum. A long-term retrospective review from Memorial Sloan-Kettering Cancer Center noted that in

23% of gastrectomies in which complete resection of cancer was accomplished, adjacent organs had to be removed, the most common being the spleen.[128] There was long-term survival in this patient population, but it was emphasized that this aggressive surgery should be employed only when removal of all gross disease is achieved.[129] A recent randomized study from Korea showed no benefit in doing a splenectomy if splenic hilum nodes were grossly normal.[130]

Other tumors of the left upper quadrant and retroperitoneum may require splenectomy including large renal cell carcinomas, left adrenal tumors, and retroperitoneal sarcomas that may infiltrate upwards into the spleen. Often the use of splenectomy performed in these situations is to provide adequate exposure to cleanly dissect bulky disease that lies posterior to the spleen. Although the asplenic state does make patients susceptible to infections, the spleen should be viewed as an expendable organ if necessary to accomplish complete resection of malignancies and there should be no hesitation to remove the spleen in those settings to achieve the appropriate complete resection.

IATROGENIC SPLENECTOMY

A poorly reported and uncommonly discussed area of spleen surgery would be removal or preservation of the iatrogenically traumatized spleen during unrelated abdominal operations. Procedures in which there is mobilization of the left upper quadrant with reflection of the spleen and pancreas medially to expose retroperitoneal tissue, such as in left adrenalectomy, and left nephrectomy put the spleen at risk.[131] Simple mobilization of the splenic flexure of the colon can lead to bleeding from the inferior pole of the spleen that may be difficult to control. The ligaments that go directly from the omentum to the capsule of the spleen may be the most common cause of iatrogenic splenic trauma as it is quite a common practice to aggressively retract the omentum as needed for exposure. There are direct branches that are sometimes sizable from the omentum to the splenic capsule, which could result in capsular disruption and troublesome bleeding. A national database on antireflux procedures of 86,411 patients reported an incidence of iatrogenic splenectomy of 2.3%, which translates into 1987 iatrogenic splenectomies for that indication alone.[132]

Probably the best data for the incidence of iatrogenic splenectomy come from the recently reported series from Vanderbilt, which listed 73 iatrogenic splenectomies over a 10-year period or an average of 7 per year.[26] This comprised 8.1% of all splenectomies performed during that time interval. There are probably additional numerous times minor or moderate injuries are inadvertently made to the spleen during unrelated surgeries in which the spleen was not removed but was repaired or salvaged. Just as in trauma to the spleen, the techniques of splenorrhaphy can be employed to preserve the spleen. A recent report indicates that the use of a mesh wrap splenorrhaphy even in the setting of bowel surgery does not lead to an increased incidence of infection.[31] For minor capsular disruption, the use of the argon beam coagulator for surface cautery is a helpful technique.

Several studies have looked at the incidence and effects of inadvertent splenic injury during colectomy. The Mayo Clinic surveyed 13,897 colectomies and found 59 splenic injuries (0.42%). The majority of these occurred during mobilization of the splenic flexure.[133] The 30-day morbidity rate for this subgroup of patients was 34% and, most concerning, the mortality rate was 17%. There were no clear episodes of sepsis. A second large study from the California Cancer Registry of almost 42,000 patients showed that there was a similar rate of inadvertent splenectomy of 0.58%.[134] Again, this was associated with a distal transverse colon or splenic flexure primary and increased the length of hospital stay by 37.4%. It also increased the probability of perioperative death to 40%. In a large study using the National Inpatient Sample database reviewing 975,825 patients undergoing colectomy between 2006 and 2008, the rate of splenic injury was 0.96%, 84.75% of which cases were treated with total splenectomy, with the majority of remainder being treated by splenorrhaphy (13.6%).[135] Factors independently associated with splenic injury included, not unexpectedly, transverse, left or total colectomy, but also open operation, malignant tumor, diverticulitis, teaching hospital status, peripheral vascular disease, and emergent admission. Other studies have also found a lower

incidence of splenic injury in laparoscopic versus open colonic resections and to what extent this is attributable to technical differences (e.g., better visualization laparoscopically in dissecting the splenic flexure) or to patient selection remains to be defined.

The primary teaching point regarding iatrogenic injuries is that the best way to preserve the spleen is not to damage it in the first place. This requires caution in mobilizing tissue in and around the spleen as well as visual inspection of the attachments of the spleen prior to blunt mobilization. Whenever possible, the spleen should be attempted to be preserved to decrease the risk of postsplenectomy sepsis.

DIAGNOSTIC SPLENECTOMY

One indication for splenectomy is for diagnosis in an otherwise asymptomatic patient. The situation in which splenectomy may be needed to make a diagnosis includes when a dissecting mass lesion is seen within the spleen on CT scan, ultrasound, or MRI scan for which a definitive diagnosis cannot be made radiographically. Another example is when patients have either palpable spleens on physical examination or enlarged spleens by scan and otherwise have no clear diagnostic disorder. Table 73-9 lists the final pathology diagnoses in spleens removed for these two indications over a 10-year period in two major academic medical centers.[24] In that series, a total of 122 diagnostic splenectomies were performed, 52 of which were for a splenic mass and 41 for splenomegaly with no other clear diagnosis. An additional 29 were done to further characterize a known hematologic malignancy.

For the patients who have an isolated splenic mass, 60% turned out to be malignant lesions and 40% turned out to be benign lesions (Table 73-9).[24] The majority of the malignant lesions were lymphoma with another large group being metastatic carcinomas including some in which the primary diagnosis had not been made previously. There were two patients with metastatic sarcoma to the spleen. In the benign diagnoses, more than half were cysts and there were also splenic hamartomas and splenic hemangiomas. In a recent series of patients undergoing splenectomy at Memorial Sloan-Kettering Cancer Center for lesions identified on imaging, the incidence of malignancy in the splenectomy specimen was 63% (93 of 148 cases).[136] The most common malignant pathologies were ovarian cancer, melanoma, and colorectal cancer. Prior history of cancer was the only independent predictor associated with malignant histology in the spleen specimen.

Table 73-9 Final Pathologic Diagnoses in 122 Spleens Removed for Diagnostic Purposes

Total Number of Diagnostic Splenectomies		122
Indication	**Diagnosis**	
Splenic mass		52
	Lymphomas	17
	Metastatic Cancer	14
	Carcinoma	12
	Sarcoma	2
Benign		21
	Cysts	11
	Hamartoma	3
	Hemangioma	3
	Other	4
Splenomegaly		41
	Lymphoma	24
	Benign Lymphoid Proliferation	5
	Benign Vascular	4
	Granulomatous Disease	4
	Infarction/Hemorrhage	4
Categorize Lymphoma		29
	Malignant (successful)	28
	Benign	1

Adapted from Kraus MD, Fleming MD, Vonderheide RH. The spleen as a diagnostic specimen: A review of 10 years' experience at two tertiary care institutions. *Cancer* 2001;91(11):2001–2009.

In terms of diagnosis of an isolated splenic mass, the majority of these lesions could have been diagnosed by doing a fine needle aspiration biopsy. Certain of these lesions such as the cystic lesions or the hemangiomas would have classic appearance on gadolinium enhanced MRI scan and it is another imaging modality that could be utilized to sort out mass lesions without tissue biopsy. Although there may be some hesitation to do fine needle aspiration biopsies on splenic lesions, due to the risk of bleeding for most mass lesions this would have made the diagnosis and with the exception of splenic hemangiomas essentially all of these lesions could be aspirated without any significant consequence.

The second diagnostic indication for splenectomy is unexplained splenomegaly. In this series over 10 years there were 41 cases, or 4 cases per year at these two hospitals in which a massively enlarged spleen was removed purely for diagnosis.[24] The majority of these (58%) turned out to be lymphoma. The remaining 42% were split relatively evenly between benign lymphoid proliferation, benign vascular lesions, granulomatous disease, as well as splenic infarction and hemorrhage. The role of fine needle aspiration and other percutaneous biopsy for splenomegaly is quite limited as there is considerable risk of bleeding and this form of biopsy would generally be low yield in terms of establishing a diagnosis for this indication.

Another type of diagnostic procedure would be a staging laparotomy for Hodgkin

disease. Discussion of this procedure is largely of historical interest as it has limited use in today's current practice in treating this form of lymphoma. A standard practice for pathologic staging between 1960 and 1990 was performance of a staging laparotomy in most patients with Hodgkin disease. The reason to perform this invasive procedure was based on reports that laparotomy altered the clinical stage of disease in approximately 35% of patients and would impact on therapeutic management. Staging laparotomy was typically performed via an upper abdominal midline incision.[137] This included exploration of the entire abdomen for any abnormal lymph nodes including nodes identified by lymphogram. Even if no abnormalities were found, multiple tissues were removed for pathologic assessment. This included removal of the spleen, bilobar hepatic wedge resections, and bilobar hepatic core biopsies, and multiple lymph nodes samplings.

There are several reasons why the incidence of performing staging laparotomy has decreased over the past 10 to 15 years,[138] and the primary reason is that it does not alter treatment of Hodgkin disease based on results of recent clinical series. The treatment of patients with stage IB, IIB, IIIB, IVB, IIIA, and IVA Hodgkin disease almost always involves systemic chemotherapy. The only patients who could theoretically benefit from staging laparotomy at present are patients with stage IA or IIA Hodgkin disease who typically may receive treatment with radiation therapy. Even in this subgroup of patients, there is a trend toward not performing staging laparotomy. First, many oncologists use combination chemotherapy even for early-stage disease. Second, for patients who were treated with radiation therapy alone for stage IA and IIA disease, it has been demonstrated in several recent clinical series that ultimate outcome is equivalent whether these patients undergo staging laparotomy or whether they are treated up front with radiation therapy.[139,140] The reason is that if these patients recur outside of the radiation field during long-term follow-up, they can frequently be salvaged with systemic chemotherapy. Third, performance of staging laparotomy is obviously a major abdominal operation with potential for morbidity and also the reality that treatment of Hodgkin disease will be delayed typically between 4 and 6 weeks. Finally, there are data that patients who survive Hodgkin disease and receive combination chemotherapy are at increased risk for the development of a secondary malignancy that is primarily acute, non–lymphocytic leukemia (ANLL).[141,142] In some series, the risk of developing ANLL is increased up to 10-fold in patients who have undergone splenectomy as part of their staging work-up for Hodgkin disease compared with patients undergoing similar chemotherapy regimens who did not undergo splenectomy. For all of these reasons, this procedure, which accounted for a large number of the splenectomies performed in major tertiary referral centers and cancer centers, is rarely performed at the present time.

VASCULAR DISORDERS OF THE SPLEEN

Vascular problems with the spleen that can lead to splenectomy include both the venous and arterial problems. The most common situation would be splenic vein thrombosis and splenectomy in this setting is curative for the patient. Splenic artery aneurysms are one of the more common visceral aneurysms and also can be an indication for splenectomy.

Splenic Vein Thrombosis

Splenic vein thrombosis is an unusual cause of upper gastrointestinal hemorrhage that can be cured by splenectomy. The pathophysiology of this disease is an isolated thrombosis of the splenic vein as it travels along the posterior pancreatic body and tail. The splenic venous outflow is then diverted to the short gastric vessels as collateral venous outflow channels. This increased flow via the short gastric veins leads to a high pressure with a dilatation of the submucosal venous plexus primarily in the gastric cardia and fundus with eventual development of gastric varices.[143]

The cause of the splenic vein thrombosis does not involve any pathology of the spleen, but rather typically pathology of the pancreas and possibly the stomach. Pancreatitis or pancreatic pseudocyst is the cause of splenic vein thrombosis in more than 50% of patients in most series. Pancreatic carcinoma with direct invasion and infiltration of the splenic vein is the second most common cause. Other unusual causes may be a penetrating gastric ulcer posteriorly or retroperitoneal fibrosis.

The diagnosis is made in patients who have upper gastrointestinal bleeding with only gastric varices on endoscopy. Because there is no portal vein hypertension and no cirrhosis of the liver, there are no esophageal varices. The spleen may or may not be enlarged but again there are no other signs and symptoms of cirrhosis. Definitive diagnosis in the past has been made by a celiac angiogram that demonstrates absence of the splenic vein with collateral flow via the gastric veins. Magnetic resonance angiogram/venograms, as well as high-resolution ultrasound, may also make the diagnosis.

Splenectomy is curative as it removes the blood flow via the splenic artery through this organ. This removes all the excess collateral flow, which leads to the venous hypertension and the associated symptoms resolve. Whenever splenic vein thrombosis is diagnosed, even if the patient has not had an episode of bleeding, elective splenectomy should be performed as a prophylactic measure.

Patients with portal hypertension and cirrhosis or partial vein thrombosis have a complex collection of symptoms that include hypersplenism with splenomegaly and thrombocytopenia and anemia. However, the operative risk associated with portal vein hypertension is excessive and splenectomy is virtually never indicated in this setting.

Splenic Artery Aneurysm

Splenic artery aneurysm is uncommon even though it is the second most frequent abdominal artery to undergo aneurysmal changes.[144] Splenic aneurysms occur twice as often in women than in men. Patients can be divided into two distinct groups. First, there are elderly patients whose aneurysms are manifestations of atherosclerosis. Second, young women have apparent congenital predisposition to form splenic artery aneurysms. In these young women, there is an increased risk of rupture of these aneurysms during pregnancy. Inflammatory processes such as pancreatitis may involve the splenic artery and occasionally lead to aneurysm, but more frequently lead to acute bleeding.

Splenic artery aneurysms are typically asymptomatic and may be initially identified as a widened rim of calcification in the left upper quadrant defining the aneurysm boundaries. They may also be discovered as incidental findings on CT scan. If symptomatic, patients experience left upper quadrant pain, nausea, and vomiting. The presence of symptoms suggesting pending aneurysmal rupture and urgent splenectomy with ligation of the splenic arteries is indicated.

When a calcified atherosclerotic splenic artery aneurysm is discovered in a patient older than 60 years with no splenomegaly and no symptoms, surgical excision is not indicated and the aneurysm may be followed to look for signs of enlargement. In younger patients who have a symptomatic aneurysm identified, particularly young women of child-bearing age, an elective splenectomy is recommended to prevent rupture. Nonsurgical approaches include embolization of the splenic artery in patients who are at poor risk for open laparotomy.[144]

MISCELLANEOUS INDICATIONS FOR SPLENECTOMY

Splenectomy may be performed infrequently for miscellaneous indications, including splenic cysts, infectious cysts, and splenic abscesses. Also included in the discussion of this category is the frequently described wandering spleen that is a normal spleen that lacks the normal ligamental attachments to keep it in the left upper quadrant. This can present in a variety of ways from an undiagnosed mass to a torsion of the splenic hilum causing acute abdominal pain.

Table 73-10 Primary Neoplasms and Cysts of Spleen

Hemangioma
Hemangioendothelioma
Lymphangioma
Pseudotumor
Mycobacterial pseudotumor
Hamartomas
Primary cyst
Echinococcal cyst

Cysts of the Spleen

The splenectomy is performed as described earlier often for hematologic malignancies, including multiple forms of leukemias and lymphoma primarily for symptoms of hypersplenism or splenomegaly, or as a staging procedure. Splenectomy for primary neoplasms of the spleen is an infrequent indication. These primary neoplastic processes are listed in Table 73-10.

Hemangioma is most common benign primary neoplasm of the spleen. It is often an incidental finding and may be solitary or multiple. During operation, it can be identified as a more intensely bluish-purple colored lesion when seen from the surface compared to the reddish-purple color of the splenic parenchyma. Hemangiomas can be identified with excellent sensitivity and specificity by MRI characteristics. It is ill-advised to perform a biopsy of a lesion that may be a splenic hemangioma.[145,146] Hemangiomas of the spleen rarely cause symptoms, but massive hemangiomas either rupture spontaneously or make the spleen more susceptible to a traumatic rupture. In cases of massive hemangioma with capsular distension with pain, either a splenectomy or partial splenectomy may be indicated.

Hemangioendothelioma is a neoplasm that is thought to be slightly more aggressive than the typical benign hemangioma. It is felt to be pathologically an intermediate lesion between benign hemangioma and malignant angiosarcoma. It is not felt to have metastatic potential and generally is an incidental finding. Larger lesions may cause symptoms or be noted for their size and rupture either spontaneously or with minor trauma, all circumstances in which patients with these lesions may undergo splenectomy.

Lymphangiomas also occur in the spleen and are much less common than hemangiomas. They may be multiple or solitary and can be identified by a lighter color and compressibility when seen in surgery.

Two mass lesions that occur in the spleen that are not true neoplasms are hamartomas and inflammatory pseudotumors. Hamartomas are focal development of abnormalities that occur in spleen and other solid organs such as the liver. Hamartomas contain normal cellular elements and are again nonneoplastic but have a random fibrotic organization.[147] The major significance of hamartomas is that they are identified either at laparotomy as incidental findings or they are seen as incidental lesions on CT scans done for other reasons.[148] Inflammatory pseudotumors are described throughout most organs and have also been described in the spleen. These sometimes are quite large with a wide variety of reactive cells. A subcategory of inflammatory pseudotumors of the spleen is related to mycobacterial infection, particularly in HIV-positive patients. There have been reports of primary splenic pregnancy that is considered the rarest site of ectopic pregnancies.

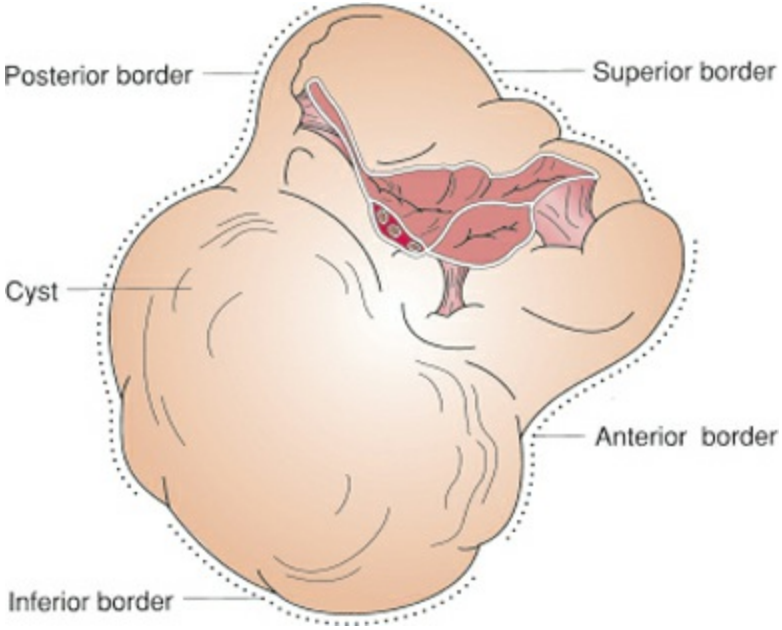

Figure 73-12. The visceral surface of a spleen with a true congenital splenic cyst.

Cysts of the spleen are relatively common lesions seen across all age groups, may be multifocal, and are not typically of parasitic origin. The diagnosis of splenic cysts can be ascertained by ultrasound or CT scan. These benign lesions have no clinical significance unless they reach a large size. As discussed earlier in the history of splenic surgery, the first reported case of a successful elective splenectomy was done for a splenic cyst. This was an enormous cyst at the tip of the spleen and was felt to be likely an ovarian mass and found to be arising from the spleen at laparotomy (Fig. 73-12). Today there would be a tendency to do a cyst enucleation or partial splenectomy for peripheral cystic lesions that are large and symptomatic. An alternative approach is unroofing the cyst and leaving a portion of the cyst wall in place and this can frequently be done laparoscopically.[149]

The only parasitic cyst involving the spleen is from *Echinococcus granulosus* or a hydatid cyst. The incidence of echinococcal cyst in the spleen compared to the liver is a ratio of approximately 30:1. However, the spleen is the third most common site of echinococcal cysts behind the liver and lung.[150] Diagnosis should be suspected in patients in areas such as New Zealand, Australia, and parts of the Western United States where echinococcal disease is common. The complement fixation test is the most reliable serologic study for this organism. The treatment of echinococcal cysts is splenectomy. As with echinococcal cysts of the liver, it is of utmost importance not to rupture the cyst and expose the patient to the scoleces. For large and peripheral cysts in which risk of rupture is high, the contents of the cyst should be carefully aspirated and replaced with hypertonic saline.[151] In a recent report from Greece, surgeons preserved 8 out of 19 spleens with echinococcal cysts by doing partial splenectomy.[150]

Abscess of the Spleen

Splenic abscess is uncommon but is an important disease because it is associated with a significant mortality rate and may be cured by splenectomy.[152] In most series, the mortality rate ranges between 40% and 100%.[153] The typical patient has hematogenous seeding of the spleen by bacteria from a remote source such as endocarditis or from intravenous drug abuse.[154] There may be in some cases direct spread of infection from adjacent intra-abdominal sources. Finally, splenic trauma treated conservatively may eventually result in an infected splenic hematoma. In 80% of the cases, there is an additional source of infection in locations other than the spleen, and in only 20% of cases is the splenic abscess the sole source of sepsis identified. Enteric organisms account for two-thirds of the splenic abscesses and staphylococcus and streptococcus comprise the remainder of the cases.

Patients typically present with signs and symptoms of sepsis including fever, malaise, and leukocytosis. When the spleen is the sole site of infection, patients will have significant left upper quadrant tenderness and guarding. Abdominal x-ray films may show gas in the spleen and an ultrasound or CT scan with contrast will be diagnostic to show an abscess with reactive rim.

The treatment of choice for patients who can undergo a laparotomy and have the splenic abscess as an isolated or prominent component of septic syndrome is splenectomy. If the spleen is the only source of infection, removal of the spleen should be curative and result in the recovery of the patient. If patients have multiple sites of infection or are too sick to undergo laparotomy, percutaneous drainage of splenic abscesses may be attempted but this is not successful because of frequent spillage and assimilation of bacteria in the left upper quadrant of the abdomen.

Ectopic Spleen (Wandering Spleen)

Ectopic spleens, or the so-called wandering spleens, occur because of either extreme laxity or absence of the normal ligaments that attach the spleen to the left upper quadrant. This allows the spleen to essentially drop to the lower abdomen in either the right lower quadrant or left lower quadrant by the force of gravity attached by its vascular pedicle.[155] This condition of a wandering spleen occurs 13 times more frequently in women than in men. The wandering spleen presents most commonly in adults but can cause symptoms in children. The diagnosis may be made by palpable lower abdominal mass confirmed by a CT scan or a nuclear imaging spleen scan to be splenic tissue. The ectopic spleen creates symptoms typically when there is torsion of the pedicle causing acute ischemia and acute pain. The treatment for a wandering spleen as an incidental finding at laparotomy or if the torsion can be corrected and the spleen appears to be viable is to do a splenopexy tacking it to its native position in the left upper quadrant. If the spleen appears infarcted, then a splenectomy must be performed.[156] The wandering spleen is ideally suited for laparoscopic splenectomy as it is generally free from ligaments or attachments and other organs.[157]

SPLENECTOMY: OPERATIVE TECHNIQUE

The choices of operations available currently to approach the spleen in an elective manner are open splenectomy, laparoscopic splenectomy, or partial splenectomy. Table 73-11 lists indications for splenectomy and whether a partial splenectomy is indicated. Certain principles apply to all patients undergoing elective splenectomy. First, all patients should receive appropriate preoperative vaccination with Pneumovax (pneumococcal polyvalent vaccine) and possibly also vaccination against *Haemophilus influenzae* and *Neisserian meningococcus* 10 to 14 days prior to the procedure if possible. Patients must have appropriate blood products ready as often patients are anemic and thrombocytopenic due to hypersplenism as described earlier.

Table 73-11 Operative Indications for Splenectomy and If Total or Partial Splenectomy Is Indicated

Disease	Need for Splenectomy	Partial Splenectomy
Hereditary spherocytosis	Always	Yes
Hereditary elliptocytosis	Sometimes	Yes
Thalassemia	Sometimes	Yes
Sickle cell anemia	Rarely	No
Wiskott–Aldrich syndrome	Sometimes	No
Autoimmune hemolytic anemia	Usually	No
Autoimmune neutropenia	Sometimes	No
Immune thrombocytopenia purpura	Usually	No
Thrombotic thrombocytopenia purpura	Sometimes	No
Hairy cell leukemia	Rarely[a]	No
Chronic lymphocytic leukemia	Sometimes	No
Chronic myelogenous leukemia	Sometimes	No
Non-Hodgkin lymphoma	Sometimes	No
Angiogenic myeloid metaplasia	Sometimes	Yes
Mastocytosis	Rarely	No
Gaucher disease	Rarely[a]	Yes
Hodgkin disease	Rarely[b]	No
Splenic vein thrombosis	Always	No
Splenic abscess	Usually	No
Splenic cyst	Rarely	Yes
Echinococcal cyst	Always	No

[a]Splenectomy rarely indicated in current practice because of effective medical therapy.
[b]Splenectomy rarely indicated because of change in current therapy.

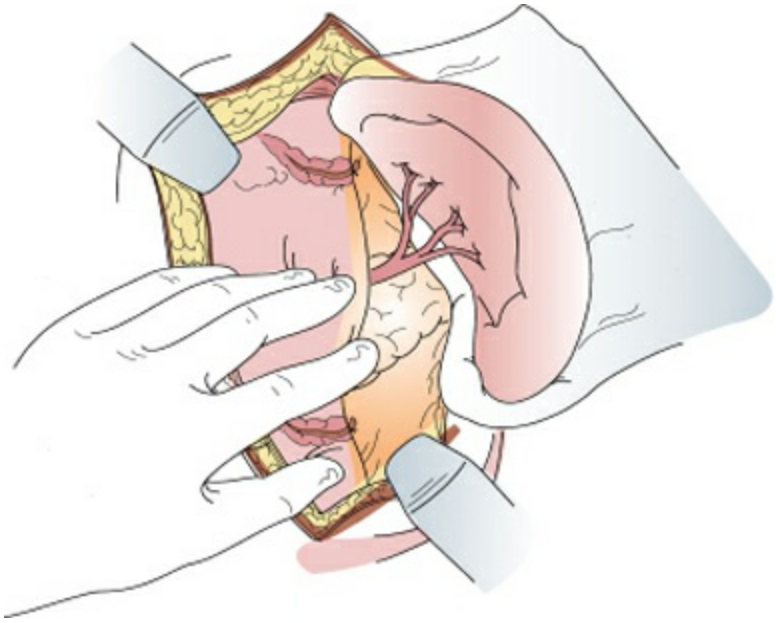

Figure 73-13. Lateral mobilization permits the spleen to reach the surface of a midline wound despite the presence of intact hilar vessels.

The operative technique for open splenectomy involves either a midline abdominal incision or a left subcostal incision. For patients with massive splenomegaly defined as >1,500 g in adults and >1,000 g in children, a long midline incision should be employed.[158] The components of the splenectomy include division of the avascular lateral and posterior attachments to mobilize the spleen (splenophrenic, splenorenal, and splenocolic ligaments), ligation of the short gastric vessels separating the upper half of the spleen from the greater curvature of the stomach, and ligation of splenic hilar vessels in a controlled manner to avoid injury to the pancreatic tail. Although one approach particularly for small spleens that are mobile is to initially divide the lateral attachments and place packs in the left upper quadrant to elevate the spleen and then proceed with the vascular dissection (Fig. 73-13), this should be discouraged particularly in patients who are thrombocytopenic or patients with massive splenomegaly. In this situation, splenectomy should start by obtaining vascular control before manipulating the spleen, which can lead to capsular rupture and significant blood loss.

The preferred operative approach in patients with splenomegaly[159] and hypersplenism would be to first divide the attachments of the left lateral segment of the liver and retract this to the right side of the abdomen exposing the greater curvature of the stomach. Then, starting at the mid portion of the greater curvature of the stomach, the branches of the left gastroepiploic artery and vein including short gastric vessels are ligated sequentially, completely dissociating the stomach from the superior portion of the spleen (Fig. 73-14). Through this window into the lesser sac created by dissecting the short gastric vessels, the splenic artery can be identified at variable locations along the superior border of the pancreas. A loop of this tortuous artery at its most superior or cranial portion is safest as at those points it is farthest away from the splenic vein as well as away from pancreatic parenchyma. The artery may be simply ligated once or twice with heavy silk ties at that location and does not need to be divided. By dividing short gastric arteries as well as ligating the main splenic artery, the vast majority if not all of blood flow into the spleen

is controlled before manipulating the spleen to mobilize it. If capsular disruption occurs, the amount of blood loss thus is greatly minimized. Following vascular control, the lateral and posterior attachments are divided and the spleen is elevated to near the level of the abdominal wall musculature ventrally. The splenic hilum can then be dissected tying vessels in a controlled manner. Upon completion of splenectomy, the use of drains in the surgical bed is not routinely indicated unless there is concern for or confirmed pancreatic injury.

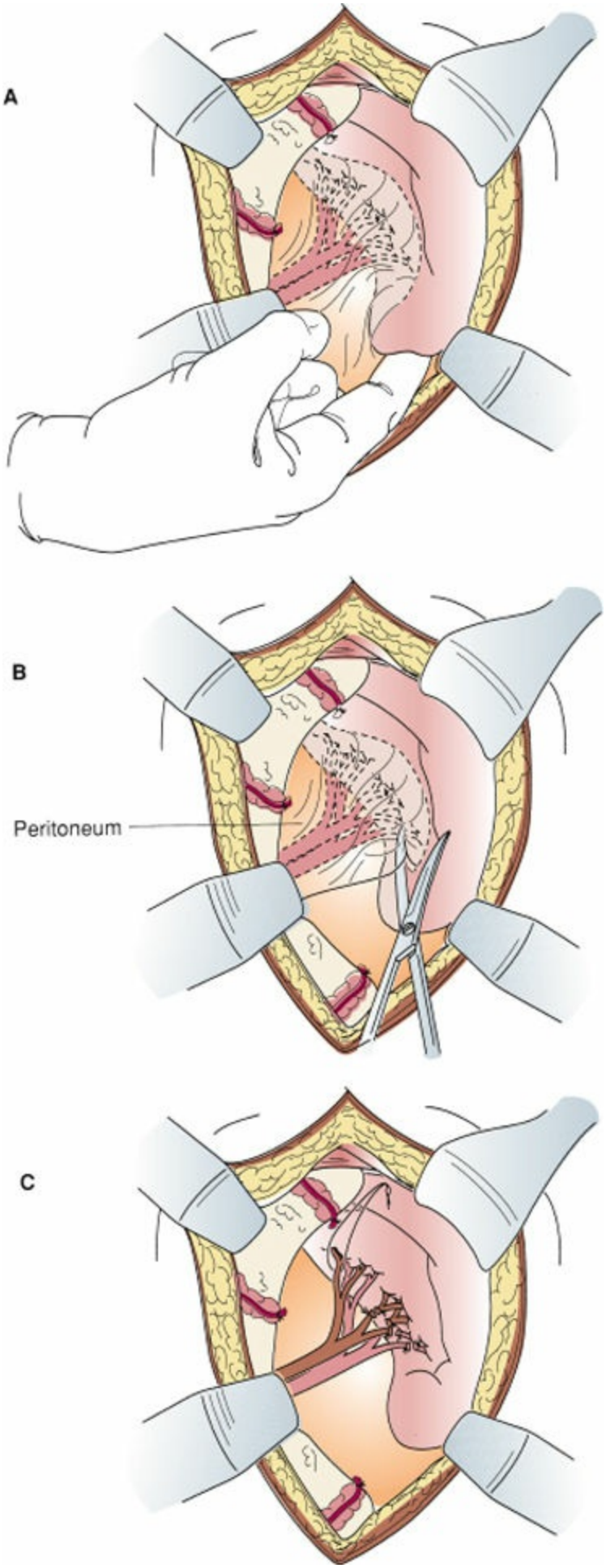

Figure 73-14. Technique for elective splenectomy. **A:** The inferior pole is reflected laterally by the assistant's fingers, exposing the lower edge of the hilar pleritoneal envelope. **B:** The hilar peritoneum is opened, here shown progressing

from inferior to superior. **C:** Individual vessels are identified and suture is ligated.

For patients with ITP, platelets should not be given until the spleen is either removed or at least until the arterial inflow is controlled because of clearance of transfused platelets by the spleen in this disease. Similarly, for this disease as well as other diseases in which the spleen is the site of platelet or blood cell destruction, it is important to identify and remove accessory spleens. The majority of the accessory spleens occur in the splenic hilum and they can also occur in the omentum, along the superior border of the pancreas, in the bowel mesentery, and in the pelvis in some situations. The incidence of accessory spleens and open splenectomy ranges between 15% and 30%.

Partial splenectomy can be performed on the basis of the segmental blood supply to the spleen. The spleen is mobilized with good visualization. The inferior segmental arteries are generally ligated and the artery and veins are ligated as a predemarcation of blood flow to the spleen. The splenic parenchyma is then transected and the cut to the surface can be controlled using materials that induce coagulation or the argon beam coagulator.[160,161]

In the past 5 to 10 years, the standard practice for an elective splenectomy in many large centers has become a laparoscopic approach.[23,162,163] Even patients with massive splenomegaly are frequently now being approached with a laparoscopic splenectomy with the use of a hand port.[163] In one series, there were no conversions in 49 patients with splenomegaly defined as splenic length >17 cm or spleen weight >600 g, although in 12 patients with splenic length >22 cm, a hand-assisted approach was used.[164] Another series noted a higher incidence of conversion to an open procedure when the spleen weighed more than 2,000 g.[165]

The technique of laparoscopic splenectomy can either be typically performed with patients in the supine position with a roll under their hips to prop that portion of the abdomen up approximately 30 degrees or it can be done with the patient in the lateral decubitus approach. Typically one 12-mm port and two or three 5-mm ports (depending upon the size of the spleen) are positioned below the costal margin from the subxiphoid area to the anterior axillary line (and laterally off the tip of the 11th rib for the additional port in cases of larger spleens). The omental, inferior attachments and the short gastric vessels are divided with a harmonic scalpel device. It has been reported that careful exposure of the splenic hilum with the direct ligation of the vessels is a much safer technique than the laparoscopic equivalent of a trauma splenectomy in which the hilum is staples without precise vessel dissection.[166] Once the vessels are ligated, the spleen is placed into a large plastic bag and brought to the port and this allows careful morselization of the spleen without having to enlarge the incision and without fracture and spillage elsewhere in the abdomen. The laparoscopic approach has been successfully applied for cases of massive splenomegaly[167] and partial splenectomy.[168] In some cases, the use of a handport can facilitate safe removal of the spleen, particularly when very enlarged. In one study, there was no difference in morbidity between patients receiving conventional laparoscopic resection and those facilitated by a hand port, although the length of hospital stay and duration of surgery were longer in the latter group, likely

attributable to the fact that those patients tended to be older, have larger spleens, and carry a malignant diagnosis.[169] More recently, the single incision/single-port laparoscopic surgery approach has also been successfully applied for splenectomy but remains a technically more demanding approach with less well-defined benefits over conventional laparoscopy.[170] Similarly, robotic-assisted splenectomy has been reported with successful outcomes and low conversion rates, but its benefit over conventional laparoscopy remains to be defined.[171]

Laparoscopic splenectomy has also been reported for removal of the wandering spleen.[157] In this indication, it is actually a much easier operation as the spleen is free and the hilum is very easily exposed. The removal of accessory spleens can be done laparoscopically as well and reports indicate that adding a hand port for palpation can assist in this type of procedure.[172] In one study, laparoscopy was found to be more sensitive than CT scan for identification of accessory spleens.[173]

A recent new technique has been added to treatment of splenic disorders that is radiofrequency ablation.[174,175] Radiofrequency ablation was developed in the mid-1990s primarily to treat liver lesions. There are a variety of commercial products that essentially destroy tissue indiscriminately by heating to 100°C. The largest experience is with either primary or metastatic tumors in the liver but this has also been utilized in treatment of bone metastasis, kidney lesions, lung lesions, and breast cancer. Recent reports indicate that radiofrequency ablation probes can be used successfully as a minimally invasive technique to treat splenic disorders such as thalassemia. There also may be a role for radiofrequency ablation in terms of treating trauma to the spleen as a way to control severe injuries hemostatically.[175,176]

Sequelae of Splenectomy and Hyposplenism

Splenectomy can have an impact on immune function and coagulative state in patients. The impact of splenectomy in immune function is most importantly manifested by the phenomenon of overwhelming postsplenectomy sepsis.[177,178] This was initially recognized as an important epidemiologic phenomenon in the early 1950s and multiple studies of splenectomized patients define key features of this increased susceptibility to infection. It is clear that the risk of postsplenectomy sepsis is inversely related to age.[179] The younger the child is the more impact and greater risk of developing overwhelming postsplenectomy sepsis.[180] This feature has clinical implications as elective splenectomies are not performed for patients with hereditary erythrocyte syndromes until after the ages of 6 to 10 years. In adults, there is still anywhere between a 40% to 60% increased risk of sepsis compared with patients with normal splenic function. These postsplenectomy septic episodes typically occur within the first 2 years of splenectomy in 80% of the cases. In adults, the reason for the splenectomy also relates to the incidence of sepsis. In trauma, the instance of sepsis in a large series was 1.4% whereas in thalassemia the incidence was 24.8%. Patients with any associated immunodeficiency such as malignancies or patients undergoing chemotherapy for treatment of Hodgkin disease are also at increased risk for sepsis. The mortality rate of postsplenectomy sepsis is between 50% and 60% in most series.

8 The types of organisms that account for infection are typically encapsulated organisms. These bacteria may have special features that allow them to be opsonized and cleared from a circulation by the spleen making them more dangerous in hyposplenic or splenectomized patients. The most common organism causing postsplenectomy sepsis is *Streptococcus pneumoniae,* which accounts for 50% of septic episodes in most series. In decreasing order of frequency, other bacteria associated with postsplenectomy sepsis are *Hemophilus influenza, Neisseria meningitidis,* β-hemolytic streptococcus, *Staphylococcus aureus, Escherichia coli,* and *Pseudomonas* species.[179] The current recommendations for patients who are having elective splenectomy would be to vaccinate susceptible individuals to pneumococcus strains (Table 73-12).[179] This is ideally done 2 weeks before the operation if possible, but should be done at any time preoperatively or even postoperatively if the patient was not vaccinated. Recent studies have shown that administration of vaccine with the first postoperative visit does not lead to beneficial immune stimulation. Waiting for 14 days postoperatively is equivalent to waiting 1 month or longer.[181] Therefore, vaccination starting at 2 weeks after an unplanned splenectomy is ideal timing. There are choices of polyvalent vaccines including pneumovax 23 and Pnu-Immune 23, both of which provide protection against virtually all common strains of pneumococcus.[181] For patients who are at particularly high risk because they may be immunosuppressed, there are also polyvalent vaccines against *Neisseria meningitides* and *Haemophilus influenzae* type B. Patients younger than 2 years and patients receiving chemotherapy for malignant disease may not be able to generate an immune response to vaccines and should be vaccinated either after the age of 2 years or when not receiving chemotherapy, respectively. Finally, because of the risk of very

rapid progression of sepsis in a postsplenectomy state, patients who have had splenectomy for any reason should be given a Medic-Alert bracelet.

Table 73-12 Guidelines for Prevention of Postsplenic Sepsis

Vaccinate with polyvalent pneumococcal vaccine at least 10–14 days prior to splenectomy if possible
If splenectomy is urgent wait, until at least 14 days postprocedure to vaccinate
For high-risk patients (immunosuppressed, children <10 years of age), meningococcal vaccine and haemophilus influenzae vaccine
Antibiotic prophylaxis for children <5 years of age
Early antibiotic treatment for initial signs of infection
Medic-Alert bracelet

Two recent studies highlight the incidence of increased relative risk and the number of infections after splenectomy. The relative risk for infection within 90 days of a splenectomy was 10.2% compared with 0.6% in the general population. In patients undergoing appendectomy for acute appendicitis a control group undergoing an abdominal procedure, there was still increased risk of infection in splenectomy of 10.2% compared with patients who had appendectomy of 4.2%.[182] The relative risk of postsplenectomy infection decreased over time with an overall hazard ratio of 4.6-fold between 90 days and 365 days after splenectomy and 2.5-fold for more than 365 days after splenectomy.[182] There is definite evidence of that use of vaccination decreases this risk of infection. Another large national study from Scotland showed that the overall rate of first severe infection was 7.0 per 100 person-years after splenectomy. In that subgroup of patients who had a severe infection, the rate of subsequent infections was significantly increased and the second severe infection rate was 44.9 per 100 person-years and a third episode of severe infection was 109.3 per 100 person-years.[183] This would indicate that the patients who had significant postsplenectomy sepsis should be observed very closely and counseled on seeking medical attention for any sign of any infectious process. There are also accumulating data with the increased trend particularly in blunt splenic trauma and other hematologic diseases for spleen-preserving procedures such as splenorrhaphy or partial splenectomy, that there are still increased risks of infection in these patients that are comparable with those of patients who have a complete splenectomy.[184]

A recent survey of practicing surgeons indicated patterns of utilization of immunization for splenectomy patients. Of the practices, essentially universally 99.2% of active surgeons said they do immunize patients they treat with splenectomy.[185] Virtually every one administers vaccine to pneumococcus. Most (72.4%) practicing surgeons routinely use a *Haemophilus influenzae* type vaccine, 62.8% give meningococcal vaccination, and 56.7% utilize all three vaccines. A small portion of practicing surgeons immunize their patients who have splenorrhaphy (15.7%) and a very small proportion immunize patients who have splenic injury but who are managed nonoperatively. Current guidelines would be that all patients with elective splenectomies should have prophylactic immunization

prior to surgery whereas patients who have unexpected splenectomy should have immunization on or after 14 days after the procedure. All patients should get pneumococcal vaccines and patients at high risk should have vaccination for *H. influenzae* and meningococcus.[185,186] Revaccinations may be considered at appropriate time intervals, taking into account the age and immune status of the patient, although these are not typically needed for *H. influenzae*.

For decades, it has been known that patients after splenectomy are susceptible to infections as described earlier. It has only recently been realized that there are a variety of vascular complications that occur to a greater degree in patients with splenectomy than in cohort of abdominal surgery patients without splenectomy.[187] These include arterial thrombosis, venous thrombosis, and pulmonary artery hypertension. Data from patients with hereditary spherocytosis who have undergone splenectomy report between a 5.6- and 7.2-fold increase in ischemic heart disease compared with patients who do not have splenectomy. The most marked finding for arterial events occurs in thalassemia in which patients who undergo splenectomy have a 20-fold increase in arterial atherosclerosis of arterial structures. Acute portal venous thrombosis is reported after splenectomy in one series up to 4.8% for a variety of patients.[188] It is clearly seen more commonly after splenectomy in patients with cirrhosis and hypersplenism where the rate of portal vein thrombosis (PVT) may be 30% to 40%.[189] A recent study suggests that splenic volume may predict the likelihood of patients with cirrhosis developing PVT, with spleen volumes >450 mL associated with significantly increased risk for PVT.[190] Prophylactic anticoagulation may be considered in these high-risk patients.[191] Moreover, while some earlier study data suggested a higher incidence of PVT in patients undergoing laparoscopic surgery when postoperative imaging is routinely performed,[192] there does not appear to be a clear association between the surgical approach (laparoscopy vs. open) of splenectomy and the incidence of clinically apparent PVT, despite concerns of pneumoperitoneum and perhaps more commonly longer splenic vein stump length in laparoscopic cases leading to a more thrombotic state in the portal venous system. In one recent study of 162 splenectomised patients, the incidence of PVT was 1 of 60 (1.7%) in open splenectomy patients and 3 of 102 (2.9%) in laparoscopic splenectomy patients.[193] The incidence of venous thrombosis may go beyond the mesenteric/portal venous system and include deep venous thrombosis in the pelvis and lower extremities as well as subsequent pulmonary embolus to a much greater extent. This also has led to increased evidence of pulmonary arterial hypertension in patients after splenectomy for hematologic diseases. A large retrospective analysis of 375,748 patients undergoing abdominal surgery found patients undergoing splenectomy to be at highest risk for venous thromboembolic events.[194]

The pathogenesis of these vascular events after splenectomy is likely multifactorial.[187] They may involve some elements of hypocoagulative state due to altered platelet function and number. There may be some disturbances in vascular epithelium related to the other blood elements that are altered after splenectomy. The spleen moreover may also play an important role in clearing certain cellular microparticles that may have a prothrombotic effect, such as phosphatidyl-serine.[195] There is also evidence that there may be some

changes in lipid profiles after splenectomy that would promote atherosclerosis and thrombosis.[187] Although these vascular events clearly are increased in frequency, they nonetheless occur in a minority of patients but would argue toward using splenectomy conservatively particularly in certain high-risk individuals such as patients with thalassemia.

Finally, splenectomy may increase the risk of development of certain malignancies. In one recent study of 8149 cancer- free American veterans who had undergone splenectomy with long-term follow-up, there was an increase noted in various both solid and hematologic malignancies, many of these occurring years following surgery.[25] Other studies have shown less consistent associations of splenectomy with subsequent malignancy; one Danish and one Swedish study found an increased incidence of malignancy among patients undergoing splenectomy only for nontrauma-related etiologies.[142,196] Further study is needed to define the precise association between splenectomy and subsequent malignancy.

References

1. McClusky DA III, Skandalakis LJ, Colborn GL, et al. Tribute to a triad: history of splenic anatomy, physiology, and surgery–part 1. *World J Surg* 1999; 23(3):311–325.
2. Morgenstern L. A history of splenectomy. In: Hiatt JR, Morgenstern L, eds. *Surgical diseases of the spleen.* Berlin, Germany: Springer-Verlag.
3. Morgenstern L. Love in the time of spleen: a personal memoir. *J Am Coll Surg* 2006;202(2):335–339.
4. McClusky DA III, Skandalakis LJ, Colborn GL, et al. Tribute to a triad: history of splenic anatomy, physiology, and surgery—part 2. *World J Surg* 1999;23(5):514–526.
5. Patterson KD, Drysdale TA, Krieg PA. Embryonic origins of spleen asymmetry. *Development* 2000;127(1):167–175.
6. Brendolan A, Rosado MM, Carsetti R, et al. Development and function of the mammalian spleen. *Bioessays* 2007;29(2):166–177.
7. Sprogoe-Jakobsen S, Sprogoe-Jakobsen U. The weight of the normal spleen. *Forensic Sci Int* 1997;88(3):215–223.
8. Ravaglia G, Forti P, Biagi F, et al. Splenic function in old age. *Gerontology* 1998;44(2):91–94.
9. Hoefs JC, Wang FW, Lilien DL, et al. A novel, simple method of functional spleen volume calculation by liver-spleen scan. *J Nucl Med,* 1999;40(10):1745–1755.
10. Skandalakis PN., Colborn GL, Skandalakis LJ, et al. The surgical anatomy of the spleen. *Surg Clin North Am* 1993;73(4):747–768.
11. Desai DC, Hebra A, Davidoff AM, et al. Wandering spleen: a challenging diagnosis. *South Med J,* 1997;90(4):439–443.
12. Liu DL, Xia S, Xu W, et al. Anatomy of vasculature of 850 spleen specimens and its application in partial splenectomy. *Surgery* 1996;119(1):27–33.
13. Kraus MD. Pathology of the spleen. Introduction. *Semin Diagn Pathol* 2003;20(2):83.
14. Mebius RE, Kraal G. Structure and function of the spleen. *Nat Rev Immunol* 2005;5(8):606–616.
15. Espersen K, Frandsen H, Lorentzen T, et al. The human spleen as an erythrocyte reservoir in diving-related interventions. *J Appl Physiol* 2002; 92(5):2071–2079.
16. Peters AM. Splenic blood flow and blood cell kinetics. *Clin Haematol* 1983;12(2):421–447.
17. Phom H, Kumar A, Tripathi M, et al. Comparative evaluation of Tc-99m-heat-denatured RBC and Tc-99m-anti-D IgG opsonized RBC spleen planar and SPECT scintigraphy in the detection of accessory spleen in postsplenectomy patients with chronic idiopathic thrombocytopenic purpura. *Clin Nucl Med* 2004;29(7):403–409.
18. Werre JM, Willekens FL, Bosch FH, et al. The red cell revisited—matters of life and death. *Cell Mol Biol* 2004;50(2):139–145.
19. Zoli G, Corazza GR, D'Amato G, et al. Splenic autotransplantation after splenectomy:

tuftsin activity correlates with residual splenic function. *Br J Surg* 1994;81(5):716–718.

20. Feder HM Jr, Pearson HA. Assessment of splenic function in familial asplenia. *N Engl J Med* 1999;341(3):210–212.
21. William BM, Corazza GR. Hyposplenism: a comprehensive review. Part I: Basic concepts and causes. *Hematology* 2007;12(1):1–13.
22. Resende V, Petroianu A. Functions of the splenic remnant after subtotal splenectomy for treatment of severe splenic injuries. *Am J Surg* 2003; 185(4):311–315.
23. Singla A, Li Y, Ng SC, et al. Is the growth in laparoscopic surgery reproducible with more complex procedures? *Surgery* 2009;146(2):367–374.
24. Kraus MD, Fleming MD, Vonderheide RH. The spleen as a diagnostic specimen: a review of 10 years' experience at two tertiary care institutions. *Cancer* 2001;91(11):2001–2009.
25. Kristinsson SY, Gridley G, Hoover RN, et al. Long-term risks after splenectomy among 8,149 cancer-free American veterans: a cohort study with up to 27 years follow-up. *Haematologica* 2014;99(2):392–398.
26. Rose AT, Newman MI, Debelak J, et al. The incidence of splenectomy is decreasing: lessons learned from trauma experience. *Am Surg* 2000; 66(5):481–486.
27. Peitzman AB, Ford HR, Harbrecht BG, et al. Injury to the spleen. *Curr Probl Surg* 2001;38(12):932–1008.
28. Upadhyaya P. Conservative management of splenic trauma: history and current trends. *Pediatr Surg Int* 2003;19(9/10):617–627.
29. Harbrecht BG, Zenati MS, Ochoa JB, et al. Evaluation of a 15-year experience with splenic injuries in a state trauma system. *Surgery* 2007;141(2): 229–238.
30. Gavant ML, Schurr M, Flick PA, et al. Predicting clinical outcome of nonsurgical management of blunt splenic injury: using CT to reveal abnormalities of splenic vasculature. *AJR Am J Roentgenol* 1997;168(1):207–212.
31. Berry MF, Rosato EF, Williams NN. Dexon mesh splenorrhaphy for intraoperative splenic injuries. *Am Surg* 2003;69(2):176–180.
32. Carobbi A, Romagnani F, Antonelli G, et al. Laparoscopic splenectomy for severe blunt trauma: initial experience of ten consecutive cases with a fast hemostatic technique. *Surg Endosc* 2010;24(6):1325–1330.
33. Uecker J, Pickett C, Dunn E. The role of follow-up radiographic studies in nonoperative management of spleen trauma. *Am Surg* 2001;67(1):22–25.
34. Konstantakos AK, Barnoski AL, Plaisier BR, et al. Optimizing the management of blunt splenic injury in adults and children. *Surgery* 1999; 126(4):805–812; discussion 812–813.
35. Gaunt WT, McCarthy MC, Lambert CS, et al. Traditional criteria for observation of splenic trauma should be challenged. *Am Surg* 1999;65(7):689–691; discussion 691–692.

36. Khan ZA, Dikki PE. Return of a normal functioning spleen after traumatic splenectomy. *J R Soc Med* 2004;97(8):391–392.
37. Rajani RR, Claridge JA, Yowler CJ, et al. Improved outcome of adult blunt splenic injury: a cohort analysis. *Surgery,* 2006;140(4):625–631; discussion 631–632.
38. Cirocchi R, Boselli C, Corsi A, et al. Is non-operative management safe and effective for all splenic blunt trauma? A systematic review. *Crit Care* 2013. 17(5):R185.
39. Duchesne JC, Simmons JD, Schmieg RE Jr, et al. Proximal splenic angioembolization does not improve outcomes in treating blunt splenic injuries compared with splenectomy: a cohort analysis. *J Trauma* 2008;65(6): 1346–1351; discussion 1351–1353.
40. Wei B, Hemmila MR, Arbabi S, et al. Angioembolization reduces operative intervention for blunt splenic injury. *J Trauma* 2008;64(6):1472–1477.
41. Smith HE, Biffl WL, Majercik SD, et al. Splenic artery embolization: have we gone too far? *J Trauma* 2006;61(3):541–544; discussion 545–546.
42. Zarzaur BL, Vashi S, Magnotti LJ, et al., The real risk of splenectomy after discharge home following nonoperative management of blunt splenic injury. *J Trauma* 2009;66(6):1531–1536; discussion 1536–1538.
43. McCray VW, Davis JW, Lemaster D, et al. Observation for nonoperative management of the spleen: how long is long enough? *J Trauma* 2008; 65(6):1354–1358.
44. Renzulli P, Hostettler A, Schoepfer AM, et al. Systematic review of atraumatic splenic rupture. *Br J Surg* 2009;96(10):1114–1121.
45. Cines DB, Bussel JB. How I treat idiopathic thrombocytopenic purpura (ITP). *Blood* 2005;106(7):2244–2251.
46. Morris KT, Horvath KD, Jobe BA, et al. Laparoscopic management of accessory spleens in immune thrombocytopenic purpura. *Surg Endosc* 1999;13(5):520–522.
47. Ballem PJ, Belzberg A, Devine DV, et al. Kinetic studies of the mechanism of thrombocytopenia in patients with human immunodeficiency virus infection. *N Engl J Med* 1992;327(25):1779–1784.
48. Cersosimo RJ. Romiplostim in chronic immune thrombocytopenic purpura. *Clin Ther* 2009;31(9):1887–1907.
49. Hoo M, Lv B, He Q, et al. Both splenic CD5(+) B and CD5(-) B cells produce platelet glycoprotein-specific autoantibodies in chronic ITP. *Thromb Res* 2003;110(1):1–5.
50. Bromberg ME. Immune thrombocytopenic purpura—the changing therapeutic landscape. *N Engl J Med* 2006;355(16):1643–1645.
51. Bussel JB, Kuter DJ, George JN, et al. AMG 531, a thrombopoiesis-stimulating protein, for chronic ITP. *N Engl J Med* 2006;355(16):1672–1681.
52. Cohen YC, Djulbegovic B, Shamai-Lubovitz O, et al. The bleeding risk and natural history of idiopathic thrombocytopenic purpura in patients with persistent low platelet counts. *Arch Intern Med* 2000;160(11):1630–1638.
53. Dan K, Gomi S, Kuramoto A, et al. A multicenter prospective study on the treatment

of chronic idiopathic thrombocytopenic purpura. *Int J Hematol* 1992;55(3):287–292.
54. Andersen JC. Response of resistant idiopathic thrombocytopenic purpura to pulsed high-dose dexamethasone therapy. *N Engl J Med* 1994; 330(22):1560–1564.
55. Sandler SG. The spleen and splenectomy in immune (idiopathic) thrombocytopenic purpura. *Semin Hematol* 2000;37(1) (suppl 1):10–12.
56. Kojouri K, Vesely SK, Terrell DR, et al. Splenectomy for adult patients with idiopathic thrombocytopenic purpura: a systematic review to assess long-term platelet count responses, prediction of response, and surgical complications. *Blood* 2004;104(9):2623–2634.
57. Targarona EM, Espert JJ, Balague C, et al. Residual splenic function after laparoscopic splenectomy: a clinical concern. *Arch Surg* 1998;133(1): 56–60.
58. Sampath S, Meneghetti AT, MacFarlane JK, et al. An 18-year review of open and laparoscopic splenectomy for idiopathic thrombocytopenic purpura. *Am J Surg* 2007;193(5):580–583; discussion 583–584.
59. Godeau B, Porcher R, Fain O, et al., Rituximab efficacy and safety in adult splenectomy candidates with chronic immune thrombocytopenic purpura: results of a prospective multicenter phase 2 study. *Blood* 2008; 112(4):999–1004.
60. Arnold DM, Dentall F, Crowther MA, et al. Systematic review: Efficacy and safety of rituximab for adults with idiopathic thrombocytopenic purpura. *Ann Intern Med* 2007;146(1):25–33.
61. Arnold DM, Nazi I, Santos A, et al. Combination immunosuppressant therapy for patients with chronic refractory immune thrombocytopenic purpura. *Blood* 2010;115(1):29–31.
62. Schipperus M, Fijnheer R. New therapeutic options for immune thrombocytopenia. *Neth J Med* 2011;69(11):480–485.
63. Kuter DJ, Bussel JB, Lyons RM, et al. Efficacy of romiplostim in patients with chronic immune thrombocytopenic purpura: a double-blind randomised controlled trial. *Lancet* 2008;371(9610):395–403.
64. Cheng G, Saleh MN, Marcher C, et al., Eltrombopag for management of chronic immune thrombocytopenia (RAISE): a 6-month, randomised, phase 3 study. *Lancet* 2011;377(9763):393–402.
65. Onundarson PT, Rowe JM, Heal JM, et al. Response to plasma exchange and splenectomy in thrombotic thrombocytopenic purpura. A 10-year experience at a single institution. *Arch Intern Med* 1992;152(4):791–796.
66. Wells AD, Majumdar G, Slater NG, et al. Role of splenectomy as a salvage procedure in thrombotic thrombocytopenic purpura. *Br J Surg* 1991;78(11):1389–1390.
67. Aqui NA, Stein SH, Konkle BA, et al. Role of splenectomy in patients with refractory or relapsed thrombotic thrombocytopenic purpura. *J Clin Apher* 2003;18(2):51–54.
68. Modic M, Cernelc P, Zver S. Splenectomy: the last option of immunosuppressive therapy in patients with chronic or relapsing idiopathic thrombotic thrombocytopenic

purpura? *Transplant Proc* 2002. 34(7):2953–2954.
69. Rice HE, Oldham KT, Hillery CA, et al. Clinical and hematologic benefits of partial splenectomy for congenital hemolytic anemias in children. *Ann Surg* 2003;237(2):281–288.
70. Balint GP, Balint PV. Felty's syndrome. *Best Pract Res Clin Rheumatol* 2004; 18(5):631–645.
71. van Krieken JH, Breedveld FC, de Velde J. The spleen in Felty's syndrome: a histological, morphometrical, and immunohistochemical study. *Eur J Haematol* 1988;40(1):58–64.
72. Blumfelder TM, Logue GL, Shimm DS. Felty's syndrome: effects of splenectomy upon granulocyte count and granulocyte-associated IgG. *Ann Intern Med* 1981;94(5):623–628.
73. Logue GL, Huang AT, Shimm DS. Failure of splenectomy in Felty's syndrome. The role of antibodies supporting granulocyte lysis by lymphocytes. *N Engl J Med* 1981;304(10):580–583.
74. Perrotta S, Gallagher PG, Mohandas N. Hereditary spherocytosis. *Lancet* 2008;372(9647):1411–1426.
75. Eber S, Lux SE. Hereditary spherocytosis—defects in proteins that connect the membrane skeleton to the lipid bilayer. *Semin Hematol* 2004; 41(2):118–141.
76. Bolton-Maggs PH, Stevens RF, Dodd NJ, et al. Guidelines for the diagnosis and management of hereditary spherocytosis. *Br J Haematol* 2004;126(4):455–474.
77. Reliene R, Mariani M, Zanella A, et al. Splenectomy prolongs in vivo survival of erythrocytes differently in spectrin/ankyrin- and band 3-deficient hereditary spherocytosis. *Blood* 2002;100(6):2208–2215.
78. Tsereteli Z, Smith CD, Branum GD, et al. Are the favorable outcomes of splenectomy predictable inpatients with idiopathic thrombocytopenic purpura (ITP)? *Surg Endosc* 2001;15(12):1386–1389.
79. Olivieri NF, Nathan DG, MacMillan JH, et al. Survival in medically treated patients with homozygous beta-thalassemia. *N Engl J Med* 1994; 331(9):574–578.
80. Pinca A, Di Palma A, Soriani S, et al. Effectiveness of partial splenic embolization as treatment for hypersplenism in thalassaemia major: a 7-year follow up. *Eur J Haematol,* 1992;49(2):49–52.
81. Idowu O, Hayes-Jordan A. Partial splenectomy in children under 4 years of age with hemoglobinopathy. *J Pediatr Surg* 1998;33(8):1251–1253.
82. al-Salem AH, al-Dabbous I, Bhamidibati P. The role of partial splenectomy in children with thalassemia. *Eur J Pediatr Surg* 1998;8(6):334–338.
83. Levasseur DN, Ryan TM, Reilly MP, et al. A recombinant human hemoglobin with anti-sickling properties greater than fetal hemoglobin. *J Biol Chem* 2004;279(26):27518–27524.
84. Corash L, Shafer B, Blaese RM. Platelet-associated immunoglobulin, platelet size, and

the effect of splenectomy in the Wiskott-Aldrich syndrome. *Blood* 1985;65(6):1439–1443.

85. Mullen CA, Anderson KD, Blaese RM. Splenectomy and/or bone marrow transplantation in the management of the Wiskott-Aldrich syndrome: long-term follow-up of 62 cases. *Blood* 1993;82(10):2961–2966.
86. Vermi W, Blanzuoli L, Kraus MD, et al., The spleen in the Wiskott-Aldrich syndrome: Histopathologic abnormalities of the white pulp correlate with the clinical phenotype of the disease. *Am J Surg Pathol* 1999;23(2):182–191.
87. Elliott MA, Tefferi A. Splenic irradiation in myelofibrosis with myeloid metaplasia: A review. *Blood Rev* 1999;13(3):163–170.
88. Delpero JR, Houvenaeghel G, Gastaut JA, et al. Splenectomy for hypersplenism in chronic lymphocytic leukaemia and malignant non-Hodgkin's lymphoma. *Br J Surg* 1990;77(4):443–449.
89. Thiruvengadam R, Piedmonte M, Barcos M, et al. Splenectomy in advanced chronic lymphocytic leukemia. *Leukemia* 1990;4(11):758–760.
90. Neal TF Jr, Tefferi A, Witzig TE, et al. Splenectomy in advanced chronic lymphocytic leukemia: A single institution experience with 50 patients. *Am J Med* 1992. 93(4):435–440.
91. Seymour JF, Cusack JD, Lerner SA, et al. Case/control study of the role of splenectomy in chronic lymphocytic leukemia. *J Clin Oncol* 1997; 15(1):52–60.
92. Savage DG, Szydlo RM, Goldman JM. Clinical features at diagnosis in 430 patients with chronic myeloid leukaemia seen at a referral centre over a 16-year period. *Br J Haematol* 1997;96(1):111–116.
93. Hester JP, Waddell CC, Coltman CA Jr, et al. Response of chronic myelogenous leukemia patients to COAP-splenectomy. A Southwest Oncology Group study. *Cancer* 1984;54(9):1977–1982.
94. The Italian Cooperative Study Group on Chronic Myeloid Leukemia. Results of a prospective randomized trial of early splenectomy in chronic myeloid leukemia. *Cancer* 1984;54(2):333–338.
95. Bouvet M, Babiera GV, Termuhlen PM, et al. Splenectomy in the accelerated or blastic phase of chronic myelogenous leukemia: A single-institution, 25-year experience. *Surgery* 1997;122(1):20–25.
96. Morel P, Dupriez B, Gosselin B, et al. Role of early splenectomy in malignant lymphomas with prominent splenic involvement (primary lymphomas of the spleen). A study of 59 cases. *Cancer* 1993;71(1):207–215.
97. Nair S, Shukla J, Chandy M. Non-Hodgkin's lymphoma presenting with prominent splenomegaly—clinicopathologic diversity in relationship to immunophenotype. *Acta Oncol* 1997;36(7):725–727.
98. Lehne, G, Hannisdal E, Langholm R, et al. A 10-year experience with splenectomy in patients with malignant non-Hodgkin's lymphoma at the Norwegian Radium

Hospital. *Cancer* 1994;74(3):933–939.

99. Tsimberidou AM, Catovsky D, Schlette E, et al. Outcomes in patients with splenic marginal zone lymphoma and marginal zone lymphoma treated with rituximab with or without chemotherapy or chemotherapy alone. *Cancer* 2006;107(1):125–135.
100. Brodsky J, Abcar A, Styler M. Splenectomy for non-Hodgkin's lymphoma. *Am J Clin Oncol.* 1996;19(6):558–561.
101. Grever MR. How I treat hairy cell leukemia. *Blood* 2010;115(1):21–28.
102. Tallman MS, Hakimian D, Peterson L. Massive splenomegaly in hairy cell leukemia. *J Clin Oncol* 1998;16(3):1232–1233.
103. Katz SC, Pachter HL. Indications for splenectomy. *Am Surg* 2006;72(7): 565–580.
104. Smalley RV, Connors J, Tuttle RL, et al. Splenectomy vs. alpha interferon: a randomized study in patients with previously untreated hairy cell leukemia. *Am J Hematol* 1992;41(1):13–18.
105. Saven, A, Piro L. Newer purine analogues for the treatment of hairy-cell leukemia. *N Engl J Med* 1994;330(10):691–697.
106. Grever M, Kopecky K, Foucar MK, et al. Randomized comparison of pentostatin versus interferon alfa-2a in previously untreated patients with hairy cell leukemia: an intergroup study. *J Clin Oncol* 1995;13(4): 974–982.
107. Else M, Ruchlemer R, Osuji N, et al. Long remissions in hairy cell leukemia with purine analogs: a report of 219 patients with a median follow-up of 12.5 years. *Cancer* 2005;104(11):2442–2448.
108. Reilly JT. Pathogenesis of idiopathic myelofibrosis: present status and future directions. *Br J Haematol* 1994;88(1):1–8.
109. Kraus MD, Bartlett NL, Fleming MD, et al. Splenic pathology in myelodysplasia: a report of 13 cases with clinical correlation. *Am J Surg Pathol* 1998;22(10):1255–1266.
110. Mesa RA. How I treat symptomatic splenomegaly in patients with myelofibrosis. *Blood* 2009;113(22):5394–5400.
111. Benbassat J, Gilon D, Penchas S. The choice between splenectomy and medical treatment in patients with advanced agnogenic myeloid metaplasia. *Am J Hematol* 1990;33(2):128–135.
112. Barosi G, Ambrosetti A, Buratti A, et al. Splenectomy for patients with myelofibrosis with myeloid metaplasia: pretreatment variables and outcome prediction. *Leukemia* 1993;7(2):200–206.
113. Lopez-Guillermo A, Cervantes F, Bruguera M, et al. Liver dysfunction following splenectomy in idiopathic myelofibrosis: a study of 10 patients. *Acta Haematol* 1991;85(4):184–188.
114. Mesa RA, Nagorney DS, Schwager S et al. Palliative goals, patient selection, and perioperative platelet management: outcomes and lessons from 3 decades of splenectomy for myelofibrosis with myeloid metaplasia at the Mayo Clinic. *Cancer* 2006;107(2):361–370.

115. Rialon KL, Speicher PJ, Ceppa EP, et al. Outcomes following splenectomy in patients with myeloid neoplasms. *J Surg Oncol* 2015;111:389–395.
116. Barosi G, Bergamaschi G, Marchetti M, et al. JAK2 V617F mutational status predicts progression to large splenomegaly and leukemic transformation in primary myelofibrosis. *Blood* 2007;110(12):4030–4036.
117. Tefferi A. Primary myelofibrosis: 2014 update on diagnosis, risk- stratification, and management. *Am J Hematol* 2014;89(9):915–925.
118. Passamonti, F, Cervantes F, Vannucchi AM, et al. Dynamic International Prognostic Scoring System (DIPSS) predicts progression to acute myeloid leukemia in primary myelofibrosis. *Blood* 2010;116(15):2857–2858.
119. Comperat E, Bardier-Dupas A, Camparo P, et al. Splenic metastases: clinicopathologic presentation, differential diagnosis, and pathogenesis. *Arch Pathol Lab Med* 2007;131(6):965–969.
120. Sileri P, D'Ugo S, Benavoli D, et al. Metachronous splenic metastasis from colonic carcinoma five years after surgery: a case report and literature review. *South Med J* 2009;102(7):733–735.
121. Stang A, D'Ugo S, Benavoli D, et al. Differentiation of benign from malignant focal splenic lesions using sulfur hexafluoride-filled microbubble contrast-enhanced pulse-inversion sonography. *AJR Am J Roentgenol* 2009;193(3):709–721.
122. Cohen IJ, Katz K, Freud E, et al. Long-term follow-up of partial splenectomy in Gaucher's disease. *Am J Surg* 1992;164(4):345–347.
123. Morgenstern L, Verham R, Weinstein I, et al. Subtotal splenectomy for Gaucher's disease: a follow-up study. *Am Surg* 1993;59(12):860–865.
124. Zer M, Freud E. Subtotal splenectomy in Gaucher's disease: towards a definition of critical splenic mass. *Br J Surg* 1992;79(8):742–744.
125. Rodriguez JR, Madanat MG, Healy BC, Thayer SP, Warshaw AL, Fernández- del Castillo C. Distal pancreatectomy with splenic preservation revisited. *Surgery* 2007;141(5):619–625.
126. Fernandez-Cruz L, Martínez I, Gilabert R, et al. Laparoscopic distal pancreatectomy combined with preservation of the spleen for cystic neoplasms of the pancreas. *J Gastrointest Surg* 2004;8(4):493–501.
127. Ikeguchi M, Kaibara N. Lymph node metastasis at the splenic hilum in proximal gastric cancer. *Am Surg* 2004;70(7):645–648.
128. Martin RC II, Jaques DP, Brennan MF, et al. Extended local resection for advanced gastric cancer: increased survival versus increased morbidity. *Ann Surg* 2002;236(2):159–165.
129. Martin RC II, Jaques DP, Brennan MF, et al. Achieving RO resection for locally advanced gastric cancer: is it worth the risk of multiorgan resection? *J Am Coll Surg* 2002;194(5):568–577.
130. Yu W, Choi GS, Chung HY. Randomized clinical trial of splenectomy versus splenic

preservation in patients with proximal gastric cancer. *Br J Surg* 2006;93(5):559–563.
131. Cassar K, Munro A. Iatrogenic splenic injury. *J R Coll Surg Edinb* 2002; 47(6):731–741.
132. Flum DR, Koepsell T, Heagerty P, et al. The nationwide frequency of major adverse outcomes in antireflux surgery and the role of surgeon experience 1992–1997. *J Am Coll Surg* 2002;195(5):611–618.
133. Holubar SD, Wang JK, Wolff BG, et al. Splenic salvage after intraoperative splenic injury during colectomy. *Arch Surg* 2009;144(11):1040–1045.
134. McGory ML, Zingmond DS, Sekeris E, et al. The significance of inadvertent splenectomy during colorectal cancer resection. *Arch Surg* 2007;142(7): 668–674.
135. Masoomi H. Carmichael JC, Mills S, et al. Predictive factors of splenic injury in colorectal surgery: data from the Nationwide Inpatient Sample, 2006–2008. *Arch Surg* 2012;147(4):324–349.
136. Pugalenthi A, Bradley C, Gonen M, et al. Splenectomy to treat splenic lesions: an analysis of 148 cases at a cancer center. *J Surg Oncol* 2013; 108(8):521–525.
137. Muskat PC, Johnson RA, Bowers GJ. Staging laparotomy in Hodgkin's lymphoma: 1979 to 1988. *Am J Surg* 1991;162(6):603–606; discussion 606–607.
138. Mendenhall NP, Cantor AB, Williams JL, et al. With modern imaging techniques, is staging laparotomy necessary in pediatric Hodgkin's disease? A Pediatric Oncology Group study. *J Clin Oncol* 1993;11(11):2218–2225.
139. Gospodarowicz MK, Sutcliffe SB, Clark RM, et al. Analysis of supradiaphragmatic clinical stage I and II Hodgkin's disease treated with radiation alone. *Int J Radiat Oncol Biol Phys* 1992;22(5):859–865.
140. Wasserman TH, Trenkner DA, Fineberg B, et al. Cure of early-stage Hodgkin's disease with subtotal nodal irradiation. *Cancer* 1991;68(6): 1208–1215.
141. Swerdlow AJ, Douglas AJ, Vaughan Hudson G, et al. Risk of second primary cancer after Hodgkin's disease in patients in the British National Lymphoma Investigation: relationships to host factors, histology and stage of Hodgkin's disease, and splenectomy. *Br J Cancer* 1993;68(5):1006–1011.
142. Linet MS, Nyrén O, Gridley G, et al. Risk of cancer following splenectomy. *Int J Cancer* 1996;66(5):611–616.
143. Loftus JP, Nagorney DM, Ilstrup D, et al. Sinistral portal hypertension. Splenectomy or expectant management. *Ann Surg* 1993;217(1):35–40.
144. Lambert CJ Jr, Williamson JW. Splenic artery aneurysm. A rare cause of upper gastrointestinal bleeding. *Am Surg* 1990;56(9):543–545.
145. Keogan MT, et al. Imaging-guided percutaneous biopsy of focal splenic lesions: update on safety and effectiveness. *AJR Am J Roentgenol* 1999; 172(4):933–937.
146. Lishner M, Lang R, Hamlet Y, et al. Fine needle aspiration biopsy in patients with diffusely enlarged spleens. *Acta Cytol* 1996;40(2):196–198.
147. Lee H, Maeda K. Hamartoma of the spleen. *Arch Pathol Lab Med* 2009;133(1):147–

151.
148. Yu RS, Zhang SZ, Hua JM. Imaging findings of splenic hamartoma. *World J Gastroenterol* 2004;10(17):2613–2615.
149. Mackenzie RK, Youngson GG, Mahomed AA. Laparoscopic decapsulation of congenital splenic cysts: a step forward in splenic preservation. *J Pediatr Surg* 2004;39(1):88–90.
150. Atmatzidis K, Papaziogas B, Mirelis C, et al. Splenectomy versus spleen- preserving surgery for splenic echinococcosis. *Dig Surg* 2003;20(6): 527–531.
151. Manouras AJ, Nikolaou CC, Katergiannakis VA, et al. Spleen-sparing surgical treatment for echinococcosis of the spleen. *Br J Surg* 1997;84(8):1162.
152. Alonso Cohen MA, Galera MJ, Ruiz M, et al. Splenic abscess. *World J Surg* 1990;14(4):513–516; discussion 516–517.
153. de Bree E, Tsiftsis D, Christodoulakis M, et al. Splenic abscess: a diagnostic and therapeutic challenge. *Acta Chir Belg* 1998;98(5):199–202.
154. Robinson SL, Saxe JM, Lucas CE, et al. Splenic abscess associated with endocarditis. *Surgery* 1992;112(4):781–786; discussion 786–787.
155. Misawa T, Yoshida K, Shiba H. Wandering spleen with chronic torsion. *Am J Surg* 2008;195(4):504–505.
156. Haj M, Bickel A, Weiss M, et al. Laparoscopic splenopexy of a wandering spleen. *J Laparoendosc Adv Surg Tech A* 1999;9(4):357–360.
157. Corcione F, Caiazzo P, Cuccurullo D, et al. Laparoscopic splenectomy for the treatment of wandering spleen. *Surg Endosc* 2004;18(3):554–546.
158. Nelson EW, Mone MC. Splenectomy in high-risk patients with splenomegaly. *Am J Surg* 1999;178(6):581–586.
159. Letoquart JP, La Gamma A, Kunin N, et al. Splenectomy for splenomegaly exceeding 1000 grams: analysis of 47 patients. *Br J Surg* 1993;80(3): 334–335.
160. Petroianu A, da Silva RG, Simal CJ, et al. Late postoperative follow-up of patients submitted to subtotal splenectomy. *Am Surg* 1997;63(8):735–740.
161. Targarona EM, Espert JJ, Balagué C, et al. Splenomegaly should not be considered a contraindication for laparoscopic splenectomy. *Ann Surg* 1998;228(1):35–39.
162. Rescorla FJ, West KW, Engum SA, et al. Laparoscopic splenic procedures in children: Experience in 231 children. *Ann Surg* 2007;246(4):683–687; discussion 687–688.
163. Borrazzo EC, Daly JM, Morrisey KP, et al. Hand-assisted laparoscopic splenectomy for giant spleens. *Surg Endosc* 2003;17(6):918–920.
164. Kercher KW, Matthews BD, Walsh RM, et al. Laparoscopic splenectomy for massive splenomegaly. *Am J Surg* 2002;183(2):192–196.
165. Terrosu G, Baccarani U, Bresadola V, et al. The impact of splenic weight on laparoscopic splenectomy for splenomegaly. *Surg Endosc* 2002;16(1): 103–107.
166. Machado MA, Makdissi FF, Herman P, et al. Exposure of splenic hilum increases

safety of laparoscopic splenectomy. *Surg Laparosc Endosc Percutan Tech* 2004;14(1):23–25.

167. Grahn SW, Alvarez J III, Kirkwood K. Trends in laparoscopic splenectomy for massive splenomegaly. *Arch Surg* 2006;141(8):755–761; discussion 761–762.
168. Breitenstein S, Scholz T, Schäfer M, et al. Laparoscopic partial splenectomy. *J Am Coll Surg* 2007;204(1):179–181.
169. Altaf AM, Ellsmere J, Jaap Bonjer H, et al. Morbidity of hand-assisted laparoscopic splenectomy compared to conventional laparoscopic splenectomy: a 6-year review. *Can J Surg* 2012;55(4):227–232.
170. Gkegkes ID, Mourtarakos S, Iavazzo C. Single-incision laparoscopic splenectomy. *JSLS* 2014;18(3).
171. Giulianotti PC, Buchs NC, Addeo P, et al. Robot-assisted partial and total splenectomy. *Int J Med Robot* 2011;7(4):482–488.
172. Kaban GK, Czerniach DR, Perugini RA, et al. Use of a laparoscopic hand- assist device for accessory splenectomy. *Surg Endosc* 2004;18(6):1001.
173. Koshenkov VP, Pahuja AK, Németh ZH, et al. Identification of accessory spleens during laparoscopic splenectomy is superior to preoperative computed tomography for detection of accessory spleens. *JSLS* 2012; 16(3):387–391.
174. Rasekhi AR, Naderifar M, Bagheri MH, et al. Radiofrequency ablation of the spleen in patients with thalassemia intermedia: a pilot study. *AJR Am J Roentgenol* 2009;192(5):1425–1429.
175. Jiao LR, Tierris I, Ayav A, et al. A new technique for spleen preservation with radiofrequency. *Surgery* 2006;140(3):464–466.
176. Wu Y, Wan L, Li P, et al. Application of radiofrequency ablation for splenic preservation. *J Surg Res* 2015;193(2):781–787.
177. Lutwick LI. Life threatening infections in the asplenic or hyposplenic individual. *Curr Clin Top Infect Dis* 2002;22:78–96.
178. Cadili A, de Gara C. Complications of splenectomy. *Am J Med* 2008; 121(5):371–375.
179. Hansen K, Singer DB. Asplenic-hyposplenic overwhelming sepsis: postsplenectomy sepsis revisited. *Pediatr Dev Pathol* 2001;4(2):105–121.
180. Lane PA. The spleen in children. *Curr Opin Pediatr* 1995;7(1):36–41.
181. Shatz DV, Romero-Steiner S, Elie CM, et al. Antibody responses in postsplenectomy trauma patients receiving the 23-valent pneumococcal polysaccharide vaccine at 14 versus 28 days postoperatively. *J Trauma* 2002;53(6):1037–1042.
182. Thomsen RW, Schoonen WM, Farkas DK, et al. Risk for hospital contact with infection in patients with splenectomy: a population-based cohort study. *Ann Intern Med* 2009;151(8):546–555.
183. Kyaw MH, Holmes EM, Toolis F, et al. Evaluation of severe infection and survival after splenectomy. *Am J Med* 2006;119(3):276 e1–277 e1.
184. Nakae H, Shimazu T, Miyauchi H, et al. Does splenic preservation treatment

(embolization, splenorrhaphy, and partial splenectomy) improve immunologic function and long-term prognosis after splenic injury? *J Trauma* 2009;67(3):557–563; discussion 563–564.

185. Shatz DV. Vaccination practices among North American trauma surgeons in splenectomy for trauma. *J Trauma* 2002;53(5):950–956.
186. Mourtzoukou EG, Pappas G, Peppas G, et al. Vaccination of asplenic or hyposplenic adults. *Br J Surg* 2008;95(3):273–280.
187. Crary SE, Buchanan GR. Vascular complications after splenectomy for hematologic disorders. *Blood* 2009;114(14):2861–2868.
188. Stamou KM, Toutouzas KG, Kekis PB, et al. Prospective study of the incidence and risk factors of postsplenectomy thrombosis of the portal, mesenteric, and splenic veins. *Arch Surg* 2006;141(7):663–669.
189. Kawanaka H, Akahoshi T, Kinjo N, et al. Impact of antithrombin III concentrates on portal vein thrombosis after splenectomy in patients with liver cirrhosis and hypersplenism. *Ann Surg* 2010;251(1):76–83.
190. Iida H, Aihara T, Ikuta S, et al. Predictive factors of portal vein thrombus following splenectomy in patients with severe cirrhosis. *Hepatogastroenterology* 2014;61(134):1552–1555.
191. Lai W, Lu SC, Li GY, et al. Anticoagulation therapy prevents portal-splenic vein thrombosis after splenectomy with gastroesophageal devascularization. *World J Gastroenterol* 2012;18(26):3443–3450.
192. Ikeda M, Sekimoto M, Takiguchi S, et al. High incidence of thrombosis of the portal venous system after laparoscopic splenectomy: a prospective study with contrast-enhanced CT scan. *Ann Surg* 2005;241(2):208–216.
193. Vecchio R, Cacciola E, Cacciola RR, et al. Portal vein thrombosis after laparoscopic and open splenectomy. *J Laparoendosc Adv Surg Tech A* 2011;21(1):71–75.
194. Mukherjee D, Lidor AO, Chu KM, et al. Postoperative venous thromboembolism rates vary significantly after different types of major abdominal operations. *J Gastrointest Surg* 2008;12(11):2015–2022.
195. Frey MK, Alias S, Winter MP, et al. Splenectomy is modifying the vascular remodeling of thrombosis. *J Am Heart Assoc* 2014;3(1):e000772.
196. Mellemkjoer L, Olsen JH, Linet MS, et al. Cancer risk after splenectomy. *Cancer* 1995;75(2):577–583.

SECTION K: SURGICAL ENDOCRINOLOGY

Chapter 74

Breast Disease

Thanh U. Barbie and William E. Gillanders

Key Points

1 Any clinically suspicious mass, even in the absence of an imaging abnormality, needs to be biopsied as up to 15% of breast cancers are mammographically occult.

2 Core needle biopsy is the preferred strategy for breast cancer diagnosis. Core needle biopsy is less invasive and less expensive than excisional biopsy and facilitates definitive breast cancer treatment planning.

3 The upgrade of lobular neoplasias diagnosed on core biopsy at time of surgical excision to malignancy is 1% to 3% and as such surgical excisional biopsy is no longer indicated.

4 All expert groups in North America agree that screening mammography should be performed in women 50 years of age and older. However, differences exist about whether screening should be performed between ages 40 and 49.

5 Surgical options for the treatment of DCIS include breast-conserving surgery as a component of breast conservation therapy (partial mastectomy and postoperative radiation therapy) or simple mastectomy.

6 Sentinel lymph node biopsy has replaced axillary lymph node dissection for axillary staging, and the therapeutic impact of axillary lymph node dissection may be limited to specific subsets of breast cancer patients.

7 Local regional management of invasive breast cancer consists of breast conservation therapy (partial mastectomy with radiation therapy) or mastectomy, noting that the choice in locoregional management does not typically impact the recommendation for adjuvant medical therapy.

8 Among patients undergoing partial mastectomy, performing cavity shaving halved the rates of positive margins and reexcision.

9 A negative surgical margin for invasive breast cancer is now defined as no tumor at the ink margin. Given the potential for gaps between lesions in DCIS, a negative surgical margin is still defined as ≥ 2 mm, understanding that this practice may evolve pending more study results.

10 Nipple sparing mastectomy is a safe option for BRCA mutation carriers, with no local regional recurrences at up to 37 months of follow up.

11 Axillary radiation therapy may result in less morbidity than axillary lymph node

dissection in patients with early stage breast cancer with clinically negative axillary examinations who have ≤ 2 positive sentinel lymph nodes.

ANATOMY

Surgical Anatomy of the Breast

The boundaries of the mature adult breast are the second rib superiorly, the sixth rib inferiorly, the sternal edge medially, and the midaxillary line laterally. Breast tissue also extends into the axilla. Posteriorly, the breast lies on top of portions of the deep investing fasciae of the pectoralis major muscle, the serratus anterior muscle, the external abdominal oblique muscles, and the upper extent of the rectus sheath (Fig. 74-1). The breast is composed of skin, subcutaneous tissue, and breast parenchyma. The skin overlying the breast is thin and contains hair follicles, sebaceous glands, and exocrine sweat glands. The subcutaneous tissue is composed of fat, vasculature supplying the skin, lymphatics, and nerves. The breast parenchyma consists of parenchymal components and stroma.

Breast tissue is located within the superficial fascia of the anterior thoracic wall and consists of 15 to 20 lobes of glandular tissue that are divided by connective tissue with adipose tissue filling the space between the lobes (Fig. 74-2). Each lobe is composed of 20 to 40 lobules, which are themselves composed of 10 to 100 alveoli. Each lobe ends in a lactiferous duct that dilates into lactiferous sinuses, which then open through constricted orifices into the nipple. The suspensory ligaments of Cooper are fibrous connective bands that extend from the deep fascia to connect to the dermis, providing the breast with both support and mobility. There is significant variation in breast size with the average nonlactating breast weighing between 150 and 225 g, whereas the lactating breast may exceed 500 g.[1] The left breast is commonly slightly larger than the right.[2] The upper outer quadrant of the breast contains more breast parenchyma and is the most frequent site of both benign and malignant breast diseases.

The skin of the nipple and the areola is highly pigmented and somewhat wrinkled, composed of stratified squamous epithelium. Deep to the nipple and the areola are bundles of smooth muscle fibers that are arranged radially, circumferentially, and longitudinally, allowing for erection of the nipple from stimuli. Along the margin of the areola are sebaceous glands and sweat glands. Accessory glands known as Montgomery glands have nodular elevations (tubercles of Morgagni) that open onto the surface of the areola. The nipple and the areola are highly innervated, with the nipple containing numerous free sensory nerve endings and Meissner's corpuscles, whereas the areola contains both Ruffini-like endings and Krause-end bulbs.[3] The sensory innervation of the breast is mainly the lateral and anterior cutaneous branches of the second through sixth intercostal nerves. There is also a small region of skin over the upper portion of the breast that is supplied by the anterior or medial branches of the supraclavicular nerve that arises from the cervical plexus.

The arterial blood supply to the breast consists of the internal mammary artery (perforating branches), the posterior intercostal artery (lateral branches), and several branches of the axillary artery including the superior thoracic artery, the lateral thoracic artery, and the pectoral branches of the thoracoacromial artery. The breast's venous

system parallels its arterial system, consisting of the internal mammary veins, the posterior intercostal veins, and the axillary vein tributaries.[4]

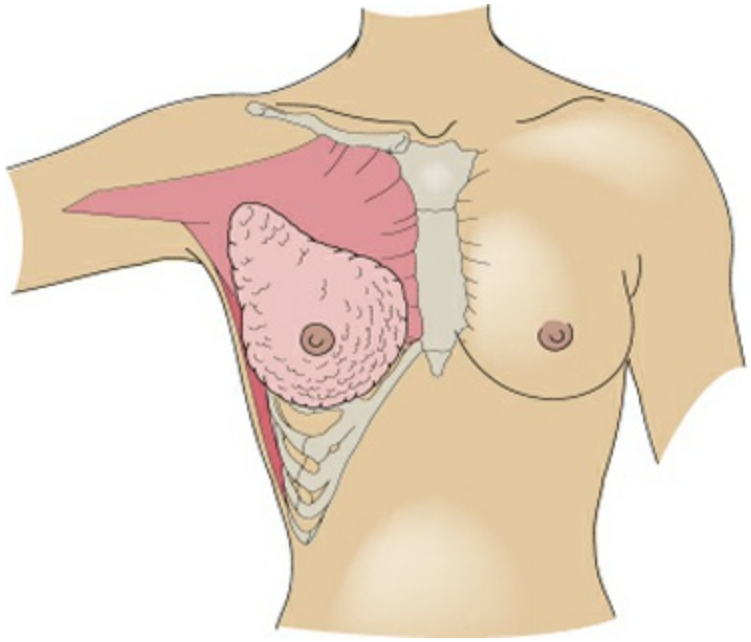

Figure 74-1. The adult female breast. The upper and medial portions of the breast rest on the pectoralis major muscle, and the inferolateral portion rests on the serratus anterior.

Lymphatic Drainage

The lymphatic flow from the breast is unidirectional through thin-walled, valveless vessels that are interconnected through three groups. The primary group of lymphatic vessels comes from within the gland in the interlobular spaces and along the lactiferous ducts. The lymphatic vessels that drain the skin, nipple/areola, and the central portion of the gland constitute the subareolar plexus. The third plexus is on the deep surface of the breast and communicates with small vessels in the deep fascia underlying the breast. More than 75% of the lymph from the breast passes to the axillary lymph nodes, whereas the remainder passes to parasternal nodes. The flow of lymph to either the axillary or the parasternal nodes is independent of the quadrant from where the lymph originated.[5] Occasionally, lymph flow can be found outside of these three interconnected plexuses, occurring along the lateral cutaneous branches of the posterior intercostal arteries, within the rectus sheath or subperitoneal plexus by following branches of the intercostal and musculophrenic vessels, or directly to subclavicular or apical nodes.[6]

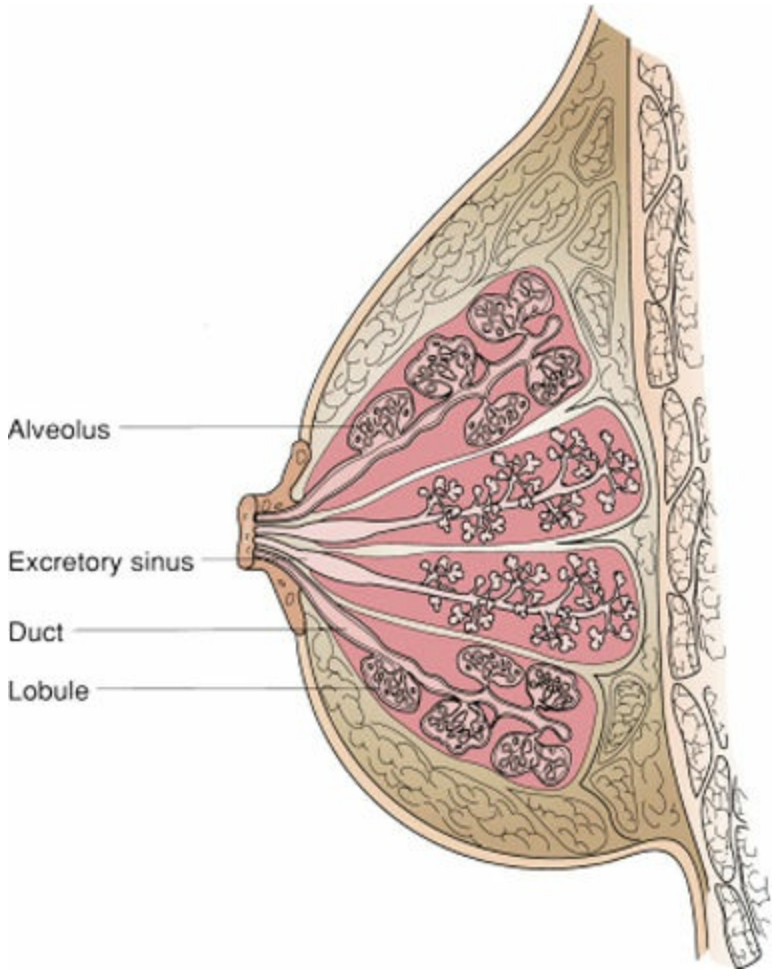

Figure 74-2. The breast consists of 15 to 20 lobes of glandular tissue. Within each lobe, the lobules are composed of branched tubuloalveolar glands. Each lobule ends in a lactiferous duct. These ducts dilate into lactiferous sinuses beneath the nipple.

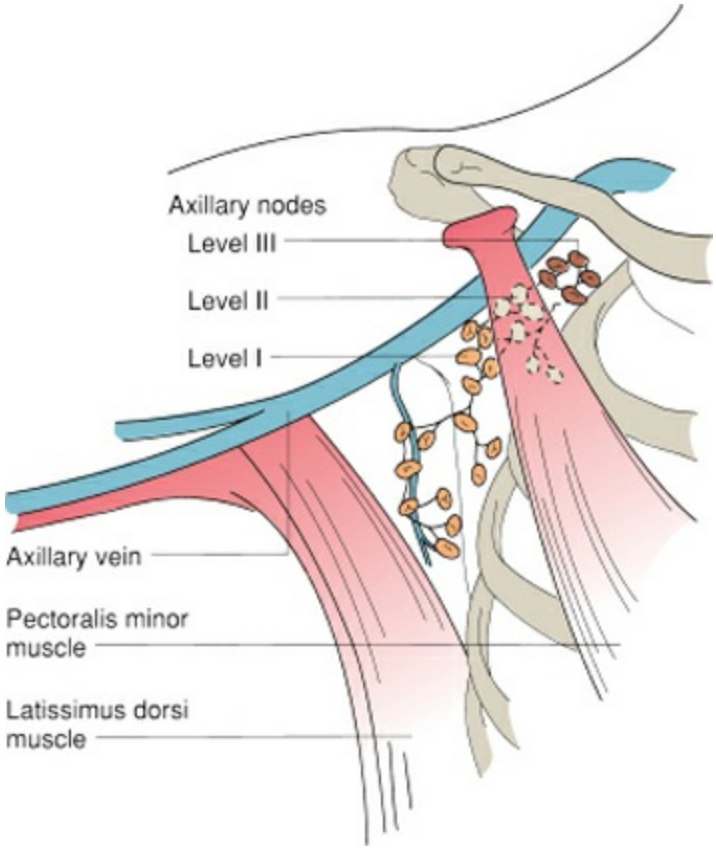

Figure 74-3. The axillary lymph nodes are divided into three levels by the pectoralis minor muscle. The level I nodes are inferior and lateral to the pectoralis minor, the level II nodes are below the axillary vein and behind the pectoralis minor, and the level III nodes are medial to the muscle against the chest wall.

The axilla is a pyramidal compartment between the upper extremity and the thoracic walls, which can be thought of as consisting of four walls, an apex, and a base. The anterior wall consists of the pectoralis major/minor and its associated fasciae. The subscapularis muscle, teres major muscle, latissimus dorsi muscle, and associated tendons form the posterior wall. The medial wall consists of the serratus anterior muscle and associated intercostal muscles of the upper four or five ribs. A thin strip of the humerus and the bicipital groove, which is between the insertion of the muscles of the anterior and posterior walls, forms the lateral wall. The apex is an aperture that extends into the posterior triangle of the neck through the cervicoaxillary canal, which is bounded by the clavicle anteriorly, the scapula posteriorly, and the first rib medially. The base of the axilla is the axillary fascia and the skin.[6]

The axillary lymph nodes have traditionally been divided into three levels, corresponding to their location relative to the pectoralis minor (Fig. 74-3). Level 1 nodes (external mammary, axillary vein, and scapular lymph node groups) are inferior and lateral to the pectoralis minor; level 2 nodes (central lymph node and some subclavicular lymph node groups) are behind the pectoralis minor; and level 3 nodes (subclavicular lymph node group) are medial to the pectoralis minor. The interpectoral nodes (Rotter nodes) are located between the pectoralis major and minor muscles along the lateral pectoral nerve. The supraclavicular nodes are contiguous with the apex of the axilla. The internal mammary nodes are located in the first six intercostal spaces within 3 cm of the edge of the sternum, with the highest concentration of nodes found in the first three

intercostal spaces.[7,8]

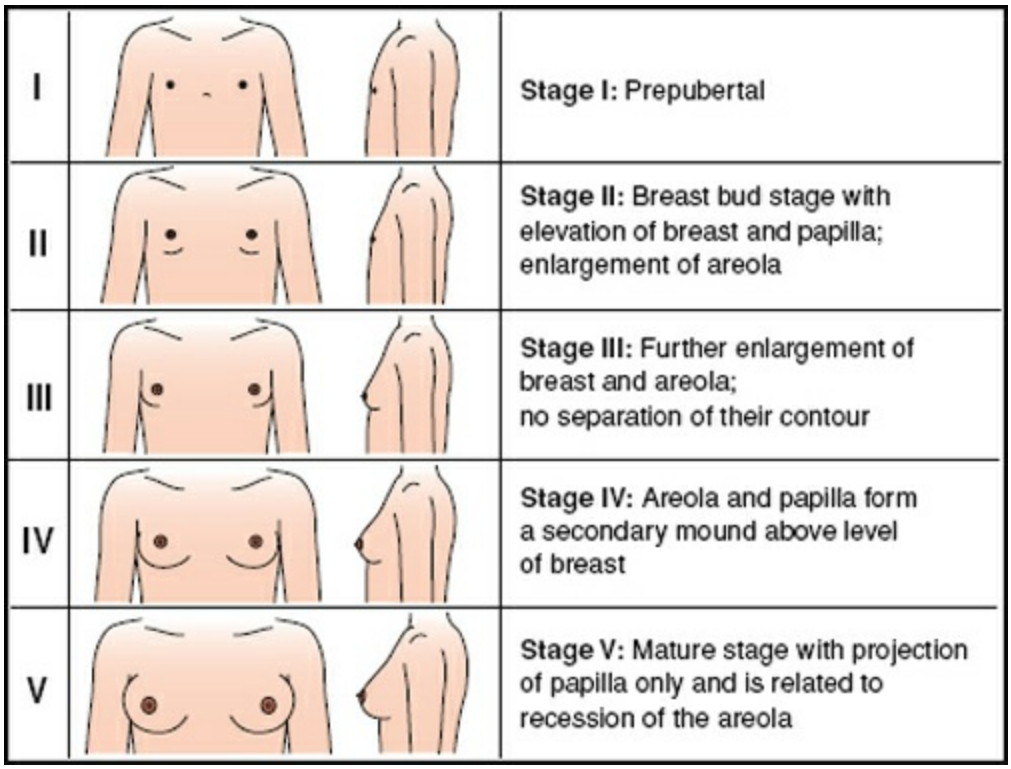

Figure 74-4. Tanner stages of breast development.

BREAST PHYSIOLOGY

Breast Development

As epidermal appendages, mammary glands likely evolved from ancient apocrine glands that were associated with hair follicles.[9] The mammary gland is a complex secretory organ consisting of multiple different cell types. Epithelial cells form the ductal network of the gland, which is embedded within a fat pad composed of adipocytes. In addition, there are vascular endothelial cells that make up the blood vessels, stromal cells including fibroblasts, and immune cells. During the three stages of mammary development (embryonic, pubertal, and pregnancy/lactation), these cells undergo an intricate series of changes under the regulation of hormones and regulatory factors, resulting in permanent changes to the mammary gland that both modify its architecture and biologic characteristics.[10] Understanding breast development and morphology is extremely important to the study of both premalignant and malignant conditions.

In humans, mammary gland development starts in the sixth week of fetal life with the formation of bilateral milk lines or ectodermal thickenings that extend from the axilla to the groin. These ridges rapidly regress except for those of the thorax, where invagination of ectoderm cells into the mesenchyme results in mammary bud formation. In the human embryo, at about 5 months, the deep layer of the mammary bud epithelium starts to proliferate and produces about 10 to 25 secondary buds, which will later correspond to lactiferous ducts. Canalization, or the formation of lumens within the solid core of these epithelial structures, occurs later in development. By birth, six to eight of these ducts are patent and empty into the nipple.[11–15] A parallel bundle of an additional 25 smaller ducts also appear and are the precursors to the milk-producing units of the breast.[16] The subareolar lymphatic plexus also develops from the ectoderm in a similar fashion,[17] while the nipple forms from the proliferation of the mesenchyme under the areola.[14]

In infants, only small ductal structures are seen within the stroma and during childhood, these structures continue to grow isometrically at a rate similar to the rest of the body until puberty.[18] These initial stages of breast development are not dependent on sex steroids but are likely governed by numerous growth factors that regulate the epithelial-mesenchymal interaction, including Lef-1,[19] parathyroid hormone-related protein, and the type 1 parathyroid hormone/parathyroid hormone-related protein receptor.[20]

During puberty, the female glands enlarge rapidly secondary to maturation of the ductal system into a lobuloalveolar system. This is characterized by thickening of the ductal epithelium, elongating ducts, and an increasing amount of periductal connective tissue. In addition, stem cells at the tips of the ductal tree form terminal end buds, which are highly proliferative and give rise to alveolar buds. In early puberty, these alveolar buds empty into a terminal ductal lobular unit and are referred to as lobules type 1. Under the influence of ovarian hormones (estrogen and progesterone), lobules type 1 will differentiate into lobules type 2, which are characterized by smaller but more numerous buds that are noted as ductules or alveoli. It has been postulated that each menstrual

cycle fosters new budding that never fully returns to the baseline of the prior cycle.[21,22] In addition to estrogen and progesterone, pubertal breast development is also dependent on other hormones and regulatory factors including prolactin, growth hormone, glucocorticoids, growth factors (hepatocyte growth factor, IGF-1, IGF-2, FGF, neuregulins especially heregulin), vitamin D receptor, metalloproteinases, and PTEN.[23–28]

As these developmental events are occurring, physical changes in the breast contour and the appearance of the nipple become evident and are illustrated as the five Tanner stages of breast development (Fig. 74-4).[29]

Menstrual Cycle

During a 28-day menstrual cycle, the mammary gland undergoes five histologic phases described by Vogel: proliferative (days 3 to 7), follicular phase of differentiation (days 8 to 14), luteal phase of differentiation (days 15 to 20), secretory (days 21 to 27), and then menstrual (days 28 to 2). The first phase starts with the proliferation of the mammary epithelium and is characterized by mitotic figures, a predominant eosinophilic cell type, dense stroma, and tight lumen. During the follicular phase, the epithelial cells start to differentiate with the appearance of multiple cellular types (luminal columnar basophilic, intermediate pale cells, and basal clear cells with hyperchromatic nucleus or myoepithelial cells). In the luteal phase, the prior dense stroma starts to loosen and the lumen starts to open with secretions. Also, the basal clear cells have prominent vacuolization, consistent with the known effects of progesterone on the glycogen content of cultured endometrial epithelium.[30] The secretory phase is notable for active apocrine secretion from luminal cells and an edematous stroma. During the menstrual phase, the stroma returns to a dense and cellular form, the lumen distends with secretions, and the basal cells have extensive vacuolization.[31] These five phases depict the morphologic changes that occur in the breast from normal ovarian hormone cycling during menses, further supporting the notion that the mammary gland is not a resting gland but one that is dynamic.

Pregnancy and Lactation

Although the pubertal phase is marked by significant lobular development, the mammary gland does not achieve full differentiation until after pregnancy and lactation. In early pregnancy, the distal ducts continue to proliferate, resulting in more lobules and more alveoli within each lobule. However, by midpregnancy, proliferation of the lobules ceases and instead alveolar cells begin to differentiate into acini by hypertrophy and the ability to secrete colostrum into the lumina of the ductules. By the third trimester, the acini become distended with colostrum and the breast's connective tissue and fat become largely replaced by glandular proliferation. In addition, the connective tissue becomes infiltrated with plasma cells, lymphocytes, and eosinophils. There is also a marked increase in vascularity. The stage of lactogenesis or the ability to synthesize and secrete milk marks the final stage of maturation of the mammary gland (lobule type 4).[32,33] Following lactation or during weaning, the mammary gland involutes with lobules type 4 returning to the prepregnancy state as lobules type 2 and 3.[34,35]

The hormones and regulatory factors that govern mammary development during pregnancy and lactation overlap with those previously discussed for pubertal breast development, with estrogen, progesterone, and prolactin playing chief roles. Other hormones and regulatory factors include intracellular signaling molecules (c-erbB, hox genes, cell–cell adhesion molecules such as E-cadherin, cell cycle protein cyclin D1, RANK-L, slug transcription factor), activins and inhibins including STAT5, hypothalamic peptides, thyrotropic-releasing hormone, and lactogenic hormones.[36–43]

Menopause

By menopause, the mammary gland is mainly replaced by fat as the glandular epithelium undergoes apoptosis. As such, the postmenopausal phase is characterized by a decrease in lobules and ducts.[44,45]

In summary, human breast development is a progressive process that is initiated during embryonic life, with glandular maturation starting at puberty, and attainment of full breast differentiation only with subsequent pregnancy and lactation.

CLINICAL EVALUATION OF THE PATIENT WITH BREAST DISEASE

Breast disease is an extremely common clinical problem. Most women who present to a breast health specialist will have benign breast disease. One of the primary goals of the evaluation is to determine whether the breast problem represents benign or malignant breast disease. With benign conditions, the goals are to reassure the patient and if indicated, provide symptomatic treatment. With a malignant condition, prompt evaluation and treatment should be undertaken, typically involving a multidisciplinary team including a breast surgeon, medical oncologist, and radiation oncologist. In this section, the tools that a clinician uses to evaluate patients with breast disease are discussed including the history, clinical breast examination (CBE), diagnostic imaging studies, and biopsy procedures.

DIAGNOSIS

Table 74-1 Medical History of a Breast Problem

General
Age at menarche
Number of pregnancies
Number of live births
Age at first birth
Family history of ovarian cancer, gynecologic cancers, and other cancers, including affected relative, age of onset, and presence of bilateral disease
History of breast biopsies (and histologic diagnosis, if available)
Premenopausal women
Date of last menstrual period Length and regularity of cycles Use of oral contraceptives
Postmenopausal women
Date of menopause Use of hormone replacement therapy
Specific
Onset
Duration
Frequency
Severity
Relationship to menstrual cycle or use of hormone replacement therapy

As the first step in the evaluation of a breast problem, it is important to elicit a relevant history. This includes the specific history related to the presenting breast problem, as well as a more general history focused on assessing breast cancer risk. This includes age at

menarche, number of pregnancies, number of live births, and age at first live birth. Family history and history of breast biopsy should also be elicited. Menopausal status (for premenopausal patients, the time in their menstrual cycle) and the use of any hormonal therapies should be assessed (Table 74-1).

Clinical Breast Examination

CBE is performed in both the sitting and supine positions (Fig. 74-5). The patient is disrobed from the waist up and then provided a front-opening gown. Visual inspection is first accomplished with the patient sitting upright with the arms relaxed to her side. The bilateral breasts are compared for size and shape. It is normal to find slight differences in breast size, with the left breast often slightly bigger than the right. Breast shape is also contrasted. Recent changes to breast size or alterations in breast shape can be concerning signs and need to be evaluated by the provider, as tumors located superficially can cause changes to the breast contour. The skin of the breasts is inspected for dimpling, edema (peau d'orange), and/or erythema. In cases of significant erythema and peau d'orange, the provider needs to consider the diagnosis of an inflammatory breast cancer (IBC) versus an infectious etiology. This is followed by close inspection of the nipples for symmetry. Although some women have a lifelong history of nipple inversion, any new history of nipple inversion needs to be regarded with a high index of suspicion. Next, the nipple–areola complex is evaluated for any eczematous changes or ulcerations (to suggest conditions such as Paget disease of the breast [PDB]). The patient is then asked to raise her arms to allow for a more complete visual inspection of the lower aspect of the breasts bilaterally. The visual examination is completed when the patient is asked to place her hands on the hips and then to contract the pectoral muscles. This allows for a final visual assessment of breast symmetry. Furthermore, tumors deep within the substance of the breast involving Cooper's ligaments can result in skin retraction and can sometimes be seen best with contraction of the pectoral muscles.



Figure 74-5. Breast examination. **A:** The patient's ipsilateral arm is supported by the examiner to relax the pectoral muscle while the axillary nodes are examined. **B:** Bimanual examination of the breast in the upright position. **C:** Bimanual examination in the supine position with the arm raised over the head.

With the patient remaining in the sitting position but now with the pectoral muscles relaxed, palpation of the regional lymph nodes of the neck, clavicles (infraclavicular and supraclavicular), and axilla is then performed. To best delineate the axillary lymph nodes, the patient should be examined with the ipsilateral arm supported. Attention is paid to evaluate the size, consistency (soft or firm), and characteristics (mobile or matted, tender or nontender) of the lymph nodes. Bimanual palpation of the breasts for masses and asymmetry completes the sitting examination.

The patient is then placed in the supine position with the ipsilateral arm raised above the head and the contralateral breast covered with the gown. The breast tissue is carefully palpated to evaluate for masses and asymmetry. It must be noted that generalized lumpiness is not a pathologic finding, with most normal breasts having more nodularity in the upper outer quadrants, at the inframammary ridge, and in the subareolar region. Comparing the breasts for symmetry by palpation may help discriminate benign findings from those that require additional evaluation. The area examined extends from the clavicle to the lower rib cage and medially from the sternal border to the midaxillary

line. In addition, the axillary tail of the breast should be carefully palpated. The three search patterns that have been described are concentric circles, radial spoke method, and the vertical strip pattern (Fig. 74-6). As the first two methods can result in a less than thorough examination of the nipple–areola complex, we prefer the vertical strip pattern as it incorporates this area. Otherwise, with the other two search patterns, a separate examination of the nipple–areola complex needs to be performed.

Diagnostic Mammography and Breast Ultrasound

1A woman who has an indeterminate or abnormal CBE will typically benefit from a diagnostic imaging evaluation, which can include targeted ultrasound, mammography, and/or MRI. It is important to note that any clinically suspicious mass, even in the absence of an imaging abnormality, needs to be biopsied as up to 15% of breast cancers are mammographically occult.[46]

Soft tissue densities and clustered microcalcifications are two common mammographic findings suggestive of breast cancer. Soft tissue densities can appear as well-defined round/oval/lobulated masses, spiculated masses, irregular masses, or as areas of architectural distortion without an obvious mass (Fig. 74-7). Nearly 90% of spiculated soft tissue masses are associated with invasive cancer whereas well-defined solid masses are rarely predictive of malignancy. Microcalcifications can have benign or malignant features, with benign calcifications often appearing rim-like, large, coarse, smooth, round, and/or oval in appearance. Calcifications that are associated with malignancy tend to be smaller in size, ranging between 0.1 and 1 mm in diameter. They are typically clustered, numbering 4 to 5/ cm^3. Histologically, these represent intraductal calcifications in areas of necrotic tumor or calcifications within mucin-secreting tumors. In addition, malignant microcalcifications can often appear in a granular or linear branching pattern, with the linear branching pattern being highly associated with malignancy (Fig. 74-8).

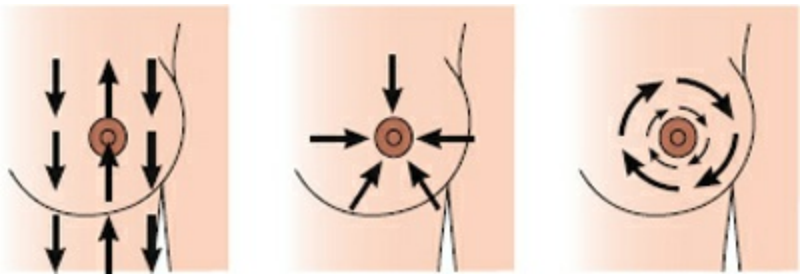

Figure 74-6. Clinical breast examination search patterns: vertical strip, radial spoke, and concentric circles.

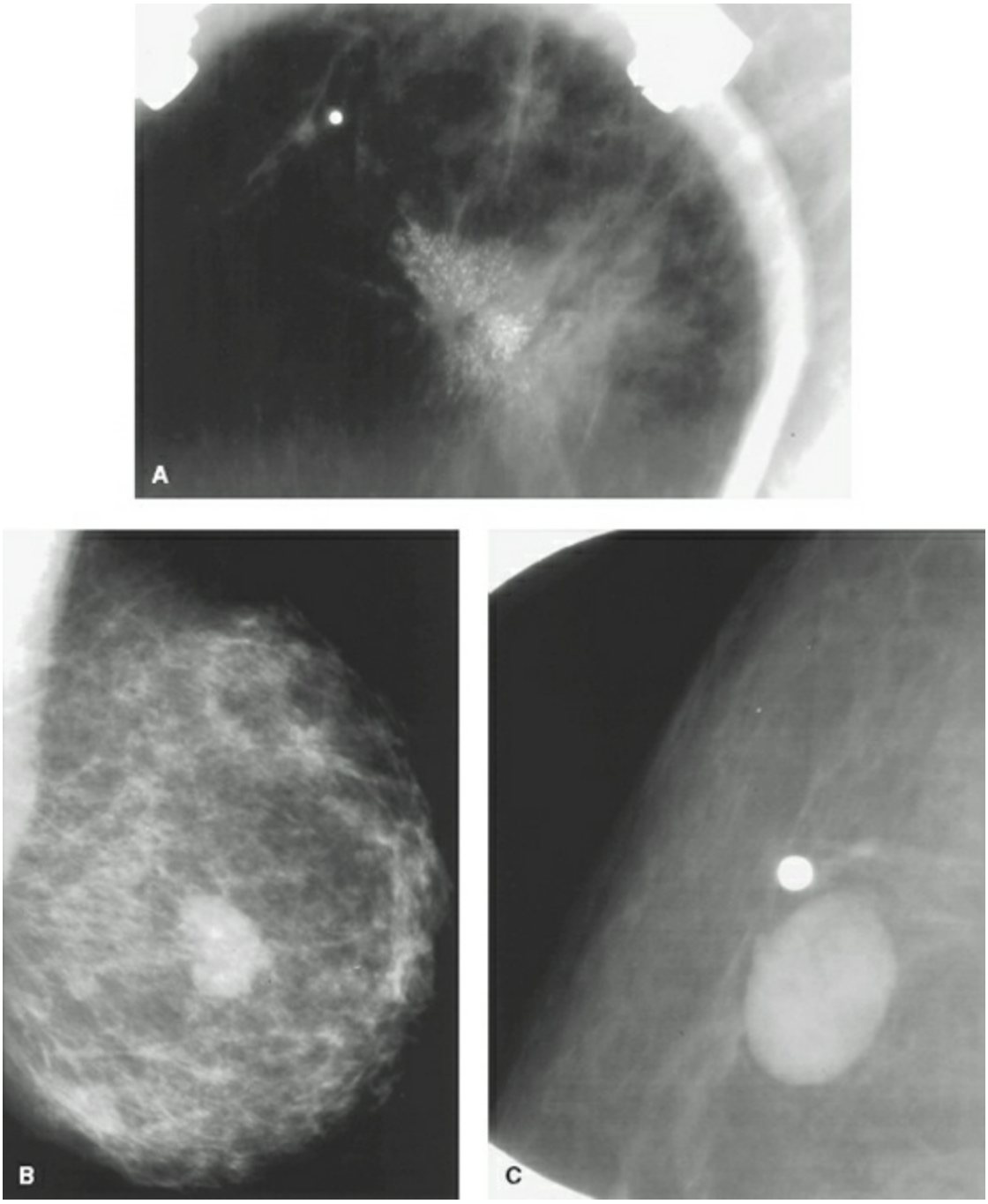

Figure 74-7. Mammographic masses. **A:** Spiculated mass with calcifications. **B:** Lobulated mass with indistinct posterior margin. **C:** Well-circumscribed mass.

Breast ultrasound is another important diagnostic imaging modality for the evaluation of breast masses and/or mammographic abnormalities. Breast ultrasound is complementary to mammography and is particularly valuable for the evaluation of breast masses. Breast ultrasound can increase the sensitivity and specificity of mammography for detection of breast cancer.[47] Ultrasound can differentiate a cystic mass from a solid one, characterize a palpable lesion that is not seen on mammography, and can assist with determining the actual size of a lesion. Ultrasonographic features that are used to characterize a lesion include shape (oval, round, lobular, irregular); margin (circumscribed, obscured, microlobulated, ill-defined, speculated); orientation (parallel or not parallel to skin); matrix echogenicity (anechoic, hypoechoic, hyperechoic); homogeneity (homogeneous, heterogeneous); and attenuation (indifferent, shadowing,

enhancement).

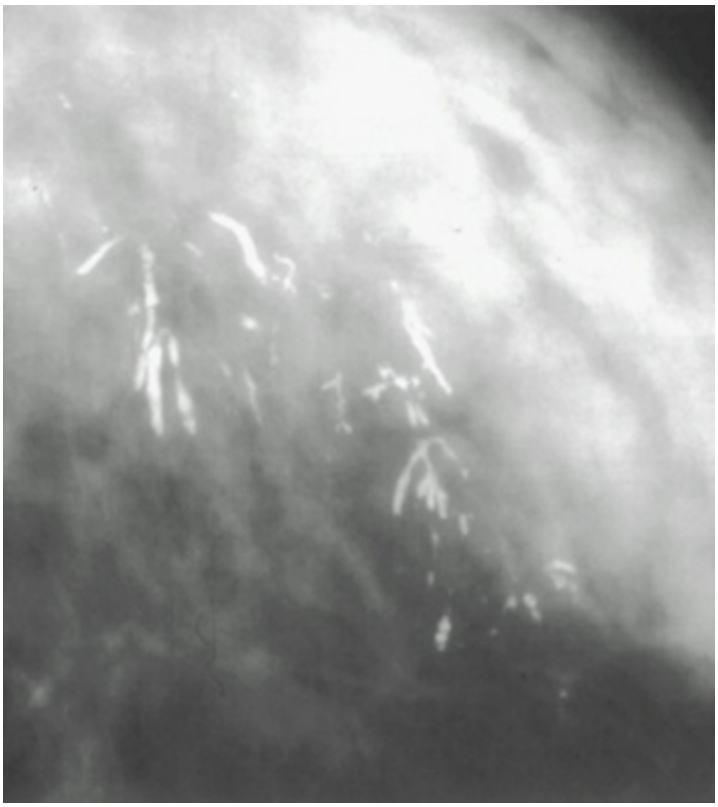

Figure 74-8. Microcalcifications. The branching, irregular appearance is classic for ductal carcinoma in situ.

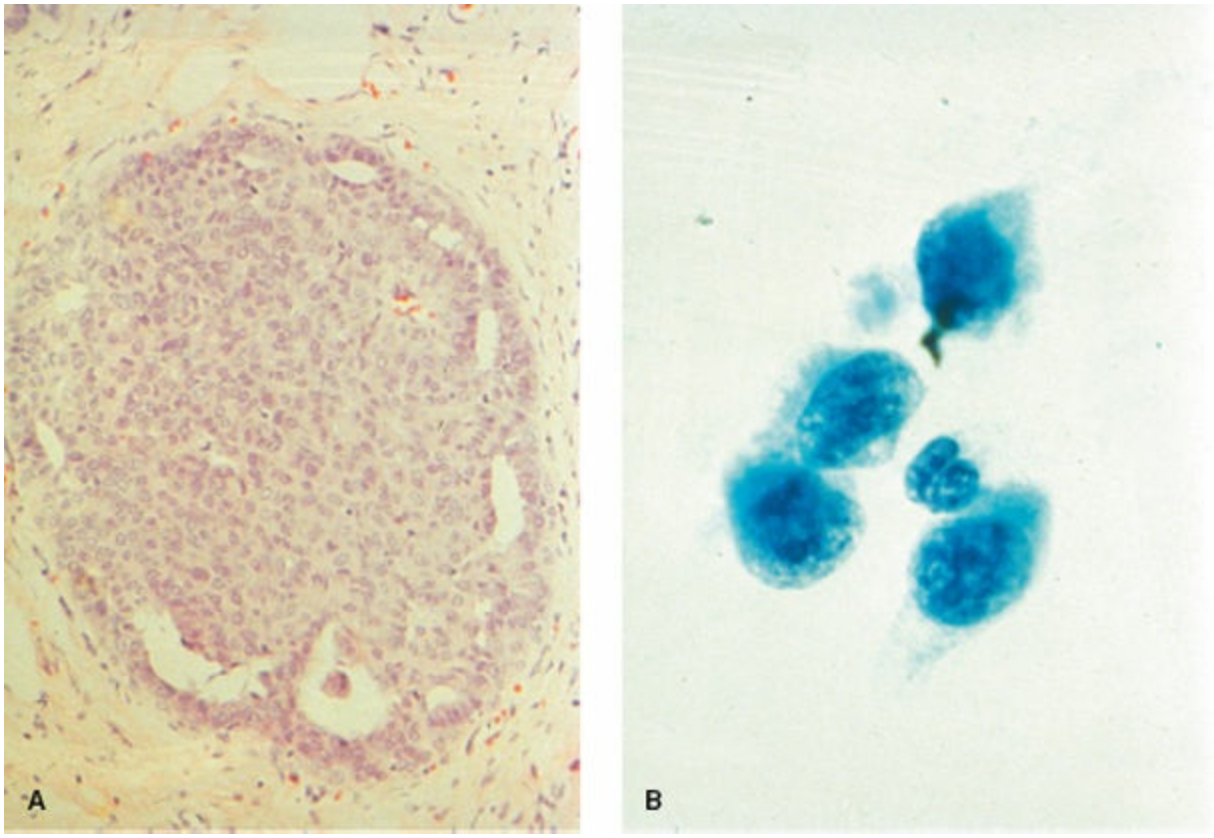

Figure 74-9. Comparison of core needle biopsy specimen **(A)** and fineneedle aspiration specimen **(B)**. Only the core specimen can demonstrate the architectural detail.

Diagnostic MRI

Gadolinium contrast-enhanced MRI is complementary to mammography and breast ultrasound. It is not typically used for the evaluation of benign breast masses but does have a high sensitivity for detection of breast cancer. As such, MRI is most commonly used to evaluate extent of disease and exclude occult breast cancers in patients with newly diagnosed breast cancer. In a meta-analysis of 44 studies, the sensitivity and specificity of diagnostic breast MRI was determined to be 90% and 72%, respectively.[48] The role of MRI in the evaluation of patients with newly diagnosed breast cancer is discussed in the section on Evaluation of the Patient with Breast Cancer.

Biopsy Procedures

Breast biopsy is one of the most common general surgery procedures performed in the United States. There are multiple different types of breast biopsy ranging from fine needle aspiration (FNA) biopsy to excisional biopsy. The different types of breast biopsy are discussed later.

Fine Needle Aspiration

FNA of the breast is the least invasive breast biopsy procedure. FNA can be used for both diagnosis and treatment and can be performed using palpation or image guidance. During FNA cells or fluids are removed from the breast using a small gauge needle (20 to 25 gauge). FNA is commonly used to sample suspicious breast and axillary lesions especially those that are palpable. Other indications include drainage of simple cysts and small abscesses. The patient is placed in the supine position on the examination table at a 30-degree angle with the arm of the involved side above the head. When lesions are lateral or in the axilla, the patient is positioned in the lateral decubitus position. Inframammary lesions may require an assistant to help retract the breast. For ultrasound guidance, the probe is positioned directly over the area of interest. As an example, for a breast cyst, the probe would be placed directly over the cyst with the cyst located at the side of the probe; this way the shortest distance to the cyst is shown. Prior to aspiration, the cyst is thoroughly scanned in all planes for septa or loculations to facilitate complete aspiration. The skin is then prepped with an antiseptic solution and further scanning is performed in a sterile fashion. With the nondominant hand steadying the cyst, 1 to 2 mL of 1% lidocaine is injected into the skin. A 20-gauge needle with a 5 or 10 mL syringe is inserted in a plane parallel to the chest wall directly toward the center of the cyst. The plunger is then slowly retracted to create a vacuum to aspirate the cyst contents. For palpable lesions not requiring ultrasound guidance, aspiration can be performed in a similar fashion. The aspiration site can be dressed with an adhesive bandage. If there is bleeding, pressure is applied for 15 minutes. Other potential complications include infection and failure to adequately sample the area of concern. In institutions with experienced cytopathologists, diagnostic FNA has a reported sensitivity of 98% and a specificity of 97%.[49] However, as the tissue architecture cannot be evaluated by FNA, the diagnosis of invasive cancer cannot be made. In the past, FNA was commonly used to sample palpable breast masses as part of the Triple Test for evaluation of palpable masses. Currently, ultrasound can more accurately assess these lesions and low suspicion lesions are followed with serial imaging. High suspicion lesions are best sampled by core needle biopsy to allow assessment of tissue architecture (Fig. 74-9).

Core Needle Biopsy

2 Core needle biopsy is also a minimally invasive strategy for breast biopsy. Given the limitations of FNA, core needle biopsy allows for more tissue to be sampled, permitting a histologic diagnosis, and offering the ability to discriminate between invasive and noninvasive breast cancer. Core needle biopsy can be performed by palpation, but

ultrasound-guided core needle biopsy typically offers superior results. Ultrasound imaging and patient preparation are similar to that described for patients undergoing FNA. The skin and planned needle tract are anesthetized with lidocaine, and a small stab incision is made with a No. 11 blade prior to needle entry. A common core biopsy device consists of a hollow 14-gauge needle (range: 18-gauge to 11-gauge) with a spring firing mechanism. More advanced devices have vacuum assistance and an automated firing mechanism. Under ultrasound guidance, the tip of the needle is guided toward the lesion, often to its edge as the needle excursion is typically approximately 2 cm. Advancing the needle beyond the abnormality can result in sampling error and/or injury to the chest wall. The device is then fired and the needle is withdrawn, with the resultant “tissue core” placed into formalin. Three tissue cores are obtained to ensure adequate sampling of the abnormality. A clip is then deployed under ultrasound guidance to mark the biopsy site for future reference. For palpable masses, the procedure can be performed without ultrasound guidance. The nondominant hand is used to steady the mass and is positioned perpendicular to the entry point of the needle device to avoid inadvertent needle stick injury.

For nonpalpable lesions that cannot be imaged by ultrasound but are present on mammography (most commonly microcalcifications), stereotactic core biopsy can be performed. Stereotactic techniques use the principle of triangulation, which allows the precise location of a breast lesion to be determined in three dimensions.[50] The patient can be upright or prone depending on the machine. More commonly, the patient is placed in the prone position on the stereotactic table, which has an opening for the breast. A mammography unit is attached beneath the table and compresses the dependent breast. An initial scout image is obtained perpendicular to the compressed breast and evaluated. The skin overlying the area of interest is then prepped and anesthetized with lidocaine injected in the skin and along the planned needle path. Using a No. 11 blade, a small stab incision is made. The needle is then advanced through the skin puncture site and toward the center of the lesion on the basis of the computed calculations. The needle is advanced to the leading edge of the lesion and its position is verified by imaging. Following biopsy, repeat images are obtained to ensure that the area of concern has been adequately biopsied. The procedure may be repeated to obtain additional cores. Most stereotactic core biopsies are performed with vacuum assistance allowing for greater accuracy. If suspicious microcalcifications are biopsied, the samples can be examined with specimen imaging to ensure the presence of microcalcifications within the biopsy samples. At the completion of the procedure, manual compression is used to obtain hemostasis, and the skin nick is closed with adhesive strips with a transparent medical dressing. An ice pack and compression dressing can also be used.

Failure to obtain an adequate sample can result in a false-negative test result, although the false-negative rate is very low. In some instances, the results of the core biopsy may not be definitive and a surgical excision is required. If the core biopsy demonstrates a concerning lesion, surgical biopsy is required to exclude a diagnosis of malignancy. In the clinical context of persistent suspicious physical examination or imaging abnormalities

(discordance between clinical and/or imaging findings and pathology results), surgical excision is required. Please see Table 74-2 for indications for surgical excision after core biopsy.

Incisional Biopsy

Incisional biopsy typically involves surgical removal of part of a large mass for diagnosis. With the advent of core needle biopsy techniques, incisional biopsy is rarely required. However, if a core needle biopsy is nondiagnostic and the mass is too large to remove without significant cosmetic compromise, an incisional biopsy can be performed for definitive diagnosis.

Table 74-2 Indications for Surgical Biopsy After Core Biopsy

Atypical ductal hyperplasia
Radial scar
Columnar cell hyperplasia with atypia
Papillary lesions
Lack of concordance between appearance of mammographic lesion and histologic diagnosis
Nondiagnostic specimen (including absence of calcifications on specimen radiograph when biopsy is performed for calcifications)

Excisional Biopsy

Excisional biopsy of the breast is the surgical removal of a breast lesion. Although core needle biopsy has largely obviated the need for excisional biopsy for diagnostic considerations, indications for this procedure still remain. Indications include breast lesions that are presumed to be benign but require excision, discordance between clinical evaluation/diagnostic imaging and pathology requiring further tissue sampling, high-risk lesions (including atypical ductal hyperplasia, radial scar, and papilloma) identified on core biopsy, abnormalities that are close to the nipple or chest wall, small breasts that are not amenable to core biopsy (given the needle excursion is often 2 cm), and for patients who cannot tolerate stereotactic core needle biopsy. In addition, excisional biopsy may be considered for complex cysts, aspirated cysts that do not completely resolve, and when follow-up imaging for a lesion with previous benign pathology from a core biopsy shows an increase in size or has suspicious changes. Excisional biopsies may also be performed for likely benign lesions that are greater than 2 cm, painful, or recurring, or where the mass represents growing cysts or fibroadenomas. Patient preference for complete removal of a benign lesion may also be an indication for excisional biopsy.

For nonpalpable lesions, the abnormality can be localized preoperatively using a needle localization wire that is placed with the patient in a sitting position with the breast compressed by a labeled grid plate. Various needles used include the Kopans needle

(check mark wire), the Hawkins needle (multiple barbs and the only retractable wire for repositioning), and the Homer needle (J wire and nontransectable needle). For lesions that are superficial and can be readily imaged by ultrasound, needle localization can be performed under ultrasound guidance. The patient is then taken to the operative setting, where excision of the lesion can be performed under local anesthesia with sedation or general anesthesia. In the operating room, the patient is placed in the supine position with the arm ipsilateral to the index lesion positioned at 90 degrees. Appropriate padding of the arm and wrists should be undertaken. The operative site is then prepped and draped in a sterile fashion. Intraoperative localization is performed by evaluating the imaging studies and palpating the needle (for nonpalpable lesions) or by direct palpation. For lesions located in the upper half of the breast, transverse or curvilinear incisions are made along Langer's lines. If an incision is needed in the lower half of the breast, radial incisions are used. When possible, periareolar or inframammary incisions are made as they result in the best cosmesis. Prior to incision, a local anesthetic is injected into the skin and along the path of the needle localization wire. The incision is then typically made directly above the palpable mass or the tip of the needle (Fig. 74-10). Alternatively, an incision can be made next to the needle and then followed down to its tip to find the target lesion. Once the skin incision is made, the thickest possible flaps, which would still result in fully removing the lesion anteriorly, are developed. The specimen is then excised with electrocautery. The specimen is oriented with sutures, with the short stitch designating the superior margin and the long stitch designating the lateral margin. Palpation of the cavity is performed to ensure complete removal of the lesion. Specimen imaging is performed to confirm excision of the lesion of interest. The skin is closed in two layers. Cyanoacrylate tissue adhesive is then applied, allowing the patient to take a shower within 24 hours. For allergies to skin glue, adhesive strips can be applied. No pressure dressing is needed. A sports bra may be worn to stabilize the breast for the first 48 hours.

Skin Punch Biopsy

For any suspicious cutaneous lesion of the breast or chest wall, a biopsy can be obtained using a punch biopsy device, which consists of a circular blade. Punch biopsy devices are available in various sizes ranging from 1 mm to 8 mm, with the 2-mm and 4-mm size most commonly used in breast biopsies. The area to be biopsied is first selected. Common sites are the most abnormal-appearing site within a lesion or the edge of an actively growing lesion. The involved skin is cleansed and infiltrated with 2 to 3 mL of 1% lidocaine. The punch device is held vertically over the skin and rotated downward using a twirling motion until the subcutaneous fat or the hub of the device is reached. The specimen is then transected at the base with iris scissors. The skin is approximated with an interrupted stitch or U-stitch.

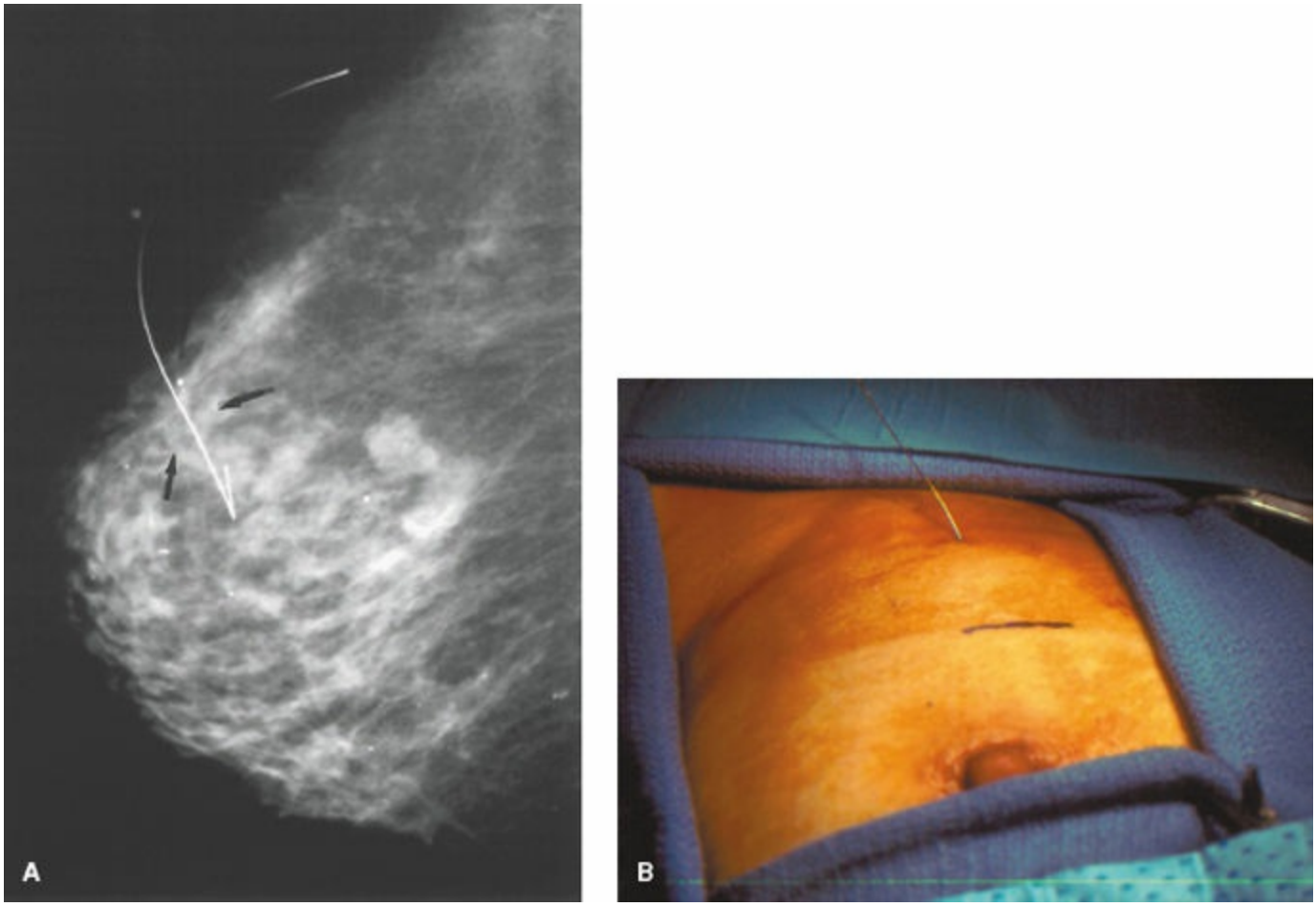

Figure 74-10. Incision placement for needle localization biopsy. **A:** The mammogram demonstrates that the lesion (*arrow*) is inferior to the point of wire entry. **B:** Incision placement inferior to wire entry to allow access to the lesion.

COMMON CLINICAL PROBLEMS AND MANAGEMENT ALGORITHMS

The most common clinical breast problems include breast masses, breast pain, nipple discharge, and breast infections. Clinical algorithms for the evaluation of these common breast problems have been developed to facilitate optimal care.

Breast Mass

A breast mass is defined as a palpable area in the breast that may be either benign or malignant. When a woman presents with a palpable breast finding, a thorough history and physical examination needs to be performed. The history should include a thorough review of the patient's medical problems and any risk factors associated with breast cancer (see the section on Management of Patients at High Risk for Breast Cancer).

In women younger than 35 years with no family history of premenopausal breast cancer or other risk factors, a targeted ultrasound is an appropriate initial imaging approach for a breast mass that appears clinically benign (Algorithm 74-1). The ultrasound is used to determine whether a dominant mass is present, as normal glandular tissue of the breast, especially in young women, may feel nodular. In a review of 605 women younger than 40 years who were referred for evaluation of a breast mass, only 36% of the masses detected by patients had a surgical correlate. Furthermore, only 29% of the masses detected by primary care providers were confirmed.[51] Consideration can then be made regarding the need for additional imaging such as mammography or an MRI. In women aged 35 years or older, the initial imaging approach to a palpable mass should include mammography and ultrasound. These studies should be obtained prior to any biopsies are performed as postbiopsy changes can distort subsequent imaging evaluation. Of note, all clinically suspicious palpable masses need to be biopsied even in the absence of imaging findings as 15% of breast cancers can be mammographically occult (Algorithm 74-2).[46] Ultrasound also provides important information about the etiology of a breast mass and can further categorize the mass as either cystic or solid. Workup of a cystic lesion typically involves aspiration of the cyst, with further evaluation based on the results of the aspiration (Algorithm 74-3). The definitive diagnosis of a breast mass is often confirmed by a core needle biopsy, although FNA is an appropriate alternative (Table 74-3). Core needle biopsy is typically preferred to excisional biopsy.

TREATMENT

Table 74-3 Management of Breast Masses Based on Core Biopsy Diagnosis

FNA Diagnosis	Treatment
Malignant	Definitive therapy
Suspicious	Surgical biopsy
Atypia	Surgical biopsy
Benign	Possible observation[a]
Nondiagnostic	Surgical biopsy

[a]See discussion in text on clinical approach to the patient with a solid breast mass.

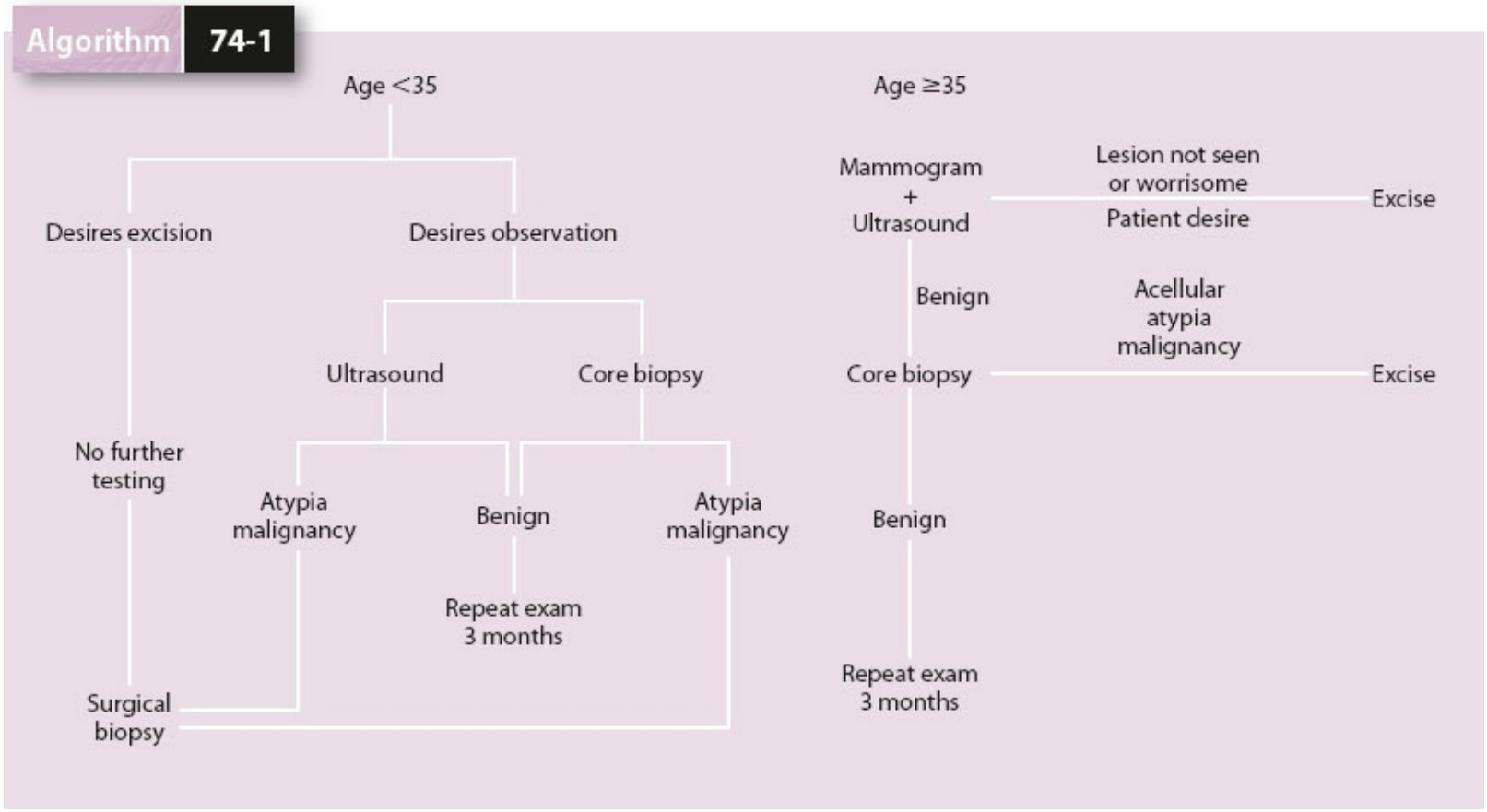

Algorithm 74-1. Diagnosis and management of the patient with a clinically benign breast mass. The use of imaging studies varies according to age because breast carcinoma is infrequent in women younger than 35 years old.

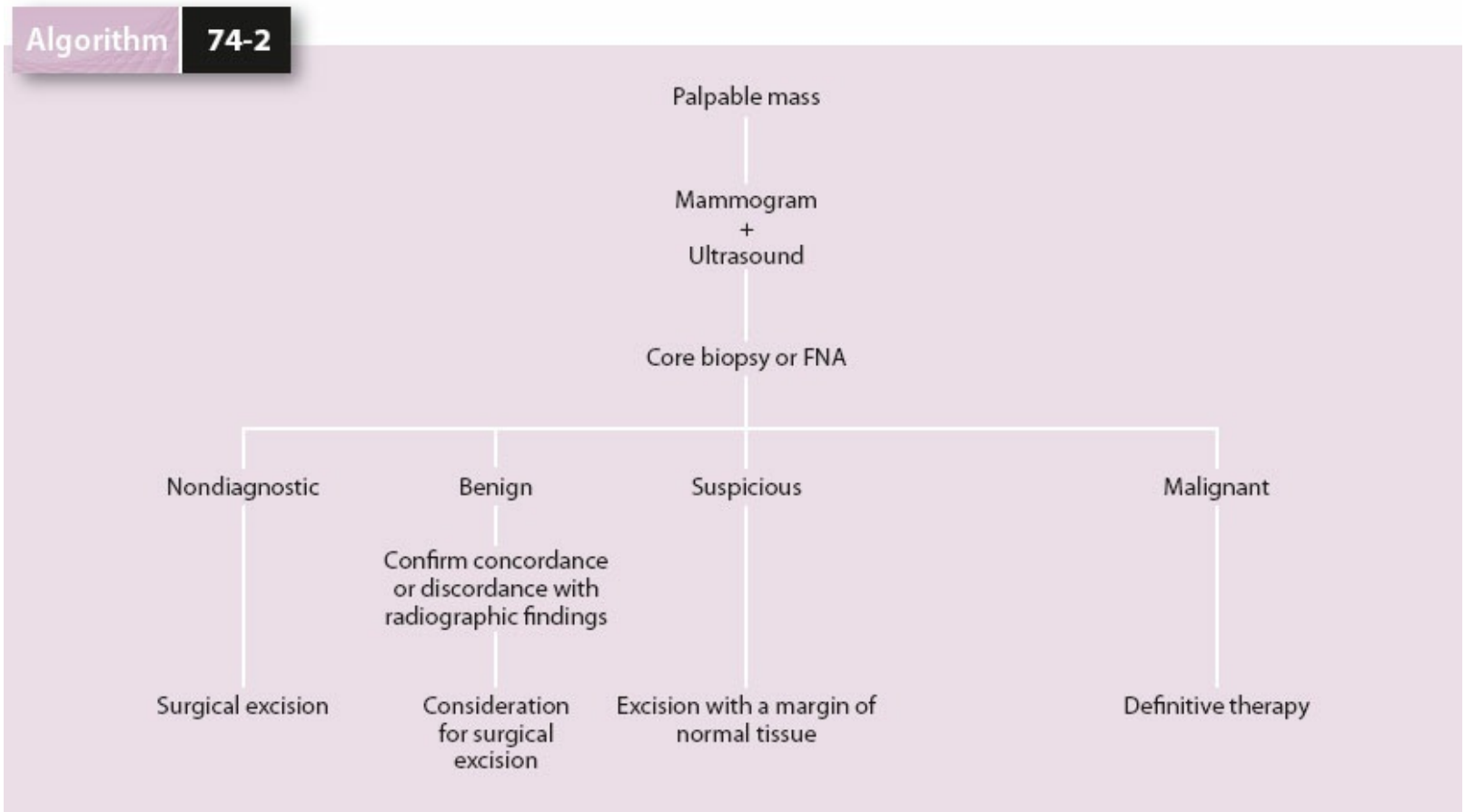

Algorithm 74-2. Diagnosis and management of the patient with a clinically indeterminate or suspicious solid breast mass. In this circumstance, imaging studies are insufficient to exclude malignancy, and tissue sampling is required.1

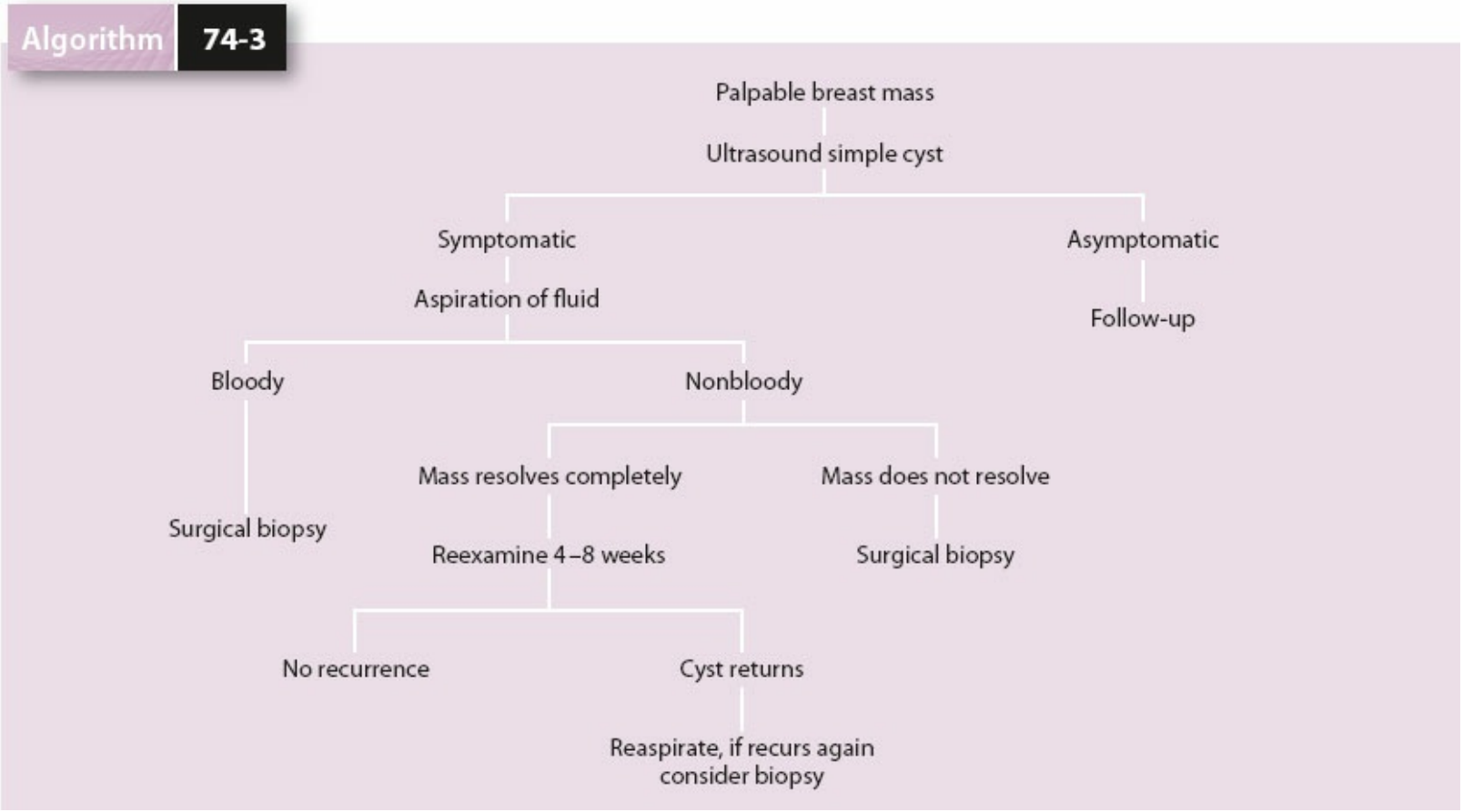

Algorithm 74-3. Diagnosis and management of the patient with a cystic lesion. Bloody fluid on aspiration, failure of the mass to resolve completely, and prompt refilling of the same cyst are indications for surgical biopsy.

Breast cysts are common causes of dominant masses in premenopausal and perimenopausal women. If a cyst is found in a postmenopausal woman in the absence of hormone therapy use, it should be regarded with a high degree of suspicion. Palpable masses that present as benign solid masses include fibroadenomas, fibrocystic disease, and fat necrosis. Fibrocystic breast disease has been used to describe a variety of benign breast disorders associated with nodular breast tissue. This term, however, should be reserved for women who have a biopsy consistent with one of the histologic components of fibrocystic change. Breast surgery, blunt trauma, injection of native or foreign substance such as fat and silicone, and radiation therapy can result in fat necrosis. On clinical examination and mammographic imaging, fat necrosis can mimic a malignancy, often leading to a biopsy. However, when oil cysts, which are circumscribed masses of mixed soft tissue density and fat with a calcified rim, are present radiographically, a definitive diagnosis of fat necrosis can be made (Fig. 74-11). See the section on Benign Breast Disease.

Breast Pain

Breast pain (mastalgia, mastodynia, idiopathic breast pain) is a common concern and is rarely (0.5% to 3.3%) representative of a breast cancer. It is noted that some IBCs can present with pain. While two-thirds of patients present with cyclical breast pain, another one-third has pain that is unrelated to the menstrual cycle and more likely to be secondary to a breast or chest wall lesion.[52]

Cyclical breast pain is associated with hormonal changes during the menstrual cycle and often occurs the week prior to the onset of menses and often dissipates once menstrual flow is established. During the menstrual cycle, the breast undergoes significant histologic changes as described by Vogel et al. (see the section on Menstrual Cycle).[31] During the secretory phase, luminal cells produce apocrine secretions and the stromal cells become edematous, which may contribute to the pathogenesis of breast pain. However, the exact physiologic events are not understood completely. Furthermore, while most women do experience mild cyclical breast pain, it is not clear why others have more pronounced pain. Cyclical breast pain is typically bilateral and involves the upper outer aspect of the breasts with radiation to the axillae or down the arms.

Noncyclical breast pain is more frequently unilateral and variable in its location in the breast. Possible etiologies include large pendulous breasts with pain resulting from stretching of the Copper's ligaments, duct ectasia, macrocysts, medications (including antidepressants, hormones, and antibiotics), and infections.[53,54] Thrombophlebitis of the lateral thoracic or superior thoracoepigastric vein (Mondor disease) is an uncommon presentation for breast pain characterized by a tender subcutaneous cord in the lateral aspect of the breast (Fig. 74-12). Mondor disease may result from trauma, radiation to the breast, and/or breast surgery. It can also occur in women with nonpalpable breast cancers, and a mammogram should be obtained when diagnosed.[55] For symptomatic relief, a patient can use anti-inflammatory medications, although Mondor disease often resolves spontaneously without the need for a specific therapy. Referred pain to the breast from the chest wall or ribs can also occur. Spinal or paraspinal problems and medical conditions (biliary, pulmonary, esophageal, and cardiac disease) can also result in referred pain.

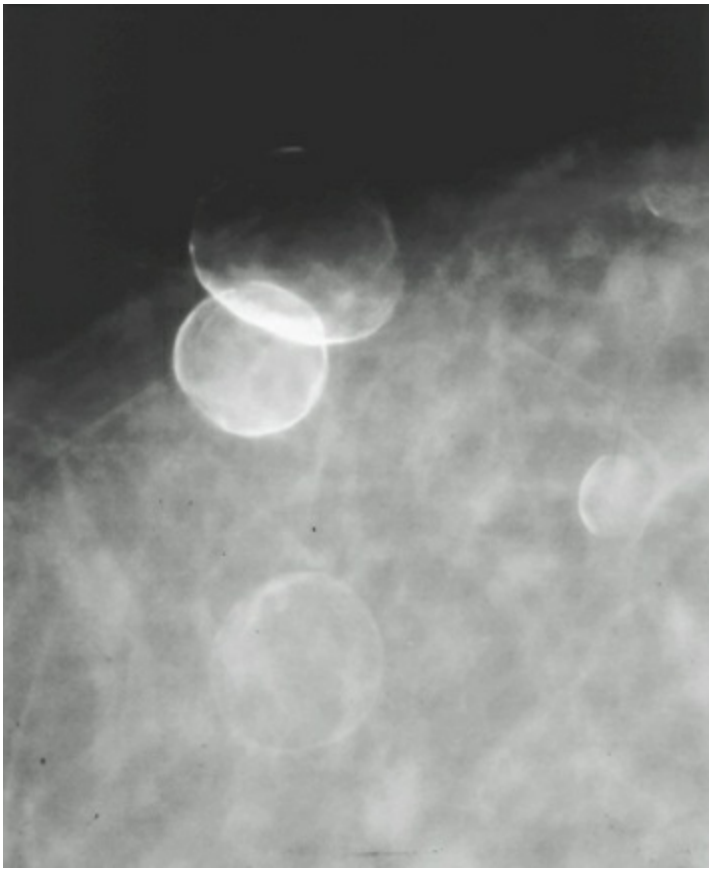

Figure 74-11. Oil cysts. The calcified rims of these cysts in a patient with a history of trauma are diagnostic.



Figure 74-12. Mondor disease. Thrombophlebitis of the thoracoepigastric vein causes retraction of the lateral portion of the breast, which crosses to the midline at the inferior areolar margin and is accompanied by a palpable cord.

The workup for breast pain should include a careful history, including questions related to the menstrual cycle, a thorough physical examination, and in women 35 years of age and older, a mammogram. If a malignancy is suspected, biopsy should be performed. If the CBE and diagnostic imaging studies are normal, reassurance that the symptoms are not consistent with breast cancer often provides significant relief for the patient.

Initial therapy for idiopathic breast pain includes lifestyle changes, the use of supportive garments such as a well-fitting brassiere with a steel underwire, a low-fat high-carbohydrate diet, and elimination of caffeine and nicotine. Oral analgesics with acetaminophen or nonsteroidal anti-inflammatory drugs (NSAIDs) should be initiated. Topical analgesic gels containing diclofenac or salicylate can be applied to the affected breast areas. If a patient is on oral contraceptives or hormone replacement therapy, discontinuation of these medications may improve pain. However, in women not using oral contraceptives with cyclical breast symptoms, the initiation of this therapy has been shown to reduce breast pain severity and duration. Although inconclusive evidence exists for the role of evening primrose oil (3,000 mg daily),[56,57] it is often part of the initial therapeutic approach. Evening primrose oil needs to be taken for at least 4 to 6 months to achieve a positive effect.

Approximately 5% of women will still have debilitating breast pain despite lifestyle changes and the initial therapies described above. For these women, therapies such as danazol, tamoxifen, bromocriptine, and gonadotropin-releasing hormone (GnRH) agonists can be considered. However, only danazol has been approved by the FDA for the treatment of idiopathic breast pain. Danazol (100 mg to 400 mg daily) is an antigonadotropin that results in a hypoestrogenic state. However, its use is often discontinued as it also induces a hyperandrogenic state, with most women having side effects of increased facial hair, acne, deepening of the voice, and adverse blood lipid profiles.[58] Tamoxifen (10 mg daily) has also been shown to be effective although side effects, including the risk of blood clots, endometrial cancer, and hot flashes limit its use.[59] As both danazol and tamoxifen have significant teratogenic effects, women on these therapies must be counseled to use an effective birth control method. Although bromocriptine and GnRH agonists have been studied for use in breast pain, they are not currently recommended because of significant side effects. Therapies that have been proven to be ineffective include diuretics, progesterone, and vitamins. Surgery to excise trigger spots (in the absence of an identifiable lesion) is not recommended, as the affected area is often replaced by a painful scar.

Nipple Discharge

Nipple discharge is a common breast symptom that often results in surgical consultation. The most common cause of pathologic nipple discharge is an intraductal papilloma, but breast cancer can also present as a pathologic nipple discharge. The first step in evaluation of nipple discharge is to determine whether the nipple discharge is pathologic or physiologic. Physiologic discharge is nonspontaneous or is elicited by manual compression of the nipple. It often involves multiple ductal orifices in the nipple and is present in both breasts. The discharge is commonly white or clear (although it can also present as yellow, green, brown, or gray fluid) and is negative on occult blood test. In contrast, pathologic nipple discharge is spontaneous, is present in a single breast/ductal orifice, and is often positive on occult blood test. However, any nipple discharge that is spontaneous is considered pathologic. Age is also predictive of breast cancer risk in women with nipple discharge. In a study involving women with pathologic nipple discharge, breast cancer was present in 3% of women younger than 40 years, 10% in those 40 to 60 years of age, and 32% in those older than 60 years.[60]

Clinical evaluation of nipple discharge includes a careful history and physical examination. The history includes questions regarding whether the discharge is spontaneous or elicited, unilateral or bilateral. The patient should be questioned regarding any recent trauma to the breast. The medical history and medications are reviewed. Medications such as oral contraceptives, metoclopramide, phenothiazines, and selective serotonin reuptake inhibitors can be associated with nipple discharge. A premenopausal woman presenting with milky fluid discharge bilaterally or galactorrhea should be evaluated for endocrine disease. Hypogonadism as suggested by amenorrhea or hot flashes/vaginal dryness should prompt a workup for hyperprolactinemia. In addition, hypothyroidism, pituitary adenoma, and chest trauma (including thoracotomy) can result in galactorrhea. When endocrine disease is suspected, patients should undergo laboratory evaluation including quantitative hCG, prolactin level, and thyroid function tests. The physical examination should include a visual field test as often these patients may show signs of bitemporal field loss or chiasmal syndrome. A careful breast examination is performed to evaluate for any dominant masses, skin changes such as eczema/infections, nipple changes such as Paget disease, or adenopathy. Each of the quadrants of the involved breast is massaged from the periphery to the nipple areolar complex and then pressure is applied to the base of the nipple areolar complex to elicit discharge. This will help define the involved quadrant of the breast and whether the discharge is from a single ductal orifice. The color of any nipple discharge should be noted, and an occult blood test should be performed.

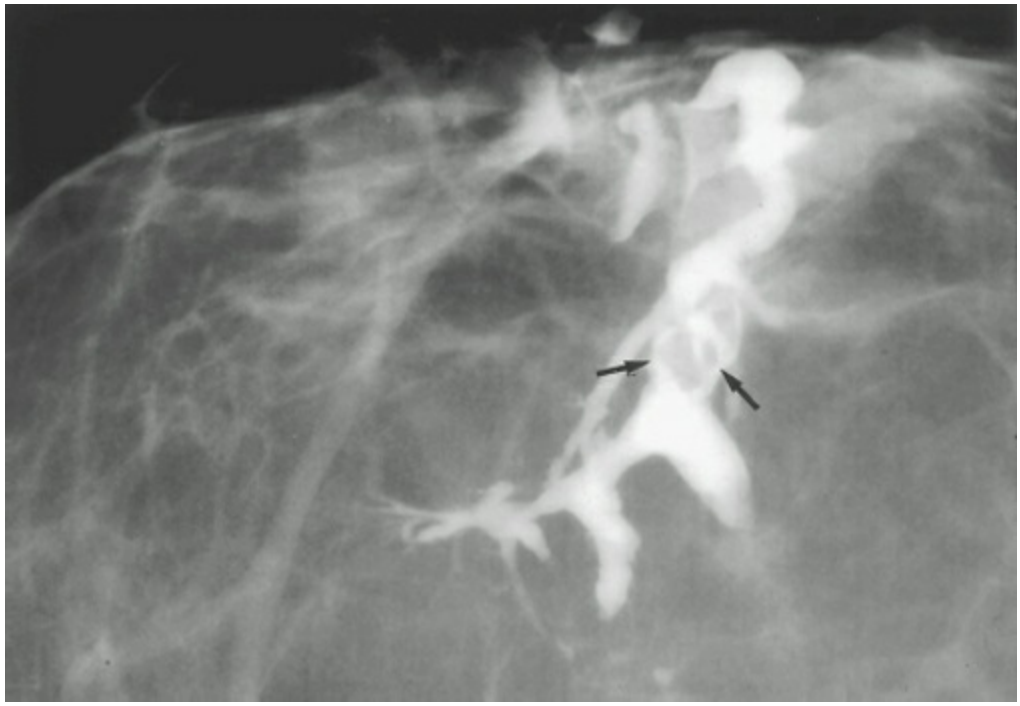

Figure 74-13. Ductogram. A large defect (*arrows*) represents an intraductal papilloma.

After initial evaluation, no further workup is required in women who have physiologic discharge, and these women should be advised to avoid manual compression of the nipples.

Imaging evaluation is indicated for patients with pathologic nipple discharge and includes an ultrasound, and for patients older than 30 years, a mammogram is also recommended. In patients with an imaging abnormality, a biopsy should be considered. Additional diagnostic tests that may be helpful include ductography and ductoscopy. Ductography is performed by instilling contrast medium into the involved duct to identify any lesions in the ductal system. Lesions will appear as a complete ductal obstruction, irregularities in the duct wall, or as an intraductal filling defect (Fig. 74-13). However, the absence of a lesion on ductography does not rule out a cancer.[61] Ductoscopy is often performed in the operating room and involves the use of a small fiberoptic ductoscope that is placed into the involved duct. The benefit of ductoscopy is that it allows for direct visualization of any potential lesions, which may result in more precise excision.

The most common etiology of pathologic nipple discharge is a papilloma, which is a benign epithelial lesion with supporting stroma that grows within a duct. When a papilloma is diagnosed by core biopsy, the standard recommendation is to proceed with surgical excision as it may be associated with atypia or ductal carcinoma in situ (DCIS). Other causes for pathologic nipple discharge include malignancy (most commonly DCIS, 5% to 15% of cases) and duct ectasia, which is characterized by ductal dilatation with loss of elastin in the duct walls and the presence of chronic inflammatory cells. It is not known, however, whether the inflammatory cells result from a primary or secondary infection and antibiotics are not recommended.

If a malignancy is identified as the etiology of a pathologic nipple discharge, it should be managed accordingly with the appropriate cancer surgery typically as the first treatment. In the absence of a known malignancy, pathologic nipple discharge should be

treated with terminal duct excision. Prior to excision, the patient should refrain from any nipple stimulation. If the involved duct can be identified intraoperatively, a lacrimal duct or instillation of methylene blue may aid with the duct excision. Terminal duct excision is commonly performed with a circumareolar incision and involves removal of the duct from its proximal to distal extent, which is often a distance of 2 to 3 cm. Alternatively, ductoscopy can be performed as previously prescribed and then the outer sheath of the cannula can be left in place as a guide for surgical excision of the involved duct. If there is difficulty isolating the involved duct or multiple ducts are involved, central or total terminal duct excision may be indicated. The potential risks of terminal duct excision include inability to breast-feed and hyposensitivity or hypersensitivity of the nipple.

Breast Infections

Breast infections are uncommon outside of the postpartum period. As such, breast infections can be classified as lactating or nonlactating infections. Lactating breast infections occur commonly during the initial 6 weeks of breast-feeding and during the process of weaning. In the initial stages of infection, a mastitis or cellulitis is typically found, with associated pain, erythema, induration, and fever. A woman should not be counseled to discontinue breast-feeding. Commonly, the cellulitis results from *Staphylococcus aureus*. Treatment includes pain management (acetaminophen, NSAIDs) and an antibiotic such as dicloxacillin. Alternative antibiotics include cephalexin and erythromycin. The mastitis should improve within 24 to 48 hours after initiation of antibiotics. If symptoms or fever persists, an abscess should be ruled out. For small or superficial abscesses, needle aspiration may be attempted. However, incision and drainage should be considered for large or complex abscesses, understanding the risks associated with milk fistula formation.

Nonlactating breast infections can present as periareolar abscesses or less commonly as peripheral abscesses. For small abscesses (less than 3 cm), needle aspiration and/or drain placement can be performed. However, for larger and/or deeper abscesses, incision and drainage may be indicated. This is commonly performed in the operating room under general anesthesia, although if the abscess is superficial or small, it may be possible to perform the incision and drainage at the bedside with infiltration of a local anesthetic. A preoperative ultrasound can be obtained to better evaluate the size and location of the abscess. The patient is placed in supine position and the surgical site is prepped and draped in the usual sterile fashion. Palpation of the abscess is performed, then using a no. 11 blade scalpel, a skin incision is made directly over the abscess. Often, the abscess is not located directly under the area of greatest erythema, and careful breast examination should be performed to localize the area of greatest fluctuance. Using a Kelly or Burlisher clamp, loculations are broken up in the cavity to fully drain the abscess. *Biopsy of the cavity should always be considered, as breast infection may be an unusual breast cancer presentation.* The abscess cavity is then copiously irrigated. For a subareolar abscess, removal of the sinus tract as well as the segmental duct should be considered. If the abscess is small, no packing is necessary. However for larger abscesses, we advocate loosely packing the wound with wet to dry gauze, which should be changed daily. Alternatively, an advanced wound care dressing can be used. The amount of the packing should be decreased daily and usually after 1 week, no further packing is needed. Alternatively, the incision can be loosely approximated with interrupted 4-0 nylon sutures leaving a 1.5-cm opening for a Penrose drain to be placed. The drain and the sutures should be removed within 4 to 7 days. Antibiotic, such as cephalexin 500 mg QID, is commonly prescribed for 7 to 10 days postoperatively, although once a wound is properly drained and cellulitis subsides, the patient can discontinue all antibiotics. For chronic subareolar abscesses, it may be necessary to completely excise the involved duct. During an acute exacerbation, patients are first treated with antibiotics and during the resolution phase, surgical excision is performed. Intraoperatively, the infected duct or fistula is

identified using a lacrimal duct probe. A radial elliptical incision is then made incorporating the entire duct from the nipple to the subareolar breast tissue. Excision is then performed with care to fully dissect the subareolar duct system from the underlying breast tissue. Interrupted suture of 4-0 plain gut is then used to reapproximate the nipple from its apex to its base. The deep dermal layer of the skin is then reapproximated with 3-0 Vicryl sutures and the skin closed in a subcuticular fashion with 4-0 monocryl. The patient should be continued on antibiotics for an additional 2 weeks.

In the setting of recurrent or persistent abscess formation or inflammatory changes despite adequate surgical management, other etiologies need to be considered including idiopathic granulomatous mastitis, Wegener's granuloma, sarcoidosis, tuberculosis, and histoplasmosis.

BENIGN BREAST DISEASE

Benign breast lesions can be classified into three groups: (1) nonproliferative breast lesions, (2) proliferative breast lesions without atypia, and (3) proliferative breast lesions with atypia (Table 74-4).

Nonproliferative Breast Lesions

Nonproliferative breast lesions include breast cysts, papillary apocrine change, epithelial-related calcifications, and mild hyperplasia of the usual type. These lesions are not associated with an increased risk of breast cancer.[62] Papillary apocrine change is characterized by proliferation of ductal epithelial cells that show apocrine features and have eosinophilic cytoplasm. Benign calcifications found in normal ducts, lobules, breast stroma, and blood vessel walls are referred to as epithelial- related calcifications. Mild hyperplasia of the usual type occurs when the number of epithelial cells within a duct is more than two but not more than four cells in depth, and the epithelial cells do not cross the lumen of the involved space.[63]

Table 74-4 Classification of Benign Breast Disease

Nonproliferative: No Increase In Risk
Cysts: micro or macro
Ductal ectasia
Simple fibroadenoma
Mastitis
Fibrosis
Metaplasia: squamous or apocrine
Mild hyperplasia
Proliferative: RR 1.5–2.0
Complex fibroadenoma
Papilloma
Sclerosing adenosis
Hyperplasia: moderate or severe
Proliferative With Atypia: RR 4.5–5.0
Atypical ductal hyperplasia
Atypical lobular hyperplasia

RR, relative risk.

The most common nonproliferative lesions of the breast are cysts, which often present clinically as solitary masses that can be associated with pain. They are fluid-filled round or ovoid structures arising from the terminal duct lobular unit when fluid accumulates because of distension and obstruction of the efferent ductule.[64] Given that cysts arise from lobular pathology, they occur mainly during lobular development, menstrual cyclic changes, and lobular involution in premenopausal and postmenopausal women, with peak incidence between 35 and 50 years of age.[65,66]

The three types of cysts are simple, complicated, and complex. Simple cysts are well circumscribed and on ultrasound have posterior acoustic enhancement. In addition, they are anechoic and do not have solid components or Doppler signals. If simple cysts are diagnosed by ultrasound, they are by definition benign and do not require further

intervention, although cyst aspiration can be performed if the patient is symptomatic. Alternatively, FNA can also be used to diagnose simple cysts. If the aspirated fluid is nonbloody and the palpable mass completely resolves, this is also diagnostic of a simple cyst and no further diagnostic evaluation is required. A follow-up CBE with or without ultrasound can be performed in 3 to 6 months to document stability, and the patient may resume routine breast cancer screening.

Unlike simple cysts that are not associated with malignancy, complicated and complex breast cysts are associated with malignancy in $<1\%$ and 1% to 23%, respectively.[67–69] On ultrasound, complicated cysts appear as masses with homogenous low-level internal echoes due to echogenic debris. However, there are no solid components, thick walls, or thick septa. Complex cysts are defined as cysts with solid components, thick walls, or thick septa. Complex cysts are characterized on ultrasound by the absence of posterior wall enhancement and the appearance of anechoic and echogenic components. Complicated cysts can be confirmed as benign by biopsy through FNA, core biopsy, or excisional biopsy. Alternatively, ultrasound imaging and mammography (if the lesion was visualized on mammography) with CBE every 6 months for 2 years can be performed to document stability. If complicated cysts develop any concerning changes such as an increase in size or development of a solid component, biopsy should be performed.[70] Complex cysts mandate biopsy. If no fluid is aspirated by FNA, then core biopsy under image guidance should be performed with care to biopsy the solid component. A metallic clip marking the biopsy site facilitates surgical excision if necessary and facilitates follow-up imaging. If pathology is concordant with imaging findings, then follow-up with CBE and ultrasound imaging every 6 to 12 months for 1 to 2 years can be performed to document stability. For any concerning changes in the appearance of the lesion or increase in size, excisional biopsy should be performed. In patients who may be noncompliant with follow-up care, surgical excision should be considered for complicated and complex breast cysts.[70]

Proliferative Breast Lesions without Atypia

Proliferative breast lesions without atypia include ductal hyperplasia, intraductal papillomas, sclerosing adenosis, radial scars, and fibroadenomas. Ductal hyperplasia is often an incidental finding noted on biopsies obtained for mammographic abnormalities or for breast masses. Ductal hyperplasia is characterized by an increased number of cells within the ductal space; however, the cells retain the cytologic features of benign cells. Ductal hyperplasia is not associated with a significant risk for subsequent breast cancer and no additional treatment is necessary.[63,71] Women with intraductal papillomas often present with pathologic nipple discharge (see section on Nipple Discharge above). These lesions consist of a monotonous array of papillary cells that grow from the wall of a duct or cyst into its lumen. Given that intraductal papillomas can harbor areas of atypia or DCIS, surgical excision is recommended when intraductal papillomas are diagnosed by core needle biopsy. If no atypia or DCIS is found at the time of excision, then no further treatment is necessary.[72–76] Sclerosing adenosis typically presents as a mammographic abnormality or a mass and requires no further treatment following biopsy, as it is a benign lobular lesion resulting from increased fibrous tissue and interspersed glandular cells.[77,78] Complex sclerosing lesions or radial scars are often found incidentally when a breast mass or radiologic abnormality is biopsied or excised. These lesions are characterized by a fibroelastic core with radiating ducts and lobules, and radial scars can appear spiculated on mammography.[79] When diagnosed on core biopsy, radial scars should be excised as 8% to 17% are associated with malignancy at surgical excision.[80–82] If the surgical excisional biopsy confirms a radial scar, no additional treatment is needed.

Fibroadenomas typically present as well-circumscribed mobile masses that are not fixed to the surrounding breast tissue. They are benign solid tumors made of glandular as well as fibrous tissue and are found most commonly in women between the ages of 15 and 35 years.[83] Fibroadenomas with benign imaging characteristics can be followed with serial CBE and ultrasound imaging to ensure stability. Alternatively, core needle biopsy can be performed to confirm the diagnosis. If a fibroadenoma is asymptomatic, surgical excision is not necessary. However, if the presumed fibroadenoma is symptomatic or increases in size, excision can be performed for symptomatic relief or to rule out a malignancy such as a phyllodes tumor.[84] Fibroadenomas that are associated with proliferative changes such as sclerosing adenosis, ductal epithelial hyperplasia, epithelial calcification, or papillary apocrine changes are referred to as complex fibroadenomas. Surgical excision of these lesions is often recommended to exclude a diagnosis of breast cancer,[85,86] although this is controversial as some advocate that these lesions can be followed similarly as simple fibroadenomas.[87]

A fibroadenoma that is greater than 10 cm in size is referred to as a giant fibroadenoma and excision is recommended, as these lesions are hard to differentiate from a phyllodes tumor.[63] Juvenile fibroadenomas occur in young women between the ages of 10 and 18 years and can vary in size from 5 to 20 cm in diameter. Surgical excision is recommended as these lesions can be cosmetically distressing for the young patient and are difficult to differentiate from a phyllodes tumor, although risk to the prepubertal breast bud is a

potential complication.[88]

Proliferative Breast Lesions with Atypia

Proliferative breast lesions with atypia include ADH, ALH, flat epithelial atypia (FEA), and LCIS. Although these lesions are not considered premalignant, they are associated with an increase in the patient's future risk of developing breast cancer (Fig. 74-14).

ADH is characterized by a proliferation of uniform epithelial cells with monomorphic round nuclei filling part, but not all, of the involved duct. ADH often presents as suspicious microcalcifications seen on mammography. In contrast, ALH is often an incidental finding found on breast biopsies performed for other reasons, such as an abnormal mammogram or breast mass. ALH is characterized by a proliferation of monomorphic, evenly spaced, dyshesive cells filling part, but not all, of the involved lobule.[63] Atypical hyperplasias are associated with an increased risk of subsequent breast cancer (relative risk [RR] 3.7 to 5.3) in both the ipsilateral breast and the contralateral breast.[89–93] In the past atypical hyperplasias (both ductal and lobular) that are diagnosed on core needle biopsy mandated a surgical excisional biopsy to exclude a diagnosis of malignancy. In case of atypical ductal hyperplasia, a surgical excisional biopsy is still recommended as an upgrade to DCIS or invasive breast cancer can occur in 10% to 20% of cases. However, in regards to lobular neoplasias (atypical lobular hyperplasia and LCIS), more recent evidence suggests that an association with malignancy may be as low as 1% (central pathology review) and 3% (local pathology review) and as such surgical excision for these lesions are no longer indicated.[94] If the diagnosis of atypical hyperplasia is made by excisional biopsy and the area is adequately sampled, reexcision is not necessary or recommended. Instead, the patient should be counseled toward risk reduction strategies that include CBE every 6 to 12 months, annual screening mammography, and consideration for chemoprevention with a selective estrogen receptor modulator (SERM) or an aromatase inhibitor (AI).[70] In addition, the patient should be counseled to perform consistent breast self-examinations (BSEs) such that she will become familiar with her breasts and report changes promptly to her provider (see the section on Management of Patients at High Risk for Breast Cancer later).

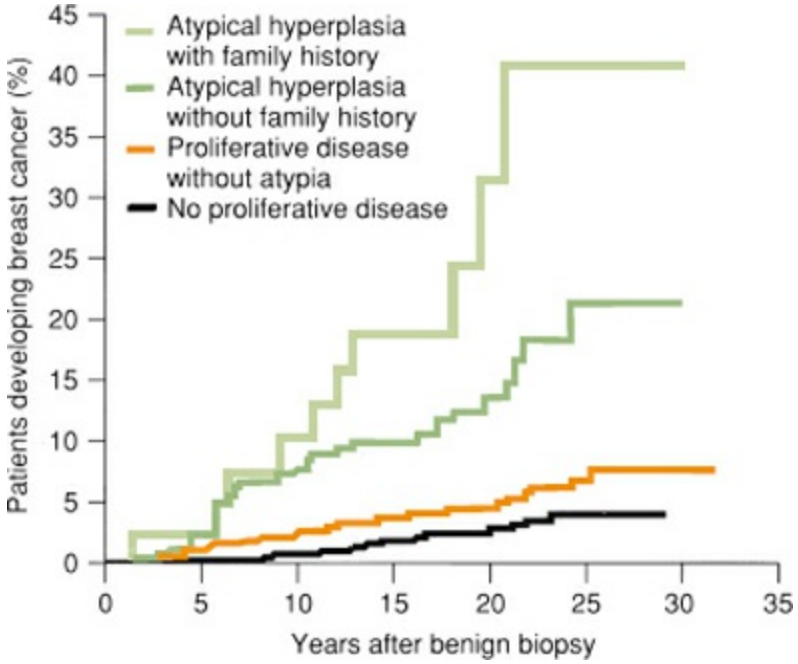

Figure 74-14. Cumulative risk for the development of invasive breast cancer after a biopsy for benign breast disease. Women with atypical hyperplasia (ductal or lobular type) are at a significantly increased risk for the development of breast cancer. (Reproduced with permission from Page DL, Dupont WD. Anatomic markers of human premalignancy and risk of breast cancer. *Cancer* 1990;66:1326.)

Lobular Carcinoma In Situ

LCIS is a noninvasive lesion that arises from the lobules and terminal ducts of the breast. It is characterized by solid proliferation of small cells, with small, uniform, round to oval nuclei, and variably distinct cell borders. The cytoplasms of the cells are clear to lightly eosinophilic and occasionally there are intracytoplasmic vacuoles that may be large enough to produce signet ring cell forms. LCIS tends to have a very low proliferative index and is estrogen-receptor positive.[95] LCIS is more prevalent in premenopausal women and white women.[96,97]

3 LCIS is often diagnosed as an incidental finding on a breast biopsy that has been performed for another reason, such as an area of fibrocystic change or mammographic abnormality. Traditionally, if LCIS is identified on core biopsy, surgical excision is performed to exclude an associated cancer.[97–101] However, more recent data suggests that this potential upgrade to DCIS or invasive cancer is likely 1% to 3% and as such surgical excision is no longer indicated.[94,98–102] If LCIS is found on excisional biopsy, no further surgical intervention is needed. However, if *pleomorphic* LCIS is identified at a surgical margin on excisional biopsy, wide excision with negative margins is recommended as pleomorphic LCIS can be hard to differentiate from DCIS.[103–105]

RESULTS

Table 74-5 Risk for Breast Cancer Development After Lobular Carcinoma in Situ

Study	No. Patients	Invasive Cancer (%)	Follow-Up (yrs)	Relative Risk
Haagensen[106]	287	18	16.3	6.9
Rosen et al.[107]	99	12.5	24	9.0
Andersen[108]	47	26.4	15	12.0
Page et al.[92]	44	23	18	9.0
Salvadori et al.[109]	80	6.3	5	10.3
Ottesen et al.[110]	69	11.6	5	11.0
Bodian et al.[111]	236	26[a]	18	5.4
Fisher et al.[163]	182	33	5	—

[a]Includes intraductal and invasive cancer.

Although it is not a premalignant lesion, LCIS conveys a substantial increased risk for breast cancer. The RR of developing an invasive cancer in women with LCIS is approximately two- to threefold higher than that in women without LCIS (Table 74-5).[112] LCIS also conveys an increased risk for breast cancer to the contralateral breast. Historically, women diagnosed with LCIS were treated with bilateral prophylactic mastectomies. Most experts today consider this approach to be too aggressive given that *most* women with LCIS who do not have other contributory factors (e.g., family history of premenopausal breast cancer) will not develop an invasive breast cancer. Instead, a

careful lifetime surveillance protocol similar to that described above for atypical hyperplasias can be followed. Chemoprevention with a SERM and/or AI can also be discussed with the patient. There are currently no randomized trials to compare the efficacy of surveillance protocol versus prophylactic mastectomy in women with LCIS.

FEA is an intraductal finding that is characterized by the replacement of native epithelial cells by a single layer, or up to 3 to 5 layers of mildly atypical cells (World Health Organization definition).[113] When diagnosed on core biopsy, the risk of upgrade to a malignancy at surgical excision is 5% to 15%.[114–116] When FEA is diagnosed by excisional biopsy, no further surgery is warranted. However, if FEA is diagnosed by core needle biopsy, excisional biopsy should be performed. Alternatively, radiologic surveillance can be performed and if there is absence of a residual mammographic abnormality and core biopsy was felt to be adequate, no further surgery is needed. Excisional biopsy must be performed for any residual lesions seen. When FEA is found at the margins, wider excision is not needed.[114–117] Although FEA is an atypia, it conveys the same risk of breast cancer that is associated with benign proliferative disease without atypia and as such, patients should continue routine surveillance.[118] There are also no data to support the use of chemoprevention.

BREAST CANCER SCREENING

Breast Self-Examination

BSE has not been shown to have an impact on the rates of breast cancer diagnosis, stage at diagnosis, or breast cancer mortality. In addition, BSE may result in higher rates of breast biopsy for benign disease. The largest study conducted was the Shanghai randomized trial involving 266,064 women who were assigned to either a BSE instruction group or a control group. The BSE group received instruction on BSE with reinforcement sessions 1 and 3 years later, supervised self- examination every 6 months for 5 years, and ongoing reminders. Intensive instruction on BSE did not reduce mortality from breast cancer but increased the rate of biopsy for benign disease.[119] A review of eight other studies had similar findings.[120] The US Preventive Services Task Force (USPSTF), the Canadian Task Force on Preventive Health Care (CTFPHC), the National Comprehensive Cancer Network (NCCN), and the World Health Organization do not recommend that women receive instruction on BSE. The American Cancer Society recommends that women be educated about the benefits and limitations of BSE. The American College of Obstetricians and Gynecologists recommends breast self-awareness, which can include BSE. In women who are not at high risk for breast cancer, we do not advocate for or discourage the use of BSE; however, we do promote breast self-awareness. Proper examination technique should be reviewed for women who are already routinely performing BSE, for women at high risk for the development of breast cancer, and for breast cancer survivors.

Clinical Breast Examination

Women should undergo CBE as part of their annual physical examination. However, it is difficult to determine the effectiveness of CBE as a screening tool as it is often performed with mammography. It has been suggested that CBE may modestly improve early detection of breast cancer but at the risk of increased false-positives.[121,122] The effectiveness of CBE has not been proven by well-designed large clinical trials.[123] As such, the USPSTF, the Canadian Task Force on Preventive Health Care, and the World Health Organization do not support CBE. The American Cancer Society and the American College of Obstetricians and Gynecologists recommend CBE every 3 years. We feel that CBE is critical to the evaluation of breast disease, as such, providers of women's health have to become experts in this technique.

Screening Mammography

Screening mammography is widely performed but is not without controversy. Although systematic reviews of randomized trials have found a significant reduction in breast cancer mortality with mammographic screening in women aged 40 to 69 years, most of these studies were conducted before 1990, and there is concern that the current reduction in mortality is less as these trials were performed in an era prior to the adoption of modern treatment paradigms (multidisciplinary care and the use of adjuvant systemic treatments). In 2012, a meta-analysis of 11 randomized trials determined that the RR of breast cancer mortality for women undergoing screening mammography was 0.80 (95% confidence interval [CI], 0.73 to 0.89) compared with controls. This correlates with a RR reduction of 20%.[124] In 2014, the Canadian National Breast Screening Study concluded a 25-year follow-up analysis. The cumulative mortality from breast cancer was similar between women randomized to the mammography arm or to the control arm. For women aged 40 to 49 years, they were randomly assigned to mammography or usual care, and for women aged 50 to 59 years, they were randomly assigned to mammography plus CBE or to CBE alone. As such, the study concluded that annual mammography in women aged 40 to 59 years does not reduce mortality from breast cancer beyond that of physical examination or usual care in the era of modern adjuvant therapy. In addition, they reported that 22% (106/484) of screen-detected invasive breast cancers were overdiagnosed.[125] The primary risk of screening mammography is false-positive test results, which can result in patient anxiety, overdiagnosis, increased medical costs, and unnecessary biopsies.

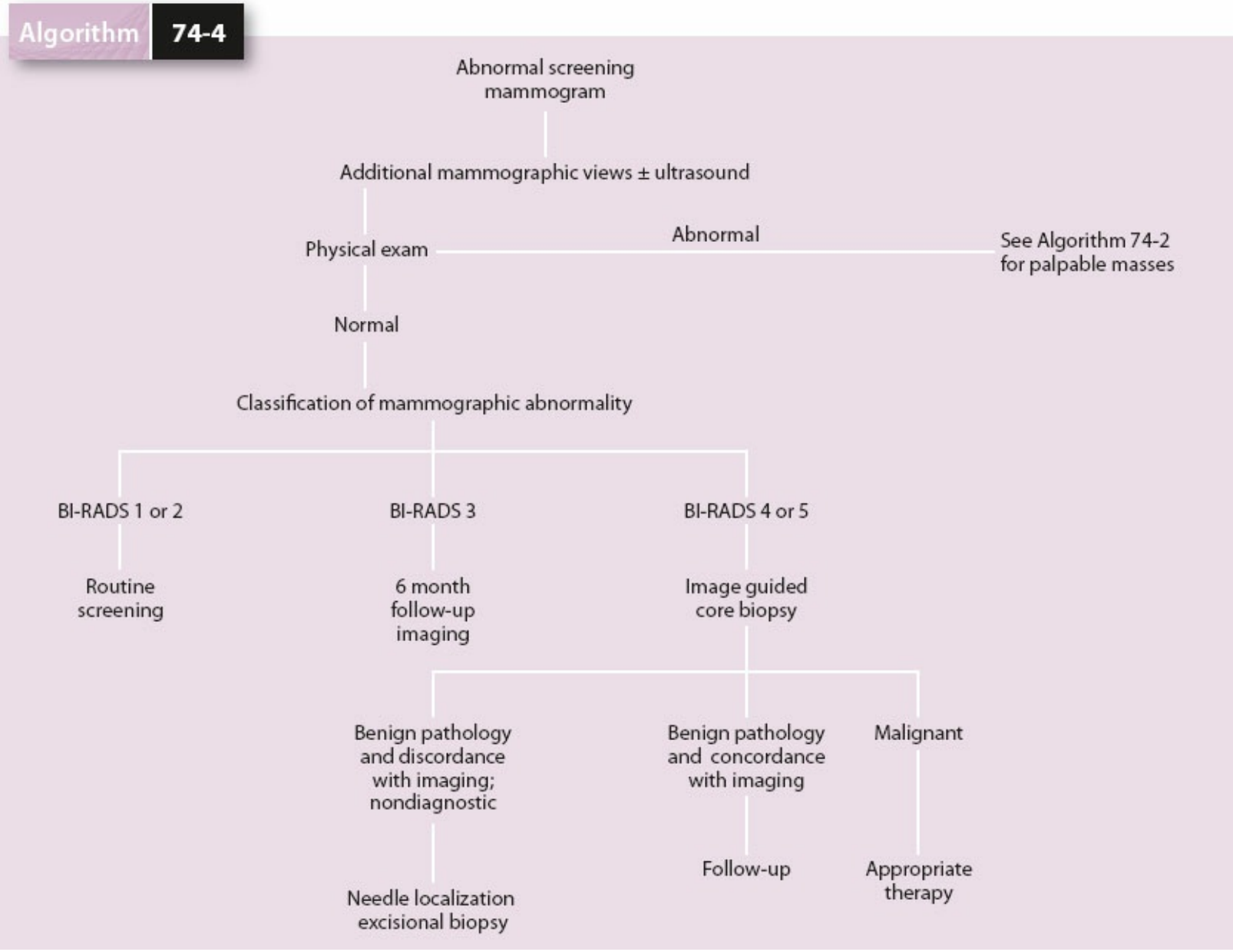

Algorithm 74-4. Management of the patient with an abnormal screening mammogram. When pathology is benign, concordance or discordance with imaging findings dictates whether surgical excisional biopsy is indicated.

4 All expert groups in North America agree that screening mammography should be performed in women 50 years of age and older. However, differences exist about whether screening should be performed between 40 and 49 years of age. The American Cancer Society, the American College of Radiology, the American Medical Association, the National Cancer Institute, the American College of Obstetricians and Gynecologists, and the NCCN all support starting routine screening mammography at the age of 40 years. Other groups including the USPSTF, the American College of Physicians, and the CTFPHC recommend initiating screening at the age of 50 years. Although most groups agree with continuing screening until the age of 74 years, some recommend stopping screening after the age of 74 years (USPSTF and the CTFPHC). Others feel that this decision should be individualized (the American College of Obstetricians and Gynecologists and the American College of Radiology). The frequency of mammography (annually or biennially) has also been debated among the various expert groups; however, most

groups in North America advocate for annual screening. Until further studies are performed, we continue to recommend annual screening mammography starting at the age of 40 years.

Routine mammography consists of two views (craniocaudal (CC) and mediolateral oblique (MLO)) of each breast. Breast positioning is instrumental to mammography, with the CC view obtained by lifting the breast and positioning it on the plate with compression applied from above, whereas the MLO view is obtained with the breast being compressed from the side. These images are then evaluated and classified according to the American College of Radiology breast imaging reporting and data system (BI-RADS)[126] (Algorithm 74-4) (Table 74-6). Screening mammography with a completely negative examination is classified as BI-RADS 1. Screening mammography with benign findings such as a cyst or a fibroadenoma is classified as BI-RADS 2. If any indeterminate or concerning findings exist on screening mammography requiring additional diagnostic imaging, then a BI-RADS 0 is assigned. Probable benign findings are classified as BI-RADS 3 with a typical recommendation of repeat imaging in 6 months. Suspicious abnormalities are classified as BI-RADS 4 or 5 with recommendation for biopsy. Screening mammography is a relatively sensitive but nonspecific test, and only 20% to 30% of abnormalities found ultimately prove to be malignant (Fig. 74-15). Methods to increase the specificity of mammography include computer- aided detection (CAD) and more recently breast tomosynthesis. CAD is a computer-based technology that recognizes mammographic patterns and assists breast imaging specialists in identifying areas of concern. Its use has been approved by the FDA since 1998.[127] More recently, the FDA approved breast tomosynthesis, also known as 3-D mammography, for routine clinical use as an adjunct to digital mammography with early findings suggesting a decrease in recall rate and an increase in cancer detection rate.[128]

CLASSIFICATION

Table 74-6 BI-RADS Classification of Mammographic Abnormalities

Category	Assessment	Recommendation
1	Negative	Routine screening
2	Benign finding	Routine screening
3	Probably benign finding	Short-interval follow-up
4 4A 4B 4C	Suspicious abnormality Low suspicion for malignancy Moderate suspicion for malignancy High suspicion for malignancy	Tissue diagnosis
5	Highly suggestive of malignancy	Tissue diagnosis
6	Known biopsy proven malignancy	Appropriate action should be taken

BI-RADS, breast imaging reporting and data system.

Screening MRI

Screening MRI is more sensitive but less specific than mammography. It is commonly used by providers as an adjunct to mammography to screen women at high risk for breast cancer; however, the effect of MRI screening on survival in high-risk groups has not been supported by any prospective randomized trial. The American Cancer Society does recommend offering annual MRI in addition to mammography to women within certain high-risk groups, such as those with BRCA mutations, first degree relatives of known BRCA mutation carriers, and those with a lifetime risk of breast cancer that is estimated to be 20 percent or higher based on risk prediction models (see the section on Management of Patients at High Risk for Breast Cancer). The NCCN has similar recommendations and also includes patients who received radiation treatment to the chest between ages 10 and 30 and those who have TP53 (Li–Fraumeni syndrome) or PTEN genetic (Cowden syndrome) mutations. The National Institute of Health and Care Excellence (UK) has similar recommendations, advocating for MRI in high-risk patients. Providers who choose to screen with MRI and mammography often do so in a staggered fashion such that the patient is undergoing imaging every 6 months.

MANAGEMENT OF PATIENTS AT HIGH RISK FOR BREAST CANCER

Risk Factors

Breast cancer is the most common cancer in women in the United States. Approximately 200,000 women and 2,000 men are diagnosed with invasive breast cancer each year.[129] Breast cancer is the most common cancer in women of every major ethnic group, and the highest rate is among Caucasian women, with 122 newly diagnosed breast cancer cases per 100,000 women each year.[130] Understanding the risk factors for breast cancer is important, as some of these risks can be modified to decrease a patient's risk through lifestyle/behavioral changes and/or the use of chemoprevention.

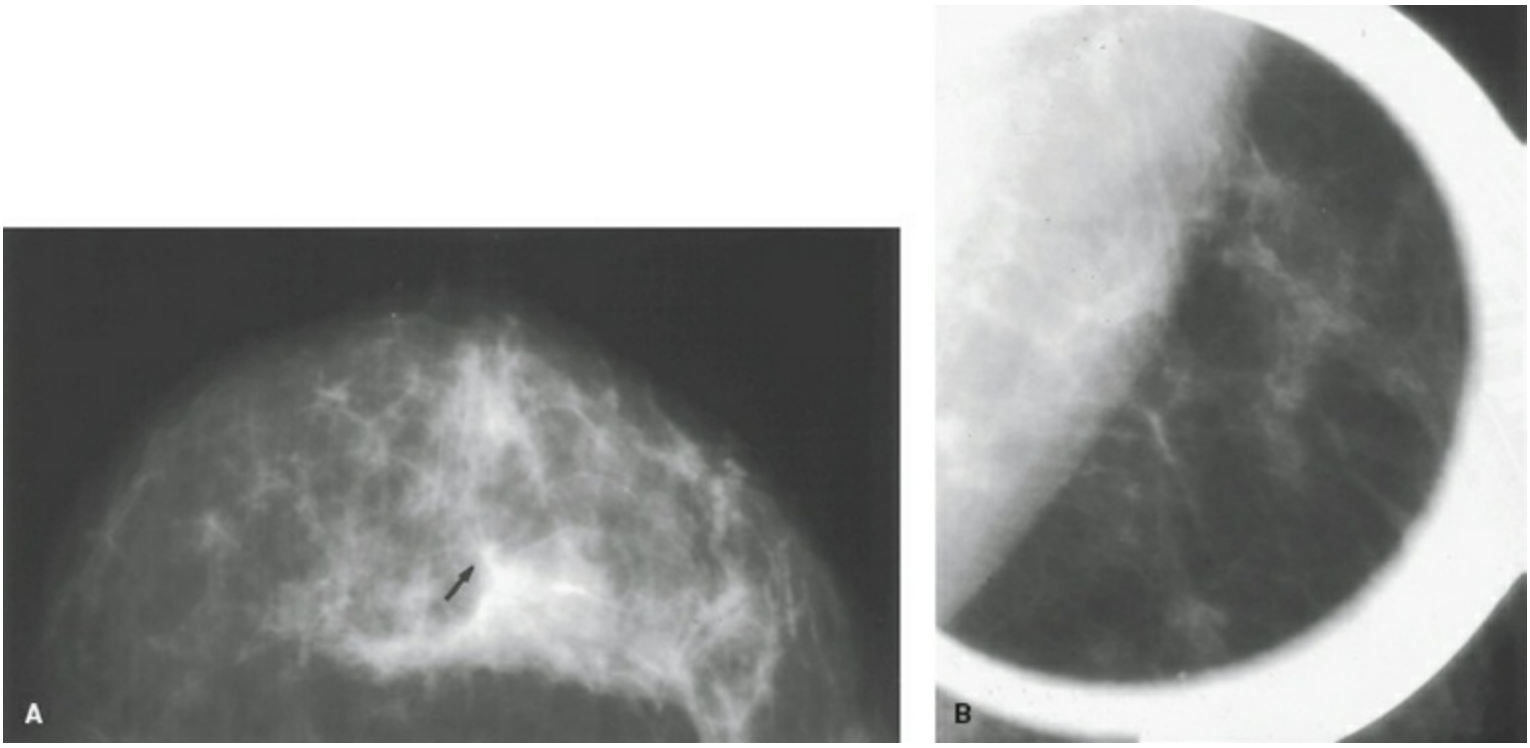

Figure 74-15. Workup of abnormal screening mammogram. **A:** Craniocaudal view showing an increased density with a slightly spiculated appearance (*arrow*). **B:** Spot magnification view of the density demonstrating normal breast tissue.

Increasing Age

As a woman ages, her risk for breast cancer increases: birth to age 49 years, 1.9% probability of developing invasive breast cancer (1 in 53); age 50 to 59 years, 2.3% (1 in 43); age 60 to 69 years, 3.5% (1 in 29); and age 70 years and older, 6.7% (1 in 15). From birth to death, the probability of developing invasive breast cancer is 12.3% or 1 in 8.[129]

Estrogen Exposure

A woman's lifetime exposure to estrogens appears to correlate with her risk for breast cancer.[131] Exposure to estrogens can be approximated by age of first menarche, age of menopause, and age of first live birth, with nulliparous women who have an early menarche and a late menopause having the highest risk. Premenopausal women who

undergo bilateral oophorectomy are at decreased risk. Given that high endogenous levels of estrogen is known to increase the risk of breast cancer in both premenopausal and postmenopausal women, the use of exogenous hormones and their associated risk for breast cancer has been studied and debated. The use of hormonal contraceptives does not appear to significantly increase the risk of breast cancer.[132] However, the use of hormone replacement therapy in postmenopausal women has been associated with an increased risk of breast cancer as reported in the Women's Health Initiative Estrogen Alone and Estrogen-Plus-Progestin Studies, which were stopped early secondary to this and other concerns.[133] In the Estrogen-Plus-Progestin study, the HRT used was a combined estrogen–progestin therapy (EPT) that was given to postmenopausal women with an intact uterus. The risk of breast cancer is relatively low, as EPT would result in an additional eight cases of breast cancer if 10,000 women took EPT for a year. More recently, it was determined that the rate of death from breast cancer among those taking EPT was 2.6 per 10,000 women per year, compared with 1.3 per 10,000 women per year among those taking placebo.[134] Short-term use for less than 3 years does not appear to significantly increase the risk of breast cancer and after the cessation of EPT use for 3 years, a woman's risk returns to baseline.

Given that lactation interrupts ovulation and modifies pituitary and ovarian hormone secretion, it has been postulated that breast-feeding can reduce breast cancer risk. This finding remains inconclusive. Limited data suggest that longer duration of lactation in premenopausal women may reduce risk.[135] A pooled analysis consisting of more than 50,000 women with breast cancer and 96,000 controls concluded that for every 12 months of breast-feeding, there was an associated 4.3% reduction in the RR of breast cancer.[136]

Environmental and Lifestyle Factors

Women who were subjected to ionizing radiation of the chest, such as for treatment of Hodgkin lymphoma or through exposure from nuclear plant accidents or the atomic bomb, have an increased risk of breast cancer. The prepuberty stage (age 10 to 14 years) appears to be the most vulnerable time for exposure, with little associated risk when exposure occurs after age of 45 years.[137–139] Alcohol use is associated with an increased risk of breast cancer and correlates with the amount of consumption, with differences noted with alcohol intake as low as three drinks per week versus those who abstain from alcohol. A meta-analysis of 110 studies shows a small but significant association (RR, 1.05; 95% CI, 1.02 to 1.08).[140,141] The relationship between cigarette use and breast cancer risk remains controversial because of unresolved issues of confounding and dose response; however, a recent meta-analysis found that smoking before menarche and before the first birth was associated with an increased risk for breast cancer.[142] Furthermore, in women diagnosed with breast cancer, lifetime cigarette smoking ($\geq$20 pack-years) was associated with an increased risk of recurrence and all-cause mortality.[143] The role of dietary factors such as fat intake, red meat and processed meat, phytoestrogens, calcium/vitamin D, and antioxidants in modifying breast cancer risk remains inconclusive. Regular physical exercise and a diet composed mainly of fruits and

vegetables likely provide protection against breast cancer.

Family History

The number of first-degree relatives with breast cancer is strongly associated with a woman's risk for the future development of breast cancer. If one first-degree relative is affected, the risk of breast cancer increases by approximately twofold, and if two first-degree relatives are affected, the risk of breast cancer is increased by approximately threefold. The age at diagnosis of the first-degree relative is also important, as a women's risk is approximately threefold higher when the diagnosis occurs before age 30 but only 1.5-fold higher if the diagnosis is after age 60.[144]

When evaluating family history, it is important to note that the majority of breast cancers are caused by sporadic mutations (mutations that occur in somatic cells that cannot be inherited). When studying the family tree of women with *sporadic breast cancer*, these women typically have no family history of breast cancer through two generations, including siblings, offspring, parents, and both maternal and paternal aunts, uncles, and grandparents. Less than 10% of breast cancers are hereditary. In families with *hereditary breast cancer*, the family tree is characterized by earlier onset of breast cancer, bilateral breast cancer, a greater frequency of primary cancers such as breast and ovary, and an autosomal dominant inheritance pattern (Fig. 74-16).[145] For women who have first- or second-degree relatives with breast cancer but do not meet the hereditary breast cancer definition noted above, these women have *familial breast cancer* where it is likely that both genetic and environmental factors play a role in their susceptibility.[137]

Most patients with hereditary breast cancer have mutations in the *BRCA1* or *BRCA2* genes, which are localized to chromosome 17q21 and chromosome 13q12.3, respectively. Both serve as tumor suppressor genes and function as gatekeepers in controlling gene transcription, regulating repair of DNA damage (especially double strand breaks during cell replication), and may play a role in the maintenance of genomic stability.[146–148] Founder mutations exist in the Ashkenazi Jewish population with specific mutations in *BRCA1* (185delAG, 5382insC) and *BRCA2* (617delT).[149] Other BRCA-specific mutations have been identified in Dutch, Scandinavian, French-Canadian, and Belgian populations.[150,151]

The lifetime risk of breast cancer in *BRCA1* and *BRCA2* mutation carriers is estimated to be as high as 85%, which is markedly elevated from a baseline risk of 12% in the general population (Table 74-7). Ovarian cancer risk is higher in *BRCA1* carriers with an estimated risk of 40% to 60% whereas *BRCA2* carriers have a risk of 15%. Among male patients with breast cancer who have a *BRCA* mutation, one-third of mutations involve *BRCA1* and two-thirds involve *BRCA2*. The risk of breast cancer in males is 1% to 5% with a *BRCA1* mutation, and 5% to 10% with a *BRCA2* mutation, versus a risk of 0.1% in the general population.[152–154] In addition, prostate and pancreatic cancer is more common in patients with *BRCA2* mutations.[155,156]

Several commercial tests exist for *BRCA1* and *BRCA2* testing. Prior to genetic testing, patients should undergo genetic counseling where the complexities of testing are discussed along with potential emotional and financial ramifications that can result from

positive test results. Ideally, genetic testing should start with a family member affected with breast or ovarian cancer or both. If that individual tests negative, further testing on an unaffected relative is unlikely to be informative. Candidates for gene testing include those with a known *BRCA1 or BRCA2* gene mutation in the family, a personal history of breast cancer at age 45 or younger, a personal history of breast cancer at age 50 or younger and a family member (parent, sibling, child, grandparent, grandchild, uncle, aunt, nephew, niece or first cousin) diagnosed with breast cancer at any age, a personal history of triple negative breast cancer (TNBC) diagnosed at age 60 or younger, a personal history of ovarian cancer, a personal or family history of male breast cancer, and Ashkenazi Jewish heritage and a personal or family history of breast or ovarian cancer.[157] Once an individual tests positive for a mutation, she should inform her first- and second-degree relatives of their risk status and the potential for DNA testing.

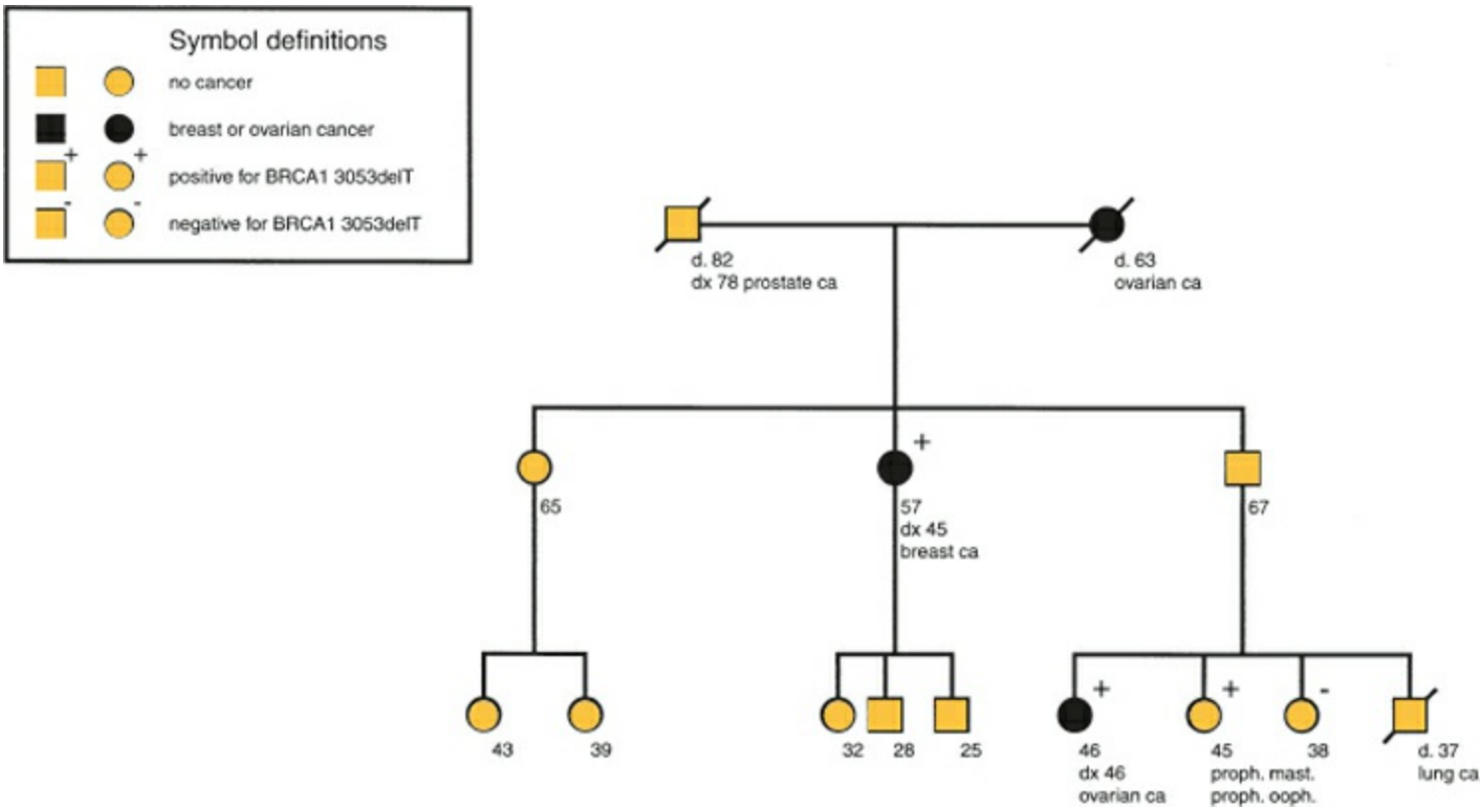

Figure 74-16. Pedigree of genetic breast cancer. The family illustrated in the pedigree carries a mutation of the *BRCA1* gene; multiple relatives are affected with breast and ovarian cancer.

Other breast cancer susceptibility genes include *p53*, *ATM*, *CDH1*, and *PTEN*. The Li–Fraumeni or SBLA syndrome corresponds with *p53* mutations and includes a broad spectrum of cancers including sarcoma, breast cancer and brain tumors, lung and laryngeal cancer, leukemia, lymphoma, and an adrenal cortical carcinoma.[158] The *ATM* gene mutation results in a childhood neurologic disorder referred to as ataxia—telangiectasia, which is characterized by progressive cerebellar and neuromotor deterioration, telangiectasia of the conjunctivae and facial skin, and growth retardation. Females with the *ATM* mutation have a five times higher risk for developing breast cancers than the general population.[159] Females with the *CDH1* or E-cadherin gene

mutation have a 70% lifetime risk for diffuse gastric cancer and a 40% risk for lobular breast cancer.[160] Distinctive mucocutaneous lesions referred to as trichilemmomas characterize Cowden disease, which is associated with an increased risk of breast, thyroid, and genitourinary tract cancers in women, resulting from a *PTEN* gene mutation.[161]

Clinical Risk Assessment

Through large population studies, numerous factors that can increase breast cancer risk have been identified as summarized in Table 74-8. In an effort to quantitate these potential risks such that preventive strategies can be better tailored, multiple risk assessment tools have been developed including the BCRAT or the Gail model 2,[162] BRCAPRO,[163] BOADICEA,[164] Tyrer-Cuzick,[165] and the Breast Cancer Surveillance Consortium.[166] The Gail model calculates risk over a defined time interval and predicts risk accurately in groups of women 35 years of age and older who undergo annual mammography. The model is not for women who have a strong family history of breast cancer (such as genetic mutation carriers) or those with LCIS. The components of the Gail model include current age, age at menarche, age at time of first live birth, number of first-degree relatives with breast cancer, number of prior breast biopsies, prior breast biopsy with atypia, and race. A sample risk calculation is shown in Figure 74-17. Women are considered to be at high risk if their 5-year risk is >1.7%, or if their lifetime risk of breast cancer is at least 20%.

Table 74-7 Estimated Lifetime Cancer Risks for *BRCA1* and *BRCA2* Mutations (To Age 70)

Type of Cancer	General Population (%)	*BRCA1* Carrier (%)	*BRCA2* Carrier
Breast cancer	8.0	40–85	40–85
Contralateral breast cancer	0.5–1/yr	40–65	40–65
Male breast cancer	0.1	1–5	5–10
Ovarian cancer	1.4	30–45	10–20

Modified from Isaacs C, Peshkin BN, Lerman C. Evaluation and management of women with a strong family history of breast cancer. In: Harris JR, Lippman ME, Morrow M, et al., eds. *Diseases of the Breast*. 3rd ed. Philadelphia, PA: Lippincott Williams & Wilkins; 2004:316.

Table 74-8 Magnitude of Known Breast Cancer Risk Factors

Relative Risk <2
Early menarche
Late menopause
Nulliparity
Proliferative benign disease
Obesity
Alcohol use
Hormone replacement therapy
Relative Risk 2–4
Age >35 first birth
First-degree relative with breast cancer
Radiation exposure
Prior breast cancer
Relative Risk >4
Gene mutation
Lobular carcinoma in situ
Atypical hyperplasia

Management

All women at high risk for breast cancer should undergo genetic counseling, with education provided about the risk factors, genetics, and natural history of breast cancer. These women should be followed with enhanced surveillance, and chemoprevention or prophylactic surgery should be considered. For women who have a genetic predisposition, such as those with a *BRCA1* or *BRCA2* mutation, many experts support aggressive surveillance including CBE biannually beginning at age 20 years and annual mammography and MRI screening performed in a staggered fashion such that imaging occurs every 6 months starting at age 25. The use of screening MRI for women at high risk is supported by numerous studies (see the section on Screening MRI). Prophylactic mastectomies can be considered at any age; many women prefer to defer this until after childbearing as they would like to breast-feed. Ovarian cancer screening for *BRCA1* and *BRCA2* carriers includes transvaginal ovarian ultrasound, serum CA-125, and annual pelvic examinations starting at age 30. When childbearing is complete, prophylactic oophorectomies should be considered. In women with a family history but no known genetic abnormality, screening mammography should begin 10 years before the age of onset in the youngest diagnosed first-degree relative or at age 40. Furthermore, in the absence of a genetic abnormality, women who have a lifetime risk of breast cancer >20% should also be monitored with annual screening MRI.

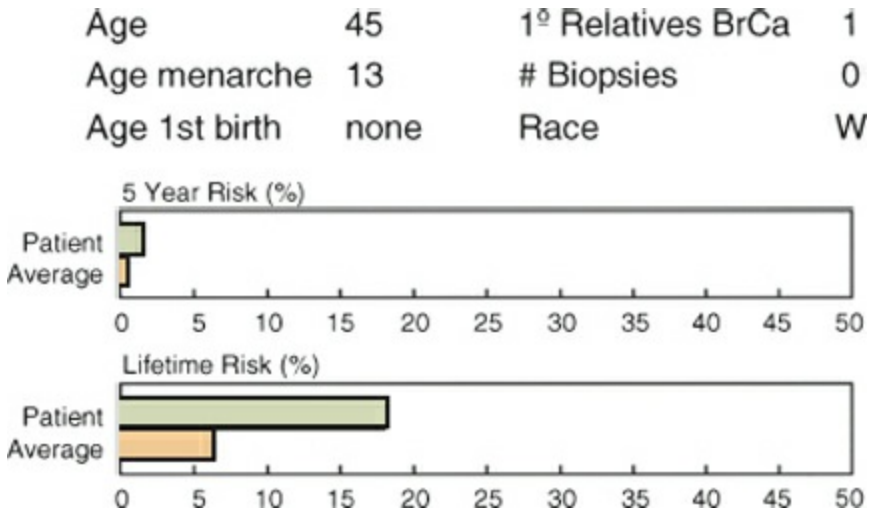

Figure 74-17. Breast cancer risk assessment according to the Gail model. This woman's 5-year risk for the development of breast cancer is 1.6%, and her lifetime risk is 18%.

In addition to its role in the treatment of breast cancer, endocrine therapy (chemoprevention) can reduce the risk of invasive and/or in situ breast cancers in women at high risk for breast cancer. Women who are known to benefit from chemoprevention include those older than 35 years with a history of LCIS, DCIS, or atypical proliferative lesions of the breast, women between 35 and 59 years of age with a Gail model risk of breast cancer >1.7% over 5 years, and women with known *BRCA1* or *BRCA2* mutations who do not undergo bilateral prophylactic mastectomies. Currently, there are no data regarding the risks and benefits of chemoprevention in male patients with breast cancer

and as such, the use of these agents in men is not recommended.

For pre- and postmenopausal women at increased risk of breast cancer, both tamoxifen and raloxifene can be used. As selective estrogen receptor modulators (SERMs), both agents block the effects of endogenous estrogen on normal breast tissue and breast cancer. Using data from four trials in the 2013 USPSTF meta-analysis, tamoxifen has been shown to reduce the risk of estrogen receptor (ER)-positive breast cancer (RR, 0.70; 95% CI, 0.59 to 0.82). Similarly, using data from two trials in the 2013 USPSTF meta-analysis, raloxifene reduced the risk of ER-positive breast cancers (RR, 0.44; 95% CI, 0.27 to 0.71).[167,168] In terms of the choice between tamoxifen and raloxifene, the STAR trial directly compared tamoxifen with raloxifene and showed that the former was slightly more effective at preventing invasive breast cancer (Fig. 74-18). However, neither reduced breast cancer-specific or all-cause mortality rates.[169]

Both tamoxifen and raloxifene have estrogenic activity on the bone resulting in a decreased incidence of fractures, while only tamoxifen has estrogenic activity on the uterus and coagulation pathways. Therefore, tamoxifen use is associated with an increased risk of endometrial cancer (4 cases in 1,000 women, RR 2.13; 95% CI, 1.36 to 3.32) and thromboembolic events (4 cases in 1,000 women; RR 1.93; 95% CI, 1.41 to 2.64),[167] with a trend toward higher stroke rates and pulmonary embolism.[170] Despite these risks, quality-of-life measures (depression, anxiety, major psychosocial outcomes) show no differences in women receiving the drug versus placebo. However, an increase in vasomotor symptoms, gynecologic symptoms, and problems of sexual functioning was noted.[171,172] As congenital anomalies have been associated with tamoxifen, women with childbearing potential must implement an effective contraceptive method. For women desiring a pregnancy, tamoxifen should be discontinued for at least 2 months prior to attempt at pregnancy.

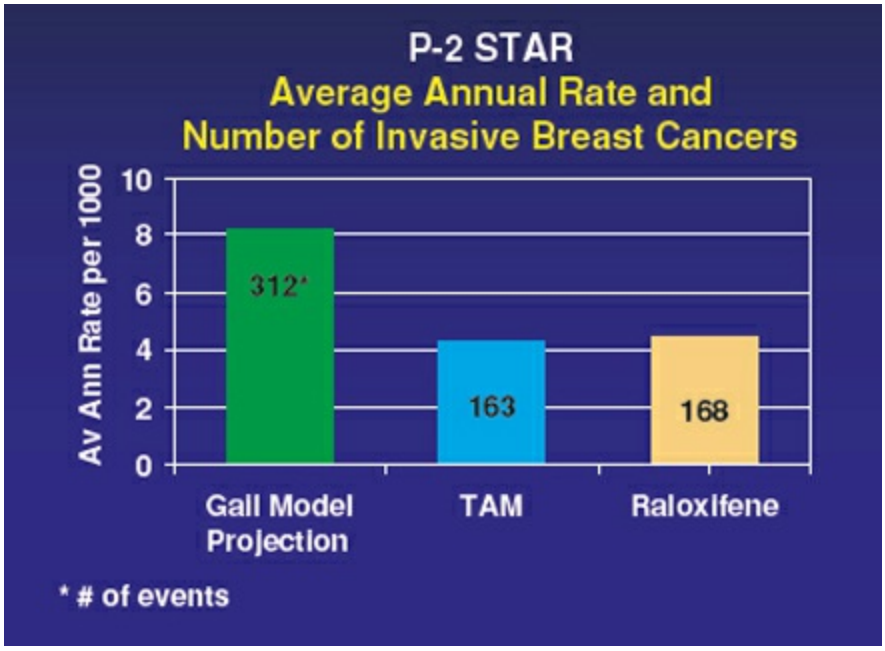

Figure 74-18. Both tamoxifen and raloxifene when taken for 5 years in the National Surgical Adjuvant Breast and Bowel Project P-2 (STAR trial) were equally effective at reducing the risk of invasive breast cancer.

In postmenopausal women, studies show that aromatase inhibitors (AIs) are a reasonable alternative to tamoxifen and raloxifene. AIs suppress plasma estrogen levels by inhibition of aromatase, an enzyme that converts androgens to estrogens. Although AIs are commonly used for breast cancer treatment, they are not approved in the United States for breast cancer prevention at this time. Also, while both the USPSTF and the American Society of Clinical Oncology (ASCO) support the use of SERMs for both premenopausal and postmenopausal women, only ASCO considers the use of exemestane as a reasonable alternative to SERMs for postmenopausal women.[173] More recently, the International Breast Cancer Intervention Study (IBIS-II trial) showed that high-risk postmenopausal women who took the AI anastrozole had a 50% reduction in the number of invasive breast cancers and DCIS compared with placebo. The side effects of anastrozole include musculoskeletal problems, hypertension, vaginal dryness, and vasomotor symptoms.[174] AIs may also be associated with a loss of bone density.

The decision to proceed with endocrine therapy chemoprevention must be individualized. In general, the data support the use of endocrine therapy versus observation. For premenopausal and postmenopausal women, tamoxifen and raloxifene are both reasonable options. If a woman's primary concern is breast cancer prevention, then tamoxifen should be chosen. However, if there are risk factors for uterine cancer and or thromboembolic complications, raloxifene is a reasonable alternative. If a postmenopausal woman does not want to take a SERM, then an AI can be prescribed.

DUCTAL CARCINOMA IN SITU

DCIS is commonly defined as the proliferation of malignant epithelial cells within the mammary ductal system with no evidence of invasion into the surrounding stroma on routine light microscopic examination (Fig. 74-19). It is further categorized by its size, nuclear grade, presence and extent of comedo necrosis, and architectural pattern. Common histologic subtypes of DCIS include comedo, cribriform, micropapillary, papillary, and solid.[175] DCIS is designated as Tis (DCIS) by the TNM staging system and considered a stage 0 breast cancer.[176] The incidence of DCIS increases with age and is uncommon in women younger than 30 years. In women aged 50 to 64 years, the risk is as high as 88 per 100,000 women.[177] Among the breast cancers diagnosed in the United States, 25% are DCIS.[178] The risk of development of metastases and/or death in women with DCIS is rare (<1%).[179]

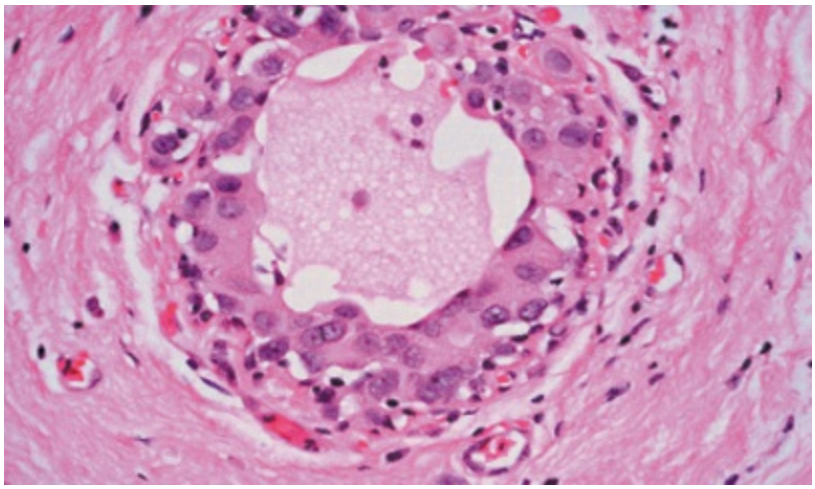

Figure 74-19. Photomicrograph of ductal carcinoma in situ. The abnormal cells do not cross the ductal basement membrane. The necrotic debris in the center of the duct is responsible for the calcification visible on mammography.

Most patients with DCIS will present with no breast-related symptoms or findings on physical examination. More than 90% of all cases of DCIS are detected on imaging studies – commonly as microcalcifications on mammography.[180,181] Prior to routine screening mammography, DCIS presented as a palpable mass, in association with nipple discharge, or as Paget disease.[182,183] Although most patients with DCIS have microcalcifications of indeterminate morphology, patterns that are highly suggestive of DCIS include linear branching or segmental types of pleomorphic microcalcifications.[181]

Once an abnormal lesion is detected by diagnostic imaging, the diagnosis of DCIS is typically confirmed by breast biopsy. Of note, when DCIS is diagnosed initially by core biopsy, 15% to 20% of lesions will be upgraded to invasive cancer at the time of definitive resection. Large, high-grade DCIS lesions are more likely to have an invasive component.[184]

5 Surgical options for the treatment of DCIS include breast-conserving surgery as a component of breast conservation therapy (BCT) (partial mastectomy and postoperative radiation therapy) or simple mastectomy. Although there is no randomized trial that has

ever compared the treatment of DCIS by mastectomy with treatment by BCT, a large number of clinical studies have shown that the local recurrence rate of BCT is 10% to 15% after 10 years and that approximately half of the local recurrences are invasive carcinoma.[185–189] Mastectomy is curative in 98% of patients with DCIS, regardless of the tumor grade or the size of the lesion.[185,186] However, both surgical treatment options are associated with equivalent long-term survival as shown in both retrospective and prospective analyses.[190–192] Given that partial mastectomy is a much less invasive surgical procedure, BCT is typically recommended over mastectomy. Mastectomy should be performed if BCT is contraindicated, or based on patient preference. BCT is contraindicated with multicentric disease, extensive disease where resection would result in poor cosmesis, and in patients who cannot receive radiation therapy. For patients undergoing mastectomy, immediate breast reconstruction options should be considered.

BCT typically includes a partial mastectomy with negative surgical margins, followed by radiation therapy to eradicate any residual disease. Radiation therapy is often recommended, except in rare circumstances (see the section on Breast Cancer in the Elderly). Four prospective, randomized clinical trials – NSABP B-17[188,189] (1998, 2001), EORTC 10853[193] (2006), United Kingdom[194] (2003), and the SweDCIS[195] (2008) have focused on the role of radiation therapy in the treatment of DCIS (Table 74-9). Despite differences in study design, the results are very similar, demonstrating a 50% to 60% reduction in local recurrence with surgical excision and radiation therapy compared to surgical excision alone. Furthermore, the results of NSABP B-17 confirm that the reduction in local recurrence persists through 12 years of follow-up. However, no survival benefit from radiation therapy was observed. Patients with comedo necrosis, uncertain margins, and/or those at highest risk for recurrence appear to benefit most from radiation therapy.[196] However, even in the most favorable subgroup (absent or slight comedo necrosis, clear margins), radiation therapy was associated with a reduction in the absolute incidence of breast recurrence by 7% at 8 years.

Given the risks, inconvenience, and cost associated with radiation therapy, attempts have been made to define a subgroup of patients with DCIS who may not require radiation therapy. The ECOG 5194 study investigated patients undergoing local excision alone in women with low-risk DCIS (low- to intermediate-grade DCIS lesions were <2.5 cm, and high-grade DCIS lesions were <1.0 cm). Margins were at least 3 mm and a postexcision mammogram was obtained for all patients to document the adequacy of surgical resection. Tamoxifen following excision was allowed but not required. At a median follow-up of 6.7 years, the local recurrence rate at 5 years was 6.1% (95% CI, 4.1% to 8.2%) for patients with low- to intermediate-grade DCIS ($n = 565$), and 15.3% (95% CI, 8.2% to 22.5%) for patients with high-grade DCIS ($n = 105$).[197] These findings suggest that local excision alone may be sufficient for select patients with low- to intermediate-grade DCIS. However, identifying these patients remains a challenge.

Table 74-9 Results of Randomized Trials of Radiotherapy in Ductal

Study	Patients (No.)	Median Follow-up (Mo)	IBTR (%)	
			E	RT
NSABP B-17[181,182]	813	44	40	17
EORTC 10853[186]	1,010	126	26	15
United Kingdom[187]	1,030	53	14	6
SweDCIS[188]	1,046	96 (mean)	27	12

DCIS, ductal carcinoma in situ; E, excision alone; EORTC, European Organization for Research and Treatment of Cancer; IBTR, ipsilateral breast tumor recurrence; NSABP, National Surgical Adjuvant Breast Project; RT, radiation therapy.

Other models that have attempted to predict the likelihood of local recurrence following excision alone in patients with DCIS include the Van Nuys Prognostic Index (VNPI)[198] and its updated version, the University of Southern California Van Nuys Prognostic Index (USC/VNPI).[199] Patients are classified into three groups on the basis of pathologic classification: (1) non–high-grade DCIS without comedo-type necrosis, (2) non–high-grade DCIS with comedo-type necrosis, and (3) high-grade DCIS with or without comedo-type necrosis. The USC/VNPI score (range is 4 to 12) is then calculated on the basis of the pathologic classification score and points given for margins, tumor size, and the patient's age. The study's conclusion is that women with an overall low score (4, 5, 6) did not require radiation therapy. However, attempt to replicate and validate the USC/VNPI score in other data sets have had varying success[200–202] and as such it is not commonly used.

More recently, gene expression analysis has been explored in an attempt to distinguish patients who may omit postexcision radiation therapy. The DCIS Recurrence Score is a multigene assay that was developed using tumors from 327 patients who participated in the ECOG5194 trial as described previously.[203] The DCIS Recurrence Score is designed to stratify patients into three groups corresponding to the 10-year risk of developing ipsilateral DCIS or invasive breast cancer. Those with a low score (<39) had a risk of ipsilateral recurrence of 12% and 5%, respectively; intermediate score (39–54) had a risk of ipsilateral recurrence of 25% and 9%; and high score (>55) had a risk of ipsilateral recurrence of 27% and 19%. It must be noted that for some patients, a 12% risk of an ipsilateral recurrence at 10 years may not justify omission of radiation therapy. Furthermore, validation of this multigene assay is required prior to its implementation into clinical practice.

Axillary lymph node involvement in DCIS is rare, and sentinel lymph node biopsy is not indicated during breast-conserving surgery. In the NSABP B-17 and B-24 trials, the axillary recurrence rates, irrespective of treatment, were 0.83 and 0.36 per 1,000 patient-years of follow-up.[204] If a patient is undergoing a mastectomy following core needle biopsy, SLN biopsy should be considered as it is possible that an occult invasive breast cancer will be identified, and SLNB is often not feasible after mastectomy. Of note, SLNB after a mastectomy has been explored through skin mapping. Radiocolloid with or

without blue dye is injected superior to the mastectomy incision into the skin flap, with successful identification of a sentinel lymph node in 13 out of 20 patients (65% success rate).[205] Our institution has had slightly higher success rates with the injection of both radiocolloid and blue dye.

After breast-conserving surgery, a postexcision mammogram should be obtained prior to the initiation of radiation therapy to ensure that there are no persistent residual suspicious calcifications. Treatment for DCIS after breast conserving surgery is not considered complete without adjuvant radiation therapy (see the section on Radiation Therapy).

There is no role for chemotherapy in DCIS. However, endocrine therapy is commonly recommended. Fifty percent to seventy-five percent of DCIS specimens express estrogen and progesterone receptors.[206,207] In the United States, only tamoxifen has been approved to prevent breast cancer recurrences in women with DCIS. Currently, no data exist to support the use of AIs in this population. The benefit of tamoxifen therapy in decreasing local recurrence rates is supported by both a meta-analysis of two randomized trials and by NSABP B-24. The meta-analysis consists of 3,375 women and shows that tamoxifen after surgery for DCIS reduces recurrence of both ipsilateral DCIS (HR, 0.75; 95% CI, 0.61 to 0.92) and contralateral DCIS (HR, 0.50; 95% CI, 0.28 to 0.87) (Fig. 74-20). There is also a trend toward decreased ipsilateral invasive cancer (HR, 0.79; 95% CI, 0.62 to 1.01) and reduced contralateral invasive cancer (HR, 0.57; 95% CI, 0.39 to 0.83). The number needed to treat in order for tamoxifen to have a protective effect against all breast events was 15. However, there was no difference in all-cause mortality (RR, 1.11; 95% CI, 0.89 to 1.39).[208] In a retrospective review of NSABP B-24, it was found that at 10 years of follow-up, patients (n = 732) with ER-positive DCIS treated with tamoxifen had significant decreases in any subsequent (invasive and/or noninvasive; ipsilateral and/or contralateral) breast cancer events compared with those who received placebo (HR, 0.58; 95% CI, 0.42 to 0.81; $p < 0.0015$).[209]

The NCCN Task Force guidelines for management of patients with DCIS who have not undergone bilateral mastectomies include consideration of tamoxifen for 5 years rather than observation, recognizing that although there is an improvement in recurrence rates, there is no proven survival benefit.[210] In women who have undergone bilateral mastectomies, the risks associated with tamoxifen use likely outweigh the benefits. Furthermore, tamoxifen is not typically recommended for patients with ER-negative DCIS.

EVALUATION OF THE PATIENT WITH BREAST CANCER

Breast cancer is a heterogenous disease that can be characterized further on the basis of clinical and pathologic features. Further characterization and staging of breast cancer in patients with newly diagnosed breast cancer can facilitate definitive treatment. Pathologic, biologic, and anatomic characteristics are used in combination to predict prognosis and response to therapy.

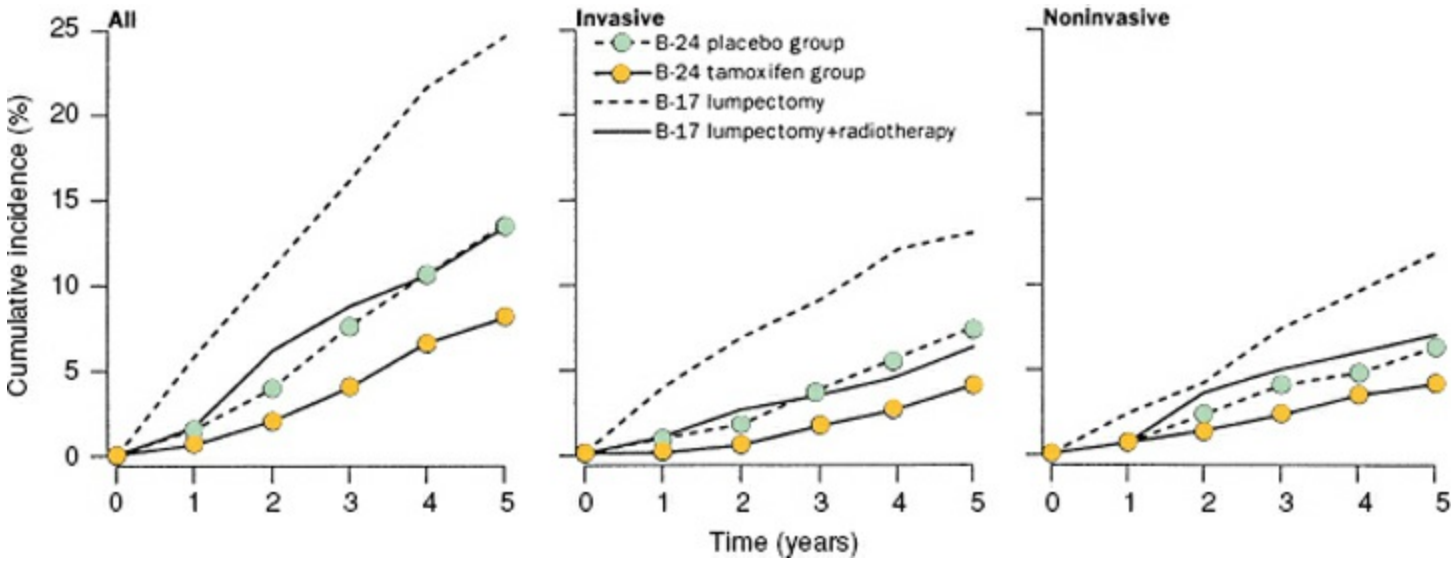

Figure 74-20. Benefits of radiation therapy and tamoxifen in ductal carcinoma in situ. The cumulative incidence of breast cancer events in the ipsilateral and contralateral breasts for patients treated in the National Surgical Adjuvant Breast and Bowel Project B-17 and B-24 trials is shown. The reduction in recurrence is greatest for patients receiving radiotherapy and tamoxifen.

AJCC TNM Staging

The seventh edition of the AJCC TNM staging system for breast cancer is an internationally accepted system used to characterize the extent of disease, predict prognosis, and facilitate medical decision-making (Table 74-10).[176] In this system, breast cancer is classified on the basis of the primary tumor type (invasive or in situ) and size (T), the presence or absence of regional lymph node involvement (N), and the presence or absence of distant metastases (M).

Noninvasive breast cancers are noted as Tis and further classified into Tis (DCIS), Tis (LCIS), and Tis (Paget). T1 tumors are invasive cancers $\leq$20 mm; T2 tumors are $>$20 mm but $\leq$50 mm; whereas T3 tumors are $>$50 mm. T4 tumors are of any size with direct extension to the chest wall and or the skin, resulting in nodules or ulcerations. Invasion of cancer into the dermis alone does not qualify as T4.

Lymph node classification criteria differ depending on whether the lymph nodes were clinically or pathologically assessed and as such are designated as cN or pN, respectively. When possible, pathologic classification is preferred. Regional lymph nodes are defined as those of the ipsilateral axilla, ipsilateral intramammary, internal mammary nodes, and supraclavicular nodes. Metastasis to any other lymph node, including cervical or to the contralateral axillary lymph node, is classified as distant disease (M1). In regard to the clinical classification of the regional lymph nodes, cN0 refers to no regional lymph node metastases. Mobile level I and II axillary lymph nodes containing metastases are considered cN1, whereas fixed or matted nodes are cN2. When metastases occur in the infraclavicular lymph nodes, ipsilateral internal mammary lymph nodes *and* axillary lymph nodes, or to the ipsilateral supraclavicular lymph nodes, it is classified as cN3.

In order to discuss the pathologic classification of regional lymph nodes, it is important to note that breast cancer metastases must be greater than 0.2 mm and exceed 200 cells in a single histologic lymph node cross-section to be considered clinically relevant. As such, pN0 refers to no regional lymph node metastases, pN1mi is used to describe micrometastases ($>$0.2 mm or $>$200 cells, but none $>$2.0 mm), and pN1 is used to describe metastases in one to three lymph nodes and/or internal mammary nodes with metastases detected by SLN biopsy but not clinically detected. pN2 disease occurs when metastases are present in four to nine axillary lymph nodes or in clinically detected internal mammary lymph nodes in the absence of axillary lymph node metastases. pN3 disease includes metastases in 10 or more axillary lymph nodes, metastases to the infraclavicular (level III axillary) lymph nodes, in clinically detected ipsilateral internal mammary lymph nodes in the presence of one or more positive level I or II axillary lymph nodes, in more than three axillary lymph nodes and in internal mammary lymph nodes with micrometastases or macrometastases detected by SLN biopsy but not clinically detected, or in ipsilateral supraclavicular lymph nodes.

Distant metastasis (M1) is defined as detectable metastases as determined by classical clinical and radiographic means and/or histologically proven larger than 0.2 mm. When no clinical or radiographic evidence of distant metastases is present but deposits of molecularly or microscopically detected tumor cells are found in circulating blood, bone

marrow, or other nonregional nodal tissue that is no larger than 0.2 mm in a patient with no symptoms of metastases, the designation used is cMO(i+).

The particular combination of the T, N, and M characteristics defines the overall breast cancer stage. Although the TNM staging system estimates predicted survival, it should not be used alone to dictate treatment.

Histologic Subtype and Tumor Grade

Most invasive breast cancers arise from epithelial elements and are categorized as carcinomas, consisting of several histologic subtypes. Based on the Surveillance, Epidemiology, and End Results (SEER) database of the National Cancer Institute between 1992 and 2001, estimated percentages of each histologic subtype of breast cancer in a series involving 135,157 women showed infiltrating ductal carcinoma (IDC) as the most common (76%), followed by invasive lobular (8%), ductal/lobular (7%), mucinous/colloid (2.4%), tubular (1.5%), medullary (1.2%), and then papillary (1%).[211]

Infiltrating ductal carcinoma is the most common type of invasive breast cancer. On gross pathologic evaluation, these lesions are typically firm, gray–white, gritty masses. Cytologic features of these cells range from low grade to highly malignant. Microscopically, these cancers are characterized by cords and nests of tumors cells with varying amounts of gland formation. As these cancer cells infiltrate the breast parenchyma, they induce a fibrous response, resulting in their characteristic irregular, stellate shape. Often, IDC is associated with a variable amount of DCIS.

STAGING

Table 74-10 Tumor, Node, Metastasis (TNM) Classification for Breast Cancer Staging

TNM Definitions	
Primary Tumor	
Tx	Primary tumor cannot be assessed
T0	No evidence of primary tumor
Tis	Carcinoma in situ, ductal or lobular or Paget disease of the nipple with no tumor
T1	Tumor 2 cm or less in greatest dimension
T2	Tumor more than 2 cm but not more than 5 cm in greatest dimension
T3	Tumor more than 5 cm in greatest dimension
T4	Tumor of any size with direct extension to the chest wall (not including pectoralis muscle), skin edema, skin ulceration, satellite skin nodules, or inflammatory carcinoma
Regional Lymph Nodes (Pathologic)	
Nx	Nodes cannot be assessed
N0	No regional node metastases histologically, no additional examination for isolated tumor cells (ITCs)
N1	Metastasis to one to three axillary nodes or in internal mammary (IM) nodes with microscopic disease detected by sentinel node biopsy, which is not clinically apparent
N2	Metastases in four to nine axillary nodes or in clinically apparent IM nodes in the absence of axillary node metastasis
N3	Metastases in 10 or more axillary nodes, or in infraclavicular nodes, or in IM nodes in the presence of one or more positive axillary nodes; or in more than three axillary nodes with IM metastases, or in supraclavicular nodes
Distant Metastases	
Mx	Distant metastasis cannot be assessed
M0	No distant metastasis
M1	Distant metastasis

Stage Grouping			
Stage 0	Tis	N0	M0
Stage I	T1	N0	M0
Stage IIA	T0	N1	M0
	T1	N1	M0
	T2	N0	M0
Stage IIB	T2	N1	M0
	T3	N0	M0
Stage IIIA	T0	N2	M0
	T1	N2	M0
	T2	N2	M0
	T3	N1	M0
	T3	N2	M0
Stage IIIB	T4	N0	M0
	T4	N1	M0
	T4	N2	M0
Stage IIIC	Any T	N3	M0
Stage IV	Any T	Any T	M1

The AJCC Staging System for Breast Cancer.
Used with the permission of the American Joint Committee on Cancer (AJCC), Chicago, Illinois. The original source for this material is the AJCC Cancer Staging Manual, Seventh Edition (2010) published by Springer Science and Business Media LLC, www.springer.com

Infiltrating lobular carcinomas (ILCs) are the second most common type of breast cancer. The incidence rate of lobular carcinoma is rising faster than the rate of ductal carcinoma in the United States. Furthermore, postmenopausal hormone therapy use may

be more strongly associated with lobular carcinoma than with ductal carcinoma. Although some ILCs may appear similar to IDC macroscopically, others may not show a mass lesion with the excised tissue appearing normal or having only a slightly firm consistency. As such, the microscopic size of ILC may be much greater than what is measured grossly. Unlike IDC, ILC induces only a minimal fibrous reaction. Microscopically, these tumors are characterized by small cells that insidiously infiltrate the mammary stroma and adipose tissue individually and in a single file pattern, often growing in a target-like configuration around normal breast ducts. LCIS or DCIS may be present with ILC. There is a higher frequency of bilateral and multicentric disease with ILC than with IDC.[212,213] Infiltrating lobular carcinomas are more common in older women and are typically larger but more differentiated than IDC. Infiltrating lobular carcinomas are almost always ER-positive. The prognosis for ILC and IDC appears to be similar; however, recent reports suggest that the short-term prognosis for ILC may be more favorable.[214,215] Infiltrating lobular carcinomas tend to metastasize later than IDC and spread to unusual locations such as the peritoneum, meninges, and the gastrointestinal tract.[216] Furthermore, lobular breast cancers have been observed in families that carry germline mutations in *CDH1*, the gene that encodes for the E-cadherin protein. The lack of E-cadherin can be used to distinguish ILC from IDC.[217,218]

Mucinous (colloid) carcinoma is a less common histologic subtype that is more common in older patients. On gross examination, these tumors have a soft gelatinous appearance and tend to be well circumscribed. Microscopically, they are characterized by nests of tumor cells, with uniform and low-grade nuclei, dispersed in large pools of extracellular mucus. These lesions have a favorable prognosis.[219,220] Another histologic subtype with favorable prognosis is tubular carcinoma, which is characterized by the presence of well-formed tubular or glandular structures infiltrating the stroma. The tumor cells are low grade and are often associated with low-grade DCIS. Metastatic disease is rare with tubular carcinoma.[221]

Medullary carcinomas are well-circumscribed, soft, tan masses with areas of hemorrhage and necrosis. Microscopically, the tumor cells are poorly differentiated, grow in a syncytial pattern, and have an intense lymphoplasmacytic infiltrate.[222] These cancers occur more frequently in younger patients and are more frequent in women with *BRCA1* mutations, although the majority of breast cancers in patients with *BRCA1* mutation are not medullary.[223] Despite their aggressive histologic appearance, medullary carcinomas are associated with a more favorable prognosis than IDC.[224,225]

Other breast cancer subtypes include macropapillary carcinomas that are highly aggressive and have a tendency for lymph node metastasis even when small in size.[226] Also likely associated with a worse prognosis, metaplastic carcinomas are well-circumscribed tumors that contain various combinations of poorly differentiated ductal adenocarcinoma, mesenchymal (sarcomatous), and other epithelial (e.g., squamous cell) components.[227] When the squamous cell component predominates, the tumors tend to be more aggressive and are frequently refractory to treatment when compared with IDC.[228,229] Unlike IDC, metaplastic breast cancers tend to have fewer T1 tumors, more node-negative tumors, more poorly differentiated or undifferentiated tumors, and have

fewer ER-positive tumors.[227] Metaplastic breast cancers are treated similarly to other invasive breast cancers.[230–232]

The grade of a breast cancer is determined by a combination of the architectural and cytologic features, usually assessed by utilizing the Ellston–Ellis modification of the Scarff–Bloom-Richardson scoring system. This system is based on three parameters including tubule formation, nuclear pleomorphism, and mitotic activity. Each category is assigned a score of 1 to 3 and then a summation score of 3 to 9. The lowest possible score is 3 with scores of 3 to 5 defined as grade 1, 6 or 7 as grade 2, and 8 or 9 as grade 3. Cells that infiltrate the stroma as solid nests of glands and where the nuclei are relatively uniform with little or no evidence of mitotic activity are referred to as well differentiated or grade 1 tumors. When the tumor cells infiltrate as solid nests with some glandular differentiation and nuclear pleomorphism is present, the tumor is categorized as grade 2 or moderately differentiated. In addition, the mitotic activity is moderate. In poorly differentiated or grade 3 tumors, solid nests of neoplastic cells without evidence of gland formation are present. In addition, there is marked nuclear atypia and high mitotic activity.[233]

Biomarker Profile (ER, PR, HER2)

As targeted therapies exist against the estrogen receptor (ER), progesterone receptor (PR), and human epidermal growth factor receptor 2 (HER2), these biomarkers have significant treatment implications. As such, when an invasive breast cancer is diagnosed, expression of these biomarkers is determined. Using immunohistochemistry and image analysis, ER and PR are considered positive if 10% of cells or greater stain positive. The Allred score is another method to quantify ER and PR expression. The Allred score integrates the percentage of cells that stain positive with the intensity of staining to give a score of 0–8.[234] The goal of the Allred score is to quantify ER expression on the basis of the likelihood that a patient with breast cancer will respond to endocrine therapy. One of the benefits of the Allred score is that by integrating both the percentage and intensity of staining, patients with $<10\%$ staining may be identified who benefit from endocrine therapy.[235] The receptor tyrosine kinase protein HER2 is a member of the epidermal growth factor receptor family and its amplification or overexpression has been shown to contribute to breast cancer development and progression. HER2 can now be targeted using monoclonal antibodies and small molecule inhibitors. Using immunohistochemistry and image analysis, HER2 is scored 0, 1+, 2+, and 3+. Positivity is noted as 3+, whereas scores of 0 and 1+ are considered negative. A score of 2+ is considered indeterminate and further testing for gene amplification can be performed using either FISH (fluorescence in situ hybridization) or CISH (chromogenic in situ hybridization). The HER2 FISH assay is based on the gene copy number and the ratio between the number of HER2 and chromosome enumeration probe 17 (CEP17) sequences, with positivity defined as a HER2/CEP17 ratio of ≥ 2.0. Positivity is also defined as HER2 copy number ≥ 6.0 signals/cell even if the HER2/CEP17 ratio is <2.0.[236] Alternatively, a more cost-effective and comparable method to FISH testing is the HER2 CISH assay.[237,238]

An emerging biomarker is the Ki-67 index. The Ki-67 antigen is present in all phases of the cell cycle except for the G0/resting phase and reflects of the proliferative potential of a breast cancer. Ki-67 is determined by IHC and noted as a percentage, where $<10\%$ is considered a low proliferative index, 10% to 20% is considered borderline, and $>20\%$ is considered high. The Ki-67 index can also be used to measure the response to endocrine therapy.

Molecular Subtyping

Recent advances in molecular biology, including the development of sophisticated techniques for gene expression profiling, have established a new taxonomy of breast cancer, defining molecular subtypes of breast cancer. This new taxonomy has had a profound impact on the clinical management of breast cancer, as the molecular subtypes differ markedly in prognosis and response to therapy. As gene expression profiling is not routinely performed on clinical specimens, molecular subtypes have been approximated on the basis of expression of the ER, PR, HER2 expression, and other biomarkers. Commonly defined subtypes include luminal A (ER+, PR+, HER2−, Ki-67 <14%), luminal B (ER+ and or PR+, HER2+/−, Ki-67 ≥14%), HER2 (ER and PR−, HER2+), and basal-like (ER, PR, and HER−).[239–241] Luminal A and B subtypes have ER expression; however, the former group has a much better overall survival.[242] Luminal B HER2+ and HER2 subtypes benefit from targeted therapies against HER2. Furthermore, both HER2 and basal-like breast cancers are known to have higher initial responses to anthracycline-based chemotherapy than the luminal subtypes but are associated with a decreased disease-free survival.[243]

Breast MRI

Although there are no data from prospective randomized trials demonstrating improved outcomes with the addition of MRI to the diagnostic evaluation of newly diagnosed breast cancers, the NCCN guidelines suggest that diagnostic MRI should be considered in patients with newly diagnosed breast cancer (1) when the clinical extent of disease appears larger than what is observed on mammography, (2) when there is concern about pectoralis muscle involvement, (3) when there is no evidence of a breast primary in the presence of axillary lymph node metastases, (4) when there is no disease identified on physical examination or mammography in the presence of PDB, (5) in women at very high risk for contralateral breast cancers such as those with *BRCA1/2* mutations, and (6) to help determine the extent of disease prior to treatment. Of note, MRI is associated with a high false-positive rate, and many MRI-detected abnormalities will need to be biopsied in order to meaningfully interpret the results of the MRI.

Table 74-11 Approach To the Axillary Nodes

Finding	Approach
Clinically negative	Sentinel lymph node biopsy
Radiographically suspicious	Fine-needle aspiration (image guided) If no metastatic disease identified, then sentinel lymph node biopsy If metastatic disease is identified, consideration for axillary lymph node dissection
Clinically suspicious	Fine-needle aspiration (image or hand guided) Follow-up management as for radiographically suspicious

Sentinel Lymph Node Biopsy

Breast cancer spread to ipsilateral axillary lymph nodes is common, occurring in 15% to 30% of patients. The presence of axillary lymph node metastases has important prognostic implications and can impact medical, surgical, and radiation oncology decision-making. However, axillary lymph node dissection (ALND) has significant risks, and the therapeutic impact of axillary surgery remains to be clearly defined.[244–246] Currently, SLNB is the procedure of choice for staging of the axilla in breast cancer. Axillary ultrasound has also been used and can facilitate evaluation of patients with an equivocal physical examination (Table 74-11).

6 The SLN hypothesis predicts that breast cancers metastasize to one or a few lymph nodes before involving other lymph nodes in the corresponding lymph node basin. Prospective studies have confirmed this hypothesis, demonstrating that the pathology of the SLN accurately predicts the pathology of the corresponding axillary lymph node basin (Table 74-12). SLNB has significantly fewer complications than ALND, with the risk of lymphedema being significantly lower (2% after SLNB versus 13% after ALND at 12 months).[247]

The SLNB procedure begins with localization of the SLN through injection of radioactive colloid and/or blue dye. Given that the combined use of both tracers appears to be complementary and that failed SLN identification is minimized when both tracers are used, this is our recommended approach. A systematic review by an expert panel convened by ASCO concluded that the use of both blue dye and radioactive colloid was associated with a trend toward a lower false-negative rate.[248]

Prior to surgery, radioactive technetium sulfur colloid is injected peritumorally, intradermally, or into the subareolar plexus. Lymphoscintigraphy can be performed to identify areas of increased radioactivity. Alternatively, a handheld gamma probe can be used to survey the axilla and identify hot spots. The patient is then brought to the operating room and positioned with the ipsilateral arm abducted up to 90 degrees. The breast, anterior chest wall, and axilla are prepped and draped in the usual standard sterile fashion. Five milliliters of blue dye (isosulfan or methylene blue dye) is injected around the tumor periphery, at the palpable edge of the biopsy cavity, or into the subareolar plexus. Blue dye should not be injected directly into the tumor itself as the lymphatics may be occluded by tumor. Likewise, blue dye should not be injected into the seroma cavity following breast surgery as the seroma cavity may not have sufficient lymphatic drainage. For these reasons, we typically inject into the subareolar plexus. Breast massage is performed for 5 minutes to dilate the breast lymphatics and facilitate lymphatic drainage.

Isosulfan blue can be used for SLNB; however, anaphylaxis requiring resuscitation can occur in 0.7% to 1.1% of cases.[249,250] Alternatively, methylene blue can be used. The risks associated with methylene blue include skin necrosis if injected intradermally, pain secondary to caustic reaction, and pulmonary edema.[251–253] These risks can be minimized by diluting the methylene blue, with common dilutions ranging from 2:3 (2 mL of methylene blue mixed with 3 mL of saline, injecting 5 mL total) to 1:4 (1 mL of

methylene blue mixed with 4 mL of saline, injecting 5 mL total). In patients taking serotonergic psychiatric mediations, methylene blue should be used with caution as the dye can prevent the action of monoamine oxidase A, resulting in toxic levels of serotonin or serotonin syndrome. This is characterized by mental status changes, muscle twitching, excessive sweating, shivering, diarrhea, trouble with coordination, and/or fever.[254]

Using a handheld gamma probe, the axilla is systematically surveyed and the skin is marked at the location of the hottest spot. A small incision is then made below the hair-bearing area of the axilla and carried down through the subcutaneous tissue. The clavipectoral fascia is incised with care to visually identify any blue lymphatics. The blue lymphatics are then followed toward the axilla to identify the sentinel lymph node(s). Successful SLN identification by blue dye is defined as the identification of any blue node or non–blue node with a blue afferent lymphatic. These lymph nodes are also evaluated with the gamma probe and the associated counts are recorded. The dissection is continued until all lymph nodes associated with a blue afferent lymphatic are removed and any remaining lymph nodes have less than 10% radioactivity compared to the most radioactive lymph node.[259–261] This often results in more than one SLN being identified and removed. Finally, palpation of the axilla is performed and any suspicious lymph nodes are also removed as gross tumor involvement can interfere with uptake of both radioactive colloid and blue dye. In the case of gross tumor involvement, the radioactive colloid and blue dye may be diverted to a lymph node other than the true SLN, giving rise to a false-negative result if palpation of the axilla and removal of suspicious lymph nodes is not performed.[262,263] Once all SLNs have been identified and removed, the clavipectoral fascia is reapproximated and the skin is closed in two layers.

RESULTS

Table 74-12 Results of Prospective, Multi-Institutional Studies of Lymphatic Mapping and Sentinel Node Biopsy

Study	No. Patients	% SN Identification	% False Negative
ACOSOG Z10[255]	5,237	98.7	N/A
ALMANAC[256]	803	96.1	6.7
NSABP B-32[257]	5,611	97.1	9.8
Sentinella/GIVOM[258]	697	95	16.7

ACOSOG, American College of Surgeons Oncology Group; ALMANAC, Axillary Lymphatic Mapping Against Nodal Axillary Clearance; GIVOM, Gruppo Interdisciplinare Veneto Oncologia Mammaria; NSABP, National Surgical Adjuvant Breast and Bowel Project; SN, sentinel node.

TREATMENT OF THE PATIENT WITH BREAST CANCER

Breast cancer is currently treated with a multidisciplinary approach. Most patients benefit from a combination of therapies that may include surgery, medical therapy, and radiation therapy. This multidisciplinary approach has resulted in a significant reduction in breast cancer mortality.[264] One important consideration is optimal coordination of surgery with the other treatment modalities. In the discussion below we will first provide an overview of how the different treatment modalities are coordinated in early stage, locally advanced, and metastatic breast cancer. After this overview, surgery, medical therapy, and radiation therapy will be discussed in more detail.

Overview

7 Most patients with newly diagnosed breast cancer have no evidence of metastatic disease and are diagnosed with *early stage* breast cancer. This includes patients with clinical stage I (T1N0), IIA (T1N1 or T2N0), or IIB (T2N1) disease. Local regional management often consists of BCT (partial mastectomy with radiation therapy) or mastectomy, noting that the choice in locoregional management does not typically impact the recommendation for adjuvant medical therapy. For patients with clinical T1N0 disease, surgery is typically the first treatment modality. For patients with clinical T2N0 or T2N1 disease, neoadjuvant chemotherapy or endocrine therapy is often the first treatment modality. The goal of neoadjuvant therapy is to shrink the primary breast cancer prior to surgery, facilitating BCT. For patients with a clinically suspicious axilla, an ultrasound-guided FNA may be helpful to determine whether there is metastatic spread to the axilla. If the FNA is negative, then the patient should undergo a SLNB at the time of surgery. For patients with a clinically negative axilla, a SLNB should be planned at the time of surgery with a decision about further management of the axilla, if any, pending the results of the SLNB. The decision to recommend chemotherapy for patients with early breast cancer is primarily dependent on tumor characteristics but also integrates the patient's overall health status and personal preference. Adjuvant chemotherapy is typically recommended when high-risk features are present such as high-grade tumor, large tumor size ($\geq$1.0 cm), unfavorable biomarker profile, or lymph node involvement. In addition, an Oncotype DX can be obtained in patients with ER$^+$/HER2-negative breast cancers and negative lymph nodes. A score of $\geq$31 often suggests that adjuvant chemotherapy will be beneficial. For patients with breast cancers that are hormone receptor-positive, endocrine therapy is typically recommended postoperatively. If adjuvant chemotherapy is recommended, then endocrine therapy is given after completion of chemotherapy. For patients with TNBC, adjuvant chemotherapy is commonly given if the tumor size is $\geq$0.5 cm. Patients who have HER2-positive breast cancers that are $\geq$1.0 cm are treated with adjuvant chemotherapy plus HER2-directed therapy. The management of HER2-positive breast cancers that are $<$1.0 cm is controversial and should be decided by the patient and her provider after a discussion of the risks and benefits of treatment. Adjuvant radiation therapy is typically recommended for all patients who are treated with BCT and a subset of patients who are treated with mastectomy (see the section on Radiation Therapy).

Patients with *locally advanced disease* (clinical stage IIB (T3N0) or stage IIIA-IIIC (T1-T3N2 disease, T4 disease)) are at a higher risk for recurrence and distant metastases, and neoadjuvant and/or adjuvant chemotherapy and radiation therapy are typically recommended (Fig. 74-21). Benefits of neoadjuvant chemotherapy in this clinical context include the ability to treat any potential systemic disease immediately and the ability to directly assess the response to treatment by physical examination and imaging, allowing for suboptimal regimens to be discontinued and other regimens to be prescribed. In patients with hormone receptor-positive disease, neoadjuvant chemotherapy is associated with a higher response rate in a shorter period of time than endocrine therapy. Endocrine

therapy in the neoadjuvant setting is often reserved for postmenopausal women who have contraindications to chemotherapy. For patients with HER2-positive breast cancer, HER2-directed therapy such as trastuzumab is often given with pertuzumab along with chemotherapy. If a patient has a limited response or cannot tolerate the neoadjuvant regimen, she should proceed with surgery. Even if patients have an excellent clinical response, they should undergo surgery to remove the area of involvement. Although BCT is an option for patients with locally advanced breast cancer (LABC) who have a significant clinical response to neoadjuvant chemotherapy, mastectomy is typically recommended for those who initially present with breast cancers that are greater than 5 cm.

Approximately 5% of patients with newly diagnosed breast cancer will present with stage IV disease, and up to 30% of patients who present with early stage breast cancer at diagnosis will develop distant metastatic disease.[265] The approach to patients with metastatic breast cancer is focused on prolonging survival and improving quality of life by minimizing cancer- related symptoms. As such, the treatment plans for these patients are highly individualized.



Figure 74-21. Locally advanced breast cancer. The breast is lifted and the upper half is bulging because of the large tumor. Distortion in the inferolateral contour is evident. The medial skin changes are caused by dermal tumor satellites.

Table 74-13 Recommendations for Adjuvant Therapy

Patient Group	Recommended Treatment
Node Negative, Low Risk	
Tumor <0.5 cm	No treatment or endocrine therapy if ER+
Special histologic types	
1–2 cm, grade 1, ER+	
Node Negative, Higher Risk	
ER+	Endocrine therapy OR chemotherapy + endocrine therapy
ER–	Chemotherapy
Any HER2+	Add trastuzumab to chemotherapy
Node Positive	
ER+	
Premenopausal	Chemotherapy + endocrine therapy
Postmenopausal	Chemotherapy + endocrine therapy OR endocrine therapy alone
ER–	Chemotherapy
Any HER2+	Add trastuzumab to chemotherapy

ER+, estrogen receptor positive; ER–, estrogen receptor negative.

For patients with hormone receptor-positive, HER2- negative disease, the preference is for endocrine therapy alone. However, for patients with rapidly progressing disease, endocrine-resistant disease, or a large tumor burden involving visceral organs, chemotherapy should be considered.[266,267] For patients with HER2$^+$ disease, HER2-directed therapies should be administered along with chemotherapy. For patients with TNBCs, chemotherapy is the only option for the treatment of metastatic disease.

When chemotherapy is indicated, the preference is for sequential single agent therapy, which includes taxanes and anthracyclines. Other options, especially for patients with bone-predominant ER$^+$ metastatic disease who have failed two trials of endocrine therapy, include capecitabine, which is derived from the antimetabolite fluorouracil. Capecitabine also may be indicated for metastatic disease to the brain as it appears to cross the blood–brain barrier.[268–270] Other agents include eribulin, gemcitabine, ixabepilone, etoposide, and platinum agents.

Although combination chemotherapy conveys a higher risk of toxicity, its use is indicated when tumor burden is large or when patients have significant symptomatic disease. This includes anthracycline-containing regimens, non–anthracycline taxane-based regimens, and combination regimens incorporating platinum salts. It is important to note that no prospective study has shown that combination chemotherapy improves overall survival compared with single agent sequential chemotherapy.

For women with metastatic breast cancer, data exist that extending chemotherapy duration is associated with improved progression-free and overall survival. However, prolonged chemotherapy can be associated with more serious toxicities such as neutropenia and neuropathy.[271,272] As such, an individualized approach should be undertaken weighing tumor response against side effects. During treatment of metastatic

disease, the patient needs to be monitored for treatment failure, which includes clinical deterioration during treatment, evidence of new metastatic disease, and increasing size of previously documented metastatic lesions.

The recommendations for adjuvant therapy are summarized in Table 74-13.

Partial Mastectomy

BCT consists of breast-conserving surgery (partial mastectomy) followed by radiation therapy (Fig. 74-22). The use of BCT is supported by six prospective randomized clinical trials demonstrating that partial mastectomy plus radiation therapy offers equivalent survival to mastectomy with a low rate of local recurrence (Table 74-14).[273–281] The local recurrence rate with BCT is 5% to 22% versus 4% to 14% with mastectomy. Of note, most recurrences after mastectomy occur within the first 3 years, but recurrences after BCT tend to occur later.[282–284] Factors that increase local recurrence rate following partial mastectomy include young age, lymph node involvement, ER$^-$ disease, and absence of radiation therapy.[285] The American College of Surgeons, the American College of Radiology, the College of American Pathologists, and the Society of Surgical Oncology have developed consensus standards of care for BCT.[286] Most patients can be offered BCT except for those with (1) multicentric disease, (2) diffuse suspicious microcalcifications on mammography, (3) a history of radiation therapy that includes a portion of the affected breast such that when combined with the current proposed treatment would result in an excessively high total radiation dose to the chest wall, (4) pregnancy (although if in the third trimester, partial mastectomy can be performed with planned breast irradiation deferred postpartum), (5) IBC, and (6) persistently positive margins after multiple attempts at breast-conserving surgery (Table 74-15).

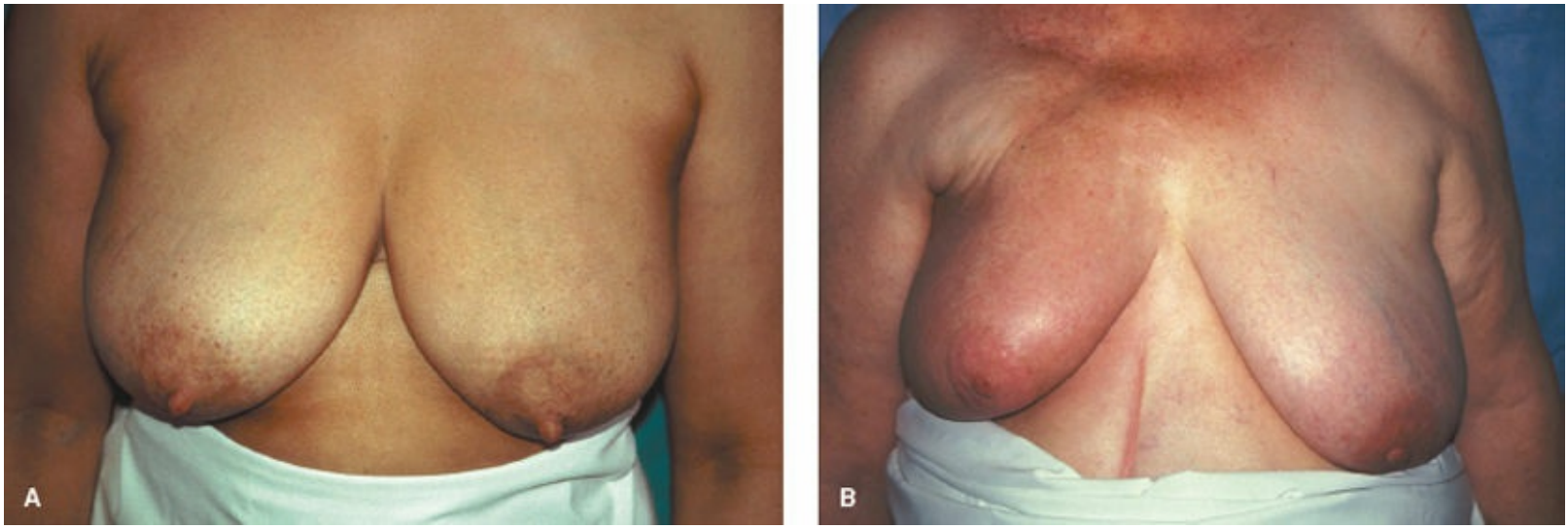

Figure 74-22. Cosmetic outcome after breast-conserving therapy with radiation. **A:** Excellent cosmetic outcome. The treated breast (*left*) is identical to the untreated breast. **B:** Fair cosmetic outcome. Significant shrinkage and loss of ptosis is evident in the treated right breast.

RESULT S

Table 74-14 Survival in Prospective Randomized Trials Comparing Breast-Conserving Therapy with Mastectomy

Trial	Follow-Up (Yrs)	Overall Survival		Local Recurrence	
		BCT (%)	Mastectomy (%)	BCT (%)	Mastectomy (%)
Institut Gustave-Roussy[287]	15	73	65	9	14
Milan I[288]	20	42	41	7	2
NSABP B-06[289]	20	46	47	14	10
NCI[290]	20	54	58	31	6
EORTC[291]	10	65	66	20	12
Danish[292]	6	79	82	3	4

BCT, breast-conserving therapy; EORTC, European Organization for Research and Treatment of Cancer; NCI, National Cancer Institute; NSABP, National Surgical Adjuvant Breast and Bowel Project.

8, 9 The operative approach for a partial mastectomy is very similar to an excisional biopsy and is sometimes referred to as a wide excision, lumpectomy, or segmental mastectomy. The considerations for placement of the incision are similar to those for excisional biopsy; however, it is best to keep the incision within the boundaries of a potential mastectomy incision, and the incision should be made directly over the lesion rather than at the wire insertion site to minimize tunneling. As negative margins are associated with lower rates of recurrence, many techniques have been developed to ensure negative margins at the time of the initial surgery. One common technique is to remove the breast cancer with surrounding normal tissue and then obtain additional shave margins. Each shave margin is labeled and oriented in relationship to the primary cancer.[293–298] In a randomized controlled trial, it was found that cavity shaving at the time of partial mastectomy halved the rates of positive margins (34% vs. 19%, $P = 0.01$) and reexcision (21% vs. 10%, $P = 0.02$).[299] Approaches to evaluate intraoperative margin status include frozen section, cytologic touch prep analysis, and intraoperative ultrasound. However, no method has proven superior and there is no established standard of care. In patients undergoing breast-conserving surgery, it is important to discuss the potential need for reexcision. A histologically positive margin is defined as a margin that has tumor present at the inked margin. Patients with a positive margin have at least a twofold increase in ipsilateral local breast cancer recurrence. As such, controversy has centered on the optimal amount of normal tissue that should be excised around the cancer to minimize local recurrence risk. A recent multidisciplinary consensus panel supports the use of "tumor at ink" as the criteria for positive margin/reexcision based on a meta-analysis that included 33 studies with 28,162 patients and 1,506 ipsilateral recurrences.[300] Like most other institutions, we have adopted this new definition of a positive margin for invasive breast cancers to guide decisions about reexcision. However, given the concern for gaps between lesions or skip lesions in DCIS, we continue to define a negative margin for this pathology as ≥ 2 mm, understanding that this practice may evolve pending more study results.

INDICATIONS/CONTRAINDICATIONS

Table 74-15 Contraindications to Breast-Conserving Therapy in Invasive Carcinoma

Absolute Contraindications

- Two or more primary tumors in separate quadrants of the breast
- Persistent positive margins after reasonable surgical attempts
- Pregnancy is an absolute contraindication to the use of breast irradiation. When cancer is diagnosed in the third trimester, it may be possible to perform breast-conserving surgery and treat the patient with irradiation after delivery
- A history of prior therapeutic irradiation to the breast region that would result in retreatment to an excessively high radiation dose
- Diffuse malignant-appearing microcalcifications

Relative Contraindications

- A history of scleroderma or active systemic lupus erythematosus
- Large tumor in a small breast that would result in cosmesis unacceptable to the patient. In this circumstance, preoperative chemotherapy should be considered.
- Very large or pendulous breasts if reproducibility of patient setup and adequate dose homogeneity cannot be ensured

Axillary Lymph Node Dissection

Until recently, ALND was performed in all patients with newly diagnosed breast cancer to facilitate staging, medical decision- making, and to minimize locoregional recurrence. More recently, SLNB has replaced ALND for axillary staging, and the therapeutic impact of ALND may be limited to specific subsets of patients with breast cancer. In the American College of Surgeons Oncology Group Z0011 trial, eligible patients had T1-T2 invasive breast cancers, no palpable adenopathy, and 1 to 2 SLNs containing metastases identified by frozen section, touch preparation, or H&E staining. Patients were randomized to undergo ALND or no further axillary treatment. Systemic therapy was at the discretion of the treating physician. Patients ineligible for the trial included those with matted lymph nodes, ≥ 3 positive nodes, gross extranodal disease, and those treated with neoadjuvant therapy.[301] After 6 years of follow-up, SLNB alone was not inferior to ALND in patients with limited sentinel lymph node involvement treated with BCT. Of note, these findings have been compared with those of the NSABP B04 trial that was conducted over a decade ago, which randomized women with clinically negative nodes to treatment with radical mastectomy, total mastectomy plus axillary radiation, or total mastectomy with delayed ALND if nodal recurrences were observed. No statistically significant survival differences were observed between any of the groups initially or at any of the analyses up to 25 years of follow-up.[244] These studies suggest that for contemporary women, ALND may not provide a survival benefit in patients who are clinically node-negative. Currently, ALND is limited to patients with positive sentinel lymph nodes who do not meet Z0011 criteria, those with a contraindication to SLNB such as those with clinically palpable pathologic lymph nodes and patients with IBC.

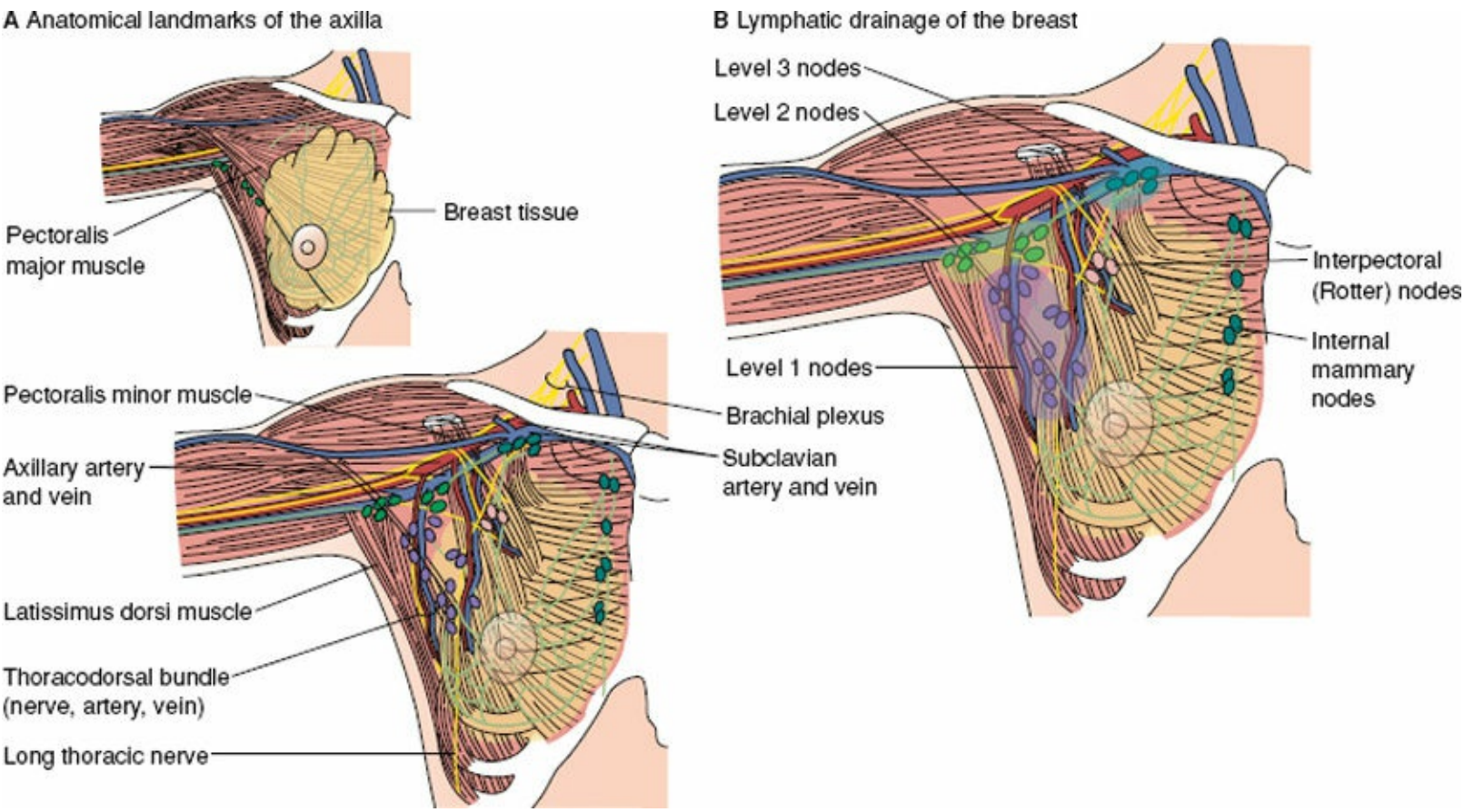

Figure 74-23. **A:** Anatomical landmarks of the axilla. The boundaries of the axillary lymph node dissection are the axillary vein superiorly, the latissimus dorsi and thoracodorsal bundle laterally, and the serratus anterior muscle and long thoracic nerve medially. **B:** Lymphatic drainage of the breast. During an axillary lymph node dissection, level 1 and 2 lymph nodes are removed.

The boundaries of an ALND are the axillary vein superiorly, the serratus anterior muscle and long thoracic nerve medially, and the latissimus dorsi muscle and thoracodorsal nerve laterally. Contemporary axillary dissection in breast cancer involves removal of the level 1 and 2 lymph nodes (Fig. 74-23).[302] Level 3 nodes are palpated and only in the presence of gross disease is dissection performed, as removal of these nodes greatly increases the risk of lymphedema and is rarely ($<1\%$) involved in the absence of level 1 and 2 diseases.[303,304] Typically, a yield of ≥ 10 axillary lymph nodes is achieved with ALND.

The procedure is performed under a general anesthetic that does not include a muscle relaxant as identification of the long thoracic and thoracodorsal nerves is critical to the dissection. Preoperative antibiotics and deep venous thrombosis prophylaxis with sequential compression devices are employed. The patient is placed in the supine position with the ipsilateral arm abducted ≤ 90 degrees. Use of a stockinette allows for mobilization of the arm during dissection. If the ALND is performed through a mastectomy incision (modified radical mastectomy), no additional incisions are required. Also, for partial mastectomies performed in the upper outer quadrant, the partial mastectomy incision can be extended to the axilla. For palpable nodes that are close to, or have eroded the skin, it is important to take the overlying skin during the dissection.

For an ALND performed during a partial mastectomy or as a separate procedure, a

curvilinear skin incision is made 1 to 2 cm below the hair-bearing area of the axilla, following Langer's lines from the border of the pectoralis major muscle to the latissimus dorsi muscle. Although flaps can be developed superiorly, inferiorly, laterally, and medially, most surgeons find that this is not necessary. Once the skin incision is made, the lateral edge of the pectoralis major muscle (PM) is palpated and the PM fascia is then opened with electrocautery. The lateral edge of the PM is then retracted medially to expose the pectoralis minor muscle (PMi), with care to avoid injury to the medial pectoral nerve, which innervates both the PM and the PMi. The tissue at the border of the PMi is then incised with care to avoid injury to the axillary vein or brachial plexus superiorly. If the arm is in a stockinette, it should be flexed medially and anteriorly to relax the PMi. The PM and PMi are then retracted and using blunt dissection, the axillary vein at the medial extent of the dissection can be identified. Further blunt dissection can be performed just below the medial aspect of the axillary vein and just lateral to the chest wall to identify the long thoracic nerve. The long thoracic nerve can also be palpated along the chest wall and once it is identified, the nerve is dissected free of surrounding tissue inferiorly to the insertion. To avoid injury, the fascial layer on the serratus anterior muscle that holds the nerve in place should not be opened. Attention is now turned to identification of the thoracodorsal nerve. Dissection is initiated midaxilla just inferior to the axillary vein. Anterior to the bundle is often the thoracoepigastric vein, which is a large superficial venous tributary arising from the axillary vein. Although the thoracoepigastric vein may need to be transected to allow for completion of the dissection, it is important to first identify the thoracodorsal nerve. The axillary fat pad/contents can then be dissected away from the thoracodorsal bundle using blunt dissection from superiorly to inferiorly with a long fine tonsil clamp. Once the long thoracic and thoracodorsal nerves are identified and dissected free of surrounding tissue, the axillary contents can be mobilized and removed. Of note, there are usually three to five intercostobrachial nerves that supply sensation to the medial–posterior aspect of the arm and run medial to lateral in the field of dissection. An attempt should be made to spare these nerves but only if they do not directly interfere with the dissection. The axillary contents are retracted inferiorly, and using electrocautery or sharp dissection, it is freed from the teres major posteriorly. The axillary contents are then sent en bloc to the pathologist. A single 15 or 19 French round Blake drain can be placed above or below the bra line. However, some surgeons do not place drains for ALNDs, as in the absence of an associated mastectomy, the drainage is often scant. If a drain is placed, it is removed when drainage is less than 30 mL per 24 hours. No antibiotic prophylaxis is necessary.

The approach to ALND described above is a medial to lateral approach with the long thoracic nerve, axillary vein, and thoracodorsal nerve identified in sequence. Alternatively, one can approach the dissection through a lateral to medial approach. With this method, once the clavipectoral fascia is incised to enter the true axilla, the anterior surface of the latissimus dorsi is identified at the lateral extent of the axillary dissection. The clavipectoral fascia is then incised along the superior and medial aspects of the axilla. Dissection is then performed to first identify the thoracodorsal nerve, then the axillary vein superiorly, and then the long thoracic nerve medially. Once all the nerves and

vascular structures are identified, the axillary contents are mobilized and removed.

Complications from ALND include motor and/or sensory nerve injury. Injury to the long thoracic nerve may result in winged scapula, whereas injury to the thoracodorsal nerve leads to weakness of internal rotation and extension, characterized by the functional inability to hold a book under the arm. Other risks include seroma formation, infection, and lymphedema.[305–307] The risk of lymphedema is lifelong and is as high as 30%.

Simple Mastectomy

A mastectomy is performed for patients with breast cancer who are not candidates for BCT or for patients who prefer a mastectomy. For women at high risk for the development of breast cancer, it can be performed as a prophylactic procedure. The goal of mastectomy is complete removal of the breast tissue while preserving muscle function and viable skin flaps for primary closure. Preoperatively, the patient is examined in the holding area, where the breast is marked and the correct site of surgery is confirmed. An intravenous antibiotic that covers skin flora, such as cefazolin, given before skin incision has been shown to significantly decrease the risk of infection in patients undergoing mastectomy (RR 0.60; 95% CI, 0.450 to 0.81).[308] The patient is then placed in the supine position with the arms abducted up to 90 degrees with padding placed beneath the arms and wrist to avoid brachial nerve and radial nerve injury. The skin is then cleansed with a preparation of chlorhexidine gluconate/isopropyl alcohol or Betadine solution and the patient is draped in a sterile fashion. The most common skin incision used is an elliptical incision in the horizontal (Stewart Incision) or diagonal plane (Orr Incision), although historically a vertical plane incision for high lying or infraclavicular lesions has also been used (Fig. 74-24). The medial border of this incision is 2 cm from the sternal edge and the lateral border is at the midaxillary line. The elliptical incision should include the skin directly over the tumor, especially if the tumor is superficial. Once the incision is made, a superior skin flap is developed in the relatively avascular plane between the skin and the breast parenchyma to the level of the clavicle. The fascia of the pectoralis major muscle is then incised from the sternum to the edge of the lateral edge of the muscle with care to preserve the internal mammary perforators. The inferior flap is then developed to the level of the rectus muscle (just at or below the level of the inframammary fold). The underlying fascia is then incised from the sternum to the mid axillary line. The medial flap is then developed similarly, connecting the superior and inferior flaps, with attention to the internal mammary perforators in this area. As these vessels tend to retract, ligation of any bleeding vessel is performed. Unlike the other skin flaps, the lateral dissection tends to be less well defined. The flap is taken down to the level of the latissimus muscle. Care should be taken to avoid the axillary contents and sensory nerves. The breast is then removed en bloc with the fascia of the pectoralis muscle by retracting the breast downward and dissecting the plane between the muscle fibers and the fascia. The wound is then irrigated with warm sterile saline, and the flaps and chest wall are then systematically inspected to ensure hemostasis. A drain is then placed to prevent seroma formation. Skin closure can be performed in different ways, such as with a 3-0 running

polydioxanone suture with a 4-0 subcuticular stitch or with interrupted 3-0 Vicryl sutures with a 4-0 subcuticular stitch. Postmastectomy, the patient is admitted to the hospital overnight to ensure adequate pain control and to monitor for acute bleeding. When drain output is less than 30 mL for 2 consecutive days, the drain is removed (typically between postoperative days 7 and 14). No antibiotic coverage is necessary while drains are in place. In less than 1% of cases, hematomas can occur and if small can be observed. For large or enlarging hematomas (encompassing greater than one-fourth of the chest wall), surgical exploration is required to evacuate the hematoma and stop any sources of bleeding. Other complications associated with mastectomy include skin flap necrosis, pneumothorax, cellulitis, neurapraxia, and lymphedema.

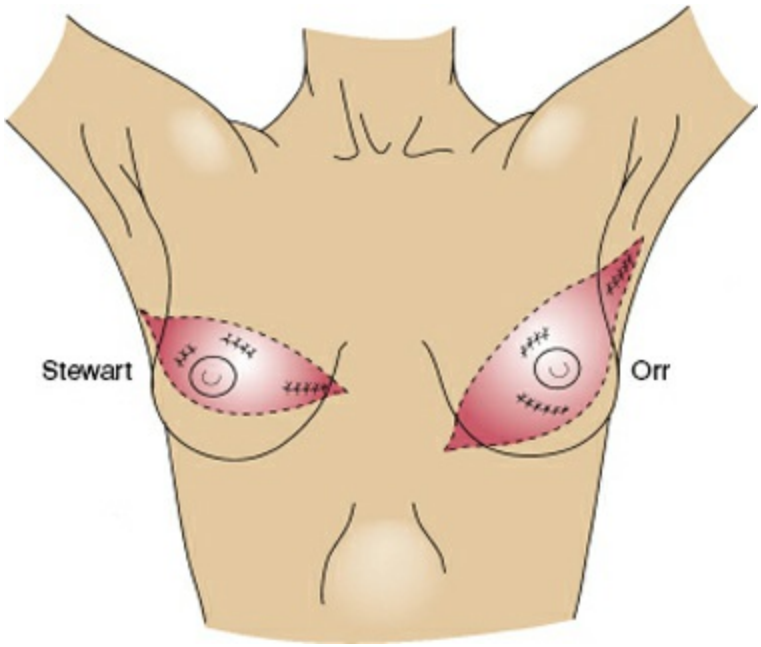

Figure 74-24. Incision placement for modified radical mastectomy. The incision should include the nipple–areola complex, biopsy scar, and excess skin of the breast.

10 If immediate reconstruction is planned, a *skin-sparing* incision is made, which often consists of making a smaller horizontal ellipse around the nipple–areola complex, a circular incision just encompassing the nipple–areola complex, or a lollipop incision (Fig. 74-25). In some circumstances, the patient may be a candidate for a *nipple-sparing mastectomy* if her breasts are small to moderate in size, often no larger than a C cup, with minimal ptosis, and the breast cancer is an acceptable distance (often at least 2 cm) from the nipple. Tumor size, histology, or lymph node status is no longer considered exclusion criteria for nipple-sparing mastectomy, and current exclusion criteria include clinical involvement of the nipple areolar complex, PDB, bloody nipple discharge, multicentric disease,[309] and/or inflammatory carcinoma.[310] Nipple-sparing mastectomies are often performed through an inframammary fold incision or a radial lateral incision. More recently, a lateral vertical incision has been described. This incision is associated with a significant reduction in hypertrophic scar formation versus the radial lateral incision.[311] Intraoperatively, a biopsy of the retroareolar margin is performed and must be histologically negative for malignancy. BRCA mutation carriers are also candidates for

nipple-sparing mastectomies. In a study of 26 patients with BRCA mutations undergoing prophylactic mastectomies, DCIS was identified in one patient compared with two cases of DCIS in the matched control group. There were no locoregional recurrences in the patients with BRCA mutations at 37 months of follow-up.[312] These findings support that nipple-sparing options are reasonable for patients with BRCA mutations.

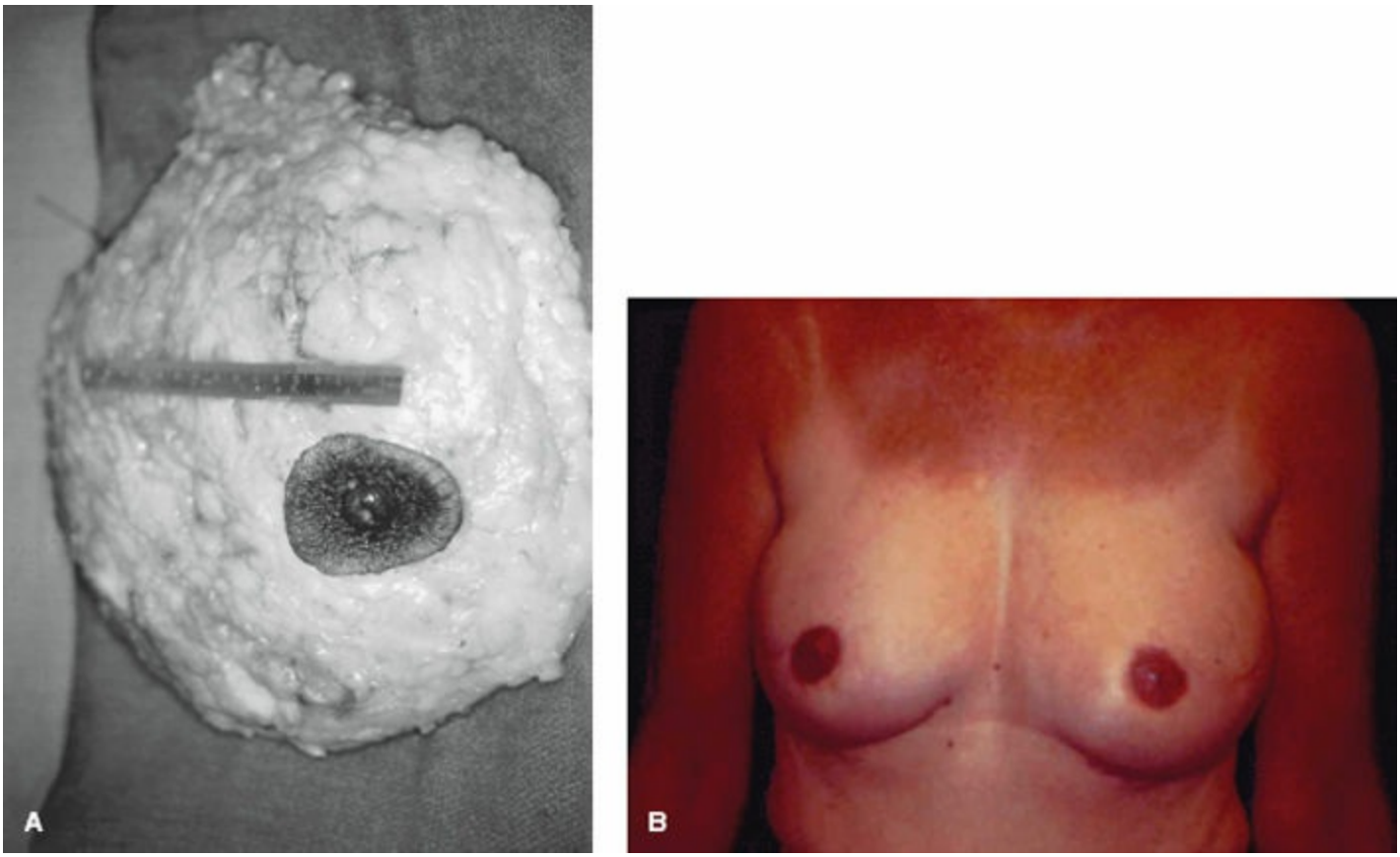

Figure 74-25. Skin-sparing mastectomy. **A:** The only skin removed was the nipple–areola complex. **B:** Cosmetic outcome after bilateral skin-sparing mastectomy and transverse rectus abdominis myocutaneous (TRAM) flap reconstruction.

Although the goal of a mastectomy is to completely remove the breast cancer and normal breast tissue, local recurrence remains a risk. The risk of local recurrence is 6% at 5 years in patients with no lymph node involvement and 16% at 5 years in patients with one to three lymph nodes involved. With the addition of radiation therapy, the risk of local recurrence decreases to 2%. When four or more lymph nodes are involved, the risk of recurrence is 26% at 5 years, decreasing to 6% with the addition of radiation therapy.[313]

In women with a personal history of breast cancer, the absolute risk of contralateral breast cancer is estimated to be 0.5% to 1.0% per year or 5% to 10% during the 10 years following diagnosis.[314] As such, most women will not develop a contralateral breast cancer. As no randomized clinical trials have been performed, it is not known whether contralateral prophylactic mastectomy (CPM) is associated with a survival benefit in women with a personal history of breast cancer. However, a survival benefit for CPM has been shown for patients with a deleterious *BRCA1* or *BRCA2* mutation.[315–318] The decision to perform a CPM must be individualized with each individual patient. Of note, a

twofold increased risk of major complications exists with CPM when compared with unilateral mastectomy.[319,320]

Breast Reconstruction

All patients undergoing mastectomy should be offered consultation with a plastic surgeon for consideration of breast reconstruction, recognizing that some women may choose to forego this procedure and prefer the use of a breast prosthesis. The two main types of breast reconstruction include implant-based and autologous tissue breast reconstruction. Implants include silicone or saline implants. Autologous tissue techniques used for breast reconstruction often include either the transverse rectus abdominis myocutaneous (TRAM) flap or the deep inferior epigastric perforator (DIEP) flap.

Breast reconstruction can be performed immediately after a mastectomy procedure (immediate reconstruction) or at a later time (delayed reconstruction). For implant-based breast reconstruction, the most common technique involves a two-stage method with placement of a tissue expander under the pectoralis major muscle at the time of the mastectomy (Fig. 74-26). The tissue expander can then be filled incrementally with saline with the first fill typically occurring 1 to 3 weeks postoperatively with additional fills every 1 to 2 weeks until the desired expansion is achieved. The tissue expander is then left in place for several months to allow for maximal skin remodeling. During the second stage, the tissue expander is removed and is replaced with a silicone or saline implant. This two-stage reconstruction method is particularly beneficial for women who will need adjuvant radiation therapy as radiation can result in flap necrosis, fibrosis, and shrinkage, resulting in poor cosmetic outcomes after immediate implant and/or tissue flap reconstruction. Instead, the tissue expander allows for skin preservation and the ability to then proceed with either an implant or autologous reconstruction at a later date. The complications associated with tissue expander placement include infection requiring removal. This occurs at a rate of 1.2% but may be higher in women being treated with chemotherapy and/or radiation therapy.[321]

Although silicone gel implants are superior to saline implants in terms of offering a more natural contour and texture, the use of silicone implants remains controversial secondary to unsubstantiated claims of a link between silicone implants and autoimmune disease first reported in 1992. Since that time, no studies have shown a causative relationship and the American College of Rheumatology and the FDA have concluded that there is no additional risk of connective tissue disease in patients with silicone implants.[322–324]

A few case reports have noted an association between breast implants (saline or silicone) and anaplastic large cell lymphoma of the breast. There have been 60 cases of ALCL reported among an estimated 5 to 10 million women with breast implants. Although a causal relationship is not proven and the potential risk is extremely low, the FDA does require breast implant manufacturers to include this finding in the product labeling.[325]

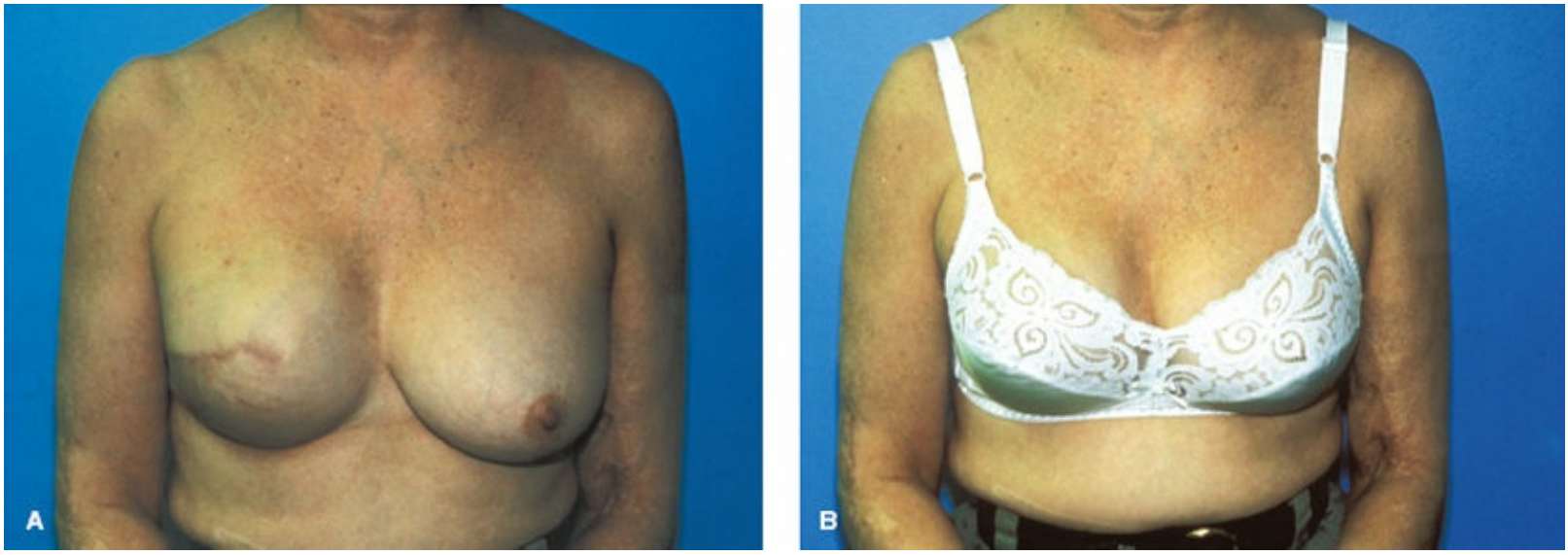

Figure 74-26. Breast reconstruction with tissue expanders. Although the breasts are not identical, this is not evident when a bra is worn.

The primary benefit of autologous tissue breast reconstruction is that the reconstructed breast appears and feels more natural than following implant-based breast reconstruction. In addition, autologous tissue breast reconstruction may be the only option in patients who have undergone chest wall radiation, as skin fibrosis may preclude implant-based breast reconstruction. A common procedure is the free TRAM flap, which involves removing skin, subcutaneous fat, muscle, and associated blood supply from the lower abdomen. The blood supply includes the deep inferior epigastric artery and vein, which are anastomosed to the internal mammary or thoracodorsal arteries and veins. The TRAM flap is contoured to replicate the native breast. Similar to the TRAM flap, the DIEP flap uses the same lower abdominal skin and subcutaneous fat but spares the rectus abdominis muscle. In both methods, the donor site is closed as a modified abdominoplasty.

Radical Mastectomy

In 1907, Halsted presented to the American Surgical Association his results of 232 patients who underwent his radical mastectomy at Johns Hopkins. Halsted's radical mastectomy involved wide excision of skin via a teardrop incision extending across the deltopectoral groove, excision of the entire pectoralis major muscle, resection of the pectoralis minor muscle to expose the axillary contents for dissection, and excision of the supraclavicular lymph nodes. In certain cases, he also removed the mediastinal nodes. Immediate skin grafting was performed to close all of the wounds.[326] With advances in breast cancer screening, adjuvant medical therapy, and radiation therapy, a concomitant evolution toward less radical surgery has ensued. A report by the American College of Surgeons Commission on Cancer demonstrated a dramatic decline in the use of the radical mastectomy from 47.9% of breast cancer cases in 1972 to 3.4% of cases in 1981.[327] Furthermore, the **modified radical mastectomy**, which consists of a simple mastectomy and ALND, was considered a satisfactory alternative to the radical mastectomy by 1980.[328] A randomized, prospective clinical study by W.A. Maddox in 1983 showed no significant differences in disease-free survival, overall survival, or local recurrence rates

at 5 years for modified radical versus radical mastectomy. These differences are likely secondary to the routine use of chemotherapy for patients with involved axillary lymph nodes by this time period.[329] When patients are not candidates for breast conservation and SLNB, a modified radical mastectomy is indicated. See the section on Axillary Lymph Node Dissection above.

Radiation Therapy

The primary indication for the use of radiation therapy in breast cancer is to reduce the risk of a locoregional recurrence following surgery and potentially improve survival by eradicating persistent locoregional disease that may be resistant to systemic therapy.

The standard approach for patients who undergo breast-conserving surgery is to deliver whole breast radiation therapy with a dose of 50 to 60 Gy. The regimen is often given in 2 Gy fractions 5 days a week for a total of 5 weeks. A 60 Gy regimen, which also includes a 10 Gy boost to the tumor bed, was found to be more effective for patients 45 years of age or younger, with a local relapse rate of 14% (60 Gy) compared to 28% (50 Gy) ($p < 0.0001$).[330] Alternative radiation therapy strategies are currently under investigation including the use of rapid fractionation schedules, such as the delivery of 41 to 42 Gy over 15 fractions and accelerated partial breast radiation. Early results show excellent clinical outcomes.[331–333]

Although most women do not require radiation therapy following mastectomy, postmastectomy radiation therapy is often recommended for women at high risk for locoregional recurrence, including women with four or more positive lymph nodes, tumor size greater than 5 cm, or with positive surgical margins. In these instances, postmastectomy radiation can reduce the rate of chest wall recurrence by 65% to 75%.[70,334–337]

11 Of note, optimal locoregional management of the axilla remains to be defined. Both surgery and radiation therapy can be used to treat disease in the axilla. Previously, ALND was the preferred treatment modality for prevention or treatment of axillary disease. More recent studies suggest that radiation therapy may be equally effective with less morbidity. The EORTC AMAROS trial randomized patients with clinical T1-T2 N0 breast cancer to ALND or radiation therapy to the axilla after a positive SLNB.[338] The two arms had comparable axillary control, but patients in the radiation therapy arm had significantly less morbidity. At 5 years, 23% of patients in the ALND arm had lymphedema compared to 11% in the radiation therapy arm. Currently, in patients with clinical T1-T2 N0 disease who undergo mastectomy with a positive SLNB, ALND is the standard approach as these patients were not included in the Z0011 study. However, findings from the AMAROS trial suggest that in this group of patients, radiation therapy may provide similar locoregional control with less morbidity.

Chemotherapy

The role of medical therapy is to eradicate breast cancer cells at the primary tumor site or at any other site in the body. Systemic therapies include but are not limited to chemotherapy, endocrine therapy, and targeted therapy.

The decision as to whether or not to treat patients with breast cancer with chemotherapy is complex. Considerations include patient age, menopausal status, AJCC TNM stage, histologic grade, biomarker profile, proliferation index, and medical comorbidities. Online calculators exist to estimate the risks and benefits of chemotherapy and other adjuvant therapies. Adjuvant! Online is a popular risk-benefit calculator that is based on population-wide data that focuses on recurrence risk and probability of survival. This is a Web-based program that is generated from collective data from the SEER database, the Early Breast Cancer Trialists Collaborative Group (EBCTCG), individual clinical trial results, and published literature.[339] Other calculators include Cancermath.net[340] and FinProg project.[341] Molecular profiling using Oncotype DX or similar molecular assay can be used for patients with node-negative $ER^+/HER2^-$ breast cancers. For Oncotype DX, a score of ≥ 31 is associated increased risk of recurrence with a recommendation for administration of chemotherapy.

Adjuvant chemotherapy is often initiated 4 to 6 weeks after surgery. Although treatment earlier is not beneficial, a delay of greater than 12 weeks may be detrimental. If adjuvant radiation therapy is indicated, it is administered starting 3 to 4 weeks after completion of chemotherapy.

Anthracyclines (Doxorubicin, Daunorubicin, Epirubicin)

These compounds are derived from *Streptomyces* bacteria and function by inhibiting DNA and RNA synthesis by intercalating between base pairs of the DNA/RNA strand, blocking DNA transcription and replication by inhibiting topoisomerase II enzyme, generating free oxygen radicals, and by inducing histone eviction form chromatin. The main adverse effect is cardiotoxicity.

Taxanes (Paclitaxel, Docetaxel)

These compounds are derived from plants of the genus *Taxus* (yews) and function by disrupting microtubule formation and inhibiting mitosis. The main adverse effect is peripheral neuropathy. Given that these compounds are not water soluble, allergic reactions to the diluent may result.

Cyclophosphamide

This compound is a nitrogen mustard alkylating agent that functions by adding an alkyl group to the guanine base of DNA, resulting in intrastrand and interstrand DNA cross-links and, therefore, interferes with DNA replication. The main adverse effects include acute myeloid leukemia, bladder cancer, hemorrhagic cystitis, and infertility.

5-Fluorouracil

This compound is an antimetabolite that works as an irreversible inhibitor of thymidylate synthase and, therefore, interferes with DNA synthesis. The main adverse effect is mucositis.

Methotrexate

This compound is both an antimetabolite and an antifolate that blocks dihydrofolate reductase and, therefore, inhibits the synthesis of folic acid, which is essential for DNA, RNA, thymidylate, and protein synthesis. The main adverse effect is ulcerative stomatitis.

Platinum Agents (Carboplatin or Cisplatin)

These compounds bind to and cause cross-links in DNA, triggering apoptosis. The main adverse effects are nephrotoxicity, neurotoxicity, and ototoxicity.

Endocrine Therapy

Patients with all stages of breast cancer that express the ER or PR are candidates for endocrine therapy. In the premenopausal setting, the focus is on blocking ovarian function and the effects of estrogen. In postmenopausal women, the ovaries are no longer the predominant source of estrogen, but instead estrogen is synthesized mainly from nonglandular sources such as subcutaneous fat. As such, blocking estrogen production is very effective in the postmenopausal population.

Blocking Ovarian Function (Leuprolide, Goserelin, Buserelin)

As the ovaries are the main source of estrogens in premenopausal women, ovarian ablation can be achieved either surgically by removal of the ovaries or through medical therapy with luteinizing hormone-releasing hormone agonists such as goserelin or leuprolide. These compounds function by binding to the gonadotropin-releasing hormone receptor, resulting in initial FSH and LH release. However, with prolonged drug exposure, desensitization of the pituitary occurs whereby the levels of LH and FSH become profoundly suppressed. This results in inhibition of the growth of ovarian follicles and steroidogenesis.

Blocking Estrogen at the Receptor (Tamoxifen, Raloxifene, Fulvestrant)

As SERMs, tamoxifen and raloxifene competitively bind to the ER and prevent estrogen from binding. As a selective estrogen receptor down-regulator (SERD), fulvestrant binds to the ER and targets it for destruction. Fulvestrant is used in postmenopausal women who have hormone receptor-positive metastatic disease who experience progression following endocrine therapy.

Blocking Estrogen Production (Anastrozole, Letrozole, Exemestane)

The enzyme aromatase converts androgenic substrates to estrogen, and, therefore, its inhibition can effectively decrease plasma levels of estrogen. Nonsteroidal AIs include anastrozole and letrozole, whose binding activity can be reversed. Exemestane is a steroidal AI that irreversibly binds aromatase and permanently inactivates it.

Targeted Therapy

Targeted Therapy for HER2+ Breast Cancers

Amplification or overexpression of the human epidermal growth factor receptor 2 (HER2) is present in approximately 20% of primary breast cancers. Given that effective targeted therapies exist for these patients, all newly diagnosed breast cancers are routinely tested for HER2 expression/amplification.

Trastuzumab is a monoclonal antibody that targets HER2$^+$ breast cancers by multiple mechanisms including (1) interfering with the homo- and heterodimerization of HER2 and inhibiting mitogen-activated protein kinase (MAPK) and phosphoinositide 3-kinase (PI3K/Akt) signaling pathways, (2) immune-mediated killing of tumors that overexpress HER2 by a mechanism referred to as antibody-dependent cellular cytotoxicity (ADCC), and (3) triggering HER2 internalization and degradation through promoting the activity of tyrosine kinase-ubiquitin ligase c-Cbl.

Pertuzumab is a monoclonal antibody that interferes with the dimerization of HER2 to HER3, therefore, interfering with MAPK and PI3K pathway activation. It also induces antibody-dependent cell-mediated cytotoxicity (ADCC).

Trastuzumab emtansine (T-DM1) is an antibody–drug conjugate that consists of trastuzumab linked with the cytotoxic agent mertansine (DM1). While trastuzumab binds to the HER2 receptor, mertansine enters the cell and destroys it by binding to tubulin. This allows toxin to be targeted specifically to the cancer cell.

Targeted Therapy for Triple Negative Breast Cancers (Experimental Options)

Although patients with TNBC often have an excellent response to chemotherapy, overall outcomes are worse compared to patients with ER$^+$ and/or HER2$^+$ disease.[236,342,343] The lack of effective targeted therapies for TNBCs likely contributes to this disparity in outcome. Drugs-targeting TNBCs are in clinical trials and include inhibitors targeted to the epidermal growth factor receptor (cetuximab), angiogenesis (bevacizumab), DNA damage or poly adenosine diphosphate-ribose polymerase (olaparib, veliparib, iniparib), the proto-oncogene Src (dasatinib), and histone deacetylase (vorinostat). Given the heterogeneity of TNBC, multitargeted therapy will likely be needed to eradicate this disease.

Treatment Regimens

Adjuvant Medical Therapy for Hormone Receptor-Positive or Negative, HER2-Negative Breast Cancer

For patients at high risk for recurrence, a regimen based on the combination of an anthracycline and taxane has been proven to be the most effective. This combination is commonly given in a dose-dense fashion (whereas traditional chemotherapy is given every 3 weeks, this requires administration every 2 weeks) with doxorubicin (60 mg/m^2) and cyclophosphamide (600 mg/m^2) for four cycles, followed by paclitaxel (175 mg/m^2) every 2 weeks for four cycles. The data to support this regimen come from an EBCTCG meta-analysis. In this study published in 2011, anthracycline-based regimens were compared to CMF (cyclophosphamide, methotrexate, and 5-Fluorouracil), and to no treatment. Both chemotherapy regimens resulted in a significant decrease in the risk of recurrence and a reduction in both breast cancer and overall mortality versus no treatment at 10 years. There was no difference between the anthracycline and CMF treatment regimens with standard doses of doxorubicin (four cycles with 60 mg/m^2 with a cumulative dose of 240 mg/m^2). However, at higher doses of anthracyclines ($>$240 mg/m^2), there was a reduction in the risk of recurrence (absolute difference of 2.6%), a reduction in breast cancer mortality (absolute difference of 4.1%), and a reduction in overall mortality (absolute difference of 3.9%) at 10 years. By 2012, taxanes were routinely combined with anthracycline-based therapies (ACTHs) and the combination regimen resulted in a reduction in the risk of recurrence (absolute difference of 4.6%), a reduction in breast cancer mortality (absolute difference of 2.8%), and a reduction in overall mortality (absolute difference of 3.2%). In addition, the benefits of taxanes were independent of age, nodal status, tumor size, tumor grade, and ER status.[344,345]

Although AC-T has been shown to result in the greatest improvement in outcome, there is no single chemotherapy regimen that is the standard of care as preferred combinations vary by institution, geographic region, and by medical oncologist. Other anthracycline-based regimens include FEC (fluorouracil 500 mg/m^2, epirubicin 100 mg/m^2, and cyclophosphamide 500 mg/m^2) given every 3 weeks for six cycles and FEC-Taxane (FEC every 3 weeks for three cycles, followed by docetaxel 100 mg/m^2) for three cycles or FEC for four cycles, followed by weekly paclitaxel (100 mg/m^2) for 8 weeks. For patients who are not candidates for anthracycline-based regimens, TC can be administered (docetaxel 75 mg/m^2 plus cyclophosphamide 600 mg/m^2) for four cycles given every 3 weeks. CMF (cyclophosphamide 100 mg/m^2 orally days 1 to 14, methotrexate 40 mg/m^2 IV days 1 and 8, and 5-fluorouracil 600 mg/m^2 IV days 1 and 8) for six cycles every 4 weeks is another alternative regimen.

After chemotherapy, for patients with ER$^+$ breast cancer, endocrine therapy should be initiated, as multiple meta-analyses have consistently shown improved survival outcomes with its use. The choice of endocrine therapy is dependent on menopausal status, with menopause being defined as the lack of menstruation for at least 12 months in the absence of tamoxifen, chemotherapy, or ovarian suppression. Menopause can also be achieved surgically with the removal of both ovaries.[70] In premenopausal women, the

preferred agent is tamoxifen, which is a SERM that inhibits the growth of breast cancer cells. In the 2011 EBCTCG meta-analysis, women who took tamoxifen for 5 years had a significant reduction in the risk of breast cancer recurrence (40%) and breast cancer mortality (30%) at 15 years.[346] For premenopausal women who cannot tolerate tamoxifen secondary to side effects, ovarian suppression should be considered and can be accomplished through surgical resection of both ovaries or by administration of a luteinizing hormone-releasing hormone agonist such as leuprolide or goserelin. Although not as effective as tamoxifen therapy, ovarian suppression results in a significant reduction in the risk of recurrence (25%) and a significant reduction in breast cancer mortality (29%) compared with observation.[265]

In postmenopausal women, AIs have consistently been shown to be superior to tamoxifen, as supported by an intention to treat meta-analysis that included 37,000 postmenopausal women with ER$^+$ breast cancer. The AI treatment group had a significant reduction in breast cancer recurrence and breast cancer mortality.[347] Furthermore, in the NCIC CTG MA.17 trial that included more than 5,000 postmenopausal women, who had completed a 5-year course of tamoxifen, followed by an additional course of letrozole or placebo – the letrozole treatment group at follow-up of 64 months had improvement in disease-free survival and overall survival.[348–350] The different AIs have been shown to have similar efficacies and as such there is not one that is preferred. Postmenopausal women, who cannot tolerate an AI because of osteoporosis, AI-associated musculoskeletal syndrome, or cardiac disease, can be treated with tamoxifen. Premenopausal women should not be treated with an AI as it can result in reactivation of ovarian function.[351,352]

The optimal duration of endocrine therapy has also recently been studied. In the Adjuvant Tamoxifen: Longer Against Shorter (ATLAS) trial, 15,000 women were assigned to treatment with tamoxifen for 5 years or 10 years. It was found that the group receiving tamoxifen for 10 years had a reduction in the risk of recurrence, significant reduction in breast cancer mortality after year 10, and a significant reduction in the incidence of contralateral breast cancer. However, this was also associated with an increased cumulative incidence of endometrial cancer (3.1% vs. 1.6%), pulmonary embolus (1.2% vs. 0.6%), and ischemic heart disease (4% vs. 2%).[353] Further supporting the use of tamoxifen for 10 years is the Adjuvant Tamoxifen-To Offer More trial that enrolled 7,000 women. The 10-year tamoxifen treatment group had a significant reduction in the risk of recurrence and a trend toward a reduction in mortality. However, there was an increased cumulative incidence of endometrial cancer and deaths from endometrial cancer. As such, women with more aggressive ER$^+$ breast cancers (high grade, tumor size >2 cm, pathologically involved lymph nodes) should be offered tamoxifen for 10 years, understanding the associated risks.[354] Similarly, in the MA.17R trial extending the use of AIs to 10 years has been shown to decrease the rate of breast cancer recurrence and the development of primary breast cancer in the contralateral breast.[355]

For patients with ER-/PR-/HER2- or TNBC, chemotherapy is critical as no targeted therapies exist for these patients. Adjuvant chemotherapy has been shown to provide a larger benefit for patients with TNBC than for those with hormone-positive disease, with

a larger reduction in the risk of recurrence and subsequently a higher absolute improvement in disease-free survival (23% vs. 7%). Furthermore, there was a larger reduction in the risk of death and as such a higher absolute improvement in overall survival (17% vs. 4%).[356] There is no standard chemotherapeutic regimen for patients with TNBC; however, anthracycline- and taxane-based therapies remain the most commonly used. Taxanes are known to be associated with a significant improvement in disease-free survival for patient with TNBCs at 7 years, as seen in the GEICAM 9906 trial comparing FEC versus FEC, followed by paclitaxel.[357] In addition, the use of platinum agents has been introduced for patients with TNBC. As most breast cancers that arise in the setting of a germline mutation in *BRCA1* are triple negative and the role of *BRCA1* relates to DNA damage response and cell cycle checkpoint control, it has been hypothesized that platinum agents (as DNA-damaging agents) would have a role in *BRCA1*-induced breast cancers. In one clinical trial involving 107 women with stage I to III breast cancers treated with cisplatin for four cycles prior to neoadjuvant chemotherapy, the pathologic complete response was 61%.[358] Given that it is known that pathologic complete response in patients with TNBCs is associated with an improvement in disease-free survival, platinum-based therapy is very promising.[359,360] However, it is not currently known how platinum agents impact survival.

Patients with TNBC have a poorer prognosis compared with patients with other breast cancer subtypes. These patients have a worse breast cancer-specific survival, worse overall survival, and a dramatic increase in death within 2 years of diagnosis. However, this risk declines substantially over time.[361] Given these risks, chemotherapy is now commonly given in the neoadjuvant setting, especially for patients with locally advanced TNBCs.

Adjuvant Medical Therapy for HER2-Positive Breast Cancer

Approximately 20% of women diagnosed with primary invasive breast cancer will have either an amplification or overexpression of the HER2. Since the introduction of trastuzumab to adjuvant chemotherapy, women with early and locally advanced HER2 positive disease have had tremendous improvements in both disease-free survival (HR for recurrence, 0.60; 95% CI, 0.50 to 0.71) and overall survival (HR for mortality, 0.68; 95% CI, 0.57 to 0.77), as evidenced in a meta-analysis of eight trials involving approximately 12,000 women that compared trastuzumab plus chemotherapy versus chemotherapy alone. The risks associated with trastuzumab therapy include congestive heart failure and a decline in left ventricular ejection fraction.[362] Trastuzumab is the only HER2-targeted therapy to result in a survival benefit when administered with chemotherapy in the adjuvant setting. Based on collective data from the Herceptin Adjuvant (HERA) trial[363] and the Protocol for Herceptin as Adjuvant therapy with Reduced Exposure (PHARE) trial,[364] the duration of adjuvant trastuzumab treatment should be 1 year.

It is recommended that women with HER2 positive, node-positive breast cancer and women with HER2-positive, node-negative tumors >1 cm in size receive both adjuvant chemotherapy and trastuzumab. Chemotherapy regimens include both anthracycline-based (ACTH: doxorubicin 60 mg/m^2 and cyclophosphamide 600 mg/m^2 every 3 weeks

for four cycles, followed by docetaxel 100 mg/m^2 every 3 weeks and trastuzumab [weekly during chemotherapy and then every 3 weeks for 1 year]) and non–anthracycline-based therapies (TCH: docetaxel 75 mg/m^2 plus carboplatin every 3 weeks for 6 cycles, with trastuzumab [weekly during chemotherapy and then every 3 weeks for 1 year]). The effectiveness of anthracycline-based chemotherapy has been validated with the National Surgical and Breast and Bowel Project (NSABP B-31) trial and the North Central Cancer Treatment Group (NCCTG) N-9831 trial. With a median follow-up of approximately 4 years, chemotherapy plus adjuvant trastuzumab resulted in superior rates of disease-free survival and overall survival.[365] Non–anthracycline-based therapy (TCH) has been contrasted with ACTH in the Breast Cancer International Research Group 006 (BCIRG-006) trial, and it was determined that ACTH demonstrated a trend toward improved disease-free and overall survival that did not reach statistical significance. However, ACTH had greater toxicity than TCH.[366] As such, both ACTH and TCH are reasonable options for women with HER2-positive breast cancer.

Although trastuzumab has significantly improved survival outcomes for patient with HER2$^+$ breast cancer and has paved the way for the era of targeted therapy in breast cancer treatment, inherent or acquired mechanisms of resistance to trastuzumab therapy can occur, resulting in the need for more effective anti-HER2 therapies.[367] A once promising HER2- directed therapy that has recently been shown to have no effect in the adjuvant setting is lapatinib, a tyrosine kinase inhibitor that has dual effects against both HER2 and the epidermal growth factor receptor. In a placebo-controlled, multicenter, randomized phase III trial, women with HER2-positive early- breast cancer who had previously received adjuvant chemotherapy but not trastuzumab were randomly assigned to receive daily lapatinib or placebo for 12 months. At a median follow-up of 48 months, there were no differences in mortality or in local/distant recurrences.[368] Furthermore, as presented in the 2014 ASCO meeting, the Adjuvant Lapatinib And/Or Trastuzumab Treatment Optimisation Study (ALTTO) showed a lack of benefit for combining lapatinib with trastuzumab as there was no impact on disease-free survival compared with adjuvant trastuzumab alone.[369] Novel HER2-targeted therapies include pertuzumab, which has been approved for HER2-positive breast cancer in both the neoadjuvant and metastatic settings in conjunction with chemotherapy and trastuzumab.[70] Overall survival benefits are not known at this time and the benefits of adjuvant pertuzumab is being explored in randomized trials. Another promising HER2-targeted therapy under clinical investigation is TDM1, which consists of trastuzumab linked with the cytotoxin mertansine, which should result in more specific and robust targeting of HER2-positive breast cancer cells.[370]

SPECIAL ISSUES IN BREAST CANCER TREATMENT

Inflammatory Breast Cancer

A common clinical presentation for IBC is *peau d'orange*, characterized by edema, warmth, and erythema. Unlike other types of breast cancer, patients with IBC often have associated pain and tenderness with an enlarged and firm breast. The nipple can also be involved with flattening, erythema, crusting, blistering, and retraction. Despite the reference to inflammation, the skin changes are not secondary to an inflammatory process but rather secondary to tumor emboli within the dermal lymphatics.[371] As noted by Sir Charles Bell in 1812, these cancers tend to be much more aggressive—"when a purple color is on the skin over the tumor accompanied by shooting pains, it is a very unpropitious beginning."[372] By 1924, Lee and Tannenbaum[373] described 28 cases of women presenting with a rare, rapidly progressive breast cancer with inflammatory features and introduced the term "inflammatory breast cancer.

IBC is an aggressive form of LABC that effects approximately 1% to 5% of women with breast cancer.[374] It is designated as primary tumor stage T4d. The consensus-based criteria for the diagnosis of IBC was determined by an international expert panel who proposed the following features: (1) rapid onset of breast erythema, edema, and/or *peau d'orange*, and/or warm breast, with or without an underlying palpable mass, (2) duration of history no more than 6 months, (3) erythema occupying at least one-third of the breast, and (4) pathologic confirmation of invasive carcinoma.[375] Furthermore, although dermal lymphatic involvement supports the diagnosis of IBC, which can be obtained with a full-thickness skin punch biopsy, it is neither necessary nor sufficient in the absence of the classical clinical findings. The diagnosis of IBC is made with clinical examination findings, followed by breast imaging, which includes mammography and ultrasound to help detect sites within the breast that can be biopsied to confirm the breast cancer. To determine extent of disease, we routinely obtain a breast MRI. A skin punch biopsy can then be performed but is not required for diagnosis. As IBC is a clinically and pathologically distinct form of LABC that is particularly fast growing, invasive, and angiogenic, nearly all women have lymph node involvement at the time of presentation and approximately a third of patients will have distant metastases.[376,377] As such, all women with IBC need to undergo complete staging including a chest/abdomen/pelvic CT scan and bone scan. Head CT should be considered if symptoms are present.

The treatment of IBC is based on multimodality treatments, similar to those described for women with LABC. However, BCT, SLN biopsy, and immediate breast reconstruction are generally considered inappropriate for patients with IBC. Treatment often consists of neoadjuvant chemotherapy that is anthracycline- and taxane-based until all signs of skin inflammation have resolved and the breast and axillary masses are deemed operable. Surgical management with a modified radical mastectomy is then performed with delayed breast reconstruction, if appropriate. Adjuvant radiation therapy follows using standard fields determined by CT planning, ensuring that the chest wall, supraclavicular, infraclavicular, and the internal mammary lymph nodes are radiated.[375] Radiation

therapy to the axillary bed after axillary dissection is often individualized. However, if the patient still remains inoperable after neoadjuvant chemotherapy, then radiation therapy ensues, with the goal that the patient will thereafter become operable. For ER^+ IBC, adjuvant endocrine therapy is given. For $HER2^+$ IBC, trastuzumab (+/− pertuzumab) is added to the neoadjuvant regimen and adjuvant trastuzumab is given to complete 1 year of treatment.

Currently, there is no optimal systemic regimen (chemotherapy or targeted therapy) identified for IBC. However, patients who obtain a complete pathologic response from chemotherapy have a significantly higher disease-free survival and overall survival.[378,379] Despite the combination of surgery and radiation therapy improving locoregional control, there is no impact on overall survival.[380] Even with multimodality treatments, the prognosis for patients with IBC remains poor with 5-year disease-free survival rates of 20% to 45% and an overall survival of 30% to 70%.[378,380–383]

Breast Cancer in the Elderly

In the United States, approximately half of newly diagnosed breast cancers are in older women, typically defined as aged 65 years or older. Older patients tend to receive less than standard therapy worldwide,[384–387] with decreased rates of surgery and use of adjuvant radiation therapy, but with increased use of primary endocrine therapy.[388] This may be secondary to more indolent tumors present in elderly women versus younger women.[379] However, after controlling for confounding factors such as comorbidity, social support, and functional status, older women are still treated less aggressively than their younger counterparts. In general, treatment approaches should not be altered for medically fit older women, except for the use of SLNB and/or radiation therapy in early ER^+ disease.

The ability to omit axillary surgery without an adverse effect on outcome in older women (age ≥ 70 years) with favorable breast cancers has been well studied and supported by multiple randomized trials. These women had clinically negative axillary examinations, small (< 2 cm) ER^+ breast cancers, and were all treated with adjuvant endocrine therapy.[390–392]

The ability to omit adjuvant radiation therapy in older women who have undergone partial mastectomy for early ER^+ breast cancer is supported by CALGB 9343. This phase III study involved 636 women (age ≥ 70 years) who had T1N0M0 ER^+ breast cancer who were treated with partial mastectomy and then randomly assigned to receive either radiation therapy plus tamoxifen (317 women) or tamoxifen alone (319 women). The primary end points studied included time to local or regional recurrence, frequency of mastectomy, breast cancer-specific survival, time to distant metastasis, and overall survival. At 10 years, 98% of patients receiving radiation therapy plus tamoxifen compared with 90% of those receiving tamoxifen alone were free from local and regional recurrences. However, there were no significant differences in time to mastectomy, time to distant metastasis, breast cancer–specific survival, or overall survival between the two groups. Ten-year overall survival was 67% (95% CI, 62% to 72%) and 66% (95% CI, 61% to 71%), respectively.[393] This led to breast-conserving surgery and endocrine therapy alone being incorporated as a category I recommendation in the current NCCN Guidelines for older women.

For older women with comorbidities, functional status limitation, or frailty, the Comprehensive Geriatric Assessment (CGA) can serve as an objective measure to aid in treatment decisions. The CGA has been used in elderly patients with cancer including those with breast cancer and ranges from 44 to 84 questions. The ELCAPA study looked at how the CGA could alter an initial treatment plan in 375 patients aged 70 years and older. Treatment plans were modified in 20.8% of cases, with most plans changed to decrease treatment intensity, although there were some regimens (10.8%) that were intensified.[394] Given how extensive the full CGA can be, other screening tools that have been developed include the Vulnerable Elders Survey-13, Barber Questionnaire, Geriatric 8, Cardiovascular Health Study, and the abbreviated CGA.

For medically frail patients, surgical management, followed by observation is

commonly offered, especially if a patient's life expectancy is limited. If surgical intervention is not an option, endocrine therapy can be offered to patients with ER^+ disease and single agent chemotherapy for those with ER^- disease. In the presence of $HER2^+$ disease, single agent HER2-directed therapy or its addition to systemic therapy can be prescribed, understanding that the latter approach carries additive risks of toxicity. Radiation therapy is not recommended unless local control of disease is needed for symptom management. Finally, palliative and supportive care services need to be offered to patients who wish to avoid both surgical and systemic therapies.

Breast Cancer during Pregnancy

Gestational breast cancer is a rare disease affecting approximately 1 in 1,000 pregnancies but may become more common as women delay childbearing.[395–398] It is defined as breast cancer that is diagnosed during pregnancy, within the first postpartum year, or anytime during lactation. Similar to nonpregnant women, women with gestational breast cancer present most often with a breast mass or skin thickening. Any mass that persists for greater than 2 weeks needs diagnostic imaging and possible biopsy.

The breast becomes engorged and hypertrophied during pregnancy making imaging more difficult. When women present with a mass in pregnancy, ultrasound is first obtained, which can differentiate between a simple cyst, a complex cyst, or a solid tumor. The majority of gestational breast cancers present as a focal solid mass.[399,400] In the presence of an abnormal ultrasound, a diagnostic mammogram can then be obtained to further determine the extent of disease and has been shown to be safe in pregnancy as long as abdominal shielding is used.[401] Although MRI with gadolinium has been shown to be more sensitive than mammography for detecting invasive breast cancer, gadolinium is contraindicated in pregnancy. MRI has also not been systemically studied for the evaluation of breast masses in pregnancy or lactation. All suspicious masses must be biopsied, even in the presence of normal imaging studies, through core needle biopsy, incisional biopsy, or excisional biopsy. In a patient who has a concerning axillary examination, FNA biopsy is indicated.

The most common histologic type of gestational breast cancer is IDCs that are poorly differentiated and diagnosed at an advanced stage. Compared to nonpregnant women, women with gestational breast cancers have less hormone receptor-positive breast cancers (approximately 25% vs. 55% to 60%).[402,403] The association between HER2 disease and gestational breast cancer is not currently known. For pregnant or lactating women with locally advanced disease, staging evaluation is necessary. Given the large cumulative radiation dose that can be associated with computed tomographic scans and the contraindication for gadolinium use (therefore limiting the utility of MRI) in pregnancy, staging imaging for pregnant women commonly includes chest radiography, an abdominal ultrasound of the liver, and a “low-dose” bone scan or a skeletal MRI.

For women diagnosed with breast cancer at an early gestational age, pregnancy termination is an option. However, studies have not shown better outcomes with early termination. In a study involving 176 patients, pregnancy did not directly affect the prognosis of breast cancer, instead poor survival was related to younger age (younger than 40 years) and to the large number of ER-negative tumors (71%).[404] Multiple subsequent studies have shown that pregnancy does not have a negative impact on overall survival.[405–407] In 2012, a meta-analysis involving 3,000 patients with gestational breast cancer who were compared to 37,100 controls found that gestational breast cancer was associated with a higher risk of death. However, this was limited to women diagnosed in the postpartum period.[408]

The treatment for breast cancer for women diagnosed in the postpartum or lactational period does not differ from that recommended for nonpregnant patients. However, for

patients receiving chemotherapy, trastuzumab, or endocrine therapy, breast-feeding is not recommended given the potential toxicity to the infant. The treatment for pregnant women does not differ significantly from established guidelines but includes modifications to ensure the safety of the developing fetus. During any trimester of pregnancy, surgical and anesthetic risks to the fetus have been shown to be minimal.[409–412] Mastectomy can be performed and for early breast cancers, this can eliminate the need for radiation therapy as it is contraindicated in pregnancy. Typical radiation doses used for breast cancer range from 46 to 60 Gy, which has been shown to convey a first trimester fetal dose of 0.04 to 0.15 Gy or a third trimester dose as high as 2 Gy.[406,413] The threshold determined for prenatal radiation exposure for fetuses under 16 weeks of gestation is 0.10 to 0.20 Gy and after 16 weeks 0.50 to 0.70 Gy to avoid risk of congenital malformations.[414] As such, breast-conserving treatment (which necessitates radiation therapy) remote from delivery is not a feasible option. Otherwise, the choice between breast-conserving surgery and mastectomy can be guided by a patient's preference and the biology of the tumor.

Although the efficacy and safety of SLN biopsy has not been well established in pregnant women with invasive breast cancers, most institutions do perform SLN biopsy for axillary staging. Isosulfan blue dye is contraindicated in pregnant women, and methylene blue when used in amniocentesis has been associated with fetal complications. However, a small series of studies using methylene blue or double-filtered technetium sulfur for SLNB have suggested its safety and success in pregnant women.[415–418] Given the small number of pregnant patients included in these studies, the potential risks of methylene blue and technetium sulfur to the fetus along with the potential inaccuracy of SLNB in pregnancy need to be discussed with the patient preoperatively. At our institution, single agent technetium sulfur is used for SLN mapping in pregnant patients.

The most common regimens used in gestational breast cancers are anthracycline-based, AC (doxorubicin plus cyclophosphamide), or FAC (fluorouracil plus AC). The exposure of the fetus during organogenesis or the first trimester to chemotherapy can be detrimental and conveys risks including congenital abnormalities, chromosomal abnormalities, and miscarriage. Although chemotherapy exposure in the second and third trimesters is not associated with organogenesis, risks of intrauterine growth restriction, lower gestational age at birth, and low birth weight occur in about half of exposed infants.[419–422] As such, chemotherapy is often initiated after the first trimester and given its association with transient neonatal myelosuppression, it should be avoided 3 to 4 weeks prior to delivery. When possible, timing of delivery is restricted to 34 or more weeks of gestation and requires confirmation of fetal lung maturity to minimize complications associated with prematurity. Given that gestational breast cancer can present as locally advanced disease, neoadjuvant chemotherapy can be first given, followed by surgery in the postpartum period, and if indicated, adjuvant radiation therapy and endocrine therapy can then be initiated. For women who are diagnosed late in pregnancy or the postpartum/lactational period, prior to commencement of chemotherapy, which may impair infertility, these women should be offered consultation with a reproductive endocrinologist to discuss fertility-preserving options.

Trastuzumab is contraindicated in pregnancy given its association with oligohydramnios, which can result in fetal death, pulmonary hypoplasia, and fetal developmental abnormalities.[423,424] The use of methotrexate and endocrine therapy is also contraindicated during pregnancy. These therapies can be initiated in the postpartum period.

Given that the majority of women diagnosed with gestational breast cancers are of reproductive age, many desire additional pregnancies. In a meta-analysis of 14 studies, 1,244 women who became pregnant following breast cancer were compared to 18,145 control patients. Pregnancy in breast cancer survivors did not convey a worse survival but suggested a protective effect. Some suggest that pregnancy may have an unknown biologic antitumor effect, although more likely this is secondary to healthier women with better prognosis choosing to reproduce over their sicker peers and, therefore, resulting in a bias toward improved survival. As most recurrences happen within the first 2 years after diagnosis and treatment, it is generally recommended that pregnant women wait 2 years before contemplating another pregnancy.

Breast Cancer in Men

Male breast cancer in the United States accounts for 0.5% to 1% of all breast cancers diagnosed annually.[425] Risk factors for male breast cancer include family history of breast cancer and genetic mutations including *BRCA1* and *BRCA2*. *BRCA2* is more commonly associated with male breast cancer and conveys a 6% lifetime absolute risk, which is an approximately 100-fold higher risk than that in the general male population.[426]As such, all men diagnosed with breast cancer need genetic counseling and BRCA testing. Other genetic mutations include *PTEN*, which is linked to Cowden syndrome, *TP53*, which is associated with Li–Fraumeni syndrome, mismatch repair genes that are linked to hereditary nonpolyposis colorectal cancer (Lynch syndrome), and *PALB2* mutations.[427,428] Other risk factors include those that increase circulating estrogens such as hormonal therapies, hepatic dysfunction, obesity, marijuana use, and thyroid disease. It is also associated with Klinefelter syndrome, which is characterized by 47XXY genotype. These male patients have atrophic testes and gynecomastia. In addition, they have high-serum concentrations of gonadotropins (follicular-stimulating hormone, luteinizing hormone) and a low-serum testosterone level, resulting in a high ratio of estrogen to testosterone. Those with Klinefelter syndrome have a 19.2- and 57.8-fold increase in the incidence of and mortality from breast cancer.[429] Primary testicular conditions (orchitis, undescended testes, testicular injury) are associated with an increased risk of male breast cancer as it can result in lower androgen production and, therefore, result in a higher than normal estrogen to androgen ratio.[430,431]

Unfortunately, men are often diagnosed with breast cancer at an advanced stage. They commonly present with a firm retroareolar mass that is painless. Workup for a suspicious breast mass in men is similar to that for women and includes a mammogram and biopsy. Ultrasound is typically less informative. The most common histologic subtype is invasive ductal carcinoma (90%). Lobular carcinoma is rarely diagnosed in men. DCIS is also less frequent in men versus women. Most male breast cancers are ER$^+$ (81.5%).[432] The staging system for male breast cancers is similar to that for women and is classified according to the TNM AJCC staging system.

The treatment of early stage male breast cancer has generally been a modified radical mastectomy. However, for a man with a clinically negative axillary examination, an expert panel from the American Society of Clinical Oncology considers SLN biopsy to be an “acceptable” method.[248] It is generally accepted that in men who have no evidence of disease in the SLN biopsy, no further axillary surgery is needed. For men who have a positive SLN, given there is a lack of data for men, they should be treated similarly to women with positive SLN biopsies. There are limited data regarding the use of breast-conserving surgery in men. A retrospective study of seven men treated with breast-conserving therapy followed for a median of 67 months reported that there was no recurrence of disease. If men do elect for a partial mastectomy, adjuvant radiation therapy is essential and is based on results showing that adjuvant radiation therapy after breast-conserving surgery for women conveys a survival advantage.[433] For men with LABC (T3N0, N1-2, or T2N2) or IBC, treatment plans are similar to that for women.

Consideration for neoadjuvant chemotherapy prior to surgery should be made. The treatment of metastatic breast cancer in males should parallel that for females.

Adjuvant chemotherapy, radiation therapy, anti-HER2 therapy, and endocrine therapy should mirror those for women. As the majority of male breast cancers are ER-positive, endocrine therapy with tamoxifen should be given. In a limited study involving 39 men, those treated with tamoxifen had better 5-year actuarial survival (61% vs. 44%) and disease-free survival (56% vs. 28%).[434] Although there are limited data, tamoxifen appears to be superior to AIs in the adjuvant setting for male breast cancer.[435] Extrapolating from the ATLAS trial for women,[353] for men with higher risk of breast cancers, consideration toward extending tamoxifen to 10 years should be considered.

Male patients with breast cancer should undergo similar posttreatment surveillance as that recommended for females. However, the role of screening mammography for the contralateral breast in these men has not been explored. It is important to recognize that male patients with breast cancer are at risk for developing secondary cancers such as those of the small intestine, rectum, skin (nonmelanoma), pancreas, and prostate.[436]

Locoregional Breast Cancer Recurrence

Breast cancer recurrence can occur after both mastectomy and BCT (partial mastectomy and radiation therapy), with the median time to recurrence after mastectomy of 2 to 3 years versus 3 to 4 years after BCT.[437–439] When breast cancer reappears on the chest wall, it is defined as a local recurrence. However, breast cancer that involves the lymph nodes such as the ipsilateral axillary, supraclavicular, infraclavicular, or internal mammary nodes is referred to as a regional recurrence. Among patients who undergo mastectomy for an operable breast cancer, 5% to 10% of patients will have a local or regional recurrence within 10 years whereas patients who undergo BCT have a risk of 10% to 15%, and in patients who forego radiation therapy after a partial mastectomy, the risk of recurrence is as high as 35%.[440] Although BCT is associated with an increased risk of locoregional recurrence, there are no differences in overall survival as supported by a single institutional National Institutes of Health randomized study (n = 237)[278] and two European randomized trails (EORTC trial 10801 and DBCG trial 82-TM). The latter involved approximately 1,800 patients with stage I and II breast cancer who were randomized to undergo a modified radical mastectomy or BCT. Patients who developed a local recurrence in these trials were then analyzed for survival and time to subsequent local recurrence after salvage treatment. There were no differences between the two groups in regard to survival and time to subsequent local recurrence after treatment of an early locoregional recurrence.[437]

The primary risk factors for postmastectomy recurrence include the size of the primary cancer and the number of positive axillary lymph nodes, where ≥4 involved nodes have been consistently shown to increase axillary recurrence rate to more than 20%.[441] In women with four or more positive lymph nodes, tumor size larger than 5 cm, or those with positive surgical margins, postmastectomy radiation therapy is often recommended as it can reduce the rate of chest wall recurrence by 65% to 75%.[70,334–336] The most common presenting sign of a postmastectomy recurrence is a clinical mass or multiple small nodules on the chest wall or overlying skin in or near the mastectomy scar/skin flaps. Other signs of a recurrence can include inflammatory changes without an associated mass and painless masses found in the axilla or the supraclavicular fossa. Workup for a recurrence should also be undertaken for patients who present with lymphedema or a brachial plexopathy. When a recurrence is suspected, a core biopsy should be obtained to confirm the diagnosis and to evaluate hormone and HER2 receptor status. In addition, a metastatic workup should be performed. The 5-year survival rate for patients based on site of recurrence is 52% for chest wall alone, 50% for axilla alone, 28% for supraclavicular nodes alone, 28% for chest wall plus axilla, and 7% when both the supraclavicular nodes and chest wall/axilla are involved.[442] The subsequent treatment plan for patients with recurrent breast cancer is complex and requires a multidisciplinary team.

After BCT, the primary risk factors for recurrence are the use of radiation therapy and pathologic margin status. When an ipsilateral breast cancer is identified, it is important to determine whether this is indeed a true recurrence versus a second primary cancer; a true

recurrence is often found within the primary tumor site or the boost volume of the treated breast. Unlike postmastectomy recurrences, which are commonly detected on physical examination, post-BCT recurrences are often identified by surveillance mammography. However, it is important to note that any physical examination changes that occur more than 1 year after completion of radiation therapy warrant further workup, even in the presence of a normal mammogram. In this setting, consideration should be made for MRI and biopsy. For any recurrent disease, biopsy is obtained to confirm diagnosis and tumor receptor status, followed by a complete metastatic staging workup. In the absence of metastatic disease, the standard approach to a local recurrence after BCT is a mastectomy, with most patients surviving at least 10 years.[443] In the setting of more advanced recurrent disease, such as that associated with skin involvement or inflammatory changes of the skin, systemic therapy may need to be considered prior to mastectomy. The decision to proceed with axillary restaging should be considered by a multidisciplinary team. Furthermore, the management of regional recurrence after BCT is complex and should be planned with a multidisciplinary approach.

Paget Disease of the Breast

Although the presentation of breast cancer is commonly associated with a mass or a mammographic abnormality, it must be considered in the setting of chronic nipple ulceration. PDB was first noted by Sir James Paget in 1874 when he described 15 women with chronic nipple ulcerations who then developed cancer of the involved breast within 2 years.[444] The hallmark of Paget disease is a scaly, raw, vesicular, or ulcerated lesion that begins on the nipple and then spreads to the areola (Fig. 74-27). This is often a unilateral process and can be associated with bloody nipple discharge. Symptoms that can occur prior to the development of clinically apparent disease include pain, burning, and pruritus. PDB is a rare disease accounting for only 1% to 3% of new cases of breast cancer in females in the United States.



Figure 74-27. Paget disease of the nipple. Depigmentation and desquamation of the nipple and areola are evident.

The diagnostic workup of PDB is to first establish the diagnosis and then to identify the underlying breast cancer that is present in 85% to 88% of cases, despite often not being associated with a breast mass or a mammographic abnormality.[445] Full-thickness wedge or punch biopsy of the nipple should be performed. PBD is characterized histologically by the presence of large cells with prominent nucleoli and a pale cytoplasm (Paget cells) occurring singly or in small groups within the epidermis of the nipple. Other characteristics of Paget cells include the presence of low-molecular-weight cytokeratins such as CK7. Approximately 50% of PDB cases express hormone receptors and between 70% and 90% of cases overexpress HER2.

For patients with PDB, a physical examination including bilateral breast examination and mammography should be performed to help identify the underlying breast cancer. Approximately one-half of patients with PDB will have an associated mammographic abnormality. Interestingly, these abnormalities can occur distant from the nipple areolar complex. If no palpable masses are found and mammography is normal, there is a greater likelihood of DCIS than an invasive cancer.[446] If mammography and breast imaging fail to locate disease, then a MRI can be obtained, recognizing that although it is highly sensitive it is not highly specific. As such, MRI-detected lesions should be biopsied to confirm the

diagnosis of a breast cancer.

The treatment of PDB is either a mastectomy or breast-conserving therapy, which includes a partial mastectomy and whole breast radiation therapy. Breast-conserving surgery includes resection of the nipple–areola complex and the underlying cancer with negative margins obtained (central lumpectomy). Given that the nipple–areola complex is removed, some women may consider this cosmetically unacceptable. Evaluation and treatment of the axilla is dependent on the underlying cancer identified. Adjuvant systemic therapy is also determined by the involved breast cancer.

Breast Sarcomas

Breast sarcomas are rare, accounting for less than 1% of all breast malignancies, characterized by its derivation from the connective tissue within the breast.[447] It is a heterogeneous disease comprising multiple histologic subtypes including fibrosarcoma (24%), angiosarcoma (24%), undifferentiated pleomorphic sarcoma (24%), myxofibrosarcoma (12%), leiomyosarcoma (8%), hemangiopericytoma (4%), and osteosarcoma (4%).[448] Primary breast sarcomas can result from genetic conditions such as with the *TP53* mutation (Li–Fraumeni syndrome which is characterized by breast sarcoma, leukemia, and adrenal cortical carcinoma), familial adenomatous polyposis and its variants, and with neurofibromatosis type 1.[448] Although the causative factor for primary disease is often not known, risk factors for secondary breast sarcomas include ionizing radiation,[449] conditions causing chronic lymphedema (Stewart–Treves syndrome),[450] chemicals such as arsenic compounds and vinyl chloride, and with immunosuppression such as with HIV.[448]

A breast sarcoma often presents as a firm, large, unilateral, and painless mass. Mammographic findings are commonly nonspecific with no associated calcifications or spiculations, presenting as noncalcified oval masses with indistinct margins or can even be associated with a normal mammogram.[451] Core biopsy is recommended to confirm the diagnosis. Given that the biology and prognosis differs significantly from invasive breast cancers, breast sarcomas are staged using the American Joint Committee on Cancer (AJCC)/International Union Against Cancer system for sarcomas arising from other sites.[452] As most breast sarcomas do not spread through the lymphatic system, even in the presence of large tumors, the lymph nodes are negative for disease. The primary site for metastases is the lung and as such chest CT should be obtained for all newly diagnosed patients.[453]

Phyllodes Tumor

Phyllodes tumors are uncommon (<0.5% of all breast malignancies) fibroepithelial breast tumors first described by Johannes Muller in 1838 as *cystosarcoma phyllodes*.[454] Given that these tumors often do not have cystic components and are not true sarcomas, they are now referred to simply as phyllodes tumors (Fig. 74-28). The malignant potential of phyllodes tumors differs widely, with some behaving like fibroadenomas and others that can degenerate histologically into sarcomatous lesions and metastasize distantly. As such, they are histologically classified as benign (50%), borderline (25%), or malignant (25%) based upon the degree of stromal cellularity and atypia, mitotic rate, and the presence or absence of stromal overgrowth and infiltrative margins. Risk factors for phyllodes tumors are not known, aside from their association with Li–Fraumeni syndrome.[455]

Patients with phyllodes tumors present with a smooth, multinodular, well-demarcated, firm mass that is both mobile and painless. The average tumor size is 4 to 7 cm. Although palpable axillary lymphadenopathy can be found in up to 20% of patients, lymph node involvement is rare.[456] Imaging is notable for a smooth multilobulated mass that resembles a fibroadenoma. Core needle biopsy is recommended for diagnosis. However, it has a false-negative rate of 25% to 30%.[457,458] As such, in the presence of a rapidly enlarging mass, excisional biopsy should be performed.



Figure 74-28. Breast asymmetry resulting from a benign phyllodes tumor. Skin changes are caused by pressure necrosis.

The treatment of all phyllodes tumors is wide excision to achieve negative histologic margins, with a goal of 1 cm. Even large tumors can be treated with breast-conserving surgery without compromising cancer-specific survival. Lymph node involvement is also very rare; in the SEER database, only 8 of 498 women had involved nodes.[459] As such, most surgeons do not routinely perform SLNB for phyllodes tumors. The use of adjuvant radiation therapy and chemotherapy is controversial; however, in the setting of a large borderline or malignant phyllodes tumor, these treatments should be considered. If systemic therapy for malignant phyllodes tumor is undertaken, it is based on guidelines

for treating sarcomas. Similar to breast sarcomas, malignant phyllodes tumors can metastasize to the lungs and as such patients should undergo chest x-ray every 6 months for 2 years and then annually. Unfortunately, once metastasis develops, the mean overall survival is 30 months.[460]

References

1. Spratt JS. Anatomy of the breast. *Major Probl Clin Surg* 1979;5:1–13.
2. Smith DJ Jr, Palin WE Jr, Katch VL, et al. Breast volume and anthropomorphic measurements: normal values. *Plast Reconstr Surg* 1986;78:331–335.
3. Giacometti L, Montagna W. The nipple and the areola of the human female breast. *Anat Rec* 1962;144:191–197.
4. Cunningham L. The anatomy of the arteries and veins of the breast. *J Surg Oncol* 1977;9:71–85.
5. Turner-Warwick RT. The lymphatics of the breast. *Br J Surg* 1959;46: 574–582.
6. Romrell L, Bland K. Anatomy of the breast, axilla, chest wall, and related metastatic sites. In: Bland Copeland, eds. *The Breast*. Saunders; 2009:21–38.
7. Copeland EM, Bland KI. The breast. In: Sabiston DC Jr, ed. *Essentials of Surgery*. Philadelphia, PA: WB Saunders; 1987.
8. Anson B, McVay C. Thoracic walls: breast or mammary region. In: Saunders W, ed. *Surgical Anatomy*. Philadelphia, PA: 1971.
9. Oftedal OT. The mammary gland and its origin during synapsid evolution. *J Mammary Gland Biol Neoplasia* 2002;7:225–252.
10. Watson CJ, Khaled WT. Mammary development in the embryo and adult: a journey of morphogenesis and commitment. *Development* 2008;135: 995–1003.
11. Russo J, Hu YF, Silva ID, et al. Cancer risk related to mammary gland structure and development. *Microsc Res Tech* 2001;52:204–223.
12. Cardiff RD, Wellings SR. The comparative pathology of human and mouse mammary glands. *J Mammary Gland Biol Neoplasia* 1999;4:105–122.
13. Jolicoeur F. Intrauterine breast development and the mammary myoepithelial lineage. *J Mammary Gland Biol Neoplasia* 2005;10:199–210.
14. Pansky B. *Review of Medical Embryology*. New York, NY: Macmillan; 1982.
15. Morehead JR. Anatomy and embryology of the breast. *Clin Obstet Gynecol* 1982;25:353–357.
16. Going JJ, Moffat DF. Escaping from Flatland: clinical and biological aspects of human mammary duct anatomy in three dimensions. *J Pathol* 2004;203:538–544.
17. Kern KA. Sentinel lymph node mapping in breast cancer using subareolar injection of blue dye. *J Am Coll Surg* 1999;189:539–545.
18. Howard BA, Gusterson BA. Human breast development. *J Mammary Gland Biol Neoplasia* 2000;5:119–137.
19. van Genderen C, Okamura RM, Farinas I, et al. Development of several organs that require inductive epithelial-mesenchymal interactions is impaired in LEF-1-deficient mice. *Genes Dev* 1994;8:2691–2703.
20. Foley J, Dann P, Hong J, et al. Parathyroid hormone-related protein maintains mammary epithelial fate and triggers nipple skin differentiation during embryonic

breast development. *Development* 2001;128:513–525.
21. Russo IH, Medado J, Russo J. Endocrine influences on the mammary gland. In: Jones T, Hunt E, eds. *Integument and Mammary Glands*. Berlin: Springer-Verlag; 1989.
22. Russo J, Russo IH. Development of human mammary glands. In: Neville MC, Daniels CW, eds. *The Mammary Gland: Development, Regulation, and Function*. New York, NY: Plenum Press; 1987:67–93.
23. Lyons WR, Li CH, Johnson RE. The hormonal control of mammary growth and lactation. *Recent Prog Horm Res* 1958;14:219–248; discussion 48–54.
24. Kleinberg DL. Early mammary development: growth hormone and IGF-1. *J Mammary Gland Biol Neoplasia* 1997;2:49–57.
25. Yang Y, Spitzer E, Meyer D, et al. Sequential requirement of hepatocyte growth factor and neuregulin in the morphogenesis and differentiation of the mammary gland. *J Cell Biol* 1995;131:215–226.
26. Colston KW, Berger U, Wilson P, et al. Mammary gland 1,25-dihydroxyvitamin D3 receptor content during pregnancy and lactation. *Mol Cell Endocrinol* 1988;60:15–22.
27. Gearing AJ, Beckett P, Christodoulou M, et al. Matrix metalloproteinases and processing of pro-TNF-alpha. *J Leukoc Biol* 1995;57:774–777.
28. Li G, Robinson GW, Lesche R, et al. Conditional loss of PTEN leads to precocious development and neoplasia in the mammary gland. *Development* 2002;129:4159–4170.
29. Marshall WA, Tanner JM. Variations in pattern of pubertal changes in girls. *Arch Dis Child* 1969;44:291–303.
30. Csermely T, Demers LM, Hughes EC. Organ culture of human endometrium. Effects of progesterone. *Obstet Gynecol* 1969;34:252–259.
31. Vogel PM, Georgiade NG, Fetter BF, et al. The correlation of histologic changes in the human breast with the menstrual cycle. *Am J Pathol* 1981; 104:23–34.
32. Russo J, Rivera R, Russo IH. Influence of age and parity on the development of the human breast. *Breast Cancer Res Treat* 1992;23:211–218.
33. Kaplan C. Endocrinology of the breast. In: GW M, ed. *The Female Breast and Its Disorders*. Baltimore, MD: Williams & Wilkins; 1990.
34. Marti A, Feng Z, Altermatt HJ, et al. Milk accumulation triggers apoptosis of mammary epithelial cells. *Eur J Cell Biol* 1997;73:158–165.
35. Lund LR, Romer J, Thomasset N, et al. Two distinct phases of apoptosis in mammary gland involution: proteinase-independent and -dependent pathways. *Development* 1996;122:181–193.
36. Barash I. Stat5 in the mammary gland: controlling normal development and cancer. *J Cell Physiol* 2006;209:305–313.
37. Robinson GW, Johnson PF, Hennighausen L, et al. The C/EBPbeta transcription factor regulates epithelial cell proliferation and differentiation in the mammary gland. *Genes Dev* 1998;12:1907–1916.

38. Chen F, Capecchi MR. Paralogous mouse Hox genes, Hoxa9, Hoxb9, and Hoxd9, function together to control development of the mammary gland in response to pregnancy. *Proc Natl Acad Sci U S A* 1999;96:541–546.
39. Sicinski P, Donaher JL, Parker SB, et al. Cyclin D1 provides a link between development and oncogenesis in the retina and breast. *Cell* 1995;82: 621–630.
40. Come C, Arnoux V, Bibeau F, et al. Roles of the transcription factors snail and slug during mammary morphogenesis and breast carcinoma progression. *J Mammary Gland Biol Neoplasia* 2004;9:183–193.
41. Yan GZ, Pan WT, Bancroft C. Thyrotropin-releasing hormone action on the prolactin promoter is mediated by the POU protein pit-1. *Mol Endocrinol* 1991;5:535–541.
42. Li M, Liu X, Robinson G, et al. Mammary-derived signals activate programmed cell death during the first stage of mammary gland involution. *Proc Natl Acad Sci U S A* 1997;94:3425–3430.
43. Daniel CW, Strickland P, Friedmann Y. Expression and functional role of E- and P-cadherins in mouse mammary ductal morphogenesis and growth. *Dev Biol* 1995;169:511–519.
44. McCarty KJ. Breast. In: Sternberg S, ed. *Histology for Pathologists*. Philadelphia, PA: Lippincott-Raven; 1997:71–82.
45. Helminen HJ, Ericsson JL. Studies on mammary gland involution. I. On the ultrastructure of the lactating mammary gland. *J Ultrastruct Res J Natl Cancer Inst* 1968;25:193–213.
46. Barlow WE, Lehman CD, Zheng Y, et al. Performance of diagnostic mammography for women with signs or symptoms of breast cancer. *J Natl Cancer Inst* 2002;94:1151–1159.
47. Flobbe K, Bosch AM, Kessels AG, et al. The additional diagnostic value of ultrasonography in the diagnosis of breast cancer. *Arch Intern Med* 2003;163:1194–1199.
48. Peters NH, Borel Rinkes IH, Zuithoff NP, et al. Meta-analysis of MR imaging in the diagnosis of breast lesions. *Radiology* 2008;246:116–124.
49. Ljung BM, Drejet A, Chiampi N, et al. Diagnostic accuracy of fine-needle aspiration biopsy is determined by physician training in sampling technique. *Cancer* 2001;93:263–268.
50. Parker SH, Burbank F, Jackman RJ, et al. Percutaneous large-core breast biopsy: a multi-institutional study. *Radiology* 1994;193:359–364.
51. Morrow M, Wong S, Venta L. The evaluation of breast masses in women younger than forty years of age. *Surgery* 1998;124:634–640; discussion 40–41.
52. Davies EL, Gateley CA, Miers M, et al. The long-term course of mastalgia. *J R Soc Med* 1998;91:462–464.
53. Iddon J, Dixon JM. Mastalgia. *BMJ* 2013;347:f3288.
54. Smith RL, Pruthi S, Fitzpatrick LA. Evaluation and management of breast pain. *Mayo*

Clin Proc 2004;79:353–372.
55. Catania S, Zurrida S, Veronesi P, et al. Mondor's disease and breast cancer. *Cancer* 1992;69:2267–2270.
56. Pruthi S, Wahner-Roedler DL, Torkelson CJ, et al. Vitamin E and evening primrose oil for management of cyclical mastalgia: a randomized pilot study. *Altern Med Rev* 2010;15:59–67.
57. Ernster VL, Goodson WH III, Hunt TK, et al. Vitamin E and benign breast "disease": a double-blind, randomized clinical trial. *Surgery* 1985;97: 490–494.
58. Pye JK, Mansel RE, Hughes LE. Clinical experience of drug treatments for mastalgia. *Lancet* 1985;2:373–377.
59. Srivastava A, Mansel RE, Arvind N, et al. Evidence-based management of mastalgia: a meta-analysis of randomised trials. *Breast* 2007;16:503–512.
60. Seltzer MH, Perloff LJ, Kelley RI, et al. The significance of age in patients with nipple discharge. *Surg Gynecol Obstet* 1970;131:519–522.
61. Cardenosa G, Doudna C, Eklund GW. Ductography of the breast: technique and findings. *AJR Am J Roentgenol* 1994;162:1081–1087.
62. Schnitt SJ. Benign breast disease and breast cancer risk: morphology and beyond. *Am J Surg Pathol* 2003;27:836–841.
63. Schnitt SJ, Collins LC. Pathology of benign breast disorders. In: Harris JR, ed. *Breast Diseases*. Philadelphia, PA: Lippincott; 2010:69.
64. Courtillot C, Plu-Bureau G, Binart N, et al. Benign breast diseases. *J Mammary Gland Biol Neoplasia* 2005;10:325–335.
65. Hughes LE, Mansel RE, Webster DJ. Aberrations of normal development and involution (ANDI): a new perspective on pathogenesis and nomenclature of benign breast disorders. *Lancet* 1987;2:1316–1319.
66. Berg WA, Sechtin AG, Marques H, et al. Cystic breast masses and the ACRIN 6666 experience. *Radiol Clin North Am* 2010;48:931–987.
67. Berg WA, Campassi CI, Ioffe OB. Cystic lesions of the breast: sonographic- pathologic correlation. *Radiology* 2003;227:183–191.
68. Daly CP, Bailey JE, Klein KA, et al. Complicated breast cysts on sonography: is aspiration necessary to exclude malignancy? *Acad Radiol* 2008;15:610–617.
69. Dixon JM, McDonald C, Elton RA, et al. Risk of breast cancer in women with palpable breast cysts: a prospective study. Edinburgh Breast Group. *Lancet* 1999;353:1742–1745.
70. *NCCN Clinical practice guidelines in oncology (breast cancer)*. 2014. Available at: http://www.consensocancermamario.com/guias/NCCN_2015.pdf
71. Guray M, Sahin AA. Benign breast diseases: classification, diagnosis, and management. *Oncologist* 2006;11:435–449.
72. Ciatto S, Andreoli C, Cirillo A, et al. The risk of breast cancer subsequent to histologic diagnosis of benign intraductal papilloma follow-up study of 339 cases.

Tumori 1991;77:41–43.

73. Lewis JT, Hartmann LC, Vierkant RA, et al. An analysis of breast cancer risk in women with single, multiple, and atypical papilloma. *Am J Surg Pathol* 2006;30:665–672.
74. Valdes EK, Feldman SM, Boolbol SK. Papillary lesions: a review of the literature. *Ann Surg Oncol* 2007;14:1009–1013.
75. Mercado CL, Hamele-Bena D, Oken SM, et al. Papillary lesions of the breast at percutaneous core-needle biopsy. *Radiology* 2006;238:801-808.
76. Wen X, Cheng W. Nonmalignant breast papillary lesions at core-needle biopsy: a meta-analysis of underestimation and influencing factors. *Ann Surg Oncol* 2013;20:94–101.
77. Wang J, Costantino JP, Tan-Chiu E, et al. Lower-category benign breast disease and the risk of invasive breast cancer. *J Natl Cancer Inst* 2004;96: 616–620.
78. Jensen RA, Page DL, Dupont WD, et al. Invasive breast cancer risk in women with sclerosing adenosis. *Cancer* 1989;64:1977–1983.
79. Mitnick JS, Vazquez MF, Harris MN, et al. Differentiation of radial scar from scirrhous carcinoma of the breast: mammographic-pathologic correlation. *Radiology* 1989;173:697–700.
80. Linda A, Zuiani C, Furlan A, et al. Radial scars without atypia diagnosed at imaging-guided needle biopsy: how often is associated malignancy found at subsequent surgical excision, and do mammography and sonography predict which lesions are malignant? *AJR Am J Roentgenol* 2010;194:1146–1151.
81. Kennedy M, Masterson AV, Kerin M, et al. Pathology and clinical relevance of radial scars: a review. *J Clin Pathol* 2003;56:721–724.
82. Patterson JA, Scott M, Anderson N, et al. Radial scar, complex sclerosing lesion and risk of breast cancer. Analysis of 175 cases in Northern Ireland. *Eur J Surg Oncol* 2004;30:1065–1068.
83. Carty NJ, Carter C, Rubin C, et al. Management of fibroadenoma of the breast. *Ann R Coll Surg Engl* 1995;77:127–130.
84. Harvey JA, Nicholson BT, Lorusso AP, et al. Short-term follow-up of palpable breast lesions with benign imaging features: evaluation of 375 lesions in 320 women. *AJR Am J Roentgenol* 2009;193:1723–1730.
85. Dupont WD, Page DL, Parl FF, et al. Long-term risk of breast cancer in women with fibroadenoma. *N Engl J Med* 1994;331:10–15.
86. El-Wakeel H, Umpleby HC. Systematic review of fibroadenoma as a risk factor for breast cancer. *Breast* 2003;12:302–307.
87. Sklair-Levy M, Sella T, Alweiss T, et al. Incidence and management of complex fibroadenomas. *AJR Am J Roentgenol* 2008;190:214–218.
88. Wechselberger G, Schoeller T, Piza-Katzer H. Juvenile fibroadenoma of the breast. *Surgery* 2002;132:106–107.

89. Marshall LM, Hunter DJ, Connolly JL, et al. Risk of breast cancer associated with atypical hyperplasia of lobular and ductal types. *Cancer Epidemiol Biomarkers Prev* 1997;6:297–301.
90. Degnim AC, Visscher DW, Berman HK, et al. Stratification of breast cancer risk in women with atypia: a Mayo cohort study. *J Clin Oncol* 2007;25:2671–2677.
91. Collins LC, Baer HJ, Tamimi RM, et al. Magnitude and laterality of breast cancer risk according to histologic type of atypical hyperplasia: results from the Nurses' Health Study. *Cancer* 2007;109:180–187.
92. Page DL, Schuyler PA, Dupont WD, et al. Atypical lobular hyperplasia as a unilateral predictor of breast cancer risk: a retrospective cohort study. *Lancet* 2003;361:125–129.
93. Hartmann LC, Sellers TA, Frost MH, et al. Benign breast disease and the risk of breast cancer. *N Engl J Med* 2005;353:229–237.
94. Nakhlis F, Gilmore L, Gelman R, et al. Incidence of adjacent synchronous invasive carcinoma and/or ductal carcinoma in-situ in patients with lobular neoplasia on core biopsy: results from a prospective multi-institutional registry (TBCRC 020). *Ann Surg Oncol* 2016;23(3):722–728.
95. Bur ME, Zimarowski MJ, Schnitt SJ, et al. Estrogen receptor immunohistochemistry in carcinoma in situ of the breast. *Cancer* 1992;69: 1174–1181.
96. Li CI, Anderson BO, Daling JR, et al. Changing incidence of lobular carcinoma in situ of the breast. *Breast Cancer Res Treat* 2002;75:259–268.
97. Rosner D, Bedwani RN, Vana J, et al. Noninvasive breast carcinoma: results of a national survey by the American College of Surgeons. *Ann Surg* 1980;192:139–147.
98. Margenthaler JA, Duke D, Monsees BS, et al. Correlation between core biopsy and excisional biopsy in breast high-risk lesions. *Am J Surg* 2006;192:534–537.
99. Brem RF, Lechner MC, Jackman RJ, et al. Lobular neoplasia at percutaneous breast biopsy: variables associated with carcinoma at surgical excision. *AJR Am J Roentgenol* 2008;190:637–641.
100. Foster MC, Helvie MA, Gregory NE, et al. Lobular carcinoma in situ or atypical lobular hyperplasia at core-needle biopsy: is excisional biopsy necessary? *Radiology* 2004;231:813–819.
101. Elsheikh TM, Silverman JF. Follow-up surgical excision is indicated when breast core needle biopsies show atypical lobular hyperplasia or lobular carcinoma in situ: a correlative study of 33 patients with review of the literature. *Am J Surg Pathol* 2005;29:534–543.
102. Menes TS, Rosenberg R, Balch S, et al. Upgrade of high-risk breast lesions detected on mammography in the Breast Cancer Surveillance Consortium. *Am J Surg* 2014;207:24–31.
103. Georgian-Smith D, Lawton TJ. Calcifications of lobular carcinoma in situ of the breast: radiologic-pathologic correlation. *AJR Am J Roentgenol* 2001;176:1255–1259.

104. Sneige N, Wang J, Baker BA, et al. Clinical, histopathologic, and biologic features of pleomorphic lobular (ductal-lobular) carcinoma in situ of the breast: a report of 24 cases. *Mod Pathol* 2002;15:1044–1050.
105. Bentz JS, Yassa N, Clayton F. Pleomorphic lobular carcinoma of the breast: clinicopathologic features of 12 cases. *Mod Pathol* 1998;11:814–1822.
106. Haagensen CD. Lobular neoplasia (lobular carcinoma in situ). In: Haagensen CD, Bodian C, Haagensen DE, eds. *Breast Carcinoma*: *Risk and Detection*. Philadelphia, PA: WB Saunders; 1981:238–291.
107. Rosen P, Kosloff C, Lieberman PH, et al. Lobular carcinoma in situ of the breast: detailed analysis of 99 patients with average follow-up of 24 years. *Am J Surg Pathol* 1978;2:225–251.
108. Andersen JA. Lobular carcinoma in situ of the breast. An approach to rational treatment. *Cancer* 1977;39:2597–2602.
109. Salvadori B, Bartoli C, Zurrida S, et al. Risk of invasive cancer in women with lobular carcinoma in situ of the breast. *Eur J Cancer* 1991;27:35–37.
110. Ottesen GL, Graversen HP, Blichert-Toft M, et al. Lobular carcinoma in situ of the female breast. Short-term results of a prospective nationwide study. The Danish Breast Cancer Cooperative Group. *Am J Surg Pathol* 1993;17:14–21.
111. Bodian CA, Perzin KH, Lattes R. Lobular neoplasia. Long term risk of breast cancer and relation to other factors. *Cancer* 1996;78:1024–1034.
112. Page DL, Kidd TE Jr, Dupont WD, et al. Lobular neoplasia of the breast: higher risk for subsequent invasive cancer predicted by more extensive disease. *Hum Pathol* 1991;22:1232–1239.
113. FA T. Intraductal proliferative lesions. In: FA T, P D, eds. *World Health Organization Classification of Tumors, Pathology and Genetics of Tumours of the Breast and Female Genital Organs*. Lyon, France: IARC Press; 2003:63.
114. Khoumais NA, Scaranelo AM, Moshonov H, et al. Incidence of breast cancer in patients with pure flat epithelial atypia diagnosed at core-needle biopsy of the breast. *Ann Surg Oncol* 2013;20:133–138.
115. Bianchi S, Bendinelli B, Castellano I, et al. Morphological parameters of flat epithelial atypia (FEA) in stereotactic vacuum-assisted needle core biopsies do not predict the presence of malignancy on subsequent surgical excision. *Virchows Arch* 2012;461:405–417.
116. Peres A, Barranger E, Becette V, et al. Rates of upgrade to malignancy for 271 cases of flat epithelial atypia (FEA) diagnosed by breast core biopsy. *Breast Cancer Res Treat* 2012;133:659–666.
117. Sudarshan M, Meguerditchian AN, Mesurolle B, et al. Flat epithelial atypia of the breast: characteristics and behaviors. *Am J Surg* 2011;201:245–250.
118. Boulos FI, Dupont WD, Simpson JF, et al. Histologic associations and long-term cancer risk in columnar cell lesions of the breast: a retrospective cohort and a nested

case-control study. *Cancer* 2008;113:2415–2421.
119. Thomas DB, Gao DL, Ray RM, et al. Randomized trial of breast self- examination in Shanghai: final results. *J Natl Cancer Inst* 2002;94: 1445–1457.
120. Baxter N, Canadian Task Force on Preventive Health C. Preventive health care, 2001 update: should women be routinely taught breast self- examination to screen for breast cancer? *CMAJ* 2001;164:1837–1846.
121. Nusbaum NJ. Role of the clinical breast examination in breast cancer screening does this patient have breast cancer? Does this patient have breast cancer? Barton MB, Harris R, Fletcher SW. JAMA 1999;282:1270–1280. *J Am Geriatr Soc* 2001;49:991–992.
122. Chiarelli AM, Majpruz V, Brown P, et al. The contribution of clinical breast examination to the accuracy of breast screening. *J Natl Cancer Inst* 2009;101:1236–1243.
123. Nelson HD, Tyne K, Naik A, et al. Screening for breast cancer: an update for the U.S. Preventive Services Task Force. *Ann Int Med* 2009;151:727–737, W237–W242.
124. Independent UKPoBCS. The benefits and harms of breast cancer screening: an independent review. *Lancet* 2012;380:1778–1786.
125. Miller AB, Wall C, Baines CJ, et al. Twenty five year follow-up for breast cancer incidence and mortality of the Canadian National Breast Screening Study: randomised screening trial. *BMJ* 2014;348:g366.
126. *Breast Imaging Reporting and Data System* (*BI-RADS*) *Atlas*. 5th ed. Reston, VA: American College of Radiology; 2013.
127. Birdwell RL. The preponderance of evidence supports computer-aided detection for screening mammography. *Radiology* 2009;253:9–16.
128. Friedewald SM, Rafferty EA, Rose SL, et al. Breast cancer screening using tomosynthesis in combination with digital mammography. *JAMA* 2014;311:2499–2507.
129. Siegel R, Ma J, Zou Z, et al. Cancer statistics, 2014. *CA Cancer J Clin* 2014;64:9–29.
130. Centers for Disease Control and Prevention. Vital signs: racial disparities in breast cancer severity—United States, 2005–2009. *MMWR Morb Mortal Wkly Rep* 2012;61:922–926.
131. Colditz GA, Rosner B. Cumulative risk of breast cancer to age 70 years according to risk factor status: data from the Nurses' Health Study. *Epidemiol Rev* 2000;152:950–964.
132. Collaborative Group on Hormonal Factors in Breast C. Breast cancer and hormonal contraceptives: collaborative reanalysis of individual data on 53 297 women with breast cancer and 100 239 women without breast cancer from 54 epidemiological studies. *Lancet* 1996;347:1713–1727.
133. Chlebowski RT, Hendrix SL, Langer RD, et al. Influence of estrogen plus progestin on breast cancer and mammography in healthy postmenopausal women: the Women's

Health Initiative Randomized Trial. *JAMA* 2003; 289:3243–3253.
134. Chlebowski RT, Anderson GL, Gass M, et al. Estrogen plus progestin and breast cancer incidence and mortality in postmenopausal women. *JAMA* 2010;304:1684–1692.
135. Newcomb PA, Storer BE, Longnecker MP, et al. Lactation and a reduced risk of premenopausal breast cancer. *N Engl J Med* 1994;330:81–87.
136. Collaborative Group on Hormonal Factors in Breast C. Breast cancer and breastfeeding: collaborative reanalysis of individual data from 47 epidemiological studies in 30 countries, including 50302 women with breast cancer and 96973 women without the disease. *Lancet* 2002;360:187–195.
137. Guibout C, Adjadj E, Rubino C, et al. Malignant breast tumors after radiotherapy for a first cancer during childhood. *J Clin Oncol* 2005;23: 197–204.
138. Pukkala E, Kesminiene A, Poliakov S, et al. Breast cancer in Belarus and Ukraine after the Chernobyl accident. *Int J Cancer* 2006;119:651–658.
139. John EM, Kelsey JL. Radiation and other environmental exposures and breast cancer. *Epidemiol Rev* 1993;15:157–162.
140. Singletary KW, Gapstur SM. Alcohol and breast cancer: review of epidemiologic and experimental evidence and potential mechanisms. *JAMA* 2001;286:2143–2151.
141. Bagnardi V, Rota M, Botteri E, et al. Light alcohol drinking and cancer: a meta-analysis. *Ann Oncol* 2013;24:301–308.
142. Gaudet MM, Gapstur SM, Sun J, et al. Active smoking and breast cancer risk: original cohort data and meta-analysis. *J Natl Cancer Inst* 2013;105: 515–525.
143. Pierce JP, Patterson RE, Senger CM, et al. Lifetime cigarette smoking and breast cancer prognosis in the After Breast Cancer Pooling Project. *J Natl Cancer Inst* 2014;106:djt359.
144. Collaborative Group on Hormonal Factors in Breast C. Familial breast cancer: collaborative reanalysis of individual data from 52 epidemiological studies including 58,209 women with breast cancer and 101,986 women without the disease. *Lancet* 2001;358:1389–1399.
145. Lynch HT, Lynch J, Conway T, et al. Hereditary breast cancer and family cancer syndromes. *World J Surg* 1994;18:21–31.
146. Gudmundsdottir K, Ashworth A. The roles of BRCA1 and BRCA2 and associated proteins in the maintenance of genomic stability. *Oncogene* 2006;25:5864–5874.
147. Miki Y, Swensen J, Shattuck-Eidens D, et al. A strong candidate for the breast and ovarian cancer susceptibility gene BRCA1. *Science* 1994;266: 66–71.
148. Wang Y, Cortez D, Yazdi P, et al. BASC, a super complex of BRCA1-associated proteins involved in the recognition and repair of aberrant DNA structures. *Genes Dev* 2000;14:927–939.
149. Struewing JP, Hartge P, Wacholder S, et al. The risk of cancer associated with specific mutations of BRCA1 and BRCA2 among Ashkenazi Jews. *N Engl J Med*

1997;336:1401–1408.
150. Peelen T, van Vliet M, Petrij-Bosch A, et al. A high proportion of novel mutations in BRCA1 with strong founder effects among Dutch and Belgian hereditary breast and ovarian cancer families. *Am J Hum Genet* 1997;60:1041–1049.
151. Huusko P, Paakkonen K, Launonen V, et al. Evidence of founder mutations in Finnish BRCA1 and BRCA2 families. *Am J Hum Genet* 1998;62: 1544–1548.
152. King MC, Marks JH, Mandell JB; New York Breast Cancer Study G. Breast and ovarian cancer risks due to inherited mutations in BRCA1 and BRCA2. *Science* 2003;302:643–646.
153. Easton DF, Bishop DT, Ford D, et al. Genetic linkage analysis in familial breast and ovarian cancer: results from 214 families. The Breast Cancer Linkage Consortium. *Am J Hum Genet* 1993;52:678–701.
154. Frank TS, Deffenbaugh AM, Reid JE, et al. Clinical characteristics of individuals with germline mutations in BRCA1 and BRCA2: analysis of 10,000 individuals. *J Clin Oncol* 2002;20:1480–1490.
155. Kirchhoff T, Kauff ND, Mitra N, et al. BRCA mutations and risk of prostate cancer in Ashkenazi Jews. *Clin Cancer Res* 2004;10:2918–2921.
156. Hahn SA, Greenhalf B, Ellis I, et al. BRCA2 germline mutations in familial pancreatic carcinoma. *J Natl Cancer Inst* 2003;95:214–221.
157. National Comprehensive Cancer Network (NCCN). NCCN clinical practice guidelines in oncology: Genetic/familial high-risk assessment—breast and ovarian, Version 1. 2014.
158. Lynch HT, Mulcahy GM, Harris RE, et al. Genetic and pathologic findings in a kindred with hereditary sarcoma, breast cancer, brain tumors, leukemia, lung, laryngeal, and adrenal cortical carcinoma. *Cancer* 1978;41:2055–2064.
159. Swift M, Chase CL, Morrell D. Cancer predisposition of ataxia-telangiectasia heterozygotes. *Cancer Genet Cytogenet* 1990;46:21–27.
160. Berx G, Van Roy F. The E-cadherin/catenin complex: an important gatekeeper in breast cancer tumorigenesis and malignant progression. *Breast Cancer Res* 2001;3:289–293.
161. Brownstein MH, Wolf M, Bikowski JB. Cowden's disease: a cutaneous marker of breast cancer. *Cancer* 1978;41:2393–2398.
162. www.cancer.gov/bcrisktool/.bib. Accessed on Jan 5, 2015.
163. www4.utsouthwestern.edu/breasthealth/cagene/. Accessed on Jan 5, 2015.
164. ccge.medschl.cam.ac.uk/boadicea. Accessed on Jan 5, 2015.
165. www.ems-trials.org/riskevaluator/. Accessed on Jan 5, 2015.
166. tools.bcsc-scc.org/BC5yearRisk/intro.htm. Accessed on Jan 5, 2015.
167. Nelson HD, Smith ME, Griffin JC, et al. Use of medications to reduce risk for primary breast cancer: a systematic review for the U.S. Preventive Services Task Force. *Ann Int Med* 2013;158:604–614.

168. Medications for risk reduction of primary breast cancer in women. http://www.uspreventiveservicestaskforce.org/uspstf/uspsbrpv.htm.
169. Vogel VG, Costantino JP, Wickerham DL, et al. Update of the National Surgical Adjuvant Breast and Bowel Project Study of Tamoxifen and Raloxifene (STAR) P-2 Trial: Preventing breast cancer. *Cancer Prevent Res* 2010;3:696–706.
170. Fisher B, Costantino JP, Wickerham DL, et al. Tamoxifen for the prevention of breast cancer: current status of the National Surgical Adjuvant Breast and Bowel Project P-1 study. *J Natl Cancer Inst* 2005;97:1652–1662.
171. Fallowfield L, Fleissig A, Edwards R, et al. Tamoxifen for the prevention of breast cancer: psychosocial impact on women participating in two randomized controlled trials. *J Clin Oncol* 2001;19:1885–1892.
172. Day R, Ganz PA, Costantino JP, et al. Health-related quality of life and tamoxifen in breast cancer prevention: a report from the National Surgical Adjuvant Breast and Bowel Project P-1 Study. *J Clin Oncol* 1999;17:2659–2669.
173. Visvanathan K, Hurley P, Bantug E, et al. Use of pharmacologic interventions for breast cancer risk reduction: American Society of Clinical Oncology clinical practice guideline. *J Clin Oncol* 2013;31:2942–2962.
174. Cuzick J, Sestak I, Forbes JF, et al. Anastrozole for prevention of breast cancer in high-risk postmenopausal women (IBIS-II): an international, double-blind, randomised placebo-controlled trial. *Lancet* 2014;383: 1041–1048.
175. Virnig BA, Tuttle TM, Shamliyan T, et al. Ductal carcinoma in situ of the breast: a systematic review of incidence, treatment, and outcomes. *J Natl Cancer Inst* 2010;102:170–178.
176. Edge SB, Byrd DR, Compton CC; American JointCommittee on Cancer. *Cancer Staging Manual*. New York, NY; Springer-Verlag; 2010.
177. Kerlikowske K. Epidemiology of ductal carcinoma in situ. *J Natl Cancer Inst Monogr* 2010;2010:139–141.
178. http://www.cancer.org/acs/groups/content/@epidemiologysurveilance/documents/c 031941.pdf. Accessed October 22, 2012.
179. Roses RE, Arun BK, Lari SA, et al. Ductal carcinoma-in-situ of the breast with subsequent distant metastasis and death. *Ann Surg Oncol* 2011;18: 2873–2878.
180. Dershaw DD, Abramson A, Kinne DW. Ductal carcinoma in situ: mammographic findings and clinical implications. *Radiology* 1989;170:411–415.
181. Holland R, Hendriks JH, Vebeek AL, et al. Extent, distribution, and mammographic/histological correlations of breast ductal carcinoma in situ. *Lancet* 1990;335:519–522.
182. Richards T, Hunt A, Courtney S, et al. Nipple discharge: a sign of breast cancer? *Ann R Coll Surg Engl* 2007;89:124–126.
183. Gunhan-Bilgen I, Oktay A. Paget's disease of the breast: clinical, mammographic,

sonographic and pathologic findings in 52 cases. *Eur J Radiol* 2006;60:256–263.

184. Houssami N, Ciatto S, Ellis I, et al. Underestimation of malignancy of breast core-needle biopsy: concepts and precise overall and category- specific estimates. *Cancer* 2007;109:487–495.
185. Boyages J, Delaney G, Taylor R. Predictors of local recurrence after treatment of ductal carcinoma in situ: a meta-analysis. *Cancer* 1999;85:616–628.
186. Lee LA, Silverstein MJ, Chung CT, et al. Breast cancer-specific mortality after invasive local recurrence in patients with ductal carcinoma-in-situ of the breast. *Am J Surg* 2006;192:416–419.
187. Solin LJ, Kurtz J, Fourquet A, et al. Fifteen-year results of breast-conserving surgery and definitive breast irradiation for the treatment of ductal carcinoma in situ of the breast. *J Clin Oncol* 1996;14:754–763.
188. Fisher B, Dignam J, Wolmark N, et al. Lumpectomy and radiation therapy for the treatment of intraductal breast cancer: findings from National Surgical Adjuvant Breast and Bowel Project B-17. *J Clin Oncol* 1998;16:441–452.
189. Fisher B, Land S, Mamounas E, et al. Prevention of invasive breast cancer in women with ductal carcinoma in situ: an update of the National Surgical Adjuvant Breast and Bowel Project experience. *Semin Oncol* 2001;28:400–418.
190. Vargas C, Kestin L, Go N, et al. Factors associated with local recurrence and cause-specific survival in patients with ductal carcinoma in situ of the breast treated with breast-conserving therapy or mastectomy. *Int J Radiat Oncol Biol Phys* 2005;63:1514–1521.
191. Wapnir IL, Dignam JJ, Fisher B, et al. Long-term outcomes of invasive ipsilateral breast tumor recurrences after lumpectomy in NSABP B-17 and B-24 randomized clinical trials for DCIS. *J Natl Cancer Inst* 2011;103:478–488.
192. Meijnen P, Oldenburg HS, Peterse JL, et al. Clinical outcome after selective treatment of patients diagnosed with ductal carcinoma in situ of the breast. *Ann Surg Oncol* 2008;15:235–243.
193. Group EBCC, Group ER, Bijker N, et al. Breast-conserving treatment with or without radiotherapy in ductal carcinoma-in-situ: ten-year results of European Organisation for Research and Treatment of Cancer randomized phase III trial 10853—a study by the EORTC Breast Cancer Cooperative Group and EORTC Radiotherapy Group. *J Clin Oncol* 2006;24:3381–3387.
194. Houghton J, George WD, Cuzick J, et al. Radiotherapy and tamoxifen in women with completely excised ductal carcinoma in situ of the breast in the UK, Australia, and New Zealand: randomised controlled trial. *Lancet* 2003;362:95–102.
195. Holmberg L, Garmo H, Granstrand B, et al. Absolute risk reductions for local recurrence after postoperative radiotherapy after sector resection for ductal carcinoma in situ of the breast. *J Clin Oncol* 2008;26:1247–1252.
196. Fisher ER, Dignam J, Tan-Chiu E, et al. Pathologic findings from the National

Surgical Adjuvant Breast Project (NSABP) eight-year update of Protocol B-17: intraductal carcinoma. *Cancer* 1999;86:429–438.

197. Hughes LL, Wang M, Page DL, et al. Local excision alone without irradiation for ductal carcinoma in situ of the breast: a trial of the Eastern Cooperative Oncology Group. *J Clin Oncol* 2009;27:5319–5324.
198. Silverstein MJ, Lagios MD, Craig PH, et al. A prognostic index for ductal carcinoma in situ of the breast. *Cancer* 1996;77:2267–2274.
199. Silverstein MJ. The University of Southern California/Van Nuys prognostic index for ductal carcinoma in situ of the breast. *Am J Surg* 2003;186: 337–343.
200. MacAusland SG, Hepel JT, Chong FK, et al. An attempt to independently verify the utility of the Van Nuys Prognostic Index for ductal carcinoma in situ. *Cancer* 2007;110:2648–2653.
201. Di Saverio S, Catena F, Santini D, et al. 259 patients with DCIS of the breast applying USC/Van Nuys prognostic index: a retrospective review with long term follow up. *Breast Cancer Res Treat* 2008;109:405–416.
202. de Mascarel I, Bonichon F, MacGrogan G, et al. Application of the van nuys prognostic index in a retrospective series of 367 ductal carcinomas in situ of the breast examined by serial macroscopic sectioning: practical considerations. *Breast Cancer Res Treat* 2000;61:151–159.
203. Solin LJ, Gray R, Baehner FL, et al. A multigene expression assay to predict local recurrence risk for ductal carcinoma in situ of the breast. *J Natl Cancer Inst* 2013;105:701–710.
204. Julian TB, Land SR, Fourchotte V, et al. Is sentinel node biopsy necessary in conservatively treated DCIS? *Ann Surg Oncol* 2007;14:2202–2208.
205. Karam A, Stempel M, Cody HS III, et al. Reoperative sentinel lymph node biopsy after previous mastectomy. *J Am Coll Surg* 2008;207:543–548.
206. Claus EB, Chu P, Howe CL, et al. Pathobiologic findings in DCIS of the breast: morphologic features, angiogenesis, HER-2/neu and hormone receptors. *Exp Mol Pathol* 2001;70:303–316.
207. Hird RB, Chang A, Cimmino V, et al. Impact of estrogen receptor expression and other clinicopathologic features on tamoxifen use in ductal carcinoma in situ. *Cancer* 2006;106:2113–2118.
208. Staley H, McCallum I, Bruce J. Postoperative tamoxifen for ductal carcinoma in situ. *Cochrane Database Syst Rev* 2012;10:CD007847.
209. Allred DC, Anderson SJ, Paik S, et al. Adjuvant tamoxifen reduces subsequent breast cancer in women with estrogen receptor-positive ductal carcinoma in situ: a study based on NSABP protocol B-24. *J Clin Oncol* 2012;30:1268–1273.
210. NCCN Guidelines Version 3. Ductal carcinoma in situ. http://www.nccn.org/professionals/physician_gls/pdf/breast.pdf. Published 2013.
211. Li CI, Uribe DJ, Daling JR. Clinical characteristics of different histologic types of

breast cancer. *Br J Cancer* 2005;93:1046–1052.

212. Orvieto E, Maiorano E, Bottiglieri L, et al. Clinicopathologic characteristics of invasive lobular carcinoma of the breast: results of an analysis of 530 cases from a single institution. *Cancer* 2008;113:1511–1520.
213. Winchester DJ, Chang HR, Graves TA, et al. A comparative analysis of lobular and ductal carcinoma of the breast: presentation, treatment, and outcomes. *J Am Coll Surg* 1998;186:416–422.
214. Li CI, Moe RE, Daling JR. Risk of mortality by histologic type of breast cancer among women aged 50 to 79 years. *Arch Intern Med* 2003;163: 2149–2153.
215. Cristofanilli M, Gonzalez-Angulo A, Sneige N, et al. Invasive lobular carcinoma classic type: response to primary chemotherapy and survival outcomes. *J Clin Oncol* 2005;23:41–48.
216. Ferlicot S, Vincent-Salomon A, Medioni J, et al. Wide metastatic spreading in infiltrating lobular carcinoma of the breast. *Eur J Cancer* 2004;40: 336–341.
217. Berx G, Cleton-Jansen AM, Strumane K, et al. E-cadherin is inactivated in a majority of invasive human lobular breast cancers by truncation mutations throughout its extracellular domain. *Oncogene* 1996;13:1919–1925.
218. De Leeuw WJ, Berx G, Vos CB, et al. Simultaneous loss of E-cadherin and catenins in invasive lobular breast cancer and lobular carcinoma in situ. *J pathol* 1997;183:404–411.
219. Thurman SA, Schnitt SJ, Connolly JL, et al. Outcome after breast- conserving therapy for patients with stage I or II mucinous, medullary, or tubular breast carcinoma. *Int J Radiat Oncol Biol Phys* 2004;59:152–159.
220. Di Saverio S, Gutierrez J, Avisar E. A retrospective review with long term follow up of 11,400 cases of pure mucinous breast carcinoma. *Breast Cancer Res Treat* 2008;111:541–547.
221. Sullivan T, Raad RA, Goldberg S, et al. Tubular carcinoma of the breast: a retrospective analysis and review of the literature. *Breast Cancer Res Treat* 2005;93:199–205.
222. Gaffey MJ, Mills SE, Frierson HF Jr, et al. Medullary carcinoma of the breast: interobserver variability in histopathologic diagnosis. *Mod Pathol* 1995;8:31–38.
223. Armes JE, Venter DJ. The pathology of inherited breast cancer. *Pathology* 2002;34:309–314.
224. Vu-Nishino H, Tavassoli FA, Ahrens WA, et al. Clinicopathologic features and long-term outcome of patients with medullary breast carcinoma managed with breast-conserving therapy (BCT). *Int J Radiat Oncol Biol Phys* 2005;62:1040–1047.
225. Huober J, Gelber S, Goldhirsch A, et al. Prognosis of medullary breast cancer: analysis of 13 International Breast Cancer Study Group (IBCSG) trials. *Ann Oncol* 2012;23:2843–2851.
226. Walsh MM, Bleiweiss IJ. Invasive micropapillary carcinoma of the breast: eighty

cases of an underrecognized entity. *Hum Pathol* 2001;32:583–589.

227. Pezzi CM, Patel-Parekh L, Cole K, et al. Characteristics and treatment of metaplastic breast cancer: analysis of 892 cases from the National Cancer Data Base. *Ann Surg Oncol* 2007;14:166–173.
228. Hennessy BT, Krishnamurthy S, Giordano S, et al. Squamous cell carcinoma of the breast. *J Clin Oncol* 2005;23:7827–7835.
229. Behranwala KA, Nasiri N, Abdullah N, et al. Squamous cell carcinoma of the breast: clinico-pathologic implications and outcome. *European J Surg Oncol* 2003;29:386–389.
230. Dave G, Cosmatos H, Do T, et al. Metaplastic carcinoma of the breast: a retrospective review. *Int J Radiat Oncol Biol Phys* 2006;64:771–775.
231. Rayson D, Adjei AA, Suman VJ, et al. Metaplastic breast cancer: prognosis and response to systemic therapy. *Ann Oncol* 1999;10:413–419.
232. Chao TC, Wang CS, Chen SC, et al. Metaplastic carcinomas of the breast. *J Surg Oncol* 1999;71:220–225.
233. Elston CW, Ellis IO. Pathological prognostic factors in breast cancer. I. The value of histological grade in breast cancer: experience from a large study with long-term follow-up. *Histopathology* 2002;41:154–161.
234. Allred DC, Harvey JM, Berardo M, et al. Prognostic and predictive factors in breast cancer by immunohistochemical analysis. *Mod Pathol* 1998;11:155–168.
235. Harvey JM, Clark GM, Osborne CK, et al. Estrogen receptor status by immunohistochemistry is superior to the ligand-binding assay for predicting response to adjuvant endocrine therapy in breast cancer. *J Clin Oncol* 1999;17:1474–1481.
236. Wolff AC, Hammond ME, Hicks DG, et al. Recommendations for human epidermal growth factor receptor testing in breast cancer: American Society of Clinical Oncology/College of American Pathologists clinical practice guidelines update. *J Clin Oncol* 2013;138(2):241–256.
237. Tanner M, Gancberg D, Di Leo A, et al. Chromogenic in situ hybridization: a practical alternative for fluorescence in situ hybridization to detect HER-2/neu oncogene amplification in archival breast cancer samples. *Am J Pathol* 2000;157:1467–1472.
238. Madrid MA, Lo RW. Chromogenic in situ hybridization (CISH): a novel alternative in screening archival breast cancer tissue samples for HER-2/neu status. *Breast Cancer Res* 2004;6:R593–R600.
239. Perou CM, Sorlie T, Eisen MB, et al. Molecular portraits of human breast tumours. *Nature* 2000;406:747–752.
240. Sorlie T, Perou CM, Tibshirani R, et al. Gene expression patterns of breast carcinomas distinguish tumor subclasses with clinical implications. *Proc Natl Acad Sci U S A* 2001;98:10869–10874.
241. Sorlie T, Tibshirani R, Parker J, et al. Repeated observation of breast tumor subtypes in independent gene expression data sets. *Proc Natl Acad Sci U S A* 2003;100:8418–8423.

242. Brenton JD, Carey LA, Ahmed AA, et al. Molecular classification and molecular forecasting of breast cancer: ready for clinical application? *J Clin Oncol* 2005;23:7350–7360.
243. Carey LA, Dees EC, Sawyer L, et al. The triple negative paradox: primary tumor chemosensitivity of breast cancer subtypes. *Clin Cancer Res* 2007; 13:2329–2334.
244. Fisher B, Jeong JH, Anderson S, et al. Twenty-five-year follow-up of a randomized trial comparing radical mastectomy, total mastectomy, and total mastectomy followed by irradiation. *N Engl J Med* 2002;347:567–575.
245. Orr RK. The impact of prophylactic axillary node dissection on breast cancer survival —a Bayesian meta-analysis. *Ann Surg Oncol* 1999;6: 109–116.
246. Clarke M, Collins R, Darby S, et al. Effects of radiotherapy and of differences in the extent of surgery for early breast cancer on local recurrence and 15-year survival: an overview of the randomised trials. *Lancet* 2005; 366:2087–2106.
247. Lucci A, McCall LM, Beitsch PD, et al. Surgical complications associated with sentinel lymph node dissection (SLND) plus axillary lymph node dissection compared with SLND alone in the American College of Surgeons Oncology Group Trial Z0011. *J Clin Oncol* 2007;25:3657–3663.
248. Lyman GH, Giuliano AE, Somerfield MR, et al. American Society of Clinical Oncology guideline recommendations for sentinel lymph node biopsy in early-stage breast cancer. *J Clin Oncol* 2005;23:7703–7720.
249. Raut CP, Hunt KK, Akins JS, et al. Incidence of anaphylactoid reactions to isosulfan blue dye during breast carcinoma lymphatic mapping in patients treated with preoperative prophylaxis: results of a surgical prospective clinical practice protocol. *Cancer* 2005;104:692–699.
250. Wilke LG, McCall LM, Posther KE, et al. Surgical complications associated with sentinel lymph node biopsy: results from a prospective international cooperative group trial. *Ann Surg Oncol* 2006;13:491–500.
251. Bleicher RJ, Kloth DD, Robinson D, et al. Inflammatory cutaneous adverse effects of methylene blue dye injection for lymphatic mapping/sentinel lymphadenectomy. *J Surg Oncol* 2009;99:356–360.
252. Teknos D, Ramcharan A, Oluwole SF. Pulmonary edema associated with methylene blue dye administration during sentinel lymph node biopsy. *J Natl Med Assoc* 2008;100:1483–1484.
253. Zakaria S, Hoskin TL, Degnim AC. Safety and technical success of methylene blue dye for lymphatic mapping in breast cancer. *Am J Surg* 2008;196:228–233.
254. at http://www.fda.gov/Drugs/DrugSafety/ucm263190.htm.
255. Posther KE, McCall LM, Blumencranz PW, et al. Sentinel node skills verification and surgeon performance: data from a multicenter clinical trial for early-stage breast cancer. *Ann Surg* 2005;242(4):593–599.
256. Goyal A, Newcombe RG, Chhabra A, et al. ALMANAC Trialists Group. Factors

affecting failed localisation and false-negative rates of sentinel node biopsy in breast cancer—results of the ALMANAC validation phase. *Breast Cancer Res Treat* 2006;99(2):203–208.

257. Krag DN, Anderson SJ, Julian TB, et al. National surgical adjuvant breast and bowel project. Technical outcomes of sentinel-lymph-node resection and conventional axillary-lymph-node dissection in patients with clinically node-negative breast cancer: results from the NSABP B-32 randomised phase III trial. *Lancet Oncol* 2007;8(10):881–888.
258. Zavagno G, De Salvo GL, Scalco G, et al. GIVOM Trialists. A randomized clinical trial on sentinel lymph node biopsy versus axillary lymph node dissection in breast cancer: results of the Sentinella/GIVOM trial. *Ann Surg* 2008;247(2):207–213.
259. Martin RC II, Edwards MJ, Wong SL, et al. Practical guidelines for optimal gamma probe detection of sentinel lymph nodes in breast cancer: results of a multi-institutional study. For the University of Louisville Breast Cancer Study Group. *Surgery* 2000;128:139–144.
260. Liu LC, Lang JE, Jenkins T, et al. Is it necessary to harvest additional lymph nodes after resection of the most radioactive sentinel lymph node in breast cancer? *J Am Coll Surg* 2008;207:853–858.
261. Chung A, Yu J, Stempel M, et al. Is the “10% rule” equally valid for all subsets of sentinel-node-positive breast cancer patients? *Ann Surg Oncol* 2008;15:2728–2733.
262. Povoski SP, Olsen JO, Young DC, et al. Prospective randomized clinical trial comparing intradermal, intraparenchymal, and subareolar injection routes for sentinel lymph node mapping and biopsy in breast cancer. *Ann Surg Oncol* 2006;13:1412–1421.
263. Hill AD, Tran KN, Akhurst T, et al. Lessons learned from 500 cases of lymphatic mapping for breast cancer. *Ann Surg* 1999;229:528–535.
264. Kesson EM, Allardice GM, George WD, et al. Effects of multidisciplinary team working on breast cancer survival: retrospective, comparative, interventional cohort study of 13 722 women. *BMJ* 2012;344:e2718.
265. Early Breast Cancer Trialists’ Collaborative G. Effects of chemotherapy and hormonal therapy for early breast cancer on recurrence and 15-year survival: an overview of the randomised trials. *Lancet* 2005;365:1687–1717.
266 Wilcken N, Hornbuckle J, Ghersi D. Chemotherapy alone versus endocrine therapy alone for metastatic breast cancer. *Cochrane Database Syst Rev* 2003;(2):CD002747.
267. Fossati R, Confalonieri C, Torri V, et al. Cytotoxic and hormonal treatment for metastatic breast cancer: a systematic review of published randomized trials involving 31,510 women. *J Clin Oncol* 1998;16:3439–3460.
268. Kopf B, De Giorgi U, Zago S, et al. Innovative therapy for patients with brain metastases: oral treatments. *J Chemother* 2004;16(suppl 5):94–97.
269. Fumoleau P, Largillier R, Clippe C, et al. Multicentre, phase II study evaluating

capecitabine monotherapy in patients with anthracycline- and taxane-pretreated metastatic breast cancer. *Eur J Cancer* 2004;40:536–542.

270. Oshaughnessy JA, Blum J, Moiseyenko V, et al. Randomized, open-label, phase II trial of oral capecitabine (Xeloda) vs. a reference arm of intravenous CMF (cyclophosphamide, methotrexate and 5-fluorouracil) as first-line therapy for advanced/metastatic breast cancer. *Ann Oncol* 2001;12:1247–1254.
271. Gennari A, Stockler M, Puntoni M, et al. Duration of chemotherapy for metastatic breast cancer: a systematic review and meta-analysis of randomized clinical trials. *J Clin Oncol* 2011;29:2144–2149.
272. Park YH, Jung KH, Im SA, et al. Phase III, multicenter, randomized trial of maintenance chemotherapy versus observation in patients with metastatic breast cancer after achieving disease control with six cycles of gemcitabine plus paclitaxel as first-line chemotherapy: KCSG-BR07-02. *J Clin Oncol* 2013;31:1732–1739.
273. Fisher B, Anderson S, Redmond CK, et al. Reanalysis and results after 12 years of follow-up in a randomized clinical trial comparing total mastectomy with lumpectomy with or without irradiation in the treatment of breast cancer. *N Engl J Med* 1995;333:1456–1461.
274. Fisher B, Anderson S, Bryant J, et al. Twenty-year follow-up of a randomized trial comparing total mastectomy, lumpectomy, and lumpectomy plus irradiation for the treatment of invasive breast cancer. *N Engl J Med* 2002;347:1233–1241.
275. Veronesi U, Salvadori B, Luini A, et al. Breast conservation is a safe method in patients with small cancer of the breast. Long-term results of three randomised trials on 1,973 patients. *Eur J Cancer* 1995;31A:1574–1579.
276. Veronesi U, Cascinelli N, Mariani L, et al. Twenty-year follow-up of a randomized study comparing breast-conserving surgery with radical mastectomy for early breast cancer. *N Engl J Med* 2002;347:1227–1232.
277. van Dongen JA, Voogd AC, Fentiman IS, et al. Long-term results of a randomized trial comparing breast-conserving therapy with mastectomy: European Organization for Research and Treatment of Cancer 10801 trial. *J Natl Cancer Inst* 2000;92:1143–1150.
278. Jacobson JA, Danforth DN, Cowan KH, et al. Ten-year results of a comparison of conservation with mastectomy in the treatment of stage I and II breast cancer. *N Engl J Med* 1995;332:907–911.
279. Poggi MM, Danforth DN, Sciuto LC, et al. Eighteen-year results in the treatment of early breast carcinoma with mastectomy versus breast conservation therapy: the National Cancer Institute Randomized Trial. *Cancer* 2003;98:697–702.
280. Arriagada R, Le MG, Rochard F, et al. Conservative treatment versus mastectomy in early breast cancer: patterns of failure with 15 years of follow- up data. Institut Gustave-Roussy Breast Cancer Group. *J Clin Oncol* 1996; 14:1558–1564.
281. Blichert-Toft M, Rose C, Andersen JA, et al. Danish randomized trial comparing breast conservation therapy with mastectomy: six years of life-table analysis. Danish

Breast Cancer Cooperative Group. *J Natl Cancer Inst Monogr* 1992:19–25.

282. Fourquet A, Campana F, Zafrani B, et al. Prognostic factors of breast recurrence in the conservative management of early breast cancer: a 25-year follow-up. *Int J Radiat Oncol Biol Phys* 1989;17:719–725.
283. Kurtz JM, Amalric R, Brandone H, et al. Local recurrence after breast- conserving surgery and radiotherapy. Frequency, time course, and prognosis. *Cancer* 1989;63:1912–1917.
284. Gage I, Recht A, Gelman R, et al. Long-term outcome following breast-conserving surgery and radiation therapy. *Int J Radiat Oncol Biol Phys* 1995;33:245–251.
285. Miles RC, Gullerud RE, Lohse CM, et al. Local recurrence after breast- conserving surgery: multivariable analysis of risk factors and the impact of young age. *Ann Surg Oncol* 2012;19:1153–1159.
286. Morrow M, Strom EA, Bassett LW, et al. Standard for breast conservation therapy in the management of invasive breast carcinoma. *CA Cancer J Clin* 2002;52:277–300.
287. Arriagada R, Le MG, Rochard F, et al. Conservative treatment versus mastectomy in early breast cancer: patterns of failure with 15 years of follow-up data. Institut Gustave-Roussy Breast Cancer Group. *J Clin Oncol* 1996;14:1558–1564.
288. Veronesi U, Cascinelli N, Mariani L, et al. Twenty-year follow-up of a randomized study comparing breast-conserving surgery with radical mastectomy for early breast cancer. *N Engl J Med* 2002;347:1227–1232.
289. Fisher B, Anderson S, Bryant J, et al. Twenty-year follow-up of a randomized trial comparing total mastectomy, lumpectomy, and lumpectomy plus irradiation for the treatment of invasive breast cancer. *N Engl J Med* 2002;347:1233–1241.
290. Poggi MM, Danforth DN, Sciuto LC, et al. Eighteen-year results in the treatment of early breast carcinoma with mastectomy versus breast conservation therapy: the National Cancer Institute Randomized Trial. *Cancer* 2003;98:697–702.
291. van Dongen JA, Voogd AC, Fentiman IS, et al. Long-term results of a randomized trial comparing breast-conserving therapy with mastectomy: European Organization for Research and Treatment of Cancer 10801 trial. *J Natl Cancer Inst* 2000;92:1143–1150.
292. Blichert-Toft M, Rose C, Andersen JA, et al. Danish randomized trial comparing breast conservation therapy with mastectomy: six years of life-table analysis. Danish Breast Cancer Cooperative Group. *J Natl Cancer Inst Monogr* 1992;(11):19–25.
293. Gibson GR, Lesnikoski BA, Yoo J, et al. A comparison of ink-directed and traditional whole-cavity re-excision for breast lumpectomy specimens with positive margins. *Ann Surg Oncol* 2001;8:693–704.
294. Hewes JC, Imkampe A, Haji A, Bates T. Importance of routine cavity sampling in breast conservation surgery. *Br J Surg* 2009;96:47–53.
295. Rizzo M, Iyengar R, Gabram SG, et al. The effects of additional tumor cavity sampling at the time of breast-conserving surgery on final margin status, volume of

resection, and pathologist workload. *Ann Surgical Oncol* 2010;17:228–234.
296. Tengher-Barna I, Hequet D, Reboul-Marty J, et al. Prevalence and predictive factors for the detection of carcinoma in cavity margin performed at the time of breast lumpectomy. *Mod Pathol* 2009;22:299–305.
297. Janes SE, Stankhe M, Singh S, et al. Systematic cavity shaves reduces close margins and re-excision rates in breast conserving surgery. *Breast* 2006;15:326–330.
298. Jacobson AF, Asad J, Boolbol SK, et al. Do additional shaved margins at the time of lumpectomy eliminate the need for re-excision? *Am J Surg* 2008;196:556–568.
299. Chagpar AB, Killelea BK, Tsangaris TN, et al. A randomized, controlled trial of cavity shave margins in breast cancer. *N Engl J Med* 2015; 373(6):503–510.
300. Moran MS, Schnitt SJ, Giuliano AE, et al. Society of Surgical Oncology-American Society for Radiation Oncology consensus guideline on margins for breast-conserving surgery with whole-breast irradiation in stages I and II invasive breast cancer. *Ann Surg Oncol* 2014;21:704–716.
301. Giuliano AE, Hunt KK, Ballman KV, et al. Axillary dissection vs no axillary dissection in women with invasive breast cancer and sentinel node metastasis: a randomized clinical trial. *JAMA* 2011;305:569–575.
302. NIH consensus conference. Treatment of early-stage breast cancer. *JAMA* 1991;265:391–395.
303. Veronesi U, Rilke F, Luini A, et al. Distribution of axillary node metastases by level of invasion. An analysis of 539 cases. *Cancer* 1987;59:682– 687.
304. Rosen PP, Lesser ML, Kinne DW, et al. Discontinuous or “skip” metastases in breast carcinoma. Analysis of 1228 axillary dissections. *Ann Surg* 1983;197:276–283.
305. Yeoh EK, Denham JW, Davies SA, et al. Primary breast cancer. Complications of axillary management. *Acta Radiol Oncol* 1986;25:105–108.
306. Lotze MT, Duncan MA, Gerber LH, et al. Early versus delayed shoulder motion following axillary dissection: a randomized prospective study. *Ann Surg* 1981;193:288–295.
307. Ivens D, Hoe AL, Podd TJ, et al. Assessment of morbidity from complete axillary dissection. *Br J Cancer* 1992;66:136–138.
308. Tejirian T, DiFronzo LA, Haigh PI. Antibiotic prophylaxis for preventing wound infection after breast surgery: a systematic review and metaanalysis. *J Am Coll Surg* 2006;205(5):729–734.
309. Spear SL, Hannan CM, Willey SC, et al. Nipple-sparing mastectomy. *Plast Reconstr Surg* 2009;123:1665–1673.
310. Fortunato L, Loreti A, Andrich R, et al. When mastectomy is needed: is the nipple-sparing procedure a new standard with very few contraindications? *J Surg Oncol* 2013;108:207–212.
311. Kamioka N, Mori H, Okazaki M. Significant reduction of hypertrophic scarring by lateral vertical incision in skin-sparing and nipple-sparing mastectomy. *J Med Dent Sci*

2010;57:203–208.
312. Peled AW, Irwin CS, Hwang ES, et al. Total skin-sparing mastectomy in BRCA mutation carriers. *Ann Surg Oncol* 2014;21:37–41.
313. Golshan M. Chapter 36. Mastectomy. In: Harris JR, Lippman ME, Morrow M, et al, eds. *Diseases of the Breast.* 4th ed. Philadelphia, PA: Lippincott Williams & Wilkins; 2010.
314. Fowble B, Hanlon A, Freedman G, et al. Second cancers after conservative surgery and radiation for stages I-II breast cancer: identifying a subset of women at increased risk. *Int J Radiat Oncol Biol Phys* 2001;51:679–690.
315. Bedrosian I, Hu CY, Chang GJ. Population-based study of contralateral prophylactic mastectomy and survival outcomes of breast cancer patients. *J Natl Cancer Inst* 2010;102:401–409.
316. Lostumbo L, Carbine NE, Wallace J. Prophylactic mastectomy for the prevention of breast cancer. *Cochrane Database Syst Rev* 2010;10(11):CD002748.
317. Zeichner SB, Zeichner SB, Ruiz AL, et al. Improved long-term survival with contralateral prophylactic mastectomy among young women. *Asian Pac J Cancer Prev* 2014;15:1155–1162.
318. van Sprundel TC, Schmidt MK, Rookus MA, et al. Risk reduction of contralateral breast cancer and survival after contralateral prophylactic mastectomy in BRCA1 or BRCA2 mutation carriers. *Br J Cancer* 2005;93:287–292.
319. Miller ME, Czechura T, Martz B, et al. Operative risks associated with contralateral prophylactic mastectomy: a single institution experience. *Ann Surg Oncol* 2013;20:4113–4120.
320. Osman F, Saleh F, Jackson TD, et al. Increased postoperative complications in bilateral mastectomy patients compared to unilateral mastectomy: an analysis of the NSQIP database. *Ann Surg Oncol* 2013;20:3212–3217.
321. Spear SL, Majidian A. Immediate breast reconstruction in two stages using textured, integrated-valve tissue expanders and breast implants: a retrospective review of 171 consecutive breast reconstructions from 1989 to 1996. *Plast Reconstr Surg* 1998;101:53–63.
322. Information on silicone gel breast implants. www.fda.gov/cdrh/breastimplants. Accessed on Jan 5, 2015.
323. Hennekens CH, Lee IM, Cook NR, et al. Self-reported breast implants and connective-tissue diseases in female health professionals. A retrospective cohort study. *JAMA* 1996;275:616–621.
324. Janowsky EC, Kupper LL, Hulka BS. Meta-analyses of the relation between silicone breast implants and the risk of connective-tissue diseases. *N Engl J Med* 2000;342:781–790.
325. http://www.fda.gov/medicaldevices/ProductsandMedicalProcedures/ImplantsandPro

Accessed on Jan 5, 2015.
326. Halsted WS. I. The results of radical operations for the cure of carcinoma of the breast. *Ann Surg* 1907;46:1–19.
327. Anonymous. *Report by the American College of Surgeons Commission on Cancer*. Chicago, IL: American College of Surgeons; 1982.
328. Moxley JH III, Allegra JC, Henney J, et al. Treatment of primary breast cancer. Summary of the National Institutes of Health Consensus Development Conference. *JAMA* 1980;244:797–800.
329. Maddox WA, Carpenter JT Jr, Laws HL, et al. A randomized prospective trial of radical (Halsted) mastectomy versus modified radical mastectomy in 311 breast cancer patients. *Ann Surg* 1983;198:207–212.
330. Omlin A, Amichetti M, Azria D, et al. Boost radiotherapy in young women with ductal carcinoma in situ: a multicentre, retrospective study of the Rare Cancer Network. *Lancet Oncol* 2006;7:652–656.
331. Shah C, McGee M, Wilkinson JB, et al. Clinical outcomes using accelerated partial breast irradiation in patients with ductal carcinoma in situ. *Clin Breast Cancer* 2012;12:259–263.
332. Ciervide R, Dhage S, Guth A, et al. Five year outcome of 145 patients with ductal carcinoma in situ (DCIS) after accelerated breast radiotherapy. *Int J Radiat Oncol Biol Phys* 2012;83:e159–e164.
333. Shah C, Vicini F, Wazer DE, et al. The American Brachytherapy Society consensus statement for accelerated partial breast irradiation. *Brachytherapy* 2013;12:267–277.
334. Ragaz J, Jackson SM, Le N, et al. Adjuvant radiotherapy and chemotherapy in node-positive premenopausal women with breast cancer. *N Engl J Med* 1997;337:956–962.
335. Recht A, Edge SB, Solin LJ, et al. Postmastectomy radiotherapy: clinical practice guidelines of the American Society of Clinical Oncology. *J Clin Oncol* 2001;19:1539–1569.
336. Harris JR, Halpin-Murphy P, McNeese M, et al. Consensus Statement on postmastectomy radiation therapy. *Int J Radiat Oncol Biol Phys* 1999; 44:989–990.
337. Favourable and unfavourable effects on long-term survival of radiotherapy for early breast cancer: an overview of the randomised trials. Early Breast Cancer Trialists' Collaborative Group. *Lancet* 2000;355:1757–1770.
338. Donker M, van Tienhoven G, Straver M, et al. Radiotherapy or surgery of the axilla after a positive sentinel node in breast cancer (EORTC 10981-22023 AMAROS): a randomised, multicentre, open-label, phase 3 non- inferiority trial. *Lancet* 15(12):1303–1310.
339. Adjuvant! breast cancer help files. www.adjuvantonline.com/index.jsp.
340. http://cancer.lifemath.net.
341. www.finprog.org/default.asp.
342. Rouzier R, Perou CM, Symmans WF, et al. Breast cancer molecular subtypes respond

differently to preoperative chemotherapy. *Clin Cancer Res* 2005;11:5678–5685.
343. Foulkes WD, Smith IE, Reis-Filho JS. Triple-negative breast cancer. *N Engl J Med* 2010;363:1938–1948.
344. Early Breast Cancer Trialists' Collaborative G, Peto R, Davies C, et al. Comparisons between different polychemotherapy regimens for early breast cancer: meta-analyses of long-term outcome among 100,000 women in 123 randomised trials. *Lancet* 2012;379:432–444.
345. Sparano JA, Wang M, Martino S, et al. Weekly paclitaxel in the adjuvant treatment of breast cancer. *N Engl J Med* 2008;358:1663–1671.
346. Early Breast Cancer Trialists' Collaborative G, Davies C, Godwin J, et al. Relevance of breast cancer hormone receptors and other factors to the efficacy of adjuvant tamoxifen: patient-level meta-analysis of randomised trials. *Lancet* 2011;378:771–784.
347. Forbes JF, Dowsett M, Bradley R, et al. Patient-level meta-analysis of randomized trials of aromatase inhibitors (AI) versus tamoxifen (Tam). *J Clin Oncol* 2014;32(suppl; abstr 529):5s.
348. Goss PE, Ingle JN, Martino S, et al. A randomized trial of letrozole in postmenopausal women after five years of tamoxifen therapy for early-stage breast cancer. *N Engl J Med* 2003;349:1793–1802.
349. Jin H, Tu D, Zhao N, et al. Longer-term outcomes of letrozole versus placebo after 5 years of tamoxifen in the NCIC CTG MA.17 trial: analyses adjusting for treatment crossover. *J Clin Oncol* 2012;30:718–721.
350. Goss PE, Ingle JN, Martino S, et al. Randomized trial of letrozole following tamoxifen as extended adjuvant therapy in receptor-positive breast cancer: updated findings from NCIC CTG MA.17. *J Natl Cancer Inst* 2005;97:1262–1271.
351. Henry NL, Xia R, Banerjee M, et al. Predictors of recovery of ovarian function during aromatase inhibitor therapy. *Ann Oncol* 2013;24: 2011–2016.
352. Guerrero A, Gavila J, Folkerd E, et al. Incidence and predictors of ovarian function recovery (OFR) in breast cancer (BC) patients with chemotherapy-induced amenorrhea (CIA) who switched from tamoxifen to exemestane. *Ann Oncol* 2013;24:674–679.
353. Davies C, Pan H, Godwin J, et al. Long-term effects of continuing adjuvant tamoxifen to 10 years versus stopping at 5 years after diagnosis of oestrogen receptor-positive breast cancer: ATLAS, a randomised trial. *Lancet* 2013;381:805–816.
354. Gray RG, Rea D, Handley K, et al. aTTom: long-term effects of continuing adjuvant tamoxifen to 10 years versus stopping at 5 years in 6,953 women with early breast cancer. *J Clin Oncol* 2013;31sl; abstr 5.
355. Goss PE, Ingle JN, Pritchard KI, et al. Extending aromatase-inhibitor adjuvant therapy to 10 years. *N Engl J Med* 2016;375:209–219.
356. Berry DA, Cirrincione C, Henderson IC, et al. Estrogen-receptor status and outcomes

of modern chemotherapy for patients with node-positive breast cancer. *JAMA* 2006;295:1658–1667.

357. Martin M, Rodriguez-Lescure A, Ruiz A, et al. Molecular predictors of efficacy of adjuvant weekly paclitaxel in early breast cancer. *Breast Cancer Res Treat* 2010;123:149–157.
358. Byrski T, Huzarski T, Dent R, et al. Pathologic complete response to neoadjuvant cisplatin in BRCA1-positive breast cancer patients. *Breast Cancer Res Treat* 2014;147:401–405.
359. Liedtke C, Mazouni C, Hess KR, et al. Response to neoadjuvant therapy and long-term survival in patients with triple-negative breast cancer. *J Clin Oncol* 2008;26:1275–1281.
360. von Minckwitz G, Untch M, Blohmer JU, et al. Definition and impact of pathologic complete response on prognosis after neoadjuvant chemotherapy in various intrinsic breast cancer subtypes. *J Clin Oncol* 2012; 30:1796–1804.
361. Lin NU, Vanderplas A, Hughes ME, et al. Clinicopathologic features, patterns of recurrence, and survival among women with triple-negative breast cancer in the National Comprehensive Cancer Network. *Cancer* 2012;118:5463–5472.
362. Moja L, Tagliabue L, Balduzzi S, et al. Trastuzumab containing regimens for early breast cancer. *Cochrane Database Syst Rev* 2012;4:CD006243.
363. Goldhirsch A, Gelber RD, Piccart-Gebhart MJ, et al. 2 years versus 1 year of adjuvant trastuzumab for HER2-positive breast cancer (HERA): an open-label, randomised controlled trial. *Lancet* 2013;382:1021–1028.
364. Pivot X, Romieu G, Debled M, et al. 6 months versus 12 months of adjuvant trastuzumab for patients with HER2-positive early breast cancer (PHARE): a randomised phase 3 trial. *Lancet Oncol* 2013;14:741–748.
365. Perez EA, Romond EH, Suman VJ, et al. Four-year follow-up of trastuzumab plus adjuvant chemotherapy for operable human epidermal growth factor receptor 2-positive breast cancer: joint analysis of data from NCCTG N9831 and NSABP B-31. *J Clin Oncol* 2011;29:3366–3373.
366. Slamon D, Eiermann W, Robert N, et al. Adjuvant trastuzumab in HER2-positive breast cancer. *N Engl J Med* 2011;365:1273–1283.
367. Vu T, Sliwkowski MX, Claret FX. Personalized drug combinations to overcome trastuzumab resistance in HER2-positive breast cancer. *Biochim Biophys Acta* 2014;1846:353–365.
368. Goss PE, Smith IE, O'Shaughnessy J, et al. Adjuvant lapatinib for women with early-stage HER2-positive breast cancer: a randomised, controlled, phase 3 trial. *Lancet Oncol* 2013;14:88–96.
369. Piccart-Gebhart MJ, Holmes AP, Baselga J, et al. First results from the phase III ALTTO trial (BIG 2–06; NCCTG [Alliance] N063D) comparing one year of anti-HER2 therapy with lapatinib alone (L), trastuzumab alone (T), their sequence (T then L), or

their combination (T + L) in the adjuvant treatment of HER2-positive early breast cancer (EBC). *J Clin Oncol* 2014;32:5s (suppl; abstr LBA4) http://abstracts.asco.org/144/AbstView_144_128258.html.

370. Verma S, Miles D, Gianni L, et al. Trastuzumab emtansine for HER2- positive advanced breast cancer. *N Engl J Med* 2012;367:1783–1791.
371. Robbins GF, Shah J, Rosen P, et al. Inflammatory carcinoma of the breast. *Surg Clin N Am* 1974;54:801–810.
372. Bell C. A System of Operative Surgery Founded on the Basis of Anatomy. Hartford, CT: Hale and Hosmer; 1812:128.
373. Lee BJ, Tannenbaum NE. Inflammatory carcinoma of the breast: a report of twenty-eight cases from the breast clinic of Memorial Hospital. *Surg Gynecol Obstet* 1924;39:580–595.
374. Chang S, Parker SL, Pham T, et al. Inflammatory breast carcinoma incidence and survival: the surveillance, epidemiology, and end results program of the National Cancer Institute, 1975–1992. *Cancer* 1998;82:2366–2372.
375. Dawood S, Merajver SD, Viens P, et al. International expert panel on inflammatory breast cancer: consensus statement for standardized diagnosis and treatment. *Ann Oncol* 2011;22:515–523.
376. Kleer CG, van Golen KL, Merajver SD. Molecular biology of breast cancer metastasis. Inflammatory breast cancer: clinical syndrome and molecular determinants. *Breast Cancer Res* 2000;2:423–429.
377. Jaiyesimi IA, Buzdar AU, Hortobagyi G. Inflammatory breast cancer: a review. *J Clin Oncol* 1992;10:1014–1024.
378. Harris EE, Schultz D, Bertsch H, et al. Ten-year outcome after combined modality therapy for inflammatory breast cancer. *Int J Radiat Oncol Biol Phys* 2003;55:1200–1208.
379. Hennessy BT, Gonzalez-Angulo AM, Hortobagyi GN, et al. Disease-free and overall survival after pathologic complete disease remission of cytologically proven inflammatory breast carcinoma axillary lymph node metastases after primary systemic chemotherapy. *Cancer* 2006;106:1000–1006.
380. Perez CA, Fields JN, Fracasso PM, et al. Management of locally advanced carcinoma of the breast. II. Inflammatory carcinoma. *Cancer* 1994;74:466–476.
381. Smoot RL, Koch CA, Degnim AC, et al. A single-center experience with inflammatory breast cancer, 1985–2003. *Arch Surg* 2006;141:567–572; discussion 72–73.
382. Baldini E, Gardin G, Evagelista G, et al. Long-term results of combined-modality therapy for inflammatory breast carcinoma. *Clin Breast Cancer* 2004;5:358–363.
383. Liauw SL, Benda RK, Morris CG, et al. Inflammatory breast carcinoma: outcomes with trimodality therapy for nonmetastatic disease. *Cancer* 2004;100:920–928.
384. Wyld L, Garg DK, Kumar ID, et al. Stage and treatment variation with age in postmenopausal women with breast cancer: compliance with guidelines. *Br J Cancer*

2004;90:1486–1491.
385. Enger SM, Thwin SS, Buist DS, et al. Breast cancer treatment of older women in integrated health care settings. *J Clin Oncol* 2006;24:4377–4383.
386. Lavelle K, Todd C, Moran A, et al. Non-standard management of breast cancer increases with age in the UK: a population based cohort of women >or = 65 years. *Br J Cancer* 2007;96:1197–1203.
387. Cyr A, Gillanders WE, Aft RL, et al. Breast cancer in elderly women (>/ = 80 years): variation in standard of care? *J Surg Oncol* 2011;103:201–206.
388. Bastiaannet E, Liefers GJ, de Craen AJ, et al. Breast cancer in elderly compared to younger patients in the Netherlands: stage at diagnosis, treatment and survival in 127,805 unselected patients. *Breast Cancer Res Treat* 2010;124:801–807.
389. Diab SG, Elledge RM, Clark GM. Tumor characteristics and clinical outcome of elderly women with breast cancer. *J Natl Cancer Inst* 2000;92: 550–556.
390. Chagpar AB, McMasters KM, Edwards MJ; North American Fareston Tamoxifen Adjuvant T. Can sentinel node biopsy be avoided in some elderly breast cancer patients? *Ann Surg* 2009;249:455–460.
391. International Breast Cancer Study G, Rudenstam CM, Zahrieh D, et al. Randomized trial comparing axillary clearance versus no axillary clearance in older patients with breast cancer: first results of International Breast Cancer Study Group Trial 10–93. *J Clin Oncol* 2006;24:337–344.
392. Martelli G, Miceli R, Costa A, et al. Elderly breast cancer patients treated by conservative surgery alone plus adjuvant tamoxifen: fifteen-year results of a prospective study. *Cancer* 2008;112:481–488.
393. Hughes KS, Schnaper LA, Bellon JR, et al. Lumpectomy plus tamoxifen with or without irradiation in women age 70 years or older with early breast cancer: long-term follow-up of CALGB 9343. *J Clin Oncol* 2013;31: 2382–2387.
394. Caillet P, Canoui-Poitrine F, Vouriot J, et al. Comprehensive geriatric assessment in the decision-making process in elderly patients with cancer: ELCAPA study. *J Clin Oncol* 2011;29:3636–3642.
395. Stensheim H, Moller B, van Dijk T, et al. Cause-specific survival for women diagnosed with cancer during pregnancy or lactation: a registry-based cohort study. *J Clin Oncol* 2009;27:45–51.
396. Salani R, Billingsley CC, Crafton SM. Cancer and pregnancy: an overview for obstetricians and gynecologists. *Am J Obstet Gynecol* 2014;211:7–14.
397. Ventura SJ. First births to older mothers, 1970–86. *Am J Public Health* 1989;79:1675–1677.
398. Voulgaris E, Pentheroudakis G, Pavlidis N. Cancer and pregnancy: a comprehensive review. *Surg Oncol* 2011;20:e175–e185.
399. Liberman L, Giess CS, Dershaw DD, et al. Imaging of pregnancy-associated breast cancer. *Radiology* 1994;191:245–248.

400. Ahn BY, Kim HH, Moon WK, et al. Pregnancy- and lactation-associated breast cancer: mammographic and sonographic findings. *J Ultrasound Med* 2003;22:491–497; quiz 8–9.
401. Behrman RH, Homer MJ, Yang WT, et al. Mammography and fetal dose. *Radiology* 2007;243:605; author reply -6.
402. Anderson BO, Petrek JA, Byrd DR, et al. Pregnancy influences breast cancer stage at diagnosis in women 30 years of age and younger. *Ann Surg Oncol* 1996;3:204–211.
403. Middleton LP, Amin M, Gwyn K, et al. Breast carcinoma in pregnant women: assessment of clinicopathologic and immunohistochemical features. *Cancer* 2003;98:1055–1060.
404. Nugent P, O'Connell TX. Breast cancer and pregnancy. *Arch Surg* 1985; 120:1221–1224.
405. Clark RM, Chua T. Breast cancer and pregnancy: the ultimate challenge. *Clin Oncol* 1989;1:11–18.
406. Gemignani ML, Petrek JA, Borgen PI. Breast cancer and pregnancy. *Surg Clin North Am* 1999;79:1157–1169.
407. Amant F, von Minckwitz G, Han SN, et al. Prognosis of women with primary breast cancer diagnosed during pregnancy: results from an international collaborative study. *J Clin Oncol* 2013;31:2532–2539.
408. Azim HA Jr, Santoro L, Russell-Edu W, et al. Prognosis of pregnancy- associated breast cancer: a meta-analysis of 30 studies. *Cancer Treat Rev* 2012;38:834–842.
409. Barron WM. The pregnant surgical patient: medical evaluation and management. *Ann Intern Med* 1984;101:683–691.
410. Mazze RI, Kallen B. Reproductive outcome after anesthesia and operation during pregnancy: a registry study of 5405 cases. *Am J Obstet Gynecol* 1989;161:1178–1185.
411. Gianopoulos JG. Establishing the criteria for anesthesia and other precautions for surgery during pregnancy. *Surg Clin North Am* 1995;75:33–45.
412. Duncan PG, Pope WD, Cohen MM, et al. Fetal risk of anesthesia and surgery during pregnancy. *Anesthesiology* 1986;64:790–794.
413. Antypas C, Sandilos P, Kouvaris J, et al. Fetal dose evaluation during breast cancer radiotherapy. *Int J Radiat Oncol Biol Phys* 1998;40:995–999.
414. http://www.bt.cdc.gov/radiation/prenatalphysician.asp.
415. Keleher A, Wendt R III, Delpassand E, et al. The safety of lymphatic mapping in pregnant breast cancer patients using Tc-99m sulfur colloid. *Breast J* 2004;10:492–495.
416. Gentilini O, Cremonesi M, Trifiro G, et al. Safety of sentinel node biopsy in pregnant patients with breast cancer. *Ann Oncol* 2004;15:1348–1351.
417. Mondi MM, Cuenca RE, Ollila DW, et al. Sentinel lymph node biopsy during pregnancy: initial clinical experience. *Ann Surg Oncol* 2007;14: 218–221.
418. Gropper AB, Calvillo KZ, Dominici L, et al. Sentinel lymph node biopsy in pregnant

women with breast cancer. *Ann Surg Oncol* 2014;21: 2506–2511.

419. Berry DL, Theriault RL, Holmes FA, et al. Management of breast cancer during pregnancy using a standardized protocol. *J Clin Oncol* 1999;17: 855–861.
420. Cardonick E, Iacobucci A. Use of chemotherapy during human pregnancy. *Lancet Oncol* 2004;5:283–291.
421. Hahn KM, Johnson PH, Gordon N, et al. Treatment of pregnant breast cancer patients and outcomes of children exposed to chemotherapy in utero. *Cancer* 2006;107:1219–1226.
422. Zemlickis D, Lishner M, Degendorfer P, et al. Maternal and fetal outcome after breast cancer in pregnancy. *Am J Obstet Gynecol* 1992;166: 781–787.
423. HERCEPTIN (trastuzumab) prescribing information. http://www.accessdata.fda.gov/drugsatfda_docs/label/2010/103792s5256lbl.pdf.
424. Zagouri F, Sergentanis TN, Chrysikos D, et al. Trastuzumab administration during pregnancy: a systematic review and meta-analysis. *Breast Cancer Res Treat* 2013;137:349–357.
425. White J, Kearins O, Dodwell D, et al. Male breast carcinoma: increased awareness needed. *Breast Cancer Res* 2011;13:219.
426. Tai YC, Domchek S, Parmigiani G, et al. Breast cancer risk among male BRCA1 and BRCA2 mutation carriers. *J Natl Cancer Inst* 2007;99: 1811–1814.
427. Ding YC, Steele L, Kuan CJ, et al. Mutations in BRCA2 and PALB2 in male breast cancer cases from the United States. *Breast Cancer Res Treat* 2011;126:771–778.
428. Boyd J, Rhei E, Federici MG, et al. Male breast cancer in the hereditary nonpolyposis colorectal cancer syndrome. *Breast Cancer Res Treat* 1999; 53:87–91.
429. Brinton LA. Breast cancer risk among patients with Klinefelter syndrome. *Acta Paediatr* 2011;100:814–818.
430. Thomas DB, Jimenez LM, McTiernan A, et al. Breast cancer in men: risk factors with hormonal implications. *Am J Epidemiol* 1992;135:734–748.
431. Thomas DB. Breast cancer in men. *Epidemiol Rev* 1993;15:220–231.
432. Chavez-Macgregor M, Clarke CA, Lichtensztajn D, et al. Male breast cancer according to tumor subtype and race: a population-based study. *Cancer* 2013;119:1611–1617.
433. Golshan M, Rusby J, Dominguez F, et al. Breast conservation for male breast carcinoma. *Breast* 2007;16:653–656.
434. Ribeiro G, Swindell R. Adjuvant tamoxifen for male breast cancer (MBC). *Br J Cancer* 1992;65:252–254.
435. Eggemann H, Ignatov A, Smith BJ, et al. Adjuvant therapy with tamoxifen compared to aromatase inhibitors for 257 male breast cancer patients. *Breast Cancer Res Treat* 2013;137:465–470.
436. Hemminki K, Scelo G, Boffetta P, et al. Second primary malignancies in patients with male breast cancer. *Br J Cancer* 2005;92:1288–1292.

437. van Tienhoven G, Voogd AC, Peterse JL, et al. Prognosis after treatment for loco-regional recurrence after mastectomy or breast conserving therapy in two randomised trials (EORTC 10801 and DBCG-82TM). EORTC Breast Cancer Cooperative Group and the Danish Breast Cancer Cooperative Group. *Eur J Cancer* 1999;35:32–38.
438. Francis M, Cakir B, Ung O, et al. Prognosis after breast recurrence following conservative surgery and radiotherapy in patients with node-negative breast cancer. *Br J Surg* 1999;86:1556–1562.
439. Dalberg K, Mattsson A, Sandelin K, et al. Outcome of treatment for ipsilateral breast tumor recurrence in early-stage breast cancer. *Breast Cancer Res Treat* 1998;49:69–78.
440. Early Breast Cancer Trialists' Collaborative G, Darby S, McGale P, et al. Effect of radiotherapy after breast-conserving surgery on 10-year recurrence and 15-year breast cancer death: meta-analysis of individual patient data for 10,801 women in 17 randomised trials. *Lancet* 2011;378: 1707–1716.
441. Katz A, Strom EA, Buchholz TA, et al. Locoregional recurrence patterns after mastectomy and doxorubicin-based chemotherapy: implications for postoperative irradiation. *J Clin Oncol* 2000;18:2817–2827.
442. Willner J, Kiricuta IC, Kolbl O. Locoregional recurrence of breast cancer following mastectomy: always a fatal event? Results of univariate and multivariate analysis. *Int J Radiat Oncol Biol Phys* 1997;37:853–863.
443. Solin LJ, Fourquet A, Vicini FA, et al. Salvage treatment for local or local-regional recurrence after initial breast conservation treatment with radiation for ductal carcinoma in situ. *Eur J Cancer* 2005;41:1715–1723.
444. Paget J. On disease of the mammary areola preceding cancer of the mammary gland. *St Bartholomew's Hosp Rep* 1874;10:87.
445. Chen CY, Sun LM, Anderson BO. Paget disease of the breast: changing patterns of incidence, clinical presentation, and treatment in the U.S. *Cancer* 2006;107:1448–1458.
446. Ikeda DM, Helvie MA, Frank TS, et al. Paget disease of the nipple: radiologic-pathologic correlation. *Radiology* 1993;189:89–94.
447. Berg JW, Hutter RV. Breast cancer. *Cancer* 1995;75:257–269.
448. Adem C, Reynolds C, Ingle JN, et al. Primary breast sarcoma: clinicopathologic series from the Mayo Clinic and review of the literature. *Br J Cancer* 2004;91:237–241.
449. Sheth GR, Cranmer LD, Smith BD, et al. Radiation-induced sarcoma of the breast: a systematic review. *Oncologist* 2012;17:405–418.
450. Sharma A, Schwartz RA. Stewart-Treves syndrome: pathogenesis and management. *J Am Acad Dermatol* 2012;67:1342–1348.
451. Smith TB, Gilcrease MZ, Santiago L, et al. Imaging features of primary breast sarcoma. *AJR Am J Roentgenol* 2012;198:W386–W393.
452. AJCC (American Joint Committee on Cancer). In: Edge SB, Byrd DR, Comptom CC,

et al, eds. *Cancer Staging Manual.* 7th ed. New York, NY: Springer; 2010:291.

453. Pollack R, Brennan M, Lawrence W Jr. Society of surgical oncology practice guidelines. Soft-tissue sarcoma surgical practice guidelines. *Oncology* 1997;11:1327–1332.

454. Müller J. *Uber den feineren Ban und Die Formen der Krankaften Geschwulste*. Berlin, G Reiner: 1838:1:54–57.

455. Birch JM, Alston RD, McNally RJ, et al. Relative frequency and morphology of cancers in carriers of germline TP53 mutations. *Oncogene* 2001;20:4621–4628.

456. Reinfuss M, Mitus J, Duda K, et al. The treatment and prognosis of patients with phyllodes tumor of the breast: an analysis of 170 cases. *Cancer* 1996;77:910–916.

457. Dillon MF, Quinn CM, McDermott EW, et al. Needle core biopsy in the diagnosis of phyllodes neoplasm. *Surgery* 2006;140:779–784.

458. Lee AH, Hodi Z, Ellis IO, et al. Histological features useful in the distinction of phyllodes tumour and fibroadenoma on needle core biopsy of the breast. *Histopathology* 2007;51:336–344.

459. Macdonald OK, Lee CM, Tward JD, et al. Malignant phyllodes tumor of the female breast: association of primary therapy with cause-specific survival from the Surveillance, Epidemiology, and End Results (SEER) program. *Cancer* 2006;107:2127–2133.

460. Kessinger A, Foley JF, Lemon HM, et al. Metastatic cystosarcoma phyllodes: a case report and review of the literature. *J Surg Oncol* 1972;4:131–147.

Chapter 75

Thyroid Gland

David T. Hughes and Paul G. Gauger

Key Points

1 The tubercle of Zuckerkandl is an anatomic feature of the thyroid that helps facilitate identification of the recurrent laryngeal nerve (RLN) and the superior parathyroid gland.

2 A nonrecurrent right laryngeal nerve is most commonly due to anomalous origin of the right subclavian artery from the distal aortic arch which then passes posterior to the esophagus (arteria lusoria); a left non-RLN is rare and due to situs inversus.

3 Ultrasound is the imaging procedure of choice for nodular thyroid disease, and surgeon-performed ultrasound helps facilitate operative planning.

4 The Bethesda Classification System for Thyroid FNA can guide further management of thyroid nodules.

5 Additional thyroid resection or adjuvant treatment with radioiodine is seldom required for an incidental papillary microcarcinoma (<1 cm) found in the surgical specimen.

6 Molecular markers including BRAF, RET, and RAS can aid in the diagnosis of thyroid cancer on fine-needle biopsy and in the management of thyroid cancer.

7 Genotype/phenotype correlation using the specific RET protooncogene mutation identified in each patient/family can help determine the appropriate age for prophylactic thyroidectomy in patients with hereditary medullary thyroid carcinoma.

8 Lymphoma of the thyroid or anaplastic thyroid cancer should be considered in the hypothyroid patient who experiences rapid growth of the thyroid.

9 Advantages of total thyroidectomy over thyroid lobectomy for differentiated thyroid carcinoma include (a) removal of multifocal intrathyroidal tumors; (b) facilitation of radioiodine imaging and ablation for residual, regional, or metastatic disease; and (c) use of serum thyroglobulin as a sensitive marker of persistent or recurrent disease.

10 Therapeutic, compartment-based lymph node dissection is indicated for patients with evidence of lymph node metastasis in thyroid cancer.

The broad indications for thyroidectomy include hyperthyroidism, thyroid nodularity, thyroid goiter, Graves disease, thyroid cancer, and prophylaxis in multiple endocrine neoplasia type 2. Understanding of the embryology, anatomy, physiology, and relevant pharmacology of thyroid disease and precise surgical technique and careful attention to

detail are necessary to prevent complications of thyroid surgery.

EMBRYOLOGY AND SURGICAL IMPLICATIONS

Developmental Embryology

The thyroid is mostly derived of endoderm from the ventral embryologic digestive tract and is the first endocrine gland to develop. A midline diverticulum arises in the area of the foramen cecum at the base of the tongue at approximately 4 weeks of gestation. The tissue descends as the median thyroid component and ultimately becomes the isthmus and the majority of each lateral lobe. The foramen cecum ruptures and resorbs during week 6 of gestational age, leaving behind a regressive fibrous thyroglossal duct (including the portion associated with the central hyoid bone). The distal end of the thyroglossal duct tract persists as a recognizable pyramidal lobe attached to the isthmus in about 30% to 50% of individuals. The lateral thyroid components develop from the caudal pharyngeal endoderm (with contribution from the fourth and fifth branchial pouches) and arise later in development than the median component.[1] The lateral components become increasingly removed from the pharynx, leaving a tapering connection on each side, which eventually detaches. The residual posterolateral projection from the lateral thyroid component is known as the tubercle of Zuckerkandl. Because of its branchial pouch origin, the lateral thyroid component is closely associated with the superior parathyroid anlage (from the fourth pouch). The lateral components contain C cells (from neural crest origin) which migrate into the superolateral portion of the lobes and eventually secrete calcitonin. The unified thyroid begins to differentiate into thyroid follicles between 8 and 11 weeks. Thyroid hormone production begins on a cellular level by the third month of gestation when iodine trapping occurs.

Congenital Abnormalities

A lingual thyroid gland is an uncommon developmental malformation of thyroid tissue erupting from the base of the tongue due to failure of the median thyroid component to descend from the foramen cecum. Treatment of lingual thyroid can include exogenous thyroid hormone to suppress thyroid-stimulating hormone (TSH), radioiodine ablation or surgical excision. Thyroglossal duct cysts occur in the midline of the neck along the path of descent of the median thyroid component. They may occur from the base of the tongue to the low central neck, although most are located just inferior to the hyoid bone. Although they are often discovered during infancy and childhood, it is not uncommon for them to present in adulthood – discovered either because of mass effect or infection. Elevation of the mass with protrusion of the tongue is very suggestive of a thyroglossal duct cyst. Resection of a thyroglossal duct cyst involves excision of the entire thyroglossal duct, the cyst, and the tract as it courses through the central portion of the hyoid bone (Sistrunk procedure). The epithelial lining usually contains some thyroid cells and thyroid carcinomas (usually of papillary type) can arise along the thyroglossal duct tract.

Ectopic thyroid tissue can be found in other areas of the central cervical compartment and the mediastinum. These can be extrathyroidal nodules associated with multinodular goiters or embryologic rests of thyroid tissue along the path of caudal migration.[2] Historically, the concept of *lateral aberrant thyroid* tissue was used to describe follicular thyroid tissue in the carotid sheath or the lateral compartments of the neck; however, it is now generally agreed that this cannot occur as an embryologic abnormality and rather this represents a regional nodal metastasis of differentiated thyroid cancer (DTC).

ANATOMY AND SURGICAL IMPLICATIONS

A normal thyroid gland weighs between 15 and 20 g. The thyroid isthmus is approximately 1 to 2 cm in transverse and vertical dimensions and normally overlies the trachea from just below the cricoid cartilage to the fourth or fifth tracheal ring. The lateral lobes lie adjacent to the thyroid cartilage and cricothyroid muscle as well as the lateral trachea and a portion of the lateral esophagus on each side. The two lobes are roughly conical and normally measure ~5 cm in craniocaudal and 2 to 3 cm in mediolateral and anteroposterior dimensions.

Muscular, Fascial, and Airway Relationships

The thyroid lies in the central compartment of the neck bordered by the contents of the carotid sheath on each side. The anterolateral surface is covered by the sternothyroid muscles, which do not completely meet in the midline above the level of the isthmus. Superficial to the sternothyroid muscles are the sternohyoid muscles that meet at the median raphe which is typically split during thyroidectomy. These muscles are innervated on the inferolateral aspect by the ansa cervicalis (ansa hypoglossi). The thyroid is invested in a thin layer of connective tissue that is an expansion of the pretracheal fascia (often called the “thyroid sheath”). The sheath is not to be confused with the thyroid capsule, which is more integral to the gland itself. The plane between the capsule and the sheath is usually easy to develop as the thyroid is mobilized away from surrounding structures. Especially near the superior portion of the thyroid, the sheath defines a coronal plane that, when opened, exposes the potential space between the pharynx/esophagus and the cervical vertebral bodies. The sheath is condensed as the anterior suspensory ligament above the isthmus. The sheath also attaches the posterior surface of the thyroid gland to the tracheal rings and is condensed posteromedially into the ligament of Berry on each side. The ligament of Berry is a firm attachment to the trachea near the cricothyroid space and is often intimately associated with the recurrent laryngeal nerve (RLN) near its insertion at the cricopharyngeus muscle. The RLN is most vulnerable to iatrogenic injury when dividing the ligament of Berry.

Vascular Relationships

The thyroid gland has a very high blood flow index per tissue mass and receives its arterial supply from a paired system of superior thyroid arteries (originating as the first branch of the external carotid arteries) and inferior thyroid arteries (originating from the thyrocervical trunks). The superior artery courses along the inferior pharyngeal constrictor muscle group and branches near the tip of the superior pole of the thyroid, usually into at least an anterior and posterior branch. The inferior thyroid artery (ITA) courses behind the carotid artery and then crosses medially to meet the thyroid lobe just below the ligament of Berry near the tracheoesophageal groove. The ITA has multiple branches that course in a plane between the sheath and the capsule of the gland. The relationship of the ITA to the RLN is an important landmark and the specific relationship between the ITA and the RLN (anterior, posterior, or interdigitated) may be variable and caution should be taken in ligation of the ITA branches during thyroidectomy. Occasionally, an arteria thyroidea ima arises from the aorta or innominate artery and courses anterior to the trachea to directly serve the inferior portion of the thyroid gland.

Venous drainage of the thyroid is by a widely anastomosing system that condenses into three main trunks. The superior thyroid veins course adjacent to the superior thyroid arteries but empty into the internal jugular vein at the level of the carotid bifurcation. Middle thyroid veins are present in more than half of patients and drain laterally to the internal jugular vein. These veins are divided early in the course of mobilizing the thyroid lobe. In tracing a vessel laterally, if it passes anterior to the carotid artery, it is a middle thyroid vein, whereas if it passes posterior to the carotid, it is the ITA. The inferior thyroid veins form nearly all of the vascular connections found at the inferior poles of the thyroid lobes and are situated anterior to the RLN. The number and configuration of these veins can be quite variable, but in general they descend along the course of the thyrothymic tract to drain into the ipsilateral brachiocephalic vein.

Neurologic Relationships

1 Two nerves have critical importance during thyroidectomy: the recurrent laryngeal nerve (RLN) (also known as the inferior laryngeal nerve) and the external branch of the superior laryngeal nerve (EBSLN). The right RLN arises from the vagus at the level of the subclavian artery and passes (recurs) around the posterior aspect of the artery before ascending into the central compartment. The right RLN takes an oblique course in the central neck and may be 1 to 2 cm lateral to the trachea low in the central neck before traveling toward its entry point at the cricothyroid. The left RLN arises from the vagus nerve as it crosses the aortic arch posterior to the ligamentum arteriosum. It passes inferior and medial to the arch and ascends to the larynx in the tracheoesophageal groove along a course that is typically linear and more vertical than the right RLN. The RLN often lies immediately posterolateral to the ligament of Berry, but it is not infrequent that it can be embedded in the fibrous connections of the ligament itself, especially the anterior branch if the RLN bifurcates outside the larynx. In a standard anatomic relationship, the tubercle of Zuckerkandl lies immediately lateral to and covers the RLN (Fig. 75-1). An uncommon, but high-risk, anatomic arrangement occurs when the RLN is found lateral to the tubercle of Zuckerkandl (Fig. 75-2). If the surgeon is unaware of this possibility (which may exist when the tubercle has undergone nodular enlargement), the nerve is subject to iatrogenic injury.[3] Up to 34% of RLNs will bifurcate proximal to the inferior border of the cricoid cartilage with the anterior branch containing the motor fibers and the posterior branch containing sensory fibers.[4] Injury to these branches can lead to hoarseness and aspiration due to motor and sensory dysfunction respectively, manifesting as hoarseness and/or aspiration.

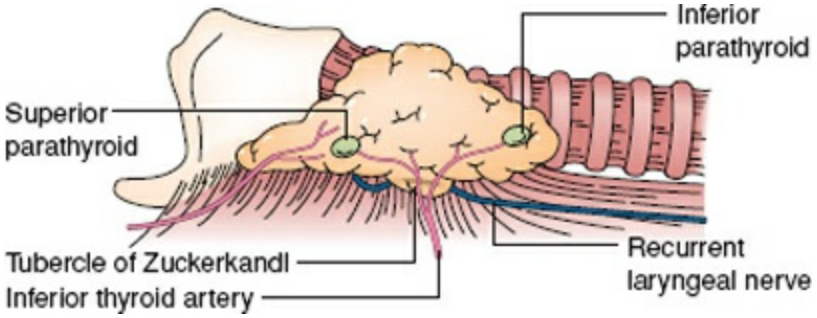

Figure 75-1. The standard anatomic relationship whereby the recurrent laryngeal nerve (RLN) passes medial to the tubercle of Zuckerkandl before its insertion into the cricothyroid interval.

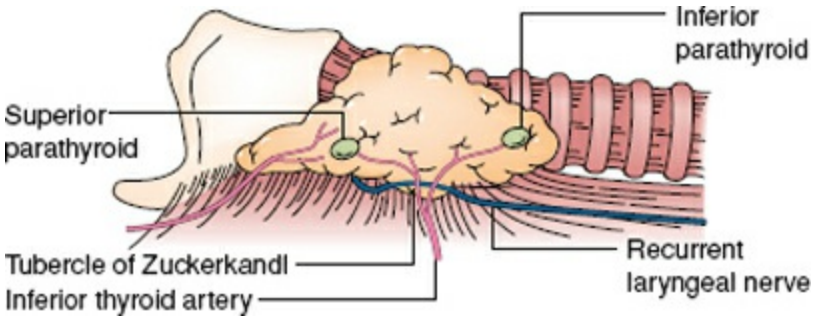

Figure 75-2. The uncommon but high-risk anatomic variation where the recurrent laryngeal nerve (RLN) courses lateral to the tubercle of Zuckerkandl, which is often enlarged. The nerve is encountered much earlier in the dissection required for thyroidectomy and is at risk of being misidentified as a vascular structure.

2 It is critical to be aware of the occasional non-RLN (also called a "direct" laryngeal nerve). This anomaly results from abnormal embryonic development of the aortic arch. The anomaly is more common on the right (approximately 0.5% to 0.7%) than on the left (approximately 0.04%). [5] On the right, a nonrecurrent nerve is the consequence of the formation of the arteria lusoria vascular abnormality, in which the innominate artery is absent and the right common carotid and right subclavian arteries originate directly from the arch. The right subclavian artery arises as a branch of the aortic arch distal to the left subclavian and takes a retroesophageal course. This anomaly can produce dysphagia due to compression of the esophagus between the posterior trachea and the subclavian artery termed *dysphagia lusoria.* A nonrecurrent left RLN requires a right-sided aortic arch (as occurs in situs inversus viscerum), the origin of the left subclavian artery abnormally sited on the aortic arch, and the displacement of the ligamentum arteriosum to the right and thus is a rarely found anomaly.

The superior laryngeal nerve (SLN) arises from the vagus at the nodose ganglion near the base of the skull and descends along the course of the internal carotid artery. At the level of the hyoid bone, it bifurcates into the internal branch (which enters the larynx at the thyrohyoid membrane to provide sensory innervation to the superior larynx) and the external branch (which provides motor innervation to the cricothyroideus muscle which contributes to variation in voice pitch and projection). The external branch has a variable course in relation to the inferior pharyngeal constrictor muscle and the branches of the superior thyroid artery which makes it vulnerable to iatrogenic injury. The Cernea classification of the anatomic variations of the SLN are depicted in Figure 75-3.[6]

Lymphatic Relationships

Lymph flows in multiple directions through a rich plexus surrounding the thyroid. The thyroid gland has intracapsular lymph channels, which provide some communication between lobes across the isthmus. The central compartment (level VI) nodal basin is comprised of the pretracheal and paratracheal nodes and those along the RLNs between the carotid sheaths laterally and extends from the hyoid bone cranially and to the level of the innominate artery caudally.[7] Within the anterior suspensory ligament near the pyramidal lobe is a small group of midline prelaryngeal lymph nodes known as the Delphian nodes. The lateral cervical nodal basins include the upper jugular (level II), midjugular (level III), and lower jugular (level IV) lymph nodes as well as the posterior triangle lymph nodes (level V) (Fig. 75-4). Thyroid cancers with regional lymph node metastases tend to involve level VI before involving levels II, III, IV, and ultimately V.[8] Level I (submental) and level VII (superior mediastinal) involvement is less common but can occur. Documented cases of "skip" metastases directly to the lateral compartment with no level VI involvement have been reported but are atypical.[9]

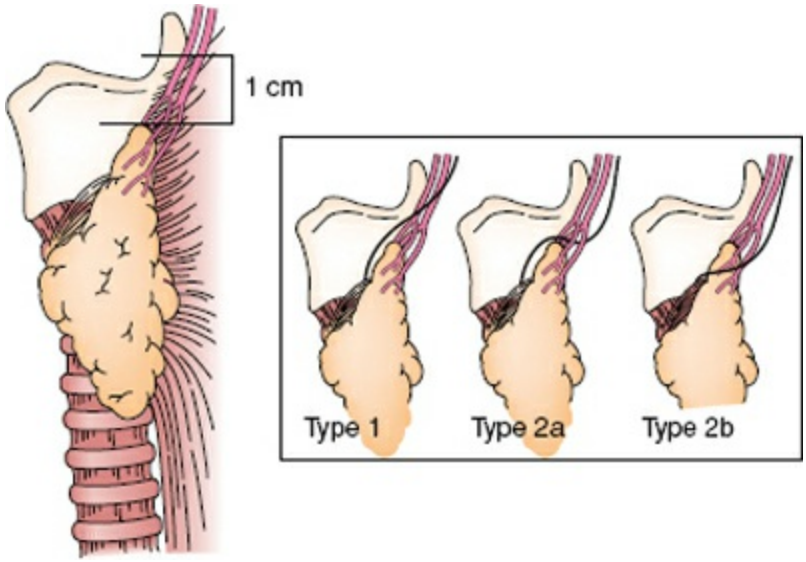

Figure 75-3. Cernea classification of the anatomic relationships between the external branch of the superior laryngeal nerve (EBSLN), the superior pole of the thyroid, and the superior thyroid artery. With type 1 anatomy, the nerve crosses the superior thyroid vessels 1 cm or more above the superior thyroid pole. With type 2 anatomy, the nerve crosses the vessels less than 1 cm above (type 2a) or even below (type 2b) the superior pole. Type 2 variants are the most vulnerable to iatrogenic injury.

Parathyroid Relationships

Parathyroid glands are encountered during thyroidectomy by virtue of their association with the thyroid gland, however, ectopic parathyroid glands will typically not be encountered. The superior parathyroid gland is usually located in a relatively constant area largely because of the embryologic association between the lateral thyroid component and the superior parathyroid anlage (both associated with the fourth branchial pouch). The tubercle of Zuckerkandl is anatomically associated with the position of the superior parathyroid gland as well as the RLN. In relation to the point at which the RLN intersects the ITA, a 2-cm circumscribed area on the cranial aspect will often contain the superior parathyroid gland. It may also be found tucked posterior to the ITA or even posteromedial to the superior thyroid pole. There is an 80% chance that a superior parathyroid gland will be found in a position similar to its contralateral partner.

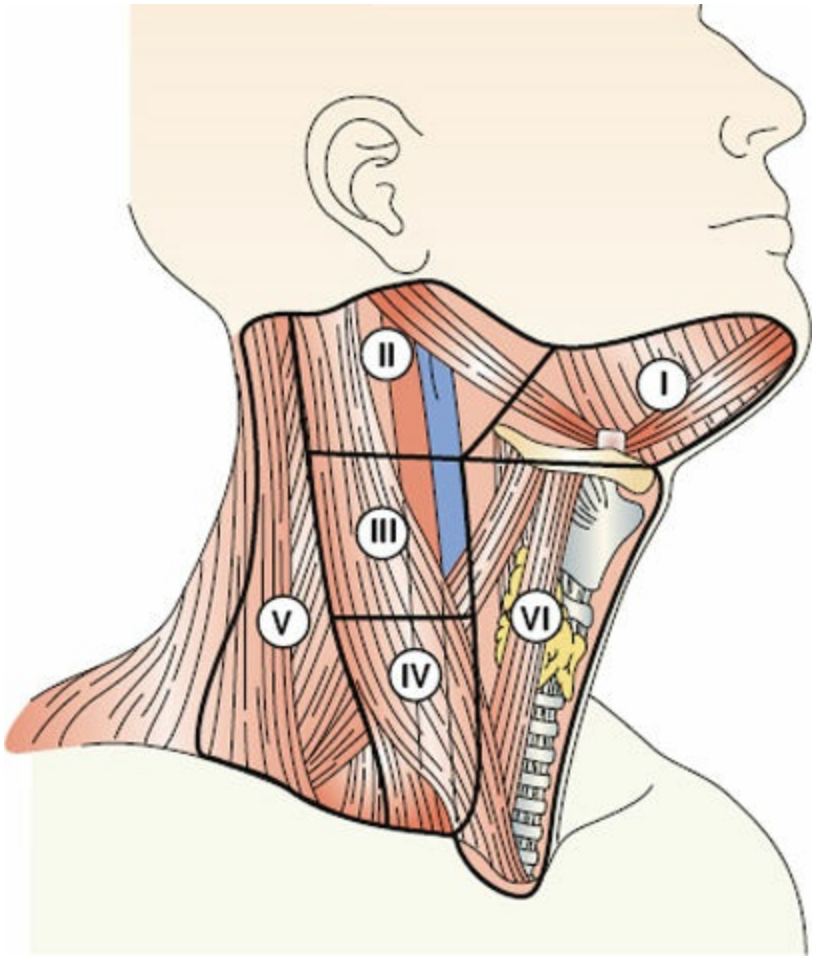

Figure 75-4. Classification scheme for regional lymph node basins in the neck.

The location of the inferior parathyroid gland is more variable. It may be found on the anterior aspect of the inferior thyroid pole or on the inferolateral aspect. It may also be in the triangular region caudal to the ITA and anterior to the RLN. If it is not in these locations, it is often embedded in fat and thymic tissue within the thyrothymic tract. The symmetry of inferior parathyroid glands from side to side is approximately 70%.

THYROID PHYSIOLOGY

Production of Thyroid Hormones

The thyroid gland produces thyroxine (T_4), triiodothyronine (T_3), and calcitonin under regulatory mechanisms. The production of thyroid hormone by the follicular cells is ultimately orchestrated by the anterior pituitary gland through its secretion of thyrotropin (TSH) to maintain a euthyroid state through a feedback loop. The production of thyroid hormone by the follicular cell (thyrocyte) is depicted in Figure 75-5. Approximately 100 to 150 μg of daily dietary iodide is required for normal thyroid hormone synthesis to occur. In most developed regions of the world, daily intake from iodine-containing foods is usually far in excess of this requirement and the kidneys excrete the iodide not utilized by the thyroid. The active uptake of iodide in the thyroid occurs on the basolateral aspect of the follicular cells through a Na^+/I^- symporter which is mediated by a Na^+/K^+-adenosine triphosphatase (ATPase) pump. Both TSH and the circulating concentration of iodide influence this symporter system. TSH acts upon the thyroid gland to regulate the synthesis of thyroglobulin (Tg), the active uptake of iodide, its incorporation with tyrosine (an oxidative reaction catalyzed by thyroid peroxidase [TPO]), the subsequent production of T_4 and T_3 (and their storage bound to Tg in the colloid component of the gland), and ultimately the release of both T_4 and T_3 into the circulation. Hormone release is an active process of micropinocytosis that involves resorption of the bound Tg from the colloid compartment into the follicular cell where enzymatic degradation releases T_4 and T_3, which is released from the basal portion of the cell into the circulation. T_4 is produced in preference to T_3 in the thyroid gland by a ratio of approximately 13:1 in normal states. T_4 has a relatively weak biologic action, so peripheral conversion to the more active T_3 hormone is required. Most of this takes place in the plasma and liver by type 1 deiodinase enzymes. All of the T_4 in the circulation is derived from the thyroid, whereas less than 20% of T_3 in the circulation is from the thyroid, the majority being produced enzymatically from monodeiodination of T_4 in the periphery. In circulation, most thyroid hormone ($>99\%$ of both T_4 and T_3) is bound to proteins such as thyroxine-binding globulin (TBG), albumin, and thyroxine-binding prealbumin. Protein-bound thyroid hormones are considered biologically inert because they do not enter cells until they are released from proteins to circulate in the very small free fraction. The half-life of T_4 is approximately 7 days, whereas the half-life of T_3 is much shorter – on the order of 8 to 12 hours.

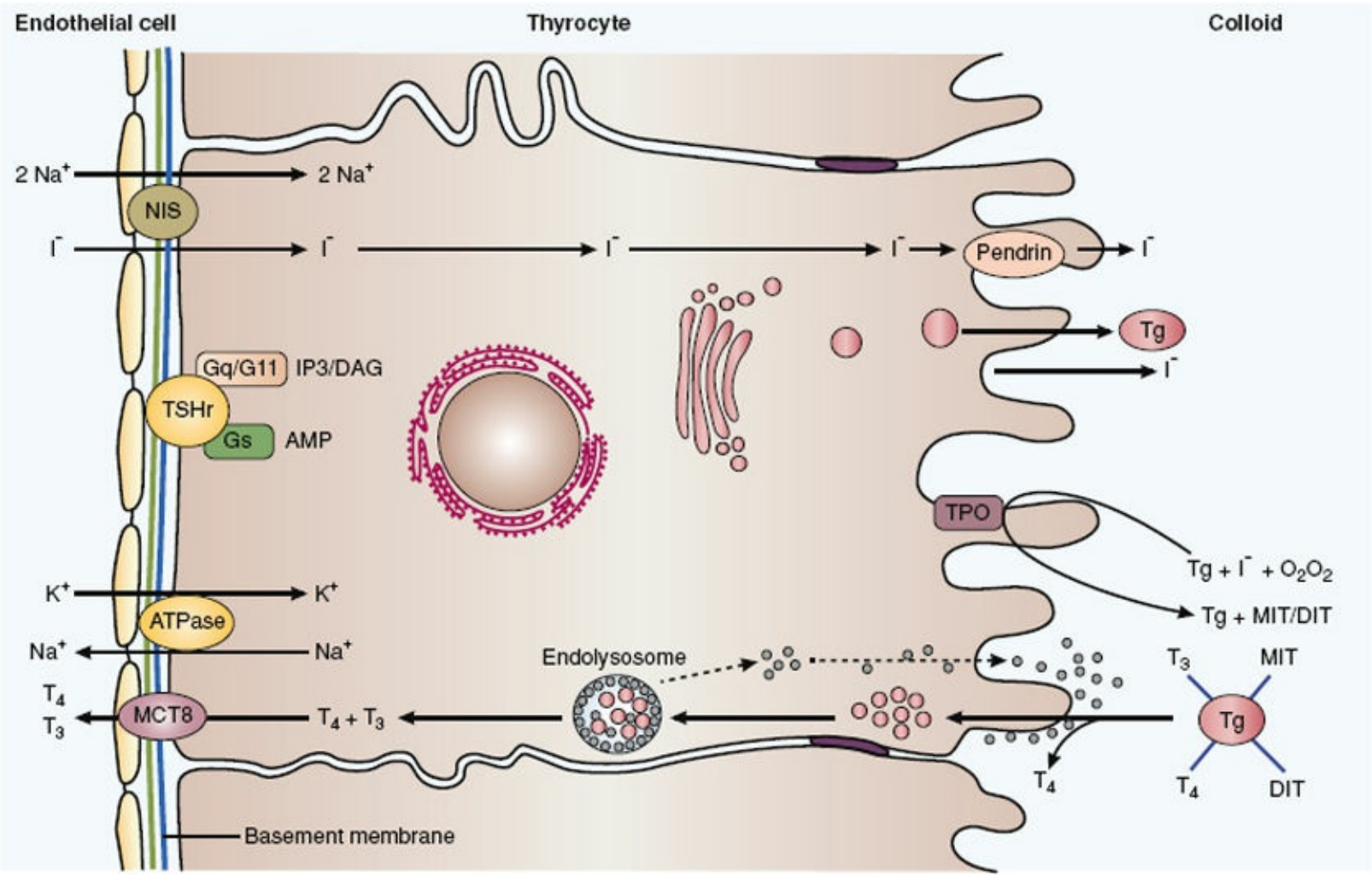

Figure 75-5. Thyroid hormone metabolism. Thyroxine (T_4) and Triiodothyronine (T_3) are produced by the thyroid follicular cell in a complex biochemical pathway. It is dependent on the movement of circulating iodide through the follicular cell and into the intracellular colloid space. T_3 and T_4 are then bound to Thyroglobulin (Tg) for eventual transport back through the follicular cell to be released into the intravascular space.

Action of Thyroid Hormones

Thyroid hormones have many effects on various body tissues. The peripheral conversion from T_4 to T_3 increases the binding affinity of thyroid hormone for the nuclear thyroid receptor protein at least 10-fold. T_3 acts within the nucleus of peripheral tissues via four T_3 nuclear receptor subtypes to activate T_3-regulated gene transcription. Ultimately, the physiologic actions of thyroid hormone relate to growth, differentiation, calorigenesis, and TSH suppression.

Calcitonin is a 32-amino-acid polypeptide that is physiologically effective in many other species, but in humans it is apparently less important. Although exogenous calcitonin may have a therapeutic effect, endogenous calcitonin secretion rarely results in an impact on serum calcium levels which are primarily mediated by parathyroid hormone.

RELEVANT LABORATORY TESTS

An understanding of the normal relationship between free T_4 (FT_4) levels and TSH levels is critical for appropriate interpretation of thyroid function tests. Thyroid function can be determined directly, by measuring FT_4 levels, or indirectly, by measuring TSH. If TSH is to be used as the primary indicator of thyroid dysfunction, an intact hypothalamic–pituitary axis is required. Normally, a log/linear inverse relationship between TSH and FT_4 is defined by the negative feedback inhibition of TSH secretion by circulating thyroxine levels, therefore minor perturbations of FT_3 and FT_4 lead to wide suppression or elevation of TSH levels. High TSH and low T_4 and T_3 levels are indicative of hypothyroidism and low TSH and high T_4 and T_3 levels are characteristic of hyperthyroidism. It is likely that each individual has a genetically determined FT_4 set point. Early subtle deviation from that set point will cause amplified changes in the TSH value, thus making TSH a very sensitive and clinically useful early indicator of thyroid dysfunction.

Thyroid-Stimulating Hormone (Thyrotropin)

As the sensitivity and specificity of current TSH assays are quite high, the indirect approach of measuring TSH levels is the most sensitive method for detecting thyroid dysfunction. The inverse relationship between TSH and FT_4 also dictates that small alterations in FT_4 will lead to a larger response in TSH, thus adding further support to this strategy. Modern methods are generally based on immunometric assays and are able to achieve a sensitivity of 0.02 mIU/L or less. At present, the normal range for TSH is considered to be 0.45 to 4.12 mIU/L.[10] The target range of TSH for patients treated with levothyroxine (LT_4) for hypothyroidism during pregnancy or after thyroidectomy have a lower target of 0.45 to 2.5–3.5 mIU/L.

Free Thyroxine and Free Triiodothyronine

Technically, it is easier to measure the total (free + protein-bound) hormone levels (measured at nanomolar levels) as compared to the very small free hormone concentrations (measured at picomolar ranges). Because T_4 is more tightly protein bound than T_3, it is less bioavailable and, consequently, very difficult to measure directly. Measuring FT_4 or free triiodothyronine (FT_3) in preference to total thyroxine (TT_4) or total triiodothyronine (TT_3) improves the ability to detect thyroid dysfunction in the presence of thyroid hormone–binding abnormalities, which are relatively common. For example, some common drugs such as phenytoin, carbamazepine, furosemide, and aspirin may compete with thyroid hormone for binding to serum proteins.

Total Thyroxine and Total Triiodothyronine

Total hormone assays require an inhibitor to block or displace the hormone from its binding proteins. This factor, along with large sample dilution, allows binding of the hormone to the antibody reagent. Because of the 10-fold lower concentrations of T_3 in the serum, the TT_3 assay requires even greater sensitivity and precision. Abnormal TT_4 and TT_3 measurements are more commonly caused by variance in the binding capacity of serum protein rather than true thyroid dysfunction.

Thyroglobulin

The primary clinical use of thyroglobulin (Tg) measurement is as a tumor marker, which serves as an index of the amount of DTC present (assuming that all normal thyroid tissue has been removed with total thyroidectomy with or without radioiodine ablation). Tg is measured in the serum by radioimmunoassay methods or by immunometric assays. The latter is more susceptible to competitive interference by thyroglobulin autoantibodies (TgAbs), which cause an artifactual decrease in the measured levels. TgAbs may be present in approximately 3% to 10% of the general population, 20% of patients with differentiated thyroid carcinoma and 80% to 100% of patients with Hashimoto thyroiditis. Sensitive quantitative TgAb determination is a critical accompaniment to serum Tg measurement because the presence of these antibodies prevents the use of Tg as an accurate tumor marker for thyroid cancer. The particular assay utilized must be sensitive enough to detect Tg levels at the lower end of the reference range (1 to 3 μg/L). Elevated TSH levels typically stimulate higher levels of Tg, therefore interpretation of Tg levels require TSH determination at the time of measurement.

Thyroid Autoantibodies

Thyroid peroxidase autoantibodies (anti-TPOab) and antithyroglobulin autoantibodies (anti-Tgab) are elevated in Hashimoto thyroiditis. A significant fraction (up to 12%) of people with no apparent thyroid disorder may also have positive anti-TPOab titers. TSH receptor autoantibodies (anti-TSHRab) are heterogeneous and may mimic the action of TSH to cause hyperthyroidism as in Graves disease or, conversely, may block the action of TSH and cause hypothyroidism as occurs in neonates of a mother with thyroid autoantibodies. Thyroid-stimulating immunogloblin (TSI) elevations suggest graves disease.

Calcitonin

Basal calcitonin levels are generally less than 16 pg/mL for healthy people and for nearly all patients with thyroid disease, other than medullary thyroid carcinoma (MTC). Therefore, calcitonin serves as a very specific tumor marker for MTC. Basal calcitonin levels are useful for diagnosis and observation of MTC patients.

THYROID IMAGING TECHNIQUES

Ultrasound (US) is the most useful imaging test for evaluation of structural thyroid pathology. Various other imaging modalities may be useful in specific circumstances.

Ultrasonography

3 US is the imaging technique of choice to evaluate the thyroid gland and its surrounding structures. It is best performed using a high-frequency "small parts" probe (7.5 to 15 mHz). As with any imaging technique that depends on individual performance of the test, a user-dependent factor exists. US can be especially useful when performed by the surgeon and allows appropriate preoperative planning. US is the most sensitive and specific technique to determine the size, number, and distribution of thyroid nodules. US often detects very small, subtle nodules that are not otherwise clinically evident. Studied prospectively, the prevalence of asymptomatic thyroid nodules (thyroid incidentalomas) detected by ultrasonography is approximately 67%, whereas physical examination identifies thyroid nodules in approximately 5% to 8%.[11] Hyperechoic nodules are often benign, whereas thyroid malignancies, regardless of cell type, are often hypoechoic. Irregular margins between the nodule and surrounding tissues raise concern for malignancy. An anechoic rim around the nodule is referred to as a "halo" sign and is more likely to be associated with a benign nodule (Figure 75-6A). Larger macrocalcifications with posterior acoustic shadowing are usually indicative of chronicity and are more likely associated with a benign nodule, whereas subtle microcalcifications, which cause a "twinkling" or "stars in the sky" effect when the transducer is moved across the nodule, are correlated with malignancy (Figure 75-6B). In practical terms, selective FNA biopsy is indicated for nodules greater than 1–1.5 cm, those with concerning US features, or those that have increased in size under serial US measurement.[12] Because US can detect nodules at a preclinical stage, it follows that proper perspective about the significance or insignificance of these nodules must be maintained. US has an important role in the preoperative staging and postoperative follow-up of patients with differentiated thyroid carcinoma and evaluation of the cervical lymph nodes with ultrasound should be considered mandatory prior to surgery. In experienced hands, it is a very sensitive technique for detecting abnormally enlarged lymph nodes or tumor recurrence within the thyroid bed, and for guiding subsequent confirmatory biopsy. It is especially important for identifying sites of recurrent thyroid cancer in those patients with negative radioactive iodine (RAI) scans or in dedifferentiated tumors that are no longer iodine avid.

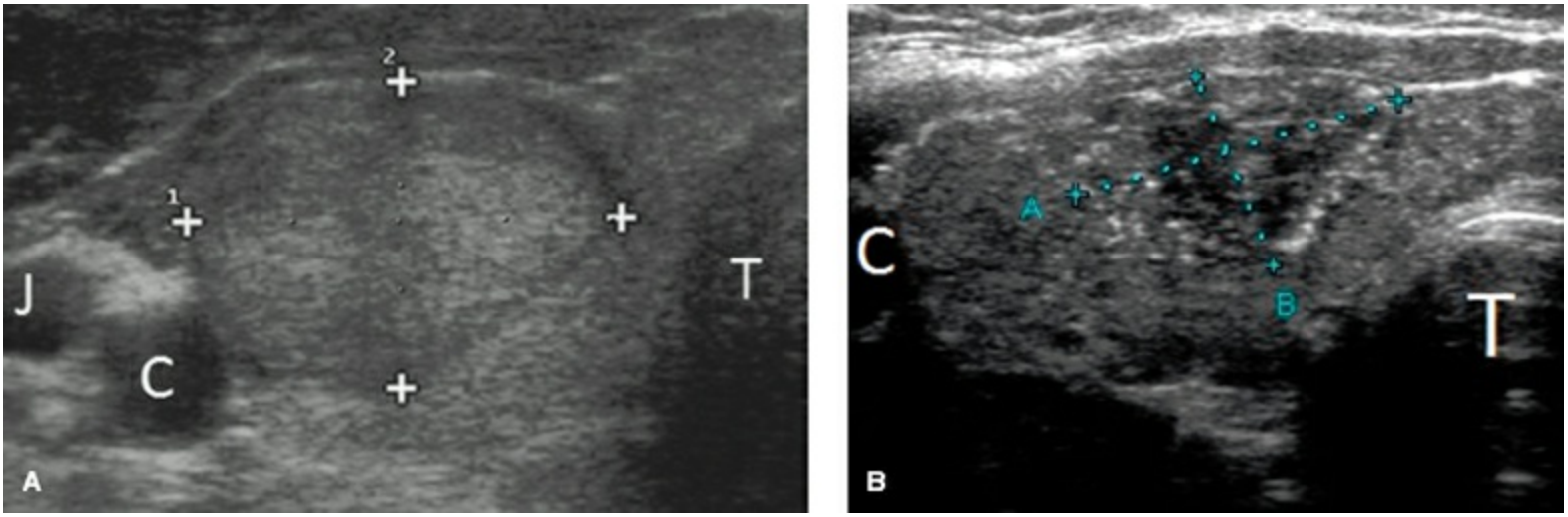

Figure 75-6. Ultrasound images of the right thyroid lobe. **(A)** benign thyroid nodule with isoechoic solid architecture and hypoechoic halo and **(B)** papillary thyroid carcinoma with microcalcifications and irregular border. C, carotid artery; J, internal jugular vein; T, trachea.

Nuclear Medicine Imaging

Radionuclide imaging provides specific information regarding the functional characteristics of the thyroid usually in the setting of hyperthyroidism; however, it provides little anatomic detail. Nuclear imaging for thyroid nodules is typically only helpful in determining if the etiology of hyperthyroidism in a nodular thyroid is due to a hyperfunctional nodule(s) or diffuse hyperplasia.

Technetium Pertechnetate ^{99m}Tc Scintigraphy

^{99m}Tc pertechnetate is the radionuclide most commonly available for thyroid imaging. The ^{99m}Tc pertechnetate component is actively trapped by functional thyroid cells in a manner similar to iodine but is not organified or stored in the thyroid. The isotope emits gamma (γ) radiation (the mechanism of scintigraphic imaging) and very small amounts of other types of radiation. Because the thyroid rapidly absorbs the injected ^{99m}Tc pertechnetate, imaging can occur early after administration and an entire study may take only an hour. A normal result demonstrates equal distribution bilaterally. Abnormal results include either concentration of the tracer in the region of a known nodule indicating an area of hyperfunction or, conversely, an area of photopenia (the “cold nodule”) indicating a region of hypofunction. Before the era of fine-needle aspiration (FNA) biopsy, photopenic nodules increased the concern for potential malignancy; however, currently nuclear imaging is typically only used to determine the etiology of hyperthyroidism in a nodular or enlarged thyroid and should not be used do determine the oncologic risk of thyroid nodules.

^{123}Iodine Scintigraphy

Because ^{123}I is trapped and organified by the thyroid gland, it can better indicate the functional characteristics of thyroid tissue. ^{123}I emits x-rays, some β particles, and γ rays. It has a short half-life of about 13 hours. After administration of an oral dose, the thyroid absorbs sufficient isotope to allow imaging by 4 hours. Images are also obtained at 24 hours, and the total fraction of dose retained by the thyroid can then be calculated as the 24-hour radioactive iodine uptake (RAIU).

^{131}Iodine Scintigraphy

^{131}I sodium iodide concentrates in the thyroid by the same mechanism as ^{123}I, but has a much longer half-life (about 8 days) and emits much more β radiation along with γ radiation at a range that is suboptimal for clear image creation. However, because of its long half-life and thorough clearance from background tissues, it remains the isotope of choice for imaging of patients with differentiated thyroid carcinoma. Treatment or ablation of residual or metastatic carcinoma (largely by the effect of β irradiation) is accomplished with larger doses of ^{131}I (typically 30 to 150 mCi) than is required for diagnostic imaging (typically 1 to 5 mCi).

Positron Emission Tomography

^{18}F fluorodeoxyglucose positron emission tomography (PET) scanning with three-

dimensional tomographic reconstruction can be very helpful in imaging thyroid carcinomas, and allows anatomic and functional evaluation. Because of the expense and the inconsistent insurance coverage, usage is currently limited to unusual circumstances such as recurrent thyroid malignancy that is otherwise occult most commonly due to loss of iodine uptake and subsequent negative ^{131}I scans. The sensitivity of PET in recurrent, radioiodine-resistant thyroid carcinomas is approximately 60% to 70% with some studies suggesting improved detection rates with TSH-stimulation or recombinant human TSH (rhTSH).[13] PET scanning is frequently used in the evaluation of other solid malignancies and occult thyroid carcinomas are discovered in 2% to 3%.[14] Incidentally discovered thyroid nodules which are focally PET-avid are malignant in 30% to 35% and require evaluation with US and FNA biopsy.[15,16]

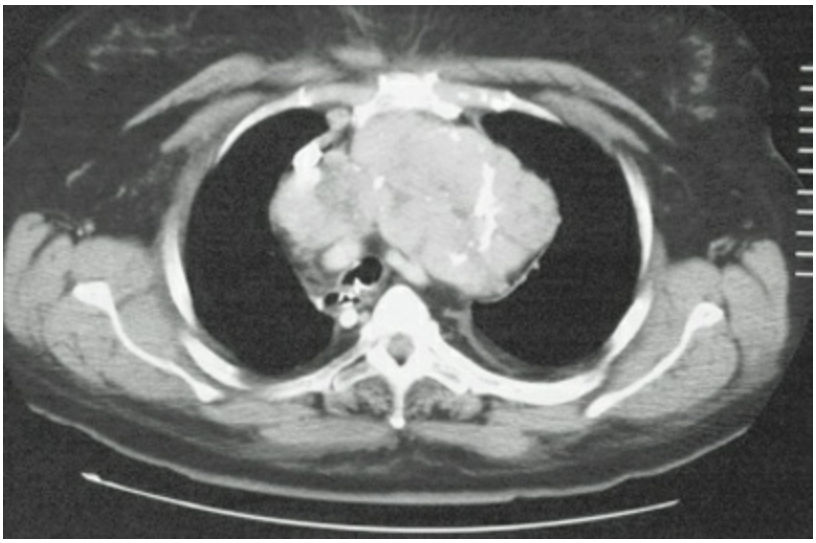

Figure 75-7. Example of a multinodular goiter with a large substernal component causing tracheal displacement and compression.

Cross-Sectional Imaging

Computed tomography (CT) scans and magnetic resonance imaging (MRI) scans are useful in certain thyroid disease states after initial US and/or nuclear imaging. CT is particularly useful to determine the extensiveness of invasive thyroid cancer suggested by physical examination findings of fixed nodules, new vocal cord paralysis, or suspicion of tracheal invasion. CT is also useful in assessing for substernal extension and tracheal deviation or compression in large goiters (Fig. 75-7). Finally, cross-sectional imaging is helpful in assessing the degree of nodal involvement in thyroid cancer especially in the low central neck and superior mediastinum, as these compartments are typically not well visualized by cervical US.

FUNCTIONAL DISORDERS AND GENERAL TREATMENT CONSIDERATIONS

Hyperthyroidism

The etiology of hyperthyroidism includes Graves disease, toxic multinodular goiter, solitary toxic adenoma, thyroiditis, TSH-secretion pituitary adenoma and excess of thyroid hormone supplementation. Typical symptoms are heat intolerance, sweating, palpitations, tremor, hyperphagia, thirst, weight loss, and sleep disturbances. Elderly patients can present with muscle wasting, atrial fibrillation, angina pectoris, or congestive heart failure. Regardless of the specific cause, the need to control hyperthyroidism before operation is critical to prevent thyroid crisis (i.e., thyroid storm). Maximal safety is assured with thionamides (methimazole or propothiouracil) combined with beta blockade.[17] Adverse reactions of thionamides include agranulocytosis and hepatic toxicity which can be monitored with white blood cell counts and liver function tests. Titration of thionamides for adequate preoperative blockade with thyroid function tests should rely on T_3 and T_4 levels because TSH levels can remain suppressed for several months even after achievement of normal T_3 and T_4 levels. Doses of beta blockers should continue through the morning of surgery and should be weaned in the postoperative setting.

Graves Disease

Dr. Robert Graves first described Graves disease in the 1830s as a toxic diffuse goiter associated with exophthalmos and palpitations. It is an autoimmune disorder characterized by the presence of thyroid-stimulating autoantibodies with a genetic predisposition and a female predominance (five to seven times greater than males). These antibodies bind to the TSH receptor on follicular cells, stimulate thyroid hormone release, and have a trophic effect on the thyroid. The autoimmune disease process may affect the eyes, causing exophthalmos secondary to inflammatory cell infiltration into the extraocular muscles and orbital connective tissue. Graves ophthalmopathy can lead to changes in visual acuity, ocular dryness, and proptosis which may be so severe as to require aggressive ophthalmologic treatment in approximately 5% of patients. Graves disease may cause pretibial myxedema which is distinguished from pedal edema by sparing of the ankles. Patients with Graves disease usually have a diffuse goiter, which may be smooth or occasionally irregular. The gland is by nature hypervascular and may occasionally have an audible bruit or palpable thrill in severe cases. T_4 and T_3 levels are increased and TSH levels are suppressed. The uptake of radioiodine (RAI) generally shows a symmetrically enlarged gland with diffuse increased 24-hour uptake.

Three main treatment modalities for Graves disease are medical therapy, radioactive iodine treatment, and thyroidectomy. Selection of therapy depends on age, disease severity, goiter size, and patient preference. Practice patterns differ dramatically across the world, especially regarding the use of radioiodine (it is less common in Europe and especially Japan compared to the United States). The most common initial treatment

involves thionamides and often beta blockade. In a small fraction of patients, antithyroid drugs may be the only therapy necessary, but in general, this strategy is considered an impermanent solution as most patients will have persistent hyperthyroidism after cessation of medication. Although the drugs may theoretically be used long term, they are associated with a small but real risk of life-threatening agranulocytosis and liver toxicity. Ultimately, most patients pursue a permanent therapy with RAI or surgery. Treatment with RAI is very effective and has not been associated with secondary risk of development of a new malignancy, yet there is still hesitancy to use this treatment in young children. RAI may take up to 6 months to provide definitive results and thus antithyroid medications must continue during this period. In a small percentage of patients, a second treatment may be necessary. After RAI treatment, 95% of patients become hypothyroid within 10 years and require thyroid hormone replacement. RAI therapy has been occasionally associated with exacerbation of Graves ophthalmopathy, although the effect is ameliorated by corticosteroids and the early addition of LT_4 posttreatment.[18–20] Because of this concern, patients with severe ophthalmopathy should consider total thyroidectomy instead of RAI to prevent such an exacerbation; however, ultimate resolution of ophthalmopathy is no more likely with surgery.

Surgery for Graves disease has the advantage of rapid correction of the hyperthyroid state. The specific operation has typically been either bilateral subtotal thyroidectomy or total thyroidectomy. Subtotal thyroidectomy attempts to remove enough tissue to resolve the hyperthyroidism but leave enough to maintain euthyroidism, however, Graves disease is dynamic and remissions after subtotal thyroidectomy occurs in approximately 10% of patients at 5 years.[21] Therefore total thyroidectomy is the preferred operation for treatment of Graves disease with the intention of eliminating the chance of recurrence, but accepting postsurgical hypothyroidism requiring thyroid hormone replacement.

Toxic Multinodular Goiter

The term *toxic multinodular goiter* (MNG) refers to thyrotoxicosis that is caused by a multinodular goiter due to an endemic or nonendemic etiology. H.S. Plummer first distinguished toxic adenomatous goiter from Graves disease. Although the eponym "Plummer disease" now more commonly refers to the patient with a solitary toxic nodule, many clinicians still include toxic MNG under the same historical blanket. Thyrotoxicosis may occur as a progression from euthyroid multinodular goiter that was initially TSH-dependent, which then progressed to a state of autonomy which is not suppressible with LT_4. Although the cause is clearly distinct, it is possible that some patients included in this diagnostic category actually have Graves disease with nodular degeneration of their diffuse goiter. Patients with toxic MNG, however, are often easily distinguished from those with Graves disease such that the typical patient is a female older than 50 years with a previous history of multinodular goiter. Thyrotoxicosis may be precipitated in an MNG with or without areas of autonomy when an iodide load is provided (Jod-Basedow phenomenon). Historically, public health efforts to iodinate salt or flour in an iodine-deficient population have caused this phenomenon to follow over a period of years. This

can occur after exposure to iodinated radiographic contrast media, expectorants, or iodide-containing drugs such as amiodarone.

Hyperthyroidism present in a patient with MNG can involve a wide spectrum of severity such that it is not uncommon for a patient having structural indications for thyroidectomy, such as continued nodular growth, substernal extension or compressive symptoms, in addition to hyperthyroidism. Thyroidectomy or radioiodine treatments are effective treatments for toxic MNG. Radioiodine treatment may require high doses or repeated treatments because of the large goiter size and low radioiodine uptake, however, remains a viable option for patients who are not surgical candidates.[17] Long-term remissions from antithyroid drug treatment are even less common or predictable than in Graves disease and are not considered a definitive therapy for toxic MNG.[22]

Solitary Toxic Adenoma

Patients with thyrotoxicosis and a dominant thyroid nodule may have a toxic adenoma. Nodules usually grow to at least 2 cm in size before hyperthyroidism is clinically evident. As expected, T_3 or T_4 or both are elevated and TSH is suppressed. US typically demonstrates a thyroid nodule with benign US characteristics and FNA is rarely helpful because the incidence of malignancy within these nodules is negligible. Thyroid scintigraphy will demonstrate a single “hot” area corresponding to the known nodule with suppression of the remainder of the thyroid. Treatment options include ^{131}I RAI therapy or thyroidectomy. RAI is effective in controlling the hyperthyroidism, but depending on nodule size, may leave behind a palpable abnormality. In particular, younger patients with sizable nodules may choose operation. The resection is typically a hemithyroidectomy and the contralateral lobe is often normal and capable of maintaining normal thyroid hormone production in 85% of patients.[23]

Hypothyroidism

Primary hypothyroidism can arise from intrinsic thyroid disease, iatrogenic thyroid removal or destruction, and antithyroid drug effects. Secondary hypothyroidism can also occur from failure of thyrotropic function (via TSH) due to pituitary gland disease, removal, or destruction. Rarely, tertiary hypothyroidism can occur with destructive disorders of the hypothalamus via decreased production of thyrotropin-releasing hormone. The most common cause of primary hypothyroidism in adult patients is Hashimoto thyroiditis. In large part, hypothyroidism is straightforward to address with exogenous LT_4 therapy. The role for surgical therapy is limited aside from patients with a structural thyroid disorder associated with underlying hypothyroidism.

Thyroiditis

Inflammatory conditions of the thyroid are a disparate family of conditions that require surgical therapy in the minority of situations. Thyroiditis can be quite prevalent in patients undergoing evaluation for thyroid surgery and a thorough understanding is required to avoid diagnostic and therapeutic misadventures.

Hashimoto Thyroiditis

Also known as chronic thyroiditis, autoimmune thyroiditis, and lymphocytic thyroiditis, this condition was described by Hashimoto in 1912 based on its histologic findings. It affects approximately 10% of the general population, has peak ages from 30 to 60 years and a female-to-male preponderance as high as 9:1. It is clearly an autoimmune condition and there is a moderate genetic predisposition, associated with human leukocyte antigen (HLA)-DR3, -DR5, and -B8. The disease prevalence is increased in iodine-sufficient regions and this may be because immunogenicity of the thyroglobulin molecule increases with the degree of iodination. The histologic changes are characterized by lymphocytic infiltration with fibrosis and germinal centers. Some follicular cells may undergo metaplasia to Hürthle cells. The typical presentation is that of a painless diffuse goiter in a young woman discovered on physical examination with or without associated hypothyroidism. Patients often note a sense of fullness in, or awareness of, the thyroid. When the associated goiter is large, compressive symptoms of dysphagia or dyspnea may occur. The goiter is typically firm and rubbery and slightly "bumpy" with prominent lateral lobes. The US appearance of the thyroid is typically heterogeneous in its echotexture with irregular capsular borders with or without distinct nodules. Nodular disease in a gland affected by Hashimoto disease should be investigated with FNA to rule out coexisting malignancy. Thyroid autoantibody titers are elevated, TPOAb primarily and TgAb secondarily. In approximately 5% of patients, a transient phase of hyperthyroidism, termed "Hashitoxicosis," occurs at the onset of disease. Following onset, approximately 5% per year will progress to hypothyroidism.[24] For the majority of patients, treatment of Hashimoto thyroiditis is limited to LT_4 therapy in those with hypothyroidism. Surgery is indicated in patients with large goiters, significant compressive symptoms, local symptoms refractory to LT_4 therapy, or the inability to rule out malignancy (typically in the setting of nodules or rapid growth).[25]

Painless or Postpartum Thyroiditis

Sporadic silent (painless) thyroiditis and postpartum thyroiditis are destruction-induced and are probably variants of the same process, distinguished only by the relationship to pregnancy.[26] Along with subacute thyroiditis, these conditions are characterized by the onset of thyrotoxicosis and a goiter, and low 24-hour RAIU. Even excluding postpartum cases, there is a female predominance by 2:1 and the age range of affected patients is broad. The cause appears to be autoimmune, but the genetic predisposition is low. There is no fever or malaise and the goiter is painless but persistent. Thyroid autoantibody titers are often high, and the erythrocyte sedimentation rate (ESR) is usually normal. Thyroid

function is dynamic and follows a pattern similar to that of subacute thyroiditis with an abrupt onset of thyrotoxicosis followed by a period of euthyroidism, then hypothyroidism. At the histologic level, lymphocytic infiltration is present along with destruction of follicular cells. If it is pregnancy associated, it is likely to relapse with future pregnancies. If symptoms of thyrotoxicosis are significant, β-adrenergic–blocking drugs may be used, but antithyroid drugs are not appropriate because the gland is not hyperfunctioning at the follicular cell level. If LT_4 therapy is instituted during the hypothyroid phase for symptomatic relief, it can be withdrawn after 6 to 9 months to determine if recovery has occurred.

Subacute Thyroiditis

Subacute thyroiditis is a common form of thyroiditis that affects women more often than men by a 5:1 ratio and often in the age group of 20 to 60 years. There are a number of synonymous terms, such as de Quervain thyroiditis, giant cell thyroiditis, pseudogranulomatous thyroiditis, subacute painful thyroiditis, and subacute granulomatous thyroiditis. The cause is not entirely certain, but it appears to be virally related and a prodrome consistent with an upper respiratory viral infection is very common. The patient often has fever, malaise, and an exquisitely painful and firm goiter that is transient. The goiter is usually unilaterally dominant, and the patient may have pain that radiates to the ipsilateral ear. Giant cells (which may also be observed on FNA) support the diagnosis and granulomas often infiltrate the thyroid. Consistent with follicular cell destruction, serum Tg levels may be elevated. Antithyroid antibodies may be present in low titers and the ESR is often high. A 24-hour RAIU is usually quite low ($<5\%$). Management is similar to painless thyroiditis in that beta blockers may be used, but antithyroid medications are not useful. Salicylates or nonsteroidal anti-inflammatory drugs (NSAIDs) are adequate to control pain in most cases, with the occasional need for oral glucocorticoids. Although the course of disease can be protracted for weeks or months, resolution is common and management is usually limited to management of symptoms.

Amiodarone-Induced Thyrotoxicosis or Thyroiditis

The antiarrhymic drug amiodarone causes thyroid dysfunction in 15% to 20% of patients. Thyroid dysfunction can include hypothyroidism and amiodarone-induced thyrotoxicosis (AIT) which has two forms: Type I which is often associated with pre-existing multinodular goiter and is the result of the iodine load provided by amiodarone; Type II is more frequent and is the result of destructive thyroiditis. Type I AIT is characterized by a diffuse or nodular goiter with increased vascularity noted on thyroid US and is primarily treated with withdrawal of amiodarone (if feasible) and initiation of methimazole with or without potassium iodide.[27] Type II AIT is characterized by a normal thyroid gland without hypervascularity on thyroid US and is treated with withdrawal of amiodarone (if feasible) and corticosteroids, while methimazole is ineffective.[27] Medical treatment of AIT is difficult because of both the long half-life of the drug and the effects of thyrotoxicosis on cardiac function in patients already with underlying heart disease. If

hyperthyroidism is severe in either type I or II, thyroidectomy may be required to resolve the thyrotoxicosis rapidly and definitively and in some cases to allow for continuation of amiodarone.

Acute Thyroiditis

Acute thyroiditis refers to a rare suppurative condition most commonly caused by the bacterial pathogens *Staphylococcus aureus* and *Streptococcus pyogenes.* A clinical prodrome, usually a viral or bacterial upper respiratory infection, may occur and the patient is often affected by a significant fever and malaise and may have radiating pain to the region of the ipsilateral ear. A painful but ultimately transient goiter may be evident, which is often the result of a thyroidal or perithyroidal abscess. The patient usually remains euthyroid and antithyroid antibody titers are normal. ESR may be elevated. Bacterial infection of the thyroid may occur via hematologic spread from a distant site or local infiltration from other head and neck infections. Recurrent cases of acute thyroiditis may be related to a fistulous communication with the pyriform sinus and is an indication for surgical intervention.

Riedel Thyroiditis

Also known as Riedel struma or invasive fibrous thyroiditis, this rare disorder affects mainly women (by a ratio of 4:1) and usually occurs between the ages of 30 and 60 years. The cause is unknown and a genetic predisposition is not apparent. The patient presents with a painless but persistent, and often progressive, goiter. Patients are usually euthyroid at presentation but may eventually become hypothyroid. They may have detectable antithyroid antibody titers and a normal ESR. If obtained, the 24-hour RAIU is often normal or somewhat decreased. Physical examination reveals an exceptionally firm goiter often described as “woody.” Most commonly, this is a diffuse, bilobar process. Histologically, the disease is characterized by extensive fibrosis, which may progress to a point of compression of adjacent structures such as the trachea and esophagus. Riedel thyroiditis is often accompanied by other equally mysterious focally sclerotic conditions such as retroperitoneal fibrosis, mediastinal fibrosis, retro-orbital fibrosis, and sclerosing cholangitis.[28] Because of its infiltrative nature, it is important to differentiate Riedel thyroiditis from thyroid carcinoma. FNA is often inadequate and core-needle or open biopsy may be required. If substantial compression exists, surgery is often required to relieve these symptoms. Extensive resection is often unsafe or impossible due to infiltration of the thyroid with the surrounding structures, and wedge resections, especially of the isthmus, may be effective in relieving tracheal compressive symptoms. Medical therapy, including corticosteroids, methotrexate, or tamoxifen, may have a positive impact in the chronic setting.[29]

NODULAR THYROID DISEASE AND GENERAL TREATMENT CONSIDERATIONS

Nontoxic Multinodular Goiter

From a world health perspective, endemic goiter is still a significant issue. Endemic goiters are caused by dietary iodine deficiency, which ultimately is also responsible for congenital hypothyroidism syndrome (historically known as endemic cretinism). Iodine deficiency in a region is addressed over time by iodination of dietary components (e.g., salt, bread flour, or vegetable oil).

In endemic goiter, T_4 levels may be normal or decreased, whereas T_3 levels are normal or often increased. This reflects an adaptive regulatory mechanism by which the thyroid preferentially shifts production to the more biologically potent T_3. Exogenous thyroxine therapy will induce a decrease in goiter size in roughly 80% of patients treated. Resection may be indicated for large size, increase in size while on T_4, or compression of the trachea, esophagus, or superior vena cava.

In most developed countries, the term *goiter* generically refers to the group of diseases causing thyroid enlargement in patients not affected by iodine deficiency. In common usage, *goiter* typically refers to patients with nodular goiter. Asymptomatic multinodular goiter is common, and unless there is concern of a malignant nodule, thyroidectomy is not usually indicated. Sometimes, because of the number of nodules of significant size (>1 cm), repeated FNA during longitudinal observation becomes impractical and patients may choose thyroidectomy to simplify management. Compressive symptoms involving the airway or esophagus causing breathing difficulties or dysphagia are an indication for thyroidectomy, as is a multinodular goiter causing subclinical or obvious thyrotoxicosis (toxic multinodular goiter). Total thyroidectomy is the procedure of choice because of the significant chance for recurrent nodular degeneration of the thyroid remnant after subtotal thyroidectomy. If a goiter develops in a substernal position, thyroidectomy is warranted because of the inability to monitor continuing growth in the mediastinum. If tracheal compression develops gradually, it may be largely asymptomatic until a critical point of narrowing is reached, which inhibits passage of air in a relatively sudden and progressive manner. Because all of the important attachments to the thyroid parenchyma remain in the neck, even very large substernal goiters can be removed through a cervical incision and less than 5% will require partial sternotomy.[30]

Solitary or Dominant Thyroid Nodule

Nodular thyroid disease is clinically appreciated in approximately 4% to 7% in the general population; however, thyroid nodules are in fact present in up to 60% of patients undergoing autopsy. The majority of thyroid nodules are benign with around 5% harboring malignancy. The incidence of thyroid cancer has been increasing with a disproportional increase in small papillary thyroid cancers.[31] This increase is only partially explained by improved surveillance. Appropriately identifying patients with malignancy that require operation while appropriately avoiding operation for the majority of patients with benign, asymptomatic nodules can be a challenging task (Algorithm 75-1).

When assessing a patient with a solitary thyroid nodule, the physician should first determine patient risk factors that increase the likelihood of malignant disease. A new thyroid nodule that occurs at the extremes of age is more likely to be malignant than one that occurs in the third through seventh decades. The risk of a solitary thyroid nodule in a child under 18 being malignant is approximately 22%.[32] Patient gender itself does not generally confer risk of malignancy, and the fact that thyroid cancer occurs in a greater number of women than men is related somewhat to the increased prevalence of nodular thyroid disease in women.

Many factors apparent on physical examination or imaging can also be used to assess the potential for malignant disease in the patient with a thyroid nodule. The consideration that nodular disease is uninodular (e.g., solitary) instead of multinodular has traditionally implied that the former situation is more concerning for malignancy, however, in the era of thyroid US, this distinction is overemphasized because at least half of nodules considered solitary by clinical examination are ultimately found to be a dominant nodule within a multinodular goiter. The characteristics of a nodule assessed by physical examination (size, firmness, and texture) have a limited ability to predict malignancy, but significant fixation to surrounding tissues can heighten the level of concern for invasive malignancy. Palpable lymphadenopathy or ultrasonographically abnormal-appearing lymph nodes in the central or lateral cervical compartments is certainly concerning for potential malignancy. Although many patients with benign thyroid disease describe hoarseness or a change in voice, this is often largely subjective and is of limited concern unless accompanied by objective hoarseness and ipsilateral RLN paralysis confirmed on laryngoscopic examination. In a patient with a firm thyroid gland in the setting of hypothyroidism, Hashimoto's thyroiditis is a common underlying etiology. Patients with rapidly enlarging, firm thyroid gland with indistinct nodularity should raise concern for thyroid lymphoma or anaplastic thyroid cancer.

A critical question in assessing any patient with a thyroid nodule is whether any history of radiation exposure exists. At least 90% of radiation-associated thyroid cancers are papillary thyroid cancer. Typical exposures to radiation in the 1940s and 1950s included external beam irradiation treatment for acne, tinea capitis, external otitis, recurrent tonsillitis, or neonatal thymic enlargement. In the current era, excessive diagnostic radiation or high-dose therapeutic irradiation (e.g., treatment of lymphoma or head and

neck malignancies) can contribute to a relevant exposure. There appears to be a linear relationship between the dose of radiation and the risk for thyroid cancer, with even a higher risk among those exposed at a young age.[33] The typical latent period between exposure and clinically evident cancer appears to be in the 3- to 8-year range. It is not clear when, if ever, the risk is no longer present. Another source of radiation exposure to the thyroid gland is nuclear fallout, related to either atomic weapons or nuclear power plant accidents, such as Chernobyl in 1986. Acute γ-radiation exposure is likely the main risk factor, but longer-term exposure to diverse radioisotopes of iodine that secondarily contaminate the regional water and food supplies may also be contributory.

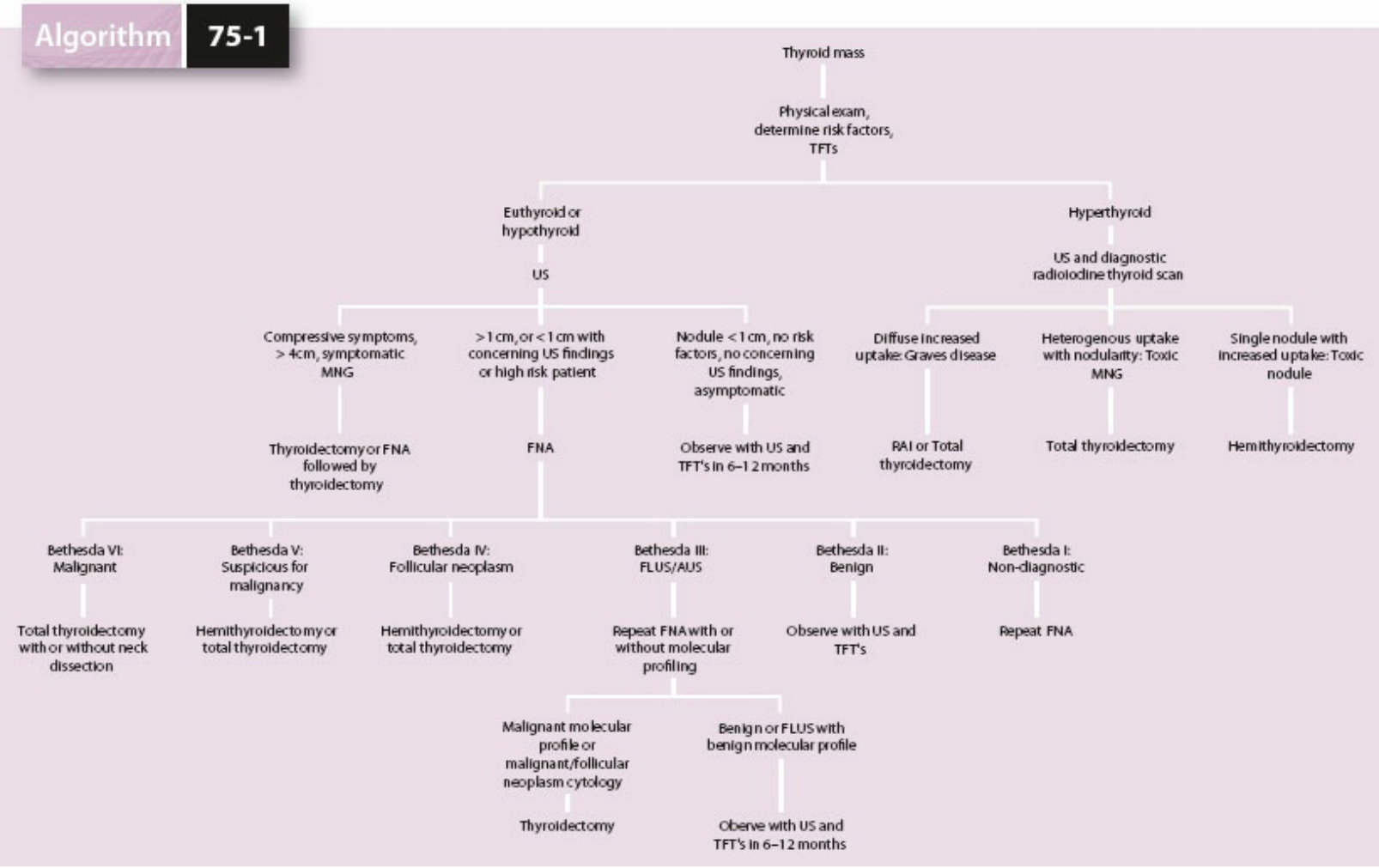

Algorithm 75-1. Management algorithm for thyroid mass. TFTs, thyroid function tests; US, ultrasound; FNA, fine-needle aspiration; FLUS, follicular lesion of undetermined significance; AUS, atypia of undetermined significance; RAI, radioactive iodine; MNG, multinodular goiter.

Another critical question to investigate is whether a family history of thyroid cancer or associated conditions exists. The key issue is to uncover a family history of medullary thyroid cancer, which suggests the potential for an inherited syndrome such as familial medullary thyroid carcinoma (FMTC) or multiple endocrine neoplasia type 2. Papillary thyroid cancer, however, may have a familial association as well, either independently or, more commonly, associated with Cowden syndrome or Gardner syndrome (familial adenomatous polyposis).

In most situations, extensive thyroid function testing is not necessary and a TSH is all that is required. After initial clinical assessment, thyroid nodular disease is often assessed by US. Relevant factors include the size of the nodule and other sonographic characteristics previously explained. Also important is whether the nodule is truly solitary or whether there are additional nodules, especially in the contralateral lobe, which may affect the specific surgical recommendations with regard to hemithyroidectomy or total thyroidectomy. Symptomatic thyroid cysts may be managed with aspiration alone, ethanol injection treatment or thyroidectomy.[34]

The utility of thyroid scintigraphy in patients with normal thyroid function tests is very limited and should not be routinely used to evaluate thyroid nodules. The only helpful role for radioiodine scan is with patients with hyperthyroidism to determine if the overproduction of thyroid hormone is due to a single thyroid nodule (toxic adenoma), multiple thyroid nodules (toxic multinodular goiter), or diffuse hyperplasia (Graves disease). In the era of US and FNA, the additional diagnostic information provided by knowing if a nodule is "cold" or "photopenic" is very limited since the indications for FNA lie primarily in the nodule size, the US appearance, and the patient's risk factors.

Thyroid Fine-Needle Aspiration Biopsy

FNA is the cornerstone of diagnostic evaluation of a thyroid nodule. Cytologic analysis of FNA samples can reliably identify colloid nodules, benign nodular hyperplasia, thyroiditis, papillary thyroid carcinoma (PTC), medullary thyroid carcinoma, and anaplastic thyroid carcinoma. FNA may suggest an extranodal thyroid lymphoma, but usually more tissue (generally in the form of core-needle biopsy, or incisional/excisional biopsy) is required for confirmation of the diagnosis and flow cytometry.

Standard disposable needles ranging in size from 23 to 27 gauge and 3- to 10-mL syringes are used for thyroid or cervical lymph node FNA. After the target nodule is located with US, FNA is performed with US guidance and multiple passes through the most concerning appearing solid portions of the nodule are made. An average of three separate biopsy maneuvers per nodule is reasonable practice. The technique does not rely heavily on aspiration or suction as the name might imply. The ideal sample remains mostly in the needle hub and barrel before expelling it onto a slide or into a fixative for cytologic preparation.

4 There are multiple cytologic classification systems used for thyroid FNA with corresponding recommendations for management. The Bethesda system is one of the more widely used systems which is outlined in Table 75-1.[35] A nondiagnostic FNA lacks the minimum of 6 groupings of thyroid cells consisting of at least 10 cells per group. The incidence of nondiagnostic biopsies can be reduced with US guidance and onsite cytopathologic analysis for adequacy of the specimen. The Bethesda system divides the prior *indeterminate* category into category III: atypia of undetermined significance/follicular lesion of undetermined significance and category IV: Follicular neoplasm. There is a recommendation for repeat FNA for category III results rather than diagnostic thyroidectomy as was typical for previously defined indeterminate nodules. The use of molecular marker analysis in indeterminate thyroid FNA specimens is an

evolving concept with several tests available which analyze FNA tissue for various genetic mutations (BRAF, RAS, RET/PTC, and others).[36] The prognostic utility of molecular testing seems most useful when cytopathology is indeterminate (Bethesda categories III and IV) and has limited added value when cytopathogic analysis is more definitive (Bethesda categories II, V, and VI). Additionally, when other indications for thyroidectomy exist such as local pressure symptoms, multiple large nodules, or patient preference, the role of these gene expression profiling tests may be limited and perhaps needlessly costly.[37] FNA classified as follicular lesions or Hürthle cell lesions (Bethesda category IV) may require at least partial thyroidectomy (e.g., lobectomy) to determine whether it is a follicular (or Hürthle cell) adenoma or follicular (or Hürthle cell) carcinoma which can be distinguished only by the demonstration of capsular or vascular invasion on surgical histopathology. FNA should have a false-positive rate of 0% to 0.5% and a false-negative rate of 0% to 5%.

Table 75-1 The Bethesda Classification System for Thyroid FNA Cytology

Bethesda Classification	Incidence of All Thyroid FNAs (%)	Cytologic Appearance	Risk of Malignancy (%)	Recommendations for Management
I: Nondiagnostic	5–10	Insufficient follicular cells for analysis	8–10	Repeat FNA
II: Benign	60–70	Hyperplastic follicular cells, colloid nodule, thyroiditis	1–4	Surveillance follow-up
III: Atypia of undetermined significance (AUS) or follicular lesion of undetermined significance (FLUS)	5	Few cells with focal features of nuclear grooves, intranuclear inclusions, atypical lymphoid infiltration	15–45	Repeat FNA with or without molecular testing
IV: Follicular neoplasm or suspicious for follicular neoplasm	5	Scant or absent colloid, microfollicular arrangement, cellular crowding, larger follicular cells	25–50	Hemithyroidectomy if solitary; total thyroidectomy if bilateral
V: Suspicious for malignancy	5	Subtle or focal nuclear and architectural changes seen in PTC, often found to be follicular variant of papillary cancer	70–80	Hemithyroidectomy or total thyroidectomy
VI: Malignant	5	Nuclear grooves, intranuclear inclusions, psammoma bodies	95–99	Total thyroidectomy with or without neck dissection

FNA, fine-needle aspiration; PTC, papillary thyroid carcinoma.

THYROID MALIGNANCY AND GENERAL TREATMENT CONSIDERATIONS

Thyroid cancers exhibit a wide spectrum of behavior, from the inconsequential, occult, well-differentiated thyroid carcinoma to the nearly uniformly fatal undifferentiated anaplastic cancers. Fortunately, at least 98% of thyroid cancers are well-differentiated and long-term prognosis is excellent. There has been an increasing incidence of thyroid cancer primarily due to increasing rates of papillary thyroid cancer with relatively stable rates of other variants.[31] The general treatment strategy for thyroid carcinomas includes surgical resection, staging of disease, appropriate adjuvant treatments, and secondary screening and follow-up.

Tumor Classification

Thyroid cancers of follicular cell origin are PTC and its variants, follicular thyroid carcinoma and Hürthle cell carcinoma (HCC). Medullary thyroid cancers are derived from parafollicular (C-cells). There is a spectrum of dedifferentiation that can occur in PTC ranging from variants such as tall cell or insular variants. Anaplastic carcinoma represents very dedifferentiated thyroid cancer and carries an aggressive phenotype and poor prognosis. A number of thyroid cancer classification systems exist. The American Thyroid Association (ATA), the Armed Forces Institute of Pathology (AFIP), and the World Health Organization (WHO) all consider papillary thyroid cancers (including classic papillary carcinoma, mixed papillary–follicular variants, follicular variants, and follicular thyroid carcinomas [FTC]) as DTC. Still, some disagreement exists about the classification of HCCs or oxyphilic carcinoma as a subtype of follicular thyroid carcinoma or as its own category. Support for considering HCC as a subtype of follicular thyroid carcinoma includes the histologic demonstration of the transition of follicular to Hürthle cells, an intact TSH receptor adenylate cyclase system in Hürthle cells, and the ability of Hürthle cells to produce thyroglobulin and thus maintain Tg positivity on immunohistochemical staining.[38] Other characteristics, however, such as higher oncogene expression in HCC than FTC and the general impression that HCC can display a more aggressive clinical course than FTC cause some to classify HCC tumors outside the FTC family.

Papillary Thyroid Carcinoma

PTC accounts for approximately 85% of thyroid carcinomas. It occurs across a wide spectrum of ages from childhood to the elderly, with peak incidence in the third and fourth decades of life, and is more common in females than males. PTC is especially prevalent in iodine-sufficient regions of the world while follicular carcinoma has relatively higher incidence in iodine-deficient regions. Papillary carcinoma arises from the follicular cells, is characterized by papillary architecture, calcifications, psammoma bodies, squamous metaplasia, and fibrosis. Cytology is diagnostically important and typical findings include large, overlapping nuclei that are optically clear (Orphan Annie nuclei) and intranuclear grooves. Greater than 30% of PTC is multicentric and found throughout the thyroid. Although multifocality does not signify a worse prognosis, this characteristics may support the rationale for total thyroidectomy. The incidence of cervical lymph node metastases varies across series and is influenced by whether lymphadenectomy is performed for prophylactic or therapeutic reasons. Central neck (level VI) lymphadenectomy performed prophylactically (in the absence of clinically detectable metastasis) demonstrates metastasis in 30% to 80%, however the clinical relevance of micrometastatic disease is debatable. Therapeutic neck dissection for clinically positive lymph node macrometastasis is recommended as the standard of care.[12] Distant metastases occur in 1% to 8% of patients with PTC typically presenting as pulmonary nodules.[39] At least 70% of PTC take up radioiodine and RAI scanning and ablation are important parts of the treatment strategy. As a whole, the prognosis for PTC is excellent, especially in those patients with tumors that define a low risk for recurrence.

Variants of Papillary Carcinoma. The follicular variant of PTC essentially combines the histologic and architectural appearance of follicular tumors with the cytologic features of papillary carcinoma. In terms of treatment and biologic behavior, this variant behaves in the same manner as classic PTC. The dilemma caused by this variant is that in contrast to classic PTC it is very difficult to diagnose on frozen section analysis. It is often interpreted as a follicular lesion with the final diagnosis deferred until formal histopathology, to identify the atypical features, is complete. More aggressive variants of papillary carcinoma include tall cell, columnar, and diffuse sclerosing types, which also exist along the spectrum of dedifferentiation. The tall cell variant is associated with more extrathyroidal extension, angiolymphatic invasion and lymph node involvement resulting in higher rates of recurrence.[40]

5 Papillary Microcarcinoma. PTCs less than 1 cm in size are considered microcarcinomas (occult or incidental tumors). They may be multifocal and are usually clinically silent until thyroidectomy is performed for another indication. Although they are by definition malignant, this group of tumors requires a different set of considerations based on their biologic behavior and patient outcome. Prognosis is exceptionally good, with a 0.4% cause-specific mortality rate.[41] A solitary microcarcinoma found after lobectomy is considered adequately treated with lobectomy alone and completion thyroidectomy or radioiodine scanning are not typically indicated. Somewhat in contrast, if these microcarcinomas are diagnosed preoperatively, which may be difficult because of their small size, thyroid resection is usually recommended. Some groups, however, have chosen to follow these patients closely with US and have shown that only 8% significantly increase in size, 3.8% develop new lymph node metastasis and 6.8% progress to clinical disease over 10-year observation period and that patients older than 60 years and those with contraindications to thyroidectomy may be the best candidates for this observational strategy.[41,42] However, there have also been reports of lymph node metastasis in papillary microcarcinoma and occult primary tumors not identified on histopathology, suggesting that a small subset of microcarcinomas have potential for more aggressive behavior.

Molecular Markers in Thyroid Cancer

6 Molecular testing of thyroid tumors to help characterize thyroid tumors in the pre- and postoperative setting is becoming increasingly useful. Mutations in the MAPK pathway including BRAFV600E, RAS and RET are present in the majority of papillary thyroid cancer while RAS mutations and the PAX8–PPARγ rearrangement are common in follicular thyroid cancer. In the preoperative assessment of thyroid nodules, molecular testing of FNA samples can identify presence of these mutations and if present may be useful in determining the need for and the extent of thyroidectomy and nodal dissection.[43] Mutation of the BRAF gene in papillary carcinomas is estimated to be present in up to 60% of cases and is associated with a more aggressive phenotype and increased recurrence and mortality.[44]

Follicular Carcinoma

FTC accounts for approximately 10% of thyroid cancers. Again, there is a female-to-male predominance, and the incidence begins to increase in the fifth decade of life. Determination that a follicular lesion/neoplasm is a carcinoma is contingent not only on the specific cellular architecture, but also on the findings of vascular and capsular invasion. This determination is rarely able to be made on FNA or frozen section and often requires final surgical histopathology analysis.[45] FTC is often more advanced and locally infiltrative of muscles and perithyroidal vascular structures at the time of diagnosis compared with PTC. Because of this difference in stage at diagnosis, the overall 10-year survival for patients with FTC is slightly worse than for those with PTC, but when patients are matched for age and stage with PTC, this difference largely disappears.[46] In contrast to PTC, follicular cancers are usually solitary. FTC tends to spread hematogenously and approximately one-third of patients have distant metastases of the lung and bone at the time of diagnosis. Lymph node involvement is less common than in PTC and is limited to only about 10% of patients. At least 80% of FTC will take up radioiodine, making this an important consideration in postoperative imaging and adjuvant treatment.

Minimally Invasive Follicular Carcinoma. Follicular neoplasms with demonstrable capsular invasion, but no vascular invasion, are classified as minimally invasive follicular cancers. These patients have an excellent prognosis, conceptually equivalent to patients with incidental papillary microcarcinomas. If such a tumor is found after hemithyroidectomy, completion thyroidectomy and radioiodine therapy are generally not indicated.[47]

Hürthle Cell Carcinoma

Malignant Hürthle cell neoplasms account for less than 5% of thyroid carcinomas, are more prevalent in women than men, affect patients slightly older than those with PTC or FTC and are more often associated with lymph node metastases and distant metastases. Hürthle cells are frequently present on FNA cytology and the possibility of HCC is included in the diagnostic differential for these nodules. Patients with Hashimoto disease

or colloid nodules commonly contain Hürthle cells; however, it is the nodule that contains almost entirely Hürthle cells that raises concern for HCC. If HCC is suggested by FNA cytology, a diagnostic thyroid lobectomy is required to definitively establish the nature of the tumor. Hürthle cell cancers can have higher rates of lymph node metastasis and more aggressive nature compared to PTC and FTC therefore many surgeons advocate total thyroidectomy for any Hürthle cell carcinoma. Despite a likely follicular cell origin, only around 10% of HCC tumors take up radioiodine. Surgery therefore is the mainstay of treatment and total thyroidectomy is often combined with central compartment lymphadenectomy and perhaps modified radical neck dissection if lateral compartment lymph node involvement is present.

Anaplastic Carcinoma

Although it formerly accounted for a larger fraction of thyroid malignancies, undifferentiated or anaplastic cancer now accounts for just 1% to 2% of thyroid cancers. Most commonly, it occurs in elderly patients with a long-standing history of a goiter. There is significant evidence to infer that most anaplastic thyroid cancers of the spindle cell or giant cell type arise from transformation of follicular or papillary carcinoma. Anaplastic thyroid carcinoma is one of the most aggressive and rapidly lethal malignancies known. Nearly all are too far advanced at the time of diagnosis to be adequately treated by currently available therapies. The diagnosis may be made by appropriate clinical suspicion (rapidly growing firm thyroid mass) and FNA; however, core-needle or incisional/excisional biopsy may be required. If airway compromise is present or impending, operation may include debulking and tracheostomy. Occasionally, a small anaplastic cancer is found that is confined to the thyroid or is minimally invasive to surrounding tissues. Aggressive resection may be legitimately considered, especially in a young patient. The long-term prognosis for these patients, however, is usually limited by metastatic disease, which may not be apparent at diagnosis. Adjuvant or primary palliative therapy consisting of chemotherapy and external beam radiotherapy is frequently employed. It is common to see a measurable response early in therapy, but eventual tumor progression is typical. Chemotherapeutic regimens often include some combination of taxane (paclitaxel or docetaxel) and/or doxorubicin and/or platin (cisplatin or carboplatin), however, the overall impact is often very limited.[48] Radiation therapy can be used as primary treatment often in combination with chemotherapy or as adjuvant treatment following surgery with typical total radiation doses of 40 to 60 Gy. Most often, chemotherapy and radiotherapy follow an operation performed for diagnosis or airway protection, but such a regimen may also be used occasionally as neoadjuvant therapy before an attempt at resection is undertaken. A recent trial suggested a trend toward improved survival when combretastatin A-4 (fosbretabulin), a tubulin-binding compound, was added to carboplatin/paclitaxel in the treatment of anaplastic cancer postthyroidectomy.[49] Median survival for anaplastic thyroid cancer remains low at 5 months with a 20% 1-year survival for all patients.

Staging of Differentiated Thyroid Cancer

A number of patient factors have been investigated to predict risk and prognosis for patients with DTC, such as age, gender, tumor size, involvement of lymph nodes, extrathyroidal invasion, tumor grade or histologic features, and completeness of surgical removal. Although there are differences in these systems, in general, they agree that younger patients with smaller tumors have an excellent prognosis with decreased risk of recurrence and death compared with older patients. One early prognostic staging scheme was the AGES system (age, histologic grade, extrathyroidal disease [invasion and distant metastases], and tumor size).[50] Although useful, the scheme was later modified to exclude histologic tumor grade because there was no uniform agreement on DTC grading by pathologists. Another system is the AMES system (age, metastases, extrathyroidal invasion, and tumor size), which was originally described for patients with DTC.[51] The main criticism of this scheme is that it was defined based on a patient population that included both papillary and follicular thyroid carcinomas, and that there was no accounting for those patients with low-risk versus high-risk FTC. Another useful prognostic system is the MACIS scoring system (metastases, age, completeness of resection, extrathyroidal invasion and distant metastases, and tumor size). This system calculates a composite score based on these factors, then stratifies prognosis in proportion to these scores (<6.00 is very low risk and >8.00 represents greatly increased risk).[52] The European Organization for Research on Treatment of Cancer (EORTC) based its prognostic scoring system on a multivariate analysis of patients with all types of thyroid malignancies and found that patients with scores of less than 50 had a 5-year survival rate of 95%, whereas those with scores greater than 109 had a 5-year survival rate of 5%.[53] This system has not been universally adopted for use in DTC because the high-risk, poor-prognostic group contained a large fraction of patients with anaplastic thyroid cancer. The familiar TNM system (tumor size, nodal status, and distant metastases) is also used to provide prognostic information for patients. When used for thyroid cancer, the TNM system has been modified to account for the risk-reducing influence of low patient age such that patients <45 years are limited to stage I and II diseases. (Table 75-75). This system can provide consistency when comparing patients across different series. This system, like all prognostic scoring systems, still has limited utility in guiding initial treatment decisions (e.g., extent of resection) because the important components are unable to be determined until after resection. All patients with anaplastic cancer are considered to have stage IV disease which is further subcategorized into IVa (confined to thyroid), IVb (extrathyroidal extension), and IVc (metastatic disease).

STAGING

Table 75-2 Tumor, Node, Metastasis Staging System for Differentiated Thyroid Carcinoma (Papillary and Follicular Types)

Stage	Age <45 yrs	Age >45 yrs
I	Any T, Any N, M0	T1, N0, M0
II	Any T, Any N, M1	T2, N0, M0;
III		T3, N0, M0; or T1–3, N1a, M0
IV		T4, N0, M0; or T4a, N1a, M0; or T1–3, N1b, M0
IVB		T4b, Any N, M0
IVC		Any T, Any N, M1

T1, <2 cm; T2, 2–4 cm, >4 cm; T3, >4 cm; T4a, extrathyroidal extension; T4b, invades prevertebral fascia or encases carotid artery or mediastinal vessels; N0, no nodal involvement; N1, regional nodal metastases; N1a, metastasis to level 6 lymph nodes; N1b, metastasis to unilateral, bilateral, or contralateral cervical or superior mediastinal lymph nodes; M0, no distant metastases; M1, distant metastases.

Medullary Carcinoma

MTC arises from the parafollicular C cells and accounts for about 5% to 7% of all thyroid malignancies. Approximately 75% occur in a sporadic fashion and 20% to 25% are familial due to multiple endocrine neoplasia (MEN) types 2A and 2B or familial medullary thyroid carcinoma (FMTC) syndrome. These are autosomal dominant inherited endocrinopathies related to a group of specific mutations of the RET protooncogene on chromosome 10q11.2 (Table 75-3). The familial forms of MTC have different degrees of aggressiveness: FMTC has the most indolent course, MEN 2B has the most aggressive course, and MEN 2A is intermediate. Most sporadic MTC is relatively slow growing and may be quite indolent and typically do not present before 30 years of age. However, a subset of patients with sporadic MTC have a much more aggressive course. Approximately 20% of patients thought to have sporadic MTC may in fact be index cases of FMTC. Therefore, any patient with a new diagnosis of MTC should have genetic testing for the RET protooncogene mutations associated with MEN 2 and FMTC. Appropriate screening for pheochromocytoma (which would be treated prior to thyroidectomy) and hyperparathyroidism are required. The variability in biologic behavior in sporadic and FMTC accounts for the overall 10-year survival rate of approximately 50% for all patients combined.

FNA can be diagnostic for medullary cancer, especially if the specimen is stained for calcitonin. MTC is unique in that calcitonin and carcinoembryonic antigen (CEA) are specific tumor markers used for diagnosis and to guide subsequent follow-up. The degree of calcitonin elevation roughly corresponds to extent of disease and levels >400 pg/mL should prompt evaluation for extracervical metastasis with cross-sectional imaging. Overall, MTC is more aggressive than other DTCs and is more likely to metastasize such that 50% to 75% of patients with sporadic MTC have nodal metastases at the time of diagnosis. Nodal metastasis is correlated with tumor size and contralateral cervical metastases are synonymous with systemic disease.[54] Distant metastases commonly involve the liver, lungs, and bone.

The treatment strategy for MTC is somewhat distinguished from that of PTC or FTC. Due to the high likelihood of lymph node metastases and the fact that radioiodine is not available as an effective adjuvant therapy, a more extensive initial surgical resection is warranted. With few exceptions, the minimum appropriate operation for MTC is a total thyroidectomy with central compartment lymphadenectomy (level VI).[55] Patients with lymph node involvement in the lateral compartment should undergo total thyroidectomy with central and lateral neck dissection which includes lymph node levels II, III, IV, V and VI. Following initial surgery, an undetectable serum calcitonin is associated with persistent or recurrent disease, while levels which are detectable but <150 pg/mL are often associated with locoregional disease. Experience with remedial neck dissections in an attempt to decrease calcitonin to the normal range or render it undetectable have shown varying results and requires an appropriate search for distant metastases before such an operation is planned.[56] This may include imaging tests such as CT scanning, US, somatostatin receptor scintigraphy scanning, selective venous sampling for calcitonin levels, and laparoscopy to investigate for hepatic metastases. For most patients, the strategy of observation by clinical examination, biochemical markers (with determination of calcitonin doubling time), and imaging tests is adopted with interval reassessment for resectable regional and metastatic diseases. Resection can be considered for symptomatic lesions and those in a location whereby ongoing growth could cause significant morbidity (e.g., tracheoesophageal groove). Hepatic resections for isolated bulky metastatic deposits can provide palliation. Treatment of clinically significant distant or unresectable disease with targeted agents including vandetanib (an inhibitor of RET kinase, vascular endothelial growth factor receptor [VEGFR], and epidermal growth factor [EGFR]) has shown promise in the context of the general ineffectiveness of traditional cytotoxic chemotherapy.[57] Somatostatin analogs may also be useful in slowing the growth of the tumor in some patients. External beam radiotherapy may be useful for locoregional tumor control, especially in those patients with evidence of locally aggressive or residual tumor after resection;[58] however, this should not be employed until appropriate surgical options have been exhausted. The TNM staging system for MTC is outlined in Table75-4.

Table 75-3 Disease Phenotypes Related to Mutation of the RET Protooncogene

Phenotype	Genetic Defect	Clinical Features	Prevalence (%)
MEN 2A (60%)	Germline mutations in cysteine codons of extracellular and transmembrane domains of RET	Medullary thyroid carcinoma Pheochromocytoma Hyperparathyroidism	100 10–60 5–20
MEN 2B (5%)	Germline activating mutation in tyrosine kinase domain or RET	Medullary thyroid carcinoma Pheochromocytoma Marfanoid habitus Mucosal neuromas (gut) and ganglioneuromatosis	100 50 100 100
FMTC (35%)	Germline mutations in cysteine codons of extracellular or transmembrane domains of RET	Medullary thyroid carcinoma	100

FMTC, familial medullary thyroid carcinoma; MEN, multiple endocrine neoplasia.

7 All patients with MTC (not already known to have familial mutation) should undergo evaluation for germline RET mutations. The best use of genetic testing is to identify the specific mutation in the affected family member, which then guides testing of the progeny. When other kindred members with the mutation are identified, prophylactic thyroidectomy may be performed before malignancy develops with the timing of this guided by the particular codon mutation (Table 75-4).[55] The thyroid resection must be absolutely complete because the region of thyroid remnant after a near-total or subtotal thyroidectomy is the region that is most densely populated with C cells. The association of primary hyperparathyroidism and MEN 2A should be considered during preoperative planning and enlarged parathyroid glands encountered at the time of thyroidectomy should be removed. A subtotal parathyroidectomy or total parathyroidectomy and autotransplantation (similar to that which would be considered for MEN 1) are excessive options for the parathyroid disease encountered in MEN 2A and, instead, resection may be guided by morphologic changes in the parathyroid glands and intraoperative parathyroid hormone monitoring. Children identified to have MEN 2B should undergo thyroidectomy and central compartment lymph node dissection as soon as the diagnosis is made, definitely by 2 years of age, but even by 6 months of age as guided by mutation analysis (Table 75-5).[59] If MTC is already evident at the time of RET mutation diagnosis (as opposed to only C-cell hyperplasia), patients should also undergo ipsilateral neck dissection.

STAGING

Table 75-4 Tumor, Node, Metastasis Staging System for Medullary Thyroid Carcinoma

Stage	TNM
I	T1, N0, M0
II	T2, N0, M0 T3, N0, M0
III	T1–3, N1a, M0
IVA	T4a, Any N, M0; T1–3, N1b, M0
IVB	T4b, Any N, M0
IVC	Any T, Any N, M1

T1 <2 cm; T2, 2–4 cm; T3, >4 cm or minimal extrathyroidal extension; T4a, invades larynx, trachea, esophagus or nerve; T4b, invades spine or carotid; N0, no nodal metastasis; N1a, central neck (level VI) metastasis; N1b, lateral neck or superior mediastinal metastasis (levels II,–V, VI); M0, no distant metastasis; M1, distant metastasis.
Used with the permission of the American Joint Committee on Cancer (AJCC), Chicago, Illinois. The original source for this material is the AJCC Cancer Staging Manual, Seventh Edition (2010) published by Springer Science and Business Media LLC, www.springer.com

Thyroid Lymphoma

8 Primary thyroid lymphomas are rare tumors that account for fewer than 5% of thyroid malignancies. The majority are classified as non-Hodgkin lymphomas of B-cell origin. Nearly all arise from within a background of Hashimoto thyroiditis. Most patients present with a rapidly enlarging thyroid mass and compressive symptoms (e.g., dyspnea, dysphagia, choking, and pain) and have a history of hypothyroidism. Modern immunophenotypic analysis often allows for diagnosis with a small amount of tissue obtained by FNA or core-needle sampling. Surgery is typically utilized only to establish the diagnosis with open biopsy if needle biopsy is insufficient. Definitive treatment of thyroid lymphoma includes chemotherapy and radiation. Patients with diffuse large B-cell lymphoma are generally treated with combination chemotherapy (cyclophosphamide, doxorubicin, vincristine, and prednisone [CHOP] with rituximab) followed by radiation therapy for stage IE or IIE disease.[60] In those with pure marginal zone B-cell lymphoma (MALT), some have advocated for single-modality therapy (chemotherapy or radiation) given its more indolent behavior, but this still remains controversial and would be limited to those with localized disease.[61]

Table 75-5 Age of Prophylactic Thyroidectomy Based on Genotype/Phenotype Correlation in Medullary Thyroid Carcinoma

Risk Classification	Codon Mutation	Management Recommendation
Level A – Lowest risk	533, 649, 666, 768, 790, 791, 804, 891, 912	Total thyroidectomy ± CCLND before age of 10 yrs or before based on criteria[a]
Level B – Moderate risk	609, 611, 618, 620, 630	Total thyroidectomy ± CCLND before age of 5 yrs or delayed based on criteria[a]
Level C – High risk	634	Total thyroidectomy ± CCLND before age 5 yrs
Level D – Highest risk	883, 918	Total thyroidectomy ± CCLND within first year of life

[a]A normal annual basal calcitonin, normal annual neck US, less aggressive MTC family history.
CCLND, central compartment lymph node dissection.

Metastases to the Thyroid Gland

Isolated metastases from other primary cancers can occur in the thyroid gland, although they are rare. The most common tumor type to do so is renal cell carcinoma, although it can occur from breast, lung, and gastrointestinal carcinomas, as well as melanoma and sarcoma.[62] Thyroidectomy can be useful for control of compressive symptoms.

Preoperative Ultrasound

Cervical US plays an important role for preoperative planning prior to thyroidectomy for benign disease and for thyroid cancer. US, which can be performed by the operating surgeon, provides important information including determination of the size and extent of thyroid nodules which may not be palpable on physical examination. Failure to visualize the caudal extent of the lower thyroid lobes in large goiters indicates possible substernal extension which can be further delineated with CT. Preoperative US can also evaluate the cervical lymph nodes in cases of thyroid cancer and particular attention should be paid to evidence concerning imaging appearances (lack of a hilar line, microcalcifications, and loss of the typical flattened ovoid shape) which may not be noted on physical examination alone. Detection by US of nonpalpable lymph node metastases occurs in 24% to 39% of patients with papillary thyroid cancer diagnosed by FNA.[12,63–65] Even in patients with palpable lymphadenopathy, US can alter the extent of lymphadenectomy in approximately 40% of patients undergoing initial or reoperative surgery.[65–67]

Extent of Thyroidectomy

9 Thyroidectomy is a primary treatment for DTC and is well accepted to be both effective and safe; however, some controversy persists about the extent of thyroidectomy necessary for low-risk patients. It is generally agreed that surgical options (not typically equivalent) include hemithyroidectomy with or without isthmusectomy for small (<1 cm) low-risk tumors confined to a single focus in the thyroid or total or near-total thyroidectomy for all DTCs. Subtotal thyroidectomy is not an appropriate operation for thyroid cancer. The advantages of total thyroidectomy for all DTCs of follicular cell origin include (a) removal of multifocal intrathyroidal tumors; (b) use of radioiodine to localize and treat small amounts of residual normal thyroid tissue, and more importantly, regional or distant metastases; and (c) the ability to use serum thyroglobulin as a sensitive marker of persistent or recurrent disease. If only thyroid lobectomy is performed, radioiodine treatment is usually not optimal because of the increased avidity for RAI to the normal remaining thyroid lobe compared to thyroid cancer tissue, and thyroglobulin measurements also lose their utility. It has been difficult to demonstrate a survival advantage related to extent of thyroidectomy. However, a study comparing extent of thyroid surgery in patients with PTC showed that patients with PTC greater than 1 cm who underwent total thyroidectomy had a significantly lower risk of recurrence and lower mortality compared with those undergoing thyroid lobectomy.[68]

Lymphadenectomy

10 Therapeutic lymphadenectomy is a well-established treatment of the clinically involved cervical lymph nodes. In general, regional lymph node metastases are found in 30% to 40% of patients, although wider ranges have been reported (20% to 90%).[63–65] A compartment-oriented approach to lymphadenectomy is currently preferred over the previously advocated technique of selective neck dissection or “berry picking” (removing only grossly positive nodes) if this can be performed without significantly increasing morbidity or mortality. Prophylactic central lymph node dissection (CLND) is a more controversial component of treatment for papillary thyroid cancer. Central compartment lymph node involvement is both common (can be found in up to 80% of patients with clinically negative nodes) and difficult to treat with a remedial operation in the future.[12] If prophylactic CLND is to be added to the routine performance of total thyroidectomy to treat PTC, it must be assured that the incidence of RLN injury and hypoparathyroidism is not increased. Routine prophylactic CLND can be considered for patients with papillary thyroid cancer and Hürthle cell cancer if it can be done without increasing morbidity.[12] Knowledge of the central neck lymph node status improves staging accuracy in patients over 45 years of age and may influence the use of adjuvant radioiodine treatment.[69] Residual subclinical disease, as indicated by postoperative serum thyroglobulin levels, may also be decreased using this strategy.[70] Whether prophylactic central neck dissection will have any benefit to long-term survival will be very difficult to determine given the already excellent prognosis for patients with DTC.

Radioiodine Therapy

Radioiodine may serve diagnostic and therapeutic purposes in the management of follicular-derived thyroid cancer. Low doses are used to demonstrate remaining thyroid tissue or metastatic disease as part of a diagnostic radioiodine scan, whereas higher doses are used for thyroid remnant ablation and for treatment of residual and/or recurrent disease. The timing of the initial postoperative scan is dictated by the physiology of T_4 and the fact that remnant thyroid tissue or DTC must be stimulated by elevated levels of TSH to take up RAI. Although no precise threshold has been established, a general consensus is held that the TSH at the time of RAI should be ≥ 30 mIU/mL to provide adequate stimulation for radioiodine uptake. Traditionally this has been achieved by withdrawal of supplemental thyroxine. The half-life of thyroxine is approximately 7 days, so TSH values are significantly elevated 4 to 5 weeks after total thyroidectomy or withdrawal from thyroxine treatment. To minimize the duration of hypothyroid symptoms, patients can be managed with T_3 (liothyronine) up to 2 weeks prior to scanning, as T_3 has a much shorter half-life (8 to 12 hours) than T_4. An alternative to thyroid hormone withdrawal is the use of recombinant human TSH (rhTSH) for ^{131}I uptake scans and treatment.[71] The use of rhTSH avoids the long deprivation of thyroid hormone replacement and development of hypothyroid symptoms. rhTSH can also be used to obtain stimulated serum thyroglobulin levels and ^{131}I whole-body scans during thyroid cancer surveillance.

Radioiodine therapy has a dual intended effect of treatment of residual thyroid cancer as well as ablation of any thyroid remnant tissue. The utility of radioiodine ablation of the thyroid remnant in the absence of evidence of residual thyroid cancer is debated. Radioiodine therapy is a rational adjuvant therapy for DTC because most tumor cells retain the ability to concentrate radioiodine. Several studies have shown a decreased rate of recurrence and increased disease-specific and overall survival when ^{131}I treatment is used in patients with stage III and IV diseases and with more aggressive pathologic subtypes.[72,73] Although there have been no prospective randomized trials with postoperative radioiodine, treatment is recommended for all patients with distant metastasis, primary tumors larger than 4 cm or with gross extrathyroidal extension and those with lymph node metastasis.[12] Radioiodine treatment is generally not recommended for tumors less than 1 cm (unifocal or multifocal) confined to the thyroid, in cases of undifferentiated thyroid cancer or in recurrent tumors that have lost the ability to concentrate iodine. Unfortunately as many as 30% of advanced and recurrent DTC will eventually dedifferentiate, and a portion of these cancers will lose the ability to concentrate radioiodine due to loss of the Na^+/I^- symporter function. Clinical trials are ongoing using a variety of MAPK kinase inhibitors to reverse iodine resistance and therefore make repeat radioiodine treatment a viable option.[74]

External Beam Radiotherapy

External beam radiation is rarely indicated in the treatment of thyroid cancer. Invasive variants which result in gross residual disease after surgical resection may benefit from external beam radiation to assist with local control. This is most often a consideration with tumors that invade the tracheoesophageal axis. This occurrence is frequent with poorly differentiated tumors, but it certainly can complicate advanced DTC as well. It has also been considered for patients with extensive lymph node involvement that is characterized by extranodal extension. Bone metastases are rarely treated completely with ^{131}I and, thus, external beam radiotherapy may be effective often in conjunction with zoledronic acid.[75] Complications of external beam radiation include skin erythema and desquamation and tracheoesophageal mucositis and its use should be limited to cases where additional operative attempts are unlikely.

Thyroid-Stimulating Hormone Suppression

Levothyroxine therapy to suppress TSH levels below 0.1 mU/L is commonly recommended for patients with high-risk differentiated thyroid carcinoma and between 0.1 and 0.5 mU/L for low-risk patients.[12] TSH is considered a trophic factor for these cancers, however, the efficacy of suppressive therapy is inferred from uncontrolled retrospective studies. It is important to individualize the degree of suppression in patients, balancing the risk of recurrence with the risks of subclinical hyperthyroidism (e.g., osteoporosis, cardiac arrhythmias). If a patient has no evidence of recurrence and has extremely low or undetectable thyroglobulin levels 5 to 10 years after treatment, it may be appropriate to lessen the degree of TSH suppression.

Metastatic Thyroid Cancer

In addition to radioactive iodine therapy there are multiple ongoing clinical trials of tyrosine kinase inhibitors (sorafenib, vandetanib, sunitinib, and pazopanib) in the treatment of advanced or progressive metastatic thyroid cancer with sorafenib recently obtaining FDA approval.[76] These novel drugs act to partially inhibit multiple tyrosine kinases including BRAF, MEK, and phosphatidylinositol 3-kinase (PI3K), RET and VEGFR and are often used as first-line treatment of metastatic thyroid cancer nonresponsive to radioiodine therapy prior to treatment with cytotoxic agents.

THYROID SURGERY

Thyroidectomy is a safe and effective operation for thyroid disease in the hands of an experienced surgeon. Substantial improvements in anesthesia, antisepsis, and improved hemostasis along with the substantial technical contributions of Albert Theodor Billroth, Theodor Kocher, and William Halsted, among others have provided the basis of modern thyroid surgery.

Technique

There is little, if any, place for subtotal lobar resections (e.g., nodulectomy) and only an occasional role for isthmusectomy alone. Thyroid lobectomy (hemithyroidectomy) is the total extracapsular removal of the lobe and the isthmus while preserving the parathyroid glands, the RLN, and the EBSLN. Total thyroidectomy is merely a matter of performing a thyroid lobectomy on the contralateral side during the same operation. Subtotal thyroidectomy is intentional subtotal lobar resection, either unilaterally or bilaterally, and is rarely indicated except in cases where postoperative thyroid hormone replacement is problematic. Near-total thyroidectomy involves intentionally leaving a minor amount of thyroid tissue to protect the insertion of the RLN and the superior parathyroid gland. When properly performed, near-total thyroidectomy is essentially interchangeable with total thyroidectomy when considering surgical outcomes but still requires post-operative thyroid hormone replacement.

For most thyroid procedures, the patient is placed in a supine position or a semi-Fowler position with the arms tucked to the side. A support is placed transversely under the shoulders to aid in extending the neck. This extension must not be too extreme or postoperative pain may occur in the occipitocervical region.

Thyroid resection should be performed in a logical orderly sequence as follows. After skin preparation, a curvilinear incision is made approximately one to two fingerbreadths above the clavicular heads and not any higher than the level of the cricoid cartilage, disguised in an existing skin crease when possible (Fig. 75-8). Subplatysmal skin flaps are raised to the level of the thyroid cartilage above, the sternal notch below, and laterally to the sternocleidomastoid muscles. The midline raphe is opened to expose the anterior trachea and the thyroid isthmus. The sternohyoid and sternothyroid are then separated from the underlying thyroid lobe, and the perithyroidal and paraesophageal spaces are entered. The middle thyroid veins, which can be identified as they course medial to lateral, anterior to the carotid artery are divided and ligated. If a pyramidal lobe is present, it is mobilized and divided from the fibrous tissue in any remaining thyroglossal duct tract. The anterior suspensory ligament is divided to mobilize the superior aspect of the isthmus.

Dissection of the superior pole of the thyroid must take place in the plane directly adjacent to the thyroid capsule after the largely avascular space between the pole and the cricothyroideus muscle is dissected. To do so more proximally along the superior pole vessels imperils the EBSLN. This nerve is not always visually identified during thyroidectomy, but it can nearly always be preserved by utilizing this technique and observing the anatomy carefully. The EBSLN can often be demonstrated with the help of a stimulator used in a nerve-integrity monitoring system (see below). Capsular dissection then continues at the inferior pole of the thyroid lobe with preservation of the inferior parathyroid gland followed by capsular dissection of the posterolateral aspect of the thyroid gland with preservation of the superior parathyroid gland and the RLN. Figure 75-9 indicates the plane of dissection relevant to these steps.

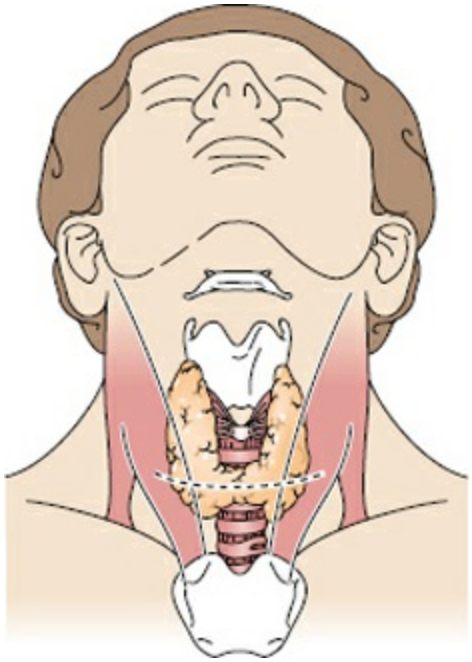

Figure 75-8. With the patient's neck extended, the line above indicates the appropriate site of incision for thyroid resection. Camouflage within an existing skin crease is often possible.

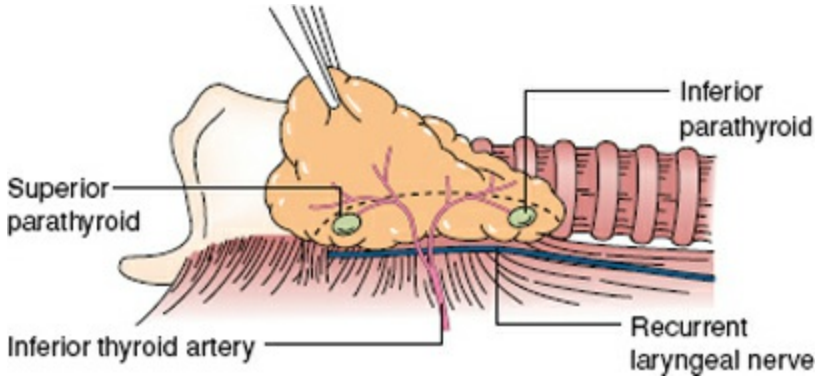

Figure 75-9. The capsular dissection necessary to preserve well-vascularized parathyroid tissue and a fully functional recurrent laryngeal nerve begins in the area outlined above.

Unequivocal identification of the RLN should occur early in the operation and involves visual identification of the nerve as it emerges from the mediastinum. Palpation can aid in the process of identification of the RLN as a slightly firm linear structure in the tracheoesophageal groove with the lobe retracted anteromedially. Although helpful in guiding early dissection, this technique cannot supplant visual confirmation. The RLN typically courses posterior to the thyroid. Progressive exposure of the entire surface of the nerve until it inserts into the cricothyroid muscle will allow for identification and preservation of nerve branches. The genu of the RLN occurs near the ligament of Berry and constant visualization of the nerve along with gentle dissection and careful division of the ligament is important to avoid injury.

The ability to routinely preserve well-vascularized parathyroid tissue during thyroidectomy is mandatory for surgeons performing these operations. Normal parathyroid tissue is subtle and may be difficult to identify. It can be distinguished from surrounding fat by a slight brownish color (similar to the color of peanut butter) and a

fine capillary vascular pattern that is not present in the adjacent fat or thymus. If a parathyroid is inadvertently removed or is devascularized it should be morcelized and then reimplanted into an easily accessible and viable muscle such as the sternocleidomastoid or strap muscle.

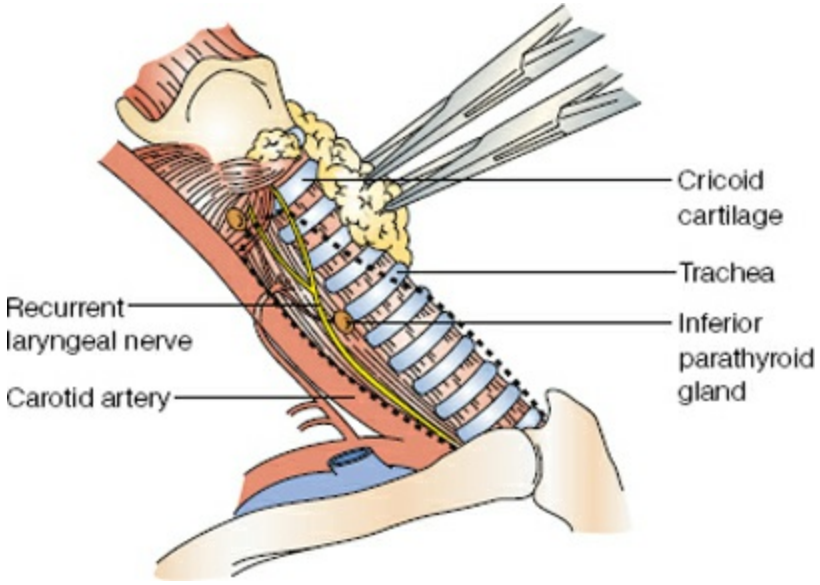

Figure 75-10. Boundaries showing high-risk area of central compartment dissection involving the vascular supply to the superior and inferior parathyroid glands and the recurrent laryngeal nerve.

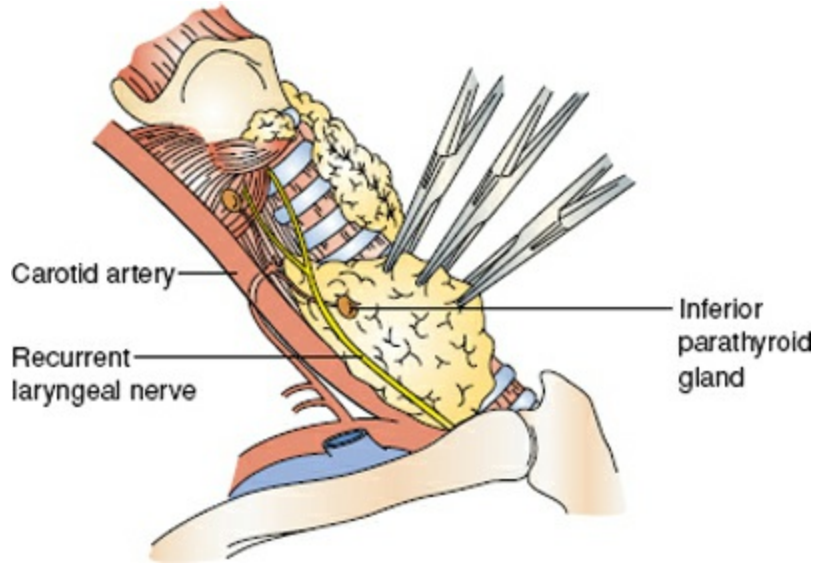

Figure 75-11. The recurrent laryngeal nerve is carefully isolated and dissected free from surrounding tissue in level VI.

The central compartment level VI lymph nodes are bordered by the hyoid bone cranially, the level of innominate artery caudally, the common carotid arteries laterally, and the prevertebral fascia posteriorly.[7] Removal of these lymph nodes is an important component of an operation to treat clinically evident lymph node metastasis in thyroid carcinoma and may have has an important role to offer in a prophylactic manner to improve nodal staging with its downstream effects on adjuvant radioiodine treatment.[69] To perform a CLND, the prelaryngeal (Delphian) lymph node(s) adjacent to the pyramidal lobe is excised. After the ipsilateral thyroid lobe is completely resected, the lateral and

medial extent of dissection is defined to mobilize the level VI nodes. The superior parathyroid gland must be carefully preserved on its vascular supply as the inferior parathyroid gland is often embedded in the nodal tissue to be removed and often requires autotransplantation (Fig. 75-10). The cervical portion of the RLN is exposed in a retrograde direction toward the mediastinum using gentle dissection to divide the overlying fibrofatty and nodal tissue (Fig. 75-11). Especially on the side ipsilateral to the primary tumor, it is important to remove the nodes located posterior to the RLN and anterior to the prevertebral fascia in addition to the more easily removed nodes located anterior to the RLN (Fig. 75-12). If the nerve is adequately mobilized, this can usually be accomplished en bloc and the nodes may even be left attached to the inferior pole of the thyroid. The block of nodal tissue is then removed down to the level VII superior mediastinal nodes at the superior margin of the innominate vein. In order to accomplish this, the cervical thymus can either be removed or preserved. If the inferior parathyroid is unable to be preserved on its vascular pedicle, it is autotransplanted into the adjacent muscle after confirmation with frozen section that it is indeed parathyroid tissue and not a metastatic lymph node (Fig. 75-13).

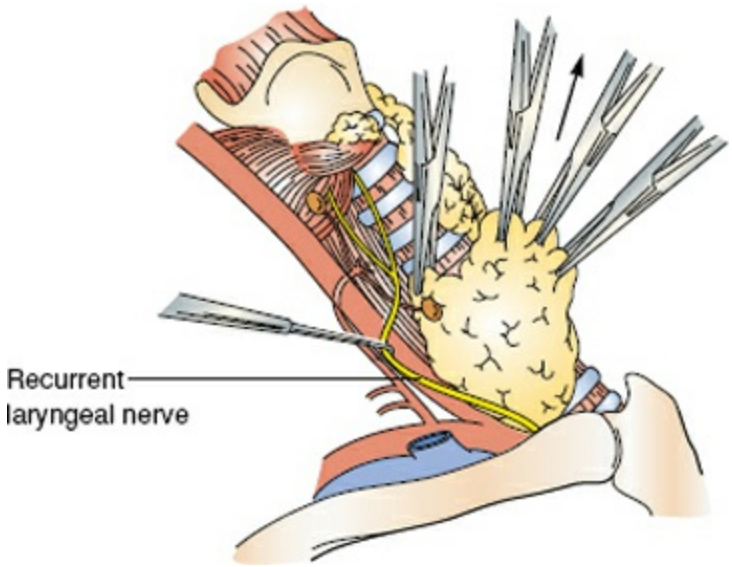

Figure 75-12. The recurrent laryngeal nerve is carefully repositioned laterally and medially as needed to dissect all fibrofatty and lymphatic tissue from level VI structures.

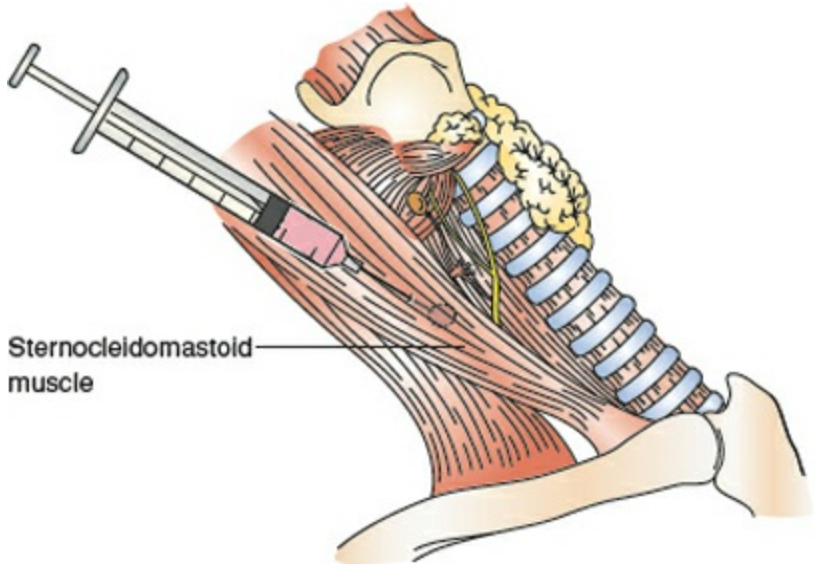

Figure 75-13. It is not uncommon for the inferior parathyroid gland(s) to become devascularized during dissection of the central compartment. Devascularized parathyroid tissue should be retrieved, minced into 1-mm pieces, and autotransplanted to the ipsilateral sternocleidomastoid muscle.

Advanced surgical energy instruments for bipolar vessel sealing and ultrasonic scalpels have now been integrated into thyroid resections. The main benefit in thyroidectomy is decreased operative time.[77–79] Most series indicate that complication rates (hematoma, RLN injury, and hypoparathyroidism) are comparable to conventional techniques. Heat generation and lateral thermal spread for a particular instrument are critical to understand and may limit safe application near the RLN and parathyroid glands.

Intraoperative monitoring of the RLN and EBSLN function is used to varying degrees with several commercially available nerve monitoring systems. Nerve monitoring requires measurement of vocal cord movement or muscle action potentials with either electrodes on the endotracheal tube or needle electrodes surgically implanted in the cricothyroid muscle. Electric stimulation of the functionally intact RLN produces adduction of the true vocal fold and a measured evoked potential signal. Similarly, stimulation of the EBSLN produces muscular twitch of the cricothyroid muscle. Intraoperative nerve monitoring can clearly aid in identification of the RLN and EBSLN, especially in reoperative procedures; however, there have been no studies demonstrating a statistically significant decrease in nerve injury rates with nerve monitoring.[80–82] Therefore, whether or not RLN monitoring is employed, prevention of injury still requires meticulous and precise surgical technique.

Modifications to the traditional transcervical approach to thyroidectomy have been developed at several centers with the goal of decreasing the size of the cervical incision or avoiding a cervical incision altogether. Although the modified transcervical approaches can be minimally invasive with smaller incisions, less dissection and possibly less postoperative pain, the remote access approaches (transaxillary, transareolar, and "facelift") are not necessarily minimally invasive and often require more extensive dissection to gain access to the thyroid and should be considered purely cosmetic in their benefits.

Table 75-6 Complications of Total Thyroidectomy

Complications	Incidence (%)
Bleeding	1
Wound infection	1
Thoracic duct leak	1
Hypoparathyroidism	
Transient	9–35
Permanent	0–4
Recurrent laryngeal nerve injury	
Initial operation	
Transient	1–10
Permanent	0–1.4
Reoperation	
Transient	0–22
Permanent	0–13
External branch of superior laryngeal nerve injury	5–28

Complications

The risk of death or major disability during thyroidectomy should be diminutive. The key outcomes by which to measure the quality of surgical care include RLN paralysis and hypoparathyroidism (Table 75-6). Although both complications can occur in a temporary fashion, the persistence or permanence (defined at 6 months after operation) of these complications is a critical measure. For most surgeons, the rate of unintended permanent RLN dysfunction should be no greater than 1% and the rate of permanent hypoparathyroidism should be no greater than 1% to 2%.

Injury to an RLN results in temporary or permanent paralysis of the vocal cord it innervates depending on the degree of injury and presence or absence of repair. At times the main RLN will bifurcate exterior to its insertion into the cricothyroid muscle. In these scenarios the anterior branch typically contains motor fibers and the posterior branch typically contains sensory fibers. Injury to these branches can result in hoarseness and aspiration respectively or in combination if the main RLN is injured. Depending on the specific branch or combination of branches injured, the cord may remain in a paramedian position (also called cadaveric position) or may remain abducted. If the contralateral cord is able to adduct to the midline or beyond, the patient may have a voice that is not particularly hoarse, but is weak. If the cord is paralyzed in the abducted position, vocal quality is very poor because of the difficulty in approximating the cords during speaking. The patient's cough also has a bovine quality where there is a lack of a sharp, percussive initiation. If both vocal cords are paralyzed, consideration of the specific cord positions is even more critical. If both cords are paralyzed in the abducted position, the patient may have a critically limited ability to phonate. In this situation, the patient may gradually develop some degree of airway obstruction as the cords gradually migrate toward the midline. If both cords are paralyzed in the paramedian position, the airway is critically narrowed. In this situation, stridor is usually apparent very soon after extubation and an emergent procedure (e.g., cricothyroidotomy or tracheostomy) may be required to reestablish a patent airway. Intraoperative recognition of RLN injury can be aided with intraoperative nerve monitoring. The particular site of injury can often be identified by progressive distal stimulation of the visualized RLN until loss of signal occurs. If a nerve transection is noted, intraoperative neural repair can be performed with variable regain of function.

Because of greater anatomic variations, the EBSLN is at higher risk for injury than the RLN during thyroidectomy.[80] The symptoms of injury to the EBSLN are usually less noticeable and may be only slightly evident to the patient, but can be important in the case of the vocal professional. Symptoms of EBSLN injury typically include early vocal fatigue, decreased pitch range, and decreased projection ability. Findings on laryngoscopy are subtle and include bowing and inferior displacement of the affected vocal cord and rotation of the posterior glottis toward the injured side. Laryngeal videostroboscopy or percutaneous electromyography of the cricothyroideus muscle may be required to detect injury in subtle cases. Because there is no effective treatment for this condition, prevention is extremely important.

Examination of vocal cord appearance and function can be performed with indirect or flexible fiberoptic laryngoscopy in a routine or patient selective manner.[83] Laryngoscopy is particularly useful in patients with persistent hoarseness or change in voice quality, those with history of prior surgery in which the recurrent laryngeal or vagus nerves were at risk of injury, those with locally advanced cancer and those with distorted anatomy due to large and/or substernal goiters.

The parathyroid glands are at risk during thyroid resection by virtue of their location which can be firmly invested within the thyroid sheath or occasionally even within the thyroid capsule. Inferior parathyroid glands are ultimately supplied by the ITA. Superior parathyroid glands are often served by the ITA but may also have contributions from the superior thyroid artery. Ligation of the trunk of the ITA proximal to the pedicle to the parathyroid glands must be avoided. Every attempt should be made to mobilize the parathyroid glands away from the thyroid tissue while preserving the blood supply. If the gland appears pale or dark and devascularized, the arterial supply is probably compromised. Such a parathyroid gland is unlikely to survive after the operation and should be autotransplanted. This may be done by mincing the gland into 1-mm pieces and inserting or injecting the pieces into well-vascularized skeletal muscle (e.g., sternocleidomastoid, strap muscle, or pectoralis).[84] With total thyroidectomy, careful dissection is even more critical than with hemithyroidectomy. Temporary hypoparathyroidism is relatively common and occurs in 20% to 40% of patients after total thyroidectomy and is due to mild devascularization or venous congestion of parathyroid glands during mobilization. Symptoms of hypocalcemia include paresthesias and numbness of the hands, feet, and lips which can be treated with oral calcium with or without vitamin D supplements (e.g., calcitriol). Severe symptomatic hypocalcemia can be treated with intravenous calcium gluconate. Temporary hypoparathyroidism complicating thyroidectomy usually resolves over days to weeks, although occasionally it may take months to do so. Hypoparathyroidism that persists longer than 6 months is usually destined to be permanent. The transient hypocalcemia after total thyroidectomy may be worse in the patient with Graves disease because of the increased bone turnover observed with hyperthyroidism; however, recovery is expected and the incidence of permanent hypoparathyroidism should be no higher than in euthyroid patients.

Regardless of the specific extent or technique of thyroidectomy, these complications can largely be avoided or ameliorated by delicate and deliberate surgical technique. A thorough understanding of the function and anatomy, both normal and abnormal, of the thyroid gland, and of the rationale behind various treatment options, is critical to ensure the best outcomes for our patients.

DISCLOSURES

The authors have nothing to disclose.

References

1. Gauger P, Delbridge LW, Thompson NW, et al. Incidence and importance of the tubercle of Zuckerkandl in thyroid surgery. *Eur J Surg* 2001;167:249–254.
2. Sackett W, Reeve TS, Barraclough B, et al. Thyrothymic thyroid rests: incidence and relationship to the thyroid gland. *J Am Coll Surg* 2002;195:635–640.
3. Bliss R, Gauger PG, Delbridge LW. Surgeon's approach to the thyroid gland: surgical anatomy and the importance of technique. *World J Surg* 2000;2:891–897.
4. Kandil E, Abdel Khalek M, Aslam R, et al. Recurrent laryngeal nerve: significance of the anterior extralaryngeal branch. *Surgery* 2011;149:820–824.
5. Toniato A, Mazzarotto R, Piotto A. Identification of the nonrecurrent laryngeal nerve during thyroid surgery: 20-year experience. *World J Surg* 2004; 28:659–661.
6. Cernea C, Ferraz AR, Nishio S, et al. Surgical anatomy of the external branch of the superior laryngeal nerve. *Head Neck* 1992;14:380–383.
7. Carty SE, Cooper DS, Doherty GM, et al. American Thyroid Association. Consensus statement on the terminology and classification of central neck dissection for thyroid cancer. *Thyroid* 2009;19(11):1153–1158.
8. Kupferman ME, Patterson M, Mandel SJ, et al. Patterns of lateral neck metastases in papillary thyroid carcinoma. *Arch Otolaryngol Head Neck Surg* 2004;130:857–860.
9. Machens A, Holzhausen JJ, Dralle H. Skip metastases in thyroid cancer leaping the central lymph node compartment. *Arch Surg* 2004;139:43–45.
10. Garber JR, Cobin RH, Gharib H, et al. Clinical practice guidelines for hypothyroidism in adults: cosponsored by the American Association of Clinical Endocrinologists and the American Thyroid Association. *Endocr Pract* 2012; 18(6):88–1028.
11. Tan G, Gharib H. Thyroid incidentalomas: management approaches to nonpalpable nodules discovered incidentally on thyroid imaging. *Ann Intern Med* 1997;126:226–231.
12. Cooper DS, Doherty GM, Haugen BR, et al. American Thyroid Association. Revised American Thyroid Association guidelines for patients with thyroid nodules and differentiated thyroid cancer. *Thyroid* 2009;19(11):1167–1214.
13. Chin B, Patel P, Cohade C, et al. Recombinant human thyrotropin stimulation of fluoro-D-glucose positron emission tomography uptake in well-differentiated thyroid carcinoma. *JCEM* 2004;89:91–95.
14. Shie P, Cardarelli R, Sprawls K, et al. Systemic review: Prevalence of malignancy incidental thyroid nodules identified on fluorine-18 fluorodeoxyglucose positron emission tomography. *Nucl Med Commun* 2008;30:742–748.
15. Kang BJ, O JH, Baik JH, et al. Incidental thyroid uptake on F-18 FDG PET/CT: correlation with ultrasonography and pathology. *Ann Nucl Med* 2009;23:729–737.
16. Bertagna F, Treglia G, Piccardo A, et al. F18-FDG-PET/CT thyroid incidentalomas: a wide retrospective analysis in three Italian centres on the significance of focal uptake and SUV value. *Endocrine* 2013;43:678–685.

17. Bahn RS, Burch HD, Cooper DS, et al. Hyperthyroidism and other causes of thyrotoxicosis: Management guidelines of the American Thyroid Association and the American Association of Clinical Endocrinologists. *Thyroid* 2011;21:593–646.
18. Tallstedt L, Lundell G, Blomgren H, et al. Does early administration of thyroxine reduce the development of Graves' ophthalmopathy after radioiodine treatment? *Eur J Endocrinol* 1994;130:494–497.
19. Tallstedt L, Lundell G, Torring O, et al. Occurrence of ophthalmopathy after treatment for Graves' hyperthyroidism. The Thyroid Study Group. *N Engl J Med* 1992;326:1733–1738.
20. Bartalena L, Marcocci C, Bogazzi F, et al. Use of corticosteroids to prevent progression of Graves' ophthalmopathy after radioiodine therapy for hyperthyroidism. *N Engl J Med* 1989;321:1349–1352.
21. Sundaresh V, Brito JP, Wang Z, et al. Comparative effectiveness of therapies for Graves' hyperthyroidism: a systematic review and network meta-analysis. *J Clin Encocrinol Metab* 2013;98:3671–3677.
22. van Soestbergen M, Van Der Vijver J, Graafland A. Recurrence of hyperthyroidism in multinodular goiter after long-term drug therapy: a comparison with Graves' disease. *J Endocrinol Invest* 1992;15:797–800.
23. Stoll SJ, Pitt SC, Liu J, et al. Thyroid hormone replacement after thyroid lobectomy. *Surgery* 2009;146:554–558
24. Tunbridge W, Brewis M, French JM, et al. Natural history of autoimmune thyroiditis. *Br Med J Clin Res* 1981;282:258–262.
25. McManus C, Luo J, Sippel R, et al. Should patients with symptomatic Hashimoto's thyroiditis pursue surgery? *J Surg Res* 2011;170:52–55.
26. Smallridge R, DeKeyser FM, VanHerle AJ, et al. Thyroid iodine content and serum thyroglobulin: cues to the natural history of destruction-induced thyroiditis. *J Clin Endocrinol Metab* 1986;62:1213–1219.
27. Bartalena L, Brogioni S, Grasso L, et al. Treatment of amiodarone-induced thyrotoxicosis: a difficult challenge: results of a prospective study. *J Clin Endocrinol Metab* 1996;81:2930–2933.
28. Violaris N, Windle-Taylor PC. Idiopathic fibrosis of the upper aero-digestive tract. *J Laryngol Otol* 1989;103:333–334.
29. Few J, Thompson NW, Angelos P, et al. Riedel's thyroiditis: treatment with tamoxifen. *Surgery* 1996;120:998–999.
30. White ML, Doherty GM, Gauger PG. Evidence-based management of substernal goiter. *World J Surg* 2008;32:1285–1300.
31. Hughes DT, Haymart MR, Miller BS, et al. The most commonly occurring papillary thyroid cancer in the United States is now a microcarcinoma in a patient older than 45 years. *Thyroid* 2011;21:231–236.
32. Gupta A, Ly S, Castroneves L, et al. A standardized assessment of thyroid nodules in

children confirms higher cancer prevalence than in adults. *J Clin Endocrinol Metab* 2013;98:3238–3245.

33. Leeman-Neill RJ, Brenner AV, Little MP, et al. RET/PTC and PAX8/PPAR$_\gamma$ chromosomal rearrangements in post-Chernobyl thyroid cancer and their association with iodine-131 radiation dose and other characteristics. *Cancer* 2013;119:1792–1799.
34. Guglielmi R, Pacella CM, Bianchini A, et al. Percutaneous ethanol infection treatment in benign thyroid lesions: role and efficacy. *Thyroid* 2004;14:125–131.
35. Baloch ZW, LiVolsi VA, Asa SL, et al. Diagnostic terminology and morphologic criteria for cytologic diagnosis of thyroid lesions: a synopsis of the national cancer institute thyroid fine-needle aspiration state of the science conference. *Diagn Cytopathol* 2008;36:425–437.
36. Kouniavsky G, Zeiger MA. The quest for diagnostic molecular markers for thyroid nodules with indeterminate or suspicious cytology. *J Surg Onc* 2012;105:438–443.
37. Dedhia PH, Rubio GA, Cohen MS, et al. Potential effects of molecular testing of indeterminate thyroid nodule fine needle aspiration biopsy on thyroidectomy volume. *World J Surg* 2014;38:634–638.
38. Montone KT, Baloch ZW, LiVolsi VA. The thyroid Hürthle (oncocytic) cell and its associated pathologic conditions: a surgical pathology and cytopathology review. *Arch Pathol Lab Med* 2008;132:1241–1250.
39. Lin JD, Chao TC, Chou SC, et al. Papillary thyroid carcinomas with lung metastases. *Thyroid* 2004;14:1091–1096.
40. Beninato T, Scognamiglio T, Kleiman DA, et al. Ten percent tall cells confer the aggressive features of the tall cell variant of papillary thyroid carcinoma. *Surgery* 2013;154:1331–1336.
41. Ito Y, Miyauchi A, Inoue H, et al. An observation trial for papillary thyroid microcarcinoma in Japanese patients. *World J Surg* 2010;34:28–35.
42. Ito Y, Miyauchi A, Kihara M, et al. Patient age is significantly related to the progression of papillary microcarcinoma of the thyroid under observation. *Thyroid* 2014;24:27–34.
43. Yip L, Wharry LI, Armstrong MJ, et al. A clinical algorithm for fine-needle aspiration molecular testing effectively guides the appropriate extent of initial thyroidectomy. *Ann Surg* 2014;260:163–168.
44. Xing M, Alzahrani AS, Carson KA, et al. Association between BRAF V600E mutation and mortality in patients with papillary thyroid cancer. *JAMA* 2013;309:1493–1501.
45. Callcut RA, Selvaggi SM, Mack E, et al. The utility of frozen section evaluation for follicular thyroid lesions. *Ann Surg Oncol* 2004;11:94–98.
46. Kuo EJ, Roman SA, Sosa JA. Patients with follicular and Hürthle cell microcarcinomas have compromised survival: a population level study of 22,738 patients. *Surgery* 2013;154:1246–1253.

47. Goffredo P, Cheung K, Roman SA, et al. Can minimally invasive follicular thyroid cancer be approached as a benign lesion?: a population-level analysis of survival among 1,200 patients. *Ann Surg Oncol* 2013;20:767–772.
48. Smallridge RC, Ain KB, Asa SL, et al. American thyroid association guidelines for management of patients with anaplastic thyroid cancer. *Thyroid* 2012;22:1104–1039.
49. Sosa JA, Balkissoon J, Lu S, et al. Thyroidectomy followed by foxbretabulin (CA4P) combination regimen appears to suggest improvement in patient survival in anaplastic thyroid cancer. *Surgery* 2012;152:1078–1087.
50. Hay I, Grant CS, Taylor WF, et al. Ipsilateral lobectomy versus bilateral lobar resection in papillary thyroid carcinoma: a retrospective analysis of surgical outcome using a novel prognostic scoring system. *Surgery* 1987;102:1088–1095.
51. Cady B, Rossi R. An expanded view of risk-group definition in differentiated thyroid carcinoma. *Surgery* 1988;104:947–953.
52. Hay I, Bergstralh EJ, Goellner JR, et al. Predicting outcome in papillary thyroid carcinoma: development of a reliable prognostic scoring system in a cohort of 1779 patients surgically treated at one institution during 1940 through 1989. *Surgery* 1993;114:1050–1057.
53. Byar D, Green SB, Dor P, et al. A prognostic index for thyroid carcinoma: a study of the E.O.R.T.C. thyroid cancer cooperative group. *Eur J Cancer* 1979;15:1033–1041
54. Moley JF, DeBenedetti MK. Patterns of nodal metastases in palpable medullary thyroid carcinoma. Recommendations for extent of node dissection. *Ann Surg* 1999;229:880–887.
55. Kloos RT, Eng C, Evans DB, et al. Medullary thyroid cancer: management guidelines of the American Thyroid Association. *Thyroid* 2009;19:565–612.
56. Fialkowski E, Debenedetti M, Moley J. Long-term outcome of reoperations for medullary thyroid carcinoma. *World J Surg* 2008;32:754–765.
57. Wells SA Jr, Robinson BG, Gagel RF, et al. Vandetanib in patients with locally advanced or metastatic medullary thyroid cancer: a randomized, double-blind phase III trial. *J Clin Oncol* 2012;30:134–141.
58. Fersht N, Vini L, A'Hern R, et al. The role of radiotherapy in the management of elevated calcitonin after surgery for medullary thyroid cancer. *Thyroid* 2001;11:1161–1168.
59. Skinner M, DeBenedetti MK, Moley JR, et al. Medullary thyroid carcinoma in children with multiple endocrine neoplasia types 2A and 2B. *J Pediatr Surg* 1996;31:177–181.
60. Jonak C, Troch M, Mullauer L, et al. Rituximab plus dose-reduced cyclophosphamide, mitoxantrone, vincristine and prednisolone are effective in elderly patients with diffuse large B-cell lymphoma of the thyroid. *Thyroid* 2010;20:425–427.
61. Tsang RW, Gospodarowicz MK, Pintilie M, et al. Localized mucosa-associated lymphoid tissue lymphoma treated with radiation therapy has excellent clinical

outcome. *J Clin Oncol* 2003;21:4157–4164.
62. Mirallie E, Rigaud J, Mathonnet M, et al. Management and prognosis of metastases to the thyroid gland. *J Am Coll Surg* 2005;200:203–207.
63. Choi JS, Chung WY, Kwak JY, et al. Staging of papillary thyroid carcinoma with ultrasonography: performance in a large series. *Ann Surg Oncol* 2011;18:3572–3578.
64. Loh K, Greenspan FS, Gee L, et al. Pathological tumor-node-metastasis (pTNM) staging for papillary and follicular thyroid carcinomas: a retrospective analysis of 700 patients. *J Clin Endocrinol Metab* 1997;82:3553–3562.
65. Stulak JM, Grant CS, Farley DR, et al. Value of preoperative ultrasonography in the surgical management of initial and reoperative papillary thyroid cancer. *Arch Surg* 2006;141(5):494–496.
66. Kouvaraki MA, Shapiro SE, Fornage BD, et al. Role of preoperative ultrasonography in the surgical management of patients with thyroid cancer. *Surgery* 2003;134(6):946–955.
67. Solorzano CC, Carneiro DM, Ramirez M, et al. Surgeon-performed ultrasound in the management of thyroid malignancy. *Am Surg* 2004;70(7):580–582.
68. Bilimoria K, Bentrem DJ, Ko CY, et al. Extent of surgery affects survival for papillary thyroid cancer. *Ann Surg* 2007;246(3):375–384.
69. Hughes DT, White ML, Miller BS, et al. Influence of prophylactic central lymph node dissection on postoperative thyroglobulin levels and radioiodine treatment in papillary thyroid cancer. *Surgery* 2010;148:1100–1106.
70. Popadich A, Levin O, Lee JC, et al. A multicenter cohort study of total thyroidectomy and routine central lymph node dissection for cN0 papillary thyroid cancer. *Surgery* 2011;150:1048–1057.
71. Mazzaferri EL, Kloos RT. Using recombinant human TSH in the management of well-differentiated thyroid cancer: current strategies and future directions. *Thyroid* 2000;10(9):767–778.
72. Jonklaas J, Sarlis JN, Litofsky D, et al. Outcomes of patients with differentiated thyroid carcinoma following initial therapy. *Thyroid* 2006;16:1229–1242.
73. Jung TS, Kim TY, Kim KW, et al. Clinical features and prognostic factors for survival in patients with poorly differentiated thyroid carcinoma and comparison to the patients with aggressive variants of papillary thyroid carcinoma. *Endocr J* 2007;54:265–274.
74. Ho AL, Grewal RK, Leboeuf R, et al. Selumetinib-enhanced radioiodine uptake in advanced thyroid cancer. *NEJM* 2013;368:623–632.
75. Orita Y, Sugitani I, Toda K, et al. Zoledronic acid in the treatment of bone metastases from differentiated thyroid carcinoma. *Thyroid* 2011;21:31–35.
76. Kloos RT, Ringel MD, Knopp MV, et al. Phase II trial of sorafenib in metastatic thyroid cancer. *J Clin Oncol* 2009;27:1675.
77. Franko J, Kish KJ, Pezzi CM, et al. Safely increasing the efficiency of thyroidectomy

using a new bipolar electrosealing device (LigaSure) versus conventional clamp-and-tie technique. *Am Surg* 2006;72:132–136.

78. Siperstein A, Berber E, Morkoyun E. The use of the harmonic scalpel vs. conventional knot tying for vessel ligation in thyroid surgery. *Arch Surg* 2002;137:137–142.
79. Cardon C, Fajardo R, Ramirez J. A randomized, prospective, parallel group study comparing the harmonic scalpel to electrocautery in thyroidectomy. *Surgery* 2005;137:337–3341.
80. Barczynski M, Konturek A, Stopa M, et al. Randomized controlled trial of visualization versus neuromonitoring of the external branch of the superior laryngeal nerve during thyroidectomy. *World J Surg* 2012;36:1340–1347.
81. Dralle H, Sekulla C, Haerting J, et al. Risk factors of paralysis and functional outcome after recurrent laryngeal nerve monitoring in thyroid surgery. *Surgery* 2004;136:1310–1322.
82. Yarbrough D, Thompson GB, Kasperbauer JL, et al. Intraoperative electromyographic monitoring of the recurrent laryngeal nerve in reoperative thyroid and parathyroid surgery. *Surgery* 2004;136:1107–1115.
83. Schlosser K, Zeuner M, Wagner M, et al. Laryngoscopy in thyroid surgery-essential standard or unnecessary routine? *Surgery* 2007;142:858–864.
84. Gauger P, Reeve TS, Wilkinson M, et al. Routine parathyroid autotransplantation during total thyroidectomy: the influence of technique. *Eur J Surg* 2000;166:605–609.

Chapter 76

Parathyroid Glands

Gerard M. Doherty

Key Points

1 The normal parathyroid glands are flat, ovoid, and red-brown to yellow. Their dimensions are 5 to 7 mm × 3 to 4 mm × 0.5 to 2 mm, and they weigh between 30 and 50 mg each.

2 Parathyroid hormone (PTH) is the single most important hormonal regulator of calcium and phosphate metabolism in humans with direct effects on the skeleton and kidney and indirect effects on the intestine, mediated through vitamin D.

3 The demonstration of an elevated plasma PTH concentration alone does not establish the diagnosis of hyperparathyroidism; with a simultaneous elevated serum calcium level, this finding is virtually diagnostic.

4 A large proportion of patients with the diagnosis of hyperparathyroidism are minimally or asymptomatic and the appropriate treatment for these patients remains controversial.

5 It is routinely possible to identify abnormal parathyroid glands prior to operation for most patients, allowing the surgeon to know where to start the exploration; intraoperative PTH measurement can be used to confirm removal of all hyperfunctioning parathyroid tissue, that is, when to stop the operation.

ANATOMY

1 Typically, each person has four parathyroid glands – two superior and two inferior (Fig. 76-1).[1] The normal parathyroid glands are flat, ovoid, and red-brown to yellow. They measure 5 to 7 mm × 3 to 4 mm × 0.5 to 2 mm and weigh between 30 and 50 mg each. The lower glands are usually larger than the upper glands. The superior glands are most often embedded in the fat on the upper posterior surface of the thyroid lobe near the site where the recurrent laryngeal nerve enters the larynx. The inferior glands are usually more ventral and lie close to or within the portion of the thymus gland that extends from the inferior pole of the thyroid gland into the chest. Although this anatomy is fairly consistent, substantial variations from the usual can occur, and it is essential that the surgeon have a thorough understanding of these anatomic variations.

Variations in parathyroid gland anatomy are primarily caused by differences in patterns of embryogenesis. During the fourth and fifth weeks of fetal development, a series of four pharyngeal pouches develop (Fig. 76-2). The superior parathyroid gland arises from the fourth pharyngeal pouch in conjunction with the lateral thyroid, and the inferior gland arises from the third pouch along with the thymus. The derivatives of each pouch then migrate together so that the superior parathyroid gland usually remains in close association with the upper pole of the thyroid, although it may occasionally be loosely attached by a long vascular pedicle, migrating caudad along the esophagus into the posterior mediastinum. Occasionally, a gland may be totally embedded in the thyroid parenchyma. The inferior parathyroid gland descends with the thymus, but this migration is extremely variable. Inferior glands can be found anywhere from the pharynx to the mediastinum. Regardless of their location, they usually adhere to the thymus or are within the thyrothymic ligament. Supernumerary glands can be identified in up to 15% of patients, most often in association with the thymus. Autopsy studies suggest that four parathyroid glands are virtually always present.

The arterial supply to both the superior and inferior parathyroid glands is usually from the inferior thyroid artery, although it may arise from the superior thyroid or thyroidea ima arteries or from the rich anastomosis of vessels supplying the larynx, trachea, and esophagus. A mediastinal parathyroid gland that descended during embryonic development usually receives its blood supply from either the internal mammary artery or small arteries within the thymus; however, an enlarged parathyroid gland that grows into the mediastinum usually carries with it the corresponding branch of the inferior thyroid artery. The inferior, middle, and superior thyroid veins, which drain the parathyroid glands, empty into the internal jugular vein or the innominate vein.

Histologically, the normal adult parathyroid gland is about half parenchyma and half stroma, including fat cells (Fig. 76-3). In children, the gland is almost entirely composed of parenchymal chief cells. Beginning at puberty, adipocytes appear and, with age, occupy an increasing proportion of the gland. Also with increasing age, acidophilic, mitochondria-rich oxyphil cells are present in increasing numbers and are intermixed with the glycogen-laden, polygonal, water-clear cells. The functional significance of the various cell types remains unclear, although the water-clear cells and oxyphil cells are

probably derived from the chief cells and secrete parathyroid hormone (PTH).

PHYSIOLOGY

The primary physiologic role of the parathyroid gland is the endocrine regulation of calcium and phosphate metabolism. Average daily exchanges of these ions from the gastrointestinal tract, bone, and kidney are shown in Figure 76-4.

Calcium

Calcium ion plays a critical role in all biologic systems. It participates in enzymatic reactions and is a mediator in hormone metabolism. Calcium is intimately involved in the physiology of neurotransmission, muscle contraction, and blood coagulation. It is the major cation in bone and teeth. It represents about 2% of the average body weight, and almost all calcium is contained in the skeleton. The normal range of serum calcium is 9 to 10.5 mg/dL (4.5 to 5.2 mEq/L), and the daily variation in a normal person is generally less than 10%. About half of the total serum calcium is in an ionized, biologically active form; 40% is bound to serum protein, mainly albumin, and 10% forms compounds with organic ions, such as citrate. The total serum calcium concentration is a function of the serum protein content, and because hydrogen ion competes with calcium for the same binding sites on albumin, the body fluid pH is important. In general, for every change of 1 g/dL in the serum albumin level, a direct alteration of 0.8 mg/dL occurs in the serum calcium concentration. Almost all the physiologically important activity of calcium is represented by the unbound, or free, fraction.

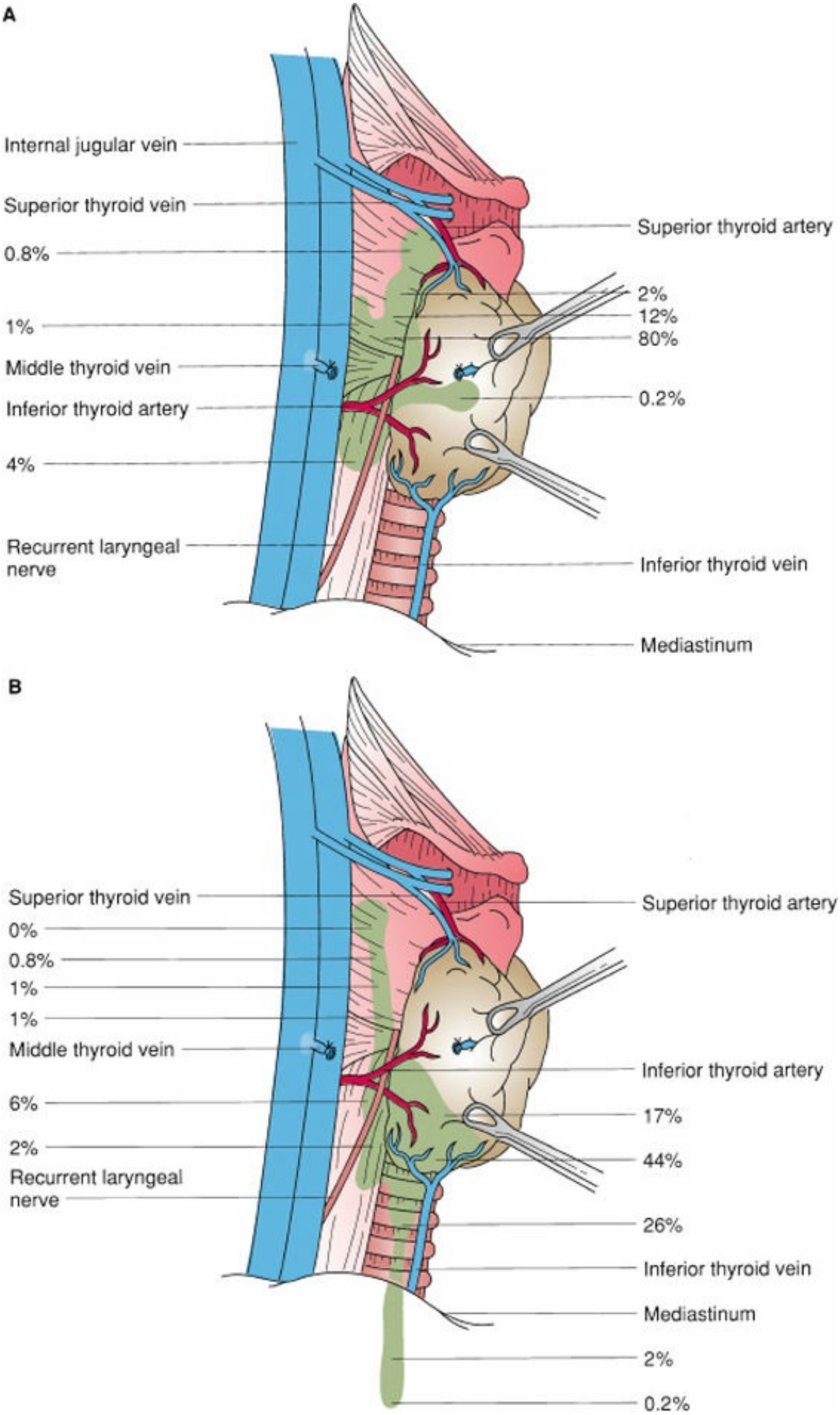

Figure 76-1. Schematic illustration of the location of the superior (**A**) and inferior (**B**) parathyroid glands from 503 autopsy studies. The more common locations are indicated by the shaded areas. The numbers represent the percentage of glands found at each location. Typically, the glands were posterolateral to the thyroid and above or below the junction of

the inferior thyroid artery with the recurrent laryngeal nerve.

Calcium is absorbed in its inorganic form from the duodenum and proximal jejunum. The rate of absorption is precisely regulated according to body calcium status. The calcium in the extracellular fluid is constantly being exchanged with that in the intracellular fluid, the exchangeable bone, and the glomerular filtrate. Calcium reabsorption by the kidney is closely related to that of sodium, and about 99% of the filtered load is reabsorbed under normal conditions.

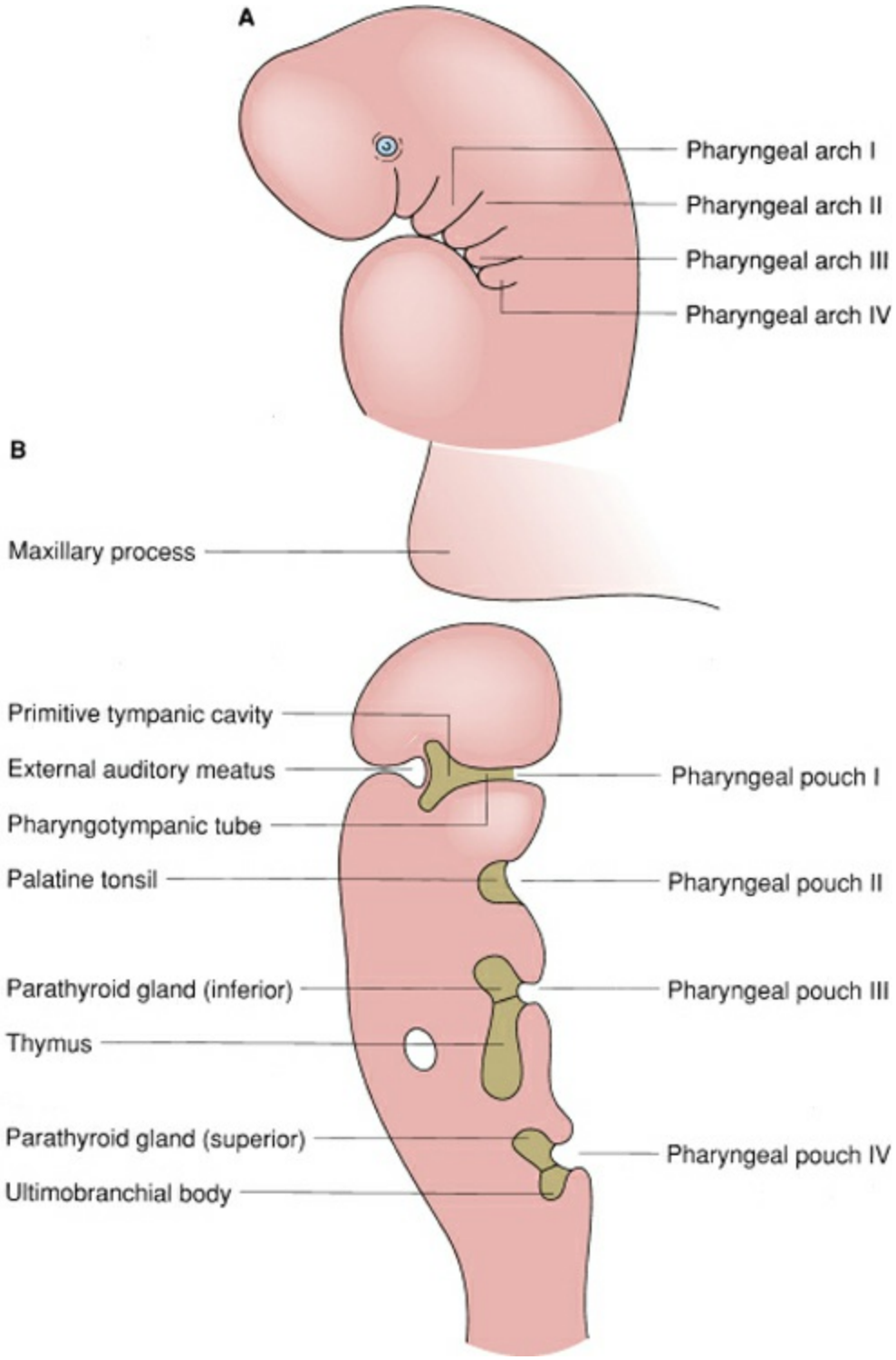

Figure 76-2. **A:** Pharyngeal arches in a 5-week embryo. The corresponding pouches extend from within the pharynx into each arch. **B:** Schematic representation of the differentiating epithelium of the respective pharyngeal pouches.

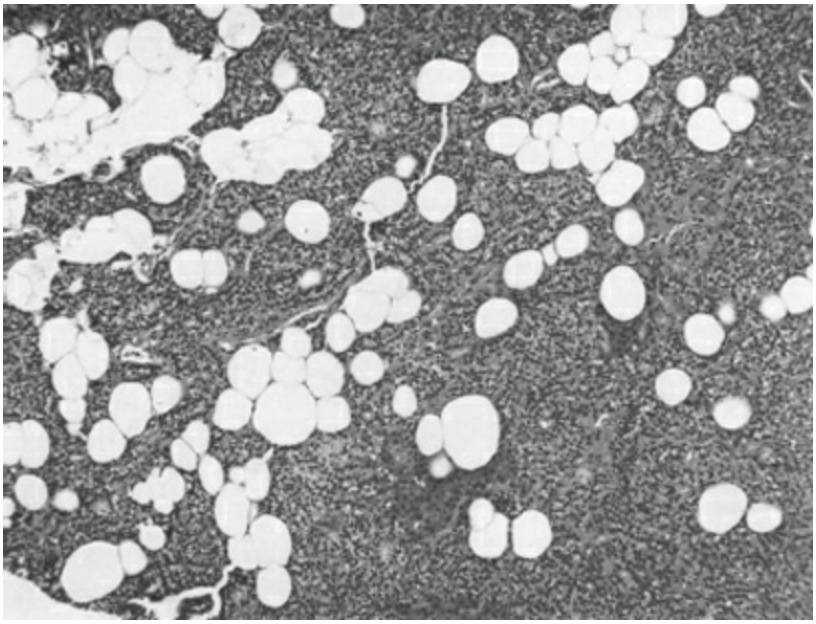

Figure 76-3. A normal adult parathyroid is composed of about half parenchyma and half fat ($\times 150$).

Phosphate

Phosphate anion is also an integral component of most biologic systems. It is critical to the pathways of glycolysis and is the functional group for a number of high-energy transfer compounds, including adenosine triphosphate. It is also the major anion in crystalline bone. Normal levels of plasma phosphate range from 2.5 to 4.3 mg/dL, and the level varies inversely with the serum level of calcium. The relation is such that the product of plasma calcium and phosphate is relatively constant ranging between 30 and 40 (with calcium and phosphate both expressed in mg/dL). When the product is above this level, the potential for the precipitation of calcium phosphate in body tissues increases.

In contrast to the percentage of calcium absorbed, the percentage of phosphate absorbed from the diet is relatively constant, and excretion usually provides the major mechanisms for regulating phosphate balance (Fig. 76-4). Unlike stores of calcium, the readily exchangeable soft tissue stores of phosphate, such as those in muscle, are large.

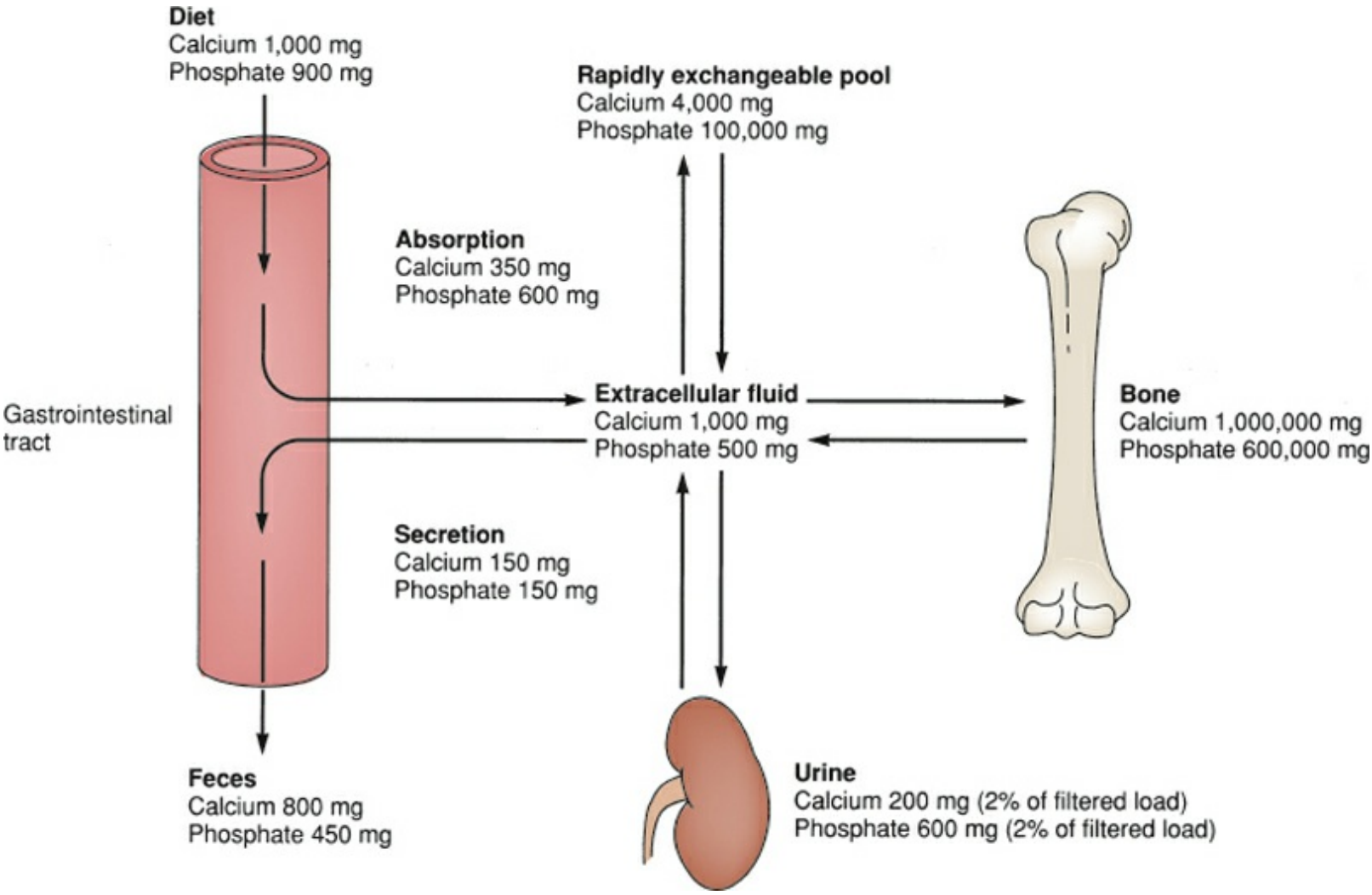

Figure 76-4. Average daily calcium and phosphate turnover in humans.

Regulation of Calcium and Phosphate Metabolism

The maintenance of calcium and phosphate homeostasis depends on major contributions from three organ systems – the gastrointestinal tract, the skeleton, and the kidneys – with minor contributions from the skin and liver.[2] The primary hormonal regulators of this metabolism are PTH, vitamin D, and calcitonin. The actions of each of these hormones in the organs are summarized in Table 76-1.

Parathyroid Hormone

2 PTH is the single most important hormonal regulator of calcium and phosphate metabolism in humans. It has direct effects on the skeleton and kidney and indirect effects on the intestine, mediated through vitamin D. In target tissues, PTH binds first to membrane receptors, activating adenyl cyclase to generate cyclic adenosine monophosphate (cAMP), which regulates other intracellular enzymes.

In bone, the effects of PTH are complex, stimulating both resorption and the formation of new bone. However, sustained elevations of PTH stimulate osteoclasts and inhibit osteoblasts. Osteocytes, in the matrix of cortical bone, may also act to reabsorb matrix in response to PTH, a process referred to as *osteocytic osteolysis*. Calcium and phosphate mobilization in response to PTH occurs in two phases. Initially, mineral is mobilized from areas of rapid equilibrium. This phase is followed by a more sustained release mediated by newly synthesized lysosomal and hydrolytic enzymes. In the kidney, PTH increases the reabsorption of extracellular fluid calcium at any given concentration, although excess secretion, because of hypercalcemia, increases the net daily amount of urinary calcium excretion. Reabsorption in the proximal tubule and loop of Henle is linked with sodium transport such that factors that alter sodium transport concomitantly alter calcium reabsorption. In contrast, reabsorption in the distal nephron is independent of sodium and directly influenced by PTH. PTH also increases phosphate excretion. This action is accompanied by enhanced bicarbonate secretion. PTH probably has only indirect effects on the gastrointestinal tract, by stimulating the hydroxylation of 25-hydroxyvitamin D to 1,25-dihydroxyvitamin D in the kidney.

Table 76-1 Hormonal Regulation of Calcium and Phosphate Metabolism

Location	Parathyroid Hormone	Vitamin D	Calcitonin
Gastrointestinal tract	No direct effect	Stimulates calcium and phosphate absorption	No direct effect
Skeleton	Stimulates calcium and phosphate resorption	Stimulates calcium and phosphate resorption	Inhibits calcium and phosphate resorption
Kidneys	Stimulates calcium resorption	No direct effect	Inhibits calcium and phosphate resorption

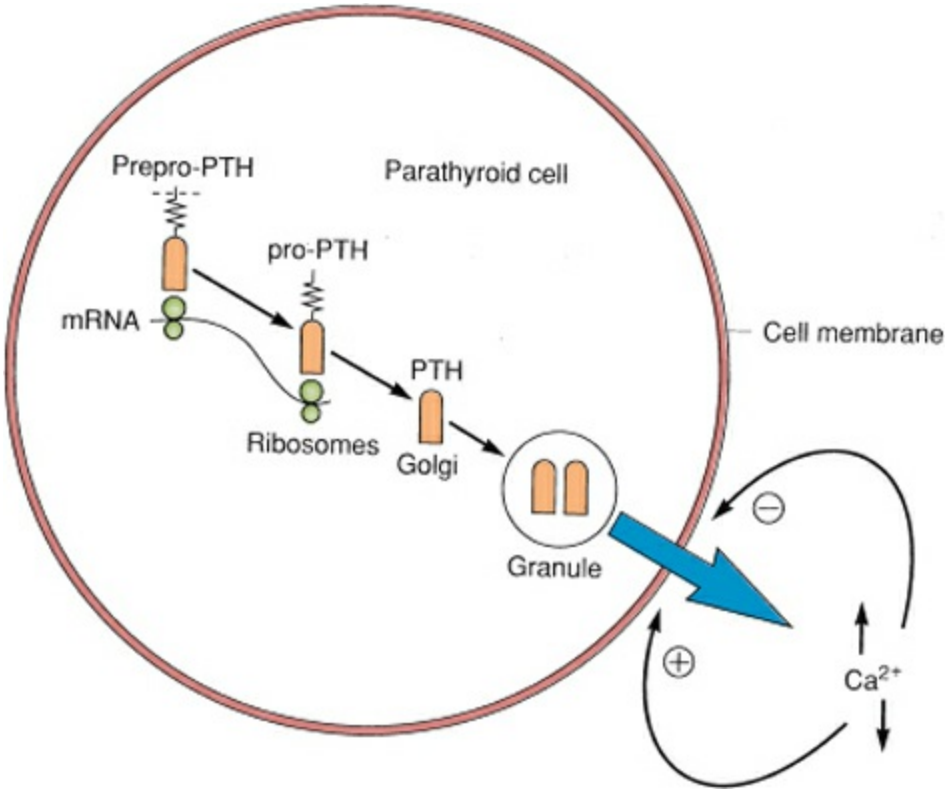

Figure 76-5. The parathyroid gland produces a precursor of PTH, prepro-PTH, that is sequentially cleaved to pro-PTH and PTH. PTH secretion is controlled by the extracellular fluid calcium concentration.

PTH is synthesized initially as a precursor, preproPTH, which is sequentially cleaved in the parathyroid gland to proPTH and then to PTH (Fig. 76-5). Secretion of this 84-amino-acid molecule is controlled by a negative feedback loop with extracellular fluid calcium. Most PTH is secreted in this form and then cleaved in the liver into N- and C-terminal fragments. The N-terminus contains most of the biologic activity and is rapidly degraded by the liver, whereas the inactive C-terminus is slowly metabolized by the kidney.

Vitamin D

Vitamin D acts at two major sites. It increases intestinal absorption of calcium and phosphate. In addition, in the skeleton, it promotes mineralization and enhances PTH-mediated mobilization of calcium and phosphate. It has no known direct effect on the kidney.

Vitamin D_3, or cholecalciferol, is produced normally by the action of sunlight on 7-dehydrocholesterol in the skin (Fig. 76-6). It is then hydroxylated in the liver (25 position) and kidney (1 position) to form the active 1,25-dihydroxyvitamin D_3 (calcitriol). Vitamin D_2 is normally present in yeast and fungi but not in humans. It is the major pharmacologic source of vitamin D. Pharmaceutical preparations include vitamin D_2 (ergocalciferol), 25-hydroxycholecalciferol (calcifediol), and 1,25-dihydroxycholecalciferol (calcitriol). 1-Hydroxycholecalciferol and dihydrotachysterol are synthetic preparations that require only 25-hydroxylation for activity and so are useful for supplementation in patients with renal failure, who lack the 1-hydroxylase.

Calcitonin

Calcitonin is a 32-amino-acid protein produced by the parafollicular C (calcitonin) cells of the thyroid. The C cells are embryologically derived from the neural crest and, in lower animals, are found in the ultimobranchial bodies, which are glandular structures derived from the lowest branchial pouch. In humans, these structures are incorporated into the superior and lateral aspects of the thyroid lobes.

Total thyroidectomy, with removal of all the C cells, is well tolerated. Calcitonin is not essential for the normal control of calcium metabolism in adult humans. It does inhibit bone resorption and can produce hypocalcemia in experimental animals. It also increases urinary calcium and phosphate excretion. These effects are mediated primarily through cAMP. Several secretagogues for calcitonin have been identified, including catecholamines, gastrin, and cholecystokinin, but the most potent appear to be calcium and pentagastrin. Exogenously administered calcitonin can be useful pharmacologically to reduce serum calcium levels.

Mineral Homeostasis

Under normal conditions, serum calcium and phosphate levels vary minimally during the course of the day. Regulation occurs primarily through PTH but also through a series of feedback loops involving vitamin D and calcitonin (Fig. 76-7). A fall in serum-ionized calcium increases PTH secretion and stimulates the production of 1,25-dihydroxyvitamin D_3. Conversely, increases in serum calcium inhibit PTH secretion and the formation of active calciferol.

Pathophysiology

Diseases of the parathyroid glands present almost exclusively as disorders of calcium metabolism. Hypercalcemia is the most common manifestation, and in the patient who presents with an elevated serum calcium level, the differential diagnosis can be complex. A thorough understanding of both hypercalcemia and hypocalcemia is essential for the successful treatment of patients undergoing parathyroid surgery. Primary disorders of plasma phosphate are not usually related to surgical disease and are not discussed in detail here.

HYPERCALCEMIA

Hypercalcemia is a relatively common clinical problem.[3,4] In the general population and in hospital outpatients, the incidence is between 0.1% and 0.5%. Most patients in this group have primary hyperparathyroidism. In contrast, hypercalcemia is identified in almost 5% of hospitalized patients, and nearly two-thirds of them have a malignancy.

Clinical Manifestations

The symptoms of hypercalcemia are varied and nonspecific (Table 76-2). Severity is a function of both the magnitude and rapidity of onset of the hypercalcemia. Many of the manifestations are subtle and are evident only in retrospect, after the patient has been successfully treated for the cause of the elevated calcium. Specific symptoms and diagnostic tests are addressed in more detail in the section on hyperparathyroidism.

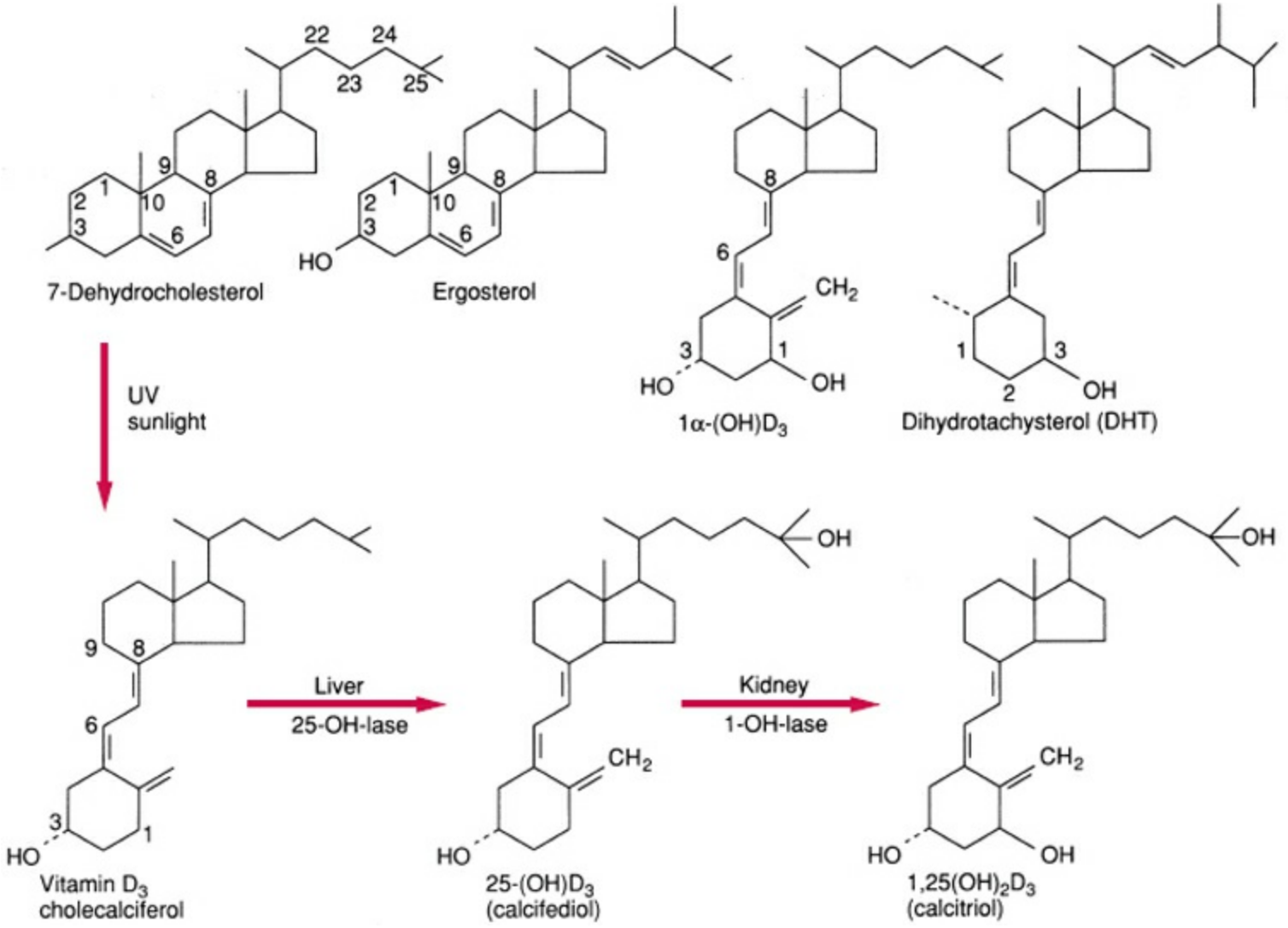

Figure 76-6. Schematic illustration of the synthesis of vitamin D_3. Ergosterol, 1-alpha-hydroxyvitamin D_3, and dihydrotachysterol are synthetic preparations of vitamin D.

Differential Diagnosis

Although the diagnosis of primary hyperparathyroidism can, after appropriate investigation, be established with confidence in most patients, all causes of hypercalcemia must be considered and excluded. The multiple causes of hypercalcemia are listed in Table 76-3.

Etiology

Hyperparathyroidism

The diagnosis of hyperparathyroidism is discussed in detail later. Patients typically have elevated plasma concentrations of calcium and PTH, increased urinary excretion of calcium, and a low plasma concentration of phosphate.

Malignancy

Generally, patients with hypercalcemia and malignancy (humoral hypercalcemia of malignancy) can be classified into two groups.[5–7] Patients with solid tumors, such as lung carcinoma (25% of all cases of humoral hypercalcemia of malignancy); breast carcinoma (20%); squamous cell carcinoma of the head, neck, esophagus, or female genital tract (19%); or renal cell cancer (8%), account for three-fourths of all cases. Humoral hypercalcemia of malignancy in this setting generally appears late in the disease, with nearly all patients having known, or readily evident, malignancy. These patients have elevated levels of serum calcium, low levels of serum phosphorus, and elevated levels of urinary cAMP, consistent with increased PTH activity but normal or low-serum PTH levels. The hypercalcemia is now known to be caused by PTH-related protein secreted by the tumor, rather than by the bony metastases that many of these patients have because of the advanced nature of their cancers. In the second group, accounting for one-fourth of cases, are patients with hematologic malignancies, such as multiple myeloma, certain lymphomas and leukemias, and a subset of the patients with breast cancer. These patients have elevated levels of serum calcium, but in contrast to most patients with solid tumors and humoral hypercalcemia of malignancy, they have elevated levels of serum phosphate and low levels of urinary cAMP. These patients always have lytic bony lesions and histologically demonstrate increased osteoclast bone resorption adjacent to tumor cells. This osteoclast-activating activity is an effect of cytokines, mainly interleukin-1 beta and tumor necrosis factor-beta (lymphotoxin). These cytokines promote local net bone resorption and thus produce hypercalcemia and hyperphosphatemia.

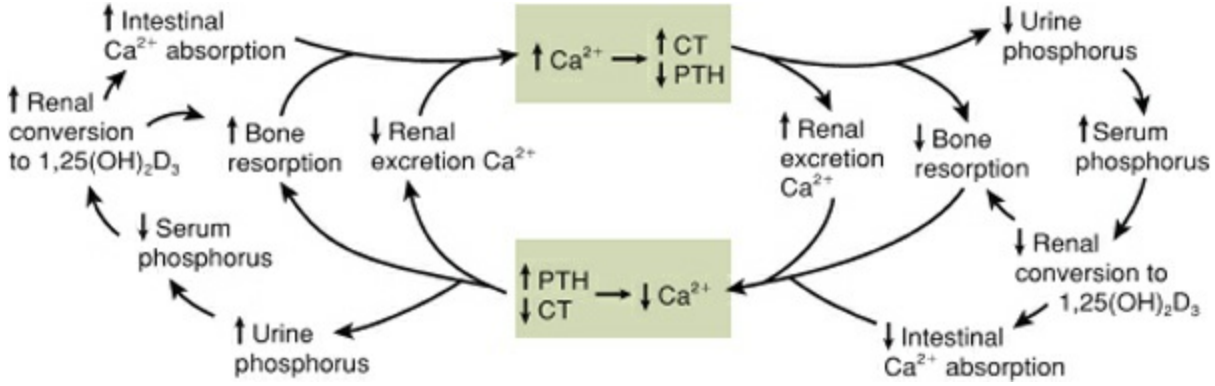

Figure 76-7. Feedback loops involved in the regulation of serum calcium and phosphorus. PTH, parathyroid hormone; CT, calcitonin.

Table 76-2 Clinical Features of Hypercalcemia

Neurologic
- Lethargy
- Confusion
- Coma
- Headache
- Depression
- Paranoia
- Muscle weakness
- Hyporeflexia
- Incontinence
- Memory loss
- Hearing loss
- Ataxia

Gastrointestinal
- Constipation
- Anorexia
- Nausea and vomiting
- Polydipsia
- Weight loss
- Pancreatitis
- Peptic ulcer
- Abdominal pain

Cardiovascular
- Electrocardiogram changes (short QT interval, widened T-wave)
- Bradycardia
- Heart block
- Hypertension

Renal
- Polyuria
- Uremia
- Renal colic
- Nephrocalcinosis

Other
- Band keratopathy
- Conjunctivitis
- Change in vision
- Pruritus
- Thrombosis
- Myalgia

Vitamin D and Vitamin A Intoxication

When administered in excess, vitamins A and D can produce hypercalcemia. Affected patients tend to have normal or elevated serum phosphate levels associated with a low PTH level. Metastatic calcification may occur.

Thiazide Diuretics

Thiazides may increase serum calcium levels to a mild degree, primarily through hemoconcentration and decreased renal excretion. Serum phosphate may also be depressed. It often takes several weeks for the hypercalcemia to resolve after the medication is discontinued.

Hyperthyroidism

Hyperthyroidism is associated with increased bone resorption. Often, the plasma PTH is low, and a history of other thyrotoxic symptoms can be elicited. The hypercalcemia usually resolves as the patient becomes euthyroid.

Milk–Alkali Syndrome

Typically, the milk–alkali syndrome occurs in patients with peptic ulcers who consume large quantities of milk and absorbable antacids. Usually, some degree of renal failure is present. PTH levels are low. This syndrome has become much less common with the increased use of nonabsorbable antacids, histamine 2-receptor antagonists, and proton

pump inhibitors as therapy for peptic ulcer disease.

Table 76-3 Causes of Hypercalcemia

- Hyperparathyroidism
- Malignancy
- Vitamin A or D intoxication
- Thiazide diuretics
- Hyperthyroidism
- Milk–alkali syndrome
- Sarcoidosis and other granulomatous diseases
- Familial hypocalciuric hypercalcemia
- Immobilization
- Paget disease
- Lithium therapy
- Addisonian crisis
- Idiopathic hypercalcemia of infancy

Sarcoidosis and Other Granulomatous Diseases

These syndromes are associated with hypersensitivity to vitamin D. The granulomas can convert inactive vitamin D to its active form. Patients have elevated plasma globulins and low PTH levels. The administration of large doses of corticosteroids for 10 days usually reduces the hypercalcemia. Biopsy of lymph nodes or the liver may confirm the diagnosis.

Familial Hypocalciuric Hypercalcemia

This disease is an asymptomatic, autosomal dominant condition characterized by mild to moderate hypercalcemia, hypocalciuria, and normal or only slightly elevated PTH levels. It develops in people heterozygous for a mutation in the calcium-sensing receptor.[8–10] The mutation causes an increase in the set point for extracellular calcium concentration, so that the "normal" calcium level is higher in these people than in the normal population. No treatment is necessary, although people with this disease should receive genetic counseling. Neonatal severe hyperparathyroidism, which can be fatal, develops in children homozygous for mutations in this receptor. Treatment for neonates with this disease is controversial, but they appear to benefit from early surgical management.

Immobilization

Immobilization produces hypercalcemia by increasing the ratio of bone resorption to bone formation. These patients can usually be distinguished by history, although on laboratory evaluation they have elevated serum levels of calcium and phosphate and a decreased serum concentration of PTH. Often, hypercalciuria is present, which may lead to the development of renal stones. Treatment is early mobilization and forced diuresis.

Other Causes

A variety of other diseases may produce hypercalcemia. For example, Paget disease (osteitis deformans) typically causes mild elevations in serum calcium. Paget disease can be diagnosed on the basis of the characteristic radiographic lesion. Adrenal insufficiency may be associated with hypercalcemia, although the symptoms are typically those of the primary abnormality. Lithium therapy appears to produce hypercalcemia by altering the parathyroid set point for inhibition by calcium, and, over long courses of therapy, may also be associated with hyperparathyroidism. Idiopathic hypercalcemia of infancy is a rare disorder that is probably the result of hypersensitivity to vitamin D. It occurs in infants with mental retardation and is satisfactorily treated with glucocorticoids. Other causes include aluminum-induced renal osteomalacia and a host of analytic errors related to improper specimen collection with prolonged tourniquet times, tube contamination, and instrument drift.

Medical Treatment

Although the choice of therapy is tailored to the cause of the hypercalcemia, several general measures can prove effective.[11,12]

For the patient with mild hypercalcemia, a trial of a decrease in dietary calcium is indicated. A reduction in intake of milk and other dairy products is suggested, along with discontinuation of thiazide diuretics and vitamin D preparations. Mobilization prevents bone demineralization.

Patients with more marked hypercalcemia or severe symptoms should be admitted to the hospital for treatment, with careful observation and monitoring. In the patient with severe hyperparathyroidism, although the definitive therapy is surgical, it is unwise to proceed with neck exploration until the calcium has been reduced to near-normal levels. The mainstay of therapy is intravenous hydration, preferably with normal saline solution in sufficient quantities to maintain the urine output above 100 mL/hr. These patients are often dehydrated before therapy, and fluid can be administered intravenously at a rate of 200 mL/hr. Caution must be exercised in older patients, whose cardiac reserve may be marginal. This therapy exploits the parallel handling of calcium and sodium by the kidneys. The diuretic furosemide also increases sodium and calcium excretion but should not be used until the patient is well hydrated.

The end points of therapy are a decrease in the serum calcium level and a reduction of symptoms. Diuresis with saline solution is usually effective when the hypercalcemia results from hyperparathyroidism or a benign cause. In contrast, the hypercalcemia of malignancy may produce severe symptoms associated with extremely high serum calcium levels that are difficult to control. In this setting, a variety of other measures may be considered (Table 76-4). Some of the agents used to treat hypercalcemia cause significant toxicity, and close patient monitoring is required during treatment. Calcitonin is a fairly weak hypocalcemic agent, but it acts rapidly and is associated with less toxicity than many of the other drugs.[12] Salmon calcitonin is the most potent preparation. Treatment with glucocorticoids is particularly efficacious in patients with sarcoidosis and other granulomatous diseases. Plicamycin has proved useful in patients with hypercalcemia of malignancy, but it causes a cumulative toxicity (thrombocytopenia, hepatotoxicity, and nephrotoxicity). Bisphosphonates inhibit osteoclast activity directly. These agents are administered orally or parenterally and are particularly efficacious, although long-term use may be associated with significant osteomalacia.[7] Prostaglandin synthetase inhibitors were initially considered useful, but their efficacy has proved to be limited. Intravenous phosphates and chelating agents have largely been abandoned because of their severe toxicity; however, oral phosphates may be beneficial in patients requiring prolonged therapy.

HYPOCALCEMIA

Hypocalcemia can occur as a consequence of various acquired and hereditary diseases.[13] Generally, these disorders produce a deficiency or defect in the action of either PTH or vitamin D. It is most commonly a significant clinical problem after neck operation for thyroid disease. Chronic vitamin D deficiency is associated with compensatory PTH excess. The end result is rickets in children or osteomalacia in adults.

TREATMENT

Table 76-4 Treatment of Hypercalcemia

Therapy of Primary Disease
■ Tumor resection (hypercalcemia of malignancy)
■ Parathyroidectomy (primary hyperparathyroidism)
Expansion of extracellular volume
■ Infusion of saline solution
■ Enhancement of urinary calcium excretion
■ Extracellular volume expansion
■ Loop diuretics (furosemide and ethacrynic acid)
Inhibition of Bone Resorption
■ Calcitonin
■ Glucocorticoids
■ Plicamycin (mithramycin)
■ Bisphosphonates
■ Gallium nitrate
Reduction of Intestinal Calcium Absorption
■ Low-calcium diet
■ Glucocorticoids
Other Treatments
■ Dialysis
■ Mobilization
■ Oral phosphate
■ Estrogens or progestogens (postmenopausal women with primary hyperparathyroidism)
■ Chloroquine (sarcoidosis)

Modified from Attie MF. Treatment of hypercalcemia. *Endocrinol Metab Clin North Am* 1989;18(3):807–828.

Clinical Features

The major signs and symptoms of hypocalcemia are a direct consequence of the reduction in plasma levels of ionized calcium, which increases neuromuscular excitability (Table 76-5). The earliest clinical manifestations are numbness and tingling in the circumoral area, fingers, and toes. Mental symptoms are also common. Patients become anxious, depressed, and occasionally confused. Tetany may develop, characterized by carpopedal spasm, tonic–clonic convulsions, and laryngeal stridor. The magnitude of symptoms at any given plasma concentration of ionized calcium varies from patient to patient. On physical examination, contraction of the facial muscles is elicited by tapping anterior to the ear, over the facial nerve (Chvostek sign), although this sign may be present in 10% of normocalcemic patients. Trousseau sign is elicited by occluding blood flow to the forearm for 3 minutes. The development of carpal spasm indicates hypocalcemia, although the test is unpleasant and clinically impractical.

Etiology

Some of the causes of hypocalcemia are listed in Table 76-6. The most common cause of hypocalcemia by far is excision of or damage to the parathyroid glands during thyroid surgery.

Postoperative Hypoparathyroidism

Postoperative hypoparathyroidism commonly develops after total thyroidectomy.[13,14] Most patients undergoing operation on the thyroid experience some alteration in serum calcium, although they often are asymptomatic; the low calcium probably represents contusion or temporary alteration of the blood supply to the parathyroid glands. The hypocalcemia is usually transient and is not treated unless significant symptoms develop. Occasionally, in hyperparathyroid patients who have parathyroidectomy and significant bone disease, a marked skeletal deposition of calcium and symptomatic hypocalcemia occurs, the so-called *bone hunger*. The plasma calcium usually reaches its nadir at 48 to 72 hours after surgery and then slowly returns to normal within several days. These patients may require calcium and vitamin D therapy for weeks or months after parathyroidectomy.

Table 76-5 Clinical Features of Hypocalcemia

Neurologic
■ Circumoral paresthesia
■ Light-headedness
■ Depression
■ Anxiety
■ Confusion
■ Chvostek sign
■ Trousseau sign
■ Irritability
■ Laryngeal spasm
■ Seizures
Musculoskeletal
■ Tetany
■ Cramps
■ Involuntary twitching
■ Osteomalacia
Cardiovascular
■ Electrocardiogram changes (prolonged QT interval, T-wave peaking)
■ Arrhythmia
■ Tachycardia, hypotension
Other Features
■ Lenticular cataracts

Idiopathic Hypoparathyroidism

A less common form of hypoparathyroidism is idiopathic lack of function. It occurs both sporadically and in families. In some cases, it develops as part of a polyglandular disorder and is thought to have an autoimmune basis. DiGeorge syndrome is a group of congenital disorders involving the branchial pouches that produce partial or complete agenesis of the thymus and parathyroid glands. Hypoparathyroidism can also develop in newborns as a result of prenatal suppression of the fetal parathyroid glands as a consequence of maternal hypercalcemia.[15] It is also common in otherwise normal but premature infants.

Table 76-6 Causes of Hypocalcemia

- Hypoparathyroidism
- Vitamin D deficiency
- Pseudohypoparathyroidism
- Hypomagnesemia
- Malabsorption
- Pancreatitis
- Hypoalbuminemia
- Chelation of calcium
- Osteoblastic metastases
- Toxic shock syndrome
- Hyperphosphatemia

Vitamin D Deficiency

Vitamin D deficiency can occur as a result of dietary deficiency or lack of sun exposure. Likewise, renal disease produces a decrease in the 1-hydroxylase activity necessary for the formation of active vitamin D. The result is a decrease in calcium absorption and an increased secretion of PTH by the stimulated parathyroid glands. Osteomalacia, abnormal fractures, and the deformities of rickets may result.

Pseudohypoparathyroidism

Pseudohypoparathyroidism is a familial disease characterized by a rotund appearance, shortening of the extremities, and sometimes mental deficiency. The defect is not in PTH secretion; in fact, most patients have elevated plasma levels of PTH with evidence of increased bone resorption. Rather, the kidney is unresponsive to the hormone, and as a consequence, hypocalcemia and hyperphosphatemia develop. The deficit appears to be in the renal adenyl cyclase system.

Hypomagnesemia

This unusual deficit may result from chronic alcoholism, malabsorption, parenteral nutrition, or increased renal clearance during therapy with aminoglycosides. The deficit appears to block the physical response to PTH in addition to its release from the parathyroid gland.

Other Causes

In short-gut syndrome, after extensive small-bowel resection or bypass, or after some forms of bariatric surgery, vitamin D and calcium may be absorbed in insufficient quantities. In pancreatitis, the massive soft tissue destruction and saponification that occur with hemorrhagic disease may sequester significant amounts of calcium in the retroperitoneum. Some undefined systemic factor also appears to contribute to hypocalcemia in these patients. Hypoalbuminemia causes a reduction in the total plasma calcium level, although the level of ionized calcium remains within the normal range and patients are asymptomatic. Circulatory substances, such as the citrate used to anticoagulate banked blood and radiographic contrast media, may bind to calcium. In patients with osteoblastic metastases, particularly associated with prostate carcinoma, hypocalcemia has been attributed to increased calcium flux into the lesions. Toxic shock syndrome is sometimes associated with hypocalcemia, but the mechanism has not been defined. Acute hyperphosphatemia, as a consequence of exogenous administration of phosphate or during the cytolytic chemotherapy of highly responsive tumors (e.g., Burkitt lymphoma and acute lymphoblastic leukemia), may produce symptomatic hypocalcemia associated with soft tissue calcification.

Treatment

The treatment of hypocalcemia is summarized in Table 76-7. For acute symptomatic hypocalcemia, calcium should be administered intravenously. Calcium gluconate is less irritating to the veins than calcium chloride, and the calcium release is slower, without a risk for overcorrection. Usually, 20 to 30 mL of 10% solution is infused over a 15- to 20-minute period, and then 50 to 100 mL is administered over the next 12 hours in adults. A practical guide after an initial bolus dose includes 60 mL of 10% calcium gluconate in a 500-mL bag of dextrose 5% in water, infused at 1 mL/kg/hr, and adjusted every 4 hours based on the serum level of calcium and patient symptoms. Bicarbonate precipitates any calcium infused through the same intravenous line. Serum magnesium should always be measured, and hypomagnesemia should be corrected if present. In patients with convulsions from advanced tetany, diphenylhydantoin therapy is useful, but symptoms should never be allowed to progress to this point.

Table 76-7 Treatment of Hypocalcemia

Symptom or Goal	Treatment
Symptomatic hypocalcemia	Oral calcium carbonate or intravenous calcium gluconate, and possibly vitamin D supplements to increase the efficiency of absorption of oral supplements
Symptomatic tetany	Intravenous calcium gluconate
Correction of hypomagnesemia	Intravenous magnesium chloride
Vitamin D supplementation	Ergocalciferol, calcifediol (liver disease), calcitriol (renal disease)
Long-term therapy	Calcium carbonate; low-phosphate, low-oxalate diet; parathyroid grafting (immunosuppressed or cryopreserved autograft)

Long-term therapy is gauged on the basis of symptoms. In the postoperative patient, the continued stimulus of mild hypocalcemia to any remaining parathyroid gland tissue may prove useful. Concomitant therapy with calcium and vitamin D is effective in a timely fashion. A starting dose of 2 g of oral calcium carbonate per day in divided doses is usually well tolerated. Vitamin D can be administered as calcitriol, an active synthetic vitamin D analog. Most adults respond to a dose of 0.5 to 1.0 mcg/day; reduced doses may be necessary for patients with renal dysfunction.

HYPERPARATHYROIDISM

Definitions

Parathyroid neoplasms are rarely identified by physical enlargement but rather are sought because of the peripheral effects of excess hormone. Primary hyperparathyroidism develops spontaneously, without apparent cause but possibly in response to exogenous stimuli. When the normal control of serum calcium is disturbed and the autonomous production of PTH is increased, the state is referred to as *primary hyperparathyroidism.* This category includes both benign single- and multiple-gland enlargements and the much rarer parathyroid carcinoma. In some cases, the disease is familial. In contrast, *secondary hyperparathyroidism* occurs when a defect in mineral homeostasis leads to a compensatory increase in parathyroid function. This occurs most commonly in response to renal disease but may also develop as a consequence of the hypocalcemia associated with some diseases of the gastrointestinal tract, bones, or other endocrine organs. Occasionally, with prolonged secondary stimulation, the hyperfunctioning glands are no longer physiologically responsive to an increase in ionized calcium. This uncommon (affecting about 2% of patients after renal transplantation), relatively autonomous state referred to as *tertiary hyperparathyroidism,* develops most commonly after renal transplantation when the renal defect in calcium homeostasis is corrected.

Incidence

The advent in the 1970s of the widespread assessment of serum calcium as part of automated multichannel analysis has considerably altered our understanding of hyperparathyroidism. Before that time, primary hyperparathyroidism was thought to be a relatively rare condition. Most patients presented with symptoms of disease, usually renal stones or bony manifestations. Currently, most patients are asymptomatic or have only vague symptoms or signs that can be related to hyperparathyroidism.[16,17] Occasionally, patients recognize that they had symptoms only after their well-being improves following parathyroidectomy. Incidence varies with both age and gender (Table 76-8), but hyperparathyroidism is believed to develop in about 50 to 100 people per 100,000 in the general population, with approximately 50,000 new cases occurring annually in the United States.[18] Marked variations have been noted worldwide; the reasons for these differences remain unclear.

Table 76-8 Age-Specific and Gender-Specific Incidence of Primary Hyperparathyroidism

	New Cases Per 100,000	
Age (yrs)	Men	Women
<39	5	8
40–50	26	104
>60	92	189
Total	18	56

Adapted from Heath H III, Hodgson SF, Kennedy MA. Primary hyperthyroidism: incidence, morbidity, and potential economic impact in a community. *N Engl J Med* 1980;302:189.

Etiology

The cause of primary hyperparathyroidism is not known. Although the sequence of progression from secondary to tertiary disease in response to chronic stimulation has a logical appeal, it is difficult to draw parallels with primary disease. Most patients with primary hyperparathyroidism have disease of a single rather than of multiple glands, which is not what might be predicted if an external stimulus were part of the pathophysiology. Hyperparathyroidism is most common in postmenopausal women, the population group with the highest incidence of osteoporosis and the most significant alterations in calcium and phosphate metabolism. Loss of renal function with aging is associated with elevations in PTH and decreases in phosphate clearance. It has been suggested but not demonstrated that a renal calcium leak, if sufficient, might result in a chronic calcium deficit stimulating the parathyroid glands.

Genetic studies of parathyroid adenomas have described an oncogene (*PRAD1*) that may be one step in the path to neoplasia in these tumors. Overexpression of the normal *PRAD1* gene, also known as *cyclin D1,* allows progression of the cell cycle from the G1 phase to the S phase, thus promoting cellular growth and division. *PRAD1* is overexpressed in 20% to 40% of parathyroid adenomas; further research may reveal other genetic alterations that contribute to the neoplastic growth. The *MEN1* tumor-suppressor gene has also been implicated in the molecular pathogenesis of sporadic hyperparathyroidism. About 15% to 20% of sporadic parathyroid adenomas have either somatic mutation or biallelic deletion of the *MEN1* gene.[19,20]

Hyperparathyroidism occurs in several familial forms. It is a major component of the multiple endocrine neoplasia (MEN) syndromes types 1 and 2A. The parathyroid disease of MEN-1 syndrome is multiple parathyroid adenomas that appear with increasing frequency over the patient's lifetime.[21] In other families, hyperparathyroidism is inherited in an autosomal dominant fashion without other manifestations of MEN-1 or MEN-2; some have osseous abnormalities (tumor–jaw syndrome) and some apparently have isolated disease.

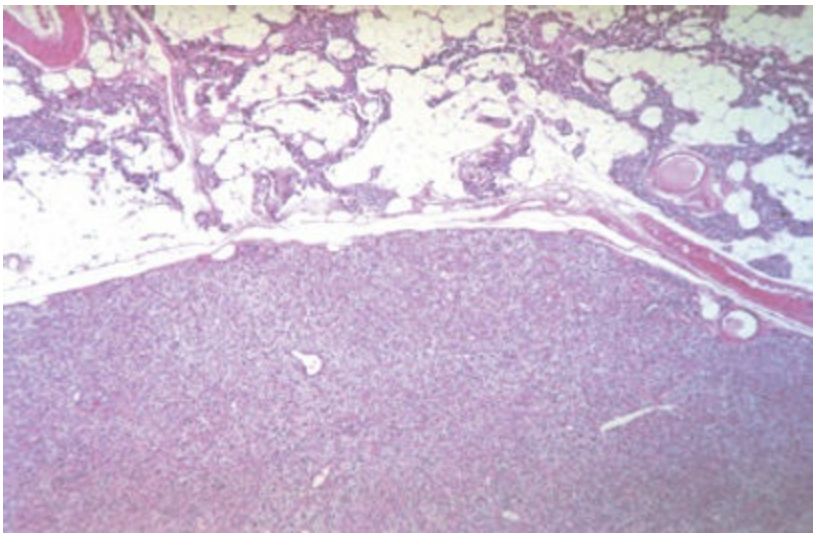

Figure 76-8. Parathyroid adenoma. The tumor consists of sheets of neoplastic chief cells and is separated from normal parenchyma by a thin capsule.

Pathology

Single-Gland Versus Multiple-Gland Disease

Microscopically, the cell most commonly involved in primary hyperparathyroidism is the chief cell. Less frequently, the oxyphil cell is the predominant cell type. Diseased glands typically have an increase in the proportion of stromal cells and a reduction in the proportion of stromal fat. Single diseased glands, or adenomas, have been classically described with a predominance of chief cells centering in a single focus, with a compressed rim of surrounding normal tissue (Fig. 76-8). In contrast, parathyroid hyperplasia has been characterized as a diffuse proliferation of clear cells in multiple glands, with little remaining normal tissue (Fig. 76-9). These criteria have proved totally unreliable. Although pathologic studies can usually distinguish parathyroid glands from other tissue, they may not prove useful beyond this capacity. Intraoperative decisions frequently depend on recognizing disease of one or more parathyroid glands, and in this regard, the histologic description of adenoma or hyperplasia is generally unreliable in primary hyperparathyroidism.[22]

Patients with multiple-gland disease may have one gland that appears to be an adenoma and another that appears diffusely involved or even histologically normal with gross enlargement. The most reliable index of abnormality is the determination of glandular enlargement by visual inspection. The incidence of single- and multiple-gland enlargement as judged by visual inspection in 66 consecutive patients with hyperparathyroidism is shown in Table 76-9. The visual assessment and judgment of the experienced surgeon have proved to be an effective basis for intraoperative decisions. This approach requires that all four parathyroid glands be evaluated at the time of operation. However, the recent ability to rapidly measure PTH during operation has provided a method to assess gland function rather than size. This experience indicates that there may be more enlarged glands than there are hyperfunctioning glands.[23]

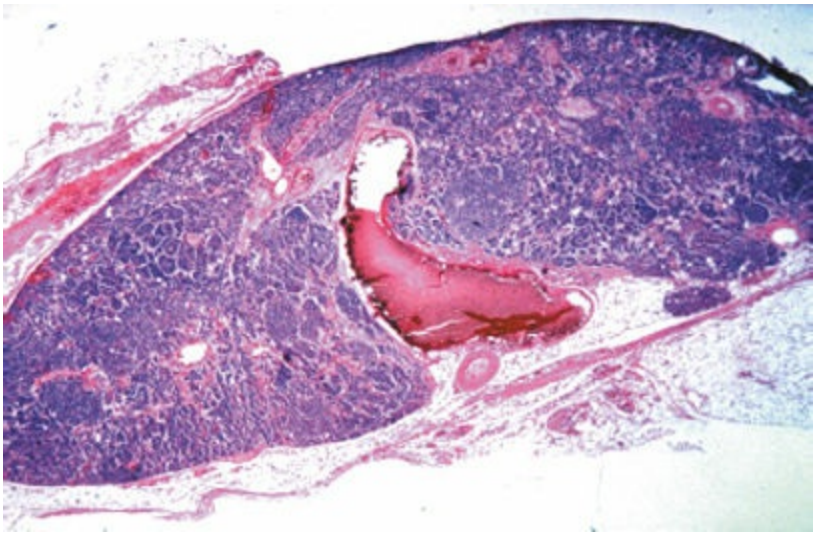

Figure 76-9. Primary parathyroid hyperplasia. The normal adipose tissue of the gland has been replaced by sheets and trabeculae of hyperplastic chief cells.

Table 76-9 Gland Enlargement in 1,002 Consecutive Patients with Primary Hyperparathyroidism

Pathology	Patient, *n*	Percentage
Adenoma	788	78%
Double adenoma	98	9.8%
Hyperplasia	116	11.6%

From Hughes DT, Miller BS, Park PB, Cohen MS, et al. Factors in conversion from minimally invasive parathyroidectomy to bilateral parathyroid exploration for primary hyperparathyroidism. *Surgery* 2013;154(6):1428–1434.

Carcinoma

Parathyroid carcinoma is a rare entity, and the histologic diagnosis can be exceedingly difficult. The surgeon may suspect the diagnosis when dense invasion and scarring are encountered, although this may also be secondary to some other inflammatory disease in the neck. Pathologic criteria include marked mitotic activity, dense fibrous stroma, and evidence of local invasion into the capsule or surrounding vessels.[24] Malignant-appearing tumors, however, may pursue an apparently benign clinical course; the converse is less frequently true. The only reliable criteria of malignancy are metastases, most commonly to the lymph nodes, lung, or liver, and true local invasion.

Systemic Effects

The use of automated technology for determining serum calcium has changed not only the estimated incidence of hyperparathyroidism but also the usual mode of presentation. Before screening, three-fourths of patients presented with renal disease, particularly nephrolithiasis; one-third to one-half had skeletal manifestations, and rare patients had both. Most recent series suggest that at least half of the patients in whom hyperparathyroidism is diagnosed do not have renal or osseous disease and many are minimally symptomatic or asymptomatic. Manifestations of the disease are protean but generally nonspecific, and they may be difficult to elicit in the history. A significant proportion of patients present without a readily quantifiable index of disease severity. This finding has created some controversy about the need for surgery in the asymptomatic patient and particularly for the elderly or high-risk patient.[18,25]

The earliest complaints are often the vague symptoms of hypercalcemia. These vary with the magnitude of plasma calcium elevation and can include muscle weakness, anorexia, nausea, constipation, polyuria, and polydipsia. These nonspecific symptoms may or may not cause the patient to seek medical attention. Some symptomatic patients have evidence of chronic disease involving the kidney or skeleton. Usually, only one of these systems is significantly involved in any individual patient. The treatment of hyperparathyroidism is designed to eliminate or halt the progression of the complications of the disease. Symptomatic patients can be divided into two groups. Members of the first group have renal manifestations, a slower onset of symptoms, and generally lower serum calcium concentrations. Patients in the second group have a more rapid onset of symptoms, higher serum calcium levels, and significant bone disease. No recognizable histologic or physiologic characteristics distinguish patients with renal disease from those with bone disease.



Figure 76-10. Abdominal film demonstrating nephrocalcinosis, or diffuse calcification of the renal parenchyma (*arrows*).

Renal Manifestations

Renal complications develop because the hypercalcemia leads to an increase in urinary calcium excretion and because PTH increases the excretion of phosphate and produces urinary alkalosis. Both these events predispose to stone formation. Urinary stones can be treated surgically or with lithotripsy, and subsequent definitive treatment of the hyperparathyroidism reduces the rate of reformation. Of patients who present for the first time with renal colic, 5% to 10% are found to have primary hyperparathyroidism. Nephrocalcinosis (Fig. 76-10) is calcification of the renal parenchyma and occurs in 5% to 10% of patients with hyperparathyroidism. It causes more significant renal damage than nephrolithiasis does. In general, the more severe the renal damage, the less likely it is that nephrocalcinosis will regress after parathyroidectomy.

The incidence of hypertension in hyperparathyroidism increases with the degree of renal impairment. Hypertension may be a significant cause of the morbidity associated with hyperparathyroidism, but although a decrease in blood pressure has been demonstrated in some patients after parathyroidectomy, the correlation between the two conditions is not clear.

Skeletal Manifestations

Parathyroid bone disease in its most classic and severe form, osteitis fibrosa cystica, is seldom encountered; however, 5% to 15% of patients with parathyroid bone disease present with significant symptoms of skeletal disease. Most commonly, these symptoms include bone pain and pathologic fractures.

Bone changes are often demonstrable on detailed plain radiographs of the hands (Fig.

76-11). Characteristically, subperiosteal resorption is evident on the radial aspect of the middle phalanx of the second or third finger. Because of tufting of the distal phalanges, clubbing may be evident on physical examination. Other findings that typically involve the skull and long bones include bone cysts, “brown” tumors (i.e., localized proliferations of osteoclasts), and diffuse demineralization or granularity. More subtle bone loss can be detected by iliac crest bone biopsy or dual energy x-ray absorptiometry scan. The risk of bone fracture increases with increasing severity of bone loss.



Figure 76-11. Magnification radiograph of the fingers in hyperparathyroidism. Subperiosteal cortical resorption (*arrows*) typically is most visible on the radial aspect of the middle phalanges.

Gastrointestinal Manifestations

Hypercalcemia is clearly associated with nonspecific gastrointestinal complaints, including nausea, vomiting, constipation, and anorexia, but attempts to demonstrate a definite relation between hyperparathyroidism and either peptic ulcer disease or pancreatitis remain unconvincing. Hypercalcemia stimulates gastric acid secretion experimentally and clinically, and has been associated with pancreatitis. Therefore, a theoretic rationale for the complex of hyperparathyroidism and gastrointestinal symptoms does exist.

Neuromuscular Manifestations

Neurologic and muscular complaints are those of hypercalcemia in general. Fatigability

and proximal muscle weakness are among the most debilitating manifestations. Atrophy of type II muscle fibers, consistent with a neuropathic and not a myopathic cause, has been demonstrated. Sensory complaints include dysesthesia, a reduced vibratory sense, and stocking–glove sensory deficits.

Psychological Manifestations

The emotional disturbances of hyperparathyroidism are often subtle and difficult to quantify. As with other forms of hypercalcemia, they range from depression or anxiety to psychosis and coma. Patients undergoing parathyroidectomy frequently experience a sense of well-being and relief from fatigue and dullness postoperatively, even if they may have had no noticeable complaints preoperatively.

Other Manifestations

A variety of signs and symptoms of soft tissue calcification have been described. Nonspecific arthralgia, particularly involving the proximal interphalangeal joints of the hands, is characteristic. The incidence of chondrocalcinosis is increased. Pruritus, vascular and cardiac calcification, and band keratopathy of the cornea have all been noted. Some reports have suggested an increased risk of malignancy and coronary artery disease, but the effects remain unsubstantiated, and it is not clear if the mortality risk is modifiable by correction of hyperparathyroidism.[26–28]

Physical Findings

Except in patients with the classic deformities of advanced bone disease, the physical examination is seldom helpful. Diseased parathyroid glands are infrequently palpable, except in patients with parathyroid carcinoma. A mass in the anterior neck in a patient with primary hyperparathyroidism is most commonly a thyroid nodule.

Laboratory Findings

Tests for calcium, PTH, phosphate, bicarbonate, and magnesium, in addition to other laboratory tests, are useful to establish the diagnosis of hyperparathyroidism.

Calcium. Hypercalcemia is the single most important diagnostic finding; however, particularly in early or mild cases, serial analysis may show fluctuations in and out of the normal range. Coexistent hypoalbuminemia and acidosis may produce an apparently normal total serum level of calcium, even though the ionized fraction is actually elevated. Serum concentrations of ionized calcium may be helpful in the patient with intermittent or mild hypercalcemia.

3 Parathyroid Hormone. PTH measurement is an important method for establishing the diagnosis of hyperparathyroidism. Because of the heterogeneity of the various circulating forms of PTH, measurement of C-terminal or N-terminal fragments give conflicting and confusing results. Intact hormone assays and whole molecule assays are the most dependable. The demonstration of an elevated plasma PTH concentration alone does not

establish the diagnosis of hyperparathyroidism. With a simultaneous elevated serum calcium level, this finding is virtually diagnostic (Fig. 76-12).

Phosphate. PTH increases renal phosphate excretion and, in about half of patients, produces hypophosphatemia. In the presence of renal disease, however, the serum phosphate levels may be normal or significantly elevated.

Bicarbonate. PTH also increases bicarbonate excretion, so that a hyperchloremic metabolic acidosis may develop. It has been suggested that the finding of an elevated serum chloride-to-phosphate ratio may be helpful in the differential diagnosis of hypercalcemia. A ratio greater than 30 is considered highly suggestive of hyperparathyroidism.

Magnesium. Hypomagnesemia develops in 5% to 10% of patients with hyperparathyroidism. After parathyroidectomy, if both hypocalcemia and hypomagnesemia are present, it may be difficult to correct the calcium until the serum magnesium has been corrected.

Other Diagnostic Tests. A variety of special diagnostic tests for hyperparathyroidism are available. None is more specific than the measurement of serum concentrations of calcium and PTH, although they may be useful in equivocal cases. For example, the 24-hour urinary calcium excretion is usually elevated, but may be normal, in patients with hyperparathyroidism, although the finding is not specific for this disease. This test is helpful in identifying patients with familial hypercalcemic hypocalciuria, in whom the rate of urinary calcium excretion is low. Measurements of tubular reabsorption of phosphate below 30% suggest primary hyperparathyroidism. Urinary cAMP is generated specifically as a consequence of PTH activation of renal tubular adenyl cyclase. Increased urinary concentrations are identified in most patients with primary hyperparathyroidism. These measurements are rarely necessary because of the reliability of the intact PTH measurement.

Localization with Imaging Techniques

In order to try to simplify the operative approach to hyperparathyroidism, an attempt is usually made to localize enlarged glands preoperatively. In the hands of an experienced surgeon, the cure rate for hyperparathyroidism at the initial operation without preoperative localization exceeds 95% with the conventional full-neck exploration. However, technologic developments have led surgeons to pursue alternatives to the full-neck exploration. These innovations are increasingly accurate preoperative localization with ^{99m}technetium sestamibi scintigraphy, computed tomography scans with carefully timed intravenous contrast administration, or high-resolution ultrasound, combined with intraoperative intact PTH measurement that allows termination of the operation without visualization of all four parathyroid glands. Surgeons have used these technologies in various combinations to limit the extent of the neck exploration. All of the current

alternative strategies, however, depend on a preoperative parathyroid localization study to direct the exploration.

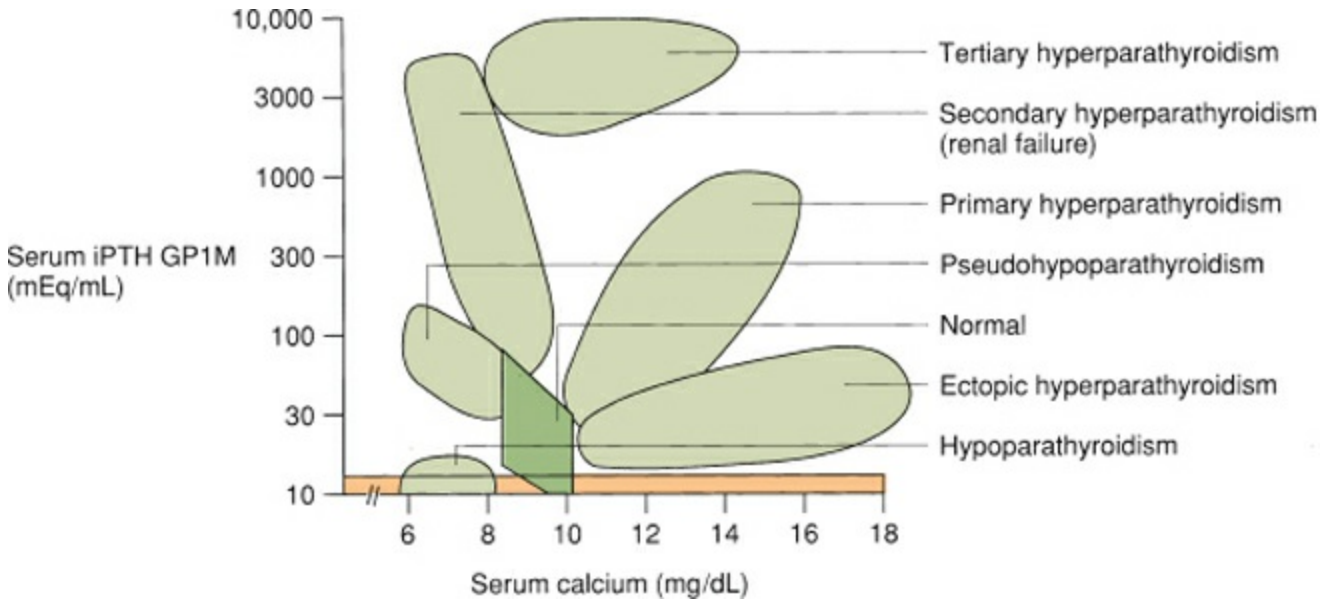

Figure 76-12. Relation between serum immunoreactive parathyroid hormone and serum calcium in patients with hypoparathyroidism, pseudohypoparathyroidism, ectopic hyperparathyroidism, and primary, secondary, and tertiary hyperparathyroidism. GP1M, guinea pig antiserum 1M.

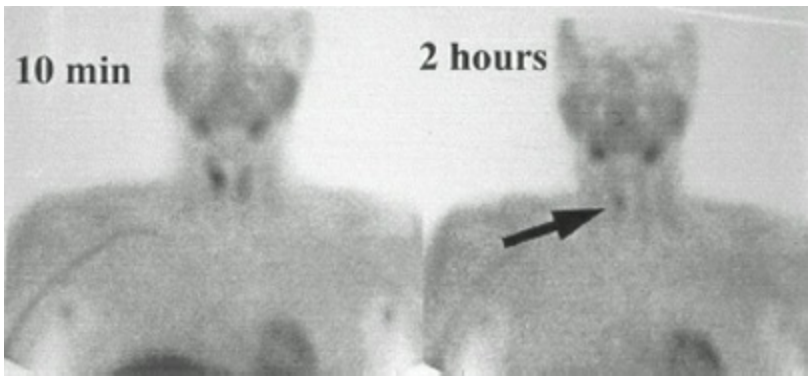

Figure 76-13. ^{99m}Technetium sestamibi scan of a patient with a parathyroid adenoma. The radionuclide is present in both thyroid and parathyroid tissues on the 10-minute film; however, by 2 hours, the radionuclide has washed out of the thyroid and remains only in the right-sided parathyroid gland. This scan shows a 794-mg right upper parathyroid adenoma (*arrow*).

The study most frequently used for imaging previously unoperated patients is ^{99m}technetium sestamibi scintigraphy (Fig. 76-13). Sestamibi scanning can identify the site of abnormal tissue in 75% to 80% of patients but has limitations in patients with small adenomas or multiple-gland disease. Sestamibi was originally developed for cardiac imaging. The use of a single nuclide with a short half-life and a high-energy profile has advantages in lateral, oblique, and three-dimensional imaging that technetium–thallium scanning, which was formerly used, does not provide.

High-resolution ultrasound examination of the neck is also used for localization of abnormal parathyroid tissue, particularly when it is available for use by the clinician. The current machines scan at high frequencies (10 to 13 MHz) that allow demonstration of

small abnormalities in the neck (Fig. 76-14). The examination is best done by a clinician in real time, as that allows the most complete assessment of the neck, rather than scans performed by a technician for later review of still pictures by the physician. The sensitivity of cervical ultrasound for abnormal parathyroid glands is about the same as for sestamibi scanning. Ultrasonography is an operator-dependent technique. It is rapid and relatively inexpensive and can direct fine-needle aspiration for cytologic confirmation and immunoassay for PTH.

In patients with persistent or recurrent hyperparathyroidism, preoperative imaging is important to guide the exploration. High-resolution real-time ultrasonography, computed tomography (CT), magnetic resonance imaging (MRI), and sestamibi scanning all appear to have comparable sensitivities of 50% to 60%. The results of these examinations may be less successful at centers without significant experience in their use.

Computed tomography is more expensive but less operator-dependent than ultrasonography. It clearly is superior in identifying deeper structures and for examining the retrosternal mediastinum. MRI is considerably more expensive than CT and has not been shown to be superior. Most surgeons prefer to have results of two or more imaging tests that confirm an abnormality before exploration in the reoperative setting.[29]

Treatment

Indications for Surgery

Generally, the only practical therapeutic option is surgery. Nephrolithiasis, bone disease, and neuromuscular symptoms all respond well to surgical intervention. In contrast, surgery in patients with renal failure, hypertension, and psychiatric symptoms is not so uniformly successful, although it benefits some patients and is usually indicated in all except those at highest risk. The question of how to manage the large group of patients with apparently asymptomatic disease requires particularly careful consideration.

Management of Asymptomatic Hyperparathyroidism

4 A large proportion of patients with the diagnosis of hyperparathyroidism are minimally symptomatic or asymptomatic. The appropriate treatment for these patients remains controversial. Although little evidence indicates that irreversible complications, such as renal failure, eventually develop in patients with asymptomatic mild disease, the natural history of the disease remains incompletely defined. Many of the manifestations of this disease may go unrecognized until they are corrected surgically. Still unanswered is the question of how much asymptomatic disease may contribute to generalized osteopenia in this predominantly postmenopausal female population.

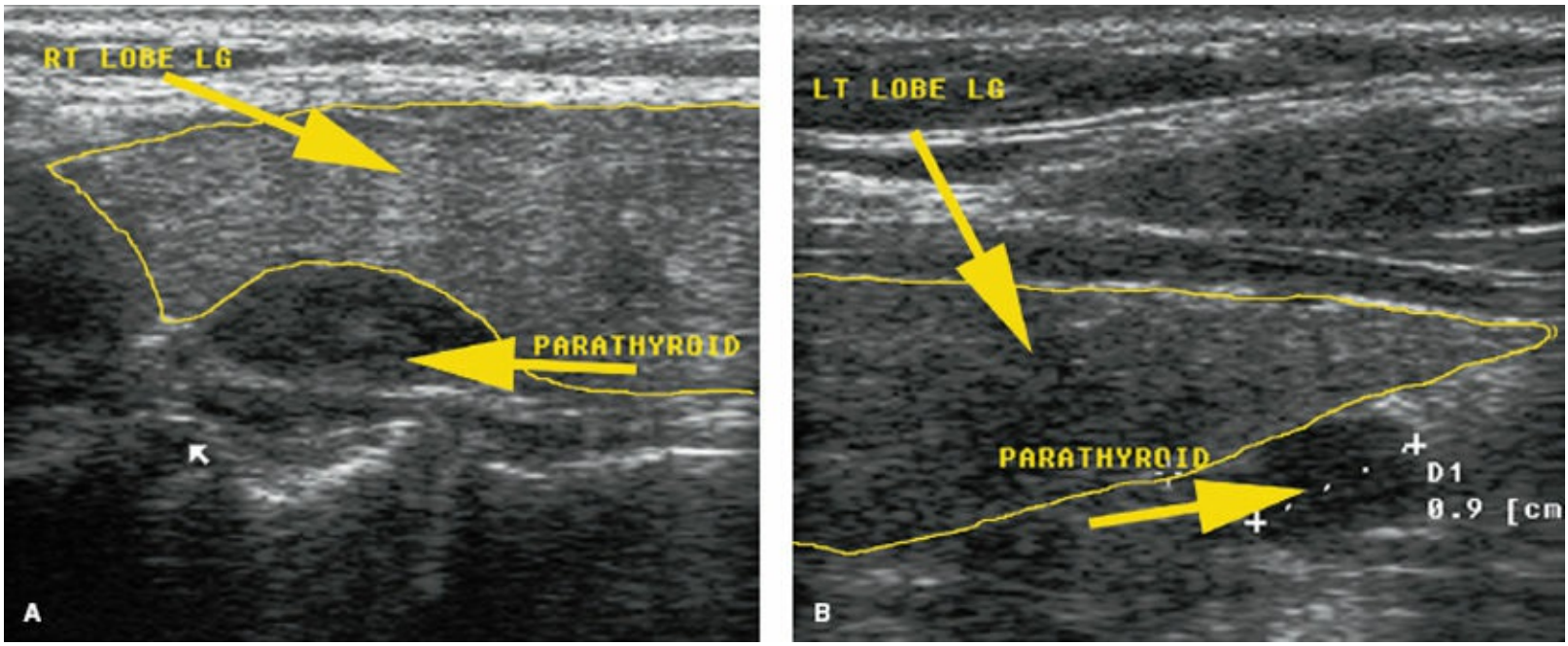

Figure 76-14. Ultrasound views of parathyroid adenomas. **A:** Sagittal image of the upper pole of the right lobe of the thyroid gland, demonstrating a hypoechoic parathyroid adenoma posterior to the thyroid parenchyma. **B:** Sagittal image of the lower pole of the left lobe of the thyroid gland with an adjacent hypoechoic parathyroid adenoma measuring 9 mm in greatest dimension.

Table 76-10 Indications/Contraindications

National Institutes of Health Consensus Development Conference's Indications for Surgical Intervention in Patients with Asymptomatic Primary Hyperparathyroidism

- Markedly elevated serum calcium (>1.0 mg/dL above normal)
- History of an episode of life-threatening hypercalcemia
- Reduced creatinine clearance
- Presence of one or more kidney stones detected by abdominal radiography
- Markedly elevated 24-hr urinary calcium excretion
- Substantially reduced bone mass as determined by direct measurement (dual energy x-ray absorptiometry T-score ≤2.5)

A recent report detailed the 15-year natural history of 116 patients with asymptomatic hyperparathyroidism.[18] Operation was recommended for those in whom symptoms or findings developed, according to the guidelines of the National Institutes of Health Consensus Conference (see later). During the monitoring period, 51% of the patients had operation, and biochemical normalization and increased bone mass were observed in those who underwent surgery. However, the patients who did not undergo operative correction continued to have biochemical abnormalities and the cortical bone mass fell significantly. These data confirm the impression of most clinicians that mild hyperparathyroidism rarely takes a precipitously worsening clinical course; however, the differential bone effects that are evident by 15 years call into question how long such patients can be monitored without correction.

In October 1990, a National Institutes of Health Consensus Development Conference reviewed the available evidence regarding the management of asymptomatic primary hyperparathyroidism.[30] After interval developments, a panel of experts reconvened in 2002, and revisited this issue.[31] The panel agreed that operation is the indicated treatment for all patients with symptoms; however, they recognized a subgroup of patients who have no symptoms attributable to hyperparathyroidism, and their conclusions included several indications for surgical intervention in these asymptomatic patients (Table 76-10).

The panel mandated close (every 6 months) follow-up for those patients not treated by operation. In addition, they recommended surgery for cases in which medical surveillance is neither desirable nor suitable, such as when a patient requests surgery, consistent follow-up is unlikely, coexistent illness complicates management, or a patient is younger than age 50 years.

This remains an area of considerable controversy, and subsequent reviews have supported similar plans with only minor revisions.[32,33] The complication rate of operation by an experienced surgeon is very low. Within a short period, the financial cost of medical follow-up exceeds that of treatment by operation. Based on these considerations, most patients should undergo operation, and those who do not must be closely followed.

Principles of Surgical Correction

Although neck exploration for hyperparathyroidism may be straightforward, it sometimes becomes an arduous procedure requiring considerable patience because of the variability in both the location and the number of diseased glands. Persistent hyperparathyroidism and the necessity for reexploration can usually be avoided by a meticulous initial procedure. Reoperation is predictably more difficult than the initial operation, and the risks for damage to the recurrent laryngeal nerves and hypoparathyroidism are greater during reoperation.

It is essential that the surgeon be confident of the preoperative diagnosis and prospectively discuss the procedure with the patient. The potential complications of damage to either the recurrent laryngeal nerve or the superior laryngeal nerve and the development of hypocalcemia require discussion. Likewise, the possibility of an unsuccessful initial operation must be explained, and the patient should recognize that reexploration, including median sternotomy, may be required. Although alternatives to full-neck exploration are often now applied, no patient should be explored by a surgeon who is unfamiliar with the principles and techniques of the conventional full-neck exploration.

For a full-neck exploration, the patient is placed under general anesthesia with a roll beneath the shoulders and the neck extended. The neck is opened through a transverse incision overlying the thyroid isthmus, and the platysma is similarly divided. Superior and inferior flaps are developed. The strap muscles are separated in the midline and retracted laterally; division is unnecessary. One lobe of the thyroid is chosen and rotated medially. Important landmarks include the tracheoesophageal groove, the recurrent laryngeal nerve, the inferior and superior thyroid arteries, and the middle thyroid vein (Fig. 76-15). In most patients, the nerve lies in the tracheoesophageal groove or just laterally. Occasionally, it may be situated more anteriorly. Uncommonly, it may originate directly from the vagus without passing around the right subclavian artery. Both of these latter variations make the recurrent nerve more susceptible to injury. The external branch of the superior laryngeal nerve, which innervates the cricothyroid muscle, usually lies medial to the superior thyroid vessels and should be carefully preserved.

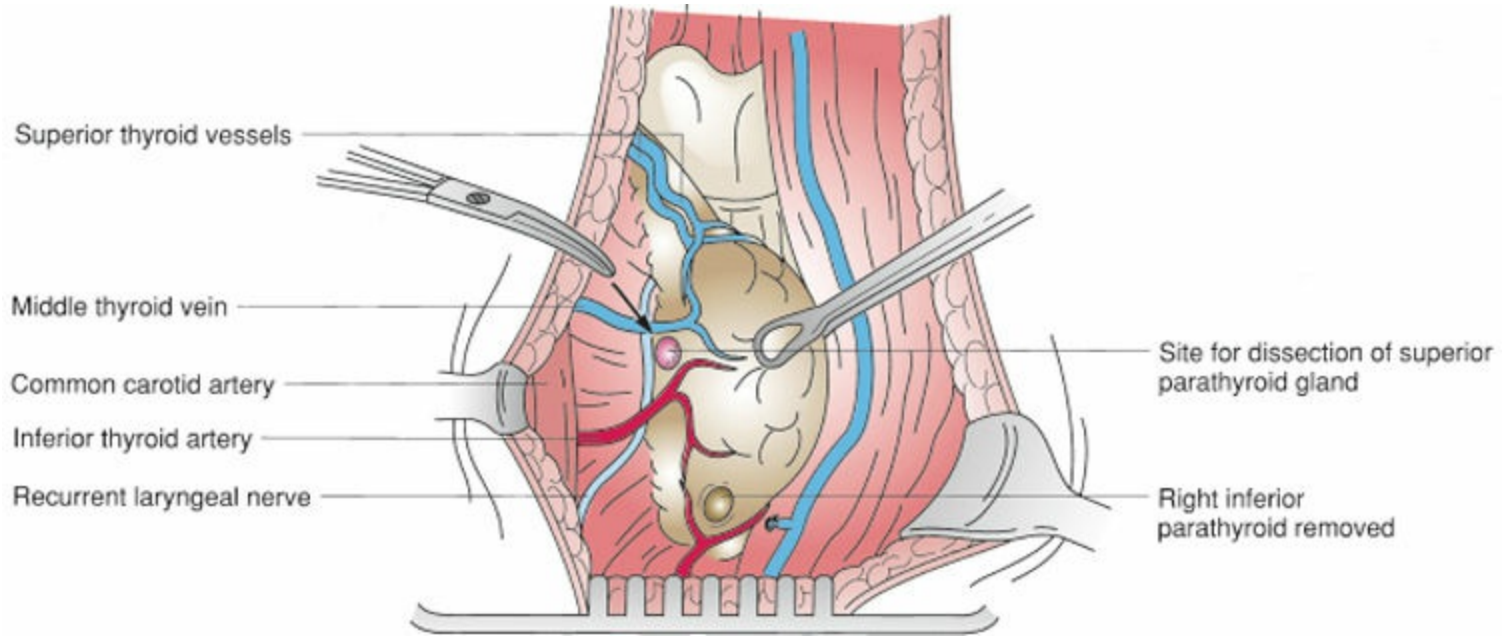

Figure 76-15. Lateral view of the right side of the neck after rotation of the thyroid lobe. The important anatomic landmarks are emphasized.

For a full-neck exploration, all four glands should be identified at the initial exploration because of the possibility of multiple-gland disease. Supernumerary glands may be present and should be sought at the initial procedure. Although a frozen section has not been helpful in differentiating diseased from normal glands, it is generally reliable for confirming the presence or absence of parathyroid tissue. Small, thin biopsy specimens are sharply incised from the gland, with extreme care taken to avoid damaging its delicate blood supply. Most surgeons use a frozen section selectively to confirm suspected abnormal parathyroid tissue or to document difficult or confusing situations.[34]

The upper glands are usually located far dorsally on the surface of the thyroid lobe at the level of the upper two-thirds of the gland. The lower glands are less constant and may be located anywhere from well above the thyroid to the anterior mediastinum. The lower glands are most typically in the region where the thyrothymic ligament attaches to the lower pole of the thyroid lobe. If the inferior glands cannot be localized, the thymic pedicle should be carefully examined and mobilized. Because of their common embryologic origin, the inferior gland is frequently associated with the thymic remnant. Parathyroid glands within the mediastinum sometimes can be removed by mobilizing the thymus through the cervical incision. If this technique is unsuccessful in identifying the parathyroid gland, the thyroid lobe on the side of the missing gland is mobilized and palpated. Intraoperative ultrasonographic examination may identify an intrathyroidal parathyroid gland. As a last resort, excision of the thyroid lobe may be indicated.

If after meticulous exploration of all these areas three or four parathyroid glands have been identified, none of which is enlarged, most surgeons favor terminating the operation.

Limited Surgical Exploration

5 With the availability of accurate preoperative localization methods, it has become routinely possible to identify abnormal parathyroid glands prior to operation for most patients. This allows the surgeon to know where to start the exploration. Then, intraoperative PTH measurement can be used to confirm removal of all hyperfunctioning parathyroid tissue, that is, when to stop the operation. This strategy of directed, limited neck exploration is applicable to about 75% of initial parathyroid explorations, and has about the same success rate as full-neck exploration.[35–37] The preoperative localization can be done by either ^{99m}technetium sestamibi nuclear medicine scan or by high-resolution ultrasound. The intraoperative PTH measurement is first assessed at the outset of the procedure, and/or immediately preceding parathyroid gland excision (the preexcision baseline). Blood samples are obtained at time intervals after parathyroid gland resection. A decrease of the PTH level by 50% from the higher of the incision or pre-excision baseline predicts long-term normocalcemia.[38] Other investigators use more sensitive criteria for the detection of multigland disease, including reduction of the PTH level into the normal range and kinetic assessments of the rate of PTH decrease.[39] This increase in sensitivity comes with the cost of decreased specificity, however. Blood samples can be obtained either centrally or peripherally.[40]

The limited nature of this operative approach also makes it easier to perform this operation under regional or local anesthetic in an ambulatory setting. However, because of the possibility of multiple gland disease or inaccurate preoperative localization, all surgeons undertaking this approach should also be skilled in the full-neck exploration for hyperparathyroidism.[41–43]

Extent of Resection

The operative procedure performed has been based on the number of enlarged glands identified at full-neck exploration; however, with the use of intraoperative PTH monitoring, it has become clear that not all enlarged parathyroid glands are hyperfunctioning.[44] In contrast, nearly all hyperfunctioning glands are enlarged and hypercellular. The full-neck exploration experience has demonstrated that removing all enlarged glands is a highly successful approach to curing hyperparathyroidism. In the absence of PTH monitoring, this remains an accepted approach. Typically, single-gland disease has been treated by simple excision, whereas any combination of two- or three-gland enlargement is treated by resecting the diseased tissue and leaving the normal glands in place. The question of whether two- or three-gland enlargement implies the presence of disease in all glands (hyperplasia) has not been resolved. If one gland is large and the remaining three are normal in size, resection of the single parathyroid cures virtually all patients. Of 76 patients with two- or three-gland disease treated by excising the large glands and leaving the normal glands, only eight (10.5%) had recurrent hypercalcemia, which tended to be mild (follow-up of 12 to 140 months postoperatively). This approach seems satisfactory in most patients.[45]

Treating patients with four-gland disease has been more difficult. In many of these

patients, the disease occurs as a component of one of the familial syndromes, particularly MEN-1. Patients with four-gland parathyroid disease can be treated by subtotal parathyroidectomy (removing three and a half glands) or by total parathyroidectomy with autotransplantation of some parathyroid tissue into the nondominant forearm. Both operations depend on meticulous identification of all parathyroid tissue for adequate results. The putative advantage of the subtotal parathyroidectomy is that it leaves the remaining parathyroid tissue with its native blood supply. Total parathyroidectomy with autograft has the advantage of removing all the abnormal parathyroid tissue from the neck and placing it in a site where reoperation for recurrent hyperparathyroidism is simpler. Over time, subtotal parathyroidectomy has become the more common approach.

The reported incidence of recurrent hypercalcemia after subtotal parathyroidectomy for nonfamilial parathyroid hyperplasia is 0% to 16%; the incidence of permanent hypoparathyroidism is 4% to 5%. Total parathyroidectomy with autograft is associated with a similar risk for permanent hypoparathyroidism in the sporadic setting (5%) and a higher reported risk for recurrent hypercalcemia (20%). Reoperation for recurrent hypercalcemia is simplified by the approach of total parathyroidectomy with autotransplantation. Thus, given the current data, sporadic parathyroid hyperplasia can be acceptably treated by either operation. In patients with MEN-1, the disease is not the same as sporadic hyperplasia. Rather, defects in the MEN-1 gene cause multiple parathyroid adenomas that arise independently over the life of the patient.[21] The operative results reflect this independent capability of all parathyroid tissue in these patients to become neoplastic. The hypercalcemia recurrence rate is 26% to 36% with long-term follow-up after subtotal parathyroidectomy, and similar after total parathyroidectomy with autograft. However, the incidence of permanent hypoparathyroidism after autograft in MEN-1 is also significant (reported as high as 46%). While both approaches are currently accepted, most experienced centers now advocate subtotal parathyroidectomy as the initial operation in MEN-1 hyperparathyroidism, and anticipate that recurrent disease is likely, manageable, and less problematic than permanent hypocalcemia.[46,47]

Technique of Parathyroid Autotransplantation

The parathyroid gland is sliced into 15 to 20 pieces and autografted into a forearm muscle bed. The sites are marked with silk sutures. This location permits easy subsequent access under local anesthesia if recurrent hypercalcemia develops. Function of the autograft is documented by (a) normocalcemia, with the autograft as the only source of PTH, (b) by measuring higher concentrations of hormone in the antecubital vein draining the graft bed than in the corresponding vein in the opposite arm, or (c) “transient parathyroidectomy,” by placing a venous occlusive tourniquet on the arm above the graft, and measuring changes over several minutes in the PTH levels drawn from the contralateral arm.[48] Lack of function is unusual outside of the MEN-1 patients; hypoparathyroidism develops in about 5% of patients. Glands can also be cryopreserved in dimethyl sulfoxide and serum. If in the postoperative period it becomes clear that the patient is aparathyroid, the cryopreserved tissue can be reimplanted under local

anesthesia.

Special Situations

Persistent or Recurrent Hyperparathyroidism

Persistent hyperparathyroidism occurs in fewer than 5% of patients after exploration by an experienced surgeon. Most commonly, it is the result of a single diseased gland remaining in the neck or the mediastinum. Recurrent disease develops after an interval of normocalcemia and may be the result of regrowth of diseased tissue, implantation from a tumor broken at the initial procedure, or recurrent parathyroid carcinoma.

In the evaluation of these patients, it is essential to document that the initial diagnosis was correct. Familial hypocalciuric hypercalcemia should be excluded by measuring urinary calcium excretion.

Reviewing the original operative notes and pathology reports may provide clues to the position of missed glands. The locations of parathyroid tumors not found at the initial operation but identified on subsequent exploration in one large series are shown in Figure 76-16.

It is generally agreed that localization studies do have a place in the management of recurrent disease. Noninvasive methods are used first, and if these are unsuccessful in identifying the diseased gland, selective angiography and venous sampling for PTH are used. The utility of the techniques vary across institutions, dependent on local experience, expertise and preference. Selective angiography localizes 50% to 80% of parathyroid glands that cannot be detected by any other modality. Venous sampling may also be helpful in some patients, although interpretation can be complicated by the collateralization that occurs postoperatively. Because it provides no direct image but indicates the side and level of the neck where the hyperfunctioning tissue is located, it may help to direct the evaluation of imaging studies and the exploration to one or the other side of the neck. Both these invasive radiographic techniques require considerable expertise. Transient cortical blindness, transverse myelitis, and cerebrovascular accidents have all been reported as complications of arteriography. Angiographic ablation of mediastinal parathyroid tissue with large doses of ionic contrast has been successful in selected patients. This technique may be used in some patients with mediastinal parathyroid adenomas who are at increased surgical risk and who have other functional parathyroid tissue remaining.[49]

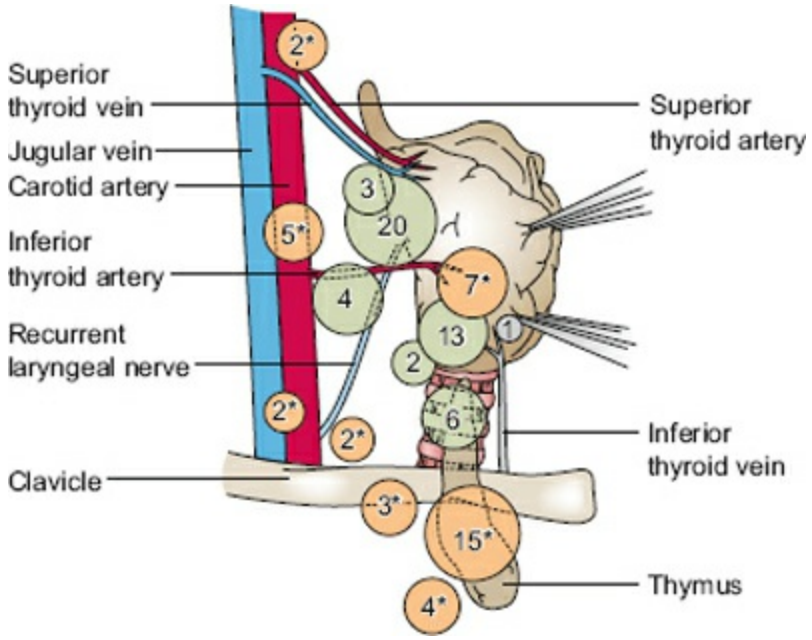

Figure 76-16. Location of parathyroid tumors missed on initial exploration but identified on subsequent operation.

Surgical reexploration can be a difficult procedure. The neck should almost always be reexplored first. If the thymic remnant has not already been removed, it should be excised at this time. Two adjunctive techniques, intraoperative ultrasonography to locate glands and intraoperative measurement of PTH to document the adequacy of resection, may be useful in patients undergoing operation for persistent disease.[29]

If the gland is not identified in the neck by means of the maneuvers described, the mediastinum is examined; most surgeons do this only if there is imaging evidence of disease in the mediastinum, rather than unguided exploration. Median sternotomy and exploration are necessary in only 1% to 2% of patients with hyperparathyroidism. Successful transcervical mediastinal exploration is sometimes possible with use of the Cooper thymectomy retractor, a substernal retractor that permits more extensive mediastinal exploration and thymectomy through a cervical incision.[50] Any remaining thymic tissue is first isolated and examined. Inferior parathyroid glands most commonly migrate into the anterior mediastinum. If the results of this exploration are negative, the area posterior and lateral to the trachea is then explored. The location of superior parathyroid glands may be as far posterior as the esophagus and as far superior as the pharynx.

Surgical reexploration is successful in experienced hands in about 80% of cases. The incidence of complications is increased. Unilateral recurrent nerve injury occurs in 5% to 10% of patients postoperatively, and permanent hypoparathyroidism in 10% to 20% of patients. Cryopreservation of excised tissue may be included as a component of the management of these patients because it allows later autotransplantation if the patient becomes hypoparathyroid postoperatively. However, the demonstration of continued PTH production by intraoperative PTH measurement makes cryopreservation unnecessary. The risks of these complications must be clearly outweighed by the clinical improvement in patients with advanced disease. Reoperation in asymptomatic patients with mild disease is controversial.

Hypercalcemic Crisis

Occasionally, patients with hyperparathyroidism become acutely hypercalcemic with severe symptoms. The pathogenesis appears to involve a cycle of uncontrolled PTH secretion followed by hypercalcemia and secondary polyuria, dehydration, and reduced renal function, which exacerbate the hypercalcemia. Serum calcium concentrations may reach 16 to 20 mg/dL, and the syndrome is manifested by rapidly developing muscle weakness, nausea and vomiting, lethargy, fatigue, and even coma. Ultrasonography, sestamibi scan, or CT scan may help to identify the enlarged gland to allow expedient correction.

Definitive treatment involves resecting the diseased parathyroid tissue, which is almost always curative. Generally, however, it is safer to lower the serum calcium level before operation.

Hyperparathyroidism in Pregnancy

Hyperparathyroidism in pregnancy is a rare disorder that not only causes hypercalcemia in the mother but also is associated with increased morbidity and mortality rates in the fetus. Even the newborn is at risk for the development of tetany. The risk for fetal complications is higher if the hyperparathyroidism is left untreated. The mother should undergo operation in the second trimester,[51] though the outcome for the pregnancy with modern management is good overall.[52]

Neonatal Hyperparathyroidism

Neonatal hyperparathyroidism occurs in infants who are homozygous for a mutation of the calcium-sensing receptor and is characterized by hypotonia, poor feeding, constipation, and respiratory distress. Each parent of these children is affected by familial hypocalciuric hypercalcemia. The 1-year survival rate in children with symptoms is less than 50%, and patients without symptoms appear to have significant bone disease. Total parathyroidectomy with autotransplantation is the treatment of choice.[53]

Secondary Hyperparathyroidism

Secondary hyperparathyroidism develops as a consequence of chronic renal failure. Phosphate retention and hyperphosphatemia reduce the serum calcium levels. This effect is aggravated by the reduction in 1-hydroxylase activity in the kidney, necessary for the activation of vitamin D_3. The secondary increase in PTH levels to compensate for the hypocalcemic effects is exacerbated by aluminum accumulation in bone. Aluminum, present both in the dialysate fluid and in phosphate-binding medications, contributes to the osteomalacia (renal osteodystrophy) that develops in all these patients after several years of dialysis. Therapy includes controlling the hyperphosphatemia with dietary restriction and phosphate-binding gels, calcium supplementation orally and in the dialysate bath, correction of acidosis, administration of vitamin D sterol, and reduction in aluminum intake in both the dialysate and the diet. Therapy should be initiated carefully because metastatic soft tissue calcification can occur. Indications for surgical therapy include persistent, symptomatic hypercalcemia that cannot be controlled medically,

particularly in prospective renal transplant patients; bone pain and abnormal fractures; ectopic calcification; and intractable pruritus. Subtotal parathyroidectomy and total parathyroidectomy with heterotopic autotransplantation both appear to be acceptable options, although reexploration for recurrent disease is less complicated after total parathyroidectomy with autotransplantation. Parathyroidectomy can enhance aluminum deposition, so any excess should be corrected preoperatively through chelation.

Parathyroid Carcinoma

Parathyroid carcinoma is a rare condition, accounting for less than 1% of all cases of hyperparathyroidism. Histologic criteria remain controversial, and the diagnosis is securely made only on the basis of local invasion or distant metastases. In comparison to patients with benign disease, these patients tend to be somewhat younger and more symptomatic. In contrast to the marked female predominance in benign disease, the male-to-female ratio in carcinoma is equal. Serum calcium, PTH, and alkaline phosphatase levels are relatively more elevated, and patients often have an elevated level of human chorionic gonadotropin. Patients may have manifestations of both renal and bone diseases. The affected gland is palpable in almost half of patients.

Initial treatment should include radical resection of the involved gland, ipsilateral thyroid lobe, and regional lymph nodes. Neither chemotherapy nor radiation therapy has shown any benefit. If the disease recurs, resection should be attempted because without treatment these patients usually succumb to uncontrolled hypercalcemia. The long-term prognosis is poor, and the opportunity for survival depends on complete initial resection.[24,54]

MULTIPLE ENDOCRINE NEOPLASIA

Although these familial disorders are typically characterized by a predisposition to the development of tumors of multiple endocrine organs, the parathyroid is characteristically involved in two of them. The disorders are all inherited in an autosomal dominant fashion, and the tumors tend to be multicentric. The tumors can be benign or malignant and can occur metachronously or synchronously. MEN-1 is characterized by the concurrence of parathyroid hyperplasia, pancreatic islet-cell tumors, and pituitary adenomas. MEN-2A consists of medullary thyroid carcinoma (MTC), pheochromocytoma, and parathyroid hyperplasia. MEN-2B includes MTC, pheochromocytoma, mucosal neuromas, and a distinctive marfanoid habitus. Together these syndromes encompass much of the spectrum of endocrine neoplasia.

Pathogenesis

The genetic abnormality in MEN-1 has been identified and described in detail.[55,56] As a tumor-suppressor gene, the first mutation is inherited and becomes unmasked only when a second mutation, in some cases a deletion, develops in susceptible tissues. The resulting complete loss of the tumor suppressor allows neoplasia to develop. The occurrence of multiple second mutations explains the characteristic multicentric involvement of these diseases. Direct genetic testing is now available for some families with known mutations.

Mutations of the *RET* protooncogene are the cause of MEN-2A.[57,58] Genetic testing is now available to identify affected family members and provide the opportunity for early treatment of MTC in affected persons.

Clinical Features and Management of Multiple Endocrine Neoplasia Type 1

Characteristically, MEN-1 presents in the third and fourth decades, without any gender predilection.[59] The syndrome is expressed with nearly complete penetrance, and autopsy studies suggest that all three organs are affected in more than 90% of patients. The phenotype varies, however; more than 90% of patients have hyperparathyroidism, but evidence of islet cell neoplasms (30% to 80%) and pituitary tumors (15% to 50%) is less common. The cause of death in carriers of the MEN-1 mutation is related to MEN-1 in about 45% of patients and often caused by malignant islet cell or carcinoid tumors.[60]

Parathyroid Disease

Hypercalcemia secondary to hyperparathyroidism is usually the first biochemical abnormality detected in MEN-1 and represents the best screening opportunity for members of affected kindreds until direct genetic screening is available in a specific family. Many of these patients are asymptomatic and have relatively mild hypercalcemia. When symptoms do develop, they typically involve the urinary tract rather than the skeleton.

Typically, the patients have four-gland disease, which may be particularly difficult to manage. The disease is characterized by metachronous development of multiple parathyroid adenomas. There is no curative operation; the two accepted approaches (subtotal parathyroidectomy and total parathyroidectomy with autograft) each have faults (see earlier). Over time, the subtotal parathyroidectomy approach is becoming the preferred choice by most surgeons.

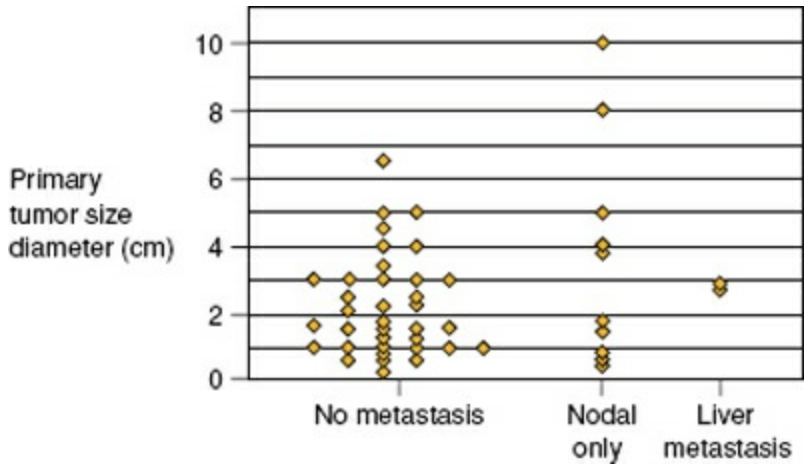

Figure 76-17. Scatter plot of largest primary tumor size versus metastatic status in 43 patients with pancreatic islet cell tumors associated with multiple endocrine neoplasia type I. Each point represents a single patient. Tumor size is not correlated with the presence of liver or lymph node metastases. (From Lowney JK, Frisella MM, Lairmore TC, et al. Islet cell tumor metastasis in multiple endocrine neoplasia type I: correlation with primary tumor size. *Surgery* 1998;124:1043–1049.)

Pancreatic Tumors

In patients with pancreatic tumors, multicentric and diffuse hyperplasia of the pancreatic

islets may occur in areas distant from any grossly evident tumor. The management of these tumors is controversial because although some patients have aggressive, malignant tumors, many patients have a fairly benign course. No reliable criteria are available to detect malignant tumors. Tumor size is often cited as a useful marker of prognosis, but substantial overlap has been noted between the sizes of primary benign and malignant tumors (Fig. 76-17).[61] Because of the difficulty in identifying the more aggressive subset, some authors have chosen a liberal policy of early operation to try to prevent metastasis and death. Pancreatic tumors are typically multicentric and frequently malignant. Somatostatin receptor scintigraphy can be a useful imaging technique to demonstrate the extent of tumor (Fig. 76-18).[62]

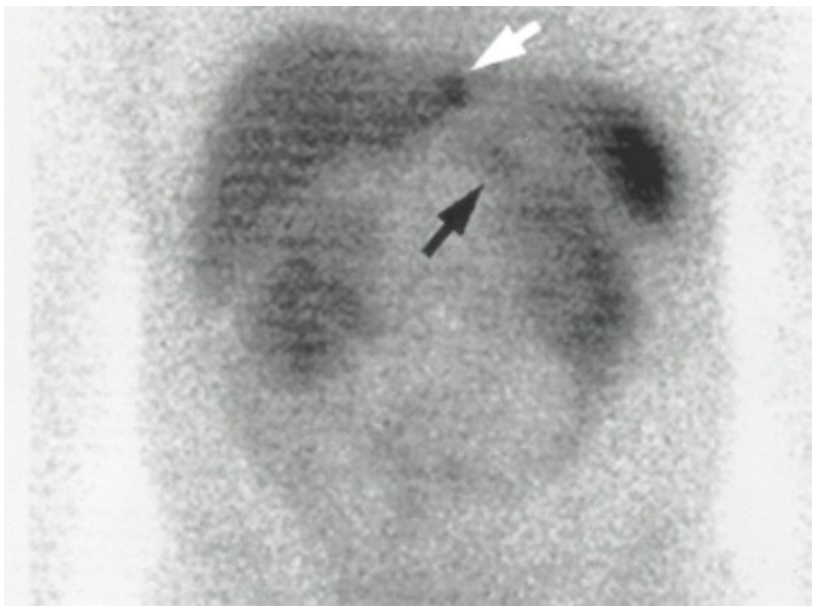

Figure 76-18. Somatostatin receptor scintigraphy in a patient with multiple endocrine neoplasia type I. This scintiscan detected an otherwise unrecognized metastasis to the left lateral segment of the liver (*white arrow*), which was resected along with the small primary tumor (*black arrow*).

Gastrinoma is the most common functional tumor in MEN-1; typically, a severe ulcer diathesis (Zollinger–Ellison syndrome) develops that is associated with secretory diarrhea. Serum gastrin levels are usually markedly elevated (>1,000 pg/mL); when levels are equivocal (250 to 1,000 pg/mL), provocative testing with secretin (2 m/kg) may be useful. An absolute serum gastrin increase of 200 pg/mL is diagnostic. The primary tumors are often in the submucosa of the duodenal wall.

Biochemical cure of these gastrinomas is almost never possible, which is different than patients with sporadic gastrinomas, although exploration can reduce the need for antisecretory medications and may reduce the risk for liver metastasis. Histamine 2-receptor antagonists or proton pump inhibitors are effective in controlling acid secretion, although very high doses may be necessary; the malignant disease is often indolent. Total gastrectomy is no longer ever necessary to eliminate acid secretion.

Insulinoma is the next most common functional pancreatic neoplasm in MEN-1. Patients present with a history of sweating, dizziness, confusion, and syncope, consistent with neuroglycopenia; these symptoms are relieved by consuming carbohydrates. The

diagnosis is verified by documenting fasting hypoglycemia associated with inappropriately elevated plasma insulin levels. Preoperative tumor localization is usually achieved by a combination of CT and arteriography. Calcium is injected into various pancreatic arteries and plasma insulin levels in the hepatic vein plasma are measured to detect a gradient after the injection of specific pancreatic arteries localizing the area of the pancreas containing the functional tumor.

Because the available medical therapy for insulinoma is limited, patients are treated operatively. Lesions in the tail of the gland can be enucleated if they are small; however, distal pancreatectomy carries little morbidity. Tumors of the head can usually be enucleated, so that pancreaticoduodenectomy can be avoided. In patients with malignant disease, metastases may respond to streptozocin, diazoxide, verapamil, or octreotide may successfully reduce insulin secretion and control symptoms. A diet of complex carbohydrates can also help stabilize serum glucose levels in the hyperinsulinemic patient.

Nonfunctional tumors are the most common pancreas lesions in MEN-1. Their management is specific to their size and risk of malignancy.

Pituitary Adenomas

Prolactin-secreting tumors occur most commonly in this setting, although Cushing disease or acromegaly develops in an occasional patient. Symptoms may result from compression of the optic chiasm, which produces bitemporal hemianopsia, or from prolactin excess, which produces amenorrhea and galactorrhea in female patients and hypogonadism in male patients.

Bromocriptine inhibits prolactin secretion and shrinks many prolactinomas. Refractory tumors and those producing other hormones can be managed by pituitary ablation or radiation.

Other Tumors

MEN-1 is associated much less frequently with adrenocortical tumors and benign thyroid adenomas. Lipomas and carcinoid tumors may also occur.

Clinical Features and Management of Multiple Endocrine Neoplasia Type 2

Like MEN-1, the MEN-2 syndromes are inherited in an autosomal dominant fashion with complete penetrance but variable phenotype. Bilateral MTC occurs in every affected patient. More frequently than the other syndromes, MEN-2B can arise as a new mutation that can be transmitted to subsequent generations.

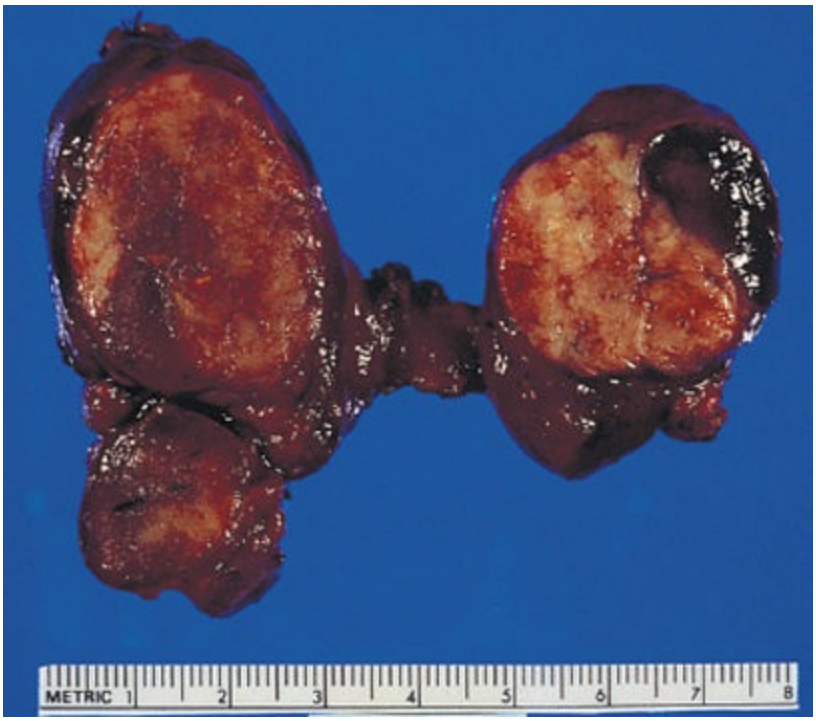

Figure 76-19. Medullary thyroid carcinoma. Coronal section of a total thyroid resection shows bilateral involvement by a firm, pale tumor.

Medullary Thyroid Carcinoma

Medullary thyroid carcinoma accounts for about 10% of all thyroid malignancies, and 20% of cases occur in the familial setting of MEN-2A, MEN-2B, or familial non-MEN MTC. It is usually the first tumor that develops in these patients and typically appears in the second or third decade. Tumors are virtually always bilateral and develop in multiple areas of the middle and upper portions of the thyroid lobe (Fig. 76-19). Occasionally, in young people, a diffuse proliferation of parafollicular C cells, termed *C-cell hyperplasia,* is present without frankly invasive carcinoma. This finding is highly suggestive of one of the familial MTC syndromes. Patients typically present with a neck mass and may have hoarseness, dysphagia, or palpable cervical adenopathy. MTC may produce a variety of hormones, including calcitonin, adrenocorticotropic hormone, prostaglandin, and serotonin. The hypercalcitoninemia is often asymptomatic, although severe diarrhea can develop.

By detecting minimal elevations of plasma calcitonin, it is possible to diagnose MTC at a clinically occult stage. Basal plasma calcitonin levels in normal subjects are in the range of 30 to 100 pg/mL. An increase to levels of 150 to 200 pg/mL occurs, however, after the administration of the potent secretagogues calcium and pentagastrin. The plasma

calcitonin levels of patients with MTC show striking increases (>1,000 pg/mL) after provocative testing, so that they can be identified readily. Patients with occult disease may have only minimally elevated basal calcitonin levels that increase in response to secretagogues. The combined infusion of calcium and pentagastrin was the most effective screening test for familial MTC before genetic testing became available. By means of provocative testing in kindred members at risk for disease, MTC was diagnosed at a preclinical stage, and a greater percentage of these patients were cured by surgical therapy. With genetic testing now available, prophylactic thyroidectomy to prevent the development of MTC is possible for all affected people.

Postoperatively, the presence of residual MTC can be readily detected by provocative testing. Meticulous reoperation in patients with recurrent or persistently elevated plasma calcitonin levels postoperatively, including mediastinal dissection on occasion, can normalize elevated plasma calcitonin levels and apparently cure many of them.[63] For the patient with unresectable metastases, few therapeutic options are available. Neither radiation nor chemotherapy is of significant benefit.

The clinical course of patients with the MEN-2 syndromes is determined primarily by the status of their MTC. In the setting of MEN-2A, the tumors are often indolent and survival prolonged, even in the presence of metastatic disease. By contrast, the tumors in patients with MEN-2B occur at an earlier age and are generally more aggressive neoplasms. Patients may succumb to the disease at a young age. As a consequence of this aggressiveness, the size of kindreds with the disease is typically small, and usually only a few generations are affected.

Pheochromocytoma

Pheochromocytomas are usually detected during the initial screening or follow-up of patients in whom MTC has already been diagnosed. They typically appear in the second or third decade of life, and about 80% are bilateral. Usually, pheochromocytomas are benign but multicentric, and they almost always arise in the adrenal medulla. In patients with MEN-2A or MEN-2B, hyperplasia of the adrenal medulla may develop first, grossly characterized by thickening of the medullary tissue in both adrenal glands.

Pheochromocytomas can be asymptomatic, but most commonly, patients have pounding frontal headaches, episodic diaphoresis, palpitations, or anxiety. Hypertension also occurs and is often episodic.

The diagnosis is made by measuring the plasma concentration of metanephrines. Patients with MEN-2A or MEN-2B and MTC should be evaluated for pheochromocytoma before they undergo thyroidectomy. If a patient is found to have both lesions, adrenalectomy should be performed first, followed by neck exploration. The abdomen is explored through a bilateral subcostal incision or, more typically, with a laparoscope.[64] Bilateral pheochromocytomas are treated by bilateral adrenalectomy. In patients with MEN-2A or MEN-2B and a unilateral pheochromocytoma, only the diseased adrenal gland is removed. In about 30% of patients treated in this manner, a tumor eventually develops in the opposite gland. In the remaining patients, this approach avoids the need for glucocorticoid and mineralocorticoid replacement and the risk for addisonian crisis. After

unilateral adrenalectomy, patients are carefully screened at 6-month or 1-year intervals with plasma metanephrine measurements.

Parathyroid Disease

Hyperparathyroidism develops in about one-third of patients with MEN-2A, although it is usually asymptomatic. Occasionally, nephrolithiasis develops. Bone disease is unusual. Frequently, enlarged parathyroid glands are found at operation for MTC, although the patient is still normocalcemic. Multiglandular chief cell hyperplasia is the predominant histologic finding in MEN-2A. Significant parathyroid disease rarely develops in MEN-2B.

Total parathyroidectomy and heterotopic autotransplantation are performed in hypercalcemic patients with MEN-2A. In normocalcemic patients with MEN-2A undergoing thyroidectomy for MTC, total parathyroidectomy and heterotopic autotransplantation are performed in one session to ensure that the complete thyroidectomy does not compromise the parathyroid blood supply and to avoid reoperation in the neck for subsequent hyperparathyroidism. Evidence suggests that these patients are more easily treated, with a lower incidence of recurrent hyperparathyroidism, than patients with MEN-1.

Nonendocrine Manifestations of Multiple

Endocrine Neoplasia Type 2B. In addition to MTC and pheochromocytoma, marked abnormalities of the nervous and musculoskeletal systems develop in patients with MEN-2B. The classic phenotype is characterized by thick lips and a thin, marfanoid habitus (Fig. 76-20A,B). The incidence of associated skeletal abnormalities is high; these include kyphosis, pectus excavatum, pes planus or cavus, and congenital dislocation of the hip. Diffuse autonomic nervous hypertrophy is another feature. Mucosal neuromas appear on the tongue (Fig. 76-20C), eyelids, lips, and pharynx. Slit-lamp examination may reveal hypertrophied corneal nerves. Ganglioneuromatosis develops in the submucosal and myenteric plexuses of the gastrointestinal tract. Constipation is common, and radiographic findings may suggest megacolon or Hirschsprung disease.



Figure 76-20. **A,B:** Characteristic appearance of patients with multiple endocrine neoplasia type IIB, including thick lips. **C:** Multiple mucosal neuromas on the tongue of a patient with MEN-2B. (From Norton JA, Froome LC, Farrell FE, et al. Multiple endocrine neoplasia type 2b: the most aggressive form of medullary thyroid carcinoma. *Surg Clin North Am* 1979;59:109.)

References

1. Akerstrom G, Malmaeus J, Bergstrom R. Surgical anatomy of human parathyroid glands. *Surgery* 1984;95:14.
2. Peacock M. Calcium metabolism in health and disease. *Clin J Am Soc Nephrol* 2010;5(Suppl 1):S23–S30.
3. Ahmad S, Kuraganti G, Steenkamp D. Hypercalcemic crisis: a clinical review. *Am J Med.* 2015;128(3):239–245.
4. Endres DB. Investigation of hypercalcemia. *Clin Biochem* 2012;45(12):954–963.
5. Ross JR, Saunders Y, Edmonds PM, et al. A systematic review of the role of bisphosphonates in metastatic disease. *Health Technol Assess* 2004;8(4):1–176
6. Strewler GJ, Nissenson RA. Hypercalcemia in malignancy. *West J Med* 1990;153:635–640.
7. Clines GA. Mechanisms and treatment of hypercalcemia of malignancy. *Curr Opin Endocrinol Diabetes Obes* 2011;18(6):339–346.
8. Pollak MR, Brown EM, Chou YH, et al. Mutations in the human Ca-sensing receptor gene cause familial hypocalciuric hypercalcemia and neonatal severe hyperparathyroidism. *Cell* 1993;75:1297–1303.
9. Pollak MR, Chou YH, Marx SJ, et al. Familial hypocalciuric hypercalcemia and neonatal severe hyperparathyroidism: effects of mutant gene dosage on phenotype. *J Clin Invest* 1994;93:1108–1112.
10. Christensen SE, Nissen PH, Vestergaard P, et al. Familial hypocalciuric hypercalcaemia: a review. *Curr Opin Endocrinol Diabetes Obes* 2011;18(6):359–370.
11. LeGrand SB, Leskuski D, Zama I. Narrative review: furosemide for hypercalcemia: an unproven yet common practice.. *Ann Intern Med* 2008;149(4):259–263.
12. Martinez-Zapata MJ, Roque M, Alonso-Coello P, et al. Calcitonin for metastatic bone pain.[update of Cochrane Database Syst Rev 2003;(3):CD003223; PMID: 12917954]. *Cochrane Database Syst Rev* 2006;3:CD003223.
13. Pallotti F, Seregni E, Ferrari L, et al. Diagnostic and therapeutic aspects of iatrogenic hypoparathyroidism. *Tumori* 2003;89(5):547–549.
14. Lo CY. Postthyroidectomy hypocalcemia. *J Am Coll Surg* 2003;196(3):497–498.
15. Ip P. Neonatal convulsion revealing maternal hyperparathyroidism: an unusual case of late neonatal hypoparathyroidism. *Arch Gynecol Obstet* 2003;268(3):227–229.
16. Heath H. Clinical spectrum of primary hyperparathyroidism: evolution with changes in medical practice and technology. *J Bone Miner Res* 1991;6(Suppl 2):S63–S70.
17. Heath H, Hodgson SF, Kennedy MA. Primary hyperparathyroidism: incidence, morbidity and potential economic impact in a community. *N Engl J Med* 1980;302:189–193.
18. Rubin MR, Bilezikian JP, McMahon DJ, et al. The natural history of primary hyperparathyroidism with or without parathyroid surgery after 15 years. *J Clin*

Endocrinol Metab 2008;93(9):3462–3470.
19. Arnold A, Shattuck TM, Mallya SM, et al. Molecular pathogenesis of primary hyperparathyroidism. *J Bone Miner Res* 2002;17(Suppl 2):N30–N36.
20. Costa-Guda J, Arnold A. Genetic and epigenetic changes in sporadic endocrine tumors: parathyroid tumors. *Mol Cell Endocrinol* 2014;386(1–2):46–54.
21. Doherty GM, Lairmore TC, DeBenedetti MK. Multiple endocrine neoplasia type 1 parathyroid adenoma development over time. *World J Surg* 2004; 28(11):1139–1142.
22. Johnson SJ, Sheffield EA, McNicol AM. Best practice no 183. Examination of parathyroid gland specimens. *J Clin Pathol* 2005;58(4):338–342.
23. Gauger PG, Agarwal G, England BG, et al. Intraoperative parathyroid hormone monitoring fails to detect double parathyroid adenomas: a 2-institution experience. *Surgery* 2001;130(6):1005–1010.
24. DeLellis RA. Parathyroid carcinoma: an overview. *Adv Anat Pathol* 2005; 12(2):53–61.
25. Bilezikian JP, Khan AA, Potts JT Jr, Third International Workshop on the Management of Asymptomatic Primary H. Guidelines for the management of asymptomatic primary hyperparathyroidism: summary statement from the third international workshop. *J Clin Endocrinol Metab* 2009;94(2):335–339.
26. Hedback G, Oden A, Tisell L-E. The influence of surgery on the risk of death in patients with primary hyperparathyroidism. *World J Surg* 1991;15:399–407.
27. Hedback G, Tisell LE, Bengtsson BA, et al. Premature death in patients operated on for primary hyperparathyroidism. *World J Surg* 1990;14:829–836.
28. Hagstrom E, Hellman P, Larsson TE, et al. Plasma parathyroid hormone and the risk of cardiovascular mortality in the community. *Circulation* 2009;119(21):2765–2771.
29. Udelsman R, Donovan PI. Remedial parathyroid surgery: changing trends in 130 consecutive cases. *Ann Surg* 2006;244(3):471–479.
30. Potts JT Jr, Ackerman IP, Barker CF, et al. Diagnosis and management of asymptomatic primary hyperparathyroidism: consensus development conference statement. *Ann Intern Med* 1991;114:593–597.
31. Bilezikian JP, Potts JT Jr, Fuleihan Gel H, et al. Summary statement from a workshop on asymptomatic primary hyperparathyroidism: a perspective for the 21st century. *J Clin Endocrinol Metab* 2002;87(12):5353–5361.
32. Silverberg SJ, Clarke BL, Peacock M, et al. Current issues in the presentation of asymptomatic primary hyperparathyroidism: proceedings of the Fourth International Workshop. *J Clin Endocrinol Metab* 2014;99(10):3580–3594.
33. Bilezikian JP, Brandi ML, Eastell R, et al. Guidelines for the management of asymptomatic primary hyperparathyroidism: summary statement from the Fourth International Workshop. *J Clin Endocrinol Metab* 2014;99(10):3561–3569.
34. Oertli D, Richter M, Kraenzlin M, et al. Parathyroidectomy in primary hyperparathyroidism: preoperative localization and routine biopsy of unaltered

glands are not necessary. *Surgery* 1995;117:392–396.
35. Carty S, Worsey M, Virji M, et al. Concise parathyroidectomy: the impact of preoperative SPECT 99mTc sestamibi scanning and intraoperative quick parathormone assay. *Surgery* 1997;122:1107–1116.
36. Udelsman R, Pasieka JL, Sturgeon C, et al. Surgery for asymptomatic primary hyperparathyroidism: proceedings of the third international workshop. *J Clin Endocrinol Metab* 2009;94(2):366–372.
37. Carling T, Udelsman R. Focused approach to parathyroidectomy. *World J Surg* 2008;32(7):1512–1517.
38. Carneiro DM, Solorzano CC, Nader MC, et al. Comparison of intraoperative iPTH assay (QPTH) criteria in guiding parathyroidectomy: which criterion is the most accurate? *Surgery* 2003;134(6):973–979; discussion 9–81.
39. Gauger PG, Mullan MH, Thompson NW, et al. An alternative analysis of intraoperative parathyroid hormone data may improve the ability to detect multiglandular disease. *Arch Surg* 2004;139(2):164–169.
40. Woodrum DT, Saunders BD, England BG, et al. The influence of sample site on intraoperative PTH monitoring during parathyroidectomy. *Surgery* 2004; 136(6):1169–1175.
41. Irvin GL 3rd, Sfakianakis G, Yeung L, et al. Ambulatory parathyroidectomy for primary hyperparathyroidism. *Arch Surg* 1996;131(10):1074–1078.
42. Lowney JK, Weber B, Johnson S, et al. Minimal incision parathyroidectomy: cure, cosmesis, and cost. *World J Surg* 2000;24(11):1442–1445.
43. Carling T, Donovan P, Rinder C, et al. Minimally invasive parathyroidectomy using cervical block: reasons for conversion to general anesthesia. *Arch Surg* 2006;141(4):401–404; discussion 4.
44. Clerici T, Brandle M, Lange J, et al. Impact of intraoperative parathyroid hormone monitoring on the prediction of multiglandular parathyroid disease. *World J Surg* 2004;28(2):187–192.
45. Wells SA, Leight GS, Hensley M, et al. Hyperparathyroidism associated with the enlargement of two or three parathyroid glands. *Ann Surg* 1985; 202:533–538.
46. Carling T, Udelsman R. Parathyroid surgery in familial hyperparathyroid disorders. *J Intern Med* 2005;257(1):27–37.
47. Lairmore TC, Govednik CM, Quinn CE, et al. A randomized, prospective trial of operative treatments for hyperparathyroidism in patients with multiple endocrine neoplasia type 1. *Surgery* 2014;156(6):1326–1334; discussion 34–35.
48. Casanova D, Sarfati E, De Francisco A, et al. Secondary hyperparathyroidism: diagnosis of site of recurrence. *World J Surg* 1991;15(4):546–549; discussion 9–50.
49. Doherty GM, Doppman JL, Miller DL, et al. Results of a multidisciplinary strategy for management of mediastinal parathyroid adenoma as a cause of persistent primary hyperparathyroidism. *Ann Surg* 1992;215(2):101–106.

50. Wells SA Jr, Cooper JD. Closed mediastinal exploration in patients with persistent hyperparathyroidism. *Ann Surg* 1991;214:555–561.
51. McMullen TP, Learoyd DL, Williams DC, et al. Hyperparathyroidism in pregnancy: options for localization and surgical therapy. *World J Surg* 2010;34(8):1811–1816.
52. Abood A, Vestergaard P. Pregnancy outcomes in women with primary hyperparathyroidism. *Eur J Endocrinol* 2014;171(1):69–76
53. Egbuna OI, Brown EM. Hypercalcaemic and hypocalcaemic conditions due to calcium-sensing receptor mutations. *Best Pract Res Clin Rheumatol* 2008;22(1):129–148.
54. Marcocci C, Cetani F, Rubin MR, et al. Parathyroid carcinoma. *J Bone Miner Res* 2008;23(12):1869–1880.
55. Chandrasekharappa SC, Guru SC, Manickam P, et al. Positional cloning of the gene for multiple endocrine neoplasia-type 1. *Science* 1997;276:404–407.
56. Kouvaraki MA, Lee JE, Shapiro SE, et al. Genotype-phenotype analysis in multiple endocrine neoplasia type 1. *Arch Surg* 2002;137(6):641–647.
57. Mulligan LM, Kwok JB, Healey CS, et al. Germ-line mutation of the RET proto-oncogene in multiple endocrine neoplasia type 2A. *Nature* 1993;363:458–460.
58. Donis-Keller H, Dou S, Chi D, et al. Mutations in the RET proto-oncogene are associated with MEN 2A and FMTC. *Hum Mol Genet* 1993;2:851–856.
59. Doherty GM. Multiple endocrine neoplasia type 1. *J Surg Oncol* 2005;89(3):143–150.
60. Doherty GM, Olson JA, Frisella MM, et al. Lethality of multiple endocrine neoplasia type I. *World J Surg* 1998;22(6):581–586; discussion 6–7.
61. Lowney JK, Frisella MM, Lairmore TC, et al. Islet cell tumor metastasis in multiple endocrine neoplasia type I: correlation with primary tumor size. *Surgery* 1998;124:1043–1049.
62. Yim JH, Siegel BA, DeBenedetti MK, et al. Prospective study of the utility of somatostatin-receptor scintigraphy in the evaluation of patients with multiple endocrine neoplasia type 1. *Surgery* 1998;124(6):1037–1042.
63. Quayle FJ, Moley JF. Medullary thyroid carcinoma: including MEN 2A and MEN 2B syndromes. *J Surg Oncol* 2005;89(3):122–129.
64. Brunt LM, Lairmore TC, Doherty GM, et al. Adrenalectomy for familial pheochromocytoma in the laparoscopic era. *Ann Surg* 2002;235(5):713–720.

Chapter 77

Adrenal Gland

John A. Olson, Jr. and Douglas J. Turner

Key Points

1 Adrenocortical steroid hormones, glucocorticoids, mineralocorticoids, and androgenic steroids are all synthetic derivatives of cholesterol that are either extracted from plasma or synthesized intracellularly.

2 Catecholamines of the adrenal medulla include epinephrine, norepinephrine, and dopamine, the vasoactive synthetic derivatives of the amino acid tyrosine.

3 Cushing syndrome is adrenocorticotropic hormone (ACTH) dependent in 80% to 90% of cases, most often because of an ACTH-secreting pituitary adenoma, though ectopic ACTH-producing nonendocrine tumors (mostly non–small-cell lung cancer and bronchial carcinoids) represent 10% to 20% of cases of ACTH-dependent Cushing syndrome; the remainder have a primary adrenal cause of hypercortisolism.

4 An aldosterone-producing adrenal adenoma (Conn syndrome) is the source of primary hyperaldosteronism in 60% to 70% of cases while idiopathic bilateral adrenal hyperplasia causes most of the remaining cases of primary hyperaldosteronism; adrenocortical carcinoma is a rare cause of primary hyperaldosteronism.

5 Surgical removal by laparoscopic adrenalectomy of an aldosterone-secreting adenoma results in durable improvement of hypertension and hypokalemia in 70% to 90% of patients; management of idiopathic adrenal hyperplasia is medical, because fewer than 20% to 30% of patients with this disease are cured by adrenalectomy.

6 The congenital adrenal hyperplasias are autosomal recessive conditions resulting from inherited defects of one or several of the enzymes necessary for cortisol biosynthesis leading to ACTH overproduction and secondary hyperplasia of the adrenal cortex with shunting of cortisol precursors into adrenal androgen pathways; peripheral conversion of the excess adrenal androgens to testosterone causes virilization of the patient.

7 Adrenocortical carcinoma has an estimated incidence of 0.5 to 2 cases per million per year, is very aggressive (most patients present with locoregionally advanced or distant disease), and hormone overproduction syndromes are frequent including hypercortisolism, hyperaldosteronism, or virilization.

8 The *rule of tens* is a useful way to characterize pheochromocytoma: tumors are bilateral in 10% of cases, extraadrenal in 10%, familial in 10%, multicentric in 10%, and malignant in 10% and occur in children in 10% of cases; determination of plasma-fractionated metanephrines is the best test for diagnosis of pheochromocytoma.

9 Unsuspected adrenal masses are detected by computed tomography in between 0.6% and 1.9% of healthy patients; the goal of evaluation is to distinguish and remove those adrenal masses that are functioning or likely to be malignant versus those that are neither and can be observed.

ANATOMY

The adrenal glands are bilateral, retroperitoneal, endocrine organs located adjacent to the superior pole of each kidney. These glands appear grossly as flat, triangular structures each weighing approximately 4 g. Each adrenal gland is composed of two distinct endocrine organs, the cortex and medulla. The outer adrenal cortex is bright yellow and nodular, whereas the adrenal medulla is red-brown in color and is sandwiched between the thin layers of the cortex. The adrenals are embedded in retroperitoneal perinephric fat but can be identified as distinct structures by their golden brown, nodular appearance. The right adrenal gland abuts the inferior vena cava medially and lies in close proximity to the diaphragmatic crus posteriorly and the liver anteriorly. The left adrenal gland resides between the kidney and aorta, immediately deep to the tail of the pancreas and spleen.

Embryologically, fetal and definitive adrenal cortices arise from coelomic mesoderm near the urogenital ridge during the fourth to sixth weeks of gestation. Postnatally, the fetal cortex involutes, leaving only the definitive cortex to differentiate into the three adult zonae, the glomerulosa, fasciculata, and reticularis. The adrenal medulla develops from the neural crest during the fifth gestational week and migrates along paraaortic and paravertebral routes to join the developing cortex. Ectopic adrenal cortex and medulla may be found anywhere along their respective paths of embryologic migration. Most neural crest tissue regresses, however, extraadrenal neural crest derivatives may be found along the retroperitoneum and at the aortic bifurcation (organ of Zuckerkandl).

The adrenal cortex is composed of three distinct zones. The outer zona glomerulosa, located just beneath the fibrous gland capsule, is the site of mineralocorticoid production. The middle zona fasciculata, composed of linear arrays of large, foamy cells with lipid inclusions, is the predominant site of glucocorticoid and adrenal sex steroid biosynthesis. The inner zona reticularis is the primary location of synthesis of adrenal androgens. Both the zona fasciculata and zona reticularis respond to stimulation by adrenocorticotropic hormone (ACTH). The adrenal medulla is smaller than the cortex. Cells of the adrenal medulla appear as homogeneous sheets, with large, irregular, atypical-looking nuclei. The cytoplasm of these cells has numerous secretory granules containing catecholamines, neuron-specific enolase, and chromogranin. Catecholamines in these granules precipitate chromium salts, which is the basis for the term *chromaffin cells.*

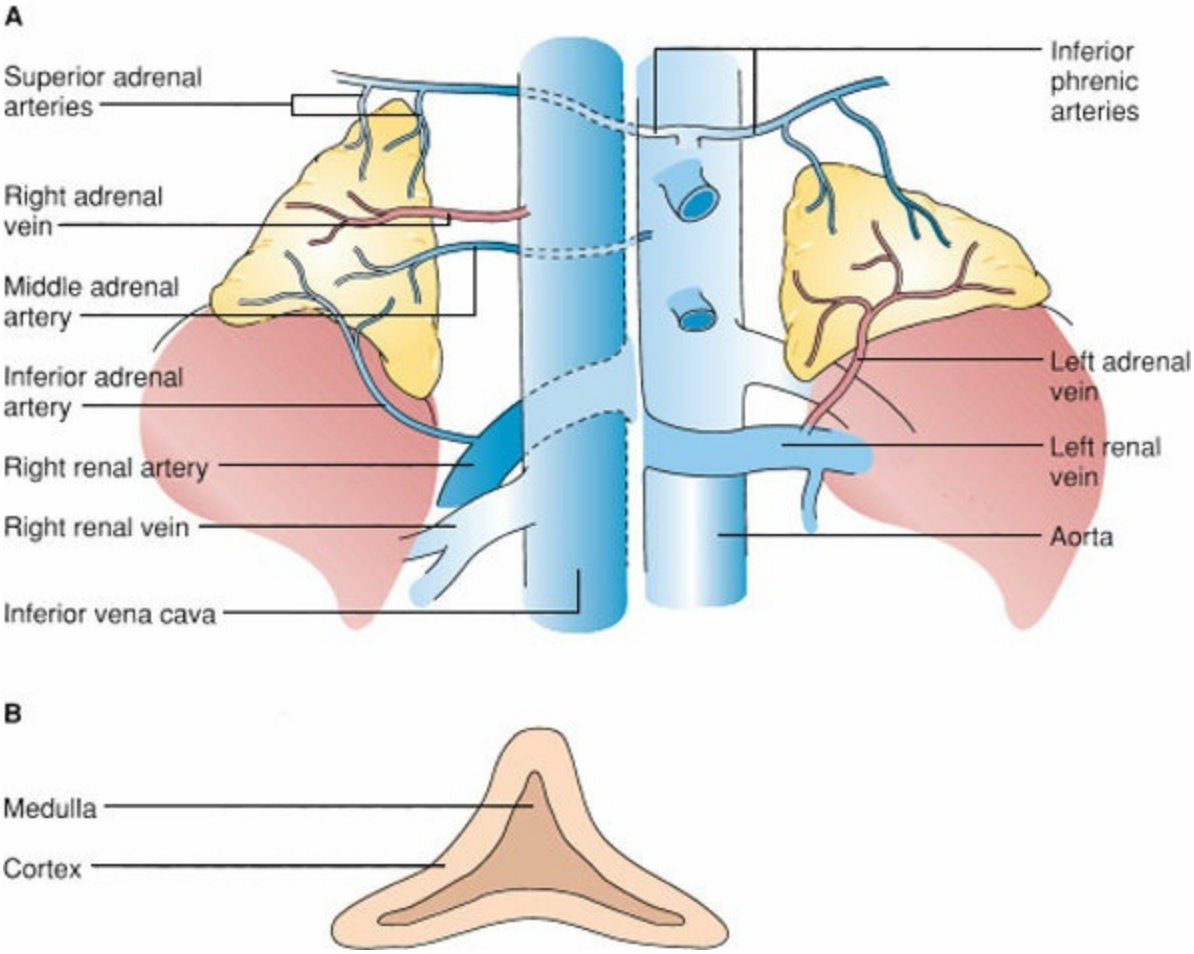

Figure 77-1. **A:** Arterial (*dark shaded*) and venous (*light shaded*) anatomy of the adrenal glands. **B:** Schematic showing outer adrenal cortex (*light shaded*) and inner adrenal medulla (*dark shaded*).

The adrenal glands have an extensive vascular supply derived from branches of the inferior phrenic artery superiorly, the aorta medially, and the renal artery inferiorly. Venous return from the right adrenal gland empties directly into the inferior vena cava through a wide but short central vein. Venous drainage from the left adrenal gland empties into a smaller vein that shares a common trunk with the left phrenic vein. Together they join the left renal vein (Fig. 77-1).

BIOCHEMISTRY AND PHYSIOLOGY

Adrenal Cortex

1 Adrenocortical steroid hormones, glucocorticoids, mineralocorticoids, and androgenic steroids are all synthetic derivatives of cholesterol that are either extracted from plasma or synthesized intracellularly (Fig. 77-2). In mitochondria of cells in the adrenal cortex, cholesterol is converted by desmolase (CYP11A1) to delta-5-pregnenolone, the common parent compound for all adrenal cortex steroids. Pregnenolone is then shunted to the three biosynthetic pathways, each compartmentalized within the adrenal according to synthetic capabilities within each zone. In the zonae fasciculata and reticularis, pregnenolone is either converted to progesterone by 3-beta-hydroxysteroid dehydrogenase or is oxidized at position 17 by 17-alpha hydroxylase (CYP17) to form 17-hydroxypregnenolone. In the zona fasciculata, progesterone is hydroxylated by CYP17 at position 17 to form 17-hydroxyprogesterone. Subsequently, 17-hydroxyprogesterone is sequentially hydroxylated at the 21 position by 21-beta hydroxylase (CYP21A2) and at position 11 by 11-beta hydroxylase (CYP11B1) to form cortisol. In the zona reticularis, the androgenic steroids dehydroepiandrostenedione (DHEA) and androstenedione are made from 17-hydroxypregnenolone and 17-hydroxyprogesterone, respectively. Collectively, the glucocorticoid and androgenic steroids are known as *17-hydroxy corticosteroids and 17-hydroxy ketosteroids.* In the zona glomerulosa, progesterone is not hydroxylated at the 17 position owing to the lack of enzyme at this location. Instead aldosterone is made from progesterone by a sequential series of hydroxylation steps at position 21 by CYP21A2, position 11 by CYP11B1, and position 18 by aldosterone synthase (CYP11B2 and P450c11as). The zona glomerulosa is well suited to aldosterone biosynthesis because of the relative lack of 17-hydroxylase and the exclusive expression of aldosterone synthase, required for the conversion of corticosterone to aldosterone.

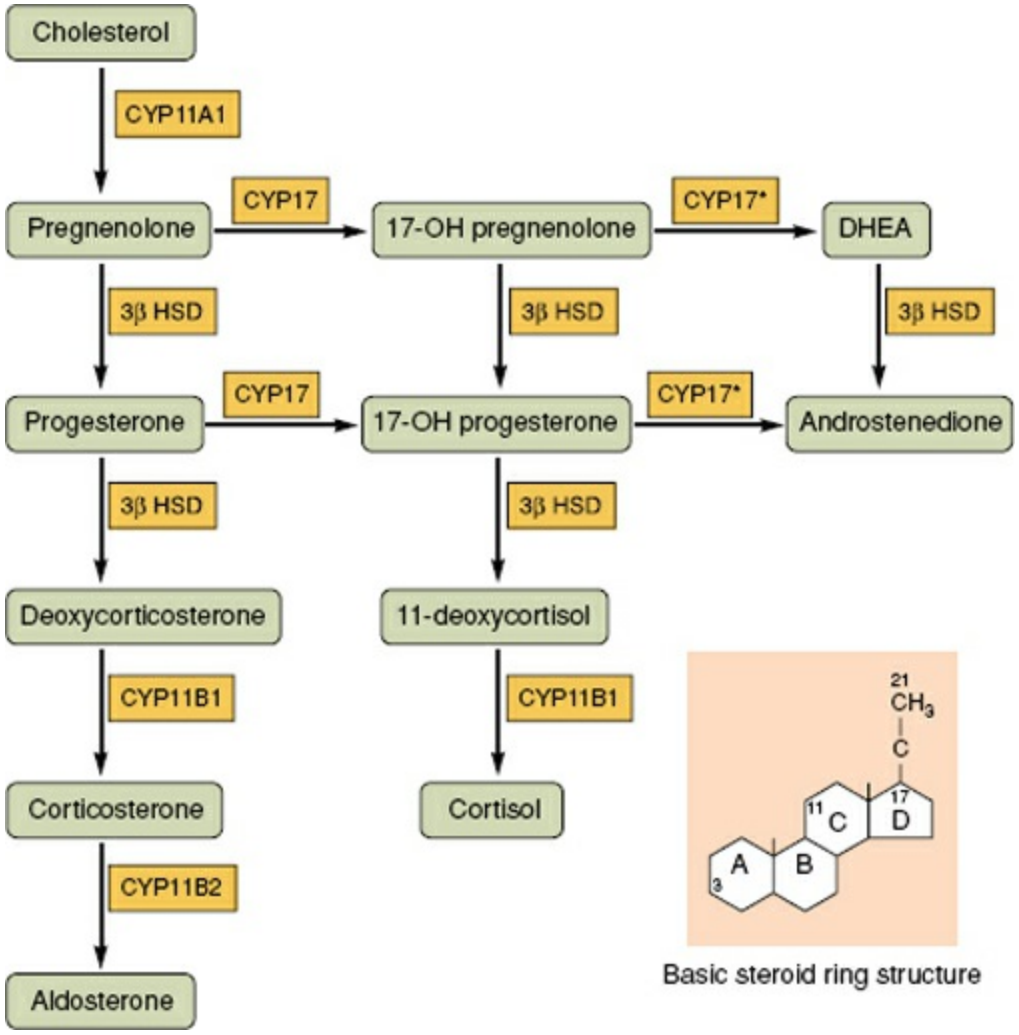

Figure 77-2. Steroid biosynthetic pathways in the adrenal cortex. Steroids and precursors are shown in square boxes. Enzymes are shown in stippled boxes. Enzyme gene symbol designations are: CYP11A1, desmolase; CYP17, 17α-hydroxylase (±17,20 lyase*); 3β-HSD, 3β-hydroxysteroid dehydrogenase; CYP21A2, 21-hydroxylase; CYP11B1, 11β-hydroxylase; CYP11B2, Aldosterone synthase. *Inset:* Basic steroid ring structure. The four basic carbon rings are designated A, B, C, and D. Individual carbons at sites of steroidegenic enzyme activity are designated numerically.

Cortisol

Cortisol is the predominant glucocorticoid in humans. Production and release of cortisol is tightly regulated by a complex feedback relationship between the hypothalamus, corticotrophs of the anterior pituitary, and cells of the adrenal cortex zonae fasciculata and reticularis. This endocrine system is called the *hypothalamic–pituitary–adrenal (HPA) axis*. Communication within the HPA axis is mediated by synthesis and secretion of corticotrophin-releasing hormone (CRH) by the hypothalamus and ACTH production by corticotrophs of the anterior pituitary (Fig. 77-3). ACTH is a cleavage product of a precursor polipeptide, proopiomelanocortin (POMC) that is built of 241-amino-acid residues within corticotroph cells of the anterior and intermediate lobes of the pituitary. Several derivatives of POMC are important biologically active substances, including ACTH. Under stimulation of hypothalamic CRH stimulus, POMC can be cleaved into ACTH and β-lipotropic hormone in the anterior lobe. ACTH acts directly on the adrenal to regulate cortisol production by cells within the zonae fasciculata and reticularis. Feedback loops involving cortisol, hypothalamic CRH, and pituitary ACTH keep the concentration

of cortisol in plasma within a narrow range of 10 to 15 μg/dL. Typical daily production of cortisol in humans ranges from 10 to 30 mg and can increase to as high as 300 mg per day under conditions of maximal stress.

In circulation, cortisol is protein bound to transcortin and albumin with a small percentage of free cortisol available to target tissues. The half-life of cortisol in circulation is 90 minutes. Cortisol is metabolized in the liver to the inactive metabolites dihydrocortisol and tetrahydrocortisol, which become conjugated to glucuronidate and excreted in the urine. These urinary metabolites, collectively known as *17-hydroxycorticosteroids,* as well as free cortisol, can be measured in the urine.

Cortisol binds to specific intracellular cytoplasmic receptors, causing translocation of activated receptor–ligand complexes to the nucleus. Biologic effects result from transcriptional activation of genes and may be grouped into intermediary metabolism, immunomodulation, and regulation of intravascular volume (Table 77-1). Important effects of cortisol on intermediary metabolism center on raising blood glucose directly and indirectly by providing substrate for gluconeogenesis by the liver. These effects include (a) stimulation of glucagon and inhibition of insulin-stimulated glucose uptake by cells; (b) decrease in peripheral protein synthesis and increase in proteolysis, thus delivering gluconeogenic amino acids to the liver; and (c) stimulation of peripheral lipolysis. In effect, cortisol acts anabolically in vital organs to preserve glucose supply and catabolically in peripheral tissues to mobilize gluconeogenic substrates. Cortisol also possesses profound anti-inflammatory and immunosuppressive activities. Impairment of cellular immunity is due to inhibition of interleukin production, impairment of monocyte and neutrophil chemotaxis despite raised leukocyte counts, and reduction of T-cell activation. Humoral immunity is inhibited by inhibition of T-cell stimulation of B cells and by direct inhibition of B-cell proliferation and activation. These immunomodulatory effects may also underlie the impairment of normal wound healing seen in states of cortisol excess. Cortisol also regulates intravascular volume through renal retention of sodium and maintains blood pressure through inotropic and chronotropic effects on the heart as well as by increasing peripheral vascular resistance. In bone, glucocorticoids promote osteopenia by inhibition of bone formation by osteoblasts.

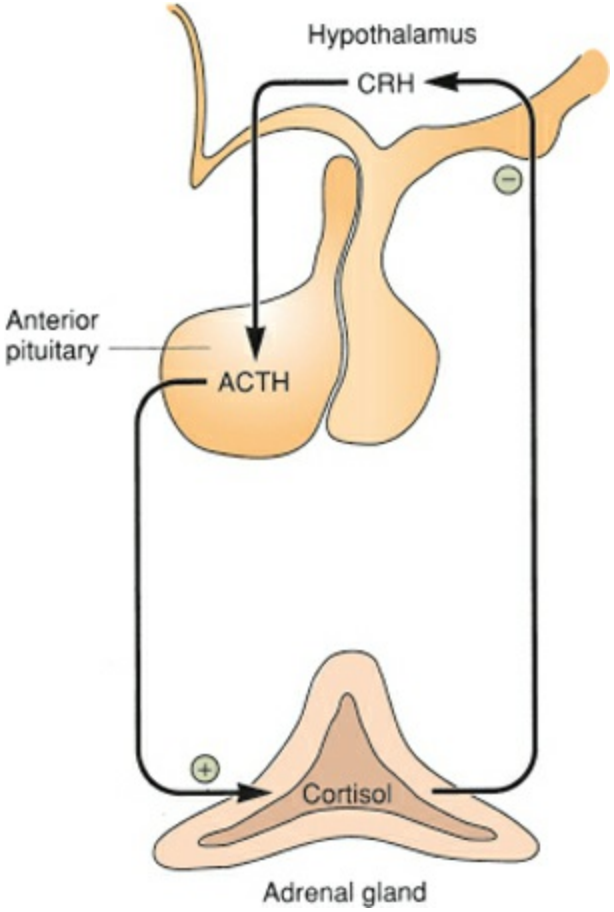

Figure 77-3. Schematic of hypothalamic–pituitary–adrenal axis for cortisol. Regulatory feedback relationships are designated with *arrows*.

Table 77-1 Systemic Effects of Cortisol

Function	Normal Amounts	Excessive Amounts
Metabolic		
Protein	Proteolysis	Muscle wasting
Glucose	Gluconeogenesis	Hyperglycemia
Fat	Low-use peripheral lipolysis	Limb thinness
	Central lipogenesis	Truncal obesity
Gastrointestinal	Mucosal cells	Ulceration
	Prostaglandin	Pancreatitis
Cardiovascular	Chronotropic, inotropic	Hypertension
	Vascular resistance	
Renal	Sodium resorption	Hypertension
Bone	Osteoblastic development	Osteoporosis
Inflammatory and immune	Circulating cells	Infection
	Soluble mediators	
	Antigen processing	
Wound healing	Fibroblasts	Striae
	Epithelial cell	Dehiscence

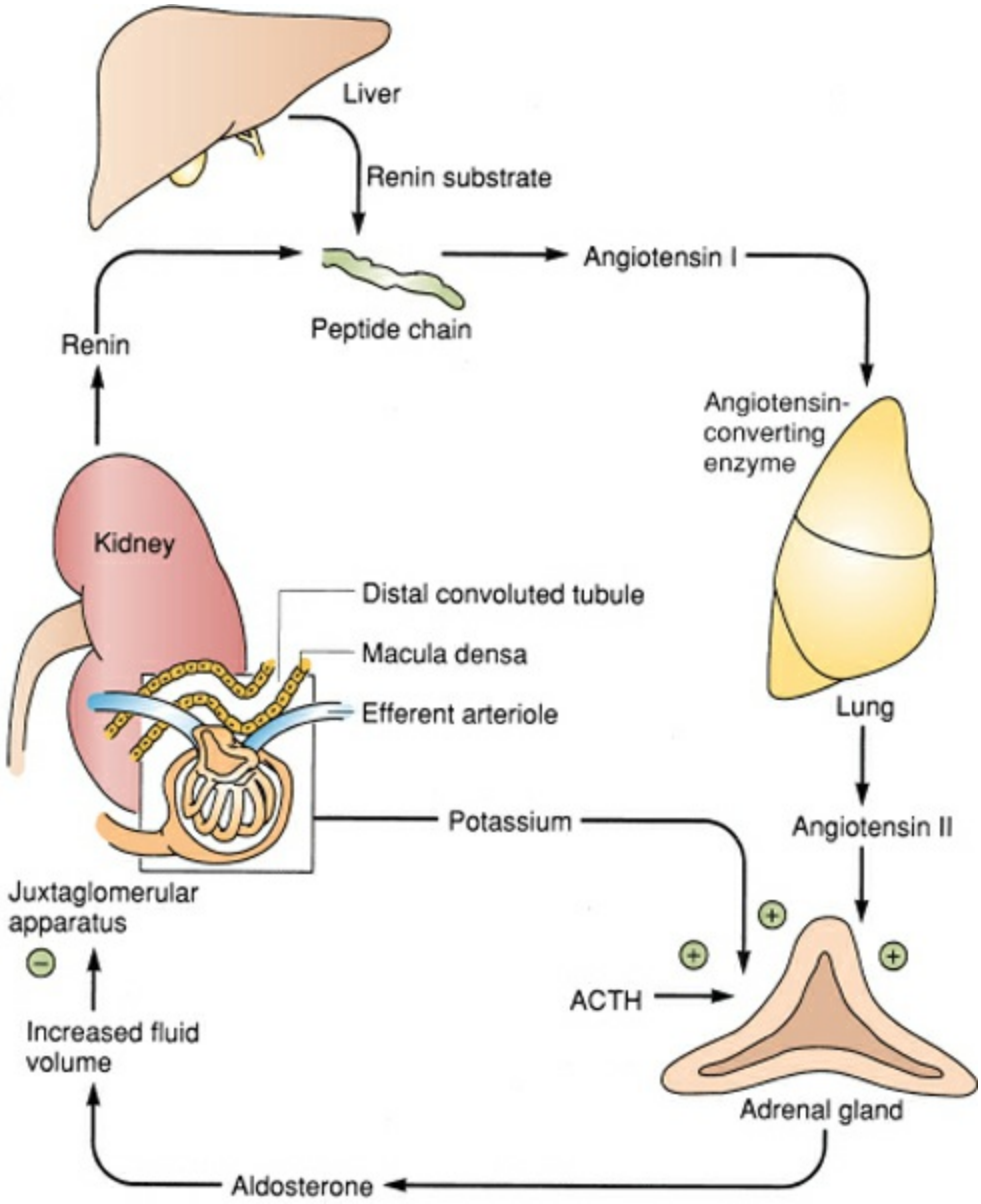

Figure 77-4. Regulatory relationships of renin, the angiotensins, and their sites of production and enzymatic conversion.

Aldosterone

Aldosterone is the principle mineralocorticoid in humans. Aldosterone secretion by the cells of the adrenal zona glomerulosa is regulated by the renin–angiotensin system and by plasma potassium (Fig. 77-4). Aldosterone is also regulated to a lesser degree by ACTH and plasma sodium concentration. Juxtaglomerular myoepithelial cells lining afferent arterioles of the kidney sense renal blood flow and pressure, and they secrete renin in response to decreased perfusion. Renin enzymatically activates angiotensinogen to the inactive decapeptide precursor, angiotensin I. Angiotensin I is converted to angiotensin II by angiotensin-converting enzyme in the lung. Angiotensin II has three major effects: (a) arteriolar vasoconstriction; (b) renal sodium retention; and (c) increased aldosterone biosynthesis, each of which results in sodium retention and potassium excretion by the kidney. These effects work together to maintain arterial blood pressure as well as blood volume. Physiologic conditions that stimulate the renin–angiotensin cascade and aldosterone release include dehydration, upright posture, and hemorrhage. Inhibitory

factors include volume repletion. Postural changes in renin–angiotensin and aldosterone are mediated by the sympathetic nervous system.

Under normal circumstances, aldosterone secretion is controlled by total body sodium and potassium levels. Excess sodium intake suppresses renin activity and leading to decreased aldosterone levels and increased renal excretion of sodium. Conversely, sodium depletion stimulates the renin–angiotensin system and aldosterone production, which promotes sodium retention by the kidney. Increased potassium intake directly decreases renin release and aldosterone production; decreasing potassium intake increases renin release. Humans with normal sodium intake typically produce 100 to 150 mg of aldosterone per day.

In circulation, aldosterone is bound to albumin and transcortin with a small percentage of free aldosterone available to target tissues. The half-life of aldosterone in plasma is 15 minutes. Aldosterone is metabolized rapidly in the liver and conjugated to glucuronidate, which is excreted in the urine. In liver failure, metabolism of aldosterone is impaired leading to elevated levels and fluid retention.

Aldosterone is the major regulator of extracellular fluid volume and potassium homeostasis (Table 77-2). Aldosterone binds to high-affinity aldosterone receptors in target tissues, including cells of the distal convoluted tubule in the kidney (the major site of action), the salivary glands, and colonic mucosa (minor sites). Stimulation of these cells results in retention of sodium and excretion of potassium. Retention of sodium in the kidney leads to passive reabsorption of water and an increase in extracellular fluid volume. To balance aldosterone-mediated retention of positively charged sodium ions, the kidney epithelium releases intracellular potassium into the distal convoluted tubule for excretion in the urine. Hydrogen ion is also released causing acidification of the urine.

Table 77-2 Effects of Aldosterone Secretion

Tubular Action	Normal Amounts	Excessive Amounts
Increased resorption of sodium	Protects against low-volume states	Hypertension Positive sodium balance Hyporeninemia
Decreased resorption of potassium	Protects against hyperkalemia	Hypokalemia Metabolic alkalosis Hyperglycemia Nocturia, polyuria Muscle weakness

Adrenal Androgens

Adrenal C-19 androgenic steroids, include DHEA and delta-4-androstenedione, are synthesized in cells of the zona reticularis. These steroids promote secondary sexual characteristics in men and virilization in women. DHEA is the major adrenal androgen, while androstenedione is relatively minor. Both are relatively weak androgens and exert

their effects on target tissue after local tissue conversion to testosterone. Unlike gonadal androgens, adrenal androgens are regulated by ACTH, not gonadotropins, and can therefore be inhibited by glucocorticoid administration.

Adrenal Medulla

2 Catecholamines of the adrenal medulla include epinephrine, norepinephrine, and dopamine. These vasoactive hormones are synthetic derivatives of the amino acid tyrosine (Fig. 77-5). The biosynthetic pathway that converts tyrosine to active catecholamines involves four sequential enzymatic reactions: (a) tyrosine is converted to L-dihydroxyphenylalanine (dopa) by tyrosine hydroxylase; (b) dopa is converted to dopamine by aromatic-L-amino acid decarboxylase; (c) dopamine is converted to norepinephrine by dopamine beta hydroxylase; and (d) norepinephrine is converted to epinephrine by phenylethanolamine-N-methyltransferase (PNMT). Epinephrine is the major (80%) catecholamine stored in the adrenal medulla, followed by norepinephrine (20%) and dopamine (<1%). Tissue expression of the enzyme PNMT is limited to cells of either the adrenal medulla or organ of Zuckerkandl, located near the aortic bifurcation, thus most extraadrenal pheochromocytomas produce norepinephrine, rather than epinephrine.

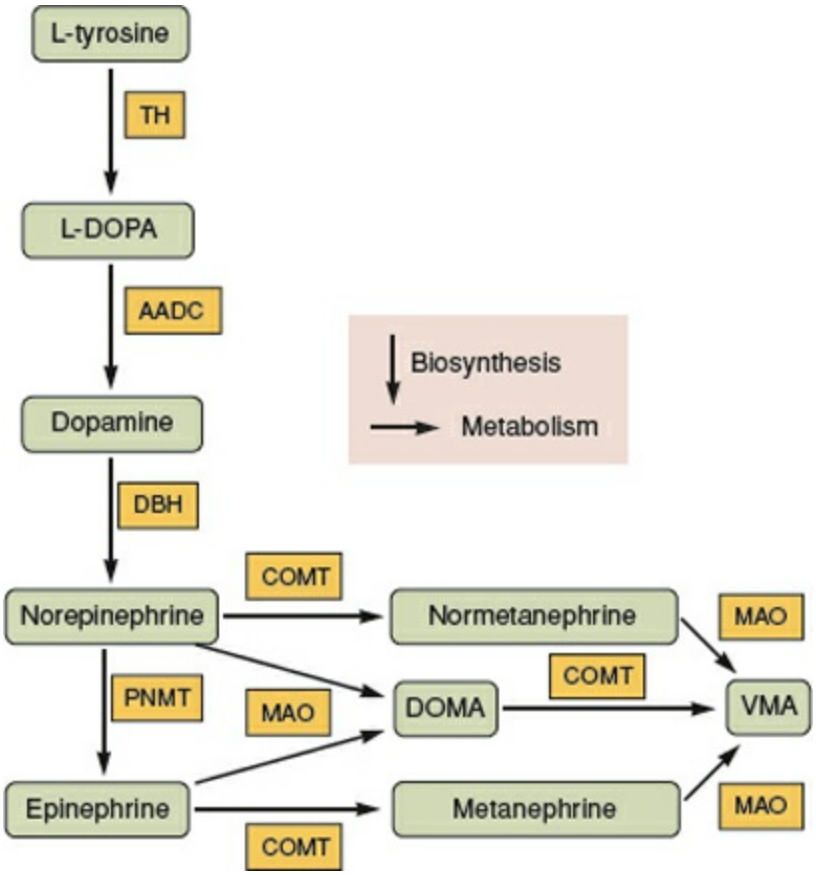

Figure 77-5. Catecholamine biosynthetic and metabolic pathways. Precursors, catecholamines, and metabolites are shown in *square boxes*. Enzymes are shown in *stippled boxes*. Enzyme gene symbol designations are: TH, tyrosine hydroxylase; AADC, aromatic-L-amino acid decarboxylase; DBH, dopamine-β-hydroxylase; PNMT, phenylethanolamine-N-methyltransferase; COMT, catechol-O-methyl-transferase; MAO, monoamine oxidase. VMA, 3-methoxy-4-hydroxy-mandelic acid.

A complex regulatory network governs synthesis and secretion of catecholamines. Factors that increase catecholamine release include splanchnic nerve stimulation, stress, and glucocorticoids. The metabolic milieu within the adrenal medulla also greatly

influences catecholamine synthesis by regulating enzymatic activity: glucocorticoids, phospholipids, cyclic adenosine monophosphate, adenosine triphosphate, protein kinase, and magnesium increase activity of PNMT and decrease catecholamine negative feedback. Catecholamines are stored and secreted from granules within cells of the medulla in association with the matrix protein chromogranin. Chromogranin A is measurable in the blood and their measurement may support the biochemical testing for pheochromocytoma, as well as other functional neuroendocrine tumors.

Catecholamines act on target tissues through membrane-bound receptors. Pharmacologic distinction of adrenergic receptors is made based on their relative responsiveness to natural and artificial bioamines. Alpha-adrenergic receptors show highest affinity for norepinephrine, less for epinephrine, and least for isoproterenol. Beta-adrenergic receptors are most responsive to isoproterenol and least to norepinephrine. In addition, specific antagonists recognize each receptor class: alpha-receptors are antagonized by phentolamine and phenoxybenzamine, and beta-receptors are blocked by propranolol and related compounds. Beta-adrenergic receptor subtypes include beta-1, which is present in cardiac muscle, adipose tissue, and small intestine, and beta-2 receptors, which are found in vascular, tracheal, and uterine smooth muscle, skeletal muscle, and liver. Alpha-adrenergic receptors are similarly subdivided: alpha-1 receptors mediate vasoconstriction whereas alpha-2 receptors modulate presynaptic norepinephrine release and platelet aggregation (Table 77-3).

Metabolism of catecholamines occurs through three mechanisms: by specific uptake by sympathetic neurons, by nonspecific uptake and degradation by peripheral tissues, and by excretion in the urine. Catecholamines are metabolized in liver and kidney by two enzymes, monoamine oxidase and catechol-O-methyltransferase (Fig. 77-5). In these tissues, monoamine oxidase and catechol-O-methyltransferase convert epinephrine or norepinephrine to normetanephrine, and metanephrine, 3,4-dihydroxy-mandelic acid, and 3-methoxy-4-hydroxy-mandelic acid. These inactive metabolites are excreted by the kidney and are measurable in the urine either as free compounds or as conjugates of glucuronide or sulfate.

Table 77-3 Catecholamine Effects

Receptor Class	Normal Amounts	Excessive Amounts
β_1	Chronotropic, inotropic Sweat glands Decreased glucose use	Tachycardia Sweating Hyperglycemia
β_2	Smooth muscle relaxation	Hypotension
α_1	Smooth muscle contraction Gluconeogenesis Glycogenolysis Suppressed insulin effects	Hypertension Hyperglycemia
$\alpha 2$	Smooth muscle contraction[a]	Pallor

[a]Platelet aggregation.

DISEASES OF THE ADRENAL CORTEX

Hypercortisolism

The term *hypercortisolism* refers to the physiologic state of glucocorticoid excess. This disorder is rare, with an estimated incidence of 10 per million population. The most common cause of hypercortisolism is the administration of exogenous steroids as immunosuppressive therapy for inflammatory disorders or after organ transplantation. Endogenous hypercortisolism, or Cushing syndrome, in all cases is caused by increased adrenal production of cortisol, which may be ACTH dependent (ACTH elevated) or independent (ACTH suppressed). Some patients with major depression or chronic alcoholism have abnormally high cortisol secretion and may appear to have clinical and biochemical features of Cushing syndrome. Pseudo-Cushing syndrome responds to treatment of the underlying disorder.

3 Cushing syndrome is ACTH dependent in 80% to 90% of cases. Such ACTH-dependent hypercortisolism is most often (80% to 90% of cases) caused by an ACTH-secreting pituitary adenoma (termed *Cushing disease*). Ectopic ACTH-producing nonendocrine tumors (mostly non–small-cell lung cancer and bronchial carcinoids) represent 10% to 20% of cases of ACTH-dependent Cushing syndrome. All causes of ACTH-dependent Cushing syndrome involve bilateral adrenal hyperplasia in response to ACTH stimulation.

Of patients with endogenous Cushing syndrome, 10% to 25% have ACTH-independent disease caused by a primary adrenal cause. A solitary adrenal adenoma is present in 80% to 90% of these patients and is often associated with atrophy of both adjacent and contralateral adrenocortical tissue. Nodular cortical hyperplasia of both glands causes the remaining cases of primary adrenal Cushing syndrome. Although nodular hyperplasia represents a diffuse process, one or more distinct nodules may simulate adenomas. Rarely tumors secrete CRH ectopically, leading to ACTH-independent (though ACTH is elevated) Cushing syndrome with secondary adrenal hypertrophy.

Signs and Symptoms

Clinical features of cortisol excess are listed in Table 77-1. Truncal obesity (*orange on toothpicks*), accumulation of fat around the head and neck (*moon facies* and *buffalo hump*), and muscle wasting are present in most patients. Patients often have purple striae and purpura on the abdomen and extremities. Hirsutism may be present in women. High blood pressure is common and is usually moderate, although malignant hypertension has been observed. Bone pain and muscle weakness (caused by proximal muscle wasting and hypokalemia) are also common. Osteoporosis is common and pathologic fractures are observed in advanced cases. Neurologic symptoms, including headache, emotional lability, depression, and even psychosis may be observed. Glucose intolerance is common but can often be managed by alterations in diet alone. The serum potassium level may be low secondary to the weak mineralocorticoid properties of cortisol. Autonomous glucocorticoid production without specific signs and symptoms of Cushing syndrome is termed subclinical Cushing syndrome. This condition is being diagnosed with increased

frequency because of the detection of adrenal incidentalomas by routine CT. A substantial percentage of incidentalomas are hormonally active, with 5% to 20% of the tumors producing glucocorticoids. The estimated prevalence of subclinical hypercortisolism is 79 cases per 100,000 persons, substantially higher than classic Cushing syndrome. Depending on the amounts of glucocorticoids secreted by the tumor, the clinical spectrum ranges from slightly attenuated diurnal cortisol rhythm to atrophy of the contralateral adrenal gland. Patients with subclinical Cushing syndrome lack the classical stigmata of hypercortisolism but have a high prevalence of obesity, hypertension, and type 2 diabetes.

Diagnosis

The investigation of suspected Cushing syndrome should answer two questions: (a) Does the patient have hypercortisolism? (b) If the answer is yes, then what is the cause? It is worthwhile to emphasize that the diagnosis of Cushing syndrome is biochemical. Radiologic investigations should not be undertaken until Cushing syndrome has been confirmed and its likely etiology characterized biochemically.

Hypercortisolism insensitive to suppression by administration of exogenous glucocorticoid is the *sine qua non* of Cushing syndrome. The low-dose dexamethasone suppression test is the best test in patients with suspected Cushing syndrome. For this test, 1 mg of dexamethasone is administered orally at 11 PM and plasma cortisol is obtained at 8 AM the following day. Normal individuals suppress cortisol to below 5 μg/dL. Patients with Cushing syndrome fail to suppress below 5 μg/dL. False-positive test results occur in 10% to 15% of cases with the overnight test and occur especially in patients with obesity or alcoholism or in those taking estrogens or phenytoin. Measurement of free cortisol (not metabolites) in three consecutive 24-hour collections of urine is also a good screening test for Cushing syndrome. Collections should include concurrent creatinine measurement to evaluate the completeness of the collection. A 24-hour urinary-free cortisol level greater than 100 μg is diagnostic of Cushing syndrome. This test may be less sensitive than the low-dose dexamethasone suppression test in mild hypercortisolism. Plasma cortisol levels can normally vary considerably during a 24-hour period, so a single random plasma cortisol level is not helpful in establishing a diagnosis of Cushing syndrome.

Once the presence of hypercortisolism is established, the next task is to determine ACTH-dependent (pituitary or ectopic source) from ACTH-independent (primary adrenal) causes. Measurement of basal ACTH by immunoradiometric assay is the best test to make this distinction. Plasma ACTH levels are normally between 10 and 100 pg. Suppression of the absolute level of ACTH below 5 pg/mL is nearly diagnostic of adrenocortical neoplasms, which secrete high levels of cortisol and inhibit ACTH release by the pituitary. Patients with pituitary neoplasms and secondary bilateral adrenocortical hyperplasia have ACTH levels that may range from the upper limits of normal (15 pg/mL) to 500 pg/mL. The highest plasma levels of ACTH (more than 1,000 pg/mL) are in patients with ACTH-producing nonendocrine tumors, such as non–small-cell lung cancer.

Although 80% to 90% of patients with ACTH-dependent Cushing syndrome have Cushing disease, a high dose dexamethasone suppression test may be required to exclude ectopic ACTH syndrome. Hypercortisolism caused by ACTH-secreting pituitary adenomas is suppressed at least partially by high dexamethasone, whereas hypercortisolism caused by adrenal tumors and ectopic ACTH-producing tumors is not suppressed. For this test 2 mg dexamethasone is administered orally every 6 hours for 2 days, and a 24-hour urine collection for free cortisol is taken during the second day. About 90% of patients with pituitary source Cushing disease have a 50% reduction in urine-free cortisol. The specificity of the test can be improved to 100% for diagnosing pituitary disease if more than 90% suppression in urinary-free cortisol is used.

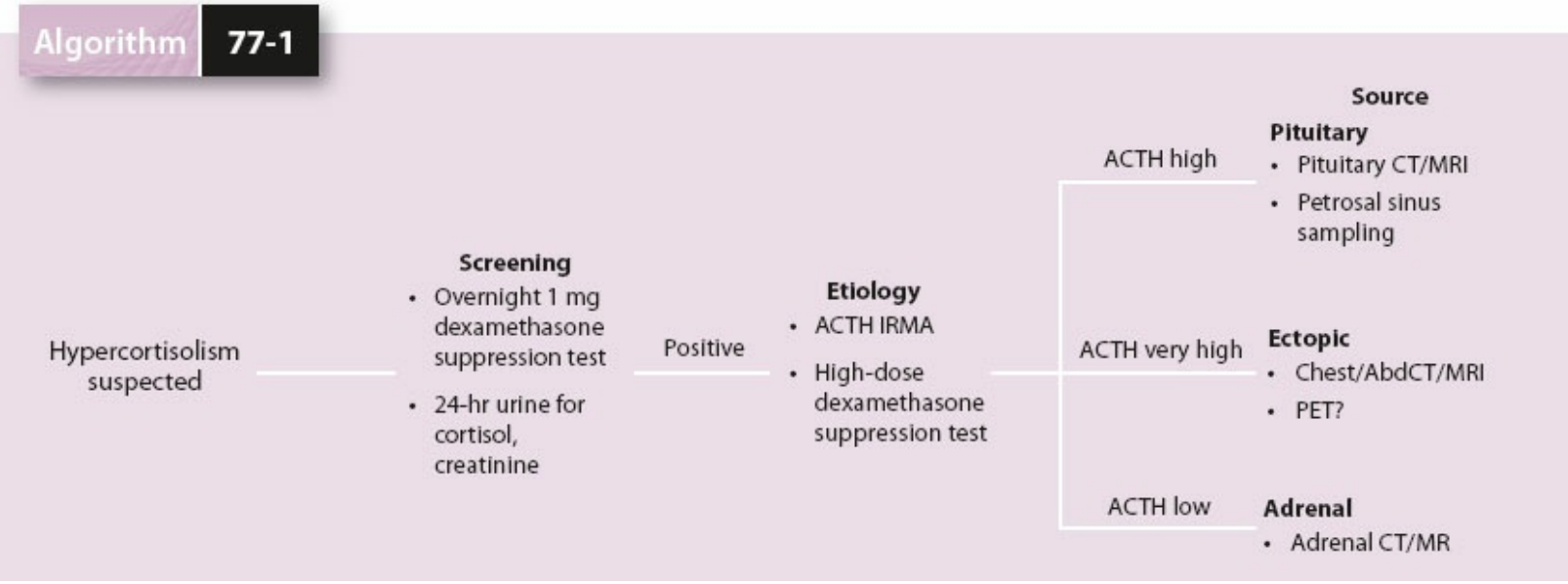

Algorithm 77-1. Diagnosis of hypercortisolism. ACTH, adrenocorticotropic hormone; IRMA, immunoradiometric assay; CT, computed tomography; MRI, magnetic resonance imaging; PET, positron emission tomography.

Biochemical testing of suspected Cushing syndrome is followed by radiologic studies. Pituitary adenomas are best imaged with gadolinium-enhanced magnetic resonance imaging (MRI) of the sella turcica, which has a sensitivity approaching 100%, although small pituitary microadenomas may be missed. Patients with ACTH-independent Cushing syndrome require thin-section CT or MRI of the adrenal, which identifies adrenal abnormalities with more than 95% sensitivity. CT or MRI of the chest may identify a source of ectopic ACTH and should be undertaken in patients with elevated ACTH and hypercortisolism that cannot be suppressed by high-dose dexamethasone.

Despite the accuracy of biochemical testing and radiographic localization, a pituitary versus ectopic source of ACTH sometimes cannot be determined. Bilateral inferior petrosal sinus sampling is the best test to settle this issue. Simultaneous bilateral petrosal sinus and peripheral blood samples are obtained before and after peripheral intravenous injection of 1 μg/kg CRH. An inferior petrosal sinus to peripheral plasma ACTH ratio of 2.0 at basal stimulated or of 3.0 after CRH administration is 100% sensitive and specific for pituitary adenoma. Comparison of right and left inferior petrosal sinus ratios may also lateralize the adenoma.

The laboratory approach to the diagnosis of Cushing syndrome is summarized in Algorithm 77-1. A careful history and physical examination form the basis for suspecting this condition. A low-dose dexamethasone suppression test and/or urinary-free cortisol measurement provide initial evidence for the diagnosis. Plasma ACTH determination and the high-dose dexamethasone suppression test are then used to identify the underlying cause of excess cortisol production by the adrenal cortex. Imaging studies support the cause of Cushing syndrome suggested by biochemical testing and localize the site for subsequent treatment.

Treatment

ACTH-dependent Cushing syndrome is best treated by removing the source of ACTH excess. In the case of Cushing disease, transsphenoidal resection of the pituitary microadenoma is successful in 80% or more of cases. If a microadenoma is not found, then hemihypophysectomy may be performed with the understanding that fertility may be impaired. Pituitary irradiation is a good treatment option when fertility is desired, when a tumor is not found or is unresectable, or cure is not achieved by transsphenoidal resection of a tumor. Debulking of unresectable primary lesions or recurrences with or without bilateral adrenalectomy may provide palliation in some patients. Treatment of ectopic ACTH syndrome involves removal of the primary lesion. Medical adrenalectomy with metyrapone, aminoglutethimide, and mitotane has been used to suppress production of corticosteroid in inoperable cases for both pituitary and ectopic sources of ACTH. Bilateral adrenalectomy is a good option for patients intolerant of mitotane.

ACTH-independent Cushing syndrome is best treated by removal of the adrenal tumor and affected gland. Small lesions, less than 6 cm in diameter, may be resected laparoscopically. Lesions larger than 6 cm or those suspected of being carcinoma require an anterior open approach. Resection of cortisol-producing benign adrenal adenomas is curative and prognosis is good following resection. Cortisol-producing adrenocortical carcinomas recur frequently following adrenalectomy, heralded by the reemergence of hypercortisolism. Micronodular pigmented hyperplasia and macronodular adrenal hyperplasia may involve both adrenal glands. These conditions are cured only by bilateral adrenalectomy. Medical adrenalectomy with mitotane or agents interfering with cortisol production is not currently recommended.

Whether patients with subclinical Cushing syndrome should undergo adrenalectomy is unclear. Several small series have demonstrated weight loss, an improvement in hypertension and glucose control following adrenalectomy for subclinical Cushing syndrome. Furthermore, patients with subclinical Cushing syndrome may progress to overt Cushing syndrome as frequently as 12.5% at 1 year. Accordingly, adrenalectomy for subclinical Cushing syndrome may be beneficial and is reasonable in young patients, patients with suppressed plasma ACTH, and patients with a recent weight gain, substantial obesity, arterial hypertension, diabetes mellitus, and osteopenia. Truly asymptomatic patients with normal plasma ACTH concentrations and the elderly or unfit may be observed. Demonstration of the benefits of surgery versus conservative treatment in patients with subclinical Cushing syndrome will require a randomized prospective trial.

All patients who undergo adrenalectomy for Cushing syndrome require perioperative and postoperative glucocorticoid replacement, since the contralateral gland is suppressed. Replacement therapy with hydrocortisone, 12 mg/m^2 per day, may be required as long as 2 years postoperatively. Adequacy of replacement is monitored clinically. The duration of replacement therapy is guided by normalization of the ACTH stimulation test.

Hyperaldosteronism

Hyperaldosteronism is a syndrome of hypertension and hypokalemia caused by autonomous adrenal secretion of the mineralocorticoid aldosterone. Hyperaldosteronism may be primary, as a result of an adrenal neoplasm with suppressed plasma renin, or may be secondary, as a result of elevated plasma renin. Primary hyperaldosteronism is twice as common in women as in men, and it usually occurs between the ages of 30 and 50 years. Screening of hypertensive patients with plasma aldosterone and plasma renin activity (PRA) has suggested that primary hyperaldosteronism may be the underlying cause of up to 15% of cases of essential hypertension.

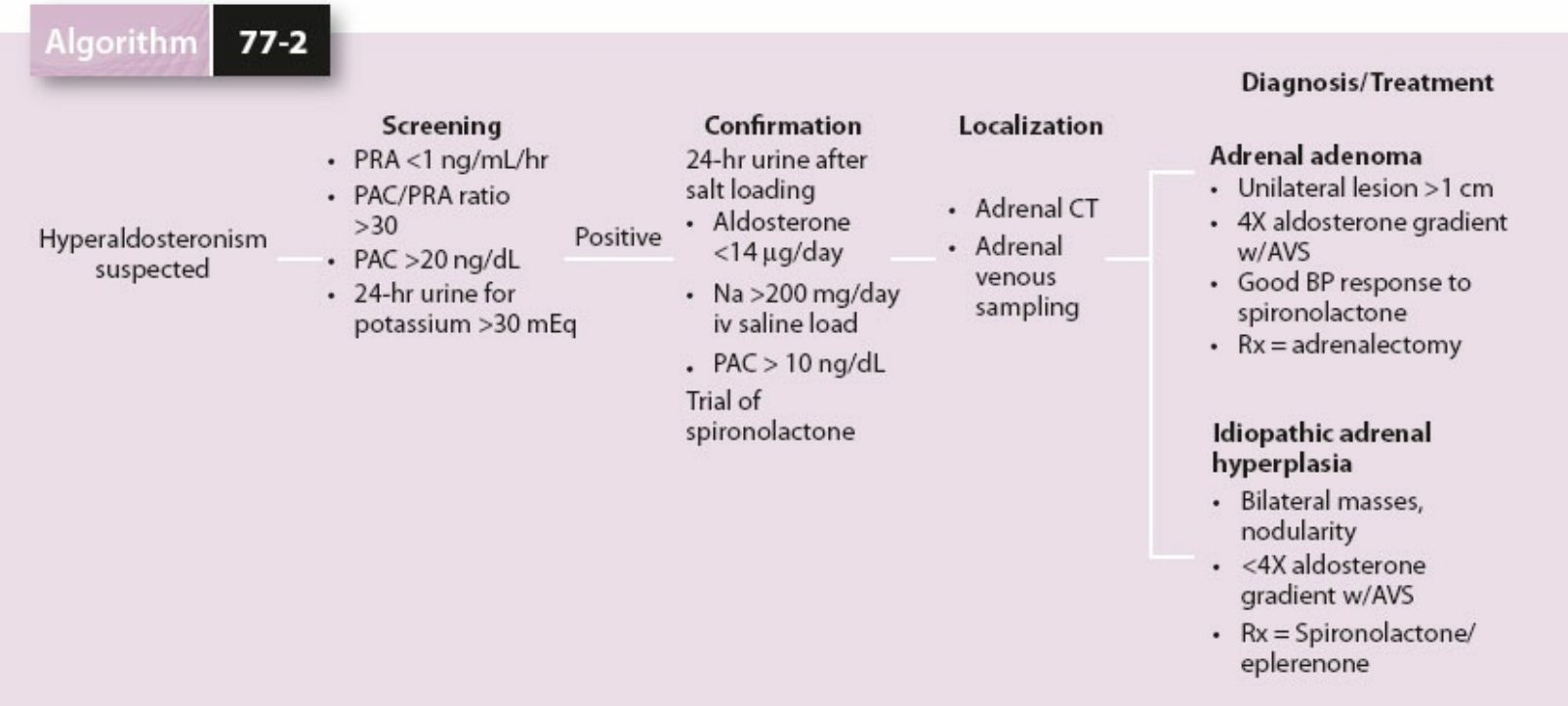

Algorithm 77-2. Diagnosis and management of hyperaldosteronism. PRA, plasma renin activity; PAC, plasma aldosterone concentration; CT, computed tomography; AVS, bilateral adrenal venous sampling.

4 An aldosterone-producing adrenal adenoma (Conn syndrome) is the source of primary hyperaldosteronism in 60% to 70% of cases. Idiopathic bilateral adrenal hyperplasia causes the remaining cases of primary hyperaldosteronism. Adrenocortical carcinoma is a rare cause of primary hyperaldosteronism. Autosomal dominant glucocorticoid-suppressible hyperaldosteronism is a rare cause of hyperaldosteronism resulting from the fusion of the ACTH-responsive 11-beta hydroxylase gene promoter to the aldosterone synthase gene in cells of the adrenal cortex.

Secondary hyperaldosteronism is a physiologic response of the renin–angiotensin system to decreased renal perfusion due to renal artery stenosis, cirrhosis, congestive heart failure, and normal pregnancy. The adrenal cortex functions normally and secretes aldosterone in response to the elevated plasma renin and angiotensin caused by these conditions. Secondary hyperaldosteronism responds to treatment of the underlying cause.

Signs and Symptoms

Clinical manifestations of primary hyperaldosteronism are attributable to hypersecretion of aldosterone by the adrenal gland (Table 77-2). Aldosterone-mediated retention of sodium and excretion of potassium and hydrogen ion by the kidney causes moderate diastolic hypertension. Edema is absent. Hypokalemia occurs spontaneously in 80% to 90% of patients with primary hyperaldosteronism but may be normal. Hypokalemia is easily provocable in the remaining patients. Potassium depletion frequently causes symptoms of muscle weakness and fatigue, polyuria and polydipsia, as well as impaired insulin secretion and fasting hyperglycemia. Primary hyperaldosteronism should be suspected in hypertensive patients with spontaneous hypokalemia (serum concentration <3.5 mEq/L), moderate hypokalemia (serum potassium concentration <3.0) during diuretic therapy despite concomitant use of oral potassium or potassium-sparing diuretics, or refractory hypertension without explanation.

Diagnosis

The clinical hallmarks of primary hyperaldosteronism are (a) diastolic hypertension without edema; (b) suppression of plasma renin in the face of volume depletion; and (c) hypersecretion of aldosterone that fails to suppress with intravascular volume expansion. Diagnostic evaluation must establish primary hyperaldosteronism, discern surgically correctable adrenal adenoma from medically treatable idiopathic hyperplasia, and localize an adrenal tumor (Algorithm 77-2).

Demonstration of an elevated plasma aldosterone concentration (PAC) in the setting of suppressed PRA is the best test to establish primary hyperaldosteronism. The ratio in normal subjects and patients with essential hypertension is 4:10 compared with more than 30 in most patients with primary hyperaldosteronism. A PAC of greater than 20 ng/dL and a PAC/PRA ratio of greater than 30 are diagnostic for aldosteronoma with almost 90% sensitivity. A serum potassium value less than 3.5 mEq/L and urinary potassium excretion greater than 30 mEq/day also support a diagnosis of primary hyperaldosteronism. Before biochemical evaluation, patients need to be potassium repleted and have an adequate sodium intake. Medications including ACE inhibitors and spironolactone should be withheld for at least 4 weeks before study.

An elevated PAC/PRA ratio alone does not establish the diagnosis of primary hyperaldosteronism, which must be confirmed by demonstrating inappropriate aldosterone secretion with salt loading. This involves a 24-hour urine collection for sodium and aldosterone after 3 days of a high-sodium diet. The 24-hour urinary excretion of aldosterone should be greater than 14 μg per 24 hours after a high-salt diet for patients with primary hyperaldosteronism. An intravenous saline infusion test or captopril challenge test is also a reliable method to confirm primary hyperaldosteronism. These tests are not usually required.

After the diagnosis of primary hyperaldosteronism is made, distinction must be made between an aldosteronoma and idiopathic adrenal hyperplasia. The first test measures aldosterone in blood collected at 8 AM from a patient who has been supine overnight. Laboratory studies are repeated 4 hours later after the patient has been upright. Aldosterone secretion in patients with an aldosteronoma is unaffected by postural changes

(<20 ng/dL), whereas, in patients with idiopathic adrenal hyperplasia, plasma aldosterone levels are elevated 33% (>20 ng/dL) or more by postural changes.



Figure 77-6. Computed tomography scan of right adrenal aldosteronoma. *Short arrow* shows aldosteronoma. *Long arrow* shows normal contralateral adrenal gland.

High-resolution adrenal computed tomography (CT) is the best test for localization of an adrenal tumor (Fig. 77-6). CT will detect an aldosterone-producing adenoma in 90% of cases overall. The presence of a unilateral adenoma greater than 1 cm on CT and supportive biochemical evidence of an aldosteronoma are generally all that is needed to make the diagnosis in most patients under 40 years of age. MRI is less effective and more costly but may be useful during pregnancy or in situations in which intravenous contrast medium injection is undesirable. The test of 6-[beta](131-I)-iodo-methyl-19-norcholesterol (NP-59) scintigraphy identifies functional tumors and discriminates aldosteronoma from adrenal hyperplasia with an overall accuracy of approximately 75%, but requires a tumor of sufficient size (>1 cm) for imaging to be dependable.

Adrenal vein sampling to lateralize the source of aldosterone production is useful in patients with hyperaldosteronism when there is no adrenal abnormality on CT or MRI or when both adrenal glands are abnormal but asymmetric. Further, patients older than 40 years, in whom the possibility of a nonfunctioning adenoma is statistically higher, may benefit from routine sampling. Percutaneous transfemoral cannulation of both adrenal veins is performed and intravenous ACTH (50 μ/hr) is administered. Simultaneous adrenal vein blood samples for aldosterone and cortisol are taken before and after ACTH injection, and their ratios are determined. The PAC is markedly higher (at least fourfold) on the side of an adenoma, whereas there is little or no left–right gradient present in cases of bilateral adrenal hyperplasia. A 10-fold gradient of cortisol in adrenal veins to a peripheral sample ensures adequacy adrenal vein cannulation. This study is greater than 90% accurate and has been shown to alter management in 30% to 50% of patients, even in those with an apparent unilateral adenoma. This test is technically difficult and may be

unsuccessful in 25% of patients. Emerging data suggest that adrenal vein sampling may be superior to CT in differentiating the source of aldosterone production in patients with hyperaldosteronism.

Treatment

5 Surgical removal of an aldosterone-secreting adenoma (Fig. 77-7) results in durable improvement of hypertension and hypokalemia in 70% to 90% of patients. Laparoscopic adrenalectomy is the preferred approach to remove these tumors. Morbidity and mortality following these procedures are almost negligible. Preoperative spironolactone or eplerenone and potassium are given to replenish potassium stores and correct alkalosis before anesthesia. Preoperatively, a significant fall in blood pressure with aldosterone receptor antagonists predicts a successful outcome after adrenalectomy. Response to adrenalectomy is also influenced by the duration and severity of hypertension and by the presence of histologic changes in the kidney. Age greater than 50 years, male sex, and the presence of multiple nodules within the adrenal is also associated with a poor response to surgery.

Management of idiopathic adrenal hyperplasia is medical because fewer than 20% to 30% of patients with this disease are cured by adrenalectomy. Idiopathic adrenal hyperplasia is treated with spironolactone or with newer aldosterone antagonist eplerenone. Other potassium sparing diuretics may be used including triamterene and amiloride. Treatment of glucocorticoid-suppressible hyperaldosteronism includes dexamethasone 0.5 to 1.0 mg daily. Glucocorticoids are used in small doses to avoid Cushing syndrome.

Congenital Adrenal Hyperplasia

6 The congenital adrenal hyperplasias are autosomal recessive conditions resulting from inherited defects of one or several of the enzymes necessary for cortisol biosynthesis (Fig. 77-8). Cortisol deficiency leads to ACTH overproduction and secondary hyperplasia of the adrenal cortex with shunting of cortisol precursors into adrenal androgen pathways. Peripheral tissues convert the excess adrenal androgens to testosterone, which causes virilization of the patient.

Most cases (>90%) of congenital adrenal hyperplasia are secondary to deficiency of 21-hydroxylase (CYP21A2) resulting from mutation of the gene on the short arm of chromosome 6. Two forms of this deficiency are recognized; partial or complete. The complete form is characterized by androgen excess at birth, with virilization, hypovolemia, hyponatremia, hyperkalemia, and hyperpigmentation. The partial form is characterized by virilization only and may present in adolescence or adulthood.



Figure 77-7. Aldosteronoma within right adrenal gland shown in Figure 77-6.

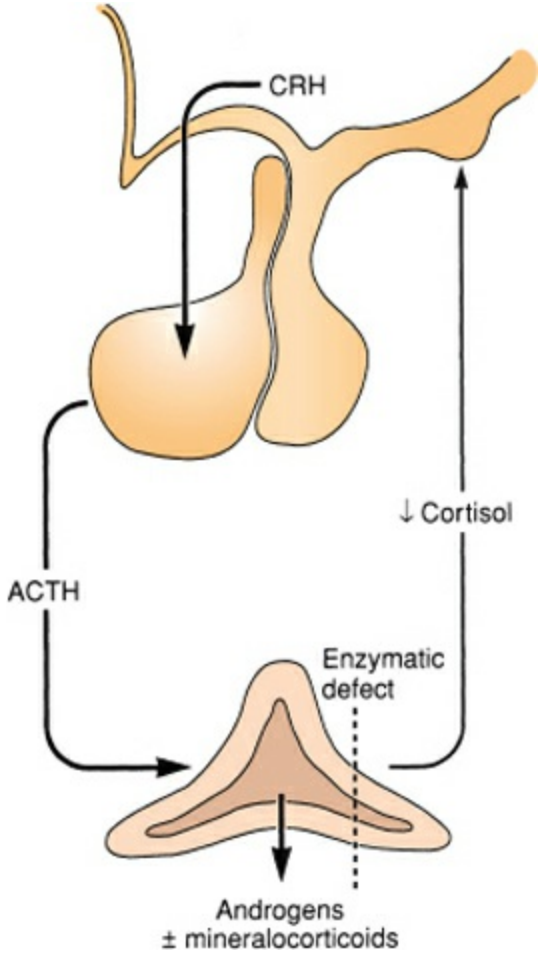

Figure 77-8. Schematic representation of the mechanism underlying congenital adrenal hyperplasias. Enzymatic defects in the adrenal gland prevent normal production of cortisol with resulting loss of negative feedback to the hypothalamus and pituitary. Chronic adrenocorticotropic hormone stimulation of the adrenal gland shunts steroid precursors through androgenic and mineralocorticoid pathways, leading to the overproduction of androgens and mineralocorticoids. The most common deficiencies are CYP21A2 (21-hydroxylase), CYP11B1 (11β-hydroxylase), and 3-β-HSD (3-β-hydroxysteroid dehydrogenase).

Of the remaining causes of congenital adrenal hyperplasia, 11-beta-hydroxylase deficiency (CYP11B1) is the second-most common cause, followed by 3-beta-hydroxydehydrogenase and 17-hydroxylase (CYP17) deficiency. Congenital lipoid adrenal hyperplasia is the most severe form of congenital adrenal hyperplasia and is often fatal (Table 77-4).

Signs and Symptoms

Prenatal adrenal virilization in females produces ambiguous external genitalia (female pseudohermaphrodism). The ovaries, fallopian tubes, and uterus develop normally and patients are fertile. Postnatal congenital adrenal hyperplasia causes virilization of females and precocious puberty of males. Females develop hirsutism, polycystic ovaries, and irregular menses. Male patients exhibit secondary sexual characteristics by age 2 or 3 years. Fertility is often impaired. Both sexes experience rapid somatic growth and short stature. Virilization, salt wasting, and hyperpigmentation are variably present with the non–21-hydroxylase forms of congenital adrenal hyperplasias.

Diagnosis

Elevated plasma 17-hydroxyprogesterone is the most characteristic abnormality found in 21-hydroxylase deficiency. Both plasma cortisol and 24-hour free urinary cortisol excretion are variably reduced. Diagnosis of other forms of the disease involves demonstration of elevated levels of enzyme substrate: corticosterone and 11-deoxycortisol for 11-beta hydroxylase; dehydroepiandrosterone and 17-delta-5 hydroxypregnenolone for 3-beta hydroxydehydrogenase; and deoxycorticosterone and corticosterone for 17-beta-hydroxylase deficiency (Table 77-4).

Treatment

The treatment of 21-hydroxylase deficiency is glucocorticoid and mineralocorticoid replacement. Clinical management is often complicated by inadequately treated hyperandrogenism or iatrogenic hypercortisolism, or both. New treatment approaches under investigation include combination therapy to block androgen action and inhibit estrogen production, and bilateral adrenalectomy in the most severely affected patients. Female patients with ambiguous genitalia may require surgical correction as infants. Treatment of congenital adrenal hyperplasias caused by other enzyme deficiencies includes steroid and electrolyte replacement and surgical correction of the external genitalia in affected female infants.

Virilizing and Feminizing Adrenal Tumors

Excess production of adrenal androgens by an adrenal adenoma or carcinoma can produce virilizing features either alone or more commonly in addition to Cushing syndrome. Development of an adrenal virilizing tumor in women causes hirsutism and masculinization. Males with these tumors may present late with signs and symptoms of tumor enlargement or distant metastases develop. Virilizing tumors secrete androgen precursor, dehydroepiandrosterone, which can be measured either directly in plasma or in urine as a 17-ketosteroid. Feminizing adrenal neoplasms are extremely rare. Abdominal CT is subsequently used to localize the lesion. Resection of tumor and involved adrenal gland is the primary treatment for patients with adrenal virilizing tumors. Tumor recurrence is heralded by return of virilization or by detection of increased 17-ketosteroids in the urine. Tumor debulking or inhibition of steroidogenesis with aminoglutethimide or mitotane may be useful in controlling signs and symptoms in patients with metastatic disease.

7 Adrenocortical Carcinoma

Adrenocortical carcinoma is a rare malignancy with an estimated incidence of 0.5 to 2 cases per million per year. Presentation peaks in the first and fifth decades of life. The prevalence is higher in females than in males (1.4 to 2:1). The cause of adrenocortical carcinoma is unknown, although somatic mutations in P53 and inheritance of this tumor in patients with germline mutations in P53 (Li Fraumeni syndrome) implicate this tumor suppressor gene in its pathogenesis (1).

Signs and Symptoms

Adrenocortical carcinoma is a very aggressive malignancy, and most patients (up to 75%) present with locoregionally advanced or distant disease. Syndromes of adrenal hormone overproduction are frequent (up to 60%) and may include hypercortisolism, hyperaldosteronism, or virilization. Patients with rapidly progressive Cushing syndrome or mixed presentations with signs of both Cushing syndrome and virilization should be suspected of having adrenocortical carcinoma. Nonfunctioning adrenocortical carcinomas present most commonly as abdominal pain or mass with vague symptoms of nausea, weight loss, and fatigue.

Diagnosis

Patients with suspected adrenocortical carcinoma should have biochemical testing to identify hormone overproduction followed by staging investigations including cross-sectional imaging and bone scans. Contrast-enhanced CT of the abdomen and chest is important to preoperatively diagnose local tumor invasion and metastatic lesions as well as to confirm a functioning contralateral kidney (Fig. 77-9). In the absence of distant metastases or local invasion, preoperative distinction between large adenomas and carcinomas can be difficult, although large (>6 cm) adrenal masses that extend to nearby structures on CT scanning should be approached as carcinomas. Biopsy of adrenal lesions suspected of being adrenocortical carcinoma is unnecessary and should be avoided. The risk of seeding and the inability of histologic examination to distinguish between adenoma and carcinoma underlie this approach. Biopsy of extraadrenal lesions may be performed to confirm metastatic disease.

Table 77-4 Congenital Adrenal Hyperplasias

Disease	21-Hydroxylase Deficiency	11β-Hydroxylase Deficiency	Aldosterone Synthase Deficiency	17α-Hydroxylase Deficiency	3β-ydroxysteroid Dehydrogenase Deficiency	Lipoid Hyperplasia
Defective gene	*CYP21*	*CYP11B1*	*CYP11B2*	*CYP17*	*HSD3B2*	*STAR*
Ambiguous genitalia	Females	Females	No	Males	Males	Males
Addisonian crisis	Present	Rare	Salt wasting only	Absent	Present	Present
Incidence (general population)	1:10–18,000	1:100,000	Rare	Rare	Rare	Rare
Hormones						
Glucocorticoids	Reduced	Reduced	Normal	Corticosterone normal	Reduced	Reduced
Mineralocorticoids	Reduced	Elevated	Reduced	Elevated	Reduced	Reduced
Androgens	Elevated	Elevated	Normal	Reduced	Reduced (males) Elevated (females)	Reduced
Estrogens	Reduced (females)	Reduced in females	Normal	Reduced	Reduced	Reduced
Physiology						
Blood pressure	Reduced	Elevated	Reduced	Elevated	Reduced	Reduced
Na balance	Reduced	Elevated	Reduced	Elevated	Reduced	Reduced
K balance	Elevated	Reduced	Elevated	Reduced	Elevated	Elevated
Acidosis	Present	Absent	Present	Absent	Present	Present
Elevated metabolites	17-OHP	DOC, 11-deoxycortisol	Corticosterone ± 18-hydroxy-corticosterone	DOC corticosterone	DHEA, $17\Delta^5$ preg	None

OHP, hydroxyprogesterone; DOC, deoxycorticosterone; DHEA, dehydroepiandrostenedione.
Modified from White PC, Speiser PW. Congenital adrenal hyperplasia due to 21-hydroxylase deficiency. *Endocr Rev* 2000;21:245–291.

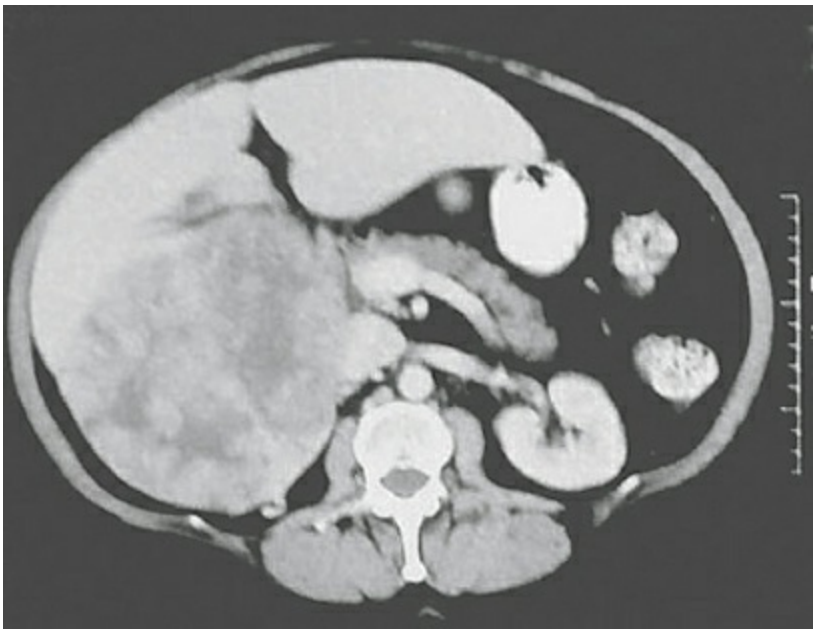

Figure 77-9. Computed tomography scan of right adrenocortical carcinoma showing invasion of liver and inferior vena cava. Note that a contralateral kidney is present and functioning.

A definitive diagnosis of adrenocortical carcinoma requires pathologic demonstration of tumor invasion to adjacent organs or spread to lymph nodes or distant sites. Practically,

any adrenal neoplasm larger than 6 cm or weighing more than 100 g should be considered malignant. Histologic features of tumor necrosis, hemorrhage, and local invasion are gross pathologic evidence of carcinoma, while cells with large, hyperchromatic nuclei and more than 20 mitoses per high-power field suggest malignancy.

Treatment

Surgical resection is the mainstay of treatment for all stages of adrenocortical carcinoma. Complete resection of locally confined tumor is the only chance for cure from adrenocortical carcinoma. However, distant or local spread is evident in 65% of cases at presentation and a minority of patients is resectable with curative intent. Recurrence rates after surgery range from 38 to 85%, depending on stage at presentation (Table 77-5).

Many patients with adrenocortical carcinoma present with metastatic disease, involving the lung, lymph nodes, liver, or bone. Resection or surgical debulking of locally advanced or metastatic lesions may provide symptomatic relief for select patients, especially those with low-grade, slow-growing, hormonally productive cancers. Symptomatic recurrent or metastatic disease is best treated by resection when feasible.

Chemotherapy for adrenocortical carcinoma usually includes mitotane, although no controlled studies have established its efficacy in this disease. Partial responses to mitotane occur in less than a third of patients, and survival is unchanged. Adjuvant chemotherapy with mitotane after complete resection for adrenocortical carcinoma is unproven and toxic so that many oncologists reserve its use for recurrent, unresectable or metastatic disease. Cisplatin in combination with mitotane or doxorubicin and 5-fluoruracil have been applied in metastatic disease with partial responses noted.

STAGING

Table 77-5 American Joint Committee on Cancer Staging of Adrenocortical Carcinoma, with 5-Year Survival Rates

Stage	Criteria	
Tumor		
T1	Tumor <5 cm, no invasion	
T2	Tumor >5 cm, no invasion	
T3	Tumor with invasion to fat	
T4	Tumor with organ invasion	
Lymph nodes		
N0	No lymph node metastasis	
N1	Lymph node metastasis present	
Metastasis		
M0	No distant metastasis	
M1	Distant metastasis present	
Stage Group	**TNM**	**5-Year Survival Rate**
I	T1 (<5 cm), N0, M0	30–45%
II	T2 (>5 cm), N0, M0	12–57%
III	T1–2, N1, M0 T3, N0, M0	5–18%
IV	Any T, any N, M1 T3–4, N1, M0	0

Used with the permission of the American Joint Committee on Cancer (AJCC), Chicago, Illinois. The original source for this material is the AJCC Cancer Staging Manual, Seventh Edition (2010) published by Springer Science and Business Media LLC, www.springer.com

The prognosis of adrenocortical carcinoma is poor. Median survival following diagnosis for all patients is approximately 18 months. Overall survival following resection for all stages of adrenocortical cancer is 15% to 47% at 5 years. Stage-specific 5-year survival is 30% to 45% for stage I, 12% to 57% for stage II, 5% to 18% for stage III, and 0 for stage IV disease.

DISEASES OF THE ADRENAL MEDULLA

Pheochromocytoma

8 Pheochromocytomas are functional adrenal tumors that arise from neuroectodermal cells of the adrenal medulla or in certain extraadrenal sites. These tumors are uncommon, occurring in 0.005% to 0.1% of persons, but occur with increased frequency in hypertensive populations (0.2% incidence) and in heritable endocrine tumor syndromes. The peak incidence of pheochromocytoma occurs during the fourth and fifth decades of life, and men and women are affected about equally. The *rule of tens* is a useful way to characterize pheochromocytoma: tumors are bilateral in 10% of cases, extraadrenal in 10%, familial in 10%, multicentric in 10%, and malignant in 10% and occur in children in 10% of cases.

Approximately 10% of pheochromocytomas are extraadrenal, although most (98%) are still located within the abdomen. Extraadrenal pheochromocytomas can occur at any site in the abdomen where chromaffin tissue is located and have been found in the paravertebral ganglia, the organ of Zuckerkandl, and the urinary bladder. Clues to the presence of extraadrenal pheochromocytoma are predominance of norepinephrine because extraadrenal sites lack the enzyme necessary to convert norepinephrine to epinephrine.

Familial pheochromocytoma is a component of two autosomal dominant syndromes: von Hippel–Lindau syndrome and multiple endocrine neoplasia (MEN) 2. Patients with von Hippel–Lindau syndrome have pheochromocytoma (usually bilateral), retinal angiomas, cerebellar hemangioblastoma, epididymal cystadenoma, renal and pancreatic cysts, and renal cell carcinoma. Patients with MEN 2A develop pheochromocytoma (usually bilateral), medullary carcinoma of the thyroid (MTC), and primary parathyroid hyperplasia. Patients with MEN 2B develop pheochromocytoma (usually bilateral), MTC, mucosal neuromas, intestinal ganglioneuromatosis, and have a characteristic marfanoid body habitus. Pheochromocytoma also occurs in neurofibromatosis type 1 and familial paraganglioma. The frequency of pheochromocytoma in these disorders is 10% to 20% in von Hippel–Lindau syndrome, 50% in MEN 2, and 0.1 to 5.7% with neurofibromatosis type 1.

In some families, patients with pheochromocytomas have no other clinical abnormalities, suggesting the existence of a separate disease limited to the formation of adrenal medullary tumors. In a study of three generations of an affected kindred, a novel mutation was found in the von Hippel–Lindau gene even though there were no other clinical manifestations of this disorder. Patients with bilateral pheochromocytoma, young patients with pheochromocytoma, and patients with paraganglioma should be screened for MEN 2 and von Hippel–Lindau syndrome.

The etiology and pathogenesis of pheochromocytoma is unknown. A genetic component seems certain because pheochromocytoma occurs not only as a part of familial syndromes but also as an isolated disorder because of mutation in the RET gene or the MEN 2 gene. Familial pheochromocytoma as well as sporadic pheochromocytoma occurs also with

mutations in the succinate dehydrogenase complex, subunit B, iron–sulfur protein (SDHB). Either germline or somatic mutations in the SDHD gene is another cause of pheochromocytoma (2).

Signs and Symptoms

Symptoms of pheochromocytoma are attributable to the effects of excessive circulating catecholamines on target tissues (Table 77-3). The classic triad of symptoms in patients with a pheochromocytoma is episodic headache, sweating, and tachycardia. Hypertension is common with pheochromocytoma and is sustained in roughly half of patients, is paroxysmal in one-third, and is absent in one-fifth. Orthostatic hypotension results from diminished plasma volume and blunted autonomic reflexes. Other symptoms include palpitations, anxiety, and tremulousness. Cardiovascular sequelae include myocardial infarction, cardiac dysrhythmias, and stroke. Gastrointestinal motility is also impaired. Asymptomatic patients with functioning tumors are rare, and nonfunctioning tumors are distinctly uncommon. Sudden death has been reported in patients with pheochromocytoma who have undergone surgical procedures or childbirth.

Diagnosis

Elevation of catecholamines and their metabolites in either urine or blood is essential for the diagnosis of pheochromocytoma. Either a 24-hour urine collection for catecholamines and their metabolites (metanephrines) or plasma-fractionated metanephrines can be used to make the diagnosis. Urine catecholamines/metanephrines are the most reliable tests with a sensitivity and specificity of 98%. Plasma fractionated metanephrines is similarly sensitive (99%), but lacks specificity (85%). Accordingly plasma fractionated metanephrines should be reserved for patients with a high pretest probability for pheochromocytoma – adrenal incidentalomas, classic symptoms, family history or genetic syndromes associated with pheochromocytoma (MEN etc.) while urine catecholamines/metanephrines are useful as screening tests for patients who are less likely to have a pheochromocytoma. Measurement of plasma catecholamines is not as useful in distinguishing patients with pheochromocytoma from those with essential hypertension. Measurement of plasma chromogranin A is nonspecific and a poor diagnostic but potentially helpful confirmatory test.

Many medications alter or interfere with measurement or either plasma or urine catecholamines. Such medications should be discontinued to ensure accurate testing. These drugs include acetaminophen, labetolol, clonidine withdrawal, tricyclic antidepressants, antipsychotics and ethanol. To control blood pressure, other antihypertensives such as calcium channel blockers may be substituted.

In normotensive or mildly hypertensive patients with elevated plasma catecholamine levels (1,000 to 2,000 pg/mL), a clonidine suppression test may be used to distinguish from pheochromocytoma. An oral 0.3-mg dose of clonidine suppresses centrally mediated release of catecholamines to less than 500 pg/mL within 2 to 3 hours but does not affect release of catecholamines by a pheochromocytoma.

Biochemical confirmation of the diagnosis should be followed by radiologic evaluation

to locate the tumor. Pheochromocytomas are best imaged with CT or MRI. Contrast-enhanced CT readily detects tumors 1 cm and larger and has sensitivity of 87% to 100% for pheochromocytoma (Fig. 77-10A). MRI is similarly sensitive, and a T2-weighted image brightness three times greater than liver is highly specific for pheochromocytoma (Fig. 77-10B,C). MRI is useful in suspected malignant pheochromocytoma to evaluate for inferior vena cava thrombus or liver invasion.

Functional nuclear imaging with iodine-131-metaiodobenzylguanidine (131-I MIBG) is a useful adjunct to cross-sectional imaging for pheochromocytoma (Fig. 77-10D). MIBG resembles norepinephrine and is taken up by adrenergic tissues including pheochromocytoma. An MIBG scan can detect tumors not detected by CT or MRI or multiple tumors when CT or MRI is positive. Multi-institutional experience with this technique has demonstrated an overall sensitivity of 77% to 87% and a specificity of 96% to 100%. This test is usually not necessary for sporadic pheochromocytoma unless urinary or plasma catecholamines and metabolites are marginally elevated, or if malignant or extraadrenal pheochromocytoma is suspected. 131-I MIBG scanning is also useful to screen patients with metastatic pheochromocytoma for high-dose 131-I MIBG therapy. 111-In-pentetreotide scintigraphy may also identify pheochromocytoma and can be used therapeutically as with 131-I MIBG.

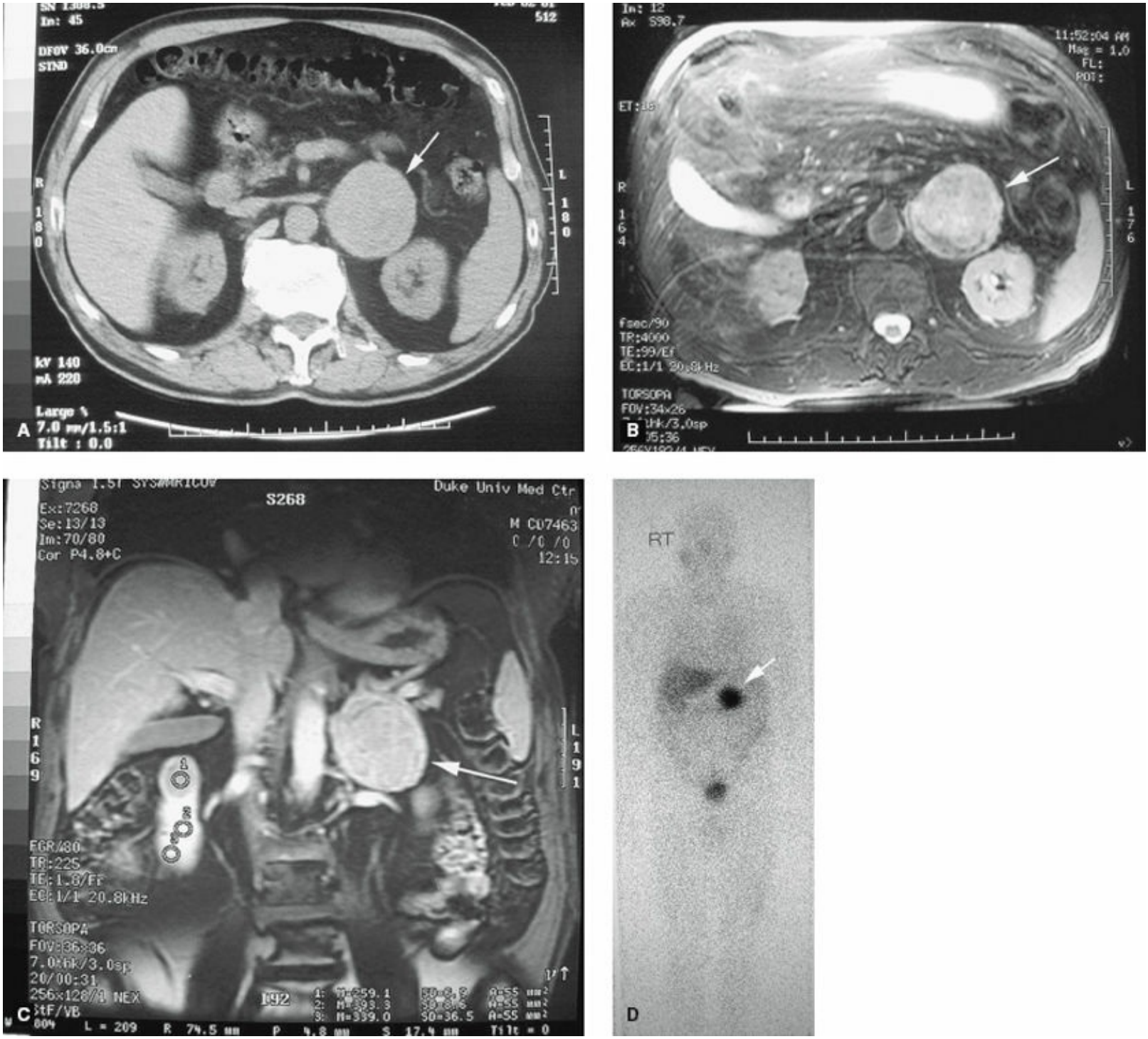

Figure 77-10. Imaging of pheochromocytoma (*arrows*). **A:** Computed tomography scan shows well-circumscribed left adrenal mass. **B:** T2-weighted magnetic resonance imaging shows the mass to be heterogeneously bright, consistent with pheochromocytoma. **C,D:** Coronal contrast enhanced MRI and near-simultaneous ^{131}I-metaiodobenzylguanine (^{131}I-MIBG) scanning show location of the pheochromocytoma and relationship to surrounding structures.

Treatment

Surgical resection is the only cure for pheochromocytoma. When the diagnosis of pheochromocytoma has been established and localization studies are completed, preoperative preparation of the patient centers on blood pressure control. Usually 1 to 3 weeks before operation alpha-adrenergic blockade is performed first with phenoxybenzamine, starting at 10 mg twice a day and increasing by 10 to 20 mg per day until blood pressure normalizes. Side effects of alpha blockade include postural

hypotension, reflex tachycardia, nasal congestion, and an inability to ejaculate. Preoperative alpha blockade also reverses the relative hypovolemia that is usually present in patients with pheochromocytoma and also prevents severe blood pressure swings during intraoperative manipulation of the tumor. Metyrapone added preoperatively to phenoxybenzamine can achieve a greater degree of sympathetic blockade.

Beta-adrenergic blockade with propranolol added after alpha blockade can manage patients who develop tachycardia or who have inducible cardiac arrhythmias or ischemia. Propranolol may enhance pressor response to endogenous norepinephrine and thus should not be given until adequate alpha blockade has been established. Propranolol can also produce profound bradycardia, myocardial depression, and congestive heart failure. Newer drug regimens to manage hypertension in pheochromocytoma include selective alpha-1-adrenergic antagonists (terazosin and doxazosin) and calcium channel blockers (nifedipine and nicardipine).

Patients with pheochromocytoma can be expected to have blood pressure volatility and high intravascular volume requirements during and immediately after surgery. Elderly patients or those with history of heart disease may require pulmonary catheter insertion and arterial line placement for careful monitoring of blood pressure and arterial pH. Anesthetic agents may trigger the release of catecholamines from pheochromocytomas. The anesthetic plane is now considered more important than the choice of agent, and both enflurane and isoflurane have been used successfully. Magnesium administration during surgery is an effective way to control blood pressure in patients with pheochromocytoma. Intraoperative hypertension is best treated with a sodium nitroprusside drip, and cardiac arrhythmias are best managed with short-acting beta-blockers (esmolol) or lidocaine.

Formerly, an anterior approach through either a midline or bilateral subcostal incisions was used exclusively to resect pheochromocytomas. Today, CT, MRI, and nuclear scans permit preoperative localization of tumor in 95% or more of cases, so that the surgical approach may be more directed using a laparoscopic approach. Regardless of approach, important common principles include minimal handling of the tumor, early isolation and ligation of the adrenal vein, and avoidance of capsular rupture. Recurrence following resection of benign pheochromocytoma is infrequent, and its presence indicates malignancy.

Recurrent, malignant pheochromocytoma can include locally advanced disease or metastasis to bone, liver, lymph nodes, lungs, and the central nervous system. Treatment of malignant pheochromocytoma involves resection of metastases when feasible and medical control of hypertension. Radiation therapy may be helpful to ameliorate pain from bony metastases. Ablative therapy with 131-I MIBG may also produce partial responses and palliation of hormonal symptoms. Radiofrequency ablation of hepatic and bone metastases can be effective in selected patients. Combination chemotherapy with cyclophosphamide, vincristine, and dacarbazine can also be effective. Overall 5-year survival for patients with malignant pheochromocytoma ranges from 36% to 60%.

Metastasis to the Adrenal Glands

The adrenal glands are frequent sites for metastases from many cancers. Carcinoma of the lung and breast account for most adrenal metastases; however, virtually any cancer including melanoma, lymphoma, and kidney and ovarian carcinoma can spread to the adrenals. Autopsy series of patients with carcinoma show that the adrenal glands are involved in more than 25% of cases. Among cancer patients, 50% to 75% of newly discovered adrenal masses represent metastases. Usually, either a primary site is obvious, or widespread disease is apparent. Biopsy of adrenal masses in patients with a history of carcinoma may be performed after pheochromocytoma is excluded. Resection of isolated adrenal metastases in select patients with long disease-free intervals from lung cancer, renal cell carcinoma and melanoma can be considered, although subsequent extraadrenal disease usually develops. Median survival after complete resection of isolated adrenal metastases from a variety of tumors ranges from 13 to 60 months with actuarial 2- and 5-year survival of 40% to 50% and 20%, respectively.

Incidental Adrenal Mass

9 Clinically inapparent adrenal masses (also called *adrenal incidentalomas*) have become commonplace over the past 20 years with the increased use of abdominal imaging such as CT and MRI. The estimated prevalence of incidental adrenal neoplasms varies by population studied and method of detection. Unsuspected adrenal masses are detected by CT in between 0.6% and 1.9% of healthy patients, a figure that is somewhat lower than the estimated prevalence of up to 8.7% based on unselected autopsy data. Patients with a prior history of malignancy have a prevalence of adrenal masses of up to 4.4%. Adrenal masses increase in frequency with advancing age, ranging from 3% in midlife to 10% in the elderly. The combination of an aging population and increased application of abdominal imaging promises to create a significant public health challenge.

Over the past 10 years, increased awareness of morbidity associated with subclinical hormone overproduction as well the increased availability of minimally invasive, laparoscopic adrenalectomy has resulted in a lower threshold for treatment of adrenal masses. The goal of evaluation is to distinguish and remove those adrenal masses that are functioning or likely to be malignant versus those that are neither and may be observed.

Expectations of the yield for the workup of adrenal masses may be informed by epidemiologic reports and reports of pathologic findings in resected incidentalomas. Epidemiologic data indicate that up to 6.5% of incidentalomas are pheochromocytoma, 7% produce aldosterone, 0.035% produce cortisol, and 0.06% is carcinoma. A recent review of 44 reports describing over 3,000 such cases reported that 41% were cortical adenomas, 19% were metastases from other primary cancers, 10% were adrenocortical carcinomas, and 8% were pheochromocytomas, with the remainder including myelolipomas and cysts.

Diagnosis

The evaluation of incidental adrenal masses, previously considered controversial, can now be standardized. Two simple questions must be answered: Is it functional? Is it malignant? The diagnostic approach should proceed to answer these questions sequentially (Table 77-6). Current opinion is that all asymptomatic patients with adrenal masses should be screened for pheochromocytoma, hypercortisolism, and hyperaldosteronism (Algorithm 77-3).

Table 77-6 Diagnosis Summary of Tests for Evaluation of Incidental Adrenal Mass

Question	Best Test	Alternative Test	Diagnosis
Is it functioning?	Plasma-fractionated metanephrines 1 mg dexamethasone suppression test Serum potassium Plasma renin/plasma aldosterone ratio	24-hr urine for catecholamines, metanephrines, VMA 24-hr urine for cortisol 24-hr urine for potassium	Pheochromocytoma Hypercortisolism Hyperaldosteronism
Is it malignant?	Computed tomography Fine-needle aspiration	Magnetic resonance imaging	Cortical adenoma Adrenocortical Carcinoma Pheochromocytoma Myelolipoma Cyst Metastasis

All patients require a complete history and physical examination, biochemical evaluation of pertinent hormones, and select imaging studies. Attention must be paid to episodes of hypertension, tachycardia, and anxiety that suggest pheochromocytoma. Physical findings such as muscle wasting, purple striae, hirsutism, and gynecomastia may suggest either Cushing syndrome or a virilizing tumor. Secondary metastases from underlying malignancy must be considered and evaluated with appropriate history, physical examination, and select tests including mammograms in women and chest radiography in all patients, especially smokers.

Biochemical testing should routinely exclude pheochromocytoma, hypercortisolism, and hyperaldosteronism. Pheochromocytoma is evaluated either by 24-hour urine collection for catecholamines, metanephrines, and 3-methoxy-4-hydroxy-mandelic acid, or by plasma fractionated metanephrines. Subclinical or clinically apparent Cushing syndrome is best evaluated with the overnight 1 mg dexamethasone suppression test. Hyperaldosteronism is best assessed by concurrent measurement of serum or plasma aldosterone and PRA.

Imaging studies usually include cross-sectional imaging with either CT or MRI. CT is the best test for identifying and characterizing most adrenal masses. Using a fast scanner and 1-m scanning intervals, both adrenal glands can be identified in 97% to 99% of patients and lesions as small as 5 mm can be readily identified. Currently, attenuation values expressed in Hounsfield units (HU) have better performance than size or other criteria to differentiate adenomas from adrenal malignancy and nonadenomas such as pheochromocytoma. Adenomas are usually lipid rich and have attenuation values less than 18 HU on unenhanced CT, a threshold with high sensitivity and specificity (85% to 95% and 93% to 100%, respectively). Generally, further workup is unnecessary when an adrenal lesion has an attenuation of less than 10 HU suggesting lipid-rich adrenal adenoma. A notable exception is lipid poor adenoma, which has higher HU density. In these cases, rapid washout of intravenous contrast suggests an adenoma. Using a 10- to 15-minute delayed enhanced CT, a washout value of 50% to 60% of the initial enhancement is used to distinguish adenoma from nonadenoma.

MRI can differentiate adenomas, metastases and pheochromocytomas, although the best MRI technique for evaluating adrenal masses is complex and controversial.

Adenomas usually show a loss in signal intensity on chemical shift MRI because of high lipid content. Malignant masses tend to be bright on T2-weighted images because of higher fluid content. Secondary metastases to the adrenal are hypointense to liver on T1-weighted images and are brighter than liver on T2-weighted images. Metastases also typically show strong contrast enhancement. Pheochromocytomas most often have low lipid content and high water content, giving low T1 signal intensities and very bright T2 signal intensities. Comparison of the adrenal mass to liver and spleen intensities on various sequences adds to specificity and sensitivity of the test.

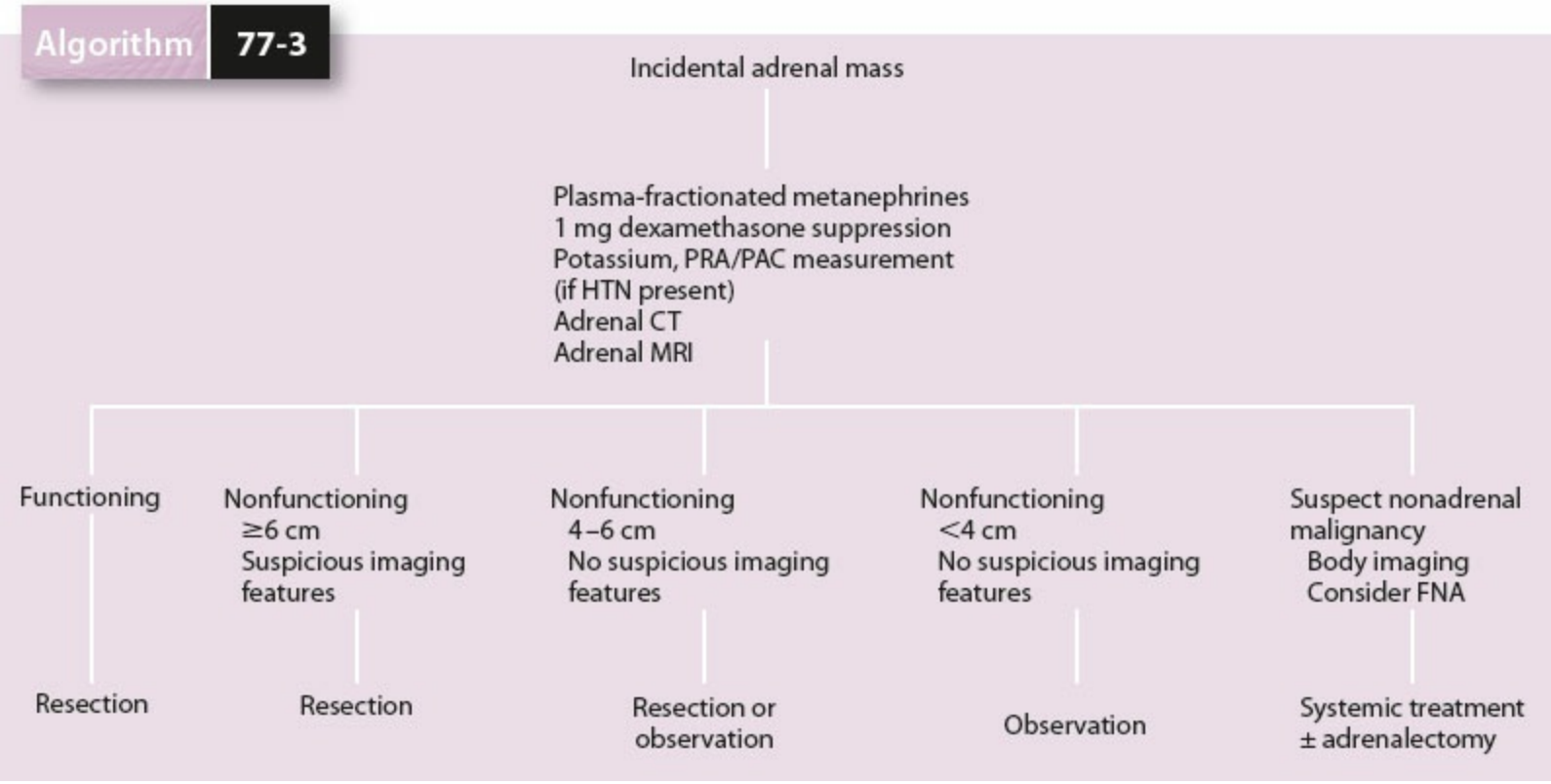

Algorithm 77-3. Diagnosis and management of the incidental adrenal mass. PRA, plasma renin activity; PAC, plasma aldosterone concentration; HTN, hypertension; CT, computed tomography; MRI, magnetic resonance imaging; FNA, fine-needle aspiration.

Masses that appear cystic may be aspirated under CT guidance. Fine-needle aspiration biopsy may be of value in patients with known extraadrenal malignancy; however, it is not indicated in the evaluation of primary adrenal neoplasms and is contraindicated if pheochromocytoma is suspected.

Treatment

Resection is indicated for all functioning adrenal incidentalomas and those suspected of harboring primary adrenal cancer. Size cutoff for resecting adrenal incidentalomas has drifted to include smaller and smaller lesions. The prevalence of primary adrenal carcinoma in adrenal incidentalomas is related to mass size. The risk of primary adrenal carcinoma is less than 2% in lesions under 4 cm while the incidence rises to 25% for lesions larger than 6 cm. Lesions larger than 6 cm and smaller lesions with suspicious

criteria on imaging should be resected. Lesions smaller than 4 cm with benign imaging characteristics should be followed. For lesions between 4 and 6 cm, either resection or observation is acceptable. Decisions should not be based on size alone, but also on imaging characteristics including CT attenuation values. Resection of secondary adrenal malignancy is not generally recommended except for highly select patients.

Adrenal Insufficiency

Adrenal insufficiency reflects inadequate glucocorticoid and mineralocorticoid production by the adrenals, either secondary to suppression of the HPA axis or by destruction or removal of the adrenal glands. The most common causes of primary adrenal insufficiency are autoimmune adrenalitis, infection, and gland replacement with metastatic disease. Chronic exogenous steroid use with HPA suppression and surgical resection of adrenal glands are important causes of secondary adrenal insufficiency.

Clinical signs and symptoms usually do not become manifest until at least 90% of the gland is destroyed. Adrenal insufficiency usually occurs gradually unless the patient experiences stress which may precipitate acute crisis.

Signs and Symptoms

Acute adrenal insufficiency usually manifests as shock in a patient with undiagnosed chronic adrenal insufficiency who has been subjected to physiologic stress. Similarly, patients with established adrenal insufficiency caused by exogenous steroid use may experience crisis if they do not increase glucocorticoid replacement during times of stress or illness. Symptoms of adrenal insufficiency reflect glucocorticoid and mineralocorticoid deficiencies. Signs and symptoms of acute insufficiency include fever, nausea, vomiting, refractory hypotension, and lethargy (Table 77-7). Acute adrenal insufficiency is a medical emergency and should be suspected in stressed patients with a history of either adrenal insufficiency or exogenous steroid use. Chronic adrenal insufficiency presents more subtly, with fatigue, weight loss, anorexia, nausea and vomiting, abdominal pain, and diarrhea.

Diagnosis

Laboratory findings of adrenal insufficiency include hyponatremia, hyperkalemia, azotemia, and fasting or reactive hypoglycemia. Hypercalcemia may also be present. The rapid ACTH stimulation test is the best test for both acute and chronic adrenal insufficiency. Synthetic ACTH (250 μg) is administered intravenously, and plasma cortisol levels are measured 30 and 60 minutes later. Normal peak cortisol response should exceed 20 μg/dL. Measurement of ACTH by IRMA is then used to distinguish primary from secondary and tertiary adrenal insufficiency. High plasma concentration of ACTH (>200 pg/dL) and low plasma cortisol (<10 mg/dL) are diagnostic of primary adrenal insufficiency. Low levels of plasma ACTH indicate secondary (pituitary) or tertiary (hypothalamic) adrenal insufficiency.

Table 77-7 Symptoms and Signs of Acute Adrenal Insufficiency

Symptoms

- Lethargy
- Confusion or disorientation
- Nausea and vomiting
- Abdominal pain

Signs

- Hypotension
- Hyponatremia, hyperkalemia, azotemia,
- Hypoglycemia
- Fever
- Anemia

Treatment

Acute adrenal insufficiency is based on clinical suspicion before laboratory confirmation is available. Intravenous volume replacement with isotonic fluids and immediate intravenous steroid replacement therapy with 4 mg dexamethasone is essential. A rapid ACTH stimulation test is then performed to establish the diagnosis of adrenal insufficiency after resuscitation and corticosteroid replacement. Hydrocortisone acetate is detected in laboratory measurement for cortisol so dexamethasone should be used for replacement of glucocorticoid function until ACTH testing is complete. Thereafter, 100 mg of hydrocortisone is administered intravenously every 6 to 8 hours and is tapered to standard replacement doses as the patient's condition stabilizes. Mineralocorticoid replacement is not required until oral intake resumes. Chronic adrenal insufficiency requires both corticosteroid and mineralocorticoid replacement. Usual daily dosing is 12 mg/m^2 of hydrocortisone and 0.05 to 0.10 mg fludrocortisone.

Patients who have known adrenal insufficiency or who have received supraphysiologic doses of corticosteroid for at least 1 week in the year preceding surgery should receive perioperative stress-dose corticosteroids. Administration of 100 mg hydrocortisone the morning of major surgery followed by 100 mg of hydrocortisone every 8 hours during the perioperative 24 hours is usually more than sufficient. Steroids can be rapidly tapered to replacement levels as the patient's condition permits.

ADRENALECTOMY

Surgical approaches to the adrenal glands include the laparoscopic approach, the anterior transabdominal approach, and less commonly, the combined thoracoabdominal approach or posterior retroperitoneal approach. Either adrenal gland can be removed using any of these approaches. The choice of approach depends on the suspected pathology, the size of the adrenal lesion, and the expertise of the surgeon. Small benign appearing tumors that are localized with confidence by imaging studies are resected using a laparoscopic or posterior approach. Posterior retroperitoneal adrenalectomy, once the most common method of adrenalectomy is less commonly used since most lesions amenable to this approach can be removed laparoscopically. Large adrenal masses and those that may harbor malignancy should be resected using an anterior approach to adequately explore the entire abdomen and gain sufficient exposure for safe resection. Very large adrenocortical carcinomas may require a thoracoabdominal approach for *en bloc* resection with involved adjacent structures. Recently, a retroperitoneal laparoscopic approach has been advocated as an alternative method for small tumors, particularly for patients with prior abdominal surgery.

Laparoscopic Adrenalectomy

Laparoscopic adrenalectomy is now the preferred approach to most small, benign adrenal lesions including functioning and nonfunctioning adenomas and pheochromocytomas. Enthusiasm for the laparoscopic approach is based on the expectation of decreased postoperative pain, faster rehabilitation, and fewer complications. Numerous studies have shown the efficacy and safety of this procedure for tumors up to 6 cm. Larger lesions can be approached by experienced surgeons in select circumstances. Importantly, expertise in open adrenalectomy is absolutely necessary for the laparoscopic surgeon to convert to an open procedure and promptly rectify any intraoperative laparoscopic complications.

Laparoscopic adrenalectomy begins with induction of general anesthesia, placement of a urinary catheter and orogastric tube, and positioning of the patient in the lateral decubitus position with the affected side up. Exposure is facilitated by extension of the operating table at the patient's waist. A total of three or four intraperitoneal ports (one camera, one retractor particular for the right side, and two working ports) are placed at least 5 cm apart in a transverse line from the lateral edge of the rectus sheath to the midaxillary line between the costal margin and iliac crest (Fig. 77-11A). Four-quadrant exploration of the peritoneal cavity is first performed with the videoscope through the medialmost port, and the videoscope is then transferred to the middle port. A retractor is placed through the medial most port to retract the viscera medially. Operating instruments are alternately placed within the abdomen through the lateral ports.

Laparoscopic adrenalectomy proceeds similar to the open anterior approach. Right adrenalectomy begins with mobilization of the liver to open the retroperitoneum and allow retraction of the right lobe of anteriorly and medially using the most medial port. The adrenal gland is then identified posterolateral to the inferior vena cava and superior to the kidney. Dissection usually begins by developing the plane between right adrenal and inferior vena cava using careful blunt dissection, with small vessels sequentially coagulated using electrosurgical or harmonic energy. The right adrenal vein is identified, carefully dissected and then doubly clipped and divided. Dissection then continues circumferentially around the gland with additional small vessels coagulated or clipped. The adrenal gland subsequently is placed in a bag and removed through an expanded port.

Left adrenalectomy is performed with mirror-image patient and port-site orientation as right adrenalectomy. After port placement, dissection begins with mobilization of the splenic flexure of the colon and spleen from the left retroperitoneum. Subsequent medial retraction of the spleen, tail of the pancreas, and stomach is accomplished with the fan or similar retractor if necessary. Often after full mobilization, no retractor is necessary, and thus only 3 ports are needed. The left adrenal gland is identified in perinephric fat at the superior renal pole. Intraoperative laparoscopic ultrasound can be useful for this on the left side, particularly in Cushing syndrome with the associated increased truncal fat. Once identified, left adrenal gland dissection proceeds circumferentially around the gland, with identification, ligation and division of the left adrenal vein at the inferiormost aspect of the dissection. Care is needed to identify and avoid the inferior phrenic vein, which

courses along the medial aspect of the left adrenal gland. Following circumferential dissection, the gland is removed.

Anterior Approach

Anterior, open adrenalectomy begins with positioning the patient in reverse Trendelenburg position with elevation of the right flank. An ipsilateral or bilateral subcostal incision allows access to either adrenal and facilitates exploration of the abdomen (Fig. 77-11B). The abdomen is opened and explored for evidence of metastatic disease, including biopsy or excision of suspicious lesions. Resection of the right adrenal gland proceeds with full mobilization and anteromedial retraction of the right hepatic lobe (Fig. 77-12A). It is important to fully expose the retrohepatic inferior vena cava. In order to uncover the inferior vena cava, the right kidney and the right adrenal gland, the hepatic flexure and transverse colon and are retracted inferiorly, usually without need for extensive mobilization. A Kocher maneuver of the duodenum is seldom necessary as the adrenal gland is superior to this area. The retroperitoneal space is entered behind the liver to expose the adrenal gland. Dissection of the gland proceeds from its inferomedial aspect, where small feeding arteries are individually clipped and divided. The vena cava is carefully dissected along its lateral border, which allows identification of the right adrenal vein where it drains directly into the inferior vena cava from the anterior aspect of the adrenal gland. The adrenal vein is ligated and divided close to the vena cava. If necessary because of hemodynamic changes during an operation for a pheochromocytoma, the adrenal vein is identified and ligated early to avoid catecholamine surges and blood pressure fluctuations during manipulation of the gland. Once the adrenal vein is ligated, arterial feeding vessels are clipped and divided sequentially, beginning at the superolateral aspect of the gland and continuing medially.

Resection of the left adrenal gland requires mobilization of the spleen, tail of pancreas and left colon. The left colon is freed from its peritoneal attachments and is reflected inferiorly. The spleen is then delivered from the left upper quadrant medially, and the splenocolic ligament is divided. The spleen, stomach, and pancreatic tail are retracted medially *en bloc* to expose the left kidney and adrenal (Fig. 77-12B). The left adrenal vein is ligated and divided at its junction with the left renal vein. The gland is dissected and the arterial vessels are ligated and divided sequentially, beginning at the superolateral aspect of the gland and continuing medially.

Thoracoabdominal Approach

The thoracoabdominal approach is used for large adrenal lesions with invasion of surrounding structures including the liver and diaphragm on the right side, and the spleen, pancreatic tail, stomach, and diaphragm on the left. The patient is positioned with the ipsilateral flank raised and arm extended cephalad. Incision is made in the tenth or eleventh intercostal space beginning at the posterior axillary line and is extended toward the midline of the abdomen (Fig. 77-11C). Retractors are placed and subsequent adrenalectomy is performed as for the anterior approach.

Posterior Approach

With the advent of laparoscopic adrenalectomy, the posterior approach is infrequently used. When laparoscopic adrenalectomy is not an option, typically because of extensive prior transperitoneal operations, the posterior approach is better tolerated and allows faster postoperative recovery compared with the anterior approach. A posterior approach becomes increasingly more difficult as tumor size increases and is not recommended for excision of large pheochromocytomas, adrenal tumors greater than 6 cm, or adrenal carcinoma.

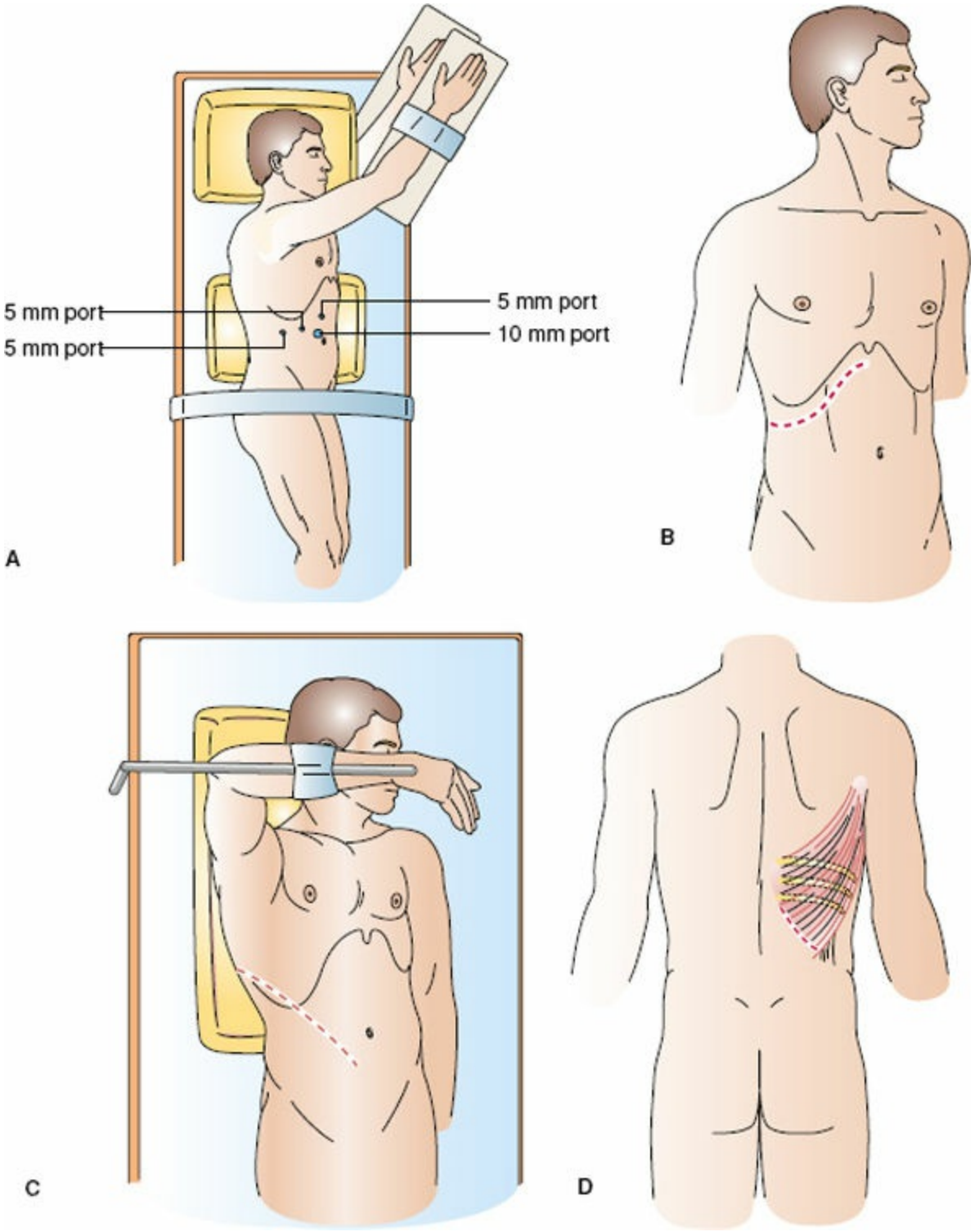

Figure 77-11. Incisions for right adrenalectomy. Shown are typical incisions for (**A**) laparoscopic approach, (**B**) open, anterior approach, (**C**) thoracoabdominal approach, and (**D**) posterior, open approach. Incisions for left adrenalectomy are positioned opposite.

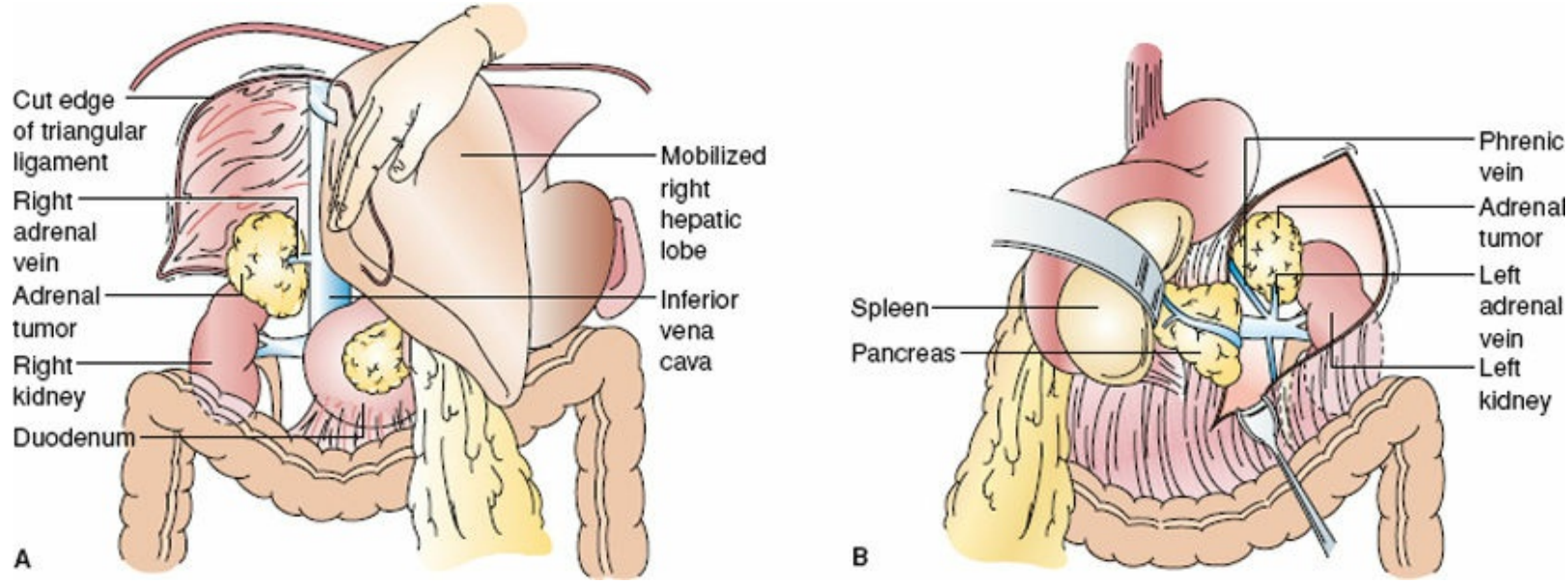

Figure 77-12. Anterior approach to right (**A**) and left (**B**) adrenalectomy. Note position of phrenic vein in relationship to the left adrenal vein and tumor.

The patient is placed prone on the operating table and flexed at the waist, which allows the abdominal contents to fall away from the retroperitoneum. The incision is made from the midline at the tenth rib and is extended inferolaterally to the superior border of the posterior iliac crest (Fig. 77-11D). Dissection proceeds through the subcutaneous fat and latissimus dorsi muscle to the lumbodorsal fascia. This fascia is incised longitudinally, and the underlying sacrospinalis muscle. The sacrospinalis muscle is retracted medially, and the twelfth rib and vascular bundle are resected as far medially as possible. The twelfth intercostal nerve is preserved and gently retracted superiorly. The retroperitoneum is entered and the diaphragm is bluntly elevated from Gerota fascia, the pleura are separated from the diaphragm, and the diaphragm is then divided. Gerota fascia is incised, and the kidney is retracted inferiorly to expose the adrenal gland. The arterial blood supply is controlled first by clipping and ligating numerous arterial vessels, which course posteriorly. The adrenal vein, located deep to the arteries, is ligated as it is encountered. On the right, the adrenal vein exits from the anterior aspect of the gland and courses to the inferior vena cava. Once the adrenal vein is divided the gland is then freed circumferentially from its lateral to medial aspect. The inferior border of the gland is dissected last to maintain attachment to the kidney and allow inferior retraction of the gland. Finally, repair of the diaphragm and any incidental pleural defects, reapproximation of the lumbodorsal fascia, and closure of the skin.

Posterior Retroperitoneal Laproscopic Adrenalectomy

Posterior retroperitoneal laproscopic adrenalectomy also known as posterior retroperitoneoscopic adrenalectomy maintains the advantages of a laparoscopic approach while avoiding the abdominal cavity. This approach is ideal for patients with prior abdominal surgery or for bilateral adrenalectomy as both adrenal glands can be removed without repositioning the patient.

Posterior retroperitoneal laparoscopic adrenalectomy begins with placing the patient in the prone jackknife position on a spinal table allowing the abdominal contents to hang forward. The hips and knees are positioned at 90-degree angles to the spine and femur and carefully padded. The first port is placed just below the tip of the 12th rib; after the incision is made the retroperitoneal space is entered sharply, a space is created bluntly with the index finger, and a blunt 10-mm trocar is placed. A second medial 10-mm trocar is placed along the paraspinous muscle at a 45-degree angle toward the adrenal gland. A lateral 5-mm port is placed 5 cm lateral to the first port in a similar fashion. Pneumoretroperitoneum to 20 to 24 mm Hg is created with CO_2 to create an adequate working space. The videoscope is transferred from the initial middle port to the medial port to complete the dissection. The retroperitoneal space beneath the diaphragm is created bluntly and sharply. The superior border of the kidney is immediately identified and Gerota fascia is entered. The upper pole of the kidney is retracted caudally and the tissue superior to the kidney which contains the adrenal gland is completely separated from the kidney. The medial dissection is then begun by carefully bluntly dissecting medial to the adrenal gland identifying the adrenal vein and dividing it between clips. Identification of the adrenal vein, particularly on the right side, is easier than with the transabdominal laparoscopic approach. Dissection is completed circumferentially around the gland using electrosurgical or harmonic energy to coagulate any small vessels. Once the gland is completely free, it is placed in a bag and removed through the middle port.

Bibliography

OMIM Online Mendelian Inheritance in Man [database online] #202300. Baltimore, MD: Johns Hopkins; 2005. Available at: http://www.ncbi.nlm.nih.gov/entrez/dispomim.cgi?id5202300. Accessed June 9, 2005.

OMIM Online Mendelian Inheritance in Man [database online] #171300. Baltimore, MD: Johns Hopkins; 2005. Available at: http://www.ncbi.nlm.nih.gov/entrez/dispomim.cgi?id5171300. Accessed June 9, 2005.

Bravo EL, Tagle R. Pheochromocytoma: state-of-the-art and future prospects. *Endocr Rev* 2003;24:539–553.

Brunt LM, Lairmore TC, Doherty GM, et al. Adrenalectomy for familial pheochromocytoma in the laparoscopic era. *Ann Surg* 2002;235:713–720.

Findling JW, Raff H. Diagnosis and differential diagnosis of Cushing syndrome. *Endocrinol Metab Clin North Am* 2001;30:729–747.

Funder JW, Carey RM, Fardella C, et al. Case detection, diagnosis, and treatment of patients with primary aldosteronism: an endocrine society clinical practice guideline. *J Clin Endocrinol Metab* 2008;93:3266–3281.

Harrison LE, Gaudin PB, Brennan MF. Pathologic features of prognostic significance for adrenocortical carcinoma after curative resection. *Arch Surg* 1999;134:181–185.

Iacobone M, Citton M, Viel G, et al. Adrenalectomy may improve cardiovascular and metabollic impairment and ameliorate quality of life in patients with adrenal incidentalomas and subclinical Cushing's syndrome. *Surgery* 2012;152:991–997.

Kalady MF, McKinlay R, Olson JA Jr, et al. Laparoscopic adrenalectomy for pheochromocytoma. A comparison to aldosteronoma and incidentaloma. *Surg Endosc* 2004;18:621–625.

Lamos EM, Munir KM.. Cushing disease: Highlighting the importance of early diagnosis for both de novo and recurrent disease in light of evolving treatment patterns. *Endocr Pract* 2014;20:945–955.

Lenders JW, Eisenhofer G, Mannelli M, et al. Phaochromocytoma. *Lancet* 2005;366:665–675.

Magill SB, Raff H, Shaker JL, et al. Comparison of adrenal vein sampling and computed tomography in the differentiation of primary aldosteronism. *J Clin Endocrinol Metab* 2001;86:1066–1071.

Mansmann G, Lau J, Balk E, et al. The clinically inapparent adrenal mass: update in diagnosis and management. *Endocr Rev* 2004;25:309–340.

Mittendorf EA, Evans DB, Lee JF, et al. Pheochromocytoma: advances in genetics, diagnosis, localization, and treatment. *Hematol Oncol Clin North Am* 2007;21:509–525.

Ng L, Libertino JM. Adrenocortical carcinoma: diagnosis, evaluation and treatment. *J Urol*

2003;169:5–11.

Pacak K, Linehan WM, Eisenhofer G, et al. Recent advances in genetics, diagnosis, localization, and treatment of pheochromocytoma. *Ann Intern Med* 2001;134:315–329.

Perrier ND, Kennamer DL, Bao R, et al. Posterior retroperitoneoscopic adrenalectomy, preferred technique for removal of benign tumors and isolated metastases. *Ann Surg* 2008;248:666–673.

Sippel RS, Chen H. Subclinical Cushing's syndrome in adrenal incidentalomas. *Surg Clin N Am* 2004;84:875–885.

Speiser PW, White PC. Congenital adrenal hyperplasia. *N Engl J Med* 2003;349:776–788.

Stojadinovic A, Ghossein RA, Hoos A, et al. Adrenocortical carcinoma: clinical, morphologic, and molecular characterization. *J Clin Oncol* 2002;20:941–950.

Turner DJ, Miskulin J. Management of adrenal lesions. *Curr Opin Oncol* 2008;21:34–40.

Werbel SS, Ober KP. Acute adrenal insufficiency. *Endocrinol Metab Clin North Am* 1993;22:303–328.

White PC, Speiser PW. Congenital adrenal hyperplasia due to 21-hydroxylase deficiency. *Endocr Rev* 2000;21:245–291.

Young WF Jr. Clinical practice: the incidentally discovered adrenal mass. *N Engl J Med* 2007;356:601–610.

Chapter 78

Pituitary Surgery

Brooke Swearingen and Nicholas A. Tritos

Key Points

1 Clinical manifestations of sellar masses may include local mass effect, pituitary hormone excess or deficiency.

2 Pituitary adenomas account for the vast majority (91% to 92%) of sellar lesions in surgical series, although the differential diagnosis is broad.

3 Incidental sellar lesions are common findings on cranial imaging performed for unrelated indications.

4 Despite recent advances in genetics and molecular biology, the pathogenesis of most sellar masses remains obscure.

5 Thorough clinical, radiologic and endocrine testing can help significantly narrow the differential diagnosis before pituitary surgery.

6 With the exception of many prolactin-secreting pituitary adenomas, transsphenoidal pituitary surgery remains first-line therapy for pituitary adenomas associated with mass effect or hormone excess.

7 There are a number of surgical techniques and approaches in current use with similar outcomes; the trend is toward increasing use of endoscopy.

8 Medical therapy is generally considered first-line treatment in patients with prolactin-secreting pituitary adenomas.

9 Medical therapy has an adjuvant role in patients with other secretory adenomas (acromegaly, Cushing disease) who are not cured after pituitary surgery.

10 Management of pituitary adenomas is best delivered in a multidisciplinary setting, where the multiple treatment options available can be individualized to a given patient.

INTRODUCTION

1 The pituitary, as the “master gland,” is responsible for the control of much of the body’s endocrine function. Directly or indirectly, it affects the function of the thyroid, adrenals, and ovaries or testes, and regulates growth, lactation, and ovulation. Its posterior lobe helps to regulate water homeostasis and parturition. Surgical disorders of the pituitary can manifest as either an endocrinopathy, with syndromes of hypo- or hypersecretion of necessary hormones, or as abnormalities caused by mass effect, especially visual field deficits, related to its anatomic location. This chapter will review the basic anatomy and endocrine physiology of the gland, as well as the diagnosis, imaging, and pathology of pituitary disorders and describe the surgical management in the setting of multidisciplinary treatment options.

ANATOMY

The pituitary lies within a bony cavity in the posterior sphenoid bone, the sella turcica, or "Turkish saddle." Anatomic boundaries are formed anteriorly and inferiorly by the sphenoid sinus, posteriorly by the dorsum sella and posterior clinoids, anterosuperiorly by the tuberculum sella, and superiorly by the diaphragm sella, a thin dural reflection over the superior margin of the gland (Fig. 78-1A,B). The lateral boundaries are formed by the cavernous sinuses. The gland itself is composed of an anterior, intermediate, and posterior lobe (the adenohypophysis, pars intermedia, and neurohypophysis or pars nervosa, respectively). Embryologically, the gland is derived from the apposition of stomodeal ectoderm (anterior lobe) and neuroectoderm (posterior lobe). The anterior lobe consists of a pars distalis, within the sella, and pars tuberalis, along the anterior infundibulum, which penetrates the diaphragm sella and connects the gland to the hypothalamus. The vascular supply is formed by the inferior hypophyseal arteries arising bilaterally from the intracavernous carotids, and supplying the neurohypophysis, and the superior hypophyseal arteries, which supply the median eminence and infundibulum as well as forming the capillary network of the hypophyseal-portal system. This portal system carries hypothalamic releasing hormones along the infundibulum to the anterior lobe. Venous drainage leaves through the cavernous and superior and inferior petrosal sinuses bilaterally and thence to the transverse sinuses and internal jugular veins. There is often a variably developed dural venous sinus, the circular sinus, usually at the level of the tuberculum sella, connecting the two cavernous sinuses, and there may be dural venous plexi of variable size and location beneath and posterior to the sella.

Important anatomic relationships, both in terms of pathologic effects and surgical approach, include the laterally placed cavernous sinuses, and superiorly the suprasellar cistern, through which course the optic nerves and chiasm. The cavernous sinuses are formed by venous drainage from the ophthalmic veins, middle and inferior cerebral veins, and sphenoparietal sinuses. Traversing structures include the intracavernous carotid artery, and multiple cranial nerves, including cranial nerve III (oculomotor), cranial nerve IV (trochlear), the ophthalmic branch of the trigeminal (V1), and the maxillary branch of the trigeminal (V2). These nerves travel in the dural reflection which forms the lateral wall of the cavernous sinus, from superior to inferior. The VIth cranial nerve (abducens) runs along the lateral aspect of the intracavernous carotid. Nerves III, IV, VI, and V1 exit into the superior orbital fissure, while V2 exits through the foramen rotundum. The optic nerves and chiasm travel above the gland, within the suprasellar cistern. Superior extension of the sellar contents, for example, from a pituitary neoplasm, can compress the chiasm from below, leading to visual abnormalities. Axons from the nasal retinal ganglion cells (which receive input from the ipsilateral temporal visual fields) cross in the chiasm en route to the opposite occipital cortex. Compression of these crossing fibers at the level of the chiasm leads to a bitemporal hemianopsia, pathognomonic of a sellar mass.

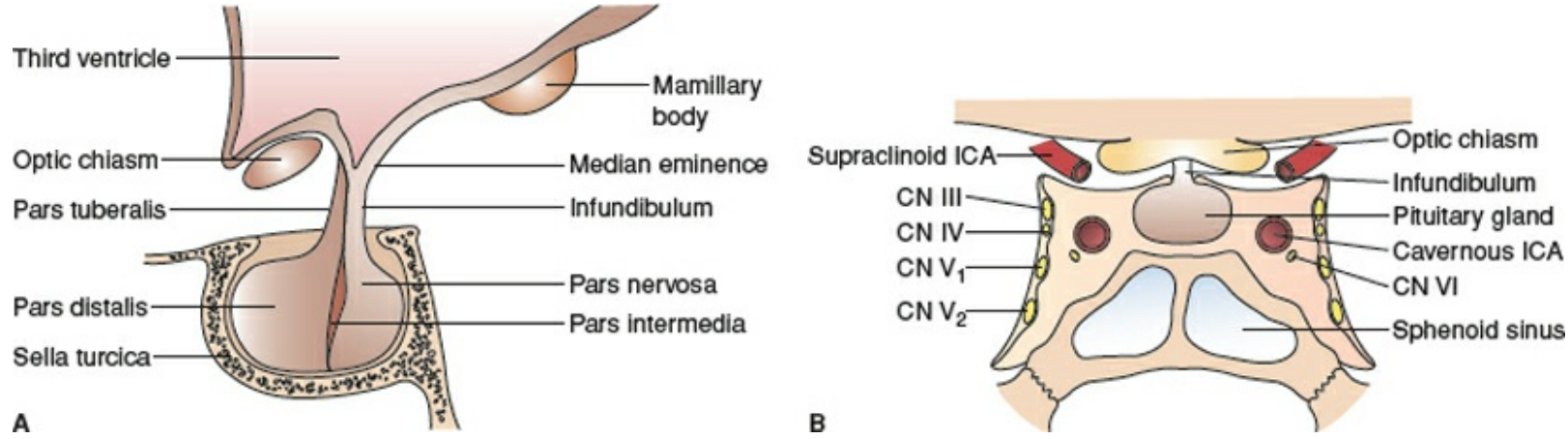

Figure 78-1. **A:** Sagittal view. **B:** Coronal view. ICA, internal carotid artery; CN, cranial nerve.

PATHOLOGY OF SELLAR LESIONS

Pituitary Adenomas

2, 3 Pituitary adenomas are the most common tumors of the sella and most important surgical pathology, but the differential diagnosis of sellar lesions is broad (Tables 78-1 and 78-2). The true incidence of adenomas is difficult to determine as it varies depending on whether the series is based upon clinically significant tumors, autopsy findings, or imaging data. The prevalence of incidental sellar masses found in imaging studies is about 10% to 22%, while it is about 14% in autopsy series.[1] The original pathologic classification was based upon staining affinity for histologic dyes, that is, acidophilic, basophilic, or chromophobe. A more recent and clinically useful pathologic classification from the WHO is based upon immunocytochemistry of various hormone subtypes. These include:

Prolactinomas (Lactotroph Adenomas)

Although less important in surgical series since the advent of dopamine agonist treatment, these are one of the most common pituitary adenomas with an incidence of 6 to 10 per million per year and a prevalence of 60 to 100 cases per million.[2] Also known as lactotroph adenomas, they arise from the prolactin-secreting cells of the adenohypophysis. They are commonly microadenomas in women, but especially in men may become large and invasive.

Table 78-1 Tumors of the Pituitary

Pituitary adenomas
Prolactin-producing adenoma
Growth Hormone-producing adenoma
Adrenocorticotropin-producing adenoma
Gonadotropin-producing adenoma
TSH-producing adenoma
Null-cell adenoma
Plurihormonal adenoma
Pituitary carcinoma
Mesenchymal tumors
Chordoma
Meningioma
Granular cell tumors
Secondary tumors

From DeLellis RA, Lloyd RV, Heitz PU, Eng C, eds. World Health Organization classification of tumors: Tumors of endocrine organs. IARC: Lyons; 2004.

Growth Hormone-Secreting Adenomas (Somatotroph Adenomas)

These tumors secrete excess levels of growth hormone, leading to gigantism in children and acromegaly in adults. The incidence of acromegaly is about 2 to 4 cases per million per year.[3] These tumors may sometimes coexpress prolactin (mammosomatotroph adenomas) and rarely TSH, as these cellular subtypes appear to arise from a common stem cell origin. They are typically invasive macroadenomas.

ACTH-Secreting Adenomas (Corticotroph Adenomas)

These tumors secrete excess levels of ACTH, leading to excess production of cortisol by the adrenal glands (Cushing disease). They are uncommon, with an estimated incidence of 1.2 to 1.7 cases per million per year.[4] Pathologic diagnosis can be difficult, given that these tumors are often quite small and surgical specimens limited. Corticotroph adenomas typically manifest loss of normal glandular architecture, with positive immunocytochemistry for ACTH.

Table 78-2 Differential Diagnosis of Nonpituitary Sellar Lesions

Tumors
Craniopharyngioma
Meningioma
Neurohypophyseal gangliocytoma
Neurohypophyseal glioma
Granular cell tumor
Germ cell tumor
Chordomas and other soft tissue and bone tumors
Metastatic tumor
Cysts and malformations
Rathke cleft cyst
Arachnoid cyst
Epidermoid cyst
Dermoid cyst
Vascular lesions
Saccular aneurysm
Cavernous malformation
Inflammatory conditions
Lymphocytic hypophysitis
Granulomatous hypophysitis

From Gejman R, Hedley-Whyte T. Pathology of pituitary adenomas and other sellar masses. In: Swearingen B, Biller BMK, eds. *Diagnosis and Management of Pituitary Disorders*. Humana Press: Totowa, NJ; 2008.

TSH-Secreting Adenomas (Thyrotroph Adenomas)

These tumors are uncommon and typically comprise less than 1% of surgical series. Patients will sometimes present with hyperthyroidism, but TSH staining without clinical hyperthyroidism is a more common scenario.[5]

Gonadotroph Adenomas

These tumors are common and comprise most of the "nonfunctioning" adenomas, as they express primarily hormone subunits, including beta FSH, LH, or alpha subunits. They become symptomatic via mass effect, with compression of normal gland leading to pituitary hypofunction, or compression of the chiasm leading to visual field abnormalities. Very rarely, patients with these tumors may present with symptoms attributed to excess gonadal steroids, such as precocious puberty, irregular menses, or psychiatric manifestations.

Null Cell Adenomas

These tumors are uncommon; they manifest no clinical or immunocytochemical evidence of hormone secretion, but this may be a function of the sensitivity of the immunocytochemical technique.

"Atypical" Adenomas and Pituitary Carcinomas

Pituitary carcinoma is extraordinarily rare. It is defined by the presence of distant metastases or CSF dissemination. While pituitary carcinomas may demonstrate extensive pleomorphism and/or necrosis, these pathologic findings are also seen in benign adenomas. The factors correlated with aggressive clinical behavior include an elevated Ki-67 labeling index (MIB-1 fraction, proliferation index) and extensive p53 reactivity.[6] "Atypical" adenomas have been defined as those tumors manifesting an MIB-1 fraction of greater than 3%, excessive p53 immunoreactivity, and increased mitotic activity.[7] Atypical adenomas are usually larger and invasive, but are not uncommon (15% in some surgical series), and the factors predisposing to malignant degeneration and metastasis are not well defined.[8]

Nonadenomatous Lesions of the Sella

Although pituitary adenomas are the most common neoplasms of the sella, a variety of other lesions can occur (Table 78-2).[9,10]

Neoplasms

Other neoplasms of the sella are uncommon but remain important in the differential diagnosis. *Craniopharyngiomas* are benign, solid, or partially cystic masses which presumably arise from remnants of Rathke pouch.[11] They occur in a bimodal distribution with peaks in childhood and in older adults. The adamantinomatous type is typical in children, and is often cystic and partially calcified. The cysts contain a "motor oil" appearing fluid, which can produce severe chemical meningitis when in contact with the CSF. The epithelium produces keratinaceous debris and cholesterol clefts. There is often a pronounced inflammatory reaction. The papillary type is seen almost exclusively in older adults. It may be cystic and/or solid, and can be densely adherent to surrounding neural structures, especially the optic nerves and hypothalamus. *Meningiomas* can arise anywhere along the intracranial dura, including within the sella. Meningiomas arising from the diaphragm sella or tuberculum sella can mimic pituitary adenomas and lead to endocrine dysfunction and chiasm compression. *Germ cell tumors* are most common in children and young adults and occur predominantly in males. The sella is the second most common location after the pineal; the most common subtype is the germinoma followed by teratomas. *Metastases* to the sella are fortunately rare, most commonly from breast and lung.[12]

Cysts

A variety of nonneoplastic cysts can occur within the sella. Although most are incidental findings seen on routine MRI imaging, large cysts can sometimes lead to endocrine dysfunction or chiasm compression. The most common cystic structure is *Rathke cleft cyst,* arising from a remnant of Rathke pouch within the pars intermedia. Rathke cysts can sometimes enlarge with time and compress surrounding structures; they may then require drainage and/or resection. Most, however, are incidental findings, and require no treatment. *Epidermoid* or *dermoid cysts* arise from ectopic squamous or dermoid tissue and can fill with keratinaceous debris. *Arachnoid cysts* are CSF containing structures which may also occur within the sella, presumably arising by means of a "one-way valve" mechanism allowing CSF to enter the cyst cavity but not exit; enlarging cysts may become clinically symptomatic.

Inflammatory Lesions

Inflammatory lesions of the sella are rare. *Lymphocytic hypophysitis,* the most common, is thought to represent an autoimmune phenomenon and is seen usually in women during or after pregnancy, often in association with other autoimmune disorders (Hashimoto thyroiditis, atrophic gastritis.) The gland is enlarged and infiltrated with inflammatory cells and pituitary dysfunction may occur. *Granulomatous hypophysitis* can arise from

infections, that is, tuberculosis or fungal, or idiopathic granulomatous inflammation, either alone or in association with sarcoidosis. The recent introduction of ipilimumab antibody therapy for melanoma has led to the recognition of a presumed immune-mediated hypophysitis associated with pituitary enlargement and dysfunction.[13] Other uncommon types of hypophysitis include xanthomatous, necrotizing, and IgG4 related.

MOLECULAR PATHOGENESIS

4 The molecular pathogenesis of pituitary adenomas remains unclear, although a number of possibilities have been suggested.[14,15] The majority of pituitary adenomas are monoclonal in origin.[16,17] The adenoma presumably arises from a single mutated cell, but the relative contributions of intrinsic genetic events and stimulation by hypothalamic hormones and local growth factors remain to be determined. Progression to malignancy with metastasis is rare, although local invasion is common. Genetic mutations predisposing to the development of pituitary adenomas include mutations in the *AIP* gene (aryl hydrocarbon receptor interacting protein) which has been found in some familial pituitary adenoma cohorts as well as some sporadic adenomas, especially in young acromegalic patients. The *MEN1* (multiple endocrine neoplasia) gene is also associated with familial adenomas, but is uncommon in sporadic disease, as is the *GNAS* mutation associated with McCune Albright syndrome. The *PRKAR1A* gene encodes a type 1A regulatory subunit of protein kinase A. Inactivating mutations of this gene are identified in 60% to 70% of patients with Carney complex, a condition of dominant inheritance, which may lead to acromegaly as a result of somatotroph hyperplasia or adenoma, as well as a variety of extrapituitary manifestations. Epigenetic modification has been suggested as a mechanism to influence gene expression without alteration in the underlying genome. Altered expression of genes encoding CDKN2A (cyclin-dependent kinase inhibitor), DAPK (death-associated protein kinase), FGFR2 (fibroblast growth factor receptor 2), among others, have been associated with sporadic pituitary adenomas. Loss of tumor suppressor genes may also be involved in adenoma pathogenesis. Loss of the *GADD45y* gene expression occurs in the majority of human pituitary adenomas, and products of the *AIP, PRKAR1A,* and *MEN1* genes may also act as tumor suppressors, with loss of these products in familial syndromes predisposing to the development of pituitary adenomas, in a “two-hit” model. Dysregulation of micro RNAs, which can regulate translation of target mRNAs, has recently been found in pituitary adenomas, and differential expression can be associated with specific tumor subtypes. It is unclear which, if any, of these abnormalities are primary as opposed to epiphenomena in pituitary tumorigenesis.

ENDOCRINE EVALUATION

5 All patients with a pituitary mass require endocrine evaluation for pituitary hypofunction, and patients with possible pituitary adenomas require evaluation for hypersecretory syndromes as well. This is best done in conjunction with an endocrinologist experienced in the management of pituitary disease.

Pituitary Hypofunction (Hypopituitarism)

It is important to determine the presence of hypopituitarism, especially in patients requiring surgical treatment, as unrecognized hypothyroidism or hypoadrenalism may have a profound effect on response to anesthesia and complicate recovery from surgery. Determination of anterior pituitary dysfunction requires measurement of free thyroxine (free T4) and thyrotropin (TSH), gonadal hormones (estradiol and testosterone), as well as gonadotropins (LH and FSH), basal and stimulated cortisol levels, and sometimes growth hormone levels and IGF1 (insulin-like growth factor 1) if clinically indicated. Central (secondary) hypothyroidism is characterized by low free T4 levels in association with low or inappropriately normal TSH. Central hypogonadism is characterized by low morning testosterone levels in men, and low estradiol levels in women, associated with low or inappropriately normal FSH and LH. Central hypoadrenalism is characterized by low morning cortisol levels in association with low or inappropriately normal ACTH. Morning serum cortisol ≤ 3 mcg/dL is diagnostic of adrenal insufficiency, whereas morning serum cortisol ≥ 18 mcg/dL assures sufficient adrenal function. Intermediate cortisol levels are indeterminate with regard to adrenocortical function and require further evaluation, including stimulation with cosyntropin or insulin tolerance testing. Growth hormone levels are normally pulsatile, which can make growth hormone insufficiency difficult to diagnose; it can be presumed in the presence of multiple hormone insufficiencies, and confirmed by appropriate stimulation testing, which can be undertaken after definitive treatment of the underlying pituitary lesion and replacement of other pituitary hormone deficiencies have been implemented. Replacement therapy, especially levothyroxine and glucocorticoid (prednisone or hydrocortisone), should be considered as soon as the diagnosis of insufficiency is confirmed, especially in those patients who require surgery. Glucocorticoid replacement should precede thyroid hormone replacement in order to avoid precipitating adrenal crisis. Posterior pituitary dysfunction, typically diabetes insipidus (DI) is uncommon as a presenting symptom; when seen in association with sellar mass, the diagnosis is unlikely to represent a pituitary adenoma. Diabetes insipidus is characterized by polyuria/polydipsia, hyposthenuria and tendency to hyperosmolar dehydration if access to water is limited or thirst is deficient; confirmation may require a water deprivation test in uncertain cases. Hyponatremia may also occur in patients at the time of their initial presentation as a consequence of the syndrome of inappropriate antidiuretic hormone secretion (SIADH), central hypoadrenalism, or hypothyroidism.

Hypersecretory Syndromes

6 Pituitary adenomas may be associated with excess hormone secretion, giving rise to well-characterized clinical syndromes. It is important to recognize these preoperatively, especially since surgical treatment in some instances is not first-line therapy. In particular, patients with prolactin-secreting pituitary adenomas may be offered a trial of medical therapy, as dopamine agonists are effective in controlling tumor size and relieving mass effect.

Excess Prolactin (Prolactinomas)

Prolactin levels in women are physiologically increased during pregnancy, and are responsible for lactation; prolactin levels in healthy men are typically low. Excess prolactin in women leads to the syndrome of amenorrhea/galactorrhea, and hypogonadism with sexual dysfunction in men. Mildly elevated prolactin levels may be related to medication effects (dopamine antagonists, e.g., psychotropic medications), a microprolactinoma, or "stalk effect." (Table 78-3). This phenomenon occurs from the loss of tonic dopamine inhibition on the lactotrophs of the pituitary by any nonspecific mass compressing the pituitary stalk. Thus a nonfunctioning tumor or other pituitary lesion of sufficient size can lead to a moderately elevated prolactin level, usually less than 200 ng/mL, and this must be distinguished from a prolactinoma, as treatments are potentially different. A large tumor in the setting of a mildly elevated prolactin level likely represents "stalk effect" rather than a true prolactinoma; a mildly elevated prolactin level in the setting of a microadenoma likely represents a true microprolactinoma. Caution is advised in the interpretation of prolactin levels in patients with large sellar masses. Giant macroprolactinomas may secrete prolactin exuberantly, giving rise to the "hook effect," an immunoassay artifact that occurs in the presence of very high serum concentrations of prolactin, leading to substantial underreporting of prolactin levels. To avoid this artifact, prolactin should be measured in serially diluted serum specimens in patients with large sellar lesions.

Excess Cortisol (Cushing Syndrome)

Hypercortisolemia of any cause is known as "Cushing syndrome." These patients may present with a wide variety of manifestations, including metabolic (central adiposity, glucose intolerance), catabolic (muscle wasting, increased fracture risk, skin thinning, spontaneous ecchymoses, increased risk of infection), cardiovascular (hypertension, thromboembolism, coronary artery disease), mineralocorticoid (edema, hypokalemia), hypogonadal, hyperandrogenic (hirsutism, acne), and psychiatric symptoms. There are a number of causes of Cushing syndrome, including (most commonly) iatrogenic, but important neoplastic causes potentially requiring surgical treatment include pituitary adenomas, adrenal adenomas/carcinomas, or the ectopic secretion of ACTH by a nonpituitary/adrenal source, usually carcinoid tumors or small cell lung cancers. Approximately 70% to 80% of patients with noniatrogenic causes of Cushing syndrome will have a pituitary adenoma (Cushing disease). The diagnosis of Cushing disease can be

difficult, and is best performed by an endocrinologist experienced in pituitary evaluation. Hypercortisolemia is determined by measurement of 24-hour urine free cortisol levels, elevated serum cortisol levels on dexamethasone suppression testing, and, more recently, by elevated late-night salivary cortisol levels. These tests help establish the presence of cortisol excess and differentiate between Cushing syndrome and other states associated with high cortisol levels (Table 78-4). ACTH dependence or independence is determined by the measurement of plasma ACTH levels; low ACTH levels (ACTH independence) is seen with adrenal disease, as the increased cortisol levels are secreted independently of central ACTH production, resulting in normal feedback inhibition of pituitary ACTH production. High or inappropriately normal ACTH levels (ACTH dependence) are seen with pituitary or ectopic sources. Normal ACTH levels in association with hypercortisolemia can also occur when diurnal variation is lost, and typically point to a central rather than adrenal source. Dexamethasone suppression testing can be performed to biochemically differentiate pituitary from ectopic sources. Classically, failure to suppress cortisol levels with high-dose dexamethasone is associated with an ectopic source, though this may also be seen with some pituitary macroadenomas. While pituitary MRI imaging may demonstrate an adenoma, typically the microadenomas of Cushing disease are very small, and may not appear on MRI in 30% to 40% of patients. In these cases confirmation of a pituitary source requires bilateral inferior petrosal sinus sampling, where ACTH levels obtained from the inferior petrosal sinuses (both before and after the intravenous administration of corticotropin-releasing hormone [CRH]) are compared to levels obtained in the vena cava; a central-peripheral ACTH ratio of greater than 3:1 after the administration of CRH is considered diagnostic of a central source, even in the absence of tumor visualization on MRI.[18]

Table 78-3 Causes of Hyperprolactinemia

Physiologic	Pathologic (Pituitary)	Pathologic (Other)
Pregnancy	Prolactin-secreting adenoma	Medications (e.g., risperidone, metoclopramide, tricyclics, opioids)
Lactation	Growth hormone and prolactin cosecreting tumor	Polycystic ovary syndrome
Food	Any sellar mass causing "stalk effect"	Primary hypothyroidism
Coitus	Empty sella	Renal failure
Nipple stimulation	Cranial irradiation	Chronic liver disease
Physical stress	Idiopathic	Chest wall lesions

Table 78-4 Conditions Associated with Cortisol Excess

Cushing Syndrome	Cortisol Excess in Patients with Some Manifestations of Cushing Syndrome (But No Tumor)	Cortisol Excess in Patients Without Manifestations of Cushing Syndrome
Pituitary adenoma (Cushing disease)	Depression	Acute illness, injury or surgery
Ectopic ACTH secretion	Alcohol dependence	Hospitalization
Adrenal tumor (adenoma, carcinoma) or hyperplasia	Severe obesity	Anorexia nervosa
Iatrogenic	Poorly controlled diabetes mellitus	High corticosteroid–binding globulin (CBG) levels
Surreptitious	Polycystic ovary syndrome Familial glucocorticoid resistance	

Excess Growth Hormone (Acromegaly)

Excess growth hormone secretion by a pituitary adenoma in childhood, prior to epiphyseal closure, leads to gigantism, while growth hormone excess in adulthood leads to acromegaly. Adult patients will typically report increased ring and shoe size, dental and jaw abnormalities with malocclusion, coarsening of facial features (often falsely attributed to aging), headache, hoarseness, skin tags, increased sweating, carpal tunnel syndrome, arthralgias, frequent snoring, and sleep apnea. Because these changes occur slowly over time, diagnosis can be delayed, and these tumors are often larger and invasive at the time of detection. Systemic changes include glucose intolerance or frank diabetes mellitus, hypertension, and cardiomyopathy. There is an increased risk of colon polyps, and possibly colon and thyroid cancer. Acromegalic patients have a mortality risk on the order of 2 to 3 times that of the general population, if growth hormone excess is not adequately controlled. Many of these changes are reversible with successful control of the disease, but skeletal abnormalities are not. Because growth hormone secretion is pulsatile, random growth hormone measurements are not diagnostic. IGF1 (somatomedin C) is a protein produced mostly in the liver in response to growth hormone levels over time; it acts to integrate the pulsatile growth hormone levels and serves as the best single indicator of disease activity. IGF1 assays are technically challenging and require gender and age adjustment, as growth hormone levels increase during childhood and adolescent development and decrease with aging, and are higher in males than females. Because growth hormone is physiologically suppressed by a glucose load, glucose-suppressed growth hormone levels have been used as an indicator of disease activity, since acromegalic patients fail to suppress and may paradoxically increase. The criterion for adequate suppression has varied with the available growth hormone assay; current best available assays require suppression to at least GH <1 ng/mL (ideally below 0.4 ng/mL). Growth hormone measurements over time (day curve) have also been used in diagnosis, but are cumbersome to determine in an outpatient setting.

TSH Adenomas

While immunocytochemical staining for TSH is not uncommon, secretion of active thyrotropin in excess leading to central hyperthyroidism is rare. These patients will manifest the clinical syndrome of hyperthyroidism with attendant systemic manifestations. The majority of these tumors are macroadenomas and may therefore be

associated with mass effect. Biochemically, they demonstrate a nonsuppressed (inappropriately normal or increased) TSH level, in the setting of elevated thyroid hormones, that is, one does not see the feedback-inhibited TSH levels associated with primary hyperthyroidism. This syndrome needs to be distinguished from resistance to thyroid hormone which can lead to a similar hormone profile.

Endocrine Evaluation of a Pituitary "Incidentaloma"

With the widespread availability of MRI imaging, it is not uncommon for the radiologist to report the incidental finding of a pituitary mass. The endocrine evaluation requires screening of pituitary hormone levels to determine possible hypo- or hyperfunction, which will help to guide further therapy. Physiologic pituitary hypertrophy can be difficult to distinguish from a true pituitary adenoma, but requires an appreciation of the clinical setting to guard against unnecessary surgical intervention. Typically, adolescents, especially adolescent females, can demonstrate physiologic hypertrophy during puberty and for a few years thereafter, and women during pregnancy or during lactation can demonstrate physiologic enlargement of the gland from lactrotroph hyperplasia. Patients with unrecognized severe primary hypothyroidism can present with pituitary enlargement, sometimes striking, as a result of thyrotroph hyperplasia, which resolves with appropriate thyroid replacement. Rarely, ectopic secretion of growth hormone releasing hormone or corticotropin releasing hormone may lead to somatotroph or corticotroph hyperplasia, respectively. All these conditions need to be distinguished from true pituitary adenomas.

NEUROLOGIC EVALUATION IN PITUITARY ADENOMAS

The primary neurologic manifestation of a pituitary mass is ophthalmologic, from compression of the optic nerves or chiasm traveling through the suprasellar cistern. Because the ipsilateral retinal ganglion cell axons cross in the optic chiasm en route to the contralateral occipital cortex, the pathognomonic finding on visual field examination is a bitemporal hemianopsia ("pie-in-the-sky"). The chiasm may sometimes be associated with a relatively short intracranial optic nerve segment ("prefixed") or a relatively long intracranial optic nerve segment ("post fixed"). Depending upon the relative position of the tumor and chiasm, compression may also lead to uni- or bilateral optic nerve dysfunction, or compression of an optic tract, with a homonymous hemianopsia. Patients may sometimes report decreased acuity, although central vision is usually preserved unless compression is severe. A unilateral decrease in color vision is a sensitive sign of an early optic neuropathy, as is an afferent pupillary defect (Marcus Gunn pupil). This can be demonstrated by the "swinging flashlight test," where light shown into the affected eye leads to a paradoxical increase in pupillary size, as the ipsilateral pupillo-constrictor fibers have been damaged by ipsilateral optic nerve compression and transmit relatively decreased retinal activity. Although pituitary adenomas will often invade the cavernous sinus and displace the cranial nerves within, cranial nerve dysfunction other than optic is uncommon. When present, and especially if of sudden onset, one should suspect a rapidly expanding mass, that is, pituitary apoplexy, or a more aggressive tumor, for example, a malignancy. Similarly, pituitary adenomas will often circumscribe but rarely constrict the cavernous carotid artery or cause neurovascular dysfunction; when present an alternate pathologic diagnosis (especially meningioma) should be considered.

IMAGING OF PITUITARY ADENOMAS

Magnetic Resonance Imaging

MRI has revolutionized the visualization of intracranial lesions in general and pituitary tumors in particular. Useful pulse sequences for imaging the sella include T1 coronal and sagittal imaging before and after gadolinium administration. Other sequences (e.g., T2 coronal) may be useful, especially in the evaluation of cystic structures (fluid is generally hyperintense on T2) and previous hemorrhage (which may be dark on T2). Because of the relative decreased vascularity of adenomas as opposed to normal gland, timing of scanning relative to the administration of gadolinium is important; adenomas are generally focally hypointense to normal gland. Dynamic scanning using thin section gradient echo sequences may improve the sensitivity of visualization with small microadenomas (e.g., in Cushing disease), but gland heterogeneity may lead to decreased specificity.

Computerized Tomography

CT scanning has largely been supplanted by MRI, but remains useful in the delineation of bony anatomy for surgical planning and navigation. In those patients who cannot have an MRI, thin section coronal CT after contrast administration can be used to demonstrate a pituitary lesion. The presence of calcification on CT scanning can assist with the differential diagnosis, for example, a calcified cystic lesion, especially in a child, is highly likely to represent a craniopharyngioma.

MRI Characteristics

The normal gland enhances relatively homogenously. It should be no greater than about 8 mm in coronal height in males and 10 mm in females. The infundibulum should be midline. The posterior pituitary may be bright on T1 without contrast (thought to represent secretory granules in axon terminals), although this is not a constant finding.

Pituitary adenomas should be focally hypointense relative to normal gland on T1 sequences after contrast. Microadenomas (<1 cm) may not significantly disrupt gland architecture. Macroadenomas (>1 cm) show upward bowing of the diaphragm sella associated with stalk deviation, and larger macroadenomas will demonstrate compression of the chiasm. The normal gland can be compressed, usually superiorly and posteriorly. The cavernous sinus is variably involved; it can be difficult to distinguish invasion as opposed to compression. Lesions surrounding the cavernous carotid are obviously invasive; lesions which circumscribe less than 25% are usually compressive. It has been suggested than lesions which circumscribe less than 67% of the carotid diameter are not invasive, but this is very variable. Adenomas can also be cystic, which may show T1 bright signal before contrast consistent with high protein fluid or hemorrhage.

Craniopharyngiomas may be cystic or solid, and intra- or suprasellar. Characteristics of the cyst fluid can vary with the protein content, with greater T1 hyperintensity associated with higher protein. The cyst wall is commonly calcified on CT, especially in children. Since the tumor is often suprasellar or arises along the stalk, the gland is typically compressed inferiorly from above.

Pituitary cysts can demonstrate variable imaging characteristics also depending upon their protein content. Rathke cleft cysts arise posteriorly in the sella, or sometimes along the stalk. They can be T1 hypo- or hyperintense depending on protein content, and can compress the gland anteriorly or from above. The cyst wall is usually thin with minimal enhancement. If there is a solid component or calcification, the diagnosis is more likely to represent a craniopharyngioma. Arachnoid cysts of the sella contain fluid isointense to CSF. There will be minimal if any enhancement of the wall, as the cyst is lined with a thin arachnoid layer. The gland is usually compressed inferiorly or anteriorly.

Other Sellar Lesions

Germinomas usually involve the posterior gland, stalk, and/or hypothalamus. They are typically brightly enhancing, and the borders are relatively indistinct. An enhancing lesion of the posterior sella associated with a pineal mass is highly likely to represent a germinoma. Germ cell tumors may disseminate along CSF pathways, leading to enhancement around the fourth ventricle. *Meningiomas* are usually brightly enhancing, often more so than the gland itself. As they arise from the dura, they can be variably located in and around the sella. If they arise from the diaphragm, they can be difficult to distinguish from adenomas, but usually compress the gland from above. Meningiomas are often associated with a dural "tail," which spreads out from the central mass of the tumor, and sometimes with focal hyperostosis. Meningiomas of the cavernous sinus can lead to carotid constriction, best seen on coronal images when comparing the transverse

diameter of the intracavernous carotids, while adenomas rarely do. *Metastases* are typically locally invasive, brightly enhancing, and rapidly growing. They can spread hematogenously to the gland, or represent focal metastases to parasellar bony structures. When invading the cavernous sinus they can lead to a cavernous sinus syndrome, while adenomas rarely do.

SURGICAL TECHNIQUE

Although the first reported pituitary operation was a craniotomy done in 1889 by Sir Vincent Horsley,[19] the first transsphenoidal approach was described in 1907 by Hermann Schloffer, a Viennese otolaryngologist, when he reached the sphenoid via a lateral rhinotomy incision.[20] Less disfiguring approaches were devised by the American neurosurgeon Harvey Cushing, who, with William Halsted, devised the sublabial approach in 1910, and another Viennese otolaryngologist, Oscar Hirsch, who described a fully endonasal procedure.[21] Variants of these approaches remain in use today. Cushing performed over 200 transsphenoidal operations with an overall mortality rate of 5% – amazingly low given the lack of imaging, antibiotics, hormone replacement, and modern visualization – but decided in 1927 that the craniotomy was the more preferred procedure. With his decision, the transsphenoidal approach fell into relative disfavor, although kept alive by Dott in Edinburgh and Guiot in Paris, who introduced the use of intraoperative fluoroscopy as a navigation technique. When Jules Hardy of Montreal described the use of the operating microscope and reported the first removal of a pituitary microadenoma in 1962, pituitary surgery entered the modern era.[22]

The transsphenoidal approach is relatively noninvasive, as it employs the nasopharynx and sphenoid sinus to access the skull base, but the surgeon is constrained to operate through a narrow corridor, to a relatively deep target, surrounded by important structures (carotids and optic apparatus). The surgeon must (1) approach and navigate to the tumor, (2) visualize the pathology, and (3) maximally resect the tumor while minimizing damage to the adjacent structures, that is, normal gland.

Approach

There are three transsphenoidal approaches to the sella in use today, in addition to the seldom necessary subfrontal craniotomy (Fig. 78-2). The sublabial approach, described by Cushing and Halsted, employs an incision in the gingiva with a submucosal dissection to the bony nasal aperture, and then a submucosal dissection along the septum to the sphenoid. Because the approach is not constrained by the width of the nares, the degree of access is relatively wide, but the gingival incision is painful, can be associated with numbness of the teeth and gums, and usually requires nasal packing to reapproximate the mucosa. The two endonasal approaches are constrained by the width of the nasal aperture, but avoid the complications associated with a gingival incision. The approach described by Hirsch uses a submucosal tunnel along the septum through an anterior mucosal incision immediately posterior to the columella; Hirsch felt that the submucosal tunnel gave him a relatively sterile field through which to access the sphenoid, important in the days prior to antibiotics, but this approach also requires nasal packing to reapproximate the mucosa to the septum, which patients find uncomfortable. The direct endonasal approach described by Griffith and Veerapen[23] and Cooke and Jones[24] uses either an incision at the insertion of the septum into the face of the sphenoid, or an enlargement of the natural ostia, with a posterior septectomy. Because there is no submucosal tunnel, nasal packing is usually not required.

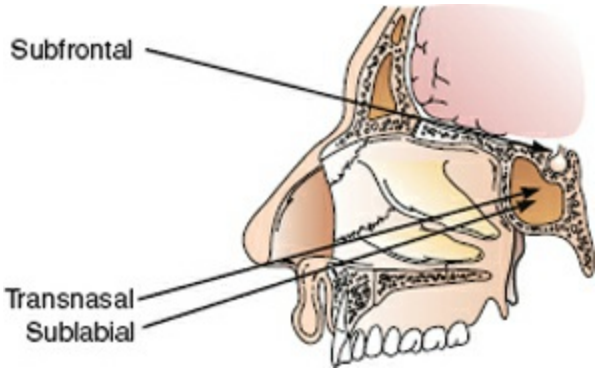

Figure 78-2. Surgical approaches to the sella.

Navigation

It is critical to maintain accurate orientation in the sellar approach, as the face of sella is bounded immediately laterally by the carotid protuberances, and superolaterally by the optic canals. The insertion of the nasal septum posteriorly is usually a midline structure and can be used for orientation, while the sphenoid septations are very variable, and can be used for orientation only when correlated with preoperative imaging. Lateral intraoperative fluoroscopy as introduced by Guiot gives immediate real-time two-dimensional (2D) orientation in a sagittal plane, although it does not provide orientation in the coronal plane. Neuronavigational devices establish a three-dimensional (3D) reference plane by registering facial anatomy with preoperative imaging, and can be used to correlate intraoperative anatomy with preoperative imaging by means of a navigational “wand” recognized by the device in real time. This gives 3D information to guide the approach, but is dependent on the accuracy of the registration, and is less valuable in determining the adequacy of resection and orientation within the tumor, as tumor anatomy can change during resection. It is used routinely at many institutions, and is especially valuable in cases where normal bony anatomy has been destroyed by tumor growth or previous surgery.

VISUALIZATION

Hardy introduced the use of the intraoperative microscope to pituitary surgery and it remains in widespread use today. After the introduction of the rigid endoscope to field of sinus surgery by otolaryngologists, its use in transsphenoidal surgery was reported by Janowski in 1992[25]; it has now been the topic of multiple reviews and has become widely accepted. Advantages of the microscopic approach are the superb optics and binocular vision; a major disadvantage is the requirements for direct line-of-sight viewing, though for smaller tumors, that is, the microadenomas of Cushing disease, this disadvantage may not be significant. The endoscope gives a wider field of view and has the ability to see at angles off the primary visual axis. However, most endoscopes offer only monocular vision with no depth of field, though 3D endoscopes are under development. Although the endoscopic technique has been touted as "less invasive," the need to supply sufficient access for both the endoscope and working instruments may actually require greater dissection of the sphenoid, ethmoids, and possibly resection of the turbinate(s). A number of meta-analyses have been published comparing the two techniques, usually using recent endoscopic results compared to older historical microscopic series. The overall results for secretory tumors, where there are defined biochemical criteria for remission, appear similar, with a possible edge to endoscopy in larger secretory tumors in association with perhaps a small increased risk of vascular complications.

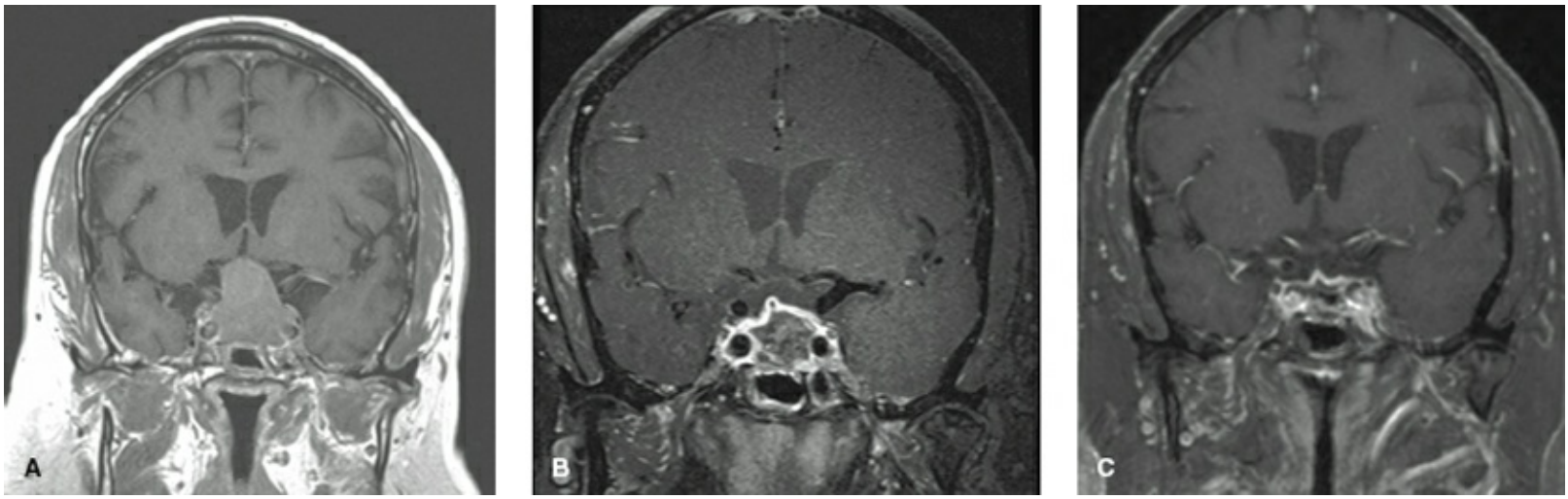

Figure 78-3. **A:** The coronal view (T1-weighted image with contrast) of a large nonfunctioning macroadenoma with significant chiasm compression. **B:** The intraoperative MRI (T1-weighted image with contrast) shows tumor removal with fat packing and hemostatic material in place. The chiasm is decompressed. **C:** The postoperative MRI at 8 weeks shows partial resorption of the fat packing and hemostatic material.

Determining the Adequacy of Resection

As most pituitary tumors are removed by internal decompression allowing collapse of the tumor capsule, there may be no direct visualization of the adequacy of resection. Endoscopic inspection of the tumor capsule can sometimes provide an indication, but prolapse of the diaphragm as the capsule collapses (itself an indication of adequacy of decompression) can make thorough internal visualization difficult. Intraoperative MRI (iMRI) imaging has proven useful in the determination of resection adequacy, as the technique allows the surgeon to visualize areas of residual tumor not seen with direct inspection. A comparison of preoperative, intraoperative, and postoperative imaging in a patient with a large nonfunctioning macroadenoma is shown in Figure 78-3. A number of studies have reviewed the utility of intraoperative imaging. Most report that additional tumor resection can be achieved in about 20% of cases, but this is partly a function of when, during the course of the procedure, the surgeon chooses to image, and premature imaging may bias the results in favor of demonstrating the utility of the iMRI.[26] In addition, imaging can show whether the chiasm has been adequately decompressed, which correlates with postoperative visual improvement, and may assist in the avoidance of postoperative complications. The iMRI equipment is costly, however, and requires significant alterations in surgical workflow and operative time, with the risk of operating in close proximity to a high-strength magnetic field. It has been debated whether resection can be better optimized with the use of the iMRI versus the endoscope, and each approach has its adherents. In those few studies combining the use of endoscopy with the iMRI, most showed that some degree of additional resection can be achieved after imaging.[27,28]

Surgical Technique

7 There are a number of variations in surgical technique, determined by the preference of the surgeon and the dictates of the anatomy. The patient is given preoperative broad-spectrum antibiotic coverage and stress-dose steroids (except for patients with Cushing disease, where preoperative steroid coverage can be held). After the induction of general endotracheal anesthesia, the patient is positioned in a semirecumbent position. The head may be turned toward the surgeon or in a neutral position if two surgeons will together be performing an endoscopic approach. The head can be held in a gel headrest or pinned using the Mayfield clamp. If neuronavigation is used, the reference fiducials are affixed and registered, or the lateral fluoroscope is positioned. The area of the proposed incision is infiltrated with local anesthesia with epinephrine as a vasoconstrictor. With a direct endonasal approach the incision is made along the posterior septum, and either the septum is fractured and deviated contralaterally, or a posterior septectomy is performed. With a microscopic approach, a nasal speculum is introduced, compressing the turbinates laterally. With the endoscopic approach, the middle turbinate may require removal to increase access. The face of the sphenoid is opened, and any septations impeding access are removed. Anatomy of the sphenoid septations gleaned from preoperative imaging can be useful in guiding the approach to the midline sella, which is drilled to dura. The dura is lightly cauterized and incised. For macroadenomas, the tumor is usually immediately evident, and can be removed with ring curettes back to normal gland. With microadenomas, especially those causing Cushing disease, detection can be difficult. The gland is hemisected into quadrants, with biopsies taken from each quadrant guided by the preoperative IPSS lateralization. If no tumor is found on frozen section analysis, a hemihypophysectomy can be performed. It is important to preserve normal gland; this can usually be distinguished by color and consistency, and, in macroadenomas, is usually compressed posteriorly and superiorly. As the resection proceeds, the diaphragm should prolapse into the field in cases of preoperative chiasm compression. After tumor removal, the resection cavity is inspected for residual tumor; 30-degree or 70-degree endoscopes are useful in visualizing areas not in direct line-of-sight. Hemostasis is achieved by packing with any number of available hemostatic materials. After hemostasis, most surgeons pack the tumor cavity with fat, muscle or absorbable hemostatic material; a water-tight seal is especially important if a CSF leak has been created. The fat is buttressed in place and the sellar floor reconstructed with septal cartilage or bone, titanium mesh, or proprietary plastic materials. Fibrin glue or other sellar sealant can be used if needed. The septum is returned to the midline. With a direct endonasal approach, nasal packing is usually not required. If a submucosal tunnel was created during the approach, nasal packing is placed; if a sublabial incision was used, the gingival mucosa is closed with a few absorbable sutures. The use of iMRI can be timed at the discretion of the surgeon. Some surgeons will maintain the sterile field and image before closure; others complete the closure (since reopening is usually straightforward) and image prior to anesthesia reversal.

Postoperative Management

Careful monitoring in the postoperative period is essential. Most patients require only one to two nights of hospitalization; an ICU stay is usually not necessary. Potential complications include postoperative hemorrhage, CSF leakage, meningitis, epistaxis, and endocrine dysfunction.

1. Postoperative hemorrhage can occur into the tumor resection cavity with resulting visual compromise, thus frequent testing of postoperative acuity and confrontation fields is necessary. Immediate reexploration may be required.
2. CSF leakage can be sometimes difficult to detect, as postoperative nasal drainage is common. If suspected, the best confirmatory test is to assay the collected fluid for tau protein (beta transferrin), which is found in CSF but not in nasal secretions or blood. If positive, treatment options include the insertion of a lumbar drain to lower CSF pressure for a few days and allow spontaneous closure of the leak, but oftentimes the optimal course is reexploration and repacking of the tumor bed with closure of the fistula.
3. Infection in the immediate postoperative period is rare. Prophylactic antibiotic coverage is maintained for 24 hours, or until the nasal packing is removed. Delayed fever, especially with signs of meningitis, requires evaluation with a lumbar puncture; an occult CSF leak should be suspected. Patients may be at increased risk of sinus infection for many months.
4. Bloody nasal secretions are common, and usually clear with nasal irrigation. Frank epistaxis is rare, usually occurs 2 or 3 weeks after surgery, and is most often caused by delayed hemorrhage from a septal branch of the spheno-palatine artery. It can sometimes be managed with nasal packing, but may require cauterization or clipping, or rarely embolization.
5. Endocrine management. Postoperative endocrine management is best done in conjunction with an endocrinologist. Monitoring for pituitary insufficiency, especially hypoadrenalism, is necessary. Some centers prophylactically treat with replacement steroids until adequate cortisol levels can be proven; early discharge (on POD #1 or #2) may require outpatient steroid supplementation until testing can be completed. Others monitor for adrenal insufficiency without replacement, though this is safest as an inpatient. After successful surgery for Cushing disease, immediate and prolonged (6 to 12 months) hypoadrenalism is expected if remission is achieved. Postoperative steroid replacement will be required until normalization of the pituitary–adrenal axis is documented. Complete postoperative hormone testing is usually performed at 6 to 8 weeks in order to establish the presence of remission of hormone excess and reassess the patient's pituitary function, including the possible development of new pituitary hormone deficiencies (occurring in 5% to 10% of patients). Conversely, pre-existing pituitary hormone deficiencies may resolve in 30% to 40% of patients postoperatively. Transient diabetes insipidus is not uncommon (about 10% to 20% of cases), but permanent DI is unlikely (approximately 1% to 2%). It is important to monitor urine

output, urine-specific gravity, and serum sodium levels in the immediate postoperative period, and treat with desmopressin (vasopressin analog devoid of pressor activity) if needed. Mild cases can be treated with *ad lib* fluid intake if the patient's thirst mechanism is intake, as it usually resolves spontaneously within a few days. Sodium levels should be monitored intermittently as an outpatient for 10 to 14 days, as SIADH can develop in a delayed fashion, and a triphasic pattern (DI → SIADH → DI) has been described. Patients with SIADH who are symptomatic from hyponatremia may present with headaches and nausea, and neurologic dysfunction – confusion and rarely seizures – can occur if the hyponatremia is severe (serum sodium $<$120 to 125 mEq/L). Mild SIADH usually responds to fluid restriction and salt supplements; symptomatic patients may require 3% hypertonic saline. It is important not to correct the hyponatremia too quickly, as central pontine myelinolysis can occur.

RESULTS AND COMPLICATIONS

Reviews of the literature on the outcome after transsphenoidal surgery require recognition of a number of factors potentially affecting the interpretation of the results. Endocrine diagnostic techniques, biochemical criteria for remission for secretory tumors, and surgical techniques have changed over the years, which can make comparison difficult. There may be a publication bias favoring newer approaches over old. Meta-analyses can be useful, but need to be interpreted with an eye to the underlying data, and most of the meta-analyses review retrospective case series rather than randomized studies. A recent meta-analysis reviewed short-term remission and recurrence data over the past 25 years and reported overall short-term surgical remission rates of 61.7% in prolactinomas, 44.4% in nonfunctioning tumors, 60.9% in acromegaly, and 72.7% in Cushing disease, with no clear-cut improvement over the interval. Because of the historical time frame, the majority of the series used the microscopic approach. The risk of recurrence per patient year at risk was reported to be 3.4% for prolactinomas, 2.2% for nonfunctioning tumors, 0.7% for acromegaly, and 2.3% for Cushing disease.[29]

Much of the recent literature describes the results with endoscopic approaches, often in comparison to historical microscopic results; no major randomized comparison has been published. One recent review included nine pooled studies; they reported a 78% rate of gross tumor removal (GTR), 81% remission rate in Cushing disease, 84% remission in acromegaly, and 82% in prolactinomas, with a 2% incidence of CSF leak and 1% incidence of permanent DI. There were two deaths (0.24%), both from vascular injury.[30] This review was overweighted by a single large study which contributed 39% of the secretory cases. An additional 12 endoscopic studies were included in a second meta-analysis, with an overall rate of GTR 68%; 72% remission in acromegaly, 75% remission in Cushing disease, and 78% remission in prolactinomas.[31] Meta-analyses comparing the microscopic and endoscopic approaches now exist, often using the same underlying data but reaching differing conclusions. Three of these are summarized in Table 78-5; one of the three shows a resection benefit with endoscopy, while two do not. In addition, a number of reviews have specifically analyzed complication rates between endoscopic and microscopic techniques.[32–34] Three of these reviews report that, in comparison to a retrospective analysis of traditional sublabial approaches, the endoscopic approach appears to show decreased operating time, length of hospital stay, risk of diabetes insipidus, nasal complications, and patient pain and discomfort. The largest study incorporated 38 studies with greater than 10 patients; a total of 5,643 patients were included.[35] This study found no significant difference in the incidence of complications with the exception of a statistically significant increased risk of vascular complications with endoscopic procedures, perhaps due to the wider exposure possible within the endoscope. The overall incidence of typical complications for both endoscopic and microscopic procedures is summarized in Table 78-6, abstracted from this review.

Table 78-5 Comparison of Endoscopic and Microscopic Approaches

Meta-Analysis	Studies Reviewed (Patients)	GTR[a]	Complication Differences	Hospital Stay
Gao et al.[36]	15(1,014)	71% endo; 58% micro ($p = 0.0001$)	Increased risk of septal perforation with micro ($p = 0.01$)	Shorter with endo
Ammirati et al.[35]	38(5,643)	69% endo; 64% micro (NS)	Increased risk of vascular complications with endo ($p < 0.0001$)	NA
Goudakos et al.[32]	11(806)	66% endo; 60% micro (NS)	DI less frequent with endo ($p = 0.003$)	Shorter with endo

[a]GTR defined as radiographic for nonfunctioning adenomas (NFA) or biochemical remission for secretory tumors.

Table 78-6 Comparison of Complication Rates in Endoscopic Versus Microscopic Surgery Based on a Meta-Analysis of 38 Studies[35]

Complications/Events	Endoscopy Studies	Proportion (95% CI)	Microscopy Studies	Proportion (95% CI)
Death	19	0.49% (0.23–0.84%)	18	0.23% (0.10–0.42%)
CSF leak	24	7% (4.84–9.52%)	19	6.34% (3.86–9.37%)
Meningitis	13	1.11% (0.642–1.71%)	14	2.08% (0.83–3.86%)
Vascular complications[a]	17	1.58% (1.07–2.19%)	12	0.5% (0.28–0.78%)
Visual loss	13	0.72% (0.37–1.19%)	14	0.60% (0.23–1.14%)
Diabetes insipidus temporary	18	9.1% (6.57–11.99%)	14	10.23% (6.5–14.69%)
Diabetes insipidus permanent	21	2.31% (1.41–3.41%)	15	4.25% (1.96–7.36%)
Hypopituitarism	17	8.51% (5.16–12.59%)	12	11.64% (5.14–20.32%)
Complete resection	22	68.77% (64.37–73%)	18	64.44% (57.62–70.98%)
Nerve injury	8	0.28% (0.05–0.71%)	7	0.53% (0.08–1.34%)

[a]Statistically significant ($p < 0.0001$)

Prolactinomas

Given the efficacy of dopamine agonist treatment, surgery for prolactinomas is rarely indicated. Nonetheless, it remains effective in selected cases, especially in smaller tumors. A large surgical series reported initial remission of 91.3% in microadenomas, with a recurrence rate of 7.1%. The overall remission rate was 53.2% including giant prolactinomas.[37]

Acromegaly

Surgery remains the most effective treatment for acromegaly, despite the availability of medical therapy. Multiple surgical series in the literature report remission rates on the order of 50% to 65% for macroadenomas, and 70% to 90% for microadenomas (Table 78-7). Results from specialized centers are generally better than those results reported from tumor registries.

Cushing Disease

Surgical results for Cushing disease are summarized in Table 78-8. Remission rates for microadenomas are generally from 70% to 90%. In those patients not in remission after the initial procedure, a second exploration is sometimes recommended, which can achieve remission in an additional 50% to 70% of patients.[46,47] While early as opposed to late reoperation is technically less challenging, delayed remissions have been reported, and it is important to determine that postoperative levels have plateaued at an elevated level before proceeding with reexploration.[48]

Table 78-7 Recent Surgical Results for Acromegaly

Study	Pts	Technique	Size Distribution	Remission
Hazer et al.[38]	214	endo		134 (62.6%)
Starke et al.[39]	113	72 endo 41 micro	20% micro 80% macro	87% micro [a]66% macro
Shin et al.[40]	53	endo	88.2% macro 46.9% invasive	27 (50.9%)
Schöfl et al.[41]	1,344	various		38.8%
Jane et al.[42]	60	endo	23% micro 67% macro	14/14 (100%) 28/46 (61%)
Hofstetter et al.[43]	24	endo	17% micro 83% macro	46% overall
Campbell et al.[44]	26	endo	15% micro 85% macro	3/4 (75%) 12/22 (54.5%)
Wagenmakers et al.[45]	40	endo	100% macro	20/40 (50%)

[a]NS difference in remission between two techniques.

Table 78-8 Recent Surgical Results for Cushing Disease

Study	Patients	Tumor Size	Remission	Recurrence (Follow-Up)
Wagenmakers et al.[49]	86	20 MRI neg 25 micro 16 macro 15 invasive macro	60% 83% 94% 40%	
Alexandraki et al.[50]	124	Micro 103 Macro 21	72.8% 42.9%	22.7% (15 yrs) 33.3%
Hameed et al.[51]	52	Micro 36 Macro 16	82.7% overall	14% (39 mos)
Hassan-Smith et al.[52]	72		72% overall	11% (4.6 yrs)
Honegger et al.[53]	83	Micro 72 Macro 11	94.5% 64%	
Roelfsema et al.[29]	Meta-analysis: 5,787 patients in 50 studies		71.3% (41–98)	Approx. 10% (4.91 yrs); 2%/yr FU

MANAGEMENT OF PITUITARY ADENOMAS BY SYNDROME

With the advent of medical therapy for some of the secretory tumors, surgical indications have changed, and surgical decision making needs to be considered in the context of the available treatment options.

Prolactinomas

8 Medical treatment with dopamine agonists (DAs) is considered first-line therapy for most patients with prolactinomas even those with large and invasive tumors.[54] Not all patients require treatment – patients with asymptomatic, stable microadenomas, who are not pursuing fertility, can often be followed expectantly. The commonly used agents – bromocriptine and cabergoline – are both oral agents with excellent efficacy, minimal side effects (usually GI disturbances, although cognitive issues and psychological effects have been reported, including depression, anxiety, and impulsivity), and are relatively inexpensive. Cabergoline is more effective and generally better tolerated than bromocriptine. High doses of cabergoline (>3 mg/d) have been associated with cardiac valvular dysfunction, but this does not appear to be a significant risk in the dose range usually prescribed for prolactinomas (typically 0.5–2.0 mg/wk, Table 78-9). Because they act as metabolic inhibitors and are not cytotoxic, lifelong therapy is usually required, although there are some reports of apparently long-term remission after discontinuation of the drugs.[55] The tumor shrinkage in response to these agents is often dramatic. Surgical treatment is indicated after the failure of medical therapy, intolerance to the medications, and in cases where the patient prefers the possibility of surgical remission to life-long medical treatment. Other indications for surgery include cerebrospinal fluid leak, occurring as a result of shrinkage of large, invasive prolactinomas in response to medical therapy, and pituitary apoplexy, which may rarely complicate use of dopamine agonists. Relative indications include cystic tumors, which may not shrink with medical treatment, and in infertile women who wish to become pregnant without medication. Long-standing visual dysfunction will often improve after tumor shrinkage from medical treatment, while rapidly progressive visual loss, especially associated with hemorrhage, mandates surgical removal. Radiation therapy can be recommended for tumors unresponsive to medical and surgical treatment. Temozolomide, an orally active alkylating agent, has been administered (“off label”) to some patients with aggressive pituitary adenomas or carcinomas (including, but not limited to, aggressive or malignant prolactinomas), and may transiently achieve tumor control.

9 Surgery remains first-line treatment in most cases, though some would argue for primary medical treatment in those cases unlikely to be surgically cured, or in patients who are not optimal surgical candidates.[56] The available medical treatments include somatostatin analogs (SSAs), dopamine agonists, and growth hormone receptor antagonists. Each treatment modality has its own relative advantages and disadvantages. Surgery is rapidly effective in lowering GH levels, leads to immediate relief of symptoms from mass effect (visual loss), and has the potential to be curative, depending upon the size and degree of tumor invasiveness. Cabergoline, the most potent dopamine agonist, is sometimes effective in acromegaly (leading to endocrine remission in 20% to 30% of cases), but usually only when the IGF1 level is minimally elevated (Table 78-10). However, it is an oral agent with minimal risk and relatively inexpensive. Its use in acromegaly is not FDA approved. The SSAs – octreotide and lanreotide – are effective in normalizing IGF1 in about 40% to 50% of patients previously selected for responsiveness to SSAs, though recent studies in unselected de novo patients report effectiveness in only 20% to 25%. They lead to tumor shrinkage to some degree also in about 40% to 50% of cases, though the shrinkage seen is usually not dramatic (unlike the shrinkage seen in prolactinomas with DAs). They are both injectable agents, given every 4 weeks in their long-acting forms, and usually well tolerated; the most common side effects are GI disturbances and occasionally cholelithiasis and hyperglycemia. Both agents are expensive. A recent study compared the use of octreotide and pasireotide in acromegaly; in de novo patients (no previous surgery) remission was achieved in 26% with pasireotide and 17% with octreotide.[57] The growth hormone receptor pegvisomant blocks the peripheral action of growth hormone and leads to dramatic lowering of the IGF1 level in up to 95% of patients, but has no direct antitumoral effect. Because of this, it is best used in combination with the SSAs in cases of incomplete response, or to control the IGF1 while awaiting the beneficial effects of radiation treatment. Arguments have been made for both pretreatment of surgical cases with SSAs, and debulking of unresectable tumors prior to medical therapy. In three randomized studies, pretreatment was shown to improve postoperative remission rates, but the control remission rate in these studies was lower than would be expected from comparisons to the literature. In a recent meta-analysis, a borderline positive affect with pretreatment was detected in 10 studies, both randomized and retrospective, which did not reach statistical significance, while the analysis of the prospective controlled trials (with historically low pretreatment remission rates) was statistically significant in showing benefit.[58] Pretreatment in symptomatic acromegalic patients can, however, improve anesthetic risk by improving attendant comorbidities, especially cardiomyopathy and airway management, and for this reason alone is sometimes worthy of consideration.[59] The indications for debulking an unresectable tumor have been debated; since SSA treatment appears to be more effective with lower IGF1 levels,[60] an argument can be made for removing as much tumor as possible and treating the remainder with medication. In cases where primary medical treatment was unsuccessful, surgical debulking has been shown to improve remission,

even if surgical "cure" cannot be achieved.[61] Radiation therapy is usually a third-line option for patients who are not in remission after surgery and do not respond or tolerate medical therapy. A flowchart for the management of acromegaly is shown in Algorithm 78-1.

Table 78-9 Medications Used to Treat Prolactin-Secreting Pituitary Adenomas

Name	Mechanism of Action	Usual Dose Range	Adverse Effects
Bromocriptine	Dopamine receptor agonist	1.25–10 mg by mouth daily (in divided doses)	Nausea, vomiting, dizziness, headache, nasal congestion, constipation, digital vasospasm, vivid dreams, anxiety, depression, impulsivity
Cabergoline	Dopamine receptor (D2 selective) agonist	0.5–2.0 mg by mouth weekly (in a single or divided doses)	Same as bromocriptine (often better tolerated by patients); high doses (>3 mg/d) have been associated with cardiac valvulopathy

Table 78-10 Medications Used to Treat Acromegaly

Name	Mechanism of Action	Usual Dose Range	Adverse Effects
Octreotide acetate	Somatostatin receptor agonist (sstr2 and sstr5)	100–500 mcg subcutaneously every 8 hrs	Gastrointestinal side effects, cholelithiasis, hyperglycemia, hypoglycemia, vitamin B12 deficiency, hypothyroidism, bradycardia, hair loss
Octreotide LAR	Somatostatin receptor agonist (sstr2 and sstr5)	10–40 mg intramuscularly every 4 wks	Same as octreotide acetate
Lanreotide depot	Somatostatin receptor agonist (sstr2 and sstr5)	60–120 mg deep subcutaneously every 4 wks	Same as octreotide acetate
Cabergoline[a]	Dopamine receptor (D2 selective) agonist	0.5–7.0 mg by mouth weekly	Nausea, vomiting, dizziness, headache, nasal congestion, constipation, digital vasospasm, vivid dreams, anxiety, depression, impulsivity; high doses (>3 mg/d) have been associated with cardiac valvulopathy
Pegvisomant	Growth hormone receptor antagonist	5–40 mg subcutaneously daily	Lipohypertrophy, skin rash, hepatotoxicity

[a]Cabergoline is not approved by the FDA for use in acromegaly.

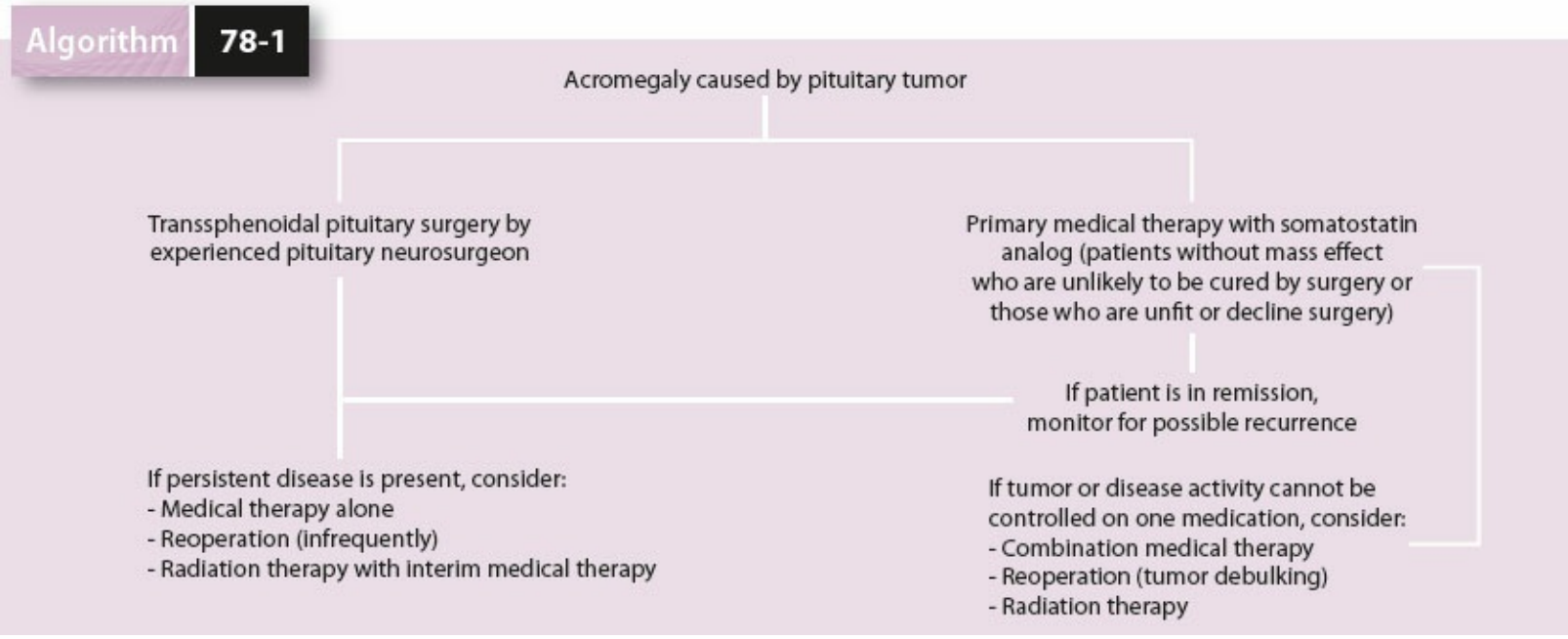

Algorithm 78-1. Treatment algorithm for acromegaly.

Table 78-11 Medications Used to Treat Cushing Disease

Name	Mechanism of Action	Usual Dose Range	Adverse Effects
Ketoconazole	Adrenal steroidogenesis inhibitor	200–600 mg by mouth two to three times daily	Nausea, dyspepsia, skin rash, hepatotoxicity, hypogonadism, gynecomastia
Metyrapone	Adrenal steroidogenesis inhibitor	250–1,000 mg by mouth four times daily	Nausea, dizziness, hirsutism, hypertension, edema, hypokalemia
Mitotane	Adrenal steroidogenesis inhibitor	0.5–3.0 g by mouth three times daily	Nausea, diarrhea, dizziness, ataxia, confusion, hepatotoxicity, rash, gynecomastia, dyslipidemia, teratogenicity
Etomidate	Adrenal steroidogenesis inhibitor	0.03 mg/kg intravenously as a bolus, followed by infusion: 0.1–0.3 mg/kg/hr	Sedation
Cabergoline	Dopamine receptor (D2 selective) agonist	0.5–7.0 mg by mouth weekly	Nausea, vomiting, dizziness, headache, nasal congestion, constipation, digital vasospasm, vivid dreams, anxiety, depression, impulsivity; high doses (>3 mg/d) have been associated with cardiac valvulopathy
Pasireotide[a]	Somatostatin receptor agonist (sstr1, 2, 3, and 5)	0.3–0.9 mg subcutaneously twice daily	Gastrointestinal side effects, cholelithiasis, hyperglycemia (more often than other somatostatin analogs), vitamin B12 deficiency, hypothyroidism, bradycardia, hair loss
Mifepristone[a]	Glucocorticoid receptor antagonist	300–1,200 mg by mouth daily	Fatigue, headache, nausea, hypokalemia, vaginal bleeding, endometrial thickening, pregnancy termination, abnormal thyroid function tests, dyslipidemia

[a]Only pasireotide and mifepristone are approved by the FDA for use in Cushing disease.

Cushing Disease

Surgical excision is generally considered to be first-line treatment; if unsuccessful, early reexploration has been recommended with some additional degree of success.[46] Surgical remission leads to immediate lowering of ACTH levels and cortisol production, and steroid replacement is required as the normal gland will remain suppressed for months. If transsphenoidal surgery is unsuccessful, a number of treatment options are available. Medical therapy can control hypercortisolemia by inhibition of cortisol production by the adrenal glands (ketoconazole,[62] metyrapone, mitotane, etomidate), at the level of the pituitary tumor by acting on somatostatin receptors (pasireotide)[63] or dopamine receptors (cabergoline),[64] or by cortisol receptor blockade (mifepristone),[65] and combination therapy has been suggested as well.[66] Medications are most commonly used in patients who have persistent hypercortisolism after pituitary surgery and are not candidates for additional surgery. Each medication has its attendant set of side effects, including liver function abnormalities with ketoconazole, hyperglycemia with pasireotide, GI disturbances with high-dose cabergoline, and hypokalemia and endometrial thickening with mifepristone; none represents optimal therapy but each may offer advantages in the individual patient (Table 78-11). Only pasireotide and mifepristone are FDA approved for use in patients with Cushing disease. Bilateral adrenalectomy remains a viable option, with immediate resolution of hypercortisolemia, but requires lifelong mineralocorticoid and glucocorticoid replacement. It is associated with radiographic progression of the pituitary adenoma in about half the cases, and a smaller number of patients may develop Nelson syndrome.[67] Radiosurgery with interim medical control is often a reasonable option after unsuccessful surgery; normalization of cortisol levels occurs in about 50% to 70% of patients within 2 years of treatment, but with a significant risk of anterior hypopituitarism.[68,69] A flowchart for the management of Cushing disease is shown in Algorithm 78-2. Recurrent Cushing disease after initially successful surgery remains a significant problem. Reported recurrence rates are approximately 2% per year,[29] but some series report an overall incidence of as high as 25%.[70] Reexploration for recurrence is a reasonable option with success rates on the order of 50%; but the alternative therapies described above merit consideration as well.[71,72]

Nonfunctioning Tumors

Surgical removal remains as first-line treatment; there are no good medical options (as the response to dopamine agonists or SSAs has been poor). Small nonfunctioning tumors (<1 cm) can be followed with serial imaging, but macroadenomas should usually be resected, especially those which are close to the chiasm or enlarging on serial scans, even without visual abnormalities. After subtotal resection it is in many cases reasonable to follow the residual tumor, with reoperation or radiation therapy reserved for those which later enlarge. Guidelines for the management of pituitary incidentalomas have been recently published.[73]

Thyrotropin-Secreting Pituitary Adenomas

Pituitary surgery is first-line therapy in most cases. Patients with hyperthyroidism can be pretreated with SSAs or methimazole in order to control hyperthyroidism preoperatively, if present. After surgery, patients with residual tumors or persistent hyperthyroidism may benefit from SSA therapy, which is very effective in controlling hyperthyroidism and also affords some degree of tumor control. Radiation therapy is an alternative option in patients who are not in remission after pituitary surgery.

SOCIOECONOMIC CONSIDERATIONS

10 A number of socioeconomic considerations now affect the practice of pituitary surgery. The volume-outcome relationship, which has been shown to be manifest in a number of surgical subspecialties, holds true here as well. This was originally suggested by a study showing improved outcomes for acromegaly with a dedicated pituitary surgeon.[74] Further studies have demonstrated a decrease in complication rate with increased experience,[75] and a significant decrease in operative mortality after pituitary surgery in high-volume as opposed to low-volume centers.[76] With the multiplicity of available treatment modalities, comparative cost–benefit analyses are now being performed. Treatment algorithms in acromegaly which incorporated transsphenoidal surgery were shown to be less expensive than those using medical therapy alone, and algorithms using primary surgery followed by adjunctive medical treatment as opposed to the converse approach were shown to be 30% less costly overall.[77] In Cushing disease, the economic burden of managing patient comorbidities was shown to significantly decrease after successful surgery.[78] Despite the introduction of new pharmacologic agents, it is likely that surgery will continue to play a major role in the treatment of pituitary disorders; given the multiplicity of options, however, care is best individualized for a given patient in a multidisciplinary setting.

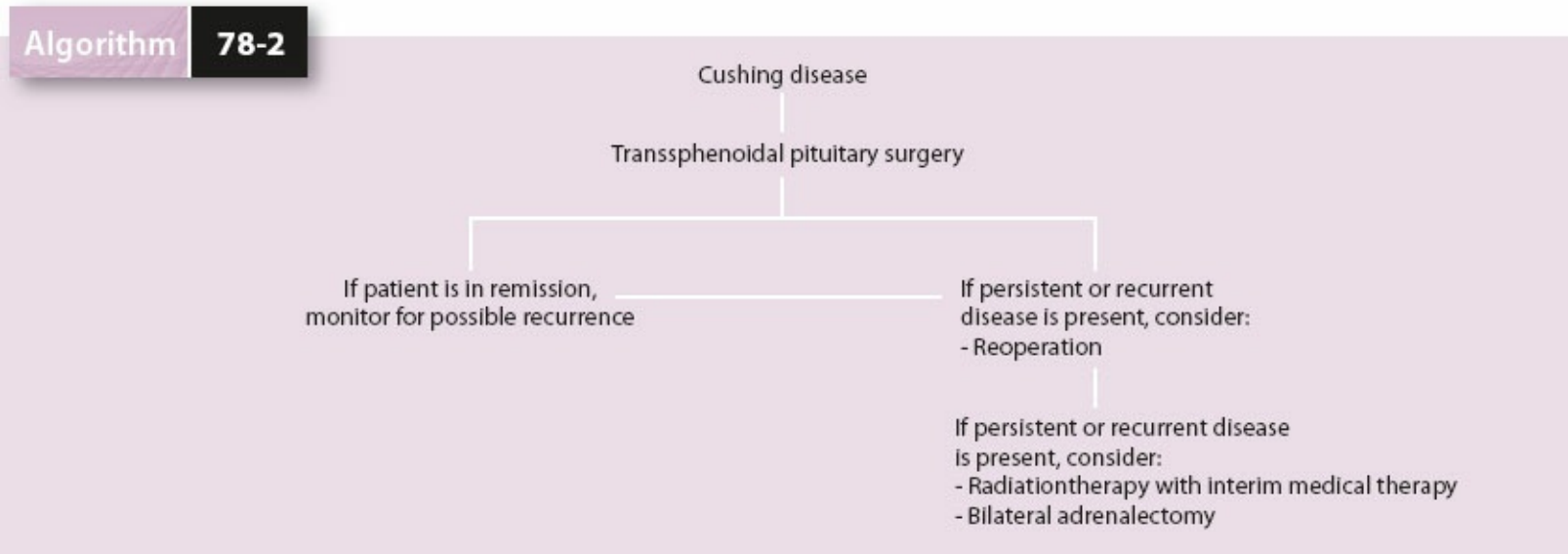

Algorithm 78-2. Treatment algorithm for Cushing disease.

References

1. Ezzat S, Asa SL, Couldwell WT, et al. The prevalence of pituitary adenomas: a systematic review. *Cancer* 2004;101:613–619.
2. Ciccarelli A, Daly AF, Beckers A. The epidemiology of prolactinomas. *Pituitary* 2005;8:3–6.
3. Holdaway IM, Rajasoorya C. Epidemiology of acromegaly. *Pituitary* 1999;2:29–41.
4. Lindholm J, Juul S, J⊘rgensen JO, et al. Incidence and late prognosis of Cushing's syndrome: a population-based study. *J Clin Endocrinol Metab* 2001;86:117–123.
5. Tritos NA, Eppakayala S, Swearingen B, et al. Pathologic and clinical features of pituitary adenomas showing TSH immunoreactivity. *Pituitary* 2013;16(3):287–293.
6. Kontogeorgos G. Predictive markers of pituitary adenoma behavior Neuroendocrinology. 2006;83(3–4):179–88.
7. DeLellis RA, Lloyd RV, Heitz PU, et al, eds. *World Health Organization Classification of Tumours: Tumours of Endocrine Organs.* Lyons, IARC; 2004.
8. Zada G, Woodmansee WW, Ramkissoon S, et al. Atypical pituitary adenomas: incidence, clinical characteristics, and implications. *J Neurosurg* 2011; 114(2):336–344.
9. Freda PU, Post KD. Differential diagnosis of sellar masses. *Endocrinol Metab Clin North Am* 1999;28(1):81–117, vi.
10. Valassi E, Biller BM, Klibanski A, et al. Clinical features of nonpituitary sellar lesions in a large surgical series. *Clin Endocrinol (Oxf)* 2010;73(6):798–807.
11. Larkin SJ, Ansorge O. Pathology and pathogenesis of craniopharyngiomas. *Pituitary* 2013;16(1):9–17.
12. Komninos J, Vlassopoulou V, Protopapa D, et al. Tumors metastatic to the pituitary gland: case report and literature review. *J Clin Endocrinol Metab* 2004;89(2):574–580.
13. Faje AT, Sullivan R, Lawrence D, et al. Ipilimumab-induced Hypophysitis: a detailed longitudinal analysis in a large cohort of patients with metastatic melanoma. *J Clin Endocrinol Metab* 2014;99(11):4078–4085.
14. Marko NF, Weil RJ. Pituitary gland: new pathways in the pathogenesis of pituitary adenomas. *Nat Rev Endocrinol* 2012;8(10):572–573.
15. Jiang X, Zhang X. The molecular pathogenesis of pituitary adenomas: an update. *Endocrinol Metab (Seoul)* 2013;28(4):245–254.
16. Alexander JM, Biller BM, Bikkal H, et al. Clinically nonfunctioning pituitary tumors are monoclonal in origin. *J Clin Invest* 1990;86(1):336–340.
17. Herman V, Fagin J, Gonsky R, et al. Clonal origin of pituitary adenomas. *J Clin Endocrinol Metab* 1990;71(6):1427–1433.
18. Oldfield EH, Doppman JL, Nieman LK, et al. Petrosal sinus sampling with and without corticotropin-releasing hormone for the differential diagnosis of Cushing's syndrome. *N Engl J Med* 1991;325(13):897–905.

19. Horsley V. Disease of the pituitary gland. *Br Med J* 1906;1:323.
20. Schloffer H: erfolgreiche operation eines hypophysentumors auf nasalem wege. *Wien Klin Wochenschr* 1907;20:621–624.
21. Hirsch O. Endonasal method of removing hypophyseal tumors. *JAMA* 1910;55:772–774.
22. Hardy J. Excision of pituitary adenomas by trans-sphenoidal approach [Article in French]. *Union Med Can* 1962;91:933–945.
23. Griffith HB, Veerapen R. A direct transnasal approach to the sphenoid sinus. Technical note. *J Neurosurg* 1987;66:140–142.
24. Cooke RS, Jones RA. Experience with the direct transnasal transsphenoidal approach to the pituitary fossa. *Br J Neurosurg* 1994;8:193–196.
25. Jankowski R, Auque J, Simon C, et al. Endoscopic pituitary tumor surgery. *Laryngoscope* 1992;102:198–202.
26. Buchfelder M, Schlaffer SM. Intraoperative magnetic resonance imaging during surgery for pituitary adenomas: pros and cons. *Endocrine* 2012;42:483–495.
27. Theodosopoulos PV, Leach J, Kerr RG, et al. Maximizing the extent of tumor resection during transsphenoidal surgery for pituitary macroadenomas: can endoscopy replace intraoperative magnetic resonance imaging? *J. Neurosurg* 2010;112(4):736–743.
28. Netuka D, Masopust V, Belšán T, et al. Benes, One year experience with 3.0 T intraoperative MRI in pituitary surgery. *Acta Neurochir Suppl* 2011; 109:157–159.
29. Roelfsema F, Biermasz NR, Pereira AM. Clinical factors involved in the recurrence of pituitary adenomas after surgical remission: a structured review and meta-analysis. *Pituitary* 2012;15(1):71–83.
30. Tabaee A, Anand VK, Barron Y, et al. Endoscopic pituitary surgery: a systematic review and meta-analysis. *J Neurosurg* 2009;111:545–554.
31. Dorward NL. Endocrine outcomes in endoscopic pituitary surgery, a literature review. *Acta Neurochir* 2010;152:1275–1279.
32. Goudakos JK, Markou KD, Georgalas C. Endoscopic versus microscopic trans-sphenoidal pituitary surgery: a systematic review and meta-analysis. *Clin Otolaryngol* 2011;36(3):212–220.
33. Rotenberg B, Tam S, Ryu WH, et al. Microscopic versus endoscopic pituitary surgery: a systematic review. *Laryngoscope* 2010;120(7):1292–1297.
34. Strychowsky J, Nayan S, Reddy K, et al. Purely endoscopic transsphenoidal surgery versus traditional microsurgery for resection of pituitary adenomas: systematic review. *J Otolaryngol Head Neck Surg* 2011;40(2):175–185.
35. Ammirati M, Wei L, Ciric I. Short-term outcome of endoscopic versus microscopic pituitary adenoma surgery: a systematic review and meta-analysis. *J Neurol Neurosurg Psychiatry* 2013;84(8):843–849.
36. Gao Y, Zhong C, Wang Y, et al. Endoscopic versus microscopic transsphenoidal

pituitary adenoma surgery: a meta-analysis. *World J Surg Oncol* 2014;12:94.

37. Kreutzer J, Buslei R, Wallaschofski H, et al. Operative treatment of prolactinomas: indications and results in a current consecutive series of 212 patients. *Eur J Endocrinol* 2008;158(1):11–18.
38. Hazer DB, Işık S, Berker D, et al. Treatment of acromegaly by endoscopic transsphenoidal surgery: surgical experience in 214 cases and cure rates according to current consensus criteria. *J Neurosurg* 2013;119(6):1467–1477.
39. Starke RM, Raper DM, Payne SC, et al.Endoscopic vs microsurgical transsphenoidal surgery for acromegaly: outcomes in a concurrent series of patients using modern criteria for remission. *J Clin Endocrinol Metab* 2013;98(8):3190–3198.
40. Shin SS, Tormenti MJ, Paluzzi A, et al. Endoscopic endonasal approach for growth hormone secreting pituitary adenomas:outcomes in 53 patients using 2010 consensus criteria for remission. *Pituitary* 2013;16(4):435–444.
41. Schöfl C, Franz H, Grussendorf M, et al; participants of the German Acromegaly Register. Long-term outcome in patients with acromegaly: analysis of 1344 patients from the German Acromegaly Register. *Eur J Endocrinol* 2012;168(1):39–47.
42. Jane JA Jr, Starke RM, Elzoghby MA, et al. Endoscopic transsphenoidal surgery for acromegaly: remission using modern criteria, complications, and predictors of outcome. *J Clin Endocrinol Metab* 2011;96(9):2732–2740.
43. Hofstetter CP, Mannaa RH, Mubita L, et al. Endoscopic endonasal transsphenoidal surgery for growth hormone-secreting pituitary adenomas. *Neurosurg Focus* 2010;29(4):E6.
44. Campbell PG, Kenning E, Andrews DW, et al. Outcomes after a purely endoscopic transsphenoidal resection of growth hormone-secreting pituitary adenomas. *Neurosurg Focus* 2010;29(4):E5.
45. Wagenmakers MA, Netea-Maier RT, van Lindert EJ, et al. Results of endoscopic transsphenoidal pituitary surgery in 40 patients with a growth hormone-secreting macroadenoma. *Acta Neurochir (Wien)* 2011;153(7):1391–1399.
46. Ram Z, Nieman LK, Cutler GB Jr, et al. Early repeat surgery for persistent Cushing's disease. *J Neurosurg* 1994;80(1):37–45.
47. Locatelli M, Vance ML, Laws ER. Clinical review: the strategy of immediate reoperation for transsphenoidal surgery for Cushing's disease. *J Clin Endocrinol Metab* 2005;90(9):5478–5482.
48. Valassi E, Biller BM, Swearingen B, et al. Delayed remission after transsphenoidal surgery in patients with Cushing's disease. *J Clin Endocrinol Metab* 2010;95(2):601–610.
49. Wagenmakers MA, Boogaarts HD, Roerink SH, et al. Endoscopic transsphenoidal pituitary surgery: a good and safe primary treatment option for Cushing's disease, even in case of macroadenomas or invasive adenomas. *Eur J Endocrinol* 2013;169(3):329–337.

50. Alexandraki KI, Kaltsas GA, Isidori AM, et al. Long-term remission and recurrence rates in Cushing's disease: predictive factors in a single-centre study. *Eur J Endocrinol* 2013;168(4):639–648.
51. Hameed N, Yedinak CG, Brzana J, et al. Remission rate after transsphenoidal surgery in patients with pathologically confirmed Cushing's disease, the role of cortisol, ACTH assessment and immediate reoperation: a large single center experience. *Pituitary* 2013;16(4):452–458.
52. Hassan-Smith ZK, Sherlock M, Reulen RC, et al. Outcome of Cushing's disease following transsphenoidal surgery in a single center over 20 years. *J Clin Endocrinol Metab* 2012;97(4):1194–1201.
53. Honegger J, Schmalisch K, Beuschlein F, et al. Contemporary microsurgical concept for the treatment of Cushing's disease: endocrine outcome in 83 consecutive patients. *Clin Endocrinol (Oxf)* 2012;76(4):560–567.
54. Klibanski A. Clinical practice. Prolactinomas. *N Engl J Med* 2010;362(13):1219–1226.
55. Colao A, Di Sarno A, Cappabianca P, et al. Withdrawal of long-term cabergoline therapy for tumoral and nontumoral hyperprolactinemia. *N Engl J Med* 2003;349(21):2023–2033.
56. Melmed S, Colao A, Barkan A, et al; Acromegaly Consensus Group. Guidelines for acromegaly management: an update. *J Clin Endocrinol Metab* 2009;94(5):1509–1517.
57. Colao A, Bronstein MD, Freda P, et al; Pasireotide C2305 Study Group. Pasireotide versus octreotide in acromegaly: a head-to-head superiority study. *J Clin Endocrinol Metab* 2014;99(3):791–799.
58. Pita-Gutierrez F, Pertega-Diaz S, Pita-Fernandez S, et al. Place of preoperative treatment of acromegaly with somatostatin analog on surgical outcome: a systematic review and meta-analysis. *PLoS One* 2013;8(4):e61523.
59. Ben-Shlomo A, Melmed S. Clinical review 154: the role of pharmacotherapy in perioperative management of patients with acromegaly. *J Clin Endocrinol Metab* 2003;88(3):963–968.
60. Newman CB, Melmed S, Snyder PJ, et al. Safety and efficacy of long-term octreotide therapy of acromegaly: results of a multicenter trial in 103 patients–a clinical research center study. *J Clin Endocrinol Metab* 1995; 80(9):2768–2775.
61. Karavitaki N, Turner HE, Adams CB, et al. Surgical debulking of pituitary macroadenomas causing acromegaly improves control by lanreotide. *Clin Endocrinol (Oxf)* 2008;68(6):970–975.
62. Castinetti F, Guignat L, Giraud P, et al. Ketoconazole in Cushing's disease: is it worth a try? *J Clin Endocrinol Metab* 2014;99(5):1623–1630.
63. Colao A, Petersenn S, Newell-Price J, et al; Pasireotide B2305 Study Group. A 12-month phase 3 study of pasireotide in Cushing's disease. *N Engl J Med* 2012;366(10):914–924. Erratum in: N Engl J Med. 2012 Aug 23;367(8):780.
64. Godbout A, Manavela M, Danilowicz K, et al. Cabergoline monotherapy in the long-

term treatment of Cushing's disease. *Eur J Endocrinol* 2010; 163(5):709–716.

65. Fleseriu M, Biller BM, Findling JW, et al; SEISMIC Study Investigators. Mifepristone, a glucocorticoid receptor antagonist, produces clinical and metabolic benefits in patients with Cushing's syndrome. *J Clin Endocrinol Metab* 2012;97(6):2039–2049.
66. Feelders RA, de Bruin C, Pereira AM, et al. Pasireotide alone or with cabergoline and ketoconazole in Cushing's disease. *N Engl J Med* 2010; 362(19):1846–1848.
67. Assié G, Bahurel H, Coste J, et al. Corticotroph tumor progression after adrenalectomy in Cushing's Disease: a reappraisal of Nelson's Syndrome. *J Clin Endocrinol Metab* 2007;92(1):172–179.
68. Wattson DA, Tanguturi SK, Spiegel DY, et al. Outcomes of proton therapy for patients with functional pituitary adenomas. *Int J Radiat Oncol Biol Phys* 2014;90(3):532–539.
69. Sheehan JP, Xu Z, Salvetti DJ, et al. Results of gamma knife surgery for Cushing's disease. *J Neurosurg* 2013;119(6):1486–1492.
70. Patil CG, Prevedello DM, Lad SP, et al. Late recurrences of Cushing's disease after initial successful transsphenoidal surgery. *J Clin Endocrinol Metab.* 2008;93(2):358–362.
71. Hofmann BM, Hlavac M, Kreutzer J, et al. Surgical treatment of recurrent Cushing's disease. *Neurosurgery* 2006;58(6):1108–1118; discussion 1108–1118.
72. Patil CG, Veeravagu A, Prevedello DM, et al. Outcomes after repeat transsphenoidal surgery for recurrent Cushing's disease. *Neurosurgery* 2008;63(2):266–270; discussion 270–271.
73. Freda PU, Beckers AM, Katznelson L, et al. Endocrine Society. Pituitary incidentaloma: an endocrine society clinical practice guideline. *J Clin Endocrinol Metab* 2011;96(4):894–904.
74. Gittoes NJ, Sheppard MC, Johnson AP, et al. Outcome of surgery for acromegaly- the experience of a dedicated pituitary surgeon. *QJM* 1999;92:741–745.
75. Ciric I, Ragin A, Baumgartner C, et al. Complications of transsphenoidal surgery: results of a national survey, review of the literature, and personal experience. *Neurosurgery* 1997;40:225–236.
76. Barker FG 2nd, Klibanski A, Swearingen B. Transsphenoidal surgery for pituitary tumors in the United States 1996–2000: mortality, morbidity, and the effects of hospital and surgeon volume. *J Clin Endocrinol Metab* 2003;88:4709–4719.
77. Biermasz NR, Roelfsma F, Pereira AM, et al. Cost-effectiveness of lanreotide Autogel in treatment algorithms of acromegaly. *Expert Rev Pharmacoecon Outcomes Res* 2009;9:223–234.
78. Swearingen B, Wu N, Chen SY, et al. Health care resource use and costs among patients with Cushing disease. *Endocr Pract* 2011;17:681–690.

SECTION L: LUNG

Chapter 79

Lung Neoplasms

Andrew C. Chang and Jules Lin

Key Points

1 Lung cancer remains the leading cause of cancer-related death in the United States.

2 Advances in molecular biology including genomic and proteomic techniques constitute promising methodologies for the diagnosis and patient-tailored management of non–small cell lung cancer (NSCLC), but to-date these strategies have not been validated for broad clinical implementation.

3 Low-dose screening chest CT can reduce lung cancer–related mortality in "at-risk" patients.

4 Common sites of distant metastases are bone, liver, adrenal glands and the central nervous system; therefore, the metastatic evaluation includes a PET scan and CT of the chest and upper abdomen, and a brain MRI.

5 Resection remains the mainstay in the treatment of lung cancer, yet only about 20% of all patients diagnosed with lung cancer are considered resectable (stages I to IIIA). VATS/robotic approaches have changed the landscape for operation although the principles of oncologic resection remain unchanged.

6 In addition to new chemotherapeutic agents, new radiation techniques, such as hyperfractionated or accelerated schedules, also merit further exploration in neoadjuvant trials with concurrent chemotherapy.

7 Taken as a whole, neoadjuvant therapy trials have demonstrated the feasibility of induction chemotherapy and radiation followed by resection for the treatment of selected stage IIIA NSCLC. Most studies show improved rates of resectability and survival in comparison with the historical experience for surgical resection or radiation alone.

8 Generally, a solitary lesion is more likely to be a metastasis if the primary tumor was a sarcoma or a melanoma. If the primary tumor originated in the head, neck, or breast, it is more likely to be a new primary lung cancer.

INTRODUCTION

1 Although population estimates of both the incidence and mortality of lung cancer have begun to decline, lung cancer remains second only to heart disease among all causes of mortality. With 224,210 new cases and 159,260 deaths projected for 2014, lung cancer is the leading cause of cancer-related death in the United States. Lung cancer is second in cancer prevalence only to prostate cancer among men and breast cancer among women, and remains the leading cause of cancer-related death for both sexes. Since 2005, both the annual incidence and mortality rates due to lung cancer have started to decrease in the United States, reflecting improvements in cancer control and prevention, particularly efforts to reduce the prevalence of smoking.[1] There is also significant regional variation in both lung cancer incidence and mortality. Among men, lung cancer mortality has decreased from 1996 through 2005 in over 80% of the 50 states and the District of Columbia, whereas among women over the same period, mortality decreased in only three states (California, New Jersey, and Texas) and has increased in 13 other states, primarily in the Midwest and South,[2] although more recently consistent rates of decline have been noted for both men and women.

The best predictor of survival for patients with lung cancer is still tumor stage. Resection remains the mainstay in the treatment of lung cancer, yet only approximately 37% of all patients diagnosed with lung cancer are considered resectable (with either local or regional disease, that is, stages I to IIIA). Even among patients who have undergone complete resection with curative intent for early-stage disease, as determined using pathologic *T*umor–*N*ode–*M*etastasis (TNM) criteria, a substantial number will have recurrence of their cancer.[3]

Clinical trials continue to demonstrate that adjuvant chemotherapy can improve survival over surgery alone for early-stage lung cancer.[4–6] Importantly, screening low-dose chest computed tomography (CT) appears to improve early detection of resectable lung cancer, with an improvement in overall survival,[7,8] albeit with a possible risk of overdiagnosis.[9] As understanding of the molecular changes occurring in lung cancer evolves, new strategies that allow for early detection and classification of lung cancer will provide valuable information for the treatment of patients.

HISTORY

Ferdinand Sauerbruch, whose interests included the physiology of pneumothorax and is considered one of the pioneers of thoracic surgery, reported the first successful lobectomy for lung carcinoma in 1920. At that time, it was believed that only total pneumonectomy would provide a cure for lung cancer. Dr. Evarts A. Graham performed the first successful single-stage pneumonectomy for a left upper lobe bronchogenic carcinoma in 1933,[10] although this was neither the first pulmonary resection nor pneumonectomy, establishing the modern era of thoracic surgery for lung cancer. Ultimately, Dr. Graham succumbed to lung cancer himself in 1957, and was outlived by his patient, Dr. James L. Gilmore, who had continued to smoke.[11]

EPIDEMIOLOGY

Recently, population studies have demonstrated sustained declines in lung cancer incidence among both men (80.0 cases per 100,000), and women (55.1 per 100,000) as of 2010. African-American men continue to have the greatest incidence of lung cancer, in excess of nearly 20% (94.7 per 100,000) over the cases reported for all men.[12,13] The decline in incidence as well as mortality may be due in part to public health efforts to promote smoking cessation.[14] In a follow-up to the Seven Countries Study of smoking-related mortality, follow-up analysis of the initial cohorts studied from Europe, the United States and Japan confirmed that cigarette smoking increased the risk for death due to lung cancer with a hazard ratio of 4.2 per pack of cigarettes smoked. Furthermore, the death rates due to lung cancer decreased to that of never-smokers after 10 years of smoking cessation.[15] Exposure to environmental “second-hand” cigarette smoke or other particulate matter air pollution can also contribute to an increased risk of lung cancer,[16,17] particularly adenocarcinoma.[17,18]

PATHOLOGIC CLASSIFICATION

Uniform classification of lung cancer is important both to provide consistent treatment for patients and to allow standardization in reports of epidemiologic, clinical, and basic scientific studies. Currently, the classification is largely histologic and is based on light microscopy findings determined from specimens obtained by resection or needle biopsy, permitting its wide application by surgical pathology laboratories where more advanced techniques might not be readily available. Nevertheless, immunohistochemical and electron microscopy analyses are important, particularly in the diagnosis of neuroendocrine tumors, or for distinguishing between primary bronchogenic adenocarcinoma and metastatic lesions. The most recent revision of the World Health Organization (WHO) classification (Table 79-79) was published in 2004[19] but is largely unchanged from the previous revision in 1999.[20] Guidelines for defining preinvasive lesions such as squamous dysplasia and carcinoma in situ are provided. Recognition and definition of the heterogeneity among adenocarcinomas is reflected in the subclassification of this group, including more restrictive definitions for bronchioloalveolar carcinoma (BAC), which has been redesignated as “adenocarcinoma in situ.[20a] Definitions for the spectrum of neuroendocrine tumors, ranging from typical and atypical carcinoid, to small cell lung cancer (SCLC) and large cell neuroendocrine carcinomas are provided.

TUMOR BIOLOGY

Genetic alterations in several regulatory pathways including apoptosis, cell cycle and mitogenic signaling have been identified in tumors of patients with non–small cell lung cancer (NSCLC). Chromosomal loss of heterozygosity (LOH) or allelic gain appears to occur more frequently among patients with adenocarcinoma and history of tobacco exposure than among patients without any smoking history. Mutations among the *Ras* oncogenes, particularly *K-ras,* are characterized by the accumulation of DNA adducts within these genes, predominantly among patients with a history of tobacco use.[21] This has been attributed to the exposure to tobacco carcinogens such as benzo[a]pyrene (BaP), its activated form, benzo[a]pyrene diol epoxide (BPDE), and N-nitrosamines. These genes encode GTP-binding proteins which participate in cellular signal transduction; their mutation results in constant Ras activation. Another family of oncogenes, *Myc,* encoding several transcription factors, is activated by gene amplification, primarily in SCLC.[21]

The tumor suppressor gene, *p53,* is the most frequently mutated gene in human cancer. Among patients with a history of tobacco use, mutations within *p53* were identified in over 50% of patients with NSCLC, particularly squamous cell carcinoma (SCC) and non–AIS adenocarcinoma.[22,23] Among patients with stage I tumors, those with mutations, particularly truncating, structural, or those that abolished DNA binding, demonstrated significantly worse actuarial survival in comparison with patients who had wild-type *p53.* In contrast those patients with missense mutations did not demonstrate significantly different survival than those with wild-type *p53.* In several clinical trials demonstrating the benefit of adjuvant chemotherapy among patients with resected NSCLC, the presence of p53 mutations was not associated with any significant survival difference among patients assigned to treatment or observation arms.[24,25] Among patients found to have mutations in the p53 gene, those treated with adjuvant chemotherapy had worse outcomes than untreated patients.[25] Investigators have also identified p53 protein expression, determined by immunohistochemical analysis, as a predictor of poor outcome in patients with stage I NSCLC.[26] Furthermore, p53 expression is associated with tumors more likely to demonstrate distant metastases.[27] Notably, patients with p53 expression detectable by immunohistochemistry appear to have improved survival following adjuvant chemotherapy compared to patients without IHC-detected p53 expression.[24]

CLASSIFICATION

Table 79-1 Histologic Classification of Lung Tumors

WHO[a]
1. Squamous cell carcinoma
Variants: 1.1 Papillary
1.2 Clear cell
1.3 Small cell
1.4 Basaloid
2. Small cell carcinoma
Variant: 2.1 Combined small cell carcinoma
3. Adenocarcinoma
3.1 Acinar adenocarcinoma
3.2 Papillary adenocarcinoma
3.3 Bronchioloalveolar carcinoma
3.4 Solid adenocarcinoma with mucin
3.5 Adenocarcinoma with mixed subtypes
Variants: Fetal, mucinous ("colloid"), mucinous cystadenocarcinoma, signet ring, clear cell
4. Large cell carcinoma
Variants: 4.1 Large cell neuroendocrine carcinoma
4.2 Others
5. Adenosquamous carcinoma
6. Carcinoma with pleomorphic, sarcomatoid, or sarcomatous elements
7. Carcinoid
7.1 Typical
7.2 Atypical
8. Carcinoma of salivary gland type
8.1 Mucoepidermoid carcinoma
8.2 Adenoid cystic carcinoma
8.3 Epithelial–myoepithelial
9. Unclassified

[a]World Health Organization. Adapted from World Health Organization *Classification of Tumors, Pathology and Genetics of Tumours of the Lung, Pleura, Thymus and Heart*. Lyon, France: IARC Press; 2004.

Epigenetic mechanisms of gene regulation also appear to participate in the tumorigenesis of lung cancer. In particular gene promoter inactivation by hypermethylation may be an important mechanism in the inactivation of tumor suppressor genes such as *p16*^{INK4a} (*p16*), an inhibitory regulator in the cyclin D-retinoblastoma cell cycle pathway. In patients with premalignant lesions such as squamous dysplasia and carcinoma in situ, both allelic loss and hypermethylation of *p16* have been identified, with associated decreases in p16 protein expression,[28] suggesting that loss of *p16* may be an important early event in NSCLC tumorigenesis.[29]

Over the past decade genome-wide studies have revolutionized the study of complex disease processes including NSCLC. Efforts by groups comprising The Cancer Genome Atlas have yielded detailed and comprehensive characterization of mutational events

across the entire cancer genome.[30,31] Distinguishing those genes that appear to be involved causally in lung cancer tumorigenesis from those genes that are regulated secondarily is critical for our understanding of this disease and for the identification of potential targets for therapeutic intervention.

Table 79-2 TNM Classification for Staging System of Non–Small Cell Lung Cancer (6th ed.)

Stage		TNM Status
IA		T1 N0 M0
IB		T2 N0 M0
IIA		T1 N1 M0
IIB		T2 N1 M0
		T3 N0 M0
IIIA		T3 N1 M0
		T1–3 N2 M0
IIIB		T4 Any N M0
		Any T N3 M0
IV		Any T any N M1
TNM Definitions		
T	TX	Positive malignant cells, but primary tumor not visualized by imaging or bronchoscopy
	T0	No evidence of primary tumor
	Tis	Carcinoma in situ
	T1	Tumor ≤3 cm, surrounded by lung or visceral pleura, without bronchoscopic evidence of invasion more proximal than the lobar bronchus[a]
	T2	Tumor with any of the following features of size or extent:
		>3 cm in greatest dimension
		Involves main bronchus, ≥2 cm distal to the carina
		Invades the visceral pleura

		Associated with atelectasis or obstructive pneumonitis that extends to the hilar region but does not involve the entire lung
	T3	Tumor of any size that directly invades any of the following: chest wall (including superior sulcus tumors), diaphragm, mediastinal pleura, parietal pericardium; or tumor in the main bronchus <2 cm distal to the carina, but without involvement of the carina; or associated atelectasis or obstructive pneumonitis of the entire lung
	T4	Tumor of any size that invades any of the following: mediastinum, heart, great vessels, trachea, esophagus, vertebral body, carina; or tumor with a malignant pleural or pericardial effusion, or with satellite tumor nodule(s) within the ipsilateral primary tumor lobe of the lung[b]
N	NX	Regional lymph nodes cannot be assessed
	N0	No regional lymph node metastasis
	N1	Metastasis to ipsilateral peribronchial and/or ipsilateral hilar lymph nodes, and involvement of intrapulmonary nodes by direct extension of the primary tumor
	N2	Metastasis to ipsilateral mediastinal and/or subcarinal lymph node(s)
	N3	Metastasis to contralateral mediastinal, contralateral hilar, ipsilateral or contralateral scalene, or supraclavicular lymph node(s)
M	MX	Presence of distant metastasis cannot be assessed
	M0	No distant metastasis
	M1	Distant metastasis present including metastatic tumor nodule(s) in the ipsilateral non–primary tumor lobe of the lung

[a]The uncommon superficial tumor of any size with its invasive component limited to the bronchial wall that may extend proximal to the main bronchus is classified as T1.
[b]Most pleural effusions associated with lung cancer are caused by tumor. There are, however, some patients in whom the pleural fluid (more than one specimen) is negative for tumor on cytopathologic examination and in whom the fluid is nonbloody and is not an exudate. In cases in which these elements and clinical judgment dictate that the effusion is not related to the tumor, the patient should be staged T1, T2, or T3, with effusion excluded as a staging element. Pericardial effusion is classified according to the same rules.

2 Targeted molecular therapy has been shown to have clinical benefit notably for patients with advanced NSCLC. For example, among patients whose tumors are shown to carry specific mutations in the epidermal growth factor receptor (*EGFR*) gene, treatment with small molecule tyrosine–kinase inhibitors targeting *EGFR* has been associated with improved progression-free survival as demonstrated by several randomized trials.[32] Whether such treatment regimens might be effective in the adjuvant setting for patients with earlier stage NSCLC who have undergone curative-intent lung resection has yet to be established, but is the focus of a recently initiated cooperative group trial. The Adjuvant Lung Cancer Enrichment Marker Identification and Sequencing Trials (ALCHEMIST) will evaluate patients with resected lung adenocarcinomas (stage IB to stage IIIA). Those subjects found to have tumors carrying activating *EGFR* mutations or the *ALK-echinoderm microtubule-associated protein-like 4* (*EML4*) fusion gene will be randomized for "maintenance" treatment with either erlotinib (*EGFR*) or crizotonib (*ALK* fusion), respectively, following completion of standard-of-care adjuvant chemotherapy with or without radiation therapy. Enrolled patients found to have neither of the targeted mutations will be followed in an observational study until tumor recurrence. These studies represent an exciting potential application of gene expression studies for use in determining patient prognosis, as well as guiding the clinical management of lung cancer and preventing over- or undertreatment of patients.

NON–SMALL CELL LUNG CANCER

Diagnosis

The diagnosis of lung cancer should be directed by the presumed stage of disease at patient presentation. Accurate and reproducible TNM staging of lung cancer allows clinicians to provide consistent treatment of lung cancer and provides the basis for uniform reporting of clinical research across institutions and study groups. In 1997, revisions in the International System for Staging Lung Cancer (Table 79-2) were adopted by the American Joint Committee on Cancer (AJCC) and the Union Internationale Contre le Cancer (UICC), based on 5,319 cases of lung cancer.[3] Revisions implemented for the most recent iteration of the TNM classification schema arose from evaluation of 67,725 cases of NSCLC with broad geographic diversity including subjects from Asia, Australia, Europe, and North America[33,34] and addressed both T[35] and M[36] designations (Table 79-3), with no changes implemented for the current nodal designations (Table 79-4).[37] Stratification of patient survival, particularly among subjects with pathologic stage IB and IIA cancers, was more distinct with application of the 7th edition criteria (Table 79-5).

Guidelines for surveillance of the incidentally detected subcentimeter nodule (<8 to 10 mm) or larger solitary pulmonary nodule (8 to 10 mm or larger) have been published by the Fleischner Society for Thoracic Imaging and Diagnosis,[38] the American College of Chest Physicians[39] and others[40] and are incorporated in a suggested algorithm (Algorithm 79-1) for evaluation of these common incidental chest findings. As with any algorithm, assessment of patient risk factors (pretest probability) for cancer[39] as well as comorbidities[38] should be taken into consideration before following these guidelines in one's practice.

3 One recent goal in the diagnosis of lung cancer has been the early detection of tumors arising in asymptomatic high prevalence populations, for example, older patients with a history of tobacco use. Low-dose chest CT screening appears to reduce lung cancer–related mortality as demonstrated by two modern clinical trials,[7,8] while remaining cost-effective.[41]

4 The aims of the initial evaluation of a patient with NSCLC are to determine whether distant metastatic disease is present and to assess the extent of intrathoracic disease. A multidisciplinary approach, involving input from pulmonary medicine, chest radiology, medical and radiation oncology, and thoracic surgery, should be undertaken in the selection of the most suitable testing for any individual patient. One general algorithm is provided (Algorithm 79-2). A thorough history and physical examination, combined with a plain chest radiograph and baseline laboratory data (complete blood cell count and measurement of serum sodium, calcium, alkaline phosphatase, and lactate dehydrogenase levels), can suggest the presence of metastatic disease. Common metastatic sites include the brain, supraclavicular lymph nodes, contralateral lung, bones, liver, and adrenal glands. Chest CT and FDG–PET body scans are obtained for noninvasive evaluation and metabolic characterization of suspected lung tumors and evidence of mediastinal or extrathoracic involvement. If necessary, biopsy by needle aspiration or operation can be

performed to obtain confirmation of malignancy and to determine the extent of disease.

If the initial clinical evaluation does not suggest the presence of distant disease, the extent of further evaluation by various scans is controversial. Some physicians always perform a complete metastatic workup with CT of the chest and abdomen, CT or MRI of the brain, and FDG–PET scan. CT scan of the chest and upper abdomen as well as FDG–PET scan have become standard, as much to evaluate the extent of the primary tumor and the status of the mediastinal lymph nodes as to detect metastases in the ipsilateral or contralateral lung, liver, or adrenals. Additional scans in asymptomatic patients may detect the 5% to 10% of metastases that are occult, but these scans are not clearly cost-effective in patients with clinical stage IA tumors. In patients who are suitable candidates for operation, who have a suspicious solitary pulmonary nodule that is of indeterminate origin despite appropriate evaluation, excisional biopsy and subsequent lobectomy for resectable lung cancer should be pursued.[42]

Multi-institutional studies have indicated a benefit for a combined modality approach in the treatment of stage IIIA NSCLC, consisting of neoadjuvant chemotherapy and radiation followed by resection.[43] Therefore tissue confirmation of mediastinal nodal involvement (Table 79-4) has implications not only for the staging but the management of patients who are otherwise candidates for resection of locoregionally advanced NSCLC.[44]

Chest CT provides only anatomic clues for tumor involvement of mediastinal lymph nodes (enlargement greater than 10 mm), as demonstrated in a recent meta-analysis of over 3,400 evaluable patients, with a pooled sensitivity of 57% and specificity of only 82%. This meta-analysis also demonstrated that FDG (^{18}F-2-fluoro-2-deoxy-D-glucose)–positron emission tomography (FDG–PET) scanning appears to provide increased sensitivity of 84% and specificity of 89% in over 1,100 patients studied for the detection of mediastinal malignancy.[45] Several single-institution and multi-institutional prospective studies have also indicated the superior diagnostic accuracy of FDG–PET imaging.[46–48] Although the overall sensitivity and specificity of FDG–PET staging was 61% and 84%, respectively, there was a significant improvement with FDG–PET over chest CT in the detection of both hilar (N1) lymph node (42% vs. 13%, $p = 0.0177$) and mediastinal (N2 and N3) tumor involvement (58% vs. 32%, $p = 0.004$). Whereas FDG–PET scanning can increase the suspicion of malignancy, its negative predictive value for mediastinal lymph node involvement does not appear to be sufficient, with a false-negative rate reported as high as 13%.[49] PET evaluation of the solitary pulmonary nodule also appears to be somewhat insensitive, with a negative predictive value for benign lesions of only 57%, indicating a false-negative rate of 47%. Reliance on this modality could lead to delayed treatment for resectable early-stage (IA) NSCLC.[50] Integrated CT–PET imaging, in which concurrently performed chest CT provides anatomic correlation for positive PET findings, appears to provide more precise staging, particularly regarding tumor and nodal status,[51] and also can be used to guide further invasive testing in the accurate staging of lung cancer.

CLASSIFICATION

Table 79-3 TNM Classification for Staging System of Non–Small Cell

Lung Cancer (7th ed.)

Stage	TNM Status
IA	T1a or b N0 M0
IB	T2a N0 M0
IIA	T1 or 2a N1 M0 T2b N0 M0
IIB	T2b N1 M0 T3 N0 M0
IIIA	T3 or 4 N0 or 1 M0 T1–3 N2 M0
IIIB	T4 N2 M0 Any T N3 M0
IV	Any T any N M1

TNM Definitions		
T	TX	Positive malignant cells, but primary tumor not visualized by imaging or bronchoscopy
	T0	No evidence of primary tumor
	Tis	Carcinoma in situ
	T1a	Tumor ≤2 cm, surrounded by lung or visceral pleura, without bronchoscopic evidence of invasion more proximal than the lobar bronchus[a]
	T1b	Tumor >2–3 cm, surrounded by lung or visceral pleura, without bronchoscopic evidence of invasion more proximal than the lobar bronchus[a]
	T2	Tumor >3 cm but ≤7 cm or tumor with any of the following features:
		Involves main bronchus, ≥2 cm distal to the carina
		Invades the visceral pleura
		Associated with atelectasis or obstructive pneumonitis that extends to the hilar region but does not involve the entire lung

		T2a Tumor >3 cm but ≤5 cm in greatest dimension, or with the above features but size cannot be determined
		T2b Tumor >5 cm but ≤7 cm in greatest dimension
	T3	Tumor >7 cm or one that directly invades any of the following: chest wall (including superior sulcus tumors), diaphragm, mediastinal pleura, parietal pericardium; or tumor in the main bronchus <2 cm distal to the carina, but without involvement of the carina; associated atelectasis or obstructive pneumonitis of the entire lung; or separate tumor nodule(s) in the same lobe
	T4	Tumor of any size that invades any of the following: mediastinum, heart, great vessels, trachea, esophagus, vertebral body, carina; separate tumor nodule(s) in a different ipsilateral lobe
N	NX	Regional lymph nodes cannot be assessed
	N0	No regional lymph node metastasis
	N1	Metastasis to ipsilateral peribronchial and/or ipsilateral hilar lymph nodes, and involvement of intrapulmonary nodes by direct extension of the primary tumor
	N2	Metastasis to ipsilateral mediastinal and/or subcarinal lymph node(s)
	N3	Metastasis to contralateral mediastinal, contralateral hilar, ipsilateral or contralateral scalene, or supraclavicular lymph node(s)
M	MX	Presence of distant metastasis cannot be assessed
	M0	No distant metastasis
	M1	Distant metastasis present
		M1a separate tumor nodule(s) in a contralateral lobe; tumor with pleural nodules or malignant pleural (or pericardial) effusion[b]
		M1b distant metastases

[a]The uncommon superficial tumor of any size with its invasive component limited to the bronchial wall that may extend proximal to the main bronchus is classified as T1.
[b]Most pleural (and pericardial) effusions associated with lung cancer are caused by tumor. There are some patients in whom the pleural fluid (more than one specimen) is negative for tumor on cytopathologic examination and in whom the fluid is nonbloody and is not an exudate. In cases in which these elements and clinical judgment dictate that the effusion is not related to the tumor, the patient should be staged T1, T2, T3 or T4, with effusion excluded as a staging element.
Used with the permission of the American Joint Committee on Cancer (AJCC), Chicago, Illinois. The original source for this material is the AJCC Cancer Staging Manual, Seventh Edition (2010) published by Springer Science and Business Media LLC, www.springer.com

Table 79-4 The Mountain–Dresler Lymph Node Map

Nodal Station	Anatomic Landmarks
N2 nodes: All N2 nodes lie within the mediastinal pleural envelope	
1. Highest mediastinal nodes	Nodes lying above a horizontal line at the upper rim of the brachiocephalic (left innominate) vein where it ascends to the left, crossing in front of the trachea at its midline.
2. Upper paratracheal nodes	Nodes lying above a horizontal line drawn tangential to the upper margin of the aortic arch and below the inferior boundary of No. 1 nodes.
3. Prevascular and retrotracheal nodes	Prevascular and retrotracheal nodes may be designated 3A (anterior to the vessels) and 3P (prevertebral); midline nodes are considered to be ipsilateral.
4. Lower paratracheal nodes	The lower paratracheal nodes on the right lie to the right of the midline of the trachea between a horizontal line drawn tangential to the upper margin of the aortic arch and a line extending across the right main bronchus at the upper margin of the upper lobe bronchus, and contained within the mediastinal pleural envelope; the lower paratracheal nodes on the left lie to the left of the midline of the trachea between a horizontal line drawn tangential to the upper margin to the aortic arch and a line extending across the left main bronchus at the level of the upper margin of the left upper lobe bronchus, medial to the ligamentum arteriosum and contained within the mediastinal pleural envelope. Researchers may want to designate the lower paratracheal nodes as No. 4s (superior) and No. 4i (inferior) subsets for study purposes; the No. 4s nodes may be defined by a horizontal line extending across the trachea and drawn tangential to the cephalic border of the azygos vein; the No. 4i nodes may be defined by the lower boundary of No. 4s and the lower boundary of No. 4 as described above.
5. Subaortic (aortopulmonary window)	Subaortic nodes are lateral to the ligamentum arteriosum or the aorta or left pulmonary artery and proximal to the first branch of the left pulmonary artery and lie within the mediastinal pleural envelope.
6. Paraaortic nodes (ascending aorta or phrenic)	Nodes lying anterior and lateral to the ascending aorta and the aortic arch or the innominate artery, beneath a line tangential to the upper margin of the aortic arch.
7. Subcarinal nodes	Nodes lying caudal to the carina of the trachea but not associated with the lower lobe bronchi or arteries within the lung.
8. Paraesophageal nodes (below carina)	Nodes lying adjacent to the wall of the esophagus and to the right or left of the midline, excluding subcarinal nodes.
9. Pulmonary ligament nodes	Nodes lying within the pulmonary ligament, including those in the posterior wall and lower part of the inferior pulmonary vein.
N1 nodes: All N1 nodes lie distal to the mediastinal pleural reflection and within the visceral pleura	
10. Hilar nodes	The proximal lobar nodes, distal to the mediastinal pleural reflection and the nodes adjacent to the bronchus intermedius on the right; radiographically, the hilar shadow may be created by enlargement of both hilar and interlobar nodes.
11. Interlobar nodes	Nodes lying between the lobar bronchi.
12. Lobar nodes	Nodes adjacent to the distal bronchi.
13. Segmental nodes	Nodes adjacent to the segmental bronchi.
14. Subsegmental nodes	Nodes around the subsegmental bronchi.

Definition of the anatomic boundaries for each lymph node region facilitates correlation between findings at operation and findings on chest computed tomography. (After Mountain CF, Dresler CM. Regional lymph node classification for lung cancer staging. *Chest* 1997;111:1718.)

Ultimately tissue confirmation of noninvasive findings should be obtained, particularly in the setting of large, prospective trials being undertaken to determine the efficacy of neoadjuvant and adjuvant therapy.[52] Noninvasive techniques for clinical staging, particularly chest CT, have a reported false-negative rate of approximately 10% to 15%. FDG–PET scan also has a reported false-positive rate of as high as 50%.[46] Clinical staging of NSCLC, particularly mediastinal lymph node involvement, can be accomplished by needle aspiration techniques from several approaches: transbronchial (TBNA) with or without endobronchial ultrasound (EBUS) guidance, transthoracic, or transesophageal. EBUS–TBNA is an accurate method for evaluation of the mediastinum, comparable to, if

not better than, the accuracy of mediastinoscopy.[53] Transesophageal endoscopic ultrasound with fine needle aspiration (EUS–FNA) appears to be particularly useful for sampling of posterior mediastinal nodes such as the subcarinal, periesophageal, or aortopulmonary window stations, particularly in patients with mediastinal lymphadenopathy in these regions. Diagnostic yield is improved with practitioner experience, sampling needle size and onsite cytology examination to determine adequacy of the obtained samples.

Cervical mediastinoscopy remains an important diagnostic modality, particularly for sampling of smaller lymph nodes, or if larger sample sizes are needed either for assessment of tissue architecture, or for supplemental molecular studies. This modality has a procedural sensitivity greater than 90%, and specificity of 100%[54] as demonstrated in a large retrospective review of a single-institutional experience, including 1,745 patients, which demonstrated a reduction in "unnecessary" exploration, low morbidity (0.6%) and minimal perioperative mortality (0.05%).[55] For patients with clinically suspicious aortopulmonary lymph node involvement (stations 5 and 6), an area which is generally not accessible by standard mediastinoscopy, anterior mediastinotomy, extended cervical mediastinoscopy, or thoracoscopy can be performed.

RESULTS

Table 79-5 IASLC Lung Cancer Staging Project: Overall 5-Year Survival by Clinical and Surgical 6th and 7th Edition TNM Stage

	Clinical Stage				Surgical Stage			
	6th ed. TNM		7th ed. TNM		6th ed. TNM		7th ed. TNM	
Stage	No. of Patients	Patients Surviving (%)	No. of Patients	Patients Surviving (%)	No. of Patients	Patients Surviving (%)	No. of Patients	Patients Surviving (%)
IA	831	50	831	50	3,666	73	3,666	73
IB	1,842	40	1,284	43	4,426	54	3,100	58
IIA	25	24	483	36	562	48	2,579	46
IIB	2,151	25	2,248	25	2,982	38	2,252	36
IIIA	3,005	18	3,175	19	3,091	25	3,792	24
IIIB	1,224	8	758	7	1,042	19	297	9
IV	2,458	2	2,757	2	183	21	266	13
TOTAL	11,536				15,952			

Adapted from Goldwstraw P, Crowley J, Chansky K, et al. The IASLC Lung Cancer Staging Project: proposals for the revision of the TNM stage groupings in the forthcoming (seventh) edition of the TNM Classification of malignant tumours. *J Thorac Oncol* 2007;2:706–714.

Patients presenting with suspected NSCLC and a pleural effusion should undergo thoracentesis, followed by thoracoscopy, should initial cytology specimens be nondiagnostic. Those patients presenting with metastatic (stage IV) disease involving a solitary distant site should obtain tissue confirmation at the site of metastasis, if technically feasible. If noninvasive testing demonstrates multiple metastases (e.g., multiple liver, brain, or bone lesions), then diagnosis of the primary lesion might provide the most efficient means of diagnosis, followed by the initiation of palliative

chemotherapy.[56]

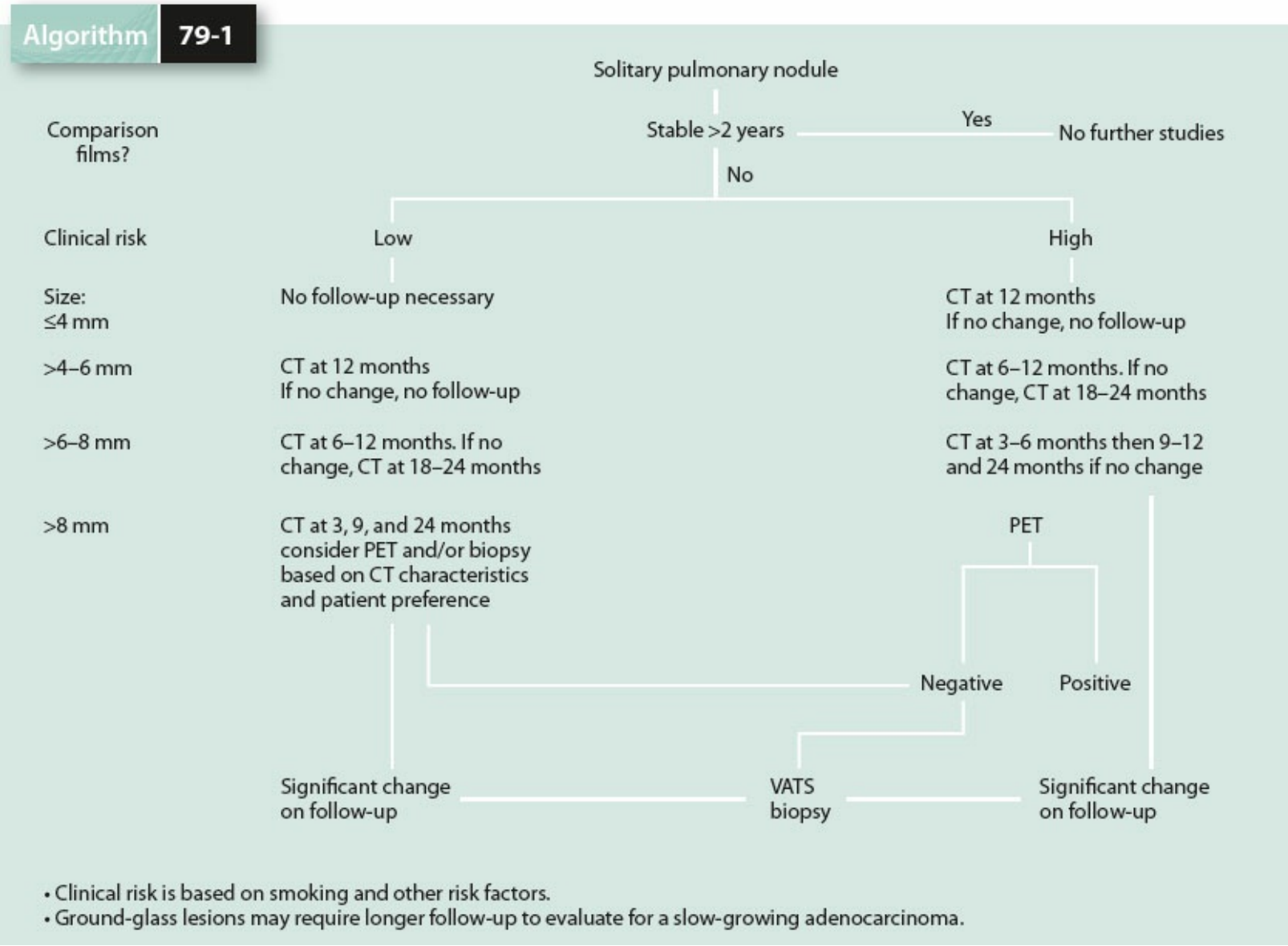

Algorithm 79-1. Management of the incidental solitary pulmonary nodule. Partially based on MacMahon H, Austin JHM, Gamsu G, et al. Guidelines for management of small pulmonary nodules detected on CT scans: a statement from the Fleischner Society. *Radiology* 2005;237:395–400.

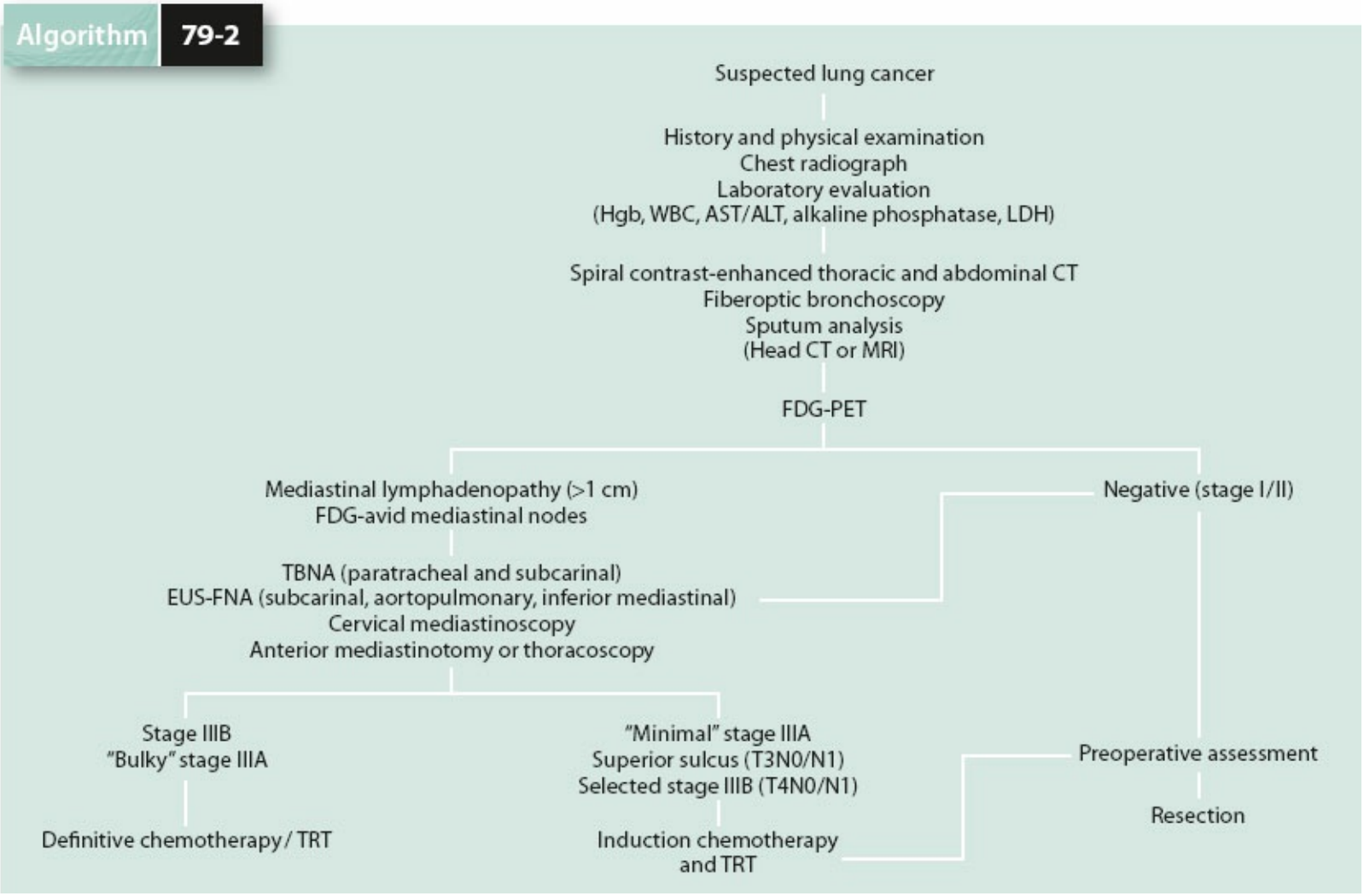

Algorithm 79-2. Evaluation of the patient who presents with a pulmonary mass.

Although newer modalities of noninvasive imaging, such as FDG–PET imaging, have improved the accuracy of staging for lung cancer,[8,49] these techniques still rely on factors such as tumor volume, tumor density, and metabolic activity. Unfortunately, current staging procedures do not yet have the sensitivity to detect all lymph node or distant hematogenous metastases.

Risk Assessment

Having established that resection is feasible, a significant number of patients with lung cancer cannot undergo operation due to associated comorbidities that increase operative mortality and postoperative morbidity. Age alone should not preclude patients with resectable disease from operation.[57] In a population with a high prevalence of prior or continuing tobacco use that has a greater predisposition to atherosclerotic cardiovascular disease, preoperative cardiovascular risk assessment with further noninvasive cardiac testing or coronary angiography, if indicated, should be considered.[58]

Preoperative spirometry, particularly the forced expiratory volume in 1 second (FEV_1), as an assessment of patients' suitability for pulmonary resection is essential. Measurement of the diffusing capacity of the lung for carbon monoxide (DLCO) provides complementary data to standard spirometry, particularly for patients with evidence of interstitial lung disease or exertional dyspnea. Generally, if a patient demonstrates FEV_1 >2 L ($>60\%$ predicted) or DLCO $>50\%$ predicted, further evaluation of pulmonary capacity prior to resection is not necessary.[59,60] Patients with limited pulmonary reserve, including those with FEV_1 <1.2 L (40% predicted) or DLCO 35% to 40% predicted, are at higher risk for significant morbidity or mortality following anatomic resection, and should undergo further evaluation.[61]

The predicted postoperative (ppo) lung function in patients with marginal pulmonary function can be calculated as follows: $ppoFEV_1$ (% predicted) = preoperative FEV_1 (% predicted) $\times$ (1 – fraction of total number of anatomic segments to be resected). Patients with $ppoFEV_1$ <0.8 L, or 35% to 40% predicted, are likely at substantially increased risk for perioperative death or complication.[62,63] For patients with heterogeneous lung disease including upper lobe predominant emphysema, quantitative perfusion scanning provides a more accurate assessment. To obtain the $ppoFEV_1$ (% predicted), the preoperative FEV_1 (% predicted) is multiplied by (100% – %perfusion of the area to be resected).

Preoperative room-air arterial blood gas testing can identify patients at greater risk for perioperative complications or death. In particular, patients with arterial oxygen concentration less than 60 mm Hg, $PaCO_2$ greater than 45 mm Hg, or oxygen saturation less than 90% may be at greater risk for pulmonary resection.

If available, further testing with formal cardiopulmonary exercise testing (CPET) to calculate maximal oxygen consumption (Vo_2 max) may allow further risk stratification in such marginal patients. In several series, patients with a Vo_2 max <10 to 15 mL/min/kg were at high risk for postoperative complication, whereas those with Vo_2 max >20 mL/min/kg underwent operation without complication or death.[63] These findings were corroborated by a recent cooperative group study (CALGB 9238) conducted to determine whether pulmonary resection could be accomplished safely in patients with peak exercise oxygen capacity >15 mL/min/kg, regardless of FEV_1. In this prospective study of 346 patients who underwent thoracotomy for NSCLC, there were 86 subjects whose peak exercise oxygen capacity was less than the threshold of <15 mL/min/kg, or 60% of predicted. This group experienced significantly more cardiorespiratory complications,

respiratory failure, or death than the remaining subjects whose peak exercise oxygen capacity was >15 mL/min/kg. From these data, the authors concluded that patients with peak exercise oxygen capacity >15 mL/min/kg, even if FEV_1 and/or DLCO were less than 70% predicted, could undergo pulmonary resection with curative intent.[64]

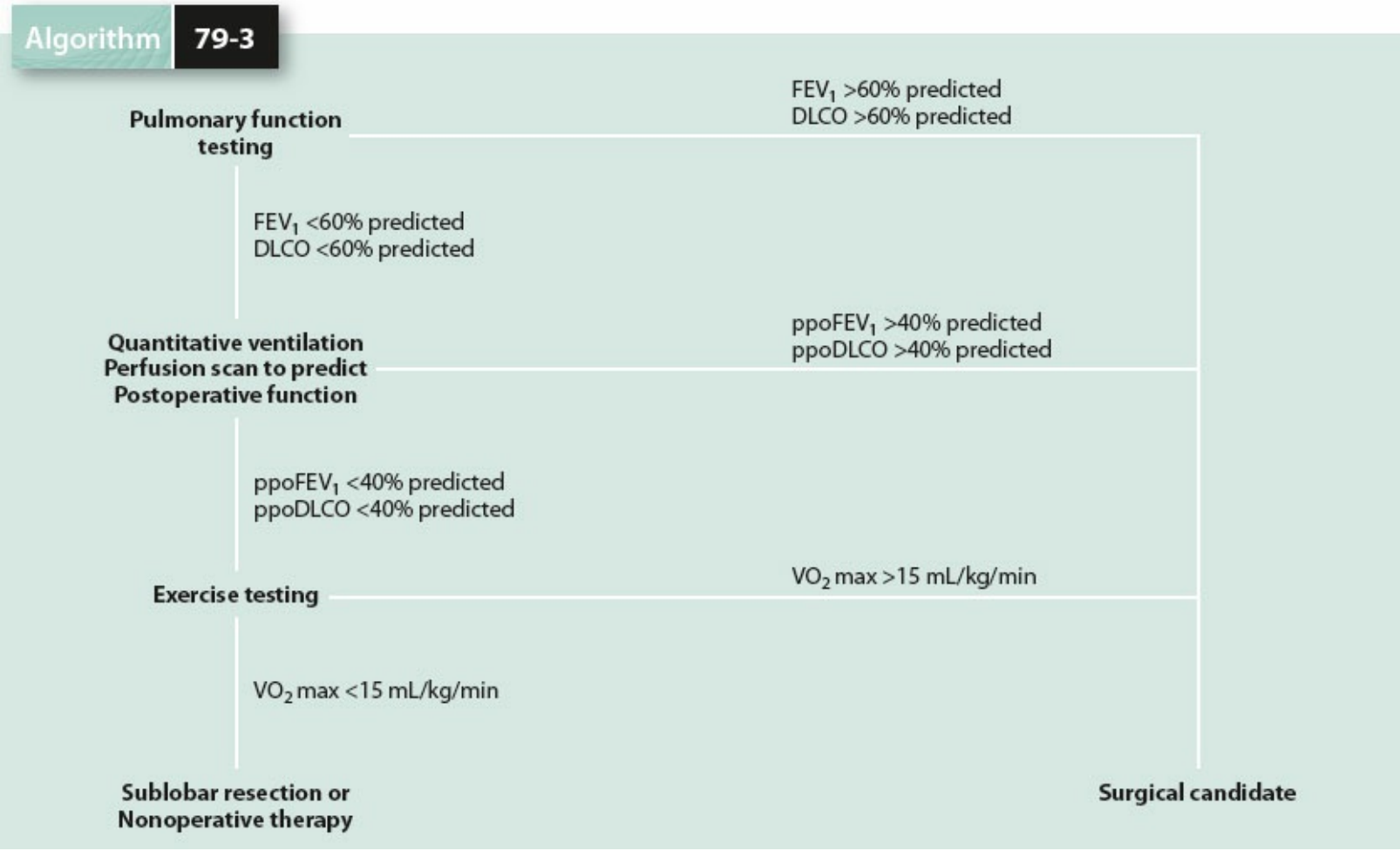

Algorithm 79-3. This algorithm illustrates the preoperative functional evaluation prior to lung cancer resection. FEV_1, forced expiratory volume in 1 second; DLCO, carbon monoxide diffusing capacity; ppo, predicted postoperative values; Vo_2 max, maximum oxygen uptake.

Informal exercise testing, particularly stair-climbing, may also aid the clinician in determining a patient's suitability for resection. Patients who are able to climb at least two flights of stairs likely will tolerate pneumonectomy, whereas those who cannot climb a single flight likely will not tolerate lobectomy. Furthermore, oxygen desaturation, greater than 4%, during exercise testing may also be an indicator for increased risk of perioperative complication. Careful preoperative physiologic assessment will allow the clinician to identify patients at increased risk for perioperative complication or death, and allow such patients to make an informed decision regarding operation.[65] Measures to minimize postoperative complications, including aggressive efforts to encourage smoking cessation, pre-and postoperative chest physiotherapy, incentive spirometry, early extubation and mobilization, and the use of postoperative thoracic epidural analgesia, are important for all patients undergoing pulmonary resection, especially those with marginal pulmonary function (Algorithm 79-3).

Treatment

5 Pulmonary resection, with definitive tumor staging, remains the mainstay of treatment for stage I, II, and selected stage III NSCLC. The extent of resection, segmentectomy, lobectomy, bilobectomy, or pneumonectomy, is determined by the location and size of the primary tumor and also whether adjacent bronchopulmonary nodes are involved. At operation, tumor extent is evaluated by examination of the parietal pleura, pericardium, and mediastinal structures. Complete resection must achieve microscopically negative bronchial and vascular margins. Potential postoperative complications after pulmonary resection are listed in Table 79-6.

Table 79-6 Postoperative Complications after Pulmonary Resection

Complication	Incidence (%)
Atrial arrhythmia	2.9–14.4
Prolonged air leak	4–7.6
Pneumonia	1–2.5
Subcutaneous emphysema	0.8–1.1
Myocardial infarction	0.4–0.9
Recurrent laryngeal nerve injury	0.4–0.7
Bronchopleural fistula	0.3–0.5
Respiratory failure	0.1–5.5
Hemorrhage	0–1.5
Empyema	0–1.1
Mortality	0.7–1.4%

[a]Includes thoracoscopic and open series. Based on Berry MF and D'Amico TA. Complications of thoracoscopic pulmonary resection. *Semin Thorac Cardiovasc Surg* 2007;19:350–354.

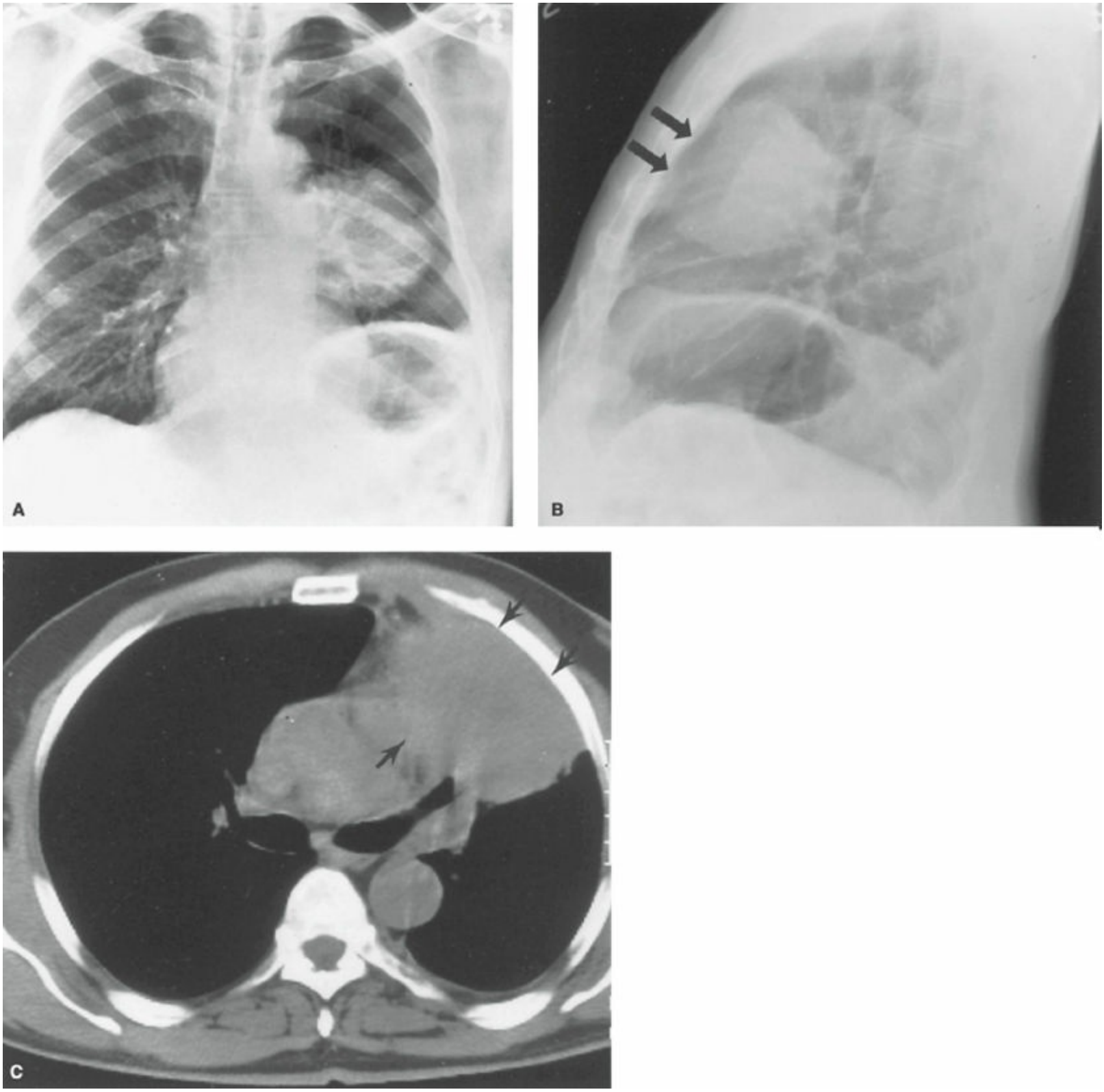

Figure 79-1. **A:** Posteroanterior chest radiograph shows an elevated left hemidiaphragm, suggestive of phrenic nerve involvement by the mass. **B:** Lateral chest radiograph shows extension of the mass into the anterior chest wall (*arrows*). **C:** Computed tomography suggests both pericardial and chest wall involvement (*arrows*). At thoracotomy, the chest wall, phrenic nerve, and pericardium were found to be involved. All were resected en bloc with the tumor.

If a tumor extends directly into the chest wall, diaphragm, or pericardium, an en bloc resection of the adjacent involved structure should be performed with the pulmonary resection. Reconstruction is performed as necessary (Fig. 79-1). If extensive endobronchial involvement is present without involvement of the surrounding vascular or

lymphatic structures, the tumor can sometimes be removed completely by lobectomy with segmental resection of the bronchus and/or pulmonary artery (bronchovascular sleeve resection), thus preserving lung function.

Patients with centrally located tumors should undergo sleeve lobectomy rather than pneumonectomy if complete resection can be achieved and such an approach is technically feasible. Several retrospective studies[66–70] have demonstrated that operative mortality is reduced among patients undergoing sleeve lobectomy (0% to 5.2%) when compared with patients undergoing pneumonectomy (1.7% to 8.9%). Moreover, overall 5-year survival is improved among patients undergoing sleeve resection, particularly among those with N0 or N1 nodal status. For peripherally located clinical stage I tumors, particularly among patients with limited pulmonary reserve or those at high risk from other comorbidities, segmental or nonanatomic "wedge" resection can be performed. Sublobar resection also may be appropriate for patients with good pulmonary function and who otherwise would be candidates for lobectomy (Table 79-7). Whether such patients are at greater risk for locoregional recurrence, as suggested in earlier series[71–73] but not borne out in modern series,[74] is under investigation in an ongoing multi-institutional prospective and randomized cooperative group clinical trial (CALGB 140503).

Although noninvasive techniques for preoperative assessment of mediastinal nodes have improved, nodal status should be confirmed by intraoperative mediastinal lymph node sampling or mediastinal lymph node dissection. Accurate pathologic staging provides not only prognostic information but is also important in the decision on whether to proceed with adjuvant chemotherapy. Systematic sampling should include tissue from at least three N2 lymph node stations, using standard nomenclature and numbering as depicted in (Table 79-4). Complete mediastinal lymph node dissection does not appear to confer increased perioperative morbidity[75] but also does not confer a survival advantage for patients with early stage (T1, T2, N0, and N1) NSCLC as staged at the time of lung resection. The long-term survival impact of mediastinal lymph node dissection has not been evaluated well for patients with clinical staging obtained solely by radiography or for patients with higher-stage NSCLC.[76–78]

Table 79-7 Criteria for Sublobar Pulmonary Resection

Peripheral nodule ≤2 cm with at least one of the following: ■ Pure adenocarcinoma in situ (AIS) histology ■ Nodule has ≥50% ground-glass appearance on CT ■ Radiologic surveillance confirms a long doubling time (≥400 days)) and minimum margins (≥2 cm or ≥ the size of the nodule)

Survival

Long-term survival after resection for NSCLC is linked to the pathologic stage of disease. The overall 5-year survival rates are shown in Table 79-5. They range from 60% to 70% for stage I tumors, from 40% to 50% for stage II tumors, and from 15% to 30% for stage IIIA tumors. Nodal involvement has the strongest adverse influence on survival. Large peripheral tumors that extend directly into the chest wall without nodal involvement (T3N0) are associated with a 5-year survival rate of 40% after complete resection, whereas involvement of mediastinal nodes is associated with only a 20% survival rate.

Some series suggest that histology also affects survival. In node-negative NSCLC, large cell neuroendocrine differentiation conferred worse survival than other types of NSCLC.[79] Different adenocarcinoma subtypes, particularly in more advanced tumors, also appear to confer worse prognosis, but the influence of histology has not been described uniformly in series to-date.[80] Delineation of tumor biology by more refined histologic and molecular analyses will be needed to define which patients might be at increased risk for recurrence or treatment resistance.

Patterns of Recurrence

The predominant sites of relapse for all stages of NSCLC after resection are distant metastases. Approximately 30% of recurrences are locoregional with tumors of both squamous and nonsquamous histology.[81] For all stages of disease, the brain is the single most common site of relapse, and brain metastases occur more frequently with nonsquamous tumors. Other common metastatic sites include bone, ipsilateral or contralateral lung, liver, and the adrenal glands.[81,82]

At least 60% of recurrences develop in the first 2 years after operation, and virtually all recurrences related to the original primary tumor occur within 5 years after surgery. Even the small proportion of patients with stage II or III disease who survive 5 years are likely to survive 10 years or more postoperatively. Recurrences of the original primary tumor are uncommon after 5 years, and after that time the occurrence of new pulmonary cancers becomes the dominant problem. The risk for development of a second lung cancer in patients with a prior history of cancer resection for NSCLC is estimated to be 2% to 3% per patient per year,[83] with a second lung cancer developing rarely in never-smokers at the time of initial resection, and at rates of 1.8% per patient-year in former smokers and 2.7% per patient-year in current smokers.[84] Patients also face a consistent risk for the development of new, nonpulmonary primary cancers during the first 5 years after operation and thereafter. New, nonpulmonary malignancies develop in a wide variety of sites, most commonly breast, colon, and prostate cancers.[81]

These data underscore the importance of long-term follow-up after resection of early-stage NSCLC. Guidelines provided by the American College of Chest Physicians[85] and the National Comprehensive Cancer Network support regular oncologic surveillance after curative-intent lung resection. In coordination with the primary or referring physician, recommended surveillance includes directed clinical assessment, every 6 to 12 months the first 2 years and then annually thereafter. Although there is no single modality to detect recurrence, follow-up should include a combination of history, physical examination, serial chest radiographs, and low-dose spiral chest CT. Neither PET scan nor MRI studies are recommended as part of routine surveillance.[85,86]

Adjuvant Therapy for NSCLC

The risk for recurrent disease, even after resection of early-stage NSCLC, has led to efforts to improve overall survival rates through the use of adjuvant therapy, even though no specific method is available to identify which patients will relapse. Various types of adjuvant therapy have been tested, including immunotherapy,[87–89] radiation, chemotherapy, and combined chemotherapy and radiation.

Radiation has been evaluated extensively as adjuvant therapy. Although early retrospective series suggested that postoperative radiation therapy (PORT) potentially improved overall survival,[90–92] subsequent relatively small randomized trials comparing adjuvant radiation with no further treatment failed to demonstrate any significant difference in overall survival.[93–97] Distant metastases remained the most common form of recurrent disease and were not affected by postoperative radiation to the mediastinum. Several of these trials[93,94,96,97] showed that radiation significantly decreased the risk for locoregional recurrence in tumors of all histologic types (Table 79-8). A meta-analysis of several randomized controlled studies of postoperative radiation therapy suggested an adverse effect on survival, particularly among patients treated with PORT with early-stage (I or II) lung cancer.[98] Postoperative thoracic radiation appears to be appropriate for patients who are at high risk for locoregional recurrence such as those found to have unexpected mediastinal (N2 or N3) nodal disease or those with evidence of residual tumor (R1 resection) at surgical margins.[99]

RESULTS

Table 79-8 Summary of Representative Randomized Trials Comparing Resection with or Without Adjuvant Radiation for Early-Stage Non–Small Cell Lung Cancer

Study	No. of Patients	NSCLC Stage[a]	Radiation Dose (Gy)	Overall Survival Difference
Van Houtte et al.[97]	224	I, II	60	NS
LCSG[96]	210	II, IIIA	50	NS
Lafitte et al.[95]	132	IB	45–60	NS
MRC[94]	308	II, IIIA	40 (15 fractions)	NS
Mayer et al.[93]	155	IA–IIIA	50–56	NS

[a]The stages are listed according to the 1997 international system for staging lung cancer.
LCSG, Lung Cancer Study Group; MRC, Medical Research Council; NS, not statistically significant; NSCLC, non–small cell lung cancer.

RESULTS

Table 79-9 Summary of Representative Randomized Trials Testing the Benefit of Adjuvant Chemotherapy after Resection of Early-Stage Non–Small Cell Lung Cancer

Study (Reference)	No. of Patients	NSCLC Stages[a]	Chemotherapy Agents	Overall Survival Difference
Hughes and Wiggins,[100]	1,002	Not stated	HN2 vs. no Rx	NS
Slack[101]	1,192	Not stated	HN2 vs. no Rx	NS
Shields et al.[102]	417	Not stated	Cytoxan vs. Cytoxan + MTX	NS
Shields et al.[103]	865	Not stated	CCNU + hydroxyurea vs. no Rx	NS
Feld et al.[105]	269	I-IIA	CAP vs. no Rx	NS
Pisters et al.[106]	72	IIIA	VP + RT vs. RT	NS
Dautzenberg et al.[107]	267	I-IIIA	COPAC, RT vs. RT	NS
Wada et al.[108]	323	I-IIIA	VP, UFT vs. UFT vs. no Rx	$p = 0.053$
Keller et al.[109]	488	II, IIIA	EP + RT vs. RT	NS
Scagliatti et al.[110]	1,209	I-IIIA	MVP vs. no Rx	NS
IALT[4,111]	1,867	I-IIIA	CDDP-based ± RT vs. RT vs. no Rx	Overall, NS; DFS, $p = 0.02$
Nakagawa et al.[112]	332	I	UFT vs. no Rx	Overall, NS; T1N0, $p = 0.036$
Winton et al.[5,113]	482	IB-II	CDDP, Vnb vs. no Rx	Overall, $p = 0.011$; DFS, $p = 0.0003$
Strauss et al.[114]	344	IB	Carboplatin, paclitaxel vs. no Rx	NS
ANITA[6]	840	I-IIIA	CDDP, Vnb vs. no Rx	Overall, $p = 0.017$

[a]The stages are listed according to the 1997 international system for staging lung cancer.[3]
ANITA, Adjuvant Navelbine International Trialist Association; CAP: cyclophosphamide, doxorubicin, cisplatin; CCNU, J-12-chlorethyl-3-cyclohexyl-J nitrosourea; CDDP, cisplatin; COPAC: cyclophosphamide, doxorubicin, cisplatin, vincristine, lomustine; Cytoxan, cyclophosphamide; DFS, disease-free survival; EP: etoposide, cisplatin; HN2, nitrogen mustard; IALT, International Adjuvant Lung Cancer Trial; M, mitomycin C; MTX, methotrexate; NS, not significant; no Rx, no adjuvant treatment; RT, radiation; UFT, tegafur plus uracil; Vnb, vinorelbine; VP: vindesine, cisplatin.

Because distant metastases are the predominant mode of relapse after resection of early-stage NSCLC, multiple randomized trials (Table 79-9) have been performed to determine if postoperative adjuvant chemotherapy improves survival. Early trials evaluated agents, including nitrogen mustards, cytoxan, methotrexate, and nitrosourea, now known to have no activity in NSCLC.[100–103] More recently, several studies have demonstrated that cisplatin-based chemotherapy regimens appear to provide a modest survival benefit. A meta-analysis of 9,387 patients entered into 52 randomized clinical trials showed a 5% survival benefit at 5 years for adjuvant cisplatin-based chemotherapy in comparison with surgery alone. Trials comparing adjuvant radiation with radiation plus chemotherapy showed an absolute survival benefit of 4% at 2 years in favor of combined-modality treatment.[104]

Recent trials of adjuvant chemotherapy in patients with completely resected NSCLC appear to indicate a therapeutic benefit. The multicenter International Adjuvant Lung Cancer Trial evaluated the effect of cisplatin-based adjuvant chemotherapy on survival after complete resection of NSCLC. A total of 1,867 patients with resected stage I, II, or III NSCLC were randomized to receive cisplatin-based chemotherapy, cisplatin-based chemotherapy and radiation, radiation alone, or no adjuvant treatment. Individual institutions administered additional chemotherapeutic agents at their discretion ("open-choice design"), with nearly half of the treated patients receiving cisplatin (100 mg/m^2) and etoposide for 3 or 4 cycles. The total dose delivered of cisplatin was greater than 240 mg/m^2 for 73.8% of treated patients. Additional agents used were vinorelbine, vinblastine, or vindesine. Cisplatin dosing varied from 80 to 120 mg/m^2/cycle, for a total

expected dose of 300 to 400 mg/m^2. Statistically significant benefits were observed for both overall (absolute difference, 4.1%) and disease-free (absolute difference, 5.1%) survival at 5 years, for patients treated with cisplatin-based chemotherapy, with or without adjuvant radiation.[4] Planned radiotherapy did not appear to provide any added benefit. In subgroup analysis, the benefits of cisplatin-based adjuvant chemotherapy appeared to confer the greatest benefit upon patients with stage III NSCLC. In longer-term follow-up, disease-free survival HR remained improved at 0.88 (95% CI 0.78 to 0.98, $p = 0.02$) for patients receiving adjuvant therapy over 7 years following operation, but the previously observed improvement in overall survival was no longer statistically significant with HR 0.91 (95% CI 0.81 to 1.02, $p = 0.10$).[115]

Several subsequent studies support the use of adjuvant chemotherapy, particularly in stage II and III lung cancer. These studies are summarized in recent meta-analyses of combined modality therapy in the treatment of resectable lung cancer,[116,117] which confirm the benefit of adjuvant chemotherapy following lung cancer resection for curative intent, with an absolute improvement in survival of 4% to 5.4% at 5 years of follow-up or beyond.

Notably, clinical trials evaluating adjuvant treatment for resected NSCLC have shown that approximately half of all patients actually received the planned dose of chemotherapy.[105,109] It remains to be determined whether patients undergoing minimally invasive approaches to pulmonary resection can tolerate adjuvant chemotherapy better than similar patients recovering from open operations. Thoracoscopic lobectomy, for example, may facilitate subsequent adjuvant chemotherapy.[118] In a series of 100 patients, 43 underwent thoracotomy and 57 had pulmonary resection performed by thoracoscopy. Those undergoing thoracoscopic resection were found to have a higher compliance rate with adjuvant treatment. Chemotherapy doses were delayed in significantly fewer patients in the thoracoscopic group (18% vs. 58%). Chemotherapy doses were reduced in only 26% of subjects undergoing thoracoscopy compared with 49% in the thoracotomy group. In addition, a significantly higher percentage of thoracoscopy patients received 75% or more of the planned regimen. There was no significant difference in the time to initiation of chemotherapy or toxicity.

Treatment of Stage III Disease

Stage III NSCLC indicates locoregionally advanced disease that encompasses several anatomic subsets which vary considerably in the likelihood that resection will provide durable oncologic benefit. Stage IIIB is generally considered unresectable. There is no role for resection for patients with T4 (stage IIIB) disease due to malignant pleural or pericardial effusion, infiltration of the heart, or those with contralateral or supraclavicular nodal metastases (N3). Several small series from specialized centers have demonstrated that curative intent operation can be considered for selected patients with invasion of mediastinal structures such as the superior vena cava, left atrium, carina, vertebrae or aorta, with consideration for induction chemoradiation, to "downstage" such tumors.[119–121] These series indicate that complete resection is essential to obtain survival benefit from this approach.

Stage IIIA includes patients with extrapulmonary disease involving the ipsilateral hemithorax, that is, T3N1 and T1–3N2. The management of patients with stage IIIA disease due to mediastinal nodal involvement (N2) has evolved considerably over the last several decades. Local therapy alone for curative intent, that is, pulmonary resection or definitive-dose radiation therapy is not recommended.

Role of Resection

The most controversial and complex part of the treatment of stage IIIA NSCLC is the management of patients with N2 disease. Reported 5-year survival rates after resection for N2 disease are usually 20% to 30% but range from zero to 40%. This variation reflects the extent of mediastinal nodal involvement, the T status of the primary tumor, and the ability to perform a complete resection. With respect to mediastinal nodal involvement, adverse prognostic factors include the presence of extracapsular nodal disease, multiple levels of involved lymph nodes and superior mediastinal nodal metastases.[122,123]

Rationale for Neoadjuvant Therapy

Although some patients with “minimal” N2 disease survive for long periods of time after resection, most have more extensive nodal involvement and do not benefit from either surgery or radiation therapy alone as their primary treatment. Efforts to improve outcomes following local control strategies have been limited by relapse at distant sites. Two early, randomized clinical trials challenged the concept of resection as the primary treatment for any patient with N2 disease. Rosell and colleagues[124,125] randomized 60 patients with stage IIIA NSCLC (16 of whom did not have N2 disease) to undergo resection or to receive three cycles of cisplatin-based chemotherapy followed by resection. The median survival of the patients who received preoperative chemotherapy was significantly longer (26 vs. 8 months) than the survival of patients who underwent only resection. A study of similar design from the M. D. Anderson Cancer Center corroborated these results.[126,127] Both trials were stopped early because of highly significant differences between the two study arms. These two studies suggested that it is appropriate to consider all patients with N2 disease diagnosed at mediastinoscopy for induction chemotherapy. Since pretreatment mediastinoscopy was not mandated in either trial, some patients who did not have N2 disease were included. The results of these trials are not universally accepted because of the small numbers of patients enrolled, the lack of systematic pretreatment staging, and the unusually poor survival of the patients in the control (surgery-only) arms.

Early Trials of Neoadjuvant Therapy

The concept of preoperative therapy followed by resection (*neoadjuvant therapy*) dates back to 1955, when Bromley and Szur[128] used radiation (at an average dose of 47 Gy) to treat 66 patients before resection. At operation, no viable tumor was found in 29 of 62 (47%) patients, but 10 patients died of complications in the first month, and only two patients survived to 5 years after operation. At the time, the natural history of NSCLC was not well understood, the methods of staging before resection not very accurate, and the risk for distant metastases not fully recognized. Effective chemotherapy did not exist and it was hoped that an approach that increased resectability might lead to better long-term survival. Thus, early neoadjuvant trials focused on the use of preoperative radiation.

Several subsequent studies further explored this approach.[129] All these trials were flawed by a lack of pretreatment staging, by the use of widely varying amounts of radiation, and by excessively long intervals between irradiation and resection. Nonetheless, it became apparent that aggressive local treatment did not improve long-term survival, even though radiation provided local control in a significant number of patients. The development of distant metastases in 50% to 80% of patients during or shortly after treatment underscored the need for systemic therapy in stage III NSCLC.

Recent Trials of Neoadjuvant Therapy

Because of a better understanding of the natural history of early-stage lung cancer and more universal adoption of the UICC/AJCC TNM staging system, recent trials have defined more uniform patient populations, so that it has been easier to interpret trial results. Although many different treatment regimens have been used in neoadjuvant trials, they can be grouped into three major categories: (a) chemoradiation without resection, (b) chemotherapy followed by resection, and (c) chemoradiation followed by resection.

Trials of Chemoradiation without Resection

These trials cannot be equated with trials of neoadjuvant therapy that include resection because patients entered into nonsurgical trials are staged clinically without tissue confirmation of mediastinal lymph node involvement. Therefore, nonsurgical trials include a mix of patients with stage IIIA and IIIB cancers, and might even include some patients with earlier-stage disease who were thought erroneously to have stage III disease because of benign mediastinal adenopathy diagnosed only by axial chest imaging.

With the acceptance of chemotherapy and radiation as standard treatment, attention has focused recently on the optimal means to deliver both modalities.[130] Several studies have demonstrated that concurrent treatment is superior to sequential chemoradiotherapy. A cochrane database systematic review identified fourteen randomized studies comparing concurrent chemoradiation and radiation therapy alone. In this meta-analysis of 2,393 subjects, concurrent therapy was associated with a reduction in risk of death at 2 years (RR 0.93; 95% CI 0.88 to 0.98; $p = 0.01$) and improved 2-year progression-free survival, locoregionally (RR 0.84; 95% CI 0.72 to 0.98; $p = 0.03$) or distant (RR 0.90; 95% CI 0.84 to 0.97; $p = 0.005$). Concurrent chemoradiotherapy also had improved survival compared with sequential chemotherapy and radiation (RR 0.86; 95% CI 0.78 to 0.95; $p = 0.003$). In a separate meta-analysis of studies evaluating the addition of sequential or concurrent chemotherapy to radiation therapy in over 1,200 patients, a substantial overall survival benefit was observed for patients receiving concurrent treatment, with an absolute benefit of 5.7% (from 18.1% to 23.8%) at 3 years and 4.5% at 5 years (from 10.6% to 15.1%).[131] Although concurrent chemoradiation was associated with less locoregional disease progression, no significant differences were observed between these two treatments, concurrent or sequential therapy, in terms of distant disease progression.[131] Toxicities, particularly esophagitis, also were greater for patients receiving concurrent chemoradiation.[131,132]

Trials of Neoadjuvant Therapy with Resection

These trials have used two different treatment strategies, induction chemotherapy alone or concurrent chemoradiation before resection. The rationale for chemotherapy alone as induction treatment is that it potentially allows the use of a more intense dose and the use of some drugs, such as mitomycin, that cannot be administered in conjunction with radiation. Proponents of this approach also believe that chemotherapy is as effective as induction treatment as is combined chemoradiation, and that separating the two modalities allows irradiation to be used postoperatively, when a higher total dose can be given. Proponents of concurrent preoperative chemoradiation believe that this approach provides adequate systemic treatment of micrometastatic disease and more effective control of bulky primary and mediastinal tumors.

Neoadjuvant Trials of Chemotherapy Alone before Resection

One of the best-known early trials to demonstrate the feasibility of combining induction chemotherapy with subsequent pulmonary resection in patients with stage III NSCLC was developed by Martini et al.[133] at Memorial Sloan-Kettering Cancer Center. In 1984, this group initiated a trial of high-dose, cisplatin-based (120 mg/m^2) chemotherapy followed by resection for patients with clinical N2 disease. Vindesine or vinblastine and subsequently mitomycin were added to form the so-called "MVP" regimen. Postoperative radiation was given to patients who had persistent mediastinal nodal tumor at thoracotomy, and all patients received two additional cycles of chemotherapy postoperatively. In 136 patients treated from 1984 to 1991, the major response rate to induction chemotherapy was 77% (105/136), and the complete resection rate was 65% (89/136). A complete pathologic response was noted in 19 patients (21%) at the time of resection. The overall survival at 5 years was 17% and the median survival was 19 months; a distinct improvement over the historical survival for this group of patients. Seven treatment-related deaths (5%) occurred in this study, five of which were postoperative.

A phase II trial, reported by the CALGB in 1995, of induction chemotherapy enrolled 74 patients, treated with two cycles of cisplatin (100 mg/m^2 on days 1 and 29) and vinblastine (5 mg/m^2 per week) without mitomycin followed by resection for patients with mediastinoscopy-proven stage IIIA N2 disease.[134] In addition, two cycles of chemotherapy and 59.4 Gy of radiation were given postoperatively. Sixty-three patients (85%) had either an objective response or stable disease after induction therapy and underwent thoracotomy, with operative mortality rate of 3.2%. Twenty-three patients (37% of thoracotomies, 31% of all patients) had a complete resection, with 3-year survival of 46%. The overall 3-year survival was 23%. The lower resectability rate in this trial than in the study performed at Memorial Sloan-Kettering potentially reflected both the multi-institutional nature of this trial and the use of a less intensive chemotherapy regimen (primarily because of the omission of mitomycin). The overall long-term survival appeared similar for the two trials.

Trials of Induction Chemoradiation Followed by Resection

The second approach to combined-modality therapy and resection for stage III NSCLC has been to combine chemotherapy and radiation preoperatively (Table 79-10). This strategy aims to control micrometastatic disease while utilizing the synergism of concurrent radiation and chemotherapy to reduce tumor bulk in the primary site and mediastinum.

The largest reported phase II neoadjuvant trial of concurrent chemotherapy and radiation was a multi-institutional study performed by the Southwest Oncology Group.[138] Both stage IIIA and stage IIIB patients were entered, although notably, pathologic documentation of the initial tumor stage, usually by mediastinoscopy, was required. The induction regimen included two cycles of cisplatin (50 mg/m^2 on days 1 and 8) and etoposide with 4,500 cGy of concurrent radiation in 25 fractions. All patients underwent thoracotomy unless their disease progressed. The objective response rate to induction therapy in the 126 eligible patients was 59%. The resectability rates were 85% for the IIIA N2 group and 80% for the IIIB group. Nearly two-thirds of the patients had no viable tumor or only minimal residual foci of tumor in their surgical specimens. The 3-year survival rate was 27% for the IIIA group and 24% for the IIIB group, with median survival of 13 and 17 months, respectively. The best predictor of survival after surgery was the absence of tumor in the mediastinal nodes at surgery (3-year survival of 44%). The majority of recurrences were distant, and the brain was the single most common site. The operative mortality rate was 6%, and the overall treatment-related mortality was 10%. An important finding of SWOG 8805 was that survival was the same for patients with stage IIIB NSCLC by virtue of T4 tumor status and patients with stage IIIA N2 disease. Patients with N3 disease had a poor overall survival. Importantly, the long-term follow-up of this study showed that the survival rates at 3 years were sustained at 6 years.[142] Important differences between the Southwest Oncology Group trial and earlier neoadjuvant trials were the careful documentation of pretreatment stage, the use of a higher dose of continuous radiation (4,500 cGy rather than 3,000 cGy of continuous or 4,000 cGy of split-course radiation), and the fully concurrent manner in which the chemotherapy and radiation were administered.

A North America Intergroup clinical trial sought to determine whether neoadjuvant therapy including resection is superior to nonsurgical treatment with chemotherapy and higher-dose radiation in patients with stage IIIA NSCLC. In the Intergroup 0139/RTOG 9309 trial,[43,140] patients with proven pN2, stage IIIA NSCLC were randomized to receive neoadjuvant chemotherapy with concurrent thoracic RT (TRT) followed by operation or continuation with definitive TRT.

Of 429 patients accrued over 92 months, 396 patients were considered eligible, and were treated with cisplatin (50 mg/m^2), on days 1 and 8, and etoposide (50 mg/m^2), on days 1 to 5, every 3 weeks for 2 cycles, as well as 45 Gy TRT. Patients randomized to resection ($n = 202$) underwent operation 4 to 6 weeks later. Patients randomized to definitive radiation ($n = 194$) continued without break to a total of 61 Gy. Following operation or completion of TRT, consolidation with 2 cycles of cisplatin and etoposide was given. Of note, less than two-thirds of patients undergoing operation received

consolidation treatment, compared with over 75% of patients receiving chemoradiation only. There was no mortality in either group during induction chemoradiation. Mortality in the surgical treatment arm was 8%, with 14 of 16 deaths occurring in patients undergoing pneumonectomy.

Table 79-10 Results of Representative Neoadjuvant Trials for Stage III Non–Small Cell Lung Cancer: Induction Chemoradiotherapy Followed by Resection

Study (Reference)	No. of Patients	Chemotherapy	Radiotherapy (Gy)	Survival	
				Median (mo)	Overall (%)
Rush–Presbyterian, Faber et al.[135]	IIIA: 85 (including 19 N0)	CDDP (60 mg/m²) + 5-FU ± VP-16 × 4	40(S), 20 fractions	21.7	40 (3 yrs)
LCSG, Weiden et al.[136]	IIIA, IIIB: 85	CDDP (75 mg/m²) + 5-FU × 2	30(C), 5 fractions	13	22 (2 yrs)[a]
CALGB, Strauss et al.[137]	IIIA: 41 (including 8 N0–1)	CDDP (100 mg/m²) + Vbl + 5-FU × 2	30(C), 15 fractions	15.5	30 (2 yrs)[a]
SWOG, Albain et al.[138]	IIIA, IIIB: 126	CDDP (50 mg/m²days 1 and 8) + VP-16 × 2	45(C), 30 fractions	13 (IIIA) 17 (IIIB)	37 (2 yrs) (IIIA) 39 (2 yrs) (IIIB)
M. D. Anderson, Taylor et al.[139]	IIIA: 107 (including 21 N1)	CDDP-based or carboplatin/paclitaxel	None	31	33 (5 yrs)
		CDDP + Vbl	Daily, 60–63(C)	27	30 (5 yrs)
		CDDP + VP-16	69.6 (H)		
North American Intergroup, Albain et al.[140]	Resection: 201 patients	CDDP (50 mg/m²) + VP-16 × 4; 2 cycles consolidation	45 (C)	22.0 (OS), 13.4 (PFS)	3 yrs: 37 (OS) 27 (PFS)
	No surgery: 191 (264 patients eligible)	CDDP (55 mg/m²) + VP-16	61 (C) 45, twice daily	22.3 (OS), 11.8 (PFS)	3 y: 34 (OS) 19 (PFS)
German Lung Cancer Cooperative Group, Thomas et al.[141]	131 resected[b] CT	Carboplatin + vindesine		32.4 (OS) 19.6 (PFS)	3 yrs: 48 (OS) 36 (PFS)
	CRT surgery (260 patients eligible) 141 resected[b] CT surgery PORT	CDDP (55 mg/m²) + VP-16	54, daily	33 (OS) 21.3 (PFS)	3 yrs: 45 (OS) 37 (PFS)

[a]From survival curve.
[b]Survival data for patients found to be resectable at thoracotomy.
CALGB, Cancer and Leukemia Group B; LCSG, Lung Cancer Study Group; RTOG, Radiation Therapy Oncology Group; SWOG, Southwest Oncology Group; 5-FU, 5-fluorouracil; CDDP, cisplatin; Vbl, vinblastine; VP-16, etoposide; (C), continuous course; (H), Hyperfractionated; (S), split course, PORT, postoperative radiation therapy; PFS, progression-free survival; OS, overall survival.

The median follow-up for the study population was 23 months (range 1 to 125 months). Progression-free survival (PFS) was improved from a median of 10.5 months to 12.8 months, and 5-year PFS from 11% to 22% with the addition of surgery. There appeared to be improved local control with the addition of surgery, with local failure occurring in only 10% of surgically treated patients compared with 22% in the nonsurgical group, although this was not statistically significant. However, no statistically significant differences were seen in overall survival, with 5-year survival of 20% and 27% for the chemoradiation alone and chemoradiation and surgery groups, respectively. This study indicated that carefully selected patients with N2-positive stage IIIA NSCLC can be treated with multimodality therapy including resection.

The role of surgery for patients whose tumors appear to require pneumonectomy remains controversial as well. In the recently published German Lung Cancer Study Group trial, patients were randomized to induction chemotherapy (cisplatin and etoposide) followed by chemoradiation (concurrent carboplatin and vindesine) and then by resection, or induction chemotherapy followed by surgery alone. Of 524 eligible patients, randomized and started on treatment, 296 underwent operation and 272 were resectable. In an intention-to-treat analysis of randomized, eligible patients, no differences in

progression-free or overall survival were observed between the treatment groups. Patients receiving preoperative chemoradiation were more likely to achieve complete resection among those with resectable tumors (98/131 vs. 84/141, $p = 0.008$), and were more likely to have evidence for mediastinal downstaging and pathologic response, but again with no significant difference observed in progression-free or overall survival. Of 104 patients who required pneumonectomy, including 39 on the right, mortality was slightly greater among patients treated with preoperative chemoradiation (7/50 vs. 3/54), but this was not statistically significant.[141] Parenchymal-preserving bronchoplastic techniques also can be considered for those patients who might otherwise require pneumonectomy.[143] Whether such technically challenging approaches can be undertaken in the setting of recent radiation therapy remains to be established.

Stimulated by the promising results of the Southwest Oncology Group 8805 trial for patients with T4 disease, Grunenwald et al.[120] performed a phase II trial of similar design for stage IIIB T4 NSCLC. The induction regimen consisted of cisplatin (100 mg/m^2), 5-fluorouracil, and vinblastine with 45 Gy of concurrent hyperfractionated (twice daily) radiation. Of 25 patients enrolled, 16 were subsequently eligible for surgery, and 12 had complete resection. No induction treatment–related or operative deaths occurred. This study confirmed that complete resection after induction therapy is feasible in a significant number of stage IIIB T4 tumors, a subset of stage IIIB tumors previously considered inoperable under any circumstances.

Current Status of Neoadjuvant Therapy and Resection

Clinical trials evaluating neoadjuvant therapy have demonstrated the feasibility of induction chemotherapy and resection for the treatment of stage III NSCLC. Most studies showed improved rates of resectability and survival in comparison with the historical experience for resection or radiation alone. The optimal treatment approach to these locally advanced tumors has not yet been fully defined, especially because neoadjuvant trials have varied with respect to eligibility criteria, inclusion of both stage IIIA and stage IIIB tumors, accuracy of pretreatment staging, and type of induction regimens. The response, resectability, and survival rates have not been uniformly reported. In some studies, instead of reporting results as a percentage of the total number of patients entered into the study, the authors reported resectability rates as a percentage of the patients with a radiographic response, and only the survival rates of patients who underwent resection were emphasized.

The potential toxicity of neoadjuvant regimens should not be overlooked. Induction regimens including high-dose cisplatin ($\geq$100 mg/m^2) or radiation doses of 4,000 to 4,500 cGy have been well tolerated, but radiation doses of 5,500 cGy or higher have been associated with an excessive risk for postoperative ARDS and bronchial stump leak. Good response rates have been achieved with chemotherapeutic agents including paclitaxel, docetaxel, gemcitabine, and carboplatin, which are tolerated better by patients. Determining the contribution of these agents in combined-modality therapy will require further trials, especially as the major form of relapse continues to be distant metastatic disease.

Future Directions

6 In addition to new chemotherapeutic agents, new radiation techniques, such as hyperfractionated or accelerated schedules, also merit further exploration in neoadjuvant trials with concurrent chemotherapy. Adelstein et al.,[144] from the Cleveland Clinic, conducted a study in which 45 patients with stage IIIA or IIIB NSCLC received induction cisplatin, paclitaxel and 30 Gy of accelerated hyperfractionated radiation therapy (1.5-Gy fraction twice daily). Resection was then performed approximately 4 weeks after induction. The overall response rate was 54%. Forty patients (89%) proceeded to operation, and 32 patients (71%) underwent complete resection. Five complete pathologic remissions were seen. Fourteen patients overall were downstaged. Patients received a consolidation dose of chemotherapy and additional radiation to a total of 60 to 63 Gy. The 2-year relapse-free survival rate was 47%, and the 2-year survival rate was 65%. No apparent therapy-related deaths occurred, but the toxicity was high, with 89% of patients experiencing significant mucositis and 20% experiencing esophagitis of grade 3 or worse. Three-dimensional conformal therapy permits higher radiation dosing (>70 Gy) of the tumor while sparing surrounding normal lung to provide improved local control.[145,146]

7 The management of stage III NSCLC is complex and still evolving. Many trials indicate that resectability and survival rates are probably improved with the use of combined-modality therapy than with radiation or resection alone. Regimens incorporating high-dose cisplatin with or without moderate-dose radiation have achieved the best results with acceptable levels of toxicity. Careful patient management leads to complete resection, and the operative risk is comparable with that of standard pulmonary resection. Importantly, combined-modality treatment requires close collaboration among medical oncologists, radiation oncologists, surgeons and pulmonologists, preferably in a multidisciplinary tumor board setting, as well as anesthesiologists at the time of operation. In the future, three key areas warrant further investigation: (a) The optimal combination and sequence of newer, less toxic chemotherapeutic agents and a variety of new radiation techniques; (b) whether concurrent chemoradiation is superior to chemotherapy alone as preoperative induction therapy; and (c) the identification of the molecular features that dictate tumor response to different chemotherapeutic agents allowing a more individualized selection of induction treatment regimens which may lead to improved long-term outcomes.

Superior Sulcus Tumors

Tumors of the superior sulcus (Fig. 79-2), described in detail by H. K. Pancoast in 1932,[147] represent an uncommon (3%) and challenging subset of NSCLC. Tumors frequently involve the brachial plexus, subclavian vessels, or spine and typically fall into two categories; T3N0–1 (stage IIB or IIIA) or T4N0–1 (stage IIIB).[148] Until the 1950s these tumors were felt to be almost universally fatal, with no benefit provided by resection. In 1961, Shaw and Paulson demonstrated that preoperative thoracic radiation followed by resection was potentially curative.[149] For the subsequent 30 to 35 years, reports demonstrated 5-year survival of approximately 25% to 30%. In a single-institutional experience, spanning 24 years, during which 225 patients underwent thoracotomy at MSKCC, 5-year survival for patients undergoing resection for Stage IIB, IIIA and IIIB superior sulcus tumors was 46%, 0% and 13%, respectively.[150] In this retrospective study, the mode of preoperative therapy, with radiation and/or chemotherapy, or adjuvant therapy did not appear to affect survival, which was influenced only by the completeness of resection and tumor (T) and nodal (N) status in a multivariate analysis. As in other retrospective series, locoregional recurrence was the most common form of relapse, occurring in 40% of patients.[151]



Figure 79-2. Gross figure of a squamous cell carcinoma showing a superior sulcus tumor (Pancoast tumor) arising from apex of the right lung. From Cagle PT. *Color Atlas and Text of Pulmonary Pathology*. Philadelphia, PA: Lippincott Williams & Wilkins; 2005.

Spurred by reports of the apparent success of neoadjuvant chemotherapy and thoracic

radiation in achieving improved local control and survival for patients with locoregionally advanced NSCLC, the Southwestern Oncology Group coordinated a phase II trial, the first prospective, multicenter trial (SWOG 9416/Intergroup 0160) for superior sulcus tumors.[152] Of 110 patients eligible, including 32 patients with T4 disease, 104 completed induction chemoradiation and 95 were eligible for operation. Patients with mediastinal lymph node metastases (N2) were excluded from this trial. Of the 88 patients who underwent thoracotomy, 83 had a complete resection, with 61 patients demonstrating complete pathologic response (R0) or minimal residual disease (R1). There were three treatment-related deaths and two perioperative deaths. Of note, intracranial and other distant metastases were more common (22% each) than locally recurrent disease only (11%). Overall 2- and 5-year survival was 55% and 41% for all patients enrolled, and 70% and 53% for patients with a complete response.

NEUROENDOCRINE TUMORS

Neuroendocrine tumors of the lung include a varied group of lesions ranging from tumors with low-grade malignant potential (typical carcinoid) to SCLC, which is among the most rapidly growing and aggressive of human tumors. Between those two extremes, atypical carcinoid and large cell neuroendocrine carcinoma have been defined.[153]

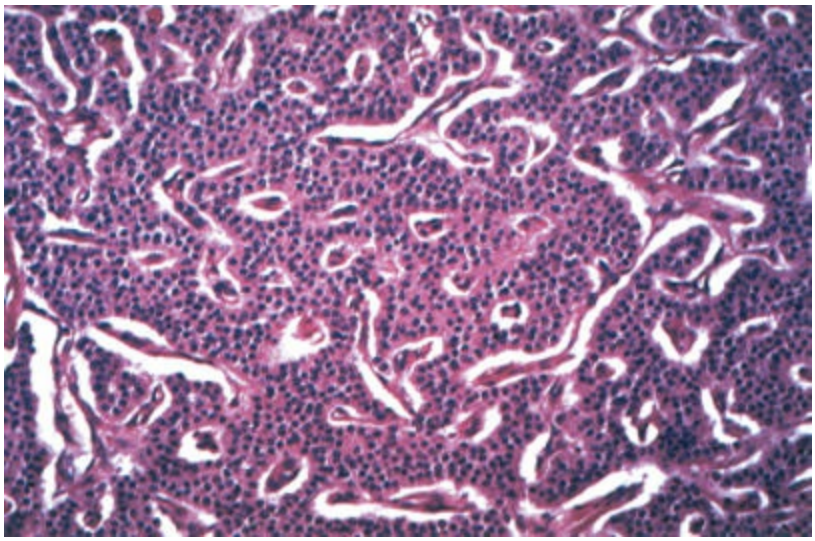

Figure 79-3. Typical carcinoid tumor of the lung. A microscopic view shows ribbons of tumor cells embedded in a vascular stroma. From Rubin E, Farber JL. *Pathology*. 3rd ed. Philadelphia, PA: Lippincott Williams & Wilkins; 1999.

Typical and Atypical Carcinoid Tumors

Carcinoid tumors, which are neoplasms with a low-grade malignant potential, account for about 2% of lung tumors in the United States. They arise from neuroendocrine stem cells of the bronchial epithelium and are classified as either typical or atypical. Histologically, typical carcinoids consist of uniform polygonal cells with round nuclei and fine granular chromatin (Fig. 79-3). Mitotic figures are rare. Atypical carcinoids show increased mitotic activity, nuclear pleomorphism, and areas of disorganized architecture and tumor necrosis (Fig. 79-4).[154]

Carcinoid tumors occur equally in both sexes and at a median age of 55 years. Half of patients present with pulmonary symptoms, including hemoptysis, dyspnea, and recurrent or persistent pneumonitis because 40% of lesions are centrally located in the main or lobar bronchi (Figs. 79-5 and 79-6). The lesions may be diagnosed by bronchoscopy, appearing as pink or purple friable endobronchial masses covered by intact epithelium. In the other half of patients, carcinoid tumors are diagnosed when radiologic abnormalities are detected on a chest roentgenogram as part of a routine examination.[155]

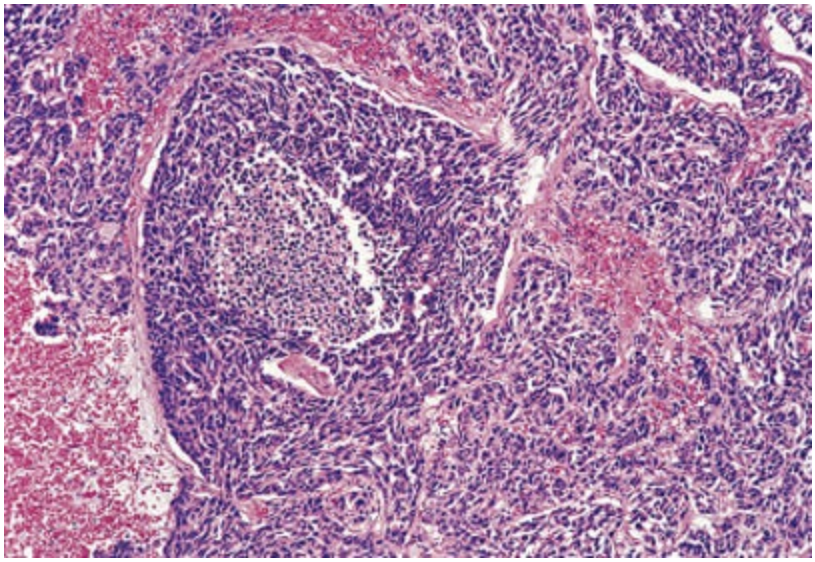

Figure 79-4. Atypical carcinoid tumor of the lung. A cellular tumor shows central necrosis and a disorganized architecture. From Rubin E, Farber JL. *Pathology*. 3rd ed. Philadelphia, PA: Lippincott Williams & Wilkins; 1999.



Figure 79-5. Gross figure of a carcinoid tumor protruding into the bronchial lumen. From Cagle PT. *Color Atlas and Text of Pulmonary Pathology*. Philadelphia, PA: Lippincott Williams & Wilkins; 2005.

Lymph node metastases occur in approximately 10% to 15% of patients at diagnosis but are more frequent in atypical carcinoids. Carcinoid syndrome is associated with bronchial carcinoids in only 2% of cases, usually in patients with metastatic disease, particularly to the liver. The most common sites of metastases are lung, bone, liver, adrenals, and brain.[155]

The standard treatment for bronchial carcinoids is complete resection, regardless of the presence of nodal involvement, with mediastinal lymph node sampling or dissection. Lobectomy can be accomplished in the majority of patients with resectable disease, although parenchymal-sparing segmentectomy or nonanatomic wedge resection can be considered particularly for patients with a typical carcinoid tumor.[156] For patients who have centrally located tumors and for which pneumonectomy might be performed, bronchoplastic techniques (i.e., sleeve lobectomy) should be considered instead.[157] Endoscopic resection is invariably associated with local recurrence and should be used only as a palliative maneuver in patients whose general medical condition precludes thoracotomy and pulmonary resection.[155]

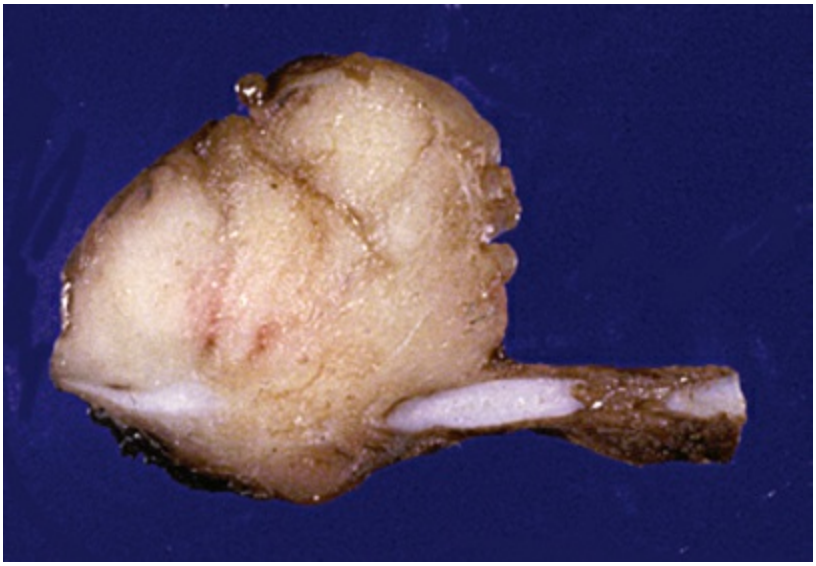

Figure 79-6. Gross figure of a resected carcinoid tumor cut in cross section to show invasion through the bronchial cartilage. From Cagle PT. *Color Atlas and Text of Pulmonary Pathology*. Philadelphia, PA: Lippincott Williams & Wilkins; 2005.

The long-term survival rate after resection exceeds 90% in patients with typical carcinoids, even when hilar or mediastinal nodal metastases are present. In contrast, patients with atypical carcinoids have a 5-year survival rate of 60% after complete resection. The outcome is more closely linked to histology than to tumor size, location, or nodal involvement. Recurrence is more frequent with tumors larger than 3 cm and in patients who present with lymph node metastases.[157,158]

Large Cell Neuroendocrine Carcinomas

Large cell neuroendocrine carcinoma is characterized by the microscopic features of neuroendocrine tumors, but the tumor cells are large, have a high mitotic rate, and frequently show necrosis (Fig. 79-7).[153,154] According to Travis et al.[159,160] large cell neuroendocrine carcinomas are related to smoking, as is SCLC, and are high-grade tumors with 5- and 10-year survival rates of 27% and 9%, respectively, despite complete resection. Few data are available concerning adjuvant therapy. For the time being, the management of large cell neuroendocrine carcinoma is identical to that of NSCLC.[161]

Small Cell Lung Cancer

Small cell carcinoma of the lung has the most aggressive clinical course of any type of pulmonary tumor and is often widely disseminated by the time of diagnosis. The proportion of patients with SCLC has been decreasing from 17% in the 1980s to 13% of lung cancer cases in 2002.[162] In contrast to non–small cell tumors, these lesions are notably responsive to chemotherapy and are rarely within the domain of the surgeon. The staging system for SCLC was developed by the Veterans Administration Lung Cancer Staging Group and divides patients into those with limited-stage (LS) and those with extensive-stage (ES) disease. This distinction was first based on what could be encompassed by a tolerable radiation portal. After clarification by the International Association for the Study of Lung Cancer, LS disease includes patients with tumors confined to one hemithorax and regional lymph nodes (hilar, ipsilateral, and contralateral mediastinal nodes, and ipsilateral and contralateral supraclavicular nodes) as well as patients with ipsilateral pleural effusion, regardless of whether the cytology is positive or negative.[163] On the other hand, both pericardial and bilateral pulmonary involvement are considered ES disease.[164]

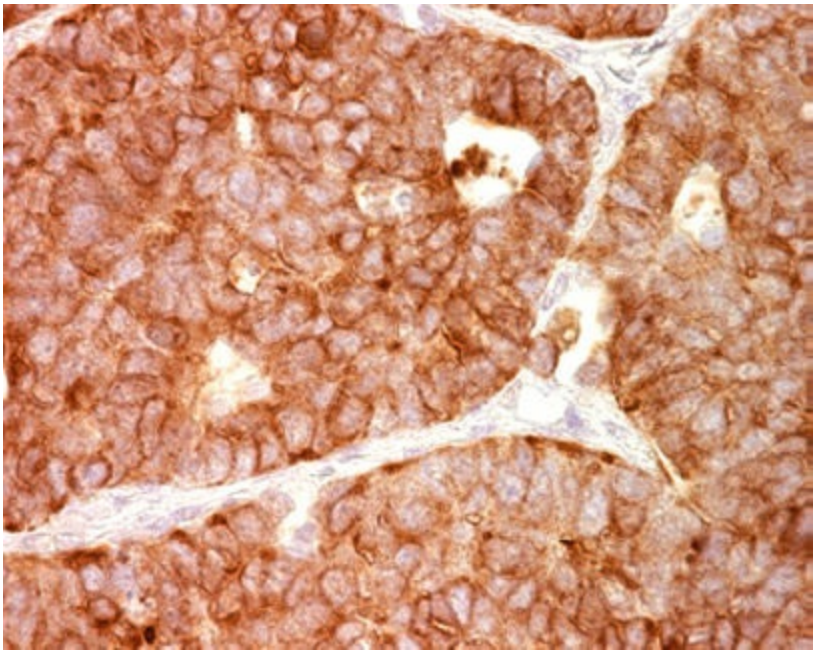

Figure 79-7. Large cell neuroendocrine carcinoma of the lung shows positive immunostaining with synaptophysin antibody. From Cagle PT. *Color Atlas and Text of Pulmonary Pathology*. Philadelphia, PA: Lippincott Williams & Wilkins; 2005.

Common sites of distant metastases are bone, liver, bone marrow, and the central nervous system, and therefore the metastatic evaluation includes a bone scan, CT of the chest and abdomen, and brain MRI. Some oncologists also perform bone marrow biopsies, but because the marrow is the sole site of extensive disease in fewer than 5% of patients, biopsies are usually judged unnecessary. After the staging process, approximately 30% to 40% of patients are found to have LS disease.

For patients with LS SCLC, response rates of 85% to 90% and complete response rates

of 50% to 60% can be expected with the combination of etoposide and cisplatin and radiation therapy.[165] The median survival is 18 to 24 months, and the 2-year survival rates are 40% to 50%. The addition of definitive-dose thoracic radiation therapy, particularly when administered concurrently or within several weeks of completing chemotherapy confers a 5% 2- to 3-year overall survival benefit.[166–168] In ES SCLC treated with chemotherapy, response rates reach 75% to 85%, although complete response is seen in only 15% to 25% of patients. The median survival is between 7 and 11 months, with a 2-year survival less than 5%.[162] Although the prognosis in SCLC depends primarily on the anatomic extent of disease, after a review of prognostic variables in its 2,580-patient SCLC database, the Southwest Oncology Group determined that the two-stage system should be extended into a four-stage system, with serum lactate dehydrogenase level, age, and pleural effusion used as additional staging criteria.[169]

The small numbers of patients with SCLC seen by the surgeon represent fewer than 10% of all patients with SCLC. Such patients have peripheral tumors with no nodal involvement or only hilar nodal involvement, which would be classified as Tl–2 N0–l (stage I or II) tumors in the TNM staging system. In the past, such tumors were often diagnosed at exploratory thoracotomy for an asymptomatic coin lesion, but with the increasing use of diagnostic percutaneous needle aspiration, more patients with early-stage SCLC are now identified preoperatively. Such patients should be evaluated in a multidisciplinary setting in conjunction with medical and radiation oncology, and resection should be considered after distant disease has been excluded. For such potentially operable patients, it has been suggested that the TNM classification be used in future trials and studies.[170,171]

Retrospective series have demonstrated a 5-year survival rate of 30% to 50% after resection of T1 N0 or T2 N0 SCLC.[170,172,173] Because of the propensity for small cell cancers to disseminate, adjuvant chemotherapy has traditionally been given to patients although no prospective, randomized trials have demonstrated whether this is of any benefit, due to the small numbers of patients available.[173] Relapse at the primary site, which is a problem for most patients with LS SCLC, is distinctly uncommon after complete resection of these early tumors.[174] Radiation therapy to the chest has been suggested after complete resection, but because insufficient information is available in the literature, and local relapse is uncommon, this is not considered standard treatment.[172,173] Given the propensity for patients to develop brain metastases, prophylactic cranial irradiation is recommended for patients with either LS- or ES SCLC with good performance status and who have completed initial therapy with either complete or partial response.[175]

As the role of resection in patients with mediastinal nodal involvement (N2 disease) is questionable, mediastinoscopy or EBUS should be considered mandatory to exclude mediastinal nodal disease.[176] This should be performed separately from thoracotomy since it can be difficult for the pathologist to diagnose small cell cancer on a frozen section. The intraoperative management of SCLC is not significantly different from that of NSCLC, and an incomplete resection does not benefit the patient.

The addition of resection after response to induction chemotherapy has been proposed

by some surgeons to cure a small number of patients with LS SCLC without mediastinal involvement.[177] To date, the LCSG has performed the only prospective, randomized trial evaluating the role of surgery in LS SCLC.[178] All patients enrolled in this study received induction chemotherapy. Objective responders were randomized either to lung resection followed by thoracic and cranial radiation or to radiation therapy alone. Because the survival rate was the same in both groups, with 2-year overall survival of 20%, this trial did not support the addition of pulmonary resection to the multimodality treatment of SCLC. More recently retrospective studies suggest better long-term survival, in selected patients with stage I SCLC, of over 50% at 5 years.[171]

Finally, the occurrence of a second primary lung carcinoma after treatment for SCLC has been reported in the few patients with prolonged survival. It should not be assumed that the new tumor is of small cell histology, and these patients should be evaluated for the possibility of resection.[179] The average risk for the development of a second lung cancer in patients who survive SCLC is approximately 6% per patient per year.[83]

Bronchial Gland Carcinomas

Bronchial gland carcinomas are rare primary tumors of the lung. They constitute about 1% of all lung neoplasms and 2% of the tumors for which resection is performed. These tumors are also called *primary salivary gland-type tumors of the lung* because the tracheal and bronchial airway submucosa and the salivary glands contain serous and mucous glands that are histologically similar.[180] Often, they are called *bronchial adenomas,* but this term is misleading because they are malignant. Care must be taken to separate these primary tumors from metastases of primitive salivary gland tumors.[181] This group of carcinomas includes adenoid cystic carcinoma, mucoepidermoid carcinoma, and the even rarer mixed tumor (pleomorphic adenoma). The only truly benign tumors are mucous gland adenomas.

The symptomatology of these tumors is determined essentially by their location and size.[181] Peripheral tumors, which are less frequent, are asymptomatic, generally presenting as a nodule on routine chest radiography. Proximally located tumors present with symptoms of bronchial irritation and obstruction, including cough, shortness of breath, hemoptysis, recurrent infection, wheezing, and stridor. Sometimes, patients have constitutional symptoms, such as weight loss and pain. On chest radiography, the nodule may be seen with pneumonia or atelectasis. Because of the slow growth of these tumors, signs and symptoms may develop over a period of years. Incompletely obstructing tumors frequently masquerade as asthma for prolonged periods of time. Smoking does not seem to be a risk factor for these tumors.

Peripheral tumors are diagnosed by percutaneous needle aspiration biopsy or by wedge resection at the time of operation. Endobronchial tumors are diagnosed by bronchoscopy. Other studies, such as CT, are rarely required to make the diagnosis but may be of value in planning therapy. Because most of these tumors do not metastasize, complete excision, with preservation of as much pulmonary tissue as possible, is the goal. Whenever possible, sleeve resections of main bronchi are performed to preserve pulmonary tissue.

Adenoid Cystic Carcinoma

Adenoid cystic carcinomas are slowly growing malignant tumors that arise from the submucosal glands of the trachea and main bronchi (Fig. 79-8). They have also been called *cylindromas, adenoid cystic basal cell carcinomas, adenomyoepitheliomas,* and *pseudoadenomatous basal cell carcinomas.* Adenoid cystic carcinomas behave much like the major and minor salivary gland tumors of the same name, to which they are microscopically identical. An important aspect of their clinical behavior is that they tend to spread in the submucosal plane along the perineural lymphatics, well beyond the obvious endoluminal component of the tumor (Fig. 79-9). In a small biopsy specimen, it can be difficult to distinguish adenoid cystic carcinoma from a conventional adenocarcinoma. Immunohistochemical stains may help the pathologist differentiate the two by showing the presence of the myoepithelial cell immunophenotype in adenoid cystic carcinoma.[181]



Figure 79-8. Tracheogram demonstrating airway obstruction by an adenoid cystic carcinoma of the upper trachea.

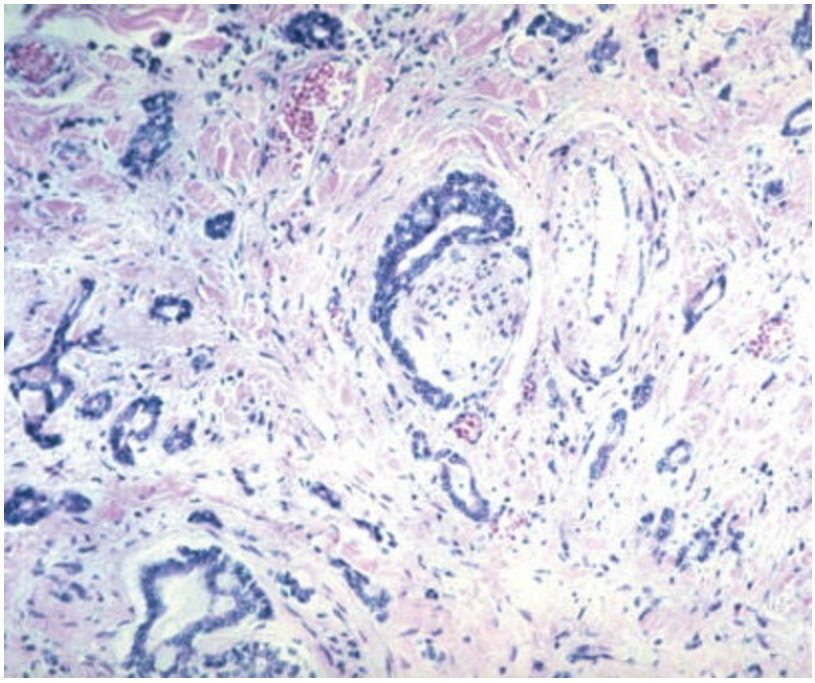

Figure 79-9. Adenoid cystic carcinoma. A photomicrograph shows perineural infiltration by the tumor. From Rubin E, Farber JL. *Pathology*. 3rd ed. Philadelphia, PA: Lippincott Williams & Wilkins; 1999.

Whenever possible, total excision by tracheal resection or tracheobronchial resection is the treatment of choice.[182–185] This is not always possible because of the extensive submucosal spread of tumor. In such cases, the tumor should be resected with grossly negative margins along with adjuvant radiation since these tumors are radiation-sensitive.

When resection is not feasible because of the extent of the lesion or the functional status of the patient, a palliative treatment option is endoscopic laser removal followed by radiation (brachytherapy, external beam irradiation, or both). When complete resection is possible, the prognosis is excellent. However, because of the slow-growing nature of the tumor and its responsiveness to radiation, prolonged survival is possible even with incomplete resection or palliative measures. Patients frequently live 10 years or more with persistent disease, including pulmonary metastases. In such cases, repeated efforts at palliation are indicated.

Mucoepidermoid Carcinoma

Mucoepidermoid carcinomas may be low- or high-grade malignancies and have the same microscopic appearance as mucoepidermoid tumors of salivary gland origin. These tumors also arise in the glandular submucosa, presenting as submucosal lesions. The distinction between a low-grade and high-grade tumor is based on mitotic activity, cellular necrosis, and nuclear pleomorphism.[180]

The principles of treatment of mucoepidermoid tumors are similar to those of carcinoid tumors. The more malignant variety must be treated as a bronchogenic carcinoma. Some authors even think that adenosquamous carcinoma is the same entity as mucoepidermoid carcinoma, but arising in the periphery of the lung.[180] The outlook for these tumors depends on the grade of malignancy and the stage of the disease. High-grade tumors have the same prognosis as bronchogenic carcinoma. Complete resection is the mainstay of treatment. Mucoepidermoid tumors are too rare to permit an evaluation of combined modality therapy for more aggressive, high-grade tumors.[180]

Mucous Gland Adenoma

Mucous gland adenomas are rare submucosal tumors that arise from mucous glands. They are also known as *bronchial cysts* and *papillary cystadenomas.* Because of their totally benign behavior, they can usually be treated by endoscopic excision. Thoracotomy and resection are indicated only if the distal lung has been destroyed by chronic infection or if endoscopic removal is technically contraindicated or incomplete.

OTHER MALIGNANT TUMORS OF THE LUNG

The lung is composed of epithelial, mesodermal, and endodermal cells, and malignant tumors may arise from any of these cells. This group represents less than 1% of all primary lung cancers and is usually subdivided into lymphoid tumors, soft-tissue sarcomas, mixed epithelial/mesenchymal tumors, and ectopic tissue tumors.[186,187] Primary pulmonary lymphomas usually are excised for confirmatory diagnosis. Sarcomas arising from soft tissue or large vessels are treated in a similar fashion to sarcomas occurring elsewhere. Treatment of the other rare tumors, including pulmonary blastomas, primary melanomas of the bronchus, and malignant teratomas, primarily involves complete resection. Radiation and chemotherapy do not have well-defined roles in the treatment of any of these tumors but are occasionally used in particular situations.

RESECTION OF PULMONARY METASTASES

Historical Background

The first report of the resection of a pulmonary metastasis performed as a separate procedure is attributed to Divis in 1926. In North America, the most quoted case of lobectomy for a metastatic carcinoma was that performed by Barney and Churchill in 1939.[188] Their patient underwent nephrectomy for an adenocarcinoma and was known to have a pulmonary mass. After the renal resection, the pulmonary tumor did not respond to radiation treatment and increased in size. Following exploration and resection of the pulmonary lesion, the patient survived disease-free for more than 20 years.

From 1940 to the mid-1960s, pulmonary metastasectomy was performed infrequently and only in highly selected patients. A total of 169 pulmonary metastasis resections were performed on 165 patients at the Mayo Clinic from 1941 to 1959.[189] This large number of operations may reflect the high volume of cases seen at the Mayo Clinic rather than the common use of resection at that time. The first principles of pulmonary resection for metastatic disease included complete removal of the primary disease, no evidence of recurrent or metastatic disease other than the lung lesion, and that the patient was in good general condition. Multiple lesions were not considered a contraindication to resection (Fig. 79-10), but it was thought that bilateral disease indicated a poor prognosis and should not be resected. Surgeons were already convinced that the resection should be as conservative of lung function as possible.

Since then, experience from several institutions suggested that more liberal indications for pulmonary metastasectomy are appropriate.[190] A striking example was the treatment of metastatic osteogenic sarcoma at Memorial Sloan-Kettering Cancer Center. From 1940 to 1965, only five such patients were treated surgically. During the same period, only 24 of 145 patients (17%) survived 5 years after resection of their primary tumors, and 118 of these patients (81%) died of pulmonary metastases. This experience prompted a more aggressive approach to the management of pulmonary metastases. Starting in 1965, a consecutive series of 22 patients with osteogenic sarcoma underwent pulmonary metastasectomy. Patients were considered for operation even if they had bilateral metastases or required multiple thoracotomies to remove all gross tumor. A total of 59 thoracotomies were performed in these 22 patients, with an overall 5-year survival rate of 32%. The dramatic improvement in survival in comparison with the historical experience strongly supported the aggressive use of pulmonary metastasectomy in these patients.[191]

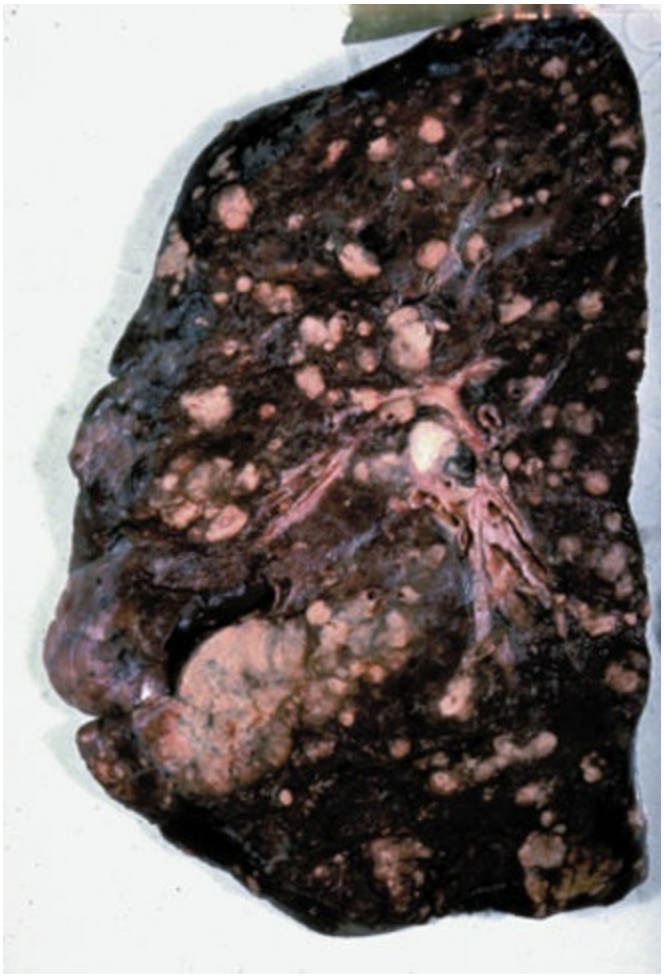

Figure 79-10. Metastatic carcinoma of the lung. A section through the lung shows numerous nodules of metastatic carcinoma, corresponding to "cannon ball" metastases seen radiologically. From Rubin E, Farber JL. *Pathology*. 3rd ed. Philadelphia, PA: Lippincott Williams & Wilkins; 1999.

During the past 30 years, resection has become a widely accepted treatment for certain pulmonary metastases; however, some of the criteria for patient selection remain controversial. In addition, advances in chemotherapy have changed the indications for resection. With some cancers, pulmonary metastasectomy is performed to prolong life expectancy, whereas with others, it serves mainly to restage disease or to provide adjuvant treatment after initial chemotherapy. The role of pulmonary metastasectomy will undoubtedly continue to evolve as improvements in systemic treatment are made.

Clinical Presentation and Diagnosis

Metastases are asymptomatic 85% of the time and are usually detected on a routine chest radiograph. Patients who undergo resection of a primary tumor with a known tendency to metastasize to the lung should have a chest radiograph as part of their routine follow-up care. On chest radiograph, metastases usually present as well-circumscribed, spherical solid masses with well-defined borders (Fig. 79-11). Cavitation is occasionally seen in large lesions with central necrosis, mostly squamous cell cancers. The distribution of lung metastases is predominantly subpleural or in the outer-third of lung fields.[192]

Metastases to the lung usually arise in the pulmonary parenchyma. Endobronchial metastases are uncommon but occur most typically with renal cell, colon, and breast cancers. Even with endobronchial metastases, half of patients are asymptomatic.[193] More often, endobronchial disease represents an extension of contiguous parenchymal disease. The extent of endobronchial tumor can affect the approach to resection. For these reasons, bronchoscopy should be performed before thoracotomy, especially if centrally located metastases are present.



Figure 79-11. Chest radiograph of a patient with bilateral pulmonary metastases from endometrial cancer. The mass in the right upper lobe is well circumscribed and has the radiographic appearance typical of a metastasis.

Hilar or mediastinal nodal involvement sometimes accompanies pulmonary metastases. Several retrospective series have indicated that metastatic nodal involvement is a poor prognostic indicator, independent of disease-free interval or number of nodules.[194,195] However, the determinants of nodal involvement and the prognostic and therapeutic implications remain poorly understood. Lymphangitic spread can occur with or without concomitant pulmonary nodules. This happens most frequently in breast cancer and produces a characteristic radiographic appearance of diffusely increased interstitial markings and a clinical presentation of severe dyspnea that is out of proportion to the

radiographic findings.

When pulmonary metastases are thought to be present on a chest radiograph, CT should be performed to determine their number, location, size, and potential resectability. Plain chest radiographs detect only lesions at least 9 mm in size. New lesions of this size seen on a chest radiograph in a patient already treated for a malignancy have a 90% chance of being malignant.[196] Even though CT can identify lesions as small as 3 mm, it often underestimates the number of pulmonary metastases (Fig. 79-12). When radiologic and surgical findings are correlated, only 75% of malignant nodules are detected by CT. Fifteen percent of CT studies overestimate the number of lung metastases for an accurate radiologic assessment of 61%.[197,198] FDG–PET scan appears to have a role as well in the preoperative evaluation of resectable pulmonary metastases, enhancing the detection of extrathoracic or mediastinal involvement that might preclude complete resection.[199]

8 Patients who present with multiple pulmonary nodules in the setting of a previously treated malignancy rarely pose a diagnostic dilemma. Patients who present with solitary pulmonary nodules are more problematic. Generally, a solitary lesion is more likely to be a metastasis if the primary tumor was a sarcoma or a melanoma. If the primary tumor originated in the head, neck, or breast, it is more likely to be a new primary lung cancer.[200] It has an equal chance of being a metastasis or a new primary if the initial tumor was of gastrointestinal or genitourinary origin. Percutaneous fine-needle aspiration biopsy usually yields a tissue diagnosis, but the necessity of a biopsy in the case of a solitary lesion is questionable. If the patient fits the criteria for resection, a biopsy of the lesion is best performed as an excisional biopsy. Because the findings on needle biopsy do not alter the recommendations for excision of a solitary lesion, this procedure should be undertaken only if the patient is not an operative candidate, if an alternative method of treatment is indicated, or if the patient requests that the diagnosis be established before consenting to operation.

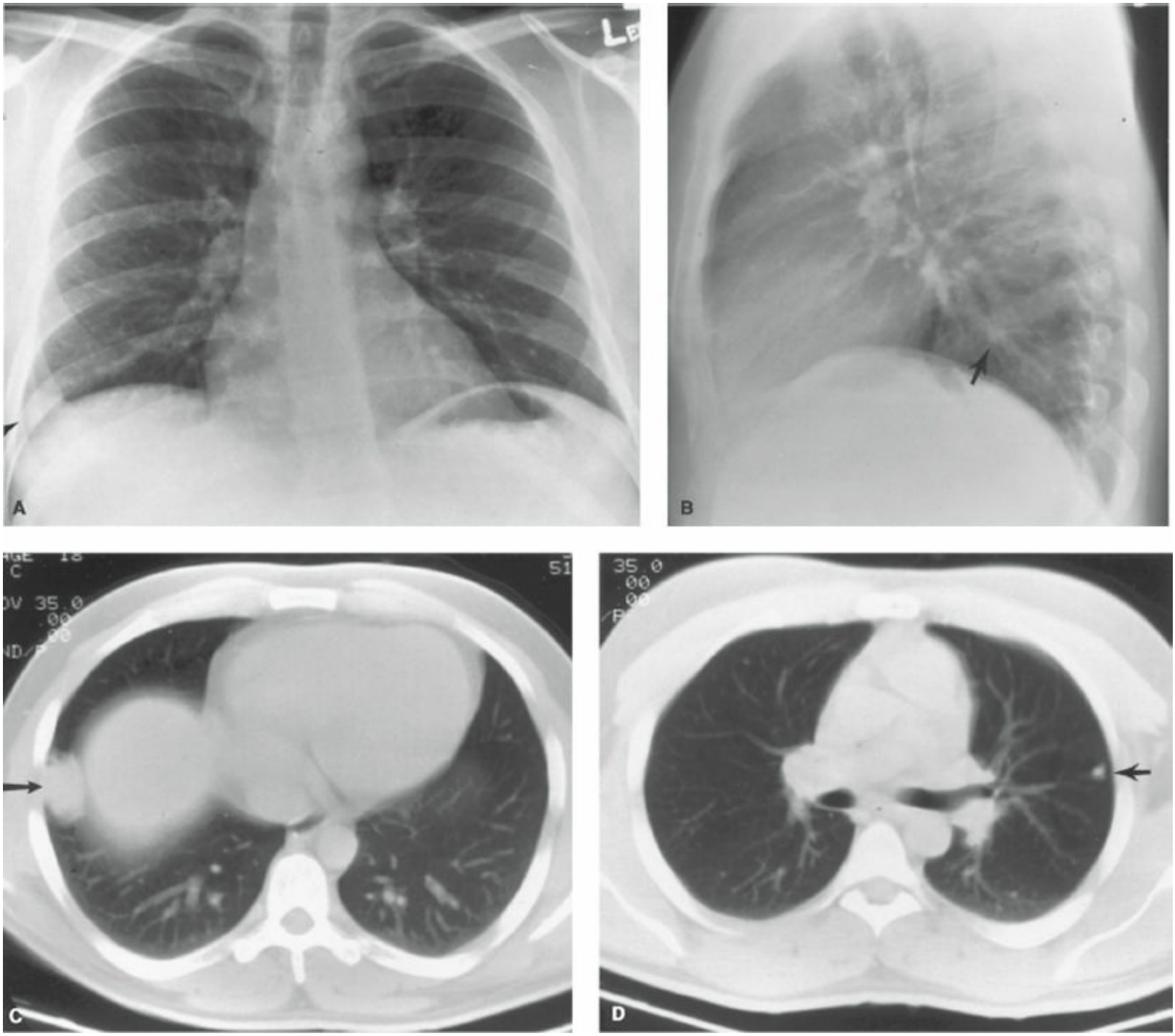

Figure 79-12. Imaging studies from a patient with metastatic embryonal rhabdomyosarcoma. Chest radiographs show a mass in the right lower lobe (*arrow,* **A)** that is best seen on the lateral view (*arrow,* **B)**. Computed tomography (CT) confirmed the presence of this mass (*arrow,* **C)** and showed an additional nodule in the left upper lobe (*arrow,* **D)**. At surgical exploration, however, multiple bilateral pulmonary metastases were found that measured less than 5 mm and therefore were not seen on CT.

Criteria for Resection

The disease-free interval, number of metastatic nodules and tumor doubling time all have been used as criteria for the resection of pulmonary metastases. Each of these remains controversial with respect to its effect on long-term outcome.[201] The disease-free interval is defined as the time from resection of the primary tumor to the diagnosis of metastases. The length of the disease-free interval is thought to be of prognostic significance and varies greatly among published reports from 7 months to 5 years.[202]

The number of metastatic nodules resected has also been considered predictive of survival. In sarcomas, some have reported that the presence of four nodules is a significant breakpoint in survival; however, the significance of the number of nodules varies among reported series. Most consider the completeness of resection the best predictor of survival.[203] Obviously, when a shower of numerous, tiny (1 to 2 mm) lesions is encountered, complete resection is not possible.

Tumor doubling time is a measure of the aggressiveness of tumor growth. The prognostic importance of tumor doubling time, however, is questioned because various doubling times, from 20 to 136 days, have been found to be significant in different studies.[202] Many do not consider this a criterion for resection. The disease-free interval, number of metastatic nodules, and tumor doubling time in fact reflect the intrinsic tumor biology.

In 1991, the International Registry of Lung Metastases was established. Five thousand two hundred six cases of pulmonary metastases were analyzed retrospectively with regard to prognostic variables.[197] Multivariate analysis showed a better prognosis for patients with germ cell tumors, a disease-free interval of 36 months or more, a single metastasis, and complete resection. A simple system of classification into prognostic groups was designed (Table 79-11).

Several guidelines must be met before a patient is considered for resection of pulmonary metastases: (a) control of the primary tumor, (b) absence of extrathoracic metastases, (c) a general medical condition that permits thoracotomy or thoracoscopy, (d) pulmonary function that allows complete resection of all metastases, and (e) lack of a more effective systemic treatment. Resection should be undertaken only if complete resection is considered technically feasible.[204]

RESULTS

Table 79-11 Survival by Prognostic Group: The International Registry of Lung Metastases

Groups	Median Survival (mo)	
I	Resectable, no risk factors (DFI ≥36 mo and single metastasis)	61
II	Resectable, 1 risk factor (DFI <36 mo and multiple metastases)	34
III	Resectable, 2 risk factors (DFI <36 mo and multiple metastases)	24
IV	Unresectable	14

DFI, disease-free interval.
From Pastorino U, Buyse M, Friendel G, et al. Long-term results of lung metastasectomy: prognostic analyses based on 5,206 cases. *J. Thorac Cardiovasc Surg* 1997;113:37–49.

If the metastatic lesion is found at the same time as a recurrence at the primary site, the recurrent primary tumor should be treated before the metastatic disease is resected to prevent further tumor seeding. When the primary tumor and the metastasis are diagnosed simultaneously, lung resection may precede operation for the primary disease if it is doubtful whether the pulmonary disease can be completely resected, and immediate subsequent resection of the primary tumor is planned.

When a patient meets the criteria for resection of one or more pulmonary metastases, the natural history of the tumor and whether effective systemic therapy is available must be considered. Experience in breast cancer, testicular cancer, and osteogenic sarcoma illustrate this point.[205] In contrast to metastatic sarcoma, which is usually confined to the lungs, metastatic breast cancer to the lungs signals the development of widely disseminated disease. Although effective systemic therapy is available, patients with a solitary metastatic lesion, long disease-free interval following treatment for the primary breast cancer and good performance status appear to have longer median and 5-year survival following pulmonary resection.[206,207]

The advent of effective chemotherapy has altered the management of pulmonary metastases of germ cell cancer and rendered an incurable disease curable. Platinum-based chemotherapy is now the primary form of treatment.[208] Resection is reserved for patients who have a complete serologic response (normal levels of ß-human chorionic gonadotropin and α-fetoprotein) with residual pulmonary lesions, evidence of persistent intrathoracic disease with elevated markers despite a full course of chemotherapy, or lesions that do not respond or that progress with chemotherapy.[209] Approximately one-third of the resected pulmonary lesions contain viable tumor, one-third contain fibrosis or necrosis, and one-third are teratomas. A teratoma is removed to prevent it from degenerating to a more malignant form of germ cell tumor and to avoid the potential complications of local tumor growth. Residual tumors are found mostly in patients with positive serology, and the prognosis is usually not as good as when no residual disease is present.[210] In addition, the presence of residual pulmonary disease, as opposed to mediastinal disease, appears to portend a worse survival. Patients who are fit for operation can derive significant long-term survival even though thoracic metastasectomy has a strictly adjuvant role in the treatment of malignant germ cell tumors.[211]

The development of more effective chemotherapy regimens for sarcomas, especially

osteogenic sarcomas, has also altered the management of pulmonary metastases in this disease. Resection is part of a multimodality treatment approach, but the manner in which chemotherapy and resection should be combined is less clear than in germ cell cancer. The timing of an operation in relation to chemotherapy depends on the number, size, and location of pulmonary metastases at diagnosis and on whether the patient has received any previous chemotherapy. Often, resection is performed between cycles of chemotherapy, with the aim of controlling both gross and micrometastatic disease. This approach allows the sensitivity of the patient's tumor to chemotherapy to be assessed, and the advisability of continuing the regimen postoperatively can be determined. The thoracic surgeon should collaborate with the medical and radiation oncologists in planning a multidisciplinary treatment program for patients with pulmonary metastases from sarcoma.

Preoperative Evaluation

The preoperative evaluation of the patient undergoing resection of pulmonary metastases is similar to that of the patient undergoing removal of a primary lung cancer. Tests including pulmonary function, arterial blood gases, and, if necessary, ventilation–perfusion lung scanning are performed to be sure that the patient has sufficient reserve to tolerate complete resection of the metastases. The pulmonary function of patients who received chemotherapy may be substantially reduced. This is particularly true of patients treated with bleomycin and mitomycin, which can markedly diminish the diffusion capacity and, occasionally and unpredictably, cause an acute respiratory distress type of syndrome postoperatively. Maintaining patients on 35% or less inspired oxygen intraoperatively is thought to help prevent this complication. Like patients with primary lung cancers, these patients should stop smoking. Patients who smoke actively up to the time of operation are at risk for postoperative atelectasis or pneumonia.

It is also important to assess the patient's general medical condition and cardiovascular status. Older patients may have underlying coronary artery disease that requires preoperative treatment and additional perioperative monitoring. The cardiac function of patients who previously received chemotherapy, especially doxorubicin, may be impaired. A preoperative radionuclide scan or echocardiogram should be performed to determine the left ventricular ejection fraction and assess whether intraoperative hemodynamic monitoring is necessary. Other drugs, such as cisplatin, can impair renal or neurologic function and may influence perioperative management.

If a patient has recently undergone chemotherapy, the timing of surgery should be planned after consultation with the medical oncologist, so that the operation is not performed when the patient is neutropenic or thrombocytopenic. Resumption of chemotherapy postoperatively should also be a joint decision between the surgeon and medical oncologist so that it does not compromise wound healing.

Surgical Technique

Two principles guide the approach to resecting pulmonary metastatic lesions; complete resection of disease and maximal sparing of functioning lung tissue. Wedge resections should be performed whenever possible. A lobectomy or even a pneumonectomy may be performed when wedge resection will not provide a complete resection. This may be necessary for recurrences (completion pneumonectomy), centrally located tumors, or multiple metastases.[212,213]

Unilateral disease is approached by a standard anterolateral or posterolateral thoracotomy incision. Patients with bilateral pulmonary metastases should have a simultaneous resection of the bilateral lesions if technically feasible. This can be accomplished by a median sternotomy or a clamshell incision (bilateral anterior thoracotomy with or without transverse sternotomy). A clamshell incision provides better exposure to the posterior aspects of the lungs, particularly the left lower lobe, which is difficult to access by a median sternotomy.[214] Bilateral pulmonary nodules may require sequential posterolateral thoracotomies if they are centrally located and good exposure of the hilar vessels is needed.

The role of VATS in the management of patients with isolated suspected pulmonary metastasis is clear when performed for diagnostic purposes. VATS wedge resection can be carried out with a high degree of success and minimal morbidity.[215] Although the use of thoracoscopy in the resection of pulmonary metastases is increasing, its use remains controversial. In a series of 318 patients reported by Petersen et al. undergoing resection of metastatic melanoma, 40 patients underwent thoracoscopic resection.[216] According to the authors, thoracoscopy has been their preferred approach to metastasectomy in the past few years utilizing chest CT for preoperative localization and ring clamp or digital palpation for intraoperative confirmation.

Gossot et al. compared 31 patients undergoing thoracoscopic resection to 29 patients undergoing thoracotomy for resection of metastatic sarcoma.[217] They found no significant difference in 1-, 3-, or 5-year survival. There was also no significant difference in disease-free survival. They recommend a minimally invasive approach for patients with less than two pulmonary nodules that are both amenable to wedge resection with no mediastinal or chest wall invasion. Thoracoscopic resection may also be beneficial in terms of causing fewer adhesions as Briccoli et al. have shown that 35% of patients undergoing metastasectomy for sarcoma will require a repeat resection resulting in acceptable survival rates as long as pulmonary function is maintained.[218]

Table 79-12 Histologic Subtypes from the International Registry of Lung Metastases

Histologic Groups	No. of Patients (%)	Subtypes
Carcinoma	2,260 (47)	Breast
		Lung
		Bowel
		Kidney
		Uterus
		Head and neck
Sarcoma	2,173 (45)	Osteosarcoma
		Other bone sarcomas
		Histiocytoma
		Leiomyosarcoma
		Synovial sarcoma
		Other soft tissue sarcoma
Other types	328 (8)	Wilms tumor
		Teratoma
		Embryonal carcinoma
		Other germ cell tumor
		Melanoma

From Pastorino U, Buyse M, Friedel G, et al. Long-term results of lung metastasectomy: prognostic analyses based on 5,206 cases. *J Thorac Cardiovasc Surg* 1997;113:37–49.

Results

Resection remains the mainstay of treatment for pulmonary metastases from solid tumors that cannot be treated effectively with chemotherapy, including melanoma, colon, renal cell, sarcoma, head and neck, and endometrial cancers. The histologic subtypes of the pulmonary metastases in the International Registry of Lung Metastases are listed in Table 79-12.[197]

Globally, the actuarial survival after complete metastasectomy is 36% at 5 years and 26% at 10 years (median survival of 35 months).[197] The experience at Memorial Sloan-Kettering Cancer Center in the resection of pulmonary metastases from renal cell carcinoma, head and neck tumors, colorectal cancers, testicular germ cell tumors, and soft-tissue sarcoma are summarized (Table 79-13). These results again demonstrate that complete resection of metastatic disease is associated with prolonged survival in carefully selected patients. Furthermore, patients who are persistently free of disease at the primary tumor location but who have recurrent resectable metastatic disease of the lung also benefit from repeated surgery.[219] Mortality rates of pulmonary metastasectomy do not differ from those of thoracic surgery performed for lung cancers, varying between 0.6% and 2%.[190,209,220] The surgical removal of pulmonary metastases is widely accepted, but its role has changed as more effective chemotherapy has become available for some cancers. It is important that the surgeon understand the indications for operation, the potential side effects of initial chemotherapy, and the ways in which resection should be integrated into the overall treatment plan for these patients.

RESULTS

Table 79-13 Results of Pulmonary Resections for Metastases at Memorial Sloan-Kettering Cancer Center

	No. of Patients	Survival (5 yrs, %)
Renal cell carcinoma (1980–1993)[224]		
Solitary metastasis	50	54
Head and neck cancer (1966–1995)[220]		
Squamous cell	41	34
Glandular tumors	36	64
Overall	83	50
Colorectal cancer (1965–1988)[225]		
Overall	144	44
Soft-tissue sarcoma[a] (1982–1997)[226]		
Complete resection	161	46
Incomplete resection	52	23
No resection	473	17
Unknown	33	
Overall	719	25
Testicular germ cell tumors (1967–1995)[209]		
(1967–1974)	22	41
(1975–1984)	69	65
(1984–1995)	66	82
Overall	157	68

[a]Survival at 3 years.

BENIGN TUMORS OF THE LUNG

Benign tumors of the lung are rare neoplasms. Few series are found in the literature, but in a 10-year surgical review (1958 to 1968) from the Mayo Clinic, 130 patients were found to have benign tumors.[221] Like malignant tumors, benign tumors arising from epithelial, mesodermal, or endodermal cell lines can develop in the lung. They may present as endobronchial lesions but are more commonly peripheral nodules.[222] Endobronchial tumors present with signs and symptoms related to airway obstruction or bleeding. Tumors arising in peripheral airways or within pulmonary parenchyma usually present as asymptomatic solitary pulmonary nodules. Types of benign lung tumors are listed in Table 79-4.

Hamartoma

The most frequent benign tumors are hamartomas, which represent 75% of benign lesions. They show a predilection for men.[223] A hamartoma consists of an abnormal arrangement of normal cells. In the lung, the most frequent component is cartilage. A hamartoma usually presents as a solitary pulmonary nodule with an extremely slow growth pattern. Classically, the radiographic appearance is that of a well-circumscribed nodule that may contain popcorn calcification. If previous chest radiographs are available, these tumors are found to have been present for many years. Their growth pattern is variable but generally slow. These lesions can be diagnosed by CT if appropriate calcification is demonstrated. Needle aspiration is frequently diagnostic of a cartilaginous benign lesion.

CLASSIFICATION

Table 79-14 Benign Tumors of the Lung

Epithelial
Polyps
Papilloma
Mucous gland adenoma
Mesenchymal
Vessel
Sclerosing hemangioma
Lymphangioma
Nerve
Granular cell tumor
Neurilemoma
Neurofibroma
Muscle
Leiomyoma
Miscellaneous
Hamartoma
Teratoma
Clear cell (sugar) tumor
Others
Lipoma
Chondroma
Fibroma
Inflammatory Pseudotumors
Plasma cell granuloma
Pulmonary hyalinizing granuloma

Controversy exists regarding whether these lesions should be excised for pathologic

diagnosis. Certainly, they do not require excision unless they are proximally located and cause symptoms related to endobronchial obstruction or when carcinoma cannot be ruled out. If transthoracic needle aspiration biopsy confirms the presence of a hamartoma, many surgeons elect to follow patients with annual chest radiography rather than surgical excision. Occasionally, significant growth during follow-up necessitates excision.

Other Benign Tumors

Other benign tumors may present as endobronchial lesions (commonly fibromas, lipomas, chondromas and granular cell myoblastomas). These tumors may be removed endoscopically but frequently require excision when the diagnosis is in doubt or if endoscopic excision has been incomplete. Peripheral tumors often are removed for diagnosis.

References

1. Siegel R, Ma J, Zou Z, et al. Cancer statistics, 2014. *CA Cancer J Clin* 2014;64(1):9–29.
2. Jemal A, Thun MJ, Ries LAG, et al. Annual report to the nation on the status of cancer, 1975–2005, featuring trends in lung cancer, tobacco use, and tobacco control. *J Natl Cancer Inst* 2008;2008:djn389.
3. Mountain C. Revisions in the international system for staging lung cancer. *Chest* 1997;111(6):1710–1717.
4. Arriagada R, Bergman B, Dunant A, et al. Cisplatin-based adjuvant chemotherapy in patients with completely resected non-small-cell lung cancer. *N Engl J Med* 2004;350(4):351–360.
5. Winton T, Livingston R, Johnson D, et al. Vinorelbine plus cisplatin vs. observation in resected non-small-cell lung cancer. *N Engl J Med* 2005;352(25):2589–2597.
6. Douillard JY, Rosell R, De Lena M, et al. Adjuvant vinorelbine plus cisplatin versus observation in patients with completely resected stage IB-IIIA non-small-cell lung cancer (Adjuvant Navelbine International Trialist Association [ANITA]): a randomised controlled trial. *Lancet Oncol* 2006; 7(9):719–727.
7. The International Early Lung Cancer Action Program Investigators. Survival of patients with stage I lung cancer detected on CT screening. *N Engl J Med* 2006;355(17):1763–1771.
8. Aberle DR, Adams AM, Berg CD, et al. Reduced lung-cancer mortality with low-dose computed tomographic screening. *N Engl J Med* 2011; 365(5):395–409.
9. Patz EF Jr, Pinsky P, Gatsonis C, et al. Overdiagnosis in low-dose computed tomography screening for lung cancer. *JAMA Intern Med* 2014;174(2):269–274.
10. Graham EA, Singer JJ. Successful removal of an entire lung for carcinoma of the bronchus. *JAMA* 1933;101:1371–1374.
11. Warren WH. Historical facets of thoracic surgery emphasizing lung cancer. In: Gruhn JG, Rosen ST, eds. *Lung Cancer: The Evolution of Concepts.* Vol 2. New York, NY: Field and Wood Medical Publishers, Inc.; 1989:73–106.
12. Jemal A, Clegg LX, Ward E, et al. Annual report to the nation on the status of cancer, 1975–2001, with a special feature regarding survival. *Cancer* 2004;101(1):3–27.
13. Edwards BK, Noone AM, Mariotto AB, et al. Annual Report to the Nation on the status of cancer, 1975–2010, featuring prevalence of comorbidity and impact on survival among persons with lung, colorectal, breast, or prostate cancer. *Cancer* 2014;120(9):1290–1314.
14. DeLancey JOL, Thun MJ, Jemal A, et al. Recent trends in black-white disparities in cancer mortality. *Cancer Epidemiol Biomarkers Prev* 2008;17(11):2908–2912.
15. Jacobs DR, Jr, Adachi H, Mulder I, et al. Cigarette smoking and mortality risk: twenty-five-year follow-up of the Seven Countries Study. *Arch Intern Med* 1999;159(7):733–740.

16. Vineis P, Alavanja M, Buffler P, et al. Tobacco and cancer: recent epidemiological evidence. *J Natl Cancer Inst* 2004;96(2):99–106.
17. Vineis P, Airoldi L, Veglia P, et al. Environmental tobacco smoke and risk of respiratory cancer and chronic obstructive pulmonary disease in former smokers and never smokers in the EPIC prospective study. *BMJ* 2005;330(7486):277.
18. Raaschou-Nielsen O, Andersen ZJ, Beelen R, et al. Air pollution and lung cancer incidence in 17 European cohorts: prospective analyses from the European Study of Cohorts for Air Pollution Effects (ESCAPE). *Lancet Oncol* 2013;14(9):813–822.
19. Travis WD, Brambilla E, Müller-Hermelink HK, et al. eds. *World Health Organization Classification of Tumors, Pathology and Genetics of Tumours of the Lung, Pleura, Thymus and Heart.* Lyon, France: IARC Press; 2004.
20. Brambilla E, Travis WD, Colby TV, et al. The new World Health Organization classification of lung tumours. *Eur Respir J* 2001;18(6):1059–1068.
20a. Travis WD, Brambilla E, Noguchi M, et al. International Association for the Study of Lung Cancer/American Thoracic Society/European Respiratory Society: international multidisciplinary classification of lung adenocarcinoma: executive summary. *Proc Am Thorac Soc* 2011;8(5):381–385.
21. Sanchez-Cespedes M. Dissecting the genetic alterations involved in lung carcinogenesis. *Lung Cancer* 2003;40(2):111–121.
22. Ahrendt SA, Hu Y, Buta M, et al. p53 mutations and survival in stage I non-small-cell lung cancer: results of a prospective study. *J Natl Cancer Inst* 2003;95(13):961–970.
23. Ahrendt SA, Chow JT, Yang SC, et al. Alcohol consumption and cigarette smoking increase the frequency of p53 mutations in non-small cell lung cancer. *Cancer Res* 2000;60(12):3155–3159.
24. Tsao M-S, Aviel-Ronen S, Ding K, et al. Prognostic and predictive importance of p53 and RAS for adjuvant chemotherapy in non–small-cell lung cancer. *J Clin Oncol* 2007;25(33):5240–5247.
25. Ma X, Rousseau V, Sun H, et al. Significance of TP53 mutations as predictive markers of adjuvant cisplatin-based chemotherapy in completely resected non-small-cell lung cancer. *Mol Oncol* 2014;8(3):555–564.
26. D'Amico TA, Aloia TA, Moore MB, et al. Molecular biologic substaging of stage I lung cancer according to gender and histology. *Ann Thorac Surg* 2000;69(3):882–886.
27. D'Amico TA, Aloia TA, Moore MB, et al. Predicting the sites of metastases from lung cancer using molecular biologic markers. *Ann Thorac Surg* 2001;72(4):1144–1148.
28. Belinsky SA, Nikula KJ, Palmisano WA, et al. Aberrant methylation of p16INK4 a is an early event in lung cancer and a potential biomarker for early diagnosis. *PNAS* 1998;95(20):11891–11896.
29. Esteller M, Corn PG, Baylin SB, et al. A gene hypermethylation profile of human cancer. *Cancer Res* 2001;61(8):3225–3229.
30. The Cancer Genome Atlas Research N. Comprehensive molecular profiling of lung

adenocarcinoma. *Nature* 2014;511(7511):543–550.
31. Kandoth C, McLellan MD, Vandin F, et al. Mutational landscape and significance across 12 major cancer types. *Nature* 2013;502(7471):333–339.
32. Lee CK, Brown C, Gralla RJ, et al. Impact of EGFR inhibitor in non–small cell lung cancer on progression-free and overall survival: a meta-analysis. *J Nat Can Inst* 2013;105(9):595–605.
33. Goldstraw P, Crowley J, Chansky K, et al. The IASLC Lung Cancer Staging Project: proposals for the revision of the TNM stage groupings in the forthcoming (seventh) edition of the TNM classification of malignant tumours. *J Thorac Oncol* 2007;2(8):706–714.
34. Groome PA, Bolejack V, Crowley JJ, et al. The IASLC Lung Cancer Staging Project: validation of the proposals for revision of the T, N, and M descriptors and consequent stage groupings in the forthcoming (seventh) edition of the TNM classification of malignant tumours. *J Thorac Oncol* 2007;2(8):694–705.
35. Rami-Porta R, Ball D, Crowley J, et al. The IASLC Lung Cancer Staging Project: proposals for the revision of the T descriptors in the forthcoming (seventh) edition of the TNM classification for lung cancer. *J Thorac Oncol* 2007;2(7):593–602.
36. Postmus PE, Brambilla E, Chansky K, et al. The IASLC Lung Cancer Staging Project: proposals for revision of the M descriptors in the forthcoming (seventh) edition of the TNM classification of lung cancer. *J Thorac Oncol* 2007;2(8):686–693.
37. Rusch VW, Crowley J, Giroux DJ, et al. The IASLC Lung Cancer Staging Project: proposals for the revision of the N descriptors in the forthcoming seventh edition of the TNM classification for lung cancer. *J Thorac Oncol*; 2(7):603–612.
38. MacMahon H, Austin JH, Gamsu G, et al. Guidelines for management of small pulmonary nodules detected on CT scans: a statement from the Fleischner Society. *Radiology* 2005;237(2):395–400.
39. Gould MK, Fletcher J, Iannettoni MD, et al. Evaluation of patients with pulmonary nodules: when is it lung cancer? ACCP evidence-based Clinical Practice Guidelines (2nd edition). *Chest* 2007;132(3_suppl):108S–130S.
40. Ost D, Fein AM, Feinsilver SH. The solitary pulmonary nodule. *N Engl J Med* 2003;348(25):2535–2542.
41. Black WC, Gareen IF, Soneji SS, et al. Cost-Effectiveness of CT Screening in the National Lung Screening Trial. *N Engl J Med* 2014;371(19):1793–1802.
42. Rivera MP, Mehta AC. Initial diagnosis of lung cancer: ACCP evidence-based clinical practice guidelines (2 nd edition). *Chest* 2007;132(3_suppl):131S–148S.
43. Albain KS, Swann RS, Rusch VW, et al. Radiotherapy plus chemotherapy with or without surgical resection for stage III non-small-cell lung cancer: a phase III randomised controlled trial. *Lancet* 2009;374(9687):379–386.
44. Mountain C, Dresler C. Regional lymph node classification for lung cancer staging. *Chest* 1997;111(6):1718–1723.

45. Silvestri GA, Gould MK, Margolis ML, et al. Noninvasive staging of non-small cell lung cancer: ACCP evidenced-based clinical practice guidelines (2 nd edition). *Chest* 2007;132(3_suppl):178S-201S.
46. Gonzalez-Stawinski GV, Lemaire A, Merchant F, et al. A comparative analysis of positron emission tomography and mediastinoscopy in staging non-small cell lung cancer. *J Thorac Cardiovasc Surg* 2003;126(6):1900–1904.
47. Kernstine KH, McLaughlin KA, Menda Y, et al. Can FDG-PET reduce the need for mediastinoscopy in potentially resectable nonsmall cell lung cancer? *Ann Thorac Surg* 2002;73(2):394–402.
48. Vesselle H, Pugsley JM, Vallieres E, et al. The impact of fluorodeoxyglucose F 18 positron-emission tomography on the surgical staging of non-small cell lung cancer. *J Thorac Cardiovasc Surg* 2002;124(3):511–519.
49. Reed CE, Harpole DH, Posther KE, et al. Results of the American College of Surgeons Oncology Group Z0050 trial: the utility of positron emission tomography in staging potentially operable non-small cell lung cancer. *J Thorac Cardiovasc Surg* 2003;126(6):1943–1951.
50. Kozower BD, Meyers BF, Reed CE, et al. Does positron emission tomography prevent nontherapeutic pulmonary resections for clinical stage IA lung cancer? *Ann Thorac Surg* 2008;85(4):1166–1170.
51. Cerfolio RJ, Ojha B, Bryant AS, et al. The accuracy of integrated PET-CT compared with dedicated pet alone for the staging of patients with nonsmall cell lung cancer. *Ann Thorac Surg* 2004;78(3):1017–1023.
52. Krasna MJ, Reed CE, Nugent WC, et al. Lung cancer staging and treatment in multidisciplinary trials: cancer and leukemia group B cooperative group approach. *Ann Thorac Surg* 1999;68(1):201–207.
53. Yasufuku K, Pierre A, Darling G, et al. A prospective controlled trial of endobronchial ultrasound-guided transbronchial needle aspiration compared with mediastinoscopy for mediastinal lymph node staging of lung cancer. *J Thorac Cardiovasc Surg* 2011;142(6):1393–1400.e1391.
54. Detterbeck FC, Jantz MA, Wallace M, et al. Invasive mediastinal staging of lung cancer: ACCP evidence-based clinical practice guidelines (2 nd edition). *Chest* 2007;132(3_suppl):202S–220S.
55. Hammoud ZT, Anderson RC, Meyers BF, et al. The current role of mediastinoscopy in the evaluation of thoracic disease. *J Thorac Cardiovasc Surg* 1999;118(5):894–899.
56. Postmus PE, Rocmans P, Asamura H, et al. Consensus report IASLC workshop Bruges, September 2002: pretreatment minimal staging for non-small cell lung cancer. *Lung Cancer* 2003;42(2, Supplement 1):3–6.
57. Burfeind WR Jr, Tong BC, O'Branski E, et al. Quality of life outcomes are equivalent after lobectomy in the elderly. *J Thorac Cardiovasc Surg* 2008;136(3):597–604.
58. Brunelli A, Cassivi SD, Fibla J, et al. External validation of the recalibrated thoracic

revised cardiac risk index for predicting the risk of major cardiac complications after lung resection. *Ann Thorac Surg* 2011;92(2):445–448.

59. Miller JI, Grossman GD, Hatcher CR. Pulmonary function test criteria for operability and pulmonary resection. *Surg Gynecol Obstet* 1981;153(6):893–895.
60. Datta D, Lahiri B. Preoperative evaluation of patients undergoing lung resection surgery. *Chest* 2003;123(6):2096–2103.
61. Pate P, Tenholder MF, Griffin JP, et al. Preoperative assessment of the high-risk patient for lung resection. *Ann Thorac Surg* 1996;61(5):1494–1500.
62. Cerfolio RJ, Allen MS, Trastek VF, et al. Lung resection in patients with compromised pulmonary function. *Ann Thorac Surg* 1996;62(2):348–351.
63. Burke JR, Duarte IG, Thourani VH, et al. Preoperative risk assessment for marginal patients requiring pulmonary resection. *Ann Thorac Surg* 2003;76(5):1767–1773.
64. Loewen GM, Watson D, Kohman L, et al. Preoperative exercise Vo2 measurement for lung resection candidates: results of Cancer and Leukemia Group B Protocol 9238. *J Thorac Oncol* 2007;2(7):619–625.
65. Beckles MA, Spiro SG, Colice GL, et al. The physiologic evaluation of patients with lung cancer being considered for resectional surgery. *Chest* 2003;123(90010):105S–114S.
66. Deslauriers J, Gregoire J, Jacques LF, et al. Sleeve lobectomy versus pneumonectomy for lung cancer: a comparative analysis of survival and sites or recurrences. *Ann Thorac Surg* 2004;77(4):1152–1156.
67. Gaissert H, Mathisen D, Moncure A, et al. Survival and function after sleeve lobectomy for lung cancer. *J Thorac Cardiovasc Surg* 1996;111(5):948–953.
68. Okada M, Yamagishi H, Satake S, et al. Survival related to lymph node involvement in lung cancer after sleeve lobectomy compared with pneumonectomy. *J Thorac Cardiovasc Surg* 2000;119(4):814–819.
69. Suen H-C, Meyers BF, Guthrie T, et al. Favorable results after sleeve lobectomy or bronchoplasty for bronchial malignancies. *Ann Thorac Surg* 1999;67(6):1557–1562.
70. Yoshino I, Yokoyama H, Yano T, et al. Comparison of the surgical results of lobectomy with bronchoplasty and pneumonectomy for lung cancer. *J Surg Oncol* 1997;64(1):32–35.
71. Ginsberg RJ, Rubinstein LV. Randomized trial of lobectomy versus limited resection for T1 N0 non-small cell lung cancer. *Ann Thorac Surg* 1995; 60(3):615–622.
72. Landreneau R, Sugarbaker D, Mack M, et al. Wedge resection versus lobectomy for stage I (T1 N0 M0) non-small-cell lung cancer. *J Thorac Cardiovasc Surg* 1997;113(4):691–700.
73. Yano T, Yokoyama H, Yoshino I, et al. Results of a limited resection for compromised or poor-risk patients with clinical stage I non-small cell carcinoma of the lung. *J Am Coll Surg* 1995;181(1):33–37.
74. Altorki NK, Yip R, Hanaoka T, et al. Sublobar resection is equivalent to lobectomy

for clinical stage 1 A lung cancer in solid nodules. *J Thorac Cardiovasc Surg* 2014;147(2):754–764.

75. Allen MS, Darling GE, Pechet TT, et al. Morbidity and mortality of major pulmonary resections in patients with early-stage lung cancer: initial results of the randomized, prospective ACOSOG Z0030 trial. *Ann Thorac Surg* 2006;81(3):1013–1020.
76. Darling GE, Allen MS, Decker PA, et al. Randomized trial of mediastinal lymph node sampling versus complete lymphadenectomy during pulmonary resection in the patient with N0 or N1 (less than hilar) non–small cell carcinoma: results of the American College of Surgery Oncology Group Z0030 trial. *J Thorac Cardiovasc Surg* 2011;141(3):662–670.
77. Darling GE, Allen MS, Decker PA, et al. Number of lymph nodes harvested from a mediastinal lymphadenectomy. *Chest* 2011;139(5):1124–1129.
78. Boffa DJ, Kosinski AS, Paul S, et al. Lymph node evaluation by open or video-assisted approaches in 11,500 anatomic lung cancer resections. *Ann Thorac Surg* 2012;94(2):347–353.
79. Robinson BM, Kennedy C, McLean J, et al. Node-negative non-small cell lung cancer: pathological staging and survival in 1765 consecutive cases. *J Thorac Oncol* 2011;6(10):1691–1696.
80. Hirsch FR, Spreafico A, Novello S, et al. The prognostic and predictive role of histology in advanced non-small cell lung cancer: a literature review. *J Thorac Oncol* 2008;3(12):1468–1481.
81. Martini N, Bains MS, Burt ME, et al. Incidence of local recurrence and second primary tumors in resected stage I lung cancer. *J Thorac Cardiovasc Surg* 1995;109(1):120–129.
82. Thomas P, Rubinstein L. Cancer recurrence after resection: T1 N0 non-small cell lung cancer. Lung Cancer Study Group. *Ann Thorac Surg* 1990;49(2):242–246.
83. Johnson BE. Second lung cancers in patients after treatment for an initial lung cancer. *J Natl Cancer Inst* 1998;90(18):1335–1345.
84. Rice D, Kim H-W, Sabichi A, et al. The risk of second primary tumors after resection of stage I nonsmall cell lung cancer. *Ann Thorac Surg* 2003;76(4):1001–1008.
85. Colt HG, Murgu SD, Korst RJ, et al. Follow-up and surveillance of the patient with lung cancer after curative-intent therapy: diagnosis and management of lung cancer, 3rd ed: American College of Chest Physicians evidence-based clinical practice guidelines. *Chest* 2013;143(5 Suppl):e437S–454S.
86. Kent MS, Korn P, Port JL, et al. Cost effectiveness of chest computed tomography after lung cancer resection: a decision analysis model. *Ann Thorac Surg* 2005;80(4):1215–1223.
87. Gail MH. A placebo-controlled randomized double-blind study of adjuvant intrapleural BCG in patients with resected T1N0, T1N1, or T2N0 squamous cell carcinoma, adenocarcinoma, or large cell carcinoma of the lung. LCSG Protocol 771.

Chest 1994;106(6 Suppl):287S–292S.

88. Ludwig Lung Cancer Study Group. Adverse effect of intrapleural Corynebacterium parvum as adjuvant therapy in resected stage I and II non-small cell carcinoma of the lung. *J Thorac Cardiovasc Surg* 1985;89(6):842–847.
89. Ratto GB, Zino P, Mirabelli S, et al. A randomized trial of adoptive immunotherapy with tumor-infiltrating lymphocytes and interleukin-2 versus standard therapy in the postoperative treatment of resected nonsmall cell lung carcinoma. *Cancer* 1996;78(2):244–251.
90. Green N, Kurohara SS, George FW 3rd, et al. Postresection irradiation for primary lung cancer: the impact of surgical adjuvant thoracic radiation therapy for patients with nonsmall cell lung carcinoma with ipsilateral mediastinal lymph node involvement. *Radiology* 1975;116(02):405–407.
91. Kirsh M, Rotman H, Argenta L, et al. Carcinoma of the lung: results of treatment over ten years. *Ann Thorac Surg* 1976;21(5):371–377.
92. Sawyer TE, Bonner JA, Gould PM, et al. The impact of surgical adjuvant thoracic radiation therapy for patients with nonsmall cell lung carcinoma with ipsilateral mediastinal lymph node involvement. *Cancer* 1997;80(8):1399–1408.
93. Mayer R, Smolle-Juettner FM, Szolar D, et al. Postoperative radiotherapy in radically resected non-small cell lung cancer. *Chest* 1997;112(4):954–959.
94. Stephens RJ, Girling DJ, Bleehen NM, et al. The role of post-operative radiotherapy in non-small-cell lung cancer: a multicentre randomised trial in patients with pathologically staged T1–2, N1–2, M0 disease. Medical Research Council Lung Cancer Working Party. *Br J Cancer* 1996;74(4):632–639.
95. Lafitte JJ, Ribet ME, Prevost BM, et al. Postresection irradiation for T2 N0 M0 non-small cell carcinoma: a prospective, randomized study. *Ann Thorac Surg* 1996;62(3):830–834.
96. The Lung Cancer Study Group. Effects of postoperative mediastinal radiation on completely resected stage II and stage III epidermoid cancer of the lung. *N Engl J Med* 1986;315(22):1377–1381.
97. Van Houtte P, Rocmans P, Smets P, et al. Postoperative radiation therapy in lung caner: a controlled trial after resection of curative design. *Int J Rad Oncol Biol Phys* 1980;6(8):983–986.
98. PORT Meta-analysis Trialist Group. Postoperative radiotherapy in non-small-cell lung cancer: systematic review and meta-analysis of individual patient data from nine randomised controlled trials. *Lancet* 1998;352(9124):257–263.
99. Burdett S, Stewart L, Group PM. Postoperative radiotherapy in non-small-cell lung cancer: update of an individual patient data meta-analysis. *Lung Cancer* 2005;47(1):81–83.
100. Hughes FA, Higgins G. Veterans Administration Surgical Adjuvant Lung Cancer Chemotherapy Study: present status. *J Thorac Cardiovasc Surg* 1962;44:295–304.

101. Slack NH. Bronchogenic carcinoma: nitrogen mustard as a surgical adjuvant and factors influencing survival. University surgical adjuvant lung project. *Cancer* 1970;25(5):987–1002.
102. Shields TW, Humphrey EW, Eastridge CE, et al. Adjuvant cancer chemotherapy after resection of carcinoma of the lung. *Cancer* 1977;40(5):2057–2062.
103. Shields TW, Higgins GA Jr., Humphrey EW, et al. Prolonged intermittent adjuvant chemotherapy with CCNU and hydroxyurea after resection of carcinoma of the lung. *Cancer* 1982;50(9):1713–1721.
104. Non-Small Cell Lung Cancer Collaborative Group. Chemotherapy in non-small cell lung cancer: a meta-analysis using updated data on individual patients from 52 randomised clinical trials. *BMJ* 1995;311(7010):899–909.
105. Feld R, Rubinstein L, Thomas PA. Adjuvant chemotherapy with cyclophosphamide, doxorubicin, and cisplatin in patients with completely resected stage I non-small-cell lung cancer. The Lung Cancer Study Group. *J Natl Cancer Inst* 1993;85(4):299–306.
106. Pisters KM, Kris MG, Gralla RJ, et al. Randomized trial comparing postoperative chemotherapy with vindesine and cisplatin plus thoracic irradiation with irradiation alone in stage III (N2) non-small cell lung cancer. *J Surg Oncol* 1994;56(4):236–241.
107. Dautzenberg B, Chastang C, Arriagada R, et al. Adjuvant radiotherapy versus combined sequential chemotherapy followed by radiotherapy in the treatment of resected nonsmall cell lung carcinoma. a randomized trial of 267 patients. GETCB (Groupe d'Etude et de Traitement des Cancers Bronchiques). *Cancer* 1995;76(5):779–786.
108. Wada H, Hitomi S, Teramatsu T. Adjuvant chemotherapy after complete resection in non-small-cell lung cancer. West Japan Study Group for Lung Cancer Surgery. *J Clin Oncol* 1996;14(4):1048–1054.
109. Keller SM, Adak S, Wagner H, et al. A randomized trial of postoperative adjuvant therapy in patients with completely resected stage II or IIIA non-small-cell lung cancer. *N Engl J Med* 2000;343(17):1217–1222.
110. Scagliotti GV, Fossati R, Torri V, et al. Randomized study of adjuvant chemotherapy for completely resected stage I, II, or IIIa non-small-cell lung cancer. *J Natl Cancer Inst* 2003;95(19):1453–1461.
111. Wakelee H, Chhatwani L. Adjuvant chemotherapy for resected non-small cell lung cancer. *Semin Thorac Cardiovasc Surg* 2008;20(3):198–203.
112. Nakagawa M, Tanaka F, Tsubota N, et al. A randomized phase III trial of adjuvant chemotherapy with UFT for completely resected pathological stage I non-small-cell lung cancer: the West Japan Study Group for Lung Cancer Surgery (WJSG)–the 4th study. *Ann Oncol* 2005;16(1):75–80.
113. Alam N, Shepherd FA, Winton T, et al. Compliance with post-operative adjuvant chemotherapy in non-small cell lung cancer: an analysis of National Cancer Institute of Canada and intergroup trial JBR.10 and a review of the literature. *Lung Cancer* 2005;47(3):385–394.

114. Strauss GM, Herndon JE II, Maddaus MA, et al. Adjuvant paclitaxel plus carboplatin compared with observation in stage IB non-small-cell lung cancer: CALGB 9633 with the Cancer and Leukemia Group B, Radiation Therapy Oncology Group, and North Central Cancer Treatment Group study groups. *J Clin Oncol* 2008;26(31):5043–5051.
115. Arriagada R, Dunant A, Pignon JP, et al. Long-term results of the International Adjuvant Lung Cancer Trial evaluating adjuvant cisplatin-based chemotherapy in resected lung cancer. *J Clin Oncol* 2010;28(1):35–42.
116. Pignon JP, Tribodet H, Scagliotti GV, et al. Lung adjuvant cisplatin evaluation: a pooled analysis by the LACE Collaborative Group. *J Clin Oncol* 2008;26(21):3552–3559.
117. NSCLC Meta-analyses Collaborative Group. Adjuvant chemotherapy, with or without postoperative radiotherapy, in operable non-small-cell lung cancer: two meta-analyses of individual patient data. *Lancet* 2010;375(9722):1267–1277.
118. Petersen RP, Pham D, Burfeind WR, et al. Thoracoscopic lobectomy facilitates the delivery of chemotherapy after resection for lung cancer. *Ann Thorac Surg* 2007;83(4):1245–1249.
119. Rendina EA, Venuta F, De Giacomo T, et al. Induction chemotherapy for T4 centrally located non-small cell lung cancer. *J Thorac Cardiovasc Surg* 1999;117(2):225–233.
120. Grunenwald DH, Andre F, Le Pechoux C, et al. Benefit of surgery after chemoradiotherapy in stage IIIB (T4 and/or N3) non-small cell lung cancer. *J Thorac Cardiovasc Surg* 2001;122(4):796–802.
121. Collaud S, Waddell TK, Yasufuku K, et al. Long-term outcome after en bloc resection of non-small-cell lung cancer invading the pulmonary sulcus and spine. *J Thorac Oncol* 2013;8(12):1538–1544.
122. Okada M, Tsubota N, Yoshimura M, et al. Prognosis of completely resected pN2 non-small cell lung carcinomas: what is the significant node that affects survival?*J Thorac Cardiovasc Surg* 1999;118(2):270–275.
123. Sagawa M, Sakurada A, Fujimura S, et al. Five-year survivors with resected pN2 nonsmall cell lung carcinoma. *Cancer* 1999;85(4):864–868.
124. Rosell R, Gomez-Codina J, Camps C, et al. A randomized trial comparing preoperative chemotherapy plus surgery with surgery alone in patients with non-small-cell lung cancer. *N Engl J Med* 1994;330(3):153–158.
125. Rosell R, Gomez-Codina J, Camps C, et al. Preresectional chemotherapy in stage IIIA non-small-cell lung cancer: a 7-year assessment of a randomized controlled trial. *Lung Cancer* 1999;26(1):7–14.
126. Roth J, Fossella F, Komaki R, et al. A randomized trial comparing perioperative chemotherapy and surgery with surgery alone in resectable stage IIIA non-small-cell lung cancer. *J Natl Cancer Inst* 1994;86(9):673–680.
127. Roth JA, Atkinson EN, Fossella F, et al. Long-term follow-up of patients enrolled in a randomized trial comparing perioperative chemotherapy and surgery with surgery

alone in resectable stage IIIA non-small-cell lung cancer. *Lung Cancer* 1998;21(1):1–6.

128. Bromley LL, Szur L. Combined radiotherapy and resection for carcinoma of the bronchus; experiences with 66 patients. *Lancet* 1955;269(6897):937–941.
129. Payne DG. Is preoperative or postoperative radiation therapy indicated in non-small cell cancer of the lung? *Lung Cancer* 1994;10(Suppl 1):S205–S212.
130. Chang JY, Kestin LL, Barriger RB, et al. ACR Appropriateness criteria® nonsurgical treatment for locally advanced non-small-cell lung cancer: good performance status/definitive intent. *Oncology* 2014;28(8):706–722.
131. Auperin A, Le Pechoux C, Rolland E, et al. Meta-analysis of concomitant versus sequential radiochemotherapy in locally advanced non-small-cell lung cancer. *J Clin Oncol* 2010;28(13):2181–2190.
132. Rowell NP, O'Rourke N P. Concurrent chemoradiotherapy in non-small cell lung cancer. *Cochrane Database Syst Rev* 2004;(4):CD002140.
133. Martini N, Kris M, Flehinger B, et al. Preoperative chemotherapy for stage IIIa (N2) lung cancer: the Sloan- Kettering experience with 136 patients. *Ann Thorac Surg* 1993;55(6):1365–1373.
134. Sugarbaker DJ, Herndon J, Kohman LJ, et al. Results of cancer and leukemia group B protocol 8935 A multiinstitutional phase II trimodality trial for stage IIIa (N2) non-small-cell lung cancer. *J Thorac Cardiovasc Surg* 1995;109(3):473–485.
135. Faber L, Kittle C, Warren W, et al. Preoperative chemotherapy and irradiation for stage III non-small cell lung cancer. *Ann Thorac Surg* 1989;47(5):669–675.
136. Weiden P, Piantadosi S. Preoperative chemotherapy (cisplatin and fluorouracil) and radiation therapy in stage III non-small-cell lung cancer: a phase II study of the Lung Cancer Study Group. *J Natl Cancer Inst* 1991;83(4):266–273.
137. Strauss G, Herndon J, Sherman D, et al. Neoadjuvant chemotherapy and radiotherapy followed by surgery in stage IIIA non-small-cell carcinoma of the lung: report of a Cancer and Leukemia Group B phase II study. *J Clin Oncol* 1992;10(8):1237–1244.
138. Albain KS, Rusch VW, Crowley JJ, et al. Concurrent cisplatin/etoposide plus chest radiotherapy followed by surgery for stages IIIA (N2) and IIIB non-small-cell lung cancer: mature results of Southwest Oncology Group phase II study 8805. *J Clin Oncol* 1995;13(8):1880–1892.
139. Taylor NA, Liao ZX, Cox JD, et al. Equivalent outcome of patients with clinical Stage IIIA non-small-cell lung cancer treated with concurrent chemoradiation compared with induction chemotherapy followed by surgical resection. *Int J Rad Oncol Biol Phys* 2004;58(1):204–212.
140. Albain KS, Scott CB, Rusch VR, et al. PL-4 Phase III study of concurrent chemotherapy and full course radiotherapy (CT/RT) versus CT/RT induction followed by surgical resection for stage IIIA(pN2) non-small cell lung cancer (NSCLC): first outcome analysis of North American Intergroup trial 0139 (RTOG 93–09). *Lung Cancer* 2003;41(Supplement 2):S4.

141. Thomas M, Rübe C, Hoffknecht P, et al. Effect of preoperative chemoradiation in addition to preoperative chemotherapy: a randomised trial in stage III non-small-cell lung cancer. *Lancet Oncol* 2008;9(7):636–648.
142. Albain K, Rusch V, Crowley J, et al. Long-term survival after concurrent cisplatin/etoposide (PE) plus chest radiotherapy (RT) followed by surgery in bulky, stages IIIA(N2) and IIIB non-small cell lung cancer (NSCLC): 6-year outcomes from Southwest Oncology Group Study 8805. *Proc of the Am Soc Clin Oncol* 1999;18:467A.
143. Burfeind WR Jr., D'Amico TA, Toloza EM, et al. Low morbidity and mortality for bronchoplastic procedures with and without induction therapy. *Ann Thorac Surg* 2005;80(2):418–421.
144. Adelstein DJ, Rice TW, Rybicki LA, et al. Accelerated hyperfractionated radiation, concurrent paclitaxel/cisplatin chemotherapy and surgery for stage III non-small cell lung cancer. *Lung Cancer* 2002;36(2):167—174.
145. Weil MD, Roach I, Mack, Pickett B, et al. 3D conformal radiotherapy in the sagittal plane for centrally located thoracic tumors. *Med Dosim* 1995;20(1):11–14.
146. Hayman JA, Martel MK, Ten Haken RK, et al. Dose escalation in non-small-cell lung cancer using three-dimensional conformal radiation therapy: update of a phase I trial. *J Clin Oncol* 2001;19(1):127–136.
147. Pancoast H. Superior pulmonary sulcus tumor: tumor characterized by pain, Horner's syndrome, destruction of bone and atrophy of hand muscles. *JAMA* 1932;99:1391–1396.
148. Vallieres E, Kraut M, Thomas C. Pancoast (superior sulcus) neoplasms. *Curr Prob Canc* 2003;27(2):81–104.
149. Shaw R, Paulson D, Kee JJ. Treatment of the superior sulcus tumor by irradiation followed by resection. *Ann Surg* 1961;154:29–40.
150. Rusch V, Parekh K, Leon L, et al. Factors determining outcome after surgical resection of T3 and T4 lung cancers of the superior sulcus. *J Thorac Cardiovasc Surg* 2000;119(6):1147–1153.
151. Detterbeck FC. Pancoast (superior sulcus) tumors. *Ann Thorac Surg* 1997;63(6):1810–1818.
152. Rusch VW, Giroux DJ, Kraut MJ, et al. Induction chemoradiation and surgical resection for superior sulcus non-small-cell lung carcinomas: long-term results of Southwest Oncology Group Trial 9416 (Intergroup Trial 0160). *J Clin Oncol* 2007;25(3):313–318.
153. Travis WD, Linnoila RI, Tsokos MG, et al. Neuroendocrine tumors of the lung with proposed criteria for large-cell neuroendocrine carcinoma. an ultrastructural, immunohistochemical, and flow cytometric study of 35 cases. *Am J Surg Pathol* 1991;15(6):529–553.
154. Vuitch F, Sekido Y, Fong K, et al. Neuroendocrine tumors of the lung. pathology and molecular biology. *Chest Surg Clin N Am* 1997;7(1):21–47.

155. McCaughan B, Martini N, Bains M. Bronchial carcinoids. review of 124 cases. *J Thorac Cardiovasc Surg* 1985;89(1):8–17.
156. Cañizares MA, Matilla JM, Cueto A, et al. Atypical carcinoid tumours of the lung: prognostic factors and patterns of recurrence. *Thorax* 2014;69(7):648–653.
157. García-Yuste M, Matilla JM, Cueto A, et al. Typical and atypical carcinoid tumours: analysis of the experience of the Spanish Multi-centric Study of Neuroendocrine Tumours of the Lung. *Eur J Cardiothorac Surg* 2007;31(2):192–197.
158. Naalsund A, Rostad H, Str⊘m EH, et al. Carcinoid lung tumors – incidence, treatment and outcomes: a population-based study. *Eur J Cardiothorac Surg* 2011;39(4):565–569.
159. Jiang S-X, Kameya T, Shoji M, et al. Large cell neuroendocrine carcinoma of the lung: a histologic and immunohistochemical study of 22 cases. *Am J Surg Pathol* 1998;22(5):526–537.
160. Travis WD, Rush W, Flieder DB, et al. Survival analysis of 200 pulmonary neuroendocrine tumors with clarification of criteria for atypical carcinoid and its separation from typical carcinoid. *Am J Surg Pathol* 1998;22(8):934–944.
161. Zacharias J, Nicholson AG, Ladas GP, et al. Large cell neuroendocrine carcinoma and large cell carcinomas with neuroendocrine morphology of the lung: prognosis after complete resection and systematic nodal dissection. *Ann Thorac Surg* 2003;75(2):348–352.
162. Govindan R, Page N, Morgensztern D, et al. Changing epidemiology of small-cell lung cancer in the United States over the last 30 years: analysis of the surveillance, epidemiologic, and end results database. *J Clin Oncol* 2006;24(28):4539–4544.
163. Micke P, Faldum A, Metz T, et al. Staging small cell lung cancer: Veterans Administration Lung Study Group versus International Association for the Study of Lung Cancer—what limits limited disease?*Lung Cancer* 2002;37(3):271–276.
164. Stahel RA, Ginsberg R, Havemann K, et al. Staging and prognostic factors in small cell lung cancer: a consensus report. *Lung Cancer* 1989; 5(4–6):119–126.
165. Shepherd FA. The role of chemotherapy in the treatment of small cell lung cancer. *Chest Surg Clin N Am* 1997;7(1):113–133.
166. Pignon JP, Arriagada R, Ihde DC, et al. A meta-analysis of thoracic radiotherapy for small-cell lung cancer. *N Engl J Med* 1992;327(23):1618–1624.
167. Warde P, Payne D. Does thoracic irradiation improve survival and local control in limited- stage small-cell carcinoma of the lung? a meta-analysis. *J Clin Oncol* 1992;10(6):890–895.
168. Fried DB, Morris DE, Poole C, et al. Systematic review evaluating the timing of thoracic radiation therapy in combined modality therapy for limited-stage small-cell lung cancer. *J Clin Oncol* 2004;22(23):4837–4845.
169. Albain KS, Crowley JJ, LeBlanc M, et al. Determinants of improved outcome in small-cell lung cancer: an analysis of the 2,580-patient Southwest Oncology Group data base. *J Clin Oncol* 1990;8(9):1563–1574.

170. Inoue M, Miyoshi S, Yasumitsu T, et al. Surgical results for small cell lung cancer based on the new TNM staging system. *Ann Thorac Surg* 2000;70(5):1615–1619.
171. van Meerbeeck JP, Fennell DA, De Ruysscher DK. Small-cell lung cancer. *Lancet* 2011;378(9804):1741–1755.
172. Kreisman H, Wolkove N, Quoix E. Small cell lung cancer presenting as a solitary pulmonary nodule. *Chest* 1992;101(1):225–231.
173. Brock MV, Hooker CM, Syphard JE, et al. Surgical resection of limited disease small cell lung cancer in the new era of platinum chemotherapy: its time has come. *J Thorac Cardiovasc Surg* 2005;129(1):64–72.
174. Shepherd FA, Evans WK, Feld R, et al. Adjuvant chemotherapy following surgical resection for small-cell carcinoma of the lung. *J Clin Oncol* 1988;6(5):832–838.
175. Le Pechoux C, Dunant A, Senan S, et al. Standard-dose versus higher-dose prophylactic cranial irradiation (PCI) in patients with limited-stage small-cell lung cancer in complete remission after chemotherapy and thoracic radiotherapy (PCI 99–01, EORTC 22003–08004, RTOG 0212, and IFCT 99–01): a randomised clinical trial. *Lancet Oncol* 2009;10(5):467–474.
176. Shah S, Thompson J, Goldstraw P. Results of operation without adjuvant therapy in the treatment of small cell lung cancer. *Ann Thorac Surg* 1992; 54(3):498–501.
177. Shepherd F, Ginsberg R, Patterson G, et al. Is there ever a role for salvage operations in limited small-cell lung cancer? *J Thorac Cardiovasc Surg* 1991;101(2):196–200.
178. Lad T, Piantadosi S, Thomas P, et al. A prospective randomized trial to determine the benefit of surgical resection of residual disease following response of small cell lung cancer to combination chemotherapy. *Chest* 1994;106(6):320S–323S.
179. Inoue H, Iwasaki M, Ogawa J, et al. Surgical resection of a second primary lung carcinoma in a survivor of small cell carcinoma. *Ann Thorac Surg* 1993;56(5):1160–1161.
180. Heitmiller R, Mathisen D, Ferry J, et al. Mucoepidermoid lung tumors. *Ann Thorac Surg* 1989;47(3):394–399.
181. Moran CA. Primary salivary gland-type tumors of the lung. *Semin Diagn Pathol* 1995;12(2):106–122.
182. Webb BD, Walsh GL, Roberts DB, et al. Primary tracheal malignant neoplasms: the University of Texas MD Anderson Cancer Center experience. *J Am Coll Surg* 2006;202(2):237–246.
183. Gaissert HA, Grillo HC, Shadmehr MB, et al. Long-term survival after resection of primary adenoid cystic and squamous cell carcinoma of the trachea and carina. *Ann Thorac Surg* 2004;78(6):1889–1897.
184. Maziak DE, Todd TR, Keshavjee SH, et al. Adenoid cystic carcinoma of the airway: thirty-two-year experience. *J Thorac Cardiovasc Surg* 1996; 112(6):1522–1532.
185. Chin H, DeMeester T, Chin R, et al. Endobronchial adenoid cystic carcinoma. *Chest* 1991;100(5):1464–1465.

186. Miller DL, Allen MS. Rare pulmonary neoplasms. *Mayo Clin Proc* 1993;68(5):492–498.
187. Berho M, Moran CA, Suster S. Malignant mixed epithelial/mesenchymal neoplasms of the lung. *Semin Diagn Pathol* 1995;12(2):123–139.
188. Barney JD, Churchill ED. Adenocarcinoma of the kidney with metastases to the lung cured by nephrectomy and lobectomy. *J Urol* 1939;42:269–276.
189. Clagett OT, Woolner LB. Surgical treatment of solitary metastatic pulmonary lesion. *Med Clin North Am* 1964;48:939–943.
190. Mountain CF, McMurtrey MJ, Hermes KE. Surgery for pulmonary metastasis: a 20-year experience. *Ann Thorac Surg* 1984;38(4):323–330.
191. Martini N, Huvos AG, Mike V, et al. Multiple pulmonary resections in the treatment of osteogenic sarcoma. *Ann Thorac Surg* 1971;12(3):271–280.
192. Crow J, Slavin G, Kreel L. Pulmonary metastasis: a pathologic and radiologic study. *Cancer* 1981;47(11):2595–2602.
193. Heitmiller RF, Marasco WJ, Hruban RH, et al. Endobronchial metastasis. *J Thorac Cardiovasc Surg* 1993;106(3):537–542.
194. Loehe F, Kobinger S, Hatz RA, et al. Value of systematic mediastinal lymph node dissection during pulmonary metastasectomy. *Ann Thorac Surg* 2001; 72(1):225–229.
195. Ercan S, Nichols FC III, Trastek VF, et al. Prognostic significance of lymph node metastasis found during pulmonary metastasectomy for extrapulmonary carcinoma. *Ann Thorac Surg* 2004;77(5):1786–1791.
196. Johnson H Jr., Fantone J, Flye MW. Histological evaluation of the nodules resected in the treatment of pulmonary metastatic disease. *J Surg Oncol* 1982;21(1):1–4.
197. Pastorino U, Buyse M, Friedel G, et al. Long-term results of lung metastasectomy: prognostic analyses based on 5206 cases. *J Thorac Cardiovasc Surg* 1997;113(1):37–49.
198. McCormack PM, Ginsberg KB, Bains MS, et al. Accuracy of lung imaging in metastases with implications for the role of thoracoscopy. *Ann Thorac Surg* 1993;56(4):863–865.
199. Pastorino U, Veronesi G, Landoni C, et al. Fluorodeoxyglucose positron emission tomography improves preoperative staging of resectable lung metastasis. *J Thorac Cardiovasc Surg* 2003;126(6):1906–1910.
200. Deleyiannis FW, Thomas DB. Risk of lung cancer among patients with head and neck cancer. *Otolaryngol Head Neck Surg* 1997;116(6):630–636.
201. Robert JH, Ambrogi V, Mermillod B, et al. Factors influencing long-term survival after lung metastasectomy. *Ann Thorac Surg* 1997;63(3):777–784.
202. Rusch VW. Pulmonary metastasectomy. current indications. *Chest* 1995;107(6):322S–331S.
203. Girard P, Baldeyrou P, Le Chevalier T, et al. Surgery for pulmonary metastases. who are the 10-year survivors? *Cancer* 1994;74(10):2791–2797.

204. McCormack P. Surgical resection of pulmonary metastases. *Semin Surg Oncol* 1990;6(5):297–302.
205. La Quaglia MP. Osteosarcoma. specific tumor management and results. *Chest Surg Clin N Am* 1998;8(1):77–95.
206. Singletary SE, Walsh G, Vauthey JN, et al. A role for curative surgery in the treatment of selected patients with metastatic breast cancer. *Oncologist* 2003;8(3):241–251.
207. Friedel G, Pastorino U, Ginsberg RJ, et al. Results of lung metastasectomy from breast cancer: prognostic criteria on the basis of 467 cases of the international registry of lung metastases. *Eur J Cardiothorac Surg* 2002;22(3):335–344.
208. Feldman DR, Bosl GJ, Sheinfeld J, et al. Medical treatment of advanced testicular cancer. *JAMA* 2008;299(6):672–684.
209. Liu D, Abolhoda A, Burt ME, et al. Pulmonary metastasectomy for testicular germ cell tumors: a 28-year experience. *Ann Thorac Surg* 1998;66(5):1709–1714.
210. Kesler KA, Rieger KM, Hammoud ZT, et al. A 25-year single institution experience with surgery for primary mediastinal nonseminomatous germ cell tumors. *Ann Thorac Surg* 2008;85(2):371–378.
211. Kesler KA, Wilson JL, Cosgrove JA, et al. Surgical salvage therapy for malignant intrathoracic metastases from nonseminomatous germ cell cancer of testicular origin: analysis of a single-institution experience. *J Thorac Cardiovasc Surg* 2005;130(2):408–415.
212. Putnam JB Jr, Suell DM, Natarajan G, et al. Extended resection of pulmonary metastases: is the risk justified? *Ann Thorac Surg* 1993;55(6):1440–1446.
213. Koong HN, Pastorino U, Ginsberg RJ. Is there a role for pneumonectomy in pulmonary metastases? *Ann Thorac Surg* 1999;68(6):2039–2043.
214. Bains MS, Ginsberg RJ, Jones W 2nd, et al. The clamshell incision: an improved approach to bilateral pulmonary and mediastinal tumor. *Ann Thorac Surg* 1994;58(1):30–32.
215. Liu H, Lin P, Hsieh M, et al. Application of thoracoscopy for lung metastases. *Chest* 1995;107(1):266–268.
216. Petersen RP, Hanish SI, Haney JC, et al. Improved survival with pulmonary metastasectomy: an analysis of 1720 patients with pulmonary metastatic melanoma. *J Thorac Cardiovasc Surg* 2007;133(1):104–110.
217. Gossot D, Radu C, Girard P, et al. Resection of pulmonary metastases from sarcoma: can some patients benefit from a less invasive approach? *Ann Thorac Surg* 2009;87(1):238–243.
218. Briccoli A, Rocca M, Salone M, et al. Resection of recurrent pulmonary metastases in patients with osteosarcoma. *Cancer* 2005;104(8):1721–1725.
219. Kandioler D, Kromer E, Tuchler H, et al. Long-term results after repeated surgical removal of pulmonary metastases. *Ann Thorac Surg* 1998;65(4):909–912.

220. Liu D, Labow DM, Dang N, et al. Pulmonary metastasectomy for head and neck cancers. *Ann Surg Oncol* 1999;6(6):572–578.

221. Arrigoni MG, Woolner LB, Bernatz PE, et al. Benign tumors of the lung. a ten-year surgical experience. *J Thorac Cardiovasc Surg* 1970;60(4):589–599.

222. Oldham HN Jr. Benign tumors of the lung and bronchus. *Surg Clin North Am* 1980;60(4):825–834.

223. Hansen CP, Holtveg H, Francis D, et al. Pulmonary hamartoma. *J Thorac Cardiovasc Surg* 1992;104(3):674–678.

224. Kavolius JP, Mastorakos DP, Pavlovich C, et al. Resection of metastatic renal cell carcinoma. *J Clin Oncol* 1998;16(6):2261–2266.

225. McCormack PM, Burt ME, Bains MS, et al. Lung resection for colorectal metastases. 10-year results. *Arch Surg* 1992;127(12):1403–1406.

226. Billingsley KG, Burt ME, Jara E, et al. Pulmonary metastases from soft tissue sarcoma: analysis of patterns of diseases and postmetastasis survival. *Ann Surg* 1999;229(5):602–610.

Chapter 80

Non-Neoplastic Thoracic Disease

Rishindra M. Reddy

Key Points

1 Surgical intervention for chest wall tumors depends on the type of lesion and goals of surgery (resection vs. diagnosis). Reconstruction varies depending on the size of the defect and location on the chest wall.

2 Thoracic outlet syndrome (TOS) may be arterial, venous, or neurogenic. Neurogenic TOS is the most difficult to diagnose and surgery for this should be performed in high-volume centers.

3 The primary treatment for a lung abscess is antibiotic therapy.

4 Hemoptysis can be life-threatening from suffocation due to a low volume of blood in the lungs, not from blood volume loss requiring transfusion.

5 Primary spontaneous pneumothoraces will recur in only 30% of patients after initial treatment. When they recur, the treatment should include a thoracoscopic evaluation and possible pleurodesis.

6 Transudative pleural effusions should be treated medically, while exudative effusions may need more intervention. One-quarter of pleural effusions in a community hospital are due to malignancy.

7 Empyema is a part of a spectrum of disease that may be treated early on with drainage alone, but may require debridement and decortication in more advanced cases.

8 Complications of tracheostomies are usually due to improper placement of the tracheostomy on the trachea (below the 3rd ring, risking a tracheoinnominate fistula) or to the use of high pressures in the cuff of the tracheostomy (causing ischemia and long-term stenosis)

9 Mediastinitis is life-threatening and warrants immediate evaluation, antibiotic therapy, and surgical drainage.

INTRODUCTION

This chapter is meant as resource for the general surgery community and surgery residents with regard to pathology in the chest. We will cover a wide variety of topics including most noncardiac congenital disease processes in the thorax.

CHEST WALL ANATOMY

The chest wall is the musculoskeletal structure that contains and protects the structures of the upper trunk or thorax. There are two openings to the thorax, the superior aperture, or the thoracic inlet, and the inferior aperture which leads to the abdominal cavity. The head and arms connect to the intrathoracic structures via the inlet, whereas the diaphragm separates the thoracic and abdominal cavities at the inferior aperture. The inferior vena cava, esophagus, and aorta all travel to the abdomen through the diaphragm at levels T8, T10, and T12, respectively.

The sternum, commonly known as the breast bone, is comprised of three parts, the manubrium, the body, and the xiphoid. The manubrium attaches to the clavicles and the first costal cartilages. The sternal angle where the manubrium and body connect is called the angle of Louis and is an important landmark. The second ribs attach to the sternum at this angle and they allow one to count the ribs from this point down, as the first ribs are not palpable. The body of the sternum contains articular facets for ribs 2 to 7 and connects to the cartilaginous xiphoid inferiorly. The xiphoid may be bifid and will eventually ossify in older adults (Fig. 80-1).

The ribs are split into two groups; the upper 7 pairs are the true ribs, with articulations to the sternum, while the lower 5 pairs are the false ribs. Ribs 8, 9, and 10 connect to each other and the upper ribs via their costal cartilage. Ribs 11 and 12 are called floating ribs as they have no anterior connection. Rib 1 is unique in its shape as it is flat, short, and extremely curved. Ribs 2 through 10 have a more standard configuration with the head containing articular facets for the vertebrae. After the neck the tubercle contains the facet for the vertebral transverse process. The costal groove along the inferior portion of the shaft houses the intercostal bundle, consisting of the nerve, artery, and vein (Fig. 80-2). Because of this inferior placement, most chest wall procedures such as thoracostomy tube placement or thoracentesis should be aimed at the superior aspect of the rib to avoid injury to this bundle.

There are three intercostal muscles, the external intercostal, the internal intercostal, and the innermost intercostal muscle. The intercostal bundle lays just external to the innermost intercostal layer (Fig. 80-3). On the inner aspect of the chest wall, the internal thoracic (mammary) artery and vein runs between the innermost intercostal muscle and the transversus thoracis muscles which connect the ribs to the lower half of the sternal body. The intercostal arteries have two sources, one posterior and one anterior. Almost all the posterior arteries arise from the descending thoracic aorta, while the anterior arteries branch off the internal thoracic artery. The intercostal nerve is a branch off the ventral ramus after it joins the sympathetic trunk. The intercostal veins follow the arteries and posteriorly drain into the azygos and hemiazygos veins. Lymphatic drainage from the posterior chest wall drains into the thoracic duct on the left and into the right lymphatic duct on the right.

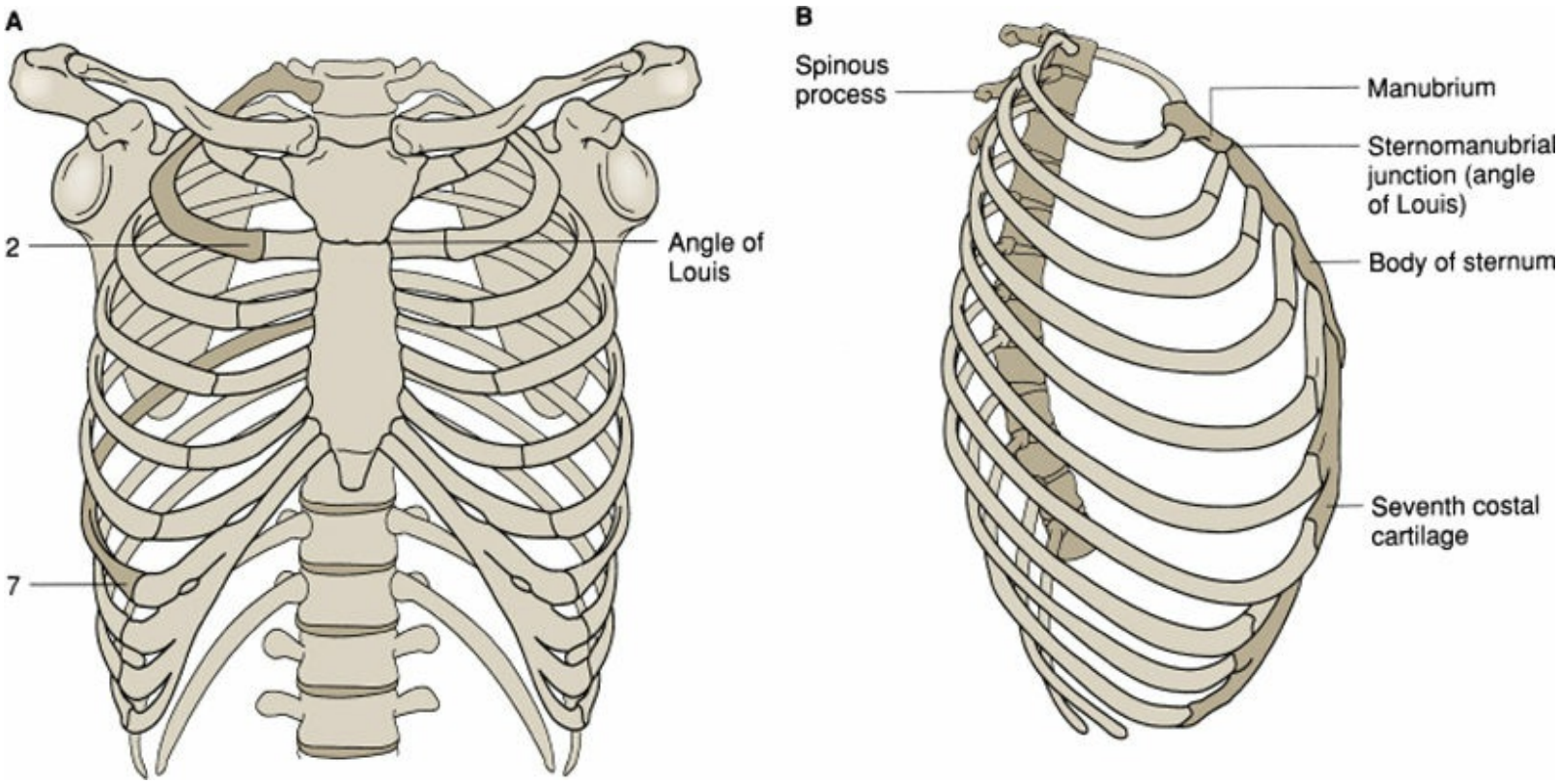

Figure 80-1. Skeletal support of the thorax. Anterior (**A**), and lateral (**B**), views. Note the anterior cartilaginous component of the upper 10 ribs, the fused costal cartilages of ribs 7 through 10, the location of the sternomanubrial junction (angle of Louis) at the level of the second rib, and the oblique course of the ribs laterally from posterior to anterior.

The muscles of the chest wall can be divided embryologically into those from the epimeres, such as the deep back muscles, innervated by the dorsal rami, and those from the hypomeres, such as the intercostals and rectus, innervated by the ventral rami. The musculature can also be classified based on respiratory function, where the primary muscles of respiration are the intercostals and the diaphragm, and the secondary, or accessory muscles are the sternocleidomastoid, scalenes, pectoralis, serratus, and abdominal wall musculature. The major back muscles include the trapezius and latissimus dorsi (Fig. 80-4). In normal breathing, the diaphragm performs a majority of the work with the intercostals supplying about a quarter of the workload. In full inspiration, the pleura extend bilaterally down to the level of the 11th and 12th ribs (Fig. 80-5).

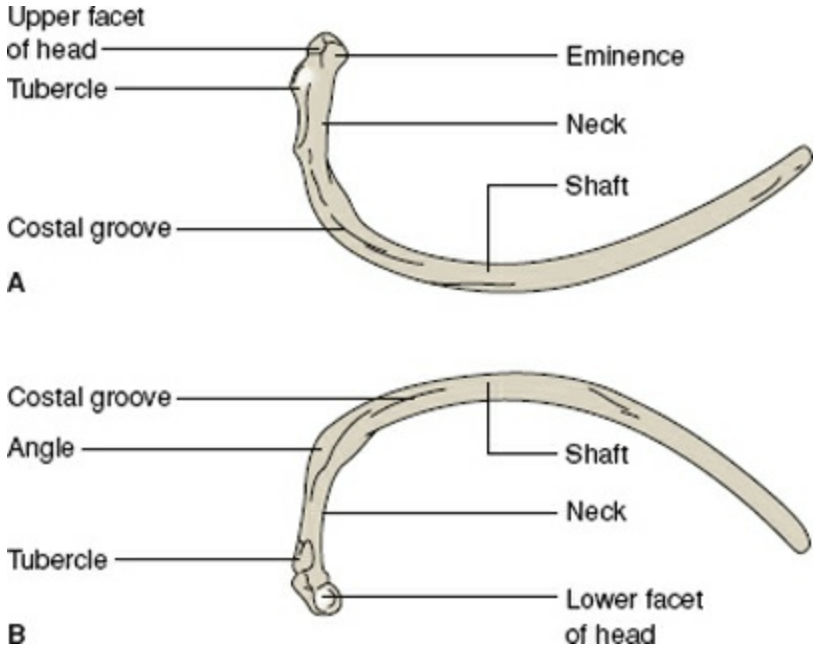

Figure 80-2. Anatomy of ribs 2 to 10 as viewed from above **(A),** and below **(B).**

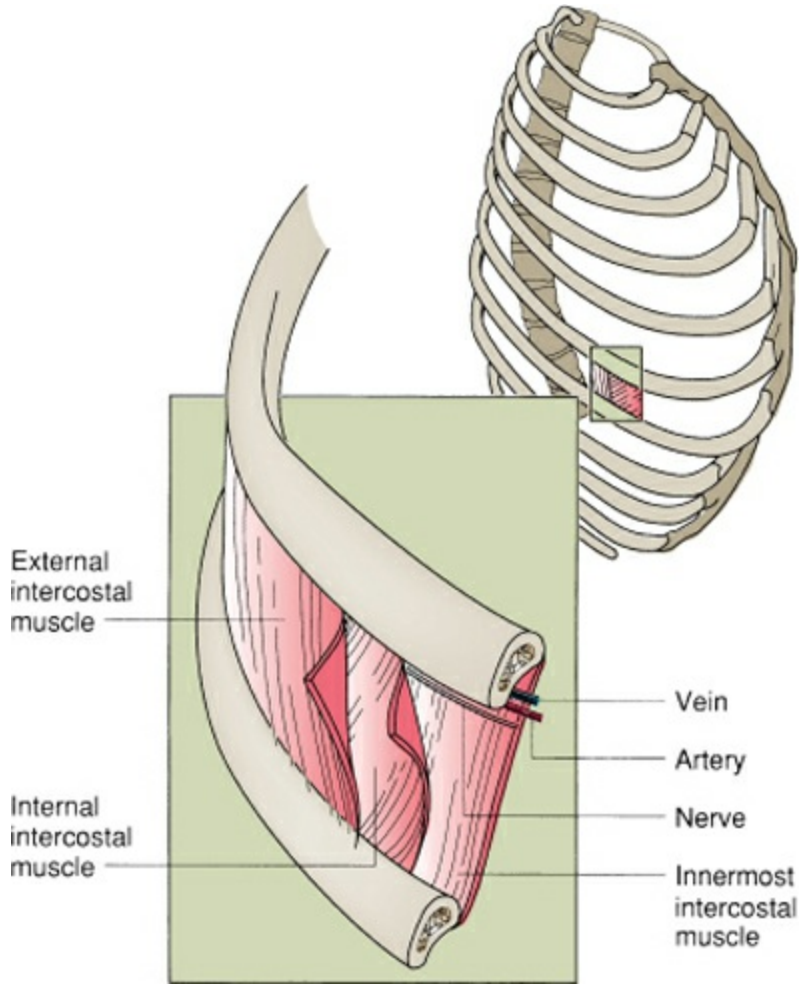

Figure 80-3. Anatomy of the intercostal space. The major intercostal muscles are the external and internal. The neurovascular bundle courses in the costal groove along the inferior aspect of the rib.

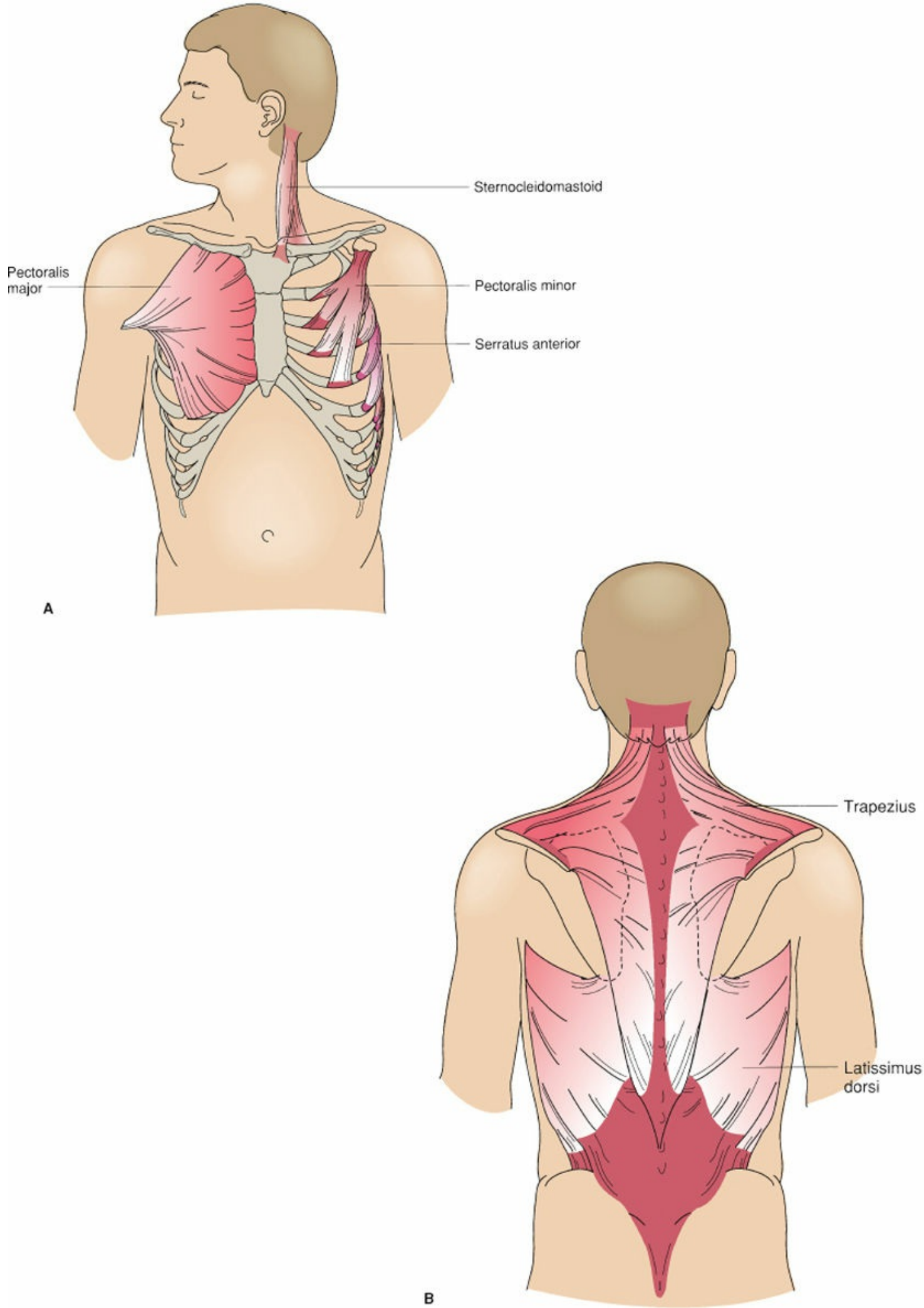
Sternocleidomastoid
Pectoralis major
Pectoralis minor
Serratus anterior
A
Trapezius
Latissimus dorsi
B

Figure 80-4. Thoracic musculature. Anterior (**A**), and posterior (**B**), views.

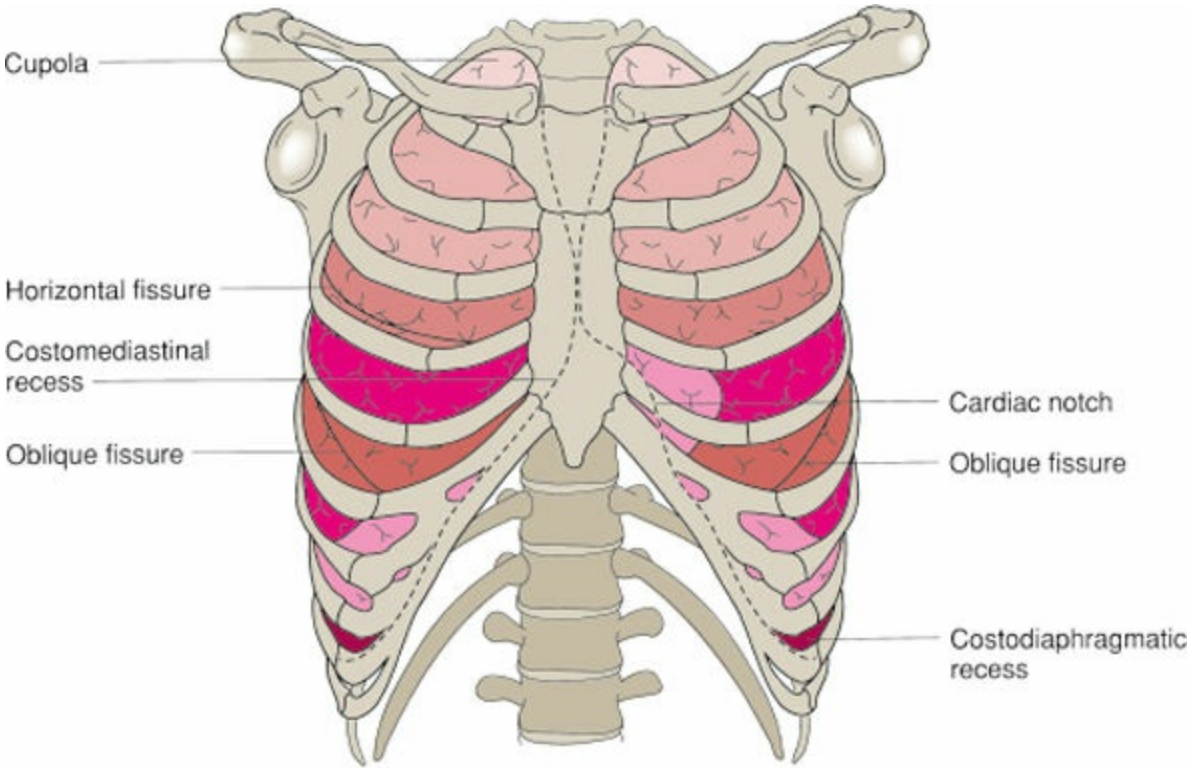

Figure 80-5. Topographic relations of the pleura to the chest wall. Laterally, the pleura extends to the level of the 11th to 12th ribs. The anterior reflection of the mediastinal and costal pleurae forms the costomediastinal recess, whereas the reflections of the costal and diaphragmatic pleurae form the costodiaphragmatic recess.

CHEST WALL NEOPLASMS

Chest wall tumors are very rare. Lesions may be divided into benign and malignant, and then further subdivided into soft tissue versus bony/cartilaginous tumors (Table 80-1). Most malignant tumors of the chest wall are either metastatic from carcinomas or sarcomas arising in other sites of the body, or from local extension of lung cancers or breast cancers.[1]

Almost all lesions will present as a mass, as pain, or as a combination of both. Occasionally they will be asymptomatic and be identified on imaging for cancer surveillance or other reasons.[2] Fever can occasionally be a presenting symptom in the setting of a systemic neoplastic process. Evaluation of these lesions includes a thorough history and physical and appropriate imaging, which may begin with plain radiographs, but should include three-dimensional imaging such as a CT scan and/or MRI. This will allow for evaluation of the depth of the lesion, the relationship of the lesion to nerve and vascular structures, and the pulmonary fields for possible metastases. Depending on the situation, PET scans may also be useful.[1] Prior films may help ascertain the rate of growth of the lesion.[3]

Surgical intervention depends on the type of lesion and the goal of surgery. Tumors that are suspected metastases may require only a needle or an incisional biopsy to confirm the diagnosis. Lesions that are possible primary tumors, whether benign or malignant, require excisional biopsies. Some low-grade malignant tumors may be underdiagnosed and considered benign if the entire specimen is not removed and examined. If a tumor is proven to be a primary malignant lesion, wide excision is required, with margins upto 4 cm.[3]

BENIGN SOFT TISSUE TUMORS

These tumors include lipomas, fibromas, hemangiomas, and neurofibromas among others. These can be removed by excisional biopsy and require no further treatment unless they recur. Inflammatory osteomyelitis can mimic tumors by causing pain.

Table 80-1 Chest Wall Tumor Classification

- Benign tumors
  - Soft tissue tumors
    - Lipomas
    - Fibromas
    - Hemangiomas
    - Neurofibromas
    - Granulomas
    - Inflammatory tumor
    - Tuberculoma
  - Bony/cartilaginous tumors
    - Osteochondromas
    - Chondromas
    - Fibrous dysplasia
    - Eosinophilic granuloma
    - Osteoid osteomas
    - Osteomyelitis
    - Chondro/osteoblastomas
- Malignant tumors
  - Soft tissue tumors
    - Melanomas and other cutaneous cancers
    - Sarcomas
    - Desmoid tumors/low-grade fibrosarcomas
    - Lymphoma
    - Malignant fibrous histiocytoma
  - Bony/cartilaginous tumors
    - Chondrosarcomas
    - Osteogenic sarcomas
    - Ewing sarcomas
    - Solitary plasmocytoma
    - Lymphoma
- Metastatic tumors
  - Breast cancer
  - Lung cancer
  - Mediastinal tumors
  - Mesothelioma
  - Other sarcomas or carcinomas

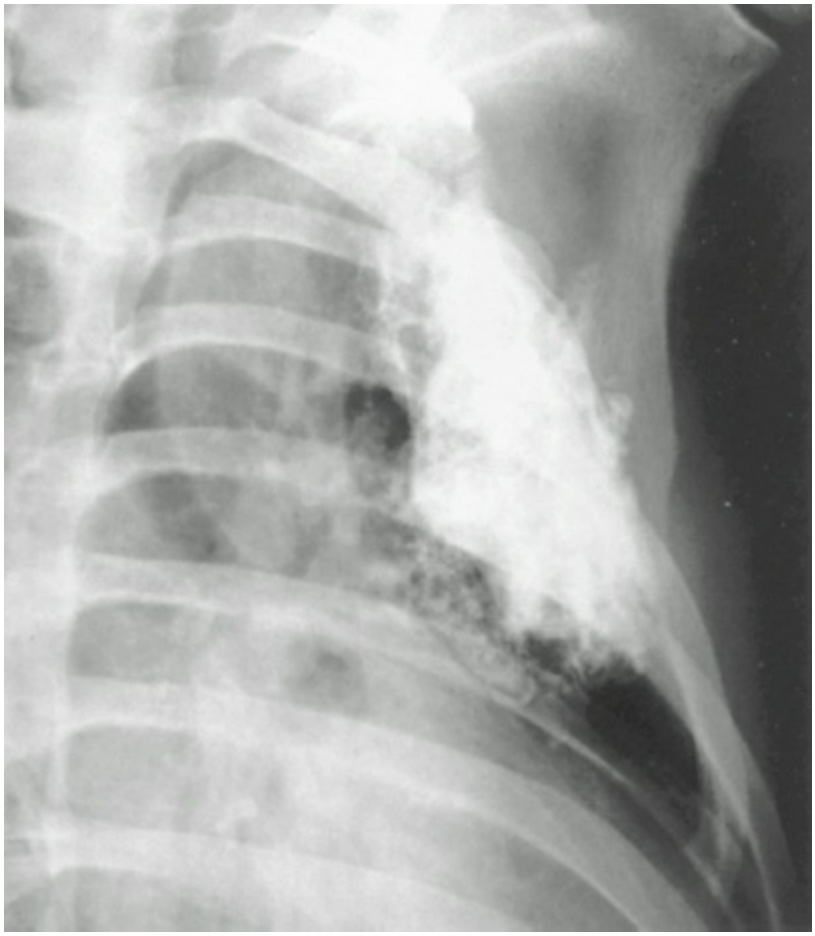

Figure 80-6. Osteochondroma of left second rib. The stippled calcification within the tumor and the intact cortex of the rib are characteristic.

BENIGN BONY/CARTILAGINOUS TUMORS

About two-thirds of benign chest wall tumors are either osteochondromas, chondromas, or fibrous dysplasia, with osteochondromas comprising almost 50% of all nonmalignant rib tumors. Osteochondromas usually present as painless masses with a male-to-female predominance of 3:1. If the lesion becomes painful it may indicate malignant degeneration.[3] They are often found on routine radiographic examinations for other reasons and have a characteristic appearance of a pedunculated bony prominence (Fig. 80-6).

Chondromas account for 15% of benign rib lesions and grow from the cartilage at the sternocostal junction.[1] They have an equal male-to-female incidence. Clinically and radiographically, it is impossible to distinguish chondromas from chondrosarcomas. It can be difficult microscopically to distinguish chondromas from low-grade chondrosarcomas as well. As a result, all chondromas must be treated as if they are potentially malignant and require complete excision.[3]

Fibrous dysplasia arises in the lateral portion or shaft of the rib and can have a “soap bubble” or “ground-glass” appearance on radiographs (Fig. 80-7). These lesions may become painful if they enlarge and can result in rib fractures. Surgical excision is needed for diagnosis and symptom relief.[4] Eosinophilic granulomas and osteoid osteomas are rare conditions that affect men more often. Patients may have multiple granulomas, including the skull and may benefit from radiotherapy as opposed to surgical resection. Osteomas may be symptomatic and if so, should be resected.

MALIGNANT SOFT TISSUE TUMORS

These lesions can range from melanomas to desmoid tumors to malignant fibrous histiocytomas (MFHs). Sarcomas also arise in the soft tissue of the chest wall, but they comprise less than 10% of all sarcomas.[2] Desmoid tumors are borderline lesions between a benign and malignant classification, and are sometimes considered low-grade fibrosarcomas.[1] Almost half of all desmoids occur in the chest wall and shoulder where they can encapsulate the brachial plexus. They require wide local excision and have a high rate of recurrence. If they encircle vital structures, they can be treated with radiotherapy after surgical excision.[3]

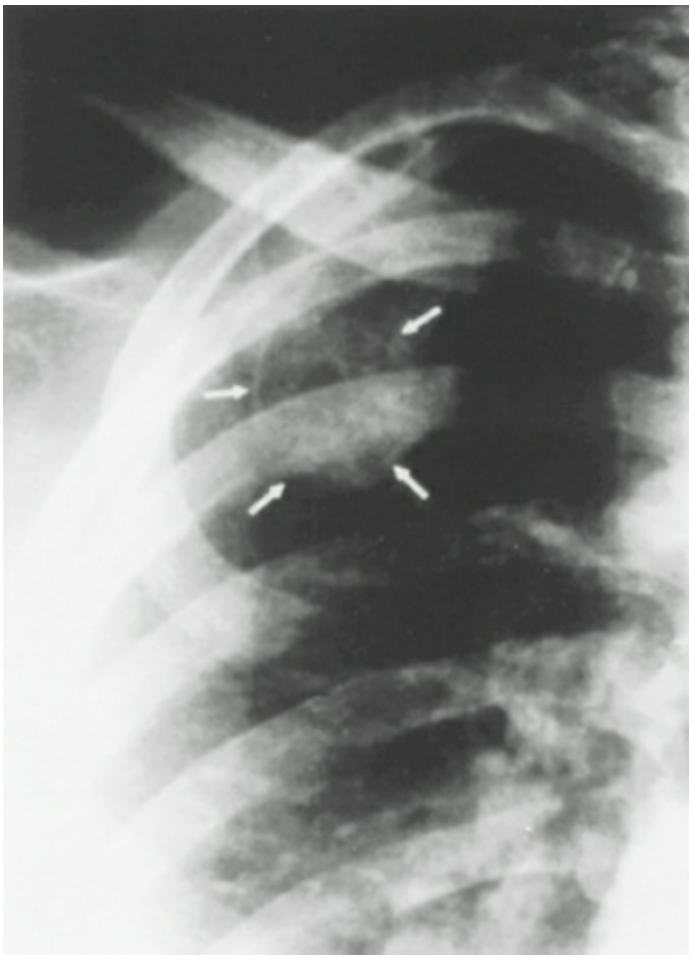

Figure 80-7. Fibrous dysplasia of the rib. Note the characteristic expansion and thinning of the cortex (*arrows*) and the central ground-glass appearance.

MFHs are the most common primary chest wall tumors. They are more frequent in men (2:1 ratio) and generally occur after the age of 50. They are slow-growing, painless, and spread along the facial planes or between muscle fibers. MFHs are unresponsive to other forms of therapy and require wide local excision. Because of the lesion's propensity for fascial plane infiltration, there is a high rate of recurrence following resection and patients who have undergone resection have a 5-year survival of under 40%.[3] Rhabdomyosarcoma is the second most common soft tissue lesion of the chest wall and usually occurs in children and younger adults. It grows rapidly from the striated muscle, but is usually painless. It is treated with wide excision followed by radiation and

chemotherapy with a reported 70% survival at 5 years.[3] A recent review of soft tissue sarcomas in the chest wall suggested that tumor size greater or less than 5 cm correlates with overall prognosis. Also, low-grade tumors had a 100% 5-year survival rate versus a 69.2% survival in high-grade tumors. There was a trend toward improved survival in patients who received a complete resection versus those left with residual disease, but it did not achieve statistical significance due to small sample size.[2]

MALIGNANT BONY/ CARTILAGINOUS TUMORS

Chondrosarcomas are the most common primary malignant bony tumors, accounting for 20% to 30% of lesions. These are well-differentiated tumors and on microscopic examination may be difficult to distinguish from their benign counterparts. Local recurrence can occur after excision and if untreated, distant metastases can develop.[3] Osteogenic sarcomas are more common in the limbs, but also occur in the ribs. Radiographs depict a characteristic "sunburst" pattern. These tend to grow quickly and often have metastases at the time of initial presentation. Patient evaluation should include a CT scan and bone scan to check for the presence of metastatic disease. Surgery with adjuvant chemotherapy is the treatment of choice for local disease.[5] Ewing sarcomas constitute 5% to 10% of chest wall tumors. They occur in children and younger adults with a male-to-female ratio of 1.6:1. Symptoms include pain, fever, and fatigue. Radiographs show a large soft tissue mass with bony destruction. Patients often present with metastatic disease, and ultimately three-quarters of patients will develop metastases. Multimodality treatment is the key to treatment. Survival may be less than 30% at 5 years in patients with metastatic disease.[6]



Figure 80-8. Plasmacytoma of the left seventh rib, showing characteristic cortical destruction and relatively large soft tissue component projecting into the chest.

Solitary plasmocytoma is a rare tumor of the plasma cells and can be part of a systemic disease in multiple myeloma. Lesions can be painful and usually occur in men over the age of 50. X-ray findings show cortical destruction of the rib (Fig. 80-8). In the setting of systemic disease, only a needle biopsy may be needed, but if the lesion is small and symptomatic, resection can be offered. For larger lesions, radiotherapy is the primary treatment.[1]

METASTATIC TUMORS

As discussed before, metastatic lesions can arise from a variety of other cancers, and treatment depends on the primary histology, time to recurrence, and goals of intervention. For isolated metastases with a long interval before recurrence, surgical resection may be warranted. Each case should be individualized and discussed within a multidisciplinary team.

CHEST WALL RECONSTRUCTION

1 Chest wall defects can result from cancer, radiation, trauma, or infection.[7] The goals of repair are to protect the thoracic cavity, minimize complications of respiration due to a flail chest, and to provide cosmetic coverage as needed. Surgical repair involves chest wall stabilization and soft tissue coverage. Stabilization depends on the size and the location of the defect. Often, if the defect is small enough, no stabilization is needed. In larger defects, or when the patient has an intrinsic lung disease limiting their ability to breathe, stabilization using prosthetic materials is warranted. Soft tissue coverage of the defect can vary from mobilization of soft tissue edges, to muscle/omental pedicled flaps, to free muscle flaps.[8]

Size and location generally determine the need for chest wall stabilization. Defects less than 5 cm anywhere in the chest wall, or defects less than 10 cm in the posterior chest wall that are anterior to the scapula do not usually need stabilization.[7,9] An alternative criteria is to use the number of ribs resected, and to avoid stabilization when a portion of three ribs or less have been removed.[10] Techniques for closure of the defect include utilizing absorbable vicryl mesh, used in the setting of infection or if small defects are present. This approach does not provide any stabilization. More definitive repairs utilize polytetrafluoroethylene (PTFE) or a polypropylene methylmethacrylate (PPM) sandwich mesh. PTFE is a flexible, soft material, while the PPM sandwich mesh resembles a hardened piece of plaster between two portions of woven mesh. Different surgeons prefer different approaches, but some of the benefits cited for the PTFE repair include greater stretch and the ability to create a water tight seal.[7] The PPM sandwich repair on the other hand allows the ability to mold the prosthetic and provides a firmer stabilization (Fig. 80-9).[9] Mortality rates from chest wall reconstruction in the setting of cancer resections have been reported at 4% in multiple series.[7,9,10]

Flap coverage of the soft tissue defect will almost always require the assistance of a plastic surgeon, and they should be involved preoperatively in the planning of a chest wall resection and reconstruction. The decision-making process for which flap to use depends on the location of the defect, the size of the defect, the corresponding size of the flap, and its vascular source. Pectoralis major flaps are the most common in the upper chest/neck region. Its blood source can be from the thoracoacromial artery or from intercostal perforators from the internal thoracic arteries (Fig. 80-10). The latissimus dorsi flap is also commonly used for large, ipsilateral defects. Its blood source is from the thoracodorsal artery or from perforators from the posterior intercostal vessels. It has a large arc of rotation from the thoracodorsal pedicle and can cover a wide area of the chest wall (Fig. 80-11). Also commonly used are rectus abdominal muscle flaps in either a vertical (VRAM) or transverse (TRAM) orientation (Fig. 80-12). External obliques can be used on the lower anterior chest wall, and the trapezius can be used in the mid back.[11] Omental flaps are extremely useful and versatile. They can be used to cover large defects or to fill cavities, such as the pleural space in the setting of a bronchopleural fistula and empyema. The omentum can be taken off of the right or left gastroepiploic artery, but using the right arterial source allows a greater arc of rotation than from the left. The

limitations of this flap are that it requires a laparotomy, although laparoscopic techniques have been described,[12] and that the size of the omentum can be variable, and difficult to assess preoperatively (Fig. 80-13).[11]

CHEST WALL CONGENITAL ABNORMALITIES AND THORACIC OUTLET SYNDROME

Pectus Excavatum and Pectus Carinatum

Chest wall deformities occur in 1/1,000 live births. They are five times more common in men than women, and pectus excavatum is five times more common than pectus carinatum. Upto 6% of people with these deformities will also have a connective tissue disorder. Scoliosis is frequently seen in this population.[13] Pectus excavatum appears as a sternal depression that can be off midline approximately 50% of the time. Pectus carinatum is the opposite, with a sternal protrusion, often described as a "pigeon chest" deformity. Less common deformities include sternal clefts, which are incomplete fusions of the sternum, and Poland syndrome, where there is an absence of a pectoralis muscle and underlying bony support in the chest wall.

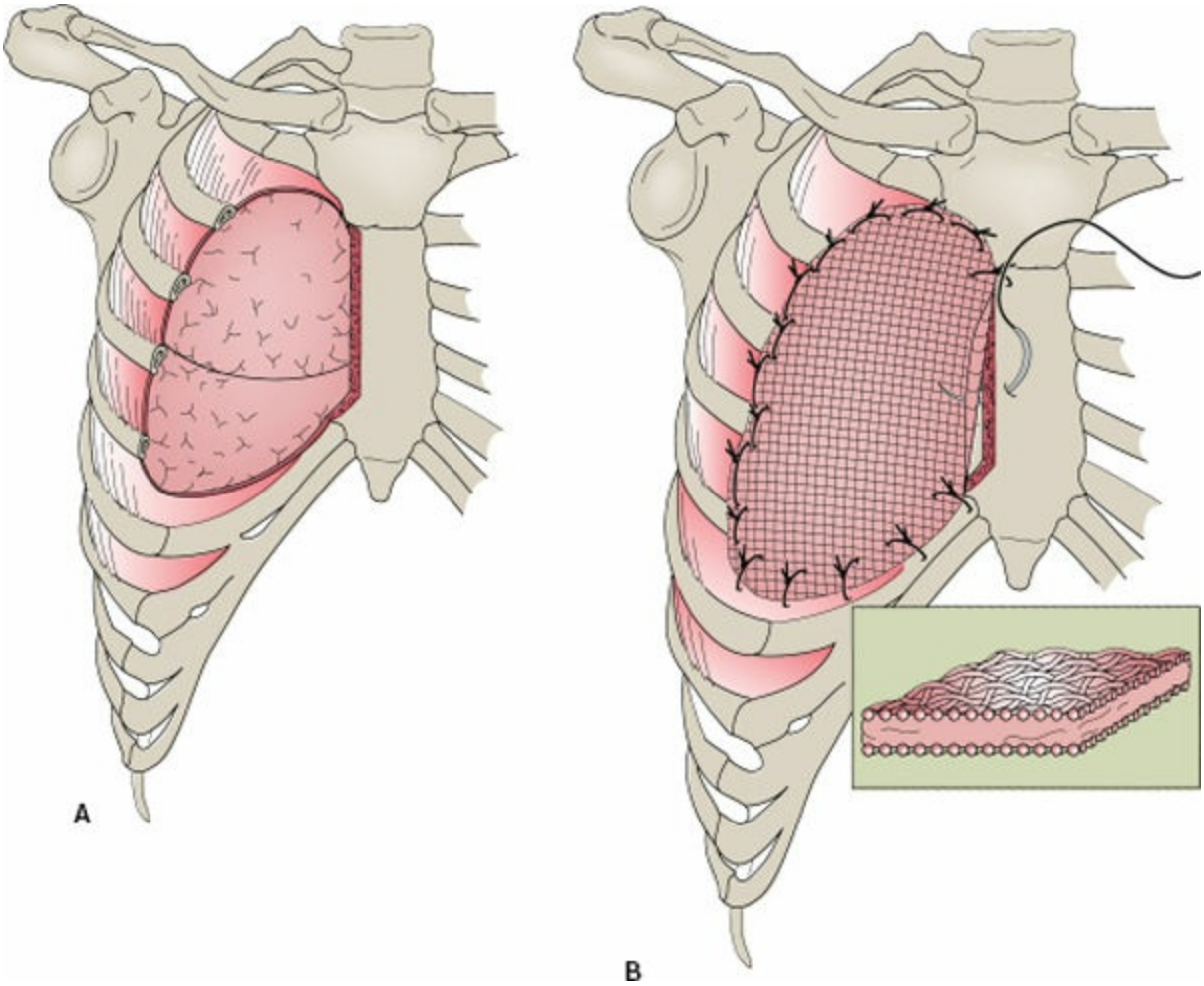

Figure 80-9. Marlex methylmethacrylate sandwich technique for chest wall reconstruction. **A:** Upper anterior chest wall defect resulting from resection of ribs two to five and a portion of sternum. **B:** Marlex methylmethacrylate prosthesis being sutured in place. Heavy, nonabsorbable sutures either encircling the ribs or passed through the sternum are used to anchor the prosthesis in place. **Inset:** Detail of prosthesis showing sandwich of hardened methylmethacrylate between two sheets of Marlex.

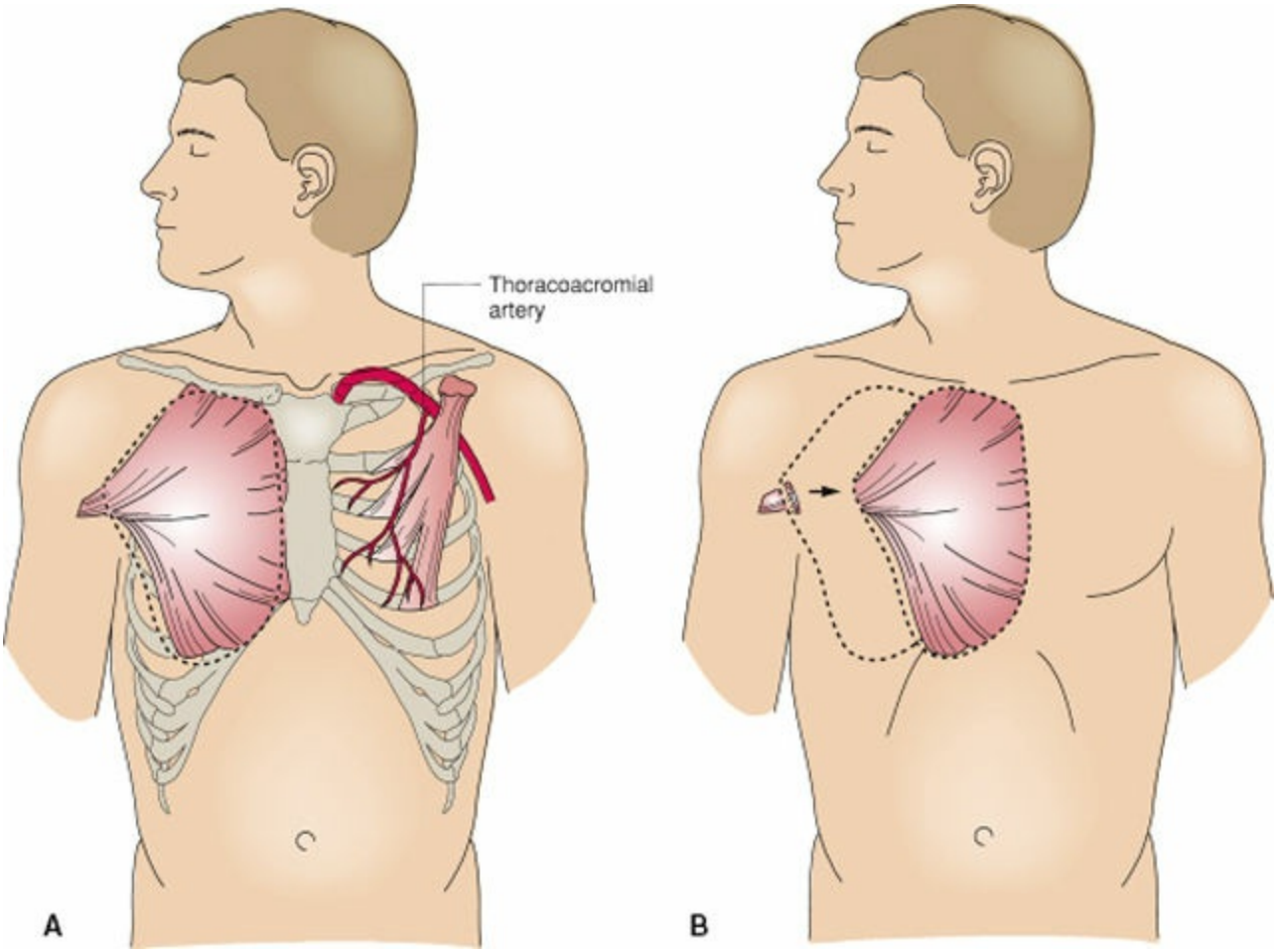

Figure 80-10. Pectoralis major muscle rotation flap. **A:** Mobilization of the flap by detaching the clavicular, sternal, and chest wall origins as well as the insertion of the muscle on the greater tubercle of the humerus. The dominant blood supply, the thoracoacromial artery, which arises from the axillary artery medial to the proximal border of the pectoralis minor muscle, is shown on the left side where the pectoralis major muscle has been removed. **B:** Medial transposition of the muscle flap, preserving the thoracoacromial neurovascular bundle.

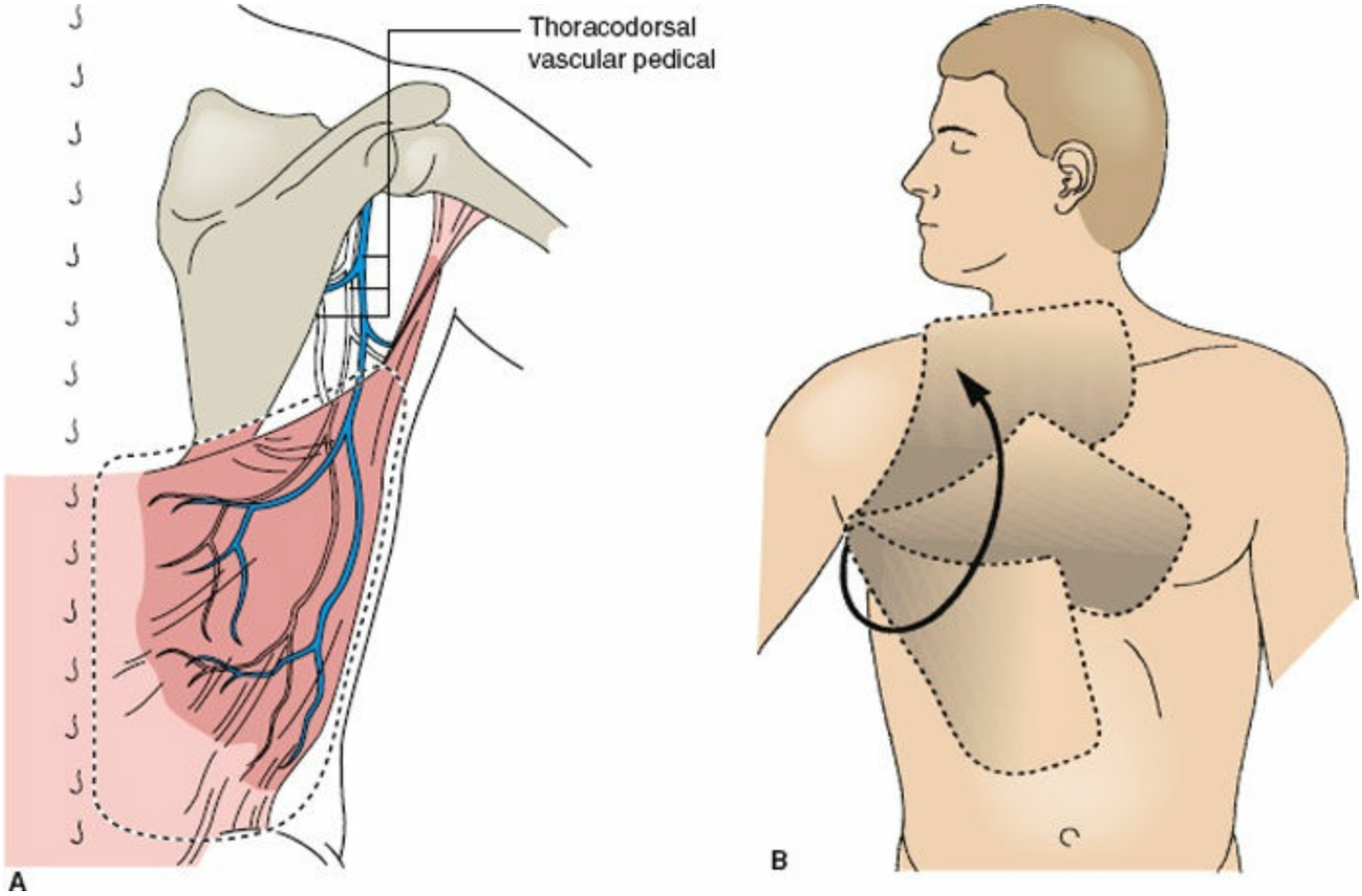

Figure 80-11. Latissimus dorsi muscle rotation flap for chest wall reconstruction. **A:** Posterior view showing detachment of the origins of the muscle. The dominant blood supply, the thoracodorsal artery, is preserved. **B:** Anterior view showing the extent to which the mobilized muscle reaches.

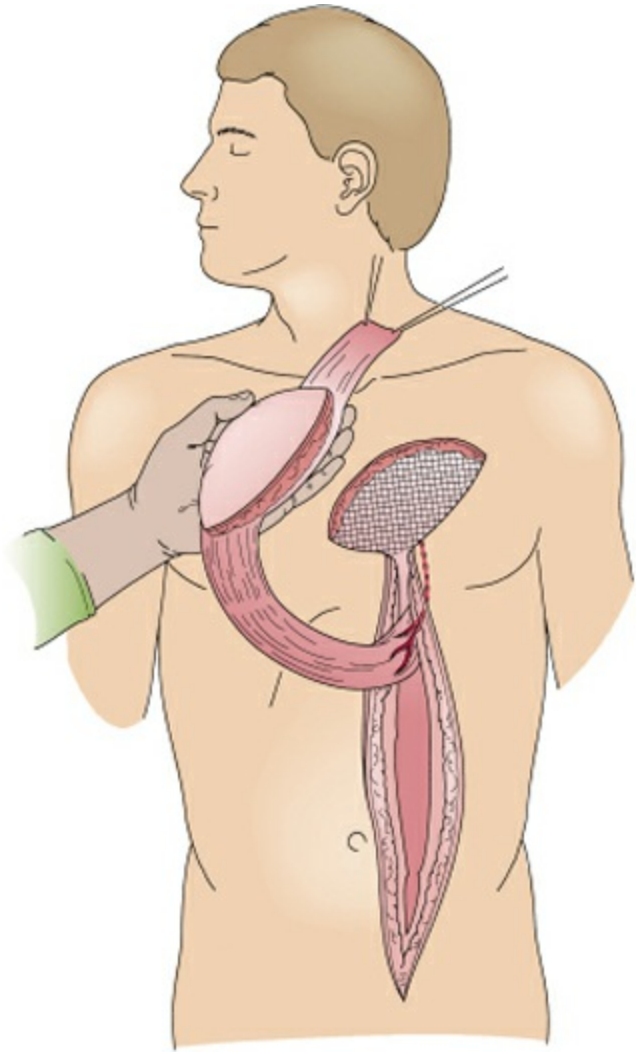

Figure 80-12. Rectus abdominis muscle rotation flap. Shown is the mobilization of the rectus abdominis muscle, which is based on the superior epigastric artery (the continuation of the internal thoracic artery), and rotation of the muscle and overlying skin to fill an anterior chest wall defect.

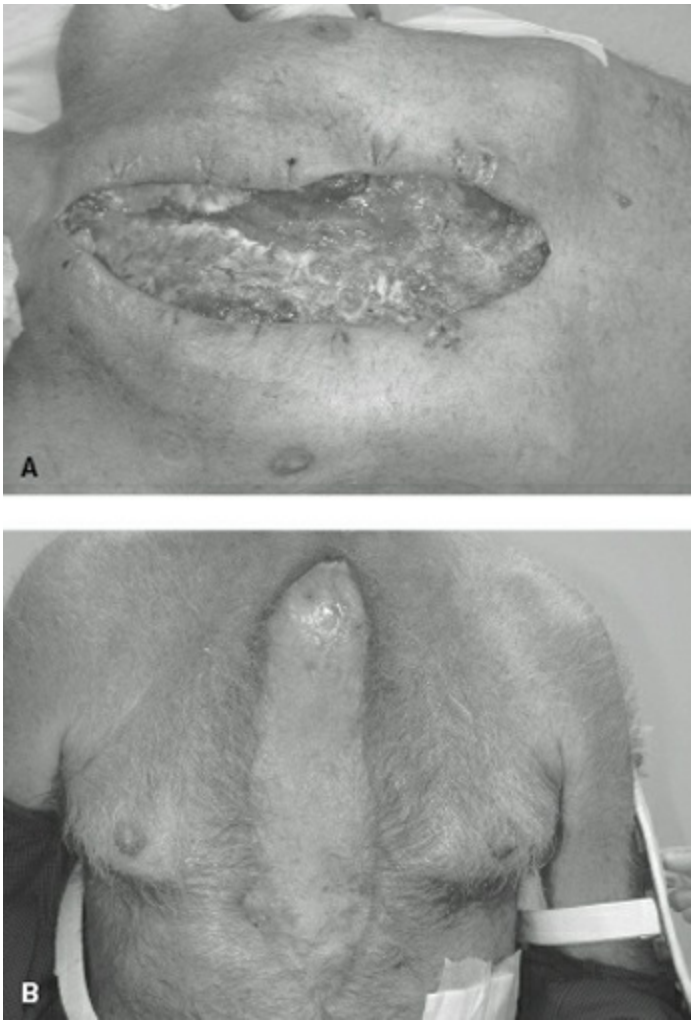

Figure 80-13. The omentum can be used to cover large defects. Shown is an open sternal wound after débridement with failed prior muscle flap (**A**), and wound 6 months after omental flap placement (**B**). (Reproduced with permission from Ghazi B, Carlson G, Losken A. Use of the greater omentum for reconstruction of infected sternotomy wounds: a prognostic indicator. *Ann Plast Surg* 2008;60(2):169–173.)

Pectus excavatum is the most common of these deformities, and the techniques for surgical correction have been evolving, including the Ravitch and Nuss procedures. Despite this, less than 15% of patients undergo surgery.[14] Most patients present as children with notable deformities. People can be physiologically asymptomatic, but can also present with fatigue, limited stamina, and cardiopulmonary limitations. The workup includes pulmonary function testing, echocardiography, and CT scans. The use of CT scans has been debated in children as the radiation exposure poses a risk. Some advocate that CT scans are needed to show the three-dimensional aspect of defect and can better reflect the right heart compression. The pectus severity index (Haller index) can be calculated by dividing the inner thorax width by the depth measured from the posterior aspect of the sternum to the anterior aspect of the spine (Fig. 80-14). Normal values are 2 to 2.2, and repair is only recommended when the index is at least greater than 3.1.[13,15] The age of the patient at which repair should be performed is also somewhat controversial, as some surgeons advocate waiting until after the age of 10, but many series have reported on a large number of patients treated at a much younger age with good outcomes.[14] There is a growing experience with treating adults also, as some patients seek repair at a later age

(Fig. 80-15).[16,17]

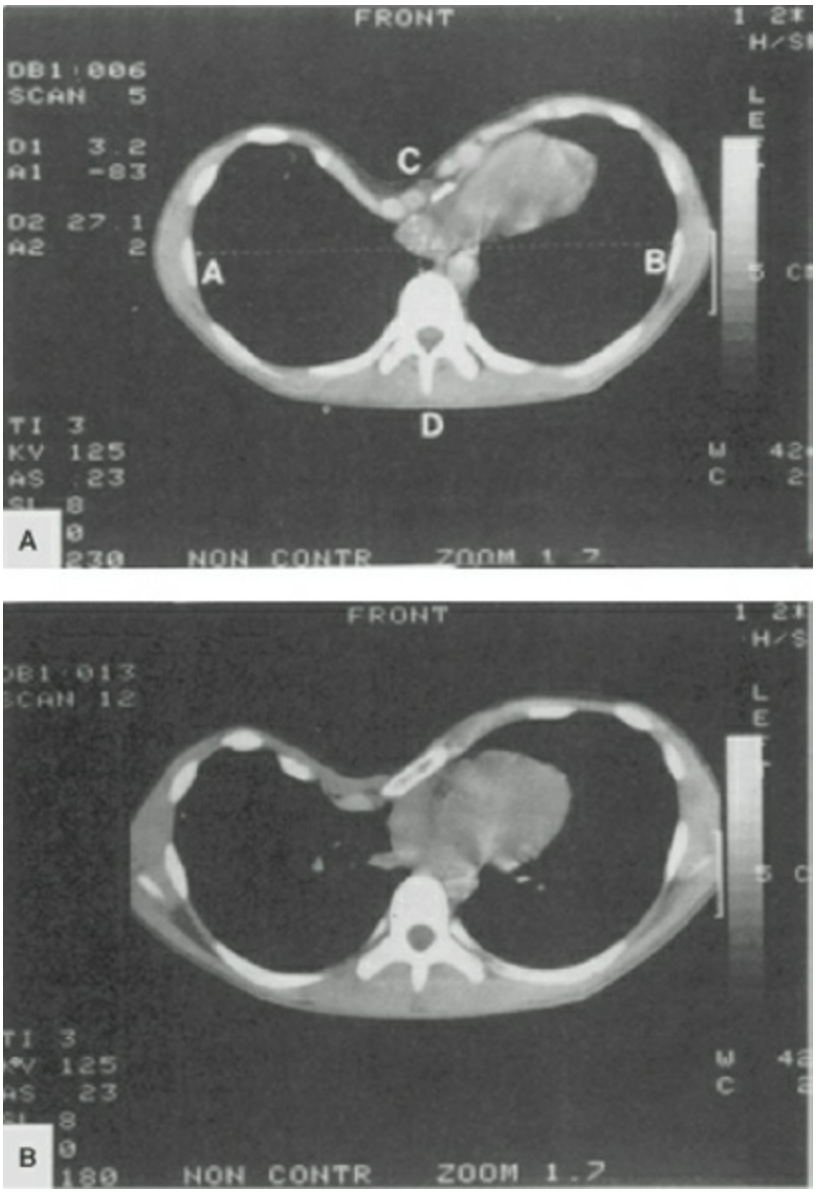

Figure 80-14. Chest CT of pectus excavatum. CT image at xiphoid with A–B (transverse diameter) and C–D (anterior–posterior diameter) indicated for the calculation of the pectus severity index A-B/C-D **(A).** CT image demonstrating angulation of the sternum to the right in the severe defect **(B).** (Reproduced with permission from Haller JA Jr, Scherer LR, Turner CS, et al. Evolving management of pectus excavatum based on a single institutional experience of 664 patients. *Ann Surg* 1989;209(5):578–582.)

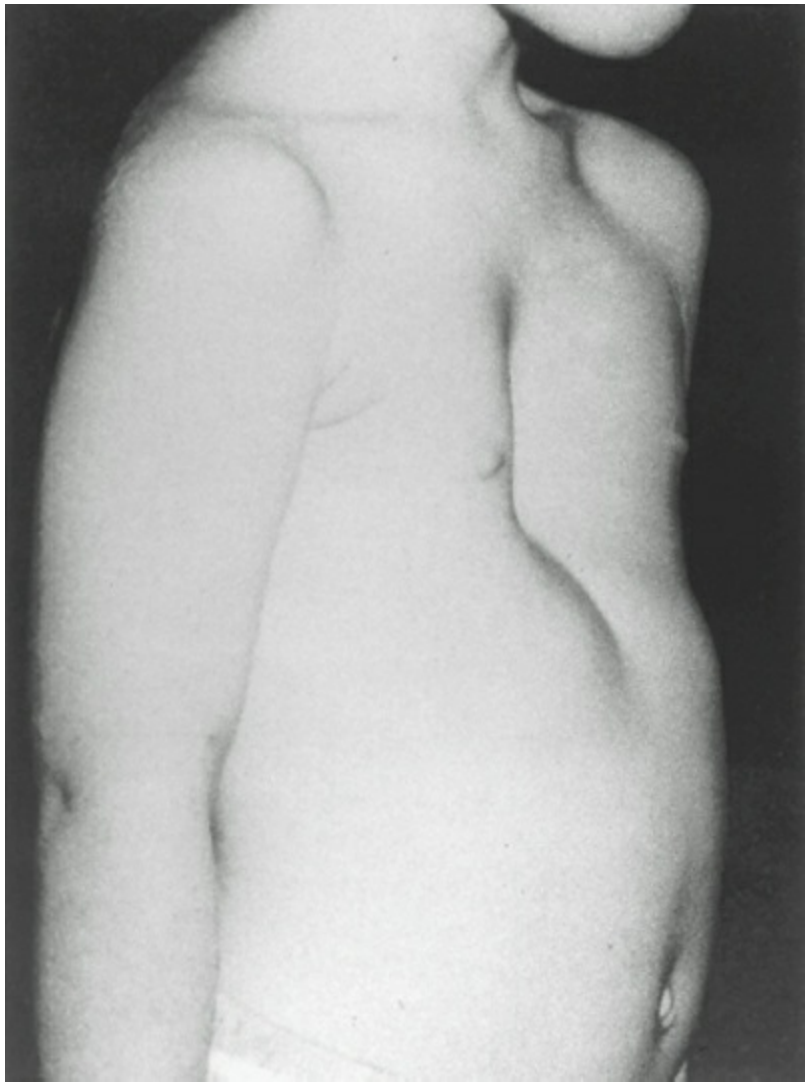

Figure 80-15. Photograph of a 4.5-year-old girl with a symmetric pectus excavatum deformity. Note that the depression extends to the sternal notch. (Adapted with permission from Shamberger RC. Chest wall deformities. In: Shields TW, ed. *General Thoracic Surgery*. 4th ed. Baltimore, MD: Williams & Wilkins; 1994:529–557.)

The most commonly used open repair was first described by Dr. Ravitch and is based on removing sections of the deformed cartilage from around the sternum laterally at the ribs, while preserving the perichondrium. Many advocate using a stabilizing bar for a minimum of 6 months, usually placed in an intrathoracic position, to minimize the occurrence of flail chest and to allow the sternum to heal in an anterior position. An essential part of the procedure is a transverse sternal wedge resection through the anterior table to allow the inferior aspect of sternum to bend forward.[13,17] Incisions may be in a vertical midline over the lower half of the sternum or in an inframammary position (Fig. 80-16). Recurrences occur in 5% to 10% of patients, with recurrence more common in patients with connective tissue disorders.

Since the 1990s, the Nuss procedure, which utilizes a minimally invasive approach, has been described and performed. The Nuss procedure utilizes one or two stabilization bars, secured to the ribs laterally in multiple points of fixation. It routinely employs thoracoscopy, either unilateral or bilateral. Skin incisions are limited to small lateral locations at the site of the bar insertion and thoracoscopic port-sites. In both the Ravitch and Nuss procedures, the stabilization bars stay in for at least 6 months.[18] As the Nuss

procedure has grown in popularity, many modifications have been made, including precise shaping of the bars and increased bar stabilization with wire fixation around the ribs to minimize bar displacement.[19]

Pectus carinatum does not have the same cardiac compression concerns as pectus excavatum, but the chest is held in an enlarged position, limiting normal respiration mechanics. Patients can have increased residual lung volumes and their respiratory physiology can mimic emphysema physiology. This can result in breathing difficulties and limited stamina.[17] The Ravitch procedure is most commonly performed to remove the deformed cartilage. Special attention is placed on the transverse sternal osteotomy, to depress the sternum and align it with the anterior ribs (Fig. 80-17).[13]

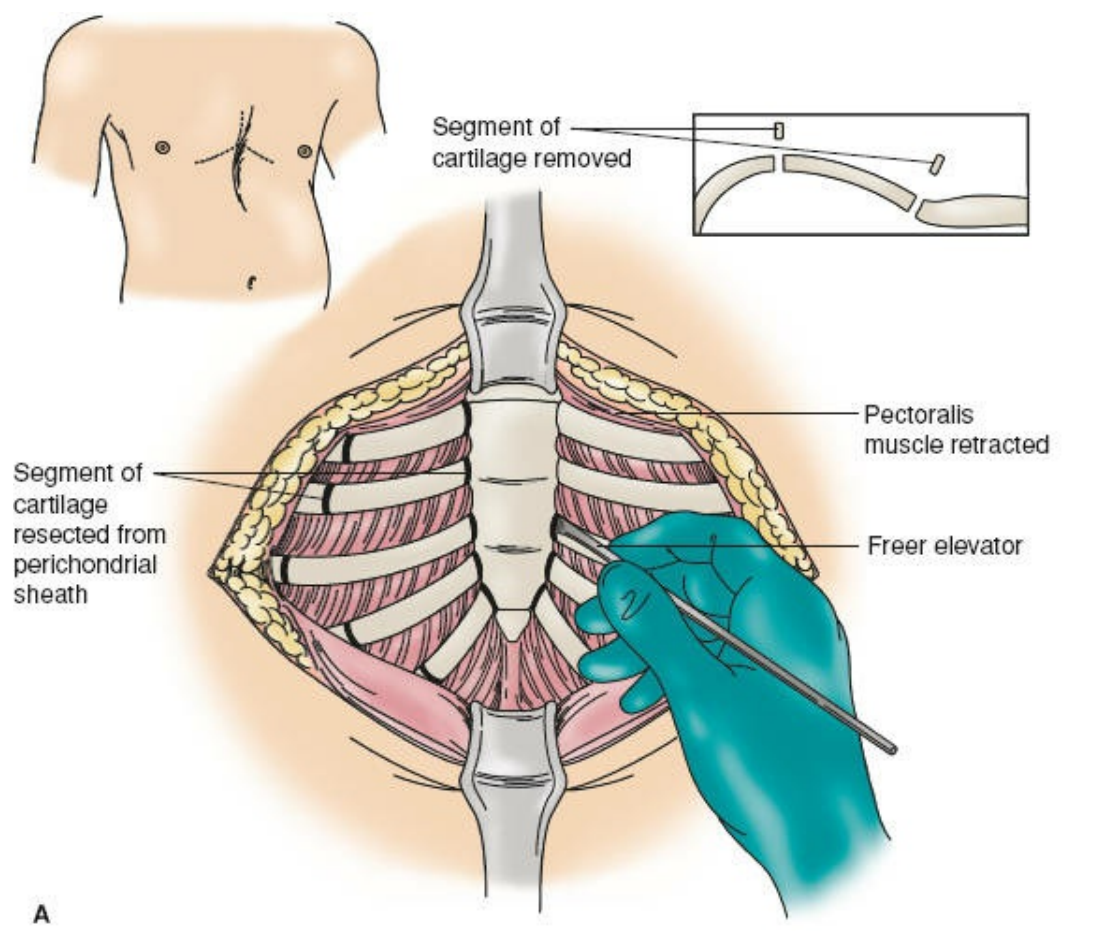
Segment of cartilage removed
Pectoralis muscle retracted
Segment of cartilage resected from perichondrial sheath
Freer elevator

A

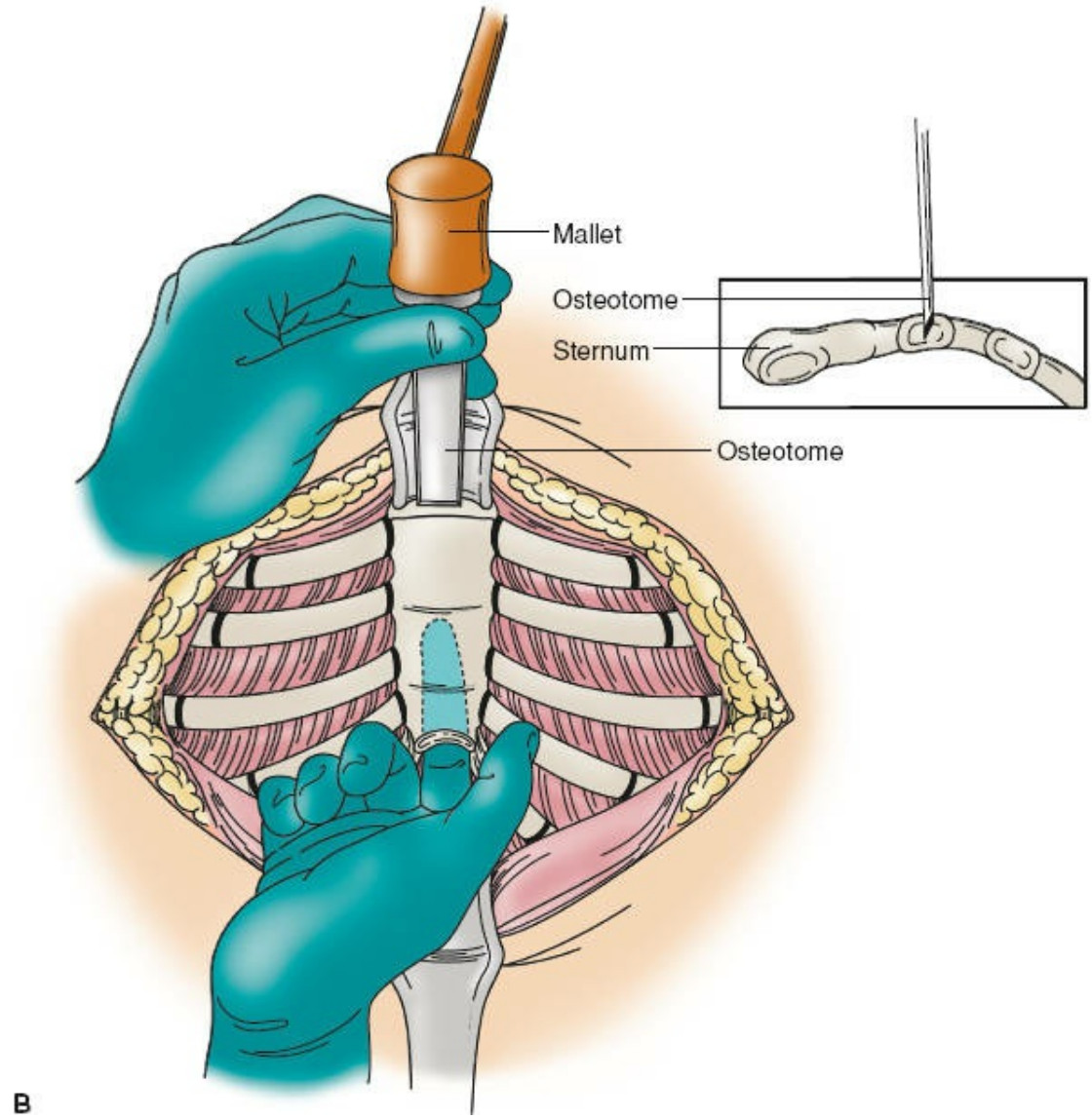
Mallet
Osteotome
Sternum
Osteotome

B

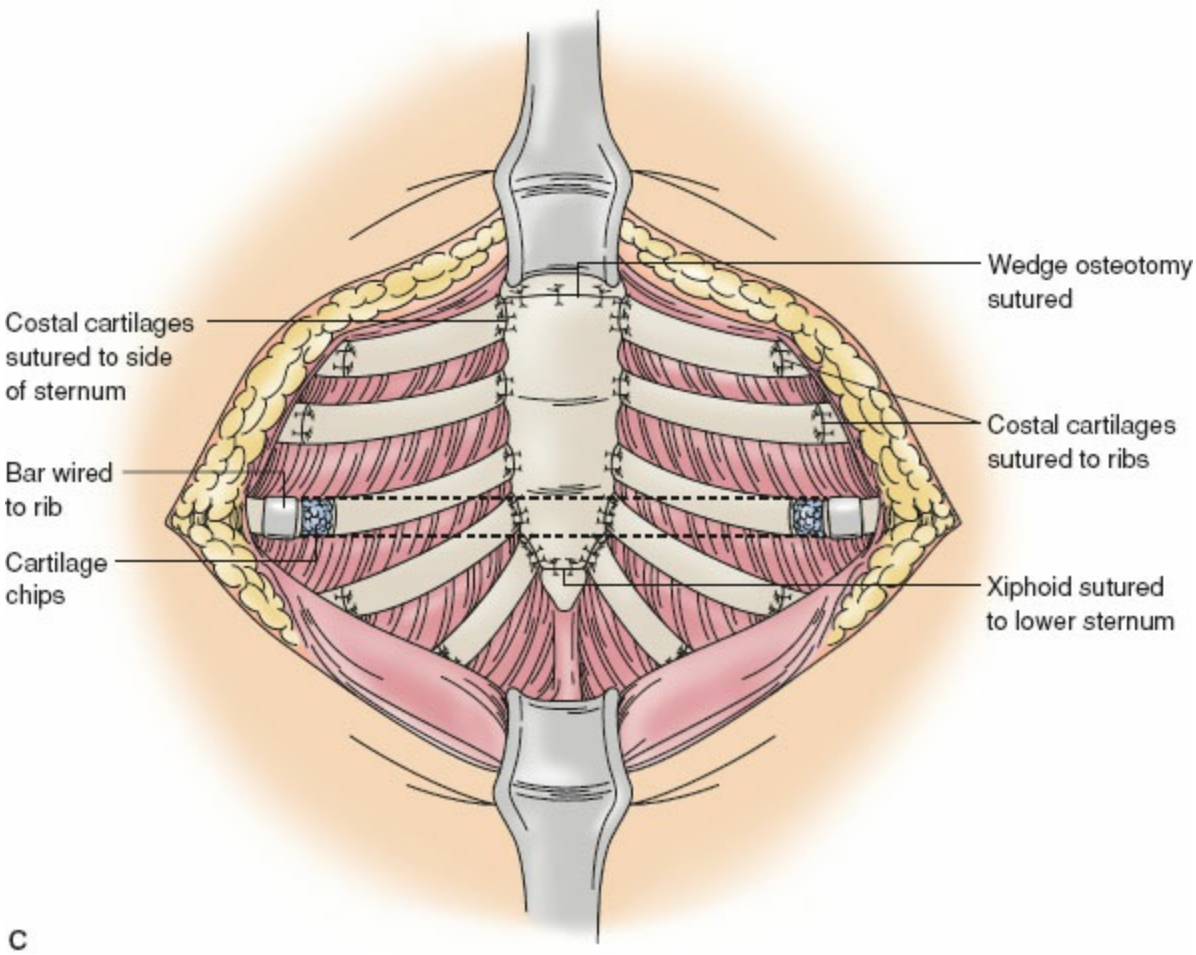

Figure 80-16. A chevron incision is made with flaps elevated. The perichondrium on the deformed cartilage is removed **(A).** A transverse wedge osteotomy is made across the anterior table of the sternum. The lower sternum is elevated to the desired level **(B).** A metal strut is placed posterior to the sternum and attached to the ribs with fine wire **(C).**

Sternal Clefts

Sternal clefts are much rarer than either pectus deformity. They result from the failure of the sternum to fuse in the midline. They can vary from minor defects with the upper half of the sternum separated, to complete dissociation and thoracic ectopia cordis (the heart being outside the chest wall). Upper sternal defects have a U- or V-shaped appearance and usually extend to the fourth intercostal space (Fig. 80-18). Repair of these defects can be easily performed by incision, complete sternotomy, oblique chondrotomies of the sternal halves, and closure. Complete sternal clefts are associated with diastasis recti and an opening between the peritoneal and pericardial cavities. Inferior clefts are associated with the pentalogy of Cantrell, a constellation of defects which include supraumbilical abdominal wall defect, lower sternal cleft, defect in the anterior diaphragm, defect in the associated pericardium, and congenital cardiac defects, often tetralogy of Fallot. With the increased use of prenatal ultrasound, most cases are diagnosed early and are being appropriately referred to specialists prior to birth.[20]

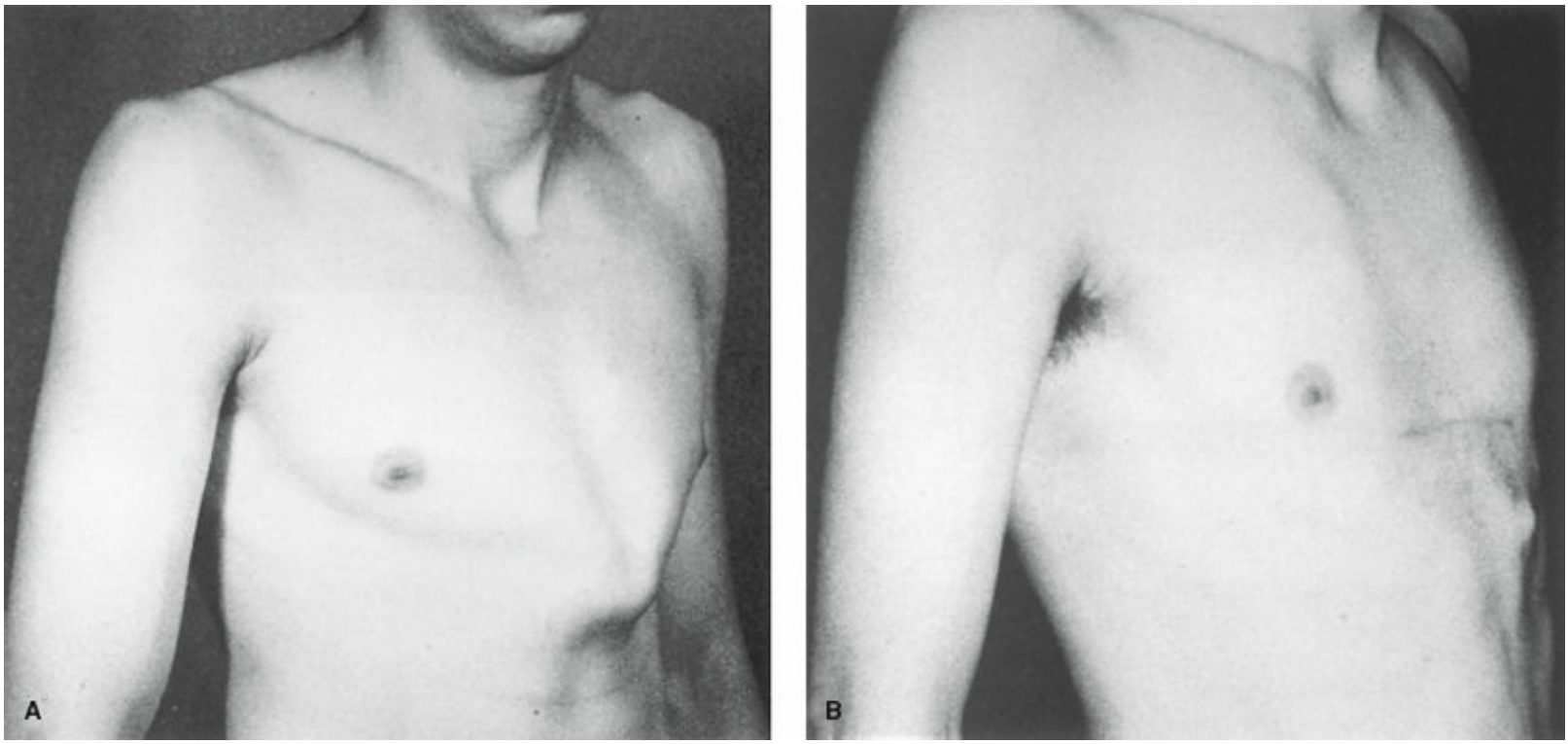

Figure 80-17. Photograph of **(A)** symmetric chondrogladiolar pectus carinatum in a 19-year-old man. Postoperative photograph **(B)** shows correction of the protruding sternum and costal cartilages. (Adapted with permission from Shamberger RC. Chest wall deformities. In: Shields TW, ed. *General Thoracic Surgery*. 4th ed. Baltimore, MD: Williams & Wilkins; 1994:529–557.)

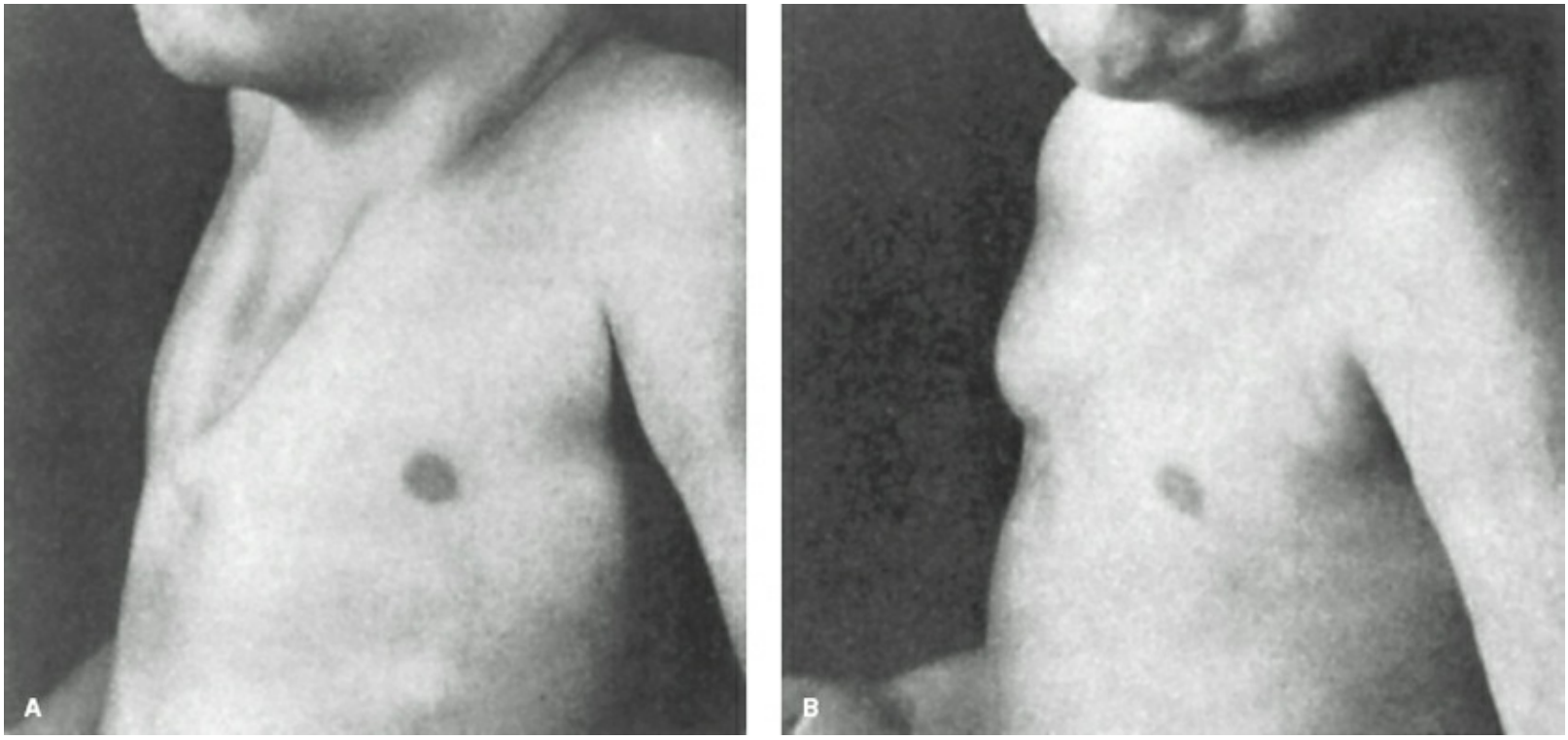

Figure 80-18. Cleft sternum at rest **(A)** and during forced expiration **(B).** Superior clefts of the sternum are variously V- or U-shaped. The appearance of the child as he cries explains the term ectopia cordis, although the heart is actually not misplaced. In the newborn, defects of this kind can be corrected by direct apposition of the sternal halves. In this child, closure of the defect was made possible by sliding chondrotomies on either side. (Reproduced with permission from Sabiston DC Jr. The surgical management of congenital bifid sternum with a partial ectopia cordis. *J Thorac Surg* 1958;35:118.)

Poland Syndrome

Poland syndrome is the clinical absence of a pectoralis muscle and underlying bony support in the chest wall, and it occurs in 1/30,000 live births. It is usually a right-sided, unilateral defect. Patients commonly have associated limb abnormalities, and may also present with renal and spinal lesions (Fig. 80-19). Clinical symptoms may be absent, though lung herniation can occur, requiring a more urgent repair. The surgical approach is usually multidisciplinary and ideally is deferred until after the patient has stopped growing. Repairs typically utilize mesh placement over the defect, and/or muscle flap placement.[21]

Thoracic Outlet Syndrome

2 The thoracic outlet in thoracic outlet syndrome (TOS) refers to the area described at the beginning of this chapter as the thoracic inlet, the correct anatomic term for the region of the first rib and the middle and anterior scalene muscles. Through these structures, the brachial plexus, subclavian artery, and subclavian vein travel to the upper limbs (Fig. 80-20). Because of the close proximity in this area, these conduits may be subjected to abnormal compression by inflammation around the muscles or abnormal bony structures such as cervical ribs, causing pain, thrombosis, and other symptoms that are described as TOS. TOS can be divided into arterial, venous, or neurogenic diseases, or a combination, depending on the symptoms and clinical findings. Vascular TOS is easier to document with vascular imaging. Neurogenic TOS is more difficult to diagnose. Unfortunately for neurogenic TOS, there is no gold standard diagnostic test to confirm the syndrome. As a result, there has been significant controversy over the diagnosis and the indications for surgical treatment, especially in light of the potential for significant postoperative complications.[22,23]

Vascular TOS can be divided into venous disease and arterial disease. Venous disease results in thrombosis of the subclavian vein and is also called Paget–Schroetter syndrome. This syndrome usually presents in men who use their upper bodies and dominant arm for work. Symptoms may present as pain, swelling, and cyanotic discoloration.[22] Contrast venography is the best test to make the diagnosis, and the radiologist should be instructed to perform positional maneuvers with the patient's arm to replicate narrowing that occurs with arm movement.[23] Arterial TOS accounts for about 5% of all cases of TOS[24] and also may result from repetitive and strenuous use. Patients will present with arm fatigue and may even have evidence of ischemia in their distal digits. Patient evaluation includes pulse examination with the arm relaxed and elevated, bruit examination for poststenotic dilatation, and blood pressure readings in both arms. Duplex scanning and angiography will often confirm the diagnosis. Decompression of the scalene muscles and any abnormal bony structures will alleviate these symptoms.[22]

Neurogenic TOS presents with limb pain, numbness, or weakness. Symptoms may be bilateral, but are usually worse in the dominant arm. The distribution may not follow a peripheral nerve pattern, thus making the diagnosis confusing, but also ruling out more distal compression syndromes such as carpal tunnel in the wrist or cubital compression at the elbow. The physical examination should be focused on duplicating the patient's symptoms. The Adson maneuver may detect artery compression and is performed by palpating the affected radial pulse, and having the patient take a deep inspiration while turning their head away from the affected arm (Fig. 80-21). The test is positive if the pulse disappears, but a positive result can also be seen in asymptomatic people without TOS. Another test requires the patient to elevate their arms in a "surrender" position and open and close their hands repeatedly. Most people with neurogenic TOS will be fatigued within a minute and be unable to continue (Fig. 80-22). Plain radiographs may show bony abnormalities, but no other imaging will help diagnose neurogenic TOS. Physical rehabilitation is the first step to treat patients with neurogenic TOS, and over a third of

patients may get a significant improvement in their symptoms. If there is no significant improvement in symptoms, then surgical intervention is suggested.[23]

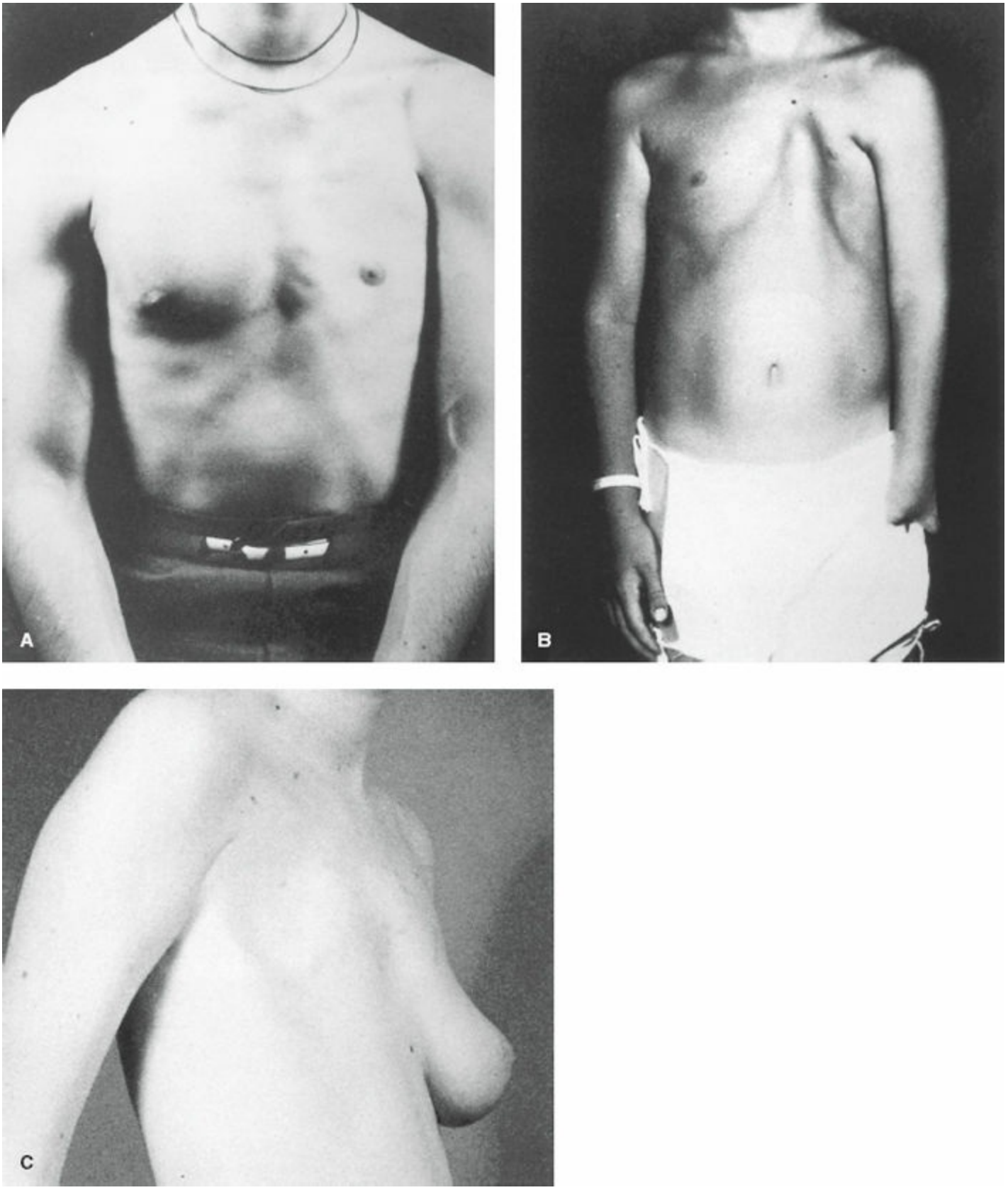

Figure 80-19. **A:** Muscular 15-year-old boy with loss of the left axillary fold, orthotopic sternum, and normal cartilages. He compensates adequately for loss of the pectoralis major and minor muscles. Surgery is not indicated in males with these findings. **B:** An 8-year-old boy with Poland syndrome. The pectoralis major and minor muscles and the serratus to the level of the fifth rib are absent. The boy has sternal obliquity, and the third to fifth ribs are short, ending in points. The corresponding cartilages are absent. The endothoracic fascia lies beneath a thin layer of subcutaneous tissue. Note

the hypoplastic nipple and ectromelia of the ipsilateral hand. **C:** A 14-year-old girl with Poland syndrome. Note the high position of the right nipple, amastia, sternal rotation, and depressed right anterior chest. The second to fourth ribs and cartilages were missing, reconstructed with rib grafts. Breast augmentation will be required at full growth. (Reproduced with permission from Shamberger RC. Chest wall deformities. In: Shields TW, ed. *General Thoracic Surgery*. 4th ed. Baltimore, MD: Williams & Wilkins; 1994:529–557.)

The surgical approach for TOS was traditionally a transaxillary first rib resection (Fig. 80-23). In recent years, a supraclavicular approach has become increasingly popular as it gives better exposure to the scalene muscles and any cervical ribs. In either approach, the first rib is exposed and the anterior and middle scalene muscles are removed from their attachments to the rib. Once this is performed, the first rib is removed (Fig. 80-24). Special attention must be paid to the phrenic nerve lying along the anterior scalene and the axillary branches off of the brachial plexus. Small drains may be placed in the apex of the thorax if the pleural space is entered.[23,25] The supraclavicular approach also gives access to perform a cervical sympathectomy if indicated for symptoms consistent with sympathetic overactivity. In patients with arterial aneurysms, reconstruction with synthetic grafts or autologous conduits such as an external iliac artery can be performed. For patients with venous TOS, care should be taken to perform a circumferential venolysis and to remove the medial aspect of the first rib.[25]

Postoperative complications include pneumothorax, lymphatic leaks, especially on the left side where the thoracic duct enters the operative field, phrenic nerve palsy, and traction injury to the brachial plexus.[24] Patients should have good pain control and may need muscle relaxants to minimize muscle spasm. There should be limited restrictions to the operated extremity to maximize movement and minimize the risk of developing a frozen shoulder. Rehabilitation should be restarted as soon as possible after surgery.[23,25] Upto 12.5% of patients may not get any symptom relief after the surgery, and long-term physical rehabilitation is recommended.[24] Patients with combined symptoms of venous and neurogenic TOS have worse outcomes when compared to patients with only venous disease. A higher percentage of patients had persistent pain in the neurogenic group as might be expected.[26] The treatment of this disease process requires a significant investment into the preoperative and postoperative care of these patients and should only be done in centers with a high volume and expertise in this syndrome.

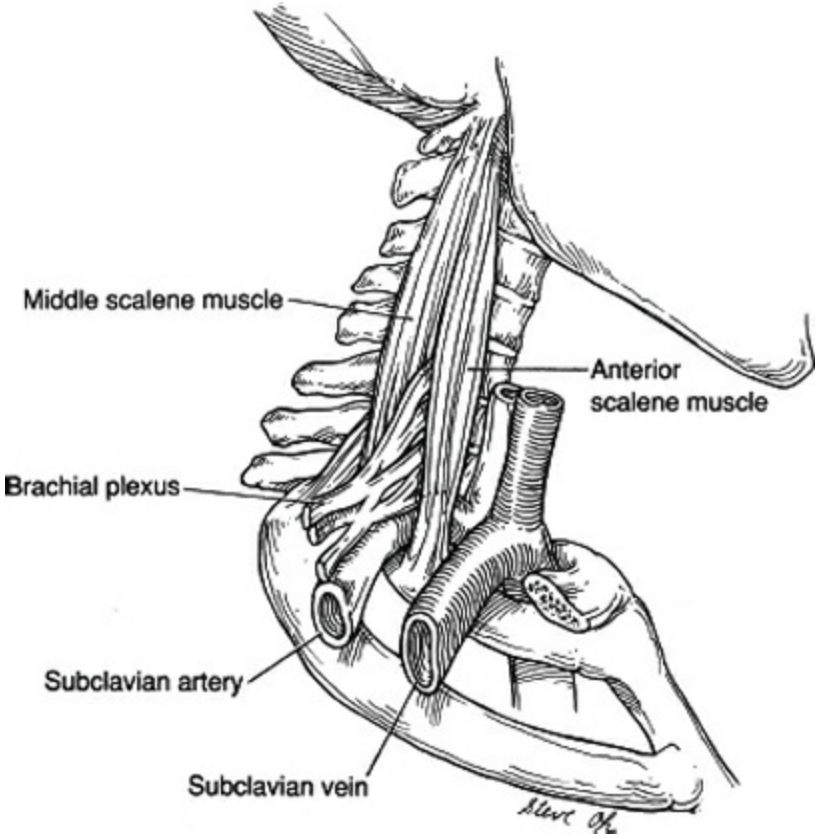

Figure 80-20. Important structures in the thoracic outlet. (Reproduced with permission from Scott-Conner CE, Dawson DL, Shirazi MK, et al. *Operative Anatomy*. 3rd ed. Philadelphia, PA: Lippincott Williams & Wilkins; 2008.)

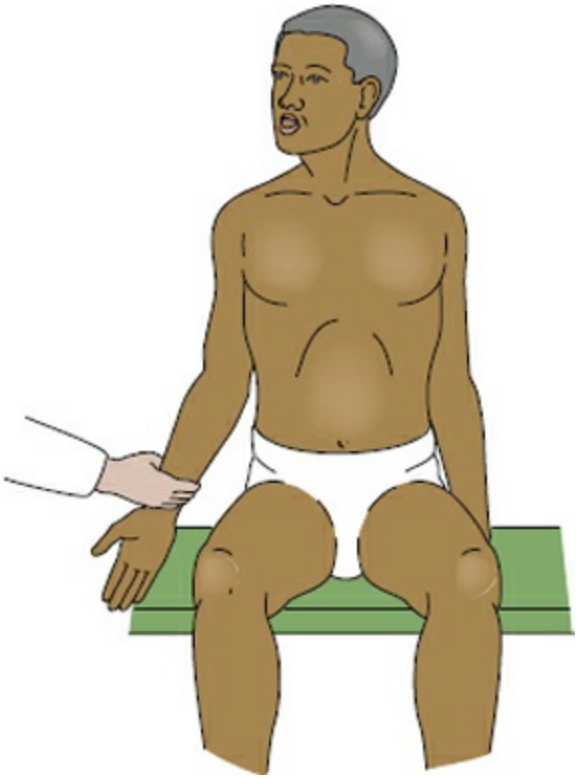

Figure 80-21. The Adson maneuver. Patient inspires and turns head away from the affected arm. The test is positive if the pulse disappears.

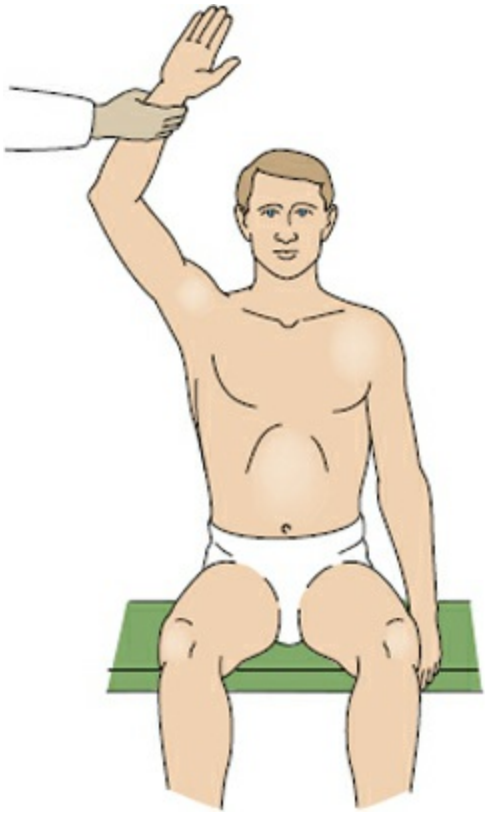

Figure 80-22. Surrender position with opening and closing of hand. Early fatigue is seen in neurogenic TOS.

NONNEOPLASTIC LUNG DISEASE

Lung Abscess and Bronchiectasis

3 Complications from pulmonary infections that require surgery are not common relative to the frequency of pneumonias in both the inpatient and outpatient community. However, in some patients, treatment of lung abscesses and bronchiectasis may include surgical intervention. Lung abscesses can result from aspiration or occur after necrotizing pneumonia. Patients may present with chest pain and fever. Routine use of antibiotics for pneumonias has dramatically reduced the rate of lung abscess sequelae. In over 80% of cases, a pathogen can be found, and in immunocompromised patients, there are usually multiple organisms involved including *Pseudomonas aeruginosa* and *Haemophilus* species. The primary treatment for lung abscesses is medical therapy with antibiotics. If a patient is clinically not improving with medical therapy alone, a guided drainage tube may be placed. A complication of this approach is the risk of a chronic air leak from a percutaneous tube placed into the lung parenchyma. Surgery may be indicated in the setting of large abscesses causing hemoptysis or other symptoms (Algorithm 80-1). Surgical resection may also be of clinical benefit in some patients by removing lung tissue damaged by necrotizing pneumonia.[27]

Bronchiectasis is the abnormal dilation of bronchi/bronchioles as the result of multiple episodes of infection and inflammation. Factors contributing to the development of this disease may be genetic, anatomic, or even systemic. Genetic causes include cystic fibrosis, which results in diminished mucus clearance and diffuse bronchiectasis in both lungs.[28] Primary ciliary dyskinesia is an autosomal recessive syndrome resulting in abnormal cilia that cannot clear secretions leading to multiple infections. Individuals with alpha-1-antitrypsin deficiency can also develop bronchiectasis. Anatomic causes include postsurgical changes or acquired diseases such as chronic obstructive pulmonary disease (COPD) that lead to an increased risk of infection, again by the inability to clear secretions. Autoimmune diseases such as rheumatoid arthritis and inflammatory bowel disease have been associated with increased rates of bronchiectasis.[28,29] Infectious causes include allergic bronchopulmonary aspergillosis and nontuberculous mycobacterium infections. Reflux disease is also being studied as a potential contributor. Most often the etiology of the disease is idiopathic.[28]

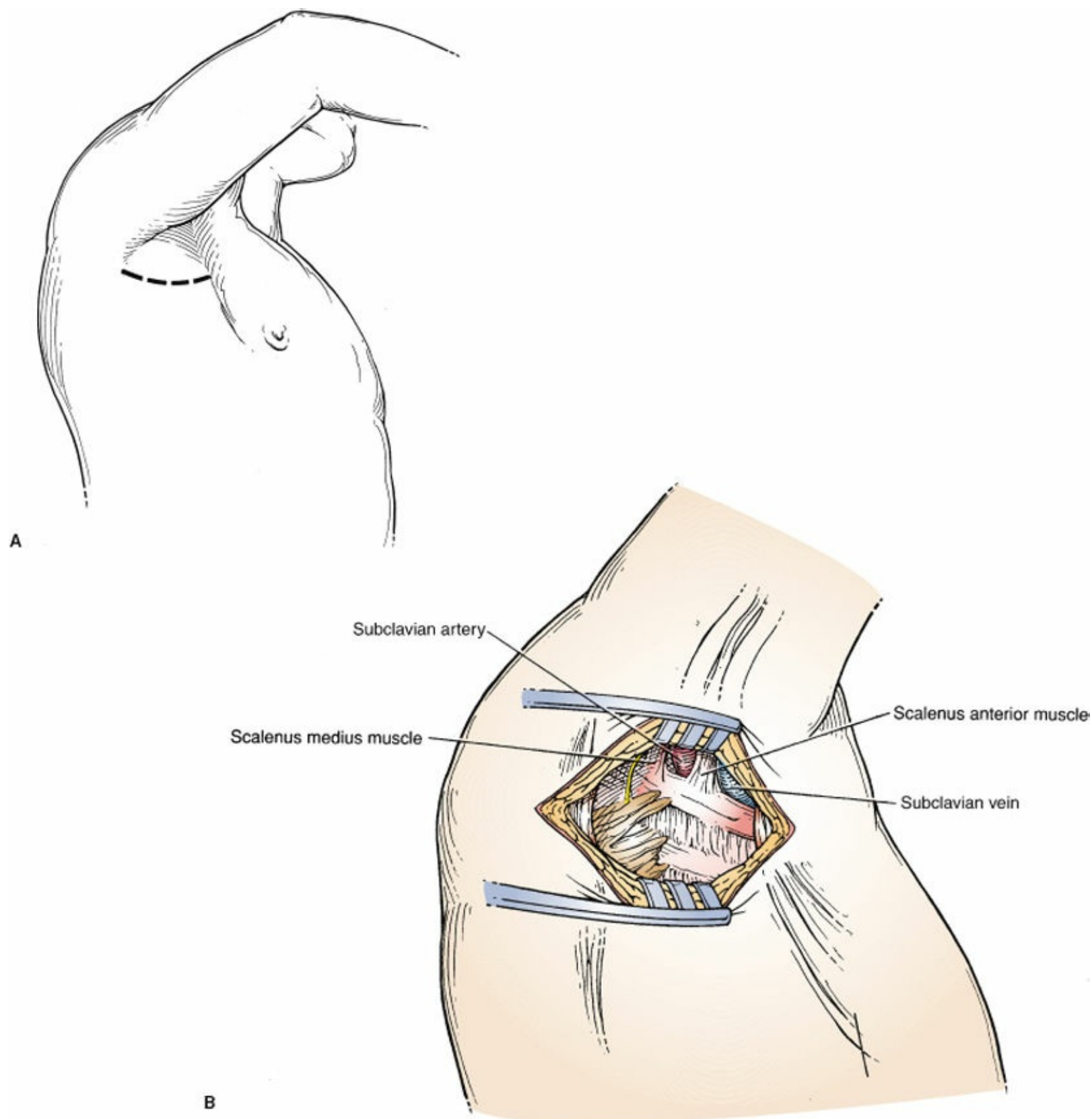

Figure 80-23. Position of the patient (**A**) and skin incision (**B**) for transaxillary approach. (Reproduced with permission from Scott-Conner CE, Dawson DL, Shirazi MK, et al. *Operative Anatomy*. 3rd ed. Philadelphia, PA: Lippincott Williams & Wilkins; 2008.)

There are estimated to be 110,000 patients in the United States being treated for noncystic fibrosis bronchiectasis each year. The diagnosis is increasingly being made as a result of an increasing number of chest CT scans being performed for other, nonrelated reasons. Patients can present with respiratory symptoms like dyspnea, hemoptysis, or

pleuritic pain, or alternatively may present only with systemic changes such as fatigue and weight loss.[28] Almost all patients will have a chronic cough with or without sputum production.[29] Pulmonary function tests may demonstrate moderate to severe airflow obstruction.[28] A chest CT scan is the optimal test to diagnose bronchiectasis (Fig. 80-25), and once the diagnosis is made, the search for an etiology should begin, including obtaining sputum cultures and blood tests for autoimmune markers such as rheumatoid factor.[29]

The treatment of the disease includes antibiotic therapy to control infection, the treatment of underlying diseases if they exist, reducing inflammation, improving secretion clearance, and surgery to remove focally damaged areas or transplantation if needed for more diffuse, severe disease. Antibiotic therapy includes inhaled tobramycin and gentamicin.[29] Macrolide antibiotics have been increasingly studied for their nonantibiotic effects. Erythromycin and clarithromycin have anti-inflammatory benefits. They disrupt the biofilm produced in *Pseudomonas* infections resulting in decreased sputum volume and improved symptoms.[30] Secretion removal is also essential to improving symptoms. Besides the standard treatments of percussive therapy and postural drainage, the use of nebulized acetylcysteine[29] or hypertonic saline[30] has been shown to improve mucus clearance.

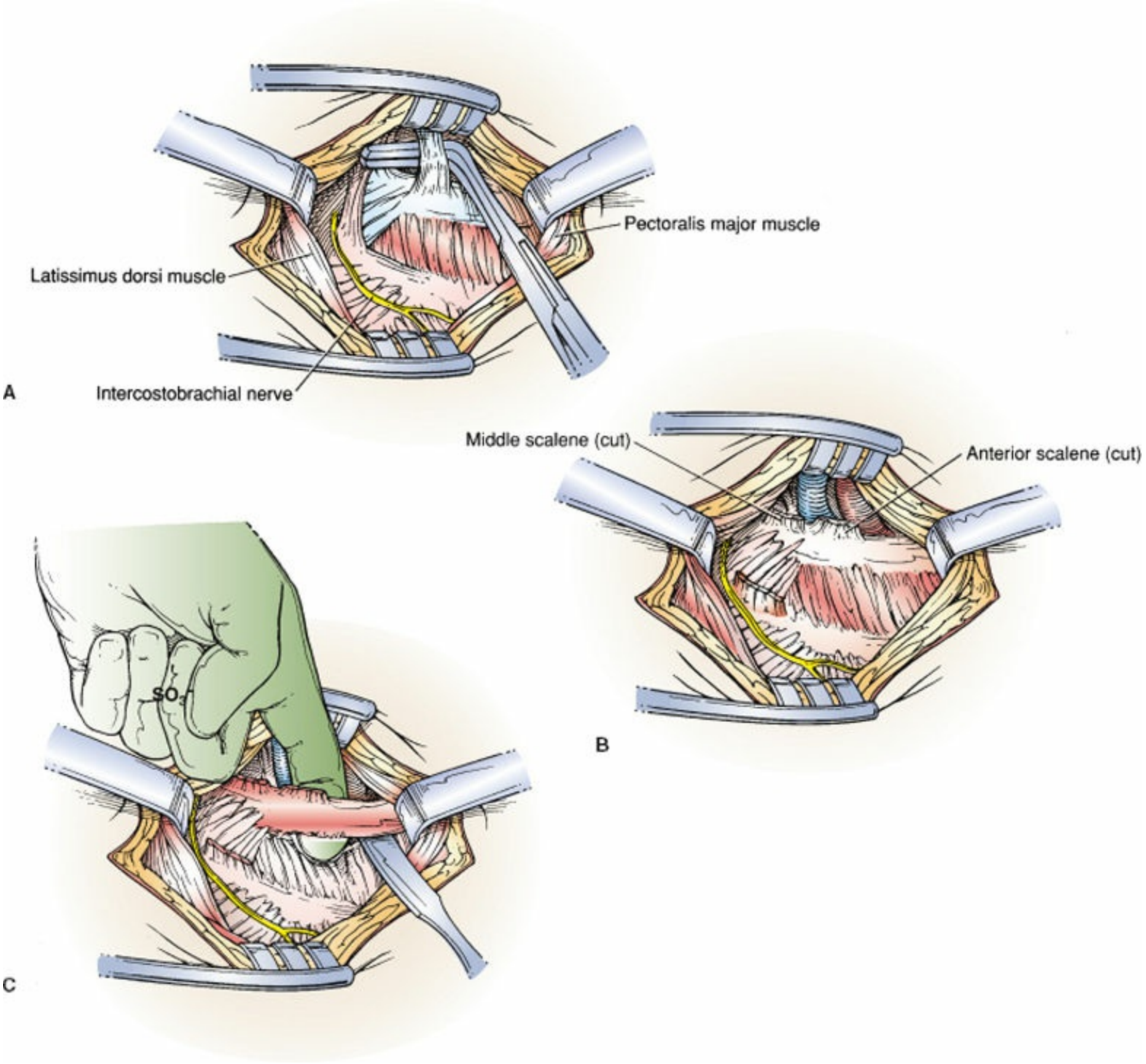

Figure 80-24. Division of the scalene muscles and the first rib. **A:** Mobilization of the scalene muscles off of the first rib. **B:** Exposure of the subclavian vessels. **C:** Mobilization of the first rib, protecting the vessels. (Reproduced with permission from Scott-Conner CE, Dawson DL, Shirazi MK, et al. *Operative Anatomy*. 3rd ed. Philadelphia, PA: Lippincott Williams & Wilkins; 2008.)

Surgical intervention may occur at many stages of the disease process. Bronchoscopy can be useful to clear secretions or to manage hemoptysis. If the bronchiectasis is localized to a single lobe, resection can eliminate the disease and the source of chronic infection. If a patient has a genetic disease such as cystic fibrosis, a double lung transplant may be the best treatment if the patient's symptoms are severe enough.[29] Pulmonary tuberculosis can have similar indications for surgical intervention when it results in bronchiectasis or hemoptysis.[31] The rise of more multidrug-resistant tuberculosis strains

has led to the increasing need for surgical intervention.[32]

Hemoptysis

4 Hemoptysis is often used to describe any blood streaking associated with cough. True hemoptysis may only be a few drops of blood, and it requires investigation. Massive hemoptysis is acutely life threatening, not from blood or volume loss, but rather from suffocation secondary to blood in the airway. The immediate goals when this is encountered are airway control, improved oxygenation, and resuscitation if needed. Intubation may or may not be necessary, depending on the volume of blood in the airway and the patient's ability to cough.[33] If the bleeding is able to be lateralized, the patient should be placed in a lateral decubitus position with the bleeding site in the dependent position. The causes of hemoptysis include cancer, infections/bronchiectasis, vascular injuries, vasculitides, and coagulopathies.[34]

In patients with hemoptysis, any coagulopathy should be corrected. Early bronchoscopy is essential and the goals are to lateralize the site of bleeding and identify the site and cause of the bleeding. Flexible bronchoscopy may be done, but rigid bronchoscopy is the best approach to maintain airway control, in particular in the setting of large volume hemoptysis. Initial treatment may include topical therapy such as cold saline lavage, bronchial tamponade, and intubation of the contralateral good lung. Double-lumen endotracheal tubes may also be useful to isolate and protect the uninvolved lung from blood from the contralateral side obstructing its lumen.[33] If a patient is stable, a chest CT scan is useful to identify tumors or other potential sources of bleeding.[34]

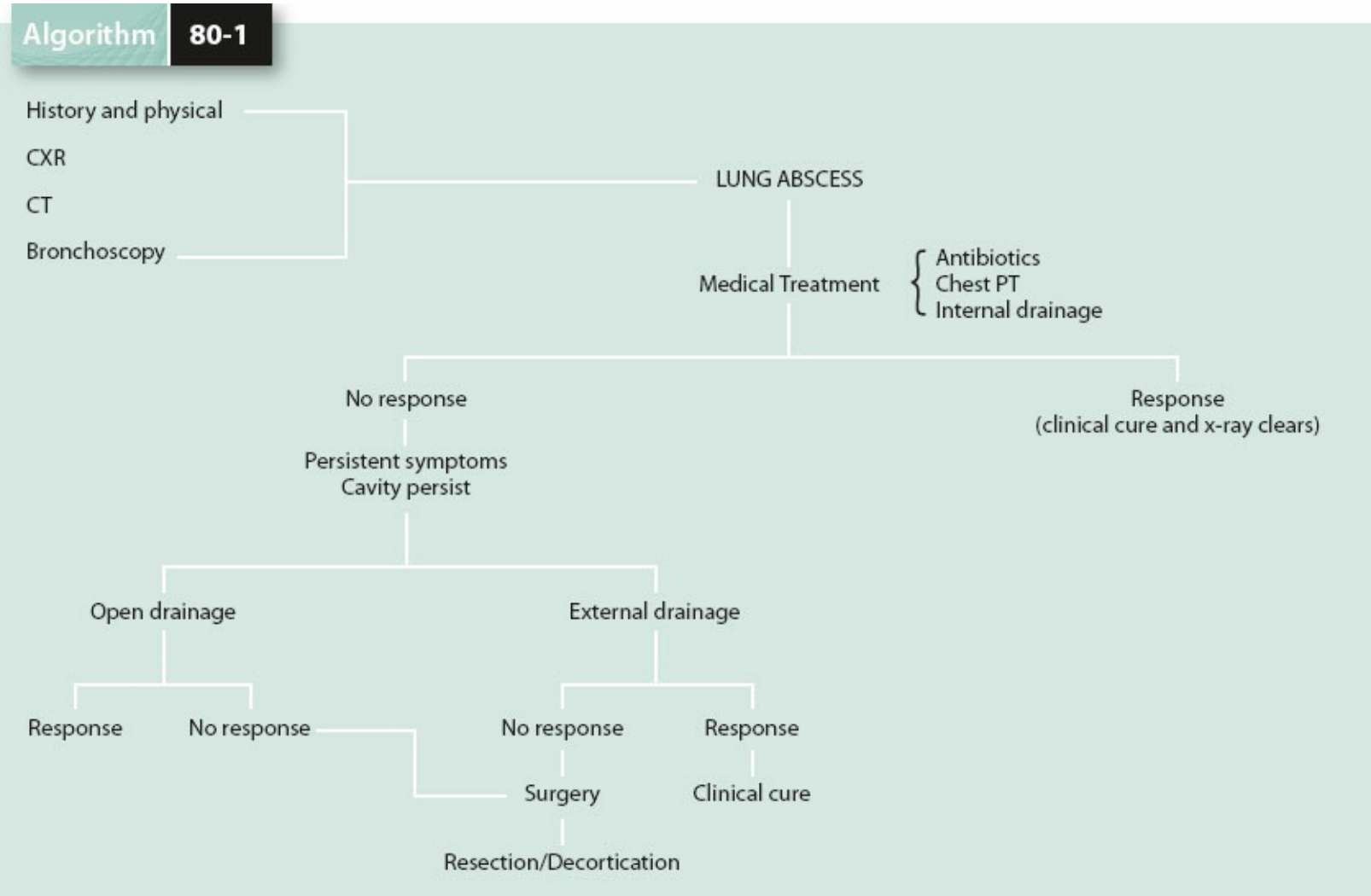

Algorithm 80-1. Algorithm for management of lung abscess. (Adapted from Shields TW, ed. *General Thoracic Surgery*, 6th ed. 2005.)

Once a patient is stabilized and appropriate diagnostic tests performed, the treatment of continued bleeding includes the use of interventional radiology and bronchial artery embolization (BAE).[35] First introduced in 1973, BAE is the best nonsurgical treatment of massive hemoptysis, with a success rate of upto 98% within 24 hours.[34] Surgery is reserved to treat the underlying condition once the patient has been stabilized and bleeding controlled by other methods. Emergent surgery to treat bleeding may have a mortality rate as high as 38%,[35] and increase to 59% in the setting of malignancy.[34] Depending on the patient's baseline lung function, a lobectomy, let alone a pneumonectomy, may not be tolerated. A risk assessment of the benefits of surgery must be performed. In the setting of a vascular etiology of the hemoptysis such as a ruptured aortic aneurysm, surgical repair is essential and should not be delayed once the patient is hemodynamically stable and the airway is controlled.[34] A detailed algorithm in the assessment and treatment of hemoptysis is shown in Algorithm 80-2.

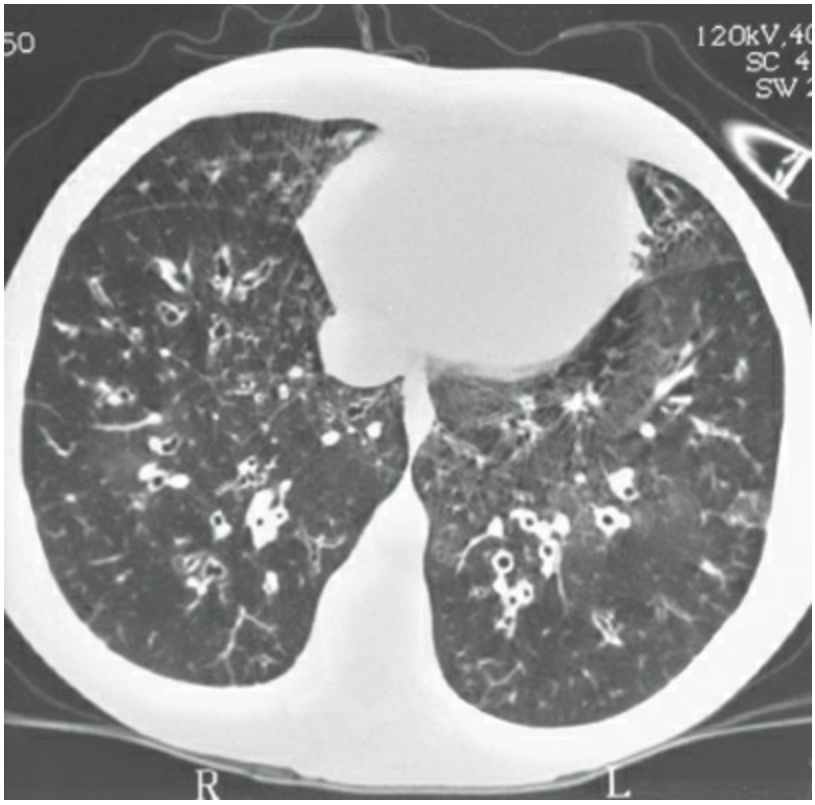

Figure 80-25. CT scan of bronchiectatic lungs. (Reproduced with permission from Shields TW, ed. *General Thoracic Surgery*, 6th ed.)

COPD and Lung Volume Reduction

COPD includes a broad group of diseases that result in airflow obstruction and hyperinflation. Medical therapy involves smoking cessation, bronchodilator treatment, steroids, home oxygen, and antibiotics as needed. Despite improvements in the medical management of this condition, patients continue to suffer severe limitations due to their breathing and exercise capacity. As a result, surgical interventions have continued to play a role in trying to ameliorate symptoms and improving survival in these patients.[36,37]

There is a more than 50-year history in the literature recording a variety of surgical approaches to help treat COPD. Interest was diminished, however, because of the high mortality associated with surgical intervention in this patient population. In the 1990s, a renewed interest in lung volume reduction surgery (LVRS) was observed following reports that this procedure was associated with a low published mortality rate and a significant improvement in FEV_1 seen on pulmonary function testing. There was a national increase in interest in the procedure, as many centers began offering it. Despite continued publication of low mortality rates, evaluation of Medicare data in 1996 showed a mortality of 23% in surgically treated patients at 12 months, and Medicare reimbursement for the procedure stopped. This led to the development of the National Emphysema Treatment Trial (NETT), a prospective randomized trial to evaluate the outcomes of LVRS compared to optimal medical treatment.[36]

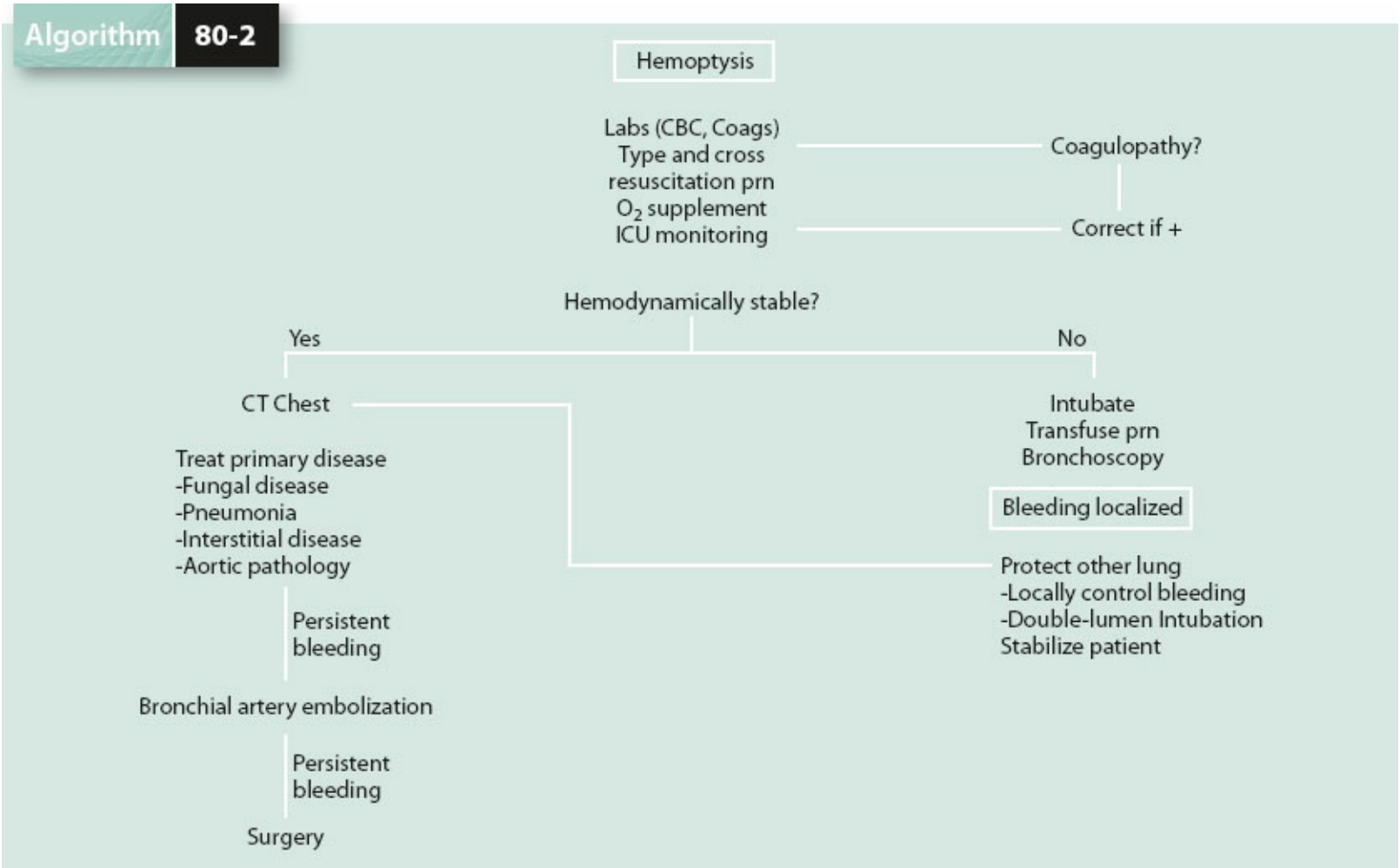

Algorithm 80-2. Hemoptysis management. (Adapted from Jean-Baptiste E. *Crit Care Med* 2000;28(5):1642–1647.)

The goal of the NETT study was to evaluate short- and long-term survival, lung function, exercise capacity, and quality of life. Centers used both median sternotomy and bilateral video-assisted thoracoscopic surgery (VATS) approaches to perform the operative procedure. Interim analysis identified a high-risk subgroup with a higher mortality. These patients had low FEV_1 (less than 20% predicted) and either a homogenous pattern of emphysema in both upper and lower lungs or a low carbon monoxide diffusing capacity (DLCO) (less than 20% predicted). The mortality at 30 days was 16% and the risk was felt to be prohibitive. As the study continued, two preoperative factors appeared to be associated with decreased mortality; dominant upper-lobe emphysema and having a higher preoperative exercise capacity. Using these factors, patients were divided into four subgroups. Patients with upper-lobe disease and a low exercise capacity, defined as achieving less than the 40th percentile on exercise testing, 25 watts for women and 40 watts for men, showed a survival advantage and improved exercise capacity after surgery. Patients with upper-lobe disease and high exercise capacity, achieving more than the 40th percentile cutoff, showed no survival advantage, but did have improved long-term exercise capacity. Patients with nonupper-lobe disease and low exercise capacity had no survival or exercise improvements, but did note an improved quality of life at 24 months. The remaining patients with nonupper-lobe disease and high exercise capacity had a higher risk of death and no significant improvement in exercise capacity or quality of life. The 30-day mortality in the nonhigh-risk subgroup was 5.5%. Long-term follow-up showed the same results in all subgroups except in the nonupper-lobe disease and low exercise capacity group. The quality of life improvement had disappeared by 3 years (Algorithm 80-3).[36] This subgroup analysis has allowed surgeons to better counsel patients as to the benefits of LVRS, based upon which group they fall in.

When the different surgical approaches where evaluated, there was no difference in mortality or benefit from sternotomy versus VATS approaches. Sternotomy patients had a longer hospital stay and higher costs noted at 6 months. The cost effectiveness of LVRS was also evaluated. The mean cost for LVRS was much higher at 1 year than for the medical therapy group, $71,515 versus $23,371, respectively.[38] In the subgroup with upper-lobe disease and low exercise capacity, at 2 years of follow-up, there was a cost of $98,000 per quality-adjusted life-year (QALY). This was predicted to fall to $21,000 at 10 years. In comparison, coronary artery bypass graft surgery has a cost of $64,000 per QALY.[38,39]

A new technique aimed to provide the same benefit of LVRS but without the surgical risk is the placement of one-way endobronchial valves. These are designed to allow air to escape the hyperinflated apical regions and not allow air to reenter. Endobronchial stents have been designed to cross bronchioles into hyperinflated regions of the lung and allow decompression. Other approaches being tested include the bronchoscopic introduction of biologic substances such as trypsin or thrombin into hyperinflated regions of the lung with the goal of causing local scarring and reduce the hyperinflation.[38] Other surgical procedures in the treatment of COPD include bullectomy in selected patients and lung transplants in patients with end-stage disease.[37]

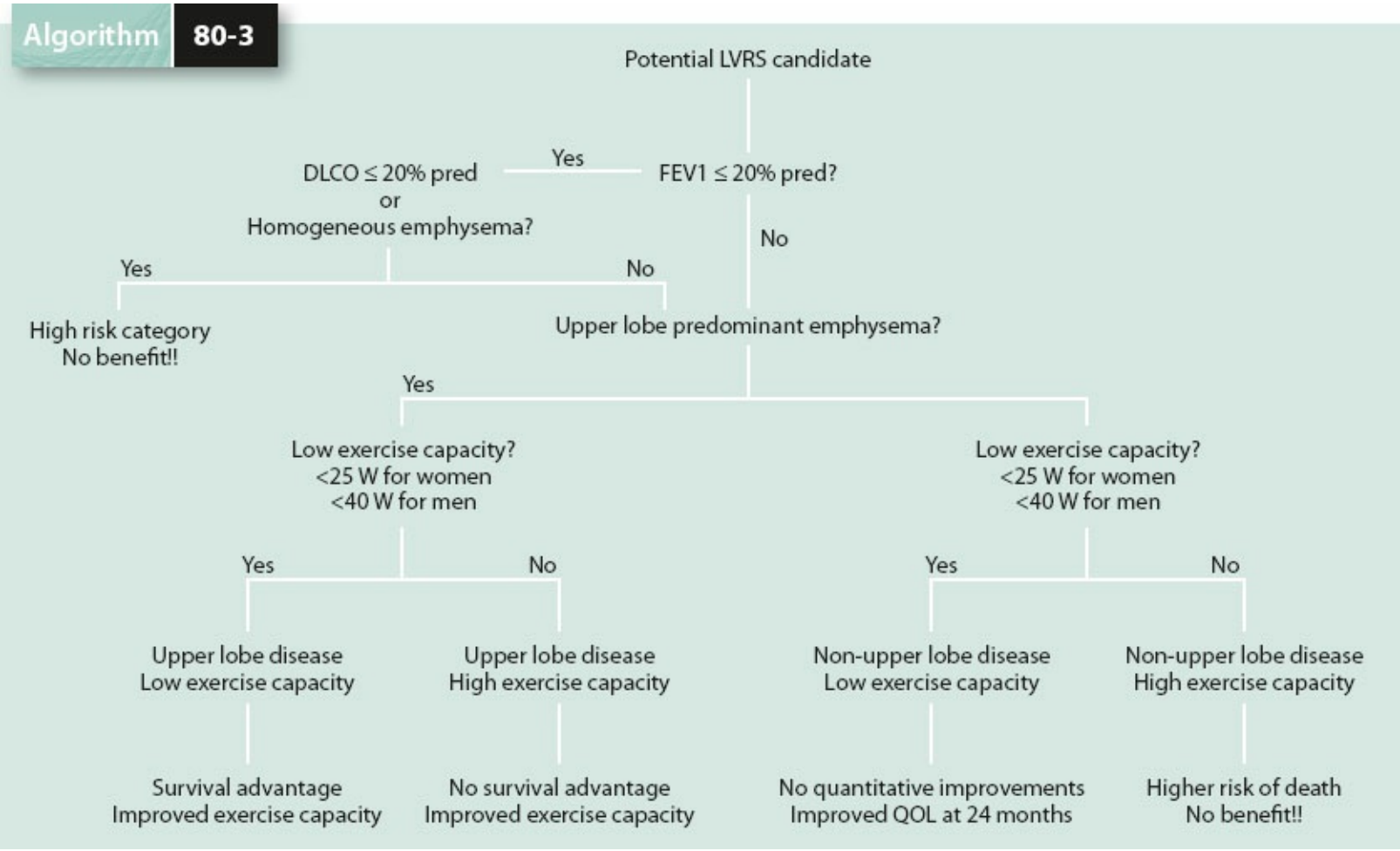

Algorithm 80-3. LVRS candidate workup. (Adapted from Martinez FJ, Chang A. *Semin Respir Crit Care Med* 2005;26(2):167–191.)

Tracheobronchial Foreign Body Aspiration

Tracheobronchial foreign body (TFB) aspiration occurs most often in children, but upto 20% of cases have been reported in adults. Risk factors in adults include older age, as elderly patients have a higher incidence of neurologic disease and an impaired cough reflex. Symptoms usually involve an episode of choking, followed by a protracted cough. Fever, dyspnea, and wheezing can also be present.[40] Chest x-ray may aid in the diagnosis if the aspirated TFB is radio-opaque or if there is associated air trapping, atelectasis, or pneumonia, however, the TFB is visible less than a quarter of the time as most foods are not radio-opaque.[41] Chest CT scans are a more sensitive imaging modality, but not necessarily more specific. Bronchoscopy should be performed if TFB aspiration is suspected. Removal of the TFB can usually be accomplished by flexible bronchoscopy but may require rigid bronchoscopy in difficult cases.[40,41]

Pneumothorax

Pneumothoraces are classified as spontaneous, primary or secondary, traumatic, or iatrogenic. Primary spontaneous pneumothoraces occur in patients with no known lung disease, whereas secondary spontaneous ones occur in patients with underlying lung pathology thought to predispose those patients to a pneumothorax. Iatrogenic pneumothoraces may occur in either the postsurgical or postprocedural setting, typically following central line placement or thoracentesis.[42] Traumatic pneumothoraces are covered elsewhere in this text.

Primary spontaneous pneumothoraces occur more frequently in men than women, with an incidence of 7 to 18 cases per 100,000 people for men, compared to an incidence rate of 1 to 6 cases per 100,000 people in women. Most cases occur in males younger than 30 years of age, and they rarely occur in people over the age of 40. Even though many patients with primary pneumothoraces do not have apparent lung disease, almost all are found to have subpleural bullae, the pathophysiology of which is unknown.[42] Most bullae are apical in location.[43] Patient symptoms can range from minimal to severe, and usually include pleuritic pain, dyspnea, or both. Tachycardia may also be present, and if a person is tachycardic and hypotensive, a tension pneumothorax must be high on the differential and appropriate needle decompression considered. A tension pneumothorax occurs when air entering the pleural cavity cannot escape and the air compresses the vena cava and even the heart, resulting in hemodynamic instability (Fig. 80-26). Urgent needle decompression followed by chest tube placement is the preferred treatment. Most spontaneous pneumothoraces occur while patients are at rest.[42,44]

5 Observation is often the treatment of a stable, small pneumothorax, defined as being less than 3 cm from the apex. For a larger pneumothorax, chest tube placement is the standard treatment, though some advocate a trial of aspiration. Most patients will have a complete resolution of their pneumothorax and not need further treatment. In the group of patients who have a persistent air leak from the initial pneumothorax, or the 30% who have a recurrent pneumothorax, usually within 2 years, further treatment is warranted. This involves some form of pleurodesis, chemical or mechanical, either via a chest tube (talc infusion), or during a thoracoscopic evaluation where apparent blebs can also be resected (Algorithm 80-4).[43,44]

Secondary spontaneous pneumothoraces can occur due to a variety of lung diseases, but COPD is the most common.[45] While primary pneumothoraces can be mild clinical events, secondary ones are much more concerning because of the baseline lung disease and poor pulmonary reserve. Observation has no role in this patient population who should undergo definitive treatment to prevent a recurrence during the first event. Here a thoracoscopic approach may be more effective in establishing an adequate pleurodesis and allow the evaluation for sources of air leaks.[44] Iatrogenic pneumothoraces can result from transthoracic needle lung biopsies, central line placement, thoracentesis, transbronchial lung biopsies, pleural biopsies, and positive pressure ventilation. Patients with underlying lung disease are at a higher risk of developing a pneumothorax after these procedures. Treatment should follow the same paradigm as for spontaneous

pneumothoraces. Patients with a small, asymptomatic, stable pneumothorax and no underlying lung disease may be safely observed, while all others should undergo placement of a chest tube.[44] Some studies have suggested immediate aspiration of air after a CT-guided lung biopsy resulting in a pneumothorax, with an 85% success rate in avoiding the need for chest tube placement.[43]

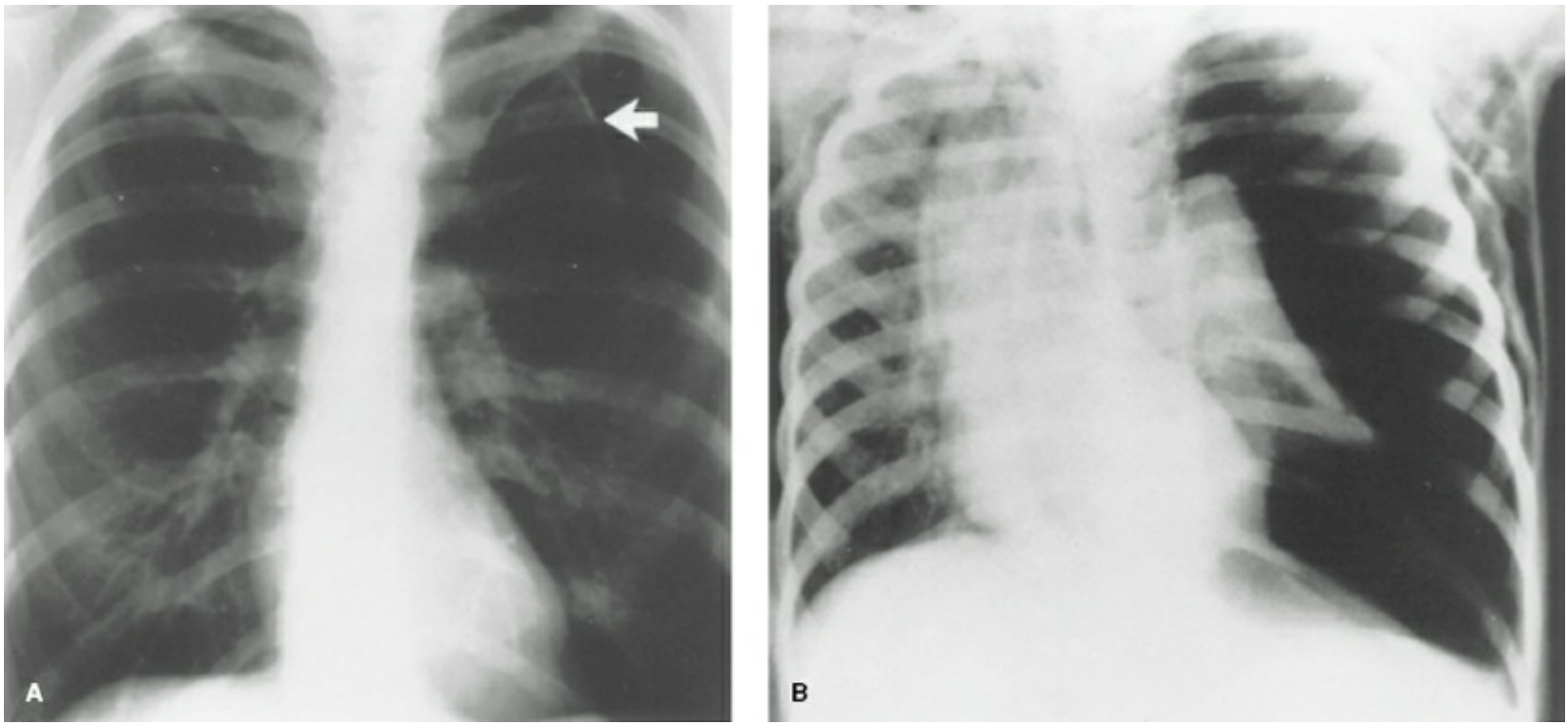

Figure 80-26. **A:** A 40% left-sided spontaneous pneumothorax (*arrow*). **B:** Progression of simple pneumothorax to a tension pneumothorax, showing the characteristic radiographic findings – virtual collapse of the entire involved lung, shift of the mediastinum to the contralateral side, and compression of the contralateral lung. Subcutaneous air dissecting along the left chest wall is also evident.

Congenital Lung Disease

Congenital malformations of the lung develop during fetal lung growth. They may be identified during an in-utero evaluation, present as respiratory distress in the newborn, or be completely asymptomatic and found in patients as adults. They can frequently occur with other congenital malformations and may be life-threatening. Lung development begins during week 3 from the foregut. It progresses through birth to approximately 2 years of age when alveolar development is complete. The five stages of lung development have been divided into the embryonic, pseuodglandular, acinar, saccular, and alveolar stages (Table 80-2). Malformations may occur at each step and lead to different pathologic conditions.[46] Four separate conditions will be discussed here; pulmonary sequestration, lobar emphysema, congenital cystic adenomatoid malformation (CCAM), and bronchogenic cysts.[47]

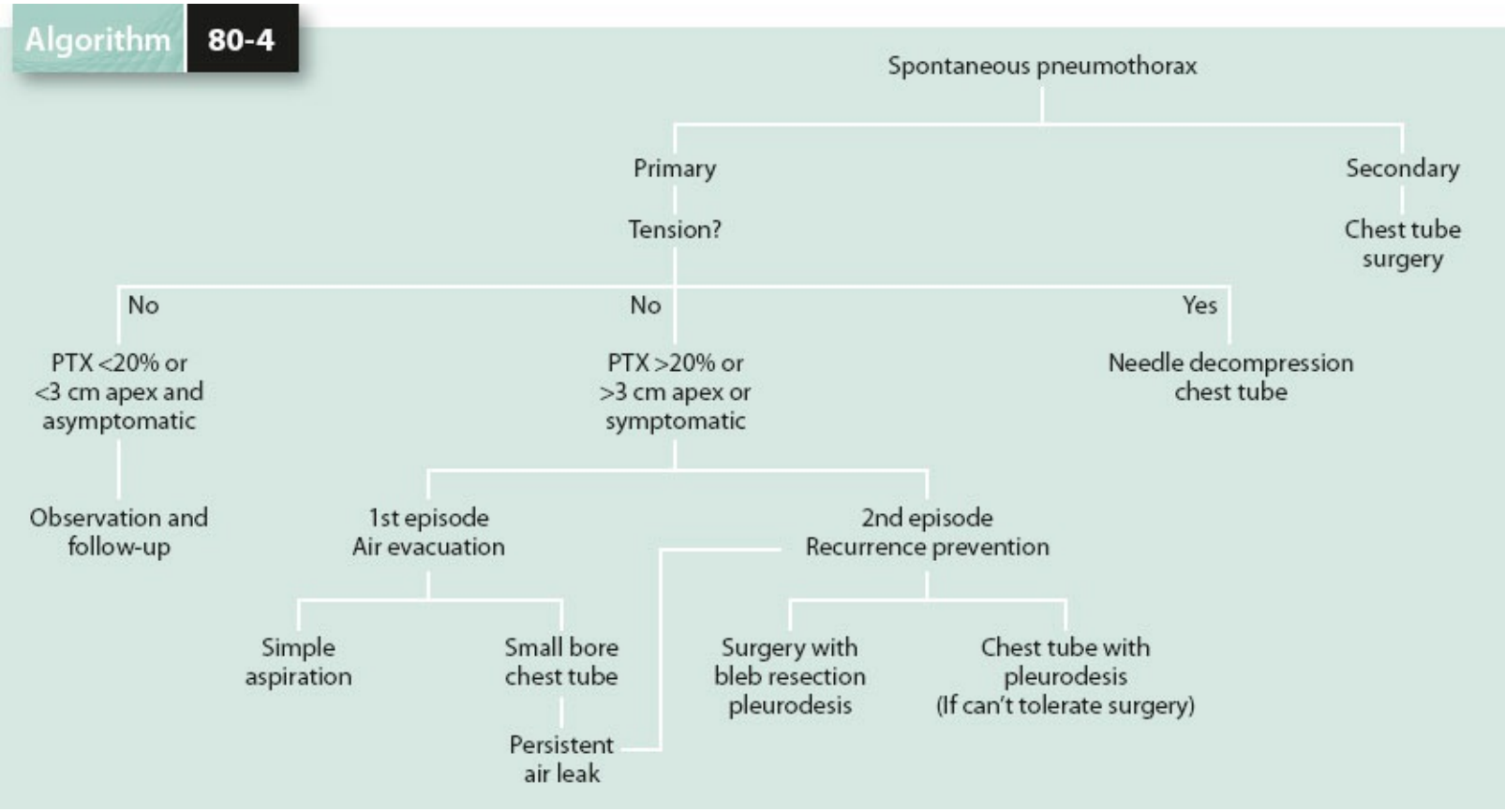

Algorithm 80-4. Algorithm to treat pneumothorax. (Adapted from Baumann MH, Noppen M. *Respirology* 2004;9(2):157–164.)

Table 80-2 Phases of Lung Development Classification

Phase	Gestation Period	Major Developments
Embryonic	26 days to 6 wks	5 lobar bronchi
Pseudoglandular	6–16 wks	Cartilage rings, cilia form
Acinar/canalicular	16–28 wks	Type I and II pneumocytes
Saccular	28–34 wks	Distal airspace development
Alveolar	34 wks to 2 years	Alveoli proliferate from 20 to 600 million

Pulmonary Sequestrations

Pulmonary sequestrations are defined as pieces of parenchymal lung separated from the respiratory tree, with the sequestration receiving its blood supply from an anomalous artery arising from the aorta, rather than having the blood supply arising from the pulmonary artery. Sequestrations have been further subdivided into extralobar and intralobar lesions, with very distinct anatomic alterations and clinical presentations. Extralobar sequestrations reside outside of the true pleural space. Venous drainage is usually into the azygos or hemiazygos veins. They are most often on the left side between the left lower lobe and diaphragm (Fig. 80-27). Upto 80% of extralobar sequestrations occur in males. Most patients present with dyspnea in the first 6 months of life. They may be diagnosed by fetal ultrasound or after birth by chest x-ray. Other congenital abnormalities are found in upto two-thirds of patients, with congenital diaphragmatic hernias present in a quarter of patients.[46] Intralobar lesions reside within the normal lung and within the normal pleura. They are almost always in the lower lobes and occur in the left side just over 50% of the time. Venous drainage is usually through the pulmonary vein. It is suggested that intralobar sequestration may be an acquired disease, caused by repeated episodes of inflammation that lead to bronchiole narrowing and scarring. Ultimately the “lobe” becomes isolated and may develop new feeding blood vessels from collateral arteries in the inferior pulmonary ligament. A complete assessment of a sequestered lesion must be performed prior to resection, and should include assessment of any potential airway or gut connection, determining the vascular supply of the sequestration, and determining if there are any other congenital malformations.[46]

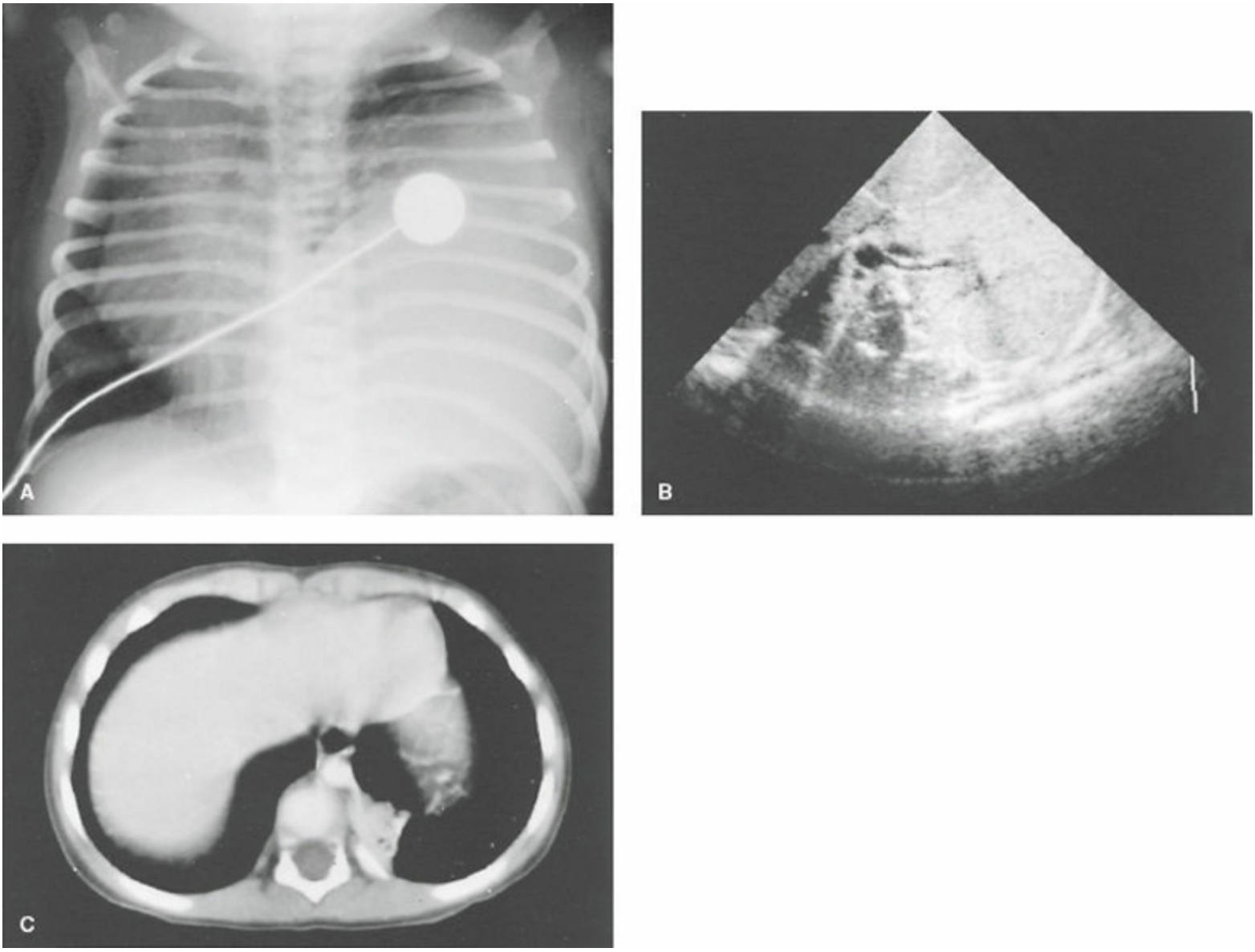

Figure 80-27. Abnormal radiograph of the chest of a newborn with respiratory distress **(A).** Ultrasound identified the anomalous vessel coursing through the diaphragm and entering the sequestration **(B).** This computed tomographic scan clearly demonstrates the anomalous artery arising from the thoracic aorta and entering the sequestered lung **(C).** (Reproduced with permission from Shields TW, ed. *General Thoracic Surgery*. 6th ed. 2005.)

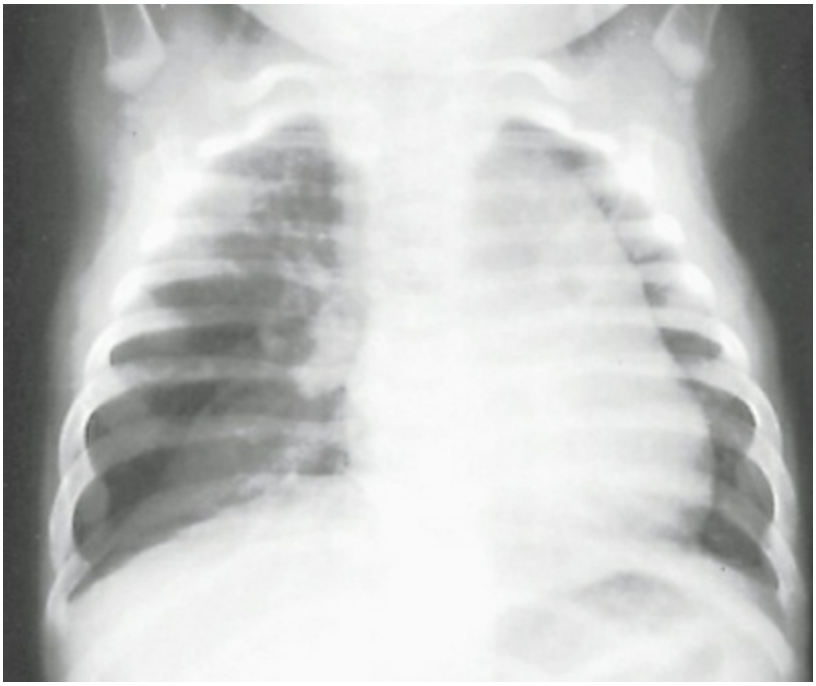

Figure 80-28. Radiograph of a newborn with lobar emphysema involving the right middle lobe. Note the compressed right lower lobe and mediastinal shift. (Reproduced with permission from Shields TW, ed. *General Thoracic Surgery*. 6th ed. 2005.)

Congenital Lobar Emphysema

Lobar emphysema is the cause of half of the episodes of newborn respiratory distress that are due to structural anomalies. Two-thirds of the cases occur in males. Distension of the distal lung occurs from obstruction of the airway, either from an intrinsic cause, such as meconium or torsion, or an extrinsic cause, such as obstructing lymph nodes. In upto half of the cases, no cause can be found. Almost all cases occur in the upper lobes, with almost equal distribution between sides. Half of the lesions will present in newborns, and the remaining 50% will reveal themselves by 6 months. Chest x-rays are diagnostic (Fig. 80-28).[46] Surgical resection may not be immediately necessary, and may be delayed until the child has grown, or until they develop a failure to thrive. Even after surgical resection, patients may have bronchomalacia and a tendency toward bronchospasm.[48]

Congenital Cystic Adenomatoid Malformation

CCAM lesions are the second most common cause (25%) of newborn respiratory distress, secondary to structural problems. Children will present either at birth or in early childhood with recurrent respiratory infections. The anomalies are due to an overgrowth of bronchioles, likely during the acinar phase of fetal lung development. Lesions can occur on either side and are usually isolated to one lower lobe. The classification system by Stocker (Table 80-3) organizes these lesions based on pathologic appearance and clinical outcome. Prenatal MRI best serves to evaluate these lesions, while postnatal chest x-ray and/or chest CT scan can be used to differentiate CCAMs from other lesions.[46] Even though lesions may be small and asymptomatic, these lesions possess the potential for malignant transformation and should be resected (Fig. 80-29).[48]

Table 80-3 The Stocker Classification of CCAM

- Type I
  75% of lesions
  Few large cysts
  Parenchymal compression
- Type II
  Numerous, <1 cm cysts
  Associated with other congenital anomalies
  Worse prognosis
- Type III
  Rarest type
  Cysts are solid and smaller (few mm in diameter)

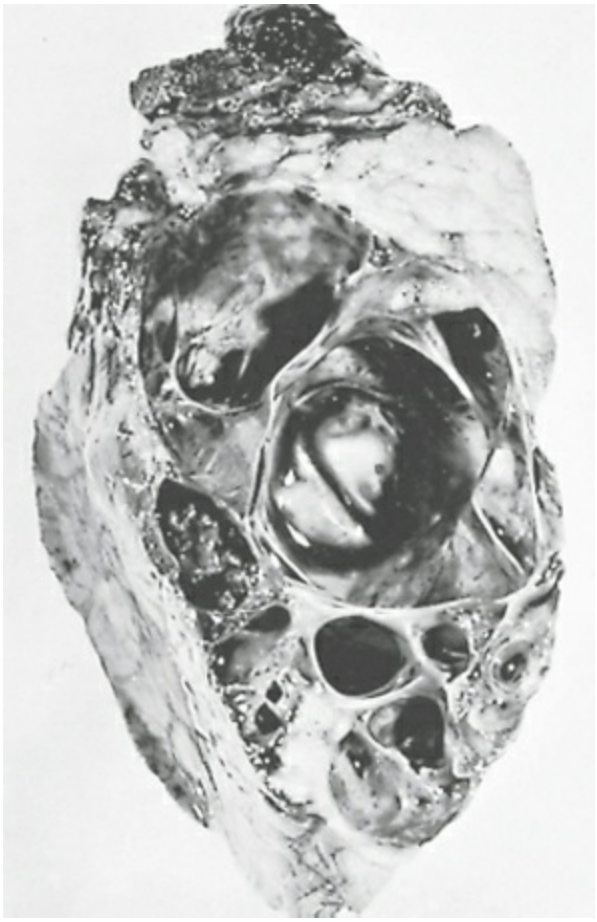

Figure 80-29. Specimen removed from an infant with a cystic adenomatoid malformation. Microscopically, there was marked proliferation of terminal bronchioles, and cartilage was lacking. (Reproduced with permission from Shields TW, ed. *General Thoracic Surgery*. 6th ed. 2005.)

Bronchogenic Cysts

Bronchogenic cysts are formed from primitive foregut tissue present in the airway. They can present as single or multiple cysts in a wide variety of locations in the thorax. They usually present in young children who develop symptoms such as stridor due to airway obstruction or compression caused by the cysts.[47] Alternatively, cysts located within the lung parenchyma can become infected and present as an abscess. Therapeutic aspiration may be temporizing, but ultimately surgery is needed.[49] Resection may have a mortality of upto 14%, but untreated lesions have a 100% mortality.[47] Most cases of congenital lung disease will present in the first 6 months of life. The main symptom is usually respiratory distress, but once children reach 1 year in age, chronic infections become the most common symptom. Diagnostic tests begin with chest x-rays, but can include ultrasound, MRI, CT scans, angiography, and bronchoscopy, depending on the lesion and location.[50] Decision-making regarding the timing of surgical resection should incorporate the patient's acuity due to symptoms and their overall ability to tolerate surgery based on size.

Pleural Disease

Pleural diseases include benign complications from systemic disease, postoperative infections, local infections, and cancers from primary and metastatic sites. Diseases involving the pleura can lead to limitations to respiration and symptoms of dyspnea. Surgical intervention may be indicated, and it is imperative for the surgeon to be able to recognize which disease processes require a surgical procedure. Pneumothoraces are discussed earlier in this chapter, and here we will cover pleural effusions, including empyemas, and malignant pleural mesotheliomas.

Table 80-4 Differential Diagnosis of Pleural Effusions

Transudative pleural effusions	Collagen vascular diseases
Congestive heart failure	Rheumatoid pleuritis
Pericardial disease	Systemic lupus erythematosus
Cirrhosis	Drug-induced lupus erythematosus
Nephrotic syndrome	Immunoblastic lymphadenopathy
Peritoneal dialysis	Sjögren syndrome
Superior vena cava obstruction	Wegener granulomatosis
Myxedema	Churg–Strauss syndrome
Pulmonary emboli	Postcardiac injury syndrome
Sarcoidosis	Asbestos exposure
Urinothorax	Sarcoidosis
Exudative Pleural Effusions	Uremia
Neoplastic diseases	Meigs syndrome
Metastatic disease	Yellow nail syndrome
Mesothelioma	Drug-induced pleural disease
Infectious diseases	Nitrofurantoin
Bacterial infections	Dantrolene
Tuberculosis	Methysergide
Fungal infections	Bromocriptine
Viral infections	Procarbazine
Parasitic infections	Amiodarone
Pulmonary embolization	Trapped lung
Gastrointestinal disease	Radiotherapy
Esophageal perforation	Electric burns
Pancreatic disease	Urinary tract obstruction
Intra-abdominal abscess	Iatrogenic injury
Diaphragmatic hernia	Ovarian hyperstimulation syndrome
Postabdominal surgery	Chylothorax
Endoscopic variceal sclerotherapy	Hemothorax

PLEURAL EFFUSIONS

Pleural effusions are a common condition that elicits a surgical consult for potential drainage and even thoracoscopic intervention to assist in the diagnosis and treatment of the condition. The essential first step in the evaluation of a new effusion is to determine if it is a transudative or exudative process. A transudative fluid collection is the result of a poorly balanced hydrostatic and/or osmotic pressure across the pleural membrane resulting in increased serum leak across the pleural barrier. Exudative processes result from inflammation or neoplastic processes that cause increased capillary leak at the pleural membrane. Because of the leaky membrane, larger proteins can enter the pleural fluid resulting in higher protein and lactate dehydrogenase (LDH) levels in the exudative fluid compared to the transudative fluid (Table 80-4).[51] One of the tests used most often to make the diagnosis is Light criteria, where the serum and pleural fluid protein and LDH levels are measured (Table 80-5). If one or more of the criteria are met, then the fluid is considered exudative.[52] Other tests have been evaluated, including measuring cholesterol ratios and the albumin gradient, but Light criteria is still the best overall test.[51]

6 Transudative effusions are most often caused by congestive heart failure. Even if a patient does not have other symptoms of heart failure, in the setting of a transudative effusion, a complete cardiac workup should be considered. Other causes include cirrhosis which may or may not be associated with ascites. Isolated right- and left-sided effusions due to liver disease have been described. Effusions can be seen in more than 20% of patients with nephrotic syndrome, and so all patients with new effusions should be evaluated for the presence of proteinuria. Rarer causes include retroperitoneal urine leaks or cerebrospinal fluid leaks.[52] Surgical interventions, such as chest tube placement, should be avoided in transudative disease settings, as patients will continue to drain fluid from their chest until the primary cause is treated. Aspiration of fluid may help temporarily while systemic treatment is instituted, but should only be done as part of a larger treatment plan.

Table 80-5 Criteria for Exudative Effusions Based on Ratio of Pleural Fluid Protein and LDH Concentrations to Serum Concentration

Protein/serum protein >0.5
LDH/serum LDH >0.6
Pleural LDH 1.67 times normal serum LDH

LDH, lactate dehydrogenase.

Exudative effusions have a number of etiologies, but malignancy is the number one cause.[52] Approximately a quarter of pleural effusions in a community hospital setting have been attributed to cancer. The malignancies that cause the effusions are, in order of decreasing frequency: lung cancer, breast cancer, and hematologic cancers such as

lymphoma. Other malignancies can also cause effusions, such as ovarian cancer.[53] The next most common causes of exudative effusions are infections, and include pneumonias causing parapneumonic effusions, tuberculosis (TB), and fungal infections. Although rarer in the United States, TB is still a common etiology worldwide. If someone is suspected of having pleural TB, the pleural fluid should be evaluated for adenosine deaminase (ADA) and gamma-interferon levels, which if low will rule out the diagnosis of TB. If other infections are suspected, the pleural fluid should be cultured. Pancreatitis may also cause an exudate, and elevated serum amylase levels will support the diagnosis. Autoimmune processes, such as rheumatoid disease and lupus, can also cause effusions. A chylothorax may present after problems with thoracic duct lymphatic drainage leading to an accumulation of lymphatic fluid, “chyle”, in one or both thoraces. The thoracic duct collects lymph from the cysterna chyli, the plexus of lymphatics in the upper abdomen, and travels anterior to the spine and just posterolateral to the aorta. It follows behind the aorta and enters the left neck where it empties into the confluence of the left internal jugular and subclavian veins (Fig. 80-30). Chylous leaks are due primarily to thoracic duct injury from trauma or surgery or lymphomas resulting in obstructed lymphatics. Pleural triglyceride and cholesterol levels will be elevated and the fluid will have a milky color. Treatment for persistent chylothoraces include thoracic duct ligation by surgery or by embolization of the site of leak in the interventional suite.[52]

The management of malignant pleural effusions includes a variety of options, but critical to the decision-making process is the knowledge of the median life expectancy in that patient due to the underlying malignancy. Chest tube drainage may be therapeutic and diagnostic, allowing fluid drainage and alleviation of symptoms of dyspnea. It will also allow determination of whether the underlying lung is able to expand. If not, it is described as a “trapped lung” and although the fluid may be gone, a persistent pneumothorax appears on chest x-rays as the lung cannot expand and fill the thorax. In these settings, an indwelling pleural drainage catheter may be the best option to intermittently drain accumulating fluid. Decortication is not recommended, as most patients with malignancy in this setting have a limited life expectancy and the success rate is low compared to decortication in the setting of an empyema. VATS exploration may also be used to remove loculated fluid collections and to evaluate for lung reexpansion after the procedure. If the lung reexpands, further treatment includes pleurodesis, utilizing talc, doxycycline, or bleomycin. These medications will cause an inflammatory reaction between the parietal and visceral pleura resulting in the lung being “stuck” in an expanded state. Mechanical pleurodesis can also be performed by mechanical debridement of the pleura via VATS. Chemical pleurodesis may be performed via VATS or through an existing thoracostomy tube. The goal of treatment in the setting of a malignant pleural effusion is palliation.[53]

Empyema

7 Empyemas are defined as frank pus in the thoracic cavity. This represents part of the continuum of disease that begins with simple parapneumonic effusion, where exudative fluid is not infected and not loculated. As the disease progresses, fluid becomes loculated with fibrinous septations and becomes infected, leading to pus and ultimately the development of a fibrinous peel. Upto half of pneumonias have an associated effusion, but less than 5% of cases lead to an empyema.[54] Other causes include surgical thoracotomies and/or other infections from nearby organs, such as esophageal injuries. Pleural infections have been categorized into three overlapping stages. The first is the exudative stage, where the fluid is thin, sterile, has a lower white blood cell (WBC) count and LDH levels, and the glucose level is still above 40 mg/dL (Table 80-6). Treatment usually involves addressing the underlying etiology, such as pneumonia. The second stage is the fibrinopurulent stage, where the fluid becomes infected and fibrin deposits accumulate on the pleura. The LDH and WBC count increases, the glucose and pH levels drop. The fluid becomes thick and purulent and the lung is often unable to expand. Chest tube drainage alone at this stage may not be effective to remove the fluid. The third stage is the organizing stage, and a thick pleural peel is created by migrating fibroblasts. At this point, a formal debridement and decortication is required to allow the lung to return to full function.[54]

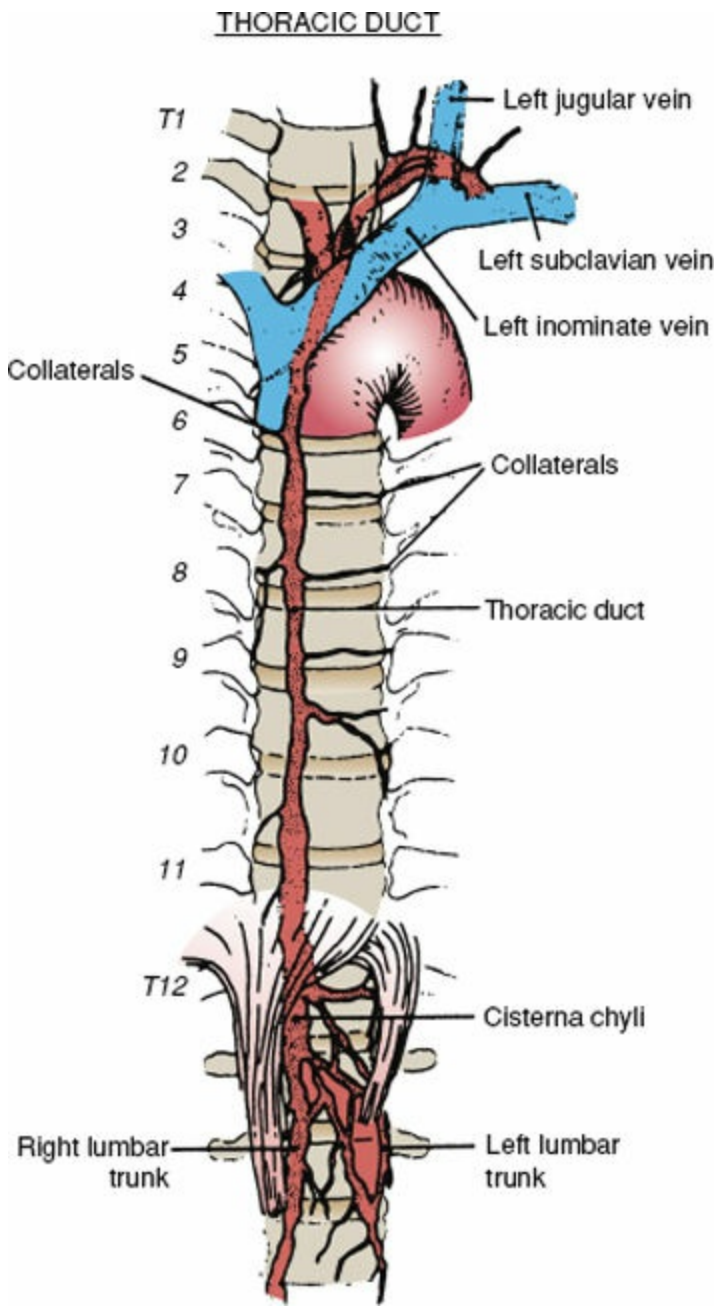

Figure 80-30. Schematic drawing of the most usual pattern and course of the thoracic duct. The single duct that enters the chest through the aortic hiatus between T12 and T10 is a relatively consistent finding and the usual site for surgical ligation.

Organisms causing empyemas have shifted from predominately *Streptococcus pneumoniae* in the preantibiotic era, to anaerobic organisms in upto three-quarters of empyemas in the current era. Imaging to evaluate the presence of an empyema begins with a simple chest x-ray, but requires a chest CT to show potential loculations. After the institution of antibiotic therapy, surgical intervention depends on the stage of the disease, but may require a VATS exploration or even a thoracotomy to debride the thorax effectively and to decorticate the pleural peel off of the lung to allow reexpansion.[54] Postpneumonectomy empyemas are an especially difficult problem as there is no lung tissue to occupy the empty thorax. Risk factors in this setting include right pneumonectomies (vs. left), the need for postoperative ventilation, lower starting hematocrit levels, and poor preoperative pulmonary function test results.[55,56] Treatments

of these empyemas are particularly difficult and may include an Eloessor flap or the Clagget procedure which allow for the creation of an open wound that allows for packing and granulation tissue to form in the empyema cavity.[57]

Table 80-6 Diagnostic Criteria for Pleural Fluid in Empyema

Stage	Fluid/Peel	WBC	LDH (cells/mm^3)	pH (IU)	Bacteria
Exudative	Thin/elastic	<1,000	<500	>7.3	Absent
Fibrinopurulent	Purulent/inelastic	>5,000	>1,000	<7.1	Present
Organizing	Thick/rigid peel	Varies	Varies	<7.1	Varies

Mesothelioma

Malignant pleural mesothelioma (MPM) is a cancer of the serosal pleura, related to the exposure to asbestos. Multiple hypotheses have been formed regarding how asbestos causes mesothelioma, and include the idea that asbestos fibers are inhaled deeply into the lung and penetrate the parenchymal surface, causing irritation of the pleura and repeated episodes of inflammation, ultimately leading to cancer. Other potential mechanisms include asbestos interfering with mitosis, inducing free-radical production, and induction of protooncogene kinases by asbestos fibers.[58] Exposure to asbestos usually occurs decades prior to presentation with mesothelioma, and has been seen in miners exposed to asbestos dust, industrial workers such as plumbers and carpenters who used asbestos products, and even in 20% of patients with no known exposure but living in industrial countries. Mesothelioma is a relatively rare malignancy, with less than 5,000 cases in the United States per year.[59]

Patients with mesothelioma may present with dyspnea or chest pain. Often, patients are asymptomatic and the diagnosis is made after abnormalities are seen on a chest x-ray performed for another reason. Radiographs may show unilateral effusions and a loss of volume on the affected side, as the lung capacity is diminished due to disease. As the disease progresses, patients may have weight loss, worsening pain, and night sweats. Median survival may be as little as 1 year from the time of diagnosis.[60] Diagnostic studies include a chest CT scan or MRI to show the extent of pleural thickening (Fig. 80-31). Lymphadenopathy or signs of local spread through the diaphragm or chest wall can also be seen with three-dimensional imaging. The pathologic diagnosis almost always requires a tissue biopsy. Cytologic examination of pleural fluid from a thoracentesis cannot differentiate between mesothelioma cells and other potential lung cancers. CT-guided biopsy of pleural thickening can often give the diagnosis, but ultimately a VATS approach or limited thoracotomy may be needed to obtain a diagnosis. If the patient is being considered for surgical resection, a limited thoracotomy in the site of a potential later incision is optimal to limit seeding of the tumor.[60]

Mesotheliomas can be categorized into epithelial, sarcomatoid, and mixed histologies. Patients with epithelial histology do better than those with a sarcomatoid histology.[60] There are a variety of staging systems for mesothelioma, including the Butchart system, the revised Brigham and Women's Hospital system, and the TNM-based system by the International Mesothelioma Interest Group (IMIG) (Table 80-7).[60,61] The IMIG system allows for better reproducibility of the interpretation of local and regional lymph node spread. Laparoscopy may be useful to evaluate the patient for transdiaphragmatic spread of the tumor, differentiating between T3 and T4 tumors.[61]

Treatment for mesothelioma may include chemotherapy, radiation therapy, and surgery. Surgical treatment ranges from a pleurodesis for palliation in the setting of effusions and unresectable disease, to pleurectomy/decortication for limited disease, and to the most aggressive treatment of an extrapleural pneumonectomy (EPP), with the goal of complete tumor resection. Less than a third of patients are candidates for any surgical intervention. Preoperative workup for an EPP should include a cardiac evaluation, and

optimal surgical candidates have pulmonary function tests with an FEV_1 of greater than 2 L/sec and an age under 70.[61] Surgery involves an en bloc removal of the lung, pleura, pericardium and diaphragm with reconstruction of the pericardium and diaphragm. Pleurectomy and decortication is reserved for very early-stage disease and involves removal of the pleura only with preservation of the lung parenchyma. Multimodality approaches have shown better results, with neoadjuvant chemotherapy and adjuvant radiation therapy.[62] Chemotherapy for advanced disease includes pemetrexed and cisplatin or the combination of gemcitabine and cisplatin. Both have shown similar levels of palliation. Radiotherapy may also be used, but is limited by the large field requiring treatment and the risks of pneumonitis and esophagitis.[58] It is best used in combination with EPP for local control after surgery, or to treat local painful areas.[61] Because of the rarity of surgical cases, most patients who are considered for surgery should be referred to high-volume centers where surgeons and other clinicians are comfortable treating this disease.

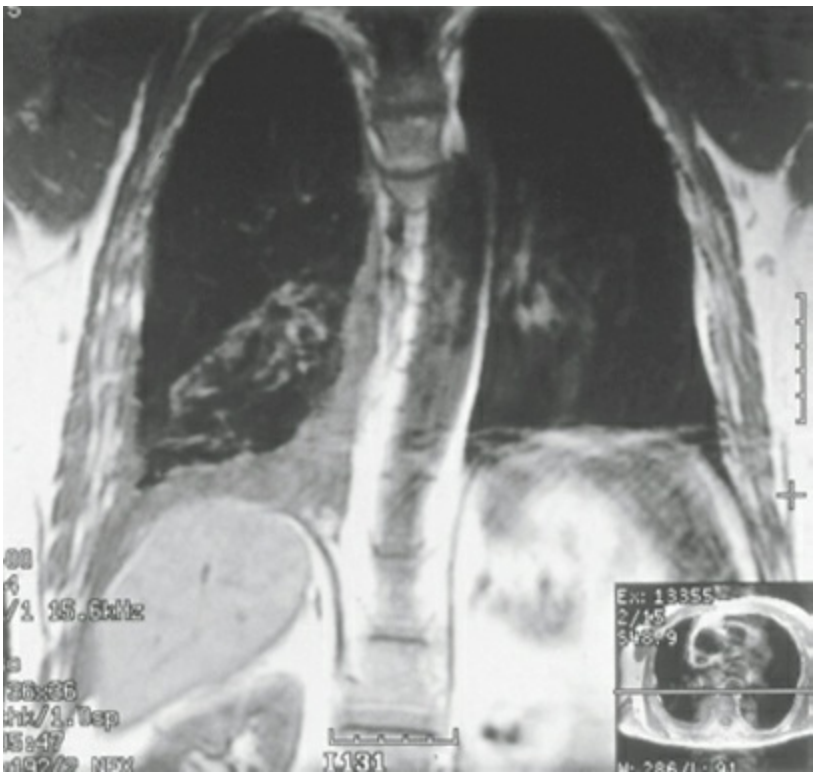

Figure 80-31. Magnetic resonance imaging of the patient in Figure 80-25 shows a large amount of tumor within the pleural space and into the diaphragmatic sulcus with no evidence of extension outside the hemithorax. (Reproduced with permission from Flores RM, Sugarbaker DJ. Malignant mesothelioma of the pleural space. *Ann Thorac Surg* 2000;70:306.)

STAGING

Table 80-7 The International Mesothelioma Interest Group (IMIG) Staging System

T–Tumor		
T1	1a	Tumor limited to the ipsilateral parietal pleura, including mediastinal and diaphragmatic pleura; noninvolvement of the visceral pleura
	1b	Tumor involving the ipsilateral parietal pleura, including mediastinal and diaphragmatic pleura; scattered foci of tumor also involving the visceral pleura
T2		Tumor involving each of the ipsilateral pleural surfaces (parietal, mediastinal, diaphragmatic, and visceral pleura) with at least one of the following features: Involvement of diaphragmatic muscle Confluent visceral pleural tumor (including the fissures) or extension of tumor from visceral pleura into the underlying pulmonary parenchyma
T3		Locally advanced but potentially resectable tumor; tumor involving all of the ipsilateral pleural surfaces (parietal, mediastinal, diaphragmatic, and visceral pleura) with at least one of the following features: Involvement of the endothoracic fascia Extension into the mediastinal fat Solitary, completely resectable focus of tumor extending into the soft tissues of the chest wall Nontransmural involvement of the pericardium
T4		Locally advanced technically unresectable tumor; tumor involving all of the ipsilateral pleural surfaces (parietal, mediastinal, diaphragmatic, and visceral) with at least one of the following features: Diffuse extension or multifocal masses of tumor in the chest wall, with or without associated rib destruction Direct transdiaphragmatic extension of tumor to the peritoneum Direct extension of tumor to the contralateral pleura Direct extension of tumor to one or more mediastinal organs Direct extension of tumor into the spine Tumor extending through to the internal surface of the pericardium with or without pericardial effusion; or tumor involving the myocardium

N–Lymph Nodes	
NX	Regional lymph nodes cannot be assessed
N0	No regional lymph node metastases
N1	Metastases in the ipsilateral bronchopulmonary or hilar lymph nodes
N2	Metastases in the subcarinal or ipsilateral mediastinal lymph nodes, including the ipsilateral internal mammary nodes
N3	Metastases in the contralateral mediastinal, contralateral internal mammary, ipsilateral or contralateral supraclavicular lymph nodes
M–Metastases	
MX	Presence of distant metastases cannot be assessed
M0	No distant metastasis
M1	Distant metastasis present

Stage	Description
I	
Ia	T1aN0M0
Ib	T1bN0M0
II	T2N0M0
III	Any T3M0
	Any N1M0
	Any N2M0
IV	Any T4
	Any N3
	Any M1

Adapted with permission from Rusch VW. A proposed new international TNM staging system for malignant pleural mesothelioma. From the International Mesothelioma Interest Group. *Chest* 1995;108:1122–1128.

Trachea

The trachea is a well-known structure to the general surgeon who may perform tracheostomies and bronchoscopies as part of their clinical practice. A thorough knowledge of the anatomy and vascular supply is essential to minimize complications such as postintubation tracheal stenosis and tracheoinnominate fistulas after tracheostomies.

Anatomy

The trachea is the connection from the cricoid cartilage to the carina that allows ventilation and mucous clearance from the lungs. It is oval shaped, with C-shaped cartilaginous rings creating the anterior and lateral borders. A soft tissue membrane forms the posterior wall to complete the oval shape. In the average male, the anterior–posterior dimension is 1.8 cm, while the lateral aspect is 2.3 cm. Tracheal length reaches almost 12 cm with almost 2 rings per centimeter. Tracheae in women are 10% to 20% smaller in size. In children, the shape is more circular, but becomes gradually more ovoid as people age. There is a significant amount of flexibility in the normal trachea, and remodeling can occur in chronic disease states such as emphysema. The inner lining consists of ciliated pseudostratified columnar epithelium with goblet and mucous cells interspersed. At the carina, the right and left mainstem bronchi split off. The right side is characterized by the quick takeoff of the right upper-lobe bronchus, with the bronchus intermedius continuing into the middle and lower-lobe bronchi. The left side has a longer mainstem bronchus with a split into the upper and lower lobes.[63] The blood supply begins with the inferior thyroid artery supplying the cervical trachea through three tracheoesophageal branches. The lower trachea is supplied by bronchial arteries arising off the aorta. As the arteries approach the trachea, they further split to supply separate segments. Even within segments, it will branch into anterior and posterior transverse intercartilaginous arteries (Fig. 80-32). Because of this segmental blood supply, there should be minimal circumferential dissection around the trachea to limit impairment of the blood supply and healing in tracheal/bronchial surgery.

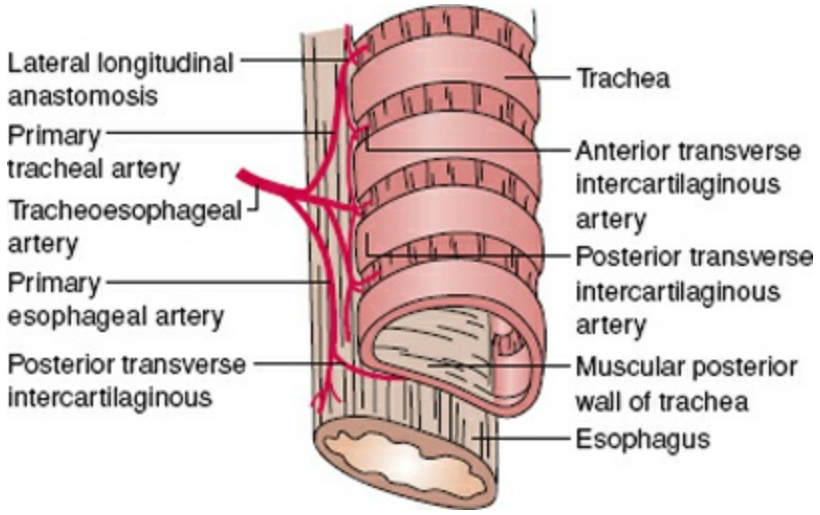

Figure 80-32. Semischematic view of the tracheal microscopical blood supply. Transverse intercartilaginous arteries derived from the lateral longitudinal anastomosis penetrate the soft tissues between each cartilage to supply a rich vascular network beneath the endotracheal mucosa.

Surgical Airways

The most common tracheal procedure is a tracheostomy. Over the last 20 years, there has been an increasing utilization of percutaneous tracheostomy. For patients who are intubated, the indication for and timing of tracheostomy depends on a multitude of factors, of which there is very little consensus in the medical literature. The goal of a tracheostomy is to limit the risk of laryngeal stenosis caused by prolonged endotracheal intubation, to improve pulmonary toilet, and to improve oral hygiene. Generally, tracheostomy should be considered after a patient has been intubated for more than 7 days, without clear expectation for immediate extubation.[64] Ideally, patients should be on minimal ventilator settings, but tracheostomy may be performed in patients with elevated oxygen (FiO_2 of upto 60%) and ventilatory (PEEP under 10) requirements. Patients requiring more support are at high risk of decompensating if they lose their airways, even if just for a moment, and the decision to perform a tracheostomy should be carefully considered in this setting.[65]

Tracheostomies are performed with the neck extended. A 2- to 3-cm incision is made approximately 2 cm above the sternal notch. Dissection is carried down through the platysma, and the strap muscles are divided longitudinally. Exposure of the trachea and the 2nd and 3rd rings may require elevation of the thyroid. Lateral traction sutures may be placed around the 2nd or 3rd rings. A vertical incision is made between rings 2 and 4 and gradually dilated. A tracheostomy tube is placed under direct vision.[64,66] Percutaneous tracheostomy placement is based on the Seldinger technique. A needle is placed percutaneously into the trachea at the estimated level of the 2nd or 3rd rings with bronchoscopic visualization. A guidewire is placed into the airway, and serial dilations performed, until a tracheostomy tube is able to be advanced over the wire.[65] Cricothyroidotomy should only be performed in the emergent setting. The cricothyroid membrane is palpated below the superior thyroid notch. A transverse incision is made to the lateral borders of the thyroid cartilage. Rapid dilation is followed by tube insertion.[64]

Complications can vary depending on the technique. For open tracheostomy, they include damage to the carotid artery, internal jugular vein, the posterior tracheal wall/anterior esophagus, and to the apex of the lung.[65] Also reported are fires due to the use of electrocautery in the setting of nitrous oxide and oxygen.[64] In percutaneous tracheostomies, complications include pneumothorax, mediastinal emphysema, paratracheal insertion, tracheoesophageal fistula, and airway loss.[65,67] Common complications include local hemorrhage and infection. Major late complications include tracheal stenosis and tracheoinnominate fistulas. Fistulas result from erosion of the tracheostomy tube into the innominate artery. I**8** mproper placement of the tracheostomy into rings lower than the 3rd ring place patients at higher risk for this complication. A sentinel bleed may be the initial presentation. Pressure on the fistula with immediate repair or ligation of the vessel is required (Fig. 80-33).[68] Postintubation stenosis is usually due to necrosis caused by high-pressure cuffs resulting in impaired blood flow to the segmental area of the trachea. This leads to the long-term loss of cartilage and narrowing of the airway. The use of low-pressure cuffs has reduced the incidence of this

complication, but not eliminated it. Bronchoscopy and dilation may alleviate symptoms, but resection of the stenotic area may be needed (Fig. 80-34).[66]

Tracheal Tumors

Benign lesions of the trachea are less common than malignant ones. They include papillomas, chondromas, hamartomas, fibromas, and hemangiomas. Papillomas are associated with the human papilloma virus and can degenerate into malignant lesions, thus requiring resection. Chondromas arise from the cartilage, and may recur after resection. Hamartomas are comprised of cartilage, epithelial and lymphatic tissue. Recurrence is rare after resection. Fibromas can be resected via bronchoscopy. Hemangiomas are the most common pediatric tracheal mass. They may regress without treatment and can be observed if not causing obstructive symptoms. Biopsy is general avoided due to bleeding risk. Surgery may be required if lesions persist.[69]

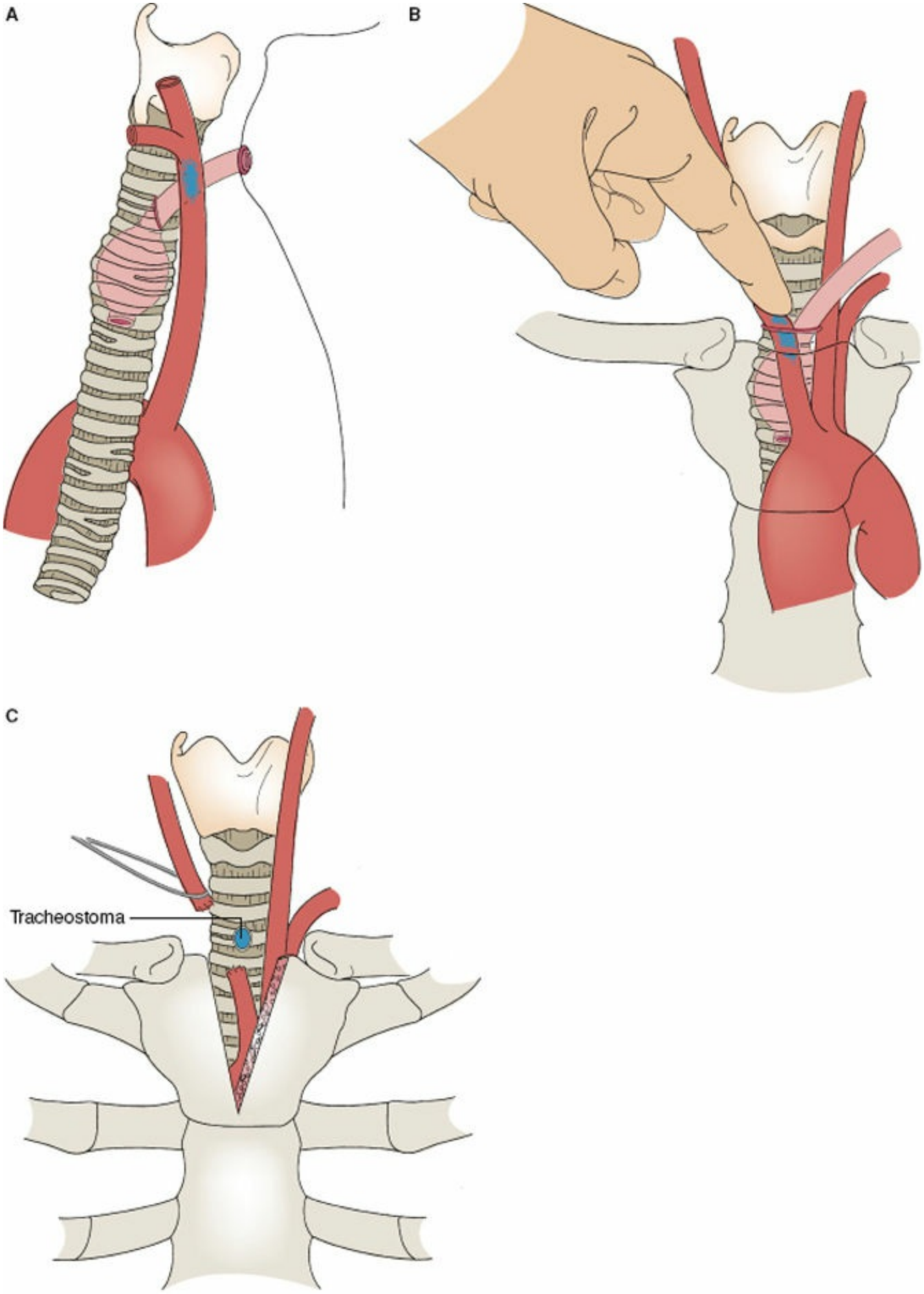

Figure 80-33. Management of tracheoinnominate artery fistula. **A:** Common mechanism of injury from erosion of innominate artery by adjacent tracheostomy tube. **B:** Emergency treatment of hemorrhage involves insertion of an endotracheal tube into the tracheostomy stoma, inflation of the cuff, and downward and outward pressure on the fistula

by the finger inserted through the tracheostomy incision to further tamponade the bleeding. **C:** Through a partial upper sternal split, the segment of involved innominate artery is resected and the oversewn ends covered with adjacent mediastinal fat or muscle. Tracheal resection is usually not necessary. A new tracheostomy tube may have to be inserted higher in the trachea or, if possible, the tracheostomy tube removed and the stoma covered with a sternohyoid muscle flap.

Although more common than benign lesions, malignant tracheal tumors are very rare with only 600 to 700 cases in the United States per year. Lesions may be primary tracheal lesions, tumors from adjacent organs growing into the trachea, or metastatic lesions.[70] Primary tumors are most commonly squamous cell carcinomas or adenoid cystic carcinomas in the trachea, followed by carcinoids in the bronchi.[70,71] Adjacent tumors may arise in the lung, esophagus, thyroid, or mediastinum. The most common cancers that cause tracheal metastases include renal cell cancers, sarcomas, breast cancers, and colon cancers.[70] Patients will present with stridor and wheezing, and have often been recently diagnosed with adult-onset asthma and treated with inhalers and even steroids without alleviation of symptoms. Hemoptysis may also occur, though it is more common in lung cancer than in tracheal disease.[71] Patients should undergo imaging such as a neck and chest CT scan to assist in making the proper diagnosis. Bronchoscopy with a flexible or rigid endoscope is essential to aid in the evaluation of the extent of disease and to control the airway if necessary. Treatment includes tracheal resection for primary tumors if possible. For metastatic disease, palliative treatment include endoluminal resection and/or radiotherapy.[71] Endoluminal treatments include mechanical core-out, YAG-laser treatment, photodynamic therapy (PDT), cryotherapy, or brachytherapy. Stenting also may play a role to maintain airway patency, either for a temporary period during radiation treatment, or in the setting of end-stage disease (Algorithm 80-5).[70]

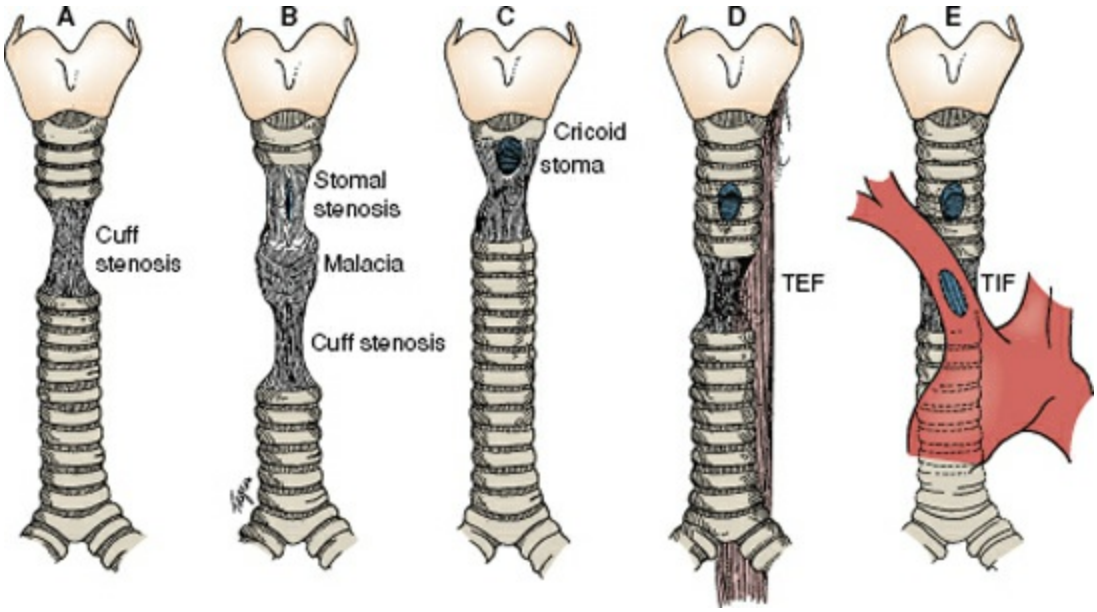

Figure 80-34. Diagrams of principal postintubation tracheal lesions. **A:** Cuff stenosis from the cuff of an endotracheal tube. **B:** Cuff stenosis from the cuff of a tracheostomy tube, usually lower in the trachea than that from an endotracheal tube. Stomal stenosis also occurs at the site of the tracheostomy itself. Malacia may occur either at the level of the cuff or in the segment between the stoma and the cuff stenosis. **C:** Cuff stenosis at the site of a high tracheostomy stoma, which has eroded into the lower margin of the cricoid cartilage. In older patients, this may erode back farther into the subglottic larynx, producing a laryngotracheal stenosis. A stoma placed in the cricothyroid membrane will, by definition, produce an intralaryngeal stenosis. **D:** Tracheoesophageal fistula (TEF) produced by pressure of the cuff against the "party wall," often abetted by an indwelling firm nasogastric tube. **E:** One type of tracheoinnominate fistula (TIF) as the result of a high-pressure cuff erosion. The more common type, but also rare, is that seen with a low-placed tracheostomy stoma, which rests against the innominate artery itself. (Reproduced with permission from Grillo HC. Surgical treatment of postintubation tracheal injuries. *J Thorac Cardiovasc Surg* 1979;78:860–875.)

Tracheomalacia and Airway Stents

Tracheomalacia occurs when the trachea loses its rigid form and the posterior membranous wall approaches the anterior wall, causing luminal narrowing and obstruction leading to dyspnea. Patients have a characteristic seal-like cough. Chest CT scans may demonstrate this condition, and pulmonary function testing in these patients will show reduced FEV_1, FVC and peak expiratory flow rates. Bronchoscopy is the best diagnostic test and reveals real-time airway collapse with expiration. Etiologies include congenital tracheomalacia, extrinsic compression, postintubation stenosis and inflammation, relapsing polychondritis, and COPD.[72] Surgical intervention may include resection for localized involvement, tracheoplasty, or stenting.[72,73] Airway stents can be divided into two groups, silicone and metal, with each type having distinct advantages (Table 80-8). Silicone stents require rigid bronchoscopy to place, have a narrower inner lumen, and are more easily displaced. Advantages to the use of silicone stents are that they are easily adjustable or removable, they do not develop tissue ingrowth, and they are nonreactive to the endoluminal lining. Metal stents can be placed by flexible bronchoscopy and conform to the trachea better. They are permanent and difficult to adjust. Placement requires fluoroscopy, and granulation tissue often grows in between metal struts making subsequent removal difficult.[70] Newer stents being developed include covered metal stents that prevent tumor in growth along the stent, but unfortunately still allow granulation tissue to grow in at the ends.[74] In addition to being useful in the setting of tracheal stenosis, they can also play an essential role in palliating posttransplant bronchial stenosis.[75]

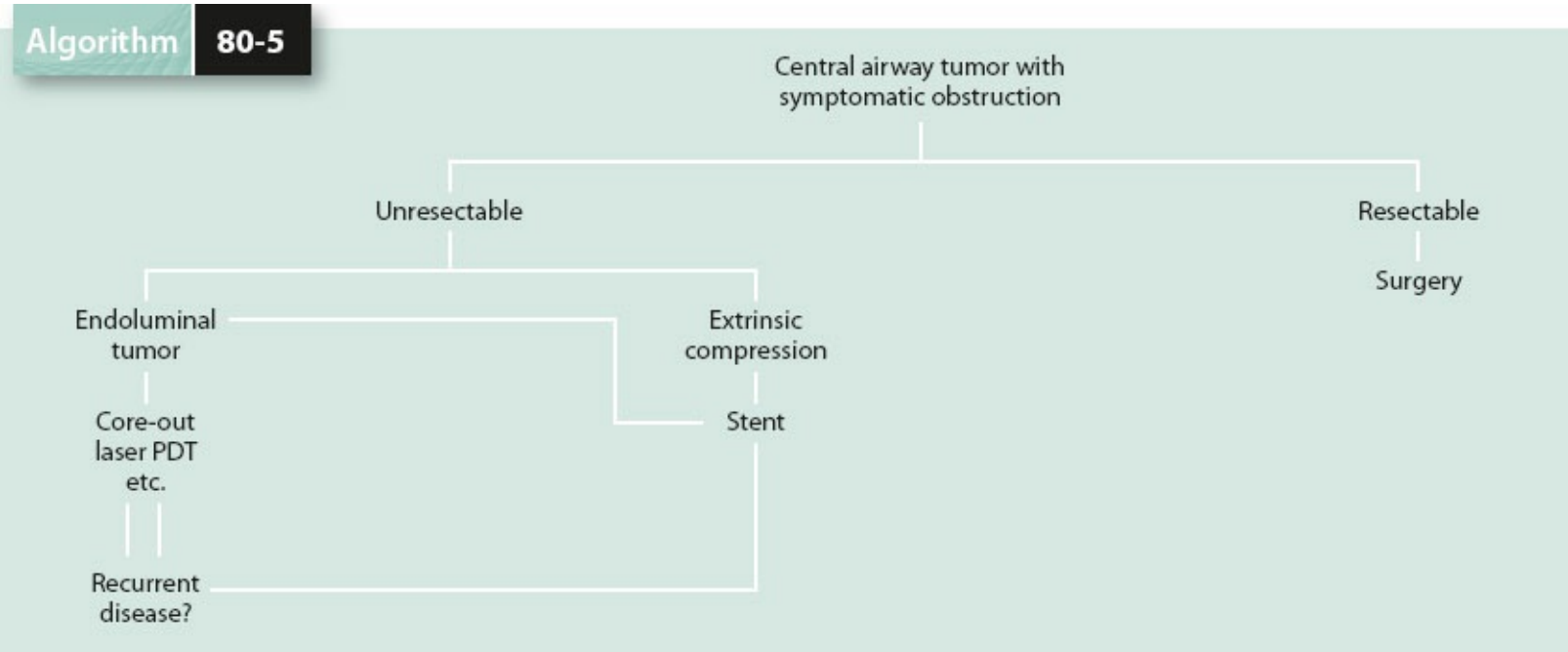

Algorithm 80-5. Algorithm for management of tracheal masses. (Adapted from Wood DE. *Surg Clin North Am* 2002;82(3):621–642.)

Table 80-8 Classification of Airway Stents

- Silicone stents
  - Advantages
    - Adjustable
    - Removable
    - Minimal granulation
  - Disadvantages
    - Gen. anesthesia/rigid bronch to place
    - Migrates
    - Secretions adhere to stent
    - Interferes with ciliary clearance
    - Smaller inner diameter
- Metal stents
  - Advantages
    - Less migration
    - Larger inner diameter
    - Less ciliary interference
    - Flexible bronch to place
  - Disadvantages
    - May need balloon dilation
    - Difficult to remove
    - Granulation and tumor ingrowth in the stent
    - Radial force may lead to necrosis/fistula

Mediastinum

The mediastinum contains a number of important structures and may be involved in different disease processes. Mediastinal infections are not as common as they were in the past, but when they present, they are life-threatening situations. The mediastinum is divided into several compartments, including the superior, anterior, middle, and posterior regions. Sometimes the lower three compartments are extended superiorly and only three are described (Fig. 80-35). The anterior mediastinum includes the fat and lymph nodes posterior to the sternum, but anterior to the pericardium. The middle compartment includes the pericardium, heart, aorta, and trachea. The posterior compartment includes the esophagus, sympathetic chain, and vertebral column (Fig. 80-36). Most lesions are found in asymptomatic patients, but presenting symptoms include dyspnea and chest pain. Symptoms may be local, related to compression on mediastinal structures, or systemic, caused by the release of cytokines or inflammatory factors, such as in lymphomas or thymomas with myasthenia gravis (MG). Imaging begins with plain radiographs, but CT scans are essential. MRI scans may be helpful to evaluate vascular or spinal involvement. PET scans are increasingly utilized as they may further aid in staging. Biopsy and/or surgical resection is required to confirm the diagnosis in almost all patients.[76]

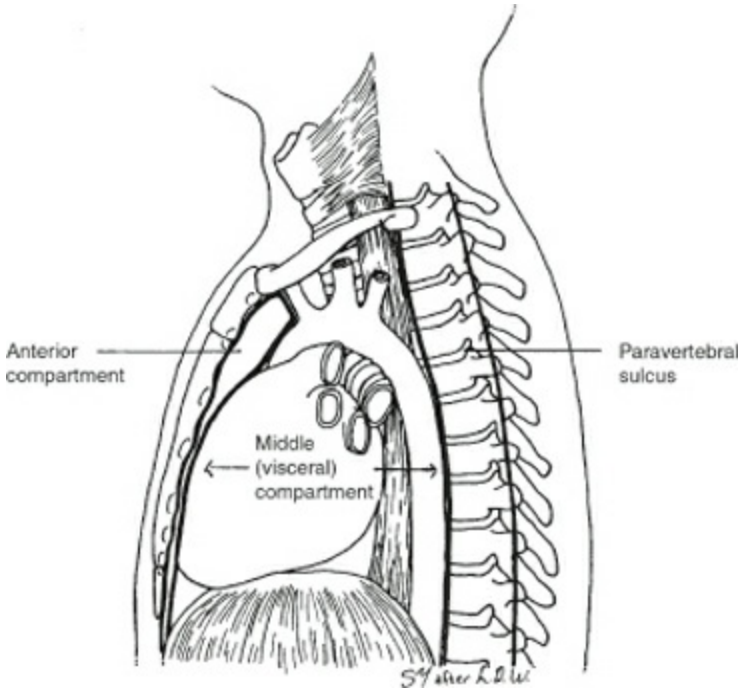

Figure 80-35. The mediastinal subdivisions. Note that the paravertebral sulcus encompasses the posterior compartment. Reproduced with permission from Shields TW, ed. *General Thoracic Surgery*. 6th ed. 2005.

Anterior Mediastinum

The anterior mediastinum can contain a variety of tumors (Table 80-9). Most common are thymomas, lymphomas, and germ cell tumors, in that order. Thymomas account for one-fifth of all anterior mediastinal masses in the adult population. They arise from the thymus gland and can be seen with autoimmune diseases such as MG and pure red cell aplasia. Tumors are usually classified by the Masaoka classification system (Table 80-10), which looks at gross and microscopic spread of the tumor, or the World Health Organization (WHO) histologic criteria, which is based upon the morphology of the epithelial cells as well as the lymphocyte to epithelial cell ratio. Diagnosis is usually made by chest CT scan. Needle biopsy of a potential thymoma is not routinely recommended for fear of seeding the needle track. When thymomas are suspected, resection is the best option, via a midline sternotomy (Fig. 80-37). Resection must take care to remove all of the tissue in the anterior compartment, including all fat and tissue around the innominate vein. Entering the pleura should be avoided if possible to minimize drop metastases into either pleural space.

Table 80-9 Location of Primary Mediastinal Masses in Adults and Children

Anterosuperior Mediastinum
Thymoma
Lymphoma
Germ cell tumor
Lymphangioma
Hemangioma
Lipoma
Carcinoma
Thyroid adenoma
Parathyroid adenoma
Middle Mediastinum
Pericardial cyst
Bronchogenic cyst
Lymphoma
Posterior Mediastinum
Neurogenic tumor
Enteric cyst

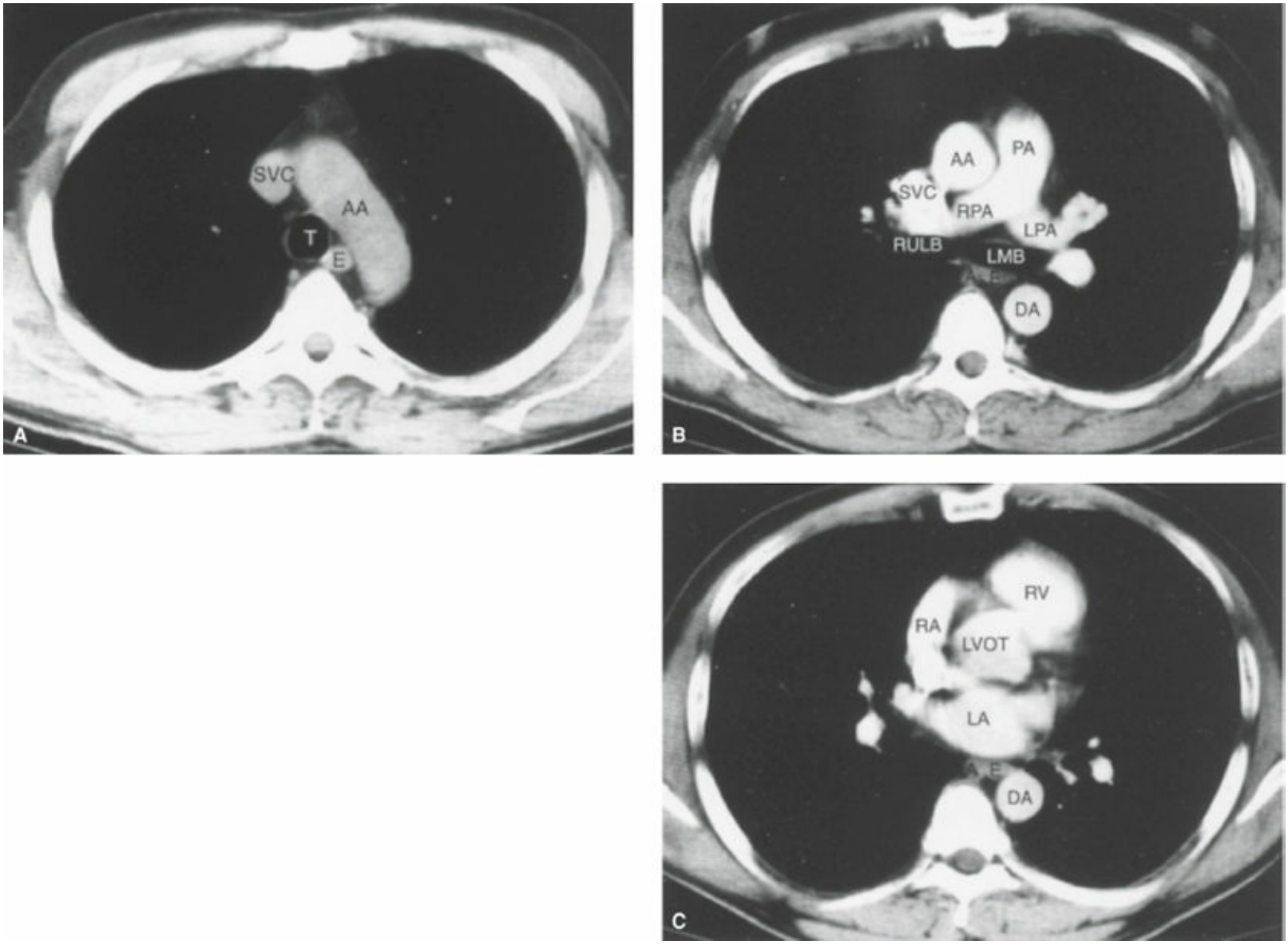

Figure 80-36. Normal mediastinal anatomy as shown with computed tomography scans. **A:** Scan at level of the aortic arch and midtrachea. T, trachea; E, esophagus; AA, aortic arch; SVC, superior vena cava. **B:** Scan at level of carina. RULB, right upper-lobe bronchus; LMB, left mainstem bronchus; AA, ascending aorta; DA, descending aorta; A, azygos vein; PA, main pulmonary artery; LPA and RPA, left and right pulmonary arteries. **C:** Scan at the level of the left atrium. LA, left atrium; RA, right atrium; LVOT, left ventricular outflow tract; RV, right ventricle.

Table 80-10 Masaoka Staging System for Thymoma

Stage	Definition
I	Macroscopically, completely encapsulated; microscopically, no capsular invasion
IIA	Macroscopic invasion in surrounding fatty tissues or mediastinal pleura
IIB	Microscopic invasion into the capsule
III	Macroscopic invasion into a neighboring organ, such as pericardium, great vessels, or lung
IVA	Pleural or pericardial dissemination
IVB	Hematogenous or lymphogenous metastases

Adapted from Masaoka A, Monden Y, Nakahara K, et al. Follow-up study of thymomas with special references to their clinical stages. *Cancer* 1981;48:2485, with permission.

Thoracoscopic approaches to resect thymomas have been described, but some surgeons question this approach due to the potential increased risk of drop metastases, and thus the potential for a poorer oncologic outcome. Neoadjuvant chemotherapy and radiation may be used to downstage Masaoka III and IV stage tumors and allow for subsequent resection. Postoperative radiation is recommended for Masaoka stage III tumors, and may be considered for stage II disease. Platinum-based chemotherapy is typically utilized in the unresectable setting.[77] MG presents with diplopia, ptosis, fatigue, and weakness. One-third to one-half of patients with thymomas have MG, but only 10% of patients with MG have thymomas. Antiacetylcholine receptor antibody levels may be measured to evaluate for MG in patients with suspected thymomas.[78] Thymic carcinomas and thymic carcinoids are other tumor types that can also arise from the thymus.

Germ cell tumors can present as benign teratomas, seminomas, and embryonal tumors, which include nonseminomatous germ cell tumors and malignant teratomas. Benign teratomas have a good prognosis and resection is the best treatment. Seminomas comprise upto half of mediastinal germ cell malignant tumors. Patients may have symptoms from local compression or systemic symptoms such as fever, weight loss, and even gynecomastia. These tumors are radiosensitive, but in locally advanced disease, chemotherapy with later surgical resection is the favored treatment. Nonseminomatous tumors include a wide variety of histologic malignancies. They usually occur in young men and are often symptomatic (Fig. 80-38). Elevated alpha-fetal protein (AFP) and beta-human chorionic gonadotropin (β-hCG) levels are seen with these tumors and should be measured. Chemotherapy is the best treatment, but patients have a poorer prognosis when compared to those with seminomas. Lymphomas in the mediastinum are usually part of a wider spectrum of disease. Two-thirds of cases are Hodgkin disease. Most patients present with symptoms of fevers, night sweats, and even weight loss. Treatment is always chemotherapy-based, and surgery in the form of a biopsy is utilized only to help make the diagnosis.[78]

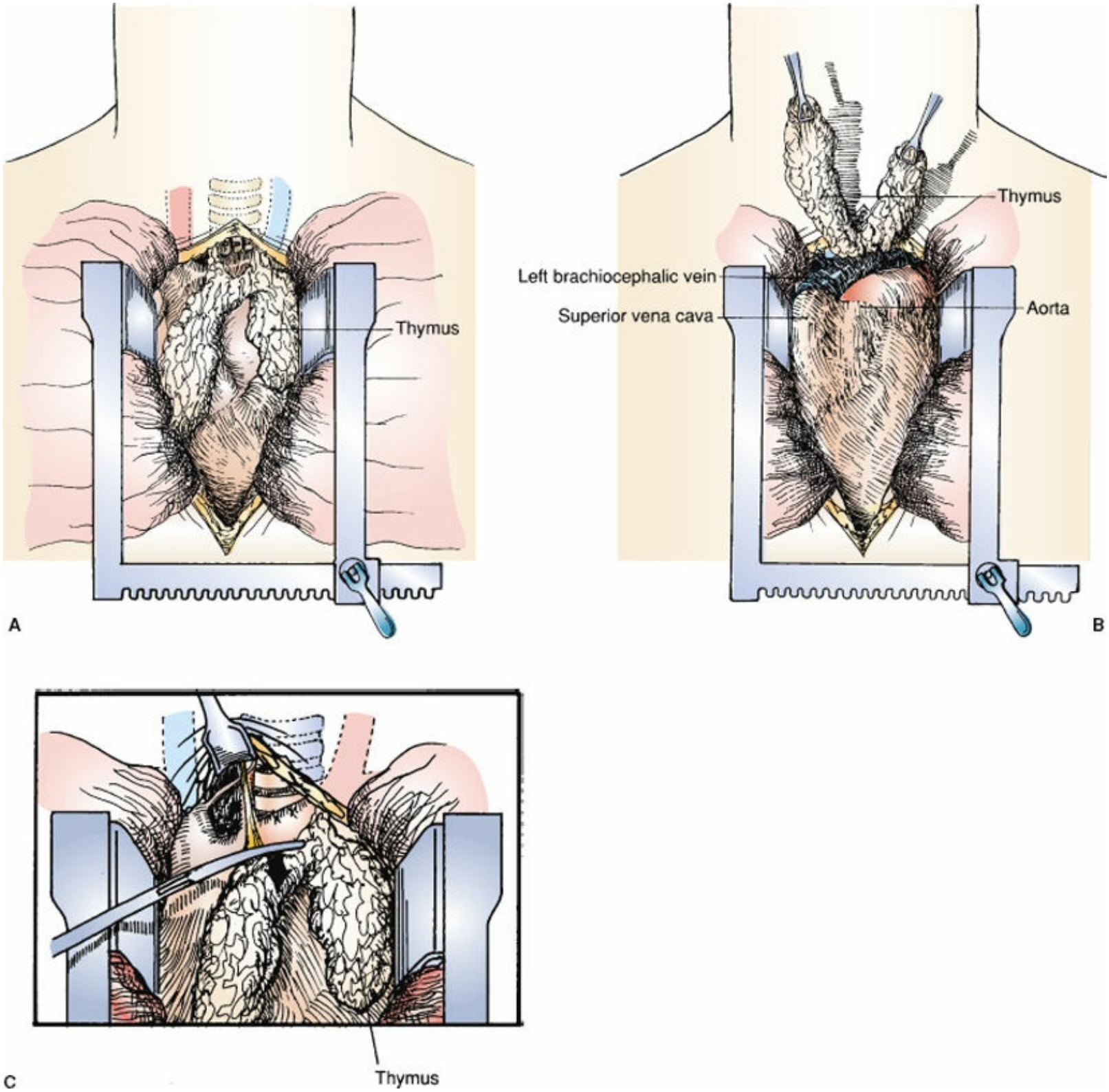

Figure 80-37. Thymic resection. **A:** Exposure of thymus via median sternotomy. **B:** Elevation of thymus completely off of the pericardium. **C:** Pulling the thymus inferiorly to resect the right superior horn (and later the left superior horn). (Reproduced with permission from Scott-Conner CE, Dawson DL, Shirazi MK, et al. *Operative Anatomy*. 3rd ed. Philadelphia, PA: Lippincott Williams & Wilkins; 2008.)

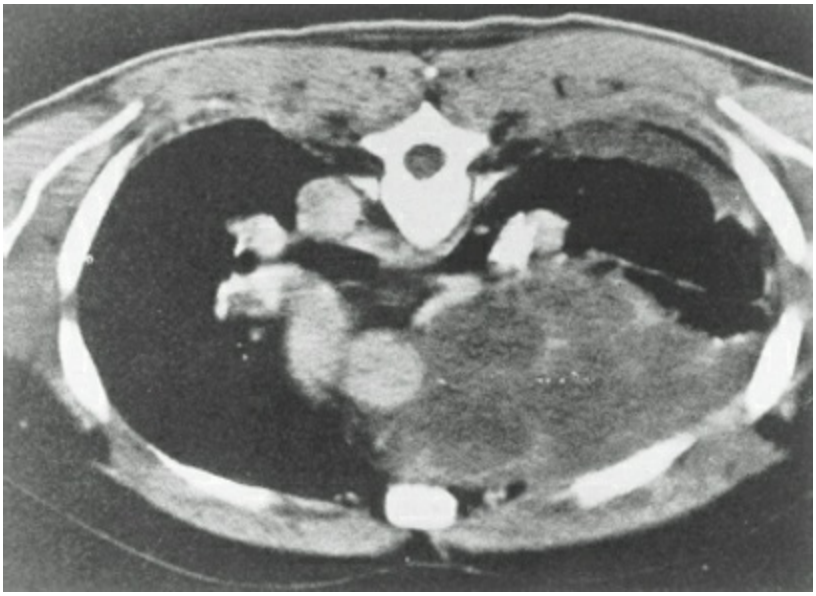

Figure 80-38. Computed tomography scan of a malignant nonseminomatous germ cell tumor of the anterior mediastinum reveals the inhomogeneous anterior mediastinal mass in contrast to the homogeneous density of a seminoma. Pleural effusion is also demonstrated in the right hemithorax. (Reproduced with permission from Shields TW. Primary lesions of the mediastinum and their investigation and treatment. In: Shields TW, ed. *General Thoracic Surgery*. Baltimore, MD: Williams & Wilkins; 1994:1724–1769.)

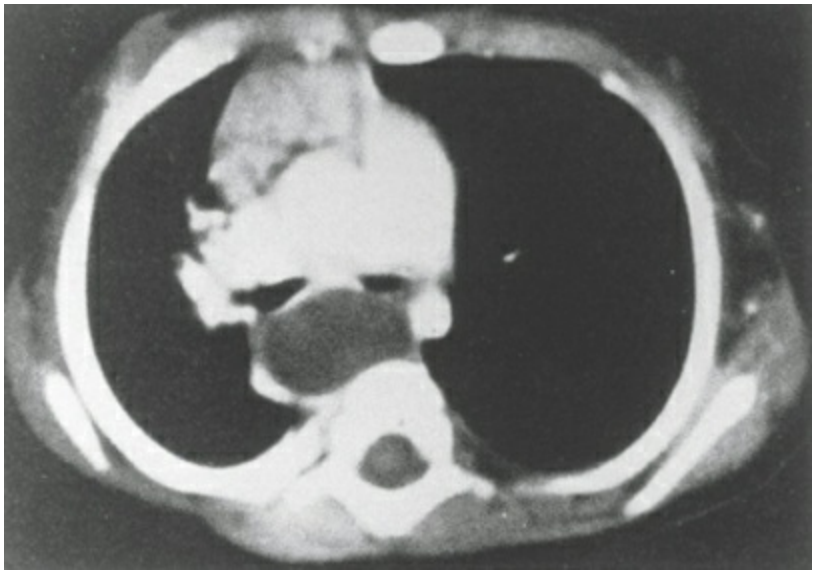

Figure 80-39. Computed tomography scan reveals a bronchogenic cyst located in the subcranial area with compression of the left mainstem bronchus with hyperinflation of the left lung and a mediastinal shift to the right. (Reproduced with permission from Shields TW. Primary lesions of the mediastinum and their investigation and treatment. In: Shields TW, ed. *General Thoracic Surgery*. Baltimore, MD: Williams & Wilkins; 1994:1764–1769.)

Middle and Posterior Mediastinum

Middle mediastinal masses include esophageal and bronchogenic cysts, pericardial cysts, lymphangiomas, and lymphomas (Fig. 80-39). For cystic lesions, surgical resection is the best treatment option. Posterior lesions include neurogenic tumors which may be benign or malignant. Almost 95% of tumors come from the sympathetic chain or intercostal nerve rami. Upto two-thirds of these tumors are benign nerve sheath tumors and are usually discovered incidentally. A MRI scan may be used to evaluate intraspinal extension.[78]

Pediatric Mediastinum

The presentation of mediastinal masses in the pediatric population varies from what is observed in adults. The rate of malignancy is slightly lower in children, and while thymomas are the most common adult masses seen, neurogenic tumors are more common in children (Table 80-11). Just over half of all mediastinal tumors arise in the posterior compartment.[79] Anterior masses may include the normal thymus in a young child. Teratomas are the most common germ cell tumor seen.[79] Vascular anomalies may be seen in children and include hemangiomas and cystic hygromas.[80] Middle compartment tumors are usually foregut cysts, as in the adult population. Posterior tumors are most often malignant neurogenic tumors, compared to more benign pathology in adults.[79]

Mediastinitis

9 Mediastinal inflammation can arise from different sources, but it is most often infectious in nature. Acute mediastinitis is life-threatening and usually results from a perforated esophagus, postcardiac procedure, or trauma. Oral infections can also result in organisms travelling through the neck into the mediastinum along fascial planes. These infections can travel as quickly as necrotizing fasciitis does in other parts of the body and should be addressed immediately. A wide variety of organisms can cause mediastinitis. Patients will have chest pain, dyspnea, and fevers. Radiographic films may show pneumomediastinum or pneumothoraces. If an esophageal perforation is suspected, an esophagogram should be performed. Treatment is broad-spectrum antibiotics and surgical drainage via a cervical incision and/or thoracotomy. Quick debridement and drainage are keys to patient survival. Minimally invasive approaches to the chest may be adequate, but surgeons should have a low threshold to perform a posterolateral thoracotomy, which may give the best exposure and opportunity to debride the chest. Sternal infections after cardiac surgery can also be a serious problem requiring drainage and debridement. Ultimate repair of the defect following debridement may involve muscle or omental flaps for sternal reconstruction.

Table 80-11 Mediastinal Tumors in Children

Type of Tumor	Incidence Reported in Series (%)
Neurogenic	35
Lymphoma	25
Germ cell	11
Primary malignancy	2
Cysts	25

Adapted from Davis RD Jr, Oldham HN Jr, Sabiston DC Jr. The mediastinum. In: Sabiston DC Jr, Spencer FC, eds. *Surgery of the Chest.* 5th ed. Philadelphia, PA: WB Saunders; 1990:507.

Chronic mediastinitis is a separate entity from acute mediastinitis and may arise from infectious sources or autoimmune disorders. Patients may be asymptomatic until a mass effect is seen on their mediastinal organs. CT scans are the best imaging modality to diagnose this condition, and surgery is reserved only for diagnosis or in the end stages of the disease to relieve compression on other organs. Sclerosing mediastinitis may be seen in patients with retroperitoneal fibrosis.[81]

Superior Vena Cava Syndrome

Superior vena cava (SVC) syndrome is a rare condition seen when a mediastinal mass compresses the SVC resulting in facial and upper body edema. Only 15,000 cases per year are seen in the United States. Patients may present with cough, dyspnea, or even stridor from upper airway edema. When patients start to have symptoms, collateral venous drainage develops to drain into the azygos vein or inferior vena cava. This process usually takes weeks. Malignant tumors are the most common cause, but venous thrombosis and nonmalignant lesions cause upto one-third of cases. CT scans are the best diagnostic test. Treatment is based on supportive care and addressing the underlying condition causing the obstruction. If a malignant tumor is causing the obstruction, chemotherapy or radiotherapy may shrink the tumor and lessen symptoms. Surgical resection with SVC reconstruction may be used in specific tumors such as locally advanced thymomas. Angioplasty and stenting may be of benefit but is usually palliative.[82] Although it is often felt to be an emergency, most cases of SVC syndrome have a slowly progressive course. When a patient develops symptoms, supportive care, including possible intubation, will allow time for collateral venous drainage to develop and symptoms to improve without other interventions. Although the median survival is typically 6 months or less in patients with SVC syndrome from malignant obstruction, some have seen long-term survivors when the primary tumors have responded to appropriate treatment.[83] When patients present with severe symptoms, it is a mistake to rush to surgical intervention without a long-term plan. Symptoms should be managed and the etiology discovered and treated appropriately.

References

1. Incarbone M, Pastorino U. Surgical treatment of chest wall tumors. *World J Surg* 2001;25(2):218–230.
2. Gross JL, Younes RN, Haddad FJ, et al. Soft-tissue sarcomas of the chest wall: prognostic factors. *Chest* 2005;127(3):902–908.
3. Pairolero PC. Chest wall tumors. In: Sellke FW, del Nido PJ, Swanson SJ, eds. *Sabiston and Spencer; Surgery of the Chest.* 7th ed. Philadelphia, PA: Elsevier Saunders; 2002:395.
4. Anderson BO, Burt ME. Chest wall neoplasms and their management. *Ann Thorac Surg* 1994;58(6):1774–1781.
5. Douglas YL, Meuzelaar KJ, van der Lei B, et al. Osteosarcoma of the sternum. *Eur J Surg Oncol* 1997;23(1):90–91.
6. Gladish G, Sabloff B, Munden R, et al. Primary thoracic sarcomas. *Radiographics* 2002;22(3):621.
7. Deschamps C, Tirnaksiz BM, Darbandi R, et al. Early and long-term results of prosthetic chest wall reconstruction. *J Thorac Cardiovasc Surg* 1999;117(3):588–591; discussion 591–592.
8. Graeber GM. Chest wall resection and reconstruction. *Semin Thorac Cardiovasc Surg* 1999;11(3):251–263.
9. Weyant MJ, Bains MS, Venkatraman E, et al. Results of chest wall resection and reconstruction with and without rigid prosthesis. *Ann Thorac Surg* 2006;81(1):279–285.
10. Chang RR, Mehrara BJ, Hu QY, et al. Reconstruction of complex oncologic chest wall defects: a 10-year experience. *Ann Plast Surg* 2004;52(5):471–479; discussion 479.
11. Skoracki RJ, Chang DW. Reconstruction of the chest wall and thorax. *J Surg Oncol* 2006;94(6):455–465.
12. Acarturk T, Swartz W, Luketich J, et al. Laparoscopically harvested omental flap for chest wall and intrathoracic reconstruction. *Ann Plast Surg* 2004;53(3):210.
13. Lopushinsky SR, Fecteau AH. Pectus deformities: a review of open surgery in the modern era. *Semin Pediatr Surg* 2008;17(3):201–208.
14. Fonkalsrud EW, Dunn JC, Atkinson JB. Repair of pectus excavatum deformities: 30 years of experience with 375 patients. *Ann Surg* 2000;231(3):443–448.
15. Kelly RE Jr. Pectus excavatum: historical background, clinical picture, preoperative evaluation and criteria for operation. *Semin Pediatr Surg* 2008;17(3):181–193.
16. Mansour KA, Thourani VH, Odessey EA, et al. Thirty-year experience with repair of pectus deformities in adults. *Ann Thorac Surg* 2003;76(2):391–395; discussion 395.
17. Jaroszewski DE, Fonkalsrud EW. Repair of pectus chest deformities in 320 adult patients: 21 year experience. *Ann Thorac Surg* 2007;84(2):429–433.
18. Nuss D. Minimally invasive surgical repair of pectus excavatum. *Semin Pediatr Surg*

2008;17(3):209–217.
19. Park HJ, Lee SY, Lee CS, et al. The nuss procedure for pectus excavatum: evolution of techniques and early results on 322 patients. *Ann Thorac Surg* 2004;77(1):289–295.
20. Engum SA. Embryology, sternal clefts, ectopia cordis, and cantrell's pentalogy. *Semin Pediatr Surg* 2008;17(3):154–160.
21. Moir CR, Johnson CH. Poland's syndrome. *Semin Pediatr Surg* 2008;17(3):161–166.
22. Mackinnon SE, Novak CB. Thoracic outlet syndrome. *Curr Probl Surg* 2002;39(11):1070–1145.
23. Thompson RW, Petrinec D. Surgical treatment of thoracic outlet compression syndromes: diagnostic considerations and transaxillary first rib resection. *Ann Vasc Surg* 1997;11(3):315–323.
24. Maxey TS, Reece TB, Ellman PI, et al. Safety and efficacy of the supraclavicular approach to thoracic outlet decompression. *Ann Thorac Surg* 2003;76(2):396–399; discussion 399–400.
25. Thompson RW, Petrinec D, Toursarkissian B. Surgical treatment of thoracic outlet compression syndromes. II. supraclavicular exploration and vascular reconstruction. *Ann Vasc Surg* 1997;11(4):442–451.
26. Divi V, Proctor MC, Axelrod DA, et al. Thoracic outlet decompression for subclavian vein thrombosis: experience in 71 patients. *Arch Surg* 2005; 140(1):54–57.
27. Mansharamani NG, Koziel H. Chronic lung sepsis: lung abscess, bronchiectasis, and empyema. *Curr Opin Pulm Med* 2003;9(3):181–185.
28. O'Donnell AE. Bronchiectasis. *Chest* 2008;134(4):815–823.
29. Barker AF. Bronchiectasis. *N Engl J Med* 2002;346(18):1383–1393.
30. Ilowite J, Spiegler P, Chawla S. Bronchiectasis: new findings in the pathogenesis and treatment of this disease. *Curr Opin Infect Dis* 2008;21(2):163–167.
31. Naidoo R. Surgery for pulmonary tuberculosis. *Curr Opin Pulm Med* 2008;14(3):254–259.
32. Souilamas R, Riquet M, Barthes FP, et al. Surgical treatment of active and sequelar forms of pulmonary tuberculosis. *Ann Thorac Surg* 2001;71(2):443–447.
33. Cahill BC, Ingbar DH. Massive hemoptysis. assessment and management. *Clin Chest Med* 1994;15(1):147–167.
34. Jean-Baptiste E. Clinical assessment and management of massive hemoptysis. *Crit Care Med* 2000;28(5):1642–1647.
35. Shigemura N, Wan IY, Yu SC, et al. Multidisciplinary management of life-threatening massive hemoptysis: a 10-year experience. *Ann Thorac Surg* 2009;87(3):849–853.
36. Edwards M, Hazelrigg S, Naunheim K. The national emphysema treatment trial: summary and update. *Thorac Surg Clin* 2009;19(2):169–185.
37. Martinez FJ, Chang A. Surgical therapy for chronic obstructive pulmonary disease. *Semin Respir Crit Care Med* 2005;26(2):167–191.

38. Shah AA, D'Amico TA. Lung volume reduction surgery for the management of refractory dyspnea in chronic obstructive pulmonary disease. *Curr Opin Support Palliat Care* 2009;3(2):107–111.
39. Trow TK. Lung-volume reduction surgery for severe emphysema: appraisal of its current status. *Curr Opin Pulm Med* 2004;10(2):128–132.
40. Swanson KL, Edell ES. Tracheobronchial foreign bodies. *Chest Surg Clin N Am* 2001;11(4):861–872.
41. Boyd M, Chatterjee A, Chiles C, et al. Tracheobronchial foreign body aspiration in adults. *South Med J* 2009;102(2):171–174.
42. Sahn SA, Heffner JE. Spontaneous pneumothorax. *N Engl J Med* 2000; 342(12):868–874.
43. Rahman NM, Davies RJ, Gleeson FV. Pleural interventions: management of acute and chronic pneumothorax. *Semin Respir Crit Care Med* 2008;29(4):427–440.
44. Baumann MH, Noppen M. Pneumothorax. *Respirology* 2004;9(2):157–164.
45. Shen KR, Cerfolio R. Decision making in the management of secondary spontaneous pneumothorax in patients with severe emphysema. *Thorac Surg Clin* 2009;19(2):233–238.
46. Mendeloff EN. Sequestrations, congenital cystic adenomatoid malformations, and congenital lobar emphysema. *Semin Thorac Cardiovasc Surg* 2004;16(3):209–214.
47. Horak E, Bodner J, Gassner I, et al. Congenital cystic lung disease: diagnostic and therapeutic considerations. *Clin Pediatr (Phila)* 2003;42(3):251–261.
48. Schwartz DS, Reyes-Mugica M, Keller MS. Imaging of surgical diseases of the newborn chest. intrapleural mass lesions. *Radiol Clin North Am* 1999;37(6):1067–1078, v.
49. Evrard V, Ceulemans J, Coosemans W, et al. Congenital parenchymatous malformations of the lung. *World J Surg* 1999;23(11):1123–1132.
50. Takeda S, Miyoshi S, Inoue M, et al. Clinical spectrum of congenital cystic disease of the lung in children. *Eur J Cardiothorac Surg* 1999;15(1):11–17.
51. Heffner J. Discriminating between transudates and exudates. *Clin Chest Med* 2006;27(2):241.
52. Light RW. The undiagnosed pleural effusion. *Clin Chest Med* 2006;27(2):309–319.
53. Putnam J Jr. Malignant pleural effusions. *Surg Clin North Am* 2002;82(4):867–883.
54. Christie NA. Management of pleural space: effusions and empyema. *Surg Clin N Am* 2010;90:919–934.
55. Wright CD, Wain JC, Mathisen DJ, et al. Postpneumonectomy bronchopleural fistula after sutured bronchial closure: incidence, risk factors, and management. *J Thorac Cardiovasc Surg* 1996;112(5):1367–1371.
56. Deschamps C, Bernard A, Nichols FC 3rd, et al. Empyema and bronchopleural fistula after pneumonectomy: factors affecting incidence. *Ann Thorac Surg* 2001;72(1):243–247; discussion 248.

57. Vallieres E. Management of empyema after lung resections (pneumonectomy/lobectomy). *Chest Surg Clin N Am* 2002;12(3):571–585.
58. Robinson BW, Musk AW, Lake RA. Malignant mesothelioma. *Lancet* 2005;366(9483):397–408.
59. Robinson BW, Lake RA. Advances in malignant mesothelioma. *N Engl J Med* 2005;353(15):1591–1603.
60. Pistolesi M, Rusthoven J. Malignant pleural mesothelioma: update, current management, and newer therapeutic strategies. *Chest* 2004;126(4):1318–1329.
61. Singhal S, Kaiser LR. Malignant mesothelioma: options for management. *Surg Clin North Am* 2002;82(4):797–831.
62. van Ruth S, Baas P, Zoetmulder FA. Surgical treatment of malignant pleural mesothelioma: a review. *Chest* 2003;123(2):551–561.
63. Minnich D, Mathisen D. Anatomy of the trachea, carina, and bronchi. *Thorac Surg Clin* 2007;17(4):571.
64. Walts PA, Murthy SC, DeCamp MM. Techniques of surgical tracheostomy. *Clin Chest Med* 2003;24(3):413–422.
65. Angel L, Simpson C. Comparison of surgical and percutaneous dilational tracheostomy. *Clin Chest Med* 2003;24(3):423.
66. Wain JC. Postintubation tracheal stenosis. *Chest Surg Clin N Am* 2003;13(2):231–246.
67. Fellerkopman D. Acute complications of artificial airways. *Clin Chest Med* 2003;24(3):445.
68. Mathisen DJ. Surgery of the trachea. *Curr Probl Surg* 1998;35(6):453–542.
69. Mathisen DJ. Tracheal tumors. *Chest Surg Clin N Am* 1996;6(4):875–898.
70. Wood DE. Management of malignant tracheobronchial obstruction. *Surg Clin North Am* 2002;82(3):621–642.
71. Gaissert H. Primary tracheal tumors. *Chest Surg Clin N Am* 2003;13(2):247.
72. Wright CD. Tracheomalacia. *Chest Surg Clin N Am* 2003;13(2):349–357, viii.
73. Jaquiss RD. Management of pediatric tracheal stenosis and tracheomalacia *Semin Thorac Cardiovasc Surg* 2004;16(3):220–224.
74. Chin CS, Litle V, Yun J, et al. Airway stents. *Ann Thorac Surg* 2008;85(2):S792–S796.
75. Mulligan MS. Endoscopic management of airway complications after lung transplantation. *Chest Surg Clin N Am* 2001;11(4):907–915.
76. Date H. Diagnostic strategies for mediastinal tumors and cysts. *Thorac Surg Clin* 2009;19(1):29–35, vi.
77. Tomaszek S, Wigle DA, Keshavjee S, et al. Thymomas: review of current clinical practice. *Ann Thorac Surg* 2009;87(6):1973–1980.
78. Duwe BV, Sterman DH, Musani AI. Tumors of the mediastinum. *Chest* 2005;128(4):2893–2909.
79. Wright CD. Mediastinal tumors and cysts in the pediatric population. *Thorac Surg Clin*

2009;19(1):47–61, vi.

80. Jaggers J, Balsara K. Mediastinal masses in children. *Semin Thorac Cardiovasc Surg* 2004;16(3):201–208.
81. Athanassiadi KA. Infections of the mediastinum. *Thorac Surg Clin* 2009; 19(1):37–45, vi.
82. Wilson LD, Detterbeck FC, Yahalom J. Clinical practice. superior vena cava syndrome with malignant causes. *N Engl J Med* 2007;356(18):1862–1869.
83. Yu JB, Wilson LD, Detterbeck FC. Superior vena cava syndrome–a proposed classification system and algorithm for management. *J Thorac Oncol* 2008;3(8):811–814.

SECTION M: VASCULAR DISEASE

Chapter 81

Congenital Heart Disease

Jennifer C. Hirsch-Romano, Richard G. Ohye, and Edward L. Bove

Key Points

1 The first successful treatment of a congenital lesion was the closure of a patent ductus arteriosus (PDA) by Gross and Hubbard in 1938. Prostaglandin inhibitors, such as indomethacin and ibuprofen, can be used to induce closure of a PDA in the premature newborn with a success rate of 80%. When this is not successful, surgical closure may be necessary in small infants. Coil occlusion can be performed in older children presenting with a PDA.

2 An atrial septal defect (ASD) is a hole in the atrial septum. ASDs are the third most common congenital heart defect, occurring in 1 out of 1,000 live births and representing 10% of congenital heart defects. ASDs cause right heart volume overload and can lead to pulmonary vascular obstructive disease later in life. The majority of ASDs are now closed with a device in the catheterization laboratory.

3 Ventricular septal defects (VSDs) are the most common congenital heart defect (with the exception of bicuspid aortic valve, which occurs in about 1.3% of the population). VSDs cause left heart volume overload.

4 Over 50% of children with trisomy 21 have a congenital heart defect. The most common heart defect in this patient population is an atrioventricular septal defect. All infants with trisomy 21 should have an echocardiogram to rule out congenital heart disease.

5 Tetralogy of Fallot (TOF) is the most common cyanotic congenital heart defect. It occurs in 0.6 per 1,000 live births and has a prevalence of about 5% among all patients with congenital heart disease. The pathologic anatomy is frequently described as having four components: ventricular septal defect, overriding aorta, pulmonary stenosis, and right ventricular hypertrophy.

6 Transposition of the great arteries is a congenital cardiac anomaly in which the aorta arises from the right ventricle and the pulmonary artery originates from the left ventricle (ventriculoarterial discordance). It is the most common congenital heart defect presenting with cyanosis in the first week of life. This malformation accounts for approximately 10% of all congenital cardiovascular malformations in infants.

7 Upper extremity hypertension with diminished femoral pulses are hallmark clinical findings in patients with aortic coarctation.

8 Coronary arteriovenous fistula is the most common major coronary anomaly.

HISTORY

Cardiac surgery, as a specialty, is notable for the rapid technical advances that have been made during the past few decades. Much of the original interest was focused on attempts to treat congenital heart defects associated with cyanosis and early mortality. **1** The first successful treatment of a congenital lesion was the closure of a patent ductus arteriosus (PDA) by Gross and Hubbard in 1938.[1] The description of the subclavian artery-to-pulmonary artery (PA) shunt by Blalock and Taussig in 1945[2] introduced the palliation of many complex cyanotic lesions – most notably, tetralogy of Fallot (TOF). The 1950s represented the decade of greatest advances, which laid the foundation for the field of cardiac surgery. Lewis and Taufic in 1952[3] performed the first open closure of an atrial septal defect (ASD) by using surface hypothermia and inflow occlusion. In 1953, Gibbon[4] performed the first repair of an ASD with the use of a pump oxygenator that became the model for modern cardiopulmonary bypass. Next, Warden et al.[5] used controlled cross-circulation with an adult as the oxygenator during intracardiac repairs. Building on the work of Gibbon, Kirklin et al.[6] then published the first series of eight intracardiac operations performed at the Mayo Clinic with the use of cardiopulmonary bypass. With these landmark efforts focused on congenital heart disease, the field of cardiac surgery was established.

ATRIAL SEPTAL DEFECT

Cardiac septation occurs between the third and sixth weeks of fetal development. The septum primum, which arises from the roof of the common atrium and descends inferiorly, initially divides the common atrium. The ostium primum is the opening below the inferior edge of the septum primum, which is obliterated as the septum primum fuses with the endocardial cushions. The ostium secundum forms in the midportion of the septum primum prior to closure of the ostium primum. The septum secundum also arises from the roof of the atrium and descends along the right side of the septum primum and covers the ostium secundum. This creates a flap valve whereby blood from the inferior vena cava may preferentially stream beneath the edge of the septum secundum and through the ostium secundum into the left atrium. After birth, the increase in left atrial pressure usually closes this pathway.

2 An ASD is a hole in the atrial septum (Fig. 81-1). ASDs are the third most common congenital heart defect, occurring in 1 out of 1,000 live births and representing 10% of congenital heart defects.[7] The most common ASD is the secundum defect, which occurs when the ostium secundum is too large for complete coverage by the septum secundum. Ostium secundum defects account for about 80% of ASDs. An ostium primum ASD, representing 10% of ASDs, occurs from failure of fusion of the septum primum with the endocardial cushions. The ostium primum defect is discussed later in the section on atrioventricular septal defects (AVSDs). A third type of ASD is the sinus venosus defect, seen in about 10% of cases. Sinus venosus ASDs are caused by abnormal fusion of the venous pathways with the atrium and are characterized by defects high in the atrial septum near the orifice of the superior vena cava or, less commonly, low in the atrial septum near the inferior vena cava. Sinus venosus defects are frequently associated with partial anomalous pulmonary venous connection, usually with the right upper pulmonary vein draining into the superior vena cava near the cavoatrial junction. The rarest type of ASD is the unroofed coronary sinus septal defect. This occurs when there is loss of the common wall between the coronary sinus and the left atrium adjacent to the atrial septum. This unroofing of the coronary sinus leads to a communication between the right and left atria at the site of the coronary sinus.

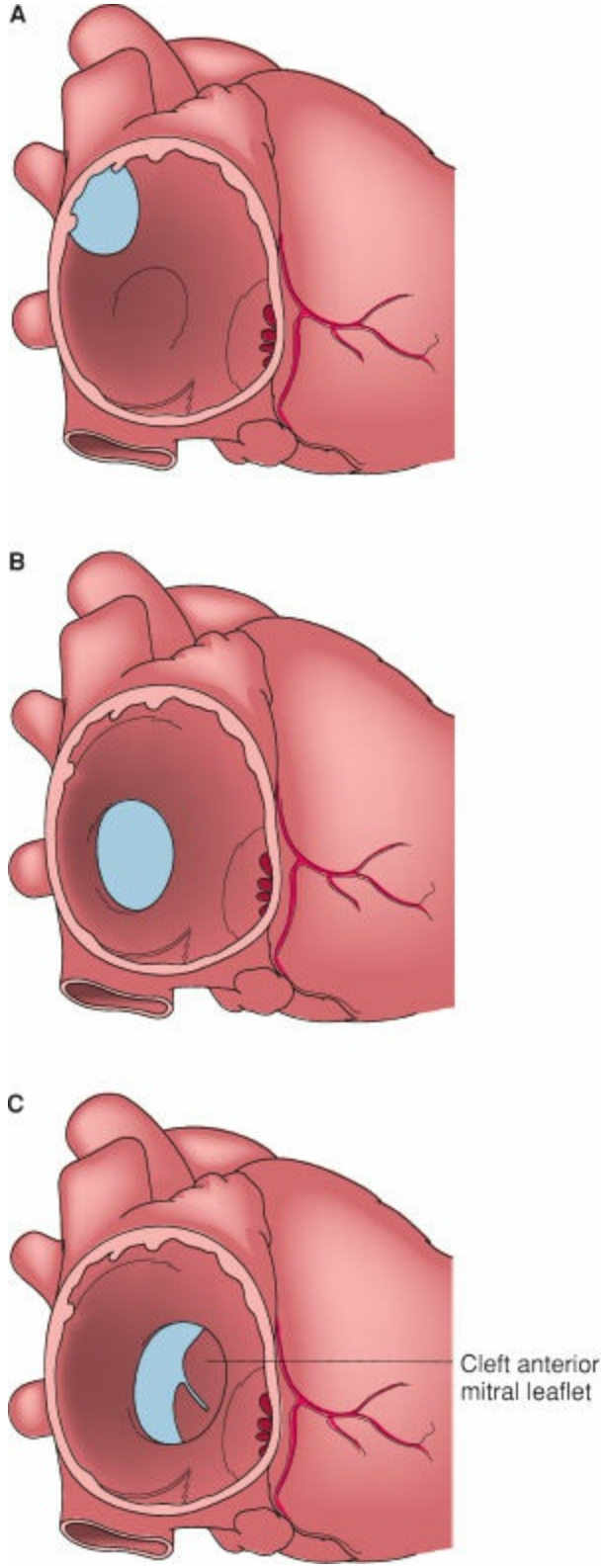

Figure 81-1. The anatomy of atrial septal defects. In the sinus venosus type **(A),** the right upper and middle pulmonary veins frequently drain to the superior vena cava or right atrium. **B:** Secundum defects generally occur as isolated lesions. **C:** Primum defects are part of a more complex lesion and are best considered as incomplete atrioventricular septal defects.

Failure of postnatal fusion of the septum secundum to the septum primum results in a persistent slit-like communication known as a patent foramen ovale (PFO). PFOs are extremely common in the general population, and autopsy studies have demonstrated a prevalence of 27%.[8] PFOs are generally considered separate from other ASDs due to the

absence of significant shunting, but they remain important clinically due to the occurrence of paradoxical embolization. A paradoxical embolus is a blood clot arising from a systemic vein that would normally pass to the lungs, but in the presence of a septal defect, may instead cross into the systemic circulation.

ASDs lead to increased pulmonary blood flow (PBF) secondary to left-to-right shunting. Shunting at the atrial level is determined by the size of the defect and by the relative ventricular compliance (i.e., blood preferentially fills the more compliant ventricle). At birth, both chambers are equally compliant, but as pulmonary vascular resistance (PVR) falls, the right ventricle remodels and becomes more compliant. Shunting across the atrial septum causes a volume load on the right heart. A volume load is created by additional venous return to a chamber during diastole.

The volume overload from an ASD is usually well tolerated, and patients are frequently asymptomatic. Symptoms tend to develop when the ratio of pulmonary to systemic blood flow (Q_p/Q_s) exceeds two. The most common symptoms are fatigue, shortness of breath, exercise intolerance, and recurrent respiratory infections. Older patients with untreated ASDs tend to develop atrial dysrhythmias, and adults may develop congestive heart failure (CHF) and right ventricular dysfunction. Pulmonary vascular obstructive disease may occur rarely as a late complication of an untreated ASD. Paradoxical embolization is also an important potential complication of an ASD.

The classic physical findings in patients with ASDs include fixed splitting of the second heart sound and a systolic ejection murmur at the left upper sternal border due to relative pulmonary stenosis (PS) (increased flow across a normal pulmonary valve). A diastolic flow murmur across the tricuspid valve is occasionally audible. A prominent right ventricular lift and increased intensity of the pulmonary component of the second heart sound may occur with pulmonary hypertension. Chest radiography shows cardiomegaly, with enlargement of the right atrium, right ventricle, and pulmonary artery. Electrocardiography (ECG) frequently demonstrates right axis deviation and an incomplete right bundle branch block. When right bundle branch block occurs with a leftward or superior axis, the diagnosis of AVSD should be considered. Echocardiography confirms the diagnosis of ASD and defines the anatomy. Cardiac catheterization is important in selected cases to assess PVR in older patients, but it is used more frequently with therapeutic intent for device closure of ASDs.

Due to the long-term complications associated with ASDs, repair is recommended for all patients with symptomatic defects and in asymptomatic patients in whom the Q_p/Q_s is greater than 1.5 or signs of right heart enlargement. Repair is usually performed in children prior to school age. Closure of ASDs may be performed surgically or using a device deployed in the cardiac catheterization laboratory.

Surgical repair is usually recommended for large secundum defects and for most other types of ASDs. The heart is exposed by median sternotomy. Other surgical approaches have been proposed, including minimally invasive techniques, but there are technical drawbacks associated with each of the alternative approaches. In most cases, a limited midline incision with a partial lower sternal split provides adequate exposure and a

cosmetically acceptable scar. The heart is carefully inspected for anomalies of systemic and pulmonary venous return.

Cardiopulmonary bypass is required with minimal cooling. The superior and inferior vena cava are separately cannulated for venous drainage, and the arterial cannula is placed in the ascending aorta. Following aortic clamping and arrest of the heart with cardioplegia, the atrial septum is exposed through a right atriotomy. Small secundum defects or PFOs may sometimes be closed primarily by suturing the edge of the septum primum to the edge of the septum secundum. More commonly, larger defects are closed using a patch (polytetrafluoroethylene or autologous pericardium) and a running polypropylene suture. When anomalous pulmonary venous drainage is present, a baffle is created to redirect the flow across the ASD. In all cases, care is taken to de-air the left atrium to avoid the complication of air embolization. Surgical closure of an ASD can be accomplished with a mortality approaching zero and minimal morbidity.[9] Common postoperative complications include atrial arrhythmias and postpericardiotomy syndrome.

The first transcatheter device closure of an ASD was performed in 1976.[10] A number of devices are currently available for percutaneous closure of secundum ASDs.[11] The contemporary success rate for device deployment is 96% with complete closure at 24 hours of 99% or greater.[12,13] The presence of a deficient rim is the most common reason for failed implantation.[13] Device closure has the advantages of fewer complications and a shorter hospitalization. Device closure of small to moderate secundum ASDs and PFOs has now become the standard of care at most large centers. Surgical closure remains the procedure of choice for large or multiple defects, insufficient rims, sinus venous–type defects, and primum ASDs.

The long-term survival for patients undergoing ASD repair in childhood is normal.[14,15] The major long-term complication following surgical closure of ASD is the development of supraventricular arrhythmias, although the risk is lowered when the ASD is closed in childhood.[15,16] The persistence of this risk despite relief of right-sided volume overload is thought to be related to incomplete atrial remodeling or due to the presence of the atriotomy scar. Longer follow-up will be required to determine whether device closure alters the risk of atrial dysrhythmias.

Occasionally, adults will present with a newly diagnosed ASD. Many studies have confirmed that ASD closure in adults over the age of 40 increases survival and limits the development of heart failure.[17,18] When the Q_p/Q_s is less than 1.5 and the ratio of pulmonary to systemic vascular resistance (R_p/R_s) is greater than 0.7, significant pulmonary vascular obstructive disease is usually present. A PVR in excess of 10 to 12 Woods units/m^2 represents a contraindication to ASD closure.

VENTRICULAR SEPTAL DEFECT

Ventricular septation is a complex process that requires accurate development and alignment of a number of structures including the muscular interventricular septum, the atrioventricular (AV) septum (arising from the endocardial cushions), and the infundibular septum (which divides the outflow tracts of the right and left ventricles). The membranous septum is a fibrous portion of the ventricular septum that is adjacent to the central fibrous body (where the mitral, tricuspid, and aortic valve annuli make contact).

3 Ventricular septal defects (VSDs) are the most common congenital heart anomalies (with the exception of bicuspid aortic valve, which occurs in about 1.3% of the population). VSDs are present in about 4 of 1,000 live births and represent about 40% of congenital heart defects.[7] VSDs are classified based on their location in the ventricular septum (Fig. 81-2). The most common defects are perimembranous (80%), which are located in the area of the membranous septum. Inlet defects (5%) are located beneath the septal leaflet of the tricuspid valve and are sometimes called AV canal-type defects. Defects located high in the ventricular septum are outlet defects (10%). Outlet VSDs are typically adjacent to both the pulmonary and aortic valves. Outlet defects are also known by several other names, including supracristal, infundibular, or doubly committed subarterial. Outlet defects are more common in the Asian population. Trabecular (or muscular) VSDs (5%) are completely bordered by muscle. Trabecular VSDs are frequently multiple and may be associated with perimembranous or outlet defects. The size of VSDs varies. By definition, a VSD is nonrestrictive when its size (or the cumulative size of multiple defects) is greater than or equal to the size of the aortic annulus.

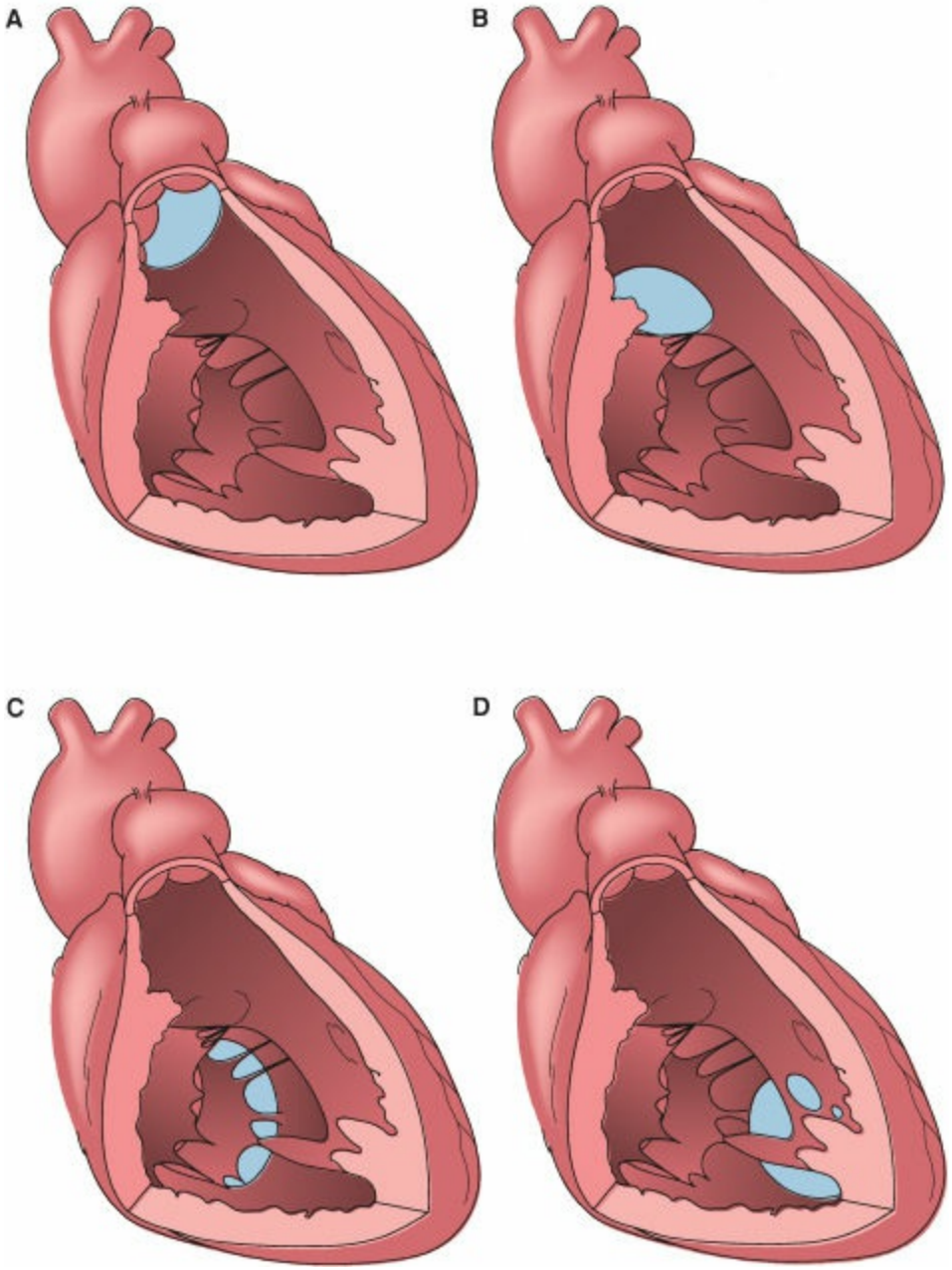

Figure 81-2. The anatomy of ventricular septal defects (VSDs) as seen through the right ventricle. **A:** Outlet, or subarterial, VSDs are generally bordered superiorly by the pulmonary valve annulus. **B:** Perimembranous VSDs are most common, extending from the membranous septum into the infundibular septum. **C:** Inlet defects are located predominantly beneath the septal leaflet of the tricuspid valve. **D:** Muscular VSDs are situated away from the valves, toward the cardiac apex.

A VSD causes increased PBF due to left-to-right shunting primarily during systole. This creates a volume load on the left heart (the left atrium and ventricle receive the increased venous return during diastole). The right ventricle is not volume loaded (blood is ejected from the left ventricle [LV] through the VSD and directly into the pulmonary circulation); however, it does experience a pressure load. The volume of shunt flow is determined by the size of the defect and by the ratio of pulmonary to systemic vascular resistance. After birth, the PVR is still high and shunting across a VSD is sometimes minimal. Over the first several weeks of life, shunting tends to increase as the PVR normally falls. Therefore, a patient with a large VSD may be asymptomatic at birth and develop severe CHF symptoms over the first 6 weeks of life.

The natural history for patients with isolated VSDs is highly variable. Most VSDs are restrictive and tend to close spontaneously during the first year of life. Large VSDs are nonrestrictive, resulting in right ventricular and pulmonary pressures that are systemic or nearly systemic, and high PBF with Q_p/Q_s ratios greater than 2.5 to 3. Moderate VSDs are restrictive, with pulmonary pressures that are one-half systemic (or less) and Q_p/Q_s ratios of 1.5 to 2.5. Small VSDs are highly restrictive; right ventricular pressures remain normal, and the Q_p/Q_s is less than 1.5. Patients with large VSDs tend to develop symptoms of CHF by 2 months of age. Patients with smaller VSDs may remain asymptomatic. In patients with outlet VSDs, prolapse of the aortic valve may occur, producing aortic insufficiency.[19] Untreated, excessive PBF leads to pulmonary vascular obstructive disease by the second year of life. The histologic changes associated with pulmonary vascular obstructive disease have been classified by Heath and Edwards based on severity.[20] Grade 1 consists of medial hypertrophy; grade 2 reflects intimal proliferation; grade 3 is characterized by intimal fibrosis and vascular occlusion; and grades 4 through 6 describe progressive vessel dilatation, angiomatoid malformation, and necrotizing arteritis. Grades 1 and 2 are considered reversible, whereas the latter stages are irreversible.

Signs of heart failure in infants with large VSDs include tachypnea, hepatomegaly, poor feeding, and failure to thrive. On physical examination, there is a holosystolic murmur at the left sternal border. Usually, the murmur is louder with smaller defects. The precordium is active. The pulmonary component of the second heart sound is accentuated in the presence of pulmonary hypertension. Chest radiography shows increased pulmonary vascular markings and cardiomegaly. ECG is significant for right ventricular hypertrophy. Patients with small VSDs have little shunting and are usually asymptomatic, having only a pansystolic murmur. Patients with moderate VSDs manifest symptoms and signs that are proportional to the degree of shunting. In patients who have developed significant pulmonary vascular obstructive disease, the volume of left-to-right shunting is decreased, and the murmur may disappear. Eisenmenger physiology results when the shunt flow reverses to right to left, creating cyanosis.

The diagnosis of VSD is confirmed by echocardiography, which accurately defines the anatomy and excludes the presence of associated defects. Cardiac catheterization is used selectively in older children and adults in whom elevated PVR is suspected. PVR is calculated by the following formula:

$$PVR = (PA_{mean} - LA)/Q_p$$

where PA_{mean} is the mean pulmonary artery pressure and LA is the left atrial pressure. The units of resistance by this formulation (using pressures in millimeters of mercury and pulmonary flow in liters per minute) are Woods units (which can be expressed in dynes/s per cm^5 by multiplying by 80). In the pediatric population, vascular resistance is frequently calculated using the cardiac output indexed to the body surface area (in square meters) with the resulting indexed resistance units of Woods units/m^2. PVR may be fixed or reactive, and, at the time of cardiac catheterization, response to nitric oxide or 100% fraction of inspired oxygen (FiO_2) may be assessed.

The management of a patient with a VSD depends on the size of the defect, the type of defect, the shunt volume, and the PVR. In general, patients with large defects who have intractable CHF or failure to thrive should undergo early surgical repair. If the congestive symptoms can be moderated by medical therapy, then surgery may be deferred until 6 months of age. Patients with moderate VSDs may be safely followed. If closure has not occurred by school age, then surgical closure is indicated. Small VSDs with a Q_p/Q_s ratio of less than 1.5 do not require closure unless there is evidence of left-sided chamber enlargement. There is a small long-term risk of endocarditis for these patients, but this can be minimized with the appropriate use of prophylactic antibiotics.[21] Patients with outlet VSDs have a risk of developing aortic insufficiency due to leaflet prolapse, and, therefore, all of these patients should undergo surgical closure.[22] Older children and adults must undergo catheterization to assess the pulmonary circulation. When there is a fixed PVR greater than 8 to 10 Woods units/m^2, then surgery is contraindicated.

Surgical closure is performed through a median sternotomy. Cardiopulmonary bypass is employed with bicaval cannulation, and the patient is typically cooled to 32°C. After aortic cross-clamping, cold cardioplegia is delivered through the aortic root to arrest the heart. Exposure of the ventricular septum is most often achieved by making a right atriotomy and retracting the leaflets of the tricuspid valve. This provides access to perimembranous, inlet, and most trabecular VSDs. Outlet VSDs are frequently best exposed via a pulmonary arteriotomy because the defect lies just beneath the valve. Trabecular VSDs located near the ventricular apex can be very difficult to expose, and an apical ventriculotomy may be necessary. Once the defect is exposed, it is closed using a polytetrafluoroethylene patch and a running polypropylene suture, although other centers may prefer other patch material or interrupted suture technique. It is important to understand the anatomy of the conduction tissue when closing VSDs. The AV node is an atrial structure that lies at the apex of an anatomic triangle (known as the triangle of Koch) formed by the coronary sinus, the tendon of Todaro (a prominent band leading from the inferior vena cava and inserting in the atrial septum), and the septal attachment of the tricuspid valve. The node then gives rise to the bundle of His, which penetrates the AV junction beneath the membranous septum. The bundle of His then bifurcates into right and left bundle branches, which pass along either side of the muscular ventricular septum. In the presence of a perimembranous VSD, the bundle of His passes along the posterior and inferior rim of the defect, generally on the left ventricular side. In this critical area, sutures must be placed superficially on the right ventricular side a few millimeters from the edge of the defect. The bundle of His also tends to run along the posterior and inferior margin of inlet VSDs. The conduction tissue is usually remote from outlet and trabecular VSDs.

PA banding is a palliative maneuver that is used to protect the pulmonary circulation from excessive blood flow. PA banding is currently performed only in patients who are felt to be poor candidates for VSD closure, either due to associated illness or due to anatomic complexity, such as multiple trabecular VSDs (“Swiss cheese” septum). Banding is performed without the need for cardiopulmonary bypass. A band is placed around the main PA and tightened to achieve a distal PA pressure of about one-half systemic. The

band is secured to the adventitia of the PA to prevent its migration. Distal migration may result in narrowing and poor growth of one or both branch pulmonary arteries, whereas proximal migration can cause deformity of the pulmonary valve. Later, when the patient is a candidate for VSD closure, the band must be removed. Repair of the main PA at the band site is also usually necessary and can typically be accomplished by scar resection and primary closure or patch repair.

Surgical closure of a VSD is associated with a mortality less than 1%.[23] Potential complications include injury to the conduction tissue and injury to the tricuspid or aortic valves. Transient heart block may result from tissue swelling or injury from retraction, but permanent heart block occurs in less than 1% of cases. When heart block develops after surgery, patients are usually observed for a period of 7 to 10 days prior to permanent pacemaker implantation. Closure of perimembranous and inlet VSDs may result in distortion of the tricuspid valve, which may cause significant regurgitation. Aortic valve injury may occur as a result of inaccurate suturing, especially in perimembranous and outlet defects. A residual VSD is seen in about 5% of cases, and reoperation is indicated when significant shunting persists (Q_p/Q_s ratio >1.5). The Q_p/Q_s ratio can be calculated by measuring oxygen saturations and using the following formula derived from the Fick equation:

$$Q_p/Q_s = (Ao - SVC)/(PV - PA)$$

where Ao is the aortic (or systemic) saturation, SVC is the saturation in the superior vena cava, PV is the saturation in the pulmonary veins (which is usually estimated to be 95% to 100%), and PA is the saturation in the pulmonary arteries. Intraoperative echocardiography is used routinely to identify residual defects, which can then be repaired before the patient leaves the operating room.

Recently, transcatheter devices have been developed to allow closure of some VSDs in the cardiac catheterization laboratory or by periventricular deployment without the use of cardiopulmonary bypass.[24,25] Device closure is optimal for large muscular defects with sufficient rims for securing the device. These defects are often difficult to visualize and close surgically. Periventricular closure allows the use of VSD device closure in smaller infants with symptomatic muscular VSDs with excellent results without the challenges of transvenous access in this population.[25] The use of devices for perimembranous VSDs remains limited by the risk of damage to the conduction system or impingement on the function of the tricuspid or aortic valves. A recent series demonstrated a 22% rate of complete heart block, which is prohibitively high in comparison to the surgical rate of complete heart block of less than 1%.[26]

ATRIOVENTRICULAR SEPTAL DEFECT

4 Defects in the embryologic development of the endocardial cushions may result in a variety of morphologic abnormalities in the AV valves and the atrial and ventricular septa. These anomalies range from ostium primum ASD to complete AVSD (or AV canal defect), with a spectrum of intermediate forms. PDA and TOF are occasionally seen in association with these defects. A high percentage of patients with abnormalities of the AV structures have trisomy 21 (Down syndrome). All infants with trisomy 21 should have an echocardiogram to rule out congenital heart disease given a prevalence of 50%.

Complete AVSD is an anomaly characterized by a common AV orifice, rather than separate mitral and tricuspid orifices, and a deficiency of endocardial cushion tissue, which results in a primum ASD and an inlet type of VSD. Complete AVSDs were subclassified by Rastelli et al.[27] into three types according to the morphology of the anterior leaflet of the common AV valve (Table 81-1). Incomplete AVSDs are variants in which there is partial fusion of the AV valves, resulting in separate right and left AV valve orifices. The ostium primum ASD is a type of incomplete AVSD in which the VSD component is absent.

Table 81-1 Rastelli Classification of Atrioseptal Ventricular Defects

Type	Description
A	The anterior bridging leaflet is divided and attached to the septum by multiple chordae.
B	The anterior bridging leaflet is attached to a papillary muscle in the right ventricle.
C	The anterior bridging leaflet is free-floating, with no attachments except to the valve annulus.

When both left and right AV valves equally share the common AV valve orifice, the AVSD is termed *balanced*. Occasionally, the orifice may favor the right AV valve (right dominance) or the left AV valve (left dominance). In marked right dominance, the left AV valve and LV are hypoplastic, and frequently coexist with other left-sided abnormalities, including aortic stenosis (AS), hypoplasia of the aorta, and coarctation. Conversely, marked left dominance results in a deficient right AV valve with associated hypoplasia of the right ventricle, PS or atresia, and TOF. Patients with severe imbalance require staged single-ventricle reconstruction.

The conduction tissue is displaced in an ASVD and is at risk during surgical repair. The AV node is located posteriorly and inferiorly of its normal position toward the coronary sinus in what has been termed the *nodal triangle*. This triangle is bounded by the coronary sinus, the posterior attachment of the inferior bridging leaflet, and the rim of the ASD. The bundle of His courses anteriorly and superiorly to run along the leftward aspect of the crest of the VSD, giving off the left bundle branch and continuing as the right bundle branch.

A number of other cardiac anomalies are associated with AVSDs including a PDA (10%)

and TOF (10%).[28] Important abnormalities of the left AV valve include single papillary muscle (parachute mitral valve) (2% to 6%) and double orifice mitral valve (8% to 14%).[29] A persistent left superior vena cava with or without an unroofed coronary sinus is encountered in 3% of patients with an AVSD. Double-outlet right ventricle (DORV) (2%) significantly complicates or may even preclude complete surgical correction.[28] Left ventricular outflow tract obstruction from subaortic stenosis or redundant AV valve tissue occurs in 4% to 7%.[30,31]

Patients with an incomplete AVSD generally present in a similar fashion as a patient with a large secundum ASD. Patients with a complete AVSD with both atrial and ventricular level shunting generally present early in infancy with signs and symptoms of CHF. In addition, moderate or severe left AV valve regurgitation occurs in approximately 10% of patients with an AVSD, worsening the clinical picture. On physical examination, the precordium is hyperactive, often with a prominent thrill. Auscultatory findings include a systolic murmur along the left sternal border, a high-pitched murmur at the apex from left AV valve regurgitation, and a middiastolic flow murmur across the common AV valve. In the presence of elevated PVR, there may be a split first heart sound. Significant cardiomegaly and pulmonary overcirculation are found on the chest radiograph. ECG reveals biventricular hypertrophy, atrial enlargement, prolonged PR interval, leftward axis, and counterclockwise frontal plane loop. Doppler/echocardiography is diagnostic, defining the atrial and ventricular level shunting, valvular anatomy, and any associated anomalies. Cardiac catheterization should be performed for patients older than 1 year of age, for patients with signs or symptoms of increased PVR, or in some cases to further evaluate other associated major cardiac anomalies. If the PVR is high, it is important to remeasure it while the child is breathing 100% oxygen with and without nitric oxide. If the pulmonary resistance falls, it implies that much of the elevated resistance is dynamic and can be managed in the perioperative period by ventilatory manipulation, supplemental oxygen, and nitric oxide. More recently, sildenafil has been shown to decrease elevation in PVR in children with CHF.[32] Markedly elevated pulmonary resistance (>10 Woods units/m^2) that does not respond to oxygen administration is generally considered a contraindication to repair.

Operative treatment is almost always necessary as soon as symptoms are observed to prevent further clinical deterioration. Even in the absence of symptoms, operation is best performed before 6 months of age. PA banding, which permits delaying the repair until the child is larger, is no longer used today except in select complex or single-ventricle cases, extremely low birth weight or prematurity, and very poor clinical condition. This approach exposes the child to the risks of two operations, and the overall mortality exceeds that of primary repair in infancy.

Correcting AVSDs requires patch closure of both septal defects, with any necessary valve reconstruction. Separate atrial and ventricular patches or a single patch for both chambers can be used.[33] During closure of the ventricular defect, the surgeon must carefully avoid injury to the conduction system, which passes along the posterior and inferior rim of the ventricular septum.

The short- and long-term success of the operation is highly dependent on the status of

the PVR and the surgeon's ability to maintain competence of the mitral valve. Although earlier reports recommend that the cleft in the left AV valve should not be closed and the valve treated as a trileaflet structure, most surgeons now believe that closure of the cleft is an important mechanism in preventing postoperative left AV valve regurgitation. Significant AV valve regurgitation at the conclusion of surgery, severe dysplasia of the left AV valve, and failure to close the cleft of the left AV valve have been identified as important risk factors for reoperation.[34] Significant postoperative left AV valve regurgitation is also a risk factor for operative and long-term mortality.[30,34] The cleft should not be completely closed in the presence of a single papillary muscle to avoid causing left AV valve stenosis. In the case of a double-orifice valve, the bridging tissue should not be divided to create a single opening in the valve.

Operative mortality is related largely to associated cardiac anomalies and left AV valve regurgitation. Mortality for repair of uncomplicated incomplete AVSDs ranges from 0% to 0.6%, and the addition of left AV valve regurgitation increases mortality to 4% to 6%.[30,35] For complete AVSDs, the mortality without left AV valve regurgitation is approximately 5%, compared with 13% when significant degrees of regurgitation are present.[30]

The majority of reoperations after repair of AVSD are due to left AV valve regurgitation or subaortic stenosis with reoperation rates at 5 years of 11% and 10%, respectively.[36] Significant postoperative AV valve regurgitation occurs in 10% to 15% of patients, necessitating reoperation for valve repair or replacement in 7% to 12%.[34,37,38] Long-term survival is excellent with rates at 1, 3, and 5 years of 98%, 95%, and 95%, respectively.[36]

TETRALOGY OF FALLOT

5 TOF is the most common cyanotic congenital heart defect. It occurs in 0.6 per 1,000 live births and has a prevalence of about 5% among all patients with congenital heart disease.[7] The pathologic anatomy is frequently described as having four components: VSD, overriding aorta, PS, and right ventricular hypertrophy (Fig. 81-3). Embryologically, the anatomy of TOF is thought to result from a single defect: anterior malalignment of the infundibular septum.[39] The infundibular septum normally separates the primitive outflow tracts and fuses with the ventricular septum. Anterior malalignment of the infundibular septum creates a VSD due to failure of fusion with the ventricular septum and also displaces the aorta over the VSD and right ventricle. Infundibular malalignment also crowds the right ventricular outflow tract, causing PS and, secondarily, right ventricular hypertrophy. Prominent muscle bands also extend from the septal insertion of the infundibular septum to the right ventricular free wall and contribute to the obstruction of the right ventricular outflow tract. The pulmonary valve is usually stenotic and is bicuspid in 58% of cases.[40] Pulmonary atresia occurs in about 7% of cases of TOF. The branch pulmonary arteries in TOF may exhibit mild diffuse hypoplasia or discrete stenosis (most frequently of the left PA at the site of ductal insertion). Coronary artery anomalies are frequently present. The origin of the left anterior descending from the right coronary artery, which occurs in 5% of cases, is clinically important because the vessel crosses the right ventricular infundibulum and is vulnerable to injury at the time of surgery. A right aortic arch is present in 25% of patients with TOF. Associated defects include ASD, complete AVSD, PDA, or multiple VSDs.

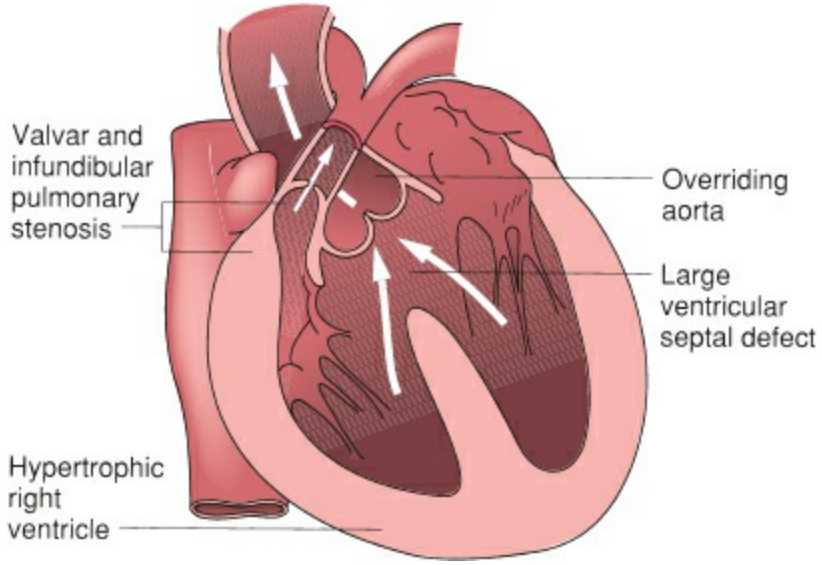

Figure 81-3. The four anatomic features of tetralogy of Fallot. The primary morphologic abnormality, anterior and superior displacement of the infundibular septum, results in a malalignment ventricular septal defect, overriding of the aortic valve, and obstruction of the right ventricular outflow. Right ventricular hypertrophy is a secondary occurrence.

Patients with TOF develop cyanosis due to right-to-left shunting across the VSD. The degree of cyanosis depends on the severity of obstruction of the right ventricular outflow tract. Frequently, cyanosis is mild at birth and may remain undetected for weeks or

months. Neonates with severe infundibular obstruction or pulmonary atresia will develop symptoms shortly after birth and will require a prostaglandin infusion to maintain ductal patency to ensure adequate PBF. In other patients, the right ventricular outflow tract obstruction is minor, and the predominant physiology is that of a large VSD with left-to-right shunting and CHF.

The occurrence of intermittent cyanotic spells is a well-known feature of TOF. The etiology of spelling is still controversial but is clearly related to a transient imbalance between pulmonary and systemic blood flow. A spell may be triggered by hypovolemia or peripheral vasodilation (e.g., after a bath or vigorous physical exertion). Spells may occur in neonates, but are most frequently reported in infants between the ages of 3 and 18 months. Most spells resolve spontaneously within a few minutes, but some spells may be fatal. Older children have been observed to spontaneously squat to terminate spells. The squatting position is thought to increase systemic vascular resistance, which thereby favors PBF.

Cyanosis is the most frequent physical finding in tetralogy. Auscultation reveals a normal first heart sound and a single second heart sound. A systolic ejection murmur is present at the left upper sternal border. Older children may develop clubbing of the fingers and toes. Chest radiography typically demonstrates a boot-shaped heart due to elevation of the cardiac apex from right ventricular hypertrophy. Pulmonary vascular markings are usually reduced. A right aortic arch may be present. An ECG shows right ventricular hypertrophy. Echocardiography is definitive, and catheterization is not necessary in most cases.

The medical management of TOF is directed toward the treatment and prevention of cyanotic spells. The immediate treatment of the spelling patient includes administration of oxygen, narcotics for sedation, and correction of acidosis. Transfusion is indicated for anemic infants. a-Agonists are useful for increasing systemic vascular resistance (which favors PBF). Some centers have used beta blockers as a form of long-term therapy to suppress the incidence of spells.

All patients with TOF should undergo surgical repair. Asymptomatic patients should be repaired electively between 4 and 6 months of age. Early repair is indicated for neonates with severe cyanosis and for infants who have had a documented spell or worsening cyanosis.

Classically, the repair of TOF was accomplished in two stages. During the first stage, PBF was augmented by creating a connection (or shunt) between a systemic artery and the PA. At the second stage, the shunt was taken down, and a complete repair was performed. The first shunt procedure was the Blalock–Taussig shunt, in which the subclavian artery was mobilized and divided distally, and an end-to-side anastomosis was created between the inferiorly deflected subclavian and the ipsilateral PA. Other shunt operations were subsequently developed and involved connections between the ascending aorta and right PA (Waterston shunt) or between the descending aorta and left PA (Potts shunt). The modified Blalock–Taussig shunt is the most common type of shunt used today and consists of an interposition graft (polytetrafluoroethylene) between the innominate or subclavian artery and the ipsilateral PA. Creation of a shunt may be accomplished with

or without the use of cardiopulmonary bypass.

Currently, one-stage repair of TOF is preferred by most centers. Initial palliation with a shunt is still indicated for some patients who are at high risk for early complete repair, such as those with multiple congenital anomalies, severe concurrent illness, intracranial hemorrhage, or an anomalous coronary artery crossing a hypoplastic infundibulum. In the absence of these risk factors, complete repair in the symptomatic neonate can be performed with lower mortality and reoperation rate compared to staged palliation.[41,42]

Complete repair of TOF is performed using a median sternotomy and cardiopulmonary bypass with bicaval venous cannulation. By a transatrial approach, the right ventricular outflow tract can be examined through the tricuspid valve. Muscle bundles obstructing the right ventricular outflow tract are divided or rarely resected. The VSD is closed with a patch. Pulmonary valvotomy is performed, when indicated, via a vertical incision in the main PA. When the pulmonary valve annulus or infundibulum is severely hypoplastic, a transannular outflow tract patch may be necessary to relieve the obstruction. When an anomalous coronary artery crosses the infundibulum, a transannular incision may be contraindicated. In these cases, and in patients with pulmonary atresia, placement of a conduit (cryopreserved homograft, valved xenograft, or bioprosthetic heterograft) between the right ventricle (via a separate ventriculotomy) and main PA will be necessary. Patients who have a transannular patch develop pulmonary insufficiency as a consequence. This is surprisingly well tolerated in most infants and children, as long as the tricuspid valve is competent. As these patients grow older, some will develop right ventricular failure due to chronic pulmonary insufficiency, and pulmonary valve implantation may be necessary, often in the second or third decade of life.[43,44]

The early mortality following repair of TOF is between 1% and 5%.[40,45] The results are worse for patients with TOF and pulmonary atresia. Long-term complications include recurrent obstruction of the right ventricular outflow tract and development of right ventricular dysfunction due to chronic pulmonary insufficiency. Actuarial survival at 20 years is 86% with excellent functional status.[46]

DOUBLE-OUTLET RIGHT VENTRICLE

Double-outlet ventricle includes a variety of malformations in which, by 50% or more, both great arteries arise from one ventricle. Although double-outlet LVs occur, a far more common anomaly is the DORV. A VSD is usually present in DORV, in addition to other defects, including discordant ventriculoarterial connections, valvar or subvalvar stenosis of the PA and aortic outflow, and single ventricle.

The physiologic consequences of DORV vary depending on the associated defects. The three most critical factors determining the net effects on the circulation are the size of the VSD, the presence or absence of PS, and the presence and degree of left-sided obstruction. As a result, DORV may clinically resemble an isolated VSD, TOF, or transposition of the great arteries (TGA).

The size and location of the VSD are important considerations in planning operative management. The VSD may be primarily directed toward the aorta, toward the PA, equally toward both arteries (doubly committed), or remote from both great vessels (noncommitted). The location of the VSD affects the direction of flow of oxygenated blood and thus affects the degree of cyanosis. VSDs in DORV seldom close spontaneously. This is fortunate, as closure would result in severe hemodynamic decompensation or death.

If the VSD is large, nonrestrictive, and committed to the aorta, it can be closed with a tunnel-like patch that directs left ventricular flow into the aorta. A restrictive VSD must be enlarged to avoid creating subaortic stenosis. For patients with DORV and PS, repair requires right ventricular outflow tract reconstruction with a patch or a valved allograft conduit, in addition to patch closure of the VSD.

DORV with transposition-type physiology (malposed great vessels with the VSD committed to the PA), also known as a Taussig–Bing anomaly, may be treated by a variety of methods, depending on the specific anatomic details. The preferred approach would be to perform an arterial switch operation, thus making the VSD committed to the aorta, and baffling the left ventricular outflow from the VSD to this neoaorta. Another preferred approach, which depends on a favorable orientation of the two great vessels and VSD, would be an intraventricular tunnel from the VSD to the aorta. A third approach utilizes the Damus–Kaye–Stanzel operation (DKS). During the DKS, the proximal PA is anastomosed end to side into the aorta. The VSD is baffled to both semilunar valves, which both connect to the aorta. An extracardiac conduit is then placed to reconstruct right ventricle-to-PA continuity. This approach may also be useful when the VSD is doubly committed or noncommitted, so that making a direct connection to either single great vessel is problematic.

The current results for correction of DORV with subaortic VSD are excellent, with a 15-year survival, including hospital mortality, of 96%.[47,48] Mortality for the more complex repairs tends to be slightly higher. Hospital mortality for an arterial switch operation with VSD closure for DORV ranges from 3.7% to 14.3%.[49,50]

TRANSPOSITION OF THE GREAT ARTERIES

6 TGA is a congenital cardiac anomaly in which the aorta arises from the right ventricle and the PA originates from the LV (ventriculoarterial discordance; Fig. 81-4). Looping refers to the right or left looping of the primitive heart tube during fetal development, which determines whether the atria and ventricles are concordant (right atrium attaches to right ventricle and left atrium attaches to LV) or discordant. Levo-TGA (l-TGA) is associated with AV discordance (right atrium attaches to LV and left atrium attaches to right ventricle), and is also termed *congenitally corrected TGA*. l-TGA is a rare variant of TGA and is beyond the scope of this chapter, which will focus on dextro-TGA (d-TGA). The defect can be subdivided into d-TGA with intact ventricular septum (IVS) (55% to 60%) and d-TGA with VSD (40% to 45%), one third of which are hemodynamically insignificant. Pulmonic stenosis (PS), causing significant left ventricular outflow tract obstruction, occurs rarely with an IVS and in approximately 10% of d-TGA/VSD.[51]

d-TGA is a relatively common cardiac anomaly and is the most common form of congenital heart disease presenting as cyanosis in the first week of life. The malformation accounts for approximately 10% of all congenital cardiovascular malformations in infants.[52] The degree of cyanosis depends on the amount of mixing between the pulmonary and systemic circulations. In d-TGA, oxygenated pulmonary venous blood is returned to the lungs and desaturated systemic blood is returned to the body. Because the two circulations exist in parallel, some mixing between them must occur to allow oxygenated blood to reach the systemic circulation and the desaturated blood to reach the lungs. Mixing may occur at a number of levels, most commonly at the atrial level through an ASD or a PFO. Generally, two levels of mixing are necessary to maintain adequate systemic oxygen delivery with a VSD or PDA serving as an additional site for cardiac mixing. In d-TGA, there can be no fixed shunt in one direction without an equal amount of blood passing in the other direction; otherwise, one circulation would eventually empty into the other. Therefore, the amount of desaturated blood reaching the lungs (effective PBF) must equal the amount of saturated blood reaching the aorta (effective systemic blood flow). Clinical characteristics are dependent on the degree of mixing and the amount of PBF. These factors relate to the specific anatomic subtype of d-TGA. Neonates with d-TGA with IVS (or small VSD) have mixing limited to the atrial level and PDA. The ASD may be restrictive and the PDA generally will close over the first days to week of life. As the degree of mixing decreases, the patient becomes increasingly cyanotic and will eventually suffer cardiovascular collapse. Fortunately, the majority of these neonates will manifest cyanosis early in life, which is recognized by a nurse or physician within the first hour in 56% and in the first day in 92%.[53] In d-TGA with a large VSD, there is additional opportunity for mixing and increased PBF. The neonate with d-TGA/VSD may only manifest mild cyanosis, which may be initially overlooked. However, generally within 2 to 6 weeks signs and symptoms of CHF will emerge. Tachypnea and tachycardia become prominent, whereas cyanosis may remain mild. Auscultatory findings are consistent with CHF with increased PBF, including a pansystolic murmur, third heart sound, middiastolic rumble, gallop, and narrowly split second heart sound with increased

pulmonary component. Neonates with d-TGA and significant PS present with severe cyanosis at birth. Lesser degrees of PS will result in varying levels of cyanosis. The ECG is normal at birth, demonstrating the typical pattern of right ventricular dominance. Although the classic chest radiographic appearance of an egg-shaped heart with a narrow superior mediastinum may be seen, this finding is often obscured by an enlarged thymic shadow. The abnormal ventriculoarterial connection is clearly seen on echocardiography, which demonstrates that the posterior great vessel arising from the LV is a PA that bifurcates soon after its origin. The anterior great vessel is the aorta and arises from the right ventricle. Associated lesions, including VSD, left ventricular outflow tract obstruction, and coarctation, may also be diagnosed. Although used less frequently, cardiac catheterization may be helpful to confirm the basic anatomy, discern associated lesions, define the coronary anatomy, and improve cardiac mixing by means of balloon atrial septostomy.

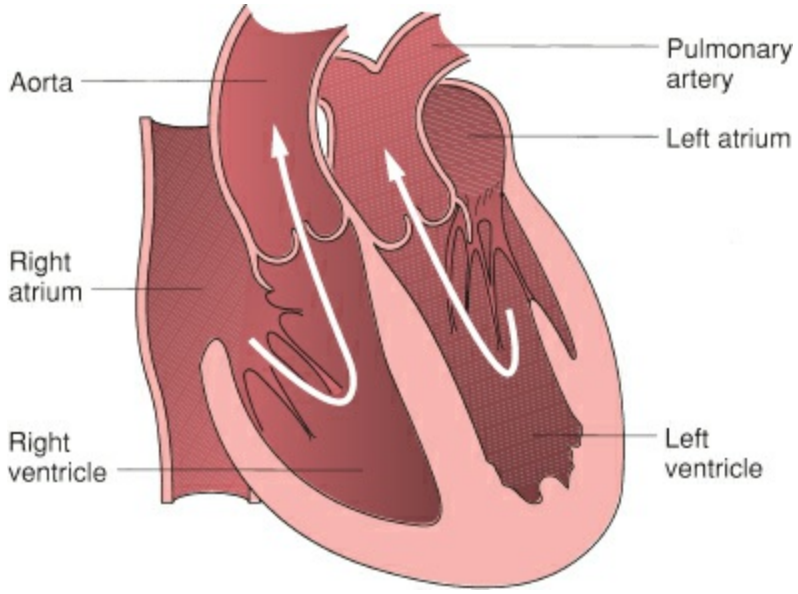

Figure 81-4. Anatomy of the most common type of transposition of the great arteries. The location of the ascending aorta is usually anterior to and to the right of the pulmonary artery.

The infant with d-TGA and severe cyanosis requires prompt diagnosis and treatment to improve mixing and increase the arterial oxygen saturation. The first intervention to improve mixing in a cyanotic newborn suspected of having d-TGA is to ensure ductal patency by beginning an infusion of prostaglandin E_1 (PGE_1). In the presence of a restrictive ASD, a balloon atrial septostomy, a technique developed by William Rashkind[54] in 1966, is performed. The procedure involves inserting a balloon-tipped catheter across the foramen ovale into the left atrium. Inflation and forcible withdrawal of the catheter tears the septum primum and enlarges the ASD. Mixing generally increases immediately, with a substantial increase in arterial oxygen saturation.

Without intervention, d-TGA is universally fatal. Untreated, 30% of neonates will die in the first week of life, 50% by the first month, 70% within 6 months, and 90% by 1 year.[55] The definitive surgical treatment of patients with d-TGA has changed dramatically in the past decade with the advent of the arterial switch operation. Before this procedure, repair

of d-TGA was generally delayed until patients were at least 6 months of age. Historically, palliative procedures were often necessary to improve the systemic saturation or protect the pulmonary vascular bed before definitive repair. If balloon atrial septostomy failed to enlarge the ASD adequately, a Blalock–Hanlon septectomy was performed. Rarely used today, this operation is a method of surgically enlarging the ASD without cardiopulmonary bypass. In patients with large VSDs, significant CHF and pulmonary hypertension are present early in life. Historically, the main PA was banded to reduce distal PA pressure and prevent the development of pulmonary vascular occlusive disease. Changes of pulmonary vascular disease may develop in about 25% of patients with hemodynamically large VSDs by 3 months of age; therefore, early reduction of PA pressure was essential. In those cases of transposition with severe left ventricular outflow tract obstruction, total pulmonary flow is reduced and systemic-to-PA shunting was undertaken until definitive repair could be accomplished.

Historically, definitive repair was achieved by redirecting venous inflow at the atrial level. First successfully performed by Senning[56] in 1959, the operation was further modified by Mustard[57] in 1964 (Fig. 81-5). In both techniques, the atrial septum is repositioned such that superior and inferior vena caval blood is rerouted to the mitral valve and then to the LV and PA. Pulmonary venous blood is redirected to the tricuspid valve and right ventricle. The right ventricle then ejects the oxygenated blood to the systemic circulation. The Mustard operation uses a large patch of pericardium or prosthetic material to create the intra-atrial baffle. In the Senning procedure, the patient's atrial tissue is used, and little or no foreign material is necessary. Although physiologic repair at the atrial level is associated with a low operative mortality rate ($<5\%$), even in infants, a number of late problems have occurred. Obstruction to vena caval inflow, particularly at the junction of the superior vena cava and the right atrium, still occurs in about 5% of patients and may be more common when the procedure is performed in an infant. Additionally, pulmonary venous obstruction may develop and is often difficult to repair. Perhaps because of the complex atrial suture lines, atrial dysrhythmias are common and occur in more than half of patients observed on a long-term basis. In addition, pacemakers may be necessary for troubling bradyarrhythmias in as many as 10% of these patients.

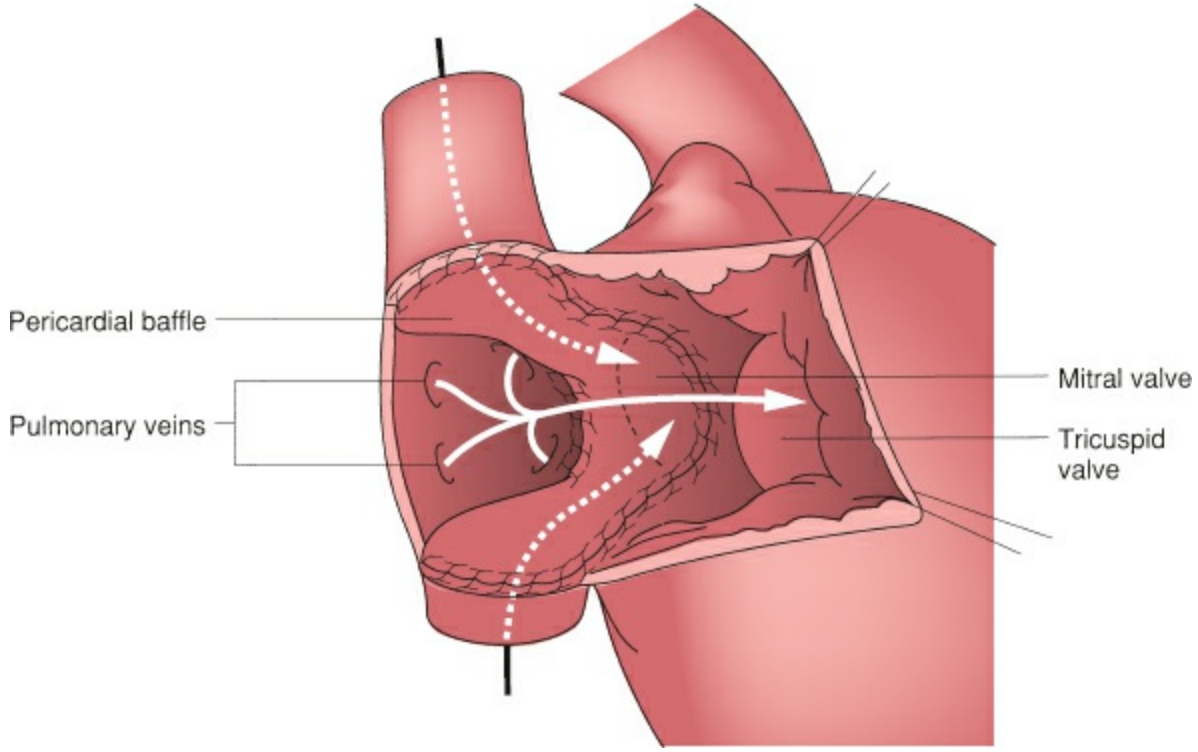

Figure 81-5. The Mustard operation for transposition of the great arteries. In this procedure, the atrial septum is excised and replaced with a pericardial baffle, so that pulmonary venous blood is redirected over the baffle to the tricuspid valve. Superior and inferior vena caval blood then drains to the mitral valve.

The most serious long-term complication of repair by either the Senning or Mustard technique has been right ventricular dysfunction. Right ventricular failure with an enlarged, poorly contractile chamber and secondary tricuspid regurgitation has been found in a significant number of these patients in long-term follow-up studies. The true incidence of significant right ventricular failure in these cases remains difficult to define and is clearly influenced by an earlier era of operation with different methods of myocardial protection and surgical technique. The fact that many of these infants underwent definitive repair after many months of significant cyanosis may also have influenced right ventricular function.

The long-term complications of atrial repair prompted a reexamination of direct arterial repair for transposing the great arteries. The “arterial switch” operation, first successfully performed by Jatene in 1975, has become the optimal surgical procedure for infants with this condition.[58] Current techniques have reduced the operative mortality to levels comparable with those of atrial repair. Additionally, because the operation is performed early in life, this approach has virtually eliminated the interim morbidity and mortality associated with postponement of surgery until at least 6 months of age. The operative technique involves transection of both great vessels and direct reanastomosis to reestablish ventriculoarterial concordance (Fig. 81-6). Additionally, the coronary arteries are removed from the anterior aorta and relocated to the posterior great vessel (neoaorta). The extensive experience gained with this procedure has confirmed that any variant of coronary artery anatomy can be successfully repaired. Certain coronary anatomy variants were previously felt to be associated with higher risk; however, this concern has been neutralized in recent series.[59,60] Many patients with d-TGA have an IVS,

and left ventricular pressure falls early in life as PVR decreases. In this situation, it is essential that the arterial repair be performed within the first 1 to 2 weeks of life, while the LV is still able to meet systemic workloads. In patients presenting later, the LV can be retrained with a preliminary PA banding and an aorticopulmonary shunt, if necessary, followed by the definitive arterial repair. Although patients with large VSDs do not require early repair because they maintain systemic left ventricular pressures, experience has indicated that, even in this subgroup, the operation is best performed within the first month of life, before secondary complications such as pulmonary hypertension, CHF, or infection develop.

Patients with fixed left ventricular outflow tract obstruction are not candidates for the arterial repair because correction would result in systemic ventricular outflow tract obstruction. Most of these patients also have large VSDs. Palliation early in life with systemic-to-PA shunting is an option, with definitive repair postponed until somatic growth results in cyanosis as the shunt is outgrown. At that time, the Rastelli procedure is performed, in which left ventricular blood is redirected through the VSD and to the anterior aorta by placement of an intraventricular patch (Fig. 81-7). The PA is ligated, and right ventricle–to–distal PA continuity is reestablished with a valved conduit. An increasing number of experienced centers currently recommend early complete repair in the neonatal period using a Rastelli procedure. Early repair eliminates the interim morbidity and mortality associated with a systemic-to-PA shunt and chronic cyanosis.

Current hospital survival for the arterial switch operation ranges from approximately 90% to 98%.[51,59–62] In earlier eras, d-TGA/IVS had a lower operative mortality than d-TGA/VSD; however, recent studies have neutralized this difference.[59,60] Complex d-TGA including d-TGA/VSD/PS and d-TGA/VSD with aortic arch hypoplasia are independent predictors of increased operative mortality.[63,64] Coronary artery anatomy does not affect mortality.[59] Long-term survival at 5 to 10 years and 15 years ranges from 87% to 93% and 86% to 88%, respectively.[60–62] The most common cause for reintervention is supravalvar PS, occurring in 3.9% to 16%.[61,62] Late follow-up of arterial switch operation patients has led to increased concern regarding coronary artery patency and neoaortic root dilation.[65]

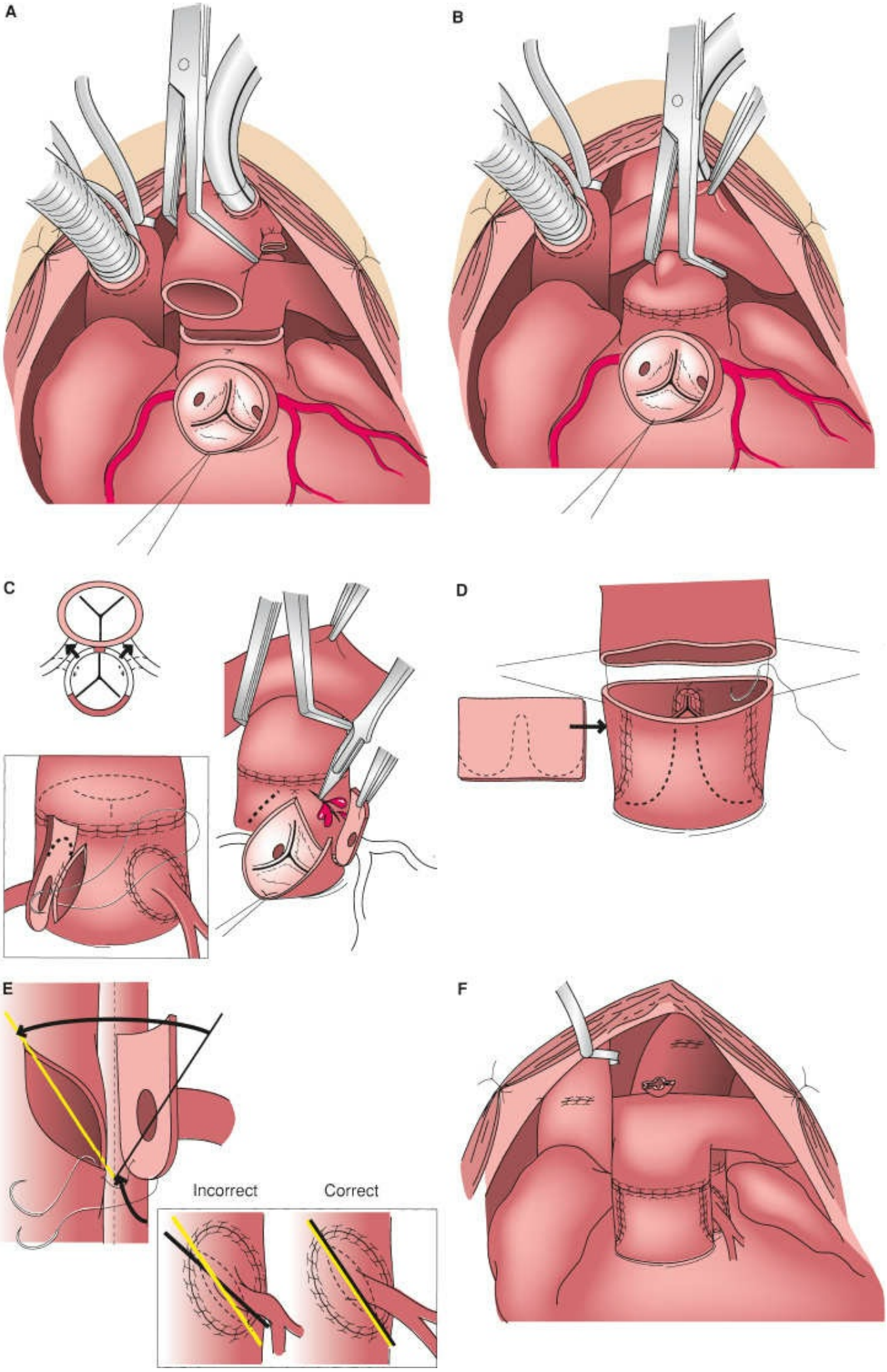
A
B
C
D
E
Incorrect
Correct
F

Figure 81-6. Arterial switch procedure for transposition of the great arteries. **A:** Division of aorta and pulmonary artery. **B:** LeCompte maneuver; posterior translocation of the aorta. **C:** Mobilization of the coronary arteries. **D:** Placement of pantaloon-shaped pericardial patch. **E:** Proper alignment of the coronary arteries on the neoaorta. **F:** Completed repair.

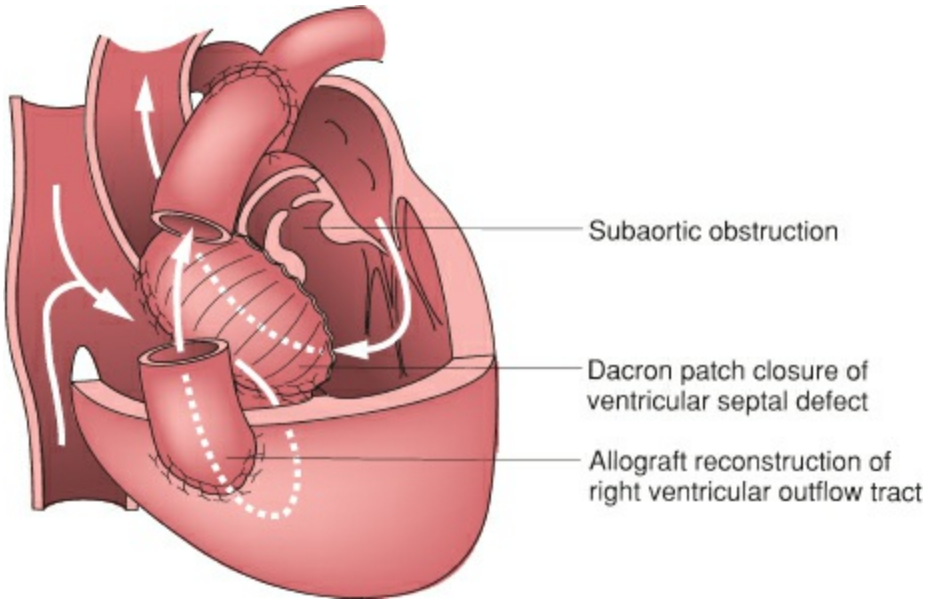

Figure 81-7. The Rastelli procedure for transposition of the great arteries with ventricular septal defect and pulmonary stenosis. A prosthetic patch placed within the right ventricle directs left ventricular blood through the defect to the aorta. The main pulmonary artery is ligated, and right ventricular blood then passes through a conduit to the distal pulmonary arteries.

TRUNCUS ARTERIOSUS

Truncus arteriosus is a rare anomaly that accounts for 0.4% to 4% of all cases of congenital heart disease.[66–68] A single arterial vessel arises from the heart, overriding the ventricular septum and giving rise to the systemic, coronary, and pulmonary circulations. Two classification schemes have been proposed: one by Collett and Edwards[69] in 1949 and the other by Van Praagh and Van Praagh[70] in 1965 (Fig. 81-8). The Collett and Edwards classification focused on the origin of the pulmonary arteries from the common arterial trunk (Table 81-2). The system offered by Van Praagh and Van Praagh, a somewhat more surgically oriented scheme, is based on the presence or absence of a VSD, the degree of formation of the aorticopulmonary septum, and the status of the aortic arch (Table 81-3).

Persistent truncus arteriosus is the result of failed development of the aorticopulmonary septum and subpulmonary infundibulum (conal septum). Normal septation leads to the development of both pulmonary and systemic outflow tracts, division of the semilunar valves, and formation of the aorta and pulmonary arteries. Failure of septation results in a VSD (absence of the infundibular septum), a single semilunar valve, and a single arterial trunk. Most cases are associated with a VSD reminiscent of the VSD associated with TOF. However, in this anomaly, the superior margin of the defect is formed by the truncal valve. The truncal valve leaflets are generally dysmorphic, and their motion may be restricted. Leaflet number is highly variable, with about 65% tricuspid, 22% quadricuspid, 9% bicuspid, and rarely unicuspid or pentacuspid.[71] As a result of these abnormally developed valve leaflets, a moderate or greater degree of truncal insufficiency is present in 20% to 26% of patients.[72,73] Mild stenosis is common; however, significant stenosis is present in only 4% to 7%.[72,73] Significant obstruction is predicted by gradients of more than 30 mm Hg in the presence of a normal cardiac output.[74] The PAs are usually of normal size and most often arise from the left posterolateral aspect of the truncal artery, often in close proximity to the truncal valve and ostium of the left coronary artery.

Other cardiac anomalies are common, with a PFO usually present. A true ASD is found in 9% to 20%, a persistent left superior vena cava in 4% to 9%, and mild tricuspid valve stenosis in 6%.[28,75] An interrupted aortic arch, most commonly type B, is present in association with truncus arteriosus (Van Praagh type A4/B4) in approximately 10% to 20%.[76,77] The arch is rightward, generally with mirror-image branching, in 21% to 36%.[75,77] Aberrant origins of the brachiocephalic vessels are reported, most commonly an aberrant right subclavian artery in 4% to 10%.[75,78] Coronary ostial abnormalities are of particular surgical significance and occur in 37% to 49% of cases.[79] The left coronary artery is frequently noted to have a high origin, not uncommonly near the takeoff of the pulmonary arteries. Rarely, the left coronary can originate from the main pulmonary trunk or a branch PA.[78] Extracardiac anomalies are reported in approximately 28% of patients with truncus arteriosus.[72] Described abnormalities include skeletal, genitourinary, and gastrointestinal deformities. As mentioned earlier, monoallelic microdeletion of chromosome 22q11 is common, with DiGeorge syndrome diagnosed in

at least 11%.[72]

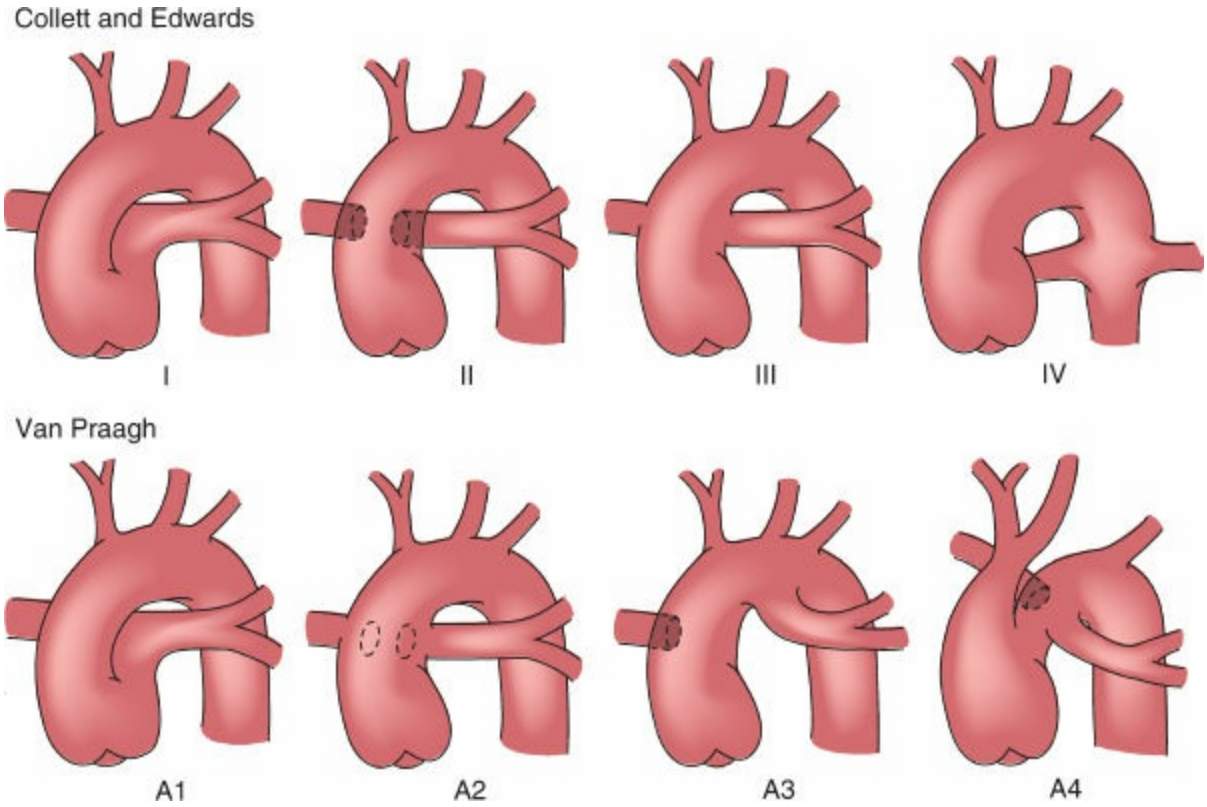

Figure 81-8. Truncus arteriosus: classification schemes as described by Collett and Edwards[69] and by Van Praagh and Van Praagh.[70] (Adapted from Hernanz-Schulman M, Fellows KE. Persistent truncus arteriosus: pathologic, diagnostic, and therapeutic considerations. *Semin Roentgenol* 1985;20:121.)

Table 81-2 Collett and Edwards Classification of Truncus Arteriosus

Type	Description
I	Common arterial trunk gives rise to a main pulmonary artery and the aorta.
II	Right and left pulmonary arteries arise directly and in close proximity from the posterior wall of the truncus.
III	Right and left pulmonary arteries arise from more widely separated orifices on the posterior truncal wall.
IV	Branch pulmonary arteries are absent. Pulmonary blood flow is derived from aorticopulmonary collaterals.

The anatomy of truncus arteriosus results in the obligatory mixing of systemic and pulmonary venous blood at the level of the VSD and truncal valve, which produces arterial saturations of 85% to 90%. The systemic arterial saturation depends on the volume of PBF, which in turn is determined by the PVR. As the PVR begins to fall, excessive pulmonary circulation ensues and leads to pulmonary congestion and signs and symptoms of CHF. This nonrestrictive left-to-right shunt may cause early development of irreversible pulmonary vascular obstructive disease.

The presence of truncal valve abnormalities poses further hemodynamic burdens. Truncal valve regurgitation leads to ventricular dilatation and low diastolic coronary perfusion pressures that can result in myocardial ischemia. Truncal valve stenosis promotes ventricular hypertrophy, increases the myocardial oxygen demand, and limits coronary and systemic perfusion, especially with the large volume of runoff into the pulmonary vascular bed.

Table 81-3 Van Praagh and Van Praagh Classification of Truncus Arteriosus

Type	Description
A	With a VSD
B	Without a VSD
1	The aorticopulmonary septum is partially developed (partially separate main pulmonary artery).
2	The aorticopulmonary septum is absent (no main pulmonary artery segment); both branch pulmonary arteries arise from the common trunk.
3	Either branch pulmonary artery is absent.
4	Hypoplasia, coarctation, atresia, or absence of the aortic isthmus is associated with a large PDA.

PDA, patent ductus arteriosus; VSD, ventricular septal defect.

Neonates with truncus arteriosus present with signs of CHF and collapsing peripheral pulses. Chest radiography shows marked cardiomegaly; pulmonary plethora, often with minimal thymus shadow; and a right aortic arch. The ECG most often depicts biventricular hypertrophy. Echocardiography is the diagnostic procedure of choice and can demonstrate the truncal vessel, the structure and function of the truncal valve, associated lesions such as interrupted aortic arch, and often the pulmonary arterial anatomy. Cardiac catheterization is not performed unless the anatomy is unclear, further information is needed about the status of the truncal valve, or the status of the pulmonary vasculature is unclear (i.e., infants older than 3 months at diagnosis).

The natural history of patients born with truncus arteriosus is early demise. Approximately 40% of infants are dead within 1 month, 70% by 3 months, and 90% by 1 year.[80] Early death is caused by CHF. Survivors may do well for a period of time until the development of pulmonary vascular obstructive disease and Eisenmenger syndrome. The ultimate treatment of truncus arteriosus is surgical correction in the neonatal period. Medical treatment is palliative and directed toward controlling CHF with fluid restriction, diuretics, digitalis, and afterload reduction. Complete repair entails separating the pulmonary arteries from the truncus, repairing the resulting defect in the aorta, closing the VSD, and restoring the continuity of the right ventricular outflow tract with an extracardiac conduit. Severe truncal valve regurgitation requires truncal valve repair[81] or replacement, which is best done with a cryopreserved allograft. An associated interrupted

aortic arch is repaired by constructing a primary end-to-end anastomosis of the distal ascending aorta with proximal augmentation if necessary.

The results of truncus arteriosus repair have improved greatly during the last two decades. Before the importance of early operation to avoid irreversible PVR was appreciated, patients underwent repair at most institutions at an average age of 2 to 5 years with high mortality rates. Ebert et al. showed that repair in the first 6 months of life is not only possible, but also preferable, reporting a mortality rate of 9%.[82] Current hospital mortality for the neonatal repair of truncus arteriosus ranges between 4.3% and 17%, with the majority of deaths occurring in complex truncus arteriosus or in truncus arteriosus with associated severe truncal valve regurgitation.[72–74,83–85] Risk factors for poor outcome identified in various studies include significant truncal regurgitation, need for truncal valve replacement, birth weight less than 2.5 kg, presence of interrupted aortic arch or coronary artery anomalies, pulmonary reconstruction with a technique other than valved heterograft or allograft, and age older than 100 days.[72–74,83–87] Other recent studies have demonstrated that interrupted aortic arch has been neutralized as a risk factor.[74,84]

AORTIC STENOSIS

AS refers to a form of left ventricular outflow tract obstruction that may occur at the valvar (70%), subvalvar (25%), or supravalvar (5%) level (Fig. 81-9). AS occurs in about 4% of patients with congenital heart disease.[7] The severity of AS may be graded by echocardiography or catheterization. Classification by echocardiography peak instantaneous pressure gradient is mild (<40 mm Hg), moderate (40 to 70 mm Hg), and severe (>70 mm Hg). Classification by catheterization peak-to-peak pressure gradient is mild (<30 mm Hg), moderate (30 to 50 mm Hg), and severe (>50 mm Hg).

Valvar AS occurs secondary to maldevelopment of the aortic valve. Most commonly, a bicuspid valve is present, although tricuspid and unicuspid valves are also represented. In valvar AS, the leaflets are thickened and frequently dysmorphic, and there is a variable degree of leaflet fusion along the commissures. The aortic annulus may be hypoplastic. In 20% of cases, valvar AS is associated with other cardiac defects, most commonly coarctation of the aorta, PDA, VSD, or mitral stenosis. Males with valvar AS outnumber females by a ratio of 4:1. There is a wide spectrum of clinical presentation of valvar AS, but patients tend to present in one of two groups: younger patients (neonates and infants) with severe AS develop symptoms of rapidly progressive CHF, whereas older patients, with less severe obstruction at birth, have a more indolent course.

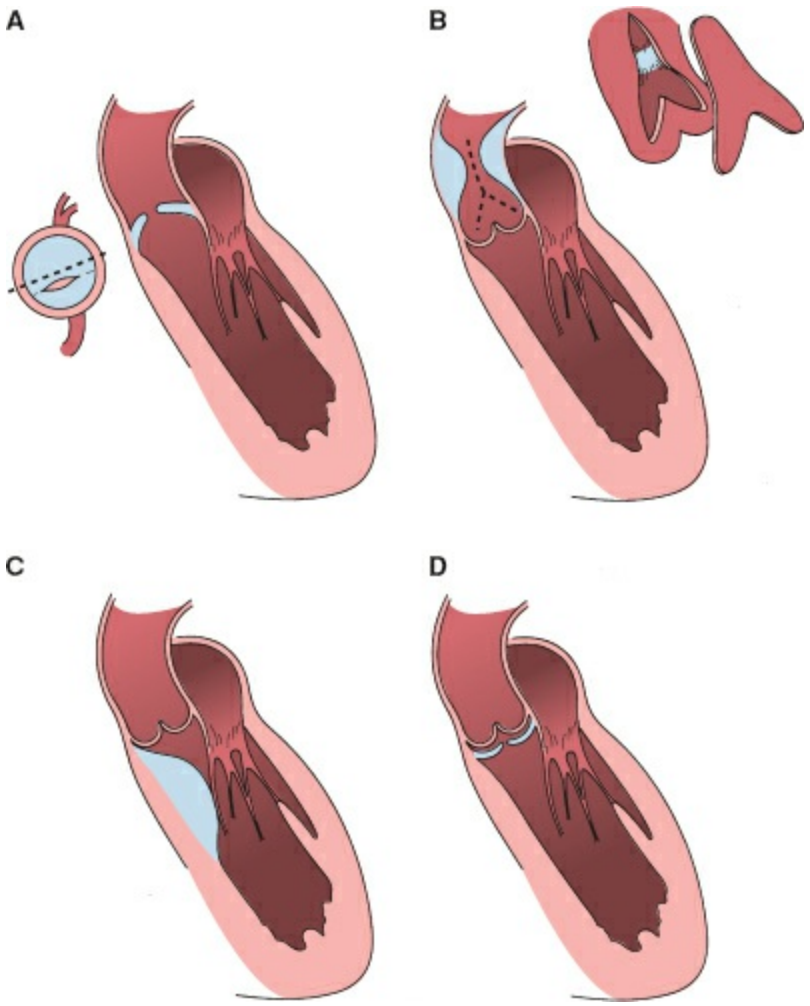

Figure 81-9. Anatomy of the types of congenital aortic stenosis. **A:** Valvar aortic stenosis. **B:** Supravalvar aortic stenosis and its repair (*inset*). **C:** Diffuse (tunnel) subvalvar aortic stenosis. **D:** Discrete subvalvar aortic stenosis.

Severe AS is usually well tolerated during fetal development. Although left ventricular output and antegrade flow across the aortic valve are decreased, the right ventricle compensates with increased output, and systemic perfusion is maintained by flow across the ductus. After birth, there is increased venous return to the left heart, and this exacerbates the pressure load created by the stenotic aortic valve, leading to left ventricular dysfunction. As the ductus closes during postnatal life, systemic malperfusion may develop with resulting hypotension, acidosis, and oliguria. Coronary perfusion is also impaired due to the combination of systemic hypotension and elevated left ventricular end-diastolic pressure. Patients with critical AS typically exhibit severe left ventricular dysfunction. These patients show signs of distress soon after birth. On examination, there is impaired distal perfusion with poor capillary refill and diminished, thready pulses. A systolic ejection murmur may be absent if the cardiac output is severely diminished. Differential cyanosis may be observed due to perfusion of the lower body with desaturated blood shunting through the ductus. The ECG shows left ventricular hypertrophy, and the chest radiograph displays cardiomegaly and pulmonary congestion. Echocardiography establishes the diagnosis.

Fetal echocardiography has allowed for early diagnosis of critical AS. For some, this may predict the progression to hypoplastic left heart syndrome or may result in irreversible left ventricular dysfunction. A few centers in the United States have been able to successfully balloon dilate the aortic valve in utero to promote left ventricular growth and preserve function in select cases.[88–90]

The neonate or infant with critical AS represents a true emergency. Endotracheal intubation and inotropic support are routine. Ductal patency is maintained with prostaglandins, and acidosis is corrected. All patients with critical AS require some form of urgent intervention. The approach is determined by the valve morphology and by the presence of associated defects. In its most extreme form, critical AS may be associated with underdeveloped left-sided cardiac chambers and therefore may represent a form of hypoplastic left heart syndrome. In these cases, single-ventricle palliation must be undertaken. For patients with adequate left-sided chambers, relief of AS may be achieved by one of the following three approaches: percutaneous balloon valvuloplasty, surgical valvotomy, or aortic valve replacement. Balloon valvuloplasty is generally considered the procedure of choice when the aortic valve annulus is adequate and there are no associated cardiac defects. Alternatively, surgical valvotomy may be accomplished by closed or open techniques. The closed approach is performed using cardiopulmonary bypass, but without aortic cross-clamping. Dilators of increasing size are passed through a ventriculotomy in the left ventricular apex and advanced across the aortic valve. Some centers prefer open surgical valvotomy, which allows a precise valvotomy under direct vision, although aortic cross-clamping with cardioplegia is necessary and results are similar to transventricular dilation. In all cases, the goal of therapy is to relieve stenosis without creating excessive aortic insufficiency. Dramatic clinical improvement is expected following balloon or surgical valvotomy, and early survivals of greater than 80% have been reported regardless of approach.[91,92] The incidence of aortic insufficiency is slightly higher following balloon valvotomy. In most cases, however, stenosis will recur and repeat

valvotomy or aortic valve replacement will eventually be required. Aortic valve replacement is problematic in the neonate due to small patient size. In these cases, many consider the best valve replacement to be a pulmonary autograft (Ross procedure)[93] with enlargement of the aortic annulus (Konno aortoventriculoplasty).[94] The Ross–Konno procedure has been used successfully for neonates with critical AS in whom the aortic annulus is hypoplastic and for selected patients in whom valvuloplasty was unsuccessful. Survival following the Ross–Konno procedure in infants has been shown to be excellent.[95] Growth of the pulmonary autograft has been documented, thereby making it an ideal valve replacement for children. Unfortunately, as part of the Ross procedure, the pulmonary valve must be replaced using a cryopreserved homograft that does not grow, and homograft replacement must be anticipated at intervals as the patient grows.

In contrast to infants with critical AS, older children with valvar AS usually present with less severe stenosis (mild or moderate), and most are asymptomatic. Symptoms of angina, syncope, and CHF are not commonly reported. Congenital valvar AS is a progressive lesion, however, and survival is dependent on the severity of stenosis and the rate of its progression. Sudden cardiac death is the most common cause of mortality. Endocarditis occurs in less than 1% of patients. The diagnosis of valvar AS in older children can frequently be made on physical examination. There is a classic systolic crescendo–decrescendo murmur at the upper sternal border, which radiates to the neck. An ejection click is often present. A visible apical impulse is suggestive of significant left ventricular hypertrophy. In severe cases, the pulse may be weak and delayed (pulsus tardus et parvus). The ECG shows left ventricular hypertrophy. The chest radiograph is usually normal. Echocardiography accurately defines the level of stenosis and its severity. Using Doppler techniques, the pressure gradient across the stenotic valve may be estimated using a simplified form of Bernoulli's equation, $P = 4V^2$, where P is the pressure gradient and V is the peak flow velocity. Cardiac catheterization is generally reserved for therapeutic intervention.

All patients with severe valvar AS should undergo intervention, as should all symptomatic patients with moderate stenosis. Asymptomatic patients with mild or moderate stenosis are generally observed. As described previously for critical AS, the techniques used to relieve AS in older patients include percutaneous balloon valvuloplasty, surgical valvulotomy, and valve replacement. Balloon valvuloplasty is usually performed as the primary intervention, and is associated with a success rate of nearly 90% and a mortality of less than 1%.[96] Open surgical valvotomy is an alternative approach with similar results.[97] For valves that are severely dysplastic, develop restenosis after intervention, or become insufficient as a result of prior intervention, valve replacement may be necessary. For older children, there are more options for valve replacement. The choices include mechanical prostheses, bioprosthetic valves, and tissue substitutes, such as porcine xenografts, cryopreserved human allografts, and pulmonary autografts (Ross procedure). The mechanical valves are the most durable, but require chronic anticoagulation. The bioprosthetic and tissue valves do not require long-term anticoagulation, but tend to deteriorate over time (with the exception of the pulmonary autograft). The pulmonary autograft has the potential advantage of growth but the

homograft used to replace the pulmonary valve will require replacement. Selection of the appropriate replacement valve is a complex decision that requires input from all involved parties.

Subvalvar AS occurs below the level of the aortic valve and may be discrete (80%) or diffuse (20%). Discrete (or membranous) subaortic stenosis is rarely seen in infants and tends to progress over time. This lesion consists of a crescentic or circumferential fibrous or fibromuscular membrane that protrudes into the left ventricular outflow tract. The pathogenesis of discrete subaortic stenosis is unknown, but it is thought to be an acquired lesion that develops secondary to a congenital abnormality of the left ventricular outflow tract in which abnormal flow patterns lead to endocardial injury with resultant fibrosis. Although the aortic valve leaflets are usually normal in discrete subaortic stenosis, the turbulent flow created by the obstruction can cause leaflet thickening and progressive aortic insufficiency. Diffuse subaortic stenosis is a more severe form that creates a long, tunnel-like obstruction. Diffuse subaortic stenosis should be distinguished from hypertrophic cardiomyopathy. Both forms of subaortic stenosis are associated with a high risk of endocarditis. The clinical findings in subvalvar AS are similar to those for valvar stenosis.

Intervention for discrete subvalvar stenosis is usually undertaken when the gradient exceeds 30 to 50 mm Hg or when aortic insufficiency is present. In these patients, resection of the membrane is readily performed by a transaortic approach. To reduce the incidence of restenosis, we advocate concurrent performance of a septal myomectomy to alter the geometry of the left ventricular outflow tract.[98] Operative mortality approaches zero. The recurrence rate of discrete stenosis following membrane resection and myomectomy has been reported to be as low as 4%.[99] Complications associated with membrane resection can include heart block, VSD, or damage to the aortic or mitral valve leaflets.

The indications for operative intervention in diffuse subaortic stenosis are similar to those for valvar stenosis. When diffuse subaortic stenosis is associated with hypoplasia of the aortic annulus, repair is best achieved with a Konno aortoventriculoplasty, whereby an incision is carried across the aortic annulus and subjacent ventricular septum, the opening patched, and an aortic valve implanted. Patients with an adequate aortic annulus may undergo a septoplasty (modified Konno), in which the septal incision is confined to the immediate subvalvar area and a patch is used to widen the left ventricular outflow tract without replacing the aortic valve. Despite the technical complexity of repair for diffuse subaortic stenosis, excellent results have been reported with high survival and freedom from reoperation.[100]

Supravalvar AS is characterized by thickening of the wall of the ascending aorta. The lesion may be localized (80%) to the region of the sinotubular ridge (at the level of the valve commissures), creating an hourglass deformity, or it may be more diffuse (20%), extending into the aortic arch and its branches. In both varieties, the aortic valve leaflets may be abnormal. The free edges of the aortic valve leaflets may adhere to the aortic wall in the region of intraluminal thickening, and this may lead to reduced coronary blood flow during diastole. Aortic wall thickening may also extend into the coronary ostia

and further impair coronary blood flow. Associated cardiac lesions are common, particularly branch PA stenoses. A genetic basis for supravalvar AS has been established.[101] About 50% of cases of supravalvar AS are associated with Williams syndrome, in which a partial deletion of chromosome 7 (including the elastin gene) leads to the triad of supravalvar stenosis, mental retardation, and a characteristic "elfin" facies. Isolated mutations in the elastin gene have also been shown to produce familial supravalvar AS with an autosomal dominant pattern of transmission. There is a significant incidence of endocarditis in patients with supravalvar AS. Sudden death is frequently reported and is probably related to coronary obstruction.

The signs and symptoms of supravalvar AS are similar to those in other forms of left ventricular outflow tract obstruction. The diagnosis is made by echocardiography, but cardiac catheterization (and more recently magnetic resonance imaging [MRI]) is essential to define the aortic, coronary, and pulmonary arterial anatomy prior to surgical intervention.

Operative intervention is indicated for patients with supravalvar AS in whom the gradient exceeds 50 mm Hg. A number of operations have been proposed for the treatment of localized supravalvar stenosis. The classic repair involves a longitudinal incision across the obstruction in the ascending aorta, which is extended into the noncoronary sinus. The thickened, hypertrophic ridge is resected by endarterectomy and the aortotomy is augmented with an elliptical patch. A variation of this repair involves creation of an inverted-Y aortotomy with one limb of the Y extended into the noncoronary sinus and the other into the right coronary sinus. A Y-shaped patch is then used to augment the aortotomy. Finally, the Brom repair is performed by transection of the ascending aorta beyond the supravalvar ridge. Separate incisions are then made through the supravalvar ridge into each sinus of Valsalva. Triangular patches are placed to augment each of these incisions, thereby relieving the supravalvar obstruction. Reconnection of the aortic root to the ascending aorta completes the repair. The repair of the diffuse type of supravalvar stenosis is performed under circulatory arrest with extensive patching of the ascending aorta, transverse arch, and involved arch arteries. Branch pulmonary stenoses are best managed using transcatheter techniques.

The results of surgery for localized supravalvar AS are generally good with low operative mortality and excellent long-term survival.[102–104] The diffuse form is more difficult to treat, and recurrence is more likely. Overall results are much worse when severe bilateral PA stenoses are present.

COARCTATION OF THE AORTA

Coarctation of the aorta is a narrowing of the proximal descending thoracic aorta distal to the origin of the left subclavian artery, near the insertion of the ductus arteriosus (or ligamentum arteriosum). The severity of luminal narrowing and the length of the aorta affected are variable. Coarctation is thought to occur as a result of ectopic tissue from the ductus arteriosus, which migrates into the wall of the adjacent aorta. After birth, as the ductus closes, the ectopic tissue in the aorta also constricts. Frequently, a posterior shelf of tissue is present at the point of most severe obstruction. The aortic obstruction caused by coarctation creates a pressure load on the LV.

The incidence of coarctation is about 0.5 per 1,000 live births, and its prevalence is 5% of congenital heart defects.[7] Coarctation is commonly associated with other heart defects including bicuspid aortic valve (in more than 50% of cases), PDA, and VSD. Other left-sided obstructive lesions may also be present, such as aortic arch hypoplasia, AS, mitral stenosis, and left ventricular hypoplasia. Coarctation is also recognized to occur in association with Turner syndrome.

Patients with severe coarctation present in the newborn period. Aortic obstruction is so significant that perfusion of the lower body is dependent on flow from the ductus arteriosus. Spontaneous ductal closure typically worsens the aortic obstruction and may lead to malperfusion of tissues distal to the coarctation. The pressure load on the LV may precipitate CHF. Patients may develop shock with severe acidosis, oliguria, and diminished distal pulses. Infants with severe coarctation will generally not survive without intervention.

7 Older children with coarctation are usually asymptomatic. The diagnosis is commonly made on the basis of hypertension in the upper extremities with decreased pulses in the lower extremities. Noninvasive blood pressure measurements in all four extremities help to quantify the severity of aortic obstruction. These older patients tend to develop extensive collateral arteries that bypass the obstruction. Life expectancy for these patients is limited due to the development of heart failure later in life. Other long-term complications of coarctation include chronic hypertension, endocarditis (frequently involving a bicuspid aortic valve), endarteritis (in the poststenotic area of the aorta at the site of the jet of turbulent flow), aortic dissection, aortic aneurysm, and intracranial hemorrhage (from Berry aneurysms, which occur more commonly in patients with coarctation).[105]

The diagnosis of coarctation can usually be made clinically. The infant with significant coarctation is frequently asymptomatic at birth, but following closure of the ductus develops signs of heart failure such as irritability, tachypnea, and poor feeding. Lower extremity pulses are absent, and upper extremity pulses may be weak. Chest radiography shows cardiomegaly and pulmonary venous congestion. There is a left ventricular strain pattern on the ECG. Echocardiography is usually diagnostic, demonstrating narrowing of the aorta at the coarctation site with a loss of pulsatility in the descending aorta.

In older children and adults with coarctation, there is usually a pressure gradient between the arms and legs, which can be demonstrated by measuring cuff pressures in all

four extremities. On chest radiography, rib notching may be evident, secondary to erosion of the inferior rib borders from the development of large intercostal collateral vessels. Echocardiography usually confirms the diagnosis. Anatomic details may also be clarified with computed tomography (CT) and MRI. Cardiac catheterization is usually not necessary.

Generally, all patients with coarctation should undergo surgical repair. For neonates, the acute medical management includes initiation of PGE_1 for the purpose of reopening the ductus; this maneuver partially relieves the aortic obstruction and augments perfusion of the lower body due to improved antegrade flow across the arch, as well as right-to-left flow across the ductus. Prostaglandins are usually effective for reopening the ductus when initiated within 7 to 10 days of life, but are less successful thereafter.

Surgical repair of coarctation is usually performed through a left posterolateral thoracotomy via the third or fourth intercostal space. Neonates with an associated hypoplastic aortic arch may require sternotomy for extended arch augmentation with either primary extended end-to-end repair or patch augmentation. For repair via thoracotomy, the descending thoracic aorta, ductus (or ligamentum), transverse aortic arch, and brachiocephalic vessels are mobilized. Care is taken to preserve the vagus nerve and its recurrent laryngeal branch. The preferred surgical approach to coarctation in infants and children is a resection with end-to-end anastomosis or extended end-to-end repair if there is associated mild distal arch hypoplasia.[106] In older children and adults, it may not be possible to perform a resection with primary repair without creating excessive tension on the anastomosis, which may lead to hemorrhage or scarring with recurrent coarctation. An alternative strategy is necessary in these cases. Patch aortoplasty may be performed in children in whom further growth is anticipated.[107,108] The subclavian flap repair augments the narrowed aorta using native arterial tissue. Blood flow to the left arm is maintained by collateral vessels, although long-term studies have demonstrated a slight discrepancy in limb length in some patients. Prosthetic patch material may also be used. By avoiding circumferential prosthetic material, growth potential of the native aorta is preserved. The disadvantage of patch repair is a high risk of aneurysm formation. In adults, in whom growth is no longer a concern, resection of the coarctation may be performed with subsequent placement of a prosthetic interposition graft (either Dacron or polytetrafluoroethylene).

One of the principal concerns during coarctation repair is interruption of distal aortic blood flow, especially to the spinal cord. The anterior spinal artery is fed by major radicular branches from intercostal arteries. In patients without well-formed collaterals, ischemia of the spinal cord may be precipitated by aortic cross-clamping, and paraplegia may result. Protective measures include induction of mild hypothermia, maintenance of a high proximal aortic pressure, and minimization of cross-clamp time. In older patients, distal aortic perfusion may be maintained by the technique of left heart bypass, in which oxygenated blood is taken from the left atrium and delivered to the femoral artery or distal aorta using a centrifugal pump.[109] This is usually not necessary due to the presence of significant collaterals. Overall, the incidence of paraplegia following coarctation repair is less than 1%.[110]

Following repair, patients may develop severe hypertension. This can be managed using intravenous beta blockers (e.g., esmolol). Uncontrolled hypertension can lead to the complication of mesenteric arteritis. Hypertension usually resolves within days to weeks after repair, although older children and adults may require lifelong antihypertensive therapy. Repair of coarctation during infancy is thought to minimize the risk of late hypertension.[111]

Transcatheter intervention for primary therapy of discrete coarctation in young children and adolescents remains controversial. Technical success rates range from 80% to 98%, with reintervention rates of 10% to 20%.[112–114] Placement of a stent has been associated with higher success rates and lower restenosis rates[114]; however, the long-term outcome of stents in this population remains unknown, and stents are not an ideal option in younger children. There is no evidence to date, therefore, that demonstrates superiority or equivalence of catheter intervention compared to surgery. In addition, there is a high complication rate of 5% to 11.7%, including recurrent coarctation, need for multiple interventions, injury to the femoral vasculature (for access), aortic dissection, and aneurysm formation.[113,115–117] On the other hand, balloon angioplasty is widely accepted for the treatment of recurrent coarctation following surgery, in which the success rate is on the order of 90% with low recurrence rates.[118–120]

The early mortality following repair of coarctation in neonates is 2% to 10%, whereas the risk in older children and adults is about 1%.[106,121] The incidence of recurrent coarctation following resection and end-to-end repair is about 4% to 8%.[106,122,123] The long-term survival following repair of coarctation is determined by the presence of associated defects and the persistence of hypertension.

PATENT DUCTUS ARTERIOSUS

The ductus arteriosus is a normal fetal vascular structure that allows blood from the right ventricle to bypass the high-resistance pulmonary vascular bed and pass directly to the systemic circulation. The ductus communicates between the main PA (or proximal left PA) and the proximal descending thoracic aorta. Histologically, the media of the ductus contains a predominance of smooth muscle cells, whereas the media of the aorta and PA contain well-developed elastic fibers. Vasocontrol of the ductus is mediated by two important mechanisms: oxygen tension and prostaglandin levels. During fetal development, low oxygen tension and high levels of circulating prostaglandin maintain ductal patency. During the final trimester, the ductus becomes less sensitive to prostaglandins and more sensitive to the effects of oxygen tension. Following birth, the rise in oxygen tension and a fall in prostaglandins (which were previously supplied principally by the placenta) lead to ductal closure, which is usually complete by 12 to 24 hours. After closure, the ductus becomes a fibrous cord known as the ligamentum arteriosum. Failure of closure of the ductus leads to the condition called PDA. PDA occurs in about 1 out of 1,200 live births and accounts for 7% of congenital heart defects.[7] The incidence is much higher in premature infants (>20%).[124] This elevated incidence is thought to be related to immaturity of the ductal wall resulting in impaired sensitivity to oxygen tension.

PDA may occur as an isolated defect, or it may occur in association with a number of other anomalies. Patency of the ductus arteriosus is desirable in a number of defects in which there is either inadequate PBF (such as pulmonary atresia) or inadequate systemic blood flow (as in severe coarctation of the aorta). The discovery that extrinsic delivery of prostaglandins can maintain ductal patency has played a critical role in improving the survival of these patients.[125]

The physiologic manifestation of PDA is shunting of blood across the ductus. The shunt volume is determined by the size of the ductus and by the ratio of pulmonary to systemic vascular resistance. At birth, the PVR drops dramatically and continues to decline over the first several weeks of life. As a result, shunting across a PDA is from left to right. Excessive PBF can lead to CHF. In extreme cases, hypotension and systemic malperfusion may result. Patients with a large PDA who survive infancy tend to develop pulmonary vascular obstructive disease. Eisenmenger physiology results when the PVR exceeds the systemic vascular resistance, producing a reversal of shunting across the ductus to right to left. This leads to cyanosis and, eventually, right ventricular failure. Small PDAs may persist to adulthood without producing any symptoms or physiologic derangement. Endocarditis and endarteritis have been reported as long-term complications of PDA.[126]

In patients with PDA, symptoms are proportional to the shunt volume and the presence of associated defects. Left-to-right shunting produces volume overload of the left heart. Infants with CHF demonstrate symptoms of tachypnea, tachycardia, and poor feeding. Older children may present with recurrent respiratory infections, fatigue, and failure to thrive. Physical findings include a widened pulse pressure and a continuous “machinery” murmur heard best along the left upper sternal border. Chest radiography shows

increased pulmonary vascular markings and left heart enlargement. Left ventricular hypertrophy and left atrial enlargement may be evident on the ECG. Echocardiography is the diagnostic method of choice. Diagnostic cardiac catheterization is performed only in older patients with suspected pulmonary hypertension to evaluate for pulmonary vascular obstructive disease. More frequently, catheterization is utilized for transcatheter occlusion of the ductus in selected cases.

PDA closure is performed for all symptomatic patients. Closure is also recommended for asymptomatic patients due to the risk of heart failure, pulmonary hypertension, and endocarditis. Closure of the ductus may be accomplished by one of three approaches: pharmacologic, surgical, and endovascular. Indomethacin and ibuprofen, which are cyclooxygenase inhibitors, stimulate PDA closure in premature infants.[127,128] Both are rarely effective in full-term infants. Due to improved side effect profile of gastrointestinal bleeding and renal dysfunction, ibuprofen is the current drug of choice.[128] The dosing regimen is 10 mg/kg intravenously, followed by 5 mg/kg intravenously at 24-hour intervals for a total of three doses. This is effective in about 70% to 80% of premature babies.[128,129] Due to their side effects, indomethacin and ibuprofen are contraindicated in patients with sepsis, renal insufficiency, intracranial hemorrhage, or bleeding disorders. Failure of ibuprofen after two complete courses results in referral for surgical closure.

The surgical approach to PDA is through a left posterolateral thoracotomy via the third or fourth intercostal space. The pleura is incised over the proximal descending thoracic aorta. This allows medial retraction of the vagus nerve. The recurrent laryngeal nerve curves behind the ductus and should be protected throughout the procedure. Dissection is then performed to demonstrate the pertinent anatomy. In many cases, the ductus is the largest vascular structure present, and it must not be confused with the aorta. Ductal tissue is extremely friable, so direct manipulation is minimized. In premature infants, the ductus is controlled with a single surgical clip; this procedure is commonly performed in the neonatal intensive care unit, thereby avoiding problems associated with patient transfer.[130,131] In older patients, occlusion of the ductus is achieved with simple silk ligature, or, preferably, by division between ligatures to minimize recurrence.

Thoracoscopic techniques have been developed to perform PDA ligation.[132] This approach has the potential benefits of decreased pain and quicker recovery. Disadvantages include a substantial learning curve and increased operating time.

A number of endovascular devices have been developed for the purpose of transcatheter occlusion of the PDA.[133–135] This approach is very successful in older infants, children, and adults with small and moderate-sized PDAs and has become the treatment of choice at many centers. Surgical therapy is reserved for PDAs having a large diameter or very short length.

Rarely, an adult will present with a significant PDA. These patients must be carefully evaluated for the presence of pulmonary vascular obstructive disease prior to ductal closure. If the patient is not a candidate for device closure, surgical closure can be problematic. Calcification of the ductal wall is common in adults, making ligation hazardous. In some cases, cardiopulmonary bypass may be required with closure of the ductus from within the PA.[136,137]

Closure of the ductus by surgical or transcatheter techniques is achieved with a mortality that approaches zero.[130] Potential complications include pneumothorax, phrenic nerve injury, recurrent laryngeal nerve injury, and chylothorax (from injury to the thoracic duct). Long-term survival should be normal following PDA ligation in most patients. Survival in premature infants depends primarily on the extent of prematurity with its attendant complications.

VASCULAR RINGS

Vascular rings comprise a spectrum of vascular anomalies of the aortic arch, pulmonary artery, and brachiocephalic vessels. The clinically significant manifestation of these lesions is a varying degree of tracheoesophageal compression. These vascular anomalies can be divided into complete vascular rings and partial vascular rings. Incomplete vascular rings include aberrant right subclavian artery, innominate artery compression, and pulmonary artery sling. The incidence of clinically significant vascular rings is 1% to 2% of all congenital heart defects.[7]

Vascular rings and pulmonary slings have been described in conjunction with other cardiac defects, including TOF, ASD, branch pulmonary artery stenosis, coarctation, AVSD, VSD, interrupted aortic arch, and aortopulmonary window. Significant associated cardiac anomalies occur in 11% to 20% of patients with a vascular ring.[138,139] A right aortic arch is generally associated with a greater incidence of coexisting anomalies.

By the end of the fourth week of embryonic development, the six aortic or branchial arches have formed between the dorsal aortae and ventral roots. Subsequent involution and migration of the arches results in the anatomically normal or abnormal development of the aorta and its branches. The majority of the first, second, and fifth arches regress. The third arch forms the common carotid artery and proximal internal carotid artery. The right fourth arch forms the proximal right subclavian artery. The left fourth arch contributes to the portion of the aortic arch from the left carotid to left subclavian arteries. The proximal portion of the right sixth arch becomes the proximal portion of the right pulmonary artery, while the distal segment involutes. Similarly, the proximal left sixth arch contributes to the proximal left pulmonary artery, and the distal sixth arch becomes the ductus arteriosus.

Children with a complete vascular ring generally present within the first weeks to months of life. Typically, children with a double aortic arch present earlier in life than those with a right arch and retroesophageal left ligamentum. In the younger age group, respiratory symptoms predominate, as liquids are generally well tolerated. Respiratory symptoms may include stridor, nonproductive cough, apnea, or frequent respiratory infections. The cough is classically described as a “seal bark” or “brassy.” These symptoms may mimic asthma, respiratory infection, or reflux, and children with vascular rings are often initially misdiagnosed. With the transition to solid food, dysphagia becomes more apparent.

The presentation of a patient with an incomplete vascular ring is variable. Children with innominate artery compression usually present within the first 1 to 2 years of life with respiratory symptoms. Aberrant right subclavian artery is the most common arch abnormality, occurring in approximately 0.5% to 1% of the population, and it rarely causes symptoms. Classically, when symptoms do occur, they present in the seventh and eighth decades, as the aberrant vessel becomes ectatic and calcified, causing *dysphagia lusoria* due to impingement of the artery on the posterior esophagus.

Children with pulmonary artery slings generally present with respiratory symptoms within the first few weeks to months of life. As with complete rings, respiratory

symptoms may include stridor, nonproductive cough, apnea, or frequent respiratory infections and may mimic other conditions, leading to misdiagnosis. Pulmonary artery slings are associated with complete tracheal rings in 30% to 40% of patients, leading to focal or diffuse tracheal stenosis.

The methods for diagnosing a vascular ring are variable, due to the variability in presentation and the spectrum of diagnostic tests available. A child with a presumptive diagnosis of asthma or tracheomalacia may be referred to a pulmonologist and a diagnosis of vascular ring made or suspected initially by chest radiograph and bronchoscopy. In some situations, the diagnosis is made by echocardiography during evaluation for concurrent cardiac defects. Regardless, the diagnosis generally begins with a chest radiograph. Complementary studies may include barium esophagogram, CT, MRI, and bronchoscopy. CT, MRI, and bronchoscopy are important modalities to define the tracheal anatomy in a patient with a pulmonary artery sling. Echocardiography may be diagnostic, and may be used to rule out other cardiac anomalies. Tracheograms and cardiac catheterizations, which have been used extensively in the past, are rarely currently indicated.

A double aortic arch occurs when the distal portion of the right dorsal aorta fails to regress. The two arches form a complete ring, encircling the trachea and esophagus. The right arch is dominant in the majority of the cases, followed by left dominant, with codominant arches being the least common. The left and right carotid and subclavian arteries generally arise from their respective arches. The ligamentum arteriosum and descending aorta usually remain on the left.

The approach to repair of a double aortic arch is via a left posterolateral thoracotomy. The pleura is incised, after identifying the vagus and phrenic nerves. The ligamentum or ductus arteriosum is divided while preserving the recurrent laryngeal nerve. The nondominant arch is then divided between two vascular clamps at the point where brachiocephalic flow is optimally preserved. If there is concern regarding the location for division, the arches can be temporarily occluded at various points while monitoring pulse and blood pressure in each limb. If there is an atretic segment, the division is done at the point of the atresia. Dissection around the esophagus and trachea in the regions of the ligamentum/ductus and nondominant arch allows for retraction of the vascular structures and lysis of any residual obstructing adhesions.

The surgical approach for a right aortic arch with retroesophageal left ligamentum arteriosum is the same as for a double arch. The ligamentum is divided and any adhesions around the esophagus and trachea are lysed. Rarely, the Kommerell diverticulum has been reported to cause compression even after division of the ligamentum. As such, it may be prudent to resect or suspend the diverticulum posteriorly.

In innominate artery compression syndrome, the aortic arch and ligamentum are in their normal leftward position. However, the innominate artery arises partially or totally to the left of midline. As the artery courses from left to right anterior to the trachea, it causes tracheal compression. The symptoms of innominate artery compression may be mild to severe. With mild symptoms and minimal tracheal compression on bronchoscopy, children can be observed expectantly as the symptoms may resolve with growth.

Indications for surgery include apnea, severe respiratory distress, significant stridor, and recurrent respiratory tract infection. Several approaches for the correction of innominate artery compression syndrome have been described. These include simple division, division with reimplantation into the right side of the ascending aorta, and suspension to the overlying sternum.

An aberrant right subclavian artery occurs when there is regression of the right fourth arch between the right common carotid and right subclavian arteries. The right subclavian then arises from the leftward descending aorta, laying posterior to the esophagus as it crosses from left to right. Although the artery can compress the esophagus posteriorly, it is rarely the cause of symptoms in children. Surgical treatment involves simple division via a left posterolateral thoracotomy. Rarely, reimplantation or grafting from the right carotid or aortic arch may be necessary.

Normally, the right and left sixth aortic arches contribute to the proximal portions of their respective pulmonary arteries. If the proximal left sixth arch involutes and the bud from the left lung migrates rightward to meet the right pulmonary artery, a pulmonary artery sling is formed. Pulmonary artery slings are associated with complete tracheal rings and tracheal stenosis in 30% to 40% of patients.

Initial attempts at the repair of a pulmonary artery sling involved reimplantation after division of the left pulmonary artery (LPA) and translocation of the trachea without cardiopulmonary bypass. These early reports had a high incidence of LPA thrombosis. This has led some authors to advocate division of the trachea and translocation of the LPA. This approach would seem sensible if the trachea were being divided in the course of tracheal reconstruction. However, currently most authors advocate the reimplantation of the LPA, which has resulted in excellent results. The procedure is done via a median sternotomy on cardiopulmonary bypass to ensure optimal visualization of the repair. Aortic cross-clamping is not necessary. The LPA is divided off of the right pulmonary artery, translocated anterior to the trachea, and reimplanted into the main pulmonary artery.

Any necessary reconstruction of the trachea is done concurrently with bronchoscopic assistance. Many techniques for tracheal reconstruction have been described, the most common of which are resection with primary reanastomosis and sliding tracheoplasty for short-segment stenosis, and rib cartilage or pericardial patch for long areas of narrowing.[140]

Over 95% of vascular rings without concurrent cardiac defects can be performed through a left thoracotomy. A right thoracotomy is indicated for the rare cases where there is a right ligamentum arteriosum. In addition, a double aortic arch with an atretic segment proximal to the right carotid artery is more easily divided through a right thoracotomy. The approach to these anomalies is the same as for a left-sided ring division, with the caveat that the right recurrent laryngeal nerve will loop around the right ligamentum.

Repair of vascular rings has been described using video-assisted thoracoscopic surgery (VATS) both with and without robotic assistance. Candidates for thoracoscopic division are limited to those patients requiring only the division of nonpatent vascular structures.

In general, VATS is used for patients greater than 15 kg due to current size limitations of the instruments.[141]

Mortality for the repair of a vascular ring is 0% to 4%, with improved survival occurring in more recent series.[138,139,142] The majority of deaths are related to other cardiac defects or respiratory infection and failure. Backer et al. reported a series of 16 patients repaired utilizing LPA division and reimplantation for pulmonary artery sling, all of whom also required tracheal reconstruction. There were no operative mortalities and one late death due to respiratory complications.[140] The major source of morbidity, as well as mortality, in this and other series is related to the tracheal reconstruction.

CORONARY ARTERY ANOMALIES

Coronary artery anomalies occur in 0.3% to 1.3% of the population.[143,144] They can be classified as minor, secondary, or major based on their clinical significance.[145] Minor defects have no functional significance and are usually detected as incidental findings at cardiac catheterization. Secondary defects have no intrinsic significance, but alter surgical management when they are present. An example of a secondary defect is an anomalous origin of the left anterior descending artery from the right coronary artery that crosses the hypoplastic infundibulum in a patient with TOF. The presence of this vessel may prevent the safe performance of a transannular incision and thereby mandate the use of a conduit. Major defects are the most important form of coronary anomaly, because they exert an intrinsically adverse effect on the myocardium. Major anomalies can be subdivided based on anatomy: coronary arteriovenous fistula, anomalous pulmonary origin of a coronary artery, anomalous aortic origin of a coronary artery, myocardial bridging, or coronary artery aneurysm.

8 Coronary arteriovenous fistula is the most common major coronary anomaly. An abnormal connection exists between a coronary artery (usually the right) and another vascular structure (usually one of the right heart chambers). Most fistulas are isolated and solitary. The fistula leads to left-to-right shunting, which can produce CHF. Other symptoms include angina, endocarditis, myocardial infarction, arrhythmia, and sudden death. The diagnosis is suggested by echocardiography and confirmed by catheterization. All symptomatic fistulas should be occluded, either surgically or by transcatheter techniques. In some cases, coronary bypass grafting may be necessary when distal flow is compromised by fistula occlusion. Treatment of asymptomatic fistulas is controversial, but occlusion should probably be undertaken when significant left-to-right shunting is present.

The second most common major coronary anomaly is origin of a coronary artery from the PA. The most common manifestation is the anomalous left coronary artery arising from the pulmonary artery (ALCAPA). The right coronary (or both coronaries) may also arise anomalously from the PA, but only in very rare cases. ALCAPA is usually well tolerated during fetal development, but after birth, the pulmonary systolic pressure usually drops (following ductal closure and decline in PVR) and the anomalous coronary is perfused with desaturated blood at low pressure. Collateral vessels develop between the normal right coronary artery and the abnormal left coronary, but the benefit is negated due to the development of coronary steal, whereby the collateral blood shunts left to right by retrograde flow in the anomalous coronary into the low-pressure PA. Most patients will present between 6 weeks and 3 months of life. Typical symptoms include irritability, difficulty in feeding, and other signs of CHF. Untreated, ALCAPA is nearly always fatal. Rarely, patients will survive to adulthood and present with symptoms of angina or sudden death. On examination, patients with ALCAPA frequently have a holosystolic murmur of ischemic mitral regurgitation. The pulmonary component of the second heart sound may be pronounced due to pulmonary hypertension. Chest radiography is significant for cardiomegaly and pulmonary edema. Electrocardiographic

evidence of ischemia and infarction is usually present. Echocardiography is usually diagnostic and is useful for assessing the severity of left ventricular dysfunction and ischemic mitral regurgitation, which are commonly present. Catheterization is occasionally necessary to clarify the anatomy, but this technique is used less frequently due to the risk of inducing life-threatening arrhythmias.

Surgical repair is indicated for all patients with ALCAPA. Historically, the initial surgical approach involved ligation of the proximal left coronary artery. This served to eliminate coronary steal and allow perfusion of the left coronary system by collaterals from the right. Despite the ease of simple ligation, most centers have abandoned this approach in favor of establishment of a two-coronary system, which offers better long-term freedom from ischemia. In older patients, this may be achieved by proximal ligation of the left coronary artery in conjunction with coronary artery bypass, ideally with a left internal mammary graft. Coronary bypass is technically difficult in neonates, and a number of alternative operations have been devised to create a direct connection between the aorta and the anomalous coronary artery. Most commonly, this can be achieved by removing the origin of the left coronary artery (along with a button of adjacent PA) and reimplanting the vessel directly into the side of the aorta. Another approach involves creation of a side-to-side connection between the aorta and PA with placement of an intrapulmonary baffle to direct flow from this connection to the anomalous left coronary ostium. With improved coronary transfer techniques learned from the arterial switch operation, direct reimplantation of the anomalous coronary artery is always feasible and preferred. Survival following surgical repair of ALCAPA has improved over the years.[146] Recent reports have suggested an operative mortality of 6% or less.[147,148] Ventricular function tends to normalize after surgery.[149] In most patients, mitral valve function also improves,[147,149] but for patients with severe mitral regurgitation, concurrent mitral valve repair may rarely be indicated.

Anomalous aortic origins of the coronary arteries are usually minor defects, but a potentially dangerous abnormality exists when the left main coronary artery arises from the right coronary sinus and passes between the PA and aorta. This defect has been associated with cardiac symptoms and sudden death, as has the origin of the right coronary artery from the left coronary sinus (usually when the right coronary is dominant).[150,151] The etiology of ischemia in both defects is thought to be related to the acute angle of origin and slit-like orifice of the anomalous vessel often with an intramural course and the extrinsic compression created by the opposing walls of the aorta and PA. These defects usually present in older patients. Symptomatic patients are treated surgically by unroofing the coronary ostia into the aorta or by coronary artery bypass.

Myocardial bridging occurs when a segment of an epicardial coronary artery (usually the left anterior descending) takes an intramyocardial course over a short segment. Although this is a common incidental finding at cardiac catheterization, this defect has been associated in some cases with myocardial ischemia. Treatment involves dividing the muscle bridge to free the coronary, coronary bypass beyond the bridge, or transcatheter stenting.

Coronary aneurysms occur rarely, usually in conjunction with an inflammatory

condition such as Kawasaki syndrome, polyarteritis nodosa, Takayasu arteritis, or syphilis. Coronary aneurysms may thrombose or lead to distal coronary stenosis or embolization. Rupture occurs uncommonly. Treatment ranges from antiplatelet therapy to coronary bypass grafting.

UNIVENTRICULAR HEART

In the univentricular heart, only one ventricular chamber is connected to the atria. To be classified as a ventricle, a chamber must receive at least half of an inlet valve. In the most common form of univentricular heart, both the mitral and tricuspid valves connect to a morphologic LV (double-inlet LV), which ejects blood through a hypoplastic outlet chamber and then, due to malposition of the great arteries, to the aorta. The outlet chamber is not considered to be a ventricle, regardless of its size, because it does not receive an inlet valve. Similarly, the intracardiac communication is not termed a VSD, but a bulboventricular foramen. Univentricular hearts are frequently associated with malpositions of the great vessels and varying degrees of obstruction to PBF. In double-inlet LV, the aorta is usually anterior and to the left of the PA.

The presentation of infants with univentricular heart is variable, depending on the amount of PBF.[152] When the pulmonary flow is excessive, cyanosis may be mild, and the dominant feature is CHF. Associated PS decreases the PBF, and the degree of cyanosis is increased. Associated lesions may further complicate the picture, such as coarctation, subaortic stenosis, or a restrictive ASD. Patients with moderate PS may achieve a well-balanced circulation with acceptable systemic oxygenation and normal PA pressure. These patients may be symptom-free well into adolescence. Most patients, however, require intervention early in life to reduce excessive PBF or to increase it in the presence of significant PS. Pulmonary vascular obstructive disease develops early when PBF is excessive. With the possible exception of patients in whom the pulmonary and systemic blood flow is well balanced, the prognosis for patients with unoperated univentricular hearts is poor, with more than half dying early of CHF or dysrhythmias.

In the presence of excessive PBF and pulmonary hypertension, operation should be performed early in life to control PBF and prevent the development of pulmonary vascular occlusive disease. Options include PA banding or division of the main PA in conjunction with a controlled aortopulmonary shunt. PA banding is a less complicated procedure; however, it is often difficult to adjust the pulmonary flow accurately, and too proximal or too distal a band can lead to distortion of the pulmonary valve or branch pulmonary arteries, which further complicates later operations. Simple division of the PA with placement of a modified Blalock–Taussig shunt can be undertaken in the presence of an adequate bulboventricular foramen providing unobstructed flow to the aorta. This option avoids the problems associated with a PA band, and more accurately controls the PBF. Another similar technique is division of the main PA, side-to-side anastomosis of the proximal PA with the native aorta, and placement of a modified Blalock–Taussig shunt (modified DKS procedure). It is not uncommon for the bulboventricular foramen to decrease in size over time due to progressive ventricular hypertrophy. Maintaining continuity from both the outlet chamber and the LV eliminates the possibility of subaortic obstruction, which can occur when the systemic blood flow depends entirely on egress through a bulboventricular foramen. In infants who are well balanced and can be safely managed medically until the age of 4 to 6 months, a hemi-Fontan or bidirectional Glenn, in which the superior vena caval flow is directed into the pulmonary arteries, can be used

to increase the effective PBF. This procedure maximizes pulmonary flow without causing a volume overload to the single ventricle. It is most commonly used as part of an interim stage to a complete atriopulmonary connection or Fontan procedure.

The ultimate goal of surgical correction in patients with a univentricular heart is the total diversion of all vena caval blood directly into the pulmonary arteries. The Fontan procedure was first successfully performed in a patient with tricuspid atresia, but has since evolved as an excellent way to establish physiologic repair for patients with more complex forms of univentricular heart.[153] The superior vena caval blood returns directly via an end-to-side anastomosis with the PA (bidirectional Glenn) or through a right atrial–PA connection (hemi-Fontan). The inferior vena caval flow is directed to the PA with an intra-atrial baffle (lateral tunnel technique, Fig. 81-10) or an extracardiac conduit. All oxygenated pulmonary venous flow empties into the ventricular chamber through the AV valves to be ejected to the systemic circulation, while superior and inferior vena caval blood flows directly to the lungs to acquire oxygen prior to returning to the heart. For the Fontan procedure to be performed with a low operative mortality and an acceptable functional result, certain criteria must be met. Normal PA pressure (<20 mm Hg) and PVR (<2 Woods units/m^2) are the most important prerequisites. Additionally, it is essential that ventricular function and AV valve function be normal. Many of the criteria originally proposed, including normal cardiac rhythm, right atrial hypertrophy, normal systemic venous return, and age older than 4 years, are of little or no importance in the current era. Although the Fontan procedure cannot be considered a truly corrective operation, it offers benefits that cannot be equaled by any of the other palliative procedures. The major advantages include restoration of normal systemic oxygen saturation and reduction of ventricular volume overload.

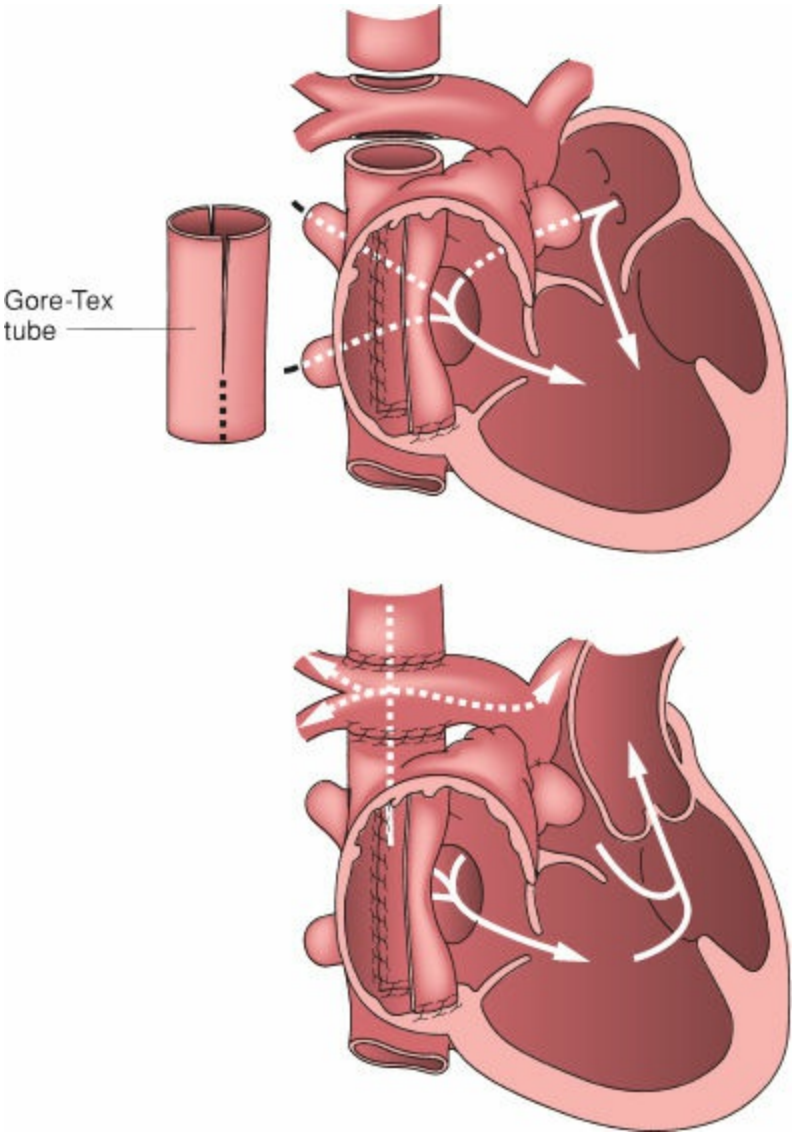

Figure 81-10. Total cavopulmonary connection for univentricular heart. The internal orifices of the superior and inferior venae cavae are connected in the right atrium with a patch cut of polytetrafluoroethylene. The superior vena cava is divided just above its junction with the right atrium, and both ends are anastomosed to the right pulmonary artery. The main pulmonary artery is ligated.

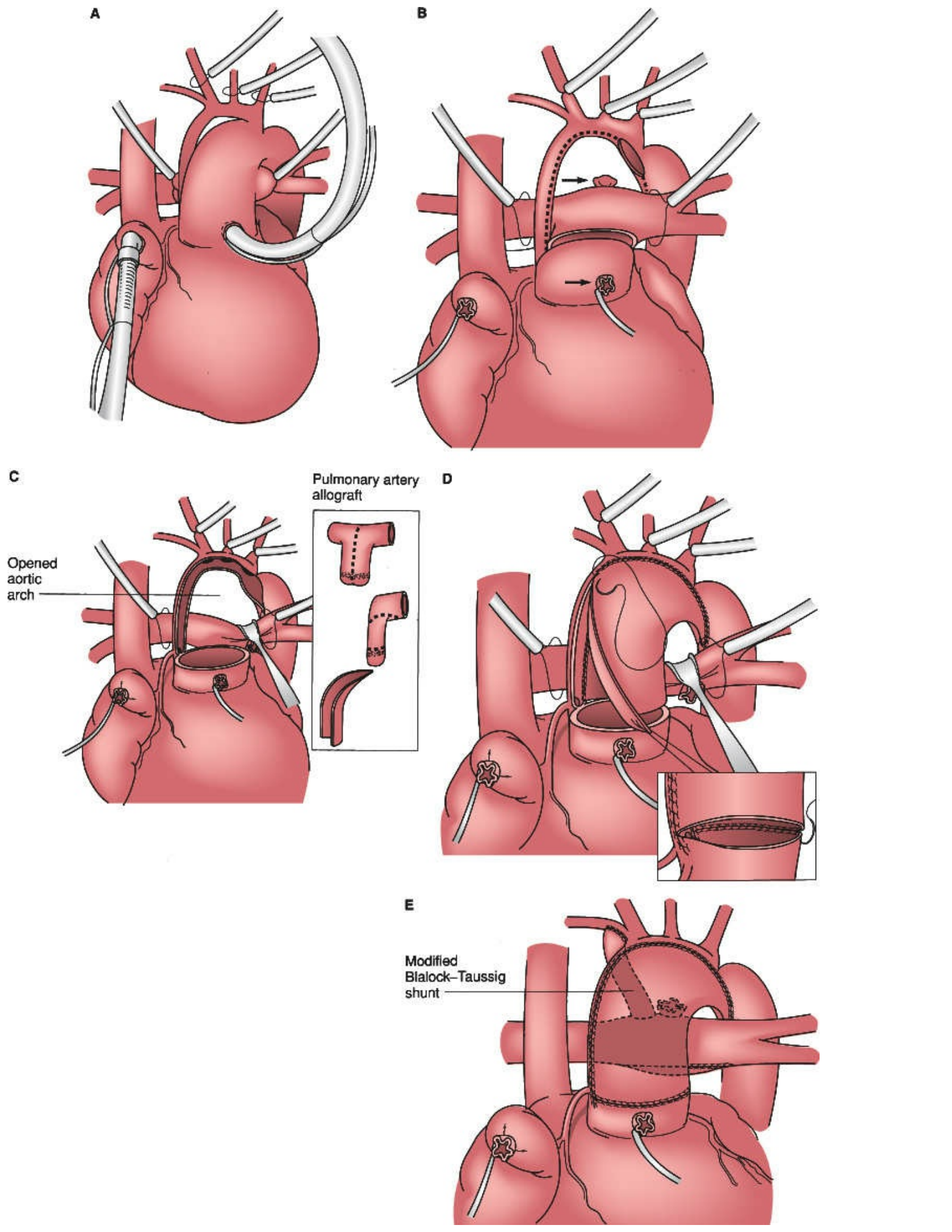
A
B
C
Pulmonary artery allograft
Opened aortic arch
D
E
Modified Blalock–Taussig shunt

Figure 81-11. Steps in the Norwood procedure for hypoplastic left-heart syndrome. **A:** Cannulation for bypass. **B:** Division of pulmonary artery and ductus arteriosus. **C:** Aortic arch opened from the origin to beyond the ductus. **D:** Pulmonary allograft used to enlarge arch and connect to the ventricle. **E:** Completed repair.

Ventricular septation procedures have also been successfully performed in patients with univentricular hearts. The subset of patients with a double-inlet LV, anterior and leftward aorta, nonrestrictive outlet foramen, and mild or no PS are best suited for septation. This anatomy allows placement of a relatively direct and straight prosthetic patch in the ventricle that separates the pulmonary and systemic circulations. The septation procedure has been associated with a relatively high morbidity, primarily related to complete heart block, so that its overall effectiveness is reduced. Few centers have continued to apply this procedure in carefully selected patients.

The current results for the Fontan are excellent, with hospital mortality ranging from 2% to 9%.[154–158] The condition of survivors is generally good and most attain a functional status of New York Heart Association class I or II. The long-term results have been reported with a 93% to 97% 5-year survival and a 91% 10-year survival.[156,157] Although long-term results are encouraging, late complications may be seen. Continued surveillance for arrhythmias, CHF, protein-losing enteropathy, and hepatic dysfunction remains important.

HYPOPLASTIC LEFT- HEART SYNDROME

Hypoplastic left-heart syndrome (HLHS) refers to a constellation of congenital cardiac anomalies characterized by marked hypoplasia or absence of the LV and severe hypoplasia of the ascending aorta. The systemic circulation is dependent on the right ventricle via a PDA and there is obligatory mixing of pulmonary and systemic venous blood in the right atrium. There is associated aortic valve stenosis or atresia, and mitral valve stenosis or atresia. The descending aorta is essentially a continuation of the ductus arteriosus, and the ascending aorta and aortic arch are a diminutive branch from this vessel. Initial management includes a prostaglandin infusion to maintain ductal patency and correction of metabolic acidosis. The patient may require intubation and ventilator adjustment to reduce supplemental oxygen and maintain a partial pressure of carbon dioxide (PCO_2) of about 40 mm Hg to avoid excessive pulmonary flow.

Treatment options for this problem include cardiac transplantation and staged reconstructive surgery. Transplantation for HLHS is generally performed with the same techniques that are standard for transplantation in older children and adults. However, it is necessary to have a generous amount of donor aortic arch that can be used to augment the hypoplastic recipient arch. Results of transplantation in neonates have been excellent in centers with extensive experience in this area, and a 2-year survival as high as 70% has been reported.[159] In the context of improving results for staged reconstruction, risks of immunosuppression, and limited donor availability, competing risk analysis favors staged repair, and most centers pursue this option as primary therapy for HLHS.[160] Transplantation is generally reserved for very high-risk patients, such as those with depressed right ventricular function or severe tricuspid regurgitation.

The first successful palliation of HLHS was reported by Norwood et al. on a series of infants operated on between 1979 and 1981.[161] This procedure has been technically refined over the years, but three essential components remain: atrial septectomy, anastomosis of the proximal PA to the aorta with homograft augmentation of the aortic arch, and aortopulmonary shunt or right ventricle–PA conduit (Fig. 81-11). As described previously for the univentricular heart, subsequent reconstructive management of HLHS includes an interim hemi-Fontan procedure or bidirectional Glenn anastomosis at 4 to 6 months of age, followed by a Fontan procedure at about 18 to 24 months.

Universally fatal only two decades ago, tremendous strides have been made in improving the outcomes for patients with HLHS. Of the three stages, the highest-risk stage of the repair remains the Norwood operation. During the 1990s, the hospital survival for the Norwood procedure across the United States was approximately 40%.[162] Currently, select centers have reported hospital survivals of 90% or greater.[163–167] Reported survivals for the hemi-Fontan and Fontan procedures have also been excellent at 98% for both operations.[155,157,168]

References

1. Gross R, Hubbard J. Surgical ligation of a patent ductus arteriosus. JAMA 1939;112:729–731.
2. Blalock A, Taussig H. The surgical treatment of malformations of the heart in which there is pulmonary stenosis or atresia. JAMA 1945;128:189.
3. Lewis F, Taufic M. Closure of atrial septal defects with the aid of hypothermia: experimental accomplishments and the report of one successful case. Surgery 1953;33:52–59.
4. Gibbon JH Jr. Application of a mechanical heart-lung apparatus to cardiac surgery. Minn Med 1954;37:171–185.
5. Warden HE, Cohen M, Read RC et al. Controlled cross-circulation for open intracardiac surgery: physiologic studies and results of creation and closure of ventricular septal defects. J Thorac Surg 1954;28:331–341.
6. Kirklin JW, DuShane JW, Patrick RT et al. Intracardiac surgery with the aid of a mechanical pump-oxygenator system (Gibbon type): report of eight cases. Proc Staff Meet Mayo Clin 1955;30:201–206.
7. Hoffman JI, Kaplan S. The incidence of congenital heart disease. J Am Coll Cardiol 2002;39(12):1890–1900.
8. Hagen PT, Scholz DG, Edwards WD. Incidence and size of patent foramen ovale during the first 10 decades of life: an autopsy study of 965 normal hearts. Mayo Clin Proc 1984;59(1):17–20.
9. Hopkins RA, Bert AA, Buchholz B, et al. Surgical patch closure of atrial septal defects. Ann Thorac Surg 2004;77(6):2144–2149; author reply 2149–2150.
10. King TD, Thompson SL, Steiner C, et al. Secundum atrial septal defect. Nonoperative closure during cardiac catheterization. JAMA 1976; 235(23): 2506–2509.
11. O'Laughlin MP. Catheter closure of secundum atrial septal defects. Tex Heart Inst J 1997;24(4):287–292.
12. Du ZD, Koenig P, Cao QL, et al. Comparison of transcatheter closure of secundum atrial septal defect using the Amplatzer septal occluder associated with deficient versus sufficient rims. Am J Cardiol 2002;90(8): 865–869.
13. Everett AD, Jennings J, Sibinga E, et al. Community use of the Amplatzer atrial septal defect occluder: results of the multicenter MAGIC Atrial Septal Defect Study. Pediatr Cardiol 2009;30(3):240–247.
14. Murphy JG, Gersh BJ, McGoon MD, et al. Long-term outcome after surgical repair of isolated atrial septal defect. Follow-up at 27 to 32 years. N Engl J Med 1990;323(24):1645–1650.
15. Roos-Hesselink JW, Meijboom FJ, Spitaels SE, et al. Excellent survival and low incidence of arrhythmias, stroke and heart failure long-term after surgical ASD closure at young age. A prospective follow-up study of 21–33 years. Eur Heart J 2003;24(2):190–197.

16. Gatzoulis MA, Freeman MA, Siu SC, et al. Atrial arrhythmia after surgical closure of atrial septal defects in adults. N Engl J Med 1999;340(11): 839–846.
17. Attie F, Rosas M, Granados N, et al. Surgical treatment for secundum atrial septal defects in patients >40 years old. A randomized clinical trial. J Am Coll Cardiol 2001;38(7):2035–2042.
18. Konstantinides S, Geibel A, Olschewski M, et al. A comparison of surgical and medical therapy for atrial septal defect in adults. N Engl J Med 1995; 333(8):469–473.
19. Momma K, Toyama K, Takao A, et al. Natural history of subarterial infundibular ventricular septal defect. Am Heart J 1984;108(5):1312–1317.
20. Heath D, Edwards JE. The pathology of hypertensive pulmonary vascular disease; a description of six grades of structural changes in the pulmonary arteries with special reference to congenital cardiac septal defects. Circulation 1958;18(4 Part 1):533–547.
21. Dajani AS, Taubert KA, Wilson W, et al. Prevention of bacterial endocarditis. Recommendations by the American Heart Association. Circulation 1997;96(1):358–366.
22. Backer CL, Idriss FS, Zales VR, et al. Surgical management of the conal (supracristal) ventricular septal defect. J Thorac Cardiovasc Surg 1991; 102(2):288–295; discussion 295–296.
23. Mavroudis C, Backer CL, Jacobs JP. Ventricular septal defect. In: Mavroudis C, Backer CL, eds. Pediatric Cardiac Surgery, 3rd ed. Philadelphia, PA: Mosby; 2003:298–320.
24. Hijazi ZM. Device closure of ventricular septal defects. Catheter Cardiovasc Interv 2003;60(1):107–114.
25. Crossland DS, Wilkinson JL, Cochrane AD, et al. Initial results of primary device closure of large muscular ventricular septal defects in early infancy using perventricular access. Catheter Cardiovasc Interv 2008;72(3):386–391.
26. Predescu D, Chaturvedi RR, Friedberg MK, et al. Complete heart block associated with device closure of perimembranous ventricular septal defects. J Thorac Cardiovasc Surg 2008;136(5):1223–1228.
27. Rastelli G, Kirklin JW, Titus JL. Anatomic observations on complete form of persistent common atrioventricular canal with special reference to atrioventricular valves. Mayo Clin Proc 1966;41(5):296–308.
28. Bharati S, Kirklin JW, McAllister HA Jr, et al. The surgical anatomy of common atrioventricular orifice associated with tetralogy of Fallot, double outlet right ventricle and complete regular transposition. Circulation 1980; 61(6):1142–1149.
29. Draulans-Noe HA, Wenink AC, Quaegebeur J. Single papillary muscle (“parachute valve”) and double-orifice left ventricle in atrioventricular septal defect convergence of chordal attachment: surgical anatomy and results of surgery. Pediatr Cardiol 1990;11(1):29–35.

30. Studer M, Blackstone EH, Kirklin JW, et al. Determinants of early and late results of repair of atrioventricular septal (canal) defects. J Thorac Cardiovasc Surg 1982;84(4):523–542.
31. Piccoli GP, Ho SY, Wilkinson JL, et al. Left-sided obstructive lesions in atrioventricular septal defects: an anatomic study. J Thorac Cardiovasc Surg 1982;83(3):453–460.
32. Schulze-Neick I, Hartenstein P, Li J, et al. Intravenous sildenafil is a potent pulmonary vasodilator in children with congenital heart disease. Circulation 2003;108(suppl 1):II167–II173.
33. Weintraub RG, Brawn WJ, Venables AW, et al. Two-patch repair of complete atrioventricular septal defect in the first year of life. Results and sequential assessment of atrioventricular valve function. J Thorac Cardiovasc Surg 1990;99(2):320–326.
34. Puga FJ. Reoperation after repair of atrioventricular canal defects. Semin Thorac Cardiovasc Surg Pediatr Card Surg Annu 1998;1:123–128.
35. Stewart S, Alexson C, Manning J. Partial atrioventricular canal defect: the early and late results of operation. Ann Thorac Surg 1987;43(5):527–529.
36. Suzuki T, Bove EL, Devaney EJ, et al. Results of definitive repair of complete atrioventricular septal defect in neonates and infants. Ann Thorac Surg 2008;86(2):596–602.
37. Minich LL, Tani LY, Pagotto LT, et al. Size of ventricular structures influences surgical outcome in Down syndrome infants with atrioventricular septal defect. Am J Cardiol 1998;81(8):1062–1065.
38. Hanley FL, Fenton KN, Jonas RA, et al. Surgical repair of complete atrioventricular canal defects in infancy. Twenty-year trends. J Thorac Cardiovasc Surg 1993;106(3):387–394; discussion 394–397.
39. Van Praagh R, Van Praagh S, Nebesar RA, et al. Tetralogy of Fallot: underdevelopment of the pulmonary infundibulum and its sequelae. Am J Cardiol 1970;26(1):25–33.
40. Hirsch JC, Bove EL. Tetralogy of Fallot. In: Mavroudis C, Backer CL, eds. Pediatric Cardiac Surgery, 3rd ed. Philadelphia, PA: Mosby; 2003:383–397.
41. Hirsch JC, Mosca RS, Bove EL. Complete repair of tetralogy of Fallot in the neonate: results in the modern era. Ann Surg 2000;232(4):508–514.
42. Tamesberger MI, Lechner E, Mair R, et al. Early primary repair of tetralogy of Fallot in neonates and infants less than four months of age. Ann Thorac Surg 2008;86(6):1928–1935.
43. de Ruijter FT, Weenink I, Hitchcock FJ, et al. Right ventricular dysfunction and pulmonary valve replacement after correction of tetralogy of Fallot. Ann Thorac Surg 2002;73(6):1794–1800; discussion 1800.
44. Discigil B, Dearani JA, Puga FJ, et al. Late pulmonary valve replacement after repair

of tetralogy of Fallot. Thorac Cardiovasc Surg 2001;121(2): 344–351.
45. Karl TR, Sano S, Pornviliwan S, et al. Tetralogy of Fallot: favorable outcome of nonneonatal transatrial, transpulmonary repair. Ann Thorac Surg 1992;54(5):903–907.
46. Bacha EA, Scheule AM, Zurakowski D, et al. Long-term results after early primary repair of tetralogy of Fallot. J Thorac Cardiovasc Surg 2001; 122(1):154–161.
47. Belli E, Serraf A, Lacour-Gayet F, et al. Biventricular repair for double-outlet right ventricle. Results and long-term follow-up. Circulation 1998;98 (suppl 19):II360–II365; discussion II365–II367.
48. Kirklin JW, Pacifico AD, Blackstone EH, et al. Current risks and protocols for operations for double-outlet right ventricle. Derivation from an 18 year experience. J Thorac Cardiovasc Surg 1986;92(5):913–930.
49. Walters HL, Pacifico AD. Double outlet ventricles. In: Mavroudis C, Backer CL, eds. Pediatric Cardiac Surgery, 3rd ed. Philadelphia, PA: Mosby; 2003:408–441.
50. Musumeci F, Shumway S, Lincoln C, et al. Surgical treatment for double-outlet right ventricle at the Brompton Hospital, 1973 to 1986. J Thorac Cardiovasc Surg 1988;96(2):278–287.
51. Kirklin JW, Barratt-Boyes BG. Complete transposition of the great arteries. In: Kirklin JW, Barratt-Boyes BG, eds. Cardiac Surgery, 2nd ed. New York: Churchill Livingston; 1993:1383–1467.
52. Fyler D. Report of the New England regional infant cardiac program. Pediatrics 1980;65(2 Pt 2):375–461.
53. Levin DL, Paul MH, Muster AJ, et al. d-Transposition of the great vessels in the neonate. A clinical diagnosis. Arch Intern Med 1977;137(10): 1421–1425.
54. Rashkind WJ. Historical aspects of surgery for congenital heart disease. J Thorac Cardiovasc Surg 1982;84(4):619–625.
55. Liebman J, Cullum L, Belloc NB. Natural history of transposition of the great arteries: anatomy and birth and death characteristics. Circulation 1969;40:237–262.
56. Senning A. Surgical correction of transposition of the great vessels. Surgery 1959;45:966–980.
57. Mustard WT. Successful two stage correction of transposition of the great vessels. Surgery 1964;55:469–472.
58. Jatene AD, Fontes VF, Paulista PP, et al. Successful anatomic correction of transposition of the great vessels. A preliminary report. Arq Bras Cardiol 1975;28(4):461–464.
59. Qamar ZA, Goldberg CS, Devaney EJ, et al. Current risk factors and outcomes for the arterial switch operation. Ann Thorac Surg 2007;84(3): 871–878; discussion 878–879.
60. Brown JW, Park HJ, Turrentine MW. Arterial switch operation: factors impacting survival in the current era. Ann Thorac Surg 2001;71(6): 1978–1984.
61. Haas F, Wottke M, Poppert H, et al. Long-term survival and functional follow-up in

patients after the arterial switch operation. Ann Thorac Surg 1999;68(5):1692–1697.
62. Losay J, Touchot A, Serraf A, et al. Late outcome after arterial switch operation for transposition of the great arteries. Circulation 2001; 104(12 Suppl 1):I121–I126.
63. Gottlieb D, Schwartz ML, Bischoff K, et al. Predictors of outcome of arterial switch operation for complex D-transposition. Ann Thorac Surg 2008;85(5):1698–1702; discussion 1702–1703.
64. Blume ED, Altmann K, Mayer JE, et al. Evolution of risk factors influencing early mortality of the arterial switch operation. J Am Coll Cardiol 1999;33(6):1702–1709.
65. Schwartz ML, Gauvreau K, del Nido P, et al. Long-term predictors of aortic root dilation and aortic regurgitation after arterial switch operation. Circulation 2004;110(11 Suppl 1):II128–II132.
66. Rowe RD, Freedom RM, Mehrizi A. The Neonate with Congenital Heart Disease. Philadelphia, PA: WB Saunders; 1981.
67. Calder L, Van Praagh R, Van Praagh S, et al. Truncus arteriosus communis. Clinical, angiocardiographic, and pathologic findings in 100 patients. Am Heart J 1976;92(1):23–38.
68. Tandon R, Hauck AJ, Nadas AS. Persistent truncus arteriosus. A clinical, hemodynamic, and autopsy study of nineteen cases. Circulation 1963; 28:1050–1060.
69. Collett RW, Edwards JE. Persistent truncus arteriosus: a classification according to anatomic type. Surg Clin North Am 1949;29:1245–1270.
70. Van Praagh R, Van Praagh S. The anatomy of common aorticopulmonary trunk (truncus arteriosus communis) and its embryologic implications: a study of 57 necropsy cases. Am J Cardiol 1965;16:406.
71. Fuglestad SJ, Puga FJ, Danielson GK, et al. Surgical pathology of the truncal valve: a study of 12 cases. Am J Cardiovasc Pathol 1988;2(1):39–47.
72. Urban AE, Sinzobahamvya N, Brecher AM, et al. Truncus arteriosus: ten-year experience with homograft repair in neonates and infants. Ann Thorac Surg 1998;66(6 suppl):S183–S188.
73. Lacour-Gayet F, Serraf A, Komiya T, et al. Truncus arteriosus repair: influence of techniques of right ventricular outflow tract reconstruction. J Thorac Cardiovasc Surg 1996;111(4):849–856.
74. Bove EL, Lupinetti FM, Pridjian AK, et al. Results of a policy of primary repair of truncus arteriosus in the neonate. J Thorac Cardiovasc Surg 1993;105(6):1057–1065; discussion 1065–1066.
75. Marcelletti C, McGoon DC, Danielson GK, et al. Early and late results of surgical repair of truncus arteriosus. Circulation 1977;55(4):636–641.
76. Nath PH, Zollikofer C, Castaneda-Zuniga W, et al. Persistent truncus arteriosis associated with interruption of the aortic arch. Br J Radiol 1980; 53(633):853–859.
77. Butto F, Lucas RV Jr, Edwards JE. Persistent truncus arteriosus: pathologic anatomy in 54 cases. Pediatr Cardiol 1986;7(2):95–101.

78. Bharati S, McAllister HA Jr, Rosenquist GC, et al. The surgical anatomy of truncus arteriosus communis. J Thorac Cardiovasc Surg 1974;67(4):501–510.
79. Shrivastava S, Edwards JE. Coronary arterial origin in persistent truncus arteriosus. Circulation 1977;55(3):551–554.
80. Kirklin J, Barrat-Boyes B. Cardiac Surgery. New York: John Wiley & Sons; 1993.
81. Backer CL. Techniques for repairing the aortic and truncal valves. Cardiol Young 2005;15(suppl 1):125–131.
82. Ebert PA, Turley K, Stanger P, et al. Surgical treatment of truncus arteriosus in the first 6 months of life. Ann Surg 1984;200(4):451–456.
83. Brown JW, Ruzmetov M, Okada Y, et al. Truncus arteriosus repair: outcomes, risk factors, reoperation and management. Eur J Cardiothorac Surg 2001;20(2):221–227.
84. Thompson LD, McElhinney DB, Reddy M, et al. Neonatal repair of truncus arteriosus: continuing improvement in outcomes. Ann Thorac Surg 2001;72(2):391–395.
85. Konstantinov IE, Karamlou T, Blackstone EH, et al. Truncus arteriosus associated with interrupted aortic arch in 50 neonates: a Congenital Heart Surgeons Society study. Ann Thorac Surg 2006;81(1):214–222.
86. Hanley FL, Heinemann MK, Jonas RA, et al. Repair of truncus arteriosus in the neonate. J Thorac Cardiovasc Surg 1993;105(6):1047–1056.
87. Rajasinghe HA, McElhinney DB, Reddy VM, et al. Long-term follow-up of truncus arteriosus repaired in infancy: a twenty-year experience. J Thorac Cardiovasc Surg 1997;113(5):869–878; discussion 878–879.
88. Selamet Tierney ES, Wald RM, McElhinney DB, et al. Changes in left heart hemodynamics after technically successful in-utero aortic valvuloplasty. Ultrasound Obstet Gynecol 2007;30(5):715–720.
89. Makikallio K, McElhinney DB, Levine JC, et al. Fetal aortic valve stenosis and the evolution of hypoplastic left heart syndrome: patient selection for fetal intervention. Circulation 2006;113(11):1401–1405.
90. Tworetzky W, Wilkins-Haug L, Jennings RW, et al. Balloon dilation of severe aortic stenosis in the fetus: potential for prevention of hypoplastic left heart syndrome: candidate selection, technique, and results of successful intervention. Circulation 2004;110(15):2125–2131.
91. McCrindle BW, Blackstone EH, Williams WG, et al. Are outcomes of surgical versus transcatheter balloon valvotomy equivalent in neonatal critical aortic stenosis? Circulation 2001;104(12 Suppl 1):I152–I158.
92. Cowley CG, Dietrich M, Mosca RS, et al. Balloon valvuloplasty versus transventricular dilation for neonatal critical aortic stenosis. Am J Cardiol 2001;87(9):1125–1127, A10.
93. Ross DN. Replacement of aortic and mitral valves with a pulmonary autograft. Lancet 1967;2(7523):956–958.
94. Konno S, Imai Y, Iida Y, et al. A new method for prosthetic valve replacement in

congenital aortic stenosis associated with hypoplasia of the aortic valve ring. J Thorac Cardiovasc Surg 1975;70(5):909–917.

95. Ohye RG, Gomez CA, Ohye BJ, et al. The Ross/Konno procedure in neonates and infants: intermediate-term survival and autograft function. Ann Thorac Surg 2001;72(3):823–830.
96. Moore P, Egito E, Mowrey H, et al. Midterm results of balloon dilation of congenital aortic stenosis: predictors of success. J Am Coll Cardiol 1996; 27(5):1257–1263.
97. Chartrand CC, Saro-Servando E, Vobecky JS. Long-term results of surgical valvuloplasty for congenital valvar aortic stenosis in children. Ann Thorac Surg 1999;68(4):1356–1359; discussion 1359–1360.
98. Lupinetti FM, Pridjian AK, Callow LB, et al. Optimum treatment of discrete subaortic stenosis. Ann Thorac Surg 1992;54(3):467–470; discussion 470–471.
99. Rayburn ST, Netherland DE, Heath BJ. Discrete membranous subaortic stenosis: improved results after resection and myectomy. Ann Thorac Surg 1997;64(1):105–109.
100. Jahangiri M, Nicholson IA, del Nido PJ, et al. Surgical management of complex and tunnel-like subaortic stenosis. Eur J Cardiothorac Surg 2000; 17(6):637–642.
101. Chowdhury T, Reardon W. Elastin mutation and cardiac disease. Pediatr Cardiol 1999;20(2):103–107.
102. McElhinney DB, Petrossian E, Tworetzky W, et al. Issues and outcomes in the management of supravalvar aortic stenosis. Ann Thorac Surg 2000; 69(2):562–567.
103. Stamm C, Kreutzer C, Zurakowski D, et al. Forty-one years of surgical experience with congenital supravalvular aortic stenosis. J Thorac Cardiovasc Surg 1999;118(5):874–885.
104. Brown JW, Ruzmetov M, Vijay P, et al. Surgical repair of congenital supravalvular aortic stenosis in children. Eur J Cardiothorac Surg 2002; 21(1):50–56.
105. Reifenstein GH, Levine SA, Gross RE. Coarctation of the aorta. A review of 104 autopsied cases of the “adult type,” 2 years of age or older. Am Heart J 1947;33(2):146–168.
106. Backer CL, Mavroudis C, Zias EA, et al. Repair of coarctation with resection and extended end-to-end anastomosis. Ann Thorac Surg 1998;66(4):1365–1370; discussion 1370–1371.
107. Backer CL, Paape K, Zales VR, et al. Coarctation of the aorta. Repair with polytetrafluoroethylene patch aortoplasty. Circulation 1995;92(9 suppl): II132–II136.
108. del Nido PJ, Williams WG, Wilson GJ, et al. Synthetic patch angioplasty for repair of coarctation of the aorta: experience with aneurysm formation. Circulation 1986;74(3 Pt 2):I32–I36.
109. Wong CH, Watson B, Smith J, et al. The use of left heart bypass in adult and recurrent coarctation repair. Eur J Cardiothorac Surg 2001;20(6): 1199–1201.
110. Brewer LA III, Fosburg RG, Mulder GA, et al. Spinal cord complications following

surgery for coarctation of the aorta. A study of 66 cases. J Thorac Cardiovasc Surg 1972;64(3):368–381.

111. Seirafi PA, Warner KG, Geggel RL, et al. Repair of coarctation of the aorta during infancy minimizes the risk of late hypertension. Ann Thorac Surg 1998;66(4):1378–1382.

112. Hornung TS, Benson LN, McLaughlin PR. Interventions for aortic coarctation. Cardiol Rev 2002;10(3):139–148.

113. Karl TR. Surgery is the best treatment for primary coarctation in the majority of cases. J Cardiovasc Med (Hagerstown) 2007;8(1):50–56.

114. Golden AB, Hellenbrand WE. Coarctation of the aorta: stenting in children and adults. Catheter Cardiovasc Interv 2007;69(2):289–299.

115. Tynan M, Finley JP, Fontes V, et al. Balloon angioplasty for the treatment of native coarctation: results of Valvuloplasty and Angioplasty of Congenital Anomalies Registry. Am J Cardiol 1990;65(11):790–792.

116. Ovaert C, McCrindle BW, Nykanen D, et al. Balloon angioplasty of native coarctation: clinical outcomes and predictors of success. J Am Coll Cardiol 2000;35(4):988–996.

117. Cooper RS, Ritter SB, Rothe WB, et al. Angioplasty for coarctation of the aorta: long-term results. Circulation 1987;75(3):600–604.

118. Hellenbrand WE, Allen HD, Golinko RJ, et al. Balloon angioplasty for aortic recoarctation: results of Valvuloplasty and Angioplasty of Congenital Anomalies Registry. Am J Cardiol 1990;65(11):793–797.

119. Hijazi ZM, Fahey JT, Kleinman CS, et al. Balloon angioplasty for recurrent coarctation of aorta. Immediate and long-term results. Circulation 1991; 84(3):1150–1156.

120. Yetman AT, Nykanen D, McCrindle BW, et al. Balloon angioplasty of recurrent coarctation: a 12-year review. J Am Coll Cardiol 1997;30(3): 811–816.

121. van Heurn LW, Wong CM, Spiegelhalter DJ, et al. Surgical treatment of aortic coarctation in infants younger than three months: 1985 to 1990. Success of extended end-to-end arch aortoplasty. J Thorac Cardiovasc Surg 1994;107(1):74–85; discussion 85–86.

122. Presbitero P, Demarie D, Villani M, et al. Long term results (15–30 years) of surgical repair of aortic coarctation. Br Heart J 1987;57(5):462–467.

123. Wright GE, Nowak CA, Goldberg CS, et al. Extended resection and end-to-end anastomosis for aortic coarctation in infants: results of a tailored surgical approach. Ann Thorac Surg 2005;80(4):1453–1459.

124. Siassi B, Blanco C, Cabal LA, et al. Incidence and clinical features of patent ductus arteriosus in low-birthweight infants: a prospective analysis of 150 consecutively born infants. Pediatrics 1976;57(3):347–351.

125. Elliott RB, Starling MB, Neutze JM. Medical manipulation of the ductus arteriosus.

Lancet 1975;1(7899):140–142.
126. Campbell M. Natural history of persistent ductus arteriosus. Br Heart J 1968;30(1):4–13.
127. Heymann MA, Rudolph AM, Silverman NH. Closure of the ductus arteriosus in premature infants by inhibition of prostaglandin synthesis. N Engl J Med 1976;295(10):530–533.
128. Sekar KC, Corff KE. Treatment of patent ductus arteriosus: indomethacin or ibuprofen? J Perinatol 2008;28(suppl 1):S60–S62.
129. Gersony WM, Peckham GJ, Ellison RC, et al. Effects of indomethacin in premature infants with patent ductus arteriosus: results of a national collaborative study. J Pediatr 1983;102(6):895–906.
130. Coster DD, Gorton ME, Grooters RK, et al. Surgical closure of the patent ductus arteriosus in the neonatal intensive care unit. Ann Thorac Surg 1989;48(3):386–389.
131. Taylor RL, Grover FL, Harman PK, et al. Operative closure of patent ductus arteriosus in premature infants in the neonatal intensive care unit. Am J Surg 1986;152(6):704–708.
132. Burke RP, Jacobs JP, Cheng W, et al. Video-assisted thoracoscopic surgery for patent ductus arteriosus in low birth weight neonates and infants. Pediatrics 1999;104(2 Pt 1):227–230.
133. Cowley CG, Lloyd TR. Interventional cardiac catheterization advances in nonsurgical approaches to congenital heart disease. Curr Opin Pediatr 1999;11(5):425–432.
134. Goyal VS, Fulwani MC, Ramakantan R, et al. Follow-up after coil closure of patent ductus arteriosus. Am J Cardiol 1999;83(3):463–466, A10.
135. Patel HT, Cao QL, Rhodes J, et al. Long-term outcome of transcatheter coil closure of small to large patent ductus arteriosus. Catheter Cardiovasc Interv 1999;47(4):457–461.
136. Omari BO, Shapiro S, Ginzton L, et al. Closure of short, wide patent ductus arteriosus with cardiopulmonary bypass and balloon occlusion. Ann Thorac Surg 1998;66(1):277–278.
137. Goncalves-Estella A, Perez-Villoria J, Gonzalez-Reoyo F, et al. Closure of a complicated ductus arteriosus through the transpulmonary route using hypothermia. Surgical considerations in one case. J Thorac Cardiovasc Surg 1975;69(5):698–702.
138. Backer CL, Mavroudis C, Rigsby CK, et al. Trends in vascular ring surgery. J Thorac Cardiovasc Surg 2005;129(6):1339–1347.
139. Woods RK, Sharp RJ, Holcomb GW III, et al. Vascular anomalies and tracheoesophageal compression: a single institution's 25-year experience. Ann Thorac Surg 2001;72(2):434–438; discussion 438–439.
140. Backer CL, Mavroudis C, Dunham ME, et al. Pulmonary artery sling: results with median sternotomy, cardiopulmonary bypass, and reimplantation. Ann Thorac Surg 1999;67(6):1738–1744; discussion 1744–1745.

141. Koontz CS, Bhatia A, Forbess J, et al. Video-assisted thoracoscopic division of vascular rings in pediatric patients. Am Surg 2005;71(4):289–291.
142. Alsenaidi K, Gurofsky R, Karamlou T, et al. Management and outcomes of double aortic arch in 81 patients. Pediatrics 2006;118(5):e1336–e1341.
143. Alexander RW, Griffith GC. Anomalies of the coronary arteries and their clinical significance. Circulation 1956;14(5):800–805.
144. Yamanaka O, Hobbs RE. Coronary artery anomalies in 126,595 patients undergoing coronary arteriography. Cathet Cardiovasc Diagn 1990;21(1): 28–40.
145. Dodge-Khatami A, Mavroudis C, Backer CL. Congenital Heart Surgery Nomenclature and Database Project: anomalies of the coronary arteries. Ann Thorac Surg 2000;69(4 suppl):S270–S297.
146. Dodge-Khatami A, Mavroudis C, Backer CL. Anomalous origin of the left coronary artery from the pulmonary artery: collective review of surgical therapy. Ann Thorac Surg 2002;74(3):946–955.
147. Huddleston CB, Balzer DT, Mendeloff EN. Repair of anomalous left main coronary artery arising from the pulmonary artery in infants: long-term impact on the mitral valve. Ann Thorac Surg 2001;71(6):1985–1988; discussion 1988–1989.
148. Ando M, Mee RB, Duncan BW, et al. Creation of a dual-coronary system for anomalous origin of the left coronary artery from the pulmonary artery utilizing the trapdoor flap method. Eur J Cardiothorac Surg 2002; 22(4):576–581.
149. Schwartz ML, Jonas RA, Colan SD. Anomalous origin of left coronary artery from pulmonary artery: recovery of left ventricular function after dual coronary repair. J Am Coll Cardiol 1997;30(2):547–553.
150. Basso C, Maron BJ, Corrado D, et al. Clinical profile of congenital coronary artery anomalies with origin from the wrong aortic sinus leading to sudden death in young competitive athletes. J Am Coll Cardiol 2000; 35(6):1493–1501.
151. Frommelt PC, Frommelt MA. Congenital coronary artery anomalies. Pediatr Clin North Am 2004;51(5):1273–1288.
152. Hawkins JA, Thorne JK, Boucek MM, et al. Early and late results in pulmonary atresia and intact ventricular septum. J Thorac Cardiovasc Surg 1990;100(4):492–497.
153. Fontan F, Fernandez G, Costa F, et al. The size of the pulmonary arteries and the results of the Fontan operation. J Thorac Cardiovasc Surg 1989; 98(5 Pt 1):711–719; discussion 719–724.
154. Cetta F, Feldt RH, O'Leary PW, et al. Improved early morbidity and mortality after Fontan operation: the Mayo Clinic experience, 1987 to 1992. J Am Coll Cardiol 1996;28(2):480–486.
155. Bove EL. Current status of staged reconstruction for hypoplastic left heart syndrome. Pediatr Cardiol 1998;19(4):308–315.
156. Stamm C, Friehs I, Mayer JE Jr, et al. Long-term results of the lateral tunnel Fontan

operation. J Thorac Cardiovasc Surg 2001;121(1):28–41.
157. Hirsch JC, Goldberg C, Bove EL, et al. Fontan operation in the current era: a 15-year single institution experience. Ann Surg 2008;248(3):402–410.
158. Hirsch JC, Ohye RG, Devaney EJ, et al. The lateral tunnel Fontan procedure for hypoplastic left heart syndrome: results of 100 consecutive patients. Pediatr Cardiol 2007;28(6):426–432.
159. Bailey LL, Gundry SR, Razzouk AJ, et al. Bless the babies: one hundred fifteen late survivors of heart transplantation during the first year of life. The Loma Linda University Pediatric Heart Transplant Group. J Thorac Cardiovasc Surg 1993;105(5):805–814; discussion 814–815.
160. Jenkins PC, Flanagan MF, Sargent JD, et al. A comparison of treatment strategies for hypoplastic left heart syndrome using decision analysis. J Am Coll Cardiol 2001;38(4):1181–1187.
161. Norwood WI, Lang P, Casteneda AR, et al. Experience with operations for hypoplastic left heart syndrome. J Thorac Cardiovasc Surg 1981; 82(4):511–519.
162. Gutgesell HP, Gibson J. Management of hypoplastic left heart syndrome in the 1990s. Am J Cardiol 2002;89(7):842–846.
163. Azakie A, Martinez D, Sapru A, et al. Impact of right ventricle to pulmonary artery conduit on outcome of the modified Norwood procedure. Ann Thorac Surg 2004;77(5):1727–1733.
164. Mair R, Tulzer G, Sames E, et al. Right ventricular to pulmonary artery conduit instead of modified Blalock-Taussig shunt improves postoperative hemodynamics in newborns after the Norwood operation. J Thorac Cardiovasc Surg 2003;126(5):1378–1384.
165. Pizarro C, Malec E, Maher KO, et al. Right ventricle to pulmonary artery conduit improves outcome after stage I Norwood for hypoplastic left heart syndrome. Circulation 2003;108(Suppl 1):II155–II160.
166. Sano S, Ishino K, Kawada M, et al. Right ventricle-pulmonary artery shunt in first-stage palliation of hypoplastic left heart syndrome. J Thorac Cardiovasc Surg 2003;126(2):504–509; discussion 509–510.
167. Hirsch JC, Gurney JG, Donohue JE, et al. Hospital mortality for Norwood and arterial switch operations as a function of institutional volume. Pediatr Cardiol 2008;29(4):713–717.
168. Douglas WI, Goldberg CS, Mosca RS, et al. Hemi-Fontan procedure for hypoplastic left heart syndrome: outcome and suitability for Fontan. Ann Thorac Surg 1999;68(4):1361–1367; discussion 1368.

Chapter 82

Valvular Heart Disease and Cardiac Tumors

Tomislav Mihaljevic, Craig M. Jarrett, Husain T. AlQattan, Shehab Ahmad Redha AlAnsari, Haris Riaz, Marijan Koprivanac, and A. Marc Gillinov

Key Points

1 The most common cause of aortic stenosis (AS) is degenerative calcific disease, followed by congenital AS due to bicuspid valve anatomy.

2 Two-dimensional (2D) echocardiography with Doppler allows precise real-time analysis of valvular anatomy and function, and is the study of choice for the diagnosis and management of valvular lesions.

3 The current indication for cardiac catheterization in patients with valvular heart disease is limited to preoperative evaluation of coronary artery disease.

4 There is no effective medical therapy for patients with severe AS. Mechanical relief of the obstruction to blood flow is the only effective treatment.

5 The most common causes of aortic regurgitation (AR) include bicuspid valve disease, rheumatic fever, and endocarditis.

6 Mitral stenosis (MS) is almost exclusively caused by rheumatic fever.

7 The most common cause of mitral regurgitation is degenerative mitral valve disease. Other causes include rheumatic valve disease, endocarditis, certain drugs, and collagen vascular diseases.

8 The most common cardiac tumors are secondary tumors, which usually originate from the lung in men and from the breast in women.

VALVULAR HEART DISEASE

Valvular Anatomy

The basic structural framework of all heart valves is provided by the fibrous cardiac skeleton (Fig. 82-1). The skeleton is a collection of dense connective tissue in the shape of four interconnected rings in the plane between the atria and the ventricles. The interconnecting areas include the right fibrous trigone, which is between the aortic and tricuspid rings and contiguous with the membranous septum, and the left trigone and fibrous continuity, which are between the aortic and mitral rings and form the posterior wall of the left ventricular (LV) outflow tract. The cardiac skeleton maintains the integrity of the valve orifices and provides points of attachment for the valve leaflets. It also serves as a partition by electrically isolating the atria and ventricles except at the atrioventricular bundle, which passes through the right fibrous trigone near the septal leaflet of the tricuspid valve (TV).

The normal aortic valve (AV) consists of three semilunar leaflets or cusps projecting outward and upward into the lumen of the ascending aorta (Fig. 82-2). The space between the free edge of each leaflet and the points of attachment to the aorta comprise the sinuses of Valsalva. Since the coronary arteries arise from two of the three sinuses, the sinuses and the respective leaflets are named the right coronary, left coronary, and noncoronary (or posterior) sinuses and leaflets.

The properties of the AV ensure minimal obstruction to flow when open and minimal flow reversal when closed. Opening and closing of the valve are passive, as it functions only in response to pressure differences between the left ventricle and aorta during the cardiac cycle. The pressure generated from ventricular contraction forces the valve open, and the subsequent recoil of blood from the aorta fills the sinuses of Valsalva and forces the leaflets closed.

There are two structures in close proximity to the AV and, therefore, susceptible to injury during AV surgery (Fig. 82-2). First, the anterior leaflet of the mitral valve (MV) is positioned under the commissure between the left and noncoronary leaflets. Second, the left bundle of His is positioned under the commissure between the right and noncoronary leaflets.

In contrast to the simplistic anatomy and passive opening and closing mechanism of the AV, the anatomy and active valve mechanism of the MV are more complex. Indeed, proper functioning of the MV depends on the organized interaction of all components of the MV apparatus, which consists of the leaflets, annulus, LV papillary muscles, and chordae tendineae.

The normal MV consists of two leaflets: the anterior and posterior leaflets. The anterior leaflet is semicircular in shape, extends from the anteromedial aspect of the mitral annulus, and encompasses approximately one-third of the annular circumference. The posterior leaflet is rectangular in shape, extends from the posterolateral aspect of the mitral annulus, and encompasses approximately two-thirds of the annular circumference. The leaflets are separated from one another at the annulus by the posteromedial and

anterolateral commissures. Both leaflets are divided by clefts into three scallops, named laterally to medially A1, A2, and A3, and P1, P2, and P3, and together comprise an average cross-sectional area of 5 to 11 cm^2.

The mitral annulus is formed anteriorly by the confluence of the right, left, and intervalvular fibrous trigones and posteriorly by a fibrous band. Since the anterior aspect of the mitral annulus is composed of the fibrous trigones, it has limited flexibility. Conversely, the posterior aspect of the annulus, which is not surrounded by any rigid structures, has more flexibility. This increased flexibility of the posterior aspect relative to the anterior aspect has important implications during the cardiac cycle. In systole the mitral annulus contracts (primarily the posterior aspect) and adopts an elliptical shape (shortening occurs perpendicular to the line of leaflet coaptation), and in diastole it relaxes and adopts a circular shape.[1,2] This dynamic motion of the annulus provides increased leaflet coaptation during systole and increased orifice area during diastole.

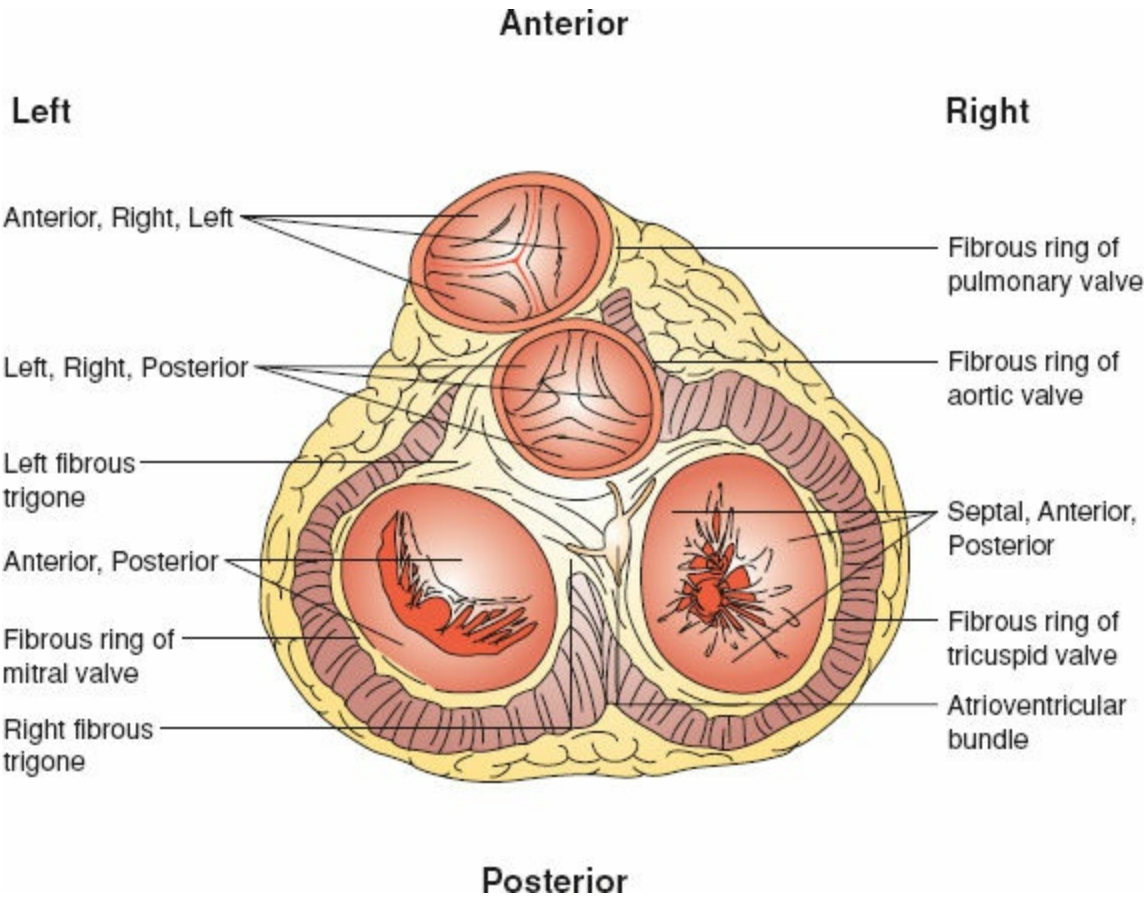

Figure 82-1. Schematic diagram of the fibrous cardiac skeleton.

Two papillary muscles arise directly from the ventricular wall: the anterolateral and posteromedial papillary muscles. Importantly, the anterolateral papillary muscle usually is supplied by two coronary arteries, the left anterior descending artery and branches of the circumflex artery. On the other hand, the posteromedial papillary muscle is usually supplied by a single coronary artery, either from the right coronary or the circumflex artery, which makes it twice as likely to rupture from ischemia and infarction as the anterolateral papillary muscle. The papillary muscles play an important role in the proper function of the MV. MV closure and appropriate leaflet coaptation are permitted by end-

diastolic and early systolic lengthening of the papillary muscles.[3]

Chordae tendineae attach the leaflets to the papillary muscles or directly to the ventricular wall and can be categorized based on the attachments. Primary chordae attach to the leaflets at the free edge to ensure proper coaptation without prolapse or flail. The secondary chordae attach along the line of coaptation and are more prominent on the anterior leaflet. Tertiary chordae arise directly from the ventricle or trabeculae carneae and are only present on the posterior leaflet. Finally, commissural chordae attach to both leaflets and arise from either papillary muscle.

The structures in close proximity to the MV and, therefore, susceptible to injury during MV surgery include the AV, the atrioventricular node, and the circumflex coronary artery (Fig. 82-3).

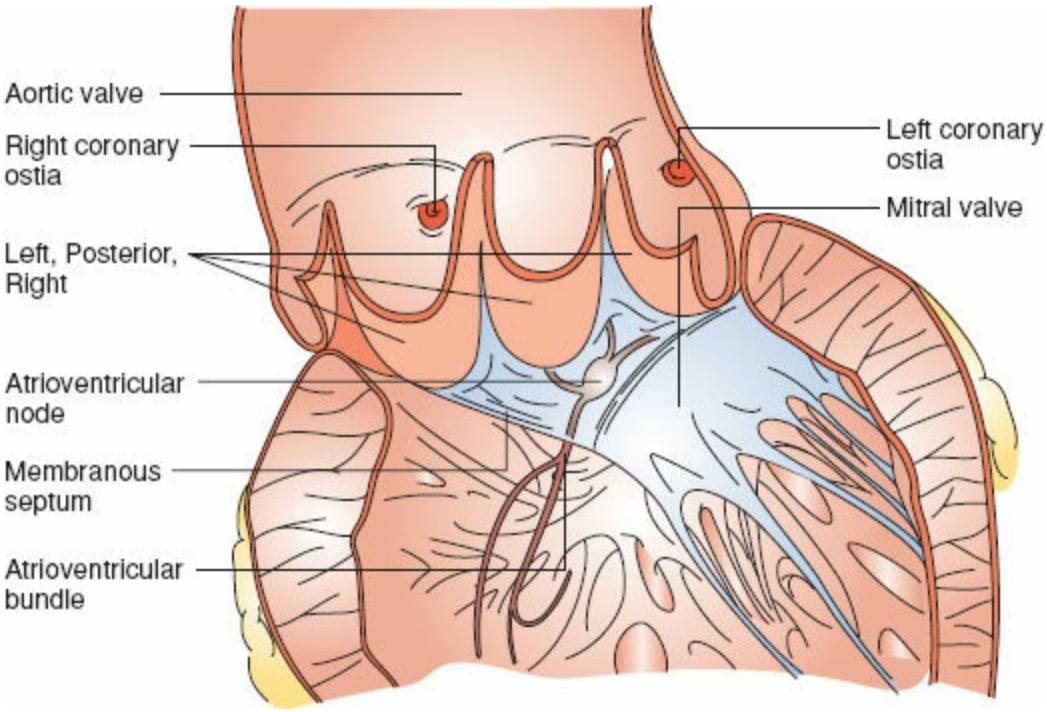

Figure 82-2. Schematic diagram of the relationship of the aortic valve to the underlying structures.

AORTIC STENOSIS

Prevalence and Etiology

1 Aortic stenosis (AS) is the most prevalent valvular heart disease in developed countries. The most common cause of AS is degenerative calcific disease, followed by congenital AS due to bicuspid valve anatomy. Rheumatic AS is becoming exceedingly uncommon in developed countries due to efficient prevention of rheumatic heart disease.

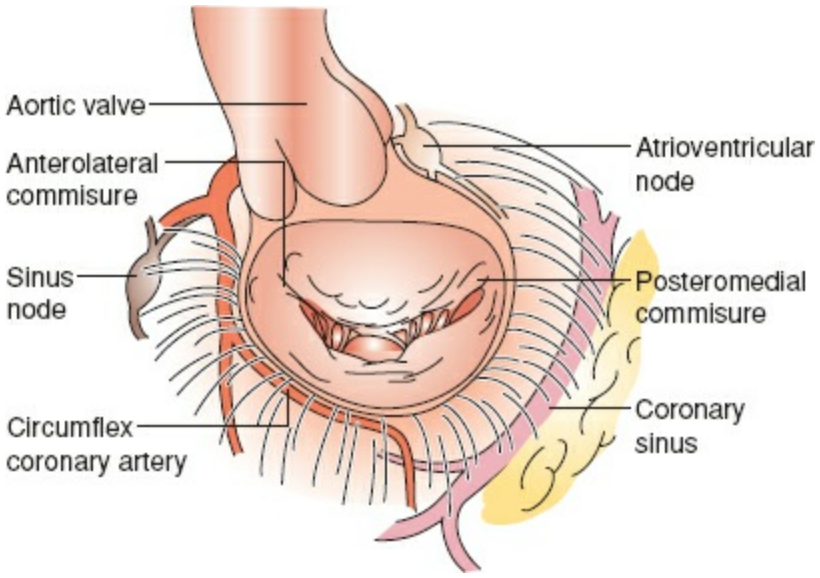

Figure 82-3. Schematic diagram of the relationship of the mitral valve to the underlying structures.

Degenerative Calcific Aortic Stenosis

The most frequent cause of AS is degenerative calcification of the AV. The prevalence of degenerative AS in persons older than 65 years, which is the most commonly affected age group, is 2%.[4] The degenerative process that leads to stiffening of the aortic leaflets is the result of proliferative and inflammatory changes with lipid accumulation and infiltration of macrophages and T lymphocytes.[4–9] Fibrosis and calcification initially affect the base of the leaflets, but ultimately progress to immobilization of the leaflets due to large calcific deposits that can extend deep into the annulus. These deposits may also extend onto the ventricular surface of the anterior leaflet of the MV, as well as into the wall of the ascending aorta. The risk factors for the development of calcific AS are similar to those for atherosclerosis and include elevated serum levels of low-density lipoprotein (LDL) cholesterol, diabetes, smoking, and hypertension.[10,11]

Bicuspid Aortic Stenosis

Calcification of bicuspid AVs, which are present in approximately 2% of the general population, represents the most common form of congenital AS. In patients with bicuspid AVs, the left and right coronary cusps are usually fused, while the noncoronary cusp is freestanding. Gradual calcification of the bicuspid valve results in AS with typical onset of symptoms in the fifth or sixth decade of life, in contrast to degenerative AS, which causes symptoms in elderly individuals. Bicuspid AS is frequently associated with degenerative

changes in the wall of the ascending aorta with resultant dilation or aneurysm formation.

Rheumatic Aortic Stenosis

Introduction of effective antibiotic therapy has resulted in a decline in the prevalence of rheumatic fever and rheumatic valve disease. Rheumatic AS is caused by inflammation and thickening of the AV leaflets, producing a mixture of AS and regurgitation. Rheumatic AS is rarely an isolated disease, and usually occurs in conjunction with MV stenosis.[12]

Pathophysiology

Regardless of the etiology of AS, the pathophysiologic consequences are similar. Narrowing of the AV to one-quarter of its normal area of 3 to 4 cm^2 produces a significant pressure gradient between the left ventricle and aorta. There is a resultant increase in LV workload and compensatory LV hypertrophy.

Even though this hypertrophy is an appropriate response to the increased afterload, there are numerous harmful effects. First, the increased wall thickness makes the ventricle stiff and less compliant. This leads to diastolic dysfunction and increased wall tension. In addition to diastolic dysfunction, systolic dysfunction, typically occurring later in the course of the disease, can develop from chronic ischemia. All of the following contribute to increased myocardial oxygen demand: increased LV muscle mass, increased wall tension, increased systolic ventricular pressure, and increased systolic ejection time. There is also decreased coronary artery perfusion, which occurs during diastole, due to increased wall tension, increased diastolic ventricular pressure, and decreased diastolic aortic pressure.[13,14] The subsequent ischemia of the subendocardium due to increased oxygen demand and decreased perfusion leads to cell death and fibrosis. Chronically, this ischemia results in systolic dysfunction.

Diagnosis

Symptoms

The most common symptoms of AS are angina pectoris, syncope, and heart failure.[15] Angina pectoris occurs in 30% to 50% of patients with severe AS. It is a reflection of myocardial ischemia caused by increased metabolic demands and decreased coronary perfusion. Coronary artery disease, which affects more than 70% of elderly patients with degenerative AV disease, causes further deterioration of myocardial perfusion and lowers the threshold for angina.

Syncope is most commonly due to reduced cerebral perfusion that occurs during exertion. Reduced cerebral perfusion is a result of decreased mean arterial pressure from peripheral vasodilation in the presence of a fixed cardiac output. Approximately 15% of patients present with syncope and only 50% of these survive for 3 years.

Congestive heart failure in patients with severe AS is typically a sign of advanced and longstanding disease. It is marked by shortness of breath and dyspnea with exertion, and results from ongoing LV outflow obstruction. Heart failure is a consequence of the aforementioned diastolic and systolic dysfunction from decreased compliance and ischemia, respectively. In addition, as the left ventricle becomes less compliant, atrial systole becomes more important for maintaining cardiac output and the onset of atrial fibrillation may result in worsening of congestive heart failure.

Some patients with severe AS may develop serious gastrointestinal bleeding secondary to angiodysplasias, occurring predominantly in the right colon, and also in the small bowel and stomach. These result from shear stress–induced platelet aggregation with reduction in high–molecular-weight multimers of von Willebrand factor.

Signs

Signs of AS include a loud systolic ejection murmur that radiates to the neck and is often accompanied by a thrill. “Pulsus parvus et tardus” describes a weak and prolonged arterial pulse characteristic of advanced AS. The weak pulse is a reflection of a narrowed pulse pressure, while the slow rise in pulse reflects a prolonged ejection of blood volume through a stenotic valve.[16]

Electrocardiogram and Imaging

2 The electrocardiogram typically shows signs of LV hypertrophy, which is found in the majority of patients with AS. Echocardiography represents the "gold standard" modality for the diagnosis of AS. Two-dimensional (2D) echocardiography with Doppler allows precise real-time analysis of ventricular and valvular anatomy and function. The most important objective of echocardiography is correct assessment of the severity of AS using Doppler echocardiography to calculate jet velocity, mean transvalvular pressure gradient, and valve orifice area (Table 82-1). It is also used to assess valve thickening and calcification, as well as reduced leaflet motion. Distinction between bicuspid and TVs is often possible, particularly when the amount of calcification is small.

DIAGNOSIS

Table 82-1 Classification of Aortic Stenosis Severity

Indicator	Mild	Moderate	Severe
Jet velocity (m/s)	<3.0	3.0–4.0	>4.0
Mean gradient (mm Hg)	<25	25–40	>40
Valve area (cm^2)	>1.5	1.0–1.5	<1.0
Valve area index (cm^2/m^2)			<0.6

Adapted from Bonow RO, Carabello BA, Chatterjee K, et al. 2008 focused update incorporated into the ACC/AHA 2006 guidelines for the management of patients with valvular heart disease. *J Am Coll Cardiol* 2008;52(13):e1–e142.

Two-dimensional echocardiography is also invaluable in detecting associated MV disease and in assessing LV hypertrophy, systolic function, and diastolic performance. Ejection fraction is used to measure LV systolic function. However, a severe decrease in ejection fraction can falsely lower estimates of severity of AS due to low-pressure gradients. Stress echocardiography with dobutamine administration may be required to properly assess the severity of valvular disease and to distinguish it from primary contractile dysfunction with lack of contractile reserve.[17]

3 Cardiac catheterization with direct measurement of the pressure gradients across the AV to calculate the severity of stenosis has been replaced by less invasive echocardiography. The current indication for cardiac catheterization is limited to preoperative evaluation of coronary artery disease.

Natural History

The natural history of AS is marked by a prolonged latent period with few symptoms and minimal morbidity. Even patients with moderately severe AS have a slow decrease in AV area, generally by approximately 0.1 cm^2 per year.[18,19] The natural history of severe AS correlates well with the onset and severity of symptoms. Life expectancy of patients with severe, untreated AS and angina is approximately 5 years. Patients presenting with syncope have life expectancies of 3 years. Presence of congestive heart failure in patients with severe, untreated AS is associated with a worse prognosis, with the time of death occurring less than 2 years from the onset of symptoms (Fig. 82-4).[20]

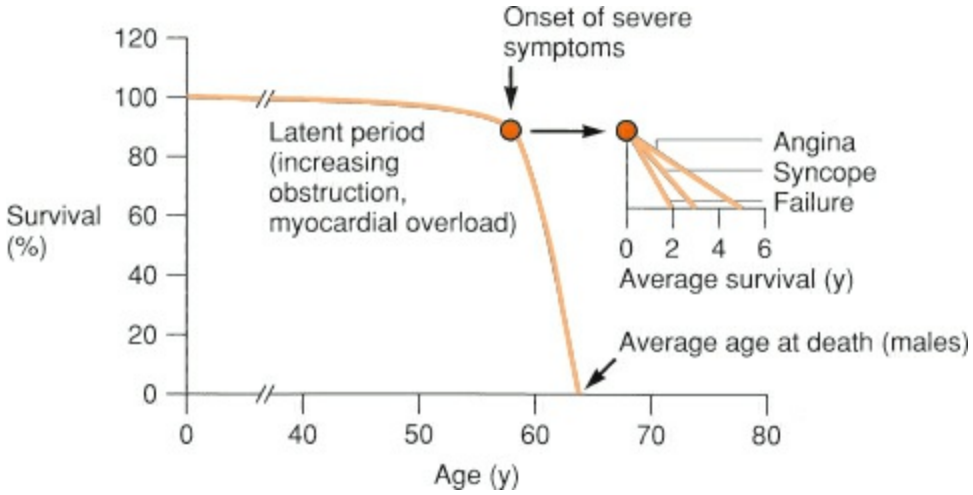

Figure 82-4. Natural history of aortic stenosis without operative treatment. Onset of symptoms identifies patients at high risk of death over the next 2 to 5 years.



Figure 82-5. St. Jude Medical Regent Valve.

Treatment

4 There is no effective medical therapy for patients with severe AS. Diuretics and digitalis may improve the symptoms of congestive heart failure. Mechanical relief of AS is accomplished by surgical AV replacement (AVR), percutaneous AVR, or percutaneous balloon aortic valvotomy (PBAV).

Surgical Aortic Valve Replacement

The primary indication for surgery is the presence of symptoms in patients with severe AS. AVR is also indicated in patients with severe AS and reduced LV function and in patients with moderate to severe AS who also require coronary, other valve, or aortic surgery.[17] Recent studies suggest that AVR may also be beneficial in patients with asymptomatic severe AS and severe LV hypertrophy.[21]

Choice of valve prosthesis for AVR is primarily influenced by the patient's age. Mechanical prostheses are made of carbon, require lifelong anticoagulation, and are very durable (Fig. 82-5). Mechanical prostheses are therefore indicated in patients younger than 65 years old. Stented biologic prostheses are most commonly made of bovine pericardium or porcine valve leaflets, do not require anticoagulation, and have a limited durability of approximately 15 years (Fig. 82-6). Biologic prostheses are used in elderly patients (older than 65 years) and in younger patients in whom long-term anticoagulation with warfarin is contraindicated (bleeding diathesis, peptic ulcer disease, etc.).

Percutaneous and Transapical Aortic Valve Replacement

Percutaneous AVR is an emerging therapy for patients previously deemed inoperable due to prohibitive operative risk. This is a novel treatment utilizing a bioprosthesis sutured to a balloon or self-expandable stainless steel or nitinol stent (Fig. 82-7). The prosthesis is introduced through the femoral artery retrogradely into the aorta and placed at the midpart of the native stenotic AV. The radial forces of the stent push the native AV aside to increase the valve orifice area. The prospective trial (Placement of Aortic Transcatheter valves: PARTNER) randomized "high-risk" patients (operative mortality >15%) to either transfemoral AVR (TF-AVR) or conventional AVR.[22] Thirty-day mortality was doubled in the conventional group, but at 1 year, survival was similar. In the "inoperable" subset, TF-AVR was shown to be significantly superior to optimal medical therapy with improvement in NYHA scores to 1–2 and a 20% improvement in mortality at 5-year follow-up. Hemodynamic benefits and valve integrity also persisted at 5 years.[23] In patients with severe peripheral vascular disease, the retrograde arterial approach cannot be used. In these patients, similar prostheses can be inserted directly into the beating heart through the LV apex (transapical approach). This approach has been shown to have a lower rate of vascular complications, postoperative heart block necessitating permanent pacemaker implantation and paravalvular regurgitation as compared to the TF-AVR with similar 1-year survival.[24–26] In conclusion, appropriately selected high-risk or inoperable patients can benefit significantly from TF-AVR in both survival and functional status, and in those where femoral access is not an option, the transapical

technique is warranted.



Figure 82-6. St. Jude Medical Epic Valve.

Percutaneous Balloon Aortic Valvotomy

PBAV is a procedure in which a balloon is placed across a stenotic AV and inflated in order to decrease the degree of valve narrowing. This procedure is a valuable tool for treatment of AS in children and young adults. Rapid development of restenosis and clinical deterioration limits its application in the treatment of adults to those with severe AS who are not candidates for conventional surgical or transcatheter AVR.

AORTIC REGURGITATION

Prevalence and Etiology

5 AR results from the improper coaptation of the AV leaflets due to either intrinsic leaflet abnormalities or aortic root distortion. The most common causes of AR include bicuspid valve disease, rheumatic fever, and endocarditis. Regurgitant bicuspid AVs are often partly calcified, which results in limited opening and closing of the valve and a mixture of AR and AS. Rheumatic fever causes inflammation and fibrosis of the leaflets, while endocarditis causes destruction of leaflets. In addition, AR can occur as a secondary phenomenon of aortic root enlargement due to Marfan syndrome, anuloaortic ectasia, or aortic dissection. Most of these causes produce chronic AR with a slow increase in LV size. Some lesions, in particular acute aortic dissection and endocarditis, cause acute AR with a sudden decrease in cardiac output.

Pathophysiology

In patients with AR, inappropriate coaptation of the aortic leaflets causes diastolic reflux of blood from the aorta into the LV with a consequent increase in LV end-diastolic volume and pressure. In chronic AR, compensatory mechanisms of the LV result in dilation and hypertrophy. LV hypertrophy and dilation ultimately result in a decrease in LV function and heart failure.

Diagnosis

Symptoms

Chronic AR is usually well tolerated and patients with even severe AR often remain asymptomatic for years. Initial symptoms of severe AR include fatigue, shortness of breath, and dyspnea on exertion. Advanced AR is marked by the onset of congestive heart failure, syncope, and angina. Acute onset of severe AR, such as in cases of aortic dissection or endocarditis-induced valve destruction, causes a sudden increase in LV end-diastolic volume and pressure with subsequent cardiogenic shock and pulmonary edema.

Signs

Lateral displacement of the point of maximum impulse is seen in chronic AR due to LV dilation and hypertrophy. The classic auscultatory findings of AR are best heard at the right sternal border of the second intercostal space and include a high-pitched, blowing holodiastolic decrescendo murmur; an S_3 heart sound; and a systolic ejection murmur.

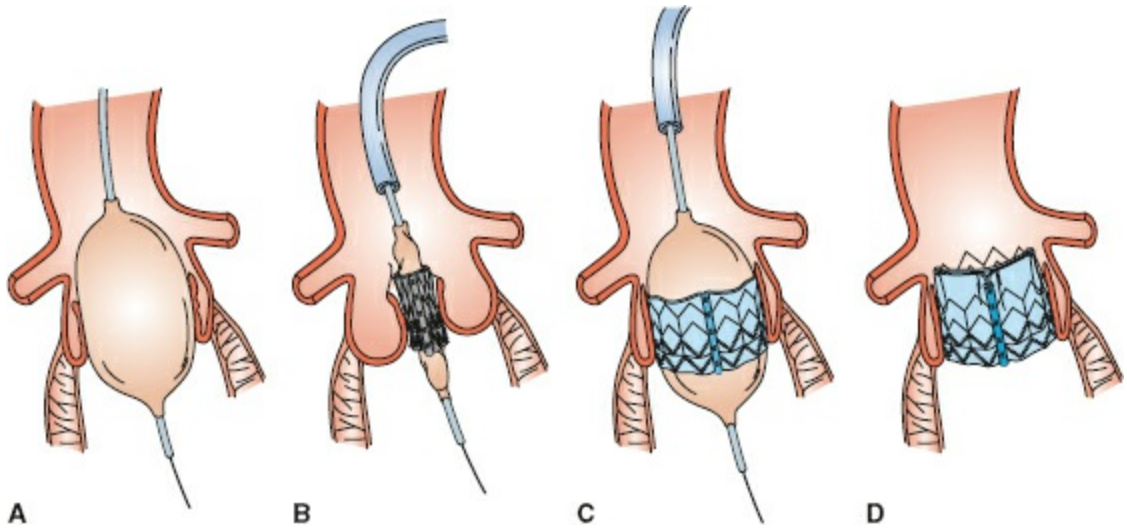

Figure 82-7. Schematic diagram of percutaneous aortic valve replacement. **A:** Balloon valvuloplasty. **B:** Balloon catheter with valve in the native diseased valve. **C:** Balloon inflation to secure the valve. **D:** Valve in place.

Table 82-2 Classification of Aortic Regurgitation Severity

Indicator	Mild	Moderate	Severe
Angiographic grade	1+	2+	3–4+
Jet width	<25% LVOT	25–65% LVOT	>65% LVOT
Regurgitant volume (mL/beat)	<30	30–59	≥60
Regurgitant fraction (%)	<30	30–49	≥50
Regurgitant orifice area (cm^2)	<0.10	0.10–0.29	≥0.30

LVOT, left ventricular outflow tract.
Adapted from Bonow RO, Carabello BA, Chatterjee K, et al. 2008 focused update incorporated into the ACC/AHA 2006 guidelines for the management of patients with valvular heart disease. *J Am Coll Cardiol* 2008;52(13):e1–e142.

Additionally, the widened pulse pressure leads to a number of interesting findings, such as bounding pulses (water-hammer pulse), Quincke pulse (pulse in fingernail bed), De Musset sign (rhythmic bobbing of the head), Duroziez sign (systolic and diastolic murmurs heard over the femoral artery when it is gradually compressed), and Müller sign (pulsations of the uvula).[16]

Imaging

Echocardiography represents the diagnostic “gold standard” for patients with AR. It allows assessment of the valvular and aortic anatomy, the severity of regurgitation, and the size and function of the left ventricle. Assessment of the severity of AR is determined by color Doppler jet width, regurgitant volume, regurgitant fraction, and regurgitant orifice area (Table 82-2). The role of coronary angiography is reduced to the preoperative diagnosis of coronary artery disease.

Natural History

The natural history of AR is strongly dependent on the presence of symptoms and LV dysfunction at the time of presentation. Asymptomatic patients with normal LV function develop symptoms and/or LV dysfunction at 6% per year. Asymptomatic patients with LV dysfunction at presentation develop cardiac symptoms at 25% per year. Finally, the mortality rate of symptomatic patients is 10% per year.[17]

Treatment

Management of patients with AR depends on the severity of symptoms and the size and function of the left ventricle. Asymptomatic patients with chronic severe AR and preserved LV size and function are treated with vasodilator medical therapy, which reduces afterload and improves forward flow.

Surgery is indicated in symptomatic patients with chronic severe AR and in asymptomatic patients with severe AR and evidence of LV dilation (end-systolic LV diameter >55 mm) or dysfunction (ejection fraction $<50\%$). Additionally, acute severe AR with consequent pulmonary edema and shock caused by endocarditis or aortic dissection is a surgical emergency.

AVR should be performed before irreversible changes in LV function occur. Mechanical valves are indicated for patients younger than 65 years of age. Stented bioprostheses are used for AVR in patients older than 65 and in younger patients with contraindications to long-term anticoagulation. AV repair can be performed in patients with severe AR caused by bicuspid valve disease or connective tissue disorders. Traditionally, patients with proximal aortic root pathology, including dissection and aneurysms with secondary AR underwent aortic root replacement with a mechanical valve. This was done regardless whether or not their native valve was diseased. The valve sparing root replacement (David procedure) has been shown to have similar morbidity and mortality with minimal risk of thromboembolism or endocarditis. Additionally, it precludes the need for anticoagulation and has an acceptably low reoperation rate. This makes it ideal for young patients, especially those with connective tissue disorders.[27–30]

MITRAL STENOSIS

Prevalence and Etiology

6 Mitral stenosis (MS) is predominantly caused by rheumatic fever. The steady rate of decline of rheumatic fever in developed countries has resulted in a similar decline in the prevalence of MS. Other far less common causes of MS include severe annular and leaflet calcification, congenital malformations, malignant carcinoid, left atrial myxoma, left atrial thrombus, and endocarditis. A definitive history of rheumatic fever can only be obtained in 50% to 60% of cases and women are affected more often than men by a 2:1 ratio.[31,32] Rheumatic fever commonly occurs in childhood or adolescence and can lead to a postinfective pancarditis, affecting to various degrees the valves, endocardium, myocardium, and pericardium. In MS due to rheumatic fever, there is leaflet thickening and calcification, chordal shortening and fusion, and commissural fusion, which all lead to a smaller, funnel-shaped mitral orifice. This deformation can also prevent complete closure of the valve, which is evidenced by concomitant regurgitation in about half of patients with MS.

Pathophysiology

The cross-sectional area of the normal MV is 4 to 5 cm^2. Normally, there is a trivial diastolic pressure gradient present to move blood across the MV from the left atrium into the left ventricle. An increasing gradient is required as the MV becomes more narrowed, and a significant transvalvular gradient first develops when there is reduction of the mitral orifice to less than 2.5 cm^2, which represents mild MS. The increased atrial pressure leads to left atrial enlargement and the pressure is subsequently transmitted retrograde into the pulmonary veins, capillaries, and arteries. The determinants of the transvalvular gradient, and therefore the determinants of the left atrial pressure, are atrial contractility, cardiac output, and heart rate. Consequently, the gradient and atrial pressure are increased if atrial kick is lost (decreased atrial contractility), flow rate across the valve increases (increased cardiac output), or transit time across the valve is shortened (increased heart rate).

Diagnosis

Symptoms

Symptoms of left-sided heart failure, such as dyspnea, orthopnea, and paroxysmal nocturnal dyspnea, are the primary indicators of MS and are typically triggered by exertion, stress, infection, pregnancy, or the abrupt onset of atrial fibrillation. The increased heart rate and cardiac output that can occur under these circumstances, and the mechanical obstruction inherent to MS, lead to an increased transvalvular gradient and left atrial pressure. The ensuing pulmonary congestion results in dyspnea. Likewise, the loss of atrial kick with atrial fibrillation increases the gradient and atrial pressure. Patients with atrial fibrillation may also present with palpitations or systemic embolization.

Patients infrequently present with hoarseness, dysphagia, hemoptysis, and symptoms of right-sided heart failure. Hoarseness and dysphagia may result if left atrial enlargement is sufficient to compress surrounding structures. Hemoptysis may occur from significant pulmonary venous hypertension. Symptoms of right-sided heart failure arise when right ventricular function is impaired due to an increased afterload from the stenotic MV and secondary pulmonary hypertension. Still, other patients may present without symptoms but have an abnormal physical examination.

Signs

The left ventricle is typically not enlarged; thus, the point of maximum impulse is not displaced. The typical auscultatory findings of MS are best heard at the apex and include a low-pitched, rumbling middiastolic murmur; an accentuated first heart sound; and an opening snap. These findings may be absent with a heavily calcified immobile valve, severe pulmonary hypertension, or low cardiac output. Physical findings of pulmonary hypertension, such as a loud pulmonic component of the second heart sound (P_2), a right ventricular heave, distended neck veins, hepatomegaly, ascites, and peripheral edema, can also be observed with MS.[16]

Imaging

Echocardiography is the principal tool used in the diagnosis of MS. It is used to assess the morphologic characteristics of the valve apparatus, which include leaflet mobility, flexibility, and thickness; presence of calcifications and subvalvular fusion; and appearance of the commissures. Additionally, Doppler echocardiography is utilized to determine the hemodynamic severity by measurement of the mean transvalvular pressure gradient, pulmonary artery systolic pressure, and valve area (Table 82-3). This morphology and severity information is fundamental in determining the timing and type of intervention to be used.[17]

The enlarged left atrium gives rise to characteristic findings on the chest radiograph, which includes displacement of the left main-stem bronchus superiorly and displacement of the esophagus posteriorly. Additionally, calcification of the mitral leaflets and enlarged pulmonary arteries with cephalization of pulmonary blood flow can be seen.

Similar to the diagnosis of other valvular heart disease, cardiac catheterization with direct pressure measurement has largely been replaced by echocardiography.

Table 82-3 Classification of Mitral Stenosis Severity

Indicator	Mild	Moderate	Severe
Mean gradient (mm Hg)	<5	5–10	>10
Pulmonary artery systolic pressure (mm Hg)	<30	30–50	>50
Valve area (cm^2)	>1.5	1.0–1.5	<1.0

Adapted from Bonow RO, Carabello BA, Chatterjee K, et al. 2008 focused update incorporated into the ACC/AHA 2006 guidelines for the management of patients with valvular heart disease. *J Am Coll Cardiol* 2008;52(13):e1–e142.

Natural History

The natural history of MS is that of a continuous decline usually consisting of a slow, stable course followed by a progressive acceleration. The latent period from rheumatic fever to the onset of symptoms is typically 20 to 40 years, with another decade before symptoms become disabling. Depending on the symptoms at presentation, the overall 10-year survival of untreated patients presenting with MS is 50% to 60%. Once disabling symptoms occur, the 10-year survival is a bleak 0% to 15%.[31–34] Mortality in untreated patients is due to pulmonary and systemic congestion, systemic embolism, pulmonary embolism, and infection.[33,35]

Treatment

For the asymptomatic patient with mild MS in sinus rhythm, prophylaxis against rheumatic fever is the only therapy indicated. A yearly history, physical examination, chest radiograph, and electrocardiogram should be obtained; serial echocardiograms are only warranted in patients with severe MS or when there is a change in symptoms.[17]

Mechanical relief is considered in symptomatic patients with moderate to severe MS. In symptomatic patients with mild MS, further exercise testing or dobutamine stress testing is useful to determine whether or not mechanical relief is warranted. Patients with a significant elevation of mean transmitral gradient (>15 mm Hg), pulmonary artery systolic pressure (>60 mm Hg), or pulmonary artery wedge pressure (>25 mm Hg) during provocative testing have hemodynamically significant MS and should be considered for mechanical relief.[17] The options for mechanical relief of MS include percutaneous balloon mitral valvotomy, open mitral commissurotomy (OMC), and MV replacement.

Percutaneous Balloon Mitral Valvotomy

Percutaneous balloon mitral valvuloplasty (PBMV) was initially introduced in 1984 marking a leap in transcatheter-based therapies for valvular heart disease. Most commonly, the catheter is introduced into the right atrium via a transseptal approach and inflated across the diseased valve.[36] This has become the standard of care for select MS patients.[17] Scoring systems have been developed to aid in patient selection. Leaflet thickness, pliability, degree of calcification of the valves and the subvalvular apparatus are central in these scoring systems with lower scores (e.g., <8 in the Wilkins score) correlating with improved outcomes.[37] Contraindications include the presence of a left atrial thrombus, moderate to severe MR, heavy annular or leaflet calcification, and severe subvalvular distortion.

Procedural mortality of PBMV is 1% to 2% in large series. Rare risks of the procedure include MR, iatrogenic creation of an atrial septal defect, perforation of the left ventricle, embolic events, and myocardial infarction.[38–42]

Success of PBMV can be measured by the increase in mitral valve area (MVA), restenosis at long-term follow-up and event-free survival (death, repeat procedure or surgery, NYHA III or IV). Overall, significant (MVA ≥ 1.5 cm^2) increase in MVA are obtained in over 80% of patients[43] with freedom from restenosis and event-free survival at 10 years at 70% and 80%, respectively.[44,45]

Open Mitral Commissurotomy

OMC permits direct inspection of the MV apparatus and allows debridement of calcium deposits, division of the commissures, and splitting of fused chordae tendineae under direct vision. Additionally, the left atrial appendage can be surgically oversewn from within the left atrium, reducing the risk of postoperative embolization. The contraindications to OMC are similar to those of PBMV.

The operative mortality of OMC is less than 2%,[46,47] and complication rates are similar

to those of PBMV.[48,49] Short- and long-term hemodynamic results and symptomatic results are similar between PBMV and OMC in younger patients with less severe valve pathology (lower Wilkins scores).[48] More favorable results are seen with OMC in older patients with subvalvular fusion, leaflet calcification, and less valve flexibility (higher Wilkins scores).[49]

Mitral Valve Replacement

MV replacement is necessary in symptomatic patients with moderate to severe MS when there is a significant amount of calcification or subvalvular fusion, since PBMV and OMC are less likely to be successful. MV replacement is also necessary in symptomatic patients with moderate to severe MS and concomitant moderate to severe MR.[17] The choice of valve prosthesis for MV replacement is determined in a similar manner as choosing the prosthesis for AVR. Biologic prostheses are used in the elderly and those in whom long-term warfarin is contraindicated. Regardless of the prosthesis used, it is well established that preservation of the papillary muscle attachments to the annulus plays an important role in the maintenance of LV function.[50–54] The operative mortality of MV replacement is 5% to 6% and freedom from reoperation at 15 years is 50% to 75%.[55]

MITRAL REGURGITATION

Prevalence and Etiology

8 Since competency of the MV is dependent on the entire MV apparatus, dysfunction of any one of the components can lead to mitral regurgitation (MR). The most common overall cause of MR is degenerative MV disease. Other causes of MR include rheumatic valve disease, endocarditis, certain drugs, and collagen vascular disease. In some cases, functional MR develops as a result of dilation of the LV from cardiomyopathy or severe ischemic heart disease. Finally, rupture of a papillary muscle from myocardial infarction or endocarditis, or rupture of a chord can lead to the onset of acute, severe MR.

Pathophysiology

MR is caused by deficient coaptation of the MV leaflets, which results in blood flow from the left ventricle into the left atrium during systole. Regardless of etiology, the pathophysiology of chronic MR is similar. MR results in gradual enlargement of the left atrium as a result of volume overload. Decrease in the functional stroke volume causes an increase in LV size with a subsequent decrease in LV function.

On the other hand, the pathologic process that takes place in acute MR is quite different. Sudden volume overload results in an increase in LV preload and a decrease in forward stroke volume, since compensatory LV eccentric hypertrophy has not had time to develop. Similarly, acute volume overload of the left atrium results in an increase in left atrial pressure and pulmonary congestion.

Diagnosis

Symptoms

Symptoms of chronic MR include fatigue, dyspnea on exertion, and shortness of breath. More advanced stages of disease are characterized by the development of heart failure. Acute, severe MR is characterized by acute pulmonary edema and cardiogenic shock.

Signs

The point of maximum impulse is typically laterally displaced. The classic auscultatory findings of MR are best heard at the apex and include a high-pitched, blowing, holosystolic murmur radiating to the axilla; a diminished S_1; and an S_3.

Imaging

Echocardiography is used to assess the severity of MR, morphology of the MV, and size and function of the LV and atrium. Assessment of the severity of MR is determined by the jet area/left atrial area, regurgitant volume, regurgitant fraction, and regurgitant orifice area (Table 82-4). Additionally, magnetic resonance imaging (MRI) allows accurate measurements of the severity of regurgitation and quantification of regurgitant volumes, along with assessment of LV size and function.

Natural History

Patients with mild to moderate MR usually remain asymptomatic with little or no hemodynamic compromise for many years. In patients with severe MR caused by flail leaflets, mortality is 6% to 7% per year, and 90% of patients die or require an MV operation within 10 years.[56]

Treatment

Given most recent guidelines, surgery should be performed early, before signs of LV function deterioration, and even asymptomatic patients with severe MR should be offered surgery if there is a high probability of successful repair and low mortality risk.[57,58] MV repair is preferred surgical therapy for most patients with MR, since it preserves the native valve and avoids the need for anticoagulation, which is required in the majority of patients who undergo valve replacement.[59] Preservation of the MV and chordae preserves LV function and improves survival. Success rates of MV repair depend on the etiology of regurgitation. Durable MV repair can be accomplished in more than 90% of patients with degenerative MV disease. Standard techniques for MV repair include resection of the prolapsed portion of the MV leaflet, leaflet reconstruction, and insertion of an annuloplasty ring (Fig. 82-8).

Table 82-4 Classification of Mitral Regurgitation Severity

Indicator	Mild	Moderate	Severe
Angiographic grade	1+	2+	3–4+
Jet size			Wall-impinging jet of any size
Jet area/left atrial area (%)	<20	20–40	>40
Regurgitant volume (mL/beat)	<30	30–59	≥60
Regurgitant fraction (%)	<30	30–49	≥50
Regurgitant orifice area (cm^2)	<0.20	0.20–0.39	≥0.40

Adapted from Bonow RO, Carabello BA, Chatterjee K, et al. 2008 focused update incorporated into the ACC/AHA 2006 guidelines for the management of patients with valvular heart disease. *J Am Coll Cardiol* 2008;52(13):e1–e142.

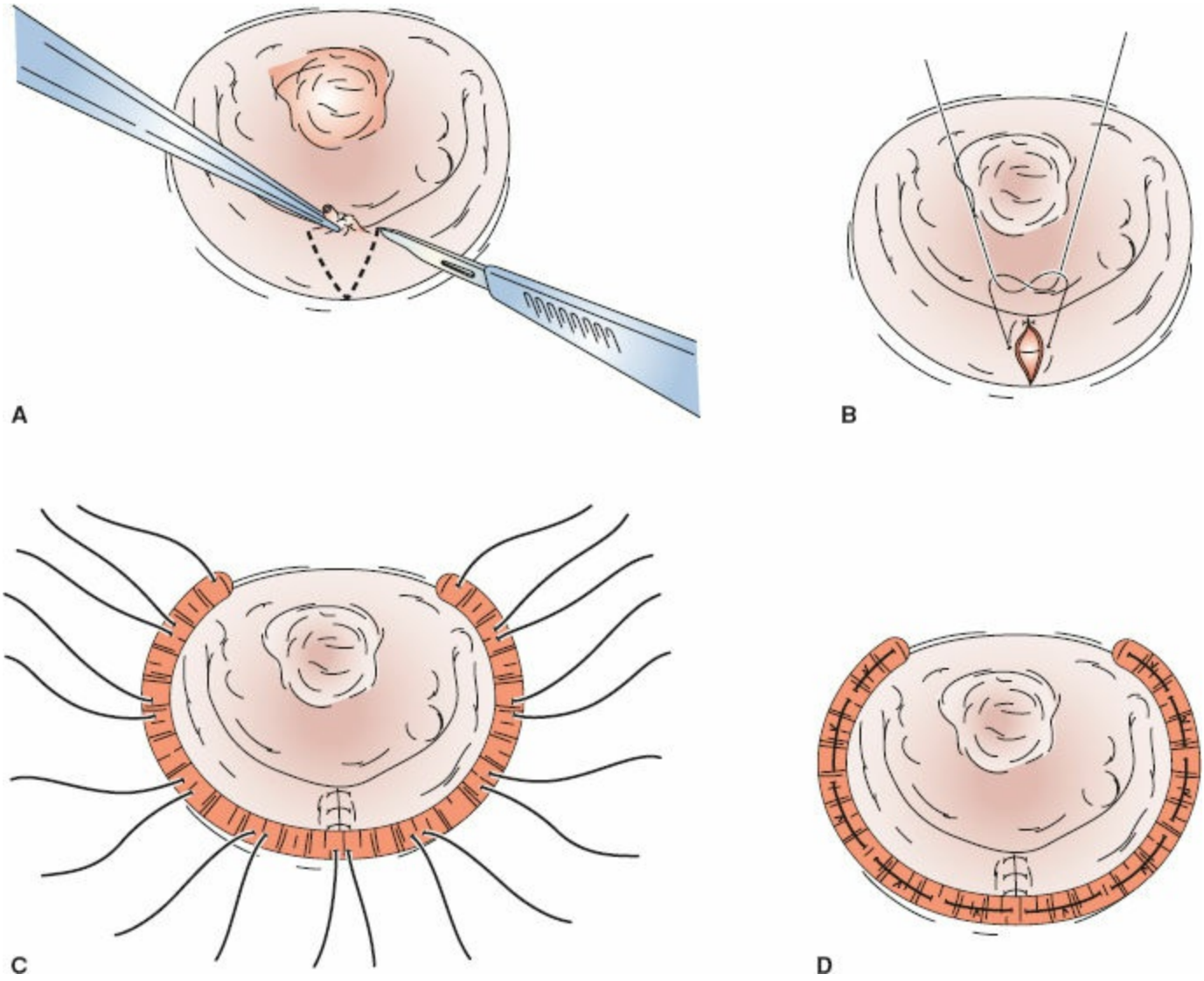

Figure 82-8. Schematic diagram of posterior mitral valve repair and insertion of annuloplasty ring.

Mortality of isolated MV repair is less than 1%, with greater than 90% freedom from reoperation at 10 years. Functional MR is usually repaired with the use of an undersized annuloplasty ring to reduce the diameter of the mitral annulus and restore valve competency. MV repair is also the preferred surgical therapy in patients with MV endocarditis. Resection of all infected valve tissue is the mainstay of valvular reconstruction in patients with endocarditis. This is followed by leaflet reconstruction, commonly with the use of an autologous pericardial patch and an annuloplasty (Fig. 82-9).

MV repair is indicated for patients in whom adequate MV repair cannot be accomplished. Mechanical valve replacements are indicated in patients younger than 65 years of age and stented bioprostheses are indicated in the elderly.

Isolated MV repair and replacement are traditionally performed through a full sternotomy. Minimally invasive approaches, which include partial upper and lower sternotomy and right mini anterolateral thoracotomy, decrease the degree of surgical trauma and blood loss and allow faster recovery with less postoperative pain, sternal wound complications, and better cosmetic result.[60–62] Robotically assisted MV repair, which is performed through small port-like incisions, is the least invasive surgical

approach that eliminates the need for sternotomy or thoracotomy, and as such provides faster postoperative recovery in hospital as well as after discharge (Fig. 82-10).[63–66]

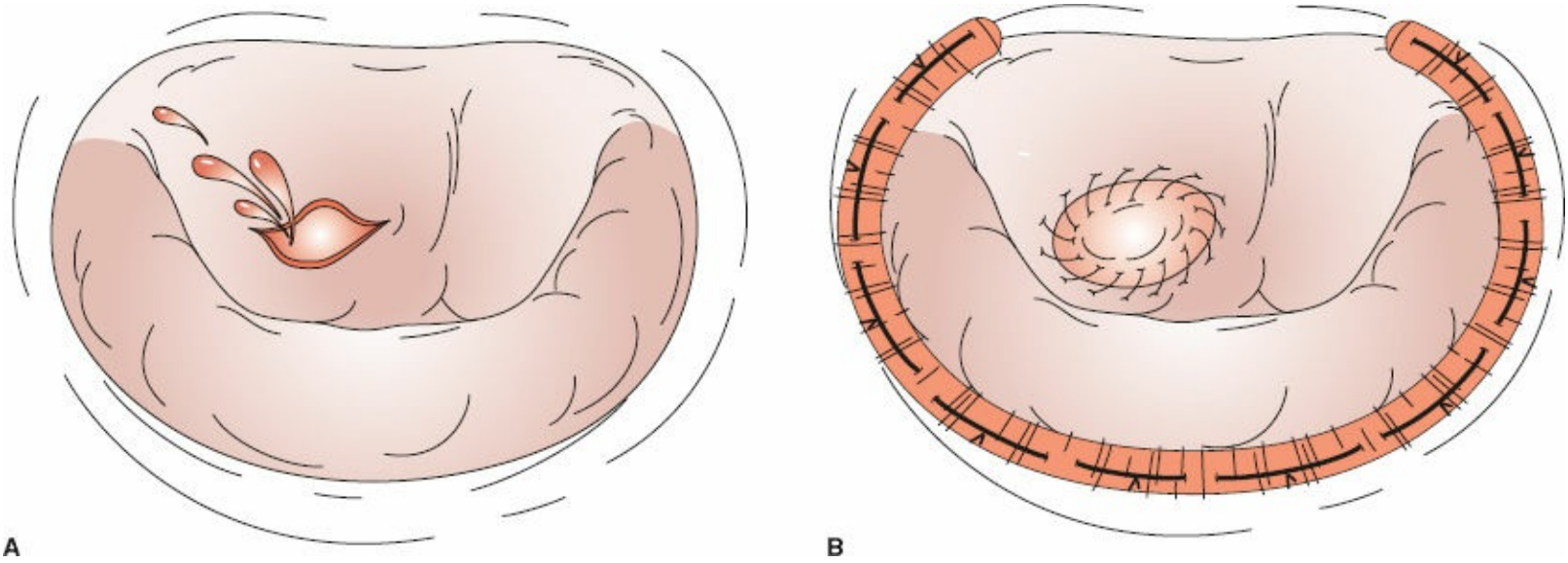

Figure 82-9. Schematic diagram of mitral valve repair with autologous pericardial patch and insertion of an annuloplasty ring.

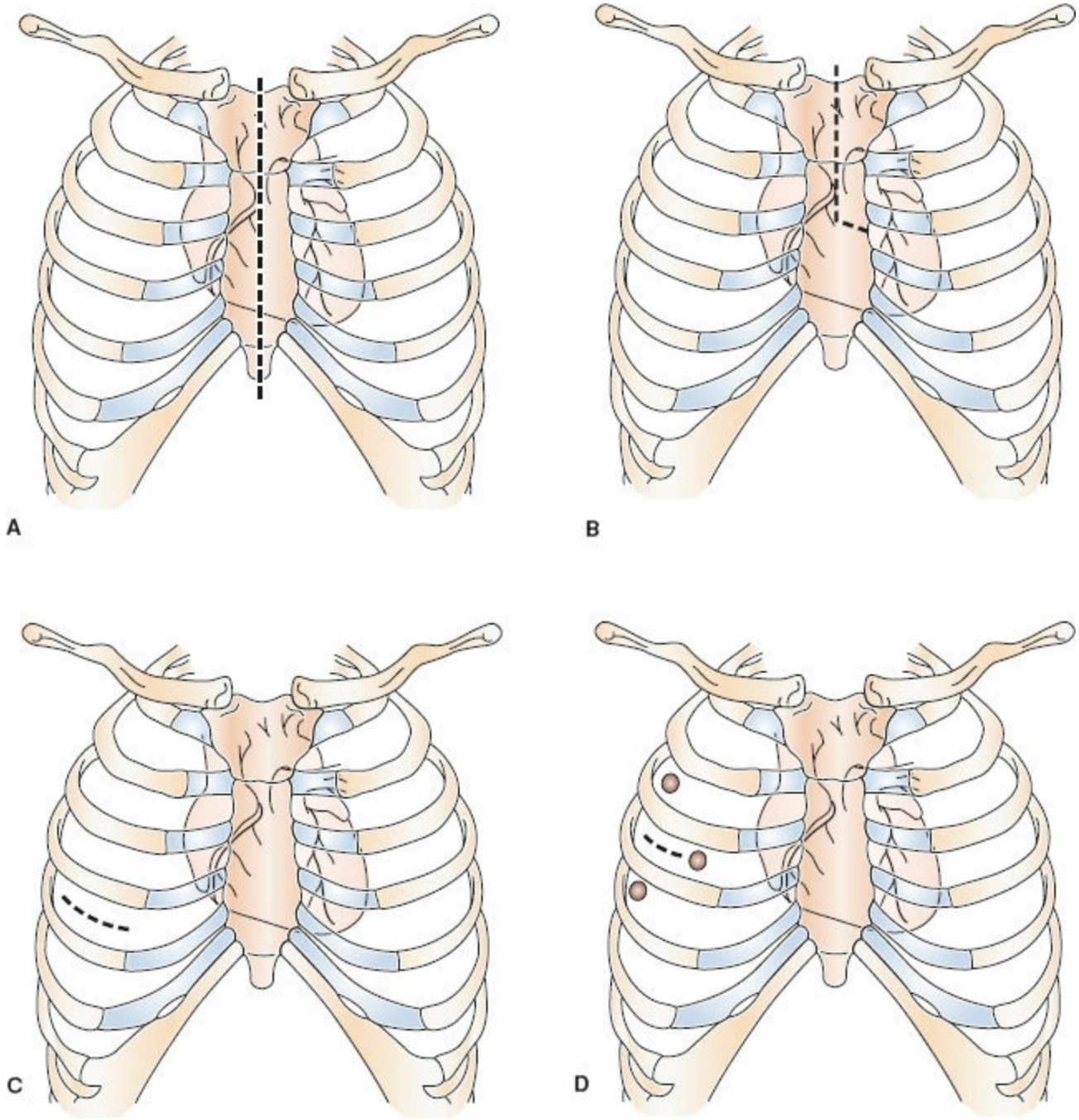

Figure 82-10. Surgical approaches to the mitral valve. **A:** Full sternotomy. **B:** Partial sternotomy. **C:** Limited right anterolateral mini-thoracotomy. **D:** Robotically assisted.

In patients with severe MR who are determined to be at prohibitive risk for surgery given existing comorbidities alternative treatment option is percutaneous MV repair. MitraClip system is a percutaneously delivered device that offers similar mortality and symptomatic improvement. However, due to higher rate of MR requiring repeat procedures, and less improvement in LV dimensions as compared to surgery, the latter remains the standard of care for treatment of MR among eligible patients. [67]

TRICUSPID VALVE DISEASE

TV disease is less common than AV and MV disease. Tricuspid regurgitation (TR), the most common form of TV dysfunction, can occur with anatomically normal or abnormal valves. Functional TR is caused by right ventricular dilation and consequent leaflet malcoaptation in an otherwise anatomically normal valve. Right ventricular enlargement occurs in patients with pulmonary hypertension, most commonly caused by longstanding MV dysfunction. TV endocarditis most commonly occurs in intravenous drug users and causes TR by destruction of the leaflets.

Echocardiography is used to assess the degree of TR, anatomy of the TV, right ventricular function, and pulmonary pressures.

Mild to moderate degrees of TR often resolve spontaneously once the MV disease causing the pulmonary hypertension is corrected. Severe functional TR is corrected by reduction in the diameter of the tricuspid annulus, most commonly using an annuloplasty ring. Severe endocarditis requires complete resection of infected valve tissue, followed by TV replacement with a bioprosthesis. In active drug users, insertion of a valve prosthesis may be delayed by several months to decrease the risk of recurrent endocarditis.

Valve Prostheses

Development of valve prostheses has transformed the treatment of valvular heart disease. Numerous types of prostheses are currently available for clinical use, and they differ in design, biocompatibility, and hemodynamic characteristics. They are broadly classified into mechanical and bioprosthetic.

Contemporary mechanical valves are bileaflet valves composed of carbon material that is mounted on a sewing ring (Fig. 82-5). Mechanical valve prostheses are durable and have excellent hemodynamic performance. Patients with mechanical prostheses require lifelong anticoagulation with warfarin, which results in a 1% to 3% risk of bleeding per year. These characteristics make mechanical valves the prosthesis of choice for younger patients with no contraindications to long-term anticoagulation.[17]

Biologic prostheses are composed of valve leaflets created from bovine pericardium or porcine valve leaflets mounted on a sewing ring (Fig. 82-6). Biologic prostheses have slightly inferior hemodynamic characteristics when compared with mechanical prostheses and a limited durability of 10 to 15 years. However, bioprostheses are not thrombogenic and therefore do not require anticoagulation. Bioprostheses are generally indicated in older individuals and younger patients who have contraindications to long-term anticoagulation.

There has been an increased use of bioprostheses in younger individuals due to recent improvements in design of the prostheses, expected increases in valve durability, and decreased risk of reoperations.

Aortic homografts are cryopreserved allografts that are composed of AVs and ascending aortas. Homografts are not thrombogenic, have excellent hemodynamic characteristics, and have high resistance to infection. Homografts are indicated in patients with AV endocarditis. Their use for primary AVR is limited due to the complexity of the operation and limited durability (10 years).

CARDIAC TUMORS

Cardiac tumors can be located in the epicardium, myocardium, endocardium, or any combination of the three. In general, tumors that involve the parietal pericardium are not classified as cardiac tumors.

8 Tumors of the heart are classified as either primary or secondary. Primary tumors arise in the heart and are either benign or malignant. Secondary tumors are metastases from primary tumors arising elsewhere and hence are always malignant. Primary tumors are rare, with an autopsy incidence of less than 0.1%.[68] Secondary tumors are observed more commonly, with a postmortem incidence of about 1%.[69]

Cardiac tumors present with variable symptoms. Symptoms are frequently determined by the intracardiac location of the tumor. Intracavitary tumors can obstruct blood flow, causing signs and symptoms that mimic those of valvular heart disease. Intracavitary tumors can also cause embolic events, resulting in symptoms related to the site of embolization. Intramyocardial tumors can trigger cardiac rhythm disturbances, including sudden death.[70] Cardiac tumors can also cause systemic symptoms mimicking collagen vascular disease, malignancy, or infective endocarditis.[70]

BENIGN PRIMARY CARDIAC TUMORS

Myxomas

Definition, Incidence, and Prevalence

Myxomas are the most common primary cardiac tumors. They are benign. Although myxomas have been reported in both genders and in all age groups, they most often occur in women in the third to sixth decades of life. Myxomas are usually sporadic, but at least 7% occur as part of an autosomal dominant syndrome.

Morphology

Arising from the endocardium, myxomas usually extend into a cardiac chamber. They are generally polypoid, pedunculated lesions with a smooth surface that may be covered with thrombus (Fig. 82-11A). The tumors range in size from 1 to 15 cm, but are most commonly about 5 cm.[71–74] Myxomas are thought to arise from pluripotent mesenchymal cells. Histologically, myxomas consist of a matrix of acid mucopolysaccharide (Fig. 82-11B).[68] Myxomas most commonly occur in the atria. Approximately 75% arise in the left atrium, and 15% to 20% arise in the right atrium.[73] The remainder of myxomas are located in the ventricles.

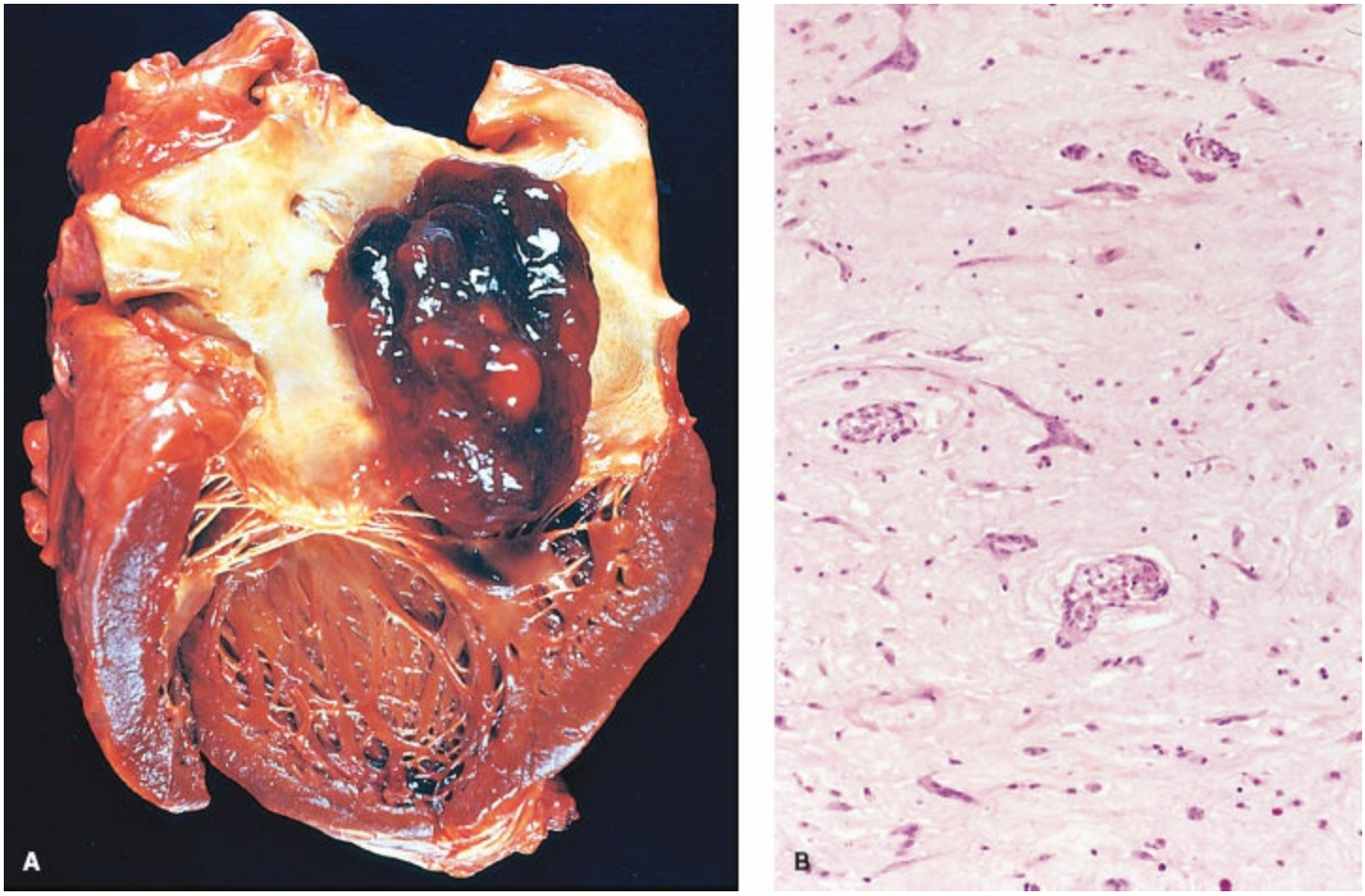

Figure 82-11. Left atrial myxoma. **A:** Gross photograph showing large pedunculated lesion arising from the left atrium and extending into the mitral valve orifice. **B:** Microscopic appearance, with abundant acid mucopolysaccharide, scattered collections of myxoma cells, and abnormal vascular formations (*arrow*). (Reproduced with permission from Kumar V, Abbas AK, Fausto N. *Robbins and Cotran Pathologic Basis of Disease*. 7th ed. Philadelphia, PA: Elsevier; 2005.)

Clinical Characteristics

Many patients with myxomas are asymptomatic. The myxoma may be detected by routine screening echocardiography performed for other indications. Asymptomatic myxomas should be excised in order to prevent emboli, valvular dysfunction, or constitutional symptoms.

Patients with myxomas can have a variety of symptoms. In the sporadic form, classic findings include emboli, congestive heart failure caused by obstruction of cardiac blood flow, and constitutional symptoms. These sequelae are related to the location, size, and mobility of the tumor. Because most myxomas arise in the left atrium, systemic embolization is common, occurring in 30% to 50% of cases.[75–77]

Myxomas also can display signs and symptoms related to cardiac obstruction. Typically, the findings are related to the tumor's ability to impede filling of the ventricles; in such instances, signs and symptoms may mimic those of mitral or TV stenosis. Constitutional symptoms include fever, malaise, rash, weight loss, and myalgia.

Diagnosis

Echocardiography is the imaging modality of choice for diagnosis of myxomas. In cases of

diagnostic uncertainty, MRI and computed tomography (CT) may be helpful. Final diagnosis is confirmed by pathologic examination.

Management

Surgical resection is the mainstay of treatment. Great care must be taken to minimize manipulation of the heart before cross-clamping the aorta to reduce the risk of intraoperative tumor embolization. A variety of approaches are available for resection of left atrial tumors. In the absence of other cardiac disease, a minimally invasive or robotically assisted operation can be employed to speed postoperative recovery. The tumor is resected en bloc. Tumors that arise from a relatively well-defined pedicle can be excised without full-thickness excision of a button of atrial wall. The results of surgical excision are good with a low risk of morbidity and mortality (0% to 3%).[78–80] A variety of approaches are available for resection of left atrial tumors. In the absence of other cardiac disease, a minimally invasive including robotically assisted operation can be employed due to superior postoperative recovery and patient satisfaction, with equal safety and effectiveness.[81–83]

Other Benign Primary Tumors

Rhabdomyoma

Rhabdomyoma is the most common cardiac tumor in children and the second most common benign cardiac tumor overall.[73] Most occur in children younger than 1 year of age. Rhabdomyoma is a benign tumor composed of cardiac myocytes. About one-half of patients with rhabdomyoma have tuberous sclerosis, and about one-half of patients with tuberous sclerosis develop rhabdomyomas.[84] These tumors occur sporadically or in conjunction with other rare congenital heart malformations.

Rhabdomyomas usually are found deep in the myocardium; they may extend into the cardiac chambers. They are of variable size, ranging from 1 mm to several centimeters. Most rhabdomyomas are multicentric and involve both ventricles. Because of their morphologic appearance and multicentric nature, rhabdomyomas are classified as hamartomas rather than as true tumors.[85] Pathologically, they are distinguishable from the surrounding myocardium by their firm, gray, nodular characteristics.[86]

Most children with rhabdomyomas display cardiac arrhythmias or obstructive symptoms in the first few days or weeks of life. Rhabdomyomas causing significant intracardiac obstruction to blood flow can result in death within 24 hours of birth; patients with less severe disease may be asymptomatic for years. The diagnosis is usually made by echocardiography. One of the curiosities of this tumor is the well-documented tendency for these tumors to regress.[87,88]

In most cases these tumors are not resected. Surgical resection is reserved for masses that cause significant cardiac obstruction.[89,90] Given the multicentricity of the lesions and their limited growth potential, the operative approach is conservative debulking, with the goal being relief of outflow obstruction with preservation of electrical conduction and myocardial and valvular function.

Lipomas

Lipomas are encapsulated masses of adipose tissue that usually arise from the myocardium or pericardium.[73] They are usually small but can grow to be massive. Lipomas involving the pericardium may be mistaken for pericardial cysts and may be associated with pericardial effusions. Although most of these tumors are identified after death, they can be diagnosed by echocardiography and MRI. Most cardiac lipomas can be observed. However, lipomas causing obstructive symptoms or arrhythmias should be resected.

Papillary Fibroelastoma

Papillary fibroelastomas are the most common tumors affecting cardiac valves.[91,92] They usually involve the valves of the left side of the heart, and typically occur in adult patients.[93] Although papillary fibroelastomas usually are asymptomatic, when symptoms occur, they are most frequently related to embolization. The tumors are identified by echocardiography. Surgical excision is advised, even in asymptomatic patients.[91,94,95] When resection is performed, a minimally invasive surgical approach is generally

possible.

Malignant Primary Cardiac Tumors

Angiosarcoma

Most malignant cardiac tumors are metastases from other malignancies.[74] Almost all primary malignant tumors of the heart are sarcomas[96]; angiosarcoma is the most common malignant primary cardiac tumor.[73] Angiosarcomas are usually solitary, large bulky masses that originate in the right atrium (Fig. 82-12). They may extend into the right atrial cavity, causing valvular obstruction, right-sided heart failure, or hemorrhagic pericardial effusion with tamponade.[96] Most of these tumors metastasize, most commonly to the lung, liver, or brain.[97] Angiosarcomas are very aggressive, and survival after diagnosis ranges from 3 to 15 months.[85] Given their rapid growth and poor prognosis, surgical resection is rarely successful.

Rhabdomyosarcoma

Rhabdomyosarcoma is the second most common cardiac sarcoma. Like angiosarcoma, it is more common in men.[98–100] Unlike angiosarcoma, rhabdomyosarcoma does not have a predilection for a particular cardiac chamber.[73] It may occur at multiple sites and extend into the pericardium. Patients may have cardiac obstructive or constitutional symptoms. Prognosis is poor, and surgical resection is usually ineffective.

Secondary Cardiac Tumors: Metastases to the Heart

Metastatic tumors to the heart, or secondary tumors, are much more common than are primary cardiac tumors. Secondary tumors are usually carcinomas rather than sarcomas because of the relative frequency of these cancers.[96] Hematogenous spread is the most common mode of metastasis, but lymphatic spread and direct extension also occur.

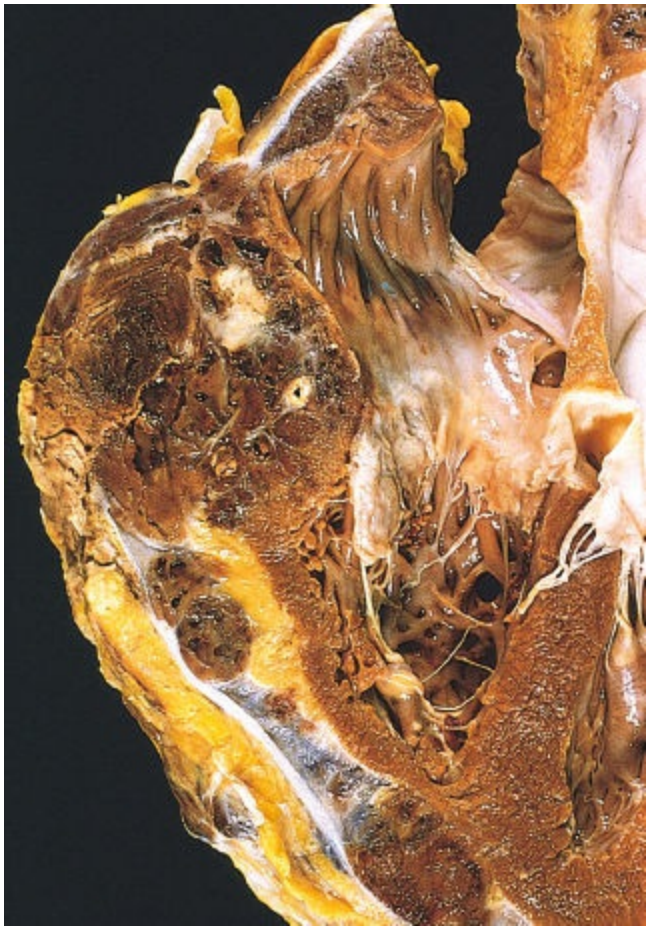

Figure 82-12. Gross photograph of angiosarcoma of the right ventricle. (Reproduced with permission from Kumar V, Abbas AK, Fausto N. *Robbins and Cotran Pathologic Basis of Disease*. 7th ed. Philadelphia, PA: Elsevier; 2005.)

Symptoms occur most commonly in patients with pericardial metastases rather than intramural or intracavitary involvement. The symptoms associated with metastases are congestive heart failure and arrhythmias. Metastases to the heart should be suspected in patients with known neoplasms who develop congestive heart failure.

Carcinoma of the lung and breast may directly invade the parietal and visceral pericardium, causing myocardial restriction and pericardial effusion.[96] Melanoma commonly metastasizes to the myocardium, as do leukemia and lymphoma. The treatment of metastatic tumors depends on the tumor type and symptoms. Given the late stage at which cardiac metastases occur and the poor prognosis, few of these patients are candidates for cardiac surgical intervention. Lymphoma and leukemia may respond to chemotherapy or radiotherapy. Symptomatic malignant pericardial effusions may be drained by creation of a pericardial window, temporarily relieving symptoms.

References

1. Tsakiris AG, Von Bernuth G, Rastelli GC, et al. Size and motion of the mitral valve annulus in anesthetized intact dogs. *J Appl Physiol* 1971;30(5): 611–618.
2. Ormiston JA, Shah PM, Tei C, et al. Size and motion of the mitral valve annulus in man. I. A two-dimensional echocardiographic method and findings in normal subjects. *Circulation* 1981;64(1):113–120.
3. Marzilli M, Sabbah HN, Stein PD. Mitral regurgitation in ventricular premature contractions. The role of the papillary muscle. *Chest* 1980; 77(6):736–740.
4. Otto CM, Lind BK, Kitzman DW, et al. Association of aortic-valve sclerosis with cardiovascular mortality and morbidity in the elderly. *N Engl J Med* 1999;341(3):142–147.
5. Ghaisas NK, Foley JB, O'Briain DS, et al. Adhesion molecules in nonrheumatic aortic valve disease: endothelial expression, serum levels and effects of valve replacement. *J Am Coll Cardiol* 2000;36(7):2257–2262.
6. O'Brien KD, Shavelle DM, Caulfield MT, et al. Association of angiotensin-converting enzyme with low-density lipoprotein in aortic valvular lesions and in human plasma. *Circulation* 2002;106(17):2224–2230.
7. Olsson M, Thyberg J, Nilsson J. Presence of oxidized low density lipoprotein in nonrheumatic stenotic aortic valves. *Arterioscler Thromb Vasc Biol* 1999;19(5):1218–1222.
8. Galante A, Pietroiusti A, Vellini M, et al. C-reactive protein is increased in patients with degenerative aortic valvular stenosis. *J Am Coll Cardiol* 2001;38(4):1078–1082.
9. Rajamannan NM, Gersh B, Bonow RO. Calcific aortic stenosis: from bench to the bedside–emerging clinical and cellular concepts. *Heart* 2003; 89(7):801–805.
10. Mohler III ER, Gannon F, Reynolds C, et al. Bone formation and inflammation in cardiac valves. *Circulation* 2001;103(11):1522–1528.
11. Rajamannan NM, Subramaniam M, Rickard D, et al. Human aortic valve calcification is associated with an osteoblast phenotype. *Circulation* 2003;107(17):2181–2184.
12. Alpert JS. Aortic stenosis: A new face for an old disease. *Arch Intern Med* 2003;163(15):1769–1770.
13. Bache RJ, Vrobel TR, Ring WS. Regional myocardial blood flow during exercise in dogs with chronic left ventricular hypertrophy. *Circ Res* 1981; 48(1):76–87.
14. Marcus ML, Doty DB, Hiratzka LF et al. Decreased coronary reserve. A mechanism for angina pectoris in patients with aortic stenosis and normal coronary arteries. *N Engl J Med* 1982;307(22):1362–1366.
15. Carabello BA. Evaluation and management of patients with aortic stenosis. *Circulation* 2002;105(15):1746–1750.
16. Swartz MH. *Textbook of Physical Diagnosis: History and Examination.* 4th ed. Philadelphia, PA: W.B. Saunders Company; 2001.

17. Bonow RO, Carabello BA, Chatterjee K, et al. 2008 focused update incorporated into the ACC/AHA 2006 guidelines for the management of patients with valvular heart disease: a report of the American College of Cardiology/American Heart Association Task Force on Practice Guidelines (Writing Committee to revise the 1998 guidelines for the management of patients with valvular heart disease). Endorsed by the Society of Cardiovascular Anesthesiologists, Society for Cardiovascular Angiography and Interventions, and Society of Thoracic Surgeons. *J Am Coll Cardiol* 2008;52(13):e1–e142.
18. Faggiano P, Aurigemma GP, Rusconi C, et al. Progression of valvular aortic stenosis in adults: literature review and clinical implications. *Am Heart J* 1996;132(2 Pt 1):408–417.
19. Wagner S, Selzer A. Patterns of progression of aortic stenosis: a longitudinal hemodynamic study. *Circulation* 1982;65(4):709–712.
20. Ross J Jr, Braunwald E. Aortic stenosis. *Circulation* 1968;38(suppl 1):61–67.
21. Mihaljevic T, Nowicki ER, Rajeswaran J, et al. Survival after valve replacement for aortic stenosis: implications for decision making. *J Thorac Cardiovasc Surg* 2008;135(6):1270–1278; discussion 1278–1279.
22. Svensson LG, Tuzcu M, Kapadia S, et al. A comprehensive review of the PARTNER trial. *J Thorac Cardiovasc Surg* 2013;145(3 suppl):S11–S16.
23. Kapadia SR, Leon MB, Makkar RR, et al. 5-year outcomes of transcatheter aortic valve replacement compared with standard treatment for patients with inoperable aortic stenosis (PARTNER 1): a randomised controlled trial. *Lancet* 2015;385(9986):2485–2491.
24. Panchal HB, Ladia V, Amin P, et al. A meta-analysis of mortality and major adverse cardiovascular and cerebrovascular events in patients undergoing transfemoral versus transapical transcatheter aortic valve implantation using edwards valve for severe aortic stenosis. *Am J Cardiol* 2014;114(12):1882–1890.
25. Liu Z, He R, Wu C, et al. Transfemoral versus transapical aortic implantation for aortic stenosis based on no significant difference in logistic EuroSCORE: A meta-analysis. *Thorac Cardiovasc Surg* 2015.
26. Greason KL, Suri RM, Nkomo VT, et al. Beyond the learning curve: transapical versus transfemoral transcatheter aortic valve replacement in the treatment of severe aortic valve stenosis. *J Card Surg* 2014;29(3):303–307.
27. Leshnower BG, Myung RJ, McPherson L, et al. Midterm results of DavidV valve-sparing aortic root replacement in acute type A aortic dissection. *Ann Thorac Surg* 2015;99(3):795–800.
28. Leontyev S, Trommer C, Subramanian S, et al. The outcome after aortic valve-sparing(David) operation in 179 patients: a single-centre experience. *Eur J Cardiothorac Surg* 2012;42(2):261–266.
29. Patel ND, Weiss ES, Alejo DE, et al. Aortic root operations for Marfan syndrome: a comparison of the Bentall and valve-sparing procedures. *Ann Thorac Surg*

2008;85(6):2003–2010.
30. Schoenhoff FS, Langhammer B, Wustmann K, et al. Decision-making in aortic root surgery in Marfan syndrome: bleeding, thromboembolism and risk of reintervention after valve-sparing or mechanical aortic root replacement. *Eur J Cardiothorac Surg* 2015;48(6):931–935; discussion 935–936.
31. Rowe JC, Bland EF, Sprague HB, et al. The course of mitral stenosis without surgery: ten and twenty year perspectives. *Ann Intern Med* 1960;52:741–749.
32. Wood P. An appreciation of mitral stenosis. I. Clinical features. *Br Med J* 1954;1:1051–1063.
33. Olesen KH. The natural history of 271 patients with mitral stenosis under medical treatment. *Br Heart J* 1962;24:349–357.
34. Selzer A, Cohn KE. Natural history of mitral stenosis: a review. *Circulation* 1972;45(4):878–890.
35. Roberts WC, Perloff JK. Mitral valvular disease. A clinicopathologic survey of the conditions causing the mitral valve to function abnormally. *Ann Intern Med* 1972;77(6):939–975.
36. Inoue K, Owaki T, Nakamura T, et al. Clinical application of transvenous mitral commissurotomy by a new balloon catheter. *J Thorac Cardiovasc Surg* 1984;87(3):394–402.
37. Wilkins GT, Weyman AE, Abascal VM, et al. Percutaneous balloon dilatation of the mitral valve: an analysis of echocardiographic variables related to outcome and the mechanism of dilatation. *Br Heart J* 1988;60(4):299–308.
38. Cohen DJ, Kuntz RE, Gordon SP, et al. Predictors of long-term outcome after percutaneous balloon mitral valvuloplasty. *N Engl J Med* 1992; 327(19):1329–1335.
39. Feldman T. Hemodynamic results, clinical outcome, and complications of Inoue balloon mitral valvotomy. *Cathet Cardiovasc Diagn* 1994;(suppl 2):2–7.
40. Davis K. Multicenter experience with balloon mitral commissurotomy: NHLBI balloon valvuloplasty registry report on immediate and 30-day follow-up results. *Circulation* 1992;85(2):448–461.
41. Dean LS. Complications and mortality of percutaneous balloon mitral commissurotomy: a report from the National Heart, Lung, and Blood Institute Balloon Valvuloplasty Registry. *Circulation* 1992;85(6):2014–2024.
42. Palacios IF, Sanchez PL, Harrell LC, et al. Which patients benefit from percutaneous mitral balloon valvuloplasty? Prevalvuloplasty and postvalvuloplasty variables that predict long-term outcome. *Circulation* 2002;105(12):1465–1471.
43. Kang DH, Park SW, Song JK, et al. Long-term clinical and echocardiographic outcome of percutaneous mitral valvuloplasty: randomized comparison of Inoue and double balloon techniques. *J Am Coll Cardiol* 2000;35:169–175.
44. Fawzy ME, Hegazy H, Shoukri M, et al. Long-term clinical and echocardiographic results after successful mitral balloon valvotomy and predictors of long-term

outcome. *Eur Heart J* 2005;26(16):1647–1652.

45. Tomai F, Gaspardone A, Versaci F, et al. Twenty year follow-up after successful percutaneous balloon mitral valvuloplasty in a large contemporary series of patients with mitral stenosis. *Int J Cardiol* 2014;177(3):881–885.
46. Gross RI, Cunningham JN Jr, Snively SL. Long-term results of open radical mitral commissurotomy: ten year follow-up study of 202 patients. *Am J Cardiol* 1981;47(4):821–825.
47. Halseth WL, Elliott DP, Walker EL, et al. Open mitral commissurotomy. A modern re-evaluation. *J Thorac Cardiovasc Surg* 1980;80(6):842–848.
48. Farhat MB, Ayari M, Maatouk F, et al. Percutaneous balloon versus surgical closed and open mitral commissurotomy: seven-year follow-up results of a randomized trial. *Circulation* 1998;97(3):245–250.
49. Cotrufo M, Renzulli A, Ismeno G, et al. Percutaneous mitral commissurotomy versus open mitral commissurotomy: a comparative study. *Eur J Cardiothorac Surg* 1999;15(5):646–651.
50. David TE, Uden DE, Strauss HD. The importance of the mitral apparatus in left ventricular function after correction of mitral regurgitation. *Circulation* 1983;68(3 Pt 2):II76–II82.
51. David TE, Burns RJ, Bacchus CM. Mitral valve replacement for mitral regurgitation with and without preservation of chordae tendineae. *J Thorac Cardiovasc Surg* 1984;88(5 Pt 1):718–725.
52. Hennein HA, Swain J, McIntosh CL, et al. Comparative assessment of chordal preservation versus chordal resection during mitral valve replacement. *J Thorac Cardiovasc Surg* 1990;99(5):828–836.
53. Rozich JD, Carabello BA, Usher BW, et al. Mitral valve replacement with and without chordal preservation in patients with chronic mitral regurgitation: mechanisms for differences in postoperative ejection performance. *Circulation* 1992;86(6):1718–1726.
54. Horskotte D, Schulte HD, Bircks W, et al. The effect of chordal preservation on late outcome after mitral valve replacement: a randomized study. *J Heart Valve Dis* 1993;2(2):150–158.
55. Hammermeister K, Sethi GK, Henderson WG, et al. Outcomes 15 years after valve replacement with a mechanical versus a bioprosthetic valve: final report of the Veterans Affairs randomized trial. *J Am Coll Cardiol* 2000;36(4):1152–1158.
56. Ling LH, Enriquez-Sarano M, Seward JB, et al. Clinical outcome of mitral regurgitation due to flail leaflet. *N Engl J Med* 1996;335(19):1417–1423.
57. Gillinov AM, Mihaljevic T, Blackstone EH, et al. Should patients with severe degenerative mitral regurgitation delay surgery until symptoms develop? *Ann Thorac Surg* 2010;90:481–488.
58. Nishimura RA, Otto CM, Bonow RO, et al. 2014 AHA/ACC Guideline for the management of patients with valvular heart disease: executive summary a report of

the American College of Cardiology/American Heart Association Task Force on Practice Guidelines. *Circulation* 2014;129(23):2440–2492.

59. Enriquez-Sarano M, Schaff HV, Orszulak TA, et al. Valve repair improves the outcome of surgery for mitral regurgitation: a multivariate analysis. *Circulation* 1995;91(4):1022–1028.
60. Algarni KD, Suri RM, Schaff H. Minimally invasive mitral valve surgery: does it make a difference? *Trends Cardiovasc Med* 2015;25(5):456–465.
61. McClure RS, Athanasopoulos LV, McGurk S, et al. One thousand minimally invasive mitral valve operations: early outcomes, late outcomes, and echocardiographic follow-up. *J Thorac Cardiovasc Surg* 2013;145:1199–1206.
62. Svensson LG, Atik FA, Cosgrove DM, et al. Minimally invasive versus conventional mitral valve surgery: a propensity-matched comparison. *J Thorac Cardiovasc Surg* 2010;139:926–932.
63. Chitwood WR Jr, Rodriguez E, Chu MW, et al. Robotic mitral valve repairs in 300 patients: a single-center experience. *J Thorac Cardiovasc Surg* 2008;136(2):436–441.
64. Mihaljevic T, Jarrett CM, Gillinov AM, et al. Robotic repair of posterior mitral valve prolapse versus conventional approaches: potential realized. *J Thorac Cardiovasc Surg* 2011;141(1):72–80.
65. Mihaljevic T, Koprivanac M, Kelava M, et al. Value of robotically assisted surgery for mitral valve disease. *JAMA Surg* 2014;149(7):679–686.
66. Suri RM, Antiel RM, Burkhart HM, et al. Quality of life after early mitral valve repair using conventional and robotic approaches. *Ann Thorac Surg* 2012;93:761–769.
67. Mauri L, Foster E, Glower DD, et al. 4-year results of a randomized controlled trial of percutaneous repair versus surgery for mitral regurgitation. *J Am Coll Cardiol* 2013;62(4):317–328.
68. Reynen K. Frequency of primary tumors of the heart. *Am J Cardiol* 1996; 77(1):107.
69. Lam KY, Dickens P, Chan AC. Tumors of the heart. A 20-year experience with a review of 12,485 consecutive autopsies. *Arch Pathol Lab Med* 1993; 117(10):1027–1031.
70. Shapiro LM. Cardiac tumours: diagnosis and management. *Heart* 2001; 85(2):218–222.
71. Goodwin JF. Diagnosis of left atrial myxoma. *Lancet* 1963;1(7279):464–468.
72. Hall RJ, Cooley DA, McAllister HA. Neoplastic heart disease. In: Hurst JW, ed. *The Heart, Arteries, and Veins.* 7th ed. New York, NY: McGraw-Hill; 1990:1382–1403.
73. McAllister HA, Fenoglio JJ. Tumors of the cardiovascular system, fascicle 15. In: Hartman WH, Cowan W, eds. *Atlas of Tumor Pathology.* 2nd ed. Washington, DC: Armed Forces Institute of Pathology; 1978:1–20.
74. Prichard RW. Tumors of the heart; review of the subject and report of 150 cases. *AMA Arch Pathol* 1951;51(1):98–128.
75. Bortolotti U, Maraglino G, Rubino M, et al. Surgical excision of intracardiac

myxomas: a 20-year follow-up. *Ann Thorac Surg* 1990;49(3):449–453.
76. Fyke FE III, Seqard JB, Edwards WD, et al. Primary cardiac tumors: experience with 30 consecutive patients since the introduction of two-dimensional echocardiography. *J Am Coll Cardiol* 1985;5(6):1465–1473.
77. Goodwin JF. The spectrum of cardiac tumors. *Am J Cardiol* 1968;21(3):307–314.
78. Fang BR, Chiang CW, Hung JS, et al. Cardiac myxoma–clinical experience in 24 patients. *Int J Cardiol* 1990;29(3):335–341.
79. Hanson EC, Gill CC, Razavi M, et al. The surgical treatment of atrial myxomas. Clinical experience and late results in 33 patients. *J Thorac Cardiovasc Surg* 1985;89(2):298–303.
80. St John Sutton MG, Mercier LA, Giuliani ER, et al. Atrial myxomas: a review of clinical experience in 40 patients. *Mayo Clin Proc* 1980;55(6): 371–376.
81. Yang M, Yao M, Wang G, et al. Comparison of postoperative quality of life for patients who undergo atrial myxoma excision with robotically assisted versus conventional surgery. *J Thorac Cardiovasc Surg* 2015;150(1):152–157.
82. Schilling J, Engel AM, Hassan M, et al. Robotic excision of atrial myxoma. *J Card Surg* 2012;27(4):423–426.
83. Russo MJ, Martens TP, Hong KN, et al. Minimally invasive versus standard approach for excision of atrial masses. *Heart Surg Forum* 2007;10(1):E50–E54.
84. Corno A, de Simone G, Catena G, et al. Cardiac rhabdomyoma: surgical treatment in the neonate. *J Thorac Cardiovasc Surg* 1984;87(5):725–731.
85. Brizard C, Latremouille C, Jebara VA, et al. Cardiac hemangiomas. *Ann Thorac Surg* 1993;56(2):390–394.
86. Choi JY, Bae EJ, Noh CI, et al. Cardiac rhabdomyoma in childhood tuberous sclerosis. *Cardiol Young* 1995;5(02):166–171.
87. Alkalay AL, Ferry DA, Lin B, et al. Spontaneous regression of cardiac rhabdomyoma in tuberous sclerosis. *Clin Pediatr (Phila)* 1987;26(10):532–535.
88. Beghetti M, Gow RM, Haney I, et al. Pediatric primary benign cardiac tumors: a 15-year review. *Am Heart J* 1997;134(6):1107–1114.
89. Gutiérrez de Loma J, Villagrá F, Perez de León J, et al. Rhabdomyoma of the heart: surgical treatment. *J Cardiovasc Surg (Torino)* 1982;23(2):149–154.
90. Foster ED, Spooner EW, Farina MA, et al. Cardiac rhabdomyoma in the neonate: surgical management. *Ann Thorac Surg* 1984;37(3):249–253.
91. Edwards FH, Hale D, Cohen A, et al. Primary cardiac valve tumors. *Ann Thorac Surg* 1991;52(5):1127–1131.
92. Ryan PE Jr, Obeid AI, Parker FB Jr. Primary cardiac valve tumors. *J Heart Valve Dis* 1995;4(3):222–226.
93. Darvishian F, Farmer P. Papillary fibroelastoma of the heart: report of two cases and review of the literature. *Ann Clin Lab Sci* 2001;31(3):291–296.

94. Gallo R, Kumar N, Prabhakar G, et al. Papillary fibroelastoma of mitral valve chorda. *Ann Thorac Surg* 1993;55(6):1576–1577.
95. Topol EJ, Biern RO, Reitz BA. Cardiac papillary fibroelastoma and stroke. Echocardiographic diagnosis and guide to excision. *Am J Med* 1986; 80(1):129–132.
96. Roberts WC. Primary and secondary neoplasms of the heart. *Am J Cardiol* 1997;80(5):671–682.
97. Thomas CR Jr, Johnson GW Jr, Stoddard MF, et al. Primary malignant cardiac tumors: update 1992. *Med Pediatr Oncol* 1992;20(6):519–531.
98. Hajar R, Roberts WC, Folger GM Jr. Embryonal botryoid rhabdomyosarcoma of the mitral valve. *Am J Cardiol* 1986;57(4):376.
99. Hui KS, Green LK, Schmidt WA. Primary cardiac rhabdomyosarcoma: definition of a rare entity. *Am J Cardiovasc Pathol* 1988;2(1):19–29.
100. Shirani J, Roberts WC. Clinical, electrocardiographic and morphologic features of massive fatty deposits (“lipomatous hypertrophy”) in the atrial septum. *J Am Coll Cardiol* 1993;22(1):226–238.

Chapter 83

Ischemic Heart Disease

Jonathan W. Haft

Key Points

1 Because of its unique physiology, the heart is particularly susceptible to ischemic injury.

2 Atherosclerotic plaques cause ischemia from chronic flow limitations or from unstable plaque rupture.

3 Patients with coronary artery disease will present with either chronic stable angina or an acute coronary syndrome (ACS), which consists of unstable angina, a non–ST-segment myocardial infarction, or an ST-segment myocardial infarction.

4 Several well-described complications from myocardial infarctions must be anticipated and recognized early.

5 Medical treatment of coronary artery disease includes lifestyle modifications and medications to slow the progression and stabilize atherosclerotic plaques.

6 Percutaneous intervention (PCI) of coronary lesions has improved dramatically in recent years to include drug-eluting intracoronary stents.

7 Coronary artery bypass grafting (CABG) involves creation of alternative conduits from the systemic circulation to the epicardial coronary arteries.

8 The left internal mammary artery is the superior conduit for CABG.

9 CABG remains superior to both medical treatment and PCI for patients with left main or three-vessel disease or for patients with two-vessel disease involving the left anterior descending artery associated with left ventricular dysfunction.

CORONARY ANATOMY AND PHYSIOLOGY

The right and left coronary arteries originate from the aorta just above the aortic valve cusps (Fig. 83-1). The orifices of the two arteries within the sinuses of Valsalva designate the right and left coronary cusps. The third aortic valve cusp is referred to as the noncoronary cusp. The coronary circulation is traditionally divided into three major territories: The left anterior descending (LAD) and the circumflex territories originate from the left coronary artery, and the right coronary territory usually comes from the right coronary artery.

The origin of the left coronary artery is referred to as the left main and travels posterolaterally to the left behind the pulmonary artery, where it divides into two main branches, the LAD and the circumflex coronary artery. The length of the left main coronary artery is variable, but rarely exceeds 2 cm. Unusually, the left main is absent, where the circumflex and LAD originate from the aorta via two separate ostia.

The LAD coronary artery emerges from behind the pulmonary artery and travels inferiorly within the interventricular groove to the cardiac apex, sometimes wrapping around it onto the posterior interventricular groove. The LAD gives off two different types of branches: diagonals and septals, both of which are highly variable in size and number. The diagonals take off at acute angles and perfuse the anterolateral surface of the left ventricle. Septal branches, the first of which is typically quite prominent, emerge at a right angle from the LAD and supply the interventricular septum. The LAD is the most prominent of the three coronary territories described, and carries approximately 50% of left ventricular myocardial blood flow, supplying the anterior, anterolateral, septal, and apical walls.

The circumflex coronary artery continues from the left main coronary and travels within the posterior atrioventricular groove. Branches from the circumflex are called obtuse marginal arteries, and also vary greatly in size and number. In 80% to 90% of people, the terminal branch of the circumflex supplies the posterolateral wall of the left ventricle. In the remaining 10% to 20%, the circumflex continues to the posterior interventricular septum and terminates as the posterior descending artery (PDA). This is referred to as a left dominant heart, where the left main coronary artery is supplying the posterior interventricular septum. Some patients will have a third branch of the left main referred to as the ramus intermedius, or intermediate branch. If present, this vessel is typically large, and supplies much of the anterolateral wall of the left ventricle.

The right coronary artery originates from the anterior right sinus of Valsalva and descends in the right atrioventricular groove. One or more acute marginal branches feed the right ventricular free wall. In 80% to 90% of patients, the right coronary artery continues to the posterior interventricular septum and supplies the PDA and often a variable-sized right posterolateral artery. This is referred to as a right dominant heart. Near the origin of the posterior descending branch, a small characteristic vessel can be seen supplying the atrioventricular node. This branch can become important in acute right coronary artery occlusions, resulting in life-threatening heart block and bradycardia. A small proximal branch of the right coronary artery supplies the sinus node on the

anterolateral surface of the superior vena cava.

Anomalous origin of the coronary arteries is common, occurring in 0.3% to 1% of the population, and their anatomy is varied and complex. Rarely, the left coronary arises from the pulmonary artery. This pathology is diagnosed in infancy, as the myocardium becomes profoundly ischemic when pulmonary vascular resistance falls and myocardial perfusion decreases. If left uncorrected, it is universally fatal. The coronaries may also originate from atypical aortic root sinuses, and their trajectory is variable. The most worrisome problem occurs when the LAD or left main coronary artery originates from the right sinus of Valsalva. When the LAD travels posteriorly and to the left, it courses between the pulmonary artery and the aortic root. This trajectory is described as “malignant” because of the potential for compression between the great vessels, particularly during accentuated wall stress, such as with exercise. Although there is little evidence, it is generally accepted that a revascularization strategy should be considered in symptomatic patients with “malignant” coronary anomalies or in asymptomatic patients with demonstrable ischemia on noninvasive testing.[1]

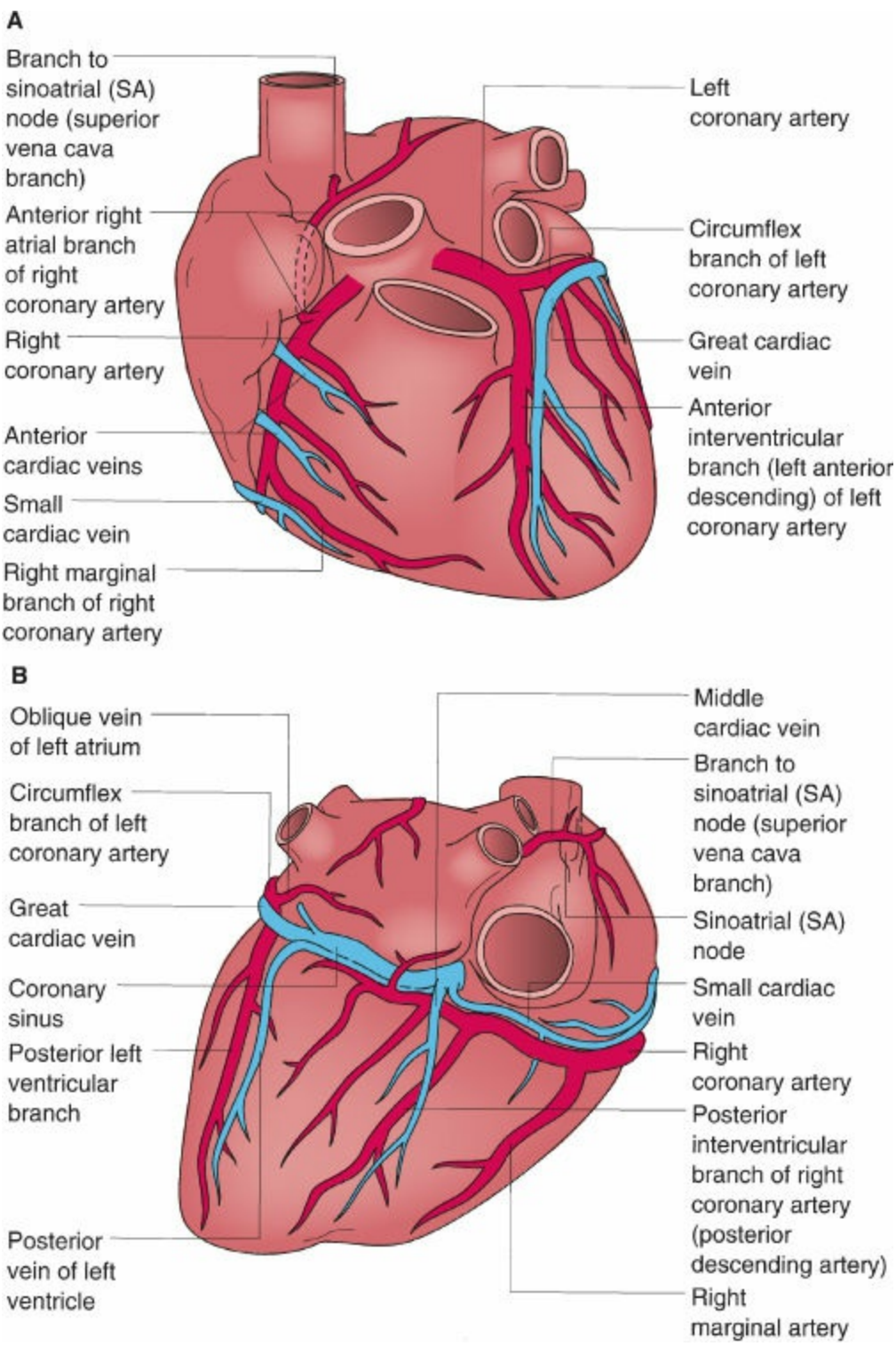

Figure 83-1. Anatomy of the cardiac circulation. **A:** Anterior view. **B:** Posterior view.

Venous anatomy is more predictable, and very little pathology within this system is encountered. Three named venous branches can be identified: the middle cardiac vein in the posterior interventricular groove, the posterior cardiac vein along the obtuse margin of the heart, and the great (or anterior) cardiac vein along the anterior interventricular groove. All three drain into one confluence known as the coronary sinus along the posterior atrioventricular groove (Fig. 83-1). The coronary sinus empties posteriorly into the right atrium between the inferior vena cava and the annulus of the tricuspid valve. In addition to these identifiable named veins, the myocardium also drains directly into all chambers of the heart via thebesian veins.

1 Myocardial work consumes an enormous amount of energy substrate. In fact, only 10% to 20% of myocardial energy requirements are related to basal functions; the remainder is utilized during the continuous energy-dependent calcium mobilization and myofilament cross-linking from cyclic contraction and relaxation. Even at rest, the heart maximally extracts oxygen delivered from the bloodstream, leaving venous saturation in the coronary sinus typically 20% or less. Thus, increased energy requirements must be met with augmentation in blood oxygen delivery. Contrarily, other less oxygen-dependent tissues, where venous saturation can be as high as 80%, can extract additional oxygen during stress. When insufficient supply of oxygen is available, as may be the case with extreme consumption or limited blood flow, anaerobic metabolism cannot generate enough energy substrate to perform myocardial contraction.[2] As a result, cardiac function deteriorates immediately and can be observed clinically essentially within heartbeats. Increases in cardiac oxygen consumption must be met with proportional increases in myocardial blood flow.

The heart and its coronary circulation have a unique capacity to dramatically increase blood flow, and thus oxygen delivery, during periods of increased needs.[3] While basal coronary blood flow is approximately 10 mL/kg, this value can increase up to sixfold with exercise by autoregulatory mechanisms and feedback loops. Specifically, adenosine accumulates from the breakdown of the energy substrate adenosine triphosphate (ATP). Vasodilatory receptors within the media of coronary arteries are particularly avid for adenosine, increasing blood flow to myocardial regions with increased energy consumption. In addition, increased myocardial activity activates nitric oxide synthase within coronary endothelial cells, producing the powerful vasodilator nitric oxide. By immediately altering the vessel diameter and thus changing the resistance properties of epicardial vessels, these two short-acting mediators can rapidly alter coronary flow rates to meet changing energy requirements.

In addition to the high metabolic requirements of the heart and its dependence on responsive changes in blood flow, the coronary circulation is further uniquely challenged. During systole, increased cavitary pressure compresses intramyocardial vessels and virtually eliminates forward flow. As a result, blood flow to the left ventricle occurs only during diastole, so that myocardial perfusion depends not only on coronary arterial patency and caliber, but also on the diastolic pressure gradient and the duration of diastole. Tachycardia not only increases oxygen consumption, but also reduces the time available for myocardial perfusion, increasing the demands for epicardial flow. The rise in ventricular diastolic pressure seen in heart failure also reduces perfusion pressure and can jeopardize ischemia in vulnerable territories. With an understanding of cardiac perfusion needs and mechanics, it is apparent why occlusive lesions in coronary arteries can restrict blood flow, producing ischemia and infarction.

CORONARY ATHEROSCLEROSIS

Atherosclerosis is a progressive multifocal disease of medium and large muscular arteries of the systemic circulation. Atherosclerotic plaques or atheromas can occur anywhere in the systemic circulation, but tend to present clinically in varying quantities in the coronary circulation, carotid arteries, splanchnic vessels, and lower extremities. The lesions tend to occur predominantly at vessel bifurcations, sharp curvatures, and other regions creating pressure wave reflections and recirculation.[4] All plaques consist of smooth muscle proliferation and intracellular and extracellular lipid deposition within the arterial intima (Fig. 83-2). The predecessor "fatty streaks" seen in the first two decades of life are small and unobstructing. However, under certain clinical circumstances, endothelial injury from cigarette smoke, hypercholesterolemia, hyperglycemia, hypertension, or other causes of inflammation initiates a cascade of events. These include endothelial dysfunction with expression of adhesion molecules, which bind circulating inflammatory cells like monocytes. The activated monocyte transmigrates into the vessel wall and ingests accumulated lipids. In turn, they release cytokines, which enhance endothelial cell adhesion molecule expression; alter endothelial cell nitric oxide production, promoting vasoconstriction and platelet activation; and stimulate activation of other inflammatory cells including neutrophils and T lymphocytes. The activated monocytes accelerate further lipid accumulation and smooth muscle cell proliferation. The end result is an enlarging plaque encroaching on the arterial lumen, separated from the bloodstream by a collagen-rich fibrous plaque.

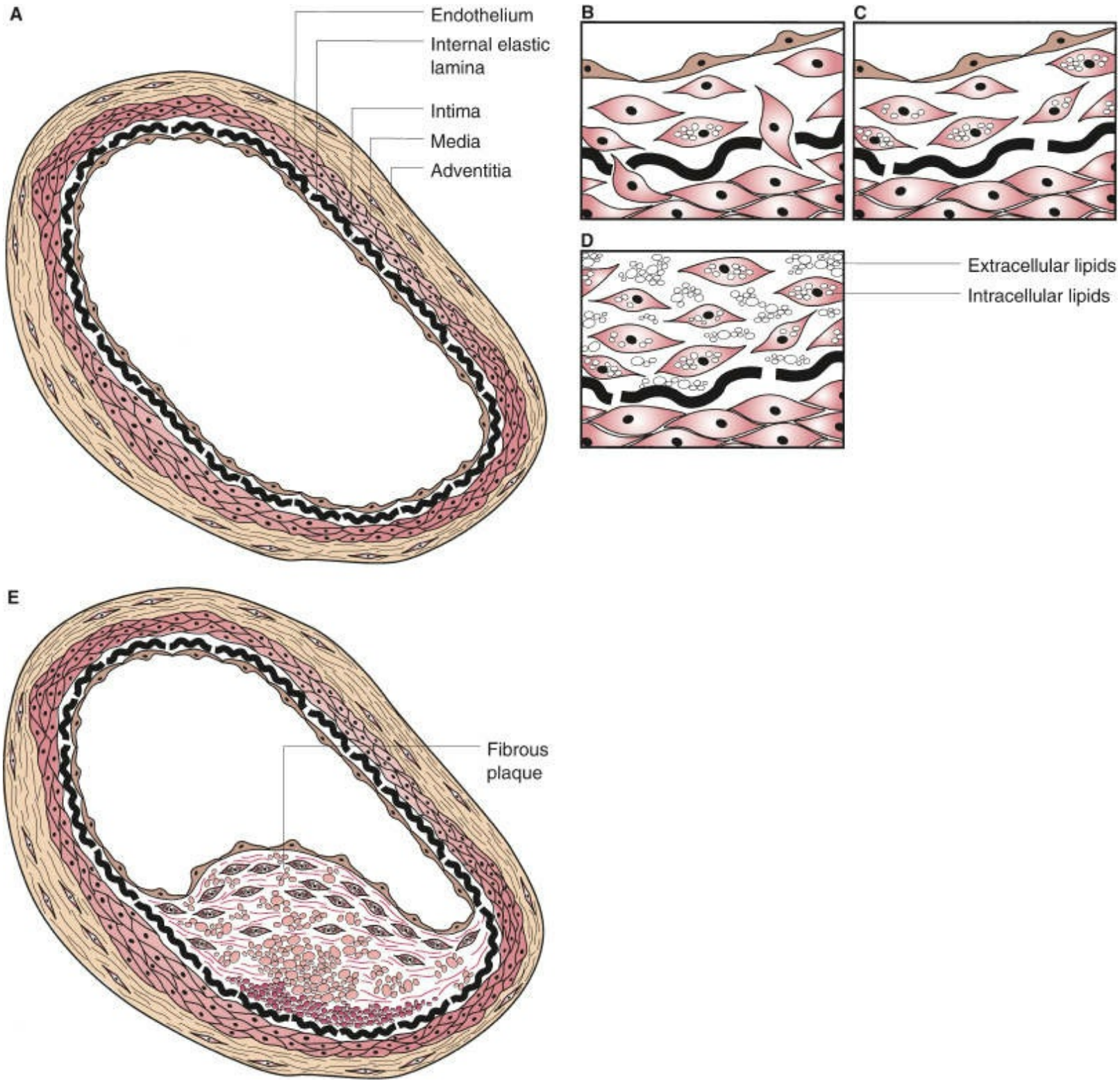

Figure 83-2. The atherosclerotic plaque. **A:** The normal muscular artery consists of an internal intima with endothelium and internal elastic lamina. The smooth muscle of the vessel wall is in the media, and the thin adventitial layer contains connective tissue and the vasa vasorum. **B:** The first phase of an atherosclerotic lesion consists of focal thickening of the intima with smooth muscle cells and extracellular matrix and an initial accumulation of intercellular lipid deposits. **C:** Extracellular lipid may also develop. **D:** Intercellular and extracellular lipid in the earliest phase is referred to as a fatty streak. **E:** A fibrous plaque results as fibroblasts that cover the proliferating smooth muscle cells laden with lipids and cell debris continue to accumulate. The lesion becomes more complex as continuing cell degeneration leads to an ingress of blood constituents and calcification.

2 Within the coronary circulation, atherosclerotic stenotic lesions are generally

restricted to the proximal regions of the large epicardial coronary arteries. In particular, stenosis found in the LAD and circumflex vessels are frequently isolated, short, and in the proximal segments. The right coronary artery, however, develops diffuse obstructions, although rarely extending into the posterior descending or intramural branches. For reasons that are unclear, atherosclerosis is rarely found within intramyocardial segments of the coronary arteries. Symptoms from these atherosclerotic plaques can occur from a variety of proposed mechanisms. First, the lesion can cause flow limitations, particularly when the luminal cross-sectional area is reduced by at least 75%. With this degree of obstruction, the vasodilatory reserve required during increased myocardial demand is restricted, resulting in transient myocardial ischemia until demand returns to baseline, also known as exertional angina. The atherosclerotic plaque also causes coronary ischemia when the lesion becomes unstable. The fibrous plaque can fracture or rupture, exposing the bloodstream to the highly thrombogenic internal plaque contents. This can lead to complete epicardial thrombosis, the presumed mechanism of ST-segment elevation myocardial infarction (STEMI). Additionally, subtotal plaque disruption can cause vasoconstriction, platelet activation, and embolization, resulting in ischemia without total occlusion of the epicardial vessel. This is the presumed mechanism of unstable angina and non–ST-segment elevation myocardial infarction (NSTEMI). Some plaques are more prone to rupture than others, and the composition of the fibrous cap may be an identifiable feature of an unstable lesion. Activation of inflammatory cells may increase the activity of matrix metalloproteinases, which degrade components of the fibrous cap. Some theorize that certain stressors can stimulate activation of these inflammatory cells, such as acute infections, extreme cold, and even emotional distress.[5] The inflammatory component of coronary artery disease has been demonstrated by the strong relationship between C-reactive protein and the incidence of acute myocardial infarctions.[6]

Although the characteristics, locations, and severity of lesions in each person can vary, a number of established risk factors appear to predispose to atherosclerosis. These include advanced age, family history, male sex, hypertension, diabetes mellitus, dyslipidemia, and cigarette smoking. Recognizing the presence of these risk factors can help identify patients at risk of coronary atherosclerosis. In addition, some of these risk factors are modifiable, and simple interventions can reduce their risk of future cardiac events.

Hypertension is strongly associated with the development of atherosclerotic heart disease and the risk of death from cardiovascular causes. Although the mechanism is uncertain, it has been suggested that an increase in shear stress at particular vessel locations may injure the vascular endothelium, predisposing to lipid deposition and plaque development. Systolic hypertension appears to be more predictive than diastolic hypertension, particularly in elderly patients. Numerous interventions can control hypertension, but the most effective appears to be lifestyle modifications including reduction in dietary sodium, exercise, and weight loss. Several classes of medications are used for blood pressure control, and each is variably efficacious in different populations of patients.[7] Unequivocally, reduction in elevated systolic blood pressure reduces the risk of death from cardiovascular disease, and in particular of atherosclerotic coronary artery disease.

Patients with diabetes are two to four times more likely to have coronary artery disease, and even more so when they are insulin dependent and in diabetic women. In addition, patients with diabetes and coronary disease have worse outcomes than age-matched nondiabetics. Unfortunately, rigorous control of elevated blood glucose concentrations by insulin does not appear to affect coronary mortality as well as control of other risk factors such as hypertension, dyslipidemia, and smoking cessation does.[8]

Dyslipidemia is associated with accelerated coronary artery disease. This includes both elevation of total cholesterol levels and an imbalance in the ratio of the subcomponents of cholesterol: high-density lipoprotein (HDL) and low-density lipoprotein (LDL).[9] HDL levels appear to be protective, as the total HDL level is inversely proportional to the risk for the development of coronary artery disease. Conversely, LDL levels are directly proportional to cardiovascular risk. Importantly, alteration in total cholesterol and the ratio of HDL to LDL by dietary changes, medications, and exercise can reduce the risk of cardiovascular events.[10]

Cigarette smoking is one of the most important risk factors for coronary artery disease. Carbon monoxide and nicotine directly adversely affect endothelial cell function. In addition, cigarette smoke can increase LDL levels, reduce HDL levels, increase fibrinogen levels, and increase platelet aggregation. Regular smokers have a four to five times higher rate of cardiovascular death than nonsmokers, and there appears to be a dose relationship, with heavier smokers having a higher prevalence of coronary disease than lighter smokers. Fortunately, the risk of developing coronary artery disease is reduced by 50% after 1 year of smoking abstinence, and at 10 years the risk is no different from that of those who never smoked.[11]

PATIENT PRESENTATION

The clinical manifestations of ischemic heart disease result from an imbalance of myocardial oxygen supply and consumption. The symptoms and acuity depend on the severity and nature of the patient's occlusive lesions, but also on his or her other medical comorbidities. As many as 25% of patients diagnosed with coronary artery disease have no clear symptoms. The diagnosis is often made based on abnormalities identified on screening tests obtained because of the presence of worrisome risk factors.

3 Chronic stable angina is the most frequent complaint of the patient with coronary artery disease. At rest, coronary blood flow is adequate to meet myocardial demand, and patients are without symptoms. However, during exercise or stress, as myocardial oxygen demand increases, the autoregulatory mechanisms to vasodilate and increase myocardial blood flow are constrained. Significant coronary obstructing atheromas become flow limiting, resulting in an imbalance of oxygen demand and supply. Chest pain develops rapidly and builds up quickly, typically described as tightness, squeezing, constricting, or aching. It is usually midsternal and radiates to the left shoulder, arm, jaw, or neck. The classically described Levine sign with a clenched fist over the sternum is a common finding. Some patients, however, will describe symptoms that are collectively referred to as "anginal equivalents." These include dyspnea, diaphoresis, nausea, abdominal pain, heartburn, and dizziness or presyncope. Although the differential diagnoses of these "atypical" symptoms are broad, they should prompt the clinician to think of coronary disease, particularly if risk factors predominate. Interestingly, women are more likely to describe atypical symptoms, resulting in late or missed diagnosis of coronary atherosclerosis. Although the clinical manifestations of angina are variable, the pathognomonic feature of chronic stable angina is that the symptoms occur predictably with exertion and are always relieved with rest. Symptoms of patients with coronary atherosclerosis can be categorized according to the Canadian Heart Association Classification scheme. Class I patients have no symptoms, class II patients have angina with significant exertion, class III patients describe angina with mild exertion, and class IV patients have angina at rest.

Acute coronary syndromes (ACSs) refer to a spectrum of accelerated coronary occlusive disease states and include unstable angina, NSTEMI, and STEMI. Approximately 1 million people are hospitalized in the United States each year with a diagnosis of ACS. Unstable angina refers to patients with chest pain or an anginal equivalent that is new in onset, occurs at rest, or occurs with increasing severity and frequency from their baseline chronic stable symptoms, also referred to as crescendo angina. Patients who develop an NSTEMI have evidence of myocardial injury with elevated blood levels of myocardial enzymes (troponin and the MB fraction of creatine kinase). Unstable angina and NSTEMI are important prognostic indicators, as 10% of patients will die of cardiovascular causes within 6 months.

STEMI represents the consequences of large epicardial vessel occlusion, typically associated with plaque rupture. Patients describe a severe retrosternal pain that persists for at least 30 minutes, but usually for several hours. The pain is frequently characterized

as crushing, squeezing, or boring, and can radiate down the left arm or into the jaw. Patients with previous chronic stable angina will report that the current pain is similar to but more intense than their baseline symptoms and has not resolved with rest or nitroglycerine. However, many patients that present with an STEMI never had chronic stable angina. Patients will often describe additional symptoms such as diaphoresis, nausea, dizziness, and epigastric pain. In emergency departments, the pain is often mistaken for gastroenteritis or indigestion, particularly in women. Often in elderly patients and those with diabetes, chest pain may not be present at all, and the only symptom associated with STEMI is heart failure from progressive loss of myocardial contractile function. Although improvements in health systems have drastically increased survival from myocardial infarction, mortality for STEMI remains near 10%.

COMPLICATIONS OF ACUTE MYOCARDIAL INFARCTIONS

4 STEMIs can create widespread myocyte necrosis, often resulting in catastrophic complications that require urgent intervention. Anticipation and early diagnosis can improve outcomes. These complications include cardiogenic shock, postinfarct ventricular septal defect (VSD), free wall rupture, and acute mitral valve regurgitation (Table 83-1).

Cardiogenic Shock

Cardiogenic shock is a state in which cardiac output is insufficient to meet metabolic demands, despite adequate intravascular filling pressures. Between 5% and 10% of patients with acute myocardial infarctions develop cardiogenic shock. A large proportion of these patients progress to shock not upon arrival, but more than 24 hours after initial presentation.[12] Overall mortality is approximately 60%, with very little improvement over recent decades. Treatments include fluids and inotropic agents to optimize myocardial contraction. Insertion of an intra-aortic balloon counterpulsation pump (IABP) can improve coronary perfusion by diastolic augmentation of perfusion pressure. This can have a profound impact by improving contractile function of peri-infarct territories. Although there is significant afterload reduction afforded by the IABP, cardiac output typically increases by only 15% to 20%. Emergent salvage revascularization can reduce mortality, with sustained benefits seen over long-term follow-up.[13] When shock persists despite using these aggressive strategies, consideration must be made regarding the patient's candidacy for mechanical circulatory support using ventricular assist devices or extracorporeal membrane oxygenation.[14] While these options may only be available in selected regional medical centers, durable long-term survival can be obtained in a highly selected patient population.[15]

Postinfarction Ventricular Septal Defect

A postinfarction VSD is an infrequent complication occurring after fewer than 1% of acute myocardial infarctions. The infarct is most commonly in the LAD territory, with the defect in the distal septum. Alternatively, a postinfarct VSD can form from acute right coronary occlusion, with the infarct predominantly in the posterobasilar septum. They typically present 5 to 10 days following initial presentation, but can occur earlier, particularly if late thrombolytic therapy was administered. The diagnosis should be considered in a patient in whom cardiogenic shock with refractory hypotension and pulmonary edema develops suddenly following a myocardial infarction. On physical examination, an unmistakable holosystolic murmur can be heard over the entire precordium. The diagnosis is confirmed with echocardiography using Doppler techniques to demonstrate flow across the interventricular septum. Right heart catheterization will reveal a step-up in oxygen saturation from the right atrium to the pulmonary artery. Medical therapy involves stabilization to optimize cardiac output and end-organ perfusion. Refractory hypotension is typical, excluding the use of afterload reducing agents. Intra-aortic balloon counterpulsation can occasionally be helpful for afterload reduction and to optimize coronary perfusion. Emergent surgical intervention is required if there is any hope of survival. Infarcted muscle is débrided, and the defect is typically closed using prosthetic material. For surgical candidates, survival rates of approximately 50% can be expected.[16]

Papillary Muscle Rupture

Severe regurgitation of the mitral valve can occur after acute myocardial infarctions, with a frequency of less than 1%. The mechanism is related to infarction of the tip or trunk of one of the papillary muscles, with resultant disruption of the mitral subvalvar apparatus and failed leaflet coaptation. Posteroinferior MIs lead to this complication two to three times more frequently than anterior infarctions, presumably because there is more collateral blood flow to the anterolateral papillary muscle compared to the posteriomedial. While chronic mitral regurgitation can be well tolerated through adaptive changes in the left atrium and pulmonary vascular bed, severe acute mitral regurgitation results in immediate heart failure, as the small left atrium offers little compliance for the massive volume overload. Papillary muscle rupture develops typically between the third and fifth days following myocardial infarction, when infarcted myocardium is at its weakest. However, it can present within the first 24 hours. Patients will describe acute-onset dyspnea, pulmonary edema, and possibly signs of cardiogenic shock. The diagnosis should be suspected in any patient after myocardial infarction with a new holosystolic murmur heard at the apex, associated with dyspnea and hypotension. Bedside surface echocardiography typically demonstrates the mitral regurgitation, and the flail leaflet may be seen. For more definitive imaging, transesophageal echocardiography (TEE) can be performed. Not only will the mitral valve pathology be clearly seen, but also alternative diagnoses such as a postinfarct VSD can be excluded. In addition to the treatments typically employed for myocardial infarctions, immediate medical therapy of ruptured papillary muscles involves afterload reduction when tolerated, with infusions of nitroglycerine or nitroprusside. If cardiac output cannot be maintained, intra-aortic balloon counterpulsation can be helpful. Definitive therapy involves prompt surgical correction. Although mortality rates are generally high, there are no survivors without surgical correction.[17] If coronary angiography demonstrated occlusive epicardial lesions in territories other than the acute infarction, simultaneous coronary bypass grafting can be performed. Under most circumstances, the diseased mitral valve is excised and replaced. Because the ventricular cavity is typically small, the valve is usually replaced with a low-profile mechanical prosthesis to avoid left ventricular outflow obstruction from the protruding struts of stented bioprosthetic valves.

Table 83-1 Complications of Acute Myocardial Infarctions

Complication	Diagnosis	Treatment
Cardiogenic shock	Echocardiography, pulmonary artery catheter	Inotropes, intra-aortic balloon pump, VAD
Ventricular septal defect	Echocardiography, cardiac catheterization	Surgical ventricular septal defect repair
Papillary muscle rupture	Echocardiography	Surgical valve replacement
Ventricular free wall rupture	Echocardiography, ventriculography	Emergent repair of ventricular defect

Ventricular Free Wall Rupture

Ventricular free wall rupture after myocardial infarction is infrequently encountered clinically, likely because of the exceedingly high mortality. The actual incidence is unknown, but may represent up to 30% of all deaths after acute myocardial infarctions. Like postinfarct VSD and papillary muscle ruptures, they tend to occur between the third and sixth days after infarction, when the myocardium is at its weakest. Free wall ruptures can present in essentially one of two ways: (a) a simple full-thickness tear with catastrophic hemorrhage and death from tamponade or (b) a complex serpiginous tear, partially contained. The latter is more likely to require surgical intervention, often presenting weeks from the initial infarction with symptoms of delayed cardiac tamponade. In rare cases, it is completely contained and may go unrecognized until a pseudoaneurysm develops, which is often diagnosed at a later date. Patients with free wall rupture will typically present with cardiogenic shock and may have features suggesting tamponade. Echocardiography will demonstrate a large pericardial effusion, frequently with echo-dense clot or ventricular wall defects. Urgent surgical intervention is required, often without coronary angiography or other time-consuming diagnostic tests. Once the pericardium is opened and cardiac tamponade is relieved, hemodynamic stability is often achieved. The site of hemorrhage is identified by the necrotic-appearing myocardium and adherent thrombus. The defect can be closed with large mattress sutures reinforced with Teflon felt strips. Care must be taken while tying the suture, as the necrotic muscle is weak and friable. Some have advocated covering the defect with a large Teflon felt patch using biologic adhesives, avoiding sutures altogether.[18] Whatever the technique, outcomes are likely determined by the hemodynamic status of the patient prior to arrival in the operating room and the quality of the remaining viable myocardium.

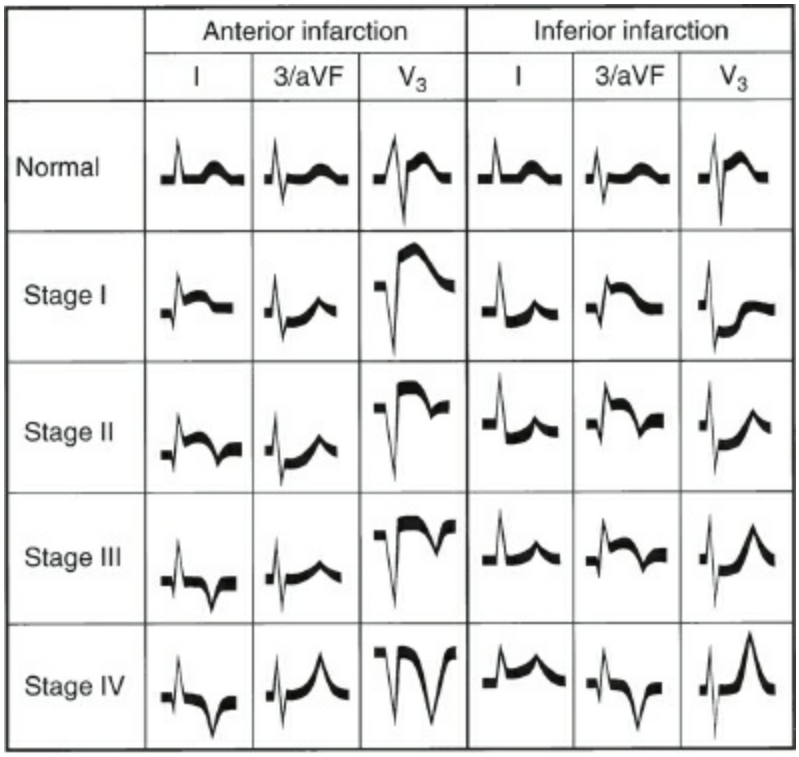

Figure 83-3. The electrocardiogram in an acute myocardial infarction.

DIAGNOSIS

The initial diagnostic tool for patients presenting with chest pain is the resting electrocardiogram (ECG). Although the majority of patients with chronic stable angina will have a normal ECG pattern, evidence of previous myocardial infarctions may be identified, either with the presence of Q waves or conduction abnormalities. Patients with an acute myocardial infarction may demonstrate ST-segment elevation (Fig. 83-3), prompting urgent intervention. Occasionally, more subtle ECG findings may provide clues that the chest pain is ischemic in etiology. Although nonspecific, these changes may include mild ST-segment depression or T-wave inversions.

During a myocardial infarction, the dying myocytes release enzymes specific to cardiac muscle into the bloodstream. These enzymes can be detected from laboratory analysis and are pathognomonic of myocardial infarction. The MB fraction of creatine kinase is cardiac specific and rises within 8 to 24 hours of infarction and returns to baseline within 2 days. Cardiac troponin has even greater specificity and serum levels rise faster than creatine kinase, improving both the speed and accuracy in the laboratory diagnosis of an acute myocardial infarction in the absence of clear ECG changes.[19]

For asymptomatic patients, or those with chronic stable angina, the most widely used diagnostic test to evaluate for coronary artery disease is exercise electrocardiography, or a “stress test.” Using standardized protocols, patients are exercised on a treadmill while the 12-lead ECG is continuously recorded. Alternatively, for those patients unable to walk, a bicycle ergometer may be used. Testing is continued until patient symptoms are noted or until the development of significant downward-sloping ST-segment depression, suggesting myocardial ischemia (Fig. 83-4). The diagnostic accuracy of exercise stress ECG testing can be enhanced with myocardial perfusion imaging. Several radioactive tracers are used clinically, the most frequent of which is thallium-201. Because of its similarities to potassium ions, it is taken up preferentially by viable cardiac myocytes. Its distribution within the myocardium is proportional to the rate of perfusion. During stress, regions of underperfused myocardium will take up less thallium, resulting in a visible defect. Following a period of rest and reperfusion, thallium uptake normalizes, demonstrating a “reversible defect.”

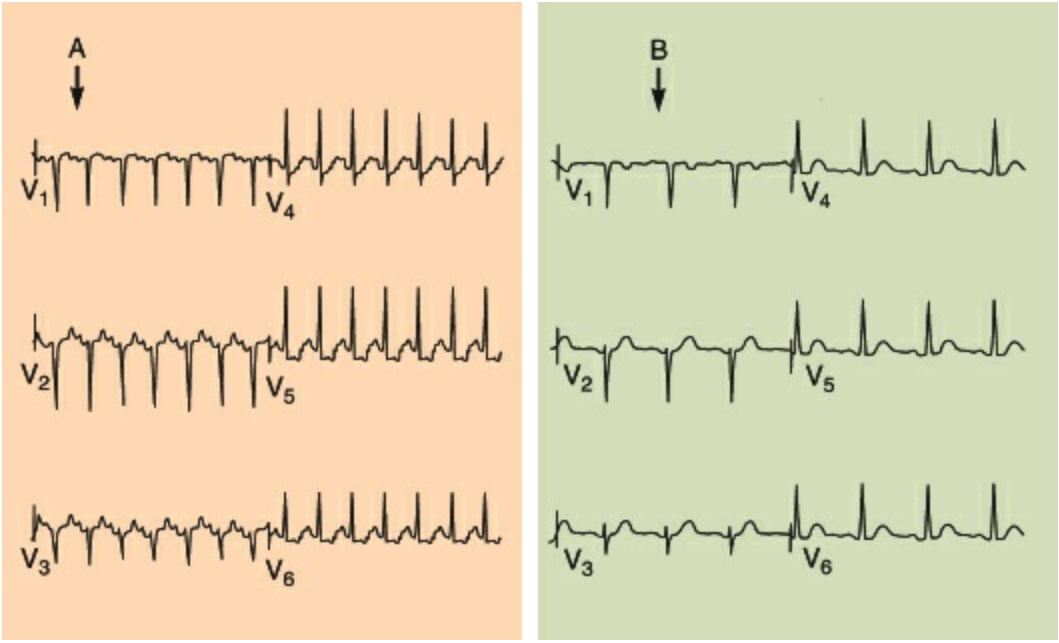

Figure 83-4. Electrocardiogram during an exercise test showing precordial leads V_1 through V_6. **A:** During exercise, depression of the ST segment and ischemia are seen in leads V_4 through V_6. **B:** These resolve after exercise is stopped.

In some cases, patients are unable to exercise because of additional physical or psychological limitations. Pharmacologic agents can substitute for exercise by increasing myocardial oxygen demand (dobutamine) or by directly vasodilating coronary arteries (adenosine or dipyridamole), thus demonstrating regions with fixed restrictions in myocardial blood flow. Echocardiography can be used as an alternative to nuclear perfusion imaging to improve the accuracy of exercise ECG testing. Regional changes in wall motion will be observed during myocardial ischemia, followed by restoration of normal myocardial contraction after rest or discontinuation of dobutamine. Echocardiography can also identify valvular abnormalities or other conditions that may influence treatment choices.

Coronary angiography, also known as cardiac catheterization, is the definitive tool for diagnosing coronary atherosclerotic disease. Indications include symptomatic patients with typical angina refractory to medical treatments, patients with significant ischemia on exercise or pharmacologic stress testing, patients with a STEMI, or patients with an NSTEMI and persistent pain despite medical treatment. Patients with valvular heart disease who are scheduled to undergo surgical correction should also undergo coronary angiography to identify coexisting coronary occlusions, which can be addressed at the time of the valve surgery. After percutaneous access is obtained in the femoral, brachial, or radial arteries, preformed catheters of varying sizes are advanced fluoroscopically to selectively engage the ostia of the left and right coronary arteries. Radio-opaque contrast is injected with imaging of the opacified coronary artery. Standardized views are obtained of both the right and left coronary systems to provide different projections to clearly define the vascular anatomy and to quantify the severity of occlusive lesions (Fig. 83-5). Automated computer analysis systems can calculate area reduction, improving interobserver consistency. Additionally, catheters can be inserted across the aortic valve into the left ventricular cavity, providing information about ventricular pressure

throughout the cardiac cycle. Contrast injection for ventriculography can illustrate ventricular systolic function, cavity size, and the presence of left-sided valvular abnormalities. New microtipped pressure sensors can be advanced across coronary lesions and document a clinically significant drop in perfusion pressure, either at rest or after provocation with vasodilating agents.[20] In addition, intravascular ultrasound imaging sensors can now be loaded onto tiny catheters and advanced into the left main coronary artery, helping to clarify the significance of lesions that may appear equivocal in severity on standard angiography.[21]

Newer imaging techniques using high-resolution multislice computed tomography (CT) scanning with three-dimensional reconstruction and magnetic resonance imaging are increasingly being utilized. These noninvasive approaches have the potential to improve the safety and convenience of coronary imaging; however, resolution remains inferior to standard coronary angiography. These techniques are often used as screening tests and are frequently followed up with traditional angiography.[22]

MEDICAL TREATMENT

5 Medical therapy of coronary artery disease is designed to slow the rate of progression of coronary artery atherosclerosis, to reduce the rate of complications from these lesions, and to control symptoms. Treatments are aimed at slowing plaque growth, reducing risk of plaque rupture, and reducing myocardial oxygen consumption. While advances in pharmacologic agents have improved the treatment of atherosclerosis and reduced mortality, lifestyle modification remains the most important intervention and the most difficult to achieve. These lifestyle modifications include cessation of cigarette smoking, weight loss, dietary control of diabetes, salt restriction, reduction in the consumption of foods high in cholesterol and fat, and exercise.

Medical therapy begins with controlling risk factors that contribute to formation and destabilization of the atherosclerotic plaque. Medical treatment alone is often satisfactory for many patients with coronary artery disease affecting only one or two epicardial vessel territories. Statins can decrease cholesterol levels and improve the ratio of LDL to HDL and have been demonstrated to reduce rates of myocardial infarction and death.[23] Statins also appear to reduce macrophage accumulation within atheromatous plaques, matrix metalloprotease activity, and collagen degradation. Angiotensin-converting enzyme (ACE) inhibitors have been shown to reduce mortality and myocardial infarction in patients with coronary artery disease.[24] Aspirin inhibits cyclooxygenase-1 (COX-1) activity and thromboxane production, irreversibly inhibiting platelet aggregation by inhibiting platelet activity, and should be prescribed to all patients unless significant contraindications exist. Aspirin has been shown to reduce death and myocardial infarctions in patients with significant coronary artery disease. By binding the catecholamine-mediated B1 receptor on cardiac myocytes, beta-blocking agents reduce myocardial oxygen consumption by reducing heart rate and contractility, and increase perfusion by extending diastolic perfusion time. Beta blockers are effective at controlling angina[26] and, in selected patients, reduce cardiovascular mortality.[27] Nitrates also reduce myocardial oxygen demand by decreasing cardiac preload via venodilation and by reducing afterload via arterial vasodilation. Some epicardial coronary vasodilation will occur, improving coronary blood flow. Nitrates can be given sublingually for immediate relief or as an oral long-acting agent for continuous control of symptoms. Headaches and tolerance are notable side effects. For patients who have refractory angina despite all revascularization and traditional medical options, a newer agent, ranolazine, has recently been introduced. It alters cardiac myocyte membrane ion channel permeability and can relieve angina with few side effects.[28]

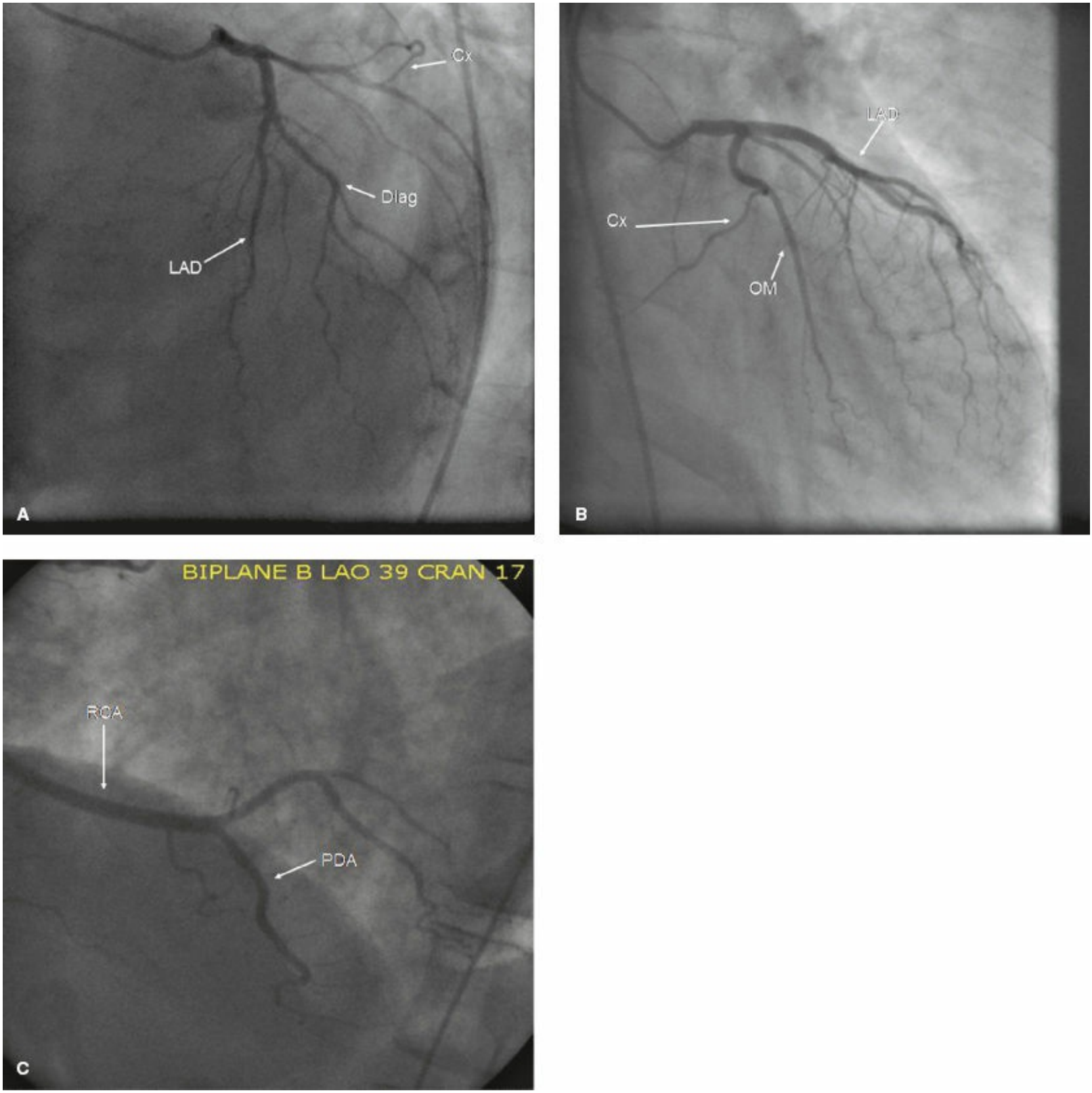

Figure 83-5. Coronary angiography. **A:** Left anterior oblique view of the left coronary artery. **B:** Right anterior oblique view of the left coronary artery. **C:** Left anterior oblique view of the right coronary artery. (Images courtesy of Brahmajee Nallamothu.)

A patient admitted to the hospital with a diagnosis of acute myocardial infarction or possible ACS should be placed in an environment with continuous ECG monitoring and the capacity to perform emergent defibrillation, since these patients are at risk of life-threatening malignant ventricular arrhythmias. Patients with evidence of ST-segment elevation should undergo emergent cardiac catheterization when possible, as will be

discussed later. For those patients in which the ECG is normal but an ACS is suspected, a stress test should be performed expeditiously to identify their risk for future coronary events and to identify patients in need of urgent cardiac catheterization.

Unless there is a strong contraindication, aspirin should be administered immediately, ideally chewed to increase the rate of bioavailability. Typically, aspirin is given by emergency transport personnel. Patients may be instructed by 911 operators to take aspirin if they describe chest pain. Institution of oxygen therapy is important to maximizing oxygen delivery, particularly for patients in whom hypoxemic respiratory dysfunction is also present. Intravenous nitroglycerine as a continuous infusion is typically effective at controlling symptoms of pain, which is essential in reducing unnecessary myocardial strain. Small randomized trials have suggested that nitroglycerine can reduce hospital mortality, although this has not been validated in larger trials.[29] When necessary, narcotics should be added, as unrelenting pain not only increases myocardial oxygen consumption, but also may contribute to plaque instability. Beta-blocking agents can reduce myocardial oxygen consumption but can also exacerbate heart failure, particularly in the setting of severely decreased systolic ventricular function. They should be considered cautiously in hemodynamically stable patients. ACE inhibitors reduce mortality after acute myocardial infarctions, particularly those with decreased ventricular function.[30] Benefits are not just restricted to the afterload reduction effects. Some evidence suggests they have a role in alteration of the myocardial intercellular matrix and scar formation.[31]

Anticoagulation is among the most important interventions in patients presenting with an acute myocardial infarction. In recent years, patients with myocardial infarctions were placed on newer antiplatelet glycoprotein (Gp) IIb/IIIa inhibitors, which affect adenosine diphosphate (ADP)-mediated platelet adhesion. Thienopyridines are a newer class of antiplatelet agents that act by binding to the ADP receptors on the platelet surface and inhibiting the GpIIb/IIIa pathway. Specific agents include clopidogrel (Plavix) and ticlopidine (Ticlid). There is strong evidence that the addition of clopidogrel to aspirin reduces death, myocardial infarction, and stroke in the setting of ACS.[32] Clopidogrel is irreversible and has a long half-life, resulting in bleeding complications, particularly if surgery is required. Surgical intervention should ideally be delayed for 3 to 5 days.[33] Abciximab (ReoPro) is a murine antibody that binds directly to the GpIIb/IIIa receptor on platelet surfaces, preventing fibrinogen binding and activation. The half-life is short, and platelet activity generally returns to normal within 24 hours. Eptifibatide (Integrilin) is a synthetic antagonist of the GpIIa/IIIb receptor and has a half-life of 3 to 4 hours. The benefit of these agents in patients with ACS treated medically is unclear, but they have become routine in the setting of percutaneous treatment of coronary stenoses. Unless contraindications exist, inhibition of the coagulation cascade is also recommended for patients with acute myocardial infarctions. Although standard unfractionated heparin has been used for many years, newer low–molecular-weight agents and direct Xa inhibitors may have advantages and are used with increasing frequency.[34,35]

With STEMI, significant myocardium is at risk, potentially resulting in either cardiogenic shock or ventricular arrhythmias. Emergency recanalization of acutely

occluded vessels can salvage cardiac function and save lives. Various fibrinolytic drugs, which convert plasminogen to plasmin, can be given emergently and restore flow in vessels obstructed by acute thrombus. A number of clinical trials were performed in the 1980s using streptokinase and demonstrated reduced survival when it was given within 12 hours.[36] Newer agents are now available including tissue plasminogen inhibitor (tPA) and reteplase, which are faster in onset and may further improve outcomes, although they are more costly.

The main drawbacks of fibrinolytic therapy are bleeding complications and failure of recanalization. Systemic intravenous thrombolytic therapy unquestionably decreases morbidity and mortality after MI and continues to be used in 40% to 50% of eligible patients. The earlier the treatment, the greater the impact, with the greatest benefit accruing in patients treated within 1 to 2 hours after the onset of symptoms.

In 1977, Dr. Andreas Gruentzig performed the first percutaneous intervention (PCI) with balloon angioplasty on a stenotic lesion in the LAD. This pioneer laid the foundation for a revolution in the treatment of coronary artery disease worldwide. Percutaneous treatment of acute STEMI is now standard practice in centers in which this therapy is available, with outcomes that are superior to pharmacologic reperfusion.[37] Although percutaneous intervention may be better than fibrinolysis, the treatment requires numerous experienced personnel and highly technologic equipment, which is not always available in every facility. Complex interhospital and intrahospital systems are now in place to improve the efficiency and application of this treatment strategy, and guidelines have defined minimum “door to balloon” times to salvage myocardium at risk.[38]

PERCUTANEOUS CORONARY INTERVENTIONS

6 Since the inception of percutaneous transcoronary balloon angioplasty (PTCA), catheter-directed treatment of coronary artery disease has evolved into one of the most commonly performed procedures worldwide. Advances in technology have improved outcomes and expanded the indications, particularly for the acutely ischemic heart. Using the same techniques described for cardiac catheterization, small, highly flexible and steerable guide wires can be advanced through the lumen of epicardial coronary arteries. Over this guide wire, balloon-tipped catheters can be advanced and centered across discrete stenotic lesions and inflated to 4 to 10 atmospheric pressures, stretching and dilating the affected vessel (Fig. 83-6). Typically, the vessel tears or cracks at the junction of the plaque and the normal vessel wall. Acute thrombosis or coronary dissection could result in immediate closure of the vessel, often necessitating emergent surgical coronary bypass grafting in approximately 5% of cases. Restenosis is common, occurring in nearly 40% to 50% of patients, either from mechanical elastic recoil or progressive neointimal hyperplasia.

The addition of stents, nitinol scaffolding devices, has nearly eliminated acute vessel occlusion, and the need for salvage surgical revascularization is below 1%. In addition, stents have greatly reduced restenosis rates down to nearly 20% and are used in nearly 90% of percutaneous procedures in the United States. The stents are delivered crimped onto a deflated balloon. With balloon inflation, the stent expands, restoring the vessel lumen to its anatomic dimensions. The stent prevents elastic recoil and coronary dissection, improving immediate outcomes, but the problem of neointimal hyperplasia remains, resulting in the persistent rates of restenosis. Stents have been improved even further by impregnating antiproliferative drugs onto the scaffolds. Sirolimus and paclitaxel are immunosuppressants that act by different mechanisms. Paclitaxel is a mitotic inhibitor, which retards microtubule breakdown. Sirolimus binds intracellularly to FK-binding protein and inhibits interleukin-2 (IL-2) production via the target of rapamycin pathway. Both sirolimus- and paclitaxel-eluting stents have further reduced the rate of target vessel restenosis and the need for repeat interventions.[39] However, reports of late stent thrombosis have raised concerns, and indefinite use of antiplatelet regimens has been recommended.[40]

CORONARY BYPASS GRAFTING

Indications

Coronary artery bypass grafting (CABG) is one of the most common and most studied surgical procedures performed in the United States. As one might expect, CABG consumes more resources than any other single cardiovascular procedure. Dozens of multicenter, prospective, randomized trials have been performed comparing the surgical treatment of coronary artery disease to both medical and percutaneous options. Some of these landmark studies will be discussed in detail later in the chapter, as proper understanding of these trials is important in determining appropriate treatment strategies for individual patients. In summary, these studies consistently demonstrate that CABG continues to be the best revascularization strategy, reducing rate of both myocardial infarctions and the need for repeat revascularization in patients with a broad degree of occlusive disease. A task force made up of numerous medical societies including the American College of Cardiology, the American Heart Association, the Society of Thoracic Surgeons (STS), and the American Association of Thoracic Surgeons recently published guidelines on the indications for coronary artery revascularization and made recommendations regarding the mode of revascularization.[41] The group considered a number of variables, including clinical symptoms and mode of presentation, the degree of ischemia determined by noninvasive imaging, and the severity of coronary disease based on angiographic imaging. In summary, patients are more likely to benefit from surgical revascularization if they have worse symptoms, more severe myocardial ischemia, and more extensive coronary artery occlusions. The recommendations are summarized in Figure 83-7, where recommendations are categorized as “appropriate,” “uncertain,” and “inappropriate.” Interestingly, these guidelines have not changed markedly over the last several decades, despite vast improvements in both medical treatment and percutaneous technology. Today, CABG remains the best mode of cardiac revascularization in symptomatic patients.

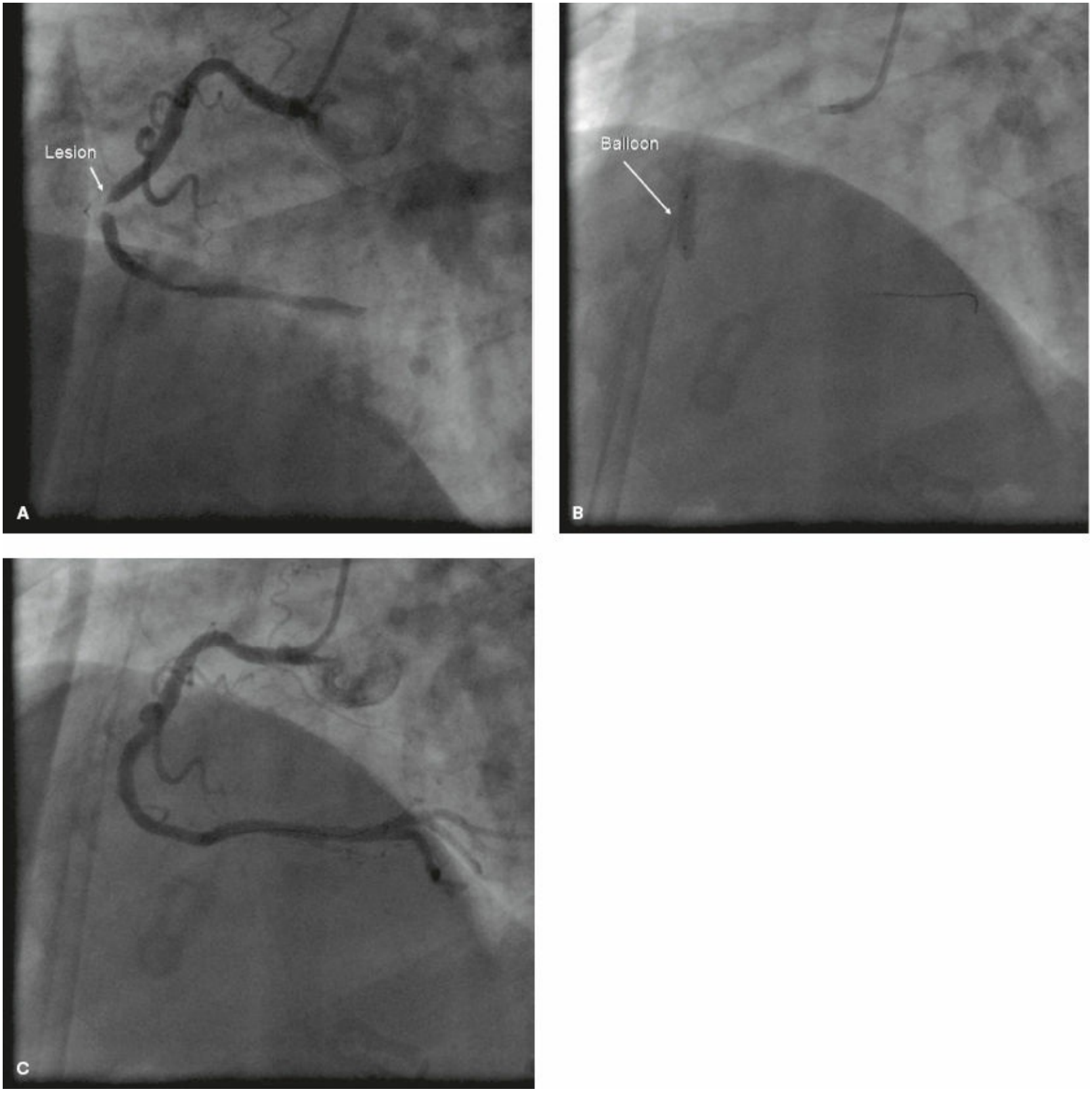

Figure 83-6. Percutaneous coronary intervention. **A:** A stenotic midright coronary artery lesion. **B:** Balloon angioplasty. **C:** Postintervention result. (Images courtesy of Brahmajee Nallamothu.)

Standard Technique

7 The basic principles in coronary bypass grafting are to restore normal unimpeded perfusion of ischemic myocardial territories by providing alternative routes for blood flow. Previous approaches to surgically revascularize the myocardium-included creation of intramyocardial tunnels and arterialization of the coronary sinus. However, it was the aortocoronary bypass pioneered by a surgeon named Rene Favaloro at the Cleveland Clinic in the late 1960s that revolutionized the treatment of coronary atherosclerosis. The technique has evolved considerably over the decades, and there remains significant variability in how this complex procedure is conducted even today.

The heart is typically exposed via a median sternotomy. This incision allows exposure of the anterior surface of the heart, as well as the great vessels, for initiation of cardiopulmonary bypass (CPB). Except for the severely hypertrophic heart, the entire epicardial surface can be exposed with manipulation and traction on the left ventricle. Alternatively, a left lateral thoracotomy can be used. This limits visualization to the obtuse margin of the heart but can be advantageous, particularly if the patient has previously had a median sternotomy with dense adhesions hazarding catastrophic injury during sternal reentry. Another alternative has been a limited left anterior thoracotomy, which exposes only a small portion of the anterior wall of the left ventricle, usually limited to revascularization of the LAD. This approach will be discussed later in the section describing minimally invasive approaches to surgical revascularization.

	CABG			PCI		
	No diabetes and normal LVEF	Diabetes	Depressed LVEF	No diabetes and normal LVEF	Diabetes	Depressed LVEF
Two-vessel coronary artery disease with proximal LAD stenosis	A	A	A	A	A	A
Three-vessel coronary artery disease	A	A	A	U	U	U
Isolated left main stenosis	A	A	A	I	I	I
Left main stenosis and additional coronary artery disease	A	A	A	I	I	I

Figure 83-7. 2009 consensus recommendations regarding coronary artery revascularization. A, appropriate; CABG, coronary artery bypass grafting; I, inappropriate; LAD, left anterior descending; LVEF, left ventricular ejection fraction; PCI, percutaneous coronary intervention; U, uncertain. (Reproduced with permission from Patel MR, Dehmer GJ, Hirshfeld JW, et al. ACCF/SCAI/STS/AATS/AHA/ASNC 2009 appropriateness criteria for coronary revascularization. *Circulation* 2009;119:1330–1353.)

The key to constructing a durable and reproducible anastomosis to small diseased epicardial vessels is creation of a quiet and bloodless surgical field. The advent of CPB using extracorporeal circulation along with cardiac standstill using cardioplegia has

allowed precisely this environment. The epicardial vessels are motionless and can be brought directly into the surgical field. Epicardial blood flow is eliminated, allowing direct visualization of the lumen without arterial control, avoiding potential clamp or snare injury to the fragile vessels.

After anticoagulation with 300 IU/kg of heparin is confirmed with an activated clotting time (ACT), the patient is cannulated in the distal ascending aorta. Patients may have significant atherosclerotic disease, and the cannulation site should be carefully inspected for mobile lesions using TEE and manual palpation. Some centers advocate epiaortic ultrasonic imaging for more accurate visualization. After insertion, the cannula is manually deaired and connected to the arterial limb of the CPB circuit (Fig. 83-8). Venous drainage is accomplished with a cannula in the right atrium, typically in the atrial appendage. Bleeding from the cannulation sites is controlled by pursestring sutures around the cannulas. Bypass is initiated by venous drainage into a reservoir, emptying the heart of venous return. Blood is pumped into a membrane oxygenator and returned into the aortic cannula, typically at a blood flow rate of 2.4 L/min per m^2 of body surface area. With full flow, ventilation of the patient can be discontinued, further improving visualization and minimizing motion in the surgical field. The extracorporeal blood is cooled, creating mild hypothermia, varying from 28°C to 32°C. Systemic cooling minimizes end-organ injury from relative hypotension or hypoperfusion from nonpulsatile blood flow.

After adequate CPB is confirmed, the heart is arrested by applying a clamp across the midascending aorta, proximal to the aortic cannulation site. This clamp isolates the native coronary vessels from the remainder of the systemic circulation. Cardioplegia is then delivered to the myocardium via a needle or catheter in the aortic root. There are a variety of cardioplegia solutions commercially available, but the most important components are dilute blood, cold temperature (8°C to 15°C), potassium at 15 to 30 mM/L, citrate for calcium binding, dextrose for myocardial substrate, and pH buffers. The cold temperature and potassium maintain the heart in diastolic arrest, reducing myocardial oxygen consumption. Cardioplegia is typically delivered intermittently, approximately every 15 to 20 minutes, to provide adequate oxygen and nutrient delivery and to minimize myocardial activity. Additionally, some surgeons utilize cardioplegia delivered in a retrograde fashion via a specially designed balloon-tipped catheter inserted into the coronary sinus. Protocols relying entirely upon antegrade delivery of cardioplegia hazard incomplete myocardial protection, particularly in territories of severe coronary artery stenosis or total occlusions. In addition, an incompetent aortic valve will limit cardioplegia delivery down the coronaries, and leaking into the left ventricle will result in significant ventricular distention. Furthermore, antegrade cardioplegia can be delivered under supraphysiologic pressures from the extracorporeal mechanical blood pumps. This can result in epicardial vessel injury and embolization of atheromatous debris, particularly in the reoperative setting in which old vein grafts often contain mobile and highly friable lesions. The use of retrograde cardioplegia can overcome these limitations, and some evidence suggests outcomes can be improved.

Conduits used for coronary bypass grafting are variable. The oldest and most

frequently chosen conduit is the greater saphenous vein because of its availability, accessibility, reasonable size match, the facility with which vascular anastomoses can be created, and the avoidance of morbidity in harvesting the vein. The adequacy and size of the vein can be assessed preoperatively using ultrasound techniques. Generally, a conduit of 2 to 4 mm in diameter is considered suitable. Alternative veins, such as the lesser saphenous vein and cephalic vein, are infrequently used for coronary bypass grafting because patency rates have been reported to be low. The greater saphenous vein can be exposed with a single long incision, beginning at the ankle, midway between the medial malleolus and the anterior tibial tendon. It is important to handle the vein gently and avoid electrocautery directly on the vein to minimize traumatic or thermal injury to the endothelial cells. The side branches are carefully ligated, and the vein is preserved in a solution of cold heparinized blood, often with vasodilating agents such as papaverine and nitroglycerine. If dissection is minimized and hemostasis is meticulously ensured, the incidence of infection and wound healing complications is generally low. Patients will complain of pain along the length of the incision, but this typically resolves after several weeks.

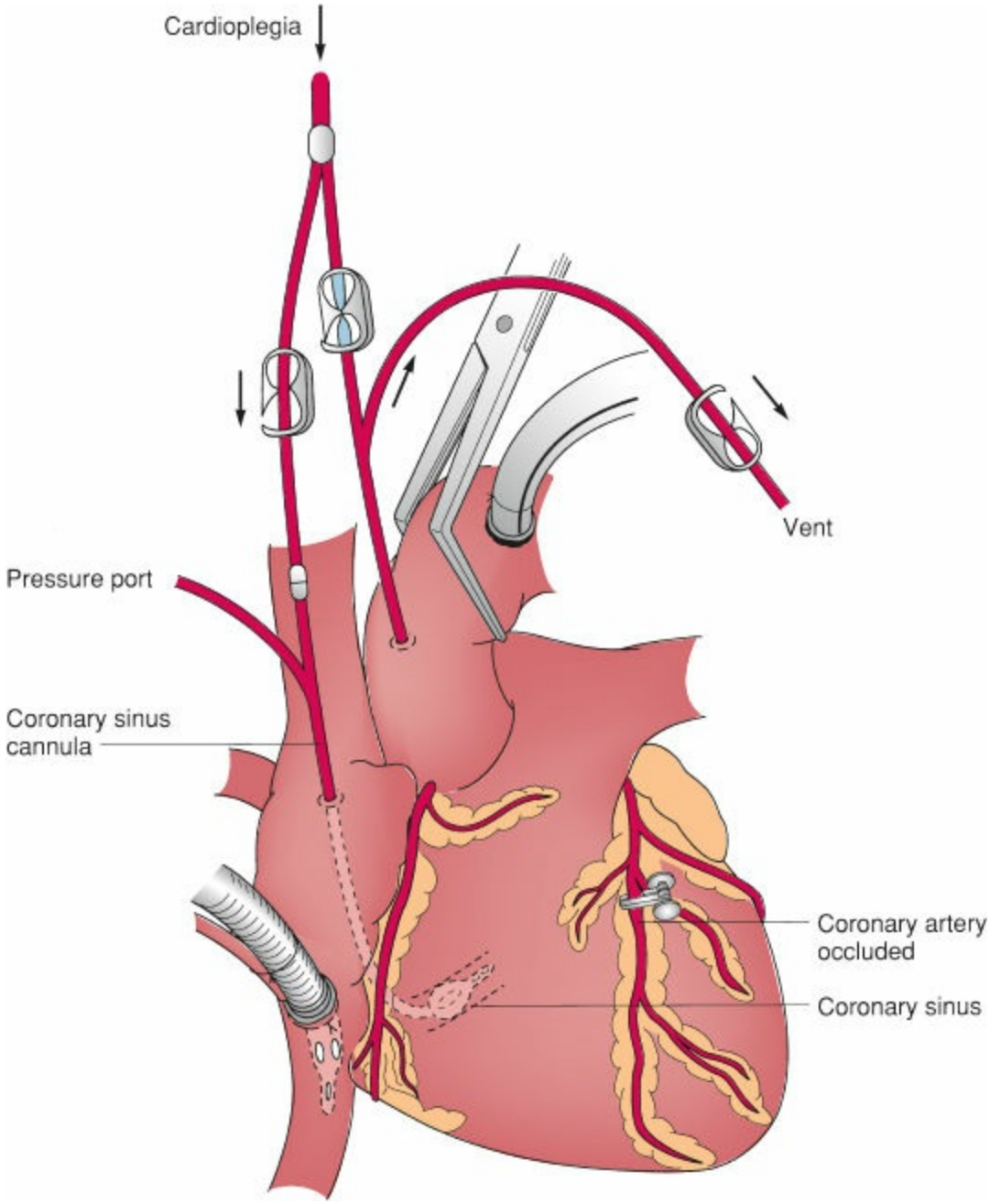

Figure 83-8. Instrumentation for cardiopulmonary bypass.

In more recent years, minimally invasive approaches using endoscopic techniques can harvest the entire length of the greater saphenous vein with three small incisions. After exposure of the vessel at the knee, a blunt dissector is used to create a tissue plane, which is then expanded with CO_2 insufflation. Direct visualization with magnifying endoscopic lenses allows identification and ligation of side branches (Fig. 83-9). The dissection proceeds both proximally and distally, until the vein has been fully mobilized. Small stab incisions allow ligation at the groin and the ankle, and extraction of the vein from the initial incision. This technique has reduced pain, has improved patient satisfaction, and appears to reduce hospital readmission from wound healing complications. However, the technique is more time consuming, which can be aggravating for the impatient surgeon. In addition, the disposable equipment is expensive, increasing the costs by approximately $500 to $1,000, depending on the manufacturer and negotiated contract pricing. More importantly, a recent nonrandomized report described the use of endoscopic vein

harvesting as an independent predictor of vein graft occlusion, hospital readmission for major cardiac adverse event, and mortality, as compared to open saphenous vein harvesting techniques.[42] This study was in contrast to the previous smaller randomized trials but raises concerns about the use of this strategy. Proponents of endoscopic vein harvesting argue that the observational trial did not describe the operator's previous experience using minimally invasive harvesting and suggest that many centers remained on the early part of their learning curve. In addition, newer technology now allows for safer delivery of bipolar electrocautery, minimizing the potential for heat transmission and endothelial injury. In addition, many centers are now administering low doses of heparin before initiating the dissection to reduce the likelihood of in situ thrombus during manipulation of the vein. It is likely that the debate regarding minimally invasive saphenous vein harvesting will continue in the near future.

8 Arterial conduits for coronary bypass grafting have been increasingly utilized because of early neointimal hyperplasia and late accelerated atherosclerosis seen in saphenous vein grafts. The most important of these arterial conduits is the left internal mammary artery, which originates from the left subclavian artery and descends caudally behind the chest wall, just lateral to the sternal edge. It gives off intercostal branches until it terminates distally as the bifurcation into the superior epigastric and musculophrenic arteries. The artery is typically mobilized as a pedicle, left intact at its origin from the subclavian artery. After completion of the median sternotomy, the left hemisternum is retracted anteriorly using an elevating self-retaining retractor (Fig. 83-10). Under direct visualization, the mammary artery, its accompanying paired veins, and a small swath of chest-wall soft tissue are gently separated from the remaining chest wall. Intercostal branches are controlled with clips and divided sharply or with cautery. The dissection proceeds proximally to the subclavian vein and distally to the terminal bifurcation of the internal mammary. A helpful marker identifying the distal extent of the dissection is the appearance of muscular transverse thoracic fibers. Caution must be taken during the proximal extent of the dissection, as the phrenic nerve traverses close posteriorly to the origin of the left internal mammary artery. Once fully mobilized, the internal mammary is divided at the distal bifurcation after heparinization and soaked in a solution of vasodilating agents to overcome spasm from manipulation.

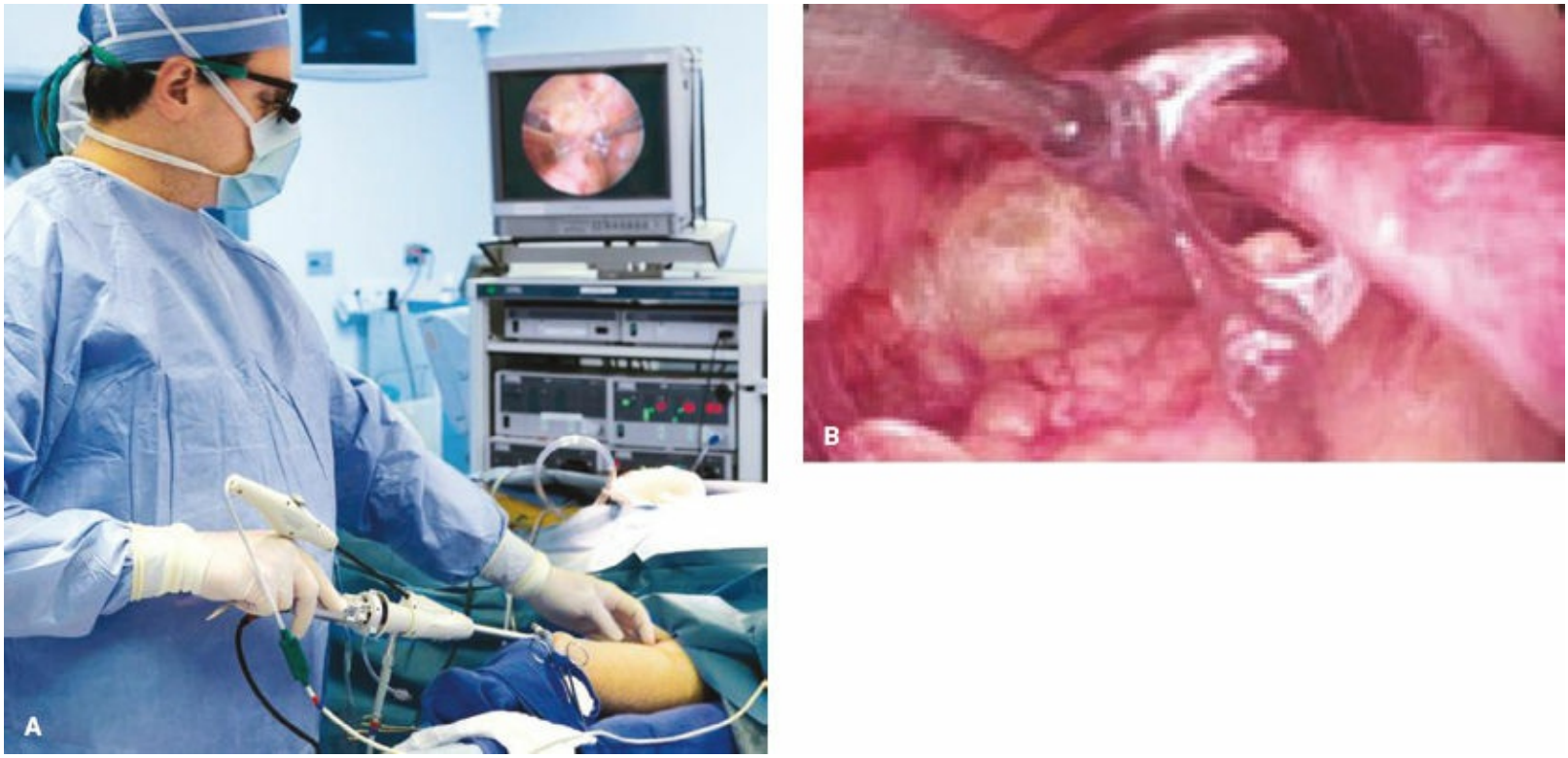

Figure 83-9. Endoscopic vein harvesting. **A:** Endoscope is inserted through a small incision in the knee. **B:** Excellent visualization of the saphenous vein with ample working space. (Images courtesy of Maquet.)

Other arterial conduits are also increasingly utilized, such as the right internal mammary artery, the radial artery, the gastroepiploic artery, and the inferior epigastric artery. The internal mammary artery tends to be spared of atherosclerotic disease, and its patency rates are excellent many years following bypass surgery. As such, many surgeons routinely harvest both internal mammary arteries to take advantage of this biologic privilege. However, utilization of both internal mammary arteries can devascularize the sternum and increase the risk of postoperative sternal wound infections, particularly in obese diabetics.[43] The radial artery can be harvested safely in the majority of patients, as a complete palmar arch allows collateral flow to the hand from the ulnar artery. Preoperative ultrasound in addition to a bedside Allen test can reliably identify patients in which hand ischemia precludes radial artery use. Although the radial artery is more resistant to late occlusions typical in saphenous vein grafts, it tends to be prone to spasm from competitive flow originating from subcritically stenosed native coronary vessels. Radial arteries should only be used on coronary targets with at least 70% proximal stenoses. The inferior epigastric artery has been used as an arterial conduit, but limitations in length and the need for an abdominal incision have diminished enthusiasm. The right gastroepiploic artery can be used, since it has more than adequate length after mobilization off of the greater curve of the stomach. It is left on its pedicle from the gastroduodenal artery and tunneled through a hole in the diaphragm. It is most frequently used to revascularize the posterior descending coronary branch, but will easily reach posterolateral branches as well. Patency has generally been reported to be excellent, but its widespread use is restricted by the additional morbidity of laparotomy and risks of intra-abdominal complications.

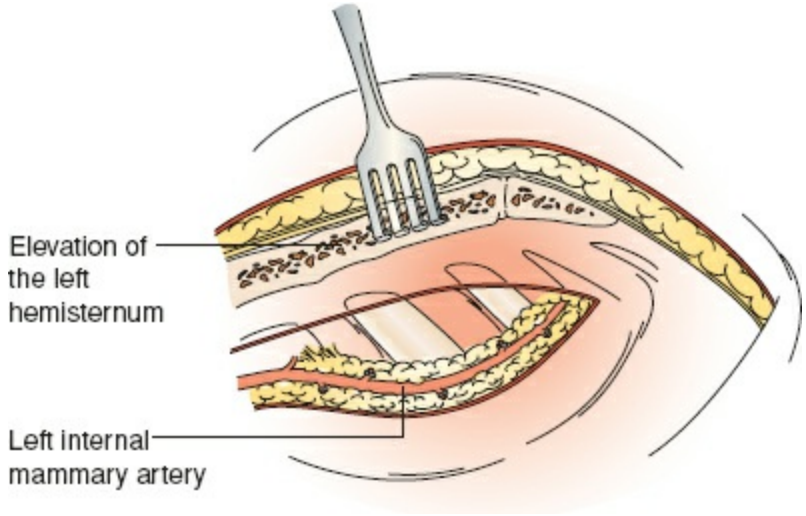

Figure 83-10. Elevation of the left hemisternum for visualization of the left internal mammary artery.

Once conduits have been harvested, CPB has been instituted, and cardioplegia infusion has resulted in adequate diastolic arrest, the heart is manipulated to expose the epicardial vessels of interest. Occasionally, the coronary arteries are in fact not on the epicardial surface but run within the epicardial fat or deep within the myocardium. This is common for intermediate branches and the LAD. Careful dissection is often required. If the midportion of the LAD cannot be found, the vessel can be opened at the apex and a small coronary probe can be inserted proximally and palpated to better localize the vessel. Care must be taken to ensure the target has been properly identified. Even the most seasoned cardiac surgeons have mistakenly anastomosed grafts to epicardial veins. Once the target vessel is properly located, an appropriate site for anastomotic construction should be identified. It is important to have a thorough understanding of the angiographic location of significant obstructions to ensure the graft is bypassing all significant lesions. The anastomotic site should ideally be relatively spared of atherosclerotic disease, although in patients with advanced diabetes this is not always possible. The vessel is dissected using a no. 64 sharp scalpel and opened vertically in the midline. This maneuver is among the most essential and challenging, and requires precision and experience. Eccentric incisions, inadvertent incisions in the posterior wall, or incisions in friable plaques can result in stenotic or leaky constructions. The arteriotomy is extended using fine Potts scissors 3 to 4 mm in length. The conduit is beveled to the appropriate length and the anastomosis is created with a continuous running polypropylene suture, usually size 7-0 or 8-0 (Fig. 83-11). Absolute technical precision is crucial, and skills required for these distal coronary anastomoses take practice and experience. A motionless and dry surgical field, 2.5 to 3.5 magnifying loupes, experienced assistance, and a steady hand are essential. Some surgeons use gentle insufflation of CO_2 to clear the field of obscuring blood and to distend the coronary artery to improve visualization of the toe and heal. After completion of the anastomosis, saphenous vein grafts or free arterial grafts can be hand injected with cold saline to visualize patency of the vessel and competence of the construction. Pedicled arterial grafts can be opened, and flow down the target will be easily visualized.

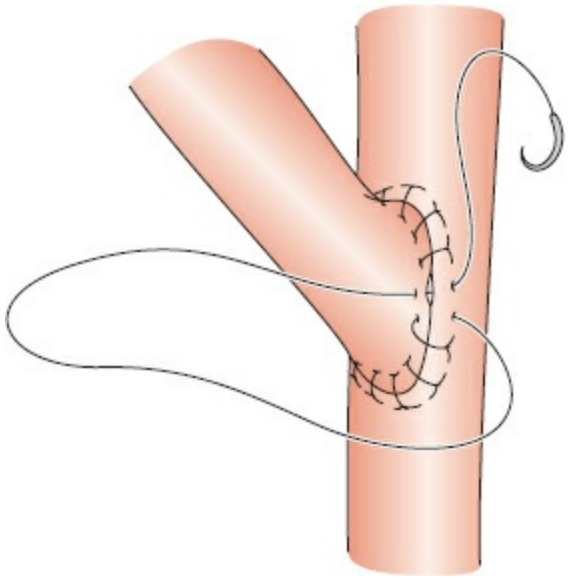

Figure 83-11. Distal coronary anastomosis with saphenous vein conduit. Excellent visualization in a quiet bloodless field is required to achieve a hemostatic and unobstructed graft.

The proximal ends of the grafts are usually connected to the ascending aorta. The grafts are cut to the appropriate length. This maneuver also requires experience, as a short graft will create tension, potentially impinging upon the distal anastomosis, and an excessively long graft may kink. The graft is distended to prevent twisting, and the aortic root is filled by infusing antegrade cardioplegia to help determine optimal graft length. One must take into account the change in geometry as the heart fills after weaning from CPB. In general, the conduits should take a straight trajectory toward their target (Fig. 83-12). An aortotomy is created using a specially designed punch of 4 or 5 mm diameter. The grafts are beveled, and the proximal anastomosis is created with continuous running 5-0 or 6-0 polypropylene. Alternatively, the aortic cross-clamp can be removed after completion of all of the distal coronary anastomoses, and a side-biting partial aortic clamp can be placed. This technique can reduce total cardioplegia time but may increase risk of atheroembolic complications from additional aortic manipulation.

After completion of all distal and proximal anastomoses and the aortic cross-clamp has been removed, the temperature of extracorporeal circulation is warmed. Ventricular fibrillation often occurs but can easily be defibrillated with a single internal shock. Ventilation of the lungs is resumed, and CPB flow is gradually reduced. Careful inspection of myocardial contractility and volume is required during weaning, as transient dysfunction often occurs. It is important to avoid distention of ventricular chambers, which causes unnecessary increased myocardial strain. A period of empty beating reperfusion is often helpful, particularly if the aortic cross-clamp period was prolonged or if the heart was severely ischemic preoperatively. Temporary sinus node or atrioventricular node conduction abnormalities are common, and it is standard to place temporary pacemaker leads on the ventricle, although permanent conduction abnormalities are very rare. Suture lines should be inspected for hemostasis, and cannulas for CPB are removed. Although not essential for routine CABG, pulmonary artery catheters and TEE are helpful in weaning from CPB. Excessive pulmonary artery

pressures or new regional wall motion abnormalities can suggest perfusion abnormalities and should prompt careful inspection of the bypass grafts. Once satisfactory hemodynamics are achieved, protamine is administered to reverse the anticoagulation of heparin. A notch in the pericardium to the left of the pulmonary artery must be created to allow unhindered passage of the pedicled left internal mammary artery to its distal target. The pericardium is typically left open after coronary bypass grafting to avoid graft kinking or compression; however, mediastinal and thymic fat can be carefully placed over the aorta and proximal anastomoses to protect them from future sternal reentry. Drains are left within the mediastinum to collect shed blood, and the sternum is closed with steel wires, cables, or plates.

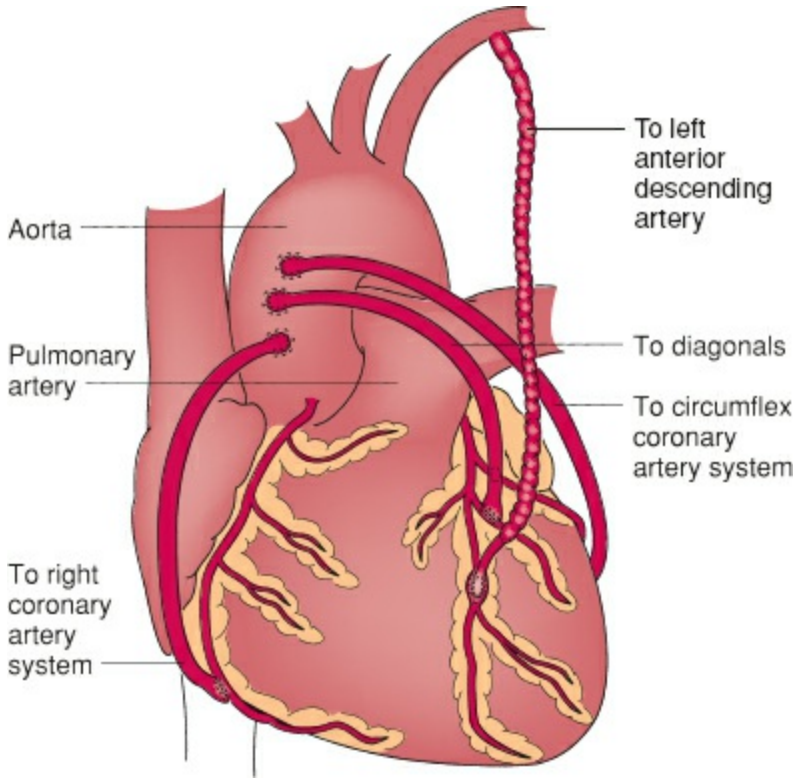

Figure 83-12. Bypass grafts take gentle curving but a direct approach to the coronary targets. The pericardium is typically left open to avoid kinking.

Off-pump Technique

While the use of CPB was essential in allowing safe and reproducible coronary anastomoses, it is now well understood that extracorporeal circulation incites a powerful inflammatory response, activating neutrophils and monocytes to release cytokines and inhibiting the clotting cascade and platelet function. Occasionally, these inflammatory changes can produce clinically relevant capillary leak, pulmonary edema, renal dysfunction, hemodynamic instability, and coagulation dysfunction. In addition, iatrogenic cardiac arrest induced by cardioplegia can infrequently result in myocardial injury and dysfunction. In order to avoid some of these adversities, attempts to perform CABG without the use of CPB have become increasingly popular in the last decade. Interestingly, CABG was originally performed without CPB in the early 1960s; however, it was largely abandoned because technically sound anastomoses could not be reliably constructed. Newer technologies are now available that have made creation of surgical bypass grafts more feasible on the full and beating heart.

The heart is exposed via a median sternotomy, identical to the approach used for standard coronary bypass grafting with CPB. Additional sutures are placed deep within the posterior pericardium, which can be used to facilitate retraction of the heart anteriorly and rightward, exposing the anterior, anterolateral, and obtuse marginal surfaces. Typically, the vessel with the most severe occlusion is grafted first, since occlusion of the vessel will result in the least myocardial ischemia and revascularization of this territory may collateralize other regions and improve tolerance to alternate vessel occlusion. For saphenous vein and free arterial grafts, the proximal anastomoses are performed first to allow immediate revascularization of ischemic territories following completion of the distal anastomoses. A dose of heparin is administered, typically 150 IU/kg, and adequate anticoagulation is confirmed with an ACT. A partial occlusion clamp is placed on the ascending aorta for control. Alternatively, newer sealing systems allow clampless control of the ascending aorta during construction of the proximal anastomoses, and sutureless connectors are available that can variably create satisfactory graft–aorta constructs. Once the proximal connections are complete, the grafts are carefully cut to the appropriate length after identification of the anticipated sites of the distal targets.

Of the potential epicardial vessels, the LAD is the easiest to expose, since it lies anteriorly. Gentle retraction on the pericardial sutures, occasionally along with a pad placed behind the heart, will usually expose the vessel adequately. The diagonal branches are exposed with slightly further rightward retraction. The obtuse marginal vessels can be exposed with the help of a suction device placed on the apex of the heart and slowly and gently retracting the apex anteriorly and rightward. This maneuver must be performed carefully, as cardiac chamber and/or outflow tracts can become compressed. The anesthesiologist must be alerted to and familiar with these maneuvers, as temporary vasoactive infusions may be required. Exposure of the right coronary artery and its branches is often the most challenging. The right ventricle can become compressed with retraction superiorly. The suction apparatus placed on the acute margin can facilitate exposure, as can stiff retraction of the right-sided pericardial edges.

Once the epicardial vessel of interest is identified, a U-shaped epicardial suction stabilizing device is applied around the vessel (Fig. 83-13). This device can reduce myocardial motion in a small region of interest, maintaining reasonable contractility. Silastic tapes loaded on blunt needles are carefully encircled around the proximal and distal portions of the coronary artery and gently retracted for blood flow control. A variable degree of ischemia may be seen on the ECG and TEE. The vessel is dissected and opened in the same way as is done for on-pump techniques. If ischemia is pronounced, small shunts can be inserted in the arteriotomy and the silastic snares released to reestablish some distal flow. Continuous insufflation of CO_2 can reduce obscuring blood from the field. The anastomosis is constructed, and competency is assessed. Electrocardiographic normalization should be seen immediately, confirming graft patency. Once all the grafts are complete, protamine is given to reverse the anticoagulation effect of heparin. Hemostasis is confirmed and closure proceeds routinely.

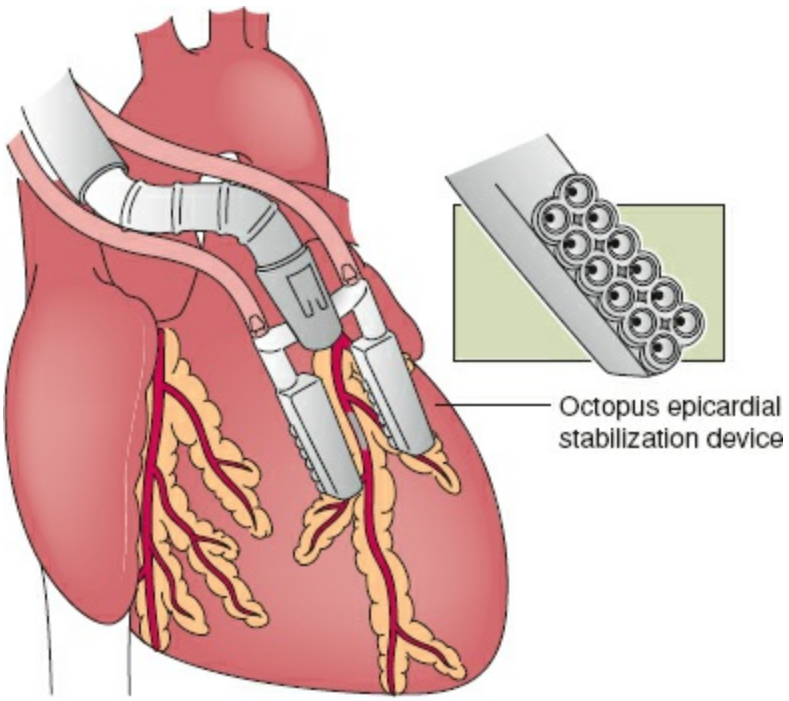

Figure 83-13. Suction-stabilizing devices allow isolation and immo-bilization of epicardial coronary targets.

Despite early enthusiasm for off-pump coronary bypass surgery, concerns regarding long-term patency of bypass grafts have prompted investigation into its true benefits and general application. A large multicenter randomized trial recently published investigated short- and midterm outcomes of patients undergoing either standard coronary bypass surgery with CPB or off-pump bypass.[44] Over 2,000 patients referred for coronary bypass grafting were randomly assigned to undergo standard versus off-pump CABG. All patients were felt to be suitable candidates for both approaches, and all surgeons had previously completed a median of 50 off-pump procedures to ensure competency. The primary endpoints were morbidity and mortality at 30 days and 1 year, and secondary endpoints were graft patency and neuropsychologic testing. Thirty-day mortality was similar in both groups (1.6% vs. 1.2% in off-pump vs. on-pump, respectively; $p = 0.47$), as was the rate of perioperative stroke (1.3% vs. 0.7%; $p = 0.28$). However, at 1 year, there was a

higher rate of cardiac death in the off-pump group (2.7% vs. 1.3%; $p = 0.03$). At 1 year, 65% of patients underwent routine cardiac catheterization, revealing a significantly reduced rate of graft patency in the off-pump group (82.6% vs. 87.8%; $p < 0.01$), particularly for saphenous vein grafts (76.6% vs. 83.8%; $p < 0.01$). Neuropsychologic testing was performed to attempt to quantify benefits from eliminating proposed neurocognitive dysfunction attributed to CPB. Fifty-four percent of randomized patients completed neuropsychologic testing at baseline and at 1 year, and interestingly, there were no significant differences observed from baseline to 1 year between off-pump and on-pump strategies. In summary, this important and well-conducted study showed no advantages and potential disadvantages of off-pump surgical revascularization in this selected cohort of patients. While there are valid criticisms of this study, these data certainly suggest that routine use of off-pump CABG is not superior, and perhaps should be reserved to selected populations. This author uses off-pump techniques for patients with a heavily calcified or atheromatous ascending aorta or those with severe renal or hepatic dysfunction.

In addition to off-pump CABG, a variety of "minimally invasive" approaches have been conceptualized. The minimally invasive direct coronary bypass (MIDCAB) involves creating a small left anterior thoracotomy. After entering the chest in the fourth intercostal space and resecting a portion of the fourth costal cartilage, a portion of the left internal mammary artery is mobilized under direct vision. Using off-pump techniques and stabilizing equipment, the internal mammary artery is anastomosed to the LAD using conventional open instruments. Although experiences at selected single centers have described satisfactory patency and reduced cost, complications, and postoperative length of stay,[45] the MIDCAB has not achieved widespread application. Technical considerations and exposure have raised concerns about graft patency, and in the era of increased percutaneous intervention, very few patients are referred with isolated single-vessel disease. Some groups have advocated for a hybrid approach, in which the LAD is surgically grafted using the MIDCAB approach and the right coronary and circumflex branches are treated percutaneously.[46] Robotic systems, such as the da Vinci (Intuitive Surgical, Sunnydale, CA), benefit from high-definition three-dimensional video visualization and precise remotely controlled instruments with 6- or 7-degree freedom of motion. They have been increasingly used in noncardiac surgery, particularly in gynecology and urologic specialties. Some centers have begun using robotic technology to harvest the internal mammary artery along its entire length, followed by a MIDCAB, also known as robotically assisted CABG (RAS-CAB).[47] Others have gone one step further, performing complete coronary revascularization using robotic instruments: the totally endoscopic coronary artery bypass (TECAB).[48,49] The procedure has been performed with or without CPB and cardiac arrest. Although in selected centers the procedure appears feasible, the widespread utilization of minimally invasive coronary artery bypass remains in question because of concerns regarding patency, particularly in light of recent evidence regarding off-pump surgery in general. Despite changes in technology, there has been little growth in minimally invasive coronary artery bypass procedures.

POSTOPERATIVE CARE

Most patients after undergoing coronary bypass grafting require very little physician intervention, particularly if the operation was conducted according to the preoperative plan. The use of clinical care pathways is now routine, and they have been demonstrated to reduce morbidity, cost, and length of hospital stay. However, complications can occur, which must be anticipated for early recognition and treatment.

Patients after cardiac surgery are routinely admitted to the intensive care setting. Most centers delay extubation until systemic warming is complete, typically within 4 to 6 hours. This also gives ample opportunity to ensure adequate hemostasis and hemodynamic stability. Many centers routinely use pulmonary artery catheters, or Swan–Ganz catheters, for assessment of intracardiac filling pressures as well as calculation of cardiac output. Cardiac output (CO) can be calculated in one of two ways: thermodilution or the modified Fick technique. Using thermodilution, room temperature saline of a known quantity is injected briskly into the right atrium. As the saline mixes with blood traveling through the right ventricle, blood is cooled. The blood temperature is then recorded in the pulmonary artery over time. A curve is generated, denoting the change in temperature from baseline, and the area under this curve is inversely proportional to the cardiac output (e.g., the higher the cardiac output, the lower the impact the small saline aliquot has on blood temperature). Clinicians should be aware that severe tricuspid regurgitation can interfere with the validity of the thermodilution technique, typically underestimating forward flow. The Fick technique relies on the principle of mass balance proposed by Adolph Fick in 1870. Oxygen consumption (VO_2) must equal the difference in oxygen content of arterial and venous blood times the cardiac output. Assumptions can be made about oxygen consumption at rest, and arterial and venous oxygen content (CaO_2 and CVO_2) can be calculated by the hemoglobin concentration and oxyhemoglobin saturation:

$$CO = VO_2/(CaO_2 - CVO_2)$$

Goals for hemodynamic stability generally include maintenance of a mean arterial pressure between 65 and 75 mm Hg and a cardiac index of at least 2 L/min per m^2. Outcomes should be individualized, as a chronically hypertensive patient may require a higher arterial pressure to maintain satisfactory tissue perfusion, and a postoperative patient with bleeding from a tenuous aortic suture line may benefit from a more restrictive blood pressure approach. Hypotension is quite common following cardiac surgery and is often related to hypovolemia, as well as vasodilation from systemic warming and an inflammatory response from extracorporeal circulation with activation of vasodilatory mediators. Intravascular hypovolemia is extremely common in the immediate perioperative period. Causes are multifactorial and include capillary leak from inflammation, venodilation from warming, unrecognized and unreplaced blood loss, and excessive diuresis, particularly if osmotic diuretics such as mannitol are given during CPB. Patients may require 2 to 3 L of fluid in the first several hours after surgery. Those with ventricular hypertrophy and diastolic dysfunction may reauire additional fluid to maintain

cardiac output. Although not essential, the pulmonary artery catheter can be instrumental in guiding fluid resuscitation. While colloids, such as albumin and hetastarch, can reduce the total volume required to maintain stability, there are no prospective randomized data clearly demonstrating its superiority with regard to outcome benefits.

Vasoconstrictors are used to treat hypotension, but should only be initiated if the patient has been adequately fluid resuscitated and myocardial function and cardiac output is preserved. a-Agonists, such as Neo-Synephrine, will increase vascular tone without increasing contractility or heart rate and do not exacerbate dysrhythmias. Similarly, vasopressin has no effect on cardiac function, but uniquely will not increase pulmonary vascular resistance, as there are no vasopressin receptors in the pulmonary vascular bed. Additionally, vasopressin preferentially constricts efferent renal arterioles rather than afferent arterioles, resulting in maintained glomerular filtration and urine output. Norepinephrine, epinephrine, and dopamine are also frequently used to counteract a vasodilatory state. These catecholamines are also inotropic agents, which can be useful if myocardial function is depressed. However, they all increase heart rate and myocardial oxygen consumption and can be arrhythmogenic.

Myocardial dysfunction can occur from stunning after cardioplegic arrest, particularly if the cross-clamp period was long. This can be problematic if systolic function is severely depressed preoperatively. Inadequate myocardial protection from insufficient cardioplegia can also result in catastrophic and unrecoverable postoperative heart failure. Unless the heart is acutely ischemic at the time of surgery, it is unusual to expect immediate improvement in contractility after surgical revascularization. In fact, the acutely ischemic heart often tolerates CPB and cardioplegia poorly. Contractility can be globally severely depressed after emergent coronary bypass grafting in the setting of a sizable STEMI, especially if the patient was in preoperative shock. If cardiac dysfunction and low cardiac output are detected intraoperatively, careful assessment of bypass graft position and patency should be undertaken. This is especially true if new wall motion abnormalities are regional.

Once surgical problems have been corrected, efforts are made to optimize myocardial contractility. Inotropic agents will improve cardiac function and can be easily titrated to the desired effect. Catecholamines, such as dopamine, epinephrine, and dobutamine, are frequently used. All of these agents, through their effects on *b* receptors, will increase heart rate, predispose to arrhythmias, and increase myocardial oxygen consumption. Nonetheless, these agents are generally safe, particularly at low doses. Phosphodiesterase inhibitors, such as milrinone, also improve contractility and have less effect on heart rate or myocardial contractility. These agents are also vasodilators, and should be used with caution in patients who are hypotensive. Both catecholamines and phosphodiesterase inhibitors exert their inotropic effects by increasing cytosolic calcium. For these agents to be effective, there must be adequate calcium stores. Infusion of supplemental calcium often potentiates the effect of both classes of drugs. Likewise, acidosis decreases the effectiveness of inotropic agents, and normalization of blood pH, either by replacement of sodium bicarbonate or hyperventilation, can have an immediate effect on myocardial function.

When postoperative ventricular dysfunction is entirely related to myocardial stunning, inotropes should be weaned within the first 24 hours. However, if postoperative cardiogenic shock is severe and refractory to high-dose inotropic infusions, insertion of an intra-aortic balloon pump should be considered. Positioned within the thoracic aorta (Fig. 83-14), balloon pump actuation is timed with the patient's ECG or arterial pressure tracing. Inflation occurs during diastole, augmenting coronary perfusion, and deflates during systole, reducing afterload and increasing cardiac output. Insertion of a ventricular assist device may be beneficial; however, many of these patients subsequently require heart transplantation, so careful patient selection is essential.

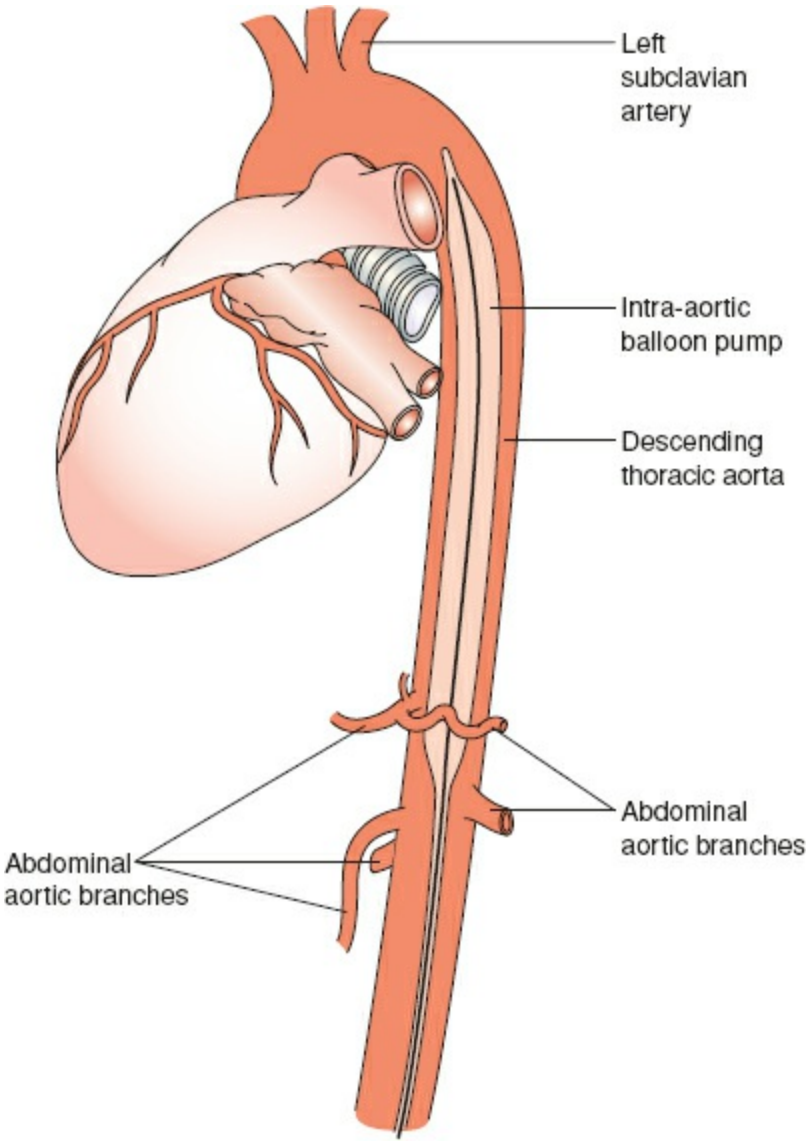

Figure 83-14. Intra-aortic balloon pump positioned within the descending thoracic aorta. The device must be positioned to not occlude the left subclavian artery or the abdominal aortic branches.

Postoperative bleeding is infrequent but can occur, especially when patients are taking irreversible platelet inhibitors. Output from mediastinal chest drains is monitored closely, and markers of coagulation are assessed. Coagulopathy should be corrected with appropriate blood component transfusions. Retransfusion of shed blood is generally avoided, as it may exacerbate coagulopathy. Return to the operating room should be considered if drainage exceeds 600 to 800 mL in 4 to 5 hours, without signs of slowing.

Inhibitors of plasminogen can be helpful in reducing postoperative coagulopathy and bleeding complications. There are three agents in this class of drug: ε-aminocaproic acid (Amicar, Xanodyne Pharmaceuticals, New Port, KY), tranexamic acid, and aprotinin (Trasylol, Bayer Leverkusen, Germany). The first two agents are synthetic binders of plasminogen or plasmin. Aprotinin is a naturally occurring serine protease inhibitor that can inhibit plasminogen, as well as many other proteases. Although meta-analysis suggested that aprotinin was superior to the other agents,[50] concerns regarding the safety of aprotinin have been raised, suggesting a higher incidence of renal failure[51] and even mortality.[52] A subsequent prospective randomized trial concluded that aprotinin was independently associated with a higher rate of death,[53] and as such its approval has been halted by the U.S. Food and Drug Administration.

There has recently been great enthusiasm for using a blood conservation strategy. Transfusion of as little as a single unit of packed red cells is independently associated with increased morbidity after coronary bypass surgery.[54] Efforts to minimize hemodilution using retrograde priming and hemofiltration can be very effective at reducing transfusion rates, but the most important adjunct to reduce blood usage is reduced transfusion triggers. Evidence exists that hemoglobin concentrations as low as 7 g/dL can be safe and are very well tolerated in intensive care unit patients.[55]

Cardiac tamponade is an infrequent but feared complication that can be fatal and is often difficult to diagnose. The classic scenario is a patient with initially high chest drainage that suddenly ceases. The patient then insidiously develops oliguria, followed by low cardiac output and refractory hypotension. Signs such as bulging neck veins, elevated central venous pressure, pulsus paradoxus, and widened mediastinal silhouette on chest radiography may be variably present. Echocardiography can establish the diagnosis by demonstrating a pericardial effusion with right atrial and right ventricular compression. However, it is important to note that echocardiography cannot rule out the diagnosis. Timely diagnosis usually requires experience and a low index of suspicion. Treatment involves immediate return to the operating room, where removal of the obstructing fluid and clot results in immediate relief of constriction and normalization of hemodynamic parameters. When tamponade occurs late, it may be treatable with percutaneous drains if the pericardial fluid content is thin and without significant clot burden.

Atrial fibrillation is extremely common following CABG, with a frequency of 25% to 30%. Its occurrence is higher for older patients and those with lung disease, and after combined CABG and valve surgery, decreased ventricular function, prolonged aortic cross-clamp period, and more severe hypothermia. Interestingly, the rate of atrial fibrillation does not appear to be reduced after off-pump CABG.[56] It most frequently occurs between the second and the fourth postoperative day, and can be precipitated by electrolyte imbalances, particularly hypokalemia or hypomagnesemia. If the rate is excessively high or the patient has significant ventricular hypertrophy, atrial fibrillation can result in hemodynamic compromise producing hypotension and oliguria. The most frequently used treatment for postoperative atrial fibrillation is amiodarone. It can achieve adequate rate control after an intravenous load of 150 mg in the majority of patients, with minimal effect on blood pressure or contractility. As a class III

antiarrhythmic, amiodarone is also very effective at facilitating conversion to sinus rhythm. When given preoperatively, amiodarone can also reduce the rate of postoperative atrial fibrillation, although bradycardia is more common in protocols that use higher doses.[57] Beta-blocking agents are also effective at achieving rate control, and when given routinely preoperatively and reinitiated immediately after surgery, they have reduced the occurrence of atrial fibrillation.[58] Diltiazem is immediately effective at controlling rapid atrial fibrillation, and is typically given as a 5- to 10-mg load, followed by a continuous infusion of 5 to 10 mg/hr. Although it is associated with hypotension, its short half-life makes this complication quite manageable. For atrial fibrillation with rapid ventricular response refractory to amiodarone, beta blockers, and diltiazem, it may be reasonable to add digoxin. This drug should be used with caution, because it is proarrhythmic. Drug concentrations should be followed and potassium levels maintained aggressively. If rapid ventricular response results in significant hemodynamic instability, electrical cardioversion should be performed. Cardioversion may also be considered if atrial fibrillation persists after 24 to 36 hours because of the risk of clot formation within the left atrial appendage. Cardioversion should not be performed if atrial fibrillation has been present for more than 48 hours. If atrial fibrillation is persistent, anticoagulation must be considered and weighed against the potential for postoperative bleeding complications. The vast majority of patients who develop atrial fibrillation after CABG will revert to sinus rhythm, and the complication rate is generally low. However, atrial fibrillation does increase the length of stay and cost of hospitalization, so efforts to reduce its incidence are necessary.

Deep sternal wound infection involving the bone occurs in approximately 0.5% to 1% of patients. Independent risk factors are obesity, diabetes, immunosuppression, use of both internal mammary arteries, chronic lung disease, and malnutrition. The most frequent organism is *Staphylococcus aureus*, although gram negatives can be seen in diabetics and immunosuppressed patients. Helpful preventative strategies include decontamination of nasal *Staphylococcus* species with mupirocin, preoperative Hibiclens wash, and tight postoperative glucose control. The diagnosis is established with sternal wound drainage and palpable sternal instability. Systemic antibiotics should be initiated and the patient returned to the operating room expeditiously for sternal débridement. Delay could result in mediastinitis with sepsis and shock. Under most circumstances, the chest wall is reconstructed with myocutaneous flaps based on the pectoralis and rectus abdominus muscles.

RESULTS OF CORONARY BYPASS GRAFTING

Overall, the mortality rate following coronary bypass grafting is between 2% and 3%. This number has been progressively declining despite rising median age and worsening severity of disease (Fig. 83-15). Improved outcomes can be attributed to advances in surgical technique, anesthetic approaches, preoperative timing and patient selection, sophistication of intensive care systems, and superior pharmacology, including antiplatelet agents, beta blockers, and statins. Increased competition, both between cardiac surgeons and with percutaneous interventionalists, and public reporting of data have undoubtedly improved efficiency and contributed significantly to better outcomes. Major morbidity is estimated to be 10% to 12%. Risk of stroke is approximately 1% to 2%, renal failure requiring renal replacement therapy is 0.5% to 1%, deep sternal wound infection is 0.5% to 1%, and need for urgent reoperation is 3% to 5%. Overall, median length of hospital stay is approximately 6 days.

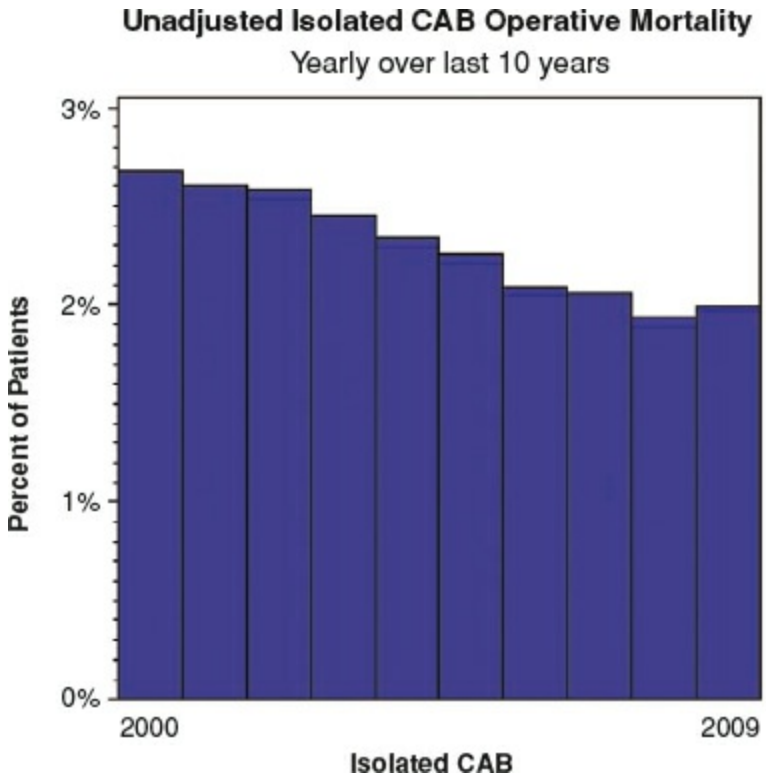

Figure 83-15. Unadjusted isolated coronary artery bypass operative mortality: 2000–2009. (This graph is reprinted from the Society of Thoracic Surgeons adult cardiac database 4th 2009 harvest report executive summary. © The Society of Thoracic Surgeons. Used with permission. All rights reserved.)

Table 83-2 Independent Predictors of Mortality Following Coronary Bypass Procedures

Variable	Odds Ratio
Age	1.05 (1.05, 1.05)
African-American race	1.34 (1.23, 1.45)
Chronic lung disease	1.41 (1.35, 1.48)
Diet controlled diabetes	1.15 (1.09, 1.21)
Insulin requiring diabetes	1.50 (1.42, 1.58)
First reoperation	2.76 (2.72, 2.91)
Immunosuppression	1.75 (1.1.57, 1.95)
Renal failure	1.88 (1.80, 1.96)
Shock	2.04 (1.90, 2.19)
Male gender	0.84 (0.80, 0.89)
NYHA class IV symptoms	1.15 (1.10, 1.20)

The STS maintains a voluntary registry for cardiac surgery outcomes. Participation throughout the United States is extremely high, and the database is generally considered an excellent representation of cardiac surgery outcomes. Overall, coronary bypass procedures have increased in volume, although at a slower pace in recent years, presumably as a result of expanded medical and percutaneous treatments. In 2008, 163,000 isolated coronary bypass procedures were submitted to the STS database. With over 1.4 million individual cases embedded in the dataset, enormous information can be obtained regarding risk factors for mortality and morbidity. Independent predictors of death are listed in Table 83-2 and include coronary reoperation, preoperative shock, dialysis dependence, immunosuppressed state, advanced age, diabetes mellitus, nonwhite race, female gender, previous stroke, advanced heart failure symptoms, peripheral vascular disease, and chronic lung disease. While the presence of these predictors are not contraindications for coronary bypass grafting, these prognostic tools are helpful both in balancing potential benefits from predicted risks and in correctly informing patients, families, and referring physicians. There are two well-described predictive models that can be used to estimate risk of death following coronary bypass surgery. Each model has been created using large voluntary registry data, one from the STS, and one created from the European registry from 128 hospitals across eight countries. Both models incorporate features related to the patients, the nature of their clinical presentation, and the planned operative intervention. Although far from perfect, both models can be very helpful in determining patient selection and preoperative optimization and in tailoring the therapy to the unique clinical circumstances.

Another risk factor for death after coronary bypass grafting that is not included in either stratification model is incomplete revascularization. Incomplete revascularization refers to failure to construct a bypass graft to a territory natively perfused by a vessel with at least a 50% proximal stenosis. Under most circumstances, the revascularization is incomplete because target vessels were unsuitable for bypassing because they were small, inaccessible, or too heavily diseased. The differences observed are typically not apparent in 30-day survival but manifest as a reduced long-term prognosis. Although the angiographic appearance of potential coronary targets may suggest unsuitability,

interpretation of vessel quality is extremely subjective and very difficult to quantify, which is why it has not been incorporated into the two large risk creation models. Nonetheless, the quality of the bypass targets should be considered when weighing the options for treatment of advanced coronary artery disease.

The purpose of coronary bypass surgery is to create unimpeded blood flow to ischemic myocardial territories. While short- and long-term mortality may reflect the adequacy of revascularization, bypass graft patency is a more precise assessment of the technical success of the operation. Patency rates are typically reported based on clinical trials in which routine angiography is performed at regular intervals, excluding biases from studies in which angiography is only performed in symptomatic patients. Saphenous vein grafts are hampered by a higher early graft loss, as much as 20% in the first year. Mechanisms include technical anastomotic problems, graft kinking, inadequate epicardial run-off, vein graft endothelial dysfunction from injury or chronic stasis, competitive flow from relatively unobstructed native coronary flow, and early development of neointimal hyperplasia. Late vein graft occlusion develops at a rate of approximately 5% per year from progressive native vessel disease and the development of accelerated vein graft atherosclerosis. Patency at 10 years is generally 40% to 50%. It remains to be seen if these outcomes improve with advances in statin and antiplatelet agents. As described previously, the internal mammary artery is generally spared of both atherosclerotic disease and early development of neointimal hyperplasia. Not surprisingly, its patency is vastly superior,[59] although these outcomes may be biased by the fact that the left internal mammary artery is typically placed on the LAD. The higher outflow of this target results in greater flow rates, reducing the risk of stagnation from limited run-off. In addition, its anterior location make it less likely to kink. Patency at 1 year is approximately 95%, and there is very little attrition over time, with 85% to 90% patency at 10 years. In fact, the use of the internal mammary artery is an independent predictor of long-term survival, presumably because of better graft outcomes.[60] The radial artery is generally intermediate to saphenous vein grafts and the internal mammary artery. Patency rates have been described as 90% at 1 year and 80% to 90% at 5 years. The radial artery is particularly prone to spasm from competitive flow, resulting in a patent but dysfunctional graft, referred to as a string sign. The radial artery should be avoided when stenotic lesions are less than 70%.

COMPARATIVE TRIALS

9 With the advent of coronary bypass surgery in the late 1960s, questions arose as to which patients are appropriate to offer this highly invasive and costly treatment. Three landmark randomized trials were constructed comparing CABG with medical treatment for a variety of patient populations. The Veterans Administration Cooperative Study,[61] the European Coronary Surgery Study,[62] and the Coronary Artery Surgery Study[63] all demonstrated that CABG improves survival as compared to medically treated patients, and the benefits of CABG are enhanced by more severe disease, as well as left ventricular dysfunction. Although these trials are now more than 30 years old and medical and surgical treatments have evolved considerably, the principles continue to apply and are repeatedly described in more contemporary series.

Although these clinical trials definitively demonstrated the superiority of CABG over medical therapy for patients with advanced coronary artery disease, the advent and widespread adoption of intracoronary balloon angioplasty raised the possibility that a less invasive approach to revascularization may be as beneficial as the surgical approach. Several multicenter clinical trials were conducted comparing CABG with angioplasty for a variety of patient populations. The most notable of these studies was the Bypass Angioplasty Revascularization Investigation, or BARI trial.[64] A total of 1,829 patients were deemed eligible and were randomized to angioplasty or CABG in 18 centers across the United States and Canada. While there were no differences for in-hospital death or 5-year survival, the rate of repeat revascularization was significantly higher in the percutaneously treated patients. Only 8% of patients in the CABG group required repeat revascularization within the first 5 years, as compared to 54% in the angioplasty group. Although survival analysis was intention to treat, 31% of patients in the angioplasty group underwent subsequent CABG. Importantly, subgroup analysis demonstrated a survival advantage at 5 years for diabetic patients treated with CABG as opposed to angioplasty (80.6% vs. 65.5%; $p = 0.003$). The BARI study demonstrated that surgical revascularization was more durable and resulted in improved survival for diabetic patients with advanced coronary artery disease.

Angioplasty alone carries a restenosis rate of 30% to 40% from at least two mechanisms. One is entirely mechanical, related to elastic recoil, and is seen within weeks of intervention. The other mechanism is related to progressive neointimal hyperplasia, likely occurring as a result of local trauma. Intracoronary stents have reduced the restenosis rate and improved outcomes of percutaneous intervention. In the setting of these advances, several multicenter, prospective, randomized trials were performed, again with the hypothesis that percutaneous intervention would be superior or equivalent to surgical revascularization for patients with advanced coronary artery disease. Among the most prominent of these studies was the SoS, or Surgery or Stent, trial.[65] A total of 988 patients from 53 medical centers in 11 countries were enrolled based on eligibility criteria, including the presence of multivessel coronary artery disease. Patients were randomly assigned to receive either coronary bypass surgery or percutaneous intervention using intracoronary stents. At a median follow-up of 2 years,

20.7% of patients in the stent arm required repeat revascularization, as compared to only 6% in the CABG arm ($p < 0.001$). Surprisingly, there was also a survival advantage seen with surgery (mortality 4.5% vs. 1.6%, stent vs. surgery, respectively; $p = 0.01$). These mortality advantages persisted with a median follow-up of 6 years (10.9% vs. 6.8%; $p = 0.02$).[66] Consistent with previous clinical trials, the survival advantage was even more pronounced for diabetics (17.6% vs. 5.4%). The SoS trial was similar to other randomized trials comparing coronary stents with CABG with respect to superior rates of repeat revascularization. However, SoS was unique in describing a mortality benefit. Some have argued that enrollment criteria were much less stringent in SoS, enrolling sicker patients with more complex anatomic lesions. SoS may therefore better reflect "real-world" practice.

Among the biggest limitations of bare metal intracoronary stents is the development of obstructing neointimal hyperplasia resulting in in-stent restenosis, which occurs at a rate of 15% to 30%. Recently, antiproliferative drugs have been incorporated into the platform of stents to inhibit this occlusive process. These drug-eluting stents have been demonstrated in prospective randomized fashion to reduce the rate of repeat revascularization, when compared to bare metal stents. Because of improved outcomes using this new technology, a prospective, multicenter, randomized trial was conducted comparing coronary bypass grafting with a strategy using drug-eluting stents for patients with left main or three-vessel coronary stenosis.[67] Eighty-five centers in the United States and Europe enrolled patients who met these criteria and whose anatomic disease was determined by both the surgeon and interventional cardiologist to be amenable to either strategy. A total of 3,075 patients were enrolled, but only 1,800 patients were randomized, 897 to CABG and 903 to PCI with the Taxus drug-eluting stent (Boston Scientific). The remaining patients were not felt to be good candidates for both procedures, and 1,077 underwent CABG and 198 underwent PCI. Outcomes of these excluded patients were collected into a separate registry. Of the randomized patients, more patients in the PCI arm had major cardiac or cerebrovascular events at 12 months (12.4% vs. 17.8%, CABG vs. PCI, respectively; $p = 0.002$). The majority of these differences were seen in the rate of repeat revascularization (5.9% vs. 13.5%; $p < 0.001$). The authors also created a numerical system to comparatively describe the complexity of the coronary anatomy. This "syntax" score was higher for chronic total occlusions, bifurcation lesions, heavily calcified vessels, and lesions greater than 20 mm in length. The differences in major cardiac or cerebrovascular events between CABG and PCI were even more pronounced in the subgroup of patients with a high "syntax" score (10.9% vs. 23.4%). This study once again demonstrated that despite improved outcomes of percutaneous treatment of coronary artery disease with drug-eluting stents, CABG remains the best therapy for patients with significant left main and three-vessel coronary artery disease. The benefits of CABG are accentuated for patients with more severe and complex disease.

These important randomized trials have consistently demonstrated that surgical coronary artery revascularization is the ideal technique to reduce symptoms, myocardial infarctions, cardiac-related future hospitalizations, and death in patients with advanced

coronary artery atherosclerosis. Improvements in nonsurgical therapy, both medical and percutaneous, have prompted recurring investigations into the comparative efficacy of coronary bypass surgery. Surgical treatment continues to successfully compete, largely because of simultaneous advances in surgical technique, intraoperative patient care, and postoperative management. Despite concerns raised every year that CABG will no longer be performed in the future, outcomes remain superior and as a result, volumes continue to rise. It is likely that surgical revascularization of the ischemic heart will continue to be the dominant strategy for many years to come.

References

1. Davies JE, Burkhart HM, Dearani JA, et al. Surgical management of anomalous aortic origin of a coronary artery. *Ann Thorac Surg* 2009;88:844–847.
2. Messer JV, Wagman RJ, Levine HJ, et al. Patterns of human myocardial oxygen extraction during rest and exercise. *J Clin Invest* 1962;41:725–742.
3. Berne RM. The role of adenosine in the regulation of coronary blood flow. *Circ Res* 1980;47:807–813.
4. Malek AM, Alper SL, Izumo S. Hemodynamic shear stress and its role in atherosclerosis. *JAMA* 1999;282:2035–2042.
5. Samnegard A, Hulthe J, Silveira A, et al. Gender specific associations between matrix metalloproteinases and inflammatory markers in post myocardial infarction patients. *Atherosclerosis* 2009;202:550–556.
6. Singh SK, Suresh MV, Voleti B, et al. The connection between C-reactive protein and atherosclerosis. *Ann Med* 2008;40:110–120.
7. Psaty BM, Lumley T, Furberg CD, et al. Health outcomes associated with various antihypertensive therapies used as first-line agents: a network meta-analysis. *JAMA* 2003;289:2534–2544.
8. Duckworth W, Abraira C, Moritz T, et al. Glucose control and vascular complications in veterans with type 2 diabetes. *New Engl J Med* 2009;360:129–139.
9. Expert Panel on Detection, Evaluation, and Treatment of High Blood Cholesterol in Adults. Executive Summary of the Third Report of the National Cholesterol Education Program (NCEP) Expert Panel on Detection, Evaluation, and Treatment of High Blood Cholesterol in Adults (Adult Treatment Panel III). *JAMA* 2001;285:2486–2497.
10. The Lipid Research Clinics Coronary Primary Prevention Trial. Results II. The relationship of reduction in incidence of coronary heart disease to cholesterol lowering. *JAMA* 1984;251:365–374.
11. Wilson K, Gibson N, Willan A, et al. Effect of smoking cessation on mortality after myocardial infarction: meta-analysis of cohort studies. *Arch Intern Med* 2000;160:939–944.
12. Hasdai D, Topol EJ, Califf RM, et al. Cardiogenic shock complicating acute coronary syndromes. *Lancet* 2000;356:749–756.
13. Hochman JS, Sleeper LA, Webb JG, et al. Early revascularization in acute myocardial infarction complicated by cardiogenic shock. SHOCK Investigators. Should we emergently revascularize occluded coronaries for cardiogenic shock. *N Engl J Med* 1999;341:625–634.
14. Bakhtiary F, Keller H, Dogan S, et al. Venoarterial extracorporeal membrane oxygenation for treatment of cardiogenic shock: clinical experiences in 45 adult patients. *J Thorac Cardiovasc Surg* 2008;135:382–388.
15. Haft JW, Pagani FD, Romano MA, et al. Short- and long-term survival of patients transferred to a tertiary care center on temporary extracorporeal circulatory support.

Ann Thorac Surg 2009;88:711–717.

16. Jeppsson A, Liden H, Johnsson P, et al. Surgical repair of post infarction ventricular septal defects: a national experience. *Eur J Cardiothorac Surg* 2005;27:216–221.
17. Russo A, Suri RM, Grigioni F, et al. Clinical outcome after surgical correction of mitral regurgitation due to papillary muscle rupture. *Circulation* 2008;118:1528–1534.
18. Vohra HA, Chaudhry S, Satur CM, et al. Sutureless off-pump repair of post-infarction left ventricular free wall rupture. *J Cardiothorac Surg* 2006;1:11.
19. Ohman EM, Armstrong PW, Christenson RH, et al., GUSTO IIA Investigators. Cardiac troponin T levels for risk stratification in acute myocardial ischemia. *N Engl J Med* 1996;335:1333–1341.
20. Tonino PA, De Bruyne B, Pijls NH, et al. Fractional flow reserve versus angiography for guiding percutaneous coronary intervention. *N Engl J Med* 2009;360:213–224.
21. Bruining N, de Winter S, Serruys PW. Intravascular ultrasound registration/integration with coronary angiography. *Cardiol Clin* 2009;27:531–540.
22. Budoff MJ, Achenbach S, Blumenthal RS, et al. Assessment of coronary artery disease by cardiac computed tomography: a scientific statement from the American Heart Association Committee on Cardiovascular Imaging and Intervention, Council on Cardiovascular Radiology and Intervention, and Committee on Cardiac Imaging, Council on Clinical Cardiology. *Circulation* 2006;114:1761–1791.
23. Ross SD, Allen IE, Connelly JE, et al. Clinical outcomes in statin treatment trials: a meta-analysis. *Arch Intern Med* 1999;159:1793–1802.
24. Yusuf S, Sleight P, Pogue J, et al. Effects of an angiotensin-converting enzyme inhibitor, ramipril, on cardiovascular events in high risk patients. *N Engl J Med* 2000;342:145–153.
25. Antiplatelet Trialists' Collaboration. Collaborative overview of randomised trials of antiplatelet therapy—I: prevention of death, myocardial infarction, and stroke by prolonged antiplatelet therapy in various categories of patients. *BMJ* 1994;308:81–106.
26. Ryden L. Efficacy of epanolol versus metoprolol in angina pectoris: report from a Swedish multicentre study of exercise tolerance. *J Intern Med* 1992; 231:7–11.
27. Chobanian AV, Bakris GL, Black HR, et al. The Seventh Report of the Joint National Committee on Prevention, Detection, Evaluation, and Treatment of High Blood Pressure: the JNC 7 report. *JAMA* 2003;289:2560–2572.
28. Chaitman BR, Skettino SL, Parker JO, et al. Anti-ischemic effects and long-term survival during ranolazine monotherapy in patients with chronic severe angina. *J Am Coll Cardiol* 2004;43:1375–1382.
29. Yusuf S, Collins R, MacMahon S, et al. Effect of intravenous nitrates on mortality in acute myocardial infarction: an overview of the randomised trials. *Lancet* 1988;1:1088–1092.

30. Rutherford JD, Pfeffer MA, Moye LA, et al., SAVE Investigators. Effects of captopril on ischemic events after myocardial infarction: results of the Survival and Ventricular Enlargement trial. *Circulation* 1994;90:1731–1738.
31. Beckwith C, Munger MA. Effect of angiotensin-converting enzyme inhibitors on ventricular remodeling and survival following myocardial infarction. *Ann Pharmacother* 1993;27:755–766.
32. Yusuf S, Zhao F, Mehta SR, et al. Effects of clopidogrel in addition to aspirin in patients with acute coronary syndromes without ST-segment elevation. *N Engl J Med* 2001;345:494–502.
33. Mehta RH, Roe MT, Mulgund J, et al. Acute clopidogrel use and outcomes in patients with non-ST-segment elevation acute coronary syndromes undergoing coronary artery bypass surgery. *J Am Coll Cardiol* 2006;48:281–286.
34. Ferguson JJ, Califf RM, Antman EM, et al. Enoxaparin vs unfractionated heparin in high-risk patients with non-ST-segment elevation acute coronary syndromes managed with an intended early invasive strategy: primary results of the SYNERGY randomized trial. *JAMA* 2004;292:45–54.
35. Yusuf S, Mehta SR, Chrolavicius S, et al. Comparison of fondaparinux and enoxaparin in acute coronary syndromes. *N Engl J Med* 2006;354:1464–1476.
36. Fibrinolytic Therapy Trialists' (FTT) Collaborative Group. Indications for fibrinolytic therapy in suspected acute myocardial infarction: collaborative overview of early mortality and major morbidity results from all randomised trials of more than 1000 patients. *Lancet* 1994;343:311–322.
37. Keeley EC, Boura JA, Grines CL. Primary angioplasty versus intravenous thrombolytic therapy for acute myocardial infarction: a quantitative review of 23 randomised trials. *Lancet* 2003;361:13–20.
38. Bradley EH, Nallamothu BK, Herrin J, et al. National efforts to improve door-to-balloon time: results from the door-to-balloon alliance. *J Am Coll Cardiol* 2009;54:2423–2429.
39. Di Lorenzo E, Sauro R, Varricchio A, et al. Long-term outcome of drug-eluting stents compared with bare metal stents in ST-segment elevation myocardial infarction: results of the paclitaxel- or sirolimus-eluting stent versus bare metal stent in primary angioplasty (PASEO) randomized trial. *Circulation* 2009;120:964–972.
40. van Werkum JW, Heestermans AA, Zomer AC, et al. Predictors of coronary stent thrombosis: the Dutch Stent Thrombosis Registry. *J Am Coll Cardiol* 2009;53:1399–1409.
41. Patel MR, Dehmer GJ, Hirshfeld JW, et al. ACCF/SCAI/STS/AATS/AHA/ ASNC 2009 appropriateness criteria for coronary revascularization. *Circulation* 2009;119:1330–1352.
42. Lopes RD, Hafley GE, Allen KB, et al. Endoscopic versus open vein-graft harvesting in coronary-artery bypass surgery. *N Engl J Med* 2009;361:235–244.

43. Savage EB, Grab JD, O'Brien SM, et al. Use of both internal thoracic arteries in diabetic patients increases deep sternal wound infection. *Ann Thorac Surg* 2007;83:1002–1006.
44. Shroyer AL, Grover FL, Hattler B, et al. On-pump versus off-pump coronary-artery bypass surgery. *N Engl J Med* 2009;361:1827–1837.
45. Mehran R, Dangas G, Stamou SC, et al. One-year clinical outcome after minimally invasive direct coronary artery bypass. *Circulation* 2000;102:2799–2802.
46. Zhao DX, Leacche M, Balaguer JM, et al. Routine intraoperative completion angiography after coronary artery bypass grafting and 1-stop hybrid revascularization results from a fully integrated hybrid catheterization laboratory/operating room. *J Am Coll Cardiol* 2009;53:232–241.
47. Ishikawa N, Watanabe G, Iino K, et al. Robotic internal thoracic artery harvesting. *Surg Today* 2007;37:944–946.
48. de Canniere D, Wimmer-Greinecker G, Cichon R, et al. Feasibility, safety, and efficacy of totally endoscopic coronary artery bypass grafting: multicenter European experience. *J Thorac Cardiovasc Surg* 2007;134:710–716.
49. Bonatti J, Schachner T, Bonaros N, et al. Robotic totally endoscopic double-vessel bypass grafting: a further step toward closed-chest surgical treatment of multivessel coronary artery disease. *Heart Surg Forum* 2007;10:E239–E242.
50. Levi M, Cromheecke ME, de Jonge E, et al. Pharmacologic strategies to decrease excessive blood loss in cardiac surgery: a meta-analysis of clinically relevant end points. *Lancet* 1999;354:1940–1947.
51. Mangano DT, Tudor IC, Dietzel C. The risk associated with aprotinin in cardiac surgery. *N Engl J Med* 2006;354:353–365.
52. Mangano DT, Miao Y, Yuylsteke A, et al. Mortality associated with aprotinin during 5 years following coronary artery bypass surgery. *JAMA* 2007;297:471–479.
53. Fergusson DA, Hebert PC, Mazer CD, et al. A comparison of aprotinin and lysine analogues in high risk cardiac surgery. *N Engl J Med* 2008;358:2319–2331.
54. Koch CG, Li L, Duncan AI, et al. Morbidity and mortality risk associated with red blood cell and blood-component transfusion in isolated coronary artery bypass grafting. *Crit Care Med* 2006;34:1608–1616.
55. Hébert PC, Wells G, Blajchman MA, et al. A multicenter, randomized, controlled clinical trial of transfusion requirements in critical care. *N Engl J Med* 1999;340:409–417.
56. Salamon T, Michler RE, Knott KM, et al. Off-pump coronary artery bypass grafting does not decrease the incidence of atrial fibrillation. *Ann Thorac Surg* 2003;75:505–507.
57. Daoud EG, Strickberger SA, Man KC, et al. Preoperative amiodarone as prophylaxis against atrial fibrillation after heart surgery. *N Engl J Med* 1997;337:1785–1791.
58. Crystal E, Connolly SJ, Sleik K, et al. Interventions on prevention of postoperative

atrial fibrillation in patients undergoing heart surgery: a meta-analysis. *Circulation* 2002;106:75–80.

59. Sabik JF, Lytle BW, Blackstone EH, et al. Comparison of saphenous vein and internal thoracic artery graft patency by coronary system. *Ann Thorac Surg* 2005;79:544–551.
60. Loop FD, Lytle BW, Cosgrove DM, et al. Influence of the internal-mammary-artery graft on 10-year survival and other cardiac events. *N Engl J Med* 1986;314:1–6.
61. Detre KM, Takaro T, Hultgren H, et al. Long-term mortality and morbidity results of the Veterans Administration randomized trial of coronary artery bypass surgery. *Circulation* 1985; 72(Suppl V):84–89.
62. Varnauskas E. Twelve-year follow-up of survival in the randomized European Coronary Surgery Study. *N Engl J Med* 1988;319:332–337.
63. Myers WO, Gersh BJ, Fisher LD, et al. Medical versus early surgical therapy in patients with triple-vessel disease and mild angina pectoris: a CASS registry study of survival. *Ann Thorac Surg* 1987;44:471–486.
64. Comparison of coronary bypass surgery with angioplasty in patients with multivessel disease. The Bypass Angioplasty Revascularization Investigation (BARI) Investigators. *N Engl J Med* 1996;335:217–225.
65. The SoS Investigators. Coronary artery bypass surgery versus percutaneous coronary intervention with stent implantation in patients with multivessel coronary artery disease: a randomised controlled trial. *Lancet* 2002;360:965–970.
66. Booth J, Clayton T, Pepper J, et al. Randomized, controlled trial of coronary artery bypass surgery versus percutaneous coronary intervention in patients with multivessel coronary artery disease: six-year follow-up from the Stent or Surgery Trial (SoS). *Circulation* 2008;118:381–388.
67. SYNTAX Investigators. Percutaneous coronary intervention versus coronary-artery bypass grafting for severe coronary artery disease. *N Engl J Med* 2009;360:961–972.

Chapter 84

Mechanical Circulatory Support for Cardiac Failure

Gordan Samoukovic and Francis D. Pagani

Key Points

1 The term "mechanical circulatory support" (MCS*) refers to a broad array of cardiac support devices distinguished by the following important features: location of the pumping chamber of the device, ventricle being supported, and pumping mechanism.

2 Indications for MCS include bridge to recovery, bridge to transplantation, and destination therapy (permanent implantation as an alternative to transplantation).

3 The major types of devices utilized for bridge to recovery are temporary, extracorporeal systems that can be inserted percutaneously.

4 Devices utilized for bridge to transplantation or destination therapy are durable, long-term devices requiring major operative implantation that facilitate patient discharge from the hospital with untethered "hands-free" mobility.

5 Delay in establishing any type of MCS results in a greater acuity and severity of illness increasing the need for biventricular support (as opposed to just left ventricular support alone). Patients requiring biventricular support have a decreased survival secondary to a greater degree of organ failure present at implant.

6 Patient selection is the most important factor in determining outcome of patients who receive MCS.

7 Major adverse events following initiation of MCS are those related to anticoagulation therapy (i.e., bleeding and hemorrhagic stroke) necessary during MCS, infection, right-sided heart failure, and the malfunction of the device (i.e., mechanical or electrical failure and pump thrombosis).

8 The Interagency Registry of Mechanically Assisted Circulatory Support (INTERMACS) is a National Institutes of Health-funded data registry to study outcomes for patients with durable, long-term implantable MCS devices.

9 Major technologic advances in device designs for temporary and long-term durable devices have incorporated continuous-flow rotary pumps with an axial or centrifugal blood flow path.

INTRODUCTION

1 The term “mechanical circulatory support” (MCS) refers to a broad array of cardiac support devices. These devices are distinguished by the following important features: (1) location of the pumping chamber of the device (extracorporeal vs. intracorporeal or “implantable”; (Fig. 84-1) (2) ventricle being supported (left ventricular assist device [LVAD] vs. right ventricular assist device [RVAD] vs. biventricular assist device [BiVAD] vs. total artificial heart [TAH]); (Fig. 84-2) and (3) pumping mechanism (pulsatile, volume displacement device vs. continuous-flow rotary device with axial or centrifugal design (Fig. 84-3). Generally, the pumping chamber of short-term support devices is extracorporeal or paracorporeal in location, while so-called “durable” long-term systems are generally intracorporeal (implantable).

INDICATIONS FOR MCS AND DEVICE SELECTION

The spectrum of MCS therapy encompasses several indications for use and a broad range of MCS device designs. Currently, there are three accepted indications for MCS based upon regulatory oversight by the U.S. Food and Drug Administration (FDA), reimbursement criteria set by the Centers for Medicare & Medicaid Services, and historical use of MCS therapy.

2 3 "Bridge to Recovery" (BTR) refers to the use of MCS in patients who are presenting with acute cardiogenic shock or decompensated heart failure, where the "optimal" medical therapy, including intravenous inotropes and/or vasoconstrictors, has failed. These patients are thought to have an expectation of myocardial recovery following a short period of temporary MCS (generally days to weeks). The short-term utilization of MCS for BTR is the most common application of MCS in the United States.[1] Examples of reversible forms of myocardial injury include acute myocardial infarction, viral myocarditis, or postcardiotomy cardiogenic shock with failure to separate from cardiopulmonary bypass (CPB) following various cardiac surgical procedures. Several types of devices can provide temporary MCS in these circumstances and include an intra-aortic balloon pump (IABP), extracorporeal ventricular assist device (VAD), or extracorporeal membrane oxygenation (ECMO)/extracorporeal life support (ECLS).[1] Generally, temporary MCS devices are implanted percutaneously allowing for rapid initiation of support and facilitating removal once cardiac function returns.[1] Certain types of extracorporeal VAD systems require major operative procedures with sternotomy for insertion. These types of systems are generally utilized for postcardiotomy support where access to the mediastinum is facilitated by prior sternotomy performed initially for the open heart operation.

4 The second indication for MCS applies to patients presenting in cardiogenic shock or decompensated heart failure refractory to optimal medical management where myocardial function is unlikely to recover and the patient is considered a candidate for heart transplantation. Durable MCS devices designed for long-term support as a BTT (Bridge to Transplant) and permit untethered patient mobility with discharge from the hospital are appropriate devices for this indication. Implantation of these types of MCS devices requires a major operative procedure usually including CPB and is ideal for patients who are hemodynamically stable with advanced symptoms and/or inotrope dependence in the absence of significant end-organ dysfunction or cardiogenic shock.

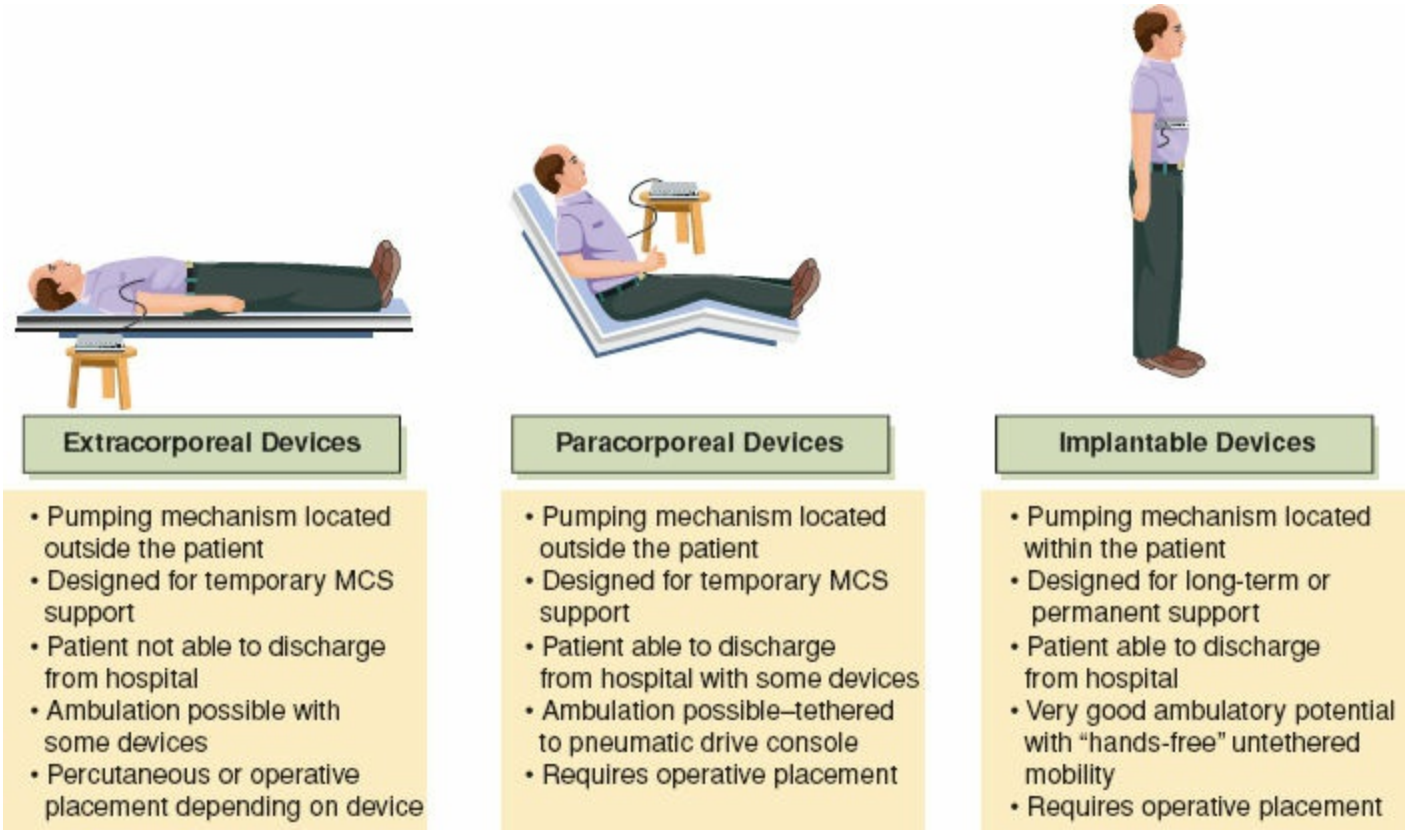

Figure 84-1. Classification of mechanical circulatory support devices by location of the pumping mechanism (extracorporeal, paracorporeal, and implantable).

The third indication for MCS applies to hemodynamically stable patients with chronic refractory symptoms of advanced heart failure due to irreversible forms of cardiomyopathy, but who are not eligible for heart transplantation. The application of long-term, durable MCS in this setting is termed "destination therapy" (DT). Similar to the BTT group, DT patients require long-term, durable, and reliable MCS devices permitting untethered "hands-free" patient mobility at home.[2] Long-term, durable MCS devices are implantable and require a major operative procedure for placement and are ideally placed in patients with significant symptoms of advanced heart failure refractory to optimal medical management but with stable hemodynamics. The survival, functional, and quality-of-life benefit of MCS for DT for the treatment of chronic advanced heart failure was established in a prospective, randomized trial known as the REMATCH Trial (**R**andomized **E**valuation of **M**echanical **A**ssistance in the **T**reatment of **C**ongestive **H**eart Failure).[2] This prospective, randomized trial evaluated the use of an implantable LVAD compared with optimal medical therapy for refractory chronic advanced heart failure. LVAD therapy significantly reduced (relative risk, 0.52; 95% confidence limit, 0.34–0.78 at 1 year) the mortality seen in the control population treated with optimal medical therapy at both 1-year and 2-year follow-up. Despite serious adverse events attributable to MCS from infection, bleeding, and device malfunction, LVAD recipients had an improved survival rate and experienced a superior quality of life compared to the medical therapy group. Currently, patients evaluated for DT must meet the following specific criteria: (1) New York Heart Association Class IV or American Heart Association Stage D heart failure symptoms; (2) a left ventricular ejection fraction of $<25\%$; (3) a peak

exercise oxygen consumption of <14 mL/kg/min (if unable to exercise be dependent on intravenous inotropes for 14 days or intra-aortic balloon pump therapy for 7 days); and (4) significant functional limitations despite the use of maximally tolerated doses of drugs outlined in the recent guidelines for heart failure treatment for at least 45 of the last 60 days.[3]

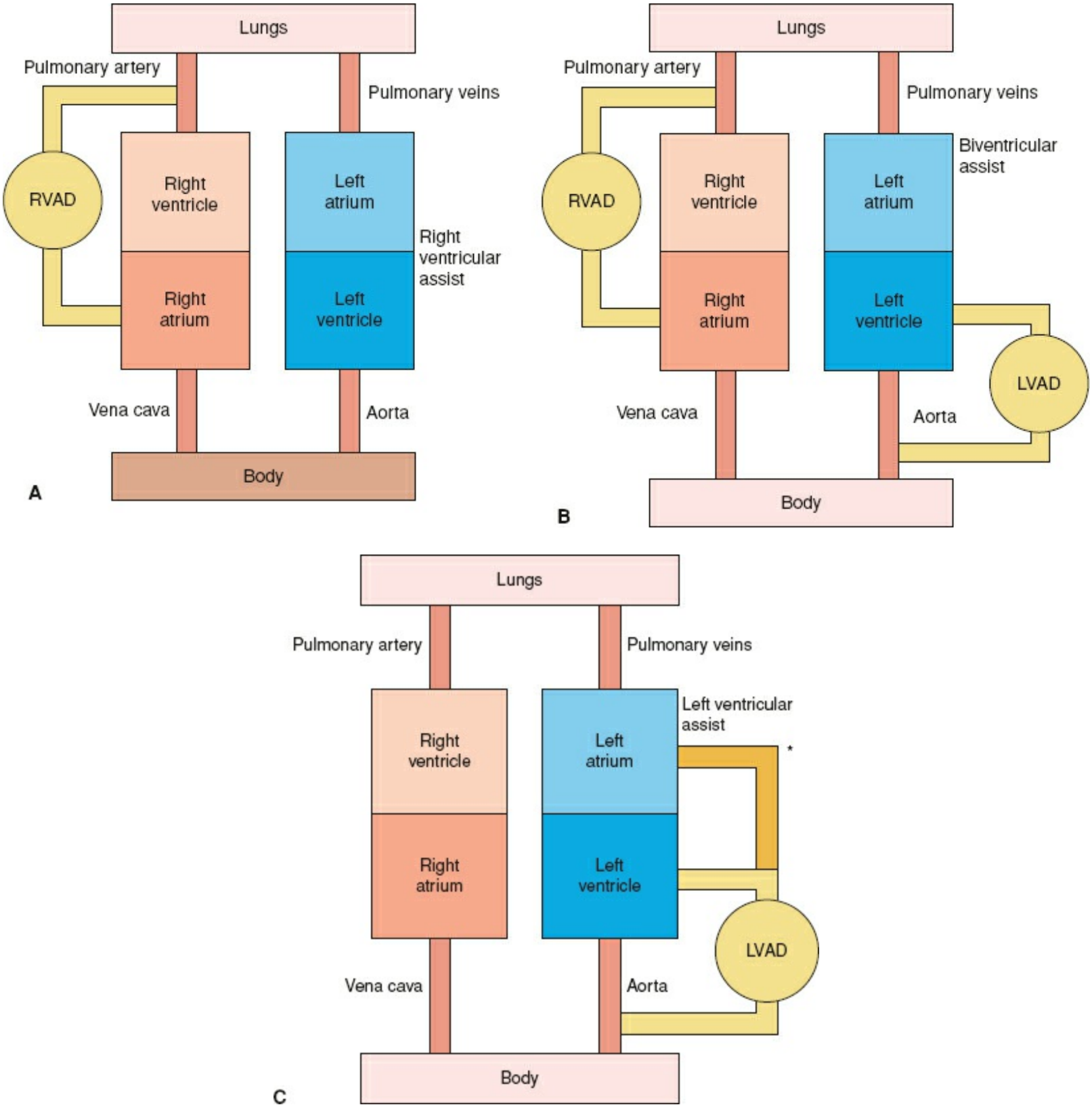

Figure 84-2. Classification of mechanical circulatory support devices by the ventricle being assisted (**A:** right ventricular assist, **B:** biventricular assist, and **C:** left ventricular assist).

The intended use and indication for MCS significantly influence MCS device selection and use. The decision to initiate MCS must be individualized and based upon the intended use, clinical setting, along with patient variables and condition, type of MCS devices available, and FDA approval and guidelines for use of each specific device. The paradigms of BTR, BTT, and DT have become integrated into the MCS-treatment algorithm, currently delivered by clinicians, regulatory agencies, and insurance payers. These paradigms do not consistently describe all clinical situations and realities of patient care and the separation of patients into BTT and DT populations has been problematic.[4] During an acute illness, many patients may fall into a gray zone with comorbidities that prevent consideration for heart transplantation but may reverse over time. Thus, clinicians may not have a clear assessment of heart transplant eligibility at the time of MCS device implant. These patients are frequently categorized as "bridge to decision or bridge to candidacy." In an attempt to normalize end-organ function that currently precludes long-term heart replacement therapies, these patients are often supported using ECMO or short-term single or BiVADs as a bridge to a durable long-term MCS device. In such cases, even if a contraindication to heart transplant existed at the time of durable MCS device implant, this contraindication may resolve with long-term MCS therapy and the patient may ultimately receive a heart transplant. The category of "bridge to candidacy" is currently not recognized by regulatory agencies but it is likely that indications for MCS will continue to evolve in the future.

TIMING OF MCS INTERVENTION

Cardiogenic Shock and Acute Heart Failure

Although established criteria for initiation of MCS do not exist and there is wide variability in clinical practice,[1] the timing of implant is paramount and directly affects outcomes. Generally, patients presenting with acute forms of myocardial injury have recognizable hemodynamic changes – a cardiac index of less than 2.2 L/min/m^2, systolic blood pressure less than 90 mm Hg, pulmonary capillary wedge pressure higher than 20 mm Hg, right atrial pressure higher than 18 mm Hg, and evidence of tissue malperfusion and multi-organ dysfunction, despite optimal medical therapy. Patient history and overall clinical setting also need to be considered in the decision to initiate MCS. When patients reach this degree of hemodynamic compromise, the mortality risk is substantial and frequently exceeds 50% at 30 days despite the availability of optimal medical therapy, invasive circulatory monitoring, thrombolysis, and IABP support.[5,6]

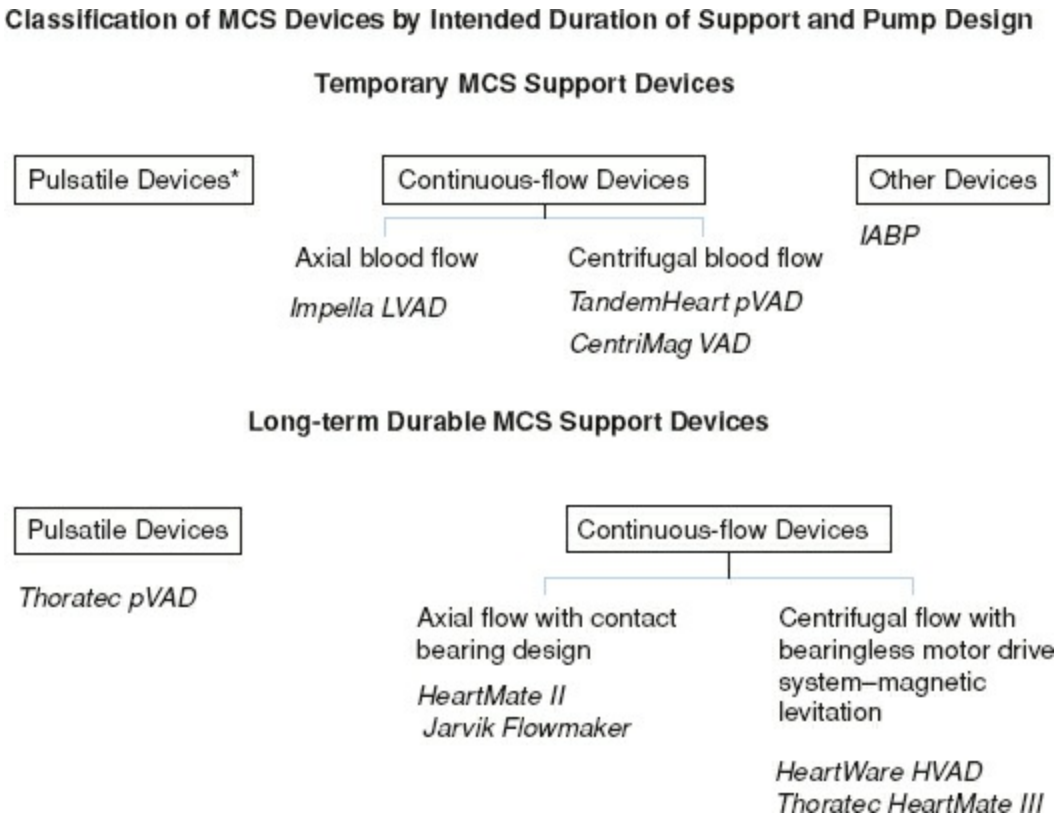

Figure 84-3. Classification of mechanical circulatory support devices by intended duration of support and pumping mechanism (pulsatile, volume displacement, or continuous-flow rotary pumps). (Impella, Abiomed Corporation, Danvers, MA; Thoratec pVAD, HeartMate II, HeartMate III, Thoratec Corporation, Pleasanton, CA; CardioWest TAH, Syncardia Systems, Tucson, AZ; TandemHeart pVAD, CardiacAssist Corporation, Pittsburgh, PA; CentriMag VAD, Levitronix LLC, Waltham, MA; Jarvik LVAD, Jarvik Heart Corporation, New York, NY; HVAD LVAD, HeartWare Corporation, Miami, FL)

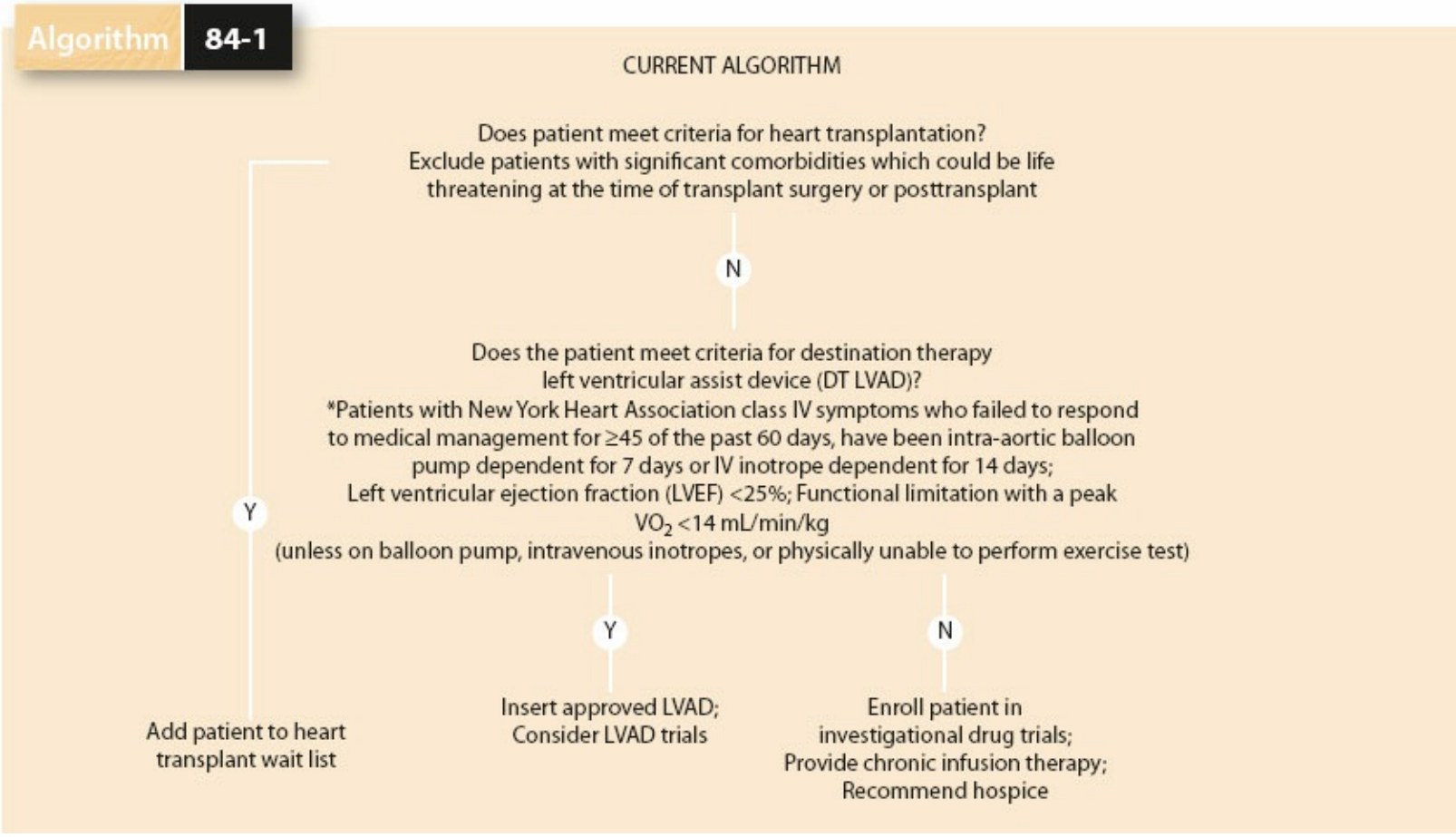

Algorithm 84-1. Current algorithm for assessing patients with advanced heart failure for heart transplantation and mechanical circulatory support. Transplant status is initially assessed to determine appropriate indication for MCS use; BTT vs. DT. (Adapted from Mancini D, Colombo PC. *J Am Coll Cardiol* 2015; 65(23):2542–2555, with permission.)

5 Data from the Abiomed BVS 5000 registry demonstrated that delay in initiating temporary MCS for more than 6 hours in the context of postcardiotomy shock or after failure to separate from CPB is associated with a significant decrease in survival rate; 44% versus 14%.[7] Delay in instituting any type of MCS with rapid progression of multiorgan failure increases the need for biventricular support as opposed to LVAD support alone.[8–12] Similarly, an episode of cardiac arrest prior to the initiation of MCS significantly impacts survival rate, decreasing it from 47% to only 7%.[7]

Chronic Heart Failure

More subtle indications to initiate MCS may be present, particularly in the group of patients suffering from chronic advanced heart failure who are being evaluated for BTT or DT. These indications include dyspnea at rest or with any or minimal effort and accompanied by resting tachycardia, progressive organ dysfunction (reflected in worsening renal or hepatic parameters), limited functional capacity, and poor quality of life despite optimal medical management with or without inotrope therapy. Deterioration in end-organ function or progressive decline in functional performance may occur in the absence of a significant change in hemodynamic parameters due to chronic adaptation to low cardiac output. In addition, patients who do not tolerate optimal medical management and experience renal insufficiency or hypotension in the setting of optimal doses of ACE inhibitors or beta blockers, as well as those who do not tolerate inotrope therapy due to refractory ventricular arrhythmias or have life-threatening coronary disease may benefit from MCS therapy (Algorithm 84-1).

Dependence on intravenous inotropes has traditionally been considered the threshold that prompts consideration of MCS[13–15] (Fig. 84-4). However, patients with advanced systolic heart failure are currently eligible for DT therapy even if they are not dependent on inotropes, provided they meet indications for DT therapy. Only 18% of durable adult LVADs are currently implanted in patients not yet dependent on intravenous inotropes.[13,14] Low implant rates in ambulatory advanced heart failure (noninotrope dependent) may reflect reluctance of both physicians and patients.[15] Ambulatory patients with advanced heart failure should have ongoing discussions about the trade-offs of living with heart failure in comparison with undergoing LVAD implantation to identify preferences and thresholds for considering elective LVAD therapy. Evidence to guide LVAD use before inotrope dependence is growing.[16]

PATIENT SELECTION AND INFLUENCE OF COMORBIDITIES ON OUTCOMES

6 Patient selection is a paramount in determining outcome in patients requiring MCS. Generally, patients should be excluded from consideration for MCS in situations where cardiac recovery is unlikely and/or heart transplantation and DT are not feasible. Under these circumstances, MCS support is generally considered futile. Other relative contraindications to MCS include irreversible renal, hepatic or respiratory failure, sepsis, or a significant cognitive deficit.

Renal Function

Renal dysfunction in context of MCS has consistently been associated with increased morbidity and mortality rates.[17,18] It is usually secondary to shock-related malperfusion and high central venous pressures but may also be worsened by drugs frequently used for heart failure therapy. Acute renal failure requiring renal replacement therapy is not necessarily a contraindication to short-term MCS but may be more of an obstacle to successful long-term MCS therapy for BTT or DT. In the setting of cardiogenic shock complicated by acute renal failure, reestablishing normal hemodynamics may facilitate resolution of the renal failure in a relatively short period of time. Duration of cardiogenic shock along with the patient's baseline renal function, therefore, plays an important role predicting the probability of recovery of renal function.

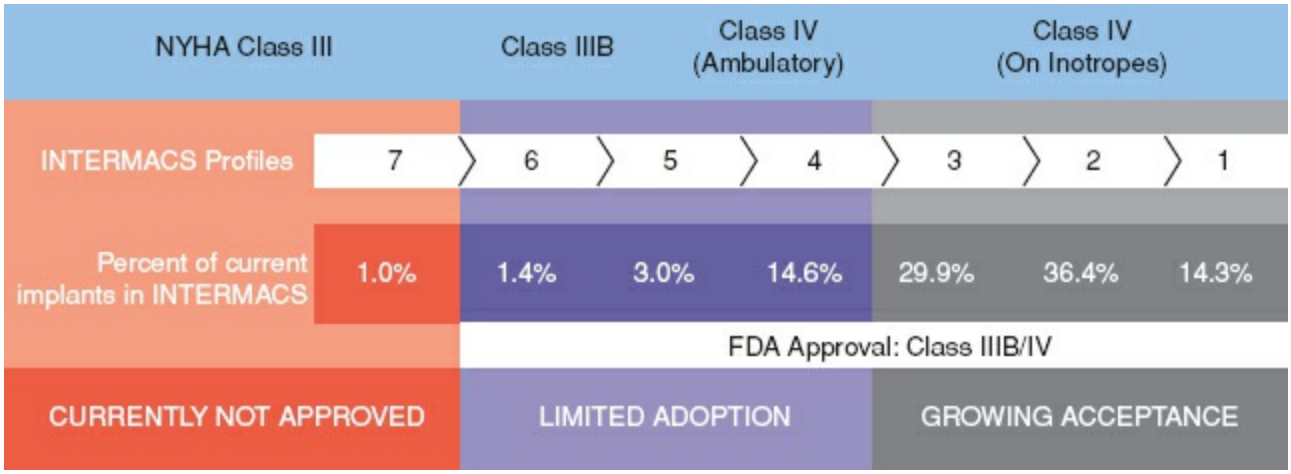

Figure 84-4. INTERMACS scale for classifying patients with advanced heart failure. Percent of implants by INTERMACS profile. Current U.S. Food and Drug Administration (FDA) approval status and acceptance in the medical community. (Adapted from Mancini D, Colombo PC. *J Am Coll Cardiol* 2015;65(23):2542–2555, with permission.)

Pulmonary Function

Cardiac failure may result in a restrictive pulmonary limitation that frequently improves as MCS aids with removal of interstitial fluid and intrathoracic effusions. Patients with a history of smoking or intrinsic lung disease identified by significant abnormalities on pulmonary function testing warrant high-resolution computed tomography to characterize the lung disease and exclude thromboembolic etiology. Echocardiography is used to rule out an intracardiac shunt. Patients with severe pulmonary disease may have a fixed pulmonary vascular resistance (not responsive to pulmonary artery vasodilators). High fixed pulmonary vascular resistance (generally >6 wood units) represents a contraindication to heart transplantation and thus BTT indication. Perioperative hypoxia as a result of significant underlying lung disease may also contribute to pulmonary vasoconstriction leading to right-sided heart failure following initiation of LVAD support. Moderate elevations in pulmonary vascular resistance can be encountered in patients with cardiogenic shock and does not preclude the successful use of MCS if reversibility or significant decrease in the pulmonary vascular resistance is achieved with inotropes or pulmonary vasodilators.

Liver Function

Previous studies have reported that total bilirubin levels and hepatic cellular enzymes more than three times normal are independent risk factors for adverse outcomes.[18,19] The etiology of the hyperbilirubinemia may be multifactorial, resulting from any combination of congestive hepatopathy, cholestasis, primary biliary, or infectious or parenchymal disease. Abnormal liver function is often associated with abnormal coagulation and low serum albumin. Attempts should be made to normalize the liver function prior to initiation of durable MCS. The presence of portal hypertension with liver cirrhosis is a contraindication to MCS. Any history of significant alcohol use should be reviewed in potential MCS patients, especially in those showing abnormalities in routine liver function tests. Patients should also be tested for presence of infectious agents such as hepatitis A, B, or C or other viruses. Liver ultrasonography is an important screening modality for patients with significant hepatomegaly and can rule out infiltrative disease, mass or other pathology that may warrant biopsy. Improvement in hepatic congestion and recovery of synthetic functions of the liver typically occur with institution of MCS.

Right-Sided Heart Failure

Left ventricular dysfunction frequently leads to coexisting right-sided heart failure. Right-sided heart failure is an important cause of mortality and morbidity following initiation of MCS and often necessitates biventricular support.[8–12,20–22] Patients with a nonischemic etiology of heart failure are three to four times more likely to require BIVAD support. These patients tend to present with early signs of renal, pulmonary, and hepatic dysfunction. BiVAD support is associated with lower survival during both short- and long-term MCS. Preoperative optimization of RV function with a goal of lowering the right atrial pressure lower than 15 mm Hg is important in reducing the need for postoperative RV support. The higher the pulmonary wedge pressure at the time of device implantation, the greater the benefit of LV decompression and hence, reduction in RV afterload that reduces the need for BIVAD support. Early adverse influences of LVAD support on RV function include a reduction in LV pressure over that of RV pressure that causes a leftward shift of the interventricular septum, causing distention of the RV and impairing systolic function of the RV by reducing the significant septal contribution to RV contractility.[23–25]

Coagulation Parameters

Coagulopathy is a common abnormality encountered in patients with refractory heart failure. An abnormal international normalized ratio (INR) in the absence of warfarin therapy is of added concern, as it may reflect chronically high right atrial pressures, leading to congestive hepatopathy and eventually fibrosis and cirrhosis. Prolonged abnormal INR and low platelet count combined with the use of anticoagulation or antiplatelet therapy are associated with significant perioperative bleeding, requiring multiple transfusions, which frequently lead to elevation of pulmonary vascular resistance, RV failure, hemodynamic instability, and multiorgan failure.[26,27] In addition, these patients are frequently malnourished and lack substrates for the liver's synthetic pathways, including those of coagulation factors, particularly factor VII. The preoperative screening for coagulation abnormalities should include prothrombin time (PT), partial thromboplastin time, INR, platelet count, platelet aggregation studies, and possibly a heparin-induced thrombocytopenia (HIT) assay. The presence or development of HIT is associated with a high risk of bleeding as well as thrombosis of MCS devices.[28]

Nutrition

Malnutrition is an important contributor to morbidity among patients on MCS. A serum albumin lower than 3.3 mg/dL appears to increase the mortality rate 6.6 times in the DT population of LVAD patients.[29,30] Significant nutritional deficiency is often associated with poor wound healing, an increased risk of infection and impaired T-lymphocyte function. Patients whose body mass index is either less than 22 or more than 36 are at risk for perioperative complications. Generally, survival of MCS patients is more adversely impacted by cachexia than obesity. Cachexia is often due to poor appetite due to elevated tumor necrosis factor and other cytokines, limitations in exertion and work of breathing, and early satiety in those with significant hepatomegaly. Delay in instituting MCS therapy may be warranted for several weeks when feasible to allow improvement of the nutritional status, preferably by enteral supplementation. Early aggressive caloric supplementation in the postoperative period is critical in preventing malnutrition and rebuilding nutritional stores.

OTHER IMPORTANT MEDICAL CONSIDERATIONS WHEN INITIATING MCS

Valvular Heart Disease

Abnormalities of the cardiac valves have important adverse consequences in patients considered for MCS and may require repair or replacement in order to successfully initiate MCS and achieve weaning from support. Mild to moderate aortic stenosis in the absence of insufficiency is not a contraindication to implantation of an MCS device. Severe aortic stenosis, however, should be corrected, preferably with a bioprosthetic valve. This is thought to facilitate future weaning and optimize native heart function if the indication for device implantation is for myocardial recovery. The presence of greater than mild aortic insufficiency can have a significant impact on the effectiveness of MCS therapy as it leads to LV distention and a decrease in subendocardial blood flow. In cases where MCS support is established via LV apical cannulation (more commonly with implantable MCS devices used for BTT or DT), reductions in LV end-diastolic pressure elicited by MCS increase the pressure gradient across the aortic valve and increase the degree of aortic insufficiency, decreasing net forward flow and compromising end-organ perfusion. The presence of aortic insufficiency can be confirmed by perioperative echocardiography and addressed by either AV replacement with a bioprosthesis or repair.[31] Patients with a mechanical valve prosthesis in the aortic valve position should have the mechanical valve replaced with a bioprosthetic valve prior to institution of LV assistance. During unloading of the LV by an LVAD, the aortic valve may not open and the mechanical valve may be prone to thrombosis. Development of aortic insufficiency after LVAD implantation may be addressed at a later date with aortic valve replacement, via either open surgical or transcatheter aortic valve replacement.[32,33]

Patients with significant mitral stenosis at the time of initiation of device support may require correction of the valvular problem before implantation of a device depending on device selection and site of cannulation. In the setting of significant mitral stenosis, LV filling is impaired, and VADs requiring apical ventriculotomy for ventricular drainage may experience limitations in device filling. This problem can be circumvented either by choosing a device that can utilize left atrial cannulation or by correcting the underlying valvular pathology (mitral valve repair or replacement with a bioprosthetic valve). Mitral regurgitation likely does not have an impact on the filling of a VAD. In situations where weaning from MCS may be feasible, correction of the mitral pathology (stenosis or regurgitation) is necessary to optimize ventricular function.

Adequate RV function is extremely important to maintain LVAD flow in the early postoperative period. Significant degrees of tricuspid regurgitation (present preoperatively or resulting from septal shift following implantation of an LVAD) can impair the flow of blood from the RV, particularly in situations of high pulmonary vascular resistance. Tricuspid regurgitation and RV dilatation contribute to elevated central venous pressure, hepatic congestion, and renal dysfunction.[20–25] It is generally recommended that moderate or more degrees of tricuspid regurgitation be repaired at the

time of LVAD implant to improve RV performance.

Coronary Artery Disease

Patients with significant obstructive coronary artery disease or patients with postcardiotomy shock following failed coronary bypass operations may experience angina during MCS. Generally, coronary artery disease does not have adverse hemodynamic consequences during the period of MCS. However, the presence of obstructive coronary disease with ongoing ischemia may limit the degree of myocardial recovery and impact the ability to wean from temporary MCS. The presence of coronary disease may contribute to ongoing myocardial ischemia and increase the risk of ventricular arrhythmias for patients supported with temporary or durable MCS.

Perioperative ischemia of the RV may be of hemodynamic significance during initiation of LVAD support. In patients who have had coronary bypass surgery and are candidates for MCS, patent bypass grafts, particularly to the right coronary artery or left anterior descending coronary artery should be preserved to reduce the risk of perioperative RV failure and arrhythmias. In highly selected situations, it may be important to perform a coronary artery bypass to the right coronary artery or left anterior descending coronary artery systems to optimize RV or septal function in the perioperative period. Routine bypass grafting of the right coronary artery is not warranted.

Arrhythmias

Atrial and ventricular arrhythmias are common in patients with cardiogenic shock and underlying cardiomyopathies. These rhythm disturbances generally persist in the immediate postoperative period and subsequently resolve with time as the hemodynamic condition of the patient improves and inotrope therapy is weaned. Recent experience has revealed that the hemodynamic consequences of ventricular arrhythmias in the late postoperative period are generally not life-threatening. In the absence of pulmonary hypertension and elevated pulmonary vascular resistance, patients may maintain life-sustaining degrees of LVAD flows during ventricular fibrillation via Fontan-like (systemic vein to pulmonary artery) circulation.[34] In the early perioperative period, some patients with refractory ventricular arrhythmias may require biventricular support until the pulmonary vasculature resistance drops and a Fontan circulation is tolerated. In situations where weaning from MCS is feasible or planned, elimination of the ventricular arrhythmias with antiarrhythmic therapy is essential.

The majority of patients undergoing implantation of a long-term durable VAD for either BTT or DT indications have an implantable cardiac defibrillator (ICD) in place for either primary or secondary prevention of ventricular arrhythmias as part of their care for advanced heart failure. Generally, these device therapies are continued following VAD implantation. Currently, for those patients who do not have an ICD at the time of VAD implant, International Society for Heart and Lung Transplantation (ISHLT) guidelines recommend routine evaluation for ICD therapy.[35] The survival benefit of ICD therapy in the setting of VAD support is, however, controversial with some studies identifying benefit and other studies finding no additional survival benefit over that obtained with VAD implantation alone.[36]

Intracardiac Shunts

Intracardiac shunts (atrial septal defects or patent foramen ovale) identified by transesophageal echocardiography prior to surgery should be closed at the time of implantation of a VAD to prevent right to left shunting.[37] As LV assistance is initiated, left atrial pressure can be reduced compared with right atrial pressures causing shunting of deoxygenated blood from the right atrium into the left resulting in systemic hypoxemia.

PATIENT OUTCOMES AND MAJOR ADVERSE EVENTS FOLLOWING INITIATION OF MCS

7 Survival and occurrence of significant adverse events following initiation of MCS therapy are dependent on the clinical presentation, indication for MCS therapy, and type of device implanted. Bleeding, stroke and thromboembolism, infection, and RV failure are the most frequent complications that occur in the early postoperative period following initiation of MCS and are more commonly encountered when devices are implanted in an emergency situation. Major adverse events most common in the late postoperative period include bleeding and thromboembolic events (e.g., stroke) with or without associated device failure.

Bleeding

Bleeding is a frequent, early complication in patients supported by MCS and may require reoperation in the early postoperative period. Risk factors for bleeding include preoperative hepatic congestion and failure, poor preoperative nutritional status, prolonged CPB times, extensive surgical dissection, reoperative surgery, multiple cannulation sites, decreased platelet function, and induction of fibrinolysis as a result of contact of blood with biomaterial surfaces during CPB and with MCS devices. Even though meticulous surgical technique is of outmost importance, it is important to note that numerous MCS centers employ various surgical techniques with equivalent results.

Nonsurgical bleeding is one of the most common adverse events within the first 30 days after durable VAD implantation.[38–42] Across studies, the most commonly reported sources of bleeding are epistaxis, GI tract bleeding, bleeding of the mediastinum and thorax, and intracranial hemorrhage.[38–43] However, the location of bleeding may vary depending on time from operation, with thoracic or mediastinal bleeding having higher, but diminishing, risk in the early postoperative period, with a later risk of GI tract bleeding. Recent data have demonstrated that support with long-term durable MCS is associated with development of acquired von Willebrand's disease caused by high shear stresses within continuous flow rotary pumps that result in degradation of high–molecular-weight von Willebrand multimers and activation of the enzyme ADAMTS13, a zinc-containing metalloprotease enzyme that cleaves von Willebrand factor.[41–43] Acquired von Willebrand disease has been associated with a high incidence of late bleeding in patients supported with long-term durable VADs manifest at mucosal sites including gastrointestinal bleeding and epistaxis and appears to accentuate previous subclinical arteriovenous malformations, commonly found in patients on MCS.[44]

RV Failure

RV failure occurs in approximately 3% to 30% of patients supported by LVAD support alone. The large variation in occurrence of RV failure is dependent on a number of important patient factors including severity of illness and timing of intervention. The etiology of RV failure is multifactorial and includes pathologies within the pulmonary vascular bed and/or RV. Factors contributing to RV failure include impaired RV function as a result of intraoperative air embolism, myocardial stunning due to poor intraoperative myocardial protection, ischemia secondary to coronary artery disease, arrhythmias, volume loading, and alteration of RV septal geometry induced by LV unloading. Several studies have demonstrated that factors such as elevated central venous pressure, reduced RV stroke work index, low preoperative pulmonary artery pressures, increased transpulmonary gradient greater than 16 mm Hg, acute decrease in pulmonary artery pressures equal to or greater than 10 mm Hg at the onset of LVAD support, degree of preoperative pulmonary edema, increased need for perioperative transfusions, increasing degree of renal and hepatic dysfunction, female gender, nonischemic etiology, and preoperative temporary MCS support, all increase the need for RV MCS following LVAD implantation.[8–13,20–25] Among the 484 patients enrolled in the HeartMate II LVAD bridge-to-transplantation clinical trial, 6% required mechanical right-ventricular support while 14% required prolonged inotrope therapy. Multivariate data analysis revealed that a central venous pressure/pulmonary capillary wedge pressure ratio greater than 0.63, need for preoperative ventilator support, and blood urea nitrogen level higher than 39 mg/dL were independent predictors of right-sided heart failure after LVAD implantation.[20] Acute unloading of the LV by MCS may cause the septum to shift leftward, increasing RV volume loading and reducing its function.[23–25] The negative consequences of this phenomenon may be offset by the reduction in pulmonary artery pressures and RV afterload caused by device-mediated LV decompression.[23–25] Hemodynamic stability can be attained with isolated mechanical LV support in the overwhelming majority of patients, even in those patients with substantial RV dysfunction, if there is effective replacement of left-sided heart function and aggressive treatment of pulmonary hypertension. More recently, the improved perioperative management of elevated pulmonary vascular resistance including the use of inhaled nitric oxide, a specific, potent pulmonary vasodilator, in combination with milrinone, isoproterenol, or dobutamine has significantly reduced the need for placement of an RVAD.[45] In patients with marked elevation of central venous pressure, multiorgan failure, and severe RV dysfunction with low pulmonary artery pressures, early biventricular support may be indicated.[45] Posttransplantation survival among the patient requiring prolonged RV support (mechanical or otherwise) tends to be lower when compared with those with preserved RV function following an LVAD implantation.[20]

Intracranial Bleeding and Thromboembolism

Intracranial hemorrhage is one of the most feared complications of MCS. The reported rates of hemorrhagic stroke are fortunately low and range from 0.01 to 0.08 events per patient-year.[44]

The occurrence of thromboembolic events following MCS is variable and depends on a number of factors including the type of device, duration of support, location and number of cannulation sites, and the presence of prosthetic valves within the heart. Approximately 10% of patients receiving MCS with implantable devices will experience a thromboembolic event or stroke.[38,39,46] This rate is in the range of 20% for patients on short-term extracorporeal MCS devices.[1] Improvement in the rate of thromboembolic events has come from more aggressive antiplatelet therapy in conjunction with warfarin, improved device design, and more frequent use of LV apical as compared with left atrial cannulation. In patients supported only for short durations, anticoagulation is usually achieved with heparin and antiplatelet therapy. Longer-term support usually requires transition to warfarin and antiplatelet therapy.

Infection

Infections can be device-related (i.e., device endocarditis, percutaneous lead or cannula site infection, pocket infection [infection external to an implanted device]) or nondevice-related (i.e., pneumonia and urinary tract infection). The incidence of early nosocomial device-related infections in patients undergoing MCS is approximately 30% in many series and is related to the acuity of illness in this population of patients.[38,39,46–51] Patients with persistent or recurrent sepsis, and those patients with device-related infections, tend to have a higher mortality rate than patients without these complications.[51] In patients on long-term MCS, infection remains an important obstacle to successful outcome.[51] Most of these late infections begin in the percutaneous driveline tract and pocket of the device. However, clinical experience has revealed that VAD infection rates can be minimized with attention to infection control guidelines, optimal implantation techniques, meticulous wound care, and the utilization of new continuous-flow rotary pump technology.[51]

Risk factors for development of infection present before device insertion include preoperative infection at remote sites (not in the area of implantation), malnutrition, prolonged hospitalization, immobilization, broad-spectrum antibiotic therapy, immunosuppressive medications, mechanical ventilation, and the presence of central venous catheters. The percutaneous lead of the device can be a port of entry for bacterial and fungal pathogens. Intracorporeal device infections can occur within the pumps themselves and on their outer surfaces, which are generally caused by biofilm-forming bacteria and fungi. Device-related infections can sometimes be successfully treated with antibiotic suppression and device exchange or removal. Infections involving the preperitoneal pocket (subfascial space created for device placement) surrounding implantable VADs require more aggressive treatment, including open drainage, debridement, omental translocation, and rerouting of the percutaneous lead through a fresh exit site. However, patients who are device-dependent and awaiting transplantation generally cannot tolerate device removal as a therapeutic option to eradicate the infection. Antibiotic suppression and transplantation remain the only chance for cure of device-related infections in these instances. These infections do not generally preclude heart transplantation. However, transplant survival is adversely influenced by the presence of MCS infections at the time of heart transplant and MCS explant.

Device Malfunction and Thrombosis

As with any mechanical device, malfunction is an anticipated occurrence. The types and severity of device malfunctions vary with each of the devices. Many devices have built-in backup systems that, in the event of catastrophic device failure, provide support to the patient. In some instances, patients supported by a VAD have enough residual LV function remaining to help sustain them until corrective measures can be taken in the event of complete device failure. New technology incorporating continuous-flow rotary pump design present new challenges to device malfunction. These devices do not contain valves to direct the flow of blood, and stoppage of the pump is associated with significant regurgitation of blood through the device resulting in significant LV distension. This phenomenon is similar to the development of acute aortic insufficiency. Fortunately, the reported frequency of this event is low.[32,33] Device malfunctions in TAHs are more problematic as there is no native heart to provide hemodynamic support in the event of a total device failure. Stringent quality control measures in fabrication and testing and very low mechanical failure rates are, therefore, even more essential with TAHs.

Pump thrombosis is potentially a catastrophic complication of VAD therapy. The variability in clinical presentation makes it a challenging diagnosis. It occurs both early and late after VAD implantation and may manifest itself with increased pump power, decreased device flow with heart failure, and hemolysis with hemoglobinuria or with embolic event (peripheral or neurologic). With echocardiography examination, worsening mitral regurgitation, left ventricular distention or persistent opening of the aortic valve, or inability to decompress the LV with increasing degrees of LVAD pump speeds may aid in confirming the diagnosis. Serum lactate dehydrogenase level seems to have established itself as the primary biochemical marker of hemolysis in this clinical context. The rates of device thrombosis initially reported at 2% to 4% in the pivotal Heartmate II trials may underrepresent the true incidence of this complication in durable VADs.[38,39,49] A recent report looking at incidence of pump thrombosis at three high-volume centers suggests an abrupt increase in the recent years and occurring at the rates of 4.7%, 7.5%, and 12.3% at 6, 12, and 24 months, respectively.[52–54] Clinically suspected thrombosis can be managed medically by intravenous anticoagulation, antiplatelet agents, or thrombolytics in some cases. Surgical treatment by pump explantation with either pump replacement or urgent heart transplantation is generally required in most circumstances.

Interagency Registry for Mechanically Assisted Circulatory Support

8 The Interagency Registry for Mechanically Assisted Circulatory Support (INTERMACS) database, sponsored by the United States National Heart, Lung and Blood Institute (NHLBI), is a registry for patients who receive implantable or “durable” MCS devices that are approved by the FDA.[13] The INTERMACS registry represents one of the largest available data repositories for the study of durable or long-term MCS device outcomes. The most recent published data analysis of MCS outcomes for VAD therapy reviews the nearly 6 years of data entry into the registry with more than 10,000 patients.[13] It includes data on a variety of pulsatile and continuous flow rotary pumps and TAHs. Survival with

LVAD support alone at 1 and 2 years continues to be 80% and 70%, respectively, and is significantly worse for those patients requiring BiVAD or TAH support[13] (Figs. 84-5 to 84-7). MCS as DT strategy continues to represent the majority of implants and the proportion of patients treated in this fashion has increased from 14.7% in 2006–2007 to 41.6% in 2011–2103[13] (Table 84-1) At the same time, the proportion of patients listed for transplantation decreased significantly: from 42.4% to 21.7%. Patients undergoing implantation of an MCS device in the presence of cardiogenic shock (i.e., INTERMACS levels 1 and 2) had worse outcomes compared with device implantation in patients with more stable forms of advanced heart failure (INTERMACS levels 3 through 7)[13] (Fig. 56-7; Table 84-2). These observations highlight the importance of proper patient selection and timing of initiation of MCS therapy on outcomes. Patients with significant organ dysfunction at the time of MCS device implant, accompanied by a greater degree of hemodynamic compromise, have a significantly higher risk of requiring BiVAD support, higher risk of major adverse events, and significantly higher risk of death during VAD support.

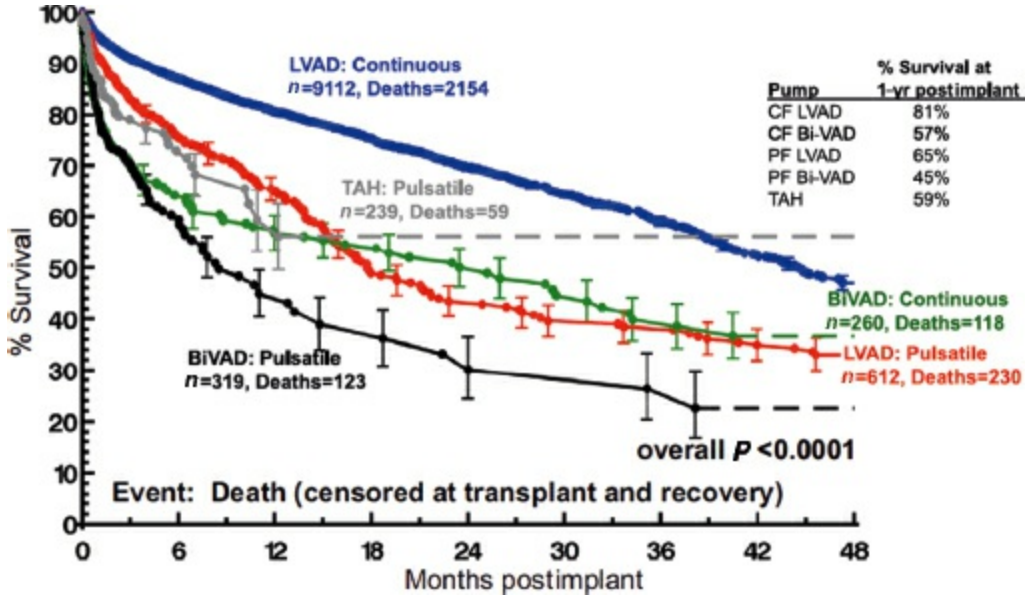

Figure 84-5. Actuarial survival for primary device implant, stratified by device type. Error bars indicate ± 1 SE. Patients are censored at transplant and recovery. CF, continuous flow; LVAD, left ventricular assist device; PF, pulsatile flow; TAH, total artificial heart. (From Kirklin JK, Naftel DC, Pagani FD, et al. Sixth INTERMACS annual report: a 10,000-patient database. *J Heart Lung Transplant* 2014;33:1304–1311, with permission.)

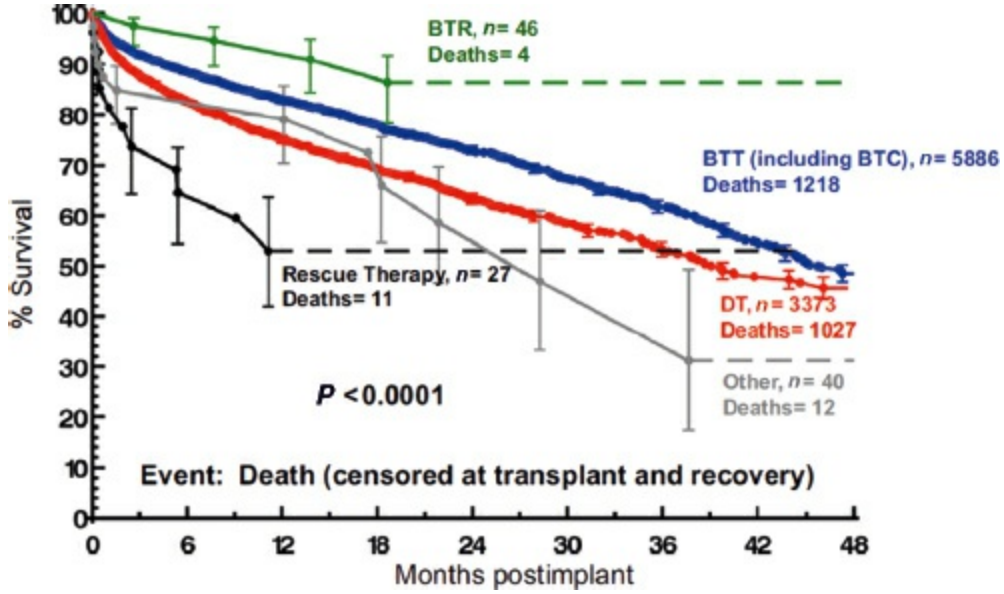

Figure 84-6. Actuarial survival for primary continuous-flow devices, stratified by strategy at implant: BTR, bridge to recovery; DT, destination therapy; BTT, bridge to transplant; BTC, bridge to candidacy. Error bars indicate ± 1 SE. (From Kirklin JK, Naftel DC, Pagani FD, et al. Sixth INTERMACS annual report: a 10,000-patient database. *J Heart Lung Transplant* 2014;33:1304–1311, with permission.)

WEANING PATIENTS FROM MCS

Weaning From Short-Term MCS

A number of factors are considered when weaning patients from MCS. Major cardiac abnormalities not addressed before or during support render the chances of weaning from MCS negligible. Optimization of volume status, afterload, cardiac rhythm, and degree of inotropic support as well as exclusion of obvious surgical pathology, such as tamponade, is paramount before attempting separation from MCS. In addition, extracardiac causes, such as pulmonary edema, elevated pulmonary vascular resistance, acute respiratory distress syndrome (ARDS), and pneumonia, may worsen right ventricular function and prevent successful weaning from MCS.

Once a patient's status has been optimized, weaning from MCS aided with echocardiographic monitoring is preferred. As device flows are reduced, transesophageal echocardiogram provides information on ventricular filling and performance and valve function. If patients maintain satisfactory hemodynamics with reduction of pump flow, they can be considered for weaning. In the setting of biventricular support, it is important that device flows on the right side be reduced before lowering left-sided device flows. This prevents pulmonary edema in the event of inadequate LV function. As device flows are reduced, native heart function begins to support the circulation. When weaning from MCS is not possible, patients should be evaluated for heart transplantation and/or bridged to a long-term MCS device.

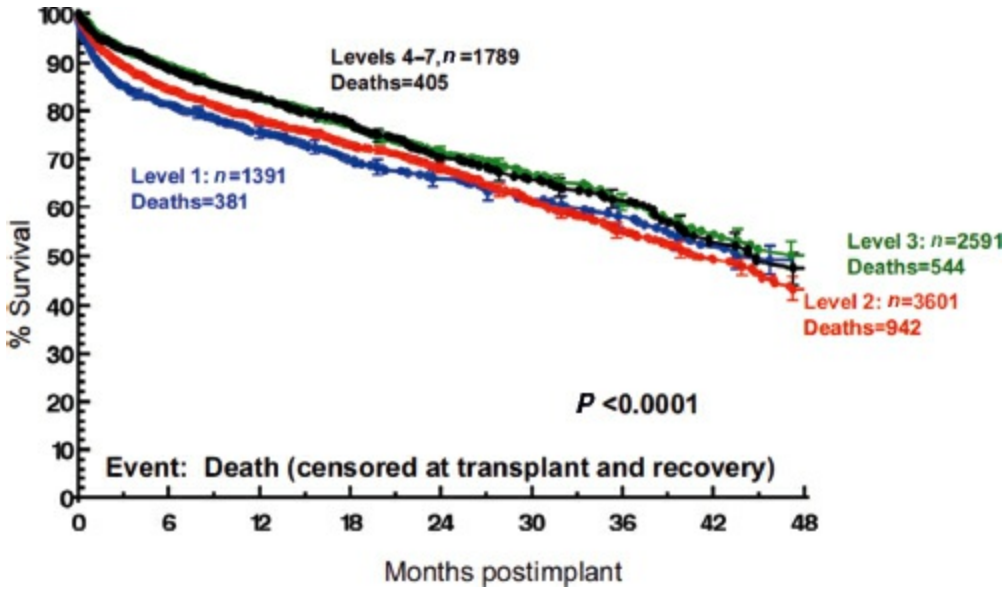

Figure 84-7. Survival analysis for patients on mechanical circulatory support by INTERMACS Profile. Error bars indicate ± 1 SE. See Table 84-2 for a description of INTERMACS Profiles. (From Kirklin JK, Naftel DC, Pagani FD, et al. Sixth INTERMACS annual report: a 10,000-patient database. *J Heart Lung Transplant* 2014;33:1304–1311, with permission.)

Table 84-1 MCS Device Implants by Implant Era and Indications for MCS Device Implantation in the INTERMACS Registry

Device Strategy at the Time of Implant	Implant Date Era						Total	
	2006–2007		2008–2010		2011–2013			
	n	%	*n*	%	*n*	%	*n*	%
BTT listed	185	42.4	1,335	39.2	1,453	21.7	2,973	28.2
BTT likely	85	19.5	884	26.0	1,474	22.0	2,443	23.2
BTT moderate	49	11.2	337	9.9	677	10.1	1,063	10.1
BTT unlikely	28	6.4	104	3.1	222	3.3	354	3.4
DT	64	14.7	666	19.6	2,786	41.6	3,516	33.4
BTR	17	3.9	38	1.1	38	1.0	93	0.9
Rescue therapy	8	1.8	24	1.0	28	0.4	60	0.6
Other	0	0.0	14	0.4	26	0.4	40	0.4
Total	436	100.0	3,402	100.0	6,704	100.0	10,542	100.0

Adapted from Kirklin JK, Naftel DC, Pagani FD, et al. Sixth INTERMACS annual report: A 10,000-patient database. *J Heart Lung Transplant* 2014;33:1304–1311.

Weaning From Long-Term MCS

Anecdotal observations from the cumulative experience with long-term MCS for BTT and recent small clinical studies have demonstrated that long-term MCS, associated with sustained mechanical unloading of the LV, can improve myocardial function even in those patients thought to have irreversible, dilated cardiomyopathies.[55–57] Several studies have demonstrated that long-term MCS can restore ventricular geometry, improve myocyte function, orientation, and size, reduce myocyte apoptosis, reduce myocardial cytokine gene and protein expression, reverse abnormal neurohormonal patterns associated with advanced heart failure, and improve myocardial mitochondrial function.[55–57] These observations have led clinicians to consider MCS alone, or in conjunction with other future possible therapies (novel medications; gene therapy; myocyte or stem cell implantation), as a potential modality to reverse end-stage cardiomyopathy. Whether these observation hold under future rigorous experimental scrutiny remains unknown at this time.

MCS DEVICES

The devices currently approved by the FDA are broadly grouped into two categories on the basis of their durability and the intended length of support and use.

Devices Intended for Short-Term MCS (Temporary Devices)

IABP

Since its first reported clinical use by Kantrowitz in 1968, the IABP has become the most frequently utilized MCS device (Fig. 84-8).[58] The IABP can be inserted percutaneously and is positioned within the descending thoracic aorta. It augments ventricular performance and cardiac output increasing diastolic coronary blood flow, decreasing myocardial oxygen consumption, and reducing left ventricular afterload. Inflation of the balloon during diastole increases diastolic pressure and coronary blood flow and deflation of the balloon during systole reduces arterial afterload facilitating LV ejection. Although the IABP has been the mainstay of circulatory support for decades, the utility of IABP in cardiogenic shock complicating acute myocardial infarction was recently challenged by the results of the SHOCK-IABP Trial.[59] This prospective study randomized 600 patients to IABP counterpulsation or no IABP counterpulsation in addition to revascularization and optimal medical therapy. The study revealed no difference in 30-day mortality, length of stay in the intensive care unit, serum lactate level, incidence of renal failure, or duration of catecholamine therapy.[59] Complications from the use of the IABP include leg ischemia, balloon rupture, infection, bleeding, false aneurysm formation, femoral neuropathy, vessel perforation with hemorrhage, and aortic dissection. Female gender, peripheral vascular disease, diabetes, smoking, advanced age, obesity, and cardiogenic shock are predisposing factors for tissue malperfusion and limb ischemia. The IABP has several disadvantages. The augmentation of cardiac output is generally small (approximately 15% in optimal circumstances) when compared with that of conventional VADs and mobilization of the patient is very limited with percutaneous approaches through the femoral arteries. The use of the axillary or subclavian arteries with direct operative placement or percutaneous insertion may permit some degrees of patient mobility.

Extracorporeal Life Support

Extracorporeal life support, traditionally referred to as “extracorporeal membrane oxygenation” is a temporary form of MCS that provides circulatory assistance while allowing for both oxygenation and carbon dioxide removal from blood.[60–63] The ECLS circuit is conceptually similar in concept to CPB; however, the inclusion of membrane or hollow-fiber oxygenators has allowed for safe application for extended periods of time (usually days to weeks). Since the first successful use of prolonged ECLS, reported by Hill in 1972,[63] ECLS has been used in a variety of both pediatric and adult clinical settings, including respiratory support, postcardiotomy support, and as a bridge to an LVAD or heart and/or lung transplantation.[64]

ECLS Achieves Circulatory by Unloading the RV. The blood is drained from the venous circulation, oxygenated it, and returned to the arterial circulation. Although it does reduce LV preload by decreasing the pulmonary venous return, ECLS does not directly unload the LV. In patients with severe LV dysfunction, the use of an IABP and catecholamines helps reduce LV afterload and improves myocardial contractility, thus

preventing blood stasis and thrombus formation within the LV. If LV function is so severely reduced that there is essentially no ejection, an atrial septostomy or insertion of a left-atrial venting system can be performed to relieve LV distention. Maintenance of some degree of pulmonary blood flow during ECLS is important in preventing pulmonary artery and vein thrombosis, while minimal ventilatory settings ensure that the oxygen saturation of the blood ejected from the left ventricle is adequate. Venovenous ECLS, unlike venoarterial ECLS, maintains flow through the heart and is used solely for pulmonary support.

Table 84-2 INTERMACS Profiles: Description of Heart Failure Symptoms and Hemodynamic Status at the Time of MCS Device Implantation and Including the Time Frame for Intervention

INTERMACS Profile Descriptions	Time Frame for Intervention
Profile 1: Critical cardiogenic shock Patients with life-threatening hypotension despite rapidly escalating inotropic support, critical organ hypoperfusion, often confirmed by worsening acidosis and/or lactate levels. *"Crash or burn."*	Definitive intervention needed within hours
Profile 2: Progressive decline Patients with declining function despite intravenous inotropic support may be manifested by worsening renal function, nutritional deprivation, inability to restore volume balance. "Sliding on inotropes." Also describes declining status in patients unable to tolerate inotropic therapy.	Definitive intervention needed within few days
Profile 3: Stable but inotrope dependent Patients with stable blood pressure, organ function, nutrition, and symptoms on continuous intravenous inotropic support (or a temporary circulatory support device or both), but demonstrating repeated failure to wean from support due to recurrent symptomatic hypotension or renal dysfunction. "Dependent stability."	Definitive intervention elective over a period of weeks to few months
Profile 4: Resting symptoms Patients can be stabilized close to normal volume status but experience daily symptoms of congestion at rest or during ADLs. Doses of diuretics generally fluctuate at very high levels. More intensive management and surveillance strategies should be considered, which may in some cases reveal poor compliance that would compromise outcomes with any therapy. Some patients may shuffle between 4 and 5.	Definitive intervention elective over period of weeks to few months
Profile 5: Exertion intolerant Comfortable at rest and with ADLs but unable to engage in any other activity, living predominantly within the house. Patients are comfortable at rest without congestive symptoms, but may have underlying refractory elevated volume status, often with renal dysfunction. If underlying nutritional status and organ function are marginal, patient may be more at risk with INTERMACS 4, and require definitive intervention.	Variable urgency, depends upon maintenance of nutrition, organ function, and activity
Profile 6: Exertion limited Patients without evidence of fluid overload is comfortable at rest, and with ADLs and minor activities outside the home but fatigues after the first few minutes of any meaningful activity. Attribution to cardiac limitation requires careful measurement of peak oxygen consumption, in some cases with hemodynamic monitoring to confirm severity of cardiac impairment. "Walking wounded."	Variable, depends upon maintenance of nutrition, organ function, and activity level
Profile 7: Advanced NYHA III A placeholder for more precise specification in future, this level included patients who are without current or recent episodes of unstable fluid balance, living comfortably with meaningful activity limited to mild physical exertion.	Transplantation or circulatory support may not currently be indicated
Modifiers for profiles	Possible profiles to modify
TCS: Temporary Circulatory Support can modify only patients in hospital (other devices would be INTERMACS devices). Includes IABP, ECMO, TandemHeart, Levitronix, BVS 5000 or AB 5000, Impella	1, 2, 3 in hospital
A – Arrhythmia: can modify any profile. Recurrent ventricular tachyarrhythmias that have recently contributed substantially to clinical compromise. This includes frequent ICD shock or requirement for external defibrillator, usually more than twice weekly.	Any profile
FF: Frequent Flyer can modify only outpatients, designating a patient requiring frequent emergency visits or hospitalizations for diuretics, ultrafiltration, or temporary intravenous vasoactive therapy.	3 if at home, 4, 5, 6. A frequent flyer would rarely be profile 7

Adapted from Stevenson LW, Pagani FD, Young JB, et al. INTERMACS profiles of advanced heart failure: The current picture. *J Heart Lung Transplant* 2009;28:535–541.

Current ECLS circuits are typically composed of a centrifugal pump with either a hollow fiber or membrane oxygenator, oxygen blender, pump console, heat exchanger, and pump cart. A roller pump is used by some centers. Cannulation technique for ECLS is extremely variable and depends on the clinical situation and the nature of support required. Percutaneous cannulation of the femoral vein and artery allows for rapid initiation of MCS in cases of acute cardiac and/or respiratory arrest. In less urgent

situations, cut-down on the internal jugular and carotid artery or respective femoral vessels can be performed. In cases of postcardiotomy failure in the operating room, venous access can be obtained by insertion of cannula in the right atrium and arterial outflow obtained by cannulation of the ascending aorta. Even though many ECLS perfusion systems are available, new portable ECMO systems such as CardioHelp (Maquet GmbH and Company, Rastatt, Germany) have now attained the FDA approval and may find a useful role in emergency situations due to the relative ease of implantation and initiation.

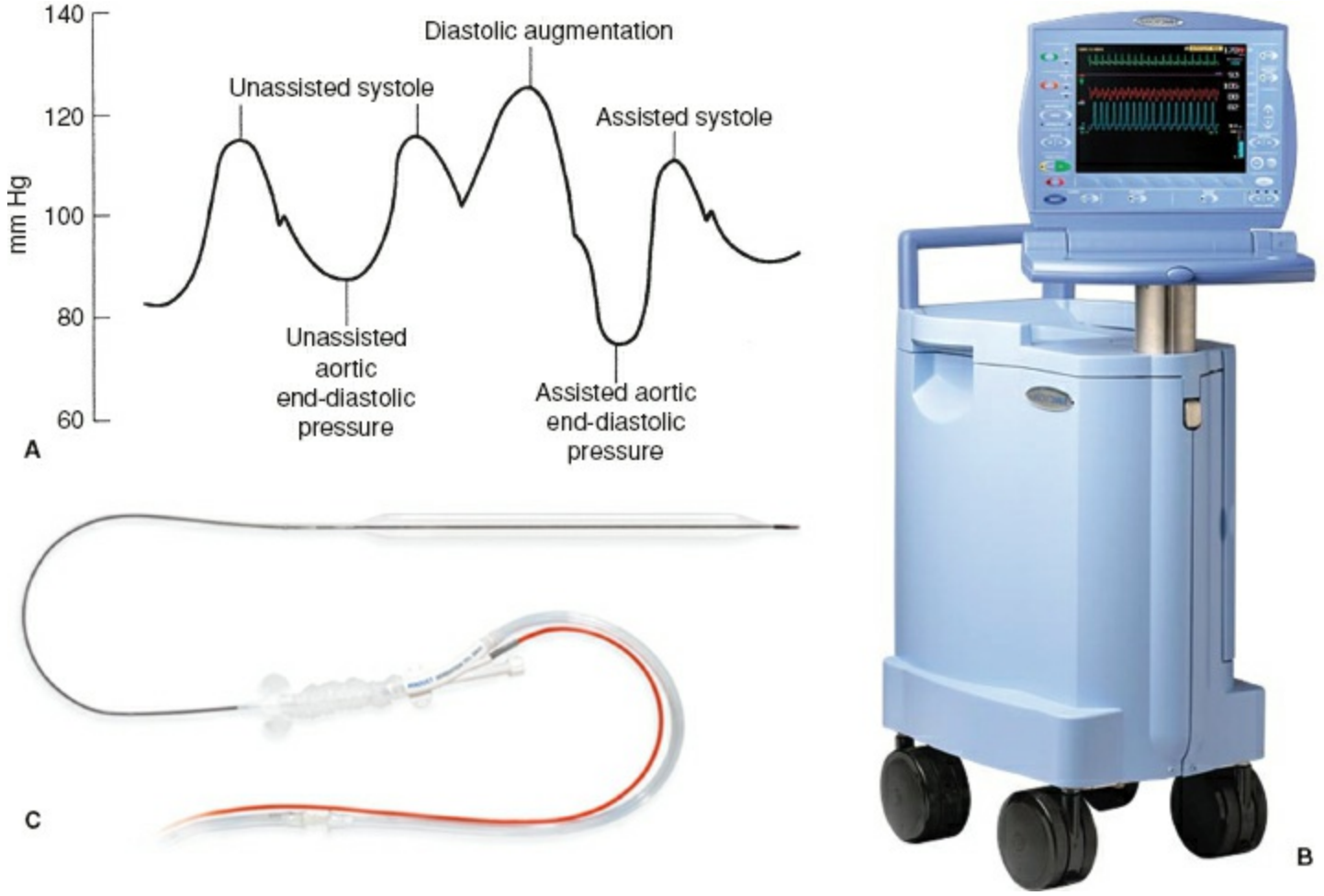

Figure 84-8. Intra-aortic balloon pump. **A:** Aortic pressure tracing during intra-aortic balloon pump support. Balloon counterpulsation is occurring after every other heartbeat (1:2 counterpulsation). With correct timing, balloon inflation (IP) begins immediately after aortic valve closure, signaled by the dicrotic notch of the arterial waveform. Compared with unassisted ejection, the pump augments diastolic blood flow by increasing peak aortic pressure during diastole. Balloon deflation before systole decreases ventricular afterload, with lower aortic end-diastolic pressure and lower peak systolic pressure. **B:** Console for the intra-aortic balloon pump. **C:** Catheter-mounted balloon is positioned within the thoracic aorta through a percutaneous or surgical approach via the femoral artery. (Photo courtesy of Maquet Cardiac Assist, Fairfield, NJ.)

Numerous large clinical series have reported successful use of ECLS for cardiac and/or respiratory support in adult, pediatric, and neonatal patients. In the largest series reported to date, Gray and colleagues[64] at the University of Michigan reported on the outcome of 2,000 patients supported with ECLS from 1973 through 2010. Of the 2,000

patients, 74% were weaned from ECLS and 64% survived to hospital discharge. In patients with respiratory failure, survival to hospital discharge was 84% in 799 neonates, 76% in 239 children, and 50% in 353 adults. Survival in patients with cardiac failure was 45% in 361 children and 38% in 119 adults. ECLS during extracorporeal cardiopulmonary resuscitation was performed in 129 patients, with 41% surviving to discharge. Survival decreased from 74% to 55% between the first and second 1,000 patients. The most common complication was bleeding at sites other than the head, with an incidence of 39%, and the least frequent complication was pump malfunction, with a 2% incidence. Intracranial bleeding or infarction occurred in 8% of patients, with a 43% survival rate.

Venovenous ECLS was the preferred method of respiratory support since 1988. For patients with cardiac failure, survival in adult patients was improved by utilizing ECLS as a bridge to longer-term implantable devices in patients who did not demonstrate early recovery of myocardial function.[65–67] Conversely, the availability of long-term implantable devices has extended the use of ECLS in situations where recovery of myocardial function is unlikely.[65–67]

Percutaneous Short-Term MCS Devices

The 2015 SCAI/ACC/HFSA/STA clinical expert consensus statement endorses the use of percutaneous MCS in carefully selected patients with severe hemodynamic compromise in a variety of clinical scenarios, including complications of acute MI, severe heart failure in the setting of nonischemic cardiomyopathy, acute allograft rejection, posttransplant RV failure, inability to separate from CPB after cardiac surgery, refractory arrhythmia, and prophylactic use during high-risk coronary interventions.[1] The choice of the device depends on the clinical setting, the ease of implantation, the hemodynamic effects of the device, and the goals of therapy. Expert operators may choose percutaneous LVAD systems over IABP to minimize pressor use and myocardial oxygen demand and improve systemic perfusion while substantially decompressing the dysfunctional ventricle and effectively augmenting the cardiac output and tissue perfusion. It is important to note, however, that the extent of clinical data pertaining to the effectiveness and safety of these devices is still limited. In addition, the cost of the devices and the operating costs substantially exceed those of the IABP.

The Tandem Heart pVAD (Cardiac Assist Technologies, Inc., Pittsburgh, PA) is currently the only available percutaneous left atrial-to-femoral artery VAD[68] (Fig. 84-9). This dual-chamber, low-speed continuous-flow, centrifugal device bypasses the LV by pumping blood extracorporeally from the left atrium to the femoral arterial system via a catheter placed across the atrial septum into the left atrium. It is a dual-chamber pump composed of an upper and a lower housing assembly, providing a conduit for inflow and outflow of blood and communication with the controller, respectively. The controller ensures hydrodynamic bearing support of the LVAD impeller and rotation at 3,000 to 7,500 rpm, as well as its cooling and delivery of local anticoagulation. The controller is a micropressor-based electromechanical drive operated on AC current or internal batteries.

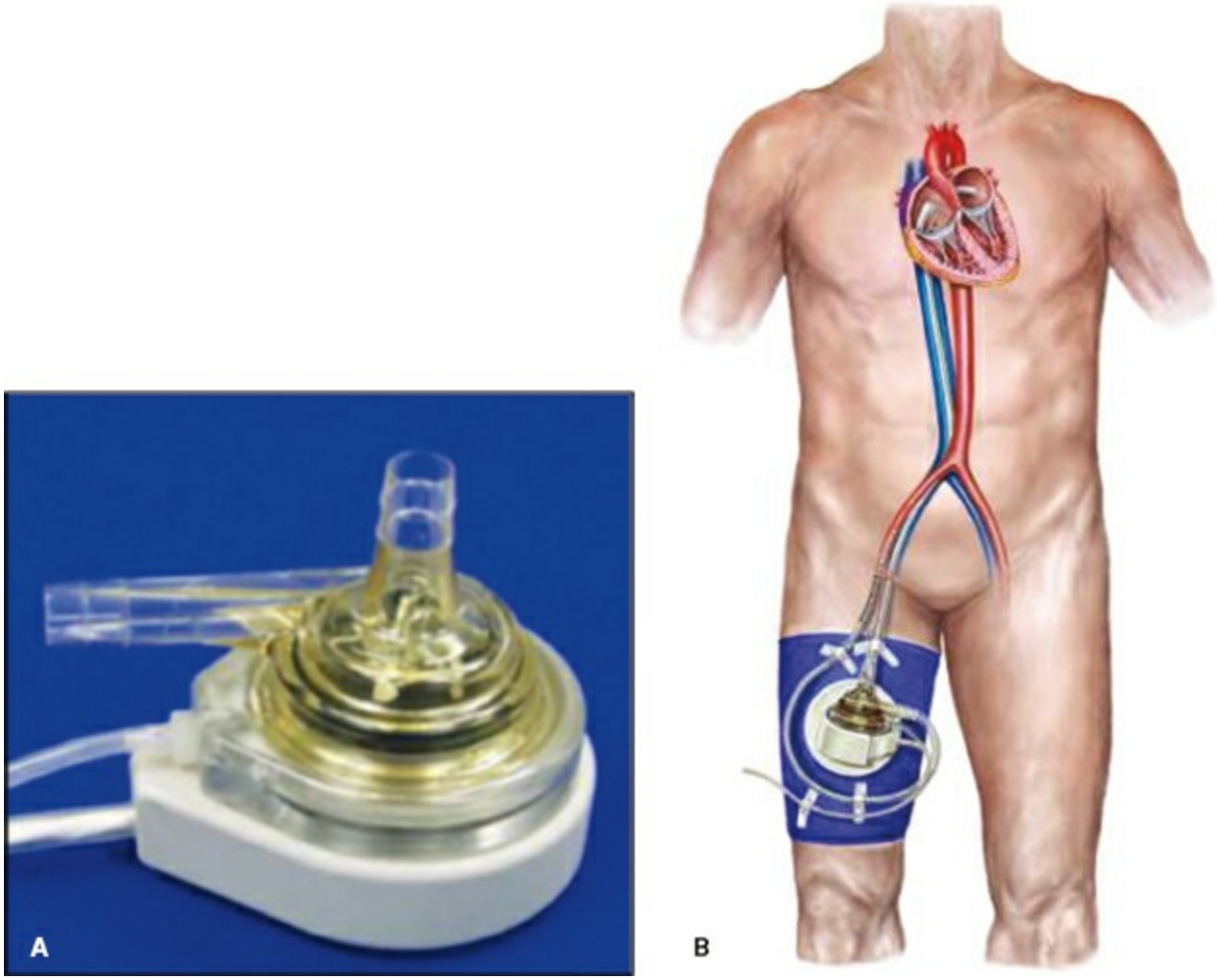

Figure 84-9. **A:** The Tandem Heart pVAD centrifugal pump (CardiacAssist Corporation, Pittsburgh, PA). The TandemHeart pVAD is an extracorporeal, continuous-flow rotary pump with centrifugal design providing temporary mechanical circulatory support to the left ventricle (left atrium to femoral artery). The TandemHeart pVAD utilizes a bearing design in the pump for impeller positioning and rotation. **B:** Schematic representation of the cannulation of the femoral artery and femoral vein with the transseptal placement of the inflow catheter within the left atrium from the femoral vein. The centrifugal pump of the Tandem Heart pVAD is secured to the patient's right thigh. (Photographs courtesy of CardiacAssist Corporation, Pittsburgh, PA.)

Implantation of the device is performed percutaneously via the right femoral vein. A standard Brockenbrough catheter inserted into the superior vena cava allows for interatrial septostomy, through which a venous inflow cannula is introduced. An arterial perfusion catheter, ranging in size from 15F to 19F, is inserted percutaneously into the right femoral artery.

Hemodynamic effects of this device are based on the parallel flow contribution to the aorta of both the device and the LV itself. This results in reduction of LV preload, myocardial oxygen consumption, filling pressures, and ventricular wall stress.[69] Depending on the size of the arterial cannula, the device flow varies from 3.5 to 5.0 L/min.

In a randomized comparison of IABP with the Tandem Heart pVAD, Thiele and colleagues[68] reported a more effective improvement in cardiac power index as well as other hemodynamic and metabolic variables with the Tandem Heart pVAD compared with

the IABP. Even though 30-day mortality rate was similar between the two groups, complications like severe bleeding and limb ischemia were encountered more frequently during VAD support.[68] The Tandem Heart pVAD is FDA-approved for temporary MCS for cardiogenic shock in patients refractory to optimal medical therapy and IABP.

Impella LVAD (Abiomed Corporation, Danvers, MA) is a continuous flow rotary pump wit axial design that propels blood from the LV across the aortic valve and into the ascending aorta[70,71] (Fig. 84-10). It is currently available in three delivery platforms for LV support including a 12F (Impella LP 2.5), 21F (Impella LP 5.0), and 14F (Impella CP) system and Impella RP, a system uniquely designed for RV support. While the Impella 2.5 and 5.0 provide maximal flow rates of 2.5 and 5.0 L/min, respectively, the Impella CP achieves maximal flows of approximately 4 L/min despite its smaller platform. The two smaller devices can be inserted percutaneously, while the larger device may require surgical cut-down. The preferred site of introduction is the femoral artery; however, the devices have been introduced via the axillary artery or directly into the aorta. The LVAD is positioned across the aortic valve with the inlet port below and outlet above the aortic valve.

The hemodynamic effects of Impella devices are based on LV unloading and augmentation of forward flow. This reduces myocardial oxygen consumption, improves mean arterial blood pressure, and reduces pulmonary capillary wedge pressure.[72] Similar to the TandemHeart, proper function of the Impella LVAD requires adequate RV function or RV support to provide sufficient preload for the devices. In a prospective, randomized clinical trial comparing the Impella LP2.5 to IABP, cardiac index was significantly increased in patients with the LP2.5 compared with patients supported with an IABP. Overall mortality rate at 30 days was similar in both groups.[70]

The Impella RP (Fig. 84-10) is a novel RVAD designed using the Impella system but adapted for right ventricular support. The pump supports the pulmonary circulation with intent to reduce right ventricular work and potentially recover right ventricular contractility. The pump is inserted percutaneously via the femoral vein and capable of delivering up to 4 L/min of blood flow from the right atrium to the pulmonary artery.

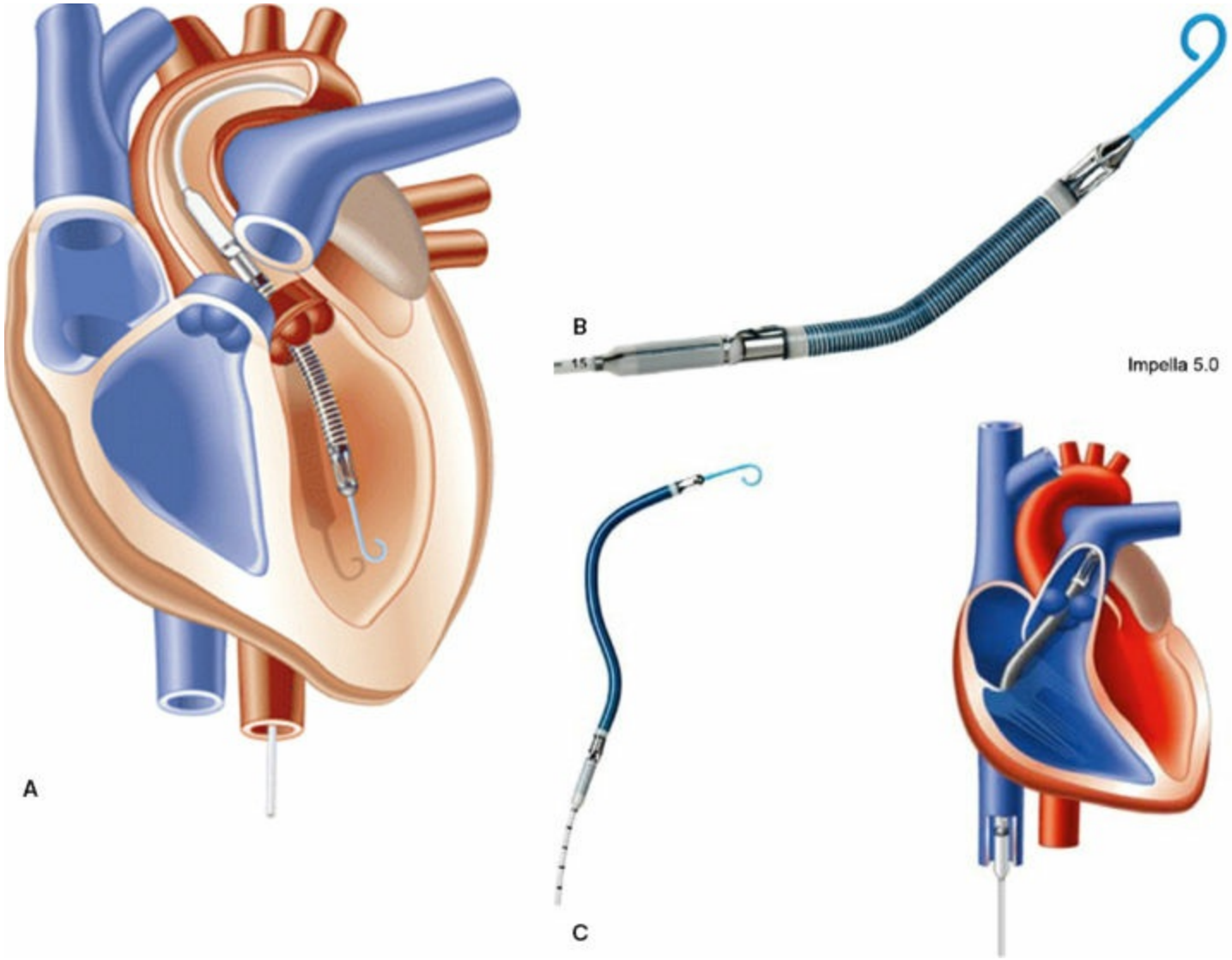

Figure 84-10. The Impella left ventricular assist device (Abiomed Inc., Danvers, MA). **A:** Diagram demonstrating positioning of the device across the aortic valve. Device inflow is within the left ventricle and device outflow is above the aortic valve. **B:** Impella 5.0. **C:** Impella RP. (Photographs courtesy of Abiomed Inc., Danvers, MA.)

The CentriMag VAD (Levitronix LLC; Waltham, MA) is an extracorporeal, continuous flow rotary pump composed of a centrifugal blood pump, a motor, a console, a flow probe, and a circuit[73,74] (Fig. 84-11). The device is based on a magnetically levitated "bearingless motor" design. The rotor located within the upper pump housing is magnetically coupled to the lower motor housing to produce rotor levitation and spin which combines the drive, the magnetic bearing and the rotor function into a single unit. The motor generates the magnetic bearing force that levitates the rotor into the pump housing while also generating the torque necessary to produce the unidirectional flow. This device can produce flows of up to 10 L/min under normal physiologic conditions, with a priming volume of 31 mL. Both left and right ventricular systems exist and have been used as a BTR, BTT, or bridge to a long-term MCS. Single-center reports have demonstrated successful use of both left and right ventricular Centri-Mag systems as a BTT, BTR, or bridge to a long-term implantable MCS.[73,74] The Centri-Mag system can be utilized in series with an oxygenator as an ECLS system.

Implantable Devices Intended for Long-Term MCS for Out-of-Hospital Use (BTT and DT Indications)

Historical Perspective

The majority of patients receiving long-term MCS in the 1990s and early 2000s were supported by devices engineered with pulsatile, volume displacement designs. These first-generation devices, now obsolete in clinical practice, were engineered with an internal reservoir chamber and inflow and outflow valves that permit cyclic filling and emptying of the device with pump actuation elicited by either pneumatic or electrical drive systems.

Extended periods of MCS highlighted limitations in the design of pulsatile, volume displacement pumps that included a large pump size restricting mobility, requirement for extensive surgical dissection for implant leading to bleeding and infection complications, a large body habitus of the recipient limiting options for device therapy for women or smaller patients, the presence of a large-diameter percutaneous lead for venting air, and audible pump operation. A critical limitation of these devices was the high incidence of reoperation for device exchange for device malfunction.[75] To overcome these limitations, newer device designs incorporating continuous-flow rotary pump technology with an axial or centrifugal blood path represent the next generation of devices for long-term MCS therapy.

Implantable, Continuous-Flow Rotary MCS Devices

9 Implantable, continuous-flow, rotary pumps with axial or centrifugal blood flow design represent a new generation of implantable VAD technology that have now completely replaced pulsatile devices for long-term MCS indications.[46–50,76] Rotary pumps have an internal impeller within the blood flow path that is suspended by contact bearings or in more recent cases by hydrodynamic or magnetic forces. Rotary pumps offer several advantages over pulsatile, volume displacement pumps. These advantages include smaller size, fewer moving parts, durability, absence of valves to direct blood flow, smaller blood contacting surfaces, and reduced energy requirements. Blood flow is accomplished by the spinning of an internal rotor as high speed that imparts significant kinetic energy to the blood. The spinning of the rotor is accomplished by actuating an electrical current and magnetic field around the rotor that contains internal magnets. Blood flow from left ventricle to the aorta occurs continuously during the systolic and diastolic phases of the cardiac cycle. Although blood flow is continuous during the cardiac cycle, phasic changes in the flow of blood occur during the cardiac cycle due to changes in ventricular pressure and aortic afterload. These phasic changes in blood flow impart a diminished pulsatility to the aortic waveform. The ability to design smaller pumps using rotary pump technology is a result of the elimination of a large blood chamber necessary with pulsatile systems. An additional important feature of these pumps is the lack of need for a compliance chamber. This feature alleviates the problem of internal compensation that is associated with conventional pulsatile pumps that, to date, has significantly hindered total internalization.

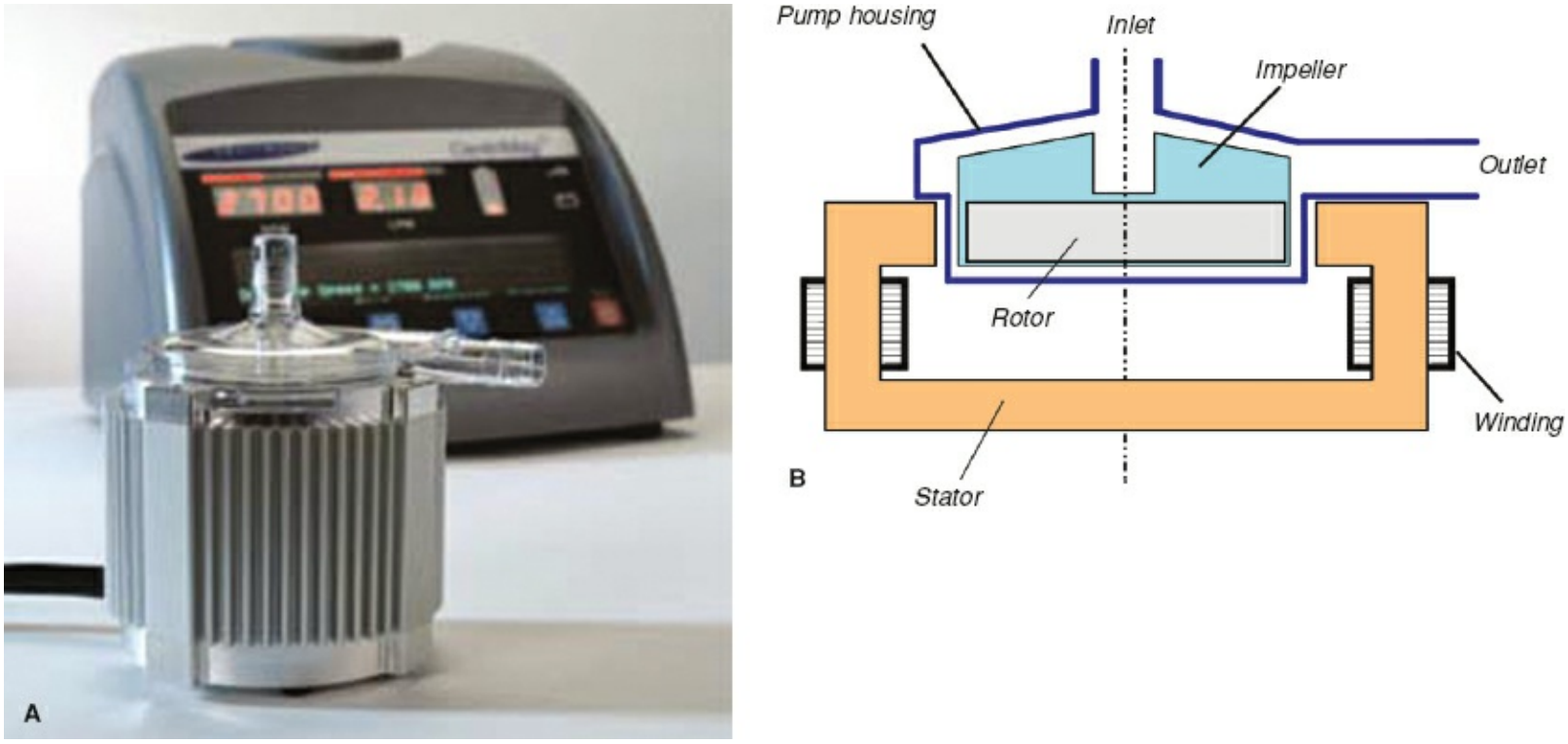

Figure 84-11. The CentriMag VAD. The CentriMag VAD is an extracorporeal, continuous-flow rotary pump with centrifugal design utilized for temporary mechanical circulatory support. The CentriMag can provide univentricular or biventricular support. **A:** The CentriMag console (background) and pump/motor (foreground). **B:** Schematic representation of the CentriMag pump. The rotor located within the upper pump housing is magnetically coupled to the lower motor housing to produce rotor levitation and spin. (Photograph courtesy of Levitronix LLC, Waltham, MA.)

Rotary pump designs incorporating pump technology with an axial blood path have accumulated significant human clinical experience. Reports from clinical trials with rotary pumps have demonstrated efficacy in providing hemodynamic support, a favorable risk to benefit assessment, and improvement in mechanical performance.[46–50,76] Furthermore, the human experience with the newer generation of rotary pumps with axial or centrifugal design has established the long-term safety of MCS with minimal pulse pressure.[77,78] Results from clinical studies have demonstrated early improvement followed by long-term stability of renal and hepatic function and no adverse effects on neurocognitive performance.[46–50] These improvements in device technology with continuous-flow rotary pumps have increased the acceptance and adoption of LVAD therapy for long-term MCS indications.

Implantable, Continuous-Flow MCS Devices (Rotary Pumps with Axial Flow Design)

HeartMate II. The HeartMate II LVAD (Thoratec Corporation, Pleasanton, CA)[38,39,47–50] (Fig. 84-12) is continuous-flow rotary pump with axial design and mechanical bearing support of the internal impeller. The sealed inflow conduit of the pump is attached to the apex of the LV and the pump sealed outflow graft is connected to the ascending aorta, creating a circuit parallel to the native circulation. A magnet within the pump's rotor assembly is rotated by the electromotive force generated by the motor itself. This

rotation is the driving force propelling the blood from the left ventricle through the pump into the ascending aorta. The flow generated by the pump depends on the rotational speed of the rotor as well as the pressure difference between the inlet and outlet of the pump. The internal pump surfaces are lined with smooth polished titanium, while the sealed inflow conduit and outflow elbow have a textured titanium microsphere surface. The percutaneous lead (drive-line) transmits commands and power from the external System Controller and power source to the LVAD itself. The system can be powered by portable batteries.

The HeartMate II was approved for BTT therapy in 2008 and for DT in 2010, following two pivotal safety and efficacy trials, and is the most utilized and studied LVAD pump to date. In a prospective, multicenter, controlled study of HeartMate II as BTT, 133 patients with end-stage heart failure while on the waiting list for heart transplantation underwent implantation of the LVAD. The primary end point (the proportions of patients who had undergone transplantation, had cardiac recovery, or had ongoing mechanical support while remaining eligible for transplantation) was evaluated at 180 days postimplantation. Three quarters of the patients reached the primary end point. Of these 100 patients, only one recovered myocardial function and had the VAD explanted. The rest were either transplanted (56 patients) or continued requiring LVAD support (43 patients). Overall actuarial survival for patients continuing to receive LVAD support was 89% at 1 month, 75% at 6 months, and 68% at 12 months.[49] A follow-up report of the initial 133 patients in addition to 148 patients entered through the Continuous Access Protocol[38] reveals that at 18-month follow-up, 157 patients (55.8%) had received a heart transplant, 58 patients (20.6%) remained alive with ongoing LVAD support, 56 patients (19.9%) died, 7 patients (2.5%) recovered cardiac function and underwent device explantation, and 3 patients (1%) were withdrawn from the study after device explantation and exchange for another type of LVAD. Overall survival rate for the patients who continued on LVAD support was 82% (95% confidence interval [CI]: 77% to 87%) at 6 months, 73% (95% CI: 66% to 80%) at 1 year, and 72% (95% CI: 65% to 79%) at 18 months. The most common adverse effects were bleeding, stroke, infection, and neuro-cognitive dysfunction, while sepsis and stroke were the primary causes of mortality. The post–FDA-approval study of the HeartMate II for Bridge to Transplant indication reported comparable results with HeartMate II in a commercial setting to those of other available devices for the same indication. The cohort of 338 patients was followed for at least 12 months or until death or transplantation. Both the 30-day mortality rate and the in-hospital mortality rate were significantly lower among the LVAD patients (4% vs. 11%, and 6% vs. 15%, respectively). Patients supported with the HeartMate spent less time in the hospital, were more likely to be discharged home, and reported better quality of life.[47]

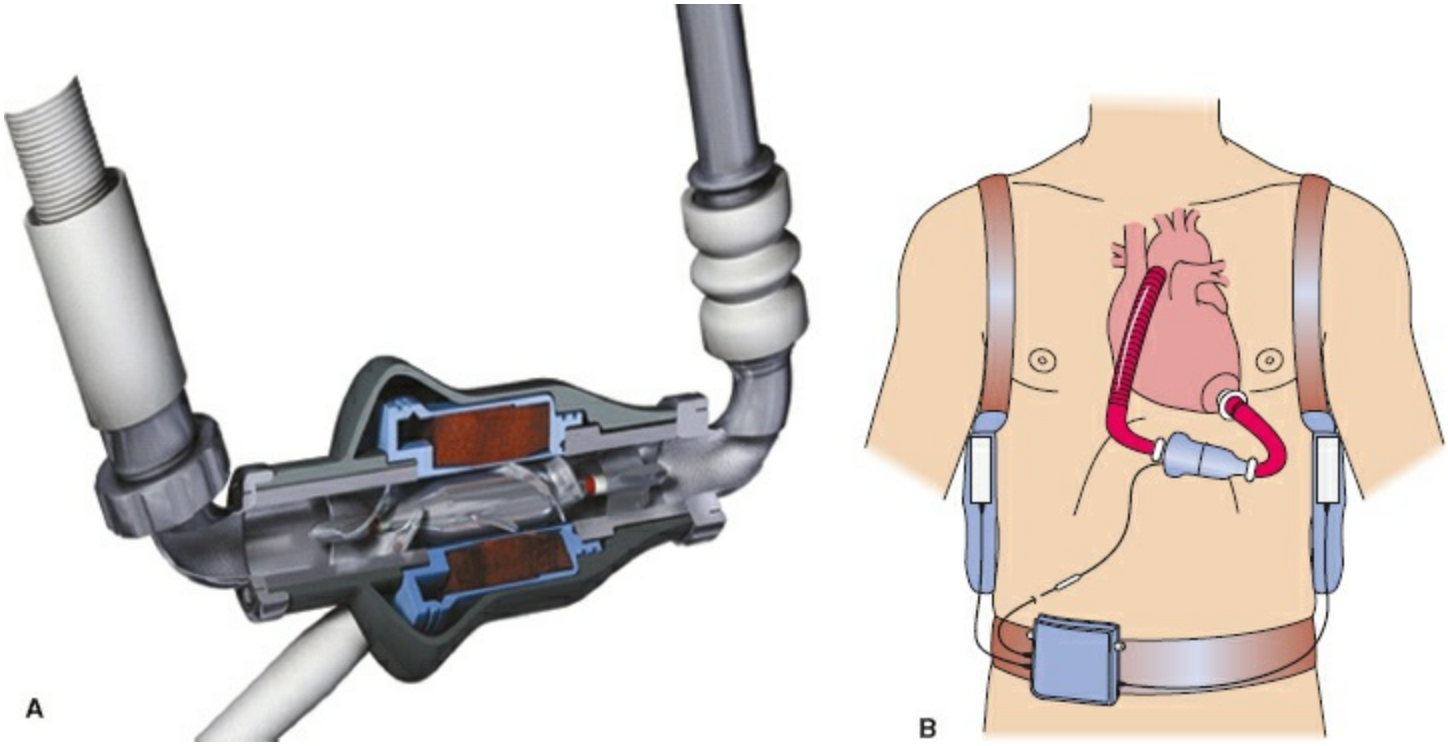

Figure 84-12. **A:** The HeartMate II LVAD (Thoratec Corporation, Pleasanton, CA) is an implantable, continuous-flow rotary left ventricular assist device with axial design intended for long-term mechanical circulatory support for bridge to transplantation or destination therapy. Schematic drawing showing internal rotor, stators, and bearings and external motor coils. (Drawing courtesy of Thoratec Corporation, Pleasantan, CA.) **B:** Schematic representation of the HeartMate II in the preperitoneal position with associated percutaneous lead, external controller, and power source (batteries).

The randomized, prospective, multicenter HeartMate II Pivotal Trial for DT enrolled 200 patients who were not eligible for cardiac transplantation. They were assigned in a 2:1 ratio to receive either the HeartMate II or HeartMate XVE and followed for at least 2 years or until death, transplantation, or device explantation. The primary composite endpoint was reached in more patients in the study group than in the control group (46% vs. 11%; hazard ratio, 0.38; 95% CI, 0.27 to 0.54; $P < 0.001$). The HeartMate II population experienced higher actuarial survival rates and lower rates of pump replacement for malfunction and thrombosis, infection, renal failure, RV failure, respiratory failure, and arrhythmias. Both groups experienced significant improvement in functional capacity and overall quality of life.[39,50] The post–FDA-approval study supported the original pivotal clinical trial findings regarding the efficacy and risk profile of the HeartMate II LVAD. Survival was best in patients who were not inotrope-dependent (INTERMACS profiles 4-7).[48]

Jarvik 2000. The Jarvik 2000 (Jarvik Heart, Inc., New York, NY) is a continuous-flow rotary pump with axial blood flow implanted intraventricularly[79–81] (Fig. 84-13). This pump is inserted through a sewing cuff attached to the apex of the left ventricle. The outflow orifice of the pump is attached to a Dacron graft for anastomosis to the descending or ascending thoracic aorta. The current adult version of the Jarvik 2000 measures 2.5 cm in diameter by 5.5 cm in length, with a weight of 85 g and a displacement volume of 25 mL. The adult pump functions at a speed of 8,000 to 12,000

rpm, achieving blood flows up to 8 L/min. Percutaneous power is delivered from external batteries via a controller unit. Internal electrical wires are brought via the left pleural cavity to the apex of the chest and then subcutaneously across the neck to the base of the skull, where a percutaneous titanium pedestal transmits fine electrical wires through the skin of the scalp. The early clinical studies suggest that this LVAD system can be used safely in selected patients to provide support until transplant or as DT.[80–82] In 2012, the FDA approved the Jarvik 2000 to undergo clinical evaluation for DT.

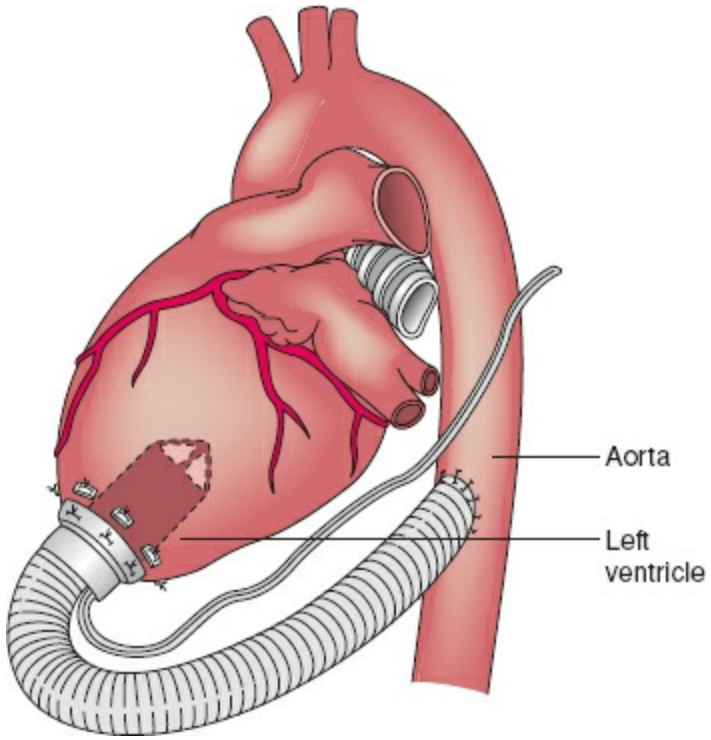

Figure 84-13. The Jarvik 2000 (Jarvik Heart Corporation, New York, NY) is an implantable, continuous-flow rotary left ventricular assist device with axial design intended for long-term mechanical circulatory support for bridge to transplant or destination therapy. Schematic representation of the placement of the Jarvik 2000 within the left ventricle.

Implantable, Continuous-Flow MCS Devices (Rotary Pumps With Centrifugal Flow Design)

Although significant improvements in pump design have occurred with continuous flow rotary pumps, the use of a mechanical bearing support for the internal impeller, typical of most axial designs, has potential limitations. The presence of rotor-suspending contact bearings in the blood path represents a potential point of frictional wear that can result in device failure and subsequent need for device exchange.[76,82,83] Rotary pumps with axial design with bearing support still demonstrate the potential for thrombus formation on the device rotor and bearing interface due to the presence of stasis and incomplete bearing "wash" of the bearings and formation of heat from frictional at the bearing surfaces.[53,54] The presence of stators to suspend and redirect blood flow also represents an obstruction within the blood flow path. Clinical studies have also documented reduced but persistent risk of thromboembolic stroke as well as hemorrhagic complications owing to the required long-term anticoagulation therapy.[44,46–50,53,54] An additional potential limitation of axial designs in general is related to their hydrodynamic performance. To observe

changes in pump flow at a fixed rotor speed, significant changes in pressure across the inlet and outlet orifices of the pump must occur.[84] This relative degree of insensitivity of the hydrodynamic performance of the pump or "steep" pressure–flow relationship can result in left ventricular collapse and "suction" when filling pressures are abruptly reduced as in the case of a sudden onset of a ventricular arrhythmia, or result in elevated filling pressures with dyspnea when return to the left atrium is abruptly increased, as with exercise. Left ventricular collapse or "suction" events can, by itself, precipitate serious ventricular arrhythmias,[85] while the inability to significantly increase pump flow with exercise may limit exercise performance in patients with axial pumps.

Implantable continuous flow rotary pumps with centrifugal flow design represent an alternative design. These devices provide continuous flow at rotational speeds that are much slower, about 2,000 to 4,000 compared with 8,000 to 15,000 rpm observed for pumps with axial flow design. The same general advantages and disadvantages of design features that apply to rotary pumps with axial flow design apply to centrifugal flow design. The major feature current centrifugal designs have is the elimination of the mechanical bearing support of the internal rotor. Current designs achieve impeller rotation and levitation with magnetic or hydrodynamic (fluid) forces eliminating the need for bearings with subsequent problems associated with bearing wear. These designs have a potential for very long durability[46,77,82,86,87] (Fig. 84-14). Impeller rotation to elicit blood flow is achieved through magnetic coupling to the pump motor. Levitation systems suspend the moving impeller within the blood field without any mechanical contact, thus eliminating frictional wear and reducing heat generation that would normally take place at the contact surface with a contact bearing design. These levitation forces may be achieved through magnetic or hydrodynamic bearing design. Magnetic forces may be passive without the consumption of power (permanent magnet) or active (induction of magnetic field with electricity) in design.[46,76,82,86,87] Hydrodynamic levitation depends on fluid forces generated by the rotating impeller to levitate the internal impeller. Pump designs can be further distinguished by the utilization of hydrodynamic levitation only, hydrodynamic levitation working in synergy with magnetic levitation for suspension, or variations of active and/or passive magnetic levitation. Active magnetic levitation of the impeller typically utilizes complex position sensing and control systems that increase requirements for a larger pump size. Hydrodynamic suspension does not utilize position sensors resulting in a less complicated electronic design and ability to miniaturize pump size. The design of any levitation system must be adequate to control the six degrees-of-freedom of movement of the suspended impeller.



Figure 84-14. Schematic representation of a continuous-flow rotary pump utilizing magnetic coupling of the internal impeller for levitation and rotation that obviates the need for bearings in the blood flow path.

Centrifugal pumps typically, although not exclusively, have a more sensitive pressure–flow relationship as compared with rotary pumps with axial design.[46,76,82,86,87] This greater sensitivity of the pressure-flow relationship in rotary pumps with centrifugal design results in greater changes in flow for any given change in pressure across the inlet and outlet orifices of the pump. This greater pump response to changes in flow may increase the margin of safety from creating suction events and improves pump flow during increases in left atrial return potentially enhancing exercise response.[76,82,86,87] The improvements in design attributes of rotary pumps with centrifugal design, such as mechanical wear, operation at low flow, and perceived improved potential for hemocompatibility, while still maintaining a manageable size, warrant further clinical investigation. Whether these attributes of rotary pumps with centrifugal design will result in significant improvement in clinical outcomes over that observed with rotary pumps with axial design is not known at this time.

HVAD. The HVAD (HeartWare Corporation, Miami, FL) is a small continuous-flow rotary pump with centrifugal and noncontact bearing design. The unique feature of the HVAD is its small design size[46,88,89] (Fig. 84-15). It has a displacement volume of 45 cc and weighs 145 g with a flow capacity of up to 10 L/min. The device is small enough to place within the pericardial cavity without the need for dissection and creation of a preperitoneal pocket. The impellor of the HVAD is suspended in place by combination of passive magnetic and hydrodynamic (i.e., fluid) bearing systems. The impeller suspension system uses a passive magnetic bearing for radial stiffness. Axial magnetic preload and hydrodynamic bearings on top of each impeller blade provide axial constraint. The magnetic bearing consists of a stack of rare-earth ring magnets, near the impeller's inside diameter that repel the magnetic force of a similar stack of magnets inside the center post. The axial alignment of the center-post magnet stack is set to provide an axial force that pushes the impeller toward the forward housing (the assembly with the inflow cannula). Physical contact between the housing and the impeller is prevented by a thin blood film generated by the hydrodynamic bearings.

The HVAD is approved for use in the United States for BTT indication and is currently

being evaluated in clinical trial for DT. The ADVANCE trial was a prospective, multicenter evaluation of the HVAD for BTT indication in the United States using a comparator group implanted contemporaneously with a commercially available device in the INTERMACS registry.[46,89] The primary outcome, success, was defined as survival on the originally implanted device, transplantation, or explantation for ventricular recovery at 180 days and was evaluated for both noninferiority and superiority. Secondary outcomes included a comparison of survival between groups and functional and quality-of-life outcomes and adverse events in the investigational device group. A total of 140 patients received the investigational pump, and 499 patients received a commercially available pump implanted contemporaneously. Success occurred in 90.7% of investigational pump patients and 90.1% of controls, establishing the noninferiority of the investigational pump ($P < 0.001$; 15% noninferiority margin). At 6 months, median 6-minute walk distance improved by 128.5 m, and both disease-specific and global quality-of-life scores improved significantly. Kaplan–Meier survival estimates at 30, 60, 180, and 360 days were 99%, 96%, 94%, and 86%, respectively, for the investigational device group and 97%, 95%, 90%, and 85%, respectively, for the INTERMACS control group. Bleeding, infections and perioperative right-sided heart failure were the most frequent complications. Inotropic support for greater than 14 days was required by 16.4% of patients. Driveline exit site infections and sepsis occurred in 12.1% and 11.4% of recipients, respectively.

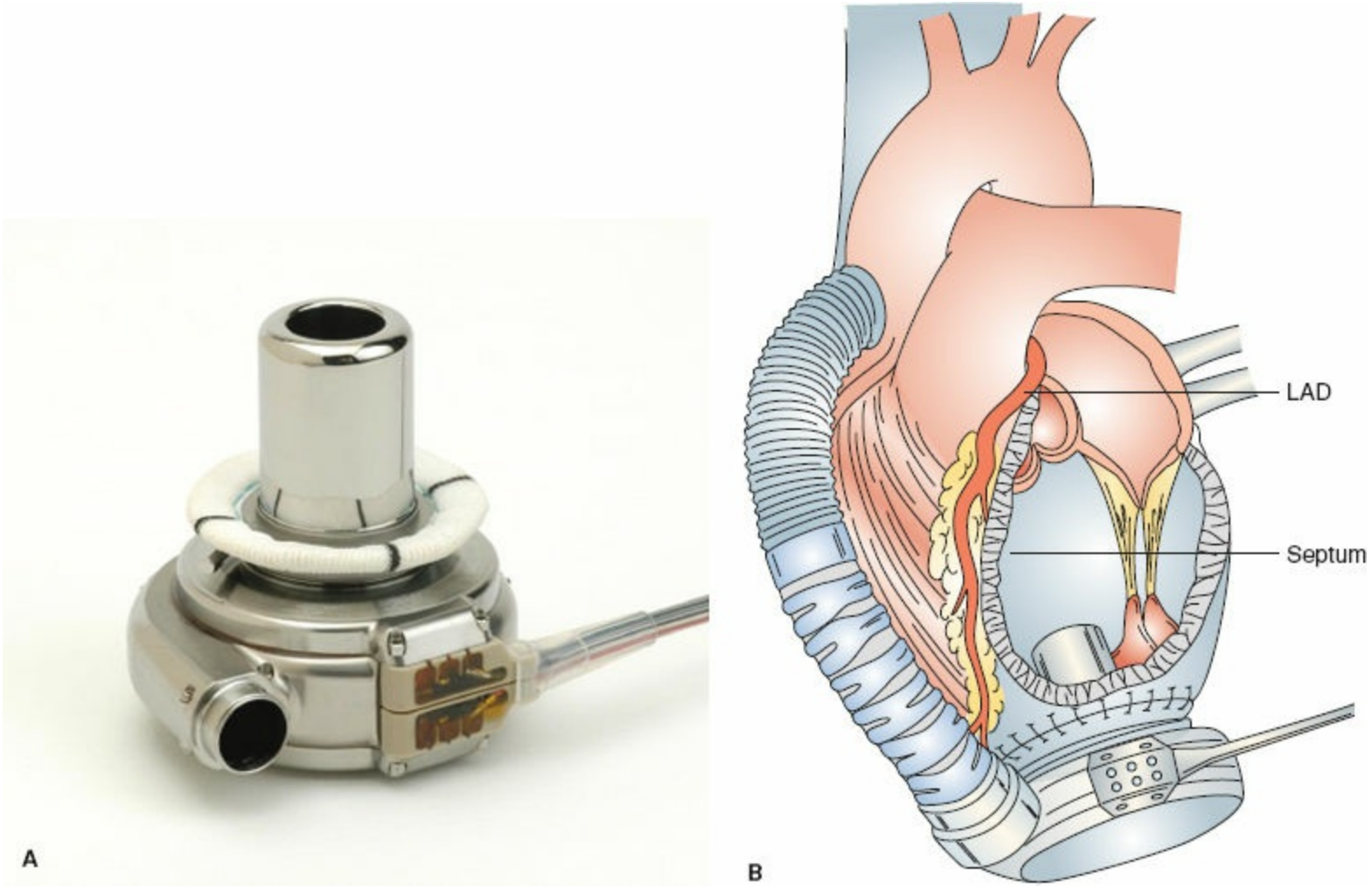

Figure 84-15. **A:** The HVAD LVAD (HeartWare Corporation, Miami, FL) is an implantable, continuous-flow rotary pump with centrifugal design. The device incorporates passive magnetic and hydrodynamic forces for impeller levitation and rotation. **B:** Schematic representation of the HVAD with the inlet cannula inserted into the apex of the left ventricle. The outflow cannulae and graft are anastomosed to the ascending aorta. (Photograph courtesy of HeartWare Corporation, Miami, FL.)

HeartMate III. The HeartMate III LVAD (Thoratec Corp, Pleasanton, CA) is a new compact intrapericardial-positioned continuous flow rotary pump with centrifugal design[86] (Fig. 84-16). The unique feature of the HeartMate III is the full magnetic levitation of the internal rotor. The design differs from currently used devices due to active control of rotation and levitation of the rotor that permits impellor movement further away from the outer housing creating larger gaps for blood flow within the device. The larger gaps may reduce blood component trauma and improve biocompatibility. The HeartMate III is currently under clinical investigation in the United States.

Following the first-in-man implantation at Hannover Medical School in Germany, the device underwent a clinical investigation in Europe and Canada through the Conformité Européene Mark clinical trial, which enrolled 50 patients with end-stage heart failure. The 6-month follow-up is in progress. The device is under investigation in a clinical trial in the United States, and the enrollment is currently ongoing.

MVAD. The MVAD (HeartWare Inc., Framingham, MA) is a novel continuous axial flow pump, approximately one-third the size of the HVAD (Fig. 84-17).[90] The contactless impeller suspension technology has a single moving part – the rotor, secured in place by a combination of passive-magnetic and hydrodynamic forces. The device allows for two distinct flow pathways – the primary flow path is through the impeller channels, and the secondary flow path is through the radial gap between the impeller and inner pump housing. The MVAD is to begin clinical evaluation in 2015.

Total Artificial Hearts

Syncardia Total Artificial Heart

The Syncardia TAH-t (SynCardia Systems Corporation, Tucson, AZ) is a pulsatile, volume displacement, TAH[91–93] (Fig. 84-18). The rigid polyurethane pump contains a flexible polyurethane diaphragm that separates blood and air chambers. Two mechanical valves located at the inflow and outflow orifices ensure unidirectional blood flow. Compressed air from the external drive console moves the diaphragm upward, pressurizing the blood chamber and causing ejection of blood. The pump has a maximum stroke volume of 70 mL and a maximum flow rate of 15 L/min, although the average flow rate is <8 L/min. Pump rate, duration of systole, and driving pressure can be adjusted to achieve optimal flow conditions. The TAH is surgically implanted in the mediastinal space after the ventricles have been excised, while the atrial cuffs are retained. The pneumatic drivelines are externalized percutaneously and attached to the drive console. Ambulation is facilitated by small portable drive systems and consoles. The Syncardia TAH-t is approved by the FDA for bridge to heart transplant indication. In a recent study, Copeland and colleagues[92] reported a survival rate of 79% to heart transplantation compared with 46% for the observational arm. One-year posttransplant survival rate was 86%. A newer design incorporating a smaller 50-cc ventricle to facilitate the use in smaller patients is currently in clinical evaluation.

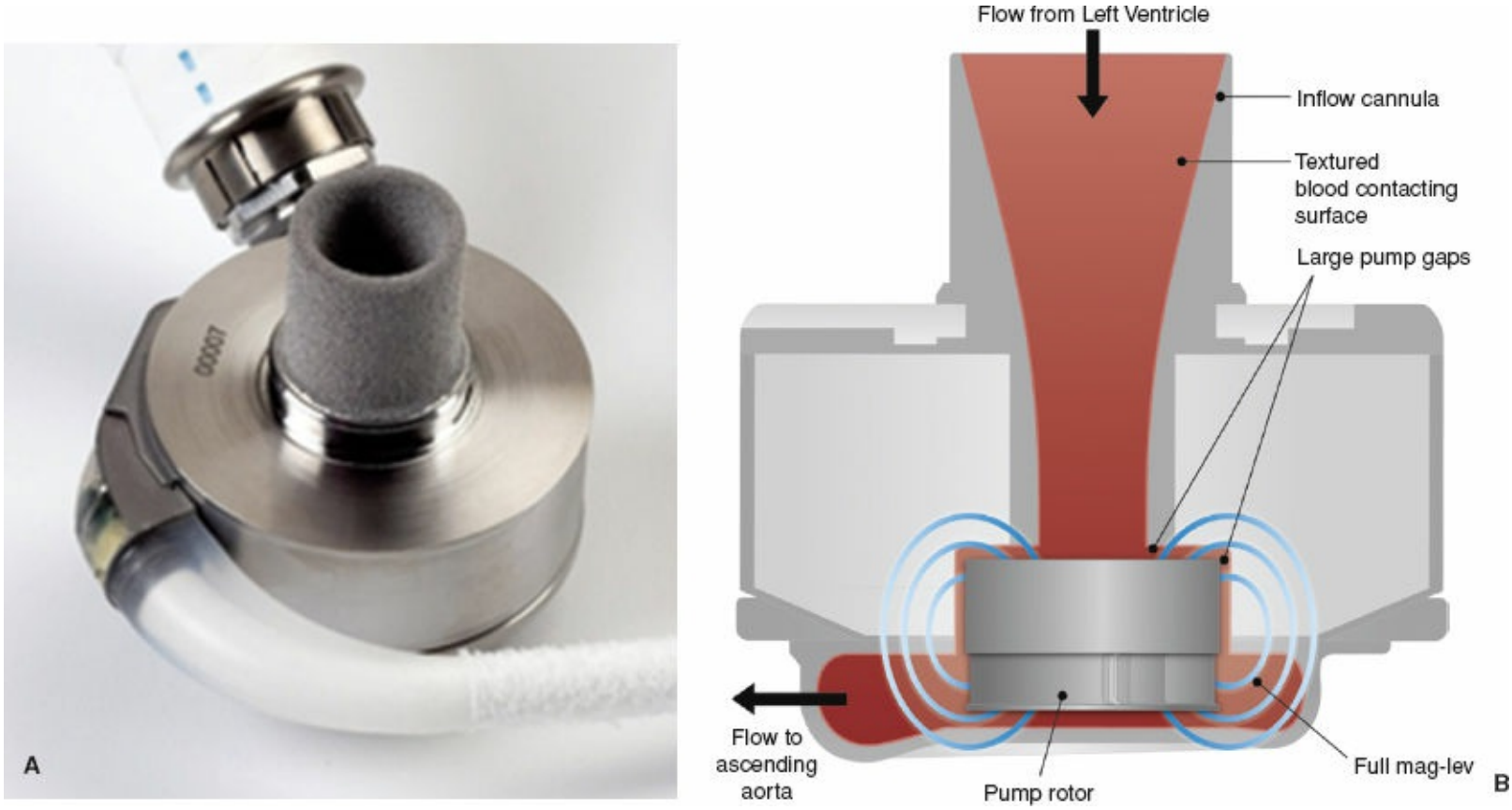

Figure 84-16. **A:** The Thoratec HeartMate III (Thoratec Corp., Pleasanton, CA) is an implantable, continuous-flow rotary pump with centrifugal design. The device incorporates complete magnetic levitation for both impeller levitation and rotation. **B:** Schematic representation of the HeartMate III showing the blood path, internal rotor, and magnetic fields that achieve levitation and rotation of the internal rotor. (From Schmitto JD, Hanke JS, Rojas SV, et al. First implantation in man of a new magnetically levitated left ventricular assist device (HeartMate III). *J Heart Lung Transplant* 2015;34:858–860.)



Figure 84-17. **A:** The HeartWare MVAD (HeartWare Inc., Miami, FL) is an implantable, continuous-flow rotary pump with axial design. The device incorporates hydrodynamic levitation (fluid forces) for radial stability and magnetic levitation for axial stability. **B:** Schematic representation of the MVAD demonstrating the blood path and internal rotor. (Photo courtesy of HeartWare, Inc., Miami, FL.)

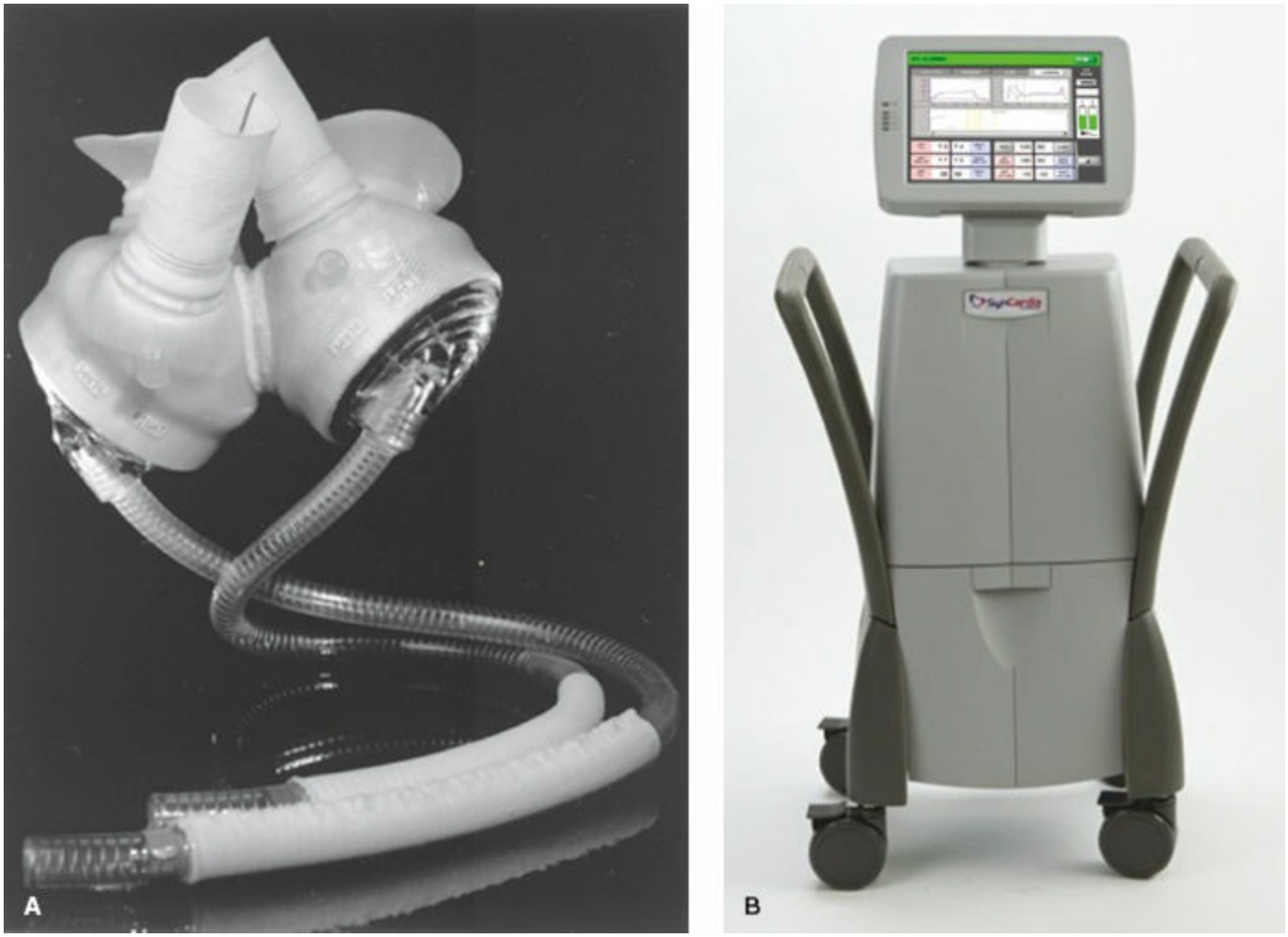

Figure 84-18. **A:** The CardioWest total artificial heart (Syncardia Systems Corporation, Tucson, AZ) is a pneumatically driven, pulsatile, volume displacement device. **B:** The device is positioned orthotopically as a complete replacement of the native heart. The device is powered by drivelines that exit the anterior abdominal wall and connect to a pneumatic drive console. (Photos courtesy of Syncardia, Inc., Tucson, AZ.)

FUTURE DIRECTIONS

Recent rapid technologic advancements and successful clinical applications of MCS have made the future of this field optimistic but uncertain. Areas of continued research include the use of wireless energy transfer to facilitate complete internalization of MCS devices, application of less invasive surgical techniques for device implantation, application of MCS devices for the pediatric population, partial support devices and device designs, and new materials to improve compatibility of the blood-device interface to reduce thromboembolic complications and need for anticoagulation. It is possible that long-term MCS will provide a viable alternative to heart transplantation and medical therapy for patients with advanced heart failure. Because of the technologic advancements, it will be difficult to predict what devices will ultimately prove to be the most efficacious. It is likely that a variety of devices will become available for use, depending on clinical circumstances and patient characteristics.

References

1. Rihal CS, Naidu SS, Givertz MM, et al. 2015 SCAI/ACC/HFSA/STS clinical expert consensus statement on the use of percutaneous mechanical circulatory support devices in cardiovascular care. *J Am Coll Cardiol* 2015;65(19):e7–e26.
2. Rose EC, Gelijns AC, Moskowitz AJ, et al. Long-term use of a left ventricular assist device for end-stage heart failure. *N Eng J Med* 2001;345:1435–1443.
3. Decision memo for ventricular assist devices for bridge-to-transplant and destination therapy (CAG-00432R). http://www.cms.gov/medicare-coverage-database/details/nca-decision-memo.aspx?NCAId=268. Accessed July 3, 2015.
4. Felker GM, Rogers JG. Same bridge, new destinations—Rethinking paradigms for mechanical cardiac support in heart failure. *J Am Coll Cardiol* 2006;47(5):930–932.
5. Hochman JS, Sleeper LA, Webb JG, et al. Early revascularization in acute myocardial infarction complicated by cardiogenic shock. *N Eng J Med* 1999;341:625–634.
6. Norman JC, Cooley DA, Igo SR, et al. Prognostic indices for survival during postcardiotomy intra-aortic balloon pumping. *J Thorac Cardiovasc Surg* 1977;74:709–720.
7. Gray LA, Champsaur GG. The BVS 5000 biventricular assist device. The worldwide registry experience. *ASAIO J* 1994;40:M460–M464.
8. Pennington DG, Merjavy JP, Swartz MT, et al. The importance of biventricular failure in patients with postoperative cardiogenic shock. *Ann Thorac Surg* 1985;39:16–26.
9. Farrar DJ, Hill JD, Pennington DG, et al. Preoperative and postoperative comparison of patients with univentricular and biventricular support with the Thoratec ventricular assist device as a bridge to cardiac transplantation. *J Thorac Cardiovasc Surg* 1997;113:202–209.
10. Fitzpatrick JR III, Frederick JR, Hsu VM, et al. Risk score derived from pre-operative data analysis predicts the need for biventricular mechanical circulatory support. *J Heart Lung Transplant* 2008;27:1286–1292.
11. Matthews JC, Koelling TM, Pagani FD, et al. The right ventricular failure risk score: a pre-operative tool for assessing the risk of right ventricular failure in left ventricular assist device candidates. *J Am Coll Cardiol* 2008; 51:2163–2172.
12. Kormos RL, Gasior TA, Kawai A, et al. Transplant candidate's clinical status rather than right ventricular function defines the need for univentricular versus biventricular support. *J Thorac Cardiovasc Surg* 1996;111:773–783.
13. Kirklin JK, Naftel DC, Pagani FD, et al. Sixth INTERMACS annual report: a 10,000-patient database. *J Heart Lung Transplant* 2014;33(12):1304–1311.
14. Stevenson LW, Pagani FD, Young JB, et al. INTERMACS profiles of advanced heart failure: the current picture. *J Heart Lung Transplant* 2009;28:535–541.
15. Mancini D, Colombo PC. Left ventricular assist devices. A rapidly evolving alternative to transplant. *J Am Coll Cardiol* 2015;65:2542–2555.

16. Estep JD, Starling RC, Horstmanshof DA, et al. Risk assessment and comparative effectiveness of left ventricular assist device and medical management in ambulatory heart failure patients (ROADMAP). *J Heart Lung Transplant* 2015;34:S80.
17. Kirklin JK, Naftel DC, Kormos RL, et al. Quantifying the effect of cardiorenal syndrome on mortality after left ventricular assist device implant. *J Heart Lung Transplant* 2013;32(12):1205–1213.
18. Miller LW. Patient selection for the use of ventricular assist devices as a bridge to transplantation. *Ann Thorac Surg* 2003;75(suppl 6):S66–S71.
19. Aaronson KD, Patel H, Pagani FD. Patient selection for left ventricular assist device therapy. *Ann Thorac Surg* 2003;75(suppl 6):S29–S35.
20. Kormos RL, Teuteberg JJ, Pagani FD, et al. Right ventricular failure in patients with the HeartMate II continuous-flow left ventricular assist device: incidence, risk factors, and effect on outcomes. *J Thorac Cardiovasc Surg* 2010;139:1316–1324.
21. Takeda K, Naka Y, Yang JA, et al. Timing of temporary right ventricular assist device insertion for severe right heart failure after left ventricular assist device implantation. *ASAIO J* 2013;59:564–569.
22. Takeda K, Takayama H, Colombo PC, et al. Incidence and clinical significance of late right heart failure during continuous-flow left ventricular assist device support. *J Heart Lung Transplant* 2015;34(5):667–674.
23. Santamore WP, Gray LA. Left ventricular contributions to right ventricular systolic function during LVAD support. *Ann Thorac Surg* 1996;61:350–356.
24. Pavie A, Leger P. Physiology of univentricular versus biventricular support. *Ann Thorac Surg* 1996;61:347–349.
25. Mandarino WA, Winowich S, Gorcsan J, et al. Right ventricular performance and left ventricular assist device filling. *Ann Thorac Surg* 1997;63:1044–1049.
26. Matthews JC, Pagani FD, Haft JW, et al. Meld score predicts LVAD operative transfusion requirements, morbidity and mortality. *Circulation* 2010; 121(2):214–220.
27. Goldstein DJ, Seldomridge JA, Chen JM, et al. Left ventricular assist device and bleeding: adding insult to injury. *Ann Thorac Surg* 1995;59:1063–1068.
28. Dewald O, Schmitz DO, Reichart B, et al. Platelet activation markers in patients with heart assist devices. *Artif Organs* 2005;29:292–299.
29. Lietz K, Long JW, Kfoury AG, et al. Outcomes of left ventricular assist device implantation as destination therapy in the post-REMATCH era: implications for patient selection. *Circulation* 2007;116:497–505.
30. Filippatos GS, Anker SD, Kremastinos DT. Pathophysiology of peripheral muscle wasting in cardiac cachexia. *Curr Opin Clin Nutr Metab Care* 2005; 8:249–254.
31. Park SJ, Liao KK, Segurola R, et al. Management of aortic insufficiency in patients with left ventricular assist devices: a simple coaptation stitch method (Park's stitch). *J Thorac Cardiovasc Surg* 2004;127:264–266.
32. Cowger J, Pagani FD, Haft JW, et al. The development of aortic insufficiency in left

ventricular assist device-supported patients. *Circ Heart Fail* 2010;3:668–674.
33. Morgan JA, Brewer RJ, Nemeh HW, et al. Management of aortic valve insufficiency in patients supported by long-term continuous flow left ventricular assist devices. *Ann Thorac Surg* 2012;94:1710–1712.
34. Salzberg SP, Lachat ML, Zünd G, et al. Left ventricular assist device (LVAD) enables survival during 7 h of sustained ventricular fibrillation. *Eur J Cardio-Thorac Surg* 2004;26:444–446.
35. Feldman D, Pamboukian SV, Teuteberg JJ, et al. The 2013 Society for Heart and Lung Transplantation guidelines for mechanical circulatory support: executive summary. *J Heart Lung Transplant* 2013;32:157–187.
36. Garan AR, Yuzefpolskaya M, Colombo PC, et al. Ventricular arrhythmias and implantable cardioverter-defibrillator therapy in patients with continuous-flow left ventricular assist devices: need for primary prevention? *J Am Coll Cardiol* 2013;61(25):2542–2550.
37. Shapiro GC, Leibowitz DW, Oz MC, et al. Diagnosis of patent foramen ovale with transesophageal echocardiography in a patient supported with a left ventricular assist device. *J Heart Lung Transplant* 1995;14:594–597.
38. Pagani FD, Miller LW, Russell SD, et al. Extended mechanical circulatory support with a continuous-flow rotary left ventricular assist device. *J Am Coll Cardiol* 2009;54:312–321.
39. Slaughter MS, Rogers JG, Milano CA, et al. Advanced heart failure treated with continuous-flow left ventricular assist device. *N Engl J Med* 2009;361:2241–2251.
40. Crow S, John R, Boyle A, et al. Gastrointestinal bleeding rates in recipients of nonpulsatile and pulsatile left ventricular assist devices. *J Thorac Cardiovasc Surg* 2009;137:208–215.
41. Geisen U, Heilman C, Beyeresdorf F, et al. Non-surgical bleeding in patients with ventricular assist devices could be explained by acquired von Willebrand disease. *Eur J Cardiothorac Surg* 2008;33:679–684.
42. Uriel N, Pak SW, Jorde UP, et al. Acquired von Willebrand syndrome after continuous-flow mechanical device support contributes to a high prevalence of bleeding during long-term support and at the time of transplantation. *J Am Coll Cardiol* 2010;56:1207–1213.
43. Dassanayaka S, Slaughter MS, Bartoli CR. Mechanistic pathway(s) of acquired von Willebrand syndrome with a continuous-flow ventricular assist device: in vitro findings. *ASAIO J* 2013;59:123–129.
44. Eckman P, John R. Bleeding and thrombosis in patients with continuous-flow ventricular assist devices. *Circulation* 2012;125:3038–3047.
45. Argiriou M, Kolokotron SM, Sakellaridis T, et al. Right heart failure post left ventricular assist device implantation. *J Thorac Dis* 2014;6(suppl 1):S52–S59.
46. Aaronson KD, Slaughter MS, Miller LW, et al. Use of an intrapericardial, continuous

flow, centrifugal pump in patients awaiting heart transplantation. *Circulation* 2012;125;3191–3200.

47. Starling RC, Naka Y, Boyle AJ, et al. Results of the post-U.S. Food and Drug Administration-approval study with a continuous flow left ventricular assist device as a bridge to heart transplantation: a prospective study using the INTERMACS (Interagency Registry for Mechanically Assisted Circulatory Support). *J Am Coll Card* 2011;57:1890–1898.
48. Jorde UP, Kushwaha SS, Tatooles AJ, et al. Results of the destination therapy post-Food and Drug Administration approval study with a continuous flow left ventricular assist device. *J Am Coll Cardiol* 2014;63(17):1751–1757.
49. Miller LW, Pagani FD, Russell SD, et al. Use of a continuous-flow device in patients awaiting heart transplantation. *N Engl J Med* 2007;357:885–896.
50. Park SJ, Milano CA, Tatooles AJ, et al. Outcomes in advanced heart failure patients with left ventricular assist devices for destination therapy. *Circ Heart Fail* 2012;5:241–248.
51. Koval CE, Rakita R. Ventricular assist device related infections and solid organ transplantation. *Am J Transplant* 2013;13:348–354.
52. Kirklin JK, Naftel DC, Kormos RL, et al. Interagency Registry for Mechanically Assisted Circulatory Support (INTERMACS) analysis of pump thrombosis in the HeartMate II left ventricular assist device. *J Heart Lung Transplant* 2014;33(1):12–22.
53. Starling RC, Moazami N, Silvestry SC, et al. Unexpected abrupt increase in left ventricular assist device thrombosis. *N Eng J Med* 2014;370:33–40.
54. Goldstein DJ, John R, Salerno C, et al. Algorithm for the diagnosis and management of suspected pump thrombus. *J Heart Lung Transplant* 2013;32:667–670.
55. Burkhoff D, Klotz S, Mancini DM. LVAD-induced reverse remodeling: basic and clinical implications for myocardial recovery. *J Card Fail* 2006;12:227–239.
56. Birks EJ, Tansley PD, Hardy J, et al. Left ventricular assist device and drug therapy for the reversal of heart failure. *N Engl J Med* 2006;355:1873–1884.
57. Guglin M, Miller L. Myocardial recovery with left ventricular assist devices. *Curr Treat Options Cardiovasc Med* 2012;14(4):370–383.
58. Kantrowitz A, Tjonneland S, Freed PS, et al. Initial clinical experience with intraaortic balloon pumping in cardiogenic shock. *JAMA* 1968;203:135.
59. Thiele H, Zeymer U, Neumann FJ, et al. Intra-aortic balloon support for myocardial infarction with cardiogenic shock. *N Engl J Med* 2012; 367(14):1287–1296.
60. Muehrcke DD, McCarthy PM Stewart RW, et al. Extracorporeal membrane oxygenation for postcardiotomy cardiogenic shock. *Ann Thorac Surg* 1996; 61:684–691.
61. Smedira NG, Wudel JH, Hlozek CC, et al. Venovenous extracorporeal life support for patients after cardiotomy. *ASAIO J* 1997;43:M444–M446.
62. McGovern GJ, Magovern JA, Benckart DH, et al. Extracorporeal membrane

oxygenation-preliminary results in patients with postcardiotomy cardiogenic shock. *Ann Thorac Surg* 1994;57:1462–1467.

63. Hill JD, O'Brien TG, Murray JJ, et al. Extracorporeal oxygenation for acute post-traumatic respiratory failure. *N Eng J Med* 1972;286:629–634.
64. Gray BW, Haft JW, Hirsch JC, et al. Extracorporeal life support: experience with 2000 patients. *ASAIO J* 2015;61:2–7.
65. Pagani FD, Aaronson KD, Dyke DB, et al. Assessment of an extracorporeal life support to LVAD bridge to heart transplant strategy. *Ann Thorac Surg* 2000;70:1977–1985.
66. Bowen FW, Carboni AF, O'Hara ML, et al. Application of "double bridge mechanical" resuscitation for profound cardiogenic shock leading to cardiac transplantation. *Ann Thorac Surg* 2001;72:86–90.
67. Smedira NG, Moazomi N, Golding CM, et al. Clinical experience with 202 adults receiving extracorporeal membrane oxygenation for cardiac failure: survival at five years. *J Thorac Cardiovasc Surg* 2001;122:92–102.
68. Thiele H, Sick P, Boudriot E, et al. Randomized comparison of intra-aortic balloon support with a percutaneous left ventricular assist device in patients with revascularized acute myocardial infarction complicated by cardiogenic shock. *Eur Heart J* 2005;26:1276–1283.
69. Kapur NK, Paruchuri V, Urbano-Morales JA, et al. Mechanically unloading the left ventricle before coronary reperfusion reduces left ventricular wall stress and myocardial infarct size. *Circulation* 2013;128:328–336.
70. Seyfarth M, Sibbing D, Bauer I, et al. A randomized clinical trial to evaluate the safety and efficacy of a percutaneous left ventricular assist device versus intra-aortic balloon pumping for treatment of cardiogenic shock caused by myocardial infarction. *J Am Coll Cardiol* 2008;52:1584–1588.
71. Sassard T, Scalabre A, Bonnefoy E, et al. The right axillary artery approach for the Impella Recover LP 5.0 microaxial pump. *Ann Thorac Surg* 2008; 85:1468–1470.
72. Raess DH, Weber DM. Impella 2.5. *J Cardiovasc Transl Res* 2009;2:168–172.
73. Haj-Yahia S, Birks EJ, Amrani M, et al. Bridging patients after salvage from bridge to decision directly to transplant by means of prolonged support with the CentriMag short-term centrifugal pump. *J Thorac Cardiovasc Surg* 2009;138:227–230.
74. John R, Liao K, Lietz K, et al. Experience with the Levitronix CentriMag circulatory support system as a bridge to decision in patients with refractory acute cardiogenic shock and multisystem organ failure. *J Thorac Cardiovasc Surg* 2007;134:351–358.
75. Dembitsky WP, Tector AJ, Park S, et al. Left ventricular assist device performance with long-term circulatory support: lessons from the REMATCH trial. *Ann Thorac Surg* 2004;78:2123–2130.
76. Takatani S. Progress of rotary blood pumps: Presidential Address, International Society for Rotary Blood Pumps 2006, Leuven, Belgium. *Artif Organs* 2007;31:329–

344.
77. Radovancevic B, Vrtovec B, de Kort E, et al. End-organ function in patients on long-term circulatory support with continuous- or pulsatile–flow assist devices. *J Heart Lung Transplant* 2007;26:815–818.
78. Westaby S, Banning AP, Jarvik R, et al. First permanent implant of the Jarvik 2000 heart. *Lancet* 2000;356:900–903.
79. Frazier OH, Myers TJ, Gregoric ID, et al. Initial clinical experience with the Jarvik 2000 implantable axial-flow left ventricular assist system. *Circulation* 2002;105:2855–2860.
80. Westaby S, Frazier OH, Beyersdorf F, et al. The Jarvik 2000 Heart. Clinical validation of the intraventricular position. *Eur J Cardiothorac Surg* 2002; 22:228–232.
81. Frazier OH, Myers TJ, Westaby S, et al. Clinical experience with an implantable, intracardiac, continuous flow circulatory support device: physiologic implications and their relationship to patient selection. *Ann Thorac Surg* 2004;77:133–142.
82. Pagani FD. Continuous-flow rotary left ventricular assist devices with 3rd generation design. *Sem Thorac Cardiovasc Surg* 2008;20:255–263.
83. Hoshi H, Shinshi T, Takatani S. Third-generation blood pumps with mechanical noncontact magnetic bearings. *Artif Organs* 2006;30:324–338.
84. Akimoto T, Yamazaki K, Litwak P, et al. Rotary blood pump flow spontaneously increases during exercise under constant pump speed: results of a chronic study. *Artif Organs* 1999;23:797–801.
85. Vollkron M, Voitl P, Ta J, et al. Suction events during left ventricular support and ventricular arrhythmias. *J Heart Lung Transplant* 2007;26:819–825.
86. Schmitto JD, Hanke JS, Rojas SV, et al. First implantation in man of a new magnetically levitated left ventricular assist device (HeartMate III). *J Heart Lung Transplant* 2015;34:858–860.
87. Moazami N, Fukamachi K, Kobayashi M, et al. Axial and centrifugal continuous flow rotary pumps: a translation from pump mechanics to clinical practice. *J Heart Lung Transplant* 2013;32:1–11.
88. Streuber M, Larbalestier R, Jansz P, et al. Results of the post-market registry to evaluate the HeartWare left ventricular assist system (ReVOLVE). *J Heart Lung Transplant* 2014;33:486–491.
89. Slaughter MS, Pagani FD, McGee EC, et al. HeartWare ventricular assist system for bridge to transplant: combined results of the bridge to transplant and continued access protocol trial. *J Heart Lung Transplant* 2013;32:675–683.
90. McGee EC, Chorpenning K, Brown MC, et al. In vivo evaluation of the HeartWare MVAD pump. *J Heart Lung Transplant* 2014;33:366–371.
91. Arabia FA, Copeland JG, Pavie A, et al. Implantation technique for the CardioWest total artificial heart. *Ann Thorac Surg* 1999;68:698–704.
92. Copeland JG, Smith RG, Arabia FA, et al. Cardiac replacement with a total artificial

heart as a bridge to transplantation. *N Engl J Med* 2004;351:859–867.
93. Copeland JG, Smith RG, Arabia FA, et al. Total artificial heart bridge to transplantation: a 9-year experience with 62 patients. *J Heart Lung Transplant* 2004;23:823–831.

---

*A comprehensive listing of abbreviations used is available at the end of this chapter.

Chapter 85

Thoracic Aortic Aneurysms and Aortic Dissection

Ravi K. Ghanta and Gorav Ailawadi

Key Points

1. The risk of thoracic aneurysm disease increases with age. Thoracic aortic aneurysms in young patients are most likely due to genetic predisposition or familial syndromes.
2. Careful planning by experienced centers is paramount to provide optimal treatment in patients with thoracic aortic aneurysms as the morbidity and mortality for surgical intervention are significant.
3. Open surgical repair remains the mainstay for aortic root, ascending aortic, and aortic arch aneurysms with very acceptable outcomes and low morbidity when performed in centers of excellence.
4. Endovascular techniques for the descending thoracic aorta have become the preferred treatment approach not only for aneurysms, but for dissections and acute traumatic aortic injuries as they often can be performed with less morbidity than that associated with open surgical treatment.
5. Aortic dissection is associated with higher operative morbidity and mortality. Stanford type A aortic dissection mandates emergent operation. Stanford type B aortic dissection may be managed medically if uncomplicated or with endovascular therapy if complicated. Management is evolving with advancements in endovascular techniques.

Aortic diseases constitute the 13th leading cause of death in the developed world. Aneurysms can affect the entire aorta, but aneurysms of the thoracic aorta, in particular, are associated with the highest morbidity and mortality (Fig. 85-1). An aortic aneurysm is defined as a dilation of the diameter of at least 50% greater than baseline. *True aortic aneurysms* affect all the layers of the aortic wall – intima, media, and adventitia – and should be distinguished from *false aneurysms (pseudoaneurysms),* which occur after trauma, surgery, or other injury and only involve the media and adventitia. Although understanding of the pathogenesis of aortic aneurysms is rapidly evolving, degradation of the aortic extracellular matrix proteins, collagen and elastin, and loss of smooth muscle cells are hallmark pathologic findings. In contradistinction to abdominal aortic aneurysms, ascending aneurysms less commonly display manifestations of atherosclerosis

or an inflammatory infiltrate.

Thoracic aortic disease is associated with significant risk primarily due to catastrophic rupture or dissection. *Aortic dissections* are intimal tears resulting in blood propagating within the medial layer, leading to true and false lumens of blood flow. False-lumen perfusion can lead to visceral organ malperfusion. Although dissections most commonly occur in aneurysms, dissections can also occur in nonaneurysmal aortas with connective tissue or other aortic wall pathologies. Chronic aortic dissections can also become aneurysmal over time, necessitating intervention. Treatment decisions concerning operative intervention in terms of both timing and extent of resection are often complex and involve multidisciplinary management (Fig. 85-2).

THORACIC AORTIC ANEURYSM

History

The first known description of an arterial aneurysm was by Galen, a Greek physician (A.D. 126–216), who described false aneurysms in injured gladiators.[1] In 1543, Andeas Versalius first described thoracic aortic aneurysms (TAAs). However, it was not until 1895 that an etiology for aneurysms was hypothesized, when Dohle identified syphilitic aortitis.[2] Aneurysms were originally treated with external or internal ligation via opening the aneurysm. In the later 19th century, Rudolph Matas developed an alternate technique of obtaining proximal and distal control, aneurysm resection, and primary reconstruction.[3] These techniques were successful in only a limited number of patients.

The modern surgical treatment of aortic disease began in the 1950s, and the ensuing 20 to 30 years saw the development and failures of many novel techniques.[4,5] In the early 1950s, the first resection of a descending thoracic aneurysm and replacement with homograft was reported. In 1952, the first excision of a saccular ascending aortic aneurysm without cardiopulmonary bypass was performed by Michael DeBakey and Denton Cooley in Houston.[6] In 1953, Dubost et al. in Paris and DeBakey and Cooley in Houston reported successful resection and reconstruction of the abdominal aorta with human aortic allograft.[7,8] The same duo performed a repair of an acute traumatic aortic transection in 1954 through a left thoracotomy with the patient's core temperature reduced to 28°C using surface cooling. They subsequently reported the first successful resection of an ascending aneurysm with cardiopulmonary bypass in 1956 and the first successful arch aneurysm repair in 1957.[9,10]

Dacron grafts, introduced by DeBakey, largely replaced human allografts, avoiding the need for maintaining large tissue banks and allowing more facilities the ability to treat these patients.[11,12] In addition, the development and refinement of the cardiopulmonary bypass machine, in large part by John Gibbon at Thomas Jefferson, revolutionized the open surgical repair of thoracic aortic disease. The importance of hypothermia for cerebral protection and specifically the use of hypothermic circulatory arrest (HCA) during aneurysm repair was established by Randy Griepp and colleagues.[13] Advances in endovascular therapies, led to the development of thoracic aortic stent grafts in 1994 by Michael Dake and colleagues.[14] With these techniques in place, modern surgical practice to treat aortic disease was established.

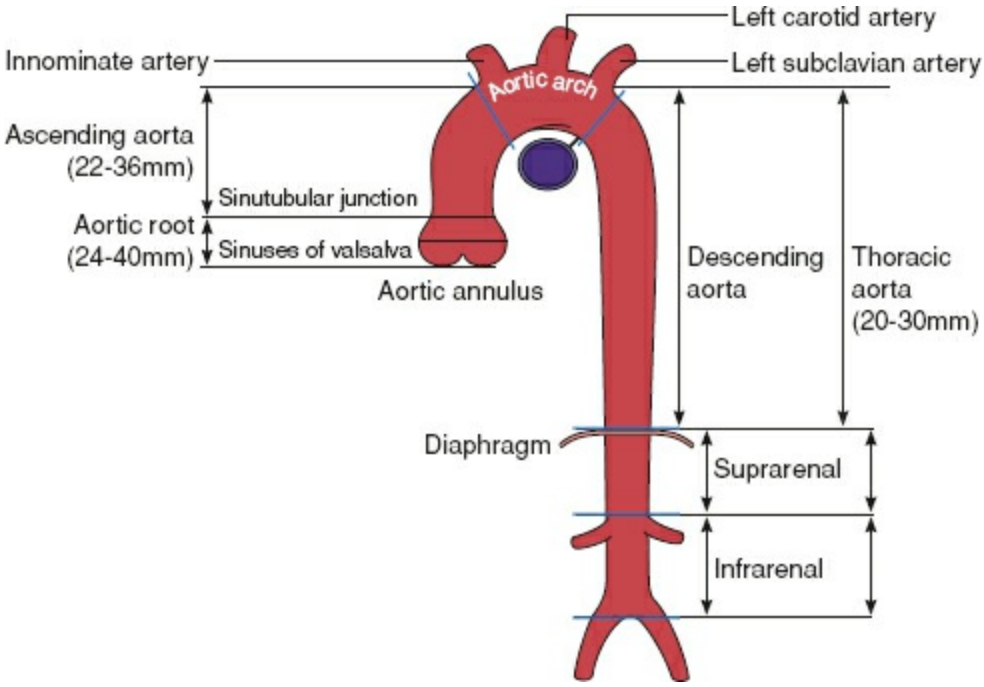

Figure 85-1. Normal anatomic aortic segments. The aortic root extends from the aortic annulus to the sinotubular junction. The aortic root is the largest diameter section of the aorta when measured at the level of the sinuses of Valsalva. The tubular or ascending segment of the aorta begins at the sinotubular junction and extends to the innominate artery. The aortic arch travels anterior to posterior and the left, giving rise to the head and upper extremity vessels. The descending thoracic aorta begins distal to the left subclavian at the level of the ligamentum arteriosum to the pulmonary artery (PA). The abdominal aorta begins at the level of the diaphragm.

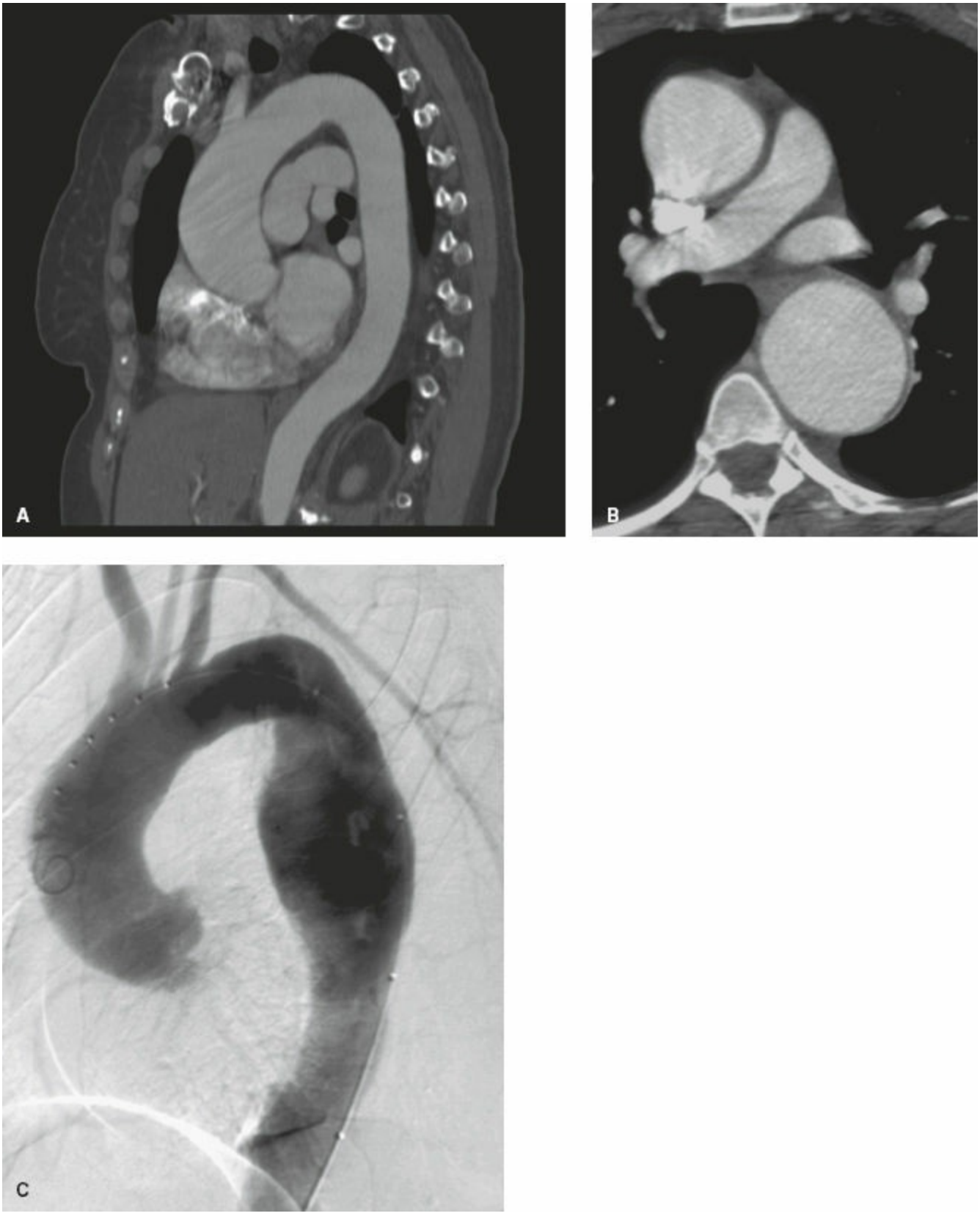

Figure 85-2. **A:** Sagittal CT scan showing an ascending aortic aneurysm. Computed tomography (**B**) and angiogram (**C**) of a patient with a fusiform descending thoracic aortic aneurysm.

Table 85-1 Risk Factors for Thoracic Aortic Aneurysms

- Anatomic
  - Annulo aortic ectasia
  - Aortic wall abnormalities
  - Bicuspid aortic valve
- Chromosomal/genetic
  - Marfan syndrome
  - Ehlers–Danlos syndrome (type 4)
  - Noonan syndrome
  - Polycystic kidney disease
  - Turner syndrome
- Congenital
  - Aortic arch hypoplasia
  - Aortic coarctation
  - Congenital aortic stenosis
- Demographic
  - Age (>60 yrs)
- Lifestyle
  - Cocaine
  - Dyslipidemia
  - Pregnancy (preeclampsia)
  - Smoking
- Vascular disease
  - Uncontrolled hypertension
  - Inflammation
    - Aortic aneurysm
    - Aortic arteritis
    - Arthrosclerosis
    - Behçet disease
    - Giant cell arteritis
    - Ormond disease
    - Syphilis
    - Takayasu arteritis
- Iatrogenic/idiopathic
  - Aortic cannulation/cross-clamping
  - Endoluminal transcatheter therapy
  - Graft anastomosis
  - Instrumentation
  - Sheehan syndrome
  - Valvular surgery

Prevalence and Classification

Thoracic aneurysms compose 25% of all aortic aneurysms. Approximately 50% of TAAs involve the ascending aorta, 10% the aortic arch, and 40% the descending aorta.[15] True thoracoabdominal aneurysms constitute less than 5% of TAAs.[16] Interestingly, during the first half of the 20th century, thoracic aneurysms were far more common than abdominal aortic aneurysms because of the predominance of infectious (syphilitic) aneurysm in the thoracic aorta. By 1964, however, less than half of aneurysms were in the thorax, primarily as a result of the decline in the incidence of syphilis.[17]

The true incidence and prevalence of TAAs is likely underreported. In a Swedish autopsy study, the prevalence of TAAs was reported as 489 per 100,000 men and 437 per 100,000 women.[16] Stratified by age, 65-year-olds had approximately 400 asymptomatic thoracic aneurysms per 100,000 autopsies, whereas 80-year-olds had a prevalence of 670 per 100,000 autopsies.[16] The mean age at diagnosis is between 60 and 70 years. Men are diagnosed 10 years earlier on average and have a 2:1 to 3:1 predominance compared to women.[15] In a study of residents in Olmstead county, the prevalence of thoracic aneurysms was 5.9 cases per 100,000 people-years prior to 1980.[18] This number increased to 10.4 cases per 100,000 people-years between 1980 and 1994.[19]

Etiology and Risk Factors

Although there has been a long-standing belief that aortic aneurysms represent a late degenerative stage of atherosclerosis, this concept has been seriously challenged, and aneurysms are now viewed in terms of genetic and molecular mechanisms.[15] Atherosclerotic disease is now thought to be associated with, rather than causative of, aneurysmal disease. Aneurysms associated with atherosclerosis of the aorta most commonly involve the descending or thoracoabdominal segments, whereas atherosclerosis is rarely associated with ascending aortic aneurysms.

1 Abnormal proteolysis, the presence of elastolytic serum enzymes and deficiencies of collagen and elastin have been implicated as factors contributing to the development of these aneurysms.[17] Atherosclerotic lesions of the thoracic aorta may ulcerate and penetrate the internal elastic lamina of the aortic wall, which can result in hemorrhage within the layers of the media leading to intramural hematoma, an entity on the continuum of aortic dissection. Once aneurysmal dilatation of the aorta has begun, it tends to progress. Whether this is due to a gradual but constant increase in size or episodic incremental increases is unknown. Associated chronic obstructive pulmonary disease (COPD), smoking, and hypertension are known to be risk factors and can increase the rate of aneurysm growth. Other disorders with genetic predisposition are also highly linked with thoracic aneurysms and include Marfan syndrome, Loeys–Dietz syndrome, Ehlers–Danlos syndrome, and Turner syndrome (Table 85-1).

Degenerative

The most common etiology for TAA formation is cystic medial degeneration. Although the underlying mechanisms for this process are unknown, pathologic features include elastic fiber fragmentation, smooth muscle cell apoptosis, and local production of matrix-degrading enzymes, specifically matrix metalloproteinases (MMPs). The degree of atherosclerosis present in the aorta is dependent on the anatomy of the aneurysm. Ascending aortic aneurysms are degenerative often without extensive atherosclerosis, although atherosclerosis is often a feature associated with degenerative descending aneurysms. The pathogenesis of aortic aneurysms appears to be linked to a reduction in functional extracellular matrix proteins, elastin and collagen, either through enzymatic degradation or deficiencies in these structural proteins. Moreover, in some diseases with genetic predisposition, there is a shift to increased expression of MMPs as well as a reduction in tissue inhibitors of MMPs (TIMPs) resulting in degradation of the extracellular matrix. For example, patients with bicuspid aortic valves are known to have altered expression of MMPs and TIMPs.[20] As such, these patients have degenerative ascending aortic aneurysms often independent of any associated functional valve disease or atherosclerosis.

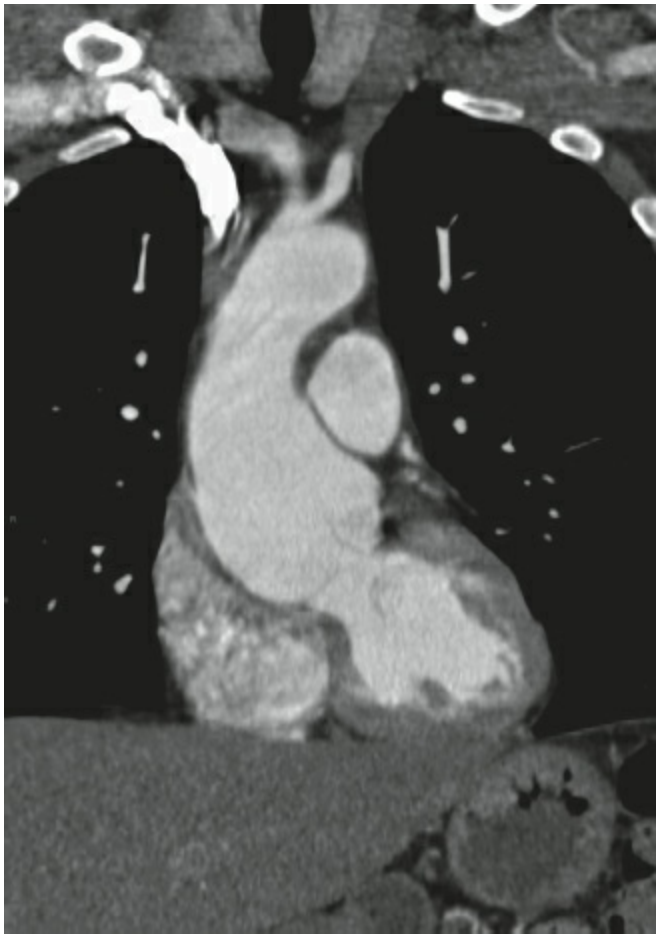

Figure 85-3. Reconstruction of a CT scan of an aortic root aneurysm in a patient with Marfan syndrome. Commonly the sinuses of Valsalva are involved with sparing of the aortic valve.

Genetically Triggered

Although the risk of TAA disease increases with age, thoracic aneurysms in young patients are most likely due to genetic predisposition or familial syndromes. Recently, several genetic etiologies linked to thoracic aneurysms have been elucidated. In particular, insights have been gained from a registry for the genetically triggered TAAs and cardiovascular conditions (GenTAC) which has genetic information on more than 1,000 patients with thoracic aneurysms secondary to hereditary or genetic predisposition.[16] The most common and notorious disease is Marfan syndrome, which is an autosomal dominant defect of the fibrillin gene located on chromosome 15. Mutation of fibrillin leads to instability of the elastic fibers in the aortic media. The prevalence of aortic dilatation in Marfan syndrome is 70% to 80% and most commonly involves the aortic root and sinuses of Valsalva, rendering the aorta prone to rupture or dissection (Fig. 85-3). Marfan syndrome presents at an early age and tends to be more common in men than women. The cardinal features of the disorder include tall stature, ectopia lentis, mitral valve prolapse, aortic root dilatation, and aortic dissection. About three quarters of patients have an affected parent, while new mutations account for the remainder of cases.

Recently, mutations of transforming growth factor receptors I and II (TGFBR I, TGFBR II) termed Loeys–Dietz syndrome have been linked with thoracic aneurysms. These patients have a classic bifid uvula. Ehlers–Danlos syndrome encompasses a group of more than 10 disorders characterized by defects of collagen synthesis. The disease can range

from hypermobility of the joints to extremely fragile skin and extreme muscle weakness. The common vascular Ehlers–Danlos (type 4) is caused by an autosomal dominant disorder of type III collagen. These patients are characterized by fragility of their blood vessels. Familial thoracic aortic aneurysms and dissections (FTAAD) is caused by mutations of the α actin II or myosin heavy chain (MYH11).[21] Turner syndrome is defined by the loss of an X chromosome (XO). Patients with Turner are prone to aneurysmal degeneration of their ascending aorta (Table 85-2).

Infectious and Inflammatory

In current practice, primary infections of the aorta are rare but do lead to aneurysms. Mycotic aneurysms can be caused by bacterial, fungal, spirochetal, or viral agents. Prior to the antibiotic era, syphilis accounted for approximately 75% of all aneurysms. Mycotic aneurysms occur due to localized infections in the aortic or arterial walls, usually as the result of bacteremia. Infection of atherosclerotic plaques themselves can also result in mycotic aneurysms. As a result of trauma or due to infected lymph nodes, infection may also spread to blood vessel walls contiguously. Pre-existing aortic aneurysms may also become infected, usually from bloodstream seeding. Although any pathogen may infect aneurysms, *Salmonella* species show a special proclivity for vascular tissues. Other organisms associated with mycotic aneurysms are *Staphylococcus* species, *Streptococcus* species, *Pasteurella multocida, Legionella anisa,* and *Escherichia coli.* Treatment consists of long-term antibiotics prior to and after surgical aneurysm resection.

Table 85-2 Known Genetic Mutations Associated with Aortic Aneurysms

Classification	Chromosome	Gene	Protein	Location	Frequency	Inheritance
Marfan	15q21.1	FBN1	Fibrillin 1	ECM	1:5,000–10,000	Dominant
Loeys–Dietz	3p24–25 9q33–34	TGFBR2 TGFBR1	TGFβ-R2 TGFβ-R1	Cell surface	Rare	Dominant
Ehlers–Danlos	2q24.3–31	COL3A1	Type III collagen	ECM	1:10,000–25,000	Dominant
ATS	20q13.1	SLC2A10	GLUT10	Intracellular	Rare	Recessive
AOS	15q22.2–24.3	Smad3	SMAD3	Intracellular	Rare	Dominant
TGFB2	1q41	TGFB2	TGFβ2	Intracellular	Rare	Dominant
Nonsyndromic						
TAAD2	3p24–25	TGFBR2	TGFβ-R2	Cell surface	~3% of TAA	Dominant
TAAD4	10q23–24	ACTA2	Actin	Intracellular	10–15% of TAA	Dominant
TAAD5	9q33–34	TGFBR1	TGFβ-R1	Cell surface	~2% of TAA	Dominant
TAAD-PDA	16p12–13 3q21.1	MYH11 MYLK	β-MHC MLCK	Intracellular Intracellular	1–2% of TAA ~1% of TAA	Dominant

ATS, arterial tortuosity syndrome; AOS, aneurysms-osteoarthritis syndrome; TAA, thoracic aortic aneurysm.
Adapted from Elefteriades JA, Pomianowski P. Practical genetics of thoracic aortic aneurysm. *Prog Cardiovasc Dis* 2013;56(1):57–67.

A host of rare inflammatory diseases of the aorta and great vessels including Takayasu arteritis, Behçet disease, Kawasaki disease, and giant cell arteritis can result in TAAs and can require surgical treatment. Giant cell arteritis is a systemic arteritis that occurs in

elderly patients, that commonly affects the temporal artery which can be biopsied for diagnosis.

Traumatic Pseudoaneurysm

Pseudoaneurysms are associated with previous operations or trauma to the aorta. Iatrogenic pseudoaneurysms occur following aortic surgery and can form at anastomotic or cannulation sites or areas where an aortic cross-clamp was placed. Infection should be strongly considered when encountering postsurgical pseudoaneurysms. Classically, rapid decelerating blunt trauma leads to aortic transection. In more than 50% of cases, the location of the aortic injury is just distal to the fixed ligamentum arteriosum, the remnant of the ductus arteriosus.[22,23] For the 20% of patients who survive this acute event, the rupture is partially contained by the aortic adventitia and pleura. Aneurysmal formation around the site of injury can occur and often dilates faster because it is an unsuspected injury, and utmost care with regard to their antihypertensive therapy has to be taken to avoid rupture. Given multisystem injuries often present in these high-speed injuries, many consider endovascular aortic repair the preferred approach for most of these patients.[24]

Diagnosis

Most TAAs are asymptomatic and are found incidentally. Symptomatic aneurysms are often diagnosed based on their anatomic sequelae. Patients with aneurysms of the ascending aorta may also present with fullness in the chest or signs and symptoms of aortic valve insufficiency. Acute chest pain may be caused by either expansion of the aneurysm or dissection of the aortic wall. Arch and descending thoracic aneurysms can present with hoarseness secondary to stretching of the left recurrent laryngeal nerve, stridor from tracheal compression, or dysphagia from esophageal compression.

There are multiple imaging modalities to diagnose TAAs and dissections. Plain chest radiograph can be suggestive whereas computed tomography (CT), magnetic resonance imaging (MRI), and transesophageal echocardiography (TEE) are definitive studies.[25] CT is widely available and provides detailed information about the size, location, and extent of aortic disease as well as anatomic detail of surrounding mediastinal and thoracic structures. In particular, CT angiography with arterial phase contrast of the chest, abdomen, and pelvis is essential for operative planning. Critical elements to be gained from the CT include the following:

1. Aneurysm size, location, and extent
2. Presence of acute or chronic aortic dissection or intramural hematoma
3. Involvement and perfusion of branch vessels For endovascular considerations, the following elements are also essential to determine:
4. Angulation of Aortic Arch and Descending Aorta
5. Size of femoral and iliac vessels
6. Proximal and distal landing zones (a minimum of 2 cm of “normal” aorta is required)
7. Tortuosity of aorta and iliac vessels
8. Involvement of great vessels and/or visceral vessels

MRI/MRA offers detailed anatomy as CT does, but does not require radiation. Moreover, MRI may be particularly useful in pregnant patients. However, MRI requires lengthy image acquisition and processing times, is not as readily available as CT, and cannot be performed in patients with significant metallic implants, such as pacemakers and defibrillators. In addition, gadolinium contrast used in MRA is also nephrotoxic.

TEE avoids the use of these agents and offers good visualization of the ascending and descending thoracic aorta as well as cardiac structures. Due to tracheal shadowing, TEE does not provide reliable visualization of the aortic arch. After CT scanning, TEE is the second most common study used to diagnose aortic dissection with 90% to 99% sensitivity. In unstable patients with a high degree of clinical suspicion for aortic dissection, a confirmatory TEE in the operating room may be safer and more expedient than CT scanning. Although widely available, TEE does require specialized training and operators.

Management and Natural History

Currently, the only assessment tool to determine the risk of catastrophic aortic dissection or rupture is related to aneurysm size and rate of growth. It is likely that other biologic factors may help stratify risk, but as yet, these have yet to be proven. Data from the Yale Center for Thoracic Aortic Disease, which have followed more than 3,000 patients with TAAs, have suggested that the risk of aortic complications in the ascending aorta increases significantly as the size approaches 6.0 cm, and in the descending thoracic aorta as the size approaches 7.0 cm.[26] Similarly, the Olmstead County registry (Minnesota) reported that a rupture rate of 16% at 3 years for 6-cm aneurysms compared to 31% for 7-cm aneurysms.[19] The Yale group has reported the annual risk of death or aortic-related complication exceeds 15% in patients with aneurysms of 6.0 cm or greater compared to 5% in patients with aneurysms smaller than 5.0 cm. Other studies have supported this pattern, reporting a mean rate of rupture or dissection of 2% per year for small aneurysms, 3% for aneurysms 5.0 to 5.9 cm, and 6.9% for aneurysms 6.0 cm or greater in diameter.[27,28] These data have formed the basis for size criteria to intervene prior to the attainment of the previously mentioned dimensions in an asymptomatic patient. Similar to other aneurysms, the growth of TAAs is indolent. The typical rate of growth for ascending aortic aneurysms is 0.1 cm/yr and for descending aneurysms is 0.3 cm/yr.[26]

Medical Management

Medical management of aortic aneurysms targets mechanisms to reduce aortic wall stress.[29] Lifestyle changes to avoid high-intensity exercise, such as weight lifting or sprinting, should be encouraged. Anti-impulse therapy is the primary pharmacologic therapy for aortic aneurysms, with a goal of reducing overall blood pressure and the rate of change in aortic pressure over time (dP/dT). While β-blockers and angiotensin-converting enzyme inhibitors/angiotensin receptor blockers are common treatments, their efficacy is unproven and studies are currently underway in patients with aortic aneurysms. Smoking cessation may be helpful in patients who have not developed COPD. The diagnosis of COPD is a significant risk factor for aortic complications. It is unclear if risk factor modification of COPD once diagnosed can influence the likelihood of aortic rupture. Frequent imaging of these patients to assess changes in size should be performed to determine if surgery should be recommended. Present surveillance recommendations from the American Heart Association are repeat imaging at 1, 3, 6, and 12 months and, if stable, annually thereafter.[29]

Surgical Indications

Since thoracic aneurysms increase in size until they rupture, the decision to intervene is critical. All symptomatic TAAs meet indications for surgical intervention. Preemptive surgical therapy should be applied at a size of 5.5 cm for ascending and arch aneurysms and 6.0 to 6.5 cm for descending aortic aneurysms in suitable surgical candidates to avoid aortic complications or death (Table 85-3).[28,30] These surgical threshold criteria should be modified for patients with Marfan syndrome or connective tissue disease in which

preemptive surgery is appropriate at 4.5 cm for root and ascending aneurysms and 5.5 cm for descending aneurysms.[31] Some have further suggested that patients with Turner syndrome be treated surgically if the aortic diameter exceeds 4.0 cm due to the aggressive nature of aortic disease in these patients. Similarly, for patients with bicuspid aortic valves a size threshold of 5.0 cm is recommended for ascending aneurysm intervention.[32] Furthermore, any patient with symptoms or rapid growth as seen on sequential CT scans should have surgical intervention in a timely manner. Growth rates exceeding 5 to 7 mm/yr for aneurysms or greater than 5 mm per 6 months for chronic aortic dissections are considered harbingers of aortic complications, and earlier intervention should be considered.

Table 85-3 Typical Size Indications for Aortic Surgery

Ascending Aorta	Size Threshold (cm)
Normal	5.5
Bicuspid aortic valve	5.0
Concomitant cardiac surgery (CABG, AVR, etc.)	4.5
Marfan syndrome or other connective tissue disorders	4.5
Turner syndrome	4.0
Descending Thoracic Aorta	
Normal	6.0
Marfan syndrome or other connective tissue disorders	5.5

Typical size indications for aortic surgery based on absolute aortic diameter. Aortic Size Index, determined by ratio of aortic diameter to body surface area, also play an important role in determining surgical indications. Growth rates also determine timing of surgical intervention.

Open Surgical Management of TAA

2 Careful planning by experienced medical personnel is paramount to providing optimal treatment in patients with TAAs as the morbidity and mortality for surgical intervention are significant. Over the years there have been substantial improvements in the intraoperative and postoperative management in patients with TAA. The approach and techniques of repair vary widely based on the location of the thoracic aneurysm.

Once the need for intervention has been determined, a full cardiac evaluation should be completed including angiographic evaluation of coronary arteries and echocardiography. The basic premise of open surgical repair for aneurysms, regardless of the situation, is replacement with an interposition graft. Cardiopulmonary bypass, cerebral and visceral organ perfusion, and protection strategies are determined by the location and extent of aneurysm resection. Intraoperative management is essential with central venous pressure and arterial monitoring as well as large-volume intravenous infusion lines. Intraoperative TEE is useful to monitor fluid status and cardiac function during the operation.

Aortic Root and Ascending Aortic Aneurysms

3 Open surgical repair remains the mainstay for aortic root, ascending aortic, and aortic arch aneurysms with very acceptable outcomes and low morbidity when performed in centers of excellence. Operations to replace aortic root and ascending aorta are approached via a median sternotomy. All pathologic segments of the aorta are evaluated and replaced if abnormal, including the aortic valve, sinuses of Valsalva, the tubular portion of the ascending aorta, and the aortic arch. Cardiopulmonary bypass is established through right atrial (venous) cannulation and either aortic, femoral, or axillary arterial cannulation. The left ventricle is vented via the right superior pulmonary vein. The use of the axillary artery for cannulation allows for selective antegrade cerebral perfusion if circulatory arrest is needed during the replacement of the aorta (Fig. 85-4).[33,34] The axillary artery is exposed via a 4-cm transverse incision 2 cm below and parallel to the clavicle. Once through the pectoral muscles, the axillary vein is isolated and retracted, exposing the axillary artery. After systemic heparinization, an 8- or 10-mm Dacron graft is anastomosed in an end-to-side fashion onto the artery. The arterial cannula is then secured to the Dacron graft. Myocardial protection is achieved by infusion of antegrade blood cardioplegia into the coronary ostia and retrograde cardioplegia into the coronary sinus accompanied by a topical hypothermia.

If the aneurysm is contained to the root or ascending aorta and does not involve the aortic arch or head vessels, the heart can be arrested with the cross-clamp proximal to the innominate artery, and mild hypothermia can be used for systemic protection while the patient is maintained on cardiopulmonary bypass. A tube graft is then anastomosed distally and proximally using running monofilament suture. The aortic valve is also assessed with the aorta open and the valve repaired or replaced as necessary (Fig. 85-5). If the dilation of the aorta extends into the arch, deep HCA allows for complete resection and reconstruction of the diseased aorta and an open distal anastomosis in a bloodless field. Cerebral protection can be augmented by maintaining antegrade cerebral perfusion via the right axillary cannula and clamping the proximal innominate artery. The distal anastomosis is then performed in a timely manner. The cross-clamp is then reapplied to the graft, and full cardiopulmonary bypass can then resume. The proximal anastomosis is then completed encompassing all diseased portions of the ascending aorta and the aortic root.

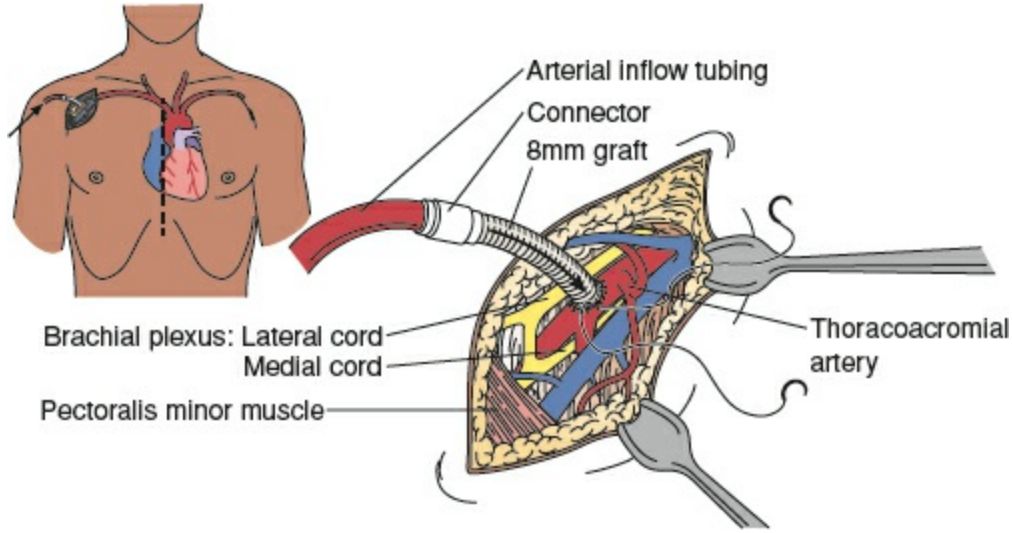

Figure 85-4. Cannulation of the right axillary artery with the use of a side graft. Once established, axillary artery cannulation can allow for antegrade cerebral perfusion throughout the aortic replacement procedure.

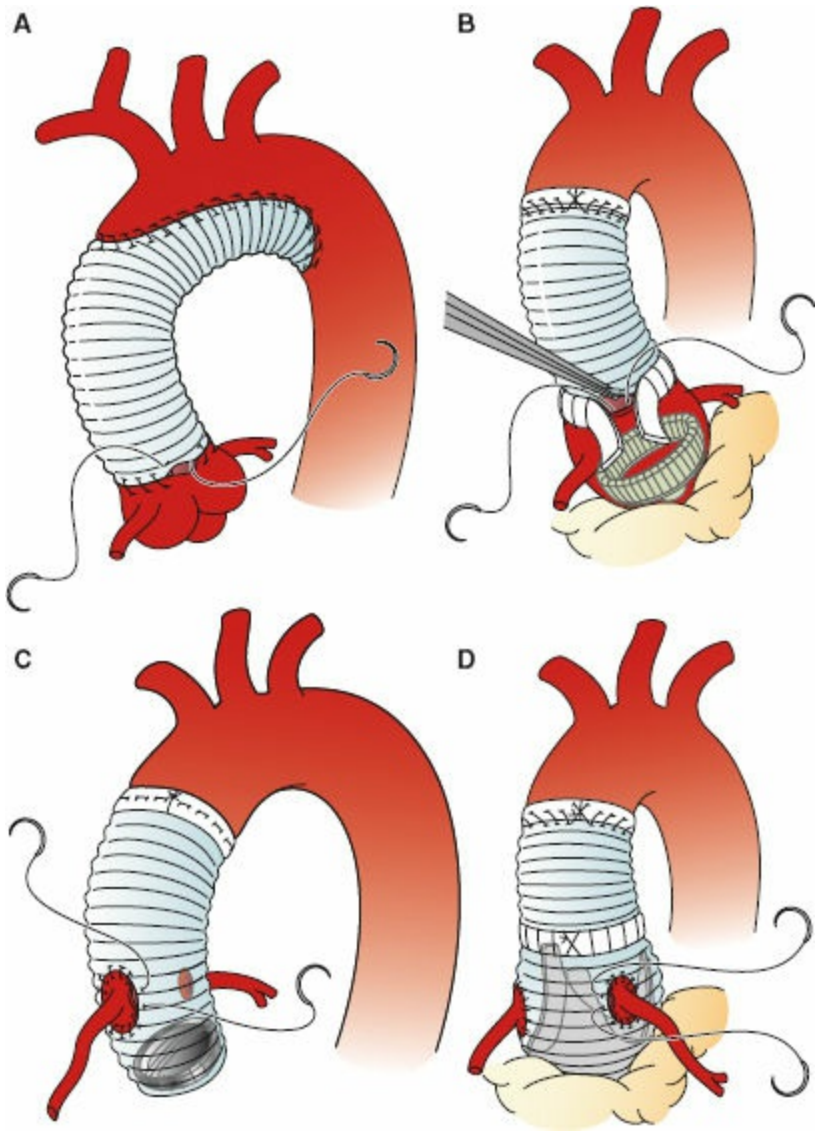

Figure 85-5. Common repair options include: (**A**) graft replacement of the ascending aorta from the sinutubular junction to the aortic arch, (**B**) graft replacement with concomitant aortic valve replacement, (**C**) total aortic root replacement and ascending aortic replacement with a valve conduit and coronary reimplantation (Bentall procedure), and (**D**) Valve-sparing aortic root reimplantation where the native aortic valve is left in-situ (David procedure).

Aneurysms involving the aortic root require isolation of the right and left coronary ostia and reimplantation into the Dacron tube graft. Care must be taken to ensure the coronary arteries are not kinked. In this setting the native aortic valve can be spared (valve-sparing root replacement) if the leaflets are normal or can be replaced with a valved conduit (Bentall procedure).

Aortic Arch Aneurysms

Operations involving replacement of the thoracic aortic arch are approached from a median sternotomy and use HCA. In this setting, the patient is cooled to 16°C to 24°C and the cardiopulmonary bypass circuit is turned off for up to 45 to 60 minutes. The use of selective antegrade cerebral perfusion (cannulation and perfusion of the right axillary artery with a clamp on the proximal innominate artery) allows perfusion of the right carotid and vertebral arteries during operations of the aortic arch, and reduces the risk of embolism and associated morbidity by maintaining some perfusion to the brain.[35] With selective antegrade cerebral perfusion, the patient may require less systemic hypothermia allowing for reduced bypass times. Replacement of the arch is often best performed with the use of a multibranched aortic graft to allow individual anastomoses to each of the three great vessels (Fig. 85-6).[35,36] This approach, rather than reimplanting an island of aortic tissue with all the great vessels, has been suggested to reduce the risk of embolization but, more importantly, minimizes the risk of late aneurysmal degeneration of the aortic patch.[36]

Descending Thoracic Aortic Aneurysms

Open surgical repair of the descending thoracic aorta is performed through a left posterolateral thoracotomy. The exact interspace depends on the proximal and distal extent of the disease. Prior to positioning, a double-lumen endotracheal tube is placed for single-lung ventilation. A variety of adjuncts have been devised to ameliorate the most common complications of stroke, paralysis, and visceral organ malperfusion during descending thoracic aneurysm repair.[36] Cerebrospinal fluid (CSF) drainage with a lumbar drain allows intra- and postoperative monitoring of CSF pressure and drainage and has been shown to reduce the incidence of paraparesis and paraplegia caused by spinal cord ischemia.[37] Other modalities used to mitigate risk of spinal cord injury include monitoring of sensory evoked potentials and motor evoked potentials.[38,39] Pharmacologic agents, including barbiturates, naloxone, and steroids, may also help reduce neurologic injury when administered during the procedure. In addition, epidural catheters are extremely beneficial for pain control and can improve early mobilization and pulmonary function.

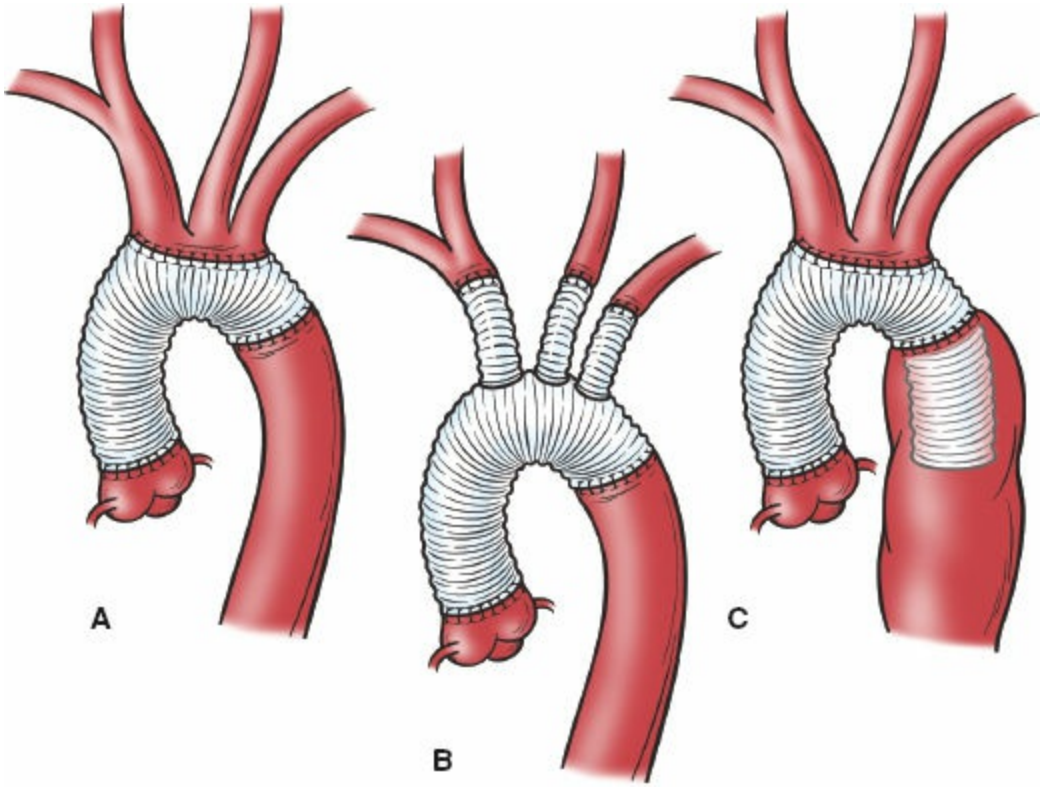

Figure 85-6. Traditional total arch repairs. **A:** Island approach. **B:** Branched graft approach. **C:**. Traditional elephant trunk (shown with concomitant island approach).

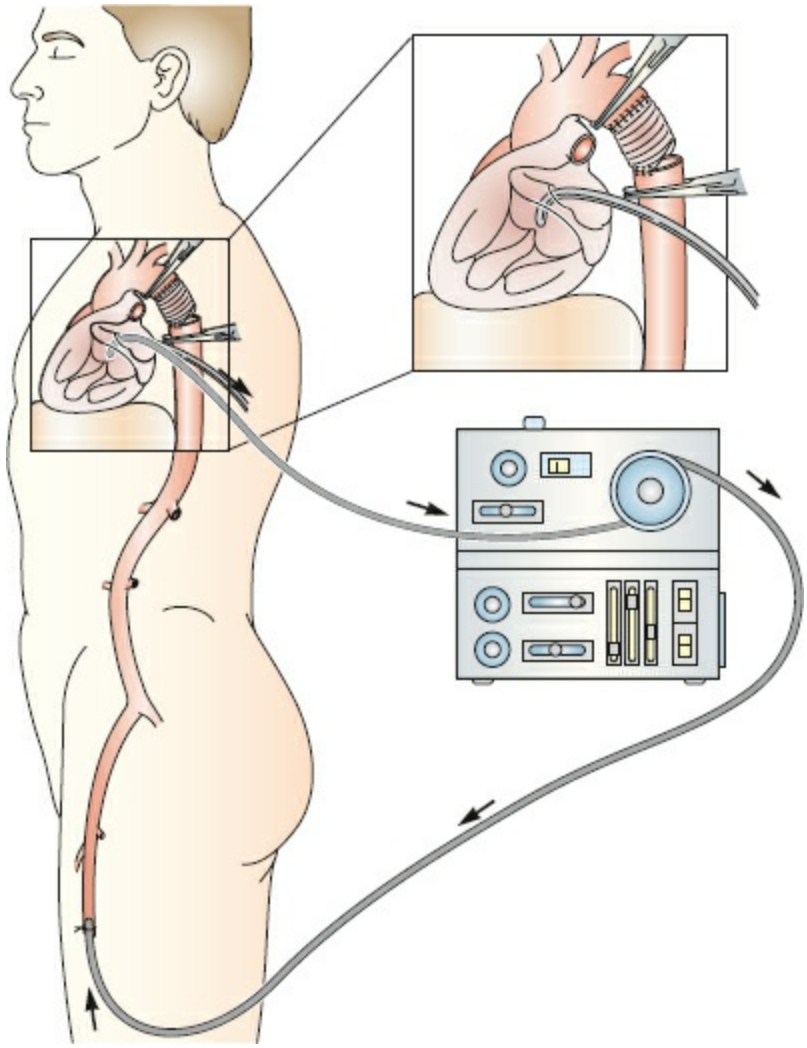

Figure 85-7. Schematic of left heart bypass whereby partial bypass is used to maintain perfusion to the viscera and lower extremities. The inflow to the Bio-Medicus pump is the left inferior pulmonary vein, and the outflow is the left femoral artery. This technique avoids the need for an oxygenator.

There are two options to perform this procedure: sequential clamping versus HCA. The use of left heart or partial cardiopulmonary bypass has been shown to decrease the risk of visceral and spinal cord ischemia. If the arch is relatively spared and enough normal aorta can be identified distal to the left common carotid artery, a proximal clamp can be placed, which allows for left heart bypass. In using left heart bypass, the left atrium via the left inferior pulmonary vein and the femoral artery are cannulated. A centrifugal pump, heparin-bonded tubing, and minimal heparinization can be used, which can result in less bleeding than in traditional cardiopulmonary bypass. With this technique, mild hypothermia is used with sequential aortic clamping, reimplantation of critical intercostal arteries, and the distal anastomosis constructed with peripheral and visceral perfusion via the femoral artery (Fig. 85-7).[40] Conversely, for patients in whom the transverse arch cannot be safely clamped, profound HCA is used for both cardiac protection and central and peripheral nervous system protection. With this technique, full cardiopulmonary bypass with cannulation of the femoral artery and femoral vein allows for cooling of the patient and deep HCA and the proximal anastomoses can be performed in a bloodless field. [41]

After clamping the aorta (or initiating HCA), the aneurysm is opened and the proximal

cuff is fashioned. An interposition graft is sutured to the proximal aorta in an end-to-end fashion. Once completed, cardiopulmonary bypass can be reinstituted and the graft clamped to perform the distal anastomoses when using HCA. The distal aorta and graft are then fashioned and an anastomosis created. Significant lumbar artery identified via preoperative computed tomographic aortography or intraoperative assessment can be reimplanted into the interposition graft. There is continued controversy regarding the necessity to perform this as this process can often take more than 30 minutes during which the aorta may be clamped. Once the affected portion of aorta has been successfully replaced, the patient can be appropriately warmed and hemostasis ensured. The patient is removed from cardiac support and thoracotomy closed in the usual manner. If the diaphragm was taken down, it should be reapproximated with interrupted nonabsorbable suture.

Endovascular Therapy

4 Thoracic endovascular aneurysm repair (TEVAR) for the descending thoracic aorta has become the preferred treatment approach not only for aneurysms but also for dissections and traumatic aortic injuries as they often can be performed with less morbidity than that associated with open surgical treatment. Endovascular stent grafts are available in a wide range of sizes and are made of polytetrafluoroethylene (PTFE) or woven polyester with steel or nitinol stents to maintain their shape. Absolute contraindications for TEVAR include insufficient proximal and distal landing zones, or excessive aortic tortuosity. Relative and debated contraindications include connective tissue disease (such as Marfan's), young age, or patients unlikely to follow-up. Patients who are not candidates for endovascular repair require open repair.

Planning for TEVAR requires careful review of all imaging. Proximal and distal landing zones with a minimum of 2-cm "normal" aorta are preferred. To prevent endoleaks, stent grafts are oversized by approximately 10% to 15% from the CT cross-sectional diameter. The size of the femoral and iliac arteries must be large enough to allow safe passage of the delivery sheaths. In general, vessels should be 7 to 8 mm depending on the size of the chosen stent graft. In some cases, an adequate proximal landing zone can only be accomplished by coverage of the left subclavian artery. If the left subclavian is covered, a carotid to subclavian bypass can be considered to prevent spinal cord ischemia, subclavian steal, and limb ischemia. In cases where the patient has a patent left internal mammary bypass graft or an incomplete circle of Willis with a left vertebral artery that terminates in a posterior inferior cerebellar artery, a carotid subclavian bypass should be performed prior to TEVAR.

TEVAR is performed by first obtaining femoral or iliac access. For smaller grafts this can be done with all percutaneous access and use of closure devices. In other cases, a femoral or iliac cutdown is performed. A stiff wire is advanced into the aortic root under fluoroscopic guidance. A separate pigtail catheter is advanced over a wire into the aortic root for aortography. The stent graft is then advanced into the appropriate position over the stiff wire. Once in place, an aortogram is performed to ensure proper positioning. A completion angiogram is performed to ensure no positioning, presence of kinks or

endoleaks, or continued filling of the aneurysm sac. A type 1A (proximal) or type 1B (distal) endoleak typically requires placement of an additional stent graft (Fig. 85-8).

Hybrid Procedures

As endovascular approaches have evolved, so too have the options for hybrid procedures combining open and endovascular surgery. Patients with combined arch and descending thoracic aneurysms are often ideal candidates for hybrid procedures. The traditional approach has been a two-stage open procedure (elephant trunk). In the first operation, the arch aneurysm is repaired under HCA via a median sternotomy. The distal end of the Dacron graft replacing the arch is sewn to the proximal descending aorta with a long cuff to allow for future repair of the descending aortic aneurysm in the second stage. In the second stage, the traditional procedure has been an open descending aneurysm repair using the long cuff left at the initial operation as the proximal new aorta. Stent graft therapy has allowed for the second stage to be performed less invasively with an endovascular approach. An alternative approach to these patients is debranching of the arch vessels via sternotomy using a trifurcated graft off the ascending aorta to the great vessels. This can be performed without the use of cardiopulmonary bypass using a side-biting clamp on the ascending aorta. This is followed by endovascular repair of the arch and descending aorta covering the native take off of the great vessels. Other patients who benefit from hybrid procedures include those with thoracoabdominal aneurysms who require debranching of visceral vessels prior to stent graft repair. The inflow for these debranching bypasses is traditionally from the iliac vessels but can include the proximal abdominal or descending thoracic aorta.

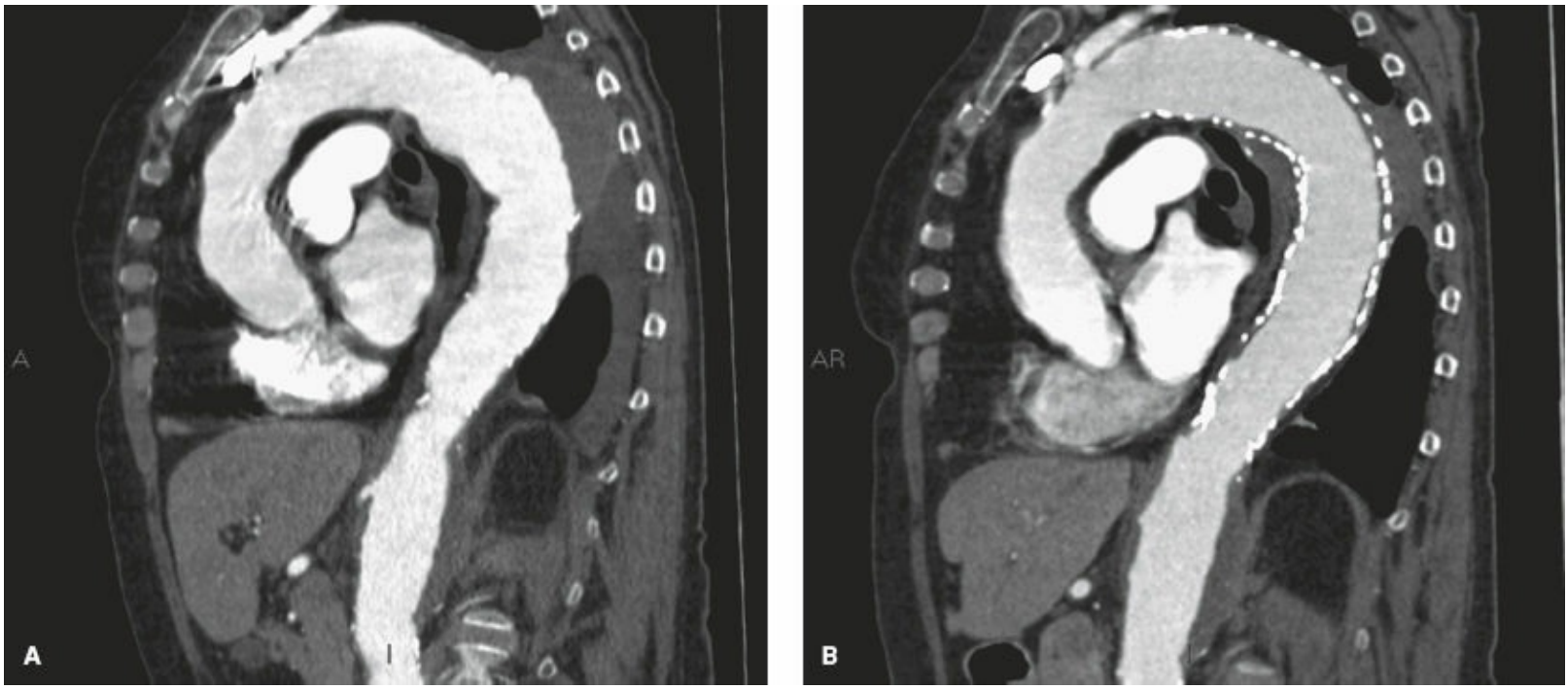

Figure 85-8. Reconstruction of a CT scan in a patient with a descending thoracic aneurysm (**A**) prior to repair, and (**B**) after endovascular stent graft repair showing successful exclusion of the aneurysm sac.

Outcomes and Complications

With advances in surgical techniques significant improvements in morbidity and mortality with aortic aneurysm surgery have been made. Important outcomes following aortic surgery include mortality, stroke, paralysis, renal failure, and freedom from reoperation. Operative mortality for elective ascending aortic aneurysm repair is low, ranging from 1.2% to 3.7% in contemporary series.[42–45] Risk factors for mortality include advanced age, coronary artery disease, heart failure, reoperative sternotomy, and need for HCA. Interestingly, patients with connective tissue disorders, such as Marfan syndrome, have a low operative mortality of 1.5%, partially due to their young age at time of presentation.[46] The primary morbidity following ascending aortic surgery is bleeding and stroke. Reexploration for bleeding occurs in 5.6% to 9.9% of patients.[45] Precise suturing with even tension and minimal aortic tissue trauma is essential to minimize bleeding risks. Use of Teflon felt material and hemostatic agents may further reduce bleeding. Neurologic injury following surgery occurs in 3.2% to 9.8% of patients.[45] Stroke is usually due to embolization of debris or thrombus from the aorta resulting in focal deficits. Diffuse injury is attributed to microemboli, insufficient cooling, and prolonged circulatory arrest. The use of cerebral perfusion appears to improve these outcomes.[47] The need for late reoperation occurs because of pseudoaneurysm formation, graft infection, or progressive aortic enlargement. Reoperation carries significantly greater operative mortality ranging from 4% to 22%.[48] Up to 60% of reoperations occur because of inadequate repair during the primary operation and can be avoided if all aneurysmal tissue is resected.[49] Some patients, particularly those with connective tissue disorders, have progressive aortic pathology and are prone to reoperation. Pseudoaneurysm formation may be the result of a technical error, infection, or inadequate resection of diseased segments. Graft infections are reported in 1.0% to 6.0% of patients, are associated with very high operative mortality and often require a homograft for repair.[50]

More extensive aortic operations involving the aortic arch are associated with greater risks of mortality and morbidity. Operative mortality has ranged from 5% to 8% in contemporary series with stroke risks of 5% to 12%.[51,52] As arch surgery requires longer circulatory arrest times, increased incidences of renal failure of 3% to 7% are noted.

Similar to ascending aneurysm surgery, mortality with open repair of descending thoracic aneurysms has significantly improved. Contemporary open elective repair is associated with an operative mortality of 5%.[53] The major complications include stroke (2% to 10%), paralysis (5% to 10%), renal failure (13%), and recurrent laryngeal nerve injury (40%). Increased extent of aortic replacement correlates with risks of paralysis. The use of adjuncts such as CSF drainage, intercostal artery reimplantation, and distal aorta perfusion with cardiopulmonary bypass or left heart bypass has significantly reduced incidence of paraplegia and renal failure.[54,55]

Endovascular therapy has emerged as the first-line therapy for descending TAAs. In most series, perioperative mortality ranges from 1.9% to 3.1% for elective TEVAR.[56] Complications include stroke (4% to 8%), paralysis (3% to 11%), and access site complications. The risk of stroke with TEVAR increases with more proximal deployment

in the arch, the presence of mobile atheroma in the arch, and history of cerebrovascular disease. Longer segment aortic coverage increases risk of paralysis. Use of adjuvants such as CSF drainage or carotid-subclavian bypass when the left subclavian is covered reduces incidence of paraplegia. Multiple studies have supported these findings reporting lower mortality, paraplegia, and renal failure following endovascular therapy versus open surgery for the descending thoracic aorta.[24,57]

Long-term data on TEVAR are limited due to its recent and evolving development. In a 5-year follow-up of the Gore TAG Food and Drug Administration trial, aneurysm-related mortality was 2.8% compared to 11.7% for nonrandomized open surgical controls.[57] The rate of endoleak was 4.3%, which in other studies, ranged from 4% to 8%. The most common endoleak is a type 1A (proximal). Graft migration can occur in 1% to 2% of patients. The rate of reintervention is estimated to be 10.8% at a median 5.6 months, primarily for type 1 and type 3 endoleaks.

THORACIC AORTIC DISSECTION

History

In 1760, King George II of England died at Kensington palace while “straining on the toilet.” His personal physician, Dr. Frank Nicholls performed an autopsy and provided the first description of a thoracic aortic dissection. He stated “in the trunk of the aorta we found a transverse fissure on its inner side, about an inch and half long, through which some blood had recently passed under its external coat and formed an elevated ecchymosis.”[58] King George died from acute aortic dissection with rupture and cardiac tamponade. The first successful surgical approaches to acute aortic dissection were described by DeBakey and associates in 1954.[59]

Prevalence and Classification

Acute aortic dissection is the most frequent lethal condition of the aorta. Aortic dissections are classified based on anatomic involvement and extent. Two classification systems are widely utilized: the Debakey and the Stanford systems. In the Debakey system, a type 1 dissection extends from the ascending aorta into the descending thoracic aorta, possibly to the aortic bifurcation (Fig. 85-9). Type 2 dissection involves the ascending aorta and terminates proximal to the left subclavian artery. Type 3 dissection starts distal to the left subclavian artery and involves the descending or abdominal aorta. The Stanford classification has become more commonly used as it readily translates to clinical decision making.[60] A Stanford type A dissection involves the ascending aorta and includes Debakey type 1 and type 2. A Stanford type B dissection involves the descending aorta only, similar to Debakey type 3. Type B dissections are now further subclassified as complicated versus uncomplicated. Complicated type B dissections are defined by uncontrolled pain, impending rupture, or visceral organ malperfusion. Acute aortic dissection is three times more frequent than thoracic or abdominal aortic rupture.[15] The estimated worldwide prevalence is 2.95 per 100,000 per year, with an estimated 2,000 new cases in the United States each year.[61] Stanford type A dissection constitutes 75% of acute aortic dissections.

Etiology and Risk Factors

Aortic dissection is initiated when a weakened aortic wall is exposed to a high impulse force. The most common primary tear occurs in the right anterior aspect of the ascending aorta, likely due to the impulse force of blood ejected from the left ventricle. Once this entry tear occurs, blood enters the aortic media and propagates, creating a false channel of flow. The false channel may propagate antegrade, retrograde, or both. When the false channel encounters a branch vessel, the origin of the branch vessel may tear off, leading to a fenestration with communication between the true and false lumens. The branch vessel will then derive some or all of its blood flow from the false lumen. The patency and origin of branch vessel perfusion is critical in determining treatment plans for patients with acute aortic dissection. Although the false lumen may end blindly 4% to 12% of patients leading to false-lumen thrombosis, the vast majority of patients have multiple fenestrations leading to false-lumen patency. In chronic dissection, the false-lumen remodels over time, leading to further aneurysm formation and possibly rupture.

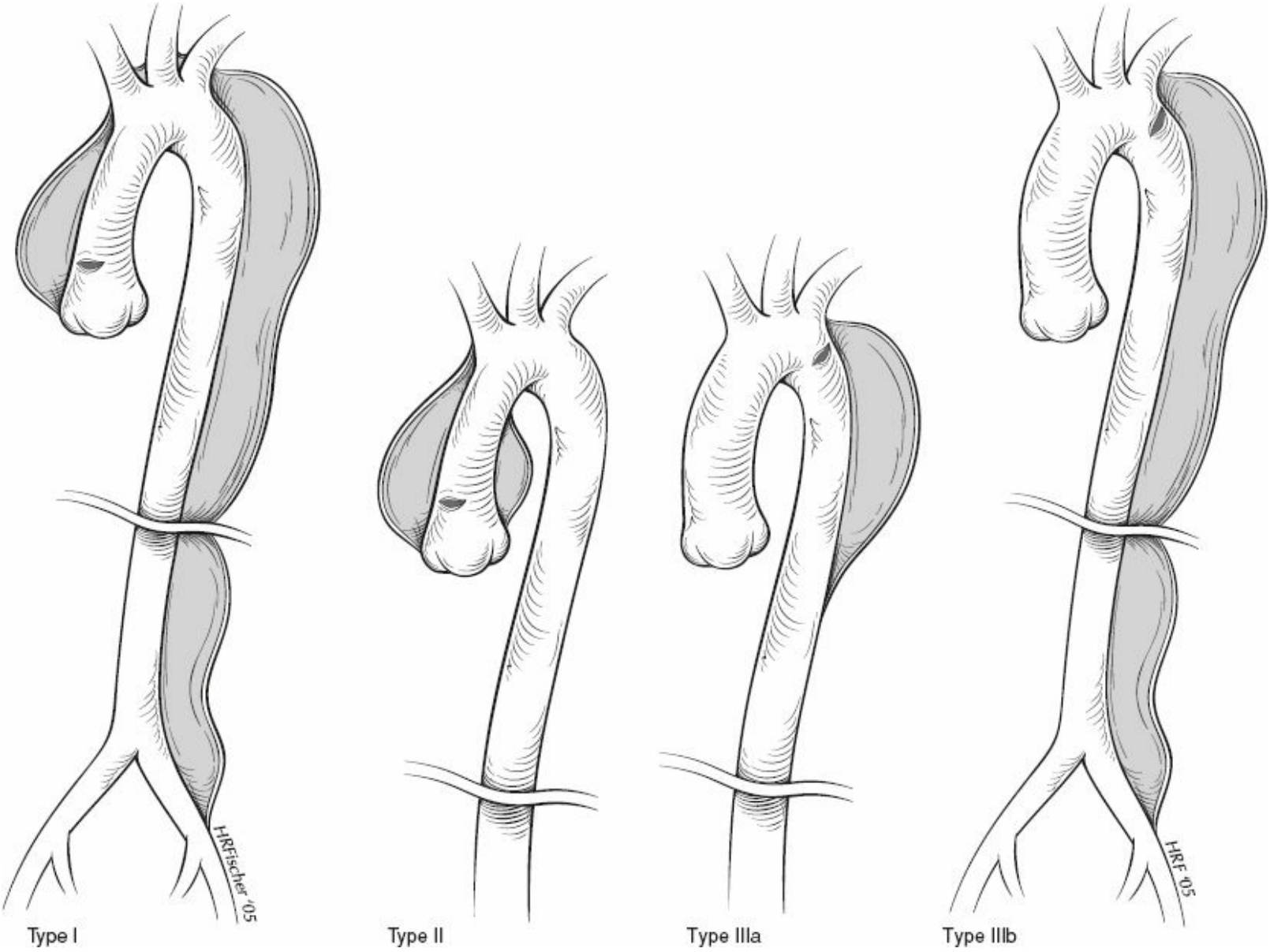

Figure 85-9. Debakey classification system for aortic dissection. Stanford type A = Debakey type 1 or type 2. Stanford type B = Debakey type 3A or 3B.

Diagnosis

Acute aortic dissection has been described as the “great imitator,” as symptoms are often ascribed to other pathologies, such as myocardial infarction, peptic ulcer disease, or musculoskeletal back pain. For this reason, diagnosis of aortic dissection can be delayed. Dissections usually present with pain involving the chest, back, or abdomen. The location of maximum pain tends to change as the dissection progresses. Involvement of branch vessels may lead to syncope, stroke, paralysis, myocardial ischemia, mesenteric ischemia, or limb ischemia. Aortic root involvement may lead to acute aortic insufficiency and symptoms of acute heart failure. Pericardial effusions can present with cardiac tamponade symptoms.

Management and Natural History

5 Once aortic dissection occurs, mortality and morbidity are high. Fifty percent of patients with acute Stanford type A dissection die within 48 hours if untreated. Data suggest a 1% per hour rate of mortality from the onset of symptoms. The most frequent causes of death are aortic rupture, tamponade, heart failure, and cerebral or visceral organ malperfusion. In contrast, acute mortality of type B aortic dissection is lower with 90% in-hospital survival.[62] Survivors of aortic dissection then develop a chronic aortic dissection characterized by aortic remodeling and progressive aneurysm enlargement. The annual growth rates for patients suffering from chronic dissections are significantly higher than nondissected aneurysms, ranging from 0.24 to 0.48 cm/yr.

Acute Stanford type A aortic dissections mandate emergent surgery. Complicated type B aortic dissections, characterized by uncontrolled pain, impending rupture, or visceral organ malperfusion, also require intervention with open or endovascular techniques. Intervention for chronic dissection is indicated for aneurysm enlargement with size criteria similar to nondissected aneurysmal disease.

Surgery for Type A Aortic Dissections

Operative intervention for acute type A aortic dissection is focused on the aortic root, ascending aorta, and aortic arch to eliminate the common causes of death of aortic rupture, cardiac tamponade, myocardial ischemia, stroke, and heart failure. A successful operation for type A dissections reconstructs the root with a well-functioning valve, replaces the ascending aorta and the proximal arch maintaining true-lumen patency of the arch vessels. Depending on the extent of the dissection, arterial cannulation can be challenging. The most common sites of cannulation include the right axillary and femoral arteries, however, alternative strategies such as cannulating the true lumen of the dissected ascending aorta using an ultrasound guided Seldinger technique may also be performed.[63] Once the patient is cooled on cardiopulmonary bypass to an adequate temperature for HCA, the ascending aorta is resected. Often this performed with selective antegrade cerebral perfusion via the right axillary artery or with retrograde cerebral perfusion by a separate cannula placed in the superior vena cava. The ascending aorta is then replaced with an interposition graft from the sinotubular junction to the aortic arch. In rare situations, the aortic arch is so disrupted, a total arch reconstruction is performed. If the aortic root is dissected, the root is reconstructed and the aortic valve resuspended (Fig. 85-10). If there is significant pre-existing aortic root disease a root replacement or valve-sparing root procedure may be performed.

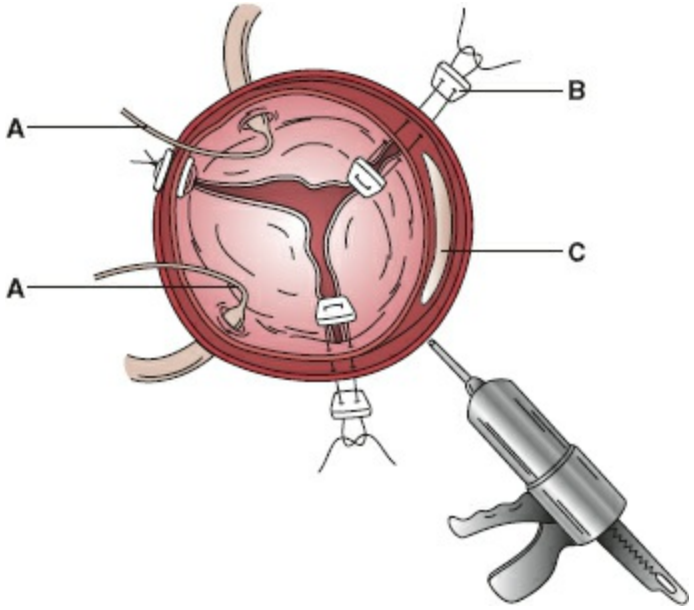

Figure 85-10. Dissected aortic root. The right and left coronary arteries (**A**) are rarely avulsed but if so require bypass. The aortic valve is resuspended using pledgeted mattress sutures (**B**) at the aortic valve commissures to allow valve coaptation. Felt and/or bioglue (**C**) is utilized to fill the dissected space as "neo media."

Endovascular Therapy

Endovascular therapy has a growing and vital role in the acute and chronic management of type A and type B aortic dissections. For acute type A aortic dissections, endovascular therapy may be urgently performed to alleviate abdominal malperfusion. In patients who present with mesenteric ischemia, endovascular fenestration, celiac or superior mesenteric artery stenting may be utilized to improve visceral perfusion prior to proximal aortic surgery.

TEVAR has an increasing and evolving role in patients with acute and chronic type B aortic dissections and residual dissections following type A dissection repair. Preoperative CT angiography must be carefully reviewed to understand the anatomy and extent of the proximal fenestrations, the true and false lumen, as well as proximal and distal landing zones (Fig. 85-11). True-lumen arterial access may be gained percutaneously or with a femoral cutdown. Intravascular ultrasound (IVUS) is typically utilized to confirm true-lumen position. For dissections, grafts are not oversized to minimize the chance of rupture or retrograde dissection. The extent of coverage depends on the pathology being treated, but typically involves coverage of the entire descending thoracic aorta. Completion aortography is essential to identify any endoleaks and ascertain visceral perfusion following device deployment.

Outcomes and Complications

Outcomes following surgery for type A aortic dissection have improved, however significant morbidity and mortality remain. The International Registry of Acute Aortic Dissections (IRAD) reported the outcomes of 526 patients at 18 centers.[64] Overall hospital mortality was 25%. The most common causes of death included aortic rupture (33%), stroke (14%), abdominal malperfusion (12%). Risk factors for increased mortality included age, extent of dissection, hemodynamic instability, and time since onset of symptoms. Long-term survival for patients who survive was 96% at 1 year and 91% at 3 years.

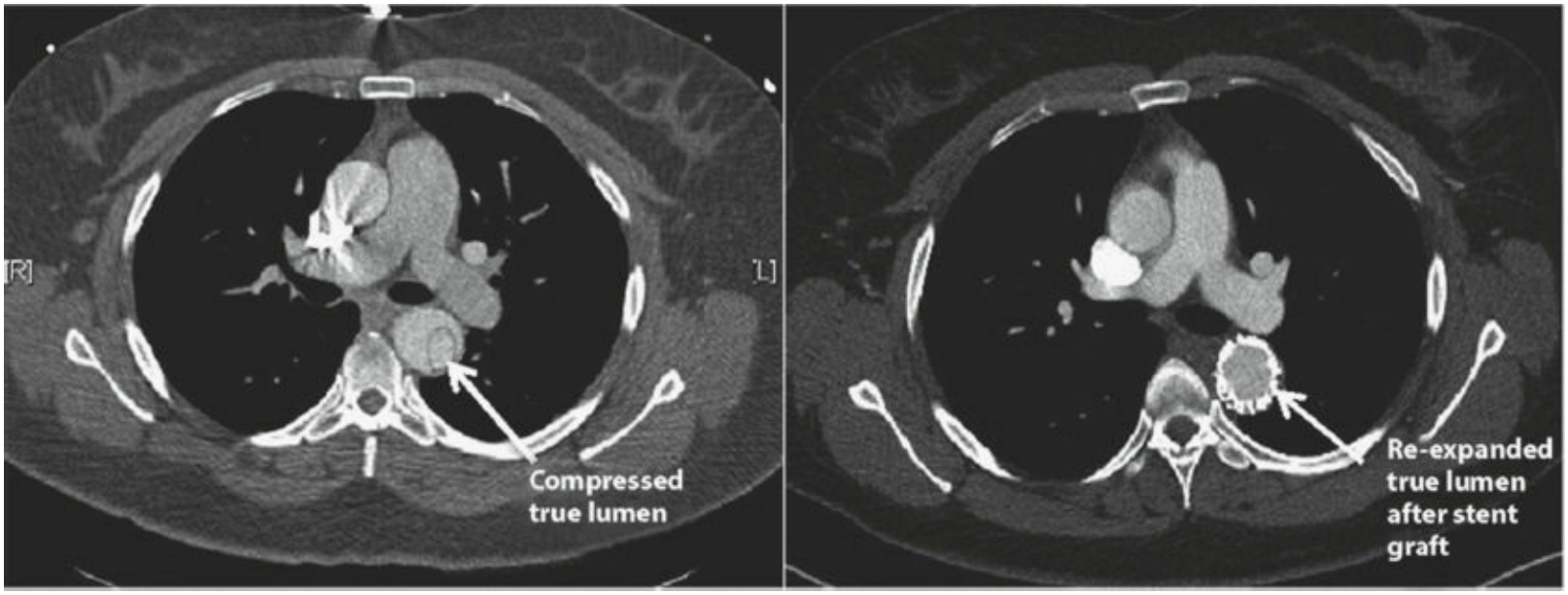

Figure 85-11. TEVAR for acute type B dissection.

Similar improvements have been made with open surgery for complicated type B dissections. In the most recent IRAD series, operative mortality was 29%, with a stroke rate of 9%, paraplegia rate of 5%, and renal failure rate of 8%.[62] Results have improved with TEVAR. In a recent meta-analysis of 609 patients with type B aortic dissection, perioperative mortality was 5% with a 3% rate of stroke and 2% rate of retrograde aortic dissection.[65] In the IRAD data, TEVAR was associated with a lower mortality (11% vs. 34%) and complication rate (21% vs. 40%) compared to open surgery. Interestingly, mortality following TEVAR was similar to those patients managed medically who presumably had uncomplicated dissections. Importantly, the IRAD data were nonrandomized and subject to treatment bias which should limit overarching conclusions. Nevertheless, the data suggest that TEVAR is associated with significantly less morbidity and mortality than open surgical repair.

Based on this favorable data with complicated type B dissections, TEVAR is now being evaluated for uncomplicated type B dissections. Uncomplicated acute type B aortic dissections have a favorable in hospital survival of 89% to 93% with medical therapy alone.[66] The long-term outcomes however are not favorable with only 78% surviving at 3 years.[67] Two European randomized trials have been conducted to evaluate the outcomes

of TEVAR for uncomplicated type B dissection. The INvestigation of STEnt grafts in Aortic Dissection (INSTEAD) trial has been recently published.[68] At 2 years, TEVAR failed to improve 2-year survival in comparison to medical therapy alone. Favorable aortic remodeling, such as true-lumen size and false-lumen thrombosis; however, occurred in 91% of TEVAR patients compared to 19% of medical only patients. The ADSORB (Acute Uncomplicated Aortic Dissection type B) trial also demonstrated favorable aortic remodeling after TEVAR.[69] In 61 randomized patients, TEVAR increased true-lumen size, decreased false-lumen size, and reduced overall aortic diameter. In longer-term data, this favorable aortic remodeling appeared to have led to improved survival. At 5 years, the INSTEAD trial data demonstrated improved aorta-specific mortality with TEVAR (6.9% vs. 19.3%) compared to medical therapy alone.[70] More long-term data are required to determine the utility of TEVAR for uncomplicated type B dissection.

CONCLUSIONS

Aneurysm disease of the thoracic aorta has a high morbidity and mortality, especially after the development of an aortic dissection. Treatment of these patients requires careful preoperative planning, meticulous protection of the viscera and spinal cord, and rigorous follow-up. Endovascular therapy has become the preferred technique for descending thoracic aortic disease and offers patients less morbidity than that associated with open surgical treatment. The best outcomes for all patients who suffer from aneurysm disease of the thoracic aorta are provided by a multidisciplinary approach with a firm understanding of the pathogenesis and natural history of the disease.

References

1. Bergqvist D. Historical aspects on aneurysmal disease. *Scand J Surg* 2008;97(2):90–99.
2. Elkin DC Jr. Aneurysm following surgical procedures : report of five cases. *Ann Surg* 1948;127(5):769–779.
3. Matas R.I. An operation for the radical cure of aneurism based upon arteriorrhaphy. *Ann Surg* 1903;37(2):161–196.
4. Swan H, Maaske C, Johnson M, et al. Arterial homografts. II. Resection of thoracic aortic aneurysm using a stored human arterial transplant. *AMA Arch Surg* 1950;61(4):732–737.
5. Lam CR, Aram HH. Resection of the descending thoracic aorta for aneurysm; a report of the use of a homograft in a case and an experimental study. *Ann Surg* 1951;134(4):743–752.
6. Cooley DA, De Bakey ME. Surgical considerations of intrathoracic aneurysms of the aorta and great vessels. *Ann Surg* 1952;135(5):660–680.
7. Dubost C, Allary M, Oeconomos N. Resection of an aneurysm of the abdominal aorta: reestablishment of the continuity by a preserved human arterial graft, with result after five months. *AMA Arch Surg* 1952;64(3):405–408.
8. Helden RA, Kirklin JW, Gifford RW Jr. The treatment of abdominal aortic aneurysms by excision and grafting. *Proc Staff Meet Mayo Clin* 1953; 28(25):707–713.
9. Cooley DA, De Bakey ME. Resection of entire ascending aorta in fusiform aneurysm using cardiac bypass. *J Am Med Assoc* 1956;162(12):1158–1159.
10. De Bakey ME, Crawford ES, Cooley DA, et al. Successful resection of fusiform aneurysm of aortic arch with replacement by homograft. *Surg Gynecol Obstet* 1957;105(6):657–664.
11. Debakey ME, Jordan GL Jr, Abbott JP, et al. The fate of Dacron vascular grafts. *Arch Surg* 1964;89:757–782.
12. Deterling RA Jr, Bhonslay SB. An evaluation of synthetic materials and fabrics suitable for blood vessel replacement. *Surgery*. 1955;38(1):71–91.
13. Ergin MA, O'Connor J, Guinto R, et al. Experience with profound hypothermia and circulatory arrest in the treatment of aneurysms of the aortic arch. Aortic arch replacement for acute arch dissections. *J Thorac Cardiovasc Surg* 1982;84(5):649–655.
14. Dake MD, Miller DC, Semba CP, et al. Transluminal placement of endovascular stent-grafts for the treatment of descending thoracic aortic aneurysms. *N Engl J Med* 1994;331(26):1729–1734.
15. Coady MA, Rizzo JA, Goldstein LJ, et al. Natural history, pathogenesis, and etiology of thoracic aortic aneurysms and dissections. *Cardiol Clin* 1999;17(4):615–635; vii.
16. Svensjo S, Bengtsson H, Bergqvist D. Thoracic and thoracoabdominal aortic aneurysm and dissection: an investigation based on autopsy. *Br J Surg* 1996;83(1):68–71.

17. Kouchoukos NT, Dougenis D. Surgery of the thoracic aorta. *N Engl J Med* 1997;336(26):1876–1888.
18. Bickerstaff LK, Pairolero PC, Hollier LH, et al. Thoracic aortic aneurysms: a population-based study. *Surgery* 1982;92(6):1103–1108.
19. Clouse WD, Hallett JW Jr, Schaff HV, et al. Improved prognosis of thoracic aortic aneurysms: a population-based study. *JAMA.* 1998;280(22):1926–1929.
20. Ikonomidis JS, Ruddy JM, Benton SM Jr, et al. Aortic dilatation with bicuspid aortic valves: cusp fusion correlates to matrix metalloproteinases and inhibitors. *Ann Thorac Surg* 2012;93(2):457–463.
21. Guo DC, Pannu H, Tran-Fadulu V, et al. Mutations in smooth muscle alpha-actin (ACTA2) lead to thoracic aortic aneurysms and dissections. *Nat Genet* 2007;39(12):1488–1493.
22. Williams JS, Graff JA, Uku JM, et al. Aortic injury in vehicular trauma. *Ann Thorac Surg* 1994;57(3):726–730.
23. Razzouk AJ, Gundry SR, Wang N, et al. Repair of traumatic aortic rupture: a 25-year experience. *Arch Surg* 2000;135(8):913–918; discussion 919.
24. Ehrlich MP, Rousseau H, Heijman R, et al. Early outcome of endovascular treatment of acute traumatic aortic injuries: the talent thoracic retrospective registry. *Ann Thorac Surg* 2009;88(4):1258–1263.
25. Nguyen BT. Computed tomography diagnosis of thoracic aortic aneurysms. *Semin Roentgenol* 2001;36(4):309–324.
26. Elefteriades JA, Botta DM Jr. Indications for the treatment of thoracic aortic aneurysms. *Surg Clin North Am* 2009;89(4):845–867, ix.
27. Coady MA, Rizzo JA, Hammond GL, et al. Surgical intervention criteria for thoracic aortic aneurysms: a study of growth rates and complications. *Ann Thorac Surg* 1999;67(6):1922–1926; discussion 53–58.
28. Davies RR, Goldstein LJ, Coady MA, et al. Yearly rupture or dissection rates for thoracic aortic aneurysms: simple prediction based on size. *Ann Thorac Surg* 2002;73(1):17–27; discussion 27–28.
29. Hiratzka LF, Bakris GL, Beckman JA, et al. 2010 ACCF/AHA/AATS/ACR/ASA/SCA/SCAI/SIR/STS/SVM guidelines for the diagnosis and management of patients with Thoracic Aortic Disease: a report of the American College of Cardiology Foundation/American Heart Association Task Force on Practice Guidelines, American Association for Thoracic Surgery, American College of Radiology, American Stroke Association, Society of Cardiovascular Anesthesiologists, Society for Cardiovascular Angiography and Interventions, Society of Interventional Radiology, Society of Thoracic Surgeons, and Society for Vascular Medicine. *Circulation* 2010;121(13):e266–e369.
30. Coady MA, Rizzo JA, Hammond GL, et al. What is the appropriate size criterion for resection of thoracic aortic aneurysms? *J Thorac Cardiovasc Surg.* 1997;113(3):476–

491; discussion 89–91.
31. Baumgartner WA, Cameron DE, Redmond JM, et al. Operative management of Marfan syndrome: the Johns Hopkins experience. *Ann Thorac Surg* 1999;67(6):1859–1860; discussion 68–70.
32. Borger MA, Preston M, Ivanov J, et al. Should the ascending aorta be replaced more frequently in patients with bicuspid aortic valve disease? *J Thorac Cardiovasc Surg* 2004;128(5):677–683.
33. Sabik JF, Nemeh H, Lytle BW, et al. Cannulation of the axillary artery with a side graft reduces morbidity. *Ann Thorac Surg* 2004;77(4):1315–1320.
34. Strauch JT, Spielvogel D, Lauten A, et al. Axillary artery cannulation: routine use in ascending aorta and aortic arch replacement. *Ann Thorac Surg* 2004; 78(1):103–108; discussion 103-8.
35. Spielvogel D, Mathur MN, Lansman SL, et al. Aortic arch reconstruction using a trifurcated graft. *Ann Thorac Surg* 2003;75(3):1034–1036.
36. Gharagozloo F, Neville RF Jr, Cox JL. Spinal cord protection during surgical procedures on the descending thoracic and thoracoabdominal aorta: a critical overview. *Semin Thorac Cardiovasc Surg* 1998;10(1):73–86.
37. Coselli JS, LeMaire SA, Koksoy C, et al. Cerebrospinal fluid drainage reduces paraplegia after thoracoabdominal aortic aneurysm repair: results of a randomized clinical trial. *J Vasc Surg* 2002;35(4):631–639.
38. Jacobs MJ, Mess W, Mochtar B, et al. The value of motor evoked potentials in reducing paraplegia during thoracoabdominal aneurysm repair. *J Vasc Surg* 2006;43(2):239–246.
39. Keyhani K, Miller CC 3rd, Estrera AL, et al. Analysis of motor and somatosensory evoked potentials during thoracic and thoracoabdominal aortic aneurysm repair. *J Vasc Surg* 2009;49(1):36–41.
40. Coselli JS. The use of left heart bypass in the repair of thoracoabdominal aortic aneurysms: current techniques and results. *Semin Thorac Cardiovasc Surg* 2003;15(4):326–332.
41. Kouchoukos NT, Masetti P, Murphy SF. Hypothermic cardiopulmonary bypass and circulatory arrest in the management of extensive thoracic and thoracoabdominal aortic aneurysms. *Semin Thorac Cardiovasc Surg* 2003;15(4):333–339.
42. Gott VL, Gillinov AM, Pyeritz RE, et al. Aortic root replacement. Risk factor analysis of a seventeen-year experience with 270 patients. *J Thorac Cardiovasc Surg* 1995;109(3):536–544; discussion 44–45.
43. Okita Y, Ando M, Minatoya K, et al. Early and long-term results of surgery for aneurysms of the thoracic aorta in septuagenarians and octogenarians. *Eur J Cardiothorac Surg* 1999;16(3):317–323.
44. Fleck TM, Koinig H, Czerny M, et al. Impact of surgical era on outcomes of patients undergoing elective atherosclerotic ascending aortic aneurysm operations. *Eur J*

Cardiothorac Surg 2004;26(2):342–347.

45. Williams JB, Peterson ED, Zhao Y, et al. Contemporary results for proximal aortic replacement in North America. *J Am Coll Cardiol* 2012;60(13):1156–1162.
46. David TE, Feindel CM, David CM, et al. A quarter of a century of experience with aortic valve-sparing operations. *J Thorac Cardiovasc Surg* 2014;148(3):872–879; discussion 9–80.
47. Hu Z, Wang Z, Ren Z, et al. Similar cerebral protective effectiveness of antegrade and retrograde cerebral perfusion combined with deep hypothermia circulatory arrest in aortic arch surgery: a meta-analysis and systematic review of 5060 patients. *J Thorac Cardiovasc Surg* 2014;148(2):544–560.
48. Szeto WY, Bavaria JE, Bowen FW, et al. Reoperative aortic root replacement in patients with previous aortic surgery. *Ann Thorac Surg* 2007;84(5):1592–1598; discussion 8–9.
49. Luciani GB, Casali G, Faggian G, et al. Predicting outcome after reoperative procedures on the aortic root and ascending aorta. *Eur J Cardiothorac Surg* 2000;17(5):602–607.
50. Yamanaka K, Omura A, Nomura Y, et al. Surgical strategy for aorta-related infection. *Eur J Cardiothorac Surg* 2014;46(6):974–980.
51. Safi HJ, Miller CC 3rd, Estrera AL, et al. Staged repair of extensive aortic aneurysms: morbidity and mortality in the elephant trunk technique. *Circulation* 2001;104(24):2938–2942.
52. LeMaire SA, Price MD, Parenti JL, et al. Early outcomes after aortic arch replacement by using the Y-graft technique. *Ann Thorac Surg* 2011; 91(3):700–707; discussion 7–8.
53. Coselli JS, Bozinovski J, LeMaire SA. Open surgical repair of 2286 thoracoabdominal aortic aneurysms. *Ann Thorac Surg* 2007;83(2):S862–S864; discussion S90–S92.
54. Estrera AL, Rubenstein FS, Miller CC 3rd, et al. Descending thoracic aortic aneurysm: surgical approach and treatment using the adjuncts cerebrospinal fluid drainage and distal aortic perfusion. *Ann Thorac Surg* 2001;72(2):481–486.
55. Safi HJ, Harlin SA, Miller CC, et al. Predictive factors for acute renal failure in thoracic and thoracoabdominal aortic aneurysm surgery. *J Vasc Surg* 1996;24(3):338–344; discussion 44–45.
56. Bhamidipati CM, LaPar DJ, Mehta GS, et al. Have thoracic endografting outcomes improved since US Food and Drug Administration approval? *Ann Thorac Surg*2011;91(5):1314–1322; discussion 22.
57. Makaroun MS, Dillavou ED, Wheatley GH, et al. Five-year results of endovascular treatment with the Gore TAG device compared with open repair of thoracic aortic aneurysms. *J Vasc Surg* 2008;47(5):912–918.
58. Criado FJ. Aortic dissection: a 250-year perspective. *Tex Heart Inst J* 2011;38(6):694–700.

59. De Bakey ME, Cooley DA, Creech O Jr. Surgical considerations of dissecting aneurysm of the aorta. *Ann Surg* 1955;142(4):586–610; discussion, 611–2.
60. Daily PO, Trueblood HW, Stinson EB, et al. Management of acute aortic dissections. *Ann Thorac Surg* 1970;10(3):237–247.
61. Hagan PG, Nienaber CA, Isselbacher EM, et al. The International Registry of Acute Aortic Dissection (IRAD): new insights into an old disease. *JAMA* 2000;283(7):897–903.
62. Fattori R, Tsai TT, Myrmel T, et al. Complicated acute type B dissection: is surgery still the best option?: a report from the International Registry of Acute Aortic Dissection. *JACC Cardiovasc Interv* 2008;1(4):395–402.
63. Reece TB, Tribble CG, Smith RL, et al. Central cannulation is safe in acute aortic dissection repair. *J Thorac Cardiovasc Surg* 2007;133(2):428–434.
64. Trimarchi S, Nienaber CA, Rampoldi V, et al. Contemporary results of surgery in acute type A aortic dissection: the International Registry of Acute Aortic Dissection experience. *J Thorac Cardiovasc Surg* 2005;129(1):112–122.
65. Eggebrecht H, Nienaber CA, Neuhäuser M, et al. Endovascular stent-graft placement in aortic dissection: a meta-analysis. *Eur Heart J* 2006;27(4):489–498.
66. Estrera AL, Miller CC, Goodrick J, et al. Update on outcomes of acute type B aortic dissection. *Ann Thorac Surg* 2007;83(2):S842–S845; discussion S6–S50.
67. Tsai TT, Fattori R, Trimarchi S, et al. Long-term survival in patients presenting with type B acute aortic dissection: insights from the International Registry of Acute Aortic Dissection. *Circulation* 2006;114(21):2226–2231.
68. Nienaber CA, Rousseau H, Eggebrecht H, et al. Randomized comparison of strategies for type B aortic dissection: the INvestigation of STEnt Grafts in Aortic Dissection (INSTEAD) trial. *Circulation* 2009;120(25):2519–2528.
69. Brunkwall J, Kasprzak P, Verhoeven E, et al. Endovascular repair of acute uncomplicated aortic type B dissection promotes aortic remodelling: 1 year results of the ADSORB trial. *Eur J Vasc Endovasc Surg* 2014;48(3):285–291.
70. Nienaber CA, Kische S, Rousseau H, et al. Endovascular repair of type B aortic dissection: long-term results of the randomized investigation of stent grafts in aortic dissection trial. *Circ Cardiovasc Interv* 2013;6(4):407–416.

Chapter 86

Pericardium

Jules Lin

Key Points

1 Prompt recognition and treatment of cardiac tamponade can be lifesaving.

2 The echocardiogram is the most useful noninvasive test in evaluating pericardial disease.

3 The electrocardiogram is important in the diagnosis of acute pericarditis and classically shows diffuse ST elevations.

4 The hemodynamic significance of a pericardial effusion depends on the volume and the rate of accumulation.

5 Postoperative tamponade should always be in the differential diagnosis with low cardiac output after cardiac surgery.

6 Distinguishing constrictive pericarditis from restrictive cardiomyopathy can be difficult but is important since the treatment is significantly different.

7 Metastatic disease is the most common cause of pericardial effusion.

8 Reconstruction of the pericardium should be considered to reduce adhesions in cases where a future redo sternotomy is likely and is important when there is a risk of cardiac herniation after an intrapericardial pneumonectomy.

1 The pericardium supports and protects the heart. The smooth pericardial surface and the small amount of normal pericardial fluid provide a frictionless chamber improving cardiac efficiency as well as serving as a barrier to infection. The pericardium can be susceptible to a variety of disease processes including inflammation, infection, malignancy, and trauma. Changes in compliance and the accumulation of pericardial fluid can impair cardiac function, and the prompt recognition and treatment of cardiac tamponade can be lifesaving.

HISTORY

Hippocrates first described the pericardium in 460 BC. Three hundred years later, Galen described a pericardial effusion and the inflammatory changes associated with pericarditis. Lower first reported pericardial tamponade in humans in 1669. Lancisi and Morgagni described constrictive pericarditis, and Laennec wrote of the “bread and butter” appearance of acute pericarditis in 1819.[1] Kussmaul described the hemodynamic changes known as pulsus parodoxus, and Beck and Griswald performed experimental studies in the 1930s leading to a better understanding of the pathophysiology of pericardial effusion.[2,3] Karaeneff first described relieving the symptoms of tamponade using pericardiocentesis in 1840.[4] Rehn reported methods to resect the pericardium in 1913.[5]

EMBRYOLOGY AND ANATOMY

The pleuropericardial membranes fuse during the fifth week of gestation dividing the thoracic cavity into pleural and pericardial spaces and forming the fibrous pericardium.[6] The serous pericardium is a single layer of mesothelial cells that produce and reabsorb pericardial fluid. The serous and fibrous pericardium form the parietal pericardium which is normally 2 mm in thickness. The visceral pericardium covers the heart and the intrapericardial great vessels. The phrenic nerves are contained in the parietal pericardium, and there is a risk of diaphragmatic paralysis with any operation on the pericardium. The pericardial folds form the oblique sinus, a blind cul-de-sac behind the left atrium, and the transverse sinus between the aorta and pulmonary artery superiorly and the left and right atrium inferiorly (Fig. 86-1). Lymphatic drainage is to the bronchial and tracheal lymph nodes and the thoracic duct. The pericardium normally produces 15 to 50 mL of serous fluid with a protein level lower than plasma.[7]

NORMAL PHYSIOLOGY

Although there are no significant consequences of the congenital absence or surgical resection of the pericardium as long as the defect does not lead to cardiac herniation, the pericardium has some function in the normal patient. The pericardium anchors the heart and prevents torsion and acute distension.[8] The pericardium contributes to the diastolic coupling of the ventricles along the Starling curve. Mechanoreceptors in the pericardium may also regulate blood pressure and heart rate. The pericardium stretches up to 20% with small changes in pressure but becomes abruptly stiff and resistant with larger volumes. Compliance depends on the rate of fluid accumulation, and the hemodynamic response is also partially dependent on intravascular volume status.

The normal pericardial pressure is less than atmospheric pressure and is the same as the intrapleural pressure. With inspiration, right-sided venous returns and preload increases. Blood pools in the lungs and decreases left-sided venous return and aortic blood flow. The arterial pressure normally decreases less than 10 mm Hg with inspiration. The normal jugular waveforms are shown in Figure 86-2. The a wave is the normal atrial contraction. The c wave reflects the bulging of the atrioventricular valve into the atrium during isovolumic ventricular systole. The v wave represents passive atrial filling from the vena cava. The x descent occurs with systolic collapse during ventricular systole and atrial relaxation. The y descent reflects diastolic collapse with opening of the atrioventricular valve and passive ventricular filling. Inspiration decreases intrathoracic pressure and leads to a lower x descent compared to the y descent.

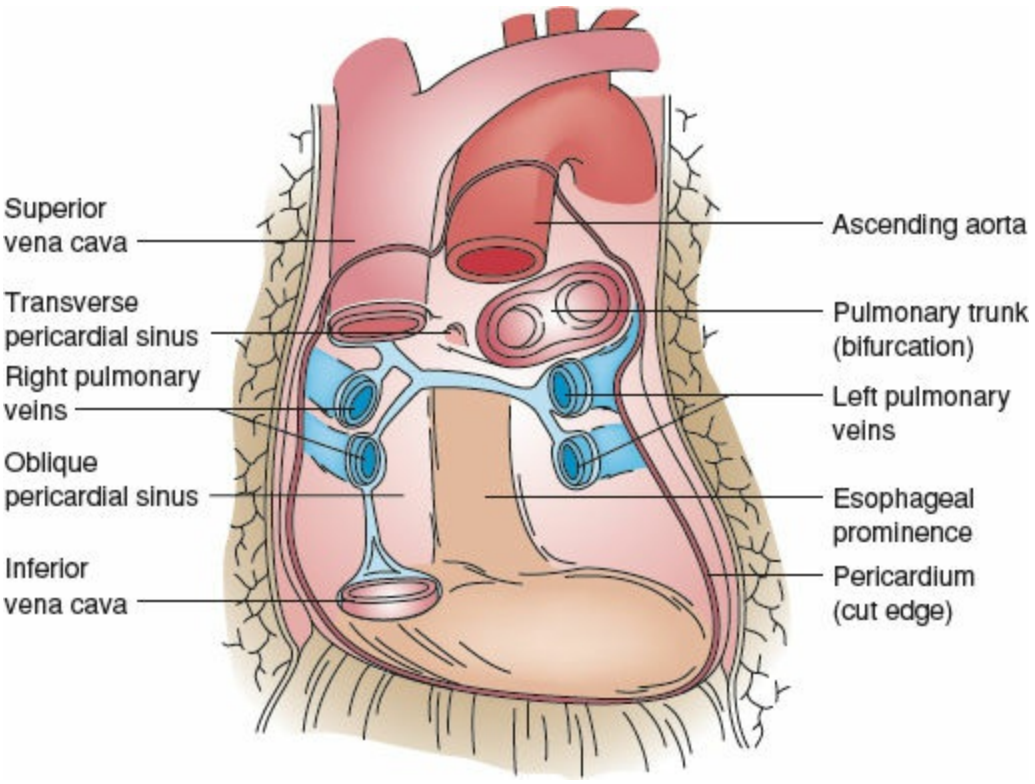

Figure 86-1. This drawing illustrates the pericardial attachments of the great vessels and pulmonary veins. The oblique sinus forms a blind cul-de-sac behind the left atrium, and the transverse sinus is a space between the aorta and pulmonary artery superiorly and the left and right atrium inferiorly.

DIAGNOSTIC STUDIES

While the electrocardiogram is nonspecific, it can be helpful in suggesting the diagnosis. In acute pericarditis the EKG classically shows diffuse ST elevations, and a low-voltage QRS is seen with a large pericardial effusion. The chest radiograph in a patient with a pericardial effusion shows an enlarged cardiac silhouette described as a water bottle. Pericardial calcification can be seen in chronic constrictive pericarditis secondary to tuberculosis.

2 The echocardiogram is the most useful noninvasive test in evaluating pericardial disease. The echocardiogram can identify an effusion, pericardial thickening, or masses. By using Doppler and assessing changes in chamber size, echocardiogram is useful in assessing hemodynamics and can help differentiate tamponade, constriction, and restriction. It can also be used to help guide procedures like pericardiocentesis. Computed tomography and magnetic resonance imaging can identify pericardial masses and pericardial thickening or calcification.[9] Cardiac catheterization provides pressure tracings that help to distinguish cardiac tamponade, constriction, and restriction. Endomyocardial biopsy can also be useful in diagnosing restrictive cardiomyopathy.

CONGENITAL ABNORMALITIES

Congenital absence of the pericardium is usually partial but can be complete. It is most common on the left side and is more frequent in males. Associated congenital cardiac defects include atrial septal defect, a bicuspid aortic valve, and pulmonary malformations. Defects on the right side can lead to cardiac herniation. Patients can present with chest pain, syncope, or death. The electrocardiogram can show a right bundle branch block. The pericardial defect can be appreciated on CT or MRI. The treatment of a partial defect is total pericardiectomy or patch closure with PTFE or bovine pericardium. Total pericardial absence is usually asymptomatic and is found incidentally.

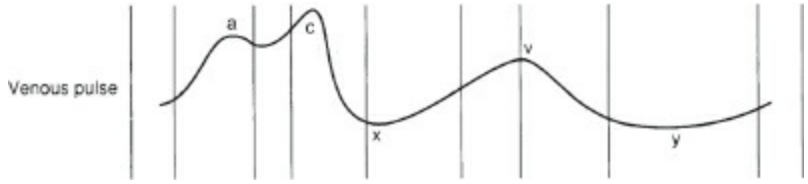

Figure 86-2. The jugular venous pulse waveform.

Pericardial cysts are rare benign cysts that generally measure 1 to 15 cm in size. They are most commonly found at the right cardiophrenic angle and are asymptomatic. Patients may present with mediastinal compression and respiratory symptoms. The differential diagnosis includes a Morgagni hernia, lipoma, mediastinal tumor, or bronchogenic cyst. CT scans are used to confirm the location and relationship to surrounding structures. The cyst is excised if the patient is symptomatic, or the diagnosis is unclear.

ACUTE PERICARDITIS

Acute pericarditis is an inflammatory process that has involved the pericardium for less than 2 weeks (Table 86-1). Patients often present with a 3- to 7-day prodrome of low-grade fevers, malaise, and muscle aches. Acute pericarditis occurs in 5% of those who present to the emergency department with nonischemic chest pain[10] and in 1% of those with ST elevation.[11] It is important to distinguish pericarditis from the chest pain of an acute myocardial infarction. Acute pericarditis usually causes sharp, pleuritic pain that can last several days. The pain most commonly radiates to the trapezius ridge and is improved by leaning forward. Patients can present with shortness of breath, a nonproductive cough, and clear lung fields. The differential diagnosis also includes aortic dissection and pneumothorax. On physical examination, a friction rub may be heard and is sometimes intermittent. The classic friction rub has three components during systole, early diastolic filling, and atrial contraction.

ETIOLOGY

Table 86-1 Causes of Pericarditis

Idiopathic
Infectious
Neoplastic
Hemopericardium
Blunt and penetrating trauma
Postcardiac surgery
Aortic dissection
Autoimmune and inflammatory
Connective tissue disorders
Postmyocardial infarction
Medication induced
Miscellaneous
Radiation induced
Hypothyroidism
Uremic

3 The electrocardiogram is important in the diagnosis and classically shows diffuse ST elevations without Q waves or T-wave inversion. PR depression can also be seen. There is a four-stage progression in the changes seen on EKG with diffuse ST elevations followed by normalization of ST segments with flattening of T waves. The EKG then evolves with T-wave inversions prior to normalization of the EKG. Pericarditis and associated myocarditis can cause elevations in creatinine kinase and troponin I.[12] The minimal workup should include an EKG, complete blood count, cultures, chemistry profile, and antibody titres for collagen diseases.

Idiopathic and Viral Pericarditis

Idiopathic causes of pericarditis are the second most common after neoplastic disease. The majority are likely viral although routine testing is not usually performed. A virus is only identified in 15% to 20% of cases with the most common being Coxsackievirus, echovirus, adenovirus, influenza, and cytomegalovirus. Patients present with chest pain, malaise, and fever and often have an elevated erythrocyte sedimentation rate. The episode is self-limited in 70% to 90% of cases.[10] Initial treatment is with nonsteroidal anti-inflammatory drugs (NSAIDs). There is a 15% to 30% relapse rate at which point specific causes such as autoimmune disorders should be investigated.[10,13] A repeat course of NSAIDs, colchicine, or steroids is generally successful. Pericardiectomy is recommended if the patient unresponsive to medical treatment or constriction develops.

Acquired Immunodeficiency Syndrome

A pericardial effusion develops in up to 20% of patients with HIV and is usually a poor prognostic sign.[14] This may be partly due to a generalized capillary leak syndrome as well as increased cytokine expression seen in the more advanced stages of HIV. Other contributing factors include tubercular and mycobacterial infections, lymphoma, Kaposi's, or congestive heart failure. The majority are idiopathic and do not require further therapy if asymptomatic. Symptomatic effusions are drained.

Tuberculous Pericarditis

Tuberculous pericarditis occurs in 1% to 8% of patients.[15] In immunocompromised patients infection by *Mycobacterium avium* or *Mycobacterium intracellulare* can lead to pericarditis. The incidence of tuberculous pericarditis has decreased although it continues to be a significant issue in immunocompromised patients, particularly HIV patients in Africa. Patients present with fever, night sweats, cough, dyspnea, and weight loss. While infection usually results from hematogenous spread, it can also extend directly from lymph nodes or through lymphatics. Pericardial changes occur in four stages including fibrinous, effusive, fibrous, and constrictive fibrous stages. Making the diagnosis from pericardial fluid alone is rare. Pericardial biopsy with acid fast staining provides the diagnosis 80% to 90% of the time. Treatment includes multidrug antitubercular therapy and pericardiocentesis. Steroids have not been shown to be beneficial for mortality or progression to constriction but leads to a faster resolution of symptoms and reaccumulation.[16] If patients present with late constriction, pericardiectomy may be required.

Purulent Pericarditis

Bacteria can be introduced into the pericardial space by direct injury, pneumonia, extension from head and neck infections, or hematogenous and lymphatic spread. Patients present with chest pain, fever, and leukocytosis. The most common organisms in adults are staphylococcus, pneumococcus, and streptococcus. Purulent pericarditis can evolve rapidly into tamponade and can be confused with septic shock. Fungal infections are less common, but immunocompromised patients and drug addicts are at greater risk. Pericardial fluid in purulent pericarditis has low glucose, high protein, and elevated LDH and neutrophils. An air–fluid level may be seen on chest radiograph with gas-producing organisms. Treatment includes antibiotics and drainage. Surgical drainage may be needed for thick fluid or refractory effusions. The prognosis for purulent pericarditis is poor with a survival of 30%.[10,17]

Uremic Pericarditis

Fifty percent of patients with untreated renal disease develop pericarditis. The incidence is decreased to approximately 20% in patients on hemodialysis. The exact cause is unknown but is not directly related to the BUN or creatinine. Other possible etiologies include hypercalcemia, viral infection, and autoimmune disease. Chest pain is usually less common, and the large effusions accumulate gradually. Treatment includes more intensive dialysis, NSAIDs, and steroids. The fluid is generally bloody and care should be taken in heparinizing these patients for dialysis. If patients develop tamponade or the effusion is unresponsive, pericardiocentesis or surgical drainage is performed.

Vasculitis, Connective Tissue Disease, and Drugs

Pericarditis can result from a variety of vasculitic and connective tissue diseases including rheumatoid arthritis, Wegener granulomatosis, rheumatic fever, lupus, scleroderma, Reiter syndrome, Behcet disease, dermatomyositis, polyarteritis nodosa, dermatomyositis, sarcoidosis, and amyloidosis. Treatment includes management of the underlying disease process and NSAIDs. Pericardiocentesis is performed if necessary. Several medications can also lead to pericarditis including warfarin, hydralazine, isoniazid, procainamide, phenytoin, dantroline, cromolyn, and methysergide.

Dressler and Postpericardiotomy Syndrome

Pericarditis can occur following acute myocardial infarction in 3% to 5%.[18] Pericarditis can develop early in the first 1 to 3 days particularly with transmural infarction. Forty percent of large Q-wave infarctions cause pericardial inflammation although the incidence is decreasing with the use of thrombolytics and early revascularization. Patients are usually asymptomatic and are found to have a pericardial rub on examination although they can present with pleuritic chest pain. Treatment is usually with NSAIDs. Steroids can prevent conversion of infarcted myocardium to scar leading to greater thinning and risk of rupture.[19,20]

Patients can also present with pericarditis 1 week to a few months after a myocardial infarction with a friction rub, typical EKG changes, and chest pain although the incidence has decreased with increased revascularization. Pericardial inflammation is thought to be from an autoimmune reaction to myocardial cells.[20] Similar symptoms can also occur after cardiac surgery, blunt trauma, and pacemaker placement. Patients can develop a pericardial effusion and even tamponade. Treatment includes NSAIDs and colchicine for 2 to 3 weeks and occasionally steroids. The syndrome is usually self-limited.

Radiation-Induced Pericarditis

Pericarditis can result from mediastinal and thoracic radiation for cancer including lymphoma and breast carcinoma and is related to the dosage delivered. With modern techniques, the incidence is 2% but can be as high as 20% if the entire pericardium is treated. Patients may develop chest pain and fever.[20] Symptoms are usually self-limited, and tamponade is rare. Delayed symptoms can develop years later and can result in pericardial constriction. Due to the history of malignancy, the etiology can be confused with a malignant effusion. If pericardial constriction develops, the treatment is pericardiectomy although the mortality is higher than for other etiologies.

PERICARDIAL EFFUSION AND TAMPONADE

Any of the etiologies mentioned above for pericarditis can also lead to a pericardial effusion. Other causes include blunt or penetrating trauma, retrograde bleeding from an aortic dissection, and a transudative effusion from congestive heart failure. Effusions due to a bacterial or fungal infection, HIV, or malignancy have a higher incidence of progressing to tamponade. Twenty percent of large symptomatic effusions of unknown cause are due to an undiagnosed cancer.[21]

4 Normally there is only a small reserve volume before pericardial fluid causes significant cardiac compression and prevents adequate cardiac filling. The hemodynamic significance of a pericardial effusion depends on the volume and the rate of accumulation. The compensatory adrenergic response to a pericardial effusion leads to tachycardia and increased contractility, and patients on beta blockers are less likely to compensate. Tamponade usually occurs when filling pressures reach 15 to 20 mm Hg although tamponade can occur at lower pressures in conditions where blood volume is reduced including dialysis, with diuretic therapy, and bleeding. Cardiac pressures become elevated and are most closely equalized during inspiration. Tamponade generally affects right heart filling first which then leads to underfilling of the left heart.[22]

Patients may present with dyspnea, tachycardia, and diaphoresis. The three classic signs of Beck triad are hypotension, jugular venous distension, and muffled heart sounds although each may be absent in patients with tamponade.[23] Symptoms can be confused with right heart failure and pulmonary embolus. The jugular waveform changes characteristically with loss of the y descent.[24] Since the total heart volume is fixed in tamponade, blood only enters the heart when blood leaves. The y descent represents opening of the tricuspid valve and is lost since no blood is ejected from the heart. Pulsus paradoxus is also noted with a fall in the systolic blood pressure of greater than 10 mm Hg with inspiration. Pulsus paradoxus is absent in left ventricular dysfunction, atrial septal defect, positive-pressure ventilation, aortic insufficiency, and regional tamponade. The EKG shows variation in the morphology of every other QRS complex, or electrical alternans, due to swinging of the heart in the pericardial effusion (Fig. 86-3). Chest radiograph shows an enlarged, rounded cardiac silhouette, and the pericardial fat pad sign is seen when the pericardial fat is separated from the heart by the effusion.

Echocardiography is the most useful test in diagnosing pericardial effusion and tamponade. Signs of tamponade include early diastolic right ventricular and right atrial collapse (Fig. 86-4) and distension of the cava that does not diminish with inspiration. Doppler is useful in evaluating blood flow and shows exaggerated respiratory variation with an increase with inspiration on the right and decrease on the left side of the heart. Echocardiography is also useful in identifying localized atrial compression which can lead to tamponade with the other changes described above.

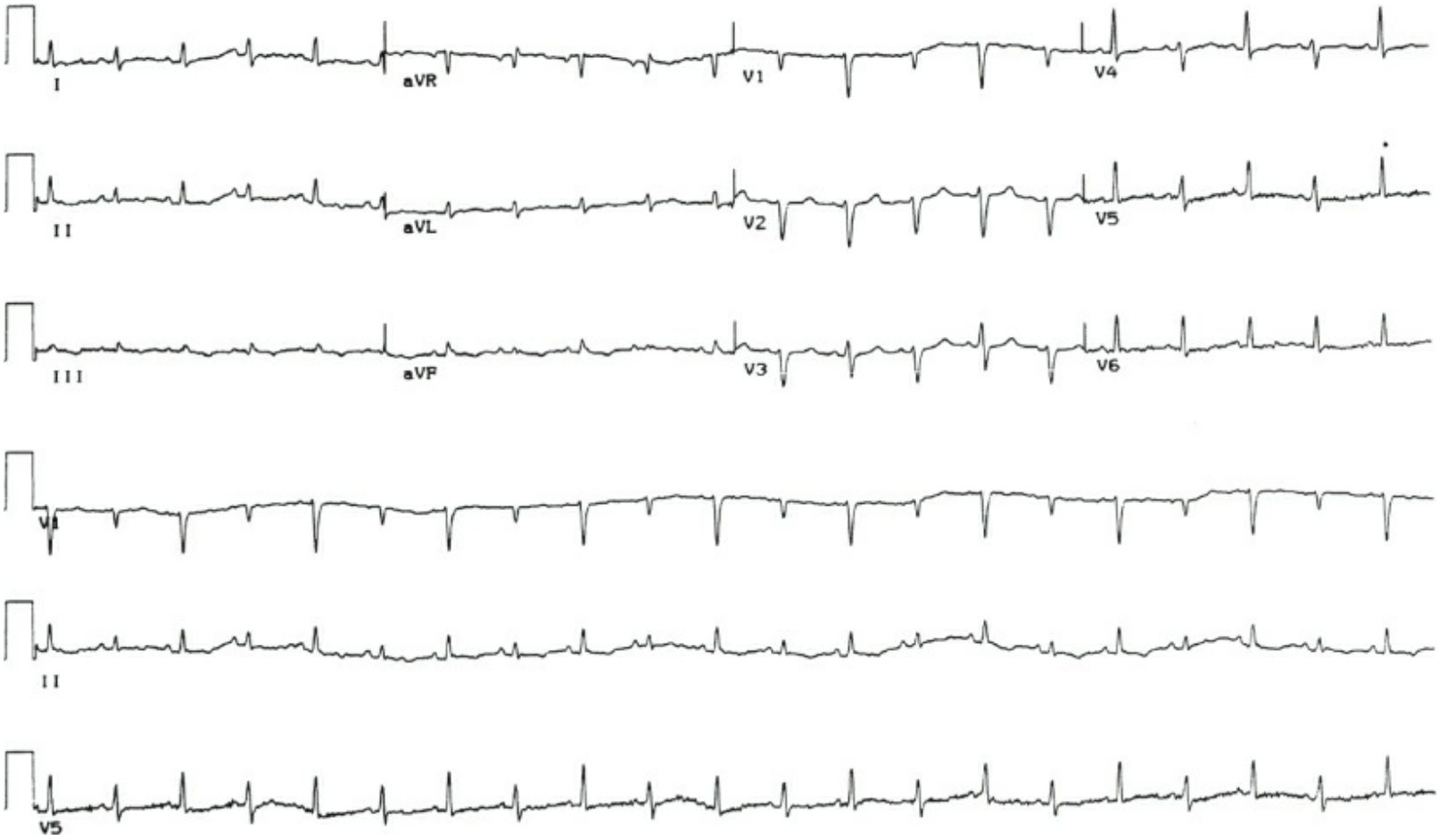

Figure 86-3. The 12-lead EKG shows electrical alternans with variation in the morphology of every other QRS complex in a patient with a large pericardial effusion. (From Joffe II, Jacobs LE, Kotler MN. Pericardial tamponade. *Circulation* 1996;94:2667, with permission.)

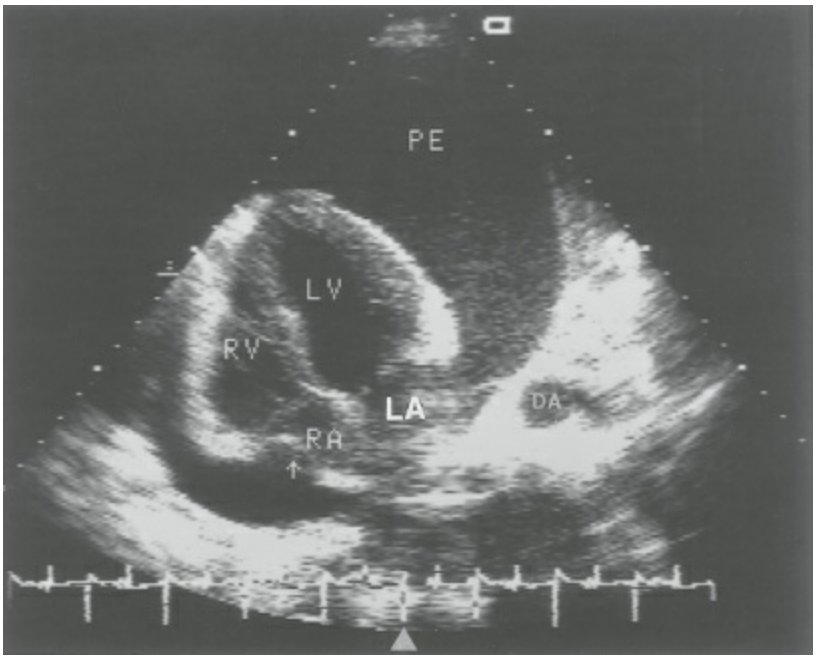

Figure 86-4. The echocardiogram shows a large pericardial effusion with diastolic right atrial collapse (*arrow*). (From Joffe II, Jacobs LE, Kotler MN. Pericardial tamponade. *Circulation* 1996;94:2667, with permission.)

If there are significant hemodynamic changes, emergent pericardiocentesis should be performed. Intravenous fluid and inotropes can temporize the hypotension but should not

delay pericardiocentesis. If the effusion is loculated or contains blood clots, open drainage may be necessary. There should be a higher suspicion for tamponade in situations involving bleeding, bacterial or tuberculous pericarditis, or an acute or increasing moderate-to-large effusion. The approach to a patient with a large pericardial effusion is outlined in Algorithm 86-1.

Postoperative Cardiac Tamponade

5 Postoperative tamponade should always be in the differential diagnosis with low cardiac output after cardiac surgery. Patients may have rising filling pressures, hypotension, and decreased urine and cardiac output. Mediastinal chest tube output may increase or abruptly stop. Hypovolemia during the postoperative period can limit the increase in filling pressures. Pulsus paradoxus may also be masked by positive pressure ventilation. On chest radiograph, the cardiac silhouette is enlarged. In the postoperative cardiac patient, the epicardial pacing wires may move farther from the pericardium with increasing tamponade on chest films. Tamponade can result from relatively small amounts of blood with localized atrial compression from blood clots. There should be a low threshold for reexploration which also provides a definitive diagnosis. Patients can also present with delayed tamponade after being started on anticoagulants.

PERICARDIAL CONSTRICTION

Constriction develops when the heart becomes constrained by a fibrotic pericardium. The process can progress over years, and the most common causes in the developed world are radiation treatment, postsurgical changes, and idiopathic. Tuberculosis was the most common cause before antitubercular drug therapy. Other causes include amyloidosis, scleroderma, sarcoidosis, hemochromatosis, and malignant disease. Patients develop signs and symptoms of right heart failure due to obstruction of the right ventricular outflow tract including hepatomegaly, ascites, and peripheral edema. Patients can also have dyspnea, pleural effusions, fatigue, and weight loss. On physical examination, a pericardial knock, or a loud third heart sound, can be heard which corresponds to the abrupt cessation of diastolic filling. Kussmaul sign is increased jugular venous distension with inspiration. Atrial fibrillation or flutter is present in up to 25% of patients, and tricuspid regurgitation is also common.

Pericardial calcification is pathognomonic but is only seen in 40% of cases. Thickened pericardium can be seen on CT or MRI (Fig. 86-5) although the pericardium was normal in thickness in 18% of patients in one series.[25] The normal pericardial thickness is 2 mm on CT and 4 mm on MRI. Echocardiography shows thickened pericardium and a septal bounce due to the abrupt displacement of the septum during early diastole. The ventricles are small with good function. Ventricular filling halts abruptly in diastole due to the limits of the stiff, fibrotic pericardium. There are signs of systemic venous congestion with a distended inferior vena cava. In contrast to tamponade, there is no decrease in early diastolic filling but a sudden decrease in late diastole (Table 86-2).[24] When the myocardium is involved by fibrosis, ventricular dysfunction is present which is associated with a poorer response to pericardiectomy.

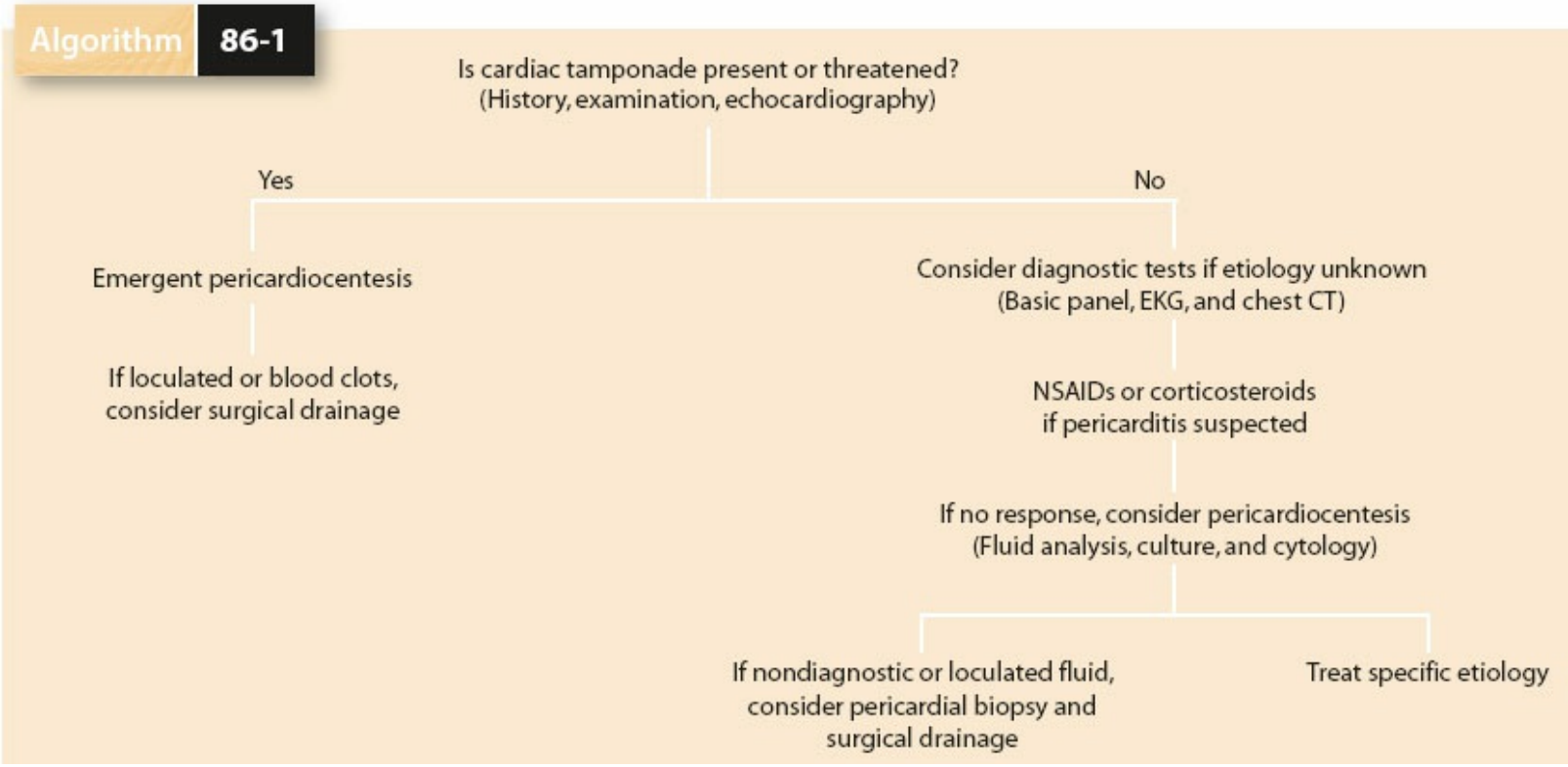

Algorithm 86-1. This algorithm outlines the initial approach to a patient with a large pericardial effusion.

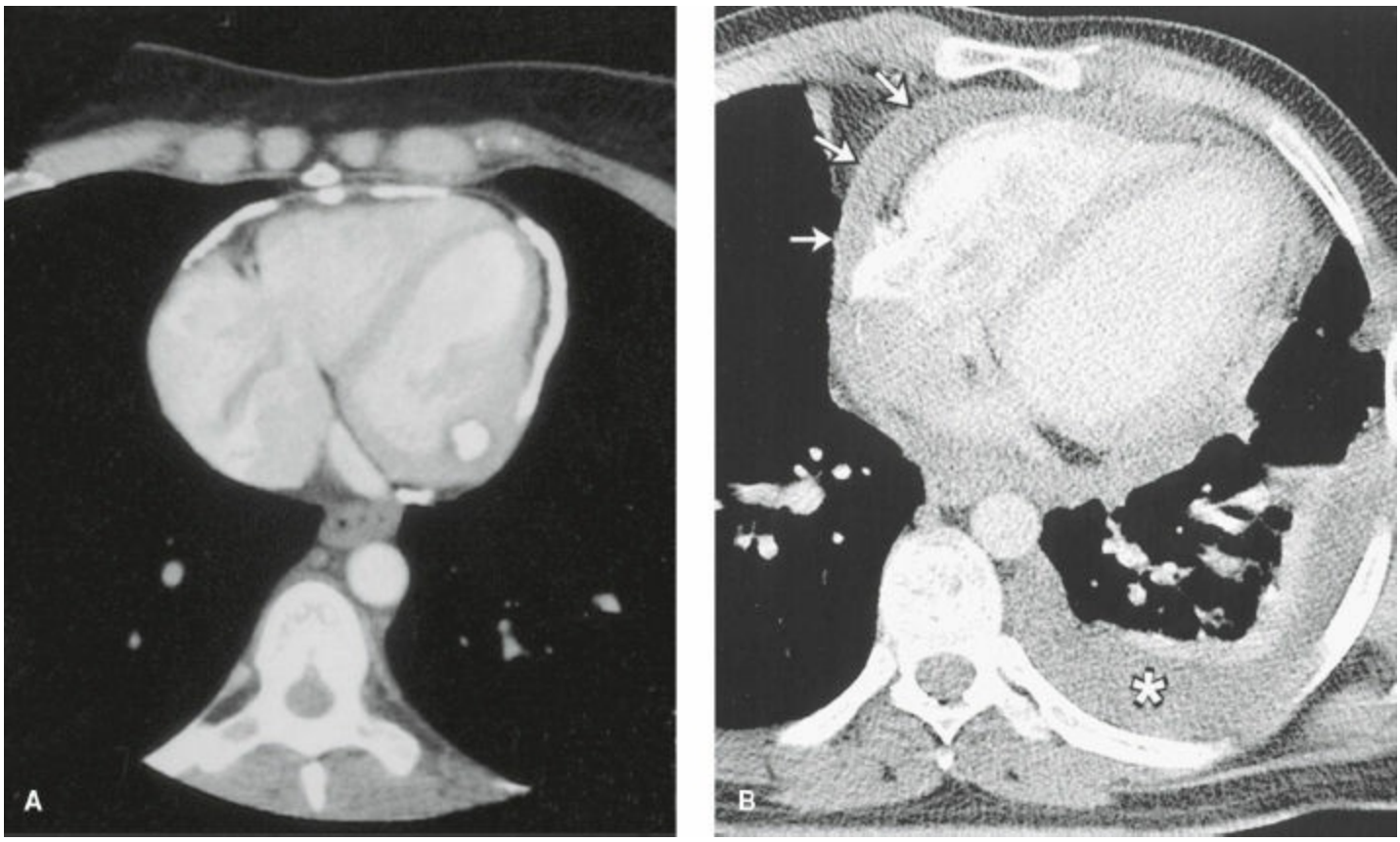

Figure 86-5. **A:** Chest CT shows extensive pericardial calcification. (From Cavendish JJ, Linz PE. Constrictive pericarditis from a severely calcified pericardium. *Circulation* 2005;112(11):e137–e139, with permission.) **B:** Chest CT shows thickening of the pericardium in a patient with constrictive pericarditis. (From Tom CW, Oh JK. A case of transient constrictive pericarditis. *Circulation* 2005;111:e364, with permission.).

On right heart catheterization, the y descent is deeper and more rapid than normal. The

right atrial waveform is M- or W-shaped. The right ventricular tracing is described as the square root sign with an early diastolic decrease with a rapid increase and plateau (Fig. 86-6). Pulmonary artery and right ventricular pressures can be moderately elevated, but more severe pulmonary hypertension suggests a different disease process. In addition, hypovolemia can mask these findings, and patients may need to be volume-challenged to see the diagnostic changes.[26]

6 Distinguishing constrictive pericarditis from restrictive cardiomyopathy can be difficult but is important since the treatment is significantly different (Table 86-3). In restrictive cardiomyopathy, there is no pericardial thickening. Decreased systolic function, mitral regurgitation, and left heart pressures greater than right are more common in restrictive cardiomyopathy. Early diastolic filling is slower. In addition, left and right ventricular pressures move in the same direction on inspiration rather than opposite directions.[27]

Constrictive pericarditis is generally progressive although it can be transient after cardiac surgery and should be observed for several months. Diuretics with fluid and salt restriction help initially, but pericardiectomy is the only definitive treatment. Tachycardia is a compensatory response, and beta and calcium channel blockers should be avoided.

NEOPLASTIC PERICARDIAL DISEASE

7 Primary tumors of the pericardium are rare and include benign fibromas, hemangiomas, lipomas, lymphangiomas, leiomyomas, and neurofibromas. Malignant pleural tumors include mesothelioma, teratoma, and fibrosarcoma. Surgical resection is therapeutic and diagnostic. Malignancies can also extend directly from the mediastinum, esophagus, and lung. Metastatic disease is the most common cause of pericardial effusion. Cardiac involvement is found in 5% to 10% of patients dying of cancer with 85% of those having pericardial involvement. The most common cancers are lung and breast carcinoma, lymphoma, melanoma, and leukemia. Patients often present with tamponade. The diagnosis is made on echocardiography or CT. Cytology of pericardial fluid is negative in 20% to 50% of cases, and pericardial biopsy may be helpful. Palliation includes sclerosing agents such as tetracycline, radiotherapy, intrapericardial chemotherapy, and catheter drainage.

DIAGNOSIS

Table 86-2 Distinguishing Cardiac Tamponade and Constrictive Pericarditis

	Tamponade	Constriction
Pulsus paradoxus	Usually present	Present in 1/3 of cases
Jugular venous waveform	Absent y descent	Prominent y descent (M or W)
Inspiratory changes in venous pressure	Decrease	Increase (Kussmaul sign)
Equal right and left pressures	Present	Present
"Square root" sign ventricular pressure	Absent	Present

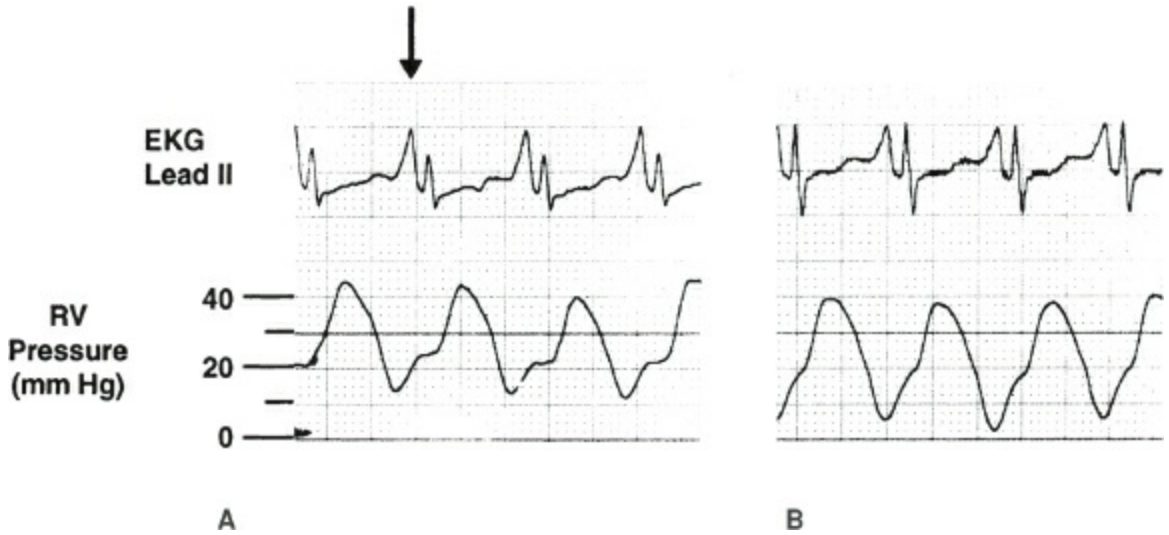

Figure 86-6. **A:** The right ventricular (RV) pressure tracing shows elevated RV diastolic pressure with the dip-and-plateau waveform known as the "square root sign." The EKG tracing shows a large P wave indicative of right atrial enlargement. **B:** The postoperative RV tracing shows normalization of the RV waveform. (From Correa SD, Amsterdam EA. Constrictive pericarditis. *Circulation* 1998;97:806, with permission.)

PERICARDIOCENTESIS

Pericardiocentesis can be diagnostic and therapeutic. Ideally, it should be performed in the catheterization laboratory so the hemodynamic response can be monitored. Normal pericardial fluid is an ultrafiltrate with an LDH 2.4 times serum and protein 0.6 times.[28] Uremic fluid is bloody. Rheumatic effusions are high in protein and leukocytes and low in glucose. Cholesterol crystals are seen with myxedema, tuberculosis, and rheumatoid arthritis.

Table 86-3 Distinguishing Constrictive Pericarditis From Restrictive Cardiomyopathy

	Restriction	Constriction
Pericardial knock	Absent	Present
Pulsus paradoxus	Absent	Present in 1/3 cases
Thickened pericardium	Absent	Present
Atrial enlargement	Biatrial	Possibly left atrial
Septal bounce	Absent	Present
Equal right and left pressures	Left 3–5 mm Hg > Right	Present
Filling pressures >25 mm Hg	Present	Uncommon
Pulmonary artery SBP >60 mm Hg	Present	Absent
"Square root" sign ventricular pressure	Variable	Present
Prominent y descent	Variable	Present

SBP, systolic blood pressure.

Generally, a 16- to 22-gauge needle is inserted to the left of the xiphoid. The needle is angled at a 45-degree angle toward the left shoulder (Fig. 86-7). An EKG lead may also be attached to the needle to monitor for an injury current, although echocardiography is more commonly used for guidance. There is a 97% success rate with a complication rate of 4.7% (Table 86-4).[29] If the effusion is anterior, a parasternal approach is used 1 to 2 cm to the left of the sternum in the fourth or fifth intercostal space. The removal of even a small amount of fluid can lead to significant hemodynamic improvement. For longer-term drainage a catheter can be placed over a guidewire. Pericardiocentesis may not be effective for purulent or bloody effusions that may require open drainage.

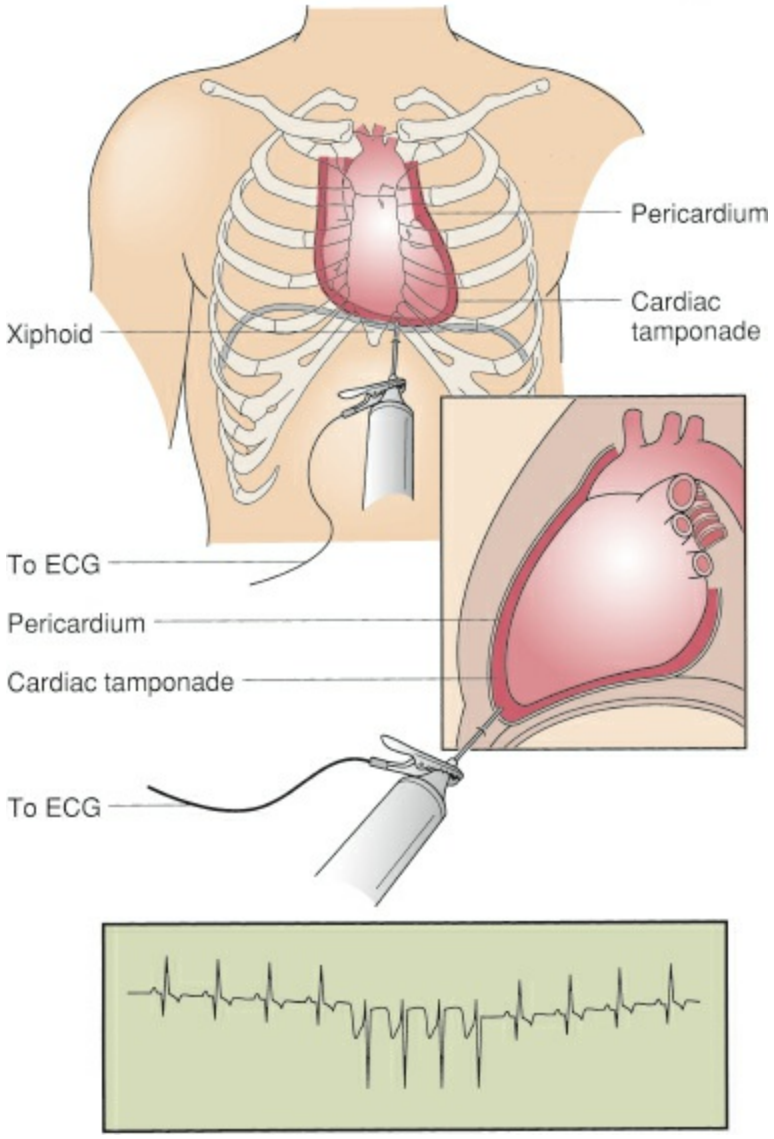

Figure 86-7. Pericardiocentesis is performed by inserting a needle to the left of the xiphoid and toward the left shoulder at a 45-degree angle. An EKG lead may be attached to the needle to monitor for Q waves indicating contact with the epicardium.

Table 86-4 Potential Complications From Pericardiocentesis

Injury to surrounding organs
Liver laceration
Lung (pneumothorax)
Coronary arteries
Myocardium
Arrhythmias
Pulmonary edema from acute left ventricular failure
Recurrence

PERICARDIAL BIOPSY AND SURGICAL DRAINAGE

Pericardial biopsy is useful when pericardiocentesis is nondiagnostic, which is not uncommon in neoplastic and tubercular effusions. This can be approached through a subxiphoid incision, anterior thoracotomy, or thoracoscopically (Fig. 86-8). Open drainage may be useful if the fluid is viscous, including bloody or purulent effusions, or in patients that have recurrent effusions. Loculated effusions may also require open drainage. The subxiphoid approach is better for purulent effusions to prevent contamination of the pleural space. Chronic or malignant effusions can be drained through a pericardial window into the left pleura. Preinduction pericardiocentesis or intravenous fluids may be necessary for patients to tolerate general anesthesia.

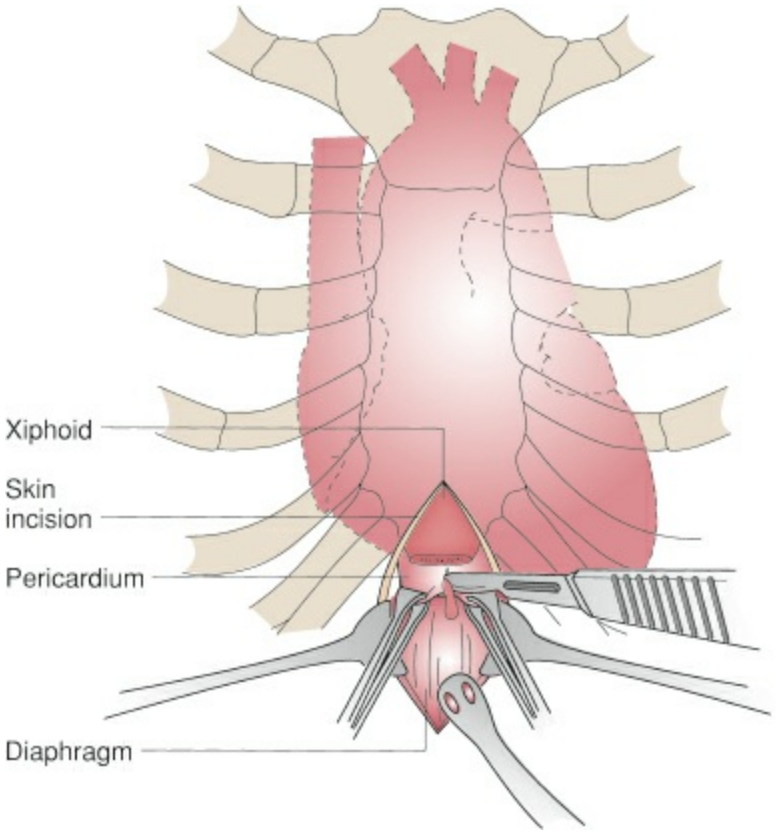

Figure 86-8. Open pericardial biopsy or drainage is performed through an upper midline incision. The xiphoid is retracted or removed providing exposure to the pericardium.

RECONSTRUCTION OF THE PERICARDIUM

Generally, the pericardium does not need to be reconstructed after routine opening of the pericardium during cardiac surgery or when resecting portions of the pericardium for adjacent tumors such as a thymoma. Primary pericardial closure is often avoided due to concerns for hemodynamic compromise and perioperative tamponade. Dantas et al. found a temporary, but clinically insignificant, decrease in hemodynamics in a study of 48 patients with primary closure of the pericardium after open heart surgery.[30]

8 Reconstruction of the pericardium should be considered in cases where a future redo sternotomy is likely such as a bioprosthetic valve that will need to be replaced or a left ventricular assist device that will be removed at the time of transplant. To prevent hemodynamic compromise, the closure should be performed without tension. A biologic mesh implant made of porcine extracellular matrix has been used to prevent adhesions and protect the right ventricle, aorta, and coronary bypass grafts. Reconstruction of the pericardium was also reported in a retrospective study of 222 patients to decrease the incidence of atrial fibrillation.[31] However, the results of a randomized trial evaluating new-onset postoperative atrial fibrillation after pericardial reconstruction using extracellular matrix (NCT01247974) have not yet been reported.

Reconstruction of the pericardium is important when there is a risk of cardiac herniation. When resection of the pericardium is required during pneumonectomy due to a central lung tumor or an extrapleural pneumonectomy for mesothelioma, the pericardium should be reconstructed to prevent herniation into the empty hemithorax.[32] Cardiac herniation must be quickly recognized if the patient becomes hypotensive postoperatively. The pericardial defect is reconstructed with a 0.1-mm Gore-Tex mesh. The mesh should be fenestrated with small incisions to allow fluid to escape decreasing the risk of tamponade. Reconstruction of the pericardium may also help to prevent inflammatory epicarditis which can lead to constrictive physiology after extrapleural pneumonectomy.[33]

PERICARDIECTOMY

Pericardiectomy is most commonly performed for constrictive pericarditis. It can be performed through a median sternotomy or a left anterior thoracotomy in the fifth intercostal space. Anterior thoracotomy allows removal of the pericardium over the left ventricle with minimal manipulation. Femoral cannulation is used if bypass is necessary. Median sternotomy is the most common approach (Fig. 86-9). Cardiopulmonary bypass increases the risk of bleeding and is used when significant cardiac manipulation is needed or the dissection is difficult. The pericardium over the left ventricle is resected first to avoid pulmonary edema from the right ventricle ejecting against a constricted left ventricle. The pericardium is removed from phrenic nerve to phrenic nerve. Some patients have an immediate improvement in hemodynamics and symptoms while others do not improve until weeks or months later. A delayed or incomplete response is thought to be due to an incomplete resection of the visceral pericardium or myocardial atrophy and fibrosis. Left ventricular function returned to normal in 40% of patients.

Perioperative mortality has been reported between 5% and 15% and is due to low cardiac output, sepsis, bleeding, and renal or respiratory failure.[34] Seventy percent of mortality is due to low cardiac output. Mortality is directly related to the patient's preoperative status[35] and is 1% for New York Heart Association class I to II, 10% for class III, and 46% for class IV.[36] Five-year survival is 84%, and 99% of late survivors were class I or II. Patients with constriction due to radiotherapy have a higher mortality which may be due to radiation-induced myocardial injury. Other poor prognostic factors are renal failure, advanced age, pulmonary hypertension, hyponatremia, and reduced cardiac output.[34,37]

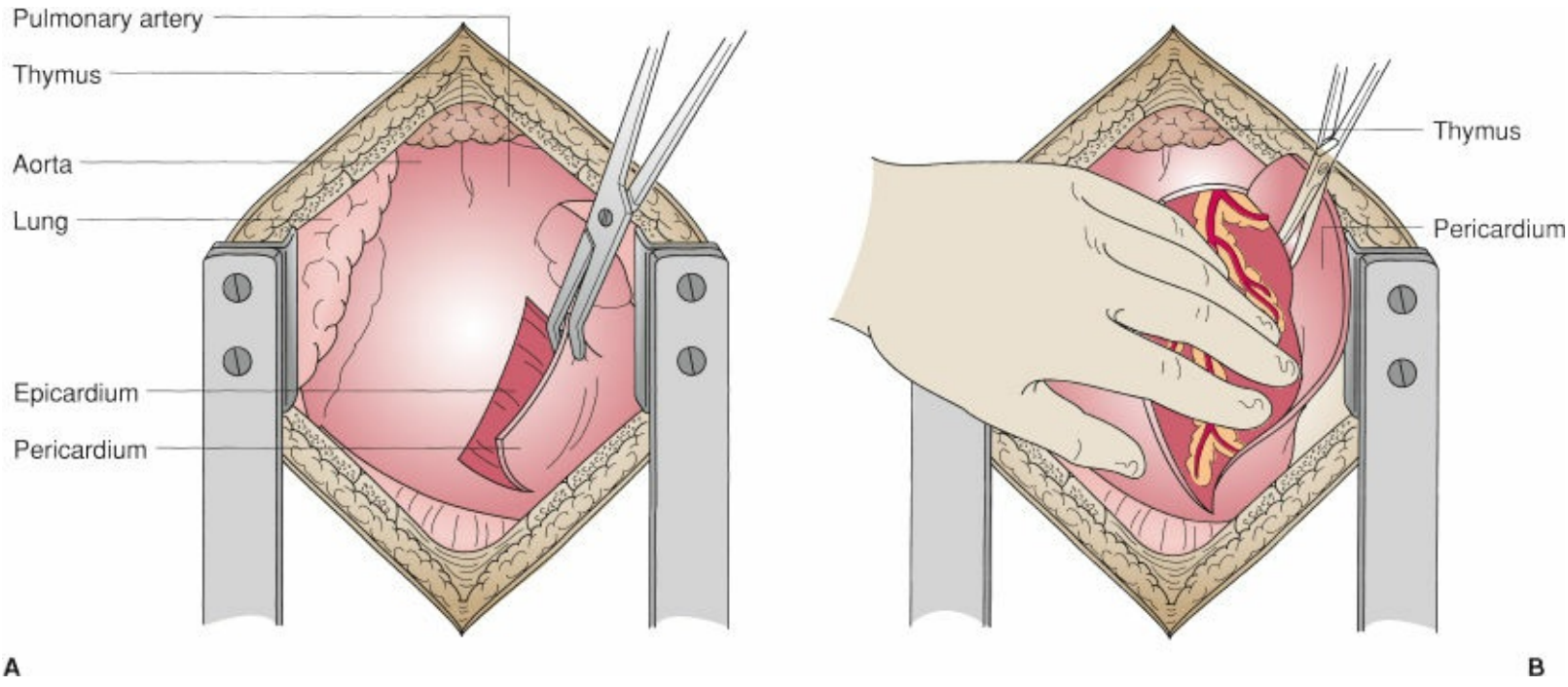

Figure 86-9. Pericardiectomy is most commonly approached through a median sternotomy. **A:** The pericardium is incised, and the fibrous pericardium dissected from the left ventricle. **B:** The heart is retracted to the right so that the pericardium can be resected from phrenic nerve to phrenic nerve.

References

1. Laennec R. *Traite d'Auscultationo oMedicale et des Maladies su Poumon et du Coeur.* Paris: Brosson & JS Chaude; 1819.
2. Beck C, Griswald RA. Pericardiectomy in the treatment of the Pick syndrome: experimental and clinical observations. *Arch Surg* 1930;21:1064.
3. Kussmaul A. Ueber schwielige Mediatino-perikarditis und dem Paradoxen Puls. *Berl Klin Wochenschr* 1873;10:433.
4. Karanaeff P. Paracentese des Brustkastens und des Pericardiums. *Med Z* 1840;9:251.
5. Rehn L. Zurexperimentellen pathologic des herzbeutels. *Verh Dtsch Ges Chir* 1913;42:339.
6. Sadler T. *Langman's Medical Embryology.* 7th ed. Baltimore, MD: Williams & Wilkins; 1995.
7. Gibson AT, Segal MB. A study of the composition of pericardial fluid with special reference to the probable mechanism of fluid formation. *J Physiol* 1978;277:367–377.
8. Spodick DH. Macrophysiology, microphysiology, and anatomy of the pericardium: a synopsis. *Am Heart J* 1992;124:1046–1051.
9. Moncada R, Kotler MN, Churchill RJ, et al. Multimodality approach to pericardial imaging. *Cardiovasc Clin* 1986;17:409–441.
10. Troughton RW, Asher CR, Klein AL. Pericarditis. *Lancet* 2004;363:717–727.
11. Brady WJ, Perron AD, Martin ML, et al. Cause of ST segment abnormality in ED chest pain patients. *Am J Emerg Med* 2001;19:25–28.
12. Imazio M, Demichelis B, Cecchi E, et al. Cardiac troponin I in acute pericarditis. *J Am Coll Cardiol* 2003;42:2144–2148.
13. Lange RA, Hillis LD. Clinical practice. Acute pericarditis. *N Engl J Med* 2004;351:2195–2202.
14. Heidenreich PA, Eisenberg MJ, Kee LL, et al. Pericardial effusion in AIDS. Incidence and survival. *Circulation* 1995;92:3229–3234.
15. Mayosi BM, Burgess LJ, Doubell AF. Tuberculous pericarditis. *Circulation* 2005;112:3608–3616.
16. Strang JI, Kakaza HH, Gibson DG, et al. Controlled clinical trial of complete open surgical drainage and of prednisolone in treatment of tuberculous pericardial effusion in Transkei. *Lancet* 1988;2:759–764.
17. Sagrista-Sauleda J, Barrabes JA, Permanyer-Miralda G, et al. Purulent pericarditis: review of a 20-year experience in a general hospital. *J Am Coll Cardiol* 1993;22:1661–1665.
18. Dressler W. A post-myocardial infarction syndrome; preliminary report of a complication resembling idiopathic, recurrent, benign pericarditis. *J Am Med Assoc* 1956;160:1379–1383.
19. Little WC, Freeman GL. Pericardial disease. *Circulation* 2006;113:1622–1632.

20. Maisch B, Seferovic PM, Ristic AD, et al. Guidelines on the diagnosis and management of pericardial diseases executive summary; the Task force on the diagnosis and management of pericardial diseases of the European society of cardiology. *Eur Heart J* 2004;25:587–610.
21. Ben-Horin S, Bank I, Guetta V, et al. Large symptomatic pericardial effusion as the presentation of unrecognized cancer: a study in 173 consecutive patients undergoing pericardiocentesis. *Medicine (Baltimore)* 2006;85:49–53.
22. Ditchey R, Engler R, LeWinter M, et al. The role of the right heart in acute cardiac tamponade in dogs. *Circ Res* 1981;48:701–710.
23. Beck C. Two cardiac compression triads. *JAMA* 1935;104:714.
24. Shabetai R, Fowler NO, Guntheroth WG. The hemodynamics of cardiac tamponade and constrictive pericarditis. *Am J Cardiol* 1970;26:480–489.
25. Talreja DR, Edwards WD, Danielson GK, et al. Constrictive pericarditis in 26 patients with histologically normal pericardial thickness. *Circulation* 2003;108:1852–1857.
26. Abdalla IA, Murray RD, Lee JC, et al. Does rapid volume loading during transesophageal echocardiography differentiate constrictive pericarditis from restrictive cardiomyopathy? *Echocardiography* 2002;19:125–134.
27. Hatle LK, Appleton CP, Popp RL. Differentiation of constrictive pericarditis and restrictive cardiomyopathy by Doppler echocardiography. *Circulation* 1989;79:357–370.
28. Ben-Horin S, Shinfeld A, Kachel E, et al. The composition of normal pericardial fluid and its implications for diagnosing pericardial effusions. *Am J Med* 2005;118:636–640.
29. Tsang TS, Enriquez-Sarano M, Freeman WK, et al. Consecutive 1127 therapeutic echocardiographically guided pericardiocenteses: clinical profile, practice patterns, and outcomes spanning 21 years. *Mayo Clin Proc* 2002;77:429–436.
30. Dantas CE, Sa MP, Bastos ES, et al. Pericardium closure after heart operations: a safety option? *Rev Bras Cir Cardiovasc* 2010;25:365–370.
31. Boyd WD, Johnson WE 3rd, Sultan PK, et al. Pericardial reconstruction using an extracellular matrix implant correlates with reduced risk of postoperative atrial fibrillation in coronary artery bypass surgery patients. *Heart Surg Forum* 2010;13:E311–E316.
32. Kobayashi H, Nomori H, Mori T, et al. Extrapleural pneumonectomy with reconstruction of diaphragm and pericardium using autologous materials. *Ann Thorac Surg* 2009;87:1630–1632.
33. Byrne JG, Karavas AN, Colson YL, et al. Cardiac decortication (epicardiectomy) for occult constrictive cardiac physiology after left extrapleural pneumonectomy. *Chest* 2002;122:2256–2259.
34. Ling LH, Oh JK, Schaff HV, et al. Constrictive pericarditis in the modern era: evolving clinical spectrum and impact on outcome after pericardiectomy. *Circulation*

1999;100:1380–1386.
35. Seifert FC, Miller DC, Oesterle SN, et al. Surgical treatment of constrictive pericarditis: analysis of outcome and diagnostic error. *Circulation* 1985;72:II264–II273.
36. McCaughan BC, Schaff HV, Piehler JM, et al. Early and late results of pericardiectomy for constrictive pericarditis. *J Thorac Cardiovasc Surg* 1985;89:340–350.
37. Bertog SC, Thambidorai SK, Parakh K, et al. Constrictive pericarditis: etiology and cause-specific survival after pericardiectomy. *J Am Coll Cardiol* 2004;43:1445–1452.

Chapter 87

Vascular Diagnostics: The Noninvasive Vascular Laboratory

Gregory L. Moneta

Key Points

1 Duplex ultrasound consists of a combination of gray-scale imaging and pulse Doppler. Because the speed of sound is relatively constant in tissue, with a pulse Doppler it can be determined when an echo is generated and when it is received. This provides range resolution enabling the operator of the duplex machine to precisely sample and interrogate blood flow at a known location.

2 When a sound wave encounters moving reflectors, such as red blood cells, the frequency of the reflected wave changes from that of the original wave generated by the transducer. This relationship is reflected in the Doppler equation: $f_r - f_o = [(2f_o v)/c] \cos \theta$, Where f_r is the received frequency, f_o is the originating frequency, v is the velocity of the reflector, c is the speed of sound in tissue, and θ is the angle of the incident sound beam with the moving reflectors, the so-called Doppler angle.

3 Arterial Doppler waveforms reflect the resistance of the circulation supplied by the artery being examined. Low resistance circulations such as cerebral and renal circulations have relatively high amounts of diastolic flow whereas high-resistance circulations, such as extremity arteries have little flow at the end of diastole.

4 Carotid stenosis is determined primarily from measurement of peak systolic velocity (PSV) and end-diastolic velocity (EDV) from pulse Doppler waveforms using criteria agreed upon in a national consensus conference.

5 Air plethysmography can be used to display pulse volume waveforms. Pulse volume recordings (PVRs) are obtained with partially inflated blood pressure cuffs that detect volume changes sequentially down a limb. Volume changes beneath the cuffs resulting from the pulse wave result in small pressure changes within the cuffs. These changes are displayed as arterial waveforms with the use of appropriate transducers and provide an overall measure of the arterial circulation in an extremity.

6 The ankle brachial index (ABI) is determined by dividing the higher ipsilateral dorsal pedal or posterior tibial artery pressure by the higher of the two brachial artery systolic pressures and is highly sensitive and specific for documenting the presence or absence of lower extremity arterial occlusive disease.

7 Measurement of ankle pressures after exercise can be used to confirm arterial disease

as an etiology for exercise-associated leg pain. Failure of the ankle pressure to drop with exercise along with failure of the ABI to decrease 20% with exercise, combined with a normal resting ABI, substantially rules out arterial insufficiency as an etiology of exercise-induced complaints of leg pain.

8 Duplex ultrasound can detect hemodynamically significant stenosis in abdominal arteries: a PSV in the superior mesenteric artery (SMA) of 275 cm/s or more indicates a $\geq$70% SMA stenosis, a celiac artery PSV of $\geq$200 cm/s indicates a $\geq$70% celiac artery stenosis whereas a ratio of the PSV in a renal artery to that in the aorta (renal–aortic ratio, RAR) of $\geq$3.5 indicates a $\geq$60% diameter-reducing renal artery stenosis.

9 The primary ultrasound diagnostic criterion for diagnosis of venous thrombosis is failure of the vein to collapse with application of pressure with the ultrasound probe.

10 In the upright position, venous reflux stimulated by cuff deflation that lasts $>$0.5 to 1 second is indicative of pathologic venous reflux.

The noninvasive vascular laboratory provides accurate, safe, and objective evidence of the presence and physiologic significance of vascular disease throughout the body. Two broad categories of testing are available in the noninvasive vascular laboratory; those based on plethysmographic techniques, and those based on ultrasound-based techniques.

PLETHYSMOGRAPHY

Plethysmographic techniques detect volume changes in limbs that occur in response to arterial and venous disease. The technology can be modified to determine digital pressures and produce pulse waveforms. Examples of plethysmographic techniques include mercury strain gauge plethysmography, air plethysmography (pulse volume recordings [PVRs]), and photoplethysmography.

ULTRASOUND

Ultrasound techniques, in particular duplex ultrasound-based technique, have largely eclipsed plethysmographic techniques. Duplex ultrasound, introduced in 1974, was first applied to carotid arteries. The technique combines information from ultrasound-generated images (B-mode) and Doppler analysis of blood flow direction and velocity, hence the term “duplex.” Duplex ultrasound is currently extensively employed for evaluation of carotid arteries, intra-abdominal arteries and veins and upper and lower extremity arteries and veins. Since inception duplex ultrasound has advanced through: (1) improved B-mode imaging, (2) better low-frequency scan heads permitting deeper penetration of the ultrasound beam from the skin surface, (3) improvements in online computer-based microprocessor software, and (4) perhaps, most importantly, the addition of color flow to the B-mode image.

Color flow superimposes a real-time color image of blood flow onto a standard gray-scale B-mode picture. Returning echoes from stationary tissues generate the B-mode image, whereas those interacting with moving substances (blood) generate a significant enough phase shift that they can be processed separately and color-coded by operator selection to give information on direction and velocity of blood flow according to the magnitude and direction of the Doppler frequency shift. It is color flow, combined with the ability of the current generation of duplex scanners to detect very low blood flow velocities (<5 cm/s), which makes duplex scanning practical on a routine basis throughout the body. Color flow permits more rapid identification of vessels to be examined and is essential for duplex examination of some vessels such as tibial arteries and veins.

BASICS OF DUPLEX ULTRASOUND

An ultrasonic wave is produced in tissue by placing a vibrating source in contact with the tissue. In medical ultrasound the vibrating source is the ultrasound *transducer* contained within the ultrasound *scan head.* The scan head steers and focuses the sound beam arising from the transducer, functions crucial in deriving an ultrasound image from returning echoes.

Ultrasound transducers convert electrical energy into vibrational energy and, conversely, turn vibrational energy of returning echoes into electrical signals that can be analyzed by the software of the duplex machine. The design of the transducer determines the frequency of the vibrations which in turn determines the wavelength of the sound wave produced. The relationship between frequency and wavelength is expressed mathematically as follows:

$$\lambda = c/f \qquad (87\text{-}1)$$

Where λ is the wavelength, c is the speed of sound in tissue and f is the incident frequency.

The speed of sound in soft tissues averages 1,540 m/s and varies only minimally from this average in soft tissues insonated in clinical applications of duplex ultrasound. The wavelength of the sound beam is the primary determinant of how well the ultrasound beam penetrates the tissue. Because the speed of sound within the tissue is, for all practical purposes, constant (1,540 m/s), the ability of ultrasound to penetrate tissue depends on the frequency of the vibrating source (transducer). As noted above, transducer frequency is determined by the design of the transducer and is thus controlled by the manufacturer of the duplex device. For examination of the carotid artery, transducer frequencies of 5 to 7.5 MHz provide optimal tissue penetration for clinical purposes.

As noted above the term duplex refers to the combination of Doppler and B-mode ("B" stands for "brightness") ultrasound in the same device. Both types of ultrasound require analysis of reflected echoes of the original sound beam initially created by placing the ultrasound transducer in contact with the tissue. The B-mode component of the duplex machine analyzes the *strength* (intensity) and *origin* of the reflected echo. The Doppler component analyzes *shifts* in frequency of the original sound wave produced by the transducer that result when the ultrasonic wave encounters moving reflectors.

B-Mode Ultrasound

As a sound wave passes through tissue, its strength moving away from the transducer depends upon the degree to which the beam is attenuated, scattered, and reflected. The strength of the reflected echo depends in part, upon relative differences in acoustic impedance between two different media. Major differences in acoustic impedance result in reflection of a large proportion of the sound beam back to the transducer, whereas small differences result in comparatively little reflection and continued propagation of the beam through the tissue.

In B-mode ultrasound, the strength of the returning echo is reflected in the brightness of the individual pixels comprising the ultrasound image. This is the ultrasound *grayscale* and the resulting image is termed a *grayscale image*. (As we will see below, the primary purpose of the grayscale image in duplex ultrasonography is to aid in properly positioning the Doppler sample volume.)

Very bright pixels represent sites of large differences in acoustic impedance between media, whereas less dramatic differences are represented by proportionally less bright pixels on the B-mode image. Thus gallstones, which differ dramatically in acoustic properties from soft tissue, result in strong echoes and proportionally brighter pixels on an ultrasound image, whereas blood, which differs little from soft tissue in acoustic characteristics, frequently cannot be distinguished from soft tissue in a grayscale image.

The strength of the reflected echo will also be dependent upon the strength of the sound beam at the point of its reflection. Grayscale images do not show the percentage of the beam reflected, but rather represent the absolute strength of the reflected echo arriving back at the transducer. Thus if the sound beam is very weak at the site of its reflection, even areas of significant differences in acoustic impedance will not result in a bright pixel on the ultrasound image.

The strength of the ultrasound beam at any point also depends on the degree to which the beam has been attenuated as it passes through the tissue. Attenuation of a sound wave as it traverses tissue weakens the wave and depends upon the tissue traversed and the frequency of the wave. The frequency of the wave depends upon the frequency of the transducer used to generate the wave (see discussion above and Equation 87-1). Sound waves resulting from higher-frequency transducers are attenuated more rapidly than those produced with lower-frequency transducers. Higher-frequency transducers therefore provide relatively weak echoes to be reflected from a deep structure and thus a comparatively poor B-mode image compared to a lower frequency transducer.

The linear resolution of an ultrasound image depends upon the ability to focus the beam. Sound beams emanating from high-frequency transducers can be more precisely focused than those from low-frequency transducers and thus provide clearer B-mode images of more superficial structures. Because the carotid artery is superficial, higher-frequency transducers can be used to provide much clearer B-mode images than is possible with deeper vessels such as the aorta, renal, or iliac arteries.

Doppler Ultrasound

In a continuous wave Doppler, a transducer continually emits vibrations into the tissue. Echoes are therefore continually reflected back to the transducer. A transducer cannot, however, simultaneously generate and receive an echo. Continuous wave Doppler therefore must have separate transmitters and receivers to both generate and receive echoes.

1 Duplex devices utilize pulse Doppler. A pulse Doppler uses the same transducer to generate and receive echoes. Because the speed of sound is relatively constant in tissue, with a pulse Doppler it can be determined when an echo is generated and when it is received and therefore it is possible to calculate the depth in the tissue where a reflected echo originated. The *sample volume* of the duplex device is thus determined by specifying from what depth one wishes the pulse Doppler to receive reflected echoes.

The transducer is *gated,* based on the total time from original sound-wave generation to arrival of the reflected echo back at the transducer, to only receive echoes from the specified depth of the sample volume. The desired "position" of the sample volume is determined by the operator of the duplex device from the B-mode image, and in duplex examination of arterial and venous flow corresponds to particular points within the lumen of the vessel examined. Because B-mode images and Doppler waveforms cannot be generated simultaneously, the technologist must continually update the B-mode image during the course of the examination to insure proper placement of the sample volume.

2 When a sound wave encounters moving reflectors, such as red blood cells, so-called Rayleigh scatters, within the lumen of an artery or vein, the frequency of the reflected wave changes from that of the original wave generated by the transducer. Velocity is a vector with both speed and direction therefore, the magnitude of the frequency shift depends upon the velocity of the moving reflectors and their angle with the incident sound beam. Because the frequency of the original sound wave is known, and the frequency of the received echo can be determined by the software of the duplex machine, the velocity of the moving reflectors (red blood cells) can be calculated provided the angle of the incident sound beam with the moving reflectors is also known. This relationship is reflected in the *Doppler equation:*

$$f_r - f_o = [(2f_o v)/c] \cos \theta \qquad (87\text{-}2)$$

Where f_r is the received frequency, f_o is the originating frequency, v is the velocity of the reflector, c is the speed of sound in tissue, and θ is the angle of the incident sound beam with the moving reflectors, the so-called *Doppler angle.*

A Doppler angle of 0 degrees is ideal for velocity calculations as the cosign of 0 is 1 and measured reflected velocity changes are therefore 100% of what actually occurred. However 0-degree Doppler angles are difficult to obtain as it is not generally possible to look directly down the lumen of a vessel from a percutaneous approach. Therefore to solve the Doppler equation for the velocity of the moving reflectors, the Doppler angle must be known. To standardize the results of duplex scanning, it has been traditionally recommended that examinations be conducted as close as possible to a Doppler angle of

60 degrees. The cosign of 60 is 0.5, therefore at this angle the measured reflected velocity is half the actual reflected velocity. Errors in velocity calculations secondary to misreading of the Doppler angle are small as a percentage of the true velocity at ≤ 60 degrees as cosigns vary comparatively little with incremental changes in angle below 60 degrees. When the Doppler angle approaches 70 degrees, changes in the cosign of the angle become more pronounced with incremental increases in angle, and errors in velocity calculations secondary to improper angle measurement become much more significant. Small errors in determining the Doppler angle when the angle of insonation is <60 degrees have little overall impact on the calculation of the velocity of the moving red cells. Indeed, Doppler angles from 45 to 60 degrees are acceptable for most clinical studies. Most often an angle of 60 degrees can be easily obtained in carotid artery and extremity artery duplex examinations and, in line with traditional teaching, 60 degrees is chosen whenever possible as the Doppler angle in such studies. In examination of intra-abdominal vessels it may be much more difficult to adhere to a 60-degree angle.

As noted above, pulse Doppler both transmits and receives echoes with the same transducer. This dual function places limits on the frequencies that can be displayed in the spectral waveform. The maximum frequency that can be displayed is half the pulse-transmitting frequency or pulse-repetition frequency (PRF), and is known as the *Nyquist limit*. If frequencies are encountered that exceed the Nyquist limit, they are flipped and appear on the reverse-flow side of the spectrum. This is termed *aliasing*. If aliasing is encountered, the PRF should be increased to increase the Nyquist limit. The PRF can be adjusted by changing the scale displayed on the right side of the spectral waveform or by adjusting the baseline. If aliasing still occurs, the operator should consider switching to a lower frequency transducer or to the use of a continuous-wave Doppler. A continuous-wave Doppler is not affected by aliasing.

Color Flow

A color flow image is produced by assigning color to Doppler shifts. Returning echoes that are not Doppler shifted are shown in grayscale. The net result is what appears to be color pasted or superimposed on a grayscale image. This pasting process can in effect obscure the edges of the grayscale image resulting in obfuscation of the true lumen of the grayscale image limiting somewhat the accuracy of color images to define stenosis. The hue and intensity of the color are determined by the direction and magnitude of the Doppler shifts. The technologist can adjust the color settings as desired. Varying shades of red and blue are generally used to distinguish flow toward or away from the transducer. By convention, red is most often assigned to arterial flow and blue to venous flow.

When the Doppler angle is 90 degrees, there is no Doppler shift. When this occurs, the assigned color is black and corresponds to the horizontal black bar serving as the baseline on the color scale that appears on the right side of a color flow image (Fig. 87-1). Aliasing can be readily recognized on a color flow image as a mosaic pattern or as a transition from red-to-blue or blue-to-red without an intervening black line. In areas of actual reverse flow, the blue and red colors are separated by a black border. Just as with pulsed Doppler, color aliasing can be reduced by increasing the PRF. This is often quite important, as an extensive mosaic pattern can obscure clear visualization of a stenotic site.

Power Doppler is a variant of color Doppler. Power Doppler, however, assigns no direction of flow to the color image and velocity information is not calculated. Any detected Doppler shift is colorized without consideration of the direction of the Doppler shift or the magnitude of the Doppler shift. It is therefore not subject to aliasing or affected by Doppler angle. Its principle utility lies in the ability to detect blood moving at very low velocity and in outlining the course of tortuous vessels. It can be quite useful in detecting flow in small distal veins and flow in arteries distal to a very high-grade stenosis.

It is tempting to try a direct estimate of the severity of a stenosis from the color flow image. However as discussed above such estimates are probably less accurate than measurements of stenosis derived from spectral analysis. Color serves primarily as a guide in locating the vessels and selecting specific sites for examination with the pulse Doppler. The absence of color can indicate extensive mural calcification and difficulty in obtaining a pulse Doppler waveform.

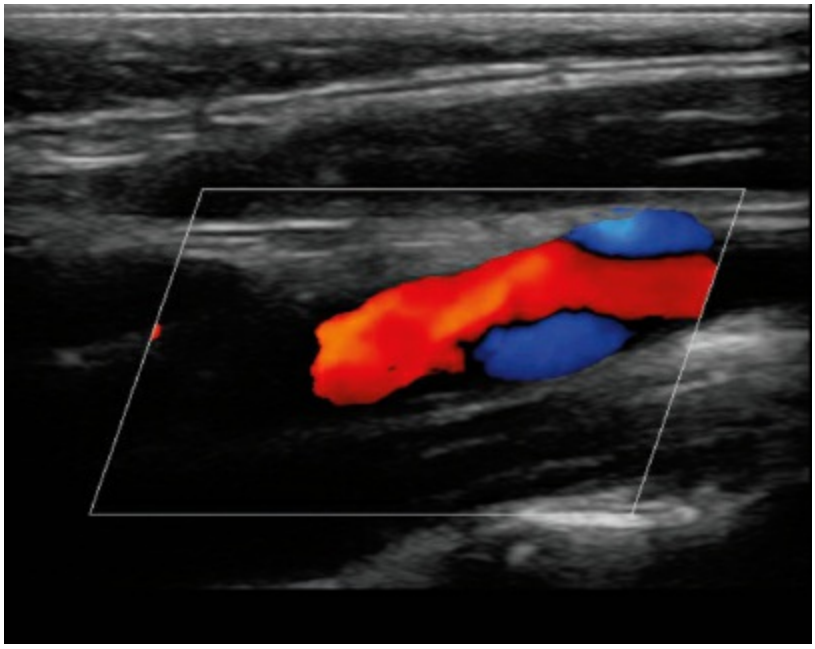

Figure 87-1. Flow separation with reverse flow along the wall of the carotid bulb as indicated by direct transition from blue to red with an intervening black line is a normal finding and indicates an artery without significant plaque.

Carotid and Vertebral Arteries

The vascular laboratory began with assessing internal carotid artery (ICA) stenosis. Doppler diagnosis of ICA stenosis, and arterial stenosis in general is based on duplex ultrasound and focuses on three areas, the prestenotic region, the stenosis itself and the poststenotic region. Detecting carotid stenosis involves a combination of spectral analysis, color and grayscale imaging and, in selected cases, power Doppler. The primary interest is in the detection of increased flow velocities within the area of suspected stenosis and therefore in most cases spectral analysis dominates in the detection of carotid stenosis. The exception is in distinguishing ICA occlusion from a very high-grade stenosis where color flow or power Doppler flow can identify very low flow in the area of the stenosis or distal to the stenosis that may not be detected by pulse Doppler.

In all cases, the pulsed Doppler and color flow findings should be crosschecked for concordance. If there is disagreement between the impression obtained with color and pulsed Doppler examinations (i.e., color Doppler suggests high-grade stenosis but velocities are only moderately elevated), the findings of both should be reviewed to resolve the discrepancy.

Common Carotid Artery (CCA) Waveforms

3 In the majority of cases, carotid stenosis or occlusion occurs in the proximal ICA at or just beyond the carotid bifurcation. A normal ICA waveform reflects the low resistance of the cerebral circulation with high flow at the end of the diastolic component of the waveform. In the presence of a distal ICA occlusion resistance to flow increases and there is decreased flow in diastole (Fig. 87-2A,B). The external carotid artery (ECA) supplies the relatively higher-resistance circulation of the scalp and face and therefore has a low-end diastolic flow component (Fig. 87-2C). The common carotid artery waveform reflects the fact that normally 80% of CCA flow is directed to the ICA. CCA end-diastolic flow is therefore generally well above baseline and exceeds ECA diastolic flow (Fig. 87-2D). In the presence of a very high-grade ICA stenosis or ICA occlusion, outflow is primarily through the higher-resistance external carotid circulation. The CCA waveform then takes on the high-flow resistance characteristics of an ECA, with flow to zero, or nearly zero, in end diastole (Fig. 87-3).[1] In addition, the PSV and the overall flow velocity may be substantially lower than normal because of reduced carotid artery flow. By observing these changes in the CCA, one can reliably predict the presence of high-grade stenosis or occlusion of the ICA.

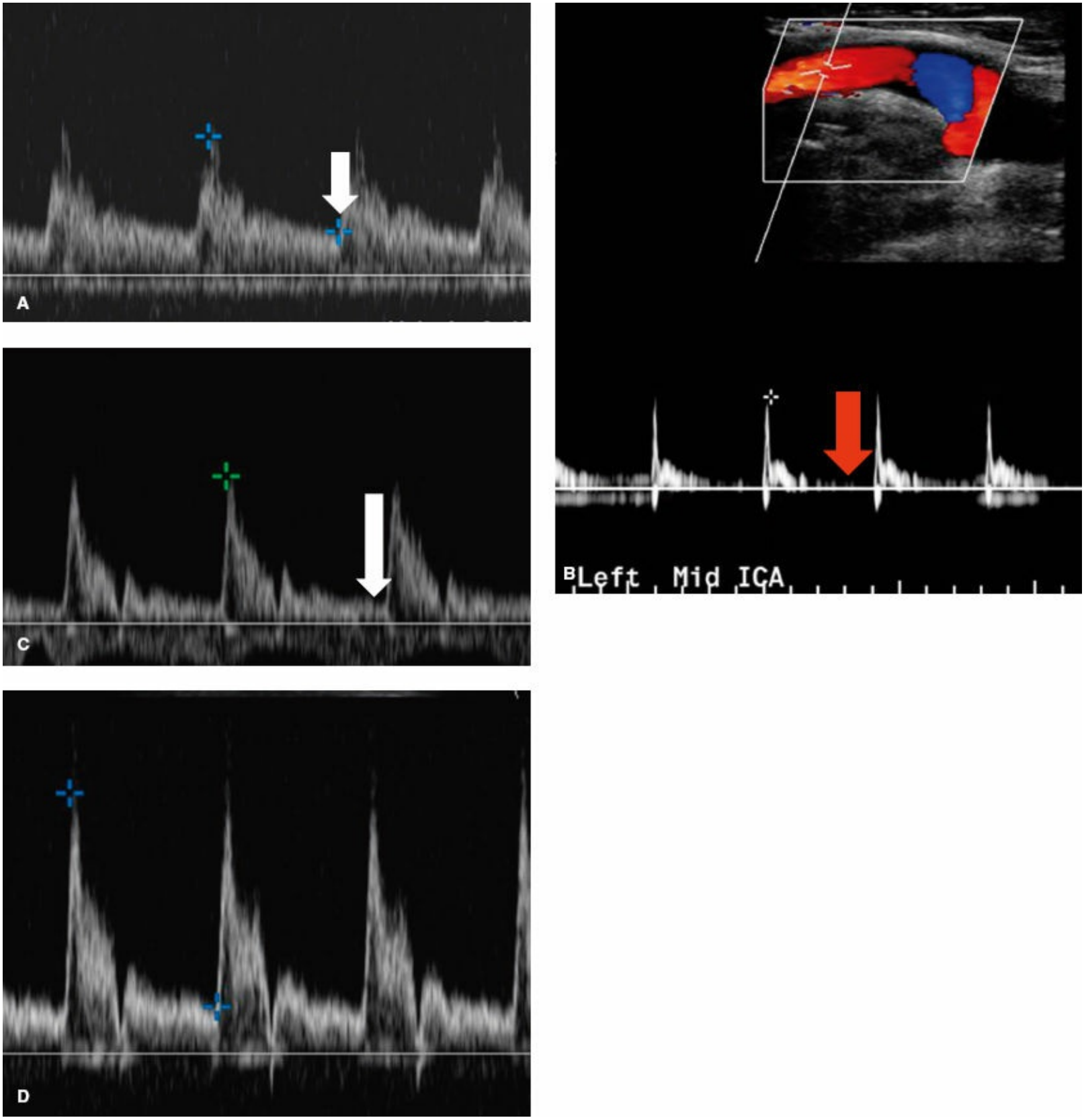

Figure 87-2. **A:** A normal internal carotid artery (ICA) waveform with high diastolic flow (*white arrow*) reflecting the low resistance of the cerebral circulation. **B:** Absence of ICA diastolic flow (*red arrow*) indicates more distal occlusion or severe stenosis of the extracranial or intracranial ICA. **C:** Normal external carotid artery waveform. The external carotid artery has low diastolic flow reflecting the high resistance circulation of the scalp and face. **D:** Normal common carotid artery waveform. The common carotid artery waveform has diastolic flow well above the baseline as the majority of flow is directed to the low resistance internal carotid artery circulation.

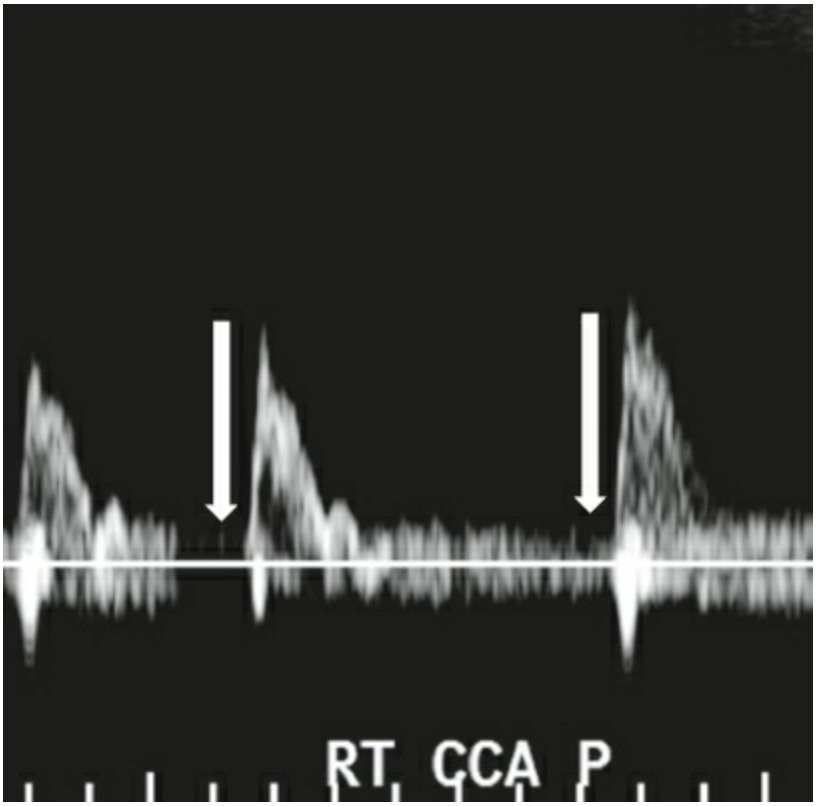

Figure 87-3. In a patient with internal carotid occlusion common carotid artery (CCA) diastolic flow approaches 0 (*arrows*) as CCA flow is now routed to the high resistance external carotid circulation.

The CCA *contralateral* to an ICA stenosis or occlusion may demonstrate an increased flow velocity with particular elevation of the velocity at the end of diastole; the so-called end-diastolic velocity (EDV). These changes represent a compensatory increase in blood flow volume in the nonobstructed ICA in response to reduced contribution to cerebral perfusion from the opposite high-grade stenotic or occluded ICA. This compensatory hemodynamic change can be substantial and flow velocities may be artificially elevated on the side with compensatory high-volume flow giving a false impression of the presence of a stenosis or a higher degree of stenosis than is actually present.[2]

In the presence of a significant stenosis at the origin of a CCA or the inominate artery, the ipsilateral CCA waveform may be dampened, with low overall peak systolic velocities (PSVs) and EDVs and a slower rise to peak systole when compared with the contralateral CCA waveform and potentially reverse flow in the ICA (Fig. 87-4A,B). The CCA flow changes seen with proximal stenosis are also important in the diagnosis of ICA stenosis because the overall reduction in flow velocity may artificially lower velocities in an ipsilateral ICA stenosis, leading to underestimation of the severity of ICA stenosis. In some cases of proximal CCA or innominate artery stenosis, the stenotic lesion may not be accessible to direct insonation by the duplex scanner. In such cases, a stenotic lesion can be suspected as the ipsilateral CCA waveform will often exhibit poststenotic turbulence low in the neck, reflecting disturbed flow distal to the more proximal stenosis.

ICA Waveforms

As noted above, the normal ICA spectral waveform is indicative of high flow in a low-resistant circulation. The systolic upstroke is rapid, PSV is <125 cm/s, and flow is maintained throughout diastole (Fig. 87-2A).[3] In the absence of plaque there is generally a clear spectral window under the outline of the spectral waveform as there is little turbulent flow. The presence of color shifts, indicating high-velocity flow, and color mosaics, indicating poststenotic turbulence, aids in selecting potential areas for examination with the pulsed Doppler.

Hemodynamic quantification of the severity of ICA stenosis is primarily achieved by analysis of Doppler spectral waveforms and measurements of peak systolic and EDV or comparison of PSVs in the ICA to those in the CCA just proximal to the carotid bifurcation, ICA/CCA ratio. As a stenosis develops, the PSV first becomes elevated. PSV is the primary measure of stenosis severity. EDV lags behind, relatively speaking, as stenosis severity progresses but rises rapidly as the stenosis becomes severe (diameter reductions of ≥60%). Thus, elevation of EDV is a good marker for high-grade stenosis (Fig. 87-5).[4] The ICA/CCA ratio is also a very important measure of stenosis severity.[5] Because it is a ratio, it compensates for abnormally high- and low-flow states that may skew the PSV and EDV upward or downward.

To accurately measure flow velocity, the sample volume must be placed within the area of greatest stenosis. Color flow imaging has demonstrated that the orientation of the stenotic jet within a stenosis is frequently not along the longitudinal axis of the vessel. This finding has resulted in controversy with regard to the proper technique of obtaining velocity waveforms at sites of stenosis. In areas of mild to moderate stenosis, use of a Doppler angle of 60 degrees to the long axis of the vessel is recommended. However, in areas of more severe stenosis and/or wall abnormalities, the Doppler angle of 60 degrees should be defined by the long axis of the stenotic flow jet, as demonstrated by color flow.

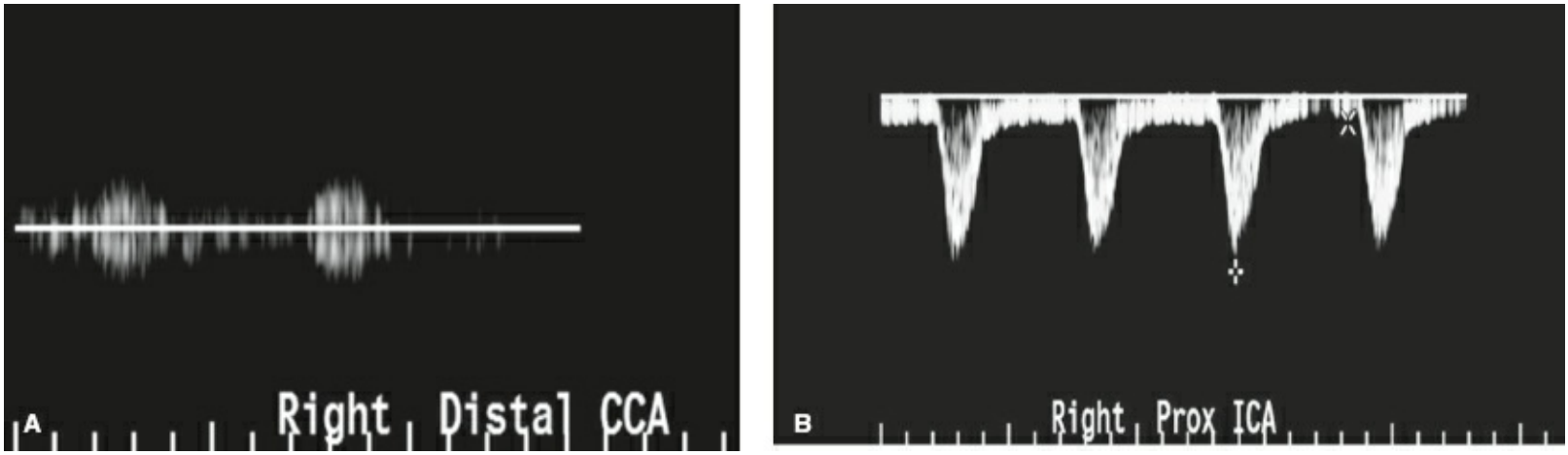

Figure 87-4. A and B: In the presence of innominate artery very high-grade stenosis or occlusion the common carotid artery (CCA) waveform will be blunted with a decreased amplitude and slowed upstroke **(A),** and there can be actually reverse flow **(B)** in the ipsilateral internal carotid artery (ICA).

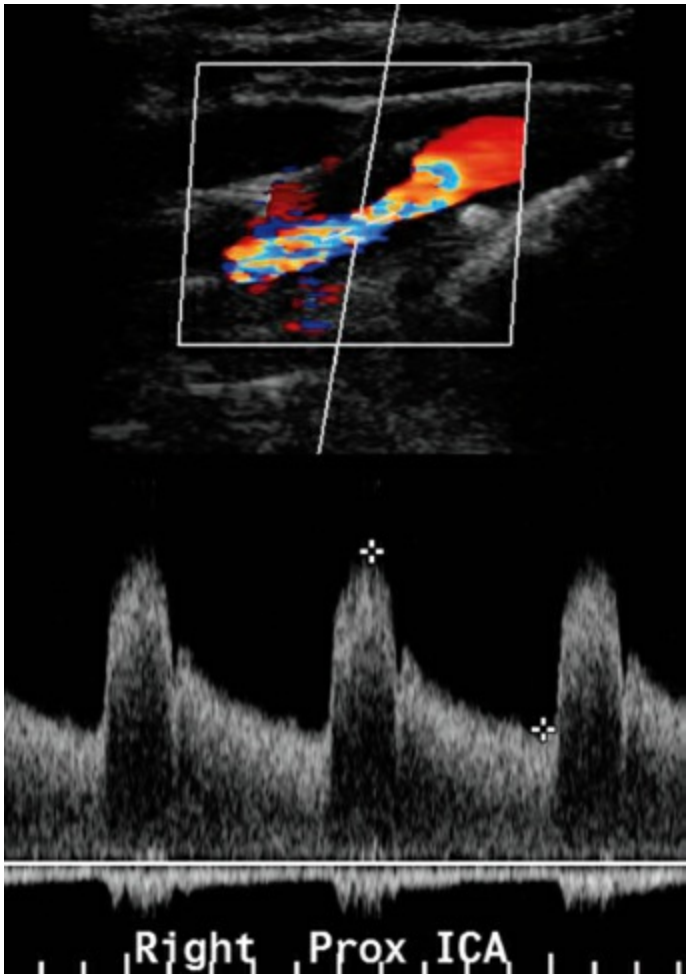

Figure 87-5. Internal carotid artery (ICA) waveform from the site of a >80% ICA stenosis. Both peak systolic and end-diastolic velocities are very elevated.

The sample volume size should be kept as small as possible, usually 1.5 mm, to detect discrete changes in flow velocity. This is important as the highest velocities may be localized to a small area in the flow stream that emanates from the stenosis. A large sample volume that incorporates flow from many points within the vessel in the generation of the spectral waveform may give the false impression of disturbed flow, potentially leading to the misdiagnosis of moderate disease in an otherwise normal vessel. In practice, the sonographer, having identified the stenosis, gently moves a small sample volume around until the point of highest velocity is found.

Damping of spectral Doppler waveforms may be seen in the region distal to the carotid stenosis when the lesion is severe enough to be flow reducing. The most common abnormality seen distal to a carotid stenosis is spectral broadening caused by disturbed blood flow or turbulence. At best, poststenotic flow disturbance is a qualitative measure of arterial stenosis; nevertheless, its detection is important. With proper gain settings, "fill-in" of the Doppler spectral waveform generally indicates the presence of carotid stenosis with diameter reduction of at least 50%. However, this level of disturbed flow occasionally can be seen with nonstenotic disease. Diagnostically, the most significant poststenotic flow disturbance produces a simultaneous forward and reverse spectral Doppler signal, accompanied by poor definition of the upper spectral border. Such disturbed flow implies the presence of severe carotid stenosis. Severely disturbed flow

distal to a highly calcified plaque may be the only substantial evidence for the presence of clinically significant stenosis if calcification prevents direct insonation of the stenosis.

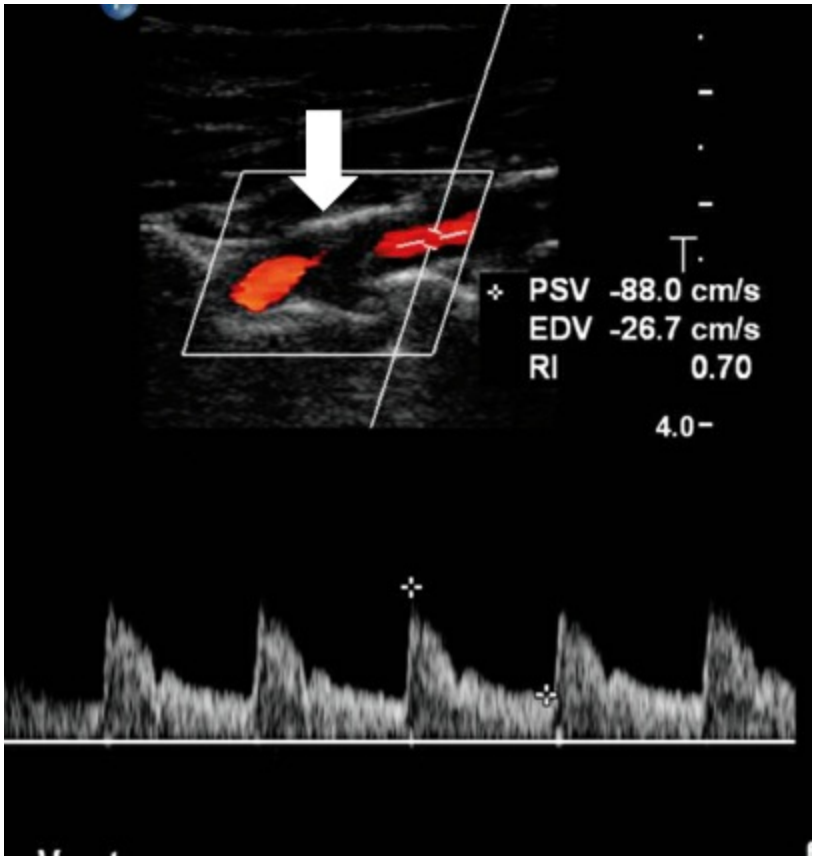

Figure 87-6. Bony landmarks of the vertebral bodies (*arrow*) mark the course of the vertebral artery.

Vertebral Artery

On rare occasions, a stenosis may be found in the cervical portion of the vertebral artery associated with cervical osteoarthritis. However, the origin of the vertebral artery from the subclavian artery is by far the most common site of disease in the vertebral artery. The vertebral artery origin lies deep in the base of the neck and may be difficult to access with ultrasound. Mean vertebral artery diameter is about 4 mm but the vertebral arteries are frequently asymmetric in size with one, most commonly the left, being larger than the right.

The vertebral artery is most commonly interrogated with ultrasound further distally in the neck, from an anteroposterior window, as it threads through the transverse processes of the cervical spine. The vertebral bodies serve as a reference to insure the vertebral artery is actually under examination (Fig. 87-6). The artery is usually seen deeper but adjacent to the vertebral vein. Color Doppler is helpful to locate the vessel. A spectral waveform from the vertebral artery in the mid-neck provides information about direction of flow, waveform shape, and velocity but does not rule out disease at the origin. The normal vertebral artery waveform is similar to that of the ICA with normal PSVs reported to be 20 to 40 cm/s.[6] Velocities up to 80 cm/s are, however, frequently seen without apparent clinical importance and may represent collateral flow through a dominant vertebral artery, or a small but disease-free, vertebral artery. Evaluation of disturbed flow distally may help determine which elevated velocities are associated with a vertebral artery stenosis and which are not. Velocity patterns are usually similar in the two vertebral arteries but systolic and diastolic velocities may differ if vertebral artery diameters are asymmetric. For this reason if there is concern for stenosis based on an elevated peak systolic velocity (PSV) in a vertebral artery, recording of vertebral artery diameters is important.

Flow in the vertebral artery is normally antegrade with a rapid upstroke and continuous diastolic flow. In cases of anatomic subclavian steal, color flow provides an important initial clue to the diagnosis as flow in the artery will be retrograde in the same direction as the vein. Spectral Doppler must still be used to verify arterial flow and will demonstrate reverse or bidirectional flow in cases of subclavian steal. Depending on the degree of subclavian stenosis the vertebral artery flow may be reversed or biphasic, with flow above and below the baseline (Fig. 87-7A,B). End-diastolic flow will be zero or near zero reflecting the high resistance of the peripheral arm circulation rather than low-resistance cerebral circulation. High-resistance vertebral artery flow may also be seen with antegrade flow and like the situation for the ICA may represent distal stenosis or occlusion of the vertebral artery or an atretic or hypoplastic distal vessel.

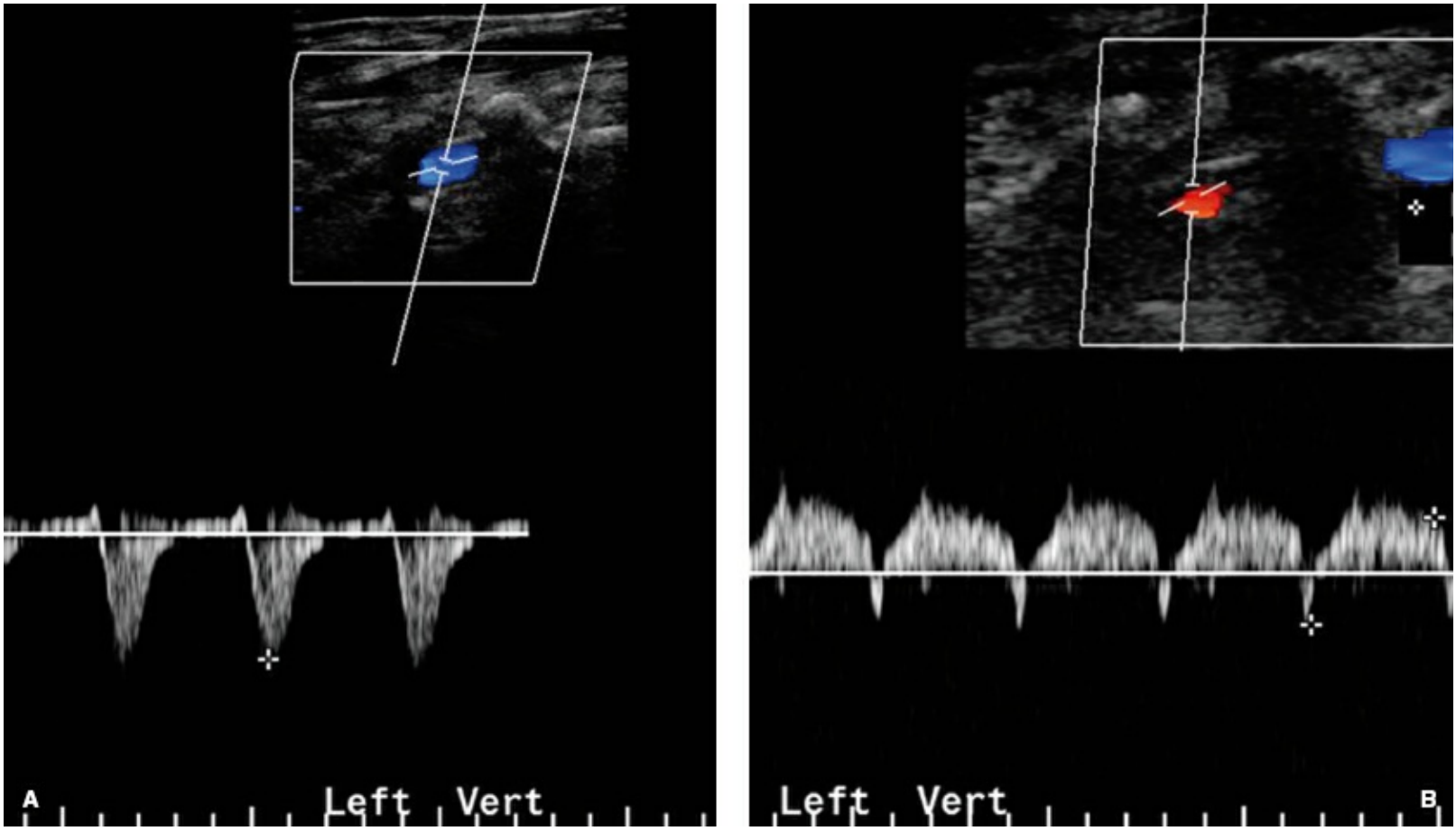

Figure 87-7. A and B: Both reverse vertebral artery flow **(A),** and vertebral flow both above and below the baseline **(B)** indicate a proximal innominate or subclavian artery stenosis.

External Carotid Artery

The ECA is smaller in diameter than the ICA at the level of the carotid bulb but similar in diameter beyond the bulb. It has little clinical significance in most cases but can serve as an important source of collateral flow to the brain in cases of ICA very high-grade stenosis, or occlusion. The ECA may also serve in such cases as a conduit for emboli to the brain; the so-called carotid stump syndrome.[7]

The ECA waveform has a sharp upstroke, a prominent dichroitic wave in late systole or early diastole, and velocity that is near or at the zero base line in end-diastole. The PSV of the ECA is normally higher than the ICA. The ECA may adopt the characteristics of the ICA in end-diastole as the resistance in the face and scalp decreases with temperature change and/or in the presence of disease. In cases of common carotid occlusion with preservation of patency of the carotid bulb, reverse flow in the ECA can provide antegrade flow in the ICA maintaining patency of the ICA even with CCA occlusion.

Classifying Carotid Stenosis

Duplex criteria for quantifying carotid artery stenosis were developed by comparing duplex-derived spectral waveforms and contrast arteriograms. Duplex-derived *categories* of stenosis are relatively broad. Sensitivities and specificities for spectral analysis of duplex-derived waveforms for detecting an ICA stenosis of >50% to 99% are between 90% and 95%. There are numerous spectral criteria for classifying ICA stenosis. Some focus on *categories* of stenosis, whereas others focus on *threshold levels* of stenosis.

One of the most widely accepted classification schemes for categories for ICA stenosis was developed at the University of Washington under the direction of Dr. Eugene Strandness. These criteria were useful in the study of the natural history of carotid atherosclerosis and in clinical practice. In the University of Washington system, velocity waveform analysis and spectral criteria were used to classify ICA angiographic stenosis as normal, 1% to 15%, 16% to 49%, 50% to 79%, and 80% to 99% stenosis and occlusion. Prospective validation of these criteria has demonstrated an overall agreement of 82% with contrast angiography. The ability of the criteria to detect carotid disease is 99% sensitive and the ability of the criteria to recognize normal arteries is 84% specific.[3]

Criteria for detecting carotid artery stenosis scanning have undergone reevaluation to remain relevant to current clinical practice. This reevaluation was stimulated by the randomized trials testing the efficacy of carotid endarterectomy (CEA) that took place over the last two decades (Table 87-1).[8–12] The trials had a profound impact on validating the indications for CEA in patients with carotid bifurcation atherosclerosis. The trials identified significant benefit, in terms of stroke reduction, for CEA in patients with specific levels of ICA stenosis. In particular, patients with symptomatic ICA stenosis >70% to 99% had dramatic benefit from CEA, whereas patients with symptomatic ICA stenosis between 50% and 69% and patients with asymptomatic ICA stenosis between 60% and 99% also benefited, albeit to a lesser extent, from CEA.

In the North American trials of CEA, ICA stenosis was calculated from arteriograms by comparing the diameter of the minimal residual lumen to the diameter of the distal cervical ICA.[13] The University of Washington duplex criteria for categories of stenosis pre-existed the endarterectomy trials and were developed comparing the diameter of the residual ICA lumen at its narrowest point with an estimate of the diameter of the ICA bulb if it were free of atherosclerosis. Because the bulb has a greater diameter than the distal ICA, the two methods of measurement do not give the same calculated percentage of angiographic stenosis for the same lesion. Calculations of angiographic stenosis using the distal ICA as the reference vessel result in lower calculated stenosis percentages than calculations using the bulb as the reference site. This effect is particularly striking for modest lesions.

Table 87-1 Major Randomized Trials Assessing Efficacy of Carotid Endarterectomy

Symptomatic Stenosis
North American Symptomatic Carotid Endarterectomy Trial (NASCET)[8]
European Carotid Surgery Trial (ECST)[9]
VA Cooperative Study # 309[10]
Asymptomatic Stenosis
Asymptomatic Carotid Atherosclerosis Study (ACAS)[11]
Asymptomatic Carotid Surgery Trial (ACST)[12]

In a review of 1,001 internal carotid angiograms, 34% of the ICAs were classified as stenosis of 70% to 99% using the ICA bulb as the reference vessel. In contrast, when the distal cervical ICA was used as the reference site, only 16% of the ICAs were classified as 70% to 99% stenosis.[14] More than 99% of the distal ICA-based calculations of stenosis were less than bulb-based calculations. Thus, the duplex stenosis criteria using the bulb as the reference vessel are not and were not directly applicable to the results of the clinical trials.

Current Criteria for ICA Stenosis

Since the randomized CEA trials were completed, additional duplex criteria were developed comparing duplex scans to angiographic ICA stenosis using the distal ICA as the reference vessel in calculating angiographic stenosis. Such criteria are considered more useful by many in selection of patients for carotid intervention because they are directly applicable to the threshold levels of carotid stenosis addressed in the CEA trials.

The initial studies addressing the issue of duplex criteria relevant to the CEA trials were performed at the Oregon Health & Science University (OHSU)[5,15] with subsequent publications from many different institutions, with many different proposed criteria for identification of clinically relevant threshold levels of ICA stenosis.[16–21]

Recognizing that duplex criteria from different centers differed for the threshold levels of angiographic stenosis determined by the CEA trials, a panel of authorities from a variety of medical specialties assembled to review the carotid ultrasound literature. The panel developed a consensus regarding the key components of the carotid ultrasound examination and reasonable criteria for stratification of ICA stenosis.[22]

The consensus committee recommended that all carotid examinations be performed with grayscale imaging, color Doppler, and spectral Doppler. Examinations should be performed by a credentialed vascular technologist in accordance with the standards of an accrediting body. Doppler waveforms should be measured with an insonation angle as close to 60 degrees as possible but not exceeding 60 degrees, and the sample volumes should be placed within the area of maximal stenosis. The panelists recommended the consistent use of relatively broad diagnostic strata to estimate the degree of ICA stenosis. The panel also concluded that Doppler is relatively inaccurate for subcategorizing ICA stenosis $<50\%$, and recommended that these lesions be reported under a single category as $<50\%$ stenosis, and that subcategories for minor degrees of stenosis not be used.

4 The consensus panel noted that PSV is easy to obtain. However, data suggest reproducibility of PSV, even among experienced vascular technologists, has sufficient problems that PSVs should not be used as a continuous variable in clinical carotid duplex scanning. Even so, the degree of stenosis estimated by ICA PSV and the degree of narrowing of the ICA lumen seen on grayscale and color Doppler should correlate with PSV as the primary parameters for determining ICA stenosis. Additional parameters such as ICA/CCA PSV ratio and ICA EDV are secondary parameters and should be employed as internal checks. They are especially useful when ICA PSV may not be representative of the extent of disease. After their discussions the consensus panel recommended criteria, stratifying ICA stenosis into specific categories relevant to the CEA trials (Table 87-2). These criteria have not been subjected to widespread retrospective or prospective evaluation and do not represent the results of any one laboratory or study. They are not meant to serve as a substitute for continuous quality assurance in individual laboratories.

BILATERAL HIGH-GRADE ICA STENOSIS

Doppler-derived flow velocities from the ICA opposite an ICA occlusion or high-grade stenosis may suggest a higher degree of narrowing than is observed angiographically.[2] This likely is because of compensatory flow. Duplex scan overestimation of stenosis is more common in less-severe categories of stenosis than in higher-severity categories.[23]

Table 87-2 Consensus Panel Recommendations for Classification of Internal Carotid Artery Stenosis[22]

Normal The ICA PSV is less than 125 cm/s and there is no visible plaque or intimal thickening. Normal arteries should also have an ICA/CCA ratio of less than 2.0 and ICA EDV of less than 40 cm/s.
ICA stenosis <50% is present when the ICA PSV is less than 125 cm/s and there is visible plaque or intimal thickening. Such arteries should also have an ICA/CCA PSV ratio of less than 2.0 and an ICA EDV of less than 40 cm/s.
ICA stenosis of 50–69% is present when the ICA PSV is 125 cm/s to 230 cm/s and there is visible plaque. Such arteries should also have an ICA/CCA PSV ratio of 2.0 to 4.0 and an ICA EDV of 40 cm/s to 100 cm/s.
ICA stenosis ≥70–99% but less than near occlusion is present when the ICA PSV is more than 230 cm/s and there is visible plaque with lumen narrowing on grayscale and color Doppler imaging. The higher the PSV, the more likely (higher positive predictive value) it is to have severe disease. Such stenosis should also have an ICA/CCA ratio of more than 4.0 and an ICA EDV of more than 100 cm/s.
Near occlusion of the ICA The velocity parameters may not apply. "Preocclusive" lesions may be associated with high, low, or undetectable velocity measurements. The diagnosis of near occlusion is therefore established primarily by demonstration of a markedly narrowed lumen with color Doppler. In some near occlusive lesions, color Doppler can distinguish between near occlusion and occlusion by demonstrating a thin wisp of color traversing the lesion.
Occlusion There is no detectable patent lumen on gray-scale imaging and no flow with spectral, color, and power Doppler. Near occlusive lesions may be misdiagnosed as occlusions when only grayscale ultrasound and spectral Doppler are used.

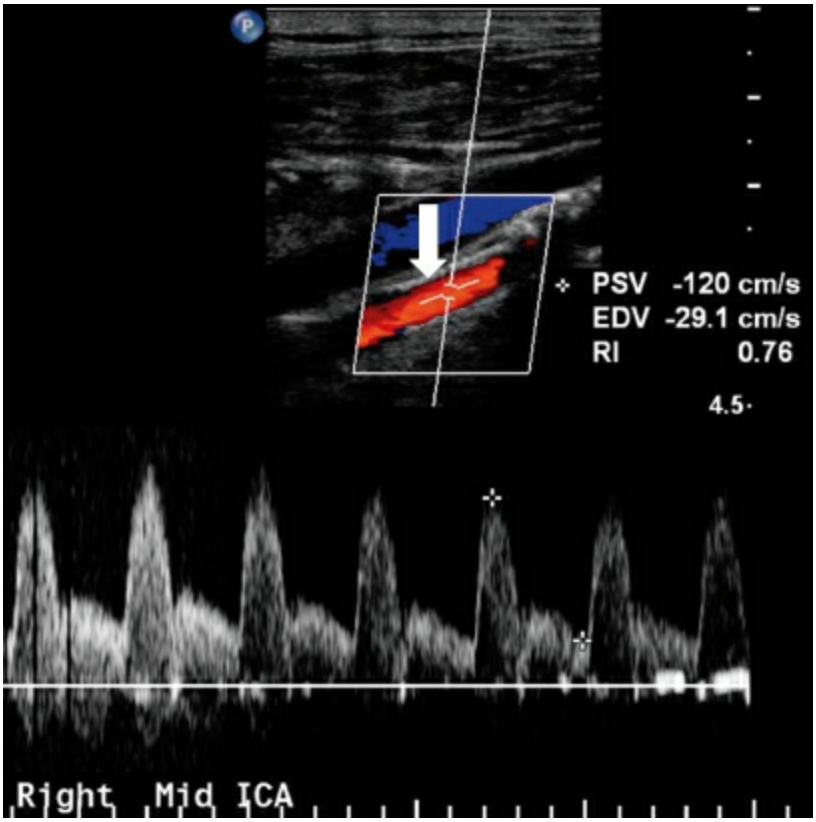

Figure 87-8. Color flow image and velocity waveforms from a stented internal carotid artery. A peak systolic velocity of 120 cm/s indicates the stent is widely patent. The stent itself is easily recognized as a hyperechoic stripe (*arrow*) parallel to the vessel wall.

Stented Carotid Arteries

Carotid artery stenosis may be selectively treated with an intraluminal stent. However, ultrasound criteria developed for native ICAs are likely not applicable to stented carotid arteries, especially to more modest lesions in the stented arteries. With rare exceptions the number of patients in studies of stented carotid arteries that have actually had severe in-stent restenosis is small. No study has correlated the degree of stenosis or increase in ICA velocities within a stented carotid artery with clinical symptoms or outcomes. Studies have also not evaluated the effect of the stented carotid artery on the opposite nonstented artery. It is generally agreed that PSVs >125 cm/s, will be needed to identify a >50% stenosis in a stented ICA. Criteria to detect high-grade stenosis in native ICAs still work reasonably well to identify high-grade stenosis in stented ICAs (Fig. 87-8).[24,25]

CCA and ECA Stenosis

Criteria used for classifying disease in the ICA have not been prospectively tested for application to the ECA or the CCA. However, as with the ICA, relative degrees of stenosis may be determined by the presence of plaque with B-mode imaging, aberration in color flow on duplex examination, spectral broadening, and increases in PSV. Greater than 50% stenosis can be inferred by the presence of a focally increased PSV followed by poststenotic turbulence. As noted above, the CCA waveform normally has attributes of the ICA and ECA. The CCA will take on the quality of the "normal" vessel (ICA or ECA) when the other is occluded. If there is a proximal CCA (or innominate artery) high-grade stenosis or occlusion, the ipsilateral CCA Doppler flow quality will be dampened with low PSVs and delayed upstroke of the waveform compared with the nonstenotic contralateral side. Poststenotic turbulence also may be seen. There are no widely employed validated criteria to give a diameter reduction for stenosis in the CCA or ECA. Greater than 50% stenosis in the ECA is often inferred by PSV >125 cm/s associated with poststenotic turbulence whereas a PSV >200 cm/s may be an appropriate threshold for $>50\%$ stenosis in the CCA.[26]

LOWER EXTREMITY ARTERIAL DISEASE

The noninvasive vascular laboratory, in combination with the history and physical examination, has a critical role in providing objective diagnosis of lower extremity arterial occlusive disease in asymptomatic patients, those with intermittent claudication, and in those with critical arterial insufficiency. Both plethysmographic and ultrasound techniques are used in the evaluation of peripheral arterial disease (PAD).

In many patients the clinical history and physical examination are all that is necessary to establish a diagnosis of intermittent claudication (IC). Almost all patients with IC have diminished or absent lower extremity pulses. However, palpation of pulses is subjective and poorly reproducible. Therefore, the pulse examination in a patient suspected of having arterial disease should be supplemented with objective testing in the noninvasive vascular laboratory. On occasion a patient will give a history suggesting IC, yet have what appear to be normal resting lower extremity pulses. In such cases, exercise testing with postexercise Doppler-measured ankle pressures and ankle–brachial systolic blood pressure ratios is crucial to confirm the diagnosis of IC secondary to arterial stenosis or occlusion (see below).

Many patients with PAD have atypical leg symptoms or are asymptomatic. Such patients have a similar increased risk of cardiovascular death as patients with typical IC symptoms, leading some to advocate for screening for PAD in patients with atypical leg symptoms or atherosclerotic risk factors.

Patients with exercise-induced lower extremity and/or buttock pain should be asked about the location of their pain, its relationship to walking, severity and duration of symptoms, and symptom progression over time. Only exercise-induced muscular pain of the calf, thigh, or buttock, relieved within a few minutes of rest and reproduced by additional walking, can be predictably improved by lower extremity arterial revascularization. There are no data on the response of atypical leg symptoms to revascularization in patients with evidence of PAD.

Ischemic pain at rest is a clinical diagnosis. It is suspected when a patient complains of pain and/or numbness in the forefoot, toes, or instep at rest. In such patients the vascular laboratory can objectively confirm and quantify the magnitude of arterial insufficiency. Ischemic pain is generally associated with an ankle pressure <50 mm Hg and an ABI ≤ 0.4.

PLETHYSMOGRAPHIC TECHNIQUES

Volume Flow

Calf or foot blood flow can be recorded with a mercury-in-silastic strain gauge. Electrical resistance of the mercury column depends on the length of the column. Changes in electrical resistance, reflect changes in the volume of the extremity, and are based on detection of minute changes in the length of the column. However, neither calf nor foot blood flow at rest differ between normal subjects and patients with even rather severe IC.[27] Hyperemic volume flow is often lower in patients with occlusive disease but such testing can be quite painful for the patient. Measurements of volume flow therefore are not very useful in the evaluation of lower extremity ischemia.

Pulse Volume Recordings (PVR)

5 Air plethysmography can be used to display pulse volume waveforms. PVRs are obtained with partially inflated blood pressure cuffs that detect volume changes sequentially down a limb. Volume changes beneath the cuffs resulting from the pulse wave result in small pressure changes within the cuffs. These changes are displayed as arterial waveforms with the use of appropriate transducers. A normal pulse volume waveform has a sharp systolic upstroke and peak, as well as a prominent dichroic notch on the downward portion of the curve. With increasing proximal arterial occlusion, the dichroitic notch is lost and the waveform bows out on the down portion of the systolic portion of the curve. The peak of the pulse wave also becomes rounded and there is loss of amplitude of the wave as disease is more severe. With even more severe disease there are nearly equal upstroke and downstroke times and in very severe proximal disease the pulse wave is absent (Fig. 87-9).[28,29] An absence of quantitative data limits the utility of PVRs. More quantitative data for the evaluation of lower extremity arterial disease are available using ultrasound-based techniques.

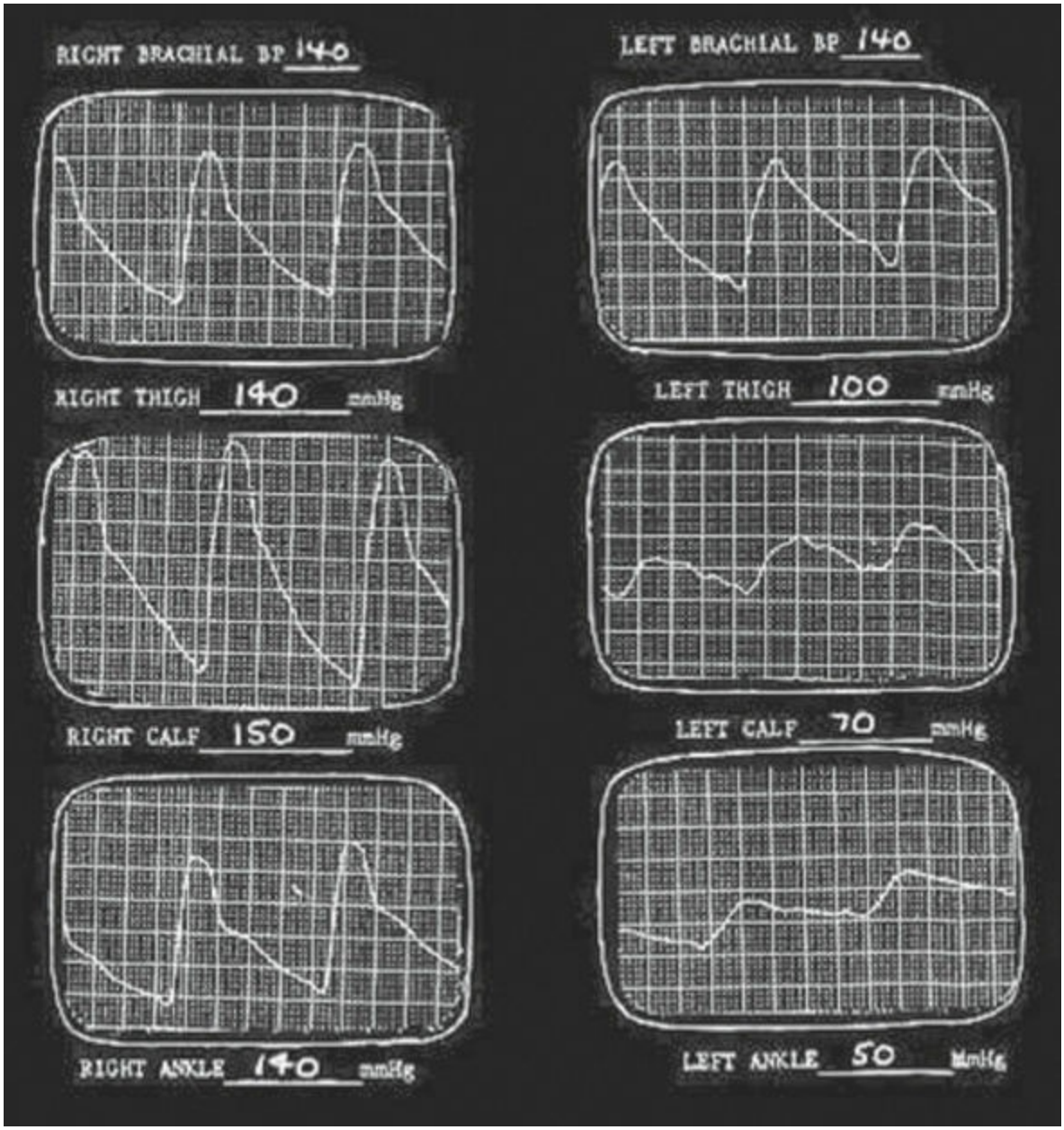

Figure 87-9. Pulse volume recordings. The plethysmographic waveforms are normal on the right and severely abnormal in the left leg with loss of amplitude of the waveform, slowing of the upstroke of the waveform and outward bowing of the downstroke of the waveform.

ULTRASOUND TECHNIQUES

Ankle–Brachial Index

6 The ankle–brachial index (ABI) is a very useful measure of overall lower extremity perfusion. The test is performed with the patient supine and having rested for a few minutes. A pneumatic pressure cuff is placed just above the ankle and inflated to supra systolic levels. A continuous wave Doppler probe is positioned over the posterior tibial or dorsalis pedal artery distal to the cuff. The cuff is deflated and the pressure reading when the Doppler signal returns is recorded. The sequence is repeated for the other ankle artery and the values compared with the highest brachial artery systolic pressure also obtained with the Doppler. For clinical purposes, the higher ipsilateral dorsal pedal or posterior tibial pressure is divided by the higher brachial artery systolic pressure, yielding an ABI for that lower extremity. The use of a ratio makes the test relatively independent of day-to-day variations in arterial blood pressure.

A normal ABI is 1.0 to 1.2, with progressively lower values corresponding to worsening arterial disease (Table 87-3). ABIs below normal indicate relative lower extremity arterial insufficiency and increased risk of cardiovascular death with the risk increasing with the magnitude of depression of the ABI. This test has several limitations. Significant bilateral subclavian or axillary artery occlusive disease results in a falsely elevated ABI. Calcified tibial arteries that can frequently occur with diabetes or renal failure may be inadequately compressed by the pressure cuff. This also results in a falsely elevated (supra systolic) ankle pressure. An ABI >1.4 should therefore also be considered abnormal. Such patients often have severe arterial disease and are also at increased risk of cardiovascular death. When the ABI may be falsely elevated, qualitative analysis of Doppler-derived analog or plethysmographic waveforms or measurement of digital systolic pressures is a more appropriate indicator of the arterial status of the lower extremity. Other problems with ABI include confusion with venous signals when the ankle arterial pressure is low or unmeasurable and relative insensitivity to certain patterns of progression of arterial disease. A tibial artery can occlude without a change in ABI if the remaining tibial vessels remain patent. High-grade stenosis may also progress to occlusion without a change in ABI.

Table 87-3 Correlation between Ankle Brachial Index and Clinical Severity of Lower Extremity Arterial Ischemia

ABI	Clinical Status
>1.3	Abnormal, significant arterial wall calcification
1.1 ± 0.1	Normal
0.6 ± 0.2	Intermittent claudication
0.3 ± 0.1	Ischemic rest pain
0.1 ± 0.1	Impending tissue necrosis

Segmental Limb Pressures

Multiple pneumatic cuffs may be used along the lower extremity to determine the arterial blood pressure at specified levels. These “segmental leg pressures” are compared with the higher brachial artery systolic pressure, with other locations in the ipsilateral leg and with the corresponding levels in the contralateral extremity. Three or four cuffs may be used. In the four-cuff technique cuffs are placed: (1) as far proximal on the thigh as possible; (2) immediately above the knee; (3) just below the knee; and (4) just proximal to the ankle. Each cuff width should be 20% greater than the diameter of the limb at the point of application to avoid falsely elevated pressure readings induced by too narrow a cuff.[30] For the thigh, this generally necessitates a single, wide, thigh cuff. Use of two cuffs above the knee, however, can permit assessment of inflow at or proximal to the common femoral artery with the proximal cuff, and permit evaluation for the presence of superficial femoral artery disease by the distal thigh cuff. With two thigh cuffs the most proximal thigh cuff is often too narrow. An artificially elevated pressure in the proximal thigh is then expected. Therefore the high-thigh index, comparing the proximal thigh pressure to the brachial pressure, is normally about 1.4 with the four-cuff technique and 1.0 to 1.1 with the three-cuff technique (Fig. 87-10).

A hand-held Doppler is used to detect the most prominent Doppler signal at the ankle. Examination proceeds proximal to distal. First the high-thigh cuff is inflated until the ankle Doppler signal is no longer audible. The cuff is then deflated and the pressure where there is return of the Doppler signal at the ankle is the high-thigh pressure. The above-knee, below-knee, and ankle pressures are similarly determined. If there is no audible ankle Doppler signal, the popliteal artery is insonated with the Doppler to determine high-thigh and above-knee pressures. Comparison of the pressures measured at each location permits an estimation of the location of occlusive lesions (Fig. 87-11).

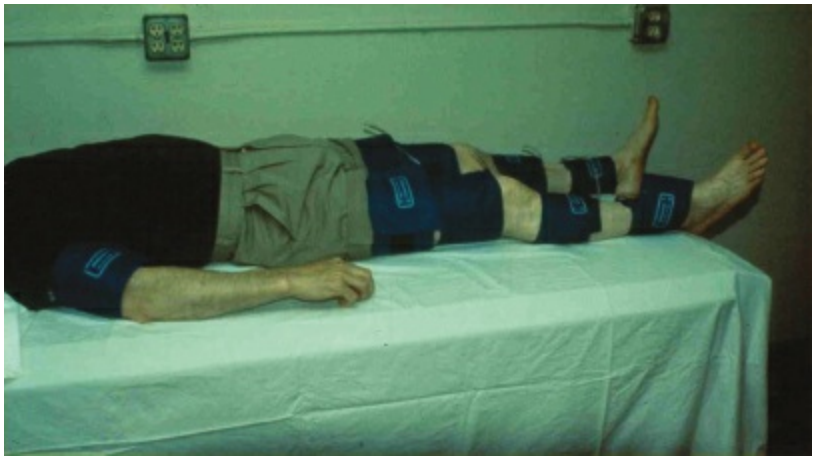

Figure 87-10. Segmental pressures multiple pneumatic cuffs may be used along the lower extremity to determine the arterial blood pressure at each level. Comparison of the pressures measured at each location permits an estimation of the location of occlusive lesions. Use of two cuffs above the knee can permit assessment of inflow at or proximal to the common femoral artery with the proximal cuff, and permit evaluation for the presence of superficial femoral artery disease by the distal thigh cuff. In many patients, however, the high-thigh cuff is relatively narrow compared to the diameter of the thigh resulting in an artificial elevation of the high-thigh pressure so that with use of four cuffs the high-thigh pressure will be 30 to 40 mm Hg higher than the highest brachial pressure.

There are multiple limitations in the interpretation of segmental limb pressures. The high-thigh pressure is subject to particular interpretation difficulties. A diminished high-thigh pressure can reflect an occlusive lesion anywhere at or proximal to the common femoral artery bifurcation. Low high-thigh pressures therefore may reflect a pressure-reducing stenosis in the ipsilateral common or external iliac artery, a common femoral artery lesion or tandem pressure-reducing lesions in the profunda femoris and the proximal superficial femoral artery or any combination of such lesions. The accuracy of segmental pressures may be affected by mural calcification resulting in artificially elevated pressures. Diminished proximal pressures may also mask gradients that exist further down the leg. Segmental pressures also do not allow differentiation between short- and long-segment occlusions, or between occluded and patent, but highly stenotic arteries.

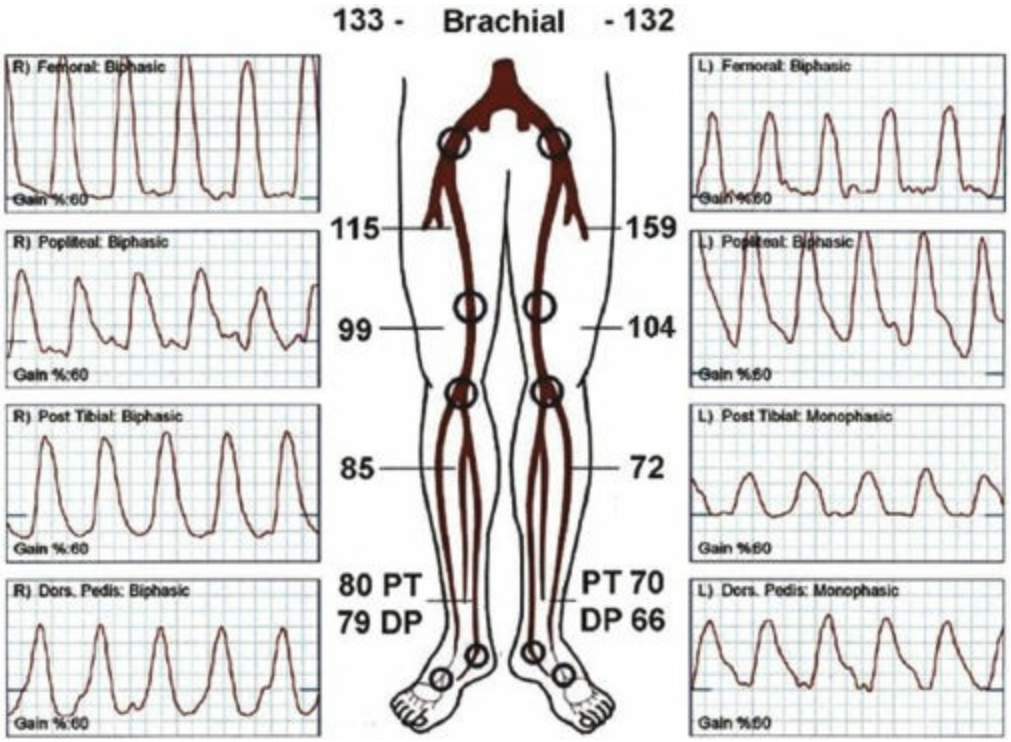

Figure 87-11. Segmental pressure examination with use of thigh, calf, and ankle cuffs. A drop in pressure of 30 mm Hg between levels indicates a hemodynamically significant stenosis between the two adjacent cuffs. This study therefore indicates a flow-reducing lesion somewhere at or proximal to the common femoral artery bifurcation on the right side and likely superficial femoral artery/popliteal artery occlusive disease on the left.

Exercise Testing

Doppler-determined pressures can be combined with treadmill exercise testing in patients without a contraindication to exercise. After determination of resting supine ankle pressures and ABIs, the patient walks on a treadmill with a predetermined incline at a predetermined rate. The test continues for 5 minutes or until the patient is forced to stop. The type, time-to-onset, and location of symptoms are recorded. At completion of the test, the patient is immediately placed supine and absolute ankle pressures and ABIs determined.

In most patients exercise testing serves only to confirm a diagnosis of claudication. It is not required in a patient with classic symptoms of claudication, absent peripheral pulses and a diminished ABI. In some cases exercise testing can document a physiologic response to revascularization or provide an objective assessment of the potential postoperative physiologic benefit.

Exercise testing is particularly useful in the infrequent patient with symptoms of claudication and who has palpable pedal pulses and/or a normal ABI. Patients with exercise-induced leg pain occurring on the basis of arterial insufficiency will show a decrease in the postexercise ankle pressures and ABI. Exercise testing can also be used to document an ischemic response to exercise in a patient with PAD and other conditions that may limit their ability to walk. Patients with COPD, arthritis, venous disease, and PAD are often more limited in their walking ability by these coexisting conditions than by their PAD. If the patients cannot complete a treadmill examination, and no ischemic pressure response to exercise occurs, it is highly unlikely their walking ability would be improved by a revascularization procedure.

The precise endpoints and techniques of exercise testing are controversial. Some laboratories exercise patients at low speeds with no inclination of the treadmill whereas others utilize various inclines and graded increases in treadmill speed. Both initial and absolute claudication distances can be determined. Initial claudication distance is the point where the patient initially experiences claudication-type pain. The absolute claudication distance is where the patient can no longer continue to walk on the treadmill.

Criteria for a positive exercise test include a decrease in the ankle pressure of 20 mm Hg or 20%, a decrease in the ABI of 0.2 in the symptomatic extremity, or failure of the ankle pressure to return to baseline within 3 minutes of completing the treadmill portion of the examination. Because systemic pressure and therefore arm pressures, depending on work load, will increase with exercise, use of the ABI alone to indicate a positive exercise test is incorrect. The ABI decrease should be accompanied by an absolute pressure drop at the ankle.

7 Failure of the ankle pressure to drop with exercise along with failure of the ABI to decrease 20% with exercise, combined with a normal resting ABI, substantially rules out arterial insufficiency as the etiology of the patient's exercise-induced complaints of leg pain. An exception is the rare patient with buttock claudication secondary to isolated internal iliac disease.

Neurogenic claudication may be confused with arterial ischemia. Patients present with symptoms of exercise-induced leg or calf pain. Careful questioning, however, reveals atypical characteristics for vascular-induced exercise-associated pain. Such characteristics include occurrence of pain with standing, pain relief when leaning forward, worsening with coughing, and prolonged time for pain to resolve following exercise. These patients often have normal ankle pressures at rest that do not decrease with exercise despite onset of symptoms. Failure of the ankle pressures to decrease with exercise may also be a clue to the presence of other uncommon conditions, such as venous claudication and chronic exercise-induced compartment syndromes.

Doppler Analog Waveform Analysis

Similar to plethysmographic waveforms, continuous-wave Doppler waveforms may also be analyzed qualitatively. Normal lower extremity Doppler waveforms are described as triphasic with a sharp systolic upstroke, an end-systolic reverse flow component followed by low flow forward through diastole. The shape of the waveform changes with increasing severity of proximal obstruction. Initially, the reverse-flow component is lost. As proximal stenosis increases, the rate of rise of the systolic upstroke is decreased, the amplitude of the waveform is diminished, and diastolic flow increases relative to systolic flow.

Continuous-wave Doppler waveforms are generally used in conjunction with measurement of segmental Doppler pressures similar to the use of PVRs. Doppler waveform analysis can also be used to assess iliac artery inflow to the common femoral artery. An attenuated common femoral artery waveform indicates proximal disease.

Peripheral Artery Duplex Scanning

Arterial duplex scanning provides detailed anatomic and hemodynamic information from the infrarenal aorta to the distal tibial vessels that cannot be determined by indirect testing. Arterial duplex scanning has been prospectively compared with angiography to establish standard criteria for normal and diseased arteries.[31] Sensitivity of duplex examination for detecting the presence of a hemodynamically important lesion (>50%) ranges from 89% at the iliac artery to 68% at the popliteal artery. Overall sensitivities for predicting interruption of patency are 90% for the anterior and posterior tibial arteries and 82% for the peroneal artery. The technique is versatile and does not appear to be significantly influenced by the presence of previous operations or multilevel disease (Fig. 87-12A,B).

Velocity Patterns and Classification of Percent Stenosis

In the absence of arterial stenosis or occlusion triphasic waveforms are maintained throughout the length of the lower extremity but PSV decreases from the iliac to the tibial vessels. There are no significant differences in velocity measurements among the three tibial arteries in normal subjects.

Important changes in the velocity waveforms that signify disease include the absence of an end-systolic reverse flow component and elevation of the PSV. A 50% reduction in arterial luminal diameter (equivalent to a cross-sectional surface area reduction of 75%) is associated with a pressure drop across the lesion. The University of Washington criteria for classification of peripheral arterial stenosis are shown in Table 87-4.[32]

Table 87-4 University of Washington Duplex Criteria for Determination of Stenosis in Lower Extremity Arteries

Degree of Stenosis (%)	Duplex Ultrasound Criteria
0	Normal waveform and velocities
1–19	Normal waveform and velocities with spectral broadening
20–49	Marked spectral broadening, 30% increase in PSV
50–99	Marked spectral broadening, 100% increase in PSV
Loss of reverse flow component of waveform	
Occluded	No detectable flow signal in well-visualized artery

PSV, peak systolic velocity.

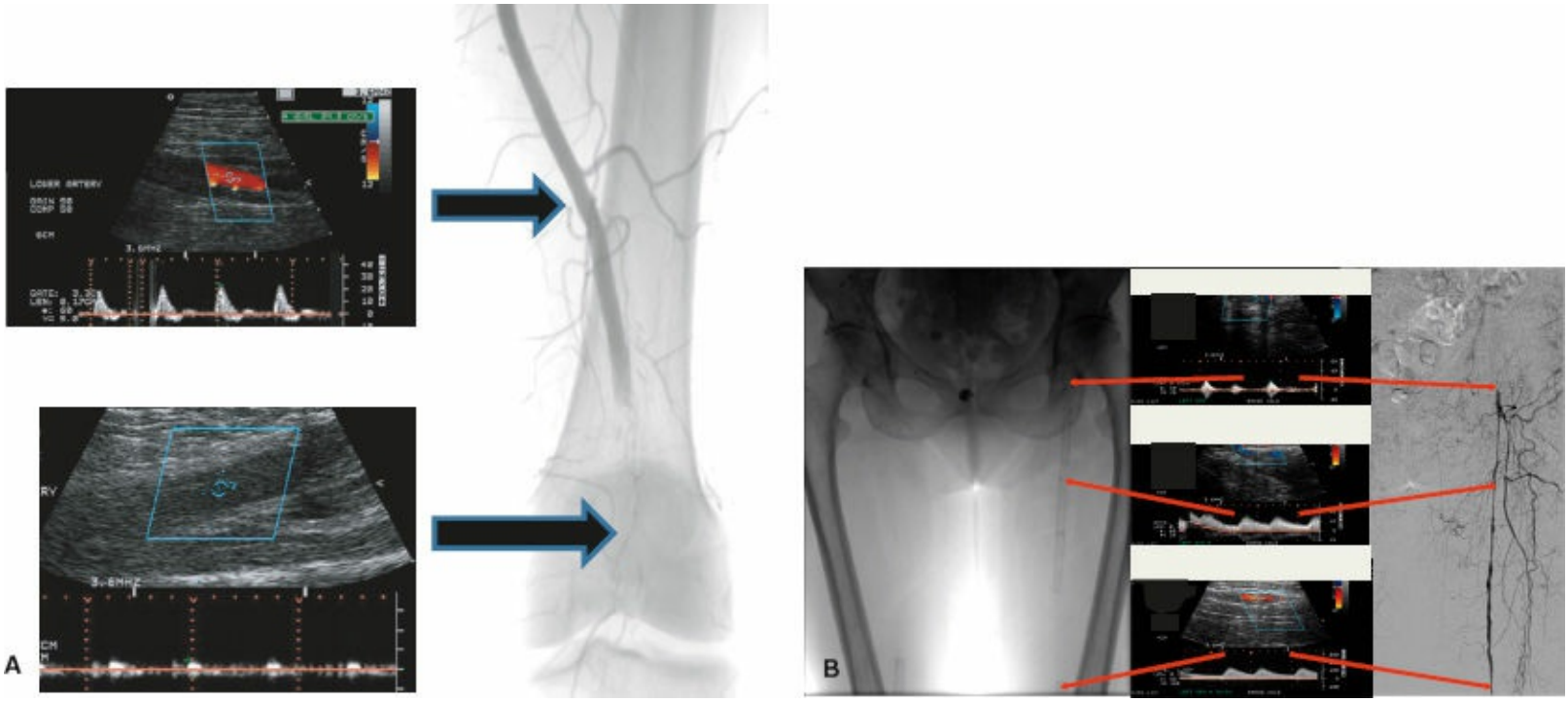

Figure 87-12. **A:** Duplex images/waveforms and corresponding angiogram of an abrupt popliteal artery occlusion. **B:** Duplex waveforms and angiographic images in a patient with severe in-stent stenosis of superficial femoral artery stents.

A PSV ratio, comparing the velocity within the stenosis to the velocity just proximal to the stenosis, is also useful for grading degree of stenosis. PSV ratios are independent of changes in blood pressure, cardiac output, and vascular compliance. Grading stenosis using the PSV ratio has been found to be highly reproducible.[33,34] Fifty percent stenosis in lower extremity arteries correlates with a PSV ratio from 1.4 to 3.0.[31,35–38] A velocity ratio of 2.0 is a reasonable compromise and is used by many vascular laboratories as indicative of a 50% peripheral arterial stenosis.

Lower extremity duplex scanning can serve as an alternative to contrast arteriography in the preoperative assessment of candidates for arterial intervention. In selected centers, successful lower extremity revascularization either by open arterial bypass grafting or with catheter-based techniques has been reported using only arterial duplex in a high percentage of cases.[39–41] The limiting factor with preoperative arterial duplex is the ability to accurately identify the best site for the distal anastomosis of a bypass graft, especially when the distal anastomotic site is below the knee.[42]

The role of duplex ultrasound scanning in the surveillance of lower extremity vein grafts has been well documented (Fig. 87-13A,B). Detection and repair of a graft-threatening stenosis detected by duplex scanning appears to improve secondary graft patency.[43–46] Twenty to thirty percent of vein grafts will develop a severe enough stenosis that revision is recommended.[47] Approximately 80% of these graft stenotic lesions develop in the first postoperative year. However, graft threatening lesions can develop at any time. Surveillance is therefore generally recommended for the life of the graft. A widely utilized protocol for vein graft duplex surveillance is every 3 months for the first year and every 6 months to yearly thereafter. The examination involves point-to-

point insonation of the proximal inflow artery, proximal anastomosis, midgraft, distal anastomosis, and the distal outflow artery. A PSV ratio of 4, or a PSV above 300 cm/s, indicates a critical graft stenosis, and repair of the lesion by open or catheter-based techniques should be considered.[48] If the PSV ratio is between 2 and 4, the patient should be evaluated again in 3 months with a duplex examination.

Aneurysms and pseudoaneurysms of lower extremity arteries are also readily identified and characterized with duplex scanning with particular attention to the diameter of the aneurysm and the presence or absence of intraluminal thrombosis (Fig. 87-14A,B).

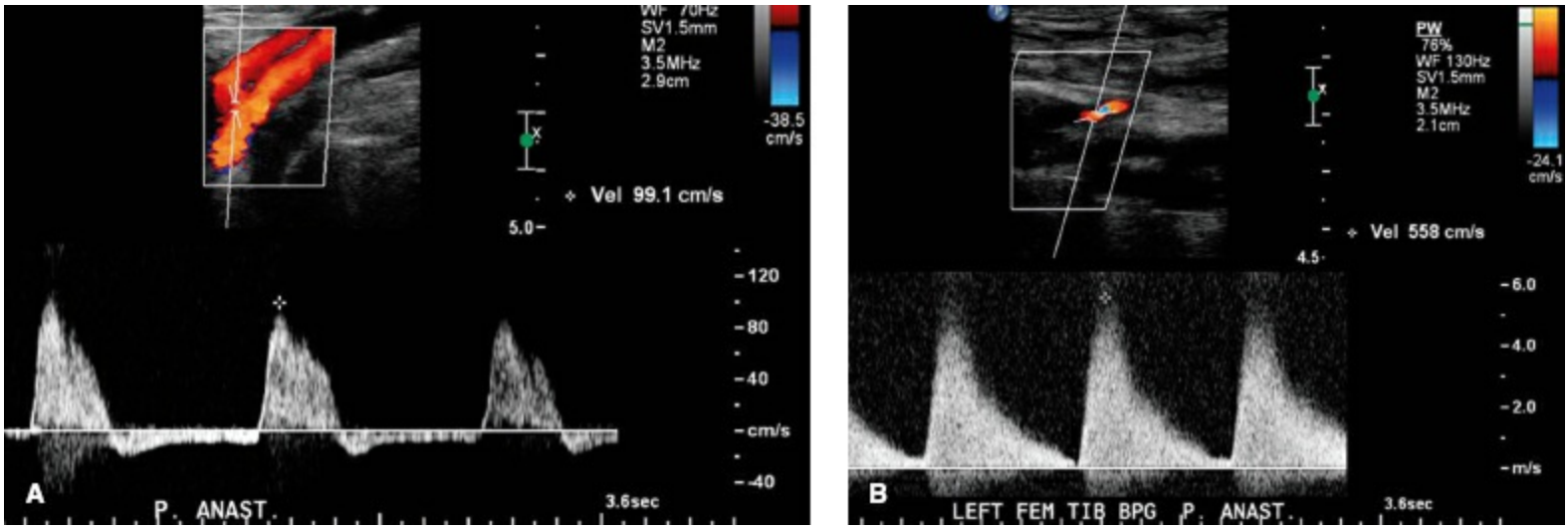

Figure 87-13. A and B: Duplex ultrasound images and velocity waveforms of normal **(A)** and stenotic **(B)** proximal anastomoses of femoral tibial bypass grafts. The abnormal study has a severe elevation in flow velocity of 558 cm/s indicating a high-grade stenosis.

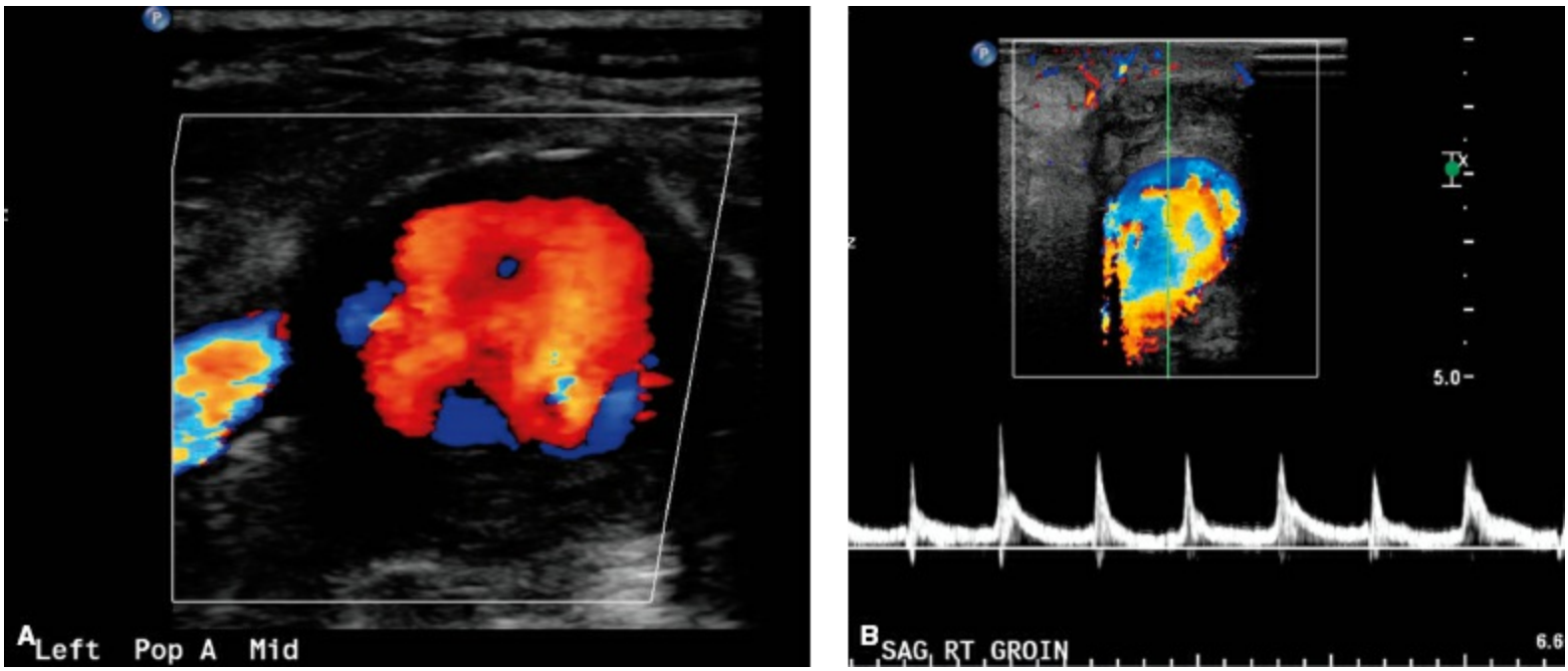

Figure 87-14. A: Native popliteal artery aneurysm with intraluminal thrombus. **B:** Large pseudo aneurysm of the right common femoral artery resulting from arterial infection from intra-arterial injection of street drugs.

Upper Extremity Arterial Evaluation

Upper extremity arterial disease is a small but important component of vascular surgical practice. Both ultrasound and plethysmographic techniques are important in the evaluation of upper extremity arterial disease.

SEGMENTAL ARM PRESSURES

Upper extremity segmental pressures are obtained by measuring blood pressure with pneumatic cuffs above the elbow, below the elbow, and above the wrist while insonating the radial or ulnar artery at the wrist using a continuous wave Doppler. Doppler-derived or plethysmographic waveforms can also be recorded at the different levels. Abnormal waveforms or pressures will help diagnose arterial disease proximal to the wrist.

A 12-cm blood pressure cuff is usually sufficient for measuring the brachial artery pressure, whereas a 10-cm blood pressure cuff is used at the wrist to measure the systolic pressure from the radial and ulnar arteries. A systolic pressure measurement is taken from the upper arm (brachial artery) and at the wrist (radial and ulnar arteries). Normally, there is not a recordable gradient between any of these sites and a normal wrist/brachial blood pressure ratio is 1.0. If there is a blood pressure difference between the two arms of more than 15 mm Hg, it is likely that there is a stenosis or occlusion somewhere on the side of the lower pressure. Abnormal waveforms and decreased pressures at the above-elbow cuff site indicate axillary, subclavian, or brachiocephalic arterial occlusive disease. Similarly, abnormalities at the below-elbow and above-wrist sites indicate brachial and proximal ulnar/radial arterial occlusive disease, respectively. If there is a blood pressure difference between levels, or between the radial and ulnar arteries, of more than 15 mm Hg it is likely caused by a stenosis or occlusion (Fig. 87-15).

DIGITAL PRESSURES AND PLETHYSMOGRAPHY

Digital pressure measurements and digital plethysmography are extremely useful in the diagnosis of upper extremity arterial disease and can be as accurate as arteriography in assessing patients with hand ischemia.[49] Photo plethysmography (PPG) or strain-gauge plethysmography can be used to measure digital blood pressure and to obtain pulse waveforms. PPG is preferred because the equipment is easier to use and more durable. An additional advantage of PPG is that it is possible to record the volume pulses from the tips of the digits. This may also be useful in documenting obstruction within the digit arteries themselves.

The photo cell is attached to the fingertip pulp with double-sided tape or small strain gauges are placed around the fingertip. One-inch (2.5 cm) blood pressure cuffs are placed around the proximal phalanx. Waveforms are recorded using pulse tracings obtained at high speed to evaluate the shape of the waveform. Waveforms are normal if the upstroke time is less than 0.2 seconds (Fig. 87-16A). They may or may not have a dichotic notch. An abnormal obstructive waveform will have a rounded peak, as opposed to the normal notched peak. Upstroke time is prolonged. The amplitude of the waveform is not important. Finger PPG waveforms are not quantitative. The amplitude of the waveform is primarily dependent on the gain setting, not blood flow.

Patients with vasospasm will often have an abnormally shaped waveform termed a “peaked pulse,” which is thought to represent abnormal elasticity and rebound of the palmar and digital vessels (Fig. 87-16B).

Finger blood pressures are measured by inflating the cuffs placed at the base of the fingers. At reduced chart recorder speed the pulsations are recorded while the blood pressure cuffs are inflated. When digit pulsations are obliterated, the cuff is slowly deflated until the pulsation returns. The pressure reading at this point is recorded and represents the digital artery pressure.

It is extremely important to measure and record finger temperature before performing digital plethysmography and obtaining finger blood pressures. If the finger temperature is less than 28 to 30°C false-positive results may be obtained secondary to cold-induced vasospasm. It is recommend that hand and/or whole-body warming be performed in patients with low finger temperatures.

Digital blood pressure is normally within 20 to 30 mm Hg of brachial pressure. A ratio of finger systolic pressure to brachial systolic pressure of greater than 0.80 is normal but does not necessarily rule out digital artery occlusive disease. It is important to remember that there are occasional patients with very distal digital artery occlusive disease with normal finger pressures since the digital cuff is around the proximal phalanx. Also, occlusive disease in a single digital artery can be missed if the other digital artery in that finger is normally patent.

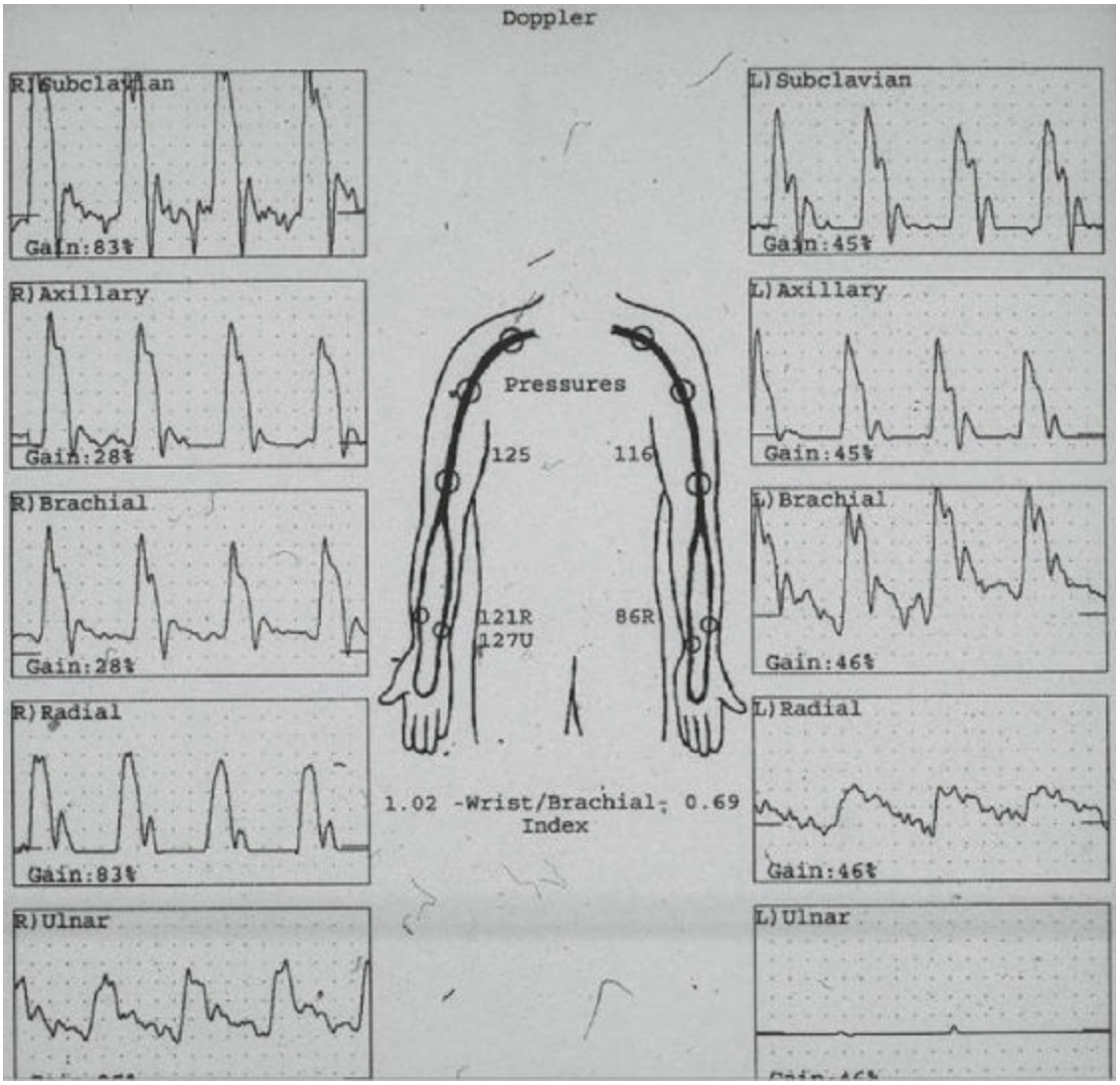

Figure 87-15. Upper extremity segmental pressures and Doppler waveforms. The findings are normal on the right and suggest radial and ulnar artery or distal brachial artery occlusive disease on the left.

COLD CHALLENGE TESTING

The simplest cold intolerance test is to measure the digital temperature recovery time after immersion of the hand in ice water for a short time period. Preimmersion digital temperatures must be above 30°C. Hand and body warming may be required prior to immersion.

Using a thermistor probe to measure finger temperatures, the patient's hand is immersed in a container of ice water for 30 to 60 seconds. After the hand is dried, the fingertip pulp temperatures are measured every 5 minutes for 45 minutes, or until the temperature returns to preimmersion levels. Normal individuals will have a recovery time to preimmersion levels of less than 10 minutes. This test is very sensitive for detecting cold-induced vasospasm but is nonspecific, with approximately one-half of patients with a positive test having no clinical symptoms of cold sensitivity.[50] Cold immersion testing is also uncomfortable and poorly tolerated by patients with significant Raynaud syndrome symptoms. Pressures often fall to unrecordable levels in such patients.

A better, but infrequently utilized, test for cold sensitivity is the digital hypothermic challenge test as described by Nielsen and Lassen (Fig. 87-17).[51] This test involves placing a finger cuff around the proximal phalanx on the test finger and perfusing the cuff with progressively cooler fluid. The pressure in the test finger is then compared with that in a reference finger that is not cooled. The Nielsen test is interpreted as positive for abnormal cold-induced vasospasm if the test finger pressure is reduced by more than 17% compared with the reference finger.

Other tests for cold-induced vasospasm include thermal entrainment, digital laser Doppler response to cold, thermography, venous occlusion plethysmography, and digital artery caliber measurement. None are widely accepted or employed.[52–54]

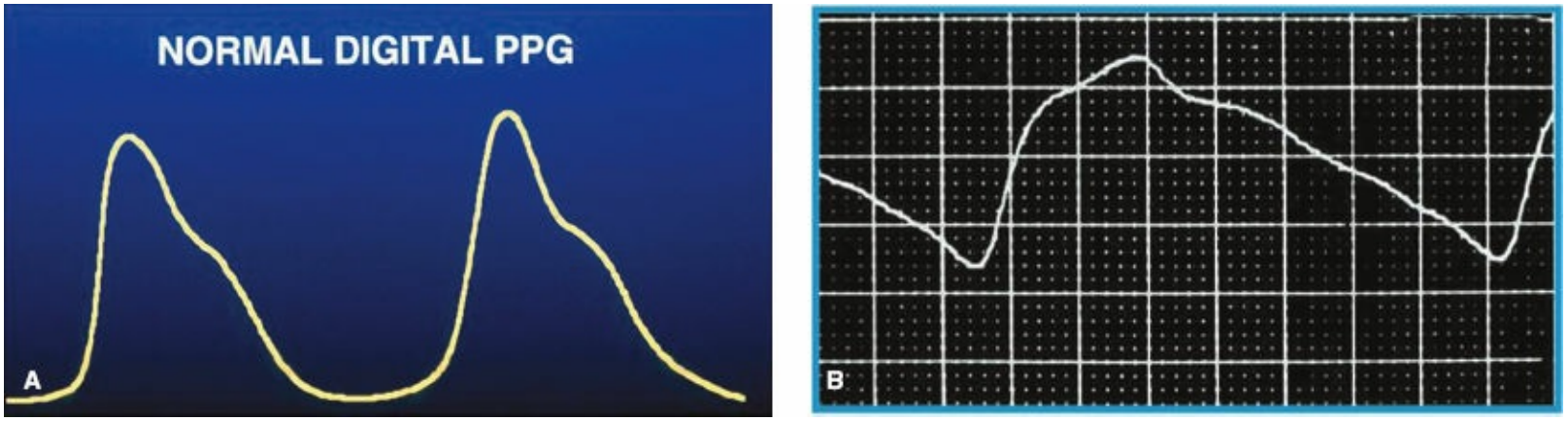

Figure 87-16. A and B: Normal **(A)** and "peaked pulse" **(B)** digital photoplethysmographic (PPG) waveforms. A normal waveform has a rapid upstroke and a sharp apex whereas an obstructive waveform would demonstrate a delayed upstroke and rounded apex. In a peaked pulse, waveform suggestive of vasospasm, the dichroitic notch slides to high on the systolic downslope of the waveform.



Figure 87-17. Device for performance of digital hypothermic challenge or Nielsen test. The cuff on the second finger is used to cool the test finger and measure digital pressure. This allows controlled application of cold to induce a vasospastic response. The fourth finger is the reference finger. Strain gauges on the finger tips are used to measure the digital pressures. See text.

UPPER EXTREMITY DUPLEX SCANNING

Duplex scanning of the upper extremity is carried out in a manner similar to arterial examination elsewhere. The origins of the brachial cephalic vessels can be difficult to visualize with duplex scanning. For examination of the origin of the subclavian artery a 3- or 5-MHz transducer with a small footprint probe using the sternal notch as a window generally gives the best images. One study found 48 of 50 right subclavian artery origins (96%) and 25 (50%) of 50 left subclavian artery origins could be visualized by color duplex scanning.[55]

Criteria for stenosis at the origins of brachial cephalic arteries are slightly different than those used elsewhere. A PSV ratio of ≥ 2 indicates stenosis at the origin of a brachial cephalic artery. Stenosis can also be implied by monophasic flow without actual visualization of a high-velocity jet and by reverse flow in a vertebral artery. Such additional criteria are necessary to assess the origins of the brachiocephalic vessels. If only PSV ratios are utilized there would be higher numbers of both false-positive and false-negative results.[55]

More distally the upper extremity arteries are relatively superficial and fairly constant in location. They are best scanned with a higher-frequency probe such as a 7.5- or 10-MHz probe. Either a sector or linear scan head may be used, but in either case a standoff or mound of acoustical gel is helpful to visualize the vessel clearly and to assess the flow pattern within it. Color facilitates identification of the vessels, and tortuosity of the upper extremity arteries may be more easily seen with color flow imaging. Stenosis, occlusions, and aneurysms of upper extremity arteries are all readily identified with ultrasound (Fig. 87-18A–C).

The interpretation of duplex findings in the upper extremity beyond the origins of the vessels is similar to the interpretation of B-mode images and Doppler signals gathered in other arterial systems.[56] Normal waveforms in the upper extremity arteries are usually triphasic. As elsewhere in the arterial system, stenosis will produce high-velocity jets, poststenotic turbulence, and dampened distal waveforms. There are, however, at present no specific frequency or velocity criteria with which to gauge the severity of stenosis in the upper extremity arteries. Some general guidelines are listed in Table 87-5. The diagnosis of arterial occlusion is made by imaging the artery and using the pulsed Doppler to show that there is no flow within the lumen.

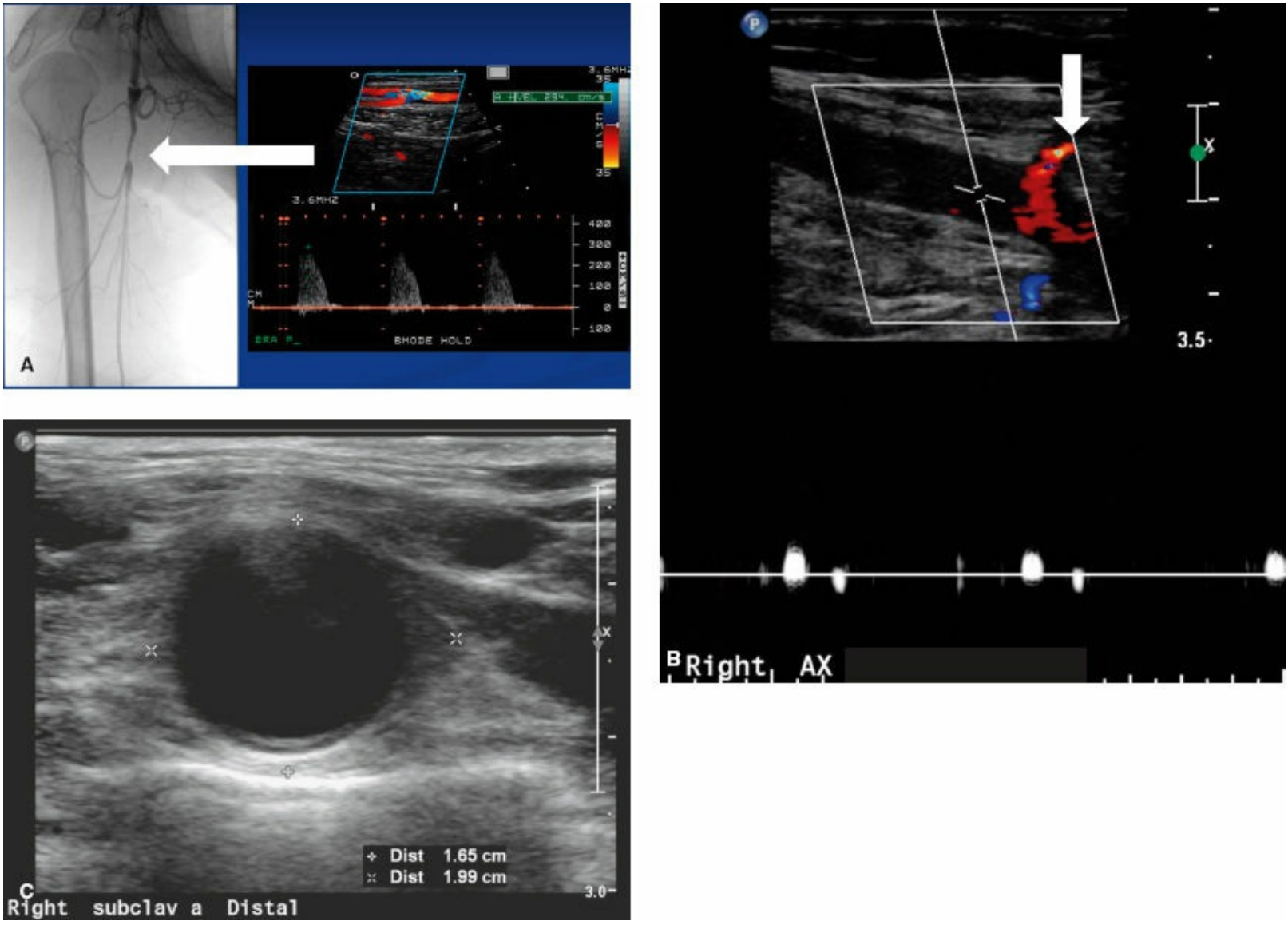

Figure 87-18. **A:** Duplex color flow image and velocity waveform with corresponding angiogram in a patient with brachial artery stenosis (*arrow*) and symptomatic arm ischemia secondary to a crutch injury. Note the loss of the end-systolic reverse flow component of the arterial waveform. **B:** Duplex image of a right axillary artery occlusion secondary to embolism. Note the occlusive waveform and reconstitution of the artery via a distal branch vessel (*arrow*). **C:** Grayscale image of a small subclavian artery aneurysm.

Table 87-5 Duplex Ultrasound Criteria for Evaluation of Upper Extremity Arterial Stenosis

Condition	Characteristics
Normal	Uniform waveforms; biphasic or triphasic waveforms; clear window beneath systolic peak
<50% diameter reduction	Focal velocity increase; spectral broadening; possibly triphasic or biphasic flow
>50% diameter reduction	Focal velocity increase; loss of triphasic or biphasic velocity waveform; poststenotic flow (color bruit)
Occlusion	No flow detected

For patients with unilateral symptoms who may have a surgically correctable lesion such as a subclavian artery aneurysm or stenosis, duplex scanning is quite useful.[57] The duplex evaluation of aneurysms is based upon the B-mode image appearance, with the most important feature being the size of the enlarged artery and the presence of intraluminal thrombus that may serve as a source of distal embolization. Presence or absence of flow within the aneurysm can be determined by the Doppler component.

Duplex scanning may be of use in patients with suspected embolization to identify proximal aneurysms, but the evaluation should also include echocardiography to look for mural thrombi and valvular lesions. While duplex scanning alone cannot be used to make the diagnosis of Takayasu arteritis, it can be a helpful adjunct in following the progression or regression of arterial involvement in response to treatment.[58]

VISCERAL ARTERIES

Mesenteric Arteries

Duplex ultrasonography can serve as a valuable noninvasive screening test for splanchnic artery stenosis in patients with possible chronic mesenteric ischemia and for follow-up of mesenteric artery reconstructions. Aneurysms and dissections of the visceral arteries can also be identified (Fig. 87-19). Despite the accuracy of duplex detection of mesenteric artery stenosis, angiographic confirmation of high-grade stenosis or occlusion of the splanchnic vessels, and appropriate history and physical examination are still required for the diagnosis of chronic mesenteric ischemia. The examination is technically difficult and is best performed by vascular technologists with extensive experience in intraabdominal ultrasound techniques.

Interpretation of Mesenteric Duplex Ultrasound Studies

In healthy individuals, fasting arterial waveforms differ in the SMA versus the CA. The arterial waveforms reflect end-organ vascular resistance. The liver and spleen have relatively high constant metabolic requirements and are therefore low-resistance organs. As a result, CA waveforms are generally biphasic, with a peak systolic component, no reversal of end-systolic flow, and a relatively high end-diastolic velocity (EDV). The normal fasting SMA velocity waveform is triphasic, reflecting the high vascular resistance of the intestinal tract at rest. There is a peak systolic component, often an end-systolic reverse flow component, and a minimal diastolic flow component (Fig. 87-20A).[59]

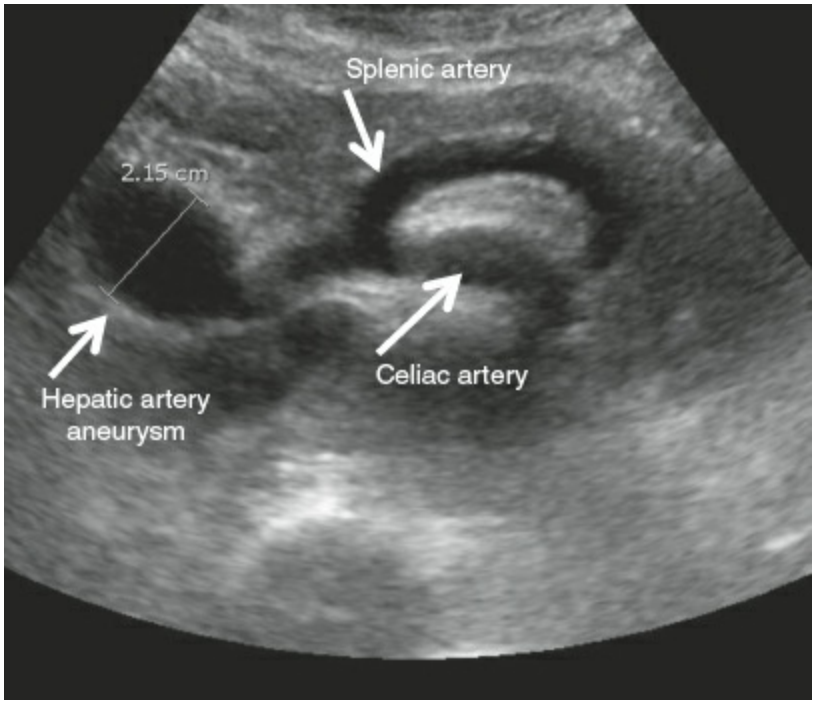

Figure 87-19. Grayscale image of a 2.15-cm hepatic artery aneurysm.

Changes in Doppler-derived arterial waveforms in response to feeding are also different in the CA and SMA. Because the liver and spleen have basically fixed metabolic demands,

there is no significant change in CA velocity waveform after eating. Blood flow in the SMA, however, increases markedly after a meal, reflecting a marked decrease in intestinal arterial resistance. The postprandial waveform changes in the SMA include a near doubling of systolic velocity, tripling of the EDV, and loss of end-systolic reversal of blood flow (Fig. 87-20B).[60]

Postprandial changes are maximal at 45 minutes after ingestion of a test meal and depend on the composition of the meal ingested. Mixed nutrient composition meals produce the greatest flow increase in the SMA when compared with equal caloric meals composed solely of fat, glucose, or protein.[61]

Detection of Mesenteric Arterial Stenosis

8 Duplex ultrasound can detect hemodynamically significant stenosis in splanchnic vessels. In a blinded prospective study of 100 patients who underwent mesenteric artery duplex scanning and lateral aortography, a PSV in the SMA of 275 cm/s or more indicated a ≥70% SMA stenosis with a sensitivity of 92%, a specificity of 96%, a positive predictive value of 80%, a negative predictive value of 99%, and an accuracy of 96% (Fig. 87-21). In the same study, a PSV of ≥200 cm/s identified a ≥70% angiographic celiac artery stenosis with a sensitivity of 87%, a specificity of 80%, a positive predictive value of 63%, a negative predictive value of 94%, and an accuracy of 82%.[62]

Other duplex criteria for mesenteric artery stenosis are also in use. An SMA EDV greater than 45 cm/s correlates with a ≥50% SMA stenosis with a specificity of 92% and a sensitivity of 100%, whereas a CA EDV of 55 cm/s or greater predicts a ≥50% CA stenosis with a sensitivity of 93%, specificity of 100%, and accuracy of 95%.[63]

Surgical revascularization of the mesenteric arteries is a standard treatment for chronic mesenteric ischemia. Most often bypass grafts are constructed to the superior mesenteric and/or celiac arteries. Mesenteric artery bypass grafts can be followed postoperatively with mesenteric artery duplex scanning. Flow velocities within mesenteric artery bypass grafts vary little with the origin of the graft (supraceliac or infrarenal aorta or a common iliac artery) and remain stable over time. Serially increasing velocities over time in a mesenteric bypass likely suggest the development of a graft or anastomotic stenosis.[64]

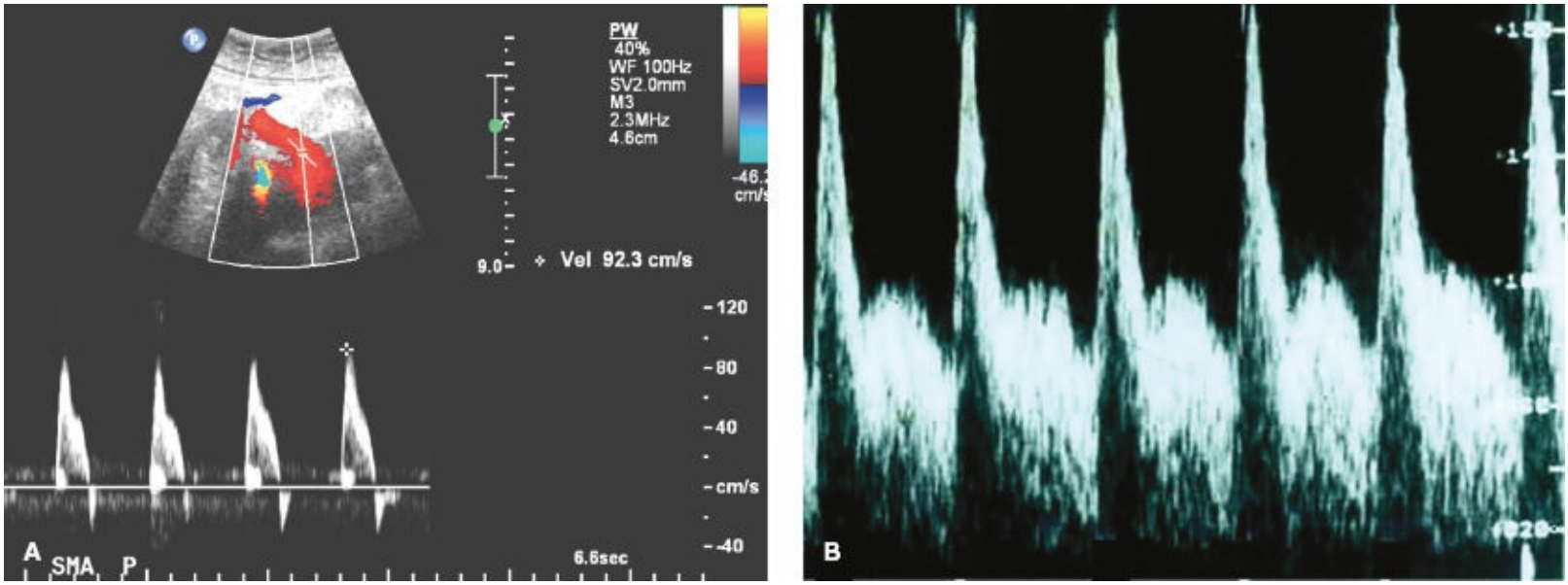

Figure 87-20. **A:** A normal fasting superior mesenteric artery (SMA) waveform may exhibit reverse flow at the end of systole and relatively low end-diastolic velocity reflecting relatively high resistance of the intestinal circulation in the fasting state. **B:** Postprandial SMA waveform. There has been, in comparison to **A,** loss of end-systolic reverse flow and an increase in end-diastolic flow as resistance in the intestinal arterial circulation falls following feeding.

Placement of an intraluminal stent is a viable alternative in many cases to surgical bypass, for the treatment of mesenteric artery stenosis. Similar to the carotid artery (see above), there is reason to suspect duplex criteria developed for stenosis in native mesenteric arteries may not be applicable without modification to stented superior mesenteric arteries. Mesenteric duplex scans pre- and postplacement of a superior mesenteric artery (SMA) stent have been compared and correlated with pressure gradients measured at the time of angiography. The data indicate that SMA stenting provides good anatomic results and significantly reduces angiographically measured pressure gradients. Duplex measured SMA PSVs are reduced poststent placement but, despite good angiographic results, remain in most cases above criteria predicting high-grade native artery SMA stenosis.[65]

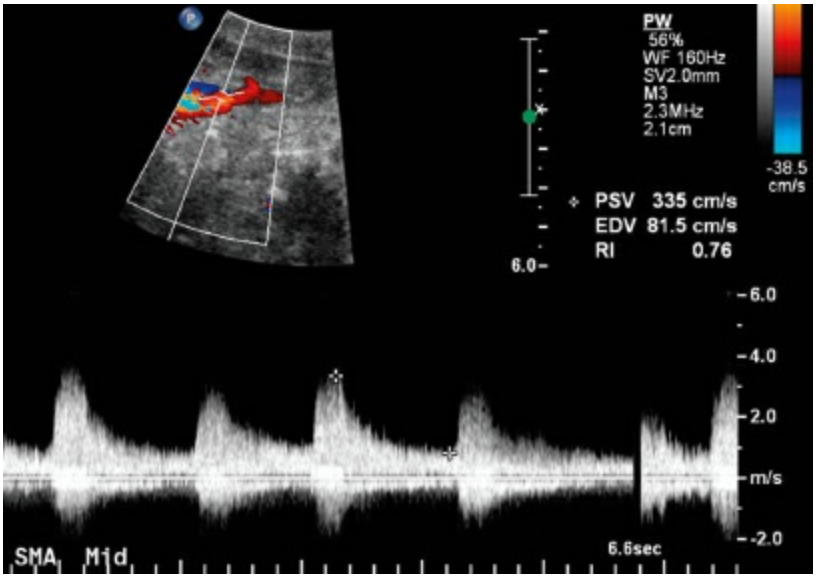

Figure 87-21. Color flow image and duplex-derived SMA waveform in a patient with possible chronic mesenteric ischemia. A peak systolic velocity of >330 cm/s indicates a high-grade SMA stenosis and is compatible with a clinical picture of chronic mesenteric ischemia.

RENAL ARTERIES

Duplex scanning of the renal arteries is useful in evaluating for renal artery stenosis in patients with possible renal vascular hypertension and can also be used to detect renal artery aneurysms (Fig. 87-22), as well as provide a measure of the health of the renal parenchyma.

Indirect Assessment of Renal Artery Stenosis

Indirect methods to assess renal artery stenosis evaluate interlobar arteries. Decreased acceleration times and/or presence of tardus/parvus waveforms (waveforms with delayed or slowed upstrokes) may suggest the presence of a main renal artery stenosis. These techniques are quicker and easier to perform than direct examination of the main renal artery but have been not widely validated. Improved visualization of main renal arteries with modern duplex scanners has made indirect methods of assessing the main renal artery essentially obsolete. These techniques are even less accurate in patients with bilateral stenosis and are not applicable in patients with a single patent renal artery.

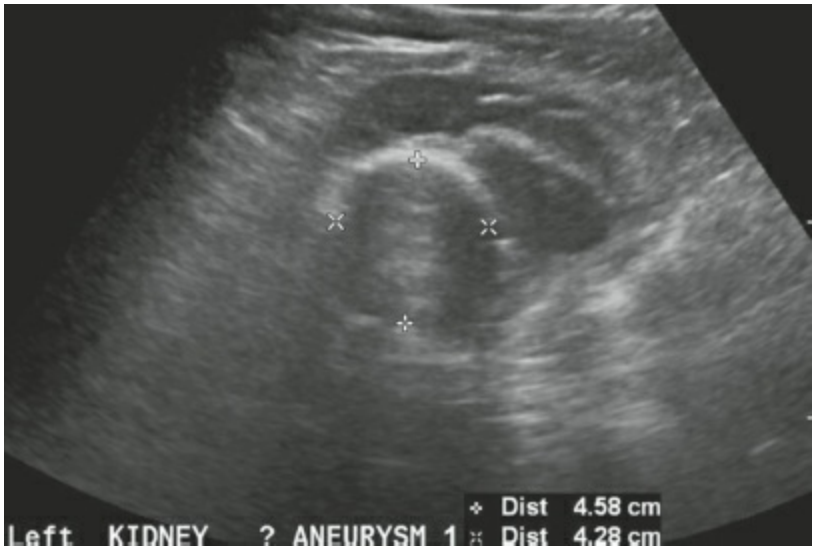

Figure 87-22. Grayscale image of a large renal artery aneurysm in the hilum of the kidney.

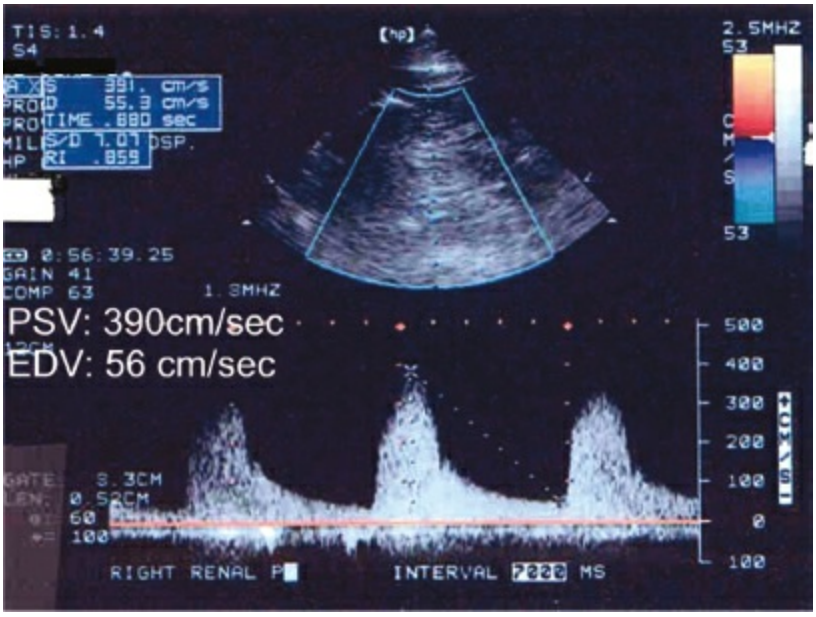

Figure 87-23. Renal artery waveform in a patient with severe hypertension. The high peak systolic velocity is compatible with a high-grade renal artery stenosis.

Direct Assessment of Renal Artery Stenosis

Normal renal arteries have a PSV less than 180 cm/s and low-resistance waveforms reflecting the high metabolic demands of the kidney. A ratio of the PSV in the renal artery to that in the aorta (renal–aortic ratio, RAR) of ≥3.5 indicates a ≥60% diameter-reducing renal artery stenosis (84% to 88% sensitivity, 97% to 99% specificity, 94% to 98% positive predictive value) (Fig. 87-23).[66] A PSV of ≥200 cm/s has also been suggested to indicate a ≥60% renal artery stenosis whereas a velocity in the renal artery of >185 cm/s has been suggested to indicate a less than 60% renal artery stenosis. Therefore a renal artery can be considered normal when PSV is <180 cm/s and the RAR is <3.5. With a PSV >180 cm/s and a RAR <3.5, the renal artery can be considered to have a <60% stenosis. RARs of >3.5 indicate >60% renal artery stenosis regardless if the renal artery PSV is less than or more than 180 cm/s.[67] When the EDV exceeds 150 cm/s, data suggest a >80% renal artery stenosis.[68] The same criteria have been used to evaluate the patency of renal arterial reconstructions, but similar to stented carotid and mesenteric arteries may need modification for stented renal arteries.[69]

Predicting Success of Renal Artery Interventions

EDVs tend to be lower in patients with renal insufficiency, indicating decreased diastolic flow and suggesting increased parenchymal resistance to blood flow. Decreased parenchymal diastolic velocities may therefore suggest renal parenchymal disease (Fig. 87-24). Many patients, 20% to 40%, treated with renal artery angioplasty and stenting or open surgical reconstructions do not have postprocedure blood pressure or renal function improvement. An estimate of resistance to flow within the renal parenchyma can be made by comparisons of EDV and PSVs of renal artery waveforms obtained from renal parenchymal arteries. The so-called resistive index (RI) is calculated as follows:

$$RI = [1 - (EDV/PSV)] \times 100$$

In effect a high RI, >0.7 is bad, suggesting renal parenchymal disease whereas a low RI is good, indicating healthy renal parenchymal tissues. Evaluation of parenchymal resistance has been suggested as a possible preprocedure predictor of clinical success of renal artery interventions.[70] Abnormal parenchymal resistance may also be a marker of renal allograft dysfunction or rejection (Fig. 87-25).

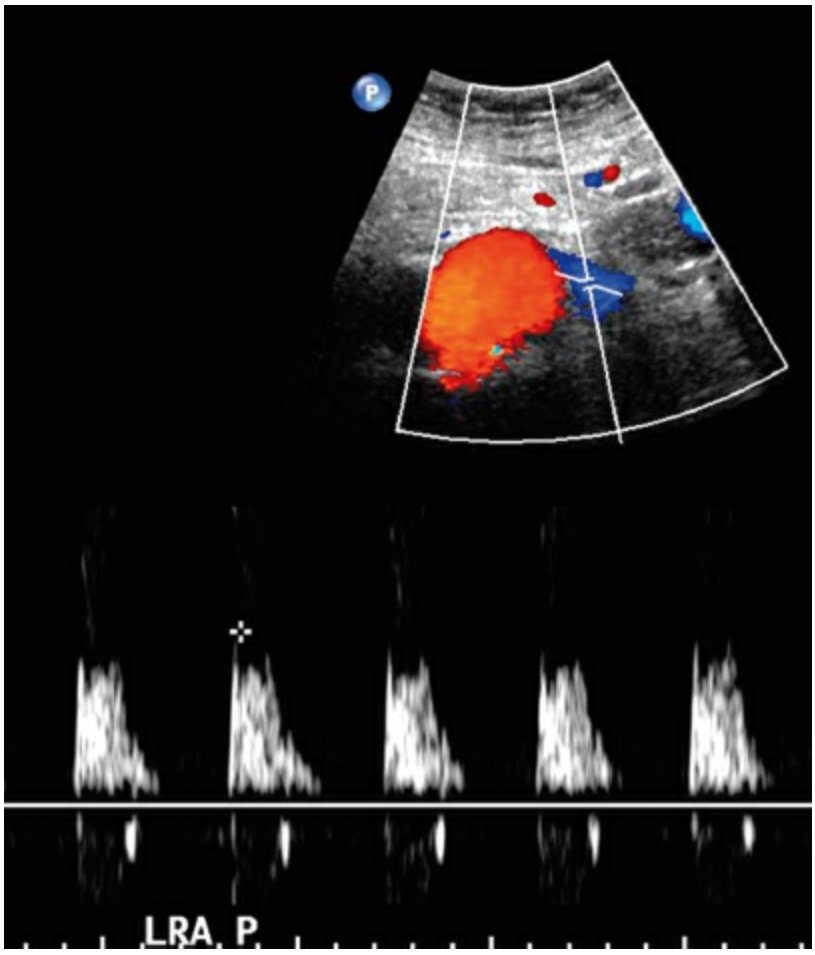

Figure 87-24. The absence of end-diastolic flow in the left renal artery indicates severe parenchymal disease of the left kidney.

VENOUS DISEASE

Acute Deep Venous Thrombosis

Physical examination is not sensitive or specific for the detection of acute deep venous thrombosis (DVT).[71] Prior to the acceptance and widespread use of venous duplex scanning, impedance plethysmography (IPG) was employed as the initial noninvasive test for patients with suspected acute lower extremity DVT. IPG is a reasonably sensitive (87%) and specific (up to 100%) test for proximal (above knee) lower extremity DVT in symptomatic patients.[72–74] However, lower sensitivities for proximal DVT (65%) have been reported in studies that exclude clinical outcomes and only report in comparison to venography. IPG may not detect nonocclusive proximal DVT, occlusive proximal DVT present in parallel venous systems, such as duplicated femoral or popliteal veins, and cannot detect DVT isolated to the calf veins.[75,76] While IPG is still sometimes used for clinical situations felt to require serial evaluations of the proximal veins, the limitations noted above make it a substandard examination for routine clinical assessment of lower extremity DVT.[77] Currently, color flow duplex scanning performed by skilled operators provides the most practical and cost-effective method for assessment of DVT of the lower and upper extremity veins as well as for detection of thrombosis in superficial veins.

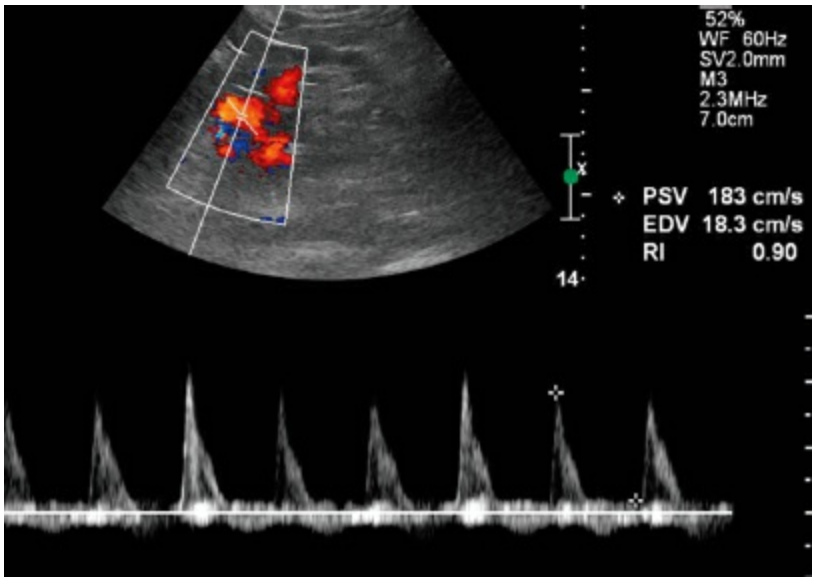

Figure 87-25. There is very little diastolic flow in the renal artery of the transplanted kidney consistent with rejection or primary allograft dysfunction.

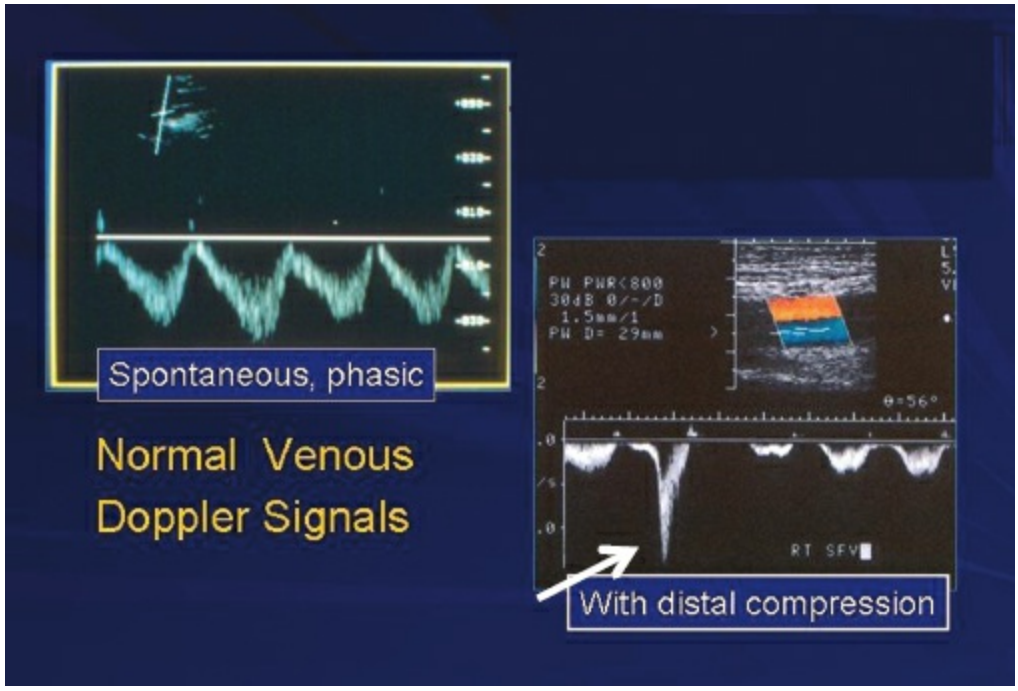

Figure 87-26. Venous flow is typically depicted below the baseline. Venous flow in the proximal lower extremity veins should be spontaneous, vary with respiration, and augment with distal compression.

At a minimum, vascular laboratory duplex ultrasound evaluation for lower extremity DVT should include examination of the common femoral, profunda femoris, femoral, and popliteal veins. Venous waveforms from the right and left common femoral veins should always be compared. A normal lower extremity examination will show patency of the veins on color flow imaging, collapsing of the veins with application of pressure by the ultrasound probe and venous flow patterns in the common femoral and femoral veins that decrease with inspiration and increase with expiration. Flow within a patent vein should also increase with application of compression distal to the site of examination (Fig. 87-26).

9 The primary ultrasound diagnostic criteria for diagnosis of venous thrombosis is failure of the vein to collapse with application of pressure with the ultrasound probe (Fig. 87-27A,B). A continuous flow pattern in one common femoral vein and not the other suggests ipsilateral iliac vein thrombosis or external compression of the ipsilateral iliac vein. Bilateral pulsatile common femoral waveforms suggest volume overload, tricuspid regurgitation, or heart failure.

Not all venous ultrasound examinations for DVT are the same. Some vascular laboratories do not include evaluation of the calf veins as part of their routine evaluation for lower extremity DVT, even in symptomatic patients. This results from outdated perceptions of inaccuracy of calf vein ultrasound evaluation for DVT. Failure to perform a complete initial examination necessitates serial ultrasound examinations or alternative strategies to detect possible extension of venous thrombi initially isolated to the calf veins. Such strategies are inefficient, ineffective for noncompliant patients, and not cost effective compared to a single stand-alone color flow duplex study of the proximal and calf veins in patients with suspected lower extremity DVT.

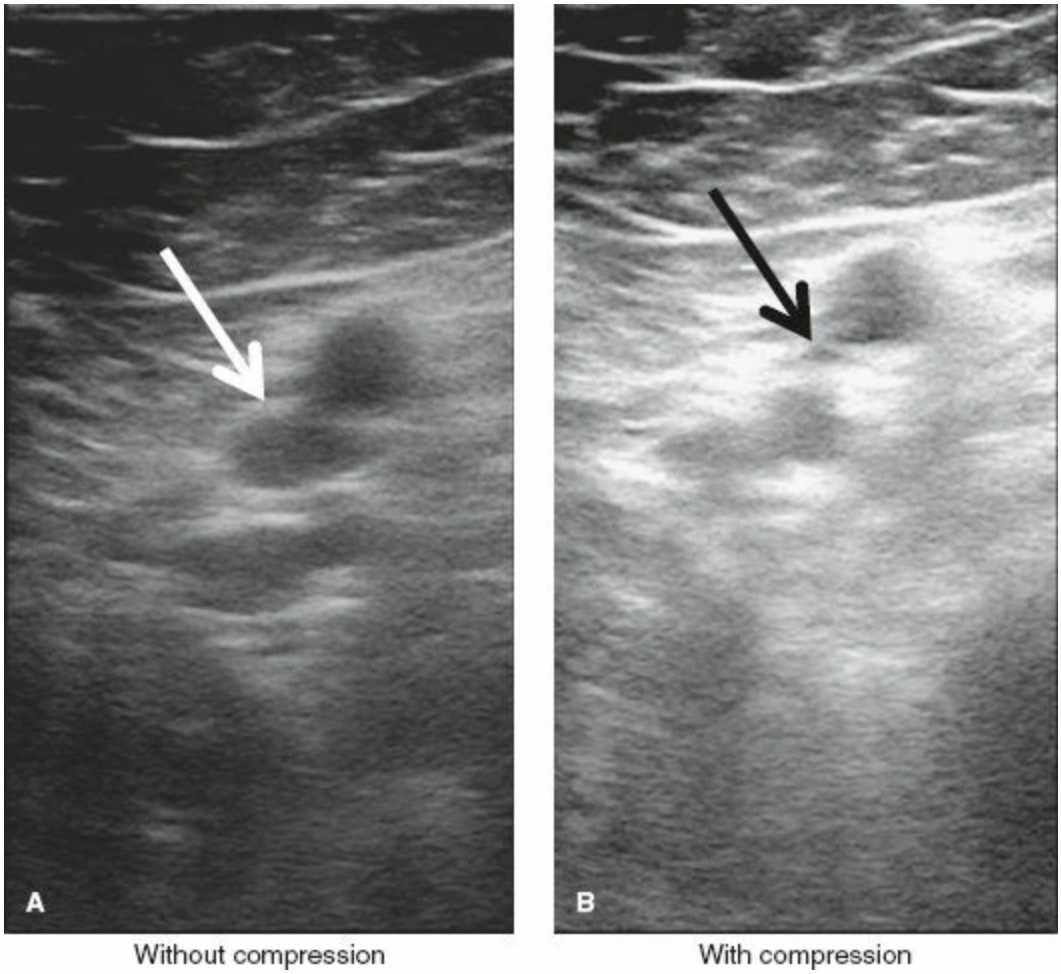

Figure 87-27. **A:** Without compression with the ultrasound probe the femoral vein is easily visible (*white arrow*). **B:** With compression the vein collapses and is no longer visible (*black arrow*). Failure of the vein to collapse with probe pressure would indicate the presence of thrombus within the vein.

Limited ultrasound studies for acute DVT may include compression ultrasound (B-mode imaging only), duplex ultrasound (B-mode imaging and Doppler waveform analysis), and color Doppler alone. The sensitivities and specificities for detecting acute DVT differ among the examinations, and different examinations are appropriate for different veins. Compression ultrasound is typically performed for evaluation of proximal deep veins, specifically the common femoral, femoral, and popliteal veins. A combination of duplex ultrasound and color Doppler is more often used for calf and iliac veins. Color flow alone may be used to assess patency of the calf veins as they are difficult to reliably compress in subjects with larger legs.

Many factors will influence which venous segments can be evaluated in an individual examination. These include the presence of morbid obesity, lower extremity edema or tenderness, or the presence of immobilization devices and bandages. Overall, a complete color and Doppler examination has become the standard of care for assessment of lower extremity DVT. It is recommended that whenever possible, a venous duplex examination to exclude the presence of DVT consist of an evaluation of both the proximal and calf veins.

A well-trained technologist can interrogate calf veins in 80% to 98% of cases using a combination of B-mode, Doppler waveform analysis, and color Doppler.[78,79] Overall

accuracy of venous ultrasonography in comparison to venography has been well established. The weighted mean sensitivity and specificity of venous ultrasonography (including all types) for the diagnosis of symptomatic proximal DVT are 97% and 94%, respectively.[77] As suggested above, in technically adequate studies, the sensitivity and specificity of color Doppler to identify isolated calf vein thrombosis exceeds 90%.[79] The high specificity of venous ultrasonography allows treatment for DVT to be initiated without further confirmatory tests, and the high sensitivity in diagnosing proximal DVT makes it possible to withhold treatment if the examination is negative.

Some ultrasound examinations are limited by practical constraints. Inability of the patient to fully cooperate with regard to positioning for the examination and/or intolerance of the pressure of the ultrasound scan head on the skin, or inability of the examiner to obtain a complete examination secondary to bandages, casts, or extremity wounds, may lead to a requirement for serial examinations. An alternative diagnostic procedure, such as catheter-based contrast, MR, or CT venography may be indicated when a complete ultrasound examination is not possible or if the patient cannot or is unlikely to return for a follow-up examination. Currently, repeat or serial venous ultrasound examinations are advisable in follow-up for a limited negative examination in symptomatic patients highly suspicious for DVT in whom an alternative form of imaging is unavailable or contraindicated.

The diagnosis of pulmonary embolism (PE), like that for DVT, also cannot be established without objective testing. Several studies have evaluated lower extremity venous ultrasound examinations in patients suspected of PE. These studies, often employing ultrasound of only the proximal veins and nuclear medicine-based ventilation perfusion (V/Q) scanning, unfortunately have little relevance to modern practice where complete proximal and distal vein ultrasound examinations are usually routine, and where CT pulmonary angiography (CTPA) or MR pulmonary angiography (MRPA) have largely supplanted V/Q scanning.

The rationale for venous ultrasonography in patients who present with symptoms of PE is that a diagnosis of DVT may indirectly suggest a diagnosis of PE, making additional investigation to exclude PE unnecessary in some clinical settings. However, ultrasound cannot make a definitive diagnosis of PE. Patients can have DVT and pulmonary symptoms or hemodynamic instability from causes other than PE.

Normal bilateral proximal venous ultrasound scans do not rule out PE. When PE is definitively present, DVT of the proximal lower extremity veins is detectable by compression ultrasound in only 50% of patients.[80] When a PE is objectively diagnosed with no evidence of lower extremity DVT, the PE may have originated from pelvic veins, arm veins, or possibly embolized completely from a lower extremity vein. An objective diagnostic test for PE is therefore indicated in most cases. Currently, in most centers this would be a CT pulmonary angiogram.

Chronic Venous Insufficiency (CVI)

The presence of venous insufficiency can also be evaluated with either air or photoplethysmography and with duplex scanning.[81] In theory, air plethysmography (APG) can provide an analysis of overall venous hemodynamics including evaluation of the individual components of venous function; reflux and the efficacy of the calf muscle pump. A flexible chamber is placed on the calf and volume changes then induced by a series of positional and exercise maneuvers. Measurements derived from these maneuvers are then used to calculate measures of venous reflux (venous filling index [VFI]), calf muscle pump function (ejection fraction [EF]) as well as a measure of overall venous function termed the residual volume fraction. Of these values VFI has the potential for being the most important. A VFI of >2 mL/s indicates abnormal reflux with values >10 mL/s indicating increased risk of cutaneous changes associated with chronic venous insufficiency. APG, however, while theoretically interesting, is used only infrequently in clinical practice.

Photoplethysmography (PPG) is a variant of plethysmography techniques to assess venous reflux. It detects changes in the blood content of the skin that theoretically reflect venous volume. It consists of a light emitting diode and a photo sensor. The diode transmits light into subcutaneous tissues. Blood attenuates light in proportion to its content in tissue. The PPG machine amplifies the difference between the transmitted and reflected signal and converts it into a waveform. To assess for venous reflux the sensor is typically applied to the medial ankle area (Fig. 87-28). The patient performs a series of plantar and dorsal flexion maneuvers of the foot decreasing the venous volume of the extremity. The time for the waveform to return to baseline is termed the venous recovery time (VRT). A normal PPG VRT is 20 seconds or greater. Shorter times indicate the presence of venous reflux. If the VRT returns to normal with the application of a superficial venous tourniquet then the reflux is confined to the superficial venous system (Fig. 87-29). If the VRT does not correct with a superficial venous tourniquet deep venous reflux is present. Neither, APG or PPG can provide information about the specific venous segments that are abnormal. That information can be provided by duplex ultrasound.

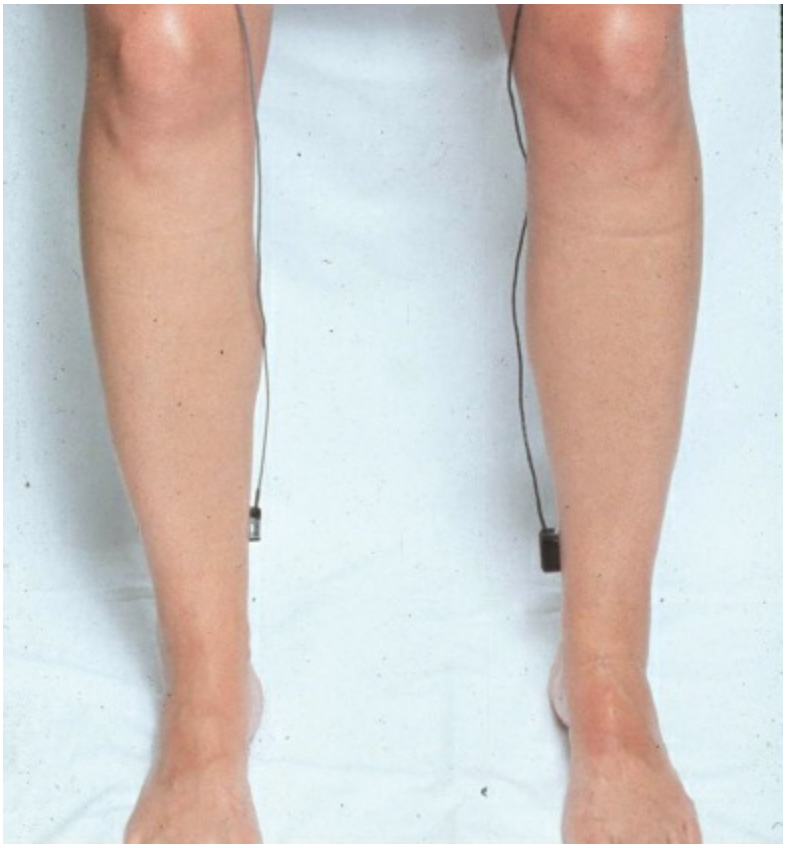

Figure 87-28. Placement of PPG probes for assessment of venous reflux.

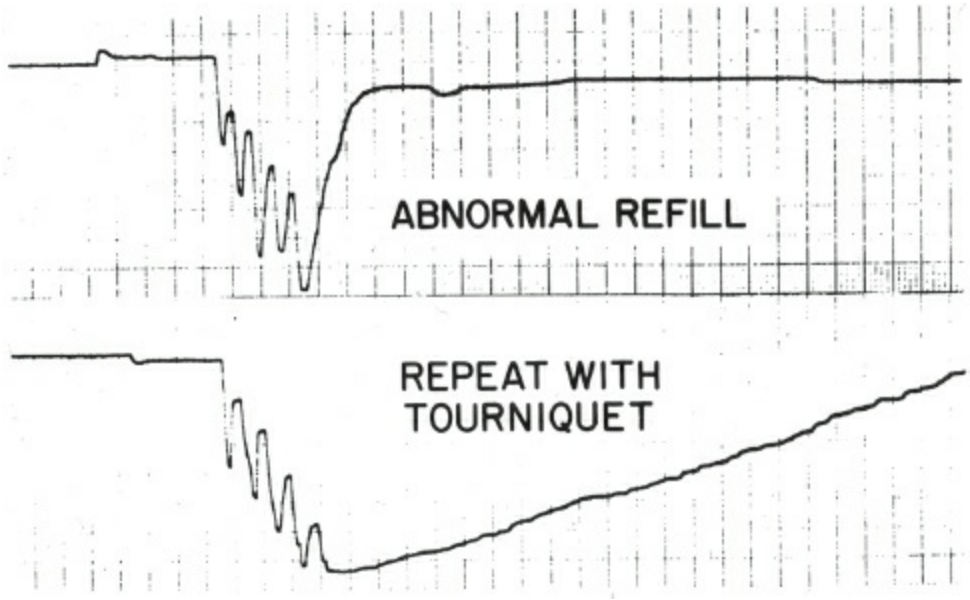

Figure 87-29. Venous PPG waveforms in a patient with superficial venous reflux. The patient is asked to perform 10 dorsal and plantar flexions of the ankle resulting in emptying the leg of venous blood. In the top panel the veins refill very rapidly indicating the presence of venous reflux. Refill slows with application of a tourniquet to occlude the superficial veins indicating this patient likely has only reflux in the superficial venous system and no deep venous reflux.

10 Duplex ultrasound can provide important physiologic and anatomic information in patients with possible CVI. Both sites of reflux and of venous obstruction can be determined in deep, superficial, and perforating veins. In patients with valve incompetence, reflux can be stimulated and then detected with duplex using a Valsalva

maneuver, manual compression proximal to the transducer, or release of compression distal to the transducer. The examination has been standardized with the patient upright and using deflation of a series of pneumatic cuffs at specific sites on the leg with the leg under examination not bearing weight. In the upright position, reflux stimulated by cuff deflation that lasts more than 0.5 second is indicative of pathologic reflux.[82] The technique allows localization of reflux to specific venous segments and can serve as a valuable preoperative planning tool to target specific venous segments for removal or reconstruction (Fig. 87-30). It has a sensitivity of 82% and specificity of 100% for the identification of competent and incompetent perforating veins. Duplex determination of reflux sites and sites of venous occlusion as a means of assessing overall venous hemodynamics is not established. Currently duplex assessment of venous reflux provides the basis of planning for the large majority of venous procedures designed to treat the manifestations of superficial venous reflux.

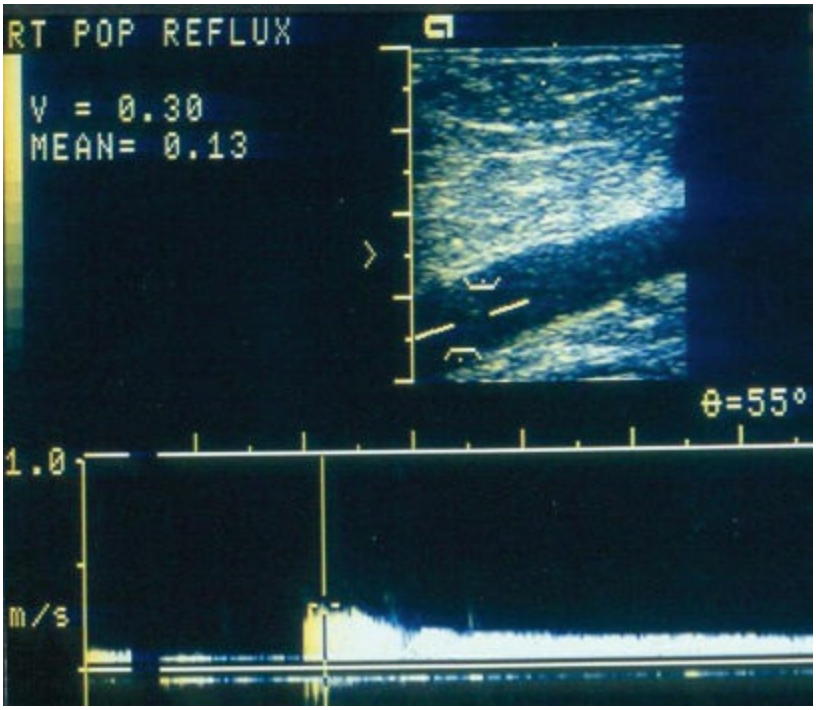

Figure 87-30. Popliteal venous waveform with cuff deflation for duplex assessment and localization of venous reflux. Reflux lasting >0.5 to 1 second is abnormal.

SELECTED MISCELLANEOUS EXAMINATIONS

Evaluation for Abdominal Aortic Aneurysm

Vascular laboratory ultrasound screening for abdominal aortic aneurysm (AAA) in males >65 years with a history of cigarette smoking has been shown to be effective in preventing aneurysm related deaths in this cohort.[83] Ultrasound is highly accurate and reproducible in measuring the diameter of infrarenal AAAs (Fig. 87-31). Typically patients with AAA diameters below accepted threshold levels for repair are followed with serial ultrasound examinations to monitor for enlargement of the aneurysm to a diameter where repair is indicated.

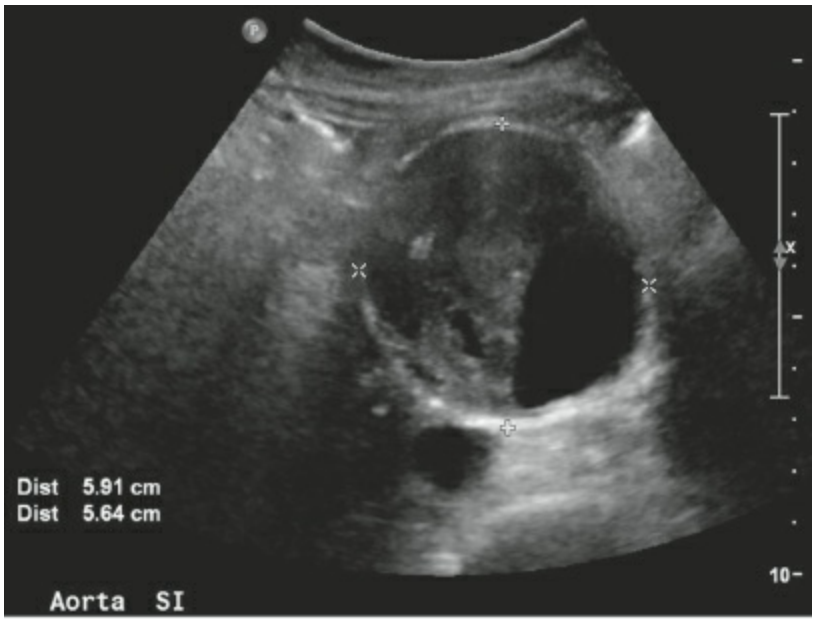

Figure 87-31. Ultrasound image of a 5.9-cm infrarenal abdominal aortic aneurysm with acentric intraluminal thrombus.

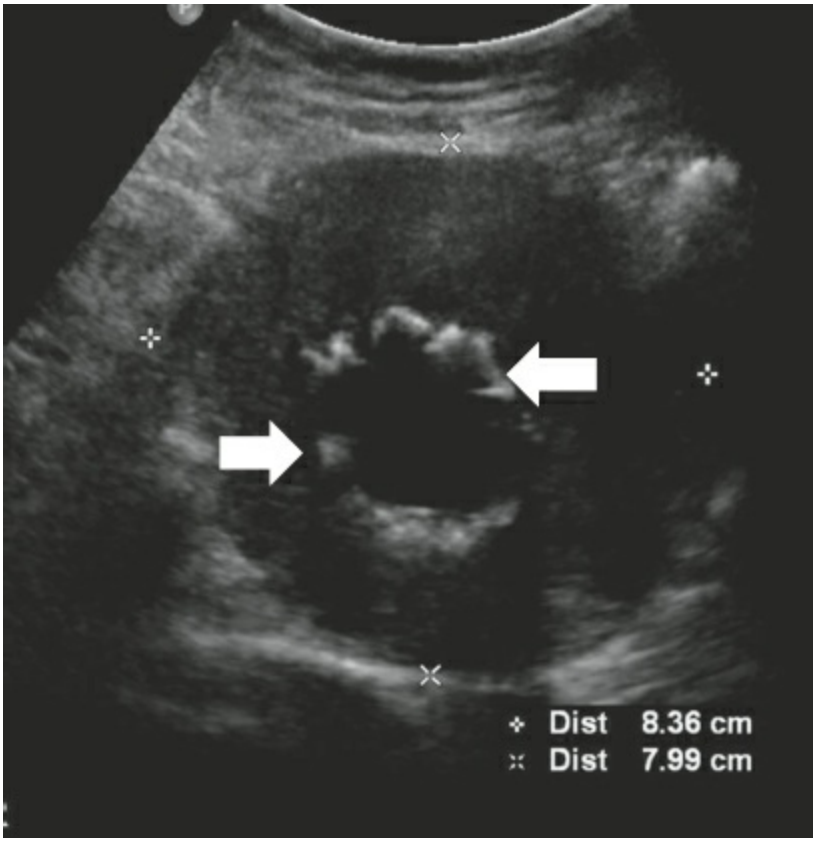

Figure 87-32. Ultrasound examination of an aortic stent graft. The aortic stent graft (*arrows*) is visible within the lumen of the residual aneurysm sac measuring 8.36 cm × 7.99 cm.

Evaluation of Aortic Endografts

Placement of endoluminal stent grafts is now standard therapy for most patients with AAA. With stent grafting of an AAA the aneurysm is left in situ and blood flow diverted through the stent graft. Some stent grafts eventually leak at proximal or distal attachment sites. AAAs with these so-called type I endoleaks are at increased risk of rupture. In addition, AAAs treated with stent grafts may also occasionally enlarge because of back pressure in the aneurysm sac from patent lumbar vessels; type II endoleak. Patients whose AAAs enlarge in association with type II endoleaks after endografting are also considered at risk for aneurysm rupture.

Standard monitoring of endoluminal stent grafts is with serial CT scans to detect endoleak and changing aneurysm sac diameter. However, there are increasing concerns about repeated doses of contrast and radiation exposure associated with serial CT scans. It now appears many stent grafts can be followed with serial duplex ultrasound examinations. Duplex ultrasound is capable of measuring sac diameter (Fig. 87-32) and detecting both type I and II endoleaks. Even if an endoleak cannot be detected by ultrasound an increase in sac diameter following stent grafting should prompt further investigation. In some centers duplex ultrasound has replaced CT scanning as the preferred method of follow-up of AAA stent grafts.[84,85]

Evaluation and Treatment of Groin Pseudoaneurysms

Pseudoaneurysms can occur as a complication of an arterial puncture in the groin performed for diagnostic or therapeutic angiography. Groin pseudoaneurysms are readily detected with duplex ultrasound (Fig. 87-33). Color flow demonstrates a typical collection of flowing blood usually anterior to the artery from which the psuedoaneurysm originates. The native artery and the pseudoaneurysm are connected by a so-called "neck." To-and-fro flow within the neck of the pseudoaneurysm is characteristic and pathognomonic of a pseudoaneurysm arising from an arterial puncture.

Treatment of pseudoaneurysms may be with direct surgical repair or, utilizing the vascular laboratory, direct compression of the pseudoaneurysm until it clots using the ultrasound scan head to both locate the pseudoaneurysm and apply pressure. Alternatively, the pseudoaneurysm is visualized with the ultrasound scan head and a needle introduced into the body of the pseudoaneurysm for injection of small amounts of thrombin to induce thrombosis of the pseudoaneurysm.[86] All techniques are effective but currently direct thrombin injection is favored in most cases as it is relatively noninvasive and less painful and more effective than prolonged compression alone.[87,88]

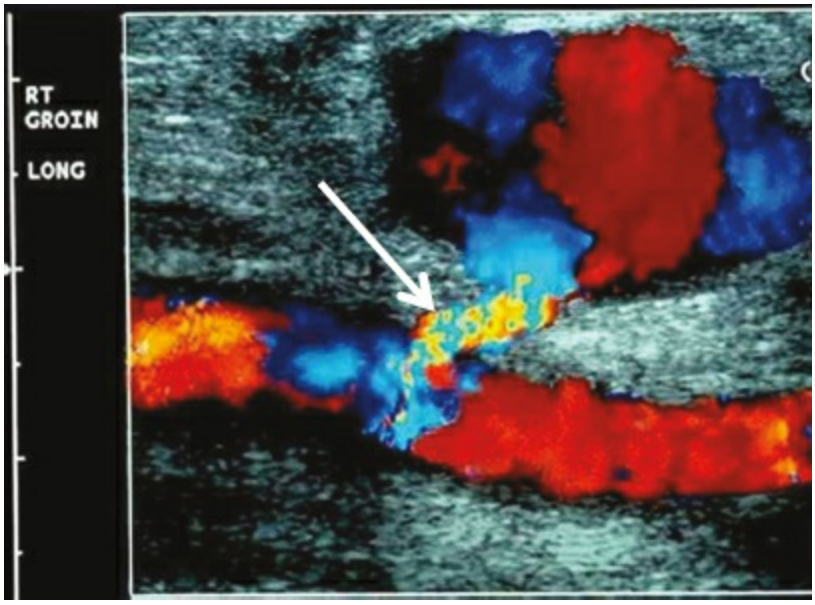

Figure 87-33. A pseudoaneurysm of the superficial femoral artery following arterial cannulation. The so-called neck of the aneurysm (*arrow*) is readily visible.

Transcutaneous Oxygen ($TCpO_2$) Measurements

Measurements of transcutaneous oxygen can be performed as an aid in predicting healing of pedal lesions or healing of an amputation at the site where the measurement is taken (Fig. 87-34). In general, a $TCpO_2$ >30 mm Hg indicates healing is likely, measurements between 20 and 30 mm Hg are equivocal for healing and measurements below 20 mm Hg indicate healing is unlikely.[89] Measurements are not influenced by the presence of diabetes but it has been suggested the level for predicting healing be increased to 40 mm Hg in patients with diabetes. The test is less accurate in the presence of edema, cellulitis, hyperkeratosis, and in older patients.



Figure 87-34. A transcutaneous oxygen probe. $TCpO_2$ measurements can serve as an aid in determining healing potential of pedal wounds or ulcers.

References

1. Roederer GO, Langlois YE, Chan AT, et al. Ultrasonic duplex scanning of the extracranial carotid arteries: improved accuracy using new features from the carotid artery. *J Cardiovasc Ultrasonography* 1982;1:373–380.
2. Abou-ZamZam AM Jr, Moneta GL, Edwards JM, et al. Is a single preoperative duplex scan sufficient for planning bilateral carotid endarterectomy? *J Vasc Surg* 2000;31:282–288.
3. Strandness DE Jr. *Duplex Scanning in Vascular Disorders.* New York, NY: Raven Press; 1990:92–120.
4. Roederer GO, Langlois YE, Jager KA, et al. A simple spectral parameter for accurate classification of severe carotid artery disease. *Bruit* 1989;3:174–178.
5. Moneta GL, Edwards JM, Chitwood RW, et al. Correlation of North American Symptomatic Carotid Endarterectomy Trial (NASCET): angiographic definition of 70% to 90% internal carotid artery stenosis with duplex scanning. *J Vasc Surg* 1993;17:152–159.
6. Bendick PJ, Glover JL. Hemodynamic evaluation of the vertebral arteries by duplex ultrasound. *Surg Clin North Am* 1990;70:235–244.
7. Kumar SM, Wang JC, Barry MC, et al. Carotid stump syndrome: outcome from surgical management. *Eur J Vasc Endovasc Surg* 2001;21:214–219.
8. North American Symptomatic Carotid Endarterectomy Trial Collaborators: NASCET. Beneficial effect of carotid endarterectomy in patients with high-grade carotid stenosis. *N Engl J Med* 1991;325:445–453.
9. European Carotid Surgery Trialists' Collaborative Group (ECST). MRC European Carotid surgery Trial: interim results for symptomatic patients with severe (70–99%) or with mild (0–29%) carotid stenosis. *Lancet* 1996; 347:1591–1593.
10. Mayberg MR, Wilson SE, Yatsu F, et al. Carotid endarterectomy and prevention of cerebral ischemia in symptomatic carotid stenosis: Veterans Affairs Cooperative Studies Program 309 Trialist Group. *JAMA* 1991;266:3289–3294.
11. Executive Committee for Asymptomatic Carotid Atherosclerosis Study: endarterectomy for asymptomatic carotid artery stenosis. *JAMA* 1995;273:1421–1428.
12. MRC Asymptomatic Carotid Surgery Trial (ACST) Collaborative Group. Prevention of disabling and fatal strokes by successful carotid endarterectomy in patients without recent neurological symptoms: randomized controlled trial. *Lancet* 2004;363:1491–1502.
13. North American Symptomatic Carotid Endarterectomy (NASCET) Steering Committee: North American symptomatic carotid endarterectomy trial: methods, patient characteristics, and progress. *Stroke* 1991;22:711–720.
14. Rothwell PM, Gibson RJ, Slattery J, et al. Equivalence of measurements of carotid stenosis: a comparison of three methods on 1001 angiograms. *Stroke* 1994;25:2435–

2439.
15. Moneta GL, Edwards JM, Papanicolaou G, et al. Screening for asymptomatic internal carotid artery stenosis: duplex criteria for discriminating 60% to 99% stenosis. *J Vasc Surg* 1995;21:989–994.
16. AbuRahma AF, Robinson PA, Stickler DL, et al. Proposed new duplex classification for threshold stenoses used in various symptomatic and asymptomatic carotid endarterectomy trials. *Ann Vasc Surg* 1998;12:349–358.
17. Carpenter JP, Lexa FJ, Davis JT. Determination of duplex Doppler ultrasound criteria appropriate to the North American symptomatic carotid endarterectomy trial. *Stroke* 1996;27:695–699.
18. Hood DB, Mattos MA, Mansour A, et al. Prospective evaluation of new duplex criteria to identify 70% internal carotid artery stenosis. *J Vasc Surg* 1996;23:254–261.
19. Carpenter JP, Lexa FJ, Davis JT. Determination of 60% or greater carotid artery stenosis by duplex Doppler ultrasonography. *J Vasc Surg* 1995;22:697–703.
20. Browman MW, Cooperberg PL, Harrison PB, et al. Duplex ultrasonography criteria for internal carotid stenosis of more than 70% diameter: angiographic correlation and receiver operating characteristic curve analysis. *Can Assoc Radiol J* 1995;46:291–295.
21. Neale ML, Chambers JL, Kelly AT, et al. Reappraisal of duplex criteria to assess significant carotid stenosis with special reference to reports from the north american symptomatic carotid endarterectomy trial and the European trial and the european carotid surgery trial. *J Vasc Surg* 1994;20:642–649.
22. Grant EG, Benson CB, Moneta GL, et al. Carotid artery stenosis: gray-scale and Doppler US diagnosis—Society of Radiologists in Ultrasound Consensus Conference. *Radiology* 2003;229:340–346.
23. Fujitani RM, Mills JL, Wang LM, et al. The effect of unilateral internal carotid arterial occlusion upon contralateral duplex study: criteria for accurate interpretation. *J Vasc Surg* 1992;16:459–467.
24. Setacci C, Chisci E, Setacci F, et al. Grading carotid intra-stent re-stenosis: a six-year follow-up study. *Stroke* 2008;30:1189–1196.
25. Lal BK, Beach KW, Roubin GS; CREST Investigators. Restenosis after carotid artery stenting and endarterectomy: a secondary analysis of CREST: a randomised controlled trial. *Lancet Neurol* 2012;11:755–763.
26. Romero JM, Hannon KM, Dick J, et al. Detection of common carotid artery stenosis using duplex ultrasonography: a validation study with computed tomographic angiography. *J Vasc Surg* 2010;51:65–70.
27. Yao JS, Nedham TN, Gourmos C. A comparative study of strain gauge plethysmography and Doppler ultrasound in the assessment of occlusive arterial disease of the lower extremities. *Surgery* 1972;71:4–9.
28. Strandness DE. *Peripheral Arterial Disease: a Physiologic Approach.* Boston: Little, Brown; 1969:112–130.

29. Kempczinski RF. Segmental volume plethysmography: the pulse volume recorder. In: Kempczinski RF, Yao JS, eds. *Practical Noninvasive Vascular Diagnosis.* Chicago: Yearbook Medical Publishers; 1987:140–153.
30. Krikendall WM, Burton AC, Epstein FH, et al. Recommendations for human blood pressure determination by sphygmomanometers: report of a subcommittee of the postgraduate education committee, American Heart Association. *Circulation* 1967;36:980–988.
31. Moneta GL, Yeager RA, Antonovic R, et al. Accuracy of lower extremity arterial duplex mapping. *J Vasc Surg* 1992;15:275–284.
32. Jager KA, Ricketts HJ, Strandness DE. Duplex scanning for evaluation of lower limb arterial disease. In: Bernstein EF, ed. *Noninvasive Diagnostic Techniques in Vascular Disease.* St Louis, MO: Mosby; 1985:619–631.
33. Whyman MR, Hoskins PR, Leng GC, et al. Accuracy and reproducibility of duplex ultrasound imaging in a phantom model of femoral artery stenosis. *J Vasc Surg* 1993;17:524–530.
34. Leng GC, Whyman MR, Donnan PT, et al. Accuracy and reproducibility of duplex ultrasonography in grading femoropopliteal stenoses. *J Vasc Surg* 1993;17:510–517.
35. Sacks D, Robinson ML, Marinelli DL, et al. Peripheral arterial Doppler ultrasonography: diagnostic criteria. *J Ultrasound Med* 1992;11:95–103.
36. Jager KA, Phillips DJ, Martin RL, et al. Noninvasive mapping of lower limb arterial lesions. *Ultrasound Med Biol* 1985;11:515–521.
37. Sensier Y, Hartshorne T, Thrush A, et al. A prospective comparison of lower limb colour-coded duplex scanning with arteriography. *Eur J Vasc Endovasc Surg* 1996;11:170–175.
38. de Smet AA, Ermers EJ, Kitslaar PJ. Duplex velocity characteristics of aortoiliac stenoses. *J Vasc Surg* 1996;23:628–636.
39. Elsman BH, Legemate DA, van der Heijden FH, et al. Impact of ultrasonographic duplex scanning on therapeutic decision making in lower-limb arterial disease. *Br J Surg* 1995;82:630–633.
40. Ascher E, Mazzariol F, Hingorani A, et al. The use of duplex ultrasound arterial mapping as an alternative to conventional arteriography for primary and secondary infrapopliteal bypasses. *Am J Surg* 1999;178:162–165.
41. Mazzariol F, Ascher E, Salles-Cunha SX, et al. Values and limitations of duplex ultrasonography as the sole imaging method of preoperative evaluation for popliteal and infrapopliteal bypasses. *Ann Vasc Surg* 1999;13:1–10.
42. Larch E, Minar E, Ahmadi R, et al. Value of color duplex sonography for evaluation of tibioperoneal arteries in patients with femoropopliteal obstruction: a prospective comparison with anterograde intraarterial digital subtraction angiography. *J Vasc Surg* 1997;25:629–636.
43. Landry GJ, Moneta GL, Taylor LM Jr, et al. Patency and characteristics of lower

extremity vein grafts requiring multiple revisions. *J Vasc Surg* 2000;32:23–31.
44. Johnson BL, Bandyk DF, Back MR, et al. Intraoperative duplex monitoring of infrainguinal vein bypass procedures. *J Vasc Surg* 2000;31:678–690.
45. Idu MM, Blankenstein JD, de Gier P, et al. Impact of a color-flow duplex surveillance program on infrainguinal vein graft patency: a five-year experience. *J Vasc Surg* 1993;17:42–52; discussion 52–53.
46. Lundell A, Lindblad B, Bergqvist D, et al. Femoropopliteal-crural graft patency is improved by an intensive surveillance program: a prospective randomized study. *J Vasc Surg* 1995;21:26–33; discussion 33–34.
47. Passman MA, Moneta GL, Nehler MR, et al. Do normal early color-flow duplex surveillance examination results of infrainguinal vein grafts preclude the need for late graft revision? *J Vasc Surg* 1995;22:476–481; discussion 482–484.
48. Mills JL Sr, Wixon CL, James DC, et al. The natural history of intermediate and critical vein graft stenosis: recommendations for continued surveillance or repair. *J Vasc Surg* 2001;33:273–278; discussion 278–280.
49. McLafferty RB, Edwards JM, Taylor LM Jr, et al. Diagnosis and long-term clinical outcome in patients presenting with hand ischemia. *J Vas Surg* 1995; 22:361–369.
50. Porter JM, Snider RL, Bardana EJ, et al. The diagnosis and treatment of Raynaud's phenomenon. *Surgery* 1975;77:11–23.
51. Nielsen SL, Lassen NA. Measurement of digital blood pressure after local cooling. *J App Physiol Respir Environ Exerc Physiol* 1977;43:907–910.
52. Lutolf O, Chen D, Zehnder T, et al. Influence of local finger cooling on laser Doppler flux and nailfold capillary blood flow velocity in normal subjects and in patients with Raynaud's phenomenon. *Microvasc Res* 1993;46:374–382.
53. Lafferty K, de Trafford JC, Roberts VC, et al. Raynaud's phenomenon and thermal entrainment: an objective test. *BMJ Clin Res* 1983;286:90–92.
54. Singh S, de Trafford JC, Baskerville PA, et al. Digital artery caliber measurement: a new technique of assessing Raynaud's phenomenon. *Eur J Vasc Surg* 1991;5:199–205.
55. Yurdakul M, Tola M, Uslu OS. Color Doppler ultrasonography in occlusive diseases of the brachiocephalic and proximal subclavian arteries. *J Ultrasound Med* 2008;27:1065–1070.
56. Strandness DE. *Duplex Scanning in Vascular Disorders.* New York, NY: Raven Press; 1993:159–196.
57. Grosveld WJ, Lawson JA, Eikelboom BC, et al. Clinical and hemodynamic significance of innominate artery lesions evaluated by ultrasonography and digital angiography. *Stroke* 1988;19:958–962.
58. Reed AJ, Fincher RM, Nichols FT. Case report: Takayasu's arteritis in a middle-aged caucasian woman: clinical course correlated with duplex ultrasonography and angiography. *Am J Med Sci* 1989;298:324–327.
59. Jagar KA, Fortner GS, Thiele BI, et al. Noninvasive diagnosis of intestinal angina. *J*

Clin Ultrasound 1984;12:588–591.

60. Gentile AT, Moneta GL, Masser P, et al. Fasting and postprandial superior mesenteric artery duplex scanning in the diagnosis of high-grade superior mesenteric artery stenosis. *Am J Surg* 1995;169:476–479.
61. Moneta GL, Taylor DC, Helton WS, et al. Duplex ultrasound measurement of postprandial intestinal blood flow: effect of meal composition. *Gastroenterology* 1988;95:1294–1301.
62. Moneta GL, Lee RW, Yeager RA, et al. Mesenteric artery duplex scanning: a blinded prospective study. *J Vasc Surg* 1993;17:79–86.
63. Zwolak, RM, Fillinger MF, Walsh DB, et al. Mesenteric and celiac duplex scanning: a validation study. *J Vasc Surg* 1998;27:1078–1087.
64. Liem TK, Segall JA, Wei W, et al. Duplex scan characteristics of bypass grafts to mesenteric arteries. *J Vasc Surg* 2007;45(5):922–928.
65. Mitchell EL, Chang EY, Landry GJ, et al. Duplex criteria for native superior mesenteric arteries stenosis overestimates stenosis in stented superior mesenteric arteries. *J Vasc Surg* 2009;50(2):335–340.
66. Taylor DC, Kettler MD, Moneta GL, et al. Duplex ultrasound in the diagnosis of renal artery stenosis: a prospective evaluation. *J Vasc Surg* 1988;7:363–369.
67. Hoffman U, Edwards JM, Carter S, et al. Role of duplex scanning for detection of atherosclerotic renal artery disease. *Kidney Int* 1991;39:1232–1238.
68. Olin JW, Piedmonte MR, Young JR, et al. The utility of duplex ultrasound scanning of the renal arteries for diagnosing significant renal artery stenosis. *Ann Intern Med* 1995;122:833–840.
69. Mohabbat W, Greenerg RK, Mastracci TM, et al. Revised duplex criteria and outcomes for renal stents and stent grafts following endovascular repair of juxtrarenal and thoracoabdominal aneurysms. *J Vasc Surg* 2009;49;827–837.
70. Radermacher J, Chavan A, Bleck J, et al. Use of Doppler ultrasonography to predict the outcome of therapy for renal-artery stenosis. *New Engl J Med* 2001;344:410–416.
71. Wells PS, Hirsh J, Anderson DR. Accuracy of clinical assessment of deep-vein thrombosis. *Lancet* 1995;345:1326–1330.
72. Hull R, van Aken WG, Hirsh J, et al. Impedance plethysmography using the occlusive cuff technique in the diagnosis of venous thrombosis. *Circulation* 1976;53:696–700.
73. Hull R, Hirsh J, Sackett DL, et al. Combined use of leg scanning and impedance plethysmography in suspected venous thrombosis: an alternative to venography. *N Engl J Med* 1977;296:1497–1500.
74. Hull R, Taylor DW, Hirsh J, et al. Impedance plethysmography: the relationship between venous filling and sensitivity and specificity for proximal vein thrombosis. *Circulation* 1978;58:898–902.
75. Hull R, Hirsh J, Sackett DL, et al. Replacement of venography in suspected venous thrombosis by impedance plethysmography and ^{125} I-fibrinogen leg scanning: a less

invasive approach. *Ann Intern Med* 1981;94:12–15.
76. Anderson DR, Lensing AW, Wells PS, et al. Limitations of impedance plethysmography in the diagnosis of clinically suspected deep vein thrombosis. *Ann Intern Med* 1993;118:25–30.
77. Kearon C, Julian JA, Math M, et al. Noninvasive diagnosis of deep vein thrombosis. McMaster Diagnostic Imaging Practice Guidelines Initiative. *Ann Intern Med* 1998;128:663–677.
78. Schindler JM, Kaiser M, Gerber A, et al. Color coded duplex sonography in suspected deep vein thrombosis. *Br J Surg* 1991;78:611–613.
79. Rose SC, Zwiebel WJ, Nelson BD, et al. Symptomatic lower extremity deep venous thrombosis: accuracy, limitations, and role of color duplex flow imaging in diagnosis. *Radiology* 1990;175:639–644.
80. Kearon C. Diagnosis of pulmonary embolism. *CMAJ* 2003;168(2):183–194.
81. Welch HG, Faliakou EC, McLaughlin RL, et al. Comparison of descending phlebography with quantitative photoplethysmography, air plethysmography and duplex quantitative valve closure time in assessing deep venous reflux. *J Vasc Surg* 1992;16:913–920.
82. van Bemmelen PS, Bedford G, Beach K, et al. Quantitative segmental evaluation of venous valvular reflux with duplex ultrasound scanning. *J Vasc Surg* 1989;10:425–431.
83. Fleming C, Whitlock EP, Beil TL, et al. Screening for abdominal aortic aneurysm: a best evidence systematic review for the U.S. preventive services task force. *Ann Intern Med* 2005;142:203–211.
84. Sanford RM, Brown MJ, Fisfwick G, et al. Duplex ultrasound scanning is reliable in the detection of endoleak following endovascular aneurysm repair. *Eur J Vasc Endovasc Surg* 2006;32:537–541.
85. Chaer RA, Gushchin A, Rhee R, et al. Duplex ultrasound as the sole long-term surveillance method post endovascular aneurysm repair: a safe alternative for stable aneurysms. *J Vasc Surg* 2009;49:845–849.
86. Cox GS, Young JR, Gray BR, et al. Ultrasound guided compression repair of postcatheterization pseudoaneurysms: results of treatment in 100 cases. *J Vasc Surg* 1994;19:683–690.
87. Kang SS, Labropoulos N, Mansour MA, et al. Expanded indications for ultrasound guided thrombin injection of pseudoaneurysms. *J Vasc Surg* 2000;31:289–296.
88. Dzijan-Horn M, Langweiser N, Groha P, et al. Safety and efficacy of a potential treatment algorithm by using manual compression repair and ultrasound guided thrombin injection for the management of iatrogenic femoral artery pseudoaneurysm in a large patient cohort. *Circ Cardivasc Interv* 2014;7:207–215.
89. Ballard JL, Eke CC, Bunt TJ, et al. A prospective evaluation of transcutaneous oxygen measurements in the management of diabetic foot problems. *J Vasc Surg*

1995;22;485–492.

Chapter 88

Vascular Infection

Jayer Chung and J. Gregory Modrall

Key Points

1 The pathogenesis of infected aneurysms involves seeding of a pre-existing aneurysm by bacteremia.

2 The pathogenesis of microbial arteritis involves hematogenous seeding of an atherosclerotic plaque.

3 The pathogenesis of infected aortitis involves direct spread of infection to the aorta by contiguous septic structures, such as vertebral osteomyelitis.

4 The pathogenesis of arterial graft infections involves seeding of the graft from intraoperative contamination, erosion of adjacent structures, or hematogenous seeding from a distant source.

5 Characteristics of a prosthetic graft that predispose to graft infection include lowering of the bacterial bioburden required to cause a graft infection, surface irregularity that permits bacterial attachment, abrogation of local defense against infection, and creation of the bacterial biofilm that protects microbes from host defenses and antibiotics.

6 The most common organisms causing arterial graft infections are skin flora, especially *Staphylococcus aureus* and *Staphylococcus epidermidis*.

7 Of the available surgical options for aortic graft infections, treatment with graft excision, aortic ligation, and extraanatomic bypass is associated with the highest risk of mortality, aortic stump blowout, and graft occlusion of the available surgical options.

8 Treatment of aortic grafts infections with graft excision and in situ reconstruction with rifampin-soaked Dacron has been associated with the highest rate of reinfection of the available surgical options.

9 Treatment of aortic grafts infections with graft excision and in situ reconstruction with femoral vein is the most time-consuming surgical option, but is associated with the lowest risk of reinfection.

10 Treatment of aortic grafts infections with graft excision and in situ reconstruction with cryopreserved human allograft has been associated with a risk of graft rupture and pseudoaneurysmal degeneration.

Vascular infections are among the most daunting conditions that a surgeon may encounter in clinical practice. Vascular infections may afflict native arteries and veins or vascular prostheses. Primary arterial infections of native arteries are rare, but highly lethal conditions.[1] Secondary infections of prosthetic vascular grafts, albeit rare, are seen more frequently and are often more challenging because of the adhesions, scarring, and inflammation in the redo operative field.[2] These infections commonly occur in a compromised patient population with significant chronic medical conditions and relative immune deficiency. The clinical presentations for vascular infections range from indolent infections detected incidentally to overt sepsis or hemorrhage.[1] The management of vascular infections is individualized, based on the clinical presentation and anatomic location of the vascular infection and the medical condition of the patient. In recent years, newer therapeutic adjuncts, such as covered stents and improved cryopreserved grafts, offer additional options to surgeons managing and treating arterial graft infections. However, the basic tenets of timely diagnosis, antibiotic administration, resuscitation, operative planning, surgical resection, and revascularization remain the mainstays of therapy in most cases.

DEFINITIONS AND PATHOGENESIS

Pathogenesis of Primary Arterial Infections

1 2 3 Arterial infections commonly result in aneurysms, or more correctly pseudoaneurysms since there is disruption of the arterial wall in many infected aneurysms. Aneurysms or pseudoaneurysms related to infection are often loosely termed "mycotic aneurysms." However, the term mycotic aneurysm was initially coined to describe an arterial aneurysm or pseudoaneurysm caused by a septic embolus from the heart that lodges in a distal artery to create a septic focus that injures the adjacent artery.[3] Pre-existing aneurysms that are subsequently seeded by bacteremia are "infected aneurysms." Arteries in which an atherosclerotic plaque becomes seeded develop "microbial arteritis." "Traumatic infected aneurysms" describe those infected aneurysms or pseudoaneurysms that develop secondary to complications of iatrogenic or other trauma. "Infected aortitis" occurs when the aorta becomes infected by contiguous septic structures, such as vertebral osteomyelitis.[3] For simplicity, we will utilize the term "primary arterial infection" to refer to all infected arterial infections that occur in the absence of prosthetic graft or stent material.

Infective endocarditis is no longer the major source of primary arterial infections. Arterial trauma, particularly due to intravenous drug use, appears to be the most prevalent cause.[1] Risk factors for primary arterial infections include trauma to the arterial wall, atherosclerosis, and pre-existing aneurysmal degeneration. In an autopsy study, Miller reaffirmed that many of infected aneurysms arise after pre-existing atherosclerotic lesions are seeded due to an episode of bacteremia, since 75% of the infected arteries had evidence of atherosclerosis in the resected specimen.[4] In Miller's study, 42% of arterial infections were located in the infrarenal aorta; the descending thoracic aorta was the next most common site of infection.[4] Immune compromise by systemic conditions or medications, such as chronic steroid use, malignancy, human immunodeficiency virus syndrome, chronic hepatitis, or malnutrition, is a common theme among patients with primary arterial infections. Predisposing conditions have been identified in nearly 70% of patients with mycotic aneurysms.[4–7]

Pathogenesis of Arterial Graft Infections

Prosthetic grafts are foreign bodies that are either seeded at the time of the operation, or become infected secondarily due to hematogenous seeding or contiguous infection.[8–10] Data from the UK Small Aneurysm Trial suggest that contemporary rates of aortic graft infections after open aortic reconstruction are approximately 2%.[11] In his study of abdominal aortic aneurysms repaired in Washington State from 1987 through 2005, Vogel found that the 2-year rate of aortic graft infections was 0.19%.[12] Infrarenal endograft implantation is associated with infection rates of less than 1%.[13–15] The infection rate of thoracic aortic endografts is less well defined due to smaller number of thoracic endografts, compared to infrarenal aortic endografts, but most authorities believe that the rates of thoracic endograft infection are similar to those described for infrarenal aortic endografts. No particular endograft design or fabric appears to alter the risk of graft infection.[13–15]

Lower extremity prosthetic grafts are at the highest risk of infection, which probably relates to the abundance of skin flora in the groin and the proximity of the graft to the incision. Infections of grafts originating from or terminating at the femoral artery complicate 4% to 6% of cases.[16,17] By comparison, carotid patches rarely become infected, with Mann reporting a single-center incidence of 0.8% over 20 years.[18] Polytetrafluoroethylene (PTFE) may be somewhat more resistant to infection than Dacron, as it has less porosity to sequester microbes.[19] Peripheral bare metal stents appear to be highly resistant to infection, with a presumed incidence of less than 0.1% based on isolated case reports.[20]

5 Prosthetic material is at risk for becoming infected for several reasons. First, a 10,000-fold lower bacterial bioburden is required to cause a graft infection, relative to healthy tissue.[21] Irregularly surfaced materials are also more likely to harbor microbes, as these surfaces create small pockets where shear stress is decreased to allow bacterial attachment.[19,22] Also, the local inflammatory response to implants abrogates the local defense against infection. Instead of being inert, the prosthetic material acts as a potent activator of host defenses, which subsequently renders them less capable of defending the graft from infection. Multiple studies have shown contact with implants causes neutrophils to lose their ability to produce superoxide and reactive oxygen species, which are critical to their bactericidal activity.[23,24] Finally, communities of bacteria form slime to create biofilms, protecting microbes from host defenses and antibiotics.[19,22,25] Quorum-sensing is prevalent in biofilms, which decreases the virulence of microorganisms and makes them more difficult to eradicate by host defenses as the bacteria proliferate.[26] This is a critical step in the pathogenesis of prosthetic graft infections caused by *Staphylococcus epidermidis* (Fig. 88-1).[19,21–26]

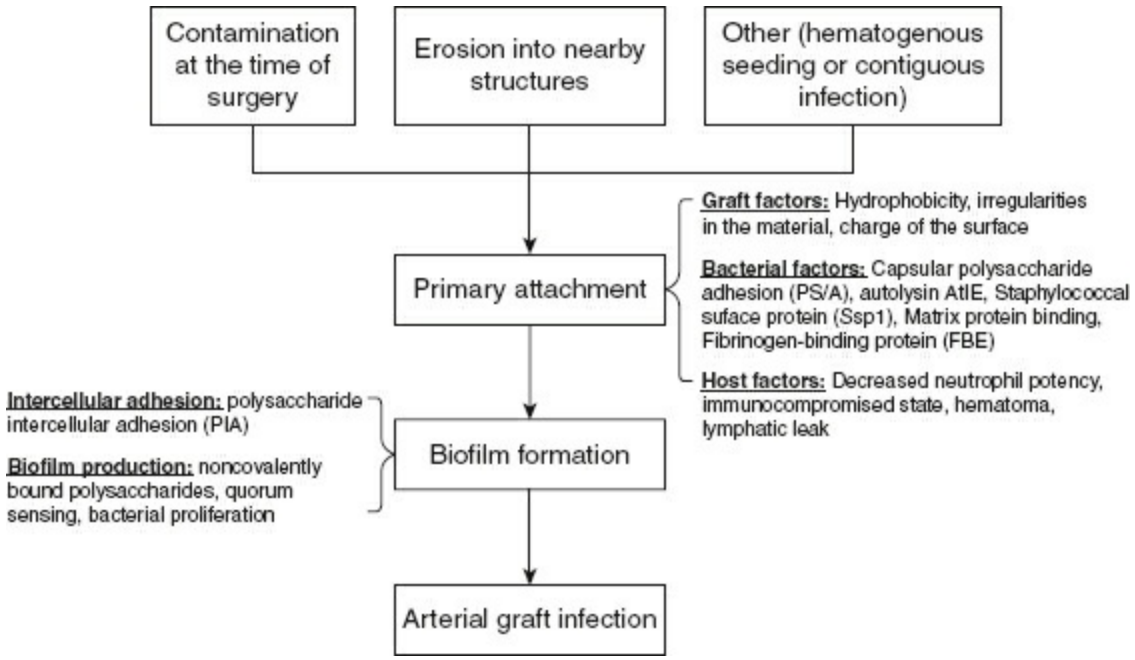

Figure 88-1. Proposed mechanism of *Staphylococcus epidermidis*–mediated graft infection.

MICROBIOLOGY

Primary Arterial Infections

For infected aortic aneurysms, blood cultures are negative in approximately one-fourth of subjects.[4] Intraoperative cultures are more reliable, although intraoperative cultures may be negative in many cases due to improper culture techniques or preoperative antibiotic administration that precludes isolation of organisms.[4–7] In other series, up to 40% of infected aneurysms had negative blood and/or tissue culture.[5] The most frequent causative organisms vary by country. Hsu et al. found that 76% of primary aortic infections in Taiwan were due to *Salmonella* strains.[7] Reports from the United States show that *Staphylococcal* species (*S. aureus* or *S. epidermidis*) are most prevalent, followed by *Escherichia coli, Streptococcal* species, and *Salmonella.* Anaerobic, mycobacterial, and fungal infections represent rare causes of arterial infections.[4,6] European series are similar to the American experience, as Muller reported that 30% of infections in his series were related to *S. aureus* and *S. epidermidis.*[5] In Muller's series, *Salmonella* was the next most frequent isolate, followed by *Aspergillus, Enterococcus, Streptococcus,* and *E. coli.*[5] The causative organisms also appear to vary based on the artery involved. Infected femoral artery aneurysms are rarely true aneurysms, but are infected pseudoaneurysms related to prior catheterizations or intravenous drug use. Skin flora, such as *S. aureus* or *Streptococcal* species, are the predominant organisms isolated from infected femoral artery pseudoaneurysms.[27]

4, **6** For prosthetic graft infections of the aorta, the causal organism is frequently not identified.[2] It is believed that most aortic graft infections occur as a consequence of intraoperative contamination by skin flora. Other sources include erosions of the graft into adequate structures and contiguous infections that cross-contaminate the graft. The main organisms responsible for aortic graft infections are *S. aureus* and *S. epidermidis,* accounting for 30% to 55% of the prosthetic vascular graft infections.[2,10,14,15] Other organisms include *Streptococcus,* gram-negative organisms, anaerobes, and fungal species.[2] Polymicrobial infections are present in one-third of subjects.[2] Fungal infections, particularly *Candida* species, are most frequently encountered with aortoenteric fistulas (AEF).[2] Anaerobic and fungal infections are also frequently associated with polymicrobial infections and sepsis.[2]

Prosthetic grafts infections involving the femoral artery are most often related to *Staphylococcal* species, which comprised 68% of the infections in one series.[16,17] *Enterococcal* and polymicrobial infections were less frequent among femoral artery grafts.[16,17] Endograft infections are predominantly caused by *Staphylococcal* species and other minor skin flora, such as *Propionibacterium.*[14,15] Similarly, *Staphylococcal* species predominate in peripheral arterial stent infections, with over 85% of the case reports attributed to Staphylococcal species.[20] In a report on carotid artery prosthetic patch infections, Mann found that 58% were related to *Staphylococcal* infection, one-third had an unidentified source due to negative cultures, and the remainder had gram-negative infections, with one beta-hemolytic *Streptococcal* infection.[18]

CLASSIFICATION OF ARTERIAL GRAFT INFECTIONS

Arterial graft infections are classified based on the time since implantation, the relationship to a surgical site infection, and the extent of prosthetic involvement. Bunt's classification, devised in 1983, describes prosthetic vascular graft infections according to the anatomic segment of the graft that is infected. A P0 graft infection involves a cavitary graft, such as aortic graft or the aortic portion of an aortobifemoral graft. P1 infections describe infections of grafts whose entire course is extracavitary, such as a lower extremity bypass graft infection. A P2 infection occurs when the extracavitary portion of a graft with an intracavitary origin becomes infected. Infected femoral limbs of aortobifemoral bypass graft represent a P2 infection. P3 infections are those involving prosthetic patches, such as a carotid patch. Pertinent descriptive qualifiers include the presence of a graft-enteric erosion, a graft-enteric fistula, or an aortic stump infection (after removal of an infected aortic graft).[28]

Early graft infections are defined as those occurring less than 4 months after graft implantation. The Szilagyi classification system classified early surgical site infections. Szilagyi I and II infections are superficial infections. Szilagyi III surgical site infections involve either native arteries or vascular graft material, which is most relevant to vascular surgeons.[29] The Szilagyi classification system was modified by Samson to further distinguish between different types of vascular infections.[30] Samson group 1 infections involve only the dermis, whereas group 2 infections extend into the subcutaneous tissues without graft involvement. Group 3 infections involve the graft, but not the arterial anastomosis. Group 4 infections involve an exposed anastomosis without bacteremia or anastomotic bleeding. Group 5 is the most serious type of infection, with an exposed anastomosis and associated bacteremia or bleeding.[30] Clinical management often varies significantly based on the extent of infection, according to these classification systems.

DIAGNOSIS

The diagnosis of primary arterial infection or prosthetic graft infection may be difficult due to the significant overlap of symptoms with other pathologies. While a thorough history and physical examination are essential, a high index of suspicion is critical to the diagnosis. Delays in diagnosis may have devastating consequences for the patient. Understanding some of the more common presentations of arterial infections can facilitate a timely diagnosis.

Common Clinical Presentations

Patients with vascular infections often present with non-specific symptoms of malaise, fever, and pain in the region of the infected artery or graft, which may be accompanied by elevations in erythrocyte sedimentation rate (ESR) or C-reactive protein (CRP).[6] These symptoms are most commonly associated with arterial infections caused by more virulent organisms, such as *S. aureus, P. aeruginosa, E. coli,* or polymicrobial infections. Arterial infections caused by lower virulence organisms, such as *S. epidermidis* or *Enterococcus,* are often even more indolent and may not be associated with local or systemic signs and symptoms.[31] Peripheral arterial infections (primary or graft infections) may exhibit local symptoms, such as erythema, swelling, tenderness, or a sinus tract with purulent drainage.[31] In contrast, local signs and symptoms are unlikely with infections of cavitary arteries or grafts.

If a primary arterial infection is suspected, the patient should be queried for potential sources of infection. Many patients with arterial or graft infections have a history of an antecedent infection, such as pneumonia or a urinary tract infection.[6] A recent gastrointestinal illness may be a source of exposure to Salmonella.[7] Other potential clues include a history or clinical stigmata of intravenous drug use or a recent invasive procedure, which could provide a mechanism for seeding of a native artery or graft.

Associated medical conditions may be cofactors in the pathogenesis of vascular infections. Any condition that produces relative immune compromise may predispose to primary arterial or graft infection. Examples include malignancy, human immunodeficiency virus syndrome, chronic hepatitis, malnutrition, and conditions that require immunosuppressive medications. Predisposing conditions have been identified in upto 70% of patients with mycotic aneurysms.[4–7] Malignancy is especially relevant due to the association between *Clostridium septicum* arterial infections and malignancy.[32] Symptomatic atherosclerosis is important to note since atherosclerotic plaques may become seeded by episodic bacteremia to create a primary arterial infection.

For patients with a history of a prior bypass involving the femoral artery, occult infections frequently present with an anastomotic pseudoaneurysm in the groin. Over 60% of femoral pseudoaneurysms are ultimately found to harbor an occult infection.[33] Mertens found that 74% of patients with infected infrainguinal bypass grafts presented with a draining wound or sinus.[34] Infections with low virulence organisms, such as *S. epidermidis,* are less likely to be present with a draining sinus because the virulence of the organisms is insufficient to incite a vigorous inflammatory response to produce the sinus tract.[31]

Graft thrombosis is another clinical presentation for an occult graft infection. Graft thrombosis is believed to predispose to subsequent graft infection.[35,36] The coagulated blood within a thrombosed prosthetic graft provides a rich media for the microorganisms to proliferate.[37] In addition, prosthetic materials are fomites that may harbor microorganisms. Some authors advocate removing occluded grafts when performing subsequent revascularization operations or amputations to prevent contiguous spread from the prior occluded grafts.[35,36]

Gastrointestinal hemorrhage is a rare, but life-threatening presentation for graft infection that must be diagnosed expeditiously. Any patient presenting with gastrointestinal hemorrhage that has a history of prior aortic surgery, especially those with vascular prostheses, must have a rapid evaluation for an AEF. AEFs often present initially with a "herald bleed," or a relatively small amount of gastrointestinal bleeding that temporarily abates prior to fatal exsanguination several hours or days later.[37–39] The mortality rate for AEFs is 30% to 77%. Delay in diagnosis is often a contributing factor among patients who die from this condition. Approximately 75% of AEFs result from a communication between the aorta and the third or fourth portion of the duodenum.[37] The vast majority of AEFs occur in the setting of prior surgical or endovascular aortic reconstruction. Rarely AEFs occur as a complication of a primary aortic infection.[40] If a portion of the graft erodes through the adjacent bowel without suture line involvement, gastrointestinal bleeding results from intestinal mucosal irritation. This phenomenon is termed "graft-enteric erosion."[41] Graft-enteric erosions are often discovered incidentally during surgery to excise an infected aortic graft.

Ureteral obstruction can occur due to a mechanical complication during the tunneling of an aortofemoral limb or as a consequence of the inflammatory reaction associated with an infected aortofemoral limb. Ureterohydronephrosis is strongly associated with aortic graft infections. Wright et al. found that the presence of a urologic complication after aortoiliac arterial reconstructions was associated with a fourfold increase in the risk of graft complications, including pseudoaneurysms, limb thrombosis, AEFs, and overt graft infections.[42] Ureteral complications are typically asymptomatic, so ureterohydronephrosis is often discovered incidentally during imaging studies for other indications and should alert the physician to the possibility of a graft infection.

Imaging for Vascular Infection

The history, physical examination, and laboratory findings for primary arterial infection or graft infections are often nonspecific, so imaging plays a pivotal role in establishing a diagnosis. Although advances in imaging techniques have improved the sensitivity and specificity significantly, no single modality is perfect. Confirming a physician's suspicion of occult infection with a low-virulence organism remains a challenge in many cases. Understanding the advantages and disadvantages of each imaging modality will allow the surgeon to choose the most appropriate examination, or combination of imaging studies, to optimize the diagnostic yield.

Computed Tomography (CT) and Computed Tomographic Angiography (CTA)

CT and CTA are the preferred imaging modalities for suspected aortic graft infections in most centers. CT is readily available in most hospitals, and standard protocols enable most centers to duplicate the diagnostic sensitivity achieved at centers of expertise. Contrast allergy, contrast-induced nephropathy, metal artifact, and radiation exposure are shortcomings of CT, but the benefit outweighs the risk in most cases. The addition of oral contrast agents can help to define the association with enteric structures if an AEF is suspected. Findings suggestive of graft infection on CT or CTA include inflammatory changes in the soft tissues surrounding the graft (Fig. 88-2), thickening of the bowel adjacent to vascular structures, loss of tissue planes around the artery or graft, and perigraft or periarterial air or fluid (Figs. 88-3 and 88-4).[43,44] The sensitivity and specificity of CT for the diagnosis of aortic graft infections may be as high as 95% and 88%, respectively,[44] although the diagnostic accuracy varies depending upon the organism and severity of the infection. The sensitivity and specificity for low-grade, indolent infections may be as low as 55% and 100%, respectively.[45,46] The presence of either fluid or air significantly enhances both the sensitivity and specify of CT scans for detecting late graft infections (>4 months postimplantation).[43,44] Early graft infections (<4 months postimplantation) present a particular challenge for diagnosis. Perigraft air is a normal finding in the periaortic tissues for 2 months after open aortic reconstruction and should not be considered indicative of an aortic graft infection.[47,48] Similarly, a small amount of perigraft fluid is normal for 3 months after arterial reconstruction.[43] After endovascular aortic aneurysm repair, Sawhney found that air was visualized in the aneurysm sac, surrounding the endograft, in 58% of patients on early postoperative CTA.[49] The air is introduced during endograft deployment and dissipates over a period of weeks after surgery.

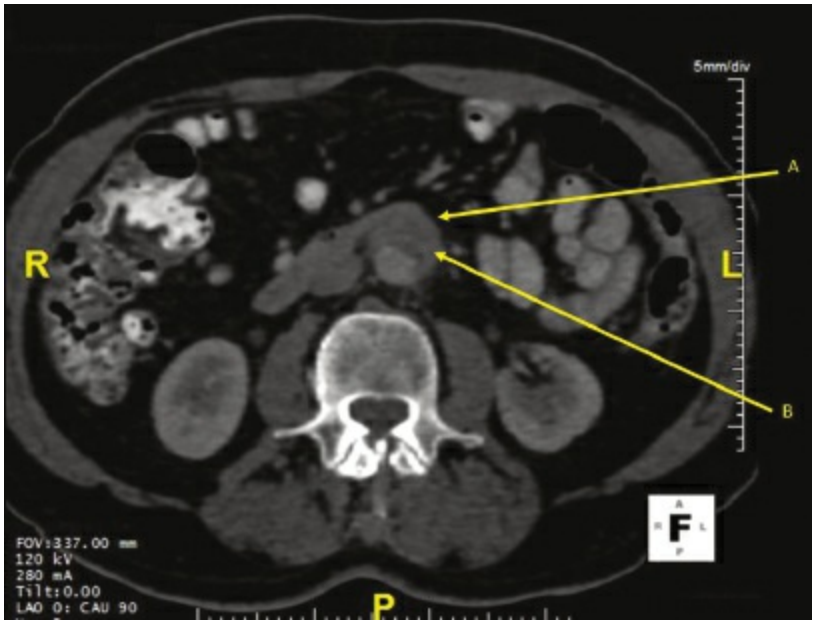

Figure 88-2. CT scan demonstrating loss of tissue planes around the artery (**A**), with small foci of air (**B**) suggesting a mycotic aneurysm.

Duplex Ultrasonography

Duplex ultrasound offers a relatively safe and inexpensive tool for evaluating native arteries and bypass grafts for signs of infection. Ultrasound circumvents the risks of contrast allergy, contrast-induced nephropathy, and radiation associated with CT. The main drawbacks of ultrasound are the lack of availability in some centers of skilled ultrasound technicians capable of arterial imaging. Overlying structures, particularly bowel gas and the lungs, and body habitus can also obscure visualization and limit the efficacy of ultrasound evaluations within the chest or abdomen.[43] Findings on duplex ultrasound that are suggestive of infection include the presence of a pseudoaneurysm, hematoma, soft tissue masses, and perigraft gas and fluid collections. A "halo sign" surrounding an infected aortofemoral limb is a hypo-acoustic shadow surrounding the graft that is indicative of perigraft fluid consistent with graft infection.[50]

Magnetic Resonance Imaging (MRI)

MRI offers some theoretical advantages over CTA for the diagnosis of vascular infections, including the avoidance of radiation and contrast-induced nephropathy. There are also clear disadvantages to MRI that have limited its utility in diagnosing graft infections. MRI studies for graft infection are time-consuming, and MRI is contraindicated for patients with certain metal implants.[47] The sensitivity and specificity for graft infection is highly variable between institutions. MRI may be as useful as CT scan in the diagnosis of arterial infections at centers with expertise with MRI for arterial infections. In a study of 40 patients with suspected arterial graft infections, Shahidi found that the sensitivity, specificity, positive predictive value, and negative predictive value of MRI were 68%, 97%, 95%, and 80%, respectively.[51] MRI may detect small collections of biofilms, the hallmark of *S. epidermidis* infections, which are notoriously difficult to diagnose.[47] MRI creates a low-intensity "halo" around infected grafts on T_1 imaging, while also creating a

hyperintense signal on T_2-weighted images.[47,52] Since gadolinium is not required, MRI may be useful in patients with chronic renal insufficiency. MRI is plagued by some of the same limitations as CT in detecting early graft infections since air and fluid are normal findings on MRI for 2 to 3 months after graft implantation.[53]

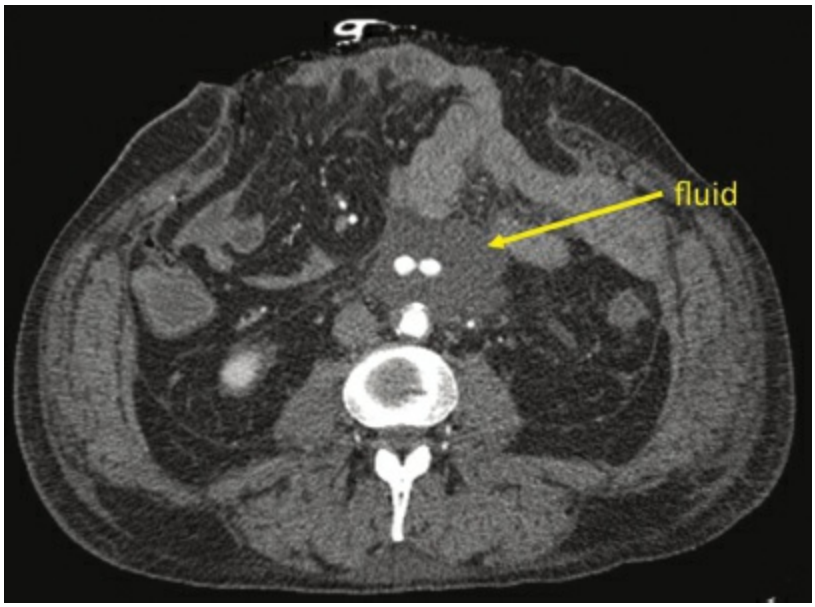

Figure 88-3. CT scan demonstrating perigraft fluid surrounding a prosthetic aortic graft as a sign of an aortic graft infection.



Figure 88-4. CT scan demonstrating perigraft air (A) surrounding an endograft as a sign of graft infection associated with a possible aortoenteric fistula.

Leukocyte Scintigraphy

Leukocyte scintigraphy may be performed using either ^{111}Indium- or ^{99m}Technetium-labeled leukocytes to localize infection within the arterial wall or graft. A theoretical advantage of leukocyte scintigraphy is the diagnosis of indolent infections with low-virulence organisms for which the symptoms are most ambiguous. Unfortunately there

are numerous pitfalls to this modality. Leukocyte scintigraphy is time-consuming, labor-intensive, and prone to false-positive results due to undesired cross-labeling of platelets that may bind to grafts.[54,55] Uptake of the radionuclide-labeled white blood cells requires intact chemotaxis and a minimum total white blood cell count of 2,000/μL.[55] The net effect of these issues is that the sensitivity and specificity for tagged white blood cell scanning is highly variable between institutions, with sensitivity and specificity both ranging between 50% and 100%.[51,54,55]

Single Photon Emission Tomography (SPECT) Scanning

SPECT scanning, when combined with CT scanning, may enhance the specificity of leukocyte scintigraphy in the detection of vascular infections.[56,57] While there are limited data available at this time, the early results appear promising. Erba recently evaluated SPECT–CT in 55 subjects with suspected vascular graft infections. SPECT–CT reduced the number of false positives by 37%, compared to CT alone. The sensitivity and specificity of SPECT–CT was 100%, which was superior to SPECT or CT alone.[57]

Fluorodeoxyglucose Positron Emitting Tomography (FDG-PET)

FDG-PET utilizes glucose labeled with ^{18}fluoride, which is utilized by cells proportional to their metabolic activity. Initially, this technique was utilized to detect occult metastases in oncology patients. Recently the protocols have been adapted for the detection of occult arterial infections.[58,59] FDG-PET can be advantageous in diagnosing endograft or peripheral stent infections since the images are less prone to metal artifact. Compared with leukocyte scintigraphy, FDG-PET offers the advantages of shorter examination times, less radiation exposure, higher resolution, and improved interobserver agreement.[60,61] Unfortunately there is a high false-positive rate for diagnosing arterial graft infections because of the inflammatory response associated with prosthetic grafts.[58] Poor uptake of the FDG-glucose can also yield nonspecific results, which is a limitation of using this test in diagnosing low-virulence infections. While the sensitivity and specificity of FDG-PET alone are inferior to CT scan alone, combining FDG-PET with CT scanning markedly improves the localization of infection and the sensitivity and specificity of the examination. Using the approach, Spacek reported a diagnostic accuracy exceeding 95% in a series of 95 grafts.[59] For FDG-PET-CT, Bruggink reported a sensitivity, specificity, positive predictive value, and negative predictive value of 93%, 70%, 82%, and 88%, respectively, which was superior to FDG-PET alone. [60] Further study is required to define the threshold for a positive FDG scan in the setting of cavitary arterial infections.[61–63] Drawbacks of the fusion technology include longer study times and increased radiation exposure. Furthermore, expertise with FDG-PET-CT techniques is not widely available. Despite these limitations, some authorities foresee the combined modality becoming the study of choice in the future.[61]

Adjunctive Diagnostic Modalities

Arteriography, endoscopy, and image-guided biopsy should be viewed as adjunctive diagnostic modalities that have a limited role in diagnosing graft infections.

Arteriography may be useful in planning reconstruction. Rarely, an occult AEF can be discovered with angiography by filling of the enteric structure.[64] Esophagogastroduodenoscopy (EGD) is typically performed to exclude other sources of upper gastrointestinal hemorrhage in a patient with a suspected AEF. EGD was successful in diagnosing AEF in approximately 25% cases in one small series of primary AEFs.[40] In spite of the low diagnostic yield, the authors recommended endoscopy in hemodynamically stable patients with a suspected AEF because of the devastating consequences of a missed diagnosis. Image-guided biopsy of the fluid or rind surrounding the affected vascular structure has been advocated when the diagnosis of graft infection is equivocal.[65,66] This approach could potentially distinguish between patients with benign early postoperative perigraft gas versus an early graft infection. However, sufficient sampling is difficult to achieve in all cases, as the tissue is often fibrotic and in close proximity to other major vascular structures and bowel.[66] Further study will be required to clarify the role of this modality in the evaluation of arterial infections.

CONSERVATIVE MANAGEMENT

Primary Arterial Infections

Hsu et al. provided insight on the outcome of conservative management of subjects with primary aortic infections.[67] Hsu examined 22 subjects with infected aortic aneurysms with perceived contraindications to surgery. The predominant organism in the cohort was *Salmonella,* with two-thirds of subjects having infections of the abdominal aorta. All subjects received culture-specific intravenous antibiotics for at least 6 to 8 weeks, or until normalization of white blood cell count, daily temperatures, and C-reactive protein levels. After the acute phase treatment, oral antibiotics were continued indefinitely. In Hsu's series, the inhospital mortality was 50% due to rupture or sepsis. The 1-year survival rate was 32%. Patients with *Salmonella* infections had a lower aneurysm-related mortality rate than patients with non-*Salmonella* infections.

Arterial Graft Infections

Calligaro advocated for complete or partial prosthetic bypass preservation in subjects with severe comorbidities precluding surgical repair.[68] Over a 20-year period, 51 extracavitary grafts (aortofemoral limbs or lower extremity bypasses) were treated with graft preservation and aggressive wound management without surgical graft resection. When wounds were present, aggressive debridement of all necrotic tissue and exudate surrounding the artery was performed. Nine cases utilized adjunctive muscle flaps to aid healing. Povidone–iodine 1% or antibiotic-soaked dressing changes were performed three times a day. With this regimen, 2 of 51 patients (4%) experienced major hemorrhage from the infected graft at 3 and 12 months after presentation. Eleven of the patients (22%) failed the treatment regimen, with nonhealing wounds or recurrent infections requiring total graft excision. Thirty-two subjects (63%) were ultimately treated successfully. Calligaro concluded that conservative management of extracavitary grafts is an acceptable option in the absence of sepsis or hemorrhage, especially when graft excision and revascularization is not feasible due to patient comorbidities. *Pseudomonas* infections, however, were particularly prone to failure with this regimen.

Building on the early reports of graft preservation therapy, subsequent reports have emerged utilizing vacuum-assisted negative pressure therapy with antibiotics and wound debridement to preserve extracavitary grafts with Szilagyi III wounds.[69,70] Wound healing with these regimens have ranged between 82% and 91% with excellent graft preservation rates.[69,70] Episodes of hemorrhage remain an issue with this approach,[69] and the failures have been associated with *Pseudomonas*.[69,70] Based on these reports, it appears that carefully selected patients with early infections involving extracavitary grafts may be treated without surgical graft excision with acceptable results.

Calligaro et al. used a nonoperative approach in six patients with intracavitary graft infections with a hostile abdomen or severe medical comorbidities.[71] All subjects underwent either open or percutaneous placement of drains along the graft with instillation of 10 mL of 1% povidone–iodine in 100 mL of normal saline or antibiotics (neomycin or a cephalosporin) three times a day. All subjects were treated concurrently with culture-directed intravenous antibiotic therapy for 6 weeks, followed by 6 months of oral antibiotic therapy. Of these 6 subjects, only one died due to sepsis. One patient ultimately required total graft excision and survived. The remaining patients (66%) were alive at last follow-up. These authors showed that in highly selected patients, conservative management can have reasonable outcomes. In the absence of larger series, this approach should be reserved for patients who are not reasonable candidates for graft excision.

SURGICAL MANAGEMENT OF AORTIC ARTERIAL AND GRAFT INFECTIONS

Surgical treatment is based upon the central tenets of appropriate resuscitation, preoperative planning, resection of all infected material and tissue, and arterial revascularization. The optimal method of arterial reconstruction remains unresolved, as few direct comparisons between approaches have been published. Based on our extensive institutional experience with a variety of techniques, we have concluded that no single approach is suitable for all patients. We advocate tailoring the treatment algorithm based on each patient's clinical presentation and the local surgical expertise.

Aortic Infections Presenting with Hemorrhage or Sepsis

A minority of patients present with septic or hemorrhagic shock. For these patients, rapid intravenous access and resuscitation are essential prior to emergent surgery. In the authors' experience, the complexity of the operations required to manage these patients mandates a rapid CTA to obtain essential anatomic information. It is recognized that some of these patients will have either acute kidney injury or chronic kidney disease, but managing the life-threatening complications of the aortic graft infection outweighs the risk of contrast-induced nephropathy. Ideally, blood and wound cultures are obtained prior to the administration of broad-spectrum gram-positive and gram-negative antibiotic therapy. The surgical approach to managing patients presenting with hemorrhage or sepsis should be individualized based on the patient's anatomy and the expertise of the surgeons.

Endografting as Bridge Therapy

Endografts are being used with increasing frequency as a method to temporize hemorrhage in patients with aortoenteric or aortobronchial fistulas.[38,39,72,73] When the anatomy permits, endografting may temporarily prevent exsanguination and allow time for resuscitation, medical stabilization, and further investigations to plan definitive surgery.[72] Endografting should not be viewed as definitive therapy since recurrent hemorrhage occurs in majority of cases without further surgical treatment.[39,73] Definitive surgery should be planned within 2 weeks of endografting, since most episodes of recurrent bleeding occurred greater than 2 weeks after initial endografting.[73] The exception to this principle is an aortobronchial fistulae for which endografting may be viewed as definitive therapy.[38]

Definitive Surgery for AEF

Definitive surgery for an AEF involves resection of the infected graft, repair of the enteric defect, and revascularization of the lower extremities. The most appropriate surgical approach to achieve these goals has been the focus of considerable debate. For decades, the most common approach to AEFs was total graft excision with ligation of the infrarenal aortic stump and extraanatomic bypass.[74–78] In recent years, a variety of groups have touted the merits of in situ reconstruction of the aorta after graft excision, using a variety of conduits. The advantages, disadvantages, and technical details of these approaches are discussed later in the chapter (see "Aortic Infections in the Stable Patient").

Aortic Ligation and Extraanatomic Bypass for AEFs

In stable patients with a small herald bleed caused by an AEF, Reilly et al. at the University of California-San Francisco advocated staging of the two component operations at an interval of several days to minimize the physiologic impact on the patient.[75] The first stage of this approach consists of performing an axillobifemoral bypass or bilateral axillary–popliteal bypasses, followed several days later by resection of the infected graft with aortic stump closure. In the patient with ongoing bleeding or hemodynamic

instability, a staged approach is not feasible. Reilly reported a 26% mortality rate with the staged approach, compared to 43% for the traditional, nonstaged.[75] A subsequent study by Seeger reported a 19% treatment-related mortality rate.[76] In addition to a high mortality rate, this approach is plagued by a significant risk of aortic stump blowout (9%), reinfection of the extraanatomic bypass graft (16%), and major amputation (16%).[75]

In Situ Aortic Reconstruction for AEFs

In response to the sobering results associated with the traditional approach, in situ aortic reconstruction has been touted as a relatively simple and effective alternative.[80–84] Oderich et al. from the Mayo Clinic reported their results using in situ rifampin-soaked grafts in 54 patients with aortic graft-enteric erosions or fistulae.[80] In their series, operative mortality was 9%, and graft reinfection occurred in 4%. A subsequent multicenter study of 37 patients with AEFs treated with either in situ prosthetic grafts ($n = 9$), extraanatomic bypass ($n = 25$), or endografting ($n = 3$), reported a 30-day mortality rate of 43% for in situ reconstructions.[82] In that series, 3 of 11 (27%) long-term survivors with in situ grafts developed reinfection of the in situ graft, which was universally fatal.

Alternative conduits for in situ reconstruction for AEFs include cryopreserved aortoiliac allograft and femoral vein. Harlander-Locke et al. published a multicenter experience with 220 patients with aortic graft infections treated with in situ cryopreserved aortoiliac allograft, which included 33 patients with AEFs.[83] The reinfection rate in patients presenting with AEFs was 12%. In situ repair with autogenous femoral vein is not appropriate in the unstable patient due to the time required for femoral vein harvest, but may be reasonable in the stable patient with a herald bleed due to an AEF. Valentine reported a 42% mortality rate in 24 patients treated with in situ femoral vein for AEFs and graft-enteric erosions, so femoral vein may not offer any advantage over the alternative conduits for AEFs.[84]

Aortic Infection with Sepsis

Sepsis caused by an aortic infection poses a challenge because temporizing with an endograft is not an option since the septic focus is not eliminated. In unstable patients, CT-guided percutaneous drainage may be a reasonable option for source control if there is a large perigraft fluid collection. In a series of 23 patients with graft infections, Belair et al. found that percutaneous drainage was associated with improved perioperative mortality, compared to surgery alone.[85] In the absence of a large perigraft fluid collection for percutaneous drainage, graft excision with extraanatomic bypass is the most reasonable approach.

Aortic Infections in the Stable Patient

Preoperative Evaluation

The incidence of coronary artery disease is high in surgical series of arterial infections, especially in subjects with infected endografts.[2,6,14] Thus, a thorough cardiovascular history, physical examination, 12-lead electrocardiogram, and echocardiogram should be obtained to evaluate for heart failure, valvular dysfunction, and pulmonary hypertension. These investigations may reveal a history of active cardiac conditions that may modify the type of operation selected or preclude surgery. Only rarely is stress testing or coronary arteriography indicated since coronary revascularization is usually contraindicated in the context of an active infection. However, this information may alter the surgical plan, provide valuable information for the anesthesiologists, and guide discussions with the patient or family regarding the expected outcomes. Pulmonary evaluations are rarely undertaken, as this information seldom alters the management of the patient. Only those patients with the most severe pulmonary insufficiency may benefit from formal testing to guide perioperative management.[86]

Operative planning is greatly facilitated by a preoperative CTA to define the arterial anatomy. Angiography of the lower extremities is reserved for cases when a concurrent infrainguinal bypass is considered likely. Noninvasive measurements of distal perfusion and lower extremity vein mapping should be performed. Ankle-brachial indices (ABIs) may forewarn the surgeon of the potential for infrainguinal revascularization after graft excision and aortoiliac reconstruction. Mapping of the bilateral greater saphenous veins and femoral–popliteal veins is essential if an autogenous conduit is contemplated. Femoral–popliteal veins with a diameter of less than 6 mm or evidence of vein wall sclerosis are inadequate for aortoiliac reconstruction.[2]

Anesthetic Considerations

Operations to excise infected aortic grafts are technically challenging, lengthy, and prone to a large volume of blood loss. The importance of a quality anesthesia team in managing these challenges cannot be over-stated. Hypothermia, hypovolemia, and intraoperative anemia must be assiduously avoided with the use of warming blankets, warmed resuscitative fluids, warm ambient operating room temperature, and a low threshold for blood and crystalloid replacement. The blood bank should be prepared to provide fresh-frozen plasma, cryoprecipitate, or platelets on short notice if coagulopathy develops. Culture data are often not available at the time of operation, so broad-spectrum antibiotic coverage for gram-positive, gram-negative, and anaerobic organisms should be redosed throughout the operation.

Aortic Ligation and Extraanatomic Bypass Versus In Situ Reconstruction

A major advantage of graft excision with extraanatomic bypass is the removal of all prosthetic graft material from the infected operative field. This approach also obviates the need to procure an aortoiliac allograft. Finally, use of an extraanatomic bypass

circumvents any reticence a surgeon may have with harvesting femoral veins since some surgeons are not familiar with the technique. The obvious pitfalls of this approach are the risk of aortic stump blowout, reinfection of the extraanatomic bypass graft, and poor long-term patency of the extraanatomic reconstruction. In situ reconstruction is appealing because it avoids the risk of aortic stump blowout and the poor long-term patency of extraanatomic bypasses. For patients with insufficient infrarenal aorta for a secure three-layer closure, in situ may be the only reasonable option. Reinfection of new graft is the obvious risk of this approach. In the following sections, we will offer technical suggestions for performing these complex operations and summarize the published results for each approach.

Aortic Graft Excision

Common to each of the described surgical approaches to aortic graft infection is the need for complete graft excision. For graft excision, aortic exposure can be performed via a transperitoneal or retroperitoneal approach. Proximal control of the infrarenal aorta can be challenging in a redo operative field, so the surgeon should be prepared to obtain proximal control of the aorta at the suprarenal or supraceliac level. When treating an AEF, we always obtain either suprarenal or supraceliac aortic control prior to mobilizing the duodenum since there may be uncontrolled hemorrhage in the absence of proximal aortic control. Balloon control is another useful adjunct in cases of severe inflammation or scarring.[50] The left renal vein may be densely adherent to the graft or the native aorta, which may necessitate its division to gain access to the aorta near the renal arteries. Once proximal control is obtained, distal control of the bilateral common iliac arteries should ensue, unless these arteries are occluded. When excising an aortofemoral graft, the femoral limbs should be controlled in the abdomen to facilitate their removal. Removal of aortofemoral grafts requires considerable dissection in the groins for control of the prosthetic graft limbs and native common femoral, superficial femoral, and profunda femoris arteries. Femoral exposure may be performed through an incision directly over the femoral limb or incisions lateral to the sartorius muscle. The lateral incision avoids some of the prior scarring and may preserve soft tissue for arterial coverage. Systemic heparin is administered prior to cross-clamping, and the graft is removed in its entirety. Any arterial tissue that appears to be abnormally friable is probably infected and should be debrided. Remnants of graft and arterial tissue should be sent for Gram stain, culture, and sensitivity testing. A critical adjunct is wide debridement of the retroperitoneum, which is believed to decrease the residual bacterial bioburden that will predispose to recurrent infection. After completing graft excision and debridement, closure of the aortic stump or in situ aortoiliac reconstruction may ensue.

Extraanatomic Bypass

For stable patients, staging of the extraanatomic bypass and graft excision should be considered, as proposed by Reilly.[75] The first stage of this approach consists of performing an axillobifemoral bypass or bilateral axillary–popliteal bypasses, meticulously avoiding any infected or contaminated planes when tunneling the new

grafts. The second stage consists of aortic graft excision, retroperitoneal debridement, and aortic stump closure. Aortic stump closure requires a meticulous three-layer closure of the aorta. The first two layers consist of two layers of nonabsorbable polypropylene suture; a vertical mattress suture, followed by running "baseball" suture. The final layer is an omental wrap secured with sutures.[75] When staging the extraanatomic bypass and graft excision, the optimal time interval between the two operations has not been defined. It has been our experience, however, that the presence of both an aortobifemoral bypass and an extraanatomic bypass creates competitive flow between the grafts that often results in thrombosis of the extraanatomic bypass graft. To minimize the risk of interval graft thrombosis, patients are anticoagulated with intravenous unfractionated heparin between operations, and a short (1 to 3 days) time interval (usually 1 to 2 days) between the two operations is planned. If the two operations are performed at the same operative setting, the clean portion of the procedure (the extraanatomic bypass) is performed prior to the infected portion of the case (graft excision) whenever feasible to minimize the risk of bacterial inoculation of the new graft.

The outcomes for graft excision with extraanatomic bypass have been sobering. In their landmark review, Yeager and Porter reported an average mortality rate of 21% with an average amputation rate of 11% and recurrent infection rate of 18%.[77] In a series of 36 patients with aortic graft infections, Seeger et al. subsequently reported a similar mortality rate (overall treatment-related mortality rate of 19%), but a lower rate of reinfection and aortic stump blowout (2.8% incidence of each complication).[76] Seeger noted that the patency of the extraanatomic bypasses was directly related to the type of graft configuration. Axillobifemoral bypasses had a primary patency of 75% at 41 months, whereas the primary patency for axillopopliteal bypasses was 0%. Similar results have been observed using this approach in treating infected abdominal aortic aneurysms. Lee reported a series of 28 patients with infected abdominal aortic aneurysms treated with aortic resection plus either in situ repair ($n = 13$) or extraanatomic bypass ($n = 15$).[87] Lee observed a 27% mortality rate for the cohort receiving extraanatomic bypass in this nonrandomized study.

In Situ Reconstruction with Cryopreserved Arterial Allografts

Experience with allograft replacement of primary or secondary arterial infections began with Alexis Carrel more than a century ago.[88] Difficulties with procurement and preservation resulted in poor quality control. Allografts were largely abandoned until their resurrection for the treatment of infectious pathologies of the ascending aorta in the 1980s.[89] Initial positive experience resulted in more widespread use, including the treatment of infected infrarenal aortic graft infections.[90] Initially, local tissue banks were responsible for procuring, preserving, and allocating allografts for clinical use. This resulted in considerable variability in the processes of preparing and storing the product, which may have impacted the quality of the product. Currently these processes have been centralized in both North America and Europe with primary suppliers of the cryopreserved allografts.

The primary advantage of cryopreserved allografts is its resistance to infection, which

is substantiated by recurrent infection rates ranging between 0% and 3.6%.[83,90–94] Primary patency was 97% at 5 years in a multi-institutional registry, which is comparable to other conduits for in situ reconstruction.[83] The primary disadvantages of cryopreserved allograft in the early experience with this conduit were graft rupture and pseudoaneurysm formation. Newer cryopreservation techniques have improved the preservation of the arterial collagen matrix, decreasing the incidence of graft rupture and pseudoaneurysmal dilation. However, it is not clear that these issues have been fully resolved. Vogt et al. reported an allograft complication rate of 16% in a cohort of 43 implants, including one intraoperative rupture and three late ruptures (>30 days after implantation).[92] In a multicenter registry of cryografts, 24% of patients experienced major complications, including eight ruptures and six pseudoaneurysms.[83] The most frequent complication, however, was persistent sepsis, occurring in 17 subjects. Other disadvantages of cryopreserved allograft include the cost of the grafts (approximately $18,000 per aortoiliac segment).[80] Moreover, these grafts are not readily available in most centers, making it less practical for infected pathologies complicated by hemorrhagic or septic shock.

In response to the early complications, Vogt recommended several techniques to prevent early adverse outcomes.[92] These included proper timing of the allograft thawing and ligature of the allograft side branches with polypropylene suture that incorporates a portion of the allograft wall. Tension on the anastomoses must be avoided, and reinforcement of the anastomosis with circumferential allograft strips and gentamycin-impregnated fibrin glue is also recommended.

In Situ Reconstruction with Rifampin-Soaked and Silver-Impregnated Grafts

Rifampin shows unique activity against *S. epidermidis* biofilms, making it an excellent choice for prosthetic graft infections.[95] Rifampin-soaked Dacron grafts (600 mg rifampin in 250 mL of normal saline, soaked for 30 minutes) with omental wrapping has been shown to have variable resistance to recurrent infection, ranging between 4% and 11.5%.[80,81] Recurrent infections have been fewer when treating AEFs, compared to prosthetic graft infections. Primary patency is also excellent, ranging between 89% and 92%, with limb salvage rates of 100%.[80,81,96] Circumferential omental wrapping of the grafts is a critical technical adjunct to decrease the risk of reinfection.[80]

Silver-impregnation relies upon the ability of silver to adsorb gram-positive and gram-negative bacterial membranes, resulting in disruption of the membrane and cell lysis. There has been no reported bacterial resistance to silver.[97] It is theorized that silver-impregnated grafts would have activity against *E. coli* and methicillin-resistant *S. aureus,* which would be an improvement over rifampin-soaked grafts.[98] The limited clinical data suggest that silver-impregnated grafts are not equivalent to rifampin-soaked grafts since the reinfection rate was 15.7% in a single-center series in France.[99,100]

In Situ Reconstruction with Autogenous Femoral Vein

Autogenous femoral vein was proposed as an alternative conduit for in situ reconstruction

for infected aortic grafts in the early 1990s.[101] Clagett described creating a "neoaortoiliac system" using femoral veins harvested from both legs. The proposed advantages of femoral vein include an innate resistance to infection and excellent long-term patency, which is borne out by the two largest series to date using femoral vein. Ali reported 187 neoaortoiliac reconstructions using femoral vein.[2] The 30-day mortality for this approach (10%) was not significantly different from other in situ reconstructions for graft infection. Predictors of mortality included preoperative sepsis and infection with *Candida glabrata, Klebsiella pneumonia, or Bacillus fragilis.* Reinfection occurred in 5%. Primary patency was 81% at 72 months. Daenens reported similar outcomes using femoral vein, including an 8% inhospital mortality rate.[102] Daenens group observed no reinfections and no cases with aneurysmal degeneration of the femoral vein graft. The 5-year primary patency was 91% with a limb salvage rate of 98%.

The major pitfall of using femoral vein for in situ reconstruction is the time required to harvest the veins. Although many surgeons have not had formal training in the technique for harvesting femoral veins, it is well within the capability of any vascular surgeon. The technique is described in detail elsewhere.[103] Briefly, femoral veins are harvested using an incision extending along the lateral edge of the sartorius muscle from the anterior superior iliac spine to the medial condyle of the femur. The sartorius muscle is reflected medially to preserve the segmental blood supply of the sartorius. Collateral vessels from the superficial femoral and popliteal arteries should be preserved during vein harvest, especially in the setting of known superficial femoral artery occlusive disease.[103] The saphenous nerve should be avoided to prevent postoperative neuralgia. The femoral vein is harvested from its confluence with the profunda vein to the knee joint to provide a length of vein required to replace an aortobifemoral bypass graft. All side branches greater than 3 mm in diameter are doubly ligated, rather than suture-ligated, since the latter may tear the wall of the vein graft. The femoral vein is divided flush with the profunda vein to avoid creating a blind stump that could serve as a nidus for thrombus formation and subsequent pulmonary embolism. The vein is then everted in its entirety, with the intimal layer on the outside, to allow excision of the venous valves. After reversion, the graft is distended and any defects are repaired with 6-0 or 7-0 polypropylene suture. The graft is used in nonreversed orientation to improve the size match at the aortic and femoral anastomoses.

Among clinicians who are not familiar with using femoral vein for aortoiliac reconstruction, there appears to be reluctance based on concerns with any venous morbidity associated with harvesting the femoral vein. Our group has extensively studied this issue.[104,105] In the early postoperative period, there is a risk of venous congestion that may produce lower leg compartment syndrome requiring fasciotomy. Early in our experience with deep vein harvest, fasciotomy was required in 17% of limbs, although many of those fasciotomies were "prophylactic."[104] With additional experience, our tolerance for acute leg swelling has increased, so fasciotomy is now rarely performed. Two preoperative predictors of a higher probability of fasciotomy were identified: concurrent harvesting of the greater saphenous vein in the same limb and a low ankle–brachial index (<0.55) in the harvested limb. Prior harvest of the ipsilateral greater

saphenous vein was not a risk factor for requiring a fasciotomy. Venous collaterals develop over time to normalize venous physiology in most patients, so long-term venous morbidity is minimal. One-third of patients experience mild chronic leg swelling, and the remainder are asymptomatic.[105] To our knowledge, no limbs have developed venous ulceration as a consequence of femoral vein harvest.

Comparisons of Arterial Reconstruction Methods for Aortic Arterial Infections

There is a dearth of direct comparisons of the various surgical options for managing graft infections in the literature. Over the past decade, there has been a trend toward various types of in situ reconstructions due to the inferior patency of extraanatomic reconstructions and the risk of aortic stump rupture.[74–78] O'Connor performed a systematic review of the literature to compare the various methods of reconstruction, comparing extraanatomic bypass, rifampin-soaked prostheses, cryopreserved allografts, and autogenous venous reconstructions.[106] Adverse events were more than 50% more frequent with extraanatomic bypass, compared to in situ reconstruction. The lowest event rates were noted with rifampin-soaked prosthetic bypasses. Early and late mortality was most likely after extraanatomic bypass. Autogenous venous reconstructions provided the lowest rate of reinfection, followed closely by cryopreserved allografts. Conduit failure was most likely with extraanatomic bypasses. The patient numbers were too low to compare the patency of rifampin-soaked bypasses with other reconstructions. Major amputation was most likely with either extraanatomic bypass or autogenous venous reconstructions. Table 88-1 summarizes the authors selected studies reporting the outcomes of various reconstructions in aortic infections.

NONAORTIC ARTERIAL AND GRAFT INFECTIONS

Lower Extremity Arterial Infections

Lower Extremity Graft Infections

The nonoperative management of Szilagyi III wounds was described previously. Older studies show that lower extremity bypass graft infections carry a postoperative major amputation and mortality rate of nearly 50% due to the underlying atherosclerotic disease burden.[107] These patients often do not have other conduit suitable for bypass, which is a major impetus for graft preservation strategies for infected extremity bypass grafts. The use of local debridement with adjunctive vacuum-assisted closure and muscle flaps has yielded promising results. Siracuse cited an estimated 1-year limb salvage rate of 71%, which was attributed to the graft preservation techniques described above.[17]

Cryopreserved human allograft veins have been touted as an alternative if a prosthetic bypass graft must be removed for infection. Unfortunately, human allograft veins have yielded relatively poor results. In a series of bypasses for critical limb ischemia using cryopreserved greater saphenous vein, primary patency at 1 and 3 years was 27% and 17%, respectively.[108] Amputation-free survival at 1 and 3 years was 43% and 23%, respectively. Cadaveric vein grafts are expensive, ranging between $7,000 and $7,500. In view of the outcomes and cost, the use of cryopreserved veins must be weighed against the outcomes of graft preservation techniques on a case-by-case basis.

Infected Common Femoral Artery Pseudoaneurysms

The management of infected common femoral artery pseudoaneurysms diverges from the management of infected pseudoaneurysms in other anatomic locations. The most frequent clinical scenarios involve infection after a history of recent arterial catheterization or intravenous drug abuse. The incidence of infection after cardiac catheterization is less than 1%, although the use of arterial closure device increases the risk due to the presence of a foreign body.[109] Aggressive debridement, removal of the closure device, and revascularization remains the mainstays of therapy. In situ repair with autogenous greater saphenous or femoral vein is preferred if arterial replacement is necessary.[27,110] A rotational muscle flap may be necessary for graft coverage in some cases. Occasionally, in situ repair may not be advisable due to the quality of the arteries or the surrounding tissue. Ligation of the native arteries in the groin and an extraanatomic bypass, such as an obturator bypass, may be preferable.[111] Ligation of the common femoral artery without reconstruction is utilized as a last resort and is less likely to threaten the limb if the femoral bifurcation remains intact.[112]

Conversely, infected common femoral artery pseudoaneurysms secondary to intravenous drug abuse should be preferentially managed with aggressive arterial and soft tissue debridement and ligation of all of the involved arteries. Immune suppression due to malnutrition and human immune deficiency virus infections, delayed presentation, and patient recidivism make arterial reconstruction hazardous in this setting. Reddy showed that ligation of the common, superficial, and profunda femoral arteries is

associated with a 33% major amputation rate.[113] Rates of major amputation are very low in other series, with some authors reporting zero amputations in their series.[114,115] Claudication is almost universal, however with debridement and femoral artery ligations.[27] Some authors recommend limiting revascularization attempts to patients with absent pedal Doppler signals after ligation of the femoral vessels, whereas others recommend amputation for all subjects with infected pseudoaneurysms due to intravenous drug abuse.[116]

Table 88-1 Complications Associated with Different Methods of Aortic Reconstruction after Aortic Graft Excision, Based on Selected Publications

	Method of Aortic Reconstruction	30-Day and Long-Term Mortality	Primary Patency	Limb Salvage	Reinfection	Pros (+)/Cons (–)
7	Extraanatomic bypass with aortic ligation[77–81]	30-day: 11–28% 1-year: 14–58%	73–75%	73–93%	3.25%	(+): Reduced morbidity (staging) (–): decreased patency, stump blowout (0–22%), increased amputation and reinfection rates
9	In situ autogenous vein[2,103]	30-day: 8–10% 5-year: 40–48%	81–91%	93–100%	0–5%	(+): resistant to reinfection, excellent long-term durability and limb salvage, cost-effective (–): time-consuming, fasciotomy in up to 25%
10	In situ allograft[94–98]	30-day: 3–20% 1-year: 7–26%	81–97%	97–100%	0–4%	(+): resistant to reinfection, excellent long-term durability and limb salvage (–): rupture and pseudoaneurysmal degeneration, cost, persistent infection
8	In situ rifampin-soaked graft[99,101,102]	30-day: 8% 1-year: 16–21%	89–100%	100%	4–12%	(+): excellent patency, convenience (–): higher reinfection rates
	In situ silver-impregnated graft[105,106]	30-day: 7–21% 1-year: 15–26%	92–100%	96–100%	4–16%	(+): excellent patency, convenience (–): highest reinfection rates

Arterial Infections in Other Sites

Carotid patch infection is a rare, but dreaded occurrence. Management entails removal of the patch, wide debridement, and primary closure of the artery versus vein patch closure. Interposition grafting with autogenous vein is often necessary after the artery is debrided adequately. Occasionally ligation of a bleeding, infected artery is necessary as a life-saving intervention.[18] In a series of carotid patch infections, the stroke rate after debridement and reconstruction was 8.1% and increased to 14% when carotid ligation was necessary.[18] Endografting is an acceptable option to control hemorrhage and permit stabilization and evaluation for definitive surgery.[117]

Case reports and small case series of infected pseudoaneurysms of the superior mesenteric, celiac, and splenic arteries have been reported.[118,119] Treatment is individualized by the patient's comorbidities and anatomy. Infected visceral artery aneurysms are prone to rapid growth and rupture.[118,119] Arteriography is often helpful to delineate the anatomic relationship of the aneurysms to nearby branch vessels and to define the quality of the collateral circulation. Excision, debridement, and arterial reconstruction with autogenous conduit remain the gold standard for infected pseudoaneurysms of main arterial trunks. Resection and arterial ligation may be an option in some cases, depending on the anatomic location due the abundant collateral circulation between the mesenteric arteries and branches.[120] Coil embolization and long-term antibiotic therapy should be reserved for surgically inaccessible aneurysms, such as intrahepatic mycotic pseudoaneurysms, since coils may become infected.[121,122]

ANTIBIOTIC THERAPY

Unfortunately, there are no guidelines directing the type, dose, duration, or route of administration of antibiotics in treating arterial infections. This reflects the wide spectrum of causal organisms that are found in arterial graft infections, with approximately one-third of subjects having polymicrobial infections. Moreover, physician preference and patient tolerance of antibiotic regimens vary considerably. In addition, culture-directed therapy is not always possible since nearly 40% of patients have negative cultures, presumably due to preoperative broad-spectrum antibiotic therapy.[4] Finally, the consequences of a reinfection are dire, so there is a tendency among physicians to overprescribe antibiotics.

Initial broad-spectrum antibiotics should include agents with activity against gram-positive bacilli, gram-negative rods, and anaerobes, as these are the most prevalent organisms in graft infections. Currently our preferred combination therapy is vancomycin, piperacillin/tazobactam, and metronidazole. Blood cultures and graft and tissue cultures should be obtained to direct therapy. Recommendations for the duration of antibiotics vary widely, ranging from 2 to 8 weeks after graft excision. If a graft or stent is not fully excised, indefinite antibiotic therapy should be considered. Fungal infections are particularly difficult to eradicate and may require the use of micafungin (FK463) due to the increasing incidence of resistance to fluconazole and its related molecules.[123]

PREVENTION OF SECONDARY ARTERIAL INFECTIONS

Meticulous surgical technique is critical to minimizing arterial graft infections. Judging from the microbial flora associated with graft infections, intraoperative contamination and surgical site infections are the most likely sources of contaminations that result in arterial graft infections. Adherence to all perioperative guidelines for reducing surgical site infections is important, but the use of prophylactic systemic antibiotics appears to be critically important. A recent meta-analysis and systematic review performed by Stewart concluded that prophylactic systemic antibiotics decreased the risk of wound and early graft infection for peripheral arterial reconstruction.[124] No benefit was seen in continuing antibiotics for greater than 24 hours, prophylactic rifampin-bonding to the grafts, suction groin wound drainage, or preoperative bathing with or without antiseptic agents.

CONCLUSIONS

Primary and secondary arterial infections constitute a myriad of some of the most technically, intellectually, and emotionally challenging cases that vascular surgeons may encounter in clinical practice. For aortic arterial infections, there is no consensus regarding the optimal method of in situ reconstruction. Autogenous vein reconstruction may be the most resistant to recurrent infection and most cost effective, but requires an additional, lengthy procedure for vein harvest. Reconstruction with either antibiotic- or silver-impregnated grafts may also be a reasonable alternative, but appears to have a higher rate of reinfection compared to the alternatives. Cryopreserved allografts have improved since their initial development, but are still hampered by a minority of hemorrhagic complications and pseudoaneurysmal degeneration. Moreover, cryopreserved allografts are considerably more expensive than the other alternatives. Extraanatomic bypass remains a viable alternative for patients unable to undergo a more extensive operation. Endovascular stent grafts are excellent tools to stabilize patients with hemorrhagic complications of arterial infections prior to definitive surgery. Arterial infections in other locations utilize the same principles of wide excision and debridement, arterial reconstruction, and appropriate antibiotic coverage whenever technically feasible.

References

1. Brown SL, Busuttil RW, Baker JD, et al. Bacteriologic and surgical determinants of survival in patients with mycotic aneurysms. *J Vasc Surg* 1984;1(4):541–547.
2. Ali AT, Modrall JG, Hocking J, et al. Long-term results of the treatment of aortic graft infection by in situ replacement with femoral popliteal vein grafts. *J Vasc Surg.* 2009;50(1):30–39.
3. Wilson SE, Van Wagenen P, Passaro E Jr. Arterial infection. *Curr Probl Surg* 1978;15(9):1–89.
4. Miller DV, Oderich GS, Aubry MC, et al. Surgical pathology of infected aneurysms of the descending thoracic and abdominal aorta: clinicopathologic correlations in 29 cases (1976 to 1999). *Hum Pathol* 2004;35(9):112–1120.
5. Muller BT, Wegener OR, Grabitz K, et al. Mycotic aneurysms of the thoracic and abdominal aorta and iliac arteries: experience with anatomic and extra-anatomic repair in 33 cases. *J Vasc Surg* 2001;33(1):106–113.
6. Oderich GS, Panneton JM, Bower TC, et al. Infected aortic aneurysms: aggressive presentation, complicated early outcome, but durable results. *J Vasc Surg* 2001;34(5):900–908.
7. Hsu RB, Chen RJ, Wang SS, et al. Infected aortic aneurysms: clinical outcome and risk factor analysis. *J Vasc Surg* 2004;40(1):30–35.
8. McCready RA, Bryant MA, Divelbiss JL, et al. Arterial infections in the new millennium: an old problem revisited. *Ann Vasc Surg* 2006;20(5):590–595.
9. Kearney RA, Eisen HJ, Wolf JE. Nonvalvular infections of the cardiovascular system. *Ann Intern Med* 1994;121(3):219–230.
10. Svensson LG, Crawford ES, Hess KR, et al. Experience with 1509 patients undergoing thoracoabdominal aortic operations. *J Vasc Surg* 1993;17(2):357–370.
11. United Kingdom Small Aneurysm Trial Participants. Long-term outcomes of immediate repair compared with surveillance of small abdominal aortic aneurysms. *N Engl J Med* 2002;346(19):1445–1452.
12. Vogel TR, Symons R, Flum DR. The incidence and factors associated with graft infection after aortic aneurysm repair. *J Vasc Surg* 2008;47(2):264–269.
13. Murphy EH, Szeto WY, Herdrich BJ, et al. The management of endograft infections following endovascular thoracic and abdominal aneurysm repair. *J Vasc Surg* 2013;58(5):1179–1185.
14. Sharif MA, Lee B, Lau LL, et al. Prosthetic stent graft infection after endovascular abdominal aortic aneurysm repair. *J Vasc Surg* 2007;46(3):442–448.
15. Heyer KS, Modi P, Morasch MD, et al. Secondary infections of thoracic and abdominal aortic endografts. *J Vasc Interv Radiol* 2009;20(2):173–179.
16. Lorentzen JE, Nielsen OM, Arendrup H, et al. Vascular graft infection: an analysis of sixty-two graft infections in 2411 consecutively implanted synthetic vascular grafts. *Surgery* 1985;98(1):81–86.

17. Siracuse JJ, Nandivada P, Giles K, et al. Prosthetic graft infections involving the femoral artery. *J Vasc Surg* 2013;57(3):700–705.
18. Mann CD, McCarthy M, Nasim A, et al. Management and outcome of prosthetic patch infection after carotid endarterectomy: a single-centre series and systematic review of the literature. *Eur J Vasc Endovasc Surg* 2012;44(1):20–26.
19. Brunstedt MR, Sapatnekar S, Rubin KR, et al. Bacterial/blood/material interactions. I. injected and preseeded slime-forming staphylococcus epidermidis in flowing blood with biomaterials. *J Biomed Mater Res* 1995;29(4):455–466.
20. Bosman WM, Borger van der Burg BL, Schuttevaer HM, et al. Infections of intravascular bare metal stents: a case report and review of literature. *Eur J Vasc Endovasc Surg* 2014;47(1):87–99.
21. Elek SD, Conen PD. The virulence of staphylococcus pyogenes for man. a study of the problem of wound infections. *Br J Exp Pathol* 1957;38(6):573–576.
22. Mack D. Molecular mechanisms of staphylococcus epidermidis biofilm formation. *J Hosp Infect* 1999;43:S113–S125.
23. Kaplan SS, Basford RE, Jeong MH, et al. Mechanisms of biomaterial-induced superoxide release by neutrophils. *J Biomed Mater Res* 1994;28(3):377–386.
24. Kaplan SS, Basford RE, Jeong MH, et al. Biomaterial-neutrophil interactions: dysregulation of oxidative functions of fresh neutrophils induced by prior neutrophil-biomaterial interaction. *J Biomed Mater Res* 1996;30(1):67–75.
25. MacKintosh EE, Patel J, Marchant RE, et al. Effects of biomaterial surface chemistry on the adhesion and biofilm formation of staphylococcus epidermidis in vitro. *J Biomed Mater Res A* 2006;78(4):836–842.
26. Xu L, Li H, Vuong C, et al. Role of the luxS quorum-sensing system in biofilm formation and virulence of staphylococcus epidermidis. *Infect Immun* 2006;74(1):488–496.
27. Bell CL, Ali AT, Brawley JG, et al. Arterial reconstruction of infected femoral artery pseudoaneurysms using superficial femoral-popliteal vein. *J Am Coll Surg* 2005;200(6):831–836.
28. Bunt TJ. Synthetic vascular graft infections. I. graft infections. *Surgery* 1983;93(6):733–746.
29. Szilagyi DE, Smith RF, Elliott JP, et al. Infection in arterial reconstruction with synthetic grafts. *Ann Surg* 1972;176(3):321–333.
30. Samson RH, Vieth FJ, Janko GS, et al. A modified classification and approach to the management of infections involving peripheral arterial prosthetic grafts. *J Vasc Surg* 1988;8(2):147–153.
31. Gonzalez I, Sarria C, Lopez J, et al. Symptomatic peripheral mycotic aneurysms due to infective endocarditis. *Medicine (Baltimore)* 2014;93(1):42–52.
32. Alpern RJ, Dowell VR JR. Clostridium septicum infections and malignancy. *JAMA* 1969;209(3):385–388.

33. Seabrook GR, Schmitt DD, Bandyk DF, et al. Anastomotic femoral pseudoaneurysm: an investigation of occult infection as an etiologic factor. *J Vasc Surg* 1990;11(5):629–634.
34. Mertens RA, O'Hara PJ, Hertzer NR, et al. Surgical management of infrainguinal arterial prosthetic graft infections: review of a thirty-five-year experience. *J Vasc Surg* 1995;21(5):782–791.
35. Marsan BU, Curl R, Pillai L, et al. The thrombosed prosthetic graft is a risk for infection of an adjacent graft. *Am J Surg* 1996;172(2):175–177.
36. Brothers TE, Robison JG, Elliott BM. Predictors of prosthetic graft infection after infrainguinal bypass. *J Am Coll Surg* 2009;208(4):557–561.
37. Rodrigues dos Santos C, Casaca R, Crespo Mendes de Almeida J, et al. Enteric repair in aortoduodenal fistulas: a forgotten but often lethal player. *Ann Vasc Surg* 2014;28(3):756–762.
38. Jonker FH, Heijman R, Trimarchi S, et al. Acute management of aortobronchial and aortoesophageal fistulas using thoracic endovascular aortic repair. *J Vasc Surg* 2009;50(5):999–1004.
39. Antoniou GA, Koutsias S, Antoniou SA, et al. Outcome after endovascular stent graft repair of aortoenteric fistula: a systematic review. *J Vasc Surg* 2009;49(3):782–789.
40. Lawlor DK, DeRose G, Harris KA, et al. Primary aorto/iliac-enteric fistula-report of 6 new cases. *Vasc Endovascular Surg* 2004;38(3):281–286.
41. Hallett JW Jr, Marshall DM, Petterson TM, et al. Graft-related complications after abdominal aortic aneurysm repair: reassurance from a 36-year population-based experience. *J Vasc Surg* 1997;25(2):277–284.
42. Wright DJ, Earnst CB, Evans JR, et al. Ureteral complications and aortoiliac reconstruction. *J Vasc Surg* 1990;11(1):29–35.
43. Orton DF, LeVeen RF, Saigh JA, et al. Aortic prosthetic graft infections: radiologic manifestations and implications for management. *Radiographics* 2000;20(4):977–993.
44. Low RN, Wall SD, Jeffrey RB Jr, et al. Aortoenteric fistula and perigraft infection: evaluation with CT. *Radiology* 1990;175(1):157–162.
45. Macedo TA, Stanson AW, Oderich GS, et al. Infected aortic aneurysms: imaging findings. *Radiology* 2004;231(1):250–257.
46. Sueyoshi E, Sakamoto I, Kawahara Y, et al. Infected abdominal aortic aneurysm: early CT findings. *Abdom Imaging* 1998;23(6):645–648.
47. Modrall JG, Clagett GP. The role of imaging techniques in evaluating possible graft infections. *Semin Vasc Surg* 1999;12(4):339–347.
48. O'Hara PJ, Borkowski GP, Hertzer NR, et al. Natural history of periprosthetic air on computerized axial tomographic examination of the abdomen following abdominal aortic aneurysm repair. *J Vasc Surg* 1984;1(3):429–433.
49. Sawhney R, Kerlan RK, Wall SD, et al. Analysis of initial CT findings after endovascular repair of abdominal aortic aneurysm. *Radiology* 2001;220(1):157–160.

50. Chung J, Clagett GP. Neoartoiliac system (NAIS) procedure for the treatment of the infected aortic graft. *Sem Vasc Surg* 2011;24(4):220–226.
51. Shahidi S, Eskil A, Lundof E, et al. Detection of abdominal aortic graft infection: comparison of magnetic resonance imaging and indium-labeled white blood cell scanning. *Ann Vasc Surg* 2007;21(5):586–592.
52. Olofsson PA, Auffermann W, Higgins CB, et al. Diagnosis of prosthetic aortic graft infection by magnetic resonance imaging. *J Vasc Surg* 1988;8(2):99–105.
53. Auffermann W, Olofsson PA, Rabahie GN, et al. Incorporation versus infection of retroperitoneal aortic grafts: MR imaging features. *Radiology* 1989;172(2):359–362.
54. Fiorani P, Speziale F, Rizzo L, et al. Detection of aortic graft infection with leukocytes labeled with technetium 99 m-hexametazime. *J Vasc Surg* 1993;17(1):87–95.
55. Palestro CJ, Torres MA. Radionuclide imaging of nonosseous infection. *Q J Nucl Med* 1999;43(1):46–60.
56. Ketai L, Hartshorne M. Potential uses of computed tomography-SPECT and computed tomography-coincidence fusion images of the chest. *Clin Nucl Med* 2001;26(5):433–441.
57. Erba PA, Leo G, Sollini M, et al. Radiolabelled leucocyte scintigraphy versus conventional radiological imaging for the management of late, low-grade vascular prosthesis infections. *Eur J Nucl Med Mol Imaging* 2014;41(2):357–368.
58. Fukuchi K, Ishida Y, Higashi M, et al. Detection of aortic graft infection by fluorodeoxyglucose positron emission tomography: comparison with computed tomographic findings. *J Vasc Surg* 2005;42(5):919–925.
59. Spacek M, Belohlavek O, Votrubova J, et al. Diagnostics of “non-acute” vascular prosthesis infection using 18 F-FDG PET/CT: our experience with 96 prostheses. *Eur J Nucl Med Mol Imaging* 2009;36(5):850–858.
60. Bruggink JL, Glaudemans AW, Saleem BR, et al. Accuracy of FDG-PET-CT in the diagnostic work-up of vascular prosthetic graft infection. *Eur J Vasc Endovasc Surg* 2010;40(3):348–354.
61. Basu S, Chryssikos T, Moghadam-Kia S, et al. Positron emission tomography as a diagnostic tool in infection: present role and future possibilities. *Semin Nucl Med* 2009;39(1):36–51.
62. Lan XL, Zhang YX, Wu ZJ, et al. The value of dual time point (18)F-FDG PET imaging for the differentiation between malignant and benign lesions. *Clin Radiol* 2008;63(7):756–764.
63. Boellard R, O’Doherty MJ, Weber WA, et al. FDG PET and PET/CT: EANM procedure guidelines for tumour PET imaging version 1.0. *Eur J Nucl Med Mol Imaging* 2010;37(1):181–200.
64. Thompson WM, Jackson DC, Johnsrude IS. Aortoenteric and paraprosthetic-enteric fistulas: radiologic findings. *AJR* 1976;127:235–242.

65. Katz BH, Black RA, Colley DP. CT-guided fine needle aspiration of a periaortic collection. *J Vasc Surg* 1987;5(5):762–764.
66. Golder W, Wolf KJ. CT-guided aspiration biopsy of infected aortic graft in a patient with hypertrophic osteoarthropathy: saline injection to improve diagnostic yield-a case report. *Acta Radiol* 2001;42(1):59–62.
67. Hsu RB, Chang CI, Wu IH, et al. Selective medical treatment of infected aneurysms of the aorta in high risk patients. *J Vasc Surg* 2009;49(1):66–70.
68. Calligaro KD, Veith FJ, Schwartz ML, et al. Selective preservation of infected prosthetic arterial grafts. analysis of a 20-year experience with 120 extracavitary-infected grafts. *Ann Surg* 1994;220(4):461–471.
69. Dosluoglu HH, Loghmanee C, Lall P, et al. Management of early (<30 day) vascular groin infections using vacuum-assisted closure alone without muscle flap coverage in a consecutive patient series. *J Vasc Surg* 2010;51(5):1160–1166.
70. Berger P, de Bie D, Moll FL, et al. Negative pressure wound therapy on exposed prosthetic vascular grafts in the groin. *J Vasc Surg* 2012;56(3):714–720.
71. Calligaro KD, Veith FJ, Yuan JG, et al. Intra-abdominal aortic graft infection: complete or partial graft preservation in patients at very high risk. *J Vasc Surg* 2003;38(6):1199–1205.
72. Marone EM, Mascia D, Kahlberg A, et al. Emergent endovascular treatment of a bleeding recurrent aortoenteric fistula as a “bridge” to definitive surgical repair. *J Vasc Surg* 2012;55(4):1160–1163.
73. Leonhardt H, Mellander S, Snygg J, et al. Endovascular management of acute bleeding arterioenteric fistulas. *Cardiovasc Intervent Radiol* 2008;31(3):542–549.
74. O’Hara PJ, Hertzer NR, Beven BG, et al. Surgical management of infected abdominal grafts: review of a 25-year experience. *J Vasc Surg* 1986;3(5):725–731.
75. Reilly LM, Stoney RJ, Goldstone J, et al. Improved management of aortic graft infection: the influence of operation sequence and staging. *J Vasc Surg* 1987;5(3):421–431.
76. Seeger JM, Pretus HA, Welborn MB, et al. Long-term outcome after treatment of aortic graft infection with staged extra-anatomic bypass grafting and aortic graft removal. *J Vasc Surg* 2000;32(3):451–459.
77. Yeager RA, Taylor LM Jr, Moneta GL, et al. Improved results with conventional management of infrarenal aortic infection. *J Vasc Surg* 1999;30(1):76–83.
78. Bandyk DF, Novotney ML, Back MR, et al. Expanded application of in situ replacement for prosthetic graft infection. *J Vasc Surg* 2001;34(3):411–420.
79. Armstrong PA, Back MR, Wilson JS, et al. Improved outcomes in the recent management of secondary aortoenteric fistula. *J Vasc Surg* 2005;42(4):660–666.
80. Oderich GS, Bower TC, Hofer J, et al. In situ rifampin-soaked grafts with omental coverage and antibiotic suppression are durable with low reinfection rates in patients with aortic graft enteric erosion or fistula. *J Vasc Surg* 2011;53(1):99–107.

81. Oderich GS, Bower TC, Cherry KJ Jr, et al. Evolution from axillofemoral to in situ prosthetic reconstruction for the treatment of aortic graft infections at a single center. *J Vasc Surg* 2006;43(6):1166–1174.
82. Batt M, Jean-Baptiste E, O'Conner S, et al. Early and late results of contemporary management of 37 secondary aorto-enteric fistulae. *Eur J Vasc Endovasc Surg* 2011;41(6):748–757.
83. Harlander-Locke MP, Harmon LK, Lawrence PF, et al. The use of cryopreserved aortoiliac allograft for aortic reconstruction in the United States. *J Vasc Surg* 2014;59(3):669–674.
84. Valentine RJ, Timaran CH, Modrall JG, et al. Secondary aortoenteric fistulas versus paraprosthetic erosions: is bleeding associated with worse outcome? *J Am Coll Surg* 2008;207(6):922–927.
85. Belair M, Soulez G, Oliva VL, et al. Aortic graft infection: the value of percutaneous drainage. *AJR Am J Roentgenol* 1998;171(1):119–124.
86. Fleisher LA, Beckman JA, Brown KA, et al. ACC/AHA 2007 guidelines on perioperative cardiovascular evaluation and care for noncardiac surgery: a report of the American College of Cardiology/American Heart Association Task Force on Practice guidelines (writing committee to revise the 2002 guidelines on perioperative cardiovascular evaluation for noncardiac surgery. *Circulation* 2007;116(17):e418-e500.
87. Lee CH, Hsieh HC, Ko PJ, et al. In situ versus extra-anatomic reconstruction for primary infected infrarenal abdominal aortic aneurysms. *J Vasc Surg* 2011;54(1):64–70.
88. Carrel A. Ultimate result of aortic transplantation. *J Exp Med* 1912;15:389–398.
89. Zwischenberger JB, Shalaby TZ, Conti VR. Viable cryopreserved aortic homograft for aortic valve endocarditis and annular abscesses. *Ann Thorac Surg* 1989;48(3):365–370.
90. Kieffer E, Bahnini A, Koskas F, et al. In situ allograft replacement of infected infrarenal aortic prosthetic grafts: results in forty-three patients. *J Vasc Surg* 1993;17(2):349–356.
91. Brown KE, Heyer K, Rodriguez H, et al. Arterial reconstruction with cryopreserved human allografts in the setting of infection: a single-center experience with midterm follow-up. *J Vasc Surg* 2009;49(3):660–666.
92. Vogt PR, Brunner-LaRocca HP, Lachat M, et al. Technical details with the use of cryopreserved arterial allografts for aortic infection: influence on early and midterm mortality. *J Vasc Surg* 2002;35(1):80–86.
93. Verhelst R, LaCroix V, Vraux H, et al. Use of cryopreserved arterial homografts for management of infected prosthetic grafts: a multi-centric study. *Ann Vasc Surg* 2000;14(6):602–607.
94. Leseche G, Castier Y, Petit MD, et al. Long-term results of cryopreserved arterial

allograft reconstruction in infected prosthetic grafts and mycotic aneurysms of the abdominal aorta. *J Vasc Surg* 2001;34(4):616–622.

95. Villain-Guillot P, Gualtieri M, Bastide L, et al. In vitro activities of different inhibitors of bacterial transcription against staphylococcus epidermidis biofilm. *Antimicrob Agents Chemother* 2007;51(9):3117–3121.
96. Bandyk DF, Novotney ML, Back MR, et al. Use of rifampin-soaked gelatin-sealed polyester grafts for in situ treatment of primary aortic and vascular prosthetic infections. *J Surg Res* 2001;95(1):44–49.
97. Mei L, Lu Z, Zhang X, et al. Polymer-Ag nanocomposites with enhanced antimicrobial activity against bacterial infection. *ACS Appl Mater Interfaces* 2014;6(18):15813–1521.
98. Koshiko S, Sasajima T, Muraki S, et al. Limitations in the use of rifampicin-gelatin grafts against virulent organisms. *J Vasc Surg* 2002;35(4):779–785.
99. Batt M, Jean-Baptiste E, O'Connor S, et al. In-site revascularisation for patients with aortic graft infection: a single centre experience with silver coated polyester grafts. *Eur J Vasc Endovasc Surg* 2008;36(2):182–188.
100. Batt M, Magne JL, Alric P, et al. In situ revascularization with silver-coated polyester grafts to treat aortic infection: early and midterm results. *J Vasc Surg* 2003;38(5):983–989.
101. Clagett GP, Bowers BL, Lopez-Viego MA, et al. Creation of a neo-aortoiliac system from lower extremity deep and superficial veins. *Ann Surg* 1993;218(3):239–248; discussion 248–249.
102. Daenens K, Fourneau I, Nevelsteen A. Ten-year experience in autogenous reconstruction with the femoral vein in the treatment of aortofemoral prosthetic infection. *Eur J Vasc Endovasc Surg* 2003;25(3):240–245.
103. Valentine RJ and Clagett GP. Aortic graft infections: replacement with autogenous vein. *Cardiovasc Surg* 2001;9(5):419–425.
104. Modrall JG, Sadjadi J, Ali AT, et al. Deep vein harvest: predicting need for fasciotomy. *J Vasc Surg* 2004;39(2):387–394.
105. Modrall JG, Hocking JA, Timaran CH, et al. Late incidence of chronic venous insufficiency after deep vein harvest. *J Vasc Surg* 2007;46(3):520–525; discussion 525.
106. O'Connor S, Andrew P, Batt M, et al. A systematic review and meta-analysis of treatments for aortic graft infection. *J Vasc Surg* 2006;44(1):38–45.
107. Edwards WH Jr, Martin RS 3rd, Jenkins JM, et al. Primary graft infections. *J Vasc Surg* 1987;6(3):235–239.
108. Chang CK, Scali ST, Feezor RJ, et al. Defining utility and predicting outcome of cadaveric lower extremity bypass grafts in patients with critical limb ischemia. *J Vasc Surg* 2014;60(6):1554–1564.
109. Biancari F, D'Andrea V, Di Marco C, et al. Meta-analysis of randomized trials on the efficacy of vascular closure devices after diagnostic angiography and angioplasty. *Am*

Heart J 2010;159(4):518–531.

110. Schneider JR, Oskin SI, Verta MJ Jr. Superficial femoral vein graft interposition in situ repair for femoral mycotic aneurysm. *Ann Vasc Surg* 2009;23(1):147–149.
111. Patel A, Taylor SM, Langan EM III, et al. Obdurator bypass: a classic approach for the treatment of contemporary groin infection. *Am Surg* 2002;68(8):653–658.
112. Arora S, Weber MA, Fox CJ, et al. Common femoral artery ligation and local debridement: a safe treatment for infected femoral artery pseudoaneurysms. *J Vasc Surg* 2001;33(5):990–993.
113. Reddy DJ, Smith RF, Elliott JP Jr, et al. Infected femoral artery false aneurysms in drug addicts: evolution of selective vascular reconstruction. *J Vasc Surg* 1986;3(5):718–724.
114. Cheng SW, Fok M, Wong J. Infected femoral pseudoaneurysm in intravenous drug abusers. *Br J Surg* 1992;79:510–512.
115. Mousavi SR, Saberi A, Tadayon N, et al. Femoral artery ligation as treatment for infected pseudo-aneurysms, secondary to drug injection. *Acta Chir Belg* 2010;110(2):200–202.
116. Padberg F Jr, Hobson R, Lee B, et al. Femoral pseudoaneurysm from drugs of abuse: ligation or reconstruction?*J Vasc Surg* 1992;15(4):642–648.
117. Sorial E, Valentino J, Given CA, et al. The emergency use of endografts in the carotid bifurcation to control hemorrhage in potentially contaminated fields. *J Vasc Surg* 2007;46(4):792–798.
118. Lorelli DR, Cambria RA, Seabrook GR, et al. Diagnosis and management of aneurysms involving the superior mesenteric artery and its branches-a report of four cases. *Vasc Endovasc Surg* 2003;37(1):59–66.
119. Serafin G, Vroegindeweij D, Boks S, et al. Mycotic aneurysm of the celiac trunk: from early CT sign to rupture. *Cardiovasc Interv Radiol* 2005;28(5):677–680.
120. Lai KM, Rosenthal D, Wellons ED, et al. Mycotic superior mesenteric aneurysm. *J Vasc Surg* 2007;45(1):191.
121. Georges RN, Lipman S, Silvestri F, et al. Endovascular treatment of mycotic hepatic artery aneurysm in the hostile abdomen-a case report. *J Vasc Surg* 2001;35(6):477–481.
122. Tierney AB, Palmer FJ. Mycotic aneurysm of the right hepatic artery presenting with obstructive jaundice. *Australas Radiol* 1987;31(1):50–52.
123. Ramirez M, Serran C, Castro C, et al. Comparative study of disc diffusion and microdilution methods in susceptibility testing of micafungin against Candida species. *J Antimicrob Chemother* 2006;58(4):861–863.
124. Stewart AH, Eyers PS, Earnshaw JJ. Prevention of infection in peripheral arterial reconstruction: a systematic review and meta-analysis. *J Vasc Surg* 2007;46(1):148–155.

Chapter 89

Cerebrovascular Disease

Martyn Knowles and Carlos H. Timaran

Key Points

1 Worldwide stroke has become the second leading cause of death

2 Atherosclerotic occlusive disease of the extracranial carotid artery accounts for a major cause of ischemic stroke

3 Duplex ultrasonography is of great use in the identification of cerebrovascular disease

4 Risk factor modification is imperative in patients with atherosclerotic cerebrovascular disease

5 Surgical treatment for occlusive carotid artery disease is preferred over medical management for symptomatic disease and severe asymptomatic disease

6 Carotid artery stenting continues to be evaluated for efficacy

7 The diagnosis of vertebrobasilar insufficiency is often difficult due to subtle symptoms shared by many organ systems

8 Endovascular management of vertebral artery disease has not been sufficiently investigated for efficacy

9 Open repair of brachiocephalic disease should be based on patient comorbidities, and high-risk patients should undergo extra-anatomic revascularization

INTRODUCTION

Stroke continues to be a common cause of death and disability. The morbidity caused by a stroke can be debilitating, worse than that of a myocardial infarction (MI). Stroke can cause permanent disability that includes aphasia, paralysis, blindness, numbness, or weakness. If transient, <24 hours, it is termed a transient ischemic attack (TIA) and manifests similarly. Long-term sequelae from stroke can have long-lasting financial and social burdens on a patient, family, and the healthcare system in general.

Atherosclerotic plaque at the bifurcation of the carotid artery extending into the internal carotid artery continues to be a common cause of CVA, accounting for approximately 40% to 60% of all ischemic strokes. Since the introduction of the carotid endarterectomy (CEA) in 1954, operative treatment of carotid artery occlusive lesions has been shown in multiple randomized trials to decrease the risk of subsequent ipsilateral ischemic strokes. More recently, endovascular carotid artery stenting (CAS) techniques have seen a surge in popularity; however, controversy still exists regarding the appropriate use of endovascular intervention, and the evaluation of surgical, endovascular, and medical management of carotid occlusive disease continues to be investigated.

Vertebral artery occlusive disease typically occurs at the origin of the vertebral arteries – due to atherosclerosis – and can cause posterior circulation symptoms, such as diplopia, drop attacks, and vertigo. The diagnosis of vertebrobasilar disease is usually more difficult than carotid occlusive disease as the symptoms are often vague and can be confused easily with other diagnoses. Treatment has traditionally been open surgical repair; however, endovascular repair is feasible although outcomes have not been evaluated extensively.

Brachiocephalic occlusive disease is most often caused by atherosclerosis and involves the origin of the great vessels. Symptoms can include stroke, TIA, and arm fatigue and weakness. Diagnosis often requires imaging and a keen physical examination. Treatment involves either extra-anatomic or transthoracic surgical repair or more recently the introduction of endovascular management with angioplasty and stenting.

This chapter provides a comprehensive review of epidemiology, pathophysiology, diagnosis, treatment, and controversy in the management of carotid artery occlusive disease, as well as vertebral artery and brachiocephalic occlusive disease.

CAROTID ARTERY OCCLUSIVE DISEASE

Epidemiology

1 Worldwide, stroke is the second most common cause of mortality and third of disability.[1] The incidence appears to be decreasing in the United States; however, is increasing in low-income countries.[2,3] In the United States, the annual incidence of a new or recurrent stroke is 795,000, of which 610,000 are first-ever strokes.[4] There appear to be a higher number of strokes in the Southeast United States as compared to other regions. Men have a higher risk of stroke at younger ages, but women have a higher risk over the age of 75 years.[4] The risk of stroke appears to be affected by race, with whites having a lower incidence than blacks and Hispanics in the United States.[5,6] The risk of first-ever strokes in blacks is twice that in whites.[7] Recently, stroke has been decreased from the third leading cause of death in the United States to the fourth. This decrease is related to a decrease in the incidence of strokes over the last few decades, up to a 40% decrease since the 1980s.[8,9] This decrease in mortality has been fueled by improvements in acute stroke care over the years. The incidence of TIA is approximately 2.3% and has a higher risk of subsequent stroke. TIAs can herald a stroke 15% of the time, usually within the first 90 days.[7] The risk factors for stroke include age over 55, male sex, hypertension, family history, atrial fibrillation, smoking, hypercholesterolemia, diabetes, obesity, renal insufficiency, and alcohol. Overall, five factors cause a significant number of strokes: hypertension, smoking, obesity, diet, and physical inactivity.[10]

PATHOGENESIS OF STROKE

The etiology of CVA in the United States is most commonly related to ischemia (87%), intracerebral hemorrhage (10%), and subarachnoid hemorrhage (3%).[4] Ischemia can be broken down into thrombosis, embolism, and hypoperfusion. Thrombosis refers to in situ obstruction of an artery, typically from atherosclerosis, dissection, or fibromuscular dysplasia (FMD). A stroke occurs from reduced flow distal to the thrombosis, and can be either large or small vessel. Large vessels include the extracranial carotid and proximal intracranial arteries. Small vessel disease is branch vessels from the intracranial vessels. Embolism refers to debris from a source, such as the heart or arterial segment, that becomes free and flows downstream until lodging in a small vessel. Hypoperfusion refers to a more global circulatory problem. Often there is a combination of etiologies that leads to a stroke such as a pre-existing lesion that becomes a source of emboli.

2 Atherosclerosis is the most common cause of disease in the extra- and intracranial carotid arteries. This etiology remains a major preventative cause of ischemic stroke. The incidence of carotid artery disease is 3.8% to 10.5% in men and 2.7% to 5.5% in women.[11,12] Although, a definitive cause of stroke is often not identified, large vessel cervical disease is a major cause in about 15% of cases (Fig. 89-1). Stroke from carotid vessel etiology also has the highest rate of recurrence at 30 days.[13]

The carotid bifurcation is an area of low flow and shear stress, due to a separation of flow between the high-resistance external carotid artery and the low-resistance internal carotid artery (Fig. 89-2). Plaque usually forms in this area due to the shear stress, and forms on the walls opposite from the flow divider. As per typical atherosclerosis formation, the inciting event is intimal injury. There is then platelet deposition, smooth muscle proliferation, fibroplasia, and loss of the luminal diameter. As the lumen diameter gets smaller, the flow velocities and turbulence increase which can lead to hypoperfusion or atheroembolization (Fig. 89-3). Furthermore, a large number of carotid plaques have a necrotic core of lipid rich debris and cholesterol. There is a fibrous cap that separates this from the lumen, which is typically a thin rim of cellular components and extracellular matrix. This thin cap can rupture and cause plaque disruption which can have severe clinical consequences. Hemorrhage within the plaque can also occur and is an important risk factor for rupture of the cap. Additionally, dense plaque inflammation with macrophage infiltration is strongly associated with cap rupture. Conversely, the presence of a thick plaque is associated with a more stable plaque.

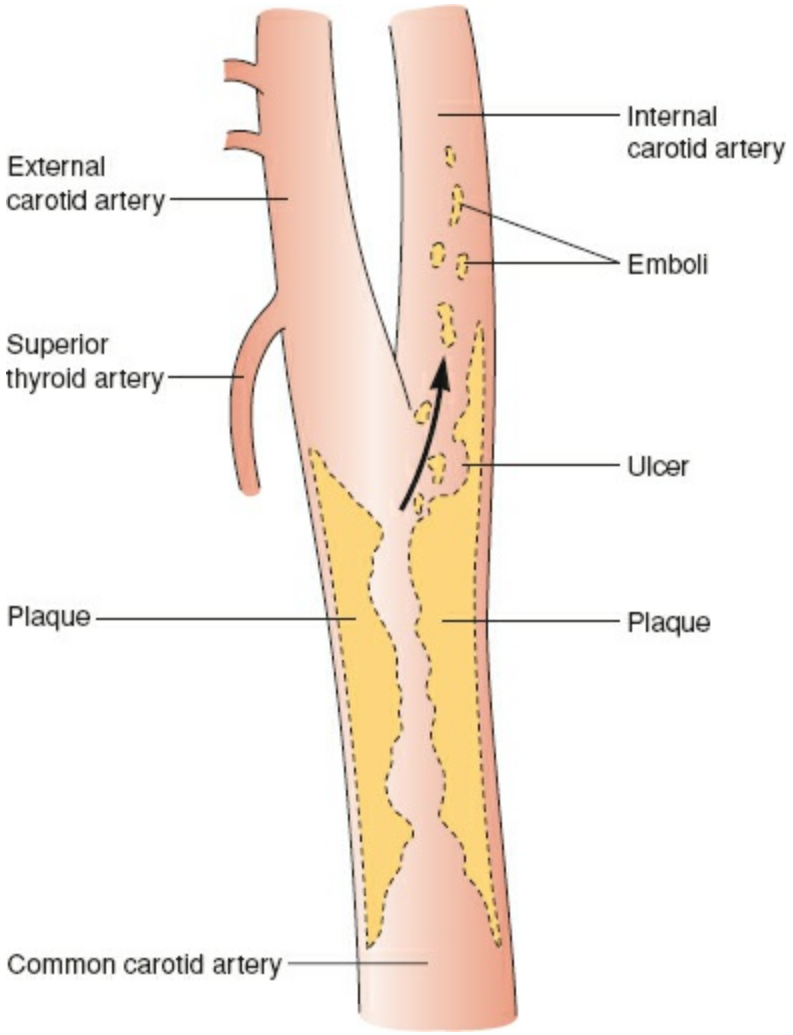

Figure 89-1. Stroke due to carotid bifurcation occlusive disease is usually caused by atheroemboli arising from the internal carotid artery, which provides the majority of blood flow to the cerebral hemisphere. With increasing degrees of stenosis in the carotid artery, flow becomes more turbulent, and the risk of atheroembolization escalates.

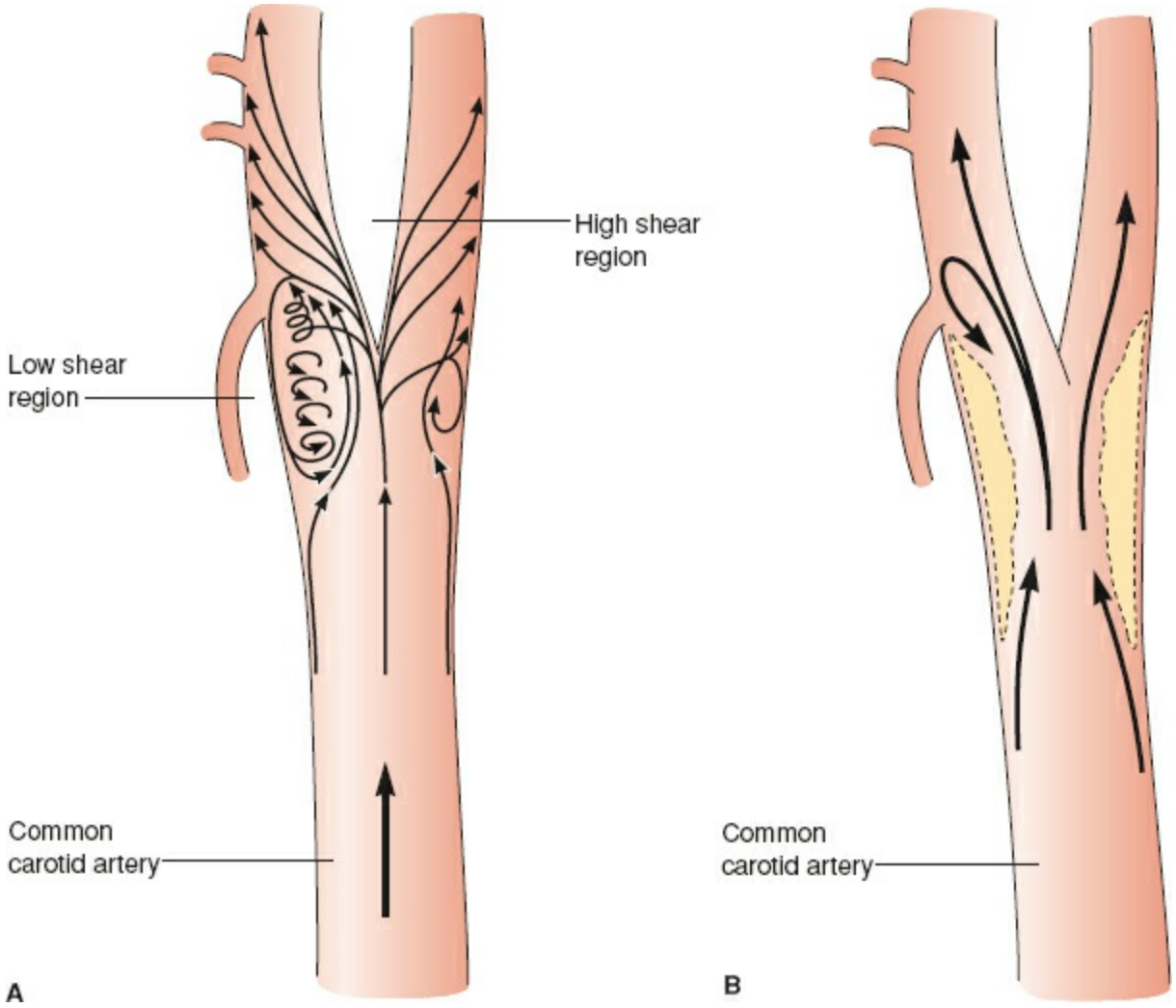

Figure 89-2. **A:** The carotid bifurcation is an area of low flow velocity and low shear stress. As the blood circulates through the carotid bifurcation, there is separation of flow into the low-resistance internal carotid artery and the high-resistance external carotid artery. **B:** The carotid atherosclerotic plaque typically forms in the outer wall opposite to the flow divider due in part to the effect of the low shear stress region, which also creates a transient reversal of flow during the cardiac cycle.

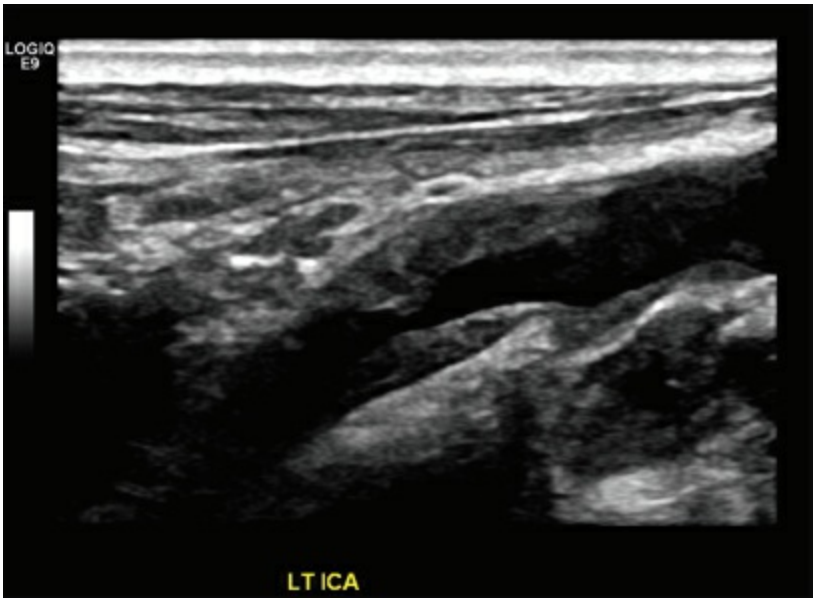

Figure 89-3. Duplex ultrasonography showing a carotid plaque with narrowing of the vessel lumen that can either embolize or cause low flow causing hypoperfusion. B-mode imaging shows a heterogeneous plaque with severe narrowing.

CLINICAL MANIFESTATIONS OF STROKE

Symptomatic carotid artery disease is classically thought of as a corresponding TIA, stroke, or amaurosis fugax. A TIA is a neurologic event that manifests stroke-like symptoms for <24 hours. These are considered a precursor of a more serious event and a large number will progress to a stroke. Symptoms correspond with a focal defect that can be related to carotid artery atherosclerosis. These symptoms typically include the anterior or middle cerebral artery circulations. Motor symptoms can include hemiparesis contralateral to the affected hemisphere. Sensory deficits can also occur in a similar fashion, such as numbness or paresthesia. Aphasia, dysphagia, or dysarthria can also occur. Amaurosis fugax is the temporary monocular blindness from cholesterol embolization to the retinal artery via the ophthalmic artery. Dizziness, syncope, vertigo, seizures, bowel or bladder incontinence, or migraines are not typically related to carotid disease and other causes must be sought. Once the symptoms progress past 24 hours, the TIA has become a full stroke. The full severity of a stroke can often take weeks to manifest as the penumbra either recovers or does not. Global ischemia is generally uncommon with carotid artery disease.

DIAGNOSTIC EVALUATION

3 Carotid artery duplex ultrasonography (DUS) is the primary diagnostic tool for the evaluation of carotid artery disease. Although the role in screening is controversial, those with concerning symptoms should undergo DUS. The benefits of DUS include excellent sensitivity for the diagnosis of occlusive carotid artery disease, but also the avoidance of radiation and the rapid availability and ease of evaluation. The decision for carotid intervention is often taken solely on the information provided by the DUS. A complete examination includes evaluation of the common, external, and internal carotid arteries, as well as the vertebral arteries, and often the subclavian arteries. The peak systolic velocity (PSV), end-diastolic velocity (EDV), and the ratio of the common carotid artery to internal carotid artery (CCA/ICA) are used to determine the severity of stenosis (Fig. 89-4). Although labs differ in their ranges, patients are typically classified into: normal, 1% to 49%, 50% to 69%, 70% to 99% or occluded (Table 89-1). Additionally, the DUS can provide important information regarding the plaque morphology. The identification of high-risk echolucent plaques can aid the practitioner in estimating the risk of neurologic symptoms. The diagnostic accuracy of DUS does, however, depend on having a skilled sonographer. Magnetic resonance angiography (MRA) and computerized tomographic angiography (CTA) are becoming more popular for diagnosis with improvements in the technology. These imaging modalities can provide important information regarding the aortic arch, tortuosity, brachiocephalic disease, carotid bifurcation location, and intracerebral collateral circulation. They can, however, overestimate the amount of stenosis and often require correlation with DUS. Angiography remains the gold standard for diagnosis; however, the procedure itself carries approximately 1% risk of neurologic complications (Fig. 89-5). Transcranial Doppler (TCD) can provide information related to the significance of a stenosis and how it alters intracerebral hemodynamics.

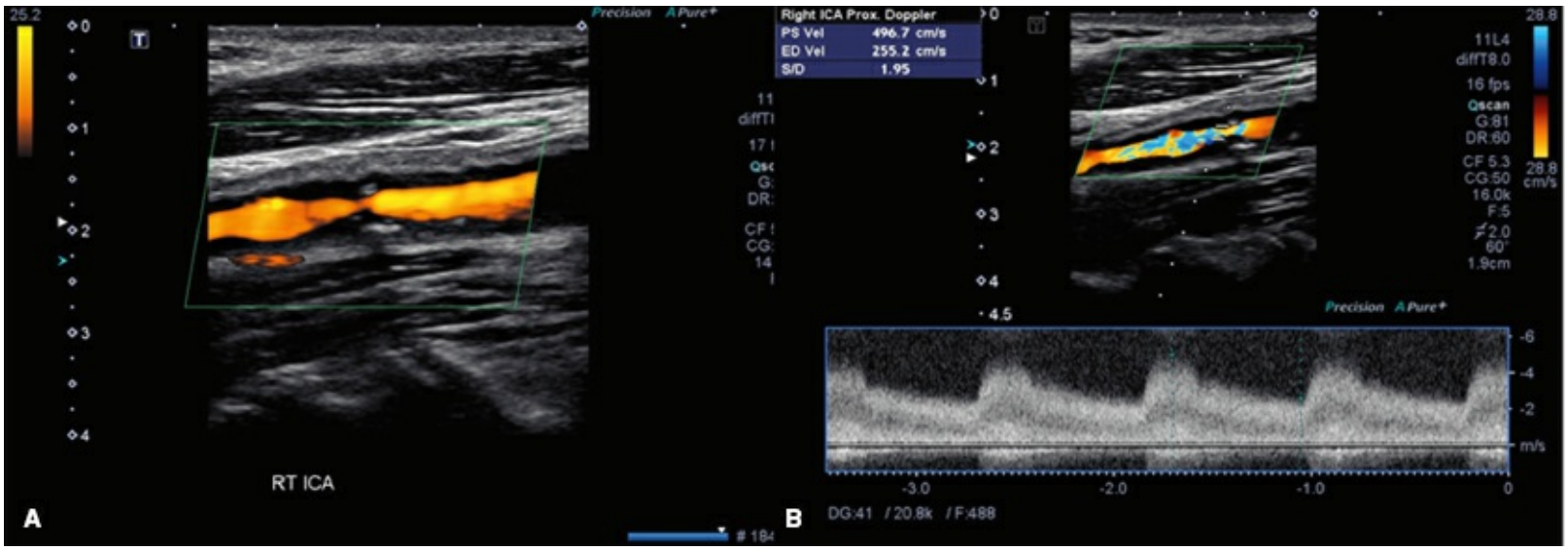

Figure 89-4. **A:** Color power Doppler shows a severe stenosis at the origin of the internal carotid artery. **B:** The peak systolic velocity is 497 cm/s, correlating to a >70% stenosis.

Table 89-1 Duplex Ultrasound Criteria for Carotid Artery Stenosis

Degree of Stenosis (%)	ICA PSV (cm/s)	ICA EDV (cm/s)	ICA/CCA Ratio	Carotid Plaque (%)
Normal	<125	<40	<2.0	None
<50	<125	<40	<2.0	<50
50–69	125–230	40–100	2.0–4.0	>50
70–99	>230	>100	>4.0	>70
Occlusion	Undetectable	Undetectable	Not applicable	100

ICA, internal carotid artery; PSV, peak systolic velocity; EDV, end-diastolic velocity; CCA, common carotid artery.

TREATMENT OF CAROTID ARTERY OCCLUSIVE DISEASE

Patients with carotid artery occlusive disease are placed into two main categories: asymptomatic or symptomatic. A recent (<6 months) TIA, stroke, and amaurosis fugax are considered symptoms of occlusive carotid disease. These patients have the highest risk of recurrence of symptoms or possible ipsilateral stroke. In patients who have a TIA, 15% will go on to a CVA, 10% within 90 days.[7] Several studies have examined the risk reduction of stroke with medical and surgical management.

SYMPTOMATIC

Patients with symptomatic lesions are at the highest risk of ipsilateral stroke, and the degree of stenosis corresponds with the risk. Validated in multiple trials – most prominently in the North American Symptomatic Carotid Endarterectomy Trial (NASCET) study – the degree of stenosis was correlated with Stroke risk. A stenosis $<50\%$ was unlikely to cause neurologic manifestations. In patients with $>50\%$ stenosis, those treated with medical therapy were more likely to progress to ipsilateral stroke than those that underwent surgical management. This benefit to surgical intervention was highest in the 70% to 99% stenosis range. In the NASCET study, symptomatic patients were assigned to medical therapy or endarterectomy with symptomatic disease and a stenosis $>50\%$. After 2 years, there was a significant reduction in ipsilateral stroke in those who underwent a CEA ([50% to 69% stenosis: 22.2% in medical patients and 16.7% in surgical patients over 5 years] and [70% to 99% stenosis: 26% in medical patients and 9% in surgical patients over a 2-year period]).[14] The European Carotid Surgery Trial (ECST) showed similar findings for severe stenosis, however, no benefit was found to surgery over medical management with mild stenosis.[15] Medical therapy has advanced since the NASCET trial with the introduction of improved antiplatelet medications such as clopidogrel, and HMG-CoA reductase inhibitors. In the NASCET trial, aspirin was the medical therapy that surgery was compared against. Aspirin is an important medication in secondary stroke prevention. It can be used alone or in combination with dipyridamole or clopidogrel. Most neurologists recommend aspirin and clopidogrel in symptomatic patients for prevention of stroke until surgical intervention is performed. Statins lower stroke risk by 30% by plaque stabilization and are important for the reduction of stroke.[16]



Figure 89-5. A carotid angiogram with digital subtraction angiography reveals a patch repair after prior endarterectomy.

Timing of intervention after stroke continues to be debated. Traditionally, surgeons waited >6 weeks prior to intervention but there is a chance of recurrent stroke which is highest in the short term. Performing the surgery too soon can also have devastating consequences such as hemorrhagic conversion of an ischemic lesion. In patients that have returned to baseline from their symptoms, the current thought is to undergo surgery somewhere between around 2 days and 2 weeks after the event.[17] If the patient doesn't return to normal or has a dense lesion on imaging, it is best to wait a few weeks. Crescendo TIA and evolving stroke are different entities and although the risk of stroke with intervention is slightly higher, urgent revascularization is warranted to prevent a large stroke.

ASYMPTOMATIC

4 Treatment for patients with symptomatic disease is well established in the literature, however, the treatment of asymptomatic carotid disease is not so clear-cut. Detection of a carotid stenosis is typically based on a DUS finding or evidence of a carotid bruit. The rate of neurologic symptoms with an asymptomatic bruit was estimated to be 4% per year.[18] One of the first and most important trials regarding asymptomatic patients was the Asymptomatic Carotid Atherosclerosis Study (ACAS) trial. In ACS, asymptomatic patients with >60% stenosis were randomly assigned to either medical management or CEA. After 5 years, best medical therapy was found to be inferior to surgery in regard to ipsilateral CVA (11% for medical management vs. 5.1% for CEA over 5 years). Therefore with endarterectomy, there was a risk reduction in stroke of 53%.[19] In Europe, the Asymptomatic Carotid Surgery Trial (ACST) showed similar results, with a benefit in patients undergoing surgery over medical management in patients with ≥60% stenosis.[20] The biggest benefit comes from severe stenosis and it is generally accepted that surgical intervention be pursued for stenosis ≥80%, with 60% to 79% remaining controversial. Antiplatelet therapy is also recommended in the form of aspirin for asymptomatic stenosis.[21] There does not appear to be a benefit to the addition of clopidogrel.[22] Best medical management with risk factor modification is mandatory for all patients with severe carotid stenosis, whether symptomatic or asymptomatic. Currently, several clinical trials are comparing carotid intervention versus best medical management for the treatment of asymptomatic carotid stenosis.

CAROTID ENDARTERECTOMY VERSUS CAROTID STENTING

The choice for intervention in symptomatic (>50% stenosis) and asymptomatic (>80% stenosis) patients is currently widely accepted. The next decision is to which treatment modality should be undertaken. CEA traces back to the 1950s and is considered the gold standard for the surgical treatment of occlusive carotid artery stenosis. Since the Food and Drug Administration (FDA) approved CAS in 2004, there was a proliferation of the technology and use for the treatment of symptomatic and asymptomatic carotid disease. High-risk patients from an anatomic or medical reason, as well as elderly patients were thought to benefit from CAS over CEA. The Stenting and Angioplasty with Protection in Patients at High Risk for Endarterectomy (SAPPHIRE) trial examined CAS versus CEA for high-risk patients (medical comorbidities and anatomical features), and CAS was associated with a lower risk of major events at 1 year, with a greater advantage in asymptomatic patients.[23] The Endarterectomy Versus Angioplasty in Patients with Symptomatic Severe Carotid Stenosis Trial (EVA-3S) trial was a European trial for symptomatic patients with >60% stenosis that was stopped prematurely due to higher 30-day stroke risk with CAS. However, embolic protection device was optional and its use was associated with similar results to CEA.[24] The Stent-Supported Percutaneous Angioplasty of the Carotid Artery versus Endarterectomy trial (SPACE) trial examined patients with ≥70% symptomatic stenosis failing to prove noninferiority of CAS to CEA.[38] Most recently, the Carotid Revascularization Endarterectomy versus Stenting Trial (CREST) examined CAS versus CEA in standard-risk patients for both symptomatic and asymptomatic patients. Overall, there was no difference between CAS and CEA long-term, but this was likely due to a higher rate of MI with CEA, and a higher rate of periprocedural CVA with CAS. Despite the similar rate of complications overall, stroke-related complications portended a worse long-term survival.[25] Currently, the Centers for Medicare and Medicaid Services (CMS) limits reimbursement for CAS to high-risk symptomatic patients with carotid stenosis >70%.

5 6 Despite some uncertainty regarding CAS versus CEA, there are some subpopulations that do better than others with a particular treatment option. Contrary to initial belief regarding advanced age as a benefit for carotid stenting, age ≥68 was associated with a significantly higher risk of stroke and death for carotid stenting.[25,26] Symptomatic patients undergoing CAS appear to have a higher risk of stroke or death if performed in <7 days after the symptomatic event.[27] There are no sufficient data to support CAS for asymptomatic patients outside high risk for CEA by anatomical factors (stoma, previous neck radiation, contralateral vocal cord paralysis, or high lesion) or severe medical comorbidities (coronary or pulmonary disease) (Table 89-2). Furthermore, patients with significant anatomical factors that put them at risk for CAS should undergo CEA (Table 89-3). Currently, ongoing clinical trials seek to determine more understanding of the patients that will benefit best from each therapy as well as the assessment of new stent designs, such as mesh-covered stents.

Table 89-2 Criteria for High-Risk Carotid Endarterectomy

Clinical Criteria
Unstable angina
NYHA class III or IV CHF
LVEF <35%
MI <6 weeks
Severe pulmonary disease
Severe renal impairment
Contralateral recurrent laryngeal nerve injury
Anatomical Criteria
High lesion above C2
Tandem lesions >70%
CEA restenosis
Cervical immobility
Prior neck irradiation
Tracheostomy
Previous neck surgery

NYHA, New York Heart Association; CHF, congestive heart failure; LVEF, left ventricular ejection fraction; MI, myocardial infarction; CEA, carotid endarterectomy.

CAROTID ENDARTERECTOMY

Technique

There are many decisions a surgeon has to consider for a CEA. First, there is the choice of anesthetic: local, regional, or general. Depending on the choice of anesthetic, there is a choice of cerebral monitoring. If the patient has the procedure under local anesthesia, their ability to respond to commands dictates the adequacy of collateral flow during clamping. If the patient is under general anesthesia, there is the choice of electroencephalogram (EEG), TCD, stump pressure measurement, or somatosensory evoked potentials (SSEPs) that guide the use of a shunt for cerebral protection. EEG is the most widely used technique of cerebral monitoring. It requires the addition of 8 to 16 leads and monitors brain activity. The use of a shunt is based on a positive test, which is a drop of fast background activity of 50%. EEG, however, is likely overly sensitive, overestimating the number of people that require a shunt.[28,29] TCD works in a similar manner, evaluating the middle cerebral artery (MCA) for changes in flow with clamping. Measuring a stump pressure requires clamping the common and external carotid artery while maintaining the internal carotid artery open and using a transducer to check the back pressure. A minimum mean pressure of 40 mm Hg has been most widely adopted for the threshold for shunting. Stump pressure measurement does, however, have a small risk of embolization. Others opt for routine shunting, allowing a consistent endarterectomy technique without anxiety. Shunting completely relieves intracerebral ischemia, but requires a safe technique with shunt placement above the superior aspect of the plaque. Routine shunting has been met with excellent results.[30,31]

Table 89-3 Contraindications to Carotid Artery Stenting

Carotid Artery Stenting Contraindications
Fresh thrombus
Severe kinking of ICA
Unstable plaque
Brachiocephalic vessel tortuosity
Brachiocephalic vessel severe stenosis or occlusion
Circumferential calcification
Poor arterial access
Acute aortic arch angle
Significant aortic arch plaque or thrombus

Correct patient positioning is paramount for a successful endarterectomy, especially for a high lesion. The patient's neck is slightly hyperextended and turned away, with a roll under the shoulder to open the neck (Fig. 89-6). A longitudinal incision is made along the anterior border of the sternocleidomastoid muscle (SCM). The use of ultrasound intraoperatively can help guide the surgeon to perform a limited incision over the

bifurcation. The platysma is divided. Care must be taken to avoid the anterior jugular vein and carefully divide any venous tributaries. By retracting the SCM laterally the internal jugular vein is identified in the carotid sheath. The facial vein is an important landmark for identification of the bifurcation and is divided, however, frequently the hypoglossal nerve can traverse at this site and care must be taken to avoid it. Often the superior belly of the omohyoid muscle is divided for exposure. Inferior and medial to the internal jugular vein is the common carotid artery which is carefully exposed. Care must be taken to avoid injuring the vagus nerve that is typically posterior to the artery, but can travel anteriorly in some cases. After the common carotid artery is dissected out, the external carotid and superior thyroid arteries are controlled. Often, dissection at the carotid bifurcation can cause reactive bradycardia because of stimulation of the carotid body. This can be improved with administration of 1% lidocaine directly into the carotid body. Care must be taken in dissecting out the internal carotid artery to avoid excessive manipulation to prevent embolization and avoid the more common location of the hypoglossal nerve that traverses the proximal artery. For high lesions, extension of the incision posteriorly in a periauricular fashion and division of the posterior belly of the digastric muscle can aid in distal exposure. If a lesion is felt to be very high, preoperative nasotracheal intubation and mandibular subluxation with temporary fixation can assist in exposure of the distal ICA.

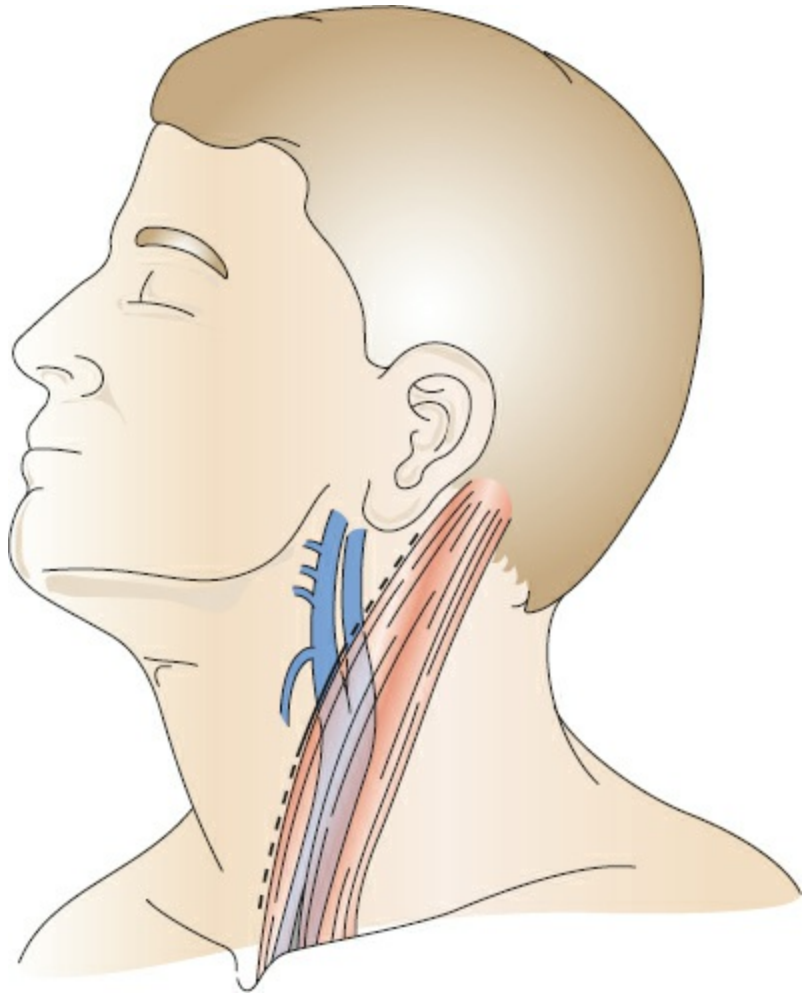

Figure 89-6. The patient's neck is slightly hyperextended and turned to the contralateral side. An incision is made along the anterior border of the sternocleidomastoid centered over the carotid bifurcation.

Once all vessels are controlled, intravenous heparin is administered (100 units/kg) prior to clamping (Fig. 89-7). As discussed previously, the choice of cerebral monitoring or routine shunting dictates how the surgeon proceeds. Typically, the internal carotid artery is clamped first to avoid embolization after ensuring the clamp site is in a normal segment of artery distal to the palpable plaque. The external and common carotid arteries are then clamped. A longitudinal arteriotomy is created from the distal common carotid artery into the internal carotid artery past the plaque. Often the ansa cervicalis limits exposure as it traverses the carotid artery, which requires its ligation once it is indeed identified as the ansa cervicalis. If necessary, a shunt can be placed from the common carotid artery to the internal carotid artery to maintain antegrade flow (Fig. 89-8). An endarterectomy can be performed to remove the plaque. Typically, a layer is teased out in the media, and the entire plaque is removed after either cutting the plaque from the proximal and distal artery or carefully pulling free trying to avoid a flap. The plaque extending into the external carotid artery is most easily dealt with by way of an eversion technique. The entire endarterectomized surface must be examined to remove flaps or debris. This is of most importance at the distal aspect in the internal carotid artery. If needed, tacking sutures with 7-0 prolene can be used to keep down a concerning endpoint to avoid a flap once flow resumes (Fig. 89-9).

At this point, closure of the arteriotomy is accomplished. Primary repair is not typically recommended due to improved short- and long-term outcomes with patch closure, and CMS uses patch closure as a quality metric during endarterectomy.[32] The choices of patch include synthetic material, such as Dacron or polytetrafluoroethylene, a biologic material, such as bovine pericardium, or an autogenous vein (Fig. 89-10). Prior to closure, the shunt is removed and careful sequential flushing of each of the vessels is performed to remove air of debris. Additionally, after closure, the internal carotid artery clamp remains on for a few seconds to allow flushing through the external carotid artery to ensure any remaining debris of thrombus does not proceed into the cerebral circulation. The heparin is typically reversed with protamine sulfate. Once hemostasis is accomplished, closure is performed by approximating the sternocleidomastoid back, closing the platysma and skin. A full neurologic examination is performed prior to extubation or exit from the operating room if performed under local anesthesia.

An eversion endarterectomy is another technique for CEA and has the benefit of not requiring prosthetic material for a patch. In the eversion technique, exposure of the vessels is similar to the standard CEA. However, with the eversion technique, the internal carotid artery is transected at the bulb. The edges of the vessel are peeled back in a plane removing the plaque as it proceeds distally. A downside of the eversion technique is the inability to easily use distal tacking sutures. Closure is primarily accomplished at the bifurcation and doesn't compromise the internal carotid artery lumen.

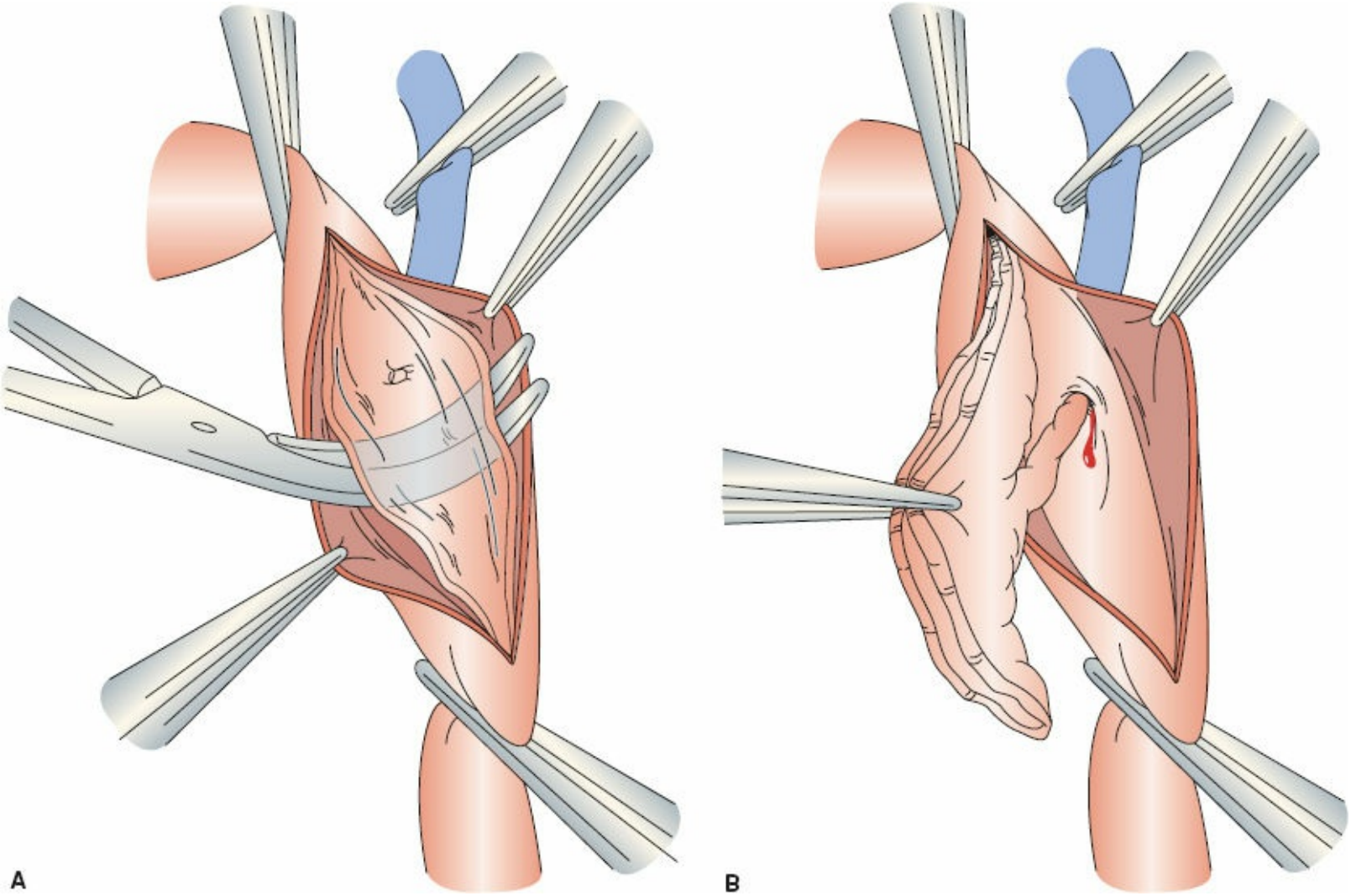

Figure 89-7. **A:** During carotid endarterectomy, vascular clamps are applied to the common carotid, external carotid, and internal carotid arteries. Carotid plaque is elevated from the carotid lumen. **B:** Carotid plaque is removed and the arteriotomy is closed either primarily or with a patch angioplasty.

COMPLETION STUDIES

Avoidance of a perioperative stroke is the primary objective during and after the endarterectomy. To minimize that risk, typically caused by a technical error such as a flap, thromboembolism, or carotid artery thrombosis, completion studies should be considered. At the completion of arterial closure, continuous wave Doppler analysis can be used to check the patency of the vessels by identifying normal Doppler flow or an area of stenosis. This is unlikely to pick up a small intimal flap or subtle stenosis. DUS is an excellent modality for examination of blood flow waveforms and B-mode imaging to identify small flaps or intimal defects. Angiography is considered the "gold standard" with contrast either injected directly into the common carotid artery or via a transfemoral approach. However, these studies have shown mixed results in the identification of defects, or can be overly sensitive and pick up defects that might not cause problems while repair increases the morbidity and mortality.[33,34]

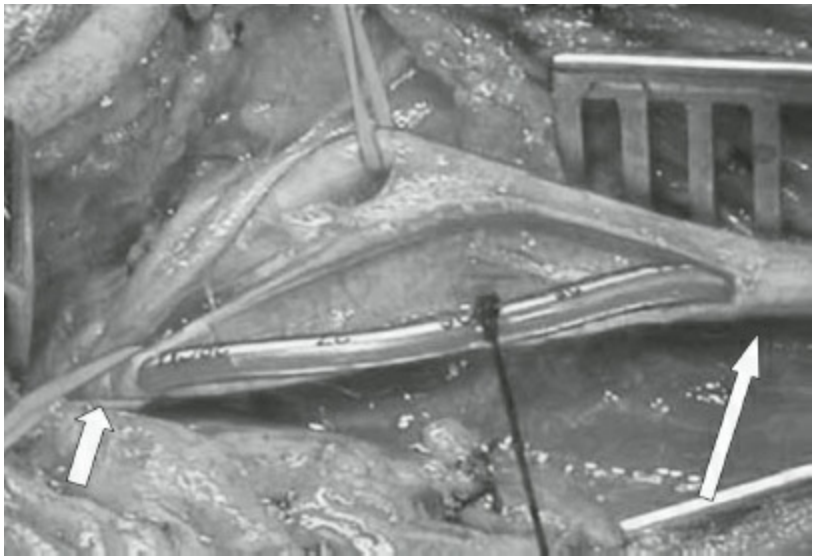

Figure 89-8. A temporary carotid shunt is inserted from the common carotid artery (*long arrow*) to the internal carotid artery (*short arrow*) during carotid endarterectomy to provide continuous antegrade cerebral blood flow.

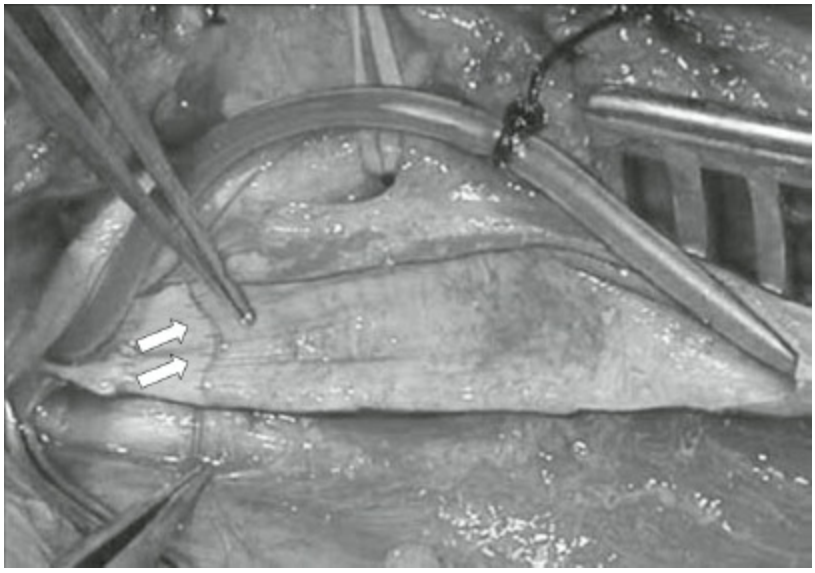

Figure 89-9. The distal transition line (left side of the figure) in the internal carotid artery where the plaque had been removed must be examined carefully and should be smooth. Tacking sutures (*arrows*) are placed when an intimal flap remains in this transition to ensure no obstruction to flow.



Figure 89-10. **A:** An autologous or synthetic patch can be used to close the carotid arteriotomy incision, which maintains the luminal patency. **B:** A completion closure of carotid endarterectomy incision using a synthetic patch.

Complications

The majority of patients tolerate the endarterectomy well and are discharged home after 24 hours. Complications can range from mild to life threatening. Postoperative blood pressure control often requires pharmacologic assistance due to carotid sinus manipulation during the procedure, but rarely persists after 24 hours. An acute ipsilateral stroke is the most dreaded complication after a CEA, especially if performed for asymptomatic disease. Cerebral ischemia can occur due to hypoperfusion or embolization during the procedure. Hypoperfusion is related to the collateral flow through the contralateral carotid artery and posterior circulation, and often relies on the status of the circle of Willis. Embolization can occur from shunt placement, the clamp site, thrombus formed during the procedure, or inadequate flushing prior to arteriotomy closure. Less frequently, the carotid artery can occlude causing a stroke. This can be related to an intimal flap, platelet adhesion from the patch, dissection, or anastomotic stricture. The importance of neurologic evaluation prior to leaving the operative suite is the quick identification of a problem, and usually requires immediate reexploration. Alternatively, if there was a normal postoperative duplex, angiography can be performed for the identification of the etiology of the stroke. The perioperative risk after CEA differs depending on the indication for the intervention. In symptomatic patients, the 30-day risk of stroke is 3.2% to 5.4%, MI 1.8% to 2.6%, and death around 1.1%.[14,24,25,38] For asymptomatic patients, the 30-day risk of stroke is 1.4% to 5.4%, MI is 2%, and death is 1.1%.[14,24,25,38] In CREST, the 30-day stroke and death rate after CEA was 3.2% in symptomatic and 1.2% in asymptomatic patients. Additionally, when identifying symptomatic patients treated by vascular surgeons, the 30-day risk of stroke and death was 1.3%, which increased to 3.9% when combined with MI. Overall with endarterectomy, CREST showed a periprocedural risk of death at 0.3%, CVA of 2.3%, and MI of 2.3%.[25]

Cardiac complications are common after CEA, and are a major cause of perioperative death.[35,36] This risk is due to the high number of patients with concomitant coronary artery disease, upward of 50% of patients. Postoperative bleeding can cause a significant hematoma that can cause respiratory compromise. An expanding hematoma should be evacuated emergently and the bleeding source identified. Cranial nerve injuries are a common complication, however, the incidence varies greatly with a range between 1% and 30%, more common experience showing an incidence of 0.5% to 4.7%.[25,37] Cranial nerve injuries are shown in Table 89-4. Cerebral hyperperfusion is an uncommon complication after CEA. The cause of hyperperfusion is disordered autoregulation of arteriolar cerebral blood flow after return of flow after a tight stenosis. Symptoms start with a headache and progress to seizures and intracerebral hemorrhage with a high mortality rate. Severe hypertension is a risk factor and requires urgent lowering of the blood pressure and anticonvulsant therapy. Contralateral severe internal carotid artery stenosis is another important risk factor for the development of cerebral hyperperfusion syndrome. Restenosis can occur after CEA. If occurring within 2 years, it is likely related to intimal hyperplasia and can improve. After 2 years, it is likely caused by

atherosclerosis. Patch infection and pseudoaneurysm formation are also other complications following CEA.

Carotid Stenting

Technique

CAS requires careful patient identification and examination of adequate preoperative imaging for procedural success. Prior to intervention, axial imaging is highly recommended. This is most generally an MRA or CTA with thin cuts. This should include imaging from the aortic arch all the way to beyond the circle of Willis. Examination of the aortic arch will identify those with anatomy that would make brachiocephalic vessel cannulation and the tracking of wires and catheters difficult. With excessive manipulation, or not identifying arch pathology, a stroke could be possible. The angle of the aortic arch, brachiocephalic ostial disease, tortuosity of brachiocephalic vessels, arch thrombus, or calcification must all be identified for safe carotid stenting. Furthermore, there are specific lesion characteristics that can make stenting more difficult or risky, such as, hypoechoic plaque, ulceration, lesion length, circumferential calcification, or thrombus. A careful physical examination must be performed to identify femoral and iliac artery anatomy that would make arterial access difficult. Although the transfemoral approach is the most common, there are a variety of other approaches that are possible, including transcervical or transradial.

Table 89-4 Cranial Nerve Injuries Associated with Carotid Endarterectomy

Cranial Nerve Injuries	
Vagus	Unilateral: rarely serious; Bilateral: vocal cord paralysis, tracheostomy
Recurrent laryngeal	Unilateral: rarely serious; Bilateral: vocal cord paralysis, tracheostomy
Superior laryngeal	Voice fatiguability, voice modulation difficulty
Hypoglossal	Unilateral: rarely serious; Bilateral: articulation, swallowing difficulty, tracheostomy
Glossopharyngeal	Dysphagia, aspiration
Marginal mandibular	Appearance of drooping ipsilateral lip
Spinal accessory	Shoulder droop, scapular winging

Prior to the carotid stenting procedure, the patient should be on dual antiplatelet therapy, typically aspirin 325 mg for at least a week prior and have received around 450 mg of clopidogrel. The procedure is either performed in an angiography suite or hybrid operating room. The patient requires arterial line placement for blood pressure control and should stay awake during the procedure for frequent neurologic checks. The patient is placed in the supine position and the groins are prepped. Retrograde femoral access is gained and the patient is heparinized (100 units/kg). Thoracic angiogram is rarely

required because previous CTA or MRA can clearly define arch anatomy. Selected catheterization is then performed. The anatomy dictates the combination of wire and catheter that will work in a particular situation. Angiography after proximal carotid artery cannulation should be performed to evaluate the stenosis for location and severity, contralateral circulation, vertebrobasilar circulation, and intracerebral circulation. These can all influence the approach to the procedure. Balloon occlusion, for instance, may not be a good option for embolic protection if preoperative imaging and angiography reveal an incomplete circle of Willis and inadequate collateral flow.

Once the decision is made to proceed with carotid stenting, selective catheterization of the ipsilateral external carotid artery is accomplished, as long as the lesion does not involve its origin, and the catheter advanced. Great care must be taken to avoid inadvertently manipulating the lesion and risk embolization distally. Once the catheter is in the external carotid artery, a long stiff 0.035-in-wire is exchanged and navigated through the arch. Significant tortuosity can often require subsequent maneuvers for success, such as breath holds or the use of special guiding sheath and selective catheter systems that can be advanced over each other seamlessly in difficult anatomy. At this point a 90-cm 6-Fr sheath is advanced into the proximal common carotid artery, again insuring that the sheath is not advanced past the beginning of the plaque. The stiff wire is removed and angiography is again performed for mapping purposes, assisting in cannulation of the internal carotid artery (Fig. 89-11). Most practitioners use embolic protection devices (EPDs) to reduce the risk of CVA during the procedure during wire manipulation, balloon angioplasty, and stent placement. There is a choice of distal filters, distal balloon occlusion, and flow stasis or reversal (Fig. 89-12). Flow stasis or reversal creates a situation where there is no antegrade flow in the internal carotid artery so embolization is unlikely to occur. After completion of any case, suction can be performed to remove any free floating debris. The benefit of flow reversal is the avoidance of having to cross the lesion unprotected. Filter protection requires wire cannulation past the lesion and placement of a filter in the distal internal carotid artery for embolic protection. The filter is removed at the completion of the case. Significant vasospasm in the distal internal carotid artery may occur when a filter is used.

The EPD is carefully advanced over a 0.014-in wire into the distal internal carotid artery and deployed. All remaining parts of the procedure occur over the EPD wire via a rapid exchange platform. Predilatation of the lesion is typically accomplished with a 4- to 5-mm balloon, but should be used sparingly as it can increase the risk of stroke. There are a variety of stents available, generally either open or closed cell. This is in regard to the structure of the stent. The stents are self-expanding and their flexibility is determined by the number of connections between the cells of the stent. The more connection, the stiffer the stent (closed cell). Decisions regarding the type of stent depend on the lesion characteristics, tortuosity, and symptomatic status. Most practitioners prefer closed-cell stents for use in symptomatic patients to lessen embolization or extrusion of the plaque through the stent (Fig. 89-13).

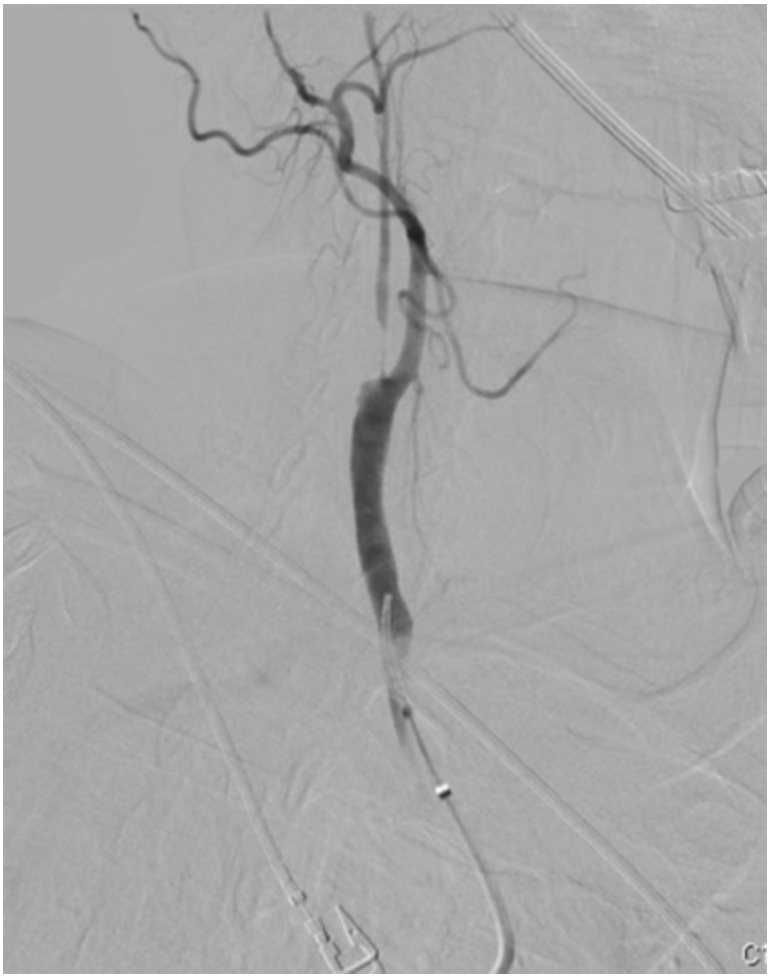

Figure 89-11. Carotid angiography shows a high-grade stenosis with "string sign" in the internal carotid artery with underfilling of the distal artery.

The size of the stent typically depends on the size of the internal and common carotid artery and comes in straight and tapered configurations. Once the stent is deployed, often postdilatation is necessary (Fig. 89-14). Care must be taken with balloon dilatation near the bulb as severe bradycardia can occur secondary to stimulation of the glossopharyngeal nerve. Atropine should be immediately available and good communication with nursing and anesthesia is important. The EPD is removed and completion angiography is performed. The sheath is then removed and the puncture site closed with a closure device or manual compression. As heparinization is not typically reversed, it is common to use a closure device, which allows early mobilization and hemodynamic stability. Throughout the procedure the patient is assessed from a neurologic standpoint. Postprocedure the patient is monitored similar to a CEA. The patient continues clopidogrel for 1 month and aspirin for life.

Complications

The most important and serious complication after carotid stenting is neurologic events. As the vast majority of patients are awake, MI is much less frequent. The risk of MI after carotid stenting is lower than CEA: 0.4 to 1.1 versus 0.6 to 2.3.[24,25,38] The EPD can cause distal ICA vasospasm, dissection, or occlusion if full of debris. A full filter should be removed slowly, a dissection treated with stenting, and nitroglycerin injection used for severe vasospasm. Acute thrombosis of the stent can cause a profound neurologic defect and usually requires immediate explantation and endarterectomy. An embolus identified on angiography can be managed with neurorescue. Options include aspiration thrombectomy, catheter-directed thrombolysis, or snare removal. Intracerebral hemorrhage is a rare complication. Other complications include access site complications, such as bleeding and pseudoaneurysms.

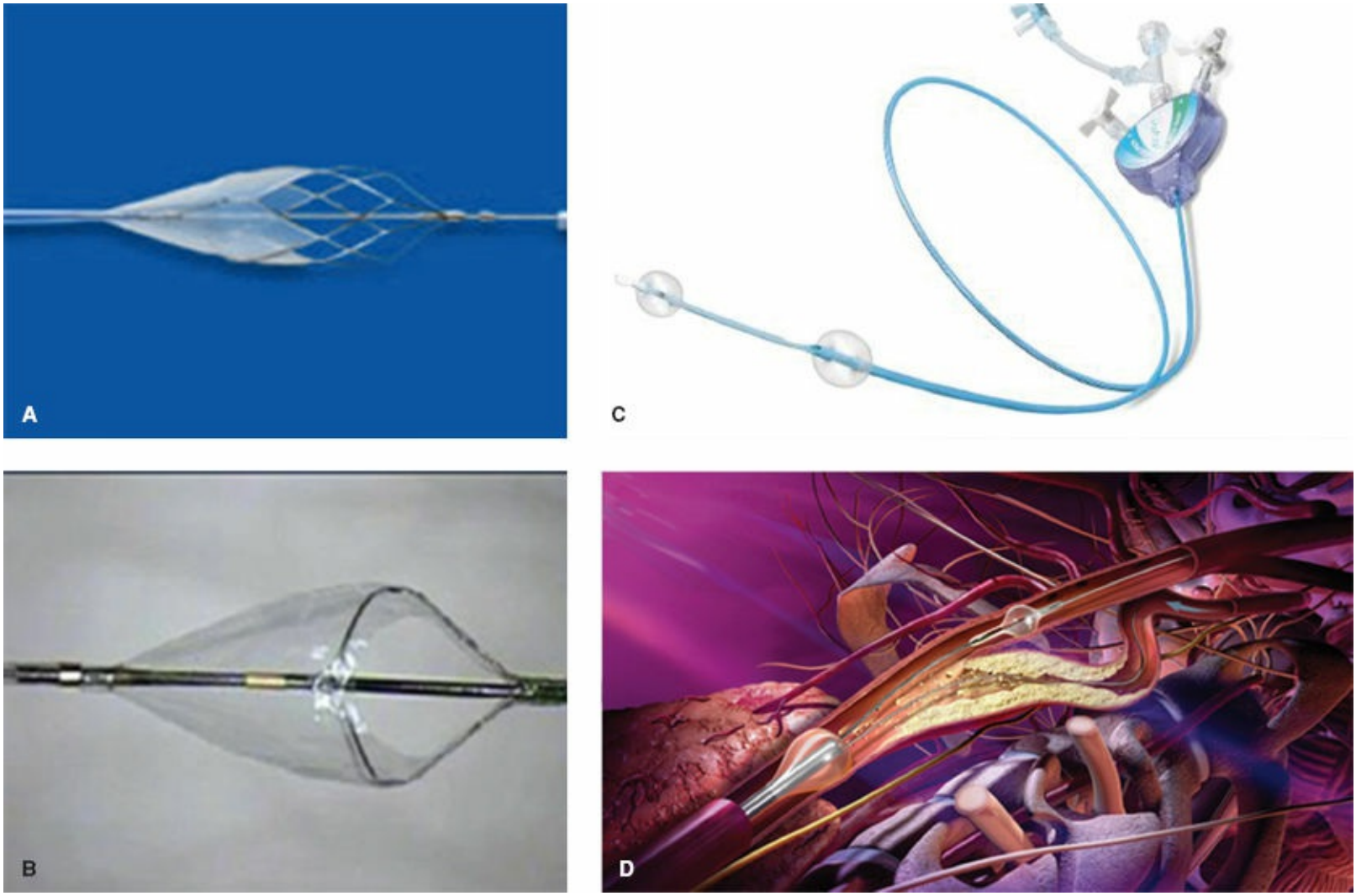

Figure 89-12. Different type of embolic protection devices. **A:** RX Accunet embolic protection system (Abbott Vascular, Redwood City, Calif.) **B:** Emboshield NAV6 embolic protection system (Abbott Vascular, Redwood City, Calif.). **C:** Mo Ma proximal cerebral protection device with balloon occlusion (Medtronic, Minneapolis, Minn.). **D:** Gore flow reversal system (W. L. Gore and Associates, Flagstaff, Ariz.).

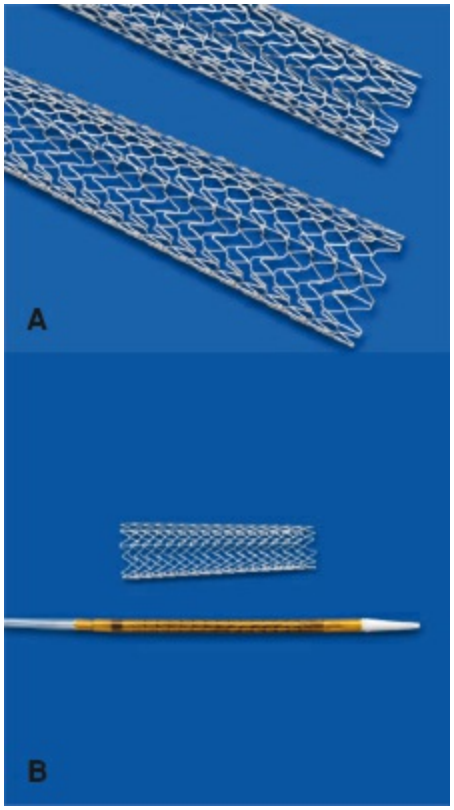

Figure 89-13. Different carotid artery stents. **A:** Xact carotid artery stent (Closed cell) (Abbott Vascular, Redwood City, Calif.) **B:** RX Acculink carotid artery stent (Open cell) (Abbott Vascular, Redwood City, Calif.)

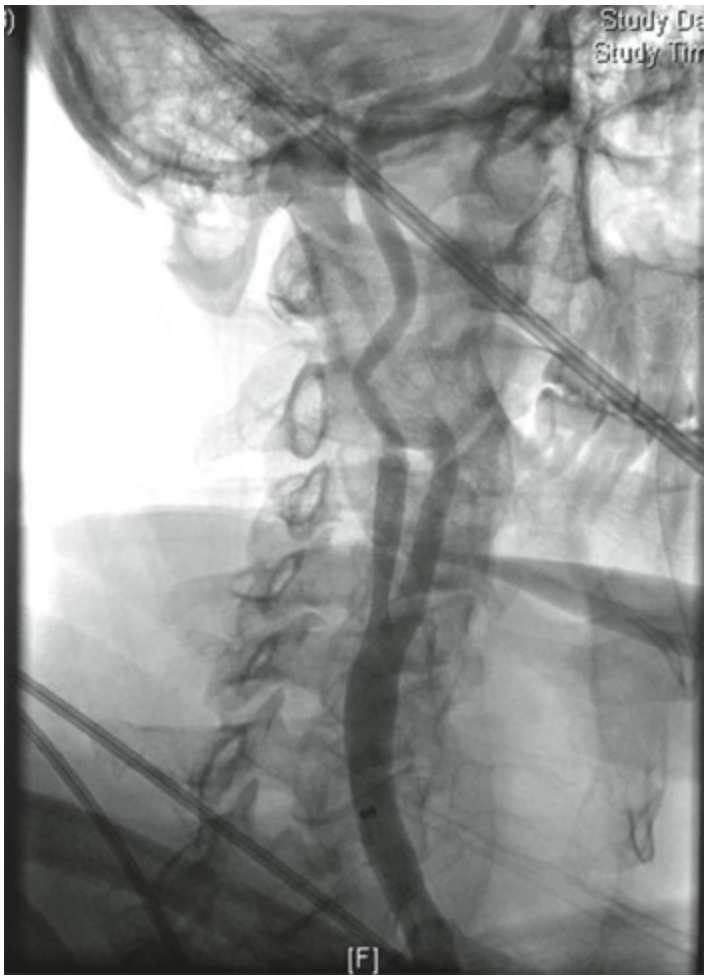

Figure 89-14. Carotid angiography after stent placement with resolution of the stenosis and improved filling in the distal artery.

Nonatherosclerotic Disease of the Carotid Artery

Carotid Coiling and Kinking. The internal carotid artery typically takes a straight path into the skull. At times there can be excessive elongation and tortuosity that makes a coil (Fig. 89-15). This can occur congenitally and is seen in children, or it occurs in adults with elongation over time due to elasticity and excessive angulation. This results in a C or S shape of the vessel. A kink is elongation with angulation that exceeds 90 degrees. Kinks can cause cerebral hypoperfusion, and rarely can embolize. Head position with rotation and either flexion or extension can exacerbate the symptoms. Treatment is indicated for ipsilateral cerebral symptoms, and other nonspecific symptoms, such as dizziness, syncope if no other causes are found. Options for treatment include transposition to a more proximal area in the common carotid artery, or segmental resection.

Fibromuscular Dysplasia

FMD is a nonatherosclerotic disorder that can affect a variety of vascular beds within the body. Most commonly found in the renal and iliac arteries, FMD is also found in the carotid and vertebral artery systems with an incidence of 0.42%.[39] Carotid FMD is associated with cerebral aneurysms. The exact etiology of FMD is unknown. There are four types of FMD, most commonly the medial fibroplasia, with the classic appearance of a "string of beads." This angiographic appearance is seen in the majority of cases and is caused by segmental encroachment of the arterial lumen and poststenotic dilatation and can be a nidus for hypoperfusion and embolization. The internal carotid artery is usually involved and the lesion avoids the bifurcation. FMD can however be associated with vertebral and renal FMD, cerebral aneurysms, and carotid aneurysms/dissection. Up to 50% of patients with internal carotid FMD have associated cerebral aneurysms.[40]

Duplex ultrasound can be used for diagnosis; however, can miss the typical appearance or identify elevated velocities. CTA has replaced a need for angiography, although angiography does remain the "gold standard." CTA or MRA is useful for the identification of intracerebral aneurysms.

The natural history of FMD is not well established. If FMD is associated with symptoms, repair is indicated. Asymptomatic patients can be treated with antiplatelet agents, however, do progress over time.[40] With concomitant atherosclerosis, identification of the cause of symptoms must be identified. Surgical treatment focuses on breaking the webs associated with FMD. This can be performed via open or endovascular means. In open repair, dilators are introduced through a common carotid arteriotomy with progressively increasing sizes. Although the technique allows for backbleeding, the risk of stroke remains from debris caused by rupturing the webs.

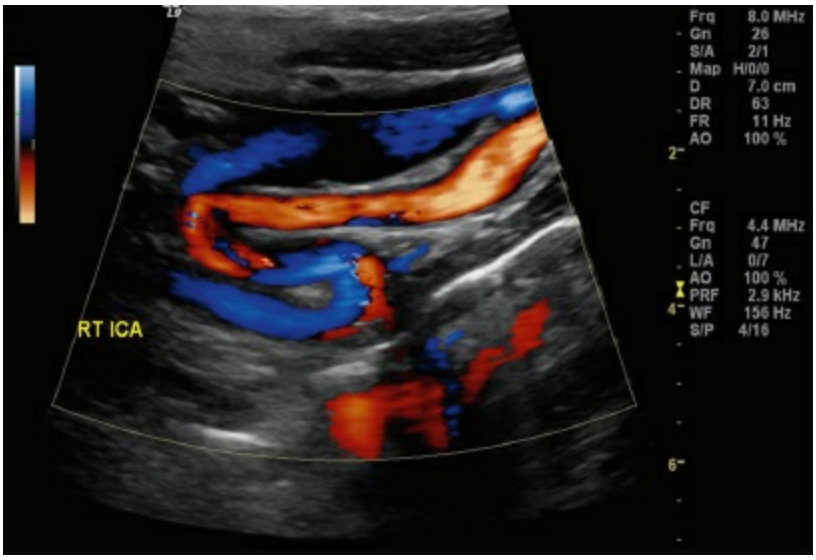

Figure 89-15. Duplex ultrasonography with color shows an extremely tortuous internal carotid artery.

CAROTID ARTERY DISSECTION

Dissection of the carotid artery can either be spontaneous or secondary to a precipitating event, such as trauma. Although carotid artery dissections account for a small number of overall strokes, they account for up to 20% of strokes in younger patients.[41] Spontaneous dissection is common in the carotid and vertebral arteries due to their mobility and proximity to bony structures. Chiropractic manipulation is a major cause of spontaneous dissection. There is usually no atherosclerosis present in patients who develop carotid dissection. The classic triad in carotid dissection is neck or head pain, Horner syndrome, and cerebral ischemia; however, it is rare to have all three. Headache is the most common symptom, typically ipsilateral frontotemporal in location. Patients can also develop TIA, CVA, nausea, amaurosis fugax, and cranial nerve palsies. CTA, MRA, and DUS are all utilized for diagnosis, and angiography remains the gold standard. The treatment options for carotid artery dissection typically begin with anticoagulation or antiplatelet therapy. There are no head-to-head trials comparing the two; however, most patients are treated for a minimum of 3 months with intravenous heparin and transition to oral anticoagulation. The indications for surgical treatment include the inability to anticoagulate, worsening symptoms on anticoagulation, aneurysm formation, or severe neurologic symptoms with severe flow limitation. Options for surgical repair include surgical bypass, patch angioplasty, or carotid ligation (thought to be safe if the stump pressure is >70 mm Hg).[42] Results of endovascular stenting are promising for the treatment of carotid dissection.

CAROTID ARTERY ANEURYSMS

Carotid artery aneurysms are uncommon at about 1%; however, pseudoaneurysms after endarterectomy can occur more frequently. True aneurysms are most frequently caused by degeneration or atherosclerosis and are typically at the carotid bifurcation or proximal internal carotid artery (Fig. 89-16). Other causes include penetrating or blunt trauma, and dissection. A pulsatile mass is the most frequent presenting symptom. Other patients can suffer from hemispheric neurologic symptoms, such as a TIA or stroke, or cranial nerve dysfunction, such as Horner syndrome. Rupture is exceedingly rare. Given the rarity of this disease entity, little is known regarding conservative management, and most undergo surgical repair with bypass, and less frequently patch repair. A balloon occlusion test is helpful prior to surgical intervention for large or distal aneurysms, and provides the possibility to bail out with ligation of the carotid artery.

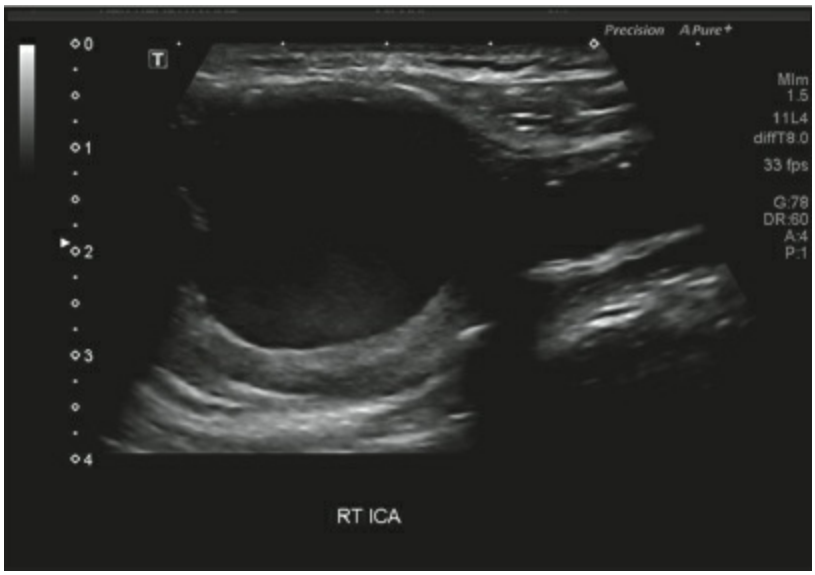

Figure 89-16. Duplex ultrasonography shows an extracranial carotid artery aneurysm in the proximal internal carotid artery.

CAROTID BODY TUMORS

Carotid body tumors arise from neural crest tissue from the third branchial arch. These masses usually arise in the adventitial tissue at the carotid bifurcation. There are multiple neural crest tumors, including carotid body tumors, paragangliomas, and glomus tumors. Paragangliomas can secrete catecholamines and have systemic effects much like pheochromocytomas. These tumors are very rare. They occur more often in situations of hypoxemia, like altitude, smoking, and chronic obstructive pulmonary disease (COPD). Malignancy is rare, approximately 5%, and can metastasize to the lymph nodes, liver, and skin. There is a hereditary pattern in carotid body tumors and can account for as much as 35% of all cases. These masses arise at the carotid bifurcation and can envelope the internal and external carotid arteries and the surrounding cranial nerves. DUS is useful for diagnosis with a characteristic splaying of the internal and external carotid arteries. Needle biopsy is not recommended for diagnosis as they are extremely hypervascular with blood flow arising from the external carotid artery. Treatment involves resection, and large masses can benefit from preoperative embolization. Surgical treatment involves similar exposure to a CEA and is carefully peeled off the underlying arteries; however, can be injured and require bypass (Fig. 89-17). There is a high risk of cranial nerve injuries with repair at approximately 10%.[43]

CAROTID TRAUMA

The extracranial carotid artery can be affected by blunt or penetrating trauma. Injury can be intimal disruption, dissection, thrombosis, pseudoaneurysm formation, or transection. Penetrating cervical trauma with concern for major arterial injury should undergo evaluation and treatment based on location. Historically, zone 2 injuries undergo surgical evaluation due to the ease of surgical exposure. Zone 1 and 3 injuries require workup for identification of an injury. Zone 1 injuries will require a median sternotomy for control, whereas zone 3 will require maneuvers similar to high exposure for an endarterectomy or the use of endovascular coil embolization or coverage with a stent graft. CTA is the modality of choice for diagnosis in carotid injury. However, angiography remains the "gold standard" for diagnosis. Medical management of a dissection includes either antiplatelet or anticoagulation. However, if a dissection degenerates into a pseudoaneurysm, intervention is required by either open or endovascular stent placement. Acute carotid thrombosis is treated with anticoagulation if the patient is asymptomatic. Revascularization is required for patients with cerebral ischemia.

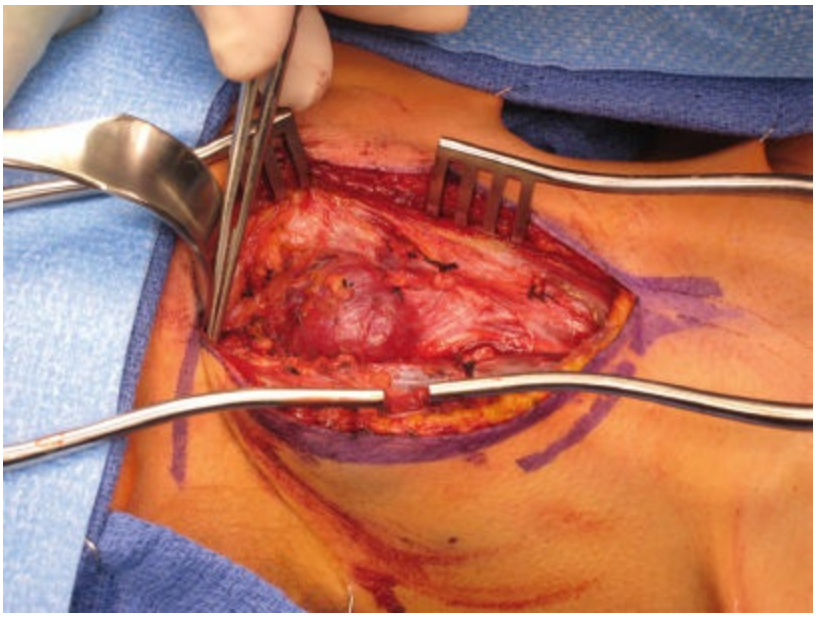

Figure 89-17. Carotid body tumor located at the bifurcation of the internal and external carotid artery.

VERTEBROBASILAR DISEASE

Anatomy

The vertebral arteries are paired arteries that arise from the subclavian arteries. Rarely, variants can occur, the most common being a direct origin of the left vertebral artery arising from the aortic arch. The vertebral artery is composed of four segments: V1 is the origin of the vessel up to the C6 transverse process, V2 is the segment that runs within the vertebral foramina to the level of C2, V3 is the next segment above C2 before it enters the base of the skull, and V4 is the intracranial portion of the artery before it joins with the contralateral side forming the basilar artery.

Clinical Findings

7 The vertebral and basilar arteries make up the posterior circulation to the brain and pathology can lead to posterior circulation ischemia. This system provides blood flow to the brainstem, cerebellum, and posterior lobes of the brain. About one-fourth of ischemic strokes involve the posterior circulation.[44] Vertebrobasilar ischemia is a commonly misdiagnosed clinical syndrome, mostly due to the more subtle and broad symptoms associated with them in comparison to the anterior circulation. The importance of correct diagnosis cannot be stressed enough as the mortality rate for posterior circulation strokes is 20% to 30% higher than for anterior circulation strokes.[45] Symptoms related to the vertebrobasilar system are bilateral in nature. Symptoms include diplopia, vertigo, drop attacks, dysphagia, ataxia, disequilibrium, and paresthesias.

Pathogenesis

The cause of vertebral artery disease can either be embolic or from low flow, with low flow causes predominating. Embolic phenomena are difficult to recognize and are more commonly from the heart, aorta, and brachiocephalic vessels. Proximal atherosclerotic lesions can embolize, and are more likely to lead to irreversible ischemia and infarction, and thus are more debilitating. Additionally, multiple foci of ischemia are common. Overall, approximately 20% of posterior circulation strokes arise from an arterial source.[44]

Low flow accounts for around 30% of posterior circulation strokes.[44] Low flow is more likely to cause transient symptoms and is due to inadequate collateral circulation. Anything that alters the flow to the posterior circulation can elicit these symptoms (end organ hypoperfusion), most likely rapid postural changes, or alteration of the cardiac output. As opposed to embolic phenomena, low flow is unlikely to cause infarction. Unlike embolism, manifestation of symptoms from hypoperfusion requires either bilateral disease or unilateral disease with poor collateral circulation from the contralateral vertebral artery and/or circle of Willis.

Differential Diagnosis

Atherosclerosis is the main cause of vertebrobasilar pathology. There are other etiologies that include dissection, trauma, FMD, aneurysms, and Takayasu disease. Given the subtle symptomatology, there are a variety of other organ systems that can mimic symptoms. Syncope or presyncope is sometimes confused with vertebrobasilar symptoms. This can be caused by a multitude of causes such as cardiac arrhythmias, vasovagal events, neurologic, psychiatric, or unexplained. Patients often describe visual changes that can be mistaken for diplopia, such as myopia or presbyopia, cataracts, floaters, amaurosis fugax, and a variety of other visual complaints. Disequilibrium and vertigo can be caused by many etiologies, and can be confused for postural instability, hearing loss, and nystagmus. In addition, a variety of metabolic disorders can mimic vertebral artery disease.

Diagnostic Evaluation

DUS is extremely useful in the identification of vertebral artery disease, however, is more difficult than the examination of the extracranial carotid arteries. This is due to the location and depth of the vessel, and evaluation of the vessel between C2 and C6 is difficult. Direct visualization of the cervical vertebral artery can identify proximal stenosis and reversal of flow. Examination of the bilateral pulses and blood pressure can further help identify significant differences between the arms, which would suggest proximal disease.

CTA and MRA are useful imaging modalities and allow careful examination of the vessels throughout their course, identify disease, and elucidate collateral circulation. MRI also allows precise identification of embolism and the diagnosis of a stroke. Angiography is considered the "gold standard." This allows careful examination of the vertebral arteries including the origin, however, multiple views are often needed for correct diagnosis. Information about collateral circulation is also shown via contralateral and anterior circulation.

Distribution of Disease

The V1 segment of the vertebral artery is the most common area of involvement with 92% of patients having atherosclerotic disease at the origin of the vertebral artery.[46] Extrinsic compression via osteophytes is common in the V2 segment, as is trauma, aneurysms, and dissections. V3 lesions are most likely caused by trauma and dissections due to the mobility of this section of the artery. V4 is infrequently the site of vertebral artery disease, but may be affected by trauma or dissection.

Open Surgical Treatment

Open reconstruction of vertebral artery disease depends on the location of disease. For a V1 lesion, transposition of the vessel to the common carotid artery is preferred. Another option is a bypass from either the common carotid or subclavian artery to the vertebral artery distal to the disease with either graft or saphenous vein. A less commonly performed procedure is the subclavian artery endarterectomy. For lesions or bleeding in the V2 location, typically proximal and distal ligation suffices. A bypass to the V3 segment can be performed if it is felt that there is not enough collateral circulation. Options for the V3 segment include bypass using saphenous vein to the C1–2 segment. The external carotid artery can also be swung over and act as a conduit, after all branches are taken. Reconstruction for the V4 segment is technically demanding, and requires exposure of the suboccipital segment via resection of the C1 transverse process.

Results are limited to case series and mainly reports from a single surgeon, with a low risk of stroke and death $<1\%$.[47] Other complications include nerve injury (vagus and recurrent laryngeal nerve), Horner syndrome, and lymphatic leak. The risk of reconstruction of the distal vertebral artery has a higher risk of stroke and death rate (3%) than proximal lesions.[48] Symptoms are alleviated in 71% to 80% of patients, with 10-year patency of 82% to 91%.[48,49]

ENDOVASCULAR TREATMENT

8 Endovascular management of vertebral artery disease has gained favor due to the relative ease of repair in contrast to the open repair. The risks that plague any cerebrovascular endovascular intervention hold true for vertebral artery disease with the risk of embolization, stroke, thrombosis, dissection, and restenosis. Distal protection can be used to decrease the risk of embolization by way of an EPD. Angioplasty alone is fraught with high rates of restenosis and the need for reintervention at close to 50%.[50] Additionally, the stroke rate appears to be quite high at 6.4% at 30 days.[51] There are small randomized trials comparing intervention with medical management.

Brachiocephalic Disease

Anatomy

The aorta arises as it emerges from the aortic valve. The ascending and transverse arch are separated into the aortic root (aortic valve, three sinuses, and the coronary arteries), tubular portion, and transverse arch. Most commonly, the aortic arch has three main trunks. These three trunks arise in order from proximal to distal; innominate artery, left common carotid artery, and left subclavian artery. There are a few variations that exist relating to these main branch vessels. Most commonly, the innominate and left common carotid artery come off the arch in one common ostia, the "bovine arch." This variant is found in 8% of whites and up to 25% of blacks.[52] Another common variant is the presence of an aortic origin for the left vertebral artery found in 6% of the population that arises between the left common carotid artery and the left subclavian artery. An aberrant right subclavian artery occurs when the origin for the right subclavian artery comes off the aorta distal to the left subclavian artery and courses posteriorly behind the arch, and occurs approximately 0.5% to 1% of the time.[53–55]

CLINICAL FINDINGS

Atherosclerosis is the most common disease that affects the brachiocephalic vessels. The clinical scenario depends on the location of disease and how many vessels are involved. Up to 40% of the time multiple vessels are involved.[56] The clinical picture depends on multiple factors. Disease of the subclavian artery typically causes embolization, arm claudication or easy fatigability. Occlusive disease involving the subclavian artery typically manifests as pain and fatigue with continued arm use. With more severe cases, rest pain and tissue loss can occur. Involvement of the origin of the subclavian artery can cause subclavian steal, vertebrobasilar insufficiency, or myocardial ischemia if proximal to a functioning LIMA coronary bypass (subclavian coronary steal). Rarely, hemiparesis or aphasia can occur. Involvement of the innominate artery can lead to a stroke, TIA, or similar symptoms to subclavian artery involvement. Common carotid disease can lead to TIA or stroke. Multivessel disease can present as a combination of all these symptoms.

DIFFERENTIAL DIAGNOSIS

Atherosclerosis is the most common cause of brachiocephalic occlusive disease. The typical picture in atherosclerosis is an ostial lesion. Vasculitides, such as Takayasu and Giant cell arteritis, can affect the brachiocephalic arteries (Fig. 89-18). There are infectious processes that can affect the brachiocephalic vessels. Syphilis and tuberculosis are the most common infectious causes of brachiocephalic disease, albeit rare, and can lead to aneurysm degeneration of the brachiocephalic artery, and most commonly the subclavian arteries. Penetrating and blunt trauma can affect the brachiocephalic vessels. Thoracic outlet obstruction, often related to cervical ribs, can cause subclavian artery aneurysms. These aneurysms can lead to embolism and distal ischemia.



Figure 89-18. Duplex ultrasonography showing thickening along the common carotid artery and narrowing of the lumen, consistent with Takayasu arteritis.

DIAGNOSTIC EVALUATION

A comprehensive physical examination is prudent for the identification of brachiocephalic disease. Absence of pulses in the extremities can signify proximal disease in either the subclavian or innominate arteries. Blood pressure measurement can identify subtle differences between the arms, with a significant finding being greater than 20 mm Hg between sides. Auscultation can identify carotid and subclavian bruits.

DUS is typically the first imaging modality used for the identification of disease. DUS can evaluate the carotid arteries with direct visualization of the majority of the extracranial system. It is often difficult to visualize the proximal vessels as they arise from the aortic arch; however, indirect findings can suggest disease. A decrease in the waveform amplitude and slope (tardus-parvus waveform) can signify significant proximal disease. Additionally, reversal of flow in a vertebral artery can signify innominate or proximal subclavian artery disease and a steal syndrome.

Other modalities include CTA and MRA (Fig. 89-19). These modalities provide excellent imaging of the aorta and brachiocephalic branches. The images, especially when used with 3D reconstructions, avoid the use of angiography for diagnosis and allow careful planning for surgical treatment. Thorough examination of the arterial flow to the brain and collateral circulation is prudent prior to surgical intervention. Gated CT in coordination with the patient's electrocardiogram allows careful identification of the mobile ascending aorta and arch and decreases motion artifact. Angiography is the "gold standard," although it has associated risks such as stroke, embolization, and arterial injury. Another option is transesophageal echocardiogram which can be used to rule out proximal extension of a dissection, or ascending, arch, and descending aortic pathology.

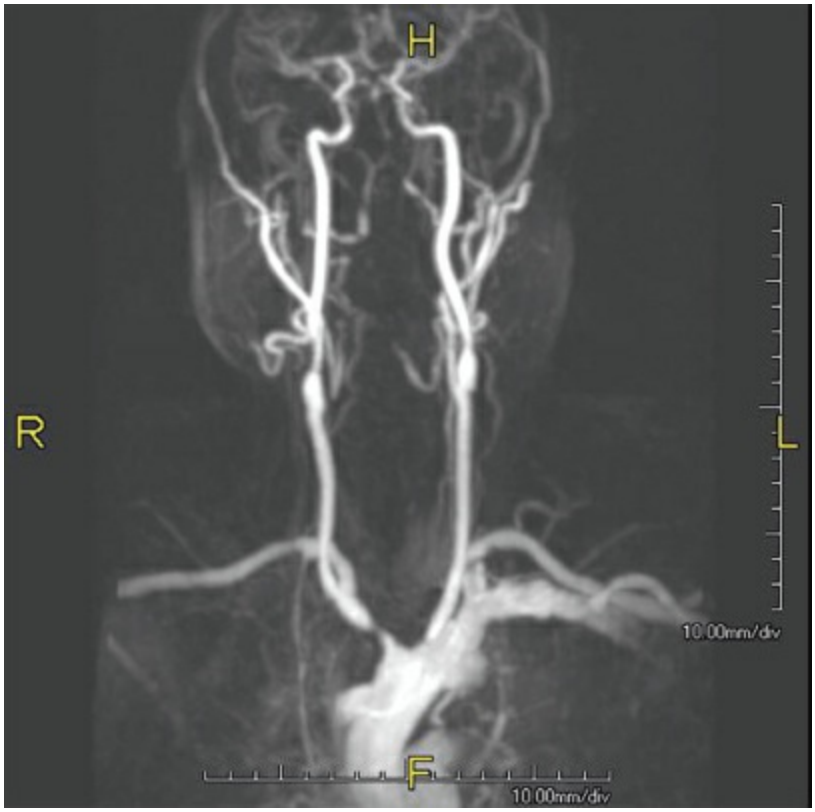

Figure 89-19. Magnetic resonance angiography (MRA) with brachiocephalic vessel disease. There is a critical stenosis of the innominate artery and left common carotid artery. There is also a severe proximal left subclavian artery stenosis.

INDICATIONS FOR REPAIR

In general, repair is indicated for symptomatic disease. Asymptomatic disease should be monitored for progression of disease and medical management of risk factors. A stroke or TIA should prompt repair due to the continued risk of embolization or low flow state. A low threshold for repair should be given to those with an internal mammary bypass and proximal subclavian artery disease. Upper extremity tissue loss, rest pain, and significant exertional pain are indications for repair.

OPEN SURGICAL TREATMENT

There are two general categories for open surgical repair of brachiocephalic disease. Those are transthoracic and extra-anatomic revascularization. Transthoracic repair requires a median sternotomy and direct revascularization. This modality is ideal for low-risk patients and those with multilevel disease. In the case of the treatment of Takayasu arteritis, debranching off the ascending aortic arch to the healthy involved vessels is best to avoid diseased arterial segments. Options for repair include aortic endarterectomy, bypass grafts, and arch replacement with bypass. Results are excellent with 10-year patency around 90%.[57,58] Complications include mortality and stroke rates of 3% to 8% and MI rates of 1.5% to 3%.[57–59]

9 Based on the patient's comorbidities and surgical risk, extra-anatomic revascularization carries the benefit of the avoidance of the risk associated with a median sternotomy. In recent years with the introduction of endovascular techniques for repair of aortic and brachiocephalic pathologies, extra-anatomic procedures are used in conjunction for hybrid repair in high-risk patients. Options for repair include a carotid–carotid bypass, axilloaxillary bypass, carotid–subclavian bypass and carotid–subclavian transposition. The transposition avoids the use of a conduit; however, is contraindicated in those with a previous left mammary bypass graft due to intolerance of proximal clamping. Results are excellent with 10-year patency greater than 80%.[56] Mortality rates are lower than those that underwent transthoracic repair at less than 1%, with slightly lower stroke and MI rates.[56,60]

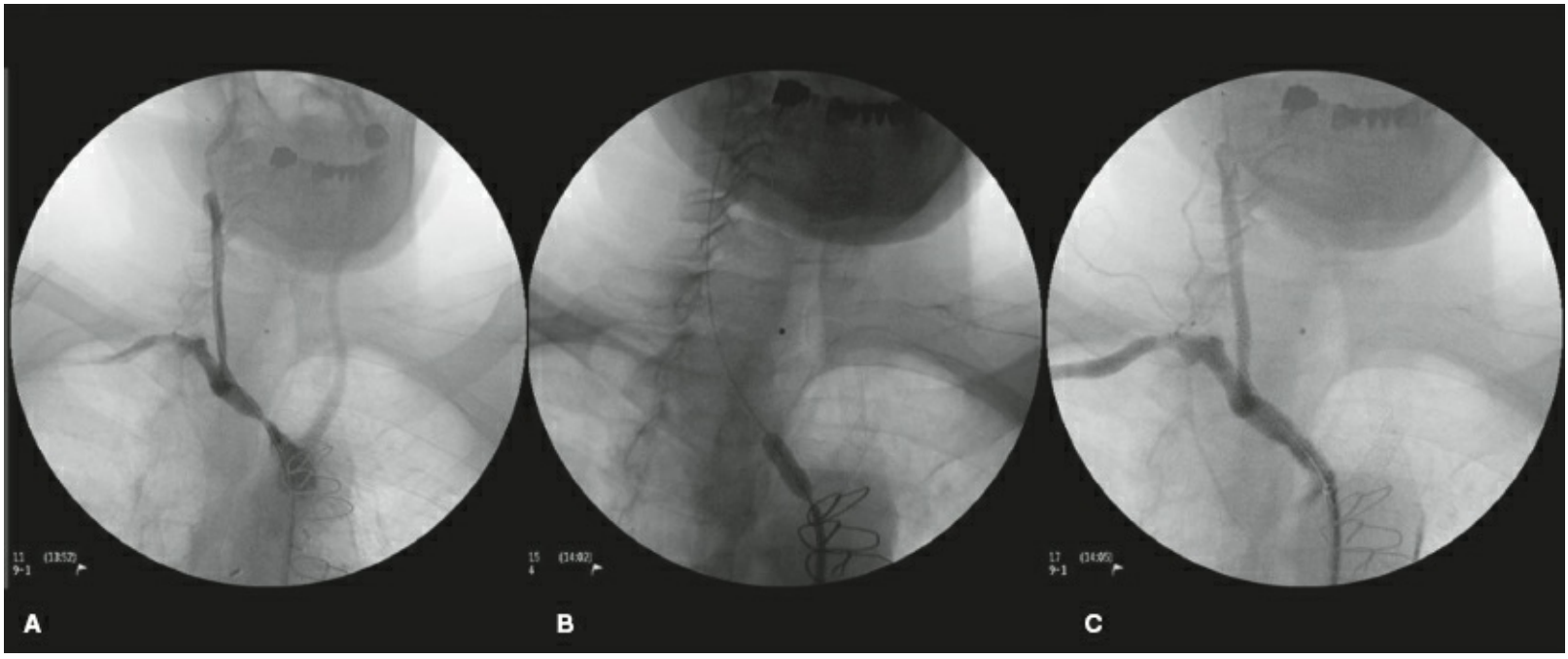

Figure 89-20. **A:** Critical stenosis of the innominate artery with distal wire access for endovascular management. **B:** Placement of a balloon-expandable stent for treatment of the innominate artery stenosis. **C:** Final angiographic run showing complete resolution of stenosis.

ENDOVASCULAR TREATMENT

As with carotid stenting, the option for endovascular treatment of brachiocephalic disease depends of the aortic anatomy, anatomical variants, baseline renal function, arch type, lesion characteristics, and proximity to branch vessels (Fig. 89-20).

Options for repair include angioplasty and stenting. This does require intraprocedural anticoagulation and antiplatelet therapy after repair. Results of repair do not appear to compare to open repair, however, there is a paucity of data regarding long-term results. One-year patency appears to be around 90% and 5-year patency drops to 77% to 89%.[61–63] Given these results, surveillance is required and follow-up procedures for assisted patency are required.

Care must be given to avoid embolization to the vertebral arteries when intervening on the subclavian arteries or the internal carotid arteries when intervening on the innominate or common carotid arteries. This is usually accomplished with a filter being placed distal to the target area of revascularization with a 0.014-in–based system. Separate access or use of the 0.014 wire with a rapid exchange system allows protection during intervention. However, the risk of embolization is low and risks associated with filter placement should be weighed.

References

1. Lozano R, Naghavi M, Foreman K, et al. Global and regional mortality from 235 causes of death for 20 age groups in 1990 and 2010: a systematic analysis for the Global Burden of Disease Study 2010. *Lancet* 2012;380:2095–2128.
2. Feigin VL, Forouzanfar MH, Krishnamurthi R, et al. Global and regional burden of stroke during 1990–2010: findings from the Global Burden of Disease Study 2010. *Lancet* 2014;383:245–254.
3. Koton S, Schneider AL, Rosamond WD, et al. Stroke incidence and mortality trends in US communities, 1987 to 2011. *JAMA* 2014;312:259–268.
4. Go AS, Mozaffarian D, Roger VL, et al. Heart disease and stroke statistics–2014 update: a report from the American Heart Association. *Circulation* 2014;129:e28–e292.
5. White H, Boden-Albala B, Wang C, et al. Ischemic stroke subtype incidence among whites, blacks, and Hispanics: the Northern Manhattan Study. *Circulation* 2005;111:1327–1331.
6. Schneider AT, Kissela B, Woo D, et al. Ischemic stroke subtypes: a population-based study of incidence rates among blacks and whites. *Stroke* 2004;35:1552–1556.
7. Roger VL, Go AS, Lloyd-Jones DM, et al. Heart disease and stroke statistics–2012 update: a report from the American Heart Association. *Circulation* 2012;125:e2–e220.
8. Rothwell PM, Coull AJ, Giles MF, et al. Change in stroke incidence, mortality, case-fatality, severity, and risk factors in Oxfordshire, UK from 1981 to 2004 (Oxford Vascular Study). *Lancet* 2004;363:1925–1933.
9. Carandang R, Seshadri S, Beiser A, et al. Trends in incidence, lifetime risk, severity, and 30-day mortality of stroke over the past 50 years. *JAMA* 2006;296:2939–2946.
10. O'Donnell MJ, Xavier D, Liu L, et al. Risk factors for ischaemic and intracerebral haemorrhagic stroke in 22 countries (the INTERSTROKE study): a case-control study. *Lancet* 2010;376:112–123.
11. Mathiesen EB, Joakimsen O, B⊘naa KH. Prevalence of and risk factors associated with carotid artery stenosis: the Troms⊘ Study. *Cerebrovasc Dis* 2001;12:44–51.
12. Kiechl S, Willeit J, Rungger G, et al. Quantitative assessment of carotid atherosclerosis in a healthy population. *Neuroepidemiology* 1994;13:314–317.
13. Petty GW, Brown RD Jr., Whisnant JP, et al. Ischemic stroke subtypes : a population-based study of functional outcome, survival, and recurrence. *Stroke* 2000;31:1062–1068.
14. Barnett HJ, Taylor DW, Eliasziw M, et al. Benefit of carotid endarterectomy in patients with symptomatic moderate or severe stenosis. North American Symptomatic Carotid Endarterectomy Trial Collaborators. *N Engl J Med* 1998;339:1415–1425.
15. Warlow CP. Symptomatic patients: the European Carotid Surgery Trial (ECST). *J Mal Vasc* 1993;18:198–201.

16. Blauw GJ, Lagaay AM, Smelt AH, et al. Stroke, statins, and cholesterol. A meta-analysis of randomized, placebo-controlled, double-blind trials with HMG-CoA reductase inhibitors. *Stroke* 1997;28:946–950.
17. Brott TG, Halperin JL, Abbara S, et al. 2011 ASA/ACCF/AHA/AANN/AANS/ACR/ASNR/CNS/SAIP/SCAI/SIR/SNIS/SVM/SVS guideline on the management of patients with extracranial carotid and vertebral artery disease: executive summary. A report of the American College of Cardiology Foundation/American Heart Association Task Force on Practice Guidelines, and the American Stroke Association, American Association of Neuroscience Nurses, American Association of Neurological Surgeons, American College of Radiology, American Society of Neuroradiology, Congress of Neurological Surgeons, Society of Atherosclerosis Imaging and Prevention, Society for Cardiovascular Angiography and Interventions, Society of Interventional Radiology, Society of NeuroInterventional Surgery, Society for Vascular Medicine, and Society for Vascular Surgery. *Circulation* 2011;124:489–532.
18. Roederer GO, Langlois YE, Jager KA, et al. The natural history of carotid arterial disease in asymptomatic patients with cervical bruits. *Stroke* 1984;15:605–613.
19. Endarterectomy for asymptomatic carotid artery stenosis. Executive Committee for the Asymptomatic Carotid Atherosclerosis Study. *JAMA* 1995;273:1421–1428.
20. Nicolaides AN, Kakkos SK, Kyriacou E, et al. Asymptomatic internal carotid artery stenosis and cerebrovascular risk stratification. *J Vasc Surg* 2010;52:1486–1496 e1–e5.
21. Mughal MM, Khan MK, DeMarco JK, et al. Symptomatic and asymptomatic carotid artery plaque. *Expert Rev Cardiovasc Ther* 2011;9:1315–1330.
22. Bhatt DL, Fox KA, Hacke W, et al. Clopidogrel and aspirin versus aspirin alone for the prevention of atherothrombotic events. *N Engl J Med* 2006;354:1706–1717.
23. Gurm HS, Yadav JS, Fayad P, et al. Long-term results of carotid stenting versus endarterectomy in high-risk patients. *N Engl J Med* 2008;358:1572–1579.
24. Mas JL, Chatellier G, Beyssen B, et al. Endarterectomy versus stenting in patients with symptomatic severe carotid stenosis. *N Engl J Med* 2006;355:1660–1671.
25. Brott TG, Hobson RW 2nd, Howard G, et al. Stenting versus endarterectomy for treatment of carotid-artery stenosis. *N Engl J Med* 2010;363:11–23.
26. Stingele R, Berger J, Alfke K, et al. Clinical and angiographic risk factors for stroke and death within 30 days after carotid endarterectomy and stent-protected angioplasty: a subanalysis of the SPACE study. *Lancet Neurol* 2008;7:216–222.
27. Carotid Stenting Trialists Collaboration, Bonati LH, Dobson J, et al. Short-term outcome after stenting versus endarterectomy for symptomatic carotid stenosis: a preplanned meta-analysis of individual patient data. *Lancet* 2010;376:1062–1073.
28. Facco E, Deriu GP, Dona B, et al. EEG monitoring of carotid endarterectomy with routine patch-graft angioplasty: an experience in a large series. *Neurophysiol Clin* 1992;22:437–446.

29. Phillips MR, Johnson WC, Scott RM, et al. Carotid endarterectomy in the presence of contralateral carotid occlusion: the role of EEG and intraluminal shunting. *Arch Surg* 1979;114:1232–1239.
30. Thompson JE. Complications of carotid endarterectomy and their prevention. *World J Surg* 1979;3:155–165.
31. Javid H, Julian OC, Dye WS, et al. Seventeen-year experience with routine shunting in carotid artery surgery. *World J Surg* 1979;3:167–177.
32. Kresowik TF, Bratzler D, Karp HR, et al. Multistate utilization, processes, and outcomes of carotid endarterectomy. *J Vasc Surg* 2001;33:227–234; discussion 234–235.
33. Wallaert JB, Goodney PP, Vignati JJ, et al. Completion imaging after carotid endarterectomy in the Vascular Study Group of New England. *J Vasc Surg* 2011;54:376–385, 85 e1–e3.
34. Kinney EV, Seabrook GR, Kinney LY, et al. The importance of intraoperative detection of residual flow abnormalities after carotid artery endarterectomy. *J Vasc Surg* 1993;17:912–922; discussion 922–923.
35. Hertzer NR, Lees CD. Fatal myocardial infarction following carotid endarterectomy: three hundred thirty-five patients followed 6–11 years after operation. *Ann Surg* 1981;194:212–218.
36. O'Donnell TF Jr, Callow AD, Willet C, et al. The impact of coronary artery disease on carotid endarterectomy. *Ann Surg* 1983;198:705–712.
37. Cunningham EJ, Bond R, Mayberg MR, et al. Risk of persistent cranial nerve injury after carotid endarterectomy. *J Neurosurg* 2004;101:445–448.
38. Group SC, Ringleb PA, Allenberg J, et al. 30 day results from the SPACE trial of stent-protected angioplasty versus carotid endarterectomy in symptomatic patients: a randomised non-inferiority trial. *Lancet* 2006;368:1239–1247.
39. Stanley JC, Fry WJ, Seeger JF, et al. Extracranial internal carotid and vertebral artery fibrodysplasia. *Arch Surg* 1974;109:215–222.
40. Mettinger KL, Ericson K. Fibromuscular dysplasia and the brain. I. Observations on angiographic, clinical and genetic characteristics. *Stroke* 1982;13:46–52.
41. Bogousslavsky J, Regli F. Ischemic stroke in adults younger than 30 years of age. Cause and prognosis. *Arch Neurol* 1987;44:479–482.
42. Ehrnefeld WK, Stoney RJ, Wylie EJ. Relation of carotid stump pressure to safety of carotid artery ligation. *Surgery* 1983;93:299–305.
43. Sen I, Stephen E, Malepathi K, et al. Neurological complications in carotid body tumors: a 6-year single-center experience. *J Vasc Surg* 2013;57:64S–8S.
44. Caplan LR, Wityk RJ, Glass TA, et al. New England Medical Center Posterior Circulation registry. *Ann Neurol* 2004;56:389–398.
45. McDowell FH, Potes J, Groch S. The natural history of internal carotid and vertebral-basilar artery occlusion. *Neurology* 1961;11(4)Pt 2:153–157.

46. Labauge R, Boukobza M, Pages M, et al. [Occlusion of the vertebral artery (100 personal cases)]. *Rev Neurol* 1987;143:490–509.
47. Berguer R, Higgins R, Nelson R. Noninvasive diagnosis of reversal of vertebral-artery blood flow. *N Engl J Med* 1980;302:1349–1351.
48. Berguer R, Morasch MD, Kline RA. A review of 100 consecutive reconstructions of the distal vertebral artery for embolic and hemodynamic disease. *J Vasc Surg* 1998;27:852–829.
49. Berguer R, Flynn LM, Kline RA, et al. Surgical reconstruction of the extracranial vertebral artery: management and outcome. *J Vasc Surg* 2000;31:9–18.
50. Investigators SS. Stenting of Symptomatic Atherosclerotic Lesions in the Vertebral or Intracranial Arteries (SSYLVIA): study results. *Stroke* 2004;35:1388–1392.
51. Coward LJ, Featherstone RL, Brown MM. Percutaneous transluminal angioplasty and stenting for vertebral artery stenosis. *Cochrane Database Syst Rev* 2005:CD000516.
52. Layton KF, Kallmes DF, Cloft HJ, et al. Bovine aortic arch variant in humans: clarification of a common misnomer. *AJNR Am J Neuroradiol* 2006;27:1541–1542.
53. Stone WM, Brewster DC, Moncure AC, et al. Aberrant right subclavian artery: varied presentations and management options. *J Vasc Surg* 1990; 11:812–817.
54. Kieffer E, Bahnini A, Koskas F. Aberrant subclavian artery: surgical treatment in thirty-three adult patients. *J Vasc Surg* 1994;19:100–109; discussion 110–111.
55. Bisognano JD, Young B, Brown JM, et al. Diverse presentation of aberrant origin of the right subclavian artery: two case reports. *Chest* 1997;112:1693–1697.
56. Berguer R, Morasch MD, Kline RA, et al. Cervical reconstruction of the supra-aortic trunks: a 16-year experience. *J Vasc Surg* 1999;29:239–246; discussion 246–248.
57. Kieffer E, Sabatier J, Koskas F, et al. Atherosclerotic innominate artery occlusive disease: early and long-term results of surgical reconstruction. *J Vasc Surg* 1995;21:326–336; discussion 336–337.
58. Berguer R, Morasch MD, Kline RA. Transthoracic repair of innominate and common carotid artery disease: immediate and long-term outcome for 100 consecutive surgical reconstructions. *J Vasc Surg* 1998;27:34–41; discussion 42.
59. Rhodes JM, Cherry KJ Jr., Clark RC, et al. Aortic-origin reconstruction of the great vessels: risk factors of early and late complications. *J Vasc Surg* 2000;31:260–269.
60. Byrne J, Darling RC 3rd, Roddy SP, et al. Long term outcome for extra-anatomic arch reconstruction. An analysis of 143 procedures. *Eur J Vasc Endovasc Surg* 2007;34:444–450.
61. Bates MC, Broce M, Lavigne PS, et al. Subclavian artery stenting: factors influencing long-term outcome. *Catheter Cardiovasc Interv* 2004;61:5–11.
62. De Vries JP, Jager LC, Van den Berg JC, et al. Durability of percutaneous transluminal angioplasty for obstructive lesions of proximal subclavian artery: long-term results. *J Vasc Surg* 2005;41:19–23.
63. Przewlocki T, Kablak-Ziembicka A, Pieniazek P, et al. Determinants of immediate

and long-term results of subclavian and innominate artery angioplasty. *Catheter Cardiovasc Interv* 2006;67:519–526.

Chapter 90

Upper Extremity Arterial Disease

Heron E. Rodriguez

Key Points

1. Presentation includes arm claudication, distal embolism, finger necrosis, and vasomotor changes described as Raynaud phenomenon.
2. Given the multiple potential etiologies of upper extremity ischemia, a thorough occupational and social history is of crucial importance.
3. Unilateral hand ischemia points toward an isolated anatomic lesion whereas bilateral hand ischemia is more often related to systemic diseases.
4. A variety of noninvasive tests are available for the initial investigation of arm ischemia and detailed, bilateral arterial imaging is mandatory for treatment planning.
5. Although endovascular revascularization is an excellent option for many causes of upper extremity ischemia, open surgical revascularization should be used for some of the diseases causing arm ischemia (i.e., thoracic outlet syndrome, hypothenar hammer syndrome, etc.)

INTRODUCTION

1 Compared to arterial occlusive lesions in the lower extremity, occlusive disease of the arteries of the upper extremity is often better tolerated and severe symptoms of ischemia are less frequent in the arms than in the legs. This not only can be attributed to the presence of an extensive collateral network, but also to the very different physiologic requirements of the upper extremities when compared to the legs. Another striking difference between arterial disease of the arms compared to that of the legs resides in its etiology. Whereas in the lower extremities, atherosclerosis is responsible for the overwhelming majority of cases of critical limb ischemia, in addition to atherosclerosis, a variety of anatomic, occupational, and iatrogenic etiologies are responsible for occlusive disease of the arms.

PRESENTATION

Patients suffering from arterial insufficiency affecting the upper extremities can present with a variety of symptoms. Arm claudication (pain during exercise) is rare and often points to a lesion in the proximal vasculature (innominate, subclavian, or axillary arteries). More commonly, patients present with skin changes affecting the hand or fingers. Splinter hemorrhages of the bed of the nail, livedo reticularis, cyanosis of segments of the fingers, and gangrene are signs of embolism or ischemia affecting the arteries of the hand (Fig. 90-1).[1] The term Raynaud phenomenon indicates an episodic series of skin changes affecting the fingers or the hand that are triggered by changes in temperature and sometimes even emotions. The classic description includes the sequential appearance of pallor, then cyanosis, then erythema. These correspond to initial vasospasm (causing pallor), desaturation of hemoglobin (causing cyanosis), and finally compensatory vasodilation, also known as reactive hyperemia (causing erythema).

Raynaud phenomenon (also called secondary Raynaud syndrome) can be the manifestation of occlusive disease or, more commonly, associated with autoimmune conditions (scleroderma, Sjögren syndrome, rheumatoid arthritis, lupus).[1] In contrast, the term *Raynaud disease* (or primary Raynaud syndrome) is used to describe a condition of unknown etiology that occurs in patients without occlusive lesions or autoimmune disease and who experience vasomotor symptoms in both arms, and sometimes even the legs, for longer than 2 years.[2]

ETIOLOGY

2 A myriad of conditions can cause upper extremity occlusive disease (Table 90-1). Atherosclerosis typically affects the origins of the supra-aortic trunks. Ostial lesions at the origin of the subclavian artery are most common. The innominate artery and distal arteries can also be affected. Involvement of multiple segments of the upper extremity circulation is possible and is often asymptomatic even in the presence of total occlusion. Patients with renal failure typically have normal proximal vessels with severe disease in the blood vessels of the forearm and hand (Fig. 90-2). In this patient population, hand ischemia tends to occur at a younger age and is frequently associated with calciphylaxis.[3]

Inflammatory conditions like Takayasu arteritis, giant cell arteritis or temporal arteritis can also affect the proximal portion of the great vessels.[4] Takayasu arteritis is a nonspecific inflammatory disease that has a predilection for young women. This so-called "pulseless disease" typically occurs in women in the second or third decades of life who present with symptoms of ischemia in the arms or the cerebrovascular territory. An initial acute inflammatory phase of the disease leads to a late chronic phase where long segments of stenosis appear in the vessels (Fig. 90-3). These lesions have a low embolic potential but typically result in ischemic symptoms due to low flow. In contrast, giant cell arteritis involves the more distal segments of the subclavian arteries and affects older people. The typical pattern of disease is that of areas of normal luminal diameter alternated with dilated or stenotic lesions. The most common symptoms are headaches and visual changes related to involvement of the cerebral vascular arteries. Buerger disease is an obliterative disease that typically affects medium and small caliber arteries. The *sine qua non* for Buerger disease is tobacco use in a young patient. It affects the lower extremities more commonly than the upper limbs and occurs more frequently in males than females.



Figure 90-1. Manifestations of upper extremity ischemia. Splinter hemorraghes in the nails arising from a proximal embolic source (**A**). Gangrene affecting the tip of the third finger (**B**). Advanced, severe gangrene in the radial artery distribution secondary to complications related to an arterial line (**C**).

Ergotamine-induced vasospasm can create ischemia of the hands and the feet. Historically, several epidemics occurred in Europe during the Middle Ages caused by the ingestion of rye contaminated by alkaloid-producing fungi. After a miraculous cure that was believed to have occurred thanks to the relics of Saint Anthony the Great, the Hospital Brothers of St. Anthony's order was founded and the term "St. Anthony's Fire" became popular. Today, most cases of ergotism are due to antimigraine drugs or recreational substance abuse.[5]

Connective tissue disorders are a common cause of upper extremity ischemia. Lesions typically affect the distal vasculature and are more common in scleroderma, rheumatoid arthritis, CREST syndrome, mixed connective tissue disorder, and lupus. Raynaud phenomenon is often the manifestation in early stages whereas digital gangrene occurs in late stages of the disease.

Peet et al. first coined the term thoracic outlet syndrome (TOS) in 1956 to encompass a

group of signs and symptoms related to compression of the brachial plexus, subclavian artery, or subclavian vein as they pass from the thorax into the axilla. Only in 1% of all cases of TOS, the artery, is the structure compressed. Although TOS is often asymptomatic, patients may present with a range of signs and symptoms, from fatigue or pain in the affected arm upon exertion and Raynaud phenomenon to critical ischemia of the upper extremity because of emboli arising from the chronically injured artery or from a mural thrombus in a poststenotic aneurysm sac. The artery is compressed as it passes through the thorax into the axilla through the narrow gap formed by the clavicle superiorly, the first rib inferiorly and the subclaveous muscle anteriorly and superiorly, as well as the scalene muscles posteriorly (Fig. 90-4). Bony anomalies, such as cervical rib or an abnormal first thoracic rib, are sometimes present. Aneurysms can also form because of repetitive trauma in branches of the subclavian artery. These aneurysms can be the source of emboli that manifest as ischemic lesions in the hands.[6] Pectoralis minor syndrome is a distinct condition caused by compression of the subclavian artery by the pectoralis minor as it travels cephalad to insert in the coracoid process (Fig. 90-4).

Ischemia caused by abnormalities in the axillary, brachial, radial, and ulnar arteries is often the result of iatrogenic etiologies. One of the most common causes of ischemia seen in our practice is due to hemodialysis access. Hand ischemia due to steal phenomenon is common and ischemia as a result of intra-arterial catheters also occurs frequently.

Occupational injuries to the arteries of the hand result in thenar or hypothenar hammer syndrome. The ulnar artery is vulnerable to injury at the hypothenar eminence, just distal to the wrist where the ulnar artery passes through Guyon canal bound by the pisiform and hamate bones. Here, the ulnar artery is cushioned only by skin, subcutaneous tissue, and the thin palmaris brevis muscle. Repetitive use of the palm of the hand as a “hammer” compresses the unprotected ulnar artery against the nearby hook of the hammate bone. Both aneurysm formation and occlusive disease can occur (Fig. 90-5). [7]

HISTORY AND PHYSICAL EXAMINATION

3 Given the frequent association of upper extremity ischemia with systemic and occupational disorders, a thorough medical and social history is mandatory. Interrogation should include inquiring about tobacco and drug use. Antimigraine medications, HIV antivirals, and most commonly recreational drugs, like cocaine and other alkaloids, can cause ergotism. Occupational history is of particular importance when evaluating upper extremity vascular issues. TOS occurs in athletes who are required to perform repetitive overhead shoulder motion (swimmers, baseball pitchers, weight lifters, etc.). Repetitive trauma to the palmar eminences (thenar and hypothenar) is typically observed in manual laborers (machinists, carpenters, and construction workers) but has also been described in athletes, musicians, and even computer workers who use their hands repetitively causing injury to the palms.

ETIOLOGY

Table 90-1 Conditions and Risks for Upper Extremity Ischemia

- Occupational injury
  - Vibration syndrome
    - Pneumatic tools
    - Chainsaws
    - Grinders
  - Electrical burns
  - Hypothenar hammer syndrome
    - Mechanical work or auto repair
    - Lathe operation
    - Carpentry
    - Electrical work
  - Occupational acroosteolysis – polyvinylchloride exposure
- Athletic activities
  - Thoracic outlet compression
    - Baseball pitching
    - Kayaking
    - Weight lifting
    - Rowing
    - Butterfly swimming
    - Golfing
  - Hand ischemia
    - Baseball catching
    - Frisbee
    - Karate
    - Handball
- Pharmacologic history
  - Ergot poisoning
  - Beta blockers
  - Drug abuse, cocaine use
  - Cytotoxic drugs
  - Dopamine overdose
- Medical conditions
  - Atherosclerosis
  - Arteritis
    - Collagen disease
      - Scleroderma
      - Rheumatic arteritis
      - Systemic lupus erythematosus
      - Dermatomyositis
    - Allergic necrotizing arteritis
      - Takayasu disease
      - Giant cell arteritis
    - Blood dyscrasias
      - Cold agglutinins
      - Cryoglobulins
      - Polycythemia vera
  - Behçet syndrome
  - Antiphospholipid syndrome
  - Thoracic outlet syndrome
  - Congenital arterial wall defects
    - Pseudoxanthoma elasticum
    - Ehlers–Danlos syndrome
  - Fibromuscular dysplasia
  - Iatrogenic injury
    - Arterial blood gas and pressure monitoring
    - Cardiac catheterization
    - Arteriography
  - Frostbite
  - Renal transplantation and related problems
    - Azotemic arteriopathy
    - Hemodialysis shunts
  - Radiation
    - Breast carcinoma
    - Hodgkin disease
  - Aneurysms of the upper extremity

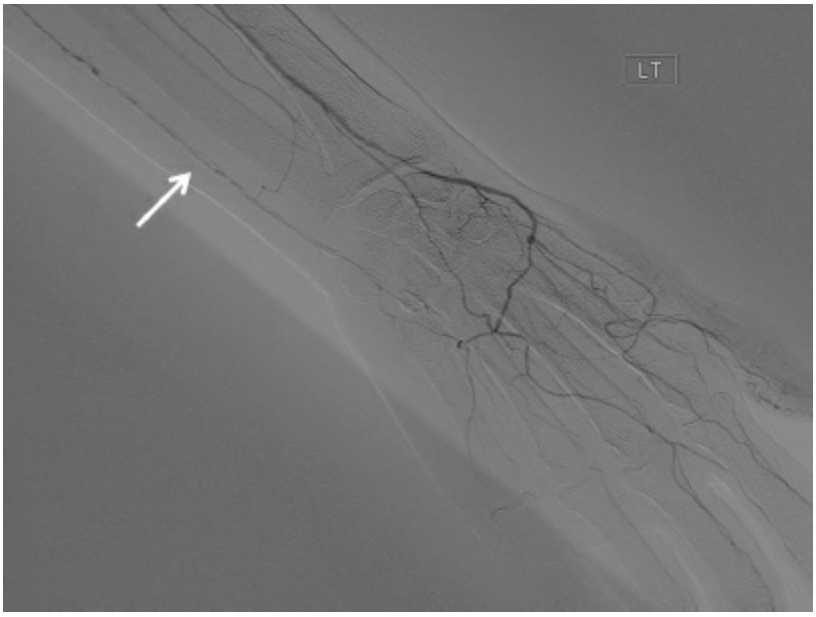

Figure 90-2. Selective left-hand angiogram in a patient with chronic renal insufficiency. There is severe, diffuse disease affecting a heavily calcified ulnar artery (*arrow*). In addition, there is lack of contrast opacification in several of the digital arteries.

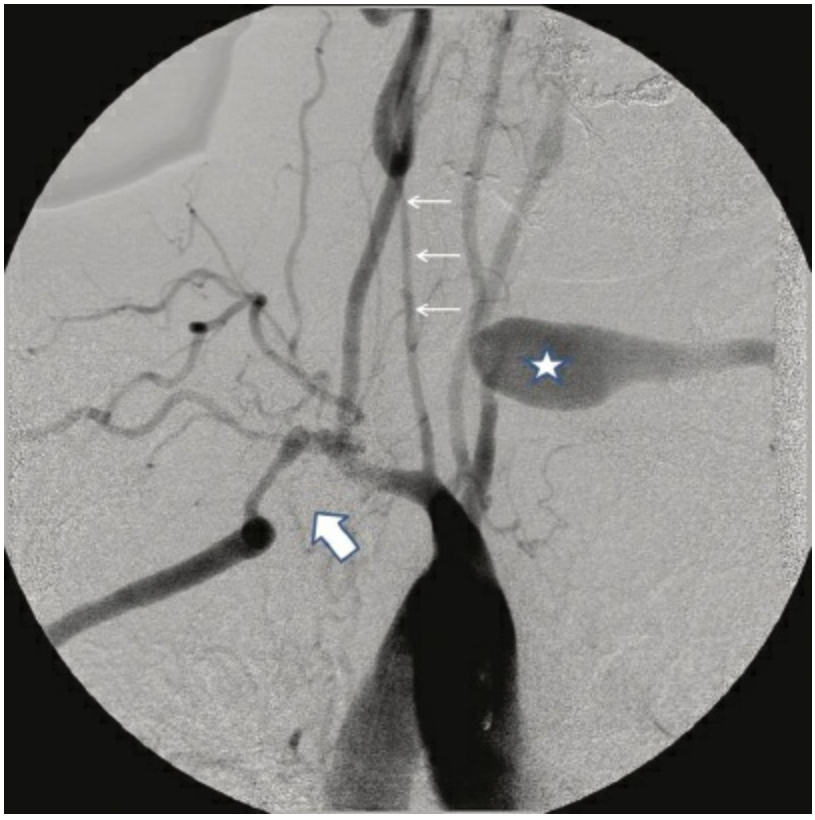

Figure 90-3. Aortogram in the right oblique projection of a patient with Takayasu arteritis. Long-segment right common carotid stenosis (*small arrows*) leading into a normal appearing carotid bifurcation. Segmental occlusion of the right subclavian artery (*block arrow*) just distal to the origin of the right vertebral. There is distal reconstitution via a large collateral. There is also an aneurysm (*star*) of a previous bypass in the left subclavian artery.

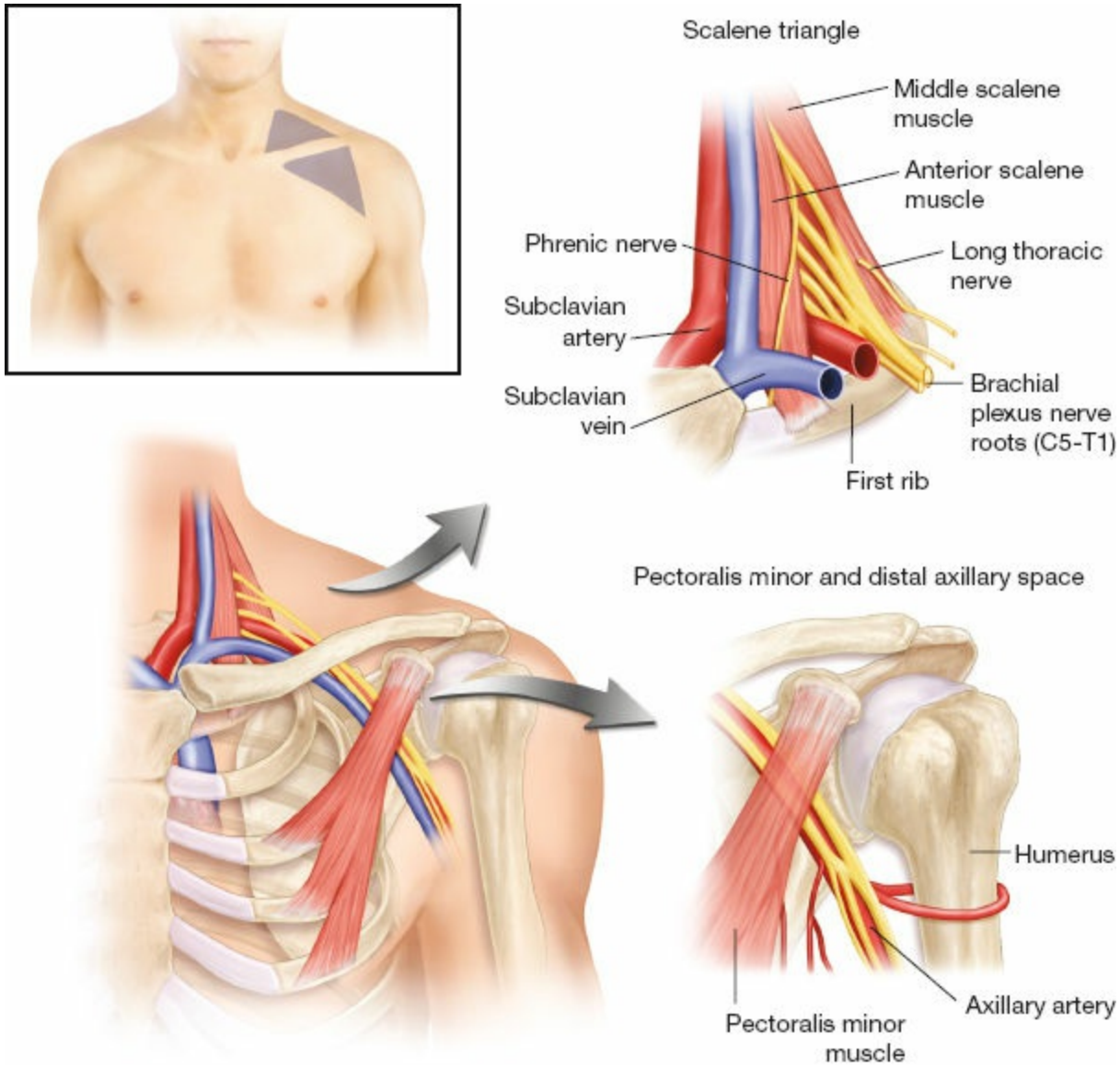

Figure 90-4. Compressive zones of the thoracic outlet. The subclavian structures can be compressed at the costoclavicular space, the scalene triangle, or distally at the border of the pectoralis minor muscle.

The presence of atherosclerotic disease in the heart or other vascular beds should also be investigated. History of connective tissue disorders or their symptoms (dysphagia, arthritis, telangiectasia, and other skin abnormalities) cannot be obviated during the evaluation of upper extremity ischemia. Changes in the appearance of the skin of the hands suggestive of Raynaud's should be explicitly investigated.

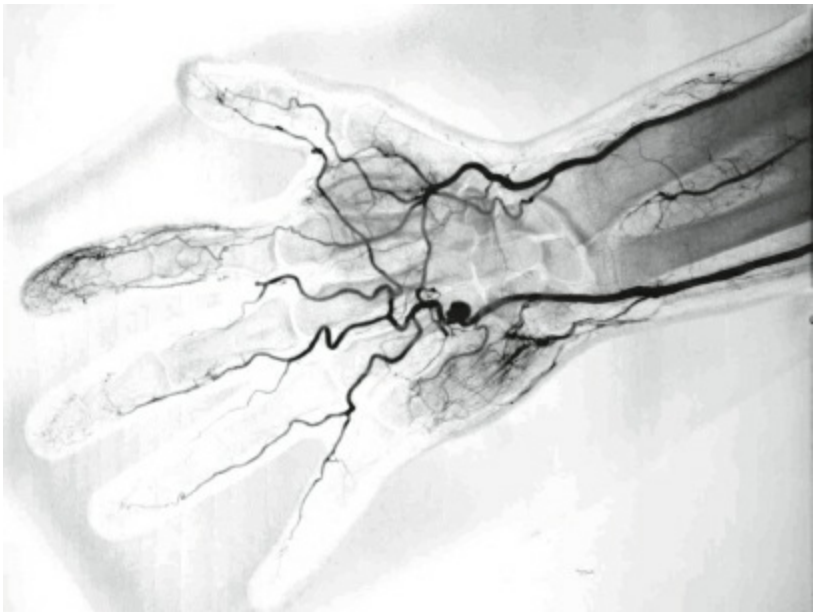

Figure 90-5. Ulnar artery aneurysm resulting from repetitive trauma in a construction worker.

It is necessary to obtain clear documentation of any prior intervention in the arm (hemodialysis access, biopsies, brachial or axillary access for cardiac catheterizations) or episodes of trauma (clavicular or rib fractures, humeral, shoulder, or elbow injuries) (Fig. 90-6).

A complete physical examination needs to include a systemic evaluation looking for signs of atherosclerotic, inflammatory, or autoimmune disease. A meticulous inspection, auscultation, and palpation of both sides of the neck, periclavicular areas, shoulders, and the entire arms and hands is done in the resting, neutral position, and also while abducting the arm. A bruit or a thrill in the periclavicular area would suggest the presence of stenosis or poststenotic dilation arising from TOS and a prominent pulse should point to an aneurysm in the subclavian artery. Comparison between the two upper extremities is of crucial importance since bilaterality often points to a systemic disorder. A careful hand examination includes inspecting for splinter hemorrhages under the beds of the nails, skin evidence of embolism or gangrene, changes in the color of the skin related to vasospasm and signs of trauma in the hand. Careful palpation of the radial, ulnar, snuffbox, and even digital pulses is done. Digital pressure is then applied to the ulnar and radial arteries in the wrist. After the patient opens and closes his or her hand, pressure is removed from one of the wrist arteries and inspection of the color of the hand and palpation of the distal pulses is repeated (Allen test). The test is normal if the entire hand recovers its color and capillary refill. If a portion of the hand fails to normalize, suspicion arises that the palmar vascular collateral circulation (palmar arch) is incomplete. Finally, blood pressure measurements in both arms are obtained and compared (brachiobrachial index).

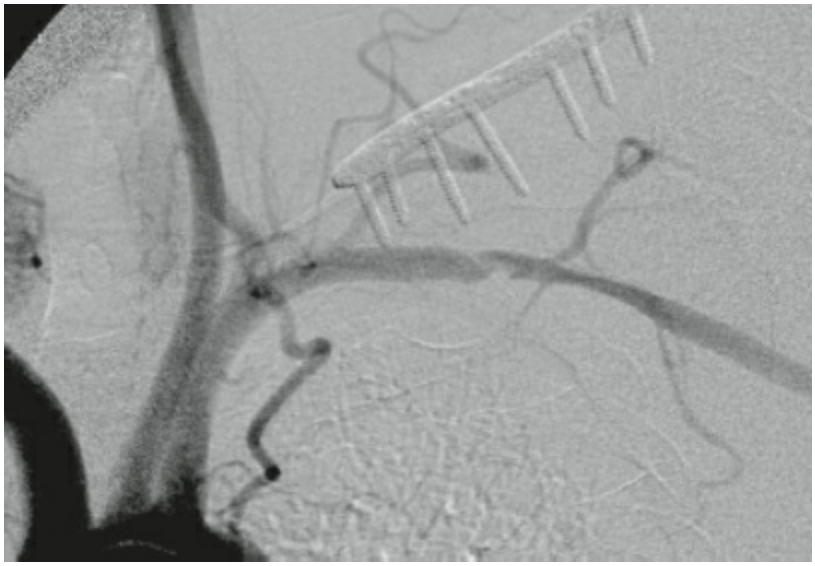

Figure 90-6. Old clavicular fracture treated with a metallic prosthesis. Notice the luminal abnormality in the subclavian artery as it crosses the clavicle. This lesion was caused by periosteal scarring and caused distal embolism in the hand.

LABORATORY AND NONINVASIVE TESTING

4 A series of serologic tests is typically obtained when autoimmune disease is suspected (Table 90-2). A variety of tests are available from the blood flow laboratory to aid in the management of upper extremity occlusive disease.[8] All patients should be subjected to segmental arterial pressure measurement and waveform analysis, at the minimum. In the upper extremities, this test usually includes photoplethysmography (PPG) of the digital vessels. The absence of triphasic flow and the presence of "blunted" PPG tracing in the affected arteries and digits, respectively, helps to localize obstructive lesions. If intermittent occlusion is suspected due to TOS, noninvasive testing can be performed along with the use of provocative maneuvers (Fig. 90-7). In patients with symptoms suggestive of vasomotor disorders (cold intolerance, color skin changes, etc.) the cold challenge test is used. In our lab, we immerse the hands in iced water and measure the digital temperatures every 5 minutes. A normal response should normalize the digital temperature within 1°C of preimmersion measurements. Patients with cold intolerance fail to restore digital temperature in 20 minutes. Several variations of this test exist.[9]

Table 90-2 Lab Tests for Systemic Causes for Hand Ischemia

Erythrocyte sedimentation rate
Rheumatoid factor
Antinuclear antibody
Immunoglobulin electrophoresis
Cryoglobulins
Cold agglutinins
VDRL (Venereal Disease Research Laboratory) test
Complement (C3, C4)
Anticardiolipin antibody
Blood cell counts

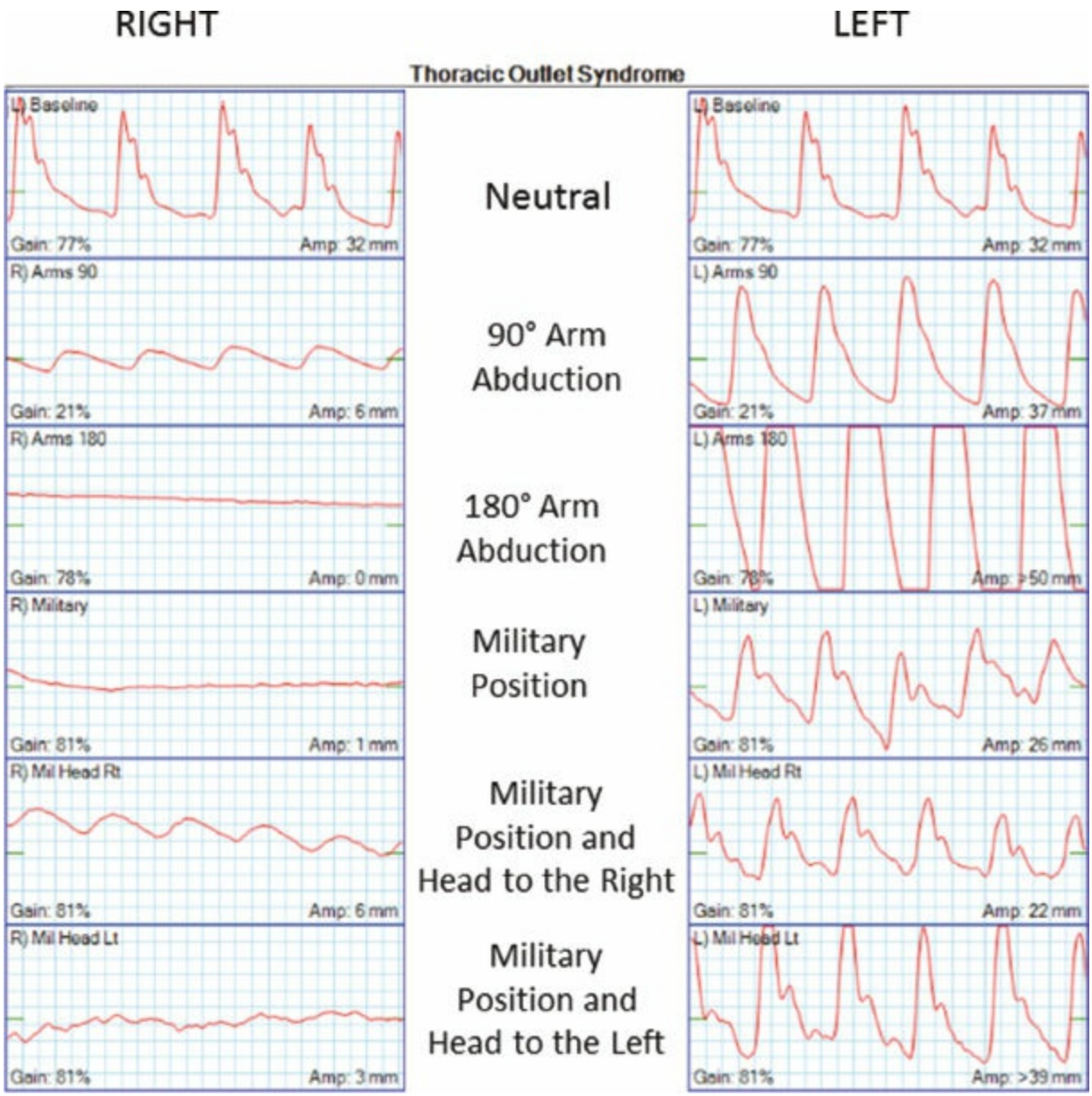

Figure 90-7. Noninvasive blood flow study in a major league baseball pitcher showing loss of normal signals during proactive maneuvers.

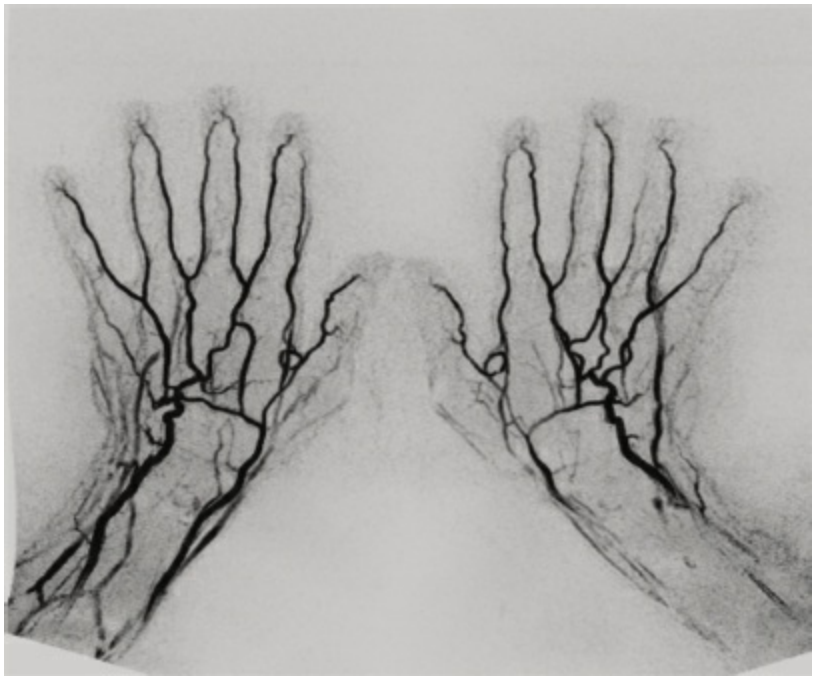

Figure 90-8. Focused magnetic resonance angiogram of the hands.

A more sophisticated version of the Adson test can also be obtained in most blood flow facilities by adding the analysis of waveforms obtained before and after ulnar and/or radial artery occlusion at the wrist. Duplex ultrasound is useful when an obstructive lesion is localized by physical examination, waveform analysis, or segmental pressure recordings. B-mode imaging and color Doppler can further define the characteristics of the lesion and its hemodynamic severity. Finally, measurement of digital PPG tracings can be obtained with and without manual pressure causing temporary occlusion of hemodialysis grafts and fistulae when evaluating arterial steal in patients with renal failure.

ANGIOGRAPHY

Accurate delineation of the arterial anatomy of both arms, from the aortic arch to the digital arteries is mandatory when obstructive lesions are suspected on clinical evaluation or by noninvasive testing. Although conventional angiography remains the gold standard, modern computed tomography angiography (CTA) and magnetic resonance angiography (MRA) has replaced this modality in many practices (Fig. 90-8). In order to obtain comparison, both upper extremities should be imaged. If TOS is suspected, provocative maneuvers are used while obtaining arterial images (Fig. 90-9). Of particular importance is obtaining clear images of the hand circulation. Typically, the deep palmar arch arises from the terminal part of the radial artery and the superficial arch by the ulnar artery. Nevertheless, several variations exist (Fig. 90-10).

MANAGEMENT

5 The specific mode for revascularization used to treat upper extremity ischemia depends on the location of the lesion, its etiology, and the available local resources and expertise. Atherosclerotic lesions affecting the origin of the subclavian or innominate arteries are most frequently treated with percutaneous transluminal angioplasty and stenting. This is more often achieved via a femoral approach but can also be performed using a retrograde brachial or even a carotid approach. Despite its popularity due to being minimally invasive, well tolerated by patients, widely available in the armamentarium of multiple disciplines and having immediate angiographic results that are usually excellent, several disadvantages should be considered when choosing this form of therapy. First, deployment of intravascular devices across the origin of the vertebral artery, across an internal mammary previously used as a coronary bypass and under the clavicle should be avoided due to the obvious possibility of catastrophic results. Second, the long-term durability of intravascular stents in the ostia of the aortic arch is not clearly established. Finally, we have seen an elevated rate of stent fractures in this position.[10] This is likely due to the extreme motion of the aortic arch and the supra-aortic trunks around the cardiac cycle. Alternatively, open surgical bypasses and transpositions can be performed via small incisions in the neck with excellent long-term results. For example, the subclavian artery can be transposed to the common carotid artery using a small transverse neck incision. This procedure allows for preservation of the vertebral artery and its long-term patency rate is virtually 100%.[11] A short carotid to subclavian bypass using prosthetic material can also be used with excellent long-term results (Fig. 90-11). Finally, in some patients the best option resides in single or multiple-branched bypasses arising from the aortic arch. A ministernotomy is used to expose the ascending arch and the bypass can be anastomosed to the aorta using a side-biting clamp thus obviating the need for cardiopulmonary bypass (Fig. 90-12).

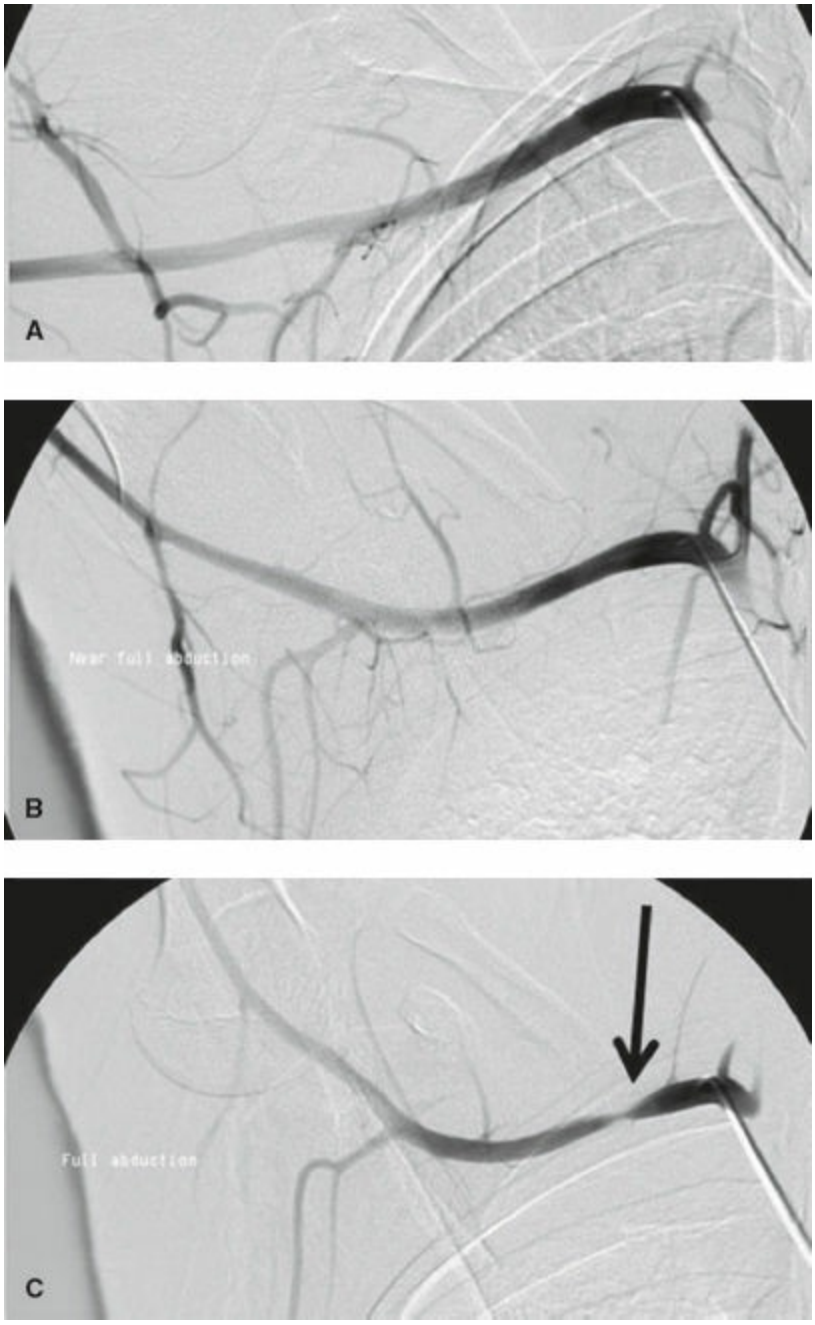

Figure 90-9. Selective digital subtraction angiography of the right arm in a patient with suspected arterial thoracic outlet syndrome. Subclavian artery stenosis is not seen when injecting contrast with the arm in neutral (**A**) and moderate abduction (**B**), but is evident when the arm is hyperabducted (**C**).

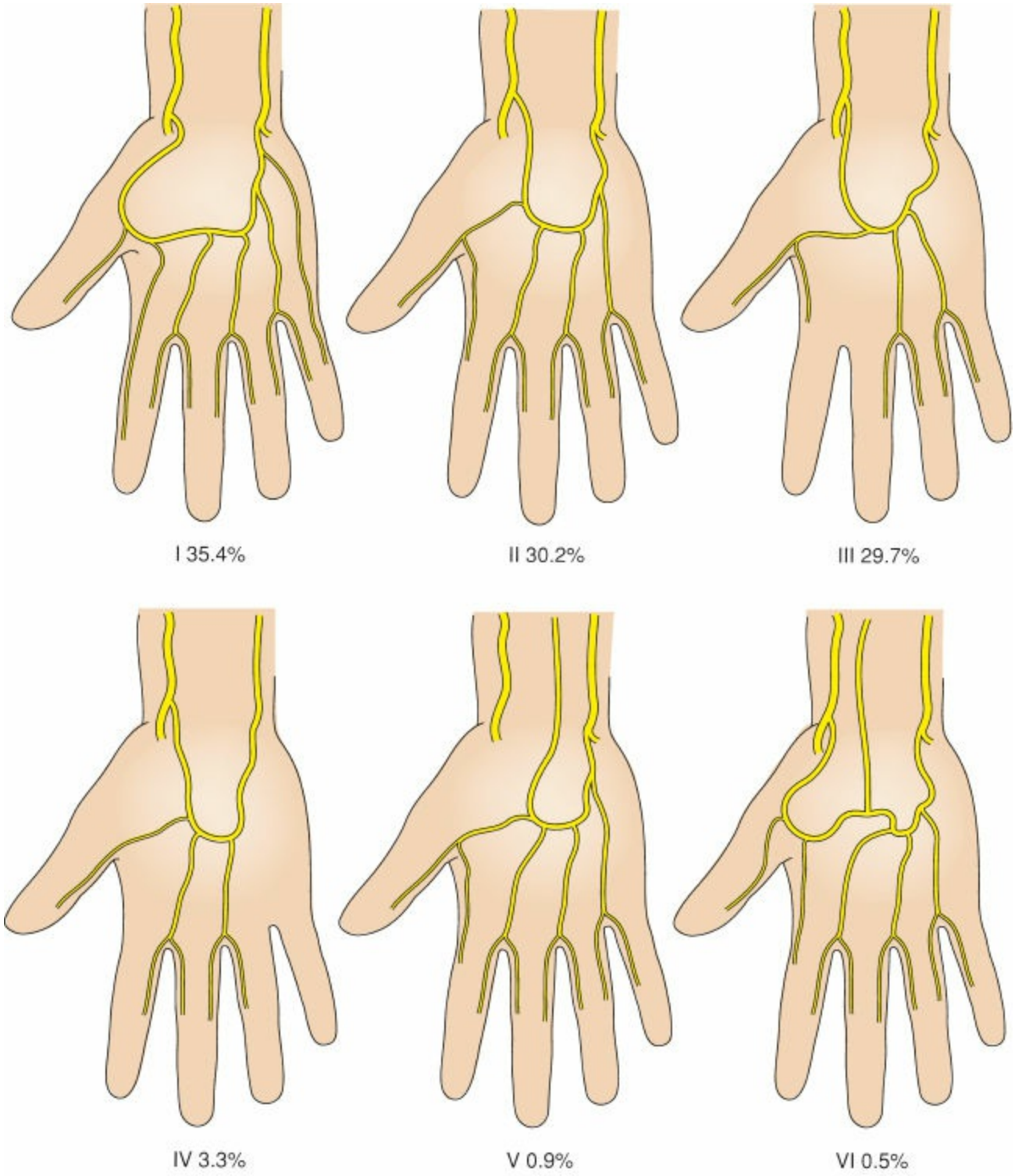

Figure 90-10. Different types of complex superficial palmar arch found on 500 hand arteriograms.

Intervention during the acute inflammatory phase of Takayasu arteritis should be avoided. Steroid and immunosuppressive therapy should be used instead and any intervention should be delayed until the acute, active phase of the disease undergoes remission.[12] This is often indicated by normalization of serologic inflammatory markers. Antiplatelet therapies may lower the frequency of ischemic events. During the chronic phase, reconstruction is carried out using similar techniques as those used for the management of atherosclerotic occlusion (Fig. 90-13).

There is little controversy about the management of patients with arterial TOS. Untreated arterial injury due to repetitive torsion and compression leads to stenosis,

poststenotic aneurysmal dilation, and distal embolism. In the majority of cases, evidence of distal embolism with compromise of the arteries of the hand is already present by the time of presentation. Thus, thoracic outlet decompression and/or arterial reconstruction is mandatory. Since the subclavian artery can be compressed at any point from the root of the neck to the pectoralis minor tendon, the decompressive approach depends on the specific anatomy of the patient. The surgical plan depends on the details obtained by imaging studies and the experience of the surgeon. In the absence of anatomic anomalies and with compression demonstrated only during arm abduction and elevation, first rib resection via the supraclavicular approach appears to be the best choice. If chronic compression has caused arterial damage, revascularization is necessary. Interposition grafts from the ipsilateral common carotid to the axillary artery are commonly used. This can best be achieved by a combination of supra- and infraclavicular exposure. Eight-millimeter PTFE grafts tunneled underneath the clavicle or subcutaneously have excellent patency rates. Excision of a cervical rib is usually done whereas full thoracic outlet decompression with scalenectomy is only necessary if concomitant neurogenic TOS exists.[13]

Other occlusive lesions of the subclavian, axillary, and brachial artery are best treated with surgical revascularization. Due to potential compression at the costoclavicular space, the high mobility of the shoulder joint and the caliber of the brachial artery, endovascular approaches are rarely indicated in this segment of the circulation. The conduit of choice for bypasses in the upper extremity is the saphenous vein. Many different configurations are available. The supraclavicular subclavian artery can be exposed by an incision at the base of the neck and used as inflow for bypasses tunneled subcutaneously over the clavicle and into the brachial artery. Alternatively, an excellent source of inflow is the common carotid artery. The outflow anastomosis can be created in the distal brachial artery, the radial or ulnar arteries in the proximal forearm (Fig. 90-14), or at the wrist and even in the arteries of the hand (Fig. 90-15).

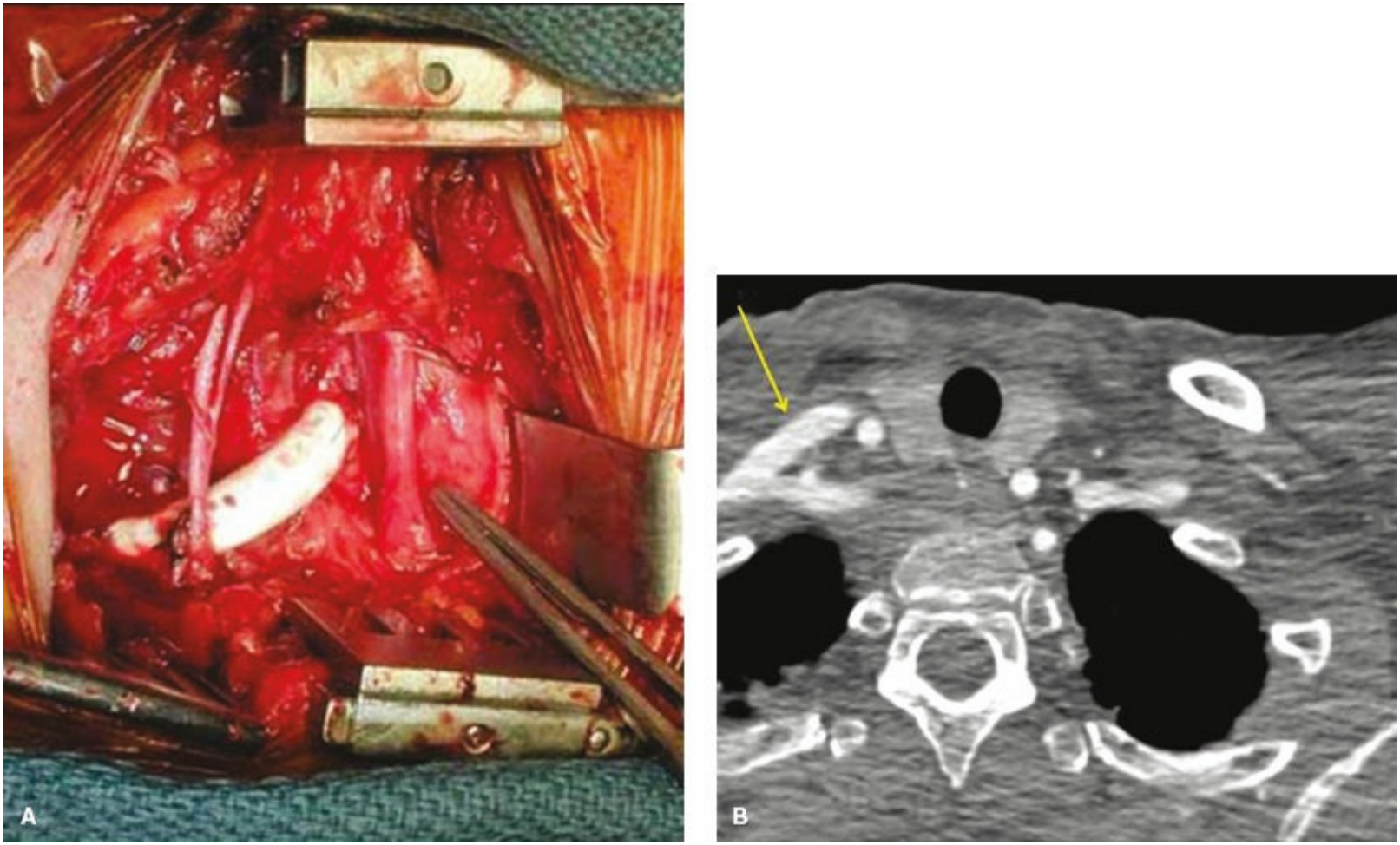

Figure 90-11. **A:** Right carotid to subclavian bypass performed via a supraclavicular incision using a prosthetic 10-mm conduit. **B:** CT scan showing patency of the bypass.

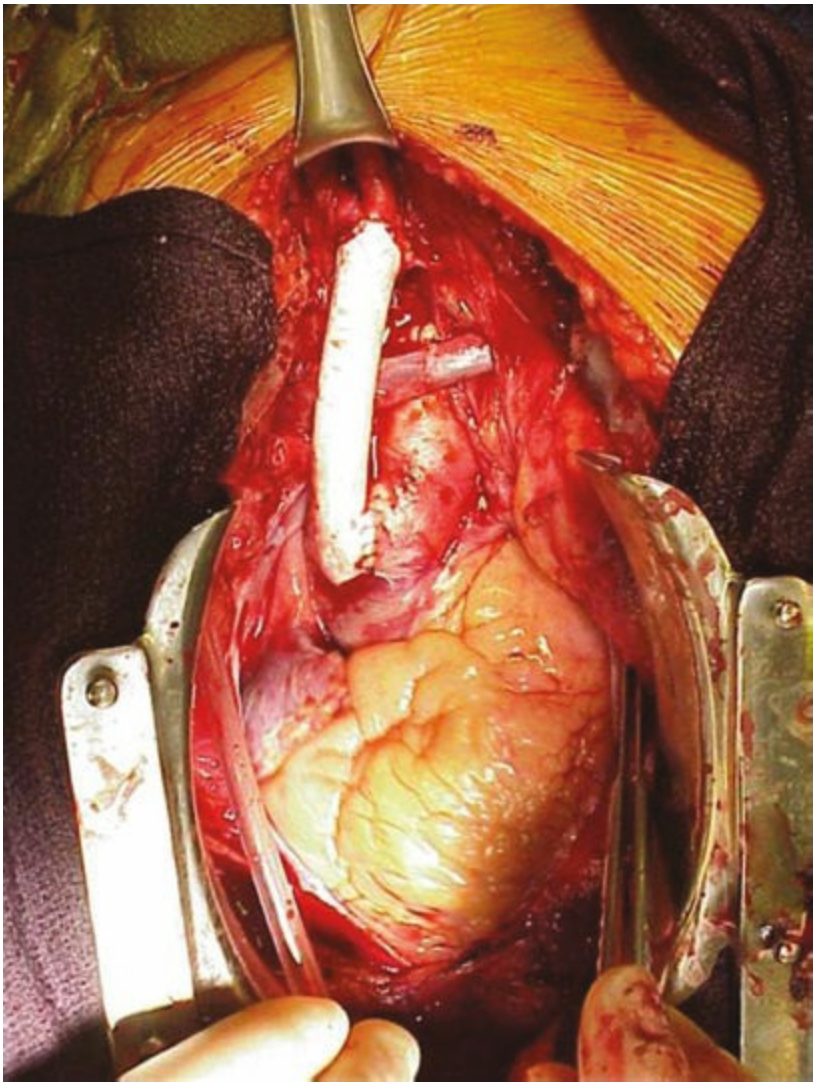

Figure 90-12. Aorto to inominate bypass. A ministernotomy is done and a side-biting clamp is used for creation of the proximal anastomosis in the ascending aorta. The distal anastomosis is created at the bifurcation of the innominate artery.

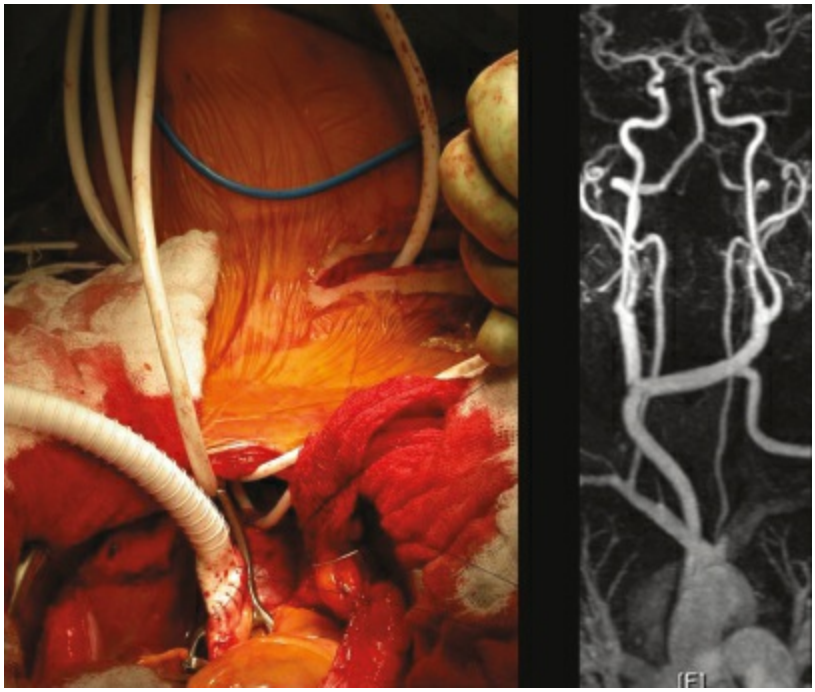

Figure 90-13. Arterial reconstruction on the patient with Takayasu arteritis shown in Figure 90-3. A median sternotomy with bilateral neck incisions was used. The proximal anastomosis was done in the ascending aorta. One branch was anastomosed in an end-to-end fashion to the right subclavian. A second branch was anastomosed to the right carotid (side-to-end) and then tunneled via the prevertebral space and anastomosed end-to-end to the left carotid bifurcation. Finally, a side arm was used to revascularize the left subclavian artery.

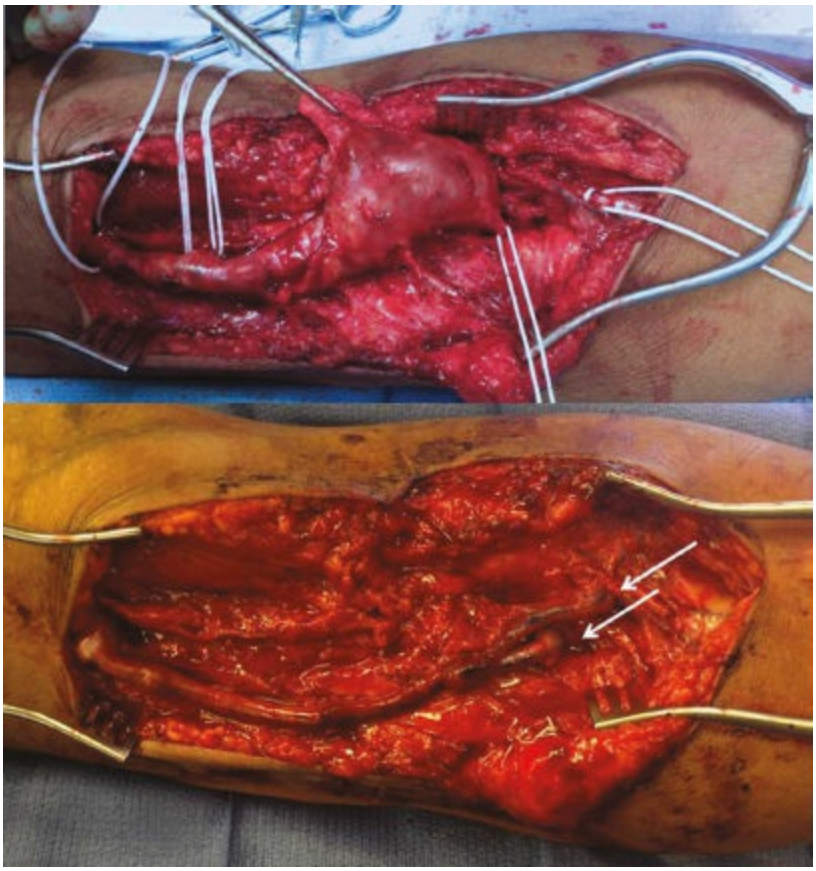

Figure 90-14. Large aneurysm of the distal brachial artery treated with a bifurcated bypass created with great saphenous vein. The distal anastomosis (*arrows*) were created into the radial and ulnar arteries just distal to the elbow.

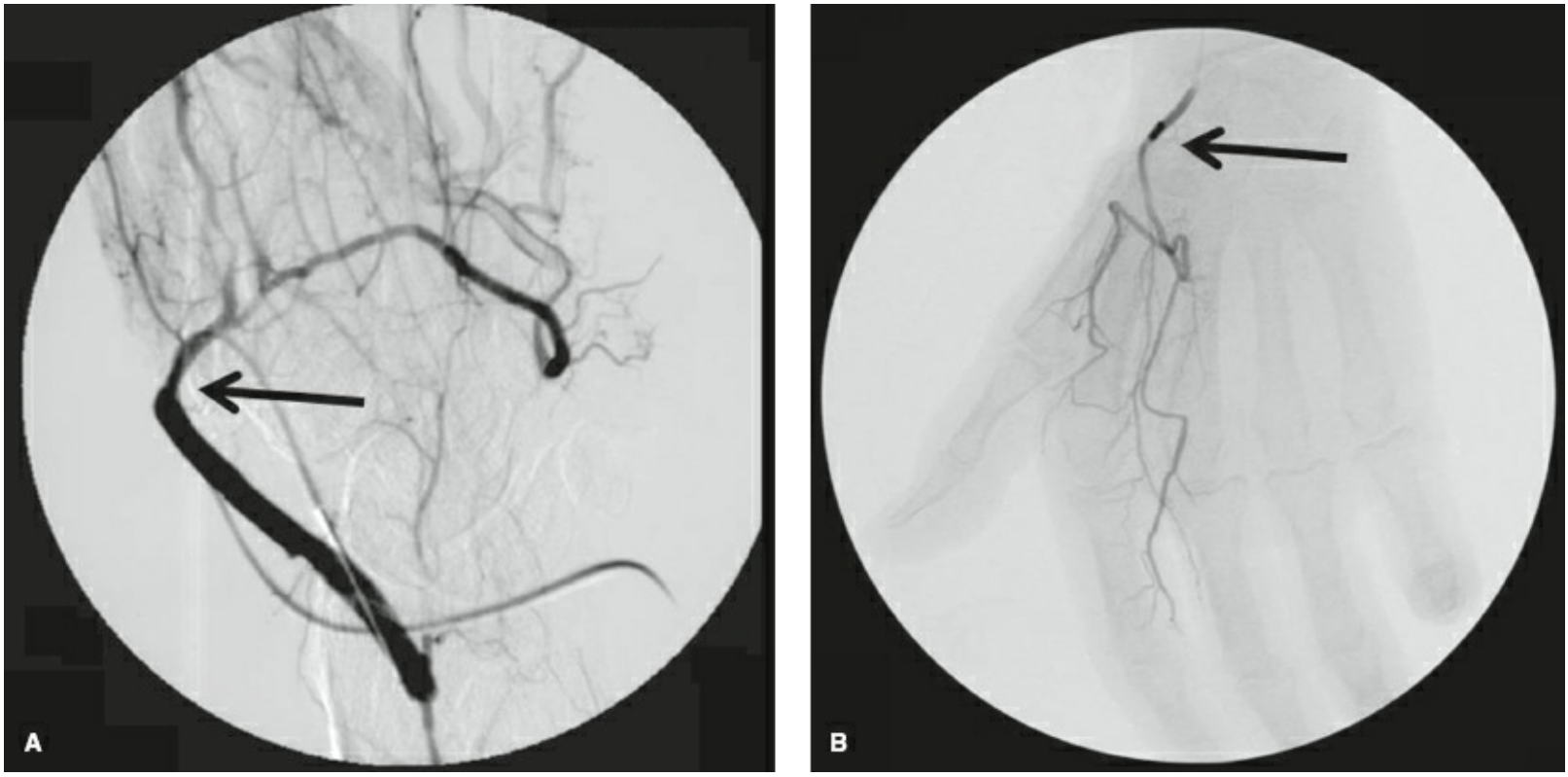

Figure 90-15. Completion angiograms of two different saphenous vein bypasses with distal anastomosis to the palmar arch (**A**) and radial artery at the snuffbox segment (**B**).

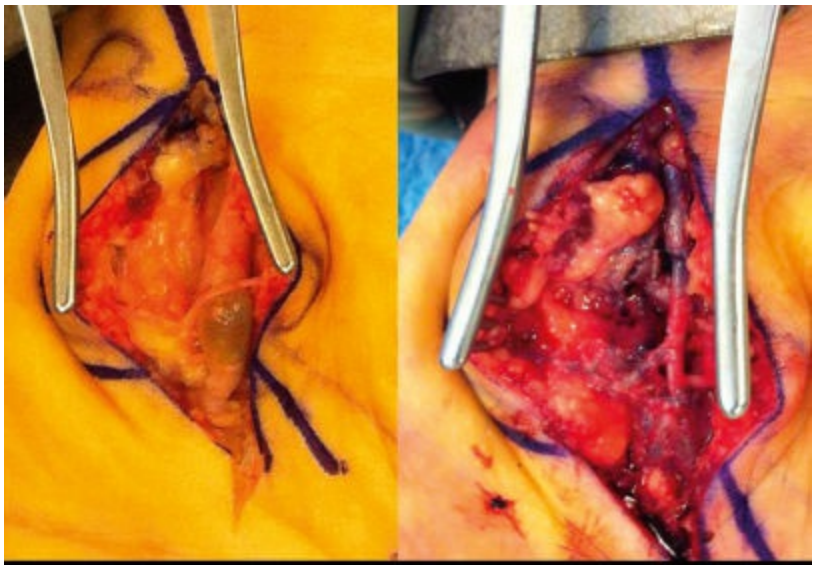

Figure 90-16. Ulnar artery aneurysm treated with arterial conduit (profunda femoris branch harvested from the thigh) in a patient with hypothenar hammer syndrome.

Patients suffering from hypothenar hammer syndrome with mild symptoms and without an aneurysm can be treated nonoperatively. Padded hand protection, avoidance of further repetitive trauma, tobacco cessation (if applicable), and the use of calcium channel blockers, antiplatelet agents, and/or anticoagulation all have been tried with some degree of success. Surgical intervention can include simple ligation of the aneurysm if there is adequate collateral circulation; typically resection of the affected segment with reconstruction is required (Fig. 90-16).

The management of Raynaud syndrome consists on the use of calcium channel blockers

and vasodilators.[13]

CONCLUSIONS

Although atherosclerosis is still the most common cause of upper extremity arterial disease, a myriad of conditions associated with occupational and social risk factors are often the cause of arm and hand ischemia. A complete history and physical examination often discloses a potential etiology and usually points to the anatomic location of the culprit lesion. Bilateral hand ischemia is often associated with systemic conditions, whereas unilaterality more commonly occurs with obstructive lesions. Accurate delineation of the anatomy by the use of imaging modalities is necessary in order to plan revascularization. Multiple endovascular and open surgical options are available for the management of upper extremity arterial disorders.

References

1. Lally EV. Raynaud's phenomenon. *Curr Opin Rheumatol* 1992;4(6):825–836.
2. Bowling JC, Dowd PM. Raynaud's disease. *Lancet* 2003;361(9374):2078–2080.
3. Kreienberg Paul B, Chang BB, Roddy SP, et al. Hand ischemia in end stage renal disease. In: Rodriguez HE, Pearce WH, Yao JST, eds. *"The Ischemic Extremity." Shelton Connecticut.* United States: People's Medical Publishing House USA; 2010:525–531.
4. Wu W, Chaer RA. Nonarteriosclerotic vascular disease. *Surg Clin North Am* 2013;93(4):833–875.
5. Ayarragaray JE. Ergotism: a change of persepective. *Ann Vasc Surg* 2014; 28(1):265–268.
6. Kee ST, Dake MD, Wolfe-Johnson B, et al. Ischemia of the throwing hand in major league baseball pitchers: embolic occlusion from aneurysms of axillary artery branches. *J Vasc Interv Radiol* 1995;6(6):979–982.
7. Kumar HR, Rodriguez HE. Thenar and hypothenar hammer syndrome. In: Gilbert R, Upchurch GR Jr, Henke PK, eds. *Clinical Scenarios in Vascular Surgery.* 2nd ed. Philadelphia, PA: Wolters Kluwer Health; 2015.
8. Sumner DS. Non-invasive assessment of upper extremity ischemia. In: Bergan JJ, Yao JST, eds. *Evaluation and Treatment of Upper and Lower Extremity Circulatory Disorders.* Orlando, FL: Grune & Stratton; 1984:75–95.
9. Karwowski JK, Johnson B, Dalman RL. Upper extremity ischemia: diagnostic techniques and clinical applications. In: Mansour MA, Labropoulos N. eds. *Vascular Diagnosis.* Philadelphia, PA: Elsevier Saunders; 2005:325–330.
10. Usman AA, Resnick SA, Benzuly KH, et al. Late stent fractures after endoluminal treatment of ostial supraaortic trunk arterial occlusive lesions. *J Vasc Interv Radiol* 2010;21(9):1364–1369.
11. Morasch MD. Technique for subclavian to carotid transposition, tips, and tricks. *J Vasc Surg* 2009;49(1):251–254.
12. Keser G, Direskeneli H, Aksu K. Management of Takayasu arteritis: a systematic review. *Rheumatology (Oxford)* 2014;53(5):793–801.
13. Miller D, Rodriguez HE. Management of vascular thoracic outlet syndrome. In: Eskandari MK, Morasch MD, Pearce WH, et al., eds, *Contemporary Vascular Surgery.* United States: People's Medical Publishing House-USA; 2011:469–476.
14. Caglayan E, Axmann S, Hellmich M, et al. Vardenafil for the treatment of Raynaud phenomenon: a randomized, double-blind, placebo-controlled crossover study. *Arch Intern Med* 2012;172(15):1182–1184.

Chapter 91

Renal and Splanchnic Vascular Disease

Dawn M. Coleman, John E. Rectenwald, and Gilbert R. Upchurch, Jr.

Key Points

1 Splanchnic vascular disease is uncommon across the spectrum of vascular surgery practice, but remains central to the specialty.

2 Intestinal ischemia may result from presplanchnic conditions that decrease total mesenteric blood flow (i.e., heart failure and hypovolemia), splanchnic conditions that decrease regional blood flow through the mesenteric circulation (i.e., thromboembolism) or postsplanchnic venous congestion (i.e., mesenteric vein thrombosis and cirrhosis).

3 The most common causes of AMI include: embolization (40% to 50%), arterial thrombosis (25% to 30%), nonocclusive mesenteric ischemia (15% to 20%), and mesenteric venous thrombosis (5% to 15%).

4 Patients with AMI warrant immediate medical management that includes the establishment of adequate intravenous access and hemodynamic monitoring, systemic anticoagulation with heparin, fluid resuscitation, correction of electrolyte abnormalities, and administration of broad-spectrum antibiotics.

5 The progression from minor symptoms to AMI and intestinal infarction is unpredictable; almost half of patients presenting with AMI describe previous symptoms of CMI.

6 Distribution of splanchnic artery aneurysms is as follows: Splenic artery (60%) > hepatic arteries (20%) > superior mesenteric artery (5.5%) > celiac artery (4%) and gastric and gastroepiploic arteries (4%) > ileocolic arteries (3%) > pancreaticoduodenal arteries (2%) > gastroduodenal artery (1.5%) > inferior mesenteric artery (<1%).

7 Renal artery occlusive disease is the most common cause of correctable HTN in adults and the third most common cause of HTN in children and should be considered in the clinical context of: (1) childhood HTN, (2) severe HTN in women <45 years of age, (3) acute and rapid escalation of mild HTN in older patients (>50 years), (4) initial diastolic BP >115 mm Hg, and (5) rapid deterioration in renal function following the administration of antihypertensive therapy (especially with ACE inhibition).

8 Medical therapy remains the mainstay of treatment for RVH with comprehensive goals of care that should encompass glycemic control, cholesterol reduction, smoking cessation, blood pressure reduction, and antiplatelet therapy with aspirin for primary

prevention. ACC/AHA guidelines support the use of ACE inhibitors (ACE-I), angiotensin receptor blockers (ARBs), calcium channel blockers, and beta blockers with a class I indication.

9 Several recent clinical trials comparing renal artery stenting to best medical management for renal artery stenosis have failed to demonstrate a conclusive clinical benefit to the endovascular treatment of renal artery stenosis.

SPLANCHNIC VASCULAR OCCLUSIVE AND ANEURYSMAL DISEASE

INTRODUCTION

1 Splanchnic vascular disease is uncommon across the spectrum of vascular surgery practice, but remains central to the specialty. Patients often seek medical attention from alternative specialists, emphasizing the importance of cross-disciplinary awareness. Acute mesenteric ischemia (AMI) remains associated with delayed diagnosis and dismal mortality despite notable progress in the diagnosis and treatment of patients with vascular disease. This section elaborates on the current treatment standards for both splanchnic vascular occlusive disease and aneurysms.

ANATOMY AND PHYSIOLOGY

Three branches of the abdominal aorta perfuse the gastrointestinal tract. The celiac artery originates at the level of T12 and branches into the left gastric, common hepatic, and splenic arteries in a classic pattern in 65% to 75% of cases.[1] Variations are noted in Table 91-1 and may include a true trifurcation of these vessels (25% of the population), replaced and accessory hepatic vasculature, a common celiacomesenteric trunk (<1% of the population), and a persistent ventral anastomosis between the proper hepatic, and a replaced right hepatic artery (off the SMA) denoted as an "arch of Buhler" (<4% of the population). Additionally, the splenic artery can be found to originate directly off the aorta, SMA, left gastric or hepatic arteries. The celiac axis supplies primarily the stomach, duodenum, spleen, liver, and pancreas. The SMA originates approximately 1 to 2 cm caudad to the celiac artery and branches into the inferior pancreaticoduodenal artery, 4 to 6 jejunal and 9 to 13 ileal branches, the middle colic artery, the right colic artery, and terminates as the iliocolic artery. The SMA supplies primarily the lower portion of the pancreas gland, jejunum, ileum, ascending colon, and the proximal half of the transverse colon. The inferior mesenteric artery (IMA) originates off the terminal aorta at the level of L3 and divides into the left colic artery, sigmoid branches and continues as the superior hemorrhoidal artery.[1] This small and most distal mesenteric branch artery supplies primarily the large bowel from the level of the midtransverse colon to the rectum.

Collateralization is a crucial concept when considering the mesenteric circulation. On the grounds of redundancy, given multiple potential sources of collateral flow, at least two of the three major branch vessels must be occluded or have a critical stenosis for mesenteric ischemia to manifest. While arterial collaterals may be small in the physiologic circulation, they have the potential to hypertrophy dramatically when increased flow is required. Figure 91-1 demonstrates several important collateral pathways. The gastroduodenal artery (GDA) and pancreaticoduodenal arcade make up the primary potential pathway for collateral flow between the celiac axis and the SMA. In addition to the aforementioned arc of Buhler, the arc of Barkow consists of arteries in the omentum (SMA branches) that connect to the right and left gastroepiploic arteries (celiac branches). The marginal artery of Drummond is the major collateral route between the SMA and IMA; it lies within the colon mesentery giving rise to the vasa recta. The arc of Riolan lies within a more central portion of the mesentery connecting the middle and left colic arteries. Finally, the IMA may also receive collateral flow from lumbar branches of the aorta, hemorrhoidal branches of the internal iliac artery, and the middle sacral artery.

Table 91-1 Normal and Variant Mesenteric Arterial Anatomy

Vessel	Incidence (%)
Celiac	
–Classic (3 branches)	65–75
–Four branches (including dorsal pancreatic artery)	5–10
–Celiacomesenteric trunk	<1
Hepatic	
–CHA from celiac artery	75
–CHA from SMA	2.5
–Replaced RHA	15–18
■ From left gastric	11–12
■ From SMA	2.5
–Accessory RHA	7–8
–Accessory LHA	2.5
Gastric	
–Left gastric artery	
■ From celiac artery	90
■ From aorta	3
■ Accessory branches from or to left hepatic artery	23
–Right gastric artery	
■ From proper hepatic artery	40
■ From left or middle hepatic artery	40
■ From RHA	10
■ From GDA	8

CHA, common hepatic artery; SMA, superior mesenteric artery; RHA, right hepatic artery; LHA, left hepatic artery; GDA, gastroduodenal artery. Adapted from: Rosenblum JD, Boyle CM, Schwartz LB. The mesenteric circulation: anatomy and physiology. *Surg Clin North Am* 1997;77:289–306.

Splanchnic venous anatomy parallels the arterial system to drain into the portal venous system. The splenic and superior mesenteric veins join to form the portal vein. Hepatic venous blood is drained by the right, middle and left hepatic veins. Portal–systemic connections are multiple and important when considering portal hypertension.

Physiologic intestinal function relies on adequate perfusion and oxygenation of the microvascular splanchnic circulation. Splanchnic blood flow is estimated as 300 to 1,200 mL/min, or about 10% to 35% of the cardiac output, with approximately 70% of this blood flow supplying the mucosa and submucosa.[1,2] Various intrinsic and extrinsic autoregulatory mechanisms including tissue metabolites, myogenic mechanisms, and the autonomic nervous system ensure adequate gut circulation through both vasoconstriction and relaxation of arterial smooth muscle. The degree of visceral artery dilation and constriction determines the relatively large fluctuations in splanchnic blood flow during fasting and postprandial states.

Duplex ultrasound demonstrates moderate to high arterial resistance in the SMA, with low diastolic flow and slight flow reversal during fasting states. Figure 91-2 demonstrates duplex ultrasonography of normal aorta and SMA. Vessel diameter, flow velocity, calculated volumetric blood flow, spectral analysis, and response to physiologic stimuli allow for precise assessment of the visceral circulation. In the postprandial period (30 to 90 minutes), low-resistance signals are noted throughout systole and diastole, indicative of dilated splanchnic arteriolar beds. Flow reversal does not occur. In contrast, low

arterial resistance signals are noted in the celiac artery circulation regardless of feeding, likely due to the influence of the low resistance hepatic vascular bed.

2 Intestinal ischemia may result from presplanchnic conditions that decrease total mesenteric blood flow (i.e., heart failure and hypovolemia), splanchnic conditions that decrease regional blood flow through the mesenteric circulation (i.e., thromboembolism) or postsplanchnic venous congestion (i.e., mesenteric vein thrombosis [MVT] and cirrhosis). Regardless of the mechanism, impaired perfusion of the intestine results in hypoxia-associated sequelae that include cytokine release, free radial production, microcirculatory damage, and bacterial translocation. Mucosal barrier function is compromised secondary to physical disruption of the mucosa, a change in normal intestinal microflora resulting from treatment with broad spectrum antibiotics, and impairment of host immune defenses.[3] Intestinal ischemia may rapidly progress to tissue necrosis causing severe metabolic derangements and ultimately multiple organ dysfunction and death. In addition to ischemia-related bowel injury, splanchnic reperfusion exaggerates injury patterns. Reperfusion injury is associated with increased microvascular permeability, increased epithelial permeability with leaking of fluid and molecules into the bowel lumen, and decreased intestinal blood flow.

ACUTE MESENTERIC ISCHEMIA

"Occlusion of the mesenteric vessels is apt to be regarded as one of those conditions of which … the diagnosis is impossible, the prognosis hopeless and the treatment almost useless".[4] AMI remains an uncommon event but carries catastrophic potential as illustrated by AJ Cokkinis' statement above from 1926. Klass is credited with the first successful restoration of arterial blood supply in an attempt to salvage AMI in 1951 by SMA embolectomy.[5,6] While clear medical and technologic progress has been made in the interim, delayed diagnosis and treatment continues to impede improvements in contemporary patient morbidity and mortality rates that approach 80%.[6,7]

AMI accounts for <1 in every 1,000 hospital admissions, presents most commonly during the seventh and eighth decades of life, and epidemiologic study suggests that women are affected with three times the frequency of males, at least in part attributed to relative female longevity.[6] A Swedish epidemiologic study cites an AMI incidence of 12.9/100,000 people years (as diagnosed by autopsy or operation).[8]

3 The most common causes of AMI are referenced above and include: embolization (40% to 50%), arterial thrombosis (25% to 30%), nonocclusive mesenteric ischemia (NOMI) (15% to 20%), and mesenteric venous thrombosis (5% to 15%).[6,8] Additional causes may include visceral malperfusion associated with aortic dissection, mesenteric arterial dissection, and trauma. Historic mortality rates for AMI are as high as 93%, although more contemporary series suggest in-hospital mortality rates of 17% to 62% and a systematic review of 45 observational studies cites a mean mortality rate of 71.6% for 3,692 patients with AMI.[8–13] While there is no validated prediction model for mortality in this clinical setting, authors have shown with logistic regression models that age, duration of symptoms, age-adjusted comorbidity, specific EKG markers, and shock index may be associated with higher mortality.[12,14,15]

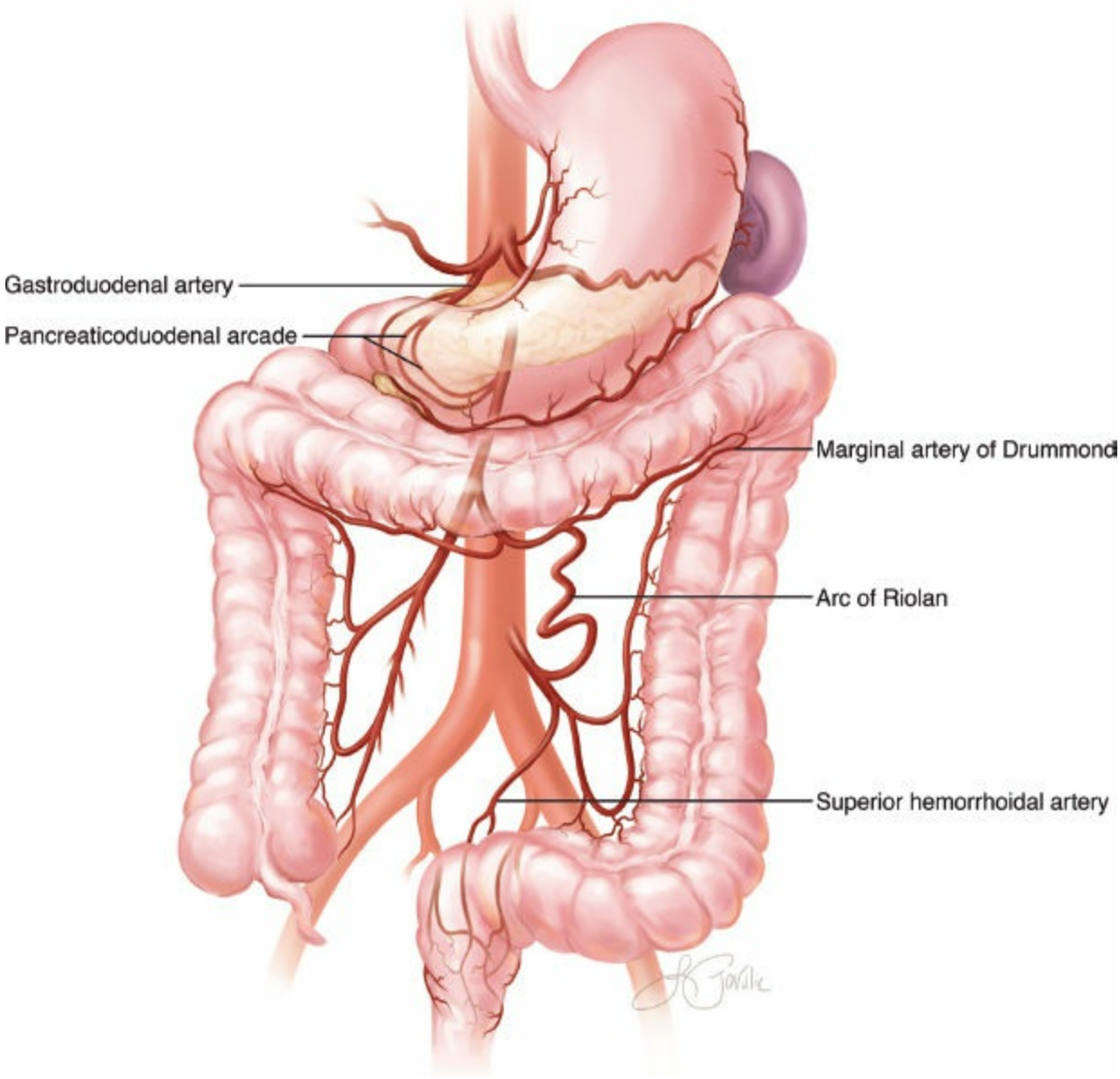

Figure 91-1. Mesenteric collateral circulation.

Patients with AMI complain predominantly of abdominal pain followed by nausea, vomiting, and diarrhea. Pain is often described as "out of proportion" to the clinical examination as tenderness to palpation may be minimal until transmural necrosis of the intestine develops. Patients can be tachycardic and demonstrate melena or heme positive stools. Fever, guarding, and rebound are typically late findings associated with bowel infarction.

Laboratory abnormalities may include hemoconcentration, leukocytosis, lactic acidosis, and elevated anion gap, amylase, aspartate aminotransferase, and lactate dehydrogenase. While a reliable biomarker for AMI remains elusive, D-dimer offers 96% to 100% sensitivity as an exclusionary test for early AMI with low specificity.[16,17] Intestinal fatty acid binding globulin (I-FABP), α-glutathione S-transferase, and D-lactate are currently promising plasma markers.[16,18] I-FABP and α-glutathione S-transferase are located in the small bowel mucosa while D-lactate originates from bacteria in the intestinal lumen as a normal product of bacterial fermentation. These markers leak into the blood stream during early ischemia from damaged enterocytes and may offer increased specificity for

small bowel ischemia.

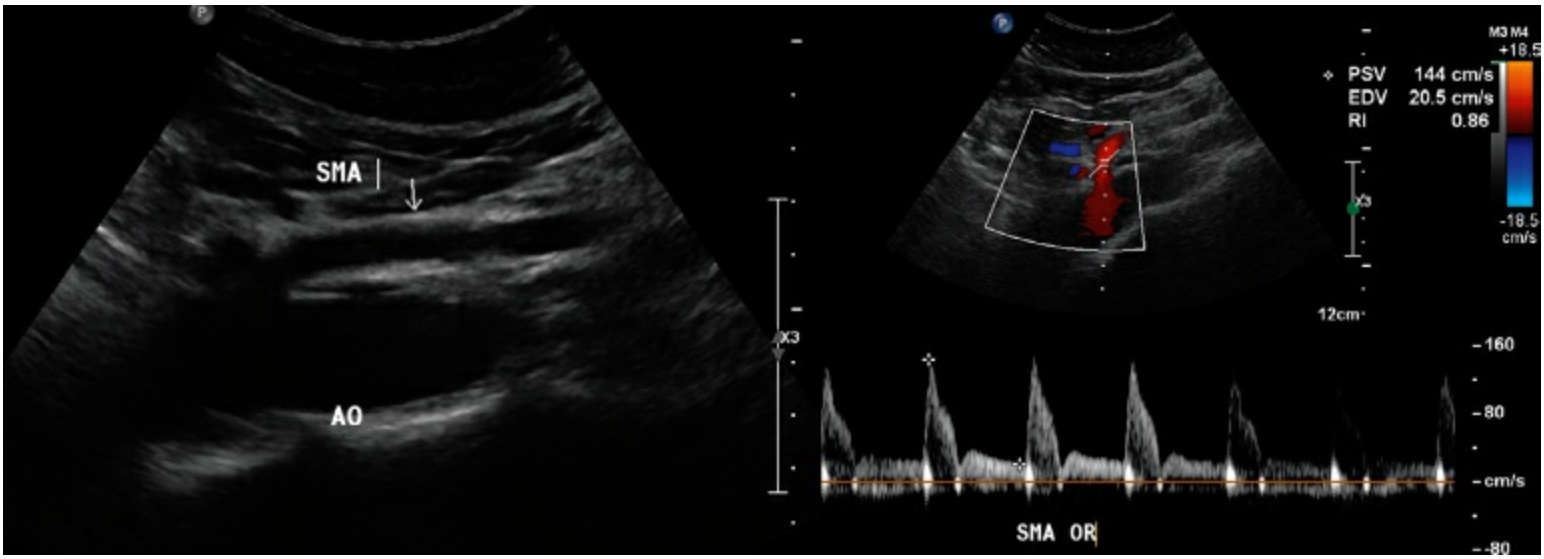

Figure 91-2. Mesenteric duplex ultrasound of a normal aorta and SMA that demonstrates moderate to high arterial resistance in the SMA, with low diastolic flow and slight flow reversal during fasting states. AO, aorta; SMA, superior mesenteric artery; PSV, peak systolic velocity; EDV, end-diastolic velocity; RI, resistive index; OR, origin.

Diagnostic work-up often starts with a plain abdominal radiograph which may reveal ileus and vascular calcifications; bowel wall edema (i.e., thumbprinting), pneumatosis (Fig. 91-3), pneumobilia, and pneumoperitoneum may become evident with advanced ischemia and infarction, respectively. High-quality computed tomography angiography (CTA) has become the gold standard for imaging AMI given near-universal availability and its ability to assess for bowel perfusion while excluding alternate sources of abdominal pain. Additionally, "biphasic" CT offers arterial and delayed phase imaging that permits visualization of the portal venous system in addition to arterial stenosis, occlusions, and bowel wall features that support the diagnosis of AMI with a negative and positive predictive value reported up to 96% and 100%, respectively.[19,20] Duplex ultrasonography, magnetic resonance angiography (MRA), diagnostic peritoneal lavage, and diagnostic laparoscopy may serve as adjuncts for diagnosis but secondary to intrinsic limitations should not be considered first line. Finally, the role for arteriography remains important and will be described further as it allows for simultaneous therapeutic measures.

Mesenteric emboli most commonly affect the SMA given its oblique orientation off the aorta. Most emboli are cardiac in origin; less common embolic sources may include proximal aortic aneurysm, atrial myxoma, and paradoxical embolus secondary to venous thromboembolism with cardiac shunting. Patient history will likely reveal atrial fibrillation, myocardial infarction, congestive heart failure or cardiomyopathy, rheumatic heart disease or ventricular aneurysm. Most emboli will spare the SMA origin and lodge distal to the middle colic artery and early jejunal branches. This pattern of ischemia, in the absence of well-formed collaterals, results in a classic pattern of ischemia that compromises the bulk of small bowel and ascending colon while sparing the proximal jejunum and distal transverse colon (Fig. 91-4).



Figure 91-3. Abdominal radiograph demonstrating diffuse ileus and intestinal pneumatosis (*arrow*) in a patient with acute mesenteric ischemia.

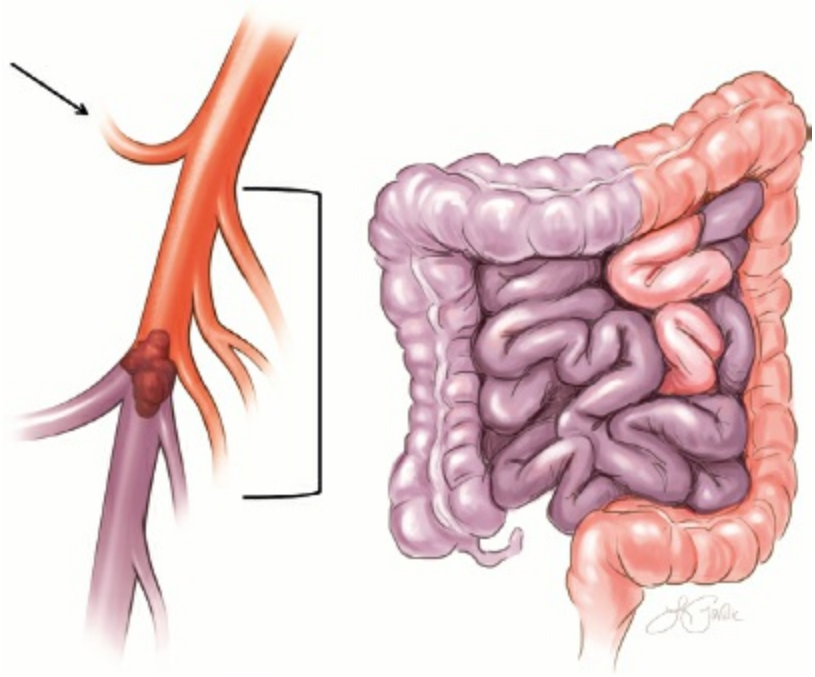

Figure 91-4. Pattern of embolic mesenteric ischemia – SMA emboli typically spare the middle colic artery (*arrow*) and proximal jejunal branches (*bracket*) resulting in an ischemic pattern that spares the jejunum and distal transverse colon.

Acute in situ arterial thrombosis typically coincides with pre-existing atherosclerotic disease. Up to 20% to 50% of patients will describe antecedent postprandial abdominal pain and weight loss consistent with CMI.[2,6,9] Clinical presentation may be more subacute given the presence of preformed collaterals that are typically absent in cases of embolic AMI. Patient history will likely reveal common cardiovascular risk factors. Figure 91-5 demonstrates the highly calcified aorta of a patient presenting with AMI and chronic

celiac artery occlusion, SMA thrombosis (encircled), and IMA occlusion.

MANAGEMENT OF AMI

4 Patients with AMI warrant immediate medical management that includes the establishment of adequate intravenous (IV) access and hemodynamic monitoring, systemic anticoagulation with heparin, fluid resuscitation, correction of electrolyte abnormalities, and administration of broad-spectrum IV antibiotics. Further vasoconstrictive insult with vasopressors should be avoided if possible. Patients with AMI and evidence of threatened bowel viability warrant immediate surgical exploration. Frankly necrotic or perforated bowel should be resected and left in discontinuity to limit contamination while definitive intestinal management should never delay revascularization.

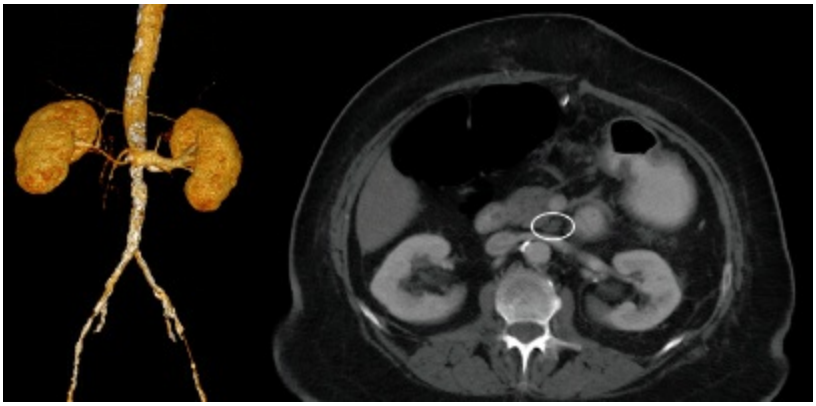

Figure 91-5. CT imaging demonstrating in situ SMA thrombosis in the setting of highly calcified aortoiliac occlusive disease and chronic celiac and IMA occlusions presenting as acute mesenteric ischemia.

SMA thromboembolectomy is the standard technique for embolic disease. Figure 91-6 illustrates anterior exposure of the SMA at the base of the colonic mesentery. Typically venous tributaries, small lymphatics, and autonomic nerve fibers require ligation to facilitate arterial exposure. The inferior pancreatic border may require mobilization for more proximal SMA exposure. The SMA is exposed and controlled proximal to the middle colic artery; the middle colic artery and jejunal branches are similarly controlled. After a therapeutic level of systemic anticoagulation is confirmed a transverse arteriotomy is created sharply (Fig. 91-7). The proximal SMA is vented; in the absence of robust and pulsatile antegrade flow a balloon thromboembolectomy should be performed with a 3-Fr or 4-Fr catheter. Distal vasculature is fragile and thromboembolectomy is best accomplished with a smaller catheter (i.e., 2 Fr or 3 Fr). During balloon thromboembolectomy the balloon should be inflated with heparinized saline (not air) as the catheter is withdrawn. The same person should control the balloon inflation that is controlling catheter removal. Finally, consider flushing regional heparin or thrombolytic agent directly into the distal SMA and branches. Balloon thromboembolectomy should be repeated until the balloon is withdrawn free of thrombus burden. Following the successful clearance of all macroscopic thrombus the arteriotomy can be repaired primarily with simple sutures of 5-0 or 6-0 monofilament suture placed in an interrupted fashion. Vein patch angioplasty should be considered over primary repair for diminutive vessels.

In cases of SMA occlusive disease with in situ thrombosis, bypass is typically required for successful revascularization. In cases of such acuity, typically single-vessel reconstruction (SMA) is all that is required. While there are multiple options for graft orientation and conduit, a retrograde bypass off the right common iliac artery oriented in a "lazy-C" configuration is most often favored (Fig. 91-8). The lateral portion of SMA is exposed cephalad to the fourth portion of the duodenum. This exposure requires opening of the peritoneum adjacent to the duodenum with full exposure of the terminal aorta and iliac arteries. Synthetic graft (i.e., 6- or 8-mm externally supported polytetrafluoroethylene) is typically favored over autogenous conduit given its favorable size match, ready availability, and resistance to kinking. Saphenous vein graft may be considered for cases of gross enteric contamination. The terminal aorta or left common iliac artery may also be used for inflow. Antegrade bypass off the supraceliac aorta may be considered in cases of prohibitive anatomy, but this exposure adds additional technical complexity and operative time combined with the physiologic stress of aortic cross-clamping.

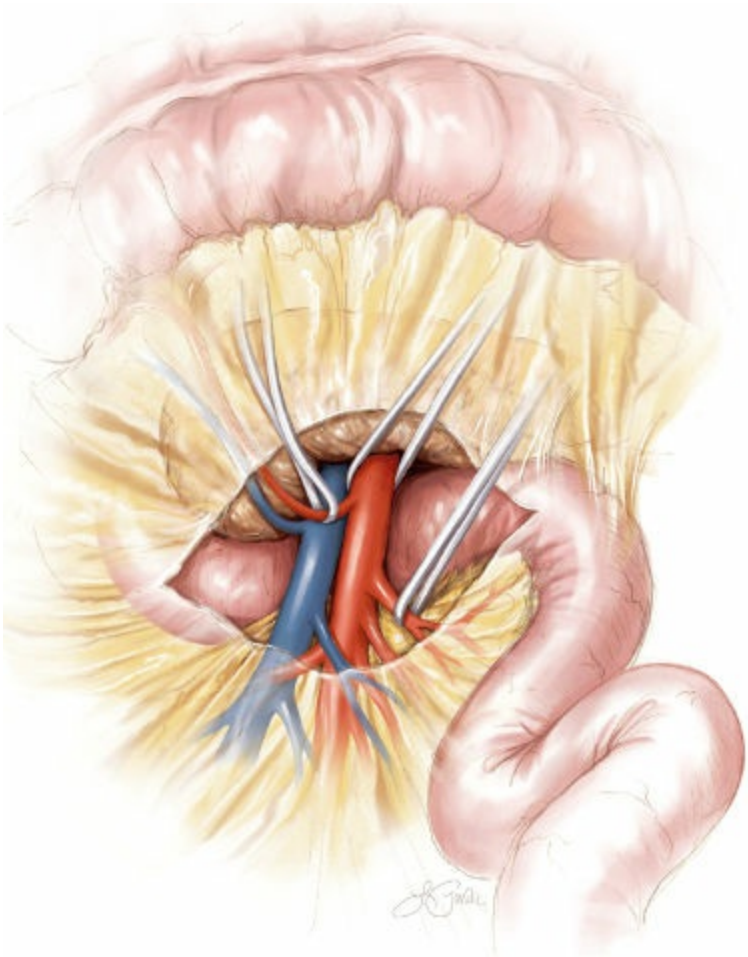

Figure 91-6. SMA exposure at the base of the colonic mesentery (*SMA encircled proximal to the middle colic artery*).

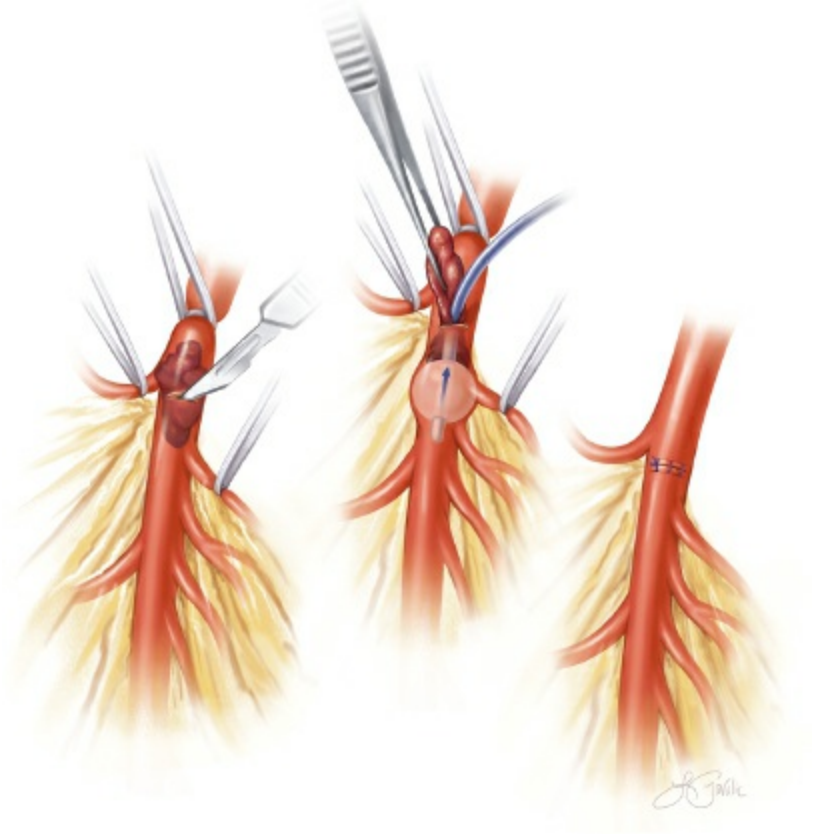

Figure 91-7. Illustration of balloon SMA thromboembolectomy through a transverse arteriotomy.

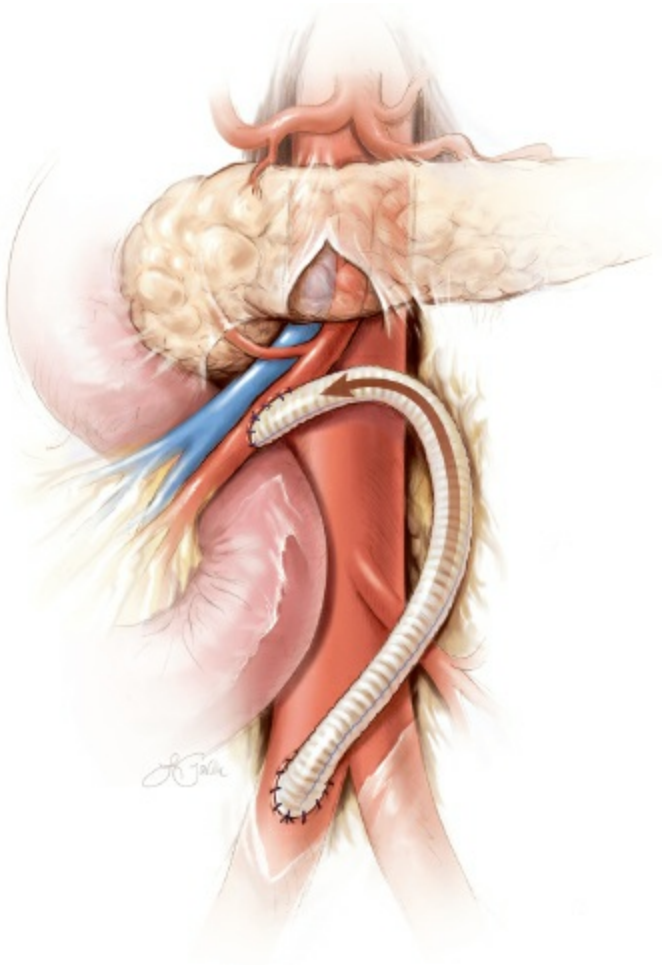

Figure 91-8. Retrograde bypass off the right common iliac artery oriented in a 'lazy-C' configuration.

While surgery has remained the standard of care for AMI over previous decades, a hybrid procedure for SMA thrombosis has become widely embraced for its efficiency and decreased invasiveness for mesenteric revascularization. This approach negates the need for aortic cross-clamping, prosthetic conduit, and difficulty with arterial quality. Retrograde open mesenteric stenting (ROMS) was first described by Milner et al. in 2006 and further popularized by Wyers et al. in a 2007 case series.[21,22] The infracolic SMA is exposed at the base of the transverse colonic mesentery as previously described for retrograde cannulation following local patch angioplasty with vein or bovine pericardium. This hybrid approach allows for simultaneous assessment and treatment of nonviable intestine with mesenteric revascularization by way of SMA stenting. The largest and most contemporary series on ROMS reports a technical success rate of 93% and primary-assisted patency rates of 91% at 12 months.[23]

Regardless of the approach to successful revascularization, intestinal viability must be assessed; this decision is typically deferred for 20 to 30 minutes following reperfusion and aided by Doppler interrogation of the mesenteric arcade, observation of serosal color, and the presence of peristalsis. Adjuncts also include the use of fluorescein with a modified Wood's lamp or perfusion fluorometer.[6] Nonviable bowel is resected and in cases of unclear viability the intestine may be left in discontinuity, the abdomen left open, and plans for a second-look laparotomy at 24 to 48 hours secured for definitive intestinal management.

Exclusive endovascular treatments for AMI are increasingly reported despite historic concerns that this approach increases time to revascularization, prohibits assessment of bowel viability, and that endovascular failure might delay traditional revascularization thereby worsening patient outcomes. Successful cases of percutaneous mechanical thrombectomy, aspiration thrombectomy, and intra-arterial thrombolysis, with or without adjuvant angioplasty and stenting, have been reported in patients without evidence of advanced bowel ischemia.[24–29] The largest single center experience with endovascular therapy for AMI reported a success rate of 87%, with failures most often requiring surgical embolectomy.[30] These authors compared outcomes following open and endovascular therapies for AMI and identified a reduction in need for laparotomy, length of bowel resected, and morbidity including acute renal failure and pulmonary failure in the endovascular group. Additionally, successful endovascular therapy was associated with improved mortality (36% vs. 50%) and those endovascular failures succumbed to similar mortality rates as the open surgical group. Most recently a National Inpatient Sample (NIS) review identified a significant increase in the utilization of endovascular therapy for AMI and reported that mortality, hospital length of stay, need for bowel resection, and need for postoperative parenteral nutrition were reduced in those patients receiving endovascular therapy in comparison to traditional open surgical revascularization.[31]

Nonatherosclerotic Mesenteric Arterial Occlusive Disease

Intestinal ischemia may result from iatrogenic injury (i.e., arterial dissection or thromboembolism during endovascular techniques), aortic dissection resulting in visceral malperfusion, trauma, inflammatory arteritides, and fibromuscular dysplasia (FMD). Indeed, these patients warrant an individualized approach to treatment. In cases of aortic dissection branch revascularization or aortic fenestration is essential. Traumatic injuries often require urgent surgical repair or revascularization. Inflammatory arteritides are typically managed medically (i.e., immunosuppression) with surgical bowel resection reserved for nonviability.

Mesenteric Vein Thrombosis

Splanchnic vein thrombosis is defined by thrombosis of the portal venous system which includes the superior mesenteric, inferior mesenteric, splenic, and portal veins. The sequelae of such may include bowel or splenic infarction and chronic portal hypertension. MVT is a less common form of intestinal ischemia that may present in a more subacute fashion. While AMI symptoms are similar to those aforementioned, patients with MVT may also complain of days to weeks of a prodrome that includes crampy abdominal pain, distension, nausea, and malaise. Whether thrombosis originates in the small or large splanchnic veins, intestinal infarction requires the involvement of venous arcades and vasa recta resulting in occlusion of venous return, venous engorgement of the bowel wall, cyanosis, and mucosal ischemia that can progress to transmural infarction.[32] Idiopathic MVT represents a minority of cases as more than 50% of patients have at least one predisposing risk factor. Risk factors for MVT include heritable and acquired thrombophilia, hypercoagulable states resulting from systemic disorders (including malignancy and heparin-induced thrombocytopenia), and local intra-abdominal processes (i.e., pancreatitis or trauma). A high index of suspicion is necessary for diagnosis given the nonspecific nature of presenting symptoms, signs, and laboratory studies.[32] CT imaging with portal phase venous contrast (CT venogram) is the imaging modality of choice. Findings suggestive of MVT include a sharply defined, enhancing venous wall with central low attenuation.[32,33] MRA, angiography, and laparoscopy are useful adjuncts. Emergent laparotomy should be considered for signs of advanced intestinal ischemia; intraoperatively blood-tinged ascites is likely to be encountered and the bowel will appear dusky, thick, and rubbery. Systemic anticoagulation is the mainstay of treatment as it reduces mortality, decreases recurrent thrombosis rates from approximately 30% to $<5\%$, and decreases mortality associated with recurrent thrombosis.[32,34–37] Additionally, with anticoagulation most patients will demonstrate partial or complete venous recanalization with time. In the absence of a defined risk factor, patients with MVT should undergo a work-up for thrombophilia. A finite duration of anticoagulation is recommended for those with a reversible provoking risk factor with cessation of anticoagulation encouraged after 3 months; remaining cases of idiopathic MVT or persistent risk warrant indefinite anticoagulation.[38] Historically open venous thrombectomy was employed for advanced cases of MVT at the time of laparotomy. More recently various systemic and percutaneous thrombolytic techniques have been applied to cases of large vessel disease; however, no large or well-controlled trials exist to guide recommendations for such over anticoagulation alone.[32,39–42]

Nonocclusive Mesenteric Ischemia

NOMI results from diffuse mesenteric vasospasm. This rare form of intestinal ischemia most often affects critically ill patients with hemodynamic instability. Risk factors include decreased cardiac output (i.e., heart failure or arrhythmia), hemodialysis, shock, vasoactive medications (i.e., vasopressors or digitalis), and drug abuse (i.e., cocaine). Angiography is required for diagnosis and will demonstrate diffuse vasoconstriction and nonopacification of branch vessels (Fig. 91-9). Treatment centers on improving mesenteric perfusion by optimizing volume status, limiting vasoactive medications and correcting contributing comorbidities. Intra-arterial infusion of vasodilators (i.e., papaverine or nitroglycerin) or IV infusion of glucagon or prostaglandin E2, which selectively increases splanchnic blood flow, have been advocated in treating this form of intestinal ischemia without robust large or well-controlled trials to support treatment guidelines.[43–45]



Figure 91-9. Nonocclusive mesenteric ischemia – mesenteric arteriogram revealing diffuse vasoconstriction and nonopacification of SMA branch vessels.

CHRONIC MESENTERIC ISCHEMIA

Symptoms of CMI are often referred to as “intestinal angina.” Ostial stenosis secondary to arteriosclerosis is the most common etiology and patients typically share risk factors of overt atherosclerosis and long-standing tobacco abuse. Additional causes of CMI may include arterial FMD, vasculitis, aortic coarctation, and connective tissue disorders. In light of aforementioned mesenteric collaterals, the responsible anatomic lesions of CMI typically affect at least two of three splanchnic arteries, although isolated lesions of the SMA distal to the middle colic branch may yield intestinal angina by excluding collateralization.[2] Patients classically present with postprandial abdominal pain that occurs within 30 minutes of eating and may last up to 4 hours postprandial. Consistent postprandial symptoms typically result in the modification of eating habits that may range from the consumption of smaller meals to “food phobia” that subsequently results in weight loss and malnutrition.

5 The progression from minor symptoms to AMI and intestinal infarction is unpredictable; almost half of patients presenting with AMI describe previous symptoms of CMI.[46] The incidence of CMI also remains unclear. Population studies suggest that up to 18% of individuals over 65 years of age have asymptomatic radiographic mesenteric stenosis.[47] Duplex ultrasonography should be considered the first-line diagnostic modality for CMI. Specifically, high-grade stenosis of the SMA and celiac artery in a fasting state are suggested by a peak systolic velocity of >275 cm/s and 200 cm/s, respectively.[48] CTA and MRA support the diagnosis of CMI while offering additional vascular anatomic evaluation such as the presence of aortic aneurysm, calcific burden, and venous anomalies that may impact open reconstruction. Aortography with anteroposterior and lateral views has been commonly cited as the gold standard for diagnosis and allows for simultaneous mesenteric arteriography, manometry, provocative measures (i.e., vasodilator infusion), and intervention (i.e., angioplasty and stenting) as appropriate. This modality is often favored over cross-sectional imaging when an endovascular approach for treatment is being considered over open revascularization. Often patients will present having undergone extensive gastrointestinal work-up (i.e., contrast motility studies, endoscopy, and laparotomy) before the diagnosis of CMI is considered.

MANAGEMENT OF CMI

Treatment goals in the management of CMI include symptomatic relief, restoration of normal weight, and the prevention of bowel infarction. Mesenteric revascularization provides immediate symptom relief in most patients. Classically, open surgical revascularization options consider patient cardiopulmonary reserve to tolerate aortic cross-clamping and aortic and arterial calcific burden to dictate vascular sites for clamping and sewing. Elective revascularization in the lower-risk patient favors two-vessel (i.e., celiac and SMA) antegrade reconstruction when anatomically feasible. Contingent on vessel calcification, the supraceliac aorta through a transperitoneal approach serves as a preferential target for inflow. After entering the lesser sac, division of the left triangular ligament allows for retraction of the left hepatic lobe. With the esophagus retracted toward the patient's left (confirmed by palpation of the existing nasogastric tube), transection of the diaphragmatic crura exposes the supraceliac aorta. The celiac trunk, common hepatic artery, and splenic artery are exposed at this time. Subsequently with retraction of the transverse mesocolon cephalad, the SMA is exposed as described above at the root of the mesentery. A retropancreatic tunnel is created that courses anterior to the renal vein. The patient is systemically anticoagulated with heparin and the proximal anastomosis can be constructed with partial aortic occlusion. Most often a knitted polyester synthetic graft is utilized for conduit. There are multiple acceptable variations that include the use of two separate aortomesenteric bypass grafts (Fig. 91-10) or the use of a bifurcated graft. It is conventional to utilize a prefabricated bifurcated graft (e.g., 14 × 7 mm) for reconstruction. In this case a short main body is beveled to create the proximal end-to-side aortic anastomosis; the left limb is tunneled through the retropancreatic tunnel and an end-to-side distal anastomosis created next to the SMA; the right limb is subsequently cut to size and beveled to create an end-to-end anastomosis to the celiac artery directly or an end-to-side anastomosis with the common hepatic artery. These authors favor the approach presented in Figure 91-11. A limb of a bifurcated knitted polyester graft is transected off the main body in such a way that there is a phalange created. This limb is specifically utilized for creation of the aorto-SMA bypass, with the phalange incorporated into the proximal aortic anastomosis as shown. The remaining limb is cut to size and beveled accordingly; the proximal anastomosis is constructed end-to-side off the aorto-SMA bypass graft and the distal anastomosis constructed end-to-side to the common hepatic artery. This facilitates a very short celiac limb with a natural lie that may reduce the risk of limb kinking or torsion. Finally, the descending thoracic aorta may serve as an alternative source for inflow when supraceliac aortic anatomy is prohibitive or has previously been utilized for revascularization (Fig. 91-12). For those patients with comorbidity or anatomy (i.e., calcification) that precludes aortic clamping, a retrograde ilio-SMA bypass is favored as described above (Fig. 91-9).

Transaortic endarterectomy is less often utilized in contemporary practice, but may be applicable for those patients with bowel perforation or contamination, hostile abdominal conditions (extensive adhesive disease or abdominal wall hernia), and bulky coral reef aortomesenteric plaque with lower extremity ischemia. A retroperitoneal approach to the

perivisceral aorta through a thoracoabdominal incision permits a longitudinal or trapdoor aortotomy, endarterectomy and repair with primary closure or patch aortoplasty as illustrated in Figure 91-13.

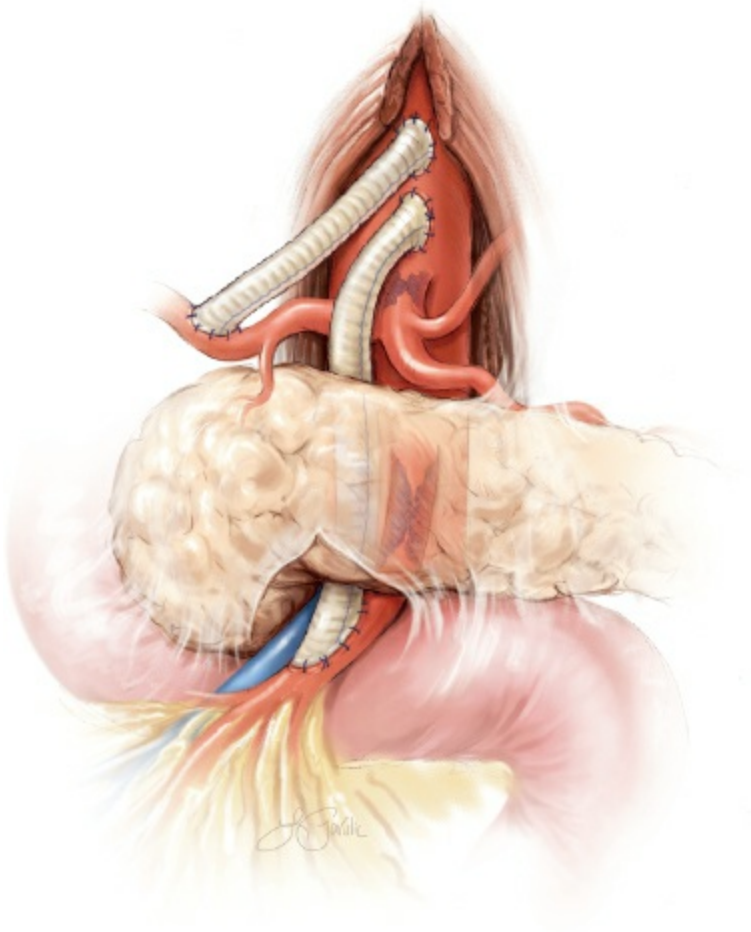

Figure 91-10. Two-vessel antegrade aortomesenteric bypass.

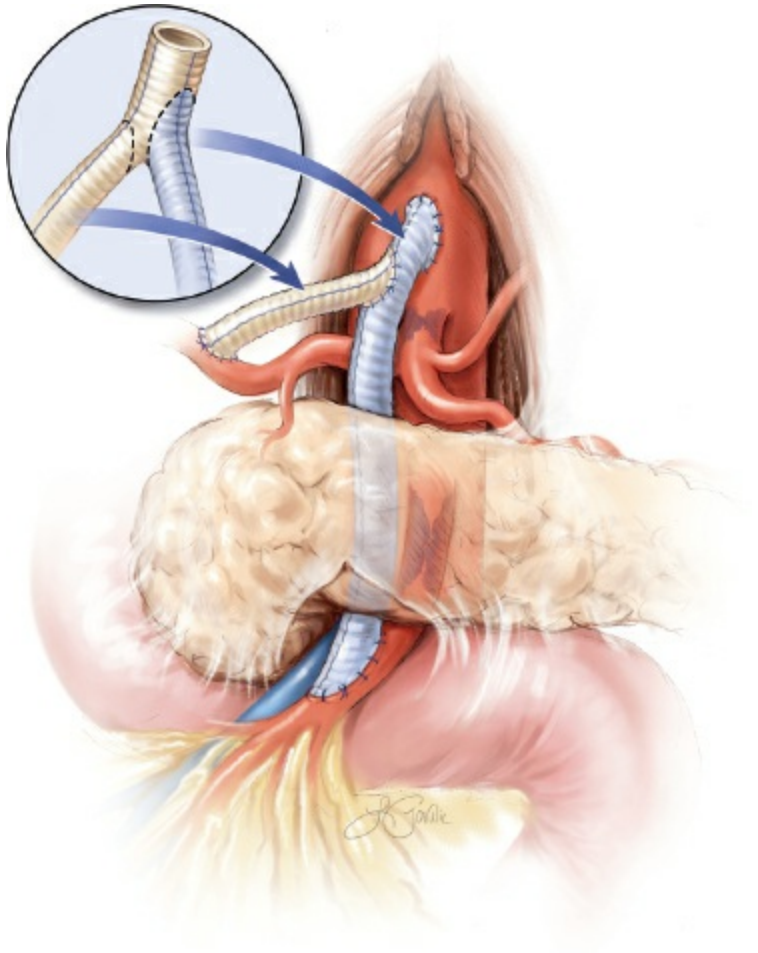

Figure 91-11. Two-vessel antegrade aortomesenteric bypass based off the supraceliac aorta using a presewn bifurcated graft.

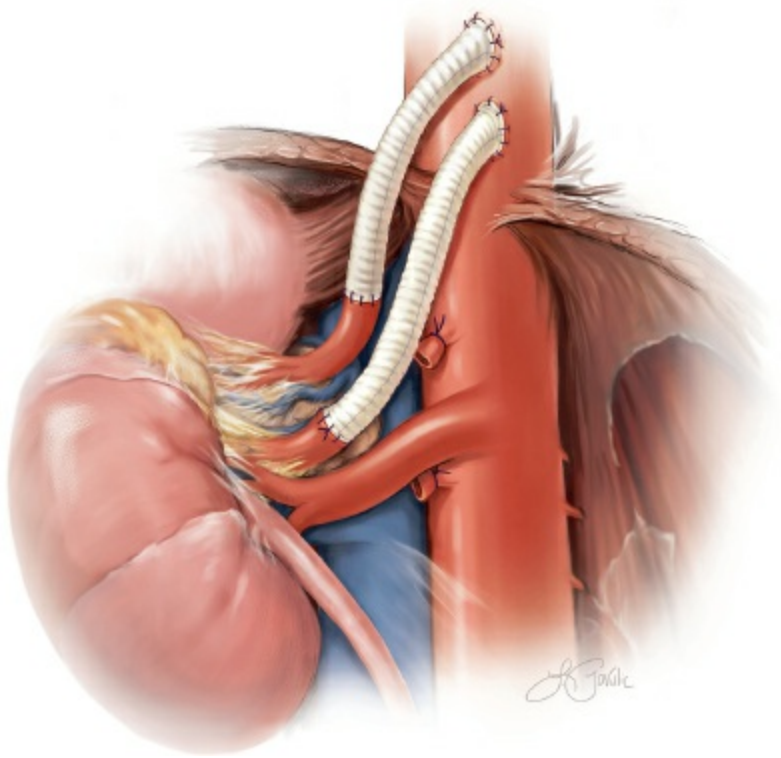

Figure 91-12. Two-vessel antegrade aortomesenteric bypass based off the supraceliac aorta using two separate grafts.

While historically criticized for high mortality rates (up to 15%), contemporary

outcomes following open mesenteric bypass at high-volume centers support mortality rates <4%, likely secondary to technical refinements, improved patient selection and advances in medical, anesthetic, and critical care management.[49–56] Open mesenteric revascularization boasts excellent symptom improvement (77% to 100%) with low recurrence rates at 3 to 5 years (0% to 32%) and perioperative morbidity rates approximating 35% to 40%.[56,57]

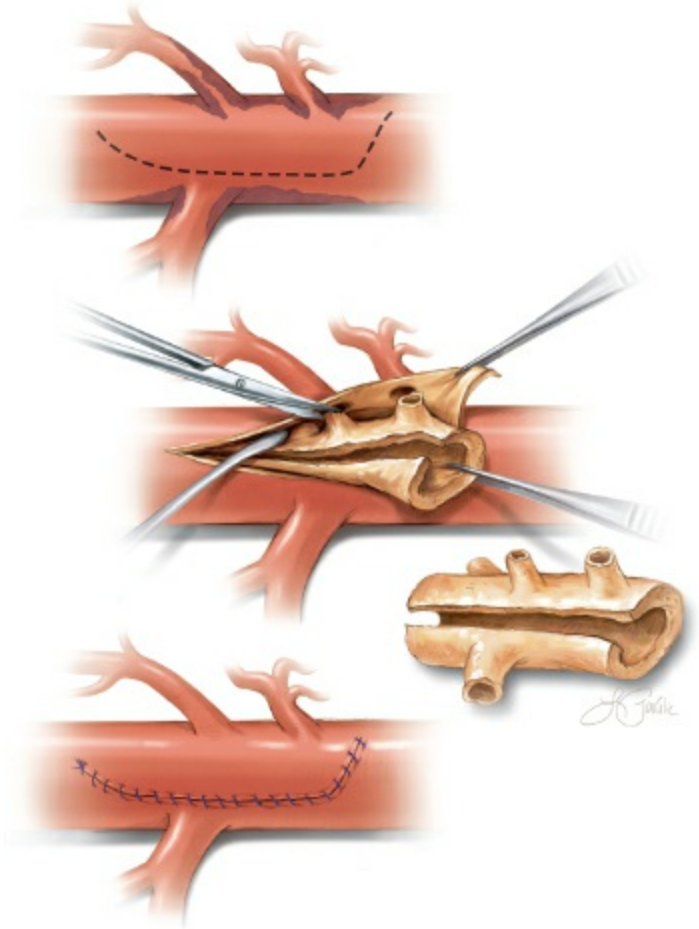

Figure 91-13. Endarterectomy of the aorta, celiac and superior mesenteric arteries through a longitudinal trapdoor aortotomy with primary closure.

Endovascular mesenteric revascularization has increasingly become utilized for chronic mesenteric ischemia. Stenting of the mesenteric vessels is recommended over angioplasty alone for favorable anatomy that includes short segment SMA stenosis (<2 cm) with minimal to moderate calcification or thrombus, although some authors support a role for stenting in the treatment of higher-risk and occluded vessels.[58,59] Endovascular revascularization offers success rates approaching 100% with immediate symptom relief. While perioperative morbidity is notably lower in comparison to open surgical revascularization, endovascular interventions are more likely to result in restenosis, recurrent symptoms, and require reintervention.[53,60–62] Primary and secondary patency rates approximate 40% and 88%, respectively at 5 years (in comparison to 88% and 97% following open revascularization) emphasizing the importance of patient counseling preoperatively and close surveillance postprocedure.[56] Two-vessel (celiac and SMA) stenting does not appear to reduce the risk of recurrent symptoms or reintervention when

compared to single-vessel (SMA) stenting and moreover, isolated celiac artery stenting carries a higher risk of recurrence.[63] Covered stents appear to be associated with less restenosis, recurrence, and reintervention in comparison to bare metal stents.[64]

A large review of mesenteric revascularization from the Nationwide Inpatient Sample between 1988 and 2006 demonstrated increased overall revascularization procedures for CMI.[65] Additionally, these authors noted that mesenteric angioplasty and stenting not only surpassed open revascularization procedures for CMI in 2002, endovascular interventions more than doubled open procedures by 2005. While endovascular interventions may be associated with decreased mortality, shorter hospital length of stay, and decreased perioperative morbidity, the data are clouded by both the expansion of treatment indications and the fact that a greater risk of restenosis and recurrent symptoms may increase overall interventions. Moreover, these reinterventions for recurrence likely carry a variable risk for in-hospital morbidity and mortality. Regardless, mesenteric stenting has become the first-line therapy for most patients with atherosclerotic CMI and maintains an important role as a temporizing measure to facilitate weight gain in the high-risk malnourished patients (as a bridge to open revascularization) and for those patients with medical comorbidities that would further complicate or prohibit open surgical revascularization.

Median Arcuate Ligament Syndrome

Median arcuate ligament syndrome (MALS) remains a controversial diagnosis, first described in the 1960s.[66] Chronic abdominal pain is associated with radiographic evidence of celiac artery compression by the overlying fibrous arch of the MAL and adjacent celiac ganglion. The pathophysiology remains poorly understood and evidence suggests both ischemic and neurogenic etiologies for pain.[67] Gastric tonometry has documented evidence of mucosal ischemia in patients prior to treatment.[68] The 7% to 21% incidence of celiac artery compression in asymptomatic patients combined with the typical robust mesenteric collaterals and widely patent superior and inferior mesenteric arteries present in these younger individuals favor a neurogenic etiology.[69,70] Specifically, compression of the celiac plexus somatic nerves by the MAL may produce abdominal pain that is improved with a celiac ganglionectomy that accompanies ligament release or percutaneous celiac plexus block.

Patients with MALS are typically females in their third decade of life. Symptoms most commonly include postprandial pain, weight loss, and less commonly nausea and diarrhea. Diagnosis is supported by duplex ultrasonography that demonstrates elevated peak systolic velocities through the celiac artery on expiration that normalize or improve with inspiration and reverse flow through the hepatic artery.[71] Cross-sectional imaging like CTA and MRA can support the diagnosis as well, and may reveal poststenotic dilation of the celiac artery. Angiography demonstrating dynamic compression or occlusion during peak expiration remains the gold standard for the diagnosis of MALS (Fig. 91-14). Additionally, as MALS remains a diagnosis of exclusion, some authors favor gastric exercise tonometry test and celiac ganglion block to support patient selection.[72]

Release of the MAL should include complete dissection and skeletonization of both the MAL and surrounding nerve ganglion. This can be accomplished through an open approach whereby the aortic hiatus and celiac artery are exposed through the lesser sac. Additionally, laparoscopic and more recently robotic techniques have been described. The most contemporary literature review and large series suggest immediate postoperative symptoms relief in approximately 80% to 90% of patients.[67,68,73–78] Adjunctive procedures for celiac artery revascularization are utilized in a minority of cases and may include celiac angioplasty, celiac artery patch angioplasty, and celiac artery bypass (i.e., aortoceliac bypass). Late symptom recurrence approximates 6% and only Reilly and colleagues have demonstrated a reduction in recurrence following MAL release with celiac artery revascularization in comparison to MAL release alone (24% vs. 44%).[67,79] Multiple authors have highlighted the importance of patient selection for treatment suggesting that specific patient criteria may correlate with successful outcomes including: consistent postprandial abdominal pain, young age, female gender, weight loss >20 lb and anatomic features of poststenotic dilation or increased collateral flow.[79–81] A reasonable approach may reserve adjunctive revascularization for those patients with objective angiographic pressure or ultrasound velocity gradients following open surgical MAL decompression or those with persistent symptoms following laparoscopic or robotic release.

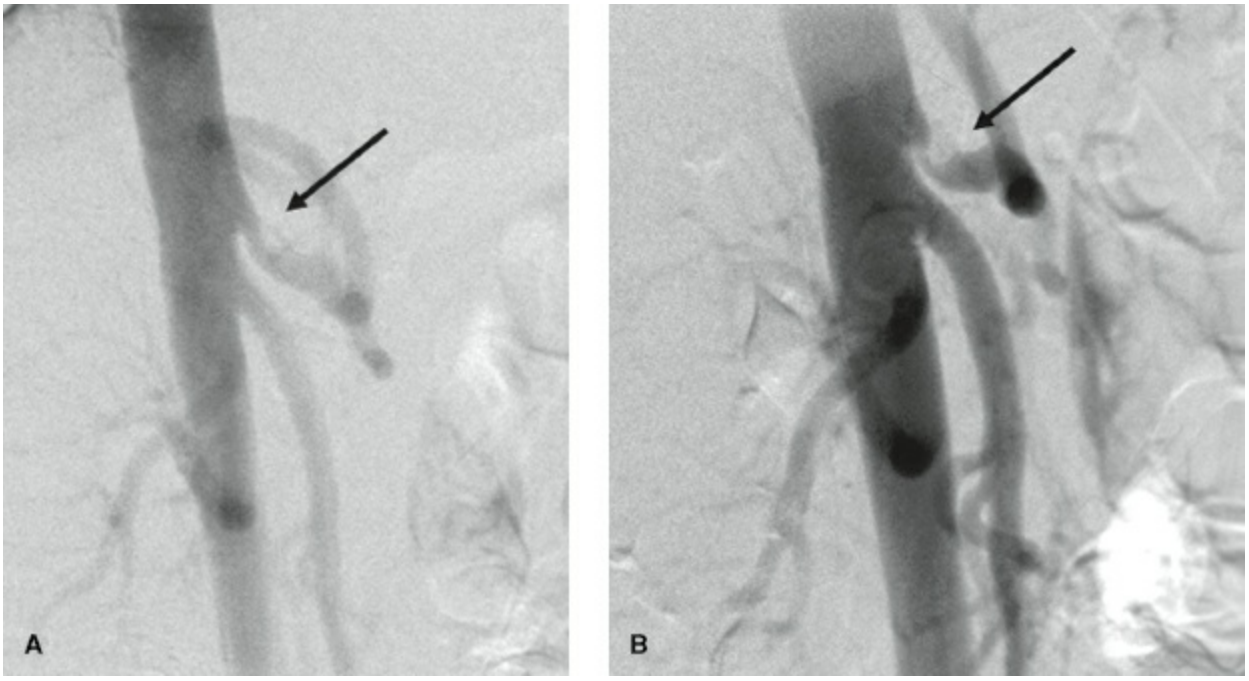

Figure 91-14. Lateral aortography demonstrating (**A**) external compression (*arrow*) of the celiac artery on peak inspiration that (**B**) worsens dynamically (*arrow*) during peak expiration.

Laparoscopic release of the MAL is increasingly employed for MALS.[67,73,77,78] While no procedure-related mortality has been reported for open or laparoscopic ligament release, there is a 9.1% incidence across series of open conversion for hemorrhage that follows laparoscopic release, which heightens morbidity and mortality risk.[67] Certainly independent operator learning curve, institutional technical enhancements, and patient selection may strongly affect this result. More recently, safe and effective robotic-assisted MAL release has been reported to offer benefits over laparoscopic release in light of improved visualization, extra degree of motion provided by robotic arms with "wrist movement" and scaled operator movements (including tremor elimination).[82]

SPLANCHNIC ARTERY ANEURYSMS

Splanchnic artery aneurysms are historically cited as rare and mainly asymptomatic. In the past, most were syphilitic or mycotic, while contemporary visceral aneurysms are largely true aneurysms caused by atherosclerosis or medial degeneration.[83] True aneurysms are defined by the involvement of all three arterial wall layers (intima, media, and adventitia) while false aneurysms, or pseudoaneurysms, represent a collection of extravasating blood outside of the artery that remains confined next to the vessel by surrounding tissue. The incidence of splanchnic artery aneurysms is estimated at 0.1% to 2% and autopsy series suggest a prevalence that may approach 10%.[84,85] A minority of aneurysms present with life-threatening rupture and while historic-associated mortality rates approached 25% to 70%; more contemporary series suggest mortality rates of 15%, possibly reflecting improvements in perioperative management and the increasing use of endovascular techniques.[86] Most splanchnic aneurysms are asymptomatic however, and diagnosed as incidental findings by cross-sectional imaging.[87] False aneurysms may carry a higher rate of rupture in comparison to true aneurysms (76% vs. 3% in once series).[88]

The natural history of these aneurysms remains elusive in light of their rarity and anecdotal, mainly institutional and retrospective, evidence to date. Indications for intervention remain conservative, especially as no significant difference has been identified between the diameters of ruptured and nonruptured aneurysms.[88] Additionally, aneurysm calcification and intraluminal thrombus are not associated with rupture risk. Treatment is recommended for symptoms and size >2 cm or aneurysm diameter three times greater than the respective normal artery. Patients with splanchnic aneurysms generally have 10-year survival rates $>80\%$ and open surgical treatment provides excellent, durable long-term results with low perioperative mortality and morbidity following elective surgery.[86,89,90] While surgical repair has remained the mainstay of treatment, minimally invasive endovascular techniques continue to evolve and are increasingly applied for both elective treatment and that of rupture. Endovascular intervention with local anesthesia offers excellent technical success, negligible morbidity and mortality in elective cases, and brief hospital stays.[86,88,90–94] Transcatheter embolization of visceral artery aneurysms offers additional advantages that include precise aneurysm localization, assessment of collateral flow, and negate the need for certain (i.e., intrahepatic) difficult arterial exposures.[83] Notably, embolization has become the standard of care for splanchnic artery pseudoaneurysm.[92,95] Additionally, endovascular therapy may offer decreased postoperative morbidity and mortality rates in cases of rupture when compared to open surgery (2.7% to 7% vs. 24% to 29%, respectively).[86,91]

6 Distribution of splanchnic artery aneurysms is as follows: Splenic artery (60%) > hepatic arteries (20%) > superior mesenteric artery (SMA) (5.5%) > celiac artery (4%) and gastric and gastroepiploic arteries (4%) > ileocolic arteries (3%) > pancreaticoduodenal arteries (2%) > GDA (1.5%) > IMA ($<1\%$).[84,87] Most patients present in the sixth decade of life.[87,88] Symptomatic patients will present with abdominal pain and frank hemorrhagic shock with rupture. Rupture may be intra-abdominal,

although erosion into a gastrointestinal lumen may result in sporadic gastrointestinal bleeding (i.e., herald bleed) and erosion into adjacent mesenteric veins results in arteriovenous fistulae. The asymptomatic patient inconsistently reveals a bruit on auscultation and rarely a palpable mass on examination. Each splanchnic aneurysm warrants individual consideration.

Splenic Artery Aneurysm

Splenic artery aneurysms account for 60% of all splanchnic artery aneurysms and are the third most common intra-abdominal arterial aneurysm. Their prevalence in the general population is very low approximating 0.16% to 0.8%.[96] These aneurysms occur two to four times more frequently in women than men and are associated with multiparity.[83,87,90,96,97] Hormonal and local hemodynamic events likely contribute to the evolution of splenic aneurysms. An etiologic classification system has previously been proposed by *Stanley and Fry* that implicates arterial dysplasia, portal hypertension, local inflammation, and hormonal and hemodynamic events in the pathogenesis of these aneurysms.[96] Hypertension is a common comorbidity affecting 50% to 60% of patients with splenic aneurysm, and up to 20% of patients will demonstrate concurrent aneurysms affecting alternate arterial beds.[94,95,98] Additional etiologic risk factors for true aneurysms may include dissection, septic emboli, polyarteritis nodosa, systemic lupus erythematosus, and connective tissue disorders like Ehlers–Danlos syndrome, while splenic pseudoaneurysms are typically attributed to chronic pancreatitis and trauma.[87] Splenic aneurysms most often arise at branch points off the mid- and distal main splenic artery. Tortuosity of the main splenic artery is common (Fig. 91-15). The majority (80%) of splenic aneurysms are solitary and saccular, although 90% of patients with portal hypertension will demonstrate multiple splenic aneurysms. Those aneurysms measuring >5 cm are often described as "giant lesions" and appear to be more common in older males.[99]

Splenic aneurysms typically rupture into the lesser sac with limited self-containment. Later hemorrhage into the peritoneal cavity results in cardiovascular collapse and the so-called "double rupture." The incidence of splenic aneurysm rupture approximates 2% to 5% and is not associated with calcification, blood pressure, or age.[84,87,95,96] Increased levels of aneurysmal peripheral calcification are associated with smaller aneurysm size at the time of diagnosis, but appear to have no impact on aneurysm growth.[95] Growth rates among surveyed aneurysms (out to 3.1 years) have been calculated as 0.2 mm/yr.[95] Rupture-associated mortality is dramatically increased in the peripartum patient (68% to 75% vs. 25%), and associated fetal mortality approaches 100%.[96,98,100] Rupture in this setting occurs most commonly during the last trimester.[83] While historically a strong association between pregnancy and splenic aneurysm rupture was reported, a contemporary series reporting on >67,000 consecutive live births over 5 years identified no cases of splenic artery aneurysm rupture.[98] There is no apparent role for routine screening for splenic aneurysm in the pregnant patient.[101] Rupture risk is increased two fold by liver transplantation, the mortality following which is 50%.[102,103]

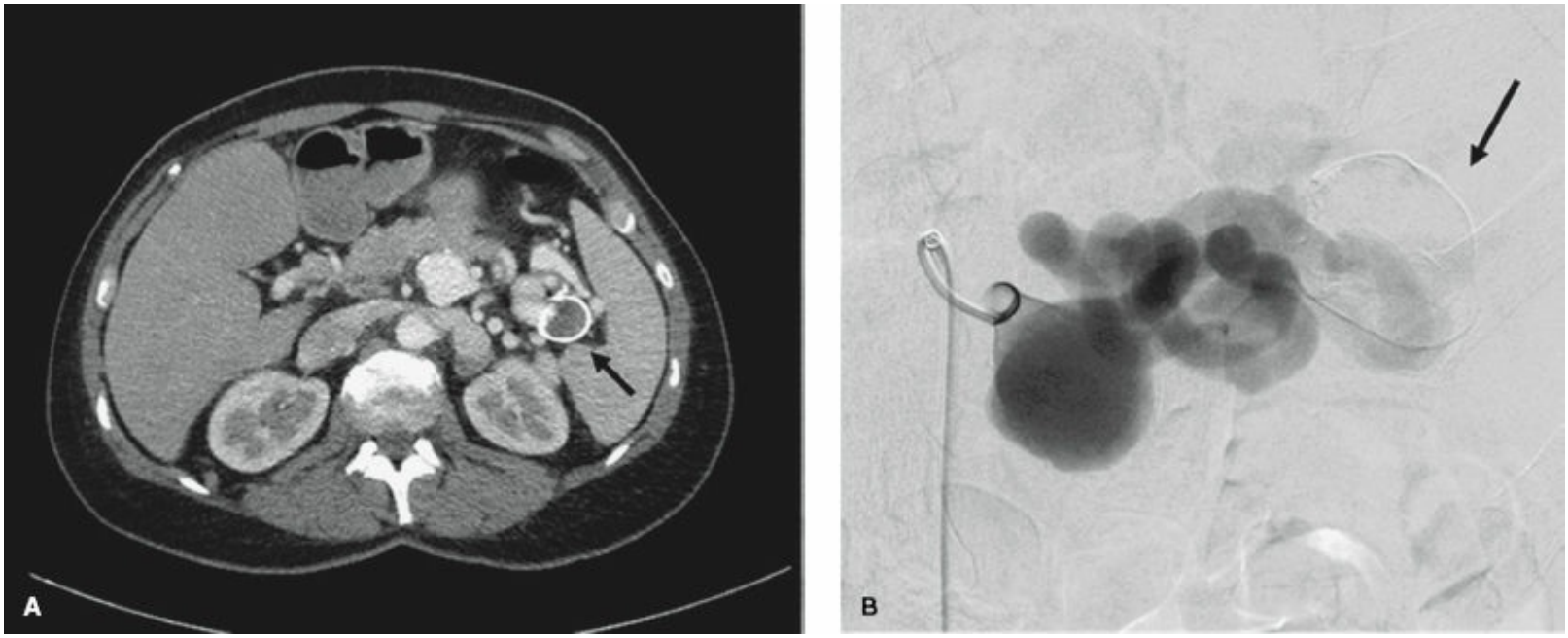

Figure 91-15. (**A**) CT angiogram and (**B**) splenic arteriogram revealing a tortuous splenic artery with two large aneurysms affecting the main splenic artery; the distal aneurysm (*arrow*) has extensive calcification and mural thrombus.

Indications for treatment include rupture, symptoms, size >2.0 to 2.5 cm and any size asymptomatic aneurysm at the time of liver transplantation or in women of childbearing age.[87,95,104,105] Historically, the open surgical treatment of splenic artery aneurysms included aneurysm resection or splenectomy. Recognizing the immunologic benefits of splenic preservation, arterial ligation, and aneurysm excision is preferred when possible; however, those patients with multiple and perihilar aneurysms may still require splenectomy. Laparoscopic and robotic techniques at ligation, aneurysm resection and splenectomy have become common-place offering negligible risk of open conversion, need for reoperation and mortality.[106–108] Splenic vaccinations and education regarding the need for booster vaccinations at regular 5-year intervals should be provided. Perioperative morbidity and mortality are estimated as 9% to 25% and 1% to 5%, respectively, across series.[95,96,109–111]

More recently, endovascular therapy has been utilized with increasing frequency for both elective and ruptured cases boasting decreased early morbidity, mortality, and hospital length of stay. While only 2% of all splenic aneurysms were managed with endovascular therapies in 1999, this proportion increased to 70% between the years 2010 and 2013.[111] Embolization with coils, gelfoam, glue, thrombin, and vascular plugs has been advocated for saccular aneurysms with narrow necks (Fig. 91-16). Larger vessels with complex wide-neck aneurysms may be better approached with covered stents or stent-assisted coil embolization.[112] Technical success for endovascular treatment is 93% to 98%, limited primarily by vessel tortuosity that may be overcome with newer, steerable catheters.[95,111,113,114] Conversion to open surgery is rarely necessary (<2%) to accomplish successful aneurysm exclusion.[111] Postembolization syndrome (PES) complicates 10% to 30% of cases across series and may include left upper quadrant pain, fever, ileus, platelet dysfunction, leukocytosis, and pancreatitis following embolization

with and without radiographic evidence of splenic infarction.[95,111,114,115] Up to 21% of patients will demonstrate major splenic infarct and may require reintervention for splenic abscess by way of percutaneous drainage or splenectomy.[95,113] Portal hypertension appears to increase dramatically the risk of major splenic infarction.[113] With late follow-up, endovascular repair is associated with an average regression in aneurysm size of 1.5 mm/yr.[95] Late complications may arise at an average rate of 3.7% per year, and there is a 3.2% rate of reintervention per year following endovascular repair.[111]

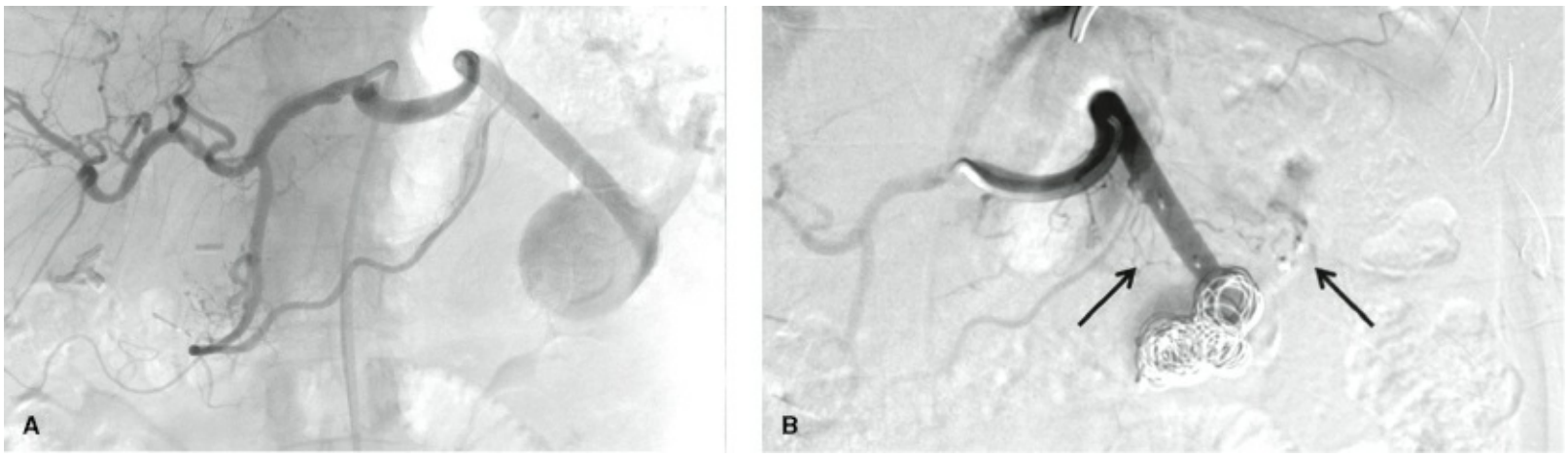

Figure 91-16. (**A**) Celiac arteriogram of a 78-year-old woman with a 4-cm splenic artery aneurysm; (**B**) Splenic arteriogram demonstrating a catheter in the proximal splenic artery. Vascular occlusion devices (*arrows*) have been positioned in the main splenic artery outflow (distal to the aneurysm) and inflow (proximal to the aneurysm) with multiple vascular coils embedded within the aneurysm sac.

Patients with splenic aneurysms have long-term survival rates that approach 90% at 10 years following aneurysm-directed treatments; cause of death is typically unrelated to aneurysm.[95] The most recent meta-analysis of splenic aneurysm therapies identifies significantly greater technical success balanced with greater 30-day mortality following open repair in comparison to significantly higher rates of acute minor complications, late complications, and reinterventions following endovascular repair.[111] Moreover, a recent decision analysis investigating the cost-effectiveness of open repair, conservative management, and endovascular repair for splenic aneurysm identified endovascular therapy as the most cost-effective treatment independent of gender and risk profile of the patient.[116]

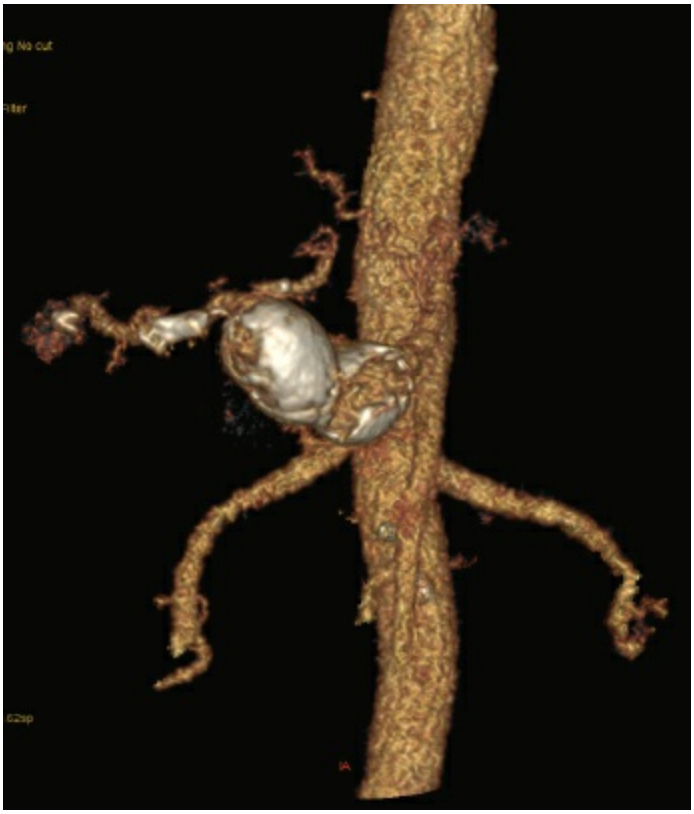

Figure 91-17. Reformatted CT angiogram demonstrating a bilobed and calcified hepatic artery aneurysm.

Hepatic Artery Aneurysm

Hepatic artery aneurysms (Fig. 91-17) account for 20% of all splanchnic artery aneurysms, affecting men twice as often as women.[83,84,117] These aneurysms are mainly solitary and while small hepatic artery aneurysms (<2 cm) are typically fusiform, larger aneurysms will more often appear saccular.[117] The vast majority of these aneurysms are extrahepatic with the common hepatic artery and right hepatic artery most often affected; 20% to 30% of hepatic aneurysms however, are intrahepatic.[84,97,117] Hepatic artery pseudoaneurysms are increasingly frequent and account for approximately 50% of hepatic artery aneurysms.[87,97] Pseudoaneurysms may result from diagnostic and therapeutic interventions that require liver penetration (e.g., biliary stents), liver transplantation, and trauma; their incidence appears to be increasing secondary to the more frequent and regular use of CT imaging following blunt liver trauma and hepatobiliary intervention.[88,97] True aneurysms present most often during the sixth decade of life and proposed etiologic mechanisms include mainly atherosclerosis and acquired medial degeneration. Polyarteritis nodosa, cystic medial necrosis, portal hypertension, infection, arterial fibrodysplasia, neurofibromatosis, and other arteriopathies are less commonly implicated.[87,117]

As with most splanchnic artery aneurysms, hepatic artery aneurysms rarely cause symptoms. Symptomatic patients will most commonly describe right upper quadrant or epigastric abdominal pain that may radiate to the back, while those patients with rapidly expanding aneurysms may describe abdominal complaints that mimic pancreatitis. Large aneurysms may erode into the stomach or duodenum resulting in gastrointestinal hemorrhage or they may obstruct the biliary tract resulting in biliary colic, hemobilia, and obstructive jaundice.[87] Additional physical examination findings like a palpable pulsatile mass and bruit are uncommon. Diagnosis is often made incidentally by cross-sectional CT/MRI, ultrasound or arteriography performed for a nonvascular indication.

Rupture appears to complicate a minority of hepatic artery aneurysms (20% to 30%) and results in an equal distribution of hemorrhage into the peritoneum and the biliary tract.[84,87] Rupture into the biliary tract results in hematobilia, hematemesis, and cholangitis; rarely is there melena and chronic anemia. Rupture-related mortality approximates 35% to 40%.[117] The relationship of rupture risk to aneurysm size remains unclear and a small series of 22 patients with a mean hepatic artery diameter of 2.3 cm (range 1.5 to 5 cm) were followed for a mean of 68.4 months without complication.[87,117] The presence of multiple aneurysms and nonatherosclerotic etiology are proposed risk factors for rupture.[117] While historically treatment was recommended for all asymptomatic aneurysms >2 cm in size, some authors have proposed elective intervention for all and any-size nonatherosclerotic aneurysms and for those patients with multiple hepatic artery aneurysms while reserving a more conservative approach for those atherosclerotic hepatic artery aneurysms measuring 2 to 5 cm in size.[117]

Open reconstruction is favored for aneurysms of the common hepatic artery by way of aneurysmectomy or exclusion. Often revascularization is not required in light of extensive foregut collaterals from the GDA and right gastric artery that preserve hepatic perfusion.

When necessary, options for reconstruction may include primary or patch angioplastic closure of the common hepatic artery, aortorenal bypass, and splenohepatic bypass. Proper hepatic artery aneurysms may be treated by aneurysmectomy requiring reconstruction using a saphenous vein interposition graft or simple aneurysmorrhaphy. Distal or intraparenchymal lesions may require resection of the involved liver parenchyma.[89] Elective open surgical repair is associated with approximately 30% morbidity and negligible mortality.[90,92,117] Additional options include transcatheter embolization, which may be an especially useful adjunct for intrahepatic arterial aneurysms obviating the need for hepatic lobectomy, and stent graft exclusion for high-risk patients.[83,87,90,92,94,118] Technical and clinical success rates with transcatheter embolization approach 100% and 79%, respectively and offers efficient control of hemorrhage, shorter hospital length of stay and lower transfusion requirements in cases of rupture specifically.[119] Transient success and recanalization is well described however, mandating thoughtful postembolization surveillance.

Superior Mesenteric Artery Aneurysm

Superior artery aneurysms account for up to 7% to 14% of all splanchnic aneurysms, depending on the series.[84,86,88,90,91] These aneurysms affect men more frequently than women in their sixth decade of life and are mainly solitary.[84,120,121] SMA aneurysms may result from infection (i.e., nonhemolytic streptococci in bacterial endocarditis), dissection (Fig. 91-18), medial degeneration, atherosclerosis, FMD, vasculitis, connective tissue disorder, and trauma.[84,88] Additionally, false aneurysms may occur in the setting of pancreatitis and complicated peptic ulcer disease.[120] Concomitant hypertension is common, affecting >20% of patients with SMA aneurysm, as are associated aortic and peripheral/splanchnic aneurysms.[90,94,121,122]

While most patients with SMA aneurysm are asymptomatic, abdominal pain is the most common symptom followed by nausea, emesis, GI bleeding, and fever in cases of mycotic aneurysm.[120–122] Clinical examination may reveal a pulsatile mass in up to one-third of patients. Diagnosis is most commonly established by CT imaging, although these aneurysms can be appreciated by ultrasound, MRI, and angiography. Complications may include AMI resulting from thromboembolism and rupture. Rupture risk has historically been considered rare and while rupture-associated mortality has historically approached 50%, more contemporary series cite 30-day mortality rates as low as 12.5% to 38%.[84,91,121] No comorbidities or aneurysm characteristics have been found to predict rupture risk.[121]



Figure 91-18. (**A**) CT angiogram and (**B**) intraoperative photo of a large 3.6-cm asymptomatic SMA aneurysm associated with extensive thoracoabdominal aortic and SMA dissection. The aneurysm was repaired by way of an SMA interposition bypass graft using nonreversed great saphenous vein; additionally the proximal SMA dissection flap was sharply fenestrated.

Surgical management of SMA aneurysm most often requires aneurysm excision (or exclusion) with revascularization, most often by way of aortomesenteric bypass.[90] Both autologous and prosthetic conduits have been described. Autologous conduit is favored in cases of mycotic aneurysm and frank contamination complicating intestinal ischemia while reinforced prosthetic conduit resists compression/kinking and future dilation.[94] Aneurysmorrhaphy and simple ligation of inflow and outflow vessels (in those patients with appropriate collateralization) have also been described with success.[84,94,120] Contemporary elective surgical results boast negligible morbidity and mortality.[94] Endovascular SMA aneurysm exclusion with a stent graft and embolization have been described and increasingly employed for patients with severe cardiopulmonary disease; these therapies remain limited by thromboembolic risks to the collateral circulation, endoleak, and limited long-term follow-up.[90,121–125] Aneurysms with a small neck distal to the SMA origin may be conducive to transcatheter embolization provided angiographic determination of collateral flow is determined as adequate.[121]

Celiac Artery Aneurysm

Celiac artery aneurysms account for approximately 4% of all splanchnic aneurysms affecting men more frequently than women in their sixth decade of life.[126,127] The incidence in the general population is unknown. Historically celiac artery aneurysms were primarily associated with infection like syphilis or tuberculosis and primarily diagnosed postmortem.[126] Contemporary etiologic risk factors include primarily atherosclerosis, developmental risk factors such as common celiacomesenteric trunk, arterial dysplasia with medial degeneration, collagen vascular disorder, trauma, and dissection.[126,127] Concomitant hypertension (20%), aortic aneurysm (18% to 40%), and alternate splanchnic aneurysms (38%) are common in patients with celiac artery aneurysm.[126,127]

As with most splanchnic artery aneurysms, celiac artery aneurysms rarely cause symptoms.[127] Symptoms may include abdominal pain, primarily epigastric in location with radiation to the back.[126] Less common associated symptoms may include nausea, emesis, dysphagia, anorexia, weight loss, and GI bleeding. Abdominal mass and bruit may be appreciated on physical examination. Diagnosis is most commonly established by CT imaging, although these aneurysms can be appreciated by ultrasound, MRI, and angiography.[127] Historically, rupture complicated approximately 70% of celiac artery aneurysms, resulting in near-certain mortality.[126] More contemporary estimates suggest rupture rates of 13% with associated 50% mortality.[126] Hypertension, aneurysm calcification, presence of thrombus, gender, and aneurysm etiology do not appear to influence risk of rupture, which has been described in aneurysms ranging in size from 2 to 6 cm.[126,127]

Treatment should be individualized for cases of rupture and elective cases for patient symptoms and aneurysm size >2 cm. Aneurysm ligation and resection, without reconstruction, has previously been endorsed for those patients with adequate foregut collateral circulation. Simple ligation and transcatheter embolization may be considered as life-saving in cases of rupture, but both offer substantial risk of perioperative hepatic and intestinal ischemia, necrosis, and patient mortality.[126–128] Aneurysmectomy with arterial reconstruction remains the preferred treatment of celiac artery aneurysms. Surgical revascularization may be accomplished by primary arterial–arterial anastomosis following aneurysm resection, direct aortic reimplantation of the celiac artery or its branches, or aortoceliac bypass. Prosthetic conduit may offer superior patency rates in comparison to autogenous reversed saphenous vein, which tends to kink.[127] Elective surgical repair offers patients symptomatic relief with a 0% to 5% risk of perioperative mortality.[127,128] Endovascular options for aneurysm treatment are increasingly described including celiac artery stent grafting.[129]

Gastric and Gastroepiploic Artery Aneurysm

Gastric and gastroepiploic artery aneurysms account for approximately 4% to 5% of all splanchnic aneurysms affecting men three times more frequently than women (Fig. 91-19).[84] Etiologic risk factors include primarily arterial dysplasia with segmental arterial mediolysis and periarterial inflammation like pancreatitis and vasculitis; atherosclerosis when present is felt to be a secondary process.[83,84,130] Gastric artery aneurysms are 10 times more common than gastroepiploic artery aneurysms. While patients may present with abdominal pain, up to 90% of patients have historically presented acutely ruptured with evidence of GI bleeding more common than intraperitoneal rupture.[83,84]

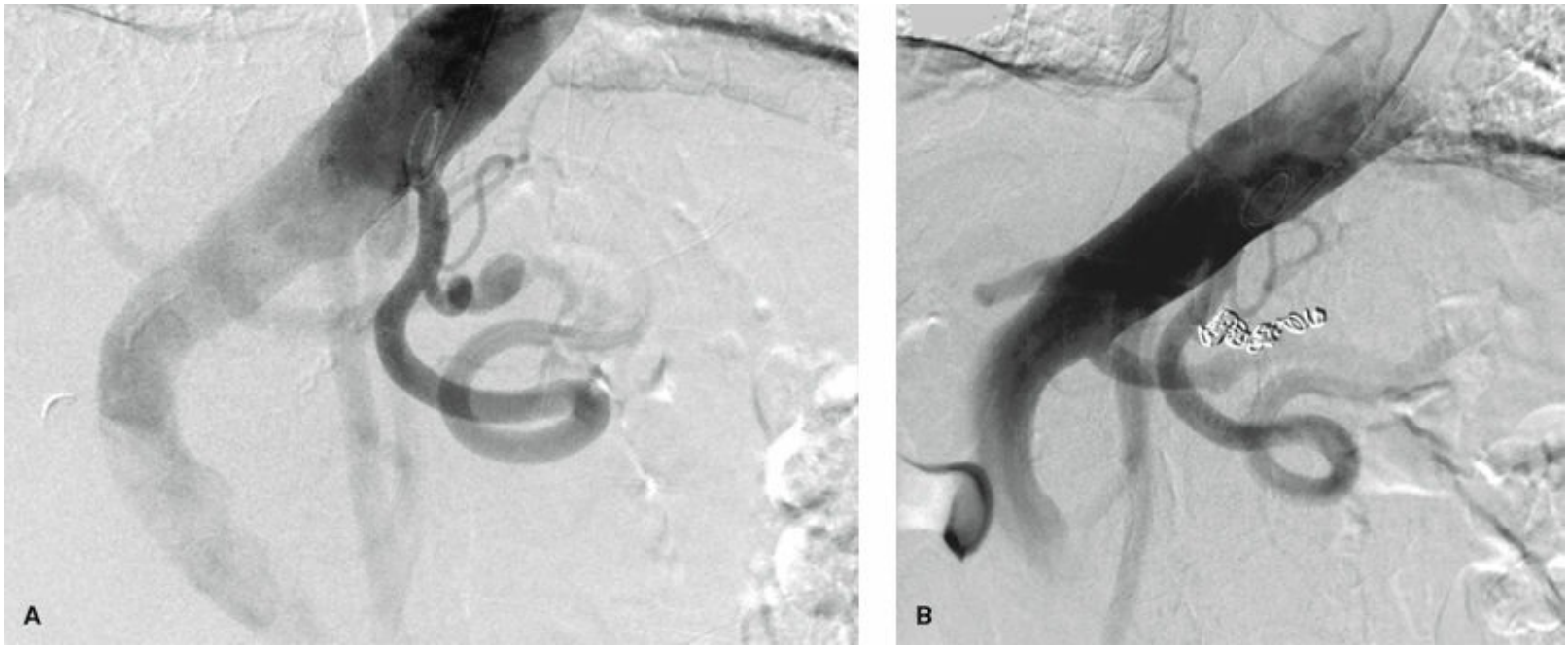

Figure 91-19. **A:** Diagnostic aortogram of an 82-year-old woman with a highly tortuous abdominal aorta, aberrant hepatic arterial anatomy, and two sequential gastric artery aneurysms measuring 10 mm in maximum diameter. **B:** Completion arteriogram following endovascular embolization.

Treatment is recommended for all gastric and gastroepiploic arterial aneurysms, regardless the size. Arteriogram is invaluable for aneurysm identification preoperatively and operative planning. Surgical management has historically relied on simple arterial ligation or excision without reconstruction while intramural aneurysms required a wedge excision of involved gastric wall.[84,89] Contemporary literature would suggest that catheter-based embolization of these arteries is the new standard for care with multiple case reports and small series documenting successful aneurysm occlusion with coils and thrombin injection.[86,131,132]

Jejunal, Ileal, and Colic Artery Aneurysm

Aneurysms of the jejunal, ileal, and colic arteries account for <3% of all splanchnic aneurysms, affecting men and women equally beyond the sixth decade of life.[84] These aneurysms are associated with medial degeneration, infection, connective tissue disorder, and polyarteritis nodosa with multiple aneurysms identified in approximately 10% of cases.[84,130,133] Atherosclerosis, when present, is felt to be a secondary process. While patients may present with abdominal pain, most have no symptoms. Rupture may complicate up to 30% of cases resulting in gastrointestinal bleeding and mortality rates that approach 20%.

Treatment is recommended for all mesenteric branch aneurysms, regardless of the size. Arteriogram is invaluable for aneurysm identification preoperatively and operative planning. Surgical management has historically relied on simple arterial ligation or excision without reconstruction.[84] Intramural aneurysms and those associated with bowel necrosis required resection of the involved intestine at the time of aneurysm exclusion. Transcatheter embolization has been increasingly utilized, especially for cases of acute rupture and GI bleeding with intestinal necrosis, perforation, and late stricture potential complications.[134–136]

Gastroduodenal and Pancreaticoduodenal Artery Aneurysm

Gastroduodenal and pancreaticoduodenal artery aneurysms account for <2% of all splanchnic aneurysm.[84] Men are affected four times more often than women during the sixth decade of life.[84] Periarterial inflammation resulting from pancreatitis with vascular necrosis or vessel erosion by pseudocyst reflects the most common etiology, while additional causes include arteriosclerosis, congenital medial degeneration, and trauma.[84] Concomitant celiac artery stenosis and occlusion are common in noninflammatory aneurysms and GDA and pancreaticoduodenal aneurysms are suggested to represent the effect of inordinately high-volume blood flow on branchings of the collateral circulation (Fig. 91-20).[137–139] Symptoms of abdominal pain are common; additional symptoms may include gastric outlet obstruction and compressive symptoms like nausea and emesis.[120,140] Rupture is also common, complicating up to 75% of inflammatory and 50% of noninflammatory aneurysms resulting most often in gastrointestinal bleeding and less commonly bleeding into the biliary or pancreatic ductal systems, peritoneum or retroperitoneum.[139] Rupture-associated mortality approximates 20% to 50%.[139,141] While it remains unclear if aneurysm size is a risk factor for rupture, rupture has been described at a small median size of 12 mm.[91,138,142]

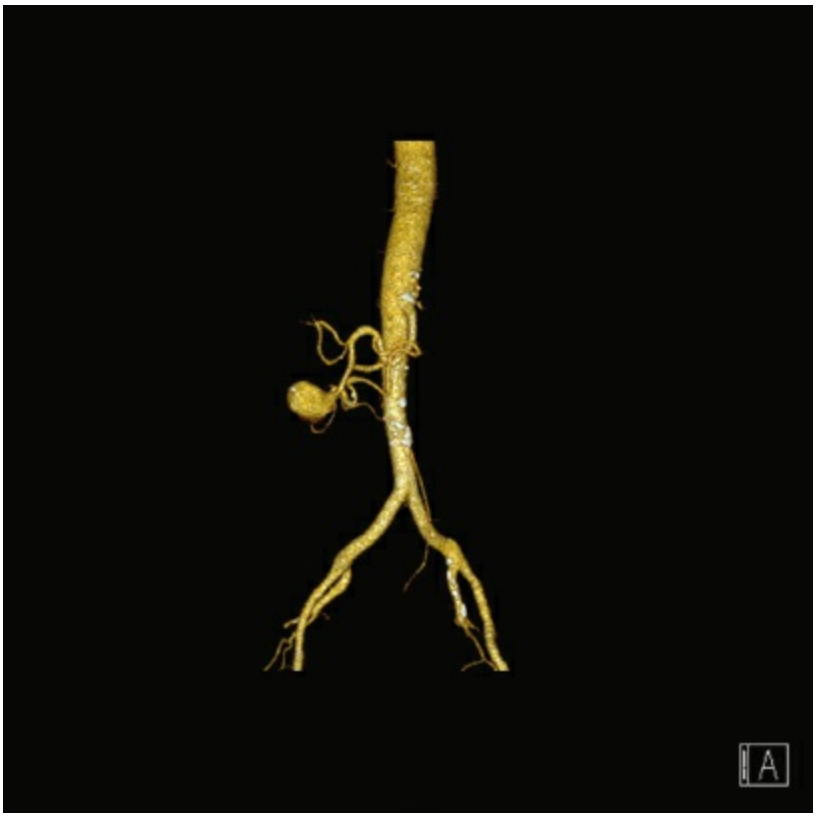

Figure 91-20. CT angiogram of an 87-year-old woman with a large 3.4-cm gastroduodenal artery aneurysm associated with celiac artery occlusion.

Open surgical repair remains appropriate for most patients. These aneurysms are most often amenable to simple ligation, aneurysm resection, or aneurysmorrhaphy without revascularization.[86,90,94,120,139,143,144] Celiac artery revascularization should be considered in select noninflammatory cases. Pancreatitis-associated inflammatory aneurysms may

require arterial branch ligation from within the aneurysm sac or pancreatic resection in severe cases. Transcatheter embolization with coils, glue, thrombin, and electrocoagulation has been successfully reported, especially for high-risk patients and those presenting with rupture.[90,118,139,141,145,146]

Inferior Mesenteric Artery Aneurysm

IMA aneurysms account for <1% of all splanchnic aneurysms. Our understanding of these aneurysms is limited to case reports. Men appear to be most commonly affected.[120] Atherosclerosis is the most common etiologic factor with additional risk factors including infection, polyarteritis nodosa, inflammatory arteritides, segmental arterial mediolysis, Behçet disease, and neurofibromatosis.[147] Concomitant celiac and SMA occlusion is common; it has been hypothesized that turbulent blood flow through tortuous marginal arteries originating from the IMA results in a high-flow state, or "jet disorder phenomenon," and subsequent dilation of the IMA and small collaterals which can lead to weakness of the arterial wall and aneurysmal disease.[147–150] Patients rarely have symptoms. Incidence of rupture approximates 20% with rupture-related mortality approaching 40%.[147]

Surgical management in cases of chronic celiac and SMA occlusion requires revascularization of at least one vessel (most commonly the SMA) to minimize intestinal ischemia during IMA aneurysm exclusion and theoretically decrease the risk of recurrent IMA aneurysm postoperatively. IMA aneurysm ligation and/or excision may be sufficient for treatment in certain cases of robust collateral intestinal circulation; in contrast certain cases will dictate IMA revascularization.[150] The role for endovascular therapy remains poorly defined.

RENAL ARTERY OCCLUSIVE AND ANEURYSMAL DISEASE

INTRODUCTION

Renovascular hypertension (RVH) is a well-defined form of secondary hypertension (HTN) that results from renal arterial insufficiency at some level. The pathophysiology of such ischemia is broad, and with both an increasing prevalence of atherosclerotic renal artery occlusive disease and ongoing clinical trials, treatment standards remain in flux.

PATHOPHYSIOLOGY OF RENOVASCULAR HYPERTENSION

Renal artery stenosis resulting in a decrease in mean renal artery perfusion pressure by 10% to 15% stimulates renin release from the kidney. Renin is a proteolytic enzyme produced by the juxtaglomerular apparatus of the kidney that cleaves angiotensinogen to form angiotensin I. Angiotensin I is further processed to angiotensin II by angiotensin-converting enzyme (ACE), which is produced in the lung endothelium and vasculature (Fig. 91-21). Angiotensin II stimulates hepatic production of renin, while providing a continuous negative feedback on the renal release of renin.[151] Angiotensin II is a potent vasopressor that increases arterial blood pressure by a variety of mechanisms (Fig. 91-22). Glomerular filtration rate (GFR) is increased via vasoconstriction of the efferent arteriole. Additionally, antidiuretic hormone (ADH) is released from the posterior pituitary gland, causing water conservation. Release of aldosterone from the adrenal glands enhances exchange of sodium in the nephron-promoting volume retention. Finally, angiotensin increases sympathetic tone. All of these mechanisms coalesce to increase arterial pressure by way of arteriolar constriction, enhanced cardiac output, and the retention of sodium and water. Renin has a half-life of 20 to 30 minutes and is primarily cleared by the liver.[152] Normal physiology and sodium balance support a “steady state” of renin activity that is approximately 50% greater in the bilateral renal veins than that in the infrarenal inferior vena cava or peripheral circulation. In cases of unilateral renal artery stenosis, HTN is characterized by renin hypersecretion from the affected kidney and suppression of renin production in the contralateral kidney.[153,154] Additionally, angiotensin-mediated vasoconstriction causes pressure diuresis of the unaffected kidney. In cases of chronic bilateral or unilateral RVH in those patients with solitary kidney, sodium retention accounts for late reductions in renin secretion.

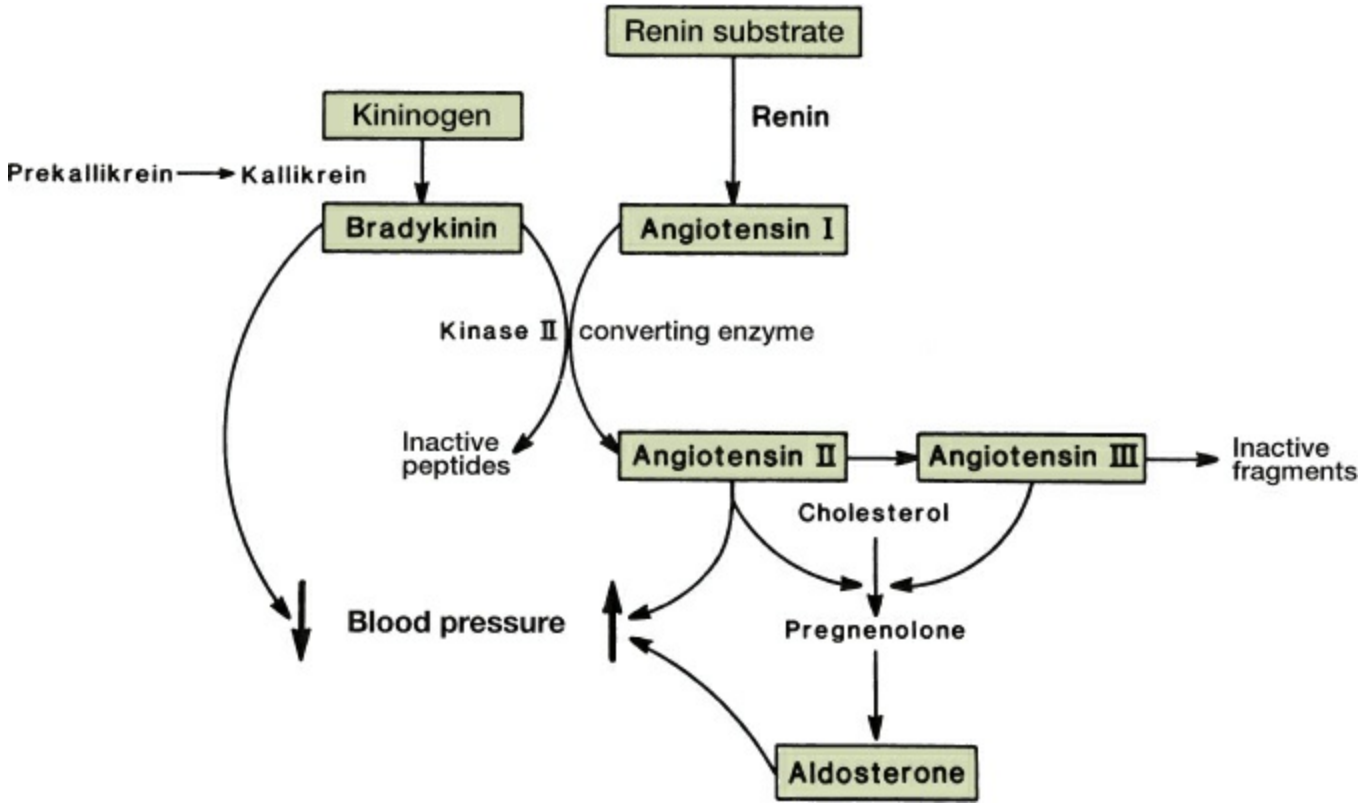

Figure 91-21. Renin–angiotensin system interrelation with aldosterone and bradykinin in blood pressure regulation. (Adapted from Stanley JC, Graham LM, Whitehouse WM Jr. Renovascular hypertension. In: Miller TA, Rowland BJ, eds. *Physiologic Basis of Modern Surgical Care*. St. Louis, MO: CV Mosby; 1988:734.)

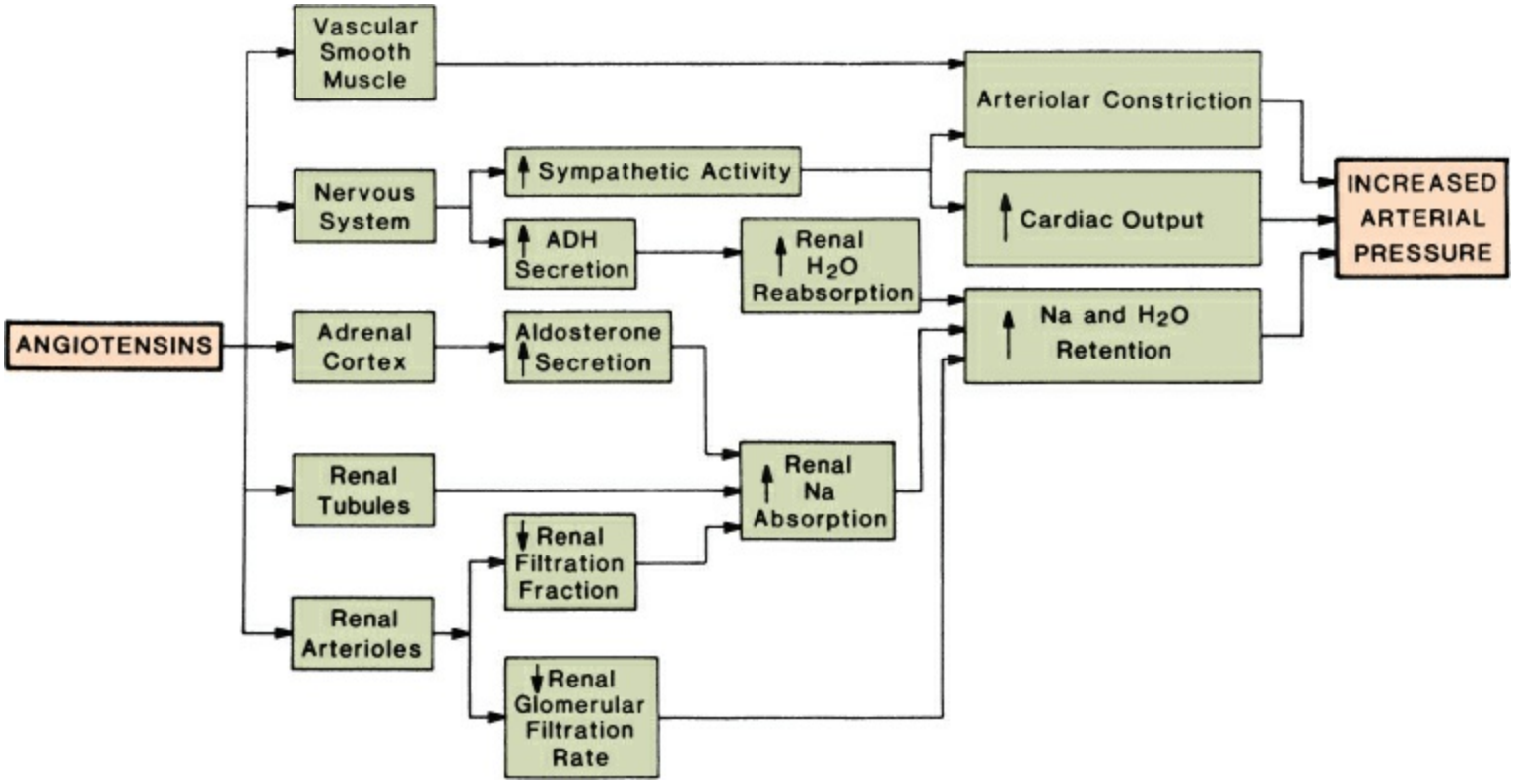

Figure 91-22. Effects of angiotensins contributing to increased arterial pressure. (Adapted from Stanley JC, Graham LM. Renovascular hypertension. In: Miller TA, ed. *Physiologic Basis of Modern Surgical Care*. 2nd ed. St. Louis, MO: Quality Medical Publishing; 1998:918.)

RENAL ARTERY OCCLUSIVE DISEASE

7 Renal artery occlusive disease is the most common cause of correctable HTN in adults and the third most common cause of HTN in children and should be considered in the clinical context of: (1) childhood HTN, (2) severe HTN in women <45 years of age, (3) acute and rapid escalation of mild HTN in older patients (>50 years), (4) initial diastolic BP >115 mm Hg, and (5) rapid deterioration in renal function following the administration of antihypertensive therapy (especially with ACE inhibition). Renovascular HTN can be notoriously resistant to traditional medical management. Clinical examination may reveal an upper abdominal bruit during systole and diastole.

Diagnostic work-up should begin with serologies to assess renal function (BUN, creatinine) and electrolyte levels. Additional blood hormone levels may help differentiate the diagnosis as high plasma renin activity supports RVH while altered aldosterone, thyroid, and catecholamine levels may indicate endocrine dysfunction. Urinalysis may reveal hematuria or azotemia concerning for intrinsic renal disease. Ultrasonography is the first-line imaging modality for screening patients with RVH. While a high-quality duplex ultrasound examination in an experienced center is extremely accurate for the diagnosis of main renal artery and ostial stenosis or occlusion, sensitivity is compromised when surveying branch or parenchymal renal arteries and technically challenging in obese patients or in the presence of abdominal gas.[155] An elevated peak systolic velocity (>180 or >200 cm/s) or elevated renal aortic ratio >3.5 (calculated by dividing the peak systolic velocity of the renal artery by the peak systolic velocity of the adjacent aorta) detects renal artery stenosis with sensitivity and specificity of 84% and 97%, respectively.[156] Ultrasonography additionally facilitates a determination of renal length and symmetry, the presence of main renal artery aneurysm (RAA), visualization of adjacent structures (i.e., obstruction, masses, aortic aneurysm), and the assessment of intrinsic vessel renovascular disease by way of the resistive index.

Axial imaging with CTA and MRA are both useful adjunctive imaging modalities that better evaluate stenosis, aneurysms, renal infarcts, dissections, and adjacent structures. These imaging modalities have collectively received a class I indication (level B evidence) as screening tests to establish the diagnosis of renal artery stenosis from the American College of Cardiology (ACC) and American Heart Association (AHA).[157] CTA offers excellent spatial resolution and generated three-dimensional multiplanar images which can be very helpful in treatment planning. CTA however, is limited by the risk of contrast-induced nephropathy and in detecting subtle FMD lesions and branch vessel involvement. Multidetector CTA offers sensitivity and specificity ranging from 86% to 93% and 90% to 100%, respectively.[158] MRA is often favored in younger patients as it offers diagnostic sensitivity and specificity of 97% and 93% without the associated risks of irradiation.[159] Gadolinium is less nephrotoxic than iodinated contrast and while it may be advantageous for those patients with mild renal insufficiency, the risk of nephrogenic systemic fibrosis prohibits the use of gadolinium contrast in those patients with a GFR ≤ 30 mL/min/1.73 m^2. MRA offers the additional benefit of estimating renal perfusion and GFR via calculations of gadolinium clearance.

Catheter-based arteriography remains the gold standard imaging modality for the diagnosis of renal artery stenosis given its unmatched spatial resolution and capacity to detect reliably branch vessel and parenchymal involvement. Additionally, pressure gradients can be measured across a stenosis (a systolic pressure gradient <10 mm Hg is considered normal); intravascular ultrasound may be used to further characterize the renal artery; and any clinically indicated therapeutic interventions can be performed in the same clinical setting.

In cases of complex and equivocal disease, renal vein renin assessments may be used to calculate the renal vein ratio. This ratio reflects a renin comparison between peripheral and renal venous blood. With unilateral renal artery stenosis, the renal vein renin ratio (RVRR) is calculated by dividing the renin activity in venous blood from the affected kidney by that from the (normal) contralateral kidney. A ratio >1.48 supports a functionally relevant renal artery stenosis.[153,154] In patients with bilateral renal artery stenosis, a renal:systemic renin index (RSRI) is calculated by subtracting systemic renin activity from individual renal vein renin activity and dividing the remainder by systemic renin activity; this index reflects individual kidney renin release.[153] As aforementioned, there is a steady state of normal renal renin release; normal renal vein renin activity from each kidney is approximately 24% higher than systemic activity (with the total of both kidneys being then 48% higher than systemic activity). Documentation of renin hypersecretion (RSRI >0.48) associated with contralateral kidney renin suppression (RSRI 0 to 0.24) provides a method to differentiate those patients that will be cured or improved of RVH following renal revascularization or nephrectomy.[153,160]

Captopril scintigraphy (also known as isotopic or captopril renography) and hypertensive urography have fallen out of favor and are no longer recommended as diagnostic studies for the diagnosis of renal artery stenosis.

Arteriosclerosis

Arteriosclerosis is the most frequent cause of RVH affecting men twice as often as women, most commonly in the sixth decade of life.[161] Ostial stenosis is most common representing “spillover” of diffuse aortic atherosclerosis, which is present in approximately 80% of patients. Arteriosclerotic renal artery stenosis affects primarily the proximal third of the vessel, with more severe distal extrarenal disease limited mainly to black patients.[162] A contemporary prospective, multicenter, population-based study of cardiovascular health has estimated the incidence of renovascular disease in men and woman aged >65 years as 6% to 7%.[161,163] Although early angiographic- and image-based studies in selected patients with arteriosclerotic RVH have suggested radiographic progression in approximately a third of renal artery lesions with 10% progressing to occlusion, this longitudinal cohort study reported anatomic progression to hemodynamically significant disease in only 4% of participants with an annualized progression rate of 0.5% per year and no disease progression to arterial occlusion. Importantly, renovascular disease has consistently been associated with cardiovascular disease across coronary, cerebrovascular, mesenteric, and peripheral vascular beds with a significant and independent relationship noted with prevalent coronary manifestations.[164–168]

Fibromuscular Dysplasia

FMD is thought to account for approximately 5% to 10% of RVH.[169,170] FMD is a nonatherosclerotic, noninflammatory vascular disease that may result in arterial stenosis, occlusion, aneurysm or dissection that affects primarily younger women.[171] The prevalence of FMD in the general population is unknown, although renal involvement is the most common phenotype comprising 58% to 75% of all FMD cases.[172,173] FMD until recently has been described by histopathologic classification.[174,175] By this classification medial fibroplasia is the most common variant accounting for 60% to 90% of FMD cases. Deposition in the media of loose collagen in zones of degenerating elastic fibrils results in the generation of fibromuscular ridges with resultant arterial stenoses alternating with areas of smooth muscle loss with consequent arterial dilation producing a classic "string of beads" appearance angiographically (Fig. 91-23).[172] The distal two-thirds of the main renal artery and its branches are most commonly affected and bilateral disease is common. Intimal fibroplasia accounts for approximately 2% to 5% of all dysplastic renal artery stenoses and presents as a smooth, focal stenosis of the distal main renal artery. This histologic variant is notable for the accumulation of fibrous tissue within the intima with a moderately cellular component with mainly intact or partially fragmented elastic lamina (Fig. 91-24). Perimedial fibroplasia and medial hyperplasia are uncommon variants.

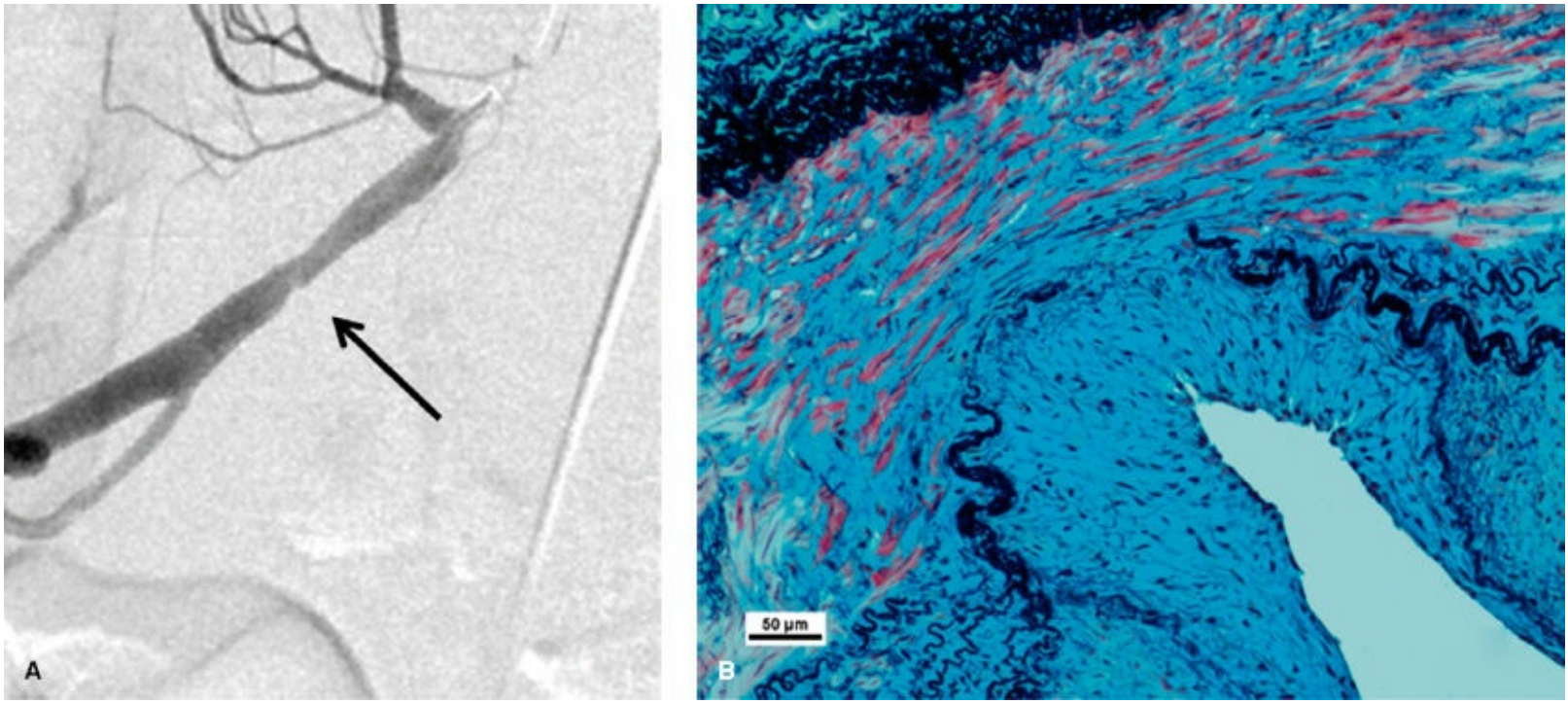

Figure 91-23. **A:** Right renal arteriogram demonstrating a radiographically subtle focal midartery stenosis (*arrow*); manometry across this lesion revealed a significant pressure gradient. **B:** Intimal fibroplasia as represented by pronounced intimal proliferation and partial fragmentation of the elastic lamina (*Movat stain, 20×*).

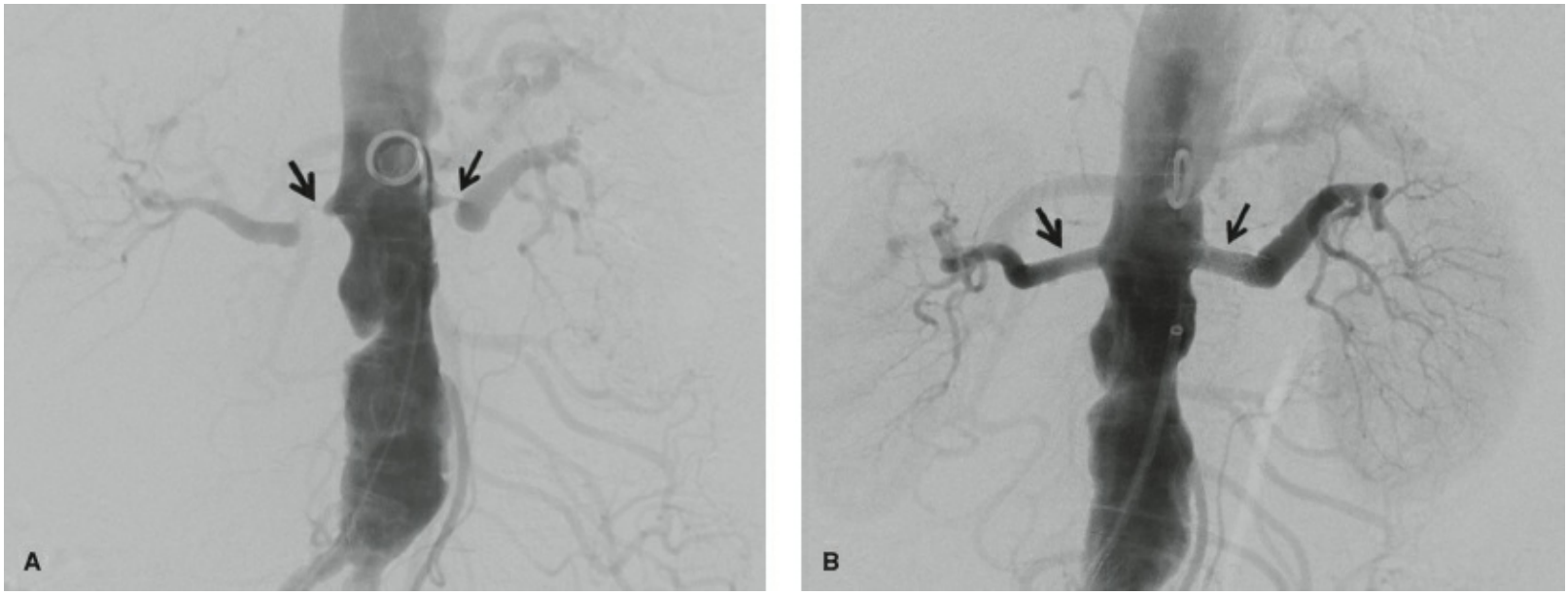

Figure 91-24. Aortogram demonstrating a highly irregular perirenal aorta with (**A**) high-grade bilateral renal artery stenosis (*arrows*) successfully treated with (**B**) bilateral renal artery stents (*arrows*). The stents are positioned with appropriate overlap into the aorta and are ballooned proximally such that they "flower" into the aorta.

MEDICAL MANAGEMENT OF RENOVASCULAR HYPERTENSION

8 Medical therapy remains the mainstay of treatment for RVH with comprehensive goals of care that should encompass glycemic control, cholesterol reduction, smoking cessation, blood pressure reduction, and antiplatelet therapy with aspirin for primary prevention. ACC/AHA guidelines support the use of ACE inhibitors (ACE-I), angiotensin receptor blockers (ARBs), calcium channel blockers, and beta blockers with a class I indication.[157] While beta blockers are often utilized first line, ACE-Is and ARBs are a mainstay of treatment for most antihypertensive regimens offering 86% to 92% efficacy.[170] Renal function monitoring is essential with the initiation of these agents as the resulting modulation of the renin–angiotensin system with renal artery stenosis affecting a solitary functioning kidney, severe bilateral RAS or advanced chronic kidney disease may result in acute renal failure.

SURGICAL AND ENDOVASCULAR MANAGEMENT OF RENAL ARTERY OCCLUSIVE DISEASE

As RAS may progress with concomitant renal atrophy, renal revascularization should be considered in select cases. Current ACC/AHA guidelines support renal revascularization for hemodynamically significant RAS in several clinical scenarios (Table 91-2).

Arterial Reconstructive Surgery for Renal Artery Occlusive Disease

Historically open revascularization procedures represented the standard of care in the treatment of RVH. The most common option for open renal revascularization remains aortorenal bypass with either autogenous reversed saphenous vein or prosthetic conduit. Alternatives may include (1) nonanatomic renal bypass based off the hepatic, splenic, or iliac arteries, (2) ex vivo renal artery reconstruction, and (3) aortorenal endarterectomy. Nonanatomic (or extra-anatomic) renal artery bypass may benefit those patients with medical comorbidities or aortic anatomy that prohibit aortic cross-clamping and aortorenal bypass.[176–180] The hepatic artery is used for a right-sided renal reconstruction, the splenic artery for a left-sided reconstruction. Ex vivo renal artery reconstruction may be considered selectively for those patients with complex, distal segmental arterial occlusive disease when balanced with the risk of prolonged operative time, disruption of pre-existing collaterals, and the need for renal cooling.[181,182] Transaortic and direct renal artery endarterectomy is particularly useful for those patients with bilateral disease, or when arteriosclerotic renal artery occlusive disease affects multiple (i.e., accessory) renal arteries.[183–185]

Table 91-2 Indications for Renal Revascularization for Hemodynamically Significant Renal Artery Stenosis

Indication	Class Recommendation	Level of Evidence
Asymptomatic bilateral or solitary viable kidney disease	2B	C
Accelerated HTN, resistant HTN, malignant HTN, HTN with unexplained unilateral small kidney, and HTN with intolerance to medication	2A	B
Progressive kidney disease with bilateral RAS or an RAS to a solitary functioning kidney	2A	B
Chronic renal insufficiency with unilateral RAS	2B	C
Recurrent unexplained congestive heart failure or sudden, unexplained pulmonary edema	1	B
Unstable angina	2A	B

Adapted from the 2005 Practice Guidelines for the management of patients with peripheral arterial disease.[157]

Open surgical revascularization offers significant blood pressure and renal function improvement in 85% and 50% of patients, respectively across high-volume centers with mortality rates of 2% to 5%.[169,186–189] While to date there has been no definitive trial comparing open surgical revascularization directly to endovascular therapy, angioplasty, and stenting appears to offer similar effectiveness with lower morbidity and mortality. As such, endovascular measures have replaced surgery as first-line therapy for RVH.[189,190] Contemporary open surgical renal reconstructions most commonly accompany hybrid endovascular interventions for aortic aneurysmal disease and may be considered for failed endovascular renal revascularization.

Endovascular Renal Revascularization

Since its introduction in 1978, percutaneous renal artery angioplasty (PTA), with or without stent placement, has virtually replaced open surgical reconstruction of arteriosclerotic renal artery stenosis. This technique has exploded in use and for over a decade has been utilized at times perhaps inappropriately as "prophylactic" therapy to treat clinically irrelevant renal artery stenoses.[191,192] Renal artery angioplasty alone risks arterial dissection from lesion/vessel recoil and early restenosis. Technical success rates of PTA may be as low as 30% to 50% in patients with significant aortic "spill over" lesions. PTA with stenting offers improved success and very reasonable long-term patency with 5-year secondary patency rates >90%.[193,194]

9 Several recent clinical trials comparing renal artery stenting (RAS) to best medical management for renal artery stenosis have failed to demonstrate a conclusive clinical benefit to the endovascular treatment of renal artery stenosis (Table 91-3).[195–199] Moreover, RAS is associated with a 1.5% to 8% risk of major morbidity that can include infected hematoma, atheroemboli, renal failure requiring dialysis, and lower extremity limb loss. Significant limitations apply to all of these studies, including design flaws and selection bias.

The appropriate patient for revascularization remains elusive. Most would suggest that those patients with refractory hypertension despite an appropriate medical regimen that includes a combination of ACE inhibition or angiotensin receptor blockade + diuretic + amlodipine with both a hemodynamically significant stenosis by manometric pressure gradient and overall preserved renal mass should still be considered for therapy.[200] Notably, evolving data have identified several promising predictors for clinical improvement following renal revascularization including bilateral RAS, mean arterial pressure >110 mm Hg, elevated baseline brain natriuretic peptide, elevated pulse pressure, and renal perfusion as measured by "renal frame count" during angiography (defined as the number of frames required for dye to pass through the renal parenchyma).[200–204] Ongoing study remains necessary to identify consistent indications for RAS and reliable clinical predictors of successful outcomes following renal revascularization.

Although randomized, controlled trials assessing renal revascularization for renal artery FMD are lacking, current guidelines support the following indications for renal revascularization in this patient cohort: (1) resistant HTN despite an appropriate three-drug regimen, (2) HTN of short duration with the goal being a cure of hypertension, (3) renal artery dissection, (4) RAA, and (5) preservation of renal function in patients with severe stenosis.[172,205] PTA of the renal artery is the procedure of choice for patients with renal artery stenosis secondary to FMD offering cure rates that approach 50%, with up to 86% of patients improved following PTA, a 20% risk of reintervention, and low risk of minor complications.[172] Hemodynamic significance must be documented by manometry prior to any intervention in these patients and success should be defined by resolution of this gradient postangioplasty. Stenting should be utilized selectively.

Table 91-3 Contemporary Clinical Trials Comparing the Effectiveness of Endovascular Renal Artery Revascularization to Medical Therapy

Trial	Number of Patients	Degree Stenosis	Indications for Renal Artery Revascularization	F/U (yrs)	BP Response	Renal Function Improvement or Stabilization
DRASTIC Trial[196] (PTA)	106	≥50%	Resistant HTN	1	No difference	N/A
STAR Trial[195] (RAS)	140	>50%	Renal impairment (GFR <80 mL/min)	2	No difference	No difference
ASTRAL[197] (RAS)	806	Variable	Refractory HTN or unexplained renal dysfunction with RAS suggested by imaging	5	No difference (systolic)[a]	Decreased progression of renal impairment and lower mean Cr level following revascularization
CORAL[198] (RAS)	931	≥60% + 20 mm Hg systolic pressure gradient -or- ≥80%	Systolic HTN ≥155 mm Hg despite at least two antihypertensives	43 mo	2.3 mm Hg reduction following RAS (vs. medical therapy) ($p = 0.03$).	No difference[b]

HTN, hypertension; PTA, angioplasty alone; RAS, renal artery stent; BP, blood pressure; Cr, creatinine.
[a]The decrease in diastolic BP was smaller in the revascularization group.
[b]Composite end point included death from cardiovascular or renal causes, myocardial infarction, stroke, hospitalization for congestive heart failure, progressive renal insufficiency, or the need for renal-replacement therapy.

Developmental Dysplasia

Renovascular HTN secondary to renal artery stenosis and abdominal aortic coarctation remain an important cause of pediatric HTN, the natural history of which risks failure to thrive, heart failure, hypertensive encephalopathy, impaired mental development, hemorrhagic stroke, and early mortality.[206] It is estimated that 5% to 10% of pediatric HTN may be explained by renovascular disease, following thoracic aortic coarctation and parenchymal renal disease in incidence.[206,207] The pathophysiology of pediatric renovascular disease remains ill defined, as are the mechanisms by which pediatric renovascular disease occur. FMD and neurofibromatosis type 1 (NF1) are reported as the most common causes of pediatric renal artery stenosis in the western world.[208] While the intimal FMD variant described above is uncommon in adults, it is the most common form identified in children with renal artery stenosis. Furthermore, histopathologic review of operative renal artery samples excised from patient with developmental arterial stenosis reveal mainly consistent findings of intimal hyperplasia, medial thinning, and disruption of the elastic lamina (Fig. 91-21).

Open surgical revascularization of renal artery stenosis remains the gold standard for children with developmental lesions.[206] Aortorenal reimplantation with spatulation of the renal artery and interrupted suture lines is favored. Alternatively aortorenal bypass using hypogastric artery as conduit is favored over autogenous venous conduit, which can dilate over time to become aneurysmal. Approximately one-third of children will demonstrate associated aortic coarctation and require concomitant patch aortoplasty or aortoaortic bypass. The University of Michigan experience reports that benefits regarding blood pressure control have accrued in 97% of children with this practice; specifically HTN has been cured in 70%, improved in 27% and unchanged in 3%.[206]

There may be a role for angioplasty for selected cases of pediatric renal artery stenosis. Certainly this procedure has gained substantial momentum in the past decade. The most robust U.S. experience includes the treatment of 19 hypertensive children aged 2 to 18 years that underwent PTA for renal artery stenosis, of which 7 patients carried the diagnosis of NF.[209] While immediate technical success was reported as 91%, only 39% of patients achieved a cure in HTN and an additional 17% of children demonstrated improvement. In total there was a 44% rate of clinical failure and these authors conclude that despite a high rate of technical success, PTA provides a clinical benefit in a smaller majority of children. This is consistent with improvement or cure rates that mainly average 50% to 60% across larger series of pediatric renal artery stenosis treated with PTA.[210–212] Notably, renal PTA for the treatment of pediatric RVH due to ostial disease may be complicated by failures requiring remedial operations that are made more complicated by such or nephrectomy.[213] Moreover, HTN cure is less likely following remedial operation (24% in comparison to 70% as referenced above).

RENAL ARTERY ANEURYSM

RAAs are rare with an incidence of 0.1% in the general population.[214–217] The natural history of RAAs appears to be that of slow to null growth with contemporary series estimating a median annualized growth rate of 0.06 to 0.6 mm.[218–220] Aneurysm growth rate does not seem to be affected by aneurysm morphology or calcification.[219] While historic series describe rupture rates as high as 14% to 30% with associated mortality of 80%, contemporary rupture rates are estimated at 3% to 5% with nongestational mortality $<10\%$.[214,217,221–224] Most ruptures are diagnosed at the time of presentation and several authors have supported no rupture during the surveillance of nonoperative RAAs.[225]

Similar to other splanchnic artery aneurysms, RAAs typically present in the sixth decade with women more commonly affected than men.[214,221] Most patients will describe no symptoms, although flank pain and hematuria are most common when symptoms do arise. Clinical examination may reveal HTN, renal bruit or a palpable abdominal mass. Aneurysms are typically solitary, saccular, located at arterial bifurcations, and affect the right renal artery more often than the left.[225] Almost 70% of RAA may be associated with FMD and up to 30% of patients will have an alternate arterial aneurysm.[214,225,226] These aneurysms are commonly identified as an incidental finding by axial imaging; CT is the most common contemporary diagnostic modality, followed by magnetic resonance imaging, ultrasonography, and catheter-based arteriography.[219] Conventional preoperative arteriography is warranted given the frequency of multiple aneurysms and arterial dysplasia affecting distal branches that may be missed on conventional cross-sectional imaging.

Currently accepted indications for RAA intervention include size >2 cm, female gender within childbearing age, symptoms like pain and hematuria, medically refractory HTN including that associated with functionally important renal artery stenosis, thromboembolism, dissection and rupture. Given the low risk of rupture, slow to null rate of growth, and improved survival following rupture some authors have suggested that a size threshold alone of 2 cm may be antiquated and too aggressive for surgical indication.[218,219] The potential for gestational rupture remains a valid indication for repair in women of child-bearing age as rupture during pregnancy has been described in aneurysms as small as 1 cm and historic reports suggest maternal and fetal mortality rates that approach 92% and 100%, respectively.[227,228] Pregnancy has previously been associated with a higher rate of RAA rupture, thought to result from increased vascular flow and hormonal changes resulting in weakening of the vessel wall elastic tissue, no large scale studies report the true incidence.[215,225] Gestational RAA ruptures occur mainly in the third trimester with only a few case reports of rupture postdelivery.[229] Notably, contemporary outcomes for both mother and fetus may be improving, as there are recent case reports of gestational rupture resulting in both maternal and fetal survival.

Approximately 70% of patients with RAA have HTN, with up to 100% affected in some series.[214,218,220–224,226,228] Hypotheses for the mechanism of HTN include (1) coexistent renal artery occlusive disease, (2) distal parenchymal embolization, (3) compression or

kinking of associated renal artery branches, and (4) hemodynamic changes from turbulent blood flow within the aneurysm results in decreased distal renal artery perfusion.[214,224] Most series suggest improvement or cure in the majority of hypertensive patients undergoing RAA reconstruction, with postoperative improvement more likely when RVH or renal artery stenosis is identified preoperatively.[221,225,228]

Open surgical repair remains the gold standard for RAA management as these procedures performed in the elective setting offer low morbidity, negligible mortality, and durable patency.[218,219,221–224,226,230,231] Options for conventional in situ reconstruction may include aneurysm resection with (1) primary angioplastic closure with or without branch reimplantation, (2) patch angioplasty, (3) primary reanastomosis, (4) interposition bypass, (5) aortorenal bypass, (6) splanchnorenal bypass, and (7) plication of small aneurysms. While complex distal branch lesions were historically treated with nephrectomy, they may rather best be approached with ex vivo repair and autotransplantation which offers excellent technical success without major morbidity or mortality.[181,232] Most recently, robotic techniques have been introduced that may become more prevalent in future practices.[233,234] Most authors advocate completion imaging before hospital discharge and long-term follow-up with surveillance imaging.

While traditional endovascular therapies for RAA have utilized coil embolization for distal and parenchymal aneurysms and stent graft exclusion for main renal artery lesions, the indications for endovascular repair have broadened with the introduction of three-dimensional detachable coils, nonadhesive liquid embolic agents (i.e., Onyx), remodeling techniques (which include balloon- and stent-assisted coiling), and flow diverter stents (i.e., the Cardiatis multilayer stent).[225,235–237] Technical success is suggested as 73% to 100% across series with highly variable rates of morbidity (13% to 60%) that include primarily radiographic evidence of end organ malperfusion from thromboembolism and subsequent postembolization syndrome, negligible evidence of arterial dissections or renal compromise, and low rates of recanalization requiring reintervention (4% to 13%).[231,238–240] Although prospective data are lacking, limited comparisons of open surgical and endovascular procedures have reported no significant difference in mortality, perioperative morbidity, freedom from reintervention, decline in renal function, or length of stay.[219,231,241]

References

1. Rosenblum JD, Boyle CM, Schwartz LB. The mesenteric circulation. Anatomy and physiology. *Surg Clin North Am* 1997;77:289–306.
2. Paterno F, Longo WE. The etiology and pathogenesis of vascular disorders of the intestine. *Radiol Clin North Am* 2008;46:877–885
3. Deitch EA. The role of intestinal barrier failure and bacterial translocation in the development of systemic infection and multiple organ failure. *Arch Surg* 1990;125:403–404.
4. Boley SJ, Brandt LJ, Sammartano RJ. History of mesenteric ischemia. The evolution of a diagnosis and management. *Surg Clin North Am* 1997;77:275–288.
5. Klass AA. Embolectomy in acute mesenteric occlusion. *Ann Surg* 1951;134: 913–917.
6. Wyers MC. Acute mesenteric ischemia: diagnostic approach and surgical treatment. *Semin Vasc Surg* 2010;23:9–20.
7. Kassahun WT, Schulz T, Richter O, et al. Unchanged high mortality rates from acute occlusive intestinal ischemia: six year review. *Langenbecks Arch Surg* 2008;393:163–171.
8. Acosta S. Epidemiology of mesenteric vascular disease: clinical implications. *Semin Vasc Surg* 2010;23:4–8.
9. Endean ED, Barnes SL, Kwolek CJ, et al. Surgical management of thrombotic acute intestinal ischemia. *Ann Surg* 2001;233:801–808.
10. Edwards MS, Cherr GS, Craven TE, et al. Acute occlusive mesenteric ischemia: surgical management and outcomes. *Ann Vasc Surg* 2003;17:72–79.
11. Acosta S, Ogren M, Sternby NH, et al. Incidence of acute thrombo-embolic occlusion of the superior mesenteric artery–a population-based study. *Eur J Vasc Endovasc Surg* 2004;27:145–150.
12. Marchena-Gomez J, Acosta-Merida MA, Hemmersbach-Miller M, et al. The age-adjusted Charlson Comorbidity Index as an outcome predictor of patients with acute mesenteric ischemia. *Ann Vasc Surg* 2009;23:458–464.
13. Ryer EJ, Kalra M, Oderich GS, et al. Revascularization for acute mesenteric ischemia. *J Vasc Surg* 2012;55:1682–1689.
14. Kougias P, Lau D, El Sayed HF, et al. Determinants of mortality and treatment outcome following surgical interventions for acute mesenteric ischemia. *J Vasc Surg* 2007;46:467–474.
15. Haga Y, Odo M, Homma M, et al. New prediction rule for mortality in acute mesenteric ischemia. *Digestion* 2009;80:104–111.
16. Acosta S, Nilsson T. Current status on plasma biomarkers for acute mesenteric ischemia. *J Thromb Thrombolysis* 2012;33:355–361.
17. Acosta S, Nilsson TK, Björck M. D-dimer testing in patients with suspected acute thromboembolic occlusion of the superior mesenteric artery. *Br J Surg* 2004;91:991–

994.
18. Evennett NJ, Petrov MS, Mittal A, et al. Systematic review and pooled estimates for the diagnostic accuracy of serological markers for intestinal ischemia. *World J Surg* 2009;33:1374–1383.
19. Kirkpatrick ID, Kroeker MA, Greenberg HM. Biphasic CT with mesenteric CT angiography in the evaluation of acute mesenteric ischemia: initial experience. *Radiology* 2003;229:91–98.
20. Aschoff AJ, Stuber G, Becker BW, et al. Evaluation of acute mesenteric ischemia: accuracy of biphasic mesenteric multi-detector CT angiography. *Abdom Imaging* 2009;34:345–357.
21. Milner R, Woo EY, Carpenter JP. Superior mesenteric artery angioplasty and stenting via a retrograde approach in a patient with bowel ischemia–a case report. *Vasc Endovascular Surg* 2004;38:89–91.
22. Wyers MC, Powell RJ, Nolan BW, et al. Retrograde mesenteric stenting during laparotomy for acute occlusive mesenteric ischemia. *J Vasc Surg* 2007;45:269–275.
23. Blauw JT, Meerwaldt R, Brusse-Keizer M, et al. Retrograde open mesenteric stenting for acute mesenteric ischemia. *J Vasc Surg* 2014;60:726–734.
24. Kuhelj D, Kavcic P, Popovic P. Percutaneous mechanical thrombectomy of superior mesenteric artery embolism. *Radiol Oncol* 2013;47:239–243.
25. Kim BG, Ohm JY, Bae MN, et al. Successful percutaneous aspiration thrombectomy for acute mesenteric ischemia in a patient with atrial fibrillation despite optimal anticoagulation therapy. *Can J Cardiol* 2013;29:1329 e5–e7.
26. Jia Z, Jiang G, Tian F, et al. Early endovascular treatment of superior mesenteric occlusion secondary to thromboemboli. *Eur J Vasc Endovasc Surg* 2014;47:196–203.
27. Yang HJ, Cho YK, Jo YJ, et al. Successful recanalization of acute superior mesenteric artery thrombotic occlusion with primary aspiration thrombectomy. *World J Gastroenterol* 2010;16:4112–4114.
28. Schoots IG, Levi MM, Reekers JA, et al. Thrombolytic therapy for acute superior mesenteric artery occlusion. *J Vasc Interv Radiol* 2005;16:317–329.
29. Resch TA, Acosta S, Sonesson B. Endovascular techniques in acute arterial mesenteric ischemia. *Semin Vasc Surg* 2010;23:29–35.
30. Arthurs ZM, Titus J, Bannazadeh M, et al. A comparison of endovascular revascularization with traditional therapy for the treatment of acute mesenteric ischemia. *J Vasc Surg* 2011;53:698–704; discussion 704-705.
31. Beaulieu RJ, Arnaoutakis KD, Abularrage CJ, et al. Comparison of open and endovascular treatment of acute mesenteric ischemia. *J Vasc Surg* 2014;59:159–164.
32. Harnik IG, Brandt LJ. Mesenteric venous thrombosis. *Vasc Med* 2010;15: 407–418.
33. Morasch MD, Ebaugh JL, Chiou AC, et al. Mesenteric venous thrombosis: a changing clinical entity. *J Vasc Surg* 2001;34:680–684.
34. Amitrano L, Guardascione MA, Scaglione M, et al. Prognostic factors in noncirrhotic

patients with splanchnic vein thromboses. *Am J Gastroenterol* 2007;102:2464–2470.
35. Abdu RA, Zakhour BJ, Dallis DJ. Mesenteric venous thrombosis–1911 to 1984. *Surgery* 1987;101:383–388.
36. Dentali F, Ageno W, Witt D, et al. Natural history of mesenteric venous thrombosis in patients treated with vitamin K antagonists: a multi-centre, retrospective cohort study. *Thromb Haemost* 2009;102:501–504.
37. Condat B, Pessione F, Hillaire S, et al. Current outcome of portal vein thrombosis in adults: risk and benefit of anticoagulant therapy. *Gastroenterology* 2001;120:490–497.
38. Kearon C, Akl EA, Comerota AJ, et al. Antithrombotic therapy for VTE disease: Antithrombotic Therapy and Prevention of Thrombosis, 9th ed: American College of Chest Physicians Evidence-Based Clinical Practice Guidelines. *Chest* 2012;141:e419S–e494S.
39. Yang S, Liu B, Ding W, et al. Acute superior mesenteric venous thrombosis: transcatheter thrombolysis and aspiration thrombectomy therapy by combined route of superior mesenteric vein and artery in eight patients. *Cardiovasc Intervent Radiol* 2015;38:88–99.
40. Wichman HJ, Cwikiel W, Keussen I. Interventional treatment of mesenteric venous occlusion. *Pol J Radiol* 2014;79:233–238.
41. Robin P, Gruel Y, Lang M, et al. Complete thrombolysis of mesenteric vein occlusion with recombinant tissue-type plasminogen activator. *Lancet* 1988;1:1391.
42. Lopera JE, Correa G, Brazzini A, et al. Percutaneous transhepatic treatment of symptomatic mesenteric venous thrombosis. *J Vasc Surg* 2002;36: 1058–1061.
43. Mesh CL, Gewertz BL. The effect of hemodilution on blood flow regulation in normal and postischemic intestine. *J Surg Res* 1990;48:183–189.
44. Oshima A, Kitajima M, Sakai N, et al. Does glucagon improve the viability of ischemic intestine? *J Surg Res* 1990;49:524–533.
45. Kamimura K, Oosaki A, Sugahara S, et al. Survival of three nonocclusive mesenteric ischemia patients following early diagnosis by multidetector row computed tomography and prostaglandin E1 treatment. *Intern Med* 2008;47:2001–2006.
46. Park WM, Gloviczki P, Cherry KJ Jr., et al. Contemporary management of acute mesenteric ischemia: factors associated with survival. *J Vasc Surg* 2002;35:445–452.
47. Hansen KJ, Wilson DB, Craven TE, et al. Mesenteric artery disease in the elderly. *J Vasc Surg* 2004;40:45–52.
48. Moneta GL, Lee RW, Yeager RA, et al. Mesenteric duplex scanning: a blinded prospective study. *J Vasc Surg* 1993;17:79–84; discussion 85–6.
49. Foley MI, Moneta GL, Abou-Zamzam AM Jr., et al. Revascularization of the superior mesenteric artery alone for treatment of intestinal ischemia. *J Vasc Surg* 2000;32:37–47.
50. Cho JS, Carr JA, Jacobsen G, et al. Long-term outcome after mesenteric artery reconstruction: a 37-year experience. *J Vasc Surg* 2002;35:453–460.

51. Illuminati G, Calio FG, D'Urso A, et al. The surgical treatment of chronic intestinal ischemia: results of a recent series. *Acta Chir Belg* 2004;104:175–183.
52. Kruger AJ, Walker PJ, Foster WJ, et al. Open surgery for atherosclerotic chronic mesenteric ischemia. *J Vasc Surg* 2007;46:941–945.
53. Atkins MD, Kwolek CJ, LaMuraglia GM, et al. Surgical revascularization versus endovascular therapy for chronic mesenteric ischemia: a comparative experience. *J Vasc Surg* 2007;45:1162–1171.
54. Oderich GS, Bower TC, Sullivan TM, et al. Open versus endovascular revascularization for chronic mesenteric ischemia: risk-stratified outcomes. *J Vasc Surg* 2009;49:1472–1479 e3.
55. Mell MW, Acher CW, Hoch JR, et al. Outcomes after endarterectomy for chronic mesenteric ischemia. *J Vasc Surg* 2008;48:1132–1138.
56. Oderich GS, Gloviczki P, Bower TC. Open surgical treatment for chronic mesenteric ischemia in the endovascular era: when it is necessary and what is the preferred technique? *Semin Vasc Surg* 2010;23:36–46.
57. Oderich GS, Malgor RD, Ricotta JJ 2nd. Open and endovascular revascularization for chronic mesenteric ischemia: tabular review of the literature. *Ann Vasc Surg* 2009;23:700–712.
58. Sarac TP, Altinel O, Kashyap V, et al. Endovascular treatment of stenotic and occluded visceral arteries for chronic mesenteric ischemia. *J Vasc Surg* 2008;47:485–491.
59. Sharafuddin MJ, Nicholson RM, Kresowik TF, et al. Endovascular recanalization of total occlusions of the mesenteric and celiac arteries. *J Vasc Surg* 2012;55:1674–1681.
60. Brown DJ, Schermerhorn ML, Powell RJ, et al. Mesenteric stenting for chronic mesenteric ischemia. *J Vasc Surg* 2005;42:268–274.
61. Sivamurthy N, Rhodes JM, Lee D, et al. Endovascular versus open mesenteric revascularization: immediate benefits do not equate with short-term functional outcomes. *J Am Coll Surg* 2006;202:859–867.
62. Tallarita T, Oderich GS, Macedo TA, et al. Reinterventions for stent restenosis in patients treated for atherosclerotic mesenteric artery disease. *J Vasc Surg* 2011;54:1422–1429 e1.
63. Malgor RD, Oderich GS, McKusick MA, et al. Results of single- and two-vessel mesenteric artery stents for chronic mesenteric ischemia. *Ann Vasc Surg* 2010;24:1094–1101.
64. Oderich GS, Erdoes LS, Lesar C, et al. Comparison of covered stents versus bare metal stents for treatment of chronic atherosclerotic mesenteric arterial disease. *J Vasc Surg* 2013;58:1316–1323.
65. Schermerhorn ML, Giles KA, Hamdan AD, et al. Mesenteric revascularization: management and outcomes in the United States, 1988–2006. *J Vasc Surg* 2009;50:341–348 e1.

66. Dunbar JD, Molnar W, Beman FF, et al. Compression of the celiac trunk and abdominal angina. *Am J Roentgenol Radium Ther Nucl Med* 1965;95:731–744.
67. Jimenez JC, Harlander-Locke M, Dutson EP. Open and laparoscopic treatment of median arcuate ligament syndrome. *J Vasc Surg* 2012;56:869–873.
68. Mensink PB, van Petersen AS, Kolkman JJ, et al. Gastric exercise tonometry: the key investigation in patients with suspected celiac artery compression syndrome. *J Vasc Surg* 2006;44:277–281.
69. Derrick JR, Pollard HS, Moore RM. The pattern of arteriosclerotic narrowing of the celiac and superior mesenteric arteries. *Ann Surg* 1959;149:684–689.
70. Park CM, Chung JW, Kim HB, et al. Celiac axis stenosis: incidence and etiologies in asymptomatic individuals. *Korean J Radiol* 2001;2:8–13.
71. Scholbach T. Celiac artery compression syndrome in children, adolescents, and young adults: clinical and color duplex sonographic features in a series of 59 cases. *J Ultrasound Med* 2006;25:299–305.
72. Skeik N, Cooper LT, Duncan AA, et al. Median arcuate ligament syndrome: a nonvascular, vascular diagnosis. *Vasc Endovascular Surg* 2011;45: 433–437.
73. Tulloch AW, Jimenez JC, Lawrence PF, et al. Laparoscopic versus open celiac ganglionectomy in patients with median arcuate ligament syndrome. *J Vasc Surg* 2010;52:1283–1289.
74. Grotemeyer D, Duran M, Iskandar F, et al. Median arcuate ligament syndrome: vascular surgical therapy and follow-up of 18 patients. *Langenbecks Arch Surg* 2009;394:1085–1092.
75. Stanley JC, Fry WJ. Median arcuate ligament syndrome. *Arch Surg* 1971;103:252–258.
76. Evans WE. Long-term evaluation of the celiac band syndrome. *Surgery* 1974;76:867–871.
77. van Petersen AS, Vriens BH, Huisman AB, et al. Retroperitoneal endoscopic release in the management of celiac artery compression syndrome. *J Vasc Surg* 2009;50:140–147.
78. Aschenbach R, Basche S, Vogl TJ. Compression of the celiac trunk caused by median arcuate ligament in children and adolescent subjects: evaluation with contrast-enhanced MR angiography and comparison with Doppler US evaluation. *J Vasc Interv Radiol* 2011;22:556–561.
79. Reilly LM, Ammar AD, Stoney RJ, et al. Late results following operative repair for celiac artery compression syndrome. *J Vasc Surg* 1985;2:79–91.
80. Williams S, Gillespie P, Little JM. Celiac axis compression syndrome: factors predicting a favorable outcome. *Surgery* 1985;98:879–887.
81. Duffy AJ, Panait L, Eisenberg D, et al. Management of median arcuate ligament syndrome: a new paradigm. *Ann Vasc Surg* 2009;23:778–784.
82. Relles D, Moudgill N, Rao A, et al. Robotic-assisted median arcuate ligament release.

J Vasc Surg 2012;56:500–503.
83. Carr SC, Pearce WH, Vogelzang RL, et al. Current management of visceral artery aneurysms. *Surgery* 1996;120:627–633; discussion 633–634.
84. Stanley JC, Wakefield TW, Graham LM, et al. Clinical importance and management of splanchnic artery aneurysms. *J Vasc Surg* 1986;3:836–840.
85. Bedford PD, Lodge B. Aneurysm of the splenic artery. *Gut* 1960;1:312–320.
86. Cochennec F, Riga CV, Allaire E, et al. Contemporary management of splanchnic and renal artery aneurysms: results of endovascular compared with open surgery from two European vascular centers. *Eur J Vasc Endovasc Surg* 2011;42:340–346.
87. Pasha SF, Gloviczki P, Stanson AW, et al. Splanchnic artery aneurysms. *Mayo Clin Proc* 2007;82:472–479.
88. Pitton MB, Dappa E, Jungmann F, et al. Visceral artery aneurysms: incidence, management, and outcome analysis in a tertiary care center over one decade. *Eur Radiol* 2015;25:2004–2014.
89. Pulli R, Dorigo W, Troisi N, et al. Surgical treatment of visceral artery aneurysms: a 25-year experience. *J Vasc Surg* 2008;48:334–342.
90. Marone EM, Mascia D, Kahlberg A, et al. Is open repair still the gold standard in visceral artery aneurysm management? *Ann Vasc Surg* 2011;25:936–946.
91. Shukla AJ, Eid R, Fish L, et al. Contemporary outcomes of intact and ruptured visceral artery aneurysms. *J Vasc Surg* 2015;61:1442–1447.
92. Sachdev U, Baril DT, Ellozy SH, et al. Management of aneurysms involving branches of the celiac and superior mesenteric arteries: a comparison of surgical and endovascular therapy. *J Vasc Surg* 2006;44:718–724.
93. Saltzberg SS, Maldonado TS, Lamparello PJ, et al. Is endovascular therapy the preferred treatment for all visceral artery aneurysms? *Ann Vasc Surg* 2005;19:507–515.
94. Ferrero E, Ferri M, Viazzo A, et al. Visceral artery aneurysms, an experience on 32 cases in a single center: treatment from surgery to multilayer stent. *Ann Vasc Surg* 2011;25:923–935.
95. Lakin RO, Bena JF, Sarac TP, et al. The contemporary management of splenic artery aneurysms. *J Vasc Surg* 2011;53:958–964; discussion 965.
96. Stanley JC, Fry WJ. Pathogenesis and clinical significance of splenic artery aneurysms. *Surgery* 1974;76:898–909.
97. Shanley CJ, Shah NL, Messina LM. Common splanchnic artery aneurysms: splenic, hepatic, and celiac. *Ann Vasc Surg* 1996;10:315–322.
98. Nanez L, Knowles M, Modrall JG, et al. Ruptured splenic artery aneurysms are exceedingly rare in pregnant women. *J Vasc Surg* 2014;60:1520–1523.
99. Akbulut S, Otan E. Management of giant splenic artery aneurysm: comprehensive literature review. *Medicine (Baltimore)* 2015;94:e1016.
100. Le Tinier B, Jungo-Nancoz C, McCarey C, et al. Rupture of maternal splenic artery

aneurysm and fetal demise. *Clin Exp Obstet Gynecol* 2015;42:381–383.
101. McMahon DP, Ward WH, Harwood JL, et al. An institutional review of splenic artery aneurysm in childbearing-aged females and splenic artery aneurysm rupture during pregnancy. Is screening justified? *Mil Med* 2012;177:96–98.
102. Ayalon A, Wiesner RH, Perkins JD, et al. Splenic artery aneurysms in liver transplant patients. *Transplantation* 1988;45:386–389.
103. Bronsther O, Merhav H, Van Thiel D, et al. Splenic artery aneurysms occurring in liver transplant recipients. *Transplantation* 1991;52:723–724.
104. Sadat U, Dar O, Walsh S, et al. Splenic artery aneurysms in pregnancy–a systematic review. *Int J Surg* 2008;6:261–265.
105. Heestand G, Sher L, Lightfoote J, et al. Characteristics and management of splenic artery aneurysm in liver transplant candidates and recipients. *Am Surg* 2003;69:933–940.
106. Obuchi T, Sasaki A, Nakajima J, et al. Laparoscopic surgery for splenic artery aneurysm. *Surg Laparosc Endosc Percutan Tech* 2009;19:338–340.
107. Pietrabissa A, Ferrari M, Berchiolli R, et al. Laparoscopic treatment of splenic artery aneurysms. *J Vasc Surg* 2009;50:275–279.
108. Giulianotti PC, Buchs NC, Coratti A, et al. Robot-assisted treatment of splenic artery aneurysms. *Ann Vasc Surg* 2011;25:377–383.
109. Trastek VF, Pairolero PC, Joyce JW, et al. Splenic artery aneurysms. *Surgery* 1982;91:694–699.
110. Abbas MA, Stone WM, Fowl RJ, et al. Splenic artery aneurysms: two decades experience at Mayo clinic. *Ann Vasc Surg* 2002;16:442–449.
111. Hogendoorn W, Lavida A, Hunink MG, et al. Open repair, endovascular repair, and conservative management of true splenic artery aneurysms. *J Vasc Surg* 2014;60:1667–76 e1.
112. Marmagkiolis K, Gobal F, Mego D, et al. Endovascular management of splenic arterial aneurysms. *Int J Cardiol* 2014;174:146–149.
113. Patel A, Weintraub JL, Nowakowski FS, et al. Single-center experience with elective transcatheter coil embolization of splenic artery aneurysms: technique and midterm follow-up. *J Vasc Interv Radiol* 2012;23:893–899.
114. Piffaretti G, Tozzi M, Lomazzi C, et al. Splenic artery aneurysms: postembolization syndrome and surgical complications. *Am J Surg* 2007;193:166–170.
115. Guillon R, Garcier JM, Abergel A, et al. Management of splenic artery aneurysms and false aneurysms with endovascular treatment in 12 patients. *Cardiovasc Intervent Radiol* 2003;26:256–260.
116. Hogendoorn W, Lavida A, Hunink MG, et al. Cost-effectiveness of endovascular repair, open repair, and conservative management of splenic artery aneurysms. *J Vasc Surg* 2015;61:1432–1440.
117. Abbas MA, Fowl RJ, Stone WM, et al. Hepatic artery aneurysm: factors that predict

complications. *J Vasc Surg* 2003;38:41–45.

118. Ikeda O, Tamura Y, Nakasone Y, et al. Nonoperative management of unruptured visceral artery aneurysms: treatment by transcatheter coil embolization. *J Vasc Surg* 2008;47:1212–1219.
119. Nagaraja R, Govindasamy M, Varma V, et al. Hepatic artery pseudoaneurysms: a single-center experience. *Ann Vasc Surg* 2013;27:743–749.
120. Shanley CJ, Shah NL, Messina LM. Uncommon splanchnic artery aneurysms: pancreaticoduodenal, gastroduodenal, superior mesenteric, inferior mesenteric, and colic. *Ann Vasc Surg* 1996;10:506–515.
121. Stone WM, Abbas M, Cherry KJ, et al. Superior mesenteric artery aneurysms: is presence an indication for intervention? *J Vasc Surg* 2002;36:234–237; discussion 237.
122. Jiang J, Ding X, Su Q, et al. Therapeutic management of superior mesenteric artery aneurysms. *J Vasc Surg* 2011;53:1619–1624.
123. Yasuda S, Imoto K, Uchida K, et al. Successful endovascular treatment of a ruptured superior mesenteric artery in a patient with Ehlers–Danlos syndrome. *Ann Vasc Surg* 2013;27:975 e1–e5.
124. Cowan S, Kahn MB, Bonn J, et al. Superior mesenteric artery pseudoaneurysm successfully treated with polytetrafluoroethylene covered stent. *J Vasc Surg* 2002;35:805–857.
125. Mendonça CT, Weingartner J, de Carvalho CA, et al. Endovascular treatment of contained rupture of a superior mesenteric artery aneurysm resulting from neurofibromatosis type I. *J Vasc Surg* 2010;51:461–464.
126. Graham LM, Stanley JC, Whitehouse WM Jr, et al. Celiac artery aneurysms: historic (1745–1949) versus contemporary (1950–1984) differences in etiology and clinical importance. *J Vasc Surg* 1985;2:757–764.
127. Stone WM, Abbas MA, Gloviczki P, et al. Celiac arterial aneurysms: a critical reappraisal of a rare entity. *Arch Surg* 2002;137:670–674.
128. Graham JM, McCollum CH, DeBakey ME. Aneurysms of the splanchnic arteries. *Am J Surg* 1980;140:797.
129. Atkins BZ, Ryan JM, Gray JL. Treatment of a celiac artery aneurysm with endovascular stent grafting–a case report. *Vasc Endovascular Surg* 2003;37:367–373.
130. Inada K, Maeda M, Ikeda T. Segmental arterial mediolysis: unrecognized cases culled from cases of ruptured aneurysm of abdominal visceral arteries reported in the Japanese literature. *Pathol Res Pract* 2007;203:771–778.
131. Lagoudianakis EE, Filis KA, Tsekouras DK, et al. Endovascular obliteration of a ruptured right gastric artery aneurysm. *Minerva Gastroenterol Dietol* 2006;52:333–337.
132. Schellhammer F, Steinhaus D, Cohnen M, et al. Minimally invasive therapy of pseudoaneurysms of the trunk: application of thrombin. *Cardiovasc Intervent Radiol* 2008;31:535–541.

133. Sellke FW, Williams GB, Donovan DL, et al. Management of intra-abdominal aneurysms associated with periarteritis nodosa. *J Vasc Surg* 1986;4:294–298.
134. Naito A, Toyota N, Ito K. Embolization of a ruptured middle colic artery aneurysm. *Cardiovasc Intervent Radiol* 1995;18:56–58.
135. Turkbey B, Peynircioglu B, Akpinar E. Isolated aneurysm of the distal branch of the jejunal artery: MDCT angiographic diagnosis and endovascular management. *Cardiovasc Intervent Radiol* 2008;31(Suppl 2):S34–S37.
136. Goffi L, Chan R, Boccoli G, et al. Aneurysm of a jejunal branch of the superior mesenteric artery in a patient with Marfan's syndrome. *J Cardiovasc Surg (Torino)* 2000;41:321–323.
137. Coll DP, Ierardi R, Kerstein MD, et al. Aneurysms of the pancreaticoduodenal arteries: a change in management. *Ann Vasc Surg* 1998;12: 286–291.
138. Suzuki K, Kashimura H, Sato M, et al. Pancreaticoduodenal artery aneurysms associated with celiac axis stenosis due to compression by median arcuate ligament and celiac plexus. *J Gastroenterol* 1998;33:434–438.
139. Moore E, Matthews MR, Minion DJ, et al. Surgical management of peripancreatic arterial aneurysms. *J Vasc Surg* 2004;40:247–253.
140. Habib N, Hassan S, Abdou R, et al. Gastroduodenal artery aneurysm, diagnosis, clinical presentation and management: a concise review. *Ann Surg Innov Res* 2013;7:4.
141. de Perrot M, Berney T, Deleaval J, et al. Management of true aneurysms of the pancreaticoduodenal arteries. *Ann Surg* 1999;229:416–420.
142. Katsura M, Gushimiyagi M, Takara H, et al. True aneurysm of the pancreaticoduodenal arteries: a single institution experience. *J Gastrointest Surg* 2010;14:1409–1413.
143. Ghariani MZ, Georg Y, Ramirez C, et al. Long-term results of surgical treatment of aneurysms of digestive arteries. *Ann Vasc Surg* 2013;27: 954–958.
144. Eckhauser FE, Stanley JC, Zelenock GB, et al. Gastroduodenal and pancreaticoduodenal artery aneurysms: a complication of pancreatitis causing spontaneous gastrointestinal hemorrhage. *Surgery* 1980;88:335–344.
145. Balachandra S, Siriwardena AK. Systematic appraisal of the management of the major vascular complications of pancreatitis. *Am J Surg* 2005;190:489–495.
146. Manazer JR, Monzon JR, Dietz PA, et al. Treatment of pancreatic pseudoaneurysm with percutaneous transabdominal thrombin injection. *J Vasc Surg* 2003;38:600–602.
147. Edogawa S, Shibuya T, Kurose K, et al. Inferior mesenteric artery aneurysm: case report and literature review. *Ann Vasc Dis* 2013;6:98–101.
148. Mandeville KL, Bicknell C, Narula S, et al. Inferior mesenteric artery aneurysm with occlusion of the superior mesenteric artery, coeliac trunk and right renal artery. *Eur J Vasc Endovasc Surg* 2008;35:312–313.
149. Tsukioka K, Nobara H, Nishimura K. A case of inferior mesenteric artery aneurysm

with an occlusive disease in superior mesenteric artery and the celiac artery. *Ann Vasc Dis* 2010;3:160–163.

150. Troisi N, Esposito G, Cefali P, et al. A case of atherosclerotic inferior mesenteric artery aneurysm secondary to high flow state. *J Vasc Surg* 2011;54:205–207.
151. Samuels AI, Miller ED Jr., Fray JC, et al. Renin–angiotensin antagonists and the regulation of blood pressure. *Fed Proc* 1976;35:2512–2520.
152. Schneider EG, Davis JO, Baumber JS, et al. Renin, aldosterone, and hypertension. The hepatic metabolism of renin and aldosterone. A review with new observations on the hepatic clearance of renin. *Circ Res* 1970;27:175–183.
153. Stanley JC, Gewertz BL, Fry WJ. Renal: systemic renin indices and renal vein renin ratios as prognostic indicators in remedial renovascular hypertension. *J Surg Res* 1976;20:149–155.
154. Vaughan ED Jr., Buhler FR, Laragh JH, et al. Renovascular hypertension: renin measurements to indicate hypersecretion and contralateral suppression, estimate renal plasma flow, and score for surgical curability. *Am J Med* 1973;55:402–414.
155. Hansen KJ, Tribble RW, Reavis SW, et al. Renal duplex sonography: evaluation of clinical utility. *J Vasc Surg* 1990;12:227–236.
156. Taylor DC, Kettler MD, Moneta GL, et al. Duplex ultrasound scanning in the diagnosis of renal artery stenosis: a prospective evaluation. *J Vasc Surg* 1988;7:363–369.
157. Hirsch AT, Haskal ZJ, Hertzer NR, et al. ACC/AHA 2005 Practice Guidelines for the management of patients with peripheral arterial disease (lower extremity, renal, mesenteric, and abdominal aortic): a collaborative report from the American Association for Vascular Surgery/Society for Vascular Surgery, Society for Cardiovascular Angiography and Interventions, Society for Vascular Medicine and Biology, Society of Interventional Radiology, and the ACC/AHA Task Force on Practice Guidelines (Writing Committee to Develop Guidelines for the Management of Patients With Peripheral Arterial Disease): endorsed by the American Association of Cardiovascular and Pulmonary Rehabilitation; National Heart, Lung, and Blood Institute; Society for Vascular Nursing; TransAtlantic Inter-Society Consensus; and Vascular Disease Foundation. *Circulation* 2006;113:e463–e654.
158. Willmann JK, Wildermuth S, Pfammatter T, et al. Aortoiliac and renal arteries: prospective intraindividual comparison of contrast-enhanced three-dimensional MR angiography and multi-detector row CT angiography. *Radiology* 2003;226:798–811.
159. Tan KT, van Beek EJ, Brown PW, et al. Magnetic resonance angiography for the diagnosis of renal artery stenosis: a meta-analysis. *Clin Radiol* 2002;57:617–624.
160. Stanley JC, Fry WJ. Surgical treatment of renovascular hypertension. *Arch Surg* 1977;112:1291–1297.
161. Hansen KJ, Edwards MS, Craven TE, et al. Prevalence of renovascular disease in the elderly: a population-based study. *J Vasc Surg* 2002;36: 443–451.

162. Novick AC, Zaki S, Goldfarb D, et al. Epidemiologic and clinical comparison of renal artery stenosis in black patients and white patients. *J Vasc Surg* 1994;20:1–5.
163. Pearce JD, Craven BL, Craven TE, et al. Progression of atherosclerotic renovascular disease: a prospective population-based study. *J Vasc Surg* 2006;44:955–962; discussion 962–963.
164. Valentine RJ, Clagett GP, Miller GL, et al. The coronary risk of unsuspected renal artery stenosis. *J Vasc Surg* 1993;18:433–439; discussion 439–440.
165. Harding MB, Smith LR, Himmelstein SI, et al. Renal artery stenosis: prevalence and associated risk factors in patients undergoing routine cardiac catheterization. *J Am Soc Nephrol* 1992;2:1608–1616.
166. Crowley JJ, Santos RM, Peter RH, et al. Progression of renal artery stenosis in patients undergoing cardiac catheterization. *Am Heart J* 1998;136:913–918.
167. Edwards MS, Hansen KJ, Craven TE, et al. Associations between renovascular disease and prevalent cardiovascular disease in the elderly: a population-based study. *Vasc Endovascular Surg* 2004;38:25–35.
168. Valentine RJ, Martin JD, Myers SI, et al. Asymptomatic celiac and superior mesenteric artery stenoses are more prevalent among patients with unsuspected renal artery stenoses. *J Vasc Surg* 1991;14:195–199.
169. Stanley JC. The evolution of surgery for renovascular occlusive disease. *Cardiovasc Surg* 1994;2:195–202.
170. Safian RD, Textor SC. Renal-artery stenosis. *N Engl J Med* 2001;344: 431–442.
171. Olin JW, Froehlich J, Gu X, et al. The United States Registry for Fibromuscular Dysplasia: results in the first 447 patients. *Circulation* 2012;125: 3182–3190.
172. Olin JW, Gornik HL, Bacharach JM, et al. Fibromuscular dysplasia: state of the science and critical unanswered questions: a scientific statement from the American Heart Association. *Circulation* 2014;129: 1048–1078.
173. Cragg AH, Smith TP, Thompson BH, et al. Incidental fibromuscular dysplasia in potential renal donors: long-term clinical follow-up. *Radiology* 1989;172:145–147.
174. McCormack LJ, Poutasse EF, Meaney TF, et al. A pathologic-arteriographic correlation of renal arterial disease. *Am Heart J* 1966;72:188–198.
175. Harrison EG Jr., McCormack LJ. Pathologic classification of renal arterial disease in renovascular hypertension. *Mayo Clin Proc* 1971;46:161–167.
176. Cambria RP, Brewster DC, L'Italien GJ, et al. The durability of different reconstructive techniques for atherosclerotic renal artery disease. *J Vasc Surg* 1994;20:76–85; discussion 86–87.
177. Chibaro EA, Libertino JA, Novick AC. Use of the hepatic circulation for renal revascularization. *Ann Surg* 1984;199:406–411.
178. Khauli RB, Novick AC, Ziegelbaum M. Splenorenal bypass in the treatment of renal artery stenosis: experience with sixty-nine cases. *J Vasc Surg* 1985;2:547–551.
179. Moncure AC, Brewster DC, Darling RC, et al. Use of the splenic and hepatic arteries

for renal revascularization. *J Vasc Surg* 1986;3:196–203.
180. Grigoryants V, Henke PK, Watson NC, et al. Iliorenal bypass: indications and outcomes following 41 reconstructions. *Ann Vasc Surg* 2007;21:1–9.
181. Murray SP, Kent C, Salvatierra O, et al. Complex branch renovascular disease: management options and late results. *J Vasc Surg* 1994;20:338–345; discussion 346.
182. van Bockel JH, van den Akker PJ, Chang PC, et al. Extracorporeal renal artery reconstruction for renovascular hypertension. *J Vasc Surg* 1991;13:101–110; discussion 110–111.
183. Dougherty MJ, Hallett JW Jr., Naessens J, et al. Renal endarterectomy vs. bypass for combined aortic and renal reconstruction: is there a difference in clinical outcome? *Ann Vasc Surg* 1995;9:87–94.
184. McNeil JW, String ST, Pfeiffer RB Jr. Concomitant renal endarterectomy and aortic reconstruction. *J Vasc Surg* 1994;20:331–336; discussion 336–337.
185. Stoney RJ, Messina LM, Goldstone J, et al. Renal endarterectomy through the transected aorta: a new technique for combined aortorenal atherosclerosis–a preliminary report. *J Vasc Surg* 1989;9:224–233.
186. Stanley JC. David M. Hume memorial lecture. Surgical treatment of renovascular hypertension. *Am J Surg* 1997;174:102–110.
187. Cherr GS, Hansen KJ, Craven TE, et al. Surgical management of atherosclerotic renovascular disease. *J Vasc Surg* 2002;35:236–245.
188. Hansen KJ, Cherr GS, Craven TE, et al. Management of ischemic nephropathy: dialysis-free survival after surgical repair. *J Vasc Surg* 2000;32:472–481; discussion 481–482.
189. Corriere MA, Edwards MS. Results of the major randomized clinical trials of renal stenting and implications for future treatment strategies. *Semin Vasc Surg* 2013;26:161–164.
190. Weibull H, Bergqvist D, Bergentz SE, et al. Percutaneous transluminal renal angioplasty versus surgical reconstruction of atherosclerotic renal artery stenosis: a prospective randomized study. *J Vasc Surg* 1993;18:841–850; discussion 850–852.
191. Knipp BS, Dimick JB, Eliason JL, et al. Diffusion of new technology for the treatment of renovascular hypertension in the United States: surgical revascularization versus catheter-based therapy, 1988–2001. *J Vasc Surg* 2004;40:717–723.
192. Balk E, Raman G, Chung M, et al. Effectiveness of management strategies for renal artery stenosis: a systematic review. *Ann Intern Med* 2006;145:901–912.
193. Blum U, Krumme B, Flugel P, et al. Treatment of ostial renal-artery stenoses with vascular endoprostheses after unsuccessful balloon angioplasty. *N Engl J Med* 1997;336:459–465.
194. Henry M, Amor M, Henry I, et al. Stent placement in the renal artery: three-year experience with the Palmaz stent. *J Vasc Interv Radiol* 1996;7:343–350.
195. Bax L, Woittiez AJ, Kouwenberg HJ, et al. Stent placement in patients with

atherosclerotic renal artery stenosis and impaired renal function: a randomized trial. *Ann Intern Med* 2009;150:840–848, W150–W151.

196. van Jaarsveld BC, Krijnen P, Pieterman H, et al. The effect of balloon angioplasty on hypertension in atherosclerotic renal-artery stenosis. Dutch Renal Artery Stenosis Intervention Cooperative Study Group. *N Engl J Med* 2000;342:1007–1014.
197. ASTRAL Investigators, Wheatley K, Ives N, et al. Revascularization versus medical therapy for renal-artery stenosis. *N Engl J Med* 2009;361:1953–1962.
198. Cooper CJ, Murphy TP, Cutlip DE, et al. Stenting and medical therapy for atherosclerotic renal-artery stenosis. *N Engl J Med* 2014;370:13–22.
199. Riaz IB, Husnain M, Riaz H, et al. Meta-analysis of revascularization versus medical therapy for atherosclerotic renal artery stenosis. *Am J Cardiol* 2014;114:1116–1123.
200. Weber BR, Dieter RS. Renal artery stenosis: epidemiology and treatment. *Int J Nephrol Renovasc Dis* 2014;7:169–181.
201. Rocha-Singh KJ, Mishkel GJ, Katholi RE, et al. Clinical predictors of improved long-term blood pressure control after successful stenting of hypertensive patients with obstructive renal artery atherosclerosis. *Catheter Cardiovasc Interv* 1999;47:167–172.
202. Silva JA, Chan AW, White CJ, et al. Elevated brain natriuretic peptide predicts blood pressure response after stent revascularization in patients with renal artery stenosis. *Circulation* 2005;111:328–333.
203. Dieter RS, Darki A, Nanjundappa A, et al. Usefulness of wide pulse pressure as a predictor of poor outcome after renal artery angioplasty and stenting. *Am J Cardiol* 2009;104:732–734.
204. Mitchell JA, Subramanian R, White CJ, et al. Predicting blood pressure improvement in hypertensive patients after renal artery stent placement: renal fractional flow reserve. *Catheter Cardiovasc Interv* 2007;69:685–689.
205. Chobanian AV, Bakris GL, Black HR, et al. The Seventh Report of the Joint National Committee on Prevention, Detection, Evaluation, and Treatment of High Blood Pressure: the JNC 7 report. *JAMA* 2003;289:2560–2572.
206. Stanley JC, Criado E, Upchurch GR Jr., et al. Pediatric renovascular hypertension: 132 primary and 30 secondary operations in 97 children. *J Vasc Surg* 2006;44:1219–1228; discussion 1228–1229.
207. Silverstein DM, Champoux E, Aviles DH, et al. Treatment of primary and secondary hypertension in children. *Pediatr Nephrol* 2006;21:820–827.
208. Tullus K, Brennan E, Hamilton G, et al. Renovascular hypertension in children. *Lancet* 2008;371:1453–1463.
209. Srinivasan A, Krishnamurthy G, Fontalvo-Herazo L, et al. Angioplasty for renal artery stenosis in pediatric patients: an 11-year retrospective experience. *J Vasc Interv Radiol* 2010;21:1672–1680.
210. Shroff R, Roebuck DJ, Gordon I, et al. Angioplasty for renovascular hypertension in children: 20-year experience. *Pediatrics* 2006;118:268–275.

211. Courtel JV, Soto B, Niaudet P, et al. Percutaneous transluminal angioplasty of renal artery stenosis in children. *Pediatr Radiol* 1998;28:59–63.
212. Casalini E, Sfondrini MS, Fossali E. Two-year clinical follow-up of children and adolescents after percutaneous transluminal angioplasty for renovascular hypertension. *Invest Radiol* 1995;30:40–43.
213. Eliason JL, Coleman DM, Criado E, et al. Remedial operations for failed endovascular therapy of 32 renal artery stenoses in 24 children. *Pediatr Nephrol* 2016;31(5):809–817.
214. Stanley JC, Rhodes EL, Gewertz BL, et al. Renal artery aneurysms. Significance of macroaneurysms exclusive of dissections and fibrodysplastic mural dilations. *Arch Surg* 1975;110:1327–1333.
215. McCarron JP Jr, Marshall VF, Whitsell JC 2nd. Indications for surgery on renal artery aneurysms. *J Urol* 1975;114:177–180.
216. Tham G, Ekelund L, Herrlin K, et al. Renal artery aneurysms. Natural history and prognosis. *Ann Surg* 1983;197:348–352.
217. Henriksson C, Lukes P, Nilson AE, et al. Angiographically discovered, non-operated renal artery aneurysms. *Scand J Urol Nephrol* 1984;18:59–62.
218. Klausner JQ, Harlander-Locke MP, Plotnik AN, et al. Current treatment of renal artery aneurysms may be too aggressive. *J Vasc Surg* 2014;59:1356–1361.
219. Klausner JQ, Lawrence PF, Harlander-Locke MP, et al. The contemporary management of renal artery aneurysms. *J Vasc Surg* 2015;61:978–984.
220. Wayne EJ, Edwards MS, Stafford JM, et al. Anatomic characteristics and natural history of renal artery aneurysms during longitudinal imaging surveillance. *J Vasc Surg* 2014;60:448–452.
221. Pfeiffer T, Reiher L, Grabitz K, et al. Reconstruction for renal artery aneurysm: operative techniques and long-term results. *J Vasc Surg* 2003; 37:293–300.
222. Hupp T, Allenberg JR, Post K, et al. Renal artery aneurysm: surgical indications and results. *Eur J Vasc Surg* 1992;6:477–486.
223. Robinson WP 3rd, Bafford R, Belkin M, et al. Favorable outcomes with in situ techniques for surgical repair of complex renal artery aneurysms. *J Vasc Surg* 2011;53:684–691.
224. English WP, Pearce JD, Craven TE, et al. Surgical management of renal artery aneurysms. *J Vasc Surg* 2004;40:53–60.
225. Coleman DM, Stanley JC. Renal artery aneurysms. *J Vasc Surg* 2015;62: 779–785.
226. Henke PK, Cardneau JD, Welling TH 3rd, et al. Renal artery aneurysms: a 35-year clinical experience with 252 aneurysms in 168 patients. *Ann Surg* 2001;234:454–462; discussion 462–463.
227. Cohen JR, Shamash FS. Ruptured renal artery aneurysms during pregnancy. *J Vasc Surg* 1987;6:51–59.
228. Martin RS 3rd, Meacham PW, Ditesheim JA, et al. Renal artery aneurysm: selective

treatment for hypertension and prevention of rupture. *J Vasc Surg* 1989;9:26–34.

229. Hwang PF, Rice DC, Patel SV, et al. Successful management of renal artery aneurysm rupture after cesarean section. *J Vasc Surg* 2011;54:519–521.
230. Chandra A, O'Connell JB, Quinones-Baldrich WJ, et al. Aneurysmectomy with arterial reconstruction of renal artery aneurysms in the endovascular era: a safe, effective treatment for both aneurysm and associated hypertension. *Ann Vasc Surg* 2010;24:503–510.
231. Tsilimparis N, Reeves JG, Dayama A, et al. Endovascular vs open repair of renal artery aneurysms: outcomes of repair and long-term renal function. *J Am Coll Surg* 2013;217:263–269.
232. Gallagher KA, Phelan MW, Stern T, et al. Repair of complex renal artery aneurysms by laparoscopic nephrectomy with ex vivo repair and autotransplantation. *J Vasc Surg* 2008;48:1408–1413.
233. Luke P, Knudsen BE, Nguan CY, et al. Robot-assisted laparoscopic renal artery aneurysm reconstruction. *J Vasc Surg* 2006;44:651–653.
234. Giulianotti PC, Bianco FM, Addeo P, et al. Robot-assisted laparoscopic repair of renal artery aneurysms. *J Vasc Surg* 2010;51:842–849.
235. Bratby MJ, Lehmann ED, Bottomley J, et al. Endovascular embolization of visceral artery aneurysms with ethylene-vinyl alcohol (Onyx): a case series. *Cardiovasc Intervent Radiol* 2006;29:1125–1128.
236. Meyer C, Verrel F, Weyer G, et al. Endovascular management of complex renal artery aneurysms using the multilayer stent. *Cardiovasc Intervent Radiol* 2011;34:637–641.
237. Manninen HI, Berg M, Vanninen RL. Stent-assisted coil embolization of wide-necked renal artery bifurcation aneurysms. *J Vasc Interv Radiol* 2008;19:487–492.
238. Etezadi V, Gandhi RT, Benenati JF, et al. Endovascular treatment of visceral and renal artery aneurysms. *J Vasc Interv Radiol* 2011;22:1246–1253.
239. Sedat J, Chau Y, Baque J. Endovascular treatment of renal aneurysms: a series of 18 cases. *Eur J Radiol* 2012;81:3973–3978.
240. Zhang Z, Yang M, Song L, et al. Endovascular treatment of renal artery aneurysms and renal arteriovenous fistulas. *J Vasc Surg* 2013;57:765–770.
241. Hislop SJ, Patel SA, Abt PL, et al. Therapy of renal artery aneurysms in New York State: outcomes of patients undergoing open and endovascular repair. *Ann Vasc Surg* 2009;23:194–200.

Chapter 92

Aortoiliac Disease

Loay S. Kabbani, Mitchell R. Weaver, and Alexander D. Shepard

Key Points

1 Aortoiliac occlusive disease is mainly the result of atherosclerosis.

2 Claudication is the most common presenting symptom of patients with significant aortoiliac occlusive disease. Some patients may complain of erectile dysfunction. Physical examination typically reveals diminished or absent femoral pulses.

3 Medical treatment of atherosclerotic aortoiliac occlusive disease is key to long-term success. This includes risk factor modification (smoking cessation, control of hypertension, lipid abnormalities, and diabetes mellitus), supervised walking programs and pharmacotherapy.

4 Smoking is the most important reversible risk factor for the development of lower extremity atherosclerotic occlusive disease.

5 Percutaneous transluminal angioplasty, with or without stenting, has become the most common therapy for aortoiliac occlusive disease.

6 Aortofemoral bypass is still the reference standard for reconstruction of advanced aortoiliac occlusive disease.

INTRODUCTION

1 Peripheral arterial disease (PAD) is usually a manifestation of systemic atherosclerosis. It affects 3% of the general population older than 40 years and 15% of those older than 70 years, with approximately 50% of patients with PAD being asymptomatic.[1–3] Atherosclerotic occlusive disease of the aorta and iliac arteries alone, or in combination with femoropopliteal or tibial occlusive disease, is the most frequent cause of chronic lower extremity arterial insufficiency.

The wide availability of computed tomographic angiography (CTA) and magnetic resonance angiography (MRA) has facilitated diagnosis, anatomic definition and subsequent intervention for aortoiliac occlusive disease (AIOD). Selection of a patient-specific treatment from an increasing array of treatment alternatives, although challenging, will frequently alleviate symptoms and reduce the risk of disease progression. Endovascular and open reconstructive procedures for AIOD have become routine, with low perioperative morbidity and mortality and excellent early and long-term outcomes.

ETIOLOGY

Anatomy and Pathophysiology

The arteries supplying blood to the lower extremities are frequently divided into abdominal, or "inflow," arteries (the aorta and iliac arteries) and infrainguinal, or "outflow," arteries (the femoropopliteal and tibial arteries).

Although atherosclerosis is a generalized disease, the earliest lesions tend to occur at arterial bifurcations and in areas of relative fixation, where disruption of normal laminar flow is greatest, and where eddy currents result in areas of low shear stress. Arteriopathies other than atherosclerosis, such as Takayasu's disease and radiation arteritis, can also involve the aortoiliac system. In slowly developing aortoiliac occlusive lesions, hemodynamic alterations lead to the enlargement of a network of auxiliary or collateral channels around the involved segments; this collateral network is usually sufficient to provide enough blood flow to meet the resting metabolic needs of the lower extremities (Figs. 92-1 and 92-2). These channels, however, do not have the capacity to increase blood flow to the level necessary to meet exercise demands of the lower extremity musculature. The lumbar, hypogastric, femoral and profunda femoris arteries are interconnected with a large vascular collateral network. Significant other collaterals join the internal mammary artery to the inferior epigastric artery and the superior mesenteric artery (SMA) to the inferior mesenteric artery (IMA) and hemorrhoidal arteries. The latter pathway gives rise to the Arc of Riolan (also known as the meandering mesenteric artery, central anastomotic mesenteric artery, or Haller's anastomosis) and the marginal artery of the colon (also known as the Marginal Artery of Drummond) (Figs. 92-1 and 92-2). The Arc of Riolan connects the proximal middle colic artery with a branch of the left colic artery. The Marginal Artery of Drummond runs in the mesentery close to the bowel as part of the vascular arcade that connects the SMA and IMA.

PRESENTATION

Aortoiliac occlusive disease secondary to atherosclerosis is largely a disease of smokers. Other risk factors include hypertension, lipid abnormalities, diabetes mellitus, male sex, older age, and genetic predisposition. Smoking is the most important reversible risk factor for the development of lower extremity atherosclerotic occlusive disease.[4–6] Patients with symptoms of AIOD usually present in their 50s and 60s, whereas patients with infrainguinal disease or multilevel disease (AIOD + infrainguinal) generally present in their 70s.[7]

2 Claudication (Latin *claudicare* = "to limp") is the term used to denote the characteristic exercise-induced, cramping pain in the muscles of the lower extremity that results from demand ischemia. Claudication is the most common presenting symptom of patients with significant aortoiliac disease. Induced by ambulation and quickly relieved by rest, claudication is usually described as a cramping pain or easy fatigability of the involved muscle groups. Although patients with aortoiliac disease classically present with claudication of the thighs, hips, and buttocks, a significant number complain of calf claudication or have significant overlap. Erectile dysfunction in men secondary to reduced hypogastric perfusion is another common complaint and may be found in as many as 30% to 50% of men with AIOD.[8] The combination of bilateral lower extremity claudication, atrophy of the lower extremity musculature, impotence, and diminished or absent femoral pulses is known as Leriche syndrome, after the French physician René Leriche.[9]

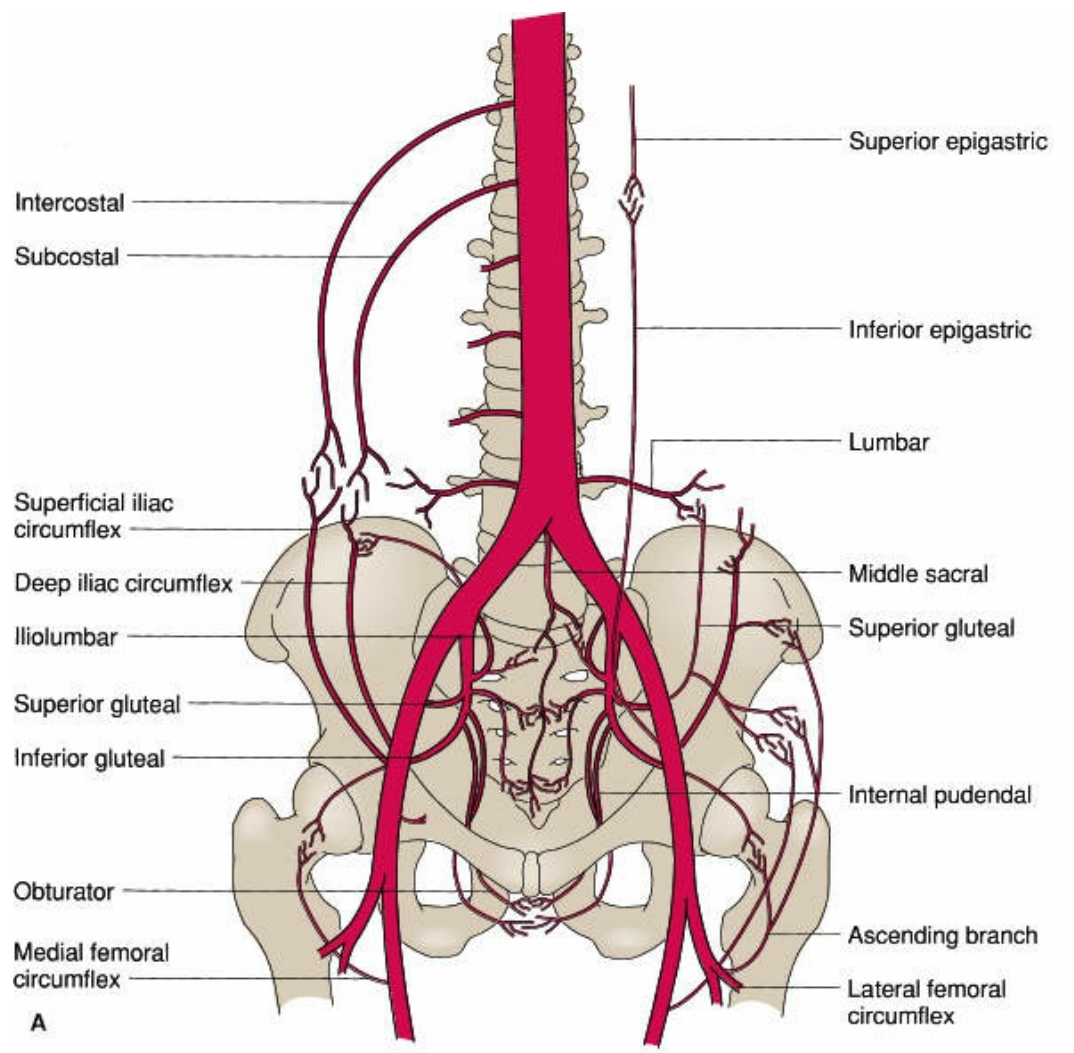
Superior epigastric
Intercostal
Subcostal
Inferior epigastric
Lumbar
Superficial iliac circumflex
Deep iliac circumflex
Middle sacral
Iliolumbar
Superior gluteal
Superior gluteal
Inferior gluteal
Internal pudendal
Obturator
Ascending branch
Medial femoral circumflex
Lateral femoral circumflex
A

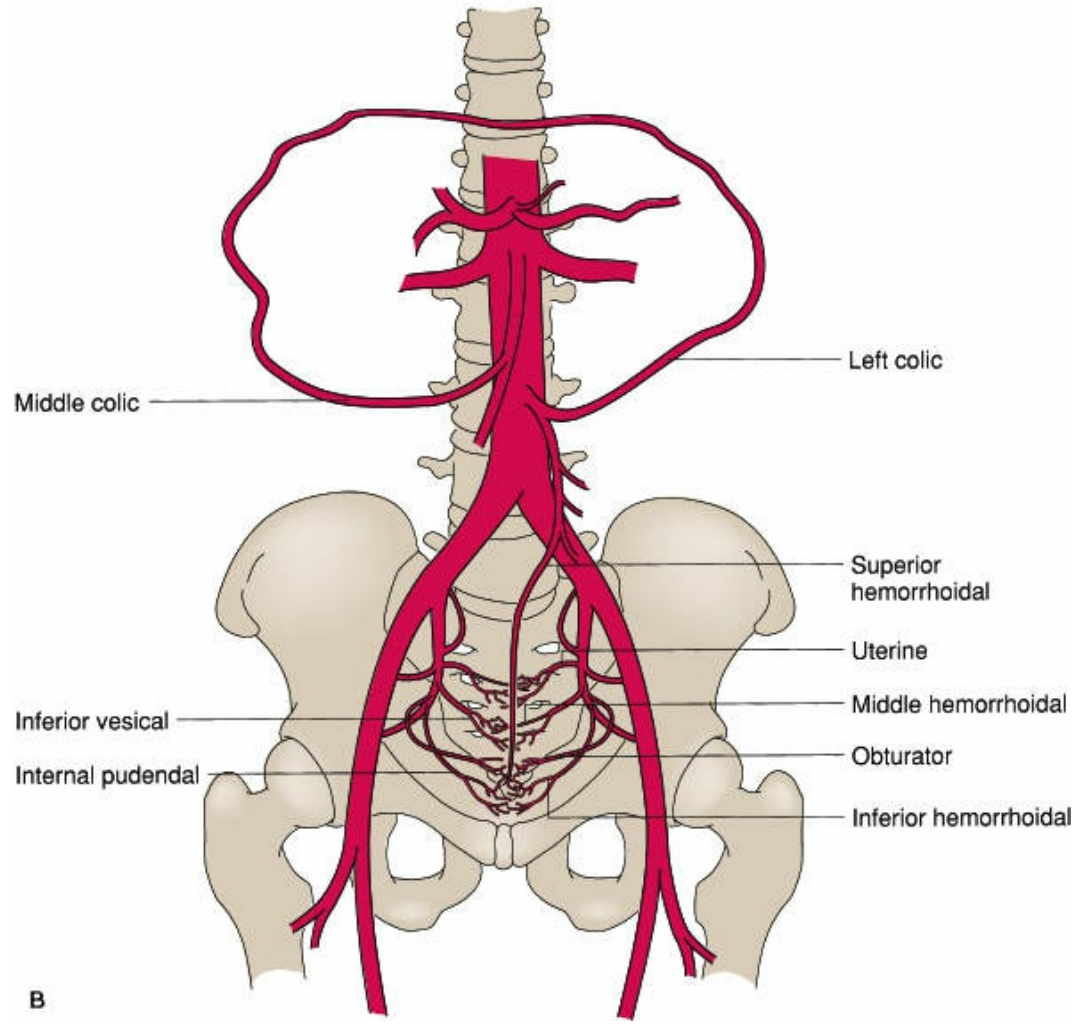
Left colic
Middle colic
Superior hemorrhoidal
Uterine
Middle hemorrhoidal
Inferior vesical
Obturator
Internal pudendal
Inferior hemorrhoidal
B

Figure 92-1. **A,B:** Major visceral and parietal collateral networks that may become prominent with aortoiliac occlusive disease.

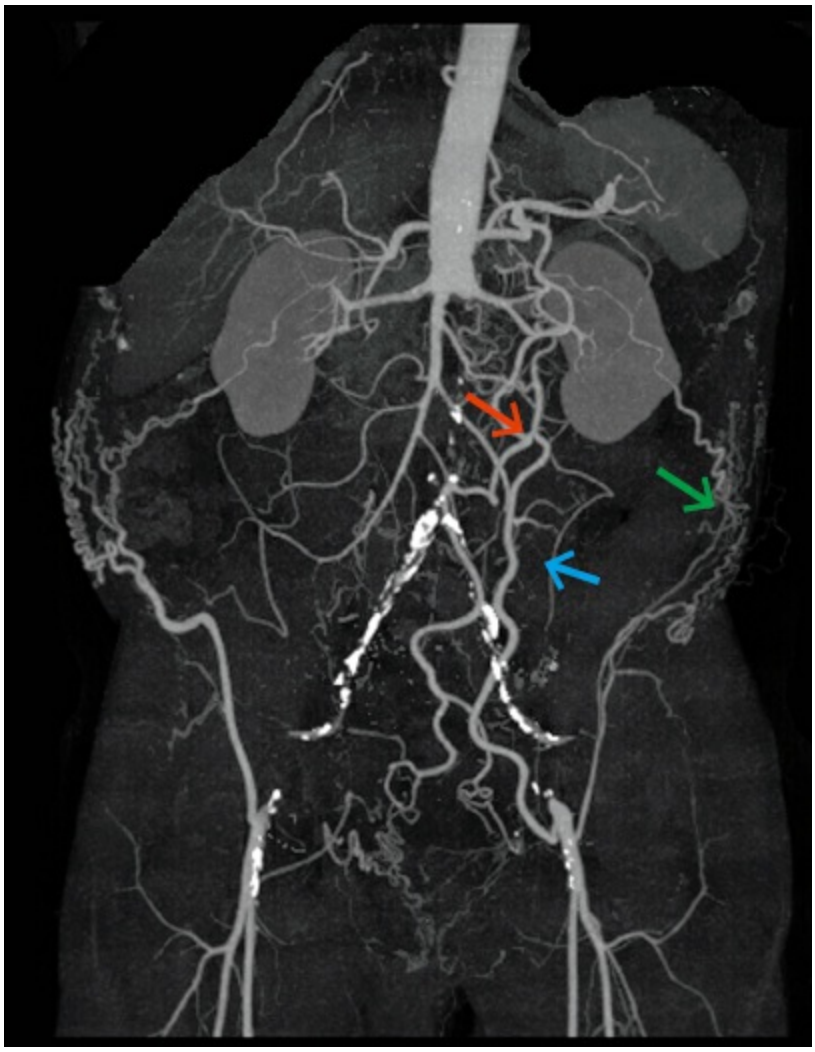

Figure 92-2. CTA with 3D reconstruction demonstrating severe aortoiliac occlusive disease with juxtarenal aortic occlusion. Note the extensive collateral networks reconstituting the inferior mesenteric artery (*red arrow*: marginal artery) and femoral arterial segments (*blue arrow*: inferior epigastric artery) (*green arrow*: subcostal arteries and superficial iliac circumflex artery collaterals).

Physical examination typically reveals diminished or absent femoral pulses. A bruit auscultated over the groins or lower abdomen is not specific for critical stenosis. Severely diseased, calcified femoral arteries may be palpable as firm, tubular structures in the groins. Normal femoral and distal pulses may be palpable, even in the presence of hemodynamically significant aortoiliac stenosis. These pulses, however, rapidly disappear following ambulation, as the increased flow demands of the exercising leg muscles lead to lowered peripheral vascular resistance and reduced distal arterial pressure. Patients with longstanding aortoiliac atherosclerosis may have disuse atrophy of the lower extremity musculature. Other common signs of lower extremity arterial occlusive disease include trophic changes, such as hair loss on the legs or toes, and thin, shiny skin on the feet; patients with severe reductions in pedal blood flow may display pedal rubor on limb dependency, coupled with pallor on elevation.

Critical limb ischemia (CLI) symptoms manifest in the lower leg or foot as ischemic rest pain, nonhealing wounds, or gangrenous changes. Such symptoms may be a manifestation of AIOD alone but almost always occur in combination with more distal femoropopliteal/tibial disease (i.e., multilevel arterial occlusive disease). In the absence of infrainguinal disease, aortoiliac collaterals are usually capable of maintaining adequate resting distal tissue perfusion.

Acute arterial occlusions from emboli lodging at the aortic, iliac or femoral bifurcation do not allow collateral pathways to mature and compensate for the sudden loss of blood supply. This situation leads to the acute onset of symptoms, with the resulting 5 “Ps” of acute ischemia: pain, pallor, pulselessness, paresthesia, and paralysis. Cholesterol crystal embolism, or “blue toe” syndrome, occurs when debris breaks free from an aortic, iliac, or more distal plaque, releasing platelet microthrombi, cholesterol crystals, and other atheromatous material into the arterial lumen.[10] Downstream embolism into the microcirculation of the lower extremities can produce dermal discoloration in a characteristic reticular pattern (livedo reticularis), digital ischemia, or even gangrene (Fig. 92-3). Such patients usually have palpable pedal pulses. Embolic events can occur spontaneously or can be induced by interventions, such as guidewire manipulation (e.g., during angiographic procedures or placement of an intra-aortic balloon pump) or clamping an artery with unstable plaque during open vascular surgery.

Clinical Pathologic Types of Aortoiliac Disease

Different patterns of AIOD have been classically identified on preoperative imaging studies.[11] Disease confined to the distal infrarenal aorta and common iliac arteries, classified as type I, accounts for only 10% of patients with inflow disease. Patients with type I disease are younger (in their 50s and 60s), more frequently female, and typically have a normal life expectancy.[12,13] These patients usually present with complaints of disabling claudication in the buttocks, hips, and thighs. Such localized disease may be amenable to percutaneous transluminal angioplasty (PTA) or, as was sometimes practiced in the past, aortoiliac endarterectomy.

Type II aortoiliac disease is more extensive and more common; the atherosclerotic plaque extends distally into the external iliac arteries and may reach the common femoral bifurcations. Such patients experience worse claudication than patients with more localized disease and may present with CLI. They are usually men, present on average a decade later in life (60s and 70s), than patients with type I disease, and tend to have diabetes, hypertension, and concomitant cerebrovascular, coronary, and visceral atherosclerosis.[12] As a result, these patients have a reduced life expectancy.[13,14]



Figure 92-3. Digital atheroembolization progressed to gangrene.

Type III disease is a combination of aortoiliac and femoropopliteal and/or tibial disease. These patients with multilevel disease are usually older than those in the other two groups and present more frequently with symptoms of CLI.[12]

One other pattern worthy of mention is aortoiliac hypoplasia. The term *small aortic*

syndrome or *hypoplastic aortic syndrome* may also be used. This pattern is encountered in young to middle-aged women who smoke cigarettes. The infrarenal aorta and iliac arteries are unusually small in caliber and hence prone to significant narrowing, even with modest disease. Operative treatment of such patients can be particularly challenging.[15]

In response to the rapidly evolving patterns of treatment of AIOD and the increasingly prominent role played by endovascular methods, the Trans-Atlantic Inter-Society Consensus for the Management of PAD (TASC II) has classified AIOD into four types, A through D (Table 92-1).[16] The value of this classification derives from its use as a template for reporting standards and as a guideline to help direct treatment decisions. Patients with focal disease (TASC II types A and B) usually benefit from endovascular interventions, while those with more advanced disease (TASC II types C and D) are usually best managed with open surgical revascularization. However, evolving endovascular approaches are now being applied to these advanced lesions as well, with acceptable results.[17] This is especially true for high-risk patients with TASC C and D disease presenting with CLI, who frequently have significant comorbidities, such as severe chronic obstructive pulmonary disease, nonreconstructible coronary artery disease, or a low cardiac ejection fraction. Although this approach may lead to less durable results than open surgical options, it is less morbid. To simplify the most current widely accepted strategy, the surgeon should apply endovascular treatment methods for type A and B patients, and lean toward open surgery for type C and D disease.

DIAGNOSIS

In most cases, diagnosis of significant AIOD and its severity can be made on the basis of history and physical examination alone. A clinical diagnosis, however, should be supplemented by noninvasive vascular testing. Such tests provide valuable information by confirming the presence of disease, assessing the degree of ischemia, objectively documenting the arterial segment(s) involved, and establishing a baseline from which the patient can be followed and appropriate interventions planned. Treatment results can be assessed by repeated testing. Such information is particularly useful in a patient with an equivocal history or physical examination. Formal imaging studies (CTA, MRA, and arteriography) are usually reserved for those patients considered for intervention.

Noninvasive Vascular Testing

Segmental Doppler-derived pressure measurements or pulse volume recordings are useful for demonstrating the physiologic significance of disease and can help localize hemodynamically significant lesions. Measurement of systolic arterial pressures at different levels of the lower extremity with a continuous wave Doppler flow probe is the simplest and most useful noninvasive method to assess arterial occlusive disease. The ratio of the ankle systolic pressure (measured at either the dorsalis pedis or the posterior tibial artery) to the brachial systolic pressure (using the higher of the two brachial pressures) is the ankle-brachial index (ABI), or pressure ratio, and is a good measure of the degree of ischemia present. Normal ABIs are generally equal to or slightly greater than 1.0 (Fig. 92-4). Peripheral arterial disease is designated when the ABI is ≤ 0.95. Patients with claudication usually have ABIs ranging from 0.50 to 0.90, whereas patients with rest pain, tissue loss, or gangrene have ABIs of < 0.50. Some patients with claudication, as a result of excellent collaterals, may have ABI of > 1.0 at rest.

Table 92-1 TASC II Classification

Type A: Limited stenoses of the common or external iliac arteries	
Type B: Short stenosis of the infrarenal aorta and short stenosis or occlusion of the iliac arteries	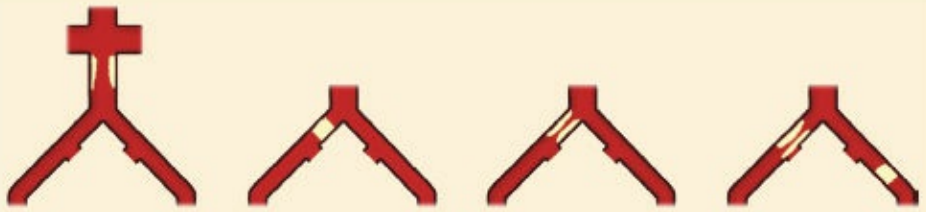
Type C: Advanced stenosis and/or occlusions of the iliac arteries, especially when calcified	
Type D: Infrarenal aortic occlusion sometimes with multiple iliac occlusions and stenoses or associated aneurysm disease	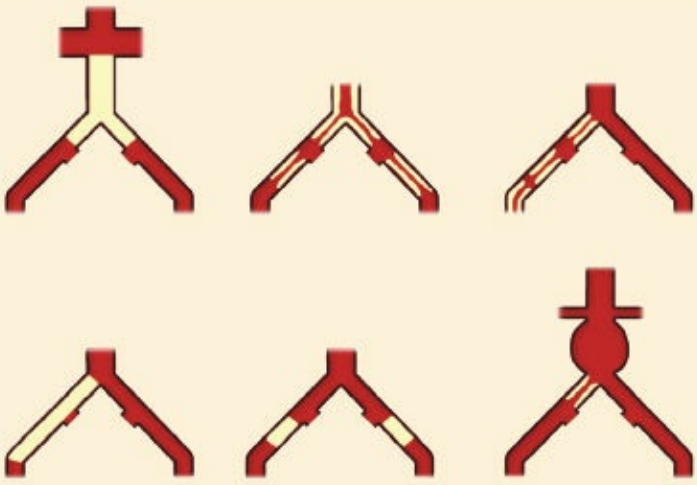

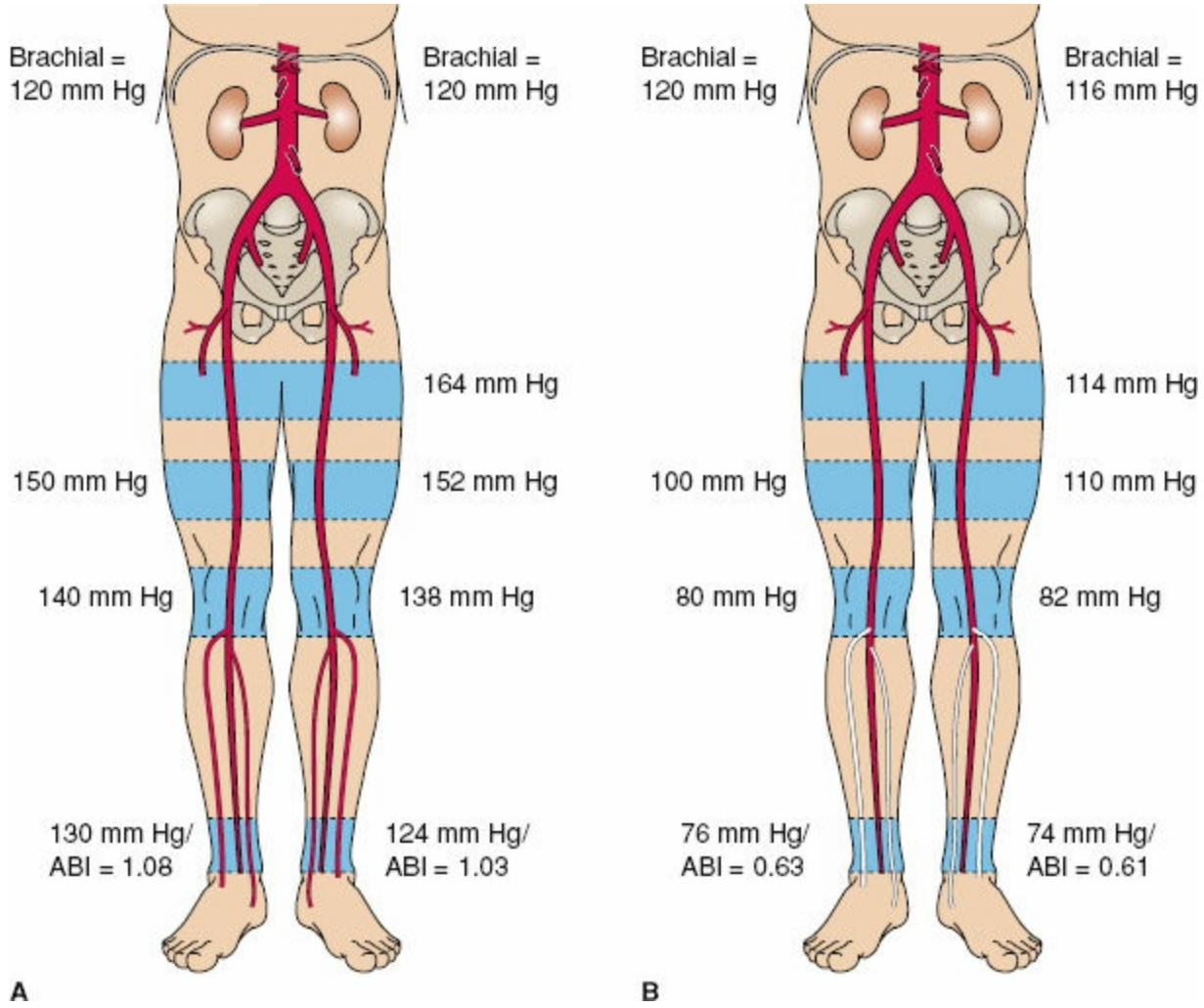

Figure 92-4. Segmental pressure measurements typical of normal results (**A**) and aortoiliac occlusive disease (**B**).

Determination of limb systolic pressures at different locations (with the "four-cuff" technique, where pressures are measured at the upper thigh, lower thigh, calf, and ankle) provides information concerning which arterial segments are involved with occlusive disease (Fig. 92-4) and helps define the presence of inflow artery disease, outflow (runoff artery) disease, or a combination of the two. A pressure drop of more than 20 mm Hg between adjacent levels indicates significant disease within the intervening arterial segment. A reduced upper thigh pressure signifies occlusive disease in the aortoiliac or common femoral segments.[18]

In patients with extensive calcification in the walls of the tibial arteries (as is frequently seen in diabetes mellitus or end-stage renal disease), the ankle pressures may not be interpretable because the vessels are too "stiff" to be properly compressed by the externally applied cuff. In this situation, the pressure in the digital arteries of the great toe can be measured, since these small vessels are generally spared calcification. A toe pressure of less than 30 mm Hg indicates severe ischemia.[19] Inspection of the Doppler-derived arterial waveforms can provide additional information.

Patients with claudication occasionally have normal or nearly normal ABIs. As described previously, in such cases the arterial stenosis is not severe enough to cause a pressure drop in the limb at rest but does produce a significant hemodynamic change under conditions of higher flow rates when the distal vasculature dilates, as occurs with

exercise. When the distal pressure drops because of vascular dilation, the stenosis prevents increased blood flow into the extremity so that a significant distal pressure drop results. The classic treadmill test involves walking on a treadmill at 1.5 miles per hour at a 14% incline for as long as the patient can go, up to 5 minutes. ABIs are measured before and after a treadmill exercise; a drop of 15% or more in the ABI following exercise is indicative of a hemodynamically significant occlusive disease.[18]

Duplex scanning of the aorta and iliac arteries has been advocated by some as a noninvasive diagnostic tool. Accurate imaging of the abdominal arteries, however, is difficult because of their deep retroperitoneal and pelvic locations, which can be further degraded by body habitus and overlying bowel gas. These problems have limited the widespread use of this modality.[20] Arteriography, CTA, and MRA may be used for diagnosis, but are usually performed when interventional therapy is contemplated, and are, therefore, discussed later.

Differential Diagnosis

The diagnosis of AIOD is usually straightforward, but occasional diagnostic difficulty may arise when other causes of lower extremity pain are present. Irritation of lumbosacral nerve roots by spinal stenosis or intervertebral disc herniation may cause buttock and leg pain that is associated with activity. Such symptoms (neurogenic claudication), however, usually cannot be reproduced at the same level of activity, frequently occur when the patient is standing, and are relieved only by sitting or lying down. In addition, the pain is usually in a classic sciatic distribution.

Degenerative arthritis of the hip joints may produce similar buttock, hip, and referred thigh pain. There is usually a history of morning stiffness that progressively improves over the course of the day. Physical examination typically reveals tenderness directly over the hip joint that is exacerbated by moving the joint.

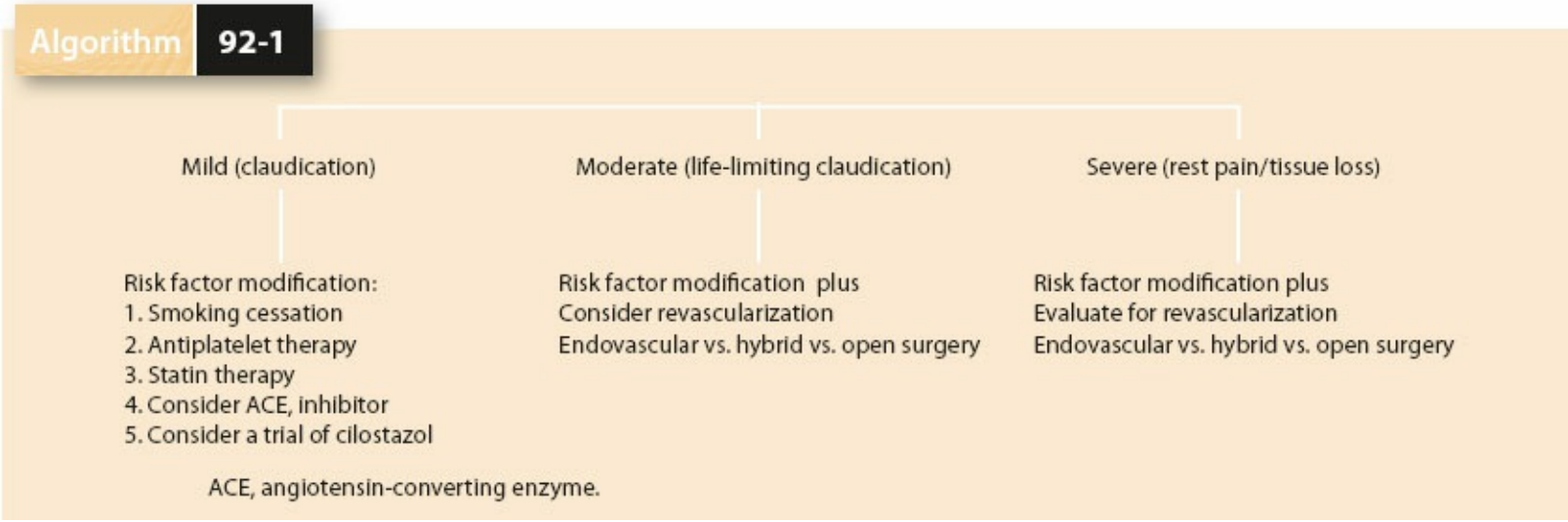

Algorithm 92-1. Patient with symptomatic aortoiliac occlusive disease.

Peripheral neuropathy, particularly that associated with diabetes mellitus, may masquerade as ischemic rest pain.

In all these situations, segmental limb pressure measurements, with or without stress testing, can be helpful in determining the contribution of arterial occlusive disease to the patient's symptoms.

TREATMENT

The aims of therapy in AIOD are to relieve symptoms and, in cases of CLI, to prevent limb loss (Algorithm 92-1). Medical therapy should be instituted in all patients with atherosclerotic disease but is insufficient as sole therapy in patients with limb-threatening ischemia.

Medical Therapy

3 Atherosclerosis is a systemic disease. Medical therapy is, therefore, key to reducing the risk associated with cardiovascular death in these patients. Risk factor modification, including treatment of diabetes mellitus, control of hypertension, and treatment of hyperlipidemia, and finally modification of lifestyle including cessation of smoking, diet, and exercise, are perhaps the most important components of the care of patients with atherosclerotic disease. Although risk factor control will not reverse the atherosclerotic process, it does limit disease progression; furthermore, some data indicate that smoking cessation lessens the severity of symptoms in many patients.[21]

Smoking Cessation

4 Smoking is associated with a subclinical inflammatory reaction.[22] The degree of damage caused by smoking is directly related to the amount of tobacco consumed. The TASC II consensus recommends that: "All patients who are smokers or former smokers should be asked about the status of tobacco use at every visit. All patients should be strongly advised to stop smoking by their physicians. All patients should be offered pharmacotherapy, behavior modification, referral to a smoking cessation program, and counseling."[14] Smoking cessation alters the progression of the atherosclerotic process and may even reduce the severity of claudication[23,24]; Furthermore, it is an important step to reduce postoperative complications.[25,26]

Exercise

Supervised exercise programs have been consistently demonstrated to improve walking time and walking distance.[27] Home and community-based therapy are effective for improving walking tolerance but are less effective than formal supervised exercise programs and are associated with a high dropout rate, underscoring the need for ongoing psychological support.[22,23,28] Outcomes of supervised exercise programs have been shown to be similar and longer lasting than those of endovascular interventions for mild claudication.[24,25] Patients are usually advised to walk until the pain occurs, rest until the pain subsides, and repeat the cycle, to a total of 30 minutes a day, three to five times per week. A 3- to 6-month trial of exercise should be initiated before intervention is considered in patients with intermittent claudication.

Diet

A well-balanced diet with low salt, low fat, and moderate amounts of added sugar intake, as per the American Heart Association guidelines, reduces the risk of chronic diseases in general, and cardiovascular disease in particular, and should be followed.[26]

Glycemic Control

The Trans-Atlantic Inter-Society Consensus (TASC II) consensus document recommends aggressive blood glucose control, with a target A1C goal of $<7.0\%$, and as close to 6.0% as possible.[16]

Antiplatelet Therapy

Some form of platelet inhibition should be considered for all atherosclerotic patients in order to reduce the risk of myocardial infarction, stroke, and death.[29] Aspirin is the agent of choice, but clopidogrel may be used if aspirin is not tolerated. The effectiveness of antiplatelet therapy in reducing symptoms of claudication is not yet established; however, the risk of PAD progression requiring revascularization is significantly reduced by antiplatelet therapy, compared with placebo.[30] Adding aspirin to clopidogrel does not reduce major vascular events. However, the risk of major life-threatening bleeding is increased.[31]

Antihypertensive Therapy

Antihypertensive therapy reduces mortality from atherosclerotic cardiovascular disease. It is, therefore, recommended in the TASC II consensus document, despite the lack of data substantiating that antihypertensive therapy alters the progression of PAD.[16]

Lipid-Lowering Therapy

Lipid-lowering therapy with at least a moderate dose of a statin medication is recommended for all patients with atherosclerotic cardiovascular disease, irrespective of the baseline low-density lipoprotein–cholesterol. Lipid-lowering therapy reduced disease progression (as measured by arteriography), helped alleviate symptoms, and improved total walking times and pain-free walking distance.[32]

Other Pharmacologic Therapy

Cilostazol and naftidrofuryl can be valuable adjuncts in selected patients with severe lifestyle-limiting claudication.[33,34] A therapeutic trial (3 to 6 months) may be tried. Although the mechanisms of action of these agents are unclear, a modest but significant reduction in claudication symptoms has been shown in controlled trials. Benefit has not been firmly established for other agents.

Indications for Revascularization

Revascularization is clearly indicated in patients with CLI; without intervention, these patients can progress to limb loss in a fairly short period of time. At 1 year following onset of CLI symptoms, it is estimated that 25% of patients will lose their limb, 25% will suffer a cardiovascular death, and 50% will be alive with their limbs intact.[35,36] Per year, 1% to 2% of patients with claudication will progress to CLI.[36]

Patients with significant or repetitive atheroembolism from an aortoiliac source represent a group that clearly benefits from early operative intervention. Removal or bypass of the culprit lesion(s) eliminates the risk for further macro- and microembolism.

The treatment of patients with claudication secondary to AIOD remains somewhat controversial and must be individualized. Patients with mild to moderate symptoms can usually be treated medically with satisfactory results, while patients with severe, disabling, and lifestyle-limiting symptoms of claudication can benefit from revascularization therapy.

Preintervention Imaging Studies

Once a decision has been made to proceed with revascularization therapy, imaging studies are paramount for developing a treatment strategy.

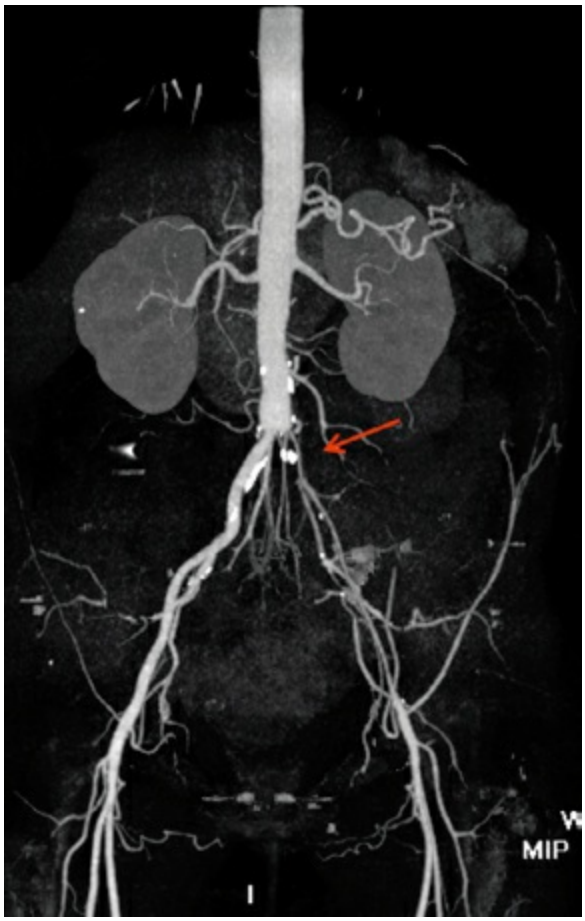

Figure 92-5. CTA 3D reconstruction showing left iliac artery chronic total occlusion (*red arrow*).

Computed Tomographic Angiography

CTA with reformatting requires the intravenous administration of iodinated contrast material, followed by a timed CT scan of the pertinent anatomy. The images are then processed into coronal, sagittal, and three-dimensional image planes (Figs. 92-2, 92-5 to 92-7). For most patients, 120 mL of iodine contrast is used (300 to 370 mg of iodine per milliliter of contrast). Sensitivity and specificity are greater than 92% and 93%, respectively, in detecting >50% stenosis. The main drawbacks of CTA are the ionizing radiation and the use of iodinated contrast, which can cause contrast-induced nephropathy.[37]

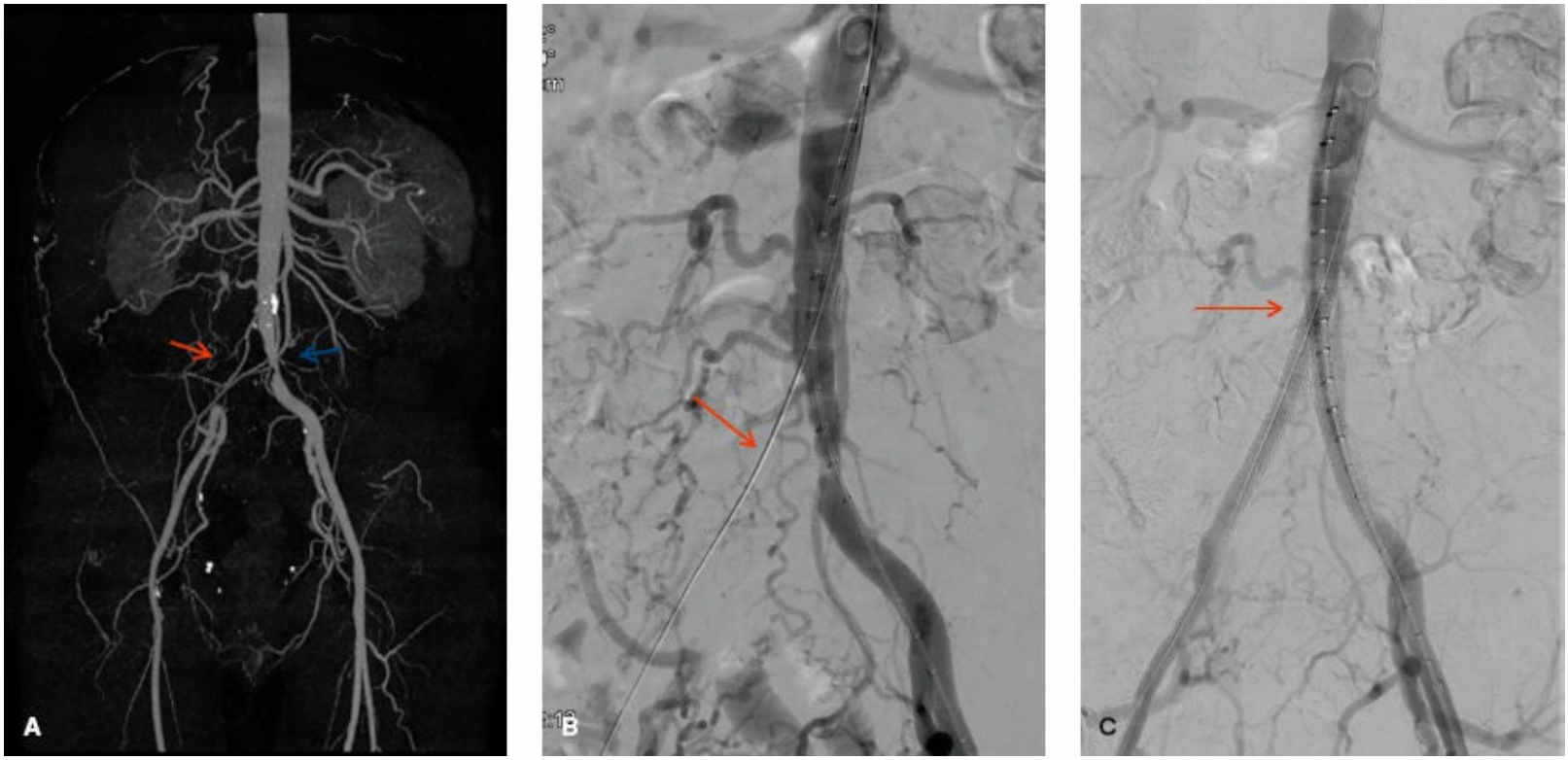

Figure 92-6. **A:** CTA 3D reconstruction demonstrating right common iliac artery chronic total occlusion (*red arrow*) and severe left common iliac artery stenosis (*blue arrow*). **B:** Abdominal aortogram redemonstrating right common iliac artery chronic total occlusion and left common iliac artery stenosis. Note successful wire traversal of the right common iliac artery occlusion (*red arrow*). **C:** Abdominal aortogram demonstrating successful endoluminal bilateral common iliac artery revascularization following percutaneous balloon angioplasty and stent placement. Note the "kissing" stents in the distal aorta (*red arrow*).

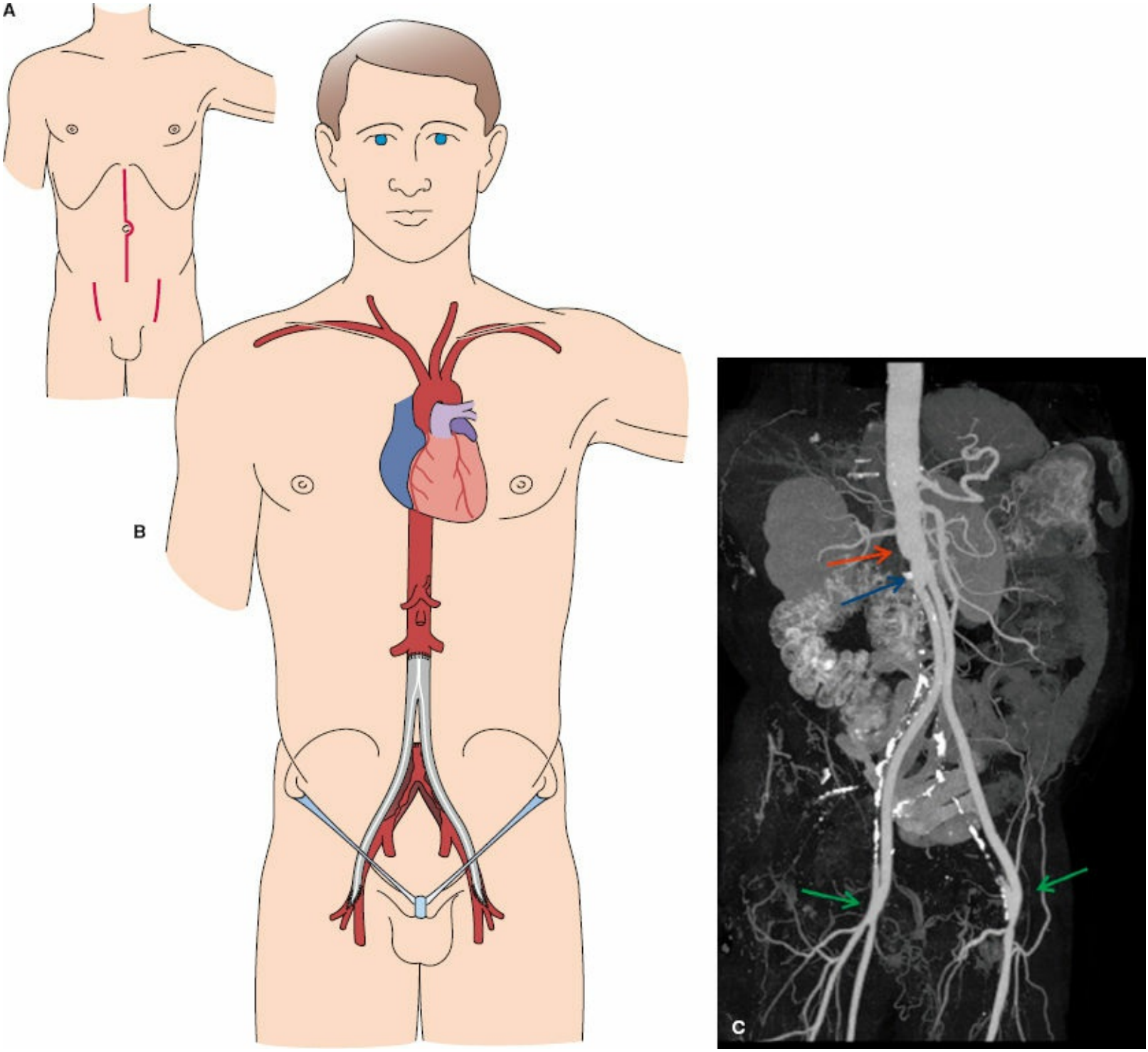

Figure 92-7. **A:** A midline abdominal incision and bilateral groin incisions overlying the common femoral arteries offer exposure for performance of aortobifemoral bypass. **B:** This image demonstrates an end-to-end proximal aortic to graft reconstruction with the respective graft limbs anastomosed end to side to the common femoral arteries. **C:** Computed tomographic angiographic postprocessed and reformatted image demonstrating open aortobifemoral arterial reconstruction of juxtarenal aortic occlusion (see Fig. 92-2, preoperative image) with prosthetic bifurcated graft. Note endarterectomy of aorta immediately distal to renal arteries (*red arrow*), followed by proximal end-to-end anastomosis between graft and aorta (*blue arrow*). Distal anastomosis to femoral arteries is performed in end to side fashion (*green arrows*).

Magnetic Resonance Angiography

Contrast-enhanced MRA uses intravenous administration of paramagnetic gadolinium-

based agents. With good technique, contrast-enhanced MRA has a sensitivity of 80% to 97%, and a specificity of 73% to 96% (Fig. 92-8).[38] The disadvantage of MRA is that it cannot be used in patients with metallic implants such as pacemakers and patients with claustrophobia. Furthermore, in patients with moderately severe renal dysfunction (glomerular filtration rate of <60 mL/min/1.72 m^2), concerns for nephrogenic systemic fibrosis secondary to gadolinium limit the use of this technology in this patient population.[39]

Digital Subtraction Arteriography

Abdominal aortography, with or without demonstration of the arterial tree below the inguinal ligament ("runoff"), is performed after a full workup is completed and may be part of the therapeutic intervention. This procedure is most commonly performed via the femoral artery with the better pulse by means of a retrograde Seldinger technique. When neither femoral artery is available, an upper extremity approach may provide good access. Hemorrhage, local hematoma, pseudoaneurysm, arterial thrombosis, or distal embolism of thrombus or atheromatous debris can occur in up to 0.8% of diagnostic procedures and in up to 6% of therapeutic procedures.[40,41] Anteroposterior views of the aortoiliofemoral segments demonstrate the extent of the occlusive process and the pattern of collateral formation. Oblique views of the iliac and femoral arteries are frequently necessary to document posterior wall plaques and stenoses at the origins of the hypogastric and deep femoral arteries. Views of the "runoff" arteries to at least the midcalf level are required to assess the degree of associated infrainguinal occlusive disease. In cases of CLI, visualization of the pedal circulation is also necessary. In patients with borderline kidney function, carbon dioxide may be utilized as a contrast agent.

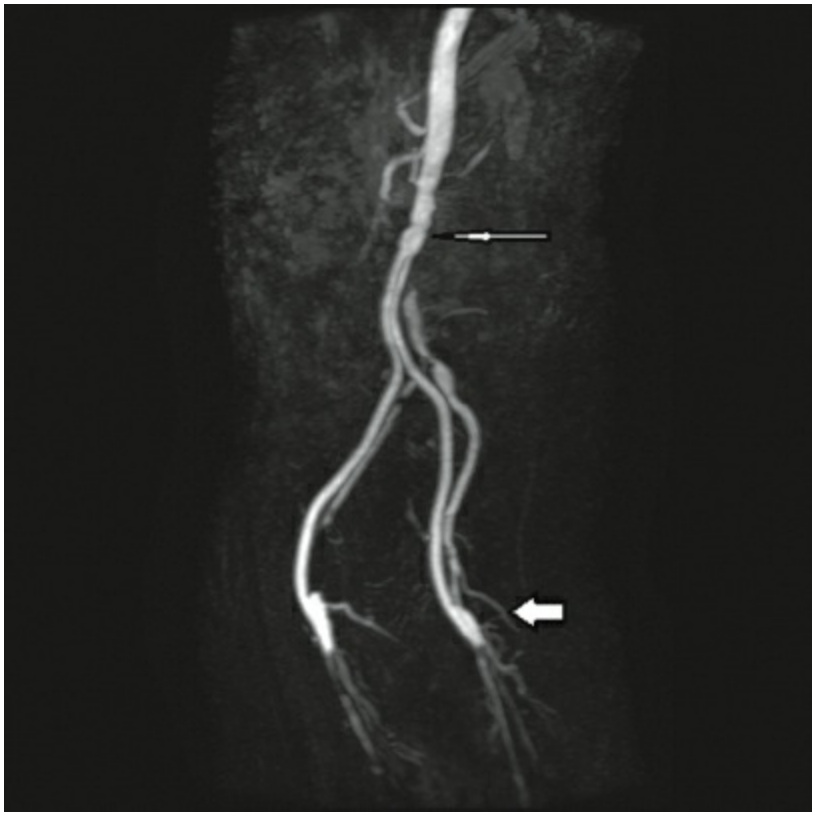

Figure 92-8. MRA of a patient who had an aortobifemoral bypass. Note the proximal anastomosis (*thin arrow*) and the distal anastomosis (*thick arrows*). Also note the retrograde flow into the iliac arteries.

Occasionally, the hemodynamic effect of a stenosis or series of stenoses along an iliac arterial segment may be difficult to determine, even with oblique views. When the significance of a stenosis remains in question, pressures proximal and distal to the lesion(s) can be measured. A systolic pressure gradient of more than 10 mm Hg (or a 5 mm Hg mean gradient) across the stenosis is indicative of a hemodynamically significant lesion.[42] For borderline cases, distal pressure measurements can be obtained before and after interarterial injection of a vasodilator (e.g., 100- to 200-μg nitroglycerin or 25-mg papaverine) to simulate the hyperemic hemodynamics of exercise. A pressure drop of more than 15% systolic pressure (or around 20 mm Hg) during hyperdynamic flow simulation is considered indicative of a hemodynamically significant stenosis.[42]

The information supplied by CTA, MRA, or arteriography is crucial to the success of a revascularization procedure. In addition to providing a detailed "road map" of the exact arterial segments involved, such imaging identifies associated anatomic variations (e.g., accessory renal arteries) and aortic wall characteristics (e.g., extensive calcification and ulcerated plaque), which may alter the operative approach and the conduct of the procedure. During an open revascularization procedure, a surgeon who knows that the aortic wall just below the renal arteries is heavily diseased with ulcerated plaque may, for example, opt to control the aorta at a more proximal level rather than risk dislodging atheromatous debris with standard infrarenal aortic clamping. Similarly, documented occlusive lesions in the visceral or renal arteries (e.g., a patent IMA with a large "meandering mesenteric artery") may best be addressed at the time of aortic reconstruction, or require particular attention to avoid complications.

Preoperative Evaluation

Evaluation of patients for whom aortoiliac revascularization is being considered should include a careful assessment of overall operative risk. Age per se is not a contraindication to an open aortic reconstruction, if it is required. A less invasive procedure of more limited durability, however, may provide a similarly excellent outcome in a patient with reduced life expectancy. Patients with significant AIOD may have atherosclerotic occlusive disease in other vascular territories (e.g., coronary and cerebral) that can increase their operative risk. The detection and treatment of significant coronary artery disease is particularly important, because myocardial infarction is the leading cause of both perioperative and late mortality. In patients with significant aortoiliac disease, more than 50% have clinical or electrocardiographic evidence of coronary disease.[43] In the Coronary Artery Revascularization Prophylaxis (CARP) trial, patients undergoing elective, open, abdominal aortic surgery for aortoiliac occlusive or aneurysmal disease at Veterans Administration hospitals were assessed for cardiac risk.[44] At an average of 2.7 years of follow-up after the aortoiliac procedure, there was no difference in outcome between those who underwent coronary revascularization prior to aortic surgery and those who did not (22% of patients who underwent coronary revascularization died, vs. 23% of those treated medically, $p = 0.92$). Only selected patients, therefore, require cardiac catheterization and occasional coronary angioplasty or bypass grafting before undergoing open aortic reconstruction, and these patients need to be stratified according to risk guidelines.[45]

Pulmonary complications occur in 10% to 15% of patients after open aortoiliac repair,[46] and lung function should be assessed preoperatively only if clinical evaluation cannot determine that the patient is at his or her best achievable baseline pulmonary function and that airflow obstruction has not been optimally relieved. There is otherwise no indication for routine preoperative pulmonary function testing, as the American College of Physicians guidelines state that routine preoperative spirometry is not useful for predicting the risk of postoperative pulmonary complications.[47] Smokers who quit more than 4 weeks before surgery have significantly lower risk of respiratory complications and improved wound healing.[48]

Choice of Revascularization Technique

A variety of surgical procedures, both endovascular and open, are available for revascularization in the patient with AIOD. Selection depends on a number of factors, including the pattern of the occlusive process, patient risk, surgeon experience, and patient preference.

Commonly used techniques include (a) catheter-based balloon dilation (angioplasty) with or without luminal stenting, (b) arterial reconstruction with an anatomically placed bypass prosthesis (aortofemoral or iliofemoral bypass), (c) arterial reconstruction with a remote (or extraanatomically placed) bypass prosthesis (axillofemoral or bifemoral, femorofemoral, thoracofemoral bypass), (d) aortoiliac endarterectomy, and (e) a hybrid approach encompassing a combination of endovascular and open procedures.

Catheter-based techniques are best suited for localized lesions of the common iliac arteries. However, it is currently being used as the main therapeutic modality for the majority of patients; it has essentially replaced endarterectomy procedures in patients with focal AIOD. Prosthetic aortofemoral bypass is the procedure of choice for most patients with advanced, extensive aortoiliac atherosclerosis and is still considered the "gold standard" for aortoiliac revascularization. Femorofemoral or iliofemoral bypass can be chosen in poor-risk patients with diffuse unilateral iliac disease, or with bilateral iliac involvement, when the stenosis in one of the iliac arteries can be appropriately treated by balloon angioplasty, with or without intraluminal stenting.

Axillofemoral or bifemoral bypass is reserved for the small subset of patients in whom standard aortic reconstruction is considered too risky, either for medical reasons (usually severe pulmonary or cardiac disease) or for technical reasons (e.g., aortic reoperations, multiple prior abdominal procedures with dense adhesions, prior abdominal irradiation, and prosthetic graft infection). The descending thoracic aorta can be considered as an alternative inflow source in the construction of a thoracofemoral bypass in a low-risk patient with a "hostile" abdomen.[49]

Endovascular Surgical Management

5 Since the very first transarterial dilation procedures by Dotter, the development of balloon angioplasty by Gruntzig, and the deployment of intra-arterial stents by Palmaz, PTA has become the most commonly performed and, in some cases, the preferred therapy for iliac artery occlusive disease.[50,51] Like open operative reconstruction, PTA, when properly selected, has a high rate of success owing to the large caliber and high rates of flow in the aortoiliac segment. The pattern of the occlusive process and patient comorbidities are primary considerations in selecting PTA as the mode of therapy. The best results are obtained with short, focal, stenotic lesions in the common iliac arteries (TASC A and B).[52] Patients with severe atherosclerotic lesions, complex aortoiliac stenoses, or occlusions (TASC C or D) may also benefit more from endovascular approaches, with many series documenting excellent short-term success. Atheromatous embolism (blue toe syndrome) from an ulcerative plaque may be treated with placement of a stent to trap the debris, relieve the stenosis, and prevent recurrent embolism.

Description of Technique

Preprocedure planning sets the stage for a successful endovascular intervention. Although not always indicated, CTA or MRA delineates the location, extent, and degree of stenosis and associated calcification (Fig. 92-6A). Other considerations include the possible need for a concomitant femoral endarterectomy. When there is significant common femoral artery disease (>50% stenosis) along with iliac occlusive disease, a hybrid approach is preferred, where in addition to PTA, a femoral endarterectomy with patch angioplasty is performed. The endarterectomy should extend as high as possible under the inguinal ligament into the external iliac artery to facilitate stent deployment into the proximal endarterectomized segment and avoid its placement in the common femoral artery itself. A hydrophilic wire with an angled tip, usually a Glidewire (Terumo Interventional Systems, Somerset, NJ) and a straight or angled catheter for support are utilized to cross the stenosis or occlusion. Common iliac artery disease is treated through an ipsilateral retrograde approach if the external iliac is open. If the common iliac artery is occluded, bilateral punctures of the femoral arteries will be necessary to perform an aortography and to delineate the extent of obstruction (Fig. 92-6B). External iliac disease is usually approached with a contralateral antegrade approach across the aortic bifurcation. Crossing total occlusions may be challenging, and reentering the true lumen from the subintimal space can be difficult. If reentry cannot be achieved from the chosen point of vascular access (e.g., the ipsilateral common femoral), an attempt may be made from a new access site (e.g., contralateral common femoral or brachial). For more challenging cases, reentry devices such as the Outback (Cordis Corp., Bridgewater, NJ) or Pioneer (Medtronic, Fridley, MN) catheters may be used. Once the lesion is successfully crossed with a wire, the mode of intervention should then be considered. The typical balloon used for common iliac arteries is 8 to 10 mm, and for external iliac arteries 6 to 8 mm. The principal cause of balloon angioplasty failure is recoil of the atherosclerotic artery or a flow-limiting dissection. Stents serve as support to oppose the elastic recoil of the media

and adventitia of the artery after angioplasty. They are also highly effective in sealing dissection planes within the atherosclerotic plaque resulting from the angioplasty procedure. Stents are also indicated in residual post-balloon stenosis (>30%), residual gradients (>10 mm Hg), ulcerative plaques that have a high risk of showering debris, and after recanalization of an occluded artery.

Self-expanding stents come precovered with a sheath and can be introduced into the lesion directly. Pulling back the sheath allows the compressed stent to assume its expanded form. Self-expanding stents may be more flexible and less likely to get crushed in the event they are deployed close to or past the inguinal ligament into the common femoral artery and are, therefore, used more frequently in the external iliac artery. With self-expanding stents, postdeployment balloon angioplasty is usually needed to achieve full expansion. These stents are usually chosen 10% to 15% larger than the intended lumen diameter; undersizing must be avoided as self-expanding stents cannot be dilated past their nominal diameter.

Balloon expandable stents are sometimes preferred to self-expanding stents in the common iliac artery, owing to their ease and precision of deployment, their better visibility under fluoroscopy, and the increased radial force of their design. These stents are usually introduced through a long sheath passed through the lesion to prevent dislodgment of the stent as it traverses the lesion. The sheath is pulled back once the stent is in satisfactory position, and the stent is deployed under fluoroscopic guidance. Balloon expandable stents are usually sized to the diameter of the normal adjacent artery. Slight undersizing of the stent can be easily managed by further dilating the stent, using a larger balloon.

The role of primary iliac artery stenting was addressed in the Dutch Iliac Stent Trial.[53] Primary angioplasty was compared to primary stenting. Stents were used in 43% of patients who underwent primary angioplasty because of poor results with dilatation alone. There was no difference between the groups at 2 years, with approximately 70% of both groups maintaining iliac artery patency. This result is in contrast to other studies that found that primary stenting for complex aortoiliac disease decreased complications and reduced overall long-term failure by up to 39%.[54,55] Most interventional vascular specialists stent iliac lesions primarily.

Covered balloon-expandable (iCast, Atrium Medical Corp, Hudson, NH) and self-expanding stents (Viabahn, W.L. Gore and Associates, Flagstaff, AZ) have been introduced and are purported to offer a longer patency rate by controlling neointimal hyperplasia that may grow through the interstices of a noncovered stent, especially in TASC C and D lesions.[56,57] Covered stents may also be useful for ulcerated plaques, because they are thought to reduce the chance of distal atheromatous embolism and for heavily calcified or tortuous iliac arteries that are more prone to rupture with balloon inflation.[58] Endovascular stent grafts, similar to those used in the treatment of abdominal aortic aneurysms, have been evaluated for the treatment of AIOD.[59] In one series, the 4-year primary and secondary patency rates were 66% and 72%, respectively. Although these rates are inferior to conventional open reconstruction, they suggest that endovascular reconstruction affords a reasonable alternative when open procedures are high risk or

contraindicated.

Intravascular ultrasound is a modality used during an intervention, rather than as an initial diagnostic tool. It is helpful in sizing iliac stenoses to choose the appropriate-size balloon and stent.[38]

Lesions just above the aortic bifurcation are usually complex, exophytic, and calcific, and usually involve both common iliac arteries. Safe and effective intervention in this situation typically requires the use of two stents, one in each iliac artery, that partially project into the aorta so that they "kiss" in the distal aorta (Fig. 92-6C). Theoretically, treating only one common iliac artery orifice (i.e., the lesion is close to the aortic bifurcation) can result in plaque shifting during the angioplasty, causing a new obstruction in the contralateral lumen. Treating both sides simultaneously avoids this complication.

Complications of Endovascular Interventions

Access site complications are the most common. These include access site hematomas and retroperitoneal bleeding (4% to 17%), pseudoaneurysms (0.5% to 3%), arterial dissection (2% to 5%), and distal embolism (1% to 11%). In experienced hands, these complications are infrequent and can usually be remedied with ultrasound-guided therapy (compression or thrombin injection), intraluminal stenting, or thrombolytic therapy.[60] Contrast-induced nephropathy, however, is a particularly troubling complication, especially in patients with preexisting renal insufficiency.[61] Low osmolality or isoosmolality agents should be used in patients with moderate renal insufficiency. Avoidance of volume depletion, non–steroidal anti-inflammatory drugs, and possibly volume expansion should be considered.[62]

The most serious intraoperative complication is arterial rupture during angioplasty (0.5% to 3%).[60] This is seen as active extravasation on the postintervention angiogram. Treatment is quick passage and reinflation of the balloon to occlude the rupture site and maintain hemodynamic control and then either deployment of a covered stent across the rupture site or open repair in the operating room.

Outcome of Endovascular Interventions

Initial technical success is quite high, in the order of 98%, for TASC A and B lesions. TASC C and D lesions may not be as amenable to endovascular intervention. Surveillance with ABIs and possible duplex ultrasound play a major role in maintaining patency in these patients. The primary patency of iliac artery stenting is 70% at 5 years, but this can improve to 85% with close surveillance and reintervention as necessary (Table 92-2).[60,63–65] Late failures are related to the initial extent of atherosclerosis and the diameter of the treated vessels.[66]

Open Surgical Management

6 Aortobifemoral (or aortofemoral for short) bypass has been the standard open surgical procedure for treating AIOD for decades. Five-year patency rates are in excess of 95%, which is unmatched by any endovascular procedure.[67,68] However, direct revascularization of the aortoiliac segment is currently reserved for patients with advanced (TASC C or D) occlusive disease, for whom the risk of surgery is acceptable and a durable long-term result is expected.

Description of the Aortofemoral Bypass Operation

Aortofemoral bypass remains the reference standard for reconstruction of advanced AIOD (Fig. 92-7).[69] The operation begins with bilateral groin incisions to expose the common, superficial, and deep femoral arteries. Starting the operation in the groins then moving to the abdomen minimizes the duration the abdomen is open. This limits fluid loss and hypothermia, and decreases the risk of graft infection. If the femoral arteries are severely atherosclerotic, the external iliac just above the inguinal ligament is often a soft, disease-free segment that is amenable to safe clamping. The profunda femoris (deep femoral) artery is a critical collateral pathway for the entire lower extremity. If disease is present at its origin, exposure beyond this segment with division of the overlying lateral circumflex femoral vein may be necessary for complete endarterectomy.

The abdominal aorta is usually exposed via a midline, transperitoneal, inframesocolic approach. The transverse colon is retracted cephalad, the ligament of Treitz taken down, and the duodenum (third and fourth portions) mobilized to the right. The left renal vein is identified in the retroperitoneum and serves as the most cephalad limit of exposure in most cases (0.3% of patients have a retroaortic left renal vein).[70] The anterior surface of the aorta is then exposed from lower border of the left renal vein to just below the IMA. Numerous lymphatics are usually encountered in the para-aortic retroperitoneal space. These should be ligated to decrease the chances of a chyle leak. The left renal vein is mobilized if more proximal aortic control is needed; this is performed by ligating the adrenal, gonadal, and lumbar branches. It is generally unnecessary to divide the renal vein. Distal control of the aorta is dictated by the extent of disease. When exposing sites for distal control, the location of the hypogastric plexus and the presacral nerves, which course anterior to the aorta and travel caudally over the aortic bifurcation and origin of the left common iliac artery, needs to be kept in mind. Injury to these nerves can result in erectile dysfunction in men while injury to the sympathetic chain can cause retrograde ejaculation. Retroperitoneal tunnels are then developed between the exposed infrarenal aorta and the groins by means of blunt finger dissection. The tunnels are directed posterior to the ureters to avoid postoperative obstructive uropathy from entrapment of the ureter between the graft limb and the native iliac artery. A retroperitoneal approach to the aorta via a left flank incision is an accepted alternative, especially in those patients with “hostile” abdomens; however, it makes creation of the tunnel for the right limb of the bypass graft slightly more challenging.[71]

A bifurcated vascular prosthesis of appropriate size is selected, typically a presealed

knitted Dacron or a polytetrafluoroethylene graft, and the patient is heparinized. With an occluding clamp below the renal arteries and another just above the IMA, the proximal anastomosis between the graft and the aorta is performed in either an end-to-end or end-to-side fashion. Though most vascular surgeons prefer an end-to-end anastomosis for technical simplicity, the end-to-side technique has been found to be just as good, depending on the pattern of occlusive lesions and need to perfuse patent hypogastric arteries.[72] The proximal anastomosis is placed as close to the renal arteries as practical to prevent future compromise of the bypass resulting from progression of atherosclerosis in the remaining infrarenal cuff. The limbs of the prosthesis are then delivered through the retroperitoneal tunnels into the groins. The distal anastomoses are performed to the common femoral arteries and should be carried onto the profunda femoral arteries if there is any disease at the femoral bifurcation. Common femoral and profunda femoris origin endarterectomy may be needed and should be carried out prior to the anastomosis. Maintaining good outflow through the profunda femoris is very important as many of these patients have concomitant superficial femoral arterial disease, which may compromise long-term graft patency. In the rare patient with tissue loss secondary to multilevel disease (AIOD associated with an occluded superficial femoral artery and compromised deep femoral collaterals), a concomitant distal bypass (femoropopliteal–tibial) may also be required.

Endarterectomy

Endarterectomy was more commonly performed in the era before reliable vascular prosthetic conduits were available. The high success rates of angioplasty and stenting for the more limited disease patterns amenable to endarterectomy have rendered aortoiliac endarterectomy essentially obsolete in most current practices.

Table 92-2 Results of Endovascular Interventions

Procedure	Technical Success	5-yr Primary Patency	5-yr Secondary Patency	Mortality
Iliac angioplasty and stenting	85–100%	60–80%	80–98%	1–6%

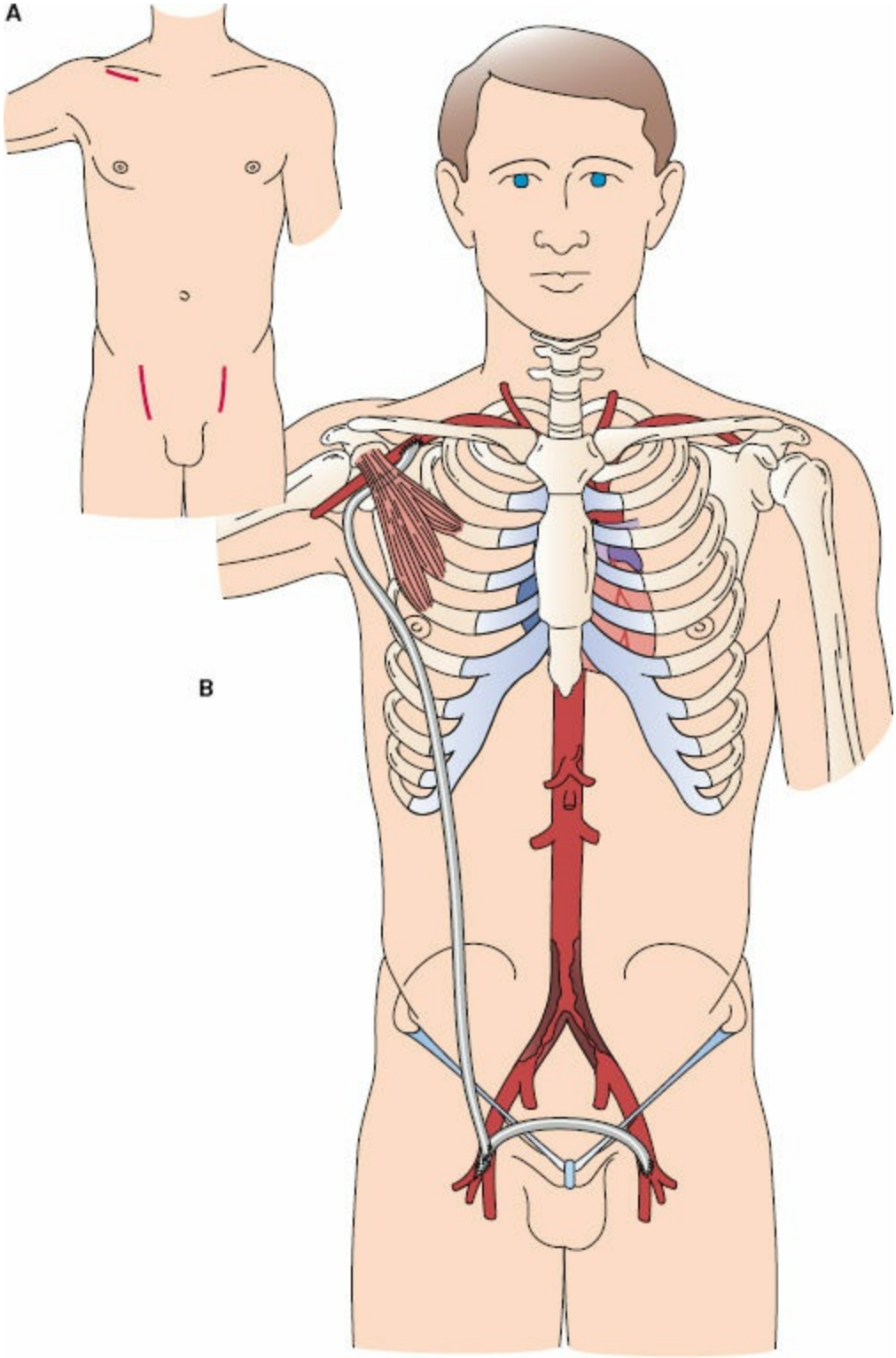

Figure 92-9. **A:** Ipsilateral infraclavicular incision and bilateral femoral incision locations for extra-anatomic axillary to bifemoral artery bypass. **B:** Image demonstrates unilateral axillary to ipsilateral femoral artery bypass graft with cross-femoral to femoral artery bypass graft.

Extra-Anatomic Bypass

Patients who are at high risk for open aortic surgery due to either physiologic or anatomic constraints and are not endovascular candidates may be better served with extra-anatomic reconstruction. Although these operations are less risky, they have a documented lower patency rate and are, therefore, reserved for patients with CLI and generally not performed for intermittent claudication.

Axillofemoral extra-anatomic reconstruction has been used for revascularization in poor-risk patients and in those with a "hostile" abdomen and has been reported to be an acceptable alternative to aortofemoral bypass (Fig. 92-9).[73] The axillary artery supplying the arm with the higher brachial blood pressure is chosen as the inflow vessel, usually the right side. The operative sequence starts with exposure of the most proximal portion of the axillary artery through an infraclavicular, pectoralis major muscle-splitting incision. The common, superficial, and deep femoral arteries are then dissected through bilateral groin incisions. An externally supported polytetrafluoroethylene graft is then passed behind the pectoralis major muscle and through a subcutaneous tunnel in the anterior axillary line, connecting the axillary incision with the ipsilateral groin incision. Next, a cross-femoral limb of the graft is delivered through a subcutaneous suprapubic tunnel connecting the two groins. An anastomosis between the proximal axillary artery and the prosthesis is then constructed in an end-graft–to–side-of-artery fashion. The distal anastomoses are performed end-to-side to the common femoral arteries and may be carried over or onto the deep femoral arteries to ensure adequate graft outflow. Providing flow through both femoral arteries (axillobifemoral bypass) rather than one ipsilateral artery (axillounifemoral) has been shown to increase flow velocities within the long main shaft of the graft and improve long-term patency of the bypass.[73] The generally accepted lower patency of the axillofemoral bypass makes it better reserved for patients with advanced aortoiliac disease who are poor surgical risks with a reduced life expectancy or those with a "hostile" abdomen.[74] For high-risk patients with diffuse advanced disease limited to one iliac artery, cross-femoral (or femoral artery–to–femoral artery) bypass or an iliofemoral bypass is a good option.[75]

Outcomes

The excellent durability of aortofemoral bypass is related to the large caliber and high flow rates of the vessels involved. Results of direct surgical revascularization are listed in (Table 92-3). Aortofemoral bypass has excellent primary graft patency rates of approximately 85% to 95% at 5 years and 75% to 88% at 10 years. Factors associated with lower long-term patency of these grafts include female sex (in part due to smaller vessel size), multilevel arterial occlusive disease, and young age (<50 years) where premature and aggressive atherosclerosis is usually present.[76,77] The most common cause of failure of surgical reconstructions is the progression of atherosclerosis or the development of anastomotic neointimal hyperplasia.[78] Axillofemoral grafts by comparison have patency rates of only 60% at 3 years. Femoral–femoral grafts are intermediate in performance with a 5-year patency of 50% to 60%.

Table 92-3 Results of Direct Surgical Revascularization

Procedure	5-yr Patency	Operative Mortality
Aortofemoral bypass	80–95%	2–4%
Femorofemoral bypass	50–60%	1–3%
Axillobifemoral bypass	30–50%	1–4%

Complications

As previously stated, aortofemoral grafting is considered the gold standard for the treatment of AIOD. Due to advancements in anesthesia and surgical critical care, aortofemoral bypass can be performed with perioperative mortality and morbidity below 5%, respectively[67] (Table 92-3). The perioperative morbidity and mortality for axillofemoral bypass is similar but is performed, in general, on a much higher risk population of patients.

Early Complications

- Postoperative cardiac events have decreased to less than 5%. This is due to diligent preoperative screening and following the excellent perioperative guidelines promoted by numerous professional societies including the use of aspirin, statins, and perioperative beta-blockers.
- Pulmonary complications are not infrequent, occurring in up to 7% of patients. Adequate pain control with epidural anesthesia to facilitate pulmonary toilet and avoiding volume overload can help reduce these complications.
- Atheroemboli can occur during the procedure, manifesting as end organ ischemia of the skin, pelvis, spinal cord, and bowel. Attention to detail during arterial clamping and flushing out the graft before unclamping can minimize this complication.
- Ischemic colitis and pelvic ischemia are rare and can be minimized by planning a procedure that maintains pelvic perfusion and blood flow to the IMA when collateral flow is insufficient to maintain left colon viability. Selective reimplantation of the IMA can be performed when poor IMA perfusion is anticipated or demonstrated. Ischemic colitis may require colectomy for treatment, but this is associated with a 50% mortality.
- Acute renal injury can result from either atheroembolism from aortic clamping close to the renal arteries or from corticomedullary renal shunting induced by the acute increase in afterload attendant with aortic clamping.
- Other possible complications include wound complications, particularly in the groin (lymphocele, lymphocutaneous fistula, wound infection), postoperative hemorrhage, erectile dysfunction in men, bowel injury, pancreatitis from retraction injury, and spinal cord ischemia. Wound complications can be particularly troublesome for axillofemoral and femoral–femoral bypasses because of the subcutaneous location of these prosthetic grafts.

Late Complications

- Graft thrombosis that is largely due to progression of native atherosclerotic disease either proximal or distal to the graft, or to anastomotic neointimal hyperplasia.
- Pseudoaneurysms from material fatigue, suture fracture, artery wall degeneration, or occult infection.
- Graft infections. A graft enteric fistula (most frequently to the third/fourth portions of the overlying duodenum) may present as a gastrointestinal bleed. Every gastrointestinal bleed in a patient with a history of aortofemoral bypass or other aortic

reconstruction should be considered to be an aortoenteric fistula until proven otherwise.

References

1. Fowkes FG, Housley E, Cawood EH, et al. Edinburgh Artery Study: prevalence of asymptomatic and symptomatic peripheral arterial disease in the general population. *Int J Epidemiol* 1991;20(2):384–392.
2. Ramos R, Quesada M, Solanas P, et al. Prevalence of symptomatic and asymptomatic peripheral arterial disease and the value of the ankle-brachial index to stratify cardiovascular risk. *Eur J Vasc Endovasc Surg* 2009;38(3):305–311.
3. Selvin E, Erlinger TP. Prevalence of and risk factors for peripheral arterial disease in the United States: results from the National Health and Nutrition Examination Survey, 1999–2000. *Circulation* 2004;110(6):738–743.
4. Kannel WB, Shurtleff D. The Framingham Study. Cigarettes and the development of intermittent claudication. *Geriatrics* 1973;28(2):61–68.
5. Violi F, Criqui M, Longoni A, et al. Relation between risk factors and cardiovascular complications in patients with peripheral vascular disease. Results from the A.D.E.P. study. *Atherosclerosis* 1996;120(1-2):25–35.
6. DeBakey ME, Glaeser DH. Patterns of atherosclerosis: effect of risk factors on recurrence and survival-analysis of 11,890 cases with more than 25-year follow-up. *Am J Cardiol* 2000;85(9):1045–1053.
7. Hughson WG, Mann JI, Garrod A. Intermittent claudication: prevalence and risk factors. *Br Med J* 1978;1(6124):1379–1381.
8. Morley JE, Kaiser FE. Sexual function with advancing age. *Med Clin North Am* 1989;73(6):1483–1495.
9. Leriche R, Morel A. The syndrome of thrombotic obliteration of the aortic bifurcation. *Ann Surg* 1948;127(2):193–206.
10. Wingo JP, Nix ML, Greenfield LJ, et al. The blue toe syndrome: hemodynamics and therapeutic correlates of outcome. *J Vasc Surg* 1986;3(3):475–480.
11. DeBakey ME, Lawrie GM, Glaeser DH. Patterns of atherosclerosis and their surgical significance. *Ann Surg* 1985;201(2):115–131.
12. Darling RC, Brewster DC, Hallett JW Jr, et al. Aorto-iliac reconstruction. *Surg Clin North Am* 1979;59(4):565–579.
13. Chen Q, Smith CY, Bailey KR, et al. Disease location is associated with survival in patients with peripheral arterial disease. *J Am Heart Assoc* 2013; 2(5):e000304.
14. Malone JM, Moore WS, Goldstone J. Life expectancy following aortofemoral arterial grafting. *Surgery* 1977;81(5):551–555.
15. Krug RT, Calligaro KD, Dougherty MJ. Claudication in the young patient. *Perspect Vasc Surg Endovasc Ther* 2000;13(2):27–38.
16. Norgren L, Hiatt WR, Dormandy JA, et al. Inter-society consensus for the management of peripheral arterial disease (TASC II). *J Vasc Surg* 2007; 45(suppl S):S5–S67.

17. Leville CD, Kashyap VS, Clair DG, et al. Endovascular management of iliac artery occlusions: extending treatment to TransAtlantic Inter-Society Consensus class C and D patients. *J Vasc Surg* 2006;43(1):32–39.
18. Rumwell C, McPharlin M. *Vascular Technology: An Illustrated Review*. 5th ed. California: Davies Publishing, Inc.;2015.
19. Yao ST. Haemodynamic studies in peripheral arterial disease. *Br J Surg* 1970;57(10):761–766.
20. Katsamouris AN, Giannoukas AD, Tsetis D, et al. Can ultrasound replace arteriography in the management of chronic arterial occlusive disease of the lower limb? *Eur J Vasc Endovasc Surg* 2001;21(2):155–159.
21. Girolami B, Bernardi E, Prins MH, et al. Treatment of intermittent claudication with physical training, smoking cessation, pentoxifylline, or nafronyl: a meta-analysis. *Arch Intern Med* 1999;159(4):337–345.
22. Cunningham MA, Swanson V, O'Carroll RE, et al. Randomized clinical trial of a brief psychological intervention to increase walking in patients with intermittent claudication. *Br J Surg* 2012;99(1):49–56.
23. Al-Jundi W, Madbak K, Beard JD, et al. Systematic review of home-based exercise programmes for individuals with intermittent claudication. *Eur J Vasc Endovasc Surg* 2013;46(6):690–706.
24. Ahimastos AA, Pappas EP, Buttner PG, et al. A meta-analysis of the outcome of endovascular and noninvasive therapies in the treatment of intermittent claudication. *J Vasc Surg* 2011;54(5):1511–1521.
25. Murphy TP, Cutlip DE, Regensteiner JG, et al; CLEVER Study Investigators. Supervised exercise versus primary stenting for claudication resulting from aortoiliac peripheral artery disease: six-month outcomes from the claudication: exercise versus endoluminal revascularization (CLEVER) study. *Circulation* 2012;125(1):130–139.
26. Eckel RH, Jakicic JM, Ard JD, et al; American College of Cardiology/American Heart Association Task Force on Practice Guidelines. 2013 AHA/ACC guideline on lifestyle management to reduce cardiovascular risk: a report of the American College of Cardiology/American Heart Association Task Force on Practice Guidelines. *Circulation* 2014;129(25 suppl 2):S76–S99.
27. Lane R, Ellis B, Watson L, et al. Exercise for intermittent claudication. *Cochrane Database Syst Rev* 2014;7:CD000990.
28. McDermott MM, Liu K, Guralnik JM, et al. Home-based walking exercise intervention in peripheral artery disease: a randomized clinical trial. *JAMA* 2013;310(1):57–65.
29. 2011 Writing Group Members; 2005 Writing Committee Members; ACCF/AHA Task Force Members. 2011 ACCF/AHA Focused Update of the Guideline for the Management of patients with peripheral artery disease (Updating the 2005 Guideline): a report of the American College of Cardiology Foundation/American Heart Association Task Force on practice guidelines. *Circulation* 2011;124(18):2020–

2045.
30. Wong PF, Chong LY, Mikhailidis DP, et al. Antiplatelet agents for intermittent claudication. *Cochrane Database Syst Rev* 2011;(11):CD001272.
31. Diener HC, Bogousslavsky J, Brass LM, et al. Aspirin and clopidogrel compared with clopidogrel alone after recent ischaemic stroke or transient ischaemic attack in high-risk patients (MATCH): randomised, double-blind, placebo-controlled trial. *Lancet* 2004;364(9431):331–337.
32. Aung PP, Maxwell HG, Jepson RG, et al. Lipid-lowering for peripheral arterial disease of the lower limb. *Cochrane Database Syst Rev* 2007;(4):CD000123.
33. De Backer TL, Vander Stichele R, Lehert P, et al. Naftidrofuryl for intermittent claudication. *Cochrane Database Syst Rev* 2008;(2):CD001368.
34. Robless P, Mikhailidis DP, Stansby GP. Cilostazol for peripheral arterial disease. *Cochrane Database Syst Rev* 2007;(1):CD003748.
35. Dormandy J, Heeck L, Vig S. The fate of patients with critical leg ischemia. *Semin Vasc Surg* 1999;12(2):142–147.
36. Hirsch AT, Haskal ZJ, Hertzer NR, et al. ACC/AHA 2005 Practice Guidelines for the management of patients with peripheral arterial disease (lower extremity, renal, mesenteric, and abdominal aortic): a collaborative report from the American Association for Vascular Surgery/Society for Vascular Surgery, Society for Cardiovascular Angiography and Interventions, Society for Vascular Medicine and Biology, Society of Interventional Radiology, and the ACC/AHA Task Force on Practice Guidelines (Writing Committee to Develop Guidelines for the Management of Patients With Peripheral Arterial Disease): endorsed by the American Association of Cardiovascular and Pulmonary Rehabilitation; National Heart, Lung, and Blood Institute; Society for Vascular Nursing; TransAtlantic Inter-Society Consensus; and Vascular Disease Foundation. *Circulation* 2006;113(11):e463–e654.
37. Heijenbrok-Kal MH, Kock MC, Hunink MG. Lower extremity arterial disease: multidetector CT angiography meta-analysis. *Radiology* 2007; 245(2):433–439.
38. Bui BT, Miller S, Mildenberger P, et al. Comparison of contrast-enhanced MR angiography to intraarterial digital subtraction angiography for evaluation of peripheral arterial occlusive disease: results of a phase III multicenter trial. *J Magn Reson Imaging* 2010;31(6):1402–1410.
39. Wiginton CD, Kelly B, Oto A, et al. Gadolinium-based contrast exposure, nephrogenic systemic fibrosis, and gadolinium detection in tissue. *AJR Am J Roentgenol* 2008;190(4):1060–1068.
40. Popma JJ, Satler LF, Pichard AD, et al. Vascular complications after balloon and new device angioplasty. *Circulation* 1993;88(4 pt 1):1569–1578.
41. Applegate RJ, Sacrinty MT, Kutcher MA, et al. Trends in vascular complications after diagnostic cardiac catheterization and percutaneous coronary intervention via the femoral artery, 1998 to 2007. *JACC: Cardiovasc Interv* 2008;1(3):317–326.

42. Cao P, Eckstein HH, De Rango P, et al. Chapter II: diagnostic Methods. *Eur J Vasc Endovasc Surg* 2011;42(suppl 2):S13–S32.
43. Szilagyi DE, Elliott JP Jr, Smith RF, et al. A thirty-year survey of the reconstructive surgical treatment of aortoiliac occlusive disease. *J Vasc Surg* 1986;3(3):421–436.
44. McFalls EO, Ward HB, Moritz TE, et al. Coronary-artery revascularization before elective major vascular surgery. *N Engl J Med* 2004;351(27):2795–2804.
45. Fleisher LA, Beckman JA, Brown KA, et al. ACC/AHA 2007 guidelines on perioperative cardiovascular evaluation and care for noncardiac surgery: executive summary: a report of the American College of Cardiology/American Heart Association Task Force on Practice Guidelines (writing committee to revise the 2002 guidelines on perioperative cardiovascular evaluation for noncardiac surgery): developed in collaboration with the American Society of Echocardiography, American Society of Nuclear Cardiology, Heart Rhythm Society, Society of Cardiovascular Anesthesiologists, Society for Cardiovascular Angiography and Interventions, Society for Vascular Medicine and Biology, and Society for Vascular Surgery. *Circulation* 2007;116(17):1971–1996.
46. Bagan P, Bouayad M, Benabdesselam A, et al. Prevention of pulmonary complications after aortic surgery: evaluation of prophylactic noninvasive perioperative ventilation. *Ann Vasc Surg* 2011;25(7):920–922.
47. Qaseem A, Snow V, Fitterman N, et al. Risk assessment for and strategies to reduce perioperative pulmonary complications for patients undergoing noncardiothoracic surgery: a guideline from the American College of Physicians. *Ann Intern Med* 2006;144(8):575–580.
48. Wong J, Lam DP, Abrishami A, et al. Short-term preoperative smoking cessation and postoperative complications: a systematic review and meta-analysis. *Can J Anaesth* 2012;59(3):268–279.
49. Passman MA, Farber MA, Criado E, et al. Descending thoracic aorta to iliofemoral artery bypass grafting: a role for primary revascularization for aortoiliac occlusive disease? *J Vasc Surg* 1999;29(2):249–258.
50. Dotter CT, Judkins MP. Transluminal treatment of arteriosclerotic obstruction. Description of a new technic and a preliminary report of its application. *Circulation* 1964;30:654–670.
51. Palmaz JC, Sibbitt RR, Tio FO, et al. Expandable intraluminal vascular graft: a feasibility study. *Surgery* 1986;99(2):199–205.
52. Johnston KW, Rae M, Hogg-Johnston SA, et al. 5-year results of a prospective study of percutaneous transluminal angioplasty. *Ann Surg* 1987;206(4):403–413.
53. Tetteroo E, van der Graaf Y, Bosch JL, et al. Randomised comparison of primary stent placement versus primary angioplasty followed by selective stent placement in patients with iliac-artery occlusive disease. Dutch Iliac Stent Trial Study Group. *Lancet* 1998;351(9110):1153–1159.
54. Bosch JL, Tetteroo E, Mali WP, et al. Iliac arterial occlusive disease: cost-

effectiveness analysis of stent placement versus percutaneous transluminal angioplasty. Dutch Iliac Stent Trial Study Group. *Radiology* 1998; 208(3):641–648.

55. Goode SD, Cleveland TJ, Gaines PA. Randomized clinical trial of stents versus angioplasty for the treatment of iliac artery occlusions (STAG trial). *Br J Surg* 2013;100(9):1148–1153.
56. Mwipatayi BP, Thomas S, Wong J, et al. A comparison of covered vs bare expandable stents for the treatment of aortoiliac occlusive disease. *J Vasc Surg* 2011;54(6):1561–1570.
57. Humphries MD, Armstrong E, Laird J, et al. Outcomes of covered versus bare-metal balloon-expandable stents for aortoiliac occlusive disease. *J Vasc Surg* 2014;60(2):337–343.
58. Rzucidlo EM, Powell RJ, Zwolak RM, et al. Early results of stent-grafting to treat diffuse aortoiliac occlusive disease. *J Vasc Surg* 2003;37(6):1175–1180.
59. Ali AT, Modrall JG, Lopez J, et al. Emerging role of endovascular grafts in complex aortoiliac occlusive disease. *J Vasc Surg* 2003;38(3):486–491.
60. Jongkind V, Akkersdijk GJ, Yeung KK, et al. A systematic review of endovascular treatment of extensive aortoiliac occlusive disease. *J Vasc Surg* 2010;52(5):1376–1383.
61. Ozsvath KJ, Darling RC III. Renal protection: preconditioning for the prevention of contrast-induced nephropathy. *Semin Vasc Surg* 2013;26(4):144–149.
62. Rudnick MR, Goldfarb S, Wexler L, et al. Nephrotoxicity of ionic and nonionic contrast media in 1196 patients: a randomized trial. The Iohexol Cooperative Study. *Kidney Int* 1995;47(1):254–261.
63. Galaria II, Davies MG. Percutaneous transluminal revascularization for iliac occlusive disease: long-term outcomes in TransAtlantic Inter-Society Consensus A and B lesions. *Ann Vascu Surg* 2005;19(3):352–360.
64. Chang RW, Goodney PP, Baek JH, et al. Long-term results of combined common femoral endarterectomy and iliac stenting/stent grafting for occlusive disease. *J Vasc Surg* 2008;48(2):362–367.
65. Sachwani GR, Hans SS, Khoury MD, et al. Results of iliac stenting and aortofemoral grafting for iliac artery occlusions. *J Vasc Surg* 2013;57(4):1030–1037.
66. Ichihashi S, Higashiura W, Itoh H, et al. Long-term outcomes for systematic primary stent placement in complex iliac artery occlusive disease classified according to Trans-Atlantic Inter-Society Consensus (TASC)-II. *J Vasc Surg* 2011;53(4):992–999.
67. Chiu KW, Davies RS, Nightingale PG, et al. Review of direct anatomical open surgical management of atherosclerotic aorto-iliac occlusive disease. *Eur J Vasc Endovasc Surg* 2010;39(4):460–471.
68. Kakkos SK, Haurani MJ, Shepard AD, et al. Patterns and outcomes of aortofemoral bypass grafting in the era of endovascular interventions. *Eur J Vasc Endovasc Surg* 2011;42(5):658–666.

69. Kadakol AK, Nypaver TJ, Lin JC, et al. Frequency, risk factors, and management of perigraft seroma after open abdominal aortic aneurysm repair. *J Vasc Surg* 2011;54(3):637–643.
70. Mayo J, Gray R, St Louis E, et al. Anomalies of the inferior vena cava. *AJR Am J Roentgenol* 1983;140(2):339–345.
71. Shepard AD, Tollefson DF, Reddy DJ, et al. Left flank retroperitoneal exposure: a technical aid to complex aortic reconstruction. *J Vasc Surg* 1991;14(3):283–291.
72. Pierce GE, Turrentine M, Stringfield S, et al. Evaluation of end-to-side v end-to-end proximal anastomosis in aortobifemoral bypass. *Arch Surg* 1982;117(12):1580–1588.
73. LoGerfo FW, Johnson WC, Corson JD, et al. A comparison of the late patency rates of axillobilateral femoral and axillounilateral femoral grafts. *Surgery* 1977;81(1):33–38; discussion 38–40.
74. Passman MA, Taylor LM, Moneta GL, et al. Comparison of axillofemoral and aortofemoral bypass for aortoiliac occlusive disease. *J Vasc Surg* 1996;23(2):263–269; discussion 269–271.
75. Pursell R, Sideso E, Magee TR, et al. Critical appraisal of femorofemoral crossover grafts. *Br J Surg* 2005;92(5):565–569.
76. Valentine RJ, Hansen ME, Myers SI, et al. The influence of sex and aortic size on late patency after aortofemoral revascularization in young adults. *J Vasc Surg* 1995;21(2):296–306.
77. Reed AB, Conte MS, Donaldson MC, et al. The impact of patient age and aortic size on the results of aortobifemoral bypass grafting. *J Vasc Surg* 2003;37(6):1219–1225.
78. Nevelsteen A, Suy R. Graft occlusion following aortofemoral Dacron bypass. *Ann Vasc Surg* 1991;5(1):32–37.

Chapter 93

Peripheral Arterial Disease

William P. Robinson III

Key Points

1 Chronic obliterative atherosclerosis of the infrainguinal vessels is the most prevalent manifestation of peripheral arterial disease (PAD) encountered by the vascular surgeon.

2 The major risk factors for the development of PAD include smoking, diabetes, advanced age, male gender, hypertension, dyslipidemia, and chronic kidney disease.

3 PAD is a powerful risk factor for cardiovascular morbidity and mortality.

4 The most common lesion seen below the inguinal ligament is that of a short-segment total occlusion of the superficial femoral artery.

5 Typically half of patients proceeding to revascularization for arterial occlusive disease have significant coronary artery disease; even more have hypertension, and almost 80% are current or prior cigarette smokers.

6 The diagnosis of infrainguinal occlusive disease is generally made based on patient symptomatology, physical examination, and noninvasive tests, such as ankle–brachial index (ABI), segmental pressure measurements, and pulse volume recordings.

7 Percutaneous endovascular therapy is often applied as first-line therapy, particularly in patients with more limited extent of anatomic disease and/or high operative risk.

8 Open surgical revascularization remains the gold standard for those patients with disabling claudication, ischemic rest pain, and ischemic ulceration or gangrene.

9 Infrainguinal arterial bypass surgery remains the signature operation distinguishing vascular surgeons from other specialists involved in the treatment of peripheral vascular disease.

10 Infrainguinal bypass surgery is best performed with autogenous vein conduit, preferably the ipsilateral greater saphenous vein if available.

11 Many of the patients undergoing surgical reconstruction for critical limb ischemia (CLI) with tissue loss will require one or more adjunctive operative procedures for salvage of their foot.

1 The term “Peripheral Arterial Disease (PAD)” broadly denotes stenotic, occlusive, and aneurysmal diseases of the aorta and its branch arteries, exclusive of the coronary arteries. In common clinical usage, PAD, which is defined as an ankle–brachial index

(ABI) <0.9, denotes atherosclerotic stenosis or occlusion of the arteries supplying the lower extremities.[1] Atherosclerotic occlusive disease of the aorta and iliac arteries is covered in Chapter 92. This chapter will cover PAD located in the femoropopliteal and tibial (infrainguinal) arteries. PAD affects 12% of the U.S. adult population and almost 20% of U.S. adults older than age 70 years.[1–3] PAD involving the lower extremities is the third leading overall cause of atherosclerotic morbidity worldwide after coronary artery disease and stroke.[4] With the aging of the American population, the prevalence of lower extremity occlusive disease has steadily increased in recent decades. Not surprisingly, therefore, the clinical manifestations and complications of atherosclerosis are the most common therapeutic challenges encountered and treated by vascular surgeons.

The tendency for atherosclerotic lesions to develop at specific anatomic sites and follow recognizable patterns of progression was first appreciated in the late 1700s by the British anatomist and surgeon John Hunter. Considered one of the forefathers of vascular surgery, his dissections of atherosclerotic aortic bifurcations are preserved at the Hunterian museum in London and presage the disease process that Leriche would give his name to 150 years later.[5] The modern era of surgical reconstruction for complex atherosclerotic occlusive disease began in earnest in 1947, when the Portuguese surgeon J. Cid dos Santos successfully endarterectomized a heavily diseased common femoral artery.[6] Four years later, building on the pioneering work of Alexis Carrel, Kunlin would report the first long-segment vein bypass in the lower extremity.[7,8] It would be another 10 years before the initial efforts to extend vein grafting to the tibial level were described by McCaughan.[9] The last three decades have seen tremendous advances in both the understanding of atherosclerosis biology and refinement in the techniques of infrainguinal surgical revascularization that have greatly improved surgeons ability to preserve limbs and improve quality of life in patients with femoropopliteal and tibial occlusive disease. Moreover, in the last two decades, advances in percutaneous treatment have revolutionized the treatment of infrainguinal occlusive disease. The concept of intravascular intervention was pioneered in the late 1960s by the radiologist Charles Dotter, and advanced greatly with the advent of the angioplasty balloon by Gruntzig in the early 1970s.[10,11] Nevertheless, endovascular intervention for infrainguinal disease was not utilized significantly until the 1990s. The technology remains in rapid development and surrounded by ongoing controversy as to its proper role.

Although a diverse range of technical skill is required of the contemporary vascular and endovascular surgeon, it is worth noting that infrainguinal arterial bypass surgery remains the signature operation distinguishing vascular surgeons from other specialists involved in the treatment of PAD. This distinction stems primarily from the fact that the outcome of infrainguinal reconstruction is highly dependent on the judgment and technical skill of the surgeon, with the end result often being either successful limb salvage or major limb amputation. This chapter reviews the surgical and endovascular management of femoropopliteal and tibial arterial occlusive disease and details standard and advanced techniques underlying successful infrainguinal operative revascularization. Endovascular intervention is introduced, though a comprehensive review of endovascular techniques used to treat femoropopliteal and tibial occlusive disease is beyond the scope

of the chapter.

INFRAINGUINAL ARTERIAL OCCLUSIVE DISEASE

Epidemiology and Risk Factors

Symptomatic PAD in the form of claudication affects more than 10 million Americans including 1% to 2% of those aged <50, 5% of those aged 50 to 70, and 10% of those aged >70. Of those aged >50 with PAD, 1% to 3% will have critical leg ischemia in the form of rest pain or gangrene.[12,13] The incidence of CLI ranges from 220 to 1,000 new cases per year in a European or American population of 1 million people.[14]

2 The risk factors for infrainguinal occlusive disease are the same as those for the development of atherosclerosis in general and include age, male gender, hypertension, diabetes mellitus (DM), smoking, dyslipidemia, family history, and homocysteinemia. Smoking and diabetes are the most powerful risk factors. Smokers are at four times the risk of symptomatic PAD than nonsmokers while diabetics are more than three times more likely to develop symptomatic PAD in comparison to nondiabetics.[14] The propensity for heavy smokers to develop superficial femoral artery disease and for diabetics to develop tibial disease should be noted. More recent evidence indicates that nonwhite ethnicity, inflammatory markers such as C-reactive protein, and perhaps chronic renal insufficiency (CRI) are also associated with an increased risk of PAD.[15–17]

Presentation and Natural History

3 Chronic obliterative atherosclerosis of the infrainguinal vessels is the most prevalent manifestation of PAD encountered by the vascular surgeon. Patients are classified into two broad categories depending upon their symptomatology: claudicants and those with critical limb ischemia (CLI). Claudication, the reproducible ischemic muscle pain resulting from inadequate oxygen delivery during exercise, is the cardinal presenting symptom. Natural history studies indicate patients with claudication have increased rates of cardiovascular mortality, but an overall low risk of limb loss.[18,19] Seventy to eighty percent of patients with claudication demonstrate a stable pattern of disease throughout their lifetime or have improvement in their symptoms as a result of risk factor modification, whereas 20% to 30% undergo operation within 5 years as a result of disease progression. Claudication will progress to CLI in only 5% to 10% of patients over their lifetime. However, PAD leading to claudication is a marker of severe systemic atherosclerotic burden and increased cardiovascular morbidity and mortality. Twenty percent of chronic instance experience a nonfatal myocardial infarction or stroke and 10% to 15% died of cardiovascular-related mortality at 5 years.[13] The annual rates of mortality and limb loss in patients with claudication are approximately 2% to 5% and 1%, respectively.[13,20]

4 The most common atherosclerotic disease pattern encountered distal to the inguinal ligament is that of a short-segment total occlusion of the superficial femoral artery. Isolated disease of this nature typically presents as calf muscle claudication. It is not uncommon, however, for patients with significant single-level lesions, even those with long-segment arterial occlusions, in the superficial femoral artery or more distal arterial beds to be only minimally symptomatic or even asymptomatic. While this can sometimes be the result of exercise limitations imposed by concomitant coronary arterial disease or other physiologic impairments such as lung disease or arthritis, it is more often a result of compensatory collateral flow. Collateral perfusion from the profunda femoral artery around a heavily diseased or occluded superficial femoral artery frequently reconstitutes the distal superficial femoral artery or popliteal artery with enough well-perfused arterial blood to ensure sufficient resting tissue perfusion. Similarly, the rich network of geniculate collaterals can sometimes compensate for a diseased popliteal arterial segment to a sufficient degree to prevent rest pain or overt tissue loss, but will usually prove insufficient to meet the increased metabolic demands of ambulation and forestall claudication.

CLI, which must be differentiated from acute limb ischemia, is the most severe form of PAD and refers to the presence of either rest pain or tissue loss in the lower limb. Rest pain occurs when blood flow is inadequate to meet resting metabolic requirements. In the lower extremity, ischemic rest pain is localized to the foot, frequently in the metatarsals or the instep, and should be easily distinguishable from benign muscle cramps in the calf commonly seen in older patients. Patients with rest pain are often awakened by severe discomfort in the forefoot and hang the affected extremity over the edge of the bed for temporary symptomatic relief. Trophic changes, such as muscle wasting, thinning of skin,

thickening of nails, and hair loss are frequently also seen in the distal affected limb. Rest pain is an ominous symptom and usually requires revascularization given the tendency for progression to tissue loss. Ischemia ulcerations usually begin as small, dry ulcers of the toes or heel area, and progress to frankly gangrenous changes of the forefoot or heel with greater degrees of arterial insufficiency (Fig. 93-1). Patients with diabetes or renal failure are more susceptible to the development of ischemic pedal ulcers. Disease progression can be very rapid, as up to 50% of patients with CLI are asymptomatic 6 months before onset of pain or ulceration.[21] Such progressive disease, affecting multiple levels of the peripheral vasculature tree, is more frequently encountered in the elderly.

The natural history of CLI is dismal as these patients are generally of advanced age and possess significant comorbidities contributing to their advanced limb ischemia. Overall, approximately 25% of patients with CLI will die at 1 year, 30% will undergo major amputation, and 45% will be alive with two limbs.[13,14] The rate of amputation is 10 times higher in diabetics than nondiabetics and 5- and 10-year mortality in patients with CLI have been reported to be 60% and 85%, respectively.[21] CLI mandates revascularization for limb salvage when feasible, as limb salvage with medical therapy and wound care is virtually futile; success rates for rest pain and tissue loss have been reported to be as low as 27% and 5%, respectively.[21]

Several identifiable patterns of infrainguinal PAD are well recognized. It is important to note that symptoms and signs of ischemia generally involve the limb one level distal to the level of hemodynamically significant disease. Patients with an extensive history of cigarette smoking typically have lesions limited to the superficial femoral artery and corresponding symptoms of calf claudication (Fig. 93-2). Patients with rest pain or ischemic tissue loss typically manifest more extensive involvement of the femoral, popliteal, or tibial arteries than patients with claudication. Those with tissue loss also more commonly have multilevel disease involving the femoropopliteal system in combination with occlusive disease of the aortoiliac vessels or the infrageniculate runoff.[22]Diabetes often targets the tibial vessels, and patients may present with frank tissue necrosis in the presence of a palpable popliteal pulse and no prior history of claudication. Alternatively, the so-called “blue toe syndrome” is a situation in which atherosclerotic debris breaks free from a more proximal source, for example, an aortoiliac or femoropopliteal plaque or a thrombus-lined aneurysm, and embolizes to the distal vessels.[23] Wire manipulation during coronary or peripheral angiographic procedures and crossclamping across a calcific aortic plaque during cardiac surgery are common sources of such emboli. The terminal target of the microembolic particles, whether cholesterol crystals, calcified plaque, and thrombus or platelet aggregates, is typically the small vessels of the toes and heel.



Figure 93-1. **A–C:** Examples of digital ischemic ulcerations resulting from progressive arterial insufficiency.

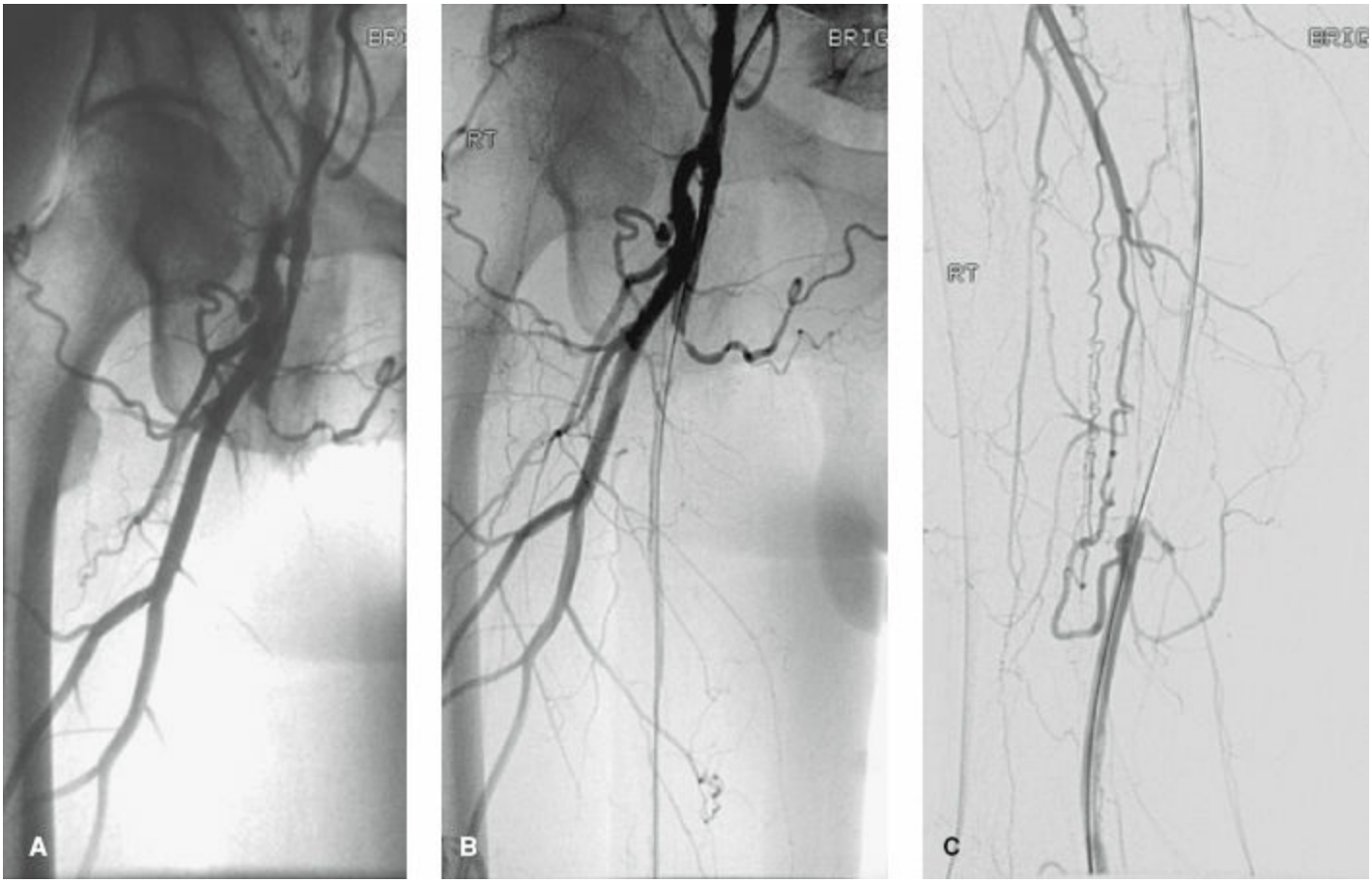

Figure 93-2. Long-segment total occlusion of superficial femoral artery in a patient with a long history of cigarette smoking and severe claudication. Proximal sfa occlusion is demonstrated (**A**), followed by wire traversal of the occlusion (**B**), which will allow endovascular treatment of the occluded segment of the sfa proximal to reconstitution of the above-knee popliteal artery (**C**).

A particularly virulent form of atherosclerotic arterial disease is often found in young female smokers.[24,25] Radiographic imaging in this subset of patients typically reveals atretic, narrowed vasculature with diffusely calcific atherosclerotic changes. Such patients invariably have an extensive smoking history, with or without other typical risk factors for atherosclerosis. Given the diminutive size of the inflow and outflow vessels, the durability of endovascular intervention is generally inferior in these patients, particularly in the face of continued cigarette use.

5 Typically half of patients proceeding to surgery for arterial occlusive disease have significant coronary artery disease, even more have hypertension, and almost 80% are current or prior cigarette smokers.[26,27] The low mortality and morbidity associated with operative intervention in recent years are in large part a result of advances in the management of concomitant coronary disease. Specifically, the importance and benefit of better preoperative identification of patients in need of initial coronary revascularization, awareness of the benefit of waiting an interval period following coronary stenting prior to proceeding with major noncoronary vascular surgery, improved perioperative pharmacologic management of patients with impaired myocardium, and more focused efforts to tailor operative and postoperative fluid administration to the individual patient's myocardial reserve are all well recognized.[28,29] Appropriate beta blockade and

the use of statins have been shown to reduce cardiovascular events and improve survival after inpatients undergoing vascular surgery, including infrainguinal bypass.[30,31] General advances in postoperative management, including pulmonary care, infection control, and blood product utilization, have further contributed to the progress seen.

Diagnosis

6 The diagnosis of infrainguinal occlusive disease is generally based on patient symptomatology, physical examination, and noninvasive tests, such as segmental pressure measurements and pulse volume recordings. Accurate history-taking and physical examination are crucial to clarifying the diagnosis and guiding a treatment management aimed at maximizing symptom relief and limb preservation. Intermittent claudication (IC) indicative of infrainguinal occlusive disease is typically a cramping, aching discomfort consistently reproducible at a given distance and relieved soon after cessation of ambulation. This must be differentiated from lower extremity pain secondary to nerve root compression or spinal stenosis which, in contradistinction to vasculogenic pain, often develops when patients maintain a stationary standing posture. Vasculogenic claudication must also be distinguished from venous claudication, hip and ankle arthritis, symptomatic Baker cyst, and chronic compartment syndrome. IC patients with isolated infrainguinal disease will likely have palpable femoral pulses but diminished popliteal and/or pedal pulses.

As is true with claudication, ischemic rest pain must be carefully distinguished from other sources of pain in the elderly population, most commonly arthralgia and neuropathy. Although tissue necrosis and gangrene are usually self-evident when caused by critical ischemia, similar lesions associated with venous stasis, severe anemia, decubitus ulcers, and diabetic neuropathy must be excluded.

Noninvasive physiologic arterial testing allows confirmation of infrainguinal occlusive disease when it is suspected based upon history and physical examination. Measurement of the ABI is the most useful diagnostic adjunct. A properly performed ABI in a claudicant without significant evidence for vascular calcification would be expected to be between 0.5 and 0.9. Ischemic rest pain generally occurs at ABI 0.4 to 0.5, whereas an ABI less than 0.4 is generally associated with tissue loss. Segmental pressure measurements at the level of the upper thigh, lower thigh, upper calf, ankle, and metatarsal level also aid in localizing the level of hemodynamically significant disease. A drop in pressure greater than 20 mm Hg between levels indicates a hemodynamically significant stenosis in the intervening arterial vasculature. In patients with DM or CRI leading to extensive vascular calcification, the ABI will often be erroneously elevated due to medial calcinosis and subsequent noncompressibility of the vessels. In such circumstances, pulse volume recordings, which ascertain the volume of blood flowing into segment of the limb, remain a reliable indicator of perfusion to the various levels of the lower extremity. Measurement of toe pressures also effectively quantitates distal perfusion as the digital arteries are generally spared of calcium which inhibits compressibility. A toe–brachial index less than 0.7 is considered abnormal. Absolute toe pressure less than 30 to 50 mm Hg generally indicates severe lower extremity occlusive disease with inadequate perfusion to heal tissue loss, particularly in diabetics.[14]

Further anatomic mapping is warranted only after the diagnosis of hemodynamically significant infrainguinal disease has been made based upon physical examination and noninvasive testing and the decision to pursue intervention has been made. The goal of

anatomic imaging is to determine if adequate revascularization is anatomically feasible and to delineate the options for both endovascular therapy and open surgical revascularization. Duplex ultrasonography, magnetic resonance angiography (MRA), and computed tomographic angiography (CTA) are increasingly being utilized as first-line modalities in planning the optimal revascularization approach, and have supplanted contrast angiography as the initial imaging study of choice in many centers.[32] Nevertheless, due to inherent limitations with each of these techniques, digital subtraction angiography remains the gold-standard technique for imaging of the vascular tree prior to intervention.[33]

Although a growing literature supports the use of duplex scanning as a stand-alone preoperative mapping modality,[31] this use requires a highly dedicated vascular laboratory and to date has not gained wide acceptance. CTA is increasingly being utilized as a preoperative road-mapping technique in institutions able to provide high-quality three-dimensional reconstructions. MRA is also particularly useful as a noninvasive screening test to determine the suitability for percutaneous therapy, as advances have solved many of the technical limitations of earlier studies (Fig. 93.3). Should a lesion amenable to percutaneous therapy be identified, angiography is then pursued. Alternatively, in some instances of femoropopliteal reconstruction, operative planning may be based solely on MRA scanning if high-quality time of flight and gadolinium-enhanced images are obtained.[34–36] In many cases, however, surgeons are reluctant to proceed to surgery without the confirmation of anatomy afforded by standard contrast angiography. This reluctance is particularly true if the distal target is at the tibial or pedal level, where anatomic detail provided by CTA and MRA remains more limited.[37]

When digital subtraction angiography is undertaken for preoperative planning, a retrograde femoral approach is typically utilized from the contralateral limb. In general, a catheter is placed in the infrarenal aorta to perform aortography and iliac angiography. If there is no aortoiliac disease which precludes catheter traversal, the wire and catheter are utilized to go “up and over” the aortic bifurcation to place the catheter in the common femoral artery of the affected limb. Lower extremity digital subtraction angiography is then carried out. Selective catheterization of the affected limb via “up and over” approach allows contrast volume to be minimized. It also allows the surgeon or interventionalist to proceed immediately with infrainguinal endovascular intervention through a single vascular access should endovascular therapy be the preferred treatment based on the patient’s presentation and infrainguinal anatomy defined in the angiogram.[33] In patients in whom noninvasive imaging indicates a widely patent common femoral and proximal superficial femoral artery and body habitus is not prohibitive, an antegrade approach can serve as useful alternative. In ambiguous lesions or when iodinated contrast must be minimized, pull-back pressure measurements, both before and after the administration of a systemic vasodilator such as papaverine or nitroglycerine or the application of a tourniquet to induce reactive hyperemia, can be useful in documenting the hemodynamic significance of a particular stenotic zone.[38] The utilization of gadolinium or carbon dioxide as contrast agents in patients with compromised renal function, although perhaps less effective in the periphery than in the aortoiliac vasculature, can minimize or

eliminate the nephrotoxic effects associated with standard iodinated contrast medium.[39,40]

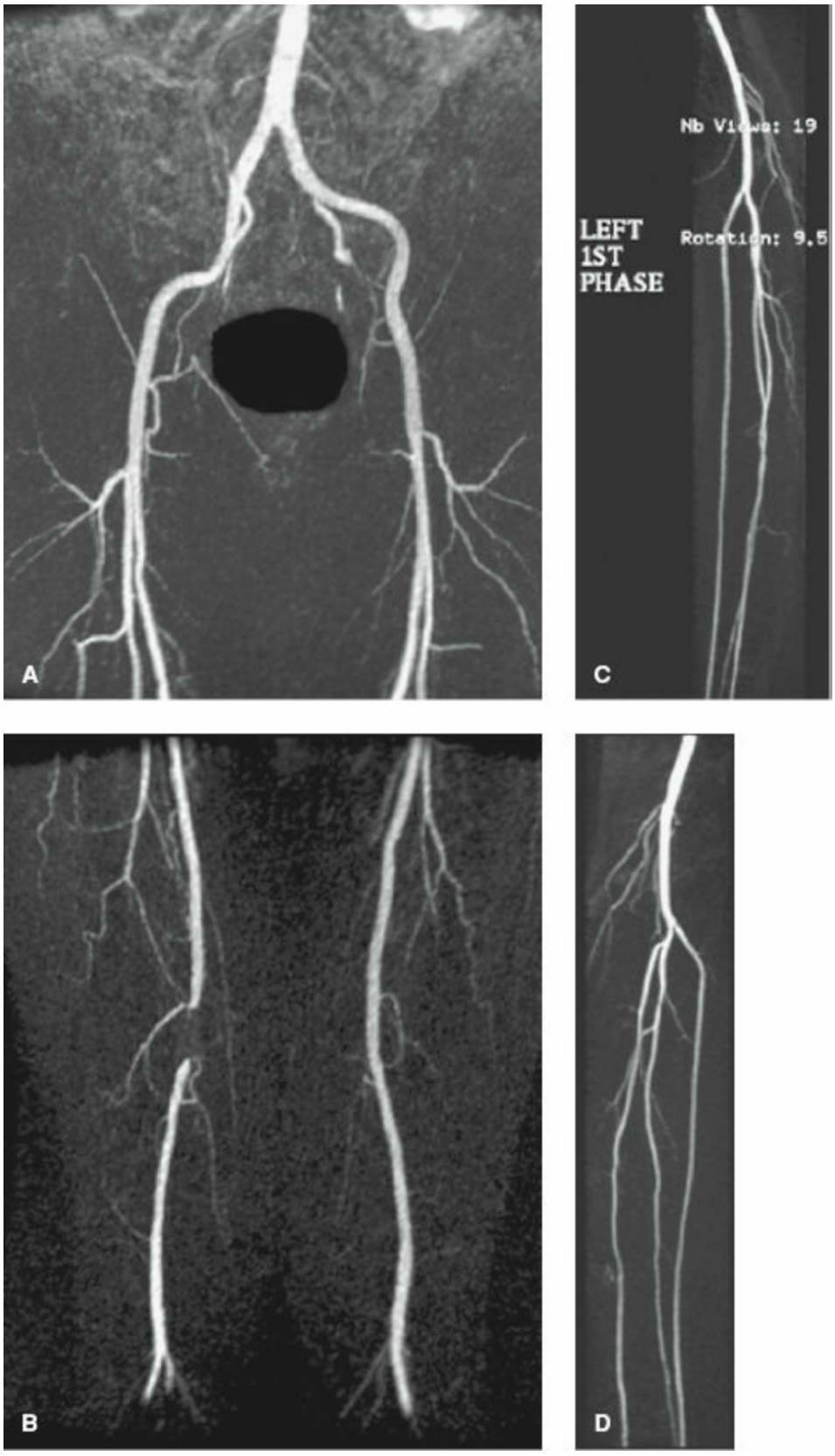

Figure 93-3. Magnetic resonance angiogram identifying patent inflow vessels (**A**), short-segment occlusion of right superficial femoral artery (**B**), and patent popliteal and tibial vessels (**C** and **D**), a lesion amenable to attempt at percutaneous therapy.

Medical Treatment

Risk factor modification remains a cornerstone of the management of lower extremity occlusive disease. Smoking cessation has been shown to reduce the risk of disease progression, amputation, cardiovascular mortality, and may lead to symptom relief in some patients. Smoking cessation has been best achieved with repeated physician assistance, group counseling, nicotine replacement or nicotinic receptor agonists, and antidepressant drug therapy in some patients. Weight and blood pressure reduction and aggressive efforts at lipid control should be addressed with every patient with atherosclerotic disease. Lipid-lowering therapy involves dietary modifications first and utilization of hydroxymethylglutaryl–coenzyme A–reductase inhibitors ("statins") to lower LDL cholesterol and fibrates or niacin to raise HDL cholesterol. Patients with lower extremity occlusive disease should have a goal LDL cholesterol of <70 mg/dL.[13] Statin therapy also has benefits in patients with PAD which are independent of their effect on lipid reduction. Stains stabilize atherosclerotic plaque and reduce vascular inflammation. Statin therapy has been shown to reduce cardiovascular events in patients with PAD.[41,42] In addition, statin therapy is associated with improved 1-year survival in patients undergoing lower extremity bypass for CLI.[31] Patients with diabetes should have aggressive control of blood glucose toward a goal hemoglobin A1C of $<7\%$. Antiplatelet therapy in the form of either aspirin or clopidogrel is a critically important element of the treatment of established occlusive disease, given its documented ability to prevent thrombosis and embolization and possibly even to arrest the progression of atherosclerosis.[43] Aspirin and clopidogrel have both been shown to reduce cardiovascular morbidity and mortality in patients with PAD.[44,45]

Strong evidence exists supporting the benefit of a supervised, structured walking program in increasing the walking distance of patients with claudication.[46] The benefit of walking outside of a structured regimen with close follow-up is more debatable.[47] Nevertheless, patients should be encouraged to "walk through" the onset of lower extremity pain, resting intermittently as required. Overall, pharmacotherapy has not had a significant impact on relieving symptoms of infrainguinal occlusive disease. There is some evidence to suggest cilastazol, a phosphodiesterase inhibitor, improves walking distance and quality of life.[48,49] While early studies showed that pentoxifylline, a rheologic agent, had beneficial effects on walking distance, later studies have questioned its clinical benefit.[50,51] Similarly, although older studies suggested that prostanoids improved healing of ischemic ulcers, the current evidence does not support the utility of any systemic drug for the relief of ischemic rest pain or the treatment of ischemic ulcerations.[52–54]

Indications for Revascularization

The two major indications for the intervention of infrainguinal arterial occlusive disease are lifestyle-limiting claudication and CLI. Less common indications for infrainguinal arterial reconstruction include trauma-related vessel disruption, popliteal artery entrapment syndrome, and femoropopliteal arterial aneurysm with thromboembolism. Infrainguinal revascularization for the treatment of peripheral vascular occlusive disease has been increasingly successful for both long-term palliation of IC and for the preservation of limbs threatened by critical ischemia.

Critical ischemia is associated with inevitable amputation for most patients unless revascularization is undertaken. Although there are certainly cases in which primary amputation represents the safest and most advisable solution in the face of irreversible ischemia, particularly in nonambulatory patients or in cases in which extensive infection or tissue necrosis is present, an attempt at revascularization is generally indicated when a limb is threatened by severe ischemia. However, given the morbidity and mortality associated with CLI, it is paramount to tailor therapy to an individual's overall medical condition and life expectancy as well as the patient's goals of therapy. In the often frail CLI population, postoperative outcomes are most strongly impacted by patients' preoperative medical condition and functional status.[55] Nevertheless, improvements in endovascular technology and techniques as well as perioperative management and surgical technique have allowed progressively more distal revascularizations to be successfully completed in an older, sicker, and challenging patient population. In general, high limb salvage (80% to 90%) rates may be anticipated for patients with critical ischemia at institutions devoted to peripheral bypass surgery.[56–58] In addition, occlusive disease of the tibial vessels, once thought to be the exclusive domain of operative bypass, is increasingly being treated percutaneously.[59] Though the long-term durability of various endovascular revascularization approaches is limited, similar rates of limb salvage from 1 to 3 years have been demonstrated.[59–61]

Claudication is a relative indication for intervention given the natural history of the disease, and it remains a subjective assessment on the part of both patient and surgeon as to the relative degree of disability a particular level of claudication pain represents. For example, two-block claudication in a younger patient whose livelihood depends on walking tolerance constitutes a more significant disability than the same degree of claudication in an older, retired individual able to attend to his or her daily affairs without significant consequence. Thus, proximal above-knee surgical reconstruction in a patient with disabling claudication and a patent popliteal artery with intact runoff may be justified in view of its minimal operative mortality, excellent long-term palliation, and absence of added risk of limb loss beyond that expected from the natural history of the disease process. Classically, it has been thought that the benign natural history of claudication does not warrant aggressive femorotibial reconstruction in patients with diffuse superficial femoropopliteal and tibioperoneal disease, though reconstruction will often provide symptomatic benefit and can be considered in a good-risk patient.[62]

In recent years, the low morbidity of endovascular revascularization in combination

with patient desire for intervention seems to have lowered the threshold for offering catheter-based revascularization for claudication. Patients once considered most appropriate for risk factor modification, exercise therapy, and medical treatment are now increasingly being offered percutaneous revascularization.[63,64] Nevertheless, endovascular revascularization is not without risk and is at present of limited durability. It is therefore prudent to follow the classical surgical axiom that because most patients with claudication remain stable for years, it is important to allow sufficient time for collaterals to develop and enlarge; some patients may improve to such an extent that intervention proves unnecessary.[19]

Approach to Revascularization

The last two decades have seen increasing utilization of endovascular revascularization of infrainguinal occlusive disease.[64] In this light, it cannot be overemphasized that symptom status and not anatomic findings should serve as the basis for revascularization. Once the decision to intervene has been made, a variety of factors should be considered in choosing whether to proceed with an endovascular, surgical, or combined (hybrid) approach. The goals and outcomes of revascularization should be considered in the context of the individual patient's comorbidities, operative risk and overall life-expectancy, the extent of the occlusive disease present, and the expected durability of the procedure.

Anatomic variables appear to be the key determinant of the success and durability of endovascular therapy. With the promulgation of endovascular therapy has arisen, the need to classify the anatomic severity of disease in order to guide potential therapy and compare outcomes between various modes of revascularization. The Trans-Atlantic Intersociety Consensus Document on Management of Peripheral Arterial Disease (TASC) was published as the result of a multidisciplinary collaboration between key medical and surgical vascular societies in 2000 and an abbreviated update was published in 2007.[14,65] This document classified infrainguinal occlusive lesions into classes A, B, C, and D based upon the location of the lesion and the number, length, and severity of the stenoses and/or occlusions present. Their recommendations, which reflect current practice to a variable extent, include initial endovascular treatment for TASC A lesions, primary surgical treatment for TASC D lesions, and individualized tailoring of treatment for TASC B and C lesions depending upon endovascular suitability and surgical risk. While a complete description of this classification schema is beyond the scope of this chapter, a few general principles are worth noting. The patency of endovascular revascularization decreases the more distal the disease and is less in patients with stenoses that are multiple, longer, and more severe.[14,59,66] On the other hand, the success of open bypass surgery is largely dependent on the quality conduit.[67,68] Sustained hemodynamic improvement in the affected limb is the measure of effective revascularization and the goal of therapy. Neither "endovascular first" nor "bypass first" approach can be applied to all patients. Selection of the optimal revascularization strategy, at least in CLI, involves assessment of life expectancy, surgical risk, the severity of tissue loss in the limb, the anatomic pattern of disease, and the quality of vein available as a conduit for bypass. The complexity of decision-making emphasizes the importance not only of interventional expertise, but of thorough training in vascular disease and comprehensive experience in the care of vascular patients.[69]

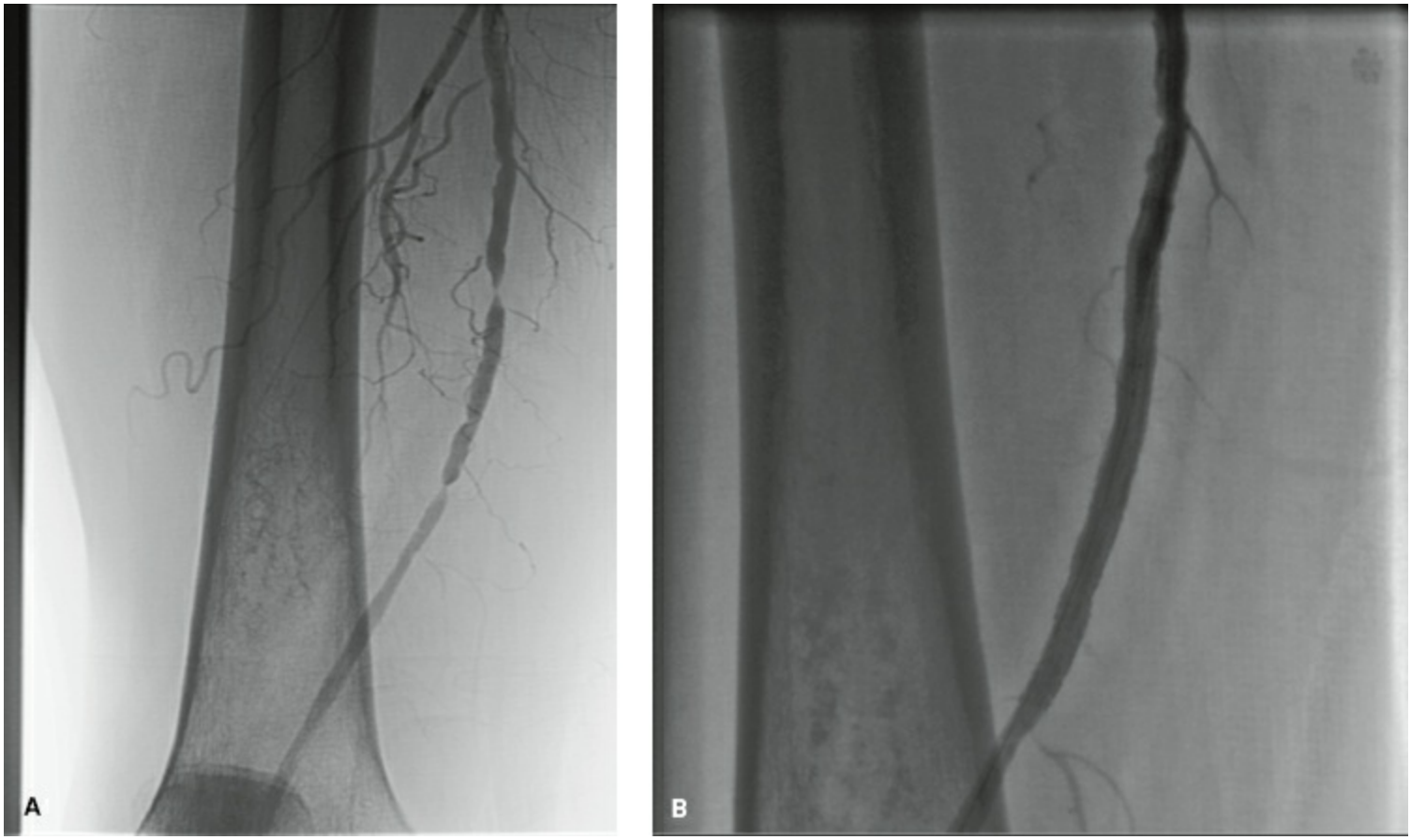

Figure 93-4. Angiogram of the right superficial femoral artery demonstrating short-segment occlusion and more diffuse stenosis in Hunter canal (**A**), which was treated with angioplasty and self-expanding bare metal stent placement (**B**).

Endovascular Therapy

A marked increase in the number and versatility of available balloons, stents, and other devices has helped to fuel the increasing application of percutaneous technology. While a complete description of endovascular treatment options and outcomes is beyond the scope of this chapter, a brief introduction is necessary. Percutaneous vascular intervention is generally performed under local anesthesia with minimal intravenous sedation as either a day surgical procedure or involving an overnight admission. Percutaneous vascular intervention first involves wires traversal of hemodynamically significant stenosis or occlusions in the arterial tree. Dilatation of the lesion with percutaneous transluminal angioplasty (PTA), with or without stenting, or obliteration of the lesion via atherectomy or other modalities is utilized to reestablish blood flow through the diseased segment (Fig. 93-4). For interventions on the femoropopliteal and tibial arteries, retrograde contralateral femoral access allows angiography of the affected limb and establishment of a stable treatment platform via an "up and over" approach across the aortic bifurcation. Ipsilateral antegrade femoral access can also be utilized. More recently, retrograde ipsilateral pedal and tibial access has been described to allow wire traversal and endovascular treatment of disease not amenable to the standard antegrade approach.[70]

Periprocedural outcomes with endovascular therapy are excellent. Technical success, which is generally defined as the presence of antegrade flow through the tree to lesion with less than 30% residual stenosis at the conclusion of the procedure, is reported at 80% to 95% for both femoropopliteal and infrapopliteal procedures.[59,71,72] Associated overall morbidity in recent reports ranges between 8% and 17% while mortality is low at approximately 0.2%. Contrast-induced nephropathy remains a common complication. With the development of hypoosmolar and isoosmolar contrast agents; the overall incidence is approximately 8%, whereas the rate of acute renal failure requiring dialysis is less than 1%.[72–74] Higher rates are found in patients with pre-existing renal failure and diabetes.[75,76]

Substantial morbidity can result from access-site complications, predominantly pseudoaneurysms, groin hematomas, and arteriovenous fistulas (AVFs), which occur in 1% to 4% of patients.[72,77] Most of them can be managed conservatively, with close observation, serial hematocrit checks, and fluid and blood product replacement. Surgery is reserved for those patients with ongoing bleeding effecting hemodynamic instability or distal ischemia, or pseudoaneurysms or AVFs that fail to resolve on serial ultrasound imaging with several weeks of careful observation. Stable pseudoaneurysms in patients without coagulopathy can also be managed with ultrasound-guided compression therapy or ultrasound-guided thrombin injection into the pseudoaneurysm sac to induce thrombosis.[78] Infection related to the placement of newer percutaneous closure devices utilized for puncture site control typically present several weeks to months after the percutaneous procedure. Rarely, maldeployment of these devices can lead to embolic or thrombotic sequelae causing compromise of distal flow.[79]

Reports indicate that endovascular therapy has good short-term efficacy for femoropopliteal disease (Table 93-1). In claudicants, PTA for femoropopliteal lesions has

generally yielded 1-year patency of approximately 77% and 65% for stenoses and occlusions, respectively.[66,80] In patients with CLI, PTA for femoropopliteal lesions has yielded 1-year primary patency of 60% and 40% for stenoses and occlusions, respectively.[80] Review of the literature does not provide compelling evidence that stent placement improves the results of all femoropopliteal PTA.[60]Many practitioners thus utilize stents selectively for failure of PTA (defined as greater than 30% residual stenosis or flow limiting dissection) in femoropopliteal lesions. However, there is strong evidence, including two randomized trials, that primary self-expanding stent placement yields higher short-term patency than PTA and/or provisional stenting for more advanced femoropopliteal lesions.[80–82] Primary self-expanding stent placement is therefore preferred over angioplasty alone for femoropopliteal occlusions and long-segment lesions by most surgeons and interventionalists. Infrapopliteal disease appears less amenable to endovascular therapy (Fig. 93-5). Primary patency is generally reported at 45% to 55% at 1 year.[59,83] Patency does not appear to be improved by stenting in the infrapopliteal segment.[84,85]

RESULTS

Table 93-1 Patency of Femoropopliteal Angioplasty and Stenting[a]

	1-year % Patency (Range)	3-year % Patency (Range)	5-year % Patency (Range)
PTA: stenosis	77 (78–80)	61 (55–68)	55 (52–62)
PTA: occlusion	65 (55–71)	48 (40–55)	42 (33–51)
PTA+stent: stenosis	75 (73–79)	66 (64–70)	
PTA+stent: occlusion	73 (69–75)	64 (59–67)	

[a]Adapted from Norgren et al. Inter-society Consensus for eh the Management of Peripheral Arterial Disease (TASC II).[14]

Lack of durability has been the Achilles heel of infrainguinal endovascular intervention. Three-year patency after PTA has generally been reported to be 43% to 61% and 30% to 48% for femoropopliteal stenoses and occlusions, respectively.[80] Five-year patency data are seldom reported but have been generally reported to be between 26% and 45% after PTA for femoropopliteal lesions.[14]

There is a scarcity of high-level data comparing PTA and bypass surgery for infrainguinal occlusive disease. Heterogeneous study populations and the lack of standardized methodology and endpoints have limited the ability to compare the effectiveness of endovascular surgical therapy.[86] In addition, there have been only four randomized trials comparing angioplasty and lower extremity bypass surgery and these have included a heterogeneous group of patients, measured different outcomes, and generally included limited anatomic detail.[87–90] Pooled analysis of these trials demonstrates that surgical bypass generally had superior patency to PTA at 1 year, but there were no differences in progression to amputation. The BASIL (Bypass vs. angioplasty in severe leg ischemia) trial which randomized 452 patients with “severe limb ischemia” to a “bypass first” or “balloon angioplasty” first strategy is the most widely

cited trial. There was no difference in the primary endpoint of amputation-free survival at 6 months, although a "surgery-first" strategy was associated with greater cost and morbidity.[87] It is necessary to note that the endovascular arm of this trial did not include adjunctive procedures such as stenting which are now frequently utilized in current day practice. Upon long-term follow-up of at least 3 years and more than 5 years in the majority of patients, bypass was associated with improved overall survival and a strong trend toward improved amputation-free survival in patients who survived at least 2 years. In addition, most balloon angioplasty patients ultimately required bypass surgery. Bypass after failed balloon angioplasty had significantly worse patency than that of primary bypass.[91] This finding corroborated other reports demonstrating that surgical bypass after failed endovascular treatment is inferior to primary bypass, indicating that a universal "endovascular first" approach may not be appropriate as failed endovascular intervention may "burn bridges" for surgical revascularization. Careful consideration must be given to the best initial therapy for infrainguinal occlusive disease.[92]

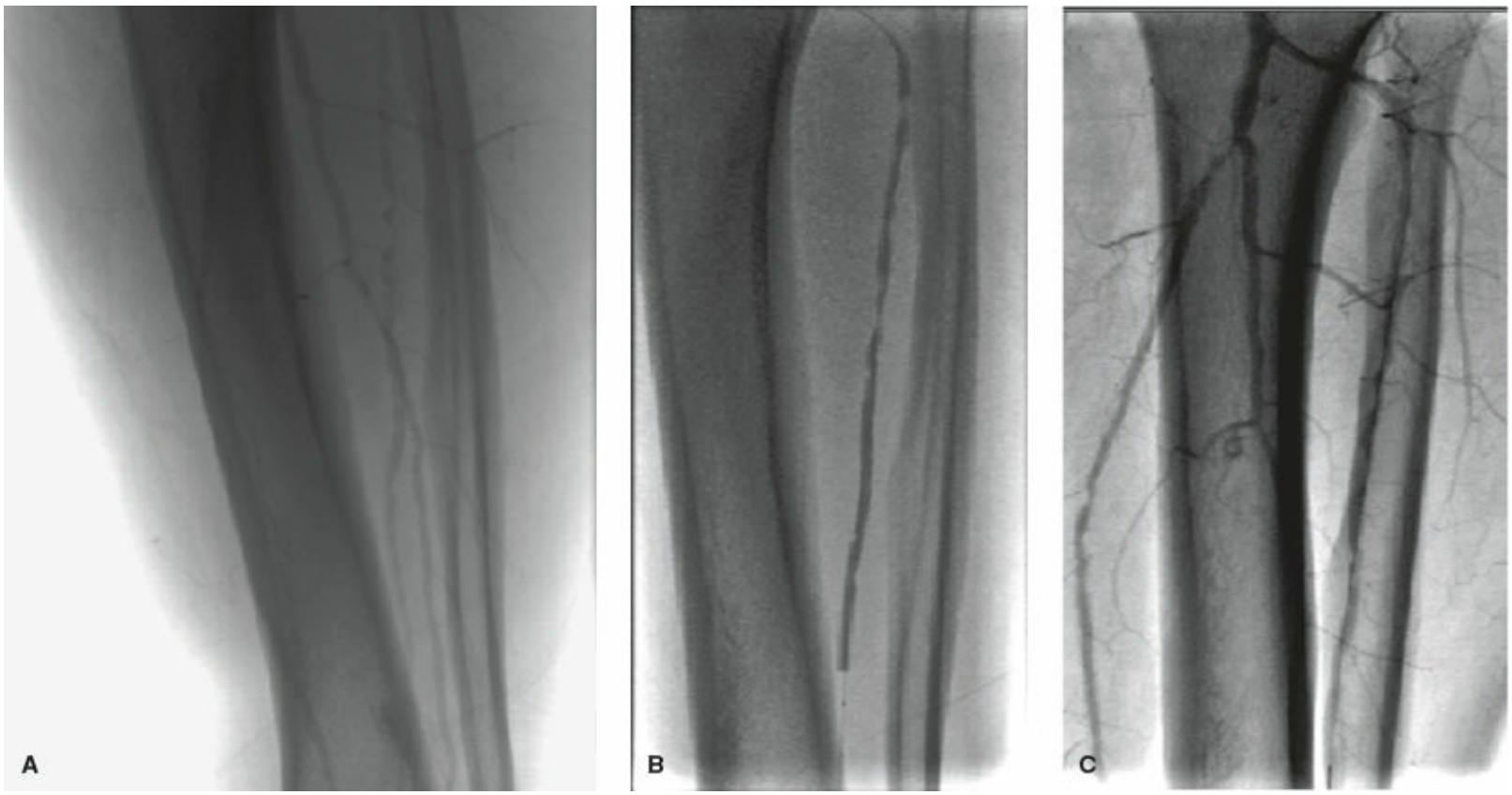

Figure 93-5. Angiogram of the tibial arteries showing diffuse anterior tibial artery high-grade stenosis (**A**) which was treated with long-segment balloon angioplasty, (**B**) completion angiogram showed patent anterior tibial artery with no significant residual stenosis (**C**).

7 8 For patients with favorable anatomy and significant operative risk, and for the treatment of claudication in general, percutaneous therapy has assumed a primary initial role. When medical therapy or percutaneous treatment has proven inadequate, open surgical revascularization remains the gold standard for those patients with disabling claudication. Furthermore, until the efficacy and durability of infrainguinal percutaneous intervention is better defined, surgical revascularization remains the gold standard for

any patient with CLI, especially those with extensive tissue loss. The relative roles of surgical and percutaneous intervention are actively being refined. It nevertheless appears that the rising popularity and success of femoral and tibial wire-based interventions may be reducing the volume, or ultimately just delaying the timing of, subsequent infrainguinal reconstructive surgery. Furthermore, many patients are best treated with a combination of percutaneous and open surgical therapy, often in a single procedure (hybrid procedure). In many instances, endovascular and open surgical revascularization are thus complementary modes of therapy.

Operative Management

9 Successful infrainguinal arterial bypass requires sound planning as well as technical expertise. As such, it remains the signature operation which distinguishes vascular surgeons from other specialists involved in the treatment of PAD. Successful infrainguinal bypass grafting requires adequate arterial inflow. While aortobifemoral, femorofemoral, and axillofemoral bypass grafting remain routinely performed inflow procedures, aortoiliac angioplasty and stenting are increasingly becoming the preliminary procedures performed to attain sufficient inflow prior to construction of a more distal bypass graft. At times, the necessity of improving the inflow to support an infrainguinal graft is determined intraoperatively, either by direct visual assessment of the arterial flow at the desired donor site or by comparison of a transduced pressure tracing from the donor site with that of a systemic pressure tracing, typically obtained from a radial arterial line. Of equal importance to the outcome of any infrainguinal graft is target vessel selection. In general, the target vessel should be the least diseased artery that is the dominant supply to the foot. If tissue necrosis is present, restoration of pulsatile flow to the foot is often required to obtain full and sustained wound healing.

Infrainguinal surgical bypass can be performed under general anesthesia, or in the appropriate patient, under regional, spinal, or epidural anesthesia. In cases involving multiple sites of dissection, such as those necessitating more tedious arm vein or lesser saphenous vein harvesting, the procedures are particularly amenable to a two-team approach, with the time saved having direct benefit in minimizing the total anesthetic load and physiologic insult. The patient is sterilely prepped and draped from the midabdomen down to the foot. It is our practice to work from proximal to distal, first exploring the inflow artery and exposing the venous conduit. We then explore the site proposed for the distal anastomosis, as high-quality preoperative imaging has already defined a suitable target vessel.

For patients with superficial femoral artery disease, the initial dissection is most commonly at the level of the common femoral artery. This vessel is exposed through a longitudinal or oblique incision centered directly over the femoral pulse. Lymphatic tissue overlying the femoral vessels is best ligated and divided to prevent the postoperative development of lymph fistulas or lymphoceles. The severity of any concomitant common femoral and profunda femoral disease and the level of reconstruction planned dictate the extent of exposure of the femoral vessels. In most instances, the dissection extends from the inguinal ligament to the common femoral artery bifurcation, where the origins of the superficial and profunda femoral arteries are individually isolated.

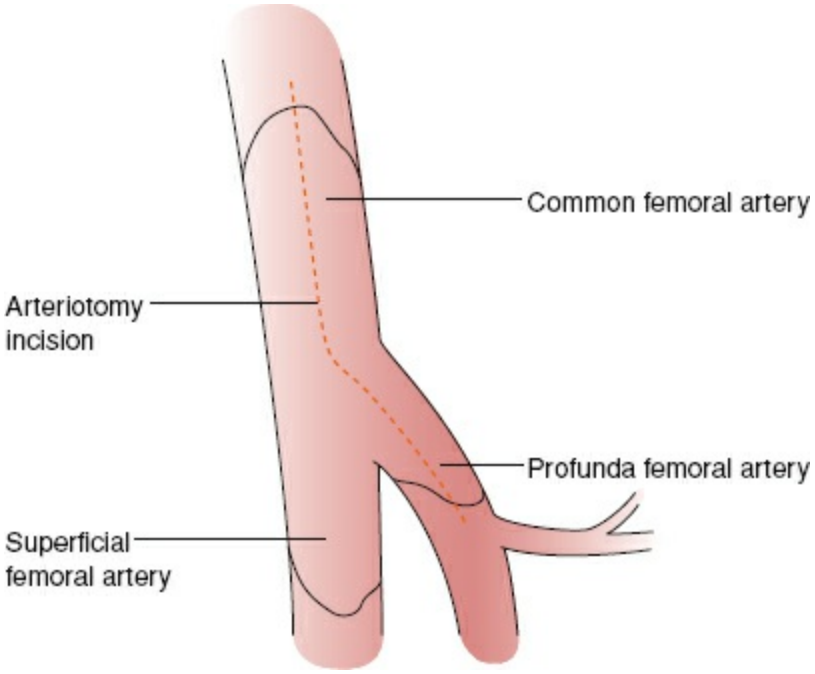

Figure 93-6. In the setting of orificial profunda femoral artery disease, extending the common femoral arteriotomy into the origin of the profunda and performing a profundaplasty will maximize profunda flow in the event of graft thrombosis.

If a profundaplasty is required, the dissection is extended distally along a sufficient length of the profunda femoral artery to attain an endpoint suitable for clamping and sewing (Fig. 93-6). Similarly, the inguinal ligament can be partially divided to facilitate access to the distal external iliac artery in cases in which a more extensive proximal endarterectomy is necessary. In these circumstances, it is customary to close the endarterectomized bed with a vein, bovine pericardial or Dacron patch, onto which the proximal anastomosis can subsequently be attached.[93] In patients with a hostile groin crease from prior surgery or radiation therapy or in obese, diabetic patients with an intertriginous rash at the inguinal crease, meticulous skin preparation, close attention to draping, careful surgical technique, and judicious use of a short course of intravenous antibiotic therapy help minimize the chances of a postoperative wound or graft infection.

If all or part of the superficial femoral artery is spared of significant atherosclerotic involvement, the proximal anastomosis can be moved distally as dictated by the particular anatomic pattern of disease, and a so-called “distal origin graft” can be fashioned (Fig. 93-7).[94] This situation is particularly applicable to the diabetic population, in whom infrapopliteal disease is the rule and sparing of the superficial femoral and popliteal arteries is not uncommon. It is also utilized in situations in which conduit is sparse, and a moderately diseased proximal vessel is accepted as an inflow source for a more distal origin bypass graft in the interests of performing a fully autologous vein graft rather than utilizing prosthetic material. An increasingly popular approach when only limited conduit is available is to combine, either concurrently in the operating room or as a staged preoperative procedure, catheter-based treatment of the superficial femoral or popliteal artery inflow with more distal bypass.[95]

The above-knee popliteal vessel is easily exposed through a medial thigh incision, with

subsequent posterolateral retraction of the sartorius muscle. The popliteal artery with its accompanying vein and nerve is found just posterior to the femur. The vessel is palpated to determine the presence of atherosclerotic plaque, which will guide the extent of dissection and the optimal bypass target site. The below-knee popliteal artery is also exposed through a medial incision in the proximal calf (Fig. 93-8). If the saphenous vein is to be harvested, the incision is made directly over the vein to minimize the creation of devascularized skin flaps. With the exposed vein carefully protected, the incision is carried through the deep muscular fascia and the medial head of the gastrocnemius is reflected posterolaterally to expose the below-knee popliteal fossa. The distal popliteal artery is then dissected free from the adjacent tibial nerve posteriorly and popliteal vein medially. If the distal target is the tibioperoneal trunk, the dissection is continued along the anteromedial surface of the distal popliteal artery after dividing the origin of the soleus muscle from the tibia (Fig. 93-9). In instances in which the below-knee popliteal artery has previously been exposed or where sepsis is involved, a lateral approach with excision of a segment of proximal fibula is a useful alternative approach to the below-knee popliteal artery.



Figure 93-7. Arteriogram indicating preservation of the superficial femoral artery and popliteal arteries (**A**,**B**,**C**) with mid-calf occlusions of all three infrageniculate vessels (**D**), with reconstitution of the dorsalis pedis artery in the foot (**E**). This anatomic pattern of disease is amenable to "distal origin" vein grafting from the below-knee popliteal or proximal posterior tibial artery to the dorsalis pedis artery.

Although exposure of the proximal posterior tibial and peroneal vessels can be gained by extending the tibioperoneal trunk dissection distally, more distal exposure of these vessels is best gained through targeted medial incisions. The posterior tibial artery is found beneath the divided musculotendinous origin of the soleus muscle, and the peroneal artery is deeper and more lateral. The posterior tibial artery at the level of the ankle is a relatively easier target given the proximity of the vessel to the skin surface. The initial incision is made just posterior to the medial malleolus, and the artery exposed by division of the overlying retinaculum. Further distal dissection allows access to the bifurcation and medial and lateral plantar branches.[70] The more distal peroneal artery may be approached laterally via an incision placed over the distal fibula. Excision of a short segment of fibula will expose the underlying artery.

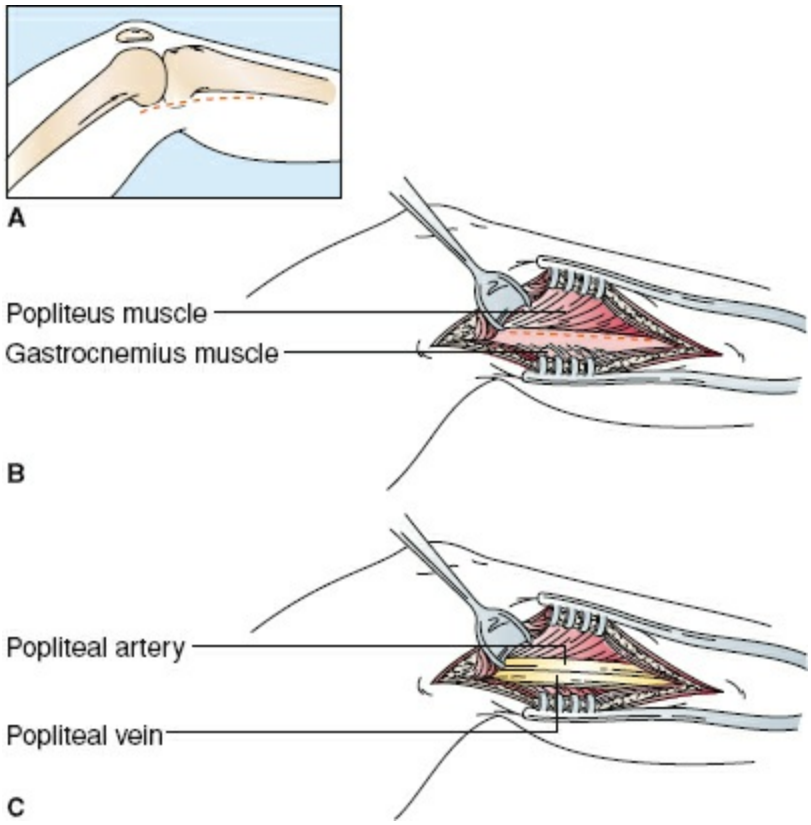

Figure 93-8. Exposure of the popliteal artery below the knee. The medial incision is made directly overlying the course of the greater saphenous vein (**A**), with posterior retraction of the gastrocnemius muscle (**B**), to reveal the popliteal vessels in the popliteal fossa (**C**).

The anterior tibial artery is typically approached from the anterolateral aspect of the calf (Fig. 93-9) and is found deep within the anterior compartment with the adjacent deep peroneal nerve and anterior tibial veins. It is best identified by developing the intermuscular plane between the tibialis anterior muscle belly medially and the extensor digitorum longus laterally. The dorsalis pedis artery is easily exposed through an axial incision on the dorsum of the foot just lateral to the extensor hallucis longus tendon (Fig. 93-9). The artery lies just deep to the extensor retinaculum.

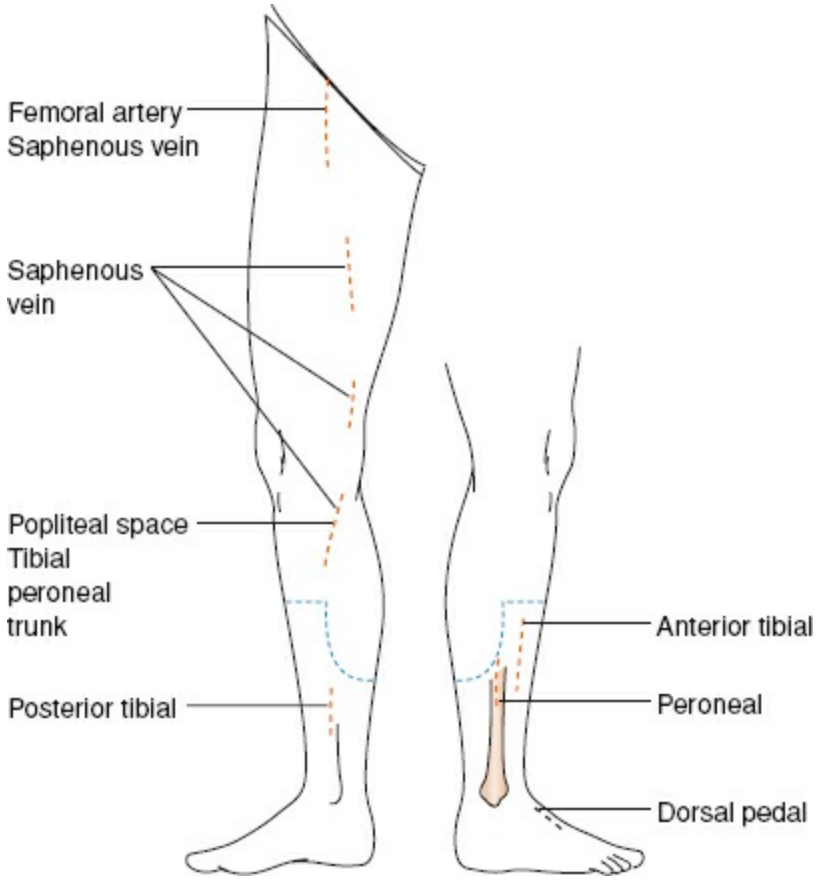

Figure 93-9. Placement of incisions for femoropopliteal and femorotibial bypass and for greater saphenous vein harvest. These should avoid the incision lines for a below-knee amputation.

Autogenous Vein Bypass

10 Infrainguinal bypass surgery is best performed with autogenous vein conduit, preferably the ipsilateral greater saphenous vein if available.[96] This preference is particularly true for grafts extending below the knee, where prosthetic conduits of Dacron or polytetrafluoroethylene have significantly poorer patency rates. The first report of a femoropopliteal bypass graft using autogenous greater saphenous vein in a reversed orientation was by Kunlin in 1951.[8] Given the orientation of the vein valves, the vein can be reversed such that the distal end of the vein is sewn to the proximal inflow artery and the larger proximal end of the vein is sewn to the distal outflow artery. However, it is our general practice to utilize the greater saphenous vein in the nonreversed orientation as will be discussed shortly. The vein is harvested through a long incision overlying the course of the vein or by more tedious but less invasive sequential skip incisions with intervening cutaneous skin bridges (Fig. 93-7). All side branches are ligated and after harvest, the vein is cannulated and gently dilated with a solution containing heparin and papaverine to assess its suitability. Veins with chronic fibrosis or that fail to dilate to a diameter of 3 mm or greater will likely have poor long-term function.

An alternative and less invasive approach to saphenous vein harvest involves the use of endoscopic technology. In the case of harvesting of the greater saphenous vein, small skin incisions are made over the saphenofemoral junction and the distal vein, and guided by a videoscope inserted distally and advanced proximally, the side branches of the vein are serially identified and either cauterized or clip-ligated. The vein is then divided distally and proximally and removed, leaving the overlying skin undisturbed. Advocates of this method cite a significant reduction in wound complication rates and reduced rates of hospital stay.[97] Although it has not been widely adopted by vascular surgeons, the technique does have particular theoretical appeal in cases, for example, when contralateral saphenous vein is to be utilized or the healing potential of the donor leg is compromised.[98]

For prosthetic grafts, a tunnel is usually fashioned through the subsartorial plane between the groin incision and the above-knee popliteal space in the interests of protecting the graft from subsequent infection. For vein conduits, it remains the surgeon's preference as to whether the graft is tunneled deeply or in a superficial location in the subcutaneous space. The more superficial configuration greatly facilitates ongoing clinical examination and ultrasonographic surveillance as well as later surgical revision, but carries a risk of graft exposure should there be wound healing problems. Occlusion from trauma to grafts placed superficially has been of theoretic, but not practical concern.

It is our practice to perform the proximal anastomosis prior to the distal anastomosis. First, this allows confirmation of adequate inflow before the bypass is performed. Second, performance of the proximal anastomosis first allows the graft to be tunneled and tailored to appropriate length under arterial pressure. This is of critical importance to prevent kinking along the length of the graft. Some surgeons also prefer to mark the distended graft to ensure against mechanical twisting of the graft during the tunneling process. An additional benefit of performing the proximal anastomosis first is that adequacy of flow

through the graft can be assessed, both before and after tunneling, with brief release of the clamp.

Prior to occluding the inflow vessel, the patient is systemically anticoagulated with 5,000 to 10,000 units of heparin. Additional heparin is given throughout the procedure to maintain the activated clotting time near the target range of 250 to 300 seconds. After allowing sufficient time for the heparin to circulate, atraumatic vascular clamps are placed proximally and distally and the artery is incised. The vein is then spatulated and a beveled anastomosis carried out. Typically a 5-0 monofilament suture of polypropylene is used for the femoral anastomosis, a 6-0 is used at the popliteal level, and a very fine 7-0 suture used at the tibial or pedal level. If the target tibial vessel is deep within the calf and visibility is challenging, a technique of "parachuting" the heel of the distal anastomosis is often employed. After completing the proximal anastomosis, the graft is carefully tunneled under arterial pressure. Occasionally, such extensive calcification of the target vessel is encountered that the risk of a significant injury from clamping, even with the minimally traumatic clamps in use today, is prohibitively high. In such cases, proximal inflow and distal artery back-bleeding can be controlled by occlusion balloons placed intraluminally. For distal anastomoses at the knee or more distal level, another alternative technique is the use of a proximally placed sterile pneumatic tourniquet. This technique is particularly advantageous when sewing to diminutive distal tibial or pedal targets, where the impact of a crush injury or plaque dislodgment on graft function could be considerable. Removing the need for clamps by using the tourniquet has two further advantages. First, it improves the operative visibility. Second, and more importantly, given that less longitudinal and circumferential dissection is needed, the degree of vessel spasm and venous bleeding that frequently accompanies vessel exposure at this level is kept to a minimum.

Flow through the graft and the outflow arteries are assessed following completion of the bypass with a continuous-wave Doppler. Ideally, a contrast angiogram is also performed after directly cannulating the proximal graft (Fig. 93-10); this allows for immediate repair of any technical defects that are identified, such as intraluminal thrombus, twisting or kinking of the graft, or retained valve cusps.[73] Intraoperative completion duplex ultrasonography is an additional sensitive screen for hemodynamically significant abnormalities within the graft, and its use further serves to prevent early graft loss caused by correctable technical problems.[99,100]

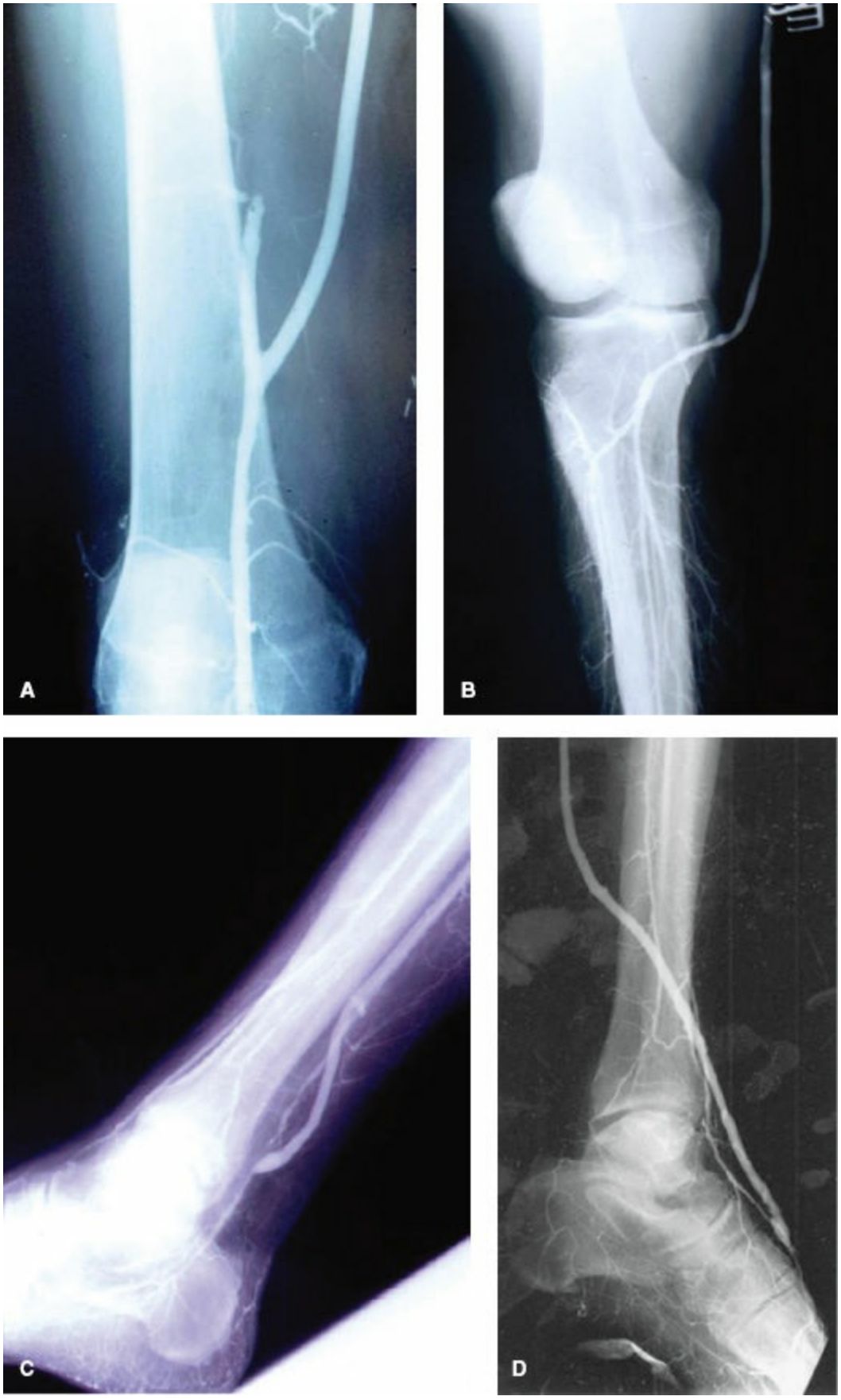

Figure 93-10. Intraoperative completion arteriograms of distal anastomoses to the above-knee popliteal (**A**), below-knee popliteal (**B**), distal posterior tibial (**C**), and dorsalis pedis (**D**) arteries.

RESULTS

Table 93-2 Five-Year Patency and Limb Salvage Results of Infrainguinal Bypass Grafting

Study	Patients, *n*	Conduit	Primary Patency	Secondary Patency	Limb Salvage
Conte, 2001[58]	1,642	Autogenous vein	63	73	85
Belkin, 1996[56]	568	In situ vein	72	82	90
	189	Nonreversed vein	65	65	82
Shah, 1995[57]	2,058	In situ vein	72	81	95
Taylor, 1990[103]	564	Reversed vein	75	81	90
Veith, 1986[96]	338	PTFE to popliteal	38		70
	254	PTFE to tibial	12[a]		61[a]

[a]4-year data.
PTFE, polytetrafluoroethylene.

Current reports of the 5-year results of reversed saphenous vein graft using modern techniques have been excellent, with primary and secondary patency rates of up to 75% and 80%, respectively and limb salvage rates greater than 90% (Table 93-2).[69,101–103]

In Situ Grafting

There has been ongoing enthusiasm in some circles for in situ vein bypass grafting, whereby except for its proximal and distal extent, the greater saphenous vein is left undisturbed in its native bed. This technique was first described in 1962, but was later popularized by Leather and Karmody in the late 1970s.[104,105] Recent reports of in situ saphenous vein grafting have indicated 5-year graft patency rates of up to 80% and limb salvage rates of 84% to 95% (Table 93-1).[57,102,106–108]

The in situ approach minimizes trauma to the vein during excision and handling and in theory enhances preservation of the vasovasorum and endothelium. It further lowers the considerable risk of wound healing complications seen with traditional vein harvesting, increases vein utilization, and facilitates the creation of more technically precise anastomoses because the proximal and distal vein diameters are more closely matched to those of the inflow and outflow target vessels (Fig. 93-11). The extent of the proximal vein mobilization is dictated by the location of the saphenofemoral junction relative to the proposed site of the proximal anastomosis. It may at times be necessary to perform an endarterectomy of the superficial femoral artery if the length of proximal vein is insufficient. Lysis of the valve cusps is obligatory given the nonreversed configuration, and is facilitated by newer, less traumatic valvulotomes that function safely through the blinded segments of undissected graft. Critics of this technique argue that the advantages listed above have not translated into improved graft function or patency. They further argue that the time required and dissection involved in finding and ligating substantial side branches that can develop into physiologically important AVFs that "steal" distal flow obviates the stated benefits of this approach.

Angioscopic-assisted valve lysis has been employed for over a decade, but has not gained widespread favor. Although there is a significant learning curve with this technology and operative times, at least initially, are significantly prolonged, advocates cite fewer wound complications, shorter hospital stays, and decreased recuperative periods as potential benefits. Proponents of routine angioscopy for direct visualization of valve lysis stress its particular utility in demonstrating such unsuspected endoluminal

venous pathology as phlebitic strictures, webs, and fibrotic valve cusps.[109] This adjunct may be particularly useful in cases in which arm vein is used because endoluminal pathology is more frequently encountered and is presumably responsible, in part, for suboptimal results.[110]

Nonreversed Saphenous Vein Grafts

Recognizing the many practical advantages inherent to the in situ technique, some surgeons have modified the approach to infrainguinal bypass grafting with venous conduit to incorporate several of the same principles.[56] In particular, if the harvested vein is tapered to any significant extent, it is used in a nonreversed fashion. By optimizing the size matching between the artery and vein at both the proximal and distal anastomosis sites as discussed previously, one can often accept for use, smaller veins than would be unsuitable for reversed vein grafting. The nonreversed configuration also allows preservation of the saphenous vein hood, which both extends the available conduit length and is especially beneficial when the femoral artery is thick walled and diseased.

The vein is harvested and dilated in a similar fashion to reversed vein grafts and the cusps of the proximal valve of the greater saphenous vein are excised under direct vision with fine Potts scissors. There are currently two main types of valvulotomes available. The modified Mills valvulotome is a short, metal, hockey stick-shaped cutter that can be introduced through the distal end of the vein or through the side branches. After the proximal anastomosis is performed, and with the perfused conduit on gentle stretch, the valves are carefully lysed in a sequential fashion by pulling the valvulotome inferiorly. An alternative, recently designed self-centering valvulotome allows lysis of all valves in a single pass and is thought by some to be less traumatic. Once acceptable pulsatile flow is ensured, the distal anastomosis is performed in the standard fashion.

It is important to note that similar patency rates have consistently been demonstrated regardless of which technique is applied, and so surgeon preference and comfort level is an acceptable reason for choosing one method over another.[107,108]

Prosthetic Bypass

It is recommended that infrainguinal bypass surgery be performed with saphenous vein or an autologous substitute whenever feasible given the clearly demonstrated enhanced patency rates.[51,111] Some institutions more frequently rely on prosthetic grafts. When the distal target is the above-knee popliteal artery and the tibial outflow is relatively well preserved, this is an acceptable approach, as patency rates in this situation approach those of vein grafts.[112] A variety of surgical adjunctive procedures, from patching the distal anastomotic target vessel to the creation of a distal AVF or various autogenous vein cuffs interposed between the distal prosthetic and the target artery, have all been attempted as a means of improving the patency rates of grafts extending below the knee.[113] Polyester (Dacron) and polytetrafluoroethylene (Teflon) grafts are the two main types of prosthetic available and, as in other anatomic positions, available data show generally equal results with either choice. The entire procedure is carried out through two small proximal and distal incisions between which the graft is tunneled anatomically. The selection of a 6-, 7-, or 8-mm graft is dictated by the size of the native vessels.

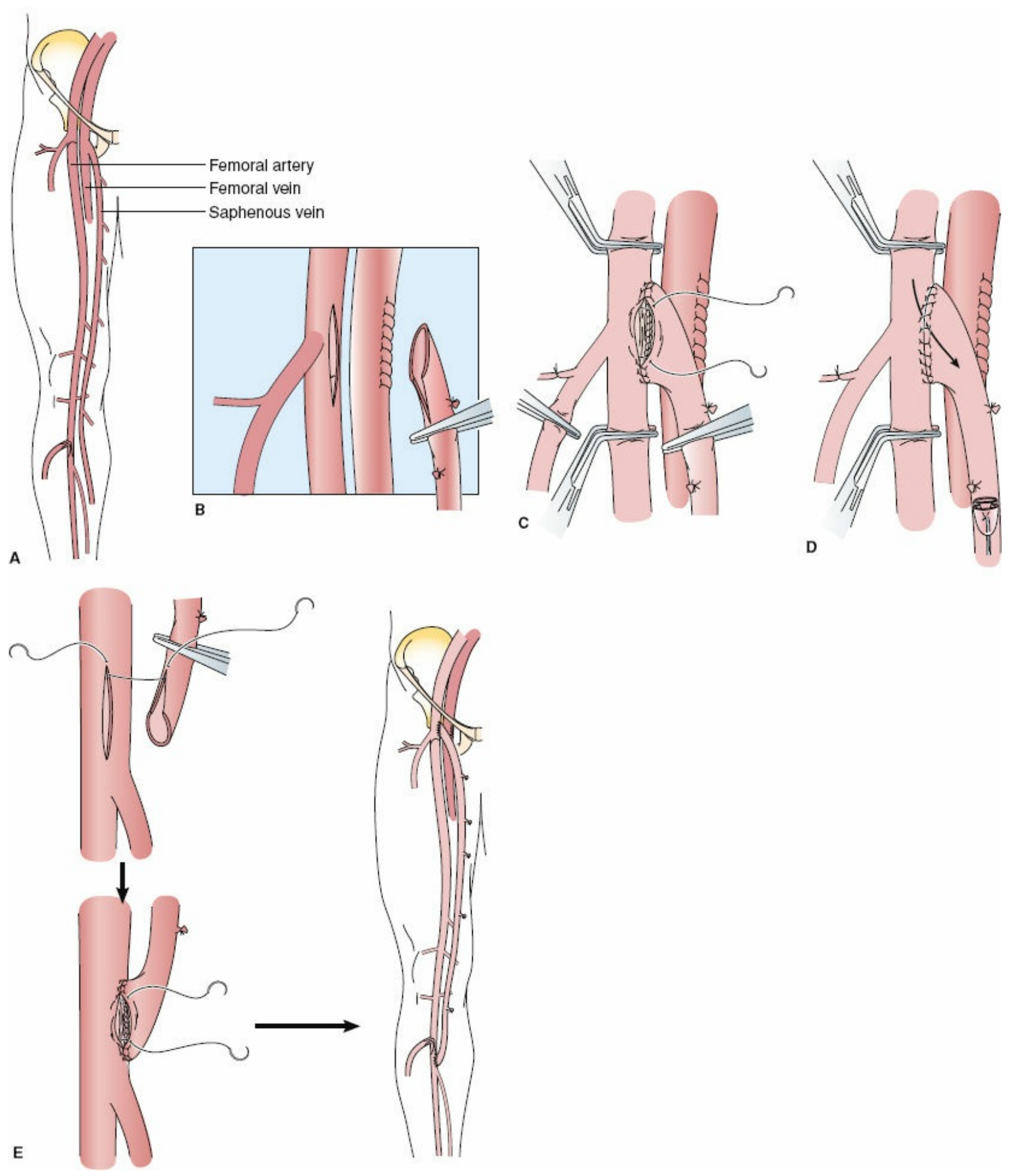

Figure 93-11. **A:** In the in situ method of infrainguinal reconstruction, the saphenous vein is left undisturbed in its native bed except for at the proximal and distal anastomotic sites, in this case, the common femoral artery and the tibioperoneal trunk, respectively. **B:** The saphenofemoral junction is transected in the groin, the venotomy in the

femoral vein is oversewn and the proximal end of the saphenous vein spatulated is prepared for anastomosis. **C:** After the first venous valve is excised under direct vision, the graft is anastomosed end-to-side to the femoral artery. Flow is then restored through the vein graft and the valvulotome passed from the distal end to lyse the residual valves (**D**), before the distal anastomosis is performed (**E**).

Reoperative Bypass Surgery

As the patient population treated by vascular surgeons has increased in age, and more and more challenging cases are accepted for primary treatment, there has been a corresponding increase in the incidence of reoperative bypass surgery performed for infrainguinal arterial occlusive disease. Such reoperative procedures are particularly challenging, both because of the scarring present at the inflow and outflow target sites and because there is typically a lack of ipsilateral greater saphenous vein. Whenever possible, the first problem is addressed by choosing anastomotic sites just above or below the previous touchdown points, thereby avoiding dissection through often densely scarred tissue planes. When ipsilateral greater saphenous vein is absent because of prior infrainguinal or coronary artery bypass surgery or prior saphenous vein stripping, there are a number of alternative conduit sites available. Investigators examining the consequence of using the contralateral greater saphenous vein in these situations found it to be the optimal conduit; despite the presumably high incidence of contralateral lower extremity as well as coronary occlusive disease in this population, the short- and long-term impact was found to be minimal.[90]

In the absence of any greater saphenous vein, preoperative venous duplex ultrasonography is employed to evaluate the cephalic and basilic veins of the arms and the lesser saphenous veins of the legs in an effort to determine the best conduit available. Often the veins distal to the antecubital crease are scarred and of small caliber, but their more proximal counterparts are often of excellent size and quality. The use of arm veins in general can be technically challenging and for that reason has not been universally adopted. The dissection of the basilic vein can be particularly tedious as it has multiple side branches and lies adjacent to several important nerves. As arm veins are often relatively short, a venovenostomy is often required to create composite grafts long enough to complete the arterial reconstruction (Fig. 93.12). This is performed with generous spatulation of each vein hood to create a widely patent vein-to-vein anastomosis. Given their thin-walled nature, arm vein grafts are also quite prone to twisting and kinking, and special care must to taken during the tunneling process to avoid these problems. The more proximal arm veins can be relatively large, and it is often advantageous to use one or more of the segments in a nonreversed fashion to better match the graft to the inflow vessel size.

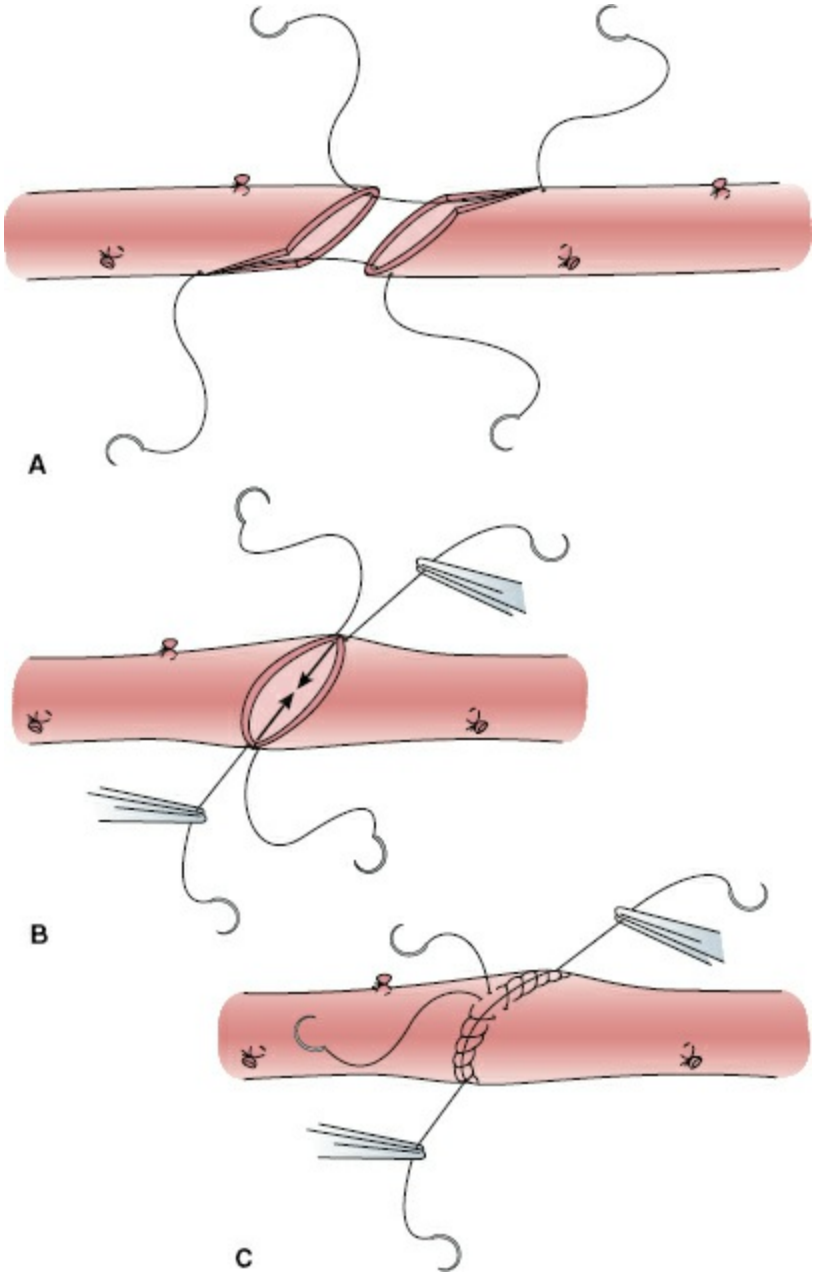

Figure 93-12. Creation of a composite graft from two or more segments of arm vein or lesser saphenous vein (**A**) is sometimes necessary to obtain the desired length of fully autogenous conduit for infrainguinal bypass. A widely spatulated venovenostomy (**B** and **C**) is optimal.

Not surprisingly, the results of reoperative infrainguinal bypass surgery do not match those of primary reconstruction. With autogenous vein, 5-year patency rates of 60% and limb salvage rates of 70% to 80% have been reported.[27,114] Coumadin is often used postoperatively in patients with compromised outflow or in whom the conduit was of marginal quality and has been associated with improved long-term patency.[115]

Postreconstruction Management

11 Many patients undergoing surgical reconstruction for critical ischemia with tissue loss require one or more adjunctive operative procedures of their foot. Small, uninfected ulcerations of the toe or foot often can be safely managed conservatively. However, larger, gangrenous lesions of the toe, forefoot, or heel usually require débridement of all necrotic tissue at the completion of the revascularization procedure. If the ischemia is particularly severe or infection is present, a toe or transmetatarsal amputation may be necessary in order to achieve a margin of healthy tissue. This is particularly important in patients with diabetes or end-stage renal disease, in whom persistent infection or necrosis can result in limb loss despite the presence of a well-revascularized extremity. The wounds are usually left open and treated with moist occlusive dressings or negative-pressure wound therapy. Serial débridements on the ward or in the operating room are often necessary for the larger wounds, which can then be surgically closed after an interval healing period or allowed to slowly close via secondary intention over time.

Unless otherwise contraindicated, all patients are maintained indefinitely on an antiplatelet regimen with either aspirin or clopidogrel following surgical bypass. As stated previously, in cases in which a graft is at increased risk of failure, such as in the setting of reoperation or in cases in which compromised outflow or a marginal conduit was accepted, the antiplatelet agent may be supplemented with heparin and then warfarin.[115] Patients with distal calf or pedal incisions should have consistent leg elevation in the early postoperative period to minimize leg swelling and wound healing complications. Thereafter, aggressive rehabilitation maximizes the chances of, and shortens the time to a return to full function after extensive reconstructive surgery. Ongoing risk factor modification in the form of smoking cessation, lipid reduction, exercise, blood pressure management, and diabetic blood sugar control is of further paramount importance in minimizing the risk of disease progression or recurrence.[116]

Graft Failure and Surveillance

Postoperative graft failures are typically classified according to the time interval from surgery as early, intermediate, or late. Graft thrombosis occurring within 30 days, the so-called "early graft failures," are generally thought to be a result of technical or judgment errors by the surgeon. Included in this list would be such technical errors as twists, kinks, incompletely lysed valves, or anastomotic defects, as well as judgment errors in using a poor quality vein or targeting an outflow vessel with inadequate runoff to support the graft. Intermediate graft failures include those between 30 days and 2 years and are generally attributed to the proliferation of intimal hyperplasia at the anastomoses or prior valve sites within the graft (Fig. 93-13). Late graft failures occurring beyond 2 years are typically a result of the progression of atherosclerotic occlusive disease within the inflow or outflow arteries.



Figure 93-13. Arteriogram demonstrating severe stenosis of distal graft from intimal hyperplasia, likely at prior valve site.

Given the known incidence of graft failure and the potentially dire consequence in terms of limb salvage or preservation of limb function in a patient with limited options for secondary or tertiary bypass, the ability to maintain graft patency through early identification and prompt correction of graft stenosis is of paramount importance.[117] Serial postoperative surveillance scanning with duplex ultrasound has proven an excellent means of accurately identifying hemodynamically significant stenosis within the vein

graft that threaten the graft patency.[118] Velocity criteria have been developed for high-grade lesions that may warrant either more intensive surveillance or prophylactic intervention. Absolute velocities less than 40 cm/s or greater than 300 cm/s or a three-fold increase in velocity in one segment compared with that of an adjacent segment are all indicative of impending graft failure. Confirmation by angiography and expeditious treatment by percutaneous cutting balloon angioplasty, surgical patch angioplasty, or interposition grafting of such significant lesions minimizes the risk of graft thrombosis and ensures optimal long-term graft patency.

Complications

The most commonly seen major complications of infrainguinal bypass surgery are cardiac in nature, and include myocardial infarction, congestive heart failure, and arrhythmias. In a recent review spanning 20 years and involving more than 1,600 procedures, the perioperative myocardial infarction rate was 3%, and the rate of cerebrovascular accident was 1%.[101] Patients with diabetes mellitus or preoperative renal insufficiency are at particular risk for developing postoperative renal failure (defined as an elevation of serum creatinine >3 mg/dL, doubling of the serum creatinine or the need for hemodialysis), which is seen in up to 2% of patients overall. Patients undergoing lower extremity revascularization are also prone to wound complications, given the length of incisions and the prolonged operating times often required. Overall wound complications, including cellulitis and abscess formation, wound dehiscence, and skin flap necrosis, can occur in up to 40% of patients and can best be avoided by gentle handling of the tissue and the use of skin bridges and careful avoidance of skin flaps during vein harvesting.[119] Postoperative hematomas, usually caused by slow capillary or venous oozing, or seromas are seen in 5% of patients; and less commonly encountered hemorrhage, typically a result of either a slipped vein branch ligature or anastomotic disruption, is seen in less than 1% of cases.

ACKNOWLEDGMENT

This chapter is based on the previous version from the 5th edition entitled *Femoropopliteal and Tibial Occlusive Disease* by William P. Robinson, Matthew T. Menard, and Michael Belkin.

References

1. Olin JW, Allie DE, Belkin M, et al. ACCF/AHA/ACR/SCAI/SIR/SVM/SVN/SVS 2010 performance measures for adults with peripheral artery disease: a report of the American College of Cardiology Foundation/American Heart Association Task Force on performance measures, the American College of Radiology, the Society for Cardiac Angiography and Interventions, the Society for Interventional Radiology, the Society for Vascular Medicine, the Society for Vascular Nursing, and the Society for Vascular Surgery (Writing Committee to Develop Clinical Performance Measures for Peripheral Artery Disease). *Circulation* 2010;122:2583–2618.
2. Criqui MH, Fronek A, Barrett-Connor E, et al. The prevalence of peripheral arterial disease in a defined population. *Circulation* 1985;71:510–515.
3. Selvin E, Erlinger TP. Prevalence of and risk factors for peripheral arterial disease in the United States: results from the National Health and Nutrition Examination Survey, 1999-2000. *Circulation* 2004;110:738–743.
4. Fowkes FG, Rudan D, Rudan I, et al. Comparison of global estimates of prevalence and risk factors for peripheral artery disease in 2000 and 2010: a systematic review and analysis. *Lancet* 382:1329–1340.
5. Gray EA. *Portrait of a Surgeon. A Biography of John Hunter.* London: Robert Hale; 1952.
6. dos Santos JC. Sur la desobstion des thromboses arterielles anciennes. *Mem Acad Chir* 1947;73:409–411.
7. Carrel A. The surgery of blood vessels, etc. *John Hopkins Hosp Bull* 1907;190:18.
8. Kunlin J. Le traitement de l'ischemie arteritique par la greffe veineuse longue. *Rev Chir* 1951;70:206–235.
9. McCaughan JJ Jr. Surgical exposure of the distal popliteal artery. *Surgery* 1958;44:536–539.
10. Dotter CT, Judkins MP. Transluminal treatment of arteriosclerotic obstruction. description of a new technic and a preliminary report of its application. *Circulation* 1964;30:654–670.
11. Gruntzig A, Hopff H. [Percutaneous recanalization after chronic arterial occlusion with a new dilator-catheter (modification of the Dotter technique) (author's transl)]. *Dtsch Med Wochenschr* 1974;99:2502–2510, 2511.
12. Halperin JL. Evaluation of patients with peripheral vascular disease. *Thromb Res* 2002;106:V303–V311.
13. Hirsch AT, Haskal ZJ, Hertzer NR, et al. ACC/AHA 2005 guidelines for the management of patients with peripheral arterial disease (lower extremity, renal, mesenteric, and abdominal aortic): executive summary a collaborative report from the American Association for Vascular Surgery/Society for Vascular Surgery, Society for Cardiovascular Angiography and Interventions, Society for Vascular Medicine and Biology, Society of Interventional Radiology, and the ACC/AHA Task Force on

Practice Guidelines (Writing Committee to Develop Guidelines for the Management of Patients With Peripheral Arterial Disease) endorsed by the American Association of Cardiovascular and Pulmonary Rehabilitation; National Heart, Lung, and Blood Institute; Society for Vascular Nursing; TransAtlantic Inter-Society Consensus; and Vascular Disease Foundation. *J Am Coll Cardiol* 2006;47:1239–1312.

14. Norgren L, Hiatt WR, Dormandy JA, et al. Inter-society consensus for the management of peripheral rrterial disease (TASC II). *J Vasc Surg* 2007;45(Suppl S):S5–S67.
15. Criqui MH, Vargas V, Denenberg JO, et al. Ethnicity and peripheral arterial disease: the San Diego Population Study. *Circulation* 2005;112:2703–2707.
16. O'Hare AM, Vittinghoff E, Hsia J, et al. Renal insufficiency and the risk of lower extremity peripheral arterial disease: results from the Heart and Estrogen/Progestin Replacement Study (HERS). *J Am Soc Nephrol* 2004;15:1046–1051.
17. Ridker PM, Stampfer MJ, Rifai N. Novel risk factors for systemic atherosclerosis: a comparison of C-reactive protein, fibrinogen, homocysteine, lipoprotein(a), and standard cholesterol screening as predictors of peripheral arterial disease. *JAMA* 2001;285:2481–2485.
18. Imparato AM, Kim GE, Davidson T, et al. Intermittent claudication: its natural course. *Surgery* 1975;78:795–799.
19. McAllister FF. The fate of patients with intermittent claudication managed nonoperatively. *Am J Surg* 1976;132:593–595.
20. Walsh DB, Gilbertson JJ, Zwolak RM, et al. The natural history of superficial femoral artery stenoses. *J Vasc Surg* 1991;14:299–304.
21. Wolfe JH, Wyatt MG. Critical and subcritical ischaemia. *Eur J Vasc Endovasc Surg* 1997;13:578–582.
22. Brewster DC, Perler BA, Robison JG, et al. Aortofemoral graft for multilevel occlusive disease. predictors of success and need for distal bypass. *Arch Surg* 1982;117:1593–1600.
23. Karmody AM, Powers SR, Monaco VJ, et al. "Blue toe" syndrome. an indication for limb salvage surgery. *Arch Surg* 1976;111:1263–1268.
24. Cronenwett JL, Davis JT Jr., Gooch JB, et al. Aortoiliac occlusive disease in women. *Surgery* 1980;88:775–784.
25. Caes F, Cham B, Van den Brande P, et al. Small artery syndrome in women. *Surg Gynecol Obstet* 1985;161:165–170.
26. Hertzer NR, Beven EG, Young JR, et al. Coronary artery disease in peripheral vascular patients. a classification of 1000 coronary angiograms and results of surgical management. *Ann Surg* 1984;199:223–233.
27. Belkin M, Conte MS, Donaldson MC, et al. Preferred strategies for secondary infrainguinal bypass: lessons learned from 300 consecutive reoperations. *J Vasc Surg* 1995;21:282–293; discussion 293–295.

28. Whittemore AD, Clowes AW, Hechtman HB, et al. Aortic aneurysm repair. reduced operative mortality associated with maintenance of optimal cardiac performance. *Ann Surg* 1980;192:414–421.
29. Kaluza GL, Joseph J, Lee JR, et al. Catastrophic outcomes of noncardiac surgery soon after coronary stenting. *J Am Coll Cardiol* 2000;35:1288–1294.
30. Poldermans D, Boersma E, Bax JJ, et al. The effect of bisoprolol on perioperative mortality and myocardial infarction in high-risk patients undergoing vascular surgery. Dutch Echocardiographic Cardiac Risk Evaluation Applying Stress Echocardiography Study Group. *N Engl J Med* 1999;341:1789–1794.
31. Schanzer A, Hevelone N, Owens CD, et al. Statins are independently associated with reduced mortality in patients undergoing infrainguinal bypass graft surgery for critical limb ischemia. *J Vasc Surg* 2008;47:774–781.
32. Foley WD, Stonely T. CT angiography of the lower extremities. *Radiol Clin North Am* 2010;48:367–396, ix.
33. Pomposelli F. Arterial imaging in patients with lower extremity ischemia and diabetes mellitus. *J Vasc Surg* 2010;52:81S–91S.
34. Carpenter JP, Owen RS, Holland GA, et al. Magnetic resonance angiography of the aorta, iliac, and femoral arteries. *Surgery* 1994;116:17–23.
35. Baum RA, Rutter CM, Sunshine JH, et al. Multicenter trial to evaluate vascular magnetic resonance angiography of the lower extremity. American College of Radiology Rapid Technology Assessment Group. *JAMA* 1995; 274:875–880.
36. Koelemay MJ, Lijmer JG, Stoker J, et al. Magnetic resonance angiography for the evaluation of lower extremity arterial disease: a meta-analysis. *JAMA* 2001;285:1338–1345.
37. Bui TD, Gelfand D, Whipple S, et al. Comparison of CT and catheter arteriography for evaluation of peripheral arterial disease. *Vasc Endovascular Surg* 2005;39:481–490.
38. Udoff EJ, Barth KH, Harrington DP, et al. Hemodynamic significance of iliac artery stenosis: pressure measurements during angiography. *Radiology* 1979;132:289–293.
39. Spinosa DJ, Kaufmann JA, Hartwell GD. Gadolinium chelates in angiography and interventional radiology: a useful alternative to iodinated contrast media for angiography. *Radiology* 2002;223:319–325; discussion 26–27.
40. Back MR, Caridi JG, Hawkins IF Jr, et al. Angiography with carbon dioxide (CO2). *Surg Clin North Am* 1998;78:575–591.
41. Heart Protection Study Collaborative Group. MRC/BHF Heart Protection Study of cholesterol lowering with simvastatin in 20,536 high-risk individuals: a randomised placebo-controlled trial. *Lancet* 2002;360:7–22.
42. Prevention of cardiovascular events and death with pravastatin in patients with coronary heart disease and a broad range of initial cholesterol levels. The Long-Term Intervention with Pravastatin in Ischaemic Disease (LIPID) Study Group. *N Eng J Med* 1998;339:1349–1357.

43. Collaborative overview of randomised trials of antiplatelet therapy–II: maintenance of vascular graft or arterial patency by antiplatelet therapy. Antiplatelet Trialists' Collaboration. *BMJ* 1994;308:159–168.
44. Clagett GP, Sobel M, Jackson MR, et al. Antithrombotic therapy in peripheral arterial occlusive disease: the Seventh ACCP Conference on Antithrombotic and Thrombolytic Therapy. *Chest* 2004;126:609S-626S.
45. CAPRIE Steering Committee. A randomised, blinded, trial of clopidogrel versus aspirin in patients at risk of ischaemic events (CAPRIE). CAPRIE Steering Committee. *Lancet* 1996;348:1329–1339.
46. Nehler MR, Hiatt WR. Exercise therapy for claudication. *Ann Vasc Surg* 1999;13:109–114.
47. Regensteiner JG, Meyer TJ, Krupski WC, et al. Hospital vs home-based exercise rehabilitation for patients with peripheral arterial occlusive disease. *Angiology* 1997;48:291–300.
48. Dawson DL, Cutler BS, Hiatt WR, et al. A comparison of cilostazol and pentoxifylline for treating intermittent claudication. *Am J Med* 2000;109:523–530.
49. Moher D, Pham B, Ausejo M, et al. Pharmacological management of intermittent claudication: a meta-analysis of randomised trials. *Drugs* 2000;59:1057–1070.
50. Hood SC, Moher D, Barber GG. Management of intermittent claudication with pentoxifylline: meta-analysis of randomized controlled trials. *CMAJ* 1996;155:1053–1059.
51. Girolami B, Bernardi E, Prins MH, et al. Treatment of intermittent claudication with physical training, smoking cessation, pentoxifylline, or nafronyl: a meta-analysis. *Arch Intern Med* 1999;159:337–345.
52. Brass EP, Anthony R, Dormandy J, et al. Parenteral therapy with lipo-ecraprost, a lipid-based formulation of a PGE1 analog, does not alter six-month outcomes in patients with critical leg ischemia. *J Vasc Surg* 2006;43:752–759.
53. Diehm C, Abri O, Baitsch G, et al. [Iloprost, a stable prostacyclin derivative, in stage 4 arterial occlusive disease. A placebo-controlled multicenter study]. *Dtsch Med Wochenschr* 1989;114:783–788.
54. Guilmot JL, Diot E. [The role of drug therapy in the treatment of critical ischemia of the lower limbs]. *Presse Med* 1999;28:647–650.
55. Taylor SM, Kalbaugh CA, Blackhurst DW, et al. Determinants of functional outcome after revascularization for critical limb ischemia: an analysis of 1000 consecutive vascular interventions. *J Vasc Surg* 2006;44:747–755; discussion 755–756.
56. Belkin M, Knox J, Donaldson MC, et al. Infrainguinal arterial reconstruction with nonreversed greater saphenous vein. *J Vasc Surg* 1996;24:957–962.
57. Shah DM, Darling RC 3rd, Chang BB, et al. Long-term results of in situ saphenous vein bypass. analysis of 2058 cases.*Ann Surg* 1995;222:438–446; discussion 446–448.
58. Conte MS, Bandyk DF, Clowes AW, et al. Results of PREVENT III: a multicenter,

randomized trial of edifoligide for the prevention of vein graft failure in lower extremity bypass surgery. *J Vasc Surg* 2006;43:742–751; discussion 751.

59. Giles KA, Pomposelli FB, Hamdan AD, et al. Infrapopliteal angioplasty for critical limb ischemia: relation of TransAtlantic InterSociety Consensus class to outcome in 176 limbs. *J Vasc Surg* 2008;48:128–136.
60. Laird JR, Zeller T, Gray BH, et al. Limb salvage following laser-assisted angioplasty for critical limb ischemia: results of the LACI multicenter trial. *J Endovasc Ther* 2006;13:1–11.
61. Romiti M, Albers M, Brochado-Neto FC, et al.. Meta-analysis of infrapopliteal angioplasty for chronic critical limb ischemia. *J Vasc Surg* 2008;47:975–981.
62. Menard MT, Belkin M. Infrapopliteal intervention for the treatment of the claudicant. *Semin Vasc Surg* 2007;20:42–53.
63. Simons JP, Schanzer A, Nolan BW, et al. Outcomes and practice patterns in patients undergoing lower extremity bypass. *J Vasc Surg* 2012;55:1629–1636.
64. Goodney PP, Beck AW, Nagle J, et al. National trends in lower extremity bypass surgery, endovascular interventions, and major amputations. *J Vasc Surg* 2009;50:54–60.
65. Dormandy JA, Rutherford RB. Management of peripheral arterial disease (PAD). TASC Working Group. TransAtlantic Inter-Society Consensus (TASC). *J Vasc Surg* 2000;31:S1–S296.
66. DeRubertis BG, Pierce M, Chaer RA, et al. Lesion severity and treatment complexity are associated with outcome after percutaneous infra-inguinal intervention. *J Vasc Surg* 2007;46:709–716.
67. Schanzer A, Hevelone N, Owens CD, et al. Technical factors affecting autogenous vein graft failure: observations from a large multicenter trial. *J Vasc Surg* 2007;46:1180–1190; discussion 1190.
68. Robinson WP 3rd, Owens CD, Nguyen LL, et al. Inferior outcomes of autogenous infrainguinal bypass in Hispanics: an analysis of ethnicity, graft function, and limb salvage. *J Vasc Surg* 2009;49:1416–1425.
69. Conte MS. Critical appraisal of surgical revascularization for critical limb ischemia. *J Vasc Surg* 2013;57:8S–13S.
70. Rogers RK, Dattilo PB, Garcia JA, et al. Retrograde approach to recanalization of complex tibial disease. *Catheter Cardiovasc Interv* 2011;77:915–925.
71. Markose G, Bolia A. Below the knee angioplasty among diabetic patients. *J Cardiovasc Surg* 2009;50:323–329.
72. Pentecost MJ, Criqui MH, Dorros G, et al. Guidelines for peripheral percutaneous transluminal angioplasty of the abdominal aorta and lower extremity vessels. a statement for health professionals from a Special Writing Group of the Councils on Cardiovascular Radiology, Arteriosclerosis, Cardio-Thoracic and Vascular Surgery, Clinical Cardiology, and Epidemiology and Prevention, the American Heart

Association. *J Vascu Interv Radiol* 2003;14:S495–S515.

73. Srodon P, Matson M, Ham R. Contrast nephropathy in lower limb angiography. *Ann R Coll Surg Engl* 2003;85:187–191.
74. Berkseth RO, Kjellstrand CM. Radiologic contrast-induced nephropathy. *Med Clin North Am* 1984;68:351–370.
75. Kandzari DE, Rebeiz AG, Wang A, et al. Contrast nephropathy : an evidence-based approach to prevention. *Am J Cardiovasc Drugs* 2003;3:395–405.
76. MacNeill BD, Harding SA, Bazari H, et al. Prophylaxis of contrast-induced nephropathy in patients undergoing coronary angiography. *Catheter Cardiovasc Interv* 2003;60:458–461.
77. Knight CG, Healy DA, Thomas RL. Femoral artery pseudoaneurysms: risk factors, prevalence, and treatment options. *Ann Vasc Surg* 2003;17:503–508.
78. Lonn L, Olmarker A, Geterud K, et al. Prospective randomized study comparing ultrasound-guided thrombin injection to compression in the treatment of femoral pseudoaneurysms. *J Endovasc Ther* 2004;11:570–576.
79. Quinn SF, Kim J. Percutaneous femoral closure following stent-graft placement: use of the perclose device. *Cardiovasc Intervent Radiol* 2004; 27:231–236.
80. Muradin GS, Bosch JL, Stijnen T, et al. Balloon dilation and stent implantation for treatment of femoropopliteal arterial disease: meta-analysis. *Radiology* 2001;221:137–145.
81. Laird JR, Katzen BT, Scheinert D, et al. Nitinol stent implantation vs. balloon angioplasty for lesions in the superficial femoral and proximal popliteal arteries of patients with claudication: three-year follow-up from the RESILIENT randomized trial. *J Endovasc Ther* 2012;19:1–9.
82. Schillinger M, Sabeti S, Loewe C, et al. Balloon angioplasty versus implantation of nitinol stents in the superficial femoral artery. *N Engl J Med* 2006;354:1879–1888.
83. Vraux H, Hammer F, Verhelst R, et al. Subintimal angioplasty of tibial vessel occlusions in the treatment of critical limb ischaemia: mid-term results. *Eur J Vasc Endovasc Surg* 2000;20:441–446.
84. Bosiers M, Hart JP, Deloose K, et al. Endovascular therapy as the primary approach for limb salvage in patients with critical limb ischemia: experience with 443 infrapopliteal procedures. *Vascular* 2006;14:63–69.
85. Randon C, Jacobs B, De Ryck F, et al. Angioplasty or primary stenting for infrapopliteal lesions: results of a prospective randomized trial. *Cardiovasc Intervent Radiol* 2010;33:260–269.
86. Conte MS, Geraghty PJ, Bradbury AW, et al. Suggested objective performance goals and clinical trial design for evaluating catheter-based treatment of critical limb ischemia. *J Vasc Surg* 2009;50:1462–1473 e1–e3.
87. Adam DJ, Beard JD, Cleveland T, et al. Bypass versus angioplasty in severe ischaemia of the leg (BASIL): multicentre, randomised controlled trial. *Lancet*

2005;366:1925–1934.
88. Holm J, Arfvidsson B, Jivegard L, et al. Chronic lower limb ischaemia. a prospective randomised controlled study comparing the 1-year results of vascular surgery and percutaneous transluminal angioplasty (PTA). *Eur J Vasc Surg* 1991;5:517–522.
89. van der Zaag ES, Prins MH, Jacobs MJ. [Treatment of intermittent claudication; prospective randomized study in the BAESIC-Trial (bypass, angioplasty or endarterectomy patients with severe intermittent claudication)]. *Ned Tijdschr Geneeskd* 1996;140:787–788.
90. Wolf GL, Wilson SE, Cross AP, et al. Surgery or balloon angioplasty for peripheral vascular disease: a randomized clinical trial. Principal investigators and their Associates of Veterans Administration Cooperative Study Number 199. *J Vasc Interv Radiol* 1993;4:639–648.
91. Bradbury AW, Adam DJ, Bell J, et al. Bypass versus angioplasty in severe ischaemia of the leg (BASIL) trial: a survival prediction model to facilitate clinical decision making. *J Vasc Surg* 2010;51:52S-68S.
92. Nolan BW, De Martino RR, Stone DH, et al. Prior failed ipsilateral percutaneous endovascular intervention in patients with critical limb ischemia predicts poor outcome after lower extremity bypass. *J Vasc Surg* 2011;54:730–735; discussion 735–736.
93. Malone JM, Goldstone J, Moore WS. Autogenous profundaplasty: the key to long-term patency in secondary repair of aortofemoral graft occlusion. *Ann Surg* 1978;188:817–823.
94. Reed AB, Conte MS, Belkin M, et al. Usefulness of autogenous bypass grafts originating distal to the groin. *J Vasc Surg* 2002;35:48–54; discussion, 54–55.
95. Schanzer A, Owens CD, Conte MS, et al. Superficial femoral artery percutaneous intervention is an effective strategy to optimize inflow for distal origin bypass grafts. *J Vasc Surg* 2007;45:740–743.
96. Veith FJ, Gupta SK, Ascer E, et al. Six-year prospective multicenter randomized comparison of autologous saphenous vein and expanded polytetrafluoroethylene grafts in infrainguinal arterial reconstructions. *J Vasc Surg* 1986;3:104–114.
97. Rosenthal D. Endoscopic in situ bypass. *Surg Clin North Am* 1995;75:703–713.
98. Eid RE, Wang L, Kuzman M, et al. Endoscopic versus open saphenous vein graft harvest for lower extremity bypass in critical limb ischemia. *J Vasc Surg* 2014;59:136–144.
99. Bandyk DF, Johnson BL, Gupta AK, et al. Nature and management of duplex abnormalities encountered during infrainguinal vein bypass grafting. *J Vasc Surg* 1996;24:430–436; discussion 437–438.
100. Gilbertson JJ, Walsh DB, Zwolak RM, et al. A blinded comparison of angiography, angioscopy, and duplex scanning in the intraoperative evaluation of in situ saphenous vein bypass grafts. *J Vasc Surg* 1992;15:121–127; discussion 127-129.

101. Conte MS, Belkin M, Upchurch GR, et al. Impact of increasing comorbidity on infrainguinal reconstruction: a 20-year perspective. *Ann Surg* 2001; 233:445–452.
102. Fogle MA, Whittemore AD, Couch NP, et al. A comparison of in situ and reversed saphenous vein grafts for infrainguinal reconstruction. *J Vasc Surg* 1987;5:46–52.
103. Taylor LM Jr, Edwards JM, Porter JM. Present status of reversed vein bypass grafting: five-year results of a modern series. *J Vasc Surg* 1990;11:193–205; discussion 205–206.
104. Hall KV. The great saphenous vein used in situ as an arterial shunt after extirpation of the vein valves. a preliminary report. *Surgery* 1962;51:492–495.
105. Leather RP, Powers SR, Karmody AM. A reappraisal of the in situ saphenous vein arterial bypass: its use in limb salvage. *Surgery* 1979;86:453–461.
106. Donaldson MC, Mannick JA, Whittemore AD. Femoral-distal bypass with in situ greater saphenous vein. long-term results using the Mills valvulotome. *Ann Surg* 1991;213:457–464; discussion 464–465.
107. Moody AP, Edwards PR, Harris PL. In situ versus reversed femoropopliteal vein grafts: long-term follow-up of a prospective, randomized trial. *Br J Surg* 1992;79:750–752.
108. Wengerter KR, Veith FJ, Gupta SK, et al. Prospective randomized multicenter comparison of in situ and reversed vein infrapopliteal bypasses. *J Vasc Surg* 1991;13:189–197; discussion 197–199.
109. Panetta TF, Marin ML, Veith FJ, et al. Unsuspected preexisting saphenous vein disease: an unrecognized cause of vein bypass failure. *J Vasc Surg* 1992;15:102–110; discussion 110–112.
110. Marcaccio EJ, Miller A, Tannenbaum GA, et al. Angioscopically directed interventions improve arm vein bypass grafts. *J Vasc Surg* 1993;17:994–1002; discussion 1003-1004.
111. Whittemore AD, Kent KC, Donaldson MC, et al. What is the proper role of polytetrafluoroethylene grafts in infrainguinal reconstruction? *J Vasc Surg* 1989;10:299–305.
112. Quinones-Baldrich WJ, Prego AA, Ucelay-Gomez R, et al. Long-term results of infrainguinal revascularization with polytetrafluoroethylene: a ten-year experience. *J Vasc Surg* 1992;16:209–217.
113. Miller JH, Foreman RK, Ferguson L, et al. Interposition vein cuff for anastomosis of prosthesis to small artery. *Aust N Z J Surg* 1984;54:283–285.
114. Chew DK, Owens CD, Belkin M, et al. Bypass in the absence of ipsilateral greater saphenous vein: safety and superiority of the contralateral greater saphenous vein. *J Vasc Surg* 2002;35:1085–1092.
115. Sarac TP, Huber TS, Back MR, et al. Warfarin improves the outcome of infrainguinal vein bypass grafting at high risk for failure. *J Vasc Surg* 1998;28:446–457.
116. Creager MA. Medical management of peripheral arterial disease. *Cardiol Rev*

2001;9:238–245.

117. Veith FJ, Weiser RK, Gupta SK, et al. Diagnosis and management of failing lower extremity arterial reconstructions prior to graft occlusion. *J Cardiovasc Surg* 1984;25:381–384.

118. Bandyk DF, Schmitt DD, Seabrook GR, et al. Monitoring functional patency of in situ saphenous vein bypasses: the impact of a surveillance protocol and elective revision. *J Vasc Surg* 1989;9:286–296.

119. Santo VJ, Dargon PT, Azarbal AF, et al. Open versus endoscopic great saphenous vein harvest for lower extremity revascularization of critical limb ischemia. *J Vasc Surg* 2014;59:427–434.

Chapter 94

Lower Extremity Amputation

Matthew J. Sideman, Kevin E. Taubman, and Bradley D. Beasley

Key Points

1 The annual incidence of amputations is decreasing.
2 The vast majority of lower extremity amputations are performed for complications of diabetes or arterial insufficiency.
3 Emergent amputation is indicated in the face of uncontrolled or ascending infection.
4 Primary amputation is occasionally indicated in cases of treatment for lower extremity trauma.
5 Revascularization is often performed in conjunction with a minor amputation, either simultaneously or as a staged procedure.
6 The choice of amputation level depends on the indication for the procedure, the condition of the patient, and the rehabilitation potential of the patient.
7 The energy required to ambulate following a lower extremity amputation increases with ascending level of amputation.

1 Surgeons are often involved in treating patients requiring lower extremity amputation. Increasing incidence of diabetes, peripheral arterial disease, and the aging population has put more patients at risk for amputation. The explosion of endovascular interventions over the past decade has resulted in decreasing numbers of amputations performed annually.[1] A review of the Nation Hospital Discharge Survey and Medicare claims data confirms this negative trend.[2] Clinical judgment is critical to a successful outcome. Factors to consider are primary amputation, revascularization, repeat revascularization, level of amputation, and timing of amputation. The surgeon must remember that the goal is to maintain maximal function of the patient not necessarily maximal length of the limb. Consequently, experience of the surgeon has been shown to be key to a successful outcome.[3]

INDICATIONS

2 Most lower extremity amputations are performed for complications of diabetes or arterial insufficiency (Table 94-1). Chronic infection and trauma account for less than 10% of the total number of amputations. Other indications include neuroma, frostbite, malignancy, chronic pain, arterial embolization, venous insufficiency, and cryoglobulinemia.[4]

Elective lower extremity amputation in diabetic and vascular patients is indicated for gangrene (dry gangrene), gangrene with infection (wet gangrene), unremitting and unreconstructable rest pain, and nonhealing ulcers. The goal of the operation is to remove all nonviable tissue, relieve ischemic rest pain, ensure primary wound healing, and facilitate rehabilitation. Elective amputation should only be performed following an evaluation for revascularization procedure by a surgeon capable of performing such procedures. Veith et al.[5] reported that 96% of patients who underwent lower extremity arteriography for limb-threatening infrainguinal arteriosclerosis were candidates for arterial reconstruction. Advances in percutaneous management have expanded treatment options to patients who were not otherwise operative candidates. Not all patients are candidates for arteriography, including those with chronic renal insufficiency, organic brain syndrome, nonfunctional limbs, fixed joint contractures, insensate feet, and those with extensive gangrene.

Spinal cord stimulation (SCS) may offer a chance for limb salvage for patients with chronic ischemia in whom reconstruction is not an option. Based on Melzack and Wall theory for the treatment of chronic pain,[6] the mechanism of pain relief and increased blood flow in end-stage peripheral vascular disease is unclear. Despite this, there is peripheral vasodilatation on the microvascular level which leads to pain relief,[7] increased claudication distance,[8] ulcer healing,[9] and possible limb salvage.[7,10,11] The 1-year foot salvage rate is 60% to 70% on average, according to a review of the literature.[12] SCS is only appropriate when surgery for revascularization is no longer possible. Furthermore, SCS only dilates microvasculature and does nothing for the underlying, progressive peripheral vascular disease that is causing the ischemia. SCS, therefore, is only a temporizing measure, but can potentially give an extended functional period with a procedure that is well tolerated and relatively simple to perform.[12] Recently, Gersbach et al. have shown that the benefits of SCS persist longer than initially thought.[13]

3 Emergent amputation is indicated in the face of uncontrolled or ascending infection. In the case of uncontrolled sepsis, it can even be a life-saving maneuver. A diabetic patient with a foot abscess is a surgical emergency. Frequently, incision and drainage with or without a toe or a combined toe and metatarsal resection is sufficient to control the acute problem. The wounds should be left open in the setting of acute infection. If the process extends beyond the foot, a staged amputation should be performed proximal enough to control the infection. This can include an ankle disarticulation, a guillotine below-knee amputation (BKA), a knee disarticulation, or a guillotine above-knee amputation (AKA). Disarticulations have the advantage of preserving limb length and avoiding an open bone in the incision. After the infection is controlled, the appropriate

amputation can be completed. A one-stage primary AKA can be considered in patients who are nonambulatory, have infection involving the entire lower leg, have a fixed knee contracture, or those with a nonfunctional limb. Patients who are too unstable for surgery can be temporized with a cryoamputation.[14]

Table 94-1 Indications for Lower Extremity Amputation

Indication	Percentage
Complications of diabetes mellitus	60–80
Nondiabetic infection with ischemia	15–25
Ischemia without infection	5–10
Chronic osteomyelitis	3–5
Trauma	2–5
Miscellaneous (neuroma, frostbite, tumor, pain, and nonhealing wound)	5–10

From Malone JM. Lower extremity amputation. In: Moore WS, ed. *Vascular Surgery: A Comprehensive Review*. Philadelphia, PA: WB Saunders; 1993:810.

4 Primary amputation is occasionally indicated as treatment for severe lower extremity trauma. Both penetrating and blunt injuries of the lower extremities are frequently associated with vascular, nerve, bone, and extensive soft tissue injuries. Several treatment guidelines have been developed for lower extremity trauma. Lange[15] recommended primary amputation for open tibial fractures with associated vascular injuries if the posterior tibial nerve was disrupted in an adult or if the duration of warm ischemia was greater than 6 hours in a crush injury. In addition, he suggested that primary amputation was relatively indicated in patients with polytrauma, severe ipsilateral foot injuries, and in those with an expected protracted postoperative course. These suggestions are supported in work by Bosse et al.[16] demonstrating, in the case of high-energy lower extremity trauma, amputation, and reconstruction have equal functional outcomes at 2 years. Additional guidelines have been provided by Johansen et al.[17] who devised a Mangled Extremity Severity Score to predict the need for amputation based on the extent of skeletal or soft tissue damage, limb ischemia, shock, and age. Unfortunately, none of these guidelines are predictive of functional recovery in patients who undergo limb salvage.[18] Therefore, treatment with primary amputation is an extremely difficult decision and requires extensive clinical judgment as well as multidisciplinary input. Contributing factors include the severity of the injury, the overall clinical status, and the ultimate rehabilitation potential of the patient.

EVALUATION FOR REVASCULARIZATION

Modern vascular surgery techniques allow successful limb salvage in situations not previously possible. All patients who present for possible lower extremity amputation, including minor amputations, should have their peripheral vascular circulation evaluated preoperatively. Any patient with absent pedal pulses or abnormal ankle–brachial indices should be evaluated by a vascular surgeon skilled in both open and endovascular revascularization techniques. The evaluation may require only a thorough history and physical examination if there is an obvious contraindication to revascularization (e.g., nonfunctional limb, severe organic brain syndrome). Noninvasive vascular laboratory examinations are a mandatory minimum for patients with abnormal vascular examinations. Additional imaging with either multiple-slice computed tomographic angiography (CTA), magnetic resonance angiography (MRA), or contrast angiography can be done based upon the patient's initial evaluation and vascular lab results. The information obtained from these tests is heavily dependent on the quality of the machinery, the skill of the technologist, and the knowledge of the interpreting physician. All of these factors must be taken into account when deciding which test to order. Contrast angiography with selective lower extremity injections may be necessary to fully define the patient's anatomy and suitability for reconstruction; however, it is generally preferred to perform this invasive procedure for preoperative planning or for planned percutaneous intervention. Contrast arteriography should not be considered a *diagnostic* examination.

Exponential advances in endovascular techniques have occurred over the past 10 years. These have found their way into the peripheral circulation and have applicability in limb salvage. Percutaneous techniques include convention balloon angioplasty, stenting (including balloon expandable, self-expanding nitinol, and covered stents), cryoplasty, and percutaneous atherectomy (including laser, directional, and rotational). The BASIL trial showed no significant difference in amputation-free survival among patients with critical limb ischemia when randomized to open or percutaneous revascularization.[19]

In terms of surgical reconstruction, upper extremity[20] and cryopreserved cadaver vein[21] have increased the options for conduit in limb salvage situations. Prosthetic grafts with vein cuffs[22,23] provide other alternatives when appropriate autogenous conduit is not available. More recently, a heparin-bonded prosthetic graft has been introduced and early studies show promising results.[24] An operation for limb salvage should never be denied *only* for lack of conduit.

5 Re vascularization is often performed in conjunction with a minor amputation, either simultaneously or as a staged procedure. This allows management of the acute problem of sepsis and the underlying chronic ischemia. Caution must be taken if there is active infection and the only available conduit is prosthetic for fear of infecting the graft. Amputation with control of infection followed by revascularization is the more prudent course. In extreme cases, a limited amputation can be combined with revascularization and a tissue transfer (free or rotational flap) to achieve limb salvage.[25,26]

CHOICE OF AMPUTATION LEVEL

General

6 The choice of amputation level depends on the indication for the procedure, the condition of the patient, and the rehabilitation potential of the patient. The most common amputation levels are illustrated in Figure 94-1. Because most amputations are performed for complications of diabetes or arterial insufficiency, the selected level must remove all nonviable, painful tissue, allow primary healing, and maximize rehabilitation potential. Selection of the amputation level for malignant disease is dependent on the biologic characteristics of the neoplasm and will not be discussed further.

The general medical condition and the rehabilitation potential of the patient are important factors in deciding to proceed with amputation and in selecting the appropriate level. If a patient is ambulatory and independent preoperatively, the level with the greatest likelihood of maintaining function should be selected. If the patient is not ambulatory or has significant comorbid conditions, the primary wound-healing rate should be the determining factor.

Specific Situations

Aggressive attempts to salvage a distal amputation level are not indicated for patients who are unlikely to ambulate with a prosthesis.[27] For example, patients with fixed joint contractures greater than 15 degrees at the knee or 10 degrees at the hip are unlikely to ambulate with a prosthesis. BKAs are relatively contraindicated in patients with paraplegia because flexion contractures at the knee can lead to stump ulceration.

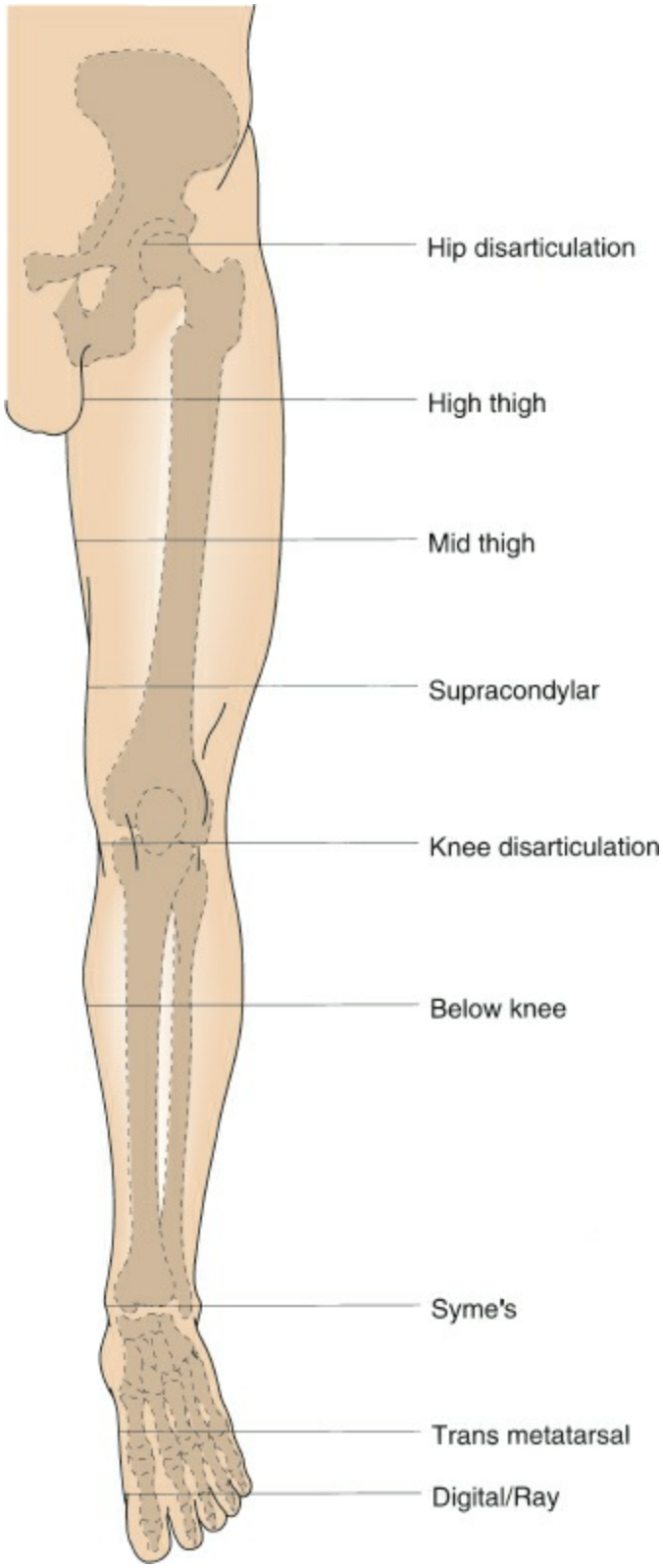

Figure 94-1. Common amputation levels for the lower extremity.

Energy Requirement

7 The energy required to ambulate following a lower extremity amputation increases with ascending level of amputation. The more proximal the amputation, the less likely a patient will be able to ambulate postoperatively. Table 94-2 illustrates the increased energy cost of the common lower extremity amputations. In clinical practice, the most significant increase is between a BKA and an AKA. Ambulation on an above-knee prosthesis requires the use of muscle groups poorly suited for that purpose. These increased energy costs are minor issues for young trauma or cancer patients; however, they represent a considerable obstacle for the older diabetic or vascular patient.

Clinical Assessment

The primary preoperative consideration for wound healing is the status of the skin and muscle blood flow. Operative technique, the patient's nutritional status, and the presence of infection also affect wound healing. Clinical judgment by an experienced surgeon accurately predicts healing of a BKA in approximately 80% of cases.[28] A palpable pulse at the level immediately proximal to the proposed amputation essentially ensures healing;[29] however, the converse is not true. Noninvasive arterial testing is the most common adjunctive test used to predict healing of a specific amputation level. Its usefulness is limited when medial sclerosis prevents vessel compression, a condition common in diabetic patients. Because the digital vessels are often spared from this process, digital pressure readings may be helpful in this setting. Transcutaneous oxygen measurement has been shown to predict primary healing although it is less able to predict failure to heal.[30,31] It has become more widely available and has supplanted previous less reliable tests that were more limited in availability. Tables 94-3 to 94-6 summarize the results of various preoperative tests to predict wound healing for toe, foot and forefoot, below-knee, and AKAs, respectively.

Table 94-2 Rehabilitation Energy Cost of Amputation at Various Levels

Amputation Level	Energy Cost
Digital or ray	Minimal (except first ray)
Transmetatarsal	Minimal during normal walking
Below-knee	30–60% increase in energy required for ambulation
Above-knee	60–100% increase in energy required for ambulation
Hip disarticulation	100–110% increase in energy required for ambulation

OPERATIVE TECHNIQUE

General Considerations

Diabetic patients who present septic require adequate fluid resuscitation, broad-spectrum antibiotics (including anaerobic coverage), and an emergent operation. Whereas maintenance of limb length and function is admirable, control of sepsis and wide débridement of all nonviable tissue are essential and potentially lifesaving. All patients require atraumatic tissue handling. Avoid forceps on the skin edge. Excessive skin flaps and dead space are also not desired. Amputations done in the face of active infection are kept open and treated with dressing changes. Consider delayed primary closure in cases where perfusion is intact.

RESULTS

Table 94-3 Preoperative Level Selection: Toe Amputation

Selection Criteria	Successful Healing, Primary and Secondary per Total
Empiric	86/115 (75%)
Presence of pedal pulses	357/365 (98%)
Doppler toe pressure >30 mm[a]	47/60 (78%)
Doppler ankle pressure >35 mm[a]	44/46 (96%)
Photoplethysmographic digit or TMA pressure >20 mm[a]	20/20 (100%)

[a]Systolic pressure (mm Hg).
TMA, transmetatarsal.
From Durham JR. Lower extremity amputation levels: indications, methods of determining appropriate level, technique, prognosis. In: Rutherford RB, ed. *Vascular surgery*, 3rd ed. Philadelphia, PA: WB Saunders; 1989:1693.

RESULTS

Table 94-4 Preoperative Level Selection: Foot and Forefoot Amputation

Selection Criteria	Successful Healing, Primary and Secondary per Total
Empiric	11/24 (46%)
	36/50 (72%)
Doppler ankle systolic pressure	
<40 mm Hg	5/9 (56%)
>40 mm Hg	20/60 (33%)
40–60 mm Hg	4/5 (80%)
>50 mm Hg	14/21 (66%)
>60 mm Hg	68/91 (75%)
>70 mm Hg	70/93 (75%)
Doppler toe systolic pressure	
>30 mm Hg	4/5 (80%)
Doppler ankle–brachial pressure index	
>0.45 (nondiabetic)	
>0.50 (diabetic)	58/60 (97%)
Photoplethysmographic toe systolic pressure	
>55 mm Hg	14/14 (100%)
>45 and <55 mm Hg	2/8 (25%)
<45 mm Hg	0/8 (0%)
Transcutaneous Po_2	
>10 mm (or a >10-mm increase on Fio_2 >1.0)	6/8 (75%)
>28 mm Hg	3/3 (100%)
Transcutaneous Pco_2	
<40 mm Hg	3/3 (100%)

From Durham JR. Lower extremity amputation levels: indications, methods of determining appropriate level, technique, prognosis. In: Rutherford RB, ed. *Vascular Surgery*, 3rd ed. Philadelphia, PA: WB Saunders; 1989:1695.

Postoperatively, the limb is elevated to minimize tissue edema and promote healing. Weight bearing on the amputation is delayed until healing is assured. This patient population requires effective prophylaxis against deep venous thrombosis and venous thromboembolism.

Digital and Ray Amputations

Digital amputations are indicated for some severe and irreducible deformities as well as gangrene or osteomyelitis localized distal to the base of the proximal phalanx. A technique for partial digital amputation is illustrated in Figure 94-2A. The circumferential or racquet-shaped skin incision is made over the distal end of the proximal phalanx, and carried down to bone. Nerves and tendons are transected under tension and allowed to retract. The proximal phalanx is divided with bone shears or power saw and the transected end smoothed with a rongeur. Soft tissue coverage can be performed with either medial/lateral flaps or dorsal/plantar flaps depending on skin tension and viability. The wound is closed only with simple interrupted skin sutures. Judicious use of subcutaneous sutures is advised due to danger of vascular compromise to the small remaining flaps. Non–weight bearing restrictions or protected weight bearing on the heel only in a rigid soled postoperative shoe or walking boot until the wound heals is recommended.

A ray amputation is indicated when the disease process extends to the metatarsal phalangeal joint. The technique is similar to a digital amputation and is illustrated in Figure 94-2B. A circumferential incision is made at the base of the involved toe and extended proximally on the dorsum of the foot over the metatarsal. The incision is extended to bone. The periosteum is cleared circumferentially and the bone is transected using a power saw at a level that will allow tension-free closure of the wound. In the case of the first or fifth toe, the incision is extended on the medial or lateral aspect of the foot, respectively. Care should be taken to bevel the distal metatarsal stump to minimize any prominence that may lead to skin breakdown with weight bearing or shoe gear wear. Typically the first metatarsal is beveled from proximal medial to distal lateral and proximal planter to distal dorsal. Metatarsals 2, 3, and 4 should be beveled from proximal plantar to distal dorsal. The 5th metatarsal is beveled from proximal lateral to distal medial and proximal plantar to distal dorsal.

In selected cases of neuropathic ulcers, the metatarsal head can be resected leaving the toe intact. A dorsal longitudinal incision is made over the metatarsal bone and the metatarsal head is resected with a power saw. Pulsed lavage and careful soft tissue inspection will help guide appropriate care for the plantar wound (i.e., packing, negative pressure therapy or ellipse of wound with closure). The dorsal wound is typically closed unless severe infection is encountered.

RESULTS

Table 94-5 Preoperative Level Selection: Below-Knee Amputation

Selection Criteria	Successful Healing, Primary and Secondary per Total
Empiric	794/974 (82%)
Doppler ankle systolic pressure	
>30 mm Hg	66/70 (94%)
Doppler calf systolic pressure	
>50 mm Hg	36/36 (100%)
>68 mm Hg	96/97 (99%)
Doppler thigh systolic pressure	
>100 mm Hg	31/31 (100%)
>80 mm Hg	104/113 (92%)
Transcutaneous $Po_2 = 0$	0/3 (0%)
>10 mm Hg	76/80 (95%)
(or >10-mm increase on $Fio_2 = 1.0$)	
>10 and <40 mm Hg	5/7 (71%)
>20 mm Hg	25/26 (96%)
>35 mm Hg	51/51 (100%)
Transcutaneous Po_2 index >0.59	17/17 (100%)
Transcutaneous Pco_2 <40 mm Hg	7/8(88%)

From Durham JR. Lower extremity amputation levels: indications, methods of determining appropriate level, technique, prognosis. In: Rutherford RB, ed. *Vascular Surgery*, 3rd ed. Philadelphia, PA: WB Saunders; 1989:1700.

Transmetatarsal Amputation

Transmetatarsal amputation (TMA) is a useful procedure that maintains a patient's ability to ambulate without the aid of a prosthesis. It is indicated when the gangrenous or infectious process involves multiple digits or a portion of the forefoot. Care must be taken to plan for the appropriate soft tissue coverage if primary closure is desired. Maximizing the plantar flap is most common, but coverage can also be gained from medial or laterally based flaps and even filleted toe flaps. If adequate soft tissue coverage is not available and a more proximal foot amputation (i.e., Chopart joint amputation) is not desired then an open amputation through the metatarsal bones can be performed. The wound is allowed to close secondarily or covered with a skin graft. Skin grafts in this position, however, are susceptible to breakdown secondary to the pressure related to ambulation.

RESULTS

Table 94-6 Preoperative Level Selection: Above-Knee Amputation

Selection Criteria	Successful Healing, Primary and Secondary per Total
Empiric	390/430 (91%)
Transcutaneous Po_2	
>10 mm (or 10-mm increase on $Fio_2 = 1.0$)	15/23 (65%)
>20 mm	12/12 (100%)
>23 mm	2/2 (100%)
>35 mm	21/24 (100%)
Transcutaneous Pco_2	
<38 mm	5/5 (100%)

From Durham JR. Lower extremity amputation levels: indications, methods of determining appropriate level, technique, prognosis. In: Rutherford RB, ed. *Vascular Surgery*, 3rd ed. Philadelphia, PA: WB Saunders; 1989:1707.

The technique is demonstrated in Figure 94-3. A skin incision is made on the dorsum of the foot immediately proximal to the metatarsal heads and extended medially and laterally to a point midway between the plantar and dorsal surfaces. The plantar incision is made along the digital crease and extended diagonally medially and laterally to connect to the dorsal incision. The dorsal incision is deepened to the periosteum, which is cleared with a small periosteal elevator. The metatarsal bones are transected 0.5 to 1.0 cm proximal to the dorsal skin incision. The plantar flap is fashioned by continuing the dissection just superficial to the metatarsal heads. Care is taken to maintain plantar flap thickness. The nerves and tendons are transected sharply under tension and allowed to retract. The plantar flap is rotated anteriorly and assessed for length. Excess tissue is excised sharply and the deep tissue is approximated with absorbable suture. The skin is closed without tension using monofilament suture or skin staples.

Weight bearing is delayed for 1 month to allow adherence of the plantar flap. Either a

soft dressing or a short leg cast can be used for a postoperative dressing.

Staging a tendo-achilles lengthening (TAL) is important to consider following (or at the same time if no infection is present) a partial foot amputation. Ulcer formation at the TMA stump site is often related to equinus formation due to the ensuing flexion/extension imbalance that occurs after resection of the forefoot. A simple triple-hemisection percutaneous TAL can effectively lengthen the achilles and reduce future pressures at the stump site.[32] Other tendon-balancing procedures may be needed to control varus and valgus contraction deformities that can develop.

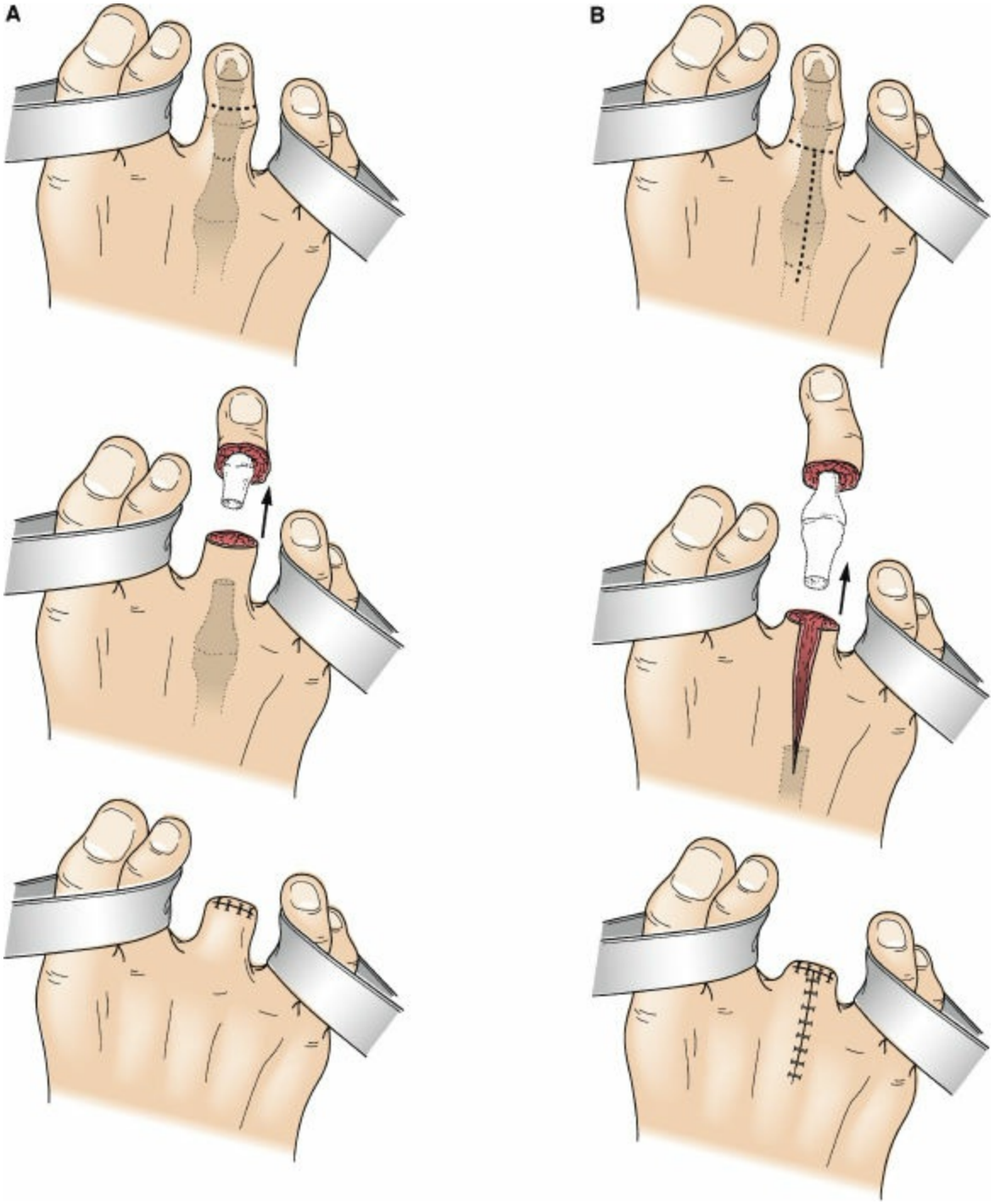

Figure 94-2. **A:** Digital amputation. A circumferential skin incision is made proximal to the gangrenous process. The proximal phalanx is transected and the soft tissue approximated. **B:** Metatarsal head resection (ray amputation). A racquet-shaped skin incision is made with the circular component extending circumferentially around the digit and the longitudinal component extending proximal to the metatarsal head. The metatarsal is transected proximal to the head and the soft tissue approximated.

Syme Amputation

The Syme amputation is a foot amputation that preserves limb length and the epiphyseal growth plates, and allows occasional ambulation without a prosthesis. It is indicated in cases of extensive foot trauma or other nonviable tissue conditions distal to the hindfoot. The Syme amputation is contraindicated if a supple intact heel pad and a well-vascularized hindfoot tissue flap are not available.

The procedure can be performed in one or two stages, as illustrated in Figure 94-4. The initial steps for both procedures are identical, except that the skin incision for the two-stage procedure is located 1.5 cm more distally. The skin incision for the one-stage procedure extends from the medial to the lateral malleolus in the horizontal and vertical planes. The dorsal incision is extended to the bone, and the tendons are transected under tension. The anterior tibial artery is identified, divided, and suture ligated. The dissection is carried into the tibiotalar joint space as the foot is forcibly plantar flexed. The ligaments are transected and the talus is dislocated. The plantar aspect of the incision is deepened to the calcaneus, and the calcaneus is sharply dissected from the plantar fascia. The plantar fascia is densely adherent and care must be taken to prevent damage to the heel pad, especially at the level of the Achilles tendon. The posterior tibial artery must be preserved, because it perfuses the heel pad. The foot is then removed. The two procedures differ from this point forward.

In the one-stage procedure, the medial and lateral malleoli are transected flush with the tibiotalar joint space, and the heel pad is rotated over the ends of the tibia and fibula. The deep fascial layers are approximated with absorbable suture and the skin is closed with monofilament suture or skin staples. Securing the distal end of the remaining plantar fascia to a small drill-hole in the distal anterior tibia will help anchor the plantar flap and reduce posterior migration. In the two-stage procedure, the heel pad is similarly positioned and the wound is closed without further bone transection. In 6 weeks, elliptical incisions are made over the medial and lateral malleoli and the distal ends of the tibia and fibula are transected flush with the ankle joint. In addition, the distal flares of the tibia and fibula are transected, creating the rectangular stump of the two-stage procedure. The wound is closed in a similar fashion. For both procedures, weight bearing is delayed for at least 4 weeks to allow heel pad fixation. A soft dressing or a short leg cast can be used.

Below-Knee Amputation

The complications of diabetes and arterial insufficiency constitute most of the indications for BKAs. Tables 94-5 and 94-6 outline the criteria used to decide between a BKA and an AKA in this setting.

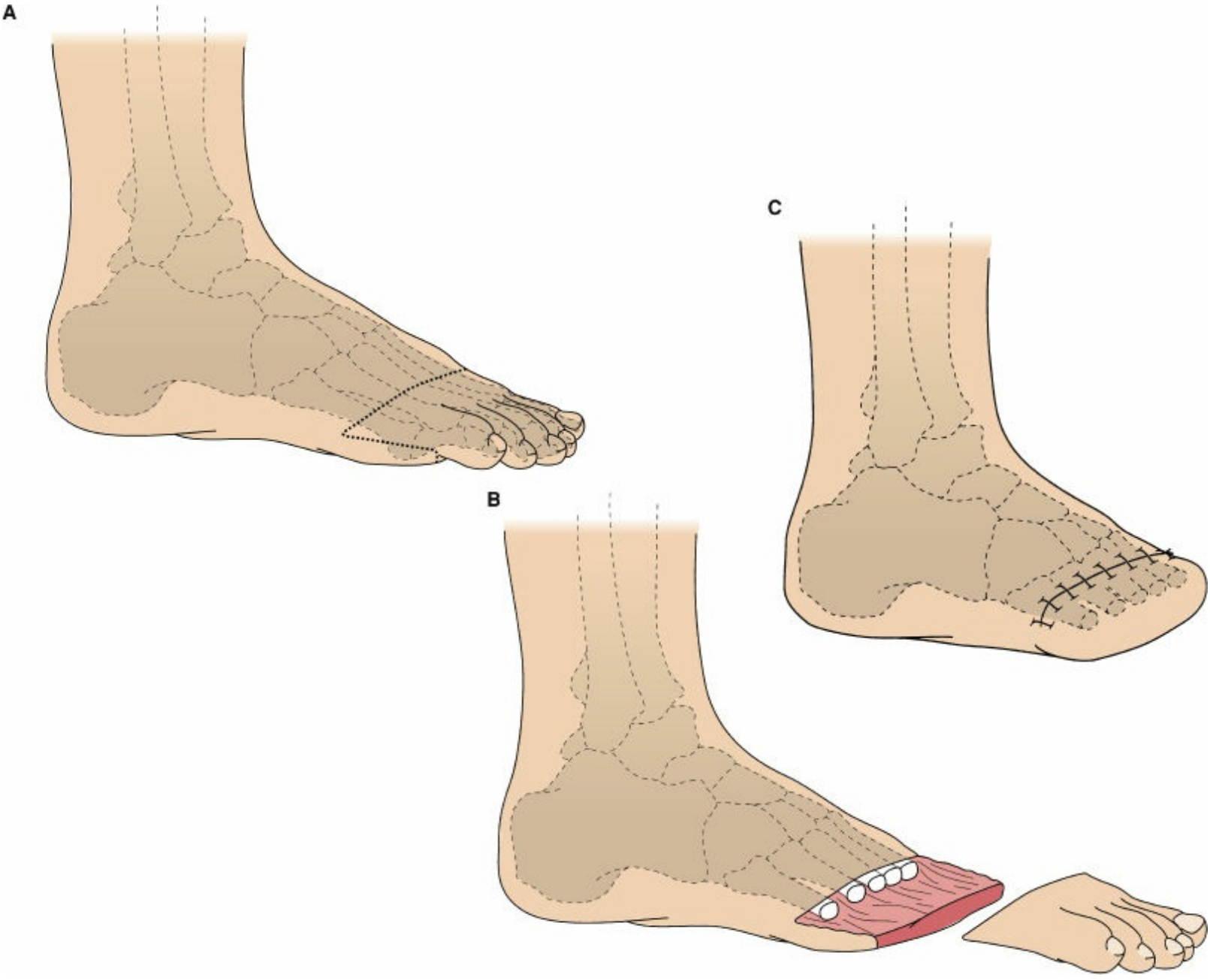

Figure 94-3. **A:** The skin incision for the transmetatarsal amputation is made on the dorsum of the foot immediately proximal to the metatarsal heads and on the plantar surface within the digital crease. **B:** The metatarsal heads are transected proximal to the skin incision and separated from the plantar soft tissue flap along a plane adjacent to the bone. **C:** The plantar soft tissue flap is rotated anteriorly and approximated.

The most common technique, using a long posterior flap, is illustrated in Figure 94-5. When gangrene, wounds, or incisions preclude the use of a posterior flap, equal anteroposterior or sagittal flaps can be used; however, the posterior flap is associated with the highest incidence of primary healing and is thus preferred whenever possible. This higher rate of healing reflects the fact that the posteriorly located gastrocnemius and

soleus muscles are supplied by the sural arteries that originate proximal to the knee.

The proposed skin incision is drawn on the leg with a marker. The tibia should be transected 10 cm distal to the tibial tuberosity and the anterior aspect of the skin incision should be 1 cm distal to the site selected for the tibial transection. The anterior incision is extended medially and laterally. The length of the anterior incision should equal two-thirds of the circumference of the leg at the proposed level of the tibial transection. The incision is then extended longitudinally along the medial and lateral aspects of the leg. The length of the longitudinal incisions should equal one-third of circumference of the leg at the level of the tibial transection. It is prudent to err on the side of making the posterior flap too long and trim excess length at the time of closure. The medial and lateral incisions are connected posteriorly. Curving the transitions of the incision prevents the accumulation of redundant tissue at the medial and lateral aspects of the completed amputation. The skin incisions should be down to the fascia to allow separation of the skin edges. This step decreases the chance of inadvertent injury to the posterior flap later in the procedure; however, the greater and lesser saphenous veins need to be ligated and transected.

The anterior aspect of the incision is deepened through the periosteum of the tibia. The muscles of the anterior compartment are divided at the level of the skin incision and the anterior tibial neurovascular bundle is identified and suture ligated. The proximal tibia is circumferentially cleared of periosteum, and transected 1 cm proximal to the skin incision. The anterior aspect of the tibia is cut on a 45-degree angle. The fibula is cleared and transected 1 cm proximal to the transected tibia. The bones are divided with either a power-driven reciprocating saw, or a manual saw. Regardless, care must be taken to avoid trauma to the anterior skin flap.

The posterior tibial and peroneal neurovascular bundles are identified and suture ligated. The tibia is retracted anteriorly and the posterior musculature is divided along the plane of the longitudinal skin incisions using an amputation knife. Extreme caution must be taken to avoid injury to the skin edges of the posterior flap during this step. Often a scalpel is needed to complete the division of the gastrocnemius tendon distally. The specimen is removed and manual compression achieves temporary hemostasis while the remaining vascular structures are identified and ligated. The posterior tibial nerve is retracted distally, ligated, transected sharply, and allowed to retract. The posterior flap is rotated anteriorly to assess thickness and length. Frequently, the musculature needs to be debulked to allow a tension-free closure. Rough edges of the bones are filed smooth and the wound is irrigated. Bone wax is not used. A closed-system drain may be placed to prevent a hematoma. The end of the tibia is covered and stabilized with the deep posterior musculature using absorbable sutures. The gastrocnemius fascia is approximated to the anterior fascia using absorbable suture. The subcutaneous tissue is closed with absorbable suture to minimize tension on the skin edges and the skin is closed with monofilament suture or staples.

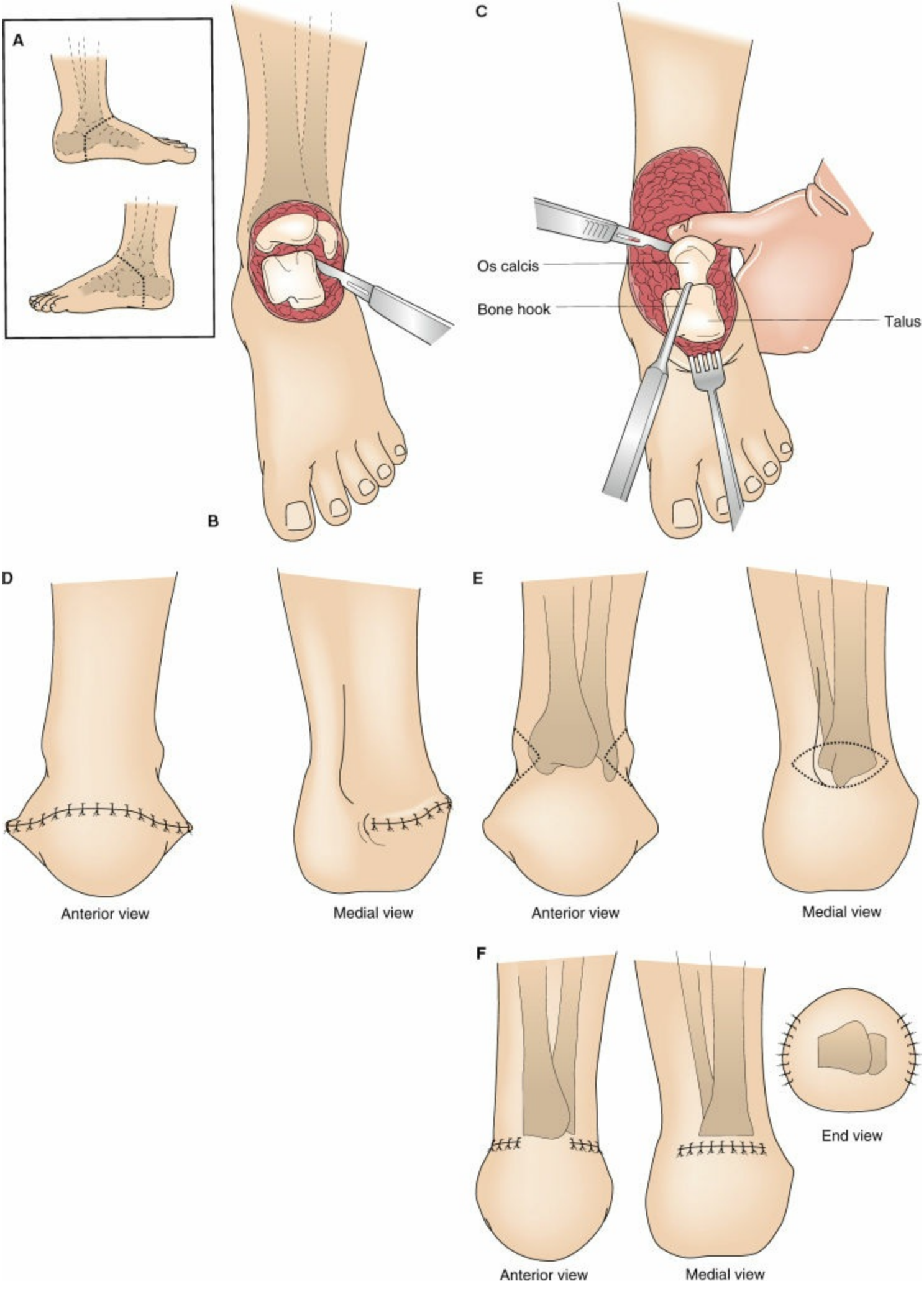
A
B
C
Os calcis
Bone hook
Talus
D
Anterior view
Medial view
E
Anterior view
Medial view
F
End view
Anterior view
Medial view

Figure 94-4. **A:** The skin incision for the one-stage Syme amputation connects the medial and lateral malleoli in both the horizontal and vertical planes. The skin incision for the two-stage procedure is located approximately 1.5 cm further distally. **B:** The incision is extended into the tibial—talar joint space, and the foot is placed in forced plantar flexion. **C:** The calcaneus is sharply dissected from the adherent plantar fascia along a plane adjacent to the bone. **D:** The heel pad is rotated anteriorly and approximated after the calcaneal dissection in the two-stage procedure and after the additional transection of the medial and lateral malleoli in the one-stage procedure. **E:** Elliptic incisions are made over the medial and lateral malleoli during a second operation for the staged procedure. The medial and lateral malleoli are transected flush with the ankle joint, and the distal flares of the tibia and fibula are removed. **F:** The two-stage procedure results in a less bulbous, more cosmetically acceptable residual limb.

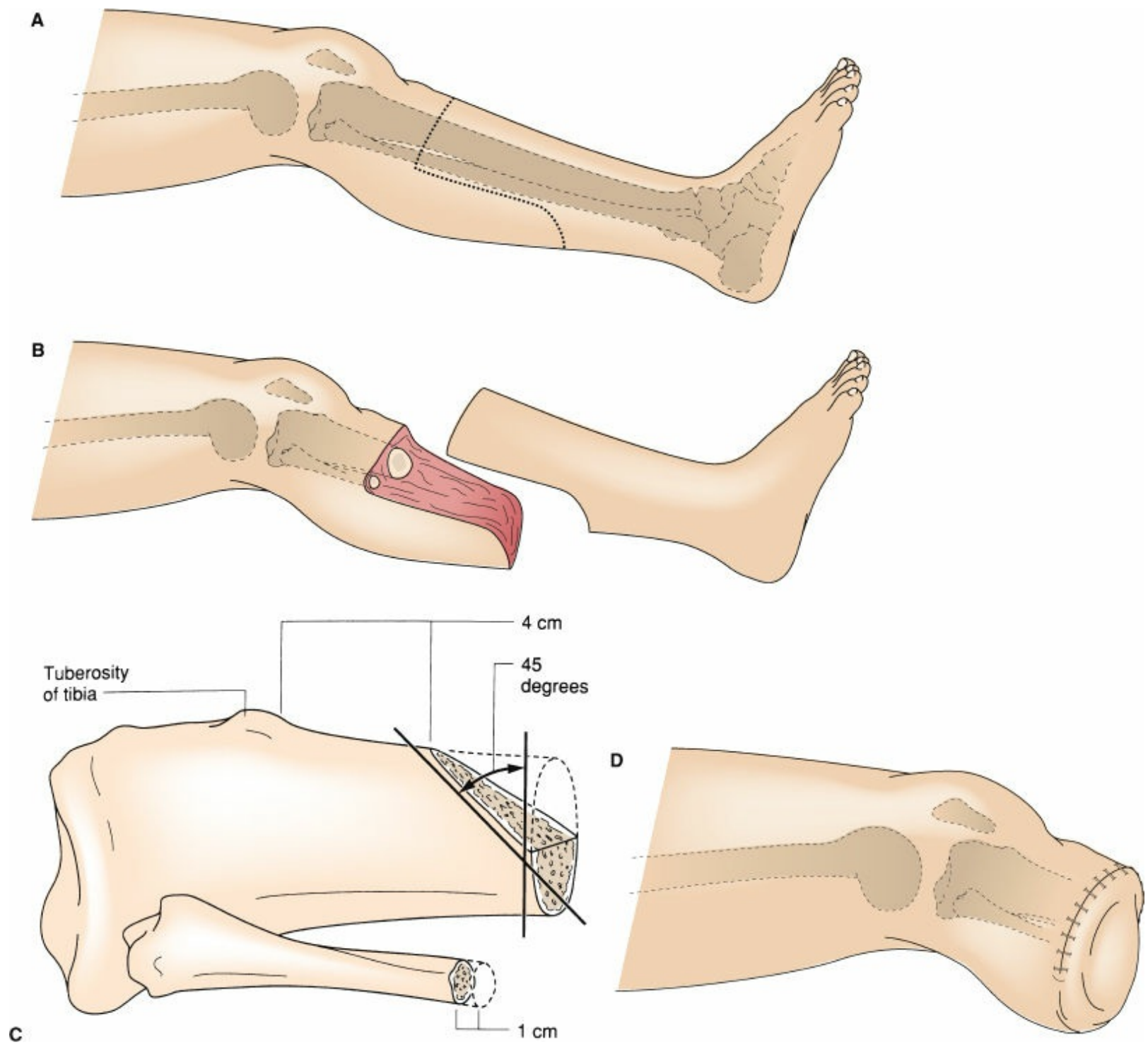

Figure 94-5. **A:** The skin incision for a below-knee amputation based on a posterior flap is made 11 cm distal to the tibial tuberosity and extended medially and laterally to the midpoint of the calf. The length of the posterior flap is about 2 cm longer than the diameter of the calf at the point of the proximal incision. **B:** The tibia is transected 1 cm proximal to the skin incision. The fibula is transected an additional 1 cm proximal to the level of the tibial transection, and the posterior calf muscles are incised along the plane of the skin incision. **C:** The anterior aspect of the tibia is beveled at an angle of about 45 degrees, and the bone edges are filed. **D:** The posterior flap is rotated anteriorly and approximated.

The length of the BKA may be shortened if required by the infectious or gangrenous process. Although not ideal, a short BKA is functionally superior to an AKA. In the extreme case, the tibia can be transected at the level of the tibial tuberosity and the stump can still be fit with a prosthesis. If a BKA is necessary at this level, the biceps tendon and collateral ligament should be sutured to the tibia, the common peroneal nerve

should be transected above the knee, and the fibula should be removed.

A variation of the BKA is the osteomyoplastic transtibial amputation also known as the Ertl amputation. This technique has been well described[33] and involves creating a bone bridge between the tibia and the fibula using a piece of the amputated fibula. Proposed advantages of this technique include a more stable end-bearing of the stump and prevention of fibular instability.

In the face of extensive foot infection, an open (guillotine) amputation should be performed as the first part of a staged procedure. A circumferential incision is made in the distal leg just proximal to the malleoli. The fascia is divided, and the tibia and fibula are dissected free. The bones are divided at the level of the skin incision. All major neurovascular bundles are suture ligated and the remaining soft tissue is divided to complete the amputation. Several sutures are placed through the skin and underlying fascia to prevent retraction. The wound is left open and dressed. A negative pressure dressing may be used and simplifies wound care. A definitive BKA is delayed until the infectious process has resolved which typically occurs within a week. Ankle disarticulation is an alternative to a guillotine BKA. An incision is made at the level of the ankle joint. Vascular structures are suture ligated. The tendons are divided sharply entering the ankle joint. The capsule is circumferentially incised removing the foot from the leg. The wound is packed open.

Above-Knee Amputation

An AKA is indicated for patients requiring an amputation with a fixed-knee contracture, a nonfunctional limb, or insufficient circulation to heal a BKA. Typically, a transverse fish-mouth incision is made in the lower thigh. The initial skin incision should be carried through the subcutaneous tissue to allow the edges to separate. This step will decrease the likelihood of inadvertent injury to the posterior skin flap during transection of the posterior muscle groups. The greater saphenous vein needs to be identified and ligated. The dissection is carried down to the femur that is cleared using a periosteal elevator to a level 2 to 3 cm proximal to the skin incision. The superficial femoral artery is dissected free and suture ligated. The bone is transected with a reciprocating or manual saw, and the posterior muscle flap is divided with an amputation knife. Manual compression with a laparotomy pad on the newly divided stump will easily control hemorrhage while vessels are identified and ligated or electrocoagulated. The sciatic nerve is identified and placed on gentle traction. It is then highly ligated, sharply divided, and allowed to retract into the wound. The flaps should be power irrigated and hemostasis assured. The fascia is then closed with absorbable suture. The subcutaneous tissue is closed with absorbable suture to minimize tension on the skin edges and the skin is closed with monofilament suture or staples. Alternative incisions can be made to accommodate surgical wounds. Most AKA wounds will heal even when the femoral pulse is nonpalpable. More proximal thigh amputations are performed when arterial perfusion is in question.

Hip Disarticulation

Lower extremity amputation at the level of the hip is an uncommon operation. The indications include malignancy, trauma, and infection and, rarely, because of complications of arterial insufficiency. Hip disarticulation performed for an ischemic AKA is often associated with complications in the absence of revascularization.[34] This technique is well described.

Cryoamputation

Rarely, a patient may require an emergent amputation yet have overwhelming medical problems that preclude any operative intervention. In this situation, a temporizing cryoamputation (aka, medical or physiologic amputation) is indicated.[14] A tourniquet is placed proximal to the infectious or gangrenous process and the extremity is packed in dry ice. This prevents the systemic release of muscle degradation products and allows the required procedure to be delayed while the patient's condition can be stabilized. This technique can be performed at any level on the extremity. Consideration of the level of tourniquet application is extremely important to preserve as much viable tissue as possible and avoid higher levels of limb loss. The dry ice should be placed about 3 inc below the tourniquet to reduce the chance of the "freeze line" extending proximal to the tourniquet. Adequate pain management should always be employed.

It should be noted that the use of cryoamputation constitutes a commitment to eventual surgical amputation (primary or staged). Once initiated, maintenance of the physiologic amputation is vital until definitive surgical removal is possible. As the frozen tissues thaw, a systemic inflammatory response syndrome (SIRS) or sepsis with hemodynamic instability may occur as inflammatory mediators are liberated back into the circulatory system. The ideal timing to proceed to the operating room would be as soon as reasonably possible. However, the literature describes the successful maintenance of this technique over many days if necessary.[14,35,36]

Other Lower Extremity Amputations

Three additional partial-foot amputations have been well described. A Lisfranc amputation is performed at the tarsometatarsal joint level and may be an option if there is inadequate soft tissue coverage for a TMA.[37] A Chopart amputation is performed at the level of the calcaneocuboid–talonavicular bones. Consideration of adding a percutaneous heel-cord lengthening with these amputations has been recommended.[38] A partial calcanectomy hindfoot amputation has shown good utility for chronic posterior heel wounds and calcaneal osteomyelitis.[39,40] This amputation involves removal of the posterior body of the calcaneus behind the posterior facet of the subtalar joint. Primary closure is typically possible and patients can ambulate following this procedure using a custom orthotic with a heel filler. Knee disarticulation is a useful amputation for patients with immature growth plates. It is superior to an AKA and allows end-weight-bearing, improved proprioception, and improved prosthetic control. The required prosthesis is bulky and less cosmetically appealing than that used for a BKA. The technique is well described.[41] Rotationplasty is an uncommon procedure performed primarily for treatment of osteogenic sarcoma of the thigh.[42] It involves nerve-sparing resection of the femur and knee, 180-degree rotation of the leg, and reattachment of the leg. This results in a functional, sensate foot that can easily be fit with a prosthesis.

Wound Dressings

An important consideration after amputation is the type of wound dressings applied to the stump. Two important factors in the success of an amputation are time-to-rehabilitation and complete wound healing, both of which are influenced by postoperative wound care.[43] With transtibial amputations, there are a number of options, such as soft gauze dressings with elastic wrap, rigid plaster dressings without immediate prosthesis, rigid plaster with immediate postoperative prosthesis, and prefabricated pneumatic postoperative prosthesis. Several studies have compared two or more of these options. Endpoints are not standardized, however, and most studies are not randomized and prospective, making comparisons and meta-analysis difficult.[43]

Benefits and drawbacks are found for each postoperative option.[43] Gauze dressings with elastic wrap are simple and low cost and provide good accessibility to evaluate wound healing. On the other hand, they may lead to higher rates of joint contraction, increased time to ambulation, and risk pressure ischemia from poorly placed elastic wrap. Despite these drawbacks, no convincing data show that soft gauze dressings are inferior to other options.[43,44] A removable knee immobilizer may be used in conjunction with gauze dressings to minimize the risk of joint contracture.

Rigid plaster casts help with joint contracture and protect the wound from trauma. With addition of a temporary prosthesis, the rigid plaster also promotes early ambulation. The plaster, however, does not provide easy access to evaluate and care for the wound and if not fitted properly will result in sheer stress and thereby break down the wound. Consequently, a level of skill in plaster placement is required of the surgical team to make appropriate and often frequent plaster changes.[43]

Finally, a prefabricated pneumatic postoperative prosthesis allows early ambulation and weight bearing, easy wound access for examination, prevention of joint contracture, and wound protection. The prosthesis, however, is bulky and upfront is more expensive than the simple gauze. Prospective studies have demonstrated statistically fewer postoperative complications with the pneumatic prosthesis and statistically fewer limbs requiring higher revisions.[45]

RESULTS

Table 94-7 Amputation Mortality

Category	Percentage	Number
Below-knee	2	25/1,200
Above-knee	9	54/609
Diabetic vs. nondiabetic	No difference	
After amputation revision	5.5	12/218

From Frang RD, Tayor LM, Porter JM. Amputations. In: Porter JM, Taylor LM, eds. *Basic Data Underlying Clinical Decision Making in Vascular Surgery*. St. Louis, MO: Quality Medical; 1994:154.

Complications

Morbidity and Mortality

Operative mortality depends on the indication and the level. Mortality rates for major lower extremity amputations in vascular and diabetic patients have been reported to be between 0% and 35%.[46] Combined mortality rates from multiple series are shown in Table 94-7.[47] Cardiovascular causes account for two-thirds of these deaths, with myocardial infarction responsible for one-third.[47] These review data are further supported by recent studies by Sandnes et al.[48] and Aulivola et al.[49]

Long-term survival following major amputation in the vascular population is shown in Table 94-8. The 5-year survival rate is only 37% compared with 85% for age-matched controls.[50]

Deep Venous Thrombosis and Pulmonary Embolism

The incidence of deep venous thrombosis following lower extremity amputation ranges from 4% to 38%.[51–53] Prophylactic measures including subcutaneous heparin, low–molecular-weight heparins, early mobilization, and pneumatic compression devices should be used as indicated.

Stump Complications

Stump complications include nonhealing, infection, hematoma, contractures, ulceration, phantom pain, and trauma. Although most amputations heal primarily, a small percentage do not. Amputation at a more proximal level usually is successful. Postoperative infections complicate 12% to 28% of all amputations with the percentage higher in cases performed for infection.[54] Local wound care with drainage, débridement and dressing changes, and systemic antibiotics should be instituted. Wound hematomas are best treated with prevention. Meticulous hemostasis and avoidance of subcutaneous cavities decrease their incidence. Hematomas should be treated in the operating room with evacuation, irrigation, and closure of the wound.

RESULTS

Table 94-8 Survival after Amputation for Ischemia

Time (y)	Survival Rate (%)
1	75
2	60
3	50
4	45
5	37

From Frang RD, Taylor LM, Porter JM. Amputations. In: Porter JM, Taylor LM, eds. *Basic Data Underlying Clinical Decision Making in Vascular Surgery*. St. Louis, MO: Quality Medical; 1994:115, with permission.

Joint contractures complicate 1% to 3% of all amputations.[50,54] These contractures can

occur rapidly postoperatively and are best treated by prevention. Rehabilitation specialists and physical therapists should evaluate patients preoperatively. Active and passive range of motion should be initiated immediately postoperatively. Adequate pain medication, ideally with patient-controlled or epidural anesthesia,[55,56] is crucial. Pillows and bed positions that result in hip or knee flexion are to be strictly avoided.

Ulcers tend to develop over bony prominences. Poorly fitting prostheses or shoes are the most common causes. Diabetic patients with peripheral neuropathy are especially susceptible to the development of ulcers following toe and limited foot amputations. They can also form on the anterior aspect of AKAs secondary to the disproportional contraction of the hip flexors relative to the hip extensors. Local wound care and bedrest usually lead to healing if the ulcer is superficial. Deep skin ulcers with involvement of the soft tissue and the underlying bone are more complicated. They often suggest borderline perfusion of the stump and require formal revision to a higher level to treat definitively.

Another option in complicated wound closure is negative-pressure wound dressing, which has been used for a wide range of difficult-to-heal lesions. Studies indicate that this dressing technique decreases wound volume, whereas traditional moist gauze dressings do not.[57] The dressings result in granulation tissue and healing in otherwise difficult tissue beds, such as diabetic foot ulcers[58] and decubitus pressure ulcers.[59] In addition to helping contract the size of the wound, negative-pressure dressings also decrease the number and frequency of dressing changes drastically when compared with wet-to-dry dressings.

Neuromas are regenerative nerve tissues that form in response to transection. They can lead to pain if trapped in the fibrous scar or if irritated by a prosthesis. Proximal nerve division under tension during the original operation decreases the incidence of this complication. Symptomatic neuromas should be treated with proximal resection of the nerve because local excision of the neuroma is rarely adequate.

Some element of phantom extremity pain occurs in nearly all amputations,[60] although these complaints are not always directed to the treating surgeon. It is necessary to describe these common symptoms to the patient and specifically inquire about their presence. The pain is disabling in 5% to 30%[61] of patients surveyed. Currently, pain is felt to be a component of a central pain syndrome and unrelated to either a neuroma or the perception of an intact extremity. Although there is no universally effective treatment, Malone[46] has reported a low incidence with an aggressive rehabilitation program, including immediate prosthetic fitting.

Trauma to a limb following an amputation can convert a healed amputation to a nonhealing wound requiring a more proximal amputation. Perioperatively, patients with a BKA have to be observed closely to prevent attempted ambulation. Diabetic patients with retinopathy should not walk barefoot following toe and foot amputations secondary to the risk that minor trauma may lead to a major wound healing problem.

Additional Amputation

The incidence of future amputation in vascular patients is not insignificant. Snyder et al. evaluated outcomes after forefoot amputations and found that 26% underwent a

subsequent forefoot amputation and 37% had a more proximal amputation over 2 years.[62] Cruz et al. demonstrated 17% contralateral amputation in their series.[63] These dismal figures reflect the systemic nature of the underlying diseases and emphasize the importance of appropriate foot care, patient education, close follow-up, and early intervention.[64] A concerted multidisciplinary approach can dramatically decrease the incidence of initial and subsequent lower extremity amputation.[65]

Special Situations

In selected cases, hyperbaric oxygen (HBO) therapy can provide benefit in treating nonhealing amputation sites. Patients require thorough evaluation of their cardiopulmonary status before initiating such treatment. In addition, the treating vascular surgeon has to determine that revascularization is completed or is not indicated. Patients may benefit from treatment if there is a substantial increase in transcutaneous oxygen pressure ($TcPO_2$) near the wound with administration of 100% oxygen. Daily treatments are typically continued for 30 days. Platelet-derived growth factor (becaplermin, regranex) is approved for use in the United States and has been effective in the management of diabetic foot ulcers and following open foot amputations or débridements. The wound must be clear of all necrotic tissue before initiating therapy.

REHABILITATION AND PROSTHETIC MANAGEMENT

General Considerations

Rehabilitation must be individualized. For some patients, successful rehabilitation means ambulation on a prosthesis and resumption of an independent lifestyle. For others, success may mean being able to pivot on the contralateral limb to be able to assist with transfer. Ambulating with a prosthesis depends on the physiologic status of the patient. Table 94-2 illustrates the dramatic increase in energy requirement with increasing level of the amputation. As expected, the chance of ambulating on a prosthesis decreases with ascending amputation level. The percentages of diabetic and vascular patients who can ambulate with amputations at various levels are shown in Table 94-9. The likelihood of ambulating postoperatively is inversely related to the patient's age and the length of the rehabilitation process.[66] Consideration should be given to inpatient rehab immediately after the acute care of the amputation is complete. Not only does this allow strengthening of the upper extremities and improved transfers, but it has been shown to reduce 1-year mortality in amputees as well.[67]

Specific Considerations

Digital and Ray Amputations

All patients who were ambulatory preoperatively should be able to achieve their preoperative functional status following a digital or ray amputation. The first digit and metatarsal head are important for weight bearing and for power. A shoe orthosis should effectively compensate for these functions when the patient has some training.

RESULTS

Table 94-9 Ambulation after Lower Extremity Amputation for Diabetes or Occlusive Disease

Amputation Level	Postoperative Ambulation (%)
Digit or ray	100
Transmetatarsal	100
Syme amputation	90–100
Below-knee	75
Above-knee	39
Hip disarticulation	<100

From Frang RD, Taylor LM, Porter JM. Amputations. In: Porter JM, Taylor LM, eds. *Basic Data Underlying Clinical Decision Making in Vascular Surgery*. St. Louis, MO: Quality Medical; 1994:155, with permission.

The most important component of postoperative rehabilitation for patients following a digital or ray amputation is education. The rate of repeat amputation (other toe, more proximal level, and contralateral limb) is extremely high. Several studies have indicated that the rate of repeat amputation is diminished with a coordinated education program.[68,69]

Transmetatarsal Amputation

A TMA minimally increases the energy requirement of ambulation; therefore, postoperative ambulation is expected following successful healing. The absence of the toes and metatarsal heads results in the loss of some forward thrust during the push-off phase of ambulation. This deficit can be overcome with either a steel-shank or a rigid, roller-soled shoe. The void in the distal shoe is filled with an insert.

Syme Amputation

The prognosis for return to bipedal ambulation following a Syme amputation is excellent. The required energy expenditure is only 10% more than baseline.[70] A significant advantage of this amputation is the ability to ambulate on the stump with only a cup slipper. Even though this activity is permitted on only a limited basis in the home, it is much more convenient for the patient, especially when arising at night. For routine activity the patient uses a prosthesis composed of a nonmotion foot attached to a leg shaft. The shaft has a cutout on the medial aspect to allow passage of the flared distal end

of the stump. The configuration of the distal end of the stump results in a bulbous ankle, which is less aesthetically pleasing than the typical below-knee prosthesis.

Below-Knee Amputation

The rehabilitation potential following a BKA is very good. Even when the indication for amputation is arterial insufficiency, approximately 75% of patients are able to ambulate with a prosthesis.[47] Multiple design options are available; however, the patellar tendon and the medial and lateral tibial flares are the weight-bearing surfaces for most prostheses. A variety of foot designs are possible to permit extension, flexion, rotation, and energy storage.

Above-Knee Amputation

Ambulation on an above-knee prosthesis is achieved by less than 40% of patients with arterial insufficiency.[47] In this patient population, the rate of ambulation on bilateral above-knee prostheses is less than 10%.[71] Most above-knee prostheses use the ischial tuberosity as the primary weight-bearing surface and are secured either by a belt or a suction socket. For younger patients, a suction socket works well. Patients with groin scars from previous revascularization attempts may benefit from a belt mechanism. The knee design depends on the patient's general condition and thigh strength. A knee that engages during the stance phase of gait is more stable and is frequently used in older patients.

References

1. Goodney P, Beck A, Nagle J, et al. National trends in lower extremity bypass surgery, endovascular interventions, and major amputations. *J Vasc Surg* 2009;50(1):54–60.
2. Gorina Y, Owens M, Elgaggal N, et al. Comparability between the rates for all-listed inpatient procedures using National Hospital Discharge Survey and Medicare claims, 1999 and 2007. *Nat Health Stat Report* 2012;(57):1–15.
3. Falstie-Jensen N, Christensen K. A model for prediction of failure in amputation of the lower limb. *Dan Med Bull* 1990;37:283–286.
4. Sanmugarajah J, Hussain S, Schwartz J, et al. Monoclonal cryoglobulinemia with extensive gangrene of all four extremities—a case report. *Angiology* 2000;51(5):431–434.
5. Veith FJ, Gupta SK, Samson RH, et al. Progress in limb salvage by reconstructive arterial surgery combined with new or improved adjunctive procedures. *Ann Surg* 1981;194:386–401.
6. Melzack R, Wall P. Pain mechanisms: a new theory. *Science* 1965;150:971–979.
7. Augustinsson LE, Carlsson CA, Holm J, et al. Epidural electrical stimulation is severe limb ischemia. pain relief, increased blood flow, and a possible limb-saving effect. *Ann Surg* 1985;202:104–110.
8. Tallis RC, Illis LS, Sedgwick EM, et al. Spinal cord stimulation in peripheral vascular disease. *J Neurol Neurosurg Psychiatry* 1983;46:478–484.
9. Meglio M, Cioni B, Dal Lago A, et al. Pain control and improvement of peripheral blood flow following epidural spinal cord stimulation: case report. *J Neurosurg* 1981;54:821–823.
10. Horsch S, Claeys L. Epidural spinal in the treatment of severe peripheral arterial occlusive disease. *Ann Vasc Surg* 1994;8(5):468–474.
11. Ubbink DT, Spincemaille GH, Prins MH, et al. Microcirculatory investigations to determine the effect of spinal cord stimulation for critical leg ischemia: the Dutch multicenter randomized controlled trial. *J Vasc Surg* 1999;30:236–244.
12. Huber SJ, Vaglienti RM, Huber JS. Spinal cord stimulation in severe, inoperable peripheral vascular disease. *Neuromodulation* 2000;3:131–143.
13. Gersbach PA, Argitis V, Gardza JP, et al. Late outcome of spinal cord stimulation for unreconstructable and limb-threatening lower limb ischemia. *Eur J Vasc Endovasc Surg* 2007;33(6):717–724.
14. Winburn GB, Wood MC, Hawkins ML, et al. Current role of cryoamputation. *Am J Surg* 1991;162:647–650.
15. Lange RH. Limb reconstruction versus amputation decision making in massive lower extremity trauma. *Clin Orthop Relat Res* 1989;(243):92–99.
16. Bosse MJ, MacKenzie EJ, Kellam JF, et al. An analysis of outcomes of reconstruction or amputation of leg-threatening injuries. *N Engl J Med* 2002;347:1924–1931.

17. Johansen K, Daines M, Howey T, et al. Objective criteria accurately predict amputation following lower extremity trauma. *J Trauma* 1990;30(5):568–572; discussion 572–573.
18. Ly TV, Travison TG, Castillo RC, et al. Ability of lower-extremity injury severity scores to predict functional outcome after limb salvage. *J Bone Joint Surg Am* 2008;90(8):1738–1743.
19. Adam DJ, Beard JD, Cleveland T, et al; BASIL trial participants. Bypass versus angioplasty in severe ischaemia of the leg (BASIL): multicentre, randomized controlled trial. *Lancet* 2005;366(9501):1925–1934.
20. Harwood T, Coe E, Flynn T, et al. The use of arm vein conduits during infrageniculate arterial bypass. *J Vasc Surg* 1992;16:420–426.
21. Leseche G, Penna C, Bouttier S, et al. Femorodistal bypass using cryopreserved venous allografts for limb salvage. *Ann Vasc Surg* 1997;11(3):230–236.
22. Raptis S, Miller J. Influence of vein cuff on polytetrafluoroethylene grafts for primary femoropopliteal bypass. *Br J Surg* 1995;82:478–491.
23. Stonebridge PA, Prescott RJ, Ruckley CV. Randomized trial comparing infrainguinal polytetrafluoroethylene bypass grafting with and without vein interposition cuff at the distal anastomosis. The Joint Vascular Research Group. *J Vasc Surg* 1997;26(4):543–550.
24. Bosiers M, Deloose K, Verbist J, et al. Heparin-bonded expanded polytetrafluoroethylene vascular graft for femoropopliteal and femorocrural bypass grafting: 1-year results. *J Vasc Surg* 2006;43(2):313–318.
25. Lepantalo M, Tukiainen E. Combined vascular reconstruction and microvascular muscle flap transfer for salvage of ischaemic legs with major tissue loss and wound complications. *Eur J Vasc Endovasc Surg* 1996;12:65–69.
26. Briggs SE, Banis JC Jr, Kaebnick H, et al. Distal revascularization and microvascular free tissue transfer: an alternative to amputation in ischemic lesions of the lower extremity. *J Vasc Surg* 1985;2(6):806–811.
27. Biancari F, Kantonen I, Alback A, et al. Limits of infrapopliteal bypass surgery for critical leg ischemia: when not to reconstruct. *World J Surg* 2000;24(6):727–733.
28. Keagy BA, Schwartz JA, Kotb M, et al. Lower extremity amputation: the control series. *J Vasc Surg* 1986;4(4):321–326.
29. Dwars BJ, Van Den Broek TA, Ravwerda JA, et al. Criteria for reliable selection of the lowest level of amputation in peripheral vascular disease. *J Vasc Surg* 1992;15:536–542.
30. Malone JM, Anderson GG, Lalka SG, et al. Prospective comparison of noninvasive techniques for amputation level selection. *Am J Surg* 1987;154:179–184.
31. Misuri A, Lucertini G, Nanni A, et al. Predictive value of transcutaneous oximetry for selection of the amputation level. *J Cardiovasc Surg* 2000;41(1):83–87.
32. Nishimoto GS, Attinger CE, Cooper PS. Lengthening the Achilles tendon for the

treatment of diabetic plantar forefoot ulceration. *Surg Clin North Am* 2003;83(3):707–726.

33. Taylor BC, Poka A. Osteomyoplastic transtibial amputation: technique and tips. *J Orthop Surg Res* 2011;6:13.
34. Endean ED, Schwarcz TH, Barker DE, et al. Hip disarticulation: factors affecting outcome. *J Vasc Surg* 1991;14(3):398–404.
35. Still JM Jr, Wray CH, Moretz WH. Selective physiologic amputation: a valuable adjunct in preparation for surgical operation. *Ann Surg* 1970; 171(1):143–151.
36. Winburn GB, Hawkins ML, Wood MC. Physiologic amputation prevents myoglobinuria from lower extremity myonecrosis. *South Med J* 1993; 86(10):1101–1105.
37. Roach J, Deutsch A, McFarlane D. Resurrection of the amputations of Lisfranc and Chopart for diabetic gangrene. *Arch Surg* 1987;122:931–934.
38. Leiberman JR, Jacobs RL, Goldstock L, et al. Chopart amputation with percutaneous heel cord lengthening. *Clin Orthop Relat Res* 1993;296:86–91.
39. Randall DB, Phillips J, Ianiro G. Partial calcanectomy for the treatment of recalcitrant heel ulcerations. *J Am Podiatr Med Assoc* 2005;95(4):335–341.
40. Lehmann S, Murphy RD, Hodor L. Partial calcanectomy in the treatment of chronic heel ulceration. *J Am Podiatr Med Assoc* 2001;91(7):369–372.
41. Burgess E. Disarticulation of the knee: a modified technique. *Arch Surg* 1977;112:1250–1255.
42. Merkel KD, Gebhardt M, Springfield DS. Rotationplasty as a reconstructive operation after tumor resection. *Clin Orthop Relat Res* 1991;270:231–236.
43. Smith DG, McFarland LV, Sangeorzan BJ, et al. Postoperative dressing and management strategies for transtibial amputations: a critical review. *J Rehabil Res Dev* 2003;40(3):213–224.
44. Kane TJ 3rd, Pollack EW. The rigid versus soft postoperative dressing controversy: a controlled study in vascular below-knee amputees. *Am Surg* 1980;46:244–247.
45. Schon LC, Short KW, Soupiou O, et al. Benefits of early prosthetic management of transtibial amputees: a prospective clinical study of a prefabricated prosthesis. *Foot Ankle Int* 2002;23:509–514.
46. Malone J. Lower extremity amputation. In: Moore W, ed. *Vascular Surgery: A Comprehensive Review*. Philadelphia, PA: WB Saunders; 1993:809.
47. Frang R, Taylor L, Porter J. Amputations. In: Porter J, Taylor L, eds. *Basic Data Underlying Clinical Decision Making in Vascular Surgery*. St. Louis, MO: Quality Medical Publishing; 1994:153.
48. Sandnes DK, Sobel M, Flum DR. Survival after lower extremity amputation. *J Am Coll Surg* 2004;199:394–402.
49. Aulivola B, Hile CN, Hamdan AD, et al. Major lower extremity amputation: outcome of a modern series. *Arch Surg* 2004;139:395–399.

50. Roon AJ, Moore WS, Goldstone J. Below-knee amputations: a modern approach. *Am J Surg* 1977;134:153–158.
51. Williams JW, Britt LG, Eades T, et al. Pulmonary embolism after amputation of the lower extremity. *Surg Gynecol Obstet* 1975;140(2):246–248.
52. Yeager RA, Moneta GL, Edwards JM, et al. Deep vein thrombosis associated with lower extremity amputation. *J Vasc Surg* 1995;22(5):612–615.
53. Burke B, Kumar R, Vickers V, et al. Deep vein thrombosis after lower limb amputation. *Am J Phys Med Rehabil* 2000;79(2):145–149.
54. Fisher DJ Jr, Clagett GP, Fry RE, et al. One-stage versus two-stage amputation for wet gangrene of the lower extremity: a randomized study. *J Vasc Surg* 1988;8(4):428–433.
55. Enneking FK, Morey TE. Continuous postoperative infusion of a regional anesthetic after an amputation of the lower extremity. a randomized clinical trial. *J Bone Joint Surg Am* 1997;79(11):1752–1753.
56. Pinzur MS, Garla PG, Pluth T, et al. Continuous postoperative infusion of a regional anesthetic after an amputation of the lower extremity. a randomized clinical trial. *J Bone Joint Surg Am* 1996;78(10):1501–1505.
57. Eginton MT, Brown KR, Seabrook GR, et al. A prospective randomized evaluation of negative-pressure wound dressings for diabetic foot wounds. *Ann Vasc Surg* 2003;17(6):645–649.
58. Armstrong DG, Lavery LA, Abu-Rumman P, et al. Outcomes of subatmospheric pressure dressing therapy on wounds of the diabetic foot. *Ostomy Wound Manage* 2002;48(4):64–68.
59. Ford CN, Reinhard ER, Yeh D, et al. Interim analysis of a prospective, randomized trial of vacuum-assisted closure versus the healthpoint system in the management of pressure ulcers. *Ann Plast Surg* 2002;49(1):55–61.
60. Iacono RP, Linford J, Sandyk R. Pain management after lower extremity amputation. *Neurosurgery* 1987;20(3):496–500.
61. Sherman RA, Sherman CJ, Parker L. Chronic phantom and stump pain among American veterans: results of a survey. *Pain* 1984;18:83–95.
62. Snyder DC, Salameh JR, Clericuzio CP. Retrospective review of forefoot amputations at a veterans affairs hospital and evaluation of post-amputation follow-up. *Am J Surg* 2006;192(5):e51–e54.
63. Cruz CP, Eidt JF, Capps C, et al. Major lower extremity amputations at a veterans affairs hospital. *Am J Surg* 2003;186(5):449–454.
64. Powell TW, Burnham SJ, Johnson, G Jr. Second leg ischemia. lower extremity bypass versus amputation in patients with contralateral lower extremity amputation. *Am Surg* 1984;50(11):577–580.
65. Van Gils CC, Wheeler LA, Mellstrom M, et al. Amputation prevention by vascular surgery and podiatry collaboration in high-risk diabetic and nondiabetic patients. the

operation desert foot experience. *Diabetes Care* 1999;22(55):678–683.

66. Harris WR. Lower-extremity amputation in elderly patients. *Can J Surg* 1987;30(5):315.
67. Stineman MG, Kwong PL, Kurichi JE, et al. The effectiveness of inpatient rehabilitation in the acute postoperative phase of care after transtibial or transfemoral amputation: study of an integrated health care delivery system. *Arch Phys Med Rehabil* 2008;89(10):1863–1872
68. Bild DE, Selby JV, Sinnock P, et al. Lower-extremity amputation in people with diabetes. epidemiology and prevention. *Diabetes Care* 1989;12(1):24–31.
69. Del Aguila MA, Reiber GE, Koepsell TD. How does provider and patient awareness of high-risk status for lower-extremity amputation influence foot-care practice? *Diabetes Care* 1994;17(9):1050–1054.
70. Waters RL, Perry J, Antonelli D, et al. Energy cost of walking amputees: the influence of level of amputation. *J Bone Joint Surg Am* 1976;58:42–46.
71. Malone J. Above the knee amputation and hip disarticulation. In: Ernst C, Stanley C, eds. *Current Therapy in Vascular Surgery*. Philadelphia, PA: BC Decker; 1991:699.

Chapter 95

Thoracoabdominal Aortic Aneurysms

Hazim J. Safi, Anthony L. Estrera, Charles C. Miller III, Kristofer M. Charlton-Ouw, Dianna Milewicz, and Ali Azizzadeh

Key Points

1 Remarkable progress has been made in the surgical treatment of thoracoabdominal aortic aneurysms.

2 The decline in mortality and complication rates can be attributed to improvements in surgical technique and perioperative care, particularly the adoption of adjunct distal aortic perfusion and cerebrospinal fluid drainage.

3 Neurologic deficit is no longer a major threat to patients, as the use of adjuncts has lowered the incidence for all thoracoabdominal aortic aneurysms to less than 2%.

4 Research that focuses on improving organ preservation, particularly for the most troublesome extent II thoracoabdominal aortic aneurysms, must be continued.

1 Etheredge reported the first successful repair of a thoracoabdominal aortic aneurysm (TAAA) using a homograft tube in 1955.[1] A year later, DeBakey used a Dacron tube graft to replace the descending thoracic aorta and infrarenal abdominal aorta.[2] Subsequently, Crawford introduced what became known as the *clamp-and-go technique,* encompassing three basic principles of aortic surgery: the inclusion technique; use of a Dacron tube graft conduit; and reimplantation of visceral and renal arteries.[3] Initially, the operation to repair TAAA had to be performed with haste in order to avoid extended periods of organ ischemia. TAAA surgery has since been transformed with the use of adjuncts that provide better organ protection and improved overall outcomes. However, sudden fatal rupture of a TAAA remains a looming and unpredictable threat. Although emergency repair of ruptured TAAA can save lives, the associated morbidity and mortality remain extremely high. Elective surgical repair of TAAA is the only effective treatment for eradicating the risk of aneurysm rupture and improving patient survival (Fig. 95-1). This chapter provides a comprehensive approach to the diagnosis and management of TAAA as well as insight into the recent surgical results and advances in organ protection.

EPIDEMIOLOGY

Aortic aneurysm disease remains a significant cause of death in the United States. Improved imaging techniques, increasing mean age of the population, and overall heightened awareness all contribute to an apparent increase in the prevalence of aortic aneurysms. However, the incidence of TAAA from population studies of the thoracic or abdominal aortic aneurysms can only be inferred. Infrarenal abdominal aortic aneurysms occur three to seven times more frequently than thoracic aortic aneurysms. However, fewer than 1,000 TAAAs, aneurysms involving both the thoracic and abdominal aorta, are repaired annually, compared with approximately 50,000 infrarenal abdominal aortic aneurysms. The estimated prevalence of abdominal aortic aneurysms varies between 2.3% and 10.7%, depending on the population studied and the size used to define an aneurysm.[4–6] The incidence of TAAAs is estimated to be 10.4 cases per 100,000 person-years.[7] The mean age of patients with a TAAA is between 59 and 69 years with a male-to-female predominance of between 2 and 4 to 1.[8]

Fewer than 40% of patients with untreated large TAAAs survive beyond 5 years, with most deaths caused by rupture.[3,8–10] TAAA studies have shown that rupture is more likely to occur when aneurysms exceed 5 cm in diameter and that the rate of rupture rises with increasing aneurysm size.[9,11–14] The median size at which TAAAs rupture is around 7 cm.[15,16] Aneurysms equal to or greater than 8 cm have an 80% risk of rupture within 1 year of diagnosis.[17] The lifetime probability of rupture for any untreated aortic aneurysm is 75% to 80%, but the size at which the aneurysm will rupture and how long it will take to reach that point cannot be easily determined. However, the average overall rate of growth for TAAAs is 0.10 to 0.42 cm per year with an exponential growth rate for aneurysms exceeding 5 cm in diameter.[11,16,18–20]

PATHOGENESIS

An aortic aneurysm is defined as a localized or diffuse dilatation that exceeds 50% of normal aortic diameter. Most TAAAs are degenerative, with an underlying pathology similar to the more frequently encountered infrarenal abdominal aortic aneurysm. Arteriosclerosis has long been implicated in the development of aortic aneurysm. However, arteriosclerosis primarily affects the intima and typically causes occlusive disease, whereas aneurysm disease usually involves the media and adventitia. Although the pathogenesis of arteriosclerotic occlusive disease and that of aneurysm disease have been shown to be distinct, the two conditions commonly occur together. Aneurysms associated with severe atheromatous disease portend the potential for poor late outcomes due to chronic occlusive branch disease and embolization. Histologically, degenerative aortic aneurysms are characterized by thinning of the media with destruction of smooth muscle cells and elastin, infiltration of inflammatory cells, and neovascularization.[21–23] A chronic inflammatory infiltrate, comprised of macrophages, as well as T and B lymphocytes, is consistently observed in the outer layer of aneurysm wall. The degree of vessel wall inflammation varies and the stimulus for cell migration remains unclear. These inflammatory cells, particularly macrophages, secrete proteases and elastase that degrade the aortic wall. In turn, elastin degradation products may act as chemotactic agents for the influx of inflammatory cells.[21] The role of matrix metalloproteinases (MMPs), the most prominent type of elastases, in the development of aortic aneurysms has emerged from both clinical and experimental studies. Increased elastases MMP2, MMP9, and MMP12 have been found in aortic aneurysmal aortic tissue.[21,24–26]

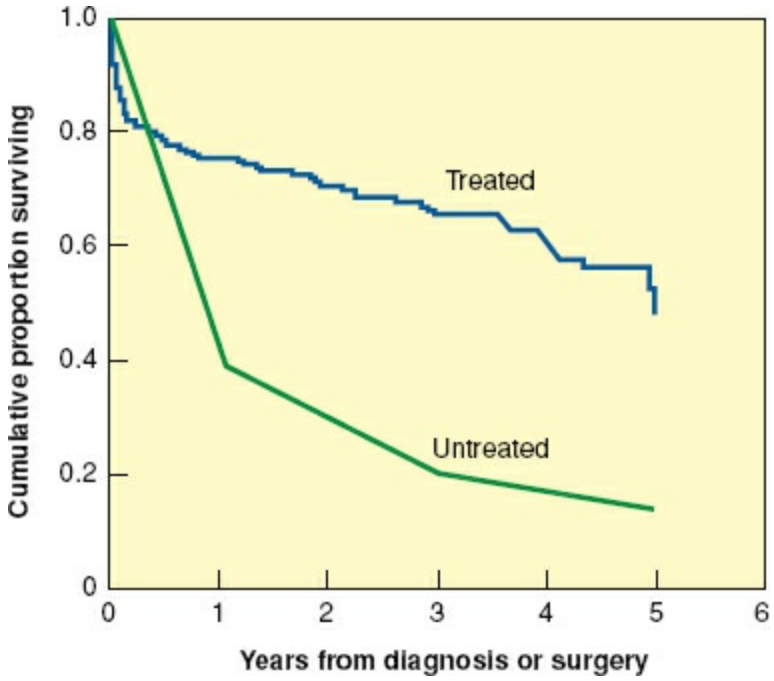

Figure 95-1. Thoracoabdominal aortic aneurysm: comparison of survival rates in untreated patients versus surgically treated patients.

Many TAAAs result from chronic ascending and descending aortic dissections. Familial clustering of aortic dissections is evident because up to 20% of patients with ascending

thoracic aortic aneurysms that predispose to aortic dissections have one or more first-degree relatives with the same affliction.[27–29] Marfan syndrome, characterized by skeletal, ocular, and cardiovascular abnormalities, is the most common inherited connective tissue disorder related to aortic aneurysm and dissection. Marfan syndrome occurs at a frequency of 1:5 to 10,000 worldwide. Aortic dilatation observed in Marfan patients has been linked to mutations in fibrillin-1 protein, encoded by the *FBN1* gene. Other known genetic syndromes that predispose individuals to TAAA and dissection include Loeys–Dietz syndrome, Ehlers–Danlos syndrome, Turner syndrome, and polycystic kidney disease.[30–33] In addition, families with multiple members who have thoracic aortic aneurysms and dissections have been reported in the literature.[34] In most of these families, the phenotype for TAAA and dissection is inherited in an autosomal dominant manner with marked variability in the age at onset of aortic disease and decreased penetrance.[34] Four genes have been identified for familial thoracic aortic aneurysms and dissections that account for 20% of this family condition. Mutations in the smooth muscle isoform of alpha-actin, encoded by *ACTA2,* are responsible for 15% of familial aortic disease. Other genes responsible for less than 2% include *MYH11, TGFBR2, and TGFBR1.*[35–38]

A small percentage of TAAAs are the result of infection (mycotic aneurysms) or trauma (pseudoaneurysms). An infected aneurysm frequently results from bacterial or septic emboli that seed an atherosclerotic aorta. Another mechanism is contiguous spread from empyema or adjacent infected lymph nodes. Although any organism can infect the aortic wall, *Salmonella, Haemophilus influenza, Staphylococcus, Mycobacterium tuberculosis,* and *Treponema pallidum spirochetes* species are the most common.[39,40] Infected aortic aneurysms are usually saccular and thought to be at greater risk for rupture. Chronic traumatic pseudoaneurysms of the aorta related to previously unrecognized traumatic transection are also prone to rupture, and surgical repair is warranted at the time of diagnosis.

Approximately 25% of TAAAs are associated with chronic aortic dissection. An estimated 20% to 40% of patients will develop aneurysms in the thoracoabdominal aorta within 2 to 5 years following acute aortic dissection.[41–43] Persistent patency of the false aortic lumen is reported to be a significant predictor of aneurysm formation.[42,44] However, the presence of chronic aortic dissection or patent false lumen has not been linked to a higher risk of aortic rupture.[45] Aneurysm disease occurs in more than one part of the aorta in approximately 20% of cases. The so-called “mega” aorta is an “extensive” aortic aneurysm involving the ascending, transverse arch, and the entire thoracoabdominal aorta. Although associated factors include Marfan syndrome and chronic aortic dissection, the cause of extensive aortic aneurysm remains unknown.

CLINICAL MANIFESTATIONS

Aortic aneurysms can cause compressive symptoms, although most do not until they reach a large size. The most frequent complaint is ill-defined chronic back pain, although pain can also occur in the chest, flank, or epigastrium. Acute changes in the characteristics and severity of pain can indicate sudden expansion or impending aortic rupture. Hoarseness, resulting from vocal cord paralysis caused by compression of the left recurrent laryngeal or vagus nerves, is frequently seen in patients with large aneurysms of the proximal descending thoracic aorta. Patients may also experience dyspnea related to compression of the tracheobronchial tree. A large aneurysm can exert pressure on the adjacent esophagus or duodenum, causing dysphagia or weight loss related to obstruction or early satiety. Direct erosion of the aneurysm into the adjacent tracheobronchial tree, esophagus, or both can cause exsanguination, presenting as massive hemoptysis or hematemesis, respectively. Less frequently, direct erosion can cause slow intermittent blood loss. Rarely, paraplegia or paraparesis can occur in patients with TAAA as a result of acute occlusion of the intercostal or spinal arteries. These findings are usually associated with acute aortic dissection, but can also result from thromboembolization. Although most aneurysms have a varying amount of mural thrombus, distal embolization causing acute mesenteric, renal, or lower extremity ischemia is infrequent.

Rupture is thought to be the first clinical manifestation of a TAAA in as many as 10% to 20% of patients (Fig. 95-2). The acute onset of severe chest, abdominal, or back pain associated with hypotension must raise the suspicion of a ruptured aneurysm. A pulsatile mass may be palpable in the abdomen. However, if the larger part of the TAAA is positioned deep within the thoracic cage, the aneurysm may not be apparent on physical examination. Although most ruptured aneurysms are fatal unless treated emergently, the ruptured arterial wall may temporarily seal for several hours or days before free rupture. In patients who are brought to the hospital alive, rupture is usually contained within the pleura or retroperitoneum. Free rupture is accompanied by severe hypotension and patients are more likely to die before reaching the hospital.

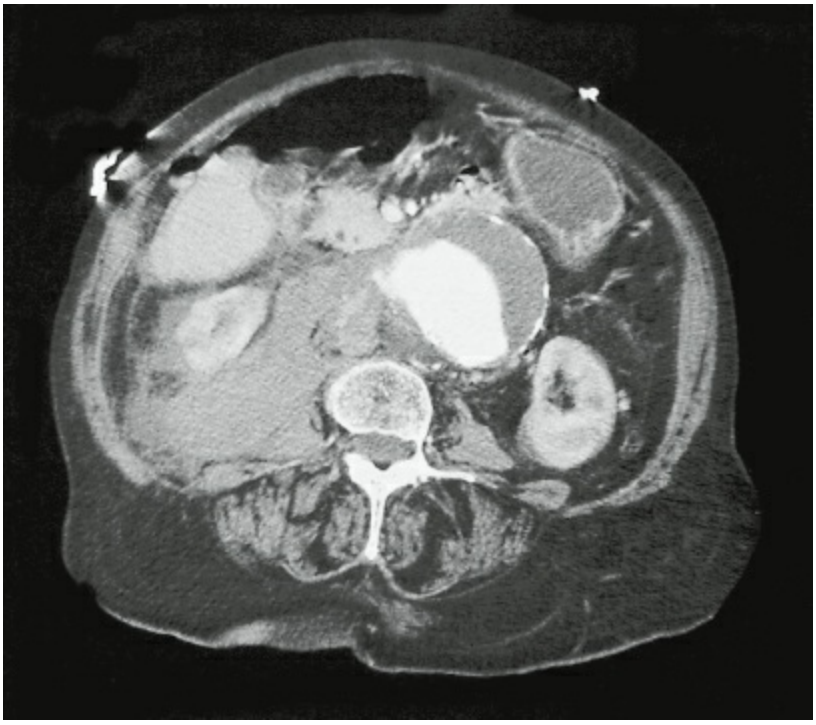

Figure 95-2. Computed tomography scan of a ruptured thoracoabdominal aortic aneurysm. Note stranding in the retroperitoneum denoting extravasation of blood.

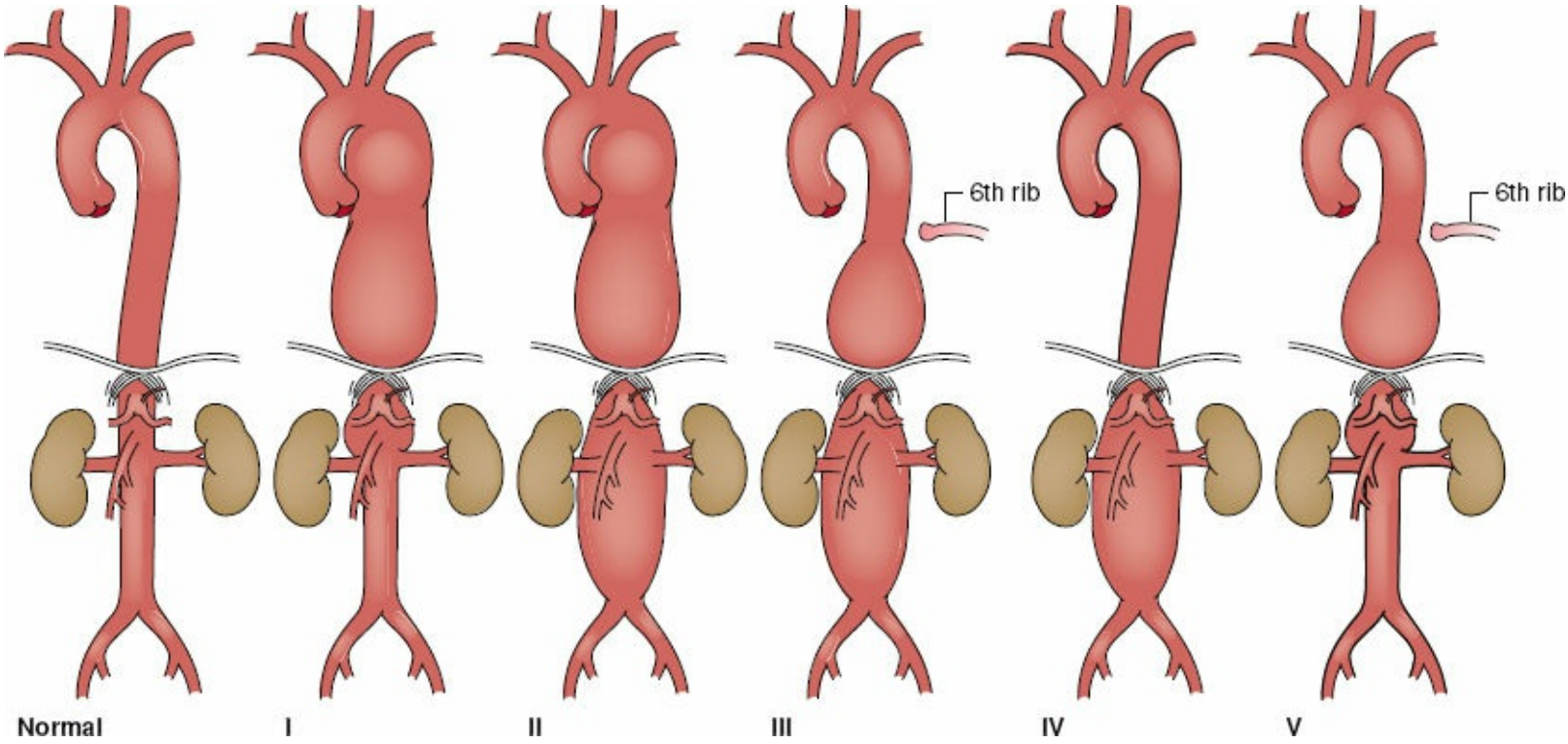

Figure 95-3. Thoracoabdominal aortic aneurysm classification. Extent I, distal to the left subclavian artery to above the renal arteries. Extent II, distal to the left subclavian artery to below the renal arteries. Extent III, from the sixth intercostal space to below the renal arteries. Extent IV, the twelfth intercostal space to the iliac bifurcation (total abdominal aortic aneurysm). Extent V, below the sixth intercostal space to just above the renal arteries.

DIAGNOSTIC IMAGING

The diagnosis of TAAA can be confirmed by various imaging modalities. Currently, computed tomography angiography (CTA) is the imaging modality of choice in defining the extent of TAAA as per the modified Crawford Classification (Fig. 95-3) and for planning operative strategy. The diameter of the entire aorta, from the ascending segment to the bifurcation, can be accurately measured at various levels on axial images assuming the centerline determination is made. The distinction between the false and true lumens in aortic dissection can be shown on CTA. CTA can also detect thrombus or inflammatory changes in the aortic wall. Furthermore, the presence of free (or contained) fluid or blood can indicate free (or contained) rupture. Thin-slice CTA image acquisition can also identify patent intercostal arteries. Coronal reformatting or three-dimensional reconstruction of axial CT images provide additional views of TAAA (Fig. 95-4). These views are often helpful for surgical planning as well as determining adjacent organ involvement. Intravenous iodinated contrast can be omitted in patients with impaired renal function because it is not required for simple sizing of TAAA.

Magnetic resonance angiography (MRA) has become widely available and is frequently used as a screening test to detect diseases of the aorta and its branches. The principal advantage of MRA over CTA is that MRA does not require intravenous iodinated contrast and, thus, can be performed safely in patients with impaired renal function. In addition, MRA avoids the radiation exposure required for CT especially when serial follow-up examinations are required. Although MRA provides better contrast resolution, its spatial resolution is poorer than that of spiral CT. In addition, CT can better demonstrate aortic calcification and intramural thrombus compared with MRA. The time required to acquire images, claustrophobia, internal metallic hardware (e.g., pacemakers or orthopedic implants), and higher cost are other limiting factors of MRA.

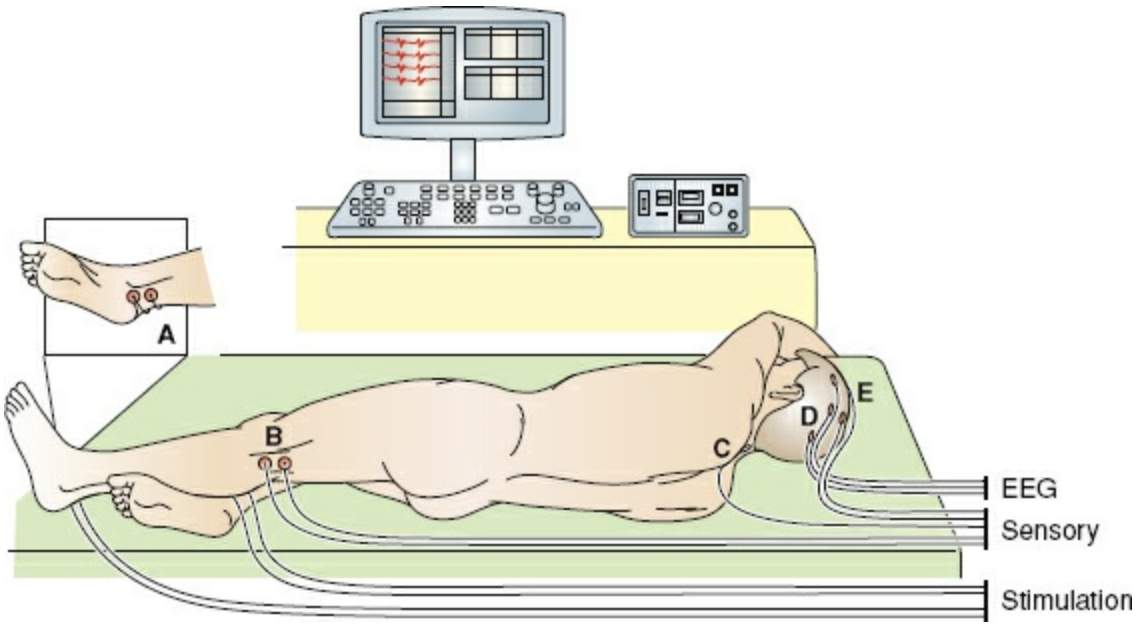

Figure 95-4. Somatosensory and motor evoked potentials are recorded at three sites: the popliteal fossa (A, B), C5 (C) and the vertex (D, E).

Transesophageal echocardiography (TEE) can provide excellent imaging of the ascending and descending thoracic aorta. TEE can be performed at the bedside or in the operating room. TEE can be used in patients who are too unstable to be transported to the CT scanner. TEE can show aortic wall disease, differentiating arteriosclerotic plaque from intimal tear due to dissection. In the operating room, TEE can also be used to locate the optimal area for aortic cross-clamping and to assess cardiac function. However, TEE is an invasive modality and requires an experienced operator for optimal visualization and interpretation. Examination of the aorta by TEE is limited to the supradiaphragmatic aorta because the ultrasound probe loses contact with the aorta as it crosses the gastroesophageal junction.

Intravascular ultrasound has become an important diagnostic modality in thoracic aortic disease as it allows very good characterization of the intraluminal relationships, especially in aortic dissection. Although relatively invasive, requiring arterial sheath access, this is becoming an important modality for planning endovascular therapies in aortic dissection. Epiaortic ultrasound has also been applied to TAAA treatment. Epiaortic ultrasound can allow better characterization of the thoracic aorta for cannulation or clamping.

PREOPERATIVE EVALUATION

The initial consultation with the TAAA patient focuses on a thorough history and physical examination, primarily to detect comorbidities, because there are generally few symptoms or physical signs related to the aneurysm itself. The extent of the TAAA is determined from imaging studies. Further evaluation of associated risk factors is performed, and consultation with a cardiologist, pulmonologist, or nephrologist is often necessary to aid in the stratification of risks.

Ischemic heart disease is prevalent in this population and is the most common cause of death in patients with a TAAA. TEE provides an excellent estimate of cardiac function. Coronary artery revascularization for critically stenosed coronary artery disease, using either percutaneous intervention (balloon angioplasty or stent) or surgical bypass, may be indicated prior to TAAA surgery, but the risk of rupture of the aneurysm must be weighed against the risk of coronary intervention and the delay caused by intervention. For patients who must undergo coronary artery bypass prior to TAAA repair, the conduit of choice is the saphenous vein graft. Use of the left internal mammary artery is avoided to prevent potential cardiac ischemia if aortic cross-clamping proximal to the left subclavian artery is required during the TAAA repair. Moreover, the internal mammary artery may be an important collateral blood supply to the spinal cord and chest wall.

Although percutaneous coronary intervention may be considered, the use of either bare metal stents or just balloon angioplasty is preferred over drug-eluting stents since drug-eluting stents require long-term administration of clopidogrel to prevent stent thrombosis. Fortunately, medical management can be adopted for most cases of mild-to-moderate coronary artery disease and in cases of severe disease that is asymptomatic with preserved ejection fraction. Patients who develop symptoms from critical disease, for example, left main or ostial left anterior descending coronary occlusive disease, should probably have this addressed prior to aneurysm repair. In very rare situations, combined and simultaneous coronary artery bypass and TAAA repair may be considered.

OPERATIVE TECHNIQUES

The patient is brought to the operating room and placed in the supine position on the operating table and prepared for surgery. The right radial artery is cannulated for continuous arterial pressure monitoring. General anesthesia is induced. Endotracheal intubation is established using a double-lumen tube for selective one-lung ventilation during surgery. A sheath is inserted in the internal jugular vein, and a pulmonary balloon-tipped catheter is floated into the pulmonary artery for continuous monitoring of the central venous and pulmonary artery pressures. Large-bore central and peripheral venous lines are established for fluid and blood replacement therapy. Temperature probes are placed in the patient's nasopharynx and bladder. Electrodes are attached to the scalp for electroencephalography and along the spinal cord for both motor- and somatosensory-evoked potential (MEP and SSEP) to assess the central nervous system and spinal cord function, respectively (Fig. 95-5). The patient is then positioned on the right side with the hips and knees flexed to open the intervertebral spaces. A lumbar catheter is placed in the third or fourth lumbar space to provide cerebrospinal fluid (CSF) pressure monitoring and drainage (Fig. 95-6). The CSF pressure is kept at 10 mm Hg or less by gravity drainage of CSF throughout the procedure. The patient is then repositioned in the right lateral decubitus position with the hips slightly turned to allow access to both groins. The operative field is scrubbed using standard aseptic solution and draped.



Figure 95-5. Sagittal computed tomography image of an extent II TAAA.

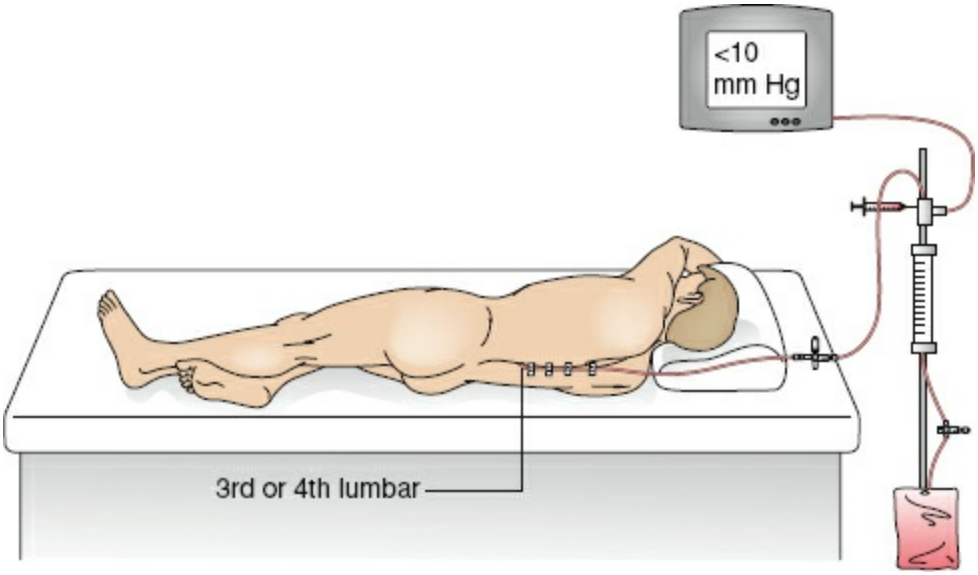

Figure 95-6. Placement of the lumbar catheter in the third or fourth lumbar space to provide cerebrospinal fluid drainage and pressure monitoring.

The incision is tailored to complement the extent of the aneurysm (Fig. 95-7). The full thoracoabdominal incision begins posteriorly between the tip of the scapula and the spinous process, curving along the sixth intercostal space to the costal cartilage, and then obliquely to the umbilicus. The latissimus dorsi muscle is divided and the insertion of the serratus anterior muscle is mobilized. The left lung is deflated and the left thoracic cavity is entered. Usually, a full thoracoabdominal exploration is necessary for extent II, III, and IV TAAAs. A modified thoracoabdominal incision begins similar to the full thoracoabdominal incision, but ends at the costal cartilage. The modified thoracoabdominal incision provides excellent exposure for surgery involving the descending thoracic aorta, extents I and V TAAA when the aneurysm ends above the renal arteries. A self-retaining retractor is placed firmly on the edges of the incision to maintain full thoracic and abdominal exposure during the procedure.

The dissection begins at the level of the hilum of the lung cephalad to the proximal descending thoracic aorta. The ligamentum arteriosum is identified and transected, taking care to avoid injury to the left recurrent laryngeal nerve. The extent of the distal abdominal aneurysm is assessed. Only the muscular portion of the diaphragm is divided and the left phrenic nerve preserved (Fig. 95-8). A retroperitoneal plane is then developed, mobilizing the spleen, bowel, and left kidney to the right side of the abdominal aorta (medial visceral rotation). To prepare for distal aortic perfusion, the patient is anticoagulated using intravenous heparin (0.5 to 1 mg/kg body weight). The pericardium is opened posterior to the left phrenic nerve to allow direct visualization of the pulmonary veins and left atrium. The left inferior pulmonary vein is cannulated. A centrifugal pump with an inline heat exchanger is attached to the outflow cannula and the arterial inflow is established through the left common femoral artery via a Dacron graft sutured to the common femoral artery in an end-to-side fashion, or the descending thoracic aorta, if the femoral artery is not accessible. The end-to-side fashion prevents ischemia to the left leg that may be associated with renal dysfunction. Distal aortic

perfusion is begun (Fig. 95-9).

Padded clamps are applied to the proximal descending thoracic aorta just distal to the left subclavian artery and the midthoracic aorta. When the proximal extent of the aneurysm is too close to the left subclavian artery, the aorta between the left common and left subclavian arteries is clamped. The left subclavian artery is clamped separately. Because of the danger of graft–esophageal fistula, the inclusion technique for the proximal anastomosis is no longer used. Instead, the aorta is transected to separate it from the underlying esophagus (Fig. 95-10A). A woven Dacron graft impregnated with collagen or gelatin for replacement is preferred. The graft is sutured in an end-to-end fashion to the descending thoracic aorta, using a running 2-0 or 3-0 monofilament polypropylene suture. The anastomosis is checked for bleeding. Pledgeted polypropylene sutures for reinforcement are placed, if necessary. Sequential clamping is used for all TAAAs. After completion of the proximal anastomosis, the middescending aortic clamp is moved distally onto the abdominal aorta at the celiac axis to accommodate intercostal reattachment. Reattachment of patent, lower intercostal arteries (T8 to T12) is performed, except in cases of occluded arteries, heavily calcified aorta, or acute aortic dissection, guided by the neuromonitoring, that is, MEPs and SSEPs. If no changes are noted in the neuromonitoring of the spinal cord, then patent intercostal arteries can be ligated without fear of spinal cord injury. If intercostal reattachment is performed, the proximal clamp is released from the aorta and reapplied on the aortic graft beyond the intercostal patch, restoring pulsatile flow to the reattached intercostal arteries (Fig. 95-10B). The distal clamp is moved onto the infrarenal aorta, the abdominal aorta is opened, and the graft is passed through the aortic hiatus. The celiac, superior mesenteric, and renal arteries are identified and perfused using 9- or 12-Fr balloon-tipped catheters, depending on the size of the ostia (Fig. 95-10C). The delivery of cold perfusate (4°C) to the viscera depends on the proximal aortic pressure, which is maintained between 300 and 600 mL/min. Renal temperature is directly monitored and kept at approximately 15°C. The visceral vessels are usually reattached using the inclusion technique. On completion of this anastomosis, the proximal clamp is moved beyond the visceral patch, restoring pulsatile flow to the viscera and kidneys (Fig. 95-10D). The final graft anastomosis is then completed at the aortic bifurcation. In most cases, an island patch accommodates reattachment of the celiac, superior mesenteric, and both renal arteries. If the right or left renal artery is located at too great a distance from other arteries, its reattachment usually requires a separate interposition bypass graft. A visceral patch is no longer used for patients with connective tissue disease (Marfan) and in patients younger than 60 years because of the high incidence of recurrent patch aneurysms in such cases. Instead, a woven Dacron commercially available graft is used with side-arm grafts of 10 mm and 12 mm for separate attachment of the celiac, superior mesenteric, and the left and right renal arteries. Similarly, in these patients, a loop graft has replaced the island patch for reattachment of the intercostal arteries.

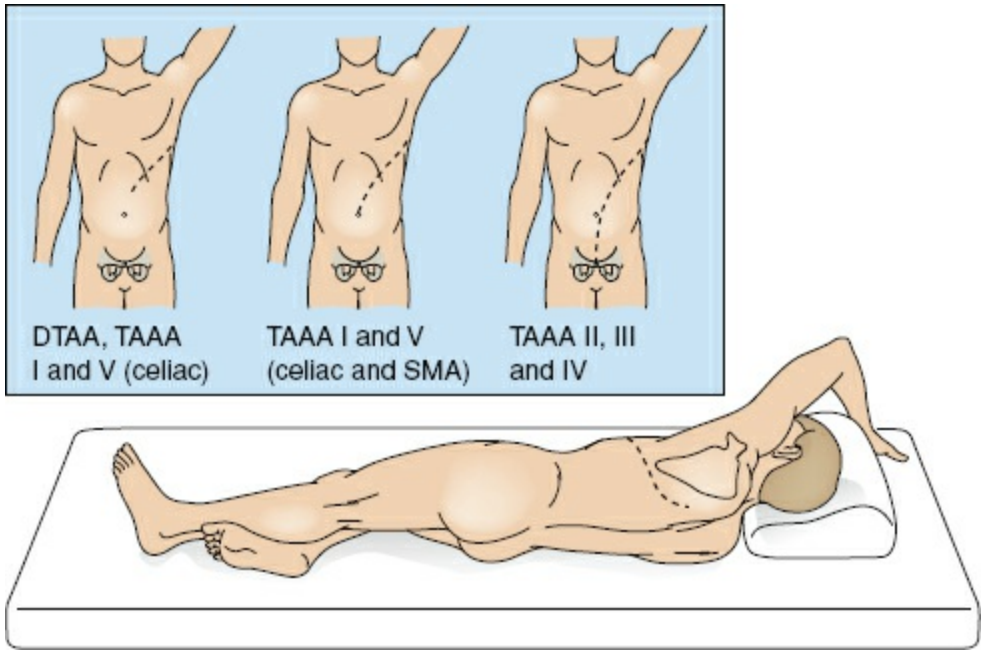

Figure 95-7. Tailoring of thoracoabdominal incisions for aneurysm extent. DTAA, descending thoracic aortic aneurysms; TAAA, thoracoabdominal aortic aneurysm; SMA, superior mesenteric artery.

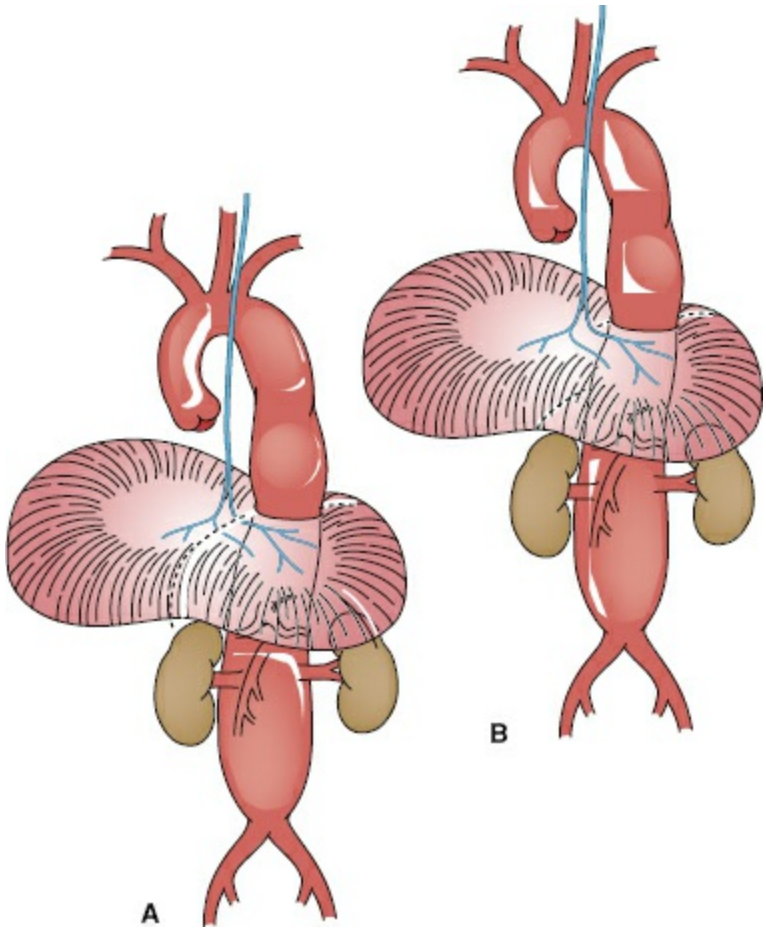

Figure 95-8. In previous surgical practice, the diaphragm was divided (**A**); currently, only the muscular portion of the diaphragm is cut (**B**).

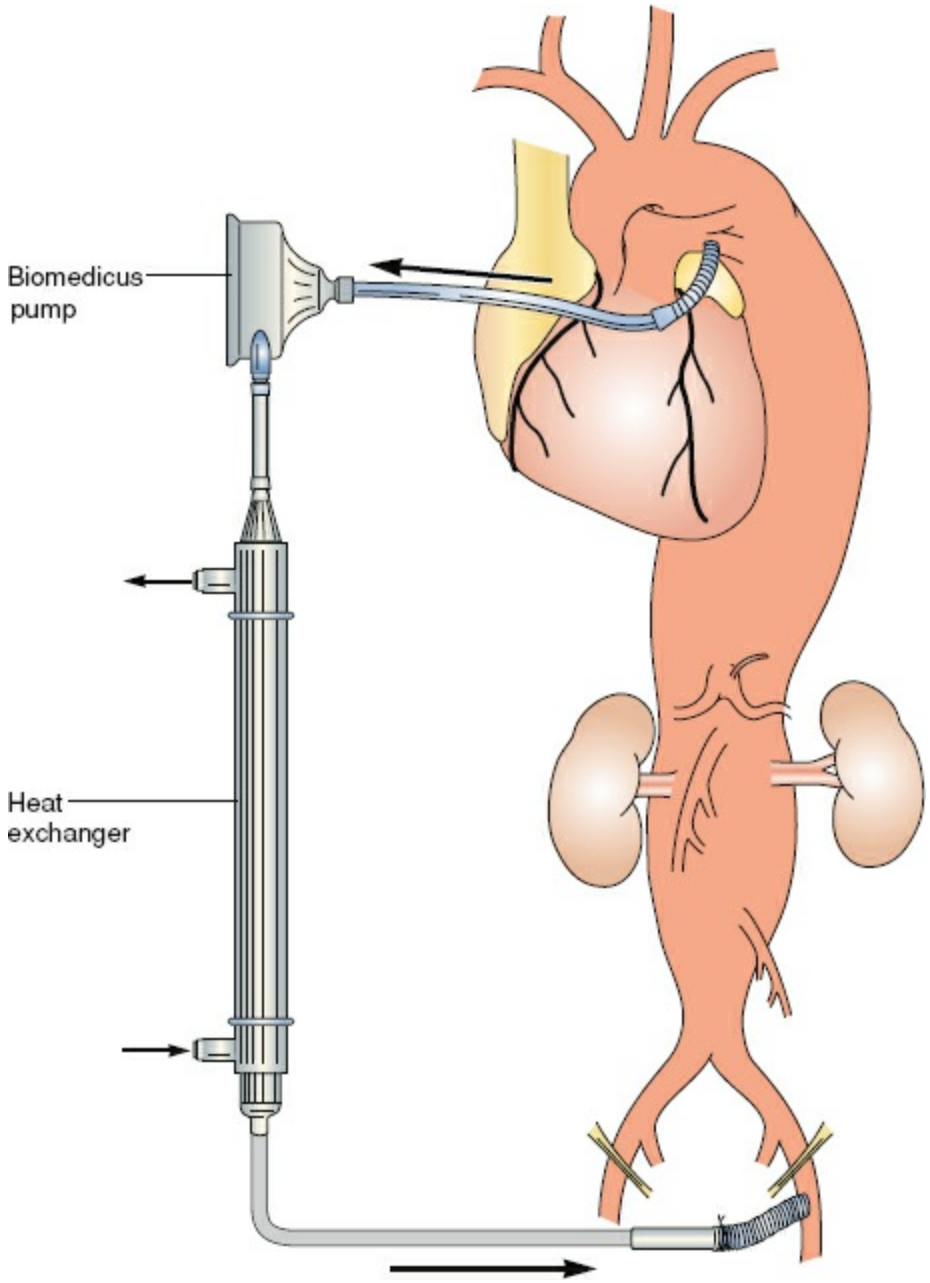

Figure 95-9. Distal aortic perfusion from the left inferior pulmonary vein to the left common femoral artery.

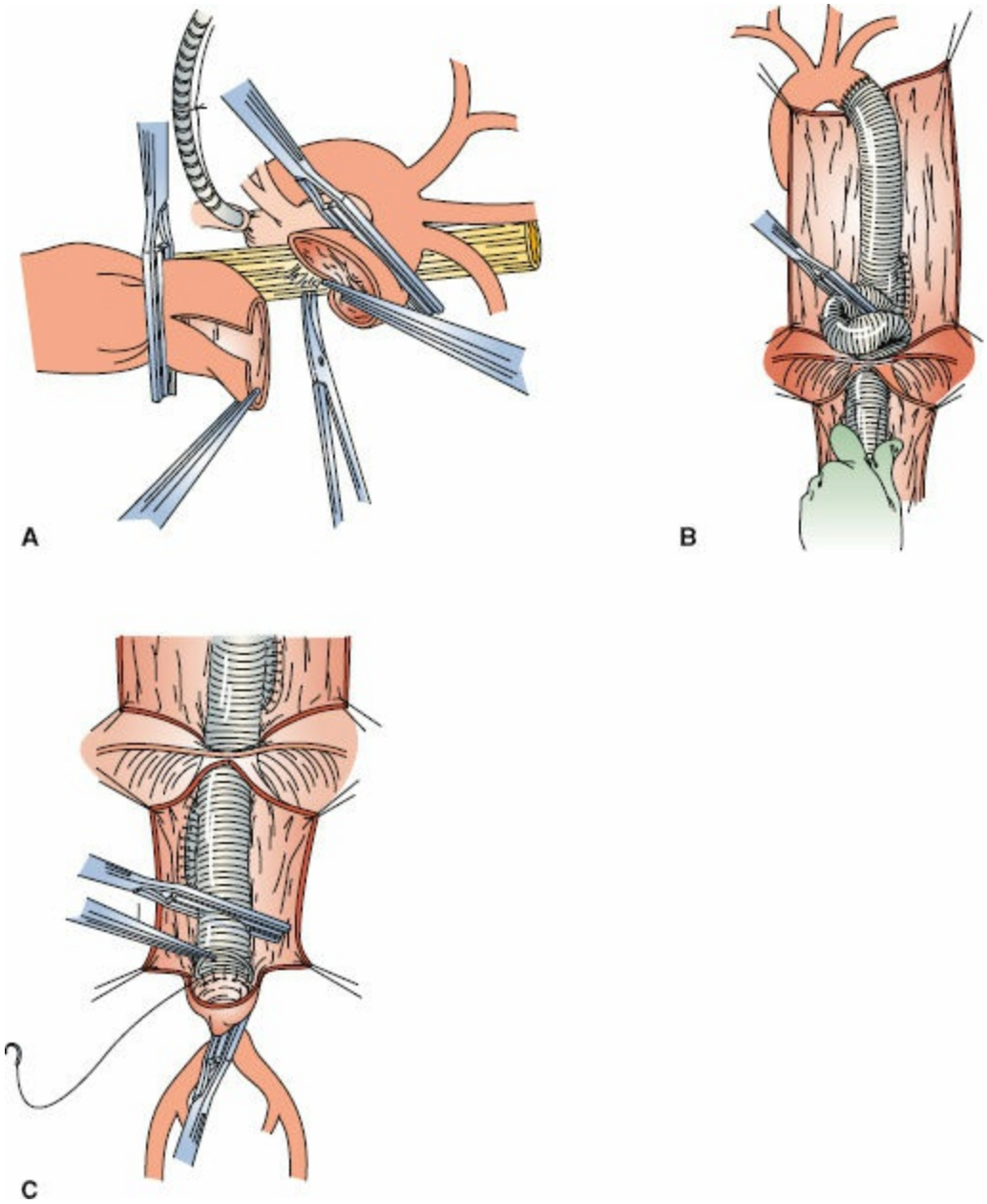

Figure 95-10. Sequential clamping and graft replacement. Padded clamps are placed on the proximal and middistal descending thoracic aorta. **A:** The proximal part of the aneurysm is opened. The aortic neck is completely transected and separated from the esophagus. The proximal anastomosis is fashioned. Subsequently, the patent lower intercostal arteries are reattached via an elliptical hole in the graft. **B:** The proximal clamp is then moved onto the graft to restore pulsatile flow to the intercostal arteries, and the graft is pulled through the hiatus into the abdomen. The distal clamp is reapplied onto the infrarenal aorta. The remainder of the aneurysm is opened. Balloon-tipped catheters are inserted into the celiac, superior mesenteric, and renal arteries to permit perfusion. **C:** An elliptical hole is made in the graft for reimplantation of the visceral and renal arteries.

The patient is weaned from partial bypass once the core body or nasopharyngeal temperature reaches 36°C. Protamine is administered (1 mg/1 mg heparin), and the atrial and femoral cannulae are removed. Once hemostasis is achieved, two or three 36-Fr chest tubes are placed in the pleural cavity for drainage. The diaphragm is reapproximated using running 1-0 polypropylene suture. The left lung is reinflated. Closure of the incision is done in a standard fashion. The patient is placed in the supine position and a single-lumen endotracheal tube is exchanged for the double-lumen tube. If the vocal cords are

swollen, the double-lumen tube is kept in place until the swelling resolves. The patient is then transferred to the intensive care unit (ICU). Figure 95-11 shows an extent II TAAA before and after surgery.

Elephant Trunk Technique for Extensive Aortic Aneurysms

Single-stage repair of extensive aneurysms involving the ascending, arch, and thoracoabdominal aorta greatly increases operative risks. The patient undergoes a lengthy procedure that requires multiple incisions, a daunting array of protective surgical adjuncts, protracted clamp times, and considerable blood loss. Staged repair is a practical solution. Prior to the introduction of the elephant trunk technique by Borst[46] in 1983, staged repair was fraught with complications, particularly excessive bleeding from the pulmonary artery and thoracic aorta in the second-stage repair of the thoracic or thoracoabdominal aorta. The elephant trunk technique resolves this problem because it allows the surgeon to avoid surgical manipulation and cross-clamping the proximal native descending thoracic aorta in the second stage.

The first stage of the elephant trunk technique is performed in a similar fashion to standard surgery of the ascending aorta and transverse arch, with the exception that either an inverted distal graft or a commercially available collared graft is inserted distally (Fig. 95-12A). The folded edge of the inverted graft or the collared portion of the elephant trunk graft is sutured to the descending thoracic aorta just distal to the left subclavian artery. When the distal anastomosis is completed, the inner portion of the inverted graft is retrieved. A side hole is made in the graft, and the aortic island containing the great vessels is reimplanted. The proximal anastomosis to the ascending aorta is completed, and the distal portion of the graft, or "elephant trunk," is left dangling in the proximal descending aorta. In the first stage, cardiopulmonary bypass, profound hypothermia, circulatory arrest, and retrograde cerebral perfusion provide protection to the brain and guard against stroke.

The second stage of the elephant trunk technique is much like standard TAAA repair, using the adjuncts distal aortic perfusion and CSF drainage. After initiation of the pump, the distal clamp is applied at the mid-descending thoracic aorta. The proximal third of the descending thoracic aorta is opened without a proximal clamp. The elephant trunk portion of the graft, inserted in the descending thoracic aorta during stage 1, is grasped quickly and clamped (Fig. 95-12B and C). The new graft is sutured to the "elephant trunk" to replace the remaining aneurysm.

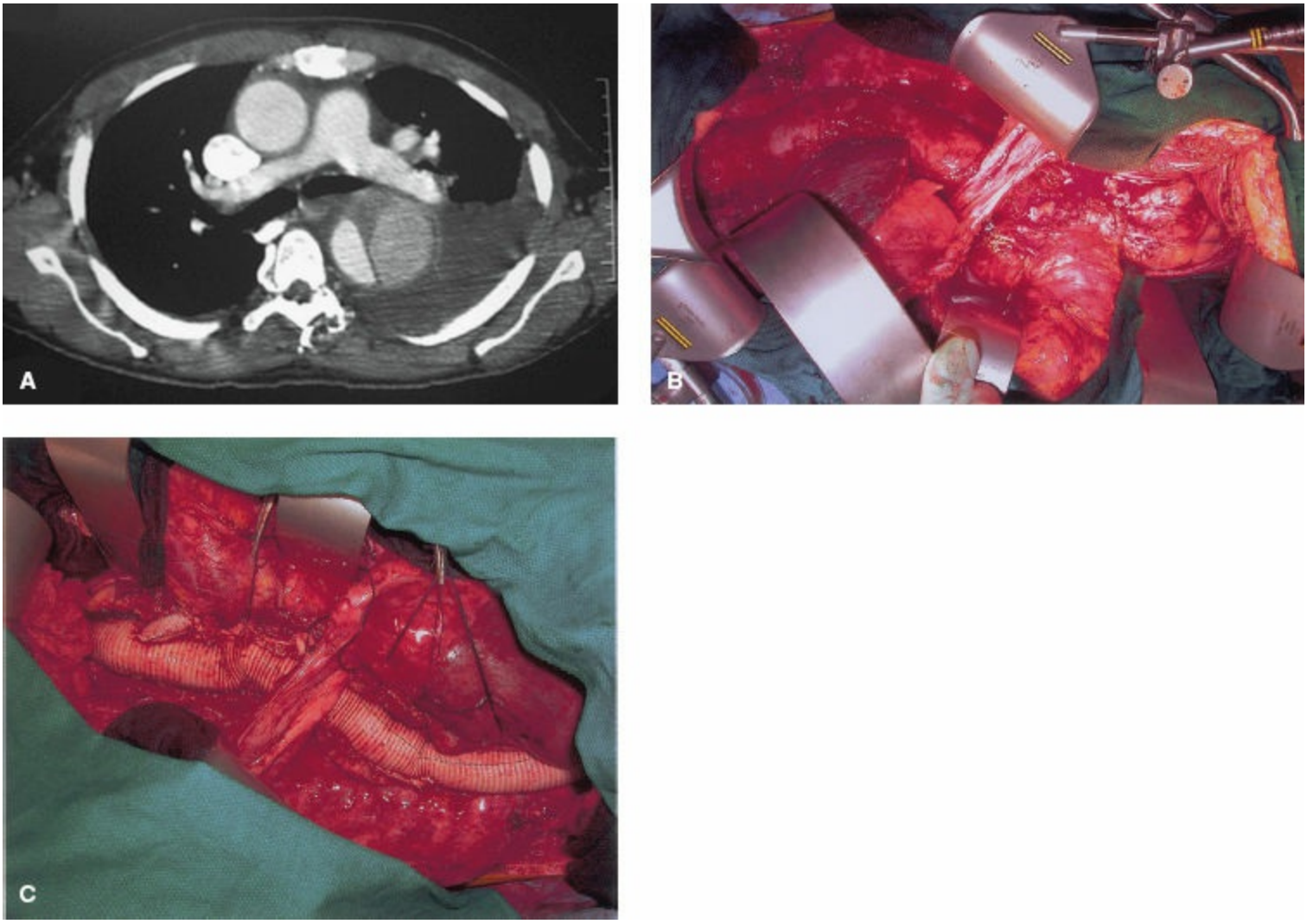

Figure 95-11. Example of TAAA extent II repair. (**A**) Preoperative computed tomography showing proximal part of the aneurysm with chronic dissection. Intraoperative photograph of the thoracoabdominal aortic aneurysm before (**B**) and after (**C**) graft replacement. The proximal anastomosis was just distal to the left subclavian artery; the patent lower intercostal arteries were reattached; the celiac, superior mesenteric and right renal arteries were reimplanted together; the left renal artery was reimplanted via an interposition bypass graft; and the distal anastomosis was to the aorta just above the bifurcation. The separate left renal artery graft was necessary because it was located far away from the remaining visceral arteries.

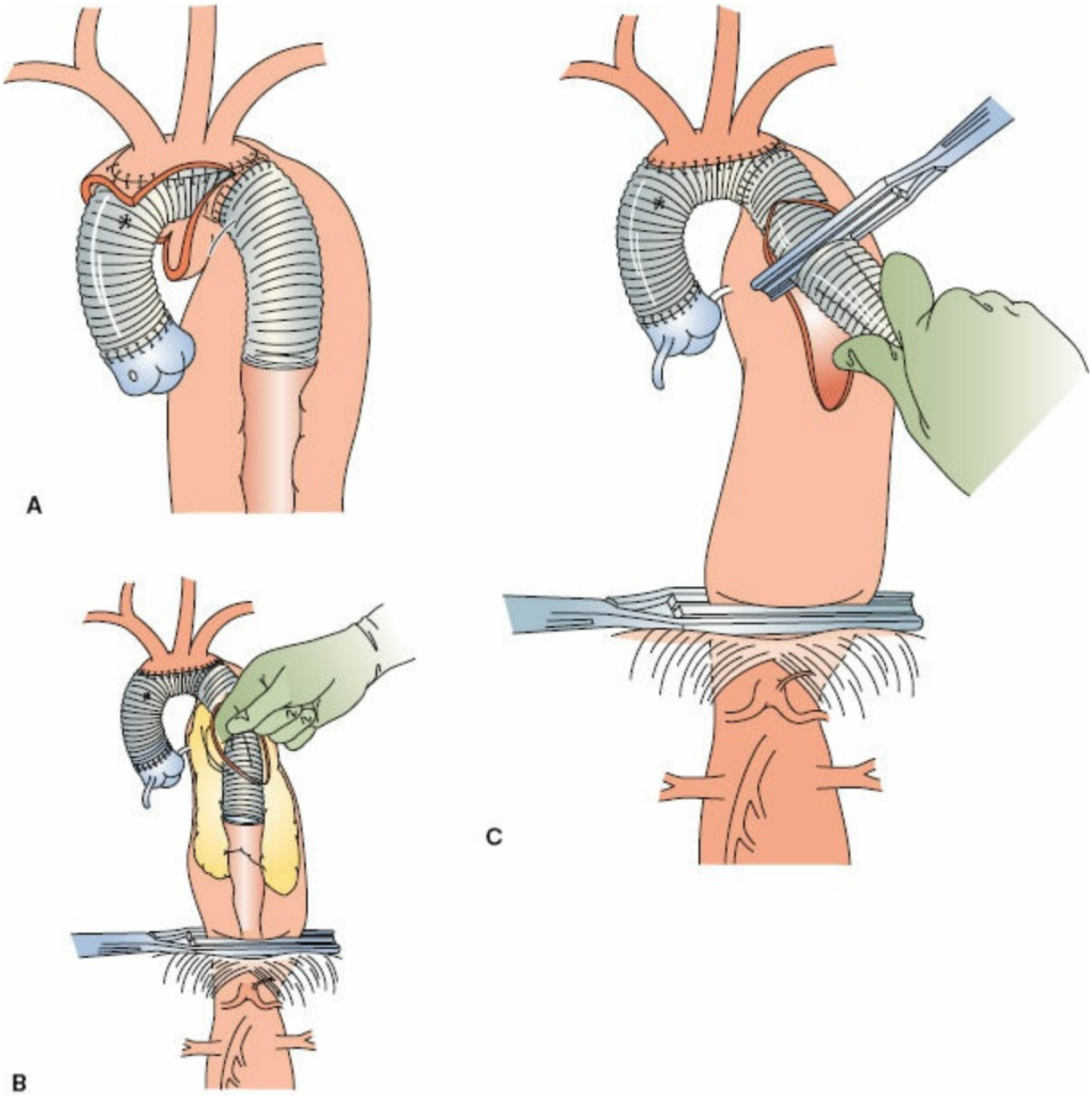

Figure 95-12. Elephant trunk technique. Illustration of completed stage 1 elephant trunk (**A**). In stage 2, the proximal aneurysm is opened and the existing graft is quickly grasped (**B**) and clamped (**C**). The remainder of the surgery follows the standard technique for thoracoabdominal aortic aneurysm.

POSTOPERATIVE MANAGEMENT

In the ICU, the patient's hemodynamic status is monitored very closely. The patient is awakened as quickly as possible to check neurologic status. Most patients may be extubated within hours of arriving to the ICU assuming swelling is minimal and hemodynamics are stable. Blood loss is liberally replaced using banked blood products. The patient's mean arterial pressure is maintained between 80 and 90 mm Hg to ensure adequate organ perfusion, particularly to the spinal cord. CSF pressure is continuously monitored. Approximately 10 to 15 mL of CSF is drained hourly to keep CSF pressure at 10 mm Hg or less. Ideally, the patient is weaned off the ventilator on the first postoperative day. Oral diet is resumed when the patient is extubated and has bowel sounds.

After the patient recovers from anesthesia and is moving all extremities, potential delayed neurologic deficit (DND) is monitored. Warning signs for DND include unstable arterial blood pressure, hypoxemia, low hemoglobin (<10 g/dL), or increased CSF pressure (>15 mm Hg). CSF drainage is discontinued on the third postoperative day. The length of stay in the ICU is about 3 to 4 days, depending on the neurologic and pulmonary status of the patient.[47] The patient is subsequently transferred to the telemetry floor. Physical therapy is initiated in the ICU and continued throughout the patient's hospital stay.

Annual CT scan follow-up is recommended to screen for the development of new aneurysms or graft-related pseudoaneurysm formation. The frequency of follow-up visits or CT scans varies based on TAAA etiology. For example, patients with remaining unoperated aortic dissection, connective tissue disorders (Marfan syndrome), family history of aortic aneurysm, or concurrent aneurysms may need closer surveillance.

SURGICAL OUTCOMES

2 Mortality rates for patients undergoing TAAA and descending thoracic aortic aneurysm repair range between 4% and 21%.[12,48–51] The variable success rates are partly related to the heterogeneity of the patient population and the expertise of the treating team. In the cumulative experience of the authors of this chapter (January 1991 to July 2012), 1,511 patients underwent TAAA and descending thoracic aortic aneurysm repair. Of these patients, 64% were men with a median age of 67 years (range, 8 to 91 years). Approximately 7% of patients had emergency surgery for free or contained rupture of TAAA or descending thoracic aortic aneurysm. Currently, the 30-day mortality rate is approximately 15%, but patients with normal renal function, that is, with calculated glomerular filtration rate (GFR) >90 mL/min/1.73 m^2, the early mortality was 5.9%. Using multivariable analysis, advanced age, renal failure, and paraplegia have been identified as important risk factors for mortality.[52] Overall, 70% of patients recover from TAAA without significant postoperative complications.[53] The 5-year survival for patients after TAAA is between 60% and 70%. Recently, negative predictors for long-term survival were found to include advanced age, extent II TAAA, renal failure, emergency surgery, cerebrovascular disease, and active tobacco smoking.[52]

Neurologic Outcomes

3 Postoperative neurologic deficit remains the most devastating complication following TAAA repair. When the descending thoracic aorta is cross-clamped, the spinal cord is quickly rendered ischemic because of the immediate interruption of perfusion to the spinal cord and consequent increased CSF pressure. Therefore, in the "cross-clamp-and-go" era, the single most important predictor of neurologic deficit was the length of clamp time. The rationale for the present method of protection is to increase the spinal cord perfusion pressure directly with distal aortic perfusion, and indirectly by reducing CSF pressure to 10 mm Hg or less. Animal and human studies have confirmed that CSF drainage reduces CSF pressure and can improve spinal cord perfusion during aortic cross-clamping.[54–56]

The adjuncts, distal aortic perfusion and CSF drainage with moderate hypothermia, were used in 1,155 of 1,511 (76%) patients. In our cumulative experience, the use of combined adjunct distal aortic perfusion and CSF drainage has been associated with a 44% reduction in the odds of neurologic deficit across all aneurysm extents. That is, the overall incidence of neurologic deficit for all patients without the use of adjunct was 4.5%, whereas it was 2.5% for those with adjunct. While aortic cross-clamp time remains a major predictor of paraplegia when plotted on a continuum, the curve has shifted to the right with longer ischemic tolerance provided by the adjuncts. In high-risk extent II aneurysms, adjuncts reduced neurologic deficit from 30% to 9% at the average aortic cross-clamp time of 75 minutes (Fig. 95-13). When all aneurysm extents are modeled together with nonadjunct cases excluded, use of adjuncts has pushed the rates down to the range of 1% to 5% and vastly increased clamp time tolerance. This combination of results has made the current statistical models insensitive to cross-clamp time, so that although the intercept for extent II aneurysms is greater, the estimates for all extents are flat across clamp time (Fig. 95-14). Clearly, the adoption of adjunct has impacted the overall incidence of neurologic deficit, and this has led us to recategorize "low" versus "high" risk, as "extent non-II" versus "extent II."[57]

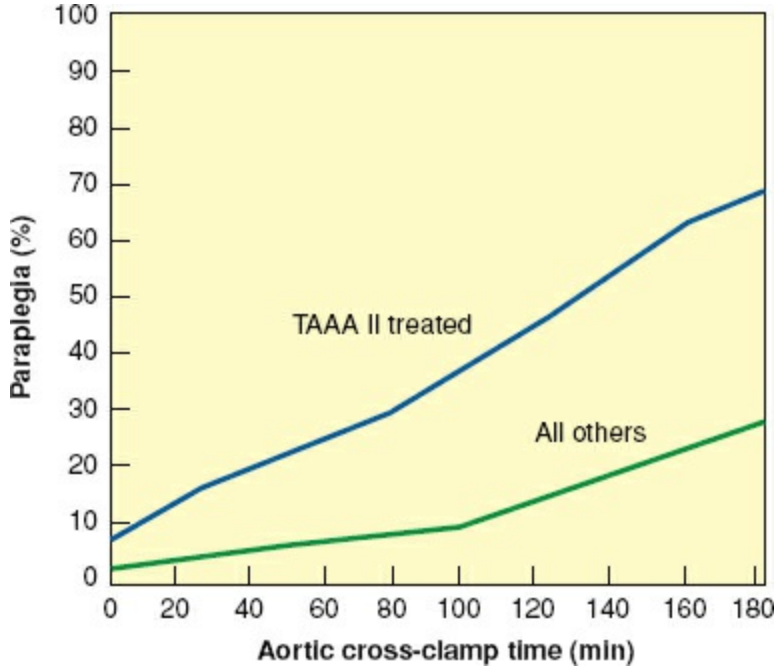

Figure 95-13. In extent II aneurysms, the probability of developing neurologic deficits increases with increasing clamp time, but the use of adjunct distal aortic perfusion and CSF drainage reduces the chances of neurologic deficit by prolonging ischemic tolerance.

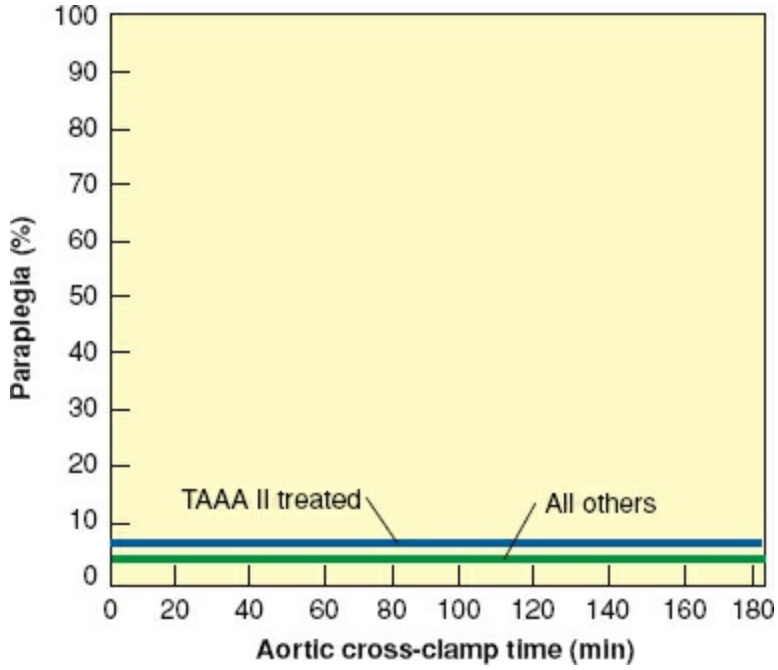

Figure 95-14. For thoracoabdominal aortic aneurysms and all other aneurysms, the use of adjuncts has made the probability of neurologic deficits low and unrelated to cross-clamp time.

Since 1991, distal aortic perfusion and CSF drainage have been utilized as adjuncts for all patients undergoing elective repair of TAAA. Overall, in a total of 1,004 patients, immediate postoperative neurologic deficit (paraplegia or paraparesis that occurs as the patient awakens from anesthesia) occurred in 2.4% of patients operated with adjuncts, and in 6.8% patients without adjuncts.[52] This combination of adjuncts has reduced the cumulative rate of neurologic deficits to 0.9% for descending thoracic aortic repair and to 3.3% for thoracoabdominal aortic repair.[52] Repair of the most

extensive TAAAs (extent II) has long been known to result in the highest incidence of neurologic deficits. In the cross-clamp-and-go era, this incidence was as high as 30% to 40%.[50] With the use of adjuncts, the rate of immediate neurologic deficits for extent II TAAA has been reduced to 7.2%[52] (Fig. 95-15). In addition to the extent of the aneurysm, other perioperative risk factors for immediate neurologic deficits include age, emergency presentation, renal dysfunction, active smoking, and cerebrovascular disease. The use of intraoperative distal aortic perfusion and perioperative CSF drainage, in combination, prevents 1 neurologic deficit in 20 cases for all patients, and 1 in 5 for extent II TAAA.[52]

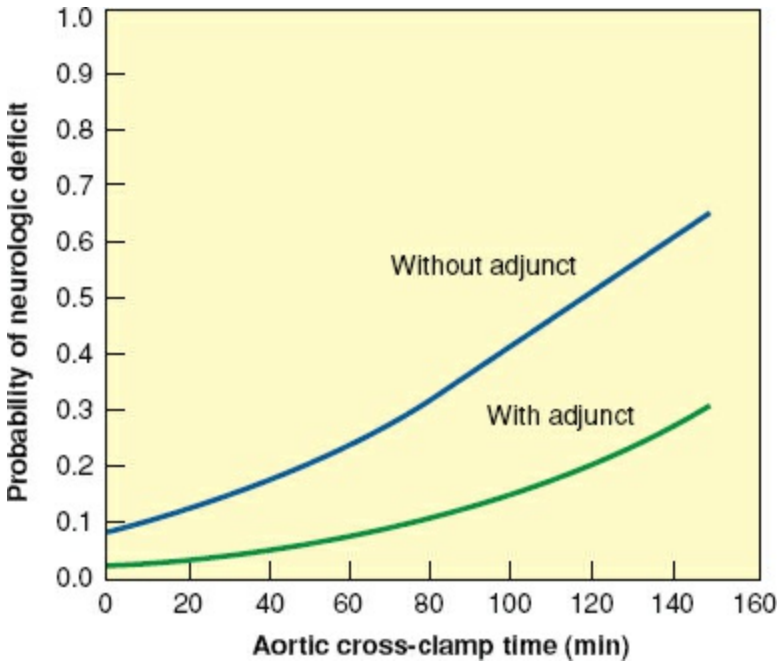

Figure 95-15. The probability of neurologic deficit increases with clamp time and is markedly higher in patients undergoing thoracoabdominal aortic aneurysm surgery without adjuncts.

Also important in spinal cord protection is the reimplantation of intercostal arteries. During the era of cross-clamp-and-go reimplantation of intercostal arteries was found to be a risk factor for postoperative neurologic deficit.[58] This link was explained by the longer cross-clamp time required to reattach the intercostal arteries. The level at which the anterior radicular artery, known as the *artery of Adamkiewicz* or *arteria radicularis magna,* originates is known to be variable. Most commonly, this artery branches from one of the lower intercostal arteries with or without additional collateral branches from nearby intercostal arteries. The anterior radicular artery is believed to be the major blood supply to the anterior spinal artery of the spinal cord. The relationship of neurologic deficit to ligation, reimplantation, and pre-existing occlusion of intercostal arteries in patients undergoing TAAA repair using adjuncts has been studied. It was found that ligation of patent lower intercostal arteries (T9 to T12) increased the risk of paraplegia.[58] Therefore, all patent lower intercostal arteries from T9 to T12 are reattached, either together as a patch to a side hole made in the Dacron graft or, when the intercostal arteries are too far apart, separately as buttons or using interposition bypass grafts. However, if the lower intercostal arteries are occluded, the patent upper intercostal

arteries will be reimplanted, because these are thought to assume a more important role in the collateral system to the anterior spinal artery in this situation.

Adequate spinal cord perfusion pressure should be maintained with avoidance of hypotension during and after surgery. Intravenous nitroprusside, in particular, can precipitate systemic hypotension, and has been shown to cause a paradoxical increase of CSF pressure.[59] Therefore, it is no longer used. A detailed account of the essential anesthetic care during TAAA repair is beyond the scope of this chapter. However, the importance of adequate maintenance of systemic arterial pressure with judicious blood transfusion cannot be overemphasized, as organ perfusion greatly depends on the systemic circulation. Clearly, the era of cross-clamp-and-go is over and the spinal cord must be provided with some form of protection.

Cord function can be assessed using intraoperative neurophysiologic monitoring with MEPs and SSEPs as performed routinely in aortic surgery.[60,61] For SSEP, probes are placed at the malleolus bilaterally, stimulating the posterior tibial nerve. Recordings are performed at three sites (Fig. 95-4), including the popliteal fossa, C5, and the vertex with a positive finding defined as a drop in amplitude by 50% and/or a change in latency by 10%. For MEP, precentral gyrus is stimulated and recording is measured at three sites, including the abductor digiti minimi, tibialis anterior, and abductor hallucis muscle. Compound muscle action potential is monitored with a positive finding defined as an all-or-none potential. If there are signal changes, as defined earlier, intraoperative corrective measures are performed, which include increasing the mean central pressure to more than 80 mm Hg, increasing distal aortic perfusion pressure to more than 60 mm Hg, lowering the CSF pressure, increasing the hemoglobin level, and attaching additional intercostal arteries. With the current use of adjunct therapy and intraoperative SSEP and MEP monitoring, the current rate of immediate neurologic deficit remains at 3.1%.[62]

Delayed Neurologic Deficits

DND refers to the onset of paraplegia or paraparesis after a period of observed normal neurologic function. Delayed-onset neurologic deficit after TAAA repair was first reported in 1988, at which time the condition was considered irreversible and beyond the surgeon's control.[63] Since then, numerous reports have described improvements in patients neurologic function by using CSF drainage for delayed-onset neurologic deficits.[64–66] DND has been observed as early as 2 hours and as late as 2 weeks following surgery (median, 3 days), in 2.7% of patients.[67] No single risk factor is responsible for DND. However, using multivariable analysis, acute dissection, extent II TAAA, and renal insufficiency were identified as significant preoperative predictors for delayed-onset neurologic deficit.[67] In a subsequent case-control study, postoperative mean arterial pressure of less than 60 mm Hg and CSF drain complications were found to be predictors in the development of delayed-onset neurologic deficit, independent of preoperative predictors (Fig. 95-16).[68]

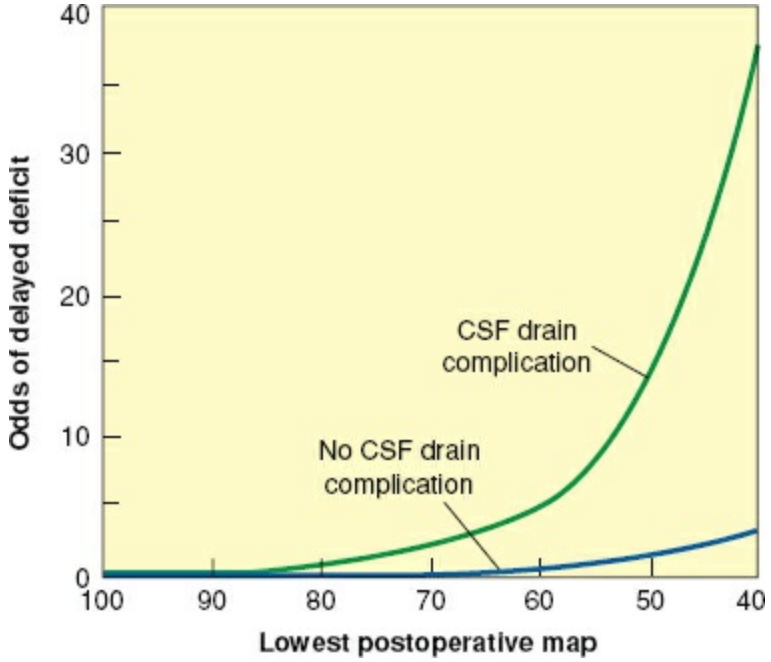

Figure 95-16. Odds of delayed neurologic deficit by lowest postoperative mean arterial blood pressure, with or without cerebrospinal fluid drain complication. Odds are referenced to one. For example, a patient with a mean arterial blood pressure of 40 mm Hg and a cerebrospinal fluid drain complication would have 40:1 odds of delayed neurologic deficit.

As improved spinal cord protection during TAAA surgery has reduced the incidence of neurologic complications, delayed-onset neurologic deficit has emerged as an important clinical entity. The exact mechanisms involved in the development of DND remain unknown. It is speculated that DND after TAAA repair may result from a "second hit" phenomenon. Adjuncts can protect the spinal cord intraoperatively and reduce the incidence of immediate neurologic deficit, but the spinal cord remains vulnerable during the early postoperative period. Additional ischemic insults caused by hemodynamic instability, malfunction of the CSF drainage catheter, or both may constitute a "second hit," causing DND. Furthermore, in the rigid, unyielding spinal column, any rise in CSF pressure could lead to an increase in compartment pressure, with consequent decreased spinal cord perfusion. Hence, CSF is drained freely when DND develops to relieve the compartment pressure.

To optimize postoperative spinal cord perfusion and oxygen delivery, mean arterial pressure is kept above 90 to 100 mm Hg, hemoglobin above 10 mg/dL, and cardiac index greater than 2.0 L/min. If DND occurs, measures to increase spinal cord perfusion are instituted immediately. The patient is placed flat in the supine position. The patency and function of the drain is ascertained at once. If the drain has been removed, the CSF drainage catheter is reinserted immediately and CSF is drained freely until the CSF pressure drops below 10 mm Hg. The systemic arterial pressure is raised, blood transfusion is liberally infused, and oxygen saturation is increased, as indicated above. CSF drainage is continued for at least 72 hours for all patients with delayed-onset neurologic deficit. Using this multifaceted approach to treating delayed-onset neurologic deficit, an improvement in neurologic function is seen in 57% of patients.[67] When the CSF drain was still in place at the onset of DND, 75% of patients recovered function; 43% recovered neurologic function if the CSF drain had to be reinserted at the time of the

DND. Patients who developed DND but did not have CSF drainage failed to recover function.

Renal Failure

Acute postoperative renal failure is defined as an increase in serum creatinine of 1 mg/dL per day for 2 consecutive days or by the need for hemodialysis. The reported rate of acute renal failure from large series of patients undergoing TAAA repair falls within the range of 5% to 40% and is associated with mortality rates as high as 70%. Patients who develop acute renal failure more frequently sustain nonrenal complications, such as respiratory failure, central nervous system dysfunction, sepsis, and gastrointestinal hemorrhage. For patients who develop postoperative renal failure, early continuous venovenous hemodialysis or daily intermittent hemodialysis is initiated. In the experience of the authors of this chapter, approximately one-third of patients who develop acute renal failure remain on hemodialysis and, predictably, these patients have a prolonged length of hospital stay. Long-term survival for patients on hemodialysis is dismal. Preoperative chronic renal insufficiency and ruptured aneurysms are known predictors of acute postoperative renal failure. Although the authors of this chapter have theorized that patients with the most extensive extent II TAAA are at highest risk for the development of postoperative renal failure, extent of TAAA has not been shown to be a significant predictor.

The goals of perioperative renal protection are to maintain adequate renal oxygen delivery, reduce renal oxygen utilization, and reduce direct renal tubular injury. However, good strategies to protect renal function during surgical TAAA repair remain elusive. The benefit of cold temperatures for metabolic suppression in organ protection is well known. Local hypothermia has been shown to protect against renal ischemia and reperfusion injury in laboratory animals, and there is some evidence that patients with cold visceral perfusion have superior survival and recovery rates. However, this strategy has not decreased the incidence of acute renal failure. The incidence of postoperative renal failure remains troublesome and the pursuit of an optimal method of renal protection continues to be a top priority.

Glomerular Filtration Rate

4 Clinically apparent renal insufficiency is a known predictor of 30-day mortality. The overall 30-day mortality was 227 of 1,511 (15%), and the 5-year survival rate was 54%. Increasingly, we are finding that mortality cannot properly be interpreted without knowledge of preoperative GFR. With normal GFR (>90 mL/min/1.73 m^2), 30-day mortality was 6%, whereas 5-year survival was 77%. With a decline in GFR to the 65 to 90 range, 30-day mortality was 8.9%. Below a GFR of 65, 30-day mortality increases to 22%. Long-term survival stratified by quartile of GFR is shown in Figure 95-17. The effect of GFR on both short-term mortality and long-term survival was highly statistically significant ($p < 0.0001$ for both measures).

Recently, in patients undergoing TAAA repair without apparent renal disease, we have found that calculated GFR is a much stronger predictor for mortality than serum creatinine.[69] We have used and appraised many different forms of renal protection, including distal aortic perfusion, warm blood visceral perfusion, antegrade cold blood visceral perfusion, retrograde cold blood perfusion, and the perioperative use of a renal protective pharmacologic agent, fenoldopam. None of these yielded overly promising results. Using multivariable analyses, we found that preoperative renal failure (creatinine >2.8 g/dL), left renal artery reattachment, visceral perfusion, and clamp-and-sew technique are predictors of acute renal failure.[57]

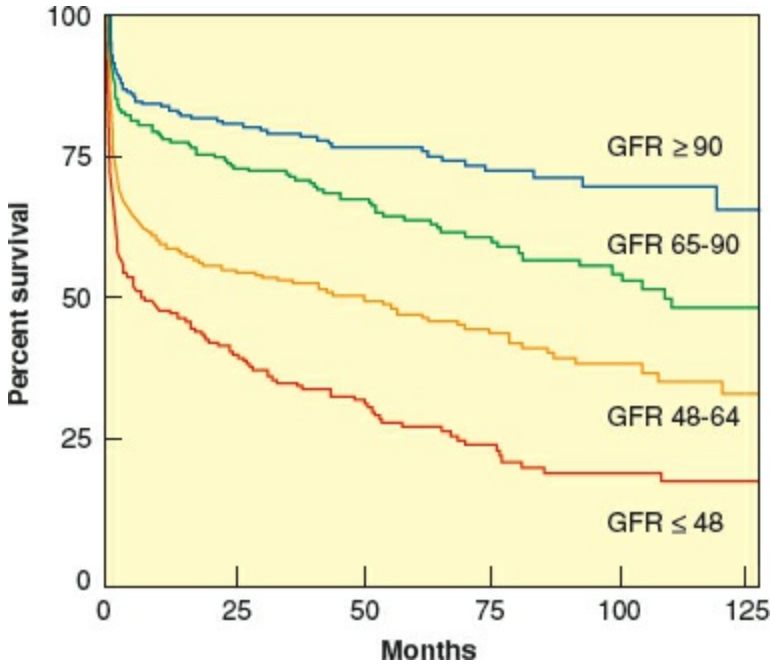

Figure 95-17. Long-term survival stratified by quartile of glomerular filtration rate.

In the past, we had used visceral perfusion without cooling or systemic heparin, and this was likely the reason for the negative effect of visceral perfusion on renal protection. We recently reviewed the impact of various adjuncts on renal function. Distal aortic perfusion has emerged as protective but only for aortic repair that does not directly involve the renal arteries. There is evidence, however, that patients treated with cold blood visceral perfusion have superior survival and recovery rates, which may be related

to improved liver protection. Thus far, none of the adjuncts evaluated have clearly prevented acute renal failure. The major predictors of postoperative renal dysfunction remain preoperative renal function, cross-clamp time, and repair extending to the renal arteries.

Excluding patients who had clinically apparent preoperative renal failure, we found that acute renal failure occurred in 344 of 1,261 (27.2%) of our patients overall. For patients with preoperative GFR above 90, renal failure was 62 of 367 (17%). When GFR was between 65 and 90, postoperative renal failure was 70 of 310 (23%). At GFRs below 65, renal failure was 212 of 584 (36%). Thirty-day mortality among patients with acute renal failure was 34% compared to 10% mortality for all other patients. Aneurysms involving the visceral vessels (extents II, III, and IV) were much more likely to produce renal failure postoperatively (39 vs. 17%, $p < 0.0001$). Approximately one-third of our patients who developed acute renal failure remained on hemodialysis, and long-term survival for patients on hemodialysis has been dismal.

Complications

A summary of complications is shown in Table 95-1. These figures are compiled from a collection of sources.[70–80]

Elephant Trunk Technique

The authors of this chapter have performed the two-staged elephant trunk procedure in 348 patients with extensive aortic aneurysms.[81] Mortality rates range from 5% to 10% after stage one and 5% to 15% for stage two, depending on renal function. For patients with normal kidneys (GFR >90), mortality for each stage was 5%. During the interval between the two stages (approximately 31 days and 6 weeks), mortality has averaged around 6.5%, ranging from 4% to 17%, depending on why the second stage was not completed. When a 5-year follow-up of patients who failed to return for second-stage repair was performed, 32% had died. Although we were unable to determine the exact cause of death for many of these patients, it is likely that a significant number of deaths were a result of aneurysm rupture. Major complications for both stages have been relatively low, with stroke rates of 2% in the first stage and no neurologic deficits in the second. Determining the optimum length of recovery time between stages has been difficult. Because these patients are vulnerable to rupture, it is currently recommended that the second-stage repair be performed after a 4- to 6-week period of recovery.

Table 95-1 Complications of Open TAAA Repair

Complication	Results
Early mortality	4–21%
Immediate neurologic deficit	2–33%
Delayed neurologic deficit	2–10%
Acute renal failure – need for dialysis	2–13%
Acute renal insufficiency	6–40%
Bleeding – reoperation for bleeding	5–10%
Vocal cord paralysis/paresis and hoarseness	10%
Cardiac complication – MI, CHF	5–15%
Pulmonary insufficiency (prolonged ventilation >48 h)	10–41%
Stroke or transient ischemic attach (reversible)	2–6%
Gastrointestinal complications (pancreatitis, ischemic colitis, small bowel, cholecystitis, hepatic insufficiency)	7–10%
Chylothorax	<1%
Hospital length of stay	10–22 days
Survival	1 yr = 60–80% 5 yr = 65–80% 10 yr = 40%

CHF, chronic heart failure; MI, myocardial infarction.

Impact of Aortic Dissection

Aortic dissection has long been considered a risk factor for neurologic deficit in patients undergoing repair of descending thoracic and TAAAs, particularly during the clamp-and-go era.[82–85] However, in a series of 729 patients operated on for descending thoracic and TAAAs, no differences were reported in neurologic outcome between those patients with and without chronic dissection. The rate of paraplegia was 3.6% with dissection versus 4.7% without dissection.[86] Several factors are likely responsible for the good neurologic outcome of patients with chronic dissection, including better surgical techniques and anesthetic care, moderate hypothermia, and reimplantation of intercostal arteries. The key element in the improved spinal cord protection; however, has been the use of the adjuncts distal aortic perfusion and CSF drainage.

In acute aortic dissection, the risk of paraplegia following graft replacement of the descending thoracic or thoracoabdominal aorta remains substantial with a neurologic deficit rate of 32%.[87] Nevertheless, acute dissection aneurysm patients are usually critically ill, undergoing surgery emergently with little time for preparation. The method of spinal cord protection employed during surgery for acute dissection is often not optimal. In particular, reimplantation of intercostal arteries is ill-advised because of the risk of catastrophic bleeding from the friable dissected tissues, and the use of the adjuncts distal aortic perfusion and CSF drainage may not be possible in the presence of hemodynamic instability.

Endovascular Repair

Since the first successful reported thoracic stent graft repair in 1994,[88] endovascular management of thoracic aortic pathology has evolved at a rapid pace. The first thoracic aortic device to receive US Food and Drug Administration (FDA) approval in the United States was the GORE TAG (WL Gore, Flagstaff, AZ) device in 2005. Since then, three additional devices, including the Valiant Thoracic (Medtronic, Santa Rosa, CA), the Zenith TX2 (Cook, Bloomington, IN), and the Relay (Bolton Medical, Sunrise, FL, USA) have received FDA approval. The benefits of endovascular therapy include decreased morbidity and mortality compared with conventional open surgery. Endovascular treatment of a TAAA would require revascularization of visceral and renal vessels. Endovascular repair is currently being performed using three different approaches, including "hybrid repair," use of parallel grafts, and custom-made branched and fenestrated devices.

The hybrid approach requires combined open debranching of the aorta with subsequent endovascular coverage of the aneurysmal segment.[89] The debranching procedures entail an open retroperitoneal or transperitoneal approach for extra-anatomical bypassing of the visceral and renal arteries from either iliac artery. This is subsequently followed by exclusion of the thoracoabdominal aorta with stent grafts. The potential benefits of hybrid repair include the avoidance of open thoracotomy, aortic cross-clamping, and single-lung ventilation. [90–92] Although this approach is technically feasible, the risk of morbidity and mortality remains discouragingly high. More recent literature has suggested that the hybrid repair has no significant difference in outcomes compared to open TAAA repair.[93–95] Indications for this approach will likely be limited to patients with TAAA who are unfit for open repair and those who are not candidates for other endovascular repair techniques (i.e., those with tortuous or inaccessible vessels, or insufficient time to order a customized stent graft).

Another approach involves the use of parallel grafts (chimneys, periscopes, or snorkels, commonly referred to as CHIMPS) to preserve blood flow to branch vessels. This technique was championed by Lobato et al. from Brazil, who reported their experience with 78 patients, 15 of whom had a TAAA.[96] Overall, they reported a technical success rate of 98.7%. Over a mean follow-up period of 17 months, the primary patency was 96.7% and early mortality was 5.1% (late: 1.3%). The reported advantages of the parallel stent grafts include the availability of a modular, off-the-shelf option that can be tailored to any anatomy.[97] This is especially useful in patients who have small and/or tortuous vessels, history of dissection, or a significant thrombus burden in the paravisceral aorta. The inherent disadvantages to this approach include potential endoleaks from the "gutters" that can lead to pressurization of the aneurysm sac. A recent systematic review of the chimney graft technique included 75 patients and a total of 96 branches, with a reported 98.9% early success rate with a perioperative mortality rate of 4%.[98]

Finally, total endovascular TAAA repair can be performed using custom-made branched and/or fenestrated devices. The largest series by Greenberg et al. on their experience

with 406 patients reported a perioperative mortality of 2.3% for extent IV, 5.2% for extent II and III, and 12.5% for extent I aneurysms.[99] The estimated 24-month survival was 82%, 74%, and 70% for extents IV, II and III, and I, respectively. Late complications included rupture in two patients. In a multicenter prospective study of 268 patients undergoing endovascular fenestrated and/or branched repair for juxtarenal, pararenal, and TAAA, Marzelle et al. reported 30-day mortality, inhospital mortality (IM), and combined mortality and severe complications (CMSC) rates of 6.7%, 10.1%, and 22.0%, respectively.[100] The authors concluded that due to the significant rate of mortality and complications, new strategies should be investigated to improve outcomes. Although significant progress has been made, the endovascular technologies continue to mature at a rapid pace. Ultimately, endovascular repair of TAAA will require modular, off-the-shelf devices that can be tailored to the variety of clinical circumstances.

ACKNOWLEDGMENTS

The authors of this chapter are grateful to G. Ken Goodrick, editor, and to Chris Akers for assistance with the illustrations.

References

1. Etheridge SN, Yee J, Smith JV, et al. Successful resection of a large aneurysm of the upper abdominal aorta and replacement with homograft. *Surgery* 1955;38:1071–1081.
2. DeBakey ME, Cooley DA, Crawford ES, et al. Clinical application of a new flexible knitted Dacron arterial substitute. *Arch Surg* 1957;74:713–724.
3. Crawford ES, Crawford JL, Safi HJ, et al. Thoracoabdominal aortic aneurysms: preoperative and intraoperative factors determining immediate and long-term results of operations in 605 patients. *J Vasc Surg* 1986;3:389–404.
4. Bickerstaff LK, Hollier LH, Van Peenen HJ, et al. Abdominal aortic aneurysms: the changing natural history. *J Vasc Surg* 1984;1:6–12.
5. Wanhainen A, Bjorck M, Boman K, et al. Influence of diagnostic criteria on the prevalence of abdominal aortic aneurysm. *J Vasc Surg* 2001;34:229–235.
6. Wilmink AB, Quick CR. Epidemiology and potential for prevention of abdominal aortic aneurysm. *Brit J Surg* 1998;85:155–162.
7. Clouse WD, Hallett JW Jr., Schaff HV, et al. Improved prognosis of thoracic aortic aneurysms: a population-based study. *JAMA* 1998;280(22):1926–1929.
8. Bickerstaff LK, Pairolero PC, Hollier LH, et al. Thoracic aortic aneurysms: a population-based study. *Surgery* 1982;92:1103–1108.
9. Perko MJ, Norgaard M, Herzog TM, et al. Unoperated aortic aneurysm: a survey of 170 patients. *Ann Thorac Surg* 1995;59:1204–1209.
10. Pressler V, McNamara JJ. Thoracic aortic aneurysm: natural history and treatment. *J Thorac Cardiovasc Surg* 1980;79:489–498.
11. Cambria RA, Gloviczki P, Stanson AW, et al. Outcome and expansion rate of 57 thoracoabdominal aortic aneurysms managed nonoperatively. *Am J Surg* 1995;170:213–217.
12. Elefteriades JA, Hartleroad J, Gusberg RJ, et al. Long-term experience with descending aortic dissection: the complication-specific approach. *Ann Thorac Surg* 1992;53:11–20.
13. Juvonen T, Ergin MA, Galla JD, et al. Prospective study of the natural history of thoracic aortic aneurysms. *Ann Thorac Surg* 1997;63:1533–1545.
14. Lobato AC, Puech-Leao P. Predictive factors for rupture of thoracoabdominal aortic aneurysm. *J Vasc Surg* 1998;27:446–453.
15. Coady MA, Rizzo JA, Hammond GL, et al. Surgical intervention criteria for thoracic aortic aneurysms: a study of growth rates and complications. *Ann Thorac Surg* 1999;67:1922–1926.
16. Davies RR, Goldstein LJ, Coady MA, et al. Yearly rupture or dissection rates for thoracic aortic aneurysms: simple prediction based on size. *Ann Thorac Surg* 2002;73:17–27.
17. Dapunt OE, Galla JD, Sadeghi AM, et al. The natural history of thoracic aortic

aneurysms. *J Thorac Cardiovasc Surg* 1994;107:1323–1332.
18. Coady MA, Rizzo JA, Hammond GL, et al. What is the appropriate size criterion for resection of thoracic aortic aneurysms? *J Thorac Cardiovasc Surg* 1997;113(3):476–491; discussion 489–491.
19. Masuda Y, Takanashi K, Takasu J, et al. Expansion rate of thoracic aortic aneurysms and influencing factors. *Chest* 1992;102:461–466.
20. Rizzo JA, Coady MA, Elefteriades JA. Procedures for estimating growth rates in thoracic aortic aneurysms. *J Clin Epidem* 1998;51:747–754.
21. Ailawadi G, Eliason JL, Upchurch GR, Jr. Current concepts in the pathogenesis of abdominal aortic aneurysm. *J Vasc Surg* 2003;38:584–588.
22. Lopez-Candales A, Holmes DR, Liao S, et al. Decreased vascular smooth muscle cell density in medial degeneration of human abdominal aortic aneurysms. *Am J Path* 1997;150:993–1007.
23. Pan JH, Lindholt JS, Sukhova GK, et al. Macrophage migration inhibitory factor is associated with aneurysmal expansion. *J Vasc Surg* 2003;37:628–635.
24. Annabi B, Shedid D, Ghosn P, et al. Differential regulation of matrix metalloproteinase activities in abdominal aortic aneurysms. *J Vasc Surg* 2002;35:539–546.
25. Longo GM, Xiong W, Greiner TC, et al. Matrix metalloproteinases 2 and 9 work in concert to produce aortic aneurysms. *J Clin Invest* 2002;110:625–632.
26. McMillan WD, Pearce WH. Increased plasma levels of metalloproteinase-9 are associated with abdominal aortic aneurysms. *J Vasc Surg* 1999;29:122–127.
27. Biddinger A, Rocklin M, Coselli J, et al. Familial thoracic aortic dilatations and dissections: a case control study. *J Vasc Surg* 1997;25(3):506–511.
28. Coady MA, Davies RR, Roberts M, et al. Familial patterns of thoracic aortic aneurysms. *Arch Surg* 1999;134:361–367.
29. Hasham SN, Willing MC, Guo DC, et al. Mapping a locus for familial thoracic aortic aneurysms and dissections (TAAD2) to 3p24-25. *Circulation* 2003;107(25):3184–3190.
30. Elsheikh M, Casadei B, Conway GS, et al. Hypertension is a major risk factor for aortic root dilatation in women with Turner's syndrome. *Clin Endocrinol* 2001;54:69–73.
31. Hossack KF, Leddy CL, Johnson AM, et al. Echocardiographic findings in autosomal dominant polycystic kidney disease. *N Engl J Med* 1988;319:907–912.
32. Pepin M, Schwarze U, Superti-Furga A, et al. Clinical and genetic features of Ehlers-Danlos syndrome type IV, the vascular type. *N Engl J Med* 2000;342:673–680.
33. Wenstrup RJ, Meyer RA, Lyle JS, et al. Prevalence of aortic root dilation in the Ehlers-Danlos syndrome. *Genet Med* 2002;4:112–117.
34. Milewicz DM, Chen H, Park ES, et al. Reduced penetrance and variable expressivity of familial thoracic aortic aneurysms/dissections. *Am J Cardiol* 1998;82:474–479.
35. Guo DC, Pannu H, Tran-Fadulu V, et al. Mutations in smooth muscle alpha-actin

(ACTA2) lead to thoracic aortic aneurysms and dissections. *Nat Genet* 2007;39:1488–1493.

36. Zhu L, Vranckx R, Khau Van Kien P, et al. Mutations in myosin heavy chain 11 cause a syndrome associating thoracic aortic aneurysm/aortic dissection and patent ductus arteriosus. *Nat Genet* 2006;38:343–349.
37. Pannu H, Tran-Fadulu V, Papke C, et al. MYH11 mutations result in a distinct vascular pathology driven by insulin-like growth factor 1 and angiotensin II. *Hum Mol Genet* 2007;16:3453–3462.
38. Pannu H, Fadulu VT, Chang J, et al. Mutations in transforming growth factor-beta receptor type II cause familial thoracic aortic aneurysms and dissections. *Circulation* 2005;112:513–520.
39. Jarrett F, Darling RC, Mundth ED, et al. Experience with infected aneurysms of the abdominal aorta. *Arch Surg* 1975;110:1281–1286.
40. Bakker-de Wekker P, Alfieri O, Vermeulen F, et al. Surgical treatment of infected pseudoaneurysms after replacement of the ascending aorta. *J Thorac Cardiovasc Surg* 1984;88:447–451.
41. Bachet JE, Termignon JL, Dreyfus G, et al. Aortic dissection. prevalence, cause, and results of late reoperations. *J Thorac Cardiovasc Surg* 1994;108:199–205.
42. Bernard Y, Zimmermann H, Chocron S, et al. False lumen patency as a predictor of late outcome in aortic dissection. *Am J Cardiol* 2001;87:1378–1382.
43. Elefteriades JA, Lovoulos CJ, Coady MA, et al. Management of descending aortic dissection. *Ann Thorac Surg* 1999;67:2002–2005.
44. Marui A, Mochizuki T, Mitsui N, et al. Toward the best treatment for uncomplicated patients with type B acute aortic dissection: a consideration for sound surgical indication. *Circulation* 1999;100(19 Suppl):II275–II280.
45. Juvonen T, Ergin MA, Galla JD, et al. Risk factors for rupture of chronic type B dissections. *J Thorac Cardiovasc Surg* 1999;117:776–786.
46. Borst HG, Walterbusch G, Schaps D. Extensive aortic replacement using “elephant trunk” prosthesis. *Thorac Cardiovasc Surg* 1983;31(1):37–40.
47. Huynh TT, Miller CC 3rd, Estrera AL, et al. Determinants of hospital length of stay after thoracoabdominal aortic aneurysm repair. *J Vasc Surg* 2002;35:648–653.
48. Cambria RP, Clouse WD, Davison JK, et al. Thoracoabdominal aneurysm repair: results with 337 operations performed over a 15-year interval. *Ann Surg* 2002;236:471–479.
49. Kouchoukos NT, Daily BB, Rokkas CK, et al. Hypothermic bypass and circulatory arrest for operations on the descending thoracic and thoracoabdominal aorta. *Ann Thorac Surg* 1995;60:67–76.
50. Svensson LG, Crawford ES, Hess KR, et al. Experience with 1509 patients undergoing thoracoabdominal aortic operations. *J Vasc Surg* 1993;17(2):357–368; discussion 368–370.

51. Shah PJ, Estrera AL, Safi HJ. Thoracoabdominal aortic aneurysm: current surgical trends. In: Safi HJ, McPherson D, eds. *Houston Aortic Symposium.* 2008.
52. Safi HJ, Miller CC 3rd, Huynh TT, et al. Distal aortic perfusion and cerebrospinal fluid drainage for thoracoabdominal and descending thoracic aortic repair: ten years of organ protection. *Ann Surg* 2003;238(3):372–381.
53. Miller CC 3rd, Porat EE, Estrera AL, et al. Analysis of short-term multivariate competing risks data following thoracic and thoracoabdominal aortic repair. *Eur J Cardiothorac Surg* 2003;23:1023–1027.
54. Coselli JS, Lemaire SA, Koksoy C, et al. Cerebrospinal fluid drainage reduces paraplegia after thoracoabdominal aortic aneurysm repair: results of a randomized clinical trial. *J Vasc Surg* 2002;35:631–639.
55. Hollier LH, Money SR, Naslund TC, et al. Risk of spinal cord dysfunction in patients undergoing thoracoabdominal aortic replacement.*Am J Surg* 1992;164:210–213.
56. Jacobs MJ, de Mol BA, Elenbaas T, et al. Spinal cord blood supply in patients with thoracoabdominal aortic aneurysms. *J Vasc Surg* 2002;35:30–37.
57. Safi HJ, Harlin SA, Miller CC 3rd, et al. Predictive factors for acute renal failure in thoracic and thoracoabdominal aortic aneurysm surgery. *J Vasc Surg* 1996; 24: 338–344.
58. Safi HJ, Miller CC 3rd, Carr C, et al. Importance of intercostal artery reattachment during thoracoabdominal aortic aneurysm repair. *J Vasc Surg* 1998;27(1):58–66; discussion 66–68.
59. Huynh TT, Miller CC 3rd, Safi HJ. Delayed onset of neurologic deficit: significance and management. *Semin Vasc Surg* 2000;13:340–344.
60. Jacobs MJ, Mess W, Mochtar B, et al. The value of motor evoked potentials in reducing paraplegia during thoracoabdominal aneurysm repair. *J Vasc Surg* 2006;43:239–246.
61. Kawanishi Y, Munakata H, Matsumori M, et al. Usefulness of transcranial motor evoked potentials during thoracoabdominal aortic surgery. *Ann Thorac Surg* 2007;83:456–461.
62. Keyhani K, Miller CC 3rd, Estrera AL, et al. Analysis of motor and somatosensory evoked potentials during thoracic and thoracoabdominal aortic aneurysm repair. *J Vasc Surg* 2009;49:36–41.
63. Crawford ES, Mizrahi EM, Hess KR, et al. The impact of distal aortic perfusion and somatosensory evoked potential monitoring on prevention of paraplegia after aortic aneurysm operation. *J Thorac Cardiovasc Surg* 1988;95:357–367.
64. Azizzadeh A, Huynh TT, Miller CC 3rd, et al. Reversal of twice-delayed neurologic deficits with cerebrospinal fluid drainage after thoracoabdominal aneurysm repair: a case report and plea for a national database collection. *J Vasc Surg* 2000;31:592–598.
65. Safi HJ, Miller CC 3rd, Azizzadeh A, et al. Observations on delayed neurologic deficit after thoracoabdominal aortic aneurysm repair. *J Vasc Surg* 1997;26:616–622.

66. Widmann MD, DeLucia A, Sharp J et al. Reversal of renal failure and paraplegia after thoracoabdominal aneurysm repair. *Ann Thorac Surg* 1998;65:1153–1155.
67. Estrera AL, Miller CC 3rd, Huynh TT, et al. Preoperative and operative predictors of delayed neurologic deficit following repair of thoracoabdominal aortic aneurysm. *J Thorac Cardiovasc Surg* 2003;126(5):1288–1294.
68. Azizzadeh A, Huynh TT, Miller CC 3rd, et al. Postoperative risk factors for delayed neurologic deficit after thoracic and thoracoabdominal aortic aneurysm repair: a case-control study. *J Vasc Surg* 2003;37(4):750–754.
69. Huynh TT, van Eps RG, Miller CC 3rd, et al. Glomerular filtration rate is superior to serum creatinine for prediction of mortality after thoracoabdominal aortic surgery. *J Vasc Surg* 2005;42(2):206–212.
70. Kouchoukos NT, Masetti P, Mauney MC, et al. One-stage repair of extensive chronic aortic dissection using the arch-first technique and bilateral anterior thoracotomy. *Ann Thorac Surg* 2008;86:1502–1509.
71. Kouchoukos NT, Masetti P, Murphy SF. Hypothermic cardiopulmonary bypass and circulatory arrest in the management of extensive thoracic and thoracoabdominal aortic aneurysms. *Semin Thorac Cardiovasc Surg* 2003;15:333–339.
72. Tabayashi K, Motoyoshi N, Saiki Y, et al. Efficacy of perfusion cooling of the epidural space and cerebrospinal fluid drainage during repair of extent I and II thoracoabdominal aneurysm. *J Cardiovasc Surg* 2008;49:749–755.
73. Coselli JS, Bozinovski J, LeMaire SA. Open surgical repair of 2286 thoracoabdominal aortic aneurysms. *Ann Thorac Surg* 2007;83:S862–S864.
74. Lemaire SA, Jones MM, Conklin LD, et al. Randomized comparison of cold blood and cold crystalloid renal perfusion for renal protection during thoracoabdominal aortic aneurysm repair. *J Vasc Surg* 2009;49(1):11–19; discussion 19.
75. Conrad MF, Crawford RS, Davison JK et al. Thoracoabdominal aneurysm repair: a 20-year perspective. *Ann Thorac Surg* 2007;83:S856–S861.
76. Rigberg DA, McGory ML, Zingmond DS, et al. Thirty-day mortality statistics underestimate the risk of repair of thoracoabdominal aortic aneurysms: a statewide experience. *J Vasc Surg* 2006;43:217–222.
77. Quinones-Baldrich WJ. Descending thoracic and thoracoabdominal aortic aneurysm repair: 15-year results using a uniform approach. *Ann Vasc Surg* 2004;18:335–342.
78. Fehrenbacher JW, Hart DW, Huddleston E, et al. Optimal end-organ protection for thoracic and thoracoabdominal aortic aneurysm repair using deep hypothermic circulatory arrest. *Ann Thorac Surg* 2007;83:1041–1046.
79. Etz CD, Halstead JC, Spielvogel D, et al. Thoracic and thoracoabdominal aneurysm repair: is reimplantation of spinal cord arteries a waste of time? *Ann Thorac Surg* 2006;82:1670–1677.
80. Etz CD, Di Luozzo G, Bello R, et al. Pulmonary complications after descending thoracic and thoracoabdominal aortic aneurysm repair: predictors, prevention, and

treatment. *Ann Thorac Surg* 2007;83:S870–S876.

81. Safi HJ, Miller CC 3rd, Estrera AL, et al. Staged repair of extensive aortic aneurysms: morbidity and mortality in the elephant trunk technique. *Circulation* 2001;104:2938–2942.
82. Svensson LG, Crawford ES, Hess KR, et al. Variables predictive of outcome in 832 patients undergoing repairs of the descending thoracic aorta. *Chest* 1993;104:1248–1253.
83. Okita Y, Tagusari O, Minatoya K, et al. Is distal anastomosis only to the true channel in chronic type B aortic dissection justified? *Ann Thorac Surg* 1999;68:1586–1591.
84. Gilling-Smith GL, Worswick L, Knight PF, et al. Surgical repair of thoracoabdominal aortic aneurysm: 10 years' experience. *Brit J Surg* 1995;82:624–629.
85. Dudra J, Shiiya N, Matsui Y, et al. Operative results of thoracoabdominal repair for chronic type B aortic dissection. *J Cardiovasc Surg* 1997; 38: 147–151.
86. Safi HJ, Miller CC 3rd, Estrera AL, et al. Chronic aortic dissection not a risk factor for neurologic deficit in thoracoabdominal aortic aneurysm repair. *Eur J Vasc Endovasc Surg* 2002;23:244–250.
87. Safi HJ, Miller CC 3rd, Reardon MJ, et al. Operation for acute and chronic aortic dissection: recent outcome with regard to neurologic deficit and early death. *Ann Thorac Surg* 1998;66:402–411.
88. Dake MD, Miller DC, Semba CP, et al. Transluminal placement of endovascular stent-grafts for the treatment of descending thoracic aortic aneurysms. *N Engl J Med* 1994;331:1729–1734.
89. Quiñones-Baldrich WJ, Panetta TF, Vescera CL, et al. Repair of type IV thoracoabdominal aneurysm with a combined endovascular and surgical approach. *J Vasc Surg.* 1999;30:555–560.
90. Zhou W, Reardon M, Peden EK, et al. Hybrid approach to complex thoracic aortic aneurysms in high-risk patients: surgical challenges and clinical outcomes. *J Vasc Surg* 2006;44:688–693.
91. Patel R, Conrad MF, Paruchuri V, et al. Thoracoabdominal aneurysm repair: hybrid versus open repair. *J Vasc Surg.* 2009;50:15–22.
92. Böckler D, Kotelis D, Geisbüsch P, et al. Hybrid procedures for thoracoabdominal aortic aneurysms and chronic aortic dissections – a single center experience in 28 patients. *J Vasc Surg.* 2008;47:724–732.
93. Lee CW, Beaver TM, Klodell CT Jr, et al. Arch debranching versus elephant trunk procedures for hybrid repair of thoracic aortic pathologies. *Ann Thorac Surg.* 2011;91(2):465–471.
94. Chiesa R, Tshomba Y, Melissano G, et al. Hybrid approach to thoracoabdominal aortic aneurysms in patients with prior aortic surgery. *J Vasc Surg* 2007;45:1128–1135.
95. Milewski RK, Szeto WY, Pochettino A, et al.. Have hybrid procedures replaced open

aortic arch reconstruction in high-risk patients? a comparative study of elective open arch debranching with endovascular stent graft placement and conventional elective open total and distal aortic arch reconstruction. *J Thorac Cardiovasc Surg.* 2010;140(3):590–597.

96. Lobato AC, Camacho-Lobato L. Endovascular treatment of complex aortic aneurysms using the sandwich technique. *J Endovasc Ther.* 2012;19(6):691–706.
97. Orr N, Minion D, Bobadilla JL. Thoracoabdominal aortic aneurysm repair: current endovascular perspectives. *Vasc Health Risk Manag.* 2014;10:493–505.
98. Tolenaar JL, van Keulen JW, Trimarchi S, et al. The chimney graft, a systematic review. *Ann Vasc Surg.* 2012;26(7):1030–1038.
99. Greenberg R, Eagleton M, Mastracci T. Branched endografts for thoracoabdominal aneurysms. *J Thorac Cardiovasc Surg.* 2010; 140(Suppl 6):S171–S178.
100. Marzelle J, Presles E, Becquemin JP. Results and factors affecting early outcome of fenestrated and/or branched stent grafts for aortic aneurysms: a multicenter prospective study. *Ann Surg.* 2015; 261(1):197–206.

Chapter 96

Abdominal Aortic Aneurysms

Adam W. Beck, Kristina A. Giles, and Thomas S. Huber

Key Points

1. An aneurysm is defined as a permanent, focal dilation of an artery that exceeds 1.5 times the normal, expected diameter.
2. The risk factors for abdominal aortic aneurysm include age, male gender, smoking, family history, hypertension, chronic obstructive pulmonary disease and the presence of other aortoiliac or peripheral aneurysms.
3. The diameter of an aneurysm is the greatest predictor of rupture as predicted by the tangential stress of the vessel wall.
4. The natural history of abdominal aortic aneurysms is to increase in size with a mean growth rate of 0.4 cm/yr.
5. The treatment of abdominal aortic aneurysm represents a balance between the risk of rupture and the operative mortality rate.
6. Infrarenal abdominal aortic aneurysms should be repaired in men when their diameter reaches 5.5 cm and in women when the diameter reaches 5 cm provided they are a reasonable operative risk.
7. CT arteriography is both the diagnostic study of choice and the sole imaging study required for operative planning.
8. Endovascular repair is the preferred choice by both patients and providers in the United States.
9. Endovascular aneurysm repair mandates long-term follow-up with serial imaging to confirm the integrity of the device and repair.

Abdominal aortic aneurysms (AAAs) are a common problem in developed countries and represent a significant public health concern globally. Operative repair is the only means to reduce the risk of rupture and the associated mortality. The treatment algorithm represents a balance between the risk of repair and the ongoing risk of rupture. The open technique has been the traditional approach since its description by Dubost et al.[1] in the early 1950s. The endovascular approach has emerged as the preferred treatment since its commercial release at the turn of the 21st century and has truly revolutionized the care of patients with AAAs.

DEFINITIONS AND CLASSIFICATIONS

1 An aneurysm is defined as a permanent, focal dilation of an artery that exceeds 1.5 times the normal, expected diameter.[2] The diameter of a normal abdominal aorta in an adult male is approximately 2 cm (range, 1.4 to 3 cm), and, therefore, a 3-cm aorta would be considered aneurysmal.[3] The abdominal aorta is consistently larger in men than in women and increases slightly with age for both genders.[4] AAAs should be differentiated from other conditions in which the size of the aorta is increased, including ectasia and arteriomegaly. In aortic *ectasia,* the diameter is increased by less than 1.5 times of the normal, expected diameter. The term *arteriomegaly* refers to a diffuse (nonfocal) enlargement of several arterial segments with increases in diameter greater than 50% of the normal expected diameter. Arterial segments in patients with arteriomegaly may be considered aneurysmal if the diameter of a segment is increased by more than 50% of the diameter of an adjacent segment. The term *aneurysmosis* denotes the presence of multiple aneurysmal segments separated by either normal, occluded, or arteriomegalic segments.

AAAs are classified primarily according to how far they extend cephalad (Fig. 96-1). More than 95% of all abdominal aortic aneurysms are classified as infrarenal.[5] These aneurysms start below the renal arteries, and may be termed “juxtarenal” when closely approximating the renal arteries, generally less than 10 mm along the centerline of flow below the renal orifices. AAAs classified as suprarenal extend above the renal orifices to the level of the superior mesenteric or celiac arteries. Aneurysms involving the thoracic and abdominal aorta are designated as thoracoabdominal aortic aneurysms and are classified according to how far they extend both cephalad and caudal (extent 1 through 4). Aneurysms that extend above the renal arteries are more complicated for both endovascular and open repair, and can be associated with greater morbidity. Some centers report similar outcomes for open juxtarenal and type IV thoracoabdominal aneurysm repair compared to infrarenal aneurysms; however, national results are more discrepant.[5–7] New techniques and endograft design have expanded the indications for endovascular repair to include select juxtarenal and thoracoabdominal aneurysms.[8–10]

Approximately 10% to 20% of all AAAs are associated with aneurysms of the iliac arteries.[11,12] Aneurysm involvement of the iliac vessels is usually confined to the common or internal iliac arteries, with aneurysmal involvement of the external iliac arteries being very rare. The management of AAAs associated with common iliac artery aneurysms may complicate both open and endovascular repair.

MAGNITUDE OF THE PROBLEM

AAAs and their sequelae are common problems in developed countries. The incidence of AAAs in the United States ranges from 1.5% in autopsy series to 3.2% among unselected adult patients screened with ultrasonography.[13] Predictably, the incidence increases among subsets of patients with defined risk factors for AAAs and approximates 50% among patients with either femoral or popliteal artery aneurysms.[13] It should be emphasized that these rates have been determined with the broad definition of an aneurysm (i.e., 1.5 times the normal vessel diameter) and do not necessarily reflect aneurysms that are of sufficient size to merit repair. Furthermore, the incidence of AAAs increased up until the end of the 20th century then has more recently plateaued and even started to decline.[14–16] Changes in incidence may be reflective of smoking trends in the United States.[17] A total of 10,597 deaths were caused by AAAs and/or dissections during 2009 and this corresponded to death rate of 3.5/100,000 as reported by the Centers for Disease Control and Prevention.[18] These numbers may be underestimated because a significant number of sudden deaths in elderly patients may be secondary to undiagnosed ruptured aneurysms. Of note, spanning the time period of the introduction of endovascular AAA repair, death rates from AAA have declined by nearly 50%.[19]

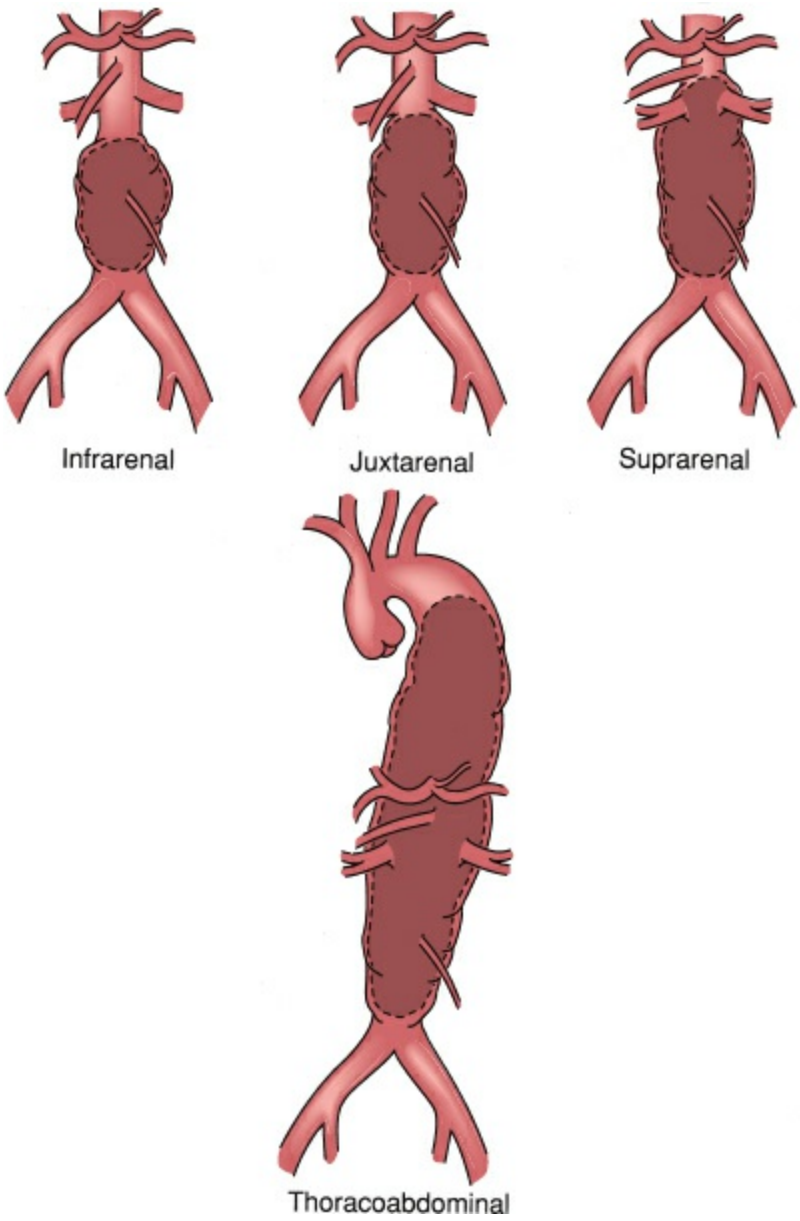

Figure 96-1. Classification of abdominal aortic aneurysms. More than 95% of all abdominal aortic aneurysms are infrarenal. Juxtarenal aneurysms extend to the level of the renal arteries, and suprarenal aneurysms to the level of the superior mesenteric. Aneurysms extending above the superior mesenteric artery and above are designated as thoracoabdominal aneurysms and are classified (Crawford extent I–IV) according to how far they extend cephalad and caudal.

PATHOGENESIS AND RISK FACTORS

The pathogenesis of AAAs remains unresolved, although it is an intense area of both experimental and clinical investigation. Multiple potential etiologic factors have been implicated including atherosclerosis,[20] hemodynamics,[21] collagen,[22] collagenase,[23] elastin,[24] elastase,[25] metalloproteinases,[26] protease inhibitors,[27] programmed cell death (apoptosis),[28] neutrophils,[29] and inflammatory mediators.[30] The etiology is likely multifactorial with interaction between both environmental and genetic factors. Unfortunately, investigation into the potential mechanisms has not resulted in any effective biologic therapies. Elucidation of the pathogenesis has been complicated by the older age of patients at presentation and the absence of suitable animal models.

2 Multiple risk factors have been identified for the development of AAAs, including age, sex, race, smoking, hypertension, hyperlipidemia, peripheral vascular disease, myocardial infarction, and family history.[31,32] Identification of these risk factors is important to facilitate screening high-risk patient populations. AAAs are a disease process of aging and are rare among persons less than 50 years of age. Indeed, the mean age among patients undergoing repair across the country was 75.5 years in a recent Medicare population study.[19] A meta-analysis of the population-based screening studies for AAAs reported that male sex had the strongest association (odds ratio, 5.69).[33] The incidence of death resulting from AAAs for men of 60 to 64 years of age is 11-fold higher than that for women of the same age, but it is only 3-fold higher for men between 85 and 90. Furthermore, men account for approximately 80% of all AAA repairs performed nationally.[19,34] The Aneurysm Detection and Management Veterans Affairs Cooperative Study Group (ADAM) reported that smoking was the strongest modifiable risk factor associated with AAAs >4 cm (odds ratio, 5.57) among the 73,451 veterans screened.[35] Similarly, Wilmink et al.[36] reported that abdominal aneurysms were 7.6 times more likely to develop in current smokers than in nonsmokers and that the duration of smoking rather than level of exposure appeared to correlate with their development. Decreasing prevalence of smoking has correlated with decreasing AAA deaths in the US and European population.[17,37] Darling et al.[38] prospectively analyzed patients undergoing repair of AAAs and reported that 15.1% had a first-degree relative with an aneurysm, in contrast to only 1.8% in the control group. Interestingly, the presence of a female family member with an aneurysm correlated with an increased risk for rupture. Larsson et al.[39] reported from a population-based control study in Sweden that the relative risk of an AAA in first-degree relatives was 1.9 (95% CI, 1.6–2.2). However, the risk of an aneurysm was not affected by the gender of the index individual or relative.

The presence of an aneurysm in the aorta, iliac, femoral, or popliteal arteries dramatically increases the risk for a new or additional AAA. Metachronous aneurysms may develop anywhere in the remaining native aorta, and are commonly seen during follow-up within the residual infrarenal aortic cuff. When this occurs, the etiology of the aneurysm is often unclear and may be related to degeneration of the native aorta, or a pseudoaneurysm that develops at the anastomosis. The incidence of aortoiliac aneurysms in patients with popliteal or femoral artery aneurysms is approximately 50%.[13]

Importantly, all patients found to have one of these peripheral artery aneurysms should undergo a computed tomography (CT) scan of the entire aorta from thorax to the iliac vessels to exclude a synchronous aneurysm in addition to being screened for other peripheral aneurysms. Interestingly, the reverse scenario is not true; patients with aortic or iliac artery aneurysms have a $<5\%$ chance of having a peripheral artery aneurysm, and evaluation beyond physical examination is likely not justified.[40]

The incidence of AAAs is increased among patients with an aortic dissection. Late or repeated operations are required in approximately 20% of patients by 10 years after an acute aortic dissection.[41] The aneurysms may develop in either the thoracic or abdominal aorta, although the former site is more common. The term *dissecting aneurysm* is frequently used to describe fusiform degenerative aneurysms, although it is a misnomer; dissection and aneurysm degeneration are separate processes, but can occur in the setting of the other. Aneurysm false lumen degeneration can occur after a dissection, and dissection of the aorta involved in an existing aneurysm can also occur. Simply, a dissection is a tear within the aortic intima itself that leads to blood flow between the layers of the aorta (within the media) and extends for a variable length resulting in a "true" and "false" lumen.

Interestingly, the prevalence of AAAs and the rate of expansion are both increased among heart transplant patients.[42–44] The responsible mechanisms remain unclear, but the obligatory chronic immunosuppression may contribute. Arguments have been made to initiate screening programs as part of pre- and posttransplant evaluations.

It is notable that the risk factors for AAA are similar to those associated with the development of atherosclerosis with the noted exception of diabetes mellitus.[45,46] Furthermore, atherosclerotic changes are found almost universally within degenerative aneurysms at the time of repair, and the two disease processes are likely related, but it is unclear how. The pathogenesis may be distinct and not necessarily causative.

PRINCIPLES OF MANAGEMENT

The treatment goals for patients with AAAs are to prolong meaningful life, relieve symptoms, and prevent rupture. Because surgical treatment is the only effective means to achieve these goals, the crucial question that must be answered is whether the patient merits repair. The decision algorithm is relatively straightforward for patients with ruptured or symptomatic aneurysms, but more difficult for patients with asymptomatic, intact aneurysms in the elective setting. The decision to recommend prophylactic intervention in the elective setting is contingent on the balance between the risk of the procedure and the risk of expectant or nonoperative management within the context of the patient's desires or wishes and their meaningful life expectancy. Appropriate assessment of these risks requires an understanding of the size-associated risk for rupture, the growth rate, and the morbidity and mortality associated with repair, as well as the natural history of a patient with the risk factors that led to aneurysm disease.

Understanding the natural history of untreated AAA requires knowledge of the physics associated with the vessel wall. The tangential stress (t) of a fluid-filled cylindrical tube is determined by the following equation:

$$t = Pr/d$$

where P is the pressure exerted by the blood (dyne/cm^2), r is the internal radius (cm), and d is the thickness (cm) of the arterial wall.[47] The tangential stress of a cylinder 0.2 cm thick with an internal radius of 0.8 cm and a fluid pressure of 150 mm Hg is 8×10^5 dyne/cm^2 (Fig. 96-2). An increase in the internal radius (diameter) of the cylinder to 2.94 cm and a concomitant decrease in the wall thickness, as might occur with an aneurysm, would increase the tangential stress to 98×10^5 dyne/cm^2. Thus, a 3-fold increase in diameter would result in a 12-fold increase in the tangential stress. Aneurysms rupture when the tangential stress exceeds the tensile strength of the vessel wall. It should be emphasized that the tangential stress varies directly with the radius of the cylinder (vessel), but is independent of its length.

3 The diameter of an AAA is the greatest predictor of rupture as would be predicted by the tangential stress of the vessel wall. The diameter of an aneurysm is determined by measuring its greatest diameter from outer wall to outer wall, preferably using an orthogonal image, throughout the extent of the aneurysm. Orthogonal refers to a cross-sectional measurement perpendicular to the long axis, along the centerline of flow to avoid overestimation due to tortuosity of the aorta. The collective annual rupture risks per aneurysm diameter are shown (Table 96-1).[48] Although there is some variability in the data, it is generally appreciated that the rupture risk for aneurysms less than 5 cm in diameter is small, but increases considerably for those greater than 5.5 cm in men and 5 cm in women. These data may be simplified by using the rule of thumb that the annual rupture risk is $\leq$5% for a 5-cm aneurysm, $\sim$5% for a 5.5-cm aneurysm, 10% for a 6-cm aneurysm, and 20% for a 7-cm aneurysm. These numbers correspond to an estimated 5-year rupture risk of 50% for 6-cm aneurysms and 100% for those of 7 cm. Notably, both the ADAM[35] and UK Small Aneurysm Trial[49] that randomized patients with small

aneurysms (4 to 5.5 cm) to open repair or surveillance reported that the rupture risk for surveillance was ≤1%/yr.

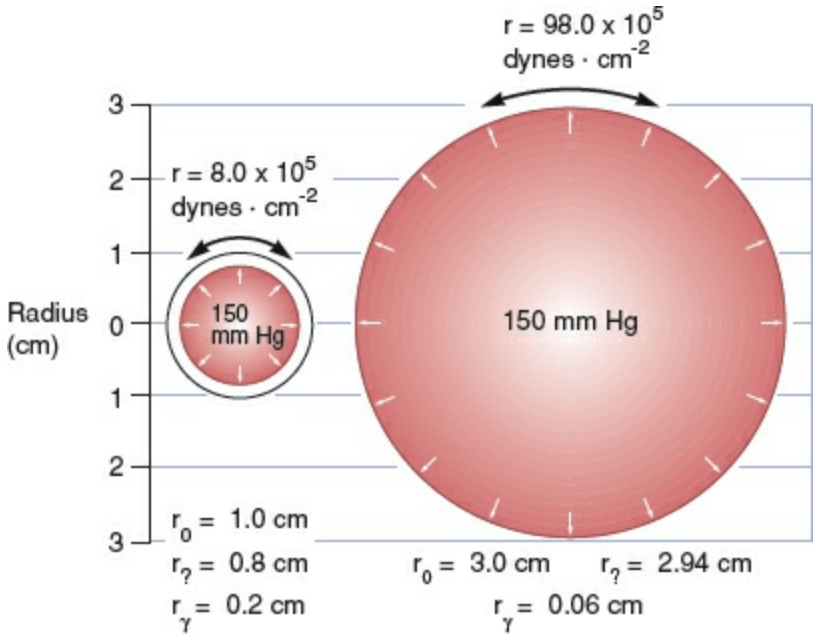

Figure 96-2. Cross-sectional view of a 2-cm-diameter cylinder that expands to a diameter of 6 cm while wall cross-sectional area remains constant. t, wall stress; d, wall thickness; r_i, inside radius; r_0, outside radius. Expansion of a 1-cm-diameter cylinder to a diameter of 3 cm with no change in wall cross-sectional area increases wall tensile stress 12-fold.

A variety of other factors have also been reported to increase the risk of aneurysm rupture including female gender,[50–52] chronic obstructive pulmonary disease,[50,53] smoking,[50] hypertension,[50,53] family history,[54] and wall stress.[55] The UK Small Aneurysm Trial reported that the rupture risk was increased for female gender (hazard ratio, 3), current smoking (hazard ratio, 1.5), severe COPD (hazard ratio, 0.6 per L FEV1), and higher mean arterial pressure (hazard ratio, 1.2/mm Hg). Fillinger et al.[56] used finite element analysis to calculate the wall stress of AAAs and reported that the wall stress of symptomatic/ruptured aneurysms exceeds those for elective aneurysms. The impact of the aneurysm growth rate on rupture risk remains unclear and has been difficult to separate from aneurysm diameter alone.[52] However, an aneurysm expansion of ≥1 cm/yr is generally considered worrisome and a potential risk factor for rupture.

Table 96-1 Estimated Annual Rupture Risk

AAA Diameter (cm)	Rupture Risk (%/yr)
<4	0
4–5	0.5–5
5–6	3–15
6–7	10–20
7–8	20–40
>8	30–50

Reproduced with permission from Brewster DC, Cronenwett JL, Hallett JW Jr, et al. Guidelines for the treatment of abdominal aortic aneurysms. Report of a subcommittee of the Joint Council of the American Association for Vascular Surgery and Society for Vascular Surgery. *J Vasc Surg* 2003;37:1106–1117.

4 The natural history of AAAs is to increase in size. The reported mean rate of growth has varied from 0.2 to 0.3 cm/yr in population studies[57–59] to 0.4 cm/yr from referral practices[60–62] with the latter figure (0.4 cm/yr) generally quoted as a reasonable estimate. Several factors including female gender, current smoking, and larger original diameter have been associated with an increased rate of growth as might be predicted from the risk factors for rupture.[57,59,63] Interestingly, early studies showed that doxycycline and coenzyme A reductase inhibitors (i.e., statins) may inhibit aneurysm growth. More recent literature has shown promise for statins inhibiting growth and rupture of AAA; however, doxycycline has been proven ineffective in a randomized trial.[63–67] It should be emphasized that these growth rates are mean values and that aneurysms do not always grow in a linear fashion, as might be predicted. The growth curve may be somewhat erratic or "staccato" with no growth detected during consecutive 6-month intervals followed by a growth of 0.6 cm during the next follow-up interval.[68] Furthermore, it should be emphasized that the past rate of growth does not predict future growth; patients should not be lulled into a false sense of security if their aneurysm is relatively stable over time, and should be encouraged to continue monitoring with a vascular specialist.

The mortality rate associated with repair of an AAA depends on the status of the aneurysm (intact/asymptomatic, intact/symptomatic, ruptured), the physiologic state of the patient (age and medical comorbidities), and the method of repair (open vs. endovascular). Population studies from Medicare and the Nationwide Inpatient Sample (NIS) have reported that operative mortality rates for *open repair of intact* aneurysms in the United States range from 4.2% to 5.4% over the past decade.[34] Predictably, the operative mortality rate increases with age, ranging from 2.2% among persons of 50 to 59 years of age to 9.2% among those >80. Interestingly, operative mortality rate has been shown to be significantly higher among women (6.1% vs. 3.7%). The mortality rate for open repair in the randomized trials comparing operative repair with surveillance for small aneurysms (UK Small Aneurysm Trial – 5.8%, ADAM – 2.7%) and open repair with endovascular repair (DREAM – 4.6%, EVAR Trial – 4.6%)[69,70] are within the range of these nationwide series. Furthermore, a literature review examining the mortality rate of open AAA repair encompassing 64 individual studies reported a collective rate of 5.5%.[71]

The reported operative mortality rate for *endovascular repair of intact* AAAs has been

consistently less than those for the open approach.[72–78] Schermerhorn et al.[74] reported that the operative mortality after endovascular aneurysm repair (EVAR) was 1.2% among Medicare beneficiaries during 2001 to 2004 while mortality within the NIS through 2005 was 1.3%. Results from the Dutch Randomized Endovascular Aneurysm Management (DREAM) Trial[70] and the Endovascular Aneurysm (EVAR) Trial[79] comparing open and endovascular repair have reported that the perioperative mortality rate is lower for endovascular repair and within the same range (DREAM – 1.2% vs. 4.6%; EVAR Trial – 1.7% vs. 4.7%).

The operative mortality rate for *open repair of intact/symptomatic* aneurysms among patients undergoing emergent repair exceeds that for elective repair and has ranged from 9% to 19%.[13,80,81] Various explanations have been proposed for this increased mortality rate relative to that for intact/asymptomatic aneurysms including failure to maximize preoperative medical conditions, increased incidence of inadvertent venous injuries, and less experienced operative teams, although the true explanation remains unclear. However, in more recent data, De Martino et al.[82] reported from the Vascular Study Group of Northern New England a perioperative mortality of 2.1% and 0% for open and endovascular repair for intact/symptomatic aneurysms, respectively. However, late mortality and in-hospital adverse events were still higher comparable to the asymptomatic cohort.

5 6 The actual mortality rate for ruptured AAAs is somewhat difficult to determine because a significant number of sudden deaths in elderly patients are likely secondary to ruptured aneurysms. It has been estimated that 50% of all patients with ruptured AAAs die outside the hospital, and that approximately 50% of those who actually undergo open repair do not survive.[13] Indeed, a meta-analysis spanning 50 years and 77 studies reported that the operative mortality rate for the *open repair of ruptured* aneurysms was 48%.[83] These figures correspond to an overall mortality rate of approximately 80% although this may be an underestimate. It is remarkable that the optimization of pre-hospital and emergency room care including a reduction in the mean transfer time from the emergency department to the operating room to 12 minutes did not appear to result in a decrease of the mortality rate of ruptured aneurysms.[84] Notably, the operative mortality rate for ruptured aneurysms treated with the open approach has improved slightly over the past few decades with Bown et al.[83] reporting a 3.5% reduction per decade.

The mortality rate for the *endovascular repair of ruptured* AAAs is lower than associated with the open approach, although data may be significantly skewed by selection bias.[19,85–91] Rayt et al.[88] reported a collective mortality rate of 24% for the endovascular approach from 31 studies encompassing 982 patients while other meta-analyses or systematic reviews have reported comparable rates.[86,89] The potential to treat ruptured AAAs with the endovascular approach may represent the greatest contribution or benefit of the technology. However, further validation is necessary since the reports cited above likely reflect both patient selection and publication bias. In population data, Giles et al.[91] and Schermerhorn et al.[19] reported that the annual number of deaths across the country from both intact and ruptured aneurysms has decreased significantly since the

introduction of EVAR.

CLINICAL PRESENTATION AND DIAGNOSIS

7 The overwhelming majority of AAAs are asymptomatic at the time of discovery. Most aneurysms are detected by abdominal or pelvic imaging studies, such as ultrasonography and CT, performed for other indications (e.g., chronic back pain, renal cysts) rather than on physical examination. Indeed, it is often difficult to palpate an AAA on physical examination because of its anatomic location in the posterior abdomen adjacent to the spine and these difficulties are exacerbated in the presence of truncal obesity. A literature review examining the accuracy of physical examination reported that the sensitivity ranged from 33% to 100%, the specificity ranged from 75% to 100%, and the positive predictive value ranged from 14% to 100%.[92] Given these fairly broad ranges, the authors concluded that physical examination could not be relied upon to exclude an AAA. Predictably, the accuracy of primary care physicians for detecting an AAA in patients with known aneurysms is only fair because of the limitations noted above and the failure to actually palpate the aorta during the physical examination. Intact abdominal aortic and iliac artery aneurysms may present with symptoms that lead to further investigation and the correct diagnosis although this is the exception rather than the rule. Rarely, enlargement of the aneurysm may cause vertebral erosion and chronic back pain. In addition, thrombosis of an AAA may cause acute ischemia in the lower torso, and aneurysms may be a source of arterial macroemboli or microemboli leading to acute ischemia of a lower extremity or digit, respectively.

Patients with intact/symptomatic or ruptured aneurysms present with abdominal or back pain related to the aneurysm itself. The character of the pain is variable and ranges from dull to sharp. The pain is usually acute in onset and persistent. It may be superimposed on more chronic abdominal or back pain, but the presentation is usually not subtle, and the pain can be differentiated from more chronic complaints. In addition, the pain may radiate from the abdomen to the back, flank, inguinal region, or genitalia. Approximately 10% of patients with ruptured AAAs present with signs and symptoms similar to those of ureteral colic or other acute urologic problems.[93] For example, the diagnosis of a ruptured aneurysm must be ruled out in a timely fashion in patients who might be at risk for AAA presenting with testicular pain who have a normal urinalysis and testicular examination.

Patients with a ruptured AAA may present anywhere along the spectrum from hemodynamically normal to profound shock. Their status depends on the ability of the tissues adjacent to the aorta to tamponade the bleeding. If the adjacent tissues effectively contain the bleeding, the patient may present in a hemodynamically stable state with essentially normal vital signs. However, it should be emphasized that this is usually a temporary situation, and health care providers should not be lulled into a false sense of security. A ruptured AAA is a true medical emergency that requires immediate operative repair regardless of the patient's hemodynamic status. Tamponade can quickly degenerate into free intraperitoneal rupture and exsanguinating hemorrhage. Furthermore, vital signs may be misleading because patients can lose up to 15% of their blood volume (class 1 shock) without any appreciable change in their pulse rate or blood pressure. If the

aneurysm initially ruptures freely into the peritoneal space, patients usually exsanguinate before they can seek medical attention.

Patients with a ruptured AAA may also present with either an aortoenteric or an aortocaval fistula, although both are relatively rare. Patients with an aortoenteric fistula may present with massive intestinal bleeding, but often present with a "sentinel" bleed that is small volume. The aorta may rupture through any portion of the bowel, although the duodenum and proximal small bowel are the most common sites. The overwhelming majority of aortoenteric fistulae result from the erosion of a prosthetic graft into the adjacent bowel (secondary aortoenteric fistula) rather than from an unrepaired aneurysm (primary aortoenteric fistula). The diagnosis of an aortoenteric fistula must be ruled out in all patients with gastrointestinal bleeding and either an AAA or a previous infrarenal aortic reconstruction. Patients with an aortocaval fistula generally present with high-output congestive heart failure, a continuous abdominal bruit, and edema of the lower extremities. The severity of the heart failure symptoms depends on the size of the fistula and the magnitude of the systemic shunt.

8 Several imaging studies are available to establish or confirm the diagnosis of an AAA. Indeed, the introduction of endovascular techniques for aneurysm repair has resulted in an evolution of these modalities. The generic imaging goals for patients with an AAA are to establish the diagnosis, determine the presence of rupture, determine the cephalad/caudal extent of the aneurysm, determine the feasibility of endovascular repair, appropriately size the aneurysm and access vessels for endovascular repair, screen for other visceral pathology, and screen for the presence of anatomic variants that would complicate operative repair, such as a left-sided vena cava or a horseshoe kidney. Although no imaging study satisfies every objective, ultrasound has emerged as the ideal *screening* study with CT arteriography being the definitive *diagnostic* test and the preferred modality for operative planning.

Abdominal ultrasound is a safe, simple, and inexpensive means of detecting AAAs (Fig. 96-3). It is relatively inexpensive and does not require the use of ionizing radiation or intravenous contrast. Furthermore, ultrasound units are portable and almost universally available in the hospital setting including the emergency room.[94] The sensitivity of ultrasound for detecting AAAs is acceptable, and the technique is reproducible within 0.3 cm in experienced hands.[95] However, the technique is quite operator-dependent and potentially confounded by the presence of bowel gas or extreme obesity. Ultrasound can accurately image the infrarenal aorta to its bifurcation but is less reliable for imaging the portions of the aorta proximal to the renal arteries and distal to the iliac vessels. Furthermore, it is not as reliable as CT for differentiating a ruptured from an intact aneurysm. However, ultrasound is an excellent tool for screening patients at high risk for an AAA and for confirming the presence of an aneurysm suspected by physical examination or clinical presentation. Further, it is a useful technique to follow patients with small aneurysms (<4 cm) when the exact measurement is not crucial. It should not be used to confirm the diagnosis of a ruptured aneurysm, nor should it be used as the sole imaging study before elective repair because it does not provide a complete image of the aorta and iliac arteries.

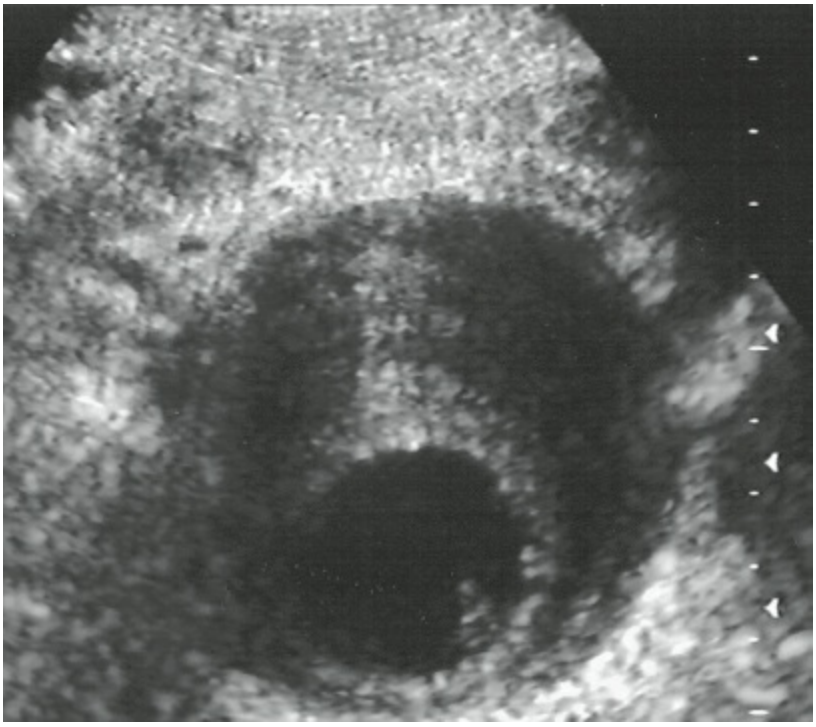

Figure 96-3. B-mode ultrasound image showing a transverse view of an infrarenal abdominal aortic aneurysm. Note the vessel wall and the large quantity of intraluminal clot surrounding the smaller, blood-filled center (*dark circle*).

CT arteriography overcomes many of the limitations of ultrasound and represents the current "gold standard" for imaging patients with AAAs (Fig. 96-4). The downside of CT is the greater expense and the potential harm that may be caused by the requisite ionizing radiation and intravenous contrast. Indeed, the evolution of EVAR and the required follow-up imaging studies have focused increased attention on the magnitude of long-term radiation injury. It is worth noting that the radiation dose associated with an abdominopelvic CT scan is 10 to 20 mGy while that for a routine chest radiograph is only 0.5 mGy. The incidence of allergic reactions to the contrast may be reduced by a steroid preparation while the potential nephrotoxicity can be reduced by acetylcysteine or sodium bicarbonate.[96,97] Of course, the renal risks can be avoided altogether by not using contrast. However, the quality of the noncontrast images is less than optimal, and is generally not useful for determining eligibility for endovascular repair. CT is very sensitive for detecting both intact and ruptured aneurysms, and the images are reproducible within 0.2 cm.[95] The quality of the CT images has continued to improve with each new generation of scanners, and the image acquisition times have decreased. Currently, CT imaging of the arterial tree from the ascending aorta to the femoral arteries can be obtained with an image acquisition time of less than 45 seconds. Given the quality and ease of imaging, CT arteriograms have essentially replaced traditional catheter-based diagnostic arteriograms for evaluation of aneurysms. Using axial CT images and 3D imaging software, a 3D image of the aorta can be obtained that allows measurements along the centerline of blood flow (Fig. 96-5), and dramatically improve the accuracy and consistency of sizing for endovascular repair.[98] CT is also helpful for detecting other intra-abdominal pathology or anatomic variants that may impact the operative approach. Specific concerns include the location of the left renal vein and other

associated venous anomalies, the location and size of the kidneys, and the characteristics of the aneurysm wall. CT is currently the sole diagnostic test performed before repair in the majority of cases and the imaging study of choice to confirm or refute the diagnosis of a ruptured AAA. In addition, CT is the serial imaging study of choice when aneurysms exceed 4 cm and approach the threshold for intervention.

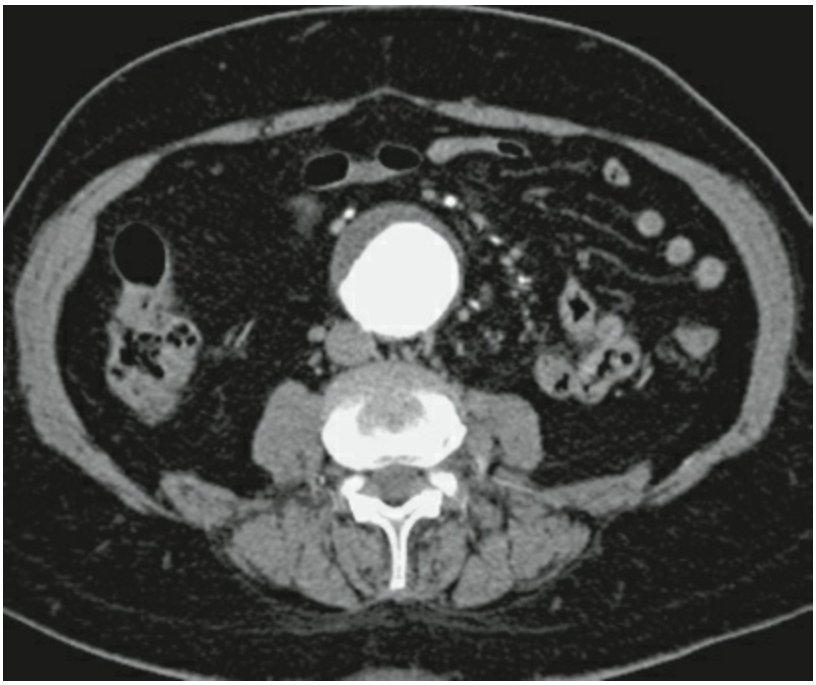

Figure 96-4. CT scan demonstrates a large abdominal aortic aneurysm. Note that the majority of the lumen is filled with contrast.



Figure 96-5. 3D CT of the aorta and the iliac, femoral, and visceral arteries is shown. Note the infrarenal abdominal aortic aneurysm that extends to the aortic bifurcation.

Both magnetic resonance imaging (MRI) and catheter-based arteriography have been used as diagnostic imaging studies for patients with AAAs. The image quality and overall sensitivity of MRI is comparable to CT, but the technology is not as widely available and most surgeons are less familiar with interpreting the images. Furthermore, the technique is relatively contraindicated for patients with ferromagnetic devices (e.g., pacemakers, joints) or renal insufficiency, and imaging critically ill patients is cumbersome, if not prohibitive.

Importantly, aneurysms are frequently diagnosed during catheter-based arteriography performed for other purposes, but this should not be viewed as a diagnostic test of choice for AAAs. An arteriogram only delineates the lumen of the vessels (i.e., aorta, iliac and femoral arteries), and thus gives no indication of aneurysm extent or diameter. AAAs are often filled with laminated thrombus and may have a relatively normal appearing lumen. The "lumenogram" produced by the contrast reflects the patent lumen rather than the "true" lumen of the vessel (and the actual cross-sectional diameter of the aneurysm).

The diagnostic approach and initial treatment for patients with a potential ruptured aneurysm merit further comment. Because of the high attendant mortality rate, prompt diagnosis and repair are necessary. In a study from the Cleveland Clinic Vascular Registry, the operative mortality rate associated with ruptured AAAs increased from 35% when the initial diagnosis was correct to 75% when incorrect.[99] Admittedly, the clinical

presentation may be confusing, and delays in diagnosis are not uncommon. The classic triad of hypotension, abdominal pain, and a pulsatile abdominal mass was present in only 50% of patients with ruptured aneurysms in a single institutional series.[100]

Elderly patients who present to the emergency room in a hemodynamically *unstable* state with abdominal or back pain can often be evaluated quickly in the emergency department with ultrasound or CTA if they are stable enough for the examination. The potential causes of shock (i.e., hypovolemic, cardiogenic, septic, neurogenic) can usually be quickly differentiated by a brief history and physical examination. However, this clinical scenario is most suggestive of hypovolemic or hemorrhagic shock resulting from an intra-abdominal catastrophe. The differential diagnosis is extensive and includes pancreatitis, mesenteric infarction, acute Addisonian crisis, and rupture of a visceral artery aneurysm in addition to rupture of an AAA. A myocardial infarction can mimic a ruptured aneurysm in this patient population and potentially confounds the diagnosis, although it can usually be confirmed by the findings on electrocardiogram. Additional diagnostic imaging has not traditionally been considered necessary in this setting and, indeed, has been considered potentially harmful due to the obligatory delay in getting patients to the operating room. Due to the dramatic reduction in CT acquisition times and the potential feasibility of endovascular repair, abdominal/pelvic CT scans are allowable in this scenario to confirm the diagnosis and plan the operative procedure, provided it can be performed expeditiously. This approach has the added advantage of reducing the number of negative abdominal explorations in critically ill patients. A natural history study of patients with ruptured AAAs not offered operative repair reported that $<15\%$ of the patients died within 2 hours of hospital admission.[101] Based upon these findings, the authors concluded that most patients with ruptured aneurysms are sufficiently stable to undergo a CT scan and this opinion has been supported by improved mortality results of EVAR for ruptured aneurysms.[89]

Several findings on CT are suggestive of a ruptured AAA including disruption of the calcium ring within the aortic wall, disruption of the aortic margins, retroperitoneal hematomas, mass lesions in the psoas region, displacement of the kidneys, abnormal soft tissues posterior to the aorta, effacement of the normal fat planes between the aorta and adjacent viscera, and abnormal retroperitoneal fluid collections (Fig. 96-6). Patients undergoing an emergent CT arteriogram to rule out a ruptured AAA should not receive oral contrast because of the delay associated with its administration and the confounding effects on the imaging of the vessels.

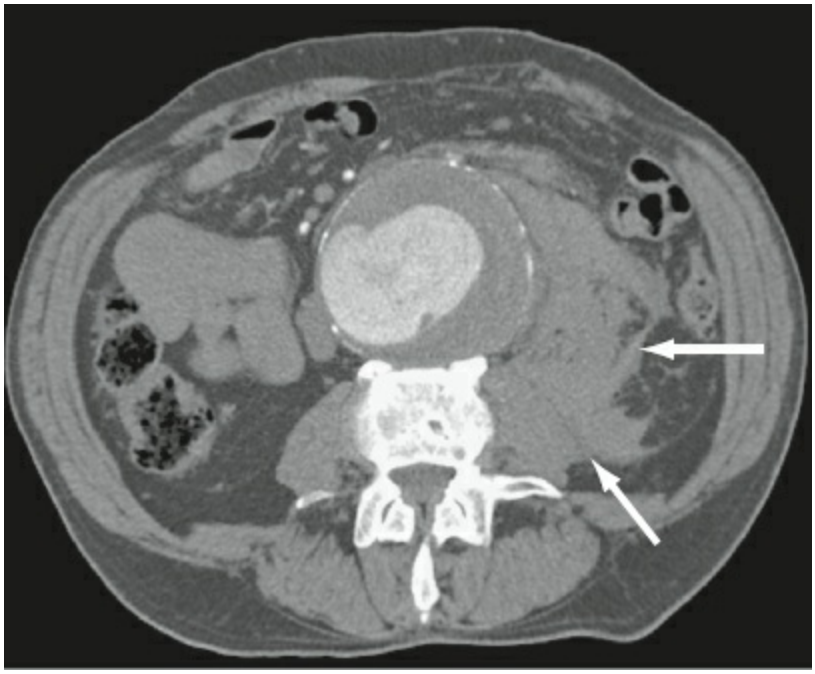

Figure 96-6. Contrast CT demonstrates a ruptured abdominal aortic aneurysm. Note the large retroperitoneal hematoma and the loss of the normal fat plane anterior and lateral to the left psoas muscle.

The diagnosis of a ruptured AAA should be considered in elderly patients that present to the emergency room hemodynamically *stable* with abdominal or back pain. Admittedly, the differential diagnosis for abdominal or back pain in this patient population is extensive, and the incidence of a ruptured AAA is small. An expeditious history and physical examination can usually determine the cause of the pain. A pulsatile abdominal aortic mass, an unexplained low hematocrit, or hemodynamic instability before presentation are particularly worrisome and increase the level of suspicion. The diagnosis of an AAA may be confirmed with a portable abdominal ultrasound in the emergency room.[94] Indeed, the current trauma algorithms include abdominal ultrasound as a diagnostic technique for blunt trauma, and many centers have ultrasound units assigned to the emergency room and personnel who are appropriately trained. If ultrasound confirms the diagnosis of an aneurysm, further evaluation with CT should be obtained to rule out rupture. Alternatively, a CT may be obtained as the sole imaging study. Any findings consistent with a ruptured aneurysm on CT mandate direct transfer to the operating room and immediate repair. Aggressive fluid resuscitation should be avoided and mild hypotension (i.e., systolic pressure >80 mm Hg) tolerated in conscious patients due to the theoretical potential to cause the aneurysm to rupture into the peritoneal cavity and/or release the tamponade effect of the retroperitoneal tissue. If an intact aneurysm is found on CT without any suggestion of rupture, the next logical question is whether the aneurysm is the source of the pain. Symptomatic aneurysms are likely associated with an increased risk of rupture although the natural history remains poorly defined. Patients with symptomatic/intact aneurysms ≥ 5 cm in diameter should be admitted to a monitored setting and scheduled for urgent operative repair, usually the following day, provided no alternative causes for the pain are identified. Additional sources of the abdominal pain should be sought in patients with aneurysms smaller than 4

cm in light of the small rupture risk. The appropriate treatment for patients with aneurysms 4 to 5 cm is less clear. These aneurysms have the potential to rupture although the risk is small. It is recommended that these patients be admitted and the source of their pain further investigated. However, urgent operative repair is recommended if no additional causes are identified.

The role of screening for AAAs in asymptomatic patients has been partially clarified. The United States Preventative Task Force has issued a position statement advocating a single screening ultrasound in males 65 to 75 years of age who have a smoking history and selective screening for males without smoking history.[102] These recommendations were based upon the results of a best-evidence systematic review that identified four population-based randomized controlled trials demonstrating that screening resulted in a reduction of aneurysm-related mortality.[103] Notably, the Preventative Task Force stated that the literature did not substantiate screening for women even among those who smoke or have a family history and stated that the harms of screening outweighed the risks for screening women who have never smoked. Screening for AAAs in this subset of elderly men has been shown to be both cost effective[104] and comparable to other screening programs in adult patients.[105] Despite the Preventative Task Force's recommendations, screening should likely be extended to other high-risk patient populations including patients with a first-degree relative with an AAA, evidence of a peripheral artery aneurysm, and those undergoing evaluation for heart transplantation. Medicare currently pays for a single screening ultrasound as part of the Welcome to Medicare physical examination for men who have smoked sometime during their life and for both men and women with a family history of AAAs.

OPERATIVE INDICATIONS

All patients with symptomatic or ruptured AAAs should undergo operative repair unless they have an underlying medical condition, such as metastatic cancer, that precludes long-term survival or their quality of life is not sufficient to justify the intervention. The latter situation entails a difficult decision, but not offering operative repair should be considered in certain cases (e.g., a debilitated, demented patient in a nursing home) after discussion with the patient if he or she is alert and coherent and with the patient's family.

The operative decision-making process for intact/asymptomatic AAAs is a complex one that needs to be tailored to the individual patient. Indeed, there is no single parameter that merits repair. The operative indications are contingent upon the size of the aneurysm, life expectancy, comorbidities, preference, and anatomic configuration. It is important to remember that the repair of an intact/asymptomatic AAA is a prophylactic operation that represents a balance between the operative risk and the future risk of rupture with the ultimate treatment goals to prolong life, relieve symptoms, and prevent rupture.

The diameter of the AAA is the best predictor of rupture as stated above and has been used as the most common indication for repair. There has been a change in the diameter-based operative criteria within the past few decades although this has been clarified more recently with level 1 evidence. It is interesting to note that the diameter threshold for good-risk patients has decreased from 6 cm to as low as 4 cm with latter recommendation from the guidelines of the national vascular surgical societies.[95] Both the UK Small Aneurysm Trial[49] and the ADAM Trial[35] concluded that it was safe to follow patients with 4- to 5.5-cm aneurysms and that early operation did not confer any long-term survival benefit. As noted above, the rupture risk for patients in the surveillance group was $<1\%$/yr. It is important to note that more than 60% of the patients in both studies ultimately underwent operative repair despite their initial randomization. A longer-term follow-up study from the UK Small Aneurysm Trial extending to 12 years did not demonstrate a survival benefit for the patients assigned to early surgery.[106] However, it is important to note that almost all of the patients that survived ultimately required repair since their aneurysms continued to grow and exceed the 5.5-cm threshold. Indeed, the relevant question may not be whether patients with small aneurysm need to be repaired, but rather when they need to be repaired. In a separate publication from the UK Small Aneurysm Trial, Brown et al.[50] reported that the rupture risk for women was over 4-fold higher, as noted above, suggesting that the 5.5-cm diameter threshold for repair may be too high for women. The proponents of smaller diameter-based thresholds for repair (i.e., <5.5 cm) have justified their approach stating that even small aneurysms rupture, aneurysms continue to increase in diameter and will likely need to be repaired, the patients' medical conditions will likely deteriorate with age, and the operative mortality/morbidity rate for small aneurysms may be less. Although the level 1 evidence does not support this lower threshold, it is important to note that the size discrepancy between a 5.2-cm and a 5.5-cm aneurysm is very small and likely within the resolution of the imaging study.

The presence of medical comorbidities predictably impacts the perioperative mortality rate and threshold for repair. Steyerberg et al.[107] identified several independent risk factors for operative mortality during open repair, including renal insufficiency (creatinine >1.8 mg/dL, congestive heart failure, ECG ischemia, pulmonary dysfunction, older age, and female gender) and these have remained consistent throughout the literature. Similarly, Beck et al.[72] developed a predictive model for both open and endovascular repair using a prospective registry from the Vascular Study Group of New England. They reported that chronic obstructive pulmonary disease, suprarenal aortic clamp, renal insufficiency and advanced age (≥70) were predictive of mortality at 1 year after open repair with the mortality ranging from 1% to 67% depending upon the number of risk factors. Congestive heart failure and larger aneurysm diameter (≥6.5 cm) were the only predictive factors after endovascular repair with the mortality ranging from 4% to 23%. The consistent, dramatic impact of renal insufficiency was further emphasized by a national series that reported a 9-fold increase in mortality. Notably, the estimated glomerular filtration rate may be a better index of renal function than serum creatinine and, therefore, likely a better predictor of adverse outcome. Life expectancy is inseparable from comorbidities, but it should be emphasized that the average life expectancy for a 60-year-old and an 85-year-old man in the United States is 18 and 5 years, respectively.[108]

Patient preference should be factored into the operative decision process. Although the level 1 evidence suggests that it is safe to follow AAAs until they reach the 5.5-cm threshold, patients may not be willing to accept this small, finite risk and desire to have their aneurysm repaired a lower threshold. Indeed, patients often echo the justification for early repair proposed by surgeons.

The anatomic configuration of the aneurysm and/or the associated structures should factor into the operative decision process as well. Any technical factors that complicate the repair likely increase the perioperative mortality/morbidity including the need for suprarenal clamp application due to the obligatory renal/visceral ischemia, venous anomalies (e.g., left-sided vena cava), renal anomalies (e.g., horseshoe kidney), and inflammatory aneurysms. Admittedly, many of these technical concerns are relevant only to the open approach and can be overcome/avoided by endovascular repair provided that it is an option from an anatomic standpoint. Anatomic concerns relevant to endovascular repair include continued aneurysm degeneration of the aortic neck or iliac arteries that may make standard infrarenal endograft repair more difficult or impossible unless early repair is undertaken.

The introduction of the endovascular approach has challenged the operative indications for intact/asymptomatic aneurysms. Indeed, the significant decrease in the perioperative mortality rate reported in both the DREAM[109] and EVAR Trials[79] appear to justify lowering the threshold. However, it is important to note that the rupture rate for aneurysms less than 5.5 cm in the UK Small Aneurysm[49] and ADAM[110] Trials was <1%/yr which is still lower than the perioperative mortality rate for endovascular repair reported from DREAM,[109] EVAR,[79] and most of the national databases.[73,74,111] Similarly, Finlayson et al.[112] used a decision analysis model to determine the optimal diameter for

open and EVAR and concluded that the endovascular approach lowers the operative threshold only for older patients in poor health.

The Joint Council of the American Association for Vascular Surgery and the Society for Vascular Surgery have released updated guidelines for the treatment of patients with AAAs that address the concerns highlighted above.[48] They recommend that a diameter of 5.5 cm is an appropriate threshold for repair in the "average patient" with an intact infrarenal aneurysm, but emphasize the importance of individualizing each case. They state that rapid aneurysm expansion (>1 cm/yr), symptoms related to the aneurysm, and female gender merit repair at a smaller diameter while consideration should be given to earlier repair in young patients provided that the operative mortality rate is acceptable. Furthermore, they recommend that a larger diameter threshold is appropriate in higher risk patients and emphasize that there does not appear to be any justification to alter the operative threshold for the endovascular approach. A reasonable approach, and one that we have adopted in our own practice, is to use 5.5 cm as a threshold for repair in men and 5 cm for women.

Patients that do not meet the threshold for operative repair should be followed closely. It is important to educate the patients about their underlying disease process and emphasize the importance of long-term follow-up. Notably, Valentine et al.[113] reported that 32% of patients with small aneurysms managed by "watchful waiting" were noncompliant with their follow-up plan. Furthermore, it is important to counsel patients about the presence of symptoms associated with rupture and the importance of seeking urgent medical attention. Guidelines have suggested that patients with aneurysms <3 cm in diameter should be re-imaged at 5 years while those with between 3 and 3.4 cm should be re-imaged at 3 years and those between 3.5 and 3.9 cm should be re-imaged at 1 year.[114] Aneurysms >4 cm should likely be re-imaged every 6 months. As noted above, abdominal ultrasound is likely the most appropriate imaging study for aneurysms <4 cm with CT more appropriate above that threshold. It is important to note that up to 50% of the patients deemed a prohibitive operative risk and not offered elective repair will ultimately die from a ruptured aneurysm.[115–119] These patients who are not candidates for elective repair should not be offered emergent repair in the event that their aneurysm ruptures or becomes symptomatic. Patients and families should be counseled on this matter preemptively to minimize difficulty and inform decisions when rupture occurs.

CHOICE OF OPEN OR ENDOVASCULAR REPAIR

After the decision to recommend operative repair has been made, the technique for repair needs to be determined. Admittedly, these decisions are somewhat interrelated since the decision to recommend operative repair in certain subsets of patients is oftentimes contingent upon whether they are candidates for the endovascular approach. The past two decades have witnessed a rapid evolution of the endovascular technique, and, indeed, this evolution has helped define our discipline. It has been clearly demonstrated that the technical success rates for endovascular graft repair are excellent and the need for intraoperative conversion to open repair negligible. The perioperative events and mid-term outcomes have been defined by level-1 evidence. Many of the technical limitations inherent to the earlier endovascular devices and anatomic limitations have been overcome. Despite the lack of definitive long-term outcome data, the endovascular approach for treatment of AAAs has been widely applied. Indeed, the endovascular approach eclipsed open repair in the United States in 2005 and recent data shows that 75% or more aneurysms are repaired in this manner.[120] The choice of open or endovascular repair is complicated and contingent upon several factors including feasibility, outcome, comorbidities, compliance, cost, and preference. It is imperative that these issues, including their respective advantages/disadvantages or strengths/weakness, be addressed with the patients during the decision process to ensure proper informed consent.

The initial determinant of the approach is the anatomic configuration of the aorta, the aneurysm, and the access vessels. The commercially available endovascular devices come in a finite range of sizes and, thus, are suitable only if specific anatomic conditions are satisfied. Although the number of available devices and their specific characteristics are constantly evolving, the “generic” endograft consists of a fabric graft (i.e., polyester or ePTFE) and a metallic endo/exoskeleton (i.e., stainless steel or nitinol) that facilitates proximal/distal fixation by the radial force of the stent (Fig. 96-7). In some devices, proximal fixation is augmented by the presence of suprarenal hooks. The “generic” devices are modular and consist of either two (main body and contralateral iliac limb) or three (main body, contralateral iliac limb, ipsilateral iliac limb) components with a variety of additional ancillary pieces that allow proximal or distal extensions at the aortic and iliac ends, respectively. The initial experience with aortoaortic or “tube graft” configurations were unsuccessful due to problems with the distal landing site at the aortic bifurcation and have been abandoned. Indeed, the current strategy is to seat the proximal component of the bifurcated system as close to the lowest renal artery as possible and the distal components as close to the iliac bifurcation as possible to improve immediate seal and fixation and decrease the potential for later aneurysm degeneration at or adjacent to seal sites.



Figure 96-7. The current commercially available infrarenal endografts in the United States are shown: Cook Zenith (**A**); Medtronic Endurant (**B**); Trivascular Ovation (**C**); Gore Excluder (**D**); Endologix Powerlink (**E**); Lombard Aorfix (**F**). These are modular devices consisting of a main body, iliac limbs/extensions and main body extensions. Note the common theme of bilateral iliac limbs and a main body. There are many differences between these endografts, which make them each uniquely suited for some patients. On the top row (**A,B,C**), the devices all utilize a bare suprarenal stent construct to facilitate fixation. On the lower row (**D,E,F**), the devices utilize active fixation with hooks (**D,F**) or anatomic fixation at the aortic bifurcation (**E**).

Although there is some variability among the commercially available devices in terms of their specific sizes and anatomic constraints, the general anatomic requirements are somewhat similar. The infrarenal abdominal aorta must have a suitable, nonaneurysmal landing zone for the endograft that measures ≥10 to 15 mm in length and ≥17 to 19

mm, but ≤32 mm in diameter (ranges reflect differences between the commercial devices). Furthermore, the proximal neck angle should be ≤60 degrees for most devices (≤75 to 90 for some newer devices), as measured by the intersection of the centerline of the infrarenal aorta at the landing zone site and the centerline of the aneurysm through the aortic bifurcation. Newer devices do allow for more neck angulation, but the operating surgeon should keep in mind that more infrarenal neck may be required in more severely angulated necks to allow for appropriate seal and fixation of the device. The infrarenal neck should be relatively free of thrombus and calcification to facilitate a seal at the implantation site. It is notable that neck length requirements were initially ≥1 cm with the first generation of devices, which was increased to ≥1.5 cm with later generations, and now has again been decreased to >1 cm with some of the most recent devices. Indeed, the longer the infrarenal neck length and, therefore, the longer the device seal zone, the better. The iliac artery should have a suitable landing zone ≥20 mm with an associated diameter between 7 and 20 mm to facilitate both anchoring the graft and passing the main device into the aorta. The distal landing zone for the iliac limbs is usually in the common iliac artery although the anatomic constraints with regards to the size of the access vessels and the introduction of the devices are relevant for both the common and external iliac vessels.

The percentage of patients that are anatomically suitable for an endograft remains unresolved and is likely contingent upon the nature of the individual surgeon/institution practice and the available devices. This percentage of suitable patients has been highly variable with report of 30% in nationwide series,[121] 55% in a regional series,[122] and 14% to 66% in institutional series.[123–125] Notably, the reasons cited for exclusion include a short infrarenal neck (54%), inadequate iliac vessels (47%), and a wide infrarenal neck (40%).[123]

A variety of techniques have been described to overcome the anatomic limitations of the endovascular approach thereby extending its feasibility. Indeed, some modification has been described to overcome almost every anatomic contraindication. Stenosis within the access vessels can be overcome by dilation (i.e., balloon angioplasty, serial dilators) or by the use of an open prosthetic conduit or endovascular stent graft conduit.[126] The open prosthetic conduit is usually anastomosed to the bifurcation of the common iliac artery and then tunneled through the retroperitoneal space below the inguinal ligament. Alternatively, an aorto-uni-iliac endograft can be configured and a femoral–femoral bypass performed. Notably, the patency rates of the femoral–femoral bypass graft in this setting have been reported to be excellent.[127,128] Aneurysm degeneration of the common iliac artery can be overcome by a variety of techniques including simply using larger-diameter graft limbs, occluding/embolizing the internal iliac artery and seating the iliac limb in the external iliac artery or by bypassing the internal iliac artery (and seating the iliac limb in the external iliac artery). Although relatively simple to perform, internal iliac artery embolization has been associated with a moderate incidence of complications including buttock/thigh claudication (30% to 40%), sexual dysfunction, neurologic deficit/paraplegia, pelvic ischemia, and gluteal compartment syndrome.[129,130] The claudication improves with time in the majority of patients, but can be quite debilitating,

particularly in patients that did not claudicate preoperatively. Many of the other complications, although somewhat rare, are irreversible and can be catastrophic. Because of these concerns, concomitant bilateral internal iliac artery occlusion/embolization should be avoided when possible. Bypass of the internal iliac artery overcomes many of these limitations and has been associated with excellent results in terms of long-term graft patency although the procedure is somewhat challenging and adds significantly to the overall magnitude of the "less-invasive" procedure.[126] Unfortunately, extending the indications for endovascular repair beyond those recommended by the manufacturers (i.e., instructions for use [IFU]) has been associated with an increase in the incidence of adverse events including decreased survival and a higher need for reintervention.[131] Iliac bifurcation devices are currently commercially available outside the United States and will soon be available inside the United States, and will allow for preservation of internal iliac arteries in select patients with appropriate anatomy.[132,133]

Consideration of the perioperative and long-term outcomes after EVAR requires introduction of the concepts of endoleak and endotension. Simply, endoleak is the perfusion of the aneurysm sac outside the lumen of the endograft while endotension is the persistent pressurization within the excluded aneurysm sac. Endoleaks have been classified as types 1 through 4 based on the mechanism of the leak (Fig. 96-8). Type 1 leaks originate at either the proximal or distal attachment sites. Type 2 leaks come from branch vessels, such as the lumbar or inferior mesenteric arteries. Type 3 leaks are caused by fabric tears or problems at the graft interfaces of the modular devices, whereas type 4 leaks are usually transient (<24 hours) trans-graft extravasations that result from the porosity of the graft and needle holes. It should be emphasized that the entire concept of an endoleak is predicated on the ability to detect contrast or blood flow outside the lumen of the endograft and is, therefore, contingent on the sensitivity and specificity of the various imaging techniques. The major concern about both endoleaks and endotension is that the pressure transmitted to the aneurysm wall may cause the aneurysm to expand and/or rupture. The clinical significance of the various endoleak types is quite different. Both type 1 and 3 endoleaks are considered major adverse outcomes associated with an increased risk of rupture, and they merit urgent/emergent treatment.[134] Type 2 endoleaks are generally considered less worrisome in terms of their rupture risk although they are associated with an increased risk for reintervention.[134] They can generally be followed with serial imaging studies, but merit evaluation/intervention if the aneurysm sac continues to enlarge. Type 4 endoleaks are self-limited and benign. The clinical significance of endotension is likewise unresolved. Indeed, the concept itself is somewhat ambiguous given the limitations of actually measuring the pressure within the aneurysm sac. It should be noted that freedom from endoleak does not necessarily mean freedom from endotension given the observation that aneurysms can continue to enlarge in the absence of an identifiable endoleak.[135]

The *perioperative* complication rates appear to be lower after endovascular repair. As noted above, the randomized, controlled DREAM and EVAR Trials reported a significant decrease in the perioperative mortality rate (DREAM – 1.2% vs. 4.6%; EVAR Trial – 1.7% vs. 4.7%).[70,79,109] The EVAR Trial also reported a trend toward a decrease in the

combined operative mortality/*severe* complication rate (9.8% vs. 4.7%, $p = 0.10$). Multiple clinical trials have reported that the overall major complication rates after both endovascular and open repair are approximately 15% although the magnitude of the complications is less for the endovascular approach and primarily includes vascular access complications (e.g., hematoma, femoral artery injury).[136] These clinical trials have likewise demonstrated that the total hospital length of stay, intensive care unit length of stay, operative blood loss, and time necessary to resume normal activities are all less for the endovascular approach.[136] In addition, Hua et al.[73] reported from the private sector NISQIP database that the perioperative complication rate after endovascular repair was 24%. Interestingly, the impact on sexual function remains unresolved. A survey of the DREAM participants demonstrated that sexual dysfunction was common after both endovascular and open repair, but returned to the baseline state at 3 months for both groups.[137] In contrast, Xenos et al.[138] reported significantly less orgasmic and erectile dysfunction after endovascular repair.

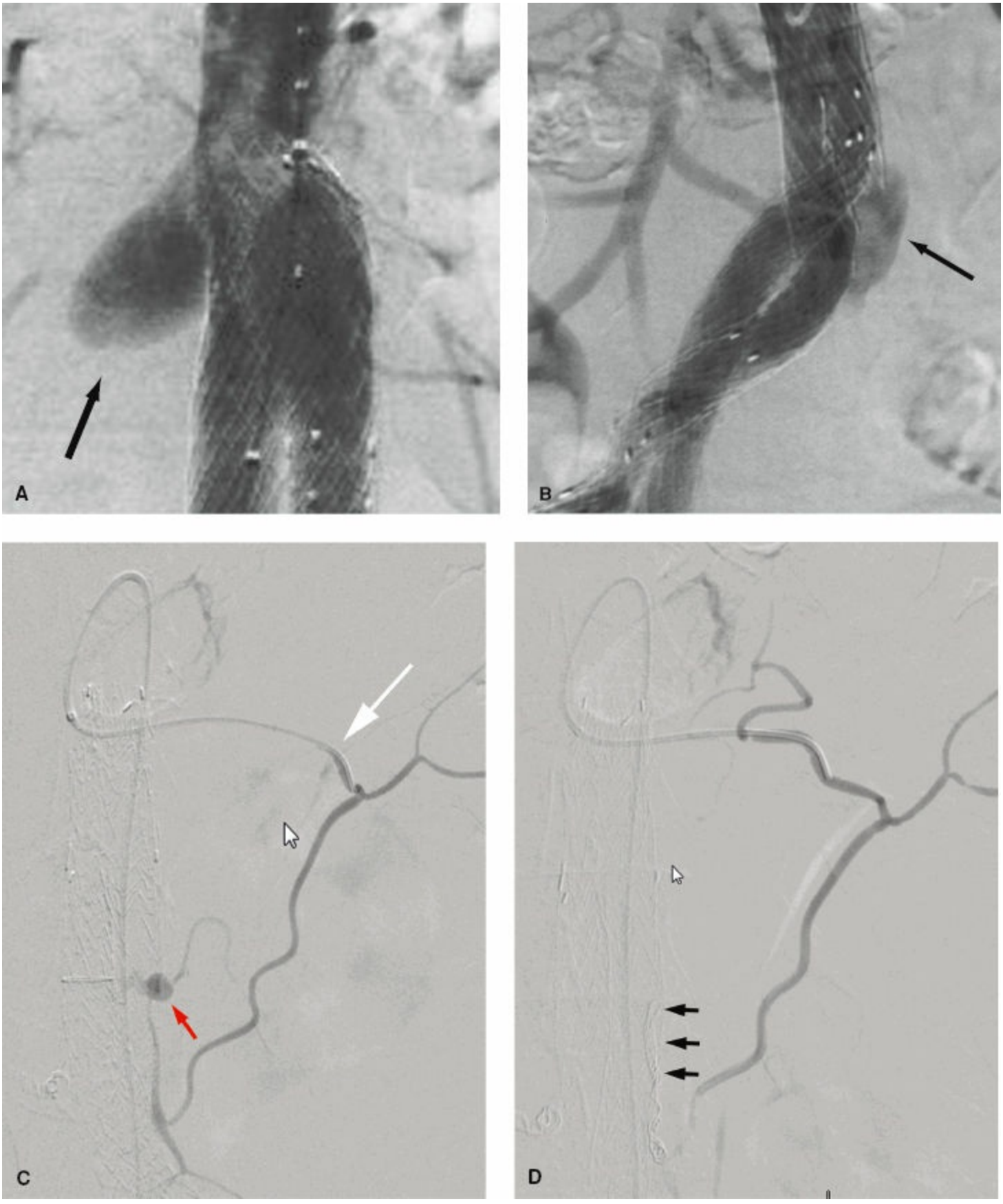

Figure 96-8. Type 1 to 4 Endoleaks. Type I and III represent the most dangerous forms of endoleaks, and represent what is essentially an unrepaired aneurysm. **A:** Type I leaks originate at either the proximal (Ia) or distal (Ib) attachement sites. Note the large blush of contrast outside of the graft lumen at the proximal fixation site, demonstrating a type Ia endoleak. **B:** Type 3 endoleaks are caused by fabric tears or problems at the graft interfaces of the modular devices. Note the contrast blush outside of the lumen of the graft at the modular interface. Type II endoleaks generally have a more benign natural history, but can cause aneurysmal growth and rupture. **C:** Demonstrates an inferior mesenteric

arteriogram from a catheter (*white arrow*) in the meandering mesenteric artery. Filling of the aneurysm sac through a patent inferior mesenteric artery (*red arrow*) is evident. **D:** Demonstrates successful embolization of the IMA with coils demonstrated by *black arrows*. Note no further filling of the aneurysm sac.

The long-term results after the EVAR and DREAM Trials have failed to document any significant benefit for the endovascular approach in terms of almost every outcome measure analyzed.[79,109] Somewhat surprisingly, there was no difference in all-cause mortality at 2 years in the DREAM Trial (survival, open – 89.6%, EVAR – 89.7%) or at 4 years in EVAR (mortality, open – 29%, EVAR – 26%). There were significant differences in terms of aneurysm-related mortality at these time points although the differences were fairly minimal and their relevance suspect. Both the complication rates (EVAR Trial; EVAR – 41%, open – 9%) and costs (EVAR Trial; EVAR – £13,257, open – £9,926) were significantly greater for the endovascular approach while there were negligible differences in the quality of life assessments.[79,139,140]

The mid-term results from the DREAM and EVAR Trials have been somewhat sobering and longer-term outcomes are necessary to further define the role of the endovascular approach. It is clear that the endovascular approach is not as secure a repair as the traditional, open alternative. The endovascular repair is associated with ongoing rupture risk that likely approaches 1%/yr.[136,141] Notably, Schermerhorn et al.[19] reported a 1.8% rupture risk among Medicare patients undergoing EVAR between 2001 and 2004. The rupture risk has been associated with poor patient selection, operator error, unrecognized/untreated endoleaks, large aneurysms, and device migration.[136,142] Interestingly, the mortality rate associated with rupture after endovascular repair may be less than for de novo ruptures.[143] Approximately 10% to 20% of patients develop an endoleak during the first year after endovascular repair.[144–146] Admittedly, not all of these require remediation. The excluded aneurysms can continue to grow and, thereby, represent a risk for rupture. This has been correlated not only with the presence of endoleak as noted above, but also with the specific device and the baseline aneurysm size.[147,148] Some type of structural failure including fabric tears, hook fractures, and suture breakage has been reported for almost every device. Design modifications have been implemented to overcome many of these deficiencies although they represent an ongoing concern that may not be manifest for years. As a consequence of all these potential limitations, reintervention is sometimes necessary either to prevent complications or to treat them. Aneurysm-related reinterventions occurred in 3.7% of patients per year after EVAR from 2001 to 2004 in the Medicare population.[149] The majority of these remedial procedures are minor endovascular procedures, however with a risk of major open procedures of 0.4%/yr.[141] In contrast, open aneurysm repair is associated with a less than 1%/yr incidence of aneurysm-related complications that require remedial procedures in long-term follow-up. Graft-related deaths have been reported in 2% of patients at 15 years.[150]

The presence of significant comorbidities and advanced age favors the endovascular approach. Although the operative threshold in regards to the aneurysm diameter measurement is the same, the endovascular approach may allow a subset of patients not

considered suitable candidates for an open operation to have their aneurysms repaired. Indeed, EVAR has been shown to be feasible in patients with hepatic insufficiency[151] and consistently safe in octogenarians.[152,153] However, a modicum of clinical judgment is necessary, and the concept that AAA repair is a prophylactic operation and that not every patient merits treatment must be kept in mind. The EVAR Trial 2 randomized patients not fit for open repair to expectant management or endovascular repair and demonstrated no difference in aneurysm-related mortality, all cause mortality, or quality of life.[140] Notably, the patients were truly "high risk" with a perioperative mortality rate of 9% and a 4-year mortality rate of almost 40%. Despite the potential nephrotoxicity associated with iodinated contrast, chronic renal insufficiency is not an absolute contraindication to endovascular repair. Strategies to reduce the associated risk can be employed including the administration of acetylcysteine and sodium bicarbonate.[96,97] Alternatively, the procedure can be performed without contrast altogether by using intravascular ultrasound (IVUS) or CO_2 as the contrast agent. Unfortunately, chronic renal insufficiency is a significant risk factor for adverse outcome after both open and endovascular repair. Furthermore, multiple studies have shown that both approaches are associated with a decrement of renal function.[154–157] The endovascular approach may be associated with a greater decrement of function postoperatively, but the findings are somewhat equivocal; suprarenal fixation of the endovascular device does not seem to be associated with a greater decrement.[157]

The known device-related complications and the uncertainty about the long-term outcome after endovascular repair mandate indefinite surveillance, although the intervals and type of imaging for surveillance remain controversial. Whatever is chosen by the practitioner, patients must agree to comply with the prescribed protocol and their ability or desire to fulfill these expectations should be factored into the specific choice of procedure. It is important to note that although the incidence of complications declines with the number of negative postoperative CT scans; new endoleaks have been discovered many years after device implantation. Similarly, it is imperative that all surgeons that offer EVAR provide conscientious, long-term follow-up.

The cost comparisons between the open and endovascular approach have been somewhat inconclusive although the endovascular approach is likely more expensive. Clearly, the EVAR-1 and EVAR-2 trials demonstrated that the endovascular approach was more expensive.[79,140] Although the shorter length of stay and lower incidence of major perioperative complications have resulted in a reduction in some of the hospital costs with EVAR, these benefits have been offset by increases in other hospital-related costs, namely the device cost. Notably, Sternbergh and Money[158] reported that the cost of the device accounted for 52% of the total cost of the endovascular repair and estimated that the costs of open and endovascular repair were $12,546 and $19,985, respectively in the AneuRx Phase II clinical trial. Analysis of the hospital costs and reimbursement associated with endovascular repair among 7 medical centers (university hospital – 3, community hospital – 4) demonstrated a net loss of $2,162.[158,159] However, others have reported that the contribution to the hospital margin on a daily basis may be superior for endovascular repair given the associated shorter duration of stay that permits higher throughput, fuller

overhead amortization, and better use of inpatient beds.[160] It is important to note that most of the analyses have focused on the hospital and device-related costs, but have failed to include the associated professional fees and the costs associated with long-term follow-up and reintervention, which all may be substantial. Importantly, Kim et al.[161] reported that reimbursement for endovascular repair does not include long-term surveillance and secondary procedures. Indeed, it has been reported that the overall cost of endovascular repair may be twice that of the open approach.[136]

Despite the various advantages and disadvantages of the approaches outlined above, patients and providers seem to prefer the endovascular approach and these preferences appear to be one of the driving forces for the widespread application of the technique. Indeed, it is uncommon for patients that are candidates for either approach to elect open repair. Notably, Williamson et al.[162] reported that 18% of all patients undergoing open repair would not undergo the procedure again. The potential to perform the endovascular repair completely percutaneously (i.e., no femoral artery exposure) clearly adds to the appeal of the approach.[163,164] It is interesting to note that these patient preferences may not be sustained. A follow-up study from the DREAM trial reported that patients undergoing endovascular repair had a better quality of life initially, but those undergoing open repair had a better quality at 6 months and beyond.[137]

The proverbial “bottom line” for the open versus endovascular debate remains somewhat unresolved, but the discussion is merely academic at this point. EVAR, when anatomically possible, has essentially become the standard of care in most practices. Notably, the Agency for Health Care Research Quality conducted an evidence-based review published in 2006 and concluded that endovascular repair for aneurysms >5.5 cm did not improve patient survival or health status relative to open repair despite the fact that the perioperative outcomes were improved.[165] Furthermore, they reported that the endovascular approach was associated with increased cost, complications, need for surveillance and need for remedial procedures. Finally, they concluded that it did not provide a benefit for patients unfit for open repair. Despite these recommendations, the trend toward dominance of EVAR over open repair has increased to a point where many vascular training programs are having difficulty with finding enough open aneurysm cases to sufficiently teach their trainees.[166]

OPERATIVE REPAIR

Preoperative Evaluation

The preoperative evaluation of patients undergoing elective AAA repair is similar to that of patients undergoing any major general or vascular surgical procedure. Patients undergoing endovascular repair should likely undergo the same preoperative work-up despite the perception that associated perioperative stresses are less. All patients should receive a complete history and a physical examination, electrocardiogram, and a chest radiograph. Routine laboratory studies, including a complete blood cell count with platelets, serum electrolytes/creatinine, and coagulation studies should be obtained. A specimen should be sent to the blood bank and the appropriate quantity of blood products cross-matched. This number can be determined from the historic operative transfusion requirements obtained from the blood bank but usually 2 to 4 units of packed red blood cells are sufficient. A thorough peripheral pulse examination should be included in the physical examination and validated with formal ankle–brachial indices. The anesthesiologist should see the patients preoperatively. In addition, patients should be started on an aspirin and a statin (HMG Co-A reductase inhibitors) and consideration made for starting a beta-blocker if they are not already on them. The ACC/AHA Guidelines on Perioperative Cardiovascular Evaluation and Care for Noncardiac Surgery recommend that the beta-blockers are “probably recommended” for vascular surgery patients who are at high cardiac risk or those with more than one clinical risk factor (risk factors – CAD, CHF, CVOD, DM, CRI).[167] However, much of the data that this recommendation was based upon have been questioned due to reports of unscrupulous academic behavior by the investigators, and many now believe that initiation of beta-blockers before major vascular surgery is unwarranted and potentially harmful.[168]

Furthermore, the ACC/AHA Guidelines recommend that patients undergoing vascular surgery should be on a statin. Notably, a recent study demonstrated that statins were associated with a decreased incidence of perioperative mortality and nonfatal myocardial infarction after aneurysm repair.[169] Indeed, all patients with atherosclerotic cardiovascular disease should likely be on aspirin, a statin medication, and an ACE inhibitor long-term as part of the AHA/ACC Guidelines for Preventing Heart Attack and Death in Patients with Atherosclerotic Cardiovascular Disease.[170]

All active medical problems, including abnormalities identified during the preoperative evaluation, should be controlled as well as possible before elective aneurysm repair. However, extensive diagnostic testing is probably unnecessary. Routine pulmonary function tests and measurement of arterial blood gases are not indicated, although they may be beneficial in selected patients with advanced chronic obstructive pulmonary disease.[171] The presence of chronic obstructive pulmonary disease often complicates postoperative ventilator management, but it is unusual for a patient’s pulmonary disease to be sufficiently severe to preclude operation.[172] Similarly, timed urine collections for creatinine clearance and other assessments of renal function have not proved beneficial despite the dramatic impact of preoperative renal insufficiency on perioperative outcome

although it may be beneficial to calculate the estimated glomerular filtration rate.

The appropriate cardiac work-up before AAA repair is evolving and is somewhat institution-dependent. This controversy has been further complicated by the publication of the CARP Trial that examined the role of coronary artery revascularization before major vascular surgery among patients with significant coronary artery disease.[173] Notably, the study reported that preoperative coronary artery revascularization did not reduce the incidence of either perioperative myocardial infarction or long-term mortality. It is important to emphasize that the overall objective of the preoperative cardiac work-up is to optimize the cardiovascular system and thereby reduce both the perioperative and long-term risk of myocardial infarction and death. Admittedly, the prevalence of coronary artery disease among patients undergoing AAA repair is quite high. Hertzer et al.,[174] in a landmark publication, reported that 25% of 1,000 patients undergoing evaluation for peripheral vascular surgery (cerebral vascular occlusive disease, lower extremity arterial occlusive disease, AAA) had severe, surgically correctable lesions detected during cardiac catheterization; 6% had severe, uncorrectable disease, and only 8% had no evidence of disease. Interestingly, the incidence of surgically correctable disease was highest among patients undergoing evaluation for AAA. The most recent edition of the ACC/AHA Guidelines hase simplified the preoperative evaluation before elective vascular procedures.[167,175] Briefly, patients with active cardiac conditions (unstable coronary syndromes, decompensated congestive heart failure, significant arrhythmias, and significant valvular disease) should be seen in consultation by a Cardiologist. Patients with good functional capacity as defined by the ability to generate at least four metabolic equivalents (METS, 4 METS – ability to walk up a flight of stairs) can undergo major vascular procedures without additional testing. Those patients that cannot generate 4 METS and have at least 3 clinical risk factors (see above) should be considered for further cardiac testing if the results will change the clinical management. Notably, there is insufficient evidence to support a reduced cardiac work-up for patients undergoing endovascular repair.[176] It is important to emphasize that although the cardiac risk of endovascular repair may be less, the subset of patients undergoing the procedure are often older and sicker.

All patients should undergo some type of imaging modality as part of their preoperative evaluation to confirm the diagnosis and plan the procedure. Indeed, determining whether a patient is an endovascular candidate and appropriately sizing the device depend on the anatomic measurements obtained at the time of imaging. A CT arteriogram of the chest, abdomen, and pelvis is the optimal imaging study to visualize the aneurysm and is the only one required in most cases. Abdominal ultrasonography is insufficient as the sole imaging study before aneurysm repair in light of its inability to accurately define the cephalad extent of the aneurysm and the involvement of the iliac vessels.

Open Repair of Intact Abdominal Aortic Aneurysms

Technique

A significant amount of preparation is required in the operating room before making the incision and this preparation needs to be coordinated among the surgical and anesthetic teams for both the open and endovascular approaches. Although the decision about the choice of anesthesia is deferred to the anesthesiologists, inhalation agents and an endotracheal tube are used most frequently. Adjunctive epidural anesthesia may improve postoperative pain control[177] and may be beneficial in patients with severe pulmonary disease.[178] Adequate intravenous access should be established to facilitate resuscitation. Central venous access is usually obtained although not necessary. Electrocardiographic leads, an arterial catheter, and a Foley catheter should be placed for continuous monitoring of the electrocardiogram, arterial pressure, and urine output, respectively. In addition, a nasogastric tube should be inserted. A Swan–Ganz pulmonary artery catheter or a transesophageal echocardiogram probe should be inserted in patients with significant cardiac disease. However, routine use of pulmonary artery catheters in patients undergoing aortic surgery is not recommended and may be associated with a higher rate of intraoperative complications.[179,180] Peripheral arterial pulses should be interrogated with either palpation or continuous-wave Doppler ultrasound and marked to facilitate confirmation after restoration of lower-extremity perfusion. Strategies to maintain core body temperature should be initiated.[179,181] Specifically, the room temperature should be increased, warming devices should be attached to all intravenous infusion lines, and either a recirculating alcohol blanket or forced-air blanket should be applied. Bush et al.[182] reported that hypothermia ($<34.5^{\circ}C$) during AAA repair was associated with multiple physiologic derangements and adverse outcomes. Of note, this does not pertain to thoracoabdominal aortic surgery where hypothermia has shown some benefits in spinal cord ischemia reduction.[183]

Use of an intraoperative autologous transfusion device should be considered. However, a recent meta-analysis of 5 randomized, controlled trials reported that there is insufficient evidence to recommend its use during vascular surgery including aortic surgery.[184] These devices should likely be used when a significant amount of blood loss is anticipated, such as during suprarenal or thoracoabdominal aortic aneurysm repairs. Furthermore, they can be helpful in patients who object to blood transfusions on religious principles. An extensive operative field from “nipples to toes” should be prepared with the use of topical antimicrobial agents. A first-generation cephalosporin or vancomycin should be administered prior to the incision.

AAAs may be repaired through several different incisions or approaches including midline, retroperitoneal, or transverse (supraumbilical straight, infraumbilical straight, infraumbilical curvilinear, bilateral subcostal). The incisions or approaches must be viewed as complementary since neither is perfect for every clinical scenario. Indeed, surgeons should be familiar with the various approaches and select the optimal one for the clinical setting. The determinants of the incision include the cephalad/caudal extent of the aneurysm, body habitus, presence of prior abdominal incisions, presence of abdominal

wall stomas, comorbidities, additional intraoperative pathology, inflammatory aneurysms, renal anomalies, requirements for concomitant procedures, urgency of aortic control, and surgeon preference. The midline approach is preferable for patients with ruptured AAAs because aortic control at the level of the diaphragm can be obtained rapidly. The bilateral subcostal approach provides the best exposure and is the incision of choice for obese patients, those with extensive iliac artery aneurysms, those patients requiring concomitant renal artery revascularization, and those patients with juxtarenal aneurysms that require suprarenal aortic control. The retroperitoneal approach is optimal for patients with multiple previous abdominal incisions ("hostile abdomen"), abdominal wall stomas, suprarenal aneurysms, inflammatory aneurysms, and horseshoe kidneys. However, the retroperitoneal approach is limited by the inability to assess the intraperitoneal structures and the limited access to the right renal artery and right iliac vessels. It was previously contended that the retroperitoneal approach posed less of a physiologic insult than the transperitoneal approach and, therefore, was ideal for patients with advanced pulmonary or cardiac disease. However, this has not been supported by a prospective, randomized trial.[185] A detailed description of the retroperitoneal approach is beyond the context of this chapter, but is available in most standard vascular surgical texts.

The sequence of steps used to repair an intact, infrarenal AAA after a bilateral subcostal incision can be summarized (Fig. 96-9). The abdomen is explored after the peritoneal cavity is entered, and both the gallbladder and colon carefully examined. The lower abdominal wall flap is immobilized to either the drapes or the pubic towel with the use of penetrating towel clips. The small bowel is manually retracted laterally to the right, and the duodenum is mobilized by incising the ligament of Treitz. The inferior mesenteric vein may be suture-ligated at this juncture to facilitate exposure. The tissue adjacent to the inferior mesenteric vein should be palpated to rule out a large, meandering mesenteric artery. This artery is an important visceral collateral and should be preserved. The retroperitoneum over the aorta is incised with the electrocautery, and the left renal vein is exposed. Self-retaining retractors (e.g., Bookwalter, Omni retractors) are then placed to facilitate further exposure. The small bowel is placed in a bowel bag, eviscerated, and retracted laterally to the right with the aid of malleable self-retaining retractors. The transverse colon and superior abdominal wall flap are retracted cephalad while the lower abdominal wall is further retracted caudal. The aorta immediately inferior to the renal arteries is exposed and both renal arteries visualized. The infrarenal aorta at this location is dissected circumferentially to facilitate placement of a transverse aortic clamp. However, this step may be omitted if a vertical clamp is used. It is important to identify the course of the renal vein and any venous anomalies on the preoperative CT scan to prevent inadvertently injuring these structures at this stage of the procedure. In the presence of a retroaortic renal vein or circumaortic collar, the aortic neck should not be dissected circumferentially and vascular control should be obtained with a vertical clamp. The retroperitoneum over the aorta is then incised further caudally and the incision extended along the course of the right common iliac artery. The extent of the caudal dissection depends on the anatomic configuration of the aneurysm. If the

aneurysm extends to the aortic bifurcation, it is sufficient to dissect only the common iliac arteries provided a suitable site for clamp application is identified. If the aneurysm extends to the distal common iliac arteries, both the internal and external iliac vessels should be dissected free. This may be facilitated on the left side by mobilizing the sigmoid colon along its peritoneal reflection and reflecting it medially. The inferior mesenteric artery is then dissected free and vascular control obtained with a vessel loop. Patients are administered 100 units/kg of intravenous heparin, and the activated clotting time is confirmed to be twice the baseline value. Supplemental doses of heparin are administered throughout the procedure as dictated by the activated clotting time. Interestingly, a recent randomized, controlled trial reported that heparin does not reduce thrombotic events or increase bleeding during aneurysm repair, but is associated with a significant reduction in myocardial events.[186]

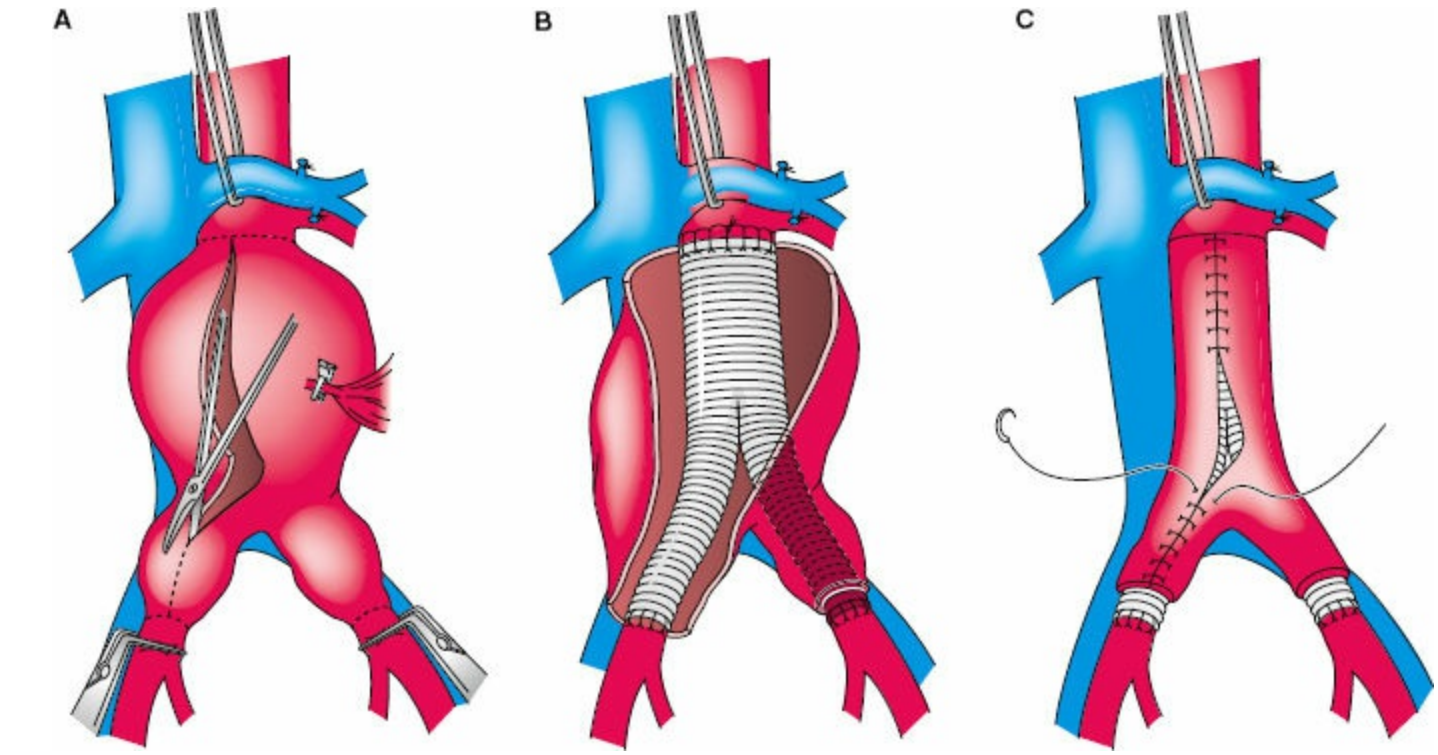

Figure 96-9. Steps involved in the standard repair of an infrarenal abdominal aortic aneurysm extending into the proximal common iliac arteries. **A:** The proximal duodenum is mobilized and the retroperitoneum overlying the aorta incised. The infrarenal aorta immediately below the renal vein is dissected. The iliac bifurcations are exposed, and vascular clamps are applied to the infrarenal aorta and distal common iliac arteries after adequate heparinization. A longitudinal arteriotomy is extended from the infrarenal aorta onto the right common iliac artery. **B:** Back bleeding from the lumbar arteries is controlled with "figure-of-eight" sutures. The proximal anastomosis is performed in an end-to-end configuration below the renal arteries. The distal anastomoses are performed at the common iliac bifurcation beyond the aneurysmal segments. The left limb of the graft is tunneled through the intact left common iliac aneurysm shell. **C:** The residual aneurysm shell is closed over the prosthetic graft, and the retroperitoneum is reapproximated to prevent erosion of the graft into the overlying bowel.

During the time required for adequate mixing of the heparin, the availability of the necessary equipment is reviewed and confirmed with the operating room personnel. The appropriately sized prosthetic graft is selected. The graft diameter is sized according to

the infrarenal aortic neck by visual inspection or with the calibrated graft rulers (i.e., "sizers"). The general "rule of thumb" is that the smaller graft should be selected when the aorta is between two graft sizes because the aorta always appears smaller after it is transected and redundant graft material at the proximal anastomosis is more difficult to correct than the opposite problem. A variety of vascular prostheses are available. Despite the contentions of the various manufacturers, there is no clear advantage for an individual graft and the choice should be determined by surgeon preference as dictated by ease of handling, cost, and availability. The distal vascular clamps are applied to the external, internal, or common iliac vessels depending on the extent of the aneurysm and the character of the vessels. Occasionally, the iliac vessels are so calcified that they cannot be safely occluded with a clamp. Vascular control may be obtained intraluminally in this setting with the use of a balloon thromboembolectomy catheter after the aneurysm has been incised. The proximal aortic clamp is applied in sequence after the distal clamps. The clamp is applied immediately below the renal arteries to facilitate an anastomosis to the proximal infrarenal aorta. The length of the infrarenal aorta should be sufficient to permit a safe anastomosis. However, a long infrarenal cuff should be avoided because it may become aneurysmal over time. Either a vertical or horizontal aortic clamp may be used. The aorta is then incised longitudinally, and the incision is extended to the distal aorta and into the iliac arteries if the distal anastomosis will be to the iliac vessels. Attempts should be made to preserve the autonomic nerves overlying the distal aorta and proximal left common iliac artery in potent men. This can usually be achieved by incising the left common iliac artery transversely beyond the aneurysmal portion and tunneling the limb of the graft through the residual shell. The intraluminal thrombus and debris are removed from within the aorta, and all back bleeding from the lumbar arteries is controlled with suture ligatures. The atheromatous debris within the aorta has been reported to be culture-positive in approximately 25% of cases although this has not been associated with long-term graft infections.[187,188] The infrarenal aorta at the level of the planned proximal anastomosis may be completely transected, or the back wall may be left intact. Completely transecting the aorta makes the proximal anastomoses slightly easier although leaving the back wall intact reinforces the anastomosis and provides the equivalent of an autogenous pledget. The proximal anastomosis is performed in an end–end configuration with a running 3-0 cardiovascular suture. All leaks in the suture line are repaired with similar 4-0 or 5-0 sutures and felt pledgets as necessary. The distal anastomosis or anastomoses are performed to the aortic bifurcation, common iliac arteries, or iliac bifurcation as dictated by the anatomy of the aneurysm. Occasionally, patients with extensive concomitant iliac disease may require anastomoses at the femoral arteries. A 3-0 cardiovascular suture is used for anastomoses at the aortic bifurcation, and a similar 4-0 suture is used for the common iliac arteries. All anastomoses are flushed to remove any intraluminal debris before flow is restored. Blood flow is restored to the pelvis and lower extremities in sequence. Attempts should be made to flush initially into the internal iliac circulation to prevent embolization to the lower extremities. This can be facilitated by manually compressing the common femoral arteries for tube graft configurations. The lower torso should be reperfused gradually (i.e., one vessel at a time

and one extremity at a time) to prevent hypotension. This process requires significant communication and coordination between the surgical and anesthetic teams. It is imperative that the patient is resuscitated prior to reperfusion and it is frequently necessary to delay this process to allow the anesthesiologists to achieve this objective. Reperfusion of the ischemic tissue causes the release of acid, potassium, and a variety of inflammatory mediators and reactive oxygen species into the systemic circulation, all of which are potentially detrimental.

The inferior mesenteric artery may be reimplanted into either the body of the graft or the left limb if it is patent. Seeger et al.[189] reported that routine reimplantation of the inferior mesenteric artery resulted in decreased rates of colonic infarction and death after aortic reconstruction. However, a more recent randomized, controlled trial demonstrated no benefit in terms of morbidity or mortality although the authors suggested it may be beneficial for older patients and those with increased blood loss.[190] The colon and lower extremities should be interrogated with the Doppler ultrasound after reperfusion, and the heparin reversed with intravenous protamine sulfate after confirmation of adequate signals. The protamine dose is estimated based on the effectiveness of protamine (1 mg of protamine per 100 units of heparin), the initial dose of heparin, the current activated clotting time, and the elapsed time from the administration of heparin. The protamine should be administered slowly to prevent any untoward hemodynamic events.[191] Notably, a recent randomized, controlled trial reported that protamine effectively reverses the heparin effect, but provides no clinical benefit during peripheral vascular surgery, including aneurysm repair.[192] The shell of the aneurysm and the overlying retroperitoneum are both closed with absorbable suture to provide a biologic tissue layer between the graft and the viscera. The retractors are then removed, the viscera are returned to their anatomic positions, the nasogastric tube is confirmed to be in the antrum, and the abdominal wall fascia is closed with standard technique. Notably, patients undergoing aortic reconstruction for aneurysmal disease have been reported to have a higher incidence of abdominal wall hernias than those undergoing reconstruction for occlusive disease.[193–195]

The configuration of the aortic reconstruction (aorto-aortic, aortoiliac, aortofemoral) depends on the extent of aneurysmal involvement and the degree of occlusive disease. Aneurysmal involvement of the common iliac vessels should be considered an extension of the aortic process and treated appropriately. Specifically, common iliac arteries larger than 2 cm should be considered aneurysmal and replaced. The entire common iliac artery must usually be replaced although it is possible to replace only the proximal segment if the aneurysmal involvement is isolated. Conversely, common iliac arteries smaller than 2 cm have a relatively benign natural history and do not need to be replaced since only a small percentage become aneurysmal and require treatment.[196,197] Despite the fact that a patient may be a candidate for an aortic tube graft, it is often easier to perform an aorto-bi-iliac graft because the terminal aorta is often very calcified. Aorto-bi-femoral bypass grafts should be reserved for the small subset of patients who truly have concomitant aneurysms and severe occlusive disease since the risks of wound complications and graft infections are greater. Indeed, the risk for graft infections is less than 0.5% for aorto-bi-

iliac grafts, but approximately 2% for aorto-bi-femoral grafts.[196–198] It is important to remember the original indication for the procedure and choose the appropriate aortic reconstruction (aorto-bi-iliac bypass for aortoiliac aneurysm, aorto-bi-femoral bypass for aortoiliac occlusive disease). Admittedly, there is a role for aorto-bi-femoral reconstructions in patients with aneurysm disease, and it is futile to attempt an aorto-bi-iliac reconstruction in patients with severe external iliac artery disease.

The postoperative care after open repair is fairly routine and predictable for the majority of patients. Patients are transferred directly from the operating room to the intensive care unit although selective use of the intensive care unit may be appropriate.[199] Most of the patients are extubated in the operating room or shortly after arrival in the intensive care unit. The intensive care unit length of stay is usually 1 to 2 days, and the median total length of stay is 8 days.[34] Patients are encouraged to get out of bed and begin ambulating in the early postoperative period (i.e., 24 to 48 hours). Preoperative prophylactic antibiotics are continued for a total of 24 hours. Nasogastric decompression is continued until bowel function returns. Oral feedings are initiated after removal of the nasogastric tube and advanced quickly to solids. Patients are discharged when they are ambulatory, can tolerate a regular diet, have normal bowel function, and are sufficiently able to care for themselves. A subset of people requires transfer to rehabilitation or extended care facility. Patients are usually seen in the clinic 2 weeks after discharge and then at 6 months thereafter. Additional clinic appointments may be necessary as dictated by any ongoing medical problems. Patients are not allowed to drive until their incisional pain has resolved and they have stopped taking pain medications. Furthermore, patients are discouraged from lifting heavy objects for the first 6 to 8 weeks to reduce the incidence of incisional hernias.

Complications and Outcome

Open repair of intact AAAs is associated with significant mortality and morbidity.[34,200,201] The attendant mortality rates have been discussed extensively in the preceding sections entitled Principles of Management and Choice of Open or Endovascular Repair. Briefly, the contemporary mortality rate across the country has consistently been $<5\%$.[72–74] The overall morbidity rate remains less clear, although the specific complications have been well defined. Huber et al.[34] reported that 33% of all patients undergoing repair of intact AAAs across the United States develop some type of perioperative complication as defined by the ICD-9 postoperative complication codes. Similarly, Hua et al.[73] reported from the National Surgical Quality Improvement Program – Private Sector that the overall incidence of 30-day morbidity after open repair was 35%.

Intraoperative complications can result from injury to the intra-abdominal structures during dissection although these technical complications are not specific to the aneurysm repair. The small bowel, colon, ureter, and major venous structures (inferior vena cava, iliac veins, left renal vein) are particularly susceptible. Iatrogenic bowel injury at the time of AAA repair is particularly problematic due to the potential to infect the prosthetic graft. If the colon is injured before the aneurysm repair, the defect in the colon should be fixed and the aneurysm repair should be aborted. If the small bowel is injured before the

aneurysm repair, the same course should likely be followed although this decision requires a modicum of clinical judgment. The infectious concerns must be balanced by the fact that the small bowel contents are sterile, a second procedure will be required to repair the aneurysm, and the small risk of aneurysm rupture during the intervening delay. Injury to the bowel during or after implantation of the aortic graft should be treated with repair of the defect, extensive irrigation, and prolonged antibiotics. Admittedly, these approaches are very conservative and it is noteworthy that multiple clinical series have attested to the safety of simultaneous aortic and gastrointestinal/urologic procedures.[202–205] The ureter is susceptible to injury at the point where it crosses over the iliac bifurcation. Injury can be avoided by a heightened awareness of this anatomic location and dissection in the tissue plane immediately on top of the common iliac vessels. Inadvertent venous injury can be associated with significant bleeding. This can usually be controlled by direct pressure using sponge sticks and suture repair. The left renal vein may be transected if necessary. It should be transected near its juncture with the vena cava, and the gonadal, adrenal, and lumbar branches should be preserved to maintain venous outflow from the kidney. Although somewhat inelegant, division of the left renal vein does not appear to affect renal function after AAA repair.[206] Transecting the common iliac artery or infrarenal aorta may facilitate exposure of the common iliac or retroaortic renal veins, respectively.

Excessive intraoperative bleeding may be encountered occasionally. Routine elective aneurysm repairs are usually associated with moderate intraoperative blood loss with a mean transfusion requirement of 1 to 2 units of packed red blood cells. Excessive bleeding may be caused by either the surgical trauma or coagulopathy. Reversal of the heparin with protamine may help correct the coagulopathic bleeding. Patients with significant bleeding and platelet counts below 50,000/mL should receive a platelet transfusion, and it should be considered for coagulopathic bleeding and counts below 100,000/mL or for those on preoperative clopidogrel or other equivalent anti-platelet medications. Transfusions of fresh frozen plasma are indicated for both patients with either significant bleeding in conjunction with prolonged coagulation studies ($>$1.5 times control value) and those with coagulopathic bleeding. Massive bleeding, defined as more than 100% of the blood volume, may induce a dilutional coagulopathy with prolongation of the coagulation studies. Additional blood products should be set up in the blood bank in the event of significant bleeding. This may require an additional blood bank specimen. Intraoperative autologous transfusion devices should also be considered if not already in use.

Ischemia of the lower extremities has been reported to occur approximately 3% of the time after open repair.[201] The causes are multiple and include distal embolization, thrombosis, clamp injury, and technical errors. The lumen of the aneurysm is frequently filled with both thrombus and atheromatous debris that may serve as a source for both macro- and microembolization. The macroemboli usually lodge at the bifurcations of the major vessels; the microemboli usually lodge in the digital vessels and, unfortunately, are not amenable to mechanical extraction. Thrombosis may result from inadequate heparinization, hypercoagulable conditions, or poor arterial runoff. The technical conduct

of the operation outlined above is designed to minimize the ischemic complications. The specific maneuvers include anticoagulation, selection of a suitable site for distal clamp application and anastomosis, intraluminal control of severely calcified vessels, flushing of the vessels before clamp removal, and sequential removal of the vascular clamps. Further intervention is mandatory if the lower extremities are found to be ischemic. Anastomotic defects should be corrected. This may simply require dissembling and redoing the anastomosis, but often requires placing the anastomosis further distal on the outflow artery. If no problems are identified at the distal anastomosis, the femoral vessels should be explored and an intraluminal thrombus removed with a balloon embolectomy catheter. A transverse arteriotomy may be created in the common femoral artery if it is anticipated that only a thrombectomy will be required; a longitudinal incision should be created if a bypass (inflow or outflow) procedure is anticipated. The transverse arteriotomy can simply be closed with interrupted sutures without narrowing the lumen in the event that an additional bypass procedure is not necessary, whereas the longitudinal arteriotomy requires a patch closure. A bypass from the aortic graft to the femoral vessels is required if adequate inflow cannot be restored with thrombectomy alone. The popliteal artery below the knee should be explored and a thrombectomy performed if the extremity is still ischemic. This may be facilitated by creating a longitudinal arteriotomy on the below knee popliteal artery that extends to the tibioperoneal trunk. This allows the passage of the balloon embolectomy catheter into all three tibial vessels under direct vision. A below knee popliteal or tibial artery bypass is required if adequate perfusion to the distal extremity is not restored after patch closure of the popliteal arteriotomy. Predictably, a complex lower-extremity revascularization in conjunction with an aortic reconstruction is associated with a significant degree of morbidity and dramatically increases the mortality rate.[207] The decision to proceed with an infrainguinal bypass depends on the status of the extremity and requires some clinical judgment. Aborting the procedure and allowing for a period of observation and re-warming is appropriate when popliteal Doppler signals are detected and the foot is cool yet not severely ischemic. Reoperation and definitive treatment may be necessary in the early postoperative period unless marked improvement is noted.

Many of the systemic complications that follow open aneurysm repair are not surprising, given the magnitude of the operation and the age/comorbidities of the patients. Cardiac complications (ischemia, infarction, arrhythmias, congestive heart failure) occur in up to 25%[200,201,208] and are the leading cause of death after open aneurysm repair in many series. Pulmonary complications (pneumonia, ventilator dependence >48 hours, acute respiratory distress syndrome) are also quite common and approximately 10% of the patients require prolonged ventilation.[200,201] Deterioration of renal function, defined by an increase in serum creatinine or blood urea nitrogen, occurs in approximately 5% of cases although acute renal failure requiring dialysis is rare (i.e., $<1\%$).[201] The potential causes of renal insufficiency in the perioperative period are numerous and include contrast nephrotoxicity, hypovolemia, atheroembolization, and the inflammatory response from the lower torso ischemia/reperfusion injury. Postoperative bleeding requiring reexploration, intra-abdominal abscess, and abdominal wound

complications are all relatively infrequent complications and are associated with all major intra-abdominal procedures.

Ischemic colitis has been reported to occur in approximately 2% to 13% of cases after open aneurysm repair.[209,210] The reported incidence depends on the diagnostic algorithm and modality (routine sigmoidoscopy vs. selective sigmoidoscopy) and is dramatically increased after ruptured aneurysm repair. Indeed, the incidence of colonic ischemia after ruptured aneurysm repair in patients undergoing routine colonoscopy is approximately 25% to 40%.[209,211] Multivariable analysis of patients undergoing both open and endovascular repair demonstrated that the duration of the procedure and preoperative renal insufficiency were also predictors of colon ischemia.[210] The sigmoid colon is affected most frequently although all the sections of the colon may be involved. The ischemia may result from inadequate resuscitation, disruption of collaterals, and/or failure to revascularize a hemodynamically significant inferior mesenteric artery. Patients usually present with bloody diarrhea in the early postoperative period. However, the diagnosis should be considered in the absence of bloody diarrhea in patients with thrombocytopenia, multiple-organ dysfunction, increasing abdominal pain/peritonitis, and generalized "failure to thrive." The diagnosis may be confirmed by endoscopy. Although sigmoidoscopy is used most frequently, a complete colonoscopy is likely optimal due to the potential involvement of the other colon segments. Treatment depends on the endoscopic findings and clinical setting. The endoscopic findings range from mucosal ischemia to transmural necrosis. Unfortunately, it is often difficult to differentiate diffuse mucosal ischemia from transmural necrosis. In the absence of peritonitis, patients with mucosal ischemia alone should be treated with bowel rest, broad-spectrum antibiotics, total parenteral nutrition, and serial endoscopic examinations. Many of these lesions resolve spontaneously without long-term sequelae although colonic strictures may develop in a subset of patients. Patients with transmural colonic necrosis should undergo laparotomy with resection of the involved segment, a proximal diverting colostomy, and a distal Hartmann's pouch. After laparotomy, they should be maintained on broad-spectrum antibiotics and parenteral nutrition. The reported mortality rate in patients with transmural necrosis may range up to 85%.[209,210] Maintaining antegrade flow through the internal iliac vessels, routinely implanting the inferior mesenteric artery, and avoiding disruption of the colonic collateral circulation may reduce the incidence of this adverse outcome.

Several other gastrointestinal complications are common after standard infrarenal AAA repair.[212] A postoperative ileus develops in essentially all patients with bowel function usually returning within 3 to 5 days. An ileus may persist beyond this time period in a subset of patients although no additional therapy is usually required. Nasogastric decompression should be continued, narcotics minimized, electrolytes normalized, and ambulation encouraged. Either calculous or acalculous cholecystitis may develop after aneurysm repair. The mortality rates reported historically for postoperative cholecystitis were significant[213] and served as the catalyst for simultaneous cholecystectomy and aneurysm repair. Although this approach has been found to be safe and not associated with an increased risk for graft infections, it is usually reserved for patients with small

stones or evidence of chronic cholecystitis. Pancreatitis may develop after AAA repair although the incidence is surprisingly low in light of the obligatory manipulation of the pancreas during repair. The treatment of pancreatitis in this setting is conservative and includes bowel rest, parenteral nutrition, and serial imaging.

Sexual dysfunction is quite common after both open and EVAR as noted above. Erectile and/or orgasmic dysfunction has been reported to occur in 5% to 18% of men undergoing aortoiliac reconstruction.[214] The responsible mechanisms include interruption of the pelvic perfusion and injury to the autonomic nerves that overlie the distal aorta/proximal common iliac arteries. Injury to these autonomic nerves disrupts the internal sphincter mechanism of the bladder and results in retrograde ejaculation. Care should be exercised during aneurysm repair to maintain pelvic perfusion and avoid nerve injury to prevent these untoward complications. It is imperative that these potential complications be discussed with patients preoperatively.

Paraplegia after open infrarenal AAA repair occurs with an incidence of 0.25%.[215] The potential mechanisms for this devastating complication include embolization, thrombosis of the spinal artery, and disruption of the spinal blood supply. Paraplegia after aneurysm repair is usually an irreversible injury. Maintaining adequate antegrade pelvic perfusion through the internal iliac arteries may minimize this complication.

The long-term outcome after open repair is generally favorable. Long-term survival is improved after aneurysm repair, although it falls short of the age-matched controls with survival rates of approximately 90%, 65%, and 40% at 1, 5, and 10 years.[2,13,216] Cardiovascular causes account for the leading cause of death.[217] This underscores the importance of long-term medical follow-up and the AHA/ACC Guidelines for preventing myocardial infarction and death.[170,217] Prosthetic aortic grafts are associated with long-term complications with a reported incidence of approximately 10% to 15% at 15 years.[136,218,219] Notably, bifurcated grafts are associated with a higher incidence of complications (13%) than tube grafts (5%).[196] The long-term graft-related complications include infection, aortoenteric fistula, thrombosis, and pseudoaneurysm formation. Additional aneurysms of a sufficient size to merit intervention develop in approximately 5% to 15% of patients in either the iliac vessels or the aorta above the prosthetic graft.[196,197] It is recommended that patients undergo CT of the complete aorta and iliac vessels 3 to 5 years postoperatively to screen for graft complications and additional aneurysms.[220]

Endovascular Repair of Intact Abdominal Aortic Aneurysms

Technique

The preoperative evaluation and preparation before endovascular AAA repair is significantly more complicated than for the open approach. The various imaging studies must be reviewed before it can be determined whether the endovascular approach is even feasible. Appropriate measurements must be taken and the necessary devices/components selected. An operative plan must be generated including specific modifications of the standard approach to overcome the patient's anatomic limitations and, thereby, extend the feasibility of the technique. Indeed, "preoperative planning, preoperative planning, and preoperative planning" have facetiously been identified as the three most important components of a successful repair.

A variety of imaging techniques (i.e., CT, catheter-based arteriography) been employed to determine the feasibility of an aneurysm for endovascular repair and select the appropriate devices/components. However, CT arteriography with 3D reconstructions has emerged as the optimal approach. It is important to emphasize that no imaging technique is perfect and, consequently, a certain degree of flexibility is necessary for the operative plan. Measurements obtained from the 3D CT tend to overestimate the actual renal artery–internal iliac artery length assumed by the graft when deployed in vivo. Similar sizing limitations are associated with the catheter-based arteriography techniques and these have been attributed to the course of the catheter, the presence of intraluminal thrombus, and the conformational changes in the aorta that result from the stiff guide wires and/or the device itself.

The various devices/components should be selected using the underlying principles that the main body of the device should sit as close to the orifices of the renal arteries as possible while the iliac limbs should extend to the orifices of the internal iliac arteries. This methodology not only provides exclusion of abnormal tissue, but also extends the length of seal and fixation of the endograft, and may provide additional column strength for grafts requiring this for durability. Furthermore, the manufacturers' recommendations for sizing and device selection should be followed, although many publications have demonstrated reasonable durability of some grafts even when used outside of the "IFU".[221] Grafts seated well below the orifices of the renal arteries have been associated with proximal migration[222] while oversizing the graft diameter beyond that recommended has been associated with both graft migration and aneurysm reexpansion.[223] The endograft is sized according to the anatomic configuration of the aneurysm and adjacent arteries, and this must be performed in advance of the procedure to ensure that the appropriate devices are available. The diameter and length of the infrarenal cuff, aneurysm, and iliac vessels must be measured precisely. In addition, the distance from the lowest renal artery to the aortic bifurcation and both renal bifurcations needs to be determined. The diameter of the proximal graft is chosen to oversize the aortic cuff and iliac arteries by approximately 10% to 20%. Additional devices should be ordered for each case including two iliac limbs and an aortic extension cuff to allow for any discrepancy between the preoperative plan and the actual course of the graft in vivo.

Each endograft procedure and device configuration is “custom fit” for an individual patient. Work sheets are available from the manufacturers to confirm the suitability of an aneurysm for endovascular repair and to aid in the selection of an appropriate device. Technical assistance is available from the various manufacturers to facilitate every step of the process from initial assessment to component selection to deployment. Furthermore, physicians typically are required to complete a training course comprised of sizing exercises and monitored deployments.

The choice of the specific endovascular device is contingent upon the anatomic constraints of the aneurysm, device associated outcome, and surgeon preference. There are specific differences between the various grafts that lend themselves to different clinical scenarios. The specific considerations include neck diameter, neck length/angulation, renal–internal iliac artery distance, common iliac artery diameter, and access vessel diameter. For example, a graft with suprarenal fixation may be more suitable for a shorter neck while a lower profile system (i.e., smaller outer diameter of the delivery sheath) may be most appropriate for patients with smaller access vessels (i.e., common femoral and external iliac arteries). Despite the initial concerns about compromising renal function, suprarenal fixation has been consistently shown to be safe.[157,224] Deployment of the various endografts is reasonably involved from a technical standpoint; thus, it is not particularly surprising that most surgeons elect to concentrate on one or two devices. All available endografts currently on the market can treat a patient with “straightforward” anatomy, and a high level of comfort with a limited number of devices has some benefit. However, a working knowledge and comfort level with all devices on the market is advised given the benefits that each graft may have over the others in certain scenarios. This allows use of a graft that best meets the individual patient’s needs.

The need for adjunctive procedures to facilitate the endovascular repair is usually determined by the preoperative imaging and should be factored into the overall plan. The major concerns include stenotic access vessels and the absence of a suitable common iliac artery landing zone due to aneurysm enlargement. The remedial procedures for small access vessels or significant occlusive disease include serial dilation or a retroperitoneal prosthetic iliac conduit. Repeated attempts to pass the devices sheaths through a diseased native vessel should be avoided and can result in vessel rupture at the common iliac bifurcation. Aneurysm degeneration of the common iliac artery can be overcome by seating the iliac limb in the external iliac artery. This necessitates either embolizing or bypassing the ipsilateral internal iliac artery. Alternatively, the iliac limb of the endograft can simply occlude the internal iliac artery flush provided the iliac bifurcation is sufficiently tapered.[225] Several reports have documented that accessory renal arteries may be covered at the time of the endograft with little clinical sequelae, although the individual patient’s baseline renal function certainly must be taken into account.

The intraoperative preparation for endovascular repair is similar to that for the open approach although there are several significant differences. The appropriate imaging equipment is mandatory. Ideally, this would entail a complete endovascular suite with a fixed fluoroscopic unit although a portable unit with the appropriate vascular software

and an imaging table is adequate. General endotracheal anesthesia, local and regional anesthesia can all be used for endovascular repair, depending on the individual patient, the clinical scenario, the planned length/complexity of the procedure, and the comfort level of the surgeon and anesthesiologist. Indeed, the endovascular approach is well suited for these less invasive alternatives particularly considering the feasibility of a completely percutaneous approach. For a straightforward endovascular repair, intraoperative autologous transfusion devices and a nasogastric tube are unnecessary. It is currently quite rare to convert to an open repair at the time of the initial implantation despite the early experience that reported a rate of up to 5%.[75,76,78,226] However, it should be emphasized that EVAR is a surgical procedure and most would agree that the procedure should be performed in an operating room with strict aseptic technique.

Although the technique for implanting the various endografts is somewhat specific to the individual device, the basic steps for deploying a "generic" modular bifurcated device using an open femoral artery exposure is illustrated (Fig. 96-10).

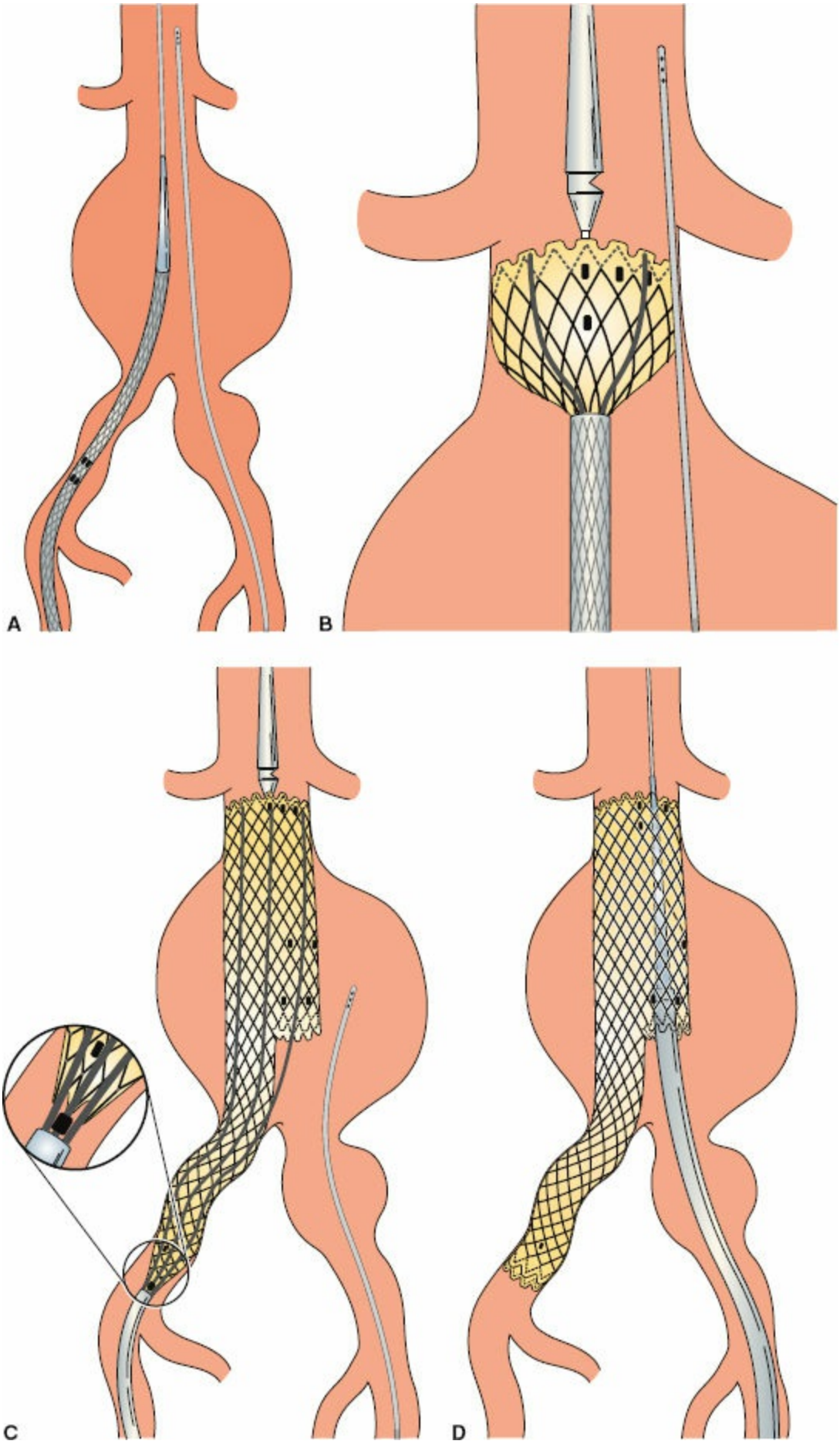
A
B
C
D

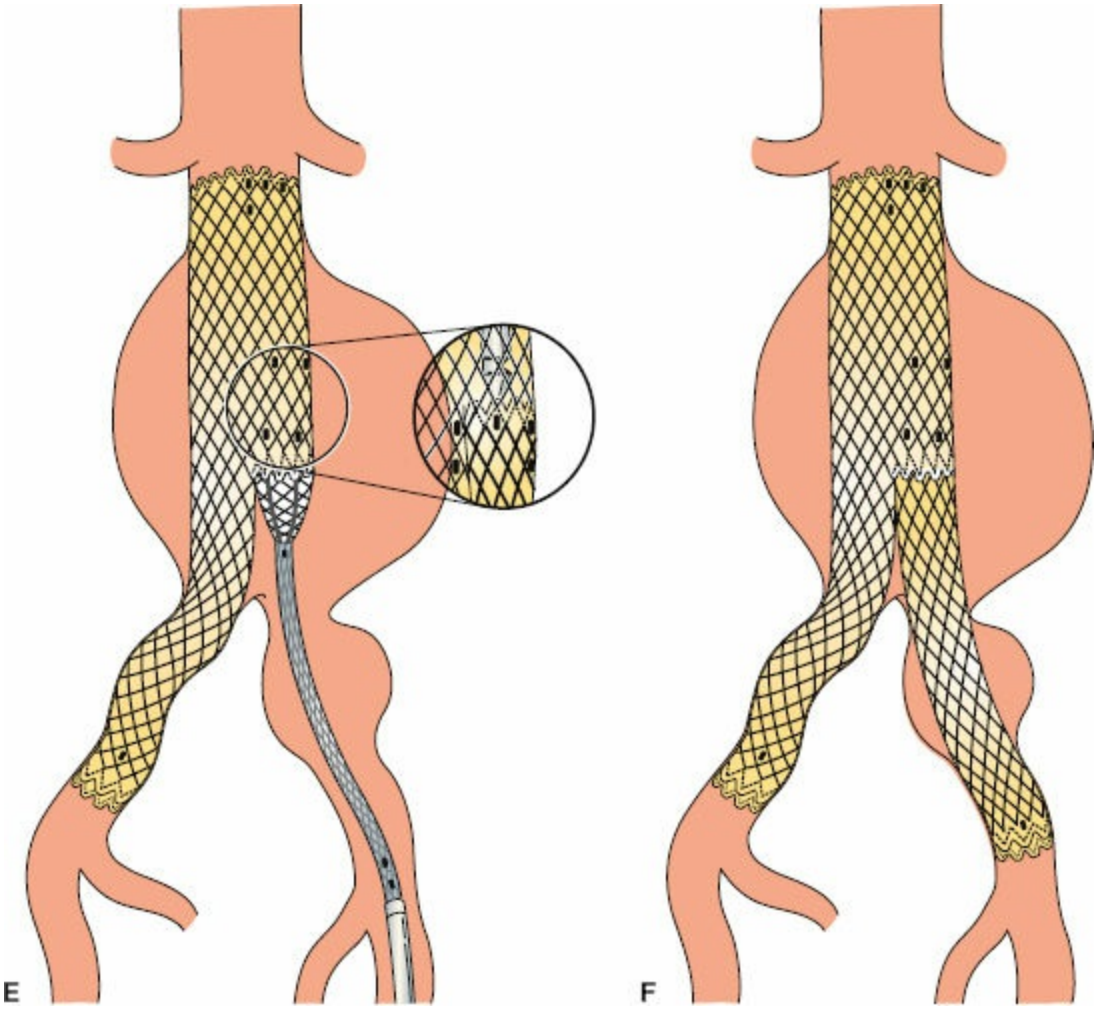

Figure 96-10. General steps involved in the endovascular repair of an abdominal aortic aneurysm. The common femoral arteries are exposed bilaterally (alternatively, and more commonly, percutaneous access is achieved and "preclose" sutures are placed) and stiff wires are introduced into the thoracic aorta under fluoroscopic guidance. An appropriate sized large diameter introducer sheath is inserted over the stiff wire into the body of the aneurysm at approximately the L3 vertebral space on the side contralateral to the one chosen for the main device. If the device is contained within its own deployment system, a sheath may not be required. **A:** The main body delivery catheter is introduced over the stiff wire through the ipsilateral groin and the upper limit of the main body positioned between the L1 and L2 vertebral bodies. An aortogram is obtained and the location of the renal arteries identified. The location of the renal arteries is marked on the imaging screen and the position of the main body finely adjusted. **B, C:** The main body is deployed exposing the opening of the contralateral docking limb. The contralateral docking limb is cannulated and a stiff wire advanced into the thoracic aorta. After confirming successful cannulation of the docking limb, deployment of the contralateral limb is deployed after marking the origin of the hypogastric artery. The hypogastric origin can be identified by using intravascular ultrasound or by obtaining a retrograde arteriogram through the sheath in the opposite oblique projection to identify the orifice of the internal iliac artery. **D,E,F:** The location of the orifice is marked on the imaging screen the contralateral limb is then introduced over the stiff wire, appropriately positioned, and deployed A compliant aortic occlusion balloon is advanced over the stiff wire and inflated in the region of the infrarenal neck to mold the proximal and distal attachment sites, and used to ensure the overlapping devices are well sealed.

Percutaneous access to the common femoral arteries has become standard for many physicians using a "preclose" methodology that involves placing a suture-based closure system that is deployed prior to delivery of the device and closed at the conclusion of the

procedure.[163,164] If the surgeon is uncomfortable with that approach, or the femoral artery anatomy precludes use of closure devices, an open exposure works well and can be done through transverse, longitudinal or oblique incisions, depending on the clinical scenario. Briefly, the common femoral arteries are exposed and an umbilical tape or vessel loop is wrapped circumferentially around the vessels at the level of the inguinal ligament to facilitate vascular control. Approximately 2 cm of the common femoral artery is dissected free. It is not usually necessary to dissect the superficial femoral and profunda femoris branches. While the dissection is being performed, the various device components are prepared on the back table by the surgical technologist. A purse string suture using a 4-0 or 5-0 cardiovascular suture can be placed on the anterior aspect of the common femoral artery and left untied until the completion of the procedure. The various catheters/sheaths may be introduced through the center of the purse string, thereby, facilitating a rapid/simple closure of the artery at the completion of the procedure. The common femoral artery on the side chosen to introduce the main body of the device (ipsilateral groin) is punctured using an angiographic needle and a 0.035-in standard working wire (e.g., Bentsen) is passed into the abdominal aorta using fluoroscopic guidance. A 5-Fr introducer sheath is advanced over the guidewire using a Seldinger technique and vessel entry is confirmed by manual contrast injection. The working wire is further advanced into the thoracic aorta and exchanged for a longer 0.035-in stiffened guidewire (e.g., Lunderquist, Meier) using a catheter. Attention is then directed to the contralateral groin and in a similar manner a guidewire is advanced into the aorta and an appropriate sized introducer sheath is inserted over the guidewire into the body of the aneurysm at approximately the L3 vertebral space. An angiographic catheter is advanced to the L1 vertebral body through the contralateral sheath and the catheter connected to the power injector. The patient is then anticoagulated with heparin using a standard protocol (100 units/kg) and therapeutic anticoagulation (ACT twice baseline) is maintained throughout the procedure. The main body delivery catheter is introduced over the stiff wire through the ipsilateral groin and the upper limit of the main body positioned between the L1–L2 vertebral bodies. Devices that do not have an integral sheath as part of their delivery system require an 18- to 22-Fr sheath to be inserted prior to introduction of the actual delivery catheter. Radiopaque markers on the graft facilitate the positioning and orientation of the main body.

As imaging has improved, multiple techniques allow for determining the proper location of endograft deployment. This may involve the use of IVUS or 3D overlay imaging, both of which can decrease the use of contrast and the radiation exposure to both the patient and practitioner. In the absence of these advanced imaging techniques, an aortogram can be obtained after delivery of the endograft to the location of the renal arteries and the renal arteries marked for device deployment. In this scenario, the flat panel or image intensifier should be adjusted to optimize visualization of the infrarenal neck. A 5- to 10-degree craniocaudal angulation is usually sufficient to account for the anterior angulation of the infrarenal neck caused by the natural lumbar lordosis of the spine and the posterior bulging of the aneurysm sac. However, the optimal angulation or orientation may be estimated based upon the preoperative 3D CT images. The location of

the renal arteries is marked on the imaging screen and the position of the main body adjusted. The main body is now deployed exposing the opening of the contralateral docking limb. Using a combination of a hydrophilic wire and a curved catheter, the contralateral docking limb is cannulated. This can be challenging at times and requires a modest degree of catheter skills. Various maneuvers including different fluoroscopic projections, different shaped catheters, and proper orientation of the contralateral docking limb prior to deployment of the main body device can facilitate this step. It is imperative to confirm that the cannulating guidewire is actually within the body of the main endograft. There are a number of methods to confirm entry into the main aortic graft, but the surgeon should use that which he/she is most comfortable. The most definitive way to determine successful cannulation of the docking limb is to use IVUS, but this can be accomplished by a number of methods. A common method is to place a reverse curve catheter such as a SOS or a pigtail catheter into the main body at the level of the neck and spinning the catheter. If the catheter spins freely, this confirms that it is not outside of the endograft where it would be trapped between the aortic wall and endograft. Alternatively, an arteriogram can be performed using a catheter within the main body, confirming that dye fills the aortic graft, but not the aneurysm on initial injection. Once this is confirmed, the contralateral wire is advanced into the proximal descending thoracic aorta under fluoroscopic guidance and exchanged for a stiff wire using a catheter.

If IVUS is used, the hypogastric artery can be identified and marked during withdrawal of the catheter after confirmation of docking limb catheterization, and the length measured using the radiopaque marks on the IVUS catheter. Alternatively, placing the imaging equipment into the proper position for optimal visualization and a retrograde injection then performed through the sheath can mark the hypogastric. The optimal angle can be variable, and is best-determined using preoperative 3D imaging. If not available, the typical angle required to see the hypogastric is in the opposite obliquity about 300 from the side of the vessel (i.e., Right Anterior Oblique for the Left internal iliac artery). The location of the orifice is marked on the imaging screen and a marker catheter is used to measure the distance from the contralateral docking limb to confirm the preoperative measurements and device selection. The contralateral limb is then introduced over the stiff wire, appropriately positioned relative to the docking limb and the orifice of the internal iliac artery, and then deployed.

After deployment of all the devices, a compliant aortic occlusion balloon is advanced over the ipsilateral stiff wire and inflated in the region of the infrarenal neck to mold the proximal attachment sites. The aortic balloon is then withdrawn and gently expanded at the main body/iliac limb overlap zone and both distal iliac artery fixation sites. A completion arteriogram is then obtained using an angiographic catheter placed through one of the introducer sheaths (Fig. 96-11). The arteriogram should adequately evaluate the proximal/distal fixation sites, the graft/graft overlap zones and the orifices of the renal/internal iliac arteries. In addition, it should include delayed imaging to help identify any endoleaks. Problems identified on the completion study should be corrected, if possible. The potential remedial procedures include balloon dilation or aortic/iliac

extension cuffs.



Figure 96-11. Completion arteriogram after an endovascular aneurysm repair is shown. The arrow marks the caudal extent of the stent graft. Note that the iliac limbs have been intentionally crossed to facilitate the cannulation of the contralateral gate.

With open femoral exposure, all sheaths, catheters, and wires are removed after the completion of the arteriogram and the femoral arteriotomy closed using the previously placed purse–string suture. When using percutaneous closure methods, the wire is typically left in during closure to allow placement of additional closure devices as necessary. Pedal Doppler signals should be confirmed prior to removal of the wire and completion of arterial closure. The heparin can then be reversed with protamine (1 mg protamine/100 units heparin) after adequate signals are detected in the feet. The groin wounds are closed in layers with absorbable suture and the final skin later is closed with a subcuticular technique.

The immediate postoperative course is typically fairly uneventful. Patients are transferred to the general care ward after recovery in the postanesthesia care unit. Patients are started on an appropriate diet the evening of the procedure and encouraged to get out of bed. Patients should be kept supine for 4 to 6 hours after the operation when a percutaneous technique is used to ensure successful hemostasis. Plain radiographs of the abdomen (4 views, optimized for metal) can be obtained on the first postoperative day for a baseline position of the grafts, but this is not routine in many centers. Most infrarenal EVAR patients are discharged home on postoperative day 1 or 2, and then seen in the outpatient clinic at 1 month with an abdominal/pelvic CT scan. It is important to note that mild fever and the finding of air around the graft on CT are common

occurrences immediately after endograft repair and have not been associated with graft infection.[227]

9 It is imperative that patients are followed long-term given the uncertainty associated with the endovascular repair and the need for remedial procedures. As noted above, new endoleaks have been identified many years after repair.[228] A variety of protocols and imaging techniques have been described although an abdominal/pelvic CT scan with contrast at 12 months and then yearly noncontrast studies seems reasonable in the absence of any identifiable problems and an aneurysm sac that is not increasing in size. Indeed, Sternbergh et al.[229] reported from a multicenter trial that the absence of an endoleak at 1 and 12 months predicted favorable long-term outcome. More frequent imaging may be indicated if the aneurysm continues to grow or there is evidence of an endoleak. The surveillance CT scans should include noncontrast and biphasic contrast views with delayed images to help identify any late endoleaks.[230] Calcified material will frequently be present in the aortic sac, and can masquerade as contrast. The noncontrasted portion of the CT will help determine the nature of this material and can be very helpful when combined with contrasted imaging. Although not part of all surveillance protocols, early plain radiographs are very helpful to identify structural changes/problems with the grafts, and are sometimes more useful than CT in identifying issues with the metal skeleton of the graft. Duplex ultrasound has been employed as a surveillance study, but its accuracy is dependent on the local expertise of the vascular laboratory.[231–233]

Complications and Outcome

The mortality rates in the recent randomized trials and national series is less than 2%,[69,70,74,111] the perioperative complication rate is $<25\%$,[73,136] the rupture risk is approximately 1%/yr,[136,141] and the incidence of remedial procedures approximately 10%/yr.[145,234] Many of the same complications that can occur after open repair can occur after endovascular repair. However, the relative incidence of the various complications is significantly different, and several complications inherent to EVAR have been identified.

A variety of potential complications may arise during insertion of the delivery catheter or introducer sheath. Indeed, access problems secondary to iliac stenosis and/or tortuosity are the most common procedure-related complication. The outer diameters of the delivery sheaths are device-dependent, but can range up to 25 Fr. Device companies are diligently working to decrease the profile of their endografts, but the outer diameter of some endografts continues to be a limitation in some patients. The cross-sectional outer diameter of a sheath corresponds to a diameter of $1/\pi$ mm (e.g., 24 Fr = 24/3.14 mm or 7.6 mm). A variety of techniques are available to correct or overcome small or diseased access vessels, and these should be factored into the preoperative plan. Excessive force during insertion of these large sheaths or delivery catheters can result in serious injury and perforation/disruption of the vessels. Predictably, this can lead to significant hemorrhage and hemodynamic changes. The diagnosis can be confirmed by arteriography and the bleeding controlled intraluminally using the device sheath or a balloon catheter. A variety of endovascular salvage techniques are possible in this setting including

deployment of either the main device or a covered stent over the disrupted artery. Most major arterial disruptions can be managed with endovascular techniques, but in the event they are unsuccessful, a retroperitoneal incision with direct control of the iliac arteries can be performed expeditiously.

Safe conduct of an EVAR is predicated by sufficient knowledge of the various salvage techniques, the necessary catheter and guidewire skills to execute these techniques and a complement of ancillary equipment. However, the adage that "prevention is better than the cure" holds true and endovascular surgeons should maintain a low threshold for constructing a retroperitoneal iliac conduit prophylactically. Further, dissection within the arterial wall of the iliac vessels or aorta may also result from misdirection or excessive force during cannulation of the vessels. When nonflow limiting, no intervention may be necessary, but if flow limitation is noted, the dissection can usually be corrected by cannulating the "true" lumen and reestablishing its integrity by deploying a peripheral (uncovered) stent. If the wire is left in place until Doppler signal is confirmed in the feet, true lumen access is maintained, making this much easier.

Graft deployment can be associated with mechanical problems related to the delivery system or inappropriate positioning. A host of mechanical problems have been described, and the list will likely expand with widespread application of the devices and the introduction of updated systems. Many of the mechanical problems are device-specific and related to the actual sequence of events and manipulations required. Troubleshooting guidelines and specific recommendations are available from the manufacturers. Deployment of the endovascular graft below the proximal target site on the infrarenal aorta may be corrected using an aortic extension cuff. Attempting to reposition the graft further proximally after deployment has not been successful and is not recommended. Deployment of the endovascular graft across the orifices of the renal arteries can potentially be corrected by displacing the graft caudally. A guidewire can be passed over the flow divider and out the contralateral groin. The entire graft can then be retracted caudally by pulling on the wires. Alternatively, a large balloon can be inflated above the flow divider and retracted. Extreme care must be exercised during these maneuvers to prevent complete dislodgement of the proximal main body from the neck. Deployment of the graft across part of the renal orifice can be corrected by placing a stent within the lumen of the renal artery and, thereby, displacing part of the main body caudally. This may be done from the femoral access or may require arm access if more extensive unintentional coverage of the branch vessel has occurred. Deployment of the endograft across the lumen of one internal iliac artery is usually tolerated provided the contralateral vessel is patent and relatively free of occlusive disease. Indeed, it is relatively common to embolize a single internal iliac artery in patients with common iliac artery aneurysms to facilitate fixation of the graft limb in the external iliac artery. With coverage of a single hypogastric artery, severe complications are rare, but buttock claudication and impotence are not.[129] Occlusion of both internal iliac arteries or occlusion of one vessel in the presence of contralateral disease may render the pelvis ischemic. In the event of unintentional hypogastric artery coverage, the iliac limb can be pushed cephalad using a sheath and its dilator. It should be emphasized that many of these remedial procedures

are not manufacturer approved and should only be attempted by experienced endovascular surgeons. Due to the advanced age of many of these patients and their attendant comorbidities, open surgical conversion should be contemplated only as a last resort after the endovascular options have been exhausted, again emphasizing the need for advanced endovascular skills.

It is relatively common to see an endoleak on the completion arteriogram. Treatment is contingent upon the specific type of leak and their associated natural history although the majority of these early endoleaks ultimately resolve.[235] Type 1a/b (a-proximal, b-distal attachment site) and type 3 (fabric tear or modular component separation/leak) endoleaks are particularly concerning and every reasonable attempt to correct these defects should be made. The aneurysm sac is often exposed to systemic pressure in the presence of a type 1 or type 3 endoleak, and, therefore, the rupture risk likely approaches that associated with the untreated aneurysm. Both the type 1 and 3 endoleaks can potentially be corrected by repeat balloon angioplasty at the proximal/distal attachment sites or at the modular interface. If these measures are not successful, additional extension devices can be deployed. With the exception of large proximal type 1 endoleaks, it is reasonable to manage most perioperative endoleaks expectantly since many seal spontaneously after reversal of the anticoagulation or within the first 6 months. Indeed, even type 1a endoleaks often thrombose before the first postoperative imaging study, although patient selection, aneurysm diameter, and risk of rupture should be carefully considered before leaving an endoleak of this nature. Thus, the surgeon should be mindful that the inability to obtain a satisfactory exclusion of the aneurysm at the time of endograft implantation does not mandate a surgical conversion at the same setting. In situations where there is concern for a persistent endoleak, an earlier postoperative CT than the usual 1-month study may be advisable.

In the event that a significant endoleak persists on postoperative imaging, the potential options include referral to another center with more expertise and branched/fenestrated capabilities, open surgical repair with removal of any or all implanted devices, or no further treatment if the patient is a poor surgical risk. Type 2 endoleaks (retrograde branch vessel related) have a relatively benign natural history and do not merit aggressive intervention unless the aneurysm continues to increase in size over time. Type 4 (trans-graft) endoleaks are self-limiting, and do not merit treatment at all. They are identified as a diffuse contrast “blush” at the time of the completion arteriography. They represent a diagnosis of exclusion and mandate that the more worrisome type 1 endoleak be excluded.

The spectrum of immediate postoperative complications after EVAR is comparable to that outlined for after open repair and will not be repeated. However, the incidence of major, systemic complications after EVAR is quite small. It is noteworthy that the incidence of both paraplegia and bowel ischemia are comparable after endovascular and open repair although the mechanisms are different and likely due to atheroembolism.[210,236,237] Indeed, diffuse embolization to the small bowel has been reported after endovascular repair and is almost uniformly fatal.[236]

The long-term complications after EVAR include endoleak, structural failure, need for

remedial procedures, need for open conversion, and rupture. These ongoing risks further emphasize the importance of conscientious lifelong surveillance. All type 1 and 3 endoleaks identified during surveillance merit further evaluation and correction given their ongoing rupture risk. Device migration has been reported to cause type 1 endoleaks and has been associated with neck length, site of deployment below the renal arteries, and surgeon/center experience.[222] The treatment of these late occurring type 1 and 3 leaks is identical to that for those occurring earlier and includes identification of the specific site and remediation with either balloon angioplasty or an additional endovascular device, although the latter is most common. Type 2 endoleaks merit intervention and treatment if the aneurysm continues to increase in diameter, although the clinical scenario is an important deciding factor in these cases. Identification of the type 2 endoleak can be challenging and may require selective catheterization of the superior mesenteric or internal iliac arteries.[238] A variety of approaches have been described to treat the type 2 endoleaks including coil embolization, laparoscopic ligation of the feeder vessels, and direct translumbar or transcaval injection of the aneurysm sac with glue or other thrombotic agents.[239,240]

Aneurysms that continue to increase in size after EVAR merit further intervention and may require open conversion due to their ongoing rupture risk. Continued aneurysm growth has been associated with the type of prosthesis and baseline size in addition to the presence of endoleak.[147] It should be emphasized that the goal of aneurysm repair is to prevent rupture/death from rupture and that endoleak and even sac enlargement are surrogate markers of potential late failure of the therapy. Indeed, even the clinical significance of an enlarging sac in the absence of a visible endoleak is controversial as long as a secure proximal and distal fixation of the endograft has been demonstrated. To confound the issue further, rupture of aneurysms without an endoleak or a change in sac diameter has also been reported, leading some to describe the phenomenon teleologically as endotension. A presumed endoleak that is not detected on a properly performed contrast CT scan is typically not identified on a catheter-based arteriogram. The proper diagnostic investigation of an endoleak should include interrogation of all the fixation sites and modular interfaces and selective injections of mesenteric and hypogastric arteries with sufficient contrast dose and proper acquisition techniques. It should be emphasized that open conversion and explant of the endovascular graft can be technically more challenging than a de novo open repair and usually requires suprarenal or supraceliac aortic control. In the absence of infection, it is not always possible (or necessary) to remove the entire device, particularly when the device has suprarenal fixation. It is possible to transect the endovascular graft near the usual site of the infrarenal aortic anastomosis and incorporate the fabric/stents of the graft into the anastomosis. Temporary distal vascular control can be achieved by clamping the limbs of the endovascular graft. The limbs of a bifurcated surgical graft may be anastomosed directly to the endograft limbs if they are securely attached to the iliac artery. In properly chosen elective patients, open conversion can be performed with similar outcomes to primary open juxtarenal AAA repair.[241]

A variety of device-specific complications, including strut fracture, fabric tears, and

buckling of the graft, have been identified, and the list will likely increase with the introduction of newer technologies. Importantly, these may present at any time throughout the postoperative period. An extensive discussion of all the potential device-related complications and their treatment is beyond the scope of this chapter. Importantly, regression of the aneurysm, although typically desirable, has been associated with significant conformational changes in the endografts and has resulted in limb thrombosis and disruption of the distal attachment sites.[242] These adverse outcomes in the presence of decrease in the aneurysm size have been termed the “paradox of success.”

REPAIR OF RUPTURED ABDOMINAL AORTIC ANEURYSMS

Open Repair

The approach to the patient with a ruptured AAA is similar to the elective scenario with the exception of several points that merit further comment. In order to achieve a reasonable result, the diagnosis should be made in an expeditious fashion and the appropriate treatment initiated quickly. The endovascular approach appears to be associated with a lower mortality rate, but this remains to be further documented given the inherent bias in terms of patient selection and publication.[85,86,88–90]

The patient should be taken emergently to the operating room once the diagnosis of a ruptured aneurysm has been made. Unnecessary delays to complete the preoperative evaluation should be avoided. Unfortunately, the diagnosis is not always made in a setting where an operating room and the appropriate resources are immediately available. In this scenario, the patient should be transferred to the appropriate setting as quickly as possible, which may require transfer to a facility able to provide a higher level of care. When the decision is made to transfer a patient with a ruptured aneurysm, the transferring physician should keep several principles in mind, with the most important being avoidance of hypertension and the concept of permissive hypotension.[243]

When bringing the patient to the operating room, the OR team and anesthesia personnel should be notified immediately upon diagnosis and instructed that the patient is en route. The necessary instrument trays should be opened, the room temperature in the operating room increased, adjunctive measures to maintain body temperature obtained, and the intraoperative autologous salvage device prepared. Notably, hypothermia has been shown to be a strong, independent predictor of mortality after ruptured aneurysm repair.[244] The blood bank should be notified and instructed to send 6 units of blood to the operating room. This should be type O negative or type-specific if cross-matched units are not available. Furthermore, the blood bank should be instructed to expedite the cross-match of additional red blood cells, fresh frozen plasma, and platelets.

On arrival at the operating room, the patient should be prepared and draped before intubation and the induction of anesthesia, which includes draping from chin to knees or toes, depending on the surgeon's preference. This allows access to both groins for endovascular proximal control, and the chest in the event that resuscitative thoracotomy is required. During the patient preop, the surgeon and assistants should gown/glove and be prepared to make the incision at the time of induction, because patients with ruptured aneurysms frequently become hypotensive after the induction of anesthesia.

A midline incision should be made and supraceliac aortic control obtained. The aorta/esophagus can be difficult to identify, especially in a hypotensive patient during a deluge of blood from the abdomen. A nasogastric tube placement quickly after induction makes identifying the gastroesophageal junction much easier, and thus the proper location of the supraceliac clamp. The esophagus should be manually moved to the patient's left and the gastrohepatic ligament, the crus of the diaphragm, and the connective tissue enveloping the aorta can be divided using blunt finger dissection. If

necessary, control of the aorta can be achieved manually by either occluding the aorta between the fingers and thumb or compressing it against the vertebral bodies. Definitive control should be obtained with an aortic clamp. Of course, care should be utilized during these maneuvers to prevent injury to the esophagus or the aorta itself.

Aortic control can also be achieved through a variety of other means: thoracotomy with occlusion of the descending thoracic aorta, intraluminal control of the infrarenal aorta with a compliant balloon placed through a femoral artery, or supraceliac control via a retroperitoneal incision, if that approach was chosen. The aortic surgeon should be familiar with these various techniques because they can be helpful in certain clinical settings, but the midline approach with supraceliac control is recommended for most ruptured *infrarenal* aneurysms. After supraceliac aortic control has been obtained, the infrarenal aorta is dissected and vascular control is achieved below the level of the renal arteries. The hematoma from the ruptured aneurysm often facilitates the dissection by displacing the normal tissue planes. However, the normal tissues may be obscured, and care should be taken not to injure the venous structures, particularly the left renal vein, which can lead to much more blood loss. The supraceliac aortic clamp can be released after infrarenal control has been obtained, and flow can be restored to the visceral vessels. It is imperative that these various steps are coordinated with the anesthesia team, and it is recommended that the supraceliac clamp be left in position to facilitate reapplication if necessary. Distal vascular control can be achieved with either vascular clamps or intraluminal balloons, depending on the character of the iliac vessels.

Patients can be heparinized after proximal and distal vascular control has been obtained, provided that the patient is doing well and the case is proceeding expeditiously.[245] However, the decision to anticoagulate the patient is contingent on a variety of factors, including the quantity of blood lost, presence of coagulopathic bleeding, body temperature, and hemodynamic status. Anticoagulation potentially reduces thrombotic complications, but it exacerbates coagulopathic bleeding. Before completion of the distal anastomoses, thromboembolectomy catheters should be passed distally through the iliac vessels to remove any thrombus or debris. It is recommended that the inferior mesenteric artery be implanted (if patent) to reduce the risk of postoperative colonic ischemia. The heparin effect can be reversed with protamine after confirmation of distal lower-extremity arterial signals. The administration of plasma, platelets, or both should be considered at this point if any evidence of coagulopathic bleeding is noted. A thromboelastogram (TEG) can be very helpful in determining the need for supplemental blood products.[246]

The postoperative course after repair of a ruptured aneurysm is predictably more complicated and protracted than after elective repair.[247–251] Both the intensive care unit and total hospital length of stay are significantly increased. The mortality and complication rates are likewise significantly increased. As noted above, the mortality rate for patients with ruptured AAAs who make it to the operating room is approximately 50%.[13] The spectrum of postoperative complications after repair of a ruptured aneurysm is essentially the same as after elective repair although the incidences are increased. The incidence of bowel ischemia may be as high as 40% and routine colonoscopy may be

indicated.[211] Abdominal compartment syndrome[252,253] and adrenal insufficiency[254] have been reported after ruptured aneurysm repair and merit consideration in patients that are not doing well. Notably, adrenal insufficiency was identified in almost 70% of patients with unexplained postoperative hypotension after ruptured aneurysm repair.[254] Predictably, long-term survival is decreased relative to patients undergoing elective repair[225] although the overall quality of life is comparable.[255]

ENDOVASCULAR REPAIR FOR RUPTURE

EVAR has the potential to greatly impact the operative mortality rate for ruptured AAAs, but depends heavily on aortic anatomy, more so than for open repair. Although the worldwide experience is relatively small, early outcomes are impressive, particularly given the significant mortality/morbidity associated with the open repair which has remained relatively constant over the past few decades.[83] Despite the appeal of the endovascular approach, its application requires a defined protocol/approach consisting of an experienced endovascular surgeon, a committed team, an available operating room with the necessary imaging equipment, and an inventory of suitable devices. Several recent studies have estimated that approximately 20% to 50% of patients with ruptured aneurysms are anatomically suitable for endovascular repair using conventional devices although this number may increase with the introduction of newer devices and/or the extension beyond the manufacturers' IFU.[256–258]

The endovascular approach for the treatment of ruptured AAAs can be briefly summarized and has been described by multiple authors.[259,260] Patients with a presumed diagnosis of a ruptured AAA that are hemodynamically stable, as defined by a systolic blood pressure >80 mm Hg and normal mentation, should undergo a rapid CT arteriogram to determine their anatomic suitability. Notably, aggressive fluid resuscitation should be avoided during this period to avoid the risk of releasing the retroperitoneal tamponade. The anatomic criteria for EVAR include an acceptable neck anatomy (length ≥ 10 mm, diameter ≤ 32 mm, freedom from prohibitive angulation [device specific]) and adequate access vessels (≥ 7 mm diameter). The operative plan is generated and the appropriate devices selected based upon the CT findings and patients are taken directly to the operating room from the scanner. Oversizing of the aortic neck $\geq 20\%$ and encroachment on the orifices of the renal arteries with adjunctive stenting are both tolerated in an attempt to limit the necessary inventory and increase the proximal fixation zone, respectively. Access to the common femoral arteries is obtained using a percutaneous approach with direct exposure and repair delayed until the completion of the procedure. In the absence of severe hypotension, the remaining conduct of the procedure is essentially the same as described in the elective setting. It is not usually necessary to occlude the aorta with an intraluminal balloon although one should be readily available in the event that the patients become hemodynamically unstable.[261,262] The criteria for an acceptable result are somewhat less in the emergent setting and persistent attempts to achieve a perfect radiographic result should be avoided. The ultimate goal is to prevent further hemorrhage and to allow the patient to be resuscitated, which does require the absence of a type I or III endoleak, but otherwise does not require an absolutely perfect radiographic result. Further interventions including conversion to open repair may be necessary at a later date, but these can usually be performed in an elective fashion.

Notably, patients treated with EVAR are at risk of developing abdominal compartment syndrome, which can be related to intra/retroperitoneal hemorrhage and/or aggressive volume resuscitation. The surgeon should consider prophylactic celiotomy or

retroperitoneal evacuation with placement of an open abdominal dressing at the conclusion of the procedure, which may be required in up to 20% of patients.[263,264]

ADDITIONAL CONSIDERATIONS

Isolated Iliac Artery Aneurysms

Isolated iliac artery aneurysms are rare and have been reported to occur with an incidence ranging from 0.03% in autopsy series[11] to 2.2% in single-institution series.[265] The common iliac artery is involved in approximately 70% of the cases, and the internal iliac artery in the remainder.[266] Aneurysmal involvement of the external iliac artery, either in combination with the common iliac artery or alone, is distinctly rare. These isolated iliac artery aneurysms should be differentiated from the common iliac artery aneurysms that occur concomitantly with AAAs. Simultaneous aneurysmal involvement of the aorta and common iliac arteries occurs in about 10% to 20% of all AAAs[11,12]; this pattern should be considered as one disease process and treated accordingly.

The natural history of isolated iliac artery aneurysms is poorly defined because of their low incidence. The clinical risk factors appear to be similar to those for AAAs with the highest incidence seen among elderly men. Unlike patients with AAAs, a significant proportion of patients with isolated iliac artery aneurysms present with symptoms.[266] These symptoms may result from either rupture or compression of adjacent structures including the bowel, ureters, iliac veins, and nerves. The clinical presentation of patients with a ruptured iliac artery aneurysm is similar to that of ruptured AAAs, and the diagnosis should be included in the differential for patients with genitourinary symptoms and normal findings on urinalysis and testicular examination. CT arteriography is optimal for confirming the diagnosis of an isolated iliac artery aneurysm. The utility of ultrasonography is limited by the posterior course of the iliac vessels and the overlying bowel. Large iliac artery aneurysms may occasionally be palpated during rectal or gynecologic examination, and ruptured iliac artery aneurysms may present with ecchymosis of the perineum.

The principles of treatment for asymptomatic, isolated iliac artery aneurysms are similar to those for AAAs, and operative repair is justified when the risk for rupture offsets the risk of repair. Unfortunately, the natural history of isolated iliac artery aneurysms and the appropriate threshold for repair remain unresolved. The reported growth rate for iliac artery aneurysms <3 cm is 0.11 cm/yr while that for aneurysms 3 to 5 cm is 0.26 cm/yr.[267] Although rupture has been reported for aneurysms smaller than 2 cm, it is rare for aneurysms smaller than 3 cm to rupture.[265,268] Operative repair is generally recommended for good-risk patients with isolated iliac artery aneurysms ≥ 3.5 cm. The frequency of surveillance imaging studies should be dictated by the size of the aneurysm with yearly studies appropriate for aneurysms <3 cm with 6 month intervals appropriate for aneurysms between 3 and 3.5 cm.[265]

The treatment or repair of isolated iliac artery aneurysms depends on the specific vessel involved and the extent of the aneurysm. Theoretically, common iliac artery aneurysms can be repaired with an interposition graft or a covered stent provided that there is a sufficient proximal and/or distal neck to sew the anastomosis or seat the graft. However, this is rarely an option because the aneurysm involvement of the vessel usually extends

over its whole length. Therefore, repair necessitates replacing the whole common iliac artery with a bifurcated graft similar to the approach for patients with combined aortic and iliac artery aneurysms. Both open and endovascular approaches are available and the concerns about the individual choice (i.e., open vs. endovascular) are likely similar to that outlined for AAAs. In addition, the principles of treatment for both the open and endovascular approach of isolated iliac artery aneurysms are similar to AAAs. In the case of open repair, the proximal anastomosis should be performed immediately below the renal arteries to prevent subsequent aneurysm degeneration of the infrarenal cuff while the distal anastomosis should be performed at the common iliac bifurcation on the involved side. The distal anastomosis on the uninvolved common iliac artery can be performed to a nonaneurysmal segment. For the endovascular repair, the graft should be seated immediately below the renal arteries and at the takeoff of the internal iliac artery on the side opposite the aneurysm. The iliac limb on the side of the aneurysm is seated in the external iliac artery and necessitates embolization, branched stent graft, or open surgical bypass of the ipsilateral internal iliac artery.

The treatment of internal iliac artery aneurysms is typically exclusion. This can be performed using either an endovascular or open approach although the former is likely preferred due to its simplicity. Bypass of an internal iliac artery aneurysm is often not possible because there is rarely a proximal or distal neck. Indeed, the aneurysmal involvement usually extends to the common iliac bifurcation and the distal aspect usually arborizes into multiple smaller vessels. The principles of the endovascular treatment include obliterating both the arterial inflow and the outflow of the aneurysm. The outflow is usually occluded using selective coil embolization, although a variety of other agents, such as glues and gelfoam, have been described. Placing a covered stent across the orifice of the internal iliac extending from the common to the external iliac vessels eliminates the inflow. The open approach requires vascular control of the distal common iliac and proximal external iliac arteries. The internal iliac artery is then opened by incising the aneurysm, and the branches are oversewn from within. The proximal internal iliac artery can be either oversewn at its takeoff, or the resultant defect at the common iliac bifurcation can be repaired with patch angioplasty. The appropriate treatment for patients with bilateral internal iliac artery aneurysms remains unclear. Exclusion of both vessels has the potential to cause severe pelvic ischemia that may not be remediable. A conservative approach is likely justified in this setting with a higher threshold for intervention appropriate for the second vessel. Treatment options include excluding only the larger vessel, attempted revascularization, and staged exclusion after sufficient time has elapsed to facilitate potential collateral development. Regardless of the treatment option, it is important to assess the status of the pelvic circulation including the profunda femoral artery and the inferior mesenteric artery, which are important collaterals to the pelvis.

INFLAMMATORY ABDOMINAL AORTIC ANEURYSMS

Approximately 5% of all AAAs are described or considered inflammatory.[269] These are characterized by a dense inflammatory response encasing the anterior and lateral walls of the infrarenal aorta with sparing of the posterior aspect. The inflammatory response consists of a dense cellular infiltrate that has a white, glistening appearance on inspection. The inflammation results in an increase in wall thickness with the difference between the inner and outer diameters of the aorta ranging from 1 to 5 cm. The cause of this inflammatory process remains unresolved, but it is likely an autoimmune phenomenon. Indeed, some type of autoimmune disorder has been identified in up to 20% of patients with inflammatory aneurysms.[270]

Patients with an inflammatory abdominal aneurysm are predominantly male and frequently present with symptoms of back or abdominal pain. The triad of a pulsatile abdominal aortic mass, abdominal pain, and an elevated erythrocyte sedimentation rate (ESR) has been described. Abdominal ultrasonography or CT may confirm the diagnosis. The anterior and lateral aspects of the aortic wall are thickened and hypoechoic on the sonogram. The CT findings are characteristic and include a thick, contrast-enhancing wall in the distribution described. An inexperienced observer may confuse the CT findings with those of a ruptured AAA. Hydronephrosis with *medial* displacement of the ureters is frequently seen in contradistinction to the lateral displacement seen with noninflammatory aneurysms. Indeed, this entity may share some pathophysiologic pathways with retroperitoneal fibrosis.

The treatment of inflammatory AAAs is essentially the same as that for the more common, noninflammatory variety. Nonoperative treatment with corticosteroids has been advocated in the past, although this approach is likely ineffective and has largely been abandoned.[271] It has been suggested that the rupture risk of inflammatory aneurysms is less than that for noninflammatory variety because the wall thickness is increased. However, this is not true, and patients should not be lulled into a false sense of security. It should be emphasized that most aneurysms rupture through their posterior or posterolateral aspect, which is not involved in the inflammatory process. The open repair of an inflammatory AAA is complicated by the fact that the adjacent structures, including the duodenum, colon, and ureters, may be involved in the process and densely adherent to the aortic wall. Using the retroperitoneal approach can reduce the technical difficulties associated with the open repair. The operative blood loss and procedure time associated with the open repair of inflammatory AAAs may be greater than the more common, uninvolved type. These potential technical difficulties should be factored into the operative indications and size-related threshold for the open approach.

EVAR may be the optimal treatment for patients with inflammatory AAAs due to the concerns about the inflammatory process and adherent structures outlined above.[272–275] Notably, Puchner et al.[275] performed a meta-analysis of patients undergoing endovascular repair for inflammatory aneurysms and reported that the inflammatory process resolved in approximately 50% of the cases. Inflammatory aneurysms can be repaired through a transperitoneal approach, and this scenario occasionally arises when the diagnosis is not

suspected preoperatively. Regardless of the open approach, no attempt should be made to mobilize the adherent structures, specifically the duodenum, because of the potential for accidental injury. Proximal aortic control can be achieved either immediately above the renal arteries or above the visceral vessels. Alternatively, intraluminal aortic control can be achieved with a balloon catheter, although this approach is less appealing. Distal control can usually be achieved at the common iliac arteries or at the level of their bifurcation. The duodenum and other adherent structures should be mobilized by incising the wall of the aneurysm and then reflecting them laterally. The proximal anastomosis can usually be performed to the infrarenal aorta from the inside of the aneurysm after opening the wall. The preoperative placement of ureteral catheters, particularly lighted catheters if available, may facilitate their identification intraoperatively and can be helpful in patients with hydronephrosis. An increased incidence of anastomotic pseudoaneurysms has been demonstrated in patients with inflammatory aneurysms after open repair and justifies long-term surveillance.[276,277]

Juxtarenal and Suprarenal Abdominal Aortic Aneurysms

The management of aneurysms extending to the level of the renal arteries or more cephalad is more complicated, and, predictably, the morbidity and mortality rates associated with open repair are increased.[278–280] Interestingly, several recent reports from centers of excellence have documented mortality rates comparable to those reported for infrarenal repairs although it is unlikely that these findings are applicable nationwide.[281–283] Repair of these complex aneurysms is complicated by the obligatory period of renal and visceral ischemia associated with aortic occlusion during the proximal anastomosis. Indeed, the renal complication rates range from 15% to 20% even from these select centers of excellence.[281–283] These increased morbidity and mortality rates should be factored into the decision algorithm and threshold for operative repair. Elective operative repair is usually recommended for patients with aneurysms 6 cm or larger in diameter in this setting although the 5.5-cm criterion may be appropriate for very good-risk patients and those with juxtarenal aneurysms who will require only a short period of suprarenal aortic occlusion.

AAAs extending to the renal arteries or more cephalad may be repaired via either a retroperitoneal or a transperitoneal approach although the former is optimal, especially with more cephalad disease. The *retroperitoneal* approach, with anterior reflection of the left kidney, obviates the concerns about the left renal vein (except when a retroaortic renal vein is present) and simplifies exposure of the abdominal aorta. The distal descending thoracic aorta is easily exposed by incising the diaphragm and its crus. Of note, the right renal artery and right common iliac artery are more difficult to expose via the retroperitoneal approach because of their trajectory of those vessels, but this is not prohibitive in most cases. The proximal anastomosis may be fashioned as a long beveled anastomosis incorporating the orifices of the renal and visceral arteries, or a Carrel patch can be fashioned from the aortic segment with reimplantation or bypass of the left renal artery in situations where the aneurysm involves the entire visceral segment.

For juxtarenal aneurysms repaired through the *transperitoneal* approach, the aorta can be clamped in the supraceliac or suprarenal position, depending on the extent of the disease and the patient's body habitus. Suprarenal clamp is preferred to avoid unnecessary visceral ischemia. Of course, if the aneurysmal tissue extends above the renal arteries, a supraceliac clamp may be required. The supraceliac exposure is similar to that described above for a ruptured infrarenal AAA, but performed in a more controlled fashion. After mobilization of the left lobe of the liver, the esophagus should be reflected left laterally. Placement of a nasogastric tube facilitates identification of the esophagus/gastroesophageal junction. The gastrohepatic ligament should be divided making note of aberrant hepatic arterial anatomy to avoid dividing a replaced hepatic vessel during this portion of the dissection. The crus of the diaphragm can be divided bluntly or sharply followed by division of the dense connective tissue surrounding the aorta for placement of the clamp. If a clamp is to be placed in the suprarenal position, this is facilitated by retracting the left renal vein superiorly or inferiorly after ligating its adrenal, gonadal, and lumbar branches. As noted previously, the left renal vein may be

ligated near its confluence with the vena cava without adverse sequelae.[206] The collaterals of the left renal vein (e.g., adrenal) should be preserved when using this approach; thus, the decision to divide this vessel should be made early. The anterior surface of the aorta at the level of the visceral vessels is encased by dense neural tissue, which can be incised. Incising the crus of the diaphragm that envelops the lateral aspect of the aorta further facilitates clamp application. The configuration of the proximal anastomosis in the setting of the transperitoneal approach depends on the extent of the aneurysm and the vessels involved.

EVAR for juxtarenal AAAs has become widely available with the FDA approval of fenestrated aortic grafts.[8,284–287] The approach is based upon constructing a suitable landing zone for the more traditional endograft in patients with an inadequate or short infernal neck. This is accomplished using an individually designed fenestrated endograft that contains orifices that correspond to the renal and visceral vessels. These fenestrations permit the introduction of individual covered stents. The worldwide experience with fenestrated EVAR is vast, and the technique has been shown to be feasible, safe, and to prevent aneurysm rupture in the short term.[8,284–287]

Further progression of repair into the visceral segment with branched/fenestrated repairs using custom aortic grafts, surgeon-modified devices, and parallel stent techniques such as “chimney” EVAR are an ongoing revolution in aortic repair, and have demonstrated acceptable results in both elective and urgent/emergent clinical scenarios. The profound complexity in the device-to-device and device-to-aorta/branch vessel interactions with these types of repair certainly make their durability questionable, and close follow-up of these patients is warranted.[288,289]

Combined endovascular and open (i.e., “hybrid”) approaches have also been used to treat the juxtarenal and more complex proximal aneurysms. These techniques are based upon constructing a suitable aortic neck to land a traditional endograft by “debranching” the renal or visceral vessels. For example, a suitable landing zone below the superior mesenteric artery (SMA) could be created for a juxtarenal aneurysm by performing bilateral iliorenal bypasses. Although theoretically appealing, a number of reports have demonstrated that mortality rates for the hybrid approach for complex aneurysms have been comparable to open repair, and these repairs have largely fallen out of favor in many centers.[290–292] Indeed, the magnitude of the revascularization procedure appears to be comparable to that of the more traditional open repair and, accordingly, the approach does not appear to extend the indications for aneurysm repair to older, sicker patients. Thus, branched/fenestrated repairs may be more suitable in these patients, if a repair is warranted at all.

Infected Abdominal Aortic Aneurysms

Infected AAAs comprise a small subset of all AAAs, accounting for less than 1% of all repairs.[293] The term *mycotic aneurysm* coined by William Osler to describe aneurysms that developed after septic cardiac emboli caused an arterial infection, has often been used to refer to all infectious etiologies for aneurysms. Unfortunately, "mycotic" is a misnomer that has led to a significant amount of confusion. A more specific classification system consists of four groups based on the underlying mechanism: (a) classic "mycotic aneurysm" caused by embolus from the heart infecting an artery; (b) microbial arteritis, in which bacteria infects an atherosclerotic but nonaneurysmal artery and leads to aneurysmal degeneration; (c) an existing aneurysm that becomes infected; (d) traumatic pseudoaneurysm with concomitant bacterial inoculation.[294] Microbial arteritis resulting from hematogenous bacterial spread currently accounts for approximately 80% of all cases of infected aortic aneurysms.[295,296] *Salmonella* causes approximately 40% of all aneurysmal infections in contemporary series with the remainder caused by *Staphylococcus, Streptococcus, Bacteroides, Arizona hinshawii, Escherichia coli,* and *Pseudomonas aeruginosa.*[294]

The diagnosis of infected aortic aneurysm is often difficult and the clinical presentation insidious. Patients may present with fever, back/abdominal pain, or both. The physical examination is often remarkable for a palpable abdominal mass and the presence of peripheral emboli. Laboratory studies are notable for an elevated leukocyte count and positive blood cultures although the latter are present only 50% of the time[296,297] and negative blood cultures do not exclude the diagnosis. CT is the most useful diagnostic study, and the features suggestive of an infected aneurysm include a periaortic mass, an aneurysm in an atypical location, periaortic fluid or gas, retroperitoneal inflammation, and frank rupture. The angiographic finding of a saccular or eccentric/irregularly shaped aneurysm in an atypical location is also suggestive of an infected aneurysm.

The treatment of an infected aneurysm requires control of hemorrhage in the presence of rupture, aggressive debridement of all infected tissues, and restoration of perfusion to the viscera and lower torso. Indeed, these treatment concerns and the management options are identical to those for patients with infected aortic grafts, which is a more common problem. Patients should be started on broad-spectrum antibiotics when the diagnosis is suspected although antibiotic therapy alone is not sufficient and the operative intervention should not be delayed in an attempt to sterilize the retroperitoneum. Patients with suspected rupture should undergo emergent exploration through either a transperitoneal or retroperitoneal approach. After vascular control has been obtained, the retroperitoneum should be explored, and intraoperative cultures along with stat Gram stain should be obtained. Several options for arterial reconstruction are available, depending on the clinical scenario and the individual patient's anatomy. These options include in situ replacement with a prosthetic or cadaveric graft, ligation of the infrarenal aorta with extra-anatomic bypass (axillo-femoral, femoral–femoral configuration), or in situ replacement with staged extra-anatomic bypass and subsequent removal of the in situ graft. The choice is contingent on the character of the aorta, degree of inflammation in

the retroperitoneum, suspected organism, and hemodynamic status. In situ replacement of the infected aneurysm with a prosthetic or cadaveric graft is a reasonable option if retroperitoneal inflammation is minimal and the Gram stain is negative. The integrity of the aortic stump at the time of ligation and the potential for dehiscence or breakdown of the suture line are major concerns. The aorta should be debrided back to grossly uninvolved tissue and sutured in two layers with a running horizontal mattress and a simple continuous technique using nonabsorbable monofilament suture. A pedicle of omentum can be mobilized and approximated next to the aortic stump to help control the retroperitoneal inflammation and minimize the risk for stump dehiscence. When the diagnosis is suspected preoperatively and no evidence of rupture is found, a staged approach with extra-anatomic bypass followed by graft removal may decrease the physiologic impact of any one procedure. The procedures are usually performed 2 to 3 days apart to allow the patients a period of recovery. Patients should be anticoagulated between procedures to prevent thrombosis of the extra-anatomic bypass resulting from competitive flow. Fortunately, the risk of graft thrombosis and graft infection during the intervening period is small.

Endovascular repair of infected aortic aneurysm has been reported and can be considered an additional alternative.[298] Although the long-term safety of EVAR in this clinical scenario remains unclear, it may serve as a temporizing approach that converts an urgent problem to an elective one. A recent meta-analysis by Kan et al.[299] reported that the endovascular approach was reasonable, but the incidence of subsequent endograft infection was significant in patients with ruptured aneurysms and those with fevers. They concluded that endovascular repair could be used as a bridge in this setting (i.e., ruptured aneurysm, febrile) prior to definitive open repair.

Infected aneurysms involving the suprarenal aorta pose a particularly challenging problem, but fortunately are uncommon. In situ replacement with a prosthetic or cadaveric graft is frequently the only available option, which can be accomplished in a number of ways, but the principle of aggressive removal of all infected tissue should be adhered to in order to avoid recurrent infection, which is typically a fatal event. If the thoracic aorta is of good quality, an antegrade debranching of the visceral segment can often be accomplished, and limits the ischemia time to the visceral/renal vessels. If there is a contained rupture of the aorta, or the tissues are particularly inflamed, it may be best to obtain proximal and distal control above and below the disrupted/infected segment before attempting to dissect the visceral/renal vessels from the inflammatory mass, which may rupture during dissection. After obtaining sites for proximal and distal aortic control, a branched prosthetic graft soaked in Rifampin is sewn to the aorta in an end-to-side manner using a side-biting clamp on the thoracic aorta, allowing antegrade perfusion during the anastomosis. It is important to leave enough good aorta below this bypass to allow a cross-clamp and separate end-to-end anastomosis. The left renal, SMA and celiac artery can be bypassed individually in some cases and then a cross-clamp placed on the aorta distal to the end-to-side graft. The aorta is then transected and aggressively debrided leaving just the right renal origin, when possible. A separate tube or bifurcated graft can then be sewn from the distal thoracic aorta to the bifurcation of the abdominal

aorta, or to the iliac/femoral arteries, as indicated. This technique limits the ischemia time on the individual viscera/renal arteries, and allows full removal of all atherosclerotic material and infected aorta along with the infected periaortic tissues after complete revascularization of the visceral segment.

Patients with infected aneurysms, regardless of the arterial reconstruction, require long-term antibiotics and follow-up. Patients should receive intravenous broad-spectrum antibiotics until cultures are available, with the total of 6 weeks of intravenous antibiotics. If culture-directed therapy is not possible, broad-spectrum antibiotics for 6 weeks is indicated. The patient should then be placed on oral antibiotics although the duration of treatment remains unresolved and many surgeons will treat the patient with lifelong suppressive antibiotics. In addition, patients should undergo serial CT scans to assess the retroperitoneum and the status of the in situ graft when applicable. The follow-up imaging regimen is typically dictated by the clinical scenario, but a CT at 2 weeks, 3 months, 6 months, and then at 6- to 12-month intervals thereafter, is common. In the event that stable imaging is obtained over the first few CT scans, later imaging may not be warranted. Predictably, the morbidity and mortality rates associated with infected AAAs are significant with a 40% mortality rate reported in a recent publication.[300]

Aortoenteric Fistulae

An aortoenteric fistula is a communication between the aorta and the bowel. The duodenum is involved most commonly at the site where it crosses anterior to the aorta, but the communication can develop between almost any portion of the intestine. Primary aortic fistulae result when an aortic aneurysm erodes into the bowel and are distinctly rare with a reported incidence of 0.04% to 0.07% in autopsy series.[301] Debonnaire et al.[302] identified 18 primary aortoenteric fistulas through a survey of 196 Belgian surgeons and reported a mortality rate of 30%. Secondary aortic fistulae result from the erosion of a prosthetic aortic graft into the bowel; are significantly more common, with a reported incidence of 0.1% to 2.0% after aortic reconstruction.[303] Notably, they can also occur after EVAR.[304] The management of both primary and secondary aortic fistulae is the same.

The diagnosis of an aortoenteric fistula is often difficult and mandates a high index of suspicion. Patients usually present with gastrointestinal bleeding manifested as either hematemesis or melena. The initial episode of gastrointestinal bleeding is often self-limited and has been described as a “herald” bleed. The diagnosis of aortoenteric fistula should be foremost among the differential when a patient with a known aneurysm or prior aortic reconstruction presents with intestinal bleeding. Patients should undergo endoscopic evaluation of the upper and lower intestinal tract to determine the source of bleeding. It is imperative that the clinical suspicion of an aortoenteric fistula be communicated to the endoscopist to ensure that the third and fourth portions of the duodenum are adequately examined, which is not typically done during routine foregut endoscopy. The endoscopic findings of erosion, thrombus, active bleeding, or visible prosthetic graft in third or fourth portion of the duodenum are diagnostic of an aortoenteric fistula and mandate emergent treatment due to the risk of massive hemorrhage. Mild duodenitis and gastritis without frank erosion are frequently seen at the time of endoscopy and do not exclude the diagnosis of an aortoenteric fistula. Notably, the findings during upper endoscopy are normal in up to 30% of patients with a documented aortoenteric fistula.[305] A CT should be performed if the results of endoscopy are inconclusive. The findings on CT that suggest an aortoenteric fistula include inflammation within the retroperitoneum, an anastomotic pseudoaneurysm, close approximation of the bowel and the prosthetic aortic graft or aneurysm, and loss of the normal tissue planes between the duodenum (or any other bowel segment) and the aorta or prosthetic graft. Occasionally, both endoscopy and CT are nondiagnostic despite the clinical suspicion of an aortoenteric fistula. Exploratory laparotomy is recommended in this setting for both diagnosis and treatment. Adherence of the bowel to the aorta at the time of the initial exploration suggests an aortoenteric fistula and mandates obtaining suitable proximal and distal control of the aorta, iliac vessels, or prosthetic graft before further dissection. The diagnosis cannot be excluded until the bowel is entirely separated from the retroperitoneum and graft.

The treatment of an aortoenteric fistula requires repair of the defect in the gastrointestinal tract in addition to repair of the aneurysm or treatment of the infected

prosthetic graft. Treatment of the gastrointestinal defect is usually straightforward and is based on standard surgical principles.[306] After the fistula is disassembled, the edges of the bowel can be debrided and a primary closure performed. A limited bowel resection or enteral diversion may be necessary. The intraoperative and longer-term management of the aortic aneurysm or prosthetic graft is the same as that outlined above for infected aortic aneurysms. In situ replacement of the prosthetic graft or infrarenal aorta using autogenous femoral vein or cryopreserved aortic allograft, ligation of the infrarenal aorta with excision of the prosthetic graft and extra-anatomic bypass, or temporary in situ aortic replacement with staged extra-anatomic bypass and subsequent graft excision are all reasonable options. The decision algorithm is based upon the hemodynamic stability of the patient, their baseline physiologic state, and the anatomy and involvement of the aorta. In older/sicker patients, the most expeditious procedure is probably best, which is often in-line replacement of the infected graft with a Rifampin-soaked Dacron graft. If the patient stabilizes afterward, a planned graft excision with aortic stump ligation and extra-anatomic axillary–femoral–femoral bypass can be performed. Replacement of the infected graft using autogenous femoral vein (neo-aorto-iliac system [NAIS]) is reasonably well tolerated in younger/healthier patients, and may be a better option that obviates the risk of aortic stump blow-out. If the visceral segment is involved, ligation of the aorta may not be possible without sacrifice of the renal arteries, and replacement using cryo-preserved aortoiliac conduit, rifampin-soaked Dacron, or autogenous femoral vein may be the best options. In any case, these patients should be maintained on long-term antibiotics and undergo serial imaging studies, as outlined for infected aneurysm patients.

Venous Anomalies

Anomalies of the vena cava and renal veins are occasionally encountered at the time of aortic reconstruction. The common anomalies are related to the embryologic development of the iliac veins and vena cava. The four most clinically relevant anomalies include duplication of the inferior vena cava (0.2% to 3.0%), left-sided vena cava (0.2% to 0.5%), circumaortic left renal vein (1.5% to 8.7%), and retroaortic renal vein (1.2% to 2.4%).[307] Patients with a duplicated inferior vena cava have large veins that run parallel to the infrarenal aorta and join together either anterior or posterior to the aorta at the level of the renal vein. In the case of a left-sided inferior vena cava, the cava runs parallel to the left side of the aorta, and the normally located right-sided vena cava is absent. The left-sided vena cava typically crosses the aorta at the level of the renal vein to become the suprarenal inferior vena cava, and the gonadal and adrenal veins on the right drain directly into the renal vein in a mirror image of the normal anatomy. The circumaortic left renal vein forms a collar of veins that surrounds the aorta at the normal level. In the case of a retroaortic left renal vein, a single vein runs posterior to the aorta at a slightly more caudal location. Notably, both duplication of the inferior vena cava and left-sided vena cava can be associated with other venous anomalies, including a circumaortic or retroaortic renal vein.

The diagnosis of the various venous anomalies can usually be made preoperatively on CT. Identification of the vena cava and left renal vein should be part of the mental checklist used when the preoperative CT scans are reviewed. The various anomalies may not become evident immediately in the operating room if missed on the preoperative imaging studies. A very prominent left renal vein at the usual location or slightly inferior is suggestive of a left-sided vena cava, whereas the absence of a left renal vein despite dissection along the anterior aspect of the aorta at the level of the SMA is suggestive of a retroaortic renal vein.

Open repair of an infrarenal AAA in a patient with a venous anomaly is essentially the same as the standard approach although additional care should be exercised to prevent inadvertent injury of the aberrant vein. Exposure of the infrarenal neck is more difficult in the presence of a duplicated or left-sided vena cava. However, sufficient exposure can usually be obtained by gentle dissection and mobilization of the venous structures. The presence of a duplicated or left-sided vena cava is a relative contraindication to the left retroperitoneal approach, but is not absolutely contraindicated. A circumaortic left renal collar or retroaortic left renal vein presents a potential hazard when the proximal aortic clamp is applied. A vertical aortic clamp is recommended and obviates the dissection on the posterior aspect of the aorta. Transecting the aorta may facilitate exposure of a retroaortic renal vein when significant bleeding is encountered.

Renal Anomalies

Congenital variations in the kidney anatomy may complicate the repair of an AAA. Specifically, aberrant kidney anatomy may complicate the dissection during open repair because they are frequently associated with multiple renal arteries, aberrant venous return, and abnormally positioned ureters. The various congenital anomalies of the upper urinary system have been classified in an attempt to standardize the approach for vascular surgeons.[308] The anomalies have been broken down into abnormalities of position, including simple ectopia, and abnormalities of both form and fusion, including horseshoe kidney, crossed renal ectopia without fusion, and crossed renal ectopia with fusion. An ectopic kidney may be positioned anywhere from the pelvis to the thorax. Common forms of ectopic kidney include the pelvic kidney, located opposite the sacrum and below the aortic bifurcation; the lumbar kidney, located opposite the sacral promontory in the iliac fossa and anterior to the iliac vessels; the abdominal kidney, located above the iliac crest adjacent to the second lumbar vertebra; and the thoracic kidney, which can be located above the diaphragm in the posterior mediastinum. In a horseshoe kidney, two distinct renal masses are fused together by either a bridge of renal parenchyma or fibrous tissue; in the overwhelming majority, the lower poles are fused. In crossed renal ectopia, the kidney mass is located on the side opposite to its insertion in the bladder. Multiple configurations of crossed ectopia with and without fusion have been described.

The preoperative objective for the various renal anomalies is to image the renal mass adequately, delineate the course of the ureter, and establish the arterial and venous supply. The approach is simplified by the fact that most patients undergo abdominal/pelvic CT as part of the preoperative evaluation. The location and position of both the kidneys and ureters, like the position of the left renal vein, should be established as part of the review of every CT scan for patients with aneurysms. Formerly, it was recommended that patients with renal anomalies undergo preoperative arteriography to confirm the location and number of renal arteries. However, this information can now be obtained from the CT arteriogram, which is now part of the routine preoperative evaluation.

Patients with renal anomalies can safely undergo repair of an AAA using either an open or endovascular approach.[309–311] However, the anomalies must of course be factored into the operative plan. The specific operative approach depends on the location of the renal mass, blood supply, course of the ureters, and presence of fusion. A left-sided retroperitoneal or transperitoneal approach with medial visceral rotation is the most helpful for open repair, particularly in patients with a horseshoe kidney. A standard transperitoneal approach with transection of the fused parenchyma can be used in patients with a horseshoe kidney although this may be associated with both significant bleeding and a urine leak and, therefore, is discouraged. The frequently encountered multiple renal arteries can be handled most expeditiously by using a Carrel patch technique, in which a cuff of aorta including the renal artery orifices is reimplanted into the aortic graft after completion of the proximal anastomosis. Endovascular repair is possible in many cases with the feasibility dictated by the location of the renal arteries in

addition to the other standard anatomic considerations. Use of the endovascular approach may require covering at least one of the renal vessels and has been associated with loss of some renal parenchyma.[309]

Coexistent Renal or Visceral Artery Occlusive Disease

Coexistent renal or visceral artery occlusive disease is frequently found in patients undergoing AAA repair. The optimal management of patients with coexistent lesions remains unresolved. The options include repair of the aneurysm alone, simultaneous repair of the aneurysm and revascularization of the renal or visceral vessels, and staged repair, with either aneurysm repair or revascularization performed first. Furthermore, the specific treatment options include both open and endovascular alternatives for the aneurysm repair and visceral/renal revascularization (i.e., angioplasty/stent). The rapid expansion of the endovascular technologies has afforded effective, safe approaches that have replaced open surgical revascularization for both renal and visceral artery lesions to a great degree. Regardless, the optimal approach represents a balance between the indications for the procedure and the associated added risk.

Renal/visceral revascularization is mandatory at the time of open aneurysm repair if the affected vessels are involved in the aneurysm, as in a suprarenal aneurysm or a horseshoe kidney. More commonly, a lower pole or accessory renal artery may arise from the aneurysm. The decision to perform a concomitant revascularization with either reimplantation or a bypass graft in this setting depends on the size of the vessel and the quantity of kidney parenchyma perfused. Revascularization is recommended for larger vessels (>2 mm) that supply a significant portion of the renal mass. The presence of any accessory renal arteries should factor into the operative plan and the general feasibility for endovascular repair. Covering small, accessory renal arteries has been reported to be safe, although it must be appreciated that this approach sacrifices some renal parenchyma.[312]

Combined aneurysm repair with renal or visceral artery revascularization may be justified if the indications for renal or visceral artery revascularization are satisfied. The traditional indications for renal revascularization included poorly controlled hypertension in a patient with a significant renal artery stenosis and rapidly progressive renal insufficiency in a patient with adequate renal mass and bilateral renal artery stenosis. However, the antihypertensive agents have improved to the point that renal revascularization is currently reserved for patients with poor blood pressure control despite optimal medical therapy with at least three separate medications, including a diuretic.[313,314] Endovascular treatment of the renal artery stenosis (when indicated) can be performed prior to open aneurysm repair or simultaneous with the endovascular approach. Although feasible, simultaneous open aneurysm repair and renal artery bypass is associated with a significant increase in the operative mortality rate relative to the aneurysm repair alone.[315,316]

The traditional indications for mesenteric revascularization include symptoms of chronic mesenteric ischemia and critical stenosis of either the SMA alone or two of the three visceral vessels. Patients with chronic mesenteric ischemia and AAAs should have their visceral occlusive disease corrected prior to aneurysm repair when possible. Repairing the aneurysm first potentially increases the risk of developing acute mesenteric ischemia in the perioperative period, and performing concomitant mesenteric

revascularization with AAA repair carries significant morbidity/mortality over and above that seen with open mesenteric revascularization alone.[317–319] Endovascular treatment with stent placement is probably the optimal treatment for the visceral lesions in this setting because of its simplicity, despite the concerns about its longer-term durability.[320–322]

The optimal treatment for patients with aneurysms and *asymptomatic* renal or visceral artery lesions remains poorly defined. Natural history studies with the use of both arteriography[323] and duplex scanning[324] have suggested that significant renal artery stenoses are preocclusive lesions that may merit intervention. However, analysis of patients with asymptomatic renal artery stenosis who underwent aortic reconstruction found that the natural history of the renal artery lesions is fairly benign when untreated and is associated only with an increase in the antihypertensive requirements.[325] Little is known about the natural history of asymptomatic mesenteric occlusive lesions. However, a small report has suggested that patients with asymptomatic severe mesenteric occlusive disease involving all three visceral vessels have a high incidence of bowel infarction.[326] Ultimately, consideration should be given to mesenteric revascularization prior to aneurysm repair in patients with severe visceral artery occlusive disease due to the potential risk of mesenteric infarction at the time of aneurysm repair as noted above.

Additional Concurrent Intra-abdominal Disease

The finding of an AAA and an additional intra-abdominal process that may require operative repair is a frequent event. A second surgical problem may be identified as part of the preoperative evaluation or discovered at the time of the exploratory laparotomy during open aneurysm repair. Alternatively, an AAA may be identified during the surgical treatment of another problem. No algorithms have been defined for the management of such concurrent problems, and the overall approach certainly requires sound clinical judgment. Options include simultaneous performance of the necessary operations, or a staged operation with repair of the AAA as either the first or second procedure. The approach depends on the risk for aneurysm rupture, natural history of the second surgical problem, and potential for infection of the prosthetic graft during simultaneous repair. Notably, both the laparoscopic and endovascular approaches have impacted the approach to patients with combined problems due to their reduced morbidity and mortality facilitates a more rapid, definitive treatment.

The generic recommendation for patients with an AAA and an additional intra-abdominal surgical problem is that the most life-threatening problem be addressed first. The natural history of untreated AAA has been defined reasonably well and has been outlined extensively earlier in this chapter. It has been suggested that the risk for aneurysm rupture is increased after major intra-abdominal surgery and that it is potentially related to an increase in collagenase activity.[327] However, this reported increased rupture risk is speculative and should not necessarily be factored into the decision algorithm. The management of concurrent colon cancer and AAA is a frequent treatment dilemma that provides an excellent illustration of the approach to these problems. Indeed, the reported incidence of colon cancer and an AAA occurring simultaneously ranges from 0.5% to 2.1%.[205] The treatment principles suggested by Szilagyi et al.[328] included the following: (a) aneurysm repair first in the presence of rupture; (b) colon resection first in the presence of hemorrhage, perforation, or obstruction; (c) aneurysm repair first in the presence of a large aneurysm and a small colon cancer; (d) colon resection first in the presence of a large colon cancer and a small aneurysm.

Simultaneous AAA repair and cholecystectomy is probably safe for patients with cholelithiasis or evidence of chronic cholecystitis. The safety of these simultaneous procedures has been documented in several series, and the concerns about an increased incidence of aortic graft infection have not been substantiated.[329] Advocates of the simultaneous approach justify the cholecystectomy by the potential requirement for a cholecystectomy in the future and the morbidity and mortality associated cholecystitis after aneurysm repair.[329] Although a consensus is not found in the literature, simultaneous AAA repair and cholecystectomy are recommended only if evidence of chronic cholecystitis or multiple small stones is present. Regardless, the cholecystectomy and other simultaneous procedures should not be performed until after the aneurysm repair is completed and the retroperitoneum closed in an attempt to reduce the hypothetical risk for graft infection.

The safety and utility of other simultaneous procedures remain poorly defined although a wide range of procedures have been combined with open aneurysm repair.[202–205] The repair of ventral hernias is often mandatory to achieve a tension-free abdominal closure and should be viewed more as an extension of the aneurysm repair than as a simultaneous procedure. Inguinal hernias may be repaired at the time of aneurysm repair, but it is uncertain whether the small risk associated with a subsequent procedure at a later date offsets the obligatory additional time for the simultaneous repair. Appendectomy[330] and small-bowel excision for Meckel's diverticulum[329] have been reported to be safe when performed concomitantly with aneurysmectomy although the natural history of the associated underlying problems in the usual age group of patients undergoing AAA repair is relatively benign.

References

1. Dubost C, Allary M, Oeconomos N. Resection of an aneurysm of the abdominal aorta: reestablishment of the continuity by a preserved human arterial graft, with result after five months. *AMA Arch Surg* 1952;64:405–408.
2. Ernst CB. Abdominal aortic aneurysm. *N Engl J Med* 1993;328:1167–1172.
3. Collin J, Araujo L, Walton J, et al. Oxford screening programme for abdominal aortic aneurysm in men aged 65 to 74 years. *Lancet* 1988;2:613–615.
4. Ouriel K, Green RM, Donayre C, et al. An evaluation of new methods of expressing aortic aneurysm size: relationship to rupture. *J Vasc Surg* 1992;15:12,8; discussion 19–20.
5. Sarac TP, Clair DG, Hertzer NR, et al. Contemporary results of juxtarenal aneurysm repair. *J Vasc Surg* 2002;36:1104–1111.
6. Tsai S, Conrad MF, Patel VI, et al. Durability of open repair of juxtarenal abdominal aortic aneurysms. *J Vasc Surg* 2012;56:2–7.
7. Patel VI, Ergul E, Conrad MF, et al. Continued favorable results with open surgical repair of type IV thoracoabdominal aortic aneurysms. *J Vasc Surg* 2011;53:1492–1498.
8. Oderich GS, Greenberg RK, Farber M, et al. Zenith Fenestrated Study Investigators. Results of the United States multicenter prospective study evaluating the Zenith fenestrated endovascular graft for treatment of juxtarenal abdominal aortic aneurysms. *J Vasc Surg* 2014;60:1420,8.e1–e5.
9. Quinones-Baldrich WJ, Holden A, Mertens R, et al. Prospective, multicenter experience with the Ventana Fenestrated System for juxtarenal and pararenal aortic aneurysm endovascular repair. *J Vasc Surg* 2013;58:1–9.
10. Greenberg R, Eagleton M, Mastracci T. Branched endografts for thoracoabdominal aneurysms. *J Thorac Cardiovasc Surg* 2010;140:S171–S178.
11. Brunkwall J, Hauksson H, Bengtsson H, et al. Solitary aneurysms of the iliac arterial system: an estimate of their frequency of occurrence. *J Vasc Surg* 1989;10:381–384.
12. Lowry SF, Kraft RO. Isolated aneurysms of the iliac artery. *Arch Surg* 1978;113:1289–1293.
13. Taylor LM Jr, Porter JM. Basic data related to clinical decision-making in abdominal aortic aneurysms. *Ann Vasc Surg* 1987;1:502–504.
14. Melton LJ 3rd, Bickerstaff LK, Hollier LH, et al. Changing incidence of abdominal aortic aneurysms: a population-based study. *Am J Epidemiol* 1984;120:379–386.
15. Choke E, Vijaynagar B, Thompson J, et al. Changing epidemiology of abdominal aortic aneurysms in England and Wales: older and more benign? *Circulation* 2012;125:1617–1625.
16. Sampson UK, Norman PE, Fowkes FG, et al. Estimation of global and regional

incidence and prevalence of abdominal aortic aneurysms 1990 to 2010. *Glob Heart* 2014;9:159–170.
17. Lederle FA. The rise and fall of abdominal aortic aneurysm. *Circulation* 2011;124:1097–1099.
18. Kochanek KD, Xu J, Murphy SL, et al. Deaths: final data for 2009. *Natl Vital Stat Rep* 2011;60:1–116.
19. Schermerhorn ML, Bensley RP, Giles KA, et al. Changes in abdominal aortic aneurysm rupture and short-term mortality, 1995–2008: a retrospective observational study. *Ann Surg* 2012;256:651–658.
20. Zarins CK, Glagov S, Vesselinovitch D, et al. Aneurysm formation in experimental atherosclerosis: relationship to plaque evolution. *J Vasc Surg* 1990;12:246–256.
21. Sho E, Sho M, Hoshina K, et al. Hemodynamic forces regulate mural macrophage infiltration in experimental aortic aneurysms. *Exp Mol Pathol* 2004;76:108–116.
22. Tilson M, Elefteriades J, Brophy C. Tensile strength and collagen in abdominal aortic aneurysm disease. In: Greenhalgh RM, Mannick JA, Powerll JT, eds. *The Cause and Management of Aneurysms.* Philadelphia, PA: W.B. Saunders; 1990:97.
23. Busuttil RW, Abou-Zamzam AM, Machleder HI. Collagenase activity of the human aorta. A comparison of patients with and without abdominal aortic aneurysms. *Arch Surg* 1980;115:1373–1378.
24. Baxter BT, McGee GS, Shively VP, et al. Elastin content, cross-links, and mRNA in normal and aneurysmal human aorta. *J Vasc Surg* 1992;16:192–200.
25. Lindholt JS, Jorgensen B, Klitgaard NA, et al. Systemic levels of cotinine and elastase, but not pulmonary function, are associated with the progression of small abdominal aortic aneurysms. *Eur J Vasc Endovasc Surg* 2003;26:418–422.
26. Newman KM, Ogata Y, Malon AM, et al. Identification of matrix metalloproteinases 3 (stromelysin-1) and 9 (gelatinase B) in abdominal aortic aneurysm. *Arterioscler Thromb* 1994;14:1315–1320.
27. Brophy CM, Marks WH, Reilly JM, et al. Decreased tissue inhibitor of metalloproteinases (TIMP) in abdominal aortic aneurysm tissue: a preliminary report. *J Surg Res* 1991;50:653–657.
28. Rowe VL, Stevens SL, Reddick TT, et al. Vascular smooth muscle cell apoptosis in aneurysmal, occlusive, and normal human aortas. *J Vasc Surg* 2000;31:567–576.
29. Grigoryants V, Hannawa KK, Pearce CG, et al. Tamoxifen up-regulates catalase production, inhibits vessel wall neutrophil infiltration, and attenuates development of experimental abdominal aortic aneurysms. *J Vasc Surg* 2005;41:108–114.
30. Newman KM, Jean-Claude J, Li H, et al. Cytokines that activate proteolysis are increased in abdominal aortic aneurysms. *Circulation* 1994;90:II224–II227.
31. Forsdahl SH, Singh K, Solberg S, et al. Risk factors for abdominal aortic aneurysms: a 7-year prospective study: the Tromso Study, 1994–2001. *Circulation.* 2009;119:2202–2208.

32. Jahangir E, Lipworth L, Edwards TL, et al. Smoking, sex, risk factors and abdominal aortic aneurysms: a prospective study of 18 782 persons aged above 65 years in the Southern Community Cohort Study. *J Epidemiol Community Health* 2015;69:481–488.
33. Cornuz J, Sidoti Pinto C, Tevaearai H, et al. Risk factors for asymptomatic abdominal aortic aneurysm: systematic review and meta-analysis of population-based screening studies. *Eur J Public Health* 2004;14:343–349.
34. Huber TS, Wang JG, Derrow AE, et al. Experience in the United States with intact abdominal aortic aneurysm repair. *J Vasc Surg* 2001;33:304,10; discussion 310–311.
35. Lederle FA, Wilson SE, Johnson GR, et al; Aneurysm Detection and Management Veterans Affairs Cooperative Study Group. Immediate repair compared with surveillance of small abdominal aortic aneurysms. *N Engl J Med* 2002;346:1437–1444.
36. Wilmink TB, Quick CR, Day NE. The association between cigarette smoking and abdominal aortic aneurysms. *J Vasc Surg* 1999;30:1099–1105.
37. Sidloff D, Stather P, Dattani N, et al. Aneurysm global epidemiology study: public health measures can further reduce abdominal aortic aneurysm mortality. *Circulation* 2014;129:747–753.
38. Darling RC 3rd, Brewster DC, Darling RC, et al. Are familial abdominal aortic aneurysms different? *J Vasc Surg* 1989;10:39–43.
39. Larsson E, Granath F, Swedenborg J, et al. A population-based case-control study of the familial risk of abdominal aortic aneurysm. *J Vasc Surg* 2009;49:47,50; discussion 51.
40. Cutler BS, Darling RC. Surgical management of arteriosclerotic femoral aneurysms. *Surgery* 1973;74:764–773.
41. Haverich A, Miller DC, Scott WC, et al. Acute and chronic aortic dissections–determinants of long-term outcome for operative survivors. *Circulation* 1985;72:II22–II34.
42. Muluk SC, Steed DL, Makaroun MS, et al. Aortic aneurysm in heart transplant recipients. *J Vasc Surg* 1995;22:689,94; discussion 695–696.
43. Vantrimpont PJ, van Dalen BM, van Riemsdijk-van Overbeeke IC, et al. Abdominal aortic aneurysms after heart transplantation. *J Heart Lung Transplant* 2004;23:171–177.
44. Englesbe MJ, Wu AH, Clowes AW, et al. The prevalence and natural history of aortic aneurysms in heart and abdominal organ transplant patients. *J Vasc Surg* 2003;37:27–31.
45. Baumgartner I, Hirsch AT, Abola MT, et al; REACH Registry investigators. Cardiovascular risk profile and outcome of patients with abdominal aortic aneurysm in out-patients with atherothrombosis: data from the Reduction of Atherothrombosis for Continued Health (REACH) Registry. *J Vasc Surg* 2008;48:808–814.
46. Lederle FA, Larson JC, Margolis KL, et al; Women's Health Initiative Cohort Study.

Abdominal aortic aneurysm events in the women's health initiative: cohort study. *BMJ* 2008;337:a1724.

47. Zierler RE, Strandness DE Jr. Hemodynamics for the vascular surgeon. In: Moore WS ed. *Vascular Surgery: A Comprehensive Review.* Philadelphia, PA: W.B. Saunders; 2005:179.
48. Brewster DC, Cronenwett JL, Hallett JW Jr, et al; Joint Council of the American Association for Vascular Surgery and Society for Vascular Surgery. Guidelines for the treatment of abdominal aortic aneurysms. Report of a subcommittee of the Joint Council of the American Association for Vascular Surgery and Society for Vascular Surgery. 2003;37:1106–1117.
49. Mortality results for randomised controlled trial of early elective surgery or ultrasonographic surveillance for small abdominal aortic aneurysms. The UK Small Aneurysm Trial Participants. *Lancet* 1998;352:1649–1655.
50. Brown LC, Powell JT. Risk factors for aneurysm rupture in patients kept under ultrasound surveillance. UK Small Aneurysm Trial Participants. *Ann Surg* 1999;230:289,96; discussion 296–297.
51. Mofidi R, Suttie SA, Howd A, et al. Outcome from abdominal aortic aneurysms in Scotland, 1991–2006. *Br J Surg* 2008;95:1475–1479.
52. Brown PM, Zelt DT, Sobolev B. The risk of rupture in untreated aneurysms: the impact of size, gender, and expansion rate. *J Vasc Surg* 2003;37:280–284.
53. Cronenwett JL, Murphy TF, Zelenock GB, et al. Actuarial analysis of variables associated with rupture of small abdominal aortic aneurysms. *Surgery* 1985;98:472–483.
54. Verloes A, Sakalihasan N, Koulischer L, et al. Aneurysms of the abdominal aorta: familial and genetic aspects in three hundred thirteen pedigrees. *J Vasc Surg* 1995;21:646–655.
55. Fillinger MF, Marra SP, Raghavan ML, et al. Prediction of rupture risk in abdominal aortic aneurysm during observation: wall stress versus diameter. *J Vasc Surg* 2003;37:724–732.
56. Fillinger MF, Raghavan ML, Marra SP, et al. In vivo analysis of mechanical wall stress and abdominal aortic aneurysm rupture risk. *J Vasc Surg* 2002;36:589–597.
57. Brady AR, Thompson SG, Fowkes FG, et al; UK Small Aneurysm Trial Participants. Abdominal aortic aneurysm expansion: risk factors and time intervals for surveillance. *Circulation* 2004;110:16–21.
58. Nevitt MP, Ballard DJ, Hallett JW Jr. Prognosis of abdominal aortic aneurysms. A population-based study. *N Engl J Med* 1989;321:1009–1014.
59. Solberg S, Singh K, Wilsgaard T, et al. Increased growth rate of abdominal aortic aneurysms in women. The Tromso study. *Eur J Vasc Endovasc Surg* 2005;29:145–149.
60. Bernstein EF, Chan EL. Abdominal aortic aneurysm in high-risk patients. Outcome of selective management based on size and expansion rate. *Ann Surg* 1984;200:255–263.

61. Delin A, Ohlsen H, Swedenborg J. Growth rate of abdominal aortic aneurysms as measured by computed tomography. *Br J Surg* 1985;72:530–532.
62. Guirguis EM, Barber GG. The natural history of abdominal aortic aneurysms. *Am J Surg* 1991;162:481–483.
63. Baxter BT, Terrin MC, Dalman RL. Medical management of small abdominal aortic aneurysms. *Circulation* 2008;117:1883–1889.
64. Mosorin M, Juvonen J, Biancari F, et al. Use of doxycycline to decrease the growth rate of abdominal aortic aneurysms: a randomized, double-blind, placebo-controlled pilot study. *J Vasc Surg* 2001;34:606–610.
65. Takagi H, Yamamoto H, Iwata K, et al; ALICE (All-Literature Investigation of Cardiovascular Evidence) Group. Effects of statin therapy on abdominal aortic aneurysm growth: a meta-analysis and meta-regression of observational comparative studies. *Eur J Vasc Endovasc Surg* 2012;44:287–292.
66. Wemmelund H, Hogh A, Hundborg HH, et al. Statin use and rupture of abdominal aortic aneurysm. *Br J Surg* 2014;101:966–975.
67. Meijer CA, Stijnen T, Wasser MN, et al; Pharmaceutical Aneurysm Stabilisation Trial Study Group. Doxycycline for stabilization of abdominal aortic aneurysms: a randomized trial. *Ann Intern Med* 2013;159:815–823.
68. Kurvers H, Veith FJ, Lipsitz EC, et al. Discontinuous, staccato growth of abdominal aortic aneurysms. *J Am Coll Surg* 2004;199:709–715.
69. Greenhalgh RM, Brown LC, Kwong GP, et al; EVAR trial participants. Comparison of endovascular aneurysm repair with open repair in patients with abdominal aortic aneurysm (EVAR trial 1), 30-day operative mortality results: randomised controlled trial. *Lancet* 2004;364:843–848.
70. Prinssen M, Verhoeven EL, Buth J, et al; Dutch Randomized Endovascular Aneurysm Management (DREAM)Trial Group. A randomized trial comparing conventional and endovascular repair of abdominal aortic aneurysms. *N Engl J Med* 2004;351:1607–1618.
71. Hallin A, Bergqvist D, Holmberg L. Literature review of surgical management of abdominal aortic aneurysm. *Eur J Vasc Endovasc Surg* 2001;22:197–204.
72. Beck AW, Goodney PP, Nolan BW, et al; Vascular Study Group of Northern New England. Predicting 1-year mortality after elective abdominal aortic aneurysm repair. *J Vasc Surg* 2009;49:838,43; discussion 843–844.
73. Hua HT, Cambria RP, Chuang SK, et al. Early outcomes of endovascular versus open abdominal aortic aneurysm repair in the National Surgical Quality Improvement Program-Private Sector (NSQIP-PS). *J Vasc Surg* 2005;41:382–389.
74. Schermerhorn ML, O'Malley AJ, Jhaveri A, et al. Endovascular vs. open repair of abdominal aortic aneurysms in the Medicare population. *N Engl J Med* 2008;358:464–474.
75. Blum U, Voshage G, Lammer J, et al. Endoluminal stent-grafts for infrarenal

abdominal aortic aneurysms. *N Engl J Med* 1997;336:13–20.

76. May J, White GH, Yu W, et al. Concurrent comparison of endoluminal versus open repair in the treatment of abdominal aortic aneurysms: analysis of 303 patients by life table method. *J Vasc Surg* 1998;27:213,20; discussion 220–221.
77. Moore WS, Rutherford RB. Transfemoral endovascular repair of abdominal aortic aneurysm: results of the North American EVT phase 1 trial. EVT Investigators. *J Vasc Surg* 1996;23:543–553.
78. Zarins CK, White RA, Schwarten D, et al. AneuRx stent graft versus open surgical repair of abdominal aortic aneurysms: multicenter prospective clinical trial. *J Vasc Surg* 1999;29:292,305; discussion 306–308.
79. EVAR trial participants. Endovascular aneurysm repair versus open repair in patients with abdominal aortic aneurysm (EVAR trial 1): randomised controlled trial. *Lancet* 2005;365:2179–2186.
80. Haug ES, Romundstad P, Aadahl P, et al. Emergency non-ruptured abdominal aortic aneurysm. *Eur J Vasc Endovasc Surg* 2004;28:612–618.
81. Soisalon-Soininen S, Salo JA, Perhoniemi V, et al. Emergency surgery of non-ruptured abdominal aortic aneurysm. *Ann Chir Gynaecol* 1999;88:38–43.
82. De Martino RR, Goodney PP, Nolan BW, et al; Vascular Study Group of New England. Optimal selection of patients for elective abdominal aortic aneurysm repair based on life expectancy. *J Vasc Surg* 2013;58:589–595.
83. Bown MJ, Sutton AJ, Bell PR, et al. A meta-analysis of 50 years of ruptured abdominal aortic aneurysm repair. *Br J Surg* 2002;89:714–730.
84. Johansen K, Kohler TR, Nicholls SC, et al. Ruptured abdominal aortic aneurysm: the Harborview experience. *J Vasc Surg* 1991;13:240,5; discussion 245–247.
85. Egorova N, Giacovelli J, Greco G, et al. National outcomes for the treatment of ruptured abdominal aortic aneurysm: comparison of open versus endovascular repairs. *J Vasc Surg* 2008;48:1092,100, 1100.e1–e2.
86. Mastracci TM, Garrido-Olivares L, Cina CS, et al. Endovascular repair of ruptured abdominal aortic aneurysms: a systematic review and meta-analysis. *J Vasc Surg* 2008;47:214–221.
87. Mureebe L, Egorova N, Giacovelli JK, et al. National trends in the repair of ruptured abdominal aortic aneurysms. *J Vasc Surg* 2008;48:1101–1107.
88. Rayt HS, Sutton AJ, London NJ, et al. A systematic review and meta-analysis of endovascular repair (EVAR) for ruptured abdominal aortic aneurysm. *Eur J Vasc Endovasc Surg* 2008;36:536–544.
89. Sadat U, Boyle JR, Walsh SR, et al. Endovascular vs open repair of acute abdominal aortic aneurysms–a systematic review and meta-analysis. *J Vasc Surg* 2008;48:227–236.
90. Verhoeven EL, Kapma MR, Groen H, et al. Mortality of ruptured abdominal aortic aneurysm treated with open or endovascular repair. *J Vasc Surg* 2008;48:1396–1400.

91. Giles KA, Pomposelli F, Hamdan A, et al. Decrease in total aneurysm-related deaths in the era of endovascular aneurysm repair. *J Vasc Surg* 2009;49:543,50; discussion 550–551.
92. Lynch RM. Accuracy of abdominal examination in the diagnosis of non-ruptured abdominal aortic aneurysm. *Accid Emerg Nurs* 2004;12:99–107.
93. Moursi MM, Stanley JC. Surgical treatment of ruptured infrarenal aortic aneurysms. In: Ernst CB, Stanley JC, eds. *Current Therapy in Vascular Surgery*. 3rd ed. St. Louis, MO: Mosby; 1995:224.
94. Moore CL, Holliday RS, Hwang JQ, et al. Screening for abdominal aortic aneurysm in asymptomatic at-risk patients using emergency ultrasound. *Am J Emerg Med* 2008;26:883–887.
95. Hollier LH, Taylor LM, Ochsner J. Recommended indications for operative treatment of abdominal aortic aneurysms. Report of a subcommittee of the Joint Council of the Society for Vascular Surgery and the North American Chapter of the International Society for Cardiovascular Surgery. *J Vasc Surg* 1992;15:1046–1056.
96. Liu R, Nair D, Ix J, et al. N-acetylcysteine for the prevention of contrast-induced nephropathy. A systematic review and meta-analysis. *J Gen Intern Med* 2005;20:193–200.
97. Merten GJ, Burgess WP, Gray LV, et al. Prevention of contrast-induced nephropathy with sodium bicarbonate: a randomized controlled trial. *JAMA* 2004;291:2328–2334.
98. Sprouse LR 2nd, Meier GH 3rd, Parent FN, et al. Is three-dimensional computed tomography reconstruction justified before endovascular aortic aneurysm repair? *J Vasc Surg* 2004;40:443–447.
99. Hoffman M, Avellone JC, Plecha FR, et al. Operation for ruptured abdominal aortic aneurysms: a community-wide experience. *Surgery* 1982;91:597–602.
100. Wakefield TW, Whitehouse WM Jr, Wu SC, et al. Abdominal aortic aneurysm rupture: statistical analysis of factors affecting outcome of surgical treatment. *Surgery* 1982;91:586–596.
101. Lloyd GM, Bown MJ, Norwood MG, et al. Feasibility of preoperative computer tomography in patients with ruptured abdominal aortic aneurysm: a time-to-death study in patients without operation. *J Vasc Surg* 2004;39:788–791.
102. LeFevre ML, U.S. Preventive Services Task Force. Screening for abdominal aortic aneurysm: U.S. Preventive Services Task Force recommendation statement. *Ann Intern Med* 2014;161:281–290.
103. Fleming C, Whitlock EP, Beil TL, et al. Screening for abdominal aortic aneurysm: a best-evidence systematic review for the U.S. Preventive Services Task Force. *Ann Intern Med* 2005;142:203–211.
104. Lindholt JS, Juul S, Fasting H, et al. Hospital costs and benefits of screening for abdominal aortic aneurysms. Results from a randomised population screening trial. *Eur J Vasc Endovasc Surg* 2002;23:55–60.

105. Wilmink AB, Quick CR, Hubbard CS, et al. Effectiveness and cost of screening for abdominal aortic aneurysm: results of a population screening program. *J Vasc Surg* 2003;38:72–77.
106. Powell JT, Brown LC, Forbes JF, et al. Final 12-year follow-up of surgery versus surveillance in the UK Small Aneurysm Trial. *Br J Surg* 2007;94:702–708.
107. Steyerberg EW, Kievit J, de Mol Van Otterloo JC, et al. Perioperative mortality of elective abdominal aortic aneurysm surgery. A clinical prediction rule based on literature and individual patient data. *Arch Intern Med* 1995;155:1998–2004.
108. Cronenwett JL. Factors influencing the long-term results of aortic aneurysm surgery. In: Yao JS, Pearce WH eds. *Vascular Surgery: Long Term Results.* East Norwalk: Appleton and Lange; 1993:171.
109. Blankensteijn JD, de Jong SE, Prinssen M, et al; Dutch Randomized Endovascular Aneurysm Management (DREAM) Trial Group. Two-year outcomes after conventional or endovascular repair of abdominal aortic aneurysms. *N Engl J Med* 2005;352:2398–2405.
110. Lederle FA, Johnson GR, Wilson SE, et al. Prevalence and associations of abdominal aortic aneurysm detected through screening. Aneurysm Detection and Management (ADAM) Veterans Affairs Cooperative Study Group. *Ann Intern Med* 1997;126:441–449.
111. Lee WA, Carter JW, Upchurch G, et al. Perioperative outcomes after open and endovascular repair of intact abdominal aortic aneurysms in the United States during 2001. *J Vasc Surg* 2004;39:491–496.
112. Finlayson SR, Birkmeyer JD, Fillinger MF, et al. Should endovascular surgery lower the threshold for repair of abdominal aortic aneurysms? i 1999;29:973–985.
113. Valentine RJ, Decaprio JD, Castillo JM, et al. Watchful waiting in cases of small abdominal aortic aneurysms- appropriate for all patients? *J Vasc Surg* 2000;32:441,8; discussion 448–450.
114. McCarthy RJ, Shaw E, Whyman MR, et al. Recommendations for screening intervals for small aortic aneurysms. *Br J Surg* 2003;90:821–826.
115. Conway KP, Byrne J, Townsend M, et al. Prognosis of patients turned down for conventional abdominal aortic aneurysm repair in the endovascular and sonographic era: Szilagyi revisited? *J Vasc Surg* 2001;33:752–757.
116. Englund R, Perera D, Hanel KC. Outcome for patients with abdominal aortic aneurysms that are treated non-surgically. *Aust N Z J Surg* 1997; 67:260–263.
117. Jones A, Cahill D, Gardham R. Outcome in patients with a large abdominal aortic aneurysm considered unfit for surgery. *Br J Surg* 1998;85:1382–1384.
118. Tambyraja AL, Stuart WP, Sala Tenna A, et al. Non-operative management of high-risk patients with abdominal aortic aneurysm. *Eur J Vasc Endovasc Surg* 2003;26:401–404.
119. Walker EM, Hopkinson BR, Makin GS. Unoperated abdominal aortic aneurysm:

presentation and natural history. *Ann R Coll Surg Engl* 1983;65:311–313.
120. Dua A, Kuy S, Lee CJ, et al. Epidemiology of aortic aneurysm repair in the United States from 2000 to 2010. *J Vasc Surg* 2014;59:1512–1517.
121. Woodburn KR, Chant H, Davies JN, et al. Suitability for endovascular aneurysm repair in an unselected population. *Br J Surg* 2001;88:77–81.
122. Arko FR, Filis KA, Seidel SA, et al. How many patients with infrarenal aneurysms are candidates for endovascular repair? The Northern California experience. *J Endovasc Ther* 2004;11:33–40.
123. Carpenter JP, Baum RA, Barker CF, et al. Impact of exclusion criteria on patient selection for endovascular abdominal aortic aneurysm repair. *J Vasc Surg* 2001;34:1050–1054.
124. Elkouri S, Martelli E, Gloviczki P, et al. Most patients with abdominal aortic aneurysm are not suitable for endovascular repair using currently approved bifurcated stent-grafts. *Vasc Endovascular Surg* 2004;38:401–412.
125. Wolf YG, Fogarty TJ, Olcott CIV, et al. Endovascular repair of abdominal aortic aneurysms: eligibility rate and impact on the rate of open repair. *J Vasc Surg* 2000;32:519–523.
126. Lee WA, Berceli SA, Huber TS, et al. Morbidity with retroperitoneal procedures during endovascular abdominal aortic aneurysm repair. *J Vasc Surg* 2003;38:459,63; discussion 464–465.
127. Clouse WD, Brewster DC, Marone LK, et al; Evt/Guidant Investigators. Durability of aortouniiliac endografting with femorofemoral crossover: 4-year experience in the Evt/Guidant trials. *J Vasc Surg* 2003;37:1142–1149.
128. Hinchliffe RJ, Alric P, Wenham PW, et al. Durability of femorofemoral bypass grafting after aortouniiliac endovascular aneurysm repair. *J Vasc Surg* 2003;38:498–503.
129. Lee WA, O'Dorisio J, Wolf YG, et al. Outcome after unilateral hypogastric artery occlusion during endovascular aneurysm repair. *J Vasc Surg* 2001;33:921–926.
130. Lyden SP, Sternbach Y, Waldman DL, et al. Clinical implications of internal iliac artery embolization in endovascular repair of aortoiliac aneurysms. *Ann Vasc Surg* 2001;15:539–543.
131. Greenberg RK, Clair D, Srivastava S, et al. Should patients with challenging anatomy be offered endovascular aneurysm repair? *J Vasc Surg* 2003;38:990–996.
132. Bisdas T, Weiss K, Donas KP, et al. Use of iliac branch devices for endovascular repair of aneurysmal distal seal zones after EVAR. *J Endovasc Ther* 2014;21:579–586.
133. Ferrer C, De Crescenzo F, Coscarella C, et al. Early experience with the Excluder(R) iliac branch endoprosthesis. *J Cardiovasc Surg (Torino)* 2014; 55:679–683.
134. Buth J, Harris PL, van Marrewijk C, et al. The significance and management of different types of endoleaks. *Semin Vasc Surg* 2003;16:95–102.
135. Gilling-Smith GL, Martin J, Sudhindran S, et al. Freedom from endoleak after

endovascular aneurysm repair does not equal treatment success. *Eur J Vasc Endovasc Surg* 2000;19:421–425.

136. Rutherford RB, Krupski WC. Current status of open versus endovascular stent-graft repair of abdominal aortic aneurysm. *J Vasc Surg* 2004; 39:1129–1139.
137. Prinssen M, Buskens E, Nolthenius RP, et al. Sexual dysfunction after conventional and endovascular AAA repair: results of the DREAM trial. *J Endovasc Ther* 2004;11:613–620.
138. Xenos ES, Stevens SL, Freeman MB, et al. Erectile function after open or endovascular abdominal aortic aneurysm repair. *Ann Vasc Surg* 2003; 17:530–538.
139. Prinssen M, Buskens E, Blankensteijn JD, DREAM trial participants. Quality of life endovascular and open AAA repair. Results of a randomised trial. *Eur J Vasc Endovasc Surg* 2004;27:121–127.
140. EVAR trial participants. Endovascular aneurysm repair and outcome in patients unfit for open repair of abdominal aortic aneurysm (EVAR trial 2): randomised controlled trial. *Lancet* 2005;365:2187–2192.
141. Harris PL, Vallabhaneni SR, Desgranges P, et al. Incidence and risk factors of late rupture, conversion, and death after endovascular repair of infrarenal aortic aneurysms: the EUROSTAR experience. European Collaborators on Stent/graft techniques for aortic aneurysm repair. *J Vasc Surg* 2000;32:739–749.
142. van Marrewijk CJ, Fransen G, Laheij RJ, et al; EUROSTAR Collaborators. Is a type II endoleak after EVAR a harbinger of risk? Causes and outcome of open conversion and aneurysm rupture during follow-up. *Eur J Vasc Endovasc Surg* 2004;27:128–137.
143. May J, White GH, Stephen MS, et al. Rupture of abdominal aortic aneurysm: concurrent comparison of outcome of those occurring after endovascular repair versus those occurring without previous treatment in an 11-year single-center experience. *J Vasc Surg* 2004;40:860–866.
144. Lifeline Registry of Endovascular Aneurysm Repair Steering Committee. Lifeline Registry of Endovascular Aneurysm Repair: registry data report. *J Vasc Surg* 2002;35:616–620.
145. Laheij RJ, Buth J, Harris PL, et al. Need for secondary interventions after endovascular repair of abdominal aortic aneurysms. Intermediate-term follow-up results of a European collaborative registry (EUROSTAR). *Br J Surg* 2000;87:1666–1673.
146. Schurink GW, Aarts NJ, van Bockel JH. Endoleak after stent-graft treatment of abdominal aortic aneurysm: a meta-analysis of clinical studies. *Br J Surg* 1999;86:581–587.
147. Bertges DJ, Chow K, Wyers MC, et al. Abdominal aortic aneurysm size regression after endovascular repair is endograft dependent. *J Vasc Surg* 2003;37:716–723.
148. Greenberg RK, Deaton D, Sullivan T, et al. Variable sac behavior after endovascular repair of abdominal aortic aneurysm: analysis of core laboratory data. *J Vasc Surg*

2004;39:95–101.
149. Giles KA, Landon BE, Cotterill P, et al. Thirty-day mortality and late survival with reinterventions and readmissions after open and endovascular aortic aneurysm repair in Medicare beneficiaries. *J Vasc Surg* 2011;53:6,12,13.e1.
150. Biancari F, Leo E, Ylonen K, et al. Value of the Glasgow Aneurysm Score in predicting the immediate and long-term outcome after elective open repair of infrarenal abdominal aortic aneurysm. *Br J Surg* 2003;90:838–844.
151. Hall J, Singh G, Hood D, et al. Management of an abdominal aortic aneurysm in a patient with end-stage liver disease. *Am J Transplant* 2004;4:666–668.
152. Biebl M, Lau LL, Hakaim AG, et al. Midterm outcome of endovascular abdominal aortic aneurysm repair in octogenarians: a single institution's experience. *J Vasc Surg* 2004;40:435–442.
153. Henebiens M, Vahl A, Koelemay MJ. Elective surgery of abdominal aortic aneurysms in octogenarians: a systematic review. *J Vasc Surg* 2008;47:676–681.
154. Garcia JM, Monzon EO, Martinez AP, et al. Comparative analysis of renal function after treatment of infrarenal abdominal aortic aneurysms with a suprarenal fixation device as opposed to open surgery. *Ann Vasc Surg* 2008;22:513–519.
155. Gawenda M, Brunkwall J. Renal response to open and endovascular repair of abdominal aortic aneurysm: a prospective study. *Ann Vasc Surg* 2008;22:1–4.
156. Mills JL S, Duong ST, Leon LR Jr, et al. Comparison of the effects of open and endovascular aortic aneurysm repair on long-term renal function using chronic kidney disease staging based on glomerular filtration rate. *J Vasc Surg* 2008;47:1141–1149.
157. Walsh SR, Boyle JR, Lynch AG, et al. Suprarenal endograft fixation and medium-term renal function: systematic review and meta-analysis. *J Vasc Surg* 2008;47:1364–1370.
158. Sternbergh WC 3rd, Money SR. Hospital cost of endovascular versus open repair of abdominal aortic aneurysms: a multicenter study. *J Vasc Surg* 2000;31:237–244.
159. Bertges DJ, Zwolak RM, Deaton DH, et al. Current hospital costs and medicare reimbursement for endovascular abdominal aortic aneurysm repair. *J Vasc Surg* 2003;37:272–279.
160. Rosenberg BL, Comstock MC, Butz DA, et al. Endovascular abdominal aortic aneurysm repair is more profitable than open repair based on contribution margin per day. *Surgery* 2005;137:285–292.
161. Kim JK, Tonnessen BH, Noll RE Jr, et al. Reimbursement of long-term postplacement costs after endovascular abdominal aortic aneurysm repair. *J Vasc Surg* 2008;48:1390–1395.
162. Williamson WK, Nicoloff AD, Taylor LM Jr, et al. Functional outcome after open repair of abdominal aortic aneurysm. *J Vasc Surg* 2001;33:913–920.
163. Lee WA, Brown MP, Nelson PR, et al. Midterm outcomes of femoral arteries after percutaneous endovascular aortic repair using the Preclose technique. *J Vasc Surg*

2008;47:919–923.
164. Lee WA, Brown MP, Nelson PR, et al. Total percutaneous access for endovascular aortic aneurysm repair ("Preclose" technique). *J Vasc Surg* 2007;45:1095–1101.
165. Wilt TJ, Lederle FA, Macdonald R, et al. Comparison of endovascular and open surgical repairs for abdominal aortic aneurysm. *Evid Rep Technol Assess (Full Rep)* 2006;(144):1–113.
166. Dua A, Upchurch GR Jr, Lee JT, et al. Predicted shortfall in open aneurysm experience for vascular surgery trainees. *J Vasc Surg* 2014;60:945–949.
167. Fleisher LA, Beckman JA, Brown KA, et al. ACC/AHA 2007 Guidelines on Perioperative Cardiovascular Evaluation and Care for Noncardiac Surgery: Executive Summary: a Report of the American College of Cardiology/American Heart Association Task Force on Practice Guidelines (Writing Committee to Revise the 2002 Guidelines on Perioperative Cardiovascular Evaluation for Noncardiac Surgery): Developed in Collaboration With the American Society of Echocardiography, American Society of Nuclear Cardiology, Heart Rhythm Society, Society of Cardiovascular Anesthesiologists, Society for Cardiovascular Angiography and Interventions, Society for Vascular Medicine and Biology, and Society for Vascular Surgery. *Circulation* 2007;116:1971–1996.
168. Bouri S, Shun-Shin MJ, Cole GD, et al. Meta-analysis of secure randomised controlled trials of beta-blockade to prevent perioperative death in non-cardiac surgery. *Heart* 2014;100:456–464.
169. Kertai MD, Boersma E, Westerhout CM, et al. A combination of statins and beta-blockers is independently associated with a reduction in the incidence of perioperative mortality and nonfatal myocardial infarction in patients undergoing abdominal aortic aneurysm surgery. *Eur J Vasc Endovasc Surg* 2004;28:343–352.
170. Smith SC Jr, Blair SN, Bonow RO, et al. AHA/ACC Guidelines for Preventing Heart Attack and Death in Patients With Atherosclerotic Cardiovascular Disease: 2001 update. A statement for healthcare professionals from the American Heart Association and the American College of Cardiology. *J Am Coll Cardiol* 2001;38:1581–1583.
171. Jayr C, Matthay MA, Goldstone J, et al. Preoperative and intraoperative factors associated with prolonged mechanical ventilation. A study in patients following major abdominal vascular surgery. *Chest* 1993;103:1231–1236.
172. Upchurch GR Jr, Proctor MC, Henke PK, et al. Predictors of severe morbidity and death after elective abdominal aortic aneurysmectomy in patients with chronic obstructive pulmonary disease. *J Vasc Surg* 2003;37:594–599.
173. McFalls EO, Ward HB, Moritz TE, et al. Coronary-artery revascularization before elective major vascular surgery. *N Engl J Med* 2004;351:2795–2804.
174. Hertzer NR, Beven EG, Young JR, et al. Coronary artery disease in peripheral vascular patients. A classification of 1000 coronary angiograms and results of surgical management. *Ann Surg* 1984;199:223–233.

175. American College of Cardiology Foundation/American Heart Association Task Force on Practice Guidelines, American Society of Echocardiography, American Society of Nuclear Cardiology, Heart Rhythm Society, Society of Cardiovascular Anesthesiologists, Society for Cardiovascular Angiography and Interventions, Society for Vascular Medicine, Society for Vascular Surgery, Fleisher LA, Beckman JA, Brown KA, et al. 2009 ACCF/AHA focused update on perioperative beta blockade incorporated into the ACC/AHA 2007 guidelines on perioperative cardiovascular evaluation and care for noncardiac surgery. *J Am Coll Cardiol* 2009;54:e13–e118.
176. Cuypers PW, Buth J. Does endovascular aortic aneurysm repair justify a reduced cardiology work-up? *J Cardiovasc Surg (Torino)* 2003;44:437–442.
177. Boylan JF, Katz J, Kavanagh BP, et al. Epidural bupivacaine-morphine analgesia versus patient-controlled analgesia following abdominal aortic surgery: analgesic, respiratory, and myocardial effects. *Anesthesiology* 1998;89:585–593.
178. Major CP Jr, Greer MS, Russell WL, et al. Postoperative pulmonary complications and morbidity after abdominal aneurysmectomy: a comparison of postoperative epidural versus parenteral opioid analgesia. *Am Surg* 1996;62:45–51.
179. Eagle KA, Berger PB, Calkins H, et al. ACC/AHA Guideline Update for Perioperative Cardiovascular Evaluation for Noncardiac Surgery–Executive Summary. A report of the American College of Cardiology/American Heart Association Task Force on Practice Guidelines (Committee to Update the 1996 Guidelines on Perioperative Cardiovascular Evaluation for Noncardiac Surgery). *Anesth Analg* 2002;94:1052–1064.
180. Valentine RJ, Duke ML, Inman MH, et al. Effectiveness of pulmonary artery catheters in aortic surgery: a randomized trial. *J Vasc Surg* 1998;27:203,11; discussion 211–212.
181. Elmore JR, Franklin DP, Youkey JR, et al. Normothermia is protective during infrarenal aortic surgery. *J Vasc Surg* 1998;28:984,92; discussion 992–994.
182. Bush HL Jr, Hydo LJ, Fischer E, et al. Hypothermia during elective abdominal aortic aneurysm repair: the high price of avoidable morbidity. *J Vasc Surg* 1995;21:392,400; discussion 400–402.
183. Wynn MM, Acher CW. A modern theory of spinal cord ischemia/injury in thoracoabdominal aortic surgery and its implications for prevention of paralysis. *J Cardiothorac Vasc Anesth* 2014;28:1100–1111.
184. Alvarez GG, Fergusson DA, Neilipovitz DT, et al. Cell salvage does not minimize perioperative allogeneic blood transfusion in abdominal vascular surgery: a systematic review. *Can J Anaesth* 2004;51:425–431.
185. Sicard GA, Reilly JM, Rubin BG, et al. Transabdominal versus retroperitoneal incision for abdominal aortic surgery: report of a prospective randomized trial. *J Vasc Surg* 1995;21:174,81; discussion 181–183.
186. Thompson JF, Mullee MA, Bell PR, et al. Intraoperative heparinisation, blood loss and myocardial infarction during aortic aneurysm surgery: a Joint Vascular Research Group study. *Eur J Vasc Endovasc Surg* 1996;12:86–90.

187. Marques da Silva R, Lingaas PS, Geiran O, et al. Multiple bacteria in aortic aneurysms. *J Vasc Surg* 2003;38:1384–1389.

188. van der Vliet JA, Kouwenberg PP, Muytjens HL, et al. Relevance of bacterial cultures of abdominal aortic aneurysm contents. *Surgery* 1996;119:129–132.

189. Seeger JM, Coe DA, Kaelin LD, et al. Routine reimplantation of patent inferior mesenteric arteries limits colon infarction after aortic reconstruction. *J Vasc Surg* 1992;15:635–641.

190. Senekowitsch C, Assadian A, Assadian O, et al. Replanting the inferior mesentery artery during infrarenal aortic aneurysm repair: influence on postoperative colon ischemia. *J Vasc Surg* 2006;43:689–694.

191. Wakefield TW, Hantler CB, Wrobleski SK, et al. Effects of differing rates of protamine reversal of heparin anticoagulation. *Surgery* 1996;119:123–128.

192. Dorman BH, Elliott BM, Spinale FG, et al. Protamine use during peripheral vascular surgery: a prospective randomized trial. *J Vasc Surg* 1995;22:248,55; discussion 256.

193. Hall KA, Peters B, Smyth SH, et al. Abdominal wall hernias in patients with abdominal aortic aneurysmal versus aortoiliac occlusive disease. *Am J Surg* 1995;170:572,5; discussion 575–576.

194. Liapis CD, Dimitroulis DA, Kakisis JD, et al. Incidence of incisional hernias in patients operated on for aneurysm or occlusive disease. *Am Surg* 2004;70:550–552.

195. Raffetto JD, Cheung Y, Fisher JB, et al. Incision and abdominal wall hernias in patients with aneurysm or occlusive aortic disease. *J Vasc Surg* 2003;37:1150–1154.

196. Calcagno D, Hallett JW Jr, Ballard DJ, et al. Late iliac artery aneurysms and occlusive disease after aortic tube grafts for abdominal aortic aneurysm repair. A 35-year experience. *Ann Surg* 1991;214:733–736.

197. Kalman PG, Rappaport DC, Merchant N, et al. The value of late computed tomographic scanning in identification of vascular abnormalities after abdominal aortic aneurysm repair. *J Vasc Surg* 1999;29:442–450.

198. Yeager RA, Porter JM. Arterial and prosthetic graft infection. In: Porter JM, Taylor LM, eds. *Basic Data Underlying Clinical Decision Making in Vascular Surgery*. St. Louis, MO: Quality Medical; 2005:90.

199. Bastounis E, Filis K, Georgopoulos S, et al. Selective use of the intensive care unit after elective infrarenal abdominal aortic aneurysm repair. *Int Angiol* 2003;22:308–316.

200. Akkersdijk GJ, van der Graaf Y, Moll FL, et al. Complications of standard elective abdominal aortic aneurysm repair. *Eur J Vasc Endovasc Surg* 1998;15:505–510.

201. Johnston KW. Multicenter prospective study of nonruptured abdominal aortic aneurysm. Part II. Variables predicting morbidity and mortality. *J Vasc Surg* 1989;9:437–447.

202. Georgopoulos S, Pikoulis E, Bacoyiannis C, et al. Combined abdominal aortic aneurysmectomy and other abdominal operations. *Scand J Surg* 2004;93:61–63.

203. Grego F, Lepidi S, Bassi P, et al. Simultaneous surgical treatment of abdominal aortic aneurysm and carcinoma of the bladder. *J Vasc Surg* 2003;37:607–614.
204. Illuminati G, Calio' FG, D'Urso A, et al. Simultaneous repair of abdominal aortic aneurysm and resection of unexpected, associated abdominal malignancies. *J Surg Oncol* 2004;88:234–239.
205. Kiskinis D, Spanos C, Melas N, et al. Priority of resection in concomitant abdominal aortic aneurysm (AAA) and colorectal cancer (CRC): review of the literature and experience of our clinic. *Tech Coloproctol* 2004;8(suppl 1):s19–s21.
206. Komori K, Furuyama T, Maehara Y. Renal artery clamping and left renal vein division during abdominal aortic aneurysm repair. *Eur J Vasc Endovasc Surg* 2004;27:80–83.
207. Harward TR, Ingegno MD, Carlton L, et al. Limb-threatening ischemia due to multilevel arterial occlusive disease. Simultaneous or staged inflow/outflow revascularization. *Ann Surg* 1995;221:498,503; discussion 503–506.
208. Blankensteijn JD, Lindenburg FP, Van der Graaf Y, et al. Influence of study design on reported mortality and morbidity rates after abdominal aortic aneurysm repair. *Br J Surg* 1998;85:1624–1630.
209. Tollefson DF, Ernst CB. Colon ischemia following aortic reconstruction. *Ann Vasc Surg* 1991;5:485–489.
210. Becquemin JP, Majewski M, Fermani N, et al. Colon ischemia following abdominal aortic aneurysm repair in the era of endovascular abdominal aortic repair. *J Vasc Surg* 2008;47:258,63; discussion 263.
211. Champagne BJ, Darling RC 3rd, Daneshmand M, et al. Outcome of aggressive surveillance colonoscopy in ruptured abdominal aortic aneurysm. *J Vasc Surg* 2004;39:792–796.
212. Valentine RJ, Hagino RT, Jackson MR, et al. Gastrointestinal complications after aortic surgery. *J Vasc Surg* 1998;28:404,11; discussion 411–412.
213. Ottinger LW. Acute cholecystitis as a postoperative complication. *Ann Surg* 1976;184:162–165.
214. Yao JS. Vasculogenic impotence. In: Ernst CB, Stanley JC, eds. *Current Therapy in Vascular Surgery*. 3rd ed. St. Louis, MO: Mosby, 1995:397.
215. Szilagyi DE. A second look at the etiology of spinal cord damage in surgery of the abdominal aorta. *J Vasc Surg* 1993;17:1111–1113.
216. Feinglass J, Cowper D, Dunlop D, et al. Late survival risk factors for abdominal aortic aneurysm repair: experience from fourteen Department of Veterans Affairs hospitals. *Surgery* 1995;118:16–24.
217. McFalls EO, Ward HB, Santilli S, et al. The influence of perioperative myocardial infarction on long-term prognosis following elective vascular surgery. *Chest* 1998;113:681–686.
218. Biancari F, Ylonen K, Anttila V, et al. Durability of open repair of infrarenal

abdominal aortic aneurysm: a 15-year follow-up study. *J Vasc Surg* 2002;35:87–93.

219. Hallett JW Jr, Marshall DM, Petterson TM, et al. Graft-related complications after abdominal aortic aneurysm repair: reassurance from a 36-year population-based experience. *J Vasc Surg* 1997;25:277,84; discussion 285–286.
220. Conrad MF, Crawford RS, Pedraza JD, et al. Long-term durability of open abdominal aortic aneurysm repair. *J Vasc Surg* 2007;46:669–675.
221. Schanzer A, Greenberg RK, Hevelone N, et al. Predictors of abdominal aortic aneurysm sac enlargement after endovascular repair. *Circulation* 2011;123:2848–2855.
222. Zarins CK, Bloch DA, Crabtree T, et al. Stent graft migration after endovascular aneurysm repair: importance of proximal fixation. *J Vasc Surg* 2003;38:1264,72; discussion 1272.
223. Sternbergh WC 3rd, Money SR, Greenberg RK, et al; Zenith Investigators. Influence of endograft oversizing on device migration, endoleak, aneurysm shrinkage, and aortic neck dilation: results from the Zenith Multicenter Trial. *J Vasc Surg* 2004;39:20–26.
224. Miller LE, Razavi MK, Lal BK. Suprarenal versus infrarenal stent graft fixation on renal complications after endovascular aneurysm repair. *J Vasc Surg* 2015;61:1340,1349.e1.
225. Wyers MC, Fillinger MF, Schermerhorn ML, et al. Endovascular repair of abdominal aortic aneurysm without preoperative arteriography. *J Vasc Surg* 2003;38:730–738.
226. Becquemin JP, Lapie V, Favre JP, et al. Mid-term results of a second generation bifurcated endovascular graft for abdominal aortic aneurysm repair: the French Vanguard trial. *J Vasc Surg* 1999;30:209–218.
227. Velazquez OC, Carpenter JP, Baum RA, et al. Perigraft air, fever, and leukocytosis after endovascular repair of abdominal aortic aneurysms. *Am J Surg* 1999;178:185–189.
228. Corriere MA, Feurer ID, Becker SY, et al. Endoleak following endovascular abdominal aortic aneurysm repair: implications for duration of screening. *Ann Surg* 2004;239:800,5; discussion 805–807.
229. Sternbergh WC 3rd, Greenberg RK, Chuter TA, et al. Zenith Investigators. Redefining postoperative surveillance after endovascular aneurysm repair: recommendations based on 5-year follow-up in the US Zenith multicenter trial. *J Vasc Surg* 2008;48:278,84; discussion 284–285.
230. Rozenblit AM, Patlas M, Rosenbaum AT, et al. Detection of endoleaks after endovascular repair of abdominal aortic aneurysm: value of unenhanced and delayed helical CT acquisitions. *Radiology* 2003;227:426–433.
231. Elkouri S, Panneton JM, Andrews JC, et al. Computed tomography and ultrasound in follow-up of patients after endovascular repair of abdominal aortic aneurysm. *Ann Vasc Surg* 2004;18:271–279.

232. Raman KG, Missig-Carroll N, Richardson T, et al. Color-flow duplex ultrasound scan versus computed tomographic scan in the surveillance of endovascular aneurysm repair. *J Vasc Surg* 2003;38:645–651.
233. Wolf YG, Johnson BL, Hill BB, et al. Duplex ultrasound scanning versus computed tomographic angiography for postoperative evaluation of endovascular abdominal aortic aneurysm repair. *J Vasc Surg* 2000;32:1142–1148.
234. Conrad MF, Adams AB, Guest JM, et al. Secondary intervention after endovascular abdominal aortic aneurysm repair. *Ann Surg* 2009;250:383–389.
235. Matsumura JS, Moore WS. Clinical consequences of periprosthetic leak after endovascular repair of abdominal aortic aneurysm. Endovascular Technologies Investigators. *J Vasc Surg* 1998;27:606–613.
236. Rockman CB, Riles TS, Landis R. Lower extremity paraparesis or paraplegia subsequent to endovascular management of abdominal aortic aneurysms. *J Vasc Surg* 2001;33:178–180.
237. Zhang WW, Kulaylat MN, Anain PM, et al. Embolization as cause of bowel ischemia after endovascular abdominal aortic aneurysm repair. *J Vasc Surg* 2004;40:867–872.
238. Kasirajan K, Matteson B, Marek JM, et al. Technique and results of transfemoral superselective coil embolization of type II lumbar endoleak. *J Vasc Surg* 2003;38:61–66.
239. Giles KA, Fillinger MF, De Martino RR, et al. Results of transcaval embolization for sac expansion from type II endoleaks after endovascular aneurysm repair. *J Vasc Surg* 2015;61:1129–1136.
240. Scali ST, Vlada A, Chang CK, et al. Transcaval embolization as an alternative technique for the treatment of type II endoleak after endovascular aortic aneurysm repair. *J Vasc Surg* 2013;57:869–874.
241. Scali ST, McNally MM, Feezor RJ, et al. Elective endovascular aortic repair conversion for type Ia endoleak is not associated with increased morbidity or mortality compared with primary juxtarenal aneurysm repair. *J Vasc Surg* 2014;60:286,294.e1.
242. Harris P, Brennan J, Martin J, et al. Longitudinal aneurysm shrinkage following endovascular aortic aneurysm repair: a source of intermediate and late complications. *J Endovasc Surg* 1999;6:11–16.
243. van der Vliet JA, van Aalst DL, Schultze Kool LJ, et al. Hypotensive hemostatis (permissive hypotension) for ruptured abdominal aortic aneurysm: are we really in control? *Vascular* 2007;15:197–200.
244. Janczyk RJ, Howells GA, Bair HA, et al. Hypothermia is an independent predictor of mortality in ruptured abdominal aortic aneurysms. *Vasc Endovascular Surg* 2004;38:37–42.
245. Chinien G, Waltham M, Abisi S, et al. Systemic administration of heparin intraoperatively in patients undergoing open repair of leaking abdominal aortic

aneurysm may be beneficial and does not cause problems. *Vascular* 2008;16:189–193.
246. Johansson PI. Goal-directed hemostatic resuscitation for massively bleeding patients: the Copenhagen concept. *Transfus Apher Sci* 2010;43:401–405.
247. Bradbury AW, Makhdoomi KR, Adam DJ, et al. Twelve-year experience of the management of ruptured abdominal aortic aneurysm. *Br J Surg* 1997;84:1705–1707.
248. Halpern VJ, Kline RG, D'Angelo AJ, et al. Factors that affect the survival rate of patients with ruptured abdominal aortic aneurysms. *J Vasc Surg* 1997;26:939,45; discussion 945–948.
249. Maziak DE, Lindsay TF, Marshall JC, et al. The impact of multiple organ dysfunction on mortality following ruptured abdominal aortic aneurysm repair. *Ann Vasc Surg* 1998;12:93–100.
250. van Dongen HP, Leusink JA, Moll FL, et al. Ruptured abdominal aortic aneurysms: factors influencing postoperative mortality and long-term survival. *Eur J Vasc Endovasc Surg* 1998;15:62–66.
251. Johnston KW. Ruptured abdominal aortic aneurysm: six-year follow-up results of a multicenter prospective study. Canadian Society for Vascular Surgery Aneurysm Study Group. *J Vasc Surg* 1994;19:888–900.
252. Bjorck M. Management of the tense abdomen or difficult abdominal closure after operation for ruptured abdominal aortic aneurysms. *Semin Vasc Surg* 2012;25:35–38.
253. Bjorck M, Wanhainen A, Djavani K, Acosta S. The clinical importance of monitoring intra-abdominal pressure after ruptured abdominal aortic aneurysm repair. *Scand J Surg* 2008;97:183–190.
254. Parikshak M, Shepard AD, Reddy DJ, et al. Adrenal insufficiency in patients with ruptured abdominal aortic aneurysms. *J Vasc Surg* 2004;39:944–950.
255. Hennessy A, Barry MC, McGee H, et al. Quality of life following repair of ruptured and elective abdominal aortic aneurysms. i 1998;164:673–677.
256. Reichart M, Geelkerken RH, Huisman AB, et al. Ruptured abdominal aortic aneurysm: endovascular repair is feasible in 40% of patients. *Eur J Vasc Endovasc Surg* 2003;26:479–486.
257. Rose DF, Davidson IR, Hinchliffe RJ, et al. Anatomical suitability of ruptured abdominal aortic aneurysms for endovascular repair. *J Endovasc Ther* 2003;10:453–457.
258. Slater BJ, Harris EJ, Lee JT. Anatomic suitability of ruptured abdominal aortic aneurysms for endovascular repair. *Ann Vasc Surg* 2008;22:716–722.
259. Lee WA, Hirneise CM, Tayyarah M, et al. Impact of endovascular repair on early outcomes of ruptured abdominal aortic aneurysms. *J Vasc Surg* 2004;40:211–215.
260. Berland TL, Veith FJ, Cayne NS, et al. Technique of supraceliac balloon control of the aorta during endovascular repair of ruptured abdominal aortic aneurysms. *J Vasc Surg* 2013;57:272–275.
261. Malina M, Veith F, Ivancev K, et al. Balloon occlusion of the aorta during

endovascular repair of ruptured abdominal aortic aneurysm. *J Endovasc Ther* 2005;12:556–559.

262. O'Donnell ME, Badger SA, Makar RR, et al. Techniques in occluding the aorta during endovascular repair of ruptured abdominal aortic aneurysms. *J Vasc Surg* 2006;44:211–215.
263. Mayer D, Pfammatter T, Rancic Z, et al. 10 Years of Emergency Endovascular Aneurysm Repair for Ruptured Abdominal Aortoiliac Aneurysms: Lessons Learned. *Ann Surg* 2009;249:510–515.
264. Djavani Gidlund K, Wanhainen A, Bjorck M. Intra-abdominal hypertension and abdominal compartment syndrome after endovascular repair of ruptured abdominal aortic aneurysm. *Eur J Vasc Endovasc Surg* 2011;41:742–747.
265. Richardson JW, Greenfield LJ. Natural history and management of iliac aneurysms. *J Vasc Surg* 1988;8:165–171.
266. Krupski WC, Bass A, Rosenberg GD, et al. The elusive isolated hypogastric artery aneurysm: novel presentations. *J Vasc Surg* 1989;10:557–562.
267. Santilli SM, Wernsing SE, Lee ES. Expansion rates and outcomes for iliac artery aneurysms. *J Vasc Surg* 2000;31:114–121.
268. Huang Y, Gloviczki P, Duncan AA, et al. Common iliac artery aneurysm: expansion rate and results of open surgical and endovascular repair. *J Vasc Surg* 2008;47:1203,1210; discussion 1210–1211.
269. Money SR, Hollier LH. Surgical treatment of inflammatory abdominal aortic aneurysms. In: Ernst CB, Stanley JC, eds. *Current Therapy in Vascular Surgery*. 3rd ed. St. Louis, MO: Mosby; 1995:229.
270. Haug ES, Skomsvoll JF, Jacobsen G, et al. Inflammatory aortic aneurysm is associated with increased incidence of autoimmune disease. *J Vasc Surg* 2003;38:492–497.
271. Baskerville PA, Browse NL. Peri-aortic fibrosis: progression and regression. *J Cardiovasc Surg (Torino)* 1987;28:30–31.
272. Chuter T, Ivancev K, Malina M, et al. Inflammatory aneurysm treated by means of transfemoral endovascular graft insertion. *J Vasc Interv Radiol* 1997;8:39–41.
273. Nevelsteen A, Lacroix H, Stockx L, et al. Inflammatory abdominal aortic aneurysm and bilateral complete ureteral obstruction: treatment by endovascular graft and bilateral ureteric stenting. *Ann Vasc Surg* 1999;13:222–224.
274. Ruppert V, Verrel F, Kellner W, et al. Endovascular repair of inflammatory abdominal aortic aneurysms: a valuable alternative? Case report and review of literature. *Ann Vasc Surg* 2004;18:357–360.
275. Puchner S, Bucek RA, Loewe C, et al. Endovascular repair of inflammatory aortic aneurysms: long-term results. *AJR Am J Roentgenol* 2006;186:1144–1147.
276. Bonati L, Rubini P, Japichino GG, et al. Long-term outcome after inflammatory abdominal aortic aneurysm repair: case-matched study. *World J Surg* 2003;27:539–

544.
277. Dalainas I, Nano G, Ranucci M, et al. Inflammatory abdominal aortic aneurysms. A 20-year experience. *J Cardiovasc Surg (Torino)* 2007;48:305–308.
278. Crawford ES, Beckett WC, Greer MS. Juxtarenal infrarenal abdominal aortic aneurysm. Special diagnostic and therapeutic considerations. *Ann Surg* 1986;203:661–670.
279. Jean-Claude JM, Reilly LM, Stoney RJ, et al. Pararenal aortic aneurysms: the future of open aortic aneurysm repair. *J Vasc Surg* 1999;29:902–912.
280. Martin GH, O'Hara PJ, Hertzer NR, et al. Surgical repair of aneurysms involving the suprarenal, visceral, and lower thoracic aortic segments: early results and late outcome. *J Vasc Surg* 2000;31:851–862.
281. Chong T, Nguyen L, Owens CD, et al. Suprarenal aortic cross-clamp position: a reappraisal of its effects on outcomes for open abdominal aortic aneurysm repair. *J Vasc Surg* 2009;49:873–880.
282. Knott AW, Kalra M, Duncan AA, et al. Open repair of juxtarenal aortic aneurysms (JAA) remains a safe option in the era of fenestrated endografts. *J Vasc Surg* 2008;47:695–701.
283. Pearce JD, Edwards MS, Stafford JM, et al. Open repair of aortic aneurysms involving the renal vessels. *Ann Vasc Surg* 2007;21:676–686.
284. Greenberg RK, Haulon S, O'Neill S, et al. Primary endovascular repair of juxtarenal aneurysms with fenestrated endovascular grafting. *Eur J Vasc Endovasc Surg* 2004;27:484–491.
285. Bicknell CD, Cheshire NJ, Riga CV, et al. Treatment of complex aneurysmal disease with fenestrated and branched stent grafts. *Eur J Vasc Endovasc Surg* 2009;37:175–181.
286. Greenberg RK, West K, Pfaff K, et al. Beyond the aortic bifurcation: branched endovascular grafts for thoracoabdominal and aortoiliac aneurysms. *J Vasc Surg* 2006;43:879,86; discussion 886–887.
287. Scurr JR, Brennan JA, Gilling-Smith GL, et al. Fenestrated endovascular repair for juxtarenal aortic aneurysm. *Br J Surg* 2008;95:326–332.
288. Scali ST, Feezor RJ, Chang CK, et al. Critical analysis of results after chimney endovascular aortic aneurysm repair raises cause for concern. *J Vasc Surg* 2014;60:865,73; discussion 873–875.
289. Scali ST, Feezor RJ, Huber TS, et al. Acute bilateral renal artery chimney stent thrombosis after endovascular repair of a juxtarenal abdominal aortic aneurysm. *J Vasc Surg* 2015;61:1058–1061.
290. Black SA, Wolfe JH, Clark M, et al. Complex thoracoabdominal aortic aneurysms: endovascular exclusion with visceral revascularization. *J Vasc Surg* 2006;43:1081,9; discussion 1089.
291. Lee WA, Brown MP, Martin TD, et al. Early results after staged hybrid repair of

thoracoabdominal aortic aneurysms. *J Am Coll Surg* 2007;205:420–431.
292. Patel R, Conrad MF, Paruchuri V, et al. Thoracoabdominal aneurysm repair: hybrid versus open repair. *J Vasc Surg* 2009;50:15–22.
293. Reddy DJ, Shepard A, Evans JR, et al. Management of infected aortoiliac aneurysms. *Arch Surg* 1991;126:873–879.
294. Ellenby MI, Ernst CB. Surgical treatment of infected abdominal aortic aneurysms. In: Ernst CB, Stanley JC, eds. *Current Therapy in Vascular Surgery*. 3rd ed. St. Louis, MO: Mosby; 1995:232.
295. Brown SL, Busuttil RW, Baker JD, et al. Bacteriologic and surgical determinants of survival in patients with mycotic aneurysms. *J Vasc Sur* 1984;1:541–547.
296. Oz MC, Brener BJ, Buda JA, et al. A ten-year experience with bacterial aortitis. *J Vasc Surg* 1989;10:439–449.
297. Ewart JM, Burke ML, Bunt TJ. Spontaneous abdominal aortic infections. Essentials of diagnosis and management. *Am Surg* 1983;49:37–50.
298. Koeppel TA, Gahlen J, Diehl S, et al. Mycotic aneurysm of the abdominal aorta with retroperitoneal abscess: successful endovascular repair. *J Vasc Surg* 2004;40:164–166.
299. Kan C, Lee H, Yang Y. Outcome after endovascular stent graft treatment for mycotic aortic aneurysm: a systematic review. *J Vasc Surg* 2007;46:906–912.
300. Fillmore AJ, Valentine RJ. Surgical mortality in patients with infected aortic aneurysms. *J Am Coll Surg* 2003;196:435–441.
301. Taheri SA, Kulaylat MN, Grippi J, et al. Surgical treatment of primary aortoduodenal fistula. *Ann Vasc Surg* 1991;5:265–270.
302. Debonnaire P, Van Rillaer O, Arts J, et al. Primary aorto enteric fistula: report of 18 Belgian cases and literature review. *Acta Gastroenterol Belg* 2008;71:250–258.
303. Pitrowski J. Management of vascular graft infection. In: Bernhard VM, Towne JB, eds. *Complications in Vascular Surgery*. St. Louis, MO: Quality Medical Publishing; 1991:235.
304. French JR, Simring DV, Merrett N, et al. Aorto-enteric fistula following endoluminal abdominal aortic aneurysm repair. *ANZ J Surg* 2004;74:397–399.
305. Berman SS, Bernhard VM. Management of primary aortoenteric fistula. In: Ernst CB, Stanley JC, eds. *Current Therapy in Vascular Surgery*. St. Louis, MO: Mosby; 1995:262.
306. Cendan JC, Thomas JB 4th, Seeger JM. Twenty-one cases of aortoenteric fistula: lessons for the general surgeon. *Am Surg* 2004;70:583,7; discussion 587.
307. Giordano JM. Venous anomalies encountered during aortic reconstruction. In: Ernst CB, Stanley JC, eds. *Current Therapy in Vascular Surgery*. St. Louis, MO: Mosby; 1995:252.
308. Gaspar MR, Waters HJ, Averbook AW. Renal ectopia and renal fusion in patients requiring abdominal operations. In: Ernst CB, Stanley JC, eds. *Current Therapy in Vascular Surgery*. St. Louis, MO: Mosby; 1995:246.
309. Davidovic LB, Kostic DM, Jakovljevic NS, et al. Abdominal aortic surgery and

horseshoe kidney. *Ann Vasc Surg* 2004;18:725–728.

310. Jackson RW, Fay DM, Wyatt MG, et al. The renal impact of aortic stent-grafting in patients with a horseshoe kidney. *Cardiovasc Intervent Radiol* 2004;27:632–636.
311. Kaplan DB, Kwon CC, Marin ML, et al. Endovascular repair of abdominal aortic aneurysms in patients with congenital renal vascular anomalies. *J Vasc Surg* 1999;30:407–415.
312. Kim B, Donayre CE, Hansen CJ, et al. Endovascular abdominal aortic aneurysm repair using the AneuRx stent graft: impact of excluding accessory renal arteries. *Ann Vasc Surg* 2004;18:32–37.
313. Nordmann AJ, Logan AG. Balloon angioplasty versus medical therapy for hypertensive patients with renal artery obstruction. *Cochrane Database Syst Rev* 2003; (3):CD002944.
314. Hirsch AT, Haskal ZJ, Hertzer NR, et al; Vascular Disease Foundation. ACC/AHA 2005 Practice Guidelines for the management of patients with peripheral arterial disease (lower extremity, renal, mesenteric, and abdominal aortic): a collaborative report from the American Association for Vascular Surgery/Society for Vascular Surgery, Society for Cardiovascular Angiography and Interventions, Society for Vascular Medicine and Biology, Society of Interventional Radiology, and the ACC/AHA Task Force on Practice Guidelines (Writing Committee to Develop Guidelines for the Management of Patients With Peripheral Arterial Disease): endorsed by the American Association of Cardiovascular and Pulmonary Rehabilitation; National Heart, Lung, and Blood Institute; Society for Vascular Nursing; TransAtlantic Inter-Society Consensus; and Vascular Disease Foundation. *Circulation* 2006; 113:e463–e654.
315. Benjamin ME, Hansen KJ, Craven TE, et al. Combined aortic and renal artery surgery. A contemporary experience. *Ann Surg* 1996;223:555,65; discussion 565–567.
316. Huber TS, Harward TR, Flynn TC, et al. Operative mortality rates after elective infrarenal aortic reconstructions. *J Vasc Surg* 1995;22:287,93; discussion 293–294.
317. Gentile AT, Moneta GL, Taylor LM Jr, et al. Isolated bypass to the superior mesenteric artery for intestinal ischemia. *Arch Surg* 1994;129:926,31; discussion 931–932.
318. Mateo RB, O'Hara PJ, Hertzer NR, et al. Elective surgical treatment of symptomatic chronic mesenteric occlusive disease: early results and late outcomes. *J Vasc Surg* 1999;29:821,31; discussion 832.
319. Derrow AE, Seeger JM, Dame DA, et al. The outcome in the United States after thoracoabdominal aortic aneurysm repair, renal artery bypass, and mesenteric revascularization. *J Vasc Surg* 2001;34:54–61.
320. Sarac TP, Altinel O, Kashyap V, et al. Endovascular treatment of stenotic and occluded visceral arteries for chronic mesenteric ischemia. *J Vasc Surg* 2008;47:485–491.
321. Silva JA, White CJ, Collins TJ, et al. Endovascular therapy for chronic mesenteric

ischemia. *J Am Coll Cardiol* 2006;47:944–950.

322. Oderich GS, Erdoes LS, Lesar C, et al. Comparison of covered stents versus bare metal stents for treatment of chronic atherosclerotic mesenteric arterial disease. *J Vasc Surg* 2013;58:1316–1323.
323. Tollefson DF, Ernst CB. Natural history of atherosclerotic renal artery stenosis associated with aortic disease. *J Vasc Surg* 1991;14:327–331.
324. Zierler RE, Bergelin RO, Isaacson JA, et al. Natural history of atherosclerotic renal artery stenosis: a prospective study with duplex ultrasonography. *J Vasc Surg* 1994;19:250,7; discussion 257–258.
325. Williamson WK, Abou-Zamzam AM Jr, Moneta GL, et al. Prophylactic repair of renal artery stenosis is not justified in patients who require infrarenal aortic reconstruction. *J Vasc Surg* 1998;28:14,20; discussion 20–22.
326. Thomas JH, Blake K, Pierce GE, et al. The clinical course of asymptomatic mesenteric arterial stenosis. *J Vasc Surg* 1998;27:840–844.
327. Swanson RJ, Littooy FN, Hunt TK, et al. Laparotomy as a precipitating factor in the rupture of intra-abdominal aneurysms. *Arch Surg* 1980;115:299–304.
328. Szilagyi DE, Elliott JP, Berguer R. Coincidental malignancy and abdominal aortic aneurysm. Problems of management. *Arch Surg* 1967;95:402–412.
329. String ST. Management of concurrent intra-abdominal disease and abdominal aortic aneurysms. In: Ernst CB, Stanley JC, eds. *Current Therapy in Vascular Surgery*. St. Louis, MO: Mosby; 1995:235.
330. Ochsner JL, Cooley DA, De Bakey ME. Associated intra-abdominal lesions encountered during resection of aortic aneurysms: surgical considerations. *Dis Colon Rectum* 1960;3:485–490.

Chapter 97

Lower Extremity Aneurysms

Amy B. Reed

Key Points

1. Femoral and popliteal aneurysms are often incidental findings on routine physical examination, but are potentially limb threatening and frequently associated with life-threatening abdominal aortic aneurysms.
2. Femoral artery aneurysms are the most common peripheral aneurysm *if* both true and false aneurysms are considered together.
3. Anastomotic aneurysms result from a disrupted suture line between a graft and the host artery.
4. Pseudoaneurysms after percutaneous intervention result from failed hemostasis.
5. Popliteal artery aneurysms often develop limb-threatening complications if not treated electively.
6. Thrombolytic therapy is a useful adjuvant in patients presenting with acute limb ischemia secondary to occlusion of a popliteal artery aneurysm and the outflow arteries.

PERIPHERAL ANEURYSMS

1 Popliteal artery aneurysms are the most frequently encountered peripheral aneurysm. Their significance comes from their potential for limb-threatening complications, rather than rupture, and their association with life-threatening abdominal aortic aneurysms. True femoral artery aneurysms are rare, with iatrogenic and anastomotic pseudoaneurysms being more common.

Incidence

While the exact incidence of femoral and popliteal aneurysms is difficult to determine, the number being recognized is increasing. An aging population, increased arterial trauma, more common use of invasive therapies for vascular disease, and increased use of imaging modalities all contribute to the rise in number of peripheral aneurysms being diagnosed. In a screening study of men between the ages of 65 and 74 years, abdominal aortic aneurysms were identified in 4.9% of patients.[1] In patients with abdominal aortic aneurysms, 6.8% had femoral artery aneurysms and 9.6% had popliteal artery aneurysms.[2] Screening of men between the ages of 65 and 80 years identified popliteal artery aneurysms in 1%.[3]

An increasing number of false aneurysms – "pseudoaneurysms" – are occurring coincident with the increased use of catheter-based diagnostic and therapeutic interventions in addition to lower extremity bypass surgery. Pseudoaneurysms can be iatrogenic, infectious, or traumatic in nature and are identified by their lack of involvement of all three vessel wall layers as is typically seen in true aneurysms. The incidence of pseudoaneurysm after diagnostic procedures is approximately 0.3% – slightly higher at 1.5% after therapeutic procedures, in general due to use of larger sheaths.[4] False aneurysms can also arise from trauma during surgery, such as orthopedic procedures. Femoral pseudoaneurysms develop after 0.08% of total hip arthroplasties, and popliteal aneurysms arise following 0.17% of total knee arthroplasties.[5]

Degenerative (often called atherosclerotic) femoral and popliteal artery aneurysms are encountered far more frequently in men than women. The male to female ratio in patients with femoral and popliteal aneurysms is about 30:1.[6–8] This predilection for men is markedly different from aortic aneurysms where male to female patient ratio is approximately 4:1.[2]

Pathogenesis

The cause of femoral and popliteal aneurysms has changed significantly since they were first recognized centuries ago. Once primarily mycotic or syphilitic in origin, most true aneurysms in the 21st century have a degenerative cause commonly called *atherosclerotic aneurysms,* whereas false aneurysms usually follow surgery or trauma. True tibial artery aneurysms are rare.

The cause of degenerative aneurysms of the femoral and popliteal vessels is not clear. One factor believed to contribute to aneurysm formation is turbulent flow beyond a relative stenosis resulting in poststenotic dilatation beyond the inguinal ligament at the groin or beyond the tendinous hiatus of the adductor magnus or the arcuate popliteal ligament and the heads of the gastrocnemius muscle at the popliteal level. Arterial wall fatigue resulting from vibration and turbulence proximal to a major branching or caused by stress during hip and knee flexion may also contribute to aneurysm formation.

The frequent occurrence of multiple peripheral aneurysms in the same patient suggests a systemic abnormality in the arterial wall, which promotes aneurysmal degeneration at locations where hemodynamic or mechanical factors put unusual stress on the arterial wall. The multiple factors that contribute to aneurysmal degeneration and are felt to contribute to degenerative femoral and popliteal aneurysms, as well as aortic aneurysms. The presence of an inflammatory infiltrate has been noted in the wall of femoral and popliteal aneurysms, similar to aortic aneurysms.[9] The exact role of this inflammatory process, with potential release of reactive oxygen species and matrix metalloproteinases, is unknown. Apoptosis of smooth muscle cells may also play a role in the formation of aneurysms by limiting the ability of the arterial wall to respond to the degenerative process.[10] These factors, however, do not explain the male predilection for femoral and popliteal aneurysm formation. X-linked genetic abnormalities for aneurysm formation in popliteal artery aneurysms have not been noted in humans.

Clinical Manifestations

Femoral and popliteal aneurysms are often asymptomatic, being detected on routine physical examination by a bounding, expansile pulse. Both femoral and popliteal artery aneurysms, however, may be accompanied by symptoms of local fullness, pain caused by pressure on the adjacent nerve, limb edema, and venous distention or thrombosis caused by compression of the adjacent vein. Patients may also present with lower extremity ischemia with intermittent claudication, rest pain, or gangrene secondary to complications of a femoral or popliteal aneurysm including thrombosis or distal embolization. Because the natural history and complication rate in femoral and popliteal aneurysms differ, they are considered separately here.

FEMORAL ARTERY ANEURYSMS

2 Femoral artery aneurysms are the most common peripheral aneurysm if both true and false aneurysms are considered together, with the vast majority being false aneurysms. Their clinical importance rests in the fact that they are limb-threatening lesions and can jeopardize the viability of the leg if thrombosis, embolization, or rupture occurs. The vast majority of true aneurysms are degenerative lesions commonly called *atherosclerotic aneurysms,* whereas false aneurysms include anastomotic, traumatic, and mycotic lesions. Rarely, femoral aneurysms develop secondary to connective tissue disorders. The femoral region is the most common site for both anastomotic aneurysms and mycotic aneurysms associated with trauma; so the presentation and surgical repair of these lesions are discussed.

Degenerative (Atherosclerotic) Aneurysms

Incidence

The exact incidence of degenerative (atherosclerotic) common femoral artery aneurysms in the general population remains undefined. They are found in 6.8% of all patients with abdominal aortic aneurysms, and 85% of patients with femoral artery aneurysms have abdominal aortic aneurysms.[2,6]

Pattern of Disease

Femoral aneurysms most frequently affect the common femoral artery. They may be classified as *type I,* those limited to the common femoral artery, or *type II,* those involving the orifice of the profunda femoris artery.[11] Type I and type II aneurysms occur with nearly equal frequency. This classification becomes important in reference to vascular reconstructive procedures, with type II aneurysms requiring more complex reconstructions to ensure continued patency of both the superficial and profunda femoris arteries. Isolated lesions of the profunda femoris artery are rare (2% of femoral artery aneurysms), and are prone to rupture because they are difficult to diagnose at the asymptomatic stage. Isolated superficial femoral artery aneurysms are also uncommon, but one-third of patients present with rupture and one-quarter with thrombosis.[12]

Femoral artery aneurysms can be limb-threatening lesions and are frequently associated with limb-threatening popliteal aneurysms and life-threatening abdominal aortic aneurysms. Multiple aneurysms are common in patients with femoral artery aneurysms. In a series of 100 patients with degenerative femoral artery aneurysms seen at a single institution, 72% of patients had bilateral femoral artery aneurysms.[6] In addition, aortoiliac aneurysms were detected in 85% of patients, thoracic aortic aneurysms in 6%, and popliteal aneurysms in 44%, of which 55% were bilateral.

Clinical Manifestations

The typical patient with a degenerative femoral artery aneurysm is a male in his sixties or seventies with the usual risk factors for atherosclerosis. Of these patients, 86% are cigarette smokers, 36% have hypertension, and 14% have diabetes mellitus.[6] Associated cardiovascular disease is common, with clinical manifestations of coronary artery disease and cerebrovascular disease present in 34% and 7%, respectively.

The clinical manifestations of femoral artery aneurysms cover the spectrum from asymptomatic to severe ischemia of the lower extremity. Although 40% of patients are asymptomatic at the time of diagnosis, the majority present with local symptoms or complaints of lower extremity ischemia.[6] Local pain or observation of a groin mass is the only complaint in 18% of patients. Lower extremity venous disease is present in 8%, being attributable to venous obstruction by the femoral artery aneurysm in 4%; but venous obstruction is rarely the sole sign of an aneurysm. Lower extremity ischemic symptoms of claudication, rest pain, or gangrene are present in 42% of patients and often lead to the diagnosis of the femoral artery aneurysm.

As with aneurysms in other locations, femoral artery aneurysms may be complicated by

embolization, thrombosis, or rarely rupture. Peripheral embolization may be identified incidentally on angiography or produce signs as mild as spotty discoloration of the toes to as severe as peripheral gangrene. Although embolization is reported in about 10% of aneurysms, the femoral artery aneurysm is not necessarily the source of these emboli because many patients have a concomitant popliteal aneurysm.[6] In larger clinical series, 1% to 16% of patients with degenerative femoral artery aneurysms present with an acute thrombosis, whereas 1% to 16% have a chronically thrombosed lesion.[6,10] Rupture is reported in 1% to 14% of aneurysms.[6,11]

Natural History

The natural history of degenerative femoral artery aneurysms is poorly defined. Most publications have reviewed aneurysms that were treated surgically. A small asymptomatic femoral artery aneurysm does not appear to pose the same threat to the limb as does a popliteal artery aneurysm. In a series of 236 patients with atherosclerotic femoral artery aneurysms, serious limb-threatening complications were documented in only 3% of the 236 aneurysms.[7]

Diagnosis

In most cases the diagnosis of femoral artery aneurysm is suspected by the finding of a pulsatile groin mass on routine physical examination or during evaluation for vascular disease. If the femoral artery aneurysm is small or thrombosed, detection on physical examination may be difficult. Although a radiograph of the region may occasionally demonstrate the calcified rim of the aneurysm, only ultrasonography, computed tomography (CT), or magnetic resonance imaging (MRI) can reliably establish the diagnosis of the femoral aneurysm. In addition, these modalities are useful in accurately defining the size of the lesion and evaluating associated aneurysmal disease in the distal aorta and popliteal regions. These findings are particularly important because life-threatening abdominal aortic aneurysms are missed on physical examination in 50% of patients with multiple aneurysms.[13] The diagnostic accuracy of arteriography is limited because it demonstrates only the residual lumen and an aneurysm filled with smooth mural thrombus may be missed, but the definition of the vascular anatomy of the lower extremity provided by angiography is helpful in planning the appropriate operative procedure (Fig. 97-1).

Treatment

Operative treatment of femoral aneurysms is indicated for those causing local symptoms and presenting with limb-threatening complications. Asymptomatic aneurysms greater than 3.5 cm in diameter should also be repaired unless the patient is a prohibitive risk for operative intervention. In patients with small, asymptomatic aneurysms, observation may be appropriate, particularly in a patient with multiple medical problems who would be at high risk for surgery. When nonoperative management is selected, the size of the aneurysm should be documented by ultrasonography. The patient should be followed at regular intervals with ultrasound scans and careful examination for occult complications.

Operative treatment should be undertaken without undue delay if the femoral aneurysm enlarges, produces symptoms, or is complicated by embolization, thrombosis, or rupture.



Figure 97-1. Arteriogram demonstrating bilateral femoral artery aneurysms that extend into the superficial femoral arteries. Unlike many patients with femoral artery aneurysms, this patient did not have an associated aortic aneurysm or popliteal aneurysms.

Surgical Strategy. The operative approach is individualized based on associated aneurysmal disease. In patients with multiple asymptomatic aneurysms, treatment is staged. The life-threatening aortic lesions are treated before limb-threatening femoropopliteal lesions. Femoral artery aneurysms are addressed after popliteal lesions unless the femoral aneurysm is repaired in combination with treatment of the aortic or popliteal aneurysm. If an aortofemoral bypass is necessary, the femoral aneurysm should be treated at the same time, to avoid later anastomotic aneurysm formation. The graft limb can be anastomosed into an interposition graft that has replaced the femoral aneurysm. Similarly, if a stent graft is placed for treatment of an abdominal aortic aneurysm in a patient with femoral artery aneurysms, the aneurysm should be repaired with an interposition graft. In patients with severe lower extremity ischemia, the femoral aneurysm is treated with an interposition graft, from which the proximal anastomosis of the required femoropopliteal or femorotibial bypass is based.

Technique. The operative procedure for treatment of an isolated femoral artery aneurysm is determined by aneurysmal involvement of the superficial and deep femoral arteries as well as by the existence of lower extremity occlusive disease. The femoral artery aneurysm is usually approached through a longitudinal groin incision. When addressing an unusually large aneurysm or a ruptured aneurysm, however, initial

proximal control of the external iliac artery through a retroperitoneal approach is advisable. After proximal and distal arterial control is obtained, the aneurysm sac is opened and the atheromatous debris removed. Small aneurysms may be excised, but routine excision of large aneurysms is not recommended as these lesions can often be adherent to the adjacent vein and nerve. For type I aneurysms, the preferred treatment is reconstruction with an interposition graft of Dacron or expanded polytetrafluoroethylene with the proximal anastomosis at the distal external iliac artery or proximal common femoral artery and the distal anastomosis at the femoral bifurcation.

For type II aneurysms with patent superficial and profunda femoris arteries, an interposition graft to the profunda femoris artery with reimplantation of the superficial femoral artery is one standard configuration. If the superficial femoral artery is chronically occluded and the patient has minimal symptoms, an interposition graft to the profunda femoris artery alone is sufficient. If the patient has severe lower extremity ischemia, this is typically followed by a standard distal reconstruction. If recent emboli or in situ thrombosis have occluded the outflow tract, percutaneous mechanical thromboembolectomy or catheter-directed thrombolytic therapy is useful before open arterial reconstruction is undertaken.

Results

Results of surgical therapy depend upon the patency of the distal vasculature. More than 80% of asymptomatic patients have excellent long-term results, whereas 68% of those presenting with lower extremity ischemia achieve satisfactory long-term outcomes.[6]

Anastomotic Pseudoaneurysms

Incidence

3 Anastomotic pseudoaneurysms result from a disrupted suture line between a graft and the host artery. The incidence varies with the location of the anastomosis and the type of graft that is used. Involvement of the femoral artery accounts for nearly 80% of these lesions, and 3% of all femoral anastomoses or 6% of femoral anastomoses after aortofemoral bypass develop this complication compared with 0.2% of aortic anastomoses.[14,15] Patient factors that are associated with increased likelihood of developing a femoral anastomotic aneurysm after aortofemoral bypass include chronic obstructive pulmonary disease, current smoking, and postoperative groin wound infection.[16] After infrainguinal bypass procedures, the incidence is higher with prosthetic grafts then autogenous vein grafts with 6% of femoral anastomoses developing aneurysms when Dacron is used compared with 0.9% when a vein graft is placed.[14] Anastomotic pseudoaneurysms are a late complication of bypass procedures; the mean interval from primary procedure to recognition is more than 6 years.[17,18]

Pathogenesis

Several factors contributing to anastomotic pseudoaneurysm formation have been identified including weakness of the arterial wall, the type of graft material and suture utilized, the presence of infection, the method of construction of the anastomosis, and the stress on the suture line from hypertension, leg motion, or excess tension on the graft limb.[14,17,18] Progressive degeneration of the recipient artery accounts for most anastomotic pseudoaneurysms, and an increased incidence has been noted following endarterectomy of the artery at the anastomosis. False aneurysms occur less frequently with saphenous vein grafts than synthetic vascular grafts, a reflection of more complete healing of autogenous tissue. With the use of monofilament synthetic suture, anastomotic pseudoaneurysms rarely result from a loss of suture integrity, although occasionally a broken suture is a factor in pseudoaneurysm formation. Although most anastomotic aneurysms are not accompanied by overt graft infection, occult infections with coagulase-negative *Staphylococcus* species may be an important factor in development of anastomotic aneurysms.[18] A higher incidence is noted in patients with wound healing complications, and the use of anticoagulants may increase such complications.

Clinical Manifestations

Femoral anastomotic pseudoaneurysms usually present as a pulsatile groin mass, which may or may not be accompanied by pain, redness, or symptoms of venous obstruction. Acute complications include hemorrhage, embolization, and occlusion. The latter may cause lower extremity ischemia with claudication, rest pain, or gangrene.

Diagnosis

The diagnosis of a false aneurysm is usually made on physical examination by the presence of a pulsatile groin mass in a patient who has undergone a femoral arterial

reconstructive procedure. The differential diagnosis includes nonpulsatile groin masses, such as hernia, lymphocele, or abscess, through which pulsation is transmitted from an underlying normal femoral artery. Diagnosis of an anastomotic disruption in one region should raise suspicion of other anastomotic pseudoaneurysms as multiple lesions are found in at least 30% of patients.[17] The presence of multiple anastomotic pseudoaneurysms suggests infection. Evaluation of an anastomotic aneurysm includes ultrasonography or CT of all anastomoses of the graft. Angiography done prior to repair of the anastomotic aneurysm is helpful in defining the proximal and distal arterial anatomy (Fig. 97-2).

Treatment

Because of the progressive nature of anastomotic pseudoaneurysms, surgical treatment is generally undertaken for all lesions >2 cm except those in high-risk patients. Principles of surgical therapy are those of primary aneurysms: obtain proximal and distal control and replace the aneurysmal segment. Securing proximal control often requires dividing the inguinal ligament to isolate the graft limb. Distal control is most easily obtained using intraluminal balloon catheters. If intrinsic arterial disease requires extension of the graft distally on the profunda femoris or superficial femoral artery, these arteries can be identified by dissection through unscarred tissue distal to the previous exposure. After débridement of the degenerated artery, an interposition graft is placed between the prosthetic graft limb and the healthy native artery. Cultures of the graft and vessel wall are essential to exclude infection as an etiologic factor in the development of the anastomotic aneurysm. If infection is obvious at the time of surgery, the approach is the same as that of any infected graft with removal of infected prosthetic material and reestablishment of blood flow, if necessary, with a bypass through an uninfected tissue route, such as an obturator, lateral femoral, or axillofemoral bypass.

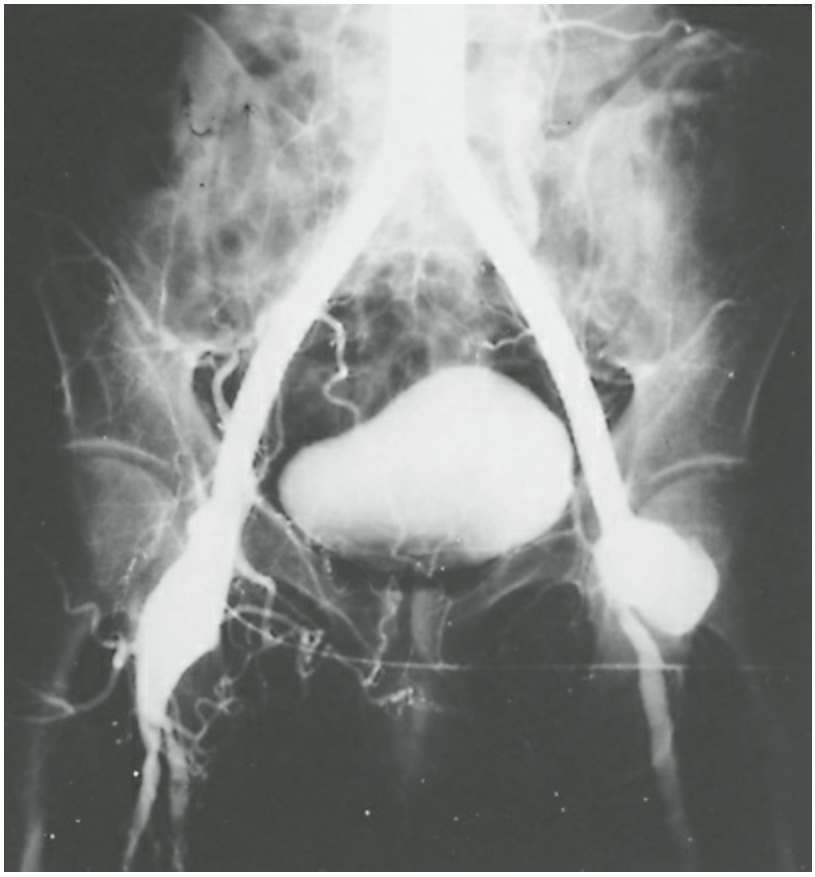

Figure 97-2. Arteriogram demonstrating bilateral femoral anastomotic aneurysms after an aortofemoral bypass and a left femoropopliteal bypass.

Results

Results of elective operations on uncomplicated anastomotic aneurysms are excellent with 2% operative mortality, 97.5% graft patency at 2 years, and 2% amputation within 2 years of surgery.[17] Recurrence is reported in less than 16% of cases.[14,15] Patients presenting with aneurysms complicated by hemorrhage, occlusion, or embolization have significantly increased operative morbidity and mortality.

Femoral Pseudoaneurysms

Incidence

The femoral artery is the preferred site for percutaneous access for both diagnostic and therapeutic angiography including endovascular grafts. In recent years, diagnostic studies for coronary and peripheral artery occlusive disease have increased as have the subsequent endovascular interventions, which have resulted in an increased number of femoral pseudoaneurysms. Because interventional techniques often require prolonged arterial cannulation, large-bore sheaths, and anticoagulation, they are accompanied by a higher rate of arterial complications than are diagnostic studies. Review of recent experience shows that pseudoaneurysms form after about 0.3% of diagnostic catheterizations and about 1.5% of catheter-based therapeutic procedures.[4,19] The use of percutaneous closure devices decreases the risk of developing a pseudoaneurysm at the arterial access site for an interventional procedure by a factor of 10 to an incidence of about 0.1%.[20,21]

Pathogenesis

4 Pseudoaneurysms from iatrogenic catheter trauma are classically defined as collections of blood in continuity with the arterial system that is not enclosed by all three layers of the arterial wall. These lesions form because of failed hemostasis at the arterial wall defect created by sheath insertion. Normally, hemostasis, aided by direct focal application of pressure or hemostatic devices, seals the defect promptly, and the arterial wall repairs itself. When hemostasis is not successfully obtained, blood under arterial pressure leaks from the artery, dissects surrounding tissue planes, and forms what is perceived on physical examination to be a pulsatile mass. The gross findings at surgery are a blood-filled cavity surrounded by a capsule. Like all pseudoaneurysms, these lesions can cause symptoms by rupture or compression of surrounding structures.

Diagnosis

The diagnosis of femoral pseudoaneurysm is suspected when a pulsatile groin mass is noted after arterial catheterization. The differential diagnosis includes hematoma, lymphadenopathy, and abscess. Arterial duplex scanning or CT is typically used to establish the diagnosis, differentiate pseudoaneurysm from hematoma, and aid in defining the communication between the mass and the arterial lumen. Color-flow duplex scanning is the diagnostic test of choice, providing accurate diagnosis, localization, and sizing of the false aneurysms.

Natural History

Color-flow duplex scanning has been used to define the incidence and natural history of pseudoaneurysms after percutaneous transluminal coronary angioplasty.[21] Many pseudoaneurysms will thrombose spontaneously within 4 weeks; however, this is less likely to occur in anticoagulated patients and those with pseudoaneurysms more than 2.0 cm in diameter. About 30% of patients with pseudoaneurysms will require intervention.[22]

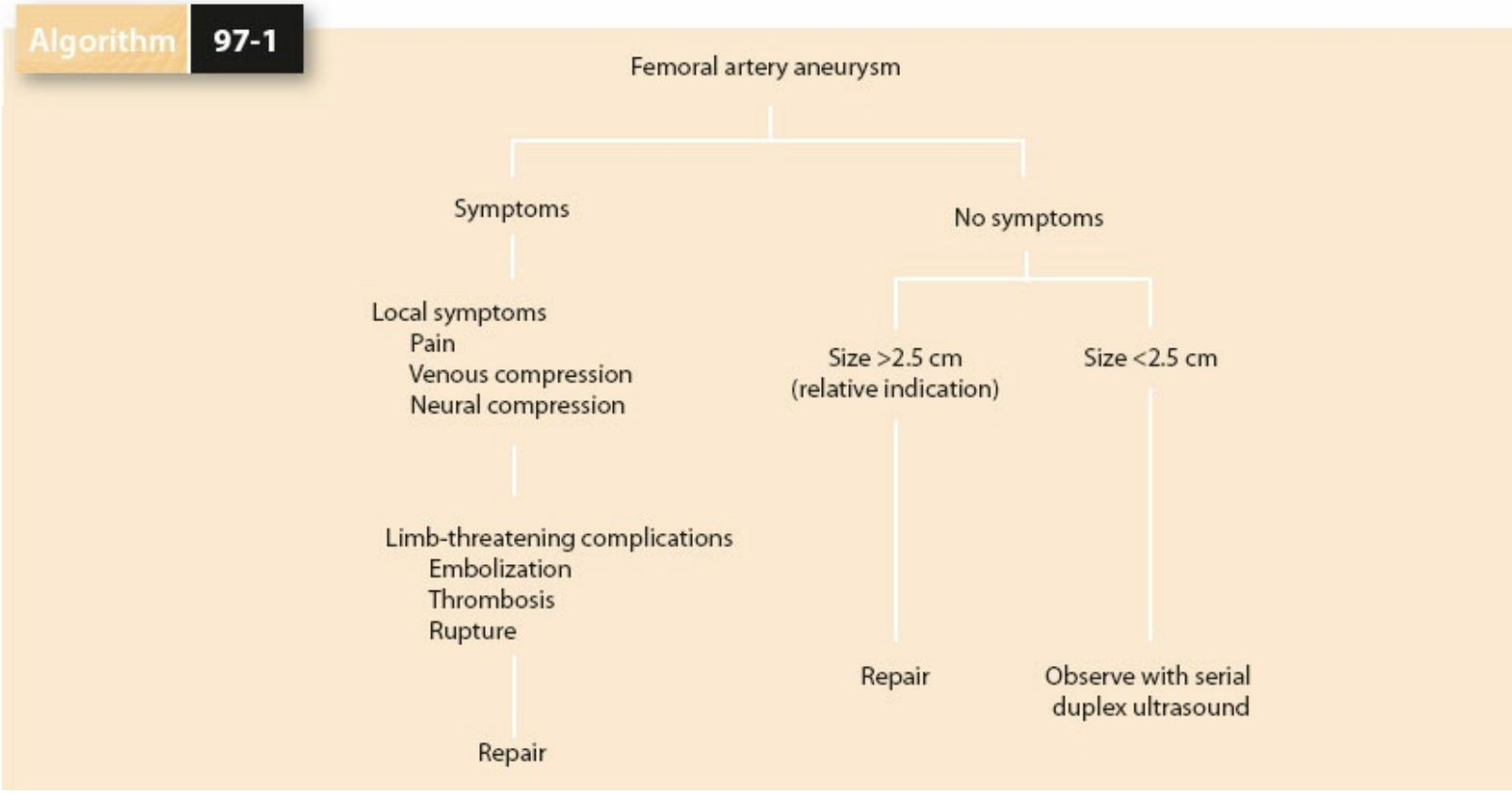

Algorithm 97-1. Management of femoral pseudoaneurysm.

Treatment

Therapy of femoral pseudoaneurysms is influenced by aneurysm size and symptoms, and whether the patient requires continuous anticoagulation (Algorithm 97-1). Surgical therapy is mandatory for all pseudoaneurysms that are acutely expanding, compressing adjacent nerves, or compromising the overlying skin. Proximal and distal arterial control is obtained, and the arterial defect is repaired directly, rarely requiring placement of more than one or two sutures.

An excellent alternative to a surgical approach, when urgent evacuation of the hematoma and arterial repair is not required, is the use of ultrasound-directed compression therapy or thrombin injection into the false aneurysm. The pseudoaneurysm is identified with a color-flow ultrasound probe, and then compressed with the scan head.[23] Real-time observation of flow in the underlying artery allows compression of the pseudoaneurysm while maintaining flow in the native vessel to prevent arterial occlusion. Pseudoaneurysm thrombosis is documented by absence of flow signals on release of scan-head pressure in the case of compression therapy. While effective, this can often be quite uncomfortable for the patient and take upward of 30 minutes of compression by the vascular technologist.

Another nonoperative treatment option of femoral pseudoaneurysms is percutaneous ultrasound-guided injection of 0.5 to 1.0 mL thrombin (1,000 U/mL) into the pseudoaneurysm away from the neck of the aneurysm.[24–26] Thrombin injection avoids the discomfort of prolonged compression and is effective in anticoagulated patients. Continuous ultrasonographic imaging is used to monitor thrombosis of the

pseudoaneurysm.

Results

Ultrasound-guided compression therapy for femoral pseudoaneurysms results in thrombosis in 80% to 90% of cases. Initial success rate is similar in patients who are anticoagulated and in those who are not, though long-term success appears to be better in patients not receiving anticoagulant therapy. In one of the largest series of pseudoaneurysms treated with ultrasound-guided compression, thrombosis was achieved in 86% of anticoagulated patients, and in 98% of those not anticoagulated, with a 20% recurrence rate in less than 24 hours in anticoagulated patients.[27] Success using this therapeutic modality requires a knowledgeable ultrasonographer and meticulous postcompression follow-up.

Thrombin injection to induce thrombosis of pseudoaneurysms is successful in 94% to 98% of patients with thrombosis occurring in less than 1 minute.[24–26] This technique can be complicated by arterial thrombosis if an excessive volume of thrombin is used and may not be appropriate for pseudoaneurysms with large necks. Remote thromboembolic events are rare and probably are not a result of a systemic effect of the thrombin. Allergic reactions to bovine thrombin occasionally occur. Large pseudoaneurysms, greater than 8 cm in diameter, and an associated arteriovenous fistula (AVF) are predictors of failure with thrombin injection.[28]

Mycotic Aneurysms

The term *mycotic aneurysm* is currently used to refer to any infected aneurysm. Mycotic aneurysms today are often a complication of parental drug abuse, but can follow arterial trauma of any form, including invasive diagnostic and therapeutic procedures. In the past, septic emboli from bacterial endocarditis were a major cause of mycotic aneurysmal degeneration, but this is less common today. With the advent of antibiotics, aneurysms secondary to syphilis or tuberculosis are rare. With the change in cause, the location of mycotic aneurysms has shifted from central to peripheral arteries with the femoral artery being the most common site.[29,30] The importance of mycotic aneurysms comes from their propensity to rupture.

Pathogenesis

The pathogenesis of mycotic aneurysms can be divided into four major categories, although other less common causes also exist.[29] First, septic emboli from bacterial endocarditis may lodge in normal arteries, causing infection that weakens the arterial wall, resulting in aneurysm formation. These lesions are often multiple. Second, during an episode of bacteremia, microorganisms may lodge in a pre-existing atherosclerotic plaque or aneurysm and begin to multiply with the same result. A third cause of mycotic aneurysms is the contiguous spread of bacteria from a local abscess. The inflammatory process destroys the arterial wall, causing pseudoaneurysm formation. Finally, trauma to the artery with concomitant contamination may result in formation of an infected pseudoaneurysm. This mechanism of mycotic aneurysm formation is being seen more frequently, coincident with the increased use of catheter-based procedures. Bacteria may be introduced concomitantly with needle puncture or by migration during prolonged arterial catheterization. Mycotic aneurysms accompanying drug abuse may be secondary to direct contamination of the arterial wall, or they may result from destruction of the vessel wall by a local abscess.

The bacteriology of arterial infections depends upon the cause of the lesion. Aneurysms secondary to bacterial endocarditis grew *Pneumococcus, Streptococcus,* and *Enterococcus* species most frequently in the past; but recently *Staphylococci, Salmonella, Escherichia coli,* and *Proteus* organisms also have been cultured.[29] *Staphylococcus aureus* is the most common pathogen in mycotic femoral artery aneurysms secondary to trauma and drug abuse, occurring in more than 65% of cases.[31] In this population, at least 50% of the *S. aureus* organisms are resistant to methicillin.

Clinical Manifestations

The typical patient with a mycotic femoral aneurysm presents with a history of chills and fever, and a tender, enlarging, pulsatile groin mass. The patient may have a history of intravenous drug use, recent arterial catheterization, penetrating trauma, or bacterial endocarditis. Local signs of infection, including tenderness, erythema, and warmth are noted on physical examination. Lower extremity edema may occur secondary to venous or lymphatic obstruction. Petechial skin lesions, splinter hemorrhages, cutaneous

abscesses, and septic arthritis may occur as a result of emboli originating from a mycotic aneurysm. A “sentinel bleed” may occur and signals impending rupture and life-threatening hemorrhage. Emergency surgery is indicated.

Diagnosis

The diagnosis of a mycotic aneurysm is usually straightforward, but distinguishing an abscess adjacent to the femoral artery from a femoral mycotic aneurysm may be difficult. In the patient with a pulsatile groin mass, laboratory findings including a leukocytosis, elevated erythrocyte sedimentation rate, and positive blood cultures are suggestive, but not specific, for a mycotic aneurysm. Multiple blood cultures or downstream arterial blood cultures may be necessary to yield positive results. Ultrasonography and CT angiography are helpful in establishing the diagnosis of an aneurysm (Fig. 97-3), but lack precision in distinguishing infected from bland aneurysms. The diagnosis of a mycotic aneurysm is confirmed at operation by demonstration of organisms on Gram stain or by positive cultures of the aneurysm wall.

Treatment

Mycotic aneurysms represent a serious life- and limb-threatening disease because their natural history is one of expansion and rupture. Therefore, mycotic aneurysms should be addressed surgically. The goal of treatment is eradication of the infection by excision of the aneurysm and débridement of adjacent infected tissue as well as by long-term antibiotic therapy. Second, adequate distal circulation must be restored. Before operative intervention is performed, the patient is started on antibiotics that are modified based on sensitivity testing of intraoperative cultures. Stent grafts have been used in selected cases of mycotic aneurysms when other approaches were not feasible; however, concern about latent infection of the stent graft oftentimes renders this more of a bridging technique than a long-term solution.



Figure 97-3. Computed tomography scan of an infected femoral anastomotic aneurysm that was diagnosed 5 years after aortofemoral graft placement.

The complexity of the operative procedure varies with the location and extent of the mycotic aneurysm. Although a direct approach to the femoral artery may be taken, a retroperitoneal exposure of the distal external iliac artery for proximal control is sometimes preferred for large or proximal femoral lesions to avoid excessive hemorrhage. When an infected femoral artery aneurysm is confined to only one arterial segment (common, superficial, or deep femoral artery), the aneurysm is excised and the proximal and distal arteries are ligated in emergent situations. In these cases in which an isolated arterial segment is ligated, severe ischemia resulting in amputation is unusual. In more than 50% of cases, however, the mycotic aneurysm involves the femoral artery bifurcation, and treatment requires resection of the femoral bifurcation and débridement to healthy arterial wall. The distal external iliac or proximal common femoral artery, as well as the superficial and deep femoral arteries, are oversewn with nonabsorbable monofilament suture. This results in significant ischemia in most patients, but with the patient heparinized, symptoms gradually improve as collateral circulation increases. The majority of patients will not need revascularization for limb salvage,[31] but up to one-third of patients will have limb-threatening ischemia.[32] In patients in whom sepsis can be adequately controlled at the initial procedure, aggressive débridement may be followed by immediate revascularization using autogenous saphenous vein graft as the conduit and covering the graft with a sartorius muscle flap.[32] Another option is to observe patients for 24 hours after arterial ligation and selectively revascularize only those patients in whom limb-threatening ischemia persists. Use of prosthetic material is avoided because of the high incidence of early and late septic complications, though can occasionally be necessary through uninfected tissue planes such as the obturator or lateral femoral route. Antibiotics are begun preoperatively and continued for at least 6 weeks postoperatively.

POPLITEAL ARTERY ANEURYSMS

5 Popliteal aneurysms are limb-threatening lesions, the vast majority of which are degenerative in etiology. Occasionally, anastomotic or traumatic popliteal aneurysms, and rarely mycotic aneurysms, are encountered in contemporary clinical practice. The remainder of this section addresses only popliteal aneurysms that are degenerative in etiology.

Incidence

Popliteal artery aneurysms are the most common degenerative true peripheral aneurysm. They occur slightly more frequently than femoral artery lesions; however, popliteal aneurysms are relatively unusual compared to abdominal aortic aneurysms. Aortic aneurysms are diagnosed with about 10 times the frequency of popliteal aneurysms.[33,34]

Pattern of Disease

Like patients with femoral artery aneurysms, multiple aneurysms occur frequently in patients with popliteal aneurysms. About 60% to 70% of patients have bilateral popliteal aneurysms, and 55% have extrapopliteal aneurysms.[35,36] Abdominal aortic aneurysms are encountered in 40% to 50%, and are particularly common in patients with bilateral popliteal aneurysms, of whom about 70% have aortic aneurysms.[35–37] Femoral artery aneurysms occur in nearly 40% of patients.[36,37] The importance of this multiplicity of aneurysms is that they may be missed on physical examination. Therefore, their presence must be determined by other studies, such as ultrasonography or CT, so that potentially life-threatening abdominal aortic aneurysms and other limb-threatening lesions are identified and managed appropriately. Even when popliteal aneurysms are initially asymptomatic, patients will develop symptoms at a mean rate of 14% per year, and one-third will develop complications requiring emergent intervention within 5 years, resulting in poorer outcomes for both life and limb.[38,39]

Clinical Manifestations

The typical patient with a popliteal aneurysm is a male in his 60s or 70s with the usual risk factors for atherosclerosis. Of patients with popliteal aneurysms, 50% to 75% are smokers, 40% to 60% have hypertension, and about 15% have diabetes mellitus.[35–37,40] Other manifestations of cardiovascular disease are also common, with 10% of patients having manifestations of cerebrovascular disease and more than 40% having evidence of significant cardiac disease.[37]

The clinical manifestations of popliteal artery aneurysms range from an asymptomatic pulsatile mass to severe lower extremity ischemia. About 40% of patients are asymptomatic at diagnosis.[7] More than 50% of patients present with symptoms of limb ischemia, usually claudication, but the ischemia may be more advanced and manifested as rest pain or gangrene. Local symptoms, including sensation of a mass, local pain, and leg swelling or phlebitis secondary to compression of the adjacent vein, account for the remainder of symptoms. A popliteal artery aneurysm may be complicated by thrombosis, embolization, or rarely rupture. Thrombosis is reported in approximately 40% of patients,[36] and embolization occurs in about 25% of cases.[36] Some patients present with classic “blue toe syndrome,” but more commonly, repeated episodes of embolization occlude the outflow vessels and result in thrombosis of the aneurysm. Rupture occurs in fewer than 5% of popliteal aneurysms;[35,36] and in these cases, the hemorrhage is usually confined to the popliteal space, thus permitting surgical intervention and arterial reconstruction in a timely fashion.

Natural History

The natural history of popliteal aneurysms is not well defined because most series are composed primarily of aneurysms that have been treated surgically. In a review of 29 reports in the English literature published between 1980 and 1994, subgroups of patients were identified whose aneurysms had been observed.[7] A mean of 35% of patients with conservative follow-up developed ischemic complications, and 25% of these required amputation even with modern therapy. Thus, a significant percentage of popliteal aneurysms will develop a complication if left untreated, and although this is not synonymous with limb loss, the amputation rate is high.

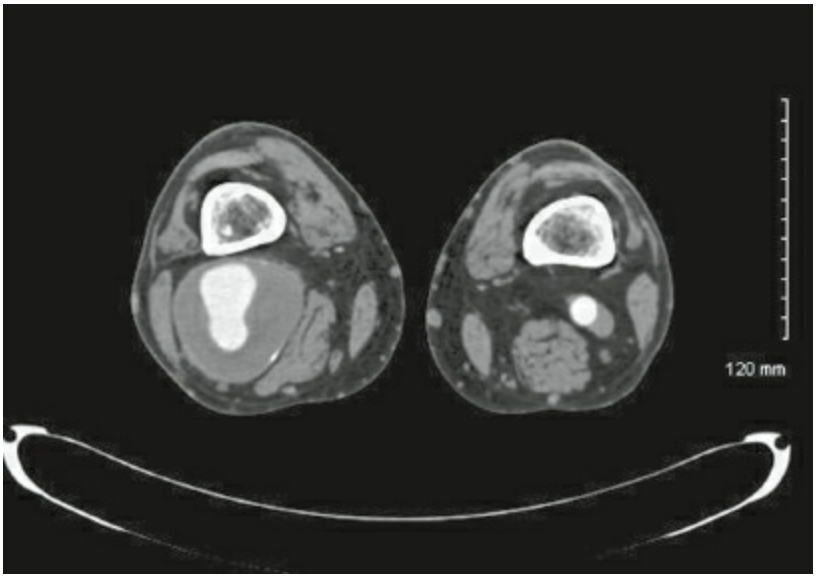

Figure 97-4. Computed tomography of large right popliteal aneurysm with significant laminar thrombus present.

Diagnosis

The diagnosis of popliteal aneurysm is usually first suspected on physical examination. Palpation of the popliteal space with the knee flexed reveals a pulsatile mass in approximately two-thirds of patients. Small aneurysms may not be palpable on physical examination, and if thrombosis has occurred the mass may be nonpulsatile. Radiographs of the knee demonstrating a calcified arterial wall occasionally suggest the diagnosis of a popliteal artery aneurysm, but it must be confirmed by duplex ultrasonography, CT (Fig. 97-4), or MRI. These diagnostic modalities can establish diagnosis of popliteal artery aneurysms and exclude other entities that could be responsible for a nonpulsatile popliteal fossa mass (tumor or Baker cyst). Ultrasonography, CT, or MRI is also useful in the detection of associated aneurysms, particularly abdominal aortic and femoral artery aneurysms. Angiography can be misleading in the diagnosis of aneurysms because intraluminal thrombus may obscure the true size of the vessel (Fig. 97-5); however, it is essential for visualization of the inflow and outflow vessels necessary for revascularization. CT angiography can be a noninvasive way to provide this information (Fig. 97-6).

Treatment

Indications

Surgical treatment is indicated for all symptomatic and many asymptomatic aneurysms. Controversy exists regarding the optimal management of small asymptomatic popliteal aneurysms because the natural history is not well defined. The incidence of complications with popliteal artery aneurysms is high, and the occurrence of complications does not correlate with the size of the aneurysm because the most common complications are embolization and thrombosis, which are not size related. In fact, in some reports the average diameter of symptomatic aneurysms is smaller than asymptomatic lesions.[40] These considerations, and the significantly higher limb loss rate after complications even when intervention is undertaken, has resulted in the recommendation for operative treatment when a popliteal aneurysm is diagnosed.

The goals of surgical treatment are to eliminate the potential for complications and to preserve or restore adequate blood flow to the limb. In patients with multiple aneurysms, the operative approach must be individualized. Generally, the life-threatening aortic aneurysm is treated first, followed by repair of the popliteal aneurysm. On the other hand, if a limb-threatening complication has occurred, treatment of the popliteal aneurysm usually takes precedence, followed by expeditious aortic aneurysm repair.



Figure 97-5. Arteriogram demonstrating a popliteal aneurysm associated with occlusion of the outflow tract presumably from repeated episodes of embolization. A bypass to the distal posterior tibial artery was successful.



Figure 97-6. Computed tomography arteriogram demonstrating right popliteal artery aneurysm and associated inflow and outflow.

Surgical Technique

Most popliteal aneurysms are easily approached through standard medial thigh and calf incisions for exposure of the distal superficial femoral artery and the distal popliteal artery, respectively. The proximal anastomosis will need to originate from the common femoral artery if the entire superficial femoral artery is aneurysmal. Occasionally, the posterior approach is preferred for lesions confined to the popliteal fossa, especially when accompanied by symptoms due to compression of adjacent structures. Most aneurysms are left in situ, bypassed using a segment of saphenous vein, and ligated proximally and distally. The conduit of choice for bypass is autologous saphenous vein, which is harvested from the thigh, reversed, and tunneled along the course of popliteal artery. The proximal and distal anastomosis may be either end-to-end or end-to-side in configuration, with the aneurysm excluded from the circulation by proximal and distal ligatures. Ligation should be adjacent to the aneurysm to minimize the number of patent collaterals that are in continuity with the aneurysm.[41] Late expansion and rupture of a bypassed and ligated popliteal aneurysm can occur when patent geniculate arteries continue to perfuse and pressurize the aneurysm. When the distal popliteal and proximal tibial vessels are occluded with recent emboli, they can sometimes be cleared using a balloon catheter or intraoperative thrombolytic therapy. Frequently, bypass grafts must be carried to the distal tibial arteries. Extensive femoral and popliteal aneurysms may require a femoral-popliteal or femoral-tibial bypass using in situ saphenous vein that originates from a prosthetic graft replacing a common femoral artery aneurysm.

Popliteal aneurysms have been treated by an endovascular approach. Small series show a primary patency rate of about 50% at 14 to 18 months,[42,43] and a cumulative patency of 74%,[44] suggesting that this approach should be reserved for the more high-risk patient who requires intervention.

6 The patient who presents with an acutely ischemic extremity secondary to popliteal aneurysm thrombosis is a management challenge. Popliteal aneurysms often thrombose because of repeated episodes of emboli to the outflow vessels, which result in their occlusion. An expeditious arteriogram may identify a suitable outflow vessel for the bypass graft. If no target vessel is identified, intra-arterial thrombolytic therapy should be initiated with the goal of lysing thrombus in the tibial arteries to identify a suitable outflow vessel for vascular reconstruction. Although the embolic process may be chronic, results with thrombolytic therapy followed by bypass of the aneurysm have been much better than surgical therapy alone for the patient with an acutely occluded aneurysm and severe leg ischemia.

Results

Excellent results are obtained in asymptomatic aneurysms with intact distal vasculature. Patients with thrombosed aneurysms or those in whom multiple episodes of embolization have occluded the tibial arteries have less optimal results. Operative mortality is in the 0 to 2% range, with asymptomatic patients fairing better than those presenting with acutely symptomatic lesions.[45,46] In patients undergoing revascularization before ischemic complications occur, 5- and 10-year graft patency rates are greater than 80% and limb salvage is 93% to 98%.[35,47] Graft patency rates in patients undergoing surgery after developing complications of their aneurysms are 60% and 48% at 5 and 10 years, respectively, and limb salvage rates are 60% to 80%.[35,47–49] Thrombolytic therapy, when successful, improves primary graft patency in patients presenting with acute limb ischemia.[50]

References

1. Ashton HA, Buxton MJ, Day NE, et al. The Multicentre Aneurysm Screening Study (MASS) into the effect of abdominal aortic aneurysm screening on mortality in men: a randomised controlled trial. *Lancet* 2002;360:1531–1539.
2. Diwan A, Sarkar R, Stanley JC, et al. Incidence of femoral and popliteal artery aneurysms in patients with abdominal aortic aneurysms. *J Vasc Surg* 2000;31:863–869.
3. Trickett JP, Scott RA, Tilney HS. Screening and management of asymptomatic popliteal aneurysms. *J Med Screen* 2002;9:92–93.
4. Lange P, Houe T, Helgstrand UJ. The efficacy of ultrasound-guided compression of iatrogenic femoral pseudo-aneurysms. *Eur J Vasc Endovasc Surg* 2001;21:248–250.
5. Calligaro KD, Dougherty MJ, Ryan S, et al. Acute arterial complications associated with total hip and knee arthroplasty. *J Vasc Surg* 2003;38:1170–1177.
6. Lawrence PF, Lorenzo-Rivero S, Lyon JL. The incidence of iliac, femoral, and popliteal artery aneurysms in hospitalized patients. *J Vasc Surg* 1995;22:409–415; discussion 415–416.
7. Lawrence PF, Harlander-Locke MP, Oderich GS, et al. The current management of isolated degenerative femoral artery aneurysms is too aggressive for their natural history. *J Vasc Surg* 2014;59(2):343–349.
8. Dawson I, Sie RB, Van Bockel JH. Atherosclerotic popliteal aneurysm. *Br J Surg* 1997;84:293–299.
9. Faggioli GL, Gargiulo M, Bertoni F, et al. Parietal inflammatory infiltrate in peripheral aneurysms of atherosclerotic origin. *J Cardiovasc Surg (Torino)* 1992;33:331–336.
10. Thompson RW, Liao S, Curci JA. Vascular smooth muscle cell apoptosis in abdominal aortic aneurysms. *Coron Artery Dis* 1997;8:623–631.
11. Cutler BS, Darling RC. Surgical management of arteriosclerotic femoral aneurysms. *Surgery* 1973;74:764–773.
12. Jarrett F, Makaroun MS, Rhee RY, et al. Superficial femoral artery aneurysms: an unusual entity?. *J Vasc Surg* 2002;36:571–574.
13. Dent TL, Lindenauer SM, Ernst CB, et al. Multiple arteriosclerotic artery aneurysms. *Arch Surg* 1972;105:338–344.
14. Szilagyi DE, Smith RF, Elliott JP, et al. Anastomotic aneurysms after vascular reconstruction: problems of incidence, etiology, and treatment. *Surgery* 1975;78:800–816.
15. Szilagyi DE, Elliott JP Jr, Smith RF, et al. A thirty-year survey of the reconstructive surgical treatment of aortoiliac occlusive disease. *J Vasc Surg* 1986;3:421–436.
16. Ylönen K, Biancari F, Leo E, et al. Predictors of development of anastomotic femoral pseudoaneurysms after aortofemoral reconstruction for abdominal aortic aneurysm. *Am J Surg* 2004;187:83–87.

17. Dennis JW, Littooy FN, Greisler HP, et al. Anastomotic pseudoaneurysms. A continuing late complication of vascular reconstructive procedures. *Arch Surg* 1986;121:314–317.
18. Seabrook GR, Schmitt DD, Bandyk DF, et al. Anastomotic femoral pseudoaneurysm: an investigation of occult infection as an etiologic factor. *J Vasc Surg* 1990;11:629–634.
19. Kresowik TF, Khoury MD, Miller BV, et al. A prospective study of the incidence and natural history of femoral vascular complications after percutaneous transluminal coronary angioplasty. *J Vasc Surg* 1991;13:328–333; discussion 333–335.
20. Knight CG, Healy DA, Thomas RL. Femoral artery pseudoaneurysms: risk factors, prevalence, and treatment options. *Ann Vasc Surg* 2003;17:503–508.
21. La Perna L, Olin JW, Goines D, et al. Ultrasound-guided thrombin injection for the treatment of postcatheterization pseudoaneurysms. *Circulation* 2000;102:2391–2395.
22. Kent KC, McArdle CR, Kennedy B, et al. A prospective study of the clinical outcome of femoral pseudoaneurysms and arteriovenous fistulas induced by arterial puncture. *J Vasc Surg* 1993;17:125–131; discussion 131–133.
23. Hertz SM, Brener BJ. Ultrasound-guided pseudoaneurysm compression: efficacy after coronary stenting and angioplasty. *J Vasc Surg* 1997;26:913–916; discussion 916–918.
24. Fram DB, Giri S, Jamil G, et al. Suture closure of the femoral arteriotomy following invasive cardiac procedures: a detailed analysis of efficacy, complications, and the impact of early ambulation in 1,200 consecutive, unselected cases. *Catheter Cardiovasc Interv* 2001;53:163–173.
25. Mohler ER 3rd, Mitchell ME, Carpenter JP, et al. Therapeutic thrombin injection of pseudoaneurysms: a multicenter experience. *Vasc Med* 2001;6:241–244.
26. Maleux G, Hendrickx S, Vaninbroukx J, et al. Percutaneous injection of human thrombin to treat iatrogenic femoral pseudoaneurysms: short- and midterm ultrasound follow-up. *Eur Radiol* 2003;13:209–212.
27. Cox GS, Young JR, Gray BR, et al. Ultrasound-guided compression repair of postcatheterization pseudoaneurysms: results of treatment in one hundred cases. *J Vasc Surg* 1994;19:683–686.
28. Kumins NH, Landau DS, Montalvo J, et al. Expanded indications for the treatment of postcatheterization femoral pseudoaneurysms with ultrasound-guided compression. *Am J Surg* 1998;176:131–136.
29. Anderson CB, Butcher HR Jr, Ballinger WF. Mycotic aneurysms. *Arch Surg* 1974;109:712–717.
30. Brown SL, Busuttil RW, Baker JD, et al. Bacteriologic and surgical determinants of survival in patients with mycotic aneurysms. *J Vasc Surg* 1984;1:541–547.
31. Gan JP, Leiberman DP, Pollock JG. Outcome after ligation of infected false femoral aneurysms in intravenous drug abusers. *Eur J Vasc Endovasc Surg* 2000;19:158–161.
32. Reddy DJ, Smith RF, Elliott JP Jr, et al. Infected femoral artery false aneurysms in

drug addicts: evolution of selective vascular reconstruction. *J Vasc Surg* 1986;3:718–724.

33. Szilagyi DE, Schwartz RL, Reddy DJ. Popliteal arterial aneurysms. Their natural history and management. *Arch Surg* 1981;116:724–728.
34. Ramesh S, Michaels JA, Galland RB. Popliteal aneurysm: morphology and management. *Br J Surg* 1993;80:1531–1533.
35. Anton GE, Hertzer NR, Beven EG, et al. Surgical management of popliteal aneurysms: trends in presentation, treatment, and results from 1952 to 1984. *J Vasc Surg* 1986;3:125–134.
36. Vermilion BD, Kimmins SA, Pace WG, et al. A review of one hundred forty-seven popliteal aneurysms with long-term follow-up. *Surgery* 1981;90:1009–1014.
37. Whitehouse WM Jr, Wakefield TW, Graham LM, et al. Limb-threatening potential of arteriosclerotic popliteal artery aneurysms. *Surgery* 1983;93:694–699.
38. Michaels JA, Galland RB. Management of asymptomatic popliteal aneurysms: the use of a Markov decision tree to determine the criteria for a conservative approach. *Eur J Vasc Surg* 1993;7:136–143.
39. Bowyer RC, Cawthorn SJ, Walker WJ, et al. Conservative management of asymptomatic popliteal aneurysm. *Br J Surg* 1990;77:1132–1135.
40. Lowell RC, Gloviczki P, Hallett JW Jr, et al. Popliteal artery aneurysms: the risk of nonoperative management. *Ann Vasc Surg* 1994;8:14–23.
41. Ascher E, Markevich N, Schutzer RW, et al. Small popliteal artery aneurysms: are they clinically significant? *J Vasc Surg* 2003;37:755–760.
42. Henry M, Amor M, Henry I, et al. Percutaneous endovascular treatment of peripheral aneurysms. *J Cardiovasc Surg (Torino)* 2000;41:871–883.
43. Gerasimidis T, Sfyroeras G, Papazoglou K, et al. Endovascular treatment of popliteal artery aneurysms. *Eur J Vasc Endovasc Surg* 2003;26:506–511.
44. Tielliu IF, Verhoeven EL, Prins TR, et al. Treatment of popliteal artery aneurysms with the Hemobahn stent-graft. *J Endovasc Ther* 2003;10:111–116.
45. Varga ZA, Locke-Edmunds JC, Baird RN, et al. A multicenter study of popliteal aneurysms. Joint Vascular Research Group. *J Vasc Surg* 1994;20:171–177.
46. Reilly MK, Abbott WM, Darling RC. Aggressive surgical management of popliteal artery aneurysms. *Am J Surg* 1983;145:498–502.
47. Roggo A, Brunner U, Ottinger LW, et al. The continuing challenge of aneurysms of the popliteal artery. *Surg Gynecol Obstet* 1993;177:565–572.
48. Dawson I, Van Bockel JH, Brand R, et al. Popliteal artery aneurysms. Long-term follow-up of aneurysmal disease and results of surgical treatment. *J Vasc Surg* 1991;13:398–407.
49. Jones WT 3rd, Hagino RT, Chiou AC, et al. Graft patency is not the only clinical predictor of success after exclusion and bypass of popliteal artery aneurysms. *J Vasc Surg* 2003;37:392–398.

50. Dorigo W, Pulli R, Turini F, et al. Acute leg ischaemia from thrombosed popliteal artery aneurysms: role of preoperative thrombolysis. *Eur J Vasc Endovasc Surg* 2002;23:251–254.

Chapter 98

Venous Disease

Thomas W. Wakefield and Michael C. Dalsing

Key Points

1 The diagnosis and treatment of acute and chronic venous disease have made significant advances in the last decade.

2 New drug therapies exist or are on the verge of impacting the treatment of acute deep venous thrombosis (DVT).

3 Chronic venous disease has experienced a resurgence of interest in the United States with new endoluminal and surgical interventions being investigated and utilized clinically.

4 Characterization of the disease is being scrutinized to allow for a better understanding of how treatment truly impacts patient outcomes.

5 The care of venous disease is an active and maturing discipline within the realm of the surgical disciplines.

INCIDENCE, RISK FACTORS, AND CATEGORIES

Venous thromboembolism (VTE), including deep venous thrombosis (DVT) and pulmonary embolism (PE), is a national healthcare concern. DVT affects greater than 250,000 patients annually, whereas PE affects greater than 200,000 patients per year. The incidence has remained constant since 1980 and increases with age.[1] The cost of treatment for both DVT and PE (termed VTE) is in the billions of dollars per year. Although Virchow triad of stasis, vessel wall injury, and hypercoagulability have defined the events that predispose to DVT formation for the past 150 years, today the understanding of events that occur at the level of the vein wall including the influence of the inflammatory response on thrombogenesis is increasingly being recognized.

Acquired risk factors for VTE include increasing age, malignancy, immobilization, surgery and trauma, oral contraceptive use, hormone replacement therapy, pregnancy and the puerperium, neurologic disease, cardiac disease, obesity, and antiphospholipid antibodies.[2] Genetic risk factors include deficiencies of antithrombin, protein C and protein S, factor V Leiden, prothrombin 20210A, blood group non-O, dysfibrinogenemia, dysplasminogenemia, hyperhomocystinemia, reduced heparin cofactor II activity, elevated levels of clotting factors (e.g., factors XI, IX, VII, VIII, X, and II), and elevations in plasminogen activator inhibitor-1 (PAI-1).[3] When a patient presents with an idiopathic VTE, there is family history of VTE, there is recurrent thrombosis, or there is thrombosis in unusual locations, workup for a hypercoagulable state may be indicated (hypercoagulable testing; Table 98-1).[2,3] Hematologic diseases associated with VTE include heparin-induced thrombocytopenia and thrombosis syndrome, disseminated intravascular coagulation, antiphospholipid antibody syndrome, thrombotic thrombocytopenic purpura, hemolytic uremic syndrome, and myeloproliferative disorders.

Most DVTs affect the iliac, femoral, or popliteal lower limb veins. Presenting symptoms include unilateral leg pain and swelling, but some DVTs are silent, with the first manifestation a PE. A recent study of 5,451 patients with ultrasound confirmed DVT revealed the most common comorbidities to be hypertension, surgery within 3 months, immobility within 30 days, cancer, and obesity.[4]

Venous Thromboembolism Diagnosis

1 Venous color duplex imaging is now standard, although D-dimer may be considered in low probability settings. The positive and negative predictive values for gray-scale imaging are inferior to color imaging. A meta-analysis of 13 studies comparing CT with ultrasound for proximal DVT found a sensitivity of 71% to 100% and specificity between 93% and 100%.[5] In symptomatic patients, sensitivity is approximately 93%, specificity 98%, accuracy 97%, with approximately 30% of studies indeterminate in the calf.[6] Data from the Prospective Investigation of Pulmonary Embolism Diagnosis II, a multicenter study of 711 patients, were used to compare the clinical value of CT Venography (CTV) after multidetector CT angiography (CTA) with venous compression ultrasonography for the diagnosis of VTE. There was 95.5% concordance between CTV and ultrasonography for the diagnosis or exclusion of DVT ($\kappa = 0.809$). Attesting to the accuracy of ultrasound, the sensitivity and specificity of combined CTA and CTV were equivalent to combined CTA and ultrasonography.[7]

The usefulness and absolute need for duplex imaging depend, to some degree, on the pretest probability for DVT. In a patient with a low pretest probability for DVT (such as a Wells score), if a D-dimer biomarker test is negative, no further testing is necessary.[8] D-Dimer requires that a high-sensitivity D-dimer assay (such as the advanced turbidimetric method or ELISA) is used. If the D-dimer is positive, then duplex must be performed even if the pretest probability is high, as a positive D-dimer and a positive risk assessment is associated with DVT in only approximately 70% of cases.[9] A highly soluble P-selectin, along with a positive Wells score, may allow for the diagnosis of DVT in greater than 90% of cases.[10] The high negative predictive value (NPV) of color duplex Doppler ultrasound both above and below the knee supports withholding anticoagulation on the basis of a good-quality negative study alone, and clinical data also support that strategy.[11] A single good-quality color duplex Doppler study is sufficient (NPV >99.5%) to exclude proximal DVT; repeat scanning is seldom indicated unless the initial study was technically suboptimal.[12] A truly negative study means that all the segments of the leg, including the external iliac, common femoral, femoral, popliteal, and calf veins, are negative by ultrasound imaging and clear by Doppler flow. In a patient with a moderate pretest probability for DVT, if duplex ultrasound is negative, no further testing is necessary. On the contrary, in a patient with a high pretest probability for DVT, the D-dimer is less useful and even a negative result would not supersede the need for imaging. The positive predictive value is high for symptomatic patients with a positive duplex ultrasound and such patients should undergo treatment. If duplex ultrasound of proximal veins is negative, either perform D-dimer (if negative, withhold anticoagulation and if positive, repeat in 1 week) or just repeat in 3 to 7 days (3 days if very suspicious, 7 days if less suspicious). If whole leg duplex is negative, no further testing is necessary. During pregnancy the aforementioned recommendations remain, but it is very important to attempt to assess for iliac vein thrombosis.

Table 98-1 Alternative Anticoagulants

Drugs	Mechanism of Action
Dabigatran etexilate	Direct thrombin (FIIa) inhibitor
Bivalirudin	Direct thrombin (FIIa) inhibitor
Argatroban	Direct thrombin (FIIa) inhibitor
Fondaparinux	Indirect FXa inhibitor
Rivaroxaban	Direct FXa inhibitor
Apixaban	Direct FXa inhibitor
Edoxaban	Direct FXa inhibitor
P-selectin inhibitors	Anti-inflammatory preventing thrombus amplification

For the diagnosis of superficial vein thrombophlebitis (SVT), duplex ultrasound is also important.[13] In a prospective epidemiologic study, including 844 patients with symptomatic SVT, 210 (24.9%) had concomitant DVT at the time of diagnosis of SVT. Of the 600 patients without DVT, over the next 3 months, 58 (10.2%) developed thromboembolic complications, including 3 (0.5%) with PE, 15 (2.8%) with DVT, 18 (3.3%) with extension, and 10 (1.9%) with recurrence of SVT. These events occurred despite the use of anticoagulant treatment. Thus, it is important to perform good duplex imaging in patients diagnosed with SVT.

Finally, in the CALISTO study, fondaparinux (Arixtra) was found effective in limiting a series of endpoints including death, PE, DVT, and extension or recurrence at days 47 and 77 after SVT diagnosis.[14] This was in patients with axial vein SVT of at least 5-cm length with the thrombus at least 3 cm from the saphenofemoral junction (SFJ). Less extensive SVT requires only symptom control with oral or topical nonsteroidal anti-inflammatory drugs (NSAIDs). Thus, it is important to document the length of the SVT, the location, and the extent of the SVT to the SFJ, when imaging.

Other conditions may be confused with DVT and include lymphedema, muscle strains, and muscle contusion. Iliac vein obstruction may lead to unilateral leg edema (May–Thurner syndrome), while the presence of a cyst behind the knee may produce unilateral lower leg pain and edema. Other causes of leg swelling include systematic problems such as cardiac, renal, or hepatic abnormalities. These systemic problems usually lead to bilateral edema.

Pulmonary Embolism

Testing for PE begins with prior probability estimation for all patients. Two of the most widely known and validated diagnostic scoring systems are the Wells criteria (or modified/dichotomous Wells criteria) and Geneva score.[15–17] They use a combination of physical examination, history, and vital signs to predict the likelihood of PE. D-Dimer testing is used to exclude PE for patients with low prior probability for DVT. D-Dimer testing has no role in diagnosis if prior probability is not low. Use of D-dimer testing in PE diagnosis requires that a high-sensitivity D-dimer assay (such as the advanced turbidimetric method or ELISA) validated at the local institution be used. Patients with both low probability and negative D-dimer require no further investigation as the NPV is 99%.[18,19]

The diagnosis of PE has involved ventilation-perfusion (V/Q) scanning and pulmonary angiography. However, newer techniques include spiral computed tomographic scanning and magnetic resonance imaging. The sensitivity of V/Q scanning was defined in PIOPED I at 98%, but specificity was low at 10%.[20] By combining clinical factors with V/Q scan, levels of sensitivity and specificity greater than 95% were achieved. With a high-probability V/Q scan, two risk factors positive for PE, the sensitivity was 97%; with one risk factor, 84%; and with no risk factors, 82%. Similarly, with a normal V/Q scan, the chance of PE was essentially 0, irrespective of the risk factor status.[21] Thus, a normal V/Q scan or a high-probability scan provided good diagnostic information that could be used to base treatment on. However, only a small portion of V/Q scans are in one of these two categories, leaving many patients needing further testing. Because of its invasive nature, pulmonary angiography is used less often today. Pulmonary arteriography is included with acute massive PE, inferior vena cava (IVC) interruption, and when planning interventional therapy, such as thrombolysis or pulmonary embolectomy.

Multidetector helical CTA is the primary imaging modality, although V/Q scanning remains viable (particularly for patients with otherwise normal lungs in whom interpretability of the test is optimal), and a positive lower-extremity color duplex Doppler study in a high-probability patient can establish the diagnosis of VTE without lung imaging. However, the problem with using only lower extremity duplex imaging is that a baseline study in the chest is not obtained for later comparisons. Multidetector scanners have significantly improved the sensitivity and specificity, as well as the positive and negative predictive value of CTA. Recent outcome studies have found the sensitivity and specificity of CTA to be greater than 95%, and a negative CTA carries a 3-month risk of VTE of 1% to 2%. CTA establishes the diagnosis of PE if it is positive in an intermediate- or high-probability patient, or in a low-probability patient with findings of a main-stem or lobar embolus. It excludes the diagnosis of PE in low-probability patients with negative scans. Discordance between prior probability and CTA findings requires further investigation, as well as technically inadequate studies.[7] Other diagnostic tests may include V/Q imaging or pulmonary angiography.

Outcome studies have found comparable results between pulmonary angiography and CTA; a negative result with either study confers approximately a 1% VTE rate within 6

months. However, because angiography is invasive, it carries a greater risk of complications and mortality. The mortality from angiography has been estimated at 0.5%, while 1% may experience major complications, including arrhythmias, hypotension, bleeding, and nephrotoxicity.[22] Without a higher standard to appeal to, one cannot discuss specificity and sensitivity of pulmonary angiography using commonly accepted definitions of these terms. Instead, the accuracy of pulmonary angiography is discussed in terms of interobserver variability in the reading of pulmonary angiograms obtained in the context of large multicenter trials. Studies demonstrate that the larger the embolus, the better the interobserver agreement. For segmental and larger emboli, agreement exceeds 95%. For subsegmental emboli, agreement is considerably less. We do not recommend pulmonary angiography, except in certain circumstances, such as with inadequacy of V/Q imaging or when catheter-directed thrombolysis is recommended.

Recently, the efficacy of magnetic resonance angiography (MRA), magnetic resonance venography (MRV), or the combination of the two in the diagnosis of acute PE has been studied.[23] The gold standard used for comparison was a composite end-point of CTA, CTA-CTV, V/Q scan, lower extremity ultrasonography, D-dimer assay, and clinical assessment. Overall, MRA and MRA-MRV were found to be poor tests for the diagnosis of PE. Approximately 25% of the 371 patients enrolled in a large multicenter study had a technically inadequate MRA, and 48% had either an inadequate MRV or MRA. Considering all patients enrolled, MRA alone identified only 57% of PEs and had a sensitivity of 78% when only patients with adequate studies were considered. The combined MRA-MRV studies had a sensitivity of 92%, but only about half of the patients had technically adequate studies. These poor results are generally felt related to the technical difficulties of MRA in identifying abrupt vessel termination and capturing adequate images of the chest vessels secondary to motion artifact. At this time, MRA-MRV is not generally recommended and only considered in centers with a great deal of experience.

Because of its low sensitivity and specificity, transthoracic or transesophageal echocardiography has limited diagnostic value for PE.[24] For critically ill patients too unstable for transport, echocardiography can suggest the diagnosis of PE by showing dilatation of the RV or hypokinesis. Commonly, acute changes in the RV pressure, size, and function are seen, indicating increased RV strain and pulmonary arterial pressures. These changes suggest PE in the absence of alternative diagnoses. Although of limited value in the diagnosis of PE, echocardiography is of great prognostic use in stratifying risk for patients with acute PE. Right ventricular dysfunction or dilatation in acute PE is associated with worse outcomes, including increased mortality rate.

Biomarkers include B-type natriuretic peptide (BNP), released by ventricular myocardial cells in response to wall stretch and volume overload. BNP is a prognostic (not diagnostic) biomarker for PE. BNP levels generally indicate RV strain due to elevated pulmonary vascular resistance in the lungs. If measured early (within 4 hours of admission for PE), elevated BNP levels ($>$90 pg/mL) demonstrate a sensitivity of 85% and a specificity of 75% in predicting PE-related outcomes. Conversely, normal BNP values in the setting of acute PE carry a 97% to 100% NPV for in-hospital death. Another

biomarker is troponin released from damaged myocardial cells. When elevated in acute PE, troponins represent myocyte ischemia and microinfarction due to acute cardiac strain of the right ventricle. Approximately 30% to 50% of patients with large PE will have elevations in troponins I and T that are mild and short-lived. They correlate with worse RV function and a high incidence of complications. Normal troponin T levels have a 97% to 100% NPV for in-hospital death. These two biomarkers are not part of routine algorithms.[19]

Axillary/Subclavian Vein Thrombosis

Thrombosis of the axillary/subclavian vein accounts for less than 5% of all cases of acute DVT. However, it may associated with PE in up to 10% to 15% of cases and additionally can also be the source of significant disability.[25] Primary axillary/subclavian vein thrombosis results from obstruction of the axillary vein in the thoracic outlet, the so-called Paget–Schroetter syndrome, noted especially in healthy muscular athletic individuals. Such thrombosis may also occur in patients with hypercoagulable states. Secondary axillary/subclavian vein thrombosis results from mediastinal tumors, congestive heart failure, and nephrotic syndrome. Patients with axillary–subclavian venous thrombosis often present with arm pain, edema, and cyanosis. Superficial venous distension may be apparent over the arm, forearm, shoulder, and even the anterior chest wall.

Upper extremity venous duplex ultrasound is used to diagnose suspected axillary–subclavian vein thrombosis. Thrombolysis and phlebography are often considered next. If phlebography is performed, it is important that the patient undergo positional phlebography with arm abduction to 120 degrees to confirm extrinsic subclavian vein compression at the thoracic outlet. Venous compromise is further evidenced by prominent collateral veins. Since a cervical rib may be the cause of such obstruction, chest x-ray film should be obtained to exclude its presence.

STANDARD THERAPY FOR VTE

Treatment

The traditional treatment of VTE is systemic anticoagulation, which reduces the risk of PE, extension of thrombosis, and thrombus recurrence. Immediate anticoagulation should be undertaken as the recurrence rate for VTE is higher if anticoagulation is not therapeutic in the first 24 hours.[26] For DVT, since duplex imaging is rapidly obtained, usually testing precedes anticoagulation while for PE, anticoagulation is recommended either simultaneous with or before testing. Recurrent DVT can still occur in up to one third of patients over an 8-year period, even with appropriate anticoagulant therapy.[27]

Unfractionated heparin or low–molecular-weight heparin (LMWH) is given along with oral anticoagulation with vitamin K antagonists (usually warfarin [Coumadin]). It is recommended that the international normalized ratio (INR) be therapeutic for 2 consecutive days before stopping heparin or LMWH.[28] LMWH has become the standard for treatment because it is administered subcutaneously, requires no monitoring (except in certain circumstances, such as renal insufficiency or morbid obesity), and is associated with a decrease in bleeding potential.[29] Compared to standard unfractionated heparin, LMWH has significantly improved bioavailability, less endothelial cell binding and protein binding, and improved pharmacokinetics.[30] The half-life of LMWH is dose independent and it is administered in a weight-based fashion. LMWHs may decrease indices of chronic venous insufficiency (CVI) compared with standard therapy when used over an extended period. Based on all of the available evidence, LMWH is now preferred over standard unfractionated heparin for the initial treatment of VTE with a level of evidence given 2B (according to the 2012 Chest consensus guidelines).[31] Warfarin should be started after heparinization is therapeutic to prevent warfarin-induced skin necrosis, as warfarin causes inhibition of protein C and S before factors II, IX, and X, leading to paradoxical hypercoagulability at the initiation of therapy. For standard unfractionated heparin, this requires a therapeutic activated partial thromboplastin time; for LMWH, warfarin is administered after an appropriate weight-based dose of LMWH is administered and allowed to circulate.

The goal for warfarin dosing is an INR between 2.0 and 3.0. The duration of anticoagulation depends on a number of factors, including the presence of continuing risk factors for thrombosis, the type of thrombosis (idiopathic or provoked), the number of times thrombosis has occurred, the status of the veins when stopping anticoagulation, and the level of D-dimer measured approximately 1 month after stopping warfarin. One study demonstrated a statistically significant advantage to resuming warfarin if the D-dimer assay is elevated over an average 1.4-year follow-up (odds ratio [OR], 4.26), and a meta-analysis has confirmed this relationship.[32] The recommended duration of anticoagulation after a first episode of VTE is 3 months.[31] After a second episode of VTE, the usual recommendation is prolonged warfarin unless the patient is very young at the time of presentation or there are other mitigating factors. VTE recurrence is increased with homozygous factor V Leiden and prothrombin 20210A mutation, protein C or protein S

deficiency, antithrombin deficiency, antiphospholipid antibodies, and cancer until resolved. In these situations, long-term warfarin is recommended. However, heterozygous factor V Leiden and prothrombin 20210A do not carry the same risk as their homozygous counterparts, and the length of oral anticoagulation is shortened for these, the most common of hypercoagulable conditions. Regarding idiopathic DVT, most believe that this diagnosis requires longer than 6 months of anticoagulation, but the actual length is unknown.[33] Taken together, criteria for discontinuing anticoagulation are given a level of evidence of 1B to 2B, depending on the clinical situation.[31,33–37] Recent evidence suggests that the decision to continue anticoagulation indefinitely after a first unprovoked proximal DVT is strengthened if the patient is male, the index event was a PE, and the D-dimer is positive 1 month after stopping anticoagulation.[38] In addition, there is growing evidence that in certain circumstances, such as active cancer, the use of LMWH is superior to LMWH converted to warfarin for long-term treatment.

Complications

Bleeding is the most common complication of anticoagulation. With standard heparin, bleeding occurs over the first 5 days in approximately 10% of patients.[39] Heparin-induced thrombocytopenia (HIT) occurs in 0.6% to 30% of patients. Although historically morbidity and mortality rates have been high, it has been found that early diagnosis and appropriate treatment have decreased these rates.[40] HIT usually begins 3 to 14 days after heparin is begun, although it can occur earlier if there has been exposure to heparin in the past. A heparin-dependent antibody binds to platelets, activates them with the release of procoagulant microparticles leading to an increase in thrombocytopenia, resulting in thrombosis.[41] Both bovine and porcine unfractionated heparin and LMWH have been associated with HIT, although the incidence and severity of the thrombosis are less with LMWH. Even small exposures to heparin can cause the syndrome. The diagnosis should be suspected with a 50% or greater drop in platelet count, when the platelet count falls less than 100,000/mL or when thrombosis occurs during heparin or LMWH therapy.[42] A highly sensitive but poorly specific ELISA test detects the antiheparin antibody in the plasma. The serotonin release assay is another test that is more specific but less sensitive.[43] When the diagnosis is made, heparin must be stopped and warfarin should not be given until an adequate alternative anticoagulant has been established and the platelet count has normalized. LMWHs cannot be used as substitutes as studies demonstrate high cross-reactivity with standard heparin antibodies. Agents that have been approved by the Food and Drug Administration (FDA) as alternatives include the direct thrombin inhibitor argatroban and bivalirudin (Table 98-1). Fondaparinux has also been found effective for treatment of HIT, but it is not FDA approved for this indication. The use of these alternative agents is given 2C and 1C evidence.[44]

Low–Molecular-Weight Heparin Special Features

When considering once-a-day to twice-a-day LMWH dosing, a meta-analysis of greater than 1,500 patients with VTE demonstrated a nonsignificant difference in the incidence of recurrent thromboembolism, thrombosis size, hemorrhagic events, and mortality.[45] Twice-a-day dosing may still be more appropriate than once-a-day dosing in patients with marked obesity and patients with cancer.[46]

LMWH has been suggested as a replacement for oral vitamin K antagonists. Rates of recanalization have been reported to be higher in certain venous segments using LMWH and the use of LMWH has been found to lead to improved outcomes in cancer patients compared to standard heparin or LMWH/warfarin therapy when used for 6 months, without differences in rates of major bleeding.[47] LMWH has also been found to provide better DVT prophylaxis than placebo when used for extended prophylaxis over 4 weeks in patients undergoing abdominal and pelvic cancer surgery.[48]

ALTERNATIVE/FUTURE MEDICAL TREATMENTS FOR DVT

Fondaparinux targets factor Xa with a 17-hour half-life for fondaparinux (Table 98-1). It exhibits no endothelial or protein binding and produces no thrombocytopenia. One disadvantage is the lack of a readily available antidote. Fondaparinux has been tested in the prophylaxis of major orthopedic surgery. In a meta-analysis involving greater than 7,000 patients, there was more than a 50% risk reduction using fondaparinux begun 6 hours after surgery compared with LMWH begun 12 to 24 hours after surgery.[49] Critical bleeding was not different, although major bleeding was increased. Fondaparinux has also been effective in prophylaxis of general medical patients, abdominal surgery patients, and for extended prophylaxis after hip fracture.[50–52] For DVT treatment, fondaparinux was found equal to LMWH, while for PE, it was found equal to standard heparin.[53,54] Dosage is based on body weight: 5 mg per body weight <50 kg; 7.5 mg per body weight 50 to 100 kg; and 10 mg per body weight >100 kg. Treatment at least for 5 days with concurrent administration of oral anticoagulation is recommended, until the INR is therapeutic at a level of 2 to 3. Fondaparinux has been approved for the treatment of DVT/PE, and for thrombosis prophylaxis in total hip, total knee, and hip-fractured patients, in the extended prophylaxis of hip-fractured patients, and in abdominal surgery patients. A number of novel oral anticoagulants are currently developed or in stages of development to either replace vitamin K antagonists in concert with initial heparin or LMWH, or to replace both heparin/LMWH and vitamin K antagonists totally as monotherapy. These agents hold the promise of not needing monitoring, being safer in terms of bleeding risk than current agents, and being of equal or improved efficacy to established anticoagulants.

2 Dabigatran targets activated factor II (factor IIa), while rivaroxaban, apixaban, and edoxaban target activated factor X (factor Xa). Dabigatran etexilate is FDA approved for stroke and systemic embolization prevention in patients with atrial fibrillation and for treating deep vein thrombosis (DVT) and PE in patients who have been treated with a parenteral anticoagulant for 5 to 10 days. In trials for VTE, out of six randomized controlled trials (RCTs), dabigatran was noninferior in three trials, superior in two trials, and inferior in one trial. In the Recover trial, which compared dabigatran 150 mg to therapeutic anticoagulation with vitamin K antagonists (INR, 2 to 3) in the treatment of DVT for 6 months, after both were given LMWH or unfractionated heparin for an average of 9 days, dabigatran was noninferior in the 6-month rate of VTE recurrence. In addition, clinically significant bleeding was not significantly different when compared with warfarin.[55] In addition, in two other VTE trials, dabigatran was found in extended duration treatment to have fewer recurrent VTEs compared with placebo.[56] Rivaroxaban is FDA approved for VTE prophylaxis in patients undergoing hip or knee replacements, for stroke and systemic embolization prevention in patients with atrial fibrillation, and for VTE treatment. Eight major trials studying VTE and rivaroxaban have been published, with rivaroxaban noninferior in 6 and superior in 2 to standard therapy. The Einstein trial evaluated rivaroxaban compared to standard anticoagulation in the treatment of acute DVT.[57] As monotherapy, rivaroxaban was found statistically noninferior to standard

therapy, without increased bleeding risk. In addition, the Einstein group added a continued treatment group compared to placebo for an additional 6 to 12 months. Extended rivaroxaban showed a significant decrease in recurrent VTE without an increase in major bleeding. A similar finding with PE has been noted.[58] In a trial for atrial fibrillation, rivaroxaban showed statically less intracranial bleeding or fatal bleeding.

Apixaban is currently FDA approved for the prevention of complications of atrial fibrillation, for prophylaxis of DVT following hip or knee replacement surgery, for the treatment of DVT/PE, and for reduction in the risk of recurrence of DVT/PE. This agent has been evaluated in six studies involving VTE, noninferior in two, superior in three, and a failure in one. In a recent study, Apixaban was given for 7 days of initial treatment for DVT, followed by a lower dose bid versus standard enoxaparin followed by warfarin for 6 months. Apixaban was noninferior to standard therapy with less bleeding.[59] Apixaban was also studied as extended treatment of VTE.[60] After a standard duration of treatment, an additional 12 months of apixaban therapy compared to placebo revealed a significant decrease in the rate of VTE without an increase in bleeding. This is the only new oral agent that has revealed superiority to standard therapy without an increase in bleeding in atrial fibrillation patients. Edoxaban administered once daily after initial treatment with heparin was noninferior to high-quality standard therapy and caused significantly less bleeding in a broad spectrum of patients with VTE, including those with severe PE.[61] Problems with these new agents include the difficulty at the present time to reliably reverse the anticoagulant effects of these drugs with only one approved medication available at the present time, the fact that there is little data available on bridging of these agents when other procedures need to be performed, and the fact that they are nongeneric. Their usefulness for VTE will dramatically improve when adequate reversal agents become clinically available.[62] The use of P-selectin inhibitors, an area of ongoing research, uses an anti-inflammatory approach to limit thrombus amplification without causing anticoagulation.

NONPHARMACOLOGIC TREATMENTS

Postthrombotic syndrome (PTS) results from loss of competence of the venous valves as a result of DVT or persistent venous obstruction, or a combination of both. It can cause significant morbidity in the form of pain, swelling, skin breakdown, and ulcerations. A Cochrane meta-analysis found a strong effect (OR 0.31) for prevention of PTS using graduated compression stockings beginning within 2 weeks of onset of DVT, with important data highlighted from two open-labeled randomized single-center studies that utilized stockings of 30 to 40 mm Hg for 2 years after DVT.[63] From these data, stockings of 30 to 40 mm Hg gradient should be recommended to most patients with DVT, for a minimum of 2 years post-DVT, and longer if they have symptoms of PTS. There is a new study that would suggest that stockings may not prevent PTS after a first proximal DVT.[64] However, there are a number of specific considerations in this study that will need to be repeated before the recommendation of stockings after DVT is reversed. In addition, ambulation with good compression does not increase the risk of PE, while significantly decreasing the incidence and severity of the PTS.[65,66] Early ambulation has the potential to decrease PTS and improve patients' quality of life (QOL). Thus, patients should be encouraged to ambulate as part of their post-DVT care recommendations.[31]

IVC Filters

The traditional indications for the use of IVC filters include a complication of anticoagulation, a contraindication to anticoagulation, and failure of anticoagulation. Protection from PE has been greater than 95% using cone-shaped wire-based permanent IVC filters.[67] Cone-shaped filters have a lower incidence of IVC thrombosis compared with basket-shaped filters, and a recent study between the two filter types was stopped early because of the high rate of IVC thrombosis with the basket-shaped device.[68] The success achieved with filters has expanded the indications, including free-floating thrombus longer than 5 cm, when bleeding risk with anticoagulation is excessive, when the risk of PE is felt to be very high, and to allow for the use of perioperative epidural anesthesia.[69–71] Filters can be permanent or optional (retrievable). If a retrievable filter is left in to become a permanent filter, the long-term fate of that filter has yet been defined.

Filters are usually placed in an infrarenal location. However, they may also be placed in the suprarenal location or in the superior vena cava. Indications for suprarenal placement include high-lying clot, pregnancy, women of childbearing potential, or a previous device that has failed or become filled with clot. Sepsis is not a contraindication to the use of wire-based filters since the trapped material can be sterilized with antibiotics. Although filters have been placed under x-ray guidance, percutaneous techniques for filter insertion using bedside external ultrasound or intravascular ultrasound are now being recommended. Transabdominal external ultrasound is difficult in the face of morbid obesity, overlying bowel gas, or open abdominal wounds. In these instances, intravascular ultrasound has been found to be more successful.[72] Other than one randomized prospective study on the use of filters as treatment of DVT (which is not how filters are traditionally used), evidence for the use of filters is given a 2C level of evidence.[73,74]

Thrombolytic and Surgical Procedures for Deep VTE

For DVT treatment, the goals are to prevent extension or recurrence of DVT, prevent PE, and minimize the late squeal of thrombosis, namely CVI. Standard anticoagulants accomplish the first two goals but not the third goal. The PTS (venous insufficiency related to venous thrombosis) occurs in up to 30% of patients after DVT and even greater with more proximal iliofemoral DVT.[27] Experimentally, prolonged contact of the thrombus with the vein wall increases damage.[75] The thrombus initiates an inflammatory response in the vein wall that can lead to vein wall fibrosis and valvular dysfunction. Systemic thrombosis in two small series revealed a decrease in the incidence of CVI with streptokinase, as opposed to systemic unfractionated heparin (UFH). However, results depend on complete thrombolysis. Because of this inability to predict complete lysis, combined with its bleeding potential thrombolysis is recommended infrequently. However, urokinase administered directly into venous thrombi has led to an increase in enthusiasm and the publication of a national thrombolysis registry.[76,77] In 473 patients, 287 of whom underwent follow-up, 312 urokinase infusions in 303 limbs were reported. Venous thrombi occurred in the iliofemoral segment in 71% of cases alone, without IVC involvement in 79%, and including the IVC in 21% of cases. Patients had acute disease in approximately two-thirds of cases, 16% had chronic disease, and 19% had combined acute and chronic disease. Approximately 30% had prior DVT. Complete thrombolysis was achieved in 31% and partial lysis in 52% of cases. The mean amount of urokinase used was 7.8 million units, and the mean time of infusion was 53.4 hours. Successful lysis was predicted by acute DVT and no history of prior DVT. Complications included major bleeding necessitating blood products in 11% and minor bleeding in 16%. Mortality rate was 0.4%, intracranial hemorrhage rate was 0.2%, and subdural hemorrhage rate was 0.2%. Total lysis was noted in only 31% of the entire series; however, in patients with acute iliofemoral DVT, no previous symptoms, and the use of the popliteal vein access site, total lysis was more frequent. At 12 months, patency was 79% if lysis was complete, 58% with greater than 50% lysis, and 32% with less than 50% lysis. Absence of valvular reflux was found in 72% of cases with complete lysis, whereas overall valvular reflux was seen in 58% of cases.

Importantly, aggressive therapies have been found to improve QOL. A small randomized study demonstrated that thrombolysis is superior to anticoagulation in patients with iliofemoral DVT.[78] Results appear to be optimized further by combining catheter-directed thrombolysis with mechanical devices, including the AngioJet™ rheolytic catheter, and the EKOS MicroSonic™ accelerated thrombolysis catheter. In addition, new devices (such as the Angiovac) are being developed specifically for large veins. With these devices, thrombolysis is hastened, the amount of thrombolytic agent is decreased, and bleeding is thus decreased. Importantly, a number of small studies have reported a decrease in PTS with catheter-directed thrombolysis for iliofemoral DVT[79] and long-term results have demonstrated patency rates over 80% with competent valves.[80] Postthrombotic morbidity correlates with residual thrombus.[81] In addition, the use of venous stents for iliac venous obstruction has been shown to decrease the incidence of

PTS and CVI.[82] To more fully elucidate the role of aggressive therapy in proximal iliofemoral venous thrombosis, a study is in progress, supported by the National Institutes of Health, to compare catheter-directed pharmacomechanical thrombolysis to standard anticoagulation for significant iliofemoral venous thrombosis, with both arms also undergoing ambulation and stocking use. This study, the Attract Trial, will evaluate anatomic, physiologic, and QOL endpoints in addition to vascular laboratory endpoints and a careful evaluation of complications.

Thrombolytic therapy for PE remains controversial. Although agents lyse thrombus effectively, recurrence rates and patient mortality rate were not reduced. However, the original studies were not powered to address this outcome. Results are best if patients are young, the embolus is less than 48 hours old, and the embolus is large. Streptokinase, urokinase, and tissue plasminogen activator have all been used.[83] All agents rapidly dissolve clot, but by 7 days, the advantages for all three agents decrease. The benefit of thrombolytic agents for PE thus appears to be greatest in patients who would die as a result of massive PE in the first hour after the PE occurs, which can occur in up to 10% of cases. However, more recent data suggest that thrombolysis may be useful in patients with right ventricular dysfunction without hemodynamic instability and it has been suggested that thrombolysis will improve outcomes if patients have evidence of right-sided heart changes.[84–89] In addition, thrombolysis therapy has been recommended in patients without hypertension who are judged to have a low risk of bleeding.[73]

Contributions to thrombolytic therapy include:

Absolute

- neurosurgery within 3 months
- active internal bleeding
- recent (<2 months) cerebrovascular accident
- intracranial disease
- recent gastrointestinal bleeding

Relative Major

- recent (<10 days) major surgery, obstetric delivery, or organ biopsy
- left-sided heart thrombus
- active peptic ulcer or gastrointestinal abnormality
- recent major trauma
- uncontrolled hypertension (systolic >180 mm Hg; diastolic >110 mm Hg)
- recent eye surgery

Relative Minor

- minor surgery or trauma
- recent cardiopulmonary resuscitation
- atrial fibrillation with mitral valve disease
- bacterial endocarditis
- hemostatic defects (i.e., renal or liver disease)

Venous Thrombectomy

Iliofemoral venous thrombectomy has been advocated to prevent impending venous gangrene. This technique results in mechanical clearing of the venous circulation and may be combined with a temporary arteriovenous fistula. Thrombectomy uses a Fogarty balloon catheter passed from the femoral vein during Valsalva maneuvers. An arteriovenous fistula is constructed so that it can be taken down by nonsurgical techniques. Complete venography in the operating room is recommended, as back-bleeding is unreliable for the assessment of complete thrombus clearance. Thrombosis recurrence rates less than 20% have been reported. The incidence of PE during the first week after thrombectomy is equivalent to the incidence with anticoagulation only. The frequency of clinical success has been reported to be between 42% and 93%.[90] The largest series of 77 legs with a follow-up period of between 5 and 13 years revealed maintenance of patency, but a steady decline in valvular competence over time.[91]

In the only comparative study of iliofemoral venous thrombosis treatment comparing thrombectomy with anticoagulation (31 patients) versus anticoagulation alone (32 patients), iliofemoral vein patency was improved (76% vs. 35%), femoropopliteal patency was improved (52% vs. 26%), and the clinical outcome was better at 6 months (40% asymptomatic vs. 7%).[91] At 10 years, the number of patients available for follow-up had decreased to 13 in the thrombectomy group and 17 in the anticoagulation-alone group. Patency remained improved in the thrombectomy group (83% vs. 41%), and absence of popliteal reflux was found in 78% of the thrombectomy-plus-anticoagulation group compared with 43% of the anticoagulation group alone.

Pulmonary Embolectomy

Surgical approaches for PE are indicated for patients with massive PE with hypotension who require large doses of vasopressors. These are often patients in whom thrombolytic agents have been unsuccessful. Open pulmonary embolectomy is associated with high rates of morbidity and mortality. Today, open pulmonary embolectomy is limited to those who require manual cardiac massage for hypotension or those in whom catheter pulmonary embolectomy fails. However, there may be a more expanded role for pulmonary embolectomy in the future.[92]

Superficial Thrombophlebitis

SVT is a well-recognized clinical entity, characterized by a painful erythematous and palpable cord-liked structure, usually compromising the lower extremities but capable of affecting any superficial vein in the body. Thrombophlebitis is believed to have a multifactorial etiology, in which Virchow triad of altered blood flow, changes in the vessel wall, and abnormal coagulation are recognized to play a significant role. SVT has been considered a benign disease requiring only conservative management with compression, nonsteroidal anti-inflammatory medications, and lower extremity elevation. Recently SVT, especially above the knee superficial thrombophlebitis, has been reported to coexist with DVT, to propagate to popliteal or femoral level and to even cause PE.[93–97] A medical approach using anticoagulant therapy appears as the treatment of choice when there is above-knee SVT with deep venous system involvement.

The incidence of SVT occurs in approximately 125,000 people in the United States per year.[98] However, the actual incidence is likely far greater as these statistics may be outdated and many cases go unreported. Approximately 54% to 65% of the reported cases affect females with an average age of 58 years.[93,99] The most frequent predisposing risk factor for SVT is varicose veins, occurring in 62% of patients. Other risk factors include immobilization, trauma, postoperative states, age >60 years, obesity, tobacco use, history of DVT or SVT, pregnancy, puerperium, autoimmune disease, use of oral contraceptives or hormonal replacement therapy, and hypercoagulable state.[93,99,100] Hypercoagulable screening should be considered in patients with ascending or worsening thrombophlebitis despite initial treatment.[101,102] Malignancy has been reported as a risk factor for developing SVT, affecting 13% to 18% of patients.[96,103]

The overall recurrence of SVT was described as 18% over 15 months, equally frequent in varicose and nonvaricose phlebitis. Deep venous reflux increases the recurrence rate to 33%, while hypercoagulable states increase the recurrence rate to 42% over the same period of time.[104]

The clinical symptoms and signs for SVT are overt. Duplex ultrasound imaging of the affected extremity should be performed to rule out extension of the process into the deep venous system or concomitant DVT.[101,105] Duplex ultrasound shows the extent of the SVT, its relation to the veins connecting with the deep vein system, and the presence of concomitant DVT. In addition, duplex ultrasound allows checking the competence of the valves in the superficial and deep veins.[105]

Complete thrombophilia workup is not routinely recommended. However, it may be indicated in selected patients with recurrent primary thrombophlebitis or aggressive thrombophlebitis.[105] Screening for underlying diseases, including malignancy or vasculitis, is performed if signs or symptoms suggest the presence of such a problem.[105]

Treatment

Several therapeutic approaches have been proposed for patients with SVT. These include ligation or vein stripping of the affected vein, elastic stockings, NSAIDs to reduce pain and inflammation, and variable doses of unfractionated heparin or LMWH followed by oral anticoagulant therapy. There is no consensus on the optimal treatment of SVT in clinical practice.

The course of treatment for SVT should be tailored accordingly to its location and concomitant DVT if there is any associated infectious process. Thrombus location in trunks of either the great or small saphenous vein (SSV) may have the highest risk of extension into the deep vein system and thus require more aggressive treatment than other locations. The treatment for primary SVT localized in the distal great saphenous vein (GSV) and tributaries veins consists of ambulation, warm soaks, compression, and NSAID agents.[106,107] If the patient presents risk factors for DVT, pharmacologic prophylaxis should be considered seriously.[105]

Titon et al. were among the first to compare different approaches on the medical treatment of SVT.[108] In a multicenter study, 117 patients were randomized into 3 groups: fixed dose LMWH calcium nadroparin ($n = 38$), adjusted-dose LMWH calcium nadroparin ($n = 39$), and the NSAID naproxen ($n = 40$) for 6 days. At day 7, heat and redness were significantly less ($P < .001$) in both groups treated with LMWH compared with those given the NSAID. In addition, at 8 weeks, persistence of symptoms and signs was less frequent in the LMWH-treated groups ($P = 0.007$). Efficacy did not differ between the fixed and weight-adjusted doses of LMWH.

The management of SVT was further addressed in a randomized, double-blind study describing 427 patients with documented acute symptomatic SVT of the legs.[109] Patients were randomly assigned to receive 40 mg of enoxaparin sodium subcutaneously; 1.5 mg/kg of enoxaparin sodium subcutaneously; oral tenoxicam 20 mg; or placebo, all once daily for 8 to 12 days. LMWH was associated with a lower incidence of SVT extension and/or recurrence, compared with placebo (OR, 0.32; 95% confidence interval [CI], 0.16 to 0.65, and OR 0.33; 95% CI, 0.16 to 0.68, respectively), without major bleeding or HIT. There was no statistical difference with respect to 12-day outcomes between the active treatment groups. However, there was a trend in favor of the LMWH.

The Vesalio Investigator Group compared two regimens of LMWH with each other.[110] A total of 164 patients were enrolled and randomized into 2 groups: prophylaxis group ($n = 81$) and treatment group ($n = 83$). After completion of 3 months, the cumulative rate of SVT progression and VTE complications did not differ between the prophylactic (8.6%; 95% CI, 3.5 to 17.0) and therapeutic (7.2%; 95% CI, 2.8 to 15.1) groups. No patient in either group developed major bleeding, while one patient in each group developed a clinically asymptomatic HIT. Clinical symptoms improved to a similar extent in both groups, and similar rates of minor extension or recurrent thrombophlebitis were observed during the follow-up period.

Prophylactic dose intravenous (IV) UFH was used as a comparator treatment in two studies.[111] Relative to elastic stocking alone, prophylactic IV UFH plus elastic stockings

was associated with an 86% reduction in SVT extension and/or recurrence (OR 0.14; 95% CI, 0.03 to 0.67). Marchiori et al.[112] compared high-dose versus low-dose IV UFH. A nonsignificant 86% reduction in VTE (OR 0.14; 95% CI 0.02 to 1.23) and a 37% (OR 0.63; 95% CI, 0.21 to 1.88) lower rate of SVT extension and/or recurrence were observed in those patients treated with high-dose UFH. There were no episodes of major bleeding and HIT.

LMWH was compared with saphenofemoral disconnection for the treatment of proximal GSV thrombophlebitis in a prospective, randomized clinical study.[113] In this study, 84 consecutive patients diagnosed as presenting SVT alone were divided into 2 groups treated with saphenofemoral disconnection under local anesthesia with a short hospital stay ($n = 45$) or enoxaparin on an outpatient basis for 4 weeks ($n = 39$). In all, 30 patients per group completed the study requirements. In the surgical group, 2 patients (6.7%) presented complications of the surgical wound, 1 (3.3%) had SVT recurrence, and 2 (6.7%) had nonfatal PE. In the enoxaparin group, there was no progression of the thrombosis to the deep venous system or PE, there were 2 cases (6.7%) of minor bleeding and 3 (10%) recurrences of SVT. Even when the study found no statistically significant difference between the 2 groups in the treatment of SVT, the LMWH group demonstrated a significant socioeconomic advantage and confirmed the efficacy of LMWH treatment in resolving symptoms and signs and preventing DVT and PE.

Prophylactic-dose LMWH has the advantage over other equally efficacious techniques in resolving symptoms and signs and preventing DVT and PE in cases without concomitant DVT. Patients treated with LMWH do not require hospitalization, present less adverse effects, do not require laboratory monitoring in most situations, and have a low risk of bleeding, and treatment is less expensive if hospitalization is not required. It is generally felt that medical management with anticoagulants versus surgical treatment is somewhat superior for minimizing complications and preventing subsequent DVT and PE development. On the contrary, surgical treatment with ligation at the SFJ combined with stripping (with or without perforator interruption) appears to minimize superficial venous thrombus extension, which ultimately provides improved pain relief.[114]

Septic thrombophlebitis requires treatment with broad-spectrum IV antibiotics. If rapid resolution of the cellulitis occurs, no treatment beyond a short course of antibiotics and standard treatment for the superficial thrombophlebitis are required. However, if the patient becomes septic, excision of the infected vein is required. With positive blood cultures, an extended course of antibiotics specific for the identified organism is indicated additionally.

The majority of episodes of uncomplicated superficial thrombophlebitis respond to conservative management. However, the recurrence rate for superficial thrombophlebitis has been estimated between 15% and 20%.[115–117] Finally, in the CALISTO study, fondaparinux was found effective in limiting a series of endpoints including death, PE, DVT, and extension or recurrence at days 47 and 77 after SVT diagnosis. This was in patients with axial vein SVT of at least 5-cm length with the thrombus at least 3 cm from the SFJ. Less extensive SVT requires only symptom control with oral or topical NSAIDs.[14]

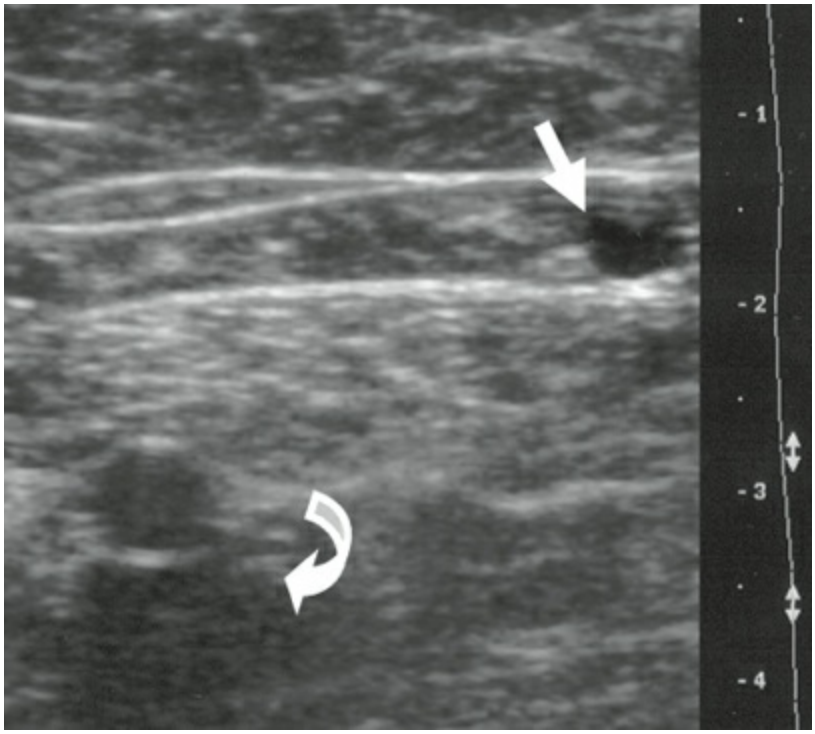

Figure 98-1. Duplex image demonstrating the superficial compartment, which contains the saphenous compartment with great saphenous vein (GSV) (*straight arrow*) lying within and the deep compartment with femoral vessels (*curved arrow*) lying within.

CHRONIC VENOUS DISEASE

Normal Venous Anatomy

The lower extremity venous system is composed of deep, perforating, and superficial veins (Fig. 98-1).[118] The common femoral, femoral, deep (profunda) femoral veins in addition to the popliteal and tibial/peroneal veins make up the deep system. The once named "superficial" femoral vein has been changed to simply "femoral vein" to prevent the confusion the term "superficial" implied when treatment of an actual DVT is required. The deep veins lie beneath the investing fascia of the muscles of the leg and thigh (the deep compartment). The saphenous veins have similarly undergone a change in name to the GSV and SSV to standardize the abbreviations that were otherwise extremely confusing. It has also become clear that the GSV and SSV lie within the subcutaneous tissue and surrounded by a separate saphenous compartment. The saphenous nerve lies within the GSV compartment below the knee, which places the nerve at risk of injury during surgery or percutaneous intervention, but if the associated sensory loss occurs, it appears to have little impact on the patient's QOL in the long term.[119] The sural nerve lies in close proximity to the SSV and within its compartment. The superficial veins that lie outside the saphenous compartment, but parallel to the GSV or SSV, are called accessory saphenous veins. The term *communicating vein* is now reserved for those veins that interconnect with other veins of the same system, and the term *perforating vein* is reserved for those that penetrate the muscular fascia to connect superficial to deep.[118] In the past, perforating veins with rather constant anatomic location have been named after their discoverer (e.g., Crockett's, Boyd's perforators), but more descriptive terms designating location are now preferred.[118] An excellent international consensus committee description of the standardized venous anatomy nomenclature of the leg and pelvic can be found in an article by Caggiati and colleagues.[120]

The variability of the lower extremity venous system is well known, but only certain anatomic variations are of importance for current surgical practice. The popliteal and femoral veins have variable anatomy and are often duplicated much like the tibial veins. The deep femoral vein often connects directly or through tributaries to the popliteal vein. Although duplication of the GSV has been estimated to be present in up to 50% of patients in some studies, it is becoming evident that duplication of the true GSV lying within the saphenous compartment is much less common.[121,122] The SFJ often has at least four branches in addition to the GSV, but the arrangement and precise location of the branches are quite variable. The most cephalic branch is generally the superficial epigastric vein and is of some importance in new techniques for managing GSV reflux since the vein acts as a landmark for percutaneous interventions and there is a desire to have it remain patent following the procedure. The SSV is rarely duplicated (4%).[123] Although the SSV appears to pierce the deep fascia in the upper third of the calf, in reality the membranous layer forming the roof of the SSV compartment is thickened while the muscular fascia disappears, which positions the SSV between the gastrocnemius muscle bellies.[123] In only 62% of limbs does the SSV actually end in the popliteal fossa and can

well end above the crease of the knee.[123] The anatomy of the perforating veins becomes extremely important when considering surgery aimed at preventing reflux into the lower leg. Certainly, removing the GSV will not prevent the impact of perforator reflux if one ignores the fact that the posterior tibial perforators (Cockett perforators of old) connect the posterior accessory GSV with the posterior tibial veins rather than the GSV proper. Similarly, not recognizing that paratibial perforators exist can result in an unsuccessful intervention aimed at preventing calf perforator reflux.[124]

With the exception of foot veins, the valves promote blood flow from superficial to deep and from caudal to cephalad in direction. The valves are made of a fine connective tissue skeleton covered by endothelium and are generally bicuspid, delicate, and extremely strong. The tibial and peroneal veins contain about 7 to 19 valves each. The popliteal vein contains one or two valves and the femoral vein has generally three. About 70% of common femoral veins have a valve located within 1 cm of the inguinal ligament. Twenty-five percent of external iliac and 10% of the internal iliac veins have a valve.[125] The common iliac vein generally has no valves. The GSV usually has more than six valves (range, 4 to 25) with at least one valve within a few centimeters of the SFJ and the SSV has an average of 7 to 10 valves range, 4 to 13.[126] Perforating veins and even larger venules have venous valves.[125]

Variable numbers of venous lakes (1 to 18 sinuses) are found in the soleus muscle. These sinuses are valveless, floppy channels linked to small-valved venous channels that prevent reflux to the superficial system. The sinuses empty into the posterior tibial vein in the proximal calf. Within the gastrocnemius muscle, there are interlacing valved venous networks that coalesce to form a pair of venous channels that empty into the popliteal vein. These intramuscular venous chambers store venous blood and are crucial to calf muscle pump function.

The veins of the abdomen and pelvis begin at the inguinal ligament as the external iliac vein that is joined medially by the internal iliac to form the common iliac vein. The internal iliac vein drains the pelvis via connections such as the obturator, gluteal, and internal pudendal veins and their interconnections. To the right of the fifth lumbar vertebrae and aorta, the common iliac veins join to form the IVC. Compression of the left iliac vein by the right common iliac artery can lead to a venous obstructive condition called May-Thurner syndrome. The IVC typically ascends to the right of the aorta and vertebral column terminating in the right atrium. Its direct tributaries are the lumbar veins, the right gonadal vein, the renal veins, the right suprarenal vein, the right inferior phrenic vein, and the hepatic veins. Other named veins generally join one of these tributaries to empty into the IVC. Because of the embryonic evolutions that lead to the "normal" IVC and its branches, variations are common. Duplication of the IVC occurs in 0.2% to 0.3% of cases, transposition or a left-sided IVC can occur in 0.2% to 0.5% of cases, and a retroaortic left renal (1.2% to 2.4%), and circumaortic left renal vein (1.5% to 8.7%) have also been reported.[127] In the face of IVC occlusion, veins of the chest and abdominal wall, the azygos and hemiazygos systems, and vertebral plexuses may play a prominent role in venous drainage of the lower extremities and abdominal/retroperitoneal cavity.

Normal Venous Physiology

Under conditions of low volume or external pressure, many veins lying within muscle are demonstrated by duplex scanning to collapse in an elliptical configuration consistent with a thin vein wall and the lack of in situ external support.[128] With muscular relaxation, veins within these compartments change from an elliptical to a circular configuration to accept venous blood being emptied from the superficial system and delivered to the lower extremity by arterial inflow. Compliance is very high; in fact, increasing the venous volume (VV) by over two and one half times results in only a 0- to 15-mm Hg increment rise in pressure.[129] This allows a significant amount of blood (at least 500 mL in the standing position) to become sequestered in the lower limb without a significant buildup of intraluminal pressure. However, once a vein reaches its full circular shape, further increases in VV result in a proportional increase in intraluminal pressure. The capacitance of the venous system has been met and sustained venous hypertension results in decompensation noted as edema. Normally, modest exercise of the muscles will expel the contained blood volume present in the veins and reset the capacitance of the venous system.

In contrast to intramuscular veins, duplex scanning demonstrates that large axial veins (e.g., femoral, popliteal) collapse in a circular manner. Supported/tethered on all sides by connective tissue, these veins are subject to equal external pressures along the vein wall and expand or collapse in a direct response to changes in volume.[130] Their compliance mimics that of an artery in that pressure changes are more reflective of volume changes. They are conduit rather than compliance vessels.

The calf muscle and possibly the thigh muscles act as a pump, the “peripheral heart,” which can generate pressures of up to 300 mm Hg during exercise.[125] Muscle contraction propels the blood toward the heart and lungs via the cephalad conduit veins. The valves in the proximal superficial and deep veins open to allow blood to move forward in response to an increased distal pressure gradient. The perforating vein valves close to prevent venous blood reflux from deep to superficial veins, thereby preventing high pressures generated in the deep system from affecting superficial structures (i.e., skin, soft tissues). In addition, blood moves centrally during exercise by compression of the superficial veins between the deep fascia and skin, but the pressure generated is only 100 to 150 mm Hg.[125] As the calf muscle relaxes, the flow/pressure gradient falls and proximal vein valve closure prevents reflux (retrograde flow). Arterial blood then slowly fills the venous system; valves in the foot veins and perforating veins open to allow the deep veins to fill from the superficial system replenishing the calf muscle pump venous sinuses.

The vein valve functions in a four-phase cycle: opening, equilibrium, closing, and closed phase. During equilibrium, flow separation occurs at the valve edge, the flow splits into two streams with one of the streams directed into the valve sinus possibly aiding in a self-cleaning step (preventing stasis). When maximally open, the two cusps create about a 35% narrowing of the outflow lumen, which may aid in outflow.[131] Interestingly, the majority of the cycle has the valve in the open position. Valve closure normally occurs

within 0.5 to 1.0 second in response to retrograde blood flow and the loss of a pressure/flow gradient.[132,133] Closure time is somewhat dependent on the stimulus to closure and a flow velocity of at least 30 cm/second is required.[134]

An IV catheter placed into a foot vein can measure changes in venous pressure over time and with movement. These measurements reflect normal venous hemodynamics in the distal superficial venous system.[125] When lying flat, a person's normal lower extremity IV pressure is about 15 mm Hg, but with standing the pressure rises to reflect the hydrostatic pressure of a column of blood from the heart to the foot catheter most reflective of the patient's height (generally ±90 mm Hg). A hemodynamic study of venous function involves pressure measurements obtained during controlled exercise. The venous filling time is the time required to arrive at a steady-state pressure after standing. Ten steps (1/second) causes a drop in pressure, and the lowest pressure, called the ambulatory venous pressure (AVP), is generally less than 45 mm Hg. The venous refilling time is the time required, following exercise and standing at rest, to reach the baseline erect pressure. It is normally greater than 20 seconds. This rather simplistic measurement reflects a complex interaction of the venous conduits, the property of the veins, and the action of the peripheral pump.[135] If one measures the venous pressure in deeper veins and in more central locations, the measurements would be considerably different, but such measurements are not commonly obtained in clinical practice.

Prevalence and Impact

3 Chronic venous disease (CVD) is a common, costly malady in Western countries. If one considers the entire spectrum of the disease, it affects more than 30 million Americans (more than half women).[136,137] Varicose veins are observed in 15% to 25% of the adult population.[138,139] *Chronic venous insufficiency* is defined as venous pathology that results in advanced clinical symptoms (edema to venous ulceration). Skin changes suggestive of venous disease are noted in 6 to 7 million US citizens, and venous ulcers occur in up to 2% of those with CVI (approximately 500,000 patients).[136,140] Population studies confirm these earlier clinical observations.[141] A population-based study that included Duplex imaging and utilized a modified CEAP classification (see later) demonstrated that in San Diego, 5.8% of those studied presented with edema while 6.2% had skin changes and/or prior or active venous ulcers.[139] The annual cost to treat venous ulcers alone is estimated at $1 billion.[142,143] It is interesting that similar findings are noted throughout Europe.[144–150] Relevant risk factors for varicose veins are advanced age, a positive family history, female gender, multiparity, and obesity when based on epidemiologic studies,[136,139,144,145,147,148,151] while the risk factors for CVI are advanced age, positive family history, and obesity.[139,144,148,149]

Pathophysiology and Etiology

Three pathophysiologic states exist: obstruction, valvular insufficiency, and calf muscle pump malfunction. These conditions reflect a failure of one or more of the components of the normal venous system and are not mutually exclusive.

Venous obstruction causes an increased resistance to blood exiting the lower extremity. There are current data to suggest that venous occlusive disease in combination with venous insufficiency is found in 55% of patients with CVI, especially those with the most severe symptoms.[152] Clearly in the past, there existed an underestimation of the importance and prevalence of occlusive disease in the pathophysiology of CVI.[152–154] The hemodynamic result is elevated IV pressure noted clinically as pain especially after exercise.[152] If the deep system is primarily involved, the increased pressure generated with each calf compression may impact the perforating veins resulting in valvular malfunction and lead to venous hypertension in the superficial system and its capillary network. Asymptomatic primary iliac venous compression is quite common with intraluminal (27 ± 5%) and varying degrees of external compression (66% to 88%) observed in the general population.[155–160] Left common iliac vein compression by the right common iliac artery, as well as external iliac vein compression from the internal iliac artery on either side, and variations thereof have been described.[159,161] It has been suggested that the nonthrombotic iliac stenosis is a "permissive lesion" not clinically significant until other components of the lower extremity venous circulation fail.[162] The good results of iliac vein stenting in patients with CVI, even in the presence of untreated reflux, demonstrate the impact that eliminating proximal obstruction has on improving overall venous hemodynamics. In one of the largest experiences treating ileofemoral venous occlusive disease involving nearly 1,000 patients, compression of the common iliac vein was seen in 36%, external iliac vein in 18%, and both sites in 46% of limbs.[162] Of these patients, 53% of limbs had nonthrombotic compressive lesions (absent history of DVT, no venographic or ultrasound findings indicating previous DVT); 40% had postthrombotic obstruction; and 7% had a combined etiology. Furthermore, 20% of the patients were men and 25% of the symptomatic lower limbs were on the right side. Intraluminal webs from repetitive trauma have been reported in 14% to 30% of symptomatic cases of May–Thurner syndrome.[161] Extrinsic compression of the iliac and pelvic veins may also be caused by tumor, fibrosis, or infection. Contents of a femoral hernia can crush the femoral vein, as can soft tissue tumors of the thigh. Arterial aneurysms can impinge on the femoral vein. The popliteal vein can be obstructed by a popliteal aneurysm or Baker cyst.[125] Aplasia of the vein or tumors of the vein wall have been described.[125,163] DVT is associated with inflammation and thrombus resolution resulting in external vein wall scarring with stiffening and thickening, as well as intraluminal recannulation with webs and bands. The venous valves are generally incorporated in the scarring process leading to even more occlusive debri within the lumen. It is a common cause of venous occlusive disease due to its rather high prevalence and can involve any part of the venous system.

Valvular insufficiency occurs throughout the lower extremity venous systems. It has

been estimated to account for 85% of symptomatic CVD cases with a 70% incidence of primarily superficial and 30% primarily deep venous insufficiency, but these observations were likely influenced by the lack of recognizing associated occlusive disease as a contributing or sole factor in the symptoms noted.[153,154] Duplex imaging studies suggest that patients with minimal symptoms tend to have isolated superficial reflux while those with edema, skin changes, and past or present ulcers have an increasing presence of perforator and deep disease. In those with more advanced venous disease, reflux alone is observed in 80%, reflux and obstruction in 17%, and only 29% had obstructive disease alone.[164,165] The presence of obstructive and reflux disease had the worse prognosis for the development of skin changes.[166] No matter the clinical stage, the superficial system is most commonly affected (90%) with GSV involvement in 70% to 80%, SSV in 15% to 20%, and nonsaphenous veins in approximately 10%. The deep veins are involved in about 30% and perforator veins in about 20%.[164,165] Those with the most severe sequelae of venous disease have superficial reflux in 74% to 93% with 17% to 54% having only superficial disease.[167–171] In such patients, 50% were noted to have superficial ± perforator disease and less than 10% had isolated deep venous reflux.[170–173] In those patients with venous ulcers, two vein systems were involved in 50% to 70% of patients, and all three systems were involved in 16% to 50% of patients. Since these duplex imaging studies mainly involve imaging of the lower extremity veins, the influence of proximal venous occlusive disease may well be underestimated. Reflux allows the transmission of high venous pressures to the lower leg when standing that cannot be relieved by exercise. Primary valvular insufficiency is rarely a consequence of congenital absence of valves.[174] There are predisposing genetic factors that can lead to primary disease including Klippel–Trenaunay syndrome, FOXC2 gene mutation, desmulin dysregulation, the Ehlers-Danlos syndrome, and a CADASIL gene mutation, to name a few, but these do not reflect the typical patient.[175,176] The muscle cell dilating effect of estrogens may explain the genesis of varicose veins noted in the first trimester of pregnancy. Prolonged exposure to high venous pressures can cause vein dilation as occurs from an arteriovenous fistula or occupations requiring prolonged periods of standing. For our standard patient, venous valve prolapse (elongated, floppy valves) and defects in the vein wall that cause the valve ring to dilate results in malfunctioning valve cusps with retained valve architecture.[177,178] Whether the vein wall changes precede valve insufficiency or the valve insufficiency causes wall distension and wall changes is less clear.[46,175] There are some data to suggest that sustained local venous hypertension might affect the local venous microcirculation. Roughly 50% of deep vein valvular dysfunction occurs secondary to DVT whereas the remainder appears to be of a primary etiology with a 10% to 20% variance, depending on the clinical experience being reported.[153,179–181] Inflammation and thrombosis associated with DVT tend to cause valve scarring, whether or not recanalization is complete, leaving a damaged valve architecture in contradistinction to primary valvular insufficiency. This classic differentiation between “primary” pathology and “secondary” (or postthrombotic) pathology does not clearly exist when subjected to direct observation of the veins and valves at surgery. In fact, the two conditions can be present in the same patient as noted some 20 years ago.[182] In these

cases, the vein wall is thickened and/or fibrotic at the valve station or there is thickening of the valve cusps and/or intima. Pathologic study of 11 such veins demonstrated clear postthrombotic changes in 6, but phlebosclerosis of a nonthrombotic origin in the remaining 5.[183] Clearly, preservation of a normal valve architecture can be explained if primary reflux and sustained high pressure on the wall are the cause of the changes noted. Another theory is that rapid resolution of acute thrombi, an event known to occur, may have allowed these valves to escape damage or the valve itself may not have been directly involved in the thrombotic process.[184] The fibrotic process involves only the vein wall and the valve cusps become floppy by virtue of a decrease in wall diameter resulting from a thickened, noncompliant vein wall.[183] The valve remains architecturally intact and can be repaired surgically.

There can be failure of calf muscle pump function. The pump becomes unable to generate the force needed to eject blood from the leg while standing, resulted in sustained venous hypertension. Patients with muscle disuse (e.g., paraplegia, traumatic injury, elderly or bedridden patients) may not have sufficient muscle for effective exercise. Pathologic conditions that result in muscle fibrosis (e.g., muscular dystrophy, multiple sclerosis) can destroy the calf muscle pump. Thrombus and scarring in the gastrocnemius and soleal veins can prevent blood from entering the pump resulting in a deficient volume for ejection with contraction. Calf pump function and ankle range of motion are progressively diminished with increasing severity of CVI.[185–188] Physical conditioning improved both pump function and muscle strength in a small, RCT, demonstrating the influence the pump can have on the lower extremity.[189] With the exception of muscle rehabilitation, very little can be offered to patients with some of these disorders.

Regardless of the etiology, the sequelae of venous hypertension/stasis are changes observed in the lower leg skin and subcutaneous tissues, the end organ. Originally, ischemia from various causes was considered the etiology of the damage noted in the lower leg.[190] More recent observations suggest that far from being simply an ischemic event, the end-organ response to venous hypertension is highly dynamic. The final answer is likely to involve a complex interaction of multiple factors that favor either continued destruction or the ultimate healing of the ulcer. Leukocytes, the extracellular matrix, fibroblasts, and a host of other factors are recruited to heal the early endothelial injury and the more delayed soft tissue injury.[190] In fact, current belief holds that the fundamental basis for CVD and ulceration is inflammation within the venous microcirculation when subjected to increased hydrostatic pressure.[191] The soft tissue injury may result in a chronic ulcer that requires growth factors to force the process to healing.[192] Research remains active in this component of venous pathophysiology. An excellent review is available for further information on the current understanding of basis venous pathophysiology.[193]

Clinical Signs and Symptoms

Venous disease presents in many ways. A telangiectasia, spider vein, is a confluence of dilated intradermal venules less than 1 mm in caliber. A reticular vein is a dilated bluish subdermal vein, usually 1 mm to less than 3 mm in diameter and usually tortuous. These venous abnormalities may or may not be accompanied by a larger, more deeply located, pathologic vein.

Hereditary varicose veins usually appear during the second decade of life. If the varicosities are due to a secondary etiology (e.g., thrombosis, trauma), they often present several years after the inciting event. These veins appear alone or in clusters as dilated, often bluish, serpentine, and palpable protrusions of branches of the GSV, SSV, or collateral veins lying beneath the skin within the subcutaneous tissues. Varicose veins generally measure 3 or more millimeters in diameter when measured in the upright position.[194] One finding thought to be an early sign of advanced disease is corona phlebectatica that is a fan-shaped pattern of small intradermal veins located around the ankle or doral foot (also called ankle flare or malleolar flare).[126,194] If the varicose veins observed are the result of proximal disease, such as pelvic reflux or obstruction; the location of the varicosities may be scrotal, perineal, vulvar or posterior/lateral in the lower extremity.[126]

Symptoms may be those associated with any type of CVD and are described as pain, edema, hyperpigmentation, stasis dermatitis or eczema, and/or venous ulcers. These changes often occur in the "gaiter" area just above the medial malleolus. Important perforating veins lay in this area. The observed hyperpigmentation is thought to result from extruded red blood cells that are degraded by macrophages leaving hemosiderin deposits. Less definable but described symptoms of CVD include tingling, burning, muscle cramping, a sensation of throbbing or heaviness, itching, restless or tiredness of the legs, and fatigue.[195] They are more specific indicators of venous disease if made worse with standing and heat and if relieved by rest and leg elevation.

Venous claudication is a pain syndrome experienced when walking and is associated with cyanosis, a sensation of increased swelling, and increased prominence of the superficial veins, which is relieved with rest in combination with elevation of the extremity.[152,196,197] It may be so severe in rare cases that amputation is requested.[198] The most severe form is observed when venous incompetence is associated with obstruction and when the obstructive process is in a more proximal locale.[199]

4 Critical to patient management and treatment evaluation is an accurate classification of the disease at any given time. Each patient should be stratified according to the *c*linical picture, the *e*tiology, the *a*natomic distribution, and the *p*athophysiology (CEAP) classification system (Table 98-2).[200] This classification system helps the physician define the venous disease so that a focused and appropriate management strategy can be formulated. An extension of the clinical classification system, the Venous Clinical Severity Score, is available to quantify the extent of venous disease and, therefore, to evaluate the patient's clinical response to treatment (Table 98-3).[201–203] The anatomic and pathophysiologic improvement following a treatment of venous disease can be scored

using the Venous Segmental Disease Score.[202] While the Venous Disability Score provides some information of what a person can do while afflicted with venous disease.[202] QOL surveys have been developed specifically for patients with venous disease to help determine the impact of the disease on the patient's life and the effect therapy has on the patient's overall well-being.[126,193,204–208] Consistent application of these surveys to the pre- and postsurgical outcome of patients has yet to be achieved but is imperative to improve our ability to precisely determine the effect and benefit of a given intervention.

Table 98-2 Clinical Classification of Chronic Venous Disease

Class	Description
0	No visible or palpable signs of venous disease
1	Telangiectasias and/or reticular veins
2	Varicose veins
3	Edema
4a	Skin changes (pigmentation and/or eczema)
4b	Skin changes (lipodermatosclerosis and/or atrophie blanche)
5	Healed venous ulcer
6	Active venous ulcer
S (in addition to the class)	Symptoms including ache, pain, tightness, skin irritation, heaviness, muscle cramps as well as other complaints attributable to venous dysfunction
A (in addition to the class)	Asymptomatic

Diagnostic Evaluation

The diagnosis of CVD begins with a thorough history and physical examination. The history is quite important to provide hints to familial coagulation disorders or events in the patient's history that may impact the care of this chronic disorder. Prior DVT, pregnancies, a family history of varicosities, obesity, or the presence of other factors associated with CDV will add support to the presence of venous disease. When performing physical examination, the location, distribution and size of varicosities, skin changes, and/or presence or indication of past ulcers should be noted. Swelling should be quantified, the location specified, and a determination made whether it is pitting or nonpitting in nature. Inspection, palpation, and auscultation (presence of a bruit) may be keys to the presence of a vascular malformation or arteriovenous fistula. Utilization of the CEAP clinical classification (Table 98-2) will provide a snapshot of the patient being examined, whereas the use of the more detailed Venous Clinical Severity Score (Table 98-3) will allow some impression of how any therapy is performing as the patient is being treated.

In addition to determining and classifying the signs and symptoms of venous disease, the history and physical examination should exclude other potential etiologies for the patient's complaints such as arterial occlusive disease, collagen vascular disorders, allergic reactions, infection, or malignancy. Appropriate confirmatory diagnostic studies may be required to confirm the clinical suspicion, such as a lower extremity arterial Doppler study, biopsy, or specific laboratory studies when the diagnosis is unclear. Such studies become most pertinent during the evaluation of advanced venous disease, especially venous ulcers.[193] Only in select patients, such as those with recurrent, early, or unusual sites of DVT or recurrent venous ulcers, evaluation for thrombophilia is recommended.[126,193]

Venous duplex ultrasonography provides a B-mode picture of the vein, as well as spectral analysis of the blood flow within, and is recommended as the first diagnostic test for all patients with suspected CVD.[209] To provide an accurate impression of the venous disease present, a standard technique is followed and has been outlined in a current review article.[126] Venous duplex imaging clearly visualizes deep, superficial, and perforator veins and often the valves that lie within the veins. The venous duplex study can help to clarify the etiology (E of CEAP; congenital, primary, or secondary), better define the anatomic location (A of CEAP; specific veins can be imaged with spectral analysis to determine reflux), and aid in determining the pathophysiology (P of CEAP; reflux, obstruction, or both) of the venous problem. Once considered unnecessary in the evaluation of patients with simple varicose veins, it has become common practice prior to intervention for superficial reflux due to anatomic variability and the need for precise targeting of veins during endoluminal intervention.[121,210–212]

Table 98-3 Venous Clinical Severity Score

Attribute	Absent 0	Mild 1	Moderate 2	Severe 3
Pain	None	Occasional, not restricting activity or requiring analgesics	Daily, moderate activity limitation, occasional analgesics	Daily, severe limiting activities, regular use of analgesics
Varicose veins[a]	None	Few, scattered: branch VVs with competent GS/SS	Multiple: single-segment GS/SS reflux	Extensive: multisegment GS/SS reflux
Venous edema[b]	None	Evening ankle edema only	Afternoon edema, above ankle	Morning edema above ankle and requiring activity change, elevation
Skin pigmentation[c]	None or focal, low intensity (tan)	Diffuse, but limited in area and old (brown)	Diffuse over gaiter distribution (lower 1/3) or recent pigmentation (purple)	Wider distribution (above lower 1/3) and recent pigmentation
Inflammation	None	Mild cellulitis, limited to marginal area around ulcer	Moderate cellulitis, involves most of gaiter area	Severe cellulitis (lower 1/3 and above) or venous eczema
Induration	None	Focal, circummalleolar (<5 cm)	Medial or lateral, less than lower third	Entire lower third of leg or more
No. of active ulcers	0	1	2–4	>4
Active ulceration, duration	None	<3 mo	>3 mo and <1 y	Not healed >1 yr
Active ulcer, size[d]	None	<2-cm diameter	2- to 4-cm diameter	>4-cm diameter
Compressive therapy[e]	Not used or not compliant	Intermittent use of stockings	Wears elastic stockings most days	Full compliance: stockings + elevation

[a]"Varicose" veins must be >4-mm diameter to qualify so that differentiation is ensured between C1 and C2 venous pathology. Occasional or mild edema and focal pigmentation over varicose veins does not qualify for C3 or C4.
[b]Presumes venous origin by characteristics (e.g., brawny [not pitting or spongy] edema), with significant effect of standing/limb elevation and/or other clinical evidence of venous etiology (i.e., varicose veins, history of DVT). Edema must be regular finding (e.g., daily occurrence). Occasional or mild edema does not qualify.
[c]Focal pigmentation over varicose veins does not qualify.
[d]Largest dimension/diameter of largest ulcer.
[e]Sliding scale to adjust for background differences in the use of compressive therapy.
GS, Greater saphenous; SS, small saphenous; VV, varicose vein.
From Rutherford RB, Padberg FT Jr, Comerota AJ, et al. Venous severity scoring: an adjunct to venous outcome assessment. *J Vasc Surg* 2000;31:1307.

Valvular insufficiency is defined as prolonged reflux time through a valve following a provocative test when duplex imaging is the diagnostic modality. To aid in the standardization of the test, rapidly deflating distal cuff technique is used in some vascular laboratories, while others use manual compression of the distal leg after which valve reflux is determined during duplex imaging.[132,133] An abnormal reverse venous flow (reflux) in the saphenous, tibial, and deep femoral veins is 0.5 seconds or greater while the femoral and popliteal veins have a cutoff value of 1 second [213] Since perforating vein reflux can also be associated with venous pathology, significant work has gone into determining how to define abnormal reflux. Current consensus and available data suggest that a "pathologic" perforating vein is defined as a vein with an outward flow of ≥ 0.5 seconds, with a diameter of > 3.5 mm, which is located beneath a healed or open venous ulcer.[126,209,212,213] The duplex examination for reflux is performed in the upright position in these reports. Many other provocative maneuvers to generate venous reflux exist (Valsalva, standardized Valsalva, etc.) in addition to performing the test in different positions (e.g., 15% Trendelenburg, sitting) and are used in many laboratories for particular patients who have difficulty standing.[214] Each may be acceptable if standardized for an individual laboratory. Venous obstruction is seen as thickened, scarred, and constricted veins with poor flow and diminished augmentation following

distal and/or proximal compression. Respiratory variation is lost as a result of local occlusive disease or proximal occlusion. Disease within the SSV should not be ignored because it can have a significant clinical impact as an isolated finding.[215] By imaging the entire lower leg venous system, the surgeon is provided a detailed roadmap of all veins with determination of obstruction or reflux within segments separated by valves. Isolated venous valvular insufficiency or obstruction may have little clinical impact on the patient, and therefore clinicians have attempted to quantify the pathology by adding up segmental disease, determining mean duration of reflux, determining peak reverse flow velocity, and so forth.[133,198] Although average scores correlate with disease severity, individual results have little predictive value and, therefore, these methods have not been widely adapted. This is often the only diagnostic tool needed for the evaluation of superficial and even perforator disease requiring treatment as a first stage in patient management.

A difficult area of investigation from a noninvasive perspective is the pelvic, abdominal, and chest veins. CT and MRI can provide details of anatomy and the effect of surrounding structures in areas not visualized by duplex evaluation.[193,216–219] These studies can be particularly useful in evaluating for pelvic congestion syndrome.[220] However, as with all vascular laboratory studies, clinical correlation is mandatory because anatomic presence does not necessarily translate into a clinical problem. For example, iliac vein compression is commonly seen in an asymptomatic population.[155–160]

Plethysmography assesses the overall hemodynamics of the lower extremity venous system. Air plethysmography (APG) can measure several venous hemodynamic parameters. A plastic cylinder filled with air is fitted over the calf and foot and changes in leg volume with positional change or exercise are detected by pressure changes in the cylinder. The venous filling index is 90% of resting standing VV divided by the time it takes to reach 90% of VV as the patient shifts from the supine to standing position (mL/second). A venous filling index of 2 mL/second or less is indicative of competent venous system and higher values suggest venous insufficiency.[221,222] After an erect baseline reading, patients exercise by dorsiflexion or heel raises to empty the calf veins. The ejection fraction is the amount of blood propelled cephalad with a single muscle contraction divided by VV. After a series of 10 ankle flexions, the volume remaining in the leg is referred to as the residual volume and, when divided by the VV, is called the residual volume fraction. An ejection fraction of greater than 60% and residual volume fraction of less than 35% suggest that the calf pump is working well.[187,223] The residual volume fraction is relatively equivalent to the AVP.[142,224] Significant outflow obstruction is determined by occluding venous outflow until a stable plateau is reached. The thigh cuff causing the venous occlusion is rapidly deflated, and the difference between maximal volume and that volume present 1 second later divided by the total calf volume is called the outflow fraction. Normally, 38% or more of venous blood is expelled from the leg in 1 second.[222] Several other plethysmographic methods (e.g., impedance, photo) and even light reflex rheography have evaluated similar venous parameters. The accuracy of these techniques to reliably eliminate the presence of significant venous occlusive disease is poor.[225] Although these plethysmographic methods can differentiate patients with severe CVI (class 3 or greater) from those without disease, stratification by symptom severity is

not possible and, therefore, its use in the treatment of patients with minor symptoms, such as varicose veins or telangiectasias, is also questionable.[214] In current clinical practice, it is being used only in complex cases or for research purposes. Current consensus encourages the use of plethysmography in the patient with advanced CVD if duplex scanning cannot provide a definitive diagnosis often underlying pathophysiology.[126]

As in acute venous disease, venography has no significant role in the initial evaluation of patients with CVD. Ascending venography can suggest venous occlusion when duplex imaging clearly demonstrates an open system.[226] Even the presence of significant collaterals on transfemoral venography may underestimate the degree of venous occlusion as documented by intravascular ultrasound.[152,227] The use of ascending venography is selectively used in specific cases to complement noninvasive studies when considering intervention in the deep venous system or in research protocols.

The technique of descending venography has been well described.[228] Descending venography is used to determine valve leaflet integrity and anatomic location and demonstrate the extent of reflux.[228] Assessment of the competence of the profunda femoris venous system in addition to the femoral system is imperative. If it is a competent system, it may be a source for a valve transposition or may predict success with an isolated proximal femoral vein repair.[229–231] Certainly, descending venography is not infallible in determining the presence or absence of a normal valve.[183] Raju et al.[183] report that descending venography misrepresented the presence of a valve in 11% of cases (a valve considered present was not at operation) and missed an intact valve in 25% of cases (a valve thought absent was actually present). However, when combined with a careful venous duplex examination, it is currently the best method available to determine preoperatively if an in situ reconstruction will be possible.

Intravenous pressure measurements can aid in the diagnosis of venous disease but is invasive and generally used only when invasive surgery of the deep system is being considered. This study can help to determine the overall magnitude of reflux and can be correlated with the incidence of venous ulceration.[142,232] Direct lower limb IV pressure measurements before and after reactive hyperemia and when compared to arm IV pressure has not consistently determined the significance of proximal venous occlusive disease such that the authors of this technique now recommend IV ultrasonography as a more reliable diagnostic tool.[225] Although IV pressure measurements and venography were once the gold standard for evaluating venous disease, duplex scanning with the addition of intravascular ultrasonographic techniques when required is the anatomic and functional test of choice in current medical practice.

Treatment Options and Results

Medical Therapy

Compression has been the mainstay of the medical treatment for all stages of CVI for centuries. The goals are to manage clinical symptoms and to control venous hypertension. Roughly speaking, there are two types of compression: elastic (e.g., support stockings or long stretch bandages) and inelastic (e.g. Unna's paste boot, short stretch bandages, multilayer [four-layer] bandage, or Velcro band devices). A graduated compression stocking is a single-layer elastic compression often used to control edema. The term *multilayer* when dealing with compression denotes a bandage that covers the leg with more than one layer because of overlapping during placement. The term *multicomponent* is a multilayer bandage with several components, such as an Unna's boot, underlying paste layer covered by an elastic wrap. In general, the more layers the less elastic and more stiff the compression. The degree to which any particular bandaging is one or the other will depend on the care provider who applies the compression along with other factors. The mechanical effect is dependent on the level and type of compression and the desired amount of compression is influenced by the underlying venous pathology being treated. Initial narrowing of deep and superficial calf veins on standing as determined by duplex imaging is observed at 20 mm Hg with improved venous hemodynamics and improved QOL data when used to treat mild disease.[233–237] Consistent narrowing of superficial and calf veins occurs at a median of 30 to 40 mm Hg pressure on standing while complete occlusion occurs at a median pressure of 70 mm Hg. Complete occlusion is not the goal. Therapeutic calf compression improves calf muscle pump function expressed as a reduction in residual volume fraction during walking.[238] Duplex imaging has demonstrated that thigh compression was helpful in reducing great saphenous and femoral vein diameter at a constant pressure of $\geq$40 mm Hg and reduced venous reflux (by APG) at 60 mm Hg.[239] Overall, these effects on the underlying veins help to improve the venous pump and decrease the VV in the lower extremity. It is interesting that elastic stocking maintain a rather constant pressure during exercise and at rest. Alternatively, inelastic wraps demonstrate a more dramatic increase in pressure during exercise since they do not stretch but have decreasing pressure with recumbence as the edema exits the leg and the bandage maintains its shape.[240] This difference in performance helps to explain why inelastic wraps are much better tolerated when left on for days and especially at night when the constant compression is not required and may be perceived as discomfort. It also explains why compression should be changed more frequently early in treatment and less frequent latter as the degree of edema requiring control lessens.

Although there has been concern that compression may impede microcirculatory flow and thereby jeopardize tissue viability,[241] it is known that compression, when used to treat edema, has a positive influence on the local skin and soft tissues by improving capillary filtration rate, decreasing the subcutaneous pressure in the perimalleolar area, promoting extracellular fluid reabsorption, and improving sodium subcutaneous tissue clearance.[242,243,244] Compression improves skin transcutaneous oxygen tension and skin capillary density in patients with venous insufficiency.[245,246] Compression can increase

microcirculatory flow velocity and ameliorate the inflammatory injury and fibrosis associated with CVI.[240,245,247,248] Cytokines, such as vascular endothelial growth factor and tumor necrosis factor, decrease with compression therapy and correlate with ulcer healing.[249] Furthermore and in contradistinction to the first statement in this paragraph, standard compression can actually increase arterial blood flow in some circumstances.[240,250] The lymphatic system is often involved in the overall pathophysiologic state of patients afflicted with venous insufficiency and performance of this outflow system is improved with compression.[246] In patients with concomtant arterial occlusive disease with an ankle to brachial systolic blood pressure ratio (ABI) of 0.80 or greater, the use of standard compression is safe and effective and actually increases arterial perfusion in affected tissues.[251–253]

In those with more advanced arterial occlusive disease defined as an ABI ≥ 0.50 (but < 0.80) or an ankle systolic pressure ≥ 60 mm Hg or toe pressure ≥ 30 mm Hg as a minimum; modified compression dressings with lower pressure ratings not to exceed the tissue perfusion pressure can improve tissue perfusion and aid in healing ulcers of mixed etiology.[253–255] These data support the current SVS/AVF practice guideline that suggests that in a patient with a venous leg ulcer and underlying arterial disease, compression bandages or stockings **are not indicated** if ABI is 0.5 or less or if the absolute ankle pressure is less than 60 mm Hg.[193]

Evidence-based medicine confirms our clinical impression and basic science findings regarding the potential benefits of compression garments for the treatment of CVI. Substantial evidence exists to demonstrate that compression is statistically beneficial for most clinical stages of symptomatic venous disease ($C_{2–6}$). A recent large systematic review evaluating the use of compression for varicose veins (C_2) demonstrated that symptoms were improved, but the analysis could not confirm that its use decreased progression of disease or prevented recurrence after invasive treatments.[256] Whether compression stockings should be the primary treatment for symptomatic varicose veins has been challenged by the recent RCT titled the Randomized Clinical Trial, Observational Study and Assessment of Cost-Effectiveness of the Treatment of Varicose Veins (REACTIV) trial.[257] This study randomized 246 patients with class C_2 disease into conservative management including compression versus high ligation, stripping, and phlebectomy. Over the span of a 2-year follow-up, there was a statistically significant benefit from surgery in quality-adjusted life-years when analyzed by two scoring systems in addition to improvements in symptomatic and anatomic measurements. Cost-effective analysis demonstrated a benefit for the surgical intervention as well. Therefore, in contradistinction to current third-payer policies, and based on available statistical data, the SVS/AVF Guidelines Committee recommends against compression therapy being considered the primary treatment of symptomatic varicose veins in those patients who are candidates for saphenous vein ablation as a grade 1B recommendation.[126] Certainly in those not candidates or those who do not desire interventional options, the Guidelines Committee suggests compression therapy (20 to 30 mm Hg) for symptomatic benefits (grade 2C).

Compression is the standard of care for patients with advanced CVD ($C_{3–6}$) and the majority of the evidence-based data investigate the benefits of treating venous ulcers since the rate and degree of healing are measurable. The SVS/AVF commissioned a comparative systematic review and meta-analysis of compression modalities and venous ulcer healing.[258] Nine RCTs provided objective data on initial ulcer size and outcomes as measured by time to complete healing or proportion of ulcers healed. The evidence suggests that venous ulcers heal more quickly with compression therapy than without compression. Most RCTs demonstrated a benefit in healing rate with various compression methods used.[259–261] In addition, the SVS/AVF commissioned analysis of compression and venous ulcer healing demonstrated low-quality evidence to support the effect of compression on ulcer recurrence.[258] Compliance with compression is a challenge for patients with chronic disease and noncompliance is associated with recurrence while the ability to maintain compression demonstrated less recurrence in most studies.[262–264] Compression comes in many forms and is a factor in venous ulcer healing potential. The SVS/AVF commissioned analysis found moderate-quality evidence to support multicomponent compression over single component compression to treat venous ulcers.[258] The best studies evaluated a multilayer (four-layer) bandage versus a single-layer bandage and demonstrated improving overall healing rates with faster closure rates.[265,266]

However, the skill of those applying the single-layer dressing might improve these results to mimic the multilayer compression.[267] These data have led the SVS/AVF Guidelines Committee to recommend that compression be used to heal venous ulcers (grade 1A), to decrease recurrence (grade 2B), and it is suggested that multicomponent compression bandages be used to treat venous ulcers (grade 2B).[126]

One last comment on the use of compression in the treatment of venous ulcers, although surgical intervention is suggested over the use of compression alone to heal venous ulcers, post–interventional compression does help to prevent recurrence. This has been demonstrated in two RCTs and in the SVS/AVF commissioned comparative systematic review and meta-analysis of surgical interventions versus conservative therapy for venous ulcer treatment.[268–270]

In the final analysis, multilayer relatively inelastic wraps are preferred for the therapy phase of venous disease (ulcer healing). When the ulcers are healed, elastic wraps, such as compression stockings, are used to maintain a stable clinical condition (maintenance phase). In addition, elevating the legs when possible during the day, avoiding prolonged periods of standing or sitting, and elevating the foot of the bed 4 to 6 in above the heart while sleeping are adjuvant components of conservative therapy.[271,272]

Intermittent pneumatic compression (IPC) provides pulsatile emptying of the venous system via compressive bladder(s) that inflate and deflate. Some data suggest a positive impact on the inflammatory injury and associate fibrosis when IPC is used to treat CVI.[240,247] A Cochrane review suggests that there is advantage in using IPC compared to no compression, but there is little evidence to suggest that the addition of IPC to compression therapy is beneficial.[273] Certainly, one RCT of 45 patients has demonstrated its use in patients with long-standing ulcers (at least 3 months' duration) comparing

standard ambulatory compression with or without the addition of IPC. At 3 months, 10 of 21 ulcers healed with the addition of IPC, while only 1 of 24 healed with standard care.[274] One study suggests that a rapid cycle method improves ulcer healing compared with a slow cycling regimen.[275] This data is the basis for a practice guideline, suggesting that IPC be employed when compression has failed, is unavailable, or cannot be used.[276]

Lifestyle changes, including exercise, improved mobility, and foot exercises, can aid in lowering the incidence of venous ulcer recurrence as demonstrated by a recent literature review.[277] Structured exercise can improve dynamic muscle strength and calf muscle pump function in patients with essentially all levels of CVI from varicose veins to venous ulceration.[189,278,279] It is unclear whether such exercise improves ulcer healing rates per se. The use of supervised active exercise to improve muscle pump function and to reduce pain and edema in patients with leg ulcers is a guideline recommendation (grade 2B).[276] In Europe and other countries, various oral agents (e.g., diosmin, rutosides) have been touted to improve the feeling of heaviness, fatigue, and even edema of CVD but these agents are not available in the United States.[126,276] A Cochrane review selected 44 studies of such agents for meta-analysis and concluded that there was insufficient evidence to support the global use of these drugs in the treatment of CVD.[280] Drugs potentially useful in treating patients with venous ulcers are available in the United States. Pentoxifylline does provide an incremental benefit in ulcer healing and has an improved outcome with higher doses but the trade-off is more gastrointestinal adverse effects.[265,281–283] For long-terms effects and as an adjunct to compressive therapy when standing or large venous ulcers, pentoxifylline, in combination with compression therapy, is recommended (grade 1B).[276] Current practice is to prescribe 400 mg of pentoxifylline three times per day and, if tolerated, the higher dose is 800 mg three times per day. Prophylactic use of systemic antibiotics in the treatment of venous ulcers is not recommended and may only select resistant organisms. One randomized clinical trial in 47 patients compared elastic support bandages only versus those also treated with systemic antibiotics. There was no statistical difference in healing rates of ulcers or in changes of the microbiologic flora.[284] Clinically, evident disease with supportive quantitative wound cultures has demonstrated beneficial effects when systemic antibiotics are used, but the data are meager.[285] Certainly, an established infection (cellulitis or deeper) must be treated as it would be at any site and is recommended best care by the SVS/AVF Guidelines Committee. In addition, the recommendation is for oral agent use for 2 weeks unless evidence of clinical infection continues (grade 1C).[276] Limb cellulitis with or without a venous ulcer generally requires systemic gram-positive antibiotic coverage as demonstrated by several studies and is a grade 1B recommendation for patient care.[276,286]

Surgical Therapy

The use of surgical intervention in the realm of venous disease as in all areas of vascular surgery is driven by the documented presence of disease, the risk of the intervention planned, and the expected outcome (Algorithm 98-1).

Telangiectasia, Reticular Veins, and Branch Varicose Veins. Percutaneous laser

energy (a lamp that produces laser light that is shined on the blemish) can be used to treat telangiectasias up to 0.7 mm in diameter with reasonable success. For matting and telangiectasias under 0.5-mm diameter, the flashlamp pumped dye laser (595-nm wavelength) is well studied.[287] The potassium titanyl phosphate (KTP) laser of wavelength 532 nm is applicable to those 0.7 mm or less.[288] Since melanin is the prime competing light absorber to hemoglobin in the body, the increased epidermal melanin in the tanned skin risks long-lasting hyperpigmentation and, therefore, percutaneous laser therapy should not be performed in those with a sun-tan.

Sclerotherapy (needle injection of caustic solutions directly into superficial veins with or without fluoroscopic guidance) has long been advocated for treating varicosities remaining after saphenous ablation, small isolated varicosities, telangiectasias, and reticular veins.[289–291] Sclerotherapy alone appears an effective treatment for branch varicosities in patients without major saphenous reflux and appears effective when combined with GSV ablation to control branch varicosities.[292–294] The FDA-approved sclerosing agents are sodium tetradecyl sulfate, sodium morrhuate, polidocanol, and glycerine. Hypertonic saline (23.4%), although not approved for sclerotherapy in the United States, has been used for many years. Pilodocanol used extensively in Europe is now commercially available in the United States and has rapidly been adopted as the workhorse for venous sclerotherapy because of very low allergic and anaphylactic reaction rates while being essentially painless with a low risk of tissue necrosis. All act to damage the vein endothelium-inducing inflammation and scarring with ultimate lumen collapse.[289,295] Foam sclerotherapy is the addition of air or other gases, such as carbon dioxide, to liquid sclerosing agents, particularly detergent sclerosants, to allow a more protracted contact of the sclerosing agent to the vein wall. This modification adds a component to the agent that converts its use to off-label. The most popular technique uses two syringes and a three-way stopcock to allow the gas to be aspirated into one of the syringes, while the other syringe contains a detergent sclerosant, which results in a 1 part of drug to 4/5 parts of gas. Pushing the mixture from one syringe to the next 20 times results in desired bubble size.[296] This technique is favored by many phlebologists especially for the treatment of larger veins, such as the saphenous vein.[292,297] Leg elevation is often employed to decrease the risk of systemic embolization during injection. The exact concentration of sclerosant, liquid or foam, used for sclerotherapy is dependent on vein size and agent used.[289,295] These interventions are generally outpatient procedures. Burning, stinging, itching, and muscle spasm are commonly observed with sclerotherapy injections.[298–300] Extravasation of the agent can cause fat or skin necrosis, ulcerations, and/or hyperpigmentation of the surrounding skin.[298,300] Posttreatment veins are often a brown color as opposed to the blue-red pretreatment color. Microthrombectomy of clotted blood trapped in treated veins appears to reduce postsclerotherapy pigmentation especially in veins 1 mm or less in diameter.[301] Other potential complications of sclerotherapy include allergic reactions and toxicity if too much agent is used at one sitting.[289,298,300] Therefore, a limited amount of sclerosing agent is typically injected during a single setting. Rarely ocular events or even cerebrovascular events have been observed following foam sclerotherapy and, therefore,

must be discussed with the patient prior to its use.[299,302] The thought is that the sclerosing agent gets into the systemic circulation and potentially even the eye or brain. The presence of a patent foramen ovale is associated with a higher frequency of transient neurologic events.[303] The use of CO_2 as the mixing gas used for foam sclerotherapy appears to decrease the risk of such adverse events.[302] On the basis of the available data, the SVS/AVF Guidelines Committee recommends that liquid or foam sclerotherapy be used to treat telangiectasia, reticular veins, and varicose veins (grade 1B).[126]

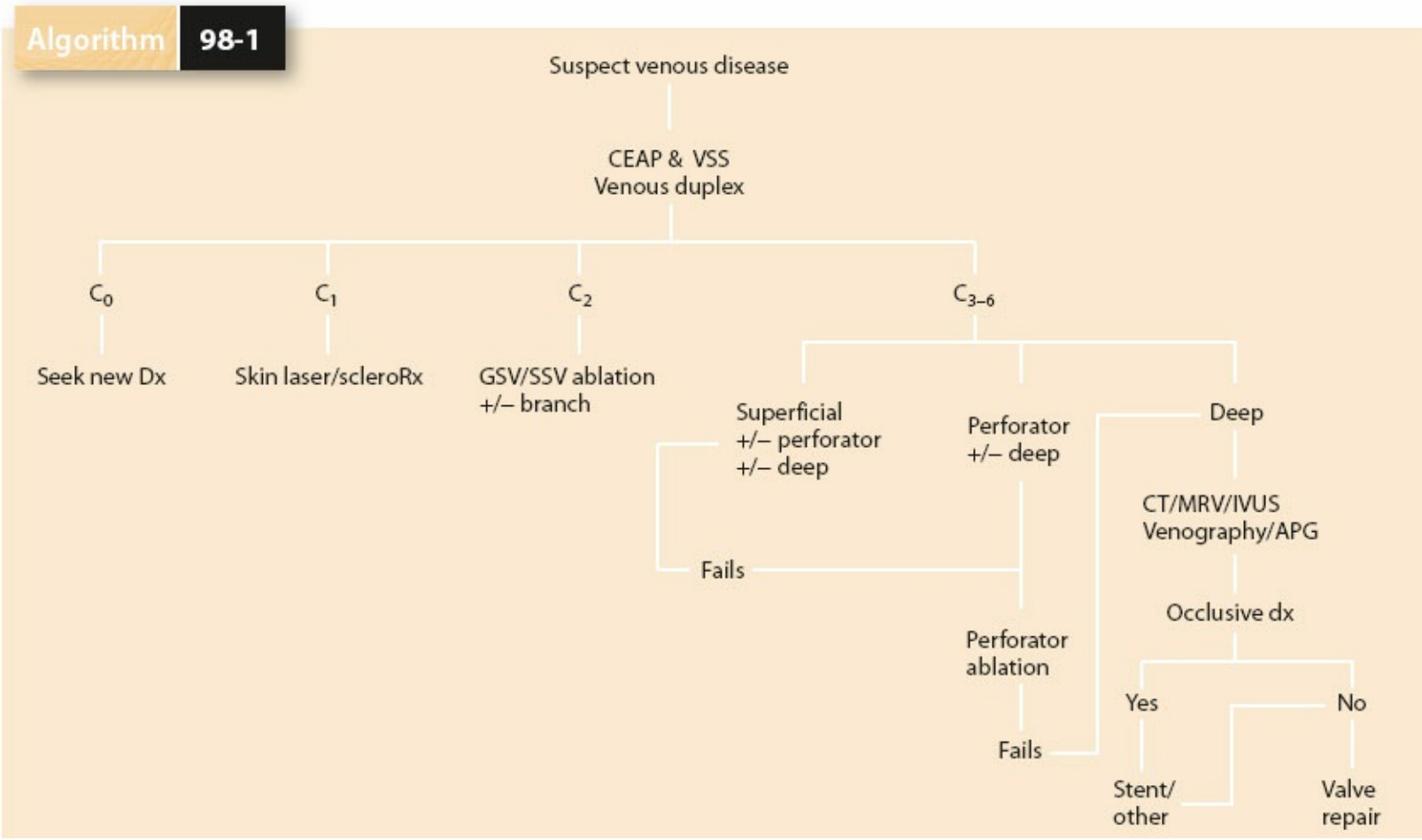

Algorithm 98-1. Treatment of chronic venous insufficiency.

Phlebectomy (ambulatory phlebectomy, stab avulsion, stab phlebectomy, microphlebectomy, and microextraction are synonymous terms) is a technique in which varicose veins are removed through small stab incisions with hooks or small mosquito clamps used to pull the vein from its bed. There are a number of phlebectomy instruments available.[304] It can be performed in an ambulatory setting with local anesthesia or in conjunction with a more invasive procedure. One small randomized controlled study suggests that this approach may have improved results over sclerotherapy.[305] Which approach is best remains a point of contention in the literature and is often physician choice. Complications are generally minor and of low risk (<2%), including development of telangiectasia, blistering, hyperpigmentation, and missed varix.[306] Tumescent anesthesia has allowed for extensive interventions with little pain and on an ambulatory basis.[307] Such field anesthesia allows for another method of

phlebectomy, powered phlebectomy, involving a modified arthroscopic shaver with transillumination that allows venous clusters to be illuminated, morcellized, and aspirated. When compared to ambulatory phlebectomy, there is no benefit in patient cosmetic scores or satisfaction and the recurrence rate at 1 year is 15% higher.[308] The added cost and lack of patient preference will likely prevent this technique from becoming widely adopted.

Saphenous Vein Stripping/Ablation. Saphenous preservation can lead to good results in the hands of very skilled interventionalist willing to interpret detailed preoperative imaging (proper patient selection) and a detailed technical approach.[309–311] It involves removal of only selected branch varicosities resulting in improved saphenous function or at least preservation of the saphenous vein without an unacceptable rate of recurrent varicosities over time. Because of the technical demands and limited data available to compare results with more standard treatments, treating saphenous veins reflux and associated varicose veins with such techniques is only suggested as appropriate in the hands of skilled interventionalists (grade 2B/C) by the SVS/AVF Guidelines Committee.[126]

If widespread saphenous insufficiency is present, some method of eliminating reflux is required for best results. Entirely removing the refluxing vein from the venous system is the current best and most studied solution. The vein can be stripped from its bed and discarded. The procedure is called saphenous vein high ligation and stripping. Lower leg deep venous occlusive disease is not an absolute contraindication to removal of the saphenous system and may actually be indicated in patients with mixed obstruction/reflux disease and is often the first step in cases of combined deep and superficial insufficiency.[312,313] Preoperatively, with the patient standing to fully dilate the veins, the varicosities are marked with a permanent marker for later operative visualization. The operation includes ligation and disconnection of the GSV at the SFJ via open incision followed by complete removal of the vein to the knee by one or more distal incisions centered over the vein. If the below-knee greater saphenous vein is incompetent based on preoperative diagnostic studies, it may also be excised. The method of vein removal may involve the introduction of long metal or plastic stripping wires with removable heads of varying size or various others devices aimed at pulling the vein from the leg.[314,315] There is even a long probe that is placed down the saphenous after cephalad exposure and to the caudal area of desired vein removal that, when activated, freezes the vein to the probe that is then pulled from the leg with the vein attached (cryostripping).[316] Both GSV and SSV can be treated by these methods taking into account required patient positioning and anatomic variability especially of concern in the case of the SSV.[314] In particular, protection of the sural nerve by limited deep dissection is helpful. Among properly selected patients undergoing GSV high ligation and stripping, recurrent saphenous varicosities will be noted in less than 25% of cases at 2 years but increases to 41% at 5 years and 62% at 11 years, depending on the rigor of patient evaluation.[315,317,318] These results serve to highlight the chronicity of varicose vein disease and place in perspective the expectations for other forms of saphenous ablation. With the addition of new ablation

technology, this approach to saphenous insufficiency has been largely replaced in the United States, but certainly not so in less wealthy healthcare systems throughout the world.

A more recent advancement that allows the saphenous vein to be removed from the venous circulation without being extracted from the body is called endovenous thermal ablation. It uses a variety of devices to ablate (burn) and permanently scar the vein such that it does not act as the conduit for venous blood (therefore no reflux of blood can take place). The two most common methods use radiofrequency-generated heat[319,320] or a laser fiber (with or without cap) that generates heat to cause a thermal injury to the vein.[321–323] Placed percutaneously or rarely by venous cut down, the respective probe is advanced into the vein to about 2 cm below the junction with the deep vein and sequentially heated throughout the length of the GSV as it is pulled back to the entrance site. Tumescent anesthesia is administered within the saphenous compartment providing anesthesia, a heat sink, and some venous compression during the procedure. The precise parameters for heating the radiofrequency ablation (RFA) probe is standardized for each pullback length (7 cm) at 120 degrees for each 20-second cycle with two treatment cycles used in the more proximal segment of the vein. The time for ablation is significantly decreased from the original device that involved a slow pull-back process and at 6 months this new technique was effective demonstrating 99.6% of veins remaining ablated.[324] This data mimics the results of the older technique which demonstrated results comparable and, in some respects, superior to open surgery.[325–329] Laser energy of various wavelengths (810 to 1,470 nm) delivered via bare-tipped fiber will cause a localized thermal injury to the vein wall.[321–323] The laser probe technique is more physician directed and involves a pullback of 1 to 2 mm/second for the first 10 cm and then 2 to 3 mm/second for the remaining vein length to deliver a 50 to 80 joules/cm when using the 810-nm diode laser. This technique rivals RFA and surgery results in the treatment of saphenous vein reflux.[330–335] Several other innovative methods of ablating the saphenous vein include, but are not limited to, steam, pharmacomechanical methods, cyanoacrylate plugs, and likely others to come which still require study to determine how each will fit into our interventional armamentarium.

Hamel-Desnos et al.[297] found GSV ultrasonography directed foam sclerotherapy to be 84% effective in eliminating reflux for 1 year. Midterm results in 175 patients reported a 2-year primary success rate of 55% with a 77% secondary success rate in preventing recurrent reflux.[336] The long-term results of the VEDICO trial would suggest that substantially more veins are present at 10 years when foam is used as a single modality than when surgery or surgery and foam are used.[292] If recurrence without reintervention is the goal, sclerotherapy appears to be at a disadvantage. Meta-analysis would suggest that over time sclerotherapy loses its advantage to other more long-lasting interventions as would select individual experiences.[289,292,293,297,337,338] Newer techniques of sclerotherapy lack long-term evaluation.

Complications of GSV surgery are rare but include wound infection, DVT, nerve damage, and hematoma formation to mention the most common.[317,339,340] Saphenous nerve injury can result in an area of numbness around the knee or foot but is often

clinically irrelevant.[119,138] Complications from SSV stripping are also typically rare but include bleeding, hematoma formation, sural nerve damage, DVT, and wound infection.[341] These same complications are reported for radiofrequency and laser ablations possibly at a slightly lower incidence for some, such as nerve paresthesia. DVT risk is about 1% for all procedures.[317,320,323,339,340,342] A complication unique to the radiofrequency and laser procedures is thermal damage to adjacent structures, such as nerve or skin, that appear to be mitigated by tumescent anesthesia.[319] Complications as well as short- and midterm freedom from recurrence for both radiofrequency and laser saphenous vein ablation compare favorably with standard stripping and both may provide patient benefit.[320,323,342]

5 Based on the previous data in addition to other publications, which can be found in a recent meta-analysis sponsored by the SVS and AVF and a consensus document, the following guidelines have been proposed regarding the treatment of C_2 (patients with varicose veins) to improve QOL and to prevent recurrence.[343] High ligation and stripping of the GSV to the knee are suggested for incompetent GSVs (grade 2B) with a 1-week period of postoperative compression (grade 1B). For the incompetent SSV, the recommendation is high ligation of the vein at the knee crease about 3 to 5 cm distal to the saphenopopliteal junction with selective stripping of the incompetent portion (grade 1B). In addition, the consensus was that endovenous thermal ablation (RFA and laser) was recommended over surgery for saphenous incompetence treatment based on reduced convalescence, pain, and morbidity (grade 1B) and over foam sclerotherapy due to improved efficacy (grade 1B). The elimination of saphenous reflux has also been found useful in treating the more advance stages of CVD (C_6), the venous ulcer. A commissioned SVS/AVF systemic review and meta-analysis of surgical interventions versus conservative therapy favored surgery over compression alone for ulcer healing with the quality of evidence low resulting in a suggestion favoring ablation over compression therapy alone to improve ulcer healing.[270,276] While the same analysis demonstrated that surgery was statistically better than compression in preventing recurrence but some design and baseline imbalances in the two instrumental RCTs decreased the level of evidence resulting in a recommendation in favor of surgery of grade 1B. In addition, in patients with a healed ulcer, ablation in addition to standard compression therapy is recommended to prevent recurrence (grade 1C) and in patient with skin changes at risk of venous ulceration, the same treatment is suggested (grade 2C).

Perforator Vein Ablation. Although effective in eliminating perforating vein reflux, open[344] or even endoscopic ligation[345] has been replaced with percutaneous methods of ablation due to decreased morbidity associated with the less invasive procedures. A systematic review of pertinent guidelines and RCTs suggests that there is no benefit in treating patients with mild/moderate venous disease by the addition of perforation ablation (ligation) and, in fact, some perforator veins revert to normal function after superficial incompetence is corrected.[346] The pertinent available data have resulted in an SVS/AVF guideline, which recommends that incompetent veins in patients with varicose veins should not be treated (grade 1B).[126] No matter the ablating energy delivered

(radiofrequency, laser or chemical) during percutaneous perforator vein ablation, ultrasonographic access, operative monitoring, and confirmation of results are routine and the procedure can be accomplished under local anesthesia. The ablating device is inserted into the pathologic perforator and is serially pulled back during activation to burn the perforator for its length or the sclerosant injected into it with a similar result. Prevention of energy delivery to the deep system prevents unwanted thrombosis and is most often accomplished by positioning the ablation device (when used) or properly compressing the vein when using sclerotherapy at or just slightly below the fascia. Various sclerosing agents have been used with minimal risk of DVT, skin infection, and an immediate success of 90% to 98% and a 2-year maintenance of occlusion of nearly 80%.[347–349] RFA demonstrates a greater than 90% early ablation rate with > 80% free of reflux at 1 year and 5 years.[350–353] Laser energy of various wavelengths has been used for this procedure with reports of ~100% occlusions immediately and 85% to 90% occlusion rate in mid-term follow-up.[351,354] The addition of perforator ablation to superficial vein incompetence ablation in patient with venous ulcers and pathologic perforator veins appears to improve healing rates and reduces recurrence.[268,346,355,356] The available data have been interpreted by the SVS/AVF Guidelines Committee to allow four basic recommendations.[276] In patients with active ulcers and both superficial and perforator incompetence to the pertinent ulcer bed, it is suggested that both are ablated to aid in ulcer healing and to prevent recurrence (grade 2C) but in patients without active ulcers the addition of perforation ablation can be simultaneous or staged on the basis of outcome (grade 2C). It is suggested that isolated "pathologic" perforators are ablated (grade 2C). It is recommended that "pathologic" perforation ablation be percutaneous rather than an open procedure to eliminate the need for incisions in areas of compromised skin (grade 1C).

Iliac Stenting and Venous Bypass. Endovascular stenting of iliac vein stenosis/obstruction involves percutaneous access of a nondiseased caudal vein (popliteal, femoral, common femoral vein) with guidewire/catheter access across the lesion under fluoroscopic guidance and generally intravascular ultrasonographic confirmation of stenosis >50%. If confirmed, dilation with 12- to 18-mm diameter percutaneous balloons, depending on the iliac to common femoral vein involved, with subsequent self-expanding stent deployment to maintain the dilation. This is accomplished from normal outflow (generally IVC) to distal normal vein even to less trochanter location within the common femoral vein if needed to ensure good inflow. Extension to below the inguinal ligament is acceptable in the treatment of venous occlusive disease.[357] Eliminating significant outflow obstruction in symptomatic patients has decreased edema, pain symptoms, and improved QOL parameters.[127,152,197,358–360] It will often result in venous ulcers healing, many of which have associated untreated lower leg venous insufficiency, at an initial rate of 68% with only 8 of 101 healed ulcers recurring within 5 years, whether preformed for primary or postthrombotic occlusion.[360] Parameters of venous reflux are not worsened following resolution of the occlusive iliac vein occlusive disease.[360] The primary and assisted primary stent patency rates at 3 years is 75% and 92% and at 6 years 69% and 89%,

respectively (Fig. 98-2).[360,361] Many studies in multiple centers now confirm these earlier results with a cumulative patency rate of 90% and ulcer healing rates of 60% to 80%.[362–367] This intervention has been performed for significant clinical symptoms (C_3 or C_2 with pain) and based solely on a greater than 50% morphologic stenosis found on transfemoral venography or intravascular ultrasonography.[152,360,361] Potential complications include DVT, access site complications, retroperitoneal hematoma, and other catheter- and balloon-related problems with essentially no mortality associated with the procedure.[225,360,361,368] When technically feasible, endovascular intervention has replaced more invasive approaches. As a result of accumulating data, the SVS/AVF Guidelines Committee has recommended venous angioplasty and stent recanalization in addition to standard compression therapy to aid in venous ulcer healing and prevention of ulcer recurrence in patients with proximal venous occlusion/severe stenosis and C_{4b}, C_5, and C_6 disease (grade 1C).

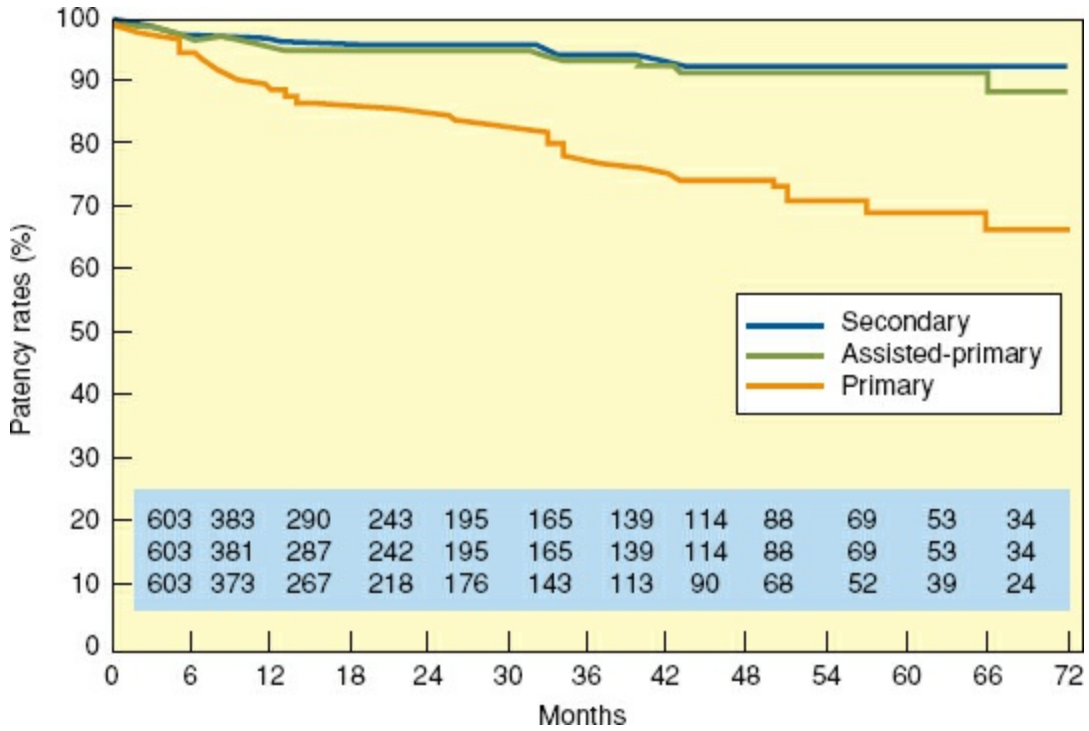

Figure 98-2. Life-table presentation demonstrates the patency rates of iliac venous stents placed for symptomatic occlusive venous disease. (After Neglén P, Hollis KC, Olivier J, Raju S. Stenting of the venous outflow in chronic venous disease: long-term stent-related outcome, clinical and hemodynamic results. *J Vasc Surg* 2007; 46:979–990.)

The open surgical procedures used to relieve proximal IVC or iliac vein occlusions utilize the native saphenous vein or polytetrafluoroethylene (PTFE) graft material as the conduit to bypass from a nondiseased distal vein to a disease-free proximal or collateral axial vein. Vena cava or bilateral iliac veins occlusion reconstructions often use PTFE grafts to allow a proper size match.[369,370] If a single iliac vein is severely stenosed or occluded and percutaneous methods have failure, cross-femoral venous bypass or direct repair of the iliac vein can be performed.[217,371] Patient survival should be considered prior to aggressive intervention if iliac vein compression is due to a cancerous encroachment. The cross-femoral venous bypass (Palma procedure) is performed by

passing a vein graft or graft material via a suprapubic subcutaneous tunnel to the contralateral femoral vein. The saphenous vein or prosthetic graft is then connected to the unaffected femoral vein by an end-to-side technique after anastomosis on the affected side. The key to success of this surgery may be graft diameter. If the native vein is less than 4.5 mm in diameter, better success may be achieved with a 10-mm diameter PTFE graft, although others would question whether PTFE is superior to vein in this location.[369,372] An arteriovenous fistula is generally used to increase flow through the graft in the immediate postoperative period. This fistula can then be ligated in 1 to 3 months or left open long term if no unwanted sequelae are noted. In one series, venous reconstruction for ileofemoral and IVC obstruction reported a 62% 3-year patency with the Palma procedure demonstrating the overall best patency (83% 4-year).[369] Mortality was minimal and wound complications rare. Based on the limited current available data, the guideline for treating bilateral proximal venous occlusion/stenosis in patients with recalcitrant venous ulceration and no endovascular option is a suggested open intervention using externally supported PTFE graft in addition to standard compression therapy (grade 2C).[193] In the same scenario, but with unilateral iliofemoral venous disease, the suggested therapy is an open surgical bypass using saphenous vein if available and sufficiently large with the alternative being a synthetic graft (grade 2C). When inflow is an issue during open operation, a distal adjunctive arteriovenous fistula (4 to 6 mm in diameter) is suggested (grade 2C).

Indications for a saphenopopliteal vein bypass are symptomatic patients with isolated femoral or popliteal vein occlusion, a patent common femoral and iliocaval system, a nonvaricosed saphenous vein, and femoral phlebitis inactive for at least 1 year. In addition, conservative therapy must have failed, and venous hypertension must be documented. These distal to proximal venous bypasses use autogenous vein as the conduit of choice and bypasses extend from distal to proximal nondiseased segments.[372] This operation is rarely performed.

Although not yet proven as a method of treating occlusive venous disease due to prior thrombosis, some data suggest that endophlebectomy (operative removal of synechiae and septa) of iliac, femoral, popliteal, and even tibial veins is possible and can result in a 77% primary patency rate at 8 months.[373]

Venous Valve Repair or Replacement

The goal of venous valve repair or replacement is the prevention of deep venous reflux and, therefore, a decrease in prolonged distal venous hypertension. These interventions are considered only after all other more easily treated venous pathology has been addressed by the surgeon in charge. During the conduct of these operations, several observations influence what the surgeon can offer a given patient. If operative handling of the suspect valve results in vasoconstriction and secondary competence (often determined by a standard “strip test”), an external valvuloplasty or a prosthetic sleeve technique may be viable options.[374] For a valve station requiring an in situ repair, careful adventitial dissection of the valve attachment lines facilitates proper venotomy when required and helps to verify the feasibility of valve repair.[180] A lack of valve attachment

lines may signify the destruction of the valve as a postthrombotic sequela, prompting something other than an in situ repair.[180] Valvuloplasty of any sort is most commonly performed in the femoral or popliteal location due to size and hemodynamic considerations.

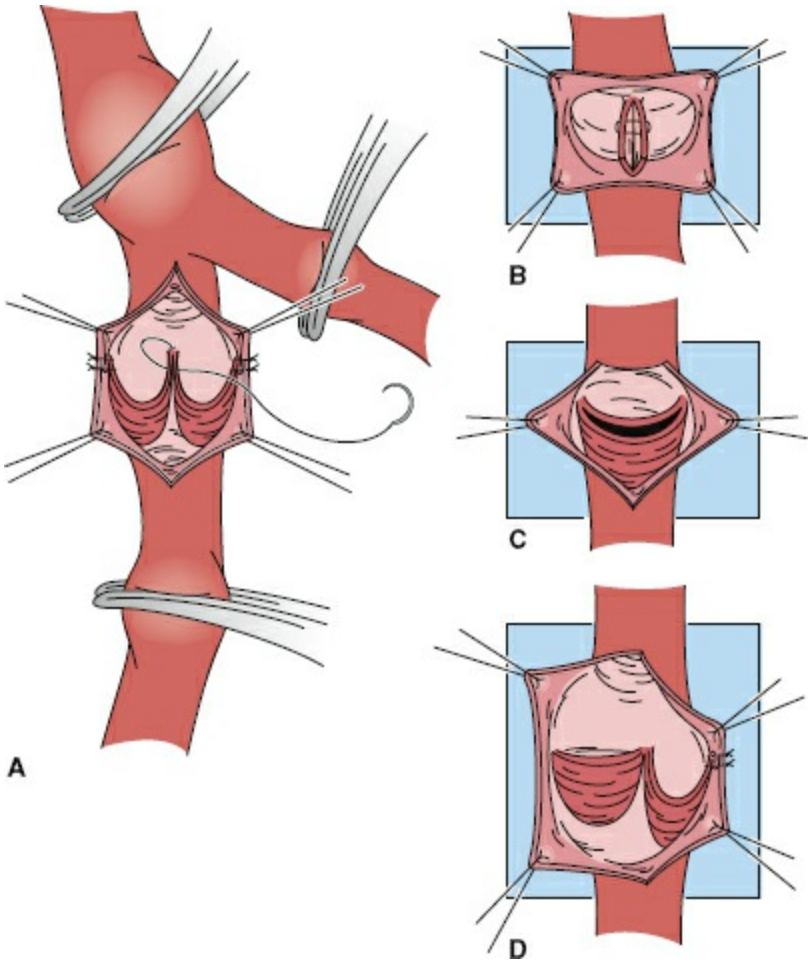

Figure 98-3. Open valvuloplasty to repair an insufficient valve can be accomplished by various venotomy incisions. **A:** The method of Kistner. **B:** The method of Raju. **C:** The method of Sottiurai. **D:** The method of Tripathi and his colleagues.

An internal valvuloplasty or an open direct valve repair has been the mainstay for the repair of primary venous valvular reflux for decades. This technique involves venotomy and suturing of the elongated valve leaflets under direct visualization with fine polypropylene suture (7 or 6 to 0) to tighten the valve cusps. Kistner and colleagues[154] reported success with a longitudinal venotomy extending through the valve commissure in 1968 (Fig. 98-3). Raju[375] championed a supracommissural approach involving a transverse venotomy at least 2.5 cm above the valve. Sottiurai[376] devised a hybrid approach (a "T"-shaped venotomy), using a supravalvular transverse venotomy with distal extension into the valve sinus. A "trapdoor" approach involving two transverse incisions (supravalvular and infravalvular) connected by a single vertical incision through the commissure has been described by Tripathi and Ktenidis (see Fig. 98-3).[377] Plication of approximately 20% of the valve leaflet length tends to restore valve competency in the majority of cases.[378]

The technique of external valvuloplasty offers the advantage of valve repair without venotomy.[379] It is performed by placing sutures transmurally through the valve attachment lines and, when tied, reduces the commissural angle and vein diameter, resulting in a competent valve. The valve leaflets are generally not captured or reefed by this method. Reported results suggest that it may be less durable than the more precise open valvuloplasty, but patient selection plays a key role.[379] A modification (limited anterior plication) involves only anterior vein dissection and then reefing of the cusps using a running mattress suture.[380] It has been described in conjunction with saphenous vein stripping and limited to the femoral vein valve. Another modification of this technique features the use of an angioscope.[381] A side branch of the GSV allows introduction of an angioscope, which is advanced into the femoral vein to a position above the incompetent valve and external sutures are then placed under direct vision.[381] Following a learning curve while using the angioscope, Raju et al.[382] demonstrated good clinical and competency data with the "transcommissural" technique without the use of the angioscope with 30 months of follow-up. In these last two methods, the venous valve cusps are actually engaged with the suture and, therefore, the cusps are tightened directly much like the open method of repair.

External banding has been employed when dissection vasospasm renders a valve spontaneously competent. The technique uses an external sleeve made of synthetic material wrapped circumferentially around the vein at the site of the valve and tightened to diminish the size of the vein lumen until the valve is competent. The sleeve is then anchored in place to the adventitia by sutures to avoid slippage. It has achieved good results when used in select patients.[229,383,384] One group of investigators has been more aggressive with this approach, utilizing the technique in patients with more severe valvular reflux and often placing multiple external cuffs.[383]

Venous valve transplantation is an option when the valve is absent or destroyed. This procedure was first reported clinically by Taheri[385] in 1982. A 2- to 3-cm segment of upper extremity vein containing a competent valve (or a reparable one) is first removed. The incompetent femoral vein is opened below the takeoff of the profunda femoris vein, and the axillary vein segment is sutured into place following the removal of an appropriate length of femoral vein. The popliteal location may be more appropriate if the femoral location does not control all axial reflux into the leg, for example, if the profunda femoral vein system is also incompetent. The proximal anastomosis may be accomplished first to confirm the competence of the newly transplanted valve and to allow distention and lengthening of the vein/valve to facilitate the distal anastomosis. For vein transplantation in trabeculated postthrombotic veins, investigators[386] have excised intraluminal synechiae to create one acceptable lumen for transplantation. Interrupted sutures are preferred to avoid suture line stenosis.[378] Valve competence is determined by the intraoperative strip test. An external sleeve can then be placed to prevent late dilatation of the repaired segment and because approximately 40% of axillary vein valves are incompetent at explant, a bench repair may be required to restore competency.[180,378,387]

A less common option for the PTS is valve transposition. If a venous valve is competent

in one of the major thigh venous systems, then a transposition procedure can be performed placing the incompetent venous system below the competent valve. Most commonly, the femoral system is incompetent and the profunda femoris valve remains competent. Here, the incompetent femoral vein can be transected and reimplanted distal to the competent valve in the profunda femoris vein. Alternatively, the incompetent femoral system can be placed below a competent valve in the GSV or when the profunda femoris venous system is incompetent, it may be placed distal to a competent valve in either the femoral vein or the GSV. A technique has been described for transposition of the ipsilateral valve-competent GSV to the femoral vein and subsequent ligation of the femoral vein proximally, yet distal to the takeoff of the profunda femoris vein to escape problems with diameter mismatch.[388] At 10 years, 55% of the patients were reported to be ulcer-free.

Aggressive venous valve surgery requires appropriate consideration of perioperative adjunctive care: prophylactic antibiotics, intraoperative heparin use especially if the vein is opened, the use of pneumatic compression devices postoperatively, and the use of LMWH or IV heparin in the postoperative period. Some use closed suction drainage of wounds to avoid hematoma and seroma formation. Warfarin should have an initial target INR range of 2.0 to 2.5 for the first 6 weeks and some would advocate a subsequent decrease to 1.7 to 2.0 until 4 months when it is discontinued. Adjustments are made to accommodate those with an increased risk of thrombosis. One suggested that long-term regimen is “minidose” warfarin, which utilizes daily doses of 1 to 2.5 mg to prevent thrombosis.[180,389] Although many surgeons encourage the use of compressive support, patients often do not comply but still have acceptable clinical results.[182,183]

Valve repair procedures are well tolerated by most patients and have a low morbidity, as well as essentially zero mortality in most series.[154] Hematoma and seroma formation are noted in less than 15% of cases, depending on the level of anticoagulation used.[182,378,390–392] DVT occurs in less than 10% of cases in most series and even if higher is not associated with clinical sequelae, while the pulmonary emboli risk is well less than 1%.[180–182,378,390–392] Wound infections have been seen in 2% to 7% of cases.[180,182,378,392]

Kistner et al. reported long-term follow-up of internal valvuloplasty spans over decades and is reported in life-table format (Fig. 98-4). Valve competency is 60% to 70% at 5 years in most series.[181–183,229,375,377,393–398] In general, a patent and competent valve translates into clinical improvement and a healed ulcer, while the reverse is true with recurrent reflux. This is true for all types of single station venous valvular reconstructions.

External valvuloplasty without direct cusp repair (isolated wall diameter reduction) appears to perform less well in all aspects than open valvuloplasty.[229,392] However, the “transcommissural” technique that does directly repair the slack valve cusps performs much like open valvuloplasty with a competency rate of more than 60% at 3 years and >70% ulcer free rate up to 5 years.[382] External banding performs adequately in select cases or as adjunctive procedures during other venous valve surgery.[229,383,384]

Valve transposition demonstrates clinical improvement in 50% to 60% of patients after 3 to 5 years of follow-up.[154,181,182,388–391,393–397] The valve competency rate varies from

30% to 80% and is reflected in the clinical improvement noted.[154,181,182,388–391,393–397]

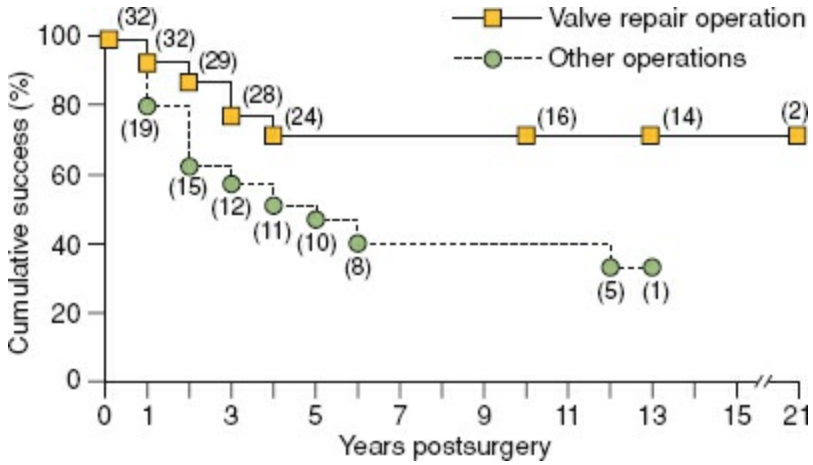

Figure 98-4. Life-table demonstrates the cumulative clinical success rate based on type of valve reconstruction procedure. The valve repair operation is valvuloplasty as performed by Kistner and associates via the Kistner technique. "Other operations" refer to valve transpositions ($n = 14$), superficial femoral vein valve transplantations ($n = 2$), and combined valve repair and transposition procedures ($n = 3$). Numbers in parentheses indicate the number of valve repairs remaining in the study at that time point. Significant difference exists between valve repair and other operations. (After Masuda EM, Kistner RL. Long-term results of venous valve reconstruction: a four to twenty-one year follow-up. *J Vasc Surg* 1994;19:391.)

Valve transplantation is undertaken in the most complex and difficult conditions. Clinical improvement is seen in about 50% of patients even at 8 years of follow-up, and it remains a good option in cases where other techniques are not possible.[153,154,379] There does not appear to be a difference between reported competency rates or clinical results when considering the location of valve repair (femoral vs. popliteal), but overall the competency rates reported are inferior to internal valvuloplasty.[376,385,397,399–404] There are data to support that contention that repairing multiple valves in the same axial system translates into longer clinical benefit, but this approach does, of course, add risks at the initial operative intervention.[382,383,392,405]

In general, patients with postthrombotic reflux tend to have more problems maintaining healed ulcers than those with a primary etiology of reflux, as noted from the results of internal valvuloplasty (generally a primary etiology) versus those requiring transplantation or a transposition operative approach.[182] Review of pertinent data has resulted in guidelines to reference when treating patients with C_{4b}, C_5, and C_6 disease.[276] It is suggested that in such patients with structurally preserved deep venous valves, individual valve repair can be offered (grade 2C). If no structurally intact exists, then valve transposition or transplantation is suggested treatment (grade 2C).

Valve Substitutes

Autogenous tissues appear to be the only material that currently can act as a substitute valve with some hope of success in the clinical arena. Using donor vein, after trimming adventitia and part of the media, to fashion semilunar cusps within the deficient recipient vein, Raju and Hardy[180] have reported acceptable clinical results. Another approach

invaginates a stump of the long saphenous vein into the femoral vein to fashion a bicuspid valve, 19 of 20 reconstructions were patent and competent at a mean of 10 months with one valve demonstrating reflux.[406] No other series have reproduced these findings to date. The newest innovation has been to use an ophthalmic knife or other fine tool to dissect the intima/media wall of the thickened postthrombotic vein wall into one or two sheets and thereby fashion the valve cusp(s).[407] This technique has been reproduced by another investigator.[408] A recent improvement has been to place two sutures on the cusp(s) to hold the valve in the semiopen position and thereby to prevent valve collapse and improve neovalve competence. The results with this modification include 21 operations (mean follow-up 11 months) with all valves competent, a 95% ulcer healing rate and two recurrences (9.5%).[409] In this highly select group of patients, the SVS/AVF Guidelines Committee suggests consideration of autogenous valve substitutes in addition to standard compression therapy to aid in venous ulcer healing and recurrence prevention (grade 2C).[276]

Venous Ulcer Wound Care

The quest to heal venous ulcers has generated a myriad of potential topical agents to aid in ulcer healing. Topical antibiotics and dressings containing antimicrobials may retard wound healing and cause allergic reactions and are not recommended for the treatment of venous ulcers.[276,410] Growth factors and cytokines in addition to compression when provided as isolated topically applied agents have not demonstrated efficacy when compared to placebo. Review of the literature demonstrates inconsistent results or studies with insufficient data to determine with any certainty the efficacy of such adjuvants.[411,412] A number of topical dressings applied on the ulcer bed and beneath the compression dressing have been investigated to determine if ulcer healing could be improved. Hydrocolloids (e.g., DuoDerm), foams (e.g., Allevyn), alginates (e.g., Sorbsan), hydrogels (e.g., Intrasite Gel, or Debrican), and others (e.g., Opsite) have been studied. Insufficient data is available to make firm conclusions, but it is clear that the nature and amount of the exudates present may provide a rationale for the benefit of one or the other of these dressings in a given patient.[413–415] The SVS/AVF 33.Guidelines Committee suggests that the wound dressing be selected, which absorbs wound exudates and protects the periulcer skin from damage (grade 2B).[276]

Surgical debridement to healthy tissue, when required, benefits the rate of ulcer healing and does not lead to a higher risk of systemic infection.[410,416–418] It is especially beneficial when evaluated as adjuvant care to the standard methods of venous ulcer wound care.[414,419] The use of local anesthetic during debridement of venous leg ulcers has been found statistically beneficial in lowering pain scores in a Cochrane analysis of six trials.[420] This and other pertinent data are the basis of recent guidelines for optimal patient care.[276] Surgical debridement is recommended to remove slough, nonviable tissue and eschar (grade 1B) using local anesthesia to minimize discomfort (grade 1B).

Hydrosurgical, enzymatic, and larval therapy are effective methods of venous ulcer debridement, but none have been found more effective than surgical debridement and can be more expensive. Current guidelines suggest each as a potential alternative to surgical

debridement when a trained practitioner is not available to provide surgical debridement (grade 2B/C).[276]

For resistant venous ulcers, defined as those that fail to demonstrate improvement in a minimum of 4 to 6 weeks of standard wound therapy, adjuvant wound therapy options should be considered.[276,421] These ulcers can be extensive, and skin grafting allows for coverage of raw surfaces to speed the healing process. Once the ulcer has a clean base of granulation tissue, a split-thickness skin graft can be applied. There are reports on improved healing with skin grafting for chronic venous ulceration.[422] Skin grafting is generally considered only when ulcer healing has not occurred following diligent conservative management.[423] An alternative or precursor to an autologous skin graft may be one of a variety of skin substitutes. A number of skin substitutes have been used to aid in venous ulcer healing (e.g., fresh allografts, porcine dermis) but for most there are insufficient data available to determine whether venous ulcer healing is improved.[424] However, the biologically active bilayered human skin equivalent with an allogenic epidermal and dermal layer has demonstrated more promise and statistically improved the time to complete healing.[414,424,425] Porcine small intestine submucosa (SIS) is primarily a collagen-based extracellular matrix with retained biologically active components. In a study of SIS and when adjusted for ulcer size, SIS was three times as likely to heal as the control group ($P = 0.007$) and at 6 months there was no recurrence in the SIS group.[419] This manuscript was included in a review of the literature as an RCT demonstrating significance when used to heal venous ulcers.[414] The use of these skin substitutes is suggested as guideline adjuvant therapy in recalcitrant venous ulcer care (grade 2 A/B).[276]

The Pelvic Congestion Syndrome

This distressing clinical condition can result from gonadal vein and/or hypogastric vein reflux. Pelvic pain is a constant complaint and can be disabiling. Gonadal vein reflux may be best managed with gonadal vein excision due to its many areas of potential reflux, but an endovascular approach using coils, sclerosants, or a combination can also be successful and is the most common approach currently.[426] Hypogastric vein reflux may be best managed by percutaneous embolization.[427] When the elimination of proximal reflux does not resolve superficial varicosities, the management involves techniques used for saphenous vein branch varicosities.

References

1. Heit JA. The epidemiology of venous thromboembolism in the community. *Arterioscler Thromb Vasc Biol* 2008;28:370–372.
2. Bauer KA, Rosendaal FR, Heit JA. Hypercoagulability: too many tests, too much conflicting data. *Hematology (Am Soc Hematol Educ Program)* 2002:353–368.
3. Henke PK, Schmaier A, Wakefield TW. *Thrombosis Due to Hypercoagulable States Chapter 34.* Elsevier Saunders; 2005.
4. Goldhaber SZ, Tapson VF. A prospective registry of 5,451 patients with ultrasound-confirmed deep vein thrombosis. *Am J Cardiol* 2004;93:259–262.
5. Thomas S, Goodacre S, Sampson F, Van Beek E. Diagnostic value of CT for deep vein thrombosis: results of a systematic review and meta-analysis. *Clin Radiol* 2008;63:299–304.
6. Theodorou SJ, Theodorou DJ, Kakitsubata Y. Sonography and venography of the lower extremities for diagnosing deep vein thrombosis in symptomatic patients. *Clin Imag* 2003;27:180–183.
7. Goodman LR, Stein PD, Matta F, et al. CT venography and compression sonography are diagnostically equivalent: data from pioped II. *Am J Roentgenol* 2007;189:1071–1076.
8. Kearon C, Ginsberg JS, Kovacs MJ, et al. Comparison of low-intensity warfarin therapy with conventional-intensity warfarin therapy for long-term prevention of recurrent venous thromboembolism. *N Engl J Med* 2003; 349:631–639.
9. Cornuz J, Ghali WA, Hayoz D, et al. Clinical prediction of deep venous thrombosis using two risk assessment methods in combination with rapid quantitative D-dimer testing. *Am J Med* 2002;112:198–203.
10. Vandy FC, Stabler C, Eliassen AM, et al. Soluble P-selectin for the diagnosis of lower extremity deep venous thrombosis. *J Vasc Surg Venous Lymphat Disord* 2013;1:117–125.
11. Johnson SA, Stevens SM, Woller SC, et al. Risk of deep vein thrombosis following a single negative whole-leg compression ultrasound. *JAMA* 2010;303:438–445.
12. Schellong SM, Schwarz T, Halbritter K, et al. Complete compression ultrasonography of the leg veins as a single test for the diagnosis of deep vein thrombosis a prospective clinical outcome study. *Thromb Haemost* 2003;89:228–234.
13. Decousus H, Quéré I, Presles E, et al. Superficial venous thrombosis and venous thromboembolism: a large, prospective epidemiologic study. *Ann Int Med* 2010;152:218–224.
14. Decousus H, Prandoni P, Mismetti P, et al. Fondaparinux for the treatment of superficial-vein thrombosis in the legs. *N Engl J Med* 2010;363:1222–1232.
15. Wells PS, Ginsberg JS, Anderson DR, et al. Use of a clinical model for safe

management of patients with suspected pulmonary embolism. *Ann Intern Med* 1998;129:997–1005.

16. Wells P, Anderson DR, Rodger M, et al. Derivation of a simple clinical model to categorize patients probability of pulmonary embolism: increasing the models utility with the simpliRED D-dimer. *Thrombo Heamost* 2000;83:416–420.
17. Wicki J, Perrier A, Perneger TV, et al. Predicting adverse outcome in patients with acute pulmonary embolism: A risk score. *Thromb Haemost* 2000;84:548–552.
18. van Belle A, Buller HR, Huisman MV, et al. Effectiveness of managing suspected pulmonary embolism using an algorithm combining clinical probability, D-dimer testing, and computed tomography. *JAMA* 2006; 295:172–179.
19. Hunt JM, Bull TM. Clinical review of pulmonary embolism: diagnosis, prognosis, and treatment. *Med Clin North Am* 2011;95:1203–1222.
20. Stein PD, Terrin ML, Gottschalk A, et al. Value of the ventilation/perfusion scan in acute pulmonary embolism. Results of the prospective investigation of pulmonary embolism diagnosis (pioped). The pioped investigators. *JAMA* 1990;263:2753–2759.
21. Worsley DF, Alavi A. Comprehensive analysis of the results of the pioped study. Prospective investigation of pulmonary embolism diagnosis study. *J Nucl Med* 1995;36:2380–2387.
22. Henzler T, Schoenberg SO, Schoepf UJ, et al. Diagnosing acute pulmonary embolism: systematic review of evidence base and cost-effectiveness of imaging tests. *J Thorac Imag* 2012;27:304–314.
23. Stein PD, Chenevert TL, Fowler SE, et al. Gadolinium-enhanced magnetic resonance angiography for pulmonary embolisma multicenter prospective study (pioped iii). *Ann Int Med* 2010;152:434–443.
24. Wilbur J, Shian B. Diagnosis of deep venous thrombosis and pulmonary embolism. *Am Fam Physician* 2012;86:913–919.
25. Prandoni P, Bernardi E. Upper extremity deep vein thrombosis. *Curr Opin Pulm Med* 1999;5:222–226.
26. Hull RD, Raskob GE, Brant RF, et al. Relation between the time to achieve the lower limit of the APTT therapeutic range and recurrent venous thromboembolism during heparin treatment for deep vein thrombosis. *Arch Intern Med* 1997;157:2562–2568.
27. Prandoni P, Lensing AW, Cogo A, et al. The long-term clinical course of acute deep venous thrombosis. *Ann Intern Med* 1996;125:1–7.
28. Bates SM, Ginsberg JS. Treatment of deep-vein thrombosis. *N Engl J Med* 2004;351:268–277.
29. Ageno W, Turpie A. Low-molecular-weight heparin in the treatment of pulmonary embolism. *Semin Vasc Surg* 2000;13:189–193.
30. van Dongen CJ, van den Belt AG, Prins MH, Lensing AW. Fixed dose subcutaneous low molecular weight heparins versus adjusted dose unfractionated heparin for venous thromboembolism. *The Cochrane Library.* 2004;(4):CD001100.

31. Kearon C, Akl EA, Comerota AJ, et al. Antithrombotic therapy for VTE disease: antithrombotic therapy and prevention of thrombosis, 9th ed: American College of Chest Physicians evidence-based clinical practice guidelines. *Chest* 2012;142(6):1698–1704.
32. Palareti G, Cosmi B, Legnani C, et al. D-Dimer testing to determine the duration of anticoagulation therapy. *N Engl J Med* 2006;355:1780–1789.
33. Ridker PM, Goldhaber SZ, Danielson E, et al. Long-term, low-intensity warfarin therapy for the prevention of recurrent venous thromboembolism. *N Engl J Med* 2003;348:1425–1434.
34. Cosmi B, Legnani C, Cini M, et al. D-Dimer levels in combination with residual venous obstruction and the risk of recurrence after anticoagulation withdrawal for a first idiopathic deep vein thrombosis. *Thromb Haemost* 2005;94:969–974.
35. Hull RD, Marder VJ, Mah AF, et al. Quantitative assessment of thrombus burden predicts the outcome of treatment for venous thrombosis: a systematic review. *Am J Med* 2005;118:456–464.
36. Kearon C. Natural history of venous thromboembolism. *Circulation* 2003;107:I22–130.
37. Prandoni P, Lensing AW, Prins MH, et al. Residual venous thrombosis as a predictive factor of recurrent venous thromboembolism. *Ann Intern Med* 2002;137:955–960.
38. Kearon C, Akl EA. Duration of anticoagulant therapy for deep vein thrombosis and pulmonary embolism. *Blood.* 2014;123(12):1794–1801.
39. Linkins L-A, Choi PT, Douketis JD. Clinical impact of bleeding in patients taking oral anticoagulant therapy for venous thromboembolism a meta-analysis. *Ann Intern Med* 2003;139:893–900.
40. Almeida JI, Coats R, Liem TK, et al. Reduced morbidity and mortality rates of the heparin-induced thrombocytopenia syndrome. *J Vasc Surg* 1998;27:309–314; discussion 315–306.
41. Greinacher A, Michels I, Mueller-Eckhardt C. Heparin-associated thrombocytopenia: the antibody is not heparin specific. *Thromb Haemost* 1992; 67:545–549.
42. Alving BM. How I treat heparin-induced thrombocytopenia and thrombosis. *Blood* 2003;101:31–37.
43. Baldwin ZK, Spitzer AL, Ng VL, et al. Contemporary standards for the diagnosis and treatment of heparin-induced thrombocytopenia (HIT). *Surgery* 2008;143:305–312.
44. Guyatt G, Akl E, Crowther M, et al; American College of Chest Physicians Antithrombotic Therapy and Prevention of Thrombosis Panel. Executive summary: antithrombotic therapy and prevention of thrombosis: American College of Chest Physicians evidence-based clinical practice guidelines. *Chest* 2012;141:7S–47S.
45. van dongen CJ, Mac Gillavry MR. Once versus twice daily LMWH for the initial treatment of venous thromboembolism. *Cochrane Database Syst Rev* 2005. doi: 10.1002/14651858.CD003074.pub2

46. Merli G, Spiro TE, Olsson C-G, et al. Subcutaneous enoxaparin once or twice daily compared with intravenous unfractionated heparin for treatment of venous thromboembolic disease. *Ann Intern Med* 2001;134: 191–202.
47. Lee AY, Levine MN, Baker RI, et al. Low-molecular-weight heparin versus a Coumadin for the prevention of recurrent venous thromboembolism in patients with cancer. *N Engl J Med* 2003;349:146–153.
48. Bergqvist D, Agnelli G, Cohen AT, et al. Duration of prophylaxis against venous thromboembolism with enoxaparin after surgery for cancer. *N Engl J Med* 2002;346:975–980.
49. Turpie AG, Bauer KA, Eriksson BI, et al. Fondaparinux vs enoxaparin for the prevention of venous thromboembolism in major orthopedic surgery: a meta-analysis of 4 randomized double-blind studies. *Arch Intern Med* 2002;162:1833–1840.
50. Wolozinsky M, Yavin YY, Cohen AT. Pharmacological prevention of venous thromboembolism in medical patients at risk. *Am J Cardiovasc Drugs* 2005;5:409–415.
51. Agnelli G, Bergqvist D, Cohen AT, et al. Randomized clinical trial of postoperative fondaparinux versus perioperative dalteparin for prevention of venous thromboembolism in high-risk abdominal surgery. *Br J Surg* 2005;92:1212–1220.
52. Eriksson BI, Lassen MR. Duration of prophylaxis against venous thromboembolism with fondaparinux after hip fracture surgery: a multicenter, randomized, placebo-controlled, double-blind study. *Arch Intern Med* 2003;163:1337–1342.
53. Buller HR, Davidson BL, Decousus H, et al. Fondaparinux or enoxaparin for the initial treatment of symptomatic deep venous thrombosis: a randomized trial. *Ann Intern Med* 2004;140:867–873.
54. Buller HR, Davidson BL, Decousus H, et al. Subcutaneous fondaparinux versus intravenous unfractionated heparin in the initial treatment of pulmonary embolism. *N Engl J Med* 2003;349:1695–1702.
55. Schulman S, Kearon C, Kakkar AK, et al. Dabigatran versus warfarin in the treatment of acute venous thromboembolism. *N Engl J Med* 2009;361:2342–2352.
56. Schulman S, Kearon C, Kakkar AK, et al. Extended use of dabigatran, warfarin, or placebo in venous thromboembolism. *N Engl J Med* 2013;368:709–718.
57. Bauersachs R, Berkowitz SD, Brenner B, et al; EINSTEIN Investigators. Oral rivaroxaban for symptomatic venous thromboembolism. *N Engl J Med* 2010;363:2499–2510.
58. Bailey AL. Oral rivaroxaban for the treatment of symptomatic pulmonary embolism. *N Engl J Med* 2012;366:1287–1297.
59. Agnelli G, Buller HR, Cohen A, et al. Oral apixaban for the treatment of acute venous thromboembolism. *N Engl J Med* 2013;369:799–808.
60. Agnelli G, Buller HR, Cohen A, et al. Apixaban for extended treatment of venous thromboembolism. *N Engl J Med* 2013;368:699–708.
61. Büller HR, Décousus H, Grosso MA, et al. Edoxaban versus warfarin for the treatment

of symptomatic venous thromboembolism. *N Engl J Med* 2013;369:1406–1415.
62. Knepper J, Horne D, Obi A, et al. A systematic update on the state of novel anticoagulants and a primer on reversal and bridging. *J Vasc Surg Venous Lymphat Disord* 2013;1:418–426.
63. Kolbach D, Sandbrink MW, Hamulyak K, et al. Non-pharmaceutical measures for prevention of post-thrombotic syndrome. *Cochrane Database Syst Rev.* 2004; (1):CD004174.
64. Kahn SR, Shapiro S, Wells PS, et al. Compression stockings to prevent post-thrombotic syndrome: a randomised placebo-controlled trial. *Lancet* 2014;383(9920):880–888.
65. Aschwanden M, Labs KH, Engel H, et al. Acute deep vein thrombosis: early mobilization does not increase the frequency of pulmonary embolism. *Thromb Haemost* 2001;85:42–46.
66. Partsch H. Ambulation and compression after deep vein thrombosis: dispelling myths. *Semin Vasc Surg* 2005;18:148–152.
67. Greenfield LJ, Proctor MC. Twenty-year clinical experience with the greenfield filter. *Cardiovasc Surg* 1995;3:199–205.
68. Usoh F, Hingorani A, Ascher E, et al. Prospective randomized study comparing the clinical outcomes between inferior vena cava greenfield and trapease filters. *J Vasc Surg* 2010;52:394–399.
69. Berry RE, George JE, Shaver WA. Free-floating deep venous thrombosis. A retrospective analysis. *Ann Surg* 1990;211:719–712; discussion 712–713.
70. Langan EM III Miller RS, Casey WJ III, et al. Prophylactic inferior vena cava filters in trauma patients at high risk: follow-up examination and risk/benefit assessment. *J Vasc Surg* 1999;30:484–488.
71. Sugerman HJ, Sugerman EL, Wolfe L, et al. Risks and benefits of gastric bypass in morbidly obese patients with severe venous stasis disease. *Ann Surg* 2001;234:41–46.
72. Chiou AC. Beside placement of IVC filters. *Endovasc Today* 2005;4: 60–63.
73. Kearon C, Kahn SR, Agnelli G, et al. Antithrombotic therapy for venous thromboembolic disease: American College of Chest Physicians evidence-based clinical practice guidelines (8th edition). *Chest* 2008;133: 454S–545S.
74. Decousus H, Leizorovicz A, Parent F, et al. A clinical trial of vena caval filters in the prevention of pulmonary embolism in patients with proximal deep-vein thrombosis [Prevention du risque d'embolie pulmonaire par interruption cave study group]. *N Engl J Med* 1998;338:409–415.
75. Meissner MH, Manzo RA, Bergelin RO, et al. Deep venous insufficiency: the relationship between lysis and subsequent reflux. *J Vasc Surg* 1993;18:596–605; discussion 606–608.
76. Semba CP, Dake MD. Iliofemoral deep venous thrombosis: aggressive therapy with catheter-directed thrombolysis. *Radiology* 1994;191: 487–494.

77. Mewissen MW, Seabrook GR, Meissner MH, et al. Catheter-directed thrombolysis for lower extremity deep venous thrombosis: report of a national multicenter registry. *Radiology* 1999;211:39–49.
78. Elsharawy M, Elzayat E. Early results of thrombolysis vs anticoagulation in iliofemoral venous thrombosis. A randomised clinical trial. *Eur J Vasc Endovasc Surg* 2002;24:209–214.
79. Enden T, Haig Y, Kl⊘w NE, et al; CaVenT Study Group. Long-term outcome after additional catheter-directed thrombolysis versus standard treatment for acute iliofemoral deep vein thrombosis (the caVenT study): a randomised controlled trial. *Lancet* 2012;379:31–38.
80. Baekgaard N, Broholm R, Just S, et al. Long-term results using catheter-directed thrombolysis in 103 lower limbs with acute iliofemoral venous thrombosis. *Eur J Vasc Endovasc Surg* 2010;39:112–117.
81. Comerota AJ, Grewal N, Martinez JT, et al. Postthrombotic morbidity correlates with residual thrombus following catheter-directed thrombolysis for iliofemoral deep vein thrombosis. *J Vasc Surg* 2012;55:768–773.
82. Raju S. Critical issues in ulcer prevention in postthrombotic disease. *J Vasc Surg* 2010;52:67S–69S.
83. Turpie AG. Thrombolytic agents in venous thrombosis. *J Vasc Surg* 1990; 12:196–197.
84. Goldhaber SZ. Pulmonary embolism. *Lancet* 2004;363:1295–1305.
85. Sharma GV, Folland ED, McIntyre KM, et al. Long-term benefit of thrombolytic therapy in patients with pulmonary embolism. *Vasc Med* 2000;5: 91–95.
86. Goldhaber SZ, Haire WD, Feldstein ML, et al. Alteplase versus heparin in acute pulmonary embolism: randomised trial assessing right-ventricular function and pulmonary perfusion. *Lancet* 1993;341:507–511.
87. Jerjes-Sanchez C, Ramirez-Rivera A, Arriaga-Nava R, et al. High dose and short-term streptokinase infusion in patients with pulmonary embolism: prospective with seven-year follow-up trial. *J Thromb Thrombolysis.* 2001;12:237–247.
88. Konstantinides S, Geibel A, Olschewski M, et al. Association between thrombolytic treatment and the prognosis of hemodynamically stable patients with major pulmonary embolism: results of a multicenter registry. *Circulation* 1997;96:882–888.
89. Eid-Lidt G, Gaspar J, Sandoval J, et al. Combined clot fragmentation and aspiration in patients with acute pulmonary embolism. *Chest* 2008;134: 54–60.
90. Eklof B, Kistner RL. Is there a role for thrombectomy in iliofemoral venous thrombosis? *Semin Vasc Surg* 1996;9:34–45.
91. Juhan CM, Alimi YS, Barthelemy PJ, et al. Late results of iliofemoral venous thrombectomy. *J Vasc Surg* 1997;25:417–422.
92. Meneveau N, Seronde MF, Blonde MC, et al. Management of unsuccessful thrombolysis in acute massive pulmonary embolism. *Chest* 2006;129: 1043–1050.
93. Lutter KS, Kerr TM, Roedersheimer LR, et al. Superficial thrombophlebitis diagnosed

by duplex scanning. *Surgery* 1991;110:42–46.
94. Bjorgell O, Nilsson PE, Jarenros H. Isolated nonfilling of contrast in deep leg vein segments seen on phlebography, and a comparison with color Doppler ultrasound, to assess the incidence of deep leg vein thrombosis. *Angiology* 2000;51:451–461.
95. Talbot S. Use of real-time imaging in identifying deep venous obstruction: a preliminary report. *Bruit* 1982;VI:41–42.
96. Barrellier MT. [superficial venous thromboses of the legs]. *Phlebologie* 1993;46:633–639.
97. Blumenberg RM, Barton E, Gelfand ML, et al. Occult deep venous thrombosis complicating superficial thrombophlebitis. *J Vasc Surg* 1998;27:338–343.
98. De Wees M. Non-operative treatment of acute superficial thrombophlebitis and deep femoral thrombosis. In: Ernst CB, Stanley JC, eds. *Current Therapy in Vascular Surgery*. Philadelphia, PA: BC Decker Inc; 1991:952–960.
99. Martinelli I, Cattaneo M, Taioli E, et al. Genetic risk factors for superficial vein thrombosis. *Thromb Haemost* 1999;82:1215–1217.
100. Hanson JN, Ascher E, DePippo P, et al. Saphenous vein thrombophlebitis (SVT): a deceptively benign disease. *J Vasc Surg* 1998;27:677–680.
101. Meissner MH, Wakefield TW, Ascher E, et al. Acute venous disease: venous thrombosis and venous trauma. *J Vasc Surg* 2007;46(suppl S):25S–53S.
102. Sullivan V, Wakefield TW. Superficial venous thrombosis. In: Pearce WH, Yao JS, eds. *Trends in Vascular Surgery*. Chicago, IL: Precept Press; 2002: 463–472.
103. Krause U, Kock HJ, Kroger K, et al. Prevention of deep venous thrombosis associated with superficial thrombophlebitis of the leg by early saphenous vein ligation. *Vasa* 1998;27:34–38.
104. Gillet JL, Perrin M, Cayman R. Thromboembolic recurrence after superficial thrombophlebitis of the lower limbs. *J Phlebol* 2002;2:103–110.
105. Blattler W, Schwarzenbach B, Largiader J. Superficial vein thrombophlebitis—serious concern or much ado about little? *Vasa* 2008;37:31–38.
106. Verlato F, Zucchetta P, Prandoni P, et al. An unexpectedly high rate of pulmonary embolism in patients with superficial thrombophlebitis of the thigh. *J Vasc Surg* 1999;30:1113–1115.
107. Samlaska CP, James WD. Superficial thrombophlebitis. I. Primary hypercoagulable states. *J Am Acad Dermatol* 1990;22:975–989.
108. Titon JP, Auger D, Grange P, et al. [Therapeutic management of superficial venous thrombosis with calcium nadroparin. Dosage testing and comparison with a non-steroidal anti-inflammatory agent]. *Ann Cardiol Angeiol (Paris)* 1994;43:160–166.
109. The Superficial Thrombophlebitis Treatment by Enoxaparin Study Group. A pilot randomized double-blind comparison of a low-molecular-weight heparin, a nonsteroidal anti-inflammatory agent, and placebo in the treatment of superficial vein thrombosis. *Ann de Cardiol* 2003;43:160–166.

110. Group TVI. High vs. low doses of low-molecular-weight heparin for the treatment of superficial vein thrombosis of the legs: a double-blind, randomized trial. *J Thromb Haemost* 2005;3:1152–1157.
111. Belcaro G, Nicolaides AN, Errichi BM, et al. Superficial thrombophlebitis of the legs: a randomized, controlled, follow-up study. *Angiology* 1999;50:523–529.
112. Marchiori A, Verlato F, Sabbion P, et al. High versus low doses of unfractionated heparin for the treatment of superficial thrombophlebitis of the leg. A prospective, controlled, randomized study. *Haematologica* 2002;87: 523–527.
113. Lozano FS, Almazan A. Low-molecular-weight heparin versus saphenofemoral disconnection for the treatment of above-knee greater saphenous thrombophlebitis: a prospective study. *Vasc Endovascular Surg* 2003;37: 415–420.
114. Sullivan V, Denk PM, Sonnad SS, et al. Ligation versus anticoagulation: treatment of above-knee superficial thrombophlebitis not involving the deep venous system. *J Am Coll Surg* 2001;193:556–562.
115. Hafner CD, Cranley JJ, Krause RJ, et al. A method of managing superficial thrombophlebitis. *Surgery* 1964;55:201–206.
116. Ascer E, Lorensen E, Pollina RM, et al. Preliminary results of a nonoperative approach to saphenofemoral junction thrombophlebitis. *J Vasc Surg* 1995;22:616–621.
117. Husni EA, Williams WA. Superficial thrombophlebitis of lower limbs. *Surgery* 1982;91:70–74.
118. Caggiati A, Bergan JJ, Gloviczki P, et al. Nomenclature of the veins of the lower limbs: an international interdisciplinary consensus statement. *J Vasc Surg* 2002;36:416–422.
119. Morrison C, Dalsing MC. Signs and symptoms of saphenous nerve injury after greater saphenous vein stripping: prevalence, severity, and relevance for modern practice. *J Vasc Surg* 2003;38:886–890.
120. Caggiati A, Bergan JJ, Gloviczki P, et al. Nomenclature of the veins of the lower limb: extensions, refinements, and clinical application. *J Vasc Surg* 2005;41:719–724.
121. Corrales NE, Irvine A, McGuinness CL, et al. Incidence and pattern of long saphenous vein duplication and its possible implications for recurrence after varicose vein surgery. *Br J Surg* 2002;89:323–326.
122. Caggiati A, Bergan JJ. The saphenous vein: derivation of its name and its relevant anatomy. *J Vasc Surg* 2002;35:172–175.
123. Caggiati A. Fascial relationships of the short saphenous vein. *J Vasc Surg* 2001;34:241–246.
124. Mozes G, Gloviczki P, Menawat SS, et al. Surgical anatomy for endoscopic subfascial division of perforating veins. *J Vasc Surg* 1996;24:800–808.
125. Browse NL, Burnand KG, Thomas ML. Disease of the veins: pathology, diagnosis, and treatment. *London: Edward Arnold* 1988:53–69.
126. Gloviczki P, Comerota AJ, Dalsing MC, et al. The care of patients with varicose veins

and associated chronic venous diseases: clinical practice guidelines of the Society for Vascular Surgery and the American Venous Forum. *J Vasc Surg* 2011:2S–48S.

127. Giordano JM, Trout HH III. Anomalies of the inferior vena cava. *J Vasc Surg* 1986;3:924–928.
128. Nehler M, Moneta GL. The lower extremity venous disease part I anatomy and physiology. *Perspect Vasc Surg* 1991;4:104.
129. Moreno AH, Katz AI, Gold LD, et al. Mechanics of distension of dog veins and other very thin-walled tubular structures. *Circ Res* 1970;27:1069–1080.
130. Moneta GL, Taylor DC, Helton WS, et al. Duplex ultrasound measurement of postprandial intestinal blood flow: effect of meal composition. *Gastroenterology* 1988;95:1294–1301.
131. Lurie F, Kistner RL, Eklof B, et al. Mechanism of venous valve closure and role of the valve in circulation: a new concept. *J Vasc Surg* 2003;38: 955–961.
132. van Bemmelen PS, Bedford G, Beach K, et al. Quantitative segmental evaluation of venous valvular reflux with duplex ultrasound scanning. *J Vasc Surg* 1989;10:425–431.
133. Mattos MA, Summer D. Direct noninvasive tests (duplex scan) for the evaluation of chronic venous obstruction and valvular incompetence. In: Gloviczki P, Yao JS, eds. *Handbook of Venous Disorders.* London: Arnold; 2001: 120–131.
134. van Bemmelen PS, Beach K, Bedford G, et al. The mechanism of venous valve closure. Its relationship to the velocity of reverse flow. *Arch Surg* 1990;125:617–619.
135. Raju S, Fredericks R, Lishman P, et al. Observations on the calf venous pump mechanism: determinants of postexercise pressure. *J Vasc Surg* 1993;17: 459–469.
136. Brand FN, Dannenberg AL, Abbott RD, et al. The epidemiology of varicose veins: the Framingham Study. *Am J Prev Med* 1988;4:96–101.
137. Coon WW, Willis PW III, Keller JB. Venous thromboembolism and other venous disease in the Tecumseh community health study. *Circulation* 1973; 48:839–846.
138. Dale WL, Cranley JJ, DeWeese JA, et al. Symposium: management of varicose veins. *Contemp Surg* 1975;6:86.
139. Criqui MH, Jamosmos M, Fronek A, et al. Chronic venous disease in an ethnically diverse population: the San Diego population study. *Am J Epidemiol* 2003;158:448–456.
140. Baker SR, Stacey MC, Jopp-McKay AG, et al. Epidemiology of chronic venous ulcers. *Br J Surg* 1988;78:864–867.
141. Heit JA, Rooke TW, Silverstein MD, et al. Trends in the incidence of venous stasis syndrome and venous ulcer: a 25-year population-based study. *J Vasc Surg* 2001;33:1022–1027.
142. Nicolaides AN. Investigation of chronic venous insufficiency: a consensus statement (France, March 5–9, 1997). *Circulation* 2000;102:E126–E163.
143. Smith J, Garratt A, Guest M, et al. Evaluating and improving health-related quality

of life in patients with varicose veins. *J Vasc Surg* 1999;30:710–719.
144. Rabe E, Pannier-Fischer F, Bromen K, et al. Bonner Venenstudie der Deutschen Gesellschaft für Phlebologieepidemiologische Untersuchung zur Frage der Häufigkeit und Ausprägung von chronischen Venenkrankheiten in der städtischen und ländlichen Wohnbevölkerung. *Phlebologie* 2003;32:1–14.
145. Carpentier PH, Maricq HR, Biro C, et al. Prevalence, risk factors, and clinical patterns of chronic venous disorders of lower limbs: a population-based study in France. *J Vasc Surg* 2004;40:650–659.
146. Chiesa R, Marone EM, Limoni C, et al. Demographic factors and their relationship with the presence of CVI signs in Italy: the 24-cities cohort study. *Eur J Vasc Endovasc Surg* 2005;30:674–680.
147. Chiesa R, Marone EM, Limoni C, et al. Chronic venous insufficiency in Italy: the 24-cities cohort study. *Eur J Vasc Endovasc Surg* 2005;30:422–429.
148. Jawien A, Grzela T, Ochwat A. Prevalence of chronic venous insufficiency in men and women in Poland: multicenter cross-sectional study in 40095 patients. *Phlebology* 2003;18:110–121.
149. Ruckley CV, Evans CJ, Allan PL, et al. Chronic venous insufficiency: clinical and duplex correlations. The Edinburgh vein study of venous disorders in the general population. *J Vasc Surg* 2002;36:520–525.
150. Rabe E, Pannier F. Epidemiology of chronic venous disorders. In: *Handbook of Venous Disorders: Guidelines of the American Venous Forum.* 3rd ed. 2009;105–110.
151. Jukkola TM, Makivaara LA, Luukkaala T, et al. The effects of parity, oral contraceptive use and hormone replacement therapy on the incidence of varicose veins. *J Obstet Gynaecol* 2006;26:448–451.
152. Neglen P, Thrasher TL, Raju S. Venous outflow obstruction: an underestimated contributor to chronic venous disease. *J Vasc Surg* 2003;38:879–885.
153. O'Donnell TF Jr. Chronic venous insufficiency: an overview of epidemiology, classification, and anatomic considerations. *Semin Vasc Surg* 1988;1:60
154. Eklof BG, Kistner RL, Masuda EM. Venous bypass and valve reconstruction: long-term efficacy. *Vasc Med* 1998;3:157–164.
155. May R. The cause of the predominately sinistral occurrence of thrombosis of the pelvic veins. *Angiology* 1957;8:419–427.
156. Ehrich WE. A frequent obstructive anomaly of the mouth of the left common iliac vein. *Am Heart J* 1943;26:737–750.
157. Mcmurrich J. The occurrence of congenital adhesions in the common iliac veins, and their relation to thrombosis of the femoral and iliac veins. *Am J Med Sci* 1943;135:342–346.
158. Cockett FB, Thomas ML, Negus D. Iliac vein compression—its relation to iliofemoral thrombosis and the post-thrombotic syndrome. *Br Med J* 1967;2:14–19.
159. Cockett FB, Thomas ML. The iliac compression syndrome. *Br J Surg* 1965;52:816–

821.
160. Kibbe MR, Ujiki M, Goodwin AL, et al. Iliac vein compression in an asymptomatic patient population. *J Vasc Surg* 2004;39:937–943.
161. Lalka SG. Management of chronic obstructive venous disease of the lower extremity. In: Rutherford RB, ed. *Vascular Surgery*. 4th ed. Philadelphia, PA: WB Saunders; 1995:1862–1882.
162. Raju S. High prevalence of nonthrombotic iliac vein lesions in chronic venous disease: a permissive role in pathogenicity. *J Vasc Surg* 2006;44:136–144.
163. Martin-Pedrosa JM, Del Blanco I, Carrera S, et al. Intravascular lipoma of the external iliac vein and common femoral vein. *Eur J Vasc Endovasc Surg* 2002;23:470–472.
164. Kistner RL, Eklof B, Masuda EM. Diagnosis of chronic venous disease of the lower extremities: the "CEAP" classification. *Mayo Clin Proc* 1996;71:338–345.
165. Labropoulos N. CEAP in clinical practice. *Vasc Surg* 1997;31:224–225.
166. Johnson BF, Manzo RA, Bergelin RO, et al. Relationship between changes in the deep venous system and the development of the postthrombotic syndrome after an acute episode of lower limb deep vein thrombosis: a one- to six-year follow-up. *J Vasc Surg* 1995;21:307–313.
167. Labropoulos N, Delis K, Nicolaides AN, et al. The role of the distribution and anatomic extent of reflux in the development of signs and symptoms in chronic venous insufficiency. *J Vasc Surg* 1996;23:504–510.
168. Labropoulos N, Giannoukas AD, Nicolaides AN, et al. The role of venous reflux and calf muscle pump function in nonthrombotic chronic venous insufficiency. Correlation with severity of signs and symptoms. *Arch Surg* 1996;131:403–406.
169. Labropoulos N, Leon M, Geroulakos G, et al. Venous hemodynamic abnormalities in patients with leg ulceration. *Am J Surg* 1995;169:572–574.
170. Labropoulos N, Giannoukas AD, Nicolaides AN, et al. New insights into the pathophysiologic condition of venous ulceration with color-flow duplex imaging: implications for treatment? *J Vasc Surg* 1995;22:45–50.
171. Hanrahan LM, Araki CT, Rodriguez AA, et al. Distribution of valvular incompetence in patients with venous stasis ulceration. *J Vasc Surg* 1991; 13:805–811; discussion 811–812.
172. Barwell JR, Davies CE, Deacon J, et al. Comparison of surgery and compression with compression alone in chronic venous ulceration (Eschar study): randomised controlled trial. *Lancet* 2004;363:1854–1859.
173. Yamaki T, Nozaki M, Sasaki K. Color duplex ultrasound in the assessment of primary venous leg ulceration. *Dermatol Surg* 1998;24:1124–1128.
174. Plate G, Brudin L, Eklof B, et al. Physiologic and therapeutic aspects in congenital vein valve aplasia of the lower limb. *Ann Surg* 1983;198:229–233.
175. Raffetto J, Khalil R. Mechanisms of varicose vein formation: valve dysfunction and

wall dilation. *Phlebology* 2008;23:85–98.

176. Anwar MA, Georgiadis KA, Shalhoub J, et al. A review of familial, genetic, and congenital aspects of primary varicose vein disease. *Circ Cardiovasc Genet* 2012;5:460–466.
177. Rose SS, Ahmed A. Some thoughts on the aetiology of varicose veins. *J Cardiovasc Surg (Torino)* 1986;27:534–543.
178. Clarke H, Smith SR, Vasdekis SN, et al. Role of venous elasticity in the development of varicose veins. *Br J Surg* 1989;76:577–580.
179. Kistner RL, Eklof B, Masuda EM. Deep venous valve reconstruction. *Cardiovasc Surg* 1995;3:129–140.
180. Raju S, Hardy JD. Technical options in venous valve reconstruction. *Am J Surg* 1997;173:301–307.
181. Perrin M. Reconstructive surgery for deep venous reflux: a report on 144 cases. *Cardiovasc Surg* 2000;8:246–255.
182. Masuda EM, Kistner RL. Long-term results of venous valve reconstruction: a four- to twenty-one-year follow-up. *J Vasc Surg* 1994;19:391–403.
183. Raju S, Fredericks RK, Hudson CA, et al. Venous valve station changes in “primary” and postthrombotic reflux: an analysis of 149 cases. *Ann Vasc Surg* 2000;14:193–199.
184. Killewich LA, Bedford GR, Beach KW, et al. Spontaneous lysis of deep venous thrombi: rate and outcome. *J Vasc Surg* 1989;9:89–97.
185. Meissner MH, Moneta G, Burnand K, et al. The hemodynamics and diagnosis of venous disease. *J Vasc Surg* 2007;46(suppl S):4S–24S
186. Kugler C, Strunk M, Rudofsky G. Venous pressure dynamics of the healthy human leg. Role of muscle activity, joint mobility and anthropometric factors. *J Vasc Res* 2001;38:20–29.
187. Araki CT, Back TL, Padberg FT, et al. The significance of calf muscle pump function in venous ulceration. *J Vasc Surg* 1994;20:872–877; discussion 878–879.
188. Back TL, Padberg FT Jr, Araki CT, et al. Limited range of motion is a significant factor in venous ulceration. *J Vasc Surg* 1995;22:519–523.
189. Padberg FT Jr, Johnston MV, Sisto SA. Structured exercise improves calf muscle pump function in chronic venous insufficiency: a randomized trial. *J Vasc Surg* 2004;39:79–87.
190. Pappas PJ, Duran WN, Hobson RW. Pathology and cellular physiology of chronic venous insufficiency. In: Gloviczki P, Yao JS, eds. *Handbook of Venous Disorders.* New York: Arnold; 2001:58–67.
191. Eberhardt RT, Raffetto JD. Chronic venous insufficiency. *Circulation* 2005;111:2398–2409.
192. Stanley AC, Park HY, Phillips TJ, et al. Reduced growth of dermal fibroblasts from chronic venous ulcers can be stimulated with growth factors. *J Vasc Surg* 1997;26:994–999; discussion 999–1001.

193. O'Donnell TF, Passman MA. Clinical practice guidelines of the Society for Vascular Surgery (SVS) and the American Venous Forum (AVF): management of venous leg ulcers [Information for authors]. *J Vasc Surg* 2014;2:A4.
194. Kistner R, Eklof B. Classification and etiology of chronic venous disease. In: *Handbook of Venous Disorders.* 3rd ed. UK: Hodder Arnold, part of Hachette UK, Hachette UK; 2009;37–46.
195. Langer RD, Ho E, Denenberg JO, et al. Relationships between symptoms and venous disease: the San Diego population study. *Arch Intern Med* 2005;165:1420–1424.
196. Killewich LA, Martin R, Cramer M, et al. Pathophysiology of venous claudication. *J Vasc Surg* 1984;1:507–511.
197. Raju S, Owen S Jr, Neglen P. The clinical impact of iliac venous stents in the management of chronic venous insufficiency. *J Vasc Surg* 2002;35:8–15.
198. Danielsson G, Eklof B, Grandinetti A, et al. Deep axial reflux, an important contributor to skin changes or ulcer in chronic venous disease. *J Vasc Surg* 2003;38:1336–1341.
199. Labropoulos N, Volteas N, Leon M, et al. The role of venous outflow obstruction in patients with chronic venous dysfunction. *Arch Surg* 1997;132:46–51.
200. Eklof B, Rutherford RB, Bergan JJ, et al. Revision of the CEAP classification for chronic venous disorders: consensus statement. *J Vasc Surg* 2004;40:1248–1252.
201. Porter JM, Moneta GL. Reporting standards in venous disease: an update. International Consensus Committee on Chronic Venous Disease. *J Vasc Surg* 1995;21:635–645.
202. Rutherford RB, Padberg FT Jr, Comerota AJ, et al. Venous severity scoring: an adjunct to venous outcome assessment. *J Vasc Surg* 2000;31:1307–1312.
203. Vasquez MA, Rabe E, McLafferty RB, et al. Revision of the venous clinical severity score: venous outcomes consensus statement: special communication of the American Venous Forum Ad Hoc Outcomes Working Group. *J Vasc Surg* 2010;52:1387–1396.
204. Lamping DL, Schroter S, Kurz X, et al. Evaluation of outcomes in chronic venous disorders of the leg: development of a scientifically rigorous, patient-reported measure of symptoms and quality of life. *J Vasc Surg* 2003;37:410–419.
205. Launois R, Reboul-Marty J, Henry B. Construction and validation of a quality of life questionnaire in chronic lower limb venous insufficiency (CIVIQ). *Qual Life Res* 1996;5:539–554.
206. Garratt AM, Macdonald LM, Ruta DA, et al. Towards measurement of outcome for patients with varicose veins. *Qual Health Care* 1993;2:5–10.
207. Smith JJ, Guest MG, Greenhalgh RM, et al. Measuring the quality of life in patients with venous ulcers. *J Vasc Surg* 2000;31:642–649.
208. Rutherford R, Moneta G, Padberg FT Jr, et al. Outcome assessment in chronic venous disease. In: *Handbook of Venous Disorders: Guidelines of the American Venous Forum.* 3rd ed. UK: Hodder Arnold, part of Hachette UK, Hachette UK; 2009:684–693.

209. Coleridge-Smith P, Labropoulos N, Partsch H, et al. Duplex ultrasound investigation of the veins in chronic venous disease of the lower limbs—UIP consensus document. Part I. Basic principles. *Eur J Vasc Endovasc Surg* 2006;31:83–92.
210. Wong JK, Duncan JL, Nichols DM. Whole-leg duplex mapping for varicose veins: observations on patterns of reflux in recurrent and primary legs, with clinical correlation. *Eur J Vasc Endovasc Surg* 2003;25:267–275.
211. Mercer KG, Scott DJ, Berridge DC. Preoperative duplex imaging is required before all operations for primary varicose veins. *Br J Surg* 1998;85: 1495–1497.
212. Labropoulos N, Mansour MA, Kang SS, et al. New insights into perforator vein incompetence. *Eur J Vasc Endovasc Surg* 1999;18:228–234.
213. Labropoulos N, Tiongson J, Pryor L, et al. Definition of venous reflux in lower-extremity veins. *J Vasc Surg* 2003;38:793–798.
214. Lynch TG, Dalsing MC, Ouriel K, et al. Developments in diagnosis and classification of venous disorders: non-invasive diagnosis. *Cardiovasc Surg* 1999;7:160–178.
215. Labropoulos N, Giannoukas AD, Delis K, et al. The impact of isolated lesser saphenous vein system incompetence on clinical signs and symptoms of chronic venous disease. *J Vasc Surg* 2000;32:954–960.
216. Stanson AW, Breen JF. Computed tomography and magnetic resonance imaging in venous disorders. In: Gloviczki P, Yao JS, eds. *Handbook of Venous Disorders.* London: Arnold; 2001:153–176.
217. Wolpert L. Magnetic resonance venography in the diagnosis and management of May-Thurner syndrome. *Vasc Endovasc Surg* 2002;36:51–57.
218. Butty S, Hagspiel KD, Leung DA, et al. Body MR venography. *Radiol Clin North Am* 2002;40:899–919.
219. Reed NR, Kalra M, Bower TC, et al. Left renal vein transposition for nutcracker syndrome. *J Vasc Surg* 2009;49:386–394.
220. Coakley FV, Varghese SL, Hricak H. CT and MRI of pelvic varices in women. *J Comput Assist Tomogr* 1999;23:429–434.
221. Bays RA, Healy DA, Atnip RG, et al. Validation of air plethysmography, photoplethysmography, and duplex ultrasonography in the evaluation of severe venous stasis. *J Vasc Surg* 1994;20:721–727.
222. Nicolaides AN, Christopoulos D. Quantification of venous reflux and outflow obstruction with air-plethysmography. In: Berstein EF, ed. *Vascular Diagnosis.* St Louis, MO: Mosby; 1993:915–921.
223. Cordts PR, Hartono C, LaMorte WW, et al. Physiologic similarities between extremities with varicose veins and with chronic venous insufficiency utilizing air plethysmography. *Am J Surg* 1992;164:260–264.
224. Criado E, Farber MA, Marston WA, et al. The role of air plethysmography in the diagnosis of chronic venous insufficiency. *J Vasc Surg* 1998;27:660–670.
225. Neglen P, Raju S. Proximal lower extremity chronic venous outflow obstruction:

recognition and treatment. *Semin Vasc Surg* 2002;15:57–64.
226. Mantoni M, Larsen L, Lund JO, et al. Evaluation of chronic venous disease in the lower limbs: comparison of five diagnostic methods. *Br J Radiol* 2002;75:578–583.
227. Neglen P, Raju S. Intravascular ultrasound scan evaluation of the obstructed vein. *J Vasc Surg* 2002;35:694–700.
228. Kistner RL, Ferris EB, Randhawa G, et al. A method of performing descending venography. *J Vasc Surg* 1986;4:464–468.
229. Raju S, Fredericks RK, Neglen PN, et al. Durability of venous valve reconstruction techniques for "primary" and postthrombotic reflux. *J Vasc Surg* 1996;23:357–366; discussion 366–367.
230. Cheatle TR, Perrin M. Venous valve repair: early results in fifty-two cases. *J Vasc Surg* 1994;19:404–413.
231. Kistner RL, Sparkuhl MD. Surgery in acute and chronic venous disease. *Surgery* 1979;85:31–43.
232. Nicolaides AN, Hussein MK, Szendro G, et al. The relation of venous ulceration with ambulatory venous pressure measurements. *J Vasc Surg* 1993;17:414–419.
233. Partsch B, Partsch H. Calf compression pressure required to achieve venous closure from supine to standing positions. *J Vasc Surg* 2005;42: 734–738.
234. Partsch H, Menzinger G, Mostbeck A. Inelastic leg compression is more effective to reduce deep venous refluxes than elastic bandages. *Dermatol Surg* 1999;25:695–700.
235. Benigni JP, Sadoun S, Allaert FA, et al. Efficacy of class 1 elastic compression stockings in the early stages of chronic venous disease. A comparative study. *Int Angiol* 2003;22:383–392.
236. Partsch H, Winiger J, Lun B. Compression stockings reduce occupational leg swelling. *Dermatol Surg* 2004;30:737–743; discussion 743.
237. Labropoulos N, Leon M, Volteas N, et al. Acute and long-term effect of elastic stockings in patients with varicose veins. *Int Angiol* 1994;13: 119–123.
238. Ibegbuna V, Delis KT, Nicolaides AN, et al. Effect of elastic compression stockings on venous hemodynamics during walking. *J Vasc Surg* 2003;37:420–425.
239. Partsch H, Menzinger G, Borst-Krafek B, et al. Does thigh compression improve venous hemodynamics in chronic venous insufficiency? *J Vasc Surg* 2002;36:948–952.
240. Partsch H. Mechanism and effects of compression therapy. In: Bergan JJ, ed. *The Vein Book*. Burlington, MA: Elsevier Inc; 2007:103–109.
241. Murthy G, Ballard RE, Breit GA, et al. Intramuscular pressures beneath elastic and inelastic leggings. *Ann Vasc Surg* 1994;8:543–548.
242. van Geest AJ, Veraart JC, Nelemans P, et al. The effect of medical elastic compression stockings with different slope values on edema. Measurements underneath three different types of stockings. *Dermatol Surg* 2000;26: 244–247.
243. Nehler MR, Moneta GL, Woodard DM, et al. Perimalleolar subcutaneous tissue pressure effects of elastic compression stockings. *J Vasc Surg* 1993;18:783–788.

244. Jones NA, Webb PJ, Rees RI, et al. A physiological study of elastic compression stockings in venous disorders of the leg. *Br J Surg* 1980;67:569–572.
245. Junger M, Steins A, Hahn M, et al. Microcirculatory dysfunction in chronic venous insufficiency (CVI). *Microcirculation* 2000;7:S3–S12.
246. Franzeck UK, Haselbach P, Speiser D, et al. Microangiopathy of cutaneous blood and lymphatic capillaries in chronic venous insufficiency (CVI). *Yale J Biol Med* 1993;66:37–46.
247. Dai G, Tsukurov O, Orkin RW, et al. An in vitro cell culture system to study the influence of external pneumatic compression on endothelial function. *J Vasc Surg* 2000;32:977–987.
248. Abu-Own A, Shami SK, Chittenden SJ, et al. Microangiopathy of the skin and the effect of leg compression in patients with chronic venous insufficiency. *J Vasc Surg* 1994;19:1074–1083.
249. Murphy MA, Joyce WP, Condron C, et al. A reduction in serum cytokine levels parallels healing of venous ulcers in patients undergoing compression therapy. *Eur J Vasc Endovasc Surg* 2002;23:349–352.
250. Mayrovitz HN. Compression-induced pulsatile blood flow changes in human legs. *Clin Physiol* 1998;18:117–124.
251. Humphreys M, Stewart A, Gohel M, et al. Management of mixed arterial and venous leg ulcers. *Br J Surg* 2007;94:1104–1107.
252. Moffatt C, Oldroyd M, Greenhalgh R, et al. Palpating ankle pulses is insufficient in detecting arterial insufficiency in patients with leg ulceration. *Phlebology* 1994;9:170–172.
253. Marston WA, Carlin RE, Passman MA, et al. Healing rates and cost efficacy of outpatient compression treatment for leg ulcers associated with venous insufficiency. *J Vasc Surg* 1999;30:491–498.
254. Mosti G, Iabichella ML, Partsch H. Compression therapy in mixed ulcers increases venous output and arterial perfusion. *J Vasc Surg* 2012;55:122–128.
255. Schuren J, Annelies V, Allen J. Venous leg ulcer patients with low ABPIs: how much pressure is safe and tolerable? *EWMA J* 2010;10:29–34.
256. Palfreyman SJ, Booth A, Michaels JA. A systematic review of intra-arterial thrombolytic therapy for lower-limb ischaemia. *Eur J Vasc Endovasc Surg* 2000;19:143–157.
257. Michaels J, Brazier J, Campbell W, et al. Randomized clinical trial comparing surgery with conservative treatment for uncomplicated varicose veins. *Br J Surg* 2006;93:175–181.
258. Mauck KF, Asi N, Elraiyah TA, et al. Comparative systematic review and meta-analysis of compression modalities for the promotion of venous ulcer healing and reducing ulcer recurrence. *J Vasc Surg* 2014;60(2) (suppl): 71S–90S.
259. O'Brien J, Grace P, Perry I, et al. Randomized clinical trial and economic analysis of

four-layer compression bandaging for venous ulcers. *Br J Surg* 2003;90:794–798.

260. Wong IK, Andriessen A, Lee DT, et al. Retracted: randomized controlled trial comparing treatment outcome of two compression bandaging systems and standard care without compression in patients with venous leg ulcers. *J Vasc Surg* 2012;55:1376–1385.
261. Rubin JR, Alexander J, Plecha EJ, et al. Unna's boot vs polyurethane foam dressings for the treatment of venous ulceration: a randomized prospective study. *Arch Surg* 1990;125:489–490.
262. Mayberry JC, Moneta GL, Taylor LM Jr, et al. Fifteen-year results of ambulatory compression therapy for chronic venous ulcers. *Surgery* 1991;109:575–581.
263. Nelson EA Bell-Syer S, Cullum NA. Compression for preventing recurrence of venous ulcers. *Cochrane Database Syst Rev* 2007;(3).
264. Franks PJ, Oldroyd MI, Dickson D, et al. Risk factors for leg ulcer recurrence: a randomized trial of two types of compression stocking. *Age Ageing.* 1995;24:490–494.
265. Nelson EA, Prescott RJ, Harper DR, et al. A factorial, randomized trial of pentoxifylline or placebo, four-layer or single-layer compression, and knitted viscose or hydrocolloid dressings for venous ulcers. *J Vasc Surg* 2007;45:134–141.
266. O'Meara S, Tierney J, Cullum N, et al. Four layer bandage compared with short stretch bandage for venous leg ulcers: systematic review and meta-analysis of randomised controlled trials with data from individual patients. *BMJ* 2009;338.
267. Partsch H, Damstra R, Tazelaar D, et al. Multicentre, randomised controlled trial of four-layer bandaging versus short-stretch bandaging in the treatment of venous leg ulcers. *Vasa* 2001;30:108–113.
268. van Gent WB, Hop WC, van Praag MC, et al. Conservative versus surgical treatment of venous leg ulcers: a prospective, randomized, multicenter trial. *J Vasc Surg* 2006;44:563–571.
269. Gohel MS, Barwell JR, Taylor M, et al. Long term results of compression therapy alone versus compression plus surgery in chronic venous ulceration (Eschar): randomised controlled trial. *BMJ* 2007;335:83.
270. Mauck KF, Asi N, Undavalli C, et al. Systematic review and meta-analysis of surgical interventions versus conservative therapy for venous ulcers. *J Vasc Surg* 2014;60:60S–70S.
271. Erickson CA, Lanza DJ, Karp DL, et al. Healing of venous ulcers in an ambulatory care program: the roles of chronic venous insufficiency and patient compliance. *J Vasc Surg* 1995;22:629–636.
272. Nicoloff AD, Moneta GL, Porter JM. Compression treatment of chronic venous insufficiency. In: Gloviczki P, Yao JS, eds. *Handbook of Venous Disorders.* 2nd ed. London: Arnold; 2001:303–308.
273. Nelson EA, Mani R, Thomas K, et al. Intermittent pneumatic compression for treating venous leg ulcers. *Cochrane Database Syst Rev.* 2011;(2):CD001899.

274. Coleridge-Smith P, Sarin S, Hasty J, Scurr JH. Sequential gradient pneumatic compression enhances venous ulcer healing. A randomized trial. *Surgery* 1990;108:871–875.
275. Nikolovska S, Arsovski A, Damevska K, et al. Evaluation of two different intermittent pneumatic compression cycle settings in the healing of venous ulcers: a randomized trial. *Med Sci Moni* 2005;11:CR337–CR343.
276. O'Donnell TF, Passman MA, Marston WA, et al. Management of venous leg ulcers: clinical practice guidelines of the Society For Vascular Surgery® and the American Venous Forum. *J Vasc Surg* 2014;60:3S–59S.
277. Brown A. Life-style advice and self-care strategies for venous leg ulcer patients: what is the evidence? *J Wound Care* 2012;21:342–350.
278. Kan YM, Delis KT. Hemodynamic effects of supervised calf muscle exercise in patients with venous leg ulceration: a prospective controlled study. *Arch Surg* 2001;136:1364–1369.
279. Pittler MH, Ernst E. Horse-chestnut seed extract for chronic venous insufficiency. A criteria-based systematic review. *Arch Dermatol* 1998;134: 1356–1360.
280. Martinez Zapata MJ, Bonfill Cosp X, Moreno RM, et al. Phlebotonics for venous insufficiency. *The Cochrane Library.* 2005;(3):CD003229.
281. Jull A, Arroll B, Parag V, Waters J. Pentoxifylline for treating venous leg ulcers. *Cochrane Database Syst Rev.* 2012;12:CD001733. doi: 10.1002/14651858.CD001733.pub3.
282. Dale J, Ruckley C, Harper D, et al. Randomised, double blind placebo controlled trial of pentoxifylline in the treatment of venous leg ulcers. *BMJ* 1999;319:875–878.
283. Falanga V, Fujitani RM, Diaz C, et al. Systemic treatment of venous leg ulcers with high doses of pentoxifylline: efficacy in a randomized, placebo-controlled trial. *Wound Repair Regen* 1999;7:208–213.
284. Alinovi A, Bassissi P, Pini M. Systemic administration of antibiotics in the management of venous ulcers. A randomized clinical trial. *J Am Acad Dermatol* 1986;15:186–191.
285. Schraibman IG. The significance of beta-haemolytic streptococci in chronic leg ulcers. *Ann Royal Coll Surg Engl* 1990;72:123.
286. Kilburn SA, Featherstone P, Higgins B, et al. Interventions for cellulitis and erysipelas. *Cochrane Database Syst Rev.* 2010;(6):CD004299.
287. Hohenleutner U, Walther T, Wenig M, et al. Leg telangiectasia treatment with a 1.5 ms pulsed dye laser, ice cube cooling of the skin and 595 vs 600 nm: preliminary results. *Lasers Surg Med.* 1998;23:72–78.
288. Bernstein EF, Kornbluth S, Brown DB, et al. Treatment of spider veins using a 10 millisecond pulse-duration frequency-doubled neodymium YAG laser. *Dermatol Surg* 1999;25:316–320.
289. Villavicencio JL. Sclerotherapy guidelines. In: Gloviczki P, Yao JS, eds. *Handbook of*

Venous Disorders. 2nd ed. New York: Arnold; 2001:253–266.

290. Kern P, Ramelet AA, Wutschert R, et al. Single-blind, randomized study comparing chromated glycerin, polidocanol solution, and polidocanol foam for treatment of telangiectatic leg veins. *Dermatol Surg* 2004;30:367–372; discussion 372.
291. Alos J, Carreno P, Lopez JA, et al. Efficacy and safety of sclerotherapy using polidocanol foam: a controlled clinical trial. *Eur J Vasc Endovasc Surg* 2006;31:101–107.
292. Belcaro G, Cesarone MR, Di Renzo A, et al. Foam-sclerotherapy, surgery, sclerotherapy, and combined treatment for varicose veins: a 10-year, prospective, randomized, controlled, trial (vedico trial). *Angiology* 2003;54:307–315.
293. Miyazaki K, Nishibe T, Sata F, et al. Stripping operation with sclerotherapy for primary varicose veins due to greater saphenous vein reflux: three-year results. *World J Surg* 2003;27:551–553.
294. Iwamoto S, Ikeda M, Kawasaki T, et al. Treatment of varicose veins: an assessment of intraoperative and postoperative compression sclerotherapy. *Ann Vasc Surg* 2003;17:290–295.
295. Field C. Sclerosing solutions. In: Bergan JJ, ed. *The Vein Book.* Boston, MA: Elsevier Academic Press; 2007:125–131.
296. Tessari L, Cavezzi A, Frullini A. Preliminary experience with a new sclerosing foam in the treatment of varicose veins. *Dermatol Surg* 2001;27: 58–60.
297. Hamel-Desnos C, Desnos P, Wollmann JC, et al. Evaluation of the efficacy of polidocanol in the form of foam compared with liquid form in sclerotherapy of the greater saphenous vein: Initial results. *Dermatol Surg* 2003;29:1170–1175; discussion 1175.
298. Goldman M. Complications and adverse sequelae of sclerotherapy. In: Bergan JJ, ed. *The Vein Book.* Boston, MA: Elsevier Academic Press; 2007: 139–155.
299. Guex JJ, Allaert FA, Gillet JL, et al. Immediate and midterm complications of sclerotherapy: report of a prospective multicenter registry of 12,173 sclerotherapy sessions. *Dermatol Surg* 2005;31:123–128; discussion 128.
300. Guex J. Complications and side-effects of foam sclerotherapy. *Phlebology* 2009;24:270–274.
301. Scultetus AH, Villavicencio JL, Kao TC, et al. Microthrombectomy reduces postsclerotherapy pigmentation: multicenter randomized trial. *J Vasc Surg* 2003;38:896–903.
302. Morrison N, Neuhardt DL, Rogers CR, et al. Comparisons of side effects using air and carbon dioxide foam for endovenous chemical ablation. *J Vasc Surg* 2008;47:830–836.
303. Ceulen RP, Sommer A, Vernooy K. Microembolism during foam sclerotherapy of varicose veins. *N Engl J Med* 2008;358:1525–1526.
304. Bergan JJ. Varicose veins: hooks, clamps, and suction. Application of new techniques to enhance varicose vein surgery. *Semin Vasc Surg* 2002;15: 21–26.

305. de Roos KP, Nieman FH, Neumann HA. Ambulatory phlebectomy versus compression sclerotherapy: results of a randomized controlled trial. *Dermatol Surg* 2003;29:221–226.
306. Ramelet AA. Complications of ambulatory phlebectomy. *Dermatol Surg* 1997;23:947–954.
307. Smith SR, Goldman MP. Tumescent anesthesia in ambulatory phlebectomy. *Dermatol Surg* 1998;24:453–456.
308. Aremu MA, Mahendran B, Butcher W, et al. Prospective randomized controlled trial: conventional versus powered phlebectomy. *J Vasc Surg* 2004;39:88–94.
309. Criado E, Lujan S, Izquierdo L, et al. Conservative hemodynamic surgery for varicose veins. *Semin Vasc Surg* 2002;15:27–33.
310. Parés JO, Juan J, Tellez R, et al. Varicose vein surgery: stripping versus the Chiva method: a randomized controlled trial. *Ann Surg* 2010;251:624–631.
311. Pittaluga P, Chastanet S, Rea B, et al. Midterm results of the surgical treatment of varices by phlebectomy with conservation of a refluxing saphenous vein. *J Vasc Surg* 2009;50:107–118.
312. Raju S, Easterwood L, Fountain T, et al. Saphenectomy in the presence of chronic venous obstruction. *Surgery* 1998;123:637–644.
313. Padberg FT, Pappas, PJ, Araki, CT. Hemodynamic and clinical improvement after superficial vein ablation in primary combined venous insufficiency with ulceration. *J Vasc Surg* 1997;26:169.
314. Dalsing MC. Lower extremity varicose vein disease. In: Cameron JL, ed. *Current Surgical Therapy*. 7th ed. St Louis, MO: Mosby; 2001:992–998.
315. Dwerryhouse S, Davies B, Harradine K, et al. Stripping the long saphenous vein reduces the rate of reoperation for recurrent varicose veins: five-year results of a randomized trial. *J Vasc Surg* 1999;29:589–592.
316. Menyhei G, Gyevnár Z, Arato E, et al. Conventional stripping versus cryostripping: a prospective randomised trial to compare improvement in quality of life and complications. *Euro J Vasc Endovasc Surg* 2008;35:218–223.
317. Larson RH, Lofgren EP, Myers TT, et al. Long-term results after vein surgery. Study of 1,000 cases after 10 years. *Mayo Clin Proc* 1974;49:114–117.
318. Winterborn RJ, Foy C, Earnshaw JJ. Causes of varicose vein recurrence: late results of a randomized controlled trial of stripping the long saphenous vein. *J Vasc Surg* 2004;40:634–639.
319. Chandler JG, Pichot O, Sessa C, et al. Treatment of primary venous insufficiency by endovenous saphenous vein obliteration. *J Vasc Surg* 2000;34:201.
320. Lurie F, Creton D, Eklof B, et al. Prospective randomized study of endovenous radiofrequency obliteration (closure procedure) versus ligation and stripping in a selected patient population (evolves study). *J Vasc Surg* 2003;38:207–214.
321. Navarro L, Min RJ, Bone C. Endovenous laser: a new minimally invasive method of

treatment for varicose veins–preliminary observations using an 810 nm diode laser. *Dermatol Surg* 2001;27:117–122.

322. Proebstle TM, Gul D, Kargl A, et al. Endovenous laser treatment of the lesser saphenous vein with a 940-nm diode laser: early results. *Dermatol Surg* 2003;29:357–361.
323. Min RJ, Khilnani N, Zimmet SE. Endovenous laser treatment of saphenous vein reflux: long-term results. *J Vasc Interv Radiol* 2003;14:991–996.
324. Proebstle TM, Vago B, Alm J, et al. Treatment of the incompetent great saphenous vein by endovenous radiofrequency powered segmental thermal ablation: first clinical experience. *J Vasc Surg* 2008;47:151–156.
325. Lurie F, Creton D, Eklof B, et al. Prospective randomised study of endovenous radiofrequency obliteration (closure) versus ligation and vein stripping (evolves): two-year follow-up. *Eur J Vasc Endovasc Surg* 2005;29:67–73.
326. Perälä J, Rautio T, Biancari F, et al. Radiofrequency endovenous obliteration versus stripping of the long saphenous vein in the management of primary varicose veins: 3-year outcome of a randomized study. *Ann Vasc Surg* 2005;19:669–672.
327. Kianifard B, Holdstock J, Whiteley M. Radiofrequency ablation (Vnus Closure®) does not cause neo-vascularisation at the groin at one year: results of a case controlled study. *Surgeon* 2006;4:71–74.
328. Stötter L, Schaaf I, Bockelbrink A. Comparative outcomes of radiofrequency endoluminal ablation, invagination stripping, and cryostripping in the treatment of great saphenous vein insufficiency. *Phlebology* 2006;21: 60–64.
329. ElKaffas KH, ElKashef O, ElBaz W. Great saphenous vein radiofrequency ablation versus standard stripping in the management of primary varicose veins—a randomized clinical trial. *Angiology* 2011;62:49–54.
330. Theivacumar N, Darwood R, Gough M. Neovascularisation and recurrence 2 years after varicose vein treatment for sapheno-femoral and great saphenous vein reflux: a comparison of surgery and endovenous laser ablation. *Euro J Vasc Endovasc Surg* 2009;38:203–207.
331. Christenson JT, Gueddi S, Gemayel G, et al. Prospective randomized trial comparing endovenous laser ablation and surgery for treatment of primary great saphenous varicose veins with a 2-year follow-up. *J Vasc Surg* 2010;52:1234–1241.
332. Pronk P, Gauw S, Mooij M, et al. Randomised controlled trial comparing sapheno-femoral ligation and stripping of the great saphenous vein with endovenous laser ablation (980 nm) using local tumescent anaesthesia: one year results. *Euro J Vasc Endovasc Surg* 2010;40:649–656.
333. Carradice D, Mekako A, Mazari F, et al. Clinical and technical outcomes from a randomized clinical trial of endovenous laser ablation compared with conventional surgery for great saphenous varicose veins. *Br J Surg* 2011;98:1117–1123.
334. Rass K, Frings N, Glowacki P, et al. Comparable effectiveness of endovenous laser

ablation and high ligation with stripping of the great saphenous vein: two-year results of a randomized clinical trial (relacs study). *Arch Dermatol* 2012;148:49–58.

335. Rasmussen LH, Bjoern L, Lawaetz M, et al. Randomized trial comparing endovenous laser ablation of the great saphenous vein with high ligation and stripping in patients with varicose veins: short-term results. *J Vasc Surg* 2007;46:308–315.
336. Myers K, Cluugh A. Treatment of small saphenous vein reflux. In: Bergan JJ, ed. *The Vein Book.* Boston, MA: Elsevier Academic Press; 2007:139–155
337. Neglen P, Einarsson E, Eklof B. The functional long-term value of different types of treatment for saphenous vein incompetence. *J Cardiovasc Surg (Torino)* 1993;34:295–301.
338. Rigby KA, Palfreyman SJ, Beverley C, Michaels JA. Surgery versus sclerotherapy for the treatment of varicose veins [systematic review]. Cochrane Peripheral Vascular Disease Group. *Cochrane Database Syst Rev.* 2008;(3).
339. Keith LM Jr, Smead WL. Saphenous vein stripping and its complications. *Surg Clin North Am* 1983;63:1303–1312.
340. Ramsheyi A, Soury P, Saliou C, et al. Inadvertent arterial injury during saphenous vein stripping: three cases and therapeutic strategies. *Arch Surg* 1998;133:1120–1123.
341. Seror P. [sural nerve neuropathy (external saphenous) linked to a disease of the small saphenous vein. Apropos of 5 cases]. *J Mal Vasc* 2000;25: 128–131.
342. Myers K, Fris R, Jolley D. Treatment of varicose veins by endovenous laser therapy: assessment of results by ultrasound surveillance. *Med J Aust* 2006;185:199–202.
343. Murad MH, Coto-Yglesias F, Zumaeta-Garcia M, et al. A systematic review and meta-analysis of the treatments of varicose veins. *J Vasc Surg* 2011;53:49S-65S.
344. DePalma R. Management of incompetent perforators: conventional techniques. In: *Handbook of Venous Disorders.* 2nd ed. London: Chapman and Hall; 2001:384–390.
345. Gloviczki P, Bergan JJ, Rhodes JM, et al. Mid-term results of endoscopic perforator vein interruption for chronic venous insufficiency: lessons learned from the North American subfascial endoscopic perforator surgery registry. The North American Study Group. *J Vasc Surg* 1999;29:489–502.
346. TenBrook JA Jr, Iafrati MD, O'Donnell TF Jr, et al. Systematic review of outcomes after surgical management of venous disease incorporating subfascial endoscopic perforator surgery. *J Vasc Surg* 2004;39:583–589.
347. Masuda EM, Kessler DM, Lurie F, et al. The effect of ultrasound-guided sclerotherapy of incompetent perforator veins on venous clinical severity and disability scores. *J Vasc Surg* 2006;43:551–556; discussion 556–557.
348. Thibault PK, Lewis WA. Recurrent varicose veins. Part 2: injection of incompetent perforating veins using ultrasound guidance. *J Dermatol Surg Oncol* 1992;18:895–900.
349. Guex JJ. Ultrasound guided sclerotherapy (USGS) for perforating veins (PV). *Hawaii Med J* 2000;59:261–262.
350. Peden E, Lumsden A. Radiofrequency ablation of incompetent perforator veins.

Perspect Vasc Surg Endovasc Ther 2007;19:73–77.
351. Elias S, Peden E. Ultrasound-guided percutaneous ablation for the treatment of perforating vein incompetence. *Vascular* 2007;15:281–289.
352. Bacon J, Dinneen A, Marsh P, et al. Five-year results of incompetent perforator vein closure using transluminal occlusion of perforator. *Phlebology* 2009;24:74–78.
353. Harlander-Locke M, Lawrence P, Jimenez JC, et al. Combined treatment with compression therapy and ablation of incompetent superficial and perforating veins reduces ulcer recurrence in patients with CEAP 5 venous disease. *J Vasc Surg* 2012;55:446–450.
354. Proebstle TM, Herdemann S. Early results and feasibility of incompetent perforator vein ablation by endovenous laser treatment. *Dermatol Surg* 2007;33:162–168.
355. van Gent W, Wittens C. Influence of perforating vein surgery in patients with venous ulceration. *Phlebology* 2013;30:127–132.
356. Luebke T, Brunkwall J. Meta-analysis of subfascial endoscopic perforator vein surgery (SEPS) for chronic venous insufficiency. *Phlebology* 2009;24:8–16.
357. Neglén P, Tackett TP Jr, Raju S. Venous stenting across the inguinal ligament. *J Vasc Surg* 2008;48:1255–1261.
358. Raju S, Owen S Jr, Neglen P. Reversal of abnormal lymphoscintigraphy after placement of venous stents for correction of associated venous obstruction. *J Vasc Surg* 2001;34:779–784.
359. Raju S, McAllister S, Neglen P. Recanalization of totally occluded iliac and adjacent venous segments. *J Vasc Surg* 2002;36:903–911.
360. Neglen P, Hollis KC, Olivier J, et al. Stenting of the venous outflow in chronic venous disease: long-term stent-related outcome, clinical, and hemodynamic result. *J Vasc Surg* 2007;46:979–990.
361. Neglen P. In-stent recurrent stenosis in stents placed in the lower extremity venous outflow tract. *J Vasc Surg* 2004;39:181–188.
362. Hartung O, Loundou A, Barthelemy P, et al. Endovascular management of chronic disabling ilio-caval obstructive lesions: long-term results. *Euro J Vasc Endovasc Surg* 2009;38:118–124.
363. Raju S, Neglén P. Percutaneous recanalization of total occlusions of the iliac vein. *J Vasc Surg* 2009;50:360–368.
364. Rosales A, Sandbaek G, J⊘rgensen J. Stenting for chronic post-thrombotic vena cava and iliofemoral venous occlusions: mid-term patency and clinical outcome. *Euro J Vasc Endovasc Surg* 2010;40:234–240.
365. Raju S. Best management options for chronic iliac vein stenosis and occlusion. *J Vasc Surg* 2013;57:1163–1169.
366. Kölbel T, Lindh M, Åkesson M, et al. Chronic iliac vein occlusion: midterm results of endovascular recanalization. *J Endovasc Ther* 2009;16:483–491.
367. Ye K, Lu X, Li W, et al. Long-term outcomes of stent placement for symptomatic

nonthrombotic iliac vein compression lesions in chronic venous disease. *J Vasc Interv Radiol* 2012;23:497–502.

368. Hartung O, Otero A, Boufi M, et al. Mid-term results of endovascular treatment for symptomatic chronic nonmalignant iliocaval venous occlusive disease. *J Vasc Surg* 2005;42:1138–1144; discussion 1144.
369. Jost CJ, Gloviczki P, Cherry KJ Jr, et al. Surgical reconstruction of iliofemoral veins and the inferior vena cava for nonmalignant occlusive disease. *J Vasc Surg* 2001;33:320–327; discussion 327–328.
370. Garg N, Gloviczki P, Karimi KM, et al. Factors affecting outcome of open and hybrid reconstructions for nonmalignant obstruction of iliofemoral veins and inferior vena cava. *J Vasc Surg* 2011;53:383–393.
371. Akers DL Jr, Creado B, Hewitt RL. Iliac vein compression syndrome: case report and review of the literature. *J Vasc Surg* 1996;24:477–481.
372. Lalka S. Autogenous venous bypass grafts for chronic iliac or infrainguinal venous occlusive disease. In: *Handbook of Venous Disorders.* 2nd ed. London: Arnold; 2001:362–373.
373. Puggioni A, Kistner RL, Eklof B, et al. Surgical disobliteration of postthrombotic deep veins—endophlebectomy—is feasible. *J Vasc Surg* 2004;39: 1048–1052; discussion 1052.
374. Camilli S, Guarnera G. External banding valvuloplasty of the superficial femoral vein in the treatment of primary deep valvular incompetence. *Int Angiol* 1994;13:218–222.
375. Raju S. Venous insufficiency of the lower limb and stasis ulceration. Changing concepts and management. *Ann Surg* 1983;197:688–697.
376. Sottiurai VS. Technique in direct venous valvuloplasty. *J Vasc Surg* 1988;8:646–648.
377. Tripathi R, Ktenidis KD. Trapdoor internal valvuloplasty—a new technique for primary deep vein valvular incompetence. *Eur J Vasc Endovasc Surg* 2001;22:86–89.
378. Raju S, Fredericks R. Valve reconstruction procedures for nonobstructive venous insufficiency: rationale, techniques, and results in 107 procedures with two- to eight-year follow-up. *J Vasc Surg* 1988;7:301–310.
379. Kistner R. Surgical technique of external venous valve repair. *Straub Found Proc* 1990;55:15–16.
380. Belcaro G, Nicolaides AN, Ricci A, et al. External femoral vein valvuloplasty with limited anterior plication (LAP): a 10-year randomized, follow-up study. *Angiology* 1999;50:531–536.
381. Gloviczki P, Merrell SW, Bower TC. Femoral vein valve repair under direct vision without venotomy: a modified technique with use of angioscopy. *J Vasc Surg* 1991;14:645–648.
382. Raju S, Berry MA, Neglen P. Transcommissural valvuloplasty: technique and results. *J Vasc Surg* 2000;32:969–976.
383. Lane RJ, Cuzzilla ML, McMahon CG. Intermediate to long-term results of repairing

incompetent multiple deep venous valves using external valvular stenting. *Anz J Surg* 2003;73:267–274.

384. Guarnera G, Furgiuele S, Mascellari L, et al. External banding valvuloplasty of the superficial femoral vein in the treatment of recurrent varicose veins. *Int Angiol* 1998;17:268–271.
385. Taheri SA, Lazar L, Elias SM, et al. Vein valve transplant. *Surgery* 1982;91:28–33.
386. Raju S, Neglen P, Doolittle J, et al. Axillary vein transfer in trabeculated postthrombotic veins. *J Vasc Surg* 1999;29:1050–1062; discussion 1062–1054.
387. Sottiurai V. Supravalvular incision for valve repair in primary valvular insufficiency. In: Bergan JJ, Kistner RL, eds. *Atlas of Venous Surgery*. Philadelphia, PA: WB Saunders; 1992:137–138.
388. Cardon JM, Cardon A, Joyeux A, et al. Use of ipsilateral greater saphenous vein as a valved transplant in management of post-thrombotic deep venous insufficiency: long-term results. *Ann Vasc Surg* 1999;13:284–289.
389. Poller L, McKernan A, Thomson JM, et al. Fixed minidose warfarin: a new approach to prophylaxis against venous thrombosis after major surgery. *Br Med J (Clin Res Ed)* 1987;295:1309–1312.
390. Welch HJ, McLaughlin RL, O'Donnell TF Jr. Femoral vein valvuloplasty: intraoperative angioscopic evaluation and hemodynamic improvement. *J Vasc Surg* 1992;16:694–700.
391. Jamieson WG, Chinnick B. Clinical results of deep venous valvular repair for chronic venous insufficiency. *Can J Surg* 1997;40:294–299.
392. Tripathi R, Sieunarine K, Abbas M, et al. Deep venous valve reconstruction for non-healing leg ulcers: techniques and results. *ANZ J Surg* 2004;74:34–39.
393. Kistner RL. Surgical repair of the incompetent femoral vein valve. *Arch Surg* 1975;110:1336–1342.
394. Ferris EB, Kistner RL. Femoral vein reconstruction in the management of chronic venous insufficiency. A 14-year experience. *Arch Surg* 1982; 117:1571–1579.
395. Eriksson I, Almgren B. Influence of the profunda femoris vein on venous hemodynamics of the limb. Experience from thirty-one deep vein valve reconstructions. *J Vasc Surg* 1986;4:390–395.
396. Lurie F, Makarova NP, Hmelniker SM. Results of deep-vein reconstruction. *Vasc Surg* 1997;31:275.
397. Perrin M. Results of deep-vein reconstruction. *Vasc Surg* 1997;31:273.
398. Perrin M, Hiltbrand B, Bayon JM. Results of valvuloplasty in patients presenting deep venous insufficiency and recurring ulceration. *Ann Vasc Surg* 1999;13:524–532.
399. Taheri SA, Elias SM, Yacobucci GN, et al. Indications and results of vein valve transplant. *J Cardiovasc Surg (Torino)* 1986;27:163–168.
400. O'Donnell TF Jr, Mackey WC, Shepard AD, et al. Clinical, hemodynamic, and anatomic follow-up of direct venous reconstruction. *Arch Surg* 1987; 122:474–482.

401. Nash T. Long term results of vein valve transplants placed in the popliteal vein for intractable post-phlebitic venous ulcers and pre-ulcer skin changes. *J Cardiovasc Surg (Torino)* 1988;29:712–716.
402. Rai DB, Lerner R. Chronic venous insufficiency disease. Its etiology. A new technique for vein valve transplantation. *Int Surg* 1991;76:174–178.
403. Bry JD, Muto PA, O'Donnell TF, et al. The clinical and hemodynamic results after axillary-to-popliteal vein valve transplantation. *J Vasc Surg* 1995;21: 110–119.
404. Sottiurai V. Results of deep-vein reconstruction. *Vasc Surg* 1997;31:276.
405. Rosales A, Slagsvold CE, Kroese AJ, et al. External venous valve plasty (EVVP) in patients with primary chronic venous insufficiency (PCVI). *Eur J Vasc Endovasc Surg* 2006;32:570–576.
406. Plagnol P, Ciostek P, Grimaud JP, et al. Autogenous valve reconstruction technique for post-thrombotic reflux. *Ann Vasc Surg* 1999;13:339–342.
407. Maleti O, Lugli M. Neovalve construction in postthrombotic syndrome. *J Vasc Surg* 2006;43:794–799.
408. Corcos L, Peruzzi G, Procacci T, et al. A new autologous venous valve by intimal flap. One case report. *Minerva Cardioangiol* 2003;51:395–404.
409. Lugi M GS, Maleti O. Neovalve construction in deep venous incompetence: comparison between two subsequent case series and related technical details. Paper presented at: The American Venous Forum 20th Annual Meeting; February 20–23, 2008; Charleston, SC.
410. Etufugh CN, Phillips TJ. Venous ulcers. *Clin Dermatol.* 2007;25:121–130.
411. Stacey MC, Mata SD, Trengove NJ, et al. Randomised double-blind placebo controlled trial of topical autologous platelet lysate in venous ulcer healing. *Eur J Vasc Endovasc Surg* 2000;20:296–301.
412. Khan MN, Davies CG. Advances in the management of leg ulcers—the potential role of growth factors. *Int Wound J* 2006;3:113–120.
413. Palfreyman SJ, Nelson EA, Lochiel R, et al. Dressings for healing venous leg ulcers. *Cochrane Database Syst Rev.* 2007;(3).
414. Lau J, Tatsioni A, Balk E, et al. *Usual Care in the Management of Chronic Wounds: a Review of the Recent Literature [Internet]*. Rockville, MD: Agency for Healthcare Research and Quality (US); 2005.
415. Limova M, Troyer-Caudle J. Controlled, randomized clinical trial of 2 hydrocolloid dressings in the management of venous insufficiency ulcers. *J Vasc Nurs* 2002;20:22–32; quiz 33–34.
416. Williams D, Enoch S, Miller D, et al. Effect of sharp debridement using curette on recalcitrant nonhealing venous leg ulcers: a concurrently controlled, prospective cohort study. *Wound Repair Regen* 2005;13:131–137.
417. Brem H, Sheehan P, Boulton AJ. Protocol for treatment of diabetic foot ulcers. *Am J Surg* 2004;187:1S–10S.

418. Cardinal M, Eisenbud DE, Armstrong DG, et al. Serial surgical debridement: a retrospective study on clinical outcomes in chronic lower extremity wounds. *Wound Repair Regen* 2009;17:306–311.

419. Mostow EN, Haraway GD, Dalsing M, et al. Effectiveness of an extracellular matrix graft (oasis wound matrix) in the treatment of chronic leg ulcers: a randomized clinical trial. *J Vasc Surg* 2005;41:837–843.

420. Briggs M, Nelson EA. Topical agents or dressings for pain in venous leg ulcers. *Cochrane Database Syst Rev.* 2003;(1).

421. Cardinal M, Eisenbud DE, Phillips T, et al. Early healing rates and wound area measurements are reliable predictors of later complete wound closure. *Wound Repair Regen* 2008;16:19–22.

422. Schmeller W, Gaber Y. Surgical removal of ulcer and lipodermatosclerosis followed by split-skin grafting (shave therapy) yields good long-term results in “non-healing” venous leg ulcers. *Acta Derm Venereol* 2000;80:267–271.

423. Jankunas V, Bagdonas R, Samsanavicius D, et al. An analysis of the effectiveness of skin grafting to treat chronic venous leg ulcers. *Wounds* 2007;19:128–137.

424. Jones J. Skin grafting for venous leg ulcers. *Cochrane Database Syst Rev* 2007;(3).

425. Falanga V, Margolis D, Alvarez O, et al. Rapid healing of venous ulcers and lack of clinical rejection with an allogeneic cultured human skin equivalent. Human Skin Equivalent Investigators Group. *Arch Dermatol* 1998;134:293–300.

426. Richardson G, Driver B. Ovarian vein ablation: coils or surgery? *Phlebology* 2006;21:16–23.

427. Scultetus AH, Villavicencio JL, Gillespie DL, et al. The pelvic venous syndromes: analysis of our experience with 57 patients. *J Vasc Surg* 2002;36:881–888.

SECTION N: PEDIATRIC SURGERY

Chapter 99

Fetal, Neonatal, and Pediatric Physiology

Samir K. Gadepalli and George B. Mychaliska

Key Points

1 Certain aspects of fetal and neonatal physiology differ markedly from adult physiology, whereas the physiology of older children and adolescents approximates adult physiology.

2 During fetal life, the right ventricle provides about 65% of the fetal cardiac output and the left ventricle ejecting the remaining 35%.

3 Prematurity and critical illness are both associated with persistent fetal circulation. Under these conditions, the RV continues to contribute a large portion of the cardiac output and the postductal saturations will be significantly lower than the preductal saturations.

4 Surfactant is a mixture of phospholipids, neutral lipids, and specific proteins that, by virtue of their amphipathic nature, decrease surface tension, stabilize small alveoli, and improve overall alveolar inflation.

5 The neonatal heart increases its cardiac output primarily through increases in heart rate.

6 The primary cause of neonatal bradycardia is hypoxia.

7 Ventricular septal defect (VSD) is the most common heart defect occurring in nearly a third of neonates with congenital heart disease.

8 Patent ductus arteriosus: fluid restriction is the first line of therapy when appropriate with indomethacin reserved for persistent cases to help stimulate closure.

9 An infant enduring water deprivation can only increase urine osmolality to 600 mOsm/kg, whereas adults can concentrate to 1,200 mOsm/kg.

10 A term newborn grows at 25 to 30 g/d over the first 6 months, doubling their birth weight by 5 months, tripling it by 12 months.

11 The enteral nutrition of choice in neonates is breast milk even in the premature or very low–birth-weight (<1,500 g) infant.

INTRODUCTION

An understanding of fetal, neonatal, and pediatric physiology is critical to understanding the pathophysiology and treatment of fetal and pediatric surgical problems. As distinct from adult physiology, fetal, neonatal, and pediatric physiology must account for varying degrees of growth and maturation and for major physiologic transitions particularly from the prenatal to the postnatal period. New insights into fetal and neonatal physiology coupled with technologic advances have led to pioneering treatment approaches for congenital anomalies and the treatment of extreme prematurity.

1 First, although the old pediatric surgical adage "children are not small adults" still holds true, the physiology of older children begins to approximate the physiology of adults. As such, this chapter focuses primarily on the unique and distinguishing physiology of the fetus and neonate. Since prematurity remains an unsolved problem, a section is also devoted to this cohort of neonates.

Second, the topic of physiology is broad and it was impossible to cover each organ system in depth. We focused on critical topics that are necessary to the practice of pediatric surgery and touched on areas that are innovative and promising.

Third, where applicable, we intended to also make this resource practical to the practice of pediatric surgery. Where applicable, we discuss specific pediatric surgical diseases to illustrate physiologic principles. Similarly, some aspects of medical management as it relates to unique physiology are discussed.

Finally, we acknowledge that our understanding of fetal, neonatal, and pediatric physiology is not static and remains an exciting area of scientific inquiry. As our knowledge grows, we can not only better understand pathophysiology of pediatric diseases, but also develop effective medical and surgical treatments.

Fetal Physiology

Fetal Morphogenesis

The human embryo begins as a single cell. During gestation, a fertilized egg divides and differentiates into more than 200 different morphologically recognizable cell types. Development begins with the fusion of the male and female gametes at fertilization. The earliest form of an embryo is called a zygote. Initially, the diploid chromosome number is restored by fusion of the two haploid gametes from each parent.

The zygote undergoes a series of mitotic divisions and by the 8- and 16-cell stage, the embryo is called a blastocyst and consists of a clump of cells termed the inner cell mass, that are surrounded by a layer of trophoblast cells. Subsequent differentiation of the trophoblast results in a double-layered membrane which is a progenitor tissue of the chorion, the fetal portion of the placenta. Once the zona pellucida is shed, the blastocyst attaches and implants within the uterine endometrium. At the beginning of the third week of development, gastrulation ensues and is characterized by morphogenetic movements resulting in a primitive streak. Some epiblast cells enter the streak, while others remain within the epiblast to become the embryonic ectoderm. At the primitive streak, sets of polarized epithelial cells within the epiblast transform into nonpolarized free cells termed mesenchyme, the second embryonic tissue. These events are mediated by adhesive molecules located on the cell surface as well as expression of homeobox genes and other signaling molecules leading to patterning of axial and nonaxial structures. The primitive streak provides a means by which subsets of epiblast cells can ingress and be distributed to more ventral regions of the embryo as the endoderm and the mesoderm. The first cells through the streak comes the endoderm followed by cells that form the notochord which defines the axis of the embryo and plays a significant role in the nervous system. Due to cleavage and gassed relation, population of cells in various stages of the termination, are brought together in new spatial relationships, which permits new tissue interactions. Subsequent organogenesis results from these tissue interactions. These interactions are mediated by a variety of signaling molecules such as growth factors, secreted factors, and transcriptions factors, produced by cells and often concentrated in the extracellular matrix. The embryology and physiology of select organ systems will now be described.

Lung Development

The respiratory system consists of elements of air conduction and exchange. The uptake of oxygen from the environment and removal of carbon dioxide serves to maintain cellular aerobic metabolism and acid–base balance. In order to effectively perform these processes, normal structural and cellular development is essential. The respiratory system must develop through five phases: embryonic, pseudoglandular, canalicular, saccular, and alveolar. The boundaries between these phases merge into each other with overlap at any given time point between areas of the lung and vary temporally between individuals.[1]

Embryonic Phase (3 to 7 Weeks). Lung growth begins around postconception (p.c.) day 25 or 26 with the outgrowth of a small diverticulum from the ventral wall of the foregut

called the primitive respiratory diverticulum or lung bud. This extends in the ventral caudal direction into the surrounding mesoderm, growing anterior and parallel to the primitive esophagus. Within a few days, the grove between the diverticulum and the foregut closes with the only luminal attachment remaining at the site of the future hypopharynx and larynx.[2] By p.c. day 28, the respiratory diverticulum bifurcates into the right and left primary bronchial buds. This is followed by a second round of branching occurring around the fifth week p.c. yielding the secondary bronchial buds. Finally, the third branching takes place during the sixth week p.c. producing 10 tertiary bronchi on the right and 8 on the left. The vascular components of the respiratory system also begin to develop with the pulmonary arteries forming as branches off the sixth aortic arch and the pulmonary veins emerging from the developing heart.

The primitive lung bud is lined by epithelium derived from endoderm which will become the epithelium lining the airways and alveoli. The lung buds grow into the surrounding mesodermal cells which will differentiate into the blood vessels, smooth muscle, cartilage, and other connective tissue. Ectoderm will eventually give rise to the innervation of the lung.[1]

Pseudoglandular Phase (5 to 17 Weeks). The lung begins to take on a glandular appearance during this stage of development. The lung is composed of multiple epithelial tubules surrounded by extensive regions of mesenchyme, giving a glandular appearance. Cellular proliferation rate increases during this stage and by p.c. week 16, all bronchial divisions are completed with further growth occurring only by elongation and widening of existing airways. The intrapulmonary arterial system develops branching in parallel with the bronchial and bronchiolar tubules. The respiratory epithelium begins to differentiate with cilia appearing in the proximal airways and cartilage begins to develop to support the airways.[1] Concurrently, closure of the pleuroperitoneal folds is completed.

Canalicular Stage (16 to 26 Weeks). This stage is named due to the appearance of vascular canals or capillaries and the increase in the interstitial compartments forming the air–blood barrier. The capillary beds rapidly expand with condensation and thinning of the mesenchyme, starting the first critical step in the formation of the gas exchange regions of the lung. The ingrowth of capillaries results in thinning in one population of overlying epithelial cells, narrowing the air–blood interface and differentiating into type I pneumocytes. In other overlying epithelial cells, lamellar bodies associated with surfactant synthesis appear, identifying type II pneumocytes. The airways continue to develop with completion of the airways through the level of the terminal bronchioles with their associated acinus. Branching of the distal airspaces continues until there are a total of 23 subdivisions.

Saccular Stage (24 to 38 weeks). During this stage, the terminal clusters of acinar tubules and buds dilate and expand into transitory alveolar saccules and ducts with a marked reduction of the surrounding mesenchymal tissue. By 24 weeks, there is a sufficiently thin alveolar-capillary membrane distance to participate in gas exchange (0.6

μm) with the efficacy of exchange being determined beyond this point by the total surface area available for exchange. By the end of this stage, three additional generations of alveolar ducts have formed and the conducting airways have developed mucous and ciliated cells. Overall, cell proliferation slows and ultrastructural cytodifferentiation occurs. The saccules consist of smooth-walled airspaces and a thick interstitial space. Type II epithelial cells continue to mature and there is an increase in surfactant synthesis, but overall levels remain low.

Alveolar Stage (36 Weeks to 2 Years). This is the final stage of lung development and is characterized by the formation of secondary alveolar septa which divide the terminal ducts and saccules into true alveolar ducts and alveoli. There is maturation of the alveolar-capillary membrane, which increases the surface area for gas exchange. As the terminal saccule restructures during this stage, the double capillary network fuse becoming a single capillary network with each capillary being simultaneously exposed to at least two alveoli. The barrier to gas exchange thins to a few nanometers. Type I and type II cells increase in number, but only type II cells are proliferating actively suggesting that type I cells are derived from type II cells.

Physiologic Control of Fetal Lung Growth

While the fetus and neonate proceed through the phases of lung growth and development, physical factors play an important role in directing and assisting in this process. While not all factors affecting this process are well understood, the role of fetal lung fluid (FLF) and mechanical distension appear to play critical roles. During fetal life, the lung produces a unique fluid, FLF that is a result of net transepithelial chloride and sodium flux and is produced within the lungs and leaves via the trachea.[3] As the fluid moves from the lung toward the oropharynx, it is either swallowed or enters the surrounding amniotic fluid. Throughout gestation, the volume of FLF increases with studies in ovine animals demonstrating FLF volume of 35 to 45 mL/kg which is significantly higher than functional residual capacity (FRC) postbirth (25 to 30 mL/kg).[4] This keeps the airway distended in order to stimulate growth.

The volume of FLF is primarily regulated by the resistance to lung liquid efflux through the upper airways and by fetal breathing movements (FBM) which include the associated diaphragmatic activity and the volume is largely independent of production. When there is no FBM (apnea), the transpulmonary pressure is usually 1 to 2 mm Hg above the amniotic sac pressure due to the elastic recoil of the chest wall. Lung fluid efflux is prevented by high resistance of the upper airways which prevent FLF loss and maintains an approximately 2 mm Hg distending pressure and fetal lung expansion.[5] During periods of FBM, the larynx actively dilates to decrease the resistance to FLF efflux allowing fluid to leave at an increased rate. To compensate during periods of FBM, rhythmic contraction of the diaphragm slows the loss of lung fluid and helps to maintain lung expansion during periods of low upper airway resistance demonstrating that FBM serve to maintain lung expansion and promote lung growth. Sustained reduction of fetal lung expansion can slow the structural development of both the vascular bed and alveolar epithelial cell

phenotypes. On the other hand, prolonged overexpansion of the fetal lungs via tracheal occlusion is a potent stimulator for fetal lung growth and tissue remodeling.[6]

Additionally, it has been observed that fetal airways undergo peristaltic contractions similar to the gut which move intraluminal contents distally and cause expansion of end buds which also likely play a role in fetal lung growth and expansion.[7] Postnatal formation of significant numbers of alveoli continues to occur for the first 1.5 to 3 years after birth with the lung growth continuing for another 15 to 18 years when the chest wall stops growing.

Fetal Circulation and Placental Gas Exchange

The umbilicoplacental circulation is critical for normal growth and development of the fetus. The umbilical artery and vein are long and muscular and the placental vascular bed is high flow and low resistance. Although the umbilical vessels are highly vasoactive, they remain nearly maximally dilated during pregnancy. The umbilical arteries arise from the internal iliac arteries and curve along either side of the bladder before entering the umbilical cord where they form a loose spiral around a single umbilical vein. The umbilical arteries branch at the fetal surface of the placenta to form many radially oriented chorionic arteries located on the surface of the chorionic plate. Veins within the villi merge progressively to return blood from the placenta to the chorionic veins on the fetoplacental surface entering a single umbilical vein. Venous blood is then returned to the fetal inferior vena cava through the parallel arrangement of the ductus venosus and the hepatic vessels. The ductus venosus plays a critical role in fetal circulation because it shunts highly oxygenated and nutrient-rich umbilical venous blood to the brain and myocardium instead of the fetal liver. The percentage of umbilical blood flow bypassing the hepatic circulation through the ductus venosus decreases from approximately 40% at midgestation to 20% at term.[8]

The fetal circulation with intra- and extracardiac shunts permits the lungs to be bypassed and results in the delivery of more highly oxygenated blood flow to the brain and heart. Due to the shunts, fetal organs receive blood from both ventricles which forms a parallel circulation. The ductus venosus, foramen ovale, and ductus arteriosus (DA) are the shunts required for fetal circulation. The first shunt encountered is the ductus venosus, which shunts half of the blood away from the liver directly to the heart. Highly oxygenated blood from the ductus venosus mixes with blood from the interior vena cava, but preferential streaming directs blood with more oxygen across the foramen ovale into the left atrium. As a result, highly oxygenated blood travels to the left ventricle and is ejected into the aorta, thus feeding the coronary arteries and arteries to the brain. In contrast, the mostly deoxygenated blood from the superior vena cava (SVC) tends to stream directly into and across the tricuspid valve into the right ventricle, where it is then ejected out the pulmonary artery. Due to the high pulmonary vascular resistance, the blood is shunted via the DA, entering the proximal descending aorta just past the left subclavian artery at the end of the aortic arch. The shunted blood entering the descending aorta perfuses the lower body and returns to the placenta via the umbilical arteries. Only 10% of the combined cardiac output (CO) perfuses the lungs (Fig. 99-1).

2 Fetal CO is described as combined ventricular output or combined CO. The right ventricle ejects against high-resistance lungs and lower body and low-resistance DA and placenta. The left ventricle ejects against high-resistance brain, upper body, and aortic isthmus. Given a lower afterload, the right ventricle provides about 65% of the fetal CO and the left ventricle ejecting the remaining 35%.

Umbilical blood flow gradually increases as the fetus grows. The umbilical blood flow during the third trimester remains fairly constant at 110 to 125 mL/min/kg of fetal weight.[9,10] Fetal biventricular CO is approximately 450 mL/min/kg and remains fairly constant. Thus, umbilical blood flow represents approximately 30% of fetal biventricular CO. The integrity of the placental circulation is essential to fetal growth and development. Total uterine blood flow increases substantially during pregnancy, but umbilicoplacental blood flow remains approximately 200 mL/min/kg of fetal weight throughout gestation. Blood flow is mediated by a number of factors including ANG II, catecholamines, arginine vasopressin (AVP), nitric oxide (NO), prostaglandins, estrogen, and progesterone. The placental has many physiologic functions. Placental transfer, not just flow, is involved in determining fetal growth. Idiopathic intrauterine growth restriction (IUGR) has been attributed to placental insufficiency due to oxygen delivery, flow, and transfer of nutrients particularly amino acid transporters. In IUGR, fetuses fail to achieve their full growth potential due to infection, drug abuse, maternal malnutrition, and placental insufficiency. Umbilical blood flow is lower in growth-restricted fetuses.[11]

Fetal Cardiac Function and Oxygen Delivery

The fetus has immature structure, function, and innervation of the heart. The fetal heart is less compliant and thus shows a reduced ability to augment CO with changes in preload. The negative increased afterload on CO is exaggerated in the fetal heart. The Frank–Starling mechanism seems to remain the major regulator of CO in the fetus.

While fetal oxygen transport system is set up to provide optimal oxygen delivery and has the capacity to adjust delivery to match demand in the setting of the intrauterine environment, this system can be stressed as it adjusts to life outside the womb. The delivery of oxygen to tissues depends on the pressure gradient between the blood and the mitochondria and varies with regional oxygen delivery, tissue oxygen consumption and hemoglobin–oxygen affinity.

Oxygen is transported through the blood stream either dissolved in aqueous solution or bound to hemoglobin. Arterial oxygen content can be calculated using the formula: arterial oxygen content = $(Hgb \times 1.36 \times SaO_2) + (0.0031 \times PaO_2)$ where Hgb is hemoglobin concentration in grams, SaO_2 is the arterial saturation of hemoglobin, and PaO_2 is the arterial partial pressure of oxygen. If hemoglobin is 100% saturated then 1g of hemoglobin can deliver 1.36 mL of oxygen. The actual amount of oxygen carried by hemoglobin is variable and is defined by the hemoglobin disassociation curve (Fig. 99-2).

Normally, hemoglobin is close to 100% saturated, however, the sigmoidal nature of the curve ensures that the hemoglobin saturation remains high even at low PaO_2. The hemoglobin disassociation curve is not static and hemoglobin's affinity for oxygen can be

influenced by a number of factors. Hemoglobin has an increased affinity for oxygen with a left shift of the oxygen disassociation curve in alkalosis, hypothermia, decreased 2,3 diphosphoglycerate (DPG) or fetal hemoglobin. Hemoglobin's affinity for oxygen decreases in the setting of acidosis, hyperthermia, or increased 2,3 DPG. This facilitates unloading of oxygen at lower flow to the peripheral tissues.

Fetal hemoglobin (HgbF) plays an important role in the transport and unloading of oxygen in the fetal and neonatal periods. Human hemoglobin consists of three basic chain structures which include the alpha chain, beta chain, and gamma chain which make hemoglobin A (HgbA) of ($\alpha 2\beta 2$) and hemoglobin F (HgbF) ($\alpha 2\gamma 2$). The beta and gamma chains differ from each other by a few amino acid residues. The fetal hemoglobin has a significantly higher affinity for oxygen which favors uptake of hemoglobin across the placenta. Near term there is a period of accelerated erythropoiesis during which HgbA synthesis predominates with a gradual orderly, and not completely understood, transition in synthesis from γ to β hemoglobin chains.[12]

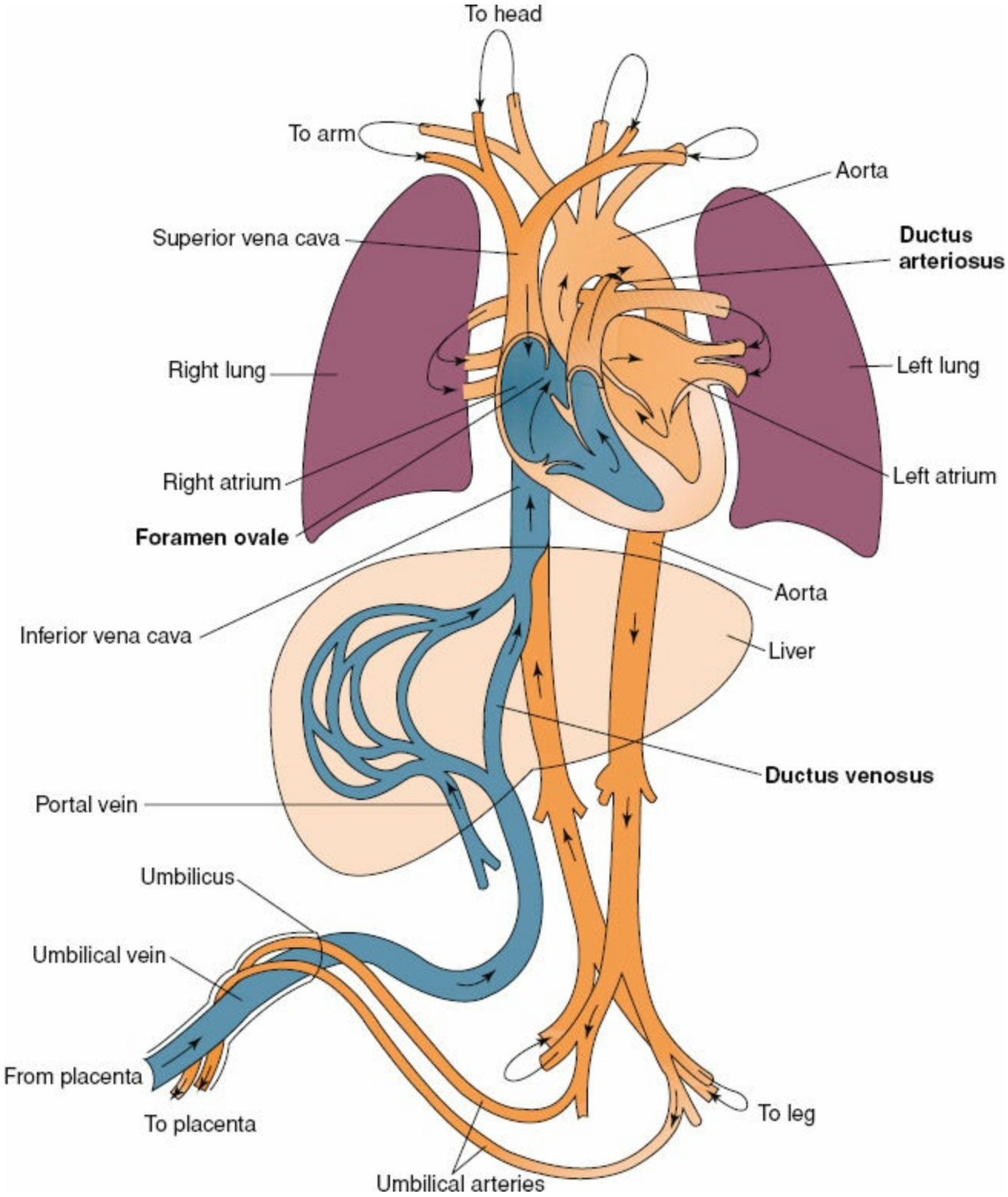

Figure 99-1. Fetal circulation. (From Rosdahl CB, Kowalski MT, eds. *Textbook of Basic Nursing.* Philadelphia, PA: Wolters Kluwer Health; 2012.)

Transition to Postnatal Life

3 One of the most critical and fascinating periods in human physiology is the changes which occur, usually in a matter of minutes, which allows a human to transition from surviving in the uterine environment to the external environment. Around the time of birth, epithelial cells cease production of lung fluid and begin to actively absorb it back into the fetal circulation. This process is facilitated by active sodium transport which is stimulated by thyroid hormone, glucocorticoids, and epinephrine.[1] During the first

breaths, pulmonary arterial pO_2 increase and pCO_2 decrease resulting in pulmonary vascular dilation, decreased pulmonary vascular resistance, and constriction of the DA. Although pulmonary vascular resistance decreases dramatically at birth, pulmonary artery pressure, pulmonary blood flow, and pulmonary vascular resistance decrease gradually over the first few weeks of life. The increased pulmonary blood flow results in an increase in left atrial pressure and as a result, the flap-like foramen ovale closes in response to higher left atrial pressures relative to right atrial pressure. The RV compliance gradually increases as well, and the resultant change in the differences in ventricular compliance allows the flap of the foramen ovale to gradually close over in the first few days to week of life, minimizing mixing, so that the outputs of the left and right ventricles become equivalent. The DA closes in the first 24 to 48 hours of life as a result of changes in direction of flow, contractile elements, an increase in pO_2, a drop in PGE synthesized by the placenta, and other humoral factors. Removal of the placenta results in a decrease in circulating prostaglandin levels and increasing pO_2 levels are a stimulus for ductal closure. When the foramen ovale or DA does not close, they are referred as patent foramen ovale (PFO) and patent ductus arteriosus (PDA). Certain clinical conditions may contribute to the persistence of fetal circulation or to the reappearance of fetal shunts under stress. Prematurity and critical illness are both associated with persistent fetal circulation. Under these conditions, the RV continues to contribute a large portion of the CO and the postductal saturations will be significantly lower than the preductal saturations. In premature infants, the transition may be much slower and the DA may not close despite the usual changes in systemic and pulmonary vascular resistance and the subsequent reversal of flow. Cessation of umbilical blood flow results in closure of the ductus venosus and increase in systemic vascular resistance. This increases the left-sided heart pressures and closes the foramen ovale. With these changes, the transition to postnatal circulation is complete and the process of postnatal pulmonary dependence is initiated.

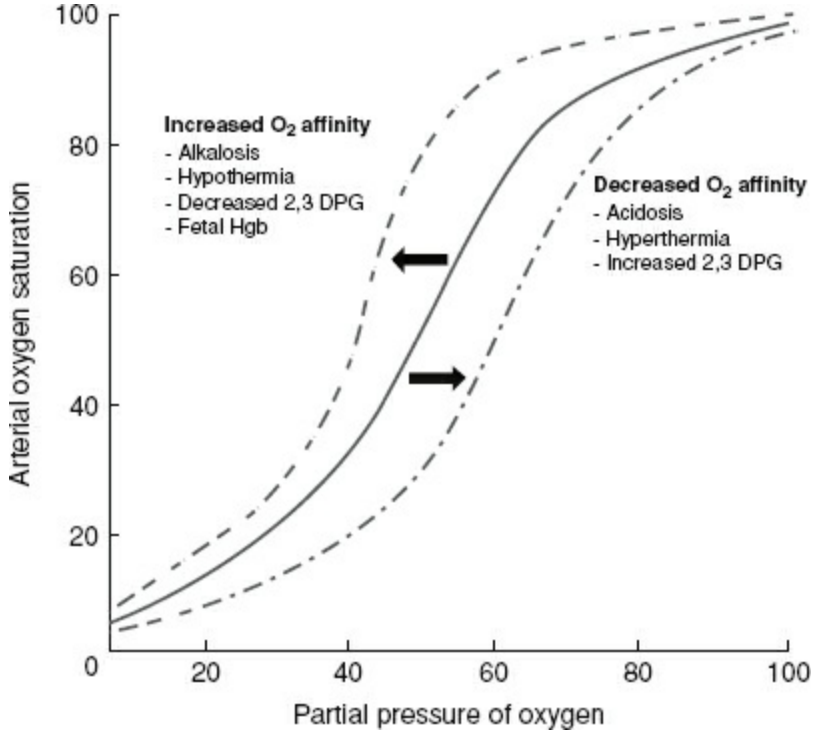

Figure 99-2. The oxygen dissociation curve shows the percent saturation of Hgb at various partial pressure of oxygen and demonstrates the equilibrium between oxyhemoglobin and deoxyhemoglobin. The sigmoidal shape is a result of the cooperative binding between the four hemoglobin polypeptide chains. An important point is the P_{50} which is the partial pressure of oxygen at which erythrocytes are 50% saturated with oxygen. When oxygen partial pressure is high, such as in the lungs, hemoglobin binds oxygen with increased affinity. When the partial pressure of oxygen decreases such as in the peripheral tissues, oxygen is preferentially unloaded. Multiple factors including acid–base, temperature, and 2,3 DPG affect hemoglobins affinity for oxygen shifting the curve resulting in more or less unloading of oxygen at a given partial pressure.

In order for gas exchange to occur in the developing lung, there needs to be intimate contact between atmospheric oxygen and capillary blood flow. This requires adequate alveolar ventilation and pulmonary blood flow. The neonate has a number of physiologic mechanisms which allow for matching alveolar ventilation (V) and pulmonary perfusion (Q) to optimize gas exchange. To accomplish this, an adequate alveolar gas volume and FRC must be established shortly after birth and sustained. Once the FRC is established, this serves as an intrapulmonary pool of oxygen. However, newborns are at increased risk for hypoxemia due to lower than adult pO2 with less intravascular reserve, FRC closer to airway closure, and high metabolic demand in infancy resulting in quicker depletion of oxygen stores.

At birth, the oxygen demand in the infant increases in most species by 100% to 150%. Consequently, fetal hemoglobin with its increased oxygen affinity which was adequate for a fetus does not provide enough oxygen diffusion and delivery in the neonate. Postnatally, the infant's affinity decreases rapidly and reaches normal adult values by 4 to 6 months which corresponds to the amount of time necessary for the replacement of fetal hemoglobin by adult hemoglobin.[13] The amount of HgbF decreases from around 75% to approximately 2% during the first year of life. Until this occurs, other mechanisms help the neonate to cope with the ex utero environment. One of the most important is an

increase in the concentration of 2,3 DPG during the first few days of life. At birth, its level is near an adult's level of 5.43 ± 1.04 and increases to 6.58 ± 1.00. This increase has a small direct effect on fetal hemoglobin, but also lowers the intracellular pH and thus decreases hemoglobin's affinity for oxygen.[14]

Surfactant

4 While many factors play a critical role in allowing for a smooth transition, one of the most clinically relevant pieces is the role surfactant in neonatal pulmonary mechanics and gas exchange. In pulmonary physiology, an important concept is surface tension and its effects on the pressure drop across an interface separating two phases of matter which was defined in the early 1800s by Young and Laplace.[15] The pressure drop necessary to maintain or inflate air sacs of a given size is proportional to its surface tension and inversely proportional to its radius. The work of breathing is consequently directly proportional to the surface tension. During development, surfactant production increases as type II pneumocytes mature and alveoli increase in size. Surfactant is a mixture of phospholipids, neutral lipids, and specific proteins that, by virtue of their amphipathic nature, decrease surface tension, stabilize small alveoli, and improve overall alveolar inflation. Surfactant reduces the hydrostatic driving force for pulmonary edema and decreases work of breathing. When deficient, it can lead to severe respiratory failure. Exogenous administration has been proven effective in prophylactic or rescue treatment for respiratory distress syndrome (RDS) in premature infants with a 40% reduction in death and a 30% to 50% reduction in the odds of pulmonary air leaks.[16] Additionally, vitamin A supplementation may reduce the risk of chronic lung disease (CLD) in extremely low–birth-weight infants and was recommended in infants under 1,000-g birth weight though further studies have failed to confirm the finding.[17,18]

Fetal Interventions

Fetal surgery has emerged as an independent subspecialty at the intersection of pediatric surgery, maternal fetal medicine, and neonatology. It is a field that has arisen from clinical necessity. Pediatric surgeons, maternal fetal medicine specialists, and neonatologists became frustrated with the management of a number of congenital structural anomalies in which the baby died or suffered severe life-long disability despite all efforts at postnatal treatment. With the advent of prenatal ultrasound in the 1970s, many conditions were diagnosed before birth. Fetuses were followed and the prenatal natural history was elucidated. It became clear that a component of organ failure was acquired because of ongoing alterations in fetal development caused by the anomaly. Thus, it made sense that fetal interventions may be of benefit – to correct the pathophysiology to restore normal fetal development in the hope of improving survival and decreasing morbidity.

Criteria that must be met to consider fetal surgery include: (a) accurate diagnosis of the condition and any associated anomalies that may have an impact on outcome; (b) reliable prediction of which individual fetuses will die or suffer serious long-term morbidity without fetal intervention; and (c) demonstration of improved fetal outcome with minimal maternal risk.

Fetal imaging is a critical component of the decision making process in fetal surgery. Prenatal detection and serial ultrasonographic evaluation of these disorders have enhanced our understanding of their natural history and pathophysiology, and have

significantly improved perinatal management. Fetal conditions that may benefit from in utero intervention by a pediatric surgeon include myelomeningocele, twin to twin transfusion syndrome, sacrococcygeal teratoma (SCT), congenital diaphragmatic hernia (CDH), and congenital lung lesions (CLLs).

Sacrococcygeal Teratoma

The evolution of high-output cardiac failure before the development of placentomegaly and hydrops in a fetus with SCT is the sole indication for fetal surgical intervention. Furthermore, SCT may lead to maternal mirror syndrome (Ballantine syndrome).[19] Fetal echocardiography and Doppler ultrasound measurements are important in the diagnostic assessment and follow-up of fetuses with these conditions. Increased aortic velocity, increased combined CO, increased cardiac-to-thoracic ratio, a dilated inferior vena cava, or reversed end-diastolic umbilical blood flow appears to be sensitive early predictors of impending hydrops and fetal demise.[20,21] For fetuses under 28 weeks estimated gestational age (EGA), open fetal surgery and resection is the treatment of choice.

Congenital Diaphragmatic Hernia

At present, the role of fetal intervention in the management of fetuses with CDH is not clear. The pathophysiology of CDH involves both pulmonary hypoplasia and pulmonary hypertension.

Although the cause of CDH remains unknown, the consequences to pulmonary development and function are well known. If the pleuroperitoneal canal has not closed when the midgut returns to the abdomen by weeks 9 to 10, the abdominal viscera herniates into the chest cavity. This affects both ipsilateral and contralateral lung development, with hypoplasia more severe on the ipsilateral side. The herniation occurs during the period of bronchial subdivisions. This stage becomes compromised with the major bronchial buds present but the number of bronchial branches significantly reduced in both ipsilateral and contralateral pulmonary specimens.[22] Consequently, alveolization is severely affected with significantly fewer normal alveoli at birth.[23]

Pulmonary vascular beds are also distinctly abnormal with a reduction in the total number of arterial branches in both the ipsilateral and contralateral pulmonary parenchyma with significant adventitial and medial wall thickening noted with a resultant increased risk for fixed and intractable pulmonary hypertension.[1] With the institution of breathing, the pulmonary vascular resistance normally decreases allowing for increased pulmonary blood flow. If the pulmonary vascular resistance remains high after the transition to postnatal life, right to left shunting of blood can occur with delivery of unsaturated blood to the systemic circulation with resultant hypoxia. The hypoxia can lead to further increases in pulmonary vascular resistance and compromises to pulmonary flow while increasing right-to-left blood shunting leading to severe and progressive respiratory failure. Postnatally, there is also a failure of the normal arterial remodeling maintaining an abnormally high vascular resistance that is only partially reversible by treatment interventions.[24]

Based on both experimental work in the laboratory and an understanding of congenital

high airway obstruction, the technique of in utero tracheal occlusion was developed to prevent egress of lung fluid and enhance lung growth.[25] Although early results did not appear superior to postnatal management,[26] Deprest and his group refined the technique and showed promising results compared to historical controls.[27] This innovative strategy is being tested in a multicenter randomized clinical trial.[28]

Congenital Lung Lesions

While CDH results in hypoplasia of the lung due to a disruption of early lung development, other CLLs including congenital pulmonary airway malformations (CPAMs), congenital lobar or segmental emphysema and pulmonary sequestrations (PS) also form space-occupying lesions during fetal development and are often diagnosed prenatally. The exact pathophysiology of CPAM development remains controversial with some authors postulating that it arises from arrested development of localized portions of the bronchial tree during the sixth to seventh week of fetal development while others believe they are hamartomatous lesions of the bronchial tree.[29] CPAMs are characterized as a multicystic lung mass resulting from a proliferation of terminal bronchiolar structures with associated suppression of alveolar growth.[30] In contrast to CDH, in cases of CPAMs and other CLL, the lung grows and then is compressed by the mass. Consequently, alveolization and bronchial branching is largely preserved in the other areas of the lungs. As a result, following resection or regression there can be normal development of other areas of lung tissue and these patients do not tend to suffer the long-term consequence of prenatal mass effect seen in patients with CDH. The postnatal morbidity and mortality is usually related to the size of the mass.

CPAM and bronchopulmonary sequestration are the most common congenital lung malformations that usually cause no physiologic perturbation prenatally. The natural history and clinical spectrum of these anomalies are variable, but they appear to depend mostly on the size of the mass and the secondary physiologic derangement. The growth of CPAMs usually plateaus between 25 to 28 weeks at which time the fetus appears to grow around the lesion. Most small- to moderate-sized lesions represent 90% to 95% of CPAMs and remain asymptomatic during fetal life. In contrast, large lesions represent 5% to 10% of CPAMs and may produce significant mass effect, which can lead to pulmonary hypoplasia and associated pulmonary hypertension, impaired fetal swallowing and polyhydramnios, and impaired fetal circulation and heart failure. Congestive heart failure in the fetus, known as nonimmune fetal hydrops, is defined by the presence of skin or scalp edema, or by fluid accumulation in two or more serous cavities (ascites, or pericardial or pleural effusions). The risk of hydrops appears to depend on the size and rate of growth of the mass, and results from compression of the SVC and impaired venous return.[31] In the past, hydrops was considered a harbinger of fetal demise, and was associated with near 100% mortality.[32] Rarely, hydrops is due to a tension hydrothorax from extralobar sequestration. As a prognostic factor, the CCAM volume ratio (CVR) has been developed to correlate the relative size of these lesions with fetal and postnatal outcome.[33] In one series in which 58 fetuses with a lung mass were followed prospectively, 75% of fetuses (12 of 16) with CVR greater than 1.6 developed hydrops, whereas only 17% (7 of 42) with CVR 1.6 or less had this complication. However, the CVR was not predictive of hydrops if a CCAM had a dominant cyst which may enlarge at an unpredictable rate. If signs of hydrops appear, the treatment options include percutaneous placement of a thoracoamniotic shunt for lesions with a dominant cyst, maternal steroids, and rarely open fetal thoracotomy and mass resection if the fetus does

not respond to steroids. Although not well understood, results from a small series of patients suggest that maternal administration of betamethasone should be first-line therapy for all fetuses with a large lung mass (CVR >1.6), and for those with hydrops.[34,35]

Preterm Labor

For every fetal surgery, there is risk of preterm delivery. Chorioamniotic membrane separation and preterm labor remain the Achilles' heel of fetal interventions.[36,37] Surgical approaches that involve a smaller hysterotomy and more minimally invasive techniques appear to lower these risks.[38] Specifically, fetoscopic and percutaneous approaches lessen the maternal and fetal risks. These techniques allow vaginal delivery after fetal surgery and appear to decrease the incidence of preterm delivery.

Preterm labor is the single biggest concern during the operation and in the postoperative period. The mother receives a 50-mg indomethacin suppository before surgery, and remains on indomethacin for 48 hours postoperatively. Daily echocardiography is essential; if there is evidence of PDA restriction, then the indomethacin is stopped. During the operation, nitroglycerin infusion can be used to help control uterine irritability and enhance relaxation. During closure of the hysterotomy, the mother is given a 6-g bolus dose of magnesium sulfate followed by a continuous infusion of 2 to 4 g per hour for up to 48 hours. Postoperatively the mother is closely monitored for pulmonary edema, fluid management, and uterine irritability. On the second to third postoperative day, usually the magnesium and indomethacin can be weaned, and the patient is converted to oral nifedipine.

Neonatal and Pediatric Lung Mechanics

The mechanical properties of the lung play an important role in pulmonary mechanics and neonatal respiratory physiology. The lung has physical properties which resist inflation including recoil, resistance, and inertance with the dynamic interaction between these processes being responsible for the effort required during normal spontaneous breathing.[39] Elastic recoil is a property of the elastic lung tissue which must be stretched for lung inflation to occur. According to Hooke's law, the pressure needed to inflate the lung must be proportion to the volume of inflation. This relationship of proportionality is change in volume divided by change in pressure or lung compliance. Dynamic compliance is the volume change divided by the peak inspiratory transthoracic pressure. Static compliance is volume change divided by peak inspiratory pressure.[40] Throughout the range of normal tidal volumes, this relationship is linear and starts to plateau at large lung volumes. On a static compliance curve, ventilation normally occurs in the steep portion were large changes in volume occur for small changes in pressure. This is not true at high or low lung volumes where large changes in pressure are necessary for smaller changes in volume.

The total compliance for the pulmonary system is made up of the compliance of the lung and the chest wall. The relationship can be expressed by the equation: respiratory system compliance (CRS) = 1/chest wall compliance (CCW) + 1/lung compliance (CL).[39] The desire for the lung to collapse is balanced by the outward elastic recoil of the chest wall with FRC occurring at the end of expiration when these forces are in equilibrium. In infants, the chest wall is composed primarily of cartilage and thus the CCW is greater in the infant and the pleural pressure is less negative. As a result of the more compliant chest wall, the neonatal lung appears more prone to collapse.[41] FRC is maintained in newborns by increasing expiratory resistance through laryngeal abduction, maintaining inspiratory muscle activation throughout expiration, and initiating high breathing frequencies to limit expiration time.[42]

Resistance to gas flow is also an important determinant of pulmonary gas movement in the neonate. Resistance to airflow arises due to friction between gas molecules and the walls of the airway and because of friction between the tissues of the lung and the chest wall. The airway resistance makes up a significantly greater proportion of the resistance making up approximately 80% of the total resistance with 50% of the airway resistance.[43] During laminar flow the pressure difference necessary for gas to flow through the airway is directly proportional to flow times a rate constant-airway resistance.[39] During turbulent flow, which occurs at branch points, sites of obstruction, and high flow, this pressure necessary to move air is directly proportional to a constant times the flow rate squared. This constant is directly proportional to the volumetric flow rate and gas density and is inversely proportional to the radius of the airway and gas viscosity. Airway diameter is possibly the most important clinical factor effecting airway resistance because airway resistance varies inversely with the radius to the fourth or fifth power. Airway resistance is decreased during inspiration as the pleural pressure becomes negative due to expansion

of the chest wall which increases airway and alveolar diameter and decreases resistance. During expiration, the pleural pressure increases and the airways are compressed. Collapse is prevented by cartilage and gas pressure in the lumen which can become a problem especially in small preterm infants with poorly supported central airways.

Work of breathing is the amount of energy required to overcome the elastic and resistive elements within the pulmonary system and move air in and out of the lungs. This is the cumulative product of distending pressure and the given volume displaced during inhalation or exhalation.[39] In neonates, this is approximately 10% of the energy expenditure of an adult and the majority of work is done by the diaphragm. One-third of the inspiratory work is presumed to overcome the resistance of gas flow in the airways.

Evaluation of Lung Function

Knowing the terminology describing static lung measurement is essential to describing pulmonary function (Fig. 99-3). Assessing lung function in the neonates can be difficult as they are unable to cooperate with the examination. However, assessing and understanding lung function is essential to understanding the physiology, pathophysiology, and response to therapeutic intervention. Tidal volume, vital capacity, inspiratory capacity, inspiratory reserve volume, and expiratory reserve volume can be measured directly using spirometer. On the other hand, total lung volume, FRC, and residual volume require specialized techniques. Over the last 50 years, technologic advances have allowed for measurements of neonatal lung function to move from the bench top to the clinic with new ventilators able to provide breath-to-breath analysis of lung function.

The respiratory cycle is determined by changes in pressure which drives air in and out of the lungs. During normal inspiration, the respiratory muscles contract moving the diaphragm inferiorly and chest wall outward resulting in a transient decrease in the transpulmonary pressure from 0 to subatmospheric. This pressure gradient peaks during midinspiration with maximal airflow at that time. It subsequently returns to 0 at the end of inspiration. As the muscles of respiration relax, the inward recoil increases the transpulmonary pressure causing an expiration of inspired air. The airflow again reaches its maximum during midexpiration and returns to zero at the end of respiration. This results in a cycle of pressure within the alveoli from negative to positive pressure during normal inspiration.

Measuring these characteristics of ventilation including pressure, volume, and flows requires specialized equipment and methodologies. Over time, the devices to measure these parameters have continued to significantly improve. Pneumotachometers are one device which can be utilized to airflow. These instruments use gas flow through a tube containing a fixed laminar flow element or flow-resistive–type device. Gas flow across the element causes changes in pressure which can be measured by pressure transducers. An additional means of measuring airflow is the use of hot wire anemometers. These devices measure the amount of current which is required to keep a fine wire a constant temperature with current increasing as airflow increases.[13,44] Volume measurements can be obtained using a flow sensor and by the integration of the flow signal over time. This

is now performed digitally.

New methods to examine lung volumes have been investigated focusing on using techniques which do not require patient cooperation or need to connect to the open airway due to difficulty with leaks and the influence attempts at measurement can have on neonate breathing patterns. For example, one such technique which has been examined and validated in adults is optoelectronic plethysmography which estimates chest wall volume using several three-dimensional markers placed on thorax. This can accurately measure lung volume changes.[45] In order to obtain meaningful static lung measurements FRC can be measured using whole body plethysmography, however, this is not a practical means for measuring FRC.[46] Other methods for measuring FRC including helium dilution, nitrogen washout, and sulfur hexafluoride washout, have been utilized but can be challenging in an uncooperative, nonmechanically ventilated infant.

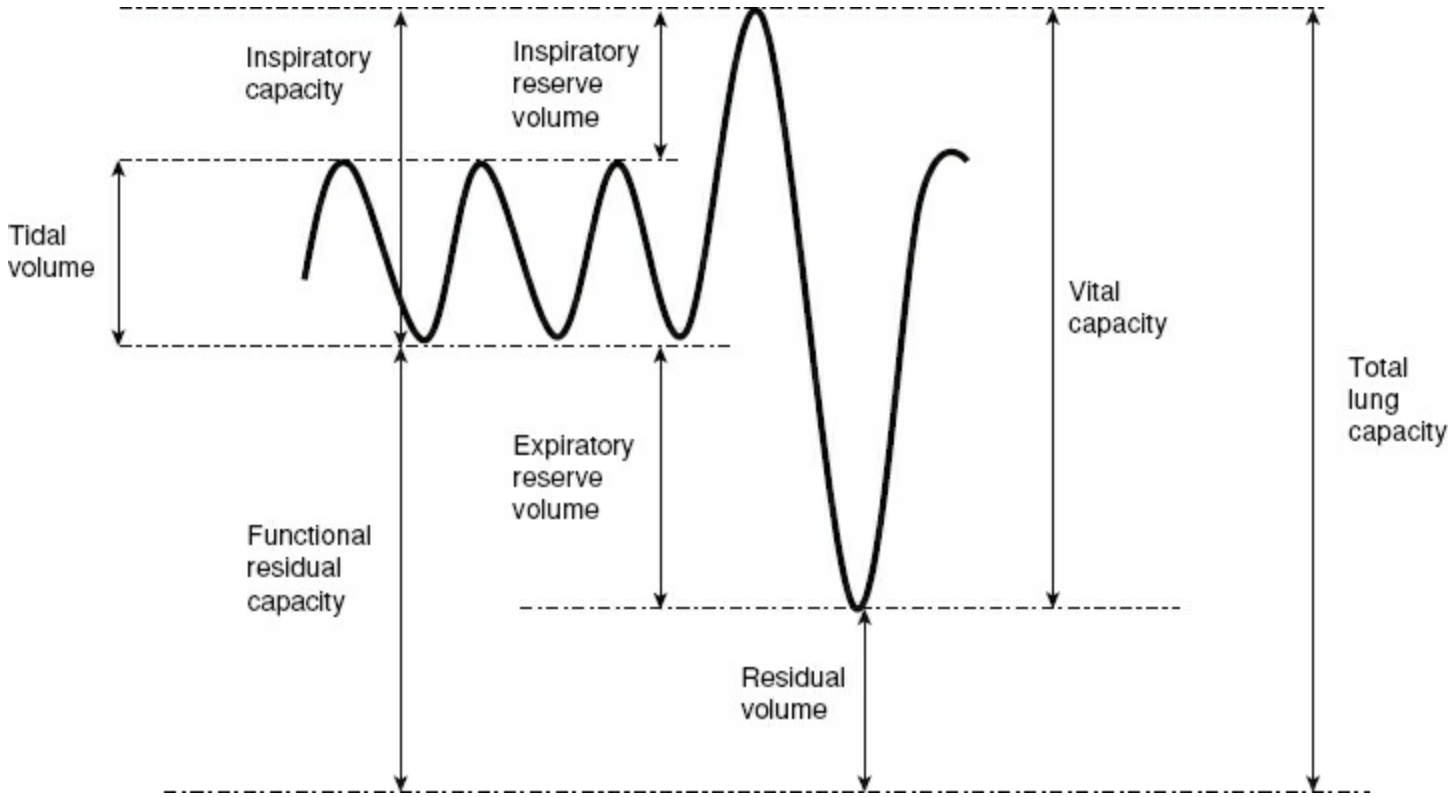

Figure 99-3. Lung measurements: Tidal volume (TV) is the amount of gas moved during one normal inspiration and expiration. Functional residual capacity (FRC) represents the volume of gas left in the lung following normal expiration. Inspiratory capacity is the maximum volume of air which can be inspired following a normal expiration. Inspiratory reserve volume is the additional amount of air which can be inspired following normal inspiration. Expiratory reserve volume is the additional amount of air which can be expired following normal expiration. Residual volume is the minimum lung volume possible, which is the air which remains in the lung following maximum expiration. Vital capacity is the maximum amount of air which can be moved, maximum inspiration following maximum expiration. Total lung capacity is the total amount of volume present in the lung.

Assisted Ventilation

While in most instances, transition from placental support to respiratory self-sufficiency occurs without complications, pediatric surgeons encounter many clinical scenarios where patients require additional assistance and mechanical support of the newborn has been a growing field with many advances. Neonatal respiratory failure has been treated with mechanical ventilation since the 1960s.[47] Initially, adult ventilators were modified for neonatal use. The first devices designed for neonates were continuous flow, time cycled, pressure limited devices to provide intermittent mandatory ventilation (IMV).[48] There were many limitations to these ventilators as physicians could only vary fraction of inspired oxygen, peak inspiratory pressure, positive end-expiratory pressure, inspiratory time, rate, and circuit flow. In the 1980s, high-frequency jet ventilation (HFJV) was introduced and has since been widely used. During the 1990s, microprocessors were incorporated into neonatal ventilators greatly expanding the scope of neonatal ventilation with clinicians able to control a greater number of variables including target modality, mode of ventilation, minute ventilation, cycling mechanism, assist sensitivity, and rise time with light weight transducers giving real time breath-to-breath information allowing easier adjustment of ventilator settings depending on patient illness.[49]

Currently, ventilators in clinical use are classified as either those which deliver tidal ventilation (conventional) or devices which deliver smaller gas volumes at rapid rates (high-frequency ventilators). Conventional ventilators have significantly improved over recent years with the addition of the microprocessor chips. They continue to have standard modes of ventilation including IMV, synchronized intermittent mandatory ventilation (SIMV), assist control ventilation (AC), and pressure support venation (PSV). These modalities can be further modified to deliver either target pressure or volume. Further description of conventional ventilators is beyond the scope of this chapter, however, the clinical utility of various modalities has been examined in recent literature. For example, a recent meta-analysis of pressure-controlled modalities versus volume-controlled modalities demonstrated a significant decrease in pneumothorax and duration of ventilation as well as a decrease in CLD in preterm infants treated with volume-controlled modes of ventilation as opposed to pressure-controlled modes.[50]

There are two types of high-frequency ventilation: HFJV and high-frequency oscillatory ventilation (HFOV). HFJV provides smaller volumes (1 to 3 mL/kg) more often at a much higher rate (240 to 660 breaths per minute) and expiration is passive. Oxygenation is proportional to mean airway pressure and ventilation is proportional to amplitude (peak inspiratory pressure vs. PEEP).[48] Jet pulsations produce high-velocity laminar flow which has the ability to bypass airway disruptions. HVOF differs in that it delivers smaller tidal volumes (1 to 2 mL/kg) and at an even faster rate (8 to 15 Hz). The lung is inflated to a static volume, and then oscillated around the mean airway pressure.

For infants who cannot be successfully ventilated using these modes of ventilation, extracorporeal life support (ECLS) can become an option. ECLS is indicated in cases of acute cardiopulmonary failure with expected organ recovery which has been unresponsive to maximal therapy.[51] The use of ECLS in neonates is based on the idea that with maximal support native function improves, through natural development or improvement, by application of medical and/or surgical treatments, or transplantation. Three clinical measurement systems have been identified to identify these patients all of which are associated with high mortality risk. However, the decision to initiate this therapy is based on clinical judgment and the patient's response to maximal medical therapy.

Dr. Robert Bartlett and his group had been studying extracorporeal support in laboratory animals for 10 years before the first neonatal extracorporeal membrane oxygenation (ECMO) patient was supported in 1975; this clinical application signified a radical shift in the treatment paradigm for neonatal respiratory failure.[52] The neonate, Esperanza, was suffering from respiratory failure secondary to meconium aspiration that was recalcitrant to conventional ventilator support. She was successfully supported and now is 37 years old.[53]

The currently accepted treatment of neonatal cardiopulmonary failure includes low-volume protective ventilation,[54] inhaled nitric oxide (iNO),[55,56] surfactant therapy,[57,58] and HFOV.[59] If the cardiac or pulmonary failure is refractory to maximal medical therapy then ECMO should be considered.[60,61] The standard application of ECMO is primarily limited to neonates $\geq$34 weeks EGA and $\geq$2 kg. Clinical experience and laboratory work suggest extracorporeal support may be effective at lower gestational ages by using "Premie ECMO" or the "Artificial Placenta (AP) (Table 99-1)."

Indications

ECLS is indicated for acute cardiopulmonary failure with high mortality/morbidity unresponsive to maximal medical treatment and with expected organ recovery. The premise is that patients can be supported with ECLS while native function improves either by allowing natural development or improvement (lung maturation and surfactant development), application of medical or surgical therapies, or by transplantation. Identification of the patients that can benefit from ECLS can be challenging.

Three clinical measurement systems have been developed and tested to assist in identifying patients that will benefit from ECLS support.

1. *Oxygenation Index (OI)* = $(MAP \times F_iO_2 \times 100) / P_aO_2$ Where MAP = mean airway pressure. This index has been evaluated[62,63] and shown that an OI >40 in three to five postductal gases was predictive of a mortality risk $\geq$80%.[64]
2. *Postductal Alveolar-Arterial Oxygen Gradient [(A-a)DO_2]* An (A-a)DO_2 of 610 Torr or greater despite 8 hours of maximal medical therapy predicted a mortality of 79%.[63]
3. *Ventilation Index* = $(Respiratory\ Rate \times PaCO_2 \times Peak\ Inspiratory\ Pressure)/1{,}000$

Rivera et al. found that a ventilation index >40 and OI >40 were associated with a

77% mortality risk. They also found that the combination of peak inspiratory pressure ≥ 40 cm H_2O and an (A-a)DO_2 >580 mm Hg was associated with a mortality of 81%.[65]

These clinical measurement systems are useful to quantitate the degree of cardiopulmonary derangement, and subsequently categorize patients into candidates for ECLS therapy or continued maximal medical therapy. However, the decision to initiate ECLS therapy is often a clinical decision based upon clinical judgment and the patient's individual response to maximal medical therapy. Patients are commonly started on ECLS therapy when they have failed maximal medical support, significant barotrauma is imminent, and are felt to have good potential for complete organ recovery.

Classic Contraindications and Possible Treatment Expansion

The classic contraindications to ECLS therapy are listed below. As ECLS treatment evolves and technology advances, many of the classic contraindications to ECLS are being challenged.

1. *EGA less than 34 weeks:* The higher incidence of intracranial bleeding in premature infants has historically precluded the use of ECLS in neonates less than 34 weeks EGA.[66,67] However, recent data indicate that ECLS can potentially be used in infants as low as 29 weeks EGA with acceptable survival and intracranial hemorrhage (ICH) rates. Ideally, development of nonthrombogenic coating of circuit components would obviate the need for systemic heparinization and decrease the risk of using ECLS in premature infants.[68–71]
2. *ICH greater than grade II:* Neonates with ICH of higher grades are at increased risk of extension of their hemorrhage with systemic heparinization. This remains true today, but the development of technologies that obviate the need for heparinization may allow the use of ECLS in neonates with pre-existing ICH in the future.[69,71–75] In addition, our experience has suggested that ECMO can be applied when expected mortality is higher in neonates with grade II ICH. In that setting, lower levels of anticoagulation are cautiously applied.
3. *Mechanical ventilation for longer than 7 to 10 days:* Classically, mechanical ventilation has been associated with higher incidence of bronchopulmonary dysplasia and irreversible fibroproliferative lung disease. The duration of pre-ECMO mechanical ventilation is being challenged; data from the Extracorporeal Life Support Organization (ELSO) registry demonstrate survival of 50% to 60% after pre-ECLS mechanical ventilation of up to 14 days.[76]
4. *Cardiac arrest which requires cardiopulmonary resuscitation (CPR):* Many centers now consider patients who suffer pre-ECLS cardiac arrest candidates for support. Survival rates up to 60% have been demonstrated in neonates who suffer cardiac arrest prior to or during cannulation.[77,78] Predictably, good outcomes are associated with effective CPR during the resuscitation.
5. *Conditions incompatible with meaningful life after therapy – profound neurologic impairment, congenital anomalies, or other conditions:* With improvement in medical and surgical care, conditions once thought to be nonsurvivable require constant

reassessment.

Outcomes

Today, ECMO is a part of routine management in the neonatal ICU. Overall survival is 85%, with 98% survival for meconium aspiration and 55% survival for diaphragmatic hernia.[52] Overall survival after ECLS for neonatal respiratory failure has recently declined. There are likely a few reasons for this decrease in survival. Since its peak in 1992 of 1,500 cases, ECLS has been used with less frequency for critically ill neonates. The fewer number of cases is due to an improvement in other modalities of support such as iNO, HFOV, and surfactant therapy. To some extent, these improvements have been realized as a result of lessons learned from early ECMO experience.[52,79–81] As a result, the neonatal patients receiving ECLS as the initial form of therapy for cardiopulmonary failure are declining, and the patients that ultimately require ECLS are probably more ill and further along the timeline of their illness.

Table 99-1 ECLS Modality by Age Group

Gestational Age (wks)	24 25 26 27 28	29 30 31 32 33	34 35 36 37 38 39 40
ECLS Treatment Modality	Artificial placenta[a]	Preemie ECMO[b]	ECMO[c]

[a]Laboratory research.
[b]Clinically feasible.
[c]Standard of care.

Modalities

ECLS aims to provide perfusion of warmed, arterialized blood into the patient.[82,83] Traditionally, venovenous (VV) support has been used for respiratory failure while venoarterial (VA) support has been utilized in cases of cardiac or combined cardiopulmonary failure. VV-ECLS can be performed through one-site or two-site cannulation. Traditionally, blood was drained through a cannula placed in the right internal jugular (IJ) vein and returned through the femoral vein, although this approach proved problematic in newborns with small femoral veins. More recently one-site or venovenous double-lumen (VVDL) cannulation has emerged as the preferred cannulation technique. In this mode, a single cannula is placed in the right IJ vein. Deoxygenated blood is drained from one port, pumped through the ECLS circuit where gas exchange occurs, and returned through a separate port on the same cannula into the right atrium. VA-ECLS provides complete cardiopulmonary support. Typically a drainage cannula is placed in the right IJ. Deoxygenated blood is pumped through the ECMO circuit and returned through a cannula in the right carotid artery. Historically, VA-ECLS has been used more than VV-ECLS in the support of neonates. However, data from the ELSO registry demonstrate that the use of VV-ECLS is increasing for neonatal cardiopulmonary failure.[83]

The first generation of ECMO support devices (known as ECMO I) was used from 1975 to 2008. However, problems with the oxygenator membrane, rotational pump, and cannulae limited expansion of the technology. Recently there has been substantial technologic improvement in ECMO system components and circuitry, defined as ECMO II.[84]

Modern hollow fiber oxygenators have several advantages over the original silicon membrane oxygenators.[85–87] The hollow fiber design provides a much lower resistance across the oxygenator membrane, allowing for the use of centrifugal pumps in the ECMO circuit. The centrifugal pumps used now consist of a rotating impeller that spins on a small bearing or is magnetically suspended.[88] Some of the newest pumps available provide pulsatile flow.[89] Additionally, the advent of the double-lumen Avalon cannula (Avalon Elite, Avalon Laboratories, Rancho Dominguez, CA) allows the percutaneous placement of a single cannula for VV-ECMO support that both drains and reinfuses blood to allow for effective circuit flow.[90,91] Further, there has been significant research effort put forth to improve the biocompatibility of circuit surface–blood interfaces.[72,73] Finally, the simplification of operating the ECMO II system makes it such that a trained ICU nurse can manage the circuit. This decreases manpower utilization, as a single ECMO technician may now oversee several patients at once.[92] These advancements provide translational development in the application and expansion of ECMO support for neonatal cardiopulmonary failure.

ECMO in Premature Neonates

Previous studies have shown poor survival with the use of ECMO in premature neonates. Bartlett's early report of ECLS in 45 moribund neonates, revealed a 55% survival rate for neonates overall. Nine of these patients were less than 35 weeks EGA – two survived (22%). All six who died had ICH.[93] A later report showed similarly worrisome survival for premature neonates less than 35 weeks EGA – 33% (3/15). One of these survived with an ICH; the other 12 patients with ICH died.[63] A study examining ICH in patients on ECLS showed that all eight of the patients less than 35 weeks EGA had ICH and that six of these died immediately after termination of ECLS while two died within 1 year of age.[66] Given these poor survival rates (22% to 33%) and the extremely high rate of ICH (75% to 100%), Cilley recommended that the use of ECLS be contraindicated in neonates of less than 35 weeks EGA. However, examination of the ELSO database between 1988 and 1991, found that survival had improved to 63% and ICH rates decreased to 37% for premature neonates born at 34 weeks EGA or younger.[66,67]

We recently performed a comprehensive analysis of the ELSO database from 1976 to 2008. This analysis showed no statistically significant difference in the risk of IVH in infants 30 to 33 weeks EGA (21%) when compared to those 34 weeks EGA (17%), $p = 0.195$.[94] The overall survival rate of 54% and ICH rate of 18% for the entire cohort of neonates on ECLS at 34 weeks EGA or younger suggest that the incidence of both mortality and ICH have decreased over time, with a more dramatic reduction observed in ICH. Although the survival for the 29- to 33-week EGA group was significantly decreased (48%) when compared to those patients with EGA 34 weeks (58%, $p = 0.011$), one could argue that these rates are clinically acceptable. Patients born at younger EGA are

expected to have a more difficult hospital course. These data suggest that ECLS in the modern era should be explored at EGA as low as 29 weeks with reasonable survival and acceptable rates of ICH.

Rationale for an Artificial Placenta – Applying Fetal Physiologic Principles to the Treatment of Extreme Prematurity. ECMO is increasingly effective for late preterm to term infants (34 to 40 weeks EGA), and it might be beneficial for some infants who are 29 to 34 weeks EGA. However, a different paradigm is required for ECLS in extremely low gestational age newborns (ELGANs, 22 to 28 weeks EGA). ELGANs are at the greatest risk for death and poor long-term outcomes.[95–97] In particular, respiratory failure in premature neonates contributes to significant mortality and long-term disability. Conventional mechanical ventilation is often inadequate to provide gas exchange and can cause trauma to the under-developed lungs. Even more advanced strategies developed to minimize the trauma of conventional ventilation, including surfactant replacement therapy, nitric oxide inhalation, and HFOV, may at times be insufficient to support these most fragile infants.[98,99] In theory, the most effective solution is to create an AP that maintains fetal circulation and obviates the need for mechanical ventilation and resultant devastating barotrauma by completely bypassing the lungs.

Definition of the Artificial Placenta

1. Maintenance of fetal circulation and the intrauterine environment
2. No mechanical ventilation
3. Simulated fetal breathing with fluid-filled lungs
4. A novel form of a pump-driven VV or arteriovenous (AV) ECLS/ECMO with outflow via the right jugular vein or umbilical artery, respectively, and inflow via the umbilical vein

A VV-ECLS AP offers several potential advantages over an AV-ECLS system. First, it eliminates the use of arterial vessels that are prone to spasm. Placing a cannula in the right atrium through the jugular vein allows for a passive drainage process that reduces potential negative pressure and cavitation in the circuit. Additionally, VV-ECLS uses the subject's own venous system as a blood reservoir, instead of requiring an external blood reservoir. Another potential advantage relates to the drainage cannula itself. Although it is feasible to advance a large cannula (10 to 12 Fr) through the umbilical artery into the aorta in preterm sheep, this is not possible in premature human infants due to umbilical artery size and vessel anatomy. It would be very difficult to place even a 6-Fr cannula through the umbilical artery of a premature human baby. On the other hand, a larger cannula (6 to 8 Fr) can be inserted into the right IJ vein in premature infants to allow for adequate drainage. Finally, a VV-ECLS AP operates in parallel with the systemic circulation. Similar to traditional VV-ECMO circuits, the fetal heart would experience little increased resistance and afterload from the parallel circuit.[83,100] Conversely, an AV-ECLS system with an oxygenator placed in series has the potential to increase stress on

the fetal heart and contribute to cardiac failure.[101]

Clinical Prognostic Factors

The ideal patient population to benefit from the AP are ELGANs (<28 weeks EGA) who fail the most aggressive pulmonary therapies, such as low peak pressure ventilation, nitric oxide inhalation, surfactant administration, and HFOV. Early identification of those with the highest mortality risk has been validated in this population using mortality prediction tools (CRIB II and SNAPPE II) based on data obtained in the first 12 hours of life.[102–104]

Potential Complications and Current Limitations

There are several potential complications and questions that must be addressed in the laboratory before the AP can be taken to the clinical setting. The first, and most pressing, is the issue of anticoagulation and the risk of intracerebral or intraventricular hemorrhage (IVH). Issues with IVH were the main driving force for limiting conventional ECMO to late-gestation newborns.[67,105] However, many of these reports were from a time before activated clotting time (ACT) was routinely followed in systematically anticoagulated neonates, leading to excessive anticoagulation. More recent studies on the pathogenesis of IVH suggest that many causes may be iatrogenic. The mechanism of injury may be either due to a disruption of cerebral blood flow or injury to the relatively weak endothelial tissue of the germinal matrix.[106,107] Disruption of cerebral blood flow can be caused by transfusion or rapid volume expansion that leads to increases in arterial pressure and cerebral blood flow, or through positive pressure ventilation that may obstruct venous outflow and result in increased cerebral perfusion pressures.[106,108] Avoiding ventilation and providing stable hemodynamics and gas exchange might afford the same protection against IVH. Nevertheless, to further minimize the risk of IVH, we propose the eventual use of nonthrombogenic surfaces in the form of biomaterials that release NO to completely eliminate the need for anticoagulation.[69,71,74,75]

Prematurity

Extremely premature infants are still “fetuses” living outside the womb and the physiology, pathophysiology, and treatment should be viewed through the lens of fetal physiology. Premature birth (<37 weeks EGA) occurs in 11% of births in the United States and remains the leading cause of morbidity and mortality in industrialized nations accounting for 60% to 80% of deaths in infants without congenital abnormalities.[109] Prematurity affects most organ systems and includes temperature instability, respiratory failure and CLD, gastrointestinal problems including necrotizing enterocolitis (NEC), ICH, and sepsis. ICH occurs in approximately 12,000 premature infants every year with 50% to 75% of the survivors developing cerebral palsy, mental retardation, or hydrocephalus and another 25% of the nondisabled survivors developing psychiatric disorders or problems with executive function.[110] Prevention, early recognition, and timely management are crucial in decreasing long-term morbidity and mortality.

The more premature the infant, the greater the risk for pulmonary complications with ELGANs born before 28 weeks EGA at greatest risk. As mentioned earlier, these infants

are born at the transitional period between the canalicular and saccular phases which is when the air–blood barrier is just beginning to thin to the point where exchange is possible. Glucocorticoids are administered to mothers undergoing preterm labor after 24 weeks in order to promote surfactant production and maturation of the fetal lung.[111,112] The exact mechanism remains unknown, however, studies have shown that anatomic maturation, in particular thinning of the alveolar wall, and synthesis of mRNAs encoding surfactant proteins increase with exposure and while with removal mRNAs decrease, anatomic changes persist.[113–115]

Operating on newborn infants, especially premature, can be technically challenging just by size alone. As the size of the infants can vary from a few hundred grams to several kilograms, surgeons must consider various technical and physiologic aspects of each procedure, choosing the safest and most effective option.

Several developmental and physiologic issues complicate surgery on premature infants. Lack of thermoregulation, inadequate skin integrity, and incomplete immune development are ubiquitous to all premature infants and can affect the morbidity of surgery. These aspects must be considered in all children, but most of all in the smallest patients, when choosing the location for surgery, transportation of the child, skin preparation, use of prophylactic antibiotics, placement of foreign bodies, postoperative wound management, and healing potential. Furthermore, specific physiologic processes inherent to the premature infant further complicate surgical planning.

Propensity for certain physiologic conditions in the neonate increases the risk of morbidity of operating on these children: hypoglycemia, apnea and respiratory distress, and neurologic development. Though patients are commonly kept nil per os (NPO) prior to surgery, to decrease the risk of aspiration with anesthesia, surgeons need to assess the risks and benefits of this approach for neonates who are at significant risk for hypoglycemia. As line access for neonates may tenuous and difficult to obtain, liberal use of enteral nutrition, appropriate timing of surgery, and early resumption of feeds in this population should be thoroughly considered. Furthermore, the use of narcotics and sedation can increase the risk of postoperative apnea and respiratory distress. The edema in the neonatal airway from intubation can contribute to early postoperative morbidity and need for reintubation or positive pressure ventilation; therefore, a conservative approach to extubation and postoperative monitoring should be used. Finally, although controversial, multiple studies suggest deleterious effects of anesthesia on the developing neonate and some recommend postponing elective procedures until children are 3 years of age.[116–120]

Thermoregulation

Fetal thermoneutrality is maintained in a warm intrauterine environment where the amniotic fluid reflects the maternal core temperature. In addition, the fetus generates 3 to 4 W/kg heat through an oxygen consumption of 8 mL/min/kg.[121] The placenta eliminates 85% of fetal heat into the maternal circulation, the remaining 15% is dissipated through conductance to amniotic fluid and to the uterine wall. The fetus is at 0.5°C to 1.0°C above the maternal core temperature.

In neonates, thermoneutrality is defined as an axillary temperature between 36.7°C and 37.3°C.[122] Soon after birth, approximately 135 to 155 W/m^2 of heat loss can occur through evaporation, radiation, convection, and conduction.[121] Therefore, a newborn exposed to cold stress must mount a variety of responses to conserve heat loss, increase heat production, and maintain core temperature. The main source of heat production is brown adipose tissue, which peaks at term gestation, used for nonshivering thermogenesis. Term newborns also increase involuntary activity, and have hypothalamic-regulated vasoconstriction to maintain thermoneutrality.[13,121]

Prematurity leads to insufficient brown fat for nonshivering thermogenesis, a larger surface area to body mass ratio, deficient subcutaneous fat and nonkeratinized thin skin, decreased ability to maintain flexion of extremities, and underdeveloped response of temperature sensors in the posterior hypothalamus to release thermogenic hormones (thyroxine and epinephrine).[13] In low–birth-weight infants, the use of a servoregular set to 36°C has been shown to increase survival as compared to setting a constant incubator temperature. Radiant warmers increased insensible water loss and did no better when compared to incubators for temperature control.[123]

Neonates needing surgery are frequently transported to and from the neonatal ICU to the operating room and radiology, leading to increased risk of heat loss. Furthermore, since fever is an infrequent sign of postoperative infection, monitoring for temperature instability is more effective. Finally, perioperative issues such as intraoperative irrigation, exposure during positioning, skin preparation, and operating room temperature can all have ill effects on the susceptible neonate's thermoregulation.

Skin Integrity

In addition to augmenting the risk of infant heat loss, poor skin integrity of neonates, especially the low birth weight or premature, has its own impact on the surgical patient. Beyond thermoregulation, the thin, underdeveloped skin has several other challenges including the use of local anesthetic, skin preparation, immune properties, bathing and wound care, and the use of an adhesive dressing. Skin provides mechanical protection, maintains thermoregulation, provides immunosurveillance, and prevents insensible loss of body fluids.[124] Skin of premature infants is thinner and more dysfunctional. The inadequate epidermal barrier allows increased water loss, absorption of chemicals, and trauma causing difficulties with fluid homeostasis, thermoregulation, infection, and toxicity.[125]

Iatrogenic injury and alteration in skin integrity can occur more often in premature infants due to several factors. At 26 weeks, the developing epidermis is only 2 to 3 cells thick. At 28 weeks, the skin is deficient in fat and zinc, increasing the potential for infection, damage, and injury.[126] Furthermore, due to the lack of protein in the subcutaneous layer, increased edema can form in the skin from excess water and sodium. The lack of sweat glands, a reduced blood supply, and lack of fat and calorie reserves, result in an increased risk of hypothermia.[126]

At birth, the baby's skin is coated with vernix caseosa (a gel like substance that has antibacterial properties) in addition to blood, meconium, and cellular debris. The baby

should not be bathed in the first 6 hours due to increased risk of hypothermia. Premature infants should have a bathing schedule approximately once every 4 days.[124] In fact, bathing has been shown to reduce skin colonization, which may increase the risk of pathologic infection. Meticulous umbilical cord cleansing in the first 1 to 2 weeks, however, can markedly reduce infection and neonatal death. Emollients containing a physiologic balance of epidermal lipids – such as cholesterol, ceramide, palmitate, and linoleate – are optimum for barrier repair.[127]

Due to specific properties of neonatal skin, preoperative preparation should be carefully approached. Since neonatal skin is relatively impermeable to alcohol, it may develop skin burns and necrosis particularly in premature infants when topical antiseptic is used on skin.[124] Therefore, alcohol-containing skin-cleansing solutions should be used with extreme caution in neonatal units. Iodinated skin disinfectants can result in significant iodine overload and severe transient hypothyroidism. Neonatal iodine exposure should be minimized whenever possible and in cases of exposure, thyroid-stimulating hormone level should be routinely measured.[128] In general, we use betadine for most neonatal procedures, and chlorprep with hardware implantation (such as central line insertion), though no consensus currently exists.

Use of topical anesthetic similarly can cause systemic toxicity from absorption. Prilocaine, a component of topical anesthetics, can cause methemoglobinemia and cyanosis in neonates. Tetracaine gel can cause contact dermatitis.[124] Furthermore, the use of lidocaine or marcaine in the subcutaneous space needs to be carefully monitored for overdose. We have used pumps that administer local anesthesia to the incision to limit systemic narcotic use in neonates with modest success.

Dressing the surgical wound in the neonate can create its own challenges. In premature infants, epidermal stripping secondary to tape and adhesive dressing removal is common and the primary cause of skin breakdown in babies in the neonatal intensive care units (NICU). On the other hand, adhesive removers should be avoided due to risk of skin injury and subsequent absorption.[129] We routinely use steristrips as the sole dressing in children; alternatively skin glue can be an adequate dressing protecting the wound from friction and body fluids (urine, emesis, or feces). For open wounds, the use of a vacuum-assisted device (WoundVac) has been described and can be used selectively.[130–132] For delicate skin, the use of Duoderm and Montgomery straps with wet-to-dry dressings is a good option.

Infection and Immune Response

Infection is the leading cause of mortality among infants in the first days of life,[133] with mortality related to neonatal sepsis responsible for 40% of the annual 3 million worldwide neonatal deaths.[134] Severe infections occur at a higher incidence and have greater mortality in very low–birth-weight premature neonates, especially in the first 3 to 7 days of life.[135] Early-onset sepsis, associated with *Escherichia coli* or group B streptococcus (GBS), typically occurs within the first 24 hours, while late-onset sepsis, associated with nosocomial coagulase-negative *Staphylococcus epidermidis,* typically occurs after the first 72-hour period, and is most prevalent among very low–birth-weight

babies.[136] In neonates, central venous catheters are arguably the largest risk factor for neonatal nosocomial sepsis as coagulase-negative *Staphylococcus* and other organisms are the most commonly isolated late-onset pathogens, as they normally colonize the skin around the site or are acquired from the hands of the staff caring for the child.[137]

Maternal factors contributing to the risk of neonatal sepsis include prematurity, low birth weight, rectovaginal colonization with GBS, prolonged rupture of membranes, maternal intrapartum fever, and chorioamnionitis.[135] Postnatal factors associated with an increased risk of sepsis include male gender, birth weight <1,000 g, hypogammaglobulinemia, intravenous alimentation, central venous catheters, the use of steroids or drugs that decrease gastric acid acidity, and prolonged duration of mechanical ventilation.[135] Although the predominant agents are bacterial, viruses including herpes simplex and enteroviruses, can cause fatal neonatal sepsis.[135] Invasive fungal infections can also contribute to mortality. Human milk, however, contains lactoferrin, an iron-binding glycoprotein that is important for innate immune host defenses at birth because it exhibits broad-spectrum antimicrobial activity and prevents invasive fungal infections.[138] Neonates with sepsis may present in or progress to septic shock, exemplified initially by cardiovascular dysfunction requiring fluid resuscitation or inotropic support.[139]

Neonates, especially those that are premature, have an "immature" innate immune system, both quantitatively and qualitatively. For example, neonatal neutrophils have three- to fourfold less bactericidal permeability-increasing protein per cell than do adult neutrophils.[140] The low immunologic profile of the newborn infant is possibly a reflection of the demands of the fetal environment, which is inherently considered sterile, and the need to avoid immune responses to maternal antigens.[136] The development of neonatal immunity is influenced by multiple factors including "maternal cytokines, antigen exposure, and precursor frequency of lymphocytes and antigen presenting cells."[138]

Neonates have dampened T-helper (Th) responses compared with adults. In fact, many murine and clinical studies have demonstrated decreased Th1-polarizing/proinflammatory responses (TNF-α, IFN-g, IL-12p70, IFN-α, IFN-γ), with increased production of Th2 polarizing (e.g., IL-6) and anti-inflammatory cytokine production (IL-10), following in vitro stimulation with bacterial products or septic challenge.[136] This inherent bias toward Th2-cell polarizing cytokines and suboptimal Th1 responses and B-cell differentiation increases neonate susceptibility to acute respiratory and diarrheal diseases.[138]

Toll-like receptors (TLR), a type of pattern recognition receptors, exist on innate immune cells, leading to "second messenger-specific intracellular signaling cascadessic [sic] that result in gene expression, cytokine/chemokine production, and cellular activation."[136] Lipopolysaccharide (LPS, endotoxin) on gram-negative bacteria is a key mediator of systemic inflammation, septic shock, and multiorgan failure and death.[141] TLR4, a receptor for LPS is critical for innate immune activation in leukocytes and is expressed on many epithelial cells. Neonatal leukocytes also demonstrate decreased responsiveness to LPS that signals through TLR4.[136] LPS signals primarily through TLR4 in conjunction with the cell surface adaptor proteins CD14 and MD265.[135] Cord blood monocytes exhibit higher expression of microRNA 146a (which regulates TLR4 signaling through the inhibition of IRAK4 – critical for downstream signaling) and appear to have

higher endotoxin tolerance. Neonatal cord blood leukocytes also demonstrate reduced MyD88 expression and impaired LPS-induced p38 MAPK phosphorylation and LPS-induced proinflammatory cytokine production.[136] These functional consequences of TLR activation in neonates are so markedly different from those in adults.

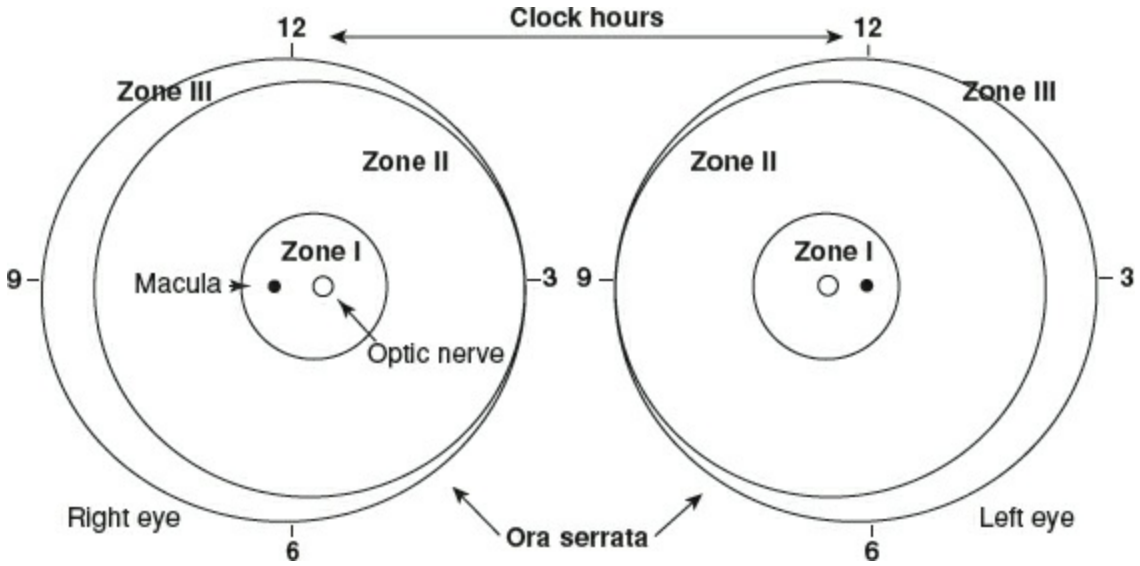

Figure 99-4. Zones of injury in ROP.

At birth, the number of neutrophils ranges from 1.5 to 28 × 109 cells/L blood, compared to steady-state levels of 4.4 × 109/L in adults.[142] Neonatal neutrophils also have lower surface expression levels of TLR4; therefore, the downstream signaling through MyD88 and p38 pathways are defective in neonates following stimulation. Adherence of neonatal neutrophils is impacted by "low levels of cell surface L-selectin and Mac-1 (CD11b/CD18) which mediate the initial loose adhesion and subsequent tight binding of neutrophils to vascular endothelium," a 50% reduction in transmigration of neonatal neutrophils to sites of infection.[138] Newborn neutrophils also exhibit a dramatic reduction in chemotaxis due to "blunted intracellular calcium influx and altered actin polymerization,"[138] limiting the ability of neutrophils to deform and penetrate the vascular endothelial lining.

Innate phagocyte function is impaired and neonatal neutrophils produce decreased extracellular traps, which phagocytes use to localize and contain pathogens.[136] The ability to degrade these pathogens is also further compromised due to the defective NADPH oxidase system and inability to generate hydroxyl radicals due to reduced lactoferrin and myeloperoxidase granules. Overall, these defects in neutrophil amplification, mobilization, and function make neonates particularly susceptible to sepsis.[138]

Antibody responses in neonates after vaccine administration are also diminished secondary to poor humoral and/or memory T-cell responses. Pertussis, for example, only produces humoral responses at 3 weeks of life, but not in newborns. Other vaccines, such as those for *Streptococcus pneumoniae* and *Haemophilus influenza,* require multiple boosters. Although, having ability to administer these vaccines at birth would be ideal, these vaccines are only effective a few months later.[136]

In our practice, we routinely use prophylactic antibiotics in neonates due to their

immature immune response and susceptibility to sepsis and septic shock. Furthermore, we favor a conservative approach to decrease postoperative complications from infection and wound-healing issues due to the impaired abilities of the neonate. When possible, elective procedures should be delayed to allow for immune development preventing further morbidity.

Retinopathy of Prematurity

Retinopathy of prematurity (ROP) is a disorder of low–birth-weight premature infants that could potentially lead to blindness due to damage of the developing retina. In nearly all term infants, the retina and retinal vasculature is fully developed, so ROP does not occur. In preterm infants, retinal development is incomplete and based on degree of immaturity, is at variable risk for damage.

The damage occurs in an orderly fashion progressing from zone 1 (most posterior) symmetrically surrounding the optic nerve head (the earliest to develop). A larger retinal area is present temporally (laterally) rather than nasally (medially) (zone III). Only zones I and II are present nasally (Fig. 99-4).

As ROP progression is orderly, timely recognition and treatment can decrease the risk of visual loss. See Table 99-2 for the schedule for detecting ROP before required treatment based on gestational age at birth.

Table 99-2 Timing of First Eye Examination Based on Gestational Age at Birth

Gestational Age at Birth (wks)	Age at Initial Examination (wks)	
	Postmenstrual	Chronologic
22[a]	31	9
23[a]	31	8
24	31	7
25	31	6
26	31	5
27	31	4
28	32	4
29	33	4
30	34	4
Older gestational age, high-risk factors[b]		4

Shown is a schedule for detecting prethreshold ROP with 99% confidence, usually before any required treatment.
[a]This guideline should be considered tentative rather than evidence based for infants with a gestational age of 22 to 23 wks because of the small number of survivors in these postmenstrual age categories.
[b]Consider timing based on severity of comorbidities.

Though peripheral retinal cryotherapy is effective in decreasing the rate of structural and visual outcomes, peripheral retinal ablation using laser photocoagulation has similar

results and is the preferred method of ablation.[143] Prevention of ROP using lower oxygen saturations (approximately 85%) was historically advocated for premature infants; however, recent randomized clinical trial has called the practice into question due to the increased mortality with the lower threshold[144] and a higher level of saturation (88% to 92%) is now commonly targeted.

Cardiac Physiology

The unique aspects of neonatal cardiac physiology, pathophysiology, and treatment approaches will be highlighted. As children become adolescents, the cardiac physiology and treatment strategy approximate adults.

5 The neonatal myocardium is immature with less cellular and structural organization, less contractile proteins, and less compliance. The CO equals the heart rate (HR) multiplied by the stroke volume (SV). The SV is dependent upon preload, myocardial contractility, and afterload. In the neonate, the response to volume on the Frank–Starling curve is attenuated compared to mature myocardium. Thus, the neonatal heart increases its CO primarily through increases in HR. Although HRs about 200 are sometimes poorly tolerated due to short filling times, caution should be employed when considering slowing the heart pharmacologically in a sick or stressed infant. The neonatal heart that is volume overloaded cannot respond to catecholamine inotropic support with the usual increase in contractility, and it often responds better to diuretics and afterload reduction. The normal HRs of infants and children are shown in Table 99-3.

Unlike mature cardiac muscle, the neonatal myocardium has an underdeveloped sarcoplasmic reticulum and is more dependent on extracellular calcium sources. Significant decreases in contractility and subsequent hypotension can be observed when ionized calcium levels fall, and the drop can be acute and dramatic. Careful attention to neonatal ionized calcium levels is essential in the perioperative period, particularly when neonates are not being fed enterally, are stressed or septic, are on loop diuretics that promote calcium loss such as furosemide, or have conditions associated with hypoparathyroidism or hypocalcemia, such as DiGeroge syndrome.[145]

6 Bradycardia can arise from the atrium or the ventricle. In neonatal resuscitation, bradycardia is concerning when the HR is less than 100 bpm. The primary cause of neonatal bradycardia is hypoxia. As such, the treatment begins with assessment of the airway and measures to oxygenation and ventilation. If the HR decreases below 60 bpm despite adequate oxygenation and ventilation, chest compressions are indicated followed by administration of epinephrine 10 mcg/kg intravenously. Other causes of sinus bradycardia include hypothermia, hypothyroidism, electrolyte disturbances (hypokalemia, hypercalcemia, and hypermagnesemia), and medications. If there is hemodynamic stability, treatment addressed the underlying cause.

Table 99-3 Normal Range of Awake and Sleeping Heart Rates in Infants and Children

Age	Awake Heart Rate (bpm)	Sleeping Heart Rate (bpm)
Neonate	100–190	80–160
Infant	100–180	75–160
Toddler	80–140	60–90
Preschooler	70–120	60–90
School age	65–110	60–90
Adolescent	60–100	50–90

Table 99-4 Normal Range of Blood Pressure in Infants and Children

Age	Systolic Pressure (mm Hg)	Diastolic Pressure (mm Hg)
Neonate	50–70	25–45
Infant	70–100	50–70
Toddler	80–110	50–80
Preschooler	80–115	50–80
School age	80–120	55–80
Adolescent	90–130	60–88

Tachycardia can arise from the atrium or ventricle. Sinus tachycardia can occur from hyperdynamic states such as sepsis, fever, seizures, thyrotoxicosis, pain, and hypoglycemia. Treatment is aimed at the underlying etiology. Tachyarrhythmias include atrial flutter, atrial fibrillation, and paroxysmal atrial tachycardia. Supraventricular tachycardia can be ectopic with variable rate and respond to esmolol, sotalol, or flecainide but reentrant SVTs usually have a fixed rate and respond to adenosine. Ventricular tachycardia and SVTs with hemodynamic instability should be cardioverted.

Clinical perfusion endpoints in term neonates include a capillary refill time of <2 seconds, normal pulses without differential between peripheral and central pulses, warm extremities, urine output greater than 1 mL/kg/hr, low serum lactate, and mixed venous saturation of $>70\%$.[146] In premature neonates, the mean arterial pressure (MAP) should be greater than or equal to 30 mm Hg.[147] However, a gestational age-based cutoff for "normal" blood pressure (goal MAP $>$ GA) is used at many tertiary centers, especially in the first 3 days after birth (Table 99-4).[137]

In term or older preterm infants, hypotension is generally managed with volume expansion (using 20 mL/kg of an isotonic solution with a repeat bolus as needed). In contrast, rapid volume expansion in extremely premature infants has a significant risk of ICH in the first few days of life.[108] Therefore, in hypotensive premature neonates, after a single bolus of saline (10 mL/kg over 60 minutes), vasoactive medications may be started.[148,149] In cases of obvious acute volume loss in preterm infants, more volume may be needed in addition.[136]

Dopamine (5 to 10 μg/kg/min) is generally the first vasoactive drug for neonates with shock.[149] Patients with depressed myocardial function may benefit from infusion of

dobutamine for both inotropy and vasodilation. Dobutamine improves and maintains systemic blood flow better than dopamine but can increase myocardial oxygen demand in high doses due to his chronotropic effect.[150] With persistent hypotension, glucocorticoids such as hydrocortisone,[151] vasopressin,[152] or other inotropes/vasoactive agents may be needed. Epinephrine or norepinephrine infusions for refractory shock in neonates have been studied to a very limited extent and should be considered for vasodilatory shock. Addition of these agents (after fluids and dopamine/dobutamine) can improve blood pressure, reduce tissue lactate, increase cerebral blood volume, and cerebral oxygen delivery in VLBW infants.[153,154] Milrinone, a phosphodiesterase inhibitor and potent pulmonary and systemic vasodilator, has not been well studied in neonatal septic shock but is commonly used in pediatric patients with septic shock to increase cardiac index, SV, and oxygen delivery while decreasing systemic vascular resistance without increasing HR or blood pressure.[150,155] Figure 99-5 demonstrates the management of neonatal and pediatric septic shock.

Congenital Heart Disease

Major neonatal cardiac abnormalities can be defined into two broad categories: acyanotic and cyanotic. Acyanotic diseases do not present with hypoxia at birth and can be monitored over the next several months. These conditions are grouped into those that increase pulmonary vascularity (from overcirculation through the pulmonary vascular system) and those with ventricular tract outflow obstruction.

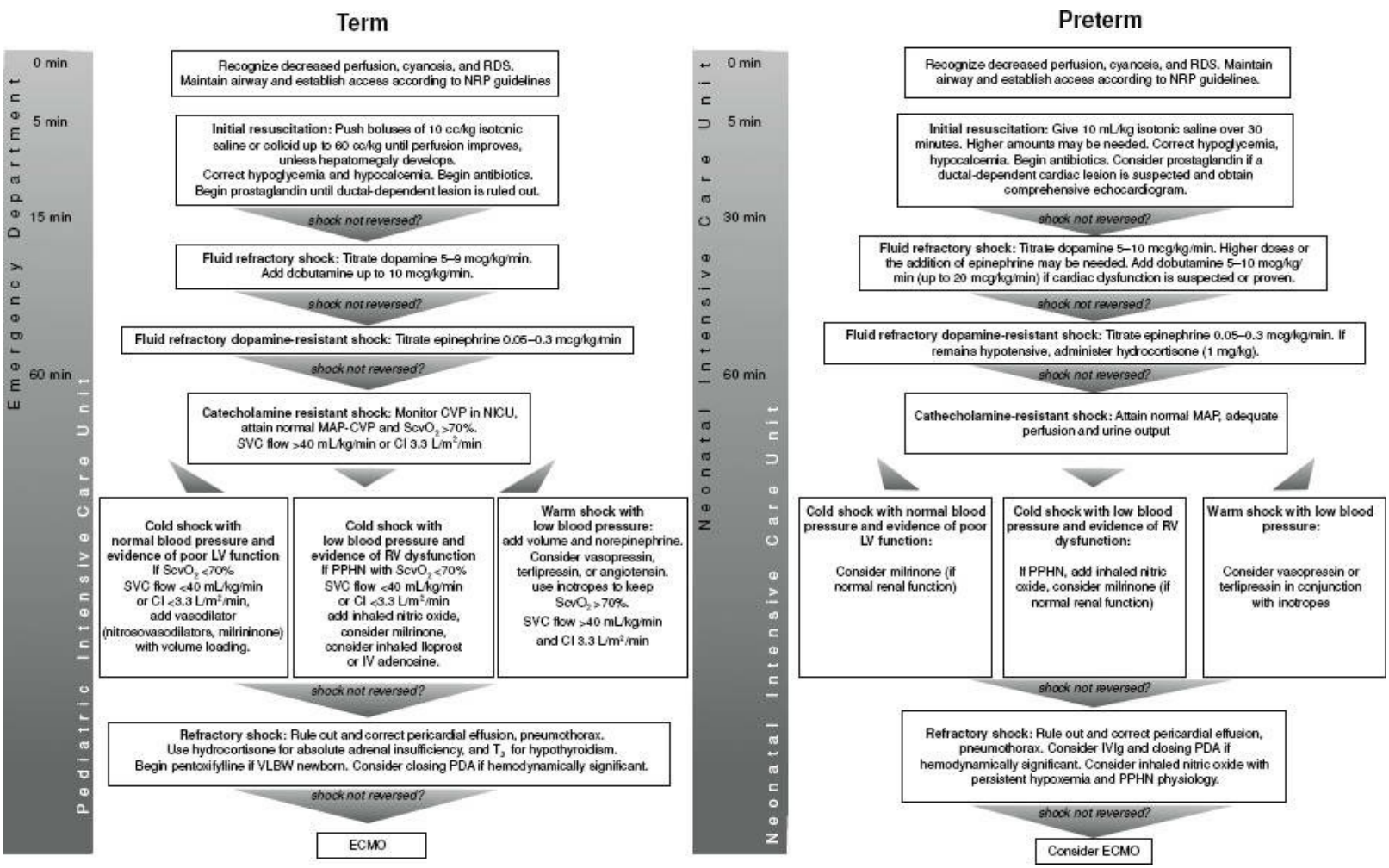

Figure 99-5. Management algorithms for septic shock in term and preterm neonates. (From Wynn JL, Wong HR. Pathophysiology and treatment of septic shock in neonates. *Clin Perinatol* 2010;37(2):439–479, with permission.)

7 Ven tricular septal defect (VSD) is the most common heart defect occurring in nearly a third of neonates with congenital heart disease, presenting at 2 to 6 weeks with a left-right shunt (depending on size of the defect). Occasionally, neonates can present with Eisenmenger syndrome from a large VSD and pulmonary vascular obstructive disease (either from an anatomic obstruction or persistent pulmonary hypertension at birth), with resultant right-to-left shunt, cyanosis, and impending death. These patients also have pulmonary hemorrhage, infections, and/or paradoxical emboli crossing over. Surgical indications for VSD include uncontrolled congestive right heart failure, increased pulmonary vascular resistance, failure to thrive despite maximal medical therapy with diuretics and fluid restriction, recurrent pulmonary infections, endocarditis, or paradoxical emboli.

Atrial septal defect (ASD) is the third most common, occurring in approximately 8% to 10% of patients with congenital heart disease. The symptoms depend on the size of defect and the relative compliances of the right and left ventricles. Surgical indications include right ventricular overload, arrhythmias, paradoxical emboli, and elevated pulmonary vascular resistance. AV septal defects, occurring more commonly in patients with Down syndrome, can have symptoms of either VSD or ASD and surgery is performed at 3 to 6 months to prevent consequences of pulmonary hypertension.

8 A PDA is when the connection between pulmonary artery to the descending aorta

does not close spontaneously in the first weeks of life. Symptoms (left-to-right shunt) depend on the size of PDA and pressures in descending aorta and pulmonary artery. Fluid restriction is the first line of therapy when appropriate with indomethacin reserved for persistent cases to help stimulate closure. In a few patients, the duct will need to be ligated when symptomatic and not responsive to nonoperative measures.

Acyanotic cases with ventricular outflow tract obstruction can occur in aortic stenosis, coarctation of the aorta, and pulmonic stenosis. In aortic stenosis, the commissures of the valve are fused and surgery is indicated with the annulus is small and balloon valvuloplasty is unsuccessful. Coarctation can present with shock in the first week after the DA spontaneously closes, and is managed with prostaglandin E1 to keep the ductus open prior to surgical repair. Postoperatively, systemic hypertension is managed with beta blockade. Pulmonic stenosis is the second most common cardiac disease and is secondary to the fusion of commissures. It is treated with balloon valvuloplasty or surgery and valve replacement.

Cyanotic heart diseases with decreased pulmonary vascularity include tetralogy of Fallot and tricuspid atresia. Tetralogy of Fallot accounts for 7% of all cardiac defects but is the most common cyanotic CHD. The tetralogy is defined by (1) pulmonic stenosis, (2) VSD, (3) aorta overriding ventricular septum, and (4) right ventricular hypertrophy. Classic “tetralogy spells” are due to elevated pulmonary pressures and subsequent diversion of flow from pulmonary to systemic circulation, and resultant hypoxemia. Infants further develop irritability, hypercapnia, and cyanosis. Treatment consists of knee-to-chest position, oxygen, morphine, IV fluid, bicarbonate, and transfusion for anemia. Surgery is indicated for increasing cyanosis or frequency of episodes.

Tricuspic atresia is a rare defect. The tricuspid valve lacks patency, and usually is associated with an ASD or foramen ovale and a hypoplastic right ventricle or pulmonary outflow tract unless a VSD is also present. The treatment consists of using a prostaglandin infusion to maintain DA patency, a modified Blalock–Taussig shunt in the first week of life, modified bidirectional Glenn anastomosis (SVC to right PA) at 6 to 9 months of age. A modified Fontan at 2 years of age is used to completely bypass right heart with flow from SVC/IVC to PA.

Cyanotic heart diseases with increased pulmonary vascularity include transposition of the great arteries, truncus arteriosus (TA), total anomalous pulmonary venous connection, and hypoplastic left heart syndrome (HLHS). In transposition of great arteries, the aorta arises from right ventricle and pulmonary artery from the left. The treatment is a stepwise approach with the use of a prostaglandin infusion, followed by balloon septostomy and repair of the defect in the first week of life with an arterial switch operation to reconnect each artery with the proper ventricle.

TA is a rare defect with a single vessel above both right and left ventricles with a large VSD. The common vessel – TA – gives rise to the aorta, coronary arteries, and pulmonary arteries. TA is associated with the DiGeorge sequence (thymic hypoplasia, third and fourth pharyngeal pouch syndrome) and patients should be evaluated for hypocalcemia (hypoparathyroid) and T-cell immunodeficiency (with only irradiated blood transfusions given to prevent graft-vs.-host disease). To repair the defect, a conduit is created from

right ventricle to pulmonary arteries with separation from the TA which supplies the cardiac and systemic circulation. The VSD is also closed to allow for the left ventricle to empty into the TA.

Total anomalous pulmonary venous connection involves an abnormal connection of pulmonary venous to systemic venous connections creating a cyanosis. Three subtypes exist: supracardiac to innominate vein, intracardiac to coronary sinus, and infracardiac below diaphragm to hepatic, portal, or umbilical venous systems. All subtypes require surgical repair upon presentation.

HLHS consists of stenosis of mitral and aortic valves, coarctation, and as the name suggests, a hypoplastic left ventricle. HLHS presents with cyanosis and shock when the DA closes and the management, similar to TA, is with a prostaglandin infusion to reopen the duct. Surgical correction includes a Norwood procedure, which includes the Blalock–Taussig shunt, followed by a Glenn procedure at 3 to 6 months and a modified Fontan at 2 years.

Renal Physiology

In utero, the fetus is nearly all water (94%) early in gestation and gradually decreases to 78% by term, though most of the volume is still extracellular. Over the following week, another 3% to 5% reduction occurs. Total body water continues to decline over the next year and a half (mostly in the extracellular component) to approximately adult levels (60%). In premature infants, both fetal and neonatal excess fluid is unloaded within the first week.

9 The glomerular filtration rate in neonates is lower than adults but quickly increases from 21 to 60 mL/min/1.73 m^2 by 2 weeks and reaches adult levels by a year and a half. Furthermore, an infant enduring water deprivation can only increase urine osmolality to 600 mOsm/kg, whereas adults can concentrate to 1,200 mOsm/kg. Insensible water losses which decrease over time can be excessive in preterm infants. Transepithelial water diffusion through the skin and through humidified inspired air from the lungs can be greater than 120 mL/kg/d.

A neonate's weight can be the best indicator of fluid status with the birth weight used to calculate fluid/medication rates until a return to birth weight in 1 to 2 weeks. In premature infants insensible losses from the respiratory tract account for 30%. From 1,500 to 2,500 g, fluid losses decrease from 30 to 60 mL/kg/d down to 10 to 15 mL/kg/d by about half with each 500 g increase in weight. In patients with an ostomy, a nasogastric tube for drainage or increased stool output from malabsorption, there may be substantial fluid and associated sodium losses that need to be accounted for in the administered fluid.

Neonatal fluid requirements should be calculated using a combination of metabolic demands, pre-existing fluid deficit, and continuing losses. Following a neonate's urine output and concentration to achieve an isotonic level of 280 mOsm/L, can help guide fluid administration. Augmenting this information with frequent monitoring of serum sodium, BUN, creatinine, and osmolarity, and urine sodium, creatinine and osmolarity allow titration of fluid to the infant's response. In neonates with a decreased urine output

despite appropriate fluid administration, calculating a FeNa (fractional sodium excretion) using the ratio of urine:serum sodium:creatinine values, helps differentiate prerenal causes (FeNa <2) from acute tubular necrosis (FeNa >3).

Hypo- and hypernatremia are defined as values below 130 mmol/L or above 150 mmol/L, respectively and reflect overall body fluid composition. With high urinary losses, hypoxic injury, or diuretic use, there may be excessive sodium loss leading to hyponatremia. The replacement should be done slowly over 24 to 48 hours by calculating the deficit ([desired level − actual level of sodium] × weight in kg × 0.6) and adding it to the maintenance fluid accounting for insensible losses. In low–birth-weight infants, preemptively adding sodium enterally can be useful to prevent hyponatremia and help with weight gain and growth.

Water retention can also lead to hyponatremia with excess dextrose solutions, renal failure or congestive heart failure with fluid restriction usually the first-line treatment and rarely using hypertonic saline if symptomatic to correct serum levels to 125 mmol/L. Occasionally, using diuretics can help with excess fluid removal but at the cost of other electrolyte losses (potassium, calcium, magnesium).

With dehydration, and with renal or gastric losses, the sodium may actually rise with fluid deficits in the 10% to 15% range. The correction should be done with caution over the next 24 to 48 hours by calculating the water deficit ([1 − (serum sodium/140)] × weight in kg × 0.6). If the patient is symptomatic (shock), resuscitation using 10 to 20 mL/kg saline from the total water deficit could be helpful. Using hypotonic fluid can be deleterious if the cause is hypovolemia and replacement with normal saline could correct the hypernatremia along with shock. In patients with hypervolemic hypernatremia, the use of loop diuretics can help with removal of excess fluid and sodium.

Nutrition and Gastrointestinal Physiology

10 A term newborn grows at 25 to 30 g/d over the first 6 months, doubling their birth weight by 5 months, tripling it by 12 months, four times the weight by 3 years, and a 20-fold increase over the first decade.[156] The body length increases by half in the first year and triples in the first decade. To sustain this pace of growth, calorie supplementation in the neonate and premature infant is paramount.

The pace of growth for the preterm infant (less than 27 weeks) is substantially slower at 10 to 20 g/d prior to the accelerated growth seen in the third trimester.[157] Moreover, fat accounts for nearly 16% of the birth weight in the term infant; whereas the premature infant has only 1% to 2% fat. Furthermore, the premature infant loses nearly 15% of its birth weight in the initial 1 to 2 weeks of life. In contrast, a term baby only loses about 7% to 10% of its weight. Therefore, though the caloric need remains high, the growth rate and gestational age must be closely accounted for when providing said calories.

Assessment of caloric need in the surgical baby is further complicated by (1) a potentially dysfunctional GI tract, (2) wound healing needs, and (3) any weight loss and malnutrition prior to surgery. Anticipating postsurgical caloric needs begins with a subjective assessment of weight loss, vomiting, fluid status, and muscle wasting, along with objective measures of weight on a standardized growth curve, and differentiating

chronic malnutrition using weight-to-height and head-circumference measures. Biochemical measures such as albumin, prealbumin, and retinol-binding protein can be inaccurate as do not have age-based norms, and can fluctuate with surgery and increased metabolic demand.[158] Bone age can be a useful measure for chronic malnutrition; however, can also be affected with long-term TPN use in the surgical patient.[159]

As stated above, the energy needs of an infant vary by age and physiologic status. The recommended daily calories and protein needs can fluctuate – therefore, the health care provider must carefully monitor weight gain, fluid status, and changes in body morphomics to determine if the provided calories match the needs of the baby. The most accurate method of measuring energy expenditure, however, is indirect calorimetry.[160]

The primary enteral carbohydrate delivered to neonates is lactose.[161] Lactase – the enzyme that breakdown lactose – is commonly found in high levels in most children below the age of 3. Nonlactose formulas are usually soy based and contain sucrose or corn syrup. Premature infants may not have adequate lactase levels; therefore hydrolyzed mixtures with lactose and glucose polymers are commonly provided.

Fats are an excellent source of energy (providing 9 kcal/g) and essential fatty acids. Withholding lipids from a neonate can lead to fatty acid deficiency within 3 days.[162] Manifestations of fatty acid deficiency include scaly skin, hair loss, diarrhea, and impaired wound healing.[163] Intralipid given with parenteral nutrition, however, can also lead to liver disease and decreasing the amount given while monitoring for fatty acid deficiency has been shown to decrease development of cholestasis.[164]

Of the 20 amino acids identified, 9 are considered essential in neonates. New tissue cannot be formed unless all the essential amino acids are present in a diet simultaneously! Furthermore, these protein requirements are higher in term neonates and infants (2 to 3 g/kg/d) than children, and even higher in preterm infants (3 to 3.5 g/kg/d).[165] The added protein needs, however, must be balanced with development of uremia secondary to the immature kidney.

While the energy needs must be met using carbohydrates (50%), fat (35%), and protein (15%), the fluid requirements, minerals and vitamin needs, and, trace elements must also be managed. Water content of infants is 75% of the body weight compared to 60% in adults. In term neonates and preterm infants, water makes up an even higher percentage. The daily consumption of fluid is nearly 10% to 15% of their body weight; compared to 2% to 4% in adults.

11 The enteral nutrition of choice is breast milk even in the premature or very low birth weight (VLBW, less than 1,500 g) infant. The American Academy of Pediatrics recommends exclusive breastfeeding for the first 6 months of life and continued breastfeeding for a year or more with the introduction of solid foods.[166] Benefits of human milk include “enhanced host defense, neurologic development, and gastrointestinal function.”[167] Human milk decreases the incidence and severity of nosocomial infections and NEC, improves visual acuity and cognitive development,[168] enhance gastric motility and increases gastric emptying time allowing the infant to absorb nutrients more efficiently, stimulates gastrointestinal growth and maturation, and provides protection of the gastrointestinal mucosa, and decreases risk of feeding

intolerance.[169]

The human-milk-fed premature infant might, however, still require nutrient supplementation, or fortification, to maintain optimal nutritional status. Furthermore, despite hospital-grade double electric breast pumps to initiate and maintain milk supply, pumping mothers struggle with low milk supply.[170] Neonatal and infant formulas are commonly used as substitutes for human breast milk. Infants receiving formula, however, are 6.5 times more likely to develop NEC than those infants receiving human milk diets alone. Use of donor human milk has been demonstrated "to decrease morbidity, nosocomial infections, NEC, urinary tract infections, gastroesophageal reflux disease, diarrhea, and length of hospital stay."[169] Pasteurization of donor milk does affect some nutritional and immunologic components, but many immunoglobulins, enzymes, hormones, and growth factors are unchanged or minimally decreased. Finally, symptoms of feeding intolerance, more commonly seen with formula-feeding, include vomiting, water-loss stools, increased abdominal girth, and increased gastric residuals.[169]

Inadequate nutrient intake is common in premature infants for a variety of reasons including an underdeveloped suck reflex, need for tube feeds, and, the variability in nutrient contents of the milk. Feeding difficulties can occur twice as commonly in premature compared to term infants.[171] Premature infants less than 28 weeks have significant difficulties with initiation and progression to maximal gavage and oral feedings. Typically, healthy premature infants achieve full oral feeding skills by 36 to 38 weeks.[172] Nonnutritive sucking has been shown in premature infants to decrease in length of stay, improved transition from tube to bottle feeds, and better bottle feeding performance and behavior.[173] Continuous tube-feeding reduces fat delivery to the infant when compared with intermittent bolus feeding.[174] Differences in nutrient contents occur with milk and donor milk due to variable "milk collection and storage, the feeding of 'spot' samples (individual samples of expressed milk from one or both breasts, or milk partially expressed from one breast), and the use of feeding tubes."[167] Furthermore, the milk is often refrigerated and/or frozen. Finally, there is a significant decline in protein from transitional to mature milk, and the concentrations of protein and sodium decline through lactation; therefore, supplementation is often recommended in the premature infant.

Intolerance of feeds in neonates could be secondary to anatomic variations including obstruction (such as congenital or acquired atresia) and dysmotility. Anatomic causes should be ruled out with imaging studies (x-rays, followed by contrast studies). In neonates, ultrasound may be useful to identify external obstructions such as enteric duplication cyst or mesenteric cyst. Bilious emesis in neonates requires an immediate evaluation for malrotation and midgut volvulus. The use of ranitidine in neonates is controversial and not recommended in premature infants due to its association with increasing incidence of NEC.[175]

In neonates that cannot tolerate enteral feeds due to immaturity, congenital anomalies, or hemodynamic instability, or enteral feeds do not meet caloric needs, the use of parental nutrition is essential. As neonates and infants have limited reserves, the use of total parenteral nutrition (TPN) should be fairly liberal. Premature infants may show

signs of starvation in 1 to 2 days and young infants require TPN if starvation extends 4 to 5 days, below the 7- to 10-day threshold used in adults. Furthermore, the return of bowel function after surgery may be delayed in premature infants, and many neonates on TPN have never been on full enteral feeds, encouraging the early use of TPN.

Neonates are usually maintained on a high dextrose solution for the first 2 days of life, unless a prolonged starvation is anticipated. Dextrose concentrations in the TPN are generally started at 10% to 12.5%, as larger amounts are associated with hyperglycemia. The concentration is slowly increased to 20% to 25%, monitoring the levels along with electrolytes regularly. The risk of developing phlebitis in peripheral veins increases when the osmolarity exceeds 600 to 900 mOsm/L,[176] translating to approximately 12.5% dextrose. Isotonic lipid infusions are also commonly coinfused with TPN protecting the peripheral veins. Finally, cycling TPN under 24 hours usually requires the child to be approximately 5 kg and to tolerate longer periods off TPN without development of hypoglycemia.

When ordering TPN, we start by calculating the total fluid and caloric needs of the child. We generally order the lipids in quantities of g/kg/d, starting at 0.5 to 1, advancing to 3 by 0.5 to 1 each day. Lipids will provide approximately 35% to 40% of the calories at goal. Protein is ordered next starting at 0.5 to 1 g/kg/d, advancing by 0.5 to 1 each day, to a goal of 2.5 to 3 g/kg/d for a newborn as stated above. Proteins should provide approximately 15% to 20% of the calories. Carbohydrates are calculated to provide 45% to 50% of the calories, starting at 4 to 6 mg/kg/min and advancing by 1 to 2 to a goal of 12 mg/kg/min. The dextrose% multiplied by the total volume over a day (rate per hour multiplied by 24 hours), times a constant 0.69, divided by the weight provides the mg/kg/min. Additives to TPN are standard with vitamins, minerals, and trace elements. The electrolytes are ordered based on laboratory values and the additives are adjusted for long term using laboratory values. Generally, we monitor the chloride-acetate ratio based on the acid–base status and our goals for a given patient, promoting the acetate to buffer a respiratory acidosis. Finally, the calcium-phosphate ratio is adjusted to provide the maximum amounts without causing formation of a precipitate. As the calculations can quickly become complex, we recommend employing a dietician or pharmacist familiar with neonatal TPN at institutions that commonly encounter the need to order long-term TPN in neonates.

Complications of TPN are categorized into metabolic, hepatobiliary, mechanical, and infectious. Metabolic complications include hyper- and hypoglycemia, metabolic derangements such as acid–base disturbances, electrolyte abnormalities, and metabolic bone disease. Hyperglycemia is secondary to excessive dextrose infused or rapid increase in the concentration. Hyperglycemia can result in osmotic diuresis, dehydration, electrolyte abnormalities, impaired phagocytosis, and liver steatosis.[177,178] Therapy for hyperglycemia includes lowering the rate of infusion, despite the loss in calories. If hyperglycemia continues, an insulin drip, separated from the TPN due an unpredictable response to insulin by neonates, can be started. Hypoglycemia occurs with a sudden drop in the rate of glucose provided. As mentioned above, cycling is not safe in this age group, and discontinuation of TPN should be done only after decreasing the rate over 1 to 2

hours. Metabolic acidosis from excess chloride or cysteine hydrochloride can cause acidosis; whereas excess acetate can cause alkalosis. Electrolyte abnormalities can occur with any of the following: sodium, potassium, magnesium, phosphate, and calcium.

Metabolic bone disease, which occasionally presents as a pathologic fracture, includes osteopenia, osteomalacia, and rickets. Calcium and phosphorus efficiency, excessive urinary losses of calcium secondary to diuretics, and excessive vitamin D intake, and aluminum toxicity can all contribute to metabolic bone disease. Maximizing calcium and phosphorus intake, and withdrawing vitamin D from these patients actually improves bone demineralization, resolution of bone pain, positive calcium balance, and normalizes active vitamin D and parathyroid hormone levels.

Hepatobiliary complications include cholestasis, steatosis, and cholelithiasis. Prematurity, prolonged TPN use, and sepsis can contribute to these complications. Cholestasis is the most common and occurs 2 to 3 weeks after initiation. Prevention strategies for cholestasis include enteral feeding, weaning from TPN, and prompt treatment of sepsis. Use of antibiotics to decrease bacterial overgrowth and translocation has been successful but measures to promote bile flow have not shown to decrease cholestasis. Use of omegaven and decreasing the lipid component of TPN has shown decreased rates of cholestasis.

Mechanical complications of TPN arise from the need for venous access. Cardiac arrhythmias, thrombosis, and infection can occur secondary to central line use. Proper positioning can avoid the rate of cardiac irritation by the catheter tip. Thrombosis can be prevented and treated with the use of prophylactic and therapeutic doses of anticoagulation. Prolonged thrombosis is a risk for line infection. Furthermore, many patients on chronic TPN lose central access secondary to chronic thrombosis. Finally, infectious complications can occur with and without a central line. Central lines require meticulous care during insertion and maintenance.[179] Fever, a sudden rise in bilirubin, and glucose intolerance are indicators of sepsis. Sepsis can occur while on TPN from microorganisms that enter the blood stream via the catheter, via infusion solutions, and from translocation from a disused, atrophic GI tract. Finally, antibiotic-coated catheters and ethanol locks have been shown to decrease rates of line infection.

Hypoglycemia

The fetal liver contains the enzymes needed for gluconeogenesis and glycogen synthesis but only glycogen synthesis occurs in utero. Glycogen deposition increases from 3.4 mg/g of liver tissue at 8 weeks gestation to 50 mg/g by term.[180] At birth, the glucose levels in the term neonate fall rapidly for the first hour from 80% to 90% of maternal levels, then rises and stabilizes by hour 3 after birth, independent of enteral intake.[180] Within 12 hours, hepatic glycogen stores reach 10% of their initial levels.[180] In fact, hypoglycemia in breast-fed term neonates is uncommon, with glucose production increasing to 4 to 6 mg/kg/min in the first few days, with glycogenolysis providing a third of the glucose production.[180] Preterm neonates, however, have increased rates of hypoglycemia because they have lower hepatic glycogen reserves, decreased activity of gluconeogenic enzymes, and a reduced ketogenic response.[180]

Following delivery and clamping of the umbilical cord, the newborn's supply of glucose is abruptly stopped. Over the next several hours, the neonate is susceptible to hypoglycemia, as defined as a serum glucose level below 47 mg/dL (2.6 mmol/L).[181] In order to prevent this hypoglycemia, the neonate relies on a steady supply of substrate, such as breastmilk, with an inability to use the relatively small amount of stored glycogen. The major energy source changes from glucose to fat during this adaptive phase. Infants born small for gestational age (<2 kg or below the 10th percentile), large for gestational age (>4 kg or above 90th percentile), intrauterine growth restriction, those with insulin-dependent mothers, or prematurely (<37 weeks) are at higher risk for hypoglycemia.[182]

Symptoms of hypoglycemia may include jitteriness, tachypnea, hypotonia, poor feeding, apnea, temperature instability, seizures, and lethargy.[183] Unfortunately, the infant may also remain asymptotic with severe hypoglycemia, highlighting the importance of screening in high-risk infants in the first hour of life. Treatment varies from observation, initiation of feeding, giving dextrose (D10 2 mg/kg bolus followed by 80 mL/kg/d) via IV, starting TPN with a glucose infusion rate (GIR) of 4 to 6 mg/kg/min at 80 mL/kg/d with steady increase in GIR based on glucose levels to target a level above 40 mg/dL.

Bilirubin Metabolism

One of the unique aspects of neonates is the extremely common, self-limited rise in bilirubin levels in the first few weeks after birth. The liver metabolizes albumin-bound bilirubin, created in the breakdown of hemoglobin, by conjugation using uridine diphosphate glucuronyl transferase (UDPGT). In term neonates, hepatic UDPGT is only expressed at about 1% of the adult levels.[180] Once hydrophilic conjugated bilirubin is excreted into small intestines, however, increased reabsorption into the blood as part of the enterohepatic circulation can also occur. The rise in bilirubin is at an earlier onset, for a longer duration, at a greater frequency, and severity in preterm neonates due to higher production from the larger proportion of senescent red blood cells, reduced ability to uptake bilirubin, and even more reduced UDPGT activity.[180]

Hyperbilirubinemia (>5 mg/dL) occurs in 60% of term and 80% of preterm infants during the first week of life.[184] It is one of the most common reasons for hospital readmission for the newborn as the peak level occurs after 3 to 5 days of life, commonly after discharge from the hospital. Etiology can be dye to prematurity, increased production, genetic disorder such as Gilbert syndrome, or poorly feeding or exclusively breast-fed late preterm infant.

Jaundice, seen initially in the mucous membranes of the inner mouth or eyes, must be categorized as physiologic or pathologic (occurring in the first 24 hours secondary to hemolysis or elevated levels for expected postnatal age and birth weight). Bilirubin toxicity starts with initial phase of sleepiness, hypotonia, poor feeding, and progresses to lethargy and irritability, and finally seizures or a coma.[185] Bilirubin-induced neurologic dysfunction (BIND) is tracked by following mental status, tone, and the infant's cry. Continued unrecognized bilirubin elevation can eventually lead to seizures,

developmental delay, hearing deficits, oculomotor disturbances, and kernicterus (permanent brain injury). There is no cure for kernicterus.[186]

Management of elevated bilirubin is guided by established nomograms. Phototherapy promotes photochemical reactions that change the shape and structure of the bilirubin: photo-isomerization converts bilirubin to water-soluble isomers that are excreted in the bile; photo-oxidation converts bilirubin to water-soluble products excreted in the urine. Fractionated bilirubin levels should be closely followed as the direct component can increase with phototherapy leading to a "bronze baby." Hydration should also be carefully monitored as the therapy can increase insensible losses. Ensuring skin integrity, thermoregulation, and monitoring stool patterns should also be part of the management. In patients with Rh or ABO incompatibility, the use of intravenous immunoglobulin may reduce the need for the next level of therapy, exchange transfusion.[187]

Exchange transfusion is similarly guided by levels on nomograms. The infant is made NPO, and requires IV access (usually umbilical access), and correction of hypoglycemia, hypocalcemia, hypotension, hypothermia, and acidosis. Thromboembolic complications, cardiac arrhythmias, sepsis, and NEC can also occur. During exchange, phototherapy should still be continued and bilirubin levels should continue to be monitored.

CONCLUSION

A thorough understanding of fetal, neonatal, and pediatric physiology is essential for understanding and treating fetal and pediatric surgical problems. Pediatric patients are not “tiny adults” and the medical and surgical approaches must be grounded in the understanding of their physiology and pathophysiology. Finally, we believe that complex fetal and neonatal surgery should be performed in centers with robust experience, which have pediatric subspecialists and facilities to care for these patients. Already, establishment of levels of care is underway to categorize various pediatric surgical institutions.[188] This should globally improve outcomes on all pediatric patients by creating overall expertise in institutions, which plays a significant role in pediatric surgical outcomes.

References

1. Wilson JM, DiFiore JW. Respiratory physiology and care. In: Coran AG, Adzick NS, eds. *Pediatric Surgery*. Philadelphia, PA: Elsevier Mosby; 2012.
2. Fraga MV, Guttentag S. Lung development. In: Gleason CA, ed. *Avery's Diseases of the Newborn a. S. U. D.* California: Los Angeles; 2012.
3. Hooper SB, Harding R. Fetal lung liquid: a major determinant of the growth and functional development of the fetal lung. *Clin Exp Pharmacol Physiol* 1995;22(4):235–247.
4. Harding R, Hooper SB. Regulation of lung expansion and lung growth before birth. *J Appl Physiol(1985)* 1996;81(1):209–224.
5. Vilos GA, Liggins GC. Intrathoracic pressures in fetal sheep. *J Dev Physiol* 1982;4(4):247–256.
6. Nardo L, Maritz G, Harding R, et al. Changes in lung structure and cellular division induced by tracheal obstruction in fetal sheep. *Exp Lung Res* 2000;26(2):105–119.
7. Schittny JC, Miserocchi G, Sparrow MP. Spontaneous peristaltic airway contractions propel lung liquid through the bronchial tree of intact and fetal lung explants. *Am J Respir Cell Mol Biol* 2000;23(1):11–18.
8. Bellotti M, Pennati G, De Gasperi C, et al. Role of ductus venosus in distribution of umbilical blood flow in human fetuses during second half of pregnancy. *Am J Physiol Heart Circ Physiol* 2000;279(3):H1256–H1263.
9. Sutton MS, Theard MA, Bhatia SJ, et al. Changes in placental blood flow in the normal human fetus with gestational age. *Pediatr Res* 1990;28(4):383–387.
10. Gill RW, Trudinger BJ, Garrett WJ, et al. Fetal umbilical venous flow measured in utero by pulsed Doppler and B-mode ultrasound. I. Normal pregnancies. *Am J Obstet Gynecol* 1981;139(6):720–725.
11. Ferrazzi E, Bellotti M, Galan H, et al. Doppler investigation in intrauterine growth restriction–from qualitative indices to flow measurements: a review of the experience of a collaborative group. *Ann N Y Acad Sci* 2001;943:316–325.
12. Wood WG, Weatherall DJ. Haemoglobin synthesis during human foetal development. *Nature* 1973;244(5412):162–165.
13. Polin RA, Fox WW, Abman SH. *Fetal and Neonatal Physiology*. 4th ed. Philadelphia, PA: Elsevier/Saunders; 2011.
14. Schroeder WA, Shelton JR, Shelton JB, et al. The amino acid sequence of the alpha chain of human fetal hemoglobin. *Biochemistry* 1963;2:1353–1357.
15. Willson DF, Notter RH. The future of exogenous surfactant therapy. *Respir Care* 2011;56(9):1369–1386; discussion 1386–1388.
16. Lacaze-Masmonteil T. Expanded use of surfactant therapy in newborns. *Clin Perinatol* 2007;34(1):179–189, ix.
17. Darlow BA, Graham PJ. Vitamin A supplementation to prevent mortality and short-

and long-term morbidity in very low birthweight infants. *Cochrane Database Syst Rev* 2011;(10):CD000501.

18. Shenai JP. Vitamin A supplementation in very low birth weight neonates: rationale and evidence. *Pediatrics* 1999;104(6):1369–1374.
19. Kuhlmann RS, Warsof SL, Levy DL, et al. Fetal sacrococcygeal teratoma. *Fetal Ther* 1987;2(2):95–100.
20. Hedrick HL, Flake AW, Crombleholme TM, et al. Sacrococcygeal teratoma: prenatal assessment, fetal intervention, and outcome. *J Pediatr Surg* 2004;39(3):430–438; discussion 430–438.
21. Olutoye OO, Johnson MP, Coleman BG, et al. Abnormal umbilical cord doppler sonograms may predict impending demise in fetuses with sacrococcygeal teratoma. A report of two cases. *Fetal Diagn Ther* 2004; 19(1):35–39.
22. Areechon W, Reid L. Hypoplasia of lung with congenital diaphragmatic hernia. *Br Med J* 1963;1(5325):230–233.
23. Pringle KC. Lung development in congenital diaphragmatic hernia. In: Puri P, ed. *Congenital Diaphragmatic Hernia.* Basel: Karger; 1989.
24. Shehata SM, Sharma HS, van der Staak FH, et al. Remodeling of pulmonary arteries in human congenital diaphragmatic hernia with or without extracorporeal membrane oxygenation. *J Pediatr Surg* 2000;35(2):208–215.
25. Hedrick MH, Estes JM, Sullivan KM, et al. Plug the lung until it grows (PLUG): a new method to treat congenital diaphragmatic hernia in utero. *J Pediatr Surg* 1994;29(5):612–617.
26. Harrison MR, Keller RL, Hawgood SB, et al. A randomized trial of fetal endoscopic tracheal occlusion for severe fetal congenital diaphragmatic hernia. *N Engl J Med* 2003;349(20):1916–1924.
27. Jani JC, Nicolaides KH, Gratacós E, et al. Severe diaphragmatic hernia treated by fetal endoscopic tracheal occlusion. *Ultrasound Obstet Gynecol* 2009;34(3):304–310.
28. Deprest J, Brady P, Nicolaides K, et al. Prenatal management of the fetus with isolated congenital diaphragmatic hernia in the era of the TOTAL trial. *Semin Fetal Neonatal Med* 2014;19(6):338–348.
29. McDonough RJ, Niven AS, Havenstrite KA. Congenital pulmonary airway malformation: a case report and review of the literature. *Respir Care* 2012; 57(2):302–306.
30. Sylvester KG, Albanese CT. Congenital bronchopulmonary malformations. In: Holcomb GW, Murphy PJ, Ostlie DJ, eds. *Ashcraft's Pediatric Surgery.* 5th ed. Philadelphia, PA: Saunder's; 2010.
31. Rice HE, Estes JM, Hedrick MH, et al. Congenital cystic adenomatoid malformation: a sheep model of fetal hydrops. *J Pediatr Surg* 1994;29(5):692–696.
32. Adzick NS, Harrison MR, Crombleholme TM, et al. Fetal lung lesions: management and outcome. *Am J Obstet Gynecol* 1998;179(4):884–889.

33. Crombleholme TM, Coleman B, Hedrick H, et al. Cystic adenomatoid malformation volume ratio predicts outcome in prenatally diagnosed cystic adenomatoid malformation of the lung. *J Pediatr Surg* 2002;37(3):331–338.
34. Peranteau WH, Wilson RD, Liechty KW, et al. Effect of maternal betamethasone administration on prenatal congenital cystic adenomatoid malformation growth and fetal survival. *Fetal Diagn Ther* 2007;22(5):365–371.
35. Tsao K, Hawgood S, Vu L, et al. Resolution of hydrops fetalis in congenital cystic adenomatoid malformation after prenatal steroid therapy. *J Pediatr Surg* 2003;38(3):508–510.
36. Sydorak RM, Hirose S, Sandberg PL, et al. Chorioamniotic membrane separation following fetal surgery. *J Perinatol* 2002;22(5):407–410.
37. Wilson RD, Johnson MP, Crombleholme TM, et al. Chorioamniotic membrane separation following open fetal surgery: pregnancy outcome. *Fetal Diagn Ther* 2003;18(5):314–320.
38. Deprest J, Gratacos E, Nicolaides KH; FETO Task Group. Fetoscopic tracheal occlusion (FETO) for severe congenital diaphragmatic hernia: evolution of a technique and preliminary results. *Ultrasound Obstet Gynecol* 2004;24(2):121–126.
39. DiBlasi RM, Richardson CP, Hansen T. Pulmonary physiology of the newborn. In: Gleason CA, Devaskar SU, Avery ME, eds. *Avery's Diseases of the Newborn.* Philadelphia, PA: Elsevier/Saunders: 2012;598–611.
40. Fry DL, Hyatt RE. Pulmonary mechanics. A unified analysis of the relationship between pressure, volume and gasflow in the lungs of normal and diseased human subjects. *Am J Med* 1960;29:672–689.
41. Krieger I. Studies on mechanics of respiration in infancy. *Am J Dis Child* 1963;105:439–448.
42. Magnenant E, Rakza T, Riou Y, et al. Dynamic behavior of respiratory system during nasal continuous positive airway pressure in spontaneously breathing premature newborn infants. *Pediatr Pulmonol* 2004;37(6):485–491.
43. Polgar G, Kong GP. The nasal resistance of newborn infants. *J Pediatr* 1965;67(4):557–567.
44. Zimova-Herknerova M, Plavka R. Expired tidal volumes measured by hot-wire anemometer during high-frequency oscillation in preterm infants. *Pediatr Pulmonol* 2006;41(5):428–433.
45. Dellaca RL, Ventura ML, Zannin E, et al. Measurement of total and compartmental lung volume changes in newborns by optoelectronic plethysmography. *Pediatr Res* 2010;67(1):11–16.
46. Hulskamp G, Lum S, Stocks J, et al. Association of prematurity, lung disease and body size with lung volume and ventilation inhomogeneity in unsedated neonates: a multicentre study. *Thorax* 2009;64(3):240–245.
47. Delivoria-Papadopoulos M, Levison H, Swyer PR. Intermittent positive pressure

respiration as a treatment in severe respiratory distress syndrome. *Arch Dis Child* 1965;40(213):474–479.

48. Donn SM. Neonatal ventilators: how do they differ? *J Perinatol* 2009; 29(Suppl 2):S73–S78.
49. Becker MA, Donn SM. Real-time pulmonary graphic monitoring. *Clin Perinatol* 2007;34(1):1–17, v.
50. Singh J, Sinha SK, Clarke P, et al. Mechanical ventilation of very low birth weight infants: is volume or pressure a better target variable? *J Pediatr* 2006;149(3):308–313.
51. Gray BW, Shaffer AW, Mychaliska GB. Advances in neonatal extracorporeal support: the role of extracorporeal membrane oxygenation and the artificial placenta. *Clin Perinatol* 2012;39(2):311–329.
52. Bartlett RH. Extracorporeal life support: history and new directions. *Semin Perinatol* 2005;29(1):2–7.
53. Bartlett RH, Gazzaniga AB, Jefferies MR, et al. Extracorporeal membrane oxygenation (ECMO) cardiopulmonary support in infancy. *Trans Am Soc Artif Intern Organs* 1976;22:80–93.
54. Duyndam A, Ista E, Houmes RJ, et al. Invasive ventilation modes in children: a systematic review and meta-analysis. *Crit Care* 2011;15(1):R24.
55. Finer NN, Barrington KJ. Nitric oxide for respiratory failure in infants born at or near term. *Cochrane Database Syst Rev* 2006;(4):CD000399.
56. Field D, Elbourne D, Hardy P, et al. Neonatal ventilation with inhaled nitric oxide vs. Ventilatory support without inhaled nitric oxide for infants with severe respiratory failure born at or near term: the INNOVO multicentre randomised controlled trial. *Neonatology* 2007;91(2):73–82.
57. El Shahed AI, Dargaville P, Ohlsson A, et al. Surfactant for meconium aspiration syndrome in full term/near term infants. *Cochrane Database Syst Rev* 2007; (3):CD002054.
58. Stevens TP, Harrington EW, Blennow M, et al. Early surfactant administration with brief ventilation vs. selective surfactant and continued mechanical ventilation for preterm infants with or at risk for respiratory distress syndrome. *Cochrane Database Syst Rev* 2007;(4):CD003063.
59. Greenough A, Dimitriou G, Prendergast M, et al. Synchronized mechanical ventilation for respiratory support in newborn infants. *Cochrane Database Syst Rev* 2008;(1):CD000456.
60. Mugford M, Elbourne D, Field D. Extracorporeal membrane oxygenation for severe respiratory failure in newborn infants. *Cochrane Database Syst Rev* 2008; (3):CD001340.
61. Itoh H, Ichiba S, Ujike Y, et al. Extracorporeal membrane oxygenation following pediatric cardiac surgery: development and outcomes from a single center

experience. *Perfusion* 2012;27(3):225–229.
62. Stolar CJ, Snedecor SM, Bartlett RH. Extracorporeal membrane oxygenation and neonatal respiratory failure: experience from the extracorporeal life support organization. *J Pediatr Surg* 1991;26(5):563–571.
63. Bartlett RH, Gazzaniga AB, Toomasian J, et al. Extracorporeal membrane oxygenation (ECMO) in neonatal respiratory failure. 100 cases. *Ann Surg* 1986;204(3):236–245.
64. Ortega M, Ramos AD, Platzker AC, et al. Early prediction of ultimate outcome in newborn infants with severe respiratory failure. *J Pediatr* 1988;113(4):744–747.
65. Rivera RA, Butt W, Shann F. Predictors of mortality in children with respiratory failure: possible indications for ECMO. *Anaesth Intensive Care* 1990;18(3):385–389.
66. Cilley RE, Zwischenberger JB, Andrews AF, et al. Intracranial hemorrhage during extracorporeal membrane oxygenation in neonates. *Pediatrics* 1986;78(4):699–704.
67. Hirschl RB, Schumacher RE, Snedecor SN, et al. The efficacy of extracorporeal life support in premature and low birth weight newborns. *J Pediatr Surg* 1993;28(10):1336–1340; discussion 1341.
68. Meinhardt JP, Annich GM, Miskulin J, et al. Thrombogenicity is not reduced when heparin and phospholipid bonded circuits are used in a rabbit model of extracorporeal circulation. *ASAIO J* 2003;49(4):395–400.
69. Annich GM, Meinhardt JP, Mowery KA, et al. Reduced platelet activation and thrombosis in extracorporeal circuits coated with nitric oxide release polymers. *Crit Care Med* 2000;28(4):915–920.
70. Frost MC, Reynolds MM, Meyerhoff ME. Polymers incorporating nitric oxide releasing/generating substances for improved biocompatibility of blood-contacting medical devices. *Biomaterials* 2005;26(14):1685–1693.
71. Zhang H, Annich GM, Miskulin J, et al. Nitric oxide-releasing fumed silica particles: synthesis, characterization, and biomedical application. *J Am Chem Soc* 2003;125(17):5015–5024.
72. Major TC, Brant DO, Burney CP, et al. The hemocompatibility of a nitric oxide generating polymer that catalyzes S-nitrosothiol decomposition in an extracorporeal circulation model. *Biomaterials* 2011;32(26):5957–5969.
73. Major TC, Brant DO, Reynolds MM, et al. The attenuation of platelet and monocyte activation in a rabbit model of extracorporeal circulation by a nitric oxide releasing polymer. *Biomaterials* 2010;31(10):2736–2745.
74. Skrzypchak AM, Lafayette NG, Bartlett RH, et al. Effect of varying nitric oxide release to prevent platelet consumption and preserve platelet function in an in vivo model of extracorporeal circulation. *Perfusion* 2007;22(3):193–200.
75. Wu B, Gerlitz B, Grinnell BW, et al. Polymeric coatings that mimic the endothelium: combining nitric oxide release with surface-bound active thrombomodulin and heparin. *Biomaterials* 2007;28(28):4047–4055.

76. Lewis DA, Gauger P, Delosh TN, et al. The effect of pre-ECLS ventilation time on survival and respiratory morbidity in the neonatal population. *J Pediatr Surg* 1996;31(8):1110–1114; discussion 1114–1115.
77. von Allmen D, Ryckman FC. Cardiac arrest in the ECMO candidate. *J Pediatr Surg* 1991;26(2):143–146.
78. del Nido PJ, Dalton HJ, Thompson AE, et al. Extracorporeal membrane oxygenator rescue in children during cardiac arrest after cardiac surgery. *Circulation* 1992;86(5 Suppl):II300–II304.
79. Clark RH, Huckaby JL, Kueser TJ, et al. Low-dose nitric oxide therapy for persistent pulmonary hypertension: 1-year follow-up. *J Perinatol* 2003;23(4):300–303.
80. Christou H, Van Marter LJ, Wessel DL, et al. Inhaled nitric oxide reduces the need for extracorporeal membrane oxygenation in infants with persistent pulmonary hypertension of the newborn. *Crit Care Med* 2000;28(11):3722–3727.
81. Clark RH, Kueser TJ, Walker MW, et al. Low-dose nitric oxide therapy for persistent pulmonary hypertension of the newborn. Clinical Inhaled Nitric Oxide Research Group. *N Engl J Med* 2000;342(7):469–474.
82. Bartlett RH. Extracorporeal life support for cardiopulmonary failure. *Curr Probl Surg* 1990;27(10):621–705.
83. Skinner SC, Hirschl RB, Bartlett RH. Extracorporeal life support. *Semin Pediatr Surg* 2006;15(4):242–250.
84. MacLaren G, Combes A, Bartlett RH. Contemporary extracorporeal membrane oxygenation for adult respiratory failure: life support in the new era. *Intensive Care Med* 2012;38(2):210–220.
85. Khoshbin E, Roberts N, Harvey C, et al. Poly-methyl pentene oxygenators have improved gas exchange capability and reduced transfusion requirements in adult extracorporeal membrane oxygenation. *ASAIO J* 2005;51(3):281–287.
86. Nishinaka T, Tatsumi E, Katagiri N, et al. Up to 151 days of continuous animal perfusion with trivial heparin infusion by the application of a long-term durable antithrombogenic coating to a combination of a seal-less centrifugal pump and a diffusion membrane oxygenator. *J Artif Organs* 2007;10(4):240–244.
87. Peek GJ, Killer HM, Reeves R, et al. Early experience with a polymethyl pentene oxygenator for adult extracorporeal life support. *ASAIO J* 2002; 48(5):480–482.
88. Mendler N, Podechtl F, Feil G, et al. Seal-less centrifugal blood pump with magnetically suspended rotor: rot-a-flot. *Artif Organs* 1995;19(7):620–624.
89. Talor J, Yee S, Rider A, et al. Comparison of perfusion quality in hollow-fiber membrane oxygenators for neonatal extracorporeal life support. *Artif Organs* 2010;34(4):E110–E116.
90. Wang D, Zhou X, Liu X, et al. Wang-Zwische double lumen cannula-toward a percutaneous and ambulatory paracorporeal artificial lung. *ASAIO J* 2008;54(6):606–611.

91. Bermudez CA, Rocha RV, Sappington PL, et al. Initial experience with single cannulation for venovenous extracorporeal oxygenation in adults. *Ann Thorac Surg* 2010;90(3):991–995.
92. Gadepalli SK, Hirschl RB. Extracorporeal life support: updates and controversies. *Semin Pediatr Surg* 2015;24(1):8–11.
93. Bartlett RH, Andrews AF, Toomasian JM, et al. Extracorporeal membrane oxygenation for newborn respiratory failure: forty-five cases. *Surgery* 1982;92(2):425–433.
94. Kim A, Erickson K, Rana A, et al. *Pushing the Boundaries of ECLS: Outcomes in < 34 week EGA Neonates.* Puerto Rico: American Pediatric Surgical Association; 2009.
95. Markestad T, Kaaresen PI, R⊘nnestad A, et al. Early death, morbidity, and need of treatment among extremely premature infants. *Pediatrics* 2005;115(5):1289–1298.
96. Behrman RE, Butler AS, eds. *Preterm Birth: Causes, Consequences, and Prevention.* Washington, DC: Institute of Medicine of the National Academics; 2006:1–4.
97. Hack M, Fanaroff AA. Outcomes of children of extremely low birthweight and gestational age in the 1990s. *Semin Neonatol* 2000;5(2):89–106.
98. Rimensberger PC. Neonatal respiratory failure. *Curr Opin Pediatr* 2002; 14(3):315–321.
99. Ventre KM, Arnold JH. High frequency oscillatory ventilation in acute respiratory failure. *Paediatr Respir Rev* 2004;5(4):323–332.
100. Gray BW, El-Sabbagh A, Rojas-Pena A, et al. Development of an artificial placenta IV: 24 hour venovenous extracorporeal life support in premature lambs. *ASAIO J* 2012;58(2):148–154.
101. Seo T, Ito T, Iio K, et al. Experimental study on the hemodynamic effects of veno-arterial extracorporeal membrane oxygenation with an automatically driven blood pump on puppies. *Artif Organs* 1991;15(5):402–407.
102. Richardson DK, Corcoran JD, Escobar GJ, et al. SNAP-II and SNAPPE-II: simplified newborn illness severity and mortality risk scores. *J Pediatr* 2001;138(1):92–100.
103. Parry G, Tucker J, Tarnow-Mordi W. CRIB II: an update of the clinical risk index for babies score. *Lancet* 2003;361(9371):1789–1791.
104. Carvalho PR, Moreira ME, Sá RA, et al. SNAPPE-II application in newborns with very low birth weight: evaluation of adverse outcomes in severe placental dysfunction. *J Perinat Med* 2011;39(3):343–347.
105. White JJ, Andrews HG, Risemberg H, et al. Prolonged respiratory support in newborn infants with a membrane oxygenator. *Surgery* 1971;70(2):288–296.
106. Milligan DW. Failure of autoregulation and intraventricular haemorrhage in preterm infants. *Lancet* 1980;1(8174):896–898.
107. Tarby TJ, Volpe JJ. Intraventricular hemorrhage in the premature infant. *Pediatr Clin North Am* 1982;29(5):1077–1104.
108. Goldberg RN, Chung D, Goldman SL, et al. The association of rapid volume

expansion and intraventricular hemorrhage in the preterm infant. *J Pediatr* 1980;96(6):1060–1063.

109. Goldenberg RL. The management of preterm labor. *Obstet Gynecol* 2002;100(5 Pt 1):1020–1037.
110. Ballabh P. Pathogenesis and prevention of intraventricular hemorrhage. *Clin Perinatol* 2014;41(1):47–67.
111. Morrison JL, Botting KJ, Soo PS, et al. Antenatal steroids and the IUGR fetus: are exposure and physiological effects on the lung and cardiovascular system the same as in normally grown fetuses? *J Pregnancy* 2012;2012:839656.
112. Polyakov A, Cohen S, Baum M, et al. Patterns of antenatal corticosteroid prescribing 1998–2004. *Aust N Z J Obstet Gynaecol* 2007;47(1):42–45.
113. Ikegami M, Polk DH, Jobe AH, et al. Effect of interval from fetal corticosteroid treatment to delivery on postnatal lung function of preterm lambs. *J Appl Physiol(1985)* 1996;80(2):591–597.
114. Liley HG, White RT, Warr RG, et al. Regulation of messenger RNAs for the hydrophobic surfactant proteins in human lung. *J Clin Invest* 1989; 83(4):1191–1197.
115. Snyder JM, Regulation of alveolarization. In: Polin RA, Fox WW, Abman SH, eds. *Fetal and Neonatal Physiology*. Philadelphia, PA: Elsevier/Saunders; 2011.
116. Davidson A, Flick RP. Neurodevelopmental implications of the use of sedation and analgesia in neonates. *Clin Perinatol* 2013;40(3):559–573.
117. Hansen TG. Anesthesia-related neurotoxicity and the developing animal brain is not a significant problem in children. *Paediatr Anaesth* 2015; 25(1):65–72.
118. Olsen EA, Brambrink AM. Anesthetic neurotoxicity in the newborn and infant. *Curr Opin Anaesthesiol* 2013;26(5):535–542.
119. Sanders RD, Hassell J, Davidson AJ, et al. Impact of anaesthetics and surgery on neurodevelopment: an update. *Br J Anaesth* 2013;110(Suppl 1):i53–i72.
120. Zhang H, Du L, Du Z, et al. Association between childhood exposure to single general anesthesia and neurodevelopment: a systematic review and meta-analysis of cohort study. *J Anesth* 2015;29(5):749–757.
121. Raju TN. Developmental physiology of late and moderate prematurity. *Semin Fetal Neonatal Med* 2012;17(3):126–131.
122. Whyte RK. Neonatal management and safe discharge of late and moderate preterm infants. *Semin Fetal Neonatal Med* 2012;17(3):153–158.
123. Flenady VJ, Woodgate PG. Radiant warmers versus incubators for regulating body temperature in newborn infants. *Cochrane Database Syst Rev* 2003;(4):CD000435.
124. Afsar FS. Skin care for preterm and term neonates. *Clin Exp Dermatol* 2009;34(8):855–858.
125. Shwayder T, Akland T. Neonatal skin barrier: structure, function, and disorders. *Dermatol Ther* 2005;18(2):87–103.
126. McGurk V, Holloway B, Crutchley A, et al. Skin integrity assessment in neonates and

children. *Paediatr Nurs* 2004;16(3):15–18.

127. Bhutta ZA, Darmstadt GL, Hasan BS, et al. Community-based interventions for improving perinatal and neonatal health outcomes in developing countries: a review of the evidence. *Pediatrics* 2005;115(2 Suppl):519–617.
128. Khashu M, Chessex P, Chanoine JP. Iodine overload and severe hypothyroidism in a premature neonate. *J Pediatr Surg* 2005;40(2):E1–E4.
129. Baharestani MM. An overview of neonatal and pediatric wound care knowledge and considerations. *Ostomy Wound Manage* 2007;53(6):34–36, 38, 40, passim.
130. Binet A, Gelas T, Jochault-Ritz S, et al. VAC® therapy a therapeutic alternative in giant omphalocele treatment: a multicenter study. *J Plast Reconstr Aesthet Surg* 2013;66(12):e373–e375.
131. Gutierrez IM, Gollin G. Negative pressure wound therapy for children with an open abdomen. *Langenbecks Arch Surg* 2012;397(8):1353–1357.
132. Oeltjen JC, Panos AL, Salerno TA, et al. Complete vacuum-assisted sternal closure following neonatal cardiac surgery. *J Card Surg* 2009;24(6):748–750.
133. Lawn JE, Cousens S, Zupan J. 4 million neonatal deaths: when? Where? Why? *Lancet* 2005;365(9462):891–900.
134. Liu L, Johnson HL, Cousens S, et al; Child Health Epidemiology Reference Group of WHO and UNICEF. Global, regional, and national causes of child mortality: an updated systematic analysis for 2010 with time trends since 2000. *Lancet* 2012;379(9832):2151–2161.
135. Wynn JL, Wong HR. Pathophysiology and treatment of septic shock in neonates. *Clin Perinatol* 2010;37(2):439–479.
136. Cuenca AG, Wynn JL, Moldawer LL, et al. Role of innate immunity in neonatal infection. *Am J Perinatol* 2013;30(2):105–112.
137. Healy CM, Palazzi DL, Edwards MS, et al. Features of invasive staphylococcal disease in neonates. *Pediatrics* 2004;114(4):953–961.
138. Basha S, Surendran N, Pichichero M, Immune responses in neonates. *Expert Rev Clin Immunol* 2014;10(9):1171–1184.
139. Haque KN. Defining common infections in children and neonates. *J Hosp Infect* 2007;65(Suppl 2):110–114.
140. Levy O, Martin S, Eichenwald E, et al. Impaired innate immunity in the newborn: newborn neutrophils are deficient in bactericidal/permeability-increasing protein. *Pediatrics* 1999;104(6):1327–1333.
141. Rittirsch D, Flierl MA, Ward PA. Harmful molecular mechanisms in sepsis. *Nat Rev Immunol* 2008;8(10):776–787.
142. Melvan JN, Bagby GJ, Welsh DA, et al. Neonatal sepsis and neutrophil insufficiencies. *Int Rev Immunol* 2010;29(3):315–348.
143. Fierson WM; American Academy of Pediatrics Section on Ophthalmology; American Academy of Ophthalmology; American Association for Pediatric Ophthalmology and

Strabismus; American Association of Certified Orthoptists. Screening examination of premature infants for retinopathy of prematurity. *Pediatrics* 2013;131(1):189–195.

144. SUPPORT Study Group of the Eunice Kennedy Shriver NICHD Neonatal Research Network; Carlo WA, Finer NN, Walsh MC, et al. Target ranges of oxygen saturation in extremely preterm infants. *N Engl J Med* 2010;362(21):1959–1969.
145. Hines MH. Neonatal cardiovascular physiology. *Semin Pediatr Surg* 2013;22(4):174–178.
146. Parker MM, Hazelzet JA, Carcillo JA. Pediatric considerations. *Crit Care Med* 2004;32(11 Suppl):S591–S594.
147. Munro MJ, Walker AM, Barfield CP. Hypotensive extremely low birth weight infants have reduced cerebral blood flow. *Pediatrics* 2004;114(6):1591–1596.
148. Seri I. Circulatory support of the sick preterm infant. *Semin Neonatol* 2001;6(1):85–95.
149. Seri I, Noori S. Diagnosis and treatment of neonatal hypotension outside the transitional period. *Early Hum Dev* 2005;81(5):405–411.
150. Osborn D, Evans N, Kluckow M. Randomized trial of dobutamine versus dopamine in preterm infants with low systemic blood flow. *J Pediatr* 2002;140(2):183–191.
151. Noori S, Friedlich P, Wong P, et al. Hemodynamic changes after low-dosage hydrocortisone administration in vasopressor-treated preterm and term neonates. *Pediatrics* 2006;118(4):1456–1466.
152. Meyer S, Gottschling S, Baghai A, et al. Arginine-vasopressin in catecholamine-refractory septic versus non-septic shock in extremely low birth weight infants with acute renal injury. *Crit Care* 2006;10(3):R71.
153. Pellicer A, Valverde E, Elorza MD, et al. Cardiovascular support for low birth weight infants and cerebral hemodynamics: a randomized, blinded, clinical trial. *Pediatrics* 2005;115(6):1501–1512.
154. Tourneux P, Rakza T, Abazine A, et al. Noradrenaline for management of septic shock refractory to fluid loading and dopamine or dobutamine in full-term newborn infants. *Acta Paediatr* 2008;97(2):177–180.
155. Barton P, Garcia J, Kouatli A, et al. Hemodynamic effects of i.v. milrinone lactate in pediatric patients with septic shock. A prospective, double-blinded, randomized, placebo-controlled, interventional study. *Chest* 1996;109(5):1302–1312.
156. Marian M. Pediatric nutrition support. *Nutr Clin Pract* 1993;8(5):199–209.
157. Rose J, Gibbons K, Carlson SE, et al. Nutrient needs of the preterm infant. *Nutr Clin Pract* 1993;8(5):226–232.
158. Merritt RJ, Kalsch M, Roux LD, et al. Significance of hypoalbuminemia in pediatric oncology patients–malnutrition or infection? *JPEN J Parenter Enteral Nutr* 1985;9(3):303–306.
159. Epstein S, Traberg H, Levine G, et al. Bone and mineral status of patients beginning total parenteral nutrition. *JPEN J Parenter Enteral Nutr* 1986;10(3):263–264.

160. Chwals WJ, Lally KP, Woolley MM. Indirect calorimetry in mechanically ventilated infants and children: measurement accuracy with absence of audible airleak. *Crit Care Med* 1992;20(6):768–770.
161. Akintorin SM, Kamat M, Pildes RS, et al. A prospective randomized trial of feeding methods in very low birth weight infants. *Pediatrics* 1997;100(4):E4.
162. Friedman Z, Danon A, Stahlman MT, et al. Rapid onset of essential fatty acid deficiency in the newborn. *Pediatrics* 1976;58(5):640–649.
163. O'Neill JA Jr, Caldwell MD, Meng HC. Essential fatty acid deficiency in surgical patients. *Ann Surg* 1977;185(5):535–542.
164. Cober MP, Killu G, Brattain A, et al. Intravenous fat emulsions reduction for patients with parenteral nutrition-associated liver disease. *J Pediatr* 2012;160(3):421–427.
165. Ziegler EE. Protein in premature feeding. *Nutrition* 1994;10(1):69–71.
166. Gartner LM, Morton J, Lawrence RA, et al; American Academy of Pediatrics Section on Breastfeeding. Breastfeeding and the use of human milk. *Pediatrics* 2005;115(2):496–506.
167. Heiman H, Schanler RJ. Enteral nutrition for premature infants: the role of human milk. *Semin Fetal Neonatal Med* 2007;12(1):26–34.
168. Anderson JW, Johnstone BM, Remley DT. Breast-feeding and cognitive development: a meta-analysis. *Am J Clin Nutr* 1999;70(4):525–535.
169. Edwards TM, Spatz DL. Making the case for using donor human milk in vulnerable infants. *Adv Neonatal Care* 2012;12(5):273–278; quiz 279–280.
170. Mitoulas LR, Lai CT, Gurrin LC, et al. Efficacy of breast milk expression using an electric breast pump. *J Hum Lact* 2002;18(4):344–352.
171. Mercado-Deane MG, Burton EM, Harlow SA, et al. Swallowing dysfunction in infants less than 1 year of age. *Pediatr Radiol* 2001;31(6):423–428.
172. Jadcherla SR, Wang M, Vijayapal AS, et al. Impact of prematurity and co-morbidities on feeding milestones in neonates: a retrospective study. *J Perinatol* 2010;30(3):201–208.
173. Pinelli J, Symington A. Non-nutritive sucking for promoting physiologic stability and nutrition in preterm infants. *Cochrane Database Syst Rev* 2005;(4):CD001071.
174. Greer FR, McCormick A, Loker J, Changes in fat concentration of human milk during delivery by intermittent bolus and continuous mechanical pump infusion. *J Pediatr* 1984;105(5):745–749.
175. Chandrasekaran M, Fleming P. Question 1: does the use of ranitidine increase the risk of NEC in preterm infants?*Arch Dis Child* 2014;99(4):390–392.
176. Isaacs JW, Millikan WJ, Stackhouse J, et al. Parenteral nutrition of adults with a 900 milliosmolar solution via peripheral veins. *Am J Clin Nutr* 1977;30(4):552–559.
177. Alexiewicz JM, Kumar D, Smogorzewski M, et al. Polymorphonuclear leukocytes in non-insulin-dependent diabetes mellitus: abnormalities in metabolism and function. *Ann Intern Med* 1995;123(12):919–924.

178. Hay WW Jr. Strategies for feeding the preterm infant. *Neonatology* 2008;94(4):245–254.
179. Freeman JJ, Gadepalli SK, Siddiqui SM, et al. Improving central line infection rates in the neonatal intensive care unit: effect of hospital location, site of insertion, and implementation of catheter-associated bloodstream infection protocols. *J Pediatr Surg* 2015;50(5):860–863.
180. Grijalva J, Vakili K. Neonatal liver physiology. *Semin Pediatr Surg* 2013;22(4):185–189.
181. Tin W. Defining neonatal hypoglycaemia: a continuing debate. *Semin Fetal Neonatal Med* 2014;19(1):27–32.
182. Harris DL, Weston PJ, Harding JE. Incidence of neonatal hypoglycemia in babies identified as at risk. *J Pediatr* 2012;161(5):787–791.
183. VanHaltren K, Malhotra A. Characteristics of infants at risk of hypoglycaemia secondary to being 'infant of a diabetic mother'. *J Pediatr Endocrinol Metab* 2013;26(9–10):861–865.
184. Bhutani VK, Stark AR, Lazzeroni LC, et al. Initial Clinical Testing Evaluation and Risk Assessment for Universal Screening for Hyperbilirubinemia Study Group. Predischarge screening for severe neonatal hyperbilirubinemia identifies infants who need phototherapy. *J Pediatr* 2013;162(3):477–482 e1.
185. Wallenstein MB, Bhutani VK. Jaundice and kernicterus in the moderately preterm infant. *Clin Perinatol* 2013;40(4):679–688.
186. Shapiro SM. Chronic bilirubin encephalopathy: diagnosis and outcome. *Semin Fetal Neonatal Med* 2010;15(3):157–163.
187. Maisels MJ, Watchko JF, Bhutani VK, et al. An approach to the management of hyperbilirubinemia in the preterm infant less than 35 weeks of gestation. *J Perinatol* 2012;32(9):660–664.
188. Oldham KT. Optimal resources for children's surgical care. *J Pediatr Surg* 2014;49(5):667–677.

Chapter 100

Fetal Intervention

George B. Mychaliska and Darrell L. Cass

Key Points

1. Four fetal conditions clearly benefit from fetal intervention: congenital cystic adenomatoid malformation (CCAM), fetal sacrococcygeal teratoma (SCT), a fetus with airway obstruction from a giant neck mass or laryngeal atresia, and twin-to-twin transfusion syndrome (TTTS).
2. Any fetal therapy requires (a) accurate diagnosis of the condition and any associated anomalies that may have an impact on outcome, (b) reliable prediction of which individual fetuses will die or suffer serious long-term morbidity without fetal intervention, and (c) that the procedure improves the outcome of the fetus with little to no maternal risk.
3. Preterm labor is the single biggest concern during the operation and in the postoperative period.
4. For a fetus with a lung mass, the only indication for fetal interv-ention is the presence of hydrops.
5. For a fetus with sacrococcygeal teratoma, increased aortic velocity, increased combined cardiac output, increased cardiac-to-thoracic ratio, a dilated inferior vena cava, or reversed end-diastolic umbilical blood flow are sensitive early predictors of impending hydrops and fetal demise; before 28 weeks' gestation, open fetal surgery and resection is the treatment of choice.
6. Fetal intervention may play a role in the management of a small cohort of fetuses with the most severe form of congenital diaphragmatic hernia (CDH).
7. An ex utero intrapartum treatment (EXIT) procedure is the treatment of choice for fetuses with a giant neck mass or congenital high airway obstruction syndrome (CHAOS).

Fetal surgery has emerged as an independent subspecialty at the intersection of pediatric surgery and maternal–fetal medicine. It is a field that has arisen from clinical necessity. Pediatric surgeons, maternal–fetal medicine specialists, and neonatologists became frustrated with the management of a number of congenital structural anomalies in which the baby died or suffered severe lifelong disability despite all efforts at postnatal treatment. With the advent of prenatal ultrasound in the 1970s, many conditions were

diagnosed before birth. Fetuses were followed, and the prenatal natural history was elucidated. It became clear that a component of organ failure was acquired because of ongoing alterations in fetal development caused by the anomaly. Thus, it made sense that fetal interventions may be of benefit to correct the pathophysiology and restore normal fetal development in the hope of improving survival and decreasing morbidity.

1 The first successful fetal intervention was reported by Sir A. W. Liley, who successfully transfused a hydropic fetus for Rh disease.[1] Although a few attempts were made at exchange transfusion by an open technique in the 1960s, modern fetal surgery was envisioned and developed by Dr. Michael Harrison at the University of California, San Francisco (UCSF) in the late 1970s.[2] It was at UCSF that the concept of a fetal treatment program was developed, permitting a true multidisciplinary approach to fetal diagnosis and treatment. The first open fetal operation was performed in 1982, at which bilateral ureterostomies were performed in a 21-week-gestation fetus with obstructive uropathy.[3] In the intervening years, tremendous progress has been made in the development of fetal surgery techniques, including advances in maternal–fetal anesthesia, tocolysis (prevention of preterm labor), and the development of less invasive surgical techniques. During this same period, there have been significant advances in neonatal surgical critical care that has improved the outcome of fetuses with congenital anomalies. Thus, fetal surgery indications must be continually reassessed in the context of emerging prenatal and postnatal therapies. At the present time, there are only three fetal conditions that show clear benefit from fetal surgery during pregnancy: congenital cystic adenomatoid malformation (CCAM), fetal SCT, and twin-to-twin transfusion syndrome (TTTS). Open fetal surgery at the end of pregnancy, the ex utero intrapartum treatment (EXIT) procedure, has proven effective for the treatment of giant neck masses and laryngeal atresia. The EXIT procedure has been expanded to treat conditions that result in impending respiratory failure at birth using the EXIT–ECMO (extracorporeal membrane oxygenation) strategy, but the efficacy of this technique is still unproven. Fetal interventions, including open, fetoscopic, and percutaneous, have been used to treat a number of other fetal disorders, such as congenital diaphragmatic hernia (CDH), myelomeningocele (MMC), urologic obstruction, chylothorax, and, most recently, congenital heart malformations. Many of these procedures are promising, but questions remain regarding the natural history of these disorders, selection criteria, and efficacy.

FETAL IMAGING AND PRENATAL DIAGNOSIS

2 Fetal imaging is a critical component of the decision-making process in fetal surgery. Criteria that must be met to consider fetal surgery include (a) accurate diagnosis of the condition and any associated anomalies that may have an impact on outcome, (b) reliable prediction of which individual fetuses will die or suffer serious long-term morbidity without fetal intervention, and (c) demonstration of improved fetal outcome with minimal maternal risk.

Most congenital defects can now be detected before birth with the use of high-resolution ultrasound, color Doppler, and fetal magnetic resonance imaging (MRI). Frequently diagnosed anomalies include diaphragmatic hernia (Fig. 100-1), congenital lung lesions (Fig. 100-2), obstructive uropathy, neural tube defects, neck masses (Fig. 100-3), congenital heart defects, and SCT. Other surgical disorders include abdominal wall defects (gastroschisis and omphalocele), intestinal atresias, and cystic and solid abdominal masses. Although ultrasound is the predominant prenatal screening and diagnostic modality, fetal MRI has proven particularly helpful in the further evaluation of central nervous system, chest, and neck anomalies.[4–6] Fetal echocardiography is essential in the evaluation of congenital heart disease and is also useful in evaluating abnormal cardiac function associated with other birth defects.[7–9]

Prenatal detection and serial ultrasonographic evaluation of these disorders have enhanced our understanding of their natural history, and have significantly improved perinatal management. Pediatric surgeons familiar with the management of congenital malformations before and after birth, along with obstetricians, neonatologists, geneticists, and other specialists, participate in family counseling and together contribute to optimal maternal–fetal management. Such multidisciplinary teams may recommend that the timing, mode (cesarean vs. vaginal delivery), or location of delivery be altered. Furthermore, in rare circumstances prenatal diagnosis permits in utero treatment of the developing fetus to prevent, reverse, or minimize fetal organ injury or death. In one study, prenatal consultation led to a change in pregnancy management in 67% of 221 pregnancies, of which 11 patients (5% of total) benefited from fetal intervention.[10]

Although most congenital anomalies are best managed with the use of appropriate medical and surgical therapy after delivery at term, rare fetal anomalies may benefit from surgery before birth. The innovations required for fetal surgery include the development of new surgical, anesthetic, and tocolytic techniques, as well as the resolution of such ethical issues as maternal safety and future maternal reproductive potential.[11–13]



Figure 100-1. Coronal section of fetal magnetic resonance image (MRI) of a 30-week fetus with left congenital diaphragmatic hernia (CDH). The stomach (*small arrow*) and intestines are herniated into the left chest. The left lung is severely hypoplastic (*large arrow*).



Figure 100-2. Coronal section of a fetal magnetic resonance image (MRI) of a 24-week fetus with a large left lung mass (bronchopulmonary sequestration). The left diaphragm is flattened and there is moderate dextroposition of the heart. A large vessel is seen coming from the low thoracic aorta (*arrow*). The congenital cystic adenomatoid malformation volume ratio (CVR) was 1.96; however, hydrops did not develop and the baby "grew around" the mass.

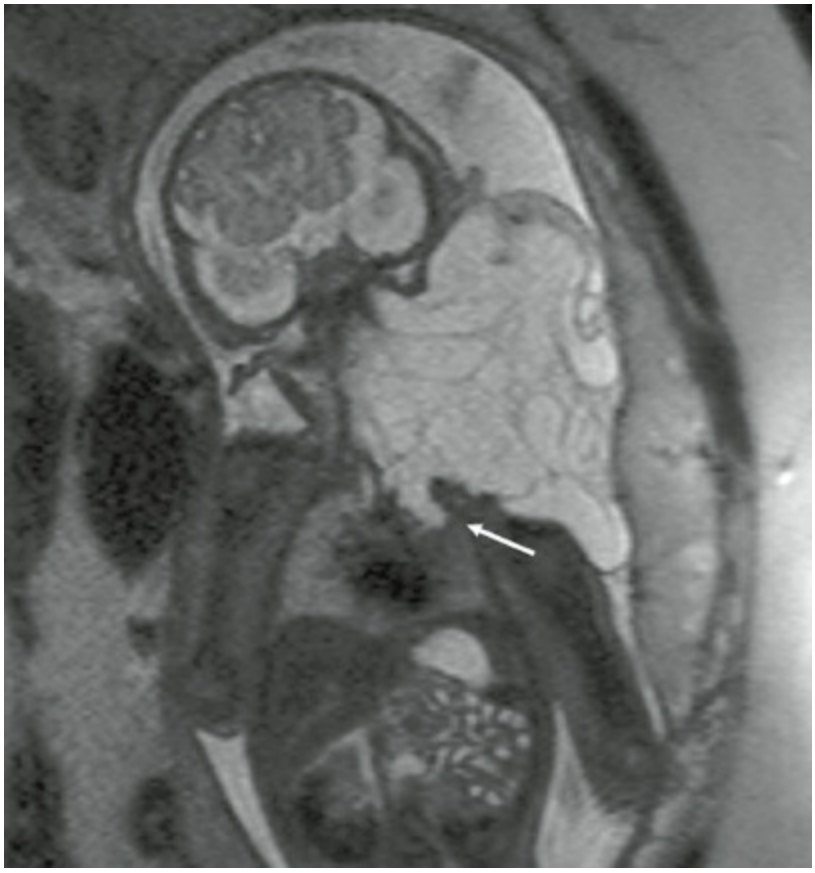

Figure 100-3. Coronal section of a fetal magnetic resonance image (MRI) of a 31-week fetus with a large left neck lymphatic malformation. The mass extends to the apex of the left chest (*arrow*). There is moderate left-to-right tracheal deviation. This fetus was delivered with an ex utero intrapartum treatment (EXIT) procedure.

MATERNAL–FETAL RISKS

Fetal surgery is unlike all other surgical specialties in that it involves two patients; the surgeon must operate on a healthy maternal patient to fix a disease in the affected fetus. This paradigm presents challenging moral and ethical conflicts that must be considered and balanced in each circumstance. Chervenak and McCullough[14] and others have helped to provide an ethical framework within which fetal surgery should exist. The keys to this framework are that (a) the fetal operation has significant chance of being lifesaving or of preventing serious or irreversible disease in the fetus; (b) the procedure involves low mortality and morbidity risk to the fetus; and (c) the operation has very low mortality and morbidity risk to the pregnant woman, including risks to future pregnancies. In light of these considerations, a number of contraindications to fetal intervention exist, including chromosomal abnormalities, the presence of other major anomalies, and significant maternal comorbidities.

There are significant maternal and fetal risks associated with fetal surgery that must be weighed for each patient. For the fetus, there is risk of preterm delivery, fetal death, or survival with poor outcome. Most indications for fetal surgery, however, are ones in which the fetus would die without it, and therefore the risk-to-benefit ratio is very favorable. For those interventions aimed at improving the outcome of fetuses with nonlethal conditions, the risk–benefit ratio is much more difficult to assess.

The risks and benefits to the mother depend on the invasiveness of the fetal surgical operation. In any intervention, benefits to the mother include the psychological reward from doing everything possible to improve the condition of the unborn baby. In selected cases, there is physiologic benefit in preventing the possibility of “mirror syndrome,” a preeclampsia like condition in which the mother’s condition “mirrors” that of a sick or dying fetus.[15] In the presence of this syndrome, fetal surgery is contraindicated and urgent fetal delivery is important to ensure maternal health. For the mother, fetal surgery adds the discomfort of one or two operations that would not have been required otherwise. For mothers who have hysterotomy other than low transverse, and for all mothers having open fetal surgery, there are theoretical risks to subsequent pregnancies and future fertility. When maternal fertility following fetal surgery was studied, however, it was found that 32 of 35 mothers were able to achieve successful subsequent pregnancies and 31 live births resulted.[11] Furthermore, if a classic cesarean section is performed during open fetal surgery, subsequent deliveries must be performed by cesarean section. Specific complications resulting from a classic cesarean section in subsequent pregnancies include uterine dehiscence and uterine rupture.[16] Postoperatively, nonhydrostatic pulmonary edema may occur in the mother. This problem was more prevalent in the early experience of open fetal surgery, but it still persists. In a trial reported by Harrison et al.[17] 3 of 11 mothers developed pulmonary edema and required oxygen after fetal surgery. In each of these patients the symptoms were mild and resolved within 48 hours. The cause of this phenomenon remains unclear, but is likely related to uterine manipulation and the release of prostaglandins or thromboplastins that alter maternal lung vascular permeability.[18] As with all obstetric surgery, blood loss may

be significant and mothers undergoing fetal surgery occasionally require blood transfusion.[19] Chorioamniotic membrane separation and preterm labor remain the Achilles' heel of fetal interventions.[20,21] Surgical approaches that involve a smaller hysterotomy and more minimally invasive techniques appear to lower these risks.[22] Specifically, fetoscopic and percutaneous approaches lessen the maternal and fetal risks.[23] These techniques allow vaginal delivery after fetal surgery and appear to decrease the incidence of preterm delivery.[24] Thus far, no maternal deaths have occurred at the major fetal surgery centers in the United States and Europe.

SURGICAL TECHNIQUES: OPEN, FETOSCOPIC, AND PERCUTANEOUS APPROACHES

Numerous technical aspects of fetal surgical procedures have evolved over 30 years of experimental and clinical work and have been reviewed in detail elsewhere.[25–28] The comprehensive care of the fetal surgery patient is labor intensive and requires multidisciplinary cooperation between all team members. In the operating room, the leader of the fetal surgery team is either a pediatric surgeon or maternal–fetal medicine specialist with specific training in fetal surgical techniques. The leader should be chosen depending on the procedure and specific expertise.[29] Responsibility for the patient's anesthesia is shared between an obstetric anesthesiologist for the mother and a pediatric anesthesiologist for the fetus. Both anesthesiologists should have special expertise in maternal–fetal anesthesia and work together as a team. A high-resolution ultrasound machine with color and enhanced Doppler is essential and used throughout the procedure to assess fetal and placental position; monitor fetal heart rate, cardiac function, and volume status; and assess amniotic fluid levels.[30] A pulse oximetry probe is placed on the fetal hand to assess fetal oxygen saturation and continuous heart rate. A peripheral intravenous catheter is often placed in the fetus for fluid, blood, and medication delivery. A surgical nursing team trained in the specific aspects of fetal surgical procedures and instrumentation is mandatory.

Open fetal surgery is performed with general and epidural anesthesia. Epidural delivery of a fentanyl/bupivacaine mixture provides optimal postoperative analgesia and minimizes uterine irritability. Intraoperatively, inhaled isoflurane titrated to an end-tidal concentration of 2% or higher is used to achieve uterine relaxation, which is critical to successful outcomes. Because of the risk of postoperative pulmonary edema, the mothers are fluid restricted during these procedures and receive as little as 500 mL of crystalloid. The patient is positioned supine with a roll under the right side to avoid compression of the inferior vena cava by the gravid uterus. The uterus is exposed through a low transverse abdominal incision. If the placenta is positioned posteriorly, subcutaneous flaps and a midline incision from the umbilicus to the pubis permit adequate uterine exposure. In cases of an anterior placenta, the fascia and rectus muscles are divided transversely so that the uterus can be tilted forward for a posterior hysterotomy. A large abdominal ring retractor is useful for abdominal wall retraction. After uterine relaxation is confirmed by palpation, the orientation of the fetus and placenta is confirmed by ultrasound. For open fetal surgery during pregnancy, a classical cesarean section incision is made. For the EXIT procedure, it is preferable to perform a low transverse hysterotomy. Two opposing traction sutures are placed with ultrasound guidance to provide hemostasis and to secure the fetal membranes to the uterine wall. The myometrium is then incised, and a hemostatic uterine stapler is used to open the uterine wall in both directions. A rubber catheter connected to a rapid infuser is inserted into the amniotic space to replace egress of amniotic fluid with warmed Ringer lactate. Infusion of warmed fluids is critical to maintain fetal temperature and amniotic volume and to minimize the risk of uterine

contractions and umbilical cord compression (Fig. 100-4).

One of the unique requirements of fetal surgery is that the surgeon must operate on the fetus and then return the fetus to the amniotic environment in such a way as to minimize disturbance to the continuing pregnancy. The uterine closure must have adequate strength to prevent rupture, must have membrane reapproximation to prevent amniotic fluid leakage, and must limit risks for preterm labor or future infertility. Currently, the uterus is closed in two layers using an outer layer of full-thickness 0 polydioxanone (PDS) retention sutures and an inner running layer of 2-0 PDS to close the myometrium and membranes. Before the closure is complete, the rapid infuser is used to restore amniotic volume and administer antibiotics. An omental pedicle is secured over the hysterotomy to seal any small leaks from the full-thickness sutures.

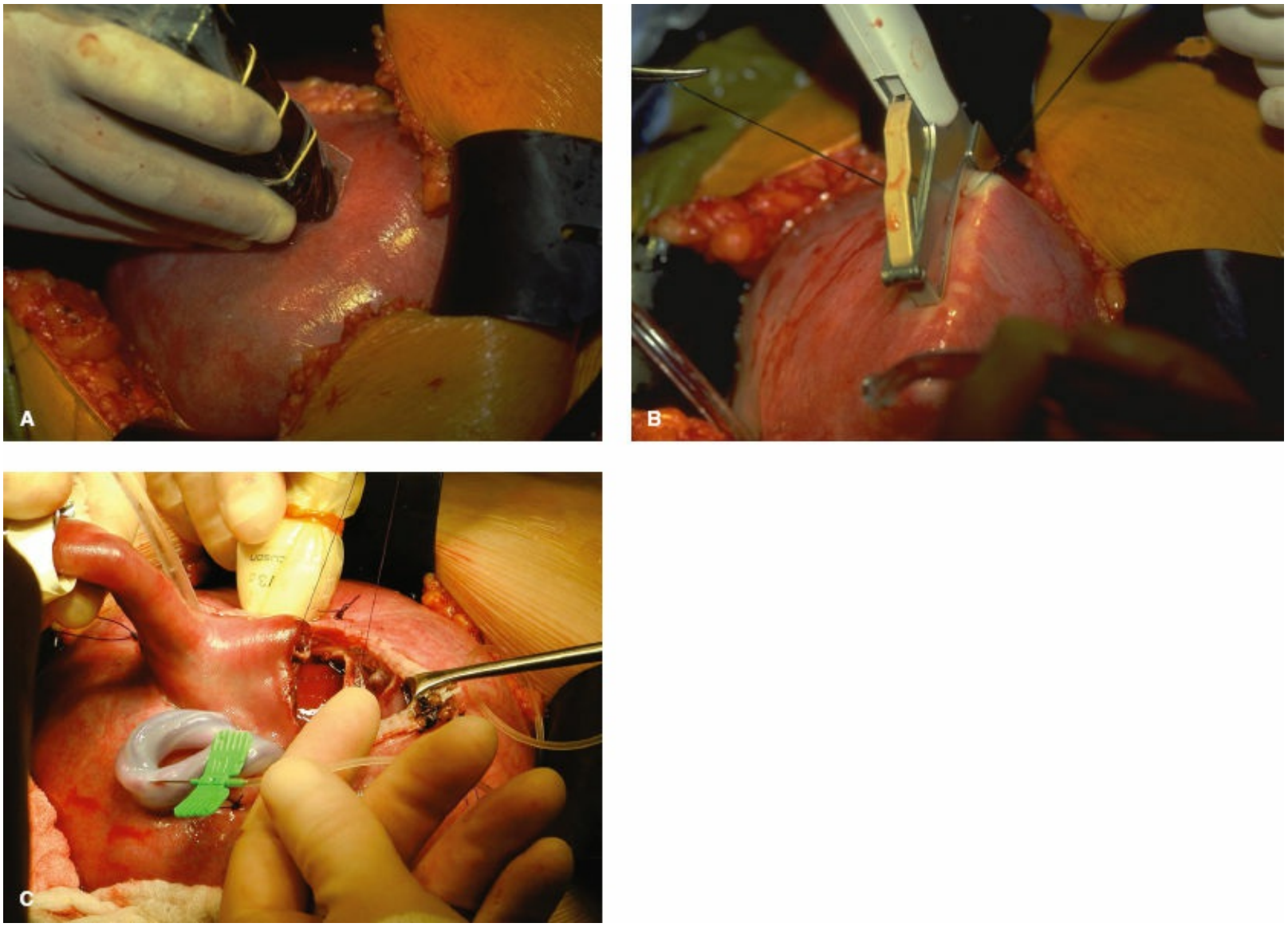

Figure 100-4. Fetal surgery of a hydropic 24-week fetus with a large left lung mass. **A:** Intraoperative ultrasound to locate the placenta and fetus. **B:** Uterine stay sutures are elevated to facilitate the use of the uterine stapler. **C:** The mass has been removed and the remaining normal left lung is evident. A bolus of crystalloid is given into the umbilical vein, and the chest is being closed.

3 Preterm labor is the single biggest concern during the operation and in the

postoperative period. The mother receives a 50-mg indomethacin suppository 4 hours before surgery, and remains on indomethacin for 48 hours postoperatively. Daily echocardiography is essential; if there is evidence of patent duct arteriosus (PDA) restriction, then the indomethacin is stopped. During the operation terbutaline or nitroglycerin infusion can be used to help control uterine irritability and enhance relaxation. During closure of the hysterotomy, the mother is given a 6-g bolus dose of magnesium sulfate followed by a continuous infusion of 2 to 4 g/h. Postoperatively the mother is observed in an intensive care unit (ICU) setting for close monitoring for pulmonary edema, fluid management, and uterine irritability. The magnesium sulfate is continued for 48 to 72 hours with close monitoring of magnesium levels and signs of toxicity. On the second to third postoperative day, usually the magnesium and indomethacin can be weaned, and the patient is converted to subcutaneous terbutaline or oral nifedipine. The patient is maintained on bed rest until the time of delivery. Postoperatively, daily ultrasound examinations help to assess the ductus arteriosus, amniotic fluid index (estimate of fetal urine output or of amniotic fluid leak), and fetal movement (marker of fetal well-being).

Fetoscopic surgery has been used most recently to permit a number of fetal surgical interventions, such as tracheal occlusion, laser ablation of communicating vessels in TTTS, and fetoscopic ablation of posterior urethral valves for fetuses with obstructive uropathy. Initially, these procedures were performed by exposing the uterus through a maternal laparotomy. More recently, surgeons have placed trocars percutaneously into the uterus through the intact maternal abdominal wall. Specially designed fetoscopic instruments have been developed that have allowed for single-port procedures.[31] Visualization during fetoscopy requires continuous irrigation through the fetoscope. This permits maintenance of uterine fluid volume, avoids risk of air embolus with gas distention of the uterus, ensures a continuously washed operative field, improves visibility by exchanging the cloudy amniotic fluid with lactated Ringer solution, and keeps the fetus warm.

RATIONALE AND OUTCOME OF FETAL SURGERY FOR SPECIFIC CONGENITAL ANOMALIES

Lung Malformations

CCAM and bronchopulmonary sequestration are the most common congenital lung malformations, and the most common fetal thoracic lesions that may benefit from fetal intervention.[32] The incidence of these lesions has been estimated at 1 in 25,000 to 35,000 pregnancies;[33] however, current referral patterns to fetal therapy centers suggest they may occur more frequently. Grossly, a CCAM is a discrete, space-occupying intrapulmonary mass that contains variable-sized cysts. These lesions do not function in normal gas exchange; however, airspaces within these masses communicate with the tracheobronchial tree. Histologically, CCAM is distinguished from other lesions and normal lung by (a) polypoid projections of the mucosa, (b) an increase in smooth muscle and elastic tissue within cyst walls, (c) an absence of cartilage (except that found in "entrapped" normal bronchi), (d) the presence of mucus-secreting cells, and (e) the absence of inflammation. In contrast, bronchopulmonary sequestrations (BPSs) (intralobar or extralobar) are masses of nonfunctioning lung tissue that are supplied by an anomalous systemic artery and do not have connection to the native tracheobronchial tree. The pathogenesis of both lesions is unknown, but they are thought to arise during the fifth to sixth week in embryonic development, and may result from abnormalities in growth signals between the branching airway epithelium and pulmonary mesenchyme.[34,35] Congenital lung lesions are commonly diagnosed by prenatal ultrasound as an echogenic solid, or cystic and solid thoracic mass. Not infrequently, these lesions may be seen to have a systemic blood supply on Doppler ultrasound. Although CCAM and BPS have been distinguished prenatally in the past by the presence or absence of a systemic vessel, it is now recognized that these lung lesions represent a continuum of pulmonary maldevelopment and there are lesions that have clinicopathologic features of both.[36,37] Fetal MRI may enhance diagnostic accuracy in examining these lesions and distinguishing them from other thoracic abnormalities, such as congenital lobar emphysema, bronchial atresia, bronchogenic cyst, and congenital diaphragmatic hernia (CDH).[38,39]

The natural history and clinical spectrum of these anomalies are variable, but they appear to depend mostly on the size of the mass and the secondary physiologic derangement. The growth of CCAMs usually plateaus between 25 and 28 weeks, at which time the fetus appears to grow around the lesion. The vast majority of small to moderate-sized CCAMs remain asymptomatic during fetal life. Approximately 15% of CCAMs will shrink significantly before birth.[40] In contrast, large lesions represent 5% to 10% of CCAMs and may produce significant mass effect, which can lead to pulmonary hypoplasia, impaired fetal swallowing and polyhydramnios, and impaired venous return and heart failure. Congestive heart failure in the fetus, known as nonimmune fetal hydrops, is defined by the presence of skin or scalp edema, or by fluid accumulation in one or more serous cavities (ascites or pericardial or pleural effusions). The risk of hydrops appears to depend on the size and rate of growth of the mass, and results from

compression of the superior vena cava and impaired venous return.[41] It has been demonstrated that hydrops is a harbinger of fetal demise, and is associated with near 100% mortality.[42] Rarely, hydrops is due to a tension hydrothorax from extralobar sequestration.[42] As a prognostic factor, the CCAM volume ratio (CVR) has been developed to correlate the relative size of these lesions with fetal and postnatal outcome.[43] In one series in which 58 fetuses with a lung mass were followed prospectively, 75% of fetuses (12 of 16) with a CVR greater than 1.6 developed hydrops, whereas only 17% (7 of 42) with a CVR of 1.6 or less had this complication. However, the CVR was not predictive of hydrops if a CCAM had a dominant cyst, which may enlarge at an unpredictable rate.

4 For a fetus with a lung mass, the only indication for fetal intervention is the presence of hydrops. Most commonly, hydrops occurs in the period of rapid growth of these lesions between 19 and 26 weeks' gestation.[32,42,43] Fetuses with a lung mass should be followed closely. It is recommended that those with a CVR less than 1.6 receive weekly ultrasound up to about 28 weeks' gestation, whereas those with a CVR greater than 1.6 should be examined as frequently as two to three times per week. If signs of hydrops appear, the treatment options include percutaneous placement of a thoracoamniotic shunt for lesions with a dominant cyst, and open fetal thoracotomy and mass resection for more solid lesions. Use of the laser or radiofrequency ablation to debulk a large CCAM cannot be recommended now because of technical limitations and inability to control energy distribution and postprocedure swelling.[44,45]

Fetal surgery for fetal lung masses requires open hysterotomy (Fig. 100-4). Intraoperative echocardiography is critical to assess fetal intravascular volume and right ventricle filling. These fetuses have tamponade physiology and generally benefit from a fluid bolus before thoracotomy. A relatively large thoracotomy is required to permit adequate exposure, and the mass is delivered slowly to prevent rapid decreased cardiac venous return. At resection, the presence of a systemic vessel must be considered.

The first successful open fetal surgery for CCAM was reported in 1990 by Harrison et al. at UCSF.[46] Since then, there have been reports of 22 open fetal resections of lung masses, with 50% survival.[32] Delays in referral and intervention, the presence of maternal "mirror" syndrome, preterm labor, chorioamnionitis, and technical difficulties associated with the procedure have limited outcomes in half of the cases. Recent evidence suggests that administration of maternal steroids may reverse the pathophysiology of hydrops, but this strategy requires further validation.[47,48]

Sacrococcygeal Teratoma

Sacrococcygeal teratoma (SCT) is the most common neonatal tumor, with an incidence of 1 in 35,000 live births.[49,50] Thought to arise from totipotent somatic cells originating in the caudal cell mass, this tumor contains multiple neoplastic tissues that lack organ specificity, are foreign to the sacrococcygeal region, and are derived from all three germ layers. The postnatal mortality of SCT is low, despite that about 10% of neonatal lesions are malignant. However, the prenatal mortality from SCT is greater than 50%. The causes of death in fetal SCT are multifactorial, but primarily involve dystocia with tumor rupture and bleeding at the time of delivery, or high-output cardiac failure and hydrops from high blood flow within the mass.[51] The evolution of high-output cardiac failure before the development of placentomegaly and hydrops in a fetus with SCT is the sole indication for fetal surgical intervention. Furthermore, SCT may lead to maternal mirror syndrome (Ballantine syndrome).[52] In this condition, the mother experiences progressive preeclampsia like symptoms, including vomiting, hypertension, peripheral edema, proteinuria, and pulmonary edema, caused by the release of placental vasoactive factors or endothelial cell toxins from the edematous placenta. This syndrome is reversed only by delivering the child and the placenta, but not by removing the SCT prenatally.

5 The diagnosis of SCT can be made by fetal ultrasound as early as 14 weeks' gestation.[53] The sonographic appearance may be cystic, solid, or mixed, and may demonstrate irregular echogenic patterns secondary to areas of tumor necrosis, cystic degeneration, internal hemorrhage, or calcification. Ultrasound is important to assess abdominal or pelvic extension, evidence of bowel or urinary tract obstruction, and the integrity of the fetal spine, and to document lower extremity function. Fetal MRI is helpful to delineate the anatomy and may be useful to distinguish these lesions from MMC, meconium pseudocyst, and obstructive uropathy. Fetal echocardiography and Doppler ultrasound measurements are important in the diagnostic assessment and follow-up of fetuses with these conditions. Increased aortic velocity, increased combined cardiac output, increased cardiac-to-thoracic ratio, a dilated inferior vena cava, or reversed end-diastolic umbilical blood flow appear to be sensitive early predictors of impending hydrops and fetal demise.[8,54] For fetuses greater than 28 weeks' gestation, these findings are an indication for emergency cesarean delivery and postnatal resection. For fetuses less than 28 weeks, open fetal surgery and resection is the treatment of choice. Minimally invasive approaches to interrupt the tumor's blood supply with radiofrequency ablation have had limited success[55] but may be alternatives for a fetus that is a poor candidate for open fetal resection.

Adzick et al.[56] reported the first successful outcome for fetal surgery resection of a fetus with a large SCT and hydrops in 1997. More recently, investigators from that center have reported 75% survival (three of four) for fetal resection of SCT. A similar high-output heart failure physiology can occur with teratomas in other locations. A fetus with a cervical teratoma and hydrops had successful fetal resection of the lesion at 24 weeks' gestation.[57]

Congenital Diaphragmatic Hernia

At present, the role of fetal intervention in the management of fetuses with congenital diaphragmatic hernia (CDH) is not clear. A hole in the posterolateral diaphragm, left sided in 80% to 85% of cases, permits abdominal viscera to herniate into the chest during fetal development, resulting in pulmonary hypoplasia and pulmonary hypertension. In current practice, more than half of the infants with CDH are diagnosed before birth. At times it can be difficult to distinguish CDH from a cystic lung mass or other cystic lesions. Fetal MRI is useful to enhance diagnostic accuracy, confirm liver position, calculate lung volumes, and further exclude associated anomalies.[6,58]

Outcome for patients with CDH varies widely, depending on the severity of disease when the disease is diagnosed.[59] The overall survival of CDH in the United States is 68%.[60] Although the survival has improved in selected centers,[61–64] the morbidity of some survivors remains high.[65] Fetuses with CDH have lower survival rates than those for live-born infants or for infants presenting to a neonatal surgical center. This paradigm has been termed the "hidden mortality" by Harrison et al.[66] and has been confirmed by multiple investigators.[67–69] In 2000, Dillon et al.[70] reviewed the outcomes from a large series of fetuses with CDH registered in the Northern Region Congenital Abnormality Survey in the United Kingdom. Between 1985 and 1997, 201 fetuses were evaluated for diaphragmatic problems, of which 187 had congenital diaphragmatic hernia (CDH) (14 had diaphragm eventration). From this cohort, 38 pregnancies were terminated, 26 of which had "multiple abnormalities," and 14 pregnancies (7%) were complicated by spontaneous miscarriage or stillbirth. The overall 1-year survival was 37%, but for live-born fetuses the survival was 50%. Furthermore, for those live-born babies with isolated CDH, the overall survival was 59%.

Ultrasound (and more recently MRI) can be used to predict fetal CDH severity. Herniation of the liver into the fetal chest and marked lung hypoplasia as estimated by a lung-to-head ratio (LHR) less than 1.0 are strong predictors of perinatal death.[71,72] Fetuses without liver herniation through the diaphragm have a reported survival rate between 75% and 93%, whereas those with "liver up" have a survival rate as low as 43%.[73] In a report that included evaluation of 174 patients with CDH, an LHR less than 0.9 was associated with only 13% survival, whereas survival was 68% for an LHR 0.9 to 1.2 and 88% for an LHR greater than 1.2.

For selected infants with severe CDH, fetal surgery has been performed in an attempt to reverse the high mortality rate. Initially, complete in utero repair of the diaphragmatic defect was attempted.[74] This approach, however, led to fetal bradycardia and immediate death after attempts to reduce the liver from the fetal chest resulted in kinking of the ductus venosus.[75] Subsequently, in utero tracheal occlusion has been used to treat fetuses with severe CDH. It has been shown that temporary tracheal occlusion, performed either as an open procedure or fetoscopically, can prevent the normal egress of lung fluid and enhance growth of the fetal lungs.[76] In a review of 15 patients treated by open fetal tracheal occlusion at Children's Hospital of Philadelphia (CHOP), survival was 100% for patients with right-sided defects (two of two) and 23% for patients with left-sided defects

(3 of 13), compared with 0% survival for a matched group of seven infants with left-sided lesions managed by conventional treatment alone. Endoscopic approaches to fetal tracheal occlusion, termed “fetoscopic” or “FETENDO,” showed more promising outcomes.[77] However, Harrison et al.[17] from UCSF reported results from a National Institutes of Health (NIH)-sponsored, prospective randomized trial that compared fetoscopic tracheal occlusion with standard postnatal care for fetuses with left-sided CDH, “liver up,” and an LHR less than 1.4. Twenty-four fetuses were randomized, but at this point the trial was stopped because of an unexpected high survival in the standard treatment group and the expectation that fetal therapy in this design would show no benefit. In this study of fetuses with liver-up CDH, the overall 90-day survival rate was 75%, a number much higher than those reported previously. Whereas 8 of 11 (73%) fetuses survived following fetoscopic tracheal occlusion, 10 of 13 (77%) survived with postnatal treatment alone, thus showing no benefit to fetal therapy in this study. As expected, a striking difference in the gestational ages was noted between the two groups. Whereas the standard treatment group delivered at a mean gestation of 37 weeks, the tracheal occlusion group delivered at a mean of 30.8 (range of 28 to 34) weeks’ gestational age. Although fetoscopic tracheal occlusion likely had an effect on lung growth, this response may have been limited by preterm labor, early delivery, and associated lung immaturity. As has been demonstrated in the treatment of other conditions, chorioamniotic membrane separation and preterm labor limit outcomes from fetal surgery.[20,21] The lack of benefit from fetal therapy may also result from the excellent outcomes that were achieved in the control group. These results certainly suggest that a standardized protocol involving prenatal steroids and expert pre- and postnatal care may improve outcome for fetuses with severe CDH.

Deprest reported results from the use of fetoscopic tracheal occlusion (FETO) in 210 patients. The procedure was performed at a median gestational age of 27 weeks. Although spontaneous preterm prelabor rupture of membranes occurred in 47% of patients, the median gestational age at delivery was 35.3 weeks. The authors estimated that in fetuses with left CDH treated with FETO, the survival rate increased from 24% to 49%.[24] The results from this trial are promising but still limited because of a lack of a randomized design and lack of standardized, centralized postnatal care in the control group of fetuses.

6 It is likely that fetal intervention may play a role in the management of a small cohort of fetuses with the most severe form of CDH. Current work is directed at accurate identification of this cohort and optimizing minimally invasive treatment approaches.

Fetal Surgery at the End of Pregnancy

Ex Utero Intrapartum Treatment Procedure

7 As an outgrowth of the fetal intervention efforts, the EXIT procedure was devised to treat fetal airway obstruction caused by large neck masses or intrinsic airway problems.[78] This approach involves a planned hysterotomy and delivery with preservation of the maternal–fetal placental circulation for oxygenation of the fetus. While on "placental bypass," up to 2 hours is available for direct laryngoscopy, bronchoscopy, endotracheal intubation, tumor resection, or tracheostomy to secure the airway (Fig. 100-5). The umbilical cord is then divided, and the fetus delivered. Indications for an EXIT procedure include the presence of a large cervical mass with evidence of airway deviation or compression. Polyhydramnios, caused by esophagus compression, is one marker for fetal tracheal compression. Recently, the tracheoesophageal displacement index (TEDI) has been described to assess the degree of tracheal deviation on fetal MRI.[79] Multiple centers have used the EXIT procedure to stabilize the airway in fetuses with large cervical tumors (e.g., teratomas or lymphatic malformations) with excellent fetal outcomes and very little additional maternal risk (Fig. 100-5).[80–82]



Figure 100-5. A 36-week fetus with a giant right neck teratoma at ex utero intrapartum treatment (EXIT) procedure. Due to significant tracheal deviation, a tracheostomy was performed on placental support.

An EXIT procedure is the treatment of choice for fetuses with congenital high airway obstruction syndrome (CHAOS). This syndrome is usually caused by laryngeal or tracheal atresia, tracheal stenosis, or a mucosal web. A fetus with this condition develops overdistended, echogenic lungs, which may compress the mediastinum, flatten or evert the diaphragm, and cause hydrops because of compromise of venous return. Fetuses with CHAOS should be delivered with an EXIT procedure to permit tracheostomy and airway control while maintaining the maternal–fetal placental circulation. For fetuses with CHAOS who develop hydrops, early delivery or prenatal tracheostomy are treatment options, depending on gestational age.[83–85]

EX UTERO INTRAPARTUM TREATMENT–EXTRACORPOREAL MEMBRANE OXYGENATION

The EXIT–ECMO procedure has been developed to treat anticipated respiratory failure at birth. The rationale for this procedure is to transition from a stable intrauterine environment to ECMO while avoiding hypoxemia, barotrauma, hemodynamic instability, and acidosis. This strategy has been applied to severe CDH. Kunisaki et al. reported the largest series of 14 patients who had EXIT–ECMO for treatment of severe CDH.[86] Inclusion criteria included liver herniation, an LHR less than 1.4, percentage of predicted lung volume by fetal MRI less than 15, and/or congenital heart disease. Overall survival was 64% for this severe subset of CDH patients. Although this therapy is promising, at this time its efficacy is unproven. Variations of this procedure include EXIT-resection for lung lesions,[87] EXIT–ECMO for fetal thoracic masses,[88] and EXIT-resection–ECMO for giant chest masses (Fig. 100-6).[89]

Myelomeningocele

MMC was the first nonlethal anomaly to be treated by fetal surgery.[90–92] MMC, or spina bifida, is a midline defect of the spine and spinal cord that leads to exposure of the contents of the neural canal. It is relatively common, and occurs in 1 of every 2,000 live births. The natural history of fetuses with this condition is variable, but generally mortality is low. Instead, affected newborns suffer lifelong disabilities, which include a combination of paraplegia, abnormalities in bowel or bladder control, sexual dysfunction, skeletal deformations, hydrocephalus, and mental impairment. More than 80% of fetuses with MMC can be identified before birth by maternal serum α-fetoprotein screening. Fetal ultrasound may detect the characteristic spine abnormalities as early as 16 weeks' gestation.



Figure 100-6. A 37-week fetus with severe congenital diaphragmatic hernia (CDH) delivered using the ex utero intrapartum treatment (EXIT)–extracorporeal membrane oxygenation (ECMO) procedure. The airway was secured and ECMO cannulas were placed on placental support.

The rationale for fetal intervention for MMC is based on compelling evidence that associated neurologic deficits do not simply result from incomplete neurulation but rather from chronic mechanical and chemical trauma caused by exposure of the neural tissue to the amniotic environment. Support for this conclusion includes the observation that fetal leg movements decrease with advancing gestational age. Furthermore, in animal models of MMC, in utero repair leads to improved neurologic function and reversal of hindbrain herniation.[93]

Human fetal interventions for MMC were initially designed to reduce intrauterine exposure of neural elements. Both fetoscopic and open techniques were attempted; however, open methods are considered the current standard. The first successful outcome of fetal surgery repair of MMC was reported by Adzick et al. in 1998.[90] Since that time multiple centers have reported positive outcomes that suggest that surgical repair of MMC before 25 weeks' gestation can preserve neurologic function, reverse the hindbrain

herniation, decrease the incidence of clubfoot, and obviate the need for postnatal placement of a ventriculoperitoneal shunt compared with historical controls.[91,92,94] No consistent improvement was seen in neurologic or bladder function, however, and these interventions did come at the cost of fetal prematurity (preterm labor) and increased maternal risk. Furthermore, lack of accurate prenatal indicators of neurologic function and absence of matched controls and long-term follow-up hamper evaluation of this approach.

Urinary Obstruction

Obstructive uropathy, one of the most common fetal structural anomalies, occurs in about 1 of 1,000 live births. Of all fetuses with urinary tract dilatation, as many as 90% do not require fetal intervention, such as those with low-pressure dilation, continued good urine output, adequate amniotic fluid volume, unilateral urinary obstruction, or advanced irreversible renal dysplasia.[95,96] Fetuses with urethral obstruction, severe bilateral hydronephrosis, and preserved renal function may be candidates for fetal intervention. Urethral obstruction, usually caused by posterior urethral valves in a male fetus, leads to decreased fetal urine output, oligohydramnios, and eventually pulmonary hypoplasia, which is often the most important factor affecting postnatal outcome. Fetuses with oligohydramnios present in the early second trimester have mortality rates in excess of 90%.[97,98]

Prenatal ultrasound is very accurate in the detection of fetal hydronephrosis and in determining the level of urinary obstruction. Because most of the amniotic fluid in middle and late pregnancy is the product of fetal urination, the presence of a normal amniotic fluid index implies the excretion of urine from at least one kidney. Decreasing amniotic fluid volume on serial ultrasound usually indicates deteriorating renal function. Furthermore, renal function can be assessed by the sonographic appearance of the renal parenchyma and by the laboratory analysis of fetal urine via percutaneous bladder aspiration. The presence of cortical cysts or increased echogenicity is highly predictive of renal dysplasia, but the absence of these findings does not exclude it.[99] Normal fetal urine chemistry includes a urinary sodium less than 100 mEq/dL, chloride less than 90 mEq/dL, osmolarity less than 200 mOsm/L, and β_2-microglobulin less than 4 mg/dL. Values greater than these suggest that the fetal kidney is unable- to reabsorb these molecules and predict poor postnatal renal function.

The greatest challenge is selecting fetuses that have severe urinary obstruction yet reversible or salvageable renal function. Presently, selection criteria for fetal intervention are a male fetus less than 30 weeks' gestation with evolving oligohydramnios, normal renal function, and no associated anomalies. Fetuses older than this are best treated by postnatal approaches. If there is evidence of lung maturation, then early delivery is recommended. The goal of fetal therapy is to adequately drain the urinary obstruction and to restore normal amniotic fluid volume. Methods of urinary tract decompression include percutaneous vesicoamniotic shunt placement, fetoscopic or open vesicostomy, and fetoscopic fulguration of posterior urethral valves.[100,101] Open fetal surgery, including vesicostomy or ureterostomy, has resulted in 50% survival, with two of eight children in one series having normal renal function.[102] Today, the most widely used and accepted means of treating bladder outlet obstruction is percutaneous insertion of a double-J vesicoamniotic shunt. Placement of a vesicoamniotic shunt is associated with 50% survival, but shunt complication rates as high as 45% may result. Direct fetoscopic ablation of posterior urethral valves holds promise for the future, though currently limited data are available to assess selection criteria and outcomes for fetuses treated by this approach.

Twin-to-Twin Transfusion Syndrome

TTTS, present in 5% to 35% of monochorionic twin pregnancies, occurs when there is unequal sharing of the monochorionic placenta. Generally, this finding can be made on prenatal ultrasound, and often the communicating placental vessels can be characterized by Doppler. Arteriovenous anastomoses lead to a net shunting of blood from the donor to recipient. The donor twin often suffers intrauterine growth retardation, cardiac failure, and oligohydramnios, whereas the recipient twin may suffer polyhydramnios, cardiomyopathy, and fetal hydrops. The smaller twin's placental cord insertion is often marginal or velamentous, whereas the larger twin's cord inserts into the placenta centrally.[103] Quintero et al.[104] have described a staging system for this condition. In stage 1, polyhydramnios and oligohydramnios occur, but the donor bladder is still visible. In stage 2, the bladder is no longer visible, and in stage 3 abnormal Doppler signals are detected in the respective umbilical arteries or veins. Stage 4 is characterized by findings of hydrops, and stage 5 is fetal death. In addition to the Quintero staging, recent studies suggest that comprehensive cardiac assessment by echocardiography may improve patient risk stratification.[9] Overall, TTTS before 26 weeks' gestation is associated with a high rate of fetal loss and perinatal death and a high incidence of brain damage in survivors.[105,106] In severe forms of TTTS, perinatal mortality rates of up to 90% have been reported.[107]

Treatment options include aminoreduction of the recipient sac, amniotic membrane septostomy, and fetoscopic ablation of communicating vessels.[108–110] Recently, endoscopic laser coagulation has become the treatment of choice for severe TTTS diagnosed before 26 weeks' gestation. In a multicenter European trial, twins with severe TTTS of all Quintero stages were randomized to undergo fetoscopic laser ablation or standard amnioreduction therapy. The trial was stopped after 142 women were randomized, because of the clear benefit of the laser approach. Endoscopic laser ablation led to improved outcomes in all variables examined, including increased fetal survival and decreased incidence of neurologic complications.[105]

Congenital Heart Defects

Fetal intervention may play a role in the management of some fetuses with rare congenital heart defects, including those with severe aortic or pulmonary stenosis, and hypoplastic left heart syndrome with intact or highly restrictive atrial septum.[111–113] There is evidence that fetuses with aortic or mitral valve stenosis may progress to hypoplastic left heart syndrome, presumably as a result of decreased ventricular filling. Furthermore, critical pulmonary stenosis or atresia with intact ventricular septum may progress to the so-called "hypoplastic right heart syndrome." Staged palliative surgery is the only therapeutic option for newborns with these conditions, and mortality remains significant. The goals of fetal intervention for these anomalies are to relieve the obstruction, restore normal cardiac physiology, and reverse the progression toward ventricular hypoplasia. In an initial report from investigators at Children's Hospital, Boston, in which 20 fetuses underwent balloon dilation of a stenotic aortic valve at 21 to 29 weeks' gestation, five fetuses died following the procedure.[113] Of 14 who were thought to have a technically successful procedure, 3 had evidence of a two-ventricle heart postnatally, thus supporting the experimental rationale. More recently, Tworetzky reported the predictors of technical success and postnatal biventricular outcome after in utero aortic valvuloplasty in 70 fetuses. The technical success rate was 74%, and 17 had biventricular circulation postnatally. The authors developed a multivariable threshold scoring system allowing highly sensitive and moderately specific identification of fetuses able to survive postnatally with a biventricular circulation.[114] Tworetzky also reported the outcomes of in utero atrial septoplasty in fetuses with hypoplastic left heart syndrome. Of 21 procedures attempted, 19 were technically successful. Although the authors could not conclude that this particular procedure improved survival given the small patient size, they did find that creation of a defect greater than 3 mm was associated with better postnatal oxygenation and less frequent need for emergent postnatal intervention.[111]

Fetal Intervention for Other Anomalies

Fetal intervention is indicated for a number of other fetal conditions, including amniotic band syndrome and twin-reversed arterial perfusion (TRAP) sequence. Fetoscopic lysis of constricting amniotic bands may lead to limb salvage and improved outcome.[115–117] Similarly, in the TRAP sequence, fetoscopic ligation or ablation of the acardiac twin's umbilical cord is the treatment of choice.[118]

FUTURE OF FETAL INTERVENTION

There will always be a role for fetal intervention in the treatment of certain specific congenital structural abnormalities. The exact nature of this role, however, is under constant reevaluation and change. The primary goal of fetal therapy is to improve the outcome of the affected fetus while minimizing maternal risks. If fetal outcomes can be improved by alternative means, such as lung liquid ventilation or other postnatal therapies that pose no risks to the mother, then indications for fetal therapy will decrease. On the other hand, as the risks and complications of fetal surgery continue to decrease, such as those related to preterm labor and chorioamniotic membrane separation, then the role for fetal interventions may increase. Increased miniaturization of fetoscopic equipment and optics, advances in robotics, newer approaches to closure of the uterus and fetal membranes, and advances in our understanding and treatment of preterm labor will enhance our ability to change the outlook for an increased number of fetuses with congenital malformations.

References

1. Liley AW. Intrauterine transfusion of foetus in haemolytic disease. *Br Med J* 1963;5365:1107–1109.
2. Bruner JP. In their footsteps: a brief history of maternal-fetal surgery. *Clin Perinatol* 2003;30:439–447.
3. Harrison MR, Golbus MS, Filly RA, et al. Fetal surgery for congenital hydronephrosis. *N Engl J Med* 1982;306:591–593.
4. Chung R, Kasprian G, Bruffer PC, et al. The current state and future of fetal imaging. *Clin Perinatol* 2009;36:685–699.
5. Estroff JA. The growing role of MR imaging in the fetus. *Pediatr Radiol* 2009;39:209–210.
6. Hubbard AM, Crombleholme TM, Adzick NS, et al. Prenatal MRI evaluation of congenital diaphragmatic hernia. *Am J Perinatol* 1999;16:407–413.
7. Bakiler AR, Ozer EA, Kanik A, et al. Accuracy of prenatal diagnosis of congenital heart disease with fetal echocardiography. *Fetal Diagn Ther* 2007;22:241–244.
8. Hedrick HL, Flake AW, Crombleholme TM, et al. Sacrococcygeal teratoma: prenatal assessment, fetal intervention, and outcome. *J Pediatr Surg* 2004; 39:430–438; discussion 430–438.
9. Shah AD, Border WL, Crombleholme TM, et al. Initial fetal cardiovascular profile score predicts recipient twin outcome in twin-twin transfusion syndrome. *J Am Soc Echocardiogr* 2008;21:1105–1108.
10. Crombleholme TM, D'Alton M, Cendron M, et al. Prenatal diagnosis and the pediatric surgeon: the impact of prenatal consultation on perinatal management. *J Pediatr Surg* 1996;31:156–162; discussion 162–163.
11. Farrell JA, Albanese CT, Jennings RW, et al. Maternal fertility is not affected by fetal surgery. *Fetal Diagn Ther* 1999;14:190–192.
12. Howell LJ, Adzick NS. Establishing a fetal therapy center: lessons learned. *Semin Pediatr Surg* 2003;12:209–217.
13. Myers LB, Cohen D, Galinkin J, et al. Anesthesia for fetal surgery. *Paediatr Anaesth* 2002;12:569–578.
14. Chervenak FA, McCullough LB. A comprehensive ethical framework for fetal research and its application to fetal surgery for spina bifida. *Am J Obstet Gynecol* 2002;187:10–14.
15. Longaker MT, Golbus MS, Filly RA, et al. Maternal outcome after open fetal surgery. A review of the first 17 human cases. *JAMA* 1991;265: 737–741.
16. Wilson RD, Johnson MP, Flake AW, et al. Reproductive outcomes after pregnancy complicated by maternal-fetal surgery. *Am J Obstet Gynecol* 2004;191:1430–1436.
17. Harrison MR, Keller RL, Hawgood SB, et al. A randomized trial of fetal endoscopic tracheal occlusion for severe fetal congenital diaphragmatic hernia. *N Engl J Med*

2003;349:1916–1924.
18. DiFederico EM, Burlingame JM, Kilpatrick SJ, et al. Pulmonary edema in obstetric patients is rapidly resolved except in the presence of infection or of nitroglycerin tocolysis after open fetal surgery. *Am J Obstet Gynecol* 1998;179:925–933.
19. Harrison MR. Fetal surgery. *Am J Obstet Gynecol* 1996;174:1255–1264.
20. Sydorak RM, Hirose S, Sandberg PL, et al. Chorioamniotic membrane separation following fetal surgery. *J Perinatol* 2002;22:407–410.
21. Wilson RD, Johnson MP, Crombleholme TM, et al. Chorioamniotic membrane separation following open fetal surgery: pregnancy outcome. *Fetal Diagn Ther* 2003;18:314–320.
22. Deprest J, Gratacos E, Nicolaides KH. Fetoscopic tracheal occlusion (FETO) for severe congenital diaphragmatic hernia: evolution of a technique and preliminary results. *Ultrasound Obstet Gynecol* 2004;24:121–126.
23. Fowler SF, Sydorak RM, Albanese CT, et al. Fetal endoscopic surgery: lessons learned and trends reviewed. *J Pediatr Surg* 2002;37:1700–1702.
24. Jani JC, Nicolaides KH, Gratacos E, et al. Severe diaphragmatic hernia treated by fetal endoscopic tracheal occlusion. *Ultrasound Obstet Gynecol* 2009;34:304–310.
25. Adzick NS, Harrison MR, Glick PL, et al. Fetal surgery in the primate. III. Maternal outcome after fetal surgery. *J Pediatr Surg* 1986;21:477–480.
26. Bianchi DW, Crombleholme TM, D'Alton ME. *Fetology: Diagnosis and Management of the Fetal Patient.* New York: McGraw-Hill; 2000.
27. Harrison MR, Adzick NS. Fetal surgical techniques. *Semin Pediatr Surg* 1993;2:136–142.
28. Harrison MR, Evans MI, Adzick NS, et al. *The Unborn Patient: The Art and Science of Fetal Therapy.* Philadelphia, PA: W.B. Saunders; 2001.
29. Harrison M. Fetal surgery: trials, tribulations, and turf. *J Pediatr Surg* 2003;38:275–282.
30. Keswani SG, Crombleholme TM, Rychik J, et al. Impact of continuous intraoperative monitoring on outcomes in open fetal surgery. *Fetal Diagn Ther* 2005;20:316–320.
31. Klaritsch P, Albert K, Van Mieghem T, et al. Instrumental requirements for minimal invasive fetal surgery. *BJOG* 2009;116:188–197.
32. Adzick NS. Management of fetal lung lesions. *Clin Perinatol* 2003;30: 481–492.
33. Laberge J, Flageole H, Pugash D. Outcome of the prenatally diagnosed congenital cystic adenomatoid lung malformation. *Fetal Diagn Ther* 2001; 16:179–186.
34. Cass DL, Quinn TM, Yang EY, et al. Increased cell proliferation and decreased apoptosis characterize congenital cystic adenomatoid malformation of the lung. *J Pediatr Surg* 1998;33:1043–1046; discussion 1047.
35. Liechty KW, Crombleholme TM, Quinn TM, et al. Elevated platelet-derived growth factor-B in congenital cystic adenomatoid malformations requiring fetal resection. *J Pediatr Surg* 1999;34:805–809; discussion 809–810.

36. Cass DL, Crombleholme TM, Howell LJ, et al. Cystic lung lesions with systemic arterial blood supply: a hybrid of congenital cystic adenomatoid malformation and bronchopulmonary sequestration. *J Pediatr Surg* 1997; 32:986–990.
37. Langston C. New concepts in the pathology of congenital lung malformations. *Semin Pediatr Surg* 2003;12:17–37.
38. Hubbard AM, Adzick NS, Crombleholme TM, et al. Congenital chest lesions: diagnosis and characterization with prenatal MR imaging. *Radiology* 1999;212:43–48.
39. Olutoye OO, Coleman BG, Hubbard AM, et al. Prenatal diagnosis and management of congenital lobar emphysema. *J Pediatr Surg* 2000;35:792–795.
40. Adzick NS. Management of fetal lung lesions. *Clin Perinatol* 2009;36: 363–376, x.
41. Rice HE, Estes JM, Hedrick MH, et al. Congenital cystic adenomatoid malformation: a sheep model of fetal hydrops. *J Pediatr Surg* 1994;29:692–696.
42. Adzick NS, Harrison MR, Crombleholme TM, et al. Fetal lung lesions: management and outcome. *Am J Obstet Gynecol* 1998;179:884–889.
43. Crombleholme TM, Coleman B, Hedrick H, et al. Cystic adenomatoid malformation volume ratio predicts outcome in prenatally diagnosed cystic adenomatoid malformation of the lung. *J Pediatr Surg* 2002;37:331–338.
44. Bruner JP, Jarnagin BK, Reinisch L. Percutaneous laser ablation of fetal congenital cystic adenomatoid malformation: too little, too late? *Fetal Diagn Ther* 2000;15:359–363.
45. Milner R, Kitano Y, Olutoye O, et al. Radiofrequency thermal ablation: a potential treatment for hydropic fetuses with a large chest mass. *J Pediatr Surg* 2000;35:386–389.
46. Harrison MR, Adzick NS, Jennings RW, et al. Antenatal intervention for congenital cystic adenomatoid malformation. *Lancet* 1990;336:965–967.
47. Peranteau W, Wilson R, Liechty K, et al. Effect of maternal betamethasone administration on prenatal congenital cystic adenomatoid malformation growth and fetal survival. *Fetal Diagn Ther* 2007;22:365–371.
48. Tsao K, Hawgood S, Vu L, et al. Resolution of hydrops fetalis in congenital cystic adenomatoid malformation after prenatal steroid therapy. *J Pediatr Surg* 2003;38:508–510.
49. Berry CL, Keeling J, Hilton C. Teratomata in infancy and childhood: a review of 91 cases. *J Pathol* 1969;98:241–252.
50. Grosfeld JL, Ballantine TV, Lowe D, et al. Benign and malignant teratomas in children: analysis of 85 patients. *Surgery* 1976;80:297–305.
51. Langer JC, Harrison MR, Schmidt KG, et al. Fetal hydrops and death from sacrococcygeal teratoma: rationale for fetal surgery. *Am J Obstet Gynecol* 1989;160:1145–1150.
52. Kuhlmann RS, Warsof SL, Levy DL, et al. Fetal sacrococcygeal teratoma. *Fetal Ther* 1987;2:95–100.

53. Holzgreve W, Mahony BS, Glick PL, et al. Sonographic demonstration of fetal sacrococcygeal teratoma. *Prenat Diagn* 1985;5:245–257.
54. Olutoye OO, Johnson MP, Coleman BG, et al. Abnormal umbilical cord Doppler sonograms may predict impending demise in fetuses with sacrococcygeal teratoma. A report of two cases. *Fetal Diagn Ther* 2004;19:35–39.
55. Paek BW, Jennings RW, Harrison MR, et al. Radiofrequency ablation of human fetal sacrococcygeal teratoma. *Am J Obstet Gynecol* 2001;184: 503–507.
56. Adzick NS, Crombleholme TM, Morgan MA, et al. A rapidly growing fetal teratoma. *Lancet* 1997;349:538.
57. Hirose S, Sydorak RM, Tsao K, et al. Spectrum of intrapartum management strategies for giant fetal cervical teratoma. *J Pediatr Surg* 2003;38:446–450; discussion 446–450.
58. Walsh DS, Hubbard AM, Olutoye OO, et al. Assessment of fetal lung volumes and liver herniation with magnetic resonance imaging in congenital diaphragmatic hernia. *Am J Obstet Gynecol* 2000;183:1067–1069.
59. Doyle NM, Lally KP. The CDH Study Group and advances in the clinical care of the patient with congenital diaphragmatic hernia. *Semin Perinatol* 2004;28:174–184.
60. The Congenital Diaphragmatic Hernia Study Group. *Report from the Congenital Diaphragmatic Hernia Study Group*. Available at http://cdhsg.net. Accessed September, 2008.
61. Boloker J, Bateman DA, Wung JT, et al. Congenital diaphragmatic hernia in 120 infants treated consecutively with permissive hypercapnea/spontaneous respiration/elective repair. *J Pediatr Surg* 2002;37:357–366.
62. Downard CD, Jaksic T, Garza JJ, et al. Analysis of an improved survival rate for congenital diaphragmatic hernia. *J Pediatr Surg* 2003;38:729–732.
63. Javid PJ, Jaksic T, Skarsgard ED, et al. Survival rate in congenital diaphragmatic hernia: the experience of the Canadian Neonatal Network. *J Pediatr Surg* 2004;39:657–660.
64. Kays DW, Langham MR Jr, Ledbetter DJ, et al. Detrimental effects of standard medical therapy in congenital diaphragmatic hernia. *Ann Surg* 1999; 230:340–348; discussion 348–351.
65. Cortes RA, Keller RL, Townsend T, et al. Survival of severe congenital diaphragmatic hernia has morbid consequences. *J Pediatr Surg* 2005;40: 36–45; discussion 45–46.
66. Harrison MR, Bjordal RI, Langmark F, et al. Congenital diaphragmatic hernia: the hidden mortality. *J Pediatr Surg* 1978;13:227–230.
67. Betremieux P, Lionnais S, Beuchee A, et al. Perinatal management and outcome of prenatally diagnosed congenital diaphragmatic hernia: a 1995–2000 series in Rennes University Hospital. *Prenat Diagn* 2002;22:988–994.
68. Skari H, Bjornland K, Haugen G, et al. Congenital diaphragmatic hernia: a meta-analysis of mortality factors. *J Pediatr Surg* 2000;35:1187–1197.
69. Stege G, Fenton A, Jaffray B. Nihilism in the 1990s: the true mortality of congenital

diaphragmatic hernia. *Pediatrics* 2003;112:532–535.
70. Dillon E, Renwick M, Wright C. Congenital diaphragmatic herniation: antenatal detection and outcome. *Br J Radiol* 2000;73:360–365.
71. Lipshutz GS, Albanese CT, Feldstein VA, et al. Prospective analysis of lung-to-head ratio predicts survival for patients with prenatally diagnosed congenital diaphragmatic hernia. *J Pediatr Surg* 1997;32:1634–1636.
72. Metkus AP, Filly RA, Stringer MD, et al. Sonographic predictors of survival in fetal diaphragmatic hernia. *J Pediatr Surg* 1996;31:148–151; discussion 151–152.
73. Albanese CT, Lopoo J, Goldstein RB, et al. Fetal liver position and perinatal outcome for congenital diaphragmatic hernia. *Prenat Diagn* 1998;18: 1138–1142.
74. Harrison MR, Adzick NS, Longaker MT, et al. Successful repair in utero of a fetal diaphragmatic hernia after removal of herniated viscera from the left thorax. *N Engl J Med* 1990;322:1582–1584.
75. Harrison MR, Adzick NS, Flake AW, et al. Correction of congenital diaphragmatic hernia in utero: VI. Hard-earned lessons. *J Pediatr Surg* 1993;28:1411–1417; discussion 1417–1418.
76. Hedrick MH, Estes JM, Sullivan KM, et al. Plug the lung until it grows (PLUG): a new method to treat congenital diaphragmatic hernia in utero. *J Pediatr Surg* 1994;29:612–617.
77. Harrison MR, Albanese CT, Hawgood SB, et al. Fetoscopic temporary tracheal occlusion by means of detachable balloon for congenital diaphragmatic hernia. *Am J Obstet Gynecol* 2001;185:730–733.
78. Mychaliska GB, Bealer JF, Graf JL, et al. Operating on placental support: the ex utero intrapartum treatment procedure. *J Pediatr Surg* 1997;32:227–230; discussion 230–231.
79. Cass DL, Cassady CI, O'Day MP, et al. *Predictors of Airway Obstruction and Outcome of Fetuses with Giant Neck Masses.* San Francisco, CA: Surgical Section, American Academy of Pediatrics; 2004.
80. Hedrick HL. Ex utero intrapartum therapy. *Semin Pediatr Surg* 2003;12:190–195.
81. Hirose S, Farmer DL, Lee H, et al. The ex utero intrapartum treatment procedure: looking back at the EXIT. *J Pediatr Surg* 2004;39:375–380; discussion 375–380.
82. Noah MM, Norton ME, Sandberg P, et al. Short-term maternal outcomes that are associated with the EXIT procedure, as compared with cesarean delivery. *Am J Obstet Gynecol* 2002;186:773–777.
83. Crombleholme TM, Sylvester K, Flake AW, et al. Salvage of a fetus with congenital high airway obstruction syndrome by ex utero intrapartum treatment (EXIT) procedure. *Fetal Diagn Ther* 2000;15:280–282.
84. DeCou JM, Jones DC, Jacobs HD, et al. Successful ex utero intrapartum treatment (EXIT) procedure for congenital high airway obstruction syndrome (CHAOS) owing to laryngeal atresia. *J Pediatr Surg* 1998;33:1563–1565.

85. Paek BW, Callen PW, Kitterman J, et al. Successful fetal intervention for congenital high airway obstruction syndrome. *Fetal Diagn Ther* 2002;17:272–276.
86. Kunisaki SM, Barnewolt CE, Estroff JA, et al. Ex utero intrapartum treatment with extracorporeal membrane oxygenation for severe congenital diaphragmatic hernia. *J Pediatr Surg* 2007;42:98–104; discussion 104–106.
87. Hedrick HL, Flake AW, Crombleholme TM, et al. The ex utero intrapartum therapy procedure for high-risk fetal lung lesions. *J Pediatr Surg* 2005;40:1038–1043; discussion 1044.
88. Kunisaki SM, Fauza DO, Barnewolt CE, et al. Ex utero intrapartum treatment with placement on extracorporeal membrane oxygenation for fetal thoracic masses. *J Pediatr Surg* 2007;42:420–425.
89. Mychaliska GB, Bryner BS, Nugent C, et al. Giant pulmonary sequestration: the rare case requiring the EXIT procedure with resection and ECMO. *Fetal Diagn Ther* 2009;25:163–166.
90. Adzick NS, Sutton LN, Crombleholme TM, et al. Successful fetal surgery for spina bifida. *Lancet* 1998;352:1675–1676.
91. Bruner JP, Tulipan N, Paschall RL, et al. Fetal surgery for myelomeningocele and the incidence of shunt-dependent hydrocephalus. *JAMA* 1999; 282:1819–1825.
92. Sutton LN, Adzick NS, Bilaniuk LT, et al. Improvement in hindbrain herniation demonstrated by serial fetal magnetic resonance imaging following fetal surgery for myelomeningocele. *JAMA* 1999;282:1826–1831.
93. Meuli M, Meuli-Simmen C, Hutchins GM, et al. In utero surgery rescues neurological function at birth in sheep with spina bifida. *Nat Med* 1995;1:342–347.
94. Farmer DL, von Koch CS, Peacock WJ, et al. In utero repair of myelomeningocele: experimental pathophysiology, initial clinical experience, and outcomes. *Arch Surg* 2003;138:872–878.
95. Glick PL, Harrison MR, Golbus MS, et al. Management of the fetus with congenital hydronephrosis II: prognostic criteria and selection for treatment. *J Pediatr Surg* 1985;20:376–387.
96. Harrison MR, Golbus MS, Filly RA, et al. Management of the fetus with congenital hydronephrosis. *J Pediatr Surg* 1982;17:728–742.
97. Crombleholme TM, Harrison MR, Golbus MS, et al. Fetal intervention in obstructive uropathy: prognostic indicators and efficacy of intervention. *Am J Obstet Gynecol* 1990;162:1239–1244.
98. Mandelbrot L, Dumez Y, Muller F, et al. Prenatal prediction of renal function in fetal obstructive uropathies. *J Perinat Med* 1991;19(suppl 1):283–287.
99. Mahony BS, Filly RA, Callen PW, et al. Fetal renal dysplasia: sonographic evaluation. *Radiology* 1984;152:143–146.
100. Quintero RA, Johnson MP, Romero R, et al. In-utero percutaneous cystoscopy in the management of fetal lower obstructive uropathy. *Lancet* 1995;346:537–540.

101. Quintero RA, Shukla AR, Homsy YL, et al. Successful in utero endoscopic ablation of posterior urethral valves: a new dimension in fetal urology. *Urology* 2000;55:774.
102. Cortes RA, Farmer DL. Recent advances in fetal surgery. *Semin Perinatol* 2004;28:199–211.
103. Fries MH, Goldstein RB, Kilpatrick SJ, et al. The role of velamentous cord insertion in the etiology of twin-twin transfusion syndrome. *Obstet Gynecol* 1993;81:569–574.
104. Quintero RA, Morales WJ, Allen MH, et al. Staging of twin-twin transfusion syndrome. *J Perinatol* 1999;19:550–555.
105. Senat MV, Deprest J, Boulvain M, et al. Endoscopic laser surgery versus serial amnioreduction for severe twin-to-twin transfusion syndrome. *N Engl J Med* 2004;351:136–144.
106. Ville Y, Hyett J, Hecher K, et al. Preliminary experience with endoscopic laser surgery for severe twin-twin transfusion syndrome. *N Engl J Med* 1995;332:224–227.
107. De Lia JE. Surgery of the placenta and umbilical cord. *Clin Obstet Gynecol* 1996;39:607–625.
108. De Lia JE, Kuhlmann RS, Harstad TW, et al. Fetoscopic laser ablation of placental vessels in severe previable twin-twin transfusion syndrome. *Am J Obstet Gynecol* 1995;172:1202–1208; discussion 1208–1211.
109. Feldstein VA, Machin GA, Albanese CT, et al. Twin-twin transfusion syndrome: the 'Select' procedure. *Fetal Diagn Ther* 2000;15:257–261.
110. Hecher K, Diehl W, Zikulnig L, et al. Endoscopic laser coagulation of placental anastomoses in 200 pregnancies with severe mid-trimester twin-to-twin transfusion syndrome. *Eur J Obstet Gynecol Reprod Biol* 2000;92:135–139.
111. Marshall AC, van der Velde ME, Tworetzky W, et al. Creation of an atrial septal defect in utero for fetuses with hypoplastic left heart syndrome and intact or highly restrictive atrial septum. *Circulation* 2004;110:253–258.
112. Tworetzky W, Marshall AC. Fetal interventions for cardiac defects. *Pediatr Clin North Am* 2004;51:1503–1513, vii.
113. Tworetzky W, Wilkins-Haug L, Jennings RW, et al. Balloon dilation of severe aortic stenosis in the fetus: potential for prevention of hypoplastic left heart syndrome: candidate selection, technique, and results of successful intervention. *Circulation* 2004;110:2125–2131.
114. McElhinney DB, Marshall AC, Wilkins-Haug LE, et al. Predictors of technical success and postnatal biventricular outcome after in utero aortic valvuloplasty for aortic stenosis with evolving hypoplastic left heart syndrome. *Circulation* 2009;120:1482–1490.
115. Crombleholme TM, Dirkes K, Whitney TM, et al. Amniotic band syndrome in fetal lambs. I: fetoscopic release and morphometric outcome. *J Pediatr Surg* 1995;30:974–978.
116. Keswani SG, Johnson MP, Adzick NS, et al. In utero limb salvage: fetoscopic release

of amniotic bands for threatened limb amputation. *J Pediatr Surg* 2003;38:848–851.
117. Quintero RA, Morales WJ, Phillips J, et al. In utero lysis of amniotic bands. *Ultrasound Obstet Gynecol* 1997;10:316–320.
118. Farmer DL, Hirose S. Fetal intervention for complications of monochorionic twinning. *World J Surg* 2003;27:103–107.

Chapter 101

Pediatric Head and Neck

Laura L. Neff and Reza Rahbar

Key Points

1 Infants are obligate nasal breathers for the first 3 to 6 months of life; therefore, any nasal obstruction can cause respiratory distress.

2 The site of the neck mass is important (midline vs. lateral) for narrowing the differential diagnoses.

3 Benign cervical lymphadenopathy is the most common neck mass in the pediatric population.

4 Although rare, always consider malignancy to avoid delay in diagnosis.

5 History is important in the work up and treatment of an airway foreign body.

INTRODUCTION

Lesions of the head and neck in the pediatric population result from a wide range of etiologies. In contrast to the adult population, the majority of pediatric neck masses are benign with only 11% of neck masses demonstrating a malignancy on biopsy.[1] In pediatrics, neck masses can be congenital, infectious, inflammatory, traumatic, lymphovascular, or neoplastic in etiology. Neck masses can range in presentation from an asymptomatic lesion to acute respiratory distress, depending on their size and location. Inflammatory cervical lymphadenitis is the most common cause of pediatric neck masses found in children. Congenital masses, such branchial cleft cysts and thyroglossal duct cysts (TGDC), often become clinically apparent when infected. Malignant processes are rare in children, and the most common malignancy seen in the pediatric neck is lymphoma. This chapter will focus on the most common head and neck pathologies found in the pediatric population along with their clinical presentation and treatment.

Imaging

Imaging is not always required for the diagnosis of a pediatric neck mass, but can be helpful in clarifying extent and size, location to vital structures, and radiologic characteristics of a lesion. Ultrasound (US), computed tomography (CT), or magnetic resonance imaging (MRI) can be helpful in narrowing the differential, but often a biopsy or excision is still required for diagnosis.

US is a good first choice for imaging of palpable lesions such as salivary gland tumors or thyroid nodules. The pediatric neck often has less subcutaneous adipose tissue, which leads to better imaging with ultrasonography.[2] US offers the ability to differentiate solid from cystic lesions, and color Doppler can determine the presence and characteristics of vascular flow within a mass.[3] US can be very helpful in determining the stage of an abscess, helping to differentiate early lymphadenopathy that can be treated with antibiotic therapy from a mature abscess that requires surgical drainage. US has the advantages of being portable, fast, does not require sedation, and does not expose the pediatric patient to ionizing radiation. Disadvantages of US include variability of the technician's skill/experience as well as lower resolution images.

CT scans and MRI provide a more detailed study of the anatomy of the neck. CT scans are readily available in emergent situations with scans completed quickly for patients who are critically ill. This speed can also help to eliminate the need for sedation and help to minimize artifact from movement. CT scans offering more osseous detail such as remodeling or erosion, as well as calcifications. The main disadvantage of CT scans is the exposure to ionizing radiation, which could potentially have carcinogenic effects in the long term.[4–6] Newer techniques offer reduced exposure with CT scans, but MRI and US should be utilized when appropriate.

MRI is the scan of choice for neck masses due to excellent soft tissue detail and avoidance of ionizing radiation. Details of the margins and possible neural spread or intracranial extension of a mass can be noted with the use of a contrast-enhanced MRI. The longer length of time required to obtain an MRI often requires sedation due to concerns of movement artifact in the pediatric population, which is the main disadvantage of the MRI.

To help with evaluating, staging, and monitoring a solid tumor, ^{18}F fluorodeoxyglucose PET (FDG-PET) is a noninvasive tool to evaluate malignancies in children. FDG-PET has the advantage of being able to differentiate recurrent or residual tumor from changes related to treatment. PET scans do expose children to ionizing radiation and also may require sedation. It is also important to keep in mind that certain tissues have a higher uptake of FDG, including the adenoids, tonsils, thymus, brown adipose tissue, bone marrow, and the spleen.[7,8]

Congenital

Congenital lesions of the head and neck are diverse and often the location of the lesion can greatly assist in narrowing the diagnosis. For example, midline lesions include TGDCs and der-moid cysts, whereas lateral neck lesions have a much broader differential.

Branchial Anomalies

The branchial apparatus in the fetus eventually develops into head and neck structures. Any deviation in the development of these structures can result in an anomaly that can present as a mass in the neck. Depending on the part of the branchial apparatus that is involved, the mass can present in different parts of the neck. Sinus tracts and fistulas tend to present at a younger age due to their physical appearance, whereas cysts usually present when they get infected and enlarge. A sinus tract has an external opening to the neck, whereas a fistula has an external and internal opening. Cartilaginous remnants can also be found in the neck.

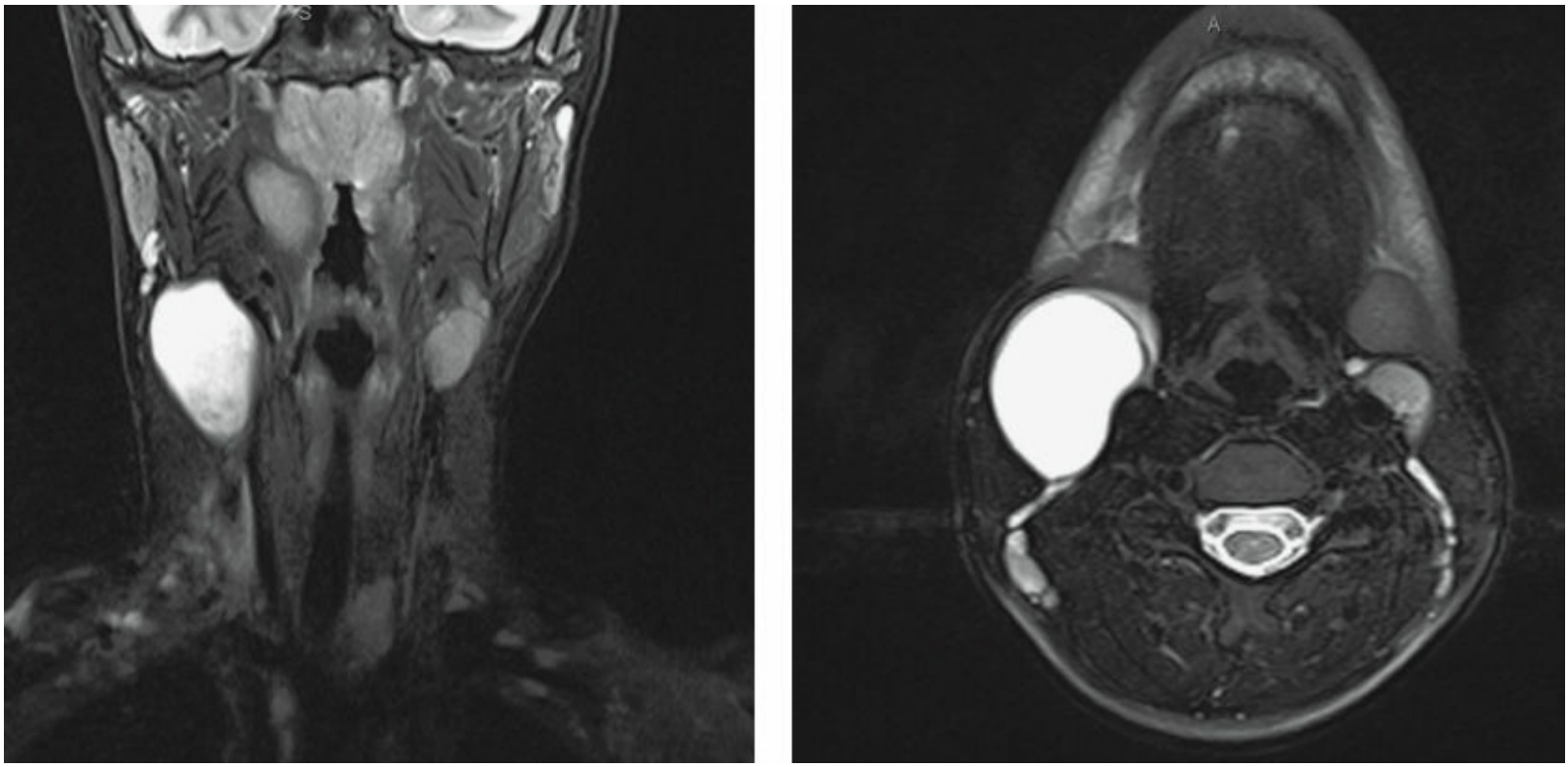

Figure 101-1. CT or MRI of second branchial cleft cysts.

These lesions often present with infection, and it is best to minimize inflammation and infection with antibiotics prior to excision, making the dissection and identification of important structures easier. Abscesses can be treated with minimal intervention, such as needle aspiration or if needed, incision and drainage. During the procedure, it is important to communicate with anesthesia to avoid paralysis for proper nerve monitoring. Radiologic imaging with CT or MRI can be helpful (Fig. 101-1). Rates of recurrence for branchial cleft cysts is quoted around 3%, but this increases to 20% in cases that have undergone a prior attempt at excision.[9]

Anatomy and Embryology

The branchial arches form during the fourth to eighth week of gestation as four pairs of well-developed ridges with associated clefts. Each has a cartilaginous center (mesoderm), a cleft (ectoderm), an internal pouch (endoderm), and a nerve (Table 101-1). These structures mature into the major structures of the head and neck (Fig. 101-2).

Table 101-1 Pharyngeal Arch Structures

Pharyngeal Arch	Muscular Contributions	Skeletal Contributions	Nerve	Artery
1st (mandibular arch)	Muscles of mastication, anterior belly of the digastric, mylohyoid, tensor tympani, tensor veli palatini	Premaxilla, maxilla, mandible (only as a model for mandible not actual formation of mandible), zygomatic bone, part of the temporal bone, the incus, and the malleus of the middle ear, also Meckel cartilage and the sphenomandibular ligament.	Trigeminal nerve (V2 and V3)	Maxillary artery, external carotid artery
2nd (hyoid arch)	Muscles of facial expression, buccinator, platysma, stapedius, stylohyoid, posterior belly of the digastric, auricular	Stapes, temporal styloid process, hyoid (lesser horn and upper part of body), stylohyoid ligament, Reichert cartilage	Facial nerve (VII)	Stapedial artery, hyoid artery
3rd	Stylopharyngeus	Hyoid (greater horn and lower part of body), thymus, inferior parathyroids	Glossopharyngeal nerve (IX)	Common carotid, internal carotid
4th	Cricothyroid muscle, all intrinsic muscles of soft palate (including levator veli palatini) *except* tensor veli palatini	Thyroid cartilage, superior parathyroids, epiglottic cartilage	Vagus nerve (X), superior laryngeal nerve	Right 4th aortic arch: subclavian artery Left 4th aortic arch:aortic arch
6th	All intrinsic muscles of larynx except the cricothyroid muscle	Cricoid cartilage, arytenoid cartilages, corniculate cartilage, cuneiform cartilages	Vagus nerve (X), recurrent laryngeal nerve	Right 6th aortic arch: pulmonary artery Left 6th aortic arch: pulmonary artery and ductus arteriosus

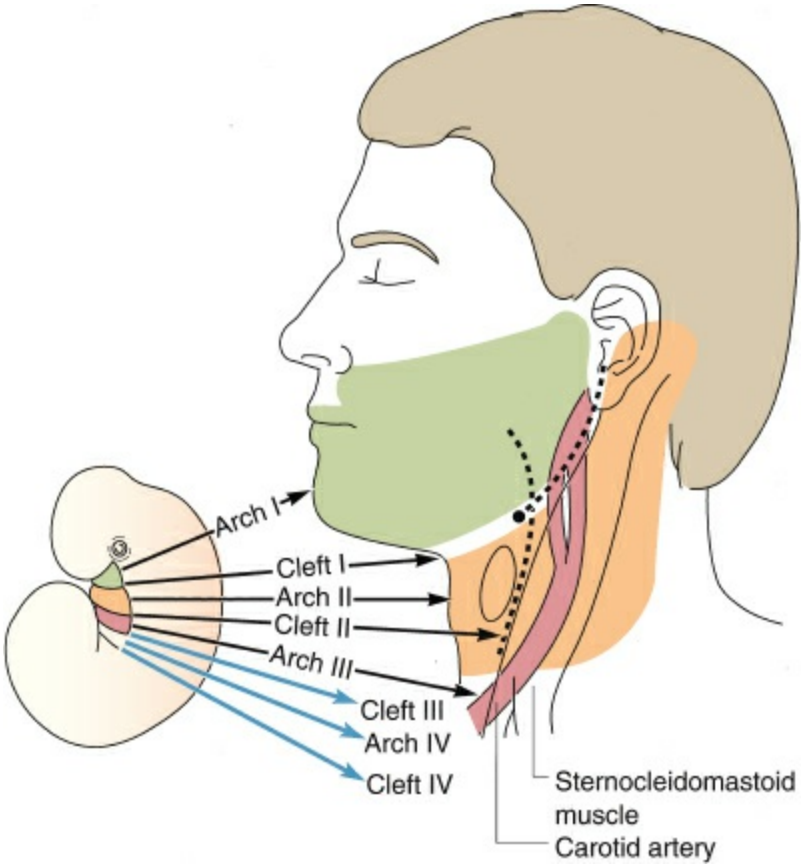

Figure 101-2. Derivation of various areas of the head and neck from the branchial arches and clefts of the embryo.

First branchial cleft anomalies, which comprise 8% of branchial cleft anomalies, are divided into type 1 and type 2.[10] Type 1 branchial cysts often present as a fistula around the conchal cartilage. The tract can follow the course of the external auditory canal and is lined by squamous epithelium.[11] Type 2 branchial lesions are found near the angle of the mandible and are composed of both epithelium and mesoderm (as opposed to only epithelial elements in type 1). Both type 1 and type 2 first branchial cleft anomalies can be closely associated with the facial nerve, although type 2 lesions are more likely to be intimately involved with the nerve. Type 2 branchial lesions can loop under the facial nerve, pushing it laterally and inferiorly.[12] The tract for a first branchial cleft usually extends from the opening near the mandible, near the posterior aspect of the parotid, and toward the external auditory canal. One should monitor the facial nerve at all times, with visualization of the face during the entire excision and avoidance of paralysis with anesthesia.

The most common branchial anomaly is derived from the second branchial cleft groove, representing 90% of branchial cleft anomalies.[13] It can occur as an isolated cyst or as a sinus tract/fistula that extends from the cervical skin to the tonsillar fossa. The cysts will often present at the time of an upper respiratory tract infection as an enlarging, tender mass. If a fistula is present, it will course through the internal and external carotid arteries, over the hypoglossal and glossopharyngeal nerves to end in the tonsillar fossa. A cyst can occur anywhere along this tract, but most commonly occurs in the anterior triangle of the neck below the hyoid.

Third and fourth branchial cleft lesions are rare. Third branchial cleft cysts present low

and anterior in the neck. Fistulas can course from the piriform fossa and drain to the anterior cervical skin. This tract pierces the thyrohyoid membrane and tracks under the glossopharyngeal nerve and internal carotid artery, but stays above the vagus nerve. These lesions can be intimately involved with the thyroid, and sometimes a hemithyroidectomy is required for repeated recurrences. An infected TGDC or third branchial cleft cyst may be the cause of suppurative thyroiditis in children.[14] The external location for a fourth branchial cleft is the same as the second and third, but the internal opening is near the apex of the piriform sinus. Fourth arch masses are extremely rare and but reports do exist. Third and fourth branchial sinus/tract dissections are similar to a second branchial cleft. Endoscopy at the beginning of the case can greatly assist in locating and resecting the tract. One promising surgical option for third or fourth sinus tracts is cauterization or sclerotherapy.[15]

The standard treatment for all types of branchial anomalies is complete surgical excision. The surgery is performed under general anesthesia and the patient is positioned with the neck slightly extended with a shoulder roll. If there is a sinus tract or fistula present, a small ellipse is made around this opening after it has been cannulated with a small lacrimal probe. A probe can be used or some use a small injection of methylene blue, although this can be messy. The tract is then dissected cephalad until the end of the sinus tract or until the internal opening of the fistula is reached. The dissection for the most common branchial cleft anomaly, the second branchial cleft, penetrates the platysma, rises along the carotid sheath and turns medially near the branches of the internal carotid artery and courses between the posterior belly of the digastric muscle and stylohyoid muscle, and over the hypoglossal nerve before ending near or in the tonsillar fossa. The tract is then ligated with absorbable suture. Often a direct laryngoscopy or simply a finger placed in the oropharynx can help to visualize the course of the tract and assist with dissection. Some patients might require a “stepladder” incision to trace the tract superiorly (Fig. 101-3).

Cartilaginous remnants are normally small and present in the subcutaneous tissue along the anterior border of the sternocleidomastoid, are usually palpable and easily resected. These rarely get infected and removal is for cosmetic indications.

Preauricular cysts, pits, and sinuses are common in children and are thought to develop from the first two branchial arches. They are more common and more often bilateral in comparison to first branchial cleft cysts and rarely become infected. The tracts extend from the skin down to the helical cartilage of the auricle and are lined with squamous epithelium. Treatment is surgical excision and the recurrence rate ranges from 19% to 40%.[16]



Figure 101-3. Picture of sinus tract.

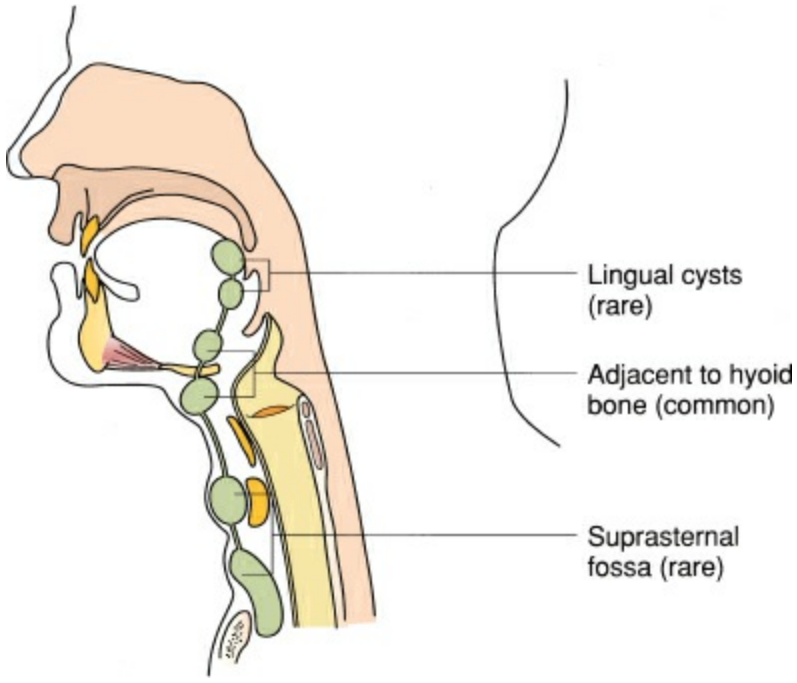

Figure 101-4. Locations of thyroglossal duct cysts.

Thyroglossal Duct Cysts

TGDCs are congenital lesions that develop from the thyroglossal duct tract that occurs during the descent of the thyroid. The thyroid descends from the foramen cecum at the

sixth week of gestation and tracts along the anterior neck in close association with the developing hyoid bone. This tract usually involutes, but if it persists the tract can present as a TGDC at any point from the foramen cecum to the thyroid (Fig. 101-4). TGDCs are the most common neck mass besides benign lymphadenopathy in the pediatric population.[17] Physical presentation reveals a midline neck mass that may move with protrusion of the tongue (Fig. 101-5). US is useful to look at the characteristics of the cyst, but is most important to determine if there is a normal thyroid gland present. In rare cases, the TGDC could be the sole functioning thyroid tissue in the patient.



Figure 101-5. Thyroglossal duct cyst.

Treatment is surgical excision and removing the entire tract with a core of tissue and the central portion of the hyoid bone can minimize recurrence. Rarely, papillary thyroid carcinoma can be found in the specimen.[18] The procedure is performed under general anesthesia with the neck extended and placement of a shoulder roll. A horizontal skin incision is made over the cyst, with no need to excise skin unless a fistulous tract or infection has involved the dermis. Careful dissection around the cyst then allows continued dissection superiorly toward the hyoid bone. Muscular attachments to the central hyoid bone are removed with cautery and the hyoid is removed en bloc with the cyst and tract. A core of tissue is then removed above the hyoid bone toward the base of tongue. The tract is then ligated with absorbable suture. Placing a gloved finger at the base of tongue can sometimes facilitate this maneuver. The wound should then be irrigated copiously and closed in a layered fashion. A drain is often used. Complete excision is considered curative and TGDCs have a recurrence rate of less than 10% when

using this method.[17]

Other midline lesions to keep in the differential include dermoid and epidermoid cysts, lymph nodes, thymic cysts, and bronchogenic cysts.

Dermoid Cysts

Dermoid cysts should be considered in the differential of any midline lesion, although they can be off midline as well. On examination, dermoid cysts present as firm masses that are soft, mobile, nontender, and grow slowly. Dermoid cysts contain tissue from the three germinal layers, which can include sweat glands and sebaceous glands. Treatment is total surgical excision. If a nasal dermoid occurs, it can penetrate the bone and a CT or MRI should be performed to rule out intracranial extension. Midline dermoid cysts are likely entrapped epithelium at the time of embryonic fusion.[19]

Thymic Cysts

Lesions of the thymus usually occur in the lower neck, but can present anywhere from the piriform sinus to the chest. The differential includes thymic cysts, thymic hyperplasia, or thymoma.

Infectious

The most common cause of a neck mass in the pediatric population is benign cervical adenopathy. Cervical lymph nodes are palpable in 40% of infants and 55% of pediatric patients on examination.[20,21] Lymph nodes that are less than 1 cm in size and asymptomatic are considered normal in children less than 12 years of age.[14] Lymphadenitis is most commonly seen in the submandibular region and cervical nodes, and the source of infection can be viral, bacterial, fungal, or neoplastic. Bacterial and viral infections causing upper respiratory infections are the most common cause of cervical lymphadenopathy. Other possible sources of cervical LAD include fungal (in immunocompromised patients), cat scratch disease, mononucleosis, atypical mycobacterium, and tuberculosis. As mentioned previously, lymphomas or metastatic disease can also present with nodal enlargement in the neck. Although rare, one should also consider Kawasaki disease, sarcoidosis, Rosai–Dorfman syndrome, and histiocytosis X.

Acute suppurative lymphadenitis is most common in the 6-month to 3-year range, with lymph node enlargement associated with an upper respiratory tract infection. The most common etiologies include *Staphylococcus aureus* and group A beta-hemolytic streptococci. There is commonly overlying skin changes with erythema and cellulitis, with an associated leukocytosis and fever. The lymph node enlarges and eventually outgrows the blood supply, resulting in central necrosis. Management can sometimes include needle aspiration of purulence, but often requires an incision and drainage with placement of a drain or packing under anesthesia. An incision is made in the area of fluctuance and blunt dissection should break up all loculations. It is important to place the incision in a place that minimizes risk to vital structures, such as the facial nerve, and allows for the best cosmesis. Antibiotics are geared toward *Staphylococcus* and *Streptococcus* but cultures

should be taken with a change in antibiotic therapy if necessary. The induration from the abscess can take several weeks to resolve, but recurrence is rare. If the abscess recurs, it should prompt investigation of a possible underlying anomaly. Viral infections rarely cause suppurative adenitis.

Lymphadenitis can also be chronic or subacute with enlargement of lymph nodes not associated with an acute infection, although sometimes can occur in a patient with recurrent URIs, tonsillitis, otitis media, or allergic rhinitis. Often the lymph node is solitary, nontender, and mobile. Excisional biopsies are recommended generally when the lymph node is larger than 2 cm and has been present for longer than 8 weeks, or has concerning characteristics such as immobility or rapid growth. Once excised, it is important to obtain cultures, histopathology, and flow cytometry.

Mycobacterial infections, usually caused by the atypical mycobacterium *Mycobacterium avium-intracellulare-scrofulaceum* (MAIS) complex, can be very challenging to manage. The pathogens are usually acquired through the mucous membranes during the eruption of teeth, not through person-to-person transmission. These lesions often cause discoloration of the skin and can fistulize over time (Fig. 101-6). Antibiotic therapy is not always curative. It most commonly occurs in children 1 to 5 years of age and often has associated asymptomatic lymphadenopathy but no fever or leukocytosis. The response to antibiotic therapy can be disheartening with little improvement and sometimes surgery is required to excise the infection. Adjuvant treatment with clarithromycin or rifabutin is often indicated, as is a consultation with the infectious disease team. In contrast, children with *M. tuberculo*sis usually have fever and respiratory symptoms along with positive findings on chest x-ray and the purified protein derivative skin test.

Cat scratch disease, caused by *Bartonella henselae,* can cause tender cervical lymph node enlargement in 25% of cases. Usually there is a history of contact with a cat within 2 weeks of the development of tender lymphadenopathy. The site of inoculation is usually an extremity. The diagnosis can be made using *B. henselae*-based serologic indirect fluorescent antibody test or enzyme immunoassays. The disease is usually self-limited with resolution in 2 to 8 weeks and no antibiotic therapy is necessary; however, rarely patients can suffer disseminated disease.[22]



Figure 101-6. Atypical mycobacterium infection.

Vascular Malformations

Infantile Hemangioma

Infantile hemangiomas (IH) are the most common tumor of infancy. IH are endothelial tumors characterized by an increased proliferation and turnover of endothelial cells, which differentiates this from other vascular malformations. IH grow rapidly during the first 9 months (proliferative phase) and then slowly regress (involuting phase). Regression is usually complete by 4 to 5 years of age.[23] They can occur anywhere in the body, with frequent involvement of the tongue and parotid gland. Usually hemangiomas occur as a solitary lesion, but 20% of patients can have multiple affected sites. On examination, hemangiomas are a well-demarcated, raised, red mass that blanches with pressure (Fig. 101-7). Known risk factors include female sex, Caucasian race, preterm birth, and low birth weight. Most hemangiomas are not visible at birth but become apparent in the first few months of life and 90% are noticeable by 6 months of age.[24] Hemangiomas can occur in the subglottic region and present with biphasic stridor, presenting between 1 and 3 months of age. Similarly, parotid hemangiomas present as an enlarging mass within the parotid gland at age 1 to 3 months. Evaluation by Doppler US showing fast-flow is diagnostic.

Treatment for most IH is conservative, as 90% are small, localized, and not problematic. IH can ulcerate, bleed, and cause deformities and in these cases local wound care can help and sometimes intralesional steroid injections may be necessary.[25] Injection with steroids can stabilize the growth of IH in 95% of patients and decrease the size in 75% of patients.[26] Systemic corticosteroid treatment can be used for large lesions that become symptomatic and are not amenable to injection. Propanolol has also been used in the treatment of IH with varying results. Patients must be monitored closely while on propranolol therapy due to possible serious side effects.



Figure 101-7. Hemangioma.



Figure 101-8. Picture of a patient with lymphatic malformation.

Lymphatic Malformation

Lymphatic malformations (LMs) are slow-flow vascular anomalies and 75% of LMs present in the head and neck. The incidence ranges from 1 in 2,000 to 4,000 births and usually occurs in the first decade of life. The lymphatic system develops around week 5 of gestation and although the mechanism for the development of an LM is not completely understood, it is generally thought to occur due to parts of the lymphatic system that fail to establish connections with the main lymphatic system or venous channels (Fig. 101-8). Histopathology of LMs shows progressive dilation of abnormal vessels and LMs are composed of vascular spaces filled with eosinophilic and protein-rich fluid. LMs are present at birth, but sometimes are not apparent until enlargement due to infection or trauma with hemorrhage. Some patients are diagnosed with LM when found on prenatal US, and can potentially obstruct the airway and may require an ex utero intrapartum treatment procedure (EXIT procedure).

LMs are divided in microcystic, macrocystic, and mixed lesions. Microcystic lesions are usually above the mylohyoid and can involve the floor of mouth, tongue, parotid, and lip. These lesions have poorly defined borders and infiltrate nearby muscle and fatty planes. Macrocystic lesions are usually below the mylohyoid and have multiple large, loculated cysts in varying size and shape. LMs can enlarge with infection or trauma, which can lead to airway obstruction, functional issues (swallowing, speech), or deformity. Imaging can be helpful to determine the extent of the lesion as well as involvement of surrounding

structures.

Treatment for these lesions is challenging and the main options include observation, sclerotherapy, or surgery. LMs are benign lesions and this must be kept in mind when planning treatment. Macrocystic lesions are more amenable to both sclerotherapy and surgical excision, whereas complete removal of microcystic lesions would often result in unacceptable morbidity due to their infiltrative nature. Subtotal resection leads to a high recurrence rate and surgery can be difficult due to previous inflammation and scarring from sclerotherapy. Radiofrequency ablation can be useful in relief of ulceration tongue lesions or oral mucosa.[27] The CO_2 laser can help with symptomatic lesions of the airway or oral cavity, which can reduce bleeding and ulceration. Recently, rapamycin or "sirolimus" has been investigated as a possible oral medication for LMs with encouraging preliminary results.[28]

Airway

Airway obstruction can occur from congenital or acquired lesions at any level from the nose to distal airway. Children can present with tachypnea, dyspnea, and chest-wall retractions and it is imperative to establish an airway while investigating the potential causes with history and physical, chest radiograph, and arterial blood gas if appropriate. Laryngoscopy and bronchoscopy are often warranted.

Infants are obligate nasal breathers and nasal obstruction, especially bilateral obstruction, can cause acute respiratory distress at birth. Choanal atresia or stenosis, piriform aperture stenosis, or nasal septal deviation can cause significant obstruction. Piriform aperture stenosis is a narrowing of the anterior nasal passageway that can also cause similar symptoms to choanal atresia. Nasal obstruction can also result from lesions such as a nasolacrimal duct cyst, encephalocele, or nasal glioma. Nasal examination and sometimes a CT scan can help to determine the diagnosis.

Macroglossia or retrognathia/micrognathia may also cause obstruction of the oral cavity in the infant. In the oropharynx, a TGDC, a vallecular cyst, or lingual thyroid can cause airway obstruction.

In the supraglottic region, laryngomalacia can affect the larynx in newborns. Laryngomalacia results from immature cartilage in the larynx and discoordination of the arytenoids and epiglottis. The diagnosis is made using a flexible laryngoscope and viewing the larynx while the patient is awake. High-pitched inspiratory stridor that is worsened with exertion, crying, or excitement is the classic description. Most children do not require any intervention, but a supraglottoplasty can be performed when laryngomalacia causes breathing or feeding difficulties. There are many different variations of the supraglottoplasty, but the basic concept is to remove excess or floppy supraglottic tissues to improve the airway.

At the level of the glottis, obstruction can occur for several reasons, including vocal cord paralysis and glottis webs. Bilateral vocal cord paralysis can present with a normal cry but biphasic stridor, whereas unilateral vocal cord paralysis usually presents with a weakened cry and no respiratory distress. A mediastinal lesion should be ruled out in patients with vocal cord paralysis and patients with bilateral vocal cord paralysis warrant a neurologic consultation for possible Arnold–Chiari malformation or hydrocephalus. A tracheotomy may be necessary for patients with bilateral vocal cord paralysis if they are in respiratory distress.

Glottic webs usually affect the anterior portion of the vocal cords and can range from a thin membrane to a thick web that can extend inferiorly to the subglottis. Patients present with dysphonia and sometimes respiratory distress. Treatment is dependent on the extent of the glottis web, which can be divided endoscopically in the majority of cases.[29]

The subglottis is the narrowest part of the airway in an infant due to the cricoid cartilage. Stenosis can occur congenitally or can be acquired after long-term intubation. Subglottic hemangiomas are another source of airway obstruction that enlarge after birth and are associated with cutaneous hemangiomas. The subglottic hemangiomas can occur

as an isolated lesion or as part of the PHACES syndrome (posterior fossa malformation, arteriovenous malformations, cardiac/aortic defects, eye anomalies, and sternal defect). Treatment can be systemic or intralesional corticosteroids, laser therapy via endoscopic approach, or open excision.

In patients with a prior intubation, one or multiple subglottic cysts may form and cause airway obstruction. Treatment entails endoscopic evaluation with marsupialization or removal with a laser or laryngeal microdebrider.

Tracheomalacia can occur in a primary or secondary form. Primary tracheomalacia is a rare congenital disease in which the tracheal cartilages collapse on expiration. Most cases of primary tracheomalacia are mild and no intervention is required, although if severe a tracheostomy may be required. Secondary tracheomalacia occurs when an extrinsic compression causes collapse of the trachea on expiration. Treatment is then tailored to the source of compression, whether a vascular anomaly or mass.

Tracheal stenosis can occur due to congenital complete tracheal rings and can involve a segment or the entire trachea. Depending on the extent of the stenosis, a tracheal resection or a slide tracheoplasty may be performed.

Acquired obstruction of the airway includes infectious sources, such as epiglottitis, and foreign-body aspiration. Although rare, epiglottitis is a life-threatening disease caused by *Haemophilus influenza* type B (90% of cases) that occurs most commonly in children ages 2 to 4 years. The *H. influenza* vaccination has reduced the number of cases, but pneumococci and B-hemolytic streptococci can also cause epiglottitis. The disease presents rapidly, with stridor, airway obstruction, drooling, odynophagia, fever, tachypnea, and tachycardia. As the disease progresses, the child will often assume the “tripod” position by leaning forward, drooling, and suffering from air hunger. It is important not to agitate the patient and obtain an airway in the operating room with a tracheostomy set available. Depending on the stability of the patient, a lateral neck film can confirm the diagnosis with the “thumbprint” sign demonstrating an edematous epiglottis. The patient should be started on antibiotic therapy and laryngoscopies performed until the patient’s epiglottis/airway edema allows for a safe extubation.

Airway foreign bodies can be life threatening and the history is of utmost importance. Combining the convincing history of a coughing/choking episode with an abnormal chest radiograph warrants a bronchoscopy. Sometimes a bronchoscopy is warranted on the history alone, as less than half of the patients with an airway foreign body have an abnormal chest radiograph.[30] If it was a witnessed aspiration, obtaining a detailed description of the object and practicing with the bronchoscopy foreign-body forceps on a similar object can be helpful if the patient is stable.

References

1. Torsiglieri AJ Jr, Tom LW, Ross AJ 3rd. Pediatric neck masses: guidelines for evaluation. *Int J Pediatr Otorhinolaryngol* 1988;16(3):199–210.
2. Fefferman NR, Milla S. Ultrasound imaging of the neck in children. *Ultrasound Clin* 2009;4(4):553–569.
3. Robson CD. Imaging of head and neck neoplasms in children. *Pediatr Radiol* 2010;40(4):499–509.
4. Lauer MS. Elements of danger – the case of medical imaging. *N Engl J Med* 2009;361(9):841–843.
5. Amis ES Jr, Butler PF; American College of Radiology. ACR white paper on radiation dose in medicine: three years later. *J Am Coll Radiol* 2010;7(11):865–870.
6. Amis ES Jr, Butler PF, Applegate KE, et al. American college of radiology white paper on radiation dose in medicine. *J Am Coll Radiol* 2007;4(5):272–284.
7. Patel PM, Alibazoglu H, Ali A, et al. Normal thymic uptake of FDG on PET imaging. *Clin Nucl Med* 1996;21(10):772–775.
8. Weinblatt ME, Zanzi I, Belakhlef A, et al. False-positive FDG-PET imaging of the thymus of a child with Hodgkin's disease. *J Nucl Med* 1997;38(6):888–890.
9. Rood SR, Johnson JT, Lipman SP, et al. Diagnosis and management of congenital head and neck masses. *American Academy of Otolaryngology – Head and Neck Surgery SIPAC 76481*. Washington, DC: US Government Printing Office; 1981:12–24.
10. Cunningham MJ. The management of congenital neck masses. *Am J Otolaryngol* 1992;13(2):78–92.
11. Lambert PR, Dodson EE. Congenital malformations of the external auditory canal. *Otolaryngol Clin North Am* 1996;29(5):741–760.
12. Ikarashi F, Nakano Y, Nonomura N, et al.. Clinical features of first branchial cleft anomalies. *Am J Otolaryngol* 1996;17(4)233–239.
13. Choi SS, Zalzal GH. Branchial anomalies: a review of 52 cases. *Laryngoscope* 1995;105:909–913.
14. Wiatrak BJ. Clinical Evaluation of the neck. In: Wetmore RF, Muntz HR, McGill T, eds. *Pediatric Otolaryngology: Principles and Practice Pathways.* New York, NY: Thieme; 2012:841–856.
15. Goff CJ, Allred C, Glade RS. Current management of congenital branchial cleft cysts, sinuses, and fistulae. *Curr Opin Otolaryngol Head Neck Surg* 2012;20(6):533–539.
16. Leopardi G, Chiarella G, Conti S, et al. Surgical treatment of recurring preauricular sinus: supra-auricular approach. *Acta Otorhinolaryngol Ital* 2008;28(6):302–305.
17. Roback SA. Telander RL. Thyroglossal duct cysts and branchial cleft anomalies. *Semin Pediatr Surg* 1994;3(3):142–146.
18. Wigley TL, Chonkich GD, Wat BY. Papillary carcinoma arising in a thyroglossal duct cyst. *Otolaryngol Head Neck Surg* 1997;116(3):386–388.

19. Grimmer JF. Congenital masses in the neck. In: Wetmore RF, Muntz HR, McGill T, eds. *Pediatric Otolaryngology: Principles and Practice Pathways.* New York, NY: Thieme;2012:857–868.
20. Bamji, M, Stone RK, Kaul A, et al. Palpable lymph nodes in healthy newborns and infants. *Pediatrics* 1986;78(4):573–575.
21. Park YW. Evaluation of neck masses in children. *Am Fam Physician* 1995;51(8):1904–1912.
22. Rolain JM, Brouqui P, Koehler JE, et al. Recommendations for treatment of human infections caused by bartonella species. *Antimicrob Agents Chemother* 2004;48(6):1921–1933.
23. Couto RA, AK Greene. Hemangiomas. In: Rahbar R, Rodriguez-Galindo C, Meara JG, et al, eds. *Pediatric Head and Neck Tumors: A-Z Guide to Presentation and Multimodality Treatment.* New York, NY: Springer;2014:183–192.
24. Oldham KT, Aiken JJ. Pediatric Head and Neck. In: Mulholland MW, Lillemoe KD, Doherty GM, et al., eds. *Greenfield Surgery: Scientific Principles and Practice.* 5th ed. Philadelphia, PA: Lippincott, Williams and Wilkins;2011.
25. Greene AK. Management of hemangiomas and other vascular tumors. *Clin Plast Surg* 2011;38(1):45–63.
26. Sloan GM, Renisch JF, Nichter LS, et al. Intralesional corticosteroid therapy for infantile hemangiomas. *Plast Reconstr Surg* 1989;83:459–467.
27. Grimmer F, Mulliken JB, Burrows PE, et al. Radiofrequency ablation of microcystic lymphatic malformation in the oral cavity. *Arch Otolaryngol Head Neck Surg* 2006;132:1251–1256.
28. Hammill AM, Wentzel M, Gupta A, et al. Sirolimus for the treatment of complicated vascular anomalies in children. *Pediatr Blood Cancer* 2011;57(6):1018–1024.
29. Amir M, Youssef T. Congenital glottic web: management and anatomical observation. *Clin Respir J* 2010;4(4):202–207.
30. Zerella JT, Dimler M, McGill LC, et al. Foreign body aspiration in children: value of radiography and complications of bronchoscopy. *J Pediatr Surg* 1998;33(11):1651–1654.

Chapter 102

The Pediatric Chest

Mary C. Santos and Robert E. Cilley

Key Points

1 Pectus excavatum repair should occur in late childhood or adolescence and is now most frequently performed with a rigid transversely oriented pectus excavatum bar that pushes the deformity back into place.

2 Pectus carinatum occurs less frequently than pectus excavatum and does not cause physiologic impairment; bracing has become the method of choice for treatment.

3 Pulmonary sequestrations (PSs) are abnormal lung tissue with anomalous systemic blood supply that can be either intralobar or extralobar lesions based on their relationship with the investing visceral pleura and adjacent normal lung tissue. They do not communicate normally with the trachea or a bronchus.

4 Congenital cystic adenomatoid malformations (CCAMs) have a normal vascular supply and communicate with the normal tracheobronchial tree. They result from excessive proliferation of bronchial structures without the development of the corresponding alveoli. Management of asymptomatic CCAMs remains controversial.

5 Benign cysts of the mediastinum are relatively common and include thymic cysts, enterogenous cysts, dermoid cysts, lymphatic malformations (cystic hygromas), and pericardial cysts. Resection is usually recommended because of the possibility of progressive enlargement with compression, hemorrhage, or infection.

6 Primary lung tumors in children are rare and include bronchial adenoma, pulmonary blastoma, inflammatory pseudotumor (composed of inflammatory cells), hamartoma and rarely bronchoalveolar carcinoma. Resection is generally the appropriate initial therapy.

7 Metastasectomy for many solid embryonal neoplasms can improve survival if the primary disease is controlled by resection.

8 Tracheoesophageal fistula can occur as esophageal atresia with proximal pouch and distal tracheoesophageal fistula (most common, at 85% to 95%), esophageal atresia without fistula (5% to 7%), tracheoesophageal fistula without esophageal atresia H type (2% to 6%), and rarer forms of this anomaly including esophageal atresia with proximal tracheoesophageal fistula and esophageal atresia with both proximal and distal tracheoesophageal fistula.

9 Approximately 75 children die from foreign-body aspiration or ingestion each year. Bronchoscopic evaluation and foreign-body removal are performed in the operating

room under general anesthesia, where the rigid bronchoscope with optical forceps can be used to remove most aspirated foreign bodies safely.

10 Congenital diaphragmatic hernia (CDH) is a physiologic emergency and not a surgical emergency. The newborn with CDH should be stabilized by nonsurgical means and delayed, well-planned surgical repair undertaken subsequently.

CHEST WALL DEFORMITIES

Deformities of the chest wall may be obvious at birth but often become more noticeable at the time of preadolescent and adolescent growth. The physical appearance may vary from barely detectable to grotesquely deforming. Although there may be some physiologic benefit from surgical correction of these deformities, restoration of a more normal appearance is equally important in the decision to operate. The impact of these deformities on normal psychosocial development, as well as the less certain evidence of cardiorespiratory impairment, constitutes adequate justification in the affected child.

Embryology, Development, and Etiology of Chest Wall Deformities

In the embryo, the ribs are derived from individual somites as mesoderm differentiates into cartilage and advances ventrally toward the developing sternum. The rib cartilage eventually approaches the sternum. The sternum itself is derived independently from two parallel bands of mesoderm that develop away from the midline. The two sternal bands fuse in a cranial-to-caudal direction and become progressively chondrified. Transverse divisions of the cartilaginous sternum differentiate into segments opposite each end of the rib pairs. At birth, small ossification centers are present in the sternum and the ribs have largely ossified. Final ossification is usually complete by mid adolescence. The process is sufficiently predictable that sternal ossification is a reliable method of determining bone age. There is a sharp demarcation in each rib between the ossified portion and the cartilaginous portion, with the latter becoming ossified only much later in life. The etiology of chest wall deformities is poorly understood.[1] Explanations include abnormal intrauterine pressure applied to the chest, abnormalities of diaphragmatic development, connective tissue abnormalities, and genetic predisposition. Abnormal, excessive, or asymmetric growth of the costal cartilages associated with the 3rd to 10th ribs is most implicated.[2] Sternal clefts are understood as a failure of fusion of some portion of the sternal bands.

Pectus Excavatum

Pectus excavatum from the Latin “hollowed chest” is the most common deformity of the anterior chest wall occurring in 1 in 400 to 1 in 1,000 children and accounting for more than 87% of chest wall deformities. A family history is present in 45% of patients.[2,3] Pectus excavatum results from abnormal regulation of the growth of the costal cartilages. There is a corresponding posterior curve in the body of the sternum beginning at the manubrium and extending to the xiphoid. The deformity is rarely precisely symmetric, with one side (usually the right) slightly more curved in than the other. Asymmetry may be pronounced with the sternum rotated nearly to the sagittal plane. The deformity may be apparent at birth but may become more apparent during growth and development, particularly during adolescence. Pectus excavatum occurs more frequently in males than females. Scoliosis is present at increased incidence in this population although rarely requires surgical correction. Patients often have an asthenic build and stoop-shouldered posture. Marfan syndrome predisposes to pectus excavatum. The diagnosis of Marfan syndrome should be considered when patients are referred for evaluation of a chest wall deformity.

At the time of surgical consultation, concerns about the cardiopulmonary implications of the chest wall deformity are often paramount in the mind of the referring physician as well as the family. Many patients will have complaints of chest pain and/or shortness of breath. Most patients are disturbed by the appearance of the deformity, and some may be profoundly depressed and dysfunctional. The physiologic consequences of the deformity are less certain. Invasive and echocardiographic assessment of cardiovascular performance has demonstrated improvement in cardiac function and resolution of mitral valve prolapse in some patients following surgical correction of pectus excavatum. Studies have also demonstrated improved body image and subjective physical ability.[2,5–9] The cardiorespiratory benefits of the repair remain controversial with more recent studies demonstrating improvement after bar removal especially with dynamic testing.[9] Multiple studies of patient and parent satisfaction have demonstrated very well to excellent results.[2,5,8–12] Clinical assessment of the severity of the deformity has included chest radiographs, computerized tomography (CT), caliper measurements, and contrast volume measurements of the cavity. The “pectus index” is defined as the ratio of the maximum internal transverse diameter of the thorax to the minimum sternovertebral distance.[7] If cardiac disease is suspected on the basis of the history and physical examination, an echocardiogram may be indicated. Static pulmonary function testing is rarely helpful but exercise testing may be helpful.

Surgical Correction of the Pectus Excavatum

1 Although pectus excavatum is diagnosed in infants and young children, repair should be deferred to teenage years. This leads to improvement in cardiopulmonary status while avoiding recurrence and acquired thoracic dystrophy of early repair.

Traditional Operations

Traditional surgical correction is performed through an inframammary incision which is kept within the nipple lines (Fig. 102-1). The operation requires the exposure of costal cartilage by elevation of the pectoral muscles from the chest wall. The involved cartilages usually from 3 to 7 and parts of 8 to 10 are removed by subperichondrial excision, with careful preservation of the perichondrial sheaths. The xiphoid is detached from the sternum and the rectus muscles are detached inferiorly. The undersurface of the sternum is dissected free of the pericardium and pleura. A transverse wedge osteotomy is created in the sternum at the point where the sternum deflects posteriorly and the posterior surface is gently fractured but not displaced. A strut is usually placed beneath the sternum to maintain the position of the sternum. The strut is usually a stainless steel bar and is removed in 6 months to 1 year.[2,4] The pectoral and rectus muscles are reapproximated. Closed suction drains are usually left in place in the submuscular layer. Patients are discharged when they are able to tolerate a diet and their pain is controlled by oral analgesics usually on the second to third postoperative day. Multimodal pain management including regional anesthesia, epidural analgesia, nonsteroidal anti-inflammatory agents, and narcotics are used. Complications may include pneumothorax not requiring therapy, wound seromas, and pleural effusions. Recurrence occurs in approximately 7% if repaired early but less than 2% undergo reoperation.[2] The incidence of reactive pectus carinatum after excavatum repair is 1%.[13] Migration of implanted struts and bars has caused the most serious problems, including cardiac injury.

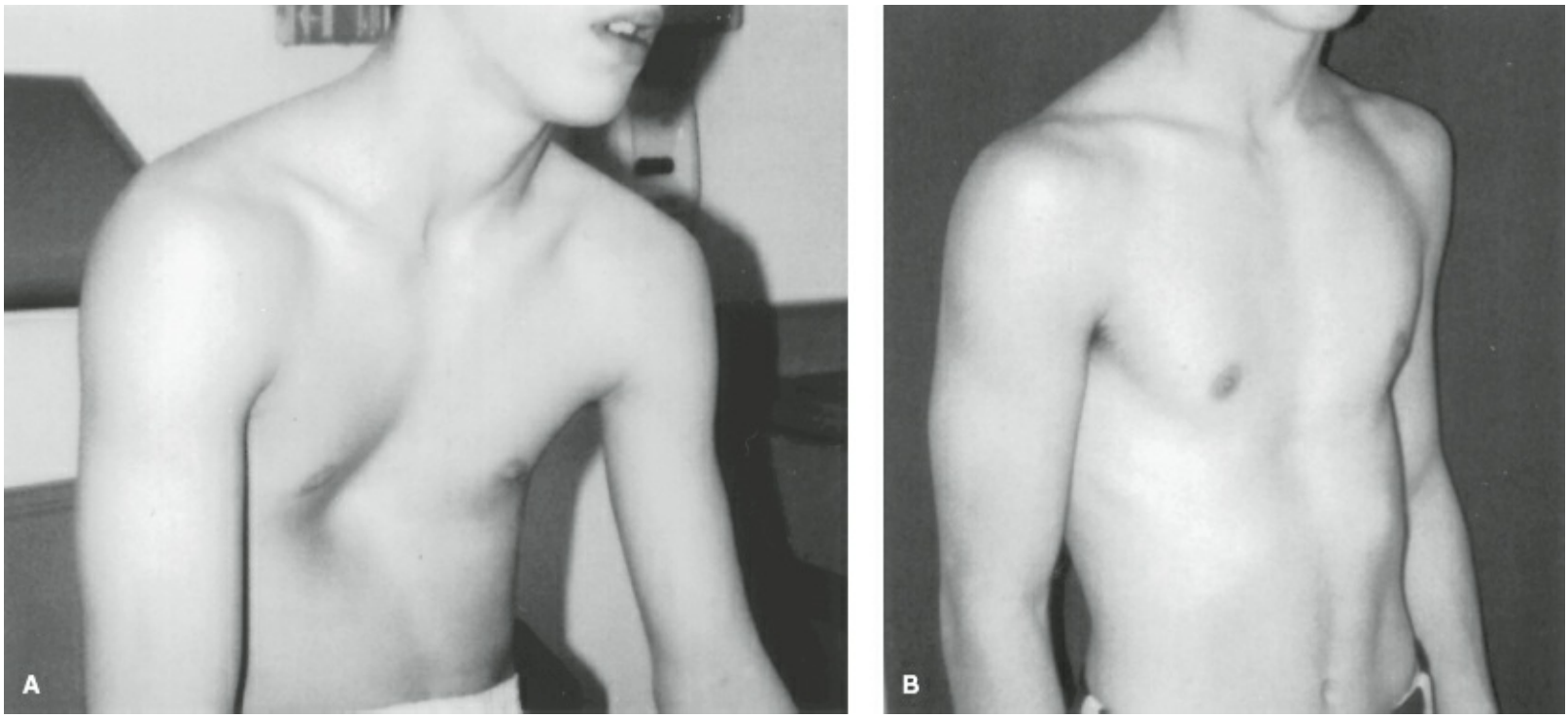

Figure 102-1. Pectus excavatum. **A:** Appearance of an adolescent male with a typical depression deformity. Note "stoop-shouldered" posture. **B:** Postoperative appearance at 6 months. Erect posture and subpectoral incision give a good cosmetic result.

The Minimally Invasive Repair/Nuss Procedure

Since the description of a technique not involving resection or osteotomy in 1998, the performance of the minimally invasive/Nuss procedure has gained widespread popularity. Using small lateral incisions, a rigid U-shaped bar is inserted transversely across the chest and then flipped and the sternum is pushed back into a normal position (Fig. 102-2).[14] Modifications of the technique including the use of stabilizers, use of two bars, and routine use of thoracoscopy have been described.[2,11,15] Reported complications have included pneumothorax, cardiac injury, bar displacement, chronic pain, pericarditis, and extraosseous bone formation.[15–17] Postoperative pain management usually involves epidural analgesia as well as intravenous and oral medications, with a recent prospective study supporting epidural for early management and patient-controlled analgesia for later management.[18] The bar is left in for up to 3 years during a period of development when most children are active and may engage in contact sports. Activity restrictions that are necessary while the bar is in place are not well defined. This technique is an important addition to the surgical treatment of chest wall deformities. Recent studies have demonstrated that the early-to-late teenage years are the appropriate time for repair.[19,20]

Other Techniques

Implantation of submuscular silastic molds to alter the chest contour may result in a very acceptable appearance.[21] This technique does not address any of the potential physiologic problems associated with pectus excavatum and has not been used widely.

Externally applied suction may also be used to treat depression deformities of the chest wall. Finally, implanted devices that use magnetic forces to pull the sternum forward show promise in correcting the defect in patients with pectus excavatum.[22,23]

Pectus Carinatum

2 Pectus carinatum, from the Latin phrase for “keel,” is a chest wall defect where there is a protrusion of the sternum and ribs. This type of defect occurs less commonly than pectus excavatum and presents in approximately 1 in 1,000 to 1 in 1,500 teenagers. Physiologic impairment is absent; however, the concern for appearance may be even greater than with depression deformities of the chest wall. Protrusion deformities may be very difficult to hide even when fully clothed. Rapid growth of the costal cartilages occurring during puberty makes the deformity more pronounced at that time. Compression bracing has been described and is currently the first line of repair for pectus carinatum with surgery reserved for failures of therapy.[24–29] Bracing is most successful with bracing for 16 to 20 hours per day. Surgery which involves the transverse sternal osteotomy or use of a minimally invasive technique with the bar passed anterior to the sternum.[22,28]

Poland Syndrome

Named after the English surgeon Sir Alfred Poland, this rare congenital syndrome occurs in 1 in 30,000 births and includes a hypoplasia or aplasia of the thoracic wall components. These features include absence of the sternal portions of the pectoralis major muscle; absence of the pectoralis minor muscle; absence of portions of the serratus anterior and external oblique muscles; forearm and hand deformities; ipsilateral hypoplasia of the nipple, breast, and chest wall subcutaneous tissues; absence or deformity of the second to fifth costal cartilages; and absence of axillary hair on the affected side. Surgical treatment includes correction of any deformed ribs, formation of the anterior axillary fold using the latissimus dorsi muscle, and creation of the ipsilateral breast in females.[30,31]

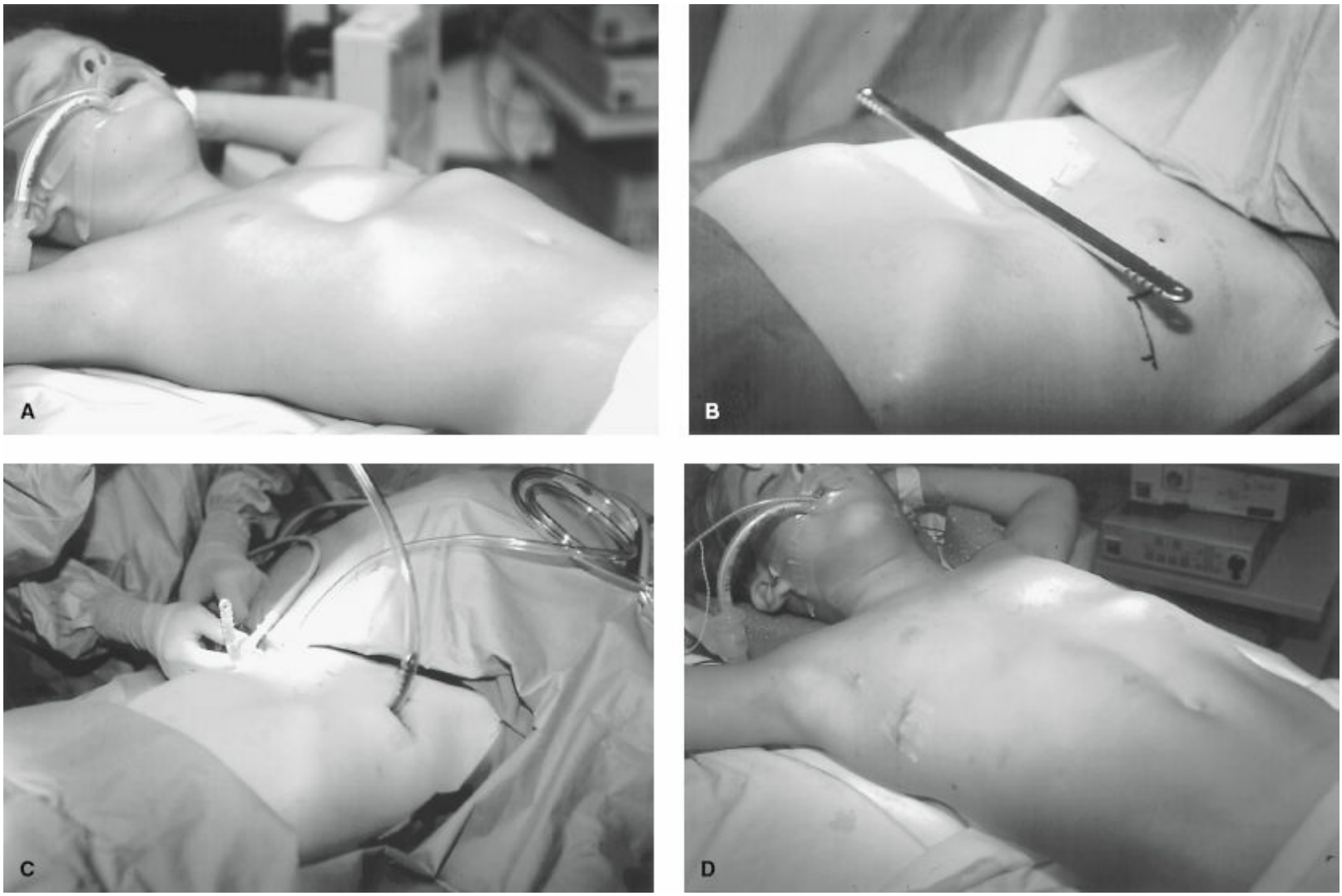

Figure 102-2. Thoracoscopically assisted Lorenz Bar insertion (Nuss procedure). **A:** Preoperative appearance with symmetrical depression deformity. **B:** Lorenz bar. **C:** Pectus excavatum bar inserted with thoracoscopic guidance. **D:** Immediate postoperative appearance. (Digital images provided by William Hardin, MD, University of Alabama, used with permission.)

Sternal Clefts

Congenital sternal clefts result from failure of midline fusion of the paired sternal bands. The cleft is usually in the superior portion of the sternum and may extend to but not include the xiphoid. The defects are rare and are usually repaired in the neonatal period when the chest is more pliable.[22,32] The purpose of the correction is to protect the underlying mediastinal structures. After subcutaneous and substernal mobilization, the fibrocartilaginous sternal bars are approximated in the midline. If the cardiac structures are at risk, more elaborate repairs are required. Typically, the cleft is incomplete and a V-shaped excision of the sternum at the most inferior aspect of the cleft may be required to avoid buckling of the sternum in that region.[22,32] Cantrell pentology refers to a distal sternal cleft, omphalocele, diaphragmatic defect, pericardial defect, and intracardiac defect. Thoracic ectopia cordis (exstrophy of the heart) may occur as a part of this abnormality and this spectrum continues to have a high mortality.[22]

Jeune Asphyxiating Thoracic Dystrophy

Jeune asphyxiating thoracic dystrophy is a rare developmental abnormality that results in the failure of chest wall growth. Traditional surgical procedures have involved sternotomies with placement of graft material to expand the chest. Most recently, the use of a vertical expandable prosthetic titanium rib (VEPTR) device allows division of the most posterior aspect of approximately the third to ninth ribs and division at the costochondral junction of the same ribs. The rib plate is then elevated to the curved VEPTR strut by wires, thus expanding the chest. This is done for both chests, and the device is serially expanded every 4 to 6 months to promote chest enlargement.[22,33]

The “Slipping Rib” Syndrome

Slipping rib syndrome is an unusual cause for recurrent lower chest and upper abdominal pain. The cause is likely an inadequacy or rupture of interchondral fibrous attachments. The symptoms tend to be a popping or clicking sensation associated with pain. Pain is usually reproducible with palpation. Surgical therapy involves excision of the affected rib and cartilage relieving pain on the involved intercostal nerve.[34,35]

“Flaring” of the Costal Margin

Patients are sometimes referred for surgical opinions regarding unusual prominence of the costal margin. The “flaring” is most pronounced when the patient is supine. This finding represents a variation of the normal development of the chest wall. Surgical correction should be avoided.

Costochondral “Tumor”

Prominence of a single costal cartilage may present as a concern of a tumor of cartilage or bone. This abnormality is usually found in preadolescents and adolescents. Patients may have undergone a diagnostic workup that includes chest radiographs, ultrasound, CT, or magnetic resonance imaging (MRI) prior to surgical consultation. This abnormality most likely represents a minor variation of a chest wall deformity, such as a pectus carinatum. The area of enlargement is rarely tender so that costochondritis is an unlikely explanation. Excision of the involved cartilage is rarely helpful. Plain radiographs or thoracic imaging are usually sufficient to exclude a tumor.[36]

CONGENITAL LUNG LESIONS

Congenital lung lesions have been characterized as lesions of defective budding, differentiation and separation of the foregut, or more recently airway maldevelopment with resultant obstruction.[37,38] These lesions include pulmonary sequestration (PS), congenital pulmonary airway malformation (CPAM), formerly CCAM, bronchogenic cyst (BC), and congenital lobar overinflation (CLO). The first three are in the family of bronchopulmonary foregut malformations. PS is characterized by aberrant blood supply, CPAM by hamartomatous lung parenchyma, and BC by an isolated cyst. There are overlaps between the elements so many lesions are found to be hybrid.[37,38] CLO is likely a secondary response to abnormal compression or obstruction of a bronchus.

Pulmonary Sequestration

3 PSs are microscopic cystic masses of nonfunctioning pulmonary tissue without a normal bronchial communication with the tracheobronchial tree. In addition, these abnormalities receive blood supply from an aberrant systemic vessel usually from the descending aorta. The lesions are most commonly found in the lower lobes, more commonly on the left. They are characterized as intralobar or extralobar based on pleural lining.

Intralobar sequestrations are incorporated into the surrounding lung and are invested by its visceral pleura. They are most common in the left medial or posterior basal segment of the lower lobe. The arterial supply is from the descending aorta and the venous return is usually into a pulmonary vein. Usually asymptomatic at birth, but aberrant air space connections can result in recurrent pneumonia.

Extralobar sequestrations occur outside of the pleura of the normal lung. They are most common in the lower left side of the chest but have been reported in a variety of locations including the retro peritoneum.[37–39] In the retroperitoneum, they may be difficult to distinguish from neuroblastoma. These have occasionally been associated with congenital diaphragmatic hernia (CDH). In extralobar PS, in addition to systemic arterial supply, the venous return is systemic. In 20% of cases, the blood supply originates from the infradiaphragmatic aorta. These lesions can present with arteriovenous shunting which in rare cases can lead to high output heart failure.

Radiographic evaluation of PS involves chest radiographs, ultrasound and CT scans with contrast enhancement to identify the vascular supply. Intralobar sequestrations are treated with lobectomy. Extralobar sequestrations may be removed by excision of the sequestration. The lesions may be removed with thoracotomy or thoracoscopy with attention to safe ligation of the vascular supply (Fig. 102-3).[37–42]

Congenital Pulmonary Airway Malformations

4 CPAMs result from overgrowth of bronchial structures at the expense of the associated alveoli associated with an abnormal supplying airway affecting a single lobe in 95% of cases. This group of anomalies represents 30% to 40% of the developmental lung bud anomalies. On gross appearance, they can be solid, cystic, or both. The malformations have a normal blood supply and communicate with the normal tracheobronchial tree. The common classification separates these lesions into three main types. Type I CPAMs consist of cysts with large, irregular widely dispersed spaces larger than 2 cm or a single large cyst with multiple small surrounding cysts and represent 50% to 65% of postnatal cases. Type II CPAM is described as numerous smaller cysts (0.5 to 2 cm) and account for 10% to 40% of cases. Type III CPAMs are made of small cystic lesions (generally 0.2 cm) or solid lesions appearing similar to immature lung devoid of cartilage and make up of 5% to 10% of cases. CPAMs generally only affect one lobe but multilobar and bilateral involvement occurs. Most commonly, the lesions are left sided and affect the lower lobes. Several genes have been implicated in the development of CPAMs including HOXB5, Fgf7, and PDGF-B.[43]

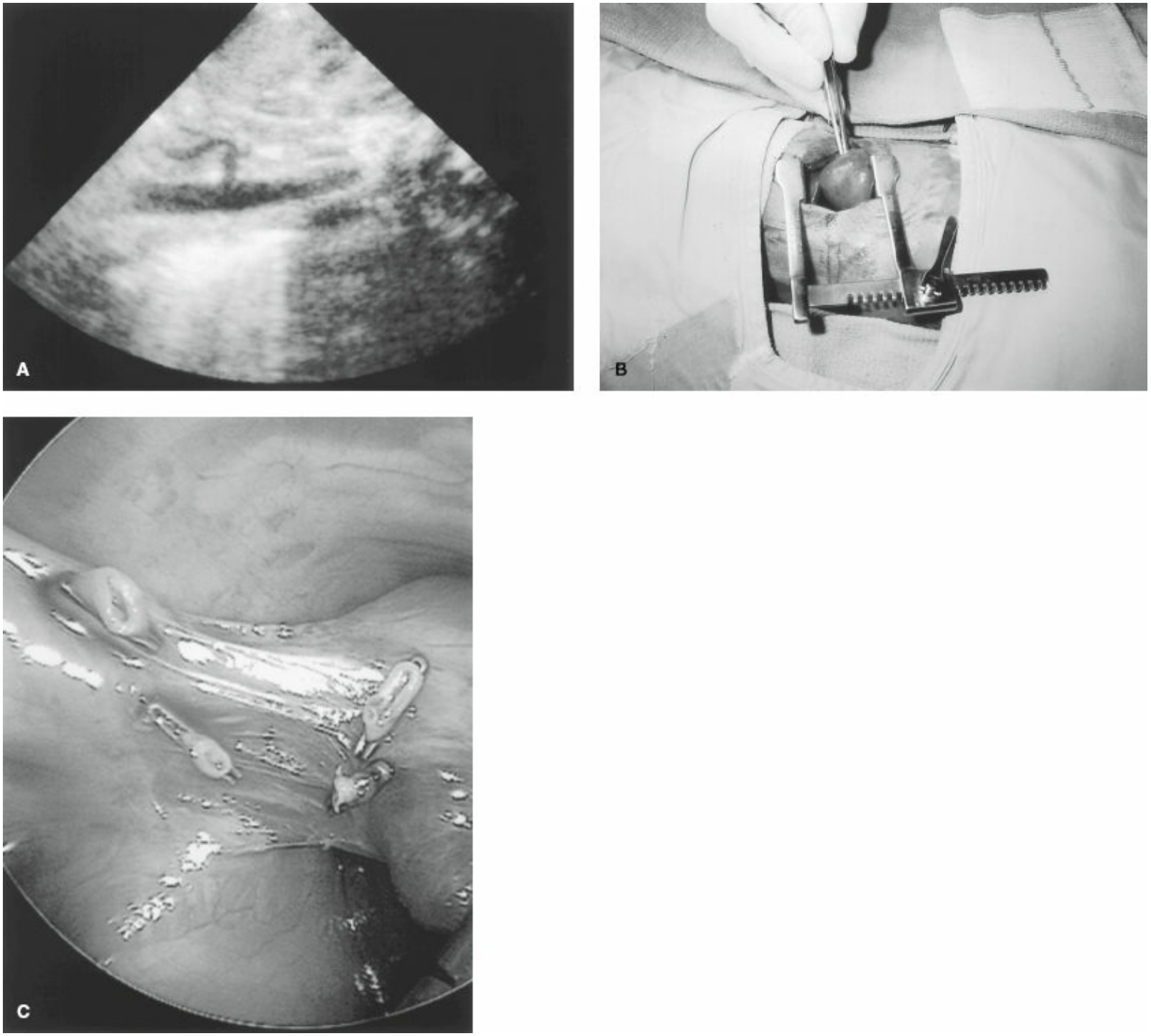

Figure 102-3. Pulmonary sequestration (PS). **A:** Sagittal ultrasound view of the aortic branch supplying an extralobar PS. **B:** Left-sided extralobar PS excised via a muscle-sparing thoracotomy. **C:** Intraoperative view of extralobar sequestration removed thoracoscopically. Note the main blood supply with clips.

Prenatal diagnosis is common occurring in 79% of cases. In fact, prenatal ultrasound has led to an increased diagnosis of lung lesions.[44] CPAMs may lead to sufficient pathophysiologic effects including life-threatening hydrops. Fetal surgery has included open resection and thoracoaminiotic shunting with survival of some of the affected fetuses.[36,42] The natural history of prenatally diagnosed CPAMs is variable and even large lesions may regress. Growth tends to plateau at 26 to 28 weeks gestation.[43,44]

The incidence is reported to be between 1:25,000 and 1:35,000 live births which likely underrepresent the incidence as historically, approximately 14% of cases are stillborn.

Although 80% are asymptomatic at birth, nearly 80% will have respiratory symptoms within the first month of life.[38] Less commonly, patients may present with pneumonia later in life (Fig. 102-4).

There is little controversy about symptomatic lesions which require resection of the involved lobe. Those with severe respiratory compromise may require resection on extracorporeal membrane oxygenation (ECMO) with excellent results. Other infants may benefit from an ex utero intrapartum treatment (EXIT) to ECMO approach when gas exchange is predicted to be compromised at delivery.[44] Treatment of asymptomatic lesions is controversial as the natural history of the lesion is unknown. There is concern for future infection and the possibility of malignancy.[37,38,45,46] Those who recommend resection favor timing between 2 and 10 months of age. With antenatal diagnosis, a CT is necessary to determine resolution of the lesion. There is evidence of inflammation in the resected lesions leading to recommendation for early resection.[47] Lesions can be resected via thoracotomy or thoracoscopy. With multilobar and bilateral disease, CT scans assist in planning lung-preserving resections. Bilateral and multilobar lesions are thought to be associated with the development of pleuropulmonary blastoma.[46]

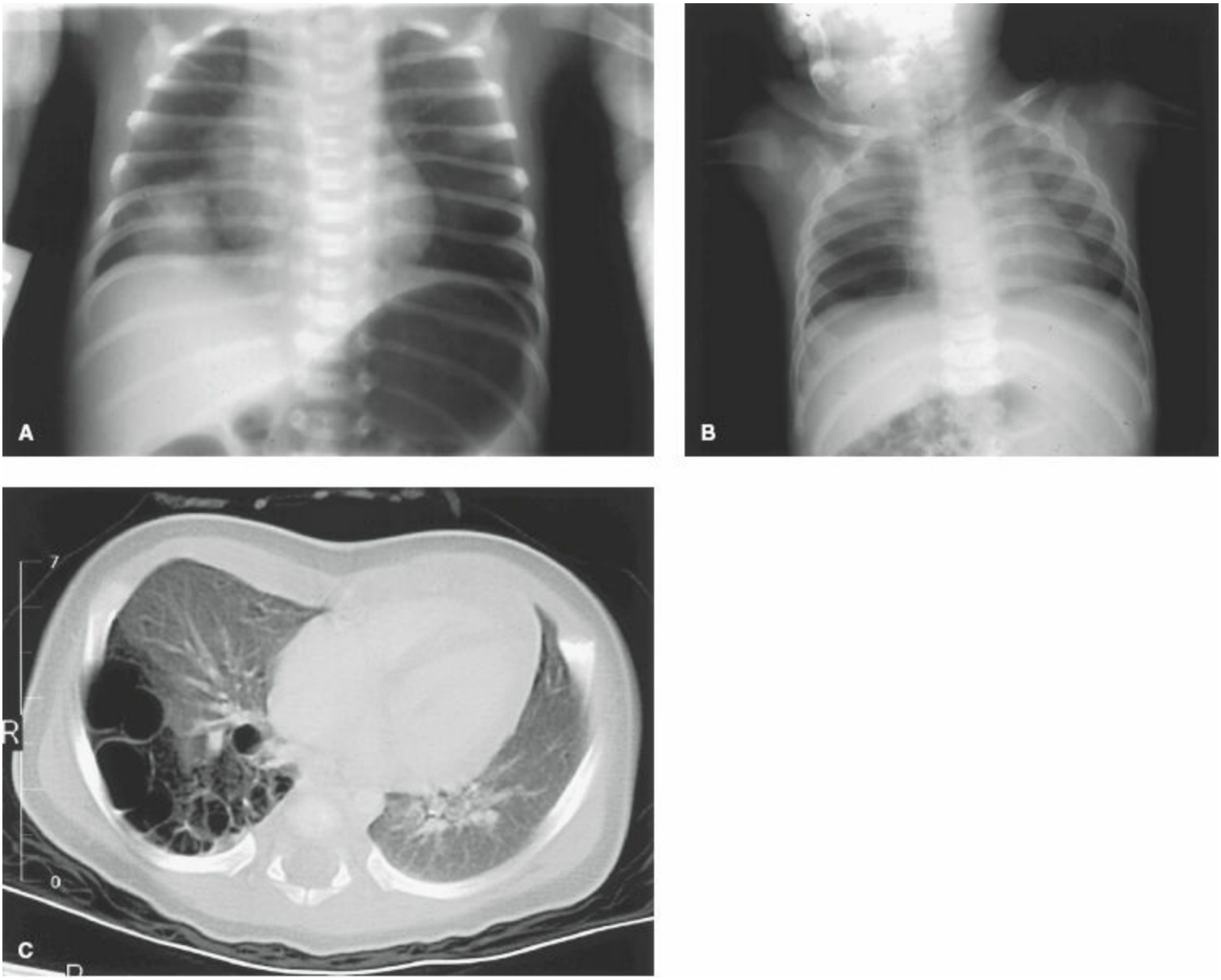

Figure 102-4. Congenital cystic adenomatoid malformation (CCAM). **A:** Newborn chest x-ray of a patient with prenatal diagnosis of CCAM. Note that immediately after birth, the mass is fluid-filled and appears as a density in the right hemithorax. **B:** Chest x-ray of the same child at 5 months of age prior to surgical excision. Note the air-filled cystic appearance of CCAM. **C:** Transverse thoracic computerized tomographic view of CCAM.

Bronchogenic Cysts

BCs are uncommon anomalies arising from defective development of the large airways. They can be mediastinal or intrapulmonary and cause symptoms of cough as well as recurrent and chronic infection. These cysts appear as discrete masses and develop from the esophageal or tracheal position of the foregut. They are usually extrapulmonary and do not communicate with the normal tracheobronchial tree. Resection via thoracotomy or thoracoscopy is recommended due to the risk of bleeding, infection, or enlargement with compression of adjacent structures (Fig. 102-5).[41,48–50]

Congenital Lobar Overinflation

CLO (previously labeled congenital lobar emphysema) is caused by abnormal development or compression of a lobar bronchus resulting in retention of fluid during fetal lung development and subsequent air trapping and overinflation after birth. The cause ranges from a deficiency of bronchial cartilage to compression from an extrinsic mass. The presentation is typically with upper lobe of either lung field and rarely multilobar. Definitive cause is rarely identified. Lobar overinflation may present as worsening respiratory distress caused by enlargement of the overinflated segment with compression of the normal surrounding lobe (Fig. 102-6). Symptomatic infants should undergo complete resection of the lobe. Care must be taken at resection as positive-pressure ventilation may worsen symptoms and require immediate thoracotomy. With relatively asymptomatic patients, symptoms will improve and allow for a nonoperative approach.[39,51]

Diagnosis

Due to the routine use of prenatal ultrasound, many cystic lesions of the lung are now detected and followed prior to birth.[37–39,44,46] Many of the patients with these lesions are asymptomatic in the perinatal period. Standard chest radiographs remain the standard for diagnosis and follow-up for lesions. Rapid thoracic CT scanning with contrast provides definitive mapping of the lesions including demonstration of aberrant vessels. Contrast esophagograms are indicated for children with dysphagia and suspicion of connection with the GI tract. In lesions with suspected aberrant arterial supply, MRI angiography can be helpful if the CT is not definitive.

Treatment

There is controversy about the management of asymptomatic lesions with proponents of resection citing the rare association with malignant pulmonary neoplasms.[37–39] Any cyst enlarging on serial radiographs should be resected due to the risk of respiratory compromise and the possibility of infection of the cyst and the surrounding tissue. The reason for long-term follow-up is the demonstration of progressive resolution.

Cysts of the Mediastinum

5 Benign cysts of the mediastinum are relatively common in the pediatric population. Most of these are relatively asymptomatic but surgery is recommended due to the possibility of enlargement with symptoms related to compression, hemorrhage, or infection. The symptoms which occur include cough, chest pain, stridor, hemoptysis, or dysphagia. The common lesions include thymic cysts, enterogenous cysts, lymphatic malformations (cystic hygromas), and pericardial cysts.

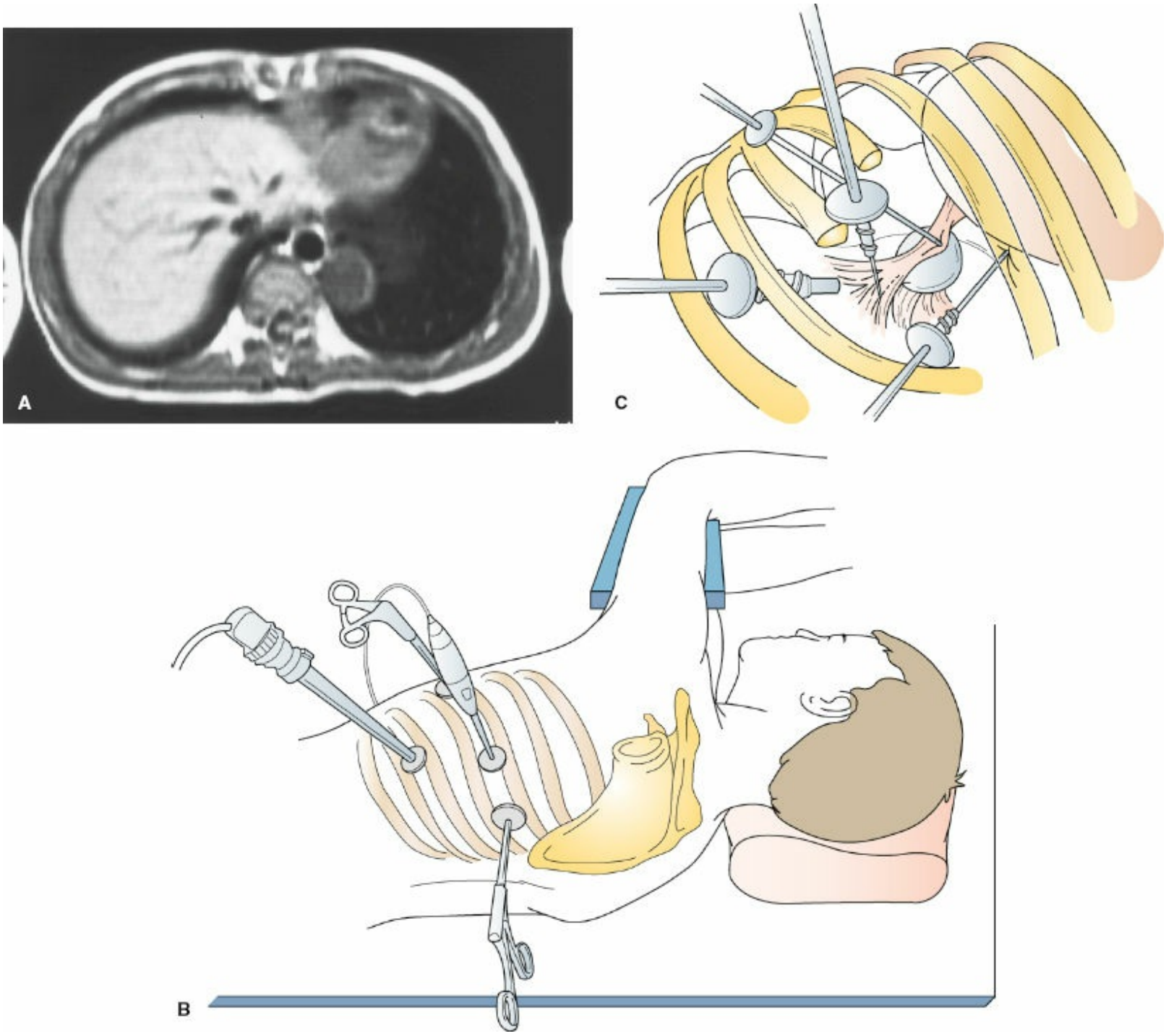

Figure 102-5. Bronchogenic cyst (BC). **A:** Transverse thoracic computerized tomographic view of a BC located in the inferior pulmonary ligament. **B:** Illustrative representation of thoracoscopic instrumentation for excision of a BC. **C:** Operative detail.

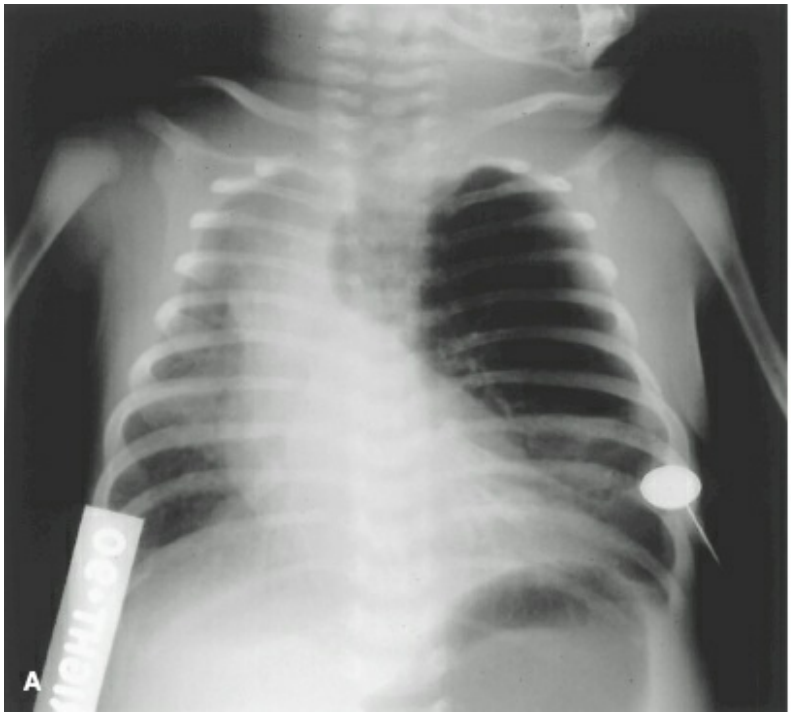

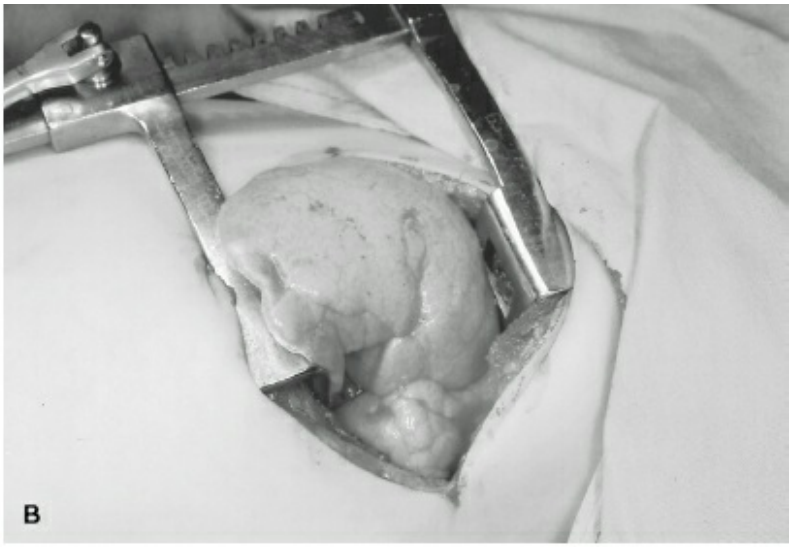

Figure 102-6. Congenital lobar overinflation. **A:** Chest radiograph demonstrating overinflation of the left upper lobe in an infant. Note the mediastinal shift. **B:** Operative photograph demonstrating an overexpanded left upper lobe decompressing through the incision.

Thymic Cysts

Thymic cysts present in the neck and mediastinum and are usually unilocular but may be multilocular. They are most commonly seen in the anterosuperior mediastinum. They are benign lesions with presence of cholesterol granulomas. Symptoms may arise from rapid expansion due to infection. Resection is recommended.[52,53]

Enteric Duplication Cysts/Enterogenous Cysts

Enteric duplication cysts are usually located in the posterior mediastinum with microscopic evidence of double-layer smooth muscle and esophageal or gastric mucosa. They are from the same spectrum as bronchopulmonary cysts. These may communicate with the stomach or esophagus and may transverse the diaphragm. The cysts may also extend into the spinal canal.[52,53] The lesions may have gastric mucosa leading to bleeding. Other symptoms may include airway compression or dysphagia (Fig. 102-7). Resection is indicated for all symptomatic lesions and is favored for asymptomatic lesions.

Lymphatic Malformations

Lymphatic malformations (cystic hygromas) are unilocular or multilocular cysts which are thin walled and derived from failure of adequate drainage of embryonic lymph sacs. These may occur in the head, neck, and mediastinum. The lesions insinuate around great vessels and nerves in the superior mediastinum. The incidence is 1 in 6,000 live births. Symptoms if present are related to enlargement (frequently due to hemorrhage) or infection. Resection while preserving vital structures is recommended although lesions have been treated with sclerotherapy. The most frequent complications are recurrence and accumulation of lymph in the resection bed.[52–54]

Pericardial Cysts

Pericardial cysts are asymptomatic and are found incidentally on chest radiograph. The cysts are found in the cardiophrenic sulcus as a discrete mass. The cysts are thin walled with a flat mesothelial lining and contain clear fluid. Resection can be performed with thoracotomy or thoracoscopy.[52,54]

THORACIC TUMORS IN CHILDREN

6 Thoracic tumors are rare in children and diagnostic evaluation must exclude evaluation for both primary and metastatic conditions. Tumors may occur in the lung or the mediastinum.[54] Primary lung neoplasms in children are extremely rare.[55,56] Metastatic lung lesions are more common in the pediatric population.[57] Mediastinal tumors reflect the nature of the section of the mediastinum in which they arise. Diagnostic evaluation begins with routine radiographs with CT scans and MRIs for further evaluation.[54]

Metastatic Lung Tumors

7 Resection of metastases in the pediatric population has been proven to be beneficial for pediatric cancers. Eradication of the primary tumor and absence of other metastases are necessary for improvement in survival.[58] Resection is considered most frequently for osteogenic sarcoma, soft tissue sarcoma, and Wilms tumor.[58,59]

Osteogenic Sarcoma

There is evidence that resection of metastases in osteogenic sarcoma improves survival if a complete resection can be performed. The factors which improve survival are ipsilateral involvement, smaller tumor size, and longer disease-free survival between diagnosis and occurrence of metastasis.[59] Metastases which are more peripheral have a better outcome compared with centrally located metastases.[60] In addition to metastectomy chemotherapy is required for elimination of micrometastatic disease. Metastases become calcified and therefore are palpable aiding with resection. There are some data that the outcomes are comparable between initial resection of metastases and resection of a second recurrence.[59] Improved survival is seen with tumor necrosis greater than 98% and disease-free interval of greater than 1 year. Mean survival after complete resection with aggressive resection is 33.6 months while mean survival without resection is 10.1 months.[61] Thoracoscopy is felt to be inappropriate for this disease process since CT scans underestimate the number of lesions which can be palpated at thoracotomy.[62] Bilateral lesions can be identified even when CT scans demonstrate only unilateral lesions leading some authors to recommend prophylactic contralateral thoracotomy. With bilateral involvement, in an appropriate population, simultaneous bilateral thoracotomy may lessen morbidity compared to the traditional staged thoracotomies.[63]

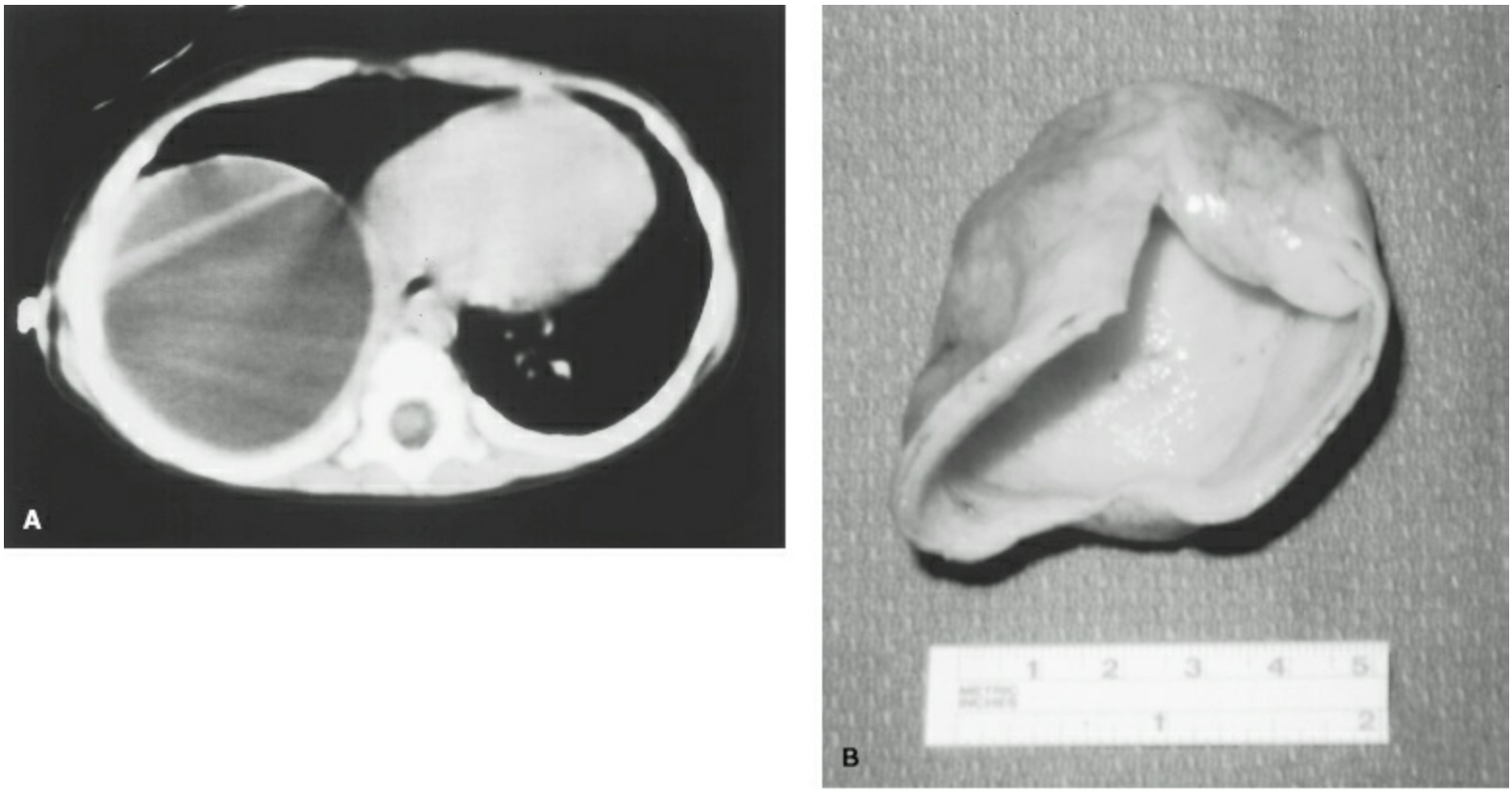

Figure 102-7. Enterogenous cyst. This represents another abnormality in the spectrum of bronchopulmonary foregut malformations. **A:** Computerized tomography demonstrating a large mass occupying the right hemithorax. **B:** Surgical specimen.

Soft Tissue Sarcomas

Nonrhabdomyosarcomas such as synovial sarcoma respond poorly to chemotherapy and radiation therapy. In these tumors, complete resection of pulmonary metastases, but not debulking improves survival.[64] Lung metastasis in rhabdomyosarcoma responded to chemotherapeutic regimens but local treatment of the metastases did not improve survival.[65] Ewing sarcoma has a high rate of pulmonary metastases which have traditionally been treated with radiation therapy. More recent data suggest that metastectomy after irradiation leads to improved survival.[66] Delayed surgery after neoadjuvant therapy with resection of the chest wall lesion leads to decreased extent of excision and a higher rate of negative margins in tumors less than 8 cm.[67]

Wilms Tumor

Pulmonary metastectomy in Wilms tumor is only indicated for persistent lesions after a 27-week regimen of chemotherapy and radiation therapy.[68] Thoracoscopy with resection of lesions is indicated for diagnostic purposes. The outcomes demonstrate that there is improved 5-year survival for patients with CT-only metastases and that lung radiation in this group does not improve survival.[69]

Primary Lung Tumors

Pediatric primary tumors are rare with comprehensive series documenting approximately 383 patients with primary malignant pulmonary neoplasm as of 1993 (Table 102-1). The majority of primary neoplasms are malignant but benign lesions also have significant morbidity due to location of the lesions. Operative exploration with total resection of all involved tissues is recommended.[56]

Bronchial Adenomas

Bronchial adenomas are the most common of the malignant lung lesions (40%) in the pediatric population and include several different histologies including carcinoid tumor, mucoepidermoid carcinoma, and adenoid cystic carcinoma. Carcinoid is the most common malignant pulmonary lesion in the pediatric population and accounts for 85% of bronchial adenomas. Mucoepidermoid carcinomas account for 10% of the adenomas and originate from mucous glands in the submucosal and respiratory mucosa. They are centrally located. Adenoid cystic carcinoma comprises 5% of the bronchial adenomas and is described as a salivary gland-type tumor. Cough, pneumonitis, fever, respiratory distress, and hemoptysis are the most common presenting symptoms. Delay in diagnosis is common due to the nonspecific symptomatology. The disease is diagnosed with chest radiograph followed by CT scan. Bronchoscopy is required for diagnosis and biopsy can be performed but there is a high risk of hemorrhage. Treatment is by surgical resection which can include lobectomy, bilobectomy, pneumonectomy, or sleeve resection with regional lymphadenectomy. Intraoperative frozen section is useful to assure complete resection and to limit lung resection. Bronchial carcinoids do not usually present with carcinoid syndrome and presentation with the syndrome is a sign of extrapulmonary disease.[56]

Table 102-1 Primary Pulmonary Neoplasms in Children

Type of Tumor	Number (%)[a]
Benign ($n = 92$)	
Inflammatory	48(52.2)
Hamartoma	22(23.9)
Neurogenic tumor	9(9.8)
Leiomyoma	6(6.5)
Mucous gland adenoma	3(3.3)
Myoblastoma	3(3.3)
Benign teratoma	1(1.1)
Malignant ($n = 291$)	
Bronchial "adenoma"	118(40.5)
Bronchogenic	49(16.8)
Pulmonary blastoma	45(15.5)
Fibrosarcoma	28(9.6)
Rhabdomyosarcoma	17(5.8)
Leiomyosarcoma	11(3.8)
Sarcoma	6(2.1)
Hemangiopericytoma	4(1.4)
Plasmacytoma	4(1.4)
Lymphoma	3(1.0)
Teratoma	3(1.0)
Mesenchymoma	2(0.7)
Myxosarcoma	1(0.3)

[a]"(%)" is percent of benign or percent of malignant tumors.
Modified from Hancock et al.[73]

Bronchogenic Carcinoma

Bronchogenic carcinoma is the second most common malignant pulmonary cancer. Bronchogenic carcinoma consists of adenocarcinoma and undifferentiated carcinomas in the pediatric population. These tumors have been associated with CPAMs but have been reported in normal lung as well.[56,70] Human papilloma virus has been associated with the squamous cell variant. Resection with ipsilateral lymphadenectomy is the treatment of choice. Prognosis for bronchogenic carcinoma is poor as the presentation tends to be with advanced stages. Symptoms are related to metastases with bone pain or tumor burden with weight loss.[56]

Pleuropulmonary Blastoma

Pleuropulmonary blastoma is the third most frequent lung tumor in children and is most common in children under 4 years of age.[56,71,72] The lesion consists of mesenchymal elements and embryonal stroma without epithelial neoplasia. The tumor is known to be part of the spectrum of tumors related to the mutation of the DICER1 gene.[71] The tumor usually presents peripherally. These tumors are associated with CPAMs. There are three types; type I consisting of multilocular cysts, type II consisting of a combination of cystic and solid components, and type III having proliferating mesenchyme without cysts.[72] Treatment is with resection and adjuvant chemotherapy. Survival in type I has been reported at 91% while type II/III have survivals of 43%.[71]


A

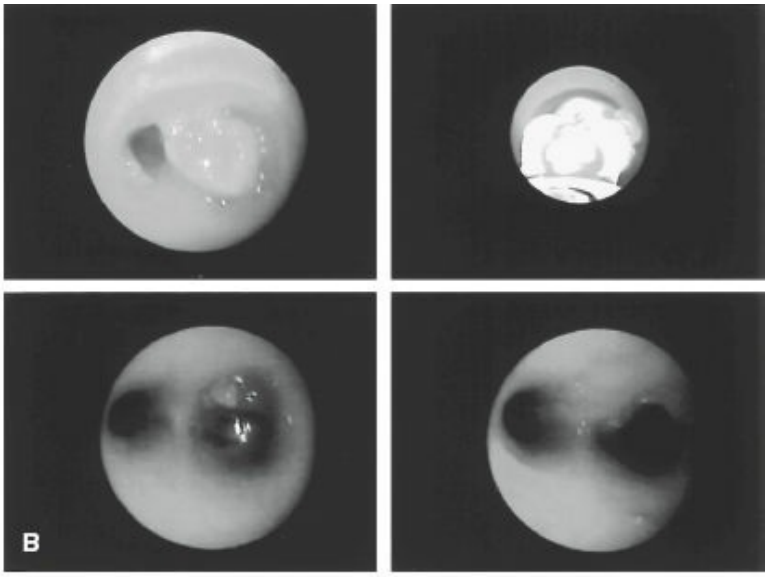
B

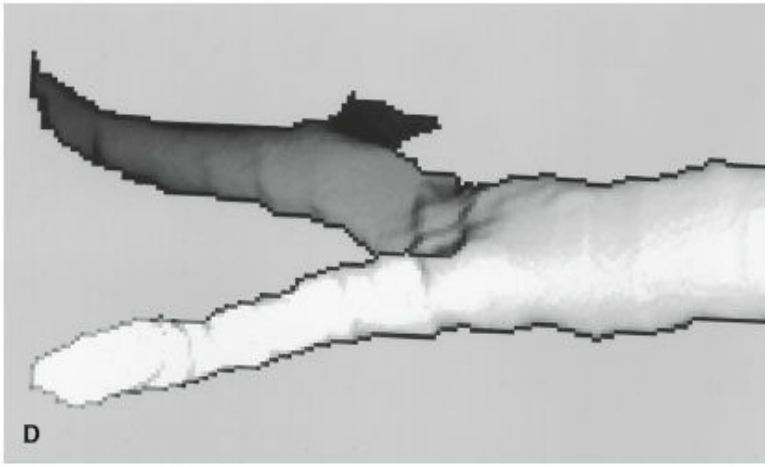
D

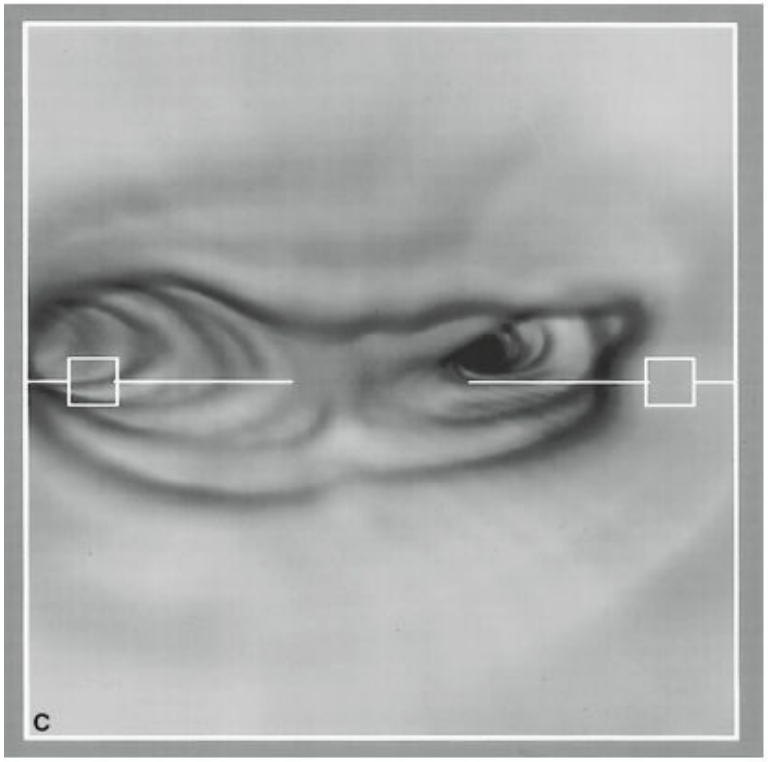
C

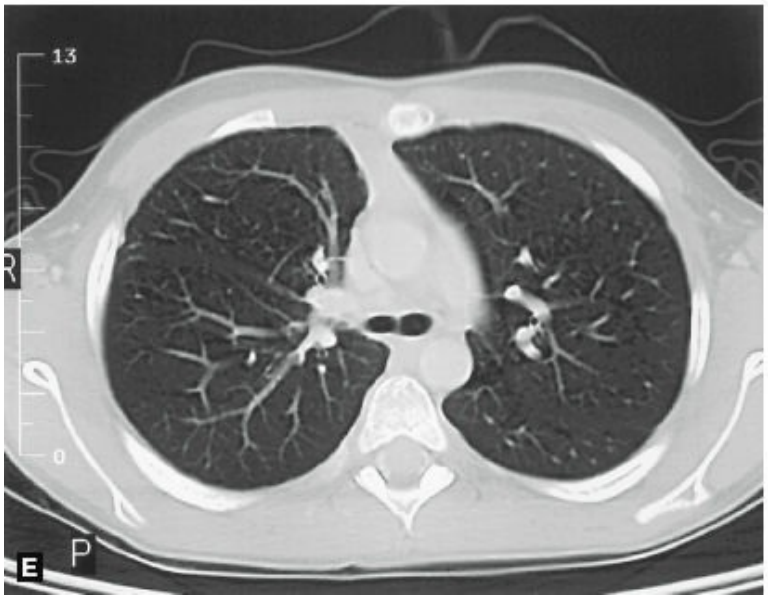
13
R
0
P
E

Figure 102-8. Lung neoplasm in an 8-year-old child: inflammatory pseudotumor. **A:** Presenting chest radiograph with right lung collapse. **B:** Biopsy of an obstructing endobronchial mass demonstrates inflammatory pseudotumor (inflammatory myofibroblastic tumor). **C:** Computerized tomographic "virtual bronchoscopy" image after initial biopsy demonstrates deformation of the right main stem bronchus and carina due to tumor infiltration. **D:** Computerized tomography reconstruction of the external appearance of airways demonstrating the deformation of the carina and right main stem bronchus. The child underwent excision of the right main stem bronchus and carina and tracheobronchial reconstruction. **E:** Postoperative transverse thoracic computerized tomography at the level of the reconstruction of the carina.

Other Malignant Tumors

Sarcomas, including fibrosarcoma, rhabdomyosarcoma, and leiomyosarcoma are the next most common primary malignant lung neoplasm in children. They may arise endobronchially or peripherally. These have been reported to arise in documented cystic disease.[73] Inflammatory pseudotumor is considered to be the most common “benign” tumor in children. The tumor is a myofibroblastic spindle cell soft tissue tumor with infiltrative plasma cells, lymphocytes, and eosinophils. Recently these have been classified as intermediary lesions with a molecular rearrangement involving the tyrosine kinase receptor anaplastic lymphoma kinase. Symptoms are nonspecific such as fever, chest pain, cough, and recurrent pneumonias.[74] These may present as an endobronchial lesion but are more often peripherally located. The lesion may invade local structures and be aggressive locally and may recur locally but spontaneous regression has been reported. Complete resection is recommended as no adjuvant regimen has gained widespread acceptance. Nonsteroidal anti-inflammatory agents have been utilized with some success (Fig. 102-8).

Hamartoma

Harmartomas are lung nodules composed of cartilage and gland-like formations in an irregular and haphazard orientation. They grow slowly and are the most common benign lesion in adults but the second most common in children.[56] Radiographically, they have a “popcorn” calcification in 10% to 25% of cases. The majority are located in the periphery of the lung. Conservative surgical resection is recommended. These may be associated with gastric smooth muscle tumors and extra-adrenal paragangliomas (Carney triad) in adolescent females; and in this age group, a workup should be performed to exclude these diagnoses.

Mediastinal Tumors

Mediastinal tumors in the pediatric population can be benign or malignant with 37% of lesions being malignant in children.[53] Tumors have a predilection for arising from the different components of the mediastinum. Neurogenic tumors are the most common mediastinal tumors in the pediatric population.[54] These tumors arise in the posterior mediastinum from the sympathetic ganglia, the intercostal nerves, and paraganglia cells.[53] These may grow very large before detection and may manifest with Horner syndrome or opsoclonus–myoclonus syndrome. The neurogenic tumors may be malignant (neuroblastoma, ganglioneuroblastoma) or benign (schwannoma, ganglioneuroma, or neurofibroma).[54,75,76] Neuroblastoma originating in the mediastinum has a better prognosis than in other sites. These tumors have more favorable biology and lower rates of N-myc amplification as well as improved rates of event-free and overall survival.[77] Diagnosis is by CT and MRI with MRI allowing improved assessment of extension into the spinal foramina.[78,79] Tumors may be resected by a thoracoscopic approach or via thoracotomy Figure 102-9.[80,81]

Neurofibromas and schwannomas arise from intercostal nerves of sympathetic nerves. The schwannomas are encapsulated without nerve fibers within the tissue. Neurofibromas are unencapsulated, have nerve fibers running through the mass and are common in patients with neurofibromatosis.[82] Isolated tumors may be removed but tumors associated with neurofibromatosis tend to extend over nerve sheaths precluding complete removal. These are associated with malignant degeneration.

Lymphomas arise in the anterior and middle mediastinum and are the most common anterior mediastinal mass in children.[79] These are usually inhomogeneous and resection is not required. Both Hodgkin and non–Hodgkin lymphoma arise in the mediastinum. Diagnostic workup involves biopsy for tissue diagnosis as the diagnosis often requires tissue subtyping.[54] Due to risk of airway compromise, the most accessible tissue, such as supraclavicular lymph nodes, should be biopsied and special care is required for biopsy of the mediastinum including partial upright positioning, spontaneous ventilation, availability of rigid bronchoscope, and avoidance of muscle relaxants. Risk of airway compromise is increased in patients with greater than 50% reduction in tracheal cross-sectional area, or those with dyspnea and orthopnea. Treatment is with chemotherapy.

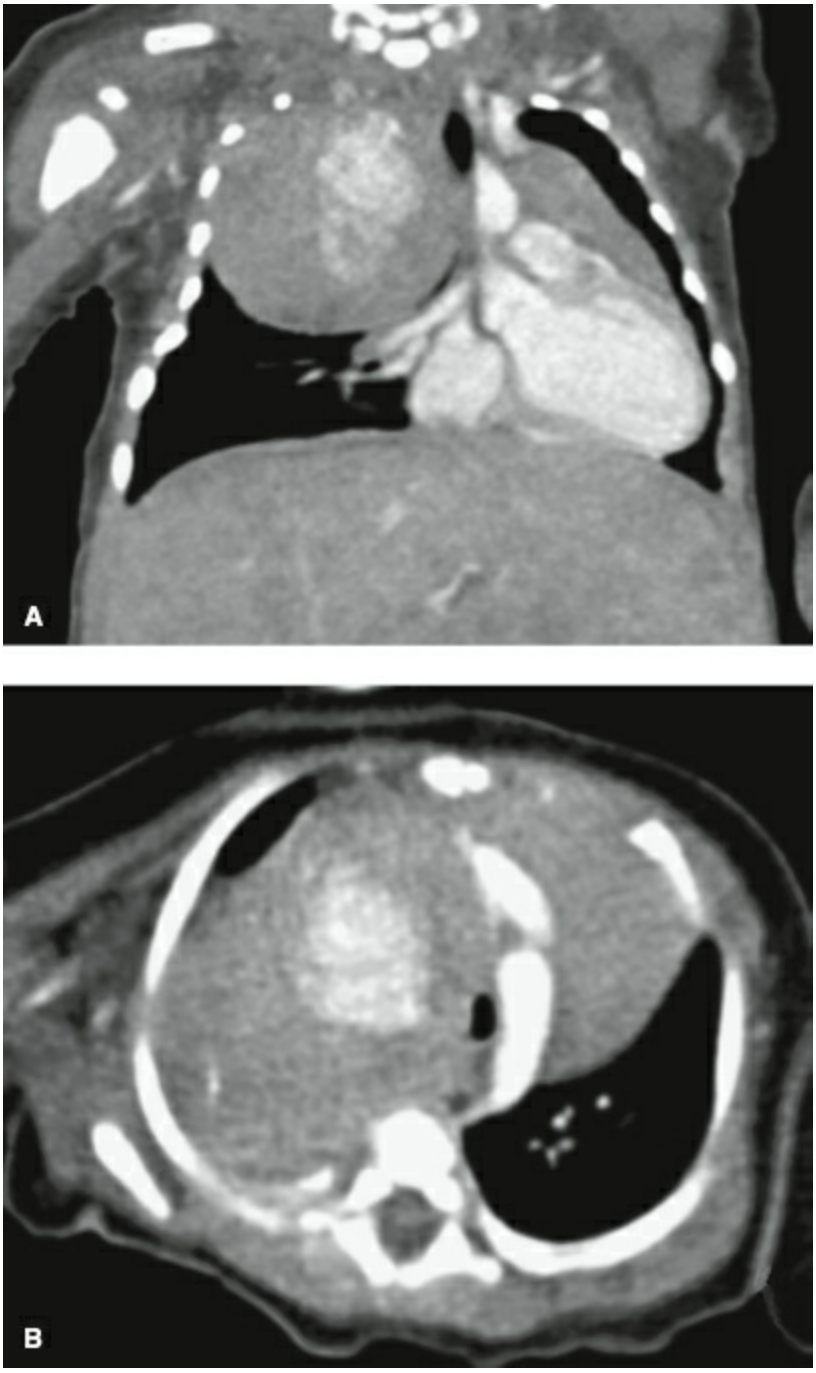

Figure 102-9. **A:** Large neural tumor in coronal view CT scan with calcifications (neuroblastoma). **B:** Same mass on transverse view.

Teratomas are the most common mediastinal germ cell tumor and are composed of all three germinal cell layers.[53,79] These lesions are benign, usually cystic and encapsulated. They frequently contain calcification on radiography (Fig. 102-10). Most are asymptomatic but may present with respiratory distress. Presenting symptoms can include stridor, tachypnea, and severe respiratory distress especially when lying supine.[82] The cysts frequently contain mature ectodermal elements such as hair, skin, and neuroglial elements and may contain bone, teeth, and fat. The tumors may be large and tend to displace rather than invade surrounding tissue.[79] Workup includes preoperative measurement of α-fetoprotein and β-HCG. Resection is the treatment of choice and confirms the diagnosis. Treatment of mature teratomas is resection. Immature teratomas which contain malignant elements are treated with chemotherapy and radiation in

addition to surgery.

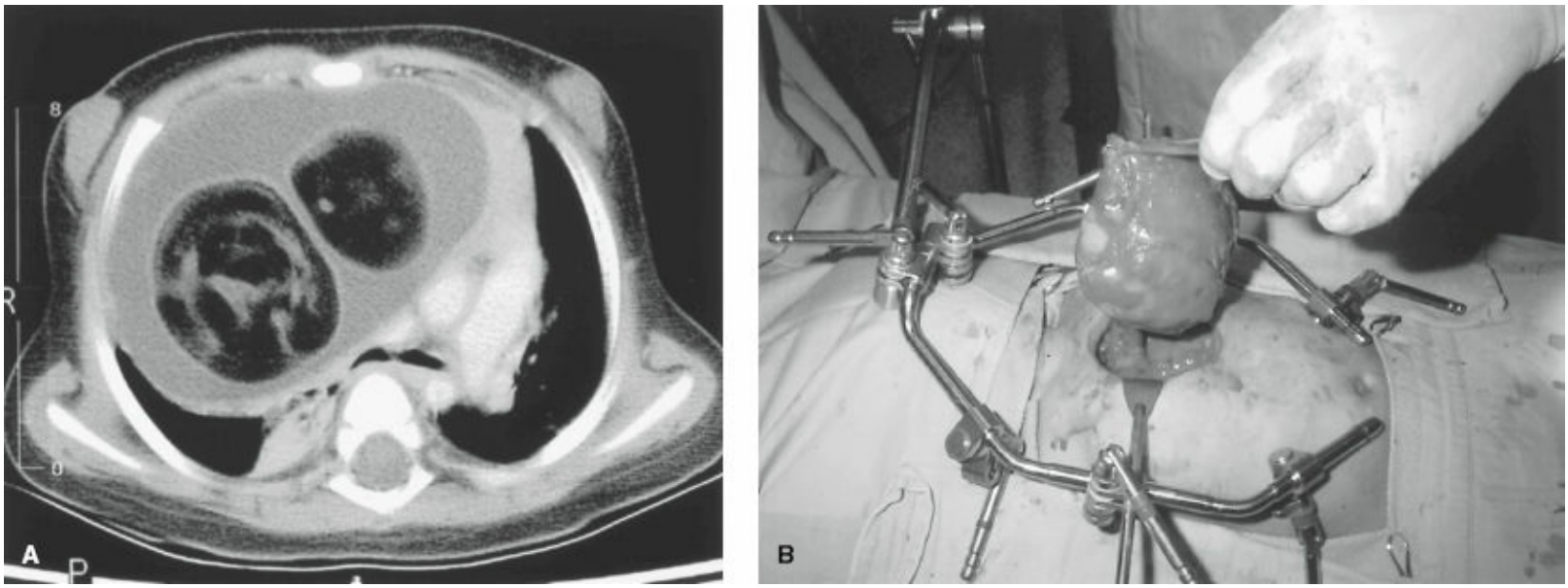

Figure 102-10. Mediastinal teratoma. **A:** Transverse thoracic computerized tomography of a large anterior mediastinal teratoma presenting with airway compression symptoms in a 9-month-old female. **B:** Tumor removal via a median sternotomy.

Other mediastinal tumors are very rare but often require surgical biopsy or extirpation. These include neurolemmoma, pheochromocytoma germ cell tumors, rhabdomyosarcomas, and thymic tumors.

Chest Wall Tumors

Ewing sarcoma, chondrosarcoma, and liposarcoma are malignant tumors which may arise from the chest wall. Local resection may require extensive chest wall excision and prosthetic reconstruction.[83] Primitive neurectodermal tumors are malignant small cell tumors carrying a poor prognosis. Improvement in survival is accomplished with multimodal therapy which includes chemotherapy, radiation, and surgery with aggressive management of pulmonary metastases.[66,67,83]

Respiratory Papillomatosis

Recurrent respiratory papillomatosis is caused by neoplastic proliferation associated with acquisition of papillomavirus during delivery. It is usually confined to the larynx and upper tracheal airway with spread in less than 1% of cases. Treatment is with laser ablation and may require multiple treatments. Prognosis is poor due to the recurrence of the disease.[78]

ESOPHAGEAL ATRESIA/TRACHEOESOPHAGEAL FISTULA

8 The first description of the classic proximal esophageal atresia with distal fistula was by Thomas Gibson in 1697. The first description of esophageal atresia was by Durston in 1670 who found a blind esophageal pouch in one pair of thoracopagus conjoined twins.[84] Initial attempts at repair or palliation were unsuccessful. Leven and Ladd reported survivors but only after staged reconstruction. The first successful primary repair was reported by Dr. Cameron Haight in 1941.[85,86] Outcomes have improved related to refinements in surgical technique and postoperative care.[84,87–91] In the modern era, survival is related to the degree of prematurity and the presence of cardiac disease.

Embryology

The development of the human respiratory system begins as a folding of the flat endodermal layer into the primitive gut tube. The respiratory system is derived from the foregut endoderm with the appearance of the laryngo–tracheal groove in the ventral floor just caudal to the level of the pharynx. Despite intense study, the precise events in morphogenesis are not well understood. There are two theories, one of which suggests that the respiratory system develops as a rapid outgrowth from the original foregut tube. This theory is consistent with the accepted pattern of rapid longitudinal growth at the distal ends of the bronchopulmonary structures. Other theories support the fusion of the lateral foregut walls resulting in the separation of the trachea from the esophagus.[92,93] The third theory based on studies of chick embryos supports the development of three folds, anterocranial (laryngeal), dorsal (pharyngoesophageal), and inferior (tracheoesophageal). The paired laryngeal and single tracheoesophageal folds appear first defining the tracheoesophageal space. Subsequently continued movement of the folds results in the definition of the separate trachea and esophagus. At the same time the pharyngoesophageal fold defines the boundary of the pharynx and esophagus.

One theory of the development of tracheoesophageal fistula is caused by failure of tracheal growth. A second theory is that there is failure of the active separation process. Another theory is the abnormal movement of the pharyngoesophageal fold leading to failure of division. Sonic hedgehog has been implicated in the development of esophageal atresia/tracheoesophageal fistula based on adriamycin-induced malfor-mations in rats.

Classification

Descriptive terminology is used to indicate the anatomic configuration of a patient with esophageal atresia. The most common type of lesion is a proximal atresia with a distal tracheoesophageal fistula which accounts for 76% to 85% of all cases in recent series.[87,88,90,91,94] Esophageal atresia without fistula occurs in approximately 3% to 17% and TEF without fistula in 4% to 6% of cases. Proximal fistula and both proximal and distal fistula occur in approximately 1% of cases each. Initially alphabetic classification schemes were devised and the most common variety of esophageal atresia/tracheoesophageal fistula is still commonly referred to as “Gross type C” (Fig. 102-11).

Incidence and Epidemiology

Esophageal atresia is relatively common occurring in 1:2,500 to 1:4,500 live births. There is a slight preponderance of males.[84,91,94] Chromosomal anomalies, congenital heart disease, and other anomalies are more common than expected.

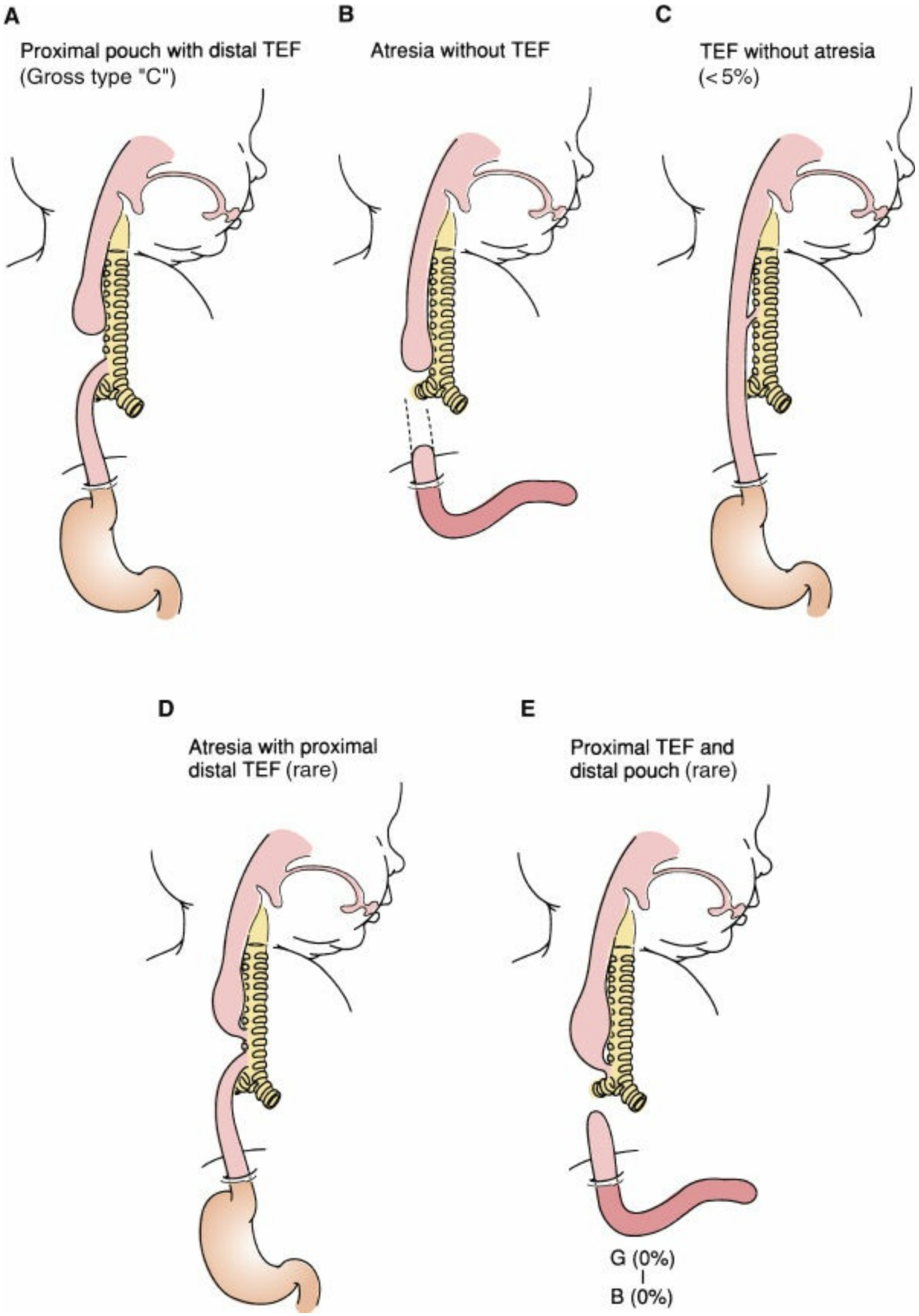

Figure 102-11. The anatomy of the variants of esophageal atresia and tracheoesophageal fistula (TEF). **A:** Proximal pouch with distal TEF (most common type occurring in 85% of patients; Gross type "C"). **B:** Esophageal atresia without TEF (5%). **C:** TEF without esophageal atresia (< 5%). **D:** Esophageal atresia with proximal and distal TEF (rare). **E:** Proximal TEF and distal pouch (rare).

Clinical Findings, Diagnosis, and Pathophysiology

Diagnosis of esophageal atresia is suspected with a history of choking with feeding and is confirmed by the inability to pass an NG tube into the stomach. Excessive drooling may be noted. Maternal polyhydramnios should raise suspicion for the diagnosis. If not diagnosed early, respiratory distress and aspiration may occur. Confirmation of the diagnosis is with radiograph identifying a tube in a proximal pouch in most cases. Occasionally injection of air to outline the pouch will be necessary for confirmation. Presence of a scaphoid abdomen with no intragastric on radiograph taken several hours after birth confirms the diagnosis of pure esophageal atresia.[96] Reflux of gastric contents through the fistula can enter the lungs which becomes more problematic in the face of respiratory compromise and is less of an issue with spontaneous ventilation. In cases of severe respiratory distress, gastrostomy or gastrostomy plus division of fistula become an emergency procedure.

Associated Anomalies

Associated anomalies are present in approximately one-half of the neonates with esophageal atresia. The most common associated anomalies are cardiovascular defects which occur in 17% to 50% of infants. Genitourinary, other gastrointestinal, skeletal neurologic, and craniofacial defects are also found. The occurrence of vertebral anomalies, anorectal malformations, cardiac, tracheoesophageal renal, and limb (usually radial) anomalies is known as the VACTERL association. Two or more of the defects must occur to be denoted as VACTERL and this occurs in 10% to 21% of cases.

Preoperative Management

Attempts at feeding are discontinued and sump tube is placed in the upper esophageal pouch. Precautions such as head-up position are advocated to decrease reflux via the fistula into the lung. Intubation is avoided as it increases the risk of reflux into the lungs via the fistula. Ventilatory support is more likely to be needed for low birth weight or prematurity. Preoperative antibiotics are given in the majority of patients.[97] Emergent bedside gastric decompression may be necessary before definitive surgery. If gastrostomy decompression does not improve ventilation, emergency operative ligation or placing an occluding distal esophageal balloon may allow for ventilation.[98]

In addition to chest radiograph, echocardiograpy is performed to determine the side of the aortic arch as well as to evaluate for major cardiac anomalies. In patients with a right-sided arch, the operative approach is modified.[99] Radiographs of the spine are also commonly performed.

In an attempt to stratify infants into groups to determine outcomes, Waterston developed criteria based on birthweight, pneumonia, and associated anomalies. With improvements in neonatal critical care, the criteria have been revised to with the current Spitz classification which uses a 1,500 g weight as the cutoff, with or without major cardiac disease. Currently survival for greater than 1,500 g infants without cardiac disease is approximately 97%, survival for either cardiac disease or less than 1,500 g approaches 82% and for both birth weight less than 1,500 g and cardiac anomaly survival is approximately 50%.[90]

Surgical Technique

In most patients, gastrostomy is unnecessary and the technique is a posterolateral right extrapleural thoracotomy (Fig. 102-12). There is no need to divide the serratus or the latissimus muscles. A more posterior approach through the auscultatory triangle affords excellent exposure. The extrapleural plane is established at the fourth intercostal space and developed sufficiently to allow control of the fistula and mobilization of the proximal pouch. Initially, the fistula is divided and ligated followed by mobilization of the proximal pouch. Anastomosis is performed in a single layer with an absorbable suture, more recently using a monofilament. If needed there are various techniques for elongation and the esophagus may be mobilized both proximally and distally. Myotomies on the upper pouch, either circular or spiral and flap tubularization have been described. A transesophageal tube is often passed during the case and can be utilized for feeding prior to performance of a postoperative esophagogram.[100]

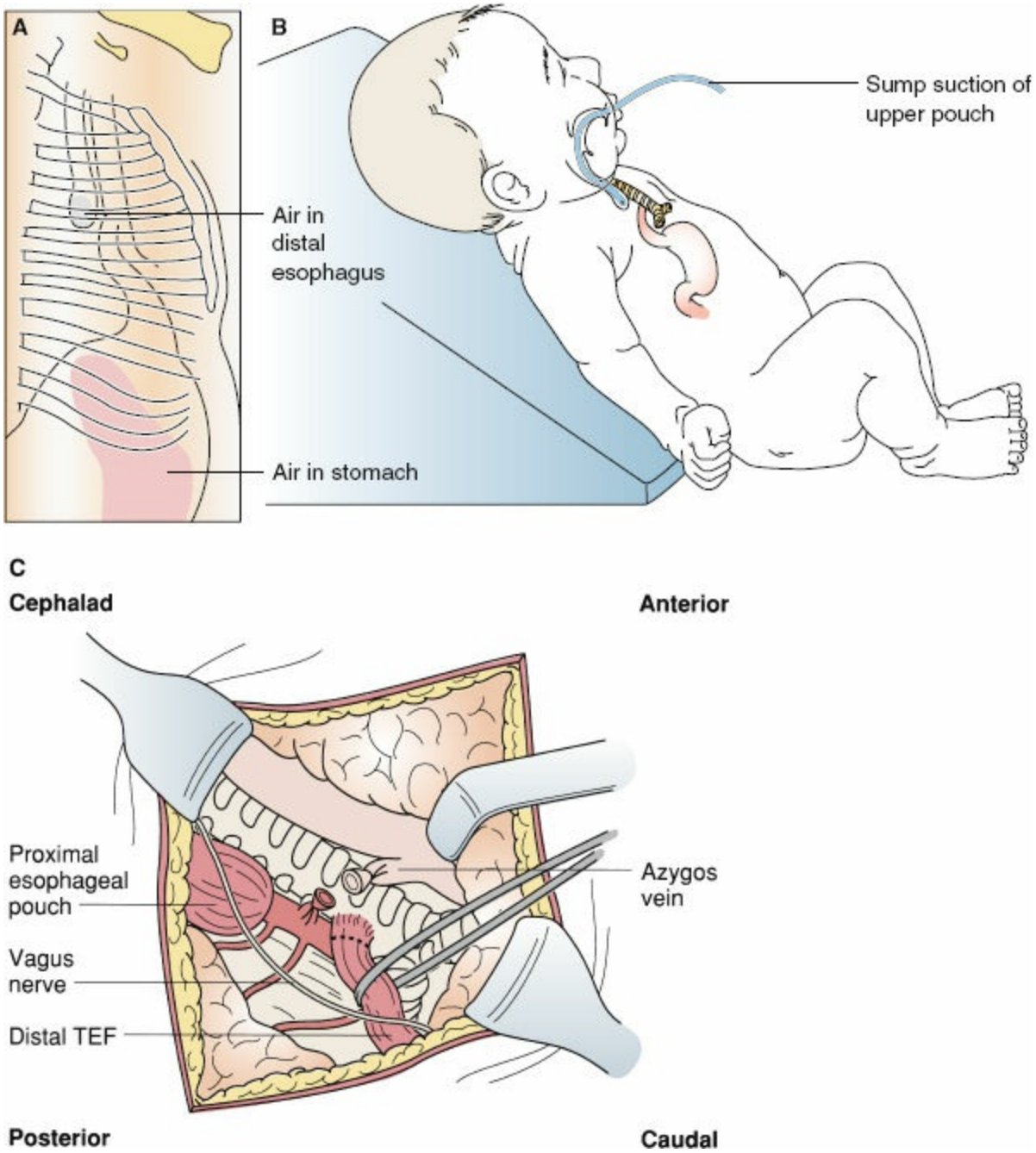

Figure 102-12. **A:** Schematic illustration of esophageal atresia with distal tracheoesophageal fistula. **B:** The initial management of this anomaly includes upright or prone posture, sump suction of the blind esophageal pouch. **C:** The right extrapleural operative approach. After division and closure of the fistula, primary esophagoesophagostomy is performed.

High-risk infants who cannot safely undergo surgical correction of their esophageal abnormality may be treated with delayed repair. A decompressive gastrostomy, proximal pouch suctioning, and parenteral nutrition are used until the infant is ready for operation. Severe respiratory failure (usually from prematurity) and structural heart disease are the most common reasons to delay esophageal surgery. A staged repair that employs gastrostomy, surgical division of the tracheoesophageal fistula, followed by esophageal anastomosis as a second thoracic operation is rarely used except as a lifesaving approach.

In the case of pure esophageal atresia without fistula, a prolonged period before definitive repair may be used to improve the likelihood of completing a primary repair. A feeding gastrostomy is the initial operative management and may be technically

challenging due to microgastria. Using bouginage the ends of the esophagus are elongated and once the ends are close, a thoracotomy is performed to repair the esophagus (Fig. 102-13). Other methods of elongation have been described with staged repair using traction sutures in the upper and lower esophagus (Fig. 102-14). Daily tensioning results in lengthening of the esophagus over a few weeks.[95] Alternatively, extrathoracic elongation may be utilized.[101,102]

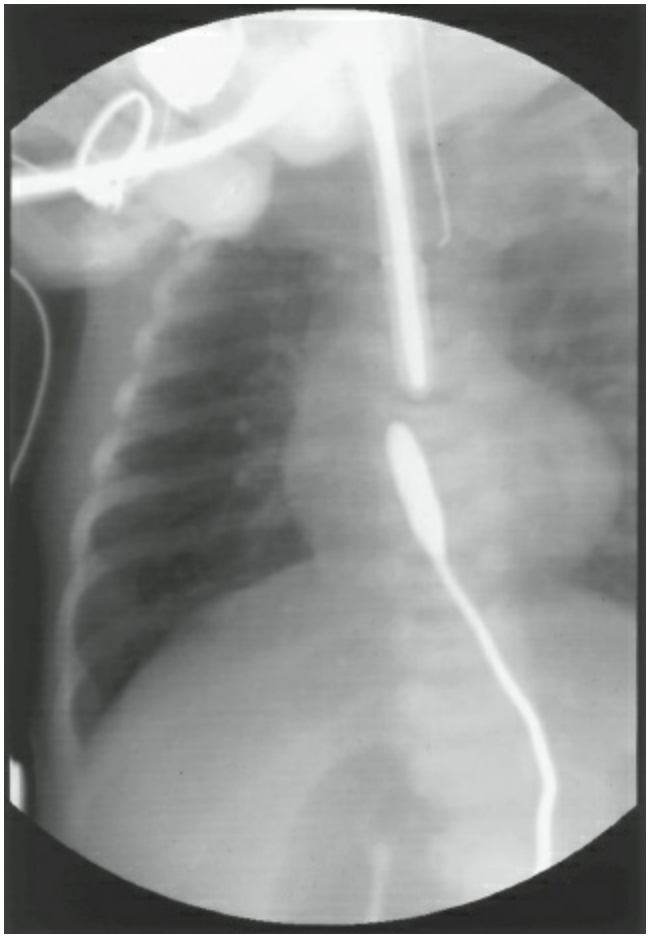

Figure 102-13. Patient with pure esophageal atresia treated initially with feeding gastrostomy, and proximal pouch stretching. This "gap-o-gram" demonstrates close approximation of a dilator in the proximal pouch and a probe placed in the distal esophagus via the gastrostomy. The child subsequently underwent primary repair of the esophagus.

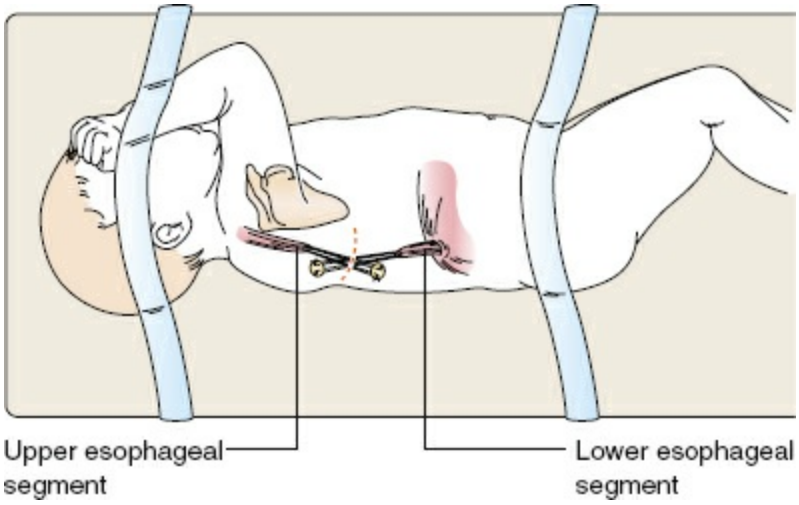

Figure 102-14. In patients with ultra-long-gap esophageal atresia, traction sutures are placed on the upper pouch and lower segment. Tension is increased daily until the segments lengthen, allowing primary repair.

Esophageal replacement is reserved for the worst cases of long-gap atresia, pure atresia or failed initial operations. The esophagus may be replaced later using stomach, gastric tube, or colon. These cases may be temporized with spit fistula and sham feeds.

Tracheoesophageal fistula with esophageal atresia is referred to as H-type fistula. The orientation is such that the opening into the trachea is always proximal to the esophageal entry site. Repair is performed via a cervical approach after bronchoscopically stenting the fistula with a small catheter. The catheter aids in dissection and care must be taken to stay in the plane of the esophagus.

Thoracoscopic approaches to the repair of esophageal atresia have been described with results demonstrating equivalent outcomes to open repair.[103,104] Thoracoscopic techniques for esophageal lengthening in long-gap atresia have also been described.[105]

Results, Complications, and Outcomes

Technical mishaps may occur during the procedure when anatomy is misidentified or dissection is carried out improperly. Injury to the vagus nerves, recurrent laryngeal nerves, posterior trachea, and adjacent vessels must be avoided.

Anastomotic leak occurs in approximately 10% to 20% of cases and most may be treated nonoperatively. The presence of a leak prolongs hospitalization.[106] When detected, the retropleural tube is left in place, the infant is not fed, and antibiotics are administered. Repeat contrast radiographs are employed to document healing prior to initiation of oral feeds.

Esophageal stricture is seen in up to 40% of infants after repair. These usually respond to a few sessions of dilation performed in the operating room with endoscopic and fluoroscopic assistance as necessary to assure the safe traverse of dilators or placement of balloon dilators.[107] More recalcitrant strictures require more frequent dilation sessions, medical and/or surgical control of gastroesophageal reflux, and occasionally reoperation with stricture resection and reanastomosis.

Recurrent tracheoesophageal stricture is reported in up to 10% of patients. These may respond to endoscopic ablation, a construct placed into the fistula or may require operative division placing tissue between the esophagus and trachea to separate the suture lines.[108]

Gastroesophageal reflux is present in nearly all patients with esophageal atresia but is asymptomatic in many. When symptomatic, it may lead to respiratory symptoms and stricture formation. Medical management with thickened feeds, acid reduction, and prokinetics is the first line of therapy. Refractory reflux may require surgical control of reflux.

Esophageal dysmotility is present in the majority or patients and may be responsible for dysphagia and recurrent respiratory problems.

Tracheomalacia occurs in approximately 10% of patients and may be diagnosed after the repair of esophageal atresia. On bronchoscopy, the trachea appears oval in shape rather than round and the anterior and posterior walls coapt during the respiratory cycle. The trachea appears to fish-mouth in the anteroposterior dimensions during spontaneous expiration. Patients may develop tracheomalacia “fits” when agitated and the condition may deteriorate with complete inspiratory block and unconsciousness. Intubation and resuscitation may be required. The symptoms are completely relieved by intubation. Patients with less severe symptoms may improve over time as the trachea grows. Severe symptoms require either tracheostomy or a tracheal suspension with an aortopexy under bronchoscopic guidance. It may be difficult to determine whether the symptoms are from gastroesophageal reflux or tracheomalacia and sometimes both an antireflux procedure and a tracheomalacia procedure may be required.[109]

Long-term results have improved and most children can look forward to normal existence. Although growth may be slow in the first 5 years of life, by 20 years of age less than one-third of the children have heights or weights below the 25th percentile.[110] Mortality remains high for infants with severe congenital heart defects and chromosomal

anomalies. Late deaths may occur related to respiratory disease (tracheomalacia, reactive airway disease, gastroesophageal reflux, and aspiration). Adult survivors of esophageal atresia repair have a normal quality of life with the exception of morbidity from esophageal, functional, and respiratory disorders.[111] The very long-term effects are unknown but Barrett esophagus and esophagitis have been reported[112] but the incidence is low and further studies are required to determine the need for long-term surveillance.

OTHER CONGENITAL ANOMALIES OF THE TRACHEA AND ESOPHAGUS

Laryngotracheoesophageal Cleft

Laryngotracheoesophageal clefts are rare anomalies resulting from the failure of normal separation of the esophagus and trachea. These are the most severe anomalies and the presence of the common aerodigestive channel plus the association of gastroesophageal reflux leads to aspiration with respiratory damage and a high mortality rate. The lesions are classified by the length of the common channel. Type I clefts involve the supraglottic larynx. Type II defects extend beyond the carina to the cervical trachea. Type III clefts involve the entire trachea and type IV defects extend onto one or both bronchi. Type III and IV clefts are frequently associated with other anomalies such as esophageal atresia, microgastria, and congenital heart disease.

Type I clefts may be repaired via an endoscopic or translaryngeal approach and do not require tracheostomy. Type II clefts require cervical exposure either laterally or via the anterior wall of the larynx and trachea. The anterior approach provides good exposure and decreases the risk of damage to neurovascular structures. The approach to type III and IV defects is via a right thoracotomy and a right neck incision. However reports of midline exposure have been described. The common channel is divided and repaired with interrupted sutures with tracheostomy.[113] Oromotor function and chronic aspiration are problems and most children require gastrostomy and many require operative control of gastroesophageal reflux.

Congenital Esophageal Stenosis

Congenital esophageal stenosis is a rare condition. The stenosis is frequently within 2 cm of the gastroesophageal junction. The true incidence is unknown but is report to be 1:25,000 to 1:50,000 live births. The narrowing of the lumen is present at birth but may not present with clinical symptoms immediately. There are three histologic subtypes: ectopic tracheobronchial remnants, segmental fibromuscular hypertrophy, and a membranous diaphragm or stenosis. These have been associated with esophageal atresia. Symptoms may only occur when solids are started. Diagnosis is by esophagograms. CT scans may confirm the diagnosis. Esophagoscopy confirms the diagnosis. Initial management is esophageal dilation. If the stenosis is due to respiratory tract remnants, need for surgery is more common. Surgery consists of resection of the stenotic segment with end-to-end anastomosis.[114]

Esophageal Duplication

Esophageal duplications are found in the posterior mediastinum and are covered by a muscular wall. Most of these are attached to the wall of the esophagus and are covered by smooth muscle. Approximately 10% communicate with the lumen of the esophagus. Neurenteric cysts communicate with the spinal canal. Although many are asymptomatic, they may present with airway or esophageal compression. In older children and adults, the presentation may be dysphagia, retrosternal pain, and epigastric discomfort. There are reports of bleeding from acid dyspepsia. Excision is recommended which may be accomplished by thoracotomy or thoracoscopy (Fig. 102-15).[53,54]

Vascular Rings

Vascular rings are a set of congenital defects in which the trachea or esophagus are encircled and compressed by vascular structures. These account for approximately 1% of all congenital cardiovascular anomalies. These rings may lead to tracheal narrowing with associated tracheomalacia. Symptoms may include stridor, respiratory distress, or dysphagia. Barium swallow may be suggestive of the lesion. CT scan and MRI are utilized to demonstrate the anomaly. Echocardiography is performed to rule out structural cardiac anomalies. Bronchoscopy may also be useful to determine the degree of tracheal narrowing. The most common type of abnormality is the double aortic arch resulting from persistence of both the right and left embryologic aortic arches. The ascending aorta bifurcates, surrounding the trachea and esophagus. Other causes of complete or incomplete rings include pulmonary artery sling and aberrant right subclavian artery. When the vascular ring is symptomatic, the patient should be treated by the appropriate division of the ring and lysis of the fibrous bands surrounding the trachea and esophagus.[115]

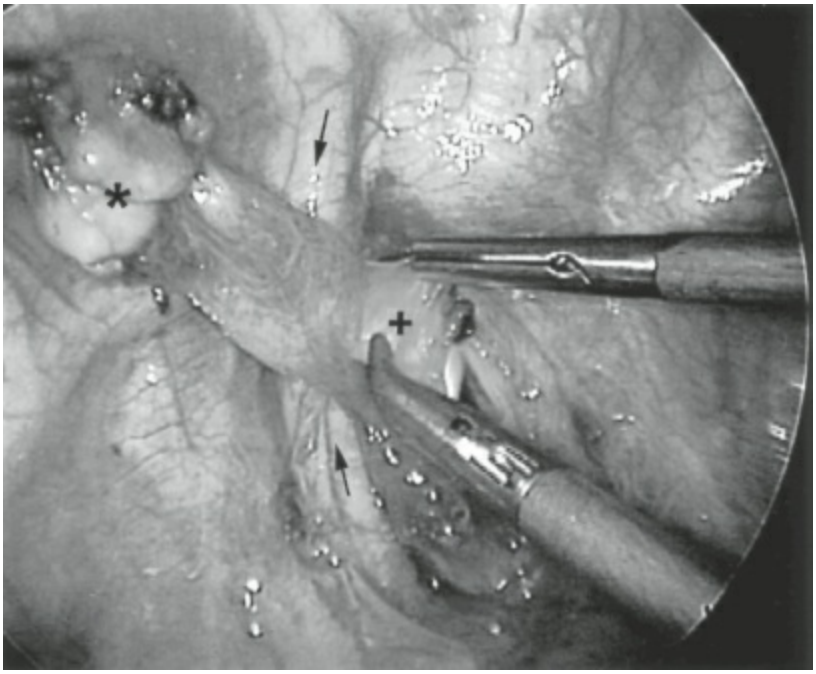

Figure 102-15. Thoracoscopic excision of an esophageal duplication cyst in a patient presenting with dysphagia. Video endoscopic view of the left superior hemithorax. (+) indicates site of original esophageal duplication cyst. Light from the intraesophageal endoscope can be seen. *Arrows* demonstrate the subclavian artery. The mass (*) is nearly excised.

Congenital Tracheal Stenosis

Congenital tracheal stenosis represents a spectrum of obstructive lesions most commonly treated with operative repair. The etiologies include complete tracheal rings, compression from anomalous cardiovascular anatomy, and tracheomalacia. Short stenosis may respond to resection and anastomosis. Longer lengths of stenosis can be managed by patch tracheoplasty and slide tracheoplasty. Use of cardiopulmonary bypass during repair may improve outcomes. In a review article outcomes were similar with the use of slide tracheoplasty and patch tracheoplasty.[116,117]

FOREIGN BODIES OF THE TRACHEOBRONCHIAL TREE

9 Foreign-body aspiration occurs commonly in infants and young children and is a potentially life-threatening event. A report in 2001 found that nonfood choking was a cause of death for 449 persons under the age of 14 with 65% of the deaths in children under 3 over a 20-year period. Choking on food causes death of approximately 75 children per year. Management is with the Hopkins rod lens system with fiberoptic illumination utilized with rigid pediatric bronchoscopes and specialized grasping devices allows for safe and reliable extraction of foreign bodies.[118–120]

Pathophysiology

Complete airway obstruction can occur at the level of the pharynx, hypopharynx, or trachea. Back blows, abdominal thrust, or the Heimlich maneuver may dislodge the obstruction and save a life. An inhaled foreign body which reaches the bronchial level may cause a ball-valve phenomenon allowing bi-directional but unequal flow of air. Air trapping and hyperinflation of the affected lobe lead to mediastinal shift. Complete blockage results in loss of volume due to atelectasis.

Foods are the most common aspirated items and include peanuts, carrots, popcorn, hotdogs, and grapes. Coins and toys are the most common nonfood items aspirated.

Clinical Presentation

Most affected children are less than 3 years of age. History of choking crisis is present in the majority of children. Other symptoms include cough, wheezing, dyspnea, and fever. The most common signs are unilateral decreased breath sounds, untilateral wheezing, and rhonchi.

Management

Chest radiographs, including bilateral lateral decubitus films are performed unless the patient is in respiratory distress. The films may demonstrate hyperinflation or failure to develop atelectasis on the affected side. In addition, the films may show pneumonia or atelectasis with a completely occluding foreign body.

Bronchoscopic evaluation and foreign-body removal is performed in the operating room under general anesthesia. The rigid bronchoscope with optical forceps can be used to retrieve most aspirated foreign bodies (Fig. 102-16). Flexible graspers, Fogarty balloon catheters, and baskets can be useful especially if the foreign body has migrated distally or has a smooth or round surface. Fluoroscopic assistance can be useful with radiopaque objects which have migrated into the peripheral airways.

Over time, pneumonia or atelectasis may develop and a foreign body presenting with chronic lung infection will require surgical resection of the associated potion of the lung.

CONGENITAL ABNORMALITIES OF THE DIAPHRAGM

10 Developmental defects of the diaphragm have surgical implications. Advances in management of neonatal respiratory failure, fetal surgery, and lung developmental biology have arisen from the clinical and laboratory evaluation of CDH (CDH, Bochdalek, or posterolateral hernia). CDH, which is relatively rare, occurring in 1 in 3,000 neonates has led to a significant amount of clinical and basic science research.

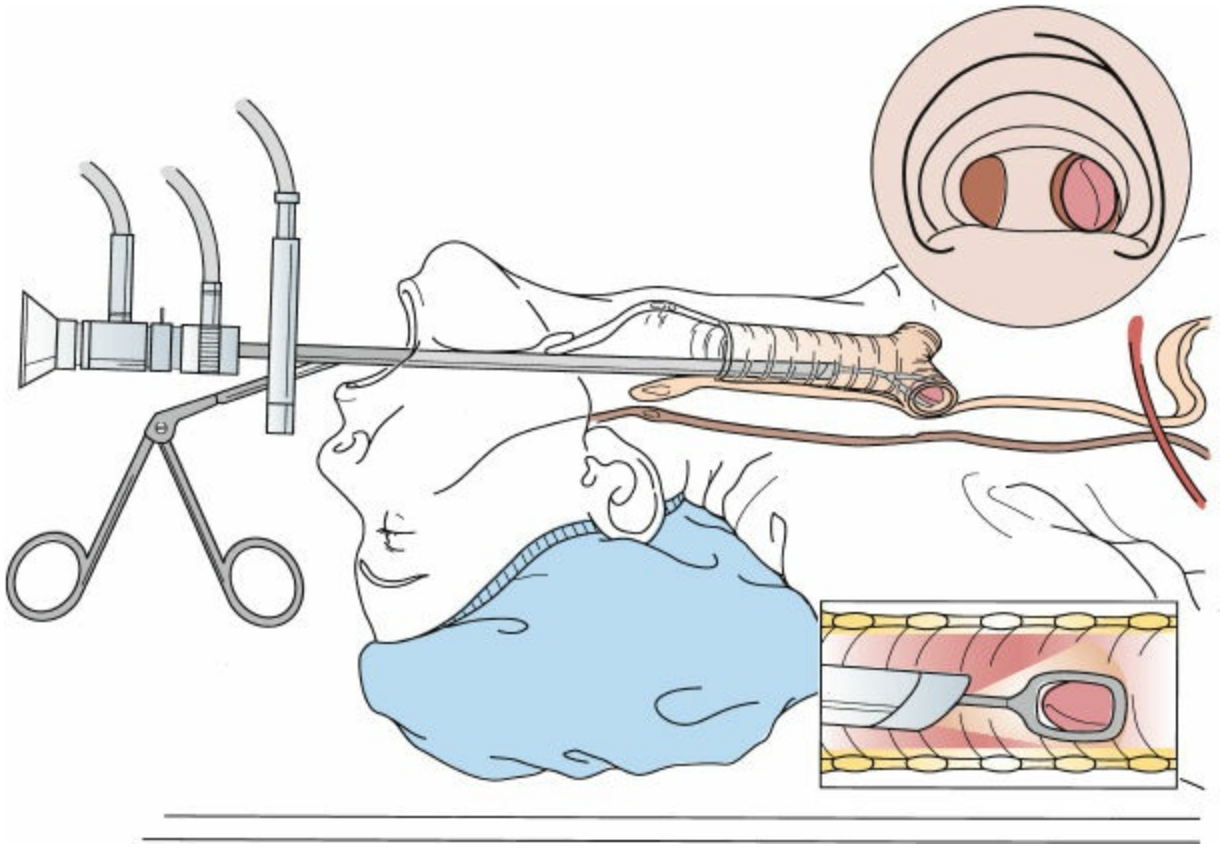

Figure 102-16. Schematic illustration of a peanut foreign body being extracted from the right main stem bronchus under direct vision.

In 1754, McCauley described the clinical course and postmortem anatomy of an infant with CDH.[121] Although Bochdalek's[122] understanding of the embryology of CDH was incorrect, this congenital defect continues to carry his name. Prior to 1940, the successful repair of this defect remained rare.[123] In 1946, Gross[124] reported the postoperative survival of an infant less than 24 hours of age. From that time until the 1980s the standard of care was emergent operative repair. At that time, CDH was considered to be an anatomic derangement treated by an anatomic correction (the thought was that by getting the bowel out of the chest, the lung compression would improve and the outcome would improve).

Until the 1980s, emergency surgery was considered the primary therapeutic goal based on mechanical concept of providing space for growth of lungs. The overall published survival rates in the 1980s were 50% with ranges from 20% to 70% based on case selection. In the late 1980s, there was a switch in management from emergency surgery to stabilization.[125] Management in the postnatal period is directed at decreasing

pulmonary hypertension while maintaining adequate oxygen saturations (between 85% and 95% preductal).[125,126] Surgical repair is deferred until after physiologic stabilization and this has led to improved survival of infant with CDH. Further improvements in therapies for pulmonary hypertension and method to increase lung growth to combat pulmonary hypoplasia should result in improvement in the survival and decreased morbidity of CDH infants.

Embryology of the Diaphragm

Mammalian lung development occurs in vivo as a coordinated developmental process that includes (a) airway and acinar development, (b) cellular differentiation, (c) biochemical maturation, (d) interstitial development including vasculature and extracellular matrix, and (e) physical growth or enlargement. These parallel developmental processes occur in such a fashion that at any one time during development, there are characteristic relationships among each component that define the so-called stages of lung development.[127–129] Hormones such as the glucocorticoids, thyroid hormone, and retinoic acid have been shown to regulate several of the crucial cellular interactions required for proper pulmonary organogenesis and differentiation. In the human embryo, respiratory tract development begins in the fourth week of gestation as a ventral out pouching of the foregut that soon has bifurcated and begun branching into the surrounding mesenchyme. The primitive, pluripotent epithelial cells differentiate into both bronchial and alveolar cell lines, under the control of the surrounding mesenchyme. By a process of asymmetric branching, the divisions are complete by the 16th week of gestation. Lung at this phase has columnar epithelium with thick mesenchyme giving rise to the descriptive term *pseudoglandular phase of development* because of its histologic appearance. The canalicular phase that follows and continues up to about the 24th gestational week is characterized by flattening of the epithelium of the distal airways, thinning of the mesenchyme, and the growth of the capillary network that surrounds the terminal airways. Gas exchange becomes functionally possible at the end of this phase. The terminal sac period that follows refers to the appearance of a thin respiratory epithelium in apposition to a capillary network capable of supporting gas exchange. True alveolar formation in humans begins shortly before or around the time of birth. Alveolar maturation and multiplication takes place after birth and may continue up to 8 years of age.

The precursors of the mesoderm-derived diaphragm begin to form during the fourth week of gestation with the appearance of the peritoneal folds from lateral mesenchymal tissue. At the same time, the septum transversum forms from the inferior portion of the pericardial cavity and serves to delineate the thoracic from the abdominal cavities. Eventually, the septum transversum leads to the formation of the central tendinous area of the fully developed diaphragm. The pleuroperitoneal folds extend from the lateral body wall and grow medially and ventrally until they fuse with the septum transversum and dorsal mesentery of the esophagus during the sixth gestational week. Complete closure of the canal takes place during the eighth week of gestation, with the right side closing before the left.[130] Muscularization of the diaphragm appears to develop from the innermost layer of thoracic mesoderm, although other mechanisms have been proposed.[131] Nitrofen-induced diaphragmatic hernias in rats have been studied with scanning electron microscopy. Normal diaphragmatic development includes the development of the pleuroperitoneal fold which connects to the mesonephric ridge and transverse septum. The lung buds protrude into the peritoneal cavity and come in close contact with the liver on the right and the stomach on the left. The lungs follow the enlarging pleural cavities and the peritoneal portion becomes smaller. A trapezoidal

structure forms laterally and is defined as the posthepatic mesenchymal plate (PHMP). The PHMP grows rapidly in a laterodorsal direction and forms the prominent ridge covering part of the liver. The opening closes from a continuous ingrowth of the PHMP.[132] In diaphragmatic hernia development, the PHMP is smaller and malformed although the pleuroperitoneal fold and the transverse septum appear normal. This leaves part of the liver uncovered and can bulge into the thorax. The lung development proceeds normally until the liver and lung approach each other and lung hypoplasia is related to the degree of herniation (Fig. 102-17).[132]

Congenital Diaphragmatic Hernia Pathology and Pathophysiology

CDH occurs in 1:3,000 to 2:4,000 live births. Approximately one-third of antenatally diagnosed infants with CDH are stillborn, with most of the deaths subscribed to other fatal anomalies. Defects are more common on the left side based on the CDH registry.[133] CDH represents a sporadic developmental anomaly with some familial cases reported. One-third of patients have associated major defects. CDH associated with an abnormal karyotype or cardiac defect is associated with a poor outcome.[134]

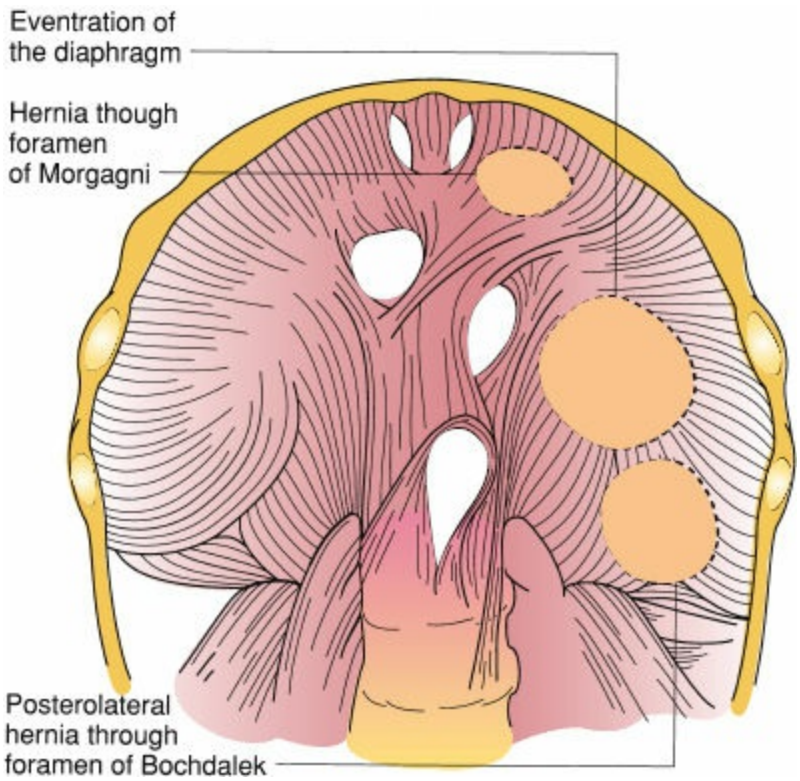

Figure 102-17. Anatomy of the diaphragm showing the location of congenital diaphragmatic defects.

The cause of CDH is unknown but is presumed that some combination of intrinsic predisposition (genetic factors) and environmental factors (teratogen or deficiency) results in abnormal diaphragm and lung development.[135] A nitrofen-induced model of CDH also inhibits retinal dehydrogenase leading to decreased retinoic acid, which has also been found in human infants with CDH.

During the early development of the diaphragm, the midgut is largely extracoelomic. If closure of the pleuroperitoneal canal has not occurred by the time the midgut returns to the abdomen during the 9th and 10th weeks of gestation, the abdominal viscera herniate through the lumbocostal trigone into the ipsilateral thoracic cavity. The resulting abnormal position of the bowel prevents its normal counterclockwise rotation and fixation. No hernia sac is present if the event occurs before complete closure of the pleuroperitoneal canal, but a nonmuscularized membrane forms a hernia sac in 10% to 15% of CDH patients. In addition to the small bowel, other intraabdominal organs such as the spleen, stomach, colon, and liver may also herniate through the diaphragmatic defect.

Left-sided CDH is characterized by a 2- to 4-cm posterolateral defect in the diaphragm through which the abdominal viscera have translocated into the ipsilateral thoracic

cavity. On a right-sided defect, the large right lobe of the liver can occupy most of the hemithorax. The hepatic veins may drain ectopically into the right atrium, and the liver and lung may be fused.[135]

The pathophysiology of CDH has been attributed to pulmonary parenchymal compression by the herniated organs and its effect on growth and maturation of the lung. An emerging school of thought attributes the pulmonary hypoplasia to an early mesenchymal developmental insult to the lung and diaphragm. Unilateral diaphragmatic hernia is associated with both ipsilateral and contralateral abnormal pulmonary development, although hypoplasia is more severe on the ipsilateral side. The lung on the side of the hernia is much smaller than its contralateral counterpart, and both are strikingly smaller than normal lungs (Fig. 102-18). The pulmonary vascular disease associated with CDH is characterized by abnormal pulmonary vascular development, abnormal vasoreactivity, and a disorganization of postnatal vascular remodeling. There are fewer capillaries which are unevenly distributed. Both the media and the adventitia have structural abnormalities consistent with increased muscularization in utero. Sonic hedgehog signaling which is involved in the development of respiratory bronchioles is delayed in CDH. Levels of several regulatory proteins are changed compared to controls but no causative relationship has been demonstrated.[136,137]

Pulmonary blood flow accounts for only 7% of cardiac output during normal fetal development. Pulmonary vascular resistance is high. The fetus preferentially shunts oxygenated blood from the placenta through the foramen ovale and ductus arteriosus in a right-to-left direction into the systemic circulation. With the institution of breathing at birth, oxygen levels rise causing pulmonary vascular resistance to fall, which in turn allows an increase in pulmonary blood flow. Increased arterial oxygen tension then also induces spontaneous closure of the ductus arteriosus. Persistent fetal circulation may develop if this process is interrupted. Elevated pulmonary vascular resistance results in right-to-left shunting of blood at either the atrial or ductal levels with the delivery of unsaturated blood into the systemic circulation. As shunting increases, the oxygen saturation in the systemic circulation falls. The resulting hypoxia further increases pulmonary vascular resistance and compromises pulmonary blood flow while increasing the right-to-left shunt flow. Factors that contribute to the persistence of high pulmonary vascular resistance in CDH lungs are thought to be the structural changes of decreased total arteriolar cross-sectional area in the involved lungs and the increased muscularization of the arterial structures that are present. Additional exacerbations of pulmonary vascular resistance may be induced by the known stimulators of pulmonary hypertension, which include hypoxia, acidosis, hypothermia, and stress. Alternations in the levels of prostaglandins, leukotrienes, catecholamines, and the renin angiotensin system had been implicated as mediators of this complex process. The combination of hypoplastic lungs and lungs prone toward increased vascular resistance often proves to be deadly; a vicious cycle may ensue in which hypoplastic lungs and associated hypoxia leads to pulmonary hypertension in a lung vasculature already prone toward reactive vasospasm. The increase in pulmonary pressures results in a greater shunt, which in turn further reduces oxygen levels.

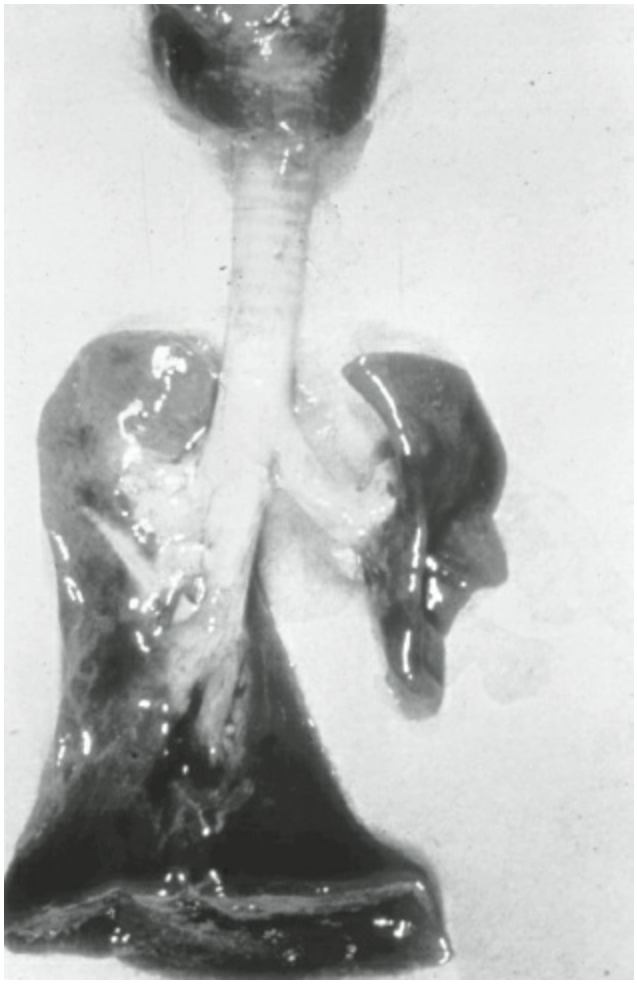

Figure 102-18. Autopsy specimen of an infant with severe pulmonary hypoplasia secondary to congenital diaphragmatic hernia. Pulmonary hypoplasia is bilateral, but the left lung is most severely affected.

Diagnosis

Diagnosis of CDH is often made on prenatal ultrasound examination and a recent population-based study demonstrated that 66% were diagnosed prenatally.[138] In addition to the defect, polyhydramnios is common. Prenatal MRI is utilized for more accurate delineation of the defect.[125] Postnatal presentation frequently includes cyanosis and respiratory distress shortly after birth in severely affected neonates. On physical examination, the patients have a scaphoid abdomen. A plain chest radiograph with loops of intestine in the chest confirms the diagnosis of CDH with an ng tube in place to confirm the position of the stomach (Fig. 102-19). After confirmation of diagnosis, echocardiography should be performed to evaluate for degree of pulmonary hypertension and to determine presence of cardiac defects. Differential diagnosis includes eventration of the diaphragm, anterior diaphragmatic hernia (Morgagni), congenital pulmonary malformations, unilateral pulmonary effusion, and primary agenesis of the lung.[139]

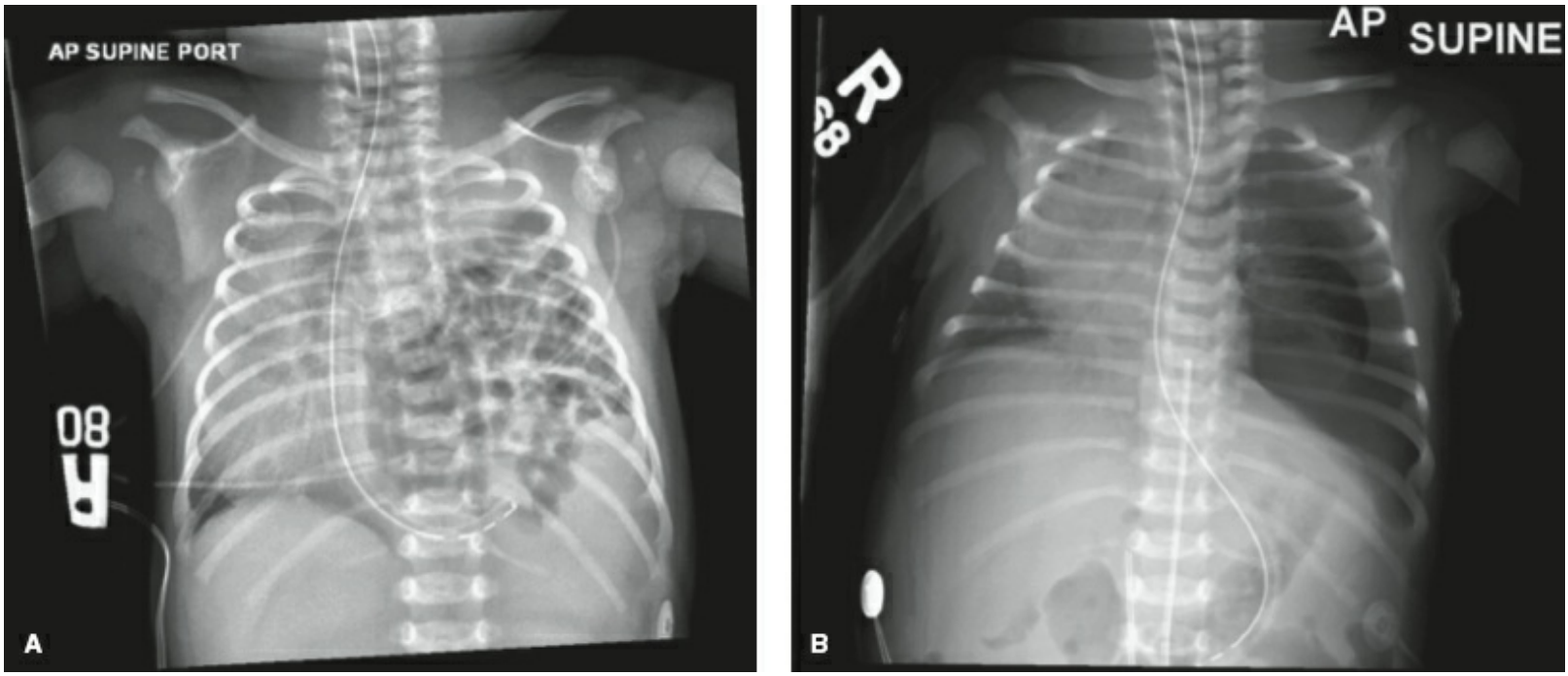

Figure 102-19. **A:** Chest radiograph of a newborn with a left congenital diaphragmatic hernia. Mediastinal structures are shifted to the right. Abdominal viscera occupy the left hemithorax. The nasogastric tube locates the stomach. The child underwent repair of the congenital diaphragmatic hernia after treatment and resolution of pulmonary hypertension. **B:** Immediate postoperative photograph demonstrates hypoplastic lung, flattening of diaphragm, and return of abdominal viscera to normal positon.

Prognostic Factors

Multiple tools for prognosis of CDH have not been successful. One method for evaluation is the lung to head ratio (LHR) which is determined by multiplying the simultaneous sonographic measurements of the size if the contralateral lung in an anteroposterior and lateromedial direction, and dividing by the head circumference. Ratios less than 1 have been associated with poor outcome. Because the LHR increases with age, the percent of predicted value for gestational age has been used with no survivors below 15% of predicted.[140] Liver above the diaphragm has also been used to determine outcome with decreased survival with liver-up. The combination of a low LHR with liver-up has a poor outcome. The size of the defect was a significant factor in survival, a major cardiac anomaly and 1-minute Apgar sores of ≤ 4 were associated with increased mortality.[141,142] Physiologic parameters have been used to develop calculations for prediction of survival including the CDHSG which utilizes birthweight and 5-minute Apgar, the CNN (Canadian Neonatal Network) equation utilizing SNAP-II scores and gestational age, and the $WHSR_{PF}$ using blood gas values in first 24 hours, with the CDHSG having the best predictive value.[138]

Treatment

At the time of antenatal diagnosis, the mother and fetus should be referred to an appropriate tertiary care perinatal center with the availability of the full array of respiratory care strategies.

Resuscitation should begin with standard neonatal resuscitation guidelines and then proceed with endotracheal intubation and nasogastric tube insertion. Bag–valve mask should be avoided. Careful management of temperature regulation, glucose homeostasis, and volume status should be performed. Fluid resuscitation should be performed with crystalloid, blood products, and colloid. Inotropes such as dopamine or dobutamine are utilized if needed. Most infants can be managed with simple pressure-cycled ventilation with a goal of maintaining a preductal PaO_2 greater than 60 correlating with saturation between 85% and 95%. Keeping peak pressures below 25 and accepting CO_2 between 45 and 65 decreases barotrauma. For failure of gentle ventilation, the next step in therapy would be the use of jet ventilator or oscillator ventilator; use of HFOV with mean airway pressure 13 to 17, frequency of 10 Hz, and amplitude of 30 to 50 keeping the contralateral lung expansion at 8 ribs.[126]

In addition to ventilatory methods, a variety of agents are utilized to modify pulmonary vascular resistance. Inhaled nitric oxide has been used in infants with approximately 30% responding. Studies have demonstrated that the results are temporary and NO should be considered a temporizing measure. Phosphodiesterase-5 inhibition with sildenafil has a vasodilatory effect but can also cause systemic hypotension worsening the shunting. In addition, the absorption is variable so dose–effect relationship is not well understood. Milrinone, a phosphodiesterase-3 inhibitor improves right ventricular function and relaxes pulmonary vessels but there is no evidence to support or discourage the use of milrinone. Recent studies have demonstrated the use of prostacyclin or prostaglandin E1 to decrease pulmonary artery pressure and pulmonary vascular resistance. Inhalation of prostacyclin seems to be preferable to IV usage. Other medications such as tyrosine kinase inhibitors and endothelin receptor antagonists may show promise.[136]

Surfactant has been demonstrated to be reduced in CDH infants. However, surfactant has not been demonstrated to improve survival.[143]

Failure to improve with ventilatory and pulmonary hypertension management strategies should prompt consideration of ECMO. ECMO can be used for an extended period of time when ventilator therapy has failed. Indication for the use of ECMO is the failure to improve in the setting of severe pulmonary hypertension. In recent years the use of ECMO has decreased but still ranges from 15% to 40% of diaphragmatic hernias; with survival following ECMO of 51%.[125]

Surgery

Delayed surgery has been demonstrated to improve survival in some studies. Current consensus is that the repair should be done in a semielective manner.

The diaphragm defect is usually approached through a subcostal incision, although the repair can be performed through a thoracotomy incision (Fig. 102-20). Both thoracoscopic and laparoscopic approaches have been described. The abdominal organs are returned to the abdomen. The defect in the diaphragm is repaired. Primary repair with nonabsorbale suture is preferred. If the defect cannot be repaired primarily due to size, a prosthetic patch such as Goretex has been utilized. The major drawback of the use of a patch, either inert or bioactive is recurrent herniation which may occur in up to 50% of infants.[144] There may have been loss of intraabdominal domain and difficulty with closing the abdomen. In these cases, a silo may be used.[145] Tube thoracostomy is used at the surgeon preference. A recent meta-analysis of minimally invasive versus open repairs demonstrated that recurrence rate is higher after MIS and operative time is longer.[146] Postoperative ventilator time and postoperative mortality were higher after open surgery but none of the studies were randomized and this may have represented selection bias.[146]

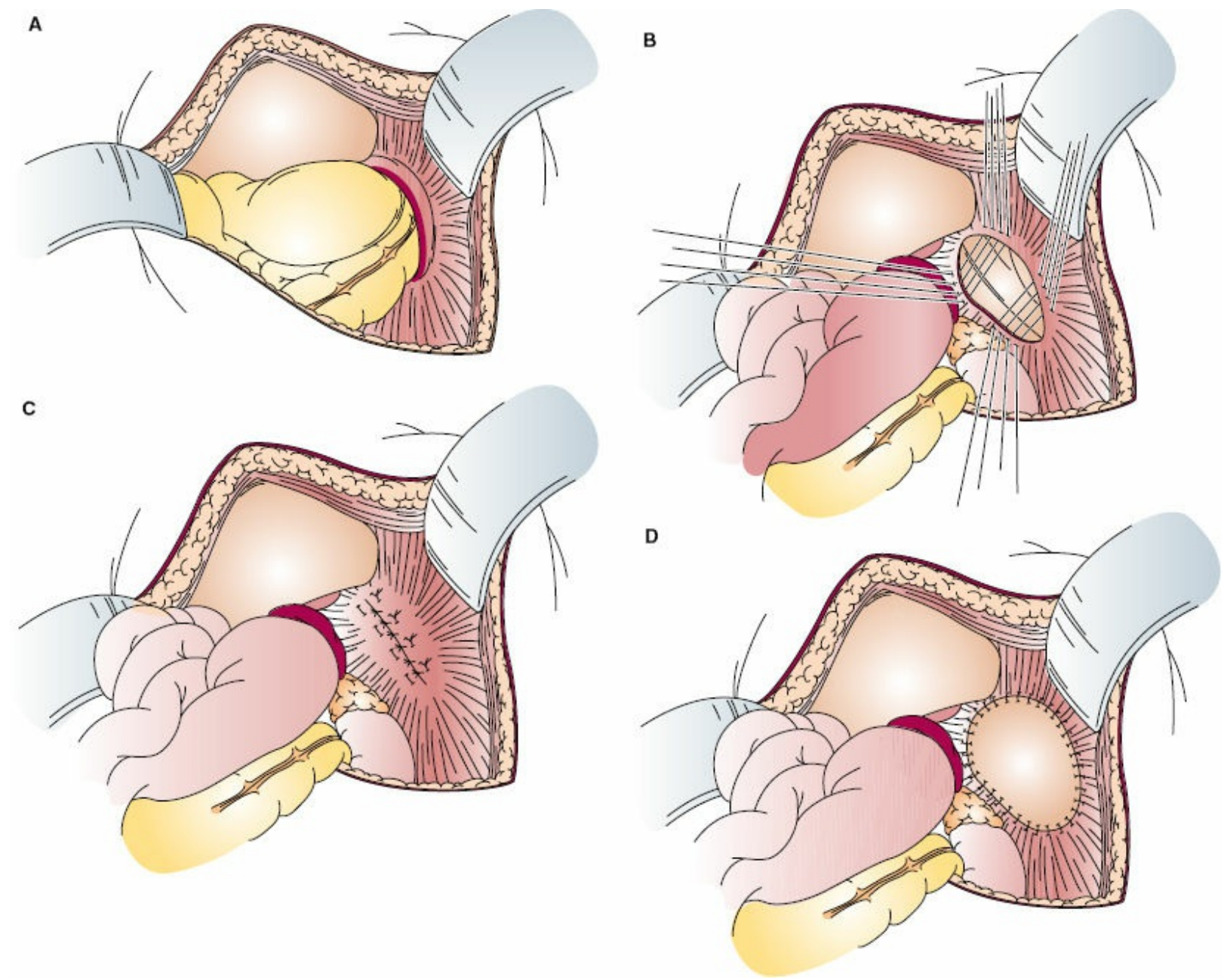

Figure 102-20. Repair of a congenital diaphragmatic hernia (CDH). **A:** Operative appearance of CDH. **B:** Placement of sutures for repair of a typical left posterolateral diaphragmatic defect. **C:** Completed repair. **D:** Prosthetic material may be used for large defects to avoid tension.

Postoperative management should continue the goals set before surgery. Continued attention to fluid status is important in the postoperative period. Weaning from the ventilator should be slow and deliberate. Refractory postoperative pulmonary hypertension is relatively common in those who required ECMO and is often treated with iNO and prostacyclin in conjunction with frequent echocardiography.

Outcome

Survival rates have been reported at 65% to 78% in the last decade improved from 50% in the past. As survival has improved, other morbidities have been demonstrated including long-term use of bronchodilators, need for gastrostomy for nutritional support, and increased rate of GERD requiring surgery. Musculoskeletal deformities also occur with scoliosis, pectus excavatum, pectus carinatum, and chest wall asymmetry described.[147] Adult survivors of CDH have demonstrated higher incidence of GERD, recurrent intestinal obstruction, and recurrent abdominal pain. Scores in the Gastrointestinal Quality of Life Index are similar to controls while there were lower scores in the Health-related Quality of Life Survey but most still had good or satisfactory scores.[148]

Evolving Therapies

Open fetal repair of diaphragmatic hernia has been performed but there was no survival benefit and there was an increase in preterm delivery so this is not currently offered. Tracheal occlusion in utero has been developed as a strategy based on observations that the lungs of neonates with congenital high airway obstruction developed hyperplastic lungs. Fetal tracheal occlusion improved lung volume but there was still impairment in the lung. Fetal endoscopic tracheal occlusion has been trialed with fewer premature deliveries. In the US trial there was no improvement in survival in a randomized trial. The European trials add a second fetal surgery to remove the balloon to allow for improvement in the development and function of type II pneumocytes and to increase surfactant production. With the European trial, vaginal delivery is possible but with the US trial, the infants were delivered by EXIT procedure, using the placenta to maintain oxygenation until an airway is secured.[140]

Foramen of Morgagni Hernia

The anterior CDH is rare and accounts for 3% to 5% of all CDHs. It is commonly diagnosed during childhood. It is frequently diagnosed from chest or abdominal radiographs being performed for presumed pneumonia or gastrointestinal symptoms (Fig. 102-21).[149] This is an anteromedial hernia at the junction of the septum transversum and the thoracic wall with contents being seen in a retrosternal position. There is a hernia sac present and the sac may contain colon, small intestine, or liver. The hernias are repaired due to the risk of segmental intestinal volvulus or obstruction. Repair may be performed through a laparoscopic approach. The sac is excised and the diaphragm is sutured to the undersurface of the posterior rectus sheath at the costal margin. Laparoscopy has been demonstrated to be an effective method for repair of this type of hernia.[150,151]

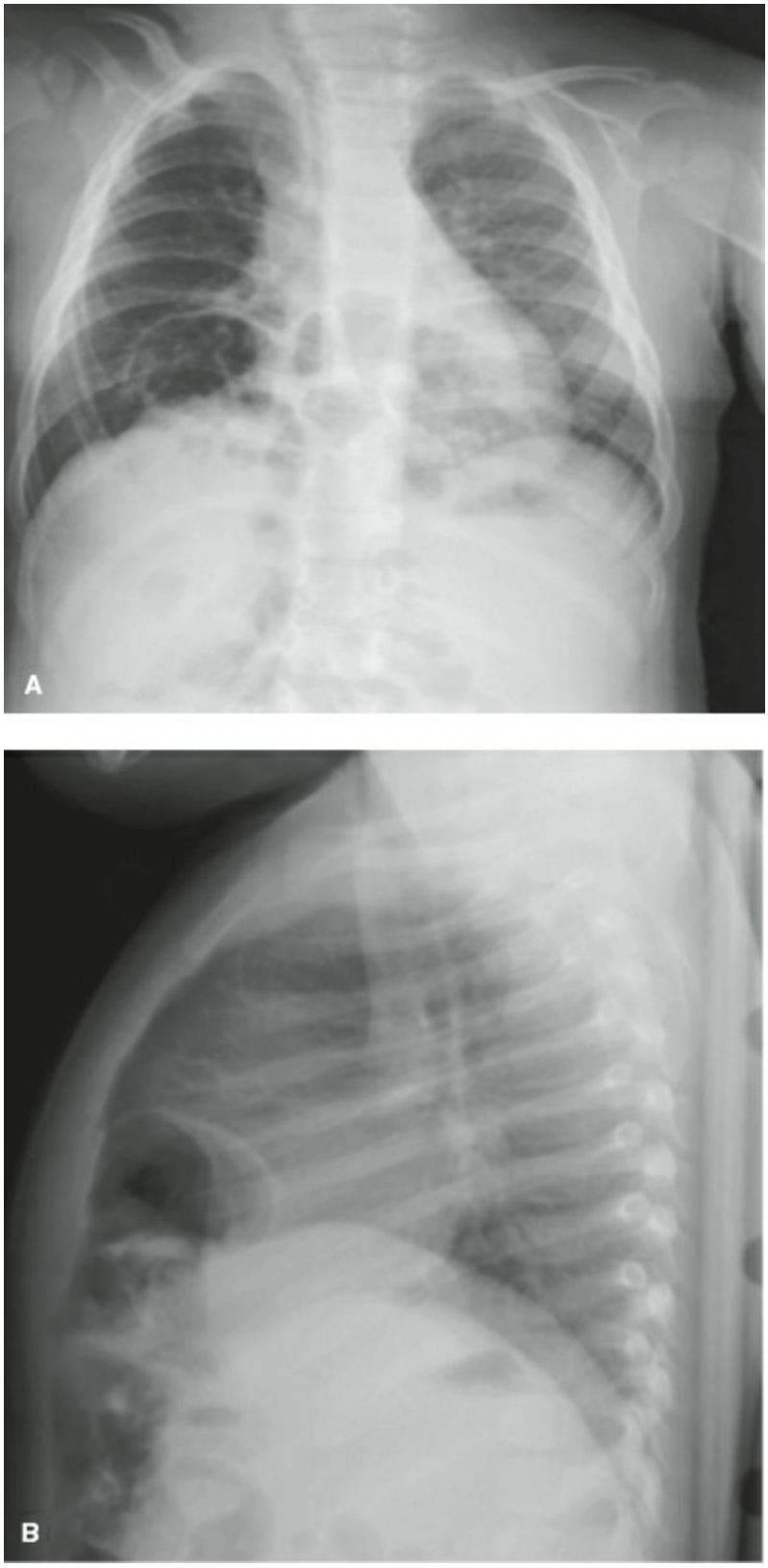

Figure 102-21. Morgagni hernia. (**A**) Anteroposterior and (**B**), lateral radiographs of patient with Morgagni hernia.

Eventration of the Diaphragm

Eventration of the diaphragm is diagnosed by the abnormal elevation of one or both hemidiaphragms and can be congenital or acquired. The congenital form may appear very similar to a diaphragmatic hernia with a sac. The cause of the congenital form is unknown although infectious causes have been implicated. The acquired form is a consequence of injury to the phrenic nerve. Small children are more likely to be affected than older children as the decreased chest size leads to dyspnea and respiratory infection. Surgery is utilized for symptomatic cases after several months of observation if symptoms are minimal. The surgical management is with plication of the diaphragm with nonabsorbale sutures. The repair may be performed through the abdomen or the chest and both thoracoscopic and laparoscopic techniques are applicable.[152]

Diaphragmatic Pacing

Ventilator-dependent children with spinal cord injury or central hypoventilation syndromes may benefit from diaphragm pacing.[153] The application of repetitive stimulus patterns to the phrenic nerves causes rhythmic contractions of the diaphragm. Phrenic nerve pacing wires are implanted at the cervical or intrathoracic level. Receivers are implanted in subcutaneous pockets, while an external microprocessor-controlled transmitter/antenna assembly activates the receiver. Patients with injured phrenic nerves (high spinal cord injury) may benefit from diaphragm pacing after intercostal-to-phrenic nerve transfer.[154]

PLEURAL DISEASES

Empyema

Empyema is the accumulation of purulent material in the pleural space. In children, empyema is most often the sequelae of bacterial pneumonia. Empyema develops when a parapneumonic effusion becomes infected or when a necrotizing pneumonia erodes into the pleural space. Empyema may also be caused by penetrating thoracic trauma, intrathroacic, or cervical esophageal perforation or as a complication from surgery on the chest. The American Thoracic Society divides the empyema process into 3 stages:

1. Exudative: Thin free-flowing fluid with a low cell count.
2. Fibrinopurulent: Frank pus is present and fibrin formation begins to cover the pleura with development of loculations.
3. Organizing: Thick peel with fibroblasts.[155]

The most common organism responsible for empyema is *Streptococcus pneumonia* despite the utilization of pneumococcal vaccinations. Other common organisms are *Staphylococcus aureus* and *Hemophilus influenza.*[156] The signs and symptoms include worsening pneumonia with fever, tachypnea, dyspnea, and sometimes cyanosis. Abdominal pain may be present. Chest radiograph demonstrates the presence of fluid and loculation. CT imaging is the best method of determining the extent of loculated fluid versus underlying pulmonary pathology (Fig. 102-22).

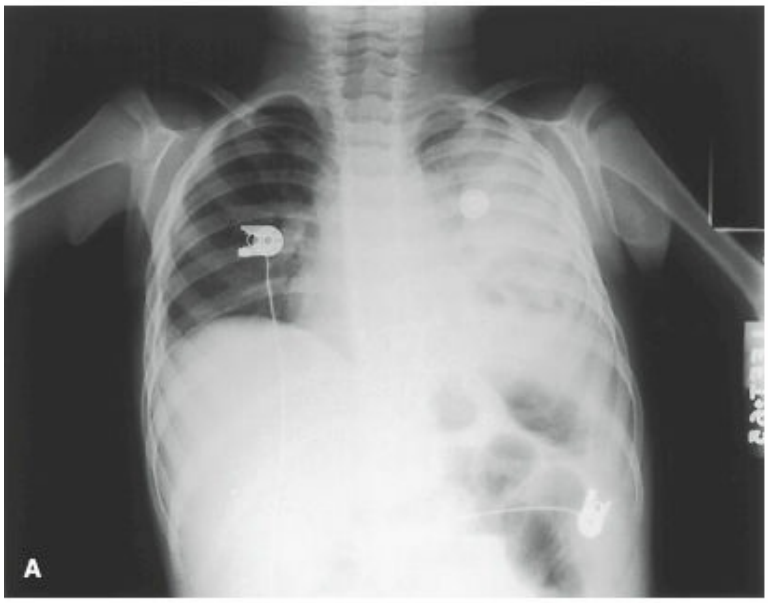
A

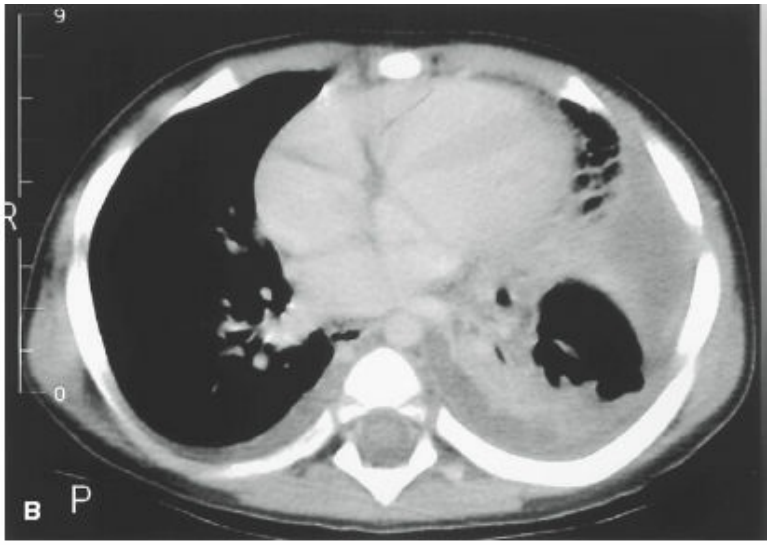
9
R
0
B
P

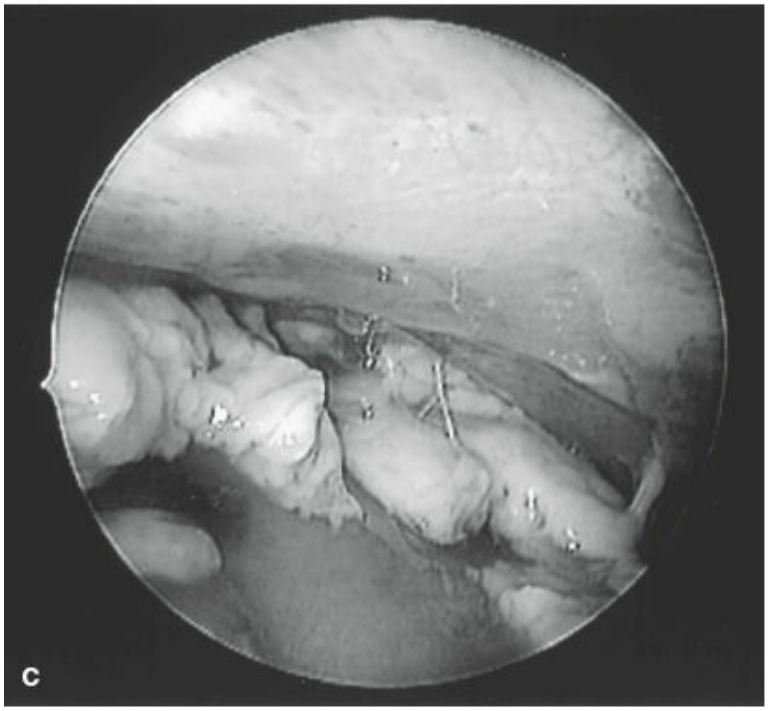
C

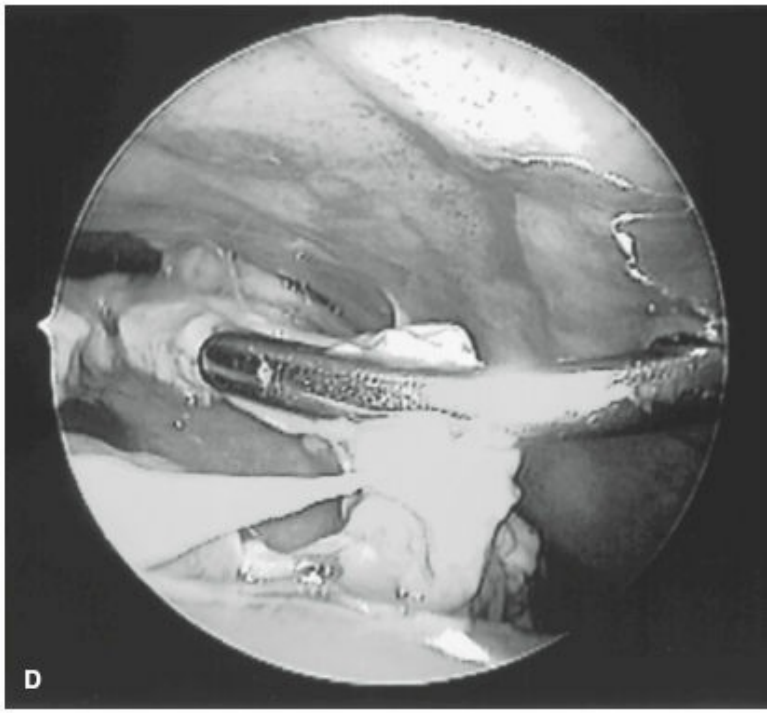
D

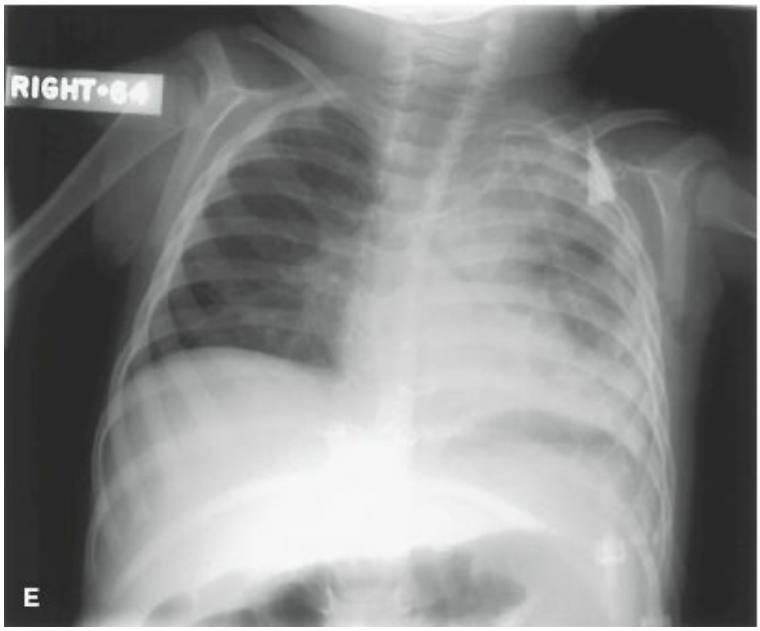
RIGHT
E

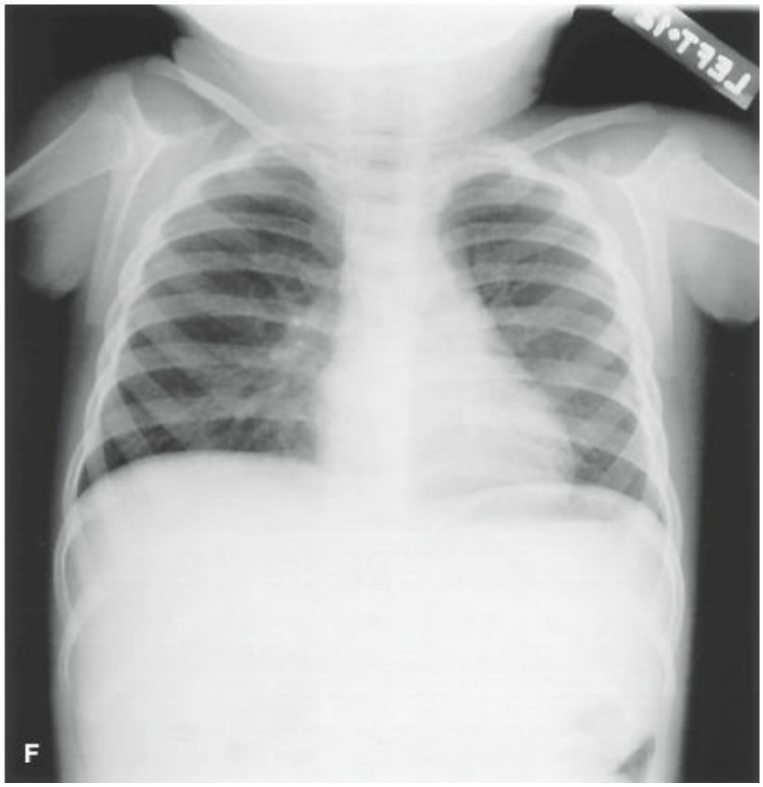
F

Figure 102-22. Video-assisted thoracoscopic treatment of complicated empyema in children. **A:** Chest radiograph of a 2-year-old child presenting with pneumonia and pleural effusion. **B:** Computerized tomography demonstrates complicated pneumonia with loculated empyema. **C:** Video endoscopic view of organized empyema debris. **D:** "Decortication" procedure includes removal of all loculated, organized debris from the hemithorax. All surfaces of the visceral and parietal pleura are accessible using video endoscopic techniques. **E:** Immediate postoperative chest x-ray shows the expected residual parenchymal lung disease. **F:** One month later, the chest radiograph findings have resolved.

With a small amount of fluid, the empyema may resolve with antibiotics alone. When the collection becomes larger, the treatment is drainage of the collection. Several trials have compared fibrinolytics to video-assisted thoracoscopy (VATS). Both VATS and chest tube with fibrinolytics have been shown to be effective with a systematic review demonstrating no superiority of VATS.[157] Other studies have demonstrated improvement after VATS.[158,159]

Pneumothorax

Spontaneous pneumothorax is relatively uncommon. The etiology seems to be lung connective tissue changes predisposing to leaks into the pleural space. This occurs in approximately 2.6 per 100,000 population of children requiring hospitalization in the United States in 2000. It has been suggested that blebs are associated with the disease. The presentation is usually with chest pain and shortness of breath but may also be associated with cough. The pain may be pleuritic in nature. Diagnosis is best confirmed with chest radiograph.[160] Chest CT has been utilized for identification of blebs but a negative examination does not predict freedom from recurrence.[161]

Treatment of pneumothorax depends on the patient. Observation with or without high flow oxygen is appropriate for the relatively asymptomatic patient. Chest tube placement is the next stage of treatment. For recurrent pneumothoraces, intrapleural sclerosing agents such as talc can be used. VATS with bleb resection and pleurodesis has also been described with good results.[162]

Chylothorax

Chylothorax which is the accumulation of chyle in the pleural space is a rare cause of effusion in children but is the most common cause of effusion in the neonate.[163] Chylothorax is associated with pulmonary lymphangiomas and lymphangiectasia. Chylothorax may also be a manifestation of Down, Turner, and Noonan syndromes. Chylothorax may occur due to trauma to the thoracic duct either iatrogenic or noniatrogenic due to blunt trauma. Malignancy and granulomatous diseases may cause obstruction of the thoracic duct leading to chylothorax.

The initial symptoms are related to accumulation of fluid in the pleural space with dyspnea, cough, and chest discomfort. Pleuritic pain and fever are rare. Diagnosis is by chest radiograph combined with findings on thoracentesis. The fluid is usually milky in appearance with triglycerides greater than 1.1 mmol/L, total cell count greater than 1,000 cells per microliter, and lymphocyte predominance greater than 80%.[164]

Management consists of expansion of the lung with thoracentesis or tube thoracostomy. Minimization of lymph flow is managed by either parenteral nutrition of diet manipulation using only dietary medium-chain fatty acids. Long-term, this can lead to life-threatening immunologic problems. Surgical management is then employed. Thoracic duct ligation can be performed either via thoracotomy or thoracoscopic approach. This may require the administration of cream via a nasogastric tube in the hours before surgery. If this fails, pleurectomy and pleurodesis or pleuroperitoneal shunting may be employed.

References

1. Sadler TW. Embryology of the sternum. *Chest Surg Clin N Am* 2000;10(2):237–244.
2. Fonkalsrud EW. Current management of pectus excavatum. *World J Surg* 2003;27(5):502–508.
3. Goretzky MJ, Kelly RE Jr, Croitoru D, et al. Chest wall anomalies: pectus excavatum and pectus carinatum. *Adolesc Med* 2004;15(3):455–471.
4. Huddleston CB. Pectus excavatum. *Semin Thorac Cardiovasc Surg* 2004 Fall;16(3):225–232.
5. Grozavu D, Ilias M, Marin D, et al. Minimally invasive repair for pectus excavatum – aesthetic and/or functional? *Chirurgia (Bucur)* 2013;108(1):70–78.
6. Johnson JN, Hartman TK, Pianoso PT, et al. Cardiorespiratory function after operation for pectus excavatum. *J Pediatr* 2008;153(3):359–364.
7. Metzelder ML, Kuebler JF, Leonhardt J, et al. Self and parental assessment after minimally invasive repair of pectus excavatum: lasting satisfaction after bar removal. *Ann Thorac Surg* 2007;83(5):1844–1849.
8. Maagaard M, Tang M, Ringgaard S, et al. Normalized cardiopulmonary exercise function in patients with pectus excavatum three years after operation. *Ann Thorac Surg* 2013;96(1):272–278.
9. Kelly RE Jr, Cash TF, Shamberger RC, et al. Surgical repair of pectus excavatum markedly improves body image and perceived ability for physical activity: multicenter study. *Pediatrics* 2008;122(6):1218–1222.
10. O'Keefe J, Byrne R, Montgomery M, et al. Longer term effects of closed repair of pectus excavatum on cardiopulmonary status. *J Pediatr Surg* 2013;48(5):1049–1054.
11. Croitoru DP, Kelly RE Jr, Goretsky MJ, et al. Experience and modification update for the minimally invasive Nuss technique for pectus excavatum repair in 303 patients. *J Pediatr Surg* 2002;37(3):437–445.
12. Lam MW, Klassen AF, Montgomery CJ, et al. Quality-of-life outcomes after surgical correction of pectus excavatum: a comparison of the Ravitch and Nuss procedures. *J Pediatr Surg* 2008;43(5):819–825.
13. Swanson JW, Colombani PM. Reactive pectus carinatum in patients treated for pectus excavatum. *J Pediatr Surg* 2008;43(8):1468–1473.
14. Nuss D, Kelly RE Jr, Croitoru DP, et al. A 10-year review of a minimally invasive technique for the correction of pectus excavatum. *J Pediatr Surg* 1998;33(4):545–552.
15. Fallon SC, Slater BJ, Nuchtern JG, et al. Complications related to the Nuss procedure: minimizing risk with operative technique. *J Pediatr Surg* 2013;48(5):1044–1048.
16. Vegunta RK, Pacheco PE, Wallace LJ, et al. Complications associated with the Nuss procedure: continued evolution of the learning curve. *Am J Surg* 2008;195(3):313–316; discussion 316–317.
17. Moss RL, Albanese CT, Reynolds, M. Major complications after minimally invasive

repair of pectus excavatum: case reports. *J Pediatr Surg* 2001;36(1):155–158.
18. St Peter SD, Weesner KA, Weissend EE, et al. Epidural vs patient-controlled analgesia for postoperative pain after pectus excavatum repair: a prospective, randomized trial. *J Pediatr Surg* 2012;47(1):148–153.
19. Zhao J, Luo L, Xiao LJ, et al. Psychological trauma of funnel chest in adolescents and the appropriate age for minimally invasive surgery repair. *Chin Med J* 2013;126(15):2876–2880.
20. Papandria D, Arlikar J, Sacco Casmassima MG, et al. Increasing age at time of pectus excavatum in children: emerging consensus? *J Pediatr Surg* 2013;48(1):191–196.
21. Marks MW, Iacobucci J. Reconstruction of congenital chest wall deformities using solid silicone onlay prostheses. *Chest Surg Clin N Am* 2000;10(2):341–355, vii.
22. Blanco FC, Elliott ST, Sandler AD. Management of congenital chest wall deformities. *Semin Plast Surg* 2011;25(1):107–116.
23. Harrison MR, Estefan-Ventura D, Fechter R, et al. Magnetic mini-mover procedure for pectus excavatum: I. development, design, and simulations for feasibility and safety. *J Pediatr Surg* 2007;42(1):81–85; discussion 85–86.
24. Frey AS, Garcia VF, Brown RL, et al. Nonoperative management of pectus carinatum. *J Pediatr Surg* 2006;41(1):40–45; discussion 40–45.
25. Stephenson JT, DuBois J. Compressive orthotic bracing in the treatment of pectus carinatum: the use of radiographic markers to predict success. *J Pediatr Surg* 2008;43(10):1776–1780.
26. Lee RT, Moorman S, Schneider M, et al. Bracing is an effective therapy for pectus carinatum: interim results. *J Pediatr Surg* 2013;48(1):184–190.
27. Emil S, Laberge JM, Sigalet D, et al. Pectus carinatum treatment in Canada: current practices. *J Pediatr Surg* 2012:47(5):862–866.
28. Cohee AS, Lin JR, Frantz FW, et al. Staged management of pectus carinatum. *J Pediatr Surg* 2013;48(2):315–320.
29. Colozza S, Butter A. Bracing in pediatric patients with pectus carinatum is effective and improves quality of life. *J Pediatr Surg* 2013;48(5):1055–1059.
30. Borshcel GH, Costantino DA, Cederna PS. Individualized implant-based reconstruction of Poland syndrome breast and soft tissue deformities. *Ann Plast Surg* 2007;59(5):507–514.
31. Arango Tomas E, Baamonde Laborda C, Algar Algar J, et al. Chest wall reconstruction with ethacrylate prosthesis in Poland syndrome. *Arch Bronconeumol* 2013;49(10):450–452.
32. Muthialu N. Primary repair of sternal cleft in infancy using combined periosteal flap and sliding osteochondroplasty. *Interact Cardiovasc Thorac Surg* 2013:16(6):923–925.
33. Waldhausen JH, Redding GJ, Song KM. Vertical expandable prosthetic titanium rib for thoracic insufficiency syndrome: a new method to treat an old problem. *J Pediatr Surg* 2007;42(1):76–80.

34. Mooney DP, Shorter NA. Slipping rib syndrome in childhood. *J Pediatr Surg* 1997;32(7):1081–1082.
35. Fu R, Iqbal CW, Jaroszewski DE, et al. Costal cartilage excision for the treatment of pediatric slipping rib syndrome. *J Pediatr Surg* 2012; 47(10)1825–1827.
36. Sapakul N, Karmazyn B. Ultrasound evaluation of costochondral abnormalities in children presenting with anterior chest wall mass. *AJR Am J Roentgenol* 2013:201(2):W336–W341.
37. Newman B. Congenital bronchopulmonary foregut malformations: concepts and controversies. *Pediatr Radiol* 2006;36(8):773–791.
38. Azizkhan RG, Crombleholme TM. Congenital cystic lung disease: contemporary antenatal and postnatal management. *Pediatr Surg Int* 2008;24(6):643–647.
39. Davenport M, Eber E. Long term respiratory outcomes of congenital thoracic malformations. *Semin Fetal Neonatal Med* 2012;17(2):99–104.
40. Rahman N, Lakhoo K. Comparison between open and thoracoscopic resection of congenital lung lesions. *J Pediatr Surg* 2009;44(2):333–336.
41. Diamond IR, Herrera P, Langer JC, et al. Thoracoscopic versus open resection of congenital lung lesions: a case-matched study. *J Pediatr Surg* 2007;42(6):1057–1061.
42. Rothenberg SS, Shipman K, Kay S, et al. Thoracoscopic segmentectomy for congenital and acquired pulmonary disease: a case for lung-sparing surgery. *J Laparoendosc Adv Surg Tech* 2013;23(12):1–5.
43. DiPrima FA, Bellia A, Inclimona G, et al. Antenatally diagnosed congenital cystic adenomatoid malformations(CCAM): research review. *J Prenat Med* 2012;6(2):22–30.
44. Khalek N, Johnson MP. Management of prenatally diagnosed lung lesions. *Semin Pediatr Surg* 2013;22(1):24–29.
45. Lo AY, Jones S. Lack of consensus among Canadian pediatric surgeons regarding the management of congenital cystic adenomatoid malformation of the lung. *J Pediatr Surg* 2008;43(5):797–799.
46. Ng C, Stanwell J, Burge DM, et al. Conservative management of antenatally diagnosed cystic lung malformations. *Arch Dis Child* 2014;99(5):432–437.
47. Pelizzo G, Barbi E, Codrich D, et al. Chronic inflammation in congenital cystic adenomatoid malformations. an underestimated risk factor? *J Pediatr Surg* 2009;44(3):616–169.
48. Kosar A, Tezel C, Orki A, et al. Bronchogenic cysts of the lung: report of 29 cases. *Heart, Lung Circ* 2009;18(3):214–218.
49. Maurin S, Hery G, Bourliere B, et al. Bronchogenic cyst: clinical course from antenatal diagnosis to postnatal thoracoscopic resection. *J Minim Access Surg* 2013;9(1):25–28.
50. Tolg C, Abelin K, Laudenbach V, et al. Open vs thorascopic surgical management of bronchogenic cysts. *Surg Endosc* 2005;19(1):77–80.
51. Mei-Zahav M, Konen O, Manson D, et al. Is congenital lobar emphysema a surgical

disease? *J Pediatr Surg* 2006;41(6):1058–1061.
52. Wick MR. Cystic lesions of the mediastinum. *Semin Diagn Pathol* 2005; 22(3):241–253.
53. Wright CD. Mediastinal tumors and cysts in the pediatric population. *Thorac Surg Clin* 2009;19(1):47–61.
54. Petroze R, McGahren ED. Pediatric chest II: benign tumors and cysts. *Surg Clin N Am* 2012;92(3):645–658.
55. Kayton ML, He M, Zakowski MF, et al. Primary lung adenocarcinomas in children and adolescents treated for pediatric malignancies. *J Thorac Oncol* 2010;5(11):1764–1771.
56. Weldon CB, Shamberger RC. Pediatric pulmonary tumors: primary and metastatic. *Semin Pediatr Surg* 2008;17(1):17–29.
57. Burnei G, Draghici I, Gavriliu S, et al. The assessment of primitive or metastatic malignant pulmonary tumors in children. *Chirurgia (Bucur)* 2013;108(3):351–359.
58. La Quaglia MP. The surgical management of metastases in pediatric cancer. *Semin Pediatr Surg* 1993;2:75–82.
59. Fuchs J, Seitz G, Handgretinger R, et al. Surgical treatment of lung metastases in patients with embryonal pediatric solid tumors: an update. *Semin Pediatr Surg* 2012;21:79–87.
60. Letourneau PA, Xiao L, Harting MT, et al. Location of pulmonary metastasis in pediatric osteosarcoma is predictive of outcome. *J Pediatr Surg* 2011;46:1333–1337.
61. Harting MT, Blakely ML, Jaffe N, et al. Long-term survival after aggressive resection of pulmonary metastases among children and adolescents with osteosarcoma. *J Pediatr Surg* 2006;41:194–199.
62. Kayton ML, Huvos AG, Casher J, et al. Computed tomographic scan of the chest underestimates the number of metastatic lesions in osteosarcoma. *J Pediatr Surg* 2006;41:200–206; discussion 200–206.
63. Zarroug AE, Hamner CE, Pham TH, et al. Bilateral staged versus bilateral simultaneous thoracotomy in the pediatric population. *J Pediatr Surg.* 2006;41:647–651.
64. Stanelle EJ, Christison-Lagay ER, Wolden SL, et al. Pulmonary metastasectomy in pediatric/adolescent patients with synovial sarcoma: an institutional review. *J Pediatr Surg* 2013;48:757–763.
65. Dantonello TM, Winkler P, Boelling T, et al. Embryonal rhabdomyosarcoma with metastases confined to the lungs: report from the CWS study group. *Pediatr Blood Cancer* 2011;56:725–732.
66. Letourneau PA, Shackett B, Xiao L, et al. Resection of pulmonary metastases in pediatric patients with Ewing sarcoma improves survival. *J Pediatr Surg.* 2011;46:332–335.
67. Denbo JW, Shannon Orr W, Wu Y, et al. Timing of surgery and the role of adjuvant

radiation therapy in ewing sarcoma of the chest wall: a single-institution experience. *Ann Surg Oncol* 2012;19(12):3809–3815.

68. Verschuur A, Van Tinteren H, Graf N, et al. Treatment of pulmonary metastases in children with stage IV neuroblastoma with risk-based use of pulmonary radiotherapy. *J Clin Oncol* 2012;30(28):3533–3539.
69. Grundy PE, Green DM, Dirks AC, et al. Clinical significance of pulmonary nodules detected by CT and Not CXR in patients treated for favorable histology Wilms tumor on National Wilms Tumor Studies-4 and 5: a report from the Children's Oncology Group. *Pediatr Blood Cancer* 2012;59(4):631–635.
70. Guddati AK, Marak CP. Pediatric primary lung adenocarcinoma in the absence of congenital pulmonary airway malformation. *Med Oncol* 2012; 29:2661–2663.
71. Bisogno G, Brennan B, Orbach D, et al. Treatment and prognostic factors in pleuropulmonary blastoma: an EXPeRT report. *Eur J Cancer* 2014;50:178–184.
72. Venkatramani R, Malogolowkin MH, Wang L, et al. Pleuropulmonary blastoma: a single-institution experience. *J Pediatr Hematol Oncol* 2012;34(5):e182–e185.
73. Hancock BJ, Di Lorenzo M, Youssef S, et al. Childhood primary pulmonary neoplasms. *J Pediatr Surg* 1993;28(9):1133–1136.
74. Messineo A, Mognato G, D'Amore ES, et al. Inflammatory pseudotumors of the lung in children: conservative or aggressive approach? *Med Pediatr Oncol* 1998;31:100–104.
75. Grosfeld JL, Skinner MA, Rescorla FJ, et al. Mediastinal tumors in children: experience with 196 cases. *Ann Surg Oncol* 1994;1(2):121–127.
76. Gun F, Erginel B, Unuvar A, et al. Mediastinal masses in children: experience with 120 cases. *Pediatr Hematol Oncol* 2012;29:141–147.
77. Vo KT, Matthay KK, Neuhaus J, et al. Clinical, biologic, and prognostic differences on the basis of primary tumor site in neuroblastoma: a report from the international neuroblastoma risk group project. *J Clin Oncol* 2014;32(28):3169–3176.
78. Newman B. Thoracic neoplasms in children. *Radiol Clin North Am* 2011;49:633–664.
79. Ranganath SH, Lee EY, Restrepo R, et al. Mediastinal masses in children. *AJR Am J Roentgenol* 2012;198:W197–W216.
80. Fraga JC, Rothenberg S, Kiely E, et al. Video-assisted thoracic surgery resection for pediatric mediastinal neurogenic tumors. *J Pediatr Surg* 2012;47:1349–1353.
81. Fraga JC, Aydogdu B, Aufieri R, et al. Surgical treatment for pediatric mediastinal neurogenic tumors. *Ann Thorac Surg* 2010;90:413–418.
82. Jaggers J, Balsara K. Mediastinal masses in children. *Semin Thorac Cardiovasc Surg* 2004 Fall;16:201–208.
83. Scalabre A, Parot R, Hameury F, et al. Prognostic risk factors for the development of scoliosis after chest wall resection for malignant tumors in children. *J Bone Joint Surg Am* 2014;96:e10.
84. Spitz L. Esophageal atresia. lessons I have learned in a 40-year experience. *J Pediatr*

Surg 2006;41:1635–1640.

85. Haight C, Towsley HA. Congenital atresia of the esophagus with tracheoesophageal fistula: extrapleural ligation of fistula and end-to-end anastomosis of esophageal segments. *Surg Gynecol Obstet* 1943;76:672–688.
86. Langston HT. The first successful total repair of congenital atresia of the esophagus with tracheoesophageal fistula. *Ann Thorac Surg* 1984; 38(1):72–74.
87. Konkin DE, O'hali WA, Webber EM, et al. Outcomes in esophageal atresia and tracheoesophageal fistula. *J Pediatr Surg* 2003;38(12):1726–1729.
88. Yagyu M, Gitter H, Richter B, et al. Esopahgeal atresia in Bremen, Germany–evaluation of preoperative risk classification in esophageal atresia. *J Pediatr Surg* 2000;35(4):584–587.
89. Choudhury SR, Ashcraft KW, Sharp RJ, et al. Survival of patients with esophageal atresia: influence of birth weight, cardiac anomaly and late respiratory complications. *J Pediatr Surg* 1999;34(1):70–73; discussion 74.
90. Lopez PJ, Keys C, Pierro A, et al. Oesophageal atresia: improved outcome in high-risk groups? *J Pediatr Surg* 2006;41:331–334.
91. Lacher M, Froehlich S, von Schweinitz D, et al. Early and long term outcome in children with esophageal atresia treated over the last 22 years. *Klin Pediatr* 2010;222:296–301.
92. Ioannides AS, Copp AJ. Embryology of oesophageal atresia. *Semin Pediatr Surg* 2009;18:2–11.
93. Metzger R, Wachowiak R, Kluth D. Embryology of the early foregut. *Semin Pediatr Surg* 2011;20:136–144.
94. Mortell AE, Azizkhan RG. Esophageal atresia repair with thoracotomy: the Cincinnati contemporary experience. *Semin Pediatr Surg* 2009;18:12–19.
95. Foker JE, Linden BC, Boyle EM Jr, et al. Development of a true primary repair for the full spectrum of esophageal atresia. *Ann Surg* 1997;226(4):533–541; discussion 541–543.
96. Gedicke MM, Gopal M, Spicer R. A gasless abdomen does not exclude distal tracheoesophageal fistula: the value of a repeat x-ray. *J Pediatr Surg* 2007;42:576–577.
97. Burge DM, Shah K, Spark P, et al. British Association of Paediatric Surgeons Congenital Anomalies Surveillance System (BAPS-CASS). Contemporary management and outcomes for infants born with oesophageal atresia. *Br J Surg* 2013;100:515–521.
98. Filston HC, Chitwood WR Jr, Schkolne B, et al. The Fogarty balloon catheter as an aid to management of the infant with esophageal atresia and tracheoesophageal fistula complicated by severe RDS or pneumonia. *J Pediatr Surg* 1982;17(2):149–151.
99. Allen SR, Ignacia R, Falcone RA, et al. The effect of a right-sided aortic arch on outcome in children with esophageal atresia and tracheoesophageal fistula. *J Pediatr Surg* 2006;41:479–483.

100. Alabbad SI, Ryckman J, Puligandla PS, et al. Use of transanastomotic feeding tubes during esophageal atresia repair. *J Pediatr Surg* 2009;44:902–905.
101. Kimura K, Nishijima E, Tsugawa C, et al. Multistaged extrathoracic esophageal elongation procedure for long gap esophageal atresia: experience with 12 patients. *J Pediatr Surg* 2001;36(11):1725–1727.
102. Seguier-Lipszyc E, Bonnard A, Aizenfisz S, et al. The management of long gap esophageal atresia. *J Pediatr Surg* 2005;40:1542–1546.
103. Al Tokhais T, Zamakhshary M, Aldekhayel S, et al Thoracoscopic repair of tracheoesophageal fistulas: a case-control matched study. *J Pediatr Surg* 2008;43:805–809.
104. Patkowski D, Rysiakiewicz K, Jaworski W, et al. Thoracoscopic repair of tracheoesophageal fistula and esophageal atresia. *J Laparoendosc Adv Surg Tech A* 2009;19(suppl 1):S19–S22.
105. van der Zee DC, Vieirra-Travassos D, Kramer WL, et al. Thoracoscopic elongation of the esophagus in long gap esophageal atresia. *J Pediatr Surg* 2007;42:1785–1788.
106. Yanchar NL, Gordon R, Cooper M, et al. Significance of the clinical course and early upper gastrointestinal studies in predicting complications associated with the repair of esophageal atresia. *J Pediatr Surg* 2001;36(5):815–822.
107. Yeming W, Somme S, Chenren S, et al. Balloon catheter dilatation in children with congenital and acquired esophageal anomalies. *J Pediatr Surg* 2002;37(3):398–402.
108. Richter GT, Ryckman F, Brown RL, et al. Endoscopic management of recurrent tracheoesophageal fistula. *J Pediatr Surg* 2008;43:238–245.
109. Nasr A, Ein SH, Gerstle JT. Infants with repaired esophageal atresia and distal tracheoesophageal fistula with severe respiratory distress: is it tracheomalacia, reflux, or both? *J Pediatr Surg* 2005;40:901–903.
110. Little DC, Rescorla FJ, Grosfeld JL, et al. Long-term analysis of children with esophageal atresia and tracheoesophageal fistula. *J Pediatr Surg* 2003;38(6):852–856.
111. Koivusalo A, Pakarinen MP, Turunen P, et al. Health-related quality of life in adult patients with esophageal atresia–a questionnaire study. *J Pediatr Surg* 2005;40:307–312.
112. Deurloo JA, Ekkelkamp S, Taminiau JA, et al. Esophagitis and Barrett esophagus after correction of esophageal atresia. *J Pediatr Surg* 2005;40:1227–1231.
113. Lipshutz GS, Albanese CT, Harrison MR, et al. Anterior cervical approach for repair of Laryngotracheoesophageal cleft. *J Pediatr Surg* 1998;33(2):400–402.
114. Michaud L, Coutenier F, Podevin G, et al. Characteristics and management of congenital esophageal stenosis: findings from a multicenter study. *Orphanet J Rare Dis* 2013;8:186.
115. Chiu PP, Rusan M, Williams WG, et al. Long-term outcomes of clinically significant vascular rings associated with congenital tracheal stenosis. *J Pediatr Surg* 2006;41:335–341.

116. The Airway Reconstruction Team. Recent challenges in the management of congenital tracheal stenosis: an individualized approach. *J Pediatr Surg* 2005;40:774–780.
117. Chiu PP, Kim PC. Prognostic factors in the surgical treatment of congenital tracheal stenosis: a multicenter analysis of the literature. *J Pediatr Surg* 2006;41:221–225; discussion 221–225.
118. Heyer CM, Bollmeier ME, Rossler L, et al. Evaluation of clinical, radiologic, and laboratory prebronchoscopy findings in children with suspected foreign body aspiration. *J Pediatr Surg* 2006;41:1882–1888.
119. Metrangelo S, Monetti C, Meneghini L, et al. Eight years' experience with foreign-body aspiration in children: what is really important for a timely diagnosis? *J Pediatr Surg* 1999;34(8):1229–1231.
120. Committee on Injury, Violence, and Poison Prevention. Prevention of choking among children. *Pediatrics* 2010;125(3):601–607.
121. McCauley G. An account of viscera herniation. *Phil Trans R Coll Phys* 1754;6:25.
122. Bochdalek VA. Einige Betrachtungen uber die Enstehung des angeborenen Zwerfekkbruches. Als Bietrag Zur pathologischen Anatomie der Hernien. *Vjscher Prakt Heilk* 1848;18:89.
123. Ladd WE, Gross RE. Congenital diaphragmatic hernia. *N Engl J Med* 1940;223:917.
124. Gross RE. Congenital hernia of the diaphragm. *Am J Dis Child* 1946;71:579.
125. Sluiter I, van de Ven CP, Wijnen RM, et al. Congenital diaphragmatic hernia: still a moving target. *Semin Fetal Neonatal Med* 2011;16:139–144.
126. van den Hout L, Schaible T, Cohen-Overbeek TE, et al. Actual outcome in infants with congenital diaphragmatic hernia: the role of a standardized postnatal protocol. *Fetal Diagn Ther* 2011;29:55–63.
127. Cilley RE. Respiratory physiology and extracorporeal life support. In: Oldham KT, Foglia RP, Colombani PM, eds. *Surgery of Infants and Children: Scientific Principles and Practice.* Philadelphia, PA: Lippincott– Raven Publishers; 1997:183–222.
128. DiFiore JW, Wilson JM. Lung development. *Semin Pediatr Surg* 1994;3:221–232.
129. Davies G, Reid L. Growth of the alveoli and pulmonary arteries in childhood. *Thorax* 1970;25:669–681.
130. Moore KL. *The Developing Human.* 3rd ed. Philadelphia, PA: WB Saunders; 1982.
131. Iritani I. Experimental study on embryogenesis of congenital diaphragmatic hernia. *Anat Embryol (Berl)* 1984;169:133–139.
132. Mayer S, Metzger R, Kluth D. The embryology of the diaphragm. *Semin Pediatr Surg* 2011;20:161–169.
133. Doyle NM, Lally KP. The CDH study group and advances in the clinical care of the patient with congenital diaphragmatic hernia. *Semin Perinatol* 2004;28(5):174–184.
134. Migliazza L, Bellan C, Alberti D, et al. Retrospective study of 111 cases of congenital diaphragmatic hernia treated with early high-frequency oscillatory ventilation and

presurgical stabilization. *J Pediatr Surg* 2007;42:1526–1532.
135. Gosche JR, Islam S, Boulanger SC. Congenital diaphragmatic hernia: searching for answers. *Am J Surg* 2005;190:324–332.
136. Vijfhuize S, Schaible T, Kraemer U, et al. Management of pulmonary hypertension in neonates with congenital diaphragmatic hernia. *Eur J Pediatr Surg* 2012;22:374–383.
137. Sluiter I, Reiss I, Kraemer U, et al. Vascular abnormalities in human newborns with pulmonary hypertension. *Expert Rev Respir Med* 2011;5(2):245–256.
138. Baird R, MacNab YC, Skarsgard ED, et al. Mortality prediction in congenital diaphragmatic hernia. *J Pediatr Surg* 2008;43:783–787.
139. Kasales CJ, Coulson CC, Meilstrup JW, et al. Diagnosis and differentiation of congenital diaphragmatic hernia from other noncardiac thoracic fetal masses. *Am J Perinatol* 1998;15(11):623–628.
140. Shue EH, Miniati D, Lee H. Advances in prenatal diagnosis and treatment of congenital diaphragmatic hernia. *Clin Perinatol* 2012;39:289–300.
141. Rashid A, Ivy D. Severe paediatric pulmonary hypertension: new management strategies. *Arch Dis Child* 2005;90(1):92–98.
142. Zamora IJ, Olutoye OO, Cass DL, et al. Prenatal MRI fetal lung volumes and percent liver herniation predict pulmonary morbidity in congenital diaphragmatic hernia (CDH). *J Pediatr Surg* 2014;49:688–693.
143. Lally KP, Lally PA, Langham MR, et al. Congenital Diaphragmatic Hernia Study Group. Surfactant does not improve survival rate in preterm infants with congenital diaphragmatic hernia. *J Pediatr Surg* 2004;39(6):829–833.
144. Grethel EJ, Cortes RA, Wagner AJ, et al. Prosthetic patches for congenital diaphragmatic hernia repair: Surgisis vs Gore-Tex. *J Pediatr Surg* 2006; 41:29–33; discussion 29-33.
145. Rana AR, Khouri JS, Teitelbaum DH, et al. Salvaging the severe congenital diaphragmatic hernia patient: is a silo the solution? *J Pediatr Surg* 2008;43(5):788–791.
146. Chan E, Wayne C, Nasr A. Minimally invasive versus open repair of Bochdalek hernia: a meta-analysis. *J Pediatr Surg* 2014;49:694–699.
147. Chiu PP, Sauer C, Mihailovic A, et al. The price of success in the management of congenital diaphragmatic hernia: is improved survival accompanied by an increase in long-term morbidity? *J Pediatr Surg* 2006;41:888–892.
148. Koivusalo A, Pakarinen M, Vanamo K, et al. Health-related quality of life in adults after repair of congenital diaphragmatic defects–a questionnaire study. *J Pediatr Surg* 2005;40:1376–1381.
149. Al-Salem AH. Congenital hernia of Morgagni in infants and children. *J Pediatr Surg* 2007;42:1539–1543.
150. Al-Salem AH, Zamakhshary M, Al Mohaidly M, et al. Congenital Morgagni's hernia: a national multicenter study. *J Pediatr Surg* 2014;49:503–507.

151. Laituri CA, Garey CL, Ostlie DJ, et al. Morgagni hernia repair in children: comparison of laparoscopic and open results. *J Laparoendosc Adv Surg Tech A* 2011;21(1):89–91.
152. Hu J, Wu Y, Wang J, et al. Thoracoscopic and laparoscopic plication of the hemidiaphragm is effective in the management of diaphragmatic eventration. *Pediatr Surg Int* 2014;30:19–24.
153. Ali A, Flageole H. Diaphragmatic pacing for the treatment of congenital central alveolar hypoventilation syndrome. *J Pediatr Surg* 2008;43(5):792–796.
154. Krieger LM, Krieger AJ. The intercostal to phrenic nerve transfer: an effective means of reanimating the diaphragm in patients with high cervical spine injury. *Plast Reconstr Surg* 2000;105:1255–1261.
155. Jaffe A, Calder AD, Owens CM, et al. Role of routine computed tomography in paediatric pleural empyema. *Thorax* 2008;63:897–902.
156. Li ST, Tancredi DJ. Empyema hospitalizations increased in US children despite pneumococcal conjugate vaccine. *Pediatrics* 2010;125:26–33.
157. Krenke K, Peradzynska J, Lange J, et al. Local treatment of empyema in children: a systematic review of randomized controlled trials. *Acta Paediatr* 2010;99:1449–1453.
158. Avansino JR, Goldman B, Sawin RS, et al. Primary operative versus nonoperative therapy for pediatric empyema: a meta-analysis. *Pediatrics* 2005;115(6):1652–1659.
159. Schultz KD, Fan LL, Pinsky J, et al. The changing face of pleural empyemas in children: epidemiology and management. *Pediatrics* 2004;113(6):1735–1740.
160. Dotson K, Johnson LH. Pediatric spontaneous pneumothorax. *Pediatr Emerg Care* 2012;28(7):715–720; quiz 721-723.
161. Laituri CA, Valusek PA, Rivard DC, et al. The utility of computed tomography in the management of patients with spontaneous pneumothorax. *J Pediatr Surg* 2011;46:1523–1525.
162. Choi SY, Kim YH, Jo KH, et al. Video-assisted thoracoscopic surgery for primary spontaneous pneumothorax in children. *Pediatr Surg Int* 2013;29:505–509.
163. Tutor JD. Chylothorax in infants and children. *Pediatrics* 2014;133:722–733.
164. Haines C, Walsh B, Fletcher M, et al. Chylothorax development in infants and children in the UK. *Arch Dis Child* 2014;99:724–730.

Chapter 103

Pediatric Abdomen

Thomas T. Sato and Marjorie J. Arca

Key Points

1 Gastroschisis occurs with an incidence rate of 1 in 2,000 live births and is characterized by exposed intestine herniating through a defect to the right of the umbilicus. In contrast, omphalocele is a midline abdominal wall defect characterized by herniated visceral contents contained within the umbilical cord covering and has a high incidence rate of associated congenital anomalies.

2 A congenital, indirect inguinal hernia is an abnormal, patent continuation of the peritoneum through the internal inguinal ring; inguinal hernia repair is the most common elective procedure in pediatric surgery.

3 Neonatal bilious emesis should be considered the result of an acute mechanical intestinal obstruction until proven otherwise; emergent surgical evaluation is warranted to determine whether intestinal malrotation with midgut volvulus is present.

4 Necrotizing enterocolitis (NEC) is a progressive, inflammatory intestinal condition of the surviving premature neonate. Perforated NEC is the most common neonatal surgical emergency.

5 Hirschsprung disease is caused by aganglionosis of the myenteric nervous system in the rectum. Most commonly, the rectosigmoid colon is involved, but the length of contiguous aganglionosis varies in length proximally. Both propulsion and reflexive relaxation may be disordered or absent in the rectum, leading to functional bowel obstruction in the neonate and chronic constipation in the older child or adolescent. Enterocolitis associated with Hirschsprung disease is a potentially life-threatening condition.

6 Intussusception is the invagination or telescoping of a proximal segment of intestine into an adjacent distal segment and is the most common cause of intestinal obstruction in infants and children 3 months to 3 years of age.

7 The incidence of biliary atresia is 1 in 8,000 to 12,000 live births and is the most common cause of chronic cholestasis in infants and children as well as the most frequent indication for pediatric liver transplantation. Early diagnosis and management is necessary for optimal outcome.

ABDOMINAL WALL DEFECTS

Gastroschisis

1 Gastroschisis occurs with an incidence of about 1 in 2,000 to 4,000 live births. Infants with gastroschisis tend to be born to mothers who are younger (teenage), white, and consumed alcohol or tobacco during pregnancy.[1–3] Familial cases of gastroschisis are distinctly rare.[4] Associated congenital anomalies are uncommon. However, in about 10% of cases, intestinal atresia or stenosis can be seen and is thought to be a result of mechanical or vascular compromise to the herniated bowel. Rarely, infants with gastroschisis have complete loss of small bowel secondary to volvulus in utero.

The pathophysiology of gastroschisis remains unknown. In normal fetal development, two umbilical veins are initially present. As the intestine returns to the abdominal cavity through the umbilicus, the right umbilical vein undergoes resorption, leaving the left umbilical vein intact. Weakness of the umbilical membrane at the site of umbilical vein resorption may allow the evisceration of the intestine through the defect. This explanation is consistent with the clinical observation that the gastroschisis defect is almost always located to the right of the umbilicus. Routine antenatal ultrasonography has documented the sequential development of gastroschisis as a consequence of a ruptured hernia of the umbilical cord in utero.[5] Therefore, gastroschisis should be considered an isolated mechanical defect of the developing umbilical cord rather than a global defect in embryogenesis.

The amount of bowel eviscerated in gastroschisis can be extensive because the bowel has not undergone complete mesenteric rotation and fixation at this particular time in embryogenesis. The bowel may be thickened and the mesentery may be foreshortened secondary to the inflammatory response induced by direct exposure to amniotic fluid. In gastroschisis, herniation of the liver is distinctly unusual (Fig. 103-1).

Omphalocele

Anatomy, Embryology, and Pathophysiology

The incidence rate of omphalocele is approximately 1 in 6,000 to 10,000 live births and has been stable over the past several decades. *Omphalocele* is a midline abdominal wall defect of varying size characterized by the presence of herniated visceral contents into the translucent sac of the umbilicus. The sac is composed of amniotic membrane, mesenchymal tissue known as *Wharton jelly,* and peritoneum. The umbilical cord attaches to the sac and may be eccentric in origin (Fig. 103-2). The sac may be inadvertently ruptured before or during delivery but it is always present. Similar to gastroschisis, intestinal malrotation is usually present. Unlike gastroschisis, the bowel is typically normal in appearance because it has not been directly exposed to the amniotic fluid. Small omphaloceles are defined as 2 to 3 cm in diameter and have only a small amount of herniated bowel within the sac. Closure of small omphaloceles is typically performed without significant physiological complications. In contrast, giant omphaloceles defined as greater than 4 cm in diameter can lead to extensive herniation of the stomach, bowel, liver, and spleen with subsequent underdevelopment of the abdominal cavity (Fig. 103-3).

Omphalocele results from incomplete closure of the anterior abdominal wall at the umbilicus during embryogenesis. During week 4 of gestation, the midgut undergoes progressive elongation in the yolk sac outside the embryonic coelomic cavity. The midgut returns to the abdominal cavity during week 10, where it undergoes normal rotation and fixation of the mesentery to the posterior abdominal wall. Normal closure of the anterior abdominal wall requires return of the midgut to the abdominal cavity, along with growth and fusion of the anterior body folds (cephalic, caudal, and two lateral) at the base of the umbilicus. Failure of growth, migration, or fusion of the lateral body folds leads to omphalocele. Failure of growth and fusion of the cephalic folds may lead to either a supraumbilical omphalocele associated with a midline sternal defect (Fig. 103-4) and a herniated heart, termed *ectopia cordis,* or a constellation of defects known as the *pentalogy of Cantrell.*[6] This sequence includes a sternal cleft, an absence of the septum transversum of the diaphragm, a pericardial defect, a cardiac defect, and an epigastric omphalocele. Infants born with either ectopia cordis or pentalogy of Cantrell have significant morbidity and often, these conditions are lethal.



Figure 103-1. Gastroschisis. The defect is to the right of the normal umbilicus, and the bowel is thickened and inflamed.

Associated anomalies are more common in infants with omphalocele than with gastroschisis, reflecting the more global abnormality of embryogenesis in omphalocele. About 50% to 60% of infants with omphalocele have at least one associated congenital anomaly involving the skeleton, gastrointestinal tract, nervous system, genitourinary system, and cardiopulmonary system.[7,8] In addition, infants with omphalocele have a higher incidence of chromosomal abnormalities and other conditions such as Beckwith–Wiedemann syndrome. A comparison of gastroschisis and omphalocele is summarized in Table 103-1.



Figure 103-2. Omphalocele. The herniated intestines and liver are visible inside the sac. The umbilical cord attaches to the sac.



Figure 103-3. Ruptured omphalocele. Although the bowel is relatively normal in appearance, the abdominal cavity is extremely underdeveloped.

Perioperative Management for Gastroschisis and Omphalocele

In contemporary practice, infants with gastroschisis can be safely delivered vaginally.[8,9] Studies comparing vaginal delivery with elective cesarean section for infants with gastroschisis demonstrated no significant differences in outcome.[10,11] Early delivery to minimize intestinal damage in gastroschisis patients has not been proved to be efficacious.[12,13] Fetal well-being has been advocated to be the primary determinant for gastroschisis. To prevent birth-related hepatic injury, cesarean section is preferable for prenatally diagnosed infants with giant omphaloceles.

After delivery, infants with either gastroschisis or omphalocele have similar initial management priorities. If necessary, an adequate airway with effective ventilation and oxygenation is established. The infant should be maintained under either an external warmer or a humidified incubator. An orogastric sump tube should be inserted early and placed on suction to prevent further intestinal distention. In gastroschisis, the herniated viscera should be examined to make certain that the mesentery is not twisted. In addition, the tightness of the opening of the abdominal wall should be assessed to ensure that there is sufficient perfusion of the bowel. The viscera should be covered with gauze plastic wrap to prevent further contamination, hypothermia, and volume depletion. Alternatively, the infant's entire lower torso can be placed inside a plastic bowel bag. Regardless of the method, the initial therapeutic goal is to provide rapid, effective temporary coverage of the viscera. Adequate support of the herniated viscera must be provided to prevent intestinal ischemia. This can be done by placing the baby on his or her side, and placing support under the intestines. With large omphaloceles, the position of the infant's liver and viscera may impair venous return from the inferior vena cava when the infant is supine, and these infants may preferentially require a left-side-down position to maintain normal hemodynamics. Intravenous dextrose and broad-spectrum antibiotics are administered. Infants with gastroschisis will have higher intravenous fluid requirements to maintain euvolemia. If the infant is not delivered at a center where definitive surgical care can be provided, urgent transport should be arranged.

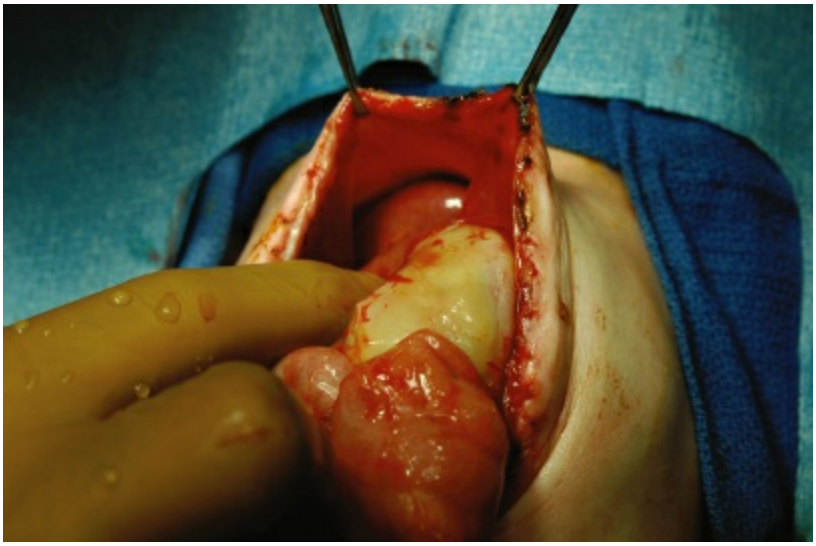

Figure 103-4. Operative exploration of giant omphalocele with abdominal wall defect, absence of the septum transversum of the diaphragm, pericardial defect, and cardiac defect.

Table 103-1 Comparison of Gastroschisis and Omphalocele

Characteristic	Gastroschisis	Omphalocele
Defect size (diameter)	2–3 cm	2–15 cm
Sac	Never	Always, may be ruptured
Gestational age	Prematurity	Term
Umbilical cord	Adjacent (left side) of defect	Attached to sac
Herniated viscera	Small bowel, stomach, colon	Small bowel, stomach, colon, liver
Malrotation	Yes	Yes
Bowel character	Inflammatory, edematous	Normal
Enteral nutrition	Delayed	Normal
Associated anomalies	Uncommon (10% atresia)	Common (50%)

Gastroschisis. Once the infant with gastroschisis has been stabilized, measures are taken to secure the viscera and, if possible, correct the abdominal wall defect. One option is to take the infant to the operating room, where reduction of the herniated viscera with primary fascial closure of the abdominal wall is an achievable goal in approximately 60% to 70% of infants with either gastroschisis. Gentle but definitive stretching of the abdominal wall is performed, and proximal decompression of the bowel is maintained with orogastric decompression. The defect may need to be enlarged to evaluate the intestinal tract fully and/or reduce the viscera into the abdominal cavity. The limiting factor in primary closure of a congenital abdominal wall defect is the increased intra-abdominal pressure generated by the reduction of the herniated viscera. Increased intra-abdominal pressure can lead to abdominal compartment syndrome. Features of neonatal abdominal compartment syndrome include impaired venous return caused by compression of the inferior vena cava, reduction of splanchnic blood flow leading to mesenteric ischemia, and respiratory compromise secondary to impaired diaphragmatic excursion.

Intraoperative measurement of intragastric or intravesical pressure, end-tidal CO_2, central venous pressure, or regional oximetry may be helpful in determining the safety of primary abdominal wall closure. If the herniated viscera cannot be reduced primarily, the viscera is placed in a constructed Silastic pouch or performed silo. Daily partial reduction of the viscera within the silo is performed. This technique allows gradual reduction of the herniated viscera into the abdominal cavity, and complete reduction is usually obtained within 3 to 7 days. The infant is returned to the operating room for removal of the temporary silo with delayed primary closure of the abdominal wall defect (Fig. 103-5). Alternatively, a large abdominal wall defect may be effectively covered with abdominal skin flaps, with delayed repair of the ventral hernia months to years later (gross closure).

In some centers, all babies with gastroschisis are managed by placing a preformed silo at the bedside after the baby is born. Thereafter, the viscera is slowly reduced into the abdomen and eventual fascial closure is attained.[14] Some studies caution that this practice may lead to longer ventilator and fluid requirements.[14,15] Another method that has been described in gastroschisis patients with noninflamed pliable intestines is to reduce the viscera with some sedation at the bedside, fold the umbilical cord stump over the skin closure, and place a pressure dressing over the defect.[16] The use of the umbilical stump has been described even for patients requiring staged or silo closure.[17] This method of closure has been shown to effect fewer days of mechanical ventilation in retrospective studies.[17–20]

Omphaloceles. Given the high incidence of associated anomalies, infants with omphalocele should undergo diagnostic investigation, guided by the clinical presentation and physical examination. These studies include chest radiography, echocardiogram, and renal ultrasound, in addition to baseline blood work. Chromosomal analysis may be necessary. Until the decision is made with respect to the timing and method of repair, the omphalocele should remain covered and protected with a gauze dressing. If the omphalocele is ruptured or torn, immediate closure or coverage is necessary.



Figure 103-5. Silastic chimney or silo for temporary coverage and staged reduction of giant omphalocele.

Closure of omphaloceles is dictated by the size of the defect, the amount of viscera extruded into the sac, and the abdominal domain. There is no standard definition of what constitutes a regular versus a giant omphalocele. Practically, a giant omphalocele has an abdominal wall defect larger than 4 cm, containing a portion of liver, and is difficult to dose primarily in the first days of life without physiologic compromise.

Omphaloceles with a small abdominal wall defect typically would have operative fascial closure with sac excision in the newborn period. Many techniques have been described to close giant omphaloceles including sac excision and temporary coverage with grafts, use of intraperitoneal tissue expanders,[21,22] and allowing the omphalocele sac to scar and then epithelialize in the latter technique.

The sac can be physically supported and left undisturbed, allowing epithelialization of the sac over several weeks to months. Antibiotic solutions or ointments are usually applied to control desiccation.[22–25] Delayed repair of the ventral hernia is required. This delay is particularly useful in the infant with a giant omphalocele and a small, underdeveloped abdominal cavity that prohibits primary closure.

Infants with repaired omphalocele usually have relatively prompt return of bowel function after definitive repair. In comparison, nearly all infants with gastroschisis have delayed intestinal function following closure. The use of total parenteral nutrition (TPN) is essential in the treatment of these infants because it allows nutritional support while the bowel inflammatory process resolves. It is not unusual for these infants to require up to 4 weeks after repair to have bowel function normalize, and time taken to achieve full enteral feeding is not affected by the use of erythromycin as a prokinetic agent.[26] Approximately 15% of infants with gastroschisis develop necrotizing enterocolitis (NEC), a diffuse, often life-threatening inflammatory complication of the neonatal intestinal tract.[27] In addition, infants with gastroschisis are at risk for nutrient malabsorption and intestinal dysmotility with inability to tolerate full enteral feeding. In particular, infants with gastroschisis and associated intestinal atresia may have pronounced intestinal dysmotility and may require long-term, sometimes lifelong, dependence on TPN for caloric intake.[28]

Long-term outcome of infants operated on for gastroschisis or omphalocele is usually dependent on the morbidity and mortality of associated conditions rather than the abdominal wall defect itself. Surgical conditions such as undescended testicles, Meckel diverticulum, and adhesive small bowel obstruction are encountered with moderate frequency. Adhesive small bowel obstruction most commonly occurs in the first-year of life and requires operative management in the majority.[29] Most children with repaired abdominal wall defects enjoy satisfactory health and quality of life, although they have been reported to have a lower degree of physical fitness measured by exercise time and maximal oxygen consumption.[30]

Umbilical Hernia

Anatomy and Embryology

Congenital umbilical hernia is the most common abdominal wall defect in infants and children. The umbilical ring begins to contract circumferentially after birth and normally is reinforced by the paired lateral umbilical ligaments (the obliterated umbilical arteries), the singular round ligament (the obliterated umbilical vein), the urachal remnant, and the transversalis fascia. Incomplete growth or impaired development of any one of these structures can lead to weakness at the umbilical ring and cause a congenital umbilical hernia.

Clinical Issues and Management

Congenital umbilical hernias generally do not pose significant problems during childhood. Rarely, an umbilical hernia presents with incarceration of intra-abdominal contents within the sac.[31] Infants and children may also present with infection or drainage at the umbilicus from associated urachal or vitelline duct remnants. The incidence rate of congenital umbilical hernia has been reported to be 25% to 50% in black infants and 4% to 9% in white infants in the first few months of life.[32] There is an increased incidence of umbilical hernia in premature infants, and there is a tendency for familial inheritance.

Diagnosis of umbilical hernia is usually made after separation of the umbilical cord remnant from the umbilicus and is often initially noted by parents or pediatrician. The size of the defect may vary from a few millimeters to several centimeters and is typically reducible and asymptomatic. Age and size of the defect are the most important factors determining spontaneous closure rates.[33] Many umbilical hernias spontaneously close within the first 2 to 3 years of life. Parents should be reassured that complications related to untreated umbilical hernia are rare. Given the high rate of spontaneous closure and the relatively asymptomatic nature of most umbilical hernias, operative repair is generally not performed during the first 2 years of life. Skin ulceration or an episode of incarceration should prompt earlier repair. Large defects with significant protrusion may necessitate surgery, and parents may desire repair if an older child appears to be self-conscious about the hernia.

Nearly all umbilical hernia repairs can be performed as outpatient surgical procedures. An incision is made along the umbilicus and the hernia sac is dissected free circumferentially. The sac is completely excised and primary fascial closure is performed. The umbilical skin is typically preserved and sutured to the fascial closure, and an acceptable cosmetic result is almost always achievable. Large umbilical hernias with redundant skin may require umbilicoplasty. The incidence of complications such as wound infection and recurrence is low.

Inguinal Hernia and Hydrocele

Anatomy, Embryology, and Pathophysiology

2 Inguinal hernias constitute one of the major surgical problems of infancy and childhood. Inguinal hernia repair is the most common elective general surgical procedure performed by pediatric surgeons. Three distinct anatomic types of inguinal hernias are observed in children: congenital indirect (99% of infants and children), direct (0.5%), and femoral (<0.5%). An *indirect inguinal hernia* is an abnormal, patent continuation of the peritoneum through the internal inguinal ring. The hernia sac originates lateral to the deep inferior epigastric vessels and descends along the spermatic cord within the cremasteric fascia. The sac can reside completely within the inguinal canal or descend through the external inguinal ring into the scrotum. A *direct inguinal hernia* originates medial to the deep inferior epigastric vessels and is external to the cremasteric fascia. The hernia sac protrudes directly through the posterior wall of the inguinal canal and can descend through the external inguinal ring and into the scrotum. A *femoral hernia* originates medial to the femoral vein and descends inferior to the inguinal ligament along the femoral canal. A femoral hernia never enters the scrotum or the labia.

The developing testicle is initially adjacent to the mesonephros and subsequently descends to the scrotum during the third trimester of gestation. The peritoneal extension that descends alongside the chorda gubernaculum of the testicle is called the processus vaginalis. A slightly higher incidence rate of right-sided indirect inguinal hernia is thought to reflect delay of right-sided testicular descent from the developing inferior vena cava and right external iliac vein. As the testicle descends into the scrotum, the processus vaginalis forms a serous covering around the testicle known as the tunica vaginalis. Normally, the patent processus vaginalis undergoes obliteration, closing the communication between the peritoneal cavity and the inguinal canal. A patent processus vaginalis can lead to a variety of anatomic conditions of the inguinal region (Fig. 103-6).

The incidence of patent processus vaginalis has been reported to be as high as 80% to 94% in newborn infants undergoing autopsy,[34] whereas in adulthood, the incidence is 20% to 30%. Infants with unilateral inguinal hernias have been found to have a patent contralateral processus vaginalis in 60% during the first few months of life. By the age of 2 years, 20% of these hernias were obliterated, and half of the remaining 40% became clinical hernias.[35] At least 30% of infants requiring placement of a ventriculoperitoneal shunt for hydrocephalus have been observed to have a patent processus vaginalis in the first few months of life, with a rapid decline in patency in older children.[36] These studies, along with contemporary use of laparoscopic exploration of the contralateral internal ring, demonstrate that although a patent processus vaginalis is common in infancy, there is some degree of obliteration that occurs with increasing age, and a patent processus vaginalis by itself does not constitute a clinical inguinal hernia.

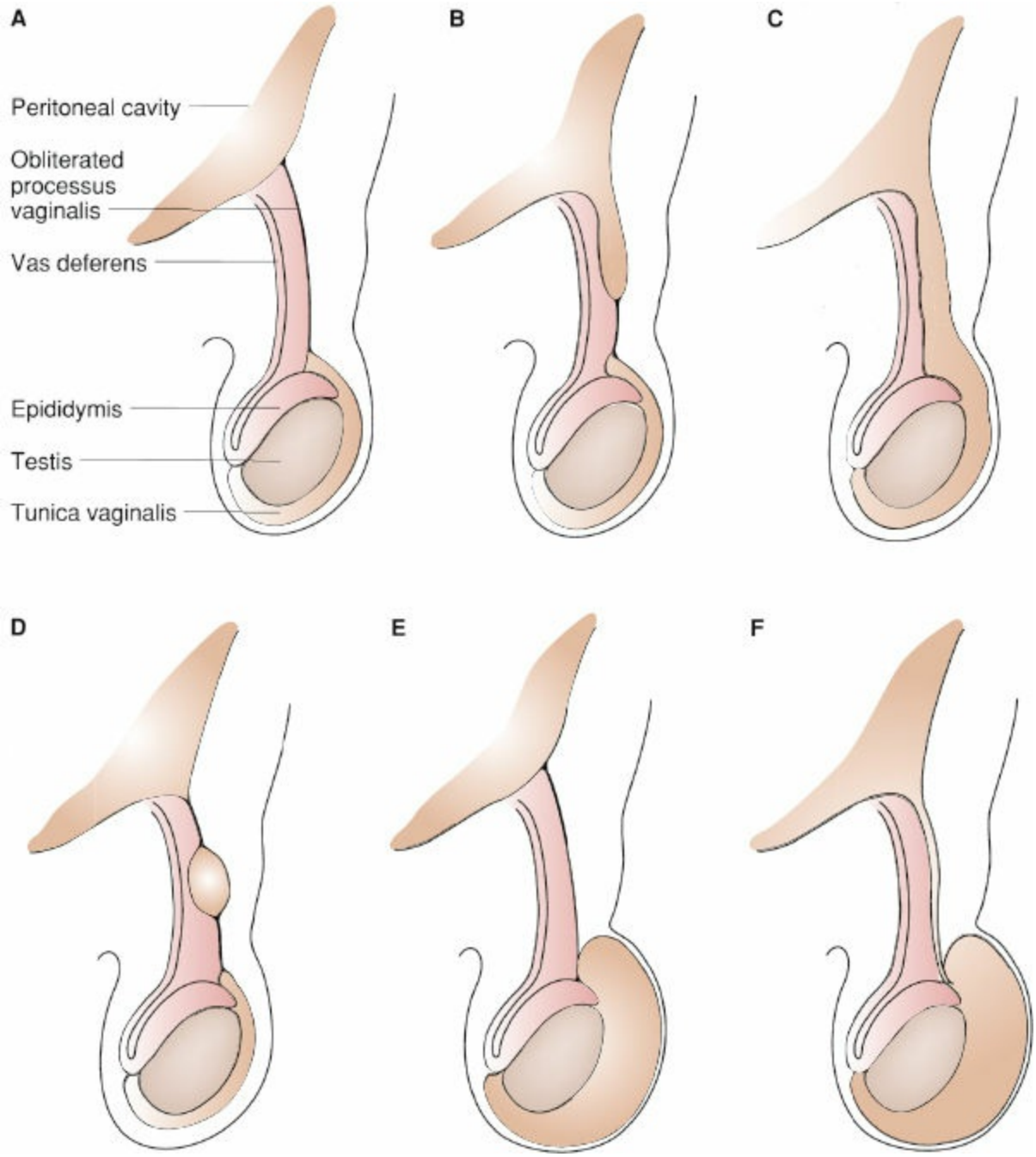

Figure 103-6. Anatomic variations that occur with different degrees of obliteration of the processus vaginalis. **A:** Normal; obliterated processus vaginalis. **B:** Proximal hernia sac; distal obliterated processus. **C:** Hernia sac extending into scrotum; no obliteration. **D:** Proximal and distal obliteration with hydrocele of the cord. **E:** Hydrocele of the scrotum, obliterated processus. **F:** Patent processus with communicating hydrocele.

Clinical Issues

Inguinal hernias occur in 1% to 3% of all children and in 3% to 5% of premature infants. There is no known inheritance pattern, but there is an increased incidence of inguinal hernia in children with connective tissue disorders such as Ehlers–Danlos syndrome and Marfan syndrome. There is a 6:1 predominance of males to females. At least 30% of children are younger than 6 months at the time of operative repair. Inguinal hernia more commonly presents as right-sided (56.2%) compared with left-sided (27.5%) or bilateral (16.2%).[37]

Most infants and children have a history of an intermittent inguinal mass or bulge that

may descend into the scrotum or labia. The hernia may become more pronounced during times of increased intra-abdominal pressure, such as crying or having a bowel movement. Most inguinal hernias in children reduce spontaneously or are reducible with gentle, manual pressure along the inguinal canal. Female infants may have an ovary and fallopian tube in the hernia sac, identified clinically as a firm, slightly mobile, nontender mass in the labia or the inguinal canal. Most parents or pediatricians give a characteristic history that is sufficient to warrant inguinal exploration, even in children in whom the hernia cannot be clinically demonstrated at the time of examination. Depending on institution and surgeon preference, infants and children with a strong history consistent with inguinal hernia and an equivocal clinical examination may be offered ultrasound or diagnostic laparoscopy to effectively confirm the diagnosis before groin exploration.[38]

Incarceration is a common consequence of untreated inguinal hernia and presents as a nonreducible mass in the inguinal canal, scrotum, or labia.[39] Clinical symptoms and signs are related to the duration of incarceration. If the incarceration has been present for several hours, the infant may be inconsolable and have feeding intolerance, pain, abdominal distention, vomiting, and lack of flatus or stool, signaling complete intestinal obstruction. The affected groin may become quite edematous, and a reactive scrotal hydrocele may evolve. Elevation of the infant's lower extremities with a pillow may help encourage spontaneous reduction. Attempts at manually reducing an incarcerated inguinal hernia should be performed by an experienced surgeon. If necessary, sedation to calm the infant before attempting manual reduction may be cautiously used. Ice packs should be avoided in infants and children. Following successful reduction of an incarcerated hernia, expedient elective repair of the hernia should be performed after the edema has subsided. If reduction of an incarcerated hernia requires several attempts and is difficult, overnight inpatient observation is warranted to rule out reduction of strangulated bowel; fortunately, this is an uncommon occurrence in the pediatric population. Inability to reduce an incarcerated hernia is a clear indication for urgent operative exploration and repair. Incarcerated inguinal hernia must be differentiated from an acute, noncommunicating hydrocele, or inguinal lymphadenitis. With acute hydrocele, it is usually possible to transilluminate the hydrocele and palpate normal cord structures above the scrotal mass. In addition, symptoms of bowel obstruction are absent with acute hydrocele. Acute lymphadenitis typically is associated with fever, erythema, and tenderness, and there may be a history of lower-extremity infection on the ipsilateral side. If the inguinal mass is not reducible and an incarcerated hernia cannot be excluded, urgent groin exploration is required.

Operative Considerations and Outcome

The diagnosis of inguinal hernia in an infant or a child is an indication for operative repair. The rationale for elective repair is to prevent the complications associated with incarceration. At least 71% of infants who require operative reduction of incarcerated inguinal hernia are younger than 11 months.[40] Therefore, an approach emphasizing timely elective repair of inguinal hernia is warranted, particularly during infancy. Delay of elective repair may be necessary in premature, extremely low–birth-weight (<1,500

g) infants and in children with other conditions such as congenital heart disease, pulmonary disease, infection, or metabolic disease.

Elective inguinal hernia repair in the pediatric age group is usually performed as an outpatient surgical procedure using general anesthesia, although spinal anesthesia is an effective alternative in selected high-risk infants.[41] A regional caudal block or local inguinal nerve block using local anesthetic is useful to diminish perioperative pain and increase patient comfort. These techniques, along with the use of rapid-acting general anesthetics, allow the vast majority of children to be discharged home within hours of operation. Overnight observation and monitoring are required for high-risk infants and children with disorders that increase anesthetic risk for postoperative apnea.

Repair of pediatric inguinal hernia relies on high ligation of the hernia sac at the internal inguinal ring. Sensory nerves deep to the external oblique aponeurosis should be identified and preserved. Careful identification and dissection of the hernia sac from the vas deferens and the testicular blood supply must be performed. The vas deferens must be carefully dissected free from the sac, and direct handling or pinching of the vas with forceps is avoided. The absence of a vas deferens or a blind-ending vas may be observed in children with cystic fibrosis (CF). In female infants, opening the hernia sac to visualize the ovary and fallopian tube may help avoid inadvertent injury to these structures during suture ligation of the sac. The distal component of the hernia sac is opened widely, and any fluid in the sac is evacuated. If the internal inguinal ring is attenuated or enlarged, it can be repaired with a few sutures. Experience with laparoscopic inguinal hernia repair using purse–string suture closure of the patent internal ring without direct inguinal exploration has been described.[42] The testicle is returned to its scrotal position by gentle traction on the gubernaculum, and the spermatic cord is carefully aligned along the inguinal canal. Postoperative pain is managed with oral acetaminophen for 24 to 48 hours; older children may require postoperative narcotics. In addition, abnormalities of the vas deferens may be associated with genitourinary anomalies. A renal ultrasound should be permed to rule out kidney malformations.

Operative exploration of the asymptomatic contralateral groin remains controversial but is often performed in infants younger than 2 years because of the reported 60% to 70% incidence of a patent processus vaginalis on the opposite side.[43] In a survey of the surgical section of the American Academy of Pediatrics, 65% of the respondents perform contralateral exploration in male patients younger than 2 years, and 84% perform exploration for female infants up to 4 years of age.[44] Direct visualization of the contralateral groin can be performed using a laparoscope inserted either through the umbilicus or through a side-viewing laparoscope inserted through the hernia sac. Experience with diagnostic laparoscopy demonstrates that approximately one-third to one-half of children have a patent processus vaginalis on the contralateral, asymptomatic groin, with higher rates in infants younger than 1 year.[45,46] This approach avoids unnecessary contralateral groin exploration in about half of all children who undergo surgery for unilateral inguinal hernia. However, the presence of a patent processus alone does not necessarily translate into a clinically significant hernia, and via systematic review, the reported risk of developing a metachronous contralateral inguinal hernia

following open unilateral hernia repair in children is 7.2%.[47]

The major risk of inguinal hernia repair in infants and children is related to general anesthesia. Complications in pediatric inguinal hernia repair include wound infection, injury to the vas deferens or testicular vessels, injury or displacement of the testicle, and recurrence. Fortunately, all these complications are infrequent. The overall complication rate is higher for children requiring emergent operation for incarcerated or strangulated hernia. Recurrent inguinal hernia following elective repair is unusual and may be an indication of an underlying connective tissue disorder such as Ehlers–Danlos syndrome.

Hydrocele

A *hydrocele* is a fluid collection that resides in the tunica vaginalis in the scrotum or the processus vaginalis in the inguinal canal. A hydrocele may be present at birth, or it may occur acutely as a result of an incarcerated hernia or torsion of the appendix testis. On examination, a hydrocele transilluminates with a bright handheld light. A hydrocele is described as either *communicating* or *noncommunicating* depending on whether there is direct patency between the hydrocele and the peritoneal cavity. A history of intermittent fluctuation in the size of the hydrocele is generally diagnostic for communicating hydrocele. A communicating hydrocele is synonymous with a patent processus vaginalis, and, therefore, a communicating hydrocele is treated operatively in the same fashion. In male patients, a hydrocele of the cord is a collection of fluid in the processus vaginalis separate from the tunica vaginalis. In female patients, fluid trapped in the processus vaginalis is considered a hydrocele of the canal of Nuck. In noncommunicating hydrocele, the isolated fluid collection is typically asymptomatic and tends to spontaneously resolve before age 12 months. Operative management of noncommunicating hydrocele is usually reserved for lesions that persist after this age, acute enlargement of the hydrocele, or if there is any question of communication.

Neonatal Intestinal Obstruction

3 A variety of congenital anatomic defects, inherited metabolic diseases, and acquired physiologic disorders may present as intestinal obstruction in a newborn. Neonatal intestinal obstruction is characterized clinically by bilious emesis and is often associated with abdominal distention. Bilious emesis in a neonate must be considered to be acute mechanical intestinal obstruction until proven otherwise. Emergent surgical evaluation is warranted for any newborn with bilious emesis. Table 103-2 provides differential diagnoses for neonatal intestinal obstruction along with salient features of the history, physical examination, and diagnostic studies.

Table 103-2 Neonatal Intestinal Obstruction

Diagnosis	History	Physical Examination	Diagnostic Studies
Intestinal atresia or stenosis	Bilious emesis Failure to pass meconium	Abdominal distention Abdominal distention	Plain abdominal film Contrast enema
Duodenal atresia or stenosis	Bilious or nonbilious emesis Feeding intolerance	Gastric distention Trisomy 21	Plain abdominal film Upper GI contrast study
Imperforate anus	Failure to pass meconium Bilious emesis (late)	Absent anus or visible fistula Abdominal distention VACTERL association	Plain chest, abdominal film Ultrasound kidneys, sacrum, rectum Echocardiogram
Necrotizing enterocolitis	High-risk, premature infant Bilious emesis	Abdominal distention Abdominal wall erythema Hematochezia, guaiac positive stool	Plain abdominal film
Meconium ileus	Cystic fibrosis (10%) Bilious emesis	Acholic meconium Abdominal distention	Plain abdominal film Contrast enema
Malrotation	Bilious emesis Term, healthy infant	No abdominal distention	Plain abdominal film Upper GI contrast study
Hirschsprung disease	Delayed passage of meconium Bilious emesis	Abdominal distention Trisomy 21	Plain abdominal film Contrast enema
Uncommon causes of obstruction (intussusception, Meckel diverticulum, duplication)		Abdominal mass, incarcerated hernia	Variable
Medical conditions associated with ileus	Bilious emesis	Sepsis, hypothyroidism, etc.	Plain abdominal film

GI, gastrointestinal; VACTERL, vertebral, anal, cardiac, tracheal, esophageal, renal, and limb anomalies.

The clinical presentation of neonatal intestinal obstruction depends, in part, on the site of obstruction and the age of the infant. Clinical examination of the infant typically provides the surgeon with a preliminary diagnosis and helps guide further diagnostic studies. Abdominal distention is a characteristic physical finding with distal bowel obstruction, whereas the abdomen may be flat in proximal obstruction. The presence of

bile in the gastric contents or stool provides clinical evidence of the location of an obstruction relative to the ampulla of Vater. Bilious emesis in an infant or child should be considered an anatomic obstruction requiring emergent surgical evaluation. An infant with bilious emesis who has already passed meconium and has tolerated feeding is unlikely to have intestinal atresia and more likely to have intestinal malrotation with midgut volvulus. If volvulus is suspected, emergent evaluation must be performed to diagnose and prevent catastrophic bowel injury or death.

Definitive diagnosis of neonatal intestinal obstruction may often be made by physical examination and readily available radiologic studies. Incarcerated inguinal hernia is an important cause of neonatal bowel obstruction, and examination leads to a straightforward diagnosis. Some congenital conditions have clearly recognizable features and may be associated with anatomic intestinal obstruction. For example, infants with trisomy 21 have a higher probability of having duodenal atresia or Hirschsprung disease than the general population. An approach to imaging the neonate suspected of having an intestinal obstruction is to obtain a plain abdominal radiograph, followed by either a contrast enema or an upper gastrointestinal series. Plain films of the newborn abdomen can be extremely useful because swallowed gas acts as a contrast agent. For example, duodenal atresia gives rise to a dilated, gas-filled stomach and duodenum proximal to the obstruction; the remainder of the bowel remains gasless, giving rise to the “double-bubble” appearance on plain films. Other causes of proximal intestinal obstruction may lead to a microcolon on contrast enema, which is a small, unused but otherwise normal colon. If a retrograde contrast enema does not pass into the dilated segment of bowel, an upper gastrointestinal series may be useful to identify a more proximal obstruction. Upper gastrointestinal series is also the most useful diagnostic test for intestinal malrotation.

Several medical conditions of the newborn appear clinically similar to mechanical intestinal obstruction (see Table 103-2). In particular, bilious emesis from ileus secondary to neonatal sepsis is not uncommon. Congenital hypothyroidism is an infrequent and medically treatable condition that can produce delayed intestinal motility that mimics mechanical intestinal obstruction.

Intestinal Atresia or Stenosis

Embryology and Anatomy

The embryonic intestine undergoes segmental development during the third week of gestation. The septum transversum demarcates the developing foregut from the midgut. The midgut can be considered a tubular structure that progressively undergoes several predictable, developmental stages: (a) elongation; (b) herniation from and reduction into the coelomic cavity; (c) rotation; and (d) fixation of the mesentery to the posterior body wall.

Several different types of intestinal atresia are clinically observed (Fig. 103-7). *Type I* atresia is an intraluminal web or diaphragm that can either be complete or fenestrated with intact seromuscular layers of bowel. *Type II* and *IIIa* atresia are believed to be a result of in utero mesenteric vascular accidents. Experimental interruption of the fetal mesenteric blood supply in utero leads to this type of atresia.[48,49] *Type IIIb* atresia, also known as the *apple-peel* or *Christmas tree deformity,* has complete mesenteric discontinuity, with the distal bowel concentrically surrounding a singular mesenteric blood supply. *Type IV* atresia has multiple segmental areas of discontinuous bowel. Type IIIb and IV atresia are thought to be consequences of major and multiple fetal mesenteric vascular interruption.

At least 90% of infants with congenital intestinal obstruction of the small bowel have complete atresia, whereas the remaining children have either stenoses or fenestrated intraluminal webs. The most common location is the distal ileum, and multiple areas of atresia are discovered in 3.6% to 20% of these infants.[38] Infants with fenestrated intraluminal webs may have a small, often eccentric opening only millimeters in diameter. These infants may not have obstructive symptoms until the introduction of solid food at 6 to 12 months of age and present with feeding intolerance, failure to thrive, or abdominal pain.

Congenital colonic atresia is a distinctly unusual condition. In a contemporary series of 277 infants treated with intestinal atresia, only 21 children had colonic atresia.[50] Similar to small bowel atresia, colonic atresia is believed to reflect fetal mesenteric vascular injury. Given the distal nature of colonic atresia, initial feeding may be well tolerated and definitive diagnosis may be delayed for several days. The diagnostic evaluation and surgical treatment of colonic atresia is identical to the approach used for small bowel atresia. Colonic atresia may be associated with abdominal wall defects, skeletal or cardiac defects, or coexisting intestinal atresia.

Clinical Presentation

The actual incidence rate of congenital intestinal atresia is unknown. Reported estimates in the United States are 3.5 to 3.75 cases per 10,000 total births.[51] Infants with jejunal or ileal atresia have a low incidence rate of significant associated anomalies. Approximately 10% of infants with gastroschisis have intestinal atresia or stenosis secondary to mechanical interruption of the mesenteric vascular supply.

Detection of maternal polyhydramnios on routine prenatal ultrasound screening can be

an indication of proximal bowel obstruction caused by the interruption of normal amniotic fluid absorption in the fetal gut.[52] Following delivery, the classic clinical presentation of intestinal atresia is bilious emesis, abdominal distention, and failure to pass meconium. The degree of abdominal distention depends on the site of obstruction, the infant's age, and the efficacy of proximal decompression. Abdominal distention may be absent with proximal intestinal atresia. Distal intestinal atresia may lead to abdominal distention with visible or palpable intestinal loops on examination. Rectal examination and evaluation of stool character remains important when intestinal obstruction is suspected.

Diagnosis

Following history and physical examination, plain radiographic abdominal films should be obtained. Plain films in jejunal or ileal atresia demonstrate marked gaseous distention of the proximal intestine with gasless distal small bowel and colon. Haustral markings are normally not apparent in the neonatal colon, and, therefore, discrimination between small bowel and colon in the newborn is difficult without intraluminal contrast. A contrast enema is generally obtained to confirm the diagnosis of jejunoileal atresia. A diminutive, unused but otherwise normal microcolon is typical of proximal intestinal obstruction. The inability to reflux contrast into the proximal, dilated small bowel segment is diagnostic for congenital intestinal obstruction. This radiographic finding, in conjunction with the clinical setting, warrants operative exploration. An upper gastrointestinal series is unnecessary and may increase the risk of further emesis and aspiration in the newborn with obstruction. Incomplete obstruction from a fenestrated intraluminal web may require more sophisticated imaging techniques such as catheter-directed enteroclysis.

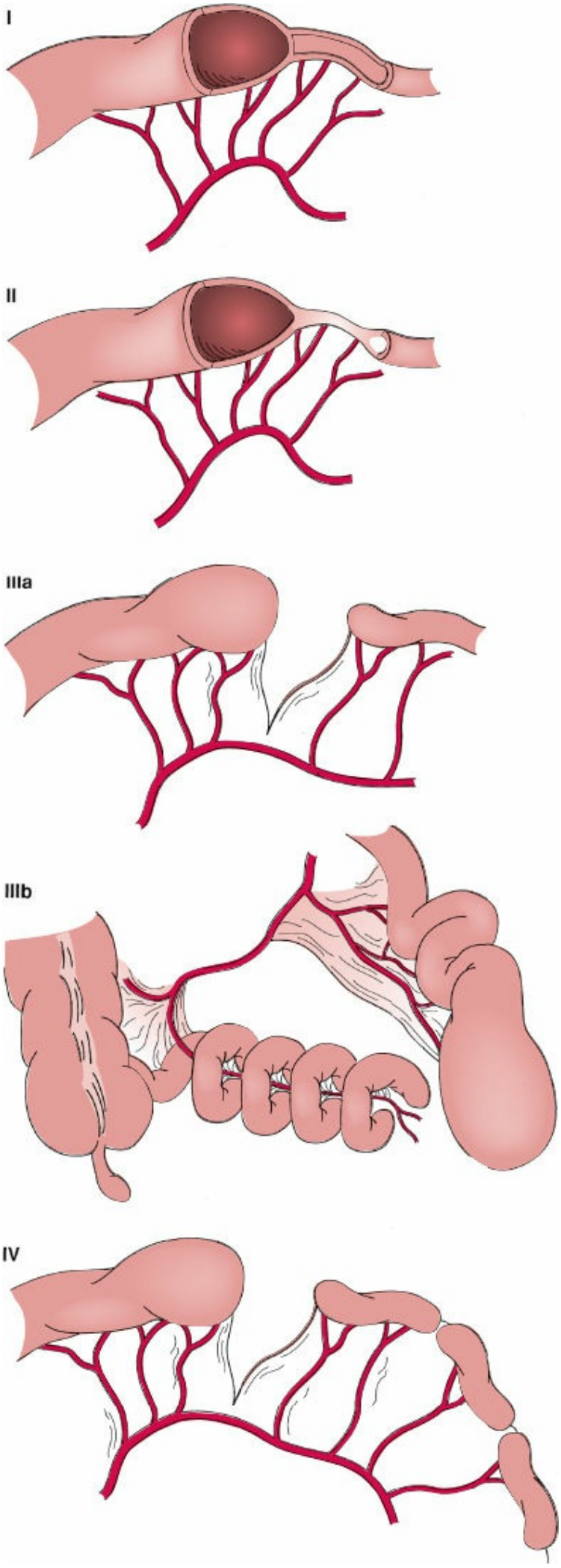
I
II
IIIa
IIIb
IV

Figure 103-7. Classification of intestinal atresia. Type I, muscular continuity with a complete web. Type II, mesentery intact, fibrous cord. Type IIIa, muscular and mesenteric discontinuous. Type IIIb, apple-peel deformity. Type IV, multiple atresias.[56]

Treatment

Anatomic lesions causing neonatal intestinal obstruction require operative treatment. Whereas malrotation with midgut volvulus requires emergent diagnostic workup and operative intervention, obstruction resulting from intestinal atresia is generally not associated with life-threatening physiologic disturbances. Therefore, initial treatment is aimed at treating any other associated problems, confirming diagnosis, and preparing the infant for an operation. During this period, the infant should always have an orogastric or nasogastric tube in place to provide proximal decompression of the obstructed bowel.

The operative strategy in treating intestinal atresia is to restore gastrointestinal tract continuity while preserving as much intestinal length as possible. The operation is straightforward and an end-to-end or end-to-oblique (end-to-back) anastomosis is typically performed (Fig. 103-8). Short-segmental bowel resection and excision of an intraluminal web or diaphragm are done when necessary. Visual inspection and instillation of intraluminal saline or air to exclude distal atresia or web prior to anastomosis is important to evaluate patency of the downstream bowel. The size discrepancy between the proximal and distal bowel is usually considerable, and delayed postoperative bowel motility is common. Some surgeons advocate the use of technical procedures to improve emptying of the proximal bowel by reducing overall bowel diameter. These procedures include resection, plication, and tapering enteroplasty. Complex atresia associated with apple-peel deformity or multiple segmental atresias may require multiple serial anastomoses to preserve as much bowel length as possible. The ileocecal valve is preserved whenever possible, allowing improved tolerance of enteral nutrition in infants with limited small bowel length. It is estimated that approximately 40 cm of small bowel without an ileocecal valve, compared with 15 to 20 cm with an ileocecal valve, is sufficient for long-term enteral feeding tolerance in the neonate.[53] Contemporary management of colonic atresia includes primary anastomosis when technically possible.

Results and Outcome

Currently, the overall survival rate for infants treated for intestinal atresia or stenosis (including duodenal atresia) exceeds 93% in most large series.[50,54] Mortality in these infants is generally related to cardiac anomalies, birth weight less than 2 kg, and associated congenital anomalies.[55] Infants with a limited amount of intestinal length for nutritional absorption (short bowel syndrome with less than 40 cm) usually require long-term TPN and are at moderate to high risk for sepsis and liver injury. Infants with normal gastrointestinal length may still have prolonged intestinal dysfunction and dysmotility for several weeks.

Congenital Duodenal Obstruction

Causes of duodenal obstruction in the newborn include duodenal atresia or stenosis, duodenal intraluminal web, and annular pancreas. Because of the common embryologic basis, clinical presentation, and treatment, these entities are considered jointly.

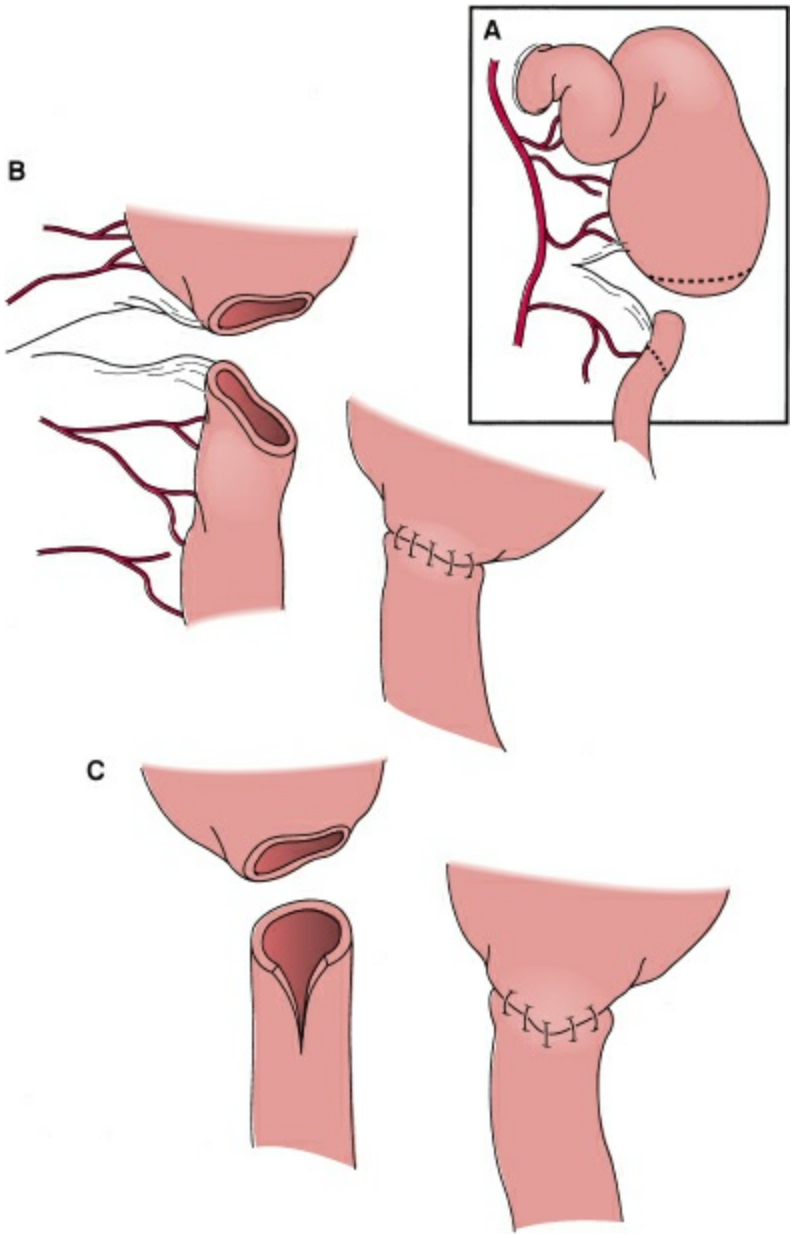

Figure 103-8. **A,B:** The end-to-oblique anastomosis for small bowel atresia. **C:** An extension of the distal enterostomy along the antimesenteric border may be used to create proximal and distal lumens of equal size for anastomosis.

Embryology and Anatomy

The duodenum is derived from both the caudal segment of the foregut and the cranial segment of the midgut. Duodenal development is intimately related to the developing pancreaticobiliary system. The fetal pancreas arises from paired dorsal and ventral foregut diverticula during week 6 of gestation. The dorsal anlage gives rise to the body and tail of the pancreas as well as the main pancreatic duct. The ventral anlage migrates 180 degrees to fuse with the dorsal gland, forming the uncinate process and the distal portion of the duct of Wirsung (Fig. 103-9). An annular pancreas is characterized by

glandular persistence surrounding the duodenum at the site of the embryonic ventral anlage. It is invariably associated with intrinsic duodenal obstruction, and a patent accessory pancreatic duct is common (Fig. 103-10).[57]

It is believed that congenital duodenal obstruction results from abnormalities of pancreatic development, failure of duodenal recanalization, or vascular compromise to the duodenum. Duodenal atresia may occur with or without seromuscular continuity, and an intraluminal duodenal web may occur with or without fenestration. The most frequent location for duodenal atresia is in the descending duodenum distal to the ampulla of Vater. Most series report a 5% to 10% incidence of duodenal atresia proximal to the ampulla, giving rise to nonbilious gastric contents and emesis. Another important variant is a periampullary web projecting distally into the duodenal or jejunal lumen, forming a "wind-sock" deformity (Fig. 103-11). In this instance, the ampulla must be clearly identified before excision and repair because of the proximity of the ampulla to the web.

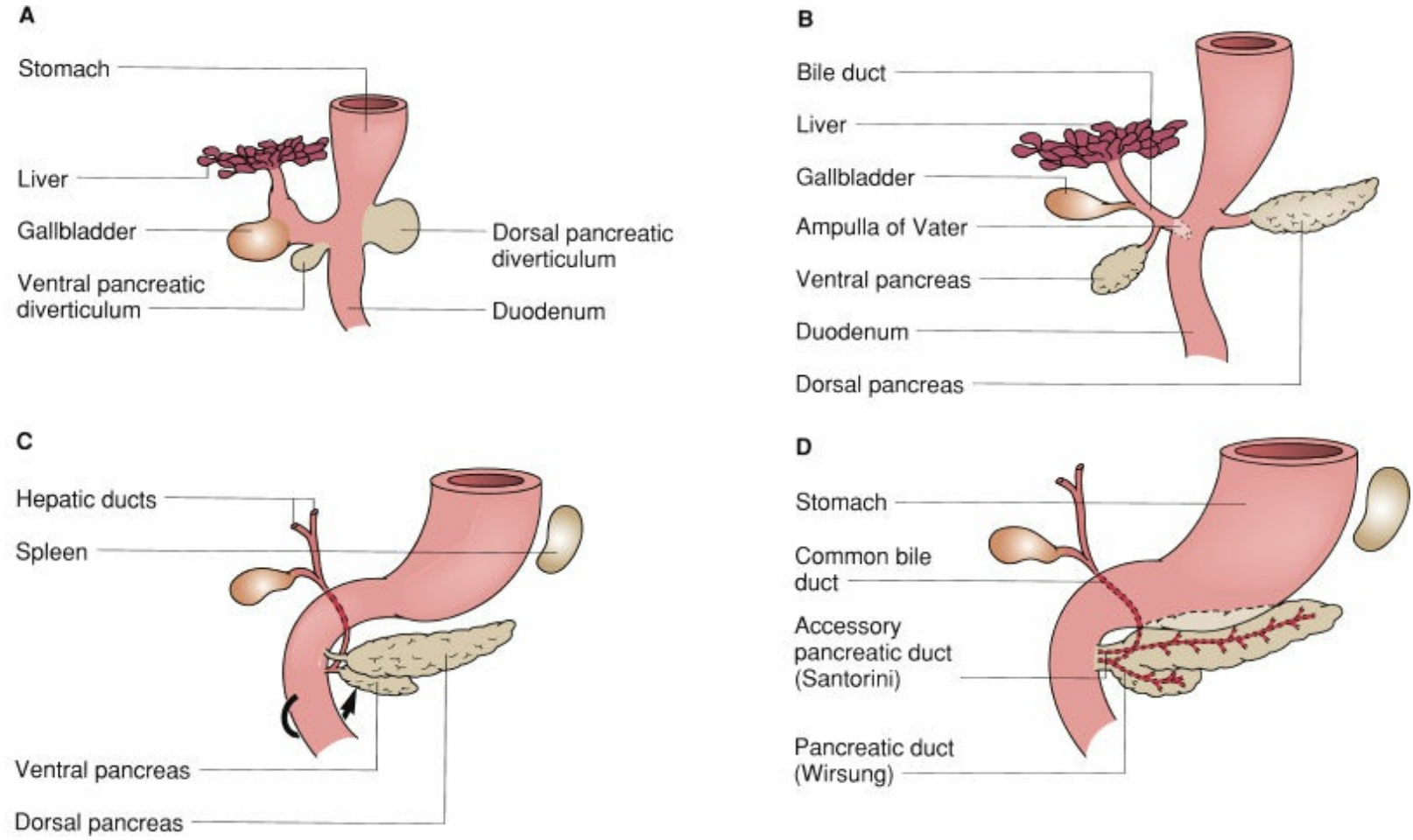

Figure 103-9. Normal embryologic development of the duodenum, pancreas, and bile ducts. **A:** Fifth gestational week. **B:** Sixth week. **C:** Seventh week. **D:** Eighth week.

Clinical Presentation

The incidence rate of congenital duodenal obstruction is estimated to be about 1 in 6,000 to 10,000 births.[58] About 30% of these infants have trisomy 21.[59] Infants born with duodenal atresia should be examined with a high degree of suspicion for trisomy 21 and undergo routine karyotype analysis. Other associated anomalies such as congenital heart

disease, genitourinary tract malformations, and musculoskeletal disorders are common in these infants, and appropriate preoperative workup is necessary.

Congenital duodenal obstruction most commonly presents in the first 24 to 48 hours of life with feeding intolerance and bilious emesis; duodenal obstruction proximal to the ampulla of Vater results in nonbilious emesis. On physical examination, infants with untreated duodenal obstruction may have a palpable epigastric mass, and gastric peristaltic waves may be visible. The collapsed and unused distal small intestine typically does not produce diffuse abdominal distention. Partial duodenal obstruction from a fenestrated web may not produce symptoms in the newborn period, and delayed diagnosis is common.

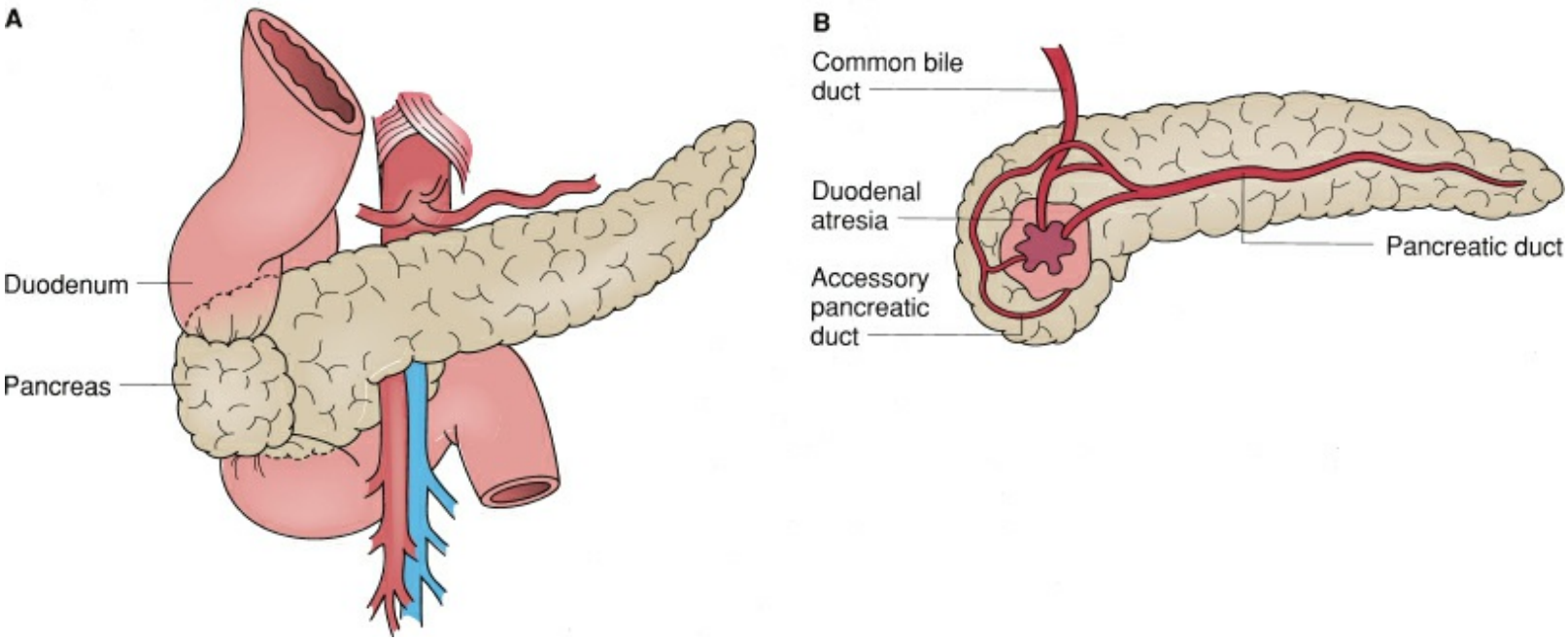

Figure 103-10. Annular pancreas. **A:** The associated duodenal atresia is shown. **B:** The relationships of the annular pancreas to the common bile duct and main and accessory pancreatic ducts are shown in cross section.

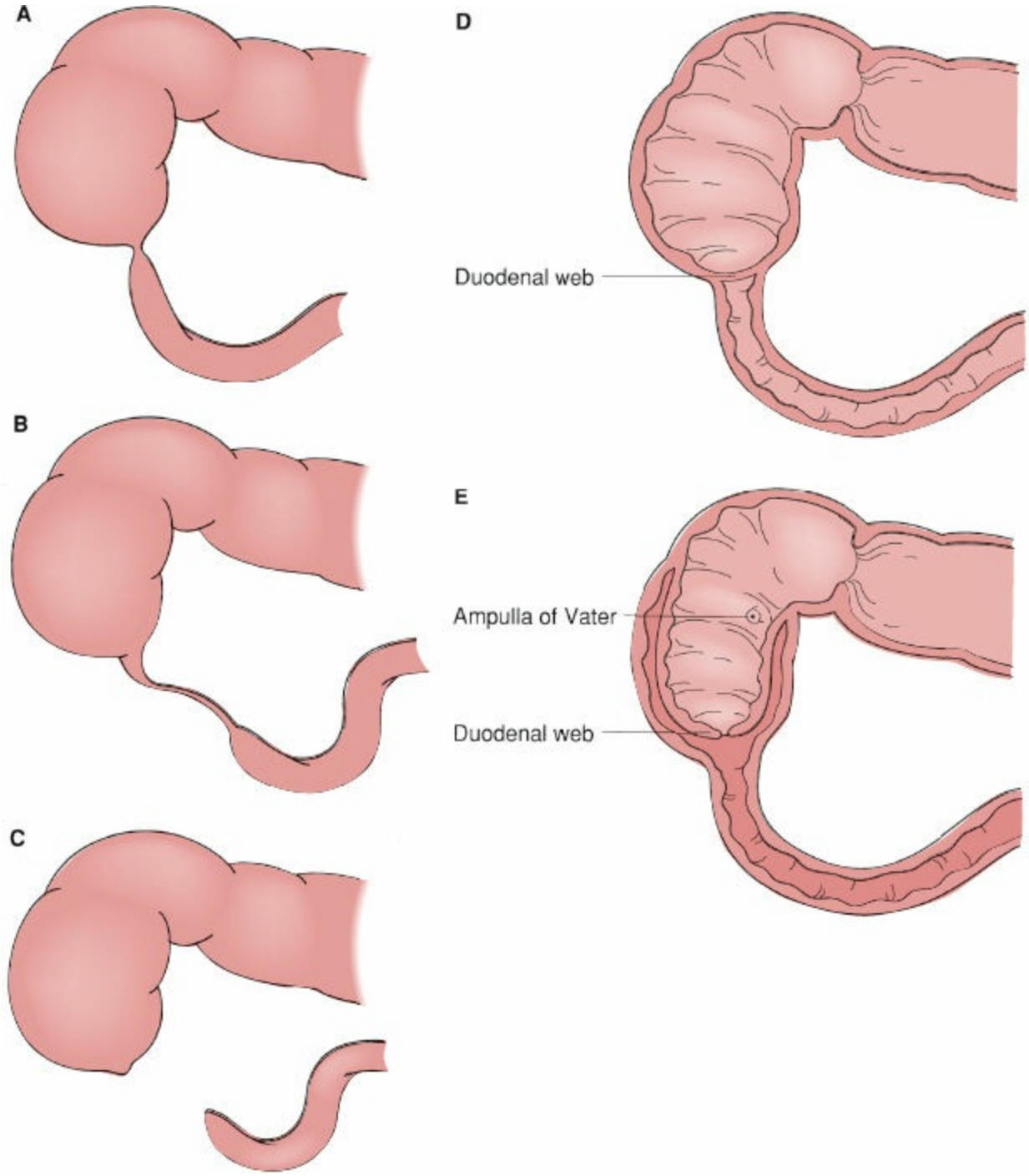

Figure 103-11. Anatomic forms of duodenal atresia (**A–C**) and webs (**D,E**). In particular, (**E**) demonstrates the unique wind-sock deformity. This lesion is important and potentially confusing because the point of obstruction is not at the apparent point of change in luminal diameter.

Diagnosis

Prenatal diagnosis of duodenal atresia is possible given contemporary fetal ultrasound techniques. Following birth, infants with suspected duodenal atresia should obtain plain abdominal radiographs. The classic radiographic finding of duodenal atresia is a double bubble from the air-filled stomach and duodenum (Fig. 103-12). In complete duodenal obstruction, no gas is seen distal to the duodenum; in this setting, the plain film is sufficiently diagnostic that no further imaging of the gastrointestinal tract is necessary. If there is incomplete obstruction, gas may be seen distally in the small or large intestine. Infants with suspected incomplete obstruction at the duodenal level may have either a

fenestrated web or volvulus secondary to malrotation. Given the need for emergent operative intervention in malrotation with acute volvulus, an urgent upper gastrointestinal series with contrast should be strongly considered to exclude a neonatal surgical emergency. Importantly, all anatomic lesions causing neonatal duodenal obstruction require operative repair using a similar approach.

Treatment

Following expedient treatment of any associated life-threatening medical conditions and preoperative evaluation, the operative goals are to restore gastrointestinal continuity without sacrificing intestinal length or absorptive surface area. Because most lesions causing congenital duodenal obstruction are near the ampulla of Vater, great care must be exercised in treatment to avoid inadvertent injury to the ampulla or the pancreas.

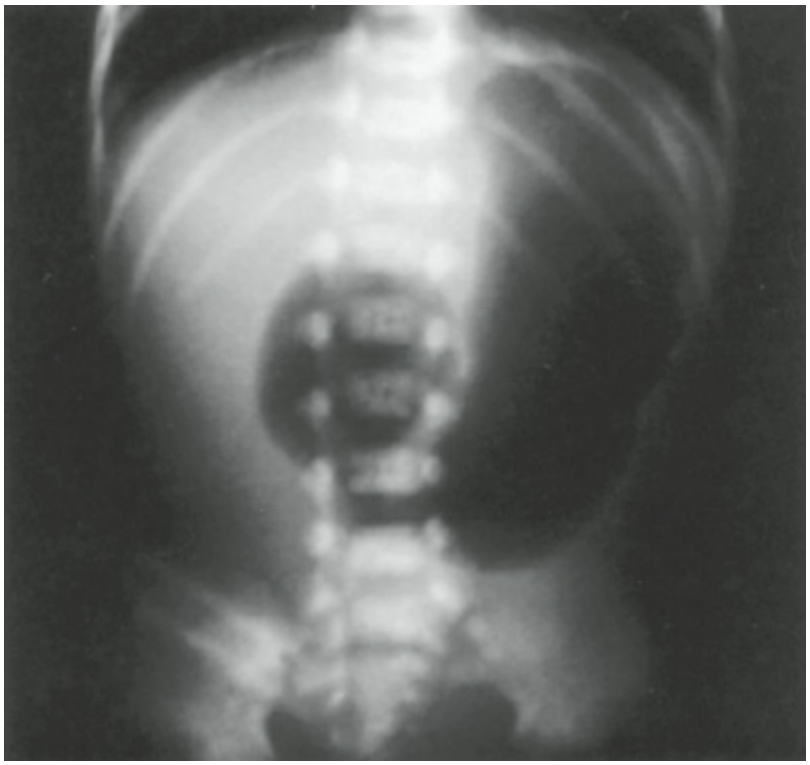

Figure 103-12. Classic radiographic appearance of duodenal atresia. There is a double bubble of gas in the stomach and the proximal duodenum, with no gas in the distal intestinal tract.

Congenital duodenal atresia is treated by duodenoduodenostomy. Duodenal obstruction secondary to annular pancreas is also treated by duodenoduodenostomy. Direct division of annular pancreas is not performed because this does not address the underlying intraluminal duodenal obstruction, and there is significant risk of injury to the accessory pancreatic duct (see Fig. 103-10).

Duodenoduodenostomy is performed by making a transverse incision in the dilated, proximal duodenum and a longitudinal incision in the unused, downstream duodenum. The lumens are sutured together to form a diamond-shaped anastomosis (Fig. 103-13).[60] Downstream duodenal patency should be demonstrated by passing a catheter or infusing saline or air distally to avoid overlooking synchronous distal intestinal atresia. Successful and efficacious laparoscopic duodenal atresia repair has also been reported.[61]

Duodenal webs are excised through a longitudinal duodenotomy. The wind-sock duodenal web must be clearly identified because the visible transition from the distended, proximal duodenum to the small, downstream duodenum may be several centimeters distal to the base of the web. The ampulla of Vater must be unequivocally identified before duodenal web excision to avoid injury. Closure of the longitudinal duodenotomy is performed transversely to avoid narrowing of the duodenum.

There is usually great size discrepancy between the dilated, proximal pouch and the distal duodenal lumen, leading some surgeons to advocate procedures designed to reduce the diameter of the proximal duodenum in an effort to facilitate improved postoperative bowel motility. The efficacy of these procedures, which include tapering duodenoplasty and duodenal plication, has been described in anecdotal fashion without randomized comparison.

Results and Outcome

After successful operative repair of duodenal atresia or stenosis, delayed gastric emptying is common and typically manifests as enteral feeding intolerance. Patience and persistence are essential during the postoperative period. Surgical outcomes after repair of congenital duodenal obstruction are excellent,[59–62] with perioperative survival exceeding 95%. Perioperative mortality is generally related to other congenital anomalies and, in particular, congenital heart disease in infants with trisomy 21. Other late problems may be encountered that reflect gastroduodenal motility issues such as poor gastric emptying, gastroesophageal reflux, and duodenal dilatation. These symptoms may appear several months to years following repair and, therefore, long-term surgical follow-up remains important.

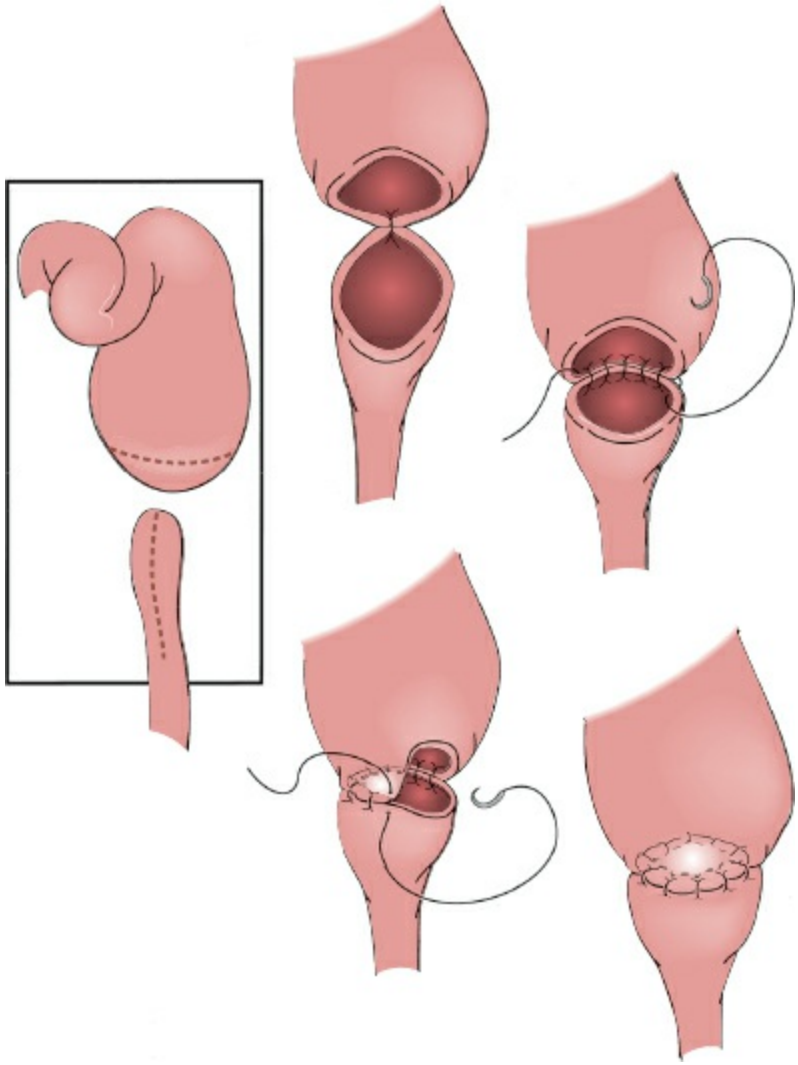

Figure 103-13. Diamond-shaped duodenoduodenostomy for repair of duodenal atresia.

Anorectal Malformations (Imperforate Anus)

Embryology

By week 5 of gestation, the fetal cloaca is identifiable with the adjacent hindgut, allantois, and vestigial tailgut (Fig. 103-14). The mesoderm of the urorectal septum extends caudally to fuse with the cloacal closing plate. Fusion of the lateral cloacal ridges completes division of the cloaca into the rectum and the urogenital sinus. The caudal aspect of the urorectal septum forms the perineal body. The anal membrane normally ruptures during week 8 of gestation, completing the patency of the distal rectum to the skin. Further development of the urogenital sinus leads to the formation of the urethra and the bladder. In female infants, the uterus and the proximal vagina develop from the müllerian ducts. The diverse anatomic variation observed with anorectal malformations is thought to reflect anomalous or interrupted development of these structures during normal embryogenesis.

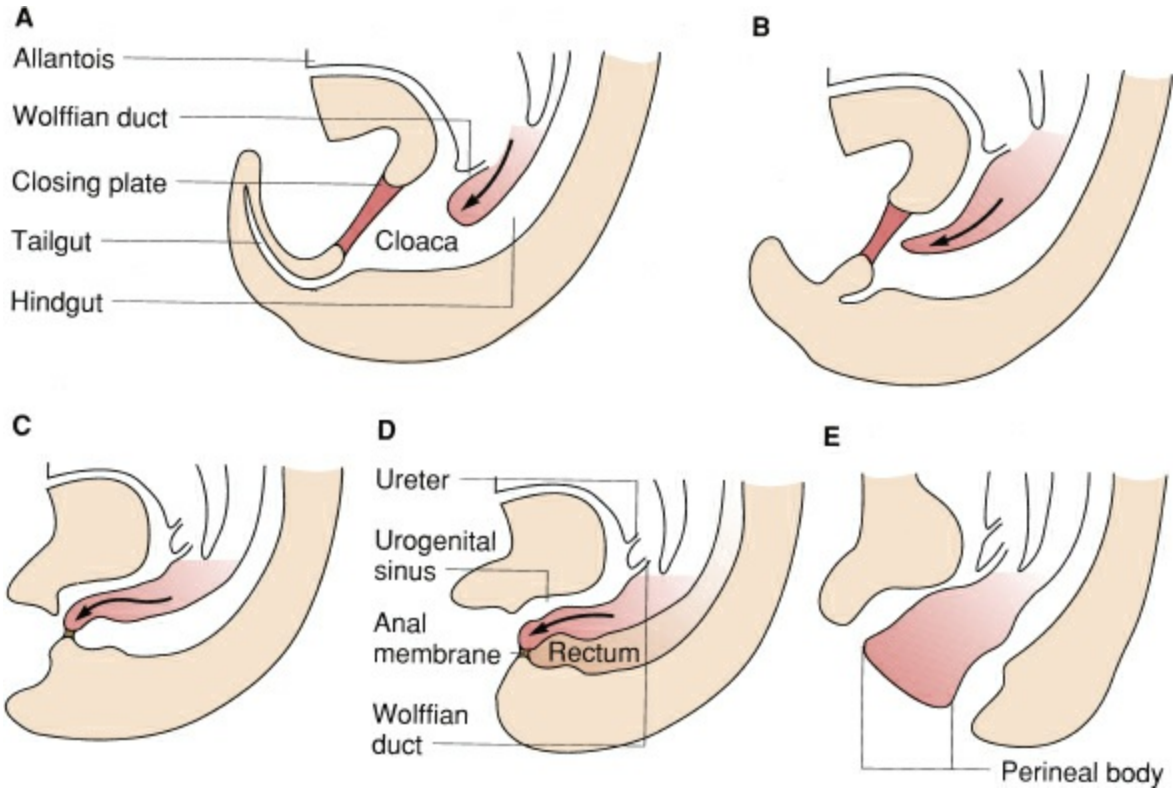

Figure 103-14. Normal embryologic division of the cloaca by the urorectal septum into the ventral urinary tract and the dorsal rectum. This process is normally completed by the ninth or tenth week of gestation.

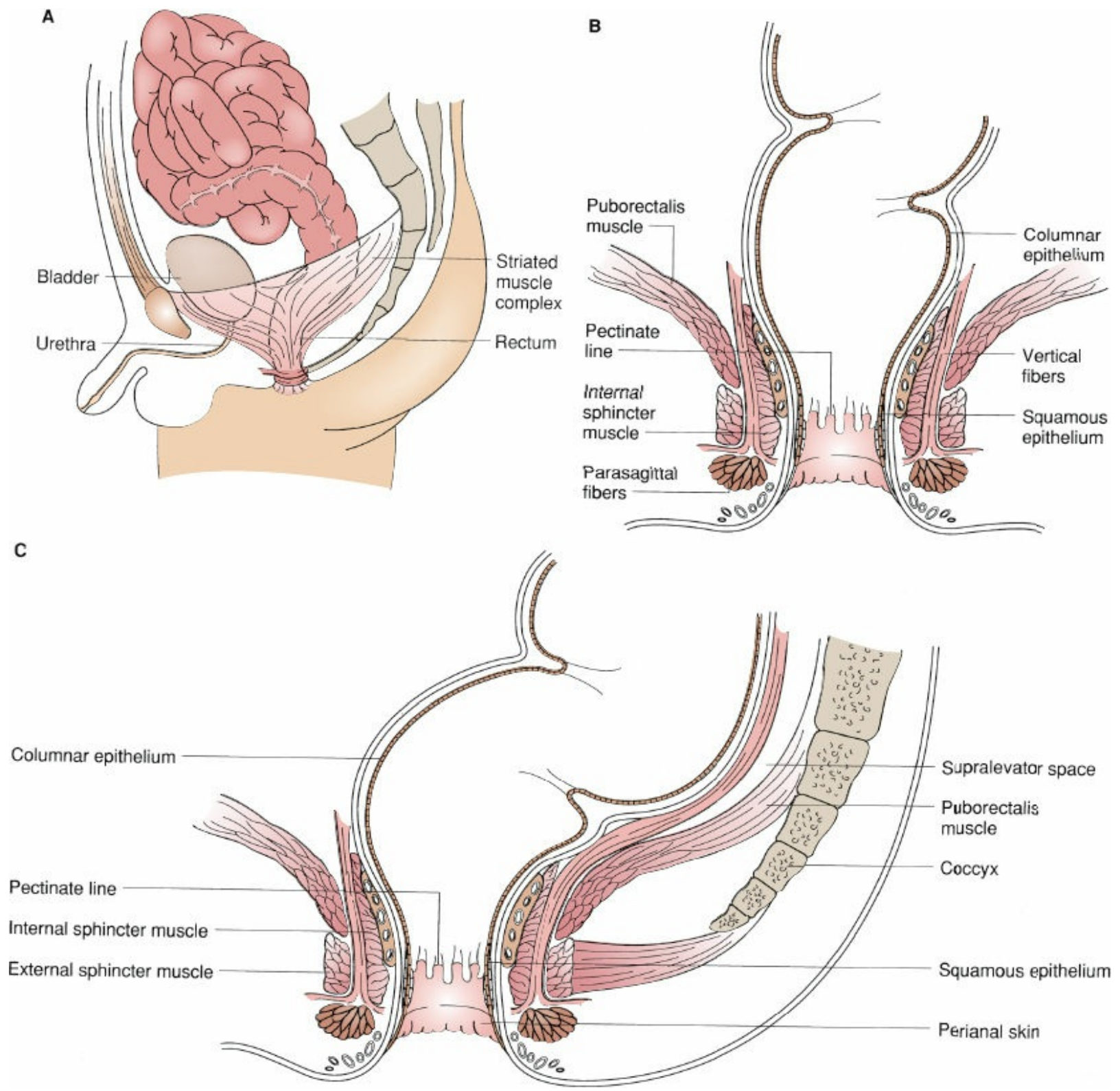

Figure 103-15. The normal relations of the pelvic striated muscle complex and the rectum. **A:** Normal male anatomy. **B:** Coronal view showing individual components of the striated muscle complex. **C:** Sagittal view of normal anatomy.

Anatomy and Classification

The normal anatomy of the anus and the rectum is reviewed in previous chapters. Normally, the rectum descends to the perineum and ultimately to the anal orifice through a striated muscle complex in the pelvis resembling a funnel. The striated muscle complex is under voluntary control and is responsible for providing fecal continence (Fig. 103-15). Contiguous portions of the *levator ani,* the *external sphincter,* and the *puborectalis* muscles

compose the *striated muscle complex*. These anatomically indistinct components of the muscle complex act together to provide control of defecation. The concept of the striated muscle complex and anatomic relationships leading to normal fecal continence with respect to anorectal malformations has evolved from both clinical and anatomic data as described by Peña.[63]

Because of the variety of anorectal malformations observed, different classification systems have been proposed in an attempt to characterize the defects. A summary of the Wingspread Classification is provided in Table 103-3. This anatomically descriptive classification scheme is useful in planning the operative management of anorectal malformations.

Table 103-3 Anatomic Classification of Anorectal Malformations

Female	Male
High	
Anorectal agenesis with rectovaginal fistula without fistula	Anorectal agenesis with rectoprostatic urethral fistula[a] without fistula
Rectal atresia	Rectal atresia
Intermediate	
Rectovestibular fistula	Rectobulbar urethral fistula
Rectovaginal fistula	Anal agenesis without fistula
Anal agenesis without fistula	
Low	
Anovestibular fistula[a]	Anocutaneous fistula[a]
Anocutaneous fistula[a,b]	Anal stenosis[a,c]
Anal stenosis[c]	Rare malformations
Cloacal malformations[d]	
Rare malformations	

[a]Relatively common lesion.
[b]Includes fistulas occurring at the posterior junction of the labia minora, often called *fourchette fistulas* or *vulvar fistulas*.
[c]Previously called *covered anus*.
[d]Previously called *rectocloacal fistulas*. Entry of the rectal fistula into the cloaca may be high or intermediate, depending on the length of the cloacal canal.

In male subjects, the two most common anorectal malformations observed are low imperforate anus with a perineal fistula (Fig. 103-16) and high anorectal agenesis with a rectoprostatic urethral fistula (Fig. 103-17). Male patients without a visible perineal fistula are assumed to have high imperforate anus with a rectourethral fistula until proven otherwise. In female subjects, the most common malformation encountered is low imperforate anus with a fistula from the rectum to either the perineal body or the vaginal vestibule (Fig. 103-18). As these malformations result from developmental arrest at various times during migration of the urogenital septum, considerable anatomic

variability exists in both male and female subjects.

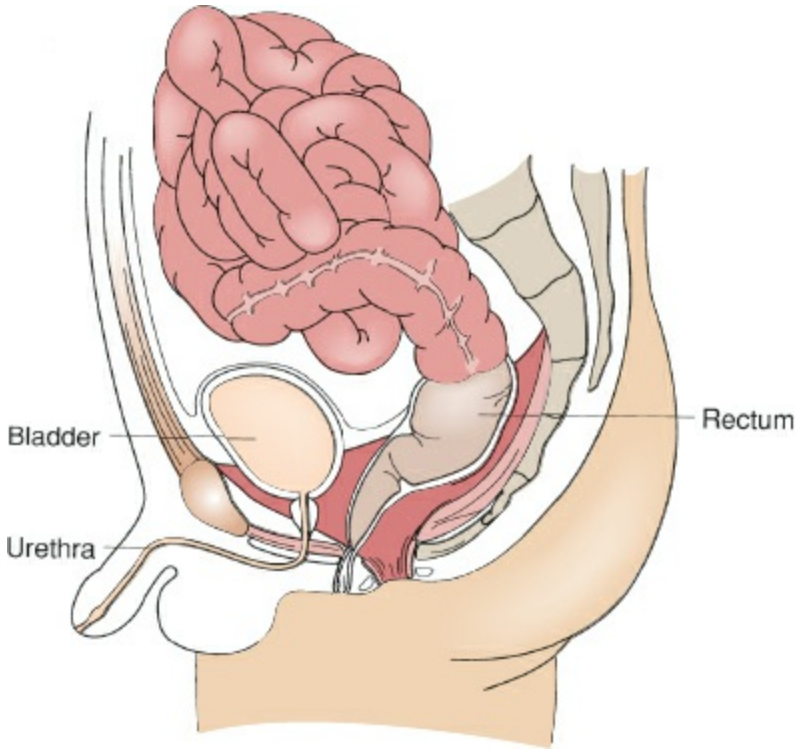

Figure 103-16. Male infant with low imperforate anus and perineal fistula. Note that the fistula is anterior to the striated muscle complex.

A common anatomic feature of imperforate anus is incomplete rectal descent to the perineum. Consequently, the rectum is not completely within the striated muscle complex. The caudal portion of the striated muscle complex remains a solid mass of striated muscle, whereas the cephalad portion may be normally positioned circumferentially around the rectal pouch. In low imperforate anus, the rectum nearly reaches the perineum, and the configuration of the striated muscle complex surrounding the rectum more closely approximates normal. With high imperforate anus, less striated muscle surrounds the rectal pouch. All anorectal malformations are considered to have some component of striated muscle complex hypoplasia and dysfunction, although the physiologic effects are variable. Low anorectal lesions have a more favorable prognosis for fecal continence than intermediate or high lesions.

Classic delineation between low and high anorectal malformations is made anatomically at the pubococcygeal line. The vast majority of low lesions have associated perineal or vestibular fistulas. High imperforate anus has a blind-ending rectal pouch above the pubococcygeal line and, therefore, above the striated muscle complex (or levator ani).

Associated Anomalies

Associated anomalies in infants with anorectal malformations are common and may be found in more than 70% of patients. The VACTERL (vertebral, anal, cardiac, tracheal, esophageal, renal, and limb) association is important and requires consideration in any infant with imperforate anus. *Vertebral anomalies* are common and include sacral dysplasia

and agenesis. Infants with sacral anomalies commonly have high imperforate anus and sacral nerve dysfunction that can lead to poor long-term fecal continence and neurogenic bladder. A variety of spinal cord malformations can also be observed in these infants, including tethered spinal cord syndromes and some myelodysplastic syndromes. During the neonatal period, these spinal lesions may be detected by using ultrasound or magnetic resonance imaging (MRI), and surgical treatment may be necessary within the first 8 to 18 months of life. *Tracheoesophageal* fistula with or without esophageal atresia is estimated to occur in about 10% of infants with anorectal malformations. *Renal anomalies* are the most common associated abnormalities with anorectal malformations and include both upper and lower tract conditions. Genitourinary screening in the form of a renal ultrasound and voiding cystourethrogram is routinely performed. *Cardiac* anomalies are common and screening echocardiography is clinically indicated. *Limb abnormalities,* in particular, involvement of the radius, complete the associated anomalies defined by the acronym.

Clinical Presentation

The incidence rate of anorectal malformations is estimated at 1 in 2,524 to 5,000 live births,[64] with a slightly higher rate in males. Careful examination of the neonatal perineum reveals the diagnosis. If unrecognized and left untreated, high imperforate anus eventually leads to signs and symptoms of complete bowel obstruction characterized by abdominal distention, feeding intolerance, and bilious emesis. Because of the nearly uniform rectourethral or rectovesicular fistula in males with high lesions, some of these infants will pass meconium or gas through the urethra during urination. In contrast, infants with low malformations typically pass meconium through a perineal or vestibular fistula within the first 24 hours of life. Occasionally, infants with large perineal fistulas are not diagnosed with an anorectal malformation until progressive constipation is noted weeks to months after birth.

In male infants, more than 95% of low malformations are associated with either a thin anal membrane or a fistula to the perineum or the scrotal raphe. The presence of a “bucket-handle” skin deformity at the presumptive anal dimple is also diagnostic of a low lesion. Infants with high malformations typically lack anal skin dimpling, have a flat gluteal contour, and may have little or absent contraction of the external sphincter with cutaneous stimulation. In female infants, 90% to 95% of low malformations have a perineal or vestibular fistula. In both male and female infants, a perineal fistula may not become apparent in the first 12 to 24 hours of life until meconium progresses distally through the rectum into the fistula.

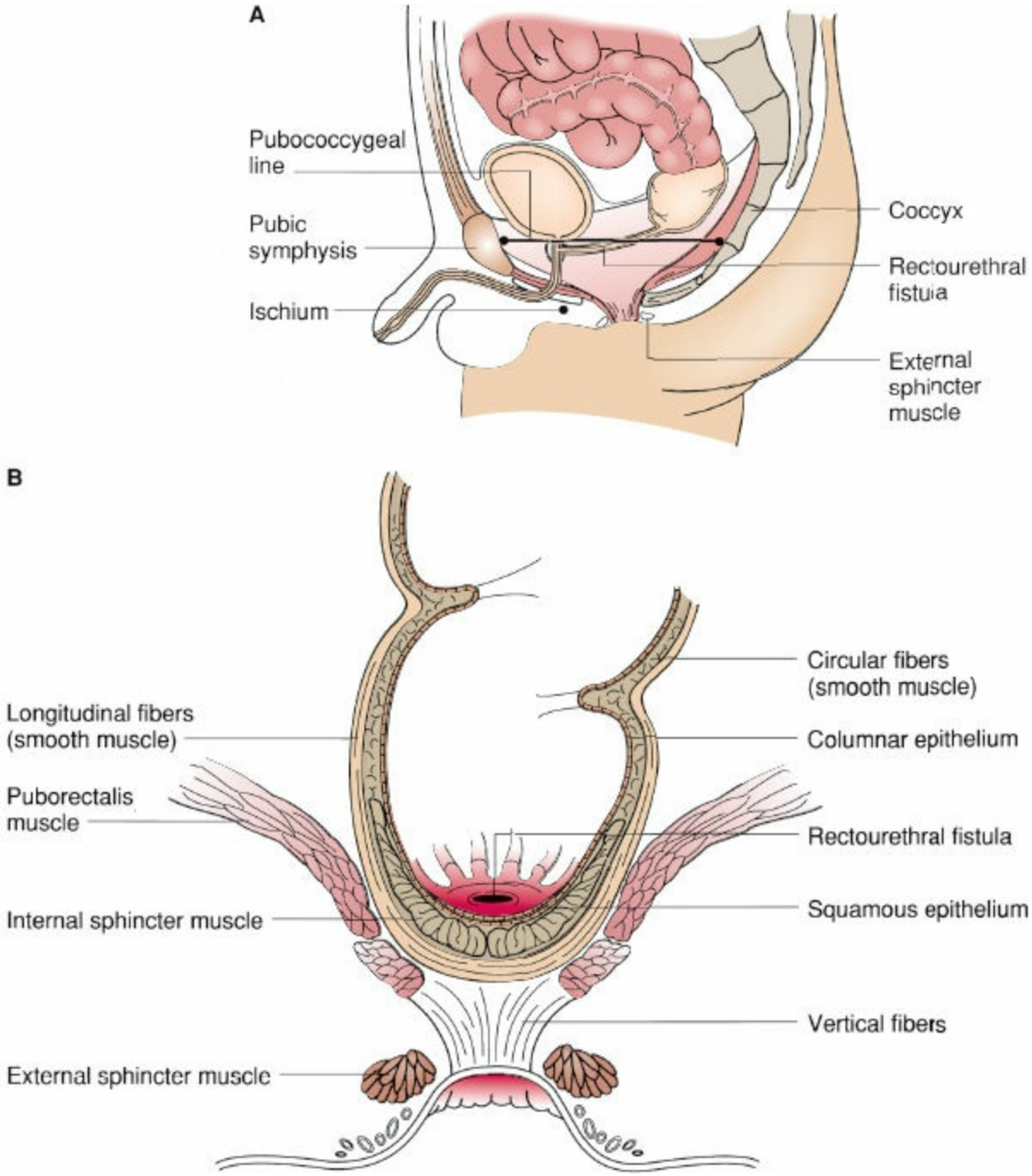

Figure 103-17. Male infant with high imperforate anus, showing the pubococcygeal line, ischium, and striated muscle complex. **A:** The rectal pouch ends cephalad to the pubococcygeal line. This location of the rectourethral fistula is typical. **B:** Coronal view showing incomplete development of the rectal pouch within the striated muscle complex. The rectourethral fistula is shown.

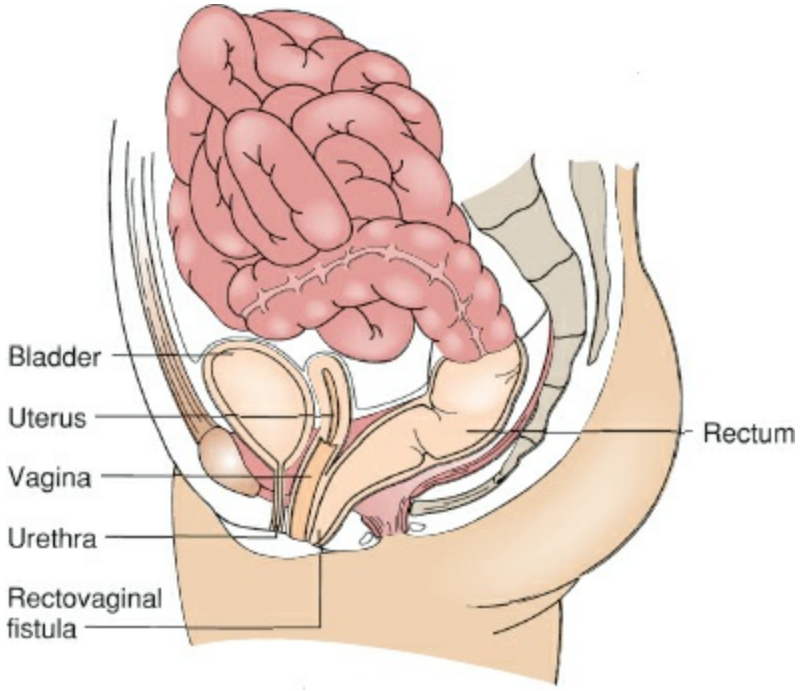

Figure 103-18. Female infant with low imperforate anus and vestibular fistula.

Diagnosis

Because surgical treatment of a high or intermediate anorectal malformation is different from that of low lesion, a primary diagnostic goal is to determine whether an infant with imperforate anus has a high or low malformation. A secondary diagnostic goal is to determine the specific anorectal malformation as it relates to the rectourethral or rectovesicular fistula.

Clinical examination of an infant with low imperforate anus almost always reveals an external fistula to the perineum or the vestibule. The classic radiographic study of newborns with imperforate anus is the Wangensteen-Rice invertogram, with a lateral view of the pelvis obtained 12 to 24 hours after birth with the infant in a head-down position. This technique has been largely replaced by ultrasound-directed imaging.[65] Real-time ultrasound is currently well-accepted as an accurate method of determining the distal extent of the rectal pouch. Computed tomography (CT) imaging and MRI can be useful in evaluating the pelvic striated muscle complex in difficult cases and, in particular, cloacal malformations. MRI is also useful in evaluation of the distal spinal cord in these infants.

If there is a suspected perineal fistula or covered anus, diagnostic needle aspiration under anesthesia may be useful. Aspiration of meconium not only localizes the rectum or fistula but can also provide an estimation of the distance between the perineum and the rectum or the fistula. In general, low lesions are within 1 cm of the perineum. An infant not clearly found to have a low lesion by physical examination, radiographic studies, or examination under anesthesia should be considered to have a high anorectal malformation and treated accordingly.

A voiding cystourethrogram is generally the procedure of choice for defining the rectourethral or rectovesical fistula. In some instances, cystoscopy is a useful adjunct before repair of high imperforate anus. For example, an infant with a large rectourethral

fistula may require cystoscopic guidance of a urinary catheter to avoid inadvertent placement of the catheter through the fistula and into the rectum.

Treatment

Imperforate anus by itself is not a life-threatening condition, and, in many instances, observation for 12 to 24 hours may help delineate the presence or absence of a fistula. The surgical management of anorectal malformations has been well described elsewhere[63] and a brief summary follows below.

Low Malformations. Definitive repair of most low anorectal malformations can be performed in the newborn period with perineal procedures that do not require diverting colostomy. Simple dilatation of the fistula or unroofing of a covered anus may relieve the anatomic obstruction. For more complex anal stenoses or anterior perineal fistulas, a formal perineal anoplasty may be required. A common perineal procedure performed is cutback anoplasty, in which the anterior fistula or anal orifice is opened posteriorly by dividing the perineum to the external sphincter. More complex alternative approaches may be preferred in female infants with low vaginal or anterior perineal fistulas. These lesions generally require circumferential mobilization of the anterior fistula with transposition to the center of the external sphincter. Anterior reconstruction of the perineal body is then performed. Transposition anoplasty is designed to position the neoanus within the center of the external sphincter and separate the neoanus from the vaginal introitus.

Intermediate and High Malformations. Infants determined to have an intermediate, high, or indeterminate anorectal malformation generally require diverting divided colostomy as initial surgical management. Care must be taken to ensure that the proximal diverting colostomy provides adequate length and mobility of the distal colon in anticipation of eventual anorectoplasty. A divided colostomy is preferred over a loop colostomy by many surgeons to provide maximal fecal diversion from the downstream rectourinary fistula. Following diverting colostomy, a distal contrast study into the rectal pouch can also define the fistula and delineate the position of the rectum relative to the perineum.

Anorectoplasty is generally performed when the infant is approximately 8 to 12 months of age. Many different approaches have been described, and considerable personal and institutional variation is common. No single approach has superior results, and all have technical merits and difficulties. The common surgical objectives in the treatment of anorectal malformations include (a) relief of the rectal obstruction; (b) creation of a new anus; (c) position the rectum as normally as possible within the striated muscle complex; and (d) divide the rectourinary fistula. In addition, preservation of the surrounding structures (prostate, urethra, seminal vesicles, vaginal wall) is essential.

For repair of high and intermediate anorectal malformations, the most widely used procedure in the United States is the posterior sagittal anorectoplasty described in detail by Peña.[63] The infant is placed prone and a posterior sagittal incision following the

gluteal crease is used. The external sphincter and the striated muscle complex are divided posteriorly along the midline to expose the rectal pouch. A muscle stimulator is used to define and map the striated muscle complex and to confirm symmetric dissection along the midline. Typically, the rectal pouch can be adequately dissected by this approach to allow enough length to reach the perineum. Infrequently, a combined abdominoperineal approach is required. The mobilized rectal pouch is opened and the rectourinary fistula identified and closed directly. The rectal pouch is placed centrally within the striated muscle complex, which is reconstructed circumferentially around the rectum. The neoanus is centered within the external sphincter and the mucosa is sutured to the perineum.

Other accepted and practiced surgical approaches to imperforate anus include a sacroperineal approach as proposed by Stephens,[66] and an approach that uses components of endorectal dissection as attributed to Rehbein.[67] Both these surgical procedures are characterized by blind pull-through of the distal rectum to the perineum without direct visualization of the striated muscle complex. Experience with laparoscopic dissection and division of the rectourinary fistula with perineal pull-through reconstruction has been reported.[68] It appears that personal preference, experience and familiarity rather than differences in outcome dictate the selection of procedure. In general, diverting colostomy in all of these procedures is maintained until the anorectoplasty has completely healed, after which the colostomy is closed electively.

Results, Complications, and Outcome

Mortality following anorectoplasty is related to the presence of associated congenital anomalies other than imperforate anus. A careful review of 284 infants undergoing repair of anorectal malformations observed an 18.7% mortality,[69] suggesting that this group is at moderate to high risk for complications and death secondary to coexisting congenital anomalies.

Complications are similar to other gastrointestinal surgical procedures and include infection, leak, recurrent fistula, or anastomotic stricture. Leak or stricture formation is observed in 5% to 10% of infants undergoing tapering rectoplasty during posterior sagittal anorectoplasty. Anorectal strictures are treated by gradual postoperative anal dilatation for weeks to months. Recurrent rectourethral fistula or urethral stricture is uncommon.

Long-term functional outcome in infants with low malformations is generally good given the relatively normal descent of the distal rectum within the striated muscle complex. Infants with higher lesions have a less predictable prognosis and are much more likely to have difficulty with fecal continence. Currently, the outcomes appear to be independent of the type of surgical reconstruction performed and more related to anatomic patient factors, including degree of rectal descent, integrity of the striated muscle complex, and sacral innervation. Few or perhaps none of these children have completely normal bowel habits after operation. About half of the infants have acceptable to good results with episodic fecal soilage that can be improved with bowel management programs enemas and cathartics.[70–72] A comprehensive bowel management program is essential in preventing fecal impaction and subsequent motility dysfunction in the rectum.

The remaining children require major adjustments in lifestyle secondary to fecal incontinence, chronic constipation, or fecal smearing and odor. In some instances, socially acceptable continence can be assisted by the use of daily antegrade enemas via a cecostomy or appendicostomy. In other situations, a permanent diverting colostomy may be desirable.

Necrotizing Enterocolitis

Pathophysiology

4 NEC is a neonatal disease characterized by an initial intestinal mucosal injury that may ultimately progress to transmural bowel necrosis. NEC is the most frequently encountered neonatal surgical emergency and a major cause of morbidity and mortality in the premature infant. Despite its frequency and extensive study, the pathogenesis remains obscure, and surgical treatment is directed largely at controlling the complications of intestinal necrosis. The development of NEC occurs in association with a variety of associated conditions, including perinatal stress, sepsis, respiratory failure, hypoxemia, hypotension, and congenital cardiac defects. In general, NEC is observed in the premature infant with multiple risk factors and potential etiologic events and conditions. Current clinical and experimental data support the concept that the pathophysiology of NEC remains enigmatic and multifactorial.

The intestinal mucosal injury observed in NEC is likely to be the end result of an ischemic insult in a susceptible host. Normally, the neonatal pulmonary and systemic vascular smooth muscle undergoes rapid structural and physiologic changes shortly after birth. The premature infant appears to be particularly vulnerable to vasoconstriction. With regard to NEC, it is hypothesized that hypoperfusion and ischemia of the premature neonatal intestinal tract may be the result of uncontrolled splanchnic vasoconstriction. This situation may be worsened in critically ill premature infants with low cardiac output states impairing oxygen delivery to the intestines.

A common characteristic of NEC is the host inflammatory response to the initiating mucosal injury. Experimental data are consistent with an important role for inflammatory mediators in the propagation of intestinal injury in NEC.[73] More than 90% of cases of NEC occur after the initiation of enteral feeding, and several studies document that the osmolarity or rate of initial feeding may be important. Although controversy exists, most neonatal centers now avoid rapid advancement of hyperosmolar enteral feedings and attempt to prevent excessive fluid volume in premature infants.[74,75] A multicenter, randomized controlled clinical trial using *Bifidobacterium* and *Lactobacillus* as a probiotic given with initial feeding demonstrated significant reduction in death from NEC in very low–birth-weight premature infants.[76]

The most common site of involvement of NEC is the terminal ileum and right colon. NEC may be localized, segmental, or it may involve the entire gastrointestinal tract. Histopathologic examination of intestinal tissue from infants with NEC demonstrates submucosal edema, hemorrhage, and microvascular thrombosis leading to transmural necrosis. The histopathology of NEC resembles that of experimental intestinal ischemia, with areas of reversible mucosal injury adjacent to areas of transmural necrosis. Dissection of intraluminal gas through the injured mucosa leads to gas within the bowel wall, known as *Pneumatosis intestinalis*. The finding of pneumatosis intestinalis is a classic radiographic and pathologic feature of NEC. Initially, the gas may be localized in the submucosa or lymphatic vessels, but it may dissect into the muscularis, the portal venous tract, or into the subserosa. Intestinal perforation, inflammatory phlegmon, and diffuse

peritonitis are common with advanced NEC.

Clinical Presentation

Over the past three decades, advancements in technology, prenatal care, and neonatology have improved overall outcome in premature infants who were previously unable to survive. In the United States alone, low–birth-weight infants (less than 2,500 g) account for more than 250,000 births a year. At least half of all infants with NEC are extremely low–birth-weight infants weighing less than 1,500 g. In a study of 302 infants with NEC treated over two decades, the average birth weight fell from 1,645 to 1,505 g, and in similar fashion, the mean gestational age fell from 32.4 weeks to 30.4 weeks.[77] NEC is estimated to occur in 1 to 3 of 1,000 live births and 30 per 1,000 low-birth-weight births.[78] NEC may also occur in term infants, and in this group, it has a tendency to involve the colon and may present without classic signs.[79] The actual incidence of NEC remains difficult to determine because the diagnosis is subjective; classic signs on physical examination and diagnostic imaging are not always uniformly present. The classic clinical signs of NEC include abdominal distention, feeding intolerance, bilious emesis, and either occult or gross blood in the stool. Gastrointestinal mucosal bleeding is present in the vast majority of cases (80% to 90%) but is rarely significant from a hemodynamic standpoint. On physical examination, abdominal tenderness with distention is common, and individual loops of thickened or fixed bowel may be palpable. Edema, erythema, crepitus, or discoloration of the abdominal wall suggests intestinal necrosis, perforation, or intra-abdominal abscess (Fig. 103-19). Hematochezia or guaiac-positive stool is typical. Systemic signs of inflammation and sepsis such as temperature instability, apnea, bradycardia, hypoxemia, acidosis, and thrombocytopenia are also common. The primary diagnostic goal during initial clinical evaluation is to determine whether irreversible, transmural intestinal necrosis is present. There is no single physical finding or laboratory test that makes this distinction.



Figure 103-19. Clinical presentation of diffuse staining of abdominal wall in an extremely low–birth-weight infant with perforated necrotizing enterocolitis.

Diagnosis

The diagnosis of NEC relies on clinical evaluation and judgment based on symptoms and signs in the appropriate setting. Table 103-4 summarizes diagnostic criteria and a staging system for NEC most commonly used in the United States.[80] Radiographic confirmation of NEC requires only plain abdominal films. During the acute inflammatory phase, contrast studies may be hazardous and are contraindicated. The classic radiographic finding of pneumatosis intestinalis (Fig. 103-20) confirms the diagnosis in the appropriate clinical setting but is variably present. Other radiographic findings consistent with NEC include thickened bowel loops, ascites, and portal venous gas. Serial abdominal films, including a left lateral decubitus or upright film, should be obtained every 6 to 8 hours during the early course of the disease. These sequential studies help document the progression or resolution of the inflammatory process and, importantly, evaluate for the presence of intestinal perforation presenting as free intraperitoneal gas or pneumoperitoneum. The presence of pneumoperitoneum mandates operative intervention; however, up to half of infants with perforated NEC do not have discernible pneumoperitoneum on plain films.

Treatment

Nonoperative. The vast majority of infants with NEC can be managed medically. Initial management of NEC includes proximal decompression with a nasogastric or orogastric tube, bowel rest, and broad-spectrum intravenous antibiotics. Prompt correction of hypotension, hypoxemia, and inadequate ventilation must be undertaken. Intravenous fluid management, with particular attention to electrolytes and acid–base status, is essential. Central venous access is secured and TPN is initiated. Oxygen delivery and cardiac performance must be maintained, which in a premature neonate may require operative closure of a patent ductus arteriosus; this approach is preferable over the use of indomethacin in the setting of NEC.[81] Serial physical examinations and blood work are useful in monitoring disease progress.

STAGING

Table 103-4 Necrotizing Enterocolitis

Stage I NEC (Suspected)
Any one or more historical factors producing perinatal stress
Systemic manifestations
Temperature instability
Lethargy
Apnea
Bradycardia
Gastrointestinal manifestations
Poor feeding
Increasing pregavage residuals
Emesis
Mild abdominal distention
Occult blood in stool
Abdominal radiographs showing distention with mild ileus
Stage II NEC (Definite)
Any one or more historical factors
Above signs and symptoms, plus
Persistent occult or gross gastrointestinal bleeding
Marked abdominal distention
Abdominal radiographs showing significant intestinal distention with
Ileus
Small-bowel edema
Pneumatosis intestinalis
Portal venous gas
Stage III NEC (Advanced)
Any one or more historical factors
Above signs and symptoms, plus: Deterioration of vital signs
Evidence of septic shock
Marked gastrointestinal hemorrhage
Abdominal radiographs showing pneumoperitoneum in addition to findings listed for stage II

From Bell MJ, Kosloske AM, Benton C, et al. Neonatal necrotizing enterocolitis: prevention of perforation. *J Pediatr Surg* 1973;8:601–605, with permission.

Most infants with NEC improve with medical management. Typically, reversal of the systemic inflammatory response occurs rapidly, and the abdominal distention and ileus resolve over a period of days. Nasogastric tube decompression and intravenous antibiotics are usually continued for 7 to 14 days. Enteral feeding usually is resumed once antibiotics have been discontinued and there has been return of gastrointestinal function. The usual course of medically treated NEC is rapid clinical response and stabilization in the first 24 to 36 hours. Infants with significant intestinal necrosis typically have signs of either pneumoperitoneum or clinical deterioration during the initial 24 to 72 hours of treatment.

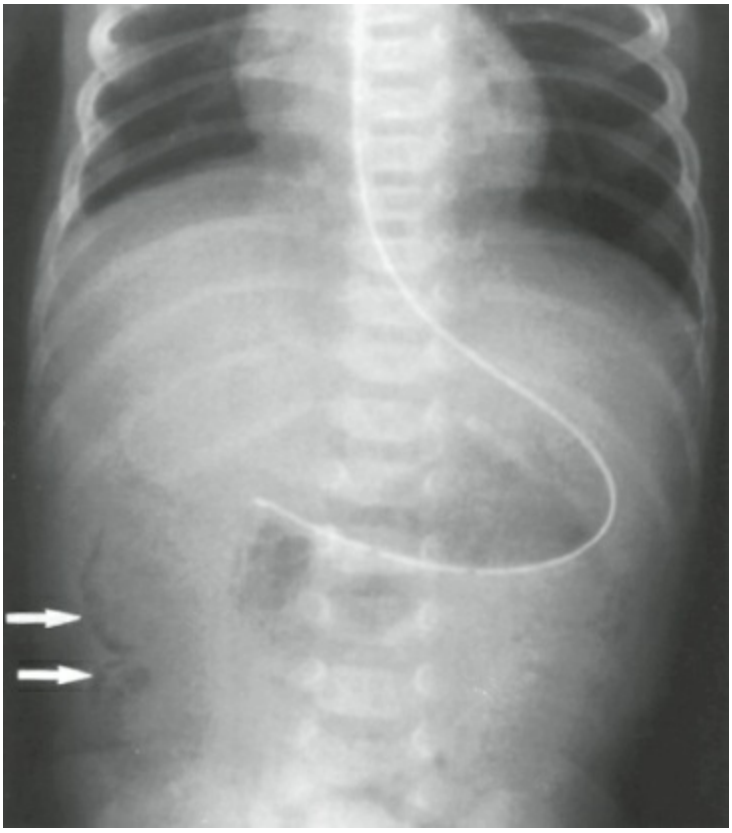

Figure 103-20. Plain abdominal film demonstrating *pneumatosis intestinalis* (*arrows*) in an infant with necrotizing enterocolitis.

Indications to abandon medical management and escalate surgical therapy include evidence of intestinal perforation or clinical deterioration with persistent or progressive systemic illness despite maximal medical therapy. Evidence of persistent or progressive systemic sepsis includes temperature instability, refractory hypotension, acidosis, hypoglycemia, neutropenia, and thrombocytopenia. Local findings such as portal venous gas, abdominal wall cellulitis, or crepitus also may signal intestinal necrosis and the need for operative intervention. A palpable, fixed abdominal mass consistent with intestinal perforation with an inflammatory phlegmon or abscess also may be a relative indication for operation. Because there is not complete agreement on what constitutes clinical deterioration, some controversy exists regarding operative indications for NEC in the absence of pneumoperitoneum. Because the interpretation of clinical deterioration criteria remains subjective, the decision to operate remains a multifactorial clinical judgment. In equivocal situations, abdominal paracentesis of ascitic fluid may be helpful in diagnosing intestinal necrosis with perforation in the absence of pneumoperitoneum if the aspirate contains bacteria or stool.[82]

Operative

Operative indications in NEC include the presence of intestinal necrosis with or without frank intestinal perforation. Conventional operative intervention is aimed at treating the complications of NEC (i.e., intestinal necrosis). In general, resection of intestine involved with NEC does not prevent further extension of disease in other involved areas of the bowel. For isolated segmental disease, the traditional surgical treatment of NEC is

resection of necrotic bowel with proximal enterostomy and distal mucous fistula placement. In infants with diffuse NEC, multiple resections with several enterostomies may be required. The primary operative goal is an expedient operation with preservation of as much intestinal length as possible, including the ileocecal valve. Because the risk of developing short-gut syndrome is substantial in infants with diffuse disease, preservation of marginal areas of involved intestine with a planned second-look operation to reevaluate intestinal viability may be useful. Accurate measurement of the remaining bowel length is important from a diagnostic and prognostic standpoint, with the length of bowel resected determined by the extent of transmural intestinal necrosis. Resection with primary anastomosis in selected infants with NEC has been reported,[83] with a recent study observing recurrent NEC in 22% and strictures in 17% of 18 treated infants following primary anastomosis.[84] Complete intestinal necrosis of the small intestine and the colon is uncommon and is not compatible with long-term survival without the sequelae of short-gut syndrome and the potential need for intestinal transplantation (Fig. 103-21).



Figure 103-21. Fulminant necrotizing enterocolitis involving the entire gastrointestinal tract in a premature infant. Note the presence of pneumatosis intestinalis.

Infants with NEC are typically fragile and premature, and complications in this population are not well tolerated. Survival in this situation may be more dependent upon disease severity and coexisting medical problems than the operative approach. For the high-risk, low–birth-weight infant, initial management with primary bedside peritoneal drainage rather than laparotomy and bowel resection may be useful as either a temporizing measure or, in some instances, a definitive procedure.[85] A multicenter, randomized controlled surgical trial comparing laparotomy with primary peritoneal drainage in premature infants with perforated NEC found that overall survival, dependence upon TPN, and length of stay were independent of the type of operation performed.[86]

Complications, Results, and Outcome

Most infants with NEC are treated successfully without operative intervention. Morbidity and mortality for this group are related primarily to problems associated with prematurity. Given the delay of bowel function and the need for TPN, cholestatic jaundice commonly occurs but is generally reversible. Infants placed on broad-spectrum antibiotics for an extended period are at risk for developing fungal sepsis. For infants with intestinal necrosis from NEC, infectious complications including wound sepsis, central venous catheter infections, and pneumonia with respiratory failure may occur.

The overall surgical complication rate in infants with NEC is at least 20% to 40%. Virtually every infant with NEC has a significant complication, an associated medical problem, or both. Immediate technical complications in treating NEC include intestinal leak, fistula formation, stoma necrosis, bleeding, and liver injury during exploration (Table 103-5). These complications are obviously magnified in the extremely low–birth-weight infant with preexisting intestinal injury. Fluid and electrolyte losses from proximal diverting enterostomies can be significant and even life-threatening in extremely low–birth-weight infants whose circulating blood volume is less than 50 to 100 mL. A review of 68 infants treated surgically for NEC observed a 26% mortality rate and a 68% complication rate related to the stoma or its closure in the perioperative survivors.[87] Complications included intestinal stricture, incisional or parastomal hernia, stoma prolapse, intussusception, wound dehiscence or infection, small bowel obstruction, and anastomotic failure. The complications associated with diverting enterostomy in this unique population provide a compelling rationale for early enterostomy closure once the inflammation from peritonitis has resolved. A prospective, randomized trial comparing resection and enterostomy with resection and primary anastomosis in the treatment of NEC has not been reported.

Table 103-5 Operations for Necrotizing Enterocolitis

Infection (wound, intra-abdominal, central venous catheter, pneumonia)
Bleeding
Stoma-related complications (stenosis, retraction, prolapse)
Electrolyte or nutritional disturbances from enterostomy output
Enterocutaneous fistula
Anastomotic leak, stenosis, failure
Adhesive small bowel obstruction
TPN-associated cholestasis
Short-bowel syndrome, malabsorption
Sepsis, cardiopulmonary failure
Intraventricular hemorrhage

Intestinal stricture formation following NEC, whether managed operatively or nonoperatively, is not uncommon. This consequence usually results from a normal host inflammatory response to transmural intestinal injury. The degree of fibrosis and subsequent stricture formation are clearly related to the severity and extent of disease. Less frequently, mesenteric vascular compromise secondary to an intra-abdominal adhesion may lead to stricture formation. Although stricture can develop anywhere in the gastrointestinal tract involved with NEC, a higher rate of demonstrable stricture is observed in the left colon, occurring in as many as 36% of medically treated infants.[88] Routine contrast enema 4 to 6 weeks after clinical resolution of NEC treated operatively or nonoperatively has been advocated in some institutions. Symptomatic strictures generally require segmental resection with anastomosis, although fluoroscopically guided balloon catheter dilatation has been reported.

Overall survival rates for infants with NEC have improved significantly over the past three decades and is currently about 60% to 80% for both operative and nonoperative groups.[89] The observed improvement in survival is thought to reflect improved neonatal intensive care, the use of TPN, and early, aggressive treatment of suspected NEC. Most neonatal intensive care units initiate aggressive medical treatment in any infant with suspected NEC. Whether surgical interventions such as resection with primary anastomosis or limited primary peritoneal drainage can improve morbidity and mortality in these critically ill infants remains to be fully determined. Long-term outcome for NEC survivors generally reflects associated problems of prematurity. In particular, many of these infants have persisting neurodevelopmental, ophthalmologic, and pulmonary diseases, but morbidity from the gastrointestinal system generally is limited to infants with short-gut syndrome following extensive bowel resection. These infants present complex ethical and management issues beyond the scope of this review. Most NEC survivors (75%) enjoy a good to excellent quality of life, suggesting that the treatment cost relative to the potential benefit for these infants is worthwhile.[90]

Meconium Ileus

Meconium ileus is a descriptive term for small bowel obstruction in a newborn infant with CF. About 10% to 20% of infants with CF initially present with meconium ileus. A review of CF is useful to understand the pathophysiology and treatment of meconium ileus.

CF is the most common fatal hereditary disease in Europe and North America. It is an autosomal recessive disorder found with a heterozygous carrier incidence rate of 1 in 20 to 25 in white populations. The estimated incidence rate of homozygous gene expression and phenotypic manifestation of CF is about 1 in 2,000 to 2,500 in this population.[91] The CF gene has been cloned and the single most common mutation characterized.[92,93] The most common point mutation is a three-base-pair deletion found in 70% to 75% of the carrier population. This mutation leads to deletion of a phenylalanine residue in amino acid position 508 of the CF transmembrane conductance regulator (*CFTR*) gene. In addition, there are about 200 more infrequent mutations of the *CFTR* gene that lead to clinical CF. The molecular heterogeneity of *CFTR* gene mutations produces practical implications in the development and use of carrier screening tests in the general population. Currently, widespread use of molecular genetic screening tests in the general population to identify asymptomatic carriers and at-risk couples without a family history of CF is not recommended; there are significant technical, ethical, and social issues that must be prospectively addressed.[94] Screening of at-risk couples with a family history of CF is recommended, however, and in this setting, carrier discovery approaches 100% so that appropriate genetic counseling can be provided. Molecular genetic screening should also be offered to parents and infants with clinically suspected CF as well as asymptomatic infants born to at-risk couples. This approach allows rapid identification and confirmation of virtually all infants homozygous for CF.

Pathophysiology

The clinical manifestations of CF are caused by an epithelial electrolyte transport defect that results in impermeability to the chloride (Cl^-) ion.[95] The epithelial defect occurs in apocrine sweat glands and the tracheobronchial tree as well as the pancreas, gastrointestinal tract, and liver. In sweat glands, failure of normal Cl^- ion reabsorption following beta-adrenergic stimulation leads to an obligate sodium chloride loss despite a normal adenosine triphosphate (ATP)-dependent sodium–potassium pump. This mechanism is the basis for the traditional diagnostic *sweat chloride test.*

Reduction of Cl^- permeability in the tracheobronchial tree leads to diminished secretion volume as well as increased absorption of sodium chloride. As a result, airway secretions in CF patients are low in volume and particularly viscous. Because of the tenacious nature of the airway secretions, airway clearance is impaired, which leads to chronic, recurrent infection with bronchitis, and pneumonia. As the disease advances, bronchiectasis and progressive pulmonary parenchymal destruction ensues. Recurrent pulmonary bacterial infection is common, and airway colonization by *Pseudomonas aeruginosa* is predictable. Chronic pulmonary disease accounts for more than 90% of the deaths in advanced CF, with a mean life expectancy approaching 30 years.

Pancreatic exocrine function is also affected by impaired Cl^- permeability. Pancreatic duct obstruction resulting from inspissated viscous secretion is followed by glandular autolysis, acinar atrophy, and pancreatic fibrosis. Pancreatic exocrine insufficiency is a classic early clinical feature of CF and is thought to account for some of the gastrointestinal manifestations of the disease. In particular, the deficiency of pancreatic proteinases, impaired chloride permeability, and abnormal epithelial mucous secretion leads to meconium ileus in the newborn, characterized by abnormally thick and viscid, protein-laden meconium that causes mechanical gastrointestinal obstruction. The obstruction is usually observed in the terminal ileum just proximal to the ileocecal valve (Fig. 103-22). Infants with meconium ileus have small pellets, or concretions, of pale, nonbilious meconium in the terminal ileum with a distal microcolon. Proximal to the obstruction, the meconium is variably mixed with gas and often is thick and tarry in consistency. The bowel containing the thick meconium is often grossly, distended, and thickened. Microscopically, the muscularis is hypertrophied; distended mucous glands with prominent goblet cells may be present. The most proximal jejunum is typically normal.

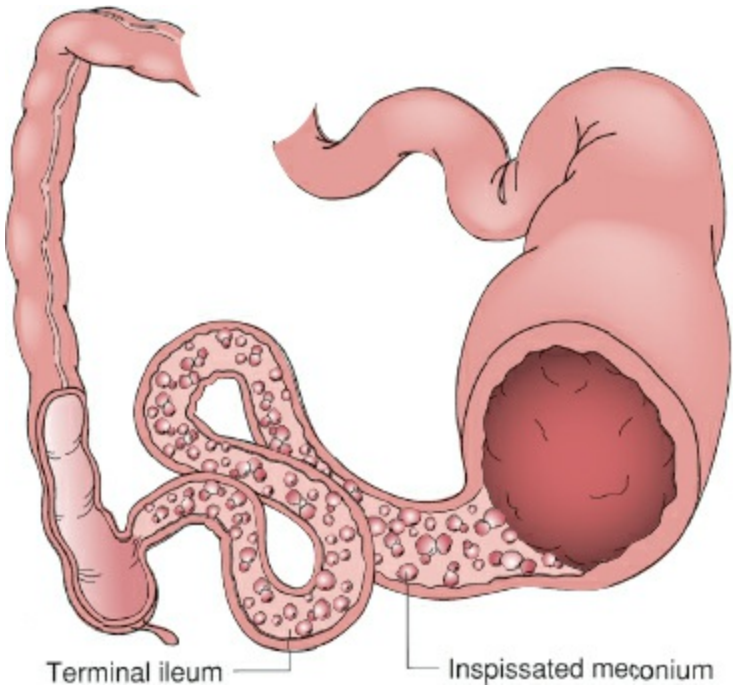

Figure 103-22. Meconium ileus causing obstruction of the terminal ileum from abnormally thick, inspissated meconium.

In utero events such as proximal volvulus of the dilated segment of ileum, perforation from distention, or atresia occur in approximately one-third to one-half of fetuses with meconium ileus. These clinical entities are characterized together as *complicated meconium ileus.* A classic clinical presentation of complicated meconium ileus is in utero intestinal perforation with sterile meconium peritonitis and formation of a calcified pseudocyst (Fig. 103-23). Gastrointestinal conditions presenting later in life occur in 10% of children with CF and include acute appendicitis, recurrent rectal prolapse, and intussusception. These conditions reflect abnormal transit of thick, inspissated stool

causing proximal distention or obstruction of the bowel lumen. Small-bowel obstruction in CF outside the neonatal period was historically called *meconium ileus equivalent,* and is now termed *distal intestinal obstruction syndrome* (DIOS). Treatment of DIOS is similar to initial nonoperative management of uncomplicated meconium ileus in the newborn discussed later. Prevention of DIOS relies on conscientious pancreatic enzyme replacement. Finally, children with CF are at risk to cholestasis secondary to obstruction of small intrahepatic bile ducts. Chronic hepatic inflammation can occur with subsequent fibrosis and cirrhosis, causing hepatic failure and portal hypertension in approximately 5% of CF patients.

Diagnostic Evaluation

In nearly all newborns with CF, the diagnosis is clinically apparent by the presence of meconium ileus, a family history of CF in a sibling, or a positive newborn screening test. Laboratory confirmation of *CFTR* gene dysfunction is performed in several ways. The historical standard for the detection of CF has been analysis of the sodium chloride content of the sweat. The most commonly used and reliable technique uses pilocarpine iontophoresis, with positive sweat test results showing sodium and chloride concentrations exceeding 60 mEq/L.[96] This test is less useful during the first 4 to 6 weeks of age because normal neonates do not reliably conserve sodium chloride in sweat. Generally, abnormal *CFTR* gene is documented by two elevated sweat chloride tests obtained on separate days. With the emergence of genetic technology capable of providing accurate assessment of *CFTR* gene mutations, the sweat test is now largely used to provide clinical confirmation of *CFTR* gene dysfunction along with molecular diagnosis of CF.

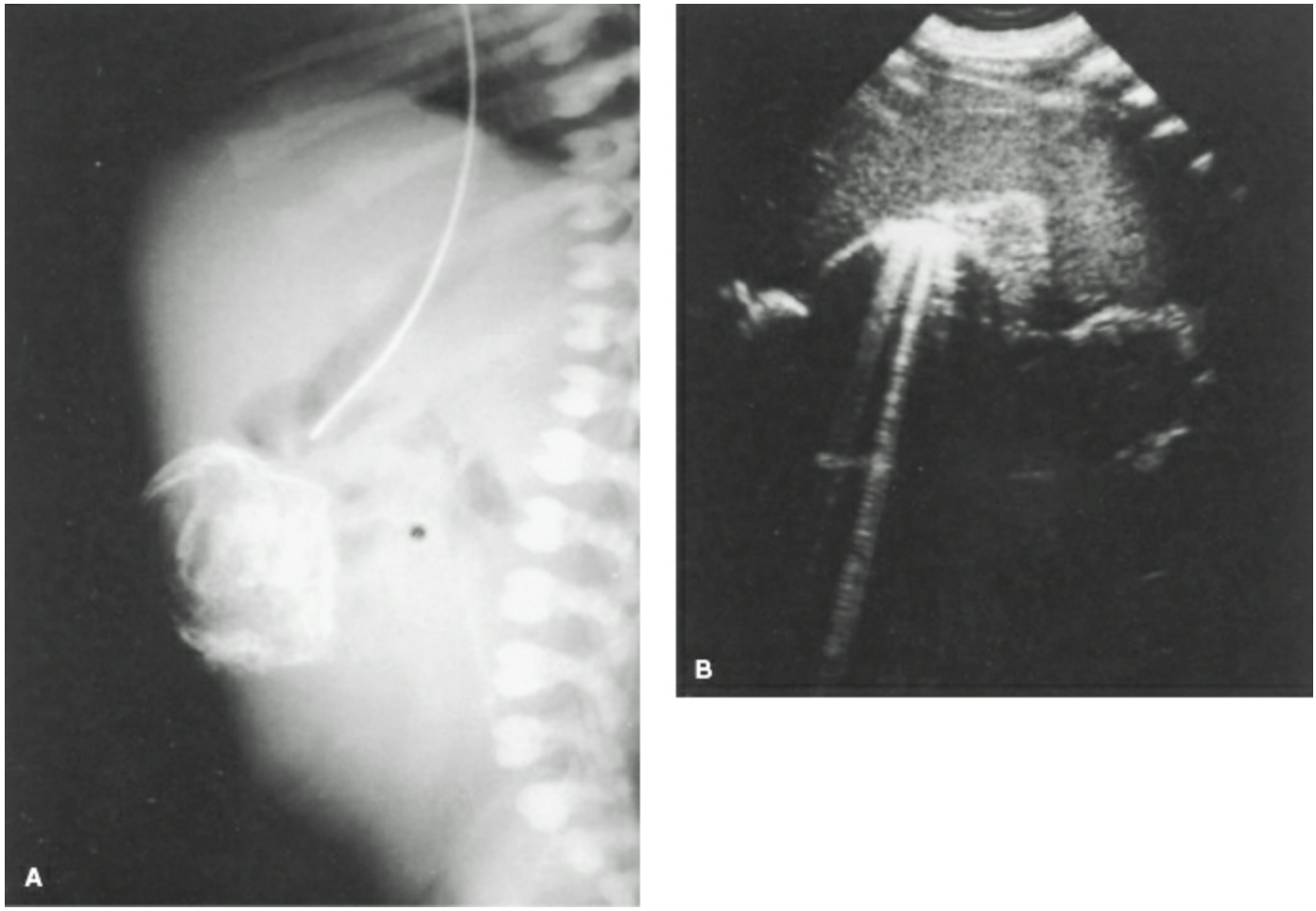

Figure 103-23. **A:** Plain film radiograph of calcified pseudocyst in complicated meconium ileus. **B:** In utero ultrasound demonstrating calcified pseudocyst.

Clinical Presentation

With routine prenatal ultrasound practices along with selected fetal DNA screening, the prenatal diagnosis of CF or meconium ileus is feasible, potentially allowing for improved management of anticipated clinical problems following delivery.[97] Initial signs of meconium ileus include neonatal bowel obstruction with abdominal distention, bilious emesis, and failure to pass meconium. On examination, the neonate may have palpable loops of meconium-filled intestine with a texture on palpation described as "doughy." Similar to other causes of proximal neonatal intestinal obstruction, rectal examination and evaluation of the meconium typically reveals clear white mucus or thick gray meconium. In utero intestinal perforation with pseudocyst formation in complicated meconium ileus may cause a palpable abdominal mass that is not particularly tender. On plain films or ultrasound, calcification is visible in the pseudocyst wall. In contrast, volvulus or intestinal perforation secondary to meconium ileus following birth generally results in diffuse peritonitis and sepsis. Intestinal atresia may also be seen as a consequence of complicated meconium ileus.

Diagnosis

Abdominal plain films may be diagnostic in meconium ileus, demonstrating multiple, distended loops of bowel (Fig. 103-24A). Fluid- or meconium-filled loops of bowel mixed

with gas give a characteristic “soap bubble” or “ground glass” appearance. Classic air-fluid levels seen in other causes of intestinal obstruction are not expected because of the tenacious, sticky intraluminal meconium. The presence of intraperitoneal calcifications or a calcified cyst is consistent with prenatal intestinal perforation of sterile meconium.

A contrast enema is useful in the evaluation and treatment of simple meconium ileus. This study usually demonstrates an unused but functionally normal microcolon (Fig. 103-24B). Reflux of contrast into the terminal ileum may confirm the presence of inspissated meconium pellets. In conjunction with a family history and plain films, this finding is sufficient evidence to confirm the diagnosis of neonatal meconium ileus. Upper gastrointestinal contrast studies are generally unnecessary and may complicate further therapeutic efforts.

Treatment

Nonoperative. Nonoperative management of simple meconium ileus is achieved in about 60% to 70% of newborns. Once the diagnosis of meconium ileus is confirmed, the initial treatment of choice is to perform retrograde irrigation of the terminal ileum with one of several solutions designed to dissipate the obstructing meconium. In the United States, several different enema techniques and a variety of contrast media have been described, including normal saline, hyperosmolar contrast agents, and dilute *N*-acetylcysteine. Initially, it was believed that using hyperosmolar contrast material was necessary to create an osmolar gradient. The resultant influx of fluid into the intestinal lumen was thought to solubilize the inspissated meconium. Recent data suggest that successful meconium clearance is not necessarily related to the osmolality of the contrast agent; however, a significantly higher overall success rate is reported with the use of Gastrografin (sodium and meglumine amidotrizoate) and the use of other solubilizing agents such as Tween-80 and *N*-acetylcysteine.[98] As long as clinical progress is being made, sequential enemas may be required to disimpact the inspissated meconium from the terminal ileum. In similar fashion, children and older patients presenting with DIOS are treated with retrograde enemas until the obstruction resolves. The distinct advantage of this treatment approach is the avoidance of general anesthesia and exploratory laparotomy. Reported complications with this approach include rare intestinal perforation, intestinal mucosal injury, and persistent obstruction resulting from meconium concretions.

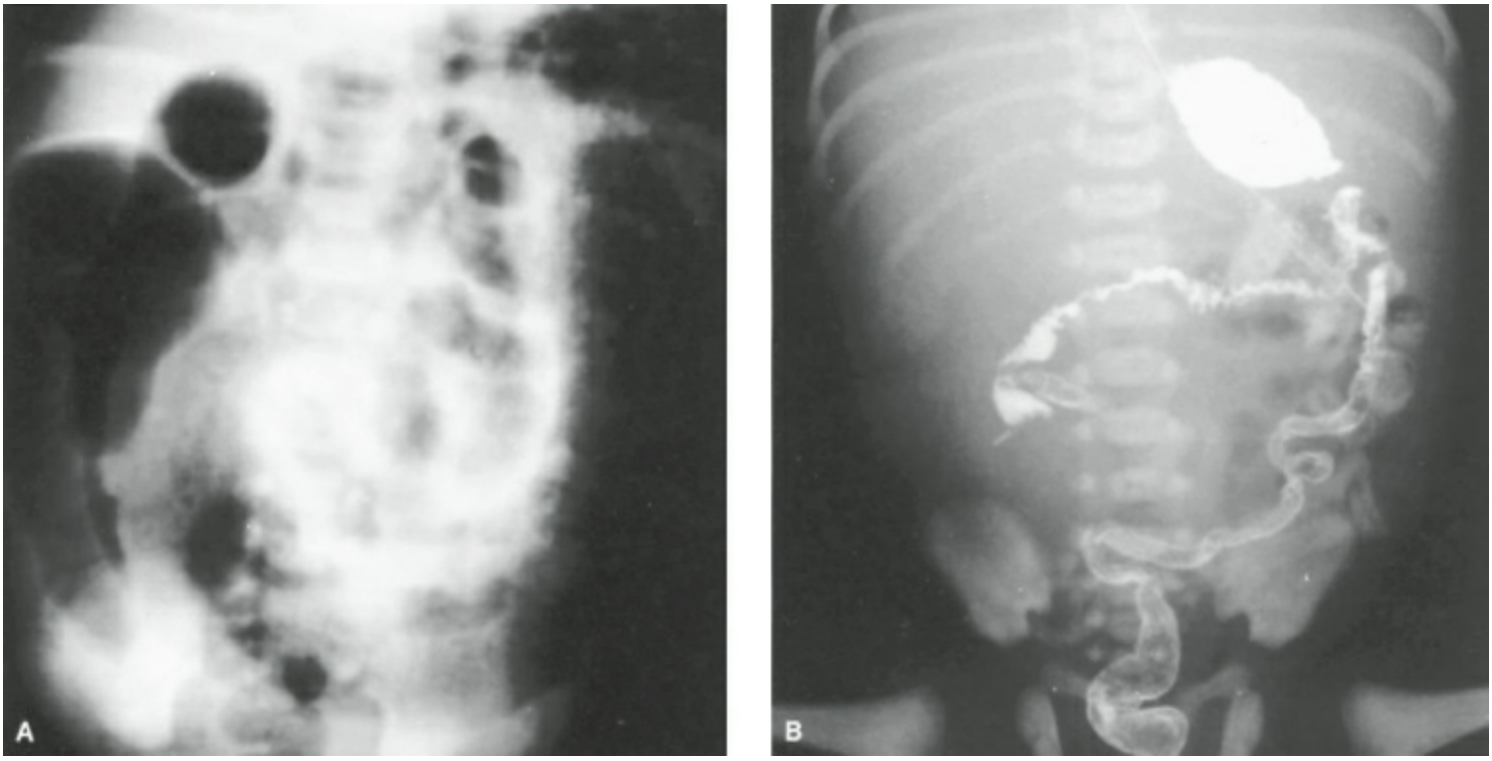

Figure 103-24. **A:** Plain radiograph of neonate with meconium ileus. **B:** Contrast enema in an infant with meconium ileus demonstrating an unused but intrinsically normal microcolon.

Operative. The major indications for operative intervention are either failure to clear the obstruction by retrograde enema or complicated meconium ileus with cyst formation, volvulus, atresia, or perforation. For simple meconium ileus with persistent obstruction despite contrast enemas, the operative goals are meconium disimpaction from the ileum and evacuation of the remaining stool from the small intestine. These steps can be accomplished by either milking the meconium downstream into the colon or solubilizing the meconium by transmural needle instillation of irrigant. However, enterotomy or enterostomy and direct irrigation of the bowel lumen are usually required to completely clear the inspissated meconium. Simple closure of the enterotomy is preferred, but segmental resection may be required if marginal or compromised intestine is found. End-to-end anastomosis is the appropriate reconstruction technique following segmental bowel resection. A temporary enterostomy may be required, and several historical techniques have been described. Another surgical option is the placement of a T-tube into the ileum for continued irrigation with dilute *N*-acetylcysteine. Following clearance of meconium from the intestine and the return of bowel function, the T-tube can be safely and simply removed.[99]

Complicated meconium ileus occurs in about one-third of patients. The surgical management of this entity is individualized. Intestinal atresia is not uncommon in meconium ileus, and the entire length of the intestine must be inspected for patency. When possible, resection of nonviable, stenotic, or perforated intestine is performed with immediate reconstruction via primary anastomosis. Patency of the downstream bowel must be confirmed to prevent anastomotic leak resulting from distal obstruction. If the infant is critically ill or has diffuse peritonitis, a safe primary anastomosis may not be possible and a diverting enterostomy is required. Stoma closure may be performed

promptly after resolution of peritonitis and inflammation.

Postoperative Care and Results. If the meconium has been successfully cleared without opening the intestine, dilute *N*-acetylcysteine may be given through the nasogastric tube or by enema. Alternatively, if a T-tube has been placed, dilute *N*-acetylcysteine or other irrigant can be used directly into the ileum. These efforts are aimed at keeping the meconium soluble and preventing recurrent ileal obstruction. Following return of bowel function, enteral feeding using breast milk or an elemental formula is started along with oral pancreatic enzyme replacement. Vigilant pulmonary therapy is routine and includes mucolytics and antibiotics when indicated. Nutritional assessment and support are essential in long-term management.

Successful nonoperative management of simple meconium ileus historically was associated with a more favorable outcome; however, the operative mortality rates of infants with meconium ileus have improved dramatically over the past several decades, and current short-term operative survival rates of 70% to 100% are reported.[100,101] Long-term survival following meconium ileus is generally determined by the course of the underlying pulmonary disease. Contemporary management of CF has produced a mean survival age that approaches 30 years in most centers. With the exception of the development of portal hypertension in about 5% of patients, intestinal manifestations of the CF are treatable. Future medical and surgical efforts to improve the long-term outcome in these patients include direct replacement of the diseased pulmonary system by lung transplantation, manipulation of the epithelial chloride transport defect with pharmacologic agents, and gene therapy directed at *CFTR* gene transfer into respiratory epithelial cells.

Meconium Plug Syndrome

Meconium plug syndrome is characterized by functional obstruction of the colon or the rectum by a meconium plug. It affects both normal and premature infants with immature gastrointestinal motility and must be differentiated from other causes of neonatal intestinal obstruction. Unlike meconium ileus, in meconium plug syndrome the colon is of normal caliber and the meconium is not inspissated. The infant's symptoms within the first few days of life are abdominal distention and bilious emesis. Spontaneous passage of meconium is often absent. On examination, the infant is normal with a patent anus and a distended abdomen. Digital rectal examination may deliver the meconium plug. Plain films of the abdomen demonstrate dilated loops of bowel consistent with distal bowel obstruction. The diagnosis is confirmed by contrast enema, which is also therapeutic in helping the meconium plug pass. The meconium plug is followed by bile-stained meconium of normal consistency. Importantly, although the vast majority of these infants are normal, a few have Hirschsprung disease or CF. Therefore, infants presenting with meconium plug syndrome should undergo routine rectal suction biopsy and have CF screening tests performed.

Malrotation

Embryology

Normal midgut fixation requires sequential growth, elongation, and rotation of the intestine beginning as early as week 5 of gestation as illustrated in Figure 103-25. Three distinct events occur during normal midgut fixation. The first stage involves herniation of the primary midgut loop into the base of the umbilical cord, where it remains until week 10 of gestation. The axis of the midgut loop is the superior mesenteric artery (SMA), with the omphalomesenteric duct at the apex of the midgut loop. The midgut loop rotates 180° counterclockwise so that the proximal half passes posterior to the SMA. The proximal portion gives rise to the proximal duodenum, which lies to the right of midline. A portion of this segment becomes the third and fourth portions of the duodenum. The distal duodenum is normally fixed to the left of the aorta at the ligament of Treitz, having rotated 270 degrees counterclockwise from its original position. The jejunoileal segment undergoes dramatic elongation, forming about six primary intestinal loops. The distal midgut loop gives rise to the cecum and the right colon, which also undergoes growth and elongation with concomitant rotation 270 degrees counterclockwise. Therefore, the cecum is initially positioned to the left, then anterior, and finally to the right of the SMA before reaching its final location.[102]

Reduction of the extracoelomic gut is the second stage of midgut development and fixation, occurring between weeks 10 and 12 of gestation. By this time, the duodenojejunal junction has passed posterior to the SMA and the midgut has rotated 180 degrees counterclockwise; however, the small intestine initially remains to the right side of midline, and the cecum and ascending colon are anterior to the SMA after return of the gut into the abdomen. Many common abnormalities of intestinal fixation occur as a result of arrested development during this 2-week period.

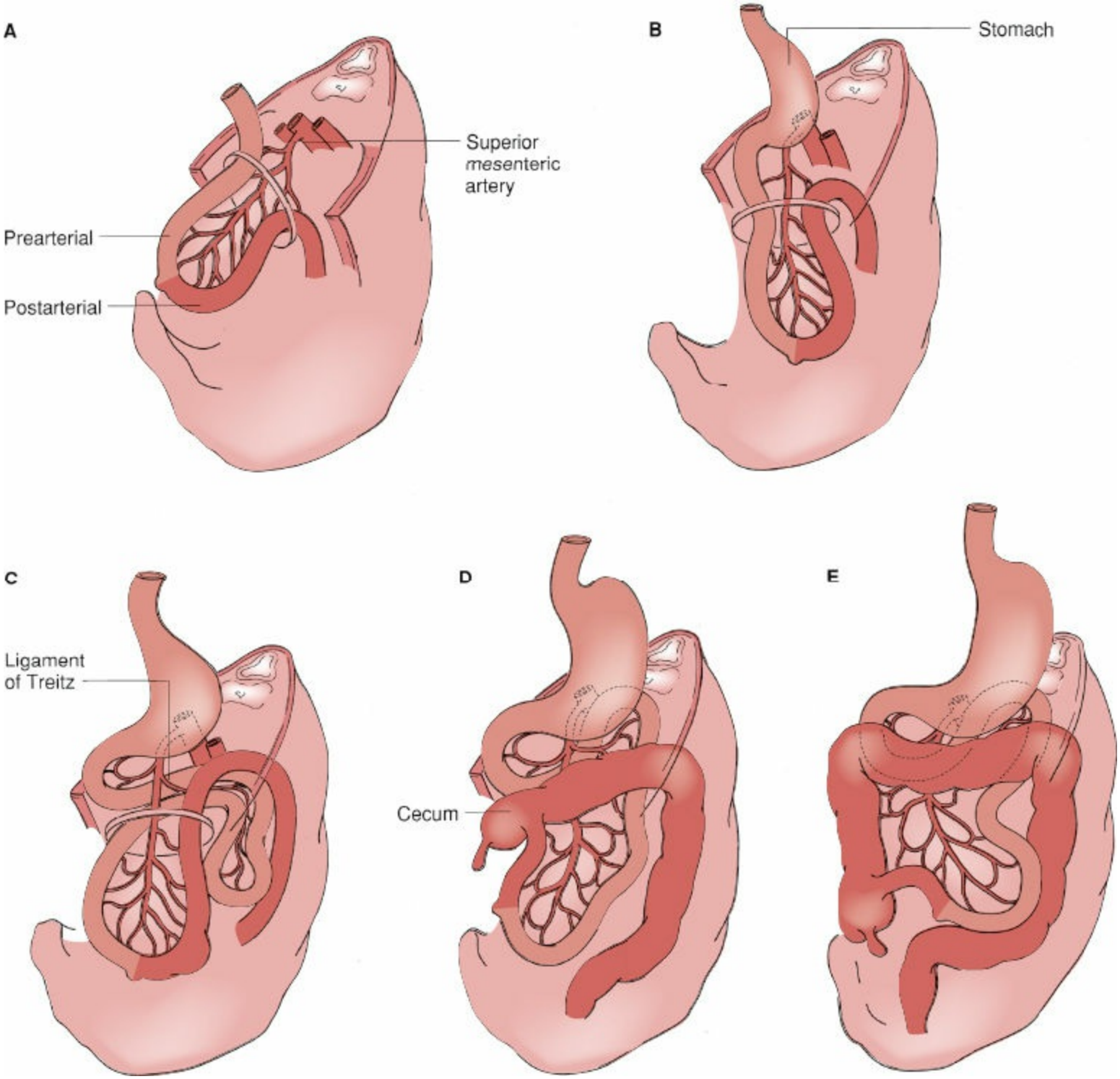

Figure 103-25. Normal midgut rotation is shown with appropriate positioning of the stomach, duodenum, small intestine, and cecum from the fifth gestational week (**A**) through completion by the 12th week (**E**).

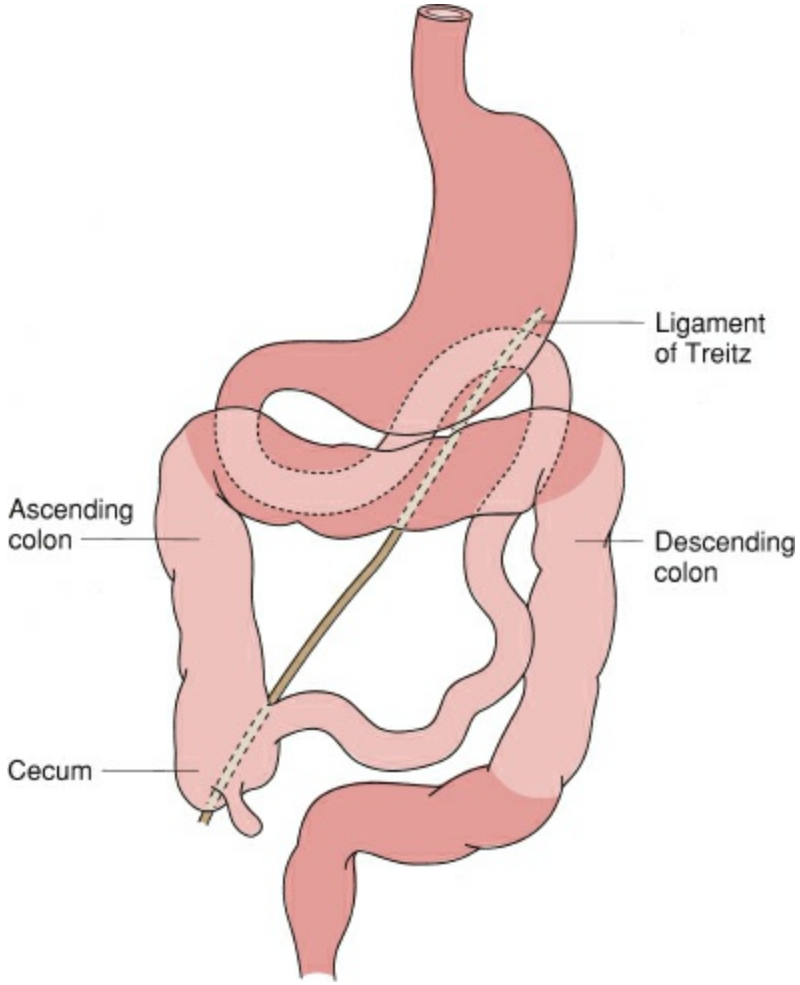

Figure 103-26. Normal oblique fixation of the midgut mesentery at the ligament of Treitz and in the right lower quadrant. The blue portions of the colon are extraperitoneal.

The final stage of midgut development is fixation of the intestine to the posterior body wall, occurring after week 12 of gestation. Cecal descent occurs at this time. Normal points of fixation include the cecum in the right iliac fossa and the duodenojejunal junction at the ligament of Treitz just to the left of the aorta and anterior to the left renal vein (Fig. 103-26). Therefore, the normal intestinal mesentery is fixed with a broad base extending from the ligament of Treitz to the cecum. This broad-based mesenteric attachment prevents volvulus from occurring. In contrast, in disorders of intestinal rotation, the base of the mesentery is neither fixed nor broad, placing the entire midgut at risk for volvulus.

Anatomy

The normal sequence required for intestinal positioning and fixation can be interrupted at any developmental stage, producing a diverse spectrum of rotational abnormalities. Some neonatal surgical conditions are nearly always associated with abnormal intestinal rotation or fixation resulting from displacement of the midgut from the abdominal cavity during embryologic development. These anomalies include omphalocele, gastroschisis, and congenital diaphragmatic hernia. The term *malrotation* has been applied generically to describe disorders of intestinal rotation and fixation, although specific definitions of the more commonly encountered lesions are provided in the following sections.

Nonrotation. This common anomaly is characterized by inadequate counterclockwise rotation of the midgut around the SMA. Instead of the normal 270-degree arc, rotation is either absent or arrested before exceeding 90 degrees (Fig. 103-27). The small intestine resides on the right side of midline, the colon resides on the left, and the cecum is anterior and near the midline. The duodenojejunal junction is to the right of midline and more caudal and anterior in position. Nonrotation carries a significant clinical risk of midgut volvulus because the mesenteric vascular pedicle is narrow. Duodenal obstruction also may occur as a result of peritoneal attachments known as *Ladd bands*. These peritoneal bands fix the cecum to the posterior body wall by passing anterior and lateral to the distal duodenum.

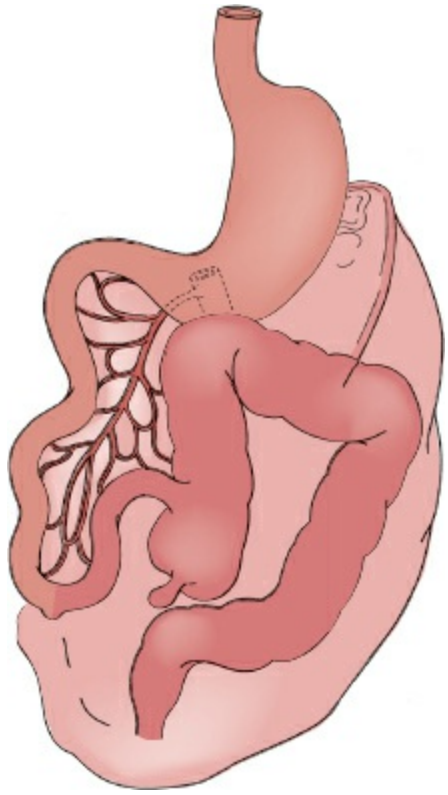

Figure 103-27. Nonrotation. The proximal segment of the small intestine resides on the right side of the abdomen, and the distal segment (*colon*) is on the left. Neither has rotated normally.

Mixed or Incomplete Rotation. This rotational abnormality is characterized by arrest of the normal rotation at or near 180 degrees rather than the normal 270 degrees (Fig. 103-28). Instead of rotating posterior and to the left of the SMA, incomplete or arrested rotation of the prearterial segment leaves the duodenojejunal junction to the right of midline. The cecum also does not complete its counterclockwise passage anterior to the SMA; it usually resides in the upper abdomen just to the left of the SMA. Similar to nonrotation, fixation of the cecum to the posterior body wall by Ladd bands places the duodenum at risk for compression or obstruction. In addition, the SMA pedicle is narrow and places the midgut at risk for volvulus.

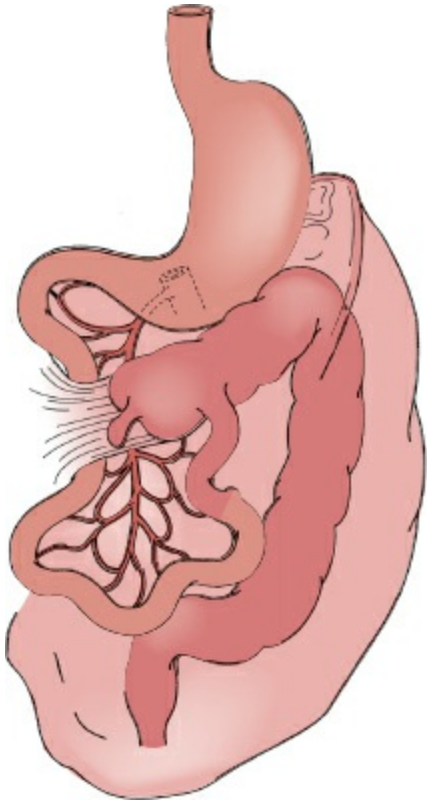

Figure 103-28. Incomplete rotation. The proximal segment has failed to rotate and is on the right. The distal segment has rotated to reside anterior to the duodenum so that cecal bands to the posterior abdominal wall may compress and obstruct the duodenum.

Mesocolic Hernias. Mesocolic hernias are rare but important anomalies characterized by failure of fixation of either the right or left mesocolon to the posterior body wall. Small bowel can become entrapped in the resulting potential cavities on either side of the abdomen. A right-sided mesocolic defect (paraduodenal hernia) is associated with nonrotation of the proximal midgut segment. Small bowel entrapment posterior to the right colon and cecum may occur. Similar entrapment of small bowel may occur from an incompletely fixed left mesocolon but is associated with normal colonic and cecal position. Entrapped small bowel in a left mesocolic hernia usually is contained within a hernia sac with the neck composed of the inferior mesenteric vein and peritoneal bands extending to the posterior body wall. Both left and right mesocolic hernias carry the potential risks of obstruction, incarceration, and strangulation of bowel.

Clinical Presentation

Abnormalities of intestinal rotation are estimated to be present in about 1% of the population. Most persons with intestinal rotational anomalies are clinically asymptomatic; therefore, some children are found to have malrotation incidentally by upper gastrointestinal contrast studies conducted for other reasons. Symptomatic malrotation is usually encountered clinically in the setting of duodenal obstruction or midgut volvulus. Duodenal obstruction may occur as a result of Ladd bands fixing the abnormally positioned cecum to the posterior body wall. These peritoneal bands cause duodenal obstruction by extrinsic compression. Children with symptomatic duodenal obstruction typically present with bilious emesis and distention of the stomach and the proximal

duodenum. Similar to proximal neonatal intestinal obstruction, newborn infants may present with bilious emesis without abdominal distention secondary to partial duodenal obstruction. A paucity of small bowel gas may be seen on plain abdominal films.

A potential consequence of intestinal malrotation is midgut volvulus. Midgut volvulus should be considered in any infant or child presenting with bilious emesis. The clinical outcome of midgut volvulus is time dependent, which is the fundamental reason that signs and symptoms of acute intestinal obstruction in an infant or a child must be pursued aggressively until a clear diagnosis is made. The devastating, life-threatening consequence of midgut volvulus is vascular insufficiency, gut ischemia, and, if untreated, infarction of the entire bowel supplied by the SMA. The initial symptoms may be subtle and limited to feeding intolerance, abdominal pain, and irritability, followed by bilious emesis. Guaiac-positive stool from mucosal injury is a common early finding. Late findings include progressive abdominal distention, hematemesis, and hypotension. Metabolic acidosis, coagulopathy, and shock may become prominent clinical features. If unrecognized or left untreated, transmural necrosis of the entire midgut will occur.

At least 50% to 75% of intestinal rotational abnormalities are discovered within the first week to month of life, and about 90% occur in children younger than 1 year.[103,104] Symptomatic infants and children require emergent surgical exploration and correction. Older children and adults initially may present with acute volvulus but also may have a history of vague symptoms of episodic intestinal obstruction and chronic abdominal pain. It is essential to recognize that, regardless of age or chronicity of symptoms, midgut volvulus from malrotation occurs in a completely unpredictable manner.[105] Therefore, it is generally recommended that patients with incidentally discovered, asymptomatic malrotation undergo operative management to reduce the risk of volvulus.

Diagnosis

As with other forms of neonatal intestinal obstruction, the diagnostic evaluation begins with a plain abdominal radiograph. Classic findings with malrotation include gastric and proximal duodenal distention with a paucity or absence of distal small bowel gas (Fig. 103-29A). The plain film alone may not differentiate malrotation from duodenal atresia or stenosis. In most cases of suspected duodenal obstruction with concern of malrotation, an upper gastrointestinal series is a conclusive imaging study (Fig. 103-29B). Malrotation with volvulus typically produces incomplete duodenal obstruction with a corkscrew or coiled appearance in the distal duodenum. Extrinsic compression of the duodenum by Ladd bands may be visible on contrast study. Duodenal atresia and stenosis may occur anywhere within the duodenum but tends to be more proximal. Complete absence of small bowel gas is typical of duodenal atresia, whereas diminished but discernible distal gas is characteristic of duodenal stenosis or malrotation with volvulus.

Other radiographic findings in malrotation include incorrect position of the duodenojejunal junction, particularly to the right of midline. Failure to achieve normal cephalad and posterior fixation is typical in malrotation and may be best appreciated on lateral views. The small bowel resides in the right side of the abdomen, the colon, and cecum on the left (Fig. 103-29C). In a symptomatic infant or child, radiographic evidence

of malrotation alone is enough to warrant emergent exploration. A contrast enema is helpful in the evaluation of neonatal intestinal obstruction, although it may not be the initial study of choice if malrotation is suspected. The classic finding on contrast enema for malrotation is cecal malposition, usually in the left abdomen or near the midline. Finally, the relative position of the SMA to the superior mesenteric vein may be assessed by ultrasound. Normally, the superior mesenteric vein is to the right of the SMA on transverse sonograms. Abnormal position of the superior mesenteric vein either ventral or to the left of the SMA is associated with malrotation.[106]

Treatment

The management of bowel obstruction from malrotation or an internal hernia is operative. Initial assessment, resuscitation, and preoperative preparation in a symptomatic newborn should be conducted simultaneously so that confirmation of malrotation can be followed immediately by laparotomy. Urgent laparotomy is required to reduce the ischemic injury to the intestine. Shock, if present, must be treated aggressively by insuring adequate gas exchange and establishing restoration of intravascular volume prior to the induction of general anesthesia. Volvulus with complete infarction of the midgut, if not immediately lethal, is survivable only with enterectomy, followed by permanent or long-term TPN support. In older, asymptomatic children with incidentally discovered malrotation, operative repair remains controversial. Given the devastating consequences of midgut volvulus, however, elective surgical correction appears warranted in most asymptomatic individuals as well.

Operative repair of malrotation is performed by Ladd procedure.[107] The first objective is to relieve the midgut volvulus, if present. This is accomplished by delivery and detorsion of the affected midgut, usually in a counterclockwise direction. Recurrent volvulus is prevented by broadening the base of the mesenteric vascular pedicle by dividing the peritoneal bands that tether the cecum, small bowel mesentery, mesocolon, and duodenum around the base of the SMA (Fig. 103-30). Once completed, the mesentery and the mesocolon open widely and the mesenteric pedicle is at low risk for recurrent volvulus.

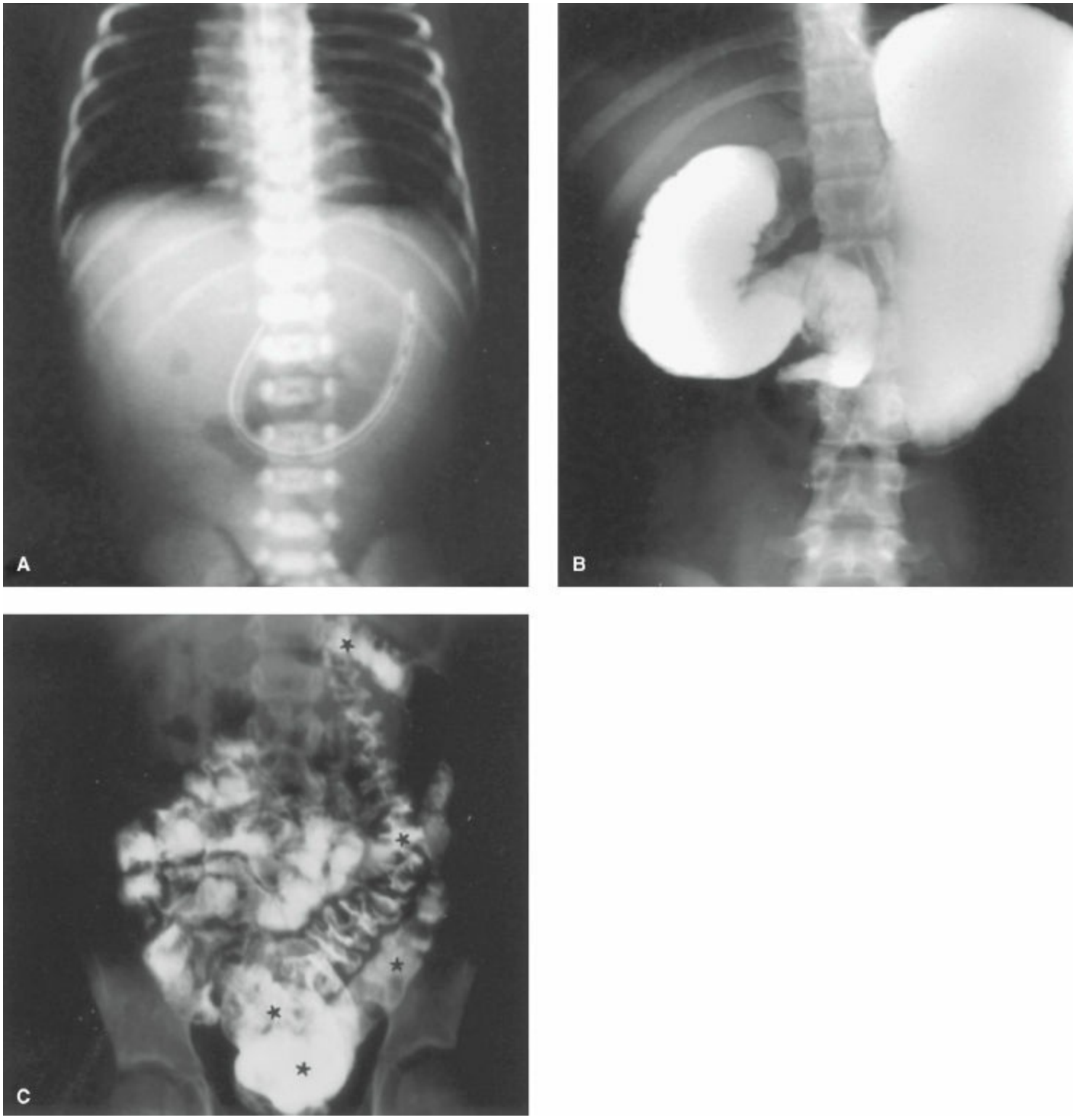

Figure 103-29. **A:** Plain radiograph of an infant with malrotation. There is a paucity of small bowel gas. **B:** Upper gastrointestinal contrast study demonstrating malrotation with midgut volvulus and duodenal obstruction. The position of the duodenojejunal junction is abnormal. **C:** Plain film showing a contrast-filled colon and cecum on the patient's left (*asterisks*). The entire small bowel is to the right of midline. These are typical radiographic findings of malrotation.

The second objective of Ladd procedure is to divide the abnormal peritoneal attachments between the cecum and the abdominal wall. A modified Kocher maneuver involving meticulous and complete mobilization of the entire duodenum with division of all anterior, lateral, and posterior attachments is performed. Duodenal and distal small bowel patency should be demonstrated using intraluminal air or saline because

synchronous intestinal webs and atresia have been reported. An appendectomy is performed to eliminate potential confusion from acute appendicitis developing in an abnormally positioned appendix. Performance of laparoscopic Ladd procedure has been demonstrated to be feasible and may help reduce time to enteral feeding and hospital length of stay; however, the long-term efficacy of this approach has been debated.[108] Fixation of the mesentery by cecal or duodenal plication to the body wall has been abandoned for lack of data supporting efficacy. Postoperative small bowel obstruction secondary to adhesions is reported in about 10% of patients.

Volvulus with intestinal necrosis is treated by preserving as much bowel length as possible. If bowel viability is unclear during initial exploration, a second-look procedure may be helpful to delineate reversible from irreversible injury. The management of nonviable bowel from volvulus is not different from other situations in which intestinal necrosis is encountered, and clinical decisions regarding resection and anastomosis are individualized. In situations in which the entire small intestine is lost and long-term survival is doubtful, treatment decisions must be made with the family.

Surgical management of right mesocolic hernia is directed at dividing the lateral peritoneal attachments of the cecum and right colon to eliminate the hernia. In addition, given the associated nonrotation of the proximal bowel, the vascular pedicle should be broadened as much as possible. Left mesocolic hernia is treated by mobilization of the inferior mesenteric vein, reduction of the small bowel from the hernia sac, and closure of the neck of the hernia sac to eliminate the potential space.

Results and Complications

Results following surgical correction of intestinal rotational abnormalities should be excellent, and life expectancy should be normal in the absence of intestinal necrosis. Recurrent volvulus and recurrent duodenal obstruction are distinctly unusual if the initial procedure is technically complete. Adhesive small bowel obstruction following Ladd procedure is reported in 1% to 10% of patients. Long-term outcome is obviously less favorable in patients with intestinal necrosis at the time of exploration.

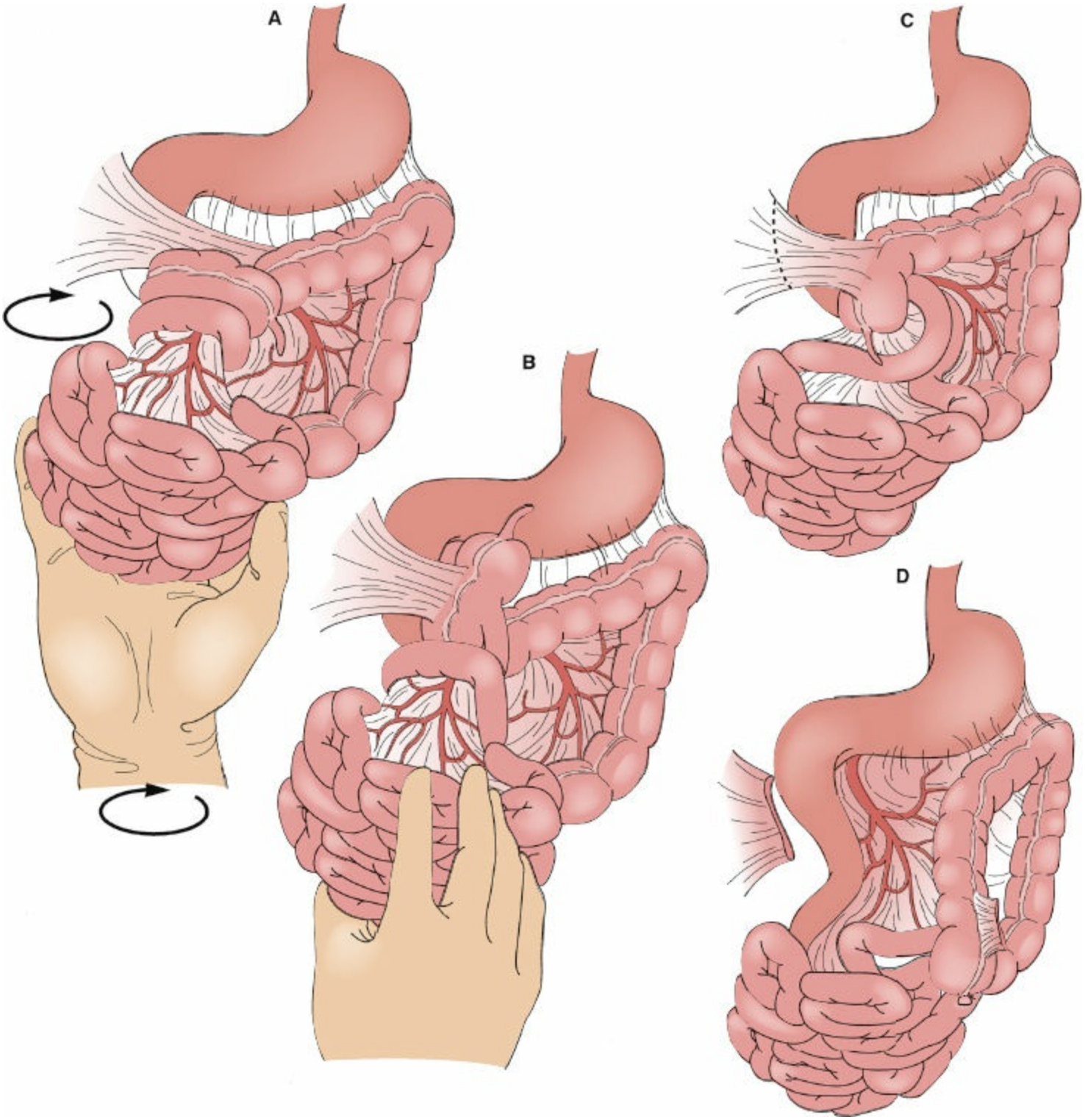

Figure 103-30. Correction of malrotation. **A,B:** Detorsion of midgut. **C,D:** Division of peritoneal attachments (Ladd bands) of cecum to abdominal cavity.

Congenital Aganglionosis (Hirschsprung Disease)

Embryology

5 Congenital aganglionosis of the intestine (Hirschsprung disease) is characterized by the absence of intestinal ganglion cells. The pathogenesis of aganglionosis remains unknown. In normal development, neuroblasts derived from neural crest precursors become evident by week 5 of gestation. The neuroblasts begin maturation and caudal migration along with vagal nerve fibers. The initial caudal migration in an intermuscular plane is followed by intramural dispersal into both superficial and deep submucosal nerve plexuses. Ultimately, the neuroblasts give rise to the ganglion cells of the myenteric nervous system, with functional maturation continuing well into infancy. The orderly migration pathway of myenteric innervation has been documented in human embryos; normally, ganglion cells can be identified in the esophagus at week 6 of gestation, in the transverse colon at week 8 of gestation, and in the rectum by week 12 of gestation.[109]

Anatomy

Hirschsprung disease is characterized by a lack of ganglion cells in the distal intestine. The length of aganglionosis is variable but most commonly involves the distal rectosigmoid colon in 75% to 80% of affected infants. In about 5% of cases, the transition zone between the normal, proximal bowel and the distal, aganglionic segment occurs in the small intestine.[110] Discontinuous aganglionosis has been reported but should be considered distinctly unusual. Therefore, in virtually all cases, the aganglionic intestinal segment is continuous with the distal rectum to the anal verge and also includes the internal sphincter. Because of this distribution, the pathogenesis of congenital aganglionosis is often attributed to failure of neuroblast migration. The characteristic lesion in the distal bowel is the aganglionosis in the intermuscular and submucosal plexuses. Large, hypertrophied, nonmyelinated nerve fibers are present within the muscularis mucosa, lamina propria, submucosa, and Auerbach intermuscular plexus. Both adrenergic and cholinergic fibers are prominent in the aganglionic segment, and acetylcholinesterase staining is useful diagnostically. Abnormalities in the peptidergic nervous system, including vasoactive intestinal peptide, substance P, and neurotensin immunoreactive fibers, are also described in the aganglionic bowel segment.[111] Deficient neuronal nitric oxide synthase mRNA and subsequent decreased local nitric oxide synthase activity in the aganglionic bowel have also been described.[112] These experimental data are consistent with the concept that a defect in nitric oxide–mediated smooth-muscle relaxation may account for some of the characteristic clinical features of Hirschsprung disease.

The transition zone between the normal, proximal bowel and the aganglionic distal bowel is distinguished grossly by distention of the proximal bowel with histologic evidence of muscular hypertrophy. The transition zone often becomes evident to direct inspection or on contrast enema during the first few weeks of life as functional obstruction leads to progressive proximal dilatation. On gross inspection, the transition zone may appear as a short funnel or cone-shaped colonic segment. The discrepancy in

bowel lumen diameter is somewhat age dependent and may be subtle in a newborn or in a child with total colonic aganglionosis. Therefore, it may be difficult for the surgeon or the radiologist to define the exact transition zone site based on gross inspection or contrast enema. Gross examination alone is not sufficient for surgical decision making, and histologic confirmation of the level of ganglion cell transition is required. Given the continuous nature of aganglionosis, a rectal biopsy performed 1 to 1.5 cm above the dentate line demonstrating ganglion cells effectively excludes Hirschsprung disease.

Neuronal intestinal dysplasia is a clinically described entity similar to or associated with Hirschsprung disease.[113,114] Despite the presence of ganglion cells, dysplastic changes in the myenteric nervous system affect bowel motility in similar fashion to aganglionosis. Clinical presentation and treatment are similar to those of classic Hirschsprung disease. There is considerable controversy regarding neuronal intestinal dysplasia, but it is reasonable to suggest that this represents an entity within the spectrum of abnormalities found in the intestinal myenteric nervous system.

Pathophysiology

Normal intestinal motility depends on coordinated propagation of segmental contraction waves immediately preceded by relaxation of the enteric smooth muscle. Patients with Hirschsprung disease lack a functional myenteric nervous system in the aganglionic segment; therefore, both propulsion and reflexive relaxation are disordered or absent in the distal bowel. Loss of neuronal nitric oxide synthase activity appears to play an important role. The internal sphincter is aganglionic and lacks the normal reflexive relaxation following rectal distention. In fact, patients with Hirschsprung disease may exhibit a paradoxical increase in sphincter tone in response to rectal distention. The functional result is tonic contraction of the aganglionic segment of bowel with ineffective peristalsis. Clinically, this presents as incomplete, distal intestinal obstruction in the newborn or as chronic constipation in the older child or adult.

Hirschsprung disease has been associated with mutations in at least three specific genes: the *RET* protooncogene, the endothelin B receptor (*EDNRB*) gene,[115] and the endothelin 3 (*EDN3*) gene. In addition, several other candidate genes are under investigation. In mice, natural and in vitro induced mutations affecting the *RET, EDNRB,* and *EDN3* genes generate intestinal aganglionosis identical to Hirschsprung disease.[116,117] Although widely accepted, it is still unknown whether the primary event in aganglionosis is failure of neuroblast migration to the distal bowel. Alternatively, ineffective microenvironmental support of neuroblasts that have already migrated may fail to promote normal neuroblast development and survival.[118]

Clinical Features

Incidence and Associations. The incidence rate of Hirsch-sprung disease is estimated at 1 per 5,000 live births with a marked male-to-female (4:1) preponderance. Most cases are sporadic, but long-segment, total colonic aganglionosis and female gender are strongly associated with familial inheritance. Genetic chromosomal analysis suggests that multiple loci may be involved, including chromosomes 13q22, 21q22, and 10q, among others.[119]

Familial Hirschsprung disease has been clearly associated with *RET* protooncogene mutations. From a clinical standpoint, mutations of the *RET* protooncogene are associated with disorders of neural crest development, namely, multiple endocrine neoplasia (MEN) types IIA and IIB as well as familial medullary thyroid carcinoma, and patients with familial Hirschsprung disease associated with RET mutation are at risk for the development of medullary thyroid carcinoma.[120] Congenital cardiac defects are present in 2% to 5% of patients with Hirschsprung disease. Other rare congenital anomalies have been reported, but a consistent and important association is a 5% to 15% incidence of trisomy 21.[108] Infants presenting with meconium plug syndrome should undergo rectal suction biopsy to exclude aganglionosis.

Presentation. Most infants with Hirschsprung disease fail to pass meconium within the first 24 to 48 hours of life. Nonspecific signs of neonatal intestinal obstruction (feeding intolerance, abdominal distention, and bilious emesis) may develop. About half of the patients with Hirschsprung disease are diagnosed as neonates. Infrequently, older children or adults are diagnosed with aganglionosis during evaluation for chronic constipation. In this setting, symptoms may be minimal to disabling, and parents or patients often develop elaborate strategies to deal with chronic constipation. Abdominal distention is characteristic, and sometimes failure to thrive and malnutrition may occur. Digital rectal examination may demonstrate spasm, and, in the presence of enterocolitis, forceful expulsion of foul-smelling, liquid stool may occur.

Enterocolitis occurs in about 10% to 30% of infants and children with Hirschsprung disease and may be the presenting clinical manifestation. Enterocolitis associated with Hirschsprung disease has an unknown pathophysiology, but obstructive stasis and bacterial overgrowth are thought to be important factors. *Clostridium difficile* and rotavirus have been implicated as important pathogenic organisms; diagnostic and treatment plans should consider these possibilities. The early presenting symptoms and signs of enterocolitis include fever, abdominal distention, and diarrhea, which may be explosive, foul smelling, and bloody. Systemic sepsis, transmural intestinal necrosis, and perforation are all possible later findings. The clinical progression can be rapid, with death occurring in as few as 12 to 24 hours if treatment is not initiated. Infants are particularly vulnerable to this complication and enterocolitis accounts for virtually all mortality directly related to Hirschsprung disease in modern pediatric surgical practice. Infants with known Hirschsprung disease and suspected enterocolitis should be treated aggressively. Initial treatment includes resuscitation, broad-spectrum antibiotics, cessation of feeding, and rectal irrigation. If the enterocolitis does not respond promptly, emergent intestinal decompression with an enterostomy proximal to the transition zone is indicated.

Diagnosis

A high index of suspicion for Hirschsprung disease should be maintained for any newborn infant with abdominal distention failing to pass meconium in 24 to 48 hours. The signs of neonatal intestinal obstruction should lead to a stereotypical workup. In the presence of

characteristic findings on history, examination, or radiographic studies, any infant suspected of having Hirschsprung disease should undergo rectal biopsy.

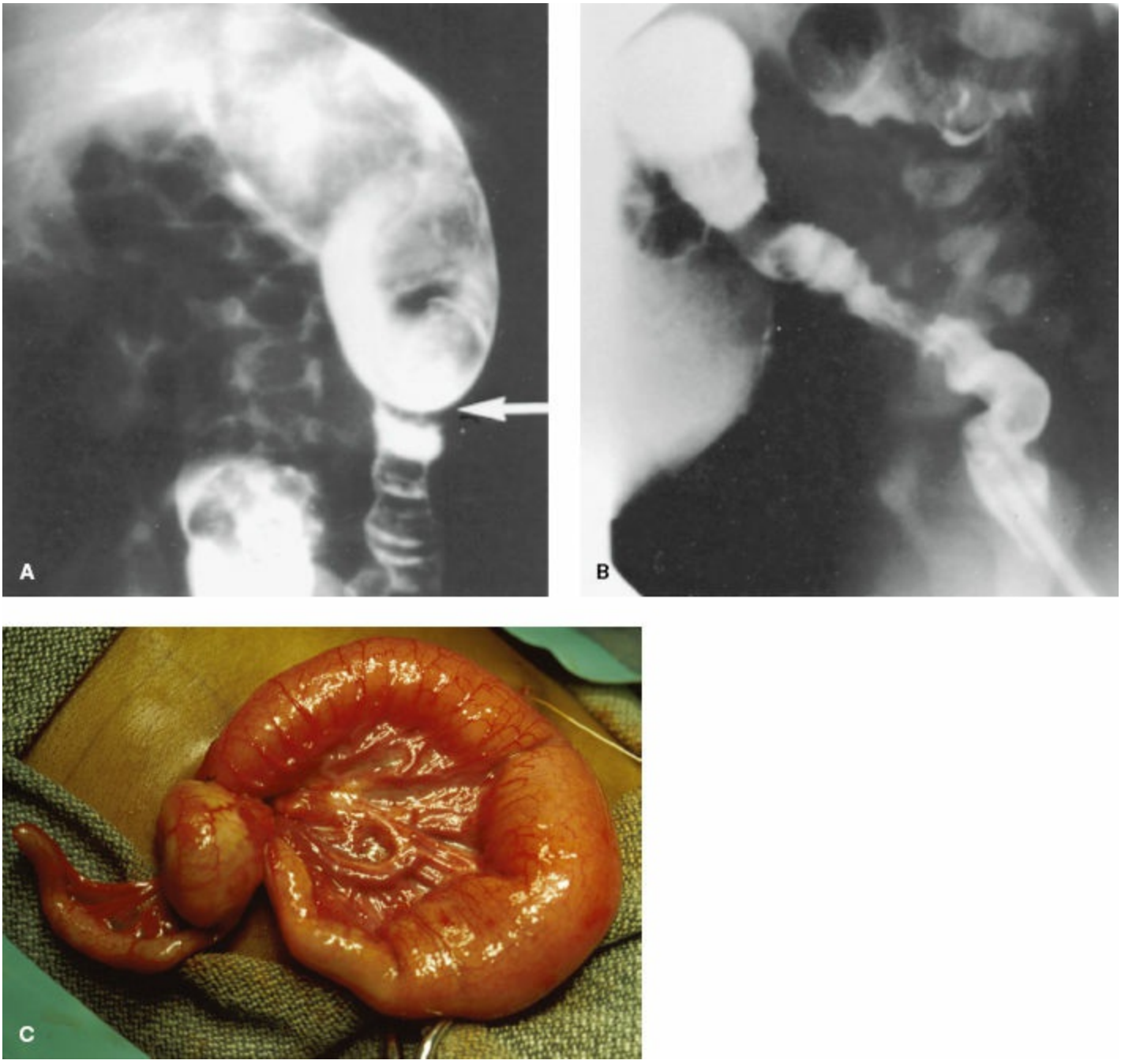

Figure 103-31. **A:** Contrast enema demonstrating a classic rectosigmoid transition zone (*arrow*) in Hirschsprung disease. **B:** Lateral view of rectum illustrates typical distal spasm of rectum. **C:** Operative photograph of rectosigmoid transition zone.

Plain Abdominal Radiographs. Plain film radiographs of the neonate with Hirschsprung disease are nonspecific and typically demonstrate distended, air-filled loops of bowel throughout the abdomen. It is often difficult to discriminate between small intestine and large intestine on plain films at this age, but the pattern is consistent with distal intestinal obstruction. Older children or adults may have a stool-filled megacolon on plain radiographs. In the presence of enterocolitis, thickened, dilated intestinal loops and pneumatosis intestinalis may be present.

Contrast Enema. When distal neonatal intestinal obstruction is suspected on plain abdominal films, a contrast enema should be performed. With an experienced pediatric radiologist, findings consistent with Hirschsprung disease can be accurately detected in most instances. The classic radiographic finding in Hirschsprung disease is a transition zone (Fig. 103-31A). A definitive transition zone may not be apparent in a neonate because proximal dilatation takes some time to develop. In addition, infants with short-segment disease or total colonic aganglionosis may not have obvious transition zones on contrast enema. In these instances, a lateral view of the rectum may show abnormal spasm (Fig. 103-31B). Contrast remaining in the rectum more than 24 hours following a study is suggestive of Hirschsprung disease.

Rectal Biopsy. The diagnostic standard for aganglionosis is the rectal biopsy. Several commercially available instruments capable of performing rectal suction biopsies are in widespread use. The rectal suction biopsy can be performed at bedside or in clinic without anesthesia in all newborns and most children up to several months of age. The desire for early diagnosis and the technical simplicity of the procedure allow liberal use of this technique. When applied liberally, the vast majority (85% to 90%) of infants undergoing this procedure have normal ganglion cells on biopsy, effectively excluding Hirschsprung disease. Using the rectal suction biopsy technique, a biopsy of the mucosa and the submucosa is obtained. This is sufficient to establish the diagnosis because ganglion cells are absent from all intramural plexuses in Hirschsprung disease. The biopsy must be taken 1 to 1.5 cm proximal to the dentate line. Complications of infection, perforation, and bleeding with rectal suction biopsy are infrequent. Full-thickness rectal biopsy under general anesthesia is reserved for older children and in infants in whom suction biopsy is inadequate. An experienced pediatric pathologist must read the biopsies for maximal diagnostic accuracy. Evaluation for ganglion cells and the axons of the myenteric neurons is performed (Fig. 103-32), which may be accomplished using conventional hematoxylin-eosin staining or histochemical staining for acetylcholinesterase. Similar histochemical staining for nitric oxide synthase can be performed. These adjunctive techniques are used routinely in some centers and can help provide additional evidence of Hirschsprung disease rather than simply demonstrating aganglionosis in the biopsy specimen. Diagnostic accuracy for Hirschsprung disease is excellent with a correctly obtained rectal suction biopsy and an experienced pediatric pathologist.[121,122]

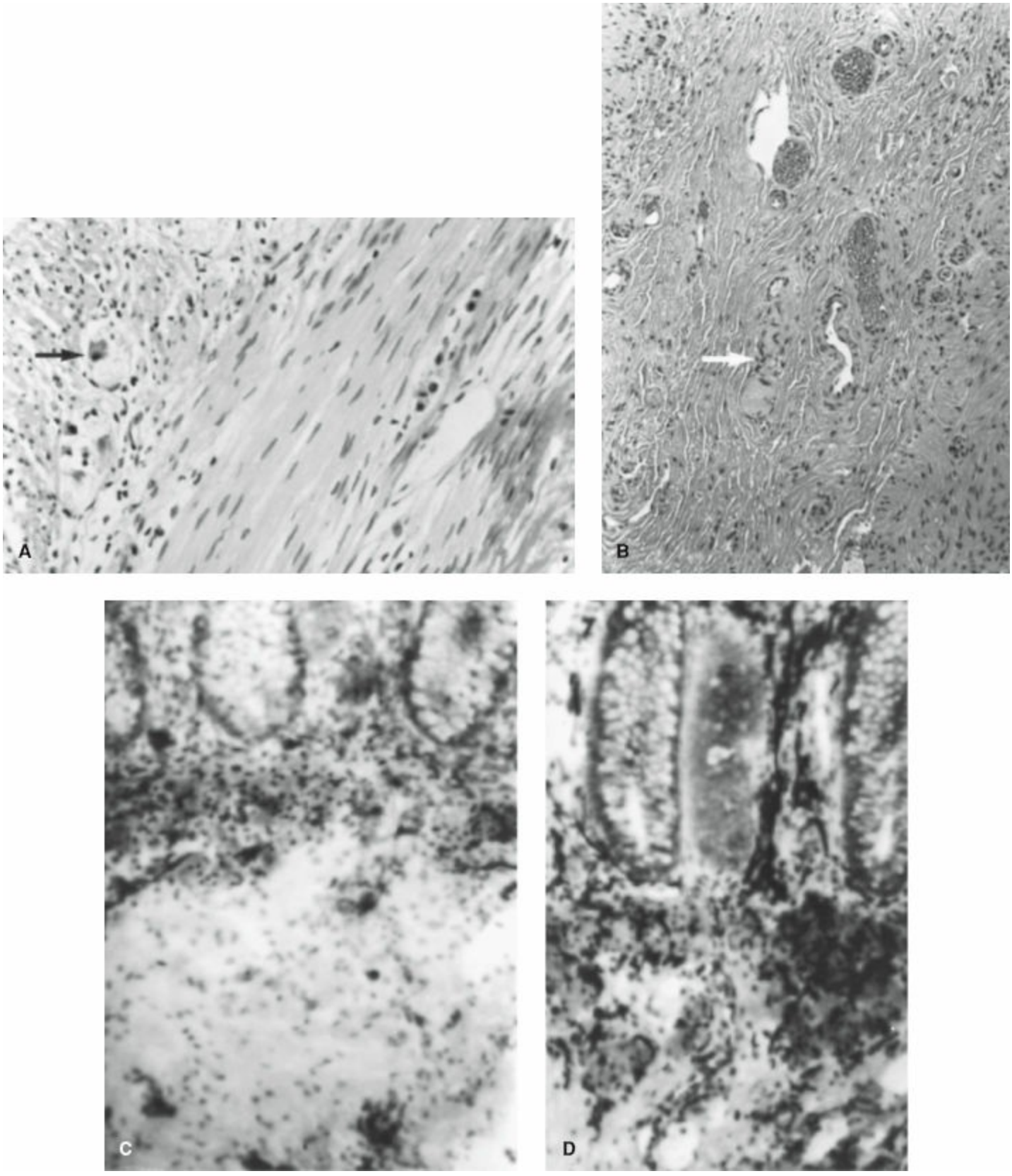

Figure 103-32. **A:** Normal rectal biopsy with ganglion cells indicated by arrow (hematoxylin-eosin). **B:** Rectal biopsy specimen with aganglionosis (hematoxylin-eosin). Note the characteristic thickened nerve fiber (*arrow*). **C:** Normal rectal biopsy using acetylcholinesterase histochemical staining. **D:** Similarly stained specimen from a patient with Hirschsprung disease. Many thickened submucosal nerve fibers stain densely black.

Anorectal Manometry. The absence of sphincter relaxation in response to rectal dilatation is consistent with Hirschsprung disease. Because of the relative ease and accuracy of rectal suction biopsy, anorectal manometry is not widely used in the United

States for the primary diagnosis of Hirschsprung disease in infancy; however, this is used in some centers around the world and, when applied carefully with an appropriate transduction probe, accurate manometric diagnosis is achievable in 85% to 90% of cases.

Treatment

Diverting colostomy should be considered for a newborn infant with Hirschsprung disease who has enterocolitis or multiple associated medical problems or anomalies. In the presence of enterocolitis, rectal irrigation and decompression can be an effective temporizing measure while resuscitation and broad-spectrum antibiotics are being instituted. Prompt proximal diversion will be required once the patient has stabilized. In the neonate, one approach following diagnosis is to perform proximal diversion by means of a colostomy (or enterostomy) placed in normal, ganglionated intestine. The diverting colostomy must be proximal to the histologic transition zone, and a series of biopsies examined by frozen section may be necessary to find the correct level for diversion. For classic rectosigmoid disease, a leveling colostomy is placed just proximal to the transition zone. This approach is generally done in two stages, with takedown of the stoma and definitive pull-through operation performed together weeks to months later, typically when the infant reaches 9 to 12 months of age. In older children, definitive pull-through is deferred until the colon has decompressed to relatively normal caliber.

For many infants and children without enterocolitis, a single-stage approach that eliminates the diverting colostomy has been advocated.[123,124] Despite a number of different operative techniques in performing a single-stage pull-through, results and outcomes appear nearly equivalent. Definitive repair of Hirschsprung disease with a single operation is desirable from technical and economical standpoint and essentially eliminates the complications associated with neonatal stomas. As with most aspects of pediatric surgery, an increasing experience with laparoscopically assisted, single-stage pull-through operations has been reported.[125] The contemporary, laparoscopic single-stage approach in the management of Hirschsprung disease has gained wide acceptance in the pediatric surgical community and is considered by many surgeons as the current standard of care for most infants and children.

Definitive Operations for Hirschsprung Disease

The major goal of operative therapy in the treatment of Hirschsprung disease is to provide resection or bypass of the distal aganglionic rectum with the performance of a low rectal anastomosis with normally innervated proximal intestine. Numerous definitive procedures were designed to treat Hirschsprung disease, and a brief description of the principal procedures in use follows. In general, the selection of a procedure depends on a surgeon's individual training and preference rather than compelling differences in outcome.[126,127]

Duhamel Procedure (Martin Modification). The key elements of the Duhamel procedure are illustrated in Figure 103-33. After minimal pelvic dissection, resection of the aganglionic colon is performed. The aganglionic rectum is left in situ. Normal

proximal colon is brought caudad into the retrorectal space, and a colorectal anastomosis is performed 1 cm above the dentate line. The original operation left the defunctionalized rectal pouch as shown, which proved problematic. The procedure has been modified by Martin to include a longer side-to-side colorectal anastomosis. Advantages of this procedure include its relative technical ease and limited pelvic dissection. Adoption of the stapled anastomosis has simplified this procedure significantly.

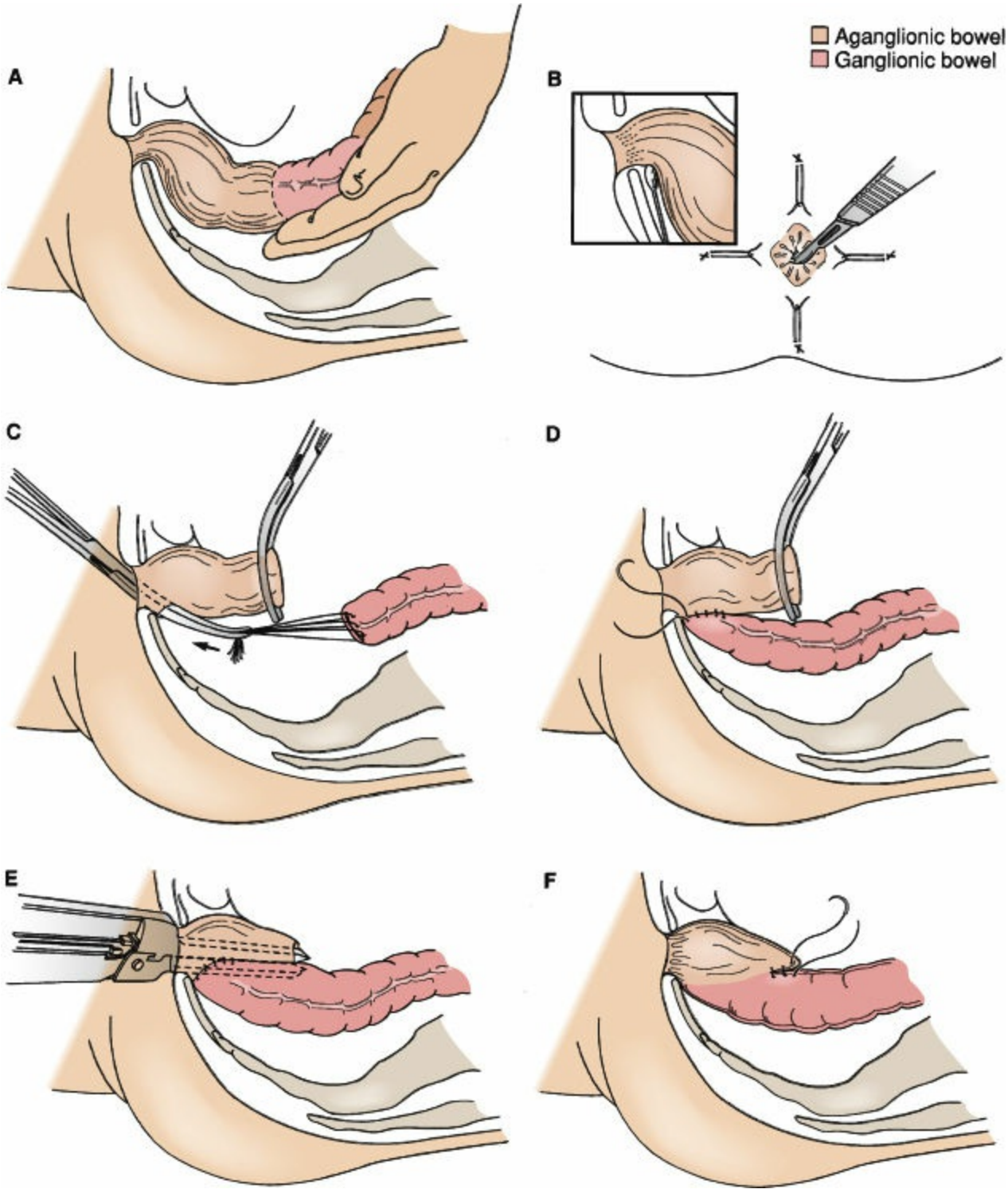

Figure 103-33. Duhamel procedure (Martin modification). **A:** Blunt retrorectal dissection. **B:** Incision in the posterior wall of the aganglionic rectum. **C:** Retrorectal pull-through after resection of the proximal aganglionic segment. **D:** End-to-side colorectal anastomosis preserving aganglionic rectum (as originally described). **E:** Stapled conversion of anastomosis into an extended side-to-side colorectal anastomosis (Martin modification). **F:** Completed procedure.

Soave Procedure. The Soave procedure is illustrated in Figure 103-34. Following resection of aganglionic colon, an endorectal dissection in the submucosal plane is performed from proximal rectum to anus. The endorectal dissection is started in the extraperitoneal rectum. This dissection is typically much easier than similar dissection for ulcerative colitis given the lack of mucosal inflammation. The dissected rectal mucosal tube is everted through the anus, excised, and normal proximal bowel is pulled through the rectal muscular cuff. The original operation did not suture the pull-through segment of proximal bowel to the rectum. A formal sutured colorectal anastomosis is now universally performed. Care must be taken to ensure that the pull-through segment is not obstructed by the muscular cuff.

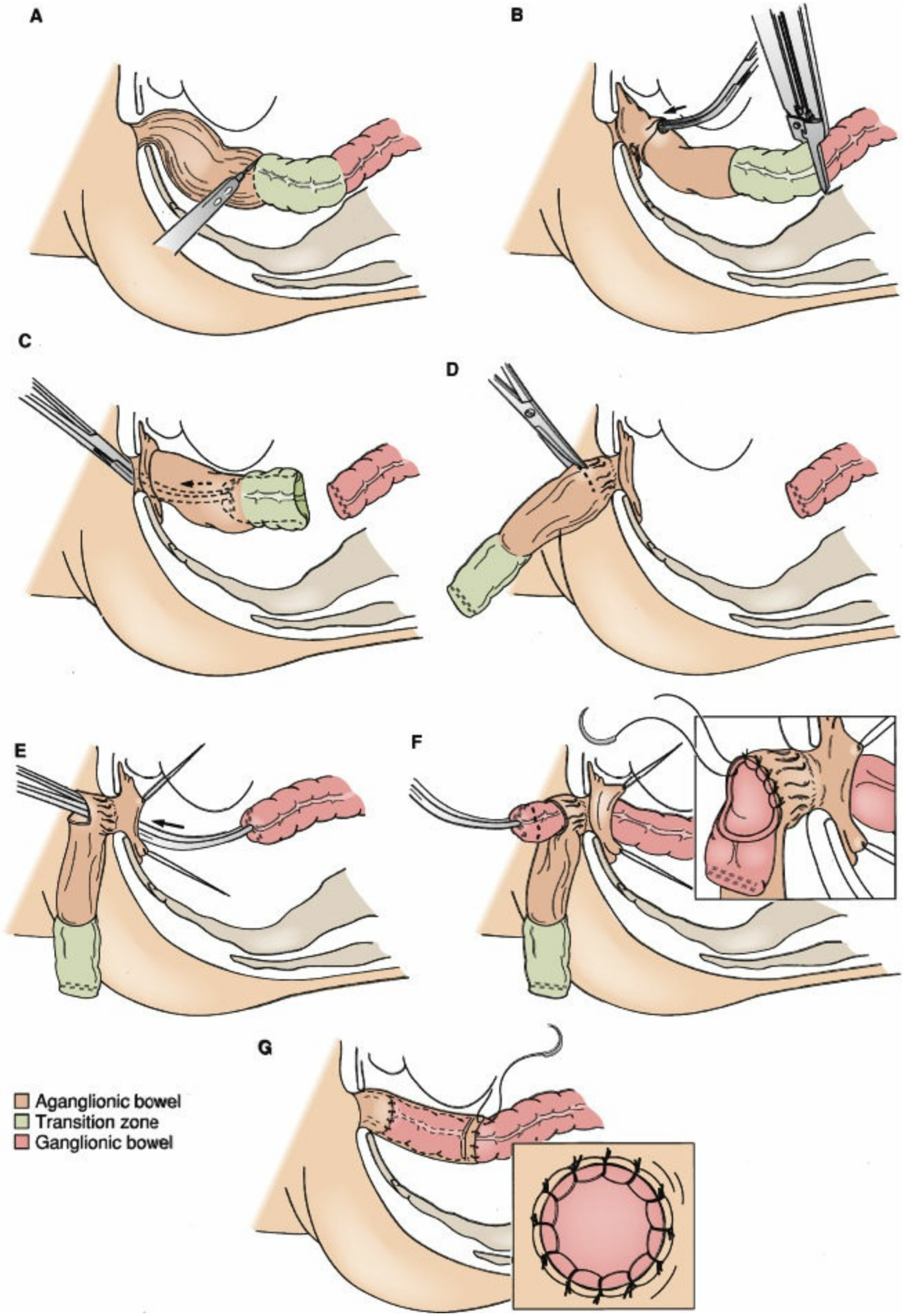

Figure 103-34. Soave endorectal procedure. **A:** Endorectal dissection initiated. **B:** Endorectal dissection complete. **C:** Eversion of the aganglionic segment and rectal mucosal tube. **D:** Incision of everted rectal tube. **E:** Endorectal pull-through. **F:** Colorectal anastomosis. **G:** Completed procedure.

Swenson Procedure. The Swenson procedure is the original definitive procedure for the treatment of Hirschsprung disease. It is somewhat more demanding from a technical standpoint, and, as such, it has been reported to have a slightly higher incidence of postoperative complications. However, long-term outcome in children who undergo a properly performed Swenson procedure is equivalent to other procedures. The basic strategy is outlined in Figure 103-35. The aganglionic segment of colon is resected and a careful, nearly complete extramural dissection of the distal rectum is performed. Care must be taken to avoid inadvertent injury to the seminal vesicles, vas deferens, ureters, and pelvic splanchnic nerves. The dissected rectum is everted through the anus onto the perineum and excised. Normal proximal bowel is pulled through and a colorectal anastomosis is performed.

Laparoscopically Assisted Endorectal Pull-through. A multi-institutional clinical experience with a laparoscopically assisted endorectal pull-through technique for the treatment of Hirschsprung disease has been reported.[125] Potential advantages of this approach include excellent visibility of the distal rectum during dissection, early return of postoperative bowel function, and decreased length of hospital stay. The early results report outcomes similar to the other established procedures. The procedure is reviewed in Figure 103-36. Complete transanal excision of the distal aganglionic segment with primary coloanal anastomosis has also been performed for short-segment or typical rectosigmoid aganglionosis as well.

Rectal Myectomy. Resection of a longitudinal strip of the posterior rectal muscular wall has been used for definitive management of ultrashort-segment Hirschsprung disease. This procedure can be performed via transanal approach combined with submucosal dissection or by a posterior sagittal approach. Although controversial, the use of rectal myectomy as a definitive operation for Hirschsprung disease may be considered most useful in the selected older child identified with ultrashort-segment disease.[128]

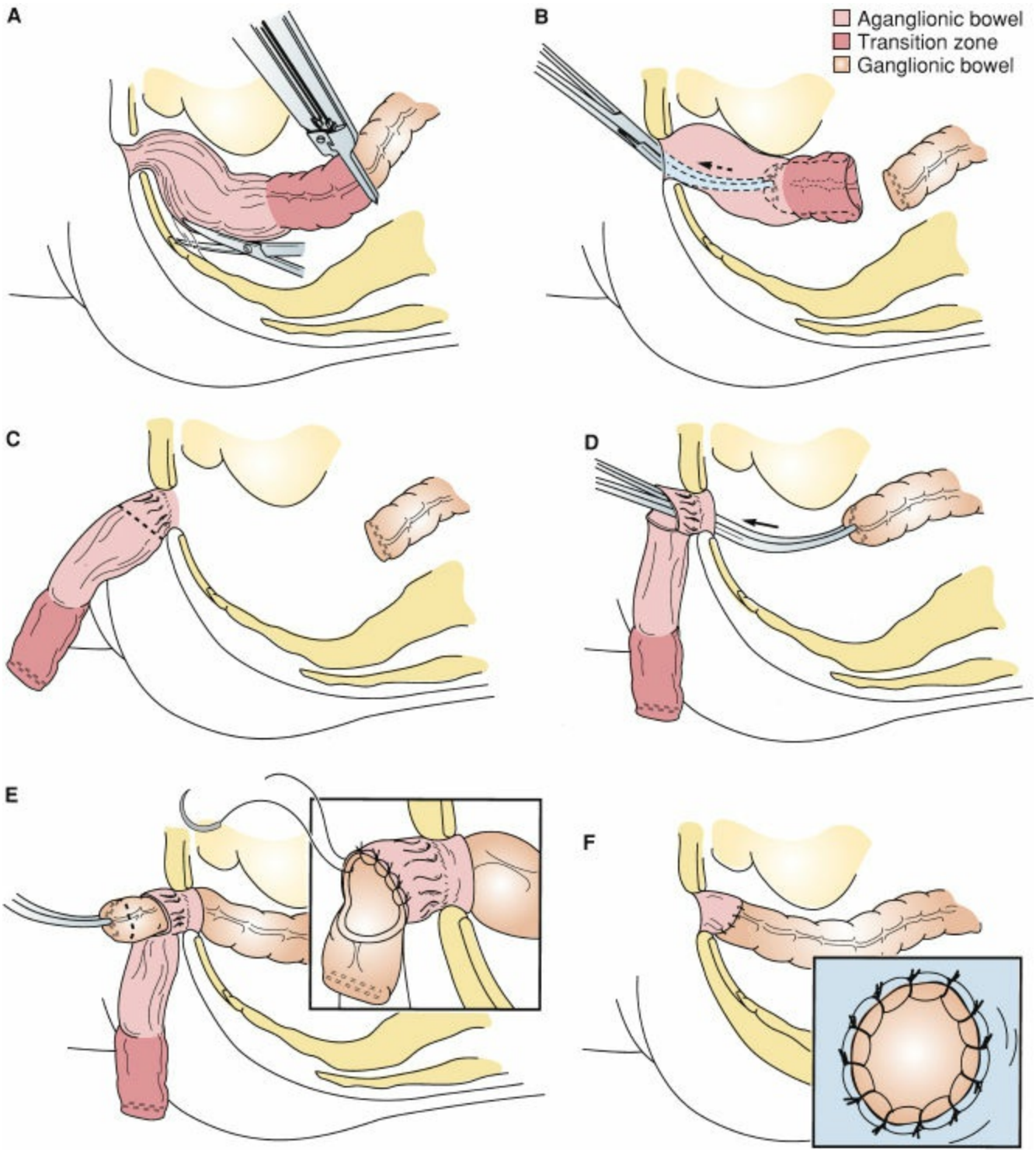

Figure 103-35. Swenson procedure. **A:** Extramural rectal dissection. **B,C:** Eversion of aganglionic segment and full-thickness rectum. **D:** Pull-through of normal, ganglionic bowel. **E:** Colorectal anastomosis. **F:** Completed procedure.

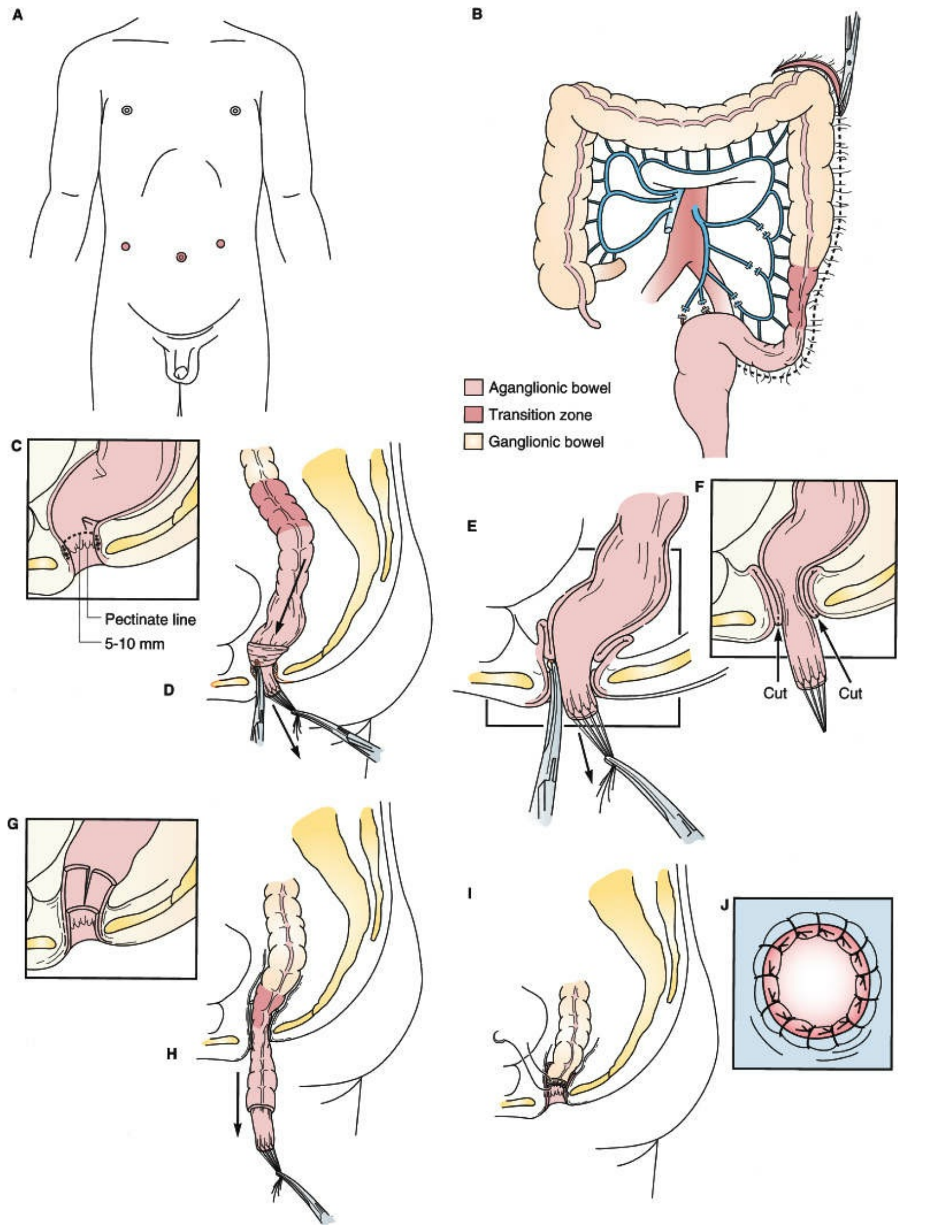
A
B
Aganglionic bowel
Transition zone
Ganglionic bowel
C
Pectinate line
5-10 mm
D
E
F
Cut
Cut
G
H
I
J

Figure 103-36. Laparoscopically assisted pull-through for Hirschsprung disease. **A:** Sites for operative trocar placement. **B:** Division of colon and rectal mesentery with mobilization of proximal colon. **C:** Circumferential incision in rectal mucosa 5- to 10-mm cephalad to the pectinate line. **D:** Mucosal traction sutures to facilitate further dissection from rectal muscular cuff. **E:** Transanal submucosal dissection is continued cephalad to meet the caudal extent of the transperitoneal rectal dissection. **F:** Circumferential incision of rectal muscular cuff. **G:** Rectal muscular cuff is split posteriorly to accommodate the pull-through segment (the pull-through segment is not shown here to clarify this maneuver). **H:** Rectum and sigmoid colon are pulled through the rectal muscular cuff to the anastomotic site. **I:** Colon is transected at appropriate site with confirmation of ganglion cells by frozen section. **J:** Transanal, end-to-end single layer colorectal anastomosis.

Total Colonic Aganglionosis. Total colonic aganglionosis is complex and, fortunately, relatively rare. Several different operative procedures have been described and treatment must be individualized. The endorectal pull-through with ileoanal anastomosis has been used with good success when most or all of the small bowel is normal. For extensive small bowel aganglionosis, an extended side-to-side anastomosis of normally innervated proximal small bowel to the aganglionic colon has been successfully performed. For complete intestinal aganglionosis, extended intestinal myectomy has been described.

Complications and Outcome

Complications resulting from definitive procedures for Hirschsprung disease include anastomotic leak, stricture, pelvic or rectal muscular cuff abscess, intestinal obstruction, and wound infection. These occur with a frequency of 1% to 10% with most experienced pediatric surgeons. Mortality from Hirschsprung disease is distinctly unusual unless enterocolitis is the presenting feature or associated medical problems or anomalies are present.

A unique complication following definitive repair of Hirschsprung disease is postoperative enterocolitis. The clinical presentation and pathogenesis have been discussed, and it remains an important and significant cause of morbidity. The incidence of postoperative enterocolitis ranges from 10% to 30% in most large series. Although rare, Hirschsprung enterocolitis can occur even in the presence of a diverting colostomy. Long-term outcomes appear quite good for all the procedures used, with 80% to 90% of patients maintaining good to excellent bowel function.

OTHER CHILDHOOD GASTROINTESTINAL DISORDERS

This review is limited to relatively common surgical conditions that are either congenital or unique in children. For other surgical conditions that can affect both children and adults, the reader is referred to other chapters in this text.

Infantile Hypertrophic Pyloric Stenosis

Anatomy and Pathophysiology

The pathogenesis of infantile hypertrophic pyloric stenosis is unknown, but data suggest that local deficiency of neuronal nitric oxide synthase in the pylorus may be responsible for the clinical manifestations of the disease.[129,130] The deficiency of neuronal nitric oxide synthase leads to a lack of nitric oxide–mediated relaxation of smooth muscle and subsequent pyloric obstruction. Luminal narrowing occurs as a result of concentric hypertrophy of the pyloric smooth muscle. Clinically, this presents as progressive gastric outlet obstruction that becomes symptomatic by 2 to 4 weeks of age. The maximal narrowing and clinical symptoms of hypertrophic pyloric stenosis occurs between 4 and 8 weeks of age. The hypertrophic pyloric muscle ultimately undergoes gradual involution over a period of weeks to months.

Clinical Presentation

The reported incidence rate of hypertrophic pyloric stenosis is approximately 0.1% to 0.4% among white infants and is slightly lower in the black population. There is a distinct familial predisposition with an approximate 7% incidence rate in children of parents with a history of pyloric stenosis. The incidence rate is about four times higher in males than in females and is higher in first-born infants.[131] There is an apparent increased risk of hypertrophic pyloric stenosis in infants receiving oral erythromycin for pertussis prophylaxis.[132] Association of pyloric stenosis in infants treated for esophageal atresia and in infants with Smith–Lemli–Opitz syndrome has been reported.[133]

Infants with hypertrophic pyloric stenosis have a history of nonbilious, postprandial emesis that becomes progressively projectile. The infant otherwise appears well and will feed vigorously until late in the clinical course. The typical age at diagnosis is between ages 2 and 12 weeks of age. A history of identified feeding intolerance and formula change is common.

The definitive clinical finding on examination is a palpable, hypertrophied pylorus in the right upper quadrant to midepigastric region, often described as a firm, mobile “olive” on examination. This is a pathognomonic finding, and in the correct clinical setting, no further diagnostic imaging studies are required. An experienced clinician should be able to palpate a hypertrophied pylorus in nearly all cases. A successful physical examination requires an empty stomach, a quiet infant, and patience; repeated examinations may be necessary. Inability to palpate the pyloric mass in a quiet or anesthetized infant should place the diagnosis of hypertrophic pyloric stenosis in question. Other physical findings include visible or palpable gastric peristaltic waves, which can also be seen with any cause of gastric or duodenal obstruction.

Late findings with advanced symptoms include dehydration and a hypochloremic, hypokalemic metabolic alkalosis from gastric fluid losses. Profound metabolic alkalosis is less common in current practice but occasionally can be encountered in an extremely dehydrated infant with a long-standing history of emesis. The intravascular volume depletion and chloride-responsive alkalosis must be corrected prior to operative repair.

The serum chloride should be restored to at least 90 to 95 mEq/L, and the measured CO_2 should be less than 30 mEq/L prior to induction of general anesthesia.

Diagnosis

If the examination is equivocal, either an upper gastrointestinal contrast series or a pyloric ultrasound examination can be performed. Both examinations are highly accurate and have sensitivity and specificity exceeding 95% in experienced hands. A typical contrast study demonstrating a narrowed, elongated pyloric channel is shown in Figure 103-37. Contrast studies have the advantage of evaluating other causes of symptomatic emesis, including gastroesophageal reflux disease, malrotation, and antroduodenal webs. The disadvantage of this approach is the presence of contrast in a poorly emptying stomach. Ultrasound examination of the pylorus is a preferred diagnostic test in most pediatric institutions. Ultrasound criteria for hypertrophic pyloric stenosis include a pyloric muscle thickness of 4 mm or greater and a pyloric channel length of 15 mm or greater. In general, the diagnosis of hypertrophic pyloric stenosis is being made at an earlier age compared with several decades ago.

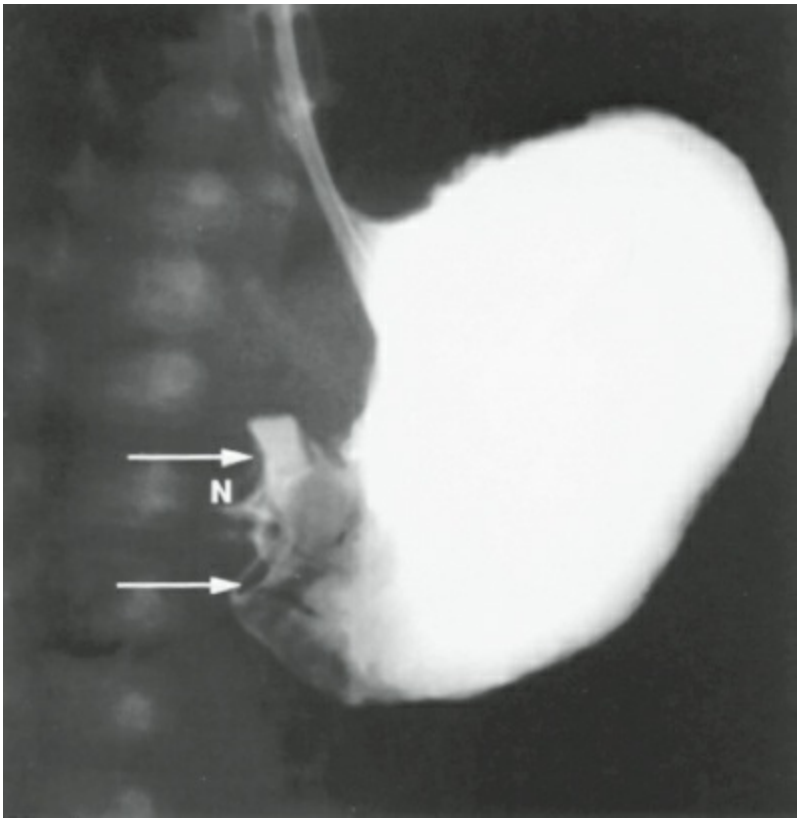

Figure 103-37. Infantile hypertrophic pyloric stenosis demonstrated by barium upper gastrointestinal series showing pyloric channel narrowing (N) and elongation with antral shouldering or cushioning (*arrows*).

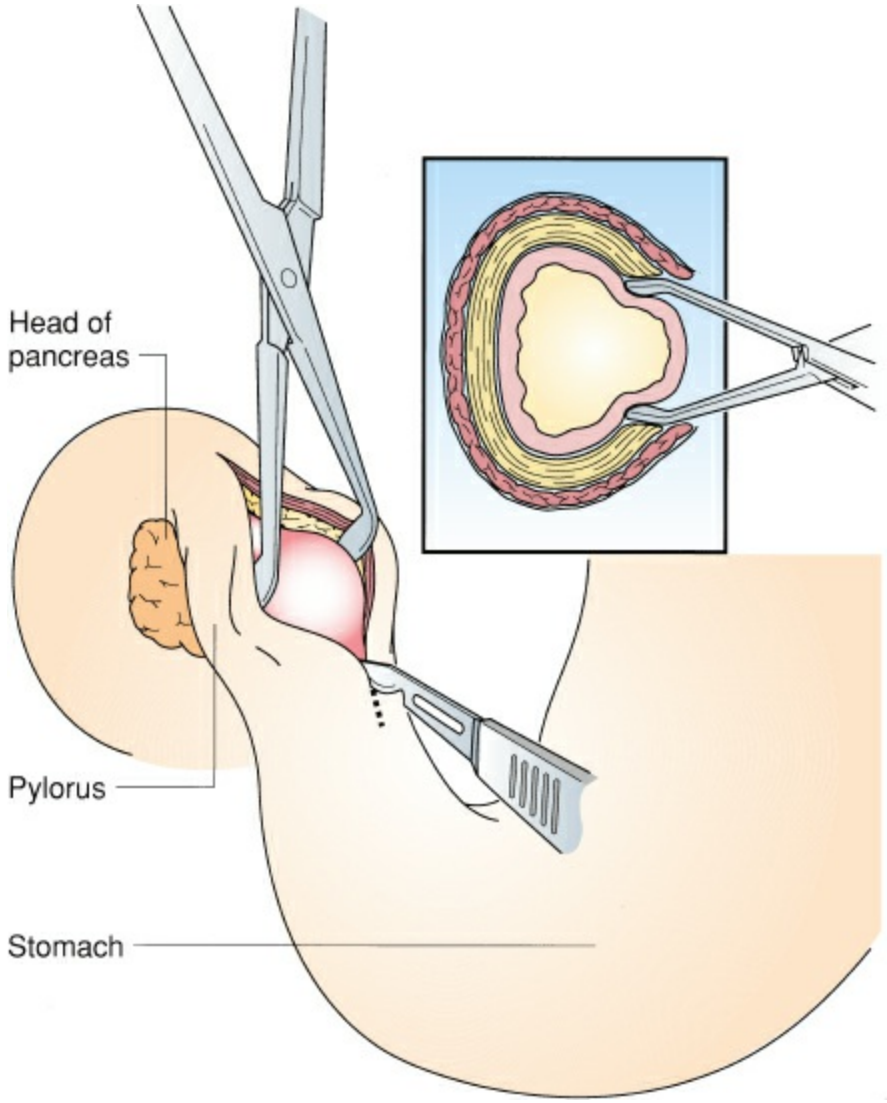

Figure 103-38. Ramstedt pyloromyotomy for infantile hypertrophic pyloric stenosis. The cross-sectional view shows herniation of the submucosa into the myotomy site, indicative of an adequate myotomy.

Treatment

Hypertrophic pyloric stenosis is a progressive situation that subsequently resolves over several weeks to months. Nonoperative treatment during this period requires either long-term parenteral or enteral nutrition and is not practical from a risk or cost standpoint. The Ramstedt pyloromyotomy has achieved universal acceptance because it offers definitive, rapid cure in virtually all infants, and morbidity rates have been negligible (Fig. 103-38). The operation is performed once the infant is rehydrated and the serum electrolytes are corrected. Typically, the pylorus is delivered through a transverse right upper quadrant incision. A single longitudinal incision is made in the hypertrophied pyloric muscle. The hypertrophied circular pyloric muscle must be meticulously divided from the stomach to the junction of the proximal duodenum. An adequate pyloromyotomy is achieved when the submucosa bulges into the myotomy site and both edges of the divided pyloric muscle are freely mobile. Laparoscopic pyloromyotomy has been demonstrated to be efficacious and safe with similar operative times and outcome to the open repair; laparoscopic pyloromyotomy has become a standard approach at most children's hospitals.[134,135]

Postoperative feeding typically is started within 6 to 8 hours after recovery from anesthesia. Most infants are tolerant of enteral feeding and can be discharged home safely within 24 hours of operation. The surgical treatment of pyloric stenosis is straightforward, and the recovery is typically uncomplicated. A population-based study reviewing 1,777 infants with pyloric stenosis demonstrated a shorter length of stay and a lower overall complication rate in infants operated on by specialty-trained pediatric surgeons compared to general surgeons.[136] Mortality following pyloromyotomy is distinctly unusual in the absence of concomitant medical problems. Complications are rare and usually represent wound infection, technical failures related to an inadequate pyloromyotomy, or inadvertent entry into the duodenum or the stomach. Rarely, infants with inadequate pyloromyotomy may require reexploration and a second myotomy on the posterior pyloric wall. Inadvertent duodenotomy or gastrotomy must be recognized and repaired.

Intussusception

Anatomy and Physiology

6 *Intussusception* is defined as the invagination or telescoping of a proximal segment of intestine into an adjacent distal segment and is the most common cause of intestinal obstruction in infants and children aged 3 months to 3 years (Fig. 103-39). The invaginated proximal bowel is referred to as the *intussusceptum* and the recipient distal bowel is called the *intussuscipiens*. This process most commonly originates in the small intestine either at or near the ileocecal valve, with the terminal ileum passing into the cecum and colon (ileocolic intussusception). In the pediatric population, the vast majority (95%) of cases are considered idiopathic because of a lack of an identifiable anatomic lesion causing the intussusception. Older children are more likely to have a pathologic lead point causing the intussusception. In similar fashion, infants and children with repeated episodes of intussusception have a greater probability of a pathologic lead point. Table 103-6 describes several factors that have been associated with the development of intussusception.

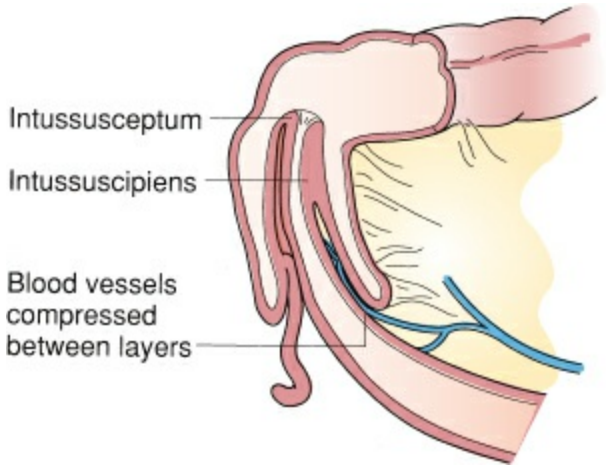

Figure 103-39. Ileocolic intussusception with the intussusceptum and intussuscipiens indicated.

Many cases of idiopathic intussusception in infants are probably caused by the normally prominent intramural lymph nodes (Peyer patches) in the terminal ileum acting as functional lead points. The anatomic consequence of intussusception is obstruction of the distal bowel. As bowel edema and inflammation progress, mesenteric vascular insufficiency from compression and congestion may occur. Incarceration, strangulation, and intestinal perforation ultimately may result if this condition remains unrecognized or untreated.

Clinical Presentation

Intussusception is estimated to occur with an incidence rate of one to four cases per 1,000 children. There is a slight (3:2) male predominance; in a large retrospective series of children with intussusception, 79% were younger than 12 months, and seasonal variation in incidence was not observed.[137] An association between the development of intussusception and the administration of a previously available, tetravalent rhesus-based

rotavirus vaccine (RotaShield, Wyeth Laboratories, Inc., Marietta, PA) was reported.[138] The currently available rotavirus vaccine does not appear to be associated with intussusception.[139]

Table 103-6 Predisposing Factors Leading to Intussusception

Anatomic Lead Points
Meckel diverticulum
Polyp
Lymphatic hypertrophy (Peyer patch)
Appendix
Duplication or enteric cyst
Lymphoma
Other neoplasm
Heterotopic pancreatic tissue
Associated Infections
Adenovirus
Rotavirus
Parasitic infestation
Other
Bleeding Disordersa
Henoch–Schönlein purpura
Hemophilia
Leukemia
Trauma
Blunt abdominal trauma
Major retroperitoneal dissections
Others
Cystic fibrosis

[a]These factors are more likely to be associated with small bowel-to-small bowel intussusception than with ileocolic intussusception.

Otherwise healthy infants who develop intussusception may have a characteristic clinical triad of abdominal pain, vomiting, and bloody stool. The typical infant develops the acute onset of severe, colicky abdominal pain. Intermittent episodes of irritability and crying may be associated with drawing the legs up to the abdomen. Between bouts of colic, the infant is often lethargic or sleepy. During periods of relative exhaustion, the abdominal examination may not be impressive; however, on careful physical examination, a palpable mass in the right abdomen may be appreciated in 80% to 90% of cases. Emesis is common and is often the presenting complaint. As intestinal obstruction progresses, intractable vomiting with abdominal distention and intravascular volume depletion may occur. Guaiac-positive stool is present in 90% to 95% of infants as a result of the ischemic mucosal injury to the intussusceptum. The passage of bloody stool mixed

with mucus, classically described as *currant-jelly stool,* may be observed.

Diagnosis

Plain radiographs of the abdomen are generally nonspecific and may show a paucity of gas in the right lower quadrant with a mass effect in the ascending colon. Late findings demonstrate mechanical small-bowel obstruction with proximal distention, air–fluid levels, and a decrease or absence of gas distally. Diagnostic enema techniques using either air or contrast approach 100% accuracy with typical ileocolic intussusception (Fig. 103-40). An approach using hydrostatic or pneumatic enema allows therapeutic reduction of intussusception as well. Ultrasound examination typically reveals a mass resembling a bull's eye or target sign, corresponding to the intussusceptum within the intussuscipiens. The target sign of intussusception also may be demonstrated by CT. Both these latter modalities do not allow for potential therapeutic reduction and may be more useful in diagnosing suspected cases of proximal jejunoileal or enteroenteral intussusception.

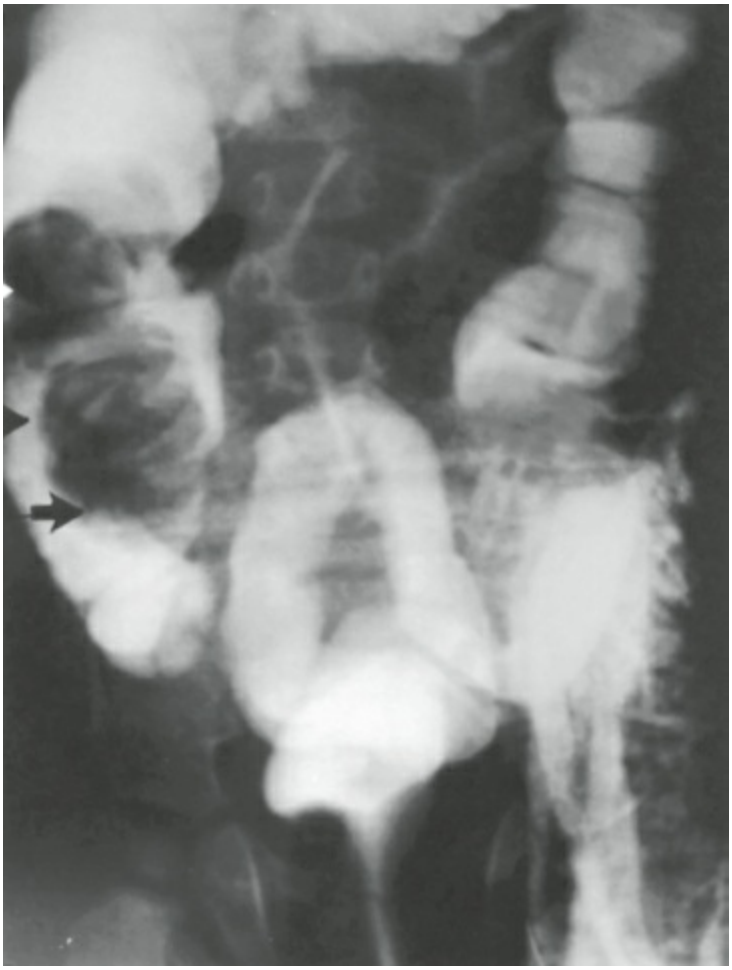

Figure 103-40. Contrast enema demonstrating classic ileocolic intussusception with the intussusceptum visible in the ascending colon (*arrows*).

Treatment

Any infant with suspected intussusception in the absence of peritonitis should undergo diagnostic hydrostatic or pneumatic enema. A high index of clinical suspicion and liberal application of this approach should be maintained. The incidence of normal contrast

enema examinations in this setting may exceed 75% in most pediatric centers, and this is justified by the considerable risk inherent in a missed diagnosis. An experienced pediatric radiologist and surgical evaluation are essential. Intravenous access and resuscitation should occur before attempts are made at diagnostic or therapeutic enemas.

Successful hydrostatic or pneumatic reduction of ileocolic intussusception is achieved in 60% to 80% of infants in most pediatric centers in the United States. Some centers prefer pneumatic enema using air as a contrast agent, and this technique appears comparable to the hydrostatic approach in both diagnosis and therapeutic reduction of intussusception. The ability to reduce intussusception using these techniques is time dependent and diminishes substantially after the duration of symptoms exceeds 24 hours. In this setting, a contrast enema is still diagnostic and potentially therapeutic if carefully performed.[140] With most experienced pediatric radiologists, the risk of perforation or reduction of a strangulated intussusceptum is low.

The technique of retrograde reduction of intussusception is straightforward. Contrast or air is introduced into the rectum by a balloon catheter, with the height of the hydrostatic column 1 m or less. Most centers use three attempts at reduction, with each attempt no longer than 3 minutes in duration. As long as progress is being made, however, attempts can be repeated until reduction is achieved. Successful reduction of ileocolic intussusception is demonstrated by observing retrograde flow of contrast or air into the terminal ileum. Inability to demonstrate retrograde flow into the ileum suggests incomplete reduction requiring surgical exploration.

Operative Management. Infants presenting with peritonitis and small-bowel obstruction with a clinical diagnosis of intussusception should undergo immediate resuscitation and exploration without attempts at retrograde enema. Surgical exploration is also required after incomplete retrograde enema reduction of intussusception or in the relatively infrequent situation of bowel perforation during diagnostic or therapeutic enema. The operative strategy is dictated by the findings. Spontaneous reduction of the intussusception is reported to occur in up to 20% to 30% of infants following induction of general anesthesia. In this situation, exploration confirming the reduction and examining the bowel for a pathologic lead point is sufficient. With persistent intussusception and viable bowel, the bowel is manually reduced, generally pushing the intussusceptum out of the distal bowel. If manual reduction cannot be performed or the intussusceptum is strangulated, then segmental resection with primary anastomosis is performed. Attempts at reducing intussusception with clearly necrotic bowel should be avoided. Diverting enterostomy as a result of peritoneal contamination usually is not required. Appendectomy is routinely performed in all infants undergoing operative exploration for intussusception. As with many aspects of pediatric surgery, a successful laparoscopic approach to the diagnosis and management of intussusception has been reported in approximately two-thirds of selected patients.[141–143]

Complications and Outcome

Retrograde techniques are successful at reducing idiopathic ileocolic intussusception in

60% to 80% of cases. Following successful enema reduction, the infant is given intravenous fluids and usually observed for 24 hours. Tolerance of oral feeding is predictably rapid. Recovery from operative reduction or bowel resection is generally no different than from other similar gastrointestinal procedures. Most infants enjoy a complete recovery with minimal or no morbidity. Recurrent intussusception after either nonoperative or operative reduction occurs in about 5% of infants and usually can be treated with repeat enema. Mortality from intussusception is rare and is almost always the result of systemic sepsis and shock from unrecognized, strangulated intestine.

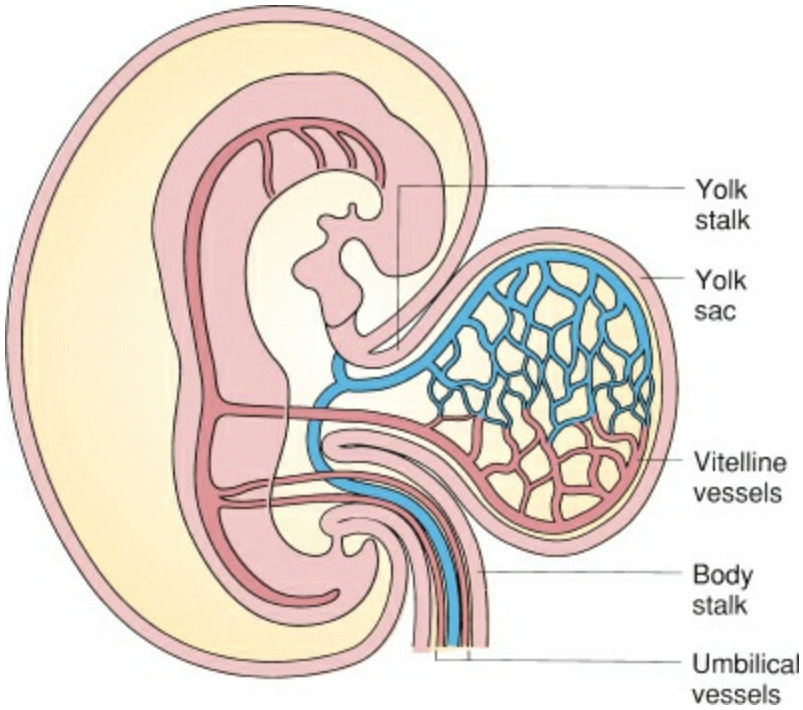

Figure 103-41. Normal embryonic relations of the yolk sac, yolk stalk, and developing gut.

Meckel Diverticulum and Related Disorders

Embryology and Anatomy

The most frequently encountered congenital anomaly of the gastrointestinal tract is Meckel diverticulum, representing one of several malformations resulting from persistence of the yolk stalk (synonymous with *vitelline duct* and *omphalomesenteric duct*) and its components. The embryonic yolk stalk connects the yolk sac and the developing midgut (Fig. 103-41). Between weeks 5 and 7 of gestation, the yolk sac involutes and the stalk fuses with the umbilical cord. Developmental failure or arrest of yolk sac involution creates a spectrum of clinical malformations as outlined in Figure 103-42, with Meckel diverticula constituting greater than 95% of these anomalies. Meckel diverticulum is a true diverticulum of variable size derived from the intestinal remnant of the yolk stalk. Typically, it is found on the antimesenteric border of the terminal ileum approximately 40 to 50 cm from the ileocecal valve in adults. The blood supply is derived from persistent vitelline vessels supplied from the SMA. About 25% of the diverticula have a fibrous or vascular attachment to the anterior abdominal wall at the umbilicus (Fig. 103-42C). Heterotopic gastric mucosa or pancreatic tissue is found in about half of the diverticula examined at autopsy. In about 75% of patients with symptomatic diverticula, gastric mucosa is present. When symptoms occur, bleeding or perforation is generally the result of peptic ulceration of the adjacent ileal mucosa and not from the diverticulum itself.

Clinical Presentation

Symptomatic yolk stalk anomalies are usually diagnosed by history and clinical examination. Umbilical drainage from a persistent fistula or sinus tract may be noted in a newborn following separation of the umbilical cord. Intestinal prolapse or passage of stool from the umbilicus signifies a patent omphalomesenteric duct. Small bowel obstruction in an otherwise healthy infant without a history of laparotomy may be a result of volvulus around an omphalomesenteric band or intussusception from a Meckel diverticulum acting as a lead point.

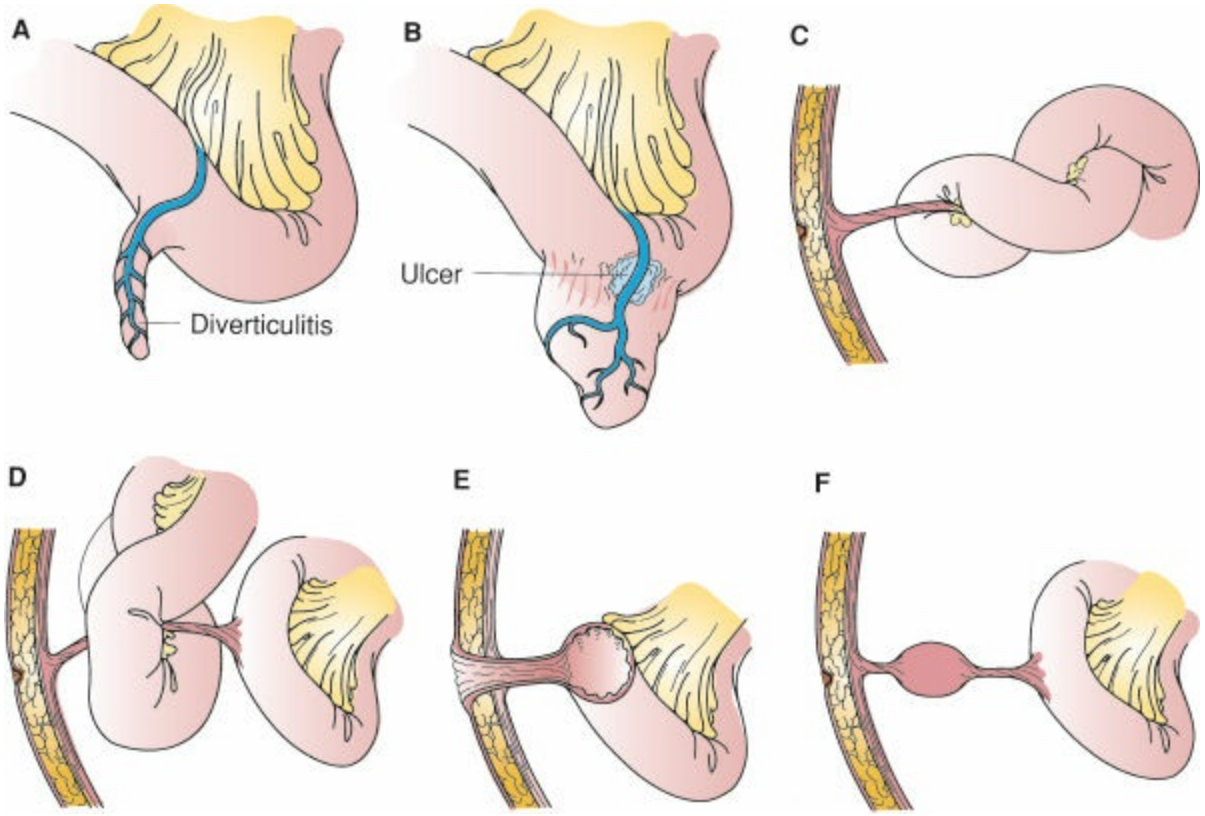

Figure 103-42. Common variants of yolk stalk malformations. **A,B:** Meckel diverticulum can manifest with inflammation (diverticulitis) or hemorrhage from acid-induced ulceration. **C,D:** Meckel diverticulum in association with abnormal band attached to the abdominal wall predisposing to volvulus and intestinal obstruction. **E:** Patent omphalomesenteric duct. **F:** Omphalomesenteric sinus and cyst formation.

The incidence rate of Meckel diverticula in the general population is about 2%, with a 2:1 male-to-female predominance. The risk of developing symptoms from the diverticulum decreases with age, and the vast majority of subjects remain asymptomatic. About half of the persons who do become symptomatic are younger than 2 years. Table 103-7 outlines several of the more common clinical presentations of symptomatic Meckel diverticulum.

Hemorrhage. Gastrointestinal bleeding related to Meckel diverticulum generally results from peptic ulceration of the adjacent ileal mucosa. Clinically, it manifests as painless, episodic hemorrhage that is typically bright red to maroon in color; melena is not characteristically seen. Bleeding from Meckel diverticulum is generally not hemodynamically significant or exsanguinating, but it can be persistent enough to require transfusion. The diagnostic test of choice is the ^{99m}Tc-pertechnetate radioisotope scan (Meckel scan) because of the high affinity of the isotope for gastric mucosa and the high probability of gastric mucosa within a symptomatic Meckel diverticulum. Diagnostic accuracy is reported to be as high as 90% for Meckel-related bleeding. Contrast studies and endoscopy have a limited role when the problem is hemorrhage from a Meckel diverticulum.

Table 103-7 Signs and Symptoms of Meckel Diverticulum

Clinical Presentation	Approximate Frequency (%)
Hemorrhage	30–35
Small bowel obstruction	30–35
Diverticulitis	20–25
Umbilical fistula	10
Other	Uncommon

Obstruction. Intestinal obstruction associated with omphalomesenteric duct anomalies usually results from either intussusception or volvulus around an abnormal attachment between the bowel and the abdominal wall. In about 5% to 10% of persons with symptomatic Meckel diverticula, intussusception is the initial symptom. In patients with Meckel diverticula whose initial symptom is small bowel obstruction, about half have intussusception, and the remainder have volvulus, internal hernias, or other mechanical causes. Intussusception secondary to a Meckel diverticula has a decreased likelihood for successful enema reduction. Small bowel obstruction from volvulus around an omphalomesenteric band requires operative exploration and treatment.

Diverticulitis. About one-third of patients with symptomatic Meckel diverticulum have acute diverticulitis. Similar to appendicitis, intraluminal obstruction at the base of a Meckel diverticulum can lead to distal inflammation, gangrene, and subsequent perforation. Peptic ulceration also can lead to local inflammation and perforation with the development of peritonitis. The signs and symptoms of Meckel diverticulitis are virtually indistinguishable from appendicitis, and exploration is both diagnostic and therapeutic.

Umbilical Anomalies. About 10% of patients with yolk stalk or persistent omphalomesenteric duct anomalies have umbilical problems. The usual clinical presentation is persistent drainage or intestinal mucosa found at the umbilicus. The diagnosis can be confirmed by contrast sonogram of the umbilical orifice or tract. Occasionally, ultrasound examination may be useful to demonstrate omphalomesenteric cysts. Ultimately, surgical exploration may be required for both diagnosis and treatment.

Meckel Diverticulum as an Incidental Finding. The management of an incidentally discovered Meckel diverticulum during abdominal exploration for other reasons is controversial. The risk of resecting an asymptomatic diverticulum must be weighed against the reasons for the operative exploration, patient age, and the potential for future symptoms from the diverticulum. Infants younger than 2 years are at greater probability of becoming symptomatic from Meckel diverticula. Resection is clearly indicated with demonstration of heterotopic gastric mucosa in the diverticulum to prevent peptic ulceration. This finding may occasionally be determined by direct palpation because the gastric mucosa is thicker than ileal mucosa. Abnormal omphalomesenteric bands to the abdominal wall should also be excised. If clinical judgment suggests that the diverticulum is at risk for luminal obstruction, resection is warranted.

Treatment

Infants and children with symptomatic umbilical abnormalities from yolk stalk remnants are usually well, and umbilical exploration with possible laparotomy can be undertaken electively. The yolk stalk remnant is excised, and, if present, the communication with the ileum is closed primarily with minimal morbidity and mortality. Operative exploration is required for patients with symptomatic Meckel diverticula. Typically, exploration can be accomplished through a variety of incisions. The treatment of choice is resection through either antimesenteric wedge excision or segmental bowel resection with primary closure or anastomosis. Laparoscopic diagnosis and management of Meckel diverticulum has also been described.[144] In the absence of associated medical problems, excellent functional outcome is expected with minimal morbidity and essentially no mortality unless intestinal necrosis has occurred.

Foreign Bodies

Ingestion of foreign bodies by infants and children is common. Toddlers in the age range of 9 months to 2 years are at particular risk given newly acquired mobility and the tendency for oral exploration. The type of foreign body and the location in the gastrointestinal tract on discovery dictate overall management.

Esophagus

Typical foreign bodies found in the esophagus include coins and small toys. In normal children, these objects become impacted at predictably narrow portions of the esophagus, including the cricopharyngeus, the esophagus at the level of the left mainstem bronchus, and the gastroesophageal junction. Previous areas of esophageal repair or injury predispose to points of obstruction. In particular, infants and children with repaired esophageal atresia, gastroesophageal reflux, or caustic esophageal injury are at risk for impaction at these sites.

Esophageal foreign bodies produce clinical symptoms of drooling, feeding intolerance (particularly to solids), dysphagia, and pain. Unrecognized foreign bodies with unusual configuration or sharp points and edges may cause esophageal perforation and mediastinitis. The diagnosis is straightforward on plain radiographs if the object is metallic or radiopaque. If a radiolucent object is suspected, an upper gastrointestinal contrast study is usually required to confirm the diagnosis. Lateral plain films of the neck or chest may be useful to differentiate between small foreign bodies in the esophagus or the trachea.

Foreign bodies impacted in the esophagus cause partial esophageal obstruction and can cause complications including aspiration, erosion, perforation, and late stricture formation. Therefore, all esophageal foreign bodies should be removed. Extraction of foreign objects can be accomplished by using balloon catheter retrieval under fluoroscopic guidance or direct visualization using endoscopy. Performed within 24 hours of ingestion, balloon catheter retrieval of esophageal foreign bodies is relatively straightforward. This technique is limited to smooth radiopaque objects such as coins to minimize the risk of esophageal perforation. The most significant risk with balloon catheter retrieval is potential aspiration from an unprotected airway, and this must be

anticipated as the foreign body traverses the pharynx. Alternatively, for esophageal coin impaction of less than 24 hours' duration in children without a history of esophageal surgery or injury, esophageal bougienage with clearance of the coin into the stomach has been successful.[145]

Retrieval of esophageal foreign bodies under direct endoscopic vision requires general anesthesia. Either flexible or rigid endoscopy systems are widely available and used with individual and institutional preferences. Esophageal perforation, the major risk, occurs in fewer than 5% of cases in most reported series. Longstanding esophageal foreign bodies may erode into the aorta and cause life-threatening hemorrhage from aortoesophageal fistula.[146]

Distal Gastrointestinal Tract

More than 95% of foreign bodies that pass beyond the gastroesophageal junction proceed uneventfully through the gastrointestinal tract. The transit time for an asymptomatic foreign body is highly variable and can take hours to weeks. Progress of an asymptomatic radiopaque foreign body can be followed by abdominal plain films, but this is rarely useful from a clinical standpoint unless it is a battery. The stool may also be screened to confirm passage of a known foreign body.

Operative exploration or endoscopic retrieval of distal gastrointestinal foreign bodies is generally reserved for clinical symptoms related to either obstruction or intestinal injury heralded by abdominal pain, vomiting, fever, or peritonitis. In addition, persistence of an asymptomatic foreign body in the stomach for several weeks is a relative indication for upper endoscopic retrieval, particularly with foreign bodies with irregular shape, configuration, or sharpness. This is a clinical judgment that is best reserved for an experienced pediatric surgeon because remarkably complex and improbable objects may pass uneventfully through the gastrointestinal tract. For asymptomatic foreign bodies lodged distal to the stomach, a relative indication for operative removal is a fixed, persistent location in the intestine longer than 1 week in duration.

Ingested batteries, in particular alkaline disc batteries, are a potentially serious hazard to children and require a more aggressive approach. Disruption of the battery casing and spillage of the contents have been reported to cause intestinal injury and perforation, presumably because of leakage of potassium or sodium hydroxide. Esophageal impaction of a battery warrants prompt removal when recognized because the risk of acquired esophageal injury, perforation, and development of traumatic tracheoesophageal fistula is present.[147] In the distal bowel, cathartics may be helpful to expedite passage of the battery. Operative removal may be necessary if the battery fails to progress distally over a few days or if symptoms related to the battery occur. Notably, the vast majority of batteries pass through the gastrointestinal tract uneventfully. Ingestion of multiple magnets can cause problems with small bowel obstruction or enteroenteric fistula formation.

Gastrointestinal Hemorrhage

The subject of gastrointestinal hemorrhage and general principles of management are

discussed elsewhere this book. The following section reviews some of the important and age-dependent clinical causes and unique issues of gastrointestinal bleeding in pediatric population. These causes are age dependent and are summarized in Tables 103-8 and 103-9.

Diagnostic workup of an infant or a child with gastrointestinal hemorrhage requires coordinated participation among pediatricians, surgeons, gastroenterologists, and radiologists. Several general principles governing the diagnostic approach to gastrointestinal bleeding in infants and children follow:

a. A clear diagnosis can be made in most situations; given the current technology available to assist with diagnosis, an aggressive approach is warranted. Diagnostic procedures such as flexible fiberoptic endoscopy, radioisotope imaging, and angiography are widely available, safe, and applicable to any age group, including the newborn. Despite these measures, in approximately 16% of cases, the cause of guaiac-positive stools in a neonate or infant remains unknown,[148] and the bleeding is self-limited.

Table 103-8 Etiology and Causes of Upper Gastrointestinal Hemorrhage[a]

Patient Age Group	Common Causes	Less Common Causes
Neonatal (0–30 days)	Gastritis Esophagitis Ingested maternal blood Peptic ulcer	Iatrogenic trauma Primary coagulopathy Vascular malformation (hemangioma, telangiectasia, arteriovenous malformation) Nasal or pharyngeal bleeding Miscellaneous (leiomyoma, gastric polyp, duplication)
Infant (30 days to 1 year)	Gastritis Esophagitis Peptic ulcer	Same as neonate, with addition of: Drugs (steroids, nonsteroidal antiinflammatory drugs) Foreign body, caustic ingestion Esophageal varices
Child (1–12 years)	Esophageal varices Esophagitis Peptic ulcer	Same as infant, with addition of: Acquired thrombocytopenia (chemotherapy)
Older child (12 years to adult)	Esophageal varices Esophagitis Peptic ulcer	Same as for child

[a]Order in appearance approximates clinical frequency.
Modified from Oldham KT, Lobe TE. Gastrointestinal hemorrhage in children. A pragmatic update. *Pediatr Clin North Am* 1985;32:1247–1263, with permission.

Table 103-9 Causes of Lower Gastrointestinal Hemorrhage[a]

Patient Age Group	Common Causes	Less Common Causes
Neonatal (0–30 days)	Benign anorectal lesions (fissure) Upper gastrointestinal hemorrhage Milk allergy Necrotizing enterocolitis Midgut volvulus	Iatrogenic trauma Primary coagulopathy Vascular malformations Enterocolitis (Hirschsprung disease, other) Miscellaneous (duplication, lymphoma, lymphangiectasia)
Infant (30 days to 1 year)	Incarcerated inguinal hernia Benign anorectal lesions Idiopathic intussusception Meckel diverticulum Infectious diarrhea Upper gastrointestinal hemorrhage Milk allergy	Same as neonate, with addition of: Acquired thrombocytopenia Ingestion of colored foodstuff (pseudohematochezia)
Child (1–12 years)	Benign anorectal lesions Juvenile polyps Intussusception Meckel diverticulum Infectious diarrhea Upper gastrointestinal hemorrhage	Same as infant, with addition of: Juvenile polyposis coli/familial polyposis coli Hemolytic uremic syndrome Henöch–Schonlein purpura Systemic vasculitis (dermatomyositis, lupus) Acquired thrombocytopenia (as above plus idiopathic thrombocytopenic purpura)
Older child (12 years to adult)	Juvenile polyps Benign anorectal lesions Inflammatory bowel disease Upper gastrointestinal hemorrhage	Same as child, except: Henöch–Schonlein purpura and hemolytic uremic syndrome less likely Meckel diverticulum

[a]Order in appearance approximates clinical frequency.
Modified from Oldham KT, Lobe TE. Gastrointestinal hemorrhage in children. A pragmatic update. *Pediatr Clin North Am* 1985;32:1247–1263, with permission.

b. The primary diagnostic investigation of choice for upper gastrointestinal bleeding is esophagogastroduodenoscopy. This procedure is optimally performed within the first 24 hours after cessation of active hemorrhage and usually requires general anesthesia. Imaging studies for active upper gastrointestinal hemorrhage are limited in their ability to aid with diagnosis.
c. Infants and children presenting with minor lower gastrointestinal bleeding are best evaluated by a careful perineal and digital rectal examination, followed by anoscopy.
d. Massive lower gastrointestinal hemorrhage in an infant or a child outside the newborn period is most likely the result of a bleeding Meckel diverticulum.
e. If a definitive source for lower gastrointestinal hemorrhage is not found on colonoscopy, evaluation for an upper gastrointestinal source, including upper endoscopy and diagnostic laparoscopy, is warranted.
f. Pain is an uncommon symptom with pediatric gastrointestinal hemorrhage and implies a more complex problem such as volvulus, ischemic bowel, or inflammatory bowel disease. Painful gastrointestinal hemorrhage in pediatric patient requires urgent evaluation and prompt diagnostic workup.
g. In contrast to that in adults, gastrointestinal bleeding in children is rarely a symptom

or sign of gastrointestinal neoplasm.

Neonates (0 to 30 Days of Age)

The most common cause of gastrointestinal hemorrhage in a neonate is gastritis. Endoscopic evaluation of newborns with symptomatic upper gastrointestinal hemorrhage demonstrates gastritis or esophagitis in 50% to 75% of cases. About 10% to 15% have swallowed maternal blood during birth, and 10% of newborns are found to have an underlying coagulopathy. Anatomic lesions requiring operative control are distinctly unusual in this age group. Significant and sometimes massive upper gastrointestinal hemorrhage may occur in a neonate without a definable anatomic lesion despite endoscopic evaluation. This finding is usually the result of gastritis, and treatment is directed at blood and volume replacement and correction of any underlying coagulopathy.

Significant conditions responsible for lower gastrointestinal bleeding in the newborn include NEC, malrotation with volvulus, enterocolitis, or bowel obstruction secondary to an incarcerated inguinal hernia. These clinical entities present with characteristic histories, findings on clinical examination, and surgical treatment guidelines previously discussed. Anorectal fissure is also common and easy to diagnose in neonates, and bleeding is typically self-limited.

Infants (30 Days to 1 Year)

Infants with upper gastrointestinal bleeding deserve comprehensive evaluation, including endoscopy, to identify potential lesions requiring operative intervention. The most common causes of lower gastrointestinal hemorrhage in this age group include infectious diarrhea, intussusception, food allergy, and bleeding Meckel diverticulum. Most of these lesions have distinct symptoms, signs, and diagnostic findings to facilitate diagnosis. Infectious diarrhea is usually accompanied by fever, feeding intolerance, possibly emesis, and abdominal pain. Fecal leukocytes may be present on stool examination, and enteric pathogens or their toxins can be identified by stool culture.

Children (1 to 12 Years)

An important surgical cause of upper gastrointestinal bleeding in this age group includes esophageal variceal bleeding from portal hypertension. Children with biliary atresia or extrahepatic portal venous obstruction account for most cases of variceal bleeding in this age group. In the acute setting, endoscopic sclerotherapy or banding is used as a temporizing measure for hemorrhage control; some investigators advocate maintenance sclerotherapy. Ultimately, for these children, orthotopic liver transplantation may offer definitive surgical treatment. The use of operative portosystemic shunts for acute variceal hemorrhage is not widely used in pediatric surgical practice in the United States.

Conditions causing lower gastrointestinal bleeding in this age group include juvenile polyps. These are benign, hamartomatous polyps and represent the single most common cause of lower gastrointestinal bleeding in children. About 20% to 30% of the polyps are palpable on digital rectal examination. A history of painless, bright red blood per rectum

during a bowel movement is typical. The bleeding results from mucosal irritation, involution, and sloughing of a pedunculated polyp and is usually not associated with hemodynamically significant hemorrhage. Tissue may be passed or the pedunculated polyp may prolapse out the anus. A hypochromic, microcytic anemia may be present. Diagnostic workup generally involves a contrast enema to identify the polyp and evaluate the colon for synchronous lesions. Colonoscopy may require general anesthesia in this age group, and endoscopic snare polypectomy is the treatment of choice for appropriate-sized polyps. Infrequently, transanal excision or open resection of larger polyps is required. In the case of multiple juvenile polyps not amenable to endoscopic polypectomy, management may be expectant based on the benign natural history characterized by involution during adolescence. Histologic confirmation is necessary to differentiate these lesions from adenomatous polyps seen in familial polyposis syndromes or Gardner syndrome.

Older Children and Adolescents (Older Than 12 Years)

Causes of both upper and lower gastrointestinal hemorrhage in this age group include most etiologic conditions found in adults. Importantly, inflammatory bowel disease is significant in this age group.

Intestinal Duplication

The embryologic origin of enteric duplication formation remains controversial, but duplication likely represents abnormal development of either a diverticulum or adjacent portion of the developing gut. In some cases, duplication cysts of the upper gastrointestinal tract may be associated with thoracic spinal cord or vertebral defects; this association appears to reflect abnormal sequestration and integration of developing primitive notochord elements in addition to duplication. The resulting lesions are described as either *cystic* or *tubular* based on their gross appearance (Fig. 103-43). All types of gastrointestinal-derived epithelia are found, but the clinically relevant finding is ectopic gastric mucosa. Duplications are commonly found along the mesenteric border of the native bowel. The muscular wall is typically well developed and intimately attached to the functional bowel. In addition, the blood supply is also shared with the functional intestine, an important surgical consideration.

Cystic Duplications

Cystic duplications may be found throughout the gastrointestinal tract. They are frequently located in the esophagus and the hindgut, particularly the rectum. Direct communication between a duplication cyst and the functional gut lumen is unusual. Typically, asymptomatic duplications are discovered as incidental mass lesions during diagnostic imaging studies, particularly when the location is the thoracic cavity or the rectum. Duplications also may present as symptomatic lesions from ectopic gastric mucosa leading to ulceration and bleeding. Other potential presenting symptoms of enteric duplication include obstruction, intussusception, perforation or traumatic rupture, torsion, infection, and occasional malignant degeneration. Useful examinations to define

the extent of the lesion include ultrasound, CT scanning, MRI studies, and contrast studies. The identification of enteric duplication on routine prenatal ultrasound examination has been reported.

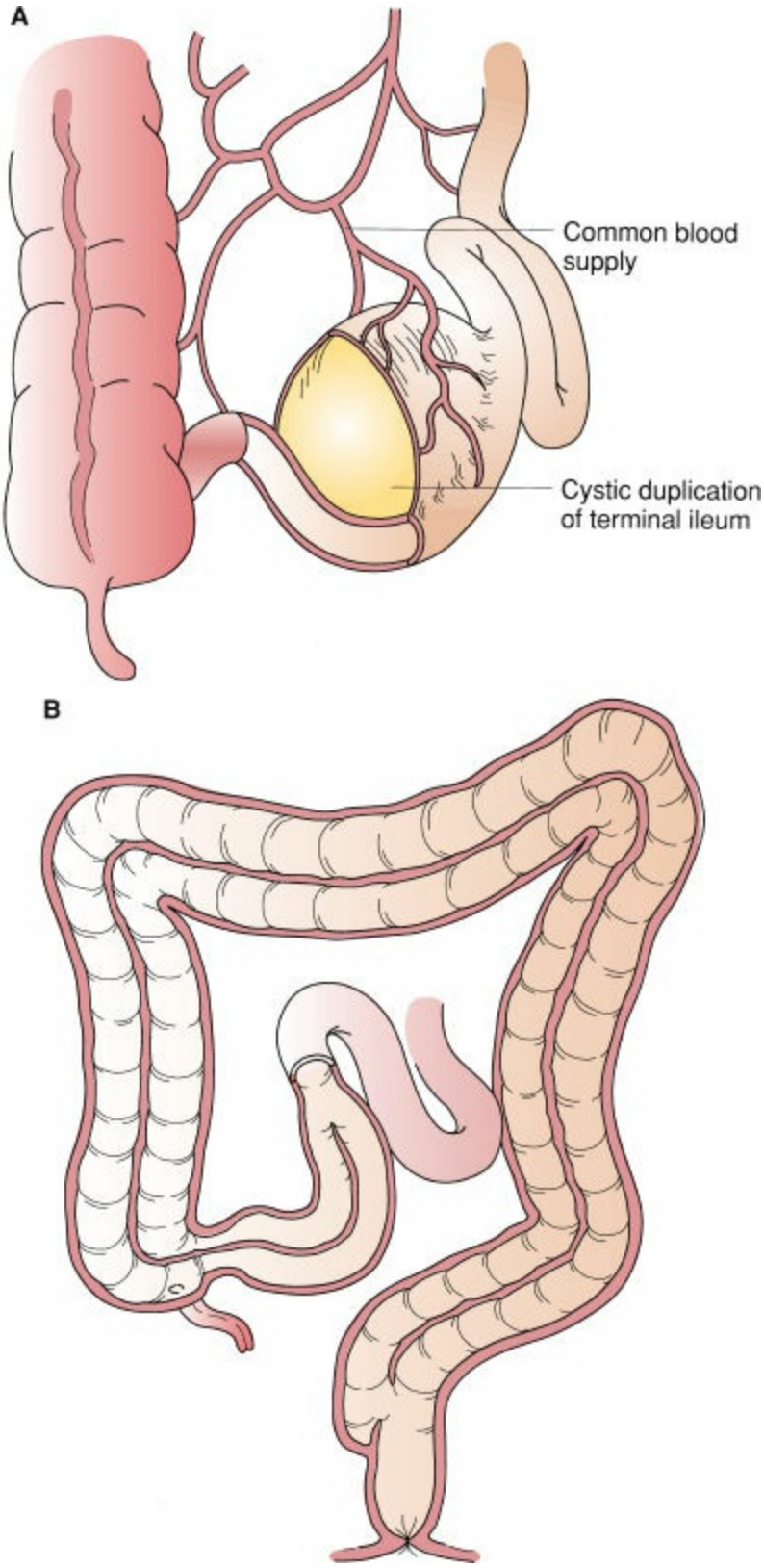

Figure 103-43. Enteric duplication. **A:** Cystic duplication of the terminal ileum. **B:** Tubular duplication of the terminal ileum and the colon.

The treatment of all cystic duplications is operative. Even in asymptomatic infants and children, uncertainty regarding the nature of the mass and the potential for subsequent

problems dictates surgical exploration. Esophageal and rectal duplication cysts are generally amenable to simple excision. In contrast, duplication cysts of the small intestine usually require segmental resection and primary anastomosis, given the intimate attachment and shared blood supply with the native bowel. For large cystic duplications involving longer segments of native bowel, individualized treatment strategies are required. One option is cyst marsupialization with resection of the duplication cyst wall with preservation of the common blood supply and wall between the cyst and the native bowel. This technique is combined with submucosal dissection and stripping of the remaining epithelium from the cyst wall. Another approach is internal drainage of the cyst into the adjacent native intestine, for example, creation of a cystoduodenostomy for duodenal duplication not amenable to local resection and anastomosis; this would be distinctly unusual.

Tubular Duplications

Tubular duplications may be found anywhere along the length of the gastrointestinal tract. They are less frequent than cystic duplications and have a tendency to involve the ileum and the colon. It is believed that tubular duplication generally reflects abnormal, disordered recanalization of the gastrointestinal tract. Similar to cystic duplications, tubular lesions share a common wall and blood supply with the native bowel. Communication between the tubular duplication and native bowel lumen is common. Tubular duplications may be extensive and can involve the entire length of terminal ileum and colon. Malformations of the entire colon and rectum are associated with genitourinary anomalies, particularly duplications of the external genitalia or bladder.

Tubular duplications manifest clinically in similar fashion to cystic lesions. Symptomatic lesions most commonly present with gastrointestinal bleeding or obstruction. Treatment is operative, and an individualized strategy is required that is based on the location and nature of the duplication. Resection with primary anastomosis may require removal of an unacceptable length of normal bowel. Marsupialization with submucosal stripping of the duplication epithelium may be particularly helpful if ectopic gastric mucosa is suspected or found. Obstruction from a long, blind-ending parallel duplication that communicates with the functional gut lumen can be treated effectively with a reentry procedure such as a distal enteroenterostomy. This approach avoids a potentially complex resection of a significant length of bowel.

The outcomes of surgical management of enteric duplications are generally excellent in the absence of other associated anomalies or medical problems. Mortality attributable to the duplication itself is unusual. Postoperative morbidity is generally dependent on the nature and location of the duplication.

Mesenteric and Omental Cysts

Mesenteric and omental cysts are rare lesions thought to result from the sequestration of lymphatic tissue during development. Mesenteric cysts are twice as common as omental cysts. Both are characterized by thin, often incomplete walls lined with endothelial cells absent of surrounding smooth muscle. They may be filled with either serous lymphatic fluid or chyle and may be unilocular or multilocular. These cysts may become extraordinarily large before producing symptoms.

Most infants and children with mesenteric or omental cysts are diagnosed prior to adolescence. Asymptomatic children are usually diagnosed incidentally during studies for other reasons. Symptomatic children present with abdominal pain, and, on examination, a soft, mobile abdominal mass is characteristic. Bleeding, rupture, obstruction, torsion, or cyst infection may be observed. Most of these lesions can be diagnosed by ultrasound or CT scan imaging. Ascites, duplication cysts, pancreatic pseudocysts, and large ovarian cysts may have a similar appearance on diagnostic imaging. Peripheral calcification and evidence of recent hemorrhage may be seen in mesenteric or omental cysts (Fig. 103-44).

The treatment for these lesions is simple excision. Total excision of mesenteric or omental cysts is generally preferable over partial excision with marsupialization. Limited resection with primary anastomosis may be required for a mesenteric cyst located adjacent to the intestinal wall, particularly if there is concern that the cyst actually may be an enteric duplication. Morbidity and mortality are generally limited to concurrent problems associated with the intestine. In particular, volvulus of a mesenteric cyst may cause vascular compromise and infarction of the adjacent intestine.

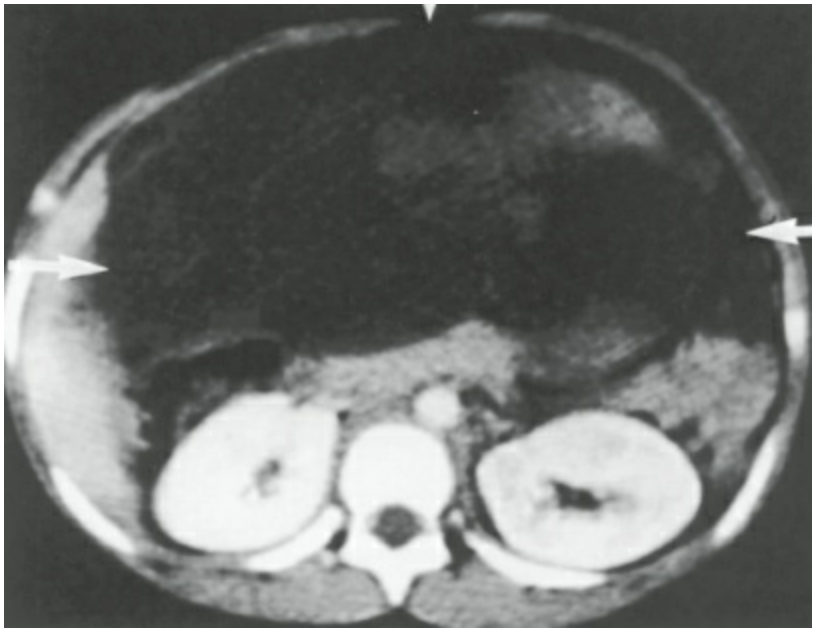

Figure 103-44. Computed tomographic scan of a child after abdominal trauma. Hemorrhage into large omental cyst is apparent (*arrows*).

Primary Peritonitis

Bacterial peritonitis without a specific, identifiable cause is referred to as *primary peritonitis*. Spontaneous bacterial peritonitis in children with ascites or nephrosis is generally included in this group. Hematogenous seeding of ascitic fluid is probably responsible for the development of spontaneous bacterial peritonitis. The infecting bacterial organisms were classically gram-positive with a variety of staphylococcal, streptococcal, and other species accounting for most cases. In a series of infants and children with primary peritonitis, more than two-thirds of the cases were caused by gram-negative organisms such as *Escherichia coli*.[149] This trend may reflect the use of antibiotic prophylaxis directed against gram-positive organisms.

The other etiologic mechanism for the development of primary peritonitis is believed to involve retrograde inoculation of the peritoneal cavity via the genitourinary tract. This etiology is characteristic of prepubertal girls 5 to 10 years of age, accounting for as many as half of the cases of primary peritonitis. The initial signs and symptoms in these children are virtually identical to those in children with perforated appendicitis: fever, emesis, abdominal pain, and tenderness on examination. Leukocytosis is characteristic, and an ileus is observed on plain abdominal films. On exploration, these children have inflammatory peritonitis without an identifiable enteric cause. Gram-negative enteric organisms are commonly cultured from the peritoneal fluid.

Infants and children with peritonitis in association with an indwelling peritoneal dialysis catheter or ventriculoperitoneal shunt may be treated successfully with intravenous broad-spectrum antibiotics. The catheter or shunt should be removed or exteriorized promptly if peritonitis does not resolve within 24 to 48 hours.[150] In association with ascites or nephrosis, diagnostic paracentesis should be performed and the peritoneal fluid examined by Gram stain and culture. If there is any diagnostic uncertainty, laparoscopic or open operative exploration may be required to exclude intestinal perforation as a cause of peritonitis. If the appendix is normal, peritoneal cultures should be obtained and a thorough, complete abdominal exploration for other causes should be performed. Appendectomy is generally performed when the diagnosis of primary peritonitis is established by a right lower-quadrant incision. Other than perforated appendicitis, distinct causes of intestinal perforation or peritonitis in this age group include perforated Meckel diverticulum, duodenal ulcer, and acute pancreatitis. About half of the peritoneal fluid cultures are positive for a single organism. Treatment with specific antibiotics is continued until the patient is afebrile with a normal white blood cell count and normal clinical examination. Following operative exploration in primary peritonitis, the morbidity is no different than that for appendectomy, and the recovery is generally uneventful.

ETIOLOGY

Table 103-10 Common Causes of Neonatal Ascites

Maternal-fetal Rh incompatibility (rare)
Structural malformations
Urinary obstruction
Congenital heart disease
Malrotation, duplications, cyst (associated with intestinal volvulus)
Biliary perforation
Ovarian ascites
Pulmonary abnormalities
Chylous ascites
Hematologic disorder
α-Thalassemia
Infection
Toxoplasmosis
Cytomegalovirus
Others
α_1-Antitrypsin deficiency
Idiopathic

Ascites

The common causes of neonatal and childhood ascites are listed in Tables 103-10 and 103-11. The clinical presentation is that of abdominal distention with bulging flanks and demonstrable fluid on palpation and percussion. Ultrasound or CT scan imaging may be useful to confirm the clinical diagnosis. Paracentesis and routine examination of the fluid for Gram stain, cell count, cytology, protein, chemistries, and culture should be performed. Chylous ascites is characterized by a white milky appearance, high lymphocyte count, and high triglyceride content. Bile-stained fluid in the absence of demonstrable bowel perforation is characteristic of biliary ascites. High-fluid amylase content is seen in pancreatic ascites, and a low protein count (<3 g/dL) is consistent with serous ascites. Elevated urea nitrogen or creatinine in the fluid may suggest urinary ascites, particularly in a male patient. Cytology should be performed to exclude peritoneal ascites secondary to malignancy, particularly in pubertal and adolescent females.

If the initial fluid does not provide a diagnosis in an otherwise normal-appearing child, a comprehensive diagnostic imaging evaluation is warranted. An echocardiogram should be obtained and either ultrasound or CT scan imaging performed to evaluate the genitourinary system, the hepatobiliary system, and the pancreas. A voiding cystourethrogram may also be indicated.

Treatment of neonatal or childhood ascites depends on the establishment of a specific diagnosis. In the absence of anatomic lesion or injury, spontaneous resolution of chylous ascites occurs in 50% to 75% of cases with the temporary cessation of enteral feeding and administration of parenteral nutrition. Persistence of chylous ascites for longer than 4 to 6 weeks is an indication for operative attempts to ligate the cisterna chyli. Neonatal biliary ascites may result from spontaneous bile duct perforation, in which case a diagnosis of CF must be considered. Transient bile duct obstruction typically leads to perforation at the junction of the cystic duct with the common duct. Simple external drainage is the treatment of choice, and complex hepatobiliary tract reconstruction in this setting is unnecessary and potentially hazardous. Urinary ascites in a male patient requires a workup that includes a voiding cystourethrogram to exclude posterior urethral valves. Urinary ascites resolves with the treatment of obstructive uropathy. Pancreatic ascites is typically self-limited, and treatment by drainage procedures is generally not required or limited for relief of persistent symptoms.

Table 103-11 Common Causes of Childhood Ascites

Serous Ascites
Cirrhosis
Budd–Chiari syndrome
Nephrosis
Right-sided heart failure
Postoperative ascites (after renal transplantation, peritoneal dialysis, ventriculoperitoneal shunt)
α_1-Antitrypsin deficiency
Other rare metabolic disorders
Chylous Ascites
Malrotation with volvulus
Small bowel obstruction
Incarcerated hernia
Lymphangioma
Trauma (includes operative trauma)
Biliary Ascites
Neonatal bile duct perforation
Cystic fibrosis
Biliary atresia
Hepatitis
Cytomegalovirus infection
Urinary Ascites (7:1 Male Predominance)
Urinary obstruction
Posterior urethral valves
Bladder perforation
Ureterocele
Neurogenic bladder
Pancreatic Ascites
Acute pancreatitis (drugs, trauma, gallstones, infection)
Pancreatic pseudocysts
Ovarian Ascites
Cysts (torsion, rupture)
Tumors
Malignant Ascites
Intra-abdominal neoplasm
Idiopathic

Massive neonatal ascites may cause hypoventilation secondary to impairment of diaphragmatic excursion, and therapeutic paracentesis may be required. Childhood ascites generally responds to adequate treatment of the underlying problem and occasionally requires medical therapy. Placement of a peritoneovenous shunt in children for intractable ascites is rare.

Rectal Prolapse

Spontaneous rectal prolapse is relatively common in toddlers and children up to 5 years of age. A peak incidence occurs at or near the time of toilet training. There is an association between straining during bowel movement and rectal prolapse; it may be more commonly observed in children with CF, myelodysplasias with sacral neuropathy, congenital anorectal malformations, Hirschsprung disease, and colorectal polyps. However, most children presenting with rectal prolapse are normal.

A history of protrusion of mucosa or full-thickness rectum with or without bleeding is usually described. Other lesions of childhood that have a similar appearance are prolapse of an intussusceptum or passage of a polyp through the anus. The rectal examination is diagnostic. If the protruding intestine is an intussusceptum, a finger can be placed adjacent to it within the rectum; this maneuver is not possible with rectal prolapse.

Nonoperative management using manual reduction is successful in most infants and children. Sedation may be required in some instances. Therapeutic interventions include stool softeners and parental instruction on manual reduction. Spontaneous resolution over a few weeks is typical. For persistent rectal prolapse in children, operative intervention is generally governed by doing the least invasive procedure possible. Unlike adults, complex operations involving bowel resection and pelvic suspension are generally unnecessary in children with rectal prolapse. The most useful and commonly used procedure is rectal submucosal injection using a sclerosant (Fig. 103-45). With the patient under general anesthesia, injection with 5% sodium morrhuate or cow's milk[151] has been performed successfully on an outpatient basis. About 90% of children can be treated successfully with a single four-quadrant sclerosant technique, but on occasion further sclerosis is necessary. Submucosal dissection or cauterization is also successful but may have a higher incidence of postoperative bleeding or stricture formation and usually requires a short period of hospitalization. The major objective in treating childhood rectal prolapse is to create a local extraperitoneal inflammatory process in the perirectal space. Morbidity is low and the long-term outcome is excellent.

PEDIATRIC LIVER

Tumors of the Liver

Primary hepatic tumors are rare in children and at least 60% to 70% are malignant.[152,153] Table 103-12 reviews the incidence rates and types of hepatic tumors presenting during infancy and childhood. Pediatric hepatic tumors often manifest as asymptomatic abdominal masses discovered by parents or pediatrician. Symptoms related to the tumor, such as pain, hemorrhage, hypertension, and precocious puberty, are less frequent. Initial diagnostic imaging studies include plain abdominal radiographs and ultrasound to assist in early determination as to whether the mass is cystic or solid and whether calcifications are present. CT scan imaging and MRI remain definitive in the ability to discern anatomic characteristics of the mass and its relationship to adjacent structures. Most children require operative exploration for either definitive excision or incisional biopsy in lesions deemed unresectable.

Benign Tumors

Of all primary liver tumors of childhood, 30% are benign. The most common benign tumors are hemangiomas, hemangioendotheliomas, mesenchymal hamartomas, cysts, focal nodular hyperplasia, and hepatic adenoma. In most large series, hemangiomas constitute about 50% of the benign hepatic tumors observed.[154]

Vascular Tumors. Infantile hepatic hemangiomas represent a clinically diverse spectrum of vascular endothelial anomalies. They are characterized by a phase of proliferative growth over the first year of life, with subsequent involution over several years. The International Society for the Study of Vascular Anomalies classifies vascular tumors into two categories based upon the presence or absence of GLUT-1, an erythrocyte-type glucose transporter protein expressed in the endothelium of the placenta and hemangiomas.[155] Therefore, hemangiomas are GLUT-1 positive, and other, more heterogeneous vascular anomalies such as vascular malformations are GLUT-1 negative. Most asymptomatic infantile hepatic hemangiomas are detected as incidental findings on diagnostic imaging studies performed for unrelated reasons. A smaller proportion will create symptoms of enlarging abdominal mass, progressive hepatic failure, high output cardiac failure due to shunting, thrombocytopenia, or hypothyroidism from excess production of type III iodothyronine deiodinase.[156]

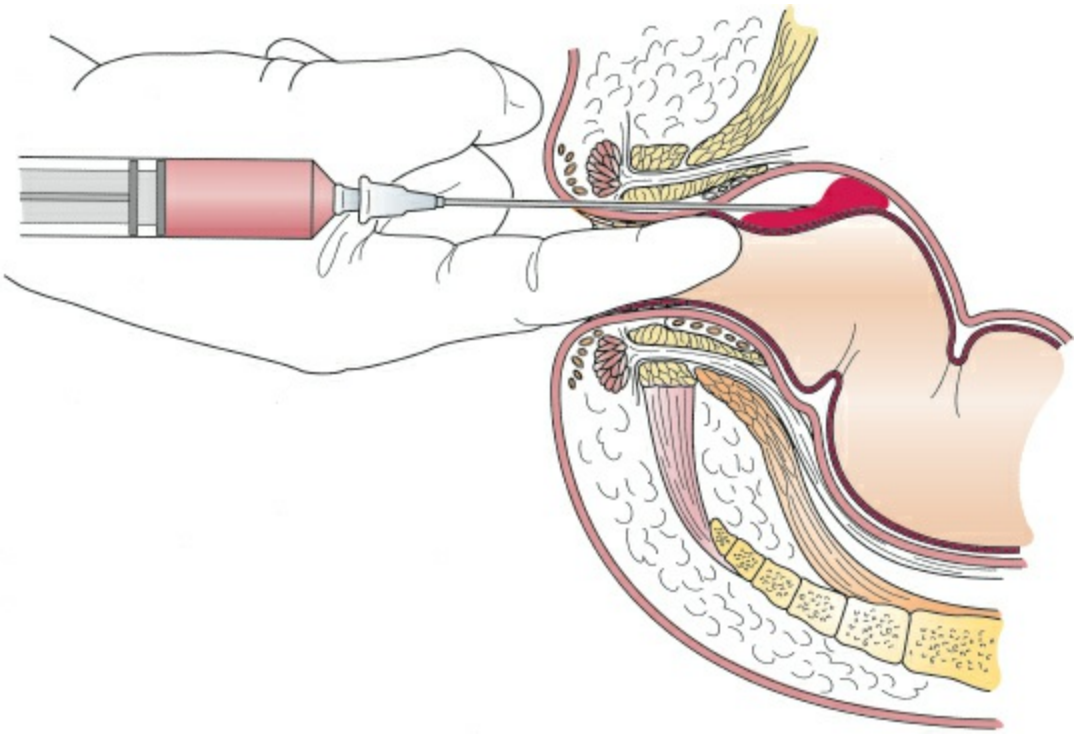

Figure 103-45. Four-quadrant injection of sclerosant into the rectal submucosa for the treatment of childhood rectal prolapse.

Most benign vascular lesions of the pediatric liver do not require operative management. Operative intervention is generally reserved for bleeding secondary to traumatic rupture symptoms not controllable with medical management. Treatment strategies remain highly individualized based upon the whether the lesions are focal, multifocal, or diffuse.[157] In the face of multifocal or diffuse disease associated with congestive heart failure and thrombocytopenia secondary to sequestration, medical treatment with corticosteroid therapy may be useful. More invasive procedures such as irradiation, selective hepatic arterial ligation, angiographic embolization, or hepatic transplantation remain useful in selected patients with uncontrollable symptoms. Chemotherapeutic agents, including recombinant alpha-interferon, low-dose vincristine, and cyclophosphamide, have been used for life-threatening vascular lesions. Hepatic resection is generally reserved for mass lesions of unknown diagnosis, ruptured vascular lesions with signs of active hemorrhage, or for symptomatic, locally resectable lesions.

Table 103-12 Incidence of Liver Tumors in Childhood

Tumor Type	Incidence Rate (%)
Benign	
Vascular tumors	13
Hemangioma	9
Hemangioendothelioma	4
Mesenchymal hamartoma	6
Focal nodular hyperplasia	2
Adenoma	2
Teratoma	2
Other	3
Malignant	
Hepatoblastoma	43
Hepatocellular carcinoma	23
Malignant mesenchymal tumor	4
Sarcoma	2
Embryonal cell carcinoma	2
Angiosarcoma	1

Hemangioendotheliomas are important vascular anomalies encountered in infants. The lesions vary in size from 1 cm to several centimeters in diameter and may be multiple (Fig. 103-46). Symptomatic neonates may present with an abdominal mass, hepatomegaly, and congestive heart failure. These infants may also experience spontaneous rupture and hemoperitoneum, with tachycardia, tachypnea, and hypovolemic shock. On examination, the infant may have other cutaneous hemangiomas visible on the skin. Affected infants may develop thrombocytopenia secondary to platelet sequestration in the vascular malformation (*Kasabach–Merritt syndrome*). CT scan imaging or MRI is diagnostic. Treatment is directed at controlling symptoms using medical management principles as discussed previously; however, hemangioendotheliomas tend to be more problematic than hemangiomas because of the tendency to occur during infancy and the more extensive, symptomatic nature of the lesions.



Figure 103-46. Selective visceral angiogram demonstrating large hepatic vascular malformation in a neonate with congestive heart failure. This finding is consistent with a bilobar hemangioendothelioma.

Mesenchymal Hamartomas. Approximately one-third of benign hepatic tumors in children are mesenchymal hamartomas. A mesenchymal hamartoma is often quite large and typically presents within the first year of life as an asymptomatic, solitary abdominal mass. CT scan imaging or MRI studies are usually diagnostic and show a solid mass that may have cystic components within the liver parenchyma. Definitive diagnosis may require open tissue biopsy, and the therapy of choice is complete excision, although spontaneous involution has been described. Simple enucleation may be adequate because these tumors tend to be well circumscribed. On occasion, formal hepatic resection may be required.[158] Recurrence is low after adequate resection.

Focal Nodular Hyperplasia. This tumor occurs primarily in female children and in adults and may be associated with the use of oral contraceptives or focal hepatic injury. Focal nodular hyperplasia is usually a well-defined, solitary mass that has characteristic findings on CT scan imaging. Open or percutaneous biopsy may be required to differentiate the lesion from hepatic adenoma. This lesion results from a focal inflammatory response of normal hepatic parenchyma surrounded by areas of micronodular fibrosis and cirrhosis. Operative management is generally unnecessary unless there is a question of diagnosis or active hemorrhage from the lesion.

Hepatic Adenoma. Adenomas are rare in infants and children and constitute less than 5% of all benign hepatic lesions in the pediatric age group. There is an association between the use of oral contraceptives, exogenous anabolic steroid use, and glycogen storage disease type I (von Gierke disease). These tend to be large, solitary lesions located in the right hepatic lobe. The typical presentation is an asymptomatic abdominal mass, although

symptoms are seen more commonly than with focal nodular hyperplasia. About 20% to 25% of patients with hepatic adenoma present with hemoperitoneum from tumor rupture. On histologic examination, these lesions are composed of normal hepatocytes without evidence of dysplasia. Operative therapy is usually directed at either making definitive diagnosis or treating hemorrhage. Enucleation or local resection is adequate and recurrence rates are low.

Hepatic Cysts. Congenital cysts of the liver may be either solitary or multiple. These cysts are thought to result from failure of the intralobular or interlobular biliary ducts to fuse during development. They may be lined with cuboidal, columnar, or squamous epithelium.[159] The presence of multiple hepatic cysts is associated with polycystic kidney disease, and development of progressive hepatic and renal failure is a potential problem with this disease. The majority of children with hepatic cysts are asymptomatic. Adjunctive diagnostic imaging, including ultrasound and CT scan imaging, may be useful.

Asymptomatic congenital hepatic cysts do not require surgical therapy. Operative therapy is reserved for symptomatic cysts. Resection or drainage by marsupialization or hepaticocystenterostomy may be required. If patency to the biliary tract is present on contrast injection study of the cyst, internal drainage is necessary.

The differential diagnosis includes hydatid disease of the liver, which is suggested by calcification and loculation of the cyst wall. Hydatid disease can be diagnosed using specific serologic tests, which is an important surgical consideration prior to exploration. Patients with echinococcal cysts should be treated with mebendazole and undergo cyst injection with hypertonic saline or other scolicidal agents into the parent cyst before surgical excision. Careful control of the cyst contents is required during echinococcal cyst excision or marsupialization.

Teratomas. Teratomas of the liver are exceedingly rare and have potential for harboring immature elements capable of transforming into malignancy. Surgical resection on discovery is recommended.

Malignant Tumors

Two thirds of childhood hepatic tumors are malignant, with hepatoblastoma constituting half of the malignancies, followed by hepatocellular carcinoma, malignant mesenchymal tumors, and sarcoma.[152] Malignant hepatic tumors are fortunately rare, and effective treatment requires a multidisciplinary approach that is best achieved in an experienced pediatric center.

Hepatoblastoma. Most hepatoblastomas are discovered in children younger than 2 years. There is a 2:1 male-to-female predominance. Hepatoblastomas usually are found as either an asymptomatic abdominal mass or symptoms of gastrointestinal obstruction from extrinsic compression by the mass. There is an association of hepatoblastoma in patients with Beckwith–Wiedemann syndrome and hemihypertrophy. On examination, a firm, palpable upper abdominal mass is notable. Obstructive jaundice is unusual. More than

90% of children with hepatoblastoma have elevated levels of alpha-fetoprotein, which is useful serum tumor marker for postoperative surveillance. In few instances, children have initial symptoms and signs of excess androgen secretion, including virilization and precocious puberty. Diagnostic imaging with CT scan imaging or MRI is essential to evaluate the extent of the tumor and evaluate for metastatic disease (Fig. 103-47).

Most children presenting with hepatoblastoma initially have unresectable disease. In the absence of metastatic disease, however, an aggressive surgical approach is used. Cure and long-term survival with hepatoblastoma requires complete surgical excision of the primary lesion. Therefore, localized, resectable tumors usually are excised by formal hepatic lobectomy or extended trisegmentectomy. Children with hepatoblastomas considered initially unresectable or with metastatic disease should undergo percutaneous or incisional biopsy to confirm the histologic diagnosis, followed by multiagent chemotherapy to reduce the size of the primary tumor and control metastases.[160,161] Delayed resection is appropriate if enough functional, normal hepatic parenchyma remain after resection. More than half of the patients who initially have unresectable hepatoblastoma can be rendered disease-free with the combination of chemotherapy and subsequent surgery. Cure rates for hepatoblastoma range from 60% to 80% if histologically clear margins and no metastatic disease are present. All patients with hepatoblastoma, regardless of stage, receive chemotherapy after resection. Unfortunately, cure cannot be expected in children treated with chemotherapy and radiation therapy alone without complete surgical resection.

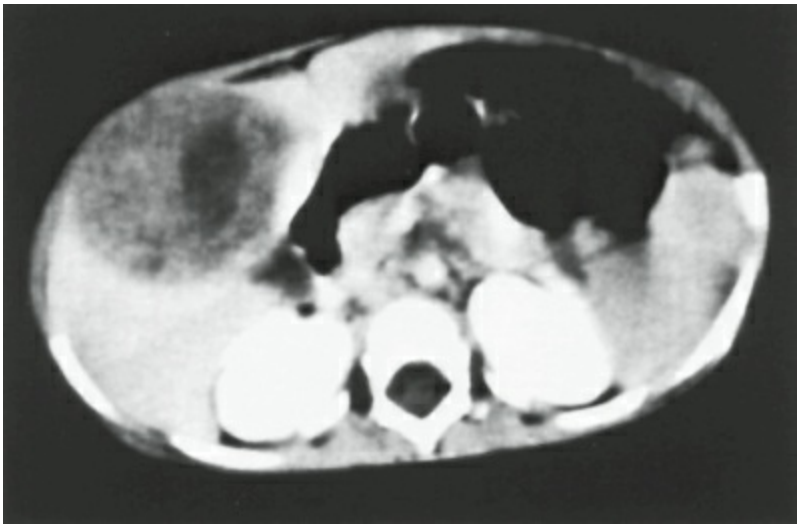

Figure 103-47. Computed tomographic scan of the abdomen demonstrating an infant with hepatoblastoma of the right hepatic lobe.

Hepatocellular Carcinoma. Hepatocellular carcinoma is significantly more common in adults but is occasionally seen in older children and adolescents. There is a male predilection (2:1) and, except for the age at diagnosis, the clinical presentation is similar to that for hepatoblastoma. Children with hepatocellular carcinoma are more likely to have jaundice and abnormal liver enzymes. The high association of cirrhosis in adults (80%) is not seen in children with hepatocellular carcinoma; only 5% of children develop

hepatocellular carcinoma in the background of cirrhosis. An increased risk of hepatocellular carcinoma is seen in children with Beckwith–Wiedemann syndrome, hemihypertrophy, von Gierke disease, hepatitis B, and Fanconi syndrome. Exposure to oral contraceptives, anabolic steroids, and some chemotherapeutic agents also has been associated with hepatocellular carcinoma. This malignancy carries a poor prognosis with an overall survival rate of 10% to 20% despite aggressive surgical resection and multiagent chemotherapy. A histologic variant, fibrolamellar hepatocellular carcinoma, carries a more favorable prognosis. As with hepatoblastoma, complete surgical resection with clear histologic margins is necessary for long-term survival and cure. In the absence of metastatic disease, unresectable hepatoblastoma or hepatocellular carcinoma in children has been successfully treated by orthotopic liver transplantation. Review of data from the United Network for Organ Sharing database demonstrates good long-term survival for both hepatoblastoma (66% 10-year survival) and hepatocellular carcinoma (58% 10-year survival) treated with liver transplantation.[162]

Malignant Mesenchymal Tumors. These rare hepatic malignancies occur in children 5 to 10 years of age; initial signs are fever, pain, and an abdominal mass, which is usually quite large on diagnosis and may have both solid and cystic components. Multidisciplinary treatment, including complete surgical resection, multiagent chemotherapy, and radiation therapy, is required for cure. In general, the prognosis of primary malignant mesenchymal tumors of the liver remains poor.

Sarcomas. Children may rarely have a primary sarcoma of the liver. Embryonal rhabdomyosarcoma of the biliary tract is distinctly unusual. It may manifest with obstructive jaundice attributable to both extrinsic and intrinsic biliary tract obstruction. Undifferentiated, embryonal sarcoma of the liver has also been described. Angiosarcoma developing in the liver may be associated with exposure to toxins such as arsenic. Aggressive surgical resection may be required, but long-term survival is uncommon. Despite radical surgery, chemotherapy, and radiation therapy, the prognosis and long-term survival of children with these malignancies remain poor, and data regarding effective drug regimens are limited.[163,164]

Liver Resection

Operative principles and techniques for hepatic resection are discussed elsewhere in this book. Several unique issues in the safe performance of hepatic resection in children should be emphasized.[165] Contemporary management of hepatic resection for tumors in children requires adequate preoperative assessment and the liberal use of intraoperative monitoring techniques. The circulating blood volume of an infant or a child is less compared to an adult, and children are sensitive to compression of the inferior vena cava causing decreased venous return to the right heart. Blood must be available for transfusion and adequate intravenous access is essential. Resection can be performed through either a subcostal incision or a right thoracoabdominal incision; in general, the ability to perform the operation safely should not be limited by the size of the incision. In children, the right and left hepatic veins are difficult to control near the inferior vena cava because of their short lengths, and intraparenchymal control from an anterior approach may be safer (Fig. 103-48). Resection may be performed using total hepatic vascular isolation by controlling the hepatic and portal inflow, the suprahepatic inferior vena cava, and the suprarenal inferior vena cava caudal to the liver. When extrahepatic biliary duct reconstruction is required, T-tube drainage is not routinely performed given the small diameter of the ducts in most children.

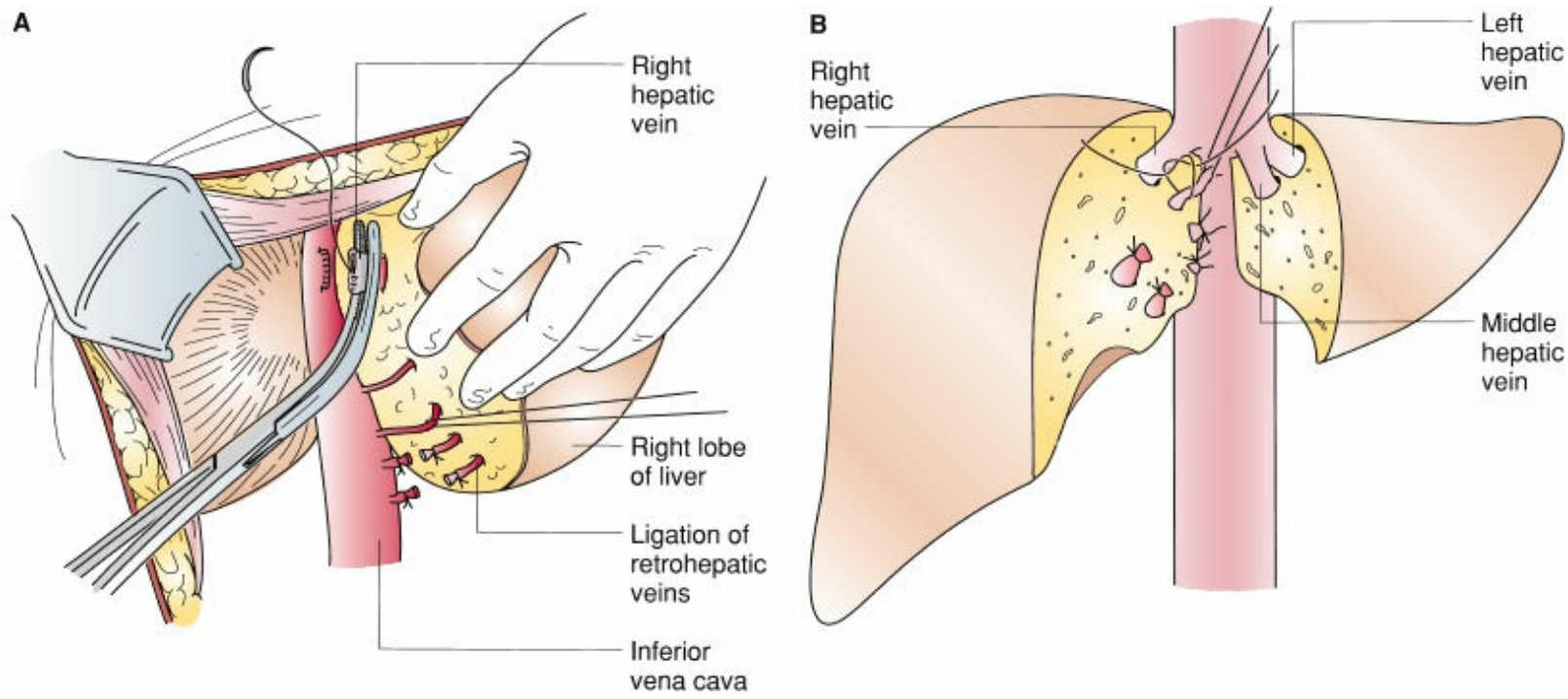

Figure 103-48. **A:** The hepatic veins in infants and children may be extremely short, making extrahepatic control impossible or dangerous. **B:** Intrahepatic control of the hepatic veins via an anterior approach may be safer in infants and children.

Hepatic Infections

Hepatic infections are generally rare in the pediatric population, and their management is similar to that used in adults. An important issue is the development of hepatic abscess in an immunocompromised child and, in particular, the association of chronic granulomatous disease with pyogenic hepatic abscess formation.

Pyogenic Abscess

The most common cause of pyogenic liver abscess before the advent of antibiotic therapy was perforated appendicitis. Now the most common causative factor in the development of pyogenic hepatic abscess in children with chronic granulomatous disease and other causes of immunosuppression.[166] Chronic granulomatous disease is an inherited disorder characterized by a defect in oxidative burst-mediated bacterial killing by neutrophils. These children develop skin, soft-tissue, and solid organ abscesses. A significant number of children with pyogenic liver abscesses have chronic granulomatous disease or other inherited/acquired immunodeficiency states. Liver abscesses are infrequently seen as a complication of umbilical vein catheterization, omphalitis, biliary tract disease, and hepatobiliary operations.

Patients with pyogenic liver abscess present with fever, jaundice, and leukocytosis. Hepatosplenomegaly and a tender liver may be found on physical examination. Diagnostic imaging with ultrasound, CT scan imaging, or MRI is useful. Common responsible organisms include staphylococcal species, streptococcal species, and *E. coli.* Gram-negative organisms and anaerobic bacteria are becoming increasingly prevalent. Treatment involves the use of broad-spectrum antibiotics. Large abscess cavities may require image-guided percutaneous drainage to expedite resolution of sepsis. Currently, few hepatic abscesses require open operative drainage. The outcome is dependent upon the underlying disease process. Recovery from the abscess is predictably good following adequate antibiotic therapy and drainage when necessary.

Amebic Abscess

Amebic abscess of the liver is uncommon in the United States, but it is endemic to areas of Central and South America. It is caused by infection with the parasite *Entamoeba histolytica.* Children with amebic dysentery develop hepatic infection as the parasite travels through the portal circulation. Patients have a history of chronic illness, fever, and abdominal pain. Examination typically demonstrates a tender right upper quadrant. Infection can be confirmed by a serum antibody test, and amebic abscess can be demonstrated by ultrasound or CT scan. Spontaneous rupture of amebic abscess is reported in as many as 10% of patients in some series.[167] The treatment of choice is the antibiotic metronidazole. Surgical resection or drainage of amebic liver abscess is typically not required for resolution.

PEDIATRIC BILIARY TRACT

Common biliary tract problems including infectious, inflammatory, and gallstone-related problems are managed similarly in both children and adults, and the management principles are discussed elsewhere in this text. Two congenital problems of the biliary tract, namely, biliary atresia and congenital cystic disease of the biliary tract (choledochal cyst), are somewhat unique to infants and children in presentation and management and are reviewed in the following discussion.

Embryology

The fetal liver and biliary tract develop between weeks 4 and 10 of gestation, representing the fusion of an endodermal foregut diverticulum with a mesodermal component from the septum transversum. The hepatocytes are derived from cords of endodermal cells in the hepatic diverticulum and ultimately give rise to the hepatic sinusoidal endothelium. The proximal hepatic diverticulum gives rise to the extrahepatic biliary tract, including the gallbladder, cystic duct, and common bile duct. As the intrahepatic and extrahepatic ductal systems develop, they unite to form a connected, arborizing system of cords composed of primitive ductular epithelial cells. These epithelial cells assume tubular configuration with ductal patency established between weeks 6 and 12 of gestation. Bile flow from the hepatocytes and into the biliary duct system is apparent by the beginning of the second fetal trimester.

This embryologic sequence appears to take place normally in infants who develop biliary atresia. In fact, the term *biliary atresia* does not reflect embryologic atresia resulting from failure of recanalization of the biliary tree. Rather, biliary atresia is caused by an uncontrollable inflammatory process that produces progressive obliteration of the normally developed extrahepatic biliary tract.

Biliary Atresia

Anatomy

7 The overall incidence rate of biliary atresia is about 1 in 8,000 to 12,000 live births and is the most common cause of chronic cholestasis in infants and children as well as the most frequent indication for pediatric liver transplantation.[168] Extrahepatic biliary atresia must be differentiated from biliary hypoplasia. Biliary hypoplasia describes a diminutive but patent biliary system and can result from many underlying situations such as neonatal hepatitis and alpha$_1$-antitrypsin deficiency. Biliary hypoplasia involves both intrahepatic and extrahepatic ductal systems.

Microscopic Anatomy. Biliary atresia is characterized by replacement of the extrahepatic biliary tract with dense, fibrous inflammatory tissue. In most cases, complete obliteration of the extrahepatic biliary tract, including the gallbladder, occurs. There appears to be gradual progression of the inflammatory process with advancing age. The common hepatic duct and common bile duct are almost uniformly obliterated by the inflammatory process. Few or absent patent ductal remnants and an absence of portal inflammation may be associated with a less favorable prognosis.[169] Intraoperative evaluation for duct patency by frozen section analysis has historically been used help guide the extent of proximal resection at the porta hepatis; however, this is no longer in widespread use. The presence of bile ducts at the porta hepatis with diameter greater than 150 μm has been reported to be associated with postoperative bile flow in up to 90% to 95% of cases.[170]

Histologic features of biliary atresia reflect hepatic parenchymal injury. Neocholangiogenesis, or biliary duct proliferation of disorganized and nonpatent ducts within the liver, is considered highly suggestive but not specific for biliary atresia. Other findings include bile pigment deposition throughout the liver. Characteristic early findings in biliary atresia include evidence for acute inflammation with neutrophil predominance in the periportal regions. Older infants and children typically have chronic inflammatory changes with considerable fibrosis. Periportal bridging fibrosis is commonly seen in intermediate stages of the disease. Ultimately, progressive biliary atresia leads to intractable cirrhosis. Nearly all patients with biliary atresia have histologic evidence of liver injury. The severity and extent of liver damage may be the most important predictor of long-term outcome and survival in biliary atresia.

Pathophysiology

Despite numerous investigations, the mechanism causing biliary atresia remains unknown. The current, widely accepted concept is that the normally developed biliary tract undergoes inflammatory sclerosis and subsequent obliteration. This process appears to occur during the first few weeks to months of life. Infants who develop biliary atresia are rarely jaundiced at birth, and biliary atresia is either rare or nonexistent in fetal autopsy studies. Clinical data are consistent with the fact that biliary atresia appears to be

a progressive, dynamic inflammatory response that is acquired during the perinatal period and targets the extrahepatic biliary tract. Early establishment of biliary drainage via portoenterostomy within the first 2 to 4 months of age may be associated with reversal of liver injury and subsequent long-term survival. Conversely, infants operated on after 120 days of life typically have obliterated bile ducts. Neonatal biliary atresia shares some clinical and morphologic features of sclerosing cholangitis in adults. Data supporting an infectious etiologic agent and, in particular, reoviruses, rotaviruses, and hepatitis C, have been reported and may play a role in some cases. In addition, other noninfectious stimuli may trigger an inflammatory response directed at the neonatal extrahepatic bile duct.[171] The actual mechanism may reflect a stereotypical inflammatory response initiated by a variety of different stimuli that is ultimately directed preferentially against the neonatal bile duct.

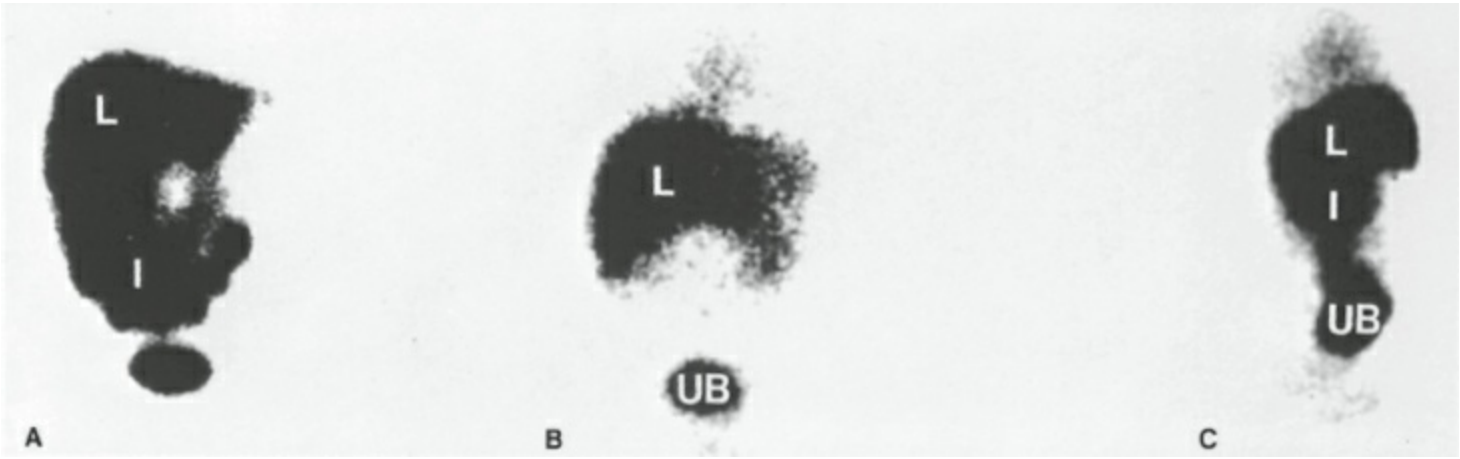

Figure 103-49. **A:** Normal scan using p-isopropyl acetanilidoiminodiacetic acid (PIPIDA) as the hepatobiliary scanning agent. At 45 minutes, isotope is clearly visible in the liver (L) and the intestine (I). **B:** Scan after phenobarbital administration in infant with biliary atresia. Even after 8 hours, isotope is apparent only in the liver and the urinary bladder (UB). **C:** Patient with cholestatic jaundice. At 65 minutes, isotope is visible in the liver (L) and the intestine (I). Hepatocyte uptake is variable but usually decreased or normal, whereas excretion into the gut is predictably present with cholestatic jaundice or hepatocellular disease.

Clinical Presentation and Diagnosis

The cardinal sign of biliary atresia is progressive neonatal jaundice during the first few weeks of life. Dark urine and acholic stools are expected findings. Progressive hyperbilirubinemia produces clinical jaundice around 2 to 4 weeks of age. The physical examination is generally unremarkable except for jaundice and possibly mild hepatomegaly. Alagille syndrome, which presents with neonatal jaundice, can usually be distinguished from biliary atresia on physical examination. Children with Alagille syndrome have biliary hypoplasia and distinctly abnormal facies, growth retardation, vertebral defects, and pulmonic stenosis.

A characteristic laboratory finding is conjugated hyperbilirubinemia consistent with obstructive jaundice. A direct fraction of bilirubin greater than 50%, or greater than 2 mg/dL, in an infant requires prompt investigation. Mild elevation of hepatic

transaminases is commonly seen. The alkaline phosphatase is significantly elevated, often in the range of 500 to 1,000 IU/L. There are no specific biochemical markers for biliary atresia, as these serum profiles can be seen in other causes of neonatal cholestasis. Late findings in biliary atresia include failure to thrive, feeding intolerance, stigmata of portal hypertension, and fat-soluble vitamin deficiency.

Table 103-13 is a partial list of the causes of neonatal cholestatic syndromes. Neonatal physiologic jaundice is commonly encountered. This condition is self-limited once the glucuronyl transferase system matures, allowing the hepatocytes to conjugate bilirubin efficiently. Because of the numerous causes of neonatal jaundice and the relative infrequency of biliary atresia, a delay in diagnosis is common. Given the age-sensitive nature of biliary atresia and the improved outcome in younger infants, the diagnostic workup should be expedient.

Table 103-13 Causes and Associations of Neonatal Cholestasis

Congenital Infectious Causes
Cytomegalovirus[a]
Rubella virus[a]
Herpes virus
Hepatitis virus B[a]
Echovirus 14, 19
Coxsackievirus B
Toxoplasmosis
Syphilis
Genetic Associations
Galactosemia
Tyrosinemia
Congenital fructose intolerance
Alpha$_1$-antitrypsin deficiency
Cystic fibrosis
Niemann–Pick disease
Trisomy 17, 18, 21
Turner syndrome
Menkes syndrome
Zellweger syndrome
Polysplenia syndrome[b]
Miscellaneous Associations
Hemolytic disease
Bacterial sepsis
Pyelonephritis
Total parenteral nutrition (prolonged)
Congestive heart failure
Hypoplastic left heart syndrome
Necrotizing enterocolitis, gastroschisis, omphalocele
Neonatal hypopituitarism
Inspissated bile syndrome (without hemolysis) neonatal shock, respiratory distress syndrome, acidosis

[a]Rarely associated with biliary atresia.
[b]Frequently associated with biliary atresia.

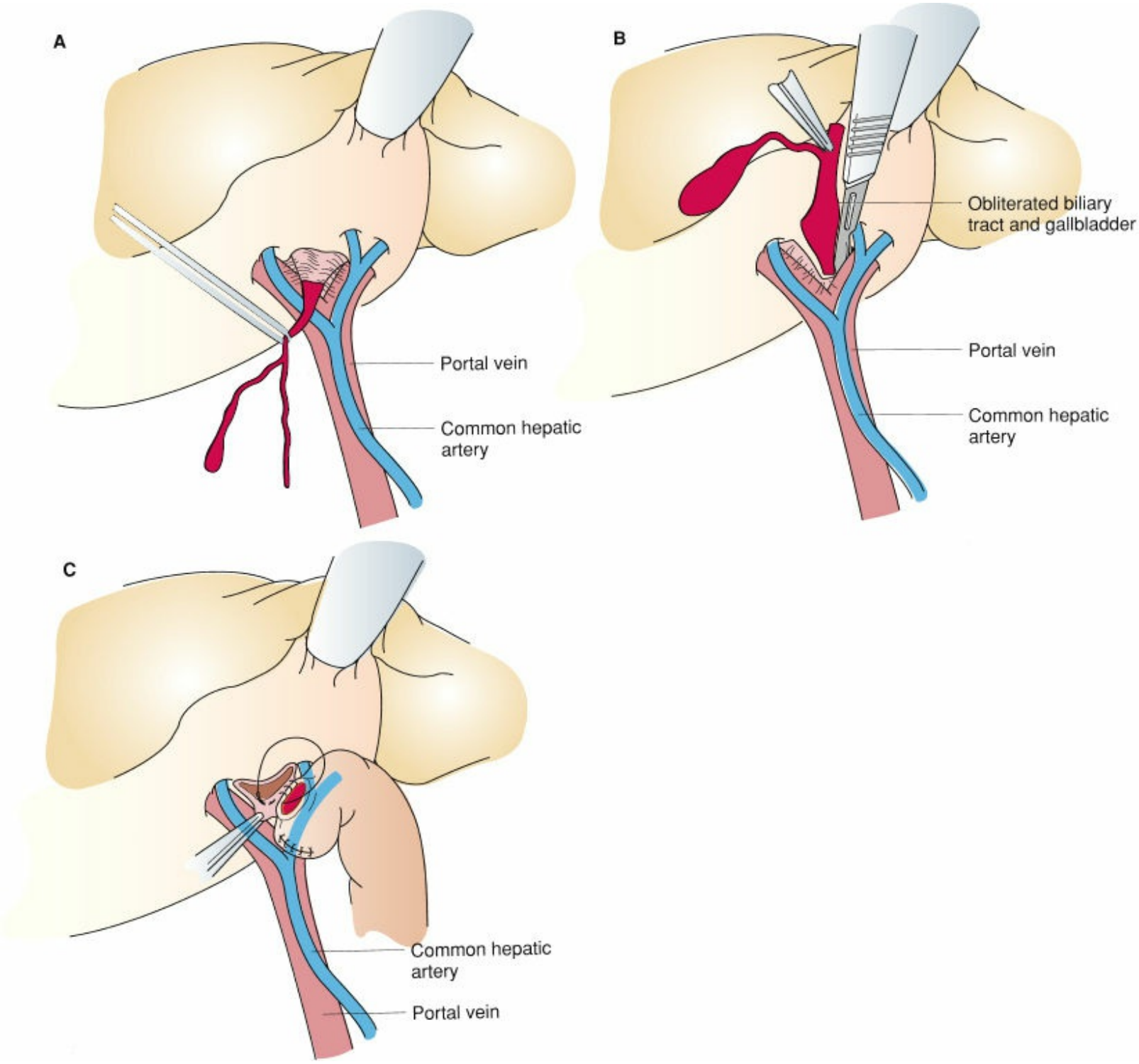

Figure 103-50. The essential features of the portoenterostomy for biliary atresia include appropriate mobilization (**A**) and transection (**B**) of the fibrous biliary tract remnant. **C:** Creation of a Roux-Y jejunal conduit with biliary enteric anastomosis completes the procedure.

Radioisotope Scanning. Pertechnetate 99 m–iminodiacetic acid (^{99m}Tc-IDA) analogues are widely used for hepatobiliary imaging and provide the basis for a sensitive and specific test for biliary atresia. The sensitivity of this diagnostic examination for biliary atresia can be 100%, with a specificity of 94%.[172] To improve sensitivity, infants are administered oral phenobarbital (5 mg/kg daily) to induce hepatic microsomal enzymes and increase hepatocyte processing of ^{99m}Tc-IDA. Both hepatic uptake of radionuclide and excretion into the gastrointestinal tract are evaluated over a timed interval. Infants with

primary hepatocellular disorders characteristically have impaired hepatocyte uptake of radionuclide, whereas normal infants and infants with biliary atresia have prompt uptake. Normal infants excrete the isotope rapidly into the gut through the biliary tract. In biliary atresia, there is no excretion into the gut because of the obliteration of the extrahepatic bile ducts (Fig. 103-49). The hepatobiliary scanning is a rapid test that can be performed simultaneously with other diagnostic examinations, for example, ultrasound. This test reliably identifies infants with choledochal cyst as well.

Other Diagnostic Tests. Several other diagnostic tests are of interest in the workup of an infant with conjugated hyperbilirubinemia in whom obstructive jaundice is suspected. MRI cholangiography is emerging as a sensitive, specific examination for the identification of extrahepatic anatomy. The important management principle is that prompt operative exploration, liver biopsy, and cholangiography should be performed in any infant in whom biliary atresia is suspected. An aggressive approach is warranted in that unnecessary delay in definitive drainage may lead to a less favorable outcome.

Ultrasound. A standard examination of the jaundiced infant is a comprehensive abdominal ultrasound, with particular attention given to the liver and the biliary tract. The most common ultrasonographic finding in biliary atresia is a diminutive or absent gallbladder without associated intrahepatic duct dilatation. Biliary tract obstruction from a choledochal cyst also can be reliably identified by ultrasound. Other rare causes of extrahepatic biliary duct obstruction are associated with proximal duct dilatation.

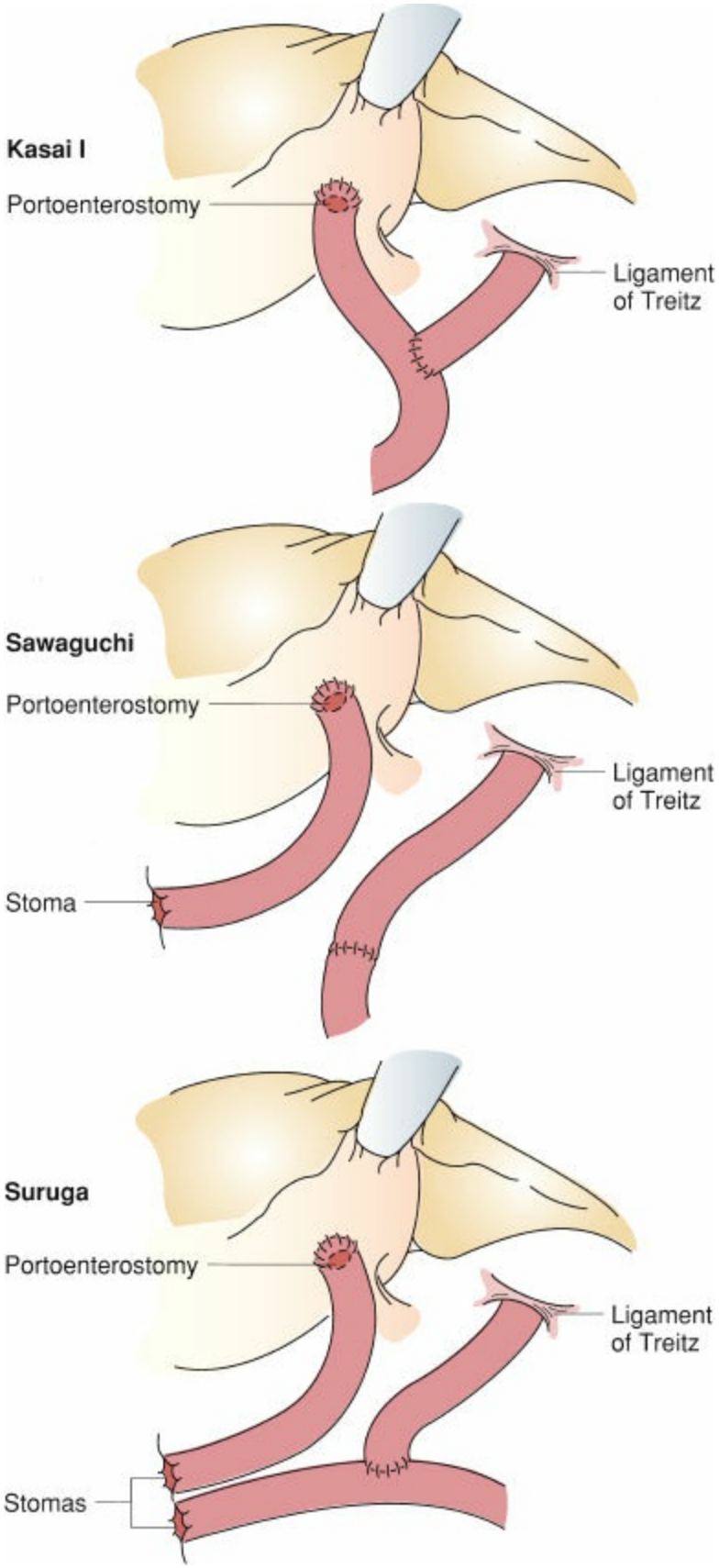

Figure 103-51. Several types of conduits have been used for biliary drainage following portoenterostomy. There are relatively few data to help in selecting from among them, and current trends emphasize simplicity. These are the three most commonly used conduits. The primary importance of this issue is that the reoperative surgeon must be familiar with the anatomic variations.

Liver Biopsy. Because the histologic findings in biliary atresia are not specific, about 20% to 25% of infants who undergo percutaneous liver biopsy remain undiagnosed. Liver

biopsy is often performed in conjunction with the workup of conjugated hyperbilirubinemia following hepatobiliary scanning and ultrasonography, but in the setting of biliary atresia, it has limited utility. The histologic examination of a percutaneous liver biopsy is probably most helpful in diagnosing nonoperative causes of neonatal jaundice, thus avoiding anesthesia and operative exploration.

Alpha$_1$-Antitrypsin Deficiency. Alpha$_1$-antitrypsin deficiency is perhaps the single most important medical condition that may be difficult or impossible to differentiate from biliary atresia. All jaundiced infants should have plasma alpha$_1$-antitrypsin levels determined before operative exploration for suspected biliary atresia. Infants with alpha$_1$-antitrypsin deficiency do not benefit from operative exploration or portoenterostomy.

Treatment

Infants with biliary atresia require surgical therapy as the initial management intervention. Medical therapy is directed to the postoperative management of the chronic liver disease. The use of sequential surgical treatment, using portoenterostomy in infancy and orthotopic liver transplantation for children with progressive hepatic failure, provides improvement in overall survival.[173,174] Limited organ availability and a higher rate of perioperative complications limit primary liver transplantation for most infants with biliary atresia younger than 1 year. In the rare instance of unrecognized biliary atresia in an older child with established hepatic dysfunction, primary orthotopic liver transplantation may be a reasonable option.

Portoenterostomy. The recommended initial procedure for the treatment of biliary atresia is portoenterostomy. Before the development of portoenterostomy in Japan by Morio Kasai during the late 1950s, all infants with biliary atresia died of chronic liver disease and cirrhosis. Current management dictates that operative exploration and portoenterostomy be performed promptly. Early intervention by portoenterostomy to provide biliary drainage has been proposed to arrest or reverse the parenchymal liver injury, but the point at which the liver injury becomes irreversible remains unknown. From a clinical standpoint, most long-term success with portoenterostomy alone appears to be achieved in infants younger than 2 to 3 months, whereas infants older than 3 to 4 months appear to have a less favorable prognosis. Portoenterostomy for this “late” group has been reported successfully in approximately one-third of infants, however, and should be considered a potential alternative in the absence of available liver transplant donors.[175]

The initial approach to the infant with suspected biliary atresia is to perform an operative cholangiogram. If the diagnosis is confirmed, a portoenterostomy is constructed (Fig. 103-50). To maximize the potential for effective biliary drainage with portoenterostomy, several technical caveats are worthy of mention. An open liver biopsy is routinely performed to document the state of parenchymal injury. The cholangiogram is generally attempted through the gallbladder. In the 10% to 15% instance of a patent distal biliary tree, treatment still requires portoenterostomy. A nonpatent, fibrous cord

rather than a normal common bile duct is found in the hepatoduodenal ligament. This cord is dissected free proximally to the level of the porta hepatis between the portal vein bifurcation. The fibrous remnant is sharply transected at this level to preserve any patent bile ducts. A short, 15- to 25-cm retrocolic, jejunal Roux-Y limb is constructed. There has been no clear advantage with longer or modified conduits with intussusception-type antireflux valves in the prevention of cholangitis.[176,177]

Previously, some surgeons preferred to exteriorize the biliary conduit (Fig. 103-51). With an exteriorized biliary conduit, postoperative bile flow is directly visible. The diverting stoma must be closed, however, and there is potential to develop parastomal variceal hemorrhage from progressive portal hypertension. In addition, fluid and electrolyte losses from the biliostomy can be significant, and there are no reported survival differences between patients with exteriorized and closed biliary conduits following portoenterostomy. Because many of these infants may ultimately require liver transplantation, there is a trend toward using a simple, closed biliary conduit with portoenterostomy. Therefore, the use of a stoma to divert the bile flow in the Roux limb has been largely abandoned.

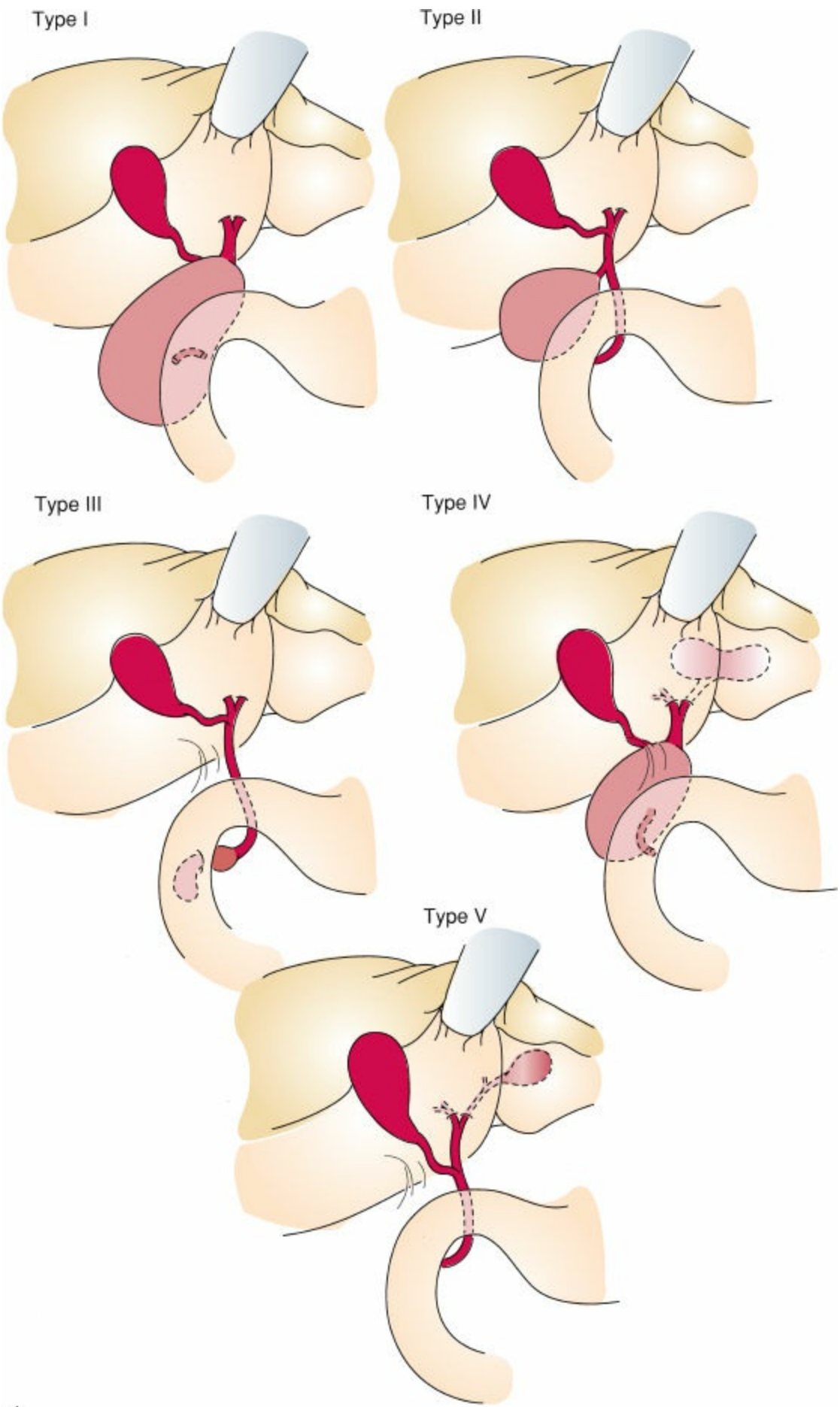

Figure 103-52. Classification of choledochal cyst.

Results and Complications. Following portoenterostomy, bile flow occurs in about 66% to 75% of all infants when operated on at less than 60 days of age; however,

establishment of bile flow may take weeks to months. The probability of bile flow appears related to age at the time of operation.

Cholangitis is a constant concern and an important postoperative problem after portoenterostomy. The clinical signs include fever, leukocytosis, and decreased bile flow in the absence of other systemic illness. All patients are at risk for the development of postoperative cholangitis, but reported postoperative rates of cholangitis are 40% to 50%. Cholangitis following portoenterostomy is characterized by a systemic inflammatory response and may be associated with progressive liver injury. Treatment is generally intravenous fluid resuscitation and broad-spectrum antibiotics. Occasionally, steroids or other antiinflammatory agents may be helpful, whereas reoperation or endoscopic revision of the portoenterostomy usually is not.[178] In an effort to determine the optimal treatment of infants with biliary atresia, a group of investigators have formed the Biliary Atresia Research Consortium (BARC).[179] The primary objectives of the consortium are to establish a clinical database and tissue repository. A retrospective BARC study of 104 children with biliary atresia treated in the United States demonstrated that at 2 years of age, 58 patients were alive with their native liver and 42 had undergone liver transplantation.[180] Data from the United Kingdom demonstrated improved measurable outcomes in children with biliary atresia treated with Kasai portoenterostomy by regionalization of care to three centers in the UK health care system.[181]

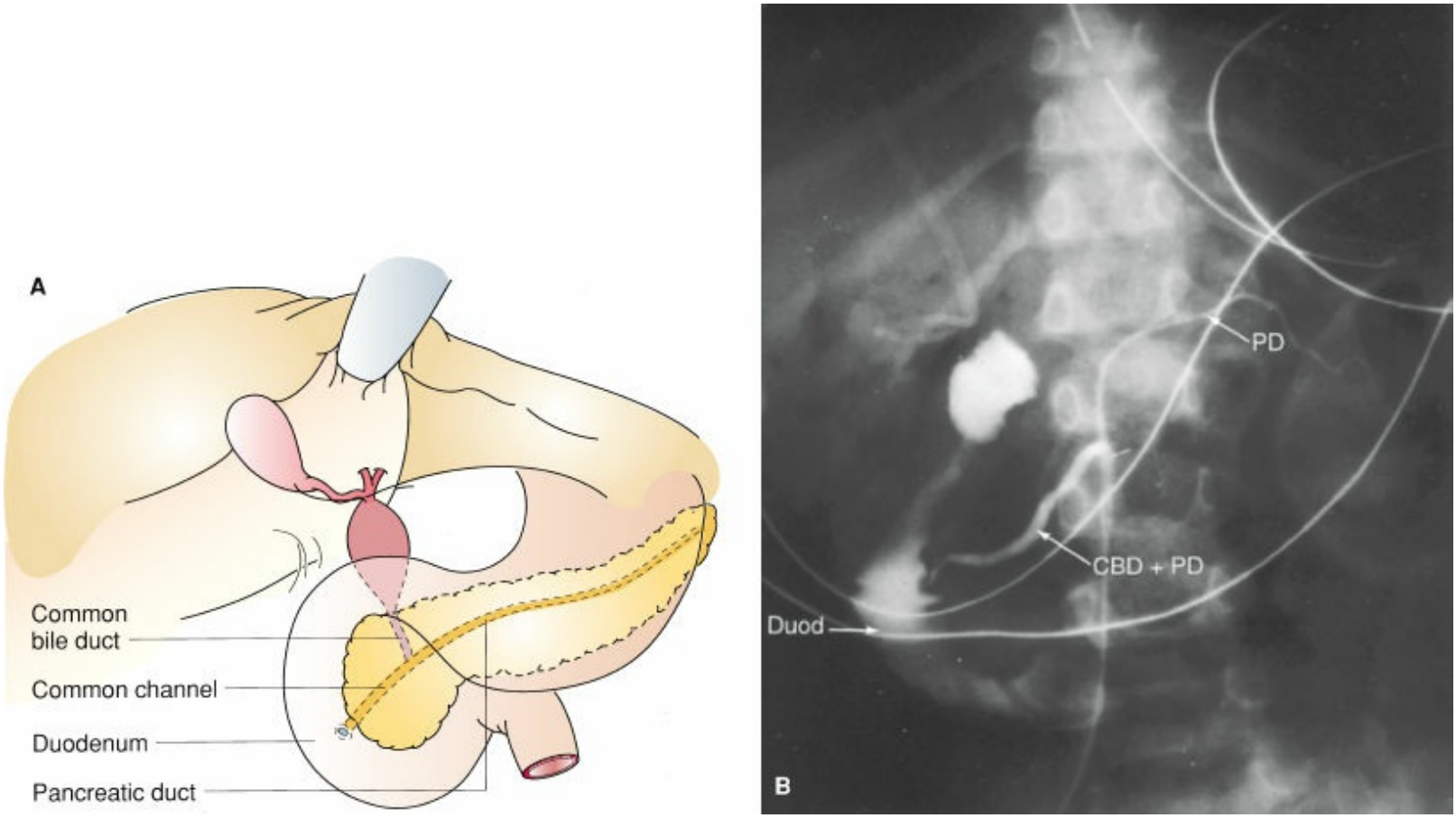

Figure 103-53. An anomalous, extramural junction between the distal common bile duct and the pancreatic duct is characteristic of type I choledochal cyst. **A:** Schematic depiction of this anatomy. **B:** Operative cholangiogram from a patient with a long extramural common channel. It has been suggested that the long common channel may allow reflux of pancreatic secretions into the common bile duct resulting in inflammation and proteinase-mediated injury to the common duct, possibly contributing to the development of the cyst itself. CBD + PD, common bile duct and pancreatic duct; Duod, duodenum; PD, pancreatic duct.

Nearly all patients with biliary atresia have residual liver injury. Hepatic synthetic failure, portal hypertension with esophageal variceal bleeding, hypersplenism, and fat-soluble vitamin deficiencies can be problematic. Most institutions report 5-year survival rates between 30% and 50% for portoenterostomy alone. About 25% to 35% of patients undergoing a portoenterostomy survive more than 10 years without liver transplantation. The remaining two-thirds of children with biliary atresia ultimately require liver transplantation for survival. Although the failure rate for portoenterostomy is high, the possibility of long-term success is notable. In addition, the limited availability of infant donor organs and the technical limitations of liver transplantation in infants younger than 1 year make portoenterostomy an accepted initial treatment of biliary atresia in most centers.

Hepatic Transplantation. Hepatic transplantation is discussed in detail elsewhere in this text. For biliary atresia, transplantation offers a means of long-term survival in children with failed portoenterostomies. The current 5-year survival of children with biliary atresia who undergo liver transplantation ranges from 75% to 94.4%.[182,183] In addition, with the use of reduced-size cadaveric donor livers as well as living-related donor livers,

the mortality rate for infants on transplant waiting lists may be decreasing. Indications for liver transplantation in biliary atresia include progressive hepatic failure despite portoenterostomy, growth retardation, and complications of portal hypertension. It is important to consider the consequences of life-long immunosuppression in these children, including the risks of infection and treatment-related malignancy.

Congenital Choledochal Cystic Disease of the Biliary Tract

Anatomy

The anatomic description and classification scheme for choledochal cystic disease initially proposed by Alonso-Lej et al. in 1959 and modified by Todani et al. are illustrated in Figure 103-52.[184,185] The most frequently encountered are type I cysts, accounting for approximately 85% to 90% of the lesions in most series. Type I cysts are characterized by fusiform dilatation of the entire common bile duct with only mild dilatation of the common hepatic duct; the intrahepatic ducts are normal. Variations are common, and biliary atresia is occasionally seen in association with choledochal cystic disease.

Type I cysts are generally quite large and often cause displacement of neighboring viscera. The fusiform dilatation usually begins at the origin of the common bile duct, generally sparing the common hepatic ducts. The distal common bile duct is diminutive and typically is distorted mechanically by the large cyst, leading to the common clinical presentation of obstructive jaundice. The junction of the distal common bile duct and the pancreatic duct is not within the normal intramural duodenum but rather is extrinsic and proximal to the duodenal wall and the sphincter of Oddi (Fig. 103-53). It remains unknown whether the configuration of a long, extramural common channel allows greater pancreatic secretion reflux into the common bile duct.

Microscopic examination of the choledochal cyst wall reveals that the normal biliary epithelium is absent or replaced by abnormal and occasionally dysplastic columnar epithelium. The cyst wall has normal smooth muscle with variable degrees of inflammation and fibrosis. The exception to this common histologic characteristic is the type III cyst, which is generally lined by normal duodenal mucosa. Choledochal cysts tend to have less inflammation in infancy and early childhood. In contrast, there is well-established inflammation involving the cyst and surrounding structures in the hepatoduodenal ligament in adolescents and adults.

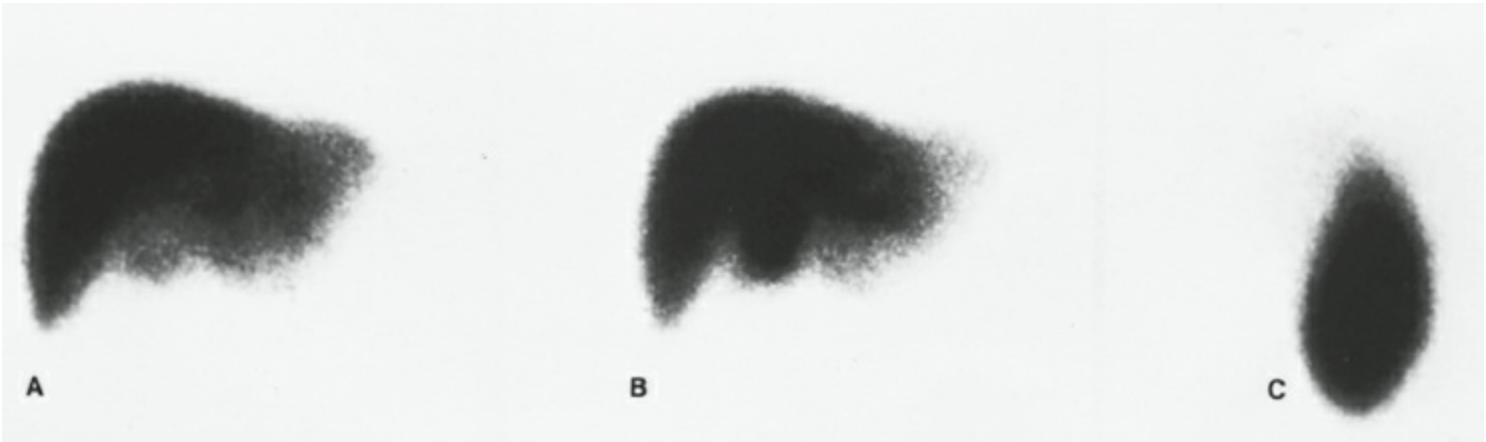

Figure 103-54. Typical ^{99M}Tc-N-substituted-2,6-dimethylphenyl carbamoylmethyl iminodiacetic acid (HIDA) scan from a child with a type I choledochal cyst. Images were made in 5 minutes (**A**), 30 minutes (**B**), and 3 hours (**C**), after isotope injection. The isotope is retained within the choledochal cyst more than 24 hours, and the pattern of hepatocyte uptake is normal.

Pathophysiology

The mechanism for the development of cystic lesions of the biliary tract is unclear. Choledochal cysts have been identified accurately by prenatal ultrasound, and it appears likely that these lesions represent abnormalities in the developing biliary tract. Several hypotheses for the development of choledochal cyst have been proposed. Whether the cystic dilatations result from abnormal recanalization of the primitive bile duct cords or from inflammation caused by reflux of pancreatic secretions into the common bile duct remains unknown. The pathophysiology of choledochal cyst is that of obstructive jaundice. The obstruction may be primarily the result of mechanical outflow obstruction of a diminutive distal common bile duct with a dilated choledochal cyst. Alternatively, a large inflammatory cyst can cause obstruction of the biliary tract and of neighboring viscera by extrinsic compression. When discovered during infancy, obstructive jaundice is usually the initial clinical finding. The liver injury is typically reversible, and progression to biliary cirrhosis is rare. The exception to this situation is type V disease, which is associated with a high incidence of hepatic fibrosis.

Other initial clinical situations include cholelithiasis and acute bacterial cholangitis secondary to diminished bile drainage. Children with type III cysts may have acute pancreatitis. Infrequently, extrinsic compression of the portal vein by a large choledochal cyst may produce symptoms and signs of portal hypertension. Abdominal pain and tenderness following minor injury may lead to an incidental diagnosis of choledochal cyst on imaging studies.

Carcinoma of the biliary tract occurs in about 3% to 5% of patients with choledochal cyst. The number of reported cases remains small in the literature, but the incidence for biliary tract neoplasm is about 1,000 times that of the normal population.[186] Patients with choledochal cyst are at increased risk for the development of biliary tract carcinoma in adolescence or early adulthood. The dysplastic cyst epithelium may be susceptible to malignant change from chronic inflammation. Interestingly, there appears to be an increased risk of malignancy to develop anywhere in the biliary tract, gallbladder, or pancreas, and not just the choledochal cyst itself.[187] Therefore, current treatment emphasizes complete cyst excision or the cyst epithelium while providing adequate biliary drainage to prevent stasis and chronic inflammation. Infants and children treated for choledochal cyst should have long-term follow-up for complications and potential malignancy.

Clinical Presentation and Diagnosis

Choledochal cysts present most commonly in infancy and early childhood with symptoms of obstructive jaundice. In older children and adults, the classic clinical triad of episodic abdominal pain, a palpable right upper-quadrant mass, and jaundice occurs in fewer than 50% of patients. Adults occasionally present with hepatomegaly or evidence of portal hypertension. The diagnosis in infants and most children can be confirmed by ultrasound examination and ^{99m}Tc-IDA imaging studies (Figs. 103-54 and 103-55). In older children, both MRI cholangiography and endoscopic retrograde cholangiopancreatography (ERCP)

are highly sensitive and specific in confirming diagnosis. These lesions also are diagnosed incidentally during radiologic imaging studies for other reasons. Partial duodenal obstruction may lead to an upper gastrointestinal series that shows extrinsic compression from a large type I cyst or an intraluminal filling defect from a type III cyst. CT imaging of the abdomen following blunt trauma may lead to the diagnosis of biliary tract dilatation. Liver biopsy is not specific in choledochal cyst and has little diagnostic role other than to document the extent of liver injury.

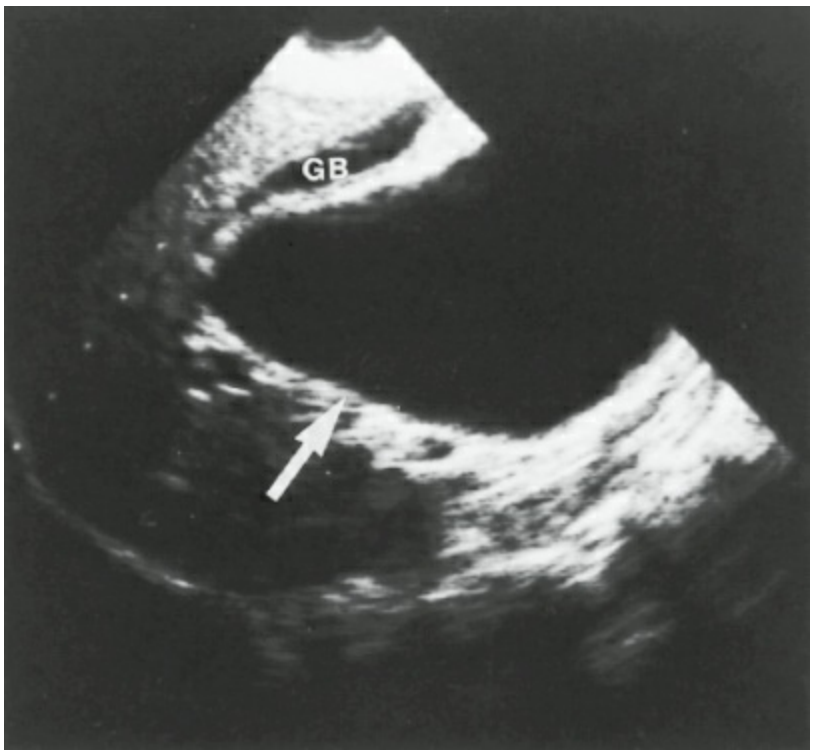

Figure 103-55. Ultrasound image of a type I choledochal cyst (*arrow;* longitudinal image). The gallbladder (GB) is also shown.

Treatment

Type I Cysts. Initial operative strategy for a type I choledochal cyst is exploration and cholangiography, usually through the gallbladder, but occasionally contrast injection must be made directly into the common bile duct. Cholecystectomy is routinely performed. Historically, internal drainage procedures without cyst excision were widely used. These procedures have been associated with a higher rate of failure because of stricture, stone formation, pancreatitis, and cholangitis. In addition, there is the potential for the development of biliary tract carcinoma in the retained cyst. Therefore, internal drainage procedures without cyst excision have been abandoned. Current consensus for the surgical management of type I choledochal cyst is performance of primary cyst excision with Roux-Y hepaticojejunostomy reconstruction (Fig. 103-56). Primary cyst excision is accomplished routinely in infants and children.[188] For adults with severe inflammation and fibrosis, dissection may present problems resulting from inflammation and adhesion of the cyst wall to the hepatoduodenal ligament. A safer approach in this situation may be intramural cyst dissection and removal of the cyst wall epithelium, leaving the

posteromedial outer cyst wall adjacent to the portal vein and hepatic artery intact.

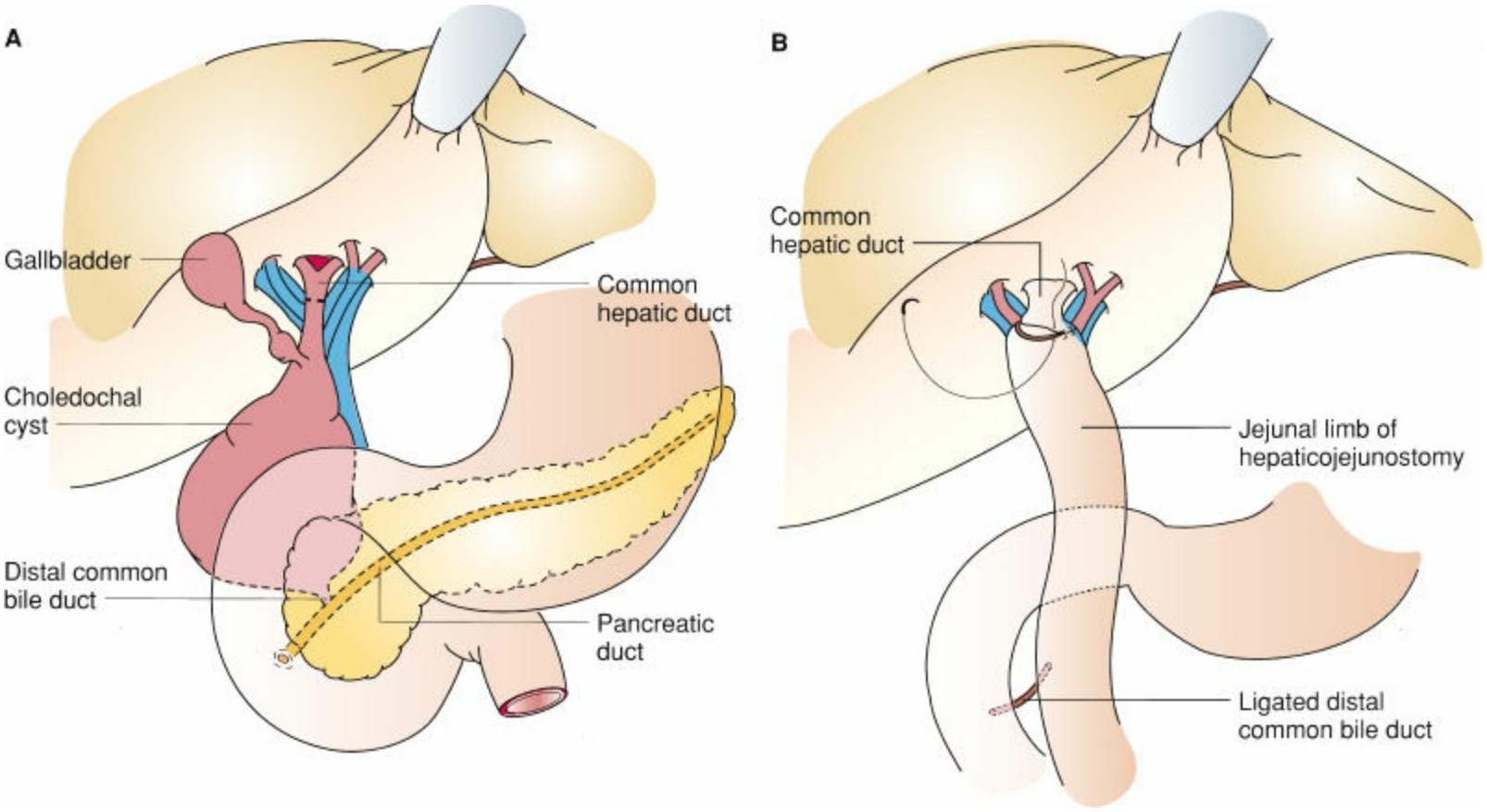

Figure 103-56. The preferred operative treatment of type I choledochal cyst consists of primary total transmural cyst excision with Roux-Y hepaticojejunostomy.

Other Types of Cysts. Type II cysts are excised completely and the choledochotomy closed primarily. Type III choledochoceles require a transduodenal approach with either marsupialization or excision of the cyst. Care must be taken to identify the ampulla, and a formal sphincteroplasty may be required to ensure adequate drainage from the biliary tract and the pancreas. Type IV and V intrahepatic cystic diseases must be approached on an individualized basis. In general, unilobar or focal cystic disease can be either resected or drained with Roux-Y jejunostomy reconstruction. Bilobar intraparenchymal disease, particularly in the setting of hepatic fibrosis, may be difficult, if not impossible, to obtain complete, adequate drainage.

Complications and Outcome. The major complications associated with operative repair of choledochal cyst include cholangitis, stricture formation, choledocholithiasis, and development of biliary tract malignancy. A summary of the incidence of complications, mortality, and reoperation for the different procedures in 955 cases reported in the literature demonstrated a clear advantage for primary cyst excision in terms of morbidity and need for reoperation, and no significant increase in mortality occurred using this approach.[189] Subsequent to this analysis in 1975, internal drainage procedures without cyst excision have been essentially replaced by primary cyst excision with hepaticojejunostomy reconstruction. Currently, several series have reported excellent

results with little or no mortality using total transmural excision of choledochal cysts.[190] Primary transmural excision with biliary tract reconstruction continues to be a safe and desirable operative approach for cystic lesions of the biliary tract.

PEDIATRIC PANCREAS

Disorders of the pancreas are uncommon in infants and children. Pancreatic disorders in children include congenital anatomic disorders, inflammatory pancreatitis, rare neoplastic lesions, and pancreatic endocrinopathies.[191] Several significant issues are relative to the pancreatic problems in the pediatric age group, and a brief overview is presented in the following discussion.

Embryology

The fetal pancreas arises from the paired dorsal and ventral foregut diverticular buds during the sixth week of gestation. The dorsal pancreatic anlage gives rise to the body and tail of the pancreas as well as the main pancreatic duct. The ventral pancreatic anlage migrates 180 degrees to fuse with the dorsal gland, forming the uncinate process and the distal portion of the duct of Wirsung (Fig. 103-57). The independent ductal systems of the developing pancreatic anlage fuse. The dorsal (Santorini) duct opens directly into the duodenum, and this anatomy is persistent in 10% to 15% of normal subjects. The ventral (Wirsung) duct opens into the duodenum by fusion with the common bile duct. Normally, the dorsal duct fuses with the ventral duct just to the right of the mesenteric vessels. Failure of the dorsal and ventral ducts to fuse normally leads to two separate pancreatic ducts, a condition known as *pancreatic divisum*. Occasionally, the ventral duct regresses and the entire pancreatic gland is drained by the accessory duct of Santorini.

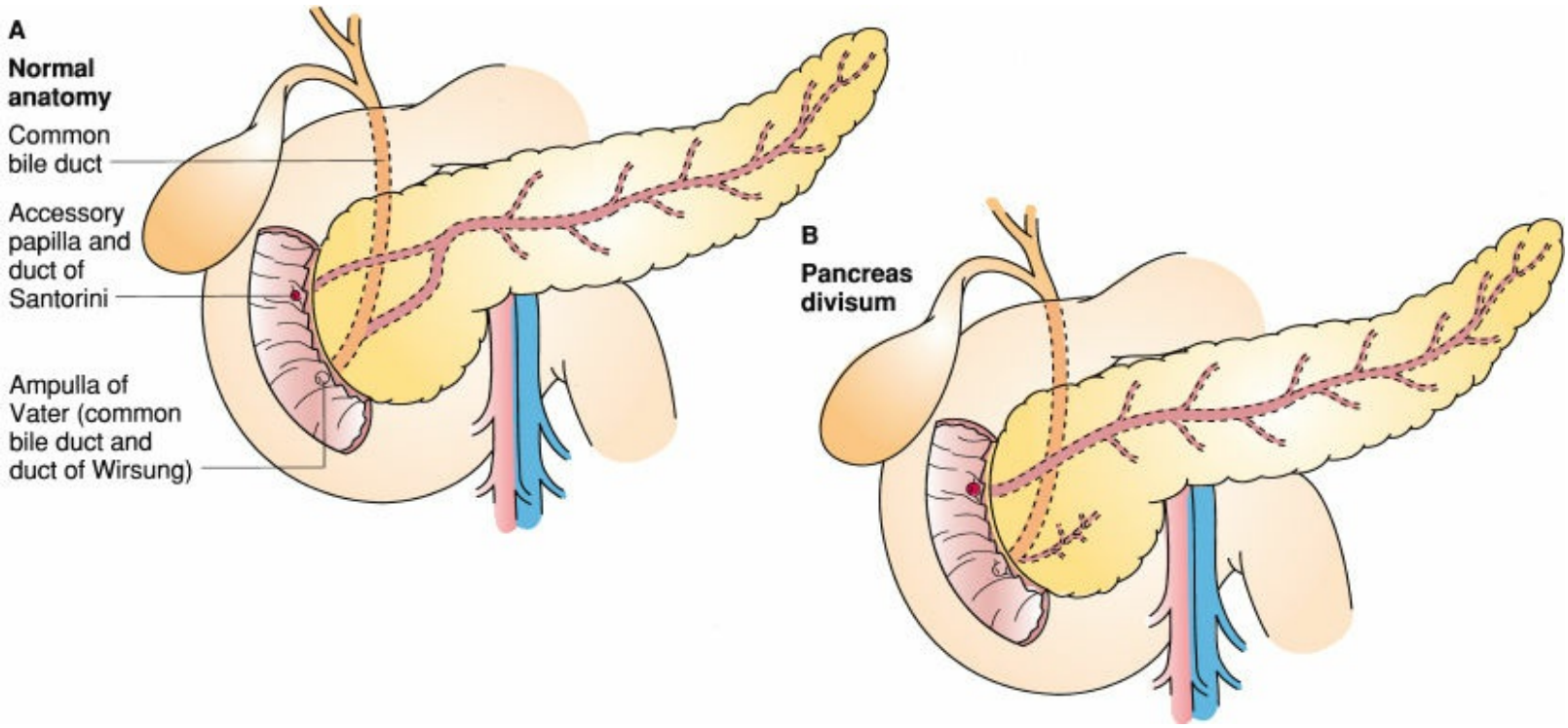

Figure 103-57. **A:** Normal pancreatic ductal anatomy. **B:** Pancreas divisum. There is no communication between the duct of Wirsung and the duct of Santorini. The duct of Wirsung is short or absent. Most of the pancreas is drained by the duct of Santorini through the accessory papilla. This anatomy is found in about 10% to 15% of normal individuals.

Primitive duct cells of the pancreas give rise to both the acinar cells and the islet cells of the normal pancreas. Primary islet cells become apparent at week 8 of gestation within the interlobular tissue, with acini becoming visible shortly thereafter. The primary islet cells regress after the fifth month of gestation and are usually nonexistent by term. Secondary islet cells arise from centroacinar proliferation during the third month of gestation. These intralobular cells migrate out of the acini in which they were formed and develop into islets that remain connected to the duct by a thin cellular stalk (the tubule of Bensley).

Exocrine pancreatic anomalies generally arise from defective development during

embryogenesis. The most common of these conditions is annular pancreas. The circumferential distribution of pancreatic tissue around the duodenum is thought to result from interrupted migration of the ventral pancreatic anlage. Less common defects include pancreatic ductal abnormalities, pancreatic duplications, heterotopic pancreatic tissue, and congenital agenesis of portions of the pancreas.

Acute Pancreatitis

Acute pancreatitis is often overlooked as a cause of abdominal pain in children; however, it is the most common disorder of the pancreas in both infants and children. Adult pancreatitis is often caused by either alcohol ingestion or gallstones. In contrast, 50% to 80% of cases in children, particularly adolescents, are posttraumatic or idiopathic in origin. An important clinical condition seen with moderate frequency is acute pancreatitis in the setting of immunosuppression, in particular, high-dose corticosteroids. Steroid-induced acute pancreatitis typically accounts for the third most common cause of pancreatitis in most children's hospitals. Other causes of acute pancreatitis include gallstones, CF, hyperlipidemia, juvenile diabetes mellitus, mumps, coxsackievirus infection, infectious mononucleosis, collagen vascular diseases, and anatomic lesions such as choledochal cyst. Medications significantly associated with acute pancreatitis include oral contraceptives, chlorothiazide, tetracyclines. azathioprine, and L-asparaginase. Valproic acid, an anticonvulsant useful in some children with seizure disorders, is associated with a particularly virulent form of acute necrotizing pancreatitis that may be life-threatening.

A child with acute pancreatitis presents with a history of midepigastric abdominal pain, anorexia, and emesis. On examination, the child usually has a tender abdomen with distention. Fever and leukocytosis are common. Serum amylase and lipase levels are elevated, although significant pancreatitis can occur despite a normal amylase level. Conversely, the lipase may be mildly elevated in the absence of clinical symptoms or signs of acute pancreatitis. Ultrasonography and CT imaging of the abdomen are probably the most commonly used adjunctive diagnostic tests. CT imaging is particularly useful in demonstrating edema of the gland as well as evaluating for peripancreatic fluid collections. While usually deferred during the acute phase of pancreatitis, ERCP or MRI cholangiography may be useful to evaluate the hepatobiliary tract anatomy once the inflammatory process has resolved.

Treatment principles for childhood acute pancreatitis are not different from strategies used in adults. The vast majority of children have simple edematous pancreatitis. Hemorrhagic pancreatitis and necrotizing pancreatitis are distinctly unusual in this age group but can be seen in immunosuppressed patients. Therefore, initial therapy is designed to be supportive and nonoperative in approach. Endotracheal intubation and mechanical ventilation may be required. Intravenous fluid resuscitation, pancreatic rest by nasogastric tube decompression, analgesia, and TPN are provided. No clinical efficacy data are available to support the widespread use of anticholinergics or somatostatin analogues for acute pancreatitis in children. Operative intervention is reserved for complications of pancreatitis such as hemorrhage, infected pancreatic necrosis, or pancreatic pseudocyst.

Recurrent pancreatitis in a child usually is associated with an anatomic abnormality or specific physiologic problem. Following recovery from the acute inflammatory event, an aggressive diagnostic workup, including consideration of ERCP or MRCP to define ductal anatomy, should be performed. In particular, the presence of pancreas divisum with

stenosis of the accessory papilla should be considered. Children with pancreatitis in the setting of cholelithiasis should undergo laparoscopic cholecystectomy after resolution of the pancreatitis.

Pancreas Divisum

Pancreas divisum occurs with failure of normal fusion between the dorsal and ventral pancreatic ducts. About 10% to 15% of normal persons have two separate pancreatic ducts, and up to 10% of asymptomatic persons undergoing ERCP have two complete ductal systems. The anatomic variant of pancreas divisum is not necessarily pathologic, but if the orifice of the accessory papilla is stenotic or obstructed, pancreatitis can occur.[192] Approximately 25% of affected individuals are thought to be at risk for developing pancreatitis. Because pancreas divisum is characterized by a dominant dorsal duct system dependent on secretion through the accessory papilla, stenosis of the accessory (lesser) papilla is probably necessary to produce pancreatic symptoms. Most of the experience with surgical treatment of pancreas divisum is reported in adults. Successful surgical management of children presenting with recurrent pancreatitis secondary to accessory papilla stenosis with pancreas divisum also has been reported.[193]

To diagnose pancreas divisum, ERCP is required. Endoscopic visualization of the major and accessory papillae is essential. Radiographic findings with pancreas divisum demonstrate a short or absent duct of Wirsung that does not communicate with the duct of Santorini (see Fig. 103-57). Definitive diagnosis of pancreas divisum is made by demonstrating two separate, parallel ductal systems.

Few pediatric patients with pancreatitis and pancreas divisum requiring operation have been reported. Most of these children were female patients who had a history of recurrent pancreatitis. The primary operative goal is to provide adequate drainage of the duct of Santorini by performing a sphincterotomy of the accessory duct. An open dorsal duct sphincterotomy appears to be more durable than endoscopic sphincterotomy. Some surgeons advocate sphincterotomy of the main papilla as well, but dorsal duct sphincterotomy alone appears effective in preventing acute pancreatitis associated with pancreas divisum. The reported surgical outcome in the limited number of children treated for pancreatitis associated with pancreas divisum is favorable.

Pancreatic Cysts

Pancreatic pseudocysts are uncommon in the pediatric age group and are usually the result of blunt traumatic abdominal injury or acute pancreatitis. Children typically present with abdominal pain, nausea, emesis, and weight loss. There may be a palpable midepigastric mass on examination. Diagnosis usually is made with ultrasound or CT imaging of the abdomen. The serum amylase and lipase are usually elevated.

In children, many small asymptomatic pseudocysts regress spontaneously with resolution of the pancreatic inflammation. Larger or symptomatic pseudocysts may require drainage. Symptoms and potential complications of untreated pseudocysts include hemorrhage, infection, perforation, gastrointestinal or biliary tract obstruction, or, rarely, development of pancreaticoenteric fistula. The decision to use either external or internal drainage procedures for a pseudocyst depends on the status of the pancreatic duct. In many centers, definitive external drainage of a large or symptomatic pseudocyst is performed with acceptable morbidity and mortality rates by an ultrasound- or CT-guided percutaneous approach.[194] Pseudocyst recurrence or persistent external drainage without resolution suggests significant pancreatic duct injury or complete ductal transection. Determination of whether a major pancreatic ductal injury is associated with a pseudocyst may be made by either percutaneous contrast injection of the pseudocyst or ERCP.[195] Pseudocysts associated with pancreatic duct injury may not resolve with percutaneous external drainage or endoscopic pancreatic duct stenting, so internal drainage procedures such as cystgastrostomy or cystojejunostomy with or without distal pancreatectomy may be required.[196]

Epithelial cysts of the pancreas are rare in children. Congenital cysts are lined by epithelium and acinar tissue and are seen most commonly in the body and tail of the pancreas. They may be associated with other syndromes such as von Hippel–Lindau disease, which is characterized by hereditary cerebellar cysts, retinal hemangioma, and pancreatic cysts. Congenital pancreatic cysts are typically asymptomatic unless they are large enough to cause compression or obstruction of the stomach or colon. In the absence of trauma, spontaneous rupture of a pancreatic epithelial cyst is rare. Treatment is cyst excision or internal drainage into the stomach or the jejunum.

Other rare cystic lesions of the pancreas in children include retention cysts. These cysts result from chronic ductal obstruction. They are characteristically lined by epithelium unless inflammatory obliteration has occurred. Enteric duplication cysts of the stomach or the duodenum can also be associated intimately with the pancreas and communicate with the pancreatic duct. Treatment of both retention cysts and enteric duplication cysts either within or associated with the pancreas includes excision, occasionally internal drainage, and, if necessary, distal pancreatectomy. Not all pancreatic cysts in children can be uniformly considered benign. Suspicious lesions should be investigated thoroughly and biopsy performed. Cystadenoma, cystadenocarcinoma, and rhabdomyosarcoma associated with a pancreatic cyst have been reported. These neoplasms are treated by anatomic pancreatic resection following histologic confirmation on biopsy.

Pancreatic Neoplasms

Childhood malignant neoplasms of the pancreas are uncommon. Typically, pancreatic malignancy in childhood is found on discovery of an asymptomatic abdominal mass. Infrequently, the lesion may be found incidentally or during a diagnostic imaging workup for abdominal trauma. Jaundice may occur with a lesion in the pancreatic head causing common bile duct obstruction. The most frequently encountered lesions include islet cell carcinoma and adenocarcinoma. The treatment of choice for localized malignant neoplasms of the pancreas is surgical resection.[197] Pancreaticoduodenectomy in children can successfully control some malignancies of the pancreatic head. To promote adequate nutrient absorption and growth, children undergoing pancreaticoduodenectomy should be considered for oral pancreatic enzyme replacement and fat-soluble vitamin supplementation.[198]

Two pancreatic neoplasms seen in childhood and adolescence deserve further discussion. The *papillary cystic neoplasm* of the pancreas occurs predominantly in younger female children, is typically slow growing with low malignant potential, and is highly curable with surgical resection.[199] This tumor is thought to be a neoplasm of the ductuloacinar primordial cells of the pancreas. The other lesion is the *pancreatoblastoma,* also referred to as *juvenile adenocarcinoma of the pancreas.* Pancreatoblastoma is somewhat more common in boys than in girls and typically has slow growth with low malignant potential as well. Histologic examination demonstrates undifferentiated ductular and acinar areas with nodules of squamous epithelium, suggesting that these tumors arise from primordial pancreatic cells. Both papillary cystic neoplasm and pancreatoblastoma have more favorable prognoses than adenocarcinoma following surgical resection.

Endocrine Lesions of the Pancreas

Zollinger–Ellison Syndrome

Childhood tumors of the endocrine pancreas are exceedingly rare. The diagnosis and management of these tumors do not differ greatly from the adult population. The most common of these lesions include gastrinoma and insulinoma. The functional endocrine tumors of the pancreas are characterized by secreted peptide products such as glucagon, vasoactive intestinal peptide, somatostatin, and pancreatic polypeptide.

Similar to adults, children with Zollinger–Ellison syndrome clinically present with symptoms related to gastric hypersecretion. Peptic ulcer disease with or without gastrointestinal hemorrhage, abdominal pain, and diarrhea are common presenting symptoms. The diagnosis is confirmed by finding elevated serum gastrin levels. The basal acid output typically is elevated as well. A paradoxical increase in serum gastrin levels is found following intravenous administration of secretin (secretin stimulation test).

Contemporary management of Zollinger–Ellison syndrome in children relies on control of gastric acid hypersecretion with the oral administration of a proton–pump inhibitor. Diagnostic imaging studies, including helical CT scanning and MRI, are useful in localization of a primary gastrinoma and evaluating for metastatic disease before exploration. Definitive treatment relies on complete excision of the primary gastrinoma, which typically is found in the right of the superior mesenteric vessels in the head of the pancreas or the duodenum. The growth and progression of gastrinoma appear to be less aggressive in children than in adults; however, total gastrectomy occasionally is required in a child to control intractable symptoms related to persistent hypergastrinemia or metastatic disease.[200]

About 25% of gastrinomas occur in the setting of MEN syndrome, reviewed elsewhere in this book. At least 90% of patients with MEN type I have hyperparathyroidism secondary to hyperplasia. In addition, 30% to 80% of patients have pancreatic islet cell tumors and 15% to 50% have pituitary tumors.

Hypoglycemia

There are diverse metabolic causes for hypoglycemia in infancy and childhood. These include endocrinopathies such as panhypopituitarism, hypothyroidism, adrenal insufficiency, and congenital adrenal hyperplasia (adrenogenital syndrome). Several inborn errors of metabolism interrupt normal glucose regulatory mechanisms. Systemic disease states, perinatal stress, and sepsis can predispose an otherwise normal infant to low blood glucose levels. Infants who remain unresponsive to glucose infusion typically have inappropriately high circulating insulin levels for a given blood glucose level. Hyperinsulinemia should be suspected in any infant or child younger than 1 year with persistent hypoglycemia. There are heterogeneous causes for hyperinsulinemic hypoglycemia, but the most common historical cause in infancy is nesidioblastosis, which is characterized by uncontrolled development of the pancreatic endocrine tissue that functions abnormally during infancy.[201,202] Clinically, these cells secrete inappropriately high amounts of insulin, causing clinical hypoglycemia in infants. Two distinct histologic

lesions appear to be responsible for congenital hyperinsulinism. Mutations in the beta cell K_{ATP} channel genes may lead to either focal, adenomatous hyperinsulinism or diffuse hyperinsulinism; both genotypes lead to phenotypic hypoglycemia if left untreated.

Infants with congenital hyperinsulinism usually become symptomatic from hypoglycemia within the first few hours or days of life. These infants commonly present with neurologic symptoms such as lethargy or generalized seizures and have corresponding fasting blood glucose levels below 40 mg/dL. The diagnosis of hyperinsulinemia is supported by the clinical features of Whipple triad that includes (a) neurologic changes with fasting or activity, (b) fasting blood glucose levels below 40 to 50 mg/dL, and (c) neurologic symptoms reversed by the administration of glucose. The diagnosis is made by demonstrating inappropriately high levels of circulating insulin for a given level of blood glucose. An insulin (IU/mL) to glucose (mg/dL) ratio that is greater than 0.5 in a fasting patient is consistent with hyperinsulinemic hypoglycemia. In infants and children, an absolute insulin level greater than 5 IU/mL in the presence of a blood glucose less than 40 mg/dL is diagnostic. Ketone body production is impaired in infants with congenital hyperinsulinism.

The initial management of a hypoglycemic infant with congenital hyperinsulinism is to provide adequate glucose concentrations to prevent permanent neurologic injury. Dextrose-containing intravenous solutions are titrated to maintain blood glucose levels greater than 40 mg/dL and may require a central venous catheter. The short-term administration of somatostatin analogues to increase blood glucose levels in hyperinsulinemic states has been demonstrated to be useful.[203] Other pharmacologic agents used to reduce insulin levels and raise blood glucose concentration include diazoxide (15 mg/kg daily). The use of streptozocin to control hyperinsulinemia most often is reserved for adults with metastatic islet cell carcinoma and is not widely used in infants because of the potential side effects.

Following initial control of blood glucose and clinical confirmation of hyperinsulinemia, operative intervention should be considered a means of providing definitive control of hypoglycemia. Diagnostic imaging using CT scan imaging, MRI, or more recently,[18] F-FDOPA PET scanning may be useful either to identify or to exclude a focal lesion.[204] Localization of focal lesions is important in that this approach may lead to effective glucose control with selective partial pancreatectomy and allow for preservation of normal pancreatic tissue and function.[205,206]

Operatively, the abdomen is explored thoroughly, and the entire pancreas must be visualized. Preoperative localization data guided by intraoperative ultrasound and frozen section analysis may identify focal lesions amenable to partial resection. In the absence of a focal lesion, the infant is presumed to have diffuse islet cell hyperplasia. In this setting, the general operative strategy is total or near total pancreatectomy.[207] Lesser procedures such as subtotal (80%) pancreatectomy do not effectively treat diffuse congenital hyperinsulinism and recurrent hypoglycemia places the infant at risk for hypoglycemic encephalopathy. Near-total pancreatectomy involves resection of the distal 95% of the gland with preservation of the spleen. The entire distal pancreas, including the uncinate process, is resected, leaving a small rim of pancreatic tissue adjacent to the duodenum

(Fig. 103-58). Total pancreatectomy is usually reserved for persistent or recurrent hypoglycemia following lesser procedures. Near-total pancreatectomy controls hypoglycemia in 90% of infants with diffuse congenital hyperinsulinism. The remaining infants with persistent hypoglycemia may require further pancreatic resection. With extensive pancreatic resection, the typical postoperative course is a transient period of hyperglycemia with subsequent stabilization of blood glucose levels. Pancreatic exocrine function is ablated and oral replacement therapy is required. Despite clinical remission following resection, however, diabetes mellitus may occur as a long-term consequence in children treated either medically or surgically for diffuse congenital hyperinsulinism.[208] Therefore, these infants need long-term metabolic follow-up for both pancreatic endocrine and exocrine function.

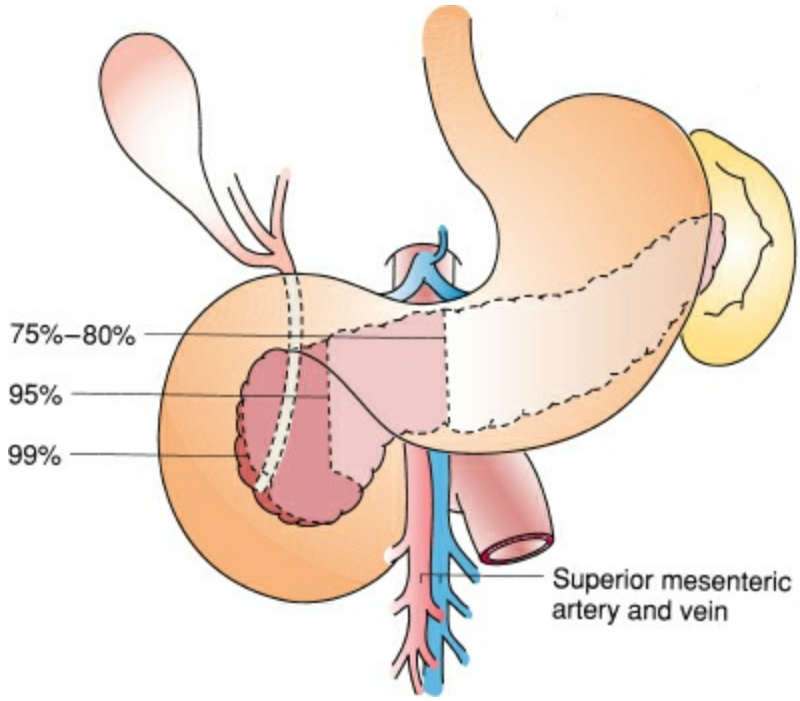

Figure 103-58. Illustration of the various degrees of pancreatic resection.

References

1. Parker SE, Mai CT, Canfield MA, et al. For the National Birth Defects Prevention Network. Updated national birth prevalence estimates for selected birth defects in the United States, 2004–2006. *Birth Defects Res A Clin Mol Teratol* 2010;88(12):1008–1016.
2. Williams LJ, Kucik JE, Alverson CJ, et al. Epidemiology of gastroschisis in metropolitan Atlanta, 1968 through 2000. *Birth Defects Res A* 2005; 73:177–183.
3. Nichols CR, Dickinson JE, Pemberton PG. Rising incidence of gastroschisis in teenage pregnancies. *J Matern Fetal Med* 1997;6:225–229.
4. Torfs CP, Curry CJ. Familial cases of gastroschisis in a population-based registry. *Am J Med Genet* 1993;45:465–467.
5. Glick PL, Harrison MR, Adzick NS. The missing link in the pathogenesis of gastroschisis. *J Pediatr Surg.* 1985;20:406–407.
6. Cantrell JR, Haller JA Jr, Ravitch MM. A syndrome of congenital defects involving the abdominal wall, sternum, diaphragm, pericardium, and heart. *Surg Gynecol Obstet* 1958;107:602–614.
7. Calzolari E, Bianchi F, Dolk H, et al. Omphalocele and gastroschisis in Europe: a survey of 3 million births 1980–1990. EUROCAT Working Group. *Am J Med Genet* 1995;58:187–194.
8. Boyd PA, Bhattacharjee A, Gould S, et al. Outcome of prenatally diagnosed anterior abdominal wall defects. *Arch Dis Child Fetal Neonatal Ed* 1998; 78:F209–F213.
9. Abdel-Latif ME, Bolisetty S, Abeywardana S, et al. Australian and New Zealand Neonatal Network. Mode of delivery and neonatal survival of infants with gastroschisis in Australia and New Zealand. *J Pediatr Surg* 2008;43(9):1685–1690.
10. Puligandla PS, Janvier A, Flageole H, et al. Routine cesarean delivery does not improve the outcome of infants with gastroschisis. *J Pediatr Surg* 2004;39(5):742–745.
11. Hadidi A, Subotic U, Goeppl M, et al. Early elective cesarean delivery before 36 weeks vs late spontaneous delivery in infants with gastroschisis. *J Pediatr Surg.* 2008;43:1342–1346.
12. Legghe HL, Masotn GC, Thonton JG, et al. A randomized controlled trial of elective preterm delivery of fetuses with gastroschisis. *J Pediatr Surg* 2008;40:1726–1731.
13. Ergün O, Barksdale E, Ergün FS, et al. The timing of delivery of infants with gastroschisis influences outcome. *J Pediatr Surg.* 2005;40(2):424–428.
14. Kidd JN Jr, Jackson RJ, Smith SD, et al. Evolution of staged versus primary closure of gastroschisis. *Ann Surg* 2003;237:759–765.
15. Lobo JD, Kim AC, Davis RP, et al. No free ride? The hidden costs of delayed operative management using a spring-loaded silo for gastroschisis. *J Pediatr Surg* 2010;45(7):1426–1432.
16. Sandler A, Lawrence J, Meehan J, et al. A “plastic” sutureless abdominal wall closure

in gastroschisis. *J Pediatr Surg* 2004;39(5):738–741.
17. Machida M, Takamizawa S, Yoshizawa K. Umbilical cord inverting technique: a simple method to utilize the umbilical cord as a biologic dressing for sutureless gastroschisis closure. *Pediatr Surg Int* 2011;27(1):95–97.
18. Riboh J, Abrajano CT, Garber K, et al. Outcomes of sutureless gastroschisis closure. *J Pediatr Surg* 2009;44(10):1947–1951.
19. Orion KC, Krein M, Liao J, et al. Outcomes of plastic closure in gastroschisis. *Surgery* 2011;150(2);177–185.
20. Davies MW, Kimble RM, Cartwright DW. Gastroschisis: ward reduction compared with tradition reduction under general anesthesia. *J Pediatr Surg* 2005;40(3):523–527.
21. Martin AE, Khan A, Kim DS, et al. The use of intraabdominal tissue expanders as a primary strategy for closure of giant omphaloceles. *J Pediatr Surg* 2009;44(1):178–182.
22. De Ugarte DA, Asch MJ, Hedrick MH, et al. The use of tissue expanders in the closure of a giant omphalocele. *J Pediatr Surg* 2004;30(4):613–615.
23. Lee SL, Beyer TD, Kim SS, et al. Initial nonoperative management and delayed closure for treatment of giant omphaloceles. *J Pediatr Surg* 2006;41(11):1846–1849.
24. Whitehouse JS, Gourlay DM, Masonbrink AR, et al. Conservative management of giant omphalocele with topical povidone-iodine and its effect on thyroid function. *J Pediatr Surg* 2010;45(6):1192–1197.
25. Pandey V, Gangopadhyay AN, Gupta DK, et al. Non-operative management of giant omphalocele with topical povidone-iodine and powdered antibiotic combination: early experience from a tertiary centre. *Pediatr Surg Int* 2014;30(4):407–411.
26. Curry JJ, Lander AD, Stringer MD, et al. A multicenter, randomized, double-blind, placebo-controlled trial of the prokinetic agent erythromycin in the postoperative recovery of infants with gastroschisis. *J Pediatr Surg* 2004;39:565–569.
27. Jayanthi S, Seymour P, Puntis JW, et al. Necrotizing enterocolitis after gastroschisis repair: a preventable complication? *J Pediatr Surg* 1998;33:705–707.
28. Phillips JD, Raval MV, Redden C, et al. Gastroschisis, atresia, dysmotility: surgical treatment strategies for a distinct clinical entity. *J Pediatr Surg* 2008; 43:2208–2212.
29. van Eijck FC, Wijnen RM, van Goor H. The incidence and morbidity of adhesions after treatment of neonates with gastroschisis and omphalocele: a 30-year review. *J Pediatr Surg* 2008;43:479–483.
30. Zaccara A, Iacobelli BD, Calzolari A, et al. Cardiopulmonary performances in young children and adolescents born with large abdominal wall defects. *J Pediatr Surg* 2003;38:478–481.
31. Papagrigoriadis S, Browse DJ, Howard ER. Incarceration of umbilical hernias in children: a rare but important complication. *Pediatr Surg Int* 1998;14:231–232.
32. Evans A. The comparative incidence of umbilical hernias in colored and white infants. *J Natl Med Assoc* 1941;33:158–162.

33. Snyder CL. Current management of umbilical abnormalities and related anomalies. *Semin Pediatr Surg* 2007;16:41–49.
34. Snyder WH Jr, Greanly EM Jr. Inguinal hernia. In: Benson CD, Mustard WT, Ravitch MM, et al., eds. *Pediatric Surgery.* Chicago, IL: Year Book Medical; 1962.
35. Rowe MI, Copelson LW, Clatworthy HW. The patent processus vaginalis and the inguinal hernia. *J Pediatr Surg* 1969;4:102–107.
36. Clarnette TD, Lam SK, Hutson JM. Ventriculo-peritoneal shunts in children reveal the natural history of closure of the processus vaginalis. *J Pediatr Surg* 1998;33:413–416.
37. Sato TT, Oldham KT. Pediatric abdomen. In: Mulholland MW, Lillemoe KD, Doherty GM, et al., eds. *Greenfield's Surgery: Scientific Principles and Practice.* 4th ed. Philadelphia, PA: Lippincott Williams & Wilkins; 2006.
38. Chou TY, Chu CC, Diau GY, et al. Inguinal hernia in children: US versus exploratory surgery and intraoperative contralateral laparoscopy. *Radiology* 1996;201:385–388.
39. Palmer BV. Incarcerated inguinal hernia in children. *Ann R Coll Surg Engl* 1978;60:121–124.
40. Rowe MI, Clatworthy HW. Incarcerated and strangulated hernias in children: a statistical study of high-risk factors. *Arch Surg* 1970;101:136–139.
41. Somri M, Gaitini L, Vaida S, et al. Postoperative outcome in high-risk infants undergoing herniorrhaphy: comparison between spinal and general anesthesia. *Anaesthesia* 1998;53:762–766.
42. Chan KL, Chan HY, Tam PK. Towards a near-zero recurrence rate in laparoscopic inguinal hernia repair for pediatric patients of all ages. *J Pediatr Surg* 2007;42:1993–1997.
43. Hrabovszky Z, Pinter AB. Routine bilateral exploration for inguinal hernia in infancy and childhood. *Eur J Pediatr Surg* 1995;5:152–155.
44. Wiener ES, Touloukian RJ, Rodgers BM, et al. Hernia survey of the Section on Surgery of the American Academy of Pediatrics. *J Pediatr Surg* 1996; 31:1166–1169.
45. Tackett LD, Breuer CK, Luks FI, et al. Incidence of contralateral inguinal hernia: a prospective analysis. *J Pediatr Surg* 1999;34:684–687.
46. Owings EF, Georgeson KE. A new technique for laparoscopic exploration to find contralateral patent processus vaginalis. *Surg Endosc* 2000;14:114–116.
47. Ron O, Eaton S, Pierro A. Systematic review of the risk of developing a metachronous contralateral inguinal hernia in children. *Brit J Surg* 2007;94:804–811.
48. Haller JA Jr, Tepas JJ, Pickard LR, et al. Intestinal atresia: current concepts of pathogenesis, pathophysiology, and operative management. *Am Surg* 1983;49:385–391.
49. Koga Y, Hayashida Y, Ikeda K, et al. Intestinal atresia in fetal dogs produced by localized ligation of mesenteric vessels. *J Pediatr Surg* 1975;10:949–953.
50. Dalla Vecchia LK, Grosfeld JL, West KW, et al. Intestinal atresia and stenosis: a 25-year experience with 277 cases. *Arch Surg* 1998;133:490–496.

51. James LM, Erickson JD, McClean AB. *Prevalence of Birth Defects.* Atlanta: Centers for Disease Control; 1992.
52. Filkins K, Russo J, Flowers WK. Third trimester ultrasound diagnosis of intestinal atresia following clinical evidence of polyhydramnios. *Prenat Diagn* 1985;5:215–220.
53. Wilmore DW. Factors correlating with a successful outcome following extensive intestinal resection in newborn infants. *J Pediatr* 1972;80:88–95.
54. Touloukian RJ. Intestinal atresia. *Clin Perinatol* 1978;5:3–18.
55. Piper HG, Alesbury J, Waterford SD, et al. Intestinal atresias: factors affecting clinical outcomes. *J Pediatr Surg* 2008;43:1244–1248.
56. Grosfeld JL. Jejunoileal atresia and stenosis. In: O'Neill JA Jr, Rowe MI, Grosfeld JL, et al., eds. *Pediatric surgery*. 5th ed. St. Louis, MO: Mosby; 1998:1145–1158.
57. Menardi G. Duodenal atresia, stenosis, and annular pancreas. In: Freeman NV, Burge DM, Griffiths M, et al., eds. *Surgery of the Newborn.* Edinburgh: Churchill Livingstone; 1994:107–115.
58. Stauffer UG, Schwoebel M. Duodenal atresia and stenosis—annular pancreas. In: O'Neill JA Jr, Rowe MI, Grosfeld JL, et al., eds. *Pediatric Surgery*. St. Louis: MO; 1998:1133–1143.
59. Stauffer UG, Irving I. Duodenal atresia and stenosis—long-term results. *Prog Pediatr Surg* 1977;10:49–60.
60. Kimura K, Mukohara N, Nishijima E, et al. Diamond-shaped anastomosis for duodenal atresia: an experience with 44 patients over 15 years. *J Pediatr Surg* 1990;25:977–979.
61. Valusek PA, Spilde TL, Tsao K, et al. Laparoscopic duodenal atresia repair using surgical U-clips: a novel technique. *Surg Endosc* 2007;21:1023–1024.
62. Weber TR, Lewis JE, Mooney D, et al. Duodenal atresia: a comparison of techniques of repair. *J Pediatr Surg* 1986;21:1133–1136.
63. Peña A. *Atlas of surgical management of anorectal malformations.* New York, NY: Springer-Verlag; 1990.
64. Spouge D, Baird PA. Imperforate anus in 700,000 consecutive liveborn infants. *Am J Med Genet* 1986;2(suppl):151–161.
65. Schuster SR, Teele RL. An analysis of ultrasound scanning as a guide in determination of "high" or "low" imperforate anus. *J Pediatr Surg* 1979; 14:798–800.
66. Ong NT, Beasley SW. Long-term continence in patients with high and intermediate anorectal anomalies treated by sacroperineal (Stephens) rectoplasty. *J Pediatr Surg* 1991;26:44–48.
67. Ito Y, Yokoyama J, Hayashi A, et al. Reappraisal of endorectal pull-through procedure. I. Anorectal malformations. *J Pediatr Surg* 1981;16:476–483.
68. Georgeson KE, Inge TH, Albanese CT. Laparoscopically assisted anorectal pull-through for high imperforate anus—a new technique. *J Pediatr Surg* 2000;35:927–930.

69. Kiesewetter WB, Hoon A. Imperforate anus: an analysis of mortalities during a 25-year period. *Prog Pediatr Surg* 1979;13:211–220.
70. Kiesewetter WB, Chang JH. Imperforate anus: a five- to thirty-year follow-up perspective. *Prog Pediatr Surg* 1977;10:111–120.
71. Bliss DP Jr, Tapper D, Anderson JM, et al. Does posterior sagittal anorectoplasty in patients with high imperforate anus provide superior fecal continence? *J Pediatr Surg* 1996;31:26–30.
72. Rintala RJ, Pakarinen MP. Imperforate anus: long- and short-term outcome. *Semin Pediatr Surg* 2008;17:79–89.
73. Lin PW, Nasr TR, Stoll BJ. Necrotizing enterocolitis: recent scientific advances in pathophysiology and prevention. *Semin Perinatol* 2008;32:70–82.
74. Anderson DM, Kliegman RM. The relationship of neonatal alimentation practices to the occurrence of endemic necrotizing enterocolitis. *Am J Perinatol* 1991;8:62–67.
75. Rayyis SF, Ambalavanan N, Wright L, et al. Randomized trial of "slow" versus "fast" feed advancements on the incidence of necrotizing enterocolitis in very low birth weight infants. *J Pediatr* 1999;134:293–297.
76. Lin HC, Hsu CH, Chen HL, et al. Oral probiotics prevent necrotizing enterocolitis in very low birth weight preterm infants: a multicenter, randomized, controlled trial. *Pediatr* 2008;122:693–700.
77. Grosfeld JL, Cheu H, Schlatter M, et al. Changing trends in necrotizing enterocolitis: experience with 302 cases in two decades. *Ann Surg* 1991;214:300–306.
78. Pokorny WJ, Garcia-Prats JA, Barry YN. Necrotizing enterocolitis: incidence, operative care, and outcome. *J Pediatr Surg* 1986;21:1149–1154.
79. Andrews DA, Sawin RS, Ledbetter DJ, et al. Necrotizing enterocolitis in term neonates. *Am J Surg* 1990;159:507–509.
80. Bell MJ, Kosloske AM, Benton C, et al. Neonatal necrotizing enterocolitis: prevention of perforation. *J Pediatr Surg* 1973;8:601–605.
81. Grosfeld JL, Chaet M, Molinari F, et al. Increased risk of necrotizing enterocolitis in premature infants with patent ductus arteriosus treated with indomethacin. *Ann Surg* 1996;224:350–355.
82. Ricketts RR. The role of paracentesis in the management of infants with necrotizing enterocolitis. *Am Surg* 1986;52:61–65.
83. Cooper A, Ross AJ, O'Neill JA Jr, et al. Resection with primary anastomosis for necrotizing enterocolitis: a contrasting view. *J Pediatr Surg* 1988;23:64–68.
84. Ade-Ajayi N, Kiely E, Drake D, et al. Resection and primary anastomosis in necrotizing enterocolitis. *J R Soc Med* 1996;89:385–388.
85. Sato TT, Oldham KT. Abdominal drain placement versus laparotomy for necrotizing enterocolitis with perforation. *Clin Perinatol* 2004;31:577–589.
86. Moss RL, Dimmitt RA, Barnhart DC, et al. Laparotomy versus peritoneal drainage for necrotizing enterocolitis and perforation. *N Engl J Med* 2006;354:2225–2234.

87. O'Connor A, Sawin RS. High morbidity of enterostomy and its closure in premature infants with necrotizing enterocolitis. *Arch Surg* 1998;133:875–880.
88. Schwartz MZ, Hayden CK, Richardson CJ, et al. A prospective evaluation of intestinal stenosis following necrotizing enterocolitis. *J Pediatr Surg* 1982;17:764–770.
89. Moss RL, Dimmitt RA, Henry MC, et al. A meta-analysis of peritoneal drainage versus laparotomy for perforated necrotizing enterocolitis. *J Pediatr Surg* 2001;36:1210–1213.
90. Patel JC, Tepas JJ III, Huffman SD, et al. Neonatal necrotizing enterocolitis: the long-term perspective. *Am Surg* 1998;64:575–579.
91. Statement from the National Institutes of Health workshop on population screening for the cystic fibrosis gene. *N Engl J Med* 1990;323:70–71.
92. Riordan JR, Rommens JM, Kerem B, et al. Identification of the cystic fibrosis gene: cloning and characterization of complementary DNA. *Science* 1989; 245:1066–1073.
93. Kerem B, Rommens JM, Buchanan JA, et al. Identification of the cystic fibrosis gene: genetic analysis. *Science* 1989;245:1073–1080.
94. Rosenstein BJ, Cutting GR. The diagnosis of cystic fibrosis: a consensus statement. Cystic Fibrosis Foundation Consensus Panel. *J Pediatr* 1998; 132:589–595.
95. Quinton PM. Cystic fibrosis: a disease in electrolyte transport. *Faseb J* 1990; 4:2709–2717.
96. Quinton PM, Bijman J. Higher bioelectric potentials due to decreased chloride absorption in the sweat glands of patients with cystic fibrosis. *N Engl J Med* 1983;308:1185–1189.
97. Irish MS, Ragi JM, Karamanoukian H, et al. Prenatal diagnosis of the fetus with cystic fibrosis and meconium ileus. *Pediatr Surg Int* 1997;12:434–436.
98. Kao SC, Franken EA Jr. Nonoperative treatment of simple meconium ileus: a survey of the Society for Pediatric Radiology. *Pediatr Radiol* 1995;25:97–100.
99. Mak GZ, Harberg FJ, Hiatt P, et al. T-tube ileostomy for meconium ileus: four decades of experience. *J Pediatr Surg* 2000;35:349–352.
100. Del Pin CA, Czyrko C, Ziegler MM, et al. Management and survival of meconium ileus: a 30-year review. *Ann Surg* 1992;215:179–185.
101. Docherty JG, Zaki A, Coutts JA, et al. Meconium ileus: a review 1972–1990. *Br J Surg* 1992;79:571–573.
102. Sato TT. Abnormal rotation and fixation of the intestine. In: Wyllie R, Hyams JS, eds. *Pediatric Gastrointestinal and Liver Disease.* London: Elsevier; 2006.
103. Andrassy RJ, Mahour GH. Malrotation of the midgut in infants and children: a 25-year review. *Arch Surg* 1981;116:158–160.
104. Ford EG, Senac MO Jr, Srikanth MS, et al. Malrotation of the intestine in children. *Ann Surg* 1992;215:172–178.
105. Powell DM, Othersen HB, Smith CD. Malrotation of the intestines in children: the effect of age on presentation and therapy. *J Pediatr Surg* 1989;24:777–780.

106. Weinberger E, Winters WD, Liddell RM, et al. Sonographic diagnosis of intestinal malrotation in infants: importance of the relative positions of the superior mesenteric vein and artery. *AJR Am J Roentgenol* 1992;159:825–828.
107. Ladd WE, Gross RE. *Abdominal Surgery of Infancy and Childhood.* Philadelphia, PA: WB Saunders; 1941.
108. Bass KD, Rothenberg SS, Chang JH. Laparoscopic Ladd's procedure in infants with malrotation. *J Pediatr Surg* 1998;33:279–281.
109. Fujimoto T, Hata J, Yokoyama S, et al. A study of the extracellular matrix protein as the migration pathway of neural crest cells in the gut: analysis in human embryos with special reference to the pathogenesis of Hirschsprung's disease. *J Pediatr Surg* 1989;24:550–556.
110. Kleinhaus S, Boley SJ, Sheran M, et al. Hirschsprung's disease—a survey of the members of the Surgical Section of the American Academy of Pediatrics. *J Pediatr Surg* 1979;14:588–597.
111. Tomita R, Munakata K, Kurosu Y. Peptidergic nerves in Hirschsprung's disease and its allied disorders. *Eur J Pediatr Surg* 1994;4:346–351.
112. Kusafuka T, Puri P. Altered mRNA expression of the neuronal nitric oxide synthase gene in Hirschsprung's disease. *J Pediatr Surg* 1997;32:1054–1058.
113. Puri P, Wester T. Intestinal neuronal dysplasia. *Semin Pediatr Surg* 1998; 7:181–186.
114. Meier-Ruge WA, Ammann K, Bruder E, et al. Updated results on intestinal neuronal dysplasia (IND B). *Eur J Pediatr Surg* 2004;14:384–391.
115. Tanaka H, Moroi K, Iwai J, et al. Novel mutations of the endothelin B receptor gene in patients with Hirschsprung's disease and their characterization. *J Biol Chem* 1998;273:11378–11383.
116. Kusafuka T, Puri P. Genetic aspects of Hirschsprung's disease. *Semin Pediatr Surg* 1998;7:148–155.
117. Robertson K, Mason I, Hall S. Hirschsprung's disease: genetic mutations in mice and men. *Gut* 1997;41:436–441.
118. Puri P, Ohshiro K, Wester T. Hirschsprung's disease: a search for etiology. *Semin Pediatr Surg* 1998;7:140–147.
119. Puffenberger EG, Kauffman ER, Bolk S, et al. Identity-by-descent and association mapping of a recessive gene for Hirschsprung disease on human chromosome 13q22. *Hum Mol Genet* 1994;3:1217–1225.
120. Romeo G, Ronchetto P, Luo Y, et al. Point mutations affecting the tyrosine kinase domain of the RET protooncogene in Hirschsprung's disease. *Nature* 1994;367:377–378.
121. Quinn FM, Surana R, Puri P. The influence of trisomy 21 on outcome in children with Hirschsprung's disease. *J Pediatr Surg* 1994;29:781–783.
122. Qualman SJ, Jaffe R, Bove KE, et al. Diagnosis of Hirschsprung disease using the rectal biopsy: multi-institutional survey. *Pediatr Dev Pathol* 1999; 2:588–596.

123. Ramesh JC, Ramanujam TM, Yik YI, et al. Management of Hirschsprung's disease with reference to one-stage pull-through without colostomy. *J Pediatr Surg* 1999;34:1691–1694.
124. Albanese CT, Jennings RW, Smith B, et al. Perineal one-stage pull-through for Hirschsprung's disease. *J Pediatr Surg* 1999;34:377–380.
125. Georgeson KE, Cohen RD, Hebra A, et al. Primary laparoscopic-assisted endorectal colon pull-through for Hirschsprung's disease: a new gold standard. *Ann Surg* 1999;229:678–682.
126. Skinner MA. Hirschsprung's disease. *Curr Probl Surg* 1996;33:389–460.
127. Saleh W, Rasheed K, Al Mohaidly M, et al. Management of Hirschsprung's disease: a comparison of Soave's and Duhamel's pull-through methods. *Pediatr Surg Int* 2004;20:590–593.
128. Sawin R, Hatch E, Schaller R, et al. Limited surgery for lower-segment Hirschsprung's disease. *Arch Surg* 1994;129:920–924.
129. Vanderwinden JM, Mailleux P, Schiffmann SN, et al. Nitric oxide synthase activity in infantile hypertrophic pyloric stenosis. *N Engl J Med* 1992; 327:511–515.
130. Saur D, Vanderwinden J, Seidler B, et al. Single-nucleotide promoter polymorphism alters transcription of neuronal nitric oxide synthase exon 1 c in infantile hypertrophic pyloric stenosis. *Proc Natl Acad Sci* 2004;101:1662–1667.
131. Rasmussen L, Green A, Hansen LP. The epidemiology of infantile hypertrophic pyloric stenosis in a Danish population, 1950–84. *Int J Epidemiol* 1989;18:413–417.
132. Honein MA, Paulozzi LJ, Himelright IM, et al. Infantile hypertrophic pyloric stenosis after pertussis prophylaxis with erythromycin: a case review and cohort study. *Lancet* 1999;354:2101–2105.
133. Schechter R, Torfs CP, Bateson TF. The epidemiology of infantile hypertrophic pyloric stenosis. *Paediatr Perinat Epidemiol* 1997;11:407–427.
134. Hall NJ, Van Der Zee J, Tan HL, et al. Meta-analysis of laparoscopic versus open pyloromyotomy. *Ann Surg* 2004;240:774–778.
135. St Peter SD, Holcomb GW, Calkins CM, et al. Open versus laparoscopic pyloromyotomy for pyloric stenosis. *Ann Surg* 2006;244:363–370.
136. Langer JC, To T. Does pediatric surgical specialty training affect outcome after Ramstedt pyloromyotomy? A population-based study. *Pediatrics* 2004;113:1342–1347.
137. Kim YS, Rhu JH. Intussusception in infancy and childhood: analysis of 385 cases. *Int Surg* 1989;74:114–118.
138. From the Centers for Disease Control and Prevention. Withdrawal of rotavirus vaccine recommendation. *JAMA* 1999;282:2113–2114.
139. Postmarketing monitoring of intussusception after RotaTeq vaccination—United States, February 1, 2006–February 15, 2007. *MMWR* 2007;56:218–222.
140. Okuyama H, Nakai H, Okada A. Is barium enema reduction safe and effective in patients with a long duration of intussusception? *Pediatr Surg Int* 1999;15:105–107.

141. Poddoubnyi IV, Dronov AF, Blinnikov OI, et al. Laparoscopy in the treatment of intussusception in children. *J Pediatr Surg* 1998;33:1194–1197.
142. Cheung ST, Lee KH, Yeung TH, et al. Minimally invasive approach in the management of childhood intussusception. *ANZ J Surg* 2007;77:778–781.
143. Bonnard A, Demarche M, Dimitriu C, et al. Indications for laparoscopy in the management of intussusception: a multicenter retrospective study conducted by the French study group for pediatric laparoscopy. *J Pediatr Surg* 2008;43:1249–1253.
144. Schier F, Hoffmann K, Waldschmidt J. Laparoscopic removal of Meckel's diverticula in children. *Eur J Pediatr Surg* 1996;6:38–39.
145. Bonadio WA, Jona JZ, Glicklich M, et al. Esophageal bougienage technique for coin ingestion in children. *J Pediatr Surg* 1988;23:917–918.
146. Stuth EA, Stucke AG, Cohen RD, et al. Successful resuscitation of a child after exsanguination due to aortoesophageal fistula from undiagnosed foreign body. *Anesthesiology* 2001;95:1025–1026.
147. Maves MD, Carithers JS, Birck HG. Esophageal burns secondary to disc battery ingestion. *Ann Otol Rhinol Laryngol* 1984;93:364–369.
148. Thompson EC, Brown MF, Bowen EC, et al. Causes of gastrointestinal hemorrhage in neonates and children. *South Med J* 1996;89:370–374.
149. McDougal WS, Izant RJ Jr, Zollinger RM Jr. Primary peritonitis in infancy and childhood. *Ann Surg* 1975;181:310–313.
150. Zurowska A, Feneberg R, Warady BA, et al. Gram-negative peritonitis in children undergoing long-term peritoneal dialysis. *Am J Kidney Dis* 2008; 51:455–462.
151. Zganjer M, Cizmic A, Cigit I, et al. Treatment of rectal prolapse in children with cow milk injection sclerotherapy: 30-year experience. *W J Gastroenterol* 2008;14:737–740.
152. Newman KD. Malignant liver tumors of children. *Semin Pediatr Surg* 1992;1:145–151.
153. Bowman LC, Riely CA. Management of pediatric liver tumors. *Surg Oncol Clin N Am* 1996;5:451–459.
154. Luks FI, Yazbeck S, Brandt ML, et al. Benign liver tumors in children: a 25-year experience. *J Pediatr Surg* 1991;26:1326–1330.
155. Hernandez F, Navarro M, Encinas JL, et al. The role of GLUT1 immunostaining in the diagnosis and classification of liver vascular tumors in children. *J Pediatr Surg* 2005;40:801–804.
156. Huang SA. Tu HM, Harney JW, et al. Severe hypothyroidism caused by type 3 iodothyronine deiodinase in infantile hemangioma. *N Engl J Med* 2000;343:185–187.
157. Christison-Lagay ER, Burrows PE Alomari A, et al. Hepatic hemangiomas: subtype classification and development of a clinical practice algorithm and registry. *J Pediatr Surg* 2007;42:62–68.
158. Isaacs H Jr. Fetal and neonatal hepatic tumors. *J Pediatr Surg* 2007; 42:1797–1803.
159. Ein SH, Stephens CA. Benign liver tumors and cysts in childhood. *J Pediatr Surg* 1974;9:847–851.

160. Tiao GM, Bobey N, Allen S, et al. The current management of hepatoblastoma: a combination of chemotherapy, conventional resection, and liver transplantation. *J Pediatr* 2005;146:204–211.
161. Pham TH, Iqbal CW, Grams JM, et al. Outcomes of primary liver cancer in children: an appraisal of experience. *J Pediatr Surg* 2007;42:834–839.
162. Austin MT, Leys CM, Feurer ID, et al. Liver transplantation for childhood hepatic malignancy: a review of the United Network for Organ Sharing (UNOS) database. *J Pediatr Surg* 2006;41:182–186.
163. Urban CE, Mache CJ, Schwinger W, et al. Undifferentiated (embryonal) sarcoma of the liver in childhood: successful combined-modality therapy in four patients. *Cancer* 1993;72:2511–2516.
164. Finegold MJ, Egler RA, Goss JA, et al. Liver tumors: pediatric population. *Liver Transpl* 2008;14:1545–1556.
165. Randolph JG, Altman RP, Arensman RM, et al. Liver resection in children with hepatic neoplasms. *Ann Surg* 1978;187:599–605.
166. Larsen LR, Raffensperger J. Liver abscess. *J Pediatr Surg* 1979;14:329–331.
167. Wells CD, Arguedas M. Amebic liver abscess. *S Med J* 2004;97:673–682.
168. Balistreri WF, Grand R, Hoofnagle JH, et al. Biliary atresia: current concepts and research directions. *Hepatology* 1996;23:1682–1692.
169. Tan CE, Davenport M, Driver M, et al. Does the morphology of the extrahepatic biliary remnants in biliary atresia influence survival? A review of 205 cases. *J Pediatr Surg* 1994;29:1459–1464.
170. Chandra RS, Altman RP. Ductal remnants in extrahepatic biliary atresia: a histopathologic study with clinical correlation. *J Pediatr* 1978;93:196–200.
171. Schmeling DJ, Oldham KT, Guice KS, et al. Experimental obliterative cholangitis: a model for the study of biliary atresia. *Ann Surg* 1991;213:350–355.
172. Kobayashi H, Stringer MD. Biliary atresia. *Semin Perinatol* 2003;8:383–391.
173. Ryckman FC, Alonso MH, Bucuvalas JC, et al. Biliary atresia—surgical management and treatment options as they relate to outcome. *Liver Transpl Surg* 1998;4(5 suppl 1):S24–S33.
174. Visser BC, Suh I, Hirose S, et al. The influence of portoenterostomy on transplantation for biliary atresia. *Liver Transpl* 2004;10:1279–1286.
175. Davenport M, Puricelli V, Farrant P, et al. The outcome of the older (>100 days) infant with biliary atresia. *J Pediatr Surg* 2004;4:575–581.
176. Ogasawara Y, Yamataka A, Tsukamoto K, et al. The intussusception antireflux valve is ineffective for preventing cholangitis in biliary atresia: a prospective study. *J Pediatr Surg* 2003;38:1826–1829.
177. Kasai M, Suzuki H, Ohashi E, et al. Technique and results of operative management of biliary atresia. *World J Surg* 1978;2:571–579.
178. Rothenberg SS, Schroter GP, Karrer FM, et al. Cholangitis after the Kasai operation

for biliary atresia. *J Pediatr Surg* 1989;24:729–732.
179. Dolgin SE. Answered and unanswered controversies in the surgical management of extra hepatic biliary atresia. *Pediatr Transplant* 2004;8:628–631.
180. Shneider BL, Brown MB, Haber B, et al. A multicenter study of the outcome of biliary atresia in the United States, 1997–2000. *J Pediatr* 2006; 148:467–474.
181. Stringer MD. Biliary atresia: service delivery and outcomes. *Semin Pediatr Surg* 2008;17:116–122.
182. Goss JA, Shackleton CR, Swenson K, et al. Orthotopic liver transplantation for congenital biliary atresia: an 11-year, single-center experience. *Ann Surg* 1996;224:276–284.
183. Cowles RA, Lobritto SJ, Ventura KA, et al. Timing of liver transplantation in biliary atresia—results in 71 children managed by a multidisciplinary team. *J Pediatr Surg* 2008;43:1605–1609.
184. Alonso-Lej F, Revor WB, Pessagno DJ. Congenital choledochal cyst, with a report of 2, and an analysis of 94 cases. *Surg Gynecol Obstet* 1959; 108:1–30.
185. Todani T, Watanabe Y, Narusue M, et al. Congenital bile duct cysts: classification, operative procedures, and review of thirty-seven cases including cancer arising from choledochal cyst. *Am J Surg* 1977;134:263–269.
186. Todani T, Tabuchi K, Watanabe Y, et al. Carcinoma arising in the wall of congenital bile duct cysts. *Cancer* 1979;44:1134–1141.
187. Fieber SS, Nance FC. Choledochal cyst and neoplasm: a comprehensive review of 106 cases and presentation of two original cases. *Am Surg* 1997;63:982–987.
188. Miyano T, Yamataka A, Kato Y, et al. Hepaticoenterostomy after excision of choledochal cyst in children: a 30-year experience with 180 cases. *J Pediatr Surg* 1996;31:1417–1421.
189. Flanigan PD. Biliary cysts. *Ann Surg* 1975;182:635–643.
190. Lipsett PA, Pitt HA, Colombani PM, et al. Choledochal cyst disease: a changing pattern of presentation. *Ann Surg* 1994;220:644–652.
191. Werlin SL. Disorders of the pancreas in children. *Curr Opin Pediatr* 1998;10:507–511.
192. Warshaw AL, Richter JM, Schapiro RH. The cause and treatment of pancreatitis associated with pancreas divisum. *Ann Surg* 1983;198:443–452.
193. Adzick NS, Shamberger RC, Winter HS, et al. Surgical treatment of pancreas divisum causing pancreatitis in children. *J Pediatr Surg* 1989;24:54–58.
194. Kagan RJ, Reyes HM, Asokan S. Pseudocyst of the pancreas in childhood: current advances in diagnosis. *Arch Surg* 1981;116:1200–1203.
195. Rescorla FJ, Plumley DA, Sherman S, et al. The efficacy of early ERCP in pediatric pancreatic trauma. *J Pediatr Surg* 1995;30:336–340.
196. Cooney DR, Grosfeld JL. Operative management of pancreatic pseudocysts in infants and children: a review of 75 cases. *Ann Surg* 1975;182:590–596.

197. Grosfeld JL, Vane DW, Rescorla FJ, et al. Pancreatic tumors in childhood: analysis of 13 cases. *J Pediatr Surg* 1990;25:1057–1062.
198. Shamberger RC, Hendren WH, Leichtner AM. Long-term nutritional and metabolic consequences of pancreaticoduodenectomy in children. *Surgery* 1994;115:382–388.
199. Wang KS, Albanese C, Dada F, et al. Papillary cystic neoplasm of the pancreas: a report of three pediatric cases and literature review. *J Pediatr Surg* 1998;33:842–845.
200. Wilson SD. Zollinger-Ellison syndrome in children: a 25-year follow-up. *Surgery* 1991;110:696–702.
201. Sempoux C, Poggi F, Brunelle F, et al. Nesidioblastosis and persistent neonatal hyperinsulinism. *Diabetes Metab* 1995;21:402–407.
202. Aynsley-Green A, Polak JM, Bloom SR, et al. Nesidioblastosis of the pancreas: definition of the syndrome and the management of the severe neonatal hyperinsulinaemic hypoglycaemia. *Arch Dis Child* 1981;56:496–508.
203. Hirsch HJ, Loo S, Evans N, et al. Hypoglycemia of infancy and nesidioblastosis: studies with somatostatin. *N Engl J Med* 1977;296:1323–1326.
204. Adzick NS, Thornton PS, Stanley CA, et al. A multidisciplinary approach to the focal form of congenital hyperinsulinism leads to successful treatment by partial pancreatectomy. *J Pediatr Surg* 2004;39:270–275.
205. Becherer A, Szabo M, Karanikas G, et al. Imaging of advanced neuroendocrine tumors with 18 F-FDOPA PET. *J Nucl Med* 2003;45:1161–1167.
206. Viola KV, Sosa JA. Current advances in the diagnosis and treatment of pancreatic endocrine tumors. *Curr Opin Oncol* 2005;17:24–27.
207. Willberg B, Muller E. Surgery for nesidioblastosis—indications, treatment, and results. *Prog Pediatr Surg* 1991;26:76–83.
208. Leibowitz G, Glaser B, Higazi AA, et al. Hyperinsulinemic hypoglycemia of infancy (nesidioblastosis) in clinical remission: high incidence of diabetes mellitus and persistent beta-cell dysfunction at long-term follow-up. *J Clin Endocrinol Metab* 1995;80:386–392.

Chapter 104

Pediatric Genitourinary System

John M. Park and Julian Wan

Key Points

1 Embryonic kidneys develop from the intermediate mesoderm, with the definitive kidney forming as result of inductive interaction between ureteric bud and metanephric mesenchyme. Paramesonephric (müllerian) and mesonephric (wolffian) ducts contribute reproductive structures.

2 Multicystic dysplastic kidney (MCDK) is the most common form of congenital cystic disease. It rarely causes any clinical problems and often involutes over time.

3 Ureteropelvic junction obstruction (UPJO) is the most common form of hydronephrosis detected in utero.

4 Ureteral duplication is a common anomaly. Upper pole ureter can be associated with either obstructing ureterocele or ectopic ureter, whereas lower pole ureter is more likely to be associated with vesicoureteral reflux.

5 Vesicoureteral reflux (VUR) is an important problem to identify and manage in children who present with urinary tract infection (UTI). VUR can lead to recurrent parenchymal renal infections, resulting in renal scarring and other lifelong problems such as hypertension and pregnancy-related complications.

6 Posterior urethral valve (PUV) is the most common congenital obstructive uropathy that leads to end-stage renal failure and renal replacement therapy. When severe, it can lead to oligohydramnios, renal failure, and pulmonary hypoplasia.

7 Hypospadias is common, occurring in 1 of 200 live births. In most cases, they are mild, presenting with urethral opening near the distal shaft and glans. When associated with cryptorchidism, the differential diagnostic possibilities must include disorders of sex development (intersex).

8 Undescended testicle occurs in 3% to 4% of full-term newborn males. If it remains ectopic beyond age 1, surgical orchidopexy should be performed prior to age 2 to 3 to preserve future fertility potential. When testicles are nonpalpable, laparoscopy is the gold standard to locate an intraabdominal testicle or confirm testicular absence.

9 Prepubertal testicular tumors are benign unless associated with an elevated alpha-fetoprotein (AFP), in which case yolk sac tumor should be suspected. Testicular sparing enucleation is appropriate for mature teratomas.

10 Patients with neurogenic bladder disorders (such as spina bifida) must be evaluated

with urodynamic pressure–volume study to characterize its urine storage and emptying function. Managing bladder pressure and emptying with clean intermittent catheterization (CIC) is paramount to preserve renal health and improve quality of life.

1 FETAL DEVELOPMENT OF GENITOURINARY SYSTEM

Kidneys develop as paired intermediate mesodermal structures stretching craniocaudally along the length of the abdomen. The embryonic kidneys, in order of their appearance, are pronephros, mesonephros, and metanephros. *Pronephros* is nonfunctional and transitory in mammals. By the fifth week, it is replaced by *mesonephros.* The *mesonephros* is thought to provide a transient excretory function and also provides substrate for subsequent reproductive structures. The final step in renal development is *metanephros,* which becomes the true functional kidney. It develops in the sacral region as a result of inductive interaction between the ureteric buds (sprouting from the distal portion of mesonephric ducts) and the condensing blastema of metanephric mesenchyme. The nephron, which consists of glomerulus, proximal tubule, loop of Henle, and distal tubule, derives from the metanephric mesenchyme, while the collecting system, consisting of collecting ducts, calyces, pelvis, and ureter, is formed from the ureteric bud. The kidneys ascend from their initial pelvic position to their final position in the upper retroperitoneum. At fifth week, the terminal portion of the endoderm-lined yolk sac dilates to become the cloaca. It is partitioned by the developing urorectal septum to form urogenital sinus anteriorly (future vesicourethral canal and vaginal vestibule) and anorectal canal posteriorly. During the fifth week, primordial germ cells migrate from the yolk sac to the posterior body wall near the mesonephros to form the genital ridges. In males, under the influence of SRY (the sex-determining region of the Y chromosome), primordial germ cells begin to differentiate into Sertoli cells, which then drive the formation of testis cords and Leydig cells (responsible for producing androgen). In females, the *paramesonephric ducts* (lying medially adjacent to the mesonephros; also known as the müllerian ducts) develop into reproductive structures, namely upper vagina, uterus, and fallopian tubes. In males, mesonephric ducts (known as the wolffian ducts) develop into vas deferens and epididymis under the influence of androgen. The presence of müllerian inhibiting substance (MIS) produced by Sertoli cells of a developing testicle causes müllerian ducts to regress in males. In females, in the absence of Sertoli and Leydig cells, mesonephric (wolffian) ducts regress and müllerian ducts continue to develop into female reproductive structures. Starting sixth week, under the influence of androgen and more importantly, dihydrotestosterone (converted intracellularly by the enzyme 5-alpha reductase), the genital tubercle elongates and the genital and urethral folds fuse in the midline to form scrotum, penis, and penile urethra. The formation of distal glandular urethra occurs by a combination of urethral fold fusion proximally and the ingrowth of ectodermal skin tag distally. Both developing testicles and ovaries move to the pelvic location by the third month. In males, with androgen-influenced regression of cranial suspensory ligament and swelling/contraction of gubernaculum, the testicles undergo inguino–scrotal descent during the third trimester.

ANOMALIES OF THE KIDNEY

Renal anomalies can be categorized into several recognized variants in position, number, and shape.[1] When the kidney does not move to the normal expected position, it is termed an *ectopic kidney*. A kidney that fails to ascend and remains near the bladder becomes a *pelvic kidney,* thought to occur in 1 of 3,000. It can travel too far and rise above the ipsilateral diaphragm to become an *intrathoracic kidney*. It can cross over to the other side and end up in a contralateral position as a *crossed ectopic kidney*. Crossed renal ectopia occurs with renal parenchymal fusion in 90%. Unlike the more commonly encountered ureteral duplication, crossed ectopic kidney's ureter crosses over the midline and drains into the bladder in the contralateral side. In 30% to 50%, ectopic kidneys can have varying degrees of hydronephrosis and vesicoureteral reflux (VUR). Most ectopic kidneys are asymptomatic and clinically insignificant, except in cases of associated ectopic ureter. The adrenal glands develop independently from the kidney, and it should be in normal position beneath the diaphragm, even if the ipsilateral kidney is ectopic. The possibility of an ectopic kidney must be entertained if a kidney is missing in the usual location during an exploratory laparotomy.

The embryonic metanephros can become fused at their caudal ends. The most common form of this anomaly is the *horseshoe kidney,* so named because the lower poles of the kidneys are linked either by a fibrous band or a section of functional tissue. It has an incidence of 0.2%. Horseshoe kidneys are notable for their low position in the body due to isthmus trapping by the inferior mesenteric artery. VUR and ureteropelvic junction obstruction (UPJO) have been found in up to 50% of patients with a horseshoe kidney.

In addition to anomalies of position and fusion, there can be an extra or *supernumerary kidney*. This very rare finding is usually discovered incidentally and occurs because there is separation of the metanephric blastema allowing a distinct kidney to develop. This should not be confused with a duplicated system where there are two collecting system draining a single kidney.

Failure of the ureteric bud to form or join the metanephric mesenchyme will result in *renal agenesis*. Bilateral renal agenesis is very rare and the infants with this condition are either stillborn or perish soon after birth due to respiratory failure. The characteristic Potter face and the presence of severe oligohydramnios are pathognomonic. When unilateral renal agenesis occurs, it is associated with a variety of other genitourinary findings; about 50% will still have a vestigial ureter, and about 30% will have VUR. Anorectal anomalies are also common. müllerian duct anomalies – such as uterine duplication or vaginal septum – occur in 25% to 50% of females with unilateral renal agenesis, and likewise, up to one-third of females with müllerian duct anomalies will have unilateral renal agenesis. It is important to note that true agenesis is relatively rare and should not be confused with a regressed dysplastic kidney, which is a common fate of a *multicystic dysplastic kidney (MCDK)*.

2 Cystic Conditions of the Kidney

Renal cystic conditions are among the most common causes of pediatric abdominal masses, especially in infants.[2] It is important to accurately diagnose them due to their different prognosis and other associated conditions (Table 104-1).

MCDK is the most common form of nonheritable renal cystic condition.[3] Prior to prenatal sonographic screening, it used to be the most common cause of an infantile palpable abdominal mass and was often confused with the UPJO. MCDK is a developmental anomaly resulting in multiple noncommunicating cysts of varying sizes and is without identifiable renal parenchyma. There is typically an associated atresia of the ureter. The classic ultrasound findings are: absence of a large central lucency (that could be confused with renal pelvis), variably sized noncommunicating cysts, and absence of renal parenchyma. MCDK is nonfunctional, and nuclear scintigraphy shows no activity. Majority of MCDK will involute and regress with time to the point that they may become undetectable on conventional ultrasound. For patients with a very large MCDK, they may not complete involution and a small residual clump of cysts may persist into adulthood. There is a high incidence (15% to 25%) of contralateral VUR. Several long-term registries have shown that patients with MCDK do well, and previous concerns of hypertension, infection, malignancy, and pain are thought to be very rare. Surgery is rarely necessary unless there is confusion about the diagnosis with a cystic Wilms tumor or failure to regress with worrisome changes on serial imaging. Rarely, it will cause any symptoms.

Table 104-1 Classification of Congenital Renal Cystic Diseases

Inheritable
Autosomal recessive (infantile) polycystic kidney disease (ARPCKD)
Autosomal dominant (adult) polycystic kidney disease (ADPCKD)
Juvenile nephronophthisis
Medullary cystic disease
Congenital nephrosis (familial nephrotic syndrome)
Familial hypoplastic glomerulocystic disease
Renal cystic syndromes (tuberous sclerosis, von Hippel–Lindau disease)
Noninheritable
Multicystic dysplastic kidney (MCDK)
Benign multilocular cyst (cystic nephroma)
Simple cysts
Medullary sponge kidney
Acquired renal cystic disease
Calyceal diverticulum

Autosomal recessive polycystic kidney disease (ARPCKD) – also known as infantile polycystic kidney disease – results from mutations in the PKHD1 gene of the

chromosomal locus 6p12.2. The classic presentation is a child born with bilateral large palpable kidneys that appear very bright on ultrasound. The hyperechogenic appearance is due to the multiple cystic surfaces reflecting the sonographic waves. Kidney function is uniformly poor, and oligohydramnios with pulmonary hypoplasia occurs in up to 50%. Among those who survive infancy, 30% progress to end-stage renal failure. Long-term survivors can also develop portal hypertension, esophageal varices, and hypersplenism due to concomitant periportal fibrosis. There is no specific therapy other than kidney transplantation.

Autosomal dominant polycystic kidney disease (ADPCKD) – adult-onset type – primarily affects the kidneys but also can have significant effects on the pancreas, liver, brain, and blood vessels. The usual onset is postpubertal with most patients progressing to renal failure by the fourth to sixth decade of life, depending on the severity of penetrance. Two gene mutations are associated: PKD1 (85%) and PKD2 (15%) on chromosome 16. These genes encode membrane proteins that affect cilium and calcium signaling. Cysts are present in the pancreas and liver, as well as cerebral berry aneurysms in the circle of Willis. Autopsies of patients with ADPCKD found that 22% have cerebral aneurysms, and about 10% of adult patients with ADPCKD die of subarachnoid hemorrhage. Though primarily a condition of adolescents and adults, pediatric care providers should be aware of ADPCKD due to the nature of its inheritance. It affects 1 in every 400 to 1,000 people.

Acquired renal cystic disease of renal failure (ARCD) is a term that refers to the development of renal cysts in patients with end-stage renal failure. Regardless of the type of therapy (peritoneal or hemodialysis), cysts can develop in the kidneys. The longer the period of time of dialysis the more prevalent the cysts become. By 10 years of dialysis, 90% will have cysts. Transplantation and the restoration of normal renal function lead to cessation and regression of the cysts. The cysts are notable because they can bleed and develop infections. More worrisome is the development of renal cell carcinoma in about 0.2% of patients with ARCD. The condition occurs in equal frequency in adults and children.

There are other conditions that are associated with renal cysts. *Tuberous sclerosis* is an autosomal dominant condition characterized by mental retardation, epilepsy, sebaceous acne, and renal mass. The renal tumors are benign hamartomas (usually angiomyolipomas), but cysts are also common. *Von Hippel–Lindau syndrome* is an autosomal dominant condition with cerebellar hemangioblastoma, retinal angiomata, pheochromocytoma, renal cell carcinoma (30% to 40% of all VHL patients), and cysts of the pancreas and kidney.

Solitary Kidney

Patients with a solitary functional kidney in most cases can be expected to live a nearly normal life with few limitations.[4] Solitary kidney can be due to surgical removal for disease, congenital malformation, trauma, regression of an MCDK, renal donation, or in rare cases, true agenesis. In general there are no limitations on sports or other activities. Participation in contact sports (such as football, rugby, and ice hockey) is allowed with the understanding that the participant use all of the needed protective gear and that the risk of injury leading to organ loss is very small but not zero. For example, in American tackle football, the risk of having cardiac arrest due to a blow to the chest, heat stroke during training, or suffering a catastrophic central nervous system injury is actually much higher than the risk of losing a kidney. For this reason the official position of the American Academy of Pediatrics is to allow participation in general. It is advisable that patients know their history and be able to identify the side of their functional kidney. It is also important to be aware that not every protective gear is subject to standardized testing and evaluation. Helmets used in American football, soccer shin guards, and eye protections are regulated, but most abdominal paddings are not. Therefore, although it would seem that protection should be helpful, use of such gear should not give a false sense of security.

3, 4 ANOMALIES OF THE URETER

Ureteropelvic Junction Obstruction (UPJO)

UPJO is the most common form of congenital ureteral obstruction and is also the most common cause of prenatally detected hydronephrosis.[5] Multiple factors lead to poor transit of fluid across the obstructed UPJ. There can be an intrinsic adynamic portion wherein the muscles lining the UPJ are aberrant. The muscle fibers are deficient and replaced with collagen. The net effect is to alter the normal propagation of the peristaltic waves. In addition to these intrinsic issues, there can be extrinsic factors such as fibrous bands or aberrant lower-pole crossing vessels trapping the ureter at the UPJ.

The classic symptoms of UPJO are flank/abdominal pain, hematuria, and infection. Inexplicable vomiting may be mistakenly termed idiopathic. Today many UPJO cases are diagnosed antenatally due to abnormal prenatal ultrasound (Figs. 104-1 and 104-2). Ultrasound findings of dilated renal pelvis and calyces without ureteral dilation are indicative of UPJO, but it cannot definitely establish the presence of a true surgical obstruction. Functional study, such as diuretic nuclear renography, is commonly required to assess both relative renal function and severity of obstruction. Magnetic resonance urography is a newer modality, which is increasingly utilized because it avoids ionizing radiation and yields excellent functional and anatomic details. Not all antenatally discovered UPJO need immediate surgery, and many could be safely observed with spontaneous resolution in some, especially those with a preserved relative renal function.



Figure 104-1. Ultrasound demonstrating dilated renal pelvis and calyces caused by ureteropelvic junction obstruction.

UPJO repair can be done effectively using an open or laparoscopic approach, with possible aid of a surgical robot. The principle is to excise the narrowed, dysplastic portion and reconnect the ureter and renal pelvis back together to create a dependent drainage (Fig. 104-3). This dismembered pyeloplasty can be done with a better than 95% success rate. Other approaches using pelvic flap are applied selectively based on the anatomy.

Ureteral Duplication

Ureteral duplication is a common anomaly of the urinary tract. The incomplete duplication has two ureters exiting the kidney, but they join prior to entering the bladder, so there is only one ureteral orifice in the bladder. A complete duplication has two ureters that enter the bladder separately, resulting in two orifices. These occur in about 1 in every 150 to 500 individuals. In a complete duplication, the upper pole ureter ends up with a more inferior and medial orifice closer to the bladder neck while the lower pole ureter has a superior and lateral orifice (Weigert–Meyer rule). The more lateral position of the lower pole ureter can result in potentially shorter submucosal tunnel, making it more prone to VUR. The more medial upper pole ureter, on the other hand, can enter ectopically into the bladder neck and proximal urethra, resulting in obstruction. In females, the ectopic upper pole ureter can drain to the vestigial Gartner duct (wolffian duct remnant) and thereby open up onto the anterior lateral vaginal wall, resulting in continuous incontinence. In males, the ectopic upper-pole ureter can insert into reproductive structures such as vas deferens and seminal vesicle, resulting in obstruction or recurrent epididiymitis. Most patients with partial or complete duplication are otherwise healthy.

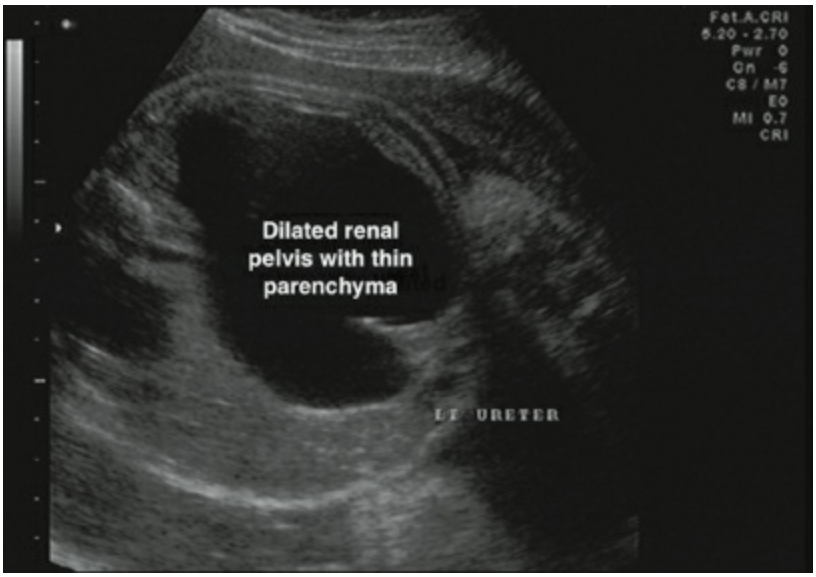

Figure 104-2. Prenatal sonography showing dilated left renal pelvis with thin parenchyma caused by ureteropelvic junction obstruction.

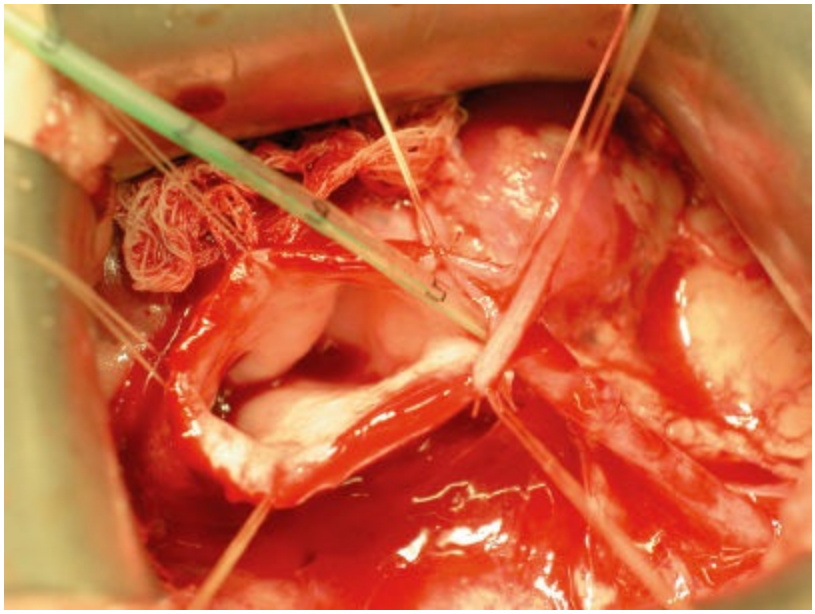

Figure 104-3. Dismembered pyeloplasty where the obstructive segment has been excised and the anastomosis is performed between the pelvic opening and spatulated ureter, creating a dependent drainage.

Ectopic Ureter

Ectopic ureter usually drains more caudal and inferior to the normal trigone. It is commonly associated with a complete duplication. In males, they can exit into the prostatic urethra, bladder neck, and epididymis (rare). In females, they can drain into the bladder neck, urethra, and vagina. For girls, an ectopic ureter that drains outside of the bladder is the classic cause of persistent day and night wetting despite otherwise excellent toilet habits. This can be a vexing condition for many patients and families, but once properly diagnosed, it offers one of the most successful surgical solutions for incontinence (Fig. 104-4). Treatment is usually upper pole partial nephrectomy or reimplant of the upper pole ectopic ureter into the bladder.

Ureterocele

Ureterocele develops as the result of a narrowed opening of the ureteral orifice.[6] The narrow opening results in submucosal and ureteral dilation that can extend all the way up to the kidney. The dilation varies in severity. It can be mild, contained wholly within the bladder wall and appear like a pearl onion (Fig. 104-5). Or it can be massive and create a cavernous space under the trigone, extending beyond the bladder neck and into the urethra (Fig. 104-6). Ureteroceles are typically associated with upper pole ureter of a complete duplication. Single-system ureteroceles do occur but are rare. Similar to UPJO, they are often found as part of an antenatal hydronephrosis evaluation. Other common presentation is symptomatic urinary tract infection (UTI) or prolapse. Infected ureterocele can cause severe sepsis and requires an emergent decompression of the ureterocele using an endoscopic transurethral puncture. Options for longer term, more definitive treatment approaches are designed depending on the salvageable function of the upper moiety. If the upper pole is functional, it is usually preserved, and the surgical approach is aimed at eliminating the distal ureteral obstruction at the ureterocele. The dilated ureter is tapered and reimplanted into the bladder after excising the ureterocele, either separately or en bloc with the normal lower-pole ureter in a common sheath. Alternatively, the upper pole ureter can be connected to the lower-pole pelvis (ureteropyelostomy) near the kidney. If the upper pole is nonfunctional, a partial nephrectomy is preferred. Advances in minimally invasive surgery make laparoscopic and robotic techniques practical in even small children.



Figure 104-4. Ectopic ureter opening outside the bladder and urethra causing continuous incontinence. Catheter is inserted into the left upper pole ectopic ureter.



Figure 104-5. Intravenous urogram demonstrating ureterocele that has an appearance of "Pearl onion."

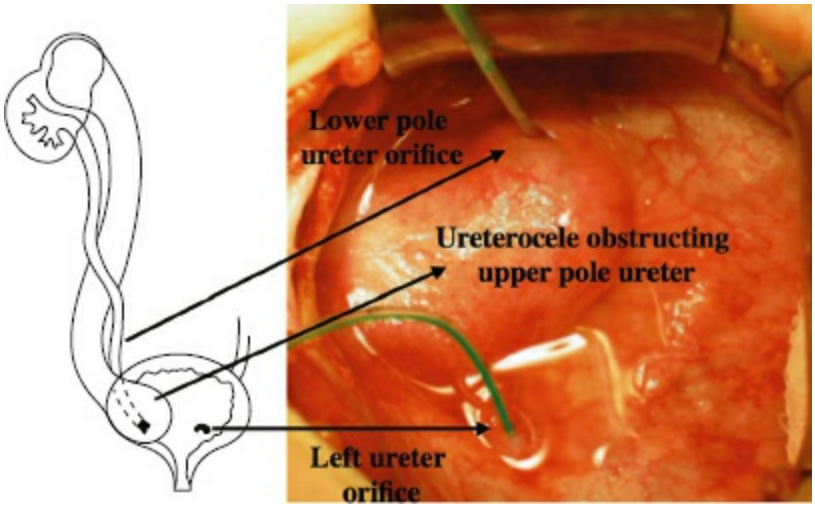

Figure 104-6. Bulging right ureterocele belonging to the upper pole. Bladder has been opened. Catheters are inserted into the right lower pole ureter and left ureter.

Megaureter

A persistently dilated ureter from the kidney all the way to the ureterovesical junction (UVJ) is referred to as megaureter.[7] They are classified by description and causation. They can be refluxing, obstructing, refluxing/obstructing, and nonobstructing/nonrefluxing. When they are due to an intrinsic abnormality of the distal ureter (such as fibrosis of the UVJ), it is a called primary megaureter. When it is caused by another condition of the bladder (such as a neurogenic bladder or bladder outlet obstruction), it is called a secondary megaureter. Primary megaureters, like UPJO and ureterocele, are often diagnosed prenatally. Majority of moderate megaureters – especially those detected in utero – improve with observation. If they require treatment because of pain, UTI, or poor renal function, they can be temporarily drained with a stent, nephrostomy, or cutaneous ureterostomy. Long-term solution requires a ureteral reimplantation with tapering of the wide ureter.

5 Vesicoureteral Reflux

The ureter transports urine from the pelvis to the bladder with active antegrade peristalsis. Once in the bladder, the urine is stored until it is emptied without sending the urine back toward the kidney. This whole process is independent of gravity. When the bladder urine moves in a retrograde manner toward the kidney, it is termed as VUR (Fig. 104-7).[8] It is an abnormality that can occur primarily due to a congenital deficiency in the UVJ submucosal tunnel or secondarily to high bladder pressures such as in patients with neurogenic bladder or posterior urethral valves (PUVs). The incidence of VUR in general population is estimated to be around 1%. The incidence is much higher in children who present with UTI and hydronephrosis. Among children age 4 years or less who present with a first-time UTI, the VUR incidence can be as high as 40%. VUR is found in 25% to 30% of children with antenatal hydronephrosis. The primary form of VUR occurs because the length of the intramural tunnel – so-called flap valve (like stepping on a straw on the ground) – is insufficient to seal the ureter during bladder filling and emptying. The secondary form usually occurs because of high storage pressure that overwhelms an otherwise normal intramuscular tunnel. Reflux is of clinical significance because it interferes with effective emptying of urine and helps bacteria ascend to the kidneys more easily, thereby transforming cystitis into potentially damaging renal parenchymal infection (pyelonephritis). Pyelonephritis in turn increases the risk of long-term kidney damage by creating parenchymal scar. Infants and children are more prone to scarring than adults. Renal scarring and damage early in life can increase the risk of hypertension and pregnancy-related complications in females.



Figure 104-7. Vesicoureteral reflux to the left lower pole ureter.

VUR severity is described using the International Reflux Study scale. Grading is important for several reasons. Most VUR patients (80%) have grades I or II with an excellent chance of spontaneous resolution (75% to 90%) over time. The higher grades (III to V) are less likely to improve with time and more often require surgery. The diagnosis of VUR depends on the demonstration of reflux on an imaging study. Voiding cystourethrogram (VCUG) is the preferred imaging modality. It offers excellent anatomical detail of the entire lower urinary tract (bladder and urethra) and reproducible grading. In males, it provides important details regarding urethra such as possible valves. The presence of other anomalies such as periureteral diverticulum can affect the clinical decision-making. Alternatively one can use nuclear cystogram (NUC) that offers less anatomical detail and a different grading system (grades 1 to 3) but is offset by the advantage of less radioactive exposure and the ability to continuously monitor reflux throughout filling and emptying. Ultrasound of the kidneys and bladder, while helpful in assessing renal size and appearance, cannot diagnose reflux. The detection of kidney scarring is usually confirmed with nuclear renal scintigraphy using DMSA (Fig. 104-8).

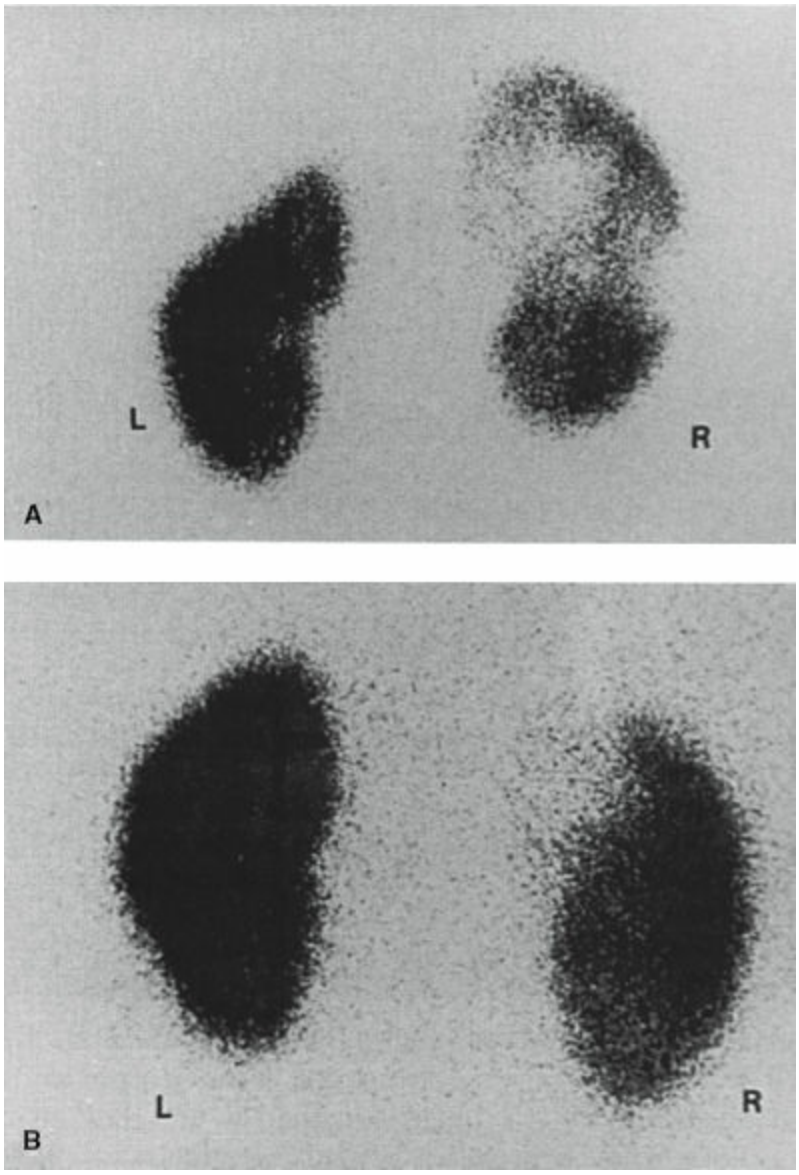

Figure 104-8. DMSA renal scintigraphy demonstrating renal parenchymal defect associated with pyelonephritis. **A:** Cortical defects seen in the right kidney during the acute phase of pyelonephritis. **B:** The same kidney 6 months later showing a persistent cortical scar involving the upper pole.

The management of children with VUR depends on their presentation and other clinical factors (Fig. 104-9). The vast majority of patients have low-grade VUR and are expected to resolve spontaneously with time. They can be managed with low-dose antibiotic prophylaxis with intermittent testing every 1 to 2 years. The most recent multi-institution randomized clinical trial suggested that antibiotic prophylaxis is beneficial in children with dilating, high-grade reflux (grade III or higher). If they cannot remain infection free and sustain breakthrough infections, surgery may be necessary to prevent recurrent renal parenchymal infection. For most patients, spontaneous resolution occurs after 4 to 5 years and those who fail to resolve may also need surgery. There are two major surgical options. There is the less invasive endoscopic approach. Using cystoscope, a small bleb of a bulking material is injected into the floor of the ureteral orifice. This creates a submucosal mound that turns the usual round oval opening into an upside-down crescent. Currently, FDA-approved dextranomer/hyaluronic acid copolymer (Deflux®) is available for this approach. The efficacy of Deflux® injection is good but not spectacular. About

70% to 75% of VUR can be corrected with this approach. Lower the grade, the more likely that injection will succeed. The long-term durability also remains unknown. The more time-tested surgery for correcting VUR is ureteral reimplantation (ureteroneocystostomy), where the ureter is revised or repositioned to create a more effective ureterovesical flap-valve mechanism by restoring the submucosal tunnel. The affected ureter is detached and mobilized. A new submucosal tunnel of sufficient length (more than 4 to 5 times the width of the ureter) is created, and the ureter is placed into it. It is critical that the muscle underneath the tunnel is firm and secure to allow the collapse of the reimplanted ureter with bladder filling and emptying. The ureter may require tapering (in megaureter or obstructed upper pole of duplication anomaly), so it can meet the needed width-to-length ratio of the tunnel. An extravesical approach is called detrusorraphy, where the muscle flaps are freed from the underlying bladder mucosa and wrapped behind the ureter at the UVJ to create a more effective flap-valve mechanism. The success rate of open surgery for VUR is very high (96% or more for grades III or less).

Traditionally, all children who present with a culture-proven UTI were recommended to undergo evaluation for VUR using ultrasound and VCUG. More recently this paradigm has been called into question because of the observation that some children seem to tolerate VUR better than others without long-term clinical problems, especially those with low-grade VUR. A modified evaluation approach using the initial ultrasound has been suggested. Because the key concern with VUR is the prevention of kidney damage and its consequences (hypertension, scarring, and loss of renal function), some argued that because most VUR are of low grade and most cases of low-grade VUR resolve spontaneously, it may be reasonable to defer VCUG for only those patients who have recurrent UTIs or whose ultrasound is abnormal. This led to a major shift in the recommendations from the American Academy of Pediatrics (AAP) in 2011. Others have argued that determining the presence of renal scarring should be the dominant factor and advocated an initial nuclear DMSA renal scintigraphy rather than ultrasound. Recently a double-blind controlled randomized clinical trial looked into the benefits of antibiotic prophylaxis. The Randomized Intervention for Children with Vesicoureteral Reflux (RIVUR) study that completed in 2014 studied 600 children with proven VUR.[9] Half received antibiotic prophylaxis and half received a placebo. Prophylaxis reduced the risk of recurrent UTI by 50%, especially in those with dilating, high-grade reflux (III to V). The occurrence of new renal scarring however did not differ significantly between the two groups.

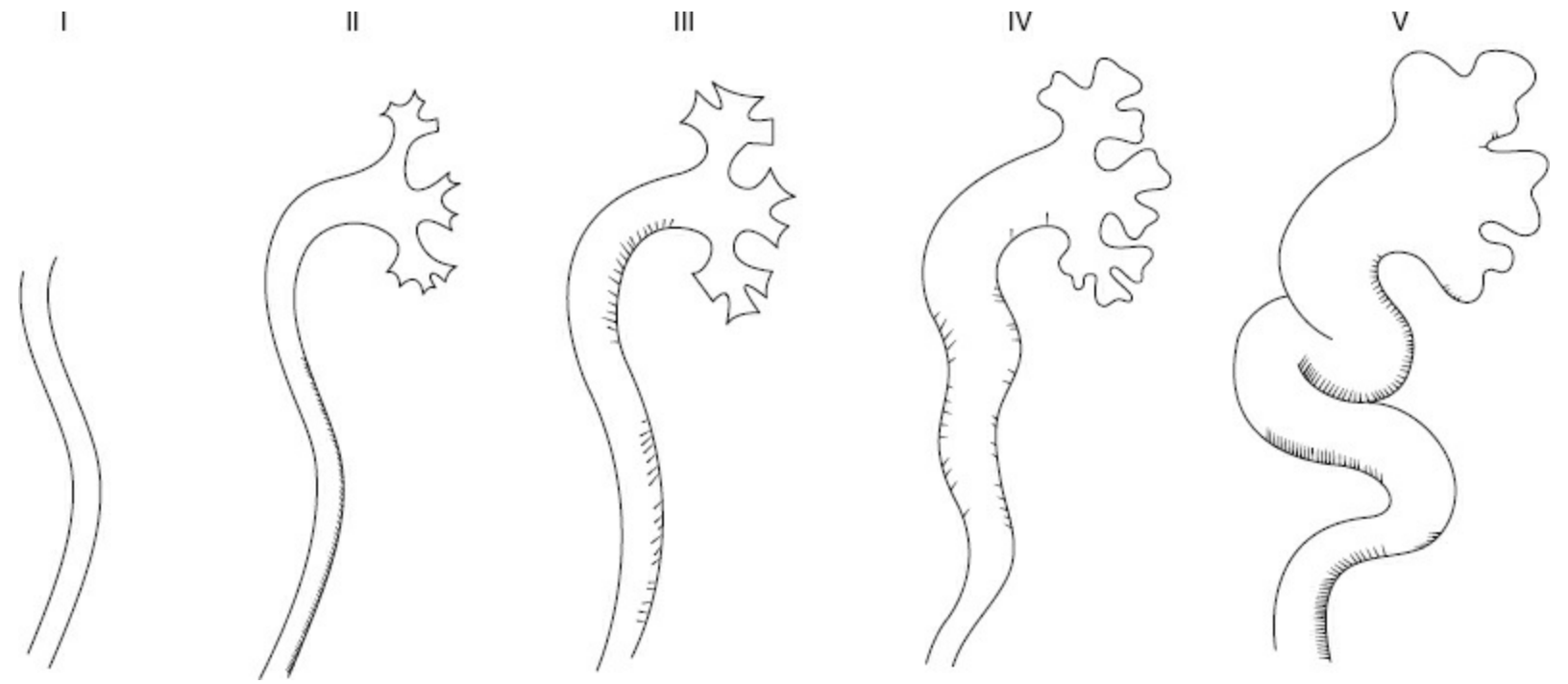

Figure 104-9. International reflux grading system. Majority of reflux are grades I or II, with high likelihood of spontaneous resolution, whereas higher grades (III to V) with dilating ureters are at a greater risk of UTI, renal injury, and nonresolution, often requiring surgery.

Women with a history of VUR may be at increased risk later in life for UTI during pregnancy regardless of whether the VUR was corrected or not. Renal scarring rather than the presence of active VUR itself appeared to be a key risk factor for pregnancy-related morbidity. In general, for girls with VUR, the families should be aware that when they become adults of child-bearing age, they need to know their medical histories, so that appropriate perinatal care and monitoring is instituted.

BLADDER ANOMALIES

Urachal Abnormality

During fetal development, urachus is the cephalad attachment of the cloaca to the allantois. As the bladder and urethral sphincter develop, it becomes atretic. It remains only as a fibrous cord from the dome of the bladder to the umbilicus. Occasionally the urachus remains patent either completely or partially. When completely open (patent urachus), urine can be found exiting the umbilicus. In other cases, there can be a deep sinus or entrapped cyst. These can be areas that can be infected due to poor drainage and present with fever, nausea, and umbilical drainage. Detection is usually made by clinical suspicion, along with abdominal ultrasound or other imaging. Because the epithelial lining of the urachus is that of the bladder and not of the skin, rarely tumors can occur. Mucinous adenocarcinoma is thought to arise from the urachal remnant in middle-aged or elderly patients. For this reason, when detected, even when asymptomatic, some have advocated prophylactic removal.

Exstrophy–Epispadias Complex

During development if the cloacal membrane fails to breakdown at the appropriate time, medial migration of the mesenchyme to form the anterior abdominal wall is affected. The bladder can end up as an exposed urothelial plate (*bladder exstrophy*) (Figure 104-10).[10] The urethra may be incompletely formed dorsally (*epispadias*). The whole lower abdomen can be exposed with the hindgut or colon being unformed with the bladder split into two halves (*cloacal exstrophy*). Pelvic bone is also abnormally developed, and there is a diastasis of pubic symphysis.

The least severe manifestation is epispadias. In males, it is a defect with a dorsally placed urethral meatus and urethra, along with dorsal penile curvature. Visually it looks like a reverse, dorsal form of hypospadias. When the meatus is very proximal, the bladder neck and continence can be affected. In females, epispadias typically present with bifid clitoris (Fig. 104-11). It is more commonly associated with bladder exstrophy, but can occur as an isolated defect. Recognition and protection of the bladder plate against contact irritation is important. If possible, primary closure of the exposed bladder plate, pelvic placement and abdominal closure should be done during infancy. Most studies have suggested that a concomitant pelvic osteotomy is beneficial for successful initial closure as well as the subsequent bladder function. Repair can be staged with closure of the bladder first, followed by later bladder neck reconstruction and epispadias repair. Alternatively a complete primary repair could be accomplished with simultaneous closure of the bladder plate and reconstruction of the epispadias and genitalia. Bladder exstrophy is associated with other anomalies including inguinal hernia and VUR.

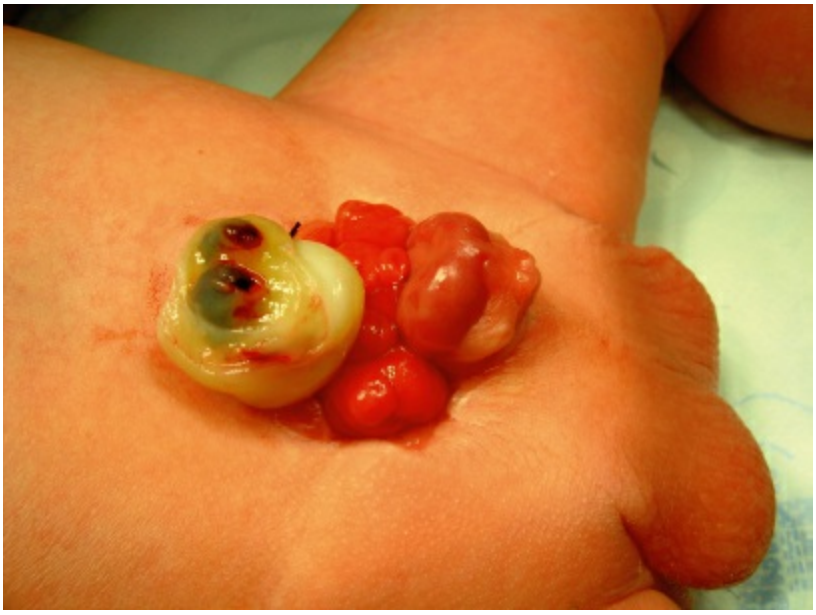

Figure 104-10. Male bladder exstrophy with associated epispadias.

The most severe form of exstrophy disease is the cloacal exstrophy. The hindgut (colon, rectum, and anus) is absent or rudimentary. The bladder plate is split into two parts on either side of the exposed cecum and hindgut remnant along with omphalocele. Initial management involves repairing the omphalocele, creating a colostomy, and dissecting the

bladder plates free and reconstruct to form a reservoir. In cloacal exstrophy, there is also spina bifida with an abnormal sacrum and lower spine.



Figure 104-11. Female epispadias with its classic bifid clitoris.

6 ANOMALIES OF THE URETHRA

Posterior Urethral Valves

One of the most important obstructive uropathy in males is PUV.[11] This condition occurs when a thin membrane of tissue forms below the verumontanum and above the external sphincter, causing a blockage of antegrade flow of urine from the bladder. This results in high voiding pressures proximally leading prostatic urethra dilation, bladder wall hypertrophy (similar to cardiac hypertrophy due to hypertension or aortic stenosis) and VUR. Most patients today are diagnosed because of antenatal hydronephrosis. Classic prenatal sonographic findings are bilateral hydroureteronephrosis, large bladder, and enlarged prostatic urethra (so-called "Keyhole" urethra). The poor bladder emptying throughout fetal development can result in dysplastic poorly functional kidneys and low urine production. Oligohydramnios (as result of low urine output) can lead to poor pulmonary development and concomitant respiratory issues. Initial postnatal treatment is to achieve immediate urethral drainage (usually with a small diameter feeding tube) and obtain VCUG when stable to establish diagnosis (Fig. 104-12). Most patients undergo endoscopic resection of the valves. If the patient is too small to accommodate an infant resectoscope (8.5 Fr), a temporary diverting vesicostomy may be appropriate. Supravesical diversion such as ureterostomy is rarely needed.

There are several long-term urologic concerns for boys with PUVs. PUV remains the leading urologic cause resulting in renal insufficiency and transplantation. The initial nadir creatinine with complete bladder drainage is prognostic. Patients with nadir values at or below 0.8 mg/dL seem to be able to transition into adulthood without needing dialysis or transplantation. The early fibrosis and hypertrophy of the bladder makes valve boys more prone to develop poorly compliant bladders. These bladders have higher than normal storage pressures and over time can lead to the development of stones, incontinence, urinary retention, and worsening renal functions. When recognized early, appropriate therapy using clean intermittent catheterization (CIC) along with antimuscarinic agents (such as oxybutynin) to relax the bladder muscle can help manage these so-called "Valve bladders."

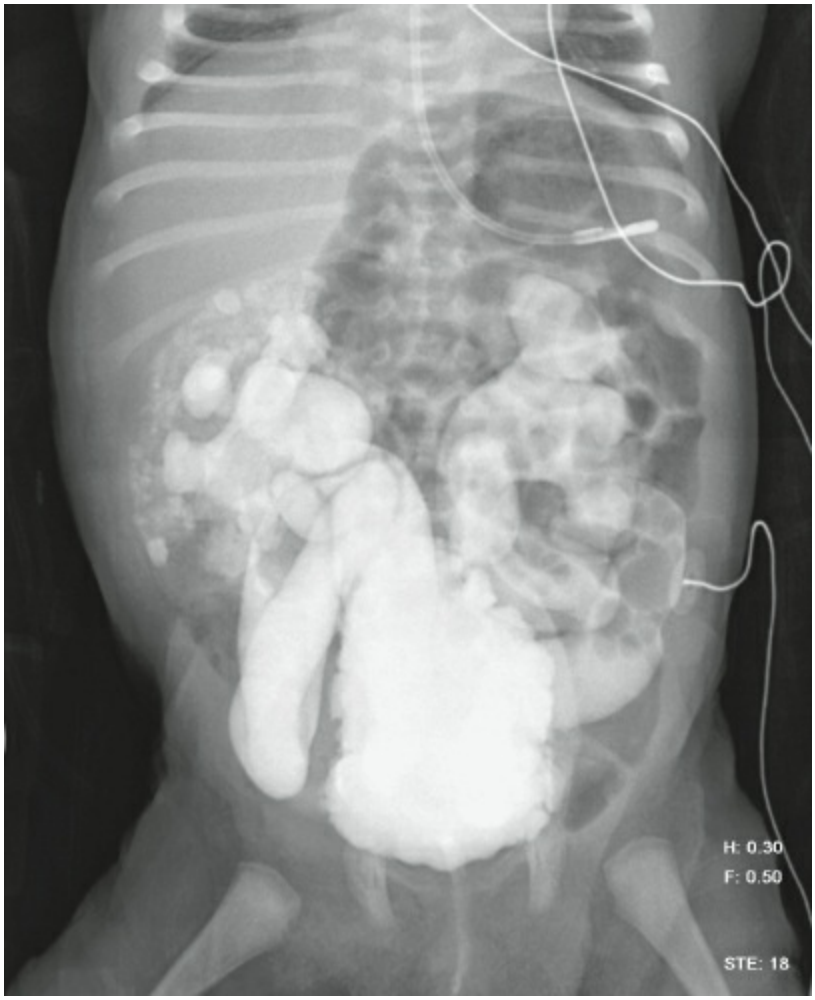

Figure 104-12. Voiding cystourethrogram of a newborn with posterior urethral valve. Bladder wall is thickened from chronic in utero obstruction. Bilateral severe vesicoureteral reflux is also shown.

7 Hypospadias

Hypospadias occurs when the ventral genital folds do not fuse completely.[12] The majority of cases do not have a known cause. There are a few important associations. When hypospadias is found concomitantly with an undescended or missing testicle, the probability of a disorder of sex development (DSD) is high enough to warrant a formal work-up. Recently there has been a growing interest in the role of endocrine disruptors. These are a class of agents that are not steroids but may act on steroid receptors. They include agents such as bisphenol A, polychlorinated biphenyls, phytoestrogens, and other common commercial and industrial compounds. They can fully or partially mimic natural hormones by binding with androgen receptor, thus altering the effect of endogenous sex hormones.

There are three anatomic elements in hypospadias: the urethral opening is low, the ventral shaft is less well developed and classically curves toward the scrotum (called chordee), and the foreskin is incomplete, being usually absent ventrally and heaped-up dorsally in a hood-like formation (Fig. 104-13). Most cases (80%) are distal with the meatus being near the tip of the penis or at the neck (corona). Not all cases require surgery. Milder forms which do not interfere with normal voiding and whose erections are sufficient for future sexual intercourse may not need correcting, other than cosmetic concerns.

Surgical repair aims to create a functional penis that allows normal stand-up voiding and straight erections with good cosmesis.[13] The urethral meatus is advanced to normal position on the glans. Any significant chordee is corrected as well. There are a variety of techniques that can be used depending on the severity of the hypospadias. These can be done as a single-stage or in multiple stages for the severe type (Fig. 104-14). The prepuce is a rich source of possible free graft and vascular flaps. When suspected of having hypospadias, a newborn should not be circumcised until a pediatric urologist has made an assessment. In some cases, particularly those who had undergone many failed prior attempts at repair, there may not be sufficient local tissue. Grafts taken from the buccal mucosa of the inner lip or cheek can be used effectively as a urethral substitute. Complications include urethrocutaneous fistula, strictures, meatal stenosis, recurrent chordee, and surface skin irregularities. Long-term follow-up is needed in these patients because complications can occur years after the total repair.



Figure 104-13. Mild hypospadias with urethral meatus located near the neck (corona), along with dorsal hood foreskin.



Figure 104-14. Severe hypospadias with perineal urethral opening along with severe ventral shaft curvature (chordee).

Disorders of Sex Development (DSD)

When the genitalia do not develop in a manner that is clearly male or female in appearance, the term disorder of sex development (DSD) is applied.[14] It supersedes older terms such as intersex and hermaphroditism. This is an evolving field and covers a spectrum of disorders, some of which can pose a significant physiologic and mental health risk. There are daunting concerns over gender assignment and genital reconstruction. For these reasons, many centers have developed specific DSD teams that aim to provide a comprehensive, integrated care. Comprised of experts from urology, general surgery, gynecology, genetics, endocrinology, social work, psychology, and ethics, they develop an organized, systematic approach to evaluating and treating the patients with DSD while keeping the family continuously educated as the child grows. Many patients, especially those who were diagnosed late or who had poor earlier experiences, can have great concerns about secrecy and confidentiality. Much of what is known of the long-term outcome remains anecdotal and incomplete, lacking robust clinical outcome data to guide management during infancy.

All patients with suspected DSD require a thorough physical examination, especially of the genitalia and perineum, along with a detailed pregnancy, family, and social history. Evaluations, including electrolytes, steroid levels and precursors, gonadotropins, and karyotype, are typically assessed with further specialized tests ordered as necessary. Imaging includes renal/pelvic ultrasound and genitogram. Magnetic resonance imaging, cystoscopy, laparoscopy, and gonadal biopsies may also be necessary. Gender assignment options are reviewed with the family after all information concerning gonads, chromosome, physiology, fertility potential, and anatomy has been gathered and discussed.

Anomalies of the Penis and Prepuce

As a newborn, most infant boys have a natural physiologic phimosis. It is inappropriate and unnecessary to retract the foreskin in most boys until they are between ages 5 and 7 years. No special care of the uncircumcised phallus is needed. Spontaneous separation due to the accumulation of shed skin cells and secreted oil (forming smegma) and normal erections that occur even in small children naturally lift the prepuce away from the glans. No forceful retraction should ever be done during early childhood, since it can be very painful, traumatic, and can result in foreskin tear that will heal as a solid scar.

The indications for neonatal circumcision, arguably the single most common procedure performed worldwide, remains controversial.[15] The clear-cut medical indications are not in dispute – phimosis, paraphimosis, and balanitis. True phimosis is the inability to retract the foreskin when the child is of an age when it should have occurred naturally. In milder cases, treatment with topical steroid ointment of the phimotic ring (such as betamethasone) can sometime loosen up the skin sufficiently that the foreskin stretches and can be retracted in up to 50%, thus avoiding circumcision. In more severe cases, circumcision is usually the most straightforward solution, but for families and patients who do not want to be circumcised a dorsal slit or partial circumcision can be performed. In paraphimosis, the foreskin is pulled back but cannot be repositioned, causing a vascular constriction in the corona. This is a true emergency because over time the prolonged retraction will cut off lymphatic and blood flow causing glandular necrosis. Emergency reduction is needed typically under general anesthesia followed by circumcision or dorsal slit at a later date. Finally for patients who have recurrent bouts of infection due to entrapment of bacteria under the foreskin (balanoposthitis), circumcision may be medically advisable. Circumcision is sometimes advised for boys who have recurrent urinary tract infections, PUVs, solitary kidney, or VUR to reduce future UTI risks.

Controversy exists for routine neonatal circumcision. This is typically performed as a religious rite, social or family custom, or concerns about future hygiene. Religious circumcisions are performed as part of a religious rite for many creeds and sects with the Jewish and Islamic faiths being two of the best known. In some cultures circumcision is done not because of a religious reason but for a social one – to be like other older male family members with circumcision. Finally there are some who have circumcision done because of a concern for future hygiene. After circumcision the covering of the glans changes from a columnar moist epithelium to a squamous dry and tougher coating. This change and the exposure of the glans were long theorized to help increase resistance to infection to sexually transmitted diseases (STD) and UTI. The data from the three large-scale randomized African studies on young men who underwent circumcision to assess its effect on STD transmission (notably HIV) demonstrated a statistically significant difference. However, clinically this effect may have limited utility because it does not prevent or cure any infection – it just proved that the tougher epithelium and a dry environment may lower infection-carrier risk. Another indication that is sometimes brought up is the risk of penile cancer. Penile cancer most commonly occurs in the prepuce, thus elective early removal is theorized to help prevent later cases. However,

the small benefit of reducing a relatively rare condition while subjecting many children to the risk of circumcision limits this argument. Meatal stenosis occurs in 5% to 7% of circumcised boys. This occurs when the meatal lips of the urethra rub or chafe against the diaper or underwear. Irritated by the urine, the raw areas heal to form a thin webbing of skin across the opening. The classic presentation is upward deflection of stream. It is also a common cause of dysuria (burning with urination) and terminal hematuria. Treatment is by splitting the web of skin (meatotomy).

8 ANOMALIES OF THE TESTICLE AND SCROTUM

Undescended or Cryptorchid Testicle

Embryologically, testicle forms just beneath the kidneys.[16] During the 12th to 18th weeks of gestation, the testicles migrate down to a pelvic position just inside the internal inguinal ring. During the third trimester, the testicle travels through the canal, exits the external inguinal ring and enters the scrotum, driven by the swelling and contraction of gubernaculum under the influence of androgen. A scrotal position is advantageous for several reasons. Descended testicles are exposed to a lower temperature environment, and this is necessary for achieving full sperm development and fertility. Undescended testicles are also at increased risk for germ cell malignancy. A scrotal position makes self-examination after puberty easier, thus facilitating an early detection. Finally, undescended testicles that are positioned near the pubic bone can be more vulnerable to injury.

Physical examination plays a key part in the diagnosis of an undescended testicle. When boys are anxious or nervous, their inguinal cremasteric muscles tense up and can draw the testicle upward into the groin. This condition is termed retractile testicles. In most cases, the retractile testicle settles in the scrotal position by the time the child is ready to start elementary school. In some, retractile testicles can ascend to the inguinal region as the boys grow older, requiring a surgical intervention. This is referred as ascending testicle, and may occur up to 5% of boys who are followed for retractile testicles.

About 3% to 4% of normal full-term boys may have an undescended testicle at birth. The incidence is higher in premature infants. By age 1 year corrected for prematurity, this number drops down to around 1%. This figure remains stable through puberty. For this reason, one must allow (typically during the first 6 months of life) to see if the testicle will descend spontaneously, but if the testicle has not dropped by 1 year of life, waiting longer will not improve the situation, and surgical orchidopexy should be considered. Furthermore, leaving a testicle in an ectopic position beyond age 2 to 3 is thought to adversely affect future sperm cell (Ad spermatogonia) development. An undescended testicle could be inside the abdomen, having never engaged the internal inguinal ring. It could be inside the inguinal canal (canalicular) or through the external ring but not in the scrotum (superficial pouch). It can be truly ectopic, such as perineal and femoral. Finally, the testicle could be aberrant, dysmorphic, atrophic, or nonexistent. These are usually testicles, which suffered some form of perinatal vascular compromise that was not recognized prior to birth. The testicle seems to “vanish” over the first year of life (thus called vanishing testicle syndrome).

For palpable undescended testicles, the approach is usually through an inguinal incision. The testicle is mobilized by detaching gubernaculum, cremasteric muscle, and internal spermatic sheath around the cord structures, and a tunnel is created from the inguinal incision to the scrotum. There is usually an associated patent processus (up to 80% in infants), and this is separated from the cord and high ligated at the internal ring. For nonpalpable testicles, the most effective initial approach is laparoscopy. The key is to

find the spermatic vessels. If spermatic vessels pass into the internal ring then the laparoscope is removed and a groin exploration is done. This may lead to a small undescended testicle, which may have been difficult to palpate in the inguinal fat. In other situations, there is an atrophic nubbin (typically within the scrotal sac) due to a probable perinatal torsion and vascular compromise. If the testicle is seen within the abdominal cavity and well away from the internal ring, the only viable surgical option may be a Fowler–Stephens orchidopexy (done as either single or two stage), where the gonadal vessel is divided and the testicle is brought down with a vassal collateral circulation (Figs. 104-15 and 104-16). In a staged orchidopexy, the dominant gonadal vessel is gently clipped laparoscopically, allowing the testicle to develop a dependence on the collateral circulation. At a second procedure 6 months or later, the gonadal vessel is divided, and the testicle is carefully brought down (either open or laparoscopically) with the vasal vessels. Laparoscopy has been shown to be the most effective in determining the absence of viable testicle (vanishing testicle syndrome). The pathognomonic finding is blind ending gonadal vessels. If a blind-ending vas is seen but not the vessels, one must continue to explore for hidden testicular tissue since there is an unusual phenomenon of testicular–epididymal dysjunction, where the testicle is disconnected from the wolffian structures (epididymis and vas). One may have to look very far to locate the vessels, even going up behind the colon and near the lower pole of the kidney. Leaving a testicular tissue trapped within the abdominal cavity will increase the risk of germ cell malignancy. There are currently no reliable imaging studies that can obviate the need for surgical exploration, and diagnostic laparoscopy remains the gold standard. Ultrasound is not recommended. Although it is noninvasive, it suffers from the negative test result prediction concern. Most importantly, the surgical decision and planning are not altered by ultrasound findings. For bilateral nonpalpable testicles, biochemical markers – such as HCG stimulation test or serum MIS level – may be useful to determine the presence or absence of functional testicular tissue.

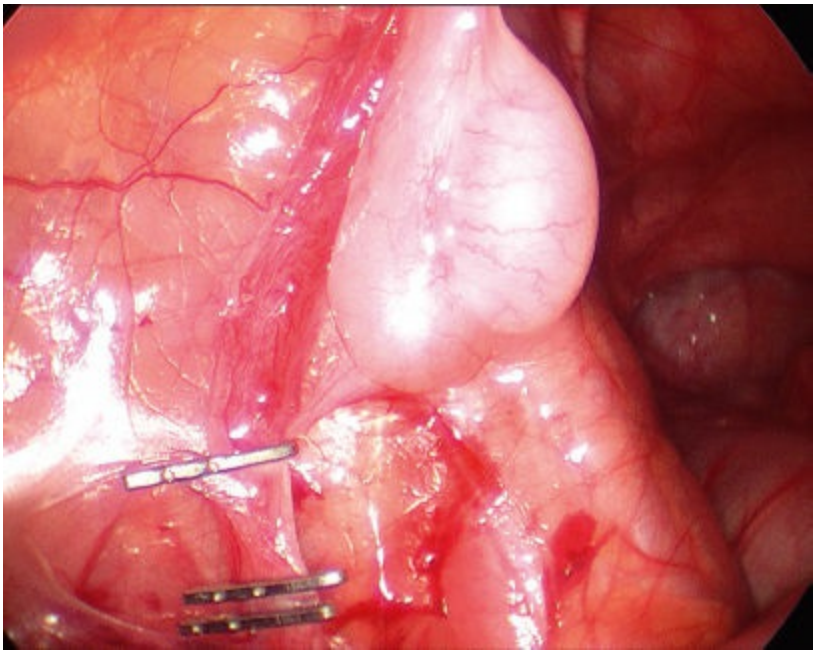

Figure 104-15. Intraabdominal testicle is gently clipped to force its dependence on the vassal collateral circulation (first-stage Fowler–Stephens orchidopexy).

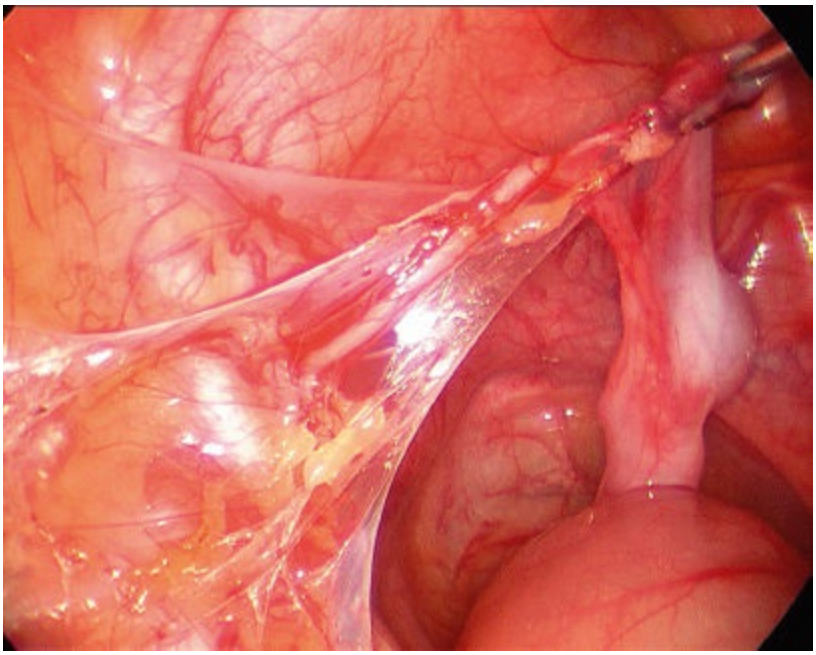

Figure 104-16. During the second-stage orchidopexy, the testicle is dissected while being attached to the vassal collateral circulation.



Figure 104-17. Left intravaginal testicular torsion. The nontorsed contralateral testicle is also explored and secured to prevent future torsion.

Torsion of Testicle and Appendages

Torsion of the testicle is the leading nontraumatic cause of loss of the testicle in boys (Fig. 104-17).[17] It is an emergent condition that occurs as result of the spermatic cord twisting. This results in occlusion of the lymphatic vessels, veins and arteries leading to ischemia, necrosis, and atrophy. If there is complete occlusion of blood flow, the testicle may be salvageable up to 6 hours after onset. After 6 hours the odds of salvage diminish exponentially. Most torsion occurs in older boys and adolescents – although it can occur at any age – with the torsion occurring inside the tunica vaginalis (intravaginal torsion). A horizontal lie (known as the bell-clapper deformity) caused by poor posterior fixation is believed to predispose toward torsion. Torsion can also occur among neonates, but this occurs due to poor gubernacular fixation and twisting of the cord outside the tunica vaginalis (extravaginal torsion). Neonatal torsion classically is associated with a prolonged labor. The testicle is very firm, and there can be a dark ecchymotic look about the scrotum. Successful salvage is very rare in perinatal torsion, and exploration is controversial due to potential anesthesia concerns. Because of the very low salvage rate, some do not advocate an emergent exploration, while others point out that if it is anesthetically safe, exploration is important because it establishes definitively not only the state of the suspected torsed testicle but allows fixation of the contralateral testicle. Metachronous torsion can occur and is difficult to monitor clinically. Exploration and preemptive fixation can prevent loss of the contralateral testicle.

The presentation is a sudden onset acute unilateral scrotal pain. The pain can be intense and lead to nausea and vomiting. With time, there will be increasing swelling and discoloration. The signs and symptoms will evolve over time. Initially there can be little swelling or redness. Later when the nerve endings have died out, the testicle and scrotum may still be swollen and ecchymotic but less painful. Various clinical clues may help guide physical examination. These include a noticeably shortened spermatic cord, absence of a cremasteric reflex, and lack of relief of discomfort with elevation, but these are often of limited practical use when faced with an anxious patient with a tender scrotum. If one has a strong clinical suspicion based on presentation, and there are no other medical or anesthetic reasons not to go to surgery, emergent exploration – without any further imaging – is appropriate. Doppler ultrasound – now readily available in most modern emergency departments – can be useful but should not delay exploration. Ultrasound can help identify other cases of acute scrotum such as torsed appendix testis, epididymitis, hernia/hydrocele, and idiopathic scrotal edema. Exploration is done through a transverse scrotal incision. If the testicle is necrotic, it should be removed to alleviate pain, and the contralateral testicle explored and sutured inside the scrotum in 3 to 4 quadrants to prevent future torsion. If a safe surgery is not an option, one may attempt a manual detorsion with a cord block. Untwisting as if one were opening a book (inside out) is the most commonly recommend technique, but it is by no means certain. Scheduling a prompt exploration is recommended even if there is relief with manual detorsion.

When the müllerian ducts atrophy in males, they can leave a remnant as a testicular appendage on the head of the testis. These can twist and mimic a full torsion. In pale-

skinned patients, the torsed appendage during early presentation can resemble a painful small blue dot that is seen through the stretched skin. Because the appendage is vestigial and functionally useless, its torsion is managed with pain relief, anti-inflammatories and exertion restrictions.

9 Prepubertal Testicular Tumors

There is a separate chapter that discusses common childhood tumors.[18] For this chapter, we will limit our discussion to prepubertal testicular tumors. Most testicular tumors are nonseminomatous germ cell tumors. They usually present as a distinct palpable painless mass in the scrotum. They can have a reactive hydrocele, and it is important to palpate the entire testicle before assuming that the hydrocele is harmless. The primary imaging study is a scrotal ultrasound and biomarkers. The two most useful biomarkers are the alpha-fetoprotein (AFP) and beta-HCG. The most common types of prepubertal tumors are teratoma and yolk sac. Teratoma is benign in prepubertal age group. Histologically they contain all three germ layers (ectoderm, mesoderm, and endoderm). Due to the benign nature, testis sparing approach is warranted. An enucleation of the mass through a tunica albuginea incision is performed if the frozen section confirms the diagnosis (Figs. 104-18 and 104-19). Yolk-sac tumors are the most common malignant prepubertal tumor. Most present early as stage 1 (limited to the testicle and completely resected), and the AFP level will be elevated in the vast majority of cases. After radical inguinal orchiectomy, most are observed with serial imaging and tumor markers, provided that other staging work up is negative, with retroperitoneal lymph node dissection and systemic adjuvant chemotherapy being reserved for those with advanced disease (persistent retroperitoneal lymph adenopathy or increased serum markers). Seminomas and mixed germ cell tumors are extremely rare in prepubertal children, and their management should be as in adults. There are gonadal stromal tumors that can mimic a germ cell tumor. The most common are Sertoli cell tumors. They occur as painless masse and usually have no major endocrine effect. Simple orchiectomy is all that is needed. Leydig cell tumors are the second most common stromal tumor. They can be associated with precocious puberty, gynecomastia, and elevated levels of 17-hydroxy ketosteroids. They can be similar to hyperplastic adrenal nodules that are found in boys with poorly controlled congenital adrenal hyperplasia.

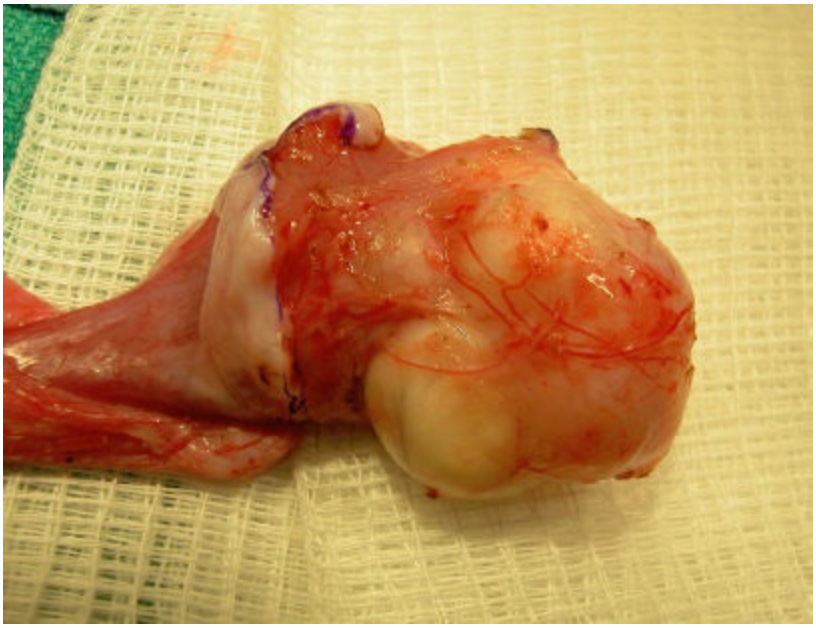

Figure 104-18. Testis-sparing enucleation of prepubertal testis tumor with cystic mass seen on the ultrasound and negative markers, likely indicating a teratoma.

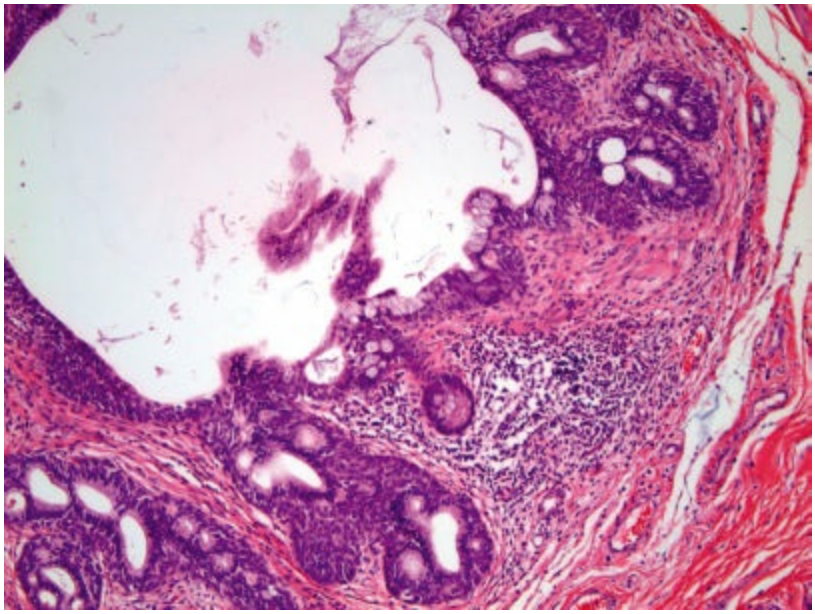

Figure 104-19. Histology of prepubertal testis tumor demonstrating mature teratomatous differentiation into ectodermal elements.

Varicocele

Varicocele is a collection of engorged varicose veins in the spermatic cord and usually is most prominent in the scrotum in the region of the pampiniform plexus. Varicoceles are graded according to their size and prominence. Grade I are varicoceles only palpable with exertion or a Valsalva maneuver. Grade II are varicoceles that can be palpated without exertion or a Valsalva maneuver and collapse when supine. Grade III varicoceles are visibly bulging and do not collapse when supine. There is also a subclinical (or grade 0) varicocele that is only detected on imaging and not on physical examination. Varicoceles are most common on the left side comprising >90% of all varicoceles. The left-sided predominance relates to the different nature of the left and right spermatic vein drainage. The right spermatic vein is shorter and inserts directly into the inferior vena cava. About 10% are bilateral. The solitary right varicocele is worrisome as it can be associated with a retroperitoneal tumor and when found warrants further evaluation with abdominal ultrasound. Varicoceles come to attention because of two major concerns. First, they can be quite sizable and uncomfortable. Second, varicoceles are associated in some cases with infertility. This is believed to be the result of two effects. The pooling of venous blood allows toxic waste products to accumulate. The pooled blood in addition may also raise the temperature of the whole scrotum. Normally, the scrotum is several degrees cooler than the deep core body temperature. At random, up to 10% to 20% of all adult males can be found to have some form of varicocele. Among men who attend infertility clinics, varicocele-associated subfertility can be as high as 40%. These observations suggest that there are many men in whom a varicocele is a trivial minor finding, but there are some in whom it can be an important reproductive issue. For boys and adolescence undergoing puberty and sexual maturation, semen analysis findings are variable and unreliable in addition to ethical concerns. For this reason, the clinical indication for intervention in boys is comparative testicular volume on ultrasound. In some, the involved testicle will have a smaller volume or lag in growth. If there is a substantial volume discrepancy (20% or greater) between the testicles, surgery is warranted. If the volumes are stable and there is no major discrepancy, observation with annual ultrasounds is recommended until the age when a semen analysis can be obtained reliably. There are several methods of treating varicocele; the most commonly used approach is via subinguinal or inguinal incision. The vas deferens and spermatic artery are identified and spared. The varicocele veins are then ligated and the segment between the ligatures is removed. The use of an operating microscope allows sparing of the lymphatics thereby reducing the risk of postsurgical hydrocele to well under 1%.

VAGINAL ANOMALIES

Labial Adhesions

Labial adhesions occur when edges of the labia minora attach in the midline and form a thin web of skin (Fig. 104-20). This can obstruct the normal path of the urinary stream leading to postmicturition spotting when the girl stands up. Treatment in very mild cases can be successfully achieved with estrogen cream applied to the surface of the webbing over several weeks. For more severe or refractory cases, surgical incision and separation under anesthesia are needed. Minor adhesion may be left alone without clinical concerns.



Figure 104-20. Labial adhesions.



Figure 104-21. Imperforate hymen.

Imperforate Hymen

Occasionally the hymen will be imperforate at birth. This will present with a bulging hydrocolpos and can be confused with a prolapsing ureterocele or bladder tumor (such as sarcoma) (Fig. 104-21). Ultrasound or MRI can usually identify the prominent fluid-filled vagina. Puncture and drainage are usually all that is required. In some older patients the condition may not be diagnosed until after the onset of menses. At this time, there may be cyclic discomfort due to the inability to allow the menstrual flow to pass creating a hydrometrocolpos. After a complete workup surgical drainage in the operating room is advisable to avoid introducing bacteria into the sterile collection; an infection can lead to pyocolpos or pyometrium leading to scarring and affecting future fertility.

Urogenital Sinus Anomalies

Between the fifth and seventh week of fetal development the urogenital sinus forms.[19] The caudal portion forms the lower-third of the vagina. The müllerian ducts form the upper two-thirds of the vagina and the uterus as well as fallopian tubes. Anomalies can occur as part of DSD conditions resulting in either vaginal agenesis or urogenital sinus (such as that seen in masculinized females with congenital adrenal hyperplasia). Surgical reconstruction is usually required to create distinct urethra and vaginal channels. Traditional surgical approach aimed at separating the vagina from the UG sinus tract and bringing it down to the perineum, but this often led to vaginal vascular compromise and stenosis. Modern techniques employ urogenital sinus mobilization en bloc, keeping the urethrovaginal confluence intact. Total mobilization has been discouraged due to concern for future urinary incontinence and pelvic prolapse. A combination of partial mobilization – leaving the anterior urethral suspensory ligaments intact – and various perineal flaps can result in an excellent outcome. The Mayer–Rokitansky–Kusterhauser syndrome occurs in normal genotypic females with vaginal and/or uterine dysgenesis. About one-third of these patients will have associated urologic issues – the most common being unilateral renal agenesis. The diagnosis is usually made incidentally or around the age of puberty due to amenorrhea. Treatment is vaginal dilation with estrogen cream or surgical vaginoplasty if dilation fails. There are also a variety of duplication anomalies and vaginal and/or uterine septums and consultation with gynecology is advisable on the necessity and timing of intervention. Typically the goals are to relieve any obstruction to restore normal menses and to preserve reproductive potential.



Figure 104-22. Prune-belly syndrome. Notice the wrinkled appearance of the abdominal wall due to deficiency of musculature. Scrotum is empty due to bilateral intraabdominal testicles.

Prune-belly Syndrome

The prune-belly syndrome (PBS) is a constellation of malformations also known as the triad syndrome or the Eagle–Barrett syndrome.[20] The syndrome has three key components: severe deficiency or absence of the abdominal wall musculature, bilateral hydroureteronephrosis, and bilateral undescended intraabdominal testicles (Fig. 104-22). There are also other associated genitourinary conditions including renal dysplasia, fusiform urethra, large bladder, patent urachus, hypoplastic prostate, and dilated proximal urethra. The underlying cause is unknown, but the current theory is that this is triggered by a severe distal urethral obstruction early in development. This theory is supported by the observation of that many of the similar effects are seen in PUVs. The newborn will present with a lax and wrinkled abdominal wall, along with empty scrotum. Renal dysplasia is frequent and when severe, it can lead to pulmonary hypoplasia. Stillbirths and early neonatal demise often occur because of the combination of poor renal and pulmonary function. Hydroureteronephrosis can be massive but is typically nonobstructive, and no procedure should be done simply to improve appearance. Nearly all of the patients are infertile with an anecdotal report of successful fertility using the assisted reproductive technology. For infants who survive into childhood, bilateral orchidopexy and abdominal wall reconstruction may be necessary. Evaluation for bladder function is also required since many will have a poor bladder muscle tone and high post void residual.

10 Neurogenic Bladder

The nervous system plays an important role in modulating the normal behavior of the lower urinary tract. There are nerve roots (emanating from the spinal cord) and peripheral pelvic nerves that carry sensory and motor signals to the bladder and urethral sphincter. Injuries or anomalies to these nerves can cause the bladder to be denervated, leading to poor emptying. At a higher level, the spinal cord up to the brain stem is critical to regulation of lower urinary tract function, especially the thoracolumbar sympathetic and sacral parasympathetic segments. The brain stem acts as the coordinating center. With filling the bladder musculature – under the influence of the sympathetic input – remains relaxed thereby keeping bladder storage pressures low until emptying occurs (driven by parasympathetic input). The higher centers in the cerebral cortex allow conscious control and inhibition of reflex activity. Without this influence the bladder fills, and at a certain volume it spontaneously empties with coordination. This is what occurs in infants prior to toilet training. When the higher centers are affected (such as due to a cerebrovascular accident, tumor, traumatic brain injury, or multiple sclerosis), this control is lost or diminished and many patients will report sudden urgency and loss of urinary control. When the spinal cord is affected, the bladder will lose its inhibitory control by the brain stem and cerebral cortex and will act autonomously. The bladder will contract earlier than full capacity, and it is termed hyperreflexia. The loss of coordination between bladder muscle and sphincter, leading to poor emptying is known as detrusor–sphincter–dyssynergia.

Patients with spinal cord injury, traumatic brain injury, and acquired conditions that affect the nervous system (e.g., diabetes mellitus, multiple sclerosis, varicella zoster, brain tumors, and encephalitis) should trigger awareness about possible urinary effects.[21] Mere urine egress from the bladder is not necessarily a sign of normal voiding. It can be due to overflow incontinence or some form of dysfunctional voiding (Valsalva voiding). Likewise continence is not necessarily a sign of neurologically coordinated normal bladder function. The storage pressures can be higher than normal. When the bladder urine storage pressures are too high, it can overcome the peristaltic pressure driving urine from the kidneys down the renal pelvis and ureter. Ideally the storage pressure should be below 40 cm H_2O.[22] Above this pressure, hydronephrosis, pyelonephritis, and loss of renal function will occur. A urology evaluation with urodynamic pressure–volume assessment of the lower urinary tract should be considered if there is any condition with significant effects on the central nervous system.

Spina bifida is the most common congenital cause of a neurogenic bladder in children. During development the spinal column does not form properly resulting in an exposed spinal cord, and patients are born with a neurogenic bladder. Surgical closure in utero is now being done in hopes that early closure can lead to better motor and bladder function, although this has not been demonstrated to date. Early evaluation of bladder storage pressures is crucial. Regular, proactive bladder pressure monitoring with cystometrogram, along with ultrasound assessment of the upper tracts, has shown to reduce urologic morbidity in these patients. Children who do not empty with a safe

bladder pressure require CIC. Patients with poor bladder compliance and high storage pressures may need antimuscarinic bladder muscle relaxants (such as oxybutynin). For older children, achieving social continence becomes important and a variety of surgical options may be considered in addition to CIC and antimuscarinics. Surgical bladder augmentation using intestinal segments (enterocystoplasty) is the most effective way to improve the bladder storage function (Fig. 104-23), but there are many well-known long-term complications, such as metabolic acidosis, mucus production, UTI, bladder stones, spontaneous perforations, and malignancy. In some patients who have difficulty with urethral CIC (such as those with severe scoliosis or girls in wheelchair), surgical creation of alternate catheterizable neourethra is an option. The Mitrofanoff procedure (the classic appendicovesicostomy where a collapsible supple appendix is implanted into the bladder within the submucosal tunnel for continence) can improve the quality of life significantly. If the bladder outlet is inadequate, surgical options include artificial urinary sphincter, bladder neck reconstruction with sling and bladder neck closure. Similarly, many patients will also choose the surgical option of Malone antegrade continence enema where a catheterizable channel is created into the colon for easy, self-administration of enema for achieving fecal continence.



Figure 104-23. Bladder augmentation using a patch of detubularized ileum.

References

1. dos Santos Junior AC, de Miranda DM, Simões Silva AC. Congenital anomalies of the kidney and urinary tract: an embryogenetic review. *Birth Defects Res C Embryo Today* 2014;102(4):374–381.
2. Glassberg KI, Stephens FD, Lebowitz RL, et al. Renal dysgenesis and cystic disease of the kidney: a report of the Committee on Terminology, Nomenclature and Classification. *J Urol* 1987;138:1085–1092.
3. Minevich E, Wacksman J, Phipps L, et al. Importance of accurate diagnosis and early close follow-up in patients with suspected MCDK. *J Urol* 1997; 158:1301–1304.
4. Westland R, Schreuder MF, van Goudoever JB, et al. Clinical implications of the solitary functioning kidney. *Clin J Am Soc Nephrol* 2014:9(5):978–986.
5. Tubre RW, Gatti JM. Surgical approaches to pediatric ureteropelvic junction obstruction. *Curr Urol Rep* 2015;16(1):72.
6. DeFoor W, Minevich E, Tackett L, et al. Ectopic ureterocele: clinical application of classification based on renal unit jeopardy. *J Urol* 2003;169(3):1092–1094.
7. Keating MA, Escola J, Snyder HM, et al. Changing concepts in management of primary obstructive megaureter. *J Urol* 1989;142:636–640; discussion 667–668.
8. Elder JS, Diaz M, Caldamone AA, et al. Endoscopic therapy for vesicoureteral reflux: a meta-analysis. I. Reflux resolution and urinary tract infection. *J Urol* 2006;175(2):716–722.
9. Hoberman A, Chesney RW. RIVUR Trial Investigators. Antimicrobial prophylaxis for children with vericoureteral reflux. *N Eng J Med* 2014; 371(11):1072–1073.
10. Inouye BM, Tourchi A, Di Carlo HN, et al. Modern management of the exstrophy-epispadias complex. *Surg Res Pract* 2014;587064.
11. Clayton DB, Brock JW 3rd. Lower urinary tract obstruction in the fetus and neonate. *Clin Perinatol* 2014;41(3):643–659.
12. Bouty A, Ayers KL, Pask A, et al. The genetic and environmental factors underlying hypospadias. *Sex Dev* 2015;9(5):239–259.
13. Pippi Salle JL, Sayed S, Salle A, et al. Proximal hypospadias: a persistent challenge. *J Pediatr Urol* 2016;12(1);e1–e7.
14. Houk CP, Lee PA. Update on disorders of sex development. *Curr Opin Endocrinol Diabetes Obes* 2012;19(1):28–32.
15. Wheeler R, Malone P. Male circumcision: risk versus benefit. *Arch Dis Child* 2013;98(5):321–322.
16. Docimo SG. Results of surgical therapy for cryptorchidism: literature review and analysis. *J Urol* 1995;154:1148–1152.
17. Jefferies MT, Cox AC, Gupta A, Proctor A. The management of acute testicular pain in children and adolescents. *BMJ* 2015;350:h1563.
18. Woo LL, Ross JH. The role of testis-sparing surgery in children and adolescents with

testicular tumors. *Urol Oncol* 2016;34(2):76–83.

19. Jenak R, Ludwikowski B, Gonzalez R. Total urogenital sinus mobilization: a modified perineal approach for feminizing genitoplasty and urogenital sinus repair. *J Urol* 2001;165(6 Pt 2):2347–2349.
20. Hassett S, Smith GH, Holland AJ. Prune belly syndrome. *Pediatr Surg Int* 2012;28(3):219–218.
21. Mourtzinos A, Stoffel JT. Management goals for the spina bifida neurogenic bladder: review from infancy to adulthood. *Eur J Pediatr Surg* 2009; 19(4):203.
22. McGuire EJ, Woodside JR, Borden TA, et al. Prognostic value of urodynamic testing in myelodysplastic patients. *J Urol* 1981;126:205–209.

Chapter 105

Childhood Tumors

Erika Adams Newman

Key Points

1 Neuroblastoma is the most common solid tumor in infants and the most common extracranial tumor in all children.

2 Neuroblastoma tumors have diverse clinical heterogeneity from complete spontaneous regression in neonates to resistant metastatic disease in school-aged children. The origin of this disparity is unknown but thought to result from diverse genetic and biologic features that predict prognosis.

3 Several nonrandom segmental genomic alterations have been identified in neuroblastoma as reliable prognostic indicators independent of age and stage. The genomic alterations that have consistently been shown to predict prognosis are DNA ploidy, *MYCN* amplification, loss of heterozygosity (LOH) of chromosome 1p, 17q gain, loss of 14q, and loss of 11q.

4 The International Neuroblastoma Risk Group (INRG) classification system defines pretreatment patient cohorts based on expected survival at diagnosis. INRG classification includes INRG stage, age, histologic category, grade of tumor differentiation, *MYCN* status, 11q alterations status, and DNA ploidy. These criteria are used to define 16 pretreatment groups that include very low-, low-, intermediate-, and high-risk categories.

5 The presence of anaplasia is the single most important prognostic indicator in Wilms tumors.

6 In the United States, the standard of care for children with Wilms tumor starts with radical nephrectomy at the time of diagnosis for resectable primary tumors, followed by chemotherapy. Radiation is administered to sites of residual and metastatic disease. Tumors with extensive intracaval and hepatic vein extension receive neoadjuvant chemotherapy and may require cardiopulmonary bypass for resection.

7 Treatment of rhabdomyosarcoma requires a multimodal approach that begins with complete surgical excision of resectable lesions and incisional biopsy for tumors that encroach upon contiguous structures, blood vessels, and nerves. Modern therapeutic protocols are based on prognostic factors and risk of subsequent relapse stratification.

8 Standard surgical care for children with hepatoblastoma is complete primary resection at diagnosis for PRETEXT I and II tumors that do not involve major central venous structures. PRETEXT III and IV tumors undergo biopsy and neoadjuvant chemotherapy

with early referral to liver transplantation for multifocal or large, central lesions.

INTRODUCTION

The surgeon is a key figure in the management of the child thought to have a malignant tumor. From diagnosis through posttherapy surveillance, the surgical team plays a pivotal role in ensuring the highest outcomes in the care of children with solid cancers. As a critical component of the pediatric oncology multimodal team, surgical decisions guide clinical pathways from the mechanisms of biopsy, central venous access for chemotherapy administration, and definitive tumor resection. Because pediatric cancers are rare with diverse presentations and histology that differ from adult cancers, the overall care of children with cancer has been improved by multidisciplinary approaches and pediatric cooperative groups that have set the standard in current oncologic care of children. The Children's Oncology Group (COG) and the Societe Internationale d'Oncologie Pediatrique (SIOP) have made significant progress in clinical and basic science studies of pediatric malignancies, and current pediatric tumor care is based upon treatment standards established through phase 1 to 3 clinical–translational trials. It is a universal goal that every child diagnosed with cancer be enrolled in a cooperative group clinical trial. These trials are aimed at further understanding pediatric tumor biology and for evolving innovative treatments that have recently led to drastic rises in survival rates for various malignancies.

Compared to adults, the classification of childhood cancer is based largely on histologic type and tumor morphology rather than primary site. The current classification scheme is the International Classification of Childhood Cancer, Third Edition (ICCC-3), based on ICD-0-3 (International Classification of Diseases).[1] The ICCC-3 classifies tumors into 12 main groups that are further characterized into 47 subgroups and is used for population-based epidemiologic studies and cancer registries such as the Surveillance, Epidemiology, and End Results (SEER) program, administered by the National Cancer Institute. Utilization of a standard classification system is useful for comparing incidence and survival across regions and time periods.

INCIDENCE OF CHILDHOOD SOLID TUMORS

Each year in the United States, approximately 12,400 children and adolescents younger than 20 years are diagnosed with cancer. Cancer is the most common cause of disease-related mortality in children, with approximately 2,500 children dying each year. Leukemia is the most common cancer diagnosis for children 1 to 5 years of age, 5 to 9 years of age, and 10 to 14 years of age, while neuroblastoma is the most common cancer in infants. For 15- 19-year-olds, lymphomas are the most common diagnosis. Pediatric solid tumors are a spectrum of different malignancies, and behind neuroblastoma, Wilms tumor is the second most common extracranial solid tumor followed by rhabdomyosarcoma (Fig. 105-1). In general, there have been no large increases or decreases in pediatric cancer incidence in the last several decades when improvement in diagnostic modalities such as magnetic resonance imaging (MRI) and ultrasound was taken into consideration.

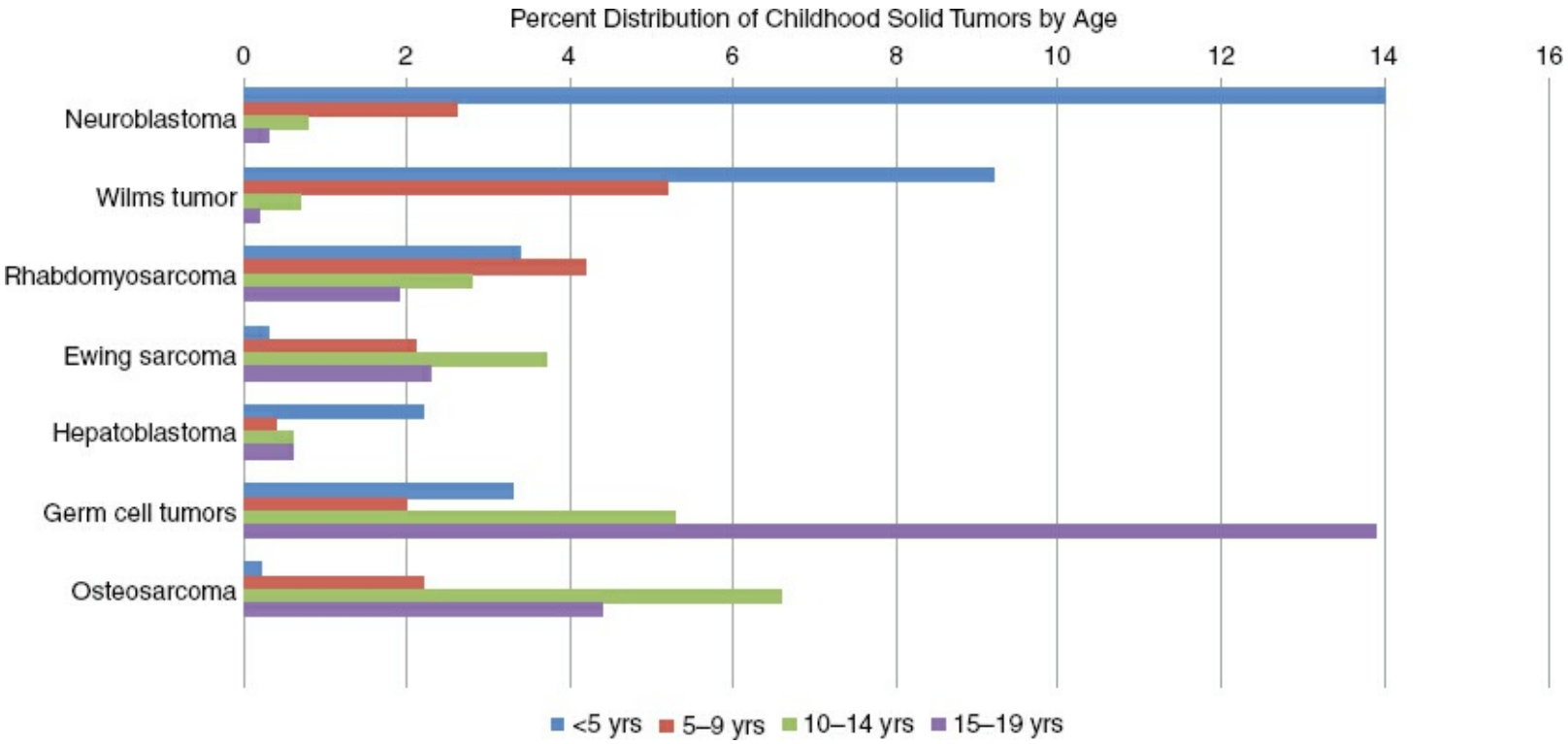

Figure 105-1. Percentage distribution of childhood solid tumors by age (SEER data, 1975–1995).

In the United States, the cancer survival rate in children has improved over time. This is largely due to multidisciplinary approaches to pediatric oncology care. There have been steady improvements in survival for childhood renal tumors, retinoblastoma, and lymphomas since the beginning of the SEER program. Although mortality rates have declined steadily for nearly all major childhood cancer categories, survival rates for high-risk tumors such as neuroblastoma and rhabdomyosarcoma have not been met with the same survival successes (Fig. 105-2).[2] Targeted immunotherapies and tumor genomic sequencing are new innovative treatment strategies that have recently provided hope for improving outcomes in resistant and refractory cases.

NEUROBLASTOMA

Epidemiology and Genetic Risk

1 In the United States, approximately 700 children are diagnosed with tumors of the sympathetic nervous system each year and of these, 650 are neuroblastoma. Neuroblastoma is the most common cancer in infancy and the most common extracranial tumor in all children. The disease accounts for 7.2% of cancers in children younger than 15 years. The incidence of neuroblastoma is slightly higher among males than among females and is highest among Caucasians from North America, Europe, Australia, and Israel.[3] The most recent SEER data have reported minimal changes in neuroblastoma incidence in the last five decades. The overall survival rate for neuroblastoma is 65% based upon SEER data from 1985 to 2000, and the disease continues to represent approximately 15% of all pediatric cancer deaths.[4,5] There is diverse variability in 5-year survival rates based on age and stage. There are no overall differences in survival by race or gender, and survival is highest among infants and patients with localized and regional disease.

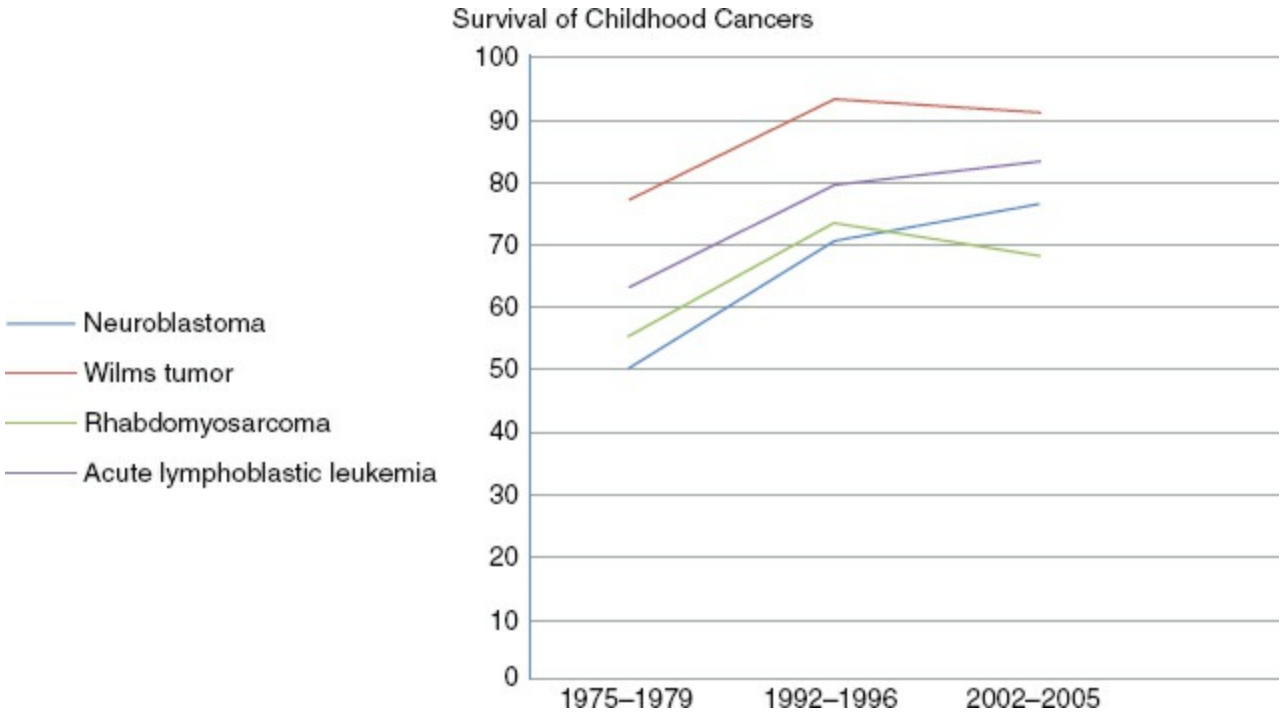

Figure 105-2. Survival of most common childhood cancer by type (SEER data, 1975–2005).

No causal factors for neuroblastoma have been identified. Studies examining maternal risks have been conflicting for prior miscarriage, induced abortion, repeat Cesarean birth, and vaginal infection.[6] There have been international case series reporting the use of maternal hormones for bleeding and ovulation induction. The largest study to date did not find significant association with infertility hormonal use, although results suggested an elevated risk of neuroblastoma in male offspring after maternal Clomid use.[7] These results warrant further evaluation but may serve as the focus of larger clinical studies. Parental occupation and environmental exposures have been studied.[8] They suggest that

the risk of several industrial occupations, particularly those related to power plant operators, painters, and electronic-related fields, should also serve as lead points for further study. A case-control study investigating parental tobacco smoking and alcohol consumption did not find any evidence for lifestyle exposures and increased risk of neuroblastoma.[9] Associations between premature delivery (<33 weeks), very low birth weight (<1,500 g), and neuroblastoma have been observed but results are inconsistent.[6] Further investigations of parental and perinatal risk factors are required in order to draw definitive conclusions.[10]

Most cases of neuroblastoma are sporadic and data for inheritance patterns are conflicting. There are studies that link neuroblastoma occurrence with other neural crest cell anomalies such as Hirschsprung disease, neurofibromatosis, and central hypoventilation syndrome.[11] These syndromes are components of the neurocristopathies and are considered alterations in neural crest cell development that may occur with inherited loss of function mutations of *PHOX2B*, a regulator of autonomic nervous system development.[12,13] Despite these findings, there is not a strong pattern of inheritance of neuroblastoma and only 1% to 2% of cases are familial in an autosomal dominant manner.[14,15] Recently, genome-wide sequencing studies have located heritable mutations in the *anaplastic lymphoma kinase* (*ALK*) gene as the cause of most hereditary neuroblastoma cases, the first example of a pediatric cancer arising due to a mutation in a critical oncogene.[16] Given this, genetic testing for *ALK* and *PHOX2B* should be considered in children with a family history of neuroblastoma. It is recommended that children in families found to have heritable mutations in *ALK* or *PHOX2B* undergo screening surveillance with ultrasound and urinary catecholamine metabolites.

ALK copy number mutations are also somatically acquired and highly associated with an aggressive clinical phenotype in 5% to 15% of neuroblastoma tumors.[17,18] Genome-wide association studies in sporadic cases of neuroblastoma have also recently discovered susceptibility genes that include *FLJ22536, NBPF23,* and *BARD1* that may increase the relative risk of malignant transformation of developing neuroblastic tissue.[19–22] In general, there is a relative paucity of recurrent somatic mutations in neuroblastoma, and the majority of tumors are likely driven by rare germline variants, copy number alterations, and epigenetic modifications.[22]

Pathology and Biologic Features

2 Neuroblastoma originates from embryonic cells of the neural crest that appear along the distribution of sympathetic nervous tissue from the neck to pelvis, most commonly in the adrenal medulla. The precise molecular mechanisms that give rise to embryonic neural crest cells that in turn give rise to neuroblastoma are unknown. The current thinking is that defects in genes that control neural crest differentiation and proliferation underlie neuroblastoma tumorigenesis. Peripheral neuroblastic tumors are categorized on a spectrum from malignant neuroblastoma to ganglioneuroblastoma and benign ganglioneuroma. Neuroblastoma tumors have diverse clinical heterogeneity from complete spontaneous regression in neonates to resistant metastatic disease in school-aged children. The origins of this disparity are unknown but may be explained by a spectrum of genetic and biologic features that are used to stratify patients for treatment.

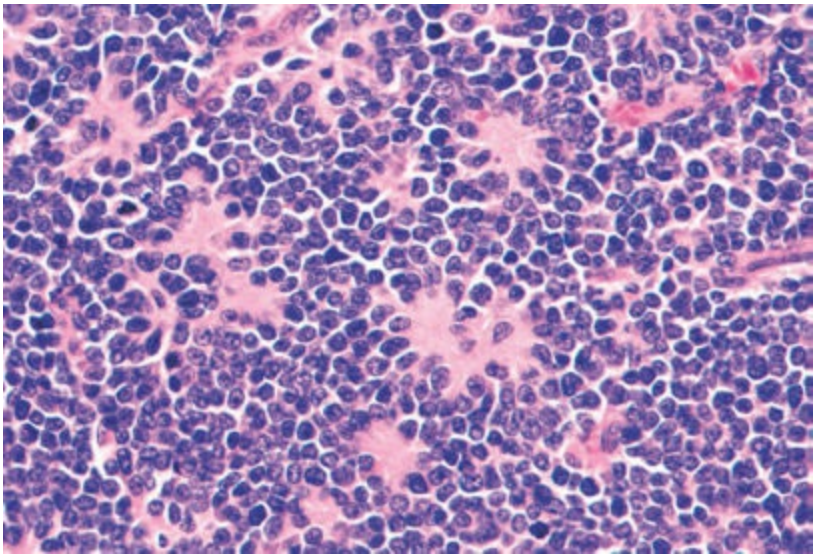

Figure 105-3. Typical neuroblastoma with small round blue cell feature and Homer–Wright pseudorosettes that palisade around blood vessels.

Neuroblastoma generally occurs in the youngest of children with a median age of presentation of 19 months.[23] The age at which a child is diagnosed with neuroblastoma is an indicator of biologic features and clinical course. Neonates and infants younger than 18 months are more likely to have disease that either spontaneously regresses or is cured without cytotoxic therapy. In contrast, older children are more likely to have refractory metastatic disease and are at high risk for death despite multimodal cytotoxic therapies. Age contributes to prognosis in a continuous manner with the optimal age cutoff between 15 and 19 months.[23] Much of this discrepancy in outcome of neuroblastoma is thought to be associated with underlying tumor biology because there is an association between age and other biologic factors such as *MYCN* amplification and histopathology. Given this, molecular analysis of neuroblastoma tumor specimen is an important factor in treatment planning and in risk stratification.

Cellular heterogeneity is a hallmark of neuroblastoma. Neuroblastic small round blue cells with hyperchromatic nuclei characterize neuroblastoma cells with varying degrees of

differentiation from immature to mature. Homer–Wright pseudorosettes that palisade around blood vessels and neuritic processes are characteristic (Fig. 105-3). Neuroblastoma cells stain for neuron-specific enolase, synaptophysin, NB84, and tyrosine hydroxylase, a neural protein staining pattern that differentiates neuroblastoma cells from other childhood tumors with similar small round blue cells.

Treatment strategies for children with neuroblastoma are largely based on risk as determined by histopathologic and biologic characteristics of the tumor. The Shimada histopathologic classification system is the most widely accepted mechanism for microscopic evaluation of neuroblastoma tumors and distinguishes favorable and unfavorable clinical groups. The International Neuroblastoma Pathology Classification System was developed on the basis of the original Shimada system.[24] Morphologic features of neuroblastic differentiation, Schwannian stromal development, mitosis–karyorrhexis index (MKI), and patient's age at diagnosis determine the important distinction between favorable and unfavorable histology (Table 105-1).

In addition to histopathology, combinations of prognostic features are utilized for risk assignment and treatment stratification in neuroblastoma. The DNA content (DNA index or ploidy) is the amount of DNA within the nucleus of tumor cells compared to normal cells and is an important indicator of treatment success. DNA index is determined by flow cytometry or by cytogenetic analysis. Hyperploidy or near-triploid tumors (DNA index >1) are whole chromosome gains and losses without structural genetic alterations and are associated with a better response to chemotherapy.[25] In contrast, diploid tumors are characterized by segmental chromosomal alterations and predict poor response to therapy.

CLASSIFICATION

Table 105-1 Shimada Histopathologic Classification of Neuroblastoma

Favorable
Stroma rich, all ages, no nodular pattern
Stroma poor, age 1.5–5y, differentiated, MKI <100
Stroma poor, age <1.5 y, MKI <200
Unfavorable
Stroma rich, all ages, nodular pattern
Stroma poor, age >5 y
Stroma poor, age 1.5–5 y, undifferentiated
Stroma poor, age 1.5–5 y, differentiated, MKI>100
Stroma poor, age > 1y, MKI >200
MKI, mitosis–karyorrhexis index (number of mitoses and karyorrhexis per 5,000 cells).

Reprinted from Shimada H, Ambros IM, Dehner LP, et al. The International Neuroblastoma Pathology Classification (the Shimada system). *Cancer* 1999;86(2):364–372. Permission granted for previous edition.

The *MYCN* oncogene is a transcription factor located on chromosome 2p and also predicts survival and risk in neuroblastoma. The amplification of *MYCN* is the best characterized genetic abnormality, occurring in approximately one-third of neuroblastoma

patients.[26,27] Significant amplification of *MYCN* within tumor cells (more than 10 copies detected by fluorescent in situ hybridization) reliably predicts poor survival and advanced-stage disease.[28] Although the molecular mechanism of *MYCN* amplification is unknown, targeted expression in transgenic mice leads to the development of neuroblastoma tumors.[29] Enhanced expression of *MYCN* increases proliferation and confers growth potential both in vitro and in vivo, adding to the notion that *MYCN* has a critical role in neuroblastoma tumorigenesis.[30] Approximately 30% of neuroblastoma tumors have *MYCN* amplification, and of these, 90% are high-stage or refractory to multimodal cytotoxic therapies.[31]

Nerve growth factor (NGF) and its receptor tyrosine kinase (TRK) also correlate with disease outcome in neuroblastoma tumors. The TRK receptors are thought to have a role in regulating growth and differentiation of normal nerve cells and have been implicated in neuroblastoma pathogenesis. The expression of TRK-A, a transmembrane TRK that is required for high-affinity binding of NGF, is strongly predictive of a favorable outcome in neuroblastoma tumors.[32,33] TRK-B, the receptor for brain-derived neurotrophic factor, is preferentially expressed in neuroblastoma tumors with *MYCN* amplification while TRK-C, the primary receptor for neurotrophin-3 (NT-3), mirrors TRK-A and is expressed primarily in lower-stage tumors with favorable outcomes.[33] The absence or lack of TRK-A correlates inversely with *MYCN* amplification and reliably predicts poor overall survival. Differential expression of TRK-A and TRK-B indicates that NGF receptors may function in growth arrest and differentiation in neuroblastoma tumors, critical factors that may have a role in clinical course.[34]

3 Several nonrandom genomic imbalances have been identified in neuroblastoma, and the presence of segmental chromosome alterations is the strongest predictor of neuroblastoma relapse.[35] The loss of heterozygosity (LOH) of chromosome 1p is a reliable prognostic factor in neuroblastoma tumors that is independent of age and stage. The loss of 1p identifies patients who are at high risk of poor survival outcomes despite otherwise favorable biologic predictors (Stage 1, 2, and 4S disease).[36] LOH at 1p is most clinically valuable in predicting patients at high risk of death in the subgroup of patients without *MYCN* amplification, specifically those with low-stage disease.[36] Gain at 17q most commonly occurs with loss of 1p in an unbalanced translocation. Unbalanced gain of chromosome arm 17q is the most frequent segmental genetic alteration in neuroblastoma cells and is also associated with adverse outcomes.[37] The gain of 17q is strongly associated with other negative risk factors including age of more than 1 year, presence of high-stage disease, *MYCN* amplification, and diploidy. The most likely candidate genes involved at 17q are NM23 and BIRC5 (surviving gene).[38] Chromosome 11q loss is found in approximately 40% of patients with neuroblastoma and is associated with high-risk disease features and decreased survival.[39] Similar to loss of chromosome 1p, loss of 11q is independently associated with decreased survival in the subgroup of patients with low-stage disease and in patients without *MYCN* amplification. In all, the genomic alterations that have consistently been shown to predict prognosis are DNA ploidy, *MYCN* amplification, loss of chromosome 1p, 17q gain, loss of 14q, and loss 11q. A systematic review of prognostic tumor markers and meta-analysis showed that of these, *MYCN*

amplification and DNA ploidy have the strongest prognostic impact.[40]

Presentation, Diagnosis, and Staging

The majority of children with neuroblastoma are diagnosed at less than 4 years of age, with median age between 19 and 22 months. Forty percent of tumors occur in the adrenal medulla, with the remaining occurring in the neck, chest, abdomen, and pelvis along the sympathetic chain. The organ of Zuckerkandl is the second most common site of neuroblastoma of abdominal origin. Compared to older children, infants are more likely to present with thoracic and cervical primary sites. Tumors at the sympathetic chain along the spinal column may expand into the intraforaminal spaces and can cause spinal cord compression (5% to 15% of patients) (Fig. 105-4). More than half of the patients may present with regional or distant spread through lymphatic and hematogenous routes. Metastatic disease most commonly involves regional lymph nodes, bone marrow, and cortical bone. The most common cortical bone sites are metaphyseal, skull, and the orbit. Patients with orbital bone metastases commonly present with periorbital ecchymosis and swelling (raccoon eyes), and cortical bone metastases may result in generalized bone pain and limping. Liver metastases occur most commonly in patients with stage 4S tumors. Neonates with stage 4S neuroblastoma may present with massive hepatomegaly, respiratory compromise, and abdominal compartment syndrome requiring urgent surgical intervention. Incidental findings on prenatal ultrasound may identify fetal neuroblastoma, and there may be associated maternal signs of catecholamine excess with excessive sweating, headaches, flushing, or anxiety.[41]

Most often patients with localized disease are asymptomatic, with tumors diagnosed on routine physical examinations or testing for other medical conditions. In contrast, children may have a mass or abdominal distention as presenting symptoms. There are several well-documented clinical syndromes that can be present at diagnosis of neuroblastoma. Opsoclonus/myoclonus syndrome and/or ataxia can occur in children with neuroblastoma and present as irregular jerking movements of the muscles. The underlying mechanism of opsoclonus is unknown but an immunologic mechanism-related antineuronal antibody is likely, and patients may have late neurologic sequelae despite tumor removal.[42] The condition may be treated with adrenocorticotrophic hormone, with plasmapheresis and intravenous gamma-globulin reserved for refractory cases.[43] Most patients with opsoclonus/myoclonus syndrome tend to have localized disease and excellent survival. Up to 50% of patients with opsoclonus/myoclonus syndrome are found to have neuroblastoma tumors while only a small percentage of patients with neuroblastoma present with opsoclonus. Neuroblastoma tumors that occur in the neck or the upper chest may present with Horner syndrome (ptosis, miosis, anhidrosis), symptoms that may not recover and often worsen with surgical excision.

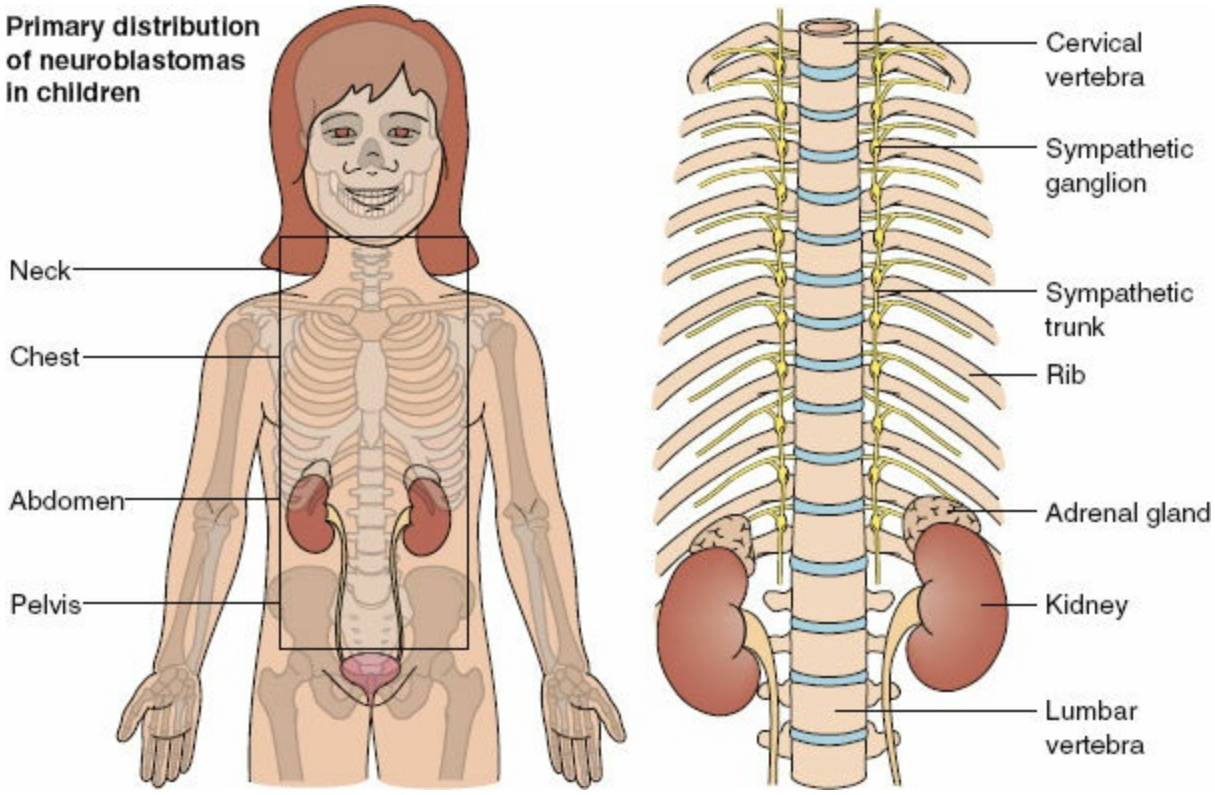

Figure 105-4. Primary distribution of neuroblastoma tumors in children.

Perinatal Neuroblastoma

The improvement of ultrasound and maternal imaging techniques has increased the diagnosis of neuroblastoma within the fetal and neonatal periods. Most perinatal tumors are located within the adrenal gland and are localized tumors. Upon detection, tumor growth is monitored with serial ultrasound prior to birth, and maternal care proceeds to ensure optimal health of the mother. As long as there are no complications, pregnancy is carried to term. Nearly all perinatal cases have favorable biology without adverse prognostic indicators, including non-*MYCN* amplification. Several lines of evidence suggest that small, localized adrenal tumors detected during the perinatal period may be managed with expectant observation without surgical resection.[44–46] Given the considerable evidence of spontaneous regression in this subset of neuroblastoma tumors and the risk of adrenal surgery in infants, the COG conducted a prospective trial (ANBL00P2) of expectant observation of infants diagnosed within the first 6 months of life.[47] This study found that observation of small adrenal masses in infants younger than 6 months, without biopsy and without surgical resection, was safe with excellent event-free and overall survival. Adrenal tumors smaller than 3 cm (16 mL) if solid or 5 cm (65 mL) if $\geq$25% cystic are safely monitored with ultrasound volume measurements, computed tomographic (CT) scan, and urine catecholamine metabolite levels. If there are signs of tumor growth or dedifferentiation, the patient is referred for surgical resection without risk of upstaging of disease.

Diagnosis

The diagnosis of neuroblastoma requires an adequate biopsy specimen and a pathologist experienced with pediatric tumors. The diagnosis is established with histologic confirmation from either tissue biopsy or the presence of tumor cells within a bone marrow biopsy and increased urinary catecholamine metabolite levels.[48] The majority of patients with neuroblastoma have elevated urinary vanillylmandelic acid and homovanillic acid levels and these should be evaluated during the diagnostic workup. Complete blood count and serum chemistries are evaluated as components of initial diagnostics. Levels of lactate dehydrogenase, ferritin, and neuron-specific enolase are biologic markers that may indicate poor prognosis in patients with neuroblastoma.[49,50] Elevated ferritin ($>$150) and lactate dehydrogenase ($>$1,000) may indicate increased risk of adverse outcomes. Seventy percent of patients present with metastatic disease at presentation; therefore, initial evaluation should include cross-sectional imaging by either computerized tomography or MRI to define the primary tumor size and to determine regional or distant spread (Fig. 105-5). Calcifications are commonly detected on imaging in patients with neuroblastoma, and the mass tends to displace structures inferiorly and toward the midline. Unless the patient has neurologic symptoms or an abnormal neurologic examination, lumbar puncture or brain imaging is not indicated. Sympathetic nervous tissue concentrates metaiodobenzylguanidine (MIBG), an analog of norepinephrine. Radioactive iodine-labeled MIBG scan is utilized in neuroblastoma staging and is used to determine treatment response.[51] MIBG scan is accurate in detecting

metastatic spread, particularly cortical bone disease that may have otherwise been missed by traditional imaging techniques. Posterior iliac crest aspirates and core biopsies are required as a component of initial diagnostic testing to exclude bone marrow involvement. PET scanning or bone scanning may be utilized in patients with non-MIBG avid disease.



Figure 105-5. Computed tomographic scan of a child with stage 3 neuroblastoma, crossing the midline displacing the aorta, vena cava, kidney, pancreas, and spleen.

Staging

4 The criteria for diagnosis and staging of neuroblastoma have traditionally been based upon the International Neuroblastoma Staging System (INSS). Standard staging criteria allows physicians to tailor treatment plans based on patient risk. INSS is the most widely accepted staging system and was established in efforts to standardize risk-group stratification by cooperative groups (Table 105-2).[48] Stage 1 is localized tumor with complete gross excision with or without microscopic residual disease and negative ipsilateral lymph nodes. Partially resected tumors and tumors without or with ipsilateral lymph node involvement are either stage 2A or 2B. A tumor that is unresectable or has contralateral lymph nodes involved is stage 3. Any tumor with distant metastases is stage 4. Stage 4S is localized neuroblastoma tumor with distant disease limited to skin, liver, or bone marrow in infants younger than 1 year. Stage 4S is a poorly understood unique subset of neuroblastoma tumors that often spontaneously regress without surgical resection or cytotoxic therapy. INSS is largely based on the surgeon's definition of resectability and surgical approach to the primary tumor and lymph nodes. There is international variation in surgical decision making and approach to locoregional disease that may alter the prognostic value of INSS staging. This has made the performance and comparison of international clinical trials difficult. Moreover, biologic prognostic factors have become increasingly important in treatment planning and risk stratification. To address this, the European International Society of Pediatric Oncology neuroblastoma group proposed radiographic characteristics of the primary tumor as useful predictors of

resectability and risk for developing postoperative complications (International Neuroblastoma Risk Group Staging System [INRGSS]).[52] INRGSS, determines the extent of locoregional disease by the presence or absence of image-defined risk factors (IDRF).[53] Stage L1 tumors are localized tumors that are confined within one body compartment and do not involve vital structures or major blood vessels, without any IDRF. L2 tumors are locoregional tumors with one or more IDRF that may involve ipsilateral continuous body compartments and have lower event-free survivals compared to L1 tumors. Stage M is distant metastatic disease and MS is limited to children younger than 18 months with skin, liver, and/or bone marrow metastases. The benefit of INRGSS is that treatment stratification is based on preoperative diagnostic imaging, rather than variable operative approaches. INRGSS now functions as one of the seven prognostic factors in the new International Neuroblastoma Risk Group (INRG) pretreatment classification system.[54] The INRG classification system defines pretreatment patient cohorts based on expected 5-year event-free survival at the time of diagnosis before treatment. INRG classification includes INRG stage, age, histologic category, grade of tumor differentiation, *MYCN* status, 11q alterations status, and DNA ploidy. These criteria are used to define 16 clinically different pretreatment groups that include very low-, low-, intermediate-, and high-risk categories in terms of 5-year event-free survivals of $>85\%$, >75 to ≤ 85, $\geq 50\%$ to ≤ 75, and $<50\%$, respectively. These clinical categories may further assist physicians and cooperative groups in risk-group stratification based on reliable expected event-free survival cutoffs. Importantly, INRG classification will allow comparison of international risk-based clinical trials with potential to enhance international collaborative efforts.

Treatment

The treatment of neuroblastoma requires a multidisciplinary approach in order to ensure the most optimal outcomes. Treatment is often multimodal with surgery, chemotherapy, radiation, bone marrow/stem cell transplantation, and immunotherapy. Risk group assignment is essential for surgical and medical treatment decisions, as therapies are tailored to risk. Patients are categorized on the basis of INRG classification as very low-, low-, intermediate-, or high-risk. In general, the overall goal is to minimize surgical risks and to limit exposure to chemotherapy in patients with localized disease and favorable biologic features.

In the United States, the current treatment of children with neuroblastoma is guided by protocols established by the COG, and it is recommended that every child diagnosed be enrolled on a clinical trial. ANBL00B1 is the most recently opened COG study that will determine risk stratification and treatment plans based on histology, *MYCN* amplification, ploidy, and serum analysis (https://clinicaltrials.gov/ct2/show/NCT00904241). This study will also further investigate other tumor biologic properties including the prevalence of segmental chromosomal alterations 1p, 11q, 14q, and 17q and analyze for independent clinical significance compared to standard prognostic indicators such as *MYCN*, INSS, and age.

STAGING

Table 105-2 International Staging Criteria for Neuroblastoma

Stage	Criteria	Overall Survival (3 Yrs)	Event-Free Survival (3 Yrs)
1	Localized tumor, complete gross resection with or without microscopic margin, all identified ipsilateral and contralateral lymph nodes negative	97%	88%
2A	Unilateral tumor, incomplete resection, negative lymph nodes	87%	72%
2B	Unilateral tumor, incomplete or complete resection, positive ipsilateral but negative contralateral lymph nodes	86%	63%
3	Infiltration of tumor across the midline with or without ipsilateral lymph node involvement; unilateral tumor with contralateral lymph node involvement, midline tumor with bilateral lymph nodes positive	62%	58%
4	Distant metastases to lymph nodes, bone marrow, cortical bone, liver, other organs	<40%	<40%
4S	Localized primary tumor with distant metastatic disease to liver, skin, bone marrow only (<10% involvement), typically neonatal presentation	75%	75%

Very Low Risk and Low Risk

For tumors that are classified as very low risk and low risk with favorable biologic characteristics (INSS stage 1, 2A/2B non-*MYCN*, no 11q alteration), survival rates are >95% with surgery alone without the need for postoperative chemotherapy.[55] Children with low-risk neuroblastoma are treated on the basis of results of the Children's Oncology Group Study P9641 that demonstrated excellent survival rates in asymptomatic low-risk patients with stages 1, 2a, and 2b neuroblastoma after surgery alone.[56] The study demonstrated 3-year overall survival of 95% or greater with surgery alone in patients with low-risk, favorable histology disease. The goal of surgery in low-risk patients is complete surgical resection without compromising surrounding organs or blood vessels.

Surgical standards for low-risk neuroblastoma are to establish diagnosis and to resect as much tumor as safely possible without damage to contiguous structures or major blood vessels. Sampling of nonadherent regional lymph nodes and obtaining adequate tissue for biologic studies is critical. Chemotherapy in this group is reserved for patients who relapse or have treatment failure. Chemotherapy is also for patients with less than partial primary tumor resection (<50%), disease that compromises organ function or is life threatening, and patients at risk of developing spinal cord compression. If utilized, low-dose chemotherapy is carboplatin, cyclophosphamide, doxorubicin, and etoposide. Chemotherapy is 6 to 24 weeks depending upon patient's age, weight, and extent of disease. Radiation is seldom given in this group and is reserved for patients with life-threatening symptoms.

Stage MS neuroblastoma tumors without *MYCN* amplification are very low-risk classification and most often spontaneously regress. Children with MS disease require biopsy of either primary or metastatic tumor for biology studies. This subset may be spared for both surgery and chemotherapy. Exceptions are patients with massive hepatomegaly causing abdominal compartment syndrome when low-dose chemotherapy and radiotherapy is given to reduce organ dysfunction. Patients with MS tumors may require decompressive laparotomy and ventilator support. In this case, attempts should be made to biopsy extra-abdominal sites, and diagnosis may also be made by bone marrow biopsy. In rare and extreme life-threatening cases, treatment may be initiated on the basis of diagnostic imaging characteristics alone.

Intermediate Risk

The intermediate-risk group encompasses a broad spectrum of neuroblastoma tumors. The survival rate for patients in this group is between 75% and 90%. All patients in this subgroup receive surgery and chemotherapy. The goals of surgical resection are similar to low-risk cases to establish the diagnosis with enough tissue for histologic and genetic testing with the most complete tumor resection, preserving organ function. If the primary tumor is resectable without damage to surrounding organs and major blood vessels, then full resection is performed with lymph node sampling for staging upfront. Many patients in the intermediate-risk group will have locoregional disease that encroaches upon surrounding organs and major blood vessels (aorta, vena cava, mesenteric vessels, kidney, spleen). The surgeon should defer to the INRG IDRF during assessment for resectability. For L2 tumors with INRG IDRF and those judged to be unresectable at diagnosis, biopsy is performed with plan for neoadjuvant chemotherapy. Delayed surgical resection after four to six cycles of induction chemotherapy minimizes surgical complications and may improve resection of the primary tumor and overall survival.[57] Moderate-dose chemotherapy for intermediate-risk tumors consists of 12 to 24 weeks of cisplatin, cyclophosphamide, doxorubicin, and etoposide. The prognosis in this subgroup depends upon patient's age, tumor histology, and biologic properties. Treatment protocols for children with intermediate-risk neuroblastoma are currently based on results of the COG trial A3961. This study demonstrated a high rate of survival with biologically based treatment assignment utilizing substantially reduced duration and doses of chemotherapy agents compared with previously used intensive regimens.[58] The promising results have reduced cytotoxic therapy for patients with regional disease and favorable biologic characteristics and provided framework for ANBL0531, a COG trial further examining reduction in cytotoxic therapy as more refined risk factors emerge.[38,59]

High Risk

High-risk neuroblastoma remains one of the most challenging problems in pediatric oncology. Survival in this group remains poor despite multimodal therapy that includes aggressive surgery, intensive cytotoxic chemotherapy, and radiation. The long-term survival is between 10% and 30%. High-risk tumors are characterized by undifferentiated neuroblasts with unfavorable histology and poor prognostic indicators (*MYCN* amplification, 11q alterations, and diploidy). The initial surgical management of high-risk tumors begins with an adequate operative biopsy and vascular access placement. Initial biopsy can be approached by open or minimally invasive techniques including thoracoscopy, laparoscopy, and percutaneous core biopsy. Obtaining an adequate sample size to allow for histologic and cytogenetic studies is of utmost importance and is the primary focus when determining biopsy technique. An initial biopsy should obtain tissue greater than 1 cm^3 of viable tumor tissue with avoidance of placement of the specimen in formalin in order to optimize cytogenetic studies. The adequacy of the biopsy specimen should be confirmed with the pediatric pathologist before leaving the operating room. Standard treatment then begins with induction chemotherapy, followed by surgical local control, myeloablative consolidation therapy, and biologic agents.

Induction chemotherapy is administered to improve tumor resectability and to decrease tumor growth. Most neuroblastoma primary tumors and bone marrow are initially sensitive to chemotherapy and will have high response rates. Standard induction therapy consists of combinations of cisplatin, cyclophosphamide, vincristine, doxorubicin, and etoposide. The response rate of induction chemotherapy correlates with survival.[60] Postinduction persistent bone lesions and bone marrow involvement predict poor overall survival.[61]

Local control is achieved with the combination of aggressive surgical resection and external-beam radiotherapy to the primary tumor site. Delayed resection with postinduction chemotherapy excision of as much of tumor as safely possible offers the highest treatment success. After induction chemotherapy consisting of four to five cycles, surgical exploration with the goal of gaining local control of the primary tumor is undertaken. Although the role of primary tumor resection in high-risk patients with neuroblastoma has been controversial, recent studies have shown that aggressive removal of all primary tumors in high-risk patients with neuroblastoma improves survival to 50% and decreases local recurrence to 10%.[62] Gross total resection of the primary tumor is defined as the removal of all visible and palpable neuroblastomas from the primary tumor site and regional lymph node tissue. The microscopic margin is nearly always positive; therefore, the goal is safe gross total resection with external beam radiation therapy to the surgical bed (2,000 to 2,100 cGy).

Safe tumor dissection typically requires exposure of the great vessels and spine (Fig. 105-6). The incision type depends on the location of the primary tumor with thoracoabdominal or transverse abdominal for large adrenal masses and midline incision for pelvic neuroblastoma. Thoracic neuroblastoma typically has favorable biology and better survival outcomes than abdominal tumors and surgical resection is often curative.

Primary thoracoscopic gross total resection is safe in neuroblastoma tumors smaller than 6 cm and may yield surgical and survival outcomes similar to open thoracotomy.[63,64] Cervical chain tumors may be approached by radical neck incisions and if located at the lower cervical region or apex of hemithorax, a trap-door incision often utilized in the setting of vascular trauma may be applied.[65] Every effort should be made to preserve the vagus and phrenic nerves. In general, for all neuroblastoma resections, organs and structures should be preserved, particularly the kidney. The operative complications to avoid are excessive blood loss, kidney and renal vessel injury, damage to surrounding major blood vessels or nerves, and postoperative infection and abscess. The tumor is removed by meticulous dissection in the peritumoral capsular plane. Early control of the aorta and the vena cava is essential as the major blood vessels are traced. The major blood vessels often include the celiac axis, superior mesenteric artery, renal vessels, and inferior mesenteric artery. Tightly adherent tumor to blood vessels or major nerves should be left rather than risk injury though neuroblastoma typically does not invade beyond the adventitia. At times, it is beneficial to divide the tumor over major blood vessels for safe exposure when en bloc resection is not possible at encased blood vessels. Pelvic neuroblastoma typically arises from the organ of Zuckerkandl or elsewhere along the sympathetic chain and is associated with excellent long-term survival, despite residual or microscopic disease. Injuries to the lumbosacral plexus or damage to innervation to the bowel or bladder should be avoided. Selective MRI for pelvic lesions may help define neural involvement and enhance surgical planning. Nerve stimulation may be useful when approaching the pelvic sidewall. The presence of residual tumor correlates with risk of recurrence. Patients with incomplete resection may benefit from higher-dose radiation.[66]

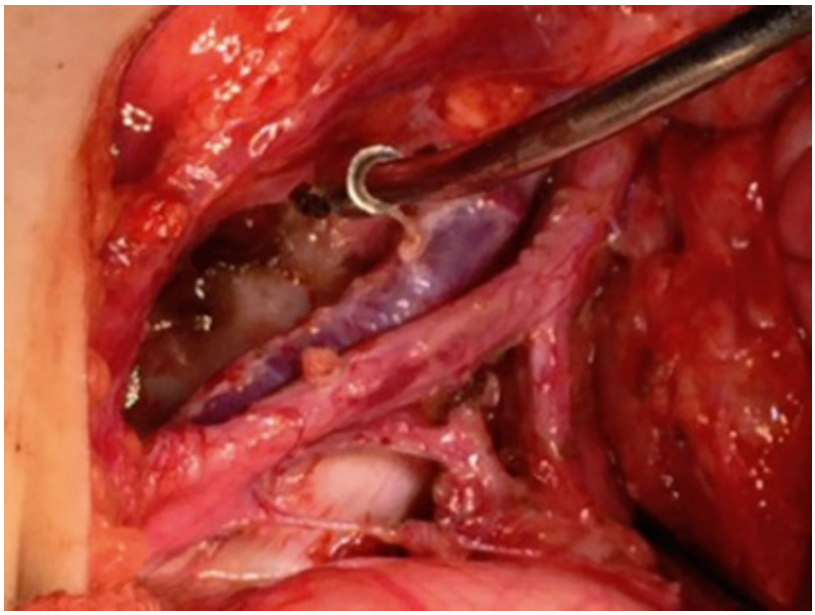

Figure 105-6. Intraoperative depiction of critical exposure during neuroblastoma resection exposing the aorta and the vena cava from bifurcation distal to proximal.

Myeloablative consolidation therapy was investigated in the CCG-3891 study that demonstrated myeloablative therapy with purged bone marrow transplant improved outcome for patients with high-risk neuroblastoma.[60] The data from this trial have been

confirmed with several international studies.[67] High-dose myeloablative megatherapy (cisplatin, etoposide, cyclophosphamide) with autologous stem cell transplantation improves outcome and progression-free survival compared to maintenance chemotherapy or observation. Over the last several decades, intensification of consolidation therapy with myeloablative doses of chemotherapy, followed by autologous stem-cell rescue has allowed for steady reduction in relapse rates in first remission and has now become standard of care for patients with high-risk disease.[68] The ability to harvest peripheral blood stem cells along with advances in transplant methodology has enhanced the safety and feasibility of bone marrow transplantation.

Maintenance and biologic therapies have also improved high-risk neuroblastoma treatment. Isotretinoin (cis-RA) is a synthetic retinoid that is now standard of care after induction, local control, and cytotoxic chemotherapy. Currently all patients with high-risk neuroblastoma receive 6 months of high-dose cis-RA therapy after myeloablative therapy and bone marrow transplantation. The COG (ANBL0032) found that the addition of monoclonal antibodies (MAB ch14,18) targeting disialoganglioside GD2 improved survival rates in patients with high-risk disease.[69,70] GD2 is a sialic acid-containing glycosphingolipid expressed uniformly on the surface of neuroblastoma cells. The Food and Drug Administration recently approved Unituxin (dinutuximab, formerly MAB ch14,18) specifically for the treatment of pediatric patients with high-risk neuroblastoma who achieve at least a partial response to prior first-line multimodality treatment.

Future Directions

Despite advances in cytotoxic and biologic multimodality therapies, up to 60% of patients with high-risk neuroblastoma relapse and there are currently no curative salvage treatment regimens. Advances in understanding neuroblastoma tumor biology are essential for the development of novel therapies for high-risk tumors. The use of high-throughput genomic sequencing technologies will aid in patient-specific prognostic data and allow for a personalized approach to treatment. The success of anti-GD2 monoclonal antibody has launched great interest and research into improving antibody-based approaches and synergistic immunotherapies. A recent study showed promise in humanized anti-GD2 engineered to target the delivery of interleukin-2 to tumor microenvironment in patients with small tumor burden.[71] The addition of MAB ch14,18 and cytokines granulocyte/macrophage colony-stimulating factor and interleukin-2 to cis-RA may prevent late relapse. Radiolabeled MIBG is also being investigated as a therapeutic agent in neuroblastoma and has a high response rate in patients with relapse and refractory disease.[51,72,73] Targeted radionucleotide has little nonhematologic toxicity though most patients experience some level of myelosuppression requiring autologous hematopoietic cell transfusion.

The challenges also remain the ability to identify patients with low-risk and intermediate-risk tumors who benefit from reduction in therapy versus those who are at risk for relapse and refractory disease. There are several large collaborative research efforts focusing on the discovery of new therapeutic targets with respect to understanding the relationship between risk and the molecular basis of neuroblastoma. One such effort is the Therapeutically Applicable Research to Generate Effective Treatments (TARGET) program (http://target.cancer.gov). TARGET in conjunction with the Cancer Genome Atlas project conducts genomic profiling and tumor sequencing for neuroblastoma along with other pediatric solid tumors with the goal of discovering novel mechanisms that drive tumorigenesis and identifying new molecular targets for drug development.

WILMS TUMOR

Epidemiology and Genetic Risk

Various tumors arise in the kidneys in children that range from benign to malignant. Wilms tumor (nephroblastoma) is the most common renal tumor in children and is the second most common solid tumor outside of the brain in infants behind neuroblastoma. Wilms tumors occur almost exclusively in the kidney. Extremely rare extrarenal sites include the retroperitoneum, pelvis, and inguinal canal.[74] The overall incidence of Wilms tumor is eight per million children younger than 15 years, with approximately 500 new cases per year in the United States.[4] Children most commonly present within the first 2 years of life, with nearly all diagnosed before the age of 5 years. The incidence of Wilms tumor varies by ethnicity with highest incidence in Africa and African-American children and lowest in East Asian populations.[75] The National Wilms Tumor Study (NWTS) reported that the median age for Wilms tumor in boys is 36 months and 43 months for girls with unilateral tumors.[76] Bilateral Wilms tumors occur in slightly younger children with median ages of 23 months for boys and 30 months for girls. The survival of children with Wilms tumor has improved significantly over the past several decades from 30% to more than 90% 5-year survival currently.[77]

Table 105-3 Syndromes Associated with Increased Susceptibility to Wilms Tumor

Syndrome	Gene	Phenotype
WAGR (Wilms tumor, aniridia, genitourinary abnormalities, mental retardation)	*11p13/WT1:* deletions, *PAX6*	Absence of iris, genitourinary defects, mental retardation; 30% develop Wilms tumors
Denys–Drash	*11p13/WT1:* point mutations	Genitourinary defects, renal mesangial sclerosis and intersex disorder; 90% develop Wilms tumors
Frasier	*11p13/WT1:* point mutations	Genitourinary defects, focal glomerular sclerosis, and intersex disorder; rarely develop Wilms tumors
Beckwith-Wiedemann	*11p15:* several genes (*IGF2*, *H19*, *p57*, and *LIT1*)	Organomegaly including tongue, hemihypertrophy, hypoglycemia, umbilical hernia, increased risk of tumors (Wilms tumor, hepatoblastoma, adrenal carcinoma); 5% develop Wilms tumors
Simpson–Golabi–Behmel	*Xq26/GPC3:* point mutations, microdeletions	Organomegaly, renal dysplasia, excess digits, diaphragmatic and heart defects; 7.5% develop Wilms tumors
Sotos	*5q35/NSD1:* point mutations, microdeletions	Overgrowth, craniofacial dysmorphism, mental retardation, and increased risk of tumors (Wilms tumor, neuroblastoma, acute lymphocytic leukemia); 5% of patients develop Wilms tumor
Perlman	Unknown	Macrosomia, visceromegaly, cryptorchidism, excess amniotic fluid, characteristic facial features; 30% of patients develop Wilms tumors
Familial Wilms tumor 1	*17q12–21*	20% of patients develop Wilms tumors
Familial Wilms tumor 2	*19q13,4*	70% of patients develop Wilms tumors

GPC3, glypican 3; *IGF2*, insulin-like growth factor 2; *NSD1*, nuclear-receptor–binding SET-domain protein 1; *PAX6*, paired box gene 6; *WT1*, Wilms tumor protein 1.
Reprinted from Rivera MN, Haber DA. Wilms' tumour: connecting tumorigenesis and organ development in the kidney. *Nat Rev Cancer* 2005;5(9): 699–712.

Most Wilms tumors are sporadic with only 1% to 2% of cases being familial. Several genetic syndromes are uniquely associated with Wilms tumor. Sporadic aniridia, hemihypertrophy, genitourinary tract abnormalities, and Beckwith–Wiedemann syndrome are known to be associated with an increased risk of Wilms tumor in children.[78] The study of patients with sporadic aniridia and Beckwith–Wiedemann syndrome led to the discovery of WT1, a tumor suppressor gene located on chromosome 11p necessary for normal renal development.[79,80] Inactivating mutations lead to the development of most Wilms tumors, and germline mutations account for most of the syndromic anomalies that are associated with chromosome 11 including WAGR (Wilms tumor, aniridia, genitourinary abnormalities, intellectual disability), Denys–Drash syndrome (pseudohermaphroditism, glomerulopathy, renal failure, Wilms tumor), and Beckwith–Wiedemann syndrome.[81] Inactivating point mutations in the *WT1* gene, located on chromosome 11p13, are associated with Denys–Drash syndrome, and LOH at the 11p15 locus (WT2) is found in Beckwith–Wiedemann syndrome, with 5% to 10% of patients having Wilms tumors.[82] Patients with WAGR syndrome have associated somatic germline mutations of 11p13. FWT1 (17q) and FWT2 (19q) have been identified in familial Wilms tumor disposition (Table 105-3).[83] Table 105-3 lists known genetic syndromes associated with increased susceptibility to Wilms tumor.

Pathology and Biologic Features

5 Wilms tumors arise from pluripotent developmental renal precursor cells. In most cases, only one kidney is affected but may present as bilateral disease in up to 6% of children. Multicentric disease is found in 7% of patients. Wilms tumors arise within the renal medulla and cortex and may invade renal calyces, renal vein, and inferior vena cava. The tumor is most commonly a well-circumscribed mass with a fibrous capsule. The most common sites of metastatic spread are lungs, lymph nodes, and liver. Wilms tumors are composed of a classic triphasic combination of blastemal, stromal, and epithelial cells. Characterization of histologic subtype is critical for risk stratification and for treatment planning. Blastemal predominance may indicate a high-risk category of patients with increased risk of recurrence.[84] Importantly, anaplastic cells characterize 7% of Wilms tumors and are defined by the presence of enlarged nuclei and hyperchromasia with multipolar polypoid mitotic figures (Fig. 105-7).[85] Compared to tumors without anaplasia, anaplastic Wilms tumors are generally found in older children and are more likely to have lymph node metastases. Differences in race are also observed with African or Latin-American children having the highest proportion of tumors with anaplasia. Tumors with diffuse anaplasia (present in more than one area of the tumor or extrarenal sites) are defined "unfavorable histology" and have higher resistance to chemotherapy than tumors without anaplasia.[86] The single most important prognostic indicator in Wilms tumors is the presence of anaplasia.

Clear cell sarcoma and rhabdoid tumor of the kidney are also unfavorable histologic subtypes and are now considered distinct entities from Wilms tumors.[77,87] Nephrogenic rests represent the persistence of developmental renal tissue in the kidney after the 36th week of gestation and 1% undergo malignant transformation to Wilms tumor. Two major categories of nephrogenic rests have been characterized, perilobar and intralobar, distinguished by their position within the renal lobe.[80] Nephrogenic rests are considered precursor lesions of Wilms tumor and are found in nearly half of cases.[88] Intralobar characterizes early developmental disturbances and occurs in aniridia and Denys-Drash syndrome, while perilobar develops later in nephrogenesis and occurs in patients with Beckwith–Wiedemann syndrome and hemihypertrophy. Nephroblastomatosis is the term used to describe the presence of diffuse nephrogenic rests and typically involves both kidneys. The presence of nephrogenic rests demonstrates the vast degree of heterogeneity in Wilms tumor biology as they either involute or progress to hyperplastic overgrowth or neoplastic induction.[77] Patients with nephrogenic rests are at risk for bilateral kidney involvement that decreases with age.

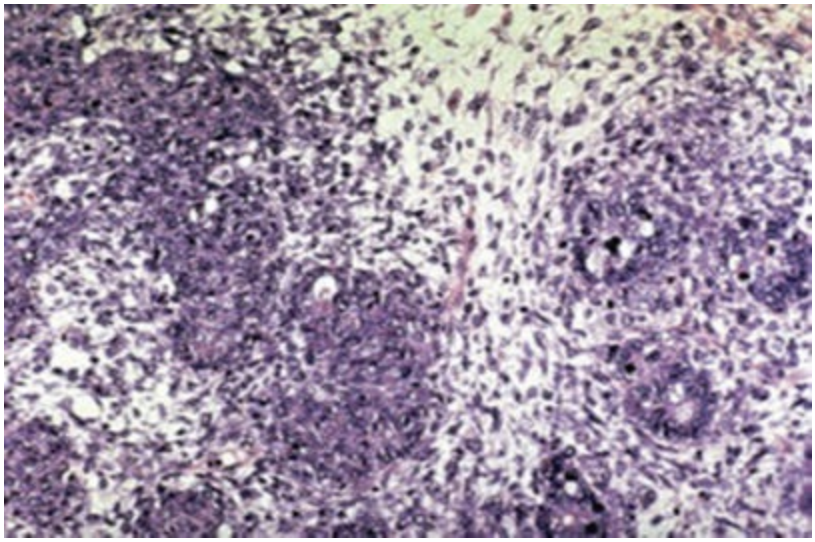

Figure 105-7. Microscopic examination of Wilms tumor showing highly cellular areas composed of undifferentiated blastemal cells with loose surrounding stroma with undifferentiated mesenchymal cells and immature tubules. (From Rubin E, Farber JL. *Pathology*. 3rd ed. Philadelphia, PA: Lippincott Williams & Wilkins; 1999, permission granted with previous edition.)

Several biologic factors have been identified in Wilms tumors that associate with risk. Tumor-specific LOH at chromosomes 1p and 16q are independent prognostic indicators and are associated with greater risk of relapse and mortality. The fifth National Wilms Tumor Study Group trial (NWTS-5) found that tumors with LOH at 16q had an adverse effect on prognosis with relapse rates three times higher and mortality rate 12 times higher than those without LOH at chromosome 16q.[89] Patients with LOH for chromosome 1p also had relapse and mortality rates higher than those without LOH at 1p.[90] LOH for both chromosomes 1p and 16q are found in up to 5% of Wilms tumors.

Presentation, Diagnosis, and Staging

Children may present with a palpable asymptomatic abdominal mass identified by parents or pediatrician during well-visit examination. If present, symptoms may include intermittent abdominal pain, gross or microscopic hematuria (25% of patients), and hypertension (25% of patients). Hypertension occasionally results from either an increase in renin secretion by the tumor or by compression of the renal artery by tumor mass effect. Intraparenchymal bleeding and preoperative rupture may occur causing systemic symptoms of fever and anemia. The mass is typically nontender and nonmobile on physical examination. The child should be examined for aniridia, macroglossia, hemihypertrophy, and genitourinary abnormalities. Signs of intravascular spread may present as ascites, hepatosplenomegaly, and cardiac murmur. Standard complete blood count and serum chemistries should be assessed though renal function is usually unaffected. Red blood cells may be present on urinalysis.

The diagnostic imaging workup is initiated with abdominal ultrasound and CT scan with oral and intravenous contrast. CT scan is the standard imaging modality that will provide information about mass location, size, extent of tumor invasion, and involvement of the contralateral kidney (Fig. 105-8). Critical examination of renal vasculature and intracaval extension is evaluated by Doppler ultrasonography. A good posteroanterior and lateral chest radiograph is obtained to determine the presence of lung metastases. It is critical to determine whether a patient with Wilms tumor has lung metastases because these patients are assigned to higher disease stage and receive radiation to the lungs and more intensive chemotherapy. There is considerable controversy regarding the utilization of chest CT scan versus plain chest radiograph to detect lung metastases in patients with Wilms tumor because of interobserver variability in interpretation.[91] If utilized for staging workup, chest CT should be performed with standardized techniques and interpretation through a central review process considered. Pulmonary metastases identified on chest CT but not on plain chest radiograph may identify a subgroup of patients at increased risk of pulmonary relapse.[92] It may be beneficial to obtain histopathologic confirmation of pulmonary metastases by surgical biopsy given the potential for upstaging and radiotherapy.[93]

In the United States, nephrectomy follows the initial diagnostic workup, allowing the combination of surgical and histologic parameters to be included in staging at diagnosis. During the procedure, the surgeon must determine tumor extent, tumor rupture, and the status of regional, paraaortic, and paracaval lymph nodes. Distant metastatic disease should also be determined by inspecting the peritoneal surfaces, diaphragm, and liver. The COG no longer recommends direct visualization and manual palpation of the contralateral kidney as long as the contralateral kidney is clear of tumor on cross-sectional imaging.

The staging of Wilms tumor is based on the anatomy of the tumor and lymph nodes as detailed by the NWTSG staging system. The staging system incorporates clinical, surgical, and pathologic information and allows stage-based approach to treatment to minimize exposure to cytotoxic agents (Table 105-4). Stage 1 tumors are limited to the kidney and

completely resected with an intact renal capsule without involvement of the renal sinus vessels. Stage 2 tumors extend beyond the kidney by either penetration of the renal capsule or invasion of sinus vessels. Biopsy before removal or local tumor spillage is classified as stage 3. Tumors that are unresectable or incompletely resected with positive margins are also stage 3 tumors. Tumors with regional lymph node metastases are stage 3 criteria as well. Stage 4 tumors have distant spread (liver, lung, bone, brain) or lymph node spread outside of the abdomen. Bilateral Wilms tumors are classified as stage 5 though precise staging for patients with bilateral Wilms tumor is based on local stage for each kidney. Advanced tumor stage at diagnosis predicts an increased risk of recurrence and tumor rupture at surgery predisposes to relapse.[94] Older age is also an adverse prognostic factor and predicts disease recurrence.[95] Tumor stage and histology are the most significant prognostic factors for children with Wilms tumor.

Treatment

Most children diagnosed with Wilms tumor are cured by multimodal therapy. Much of the success in therapy is the result of collaboration and research trials conducted by three cooperative groups, the NWTSG, now a part of the COG, the United Kingdom Children's Cancer Study Group (UKCCSG), and the SIOP. In the United States and Canada, nearly all children are treated according to protocols established by the NWTSG. The primary goals of therapy are to treat on the basis of well-defined risk groups and to achieve the highest cure rates with minimal toxicity.

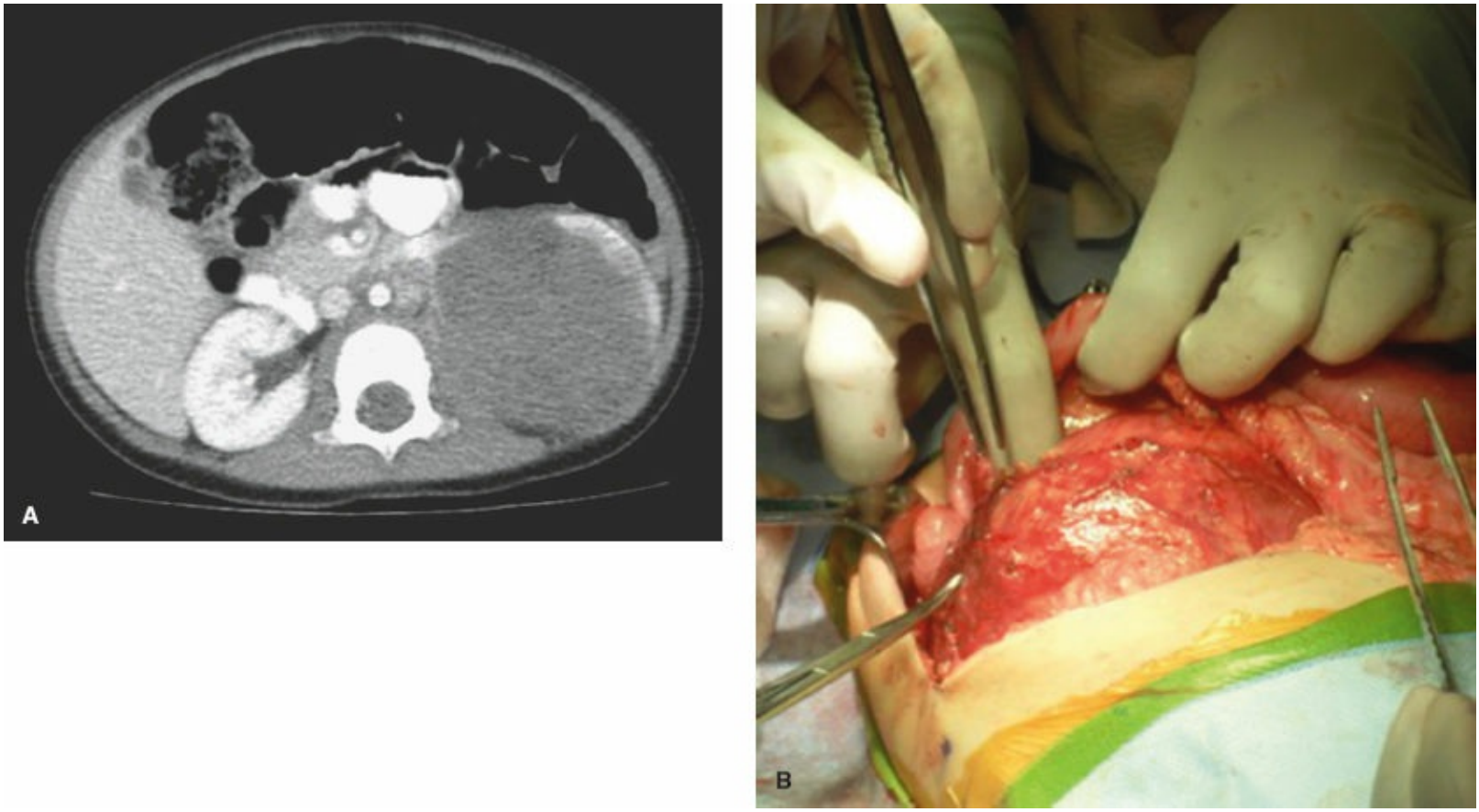

Figure 105-8. **A:** Abdominal CT scan with left Wilms tumor displacing midline organs and vessels, rim of kidney enhancing at lateral border. **B:** Intraoperative view of right Wilms tumor arising from retroperitoneum, displacing colon and midline structures, approached via a generous right supraumbilical transverse abdominal incision.

6 Surgery is a critical component of local primary tumor control and treatment outcomes. In the United States, the standard of care starts with radical nephrectomy at the time of diagnosis of resectable primary tumors, followed by chemotherapy and radiation to sites of residual and metastatic disease. Preoperative chemotherapy is given to patients with inoperable tumors, bilateral disease, solitary kidney, and for tumors with intravascular extension above the hepatic veins. A significant number of patients are downstaged after preoperative chemotherapy without altering recognizable anaplasia.[96] In contrast to this treatment approach, SIOP therapy begins with chemotherapy administration for several weeks prior to nephrectomy in all patients presenting with Wilms tumors.[97] The standard chemotherapeutic drugs with activity against Wilms tumors are vincristine and actinomycin-D. Doxorubicin is added to patients with stage 3

tumors and to those with unfavorable histology or adverse biologic prognostics markers such as LOH at chromosome 1p or 16q. Combinations of cyclophosphamide, ifosfamide, carboplatin, and etoposide are utilized for select stage 3 and 4 cases with unfavorable biology and for resistant or relapsed cases. In the United States, the optimal combination, duration, and mode of administration of chemotherapy are optimized through clinical trials and studies of the NWTSG and COG.

The first two NWTS, NWTS-I and NWTS-II, found that routine postoperative radiation was unnecessary in patients with tumors confined to the kidney and completely resected. Combination therapy of vincristine and actinomycin-D was more effective than single-agent therapy, and the addition of doxorubicin improved survival in higher-stage patients. In addition, the duration of combination chemotherapy was successfully reduced in low-stage patients from 15 months to 6 months without compromising survival outcomes.[98,99] These studies established criteria that identify unfavorable (anaplasia) and favorable histologic features that stratify patients into high-risk and low-risk treatment groups. High-risk patients are at a higher risk of recurrence and also include those with unresectable tumors, lymph node metastases, and diffuse tumor spill. This patient group benefits from intensified chemotherapy and abdominal radiation. These findings paved the way for NWTS-III that demonstrated successful treatment of stage 1 favorable histology Wilms tumors with lower dosing and further reduced duration of vincristine and actinomycin D. The 4-year relapse-free and survival rates with this regimen were 89% and 95%.[100] This study found that stage 2 patients with favorable histology were treated successfully with vincristine and actinomycin D without postoperative radiotherapy or doxorubicin, and stage 3 patients had no differences in abdominal recurrence with reduction of abdominal radiotherapy compared to patients with high-dose radiotherapy when doxorubicin was administered (10.8 Gy compared to 20 Gy). The NWTS-III also found that patients with stage 4 favorable histology tumors were successfully treated with vincristine, actinomycin D, doxorubicin and local radiotherapy based on local tumor stage. The addition of cyclophosphamide was without benefit. This group received lung radiation to both lungs (12 Gy), with 4-year relapse-free and overall survival of 79% and 80.9%. The NWTS-IV trial was largely based on improving treatment results through modifying drug administration utilizing shorter and “pulse-intensive” chemotherapy regimens compared to standard divided dose regimens.[101] The results of this study revealed that shorter pulse-intensive regimens were equivalent to standard treatment regimens in terms of overall survival with total chemotherapy duration of 6 months. Since the NWTS-IV trial, survival rates for children with Wilms tumor have steadily improved with shorter chemotherapy schedules and lower treatment costs.[102] Based on results of NWTS-IV, the current overall survival rate for children with favorable histology Wilms tumor approaches 90%. Current 10-year relapse and overall survival for stage 1 favorable histology Wilms tumors are 91% and 96%, and for stage 2 tumors, 85% and 93%, respectively.[103] NWTS-V completed enrollment in 2003 and was designed as a nonrandomized single arm therapeutic trial to treat patients with stage- and histology-specific treatment plans. In this study, patients were not randomized to therapy, rather biologic properties of tumors were assessed. The aims included determining whether

tumor LOH for chromosomes 1p and 16q was associated with poorer prognosis in patients with favorable histology Wilms tumors and to determine whether increased DNA content in tumor cells was associated with adverse outcomes.[104] LOH for 1p and 16q identified a subgroup of favorable histology patients who have a significantly increased risk of relapse and death.[90] LOH for these chromosomes is now used as an independent prognostic factor as patients with LOH for chromosome 1p and 16q have 75% relapse-free survival.

STAGING[a]

Table 105-4 Wilms Tumor Staging System

Stage	Criteria	4-Yr Survival Rate (%)
1	Tumor is limited to kidney, completely excised; no evidence of rupture, intact surface	97
2	Tumor extends beyond kidney but completely excised, infiltration through renal capsule, extension into vessels outside kidney, local or open biopsy or spillage confined to flank, no residual tumor	95
3	Residual nonhematogenous tumor	91
4	Hematogenous metastases to lung, liver, cortical bone, brain, other organs	78
5	Bilateral renal involvement at diagnosis	Same as highest unilateral stage

[a]Survival based on outcome from patients with favorable biology in the National Wilms Tumor Study-3. Courtesy of the National Wilms Tumor Study.

The NWTS-V also attempted to verify that surgery alone may have acceptable overall survival rates in a subgroup of children younger than 2 years at diagnosis with very low-risk favorable histology of Wilms tumors that weigh less than 550 g.[105] The incidence of relapse was higher in this subgroup of patients receiving surgery only, but the salvage rate was surprisingly high with long-term survival being the same as patients receiving conventional postoperative chemotherapy. Given this, cooperative group trials will further study optimal management of surgery alone in this subgroup to determine whether very low-risk patients may be spared adjuvant therapy.

Since 2006, the COG has opened four clinical trials for the treatment of children with Wilms tumors. For these therapeutic studies, patients are stratified into very low-risk, low-risk, standard-risk, and high-risk groups on the basis of tumor histology, stage, biologic assessment, tumor weight, and age. To facilitate accurate risk assessment, it is currently recommended that all patients diagnosed with Wilms tumor be enrolled and follow protocol recommendations of AREN03B2, a biology classification-based trial. The current treatment recommendations are summarized in Table 105-5 and are based on the most recent COG trials developed to build upon and refine results of previous NWTS (Table 105-5).[106] The protocol guidelines recommend that stage 1 and 2 favorable histology patients undergo initial nephrectomy and lymph node sampling, followed by vincristine and actinomycin-D chemotherapy (regimen EE-4A). Doxorubicin (regimen DD-4A) is added to the treatment plan in patients with stage 1 and 2 tumors with favorable histology and LOH at chromosome 1p and 16, as this subgroup has been shown to have an increased risk of relapse and death. Stage 1 tumors with unfavorable histology (focal

or diffuse anaplasia) have lower 10-year relapse-free and overall survival of 69% and 82% and are treated with vincristine, actinomycin-D, doxorubicin (regimen DD-4A), and abdominal radiotherapy. Stage 3 patients with favorable histology are treated with nephrectomy, lymph node sampling, vincristine, actinomycin-D, and doxorubicin (regimen DD-4A) and abdominal radiotherapy, with 10-year relapse-free and overall survival of 84% and 89%. Cyclophosphamide and etoposide (regimen M) are added to the treatment regimen for stage 3 tumors with favorable histology and LOH at chromosomes 1 and 16q. The presence of diffuse anaplasia also intensifies therapy in stage 2 and 3 tumors with the addition of cyclophosphamide, carboplatin, and etoposide for 30 weeks (regimen UH-1) and abdominal radiotherapy, with 10-year and overall survival rates of 43% and 49%. Stage 4 patients with favorable histology and pulmonary metastases are treated with nephrectomy, lymph node sampling, and vincristine, actinomycin-D, and doxorubicin for 24 weeks. In patients with stage 4 disease, the primary tumor is staged separately to determine the requirement for abdominal radiation. Lung radiotherapy is currently utilized if metastases remain detectable after 6 weeks of chemotherapy. For these reasons, it remains advantageous to resect the primary tumor prior to the initiation of chemotherapy even in patients with stage 4 disease. Based on results of NWTS-4, the 10-year relapse-free and overall survival for patients with stage 4 favorable histology Wilms tumor is 75% and 81%. Stage 4 favorable histology tumors with LOH at chromosomes 1p and 16q are treated with the addition of cyclophosphamide and etoposide (regimen M) and abdominal radiation. Stage 4 tumors with focal or diffuse anaplasia (without measurable disease) are treated with the addition of cyclophosphamide, carboplatin, and etoposide for 30 weeks (regimen UH-1) and radiotherapy. This subgroup of patients has the worst 10-year relapse-free and overall survival of 18%. Stage 5 Wilms tumors (bilateral tumors) with favorable histology have 10-year relapse-free survival and overall survival of 65% and 78%. Patients with bilateral Wilms tumors are treated with preoperative chemotherapy (vincristine, actinomycin-D, doxorubicin) and renal-sparing surgery.

Table 105-5 Recommended Therapy According to COG Protocols

Stage/Histology	Radiotherapy	Chemotherapy
Stage I FHWT, <2 yo, <550 g	None	None
Stage I FHWT, >2 yo, >550 g	None	Regimen EE-4A
Stage II FHWT	None	Regimen EE-4A
Stage I, II FHWT, LOH 1p, 16q	None	Regimen DD-4A
Stage III FHWT, no LOH 1p, 17q	Yes	Regimen DD-4A
Stage I–III focal AHWT	Yes	Regimen DD-4A
Stage I diffuse AHWT	Yes	Regimen DD-4A
Stage III, IV FHWT LOH 1p, 16q	Yes	Regimen M
Stage IV FHWT, pulmonary metastases		
Lesions resected at diagnosis	Yes	Regimen DD-4A
Lesions resolve after 6 weeks chemo	None	Regimen DD-4A
Lesions persist after 6 weeks chemo	Yes	Regimen M
Stage IV FHWT nonpulmonary metastases	Yes	Regimen M
Stage II–III diffuse AHWT	Yes	Regimen UH-1
Stage IV diffuse AHWT	Yes	Regimen UH-1

AHWT, anaplastic histology Wilms tumor; AMD, dactinomycin; CYCLO, cyclophosphamide; DOX, doxorubicin; ETOP, etoposide; FHWT, favorable histology Wilms tumor; LOH, loss of heterozygosity; regimen DD-4A, pulse-intensive AMD, VCR and DOX (24 weeks); regimen EE-4A, pulse-intensive AMD plus VCR (18 weeks); regimen M, VCR, AMD, DOX, alternating with CYCLO and ETOP (24 weeks); regimen UH-1, CYCLO, carboplatin, ETOP alternating with VCR, DOX, CYCLO (30 weeks); VCR, vincristine.
From Ko EY, Ritchey ML. Current management of Wilms' tumor in children. *J Pediatr Urol* 2009;5(1):56–65.

Surgical Considerations

Preoperative biopsies are contraindicated unless a tumor is judged unresectable. For most patients, unilateral radical ureteronephrectomy with abdominal exploration is accomplished through a wide transverse abdominal incision that will allow safe resection and regional lymph node sampling without rupture. A thoracoabdominal incision may be utilized as necessary for tumors reaching the diaphragm. Complete abdominal and pelvic exploration is performed. The contralateral kidney does not require exploration if preoperative imaging does not suggest involvement. The lateral peritoneal reflection is incised and the colon is reflected medially. Although a formal retroperitoneal lymph node dissection is not recommended, lack of adequate lymph node sampling along with the primary tumor resection automatically upstages treatment to stage 3 disease because of the risk of local relapse.[106] Gentle handling of the tumor is critical to avoid tumor rupture and spillage as there is a sixfold increase in local relapse and also automatic tumor upstaging to stage 3.[107] Both local and diffuse tumor rupture will increase relapse risk. It is often unsafe to attempt to ligate the renal vein prior to tumor manipulation given the size of most Wilms tumors as traditionally recommended by most authors. Later ligation of the renal vein after tumor mobilization has not been shown to adversely affect survival outcomes, and early ligation should not be attempted if technically difficult. The dissection is carried out along the tumor capsule and outside of Gerota fascia identifying the renal hilum and isolating the renal artery, vein, and the ureter (Fig. 105-9). The renal vein and inferior vena cava are palpated for intravascular tumor extension. The ureter is divided as distal as possible to the renal hilum though it is not necessary to remove the entire ureter. The tumor and the kidney are then removed en bloc. The adrenal gland may be left in place if it does not abut the tumor or if the tumor arises from the lower pole of the kidney.[108] Titanium clips should be utilized to identify any gross residual tumor. The tumor and the nephrectomy specimen should not be placed into fixative but delivered fresh and sterile to the pathologist to optimize histologic and cytogenetic analysis based on pediatric tumor protocols.

There have been reports of laparoscopic resection of Wilms tumor.[109] These are more likely feasible after preoperative chemotherapy with lower risk of tumor rupture, though safety has not been confirmed. Success of laparoscopy for Wilms tumor is hindered by tumor spill and by inaccurate staging.

Patient selection for preoperative chemotherapy is a critical step in surgical and treatment planning. The overall incidence of surgical complications in patients undergoing nephrectomy for Wilms tumor is 12.7%.[110] The most common surgical complications are small bowel obstruction (5.1%) and excessive hemorrhage (1.9%), followed by wound infection (1.9%) and vascular injury (1.5%) as reported by the NWTS-IV trial. Higher-stage tumors, intravascular extension, and resection of contiguous organs are risk factors associated with surgical complications. The risk of renal insufficiency after unilateral nephrectomy for Wilms tumor is low (0.25%), and patients with Denys-Drash syndrome are most at risk for progressive tumor in the remaining kidney.[111] For these reasons, nephron-sparing procedures are currently reserved for children with bilateral

Wilms tumor and for those at risk for developing renal failure and not indicated for patients with standard unilateral tumors with a normal contralateral kidney.

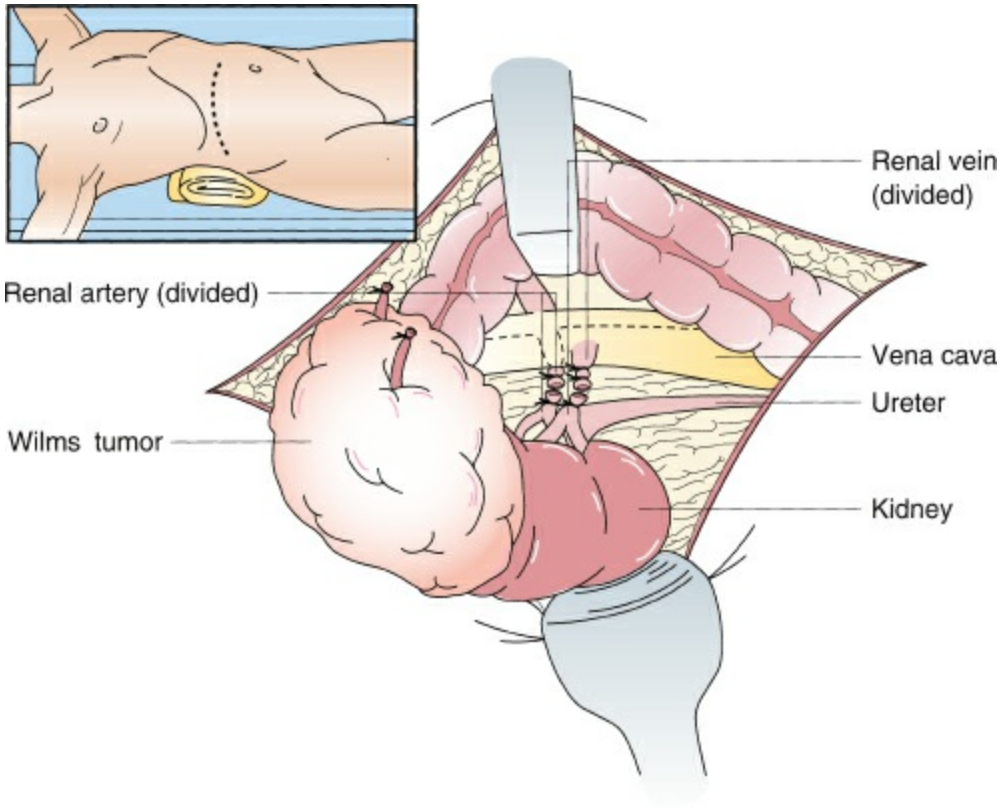

Figure 105-9. Anatomy and operative approach to resection of a Wilms tumor.

Renal Vein/Inferior Vena Cava

Four percent to 10% of patients with Wilms tumor have intravascular extension into the renal vein, inferior vena cava, and rare cases extending into the atrium. Patients may have symptoms of vascular involvement depending on the degree of venous obstruction that may include hypertension, hepatosplenomegaly, ascites, and heart failure. The preoperative ultrasonography and CT scan are accurate in detecting intravascular tumor extension, but the vessels should still be palpated prior to ligation of the renal vein during tumor excision. Studies of Wilms tumors with intravascular extension have found that preoperative chemotherapy facilitates resection by decreasing the extent of tumor thrombus. Overall frequency of complications and the 3-year relapse-free survival rates were similar between the preoperative therapy group and the upfront resection group.[112] Control of the renal vessel and vena cava below and above the tumor thrombus is essential to obtain vascular control and to minimize bleeding after venotomy. Effort should be made to avoid transecting tumor thrombus. If the patient has intracardiac tumor extension after preoperative chemotherapy, a combined thoracoabdominal incision with cardiopulmonary bypass is the safest surgical approach for tumor thrombus excision. The overall survival of children with intravascular extension is the same as children with disease limited to the kidney of similar stage and histology.[113]

Bilateral Wilms Tumor

Five to eight percent of patients with Wilms tumors present with bilateral disease. Bilateral Wilms tumor is found more frequently in patients with hemihypertrophy and genitourinary anomalies. Primary tumor excision at diagnosis is discouraged and patients may be enrolled on NWTS trials without an initial biopsy. If obtained because of uncertainty in diagnosis, core needle biopsies through a posterior approach are preferable to minimize contamination of the abdominal cavity and three-drug chemotherapy is initiated. All children with bilateral Wilms tumors should receive preoperative chemotherapy with the goal of renal preservation. The current COG protocol recommends reevaluation by abdominal CT scan after 6 weeks of chemotherapy to determine the feasibility of a renal-sparing procedure. If the tumor response is less than 50% shrinkage, the COG recommends bilateral open renal biopsies to assess tumor histology prior to additional chemotherapy. After 12 weeks of therapy, all patients should undergo surgical resection as continuing therapy beyond 12 weeks has not been shown to improve outcomes. The primary surgical goal is to spare as much renal parenchyma as possible while obtaining complete tumor resection. Children with synchronous bilateral Wilms tumor or tumor with contralateral nephrogenic rests that have complete radiographic response may not require surgical excision and have low risk for local relapse.[114] These children are monitored for recurrence by serial imaging. If partial nephrectomy is not safe after 12 weeks of chemotherapy, then nephrectomy is recommended. In NWTS-IV, children with bilateral Wilms tumor who had partial resection with complete resection of all gross disease had local relapse rate of 8% and 4-year overall survival of 81.7%.[115]

Partial Nephrectomy

Nephron-sparing surgery is utilized in patients with bilateral Wilms tumor and in select patients at high risk for bilateral disease or renal failure. Partial nephrectomy is not indicated in patients with standard unilateral Wilms tumor given the low risk of renal failure with unilateral nephrectomy. Children with Wilms tumor predisposing syndromes such as WAGR, Beckwith–Wiedemann syndrome, and Denys–Drash syndrome are predisposed to the development of tumors in the contralateral kidney and are, therefore, managed with a nephron-sparing partial nephrectomy approach for unilateral tumors. Screening imaging studies in such patients at risk of developing Wilms tumors may detect lesions that are appropriate for nephron-sparing procedures. These patients may still benefit from preoperative chemotherapy to minimize the extent of renal resection. A radionucleotide dimercaptosuccinic acid renal scan (DMSA scan) is useful to assess preoperative and postoperative renal function.

Partial nephrectomy is typically feasible only if tumor involves one pole and less than one-third of the kidney and if the collecting system and renal vein are uninvolved. For bilateral tumors, the kidney with the lowest tumor burden is addressed first to determine whether partial nephrectomy is feasible. A transverse abdominal incision is utilized for abdominal exploration and partial nephrectomy utilizing the same principles of radical nephrectomy with respect to tumor spillage. Manual compression of the kidney may control blood loss and avoid vascular ischemia. Tumor resection is accomplished by opening Gerota fascia and mass excision via wedge resection with 0.5-to 1.0-cm margin of normal renal parenchyma. Enucleation may be considered for large centrally located lesions. The specimen should be examined closely for rhabdomyomatous changes and anaplasia and nephrectomy considered in patients with positive margins or high-risk histology.[116] Renal functional outcomes after nephron-sparing surgery are assessed by serum creatinine level, glomerular filtration rate, hypertension, and proteinuria.[108] Improved surgical techniques and intraoperative ultrasound have vastly improved the safety and feasibility of nephron-sparing surgery in children at risk of postoperative renal failure.

Future Directions

Future studies will continue to focus on personalized treatment plans based on tumor biology and patient risk stratification. New COG protocols are currently in place with efforts to further improve curative outcomes while minimizing toxicity with refined stratification based on tumor-specific biologic properties. Next-generation exome sequencing has enhanced the capacity to identify disrupted molecular pathways in Wilms tumors, and there is extensive research on identifying their role in Wilms tumor development and pathogenesis.[117] There are very few known genetic alterations in Wilms tumors that have been shown to drive tumorigenesis or progression. Examples of this are the discovery of new mutations in Wilms tumor genes involved in miRNA processing including SIX1 and SIX2.[118] Mutations in this pathway may underlie high-risk Wilms tumors and serve as biomarkers and new therapeutic targets. Several researchers have found significant epigenetic alterations such as changes in DNA methylation or chromatin structure in Wilms tumors. Epigenetic changes at the imprinted region at chr11p15.5 that show an allele-specific pattern of methylation resulting in abnormal expression of IGF2. Targeting IGF2 is an active area of investigation in preclinical drug development.[119] Circulating epigenetically modified DNA and miRNAs have been detected in the blood of patients with cancer, leading researches to investigate the utilization of tracking genetic mutations in the circulation as a mechanism of diagnosis, risk stratification, and tracking tumor burden in Wilms tumor.[117,120] Other areas of intense research continue in the role of myeloablative chemotherapy and the role of autologous bone marrow transplantation in patients with relapsed Wilms tumors.

NON-WILMS RENAL TUMORS

Congenital Mesoblastic Nephroma

Congenital mesoblastic nephroma (fetal renal hamartoma) is the most common renal neoplasm in neonates and infants younger than 3 months and is considered a separate clinical entity from Wilms tumor. In contrast to Wilms tumor, classic congenital mesoblastic nephroma is considered a benign solid tumor of infancy, occurring in a younger age group with an excellent overall prognosis. Almost all cases are diagnosed within the first 6 months of life, representing 5% of renal neoplasms in children.[121] There may be a slightly higher incidence in boys.[122] Congenital mesoblastic nephroma has distinctive spindle cell histopathologic and clinical features that are generally considered benign and rarely metastasizes to other organs. Congenital mesoblastic nephroma is a mesenchymal tumor with three pathologic variants: classic congenital mesoblastic nephroma, a cellular subtype, and a mixed variant. Cellular congenital mesoblastic nephroma subtype is a more aggressive tumor and, though rare, is capable of recurrence and metastases.[123] The cellular subtype is similar in histology to infantile fibrosarcoma and may represent a visceral form of the disease while classic histology is similar to infantile fibromatosis.[124] The cellular variant of congenital mesoblastic nephroma has been found to have a translocation (t12;15) (p13;q25) that results in ETV6-NTRK3 fusion protein, a genetic alteration also found in congenital infantile fibrosarcoma.[125] Similar to congenital infantile fibrosarcoma, trisomy 11 is also found in the cellular subtype of congenital mesoblastic nephroma.[126] These chromosomal aberrations distinguish the cellular variant of congenital mesoblastic nephroma from the classic variant.

Neonates and infants with congenital mesoblastic nephroma present with a palpable abdominal mass that is indistinguishable from other solid abdominal masses on physical examination. Hematuria is often present along with vomiting and jaundice in rare cases.[127] Hypertension or hypercalcemia is rarely present. The most common diagnostic imaging studies utilized are ultrasound and CT scan detailing the presence of a unilateral solid mass with or without cystic components, necrosis, or calcifications. The mass can be detected on prenatal ultrasound and polyhydraminos may be found in up to 70% of patients.[128] The diagnostic workup precedes in much the same manner as Wilms tumor, and the lesions are often not discernible on physical examination or preoperative imaging. The standard treatment of congenital mesonephric nephroma is complete surgical resection with nephrectomy. Wide margins are recommended because these tumors can infiltrate surrounding renal parenchyma and perinephric tissues. Local recurrence, though rare, has been reported and is associated with the cellular variant.[127] Systemic chemotherapy is reserved for tumors that recur and in rare cases of metastases or unusually cellular histology.

Clear Cell Sarcoma

Clear cell sarcoma of the kidney is a rare renal neoplasm of childhood, distinct from Wilms tumor. There are approximately 20 new cases in the United States each year. The median age of diagnosis of clear cell sarcoma of the kidney is 36 months and the tumor is one of the "unfavorable histology" tumors studied by the National Wilms Tumor Study Group and the COG. There is a male predominance with male to female ratio of 2:1.[129] Clear cell sarcoma of the kidney has morphologic diversity and is composed of sarcomatous, nonepithelial cells.[130] The classic microscopic pattern of clear cell sarcoma of the kidney is cords of round or spindle-shaped cells with clear cytoplasm and frequent empty-appearing "Orphan Annie" nuclei. The cord cells are surrounded by variants of regularly spaced arborizing fibrovascular septa resulting in cord widths of between four and 10 cells.[130] The cellular septa are characteristic of clear cell sarcoma and aid in diagnosis. The cord cells range from ovoid to spindle-shaped and the septa range from thin "chicken-wire" capillaries to sheaths of fibroblast-like cells in a collagenous matrix.[129] Most tumors have the classic histologic pattern though almost all demonstrate a secondary variant pattern. There are eight variant patterns recognized: myxoid (50%), sclerosing (35%), cellular (26%), epithelioid (13%), palisading (11%), spindle cell (7%), storiform (4%), and anaplastic pattern (2.6%).[129] Necrosis is associated with poor prognosis and tumors without necrosis are more often stage 1 tumors with superior outcomes.[129]

Patients with clear cell sarcoma of the kidney present with a large unilateral abdominal mass that is best visualized by abdominal ultrasound and CT scan. The tumors are typically well circumscribed and consist of a solid mass with cystic foci components. Necrosis and hemorrhage are common. There is gross extension into the renal vein in 5% of cases. The most common site of metastatic disease is ipsilateral renal hilar lymph nodes (29%), and bone metastases are the most common mode of relapse.[129] Radiographic skeletal survey and radionucleotide bone scan are critical to determine whether there are bone metastases at diagnosis. Patients may also have lung, brain, or liver metastases and, therefore, should have chest and central nervous system (CNS) imaging prior to initiation of chemotherapy for accurate staging. The staging system is similar to Wilms tumor. There is a high rate of metastases and relapse in early-stage tumors, and intensive chemotherapy is utilized for all cases. The current COG treatment recommendations for patients with clear cell sarcoma of the kidney include radical resection of the primary tumor and involved regional lymph nodes, followed by adjuvant chemotherapy consisting of vincristine, actinomycin-D, doxorubicin, and abdominal radiotherapy (10 Gy) for all stages. Since the addition of doxorubicin to the treatment protocols of clear cell sarcoma of the kidney, patients with stage 1 disease have 6-year overall survival of 97%, stage 2 and 3 patients have 6-year survival of 75% and 77%, respectively (compared to 30% for both stages prior to doxorubicin), and stage 4 patients have 6-year survival of 50%.[129] There is active study within the COG on the benefit of the addition of cyclophosphamide and etoposide to treatment plans of patients with clear cell sarcoma of the kidney.[131] There is propensity for late relapse and patients are monitored with abdominal imaging,

chest radiography, brain MRI, and bone scanning.

Rhabdoid Tumor of the Kidney

Rhabdoid tumor of the kidney is a rare and aggressive cancer in infancy, constituting 1.8% of renal neoplasms in children. The cell of origin is unknown and the tumor was originally classified as a rhabdomyosarcomatoid subtype of Wilms but is now recognized as a distinct histologic tumor type. Histologically, rhabdoid tumors are well demarcated from the surrounding kidney and composed of solid and monotonous appearance of sheets of large cells with abundant cytoplasm, cytoplasmic inclusions, and prominent nucleoli.[132] Intense vimentin immunoreactivity is characteristic and these tumors may also stain for cytokeratin, desmin, and neurofilament. Rhabdoid tumors may have areas of necrosis and foci of sclerosis.[132] Rhabdoid tumors may occur as separate CNS primary tumors and up to 15% of patients with rhabdoid tumor of the kidney develop CNS lesions.[133] The overall prognosis of patients with rhabdoid tumor of the kidney remains poor and age is an important prognostic factor.[134] Patients diagnosed with rhabdoid tumors at less than 1 year of age have extremely poor prognoses and are at high risk for CNS tumors, while patients older than 1 year at diagnosis have better outcomes. Low stage and female gender have also been reported as features that predict improved survival.[133] Because of the small number of patients with this disease and overall poor outcomes, few other prognostic indicators have been identified. Rhabdoid tumors are characterized by loss-of-function mutations of the tumor suppressor gene *hSNF5/INI1* located at chromosome 22q11, which encodes a chromatin-remodeling protein complex (SWI/SNF).[135] This chromosomal alteration is thought to be a characteristic genetic defect for rhabdoid tumors of all sites.[136] Both acquired and germ-line mutations have been observed.[137] Although the functional consequences are not yet known, mutations in INI1 have been found to result in altered transcription of genes involved in growth and differentiation.

Patients with malignant rhabdoid tumor of the kidney present with a palpable abdominal mass and often have hematuria. The diagnostic workup proceeds with an abdominal CT scan showing a large heterogeneous solid mass with areas of necrosis, hemorrhage, or calcifications. The tumor typically involves the renal hilum. A chest radiograph or chest CT scan should be obtained to evaluate for lung metastases. Lung metastasis is present in 56% of patients with rhabdoid tumor of the kidney at diagnosis and is the most common site of metastatic spread.[133] Evaluation for CNS disease should also occur at diagnosis because of the frequency of CNS primaries and metastases in patients with rhabdoid tumors. Therapy begins with radical nephrectomy and complete surgical resection including involved regional lymph nodes with paracaval and paraaortic lymph node sampling. Meticulous sampling of any potentially involved lymph nodes is critical for accurate staging. Patients are staged according to NWTS staging system, and all patients receive intensified adjuvant chemotherapy and abdominal radiotherapy. Based on current COG protocols, children with stage 1 to 3 malignant rhabdoid tumor of the kidney are treated with cyclophosphamide, carboplatin, and etoposide alternating with vincristine, doxorubicin, and cyclophosphamide for 30 weeks (regimen UH-1). Stage 4 patients receive vincristine, doxorubicin, cyclophosphamide that is alternated with cyclophosphamide, carboplatin, etoposide, vincristine, and irinotecan for 30 weeks

(regimen UH-2). All patients receive abdominal radiotherapy. The survival rate for children with rhabdoid tumor of the kidney is dismal, with overall survival rates below 25% and very few survivors of stage 4 disease. Despite aggressive multimodal therapy, children younger than 1 year with rhabdoid tumor of the kidney have a 4-year survival of 8.8% and children older than 2 years have 4-year survival of 41.1%. Because previous protocols have had minimal successes with improving relapse and survival in children with malignant rhabdoid tumors, current COG clinical trials are examining intensive chemotherapy regimens and experimental agents in this high-risk renal tumor.[134]

Renal Cell Carcinoma

Renal cell carcinoma is rare in pediatric patients and comprises approximately 5% of all renal tumors in children and adolescents.[4] The tumor is highly aggressive with frequent distant metastases. The median age of diagnosis of renal cell carcinoma in children is 9 to 10 years, and children who have previously received cytotoxic chemotherapy may have predisposition to developing this cancer.[138] Pediatric renal cell carcinoma differs from adult renal cell cancer with distinct clinical and biologic differences. The microscopic pattern does not typically fit well within the standard adult subtypes. In general, histology is consistent with papillary adenocarcinoma, renal cell carcinoma not otherwise specified, and clear cell adenocarcinoma subtypes.[139] High nuclear grade and increased vimentin expression is found in higher-stage cases.[140] Patients with von Hippel–Lindau syndrome may present with bilateral renal cell carcinoma. Tuberous sclerosis, Birt–Hogg–Dube syndrome, and hereditary leiomyomatosis are other hereditary syndromes associated with renal cell carcinoma.[5] It is routine to test for translocations of the Xp11.2 and 6p21 loci, nonrandom genetic alterations that are characteristic of renal cell carcinoma.[141] Tumors with Xp11.2 translocations have papillary and clear cell features and are a separate entity in the World Health Organization classification of renal tumors.[142] This translocation may be present in up to 70% of pediatric renal cell carcinoma and involves the fusion of the *TFE3* gene, a transcription factor belonging to the microphtalmia (MiTF) family.[143] The translocation involving 6p21 is the second most common translocation in pediatric renal cell carcinoma and results in the fusion of TFEB, also a member of the MiTF transcription factor family.[143]

Patients may present with a large palpable abdominal mass. Abdominal pain, hematuria, weight loss, joint pain, and anorexia may also be present. Cross-sectional abdominal and pelvic imaging (CT scan or MRI) along with chest radiography and/or chest CT scan is critical to define the locoregional extent of the mass and to determine metastatic spread. Distant metastatic disease is present in up to 30% of pediatric patients at diagnosis, most commonly to lung (64%), liver (57%), and bone (42%).[143] Local lymph node involvement does not necessarily predict poor outcome in renal cell carcinoma in children.[144] Imaging may show a large nonenhancing renal mass with necrosis or hemorrhage. Calcifications are more common in children with renal cell carcinoma than Wilms tumor.[145] Compared to adults, children with renal cell carcinoma present with higher-stage and higher-grade disease.[143] Children with renal cell carcinoma are staged on the basis of the International Union Against Cancer (UICC)/American Joint Committee on Cancer (AJCC; TNM) system although some studies utilize the modified Robson staging classification system.[141,146] The overall survival at 20 years for pediatric renal cell carcinoma is 54.9%.[147]

If the mass is resectable at diagnosis, standard treatment is radical nephrectomy with lymph node sampling, followed by combination adjuvant chemotherapy, immunotherapy, and radiotherapy based on surgical pathology. The role of lymph node dissection for renal cell carcinoma has not been determined. Partial nephrectomy is reserved for patients at high risk of postoperative renal failure and multiple renal tumors, particularly patients

with genetic syndrome-related disease. There are reports of successful partial nephrectomy for small, unilateral, low-stage tumors. The role of chemotherapy is unproven, as the administration of chemotherapy has not significantly improved survival outcomes. There is some evidence that immunotherapy (IL-2) may be beneficial in select cases of renal cell carcinoma.[148] The COG recently completed a clinical trial (2006 to 2014) examining outcomes of high-risk renal tumors with complete surgical resection, intensive chemotherapy regimens, and radiotherapy. The most common agents utilized are combinations of vincristine, actinomycin-D, doxorubicin, cyclophosphamide, irinotecan, etoposide, and carboplatin (https://clinicaltrials.gov/show/NCT00335556). This prospective study should yield critical results on the optimal management of adjuvant therapy for this tumor.

RHABDOMYOSARCOMA

Epidemiology and Genetic Risk

Rhabdomyosarcoma is the most common soft tissue sarcoma in children with an overall incidence of approximately 350 cases per year in the United States.[149] The median age of presentation is 7 years of age and the majority of patients are diagnosed prior to 10 years of age. There is a slight male predominance and a slightly higher incidence in African-American children.[4] Rhabdomyosarcoma tumors are classified as embryonal, alveolar, or pleomorphic histologic subtypes. Embryonal rhabdomyosarcoma (68%) is the most frequent histologic type and occurs in children younger than 4 years.[149] Alveolar rhabdomyosarcoma (31%) and pleomorphic subtypes (1%) occur more commonly in older children. The overall incidence of rhabdomyosarcoma has not changed much in the last 30 years although there has been an increase in incidence of the alveolar subtype and in cases presenting with distant metastases.[149] The overall survival for rhabdomyosarcoma has increased from 25% to more than 80% in the last four decades. This is largely due to improvements in multimodal therapies including radical surgery, intensive combination chemotherapy, and radiotherapy. Patients with embryonal subtype have the best overall survival. Patients with smaller size tumors and favorable anatomic sites also have significant survival advantage. Age relates independently to survival outcomes with infants (<1 year of age) and adolescents (>10 years of age) more likely to have poor outcome and unfavorable histologic features.[150]

Rhabdomyosarcoma is often associated with congenital malformations, most commonly the CNS and genitourinary systems, with nearly an eightfold increase in CNS anomalies in children with rhabdomyosarcoma.[151] At least 32% of children with rhabdomyosarcoma have at least one congenital anomaly and nearly half are considered major defects. The rate of genitourinary defects in rhabdomyosarcoma is similar to that seen in children with Wilms tumors. There are also several familial syndromes associated with rhabdomyosarcoma. Children in families with Li–Fraumeni syndrome are at risk of developing rhabdomyosarcoma along with cancers of the breast, bone, brain, lung, and adrenal gland.[152] Rhabdomyosarcoma has been reported at an increased incidence in patients with neurofibromatosis type 1 and in patients with Beckwith–Wiedemann syndrome.[153–155] Environmental factors have also been found to have a role in the development of rhabdomyosarcoma. Parental use of recreational drugs has been associated with an increased risk. Several studies have suggested that cocaine and marijuana use in parents may increase the risk of rhabdomyosarcoma in offspring.[156]

Pathology and Biologic Features

Rhabdomyosarcoma is a heterogeneous group of tumors. The origin is thought to be embryonal mesenchyme that gives rise to striated skeletal muscle. Rhabdomyosarcoma can occur in any skeletal muscle group but most commonly affected sites are head and neck, trunk, and genitourinary track. The Intergroup Rhabdomyosarcoma Study Group (IRSG), now the Soft Tissue Sarcoma Committee of the COG, classifies patients with rhabdomyosarcoma into the International Classification of Rhabdomyosarcoma (ICR) that is predictive of outcome among patients with different histologic subtypes.[157] Embryonal rhabdomyosarcoma is a heterogeneous subtype with histologic features that range from primitive mesenchymal cells to highly differentiated muscle cells. The small round blue cells consist of nuclei that are generally small with a light chromatin pattern. The microscopic pattern is moderately cellular with loose myxoid stroma.[157] Embryonal rhabdomyosarcoma comprises up to 75% of rhabdomyosarcoma tumors and is considered an intermediate prognosis tumor in terms of outcomes. Alveolar rhabdomyosarcoma is associated with poor prognosis. The tumors consist of small round cells with coarse chromatin and anastomosing fibrovascular connective tissue septa forming an alveolar pattern that is similar to lung in appearance (Fig. 105-10).[157] Botryoid tumors have excellent prognosis and have similar histologic characteristics of embryonal tumors but grow into hollow spaces such as bladder or vagina, assuming a characteristic grapelike appearance. Spindle cell rhabdomyosarcoma is another subtype of embryonal rhabdomyosarcoma that occurs most commonly at paratesticular sites and generally has excellent prognosis. Pleomorphic rhabdomyosarcomas are extremely rare in children and more common in adults. Rhabdomyosarcoma is detected on immunohistochemistry by desmin, myoglobin/Myo-D, or muscle-specific actin staining.[158] Myogenic phenotype may also be determined by electron microscopy.[159]

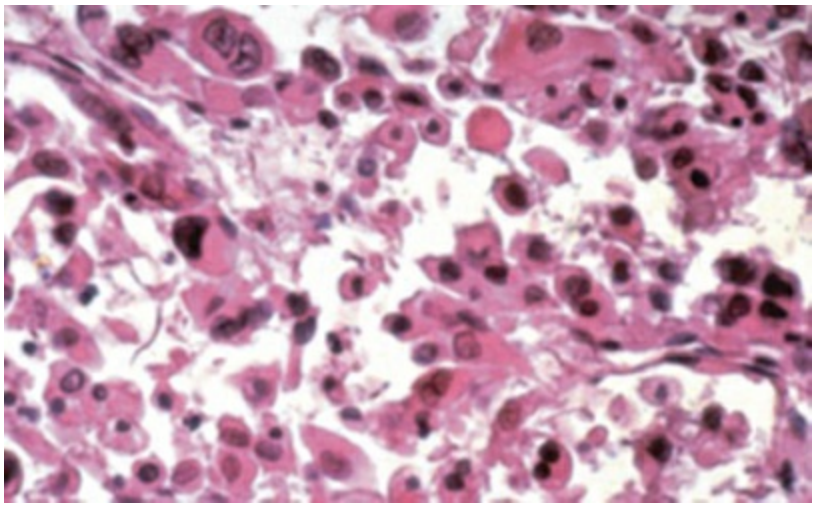

Figure 105-10. Microscopic image of typical lung-like appearance of an alveolar rhabdomyosarcoma. (From Rubin E, Farber JL. *Pathology*. 3rd ed. Philadelphia, PA: Lippincott Williams & Wilkins; 1997, with permission.)

Recurrent chromosomal alterations have been identified in rhabdomyosarcoma, particularly in alveolar subtypes.[160] Consistent translocations between chromosome 2 and

13, *t*(2:13)(q35;q14), have been identified and occur in up to 55% of alveolar rhabdomyosarcoma tumors. The translocation results in fusion of the *PAX3* and *FKHR* genes, both transcription factors that function in muscular development. The resulting gain of function fusion gene is thought to alter cellular apoptosis, growth, and oncogenesis.[161] Another *PAX* gene translocation, *t*(1;13) (p36;q14), results in fusion gene *PAX7-FKHR* and also occurs in alveolar tumors.[162] These recurrent chromosomal alterations rarely occur in embryonal rhabdomyosarcoma. Nearly 80% of alveolar tumors have PAX3-FKHR or PAX7-FKHR fusions detectable by polymerase chain reaction (PCR) and may aid in diagnosis.

Embryonic rhabdomyosarcoma is associated with allelic loss at chromosome 11p15.5, a possible tumor suppression region.[163] The mechanism of loss appears to preferentially maintain the paternal allele and lose the maternal allele, suggesting genomic imprinting.[164] Other genetic abnormalities have been identified through comparative genomic hybridization with whole chromosome gains and losses in embryonal rhabdomyosarcoma.[165] Genomic amplifications have been detected in alveolar subtypes and in embryonal rhabdomyosarcoma with anaplasia.[165]

Presentation and Diagnosis

Rhabdomyosarcoma can arise at any mesenchyme-containing site in the body. The presenting signs and symptoms depend on the site affected. Approximately 35% of all rhabdomyosarcoma tumors arise in the head and neck region and include parameningeal and nonparameningeal sites. Tumors in these areas may cause headache, facial and cervical swelling, nasal obstruction or discharge, recurrent otitis media, and cranial nerve palsies.[166] Tumors of the genitourinary track account for 25% of rhabdomyosarcoma and are most commonly located in the bladder and the prostate gland. Perineal and perianal lesions may also occur. Patients may present with a palpable abdominal or pelvis mass, hematuria, dysuria, or urinary retention. Botryoid tumors are common in the vagina and the cervix and may present with vaginal bleeding and inflammation. The friable grapelike mass may protrude from the vaginal orifice. Paratesticular rhabdomyosarcoma presents with a painless mass in the scrotum that is typically distinguishable from the testicle. Extremity rhabdomyosarcoma tumors may present as swelling and pain after a traumatic injury to the extremity involved. Chest wall, paraspinal, and abdominal wall rhabdomyosarcoma are considered trunk sites and often present with palpable masses or chest wall pain. Additional primary sites include retroperitoneum, abdomen, and pelvis. These lesions may present as a palpable abdominal mass or with abdominal pain. There is seldom mass effect such as rectal or bladder obstruction. Biliary rhabdomyosarcoma may cause jaundice, fever, and right upper quadrant abdominal pain.

The diagnostic workup for rhabdomyosarcoma includes a thorough history and physical examination, followed by cross-sectional imaging of the involved site by CT scan or MRI. Local, regional, and distal metastatic extent of disease should be determined with assessment for abnormal appearing lymph nodes. PET scan may aid in detection of disease for adequate staging.[167] Complete blood count, serum chemistries, and liver function tests are routinely evaluated. Patients with suspected rhabdomyosarcoma should have bone marrow biopsies and aspirates performed to determine metastatic spread to bone marrow. Chest CT scan or chest radiograph is required to identify lung metastases. Bone scintigraphy should be obtained to search for cortical bone metastases. For most cases, brain CT scan and cerebral spinal fluid testing are reserved for patients with known CNS lesions or symptoms. An adequate biopsy is required to histologically confirm diagnosis. If the lesion is small or judged resectable on presentation, excisional biopsy with clear microscopic margins should be performed. If the tumor involves contiguous organs, major blood vessels, or nerves then incisional biopsy is performed. It is critical that the specimen is sent fresh to the pathologist without formalin and that enough tissue is obtained for microscopic evaluation and cytogenetic analysis.

Table 105-6 TNM Pretreatment Staging System

Stage	Site	T	Size	N	M
I	Orbit, Head and neck (excluding parameningeal), genitourinary (nonbladder/prostate)	T1 or T2	a or b	N0, N1, or N2	M0
II	Bladder/prostate, extremity, head and neck (parameningeal), other (trunk, retroperitoneum)	T1 or T2	a	N0 or Nx	M0
III	Bladder/prostate, extremity, head and neck (parameningeal), other (trunk, retroperitoneum)	T1 or T2	a b	N1 N0, N1, or Nx	M0
IV	All	T1 or T2	a or b	N0 or N1	M1

Reprinted from Lawrence W Jr, Anderson JR, Gehan EA, et al. Pretreatment TNM staging of childhood rhabdomyosarcoma: a report of the Intergroup Rhabdomyosarcoma Study Group. Children's Cancer Study Group. Pediatric Oncology Group. *Cancer* 1997;80(6):1165–1170.

Staging

The most widely utilized staging system for rhabdomyosarcoma is based on the tumor, node, and metastases (TNM) staging system. TNM staging system is applied prior to treatment and assesses disease site of origin, tumor size, nodal status, and metastases as factors in prognosis (Table 105-6). This system was prospectively tested in IRSG clinical trials IRS-III and IV and reflects the biology of the tumor.[168] Most tumors are larger than 5 cm in size and 20% present with distant metastases at diagnosis (stage 4). Stage 1 tumors involve the head and neck, genitourinary (nonbladder/prostate), and biliary tract sites. Regional nodes may or may not be involved with stage 1 tumors. Stage 2 tumors involve the bladder/prostate gland, extremity, and cranial, parameningeal, retroperitoneal, and trunk sites and are smaller than 5 cm without lymph node involvement. Stage 3 tumors are the same anatomic sites as stage 2 and are larger than 5 cm with or without lymph node involvement. Any rhabdomyosarcoma tumor with distant metastases is considered stage 4 disease.

Clinical Group Assessment and Risk Status

Both stage and group assessment is used to assign risk categories and to determine treatment plan. The IRSG developed a surgical–pathologic clinical grouping system to standardize risk assessment in the IRS I and II therapeutic clinical trials. Patients are grouped into four risk groups on the basis of postoperative assessment of disease before initiating chemotherapy or radiation (Table 105-7).[169] Clinical group accurately predicts outcomes in patients with rhabdomyosarcoma.[169] Group I patients have excellent prognosis with localized tumors that are completely excised while group II patients have tumors that have microscopic residual disease or regionally invasive disease involving lymph nodes. Group III patients have gross residual disease or incisional biopsy, and group IV patients have distant metastases at presentation. Stage, clinical group, histology, age, and anatomic site are utilized to identify low, intermediate, and high-risk categories, and therapy is allocated on the basis of patient risk status. Favorable sites are orbit, head and neck (except parameningeal), genitourinary (except bladder and prostate), and biliary tract sites. Unfavorable sites are bladder/prostate, extremity, parameningeal, trunk, retroperitoneal, pelvis, and all other sites. Combinations of chemotherapy and radiotherapy are administered on the basis of risk group assignment. Alveolar and embryonal histology subgroups contrast in prognostic factors and in survival outcomes.

In patients with nonmetastatic rhabdomyosarcoma, tumors considered low-risk are embryonic rhabdomyosarcoma tumors (stage 1 or 2) located at favorable histology sites.[170] Embryonal tumors at unfavorable sites may also be assigned as low-risk group if the tumor is grossly completely resected (group 1 or II). There are two subsets of low-risk patient groups. Subset A (stage 1, group 1 or IIa; stage 2, group 1, group III orbit) is associated with worse failure-free survival (82%) in patients older than 10 years, though overall survival is the same as in younger patients (92%). This suggests excellent salvage therapy in this subgroup of patients. Low-risk subset B patients (stage 1, group IIb or IIc, stage 1, group III nonorbit; stage 2, group II, stage I, group 1 or II) with tumors larger than 5 cm also have worse failure-free survival (77%) but similar overall survival as patients with smaller tumors (93%).[170] The intermediate-risk embryonal rhabdomyosarcoma group comprises patients with unfavorable anatomic sites with tumor remaining after surgical excision. This risk group has worse survival outcomes than patients with low-risk tumors. In this group, patients with unresectable extremity rhabdomyosarcoma have extremely poor failure-free (43%) and overall (46%) survival.

Table 105-7 Surgical–Histopathologic Clinical Grouping System for the Intergroup Rhabdomyosarcoma Studies I and II

Group I: Localized tumor, completely resected
A. Confined to organ or muscle of origin
B. Infiltration outside organ or muscle of origin, regional nodes not involved
Group II: Compromised or regional resection including
A. Grossly resected tumors with "microscopic" residual
B. Regional disease, completely resected, in which nodes may be involved and/or tumor extends into an adjacent organ
C. Regional disease with involved nodes, grossly resected, evidence of microscopic residual
Group III: Incomplete resection or biopsy, gross residual disease
Group IV: Distant metastatic disease, present at presentation

Reprinted from Crist WM, Garnsey L, Beltangady MS, et al. Prognosis in children with rhabdomyosarcoma: a report of the Intergroup Rhabdomyosarcoma Studies I and II. Intergroup Rhabdomyosarcoma Committee. *J Clin Oncol* 1990;8(3):433–452, with permission.

In general, children with alveolar rhabdomyosarcoma have worse survival outcomes compared to those with embryonal histology. Patients with stage 1 or 2 tumor that is grossly resected (group 1 or 2) have 5-year failure-free survival of 80% and overall survival of 85%. Stage 1 or 2 (group III) patients have overall favorable outcomes as well. Children younger than 1 year with alveolar histology have considerably worse survival outcomes (43%). Patients with stage III tumors with nodal involvement also have poor survival outcomes (34%). Survival correlates with stage, and patients with high-risk tumors with distant metastases at diagnosis continue to have the worse expected survival of 25% despite intensified cytotoxic therapy and radiotherapy.

Treatment

Much of the treatment success of rhabdomyosarcoma is credited to successful clinical trials conducted by the IRSG and the Soft Tissue Sarcoma Committee of the COG. Multimodal therapy aims to minimize the risk of relapse and optimize curative outcomes, while also minimizing treatment toxicities. The INRG has completed five major clinical trials (IRS-I, II, III, IV, V/D) that provide the foundation upon which the current treatment schema is based for all children diagnosed with rhabdomyosarcoma. IRS-V or the "D" studies further refined treatment protocols on the basis of prognostic factors and risk stratification.[169–172]

7 The mainstay of therapy begins with surgery, either complete excision with adequate margins or incisional biopsy. The goal for surgical margins is at least 0.5 cm of normal tissue surrounding tumor. Margins should be marked and oriented to ensure that pathologists can accurately identify each microscopic margin. Contiguous structures, organs, major blood vessels, or nerves that would result in major disability should not be resected in the initial operation, rather an adequate biopsy should be obtained and chemotherapy given upfront. In contrast, lesions that are small and not invading surrounding structures may be completely resected prior to chemotherapy. Resection of rhabdomyosarcoma tumors with wide and completely clear microscopic margins is the most ideal initial procedure for all stages to obtain local tumor control. Pretreatment re-excision is recommended after the initial operation if there is gross residual tumor or microscopically involved margins prior to the administration of chemotherapy. This is critical for accurate staging and for optimal clinical group assignment. Debilitating or highly morbid operations are performed only after chemotherapy and radiation have been given in attempt to decrease tumor burden and minimize extent of resection.

Lymph node sampling is indicated for patients with lesions that involve the extremity (even if clinically negative) or for clinically positive lymph nodes for all other sites. Biopsies by open, core, or sentinel lymph node biopsy techniques are all acceptable on the basis of current COG guidelines. Staging ipsilateral retroperitoneal lymph node dissection is recommended for paratesticular rhabdomyosarcoma for all males older than 10 years and for those younger than 10 years with enlarged lymph nodes appearing on CT scan. In this group, staging ipsilateral retroperitoneal lymph node dissection is required for adequate staging and risk group assessment. A nerve-sparing ipsilateral retroperitoneal lymph node dissection is recommended. The boundaries of the dissection begin at the level of the renal veins surrounding the aorta and the vena cava, extending to the deep inguinal ring. The procedure may be performed laparoscopically or through an open abdominal incision. Patients with intermediate-risk tumors may benefit from radical debulking of clinically positive lymph nodes if feasible.

The addition of chemotherapy and radiotherapy to treatment protocols for rhabdomyosarcoma has dramatically improved survival rates. Currently, all children diagnosed with rhabdomyosarcoma receive adjuvant chemotherapy with or without radiotherapy. Current treatment protocols for patients with low-risk rhabdomyosarcoma (subgroups A and B) consist of vincristine, actinomycin-D, cyclophosphamide, and local

radiotherapy to sites of residual disease (groups II and III). A recent clinical trial from the Soft Tissue Sarcoma Committee of COG (D9602) focused on eliminating cyclophosphamide and reducing radiotherapy doses in patients with lowest risk rhabdomyosarcoma.[173] This study found that the 5-year failure-free and overall survivals were lower than similar ISR-IV patients receiving cyclophosphamide. Given these results, the COG is currently studying a more modest dose reduction of cyclophosphamide (ARST0331, closed 2012) for both low-risk subgroups with aims of maintaining the excellent outcomes of IRS-IV and further reducing toxicity.[172]

Intermediate-risk tumors are nonmetastatic and include alveolar rhabdomyosarcoma at any site (stages 1 to 3). Embryonal rhabdomyosarcoma in an unfavorable site that is incompletely excised (stage 2, 3, and group III) is also considered intermediate-risk. The standard chemotherapy for this group is vincristine, actinomycin-D, and cyclophosphamide with radiotherapy. Improvements in survival have not progressed as much in this group compared to low-risk tumors. IRS-IV did not show improvement in outcomes for intermediate-risk group patients by the addition of ifosfamide and ifosfamide/etoposide substituting for actinomycin-D and cyclophosphamide.[174] The COG recent intermediate-risk study (D9803) compared standard vincristine, actinomycin-D, and cyclophosphamide to a regimen that alternated standard therapy with vincristine, topotecan, and cyclophosphamide.[175] This regimen did not significantly improve outcomes compared to standard therapy. Results are pending from the COG's most recent trial (ARST0531, closed 2013) that randomized patients to receive standard therapy versus standard therapy alternating with vincristine and irinotecan, and earlier onset radiotherapy.[172] The actions of vincristine and irinotecan are thought to be synergistic with enhanced cytotoxic activity based on preclinical and pilot studies.

High-risk patients have metastatic disease on presentation with dismal outcomes despite intensive cytotoxic therapy. Current therapy for high-risk tumors is based on results of the COG high-risk rhabdomyosarcoma phase II window studies (D9802) and previous IRS-I-IV trials.[176] These studies were the backbone for ARST0431 (closed 2010), which treated patients with multiple combinations of intensive chemotherapy that included vincristine, actinomycin-D, doxorubicin, irinotecan, cyclophosphamide, and ifosfamide/etoposide.[177] The feasibility of concurrent early administration of radiotherapy and irinotecan is also being evaluated. Long-term follow-up on the most optimal combinations of intensified chemotherapy in high-risk patients with rhabdomyosarcoma is needed. Recently, the COG study (ARST08P1) examined novel biologic agents. Cixutumumab, a monoclonal antibody against insulin-like growth factor-I receptor (IGF-IR), and temozolomide were added to intensive chemotherapy backbone regimens. Early results are promising for improved failure-free survival with cixutumumab but overall survival remains poor.[178]

Radiotherapy in the form of external-beam radiation is utilized in group II to IV patients and in group 1 alveolar cases to enhance local control.[179] Radiotherapy is utilized as the primary means of local control in rare cases in which surgical excision carries excessive risk or concern for disfigurement (orbital and vaginal). Parameningeal tumors are treated with radiotherapy because of the high likelihood of residual disease with

surgical excision. The most commonly utilized doses range from 36 Gy to 50 Gy, and higher doses are administered to patients with group III or IV disease (50 Gy given in 28 fractions).[179] The IRSG studied a trial of hyperfractionated radiotherapy versus conventionally fractionated radiotherapy in patients with group III rhabdomyosarcoma and found no differences in failure rates or survival outcomes.[180]

Future Directions

Future clinical trials are focused on further tailoring therapies to reduce treatment toxicities and late adverse effects while improving curative outcomes. The current focus is incorporation of novel biologic agents to known active backbone chemotherapy regimens, particularly for patients with intermediate-risk and high-risk rhabdomyosarcoma. Human patient tumor-derived xenograft models are guiding future development of novel targeted therapies for this cancer. The National Cancer Institute supports the Pediatric Preclinical Testing Consortium, a program to evaluate novel molecules for genomically characterized solid tumors, including rhabdomyosarcoma (http://ctep.cancer.gov/MajorInitiatives/Pediatric_Preclinical_Testing_Program.htm).

NONRHABDOMYOSARCOMA SOFT TISSUE SARCOMA

Epidemiology

Soft tissue sarcomas in children and adolescents occur in approximately 8% of all childhood solid tumors. Nonrhabdomyosarcoma soft tissue sarcoma (NRSTS) represents approximately half of these cases, occurring in 250 to 300 children per year in the United States.[181] Infants and adolescents are more commonly affected, and there is a slightly higher incidence in males and in African Americans. NRSTS comprises 27% of sarcomas in infants (<12 months), of which, 24% are fibrosarcomas, 1.7% are malignant fibrous histiocytoma (MFH), and 1.3% are peripheral nerve sheath tumors.[182] The incidence of NRSTS has not changed in the last several decades. The overall 10-year survival has also remained steady at 73%. The tumors are distinct from rhabdomyosarcoma in terms of clinical characteristics, tumor biology, and prognosis. Most cases are sporadic although patients with Li–Fraumeni syndrome, neurofibromatosis type I (peripheral nerve sheath tumors), Gorlin syndrome (fibrosarcoma and leiomyosarcoma), and hereditary retinoblastoma have a higher risk of developing soft tissue sarcomas.[183–185] Children who are survivors of childhood cancer are at an increased risk for NRSTS, particularly those with history of receiving radiation, high-dose anthracyclines, and alkylating agents.[186]

Pathology and Biologic Features

NRSTS originates from developmental mesenchymal cells with heterogeneous histologic subtypes and diverse sites of origin. These tumors are classified on the basis of histology-specific cytogenetics of the tumor. NRSTS may have segmental chromosomal alterations (balanced translocations) or widespread genomic instability (Table 105-8). Most of the translocations found in NRSTS generate fusion proteins from two different transcription factors that disrupt normal embryonic development and drive sarcomagenesis.[187] ETV6-NTRK3 found in infantile fibrosarcoma and *anaplastic lymphoma kinase* (*ALK*) found in inflammatory myofibroblastic tumors are tumor cell–specific activated kinases that may have important roles in pathogenesis.[188] Dermatofibrosarcoma protuberans contain the *COLIA1-PDGFB* fusion gene.[189] Genetic analysis is a powerful tool for the diagnosis of NRSTS and is an important component of the histopathologic assessment. Detection of tumor-specific chromosomal alterations by RT-PCR, FISH, or high-throughput sequencing analyses often aids in confirming the diagnosis and in treatment planning.

Table 105-8 Nonrhabdomyosarcoma Tumor Characteristics

Tumor	Incidence[a,b]	Normal Counterpart[a]	Cytogenetic Abnormality[a]	Genes[a]	Common Primary Sites
Fibrosarcoma	0.6	Fibroblasts	*t*(12;15)	*TEL (ETV6), NTRK3(TRKC)*	Lower extremity, upper extremity
Desmoplastic round cell tumor[c]	Approximately 200 case reports	Lineage epithelial, neural, myogenic cells	*t*(11;22)	*EWS, WT1*	Abdomen, paratesticular, thoracic cavity
Leiomyosarcoma	0.3	Smooth muscle	Variable	Multiple gene alterations	Gastrointestinal or genito-urinary, superficial dermis, retroperitoneal, lungs, uterus, vascular
Alveolar soft parts tumor	0.1	Unknown	*t*(x;17)	*ASPL, TFE3*	Thigh, buttocks, abdominal, and chest wall
Neurofibrosar-coma	0.6	Schwann cell	Variable, abnormalities of chromosome 17	Multiple genetic alterations, NF1	Extremity, retroperitoneum, trunk
Liposarcoma	0.1	Adipocyte	*t*(12;16)	*FUS, CHOP*	Lower and upper extremity, retroperitoneum
Tendosynovial sarcoma	0.7	Synovial cells	*t*(x;18)	*SYT, SSX-1, or SSX-2*	Lower extremity (thigh, foot, posterior knee), upper extremity (shoulders, forearm)
Dermatofibrosar-coma protuberans	1.0	Fibroblasts	*t*(12;22)	*COL1A, PDGF*	Trunk, proximal extremities

[a]From Gurney J, Young J Jr, Roffers S, et al. In: Ries LAG, Smith MA, Gurney JG, et al., eds. *Cancer Incidence and Survival among Children and Adolescents: United States SEER Program 1975–1995*. Bethesda, MD: National Cancer Institute, SEER Program; 1999.
[b]Incidence age-adjusted per million younger than 20 years (excluding desmoplastic round cell tumor).
[c]From Saab R, Khoury JD, Krasin M, et al. Desmoplastic small round cell tumor in childhood: the St. Jude Children's Research Hospital experience. *Pediatr Blood Cancer* 2007;49:274–279.

Presentation, Diagnosis, and Staging

NRSTS typically presents as a painless slow-growing solid mass that may invade surrounding structures. Approximately 15% of patients present with metastatic disease at presentation, most commonly lungs.[190] Survival for patients presenting with metastatic disease remains poor (35%), and disease-free progression is only 15% despite aggressive multimodality therapy. In general, diagnostic workup for NRSTS consists of cross-sectional imaging (MRI) of the primary site along with imaging (CT scan) of chest, abdomen, and pelvis for surgical planning and adequate staging. Bone scintigraphy is used only for patients with bone pain or symptoms. Bone marrow biopsy is typically not indicated. Brain imaging is reserved for patients with CNS symptoms.

An adequate tissue specimen is required to determine the histologic subtype and grade of NRSTS. Complete surgical resection of all gross diseases is recommended at presentation unless a wide resection is not feasible or accompanied by high surgical morbidity. Multiple core needle biopsies may be sufficient though the quality and quantity of specimen must be adequate for histologic and cytogenetic studies. Fine-needle biopsy is not acceptable for diagnosis. The fresh specimen should be evaluated for routine histopathology, immunohistochemistry, and molecular studies including DNA and RNA cytogenetic studies, flow cytometry, and electron microscopy.[186] Array technologies are being increasingly utilized in analysis of NRSTS, allowing measurements of tumor RNA expression and gene copy number.[191] A pathologic tumor grade is assigned to NRSTS on the basis of extent of malignancy and is an indicator of prognosis. The grading system utilized in pediatric NRSTS was developed by the Pediatric Oncology Group using concepts of adult grading systems integrating characteristics of pediatric sarcomas.[192] The Pediatric Oncology Group grading system for NRSTS assesses mitotic rate, extent of necrosis, differentiation, and histologic type and can be used as a predictor of outcome.

The size of the mass is important in initial surgical planning and determines surgical approach.[193] Tumor size of 5 cm is utilized by the American Joint Cancer Commission staging system of sarcoma as standard “cutoff” for resectability, though this has been difficult to translate to children with small body surface areas. This was addressed by the development of an equivalency factor that is utilized to calculate prognosis of soft tissue sarcoma based on size of the mass and body surface area.[194] Although tumor size is a key prognostic factor in adult soft tissue sarcomas, the risk is not the same in patients of different body sizes, and 5-cm cutoff may not pertain to infants and children.

Extent of disease, grade, size, and age, and extent of resection all influence prognosis and survival outcomes in NRSTS.[195] Patients are grouped into low, intermediate, and high-risk (metastatic disease) categories. High-risk patients have overall survival of approximately 15%, and most patients succumb to widespread metastatic disease. Intermediate-risk patients have unresectable tumors at presentation with residual disease or large (>5 cm), high-grade tumors. The survival in this risk group is approximately 50%. Low-risk tumors are completely resectable (<5 cm or equivalent) and are low grade.[186] Low-risk patients have the best prognosis with overall survival of 90%. In general, patients with negative microscopic margins have the best outcomes, and the

addition of radiotherapy minimizes the risk of recurrence. A pediatric NRSTS staging system has not been validated. The IRSG surgicopathologic staging system for rhabdomyosarcoma is often utilized as well as the TNM sarcoma staging systems for adults. The COG is addressing the issue of staging for pediatric NRSTS in ongoing clinical studies.

Treatment

Complete surgical resection is critical in the management of NRSTS because of resistance to chemotherapy and radiotherapy. Primary tumors that appear grossly resectable should be excised upfront. If the surgeon anticipates that gross residual disease is likely following surgery or if complete excision is debilitating or disfiguring, tumor biopsy should be performed. This is typically seen with large (>5 cm), high-grade regionally invasive or metastatic tumors that will benefit from neoadjuvant chemotherapy and delayed tumor resection. Tumor debulking is generally not recommended. Large, potentially morbid resections such as amputation and pelvic exoneration are performed only after neoadjuvant therapies. In general, incisions on the extremities should be placed longitudinally and incisions on the trunk are oriented in the axial plane. If the surgeon determines that the mass is not amendable to full excision upfront, a generous incisional biopsy is required. Primary re-excision of the primary tumor is recommended if there is gross residual resectable tumor after the initial resection with at least a 0.5-cm margin. Re-excision is also recommended if the margin status is unknown. Previous scars or needle tracts should be included en bloc with the specimen. Lymph node sampling is required for abnormal appearing lymph nodes on clinical examination or imaging. Several histologic subtypes of NRSTS also require lymph node evaluation for risk assessment and staging purposes, even in patients without enlarged lymph nodes. These include synovial cell sarcoma, epithelioid sarcoma, and clear-cell sarcoma with up to 30% risk of lymph node metastases.[193] In these groups, patients without radiologic evidence of nodal metastases may benefit from sentinel lymph node mapping with technetium 99m and biopsy rather than traditional lymph node sampling, though results have been mixed.[196,197]

The most active chemotherapeutic agents for NRSTS are doxorubicin and ifosfamide, though most NRSTSs are relatively chemoresistant. Current treatment strategies are based on protocols from the COG clinical trial ARST0332 that assigned NRSTS patients to treatment groups on the basis of risk. Low-risk patients (grossly resected, low grade, any size) receive surgical excision alone with or without radiotherapy, depending on margins status. Intermediate-risk and high-risk (metastatic disease) patients are treated with ifosfamide and dose-intensive doxorubicin and radiotherapy either before or after surgical excision. The outcomes of this trial are pending. Because of the limited efficacy of chemotherapy in NRSTS, novel targeted therapeutic approaches are warranted, especially for children with high-grade or relapsed tumors.[186,195]

HEPATIC TUMORS

Hepatoblastoma

Epidemiology and Genetic Risk

Hepatoblastoma is the most common malignant liver tumor in children, occurring in 0.7 per million to 1 per million children younger than 15 years, yielding approximately 100 cases per year in the United States.[4] The incidence of hepatoblastoma has increased roughly 4% in the last three decades in the United States.[198] Hepatoblastoma occurs most commonly in infants and children between the ages of 6 months and 3 years. A slight male predominance is reported and there does not appear to be significant differences in incidence among race. The median age at diagnosis is 18 months of age. Hepatoblastoma is the third most frequent abdominal tumor after neuroblastoma and Wilms tumor. Environmental risk factors have not been confirmed. Hepatoblastoma has been found in association with prematurity and low birth weight.[199] There is a strong association with very low-birth-weight neonates (<1,500 g) though the underlying mechanism is not yet unknown.[198]

Several inherited syndromes are associated with hepatoblastoma. Patients with Beckwith–Wiedemann syndrome are at risk for developing hepatoblastoma and require routine screening.[200] Most cases are due to defective imprinting on chromosome 11p15.[201] Hepatoblastoma may also occur in children with hemihypertrophy and trisomy 18.[202] There is an increased risk of hepatoblastoma in children of families with familial adenomatous polyposis (FAP) syndrome though no specific genetic alteration in chromosome 5 has been identified.[203] There is a nonrandom association between hepatoblastoma and children with trisomy 18.[204]

Sporadic hepatoblastoma has not been characterized by any single chromosomal abnormality and cytogenetic analyses have not revealed consistent patterns. The most common genetic abnormalities are trisomies.[2,8,19,205] These genetic alterations are thought to have a role in hepatoblastoma pathogenesis, but the precise molecular mechanism is not understood.LOH of 11p15 has been detected in up to 33% of children with hepatoblastoma, and it is hypothesized that a tumor suppressor gene may be located in this region.[206] Insulin-like growth factor 2 (IGF-2), a fetal mitogen, is an imprinted gene on 11p15 affected by β-catenin mutations.[207] LOH at 11p is most often of maternal origin and commonly found in patients with Beckwith–Wiedemann syndrome. LOH has also been found at chromosome 1p and 1q and may have a role in tumorigenesis.[208] Translocations involving the *NOTCH2* gene at chromosome 1 have been detected in hepatoblastoma tumors.[209]

Pathology and Biologic Features

Hepatoblastoma displays a combination of histologic patterns that range from epithelial and mesenchymal elements. This tumor is thought to originate from undifferentiated embryonal hepatic cells that maintain pluripotency and have potential to develop into both hepatocytes and biliary epithelial cells.[210,211] Hepatoblastoma may be classified by five different histologic subtypes that carry prognostic value: well-differentiated fetal (pure fetal), embryonal, macrotrabecular (epithelial fetal or embryonal), small cell undifferentiated, and cholangioblastic (bile ducts predominate) (Table 105-9).[212,213] Of these, the most favorable outcomes are seen with well-differentiated fetal subtypes. Small cell undifferentiated tumors (anaplastic subtype) carry the worse prognosis.[214] Small cell undifferentiated tumors are often associated with low or normal serum α-fetoprotein (AFP) levels (<100) and predict adverse outcomes with poor response to chemotherapy.[215] The majority of hepatoblastoma tumors are epithelial with mixed embryonal and fetal patterns (67%), and 21% of these have mesenchymal components.[213,216] Hepatoblastoma tumors secrete interleukin 1β that induces IL-6 production, enhancing hepatocyte growth factor.[217] There is evidence that hepatocyte growth factor is secreted postoperatively and functions as a growth factor for hepatoblastoma tumor cells.[218]

Presentation, Diagnosis, and Staging

Children with hepatoblastoma present with an asymptomatic abdominal mass or abdominal swelling. Systemic symptoms such as weight loss, failure to thrive, or anorexia may indicate advanced disease. Jaundice and biliary obstruction does not typically occur in patients with hepatoblastoma. Distant metastases are present in approximately 20% of patients at diagnosis and the most common site is lungs.[219] Ultrasound and cross-sectional imaging (three-phase CT scan or MRI with EOVIST) will define segmental extension of the tumor within the liver and assess for distant metastases (Fig. 105-11). The majority of hepatoblastoma tumors are located in the right lobe of the liver (up to 70%). The tumor appears as a solid mass with low attenuation. On MRI, the lesion appears as low intensity on T_1-weighted images and high intensity on T_2-weighted images. There is no evidence that MRI is superior to CT scan for diagnosis or surveillance of hepatoblastoma. It is important to distinguish central venous structures and to evaluate the liver for multifocal disease. Chest CT scan is obtained to evaluate for lung metastases. Anemia and thrombocytosis are common in children with hepatoblastoma and are likely related to cytokine secretion by tumor cells. AFP is elevated in approximately 90% of patients with hepatoblastoma and is a useful clinical marker for monitoring tumor responsiveness and recurrence. Interpretation of AFP may be difficult because the protein is expressed in the fetus and commonly remains elevated in normal neonates and infants up to 6 months of age. AFP may also be elevated in patients with hepatitis, hepatocellular carcinoma (HCC), and germ cell tumors. A high serum cholesterol level is also detected in 50% to 60% of children with hepatoblastoma.

Table 105-9 Relative Risk of Death for Histologic Subtypes of Hepatoblastoma[a]

Histopathologic Subtype	Relative Risk of Death
Fetal	1.07
Embryonal	1.74
Mixed	0.53
Macrotrabecular pattern	1.20
Small cell undifferentiated	3.71

[a]Adjusted for age, sex, and stage compared with other histologic subtypes.

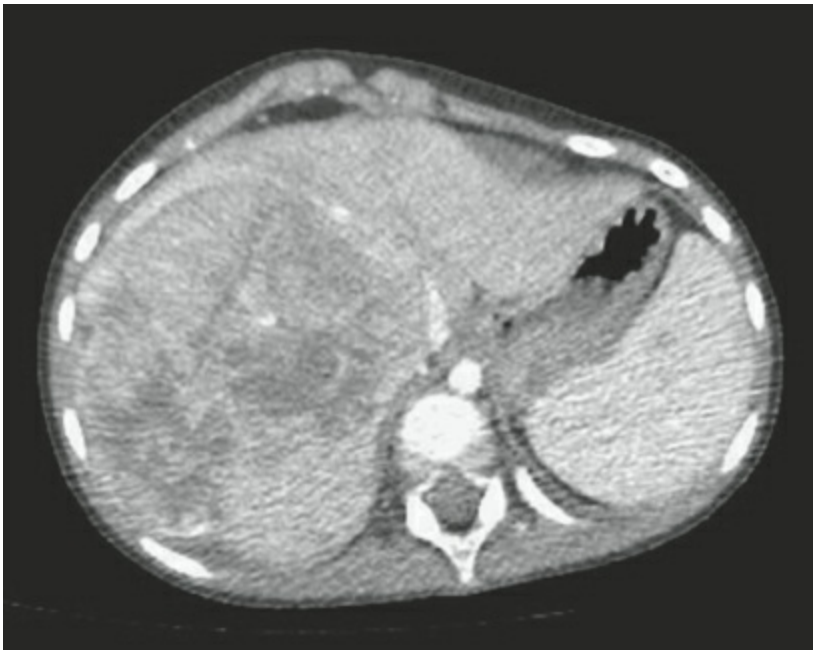

Figure 105-11. Abdominal CT scan with right hepatic lobe hepatoblastoma displacing normal hepatic vasculature and parenchyma.

Staging is based on the COG hepatoblastoma staging system (Table 105-10). This system is a postsurgical staging system that is based on outcome of the primary operation before the administration of chemotherapy.[220] Stage I (22%) is complete resection with clear margins. Stage II (0.5%) is complete gross resection with microscopic residual disease at the margins. Stage III (53%) is grossly positive margins, biopsy only at diagnosis, nodal involvement, or tumor spill. Stage IV disease (23%) is metastatic tumor at diagnosis.[221]

Table 105-10 Children's Oncology Group Staging for Hepatoblastoma

Stage I	Complete resection
Favorable histology	Purely fetal histology with low mitotic index
Other histology	All other stage I tumors
Stage II	Gross total resection with microscopic margins or total resection with preoperative or intraoperative rupture
Stage III	Unresectable tumors as determined by the attending surgeon, partially resected tumors with microscopic margins, or any tumor with lymph node involvement
Stage IV	Measurable metastatic disease to lungs or other organs

Courtesy of the Children's Oncology Group.

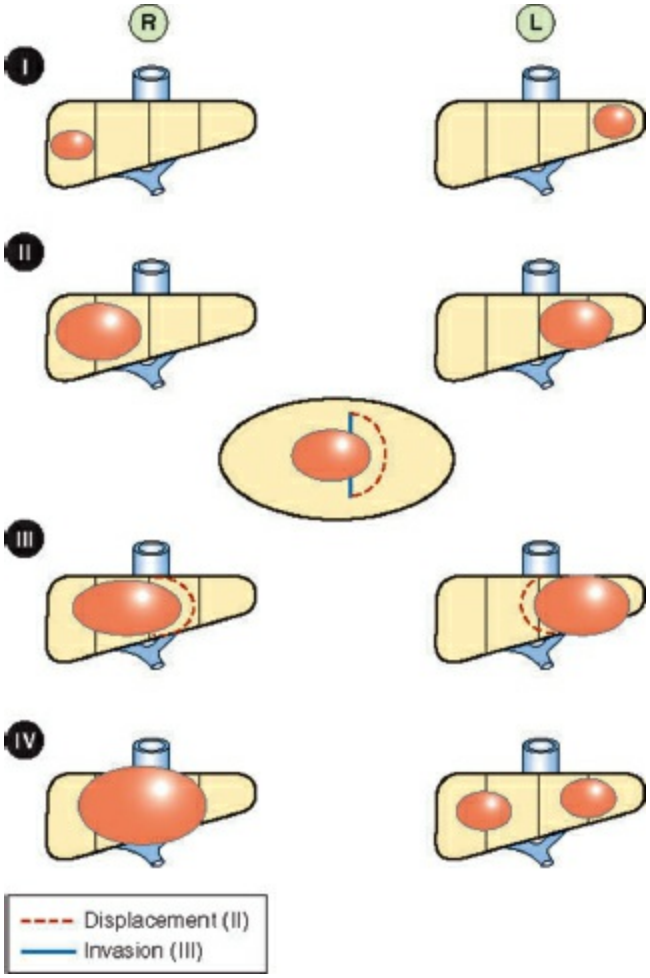

Figure 105-12. The Liver Tumor Study Group of the International Society of Pediatric Oncology (SIOP) SIOPEL-1 pretreatment extent of disease grouping system, PRETEXT groups I–IV. L, left; R, right. (From Schnater JM, Aronson DC, Plaschkes J, et al. Surgical view of the treatment of patients with hepatoblastoma: results from the first prospective trial of the International Society of Pediatric Oncology Liver Tumor Study Group (SIOPEL-1). *Cancer* 2002;94(4):1111–1120, with permission.)

PRETEXT (pretreatment extent of disease) grouping is used internationally in combination with COG stage to stratify patients on the basis of the tumor's radiographic characteristics prior to treatment.[222] PRETEXT describes the anatomic involvement and Couinaud hepatic segments affected by the tumor and can be applied to patients who have not yet had operations (Fig. 105-12).[223] PRETEXT divides the liver into four parts termed sectors. The left lobe is divided into a lateral sector (segments 2 and 3) and a medial sector (segment 4). The right lobe is divided into an anterior sector (segments 5 and 8) and a posterior sector (segments 6 and 7). PRETEXT is further annotated by V (venous involvement), P (portal vascular involvement), E (extrahepatic involvement), M (distant metastatic disease), C (caudate lobe), F (multifocal), and R (rupture prior to diagnosis) categories. Imaging is obtained after every two cycles of chemotherapy, where POST-TEXT (posttreatment of disease) is then used to reassess anatomy.

The COG utilizes COG stage, PRETEXT, histology, and AFP at diagnosis to determine risk for therapy assignment and for clinical trial standards. In general, excellent prognosis is expected for stage I tumors completely resected at diagnosis with pure fetal histology. Poor prognosis is associated with PRETEXT IV, metastatic tumors, AFP less than 100, and

tumors with small cell undifferentiated histology.[216]

Treatment

8 Complete surgical resection is the mainstay of curative therapy for hepatoblastoma. Completely resected tumors have significantly improved survival outcomes compared with all other hepatoblastoma patients. The tumor may present as large bulky disease with mass effect on surrounding abdominal structures. The umbilical fissure is typically not involved. If the tumor appears resectable, conventional resection is performed. If the mass is judged unresectable at diagnosis, incisional biopsy is performed and the patient is treated with chemotherapy prior to conventional resection. A complete preoperative evaluation is necessary to assess full extent of disease, PRETEXT grouping, and to determine a safe surgical plan that will achieve the highest survival outcomes. In the United States, tumor resection at diagnosis whenever possible is the preferred standard. This is based on the notion that a subset of patients may be spared toxicity of unnecessary neoadjuvant chemotherapy and that tumors have capacity to become resistant to prolonged chemotherapy.[220,224] The COG currently determines surgical resectability based on PRETEXT grouping. Primary resection is recommended for localized PRETEXT 1 or PRETEXT 2 tumors with >1-cm radiographic margin on the middle hepatic vein, without vena cava or contralateral portal venous invasion.[220] Neoadjuvant chemotherapy is recommended for PRETEXT III or IV tumors and for multicentric tumors with central venous invasion. Patients with pulmonary metastases also receive chemotherapy upfront. Tumor volume and AFP measurements may be utilized to monitor tumor responsiveness after each cycle. Minimal benefit is may be seen by prolonging induction therapy after cycle 2; therefore, tailoring exposure to response may help reduce toxic effects.[225]

Conventional liver resection is safe and effective in children with hepatoblastoma, and surgical techniques have been optimized in the last three decades.[226,227] An anatomic resection is recommended and is most often required. As much as 85% of hepatic parenchyma may be safely removed in children with full regeneration expected despite postoperative chemotherapy.[228] Mortality from liver resection in children should be low (0% to 3%) with technical advances such as the Cavitron Ultrasonic Surgical Aspirator (CUSA; Cooper Lasersonics, Santa Clara, CA) and metallic clip applicators for hemostasis while dividing liver parenchyma. The surgical principles include a generous incision with wide exposure using bilateral subcostal incision. Dissection of the hilum with identification and isolation of the ductal and vascular structures of the segment of resection is critical. Hepatic arterial and portal venous inflow is obstructed or ligated, allowing demarcation of the resection plane. This allows the operation to proceed with minimal blood loss. Intraoperative Doppler ultrasound is often utilized to aid in locating major venous structures traversing the tumor and for ensuring adequate resection margins of at least 1 cm.

Chemotherapy improves resectability of hepatoblastoma and improves prognosis in nearly all cases. Currently most patients diagnosed with hepatoblastoma receive chemotherapy either before or after resection of the primary tumor. Based on results from the Pediatric Oncology Group/Children's Cancer Study Group studies INT-0098 and P9645, patients with completely resected well-differentiated fetal histology (WDF or pure

fetal histology) tumors and low mitotic activity may be treated exclusively with surgery alone.[229] Children with WDF histology tumors comprise 7% of hepatoblastoma cases and have 100% event-free survival. Most hepatoblastoma tumors are sensitive to cisplatin-based chemotherapy and overall survival increased from 30% to 70% with the addition of cisplatin.[230] The COG currently recommends cisplatin, 5-fluorouracil, and vincristine for all low-risk tumors (non–well differentiated fetal histologic subtypes). Low-risk patients are patients with completely grossly resected tumors (stages I and II, PRETEXT I or II) without any small cell undifferentiated histology elements and who do not have a low diagnostic AFP (<100). This group can expect 5-year event-free survival and overall survival of 84% and 96%, respectively.[216] Intermediate-risk patients (PRETEXT II, III, or IV) are patients with gross residual disease or grossly resected disease with small cell undifferentiated histology (without metastases) and without low diagnostic AFP (<100). Those with high-risk tumors are any patients with metastatic disease and low diagnostic AFP level of <100. Patients with intermediate-risk and high-risk tumors are currently treated with cisplatin, 5-fluorouracil, vincristine, and doxorubicin. The COG is currently determining the efficacy of the addition of doxorubicin to intermediate and high-risk patients and for patients with minimal radiographic response to standard therapy. Depending on risk group protocol, patients will receive two to six cycles of cisplatin, 5-fluorouracil, vincristine with or without doxorubicin prior to primary resection or transplantation. Outcomes for patients with hepatoblastoma after surgical resection and chemotherapy were documented in INT-0098 with 5-year event-free survivals for stages I, II, III, and IV of 91%, 100%, 64%, and 25%, respectively.[230] Overall survivals were similar. The subsets of patients with stage III or IV disease who were able to have complete tumor resection and were tumor-free after induction chemotherapy had 5-year event-free survival of 83%. The role of radiotherapy in hepatoblastoma has not been defined because of the risk of hepatic toxicity and low hepatic tolerance to radiation in children. There may be a role for focal radiotherapy up to 45 Gy in patients with incomplete resection or microscopic residual disease.[231]

Liver transplantation has become a promising treatment option for children with unresectable hepatoblastoma without metastatic disease after neoadjuvant chemotherapy.[232] Liver transplantation has improved overall survival in children with large or multifocal unresectable hepatoblastoma.[233,234] Tumors with extensive major vessel involvement or multifocal disease should be referred to centers that have pediatric liver transplant expertise.[220] Primary transplantation is also recommended for multifocal PRETEXT IV tumors despite apparent clearance after chemotherapy because of the risk of persistent microscopic disease.[235] If after four cycles of chemotherapy, the tumor remains unresectable by conventional liver resection, liver transplantation is recommended. These are typically POSTTEXT IV or POSTTEXT III with major vascular involvement that would jeopardize blood supply to the contralateral lobe.[236] A review of the United Network for Organ Sharing (UNOS) database revealed that overall 1-, 5-, and 10-year graft survival was 71%, 61%, and 58% for patients receiving liver transplant for hepatoblastoma. Overall 1-, 5-, and 10-year patient survival was 79%, 69%, and 66%.[237] Other series have reported similar success.[234] The primary cause of death was metastatic and relapsed

disease. For transplantation eligibility, patients with hepatoblastoma must not have any active extrahepatic or metastatic sites that have not cleared with surgery or chemotherapy. Patients with lung metastases are not excluded from transplantation if the lung disease is clear after neoadjuvant chemotherapy. It is critical to correctly identify patients who will benefit from primary liver transplant prior to attempts at conventional resection because liver transplant after incomplete tumor resection or hepatic relapse has had disappointing results, with reported survival for “rescue” transplant of only 40%.[238]

The COG and other large international cooperative groups are investigating novel therapeutic strategies. COG AHEP-0731 is a COG study that is randomizing patients with metastatic disease to receive a novel upfront window design of vincristine, irinotecan, vincristine, irinotecan, and temsirolimus prior to standard cisplatin, 5-fluorouracil, vincristine, and doxorubicin therapy.[239] Chemotherapeutic intensification by dosing and duration has had promising preliminary results and may be beneficial in patients with high-risk hepatoblastoma. The expanding roles of antibodies and T lymphocytes as anticancer therapy for pediatric solid tumors may also hold promise as novel treatment agents for hepatoblastoma.[240]

Hepatocellular Carcinoma

HCC occurs more commonly in older children and is similar in histopathology to the disease in adults. HCC accounts for less than 0.5% of pediatric tumors and is the second most common malignant liver mass in children after hepatoblastoma. Risk factors and preexisting liver diseases for HCC include cirrhosis, type 1 glycogen storage disease, autoimmune hepatitis, and primary sclerosing cholangitis.[220] Areas endemic for hepatitis B have higher incidences of HCC in children. HCC is rare in infancy and there is a slight male predominance. HCC tumors are classified as either epithelial variant (75%) fibrolamellar (15%), and rarely poorly differentiated or clear cell.[241] Differences in outcome or treatment response among children with different histologic subtypes of HCC have not been confirmed. The fibrolamellar subtype is seen more often in younger children and rarely occurs with cirrhosis. The most common presenting symptom is hepatomegaly and abdominal pain although HCC is often indistinguishable from hepatoblastoma on physical examination, imaging, and laboratory values. The diagnostic workup mirrors hepatoblastoma and diagnosis is confirmed by histopathologic examination of tumor biopsy or resection. HCC is more likely to have multifocal nodules with intrahepatic venous and lymphatic spread. More than one-third of patients have lung metastases at diagnosis. The PRETEXT grouping system is utilized for risk assessment and to determine resectability. PRETEXT III and PRETEXT IV are the most common categories at presentation in patients with HCC.

As reported by the Intergroup Pediatric Oncology Group Study 8945/CCG 8881, 17% of patients diagnosed with HCC had stage 1 disease, none had stage 2 disease, 54% had stage 3 disease, and 28% had stage 4 disease.[221] It is not clear whether AFP levels can be used to predict outcome in HCC similarly to hepatoblastoma as study results have not been consistent.[221] The overall event-free survival for children with HCC at 5 years was 19%. Stage 1 disease had the best outcome compared to stage 3 and 4 diseases. The 5-year event-free survival for stage 1, 3, and 4 diseases was 88%, 8%, and 0%, respectively.[221] Overall survival was similar to event-free survival for each disease stage. Complete surgical resection or transplantation has the highest potential for cure in children with HCC. Unfortunately, fewer than 20% of patients with HCC have tumors that are resectable at diagnosis and multifocal tumors are common. In contrast to hepatoblastoma, HCC tumors are generally unresponsive to chemotherapy and outcomes for patients with stage 3 disease and higher are dismal. Transplantation is reserved for patients with localized tumor without any evidence of metastatic disease at presentation because of high risk of pulmonary metastatic relapse.[220] The guidelines for liver transplantation in HCC are largely derived from the adult experience using the Milan criteria (not more than three tumors, smaller than 3 cm in size, or single tumor smaller than 5 cm in size).[242] The COG studies on liver tumors and hepatoblastoma include children with HCC and treatment regimens have generally been the same. Treatment protocols for HCC currently consist of cisplatin, vincristine, doxorubicin, and 5-fluorouracil in multiple combinations. Compared to hepatoblastoma, these agents are not as effective in HCC, and patients generally remain with poor prognosis.[230] The majority

of patients do not undergo postinduction surgery or liver transplantation because of the presence of either unresectable or metastatic disease.

Alternative approaches for local control have demonstrated some benefit in children with HCC. Hepatic arterial chemoembolization in patients with refractory and unresectable disease requires cooperative group study but has been shown to be well-tolerated and may be effective in inducing surgical resectability in select cases of HCC.[243]

References

1. Foucher ES, Stiller C, Lacour B, et al. International classification of childhood cancer. *Cancer* 2005;103(7):1457–1467.
2. Linet MS, Ries LA, Smith MA, et al. Cancer surveillance series: recent trends in childhood cancer incidence and mortality in the United States. *J Natl Cancer Inst* 1999;91(12):1051–1058.
3. Stiller CA, Parkin DM. International variations in the incidence of neuroblastoma. *Int J Cancer* 1992;52(4):538–543.
4. Ries LG, Reichman ME, Lewis DR, et al. Cancer survival and incidence from the Surveillance, Epidemiology, and End Results (SEER) Program. *Oncologist* 2003;8:541–552.
5. Young JL Jr, Miller RW. Incidence of malignant tumors in U.S. children. *J Pediatr* 1975;86(2):254–258.
6. Hamrick S, Olshan AF, Neglia JP, et al. Association of pregnancy history and birth characteristics with neuroblastoma: a report from the Children's Cancer Group and the Pediatric Oncology Group. *Paediatr Perinat Epidemiol* 2001;15(4):328–337.
7. Olshan AF, Smith J, Cook MN, et al. Hormone and fertility drug use and the risk of neuroblastoma: a report from the Children's Cancer Group and the Pediatric Oncology Group. *Am J Epidemiol* 1999;150(9):930–938.
8. Olshan AF, Bunin GR, Teschke K, et al. Neuroblastoma and parental occupation. *Cancer Causes Control* 1999;10:539–549.
9. Yang Q, Olshan AF, Bondy ML, et al. Parental smoking and alcohol consumption and risk of neuroblastoma. *Cancer Epidemiol Biomarkers Prev* 2000;9(9):967–972.
10. Buck GM, Michalek AM, Chen CJ, et al. Perinatal factors and risk of neuroblastoma. *Paediatr Perinat Epidemiol* 2001;15(1):47–53.
11. Maris JM, Chatten J, Meadows AT, et al. Familial neuroblastoma: a three generation pedigree and a further association with Hirschsprung disease. *Med Pediatr Oncol* 1997;28(1):1–5.
12. Kushner BH, Hajdu SI, Helson L. Synchronous neuroblastoma and von Recklinghausen's disease: a review of the literature. *J Clin Oncol* 1985; 3:117–120.
13. Stovroff M, Dykes F, Teague WG. The complete spectrum of neurocristopathy in an infant with congenital hypoventilation, Hirschsprung's disease, and neuroblastoma. *J Pediatr Surg* 1995;30(8):1218–1221.
14. Knudson SR Jr, Strong LC. Mutation and cancer: neuroblastoma and pheochromocytoma. *Am J Hum Genet* 1972;24(5):514–532.
15. Maris JM, Kyemba SM, Rebbeck TR, et al. Molecular genetic analysis of familial neuroblastoma. *Eur J Cancer* 1997;33(12):1923–1928.
16. Mossé YP, Laudenslager M, Longo L, et al. Identification of ALK as a major familial neuroblastoma predisposition gene. *Nature* 2008;455(7215):930–935.

17. Janoueix-Lerosey I, Lequin D, Brugières L, et al. Somatic and germline activating mutations of the ALK kinase receptor in neuroblastoma. *Nature* 2008;455(7215):967–970.
18. George RE, Sanda T, Hanna M, et al. Activating mutations in ALK provide a therapeutic target in neuroblastoma. *Nature* 2008;455(7215):975–978.
19. Capasso M, Devoto M, Hou C, et al. Common variations in BARD1 influence susceptibility to high-risk neuroblastoma. *Nat Genet* 2009;41(6):718–723.
20. Maris JM, Mossé YP, Bradfield JP, et al. Chromosome 6p22 locus associated with clinically aggressive neuroblastoma. *N Engl J Med* 2008;358(24):2585–2593.
21. Diskin SJ, Hou C, Glessner JT, et al. Copy number variation at 1q21.1 associated with neuroblastoma. *Nature* 2009;459(7249):987–991.
22. Pugh TJ, Morozova O, Attiyeh EF, et al. The genetic landscape of high-risk neuroblastoma. *Nat Genet* 2013;45(3):279–284.
23. London WB, Castleberry RP, Matthay KK, et al. Evidence for an age cutoff greater than 365 days for neuroblastoma risk group stratification in the Children's Oncology Group. *J Clin Oncol* 2005;23(27):6459–6465.
24. Peuchmaur M, d'Amore ES, Joshi VV, et al. Revision of the International Neuroblastoma Pathology Classification: confirmation of favorable and unfavorable prognostic subsets in ganglioneuroblastoma, nodular. *Cancer* 2003;98(10):2274–2281.
25. Look AT, Hayes FA, Nitschke R, et al. Cellular DNA content as a predictor of response to chemotherapy in infants with unresectable neuroblastoma. *N Engl J Med* 1984;311(4):231–235.
26. Brodeur GM, Seeger RC, Schwab M, et al. Amplification of N-myc in untreated human neuroblastomas correlates with advanced disease stage. *Science* 1984;224(4653):1121–1124.
27. Seeger RC, Brodeur GM, Sather H. Association of multiple copies of the N-myc oncogene with rapid progression of neuroblastomas. *N Engl J Med* 1985;313(18):1111–1116.
28. Nakagawara A, Ikeda K, Tsuda T, et al. N-myc oncogene amplification and prognostic factors of neuroblastoma in children. *J Pediatr Surg* 1987; 22(10):895–898.
29. Weiss WA. Targeted expression of MYCN causes neuroblastoma in transgenic mice. *EMBO J* 1997;16(11):2985–2995.
30. Schweigerer L, Breit S, Wenzel A, et al. Augmented MYCN expression advances the malignant phenotype of human neuroblastoma cells: evidence for induction of autocrine growth factor activity. *Cancer Res* 1990;50(14):4411–4416.
31. Cohn SL, London WB, Huang D, et al. MYCN expression is not prognostic of adverse outcome in advanced-stage neuroblastoma with nonamplified MYCN. *J Clin Oncol* 2000;18(21):3604–3613.
32. Klein R, Jing SQ, Nanduri V, et al. The trk proto-oncogene encodes a receptor for

nerve growth factor. *Cell* 1991;65(1):189–197.
33. Brodeur GM, Nakagawara A, Yamashiro DJ, et al. Expression of TrkA, TrkB and TrkC in human neuroblastomas. *J Neurooncol* 1997;31(1–2):49–56.
34. Lucarelli E, Kaplan D, Thiele CJ. Activation of trk-A but not trk-B signal transduction pathway inhibits growth of neuroblastoma cells. *Eur J Cancer* 1997;33(12):2068–2070.
35. Schleiermacher G, Michon J, Ribeiro A, et al. Segmental chromosomal alterations lead to a higher risk of relapse in infants with MYCN-non-amplified localised unresectable/disseminated neuroblastoma (a SIOPEN collaborative study). *Br J Cancer* 2011;105(12):1940–1948.
36. Caron H, Vansluis P, Dekraker J, et al. Allelic loss of chromosome 1p as a predictor of unfavorable outcome in patients with neuroblastoma. *N Engl J Med* 1996;334(4):225–230.
37. Bown N, Cotterill S, Łastowska M, et al. Gain of chromosome arm 17q and adverse outcome in patients with neuroblastoma. *N Engl J Med* 1999;340(25):1954–1961.
38. Park JR, Eggert A, Caron H. Neuroblastoma: biology, prognosis, and treatment. *Hematol Oncol Clin North Am* 2010;24(1):65–86.
39. Attiyeh EF, London WB, Mossé YP, et al. Chromosome 1p and 11q deletions and outcome in neuroblastoma. *N Engl J Med* 2005;353(21):2243–2253.
40. Riley RD, Heney D, Jones DR, et al. A systematic review of molecular and biological tumor markers in neuroblastoma. *Clin Cancer Res* 2004;10(1):4–12.
41. Newton ER, Louis F, Dalton ME, et al. Fetal neuroblastoma and catecholamine-induced maternal hypertension. *Obstet Gynecol* 1985; 65(3 suppl):49S–52S.
42. Rudnick E, Khakoo Y, Antunes NL, et al. Opsoclonus-myoclonus-ataxia syndrome in neuroblastoma: clinical outcome and antineuronal antibodies—a report from the children's cancer group study. *Med Pediatr Oncol* 2001;36(6):612–622.
43. Russo C, Cohn SL, Petruzzi MJ, et al. Long term neurologic outcome in children with opsoclonus myoclonus associated with neuroblastoma: a report from the Pediatric Oncology Group. *Med Pediatr Oncol* 1997;28(4):284–288.
44. Holgersen LO, Subramanian S, Kirpekar M, et al. Spontaneous resolution of antenatally diagnosed adrenal masses. *J Pediatr Surg* 1996;31(1):153–155.
45. Acharya S, Jayabose S, Kogan SJ, et al. Prenatally diagnosed neuroblastoma. *Cancer* 1997;80(2):304–310.
46. Sauvat F, Sarnacki S, Brisse H, et al. Outcome of suprarenal localized masses diagnosed during the perinatal period: a retrospective multicenter study. *Cancer* 2002;94(9):2474–2480.
47. Nuchtern JG, London WB, Barnewolt CE, et al. A prospective study of expectant observation as primary therapy for neuroblastoma in young infants. *Ann Surg* 2012;256(4):573–580.
48. Brodeur GM, Pritchard J, Berthold F, et al. Revisions of the international criteria for

neuroblastoma diagnosis, staging, and response to treatment. *J Clin Oncol* 1993;11(8):1466–1477.

49. Hann HW, Evans AE, Cohen IJ, et al. Biologic differences between neuroblastoma stages IV-S and IV. Measurement of serum ferritin and E-rosette inhibition in 30 children. *N Engl J Med* 1981;305(8):425–429.
50. Zeltzer PM, Marangos PJ, Evans AE, et al. Serum neuron-specific enolase in children with neuroblastoma. Relationship to stage and disease course. *Cancer* 1986;57(6):1230–1234.
51. Yanik GA. Pilot study of iodine-131-metaiodobenzylguanidine in combination with myeloablative chemotherapy and autologous stem-cell support for the treatment of neuroblastoma. *J Clin Oncol* 2002;20(8):2142–2149.
52. Monclair T, Brodeur GM, Ambros PF, et al. The International Neuroblastoma Risk Group (INRG) staging system: an INRG Task Force report. *J Clin Oncol* 2009;27(2):298–303. Available at: http://inrgdb.org/neuroblastoma-information/staging-system/
53. Cecchetto G, Mosseri V, De Bernardi B, et al. Surgical risk factors in primary surgery for localized neuroblastoma: the LNESG1 study of the European International Society of Pediatric Oncology Neuroblastoma Group. *J Clin Oncol* 2005;23(33):8483–8489.
54. Cohn SL, Pearson AD, London WB, et al. The International Neuroblastoma Risk Group (INRG) classification system: an INRG Task Force Report. *J Clin Oncol* 2009;27(2):289–297. Available at: http://inrgdb.org/neuroblastoma-information/classification-system/
55. Perez CA, Matthay KK, Atkinson JB, et al. Biologic variables in the outcome of stages I and II neuroblastoma treated with surgery as primary therapy: a children's cancer group study. *J Clin Oncol* 2000;18(1):18–26.
56. Strother DR, London WB, Schmidt ML, et al. Outcome after surgery alone or with restricted use of chemotherapy for patients with low-risk neuroblastoma: results of Children's Oncology Group study P9641. *J Clin Oncol* 2012;30(15):1842–1848.
57. Adkins ES, Sawin R, Gerbing RB, et al. Efficacy of complete resection for high-risk neuroblastoma: a Children's Cancer Group study. *J Pediatr Surg* 2004;39(6):931–936.
58. Baker DL, Schmidt ML, Cohn SL, et al. Outcome after reduced chemotherapy for intermediate-risk neuroblastoma. *N Engl J Med* 2010; 363(14):1313–1323.
59. Twist C, London WB, Naranjo A, et al. Maintaining outstanding outcomes using response-and biology-based therapy for intermediate -risk neuroblastoma: a report from the Children's Oncology Group Study ANBL0531. *J Clin Oncol* 2014;32(15s):10006.
60. Matthay KK, Villablanca JG, Seeger RC, et al. Treatment of high-risk neuroblastoma with intensive chemotherapy, radiotherapy, autologous bone marrow transplantation, and 13- cis-retinoic acid. *N Engl J Med* 1999;341(16):1165–1173.
61. Ladenstein R, Philip T, Lasset C, et al. Multivariate analysis of risk factors in stage 4

neuroblastoma patients over the age of one year treated with megatherapy and stem-cell transplantation: a report from the European Bone Marrow Transplantation Solid Tumor Registry. *J Clin Oncol* 1998; 16(3):953–965.

62. La Quaglia MP, Kushner BH, Su W, et al. The impact of gross total resection on local control and survival in high-risk neuroblastoma. *J Pediatr Surg* 2004;39(3):412–417.
63. Malek MM, Mollen KP, Kane TD, et al. Thoracic neuroblastoma: a retrospective review of our institutional experience with comparison of the thoracoscopic and open approaches to resection. *J Pediatr Surg* 2010;45(8):1622–1626.
64. DeCou JM, Schlatter MG, Mitchell DS. Primary thoracoscopic gross total resection of neuroblastoma. *J Laparoendosc Adv Surg Tech A* 2005; 15(5):470–473.
65. Pranikoff T, Hirschl RB, Schnaufer L. Approach to cervicothoracic neuroblastomas via a trap-door incision. *J Pediatr Surg* 1995;30(4):546–548.
66. Simon T, Hero B, Bongartz R, et al. Intensified external-beam radiation therapy improves the outcome of stage 4 neuroblastoma in children >1 year with residual local disease. *Strahlenther Onkol* 2006;182(7):389–394.
67. Berthold F, Boos J, Burdach S, et al. Myeloablative megatherapy with autologous stem-cell rescue versus oral maintenance chemotherapy as consolidation treatment in patients with high-risk neuroblastoma: a randomized controlled trial. *Lancet Oncol* 2005;6(9):649–658.
68. George RE, Li S, Medeiros-Nancarrow C, et al. High-risk neuroblastoma treated with tandem autologous peripheral-blood stem cell-supported transplantation: long-term survival update. *J Clin Oncol* 2006;24(18):2891–2896.
69. Yu AL, Gilman AL, Ozkaynak MF, et al. Anti-GD2 antibody with GM-CSF, interleukin-2, and isotretinoin for neuroblastoma. *N Engl J Med* 2010;363(14):1324–1334.
70. Simon T, Hero B, Faldum A, et al. Long term outcome of high-risk neuroblastoma patients after immunotherapy with antibody ch14.18 or oral metronomic chemotherapy. *BMC Cancer* 2011;11(1):21.
71. Shusterman S, London WB, Gillies SD, et al. Antitumor activity of Hu14.18-IL2 in patients with relapsed/refractory neuroblastoma: a Children's Oncology Group (COG) phase II study. *J Clin Oncol* 2010; 28(33):4969–4975.
72. DuBois SG, Matthay KK. Radiolabeled metaiodobenzylguanidine for the treatment of neuroblastoma. *Nucl Med Biol* 2008;35:S35–S48.
73. Matthay KK, Yanik G, Messina J, et al. Phase II study on the effect of disease sites, age, and prior therapy on response to iodine-131-metaiodobenzylguanidine therapy in refractory neuroblastoma. *J Clin Oncol* 2007; 25(9):1054–1060.
74. Fernandes ET, Kumar M, Douglass EC, et al. Extrarenal Wilms' tumor. *J Pediatr Surg* 1989;24(5):483–485.
75. Stiller CA, Parkin DM. International variations in the incidence of childhood renal tumours. *Br J Cancer* 1990;62(6):1026.
76. Breslow NE, Beckwith JB. Epidemiological features of Wilms' tumor: results of the

National Wilms' tumor study. *J Natl Cancer Inst* 1982;68(3):429–436.
77. Kim S, Chung DH. Pediatric solid malignancies: neuroblastoma and Wilms' tumor. *Surg Clin North Am* 2006;86(2):469–487.
78. Slater RM, Mannens MM. Cytogenetics and molecular genetics of Wilms' tumor of childhood. *Cancer Genet Cytogenet* 1992;61(2):111–121.
79. Pritchard-Jones K. Malignant origin of the stromal component of Wilms' tumor. *J Natl Cancer Inst* 1997;89(15):1089–1091.
80. Beckwith JB, Kiviat NB, Bonadio JF. Nephrogenic rests, nephroblastomatosis, and the pathogenesis of Wilms' tumor. *Pediatr Pathol* 1990;10(1–2):1–36.
81. Rivera MN, Haber DA. Wilms' tumour: connecting tumorigenesis and organ development in the kidney. *Nat Rev Cancer* 2005;5(9):699–712.
82. Pritchard Jones K, Vujanic G. Multiple pathways to Wilms tumor: how much is genetic? *Pediatr Blood Cancer* 2006;47(3):232–234.
83. Coppes MJ, Campbell C, Williams BR. Genetics of Wilms tumor. In: *Wilms Tumor: Clinical and Molecular Characterization. Vol Molecular Biology Intelligence Unit.* Berlin, Heidelberg: Springer Berlin Heidelberg; 1995:41–56.
84. Weirich A, Leuschner I, Harms D, et al. Clinical impact of histologic subtypes in localized non-anaplastic nephroblastoma treated according to the trial and study SIOP-9/GPOH. *Ann Oncol* 2001;12(3):311–319.
85. Bonadio JF, Storer B, Norkool P, et al. Anaplastic Wilms' tumor: clinical and pathologic studies. *J Clin Oncol* 1985;3(4):513–520.
86. Faria P, Beckwith JB, Mishra K, et al. Focal versus diffuse anaplasia in Wilms tumor —new definitions with prognostic significance: a report from the National Wilms Tumor Study Group. *Am J Surg Pathol* 1996;20(8):909.
87. Beckwith JB. Wilms tumor and other renal tumors of childhood: a selective review from the National Wilms Tumor Study Pathology Center. *Human Pathol* 1983;14(6):481–492.
88. Beckwith JB. Precursor lesions of Wilms tumor: clinical and biological implications. *Med Pediatr Oncol* 1993;21(3):158–168.
89. Grundy PE, Telzerow PE, Breslow N, et al. Loss of heterozygosity for chromosomes 16q and 1p in Wilms' tumors predicts an adverse outcome. *Cancer Res* 1994;54(9):2331–2333.
90. Grundy PE, Breslow NE, Li S, et al. Loss of heterozygosity for chromosomes 1p and 16q is an adverse prognostic factor in favorable-histology Wilms tumor: a report from the National Wilms Tumor Study Group. *J Clin Oncol* 2005;23(29):7312–7321.
91. Wilimas JA, Kaste SC, Kauffman WM, et al. Use of chest computed tomography in the staging of pediatric Wilms' tumor: interobserver variability and prognostic significance. *J Clin Oncol* 1997;15(7):2631–2635.
92. Owens CM, Veys PA, Pritchard J, et al. Role of chest computed tomography at diagnosis in the management of Wilms' tumor: a study by the United Kingdom

Children's Cancer Study Group. *J Clin Oncol* 2002; 20(12):2768–2773.

93. Ehrlich PF, Hamilton TE, Grundy P, et al. The value of surgery in directing therapy for patients with Wilms' tumor with pulmonary disease. A report from the National Wilms' Tumor Study Group (National Wilms' Tumor Study 5). *J Pediatr Surg* 2006;41(1):162–167; discussion 162–167.
94. Neville HL, Ritchey ML. Wilms' Tumor. *Urol Clin North Am* 2000; 27(3):435–442.
95. Pritchard-Jones K, Kelsey A, Vujanic G, et al. Older age is an adverse prognostic factor in stage I, favorable histology Wilms' tumor treated with vincristine monochemotherapy: a study by the United Kingdom Children's Cancer Study Group, Wilms' Tumor Working Group. *J Clin Oncol* 2003; 21(17):3269–3275.
96. Zuppan CW, Weeks DA, Bruce Beckwith J, et al. The effect of preoperative therapy on the histologic features of Wilms tumor. An analysis of cases from the third national Wilms tumor study. *Cancer* 1991;68(2):385–394.
97. Tournade MF, Com-Nougué C, de Kraker J, et al. Optimal duration of preoperative therapy in unilateral and nonmetastatic Wilms tumor in children older than 6 months: results of the Ninth International Society of Pediatric Oncology Wilms' Tumor Trial and Study. *J Clin Oncol* 2001;19(2):488–500.
98. D'Angio GJ, Evans AE, Breslow N, et al. The treatment of Wilms tumor. Results of the national Wilms tumor study. *Cancer* 1976;38(2):633–646.
99. D'Angio GJ, Evans A, Breslow N, et al. The treatment of Wilms Tumor: results of the second national Wilms tumor study. *Cancer* 1981;47(9):2302–2311.
100. D'Angio GJ, Breslow N, Beckwith JB, et al. Treatment of Wilms tumor. Results of the third national Wilms' tumor study. *Cancer* 1989;64(2):349–360.
101. Green DM, Breslow NE, Beckwith JB, et al. Comparison between single-dose and divided-dose administration of dactinomycin and doxorubicin for patients with Wilms tumor: a report from the National Wilms Tumor Study Group. *J Clin Oncol* 1998;16(1):237–245.
102. Green DM, Breslow NE, Beckwith JB, et al. Effect of duration of treatment on treatment outcome and cost of treatment for Wilms tumor: a report from the National Wilms Tumor Study Group. *J Clin Oncol* 1998; 16(12):3744–3751.
103. Davidoff AM. Wilms' tumor. *Curr Opin Pediatr* 2009;21(3):357–364.
104. Metzger ML, Dome JS. Current therapy for Wilms' tumor. *Oncologist* 2005;10(10):815–826.
105. Shamberger RC, Anderson JR, Breslow NE, et al. Long-term outcomes of infants with very low risk Wilms tumor treated with surgery alone on National Wilms Tumor Study-5. *Ann Surg* 2010;251(3):555–558.
106. Ko EY, Ritchey ML. Current management of Wilms' tumor in children. *J Pediatr Urol* 2009;5(1):56–65.
107. Shamberger RC, Guthrie KA, Ritchey ML, et al. Surgery-related factors and local recurrence of Wilms tumor in National Wilms Tumor Study 4. *Ann Surg*

1999;229(2):292–297.
108. Kieran K, Ehrlich PF. Current surgical standards of care in Wilms tumor. *Urol Oncol* 2015;34(1):13–23.
109. Duarte RJ, Dénes FT, Cristofani LM, et al. Laparoscopic nephrectomy for Wilms' tumor. *Expert Rev Anticancer Ther* 2014;9(6):753–761.
110. Ritchey M. Surgical complications after primary nephrectomy for Wilms tumor: report from the National Wilms Tumor Study Group. *J Am Coll Surg* 2001;192(1):63–68.
111. Ritchey ML, Green DM, Thomas PR, et al. Renal failure in Wilms tumor patients: a report from the National Wilms Tumor Study Group. *Med Pediatr Oncol* 1996;26(2):75–80.
112. Shamberger RC, Ritchey ML, Haase GM, et al. Intravascular extension of Wilms tumor. *Ann Surg* 2001;234(1):116–121.
113. Szavay P, Luithle T, Semler O, et al. Surgery of cavoatrial tumor thrombus in nephroblastoma: a report of the SIOP/GPOH study. *Pediatr Blood Cancer* 2004;43(1):40–45.
114. Hamilton TE, Ritchey ML, Argani P, et al. Synchronous bilateral Wilms tumor with complete radiographic response managed without surgical resection: a report from the National Wilms' Tumor Study 4. *J Pediatr Surg* 2008;43(11):1982–1984.
115. Horwitz JR, Ritchey ML, Moksness J, et al. Renal salvage procedures in patients with synchronous bilateral Wilms tumors: a report from the National Wilms Tumor Study Group. *J Pediatr Surg* 1996;31(8):1020–1025.
116. Nakamura L, Ritchey M. Current management of Wilms' tumor. *Curr Urol Rep* 2010;11(1):58–65.
117. Charlton J, Pavasovic V, Pritchard Jones K. Biomarkers to detect Wilms tumors in pediatric patients: where are we now? *Future Oncol* 2015; 11(15):2221–2234.
118. Wegert J, Ishaque N, Vardapour R, et al. Mutations in the SIX1/2 pathway and the DROSHA/DGCR8 miRNA microprocessor complex underlie high-risk blastemal type Wilms tumors. *Cancer Cell* 2015;27(2):298–311.
119. Maschietto M, Charlton J, Perotti D, et al. The IGF signalling pathway in Wilms tumours—a report from the ENCCA Renal Tumours Biology-driven drug development workshop. *Oncotarget* 2014;5(18):8014–8026.
120. Sakamoto Y, Mariya Y, Sasaki S, et al. WT1 mRNA level in peripheral blood is a sensitive biomarker for monitoring minimal residual disease in acute myeloid leukemia. *Tohoku J Exp Med* 2009;219(2):169–176.
121. van den Heuvel-Eibrink MM, Grundy P, Graf N, et al. Characteristics and survival of 750 children diagnosed with a renal tumor in the first seven months of life: a collaborative study by the SIOP/GPOH/SFOP, NWTSG, and UKCCSG Wilms tumor study groups. *Pediatr Blood Cancer* 2008;50(6):1130–1134.
122. Wang Z-P, Li K, Dong K-R, et al. Congenital mesoblastic nephroma: clinical analysis

of eight cases and a review of the literature. *Oncol Lett* 2014;8(5):2007–2011.

123. Glick RD, Hicks MJ, Nuchtern JG, et al. Renal tumors in infants less than 6 months of age. *J Pediatr Surg* 2004;39(4):522–525.
124. Whittle S, Gosain A, Brown PY, et al. Regression of a congenital mesoblastic nephroma. *Pediatr Blood Cancer* 2010;55(2):364–368.
125. Knezevich SR, Garnett MJ, Pysher TJ, et al. ETV6-NTRK3 gene fusions and trisomy 11 establish a histogenetic link between mesoblastic nephroma and congenital fibrosarcoma. *Cancer Res* 1998;58(22):5046–5048.
126. Mascarello JT, Cajulis TR, Krous HF, et al. Presence or absence of trisomy 11 is correlated with histologic subtype in congenital mesoblastic nephroma. *Cancer Genet Cytogenet* 1994;77(1):50–54.
127. Howell CG, Othersen HB, Kiviat NE, et al. Therapy and outcome in 51 children with mesoblastic nephroma: a report of the national Wilms' tumor study. *J Pediatr Surg* 1982;17(6):826–831.
128. Haddad B, Haziza J, Touboul C, et al. The congenital mesoblastic nephroma: a case report of prenatal diagnosis. *Fetal Diagn Ther* 1996;11(1):61–66.
129. Argani P, Perlman EJ, Breslow NE, et al. Clear cell sarcoma of the kidney: a review of 351 cases from the National Wilms Tumor Study Group Pathology Center. *Am J Surg Pathol* 2000;24(1):4.
130. Beckwith JB, Larson E. Case 7 clear cell sarcoma of kidney. *Fetal Pediatr Pathol* 1989;9(2):211–218.
131. Seibel NL, Sun J, Anderson JR, et al. Outcome of clear cell sarcoma of the kidney (CCSK) treated on the National Wilms Tumor Study-5 (NWTS). *J Clin Oncol* 2006;24(18s):9000.
132. Waldron PE, Rodgers BM, Kelly MD, et al. Successful treatment of a patient with stage IV rhabdoid tumor of the kidney: case report and review. *J Pediatr Hematol Oncol* 1999;21(1):53–57.
133. Weeks DA, Beckwith JB, Mierau GW, et al. Rhabdoid tumor of kidney: a report of 111 cases from the National Wilms' Tumor Study Pathology Center. *Am J Surg Pathol* 1989;13(6):439.
134. Tomlinson GE, Breslow NE, Dome J, et al. Rhabdoid tumor of the kidney in the National Wilms' Tumor Study: age at diagnosis as a prognostic factor. *J Clin Oncol* 2005;23(30):7641–7645.
135. Versteege I, Sévenet N, Lange J, et al. Truncating mutations of hSNF5/INI1 in aggressive paediatric cancer. *Nature* 1998;394(6689):203–206.
136. Biegel JA, Fogelgren B, Wainwright LM, et al. Germline INI1 mutation in a patient with a central nervous system atypical teratoid tumor and renal rhabdoid tumor. *Genes Chromosomes Cancer* 2000;28(1):31–37.
137. Biegel JA, Tan L, Zhang F, et al. Alterations of the hSNF5/INI1 gene in central nervous system atypical teratoid/rhabdoid tumors and renal and extrarenal rhabdoid

tumors. *Clin Cancer Res* 2002;8(11):3461–3467.

138. Argani P, Laé M, Ballard ET, et al. Translocation carcinomas of the kidney after chemotherapy in childhood. *J Clin Oncol* 2006;24(10):1529–1534.
139. Akhavan A, Richards M, Shnorhavorian M, et al. Renal cell carcinoma in children, adolescents and young adults: a National Cancer Database Study. *J Urol* 2015;193(4):1336–1341.
140. O'Toole KM, Brown M, Hoffmann P. Pathology of benign and malignant kidney tumors. *Urol Clin North Am* 1993;20(2):193–205.
141. Carcao MD, Taylor GP, Greenberg ML, et al. Renal-cell carcinoma in children: a different disorder from its adult counterpart? *Med Pediatr Oncol* 1998;31(3):153–158.
142. Cubilla AL, Dillner J, Schellhammer PF. *World Health Organization Classification of Tumors. Pathology and Genetics of Tumours of the Urinary System and Male Genital Organs.* Lyon: IARC; 2004:281–290:chap 5.
143. Young EE, Brown CT, Merguerian PA, et al. Pediatric and adolescent renal cell carcinoma. *Urol Oncol* 2015;34(1):42–49.
144. Geller JI, Dome JS. Local lymph node involvement does not predict poor outcome in pediatric renal cell carcinoma. *Cancer* 2004;101(7):1575–1583.
145. Renshaw AA, Granter SR, Fletcher JA, et al. Renal cell carcinomas in children and young adults: increased incidence of papillary architecture and unique subtypes. *Am J Surg Pathol* 1999;23(7):795–802.
146. Guinan P, Sobin LH, Algaba F, et al. TNM staging of renal cell carcinoma: workgroup no. 3. Union International Contre le Cancer (UICC) and the American Joint Committee on Cancer (AJCC). *Cancer* 1997;80(5):992–993.
147. Indolfi P, Terenziani M, Casale F, et al. Renal cell carcinoma in children: a clinicopathologic study. *J Clin Oncol* 2003;21(3):530–535.
148. Selle B, Furtwängler R, Graf N, et al. Population-based study of renal cell carcinoma in children in Germany, 1980–2005. *Cancer* 2006;107(12):2906–2914.
149. Perez EA, Kassira N, Cheung MC, et al. Rhabdomyosarcoma in children: a SEER population based study. *J Surg Res* 2011;170(2):e243–e251.
150. Joshi D, Anderson JR, Paidas C, et al. Age is an independent prognostic factor in rhabdomyosarcoma: a report from the soft tissue sarcoma committee of the children's oncology group. *Pediatr Blood Cancer* 2004;42(1):64–73.
151. Ruymann FB, Maddux HR, Ragab A, et al. Congenital anomalies associated with rhabdomyosarcoma: an autopsy study of 115 cases. A report from the intergroup rhabdomyosarcoma study committee (representing the children's cancer study group, the pediatric oncology group, the United Kingdom children's cancer study group, and the pediatric intergroup statistical center). *Med Pediatr Oncol* 1988;16(1):33–39.
152. Li FP, Fraumeni JF. Soft-tissue sarcomas, breast cancer, and other neoplasms. A familial syndrome? *Ann Intern Med* 1969;71(4):747–752.
153. McKeen EA, Bodurtha J, Meadows AT, et al. Rhabdomyosarcoma complicating

multiple neurofibromatosis. *J Pediatr* 1978;93(6):992–993.

154. D'Agostino AN, Soule EH, Miller RH. Sarcomas of the peripheral nerves and somatic soft tissues associated with multiple neurofibromatosis (von Recklinghausen's disease). *Cancer* 1963;16(8):1015–1027.
155. Smith AC, Squire JA, Thorner P, et al. Association of alveolar rhabdomyosarcoma with the Beckwith–Wiedemann syndrome. *Pediatr Dev Pathol* 2001;4(6):550–558.
156. Grufferman S, Schwartz AG, Ruymann FB, et al. Parents' use of cocaine and marijuana and increased risk of rhabdomyosarcoma in their children. *Cancer Causes Control* 1993;4(3):217–224.
157. Newton WA, Gehan EA, Webber BL, et al. Classification of rhabdomyosarcomas and related sarcomas. Pathologic aspects and proposal for a new classification—an intergroup rhabdomyosarcoma study. *Cancer* 1995;76(6):1073–1085.
158. Qualman SJ, Coffin CM, Newton WA, et al. Intergroup rhabdomyosarcoma study: update for pathologists. *Pediatr Dev Pathol* 1998;1(6):550–561.
159. Peydró-Olaya A, Llombart-Bosch A. Electron microscopy and other ancillary techniques in the diagnosis of small round cell tumors. *Semin Diagn Pathol* 2003;20(1):25–45.
160. Turc-Carel C, Lizard-Nacol S, Justrabo E, et al. Consistent chromosomal translocation in alveolar rhabdomyosarcoma. *Cancer Genet Cytogenet* 1986;19(3–4):361–362.
161. Barr FG, Galili N, Holick J, et al. Rearrangement of the PAX3 paired box gene in the paediatric solid tumour alveolar rhabdomyosarcoma. *Nat Genet* 1993;3(2):113–117.
162. Barr FG, Nauta LE, Davis RJ, et al. In vivo amplification of the PAX3-FKHR and PAX7-FKHR fusion genes in alveolar rhabdomyosarcoma. *Hum Mol Genet* 1996;5(1):15–21.
163. Scrable HJ, Witte DP, Lampkin BC, et al. Chromosomal localization of the human rhabdomyosarcoma locus by mitotic recombination mapping. *Nature* 1987;329(6140):645–647.
164. Scrable H, Cavenee W, Ghavimi F, et al. A model for embryonal rhabdomyosarcoma tumorigenesis that involves genome imprinting. *Proc Natl Acad Sci USA* 1989;86(19):7480–7484.
165. Bridge JA, Liu J, Qualman SJ, et al. Genomic gains and losses are similar in genetic and histologic subsets of rhabdomyosarcoma, whereas amplification predominates in embryonal with anaplasia and alveolar subtypes. *Genes Chromosomes Cancer* 2002;33(3):310–321.
166. Pappo A, Barr FG, Wolden SL. Pediatric rhabdomyosarcoma: biology and results of the North American intergroup rhabdomyosarcoma trials. In: Pappo A, ed. *Pediatric Bone and Soft Tissue Sarcomas. Vol Pediatric Oncology*. Berlin, Heidelberg: Springer Berlin Heidelberg; 2006:103–132.
167. Klem ML, Grewal RK, Wexler LH, et al. PET for staging in rhabdomyosarcoma: an evaluation of PET as an adjunct to current staging tools. *J Pediatr Hematol Oncol*

2007;29(1):9–14.

168. Lawrence W, Anderson JR, Gehan EA, et al. Pretreatment TNM staging of childhood rhabdomyosarcoma: a report of the Intergroup Rhabdomyosarcoma Study Group. Children's Cancer Study Group. Pediatric Oncology Group. *Cancer* 1997;80(6):1165–1170.
169. Maurer HM, Crist W, Lawrence W, et al. The intergroup rhabdomyosarcoma study I. A final report. *Cancer* 1988;61(2):209–220.
170. Meza JL, Anderson J, Pappo AS, et al. Children's Oncology Group. Analysis of prognostic factors in patients with nonmetastatic rhabdomyosarcoma treated on intergroup rhabdomyosarcoma studies III and IV: the Children's Oncology Group. *J Clin Oncol* 2006;24(24):3844–3851.
171. Maurer HM, Gehan EA, Beltangady M, et al. The intergroup rhabdomyosarcoma study II. *Cancer* 1993;71(5):1904–1922.
172. Malempati S, Hawkins DS. Rhabdomyosarcoma: review of the Children's Oncology Group (COG) Soft Tissue Sarcoma Committee experience and rationale for current COG studies. *Pediatr Blood Cancer* 2012;59(1):5–10.
173. Raney RB, Walterhouse DO, Meza JL, et al. Results of the Intergroup Rhabdomyosarcoma Study Group D9602 protocol, using vincristine and dactinomycin with or without cyclophosphamide and radiation therapy, for newly diagnosed patients with low-risk embryonal rhabdomyosarcoma: a report from the Soft Tissue Sarcoma Committee of the Children's Oncology Group. *J Clin Oncol* 2011;29(10):1312–1318.
174. Crist WM, Anderson JR, Meza JL, et al. Intergroup rhabdomyosarcoma study-IV: results for patients with nonmetastatic disease. *J Clin Oncol* 2001;19(12):3091–3102.
175. Arndt CA, Stoner JA, Hawkins DS, et al. Vincristine, actinomycin, and cyclophosphamide compared with vincristine, actinomycin, and cyclophosphamide alternating with vincristine, topotecan, and cyclophosphamide for intermediate-risk rhabdomyosarcoma: Children's Oncology Group Study D9803. *J Clin Oncol* 2009;27(31):5182–5188.
176. Soft Tissue Sarcoma Committee of the Children's Oncology Group; Lager JJ, Lyden ER, Anderson JR, et al. Pooled analysis of phase II window studies in children with contemporary high-risk metastatic rhabdomyosarcoma: a report from the Soft Tissue Sarcoma Committee of the Children's Oncology Group. *J Clin Oncol* 2006;24(21):3415–3422.
177. Weigel B, Lyden E, Anderson JR, et al. Early results from Children's Oncology Group (COG) ARST0431: intensive multidrug therapy for patients with metastatic rhabdomyosarcoma (RMS). *ASCO Meeting Abstracts* 2010;28(15 suppl):9503.
178. Malempati S, Weigel B, Anderson JR, et al. Early results from Children's Oncology Group (COG) ARST08P1: pilot studies of cixutumumab or temozolomide with intensive multiagent chemotherapy for patients with metastatic rhabdomyosarcoma (RMS). *ASCO Meeting Abstracts* 2015; 33(15 suppl):10015.

179. Paulino AC, Okcu MF. Rhabdomyosarcoma. *Curr Probl Cancer* 2008; 32(1):7–34.
180. Donaldson SS, Meza J, Breneman JC, et al. Results from the IRS-IV randomized trial of hyperfractionated radiotherapy in children with rhabdomyosarcoma—a report from the IRSG. *Int J Radiat Oncol Biol Phys* 2001;51(3):718–728.
181. Linabery AM, Ross JA. Trends in childhood cancer incidence in the U.S. (1992–2004). *Cancer* 2008;112(2):416–432.
182. Sultan I, Casanova M, Al-Jumaily U, et al. Soft tissue sarcomas in the first year of life. *Eur J Cancer* 2010;46(13):2449–2456.
183. Kleinerman RA, Tucker MA, Abramson DH, et al. Risk of soft tissue sarcomas by individual subtype in survivors of hereditary retinoblastoma. *J Natl Cancer Inst* 2007;99(1):24–31.
184. S⊘rensen SA, Mulvihill JJ, Nielsen A. Long-term follow-up of von Recklinghausen neurofibromatosis. *N Engl J Med* 1986;314(16):1010–1015.
185. Strahm B, Malkin D. Hereditary cancer predisposition in children: genetic basis and clinical implications. *Int J Cancer* 2006;119(9):2001–2006.
186. Spunt SL, Skapek SX, Coffin CM. Pediatric nonrhabdomyosarcoma soft tissue sarcomas. *Oncologist* 2008;13(6):668–678.
187. Haldar M, Hancock JD, Coffin CM, et al. A conditional mouse model of synovial sarcoma: insights into a myogenic origin. *Cancer Cell* 2007; 11(4):375–388.
188. Duyster J, Bai RY, Morris SW. Translocations involving anaplastic lymphoma kinase (ALK). *Oncogene* 2001;20(40):5623–5637.
189. Maire G, Fraitag S, Galmiche L, et al. A clinical, histologic, and molecular study of 9 cases of congenital dermatofibrosarcoma protuberans. *Arch Dermatol* 2007;143(2):203–210.
190. Pappo AS, Rao BN, Jenkins JJ, et al. Metastatic nonrhabdomyosarcomatous soft tissue sarcomas in children and adolescents: the St. Jude Children's Research Hospital experience. *Med Pediatr Oncol* 1999;33(2):76–82.
191. West RB, van de Rijn M. The role of microarray technologies in the study of soft tissue tumours. *Histopathology* 2006;48(1):22–31.
192. Parham DM, Webber BL, Jenkins JJ, et al. Nonrhabdomyosarcomatous soft tissue sarcomas of childhood: formulation of a simplified system for grading. *Mod Pathol* 1995;8(7):705–710.
193. Hayes-Jordan A. Recent advances in non-rhabdomyosarcoma soft-tissue sarcomas. *Semin Pediatr Surg* 2012;21(1):61–67.
194. Ferrari A, Miceli R, Meazza C, et al. Soft tissue sarcomas of childhood and adolescence: the prognostic role of tumor size in relation to patient body size. *J Clin Oncol* 2009;27(3):371–376.
195. Hawkins DS, Spunt SL, Skapek SX. Children's Oncology Group's 2013 blueprint for research: soft tissue sarcomas. *Pediatr Blood Cancer* 2013;60(6):1001–1008.
196. Maduekwe UN, Hornicek FJ, Springfield DS, et al. role of sentinel lymph node biopsy

in the staging of synovial, epithelioid, and clear cell sarcomas. *Ann Surg Oncol* 2009;16(5):1356–1363.

197. Kayton ML, Delgado R, Busam K, et al. Experience with 31 sentinel lymph node biopsies for sarcomas and carcinomas in pediatric patients. *Cancer* 2008;112(9):2052–2059.
198. Spector LG, Birch J. The epidemiology of hepatoblastoma. *Pediatr Blood Cancer* 2012;59(5):776–779.
199. Feusner J, Plaschkes J. Hepatoblastoma and low birth weight: a trend or chance observation? *Med Pediatr Oncol* 2002;39(5):508–509.
200. Trobaugh-Lotrario AD, Venkatramani R, Feusner JH. Hepatoblastoma in children with Beckwith–Wiedemann syndrome: does it warrant different treatment? *J Pediatr Hematol Oncol* 2014;36(5):369–373.
201. Sparago A, Russo S, Cerrato F, et al. Mechanisms causing imprinting defects in familial Beckwith–Wiedemann syndrome with Wilms' tumour. *Hum Mol Genet* 2007;16(3):254–264.
202. Mamlok V, Nichols M, Lockhart L, et al. Trisomy 18 and hepatoblastoma. *Am J Med Genet* 1989;33(1):125–126.
203. Hughes LJ, Michels VV. Risk of hepatoblastoma in familial adenomatous polyposis. *Am J Med Genet* 1992;43(6):1023–1025.
204. Tan ZH, Lai A, Chen CK, et al. Association of trisomy 18 with hepatoblastoma and its implications. *Eur J Pediatr* 2014;173(12):1595–1598.
205. Tonk VS, Wilson KS, Timmons CF, et al. Trisomy 2, trisomy 20, and del(17p) as sole chromosomal abnormalities in three cases of hepatoblastoma. *Genes Chromosomes Cancer* 1994;11(3):199–202.
206. Albrecht S, Schweinitz von D, Waha A, et al. Loss of maternal alleles on chromosome arm 11p in hepatoblastoma. *Cancer Res* 1994;54(19):5041–5044.
207. Hartmann W, Waha A, Koch A, et al. p57KIP2 is not mutated in hepatoblastoma but shows increased transcriptional activity in a comparative analysis of the three imprinted genes p57KIP2, IGF2, and H19. *Am J Pathol* 2000;157(4):1393–1403.
208. Kraus JA, Albrecht S, Wiestler OD, et al. Loss of heterozygosity on chromosome 1 in human hepatoblastoma. *Int J Cancer* 1996;67(4):467–471.
209. Tomlinson GE, Douglass EC, Pollock BH, et al. Cytogenetic evaluation of a large series of hepatoblastomas: numerical abnormalities with recurring aberrations involving 1q12-q21. *Genes Chromosomes Cancer* 2005;44(2):177–184.
210. Ruck P, Xiao J-C. Stem-like cells in hepatoblastoma. *Med Pediatr Oncol* 2002;39(5):504–507.
211. Fiegel HC, Glüer S, Roth B, et al. Stem-like cells in human hepatoblastoma. *J Histochem Cytochem* 2004;52(11):1495–1501.
212. Gonzalez-Crussi F, Upton MP, Maurer HS. Hepatoblastoma: attempt at characterization of histologic subtypes. *Am J Surg Pathol* 1982;6(7):599.

213. Czauderna P, Lopez-Terrada D, Hiyama E, et al. Hepatoblastoma state of the art: pathology, genetics, risk stratification, and chemotherapy. *Curr Opin Pediatr* 2014;26(1):19–28.
214. Haas JE, Muczynski KA, Krailo M, et al. Histopathology and prognosis in childhood hepatoblastoma and hepatocarcinoma. *Cancer* 1989;64(5):1082–1095.
215. Trobaugh-Lotrario AD, Tomlinson GE, Finegold MJ, et al. Small cell undifferentiated variant of hepatoblastoma: adverse clinical and molecular features similar to rhabdoid tumors. *Pediatr Blood Cancer* 2009;52(3):328–334.
216. Meyers RL, Rowland JR, Krailo M, et al. Predictive power of pretreatment prognostic factors in children with hepatoblastoma: a report from the Children's Oncology Group. *Pediatr Blood Cancer* 2009;53(6):1016–1022.
217. Schweinitz DV, Hadam MR, Welte K. Production of interleukin-1β and interleukin-6 in hepatoblastoma. *Int J Cancer* 1993;53:72–734.
218. Schweinitz von D, Faundez A, Teichmann B, et al. Hepatocyte growth-factor-scatter factor can stimulate post-operative tumor-cell proliferation in childhood hepatoblastoma. *Int J Cancer* 2000;85(2):151–159.
219. Perilongo G, Brown J, Shafford E, et al. Hepatoblastoma presenting with lung metastases. *Cancer* 2000;89(8):1845–1853.
220. Meyers RL. Tumors of the liver in children. *Surg Oncol* 2007;16(3):195–203.
221. Katzenstein HM, Krailo MD, Malogolowkin MH, et al. Hepatocellular carcinoma in children and adolescents: results from the Pediatric Oncology Group and the Children's Cancer Group intergroup study. *J Clin Oncol* 2002;20(12):2789–2797.
222. Brown J, Perilongo G, Shafford E, et al. Pretreatment prognostic factors for children with hepatoblastoma—results from the International Society of Paediatric Oncology (SIOP) study SIOPEL 1. *Eur J Cancer* 2000;36(11):1418–1425.
223. Aronson DC, Schnater JM, Staalman CR, et al. Predictive value of the pretreatment extent of disease system in hepatoblastoma: results from the International Society of Pediatric Oncology Liver Tumor Study Group SIOPEL-1 study. *J Clin Oncol* 2005;23(6):1245–1252.
224. Schweinitz von D, Hecker H, Harms D, et al. Complete resection before development of drug resistance is essential for survival from advanced hepatoblastoma—a report from the German Cooperative Pediatric Liver Tumor Study HB-89. *J Pediatr Surg* 1995;30(6):845–852.
225. Lovvorn HN III, Ayers D, Zhao Z, et al. Defining hepatoblastoma responsiveness to induction therapy as measured by tumor volume and serum α-fetoprotein kinetics. *J Pediatr Surg* 2010;45(1):121–129.
226. Taylor PH, Filler RM, Nebesar RA, et al. Experience with hepatic resection in childhood. *Am J Surg* 1969;117(4):435–441.
227. Lee CS, Sung JL, Hwang LY, et al. Surgical treatment of 109 patients with symptomatic and asymptomatic hepatocellular carcinoma. *Surgery* 1986;99(4):481–

490.
228. Exelby PR, Filler RM, Grosfeld JL. Liver tumors in children in the particular reference to hepatoblastoma and hepatocellular carcinoma: American Academy of Pediatrics Surgical Section Survey 1974. *J Pediatr Surg* 1975;10(3):329–337.
229. Malogolowkin MH, Katzenstein HM, Meyers RL, et al. Complete surgical resection is curative for children with hepatoblastoma with pure fetal histology: a report from the Children's Oncology Group. *J Clin Oncol* 2011;29(24):3301–3306.
230. Ortega JA, Douglass EC, Feusner JH, et al. Randomized comparison of cisplatin/vincristine/fluorouracil and cisplatin/continuous infusion doxorubicin for treatment of pediatric hepatoblastoma: a report from the Children's Cancer Group and the Pediatric Oncology Group. *J Clin Oncol* 2000;18(14):2665–2675.
231. Habrand JL, Nehme D, Kalifa C, et al. Is there a place for radiation therapy in the management of hepatoblastomas and hepatocellular carcinomas in children? *Int J Radiat Oncol Biol Phys* 1992;23(3):525–531.
232. Koneru B, Flye MW, Busuttil RW, et al. Liver transplantation for hepatoblastoma. The American experience. *Ann Surg* 1991;213(2):118–121.
233. Faraj W, Dar F, Marangoni G, et al. Liver transplantation for hepatoblastoma. *Liver Transpl* 2008;14(11):1614–1619.
234. Tiao GM, Bobey N, Allen S, et al. The current management of hepatoblastoma: a combination of chemotherapy, conventional resection, and liver transplantation. *J Pediatr* 2005;146(2):204–211.
235. Moon SB, Shin HB, Seo JM, et al. Hepatoblastoma: 15-year experience and role of surgical treatment. *J Korean Surg Soc* 2011;81(2):134–140.
236. Meyers RL, Tiao G, de Ville de Goyet J, et al. Hepatoblastoma state of the art: pre-treatment extent of disease, surgical resection guidelines and the role of liver transplantation. *Curr Opin Pediatr* 2014;26(1):29–36.
237. Austin MT, Leys CM, Feurer ID, et al. Liver transplantation for childhood hepatic malignancy: a review of the United Network for Organ Sharing (UNOS) database. *J Pediatr Surg* 2006;41(1):182–186.
238. Otte J-B, de V de Goyet J, Reding R. Liver transplantation for hepatoblastoma: indications and contraindications in the modern era. *Pediatr Transpl* 2005;9(5):557–565.
239. Trobaugh-Lotrario AD, Katzenstein HM. Chemotherapeutic approaches for newly diagnosed hepatoblastoma: past, present, and future strategies. *Pediatr Blood Cancer* 2012;59(5):809–812.
240. Jacobs JF, Coulie PG, Figdor CG, et al. Targets for active immunotherapy against pediatric solid tumors. *Cancer Immunol Immunother* 2009;58(6):831–841.
241. Czauderna P, Mackinlay G, Perilongo G, et al. Hepatocellular carcinoma in children: results of the first prospective study of the International Society of Pediatric Oncology group. *J Clin Oncol* 2002;20(12):2798–2804.

242. Otte JB, de Ville de Goyet J. The contribution of transplantation to the treatment of liver tumors in children. *Semin Pediatr Surg* 2005;14(4):233–238.
243. Malogolowkin MH, Stanley P, Steele DA, et al. Feasibility and toxicity of chemoembolization for children with liver tumors. *J Clin Oncol* 2000; 18(6):1279–1284.

Chapter 106

The Pregnant Patient

Juan L. Martinez-Poyer and N. Scott Adzick

Key Points

1 One of the most significant advances in the reduction of morbidity of prematurity has been the use of antenatal corticosteroids.

2 To accommodate the fetus, placenta, and amniotic fluid, the uterus increases in size and weight and its walls become thinner. By the end of the first trimester, the uterus moves out of the pelvis and by 20 weeks reaches the level of the umbilicus. By term, it almost reaches the liver.

3 The etiology of preterm labor is often multifactorial, but the onset of labor from fetal and uterine stress from surgical manipulation is of most concern to the surgeon.

4 Initiation of tocolytic therapy for potential but unconfirmed preterm labor is discouraged.

5 Exposure to diagnostic levels of radiation carries little chance for spontaneous abortion, teratogenesis, or growth retardation. The increased risk of future cancer, however, does exist and must be weighted against the utility of information provided by the study.

6 Attributing abdominal pain to other etiologies, failure to pursue further investigation, and the physicians' fear of surgically induced premature labor all contribute to delayed diagnosis, higher perforation rates, diffuse peritonitis, preterm labor, and fetal loss in pregnant patients with appendicitis.

7 Cholecystectomy can be performed safely and effectively during pregnancy in all trimesters. Nonoperative management of symptomatic cholelithiasis is associated with significant recurrent bouts of symptoms, prolonged total parenteral nutrition, higher rates of preterm delivery, cesarean section, and more technically difficult cholecystectomies.

8 Adhesions remain the most common cause of intestinal obstruction in the gravid patient, with 89% to 100% of patients eventually requiring an operation.

9 Pregnant patients present with more advanced colorectal cancers than the population a whole. The necessary treatment must balance oncology outcomes with effect on the pregnancy, and decisions regarding the management of pregnancy include termination, iatrogenic prematurity, or intentional delay in treatment.

The general surgeon at some point in his or her career will be asked to operate on an obstetrical patient or be urgently consulted for intraoperative assistance with an unanticipated surgical finding or complication. To provide the best support, it is imperative that he or she is knowledgeable of the normal physiologic variations occurring during pregnancy, the frequency and nature of presentation of surgical disease, the safety and utility of diagnostic imaging modalities, and the newest surgical techniques to ensure the safety and well-being of the mother and the fetus. To achieve this goal, the concerted effort and close working relationship between various specialties cannot be overemphasized.

This chapter reviews the current data on the presentation, frequency, and treatment of some common surgical diseases during gestation, as well as their impact on pregnancy.

FETAL DEVELOPMENT

1 Human development begins immediately on fertilization of the oocyte by the sperm, but because in many cases it is very difficult to determine the exact time of fertilization, pregnancy is generally dated from the first day of the last menstrual period. However, dating using menstrual age is less accurate than early ultrasonography dating because of reliance on recall, cycle length variability, and pregnancy after cessation of oral contraceptives or following childbirth.[1,2] Ultrasonography provides a better estimate of the date of delivery than a reliable last menstrual period before 20 weeks of gestation, with an optimum for examinations performed in the first trimester when crown–rump length is within 5 days of the date of conception in 95% of the cases.[3–5] The embryonic period refers to the earliest stages of development and extends to the end of the eighth week, by which time organogenesis has occurred. The fetal period lasts from the ninth week to birth. During this period, growth and development of tissues formed during embryogenesis occur in preparation for birth. By the beginning of the third trimester, the fetus may survive if born prematurely.[6] Survival outside the womb depends on the adaptation of fetal organ systems for independent function at the time of birth. The functional status of the respiratory system is crucial in determining fetal viability. Periviable birth is defined as birth from $20^{0}/_{7}$ weeks through $25^{6}/_{7}$ weeks. Infants born before 20 weeks are considered abortions. Infants born at 20 weeks and 21 weeks do not survive. The survival data for births at 22, 23, 24, and 25 weeks of gestation, excluding infants with birth weights lower than 401 g, greater than 1,000 g, and infants with major anomalies, are 6%, 26%, 55%, and 72%, respectively.[7] Surfactant, a complex mixture of phospholipids consisting mostly of phosphatidylcholine, is necessary for reduction of surface tension at the alveolar–air interface and proper oxygen exchange. Surfactant production begins by the 20th week of gestation but is present in only small amounts before 24 weeks.[6] One of the most significant advances in the reduction of morbidity of prematurity has been the use of antenatal corticosteroids. Binding of corticosteroids in the fetal lung not only increases secretion of phosphatidylcholine but also induces morphologic development of pulmonary epithelial cells and increases neonatal lung compliance. Corticosteroids stimulate development of other organ systems as well, decreasing the incidence of necrotizing enterocolitis, intraventricular hemorrhage, periventricular leukomalacia, and death. The maximum developmental effects can be seen as early as 24 hours after maternal administration of dexamethasone or betamethasone, and administration at the first sign of premature onset of labor can improve survival, particularly before birth between 22 and 25 weeks.[8–10]

UTERINE ANATOMY AND PHYSIOLOGY OF LABOR

2 The uterus is a muscular organ responsible for reception, implantation, development, and expulsion of the fetus. In the nonpregnant woman, the uterus lies in the pelvis, weighs approximately 70 g, and has a cavity volume of 10 mL. To accommodate the fetus, placenta, and amniotic fluid, the uterus increases in size and weight and its walls become thinner. By the end of the first trimester, the uterus moves out of the pelvis and by 20 weeks reaches the level of the umbilicus. By term, its capacity is 500 to 1,000 times greater than that in the nonpregnant state. With progressive increase in size, the uterus contacts the anterior abdominal wall, displaces the bowel laterally and superiorly, and almost reaches the liver (Fig. 106-1).[11] Coupled with its ascent from the pelvis, the uterus usually rotates to the right due to the presence of the rectosigmoid on the left side of the pelvis. When the pregnant woman lies supine, the uterus rests on the vertebral column and compresses the abdominal great vessels, particularly the inferior vena cava. Right before the last weeks of pregnancy, the uterus undergoes sporadic, nonrhythmic and painless contractions that are known as Braxton Hicks contractions. The intensity of these contractions varies between 5 and 25 mm Hg. At term, these contractions become well-coordinated, reaching pressures up to 80 mm Hg. The factors responsible for the onset and maintenance of normal labor at term are not completely understood. Multiple mechanisms are responsible for the spontaneous contraction–relaxation cycles in human myometrium, including changes in intracellular calcium concentrations, alteration in membrane potential, phosphorylation and dephosphorylation of myosin light-chain kinase, activation of phosphatases, and recruitment of a number of intracellular signal pathways. During pregnancy, uterine contractility is maintained in a state of quiescence through the action of various inhibitors that include but are not limited to progesterone, prostacyclin, relaxin, parathyroid hormone–related peptide, nitric oxide, calcitonin gene-related peptide, adrenomedullin, and vasoactive intestinal peptide. Parturition begins as a consequence of release from the inhibitory effects of pregnancy on the myometrium as well as recruitment of uterine stimulants such as estrogen, oxytocin, and stimulatory prostaglandins (e.g., PGE2, PGF2α, IL-1, and IL-6). The final common pathway toward parturition appears to be maturation and activation of the fetal hypothalamic–pituitary–adrenal (HPA) axis. The result is a dramatic increase in production of the C19 steroid dehydroepiandrosterone sulfate. The cellular and molecular factors that are responsible for maturation of the fetal HPA axis seem to be associated with the gestational age-dependent upregulation of a number of critical genes within each component of the HPA axis: corticotropin-releasing hormone (CRH) from the fetal hypothalamus, proopiomelanocortin from the fetal pituitary, and Adrenocorticotropic hormone (ACTH) receptor and steroidogenic enzymes in the fetal adrenal gland. Animal models have shown that undernutrition of the mother around the time of conception leads to precocious activation of the fetal HPA and preterm birth. This suggests that, although maturation of the fetal HPA axis is developmentally regulated and the timing of parturition may be determined by a "placental clock" set shortly after implantation, stress may accelerate this clock. Levels of CRH in the maternal circulation increase from

between 10 and 100 pg/mL in nonpregnant women to between 500 and 300 pg/mL in the third trimester of pregnancy and then decrease precipitously after delivery. The source of the excess CRH is the placenta. The production of CRH by the placenta is upregulated by corticosteroids produced primarily by the fetal adrenal glands at the end of pregnancy. Under the influence of estrogen, hepatic-derived CRH-binding protein concentrations also increase in pregnancy. Circulating CRH levels increase and CRH-binding protein levels decrease before the onset of both term and preterm labor, resulting in a marked increase in free, biologically active CRH. At a molecular level, CRH acts by binding to specific nuclear receptors and affecting transcription of target genes. A number of CRH receptor isoforms dominate, and CRH promotes myometrial quiescence by inhibiting the production and increasing the degradation of prostaglandins, increasing intracellular cyclic adenosine monophosphate, and stimulating nitric oxide synthetase activity. At term, CRH acts primarily through its low-affinity receptor isoforms, which promotes myometrial contractility by stimulating prostaglandin production from the decidua and fetal membranes and potentiating the contractile effects of oxytocin and prostaglandins on the myometrium.[12]

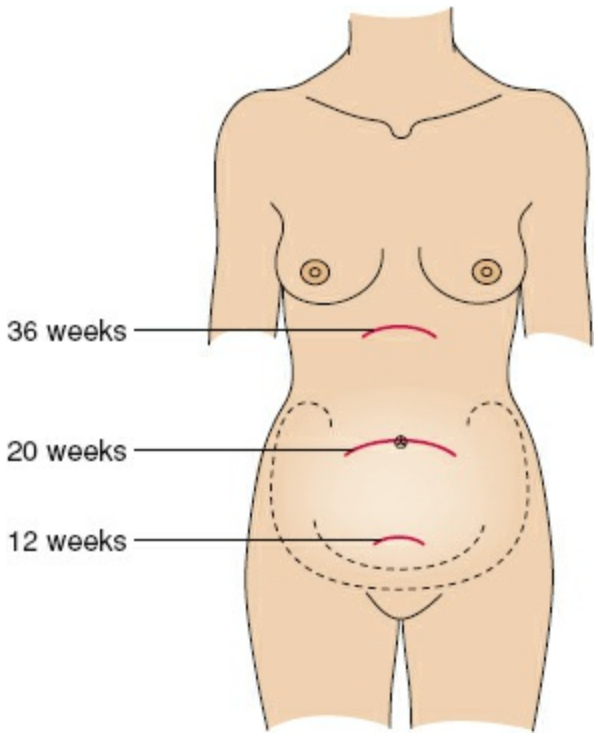

Figure 106-1. Enlarging uterus during gestation. At 12 weeks, the uterus rises out of the pelvis into the abdomen. At 20 weeks, the fundus is at the height of the umbilicus, and at 36 weeks, the uterus reaches to the upper abdomen.

PREMATURE ONSET OF LABOR

3 Preterm birth is defined as birth between $20^{0}/_{7}$ weeks and $36^{6}/_{7}$ weeks of gestation. The diagnosis is made clinically on the basis of the presence of regular uterine contractions accompanied by a change in cervical dilatation, effacement, or both, or initial presentation with regular contractions and cervical dilatation of at least 2 cm. Although only 12% of all live births in the United States fit this criterion, prematurity is responsible for approximately 70% of neonatal deaths, 36% of infant deaths, 25% to 50% of cases of long-term neurologic impairment in children, and a high cost to the health care system.[13–17] Preterm labor with intact membranes is not the only cause of preterm birth; numerous preterm births are preceded by either rupture of membranes or medical/surgical problems necessitating delivery.[18,19] The etiology of preterm labor is often multifactorial, but the onset of labor from fetal and uterine stress during surgical manipulation or intra-abdominal inflammatory processes is of most concern to the surgeon. Bacterial infection of the amniotic tissues or peritoneum leads to a local increase in eicosanoids and the onset of labor.[20] Endotoxin acts on inflammatory cells to increase production of IL-1 and IL-6, which also amplify local prostaglandin production. All of these factors can act in concert to initiate and propagate preterm labor. Uterine activation and increased expression of gap junctions as well as oxytocin receptors can be induced by uterine stretch.[21] Uterine trauma due to surgical manipulation can affect these same mechanisms, leading to premature uterine contractions. The interrelations at various levels between the inflammatory response, uterine and maternal trauma, and the initiation of labor can represent the body's attempt to expel the fetus from a hostile uterine environment.

Tocolysis

4 To date, there is no evidence that tocolytic therapy has associated direct benefit on improving neonatal outcome, except for short-term prolongation of pregnancy (up to 48 hours) to allow for the administration of antenatal steroids, transport of the patient to a tertiary care facility, and fetal neuroprotection.[22–24] In general, tocolysis is indicated between viability (24 weeks of gestation) and 34 weeks of gestation in women with preterm contractions with cervical change. However, it is accepted to administer tocolytics before viability after events known to cause preterm labor, such as intra-abdominal surgery and in utero fetal surgery although evidence of efficacy for such intervention is lacking.[25,26] Prostaglandin synthesis inhibitors, magnesium sulfate, $beta_2$-adrenergic agonists, and calcium channel blockers represent the four most common pharmacologic agents used as tocolytics. Because of the importance of prostaglandins in the initiation of uterine contraction, prostaglandin synthetase inhibitors are used to stop premature labor. Indomethacin is the nonsteroidal drug used most frequently for tocolysis because of its quick onset of action and ease of dosing. Studies report a 95% tocolytic success rate at 48 hours and a potential delay in delivery of 1 week in 80% of patients.[27] Magnesium sulfate has long been used in the treatment of preeclampsia and has gained acceptance as a tocolytic and more recently as a neuroprotective agent to reduce the risk and severity of cerebral palsy when birth is anticipated before 32 weeks of gestation. Most data support the theory that magnesium exerts its effects by calcium antagonism. High intracellular magnesium concentrations inhibit Ca^{2+} entry into myometrial cells, interfering with actin–myosin coupling. High magnesium concentrations also increase the sensitivity of K^+ channels, favoring hyperpolarization and uterine relaxation. Maternal serum levels necessary to inhibit myometrial contractility range between 4 and 9 mg/dL, two to six times normal levels.[28] $Beta_2$-adrenergic agonists used in the treatment of preterm labor include ritodrine and terbutaline. Stimulation of uterine $beta_2$ receptors leads to activation of adenylate cyclase and an increase in intracellular cyclic adenosine monophosphate (cAMP) concentration. Activation of -dependent protein kinase A inhibits myosin light-chain phosphorylation and actin–myosin coupling. Protein kinase A activity is also associated with increased Ca^{2+} efflux, decreased Ca^{2+} influx, and increased K^+ conductance. All these actions lead to myometrial relaxation. Because of reports of serious maternal side effects and possible adverse behavioral effects in offspring after in utero exposure to terbutaline, the U.S. Food and Drug Administration (FDA) issued a warning regarding the aforementioned agent and suggested that its use be limited to short-term inpatient acute tocolysis particularly in the setting of tachysystole.[29,30] Calcium channel blockers inhibit entry of calcium through voltage-dependent Ca^{2+} channels. The use of oral nifedipine can abolish uterine activity and prevent delivery with minimal maternal side effects and no reported fetal or neonatal adverse effects.[31] However, maternal and fetal side effects can be serious with other tocolytic agents. Premature constriction of the fetal ductus arteriosus and necrotizing enterocolitis with the use of indomethacin has been reported and can result in neonatal pulmonary hypertension and even death.[32,33] Maternal cardiovascular side effects, including pulmonary edema,

can occur in 5% of beta$_2$ agonist users and 10% of those treated with magnesium. Although this complication is rare, it can result in maternal death. Serum concentrations of magnesium needed for tocolysis (4 to 9 mg/dL) are not far from levels causing ablation of deep tendon reflexes (9 to 13 mg/dL) or respiratory depression (14 mg/dL). The decision to use tocolytics must be made only after the diagnosis of premature onset of labor is confirmed, and the benefits of prolonging gestation outweigh the risks of tocolysis. Initiation of tocolytic therapy for potential but unconfirmed preterm labor is discouraged.[34] Maintenance therapy with any of the aforementioned tocolytic agents has not been demonstrated to prolong pregnancy or improve neonatal outcomes after an initial treated episode of threatened preterm birth and, therefore, should not be used for this purpose.[35–37]

FETAL MONITORING

Perioperative fetal monitoring as well as the monitoring of premature uterine contractions is based on technology developed for intrapartum fetal monitoring in the late 1950s and early 1960s. Observational studies performed at that time and in the mid-1970s convincingly established a relationship between the degree of fetal acidemia and the presence and depth of decelerations and decreased or absent fetal heart rate variability.[38,39] Established heart rate patterns and variable cardiac responses to fetal and maternal stimuli reflect an intact, well oxygenated central nervous system (CNS). Identification of deviation from those patterns indicative of metabolic acidosis was hoped to decrease the incidence of hypoxic–ischemic encephalopathy and death. Meta-analysis of randomized controlled trials comparing electronic fetal monitoring with intermittent auscultation has failed to show that electronic fetal monitoring decreased neurologic morbidity and mortality.[40] Recently, researches using the US 2004-linked birth and infant death data found that the use of electronic fetal monitoring was associated with a substantial decrease in early neonatal morbidity particularly in preterm fetuses.[41] However, authorities in the field remain skeptical of the findings and have cautioned that an epidemiologic association between fetal monitoring and reduced neonatal death does not establish causation.[42] This controversy is not expected to be solved any time in the near future, but the fact is that of the approximately 4 million live births a year in the United States, 85% are assessed with fetal heart rate monitoring, making it the most common procedure in pregnancy.[43] Fetal heart rate monitoring may be performed externally or internally. Most external monitor devices use the Doppler principle with computerized logic to count and interpret the Doppler signals originating from the fetal heart and maternal uterus. Internal fetal heart rate monitoring is accomplished with a spiral device attached to the fetal scalp or other presenting part. A transcervical intrauterine pressure catheter is sometimes used to monitor more accurately the strength and frequency of uterine contractions (Fig. 106-2). Both tracings are printed on a continuous strip of paper, with the fetal heart rate plotted at the top of the graph and uterine activity at the bottom.

Fetal Heart Rate

Normal fetal heart rate during pregnancy ranges between 110 and 160 beats/min. A prolonged baseline above 160 beats/min is considered a tachycardia, whereas that below 110 beats/min is a bradycardia. These terms refer to long-term patterns, and minute-to-minute variability in the heart rate away from baseline is known as acceleration and deceleration. Normal fetal heart rate tracings express continuous adjustment in the vagal tone through variability in the heart rate. Short-term or beat-to-beat variability is superimposed on broader, long-term variability of the baseline by three to five beats/min. The fetal heart rate response governed by a nonacidotic, well-functioning vagal conduction system manifests both long-term and short-term variability, with fluctuations of peaks and troughs ranging from 6 to 25 beats/min (Fig. 106-3). Decreased heart rate variability, either long or short term, can signal diminished CNS activity. Although this can be a physiologic response of the fetal sleep–wake cycle or maternal medication and sedatives, persistently decreased reactivity can signal CNS acidosis. Fetal heart rate accelerations are normal findings in the second half of pregnancy and occur as a result of increased sympathetic stimulation and decreased parasympathetic stimulation with fetal movements. Fetal heart rate decelerations are usually encountered during uterine contractions of the intrapartum period. Evaluation of decelerations during labor and as part of intraoperative fetal monitoring can give clues to the status of the placental blood supply. A prolonged deceleration is a visually apparent decrease in the fetal heart rate baseline that is 15 minutes or more, lasting 2 minutes or more but less than 10 minutes in duration. Early decelerations are characterized by a symmetrical and gradual decrease and return of the fetal heart rate that mirror uterine contractions and reflect increased vagal tone from a transient increase in intracranial pressure. This pattern is considered a benign physiologic manifestation of a functioning autonomic nervous system and has no adverse outcome. Variable decelerations are distinctively recognized by their abrupt decrease in fetal heart rate of 15 beats/min or greater from the onset of the deceleration to the beginning of the fetal heart rate nadir of 30 seconds, lasting 15 seconds or greater, and less than 2 minutes in duration. When variable decelerations are associated with uterine contractions, their onset, depth, and duration vary with successive uterine contractions. Isolated variable decelerations have little clinical significance, but if persistent with inadequate recovery between contractions, fetal hypoxemia and acidosis can occur. Late decelerations present usually as a symmetrical and gradual decrease and return of the fetal heart rate associated with a uterine contraction. The deceleration is delayed in timing, with its nadir occurring after the peak of the contraction. Late decelerations have an ominous connotation as they usually represent significant uteroplacental compromise; causes can range from maternal hypotension due to inferior vena cava compression to hypoxia or anemia.[44] Intraoperative fetal compromise as indicated by an ominous heart rate tracing must be treated by correcting maternal hypotension or increasing oxygen delivery with increased F_{IO_2}, positional changes, aggressive fluid resuscitation, or blood transfusion. The inability to improve the intrauterine milieu can necessitate an emergent cesarean section to prevent fetal

demise.[45] The decision to use continuous fetal heart rate monitoring during nonobstetric surgery in pregnancy is controversial and should be based on gestational age, type, site, duration, and extent of the procedure. For previable pregnancies (<23 weeks), documentation of fetal heart activity by Doppler before and after the procedure suffices.[46] For viable gestations, there is less consensus for fetal heart rate monitoring, but at a minimum, simultaneous electronic fetal heart rate and contraction monitoring should be performed before and after the procedure to assess fetal well-being and the absence of contractions. If the decision is to perform intraoperative electronic fetal heart monitoring, then all the necessary provisions should be made to provide optimal safety for the mother and the fetus. These include availability of obstetric care providers, anesthesiologists, neonatologists, and nurses working as a team and ready to intervene during the surgical procedure for fetal indications. Informed operative consent should thus be obtained in anticipation for a possible emergency delivery.[47]

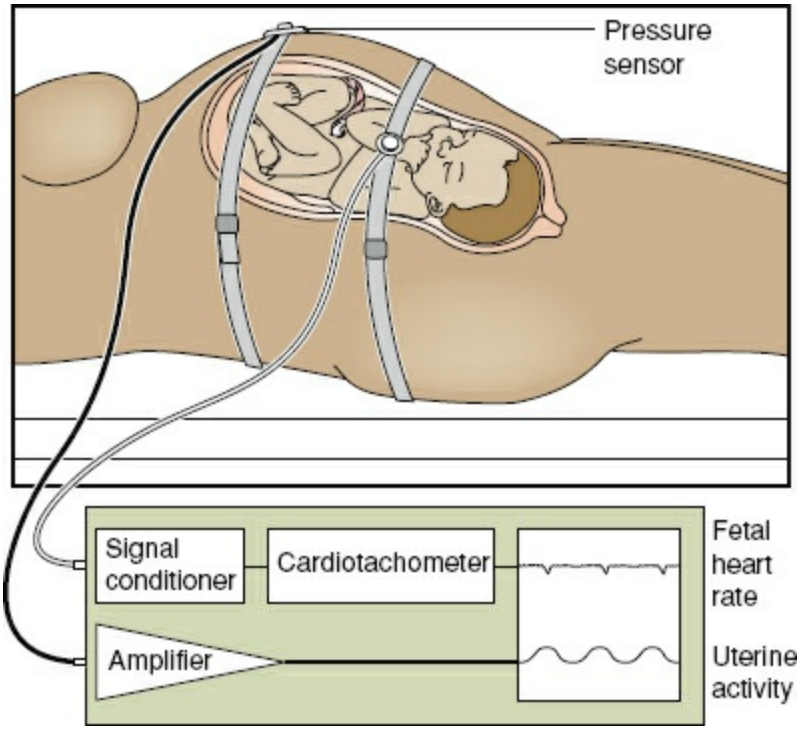

Figure 106-2. Intraoperative and postoperative fetal monitoring using noninvasive surface Doppler and pressure sensor to monitor uterine contractions. (Reproduced from Miller DA, Paul R. Antepartum–intrapartum monitoring. In: Scott JR, DiSaia PJ, Hammond CB, et al., eds. *Danforth's Obstetrics and Gynecology*. 8th ed. Philadelphia, PA: Lippincott Williams & Wilkins; 1999:243–255.)

IMAGING MODALITIES IN THE PREGNANT PATIENT

5 The most commonly used imaging modalities during pregnancy include radiography, ultrasonography, magnetic resonance imaging (MRI), and computed tomography (CT). The first and the latter are forms of ionizing radiation. The risks of ionizing radiation are an important source of anxiety for health care providers and patients that at times can force the physician to avoid the definitive diagnostic study of choice for fear that any radiation exposure would result in an anomalous fetus. This misconception could place both the mother and the fetus in greater danger from misdiagnosis. Although experimental data regarding the effects of ionizing radiation on the developing human fetus are impossible to obtain, animal exposure and follow-up of those inadvertently exposed to diagnostic and therapeutic radiation have provided some information. Retrospective studies of atomic bomb survivors in Hiroshima, Nagasaki, and victims of the atomic power plant disaster in Chernobyl have also allowed for evaluation of the effects of massive radiation exposure in utero.[48,49]

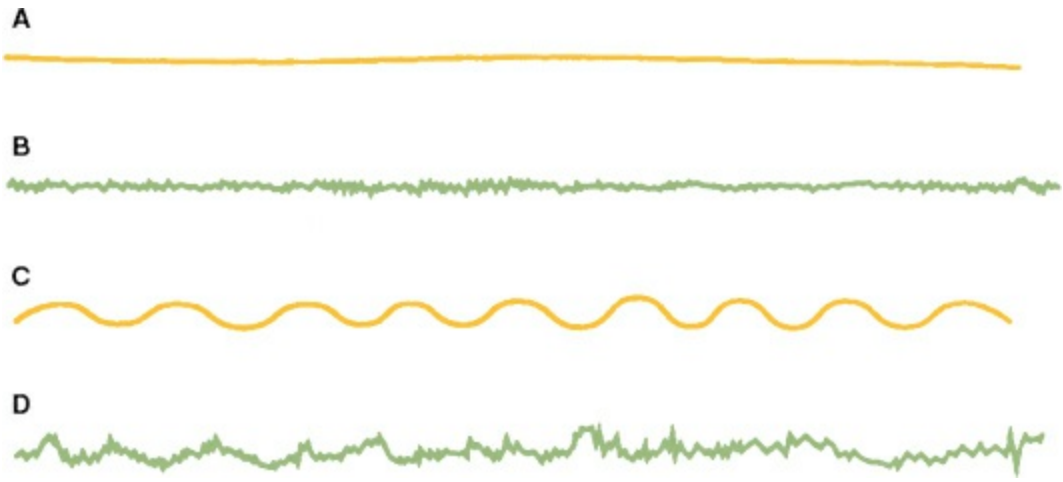

Figure 106-3. Fetal heart variability. **A:** Short-term and long-term variability both absent: abnormal. **B:** Short-term variability present, long-term variability absent: abnormal. **C:** Long-term variability present, short-term variability absent: abnormal. **D:** Both short- and long-term variability present: normal. (Reproduced from Miller DA, Paul R. Antepartum–intrapartum monitoring. In: Scott JR, DiSaia PJ, Hammond CB, et al., eds. *Danforth's Obstetrics and Gynecology*. 8th ed. Philadelphia, PA: Lippincott Williams & Wilkins; 1999:243–255.)

Ionizing Radiation

Fetal effects of ionizing radiation depend on the dose absorbed by the fetal tissue and the stage of fetal development during exposure. Exposure is defined as the amount of ionic charge created by the radiation on passing through a defined mass of air. Units traditionally used to measure the effects of ionizing radiation include the radiation absorbed dose (rad) and the roentgen equivalents man (rem). Modern units include the gray (Gy) and sievert (Sv). According to the International System of Units, Gy is the unit that describes the potential radiation exposure from medical diagnostic equipment, but rad is the predominant measure used. One gray (Gy) is strictly defined as the deposition of 1.0 joule of energy per kilogram of tissue, and 1 rad is 1% of 1 Gy. As a gross estimate, exposure to 1 roentgen gives an absorbed dose of 1 rad or 10 mGy.

Sv is generally used to measure the public exposure to radiation as it accounts for factors such as type of radiation amount of time exposed, level of protection, and distance from the radiation source. One sievert (Sv) = 1 Gy = 100 rads. It is a misconception to assume that the radiation dose that a pregnant woman is exposed to or absorbs is the same as that absorbed by the fetus as the latter is partially protected from radiation injury by a pregnant woman's surrounding soft tissues and uterus, both of which generally stop alpha and beta particles from penetration if they are not ingested, injected, or inhaled.[50,51] Radiographic evaluation of the abdomen and pelvis is most likely to expose the fetus to direct ionizing radiation, whereas examination of the extremities and chest leads to exposure from scatter radiation only (Table 106-1).[51] The potential deleterious consequences of radiation-induced ionization of vital cellular structures can be divided into four categories: (1) lethal effects, (2) teratogenic effect, (3) growth retardation, and (4) oncogenic potential. The occurrence of each effect depends upon the gestational age at the time of radiation exposure, the dose of radiation absorbed by the fetus, and fetal cellular repair mechanisms. The first three categories of adverse pregnancy outcomes have a deterministic effect whereby a threshold or No-Adverse-Effect Level exists. After exceeding the No-Adverse-Effect Level, a deterministic effect generally shows a gradient relationship with the absorbed dose – the larger the absorbed dose, the more severe the effect. On the contrary, cancer appears to have a stochastic effect in which, the probability, but not the severity of the effect, increases with the radiation dose. Stochastic effects are monoclonal, resulting in changes to the cell genome and altered differentiation and function of the affected cells.

Lethal Effects of Ionizing Radiation

The developing human is most sensitive to the lethal effects of ionizing radiation during the first 14 days after conception (3 to 4 weeks of gestational age). During this period, the "all or none" principle applies to the radiation-exposed embryo; it either survives undamaged or succumbs. At that gestational age, a dose of 100 to 200 mGy (10 to 20 rad) can be lethal for an embryo. Shortly thereafter, the threshold for fetal death increases to 250 to 500 mGy (25 to 50 rad). The estimated radiation dose to kill all embryos or fetuses less than 18 weeks of gestational age is 5,000 mGy (500 rad). At term, the fetal

risk equals the pregnant woman's risk at 20,000 mGy (2,000 rad).[52,53]

Table 106-1 Radiation Dosing to the Conceptus and Uterus from Selected Radiographic Examinations

Routine chest radiograph	8–50 mrad
Routine mammography <50 mrad	
Computed tomography, chest	25–1,000 mrad (uterus shielded and not exposed)
Computed tomography, upper abdomen	670–3,000 mrad (uterus shielded and not exposed)
Computed tomography, abdomen	2,000–3,000 mrad
Abdomen (flat plate) 250–300 mrad	
Endoscopic retrograde cholangiopancreatography with no permanent films and shielding of abdomen	4 mrad

Data from Wagner LK, Lester RG, Saldana LR. *Exposure of the Pregnant Patient to Diagnostic Radiation*. Madison, WI: Medical Physics Publishing, 1997; Wyte CD. Diagnostic modalities in the pregnant patient. *Emerg Med Clin North Am* 1994;12:9–43; and Baillie J, Cairns SR, Cotton PB. Endoscopic management of choledocholithiasis during pregnancy. *Surgery* 1990;171:1–4.

Teratogenic Effects of Ionizing Radiation

Teratogenic effects of radiation can be seen during early organogenesis in animal studies. Exposure of rats to 100 rads at various points of development reveals a very narrow window for teratogenesis. This window corresponds to weeks 2 to 4 in human development, consistent with early organ formation. Despite these experimental data, it is difficult to link any specific human malformation with radiation exposure other than those of the CNS. Microcephaly, pigmentary changes in the retina, hydrocephalus, and optic nerve atrophy have been reported at a significantly higher rate after exposure to radiation in pregnancy.[54] All patients were exposed to a minimum estimated dose of 100 rads, and no visceral, limb, or other malformations were found unless the child also exhibited CNS abnormalities. One explanation for this discrepancy is that the developmental period of the CNS is much longer, continuing throughout gestation and into the neonatal period, whereas other organs have a very narrow period during which morphologic alterations can be produced. Exposure to high doses of radiation during this narrow window is rare, and even if an isolated congenital abnormality were to occur, it would be difficult to separate this event from the background malformation rate. The extended period for CNS sensitivity to teratogenesis increases the prevalence of CNS malformation. Central nervous system malformation also occurs at threshold doses; however, low levels of exposure to 10 to 20 rads of radiation do not increase the

incidence of microcephaly in experimental animals over baseline.[55]

Growth Retardation from Ionizing Radiation

Growth retardation results from radiation-induced cellular depletion. Although catch-up growth can occur if exposure happens early in gestation, permanent cell depletion and growth retardation occur with exposure during later fetal stages.[56] Wood and colleagues[58] studied growth retardation of children exposed in utero to the Japanese atomic blasts. Those within 1,500 m from the center of the explosion were exposed to over 25 rads and, when followed through age of 17 years, were 2 to 3 cm shorter and 3 kg lighter and had a head circumference 1-cm smaller than normal. Those beyond 1,500 m from the blast received less than 25 rads and had a normal head circumference, height, and weight.[52,57,58] Further, animal and human data support the contention that exposures of less than 5 rads should not cause either anatomic malformation or growth retardation.[55]

Oncogenic Potential of Ionizing Radiation

The correlation between childhood cancer and in utero exposure to radiation has been demonstrated. Although conclusions regarding the cause-and-effect relationship of this correlation cannot be definitively established, further studies using twins[59] and extensive data analysis[60] have strengthened the argument that in utero radiation can increase the rate of childhood cancer even at doses of 1 rad. The current increase in childhood cancer is estimated at one to two cases per 3,000 children exposed to 1 rad in utero.[57] Although these risks are very small, the patient must be counseled regarding this potential danger. By reviewing the current data, it is obvious that exposure to diagnostic levels of radiation carries little chance for spontaneous abortion, teratogenesis, or growth retardation. The increased risk of future cancer, however, does exist and must be weighed against the utility of the information provided by the study.

Ultrasound

Ultrasonography uses high-frequency, acoustic radiation to create images. A surface transducer containing piezoelectric crystals converts electrical energy into sound waves. Sound waves pass through tissue layers and are reflected back to the transducer when they encounter an interface between tissues of different densities. Digital images generated at 50 to more than 100 frames per second undergo postprocessing that produces the appearance of real-time imaging. Ultrasonography is considered the first-line diagnostic imaging modality of the pregnant surgical patient because it is nonionizing, widely available, portable, and of adequate diagnostic performance. This imaging technique has been used in obstetrics for more than 50 years without reported fetal damage or harmful effects.[61,62] Ultrasonography is, however, a form of energy with effects on tissues through which the waveform penetrates. The two major mechanisms involved in potentially causing bioeffects are direct, resulting from the alternation of positive and negative pressures (mechanical or cavitation effects) and indirect, caused by heating of tissues secondary to transformation of the acoustic energy (thermal effects). Because of these theoretical concerns, several organizations have recommended that this diagnostic procedure should be performed only when there is a valid medical indication and the lowest possible ultrasonic exposure setting under the as low as reasonably achievable principle.[63–65]

Computed Tomography

In the past 10 years, the use of radiologic examinations in pregnant women has increased by 107%, with the greatest increase occurring in the use of CT.[66] Computed tomography is most valuable in the second and third trimesters, when ultrasonography is of limited value, in a patient with a large body habitus, and when MRI is inconclusive or not available.[67] Because of its sensitivity for the detection of abdominal and pelvic injury as well as retroperitoneal injury in which the clinical urgency requires prompt diagnosis, CT is the test of choice for injured pregnant patients.[68–70] When CT is performed during pregnancy, using dose-reduction protocols (e.g., abdominal and internal barium shielding) results in significant reduction in the probability of biologic effects to the fetus without sacrificing the necessary diagnostic image quality.[71]

Magnetic Resonance Imaging

Like ultrasonography, MRI uses no ionizing radiation, instead relying on the magnetic properties of tissues to create images. Four magnetic fields interact during an MRI examination to create the image. The intrinsic magnetic field of an atomic nucleus, usually that of a hydrogen proton, is combined with a strong, uniformly applied external magnetic field and a weaker magnetic field gradient. In addition, a magnetic field is intermittently generated by pulsed radio frequency waves.[52] When the radio frequency ceases, the nuclei return to their previous orientation and emit the radio frequency they absorbed. These signals are detected, stored, and processed by a computer to create an image. Theoretical concerns include the effects of fluctuating electromagnetic fields and high sound intensity levels with potential damage to the fetal ear. Other known dangers of MRI exposure include trauma from projection of small metal fragments into the eyes, interference with the operation of implantable electronic devices, position of metallic implants, and burns from heating of conductive materials in implants. Despite these concerns, present data have not conclusively documented any deleterious effects of MRI exposure on the developing conceptus or the pregnant woman.[72]

PHYSIOLOGIC CHANGES OF PREGNANCY THAT MIMIC DISEASE

Pregnancy physiology reflects the changes necessary for fetal gestation. It is characterized by the enlarging, gravid uterus and a changing hormonal milieu. These conditions predispose to certain diseases and change maternal physiology to mask the diagnosis of others. The cardiovascular system is affected by pregnancy. The cardiac output increases by 30% to 50%, as does the total blood volume. The corresponding red blood cell volume increases only by 20% to 30%, leading to a decrease in the hematocrit. Although the maternal oxygen-carrying capacity is increased and the rheologic properties of blood are optimized for maximum nutrient delivery to the fetus, a physiologic anemia develops that can be confused with a pathologic state.[73] Diagnosis of anemia due to chronic blood loss, as occurs with cancers of the gastrointestinal tract, may be delayed as the gradually decreasing hematocrit is attributed to pregnancy. Other laboratory evaluations can also mask various disease states (Table 106-2). Serum alkaline phosphatase levels gradually increase because of production of an alkaline phosphatase isozyme by the placenta. This does not reflect biliary or bone disease. Albumin levels, commonly used to measure hepatic synthetic function, decrease, and a relative leukocytosis mimics a systemic infection.

Table 106-2 Change During Pregnancy in Laboratory Values

Parameter	Change	Normal Nonpregnant Value	Late Pregnancy Value
Albumin (g/dL)	↓	3.2–3.8	2.4–3.1
Alkaline phosphatase (IU/L)	↑	30–115	100–210
Total bilirubin (mg/dL)	⇔	0.26–1.00	Unchanged
Aspartate amino-transferase (IU/L)	⇔	0–31	Unchanged
Hemoglobin (g/dL)	↓	12.0–16.0	10.5–14
Leukocyte count ($\times 10^3/mm^3$)	↑	4.5–11.0	6.0–16.0

↑, up; ↓, down; ⇔, no change. Reproduced from Martin C, Varner MW. Physiologic changes in pregnancy surgical implications. *Clin Obstet Gynecol* 1994;37:241–255, with permission.

The gastrointestinal tract undergoes a state of relaxation and decreased smooth muscle activity during pregnancy. The lower esophageal sphincter tone gradually decreases, as does gastric emptying. Prolonged small bowel transit time and decreased colonic emptying not only work to maximize nutrient and water absorption but also contribute to the constipation reported by 38% of pregnant women.[74] Although multifactorial, the actions of progesterone have been linked to inhibition of gut smooth muscle activity both

in vitro and in vivo. Because this dose-dependent inhibition can be blocked by increasing the extracellular concentration of Ca^{2+}, at least in vitro, it is proposed than progesterone works by limiting the effective Ca^{2+} available for actin–myosin coupling.[75,76] This same mechanism contributes to uterine relaxation early in pregnancy, decreased intestinal motility, and the concurrent decrease in gallbladder tone and rate of emptying. With these changes, combined with supersaturation of bile by cholesterol, pregnancy becomes a lithogenic state.[77] These effects of pregnancy are transient and gallbladder motility and volumes return to normal as early as 2 weeks after pregnancy, but the gallstones, if formed, may persist. Nausea and vomiting of pregnancy is a common occurrence affecting between 50% and 90% of all women.[78,79] These symptoms rarely extend beyond the first trimester. Other causes must be investigated if the nausea and vomiting occur later in pregnancy. Abdominal pain, although often due to a surgical pathologic process, can have many causes. Round ligament pain is described as an aching, dragging pain more often felt on the right side. It is a common occurrence until 31 weeks of gestation. Pain in the hypochondrium can result from uterine pressure on the lower ribs, and lower abdominal pain may be psychogenic, related to anxiety about the pregnancy or insecurity over the social situation.[80] It is up to the surgeon to determine the cause of abdominal pain in the pregnant patient and decide the course of diagnosis and intervention.

APPENDICITIS IN THE PREGNANT PATIENT

6 Acute appendicitis is the most common nonobstetric cause of acute surgical abdomen during pregnancy.[81] Disease is confirmed in 65% to 75% of suspected cases for an incidence of approximately 1:1,500 births.[82] Although previous series suggested that the condition had similar incidences for nonpregnant adults, equal distribution throughout pregnancy,[83] and a more common occurrence later in gestation,[84,85] a recent large case-control study indicated a lower incidence than among nonpregnant individuals, particularly in the third trimester.[86] The incidence decreases in the third trimester to 15% to 30% compared to rates ranging from 20% to 60% in the first and second trimesters.[87,88] A well-known fact is that the anatomic and physiologic changes of the gravid state make the diagnosis difficult. Attributing abdominal pain to other etiologies (e.g., pyelonephritis, false labor, and gastroenteritis), failure to pursue further investigation, and the physicians' fear of surgically induced premature labor all contribute to delayed diagnosis and timely appendectomy in pregnancy. Appendiceal perforation rates are higher when compared with those from nonpregnant populations (55% vs. 4% to 19%).[89] This is probably explained by confounding variables leading to the delay of diagnosis and therapy. Several series have documented a correlation between a delay in the diagnosis and gestational age. In the first trimester, most diagnoses were made promptly and significant delay in operation with a rate of perforation of 49% reported for patients presenting in the second trimester and a rate as high as 70% for those presenting in the third trimester.[83,90] Perforated appendicitis presents a greater infectious risk in the pregnant patient than in the population as a whole. The large uterus interferes with proper omental migration throughout the abdominal cavity and prevents the walling off of the inflammatory process. Braxton Hicks contractions disrupt adhesion formation, and the general increase in vascularity of the abdomen with greater lymphatic drainage allows rapid dissemination of infection. The high circulatory levels of adrenocorticoids in pregnancy have also been hypothesized to diminish the tissue inflammatory response and hinder containment of infection.[91–93] All of the classic signs and symptoms of appendicitis are altered by pregnancy (Table 106-3). Anorexia, nausea, and vomiting occur in 58% to 77% of pregnant patients with appendicitis.[83,90] Although anorexia, nausea, and vomiting in the first trimester are common, their occurrence during the second and third trimesters, especially if associated with abdominal pain, require a thorough investigation. In a classic 1932 study, Baer and colleagues[94] evaluated the migration of the appendix through the duration of pregnancy with barium enemas. Beginning in the first trimester, the appendix and the cecum are gradually displaced by the uterus and start a caudal migration out of the pelvis into the upper abdomen. By the third trimester, the appendiceal tip can abut the gallbladder (Fig. 106-4). The vague, referred epigastric pain due to early appendiceal obstruction is not changed by this anatomic consideration, but the location of the somatic pain is. In a large study of pregnant women with proven appendicitis, abdominal pain was present in all patients. Location of pain in the right lower quadrant, however, was common only early in gestation, and a portion of patients reported pain in the right upper quadrant. This change in symptomatology is easily

understood if the anatomic changes of the appendix are taken into consideration.[83] Both guarding and rigidity are valuable findings on physical examination but are common only in the first trimester. Elevation of the abdominal wall from the more laterally placed, upward-directed appendix and the laxity of the abdominal wall musculature caused by this distention decrease the reliability of these findings. Only 42.9% of patients in the third trimester are reported to have abdominal spasm and guarding, compared with 80% during the first trimester.[95] Psoas and obturator signs are similarly obscured as the appendix is moved from its normal location and have not been shown to have clinical significance. The results of laboratory examinations commonly used to assist in the diagnosis of appendicitis are also obscured by pregnancy. The physiologic leukocytosis of pregnancy, ranging from 5,000 to 12,000 white blood cells (WBCs)/mL, overlaps that of appendicitis. In one collected series, the WBC count of pregnant patients with proven appendicitis was not significantly elevated over these values, and only 25% of patients had a WBC count over 15,000. Most patients (50%) had WBC counts ranging between 10,000 and 15,000, and 25% had less than 10,000 WBCs/mL.[83] Urinalysis is a useful adjunct in the workup of appendicitis but again presents a dilemma in pregnancy. Urinary tract infection is common in pregnancy as the enlarging uterus compresses the right ureter. Dilatation and stagnant flow in the right collecting system can contribute to bacterial overgrowth and infection. Pyuria without bacteria can also indicate involvement of the right ureter in the appendiceal inflammatory process. The presence of pyuria and bacteriuria does not rule out appendiceal inflammation because the two conditions may coexist in 40% of pregnant patients.[90] The risk of adverse pregnancy outcomes after appendectomy during pregnancy has been reported by two large population-based studies. From the California Inpatient File of 3,133 pregnant women undergoing surgery for suspected appendicitis, the fetal loss rate was 23%, and it was doubled – 6% versus 11% – with simple versus complicated disease.[96] In the other study, the fetal loss rate within 1 week of the procedure was 22%, particularly when the surgery was performed after 23 weeks.[82] Fortunately, these same researchers noted no additional increase in the preterm birth rate among the pregnancies that continued beyond the first postoperative week. Perforated appendicitis in pregnancy rapidly leads to diffuse peritonitis, premature labor, and fetal loss.[85,97]

Table 106-3 Variation in Signs and Symptoms of Appendicitis During Pregnancy

Signs and Symptoms	First Trimester	Second Trimester	Third Trimester
Right lower quadrant pain	100%	50%	14%
Right upper quadrant pain	0%	17%	57%
Guarding (muscle spasm)	80%	50%	43%
Nausea and vomiting	53%	60%	23%
Tenderness on rectal examination	60%	17%	0%
Perforation rate	20%	49%	70%

Data from Weingold AB. Appendicitis in pregnancy. *Clin Obstet Gynecol* 1983;26:801–809; Tamir IL, Bongard FS, Klein SR. Acute appendicitis in the pregnant patient. *Am J Surg* 1990;160:571–576; and Cunningham FG, McCubbin JH. Appendicitis complicating pregnancy. *Obstet Gynecol* 1975;45:415–420.

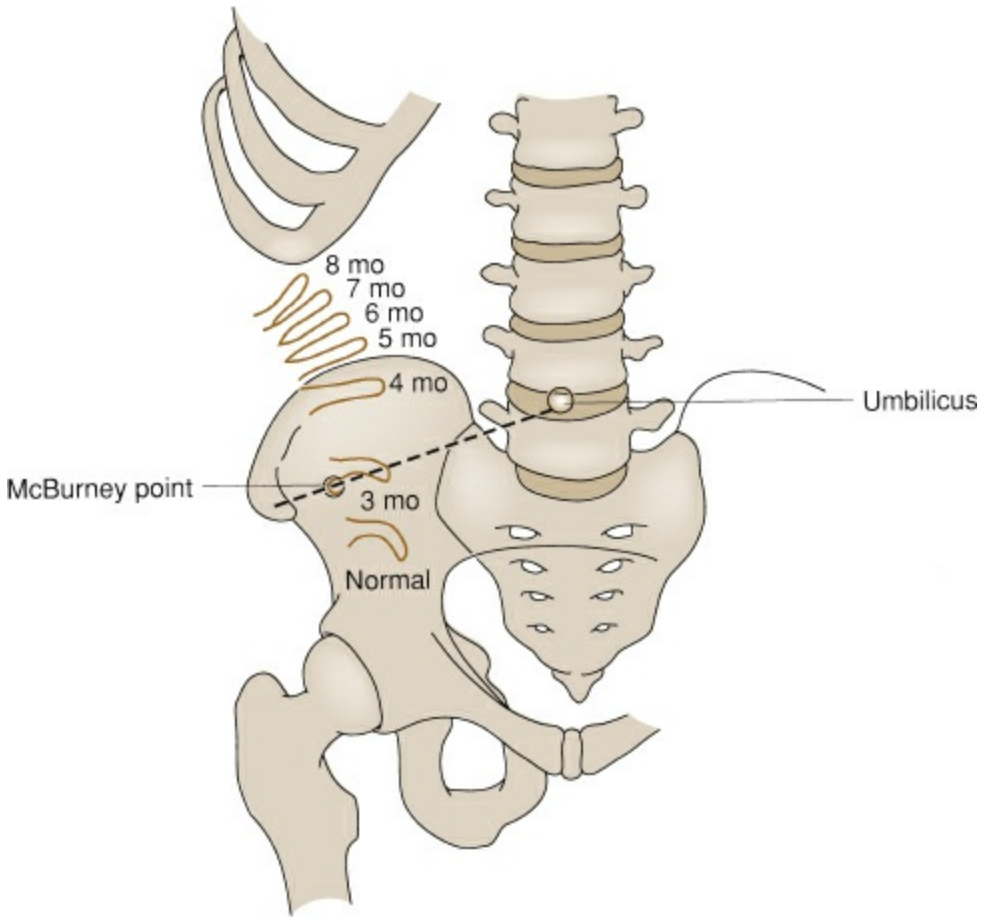

Figure 106-4. Changing location of the appendix throughout gestation.

IMAGING MODALITIES

Ultrasonography is the initial nonionizing imaging modality of choice in these patients. Findings suggesting appendicitis include visualization of a tubular structure with a diameter of more than 6.0 mm, a wall thickness of more than 3.0 mm, and lack of peristalsis (Fig. 106-5).[98,99] One study reviewed the value of ultrasonography in diagnosing appendicitis in pregnancy. That review reported a range of sensitivity of 67% to 100% and a range of specificity of 83% to 96%, compared to diagnostic performance in the general population of 86% and 96%, respectively.[100] Ultrasonography, however, does have limitations due to body habitus, intraluminal air, and operator level of experience. The examination can also be difficult because of abdominal guarding and pain during examination. Distortion of anatomic landmarks and the displacement of the appendix by the gravid uterus complicate the diagnosis. Other structures such as an inflamed salpinx can also mimic appendicitis on ultrasonogram,[101] and a dilated uterine vein during pregnancy has been mistaken for an acutely inflamed appendix.[102] Chest radiography should be considered in the evaluation of patients with suspected appendicitis because right lower lobe pneumonia may manifest with lower abdominal pain. Abdominal plain films are usually avoided unless there is suspicion for visceral perforation or bowel obstruction. Computed tomography has emerged as a highly reliable modality in the diagnosis of appendicitis. Appendiceal CT, using rectally administered contrast, can be performed within 10 to 20 minutes, does not require a waiting period for oral contrast to progress down through the cecum, and exposes the patient to only one-third the radiation of a regular CT scan.[103] Computed tomography in the nonpregnant population is more sensitive and specific than sonography (approximately 98% each) to confirm suspected appendicitis.[104] A computed tomographic scan is considered abnormal if there is an enlarged appendix (>6 mm in maximum diameter) or if there are periappendiceal inflammatory changes such as fat stranding, phlegmon, fluid collection, and extraluminal gas. Routine use of this modality has been shown to reduce costs, expedite the diagnosis, and reduce perforation rates from 22% to 14% while decreasing the incidence of negative laparotomy from 20% to 7%.[105–107] Radiation exposure is 300 mrad with a limited helical CT scan, which is one-third of the amount of the average abdominopelvic CT scan.[108] Because even low levels of radiation in utero can increase the incidence of childhood cancer, widespread use of this modality in the pregnant patient with abdominal pain may be detrimental. Reserving the CT scan for those cases in which the clinical history, physical examination, and ultrasonography are indeterminate should decrease the rate of perforation and negative exploration, just as it has in the nonpregnant population (Fig. 106-6). MRI uses nonionizing radiation, has no known adverse fetal effects, and, like CT, has the potential to image the whole abdomen. On MRI an appendix is considered abnormal when it is fluid-filled, greater than 6 or 7 mm in diameter, or demonstrates the presence of periappendiceal inflammatory changes. A study suggested that a normal appendix on MRI had a high specificity (98% to 100%) and a high negative predictive value (94% to 100%) in excluding acute appendicitis.[109] The American College of Radiology guidance documented MRI safe practices 2013 and reaffirmed its use in

pregnancy if considered necessary irrespective of gestational age. Intravenous gadolinium contrast has no known adverse effects in humans but its use should be based on whether the potential benefits to the patient exceed the theoretical risks to the fetus.[110]

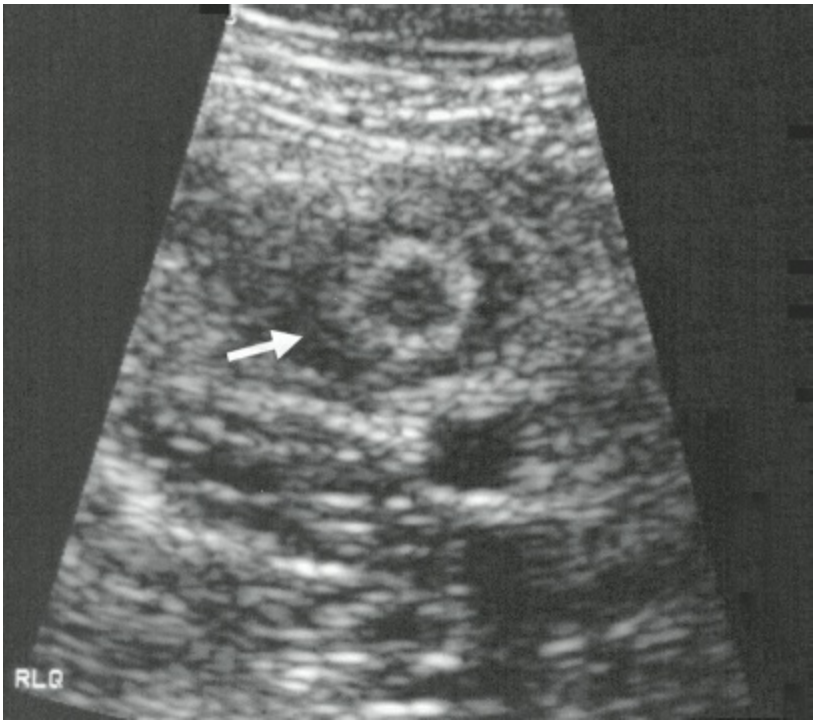

Figure 106-5. Ultrasonographic appearance of appendicitis. The appendix appears as a thick, noncompressible tubular structure with central hypoechogenicity. The walls are 5-mm thick, over the 3-mm limit for a normal appendix. (Courtesy of Dr. Beverly Coleman, Department of Radiology, Hospital of the University of Pennsylvania, Philadelphia, PA.)

Laparoscopy

Laparoscopy to evaluate the appendix is a feasible diagnostic modality during pregnancy but may be difficult during later gestation. Anatomic changes alter placement of trocars above the gravid uterus[111] and require the use of the open Hasson technique of trocar placement under direct visualization rather than blind insufflation with a Veress needle. Maneuvers to enhance operative safety of laparoscopy in pregnancy have been outlined by the Society of American Gastrointestinal Endoscopic Surgeons (Table 106-4).[112]

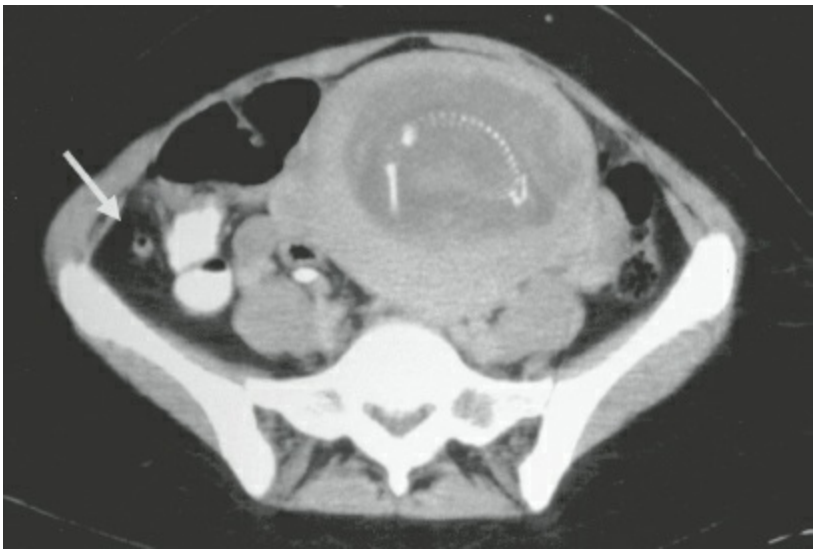

Figure 106-6. Computed tomographic (CT) scan of a woman in the 18th week of gestation presenting with a 12-hour history of right-sided abdominal pain. Abdominal examination on presentation revealed significant tenderness, and after a nondiagnostic ultrasonography, a laparotomy is considered for presumed appendicitis. A CT scan is obtained instead, revealing a normal, air filled appendix with no sign of periappendiceal inflammation (*arrow*). The laparotomy was postponed, and 12 hours later the patient aborted a septic fetus. An unnecessary laparotomy for an atypical presentation of chorioamnionitis was avoided by the judicious use of the CT scan. (Courtesy of Dr. David Weiss, Chestnut Hill Hospital, University of Pennsylvania Health System, Philadelphia, PA.)

Appendectomy

Once the diagnosis of appendicitis is made, treatment is strictly surgical. If an open procedure is chosen, a muscle splitting incision is made over the point of maximum tenderness because the appendix customarily lies beneath that point.[81,83,90] A right paramedian incision usually necessitates medial retraction of the uterus for exposure and increases the risk of precipitating premature labor. By tilting the patient 30 degrees to the left, the uterus is shifted away from the operative field and off the inferior vena cava. Because of the migration of the appendix, an incision over McBurney point in the late second and third trimesters is inadequate. If diffuse peritonitis is present, a midline incision is usually performed. Perforated appendicitis or pus in the abdominal cavity demands thorough peritoneal toilet along with the appendectomy. A periappendiceal abscess can be treated with percutaneous drainage, followed by an interval appendectomy 2 to 3 months later.[113] Perioperative antibiotics should be administered to cover gram-negative bacteria and anaerobes, usually a second- or third-generation cephalosporin, expanded-spectrum penicillin, or even triple agent therapy.[114] Unless there is gangrene, perforation, or a periappendiceal phlegmon, antimicrobial therapy can usually be discontinued after surgery. Seldom is cesarean delivery recommended at the time of appendectomy. Although uterine contractions are common, tocolytic therapy is generally not recommended. If exploration reveals a normal appendix, an appendectomy still should be performed. Although some authors question this approach because of the suggested high rate of preterm labor with a normal appendectomy,[115] most believe this to be untrue. Taking out the normal appendix adds little to morbidity while eliminating potential confusion if symptoms should recur.[83] Since it was first performed in 1980, laparoscopic appendectomy in pregnancy has spawned controversy, which continues to this date. Its use in pregnancy has been recently documented with a good safety record.[116] It has a complication rate similar to that for nonpregnant laparoscopy.[117] Its major advantages over open appendectomy include less abdominal wall trauma, less pain and narcotic use, and faster return to normal activity. However, the presence of the enlarged uterus does increase the risk of inadvertent puncture with a trocar or Veress needle.[118] In the second half of pregnancy, open laparoscopy may be preferred to avoid such complications. Unlike nonpregnant laparoscopy, no instrument should be applied to the cervix. The primary trocar is inserted after determining the size of the uterus, and the secondary trocars are inserted under direct visualization. Consideration of supraumbilical, subxiphoid insertions may be necessary. Limiting intra-abdominal pressures to less than 12 mm Hg and reducing operative time can reduce concerns about maternal hypercarbia and subsequent fetal acidosis. Laparoscopy is almost always used to treat suspected appendectomy during the first two trimesters. There were similar perinatal outcomes from the Swedish database of nearly 2,000 laparoscopic appendectomies compared with those of more 1,500 open laparotomies done before 20 weeks.[119] Conversely from their review, Wilasrusmee and coworkers[120] reported a higher fetal loss with laparoscopy.

Table 106-4 Guidelines for Laparoscopic Surgery during Pregnancy

1. Diagnostic laparoscopy is safe and effective when used selectively in the workup and treatment of acute abdominal processes in pregnancy.
2. Laparoscopic treatment of acute abdominal disease has the same indications in pregnant and nonpregnant patients.
3. Laparoscopy can be safely performed during any trimester of pregnancy.
4. Gravid patients should be placed in the left lateral decubitus position to minimize compression of the vena cava.
5. Initial abdominal access can be safely accomplished with an open (Hasson) technique, Veress needle, or optical trocar, if the location is adjusted according to fundal height and previous incisions.
6. CO_2 insufflation of 10–15 mm Hg can be safely used for laparoscopy in the pregnant patient.
7. Intraoperative CO_2 monitoring by capnography should be done during laparoscopy in the pregnant patient.
8. Intraoperative and postoperative pneumatic compression devices in early postoperative ambulation are recommended prophylaxes for deep venous thrombosis in the gravid patient.
9. Laparoscopic cholecystectomy is the treatment of choice in the pregnant patient with gallbladder disease, regardless of trimester.
10. Cholelithiasis during pregnancy may be managed with preoperative endoscopic retrograde cholangiopancreatography (ERCP) with sphincterotomy, followed by laparoscopic cholecystectomy, laparoscopic common bile duct exploration, or postoperative ERCP.
11. Laparoscopic appendectomy may be performed safely in pregnant patients with appendicitis.
12. Obstetric consultation can be obtained pre-and/or postoperatively on the basis of the severity of the patient's disease, gestational age, and availability of the consultant.
13. Tocolysis should not be used prophylactically in pregnant women undergoing surgery but should be considered perioperatively when signs of preterm labor are present.

Modified from SAGES Committee on Standards Practice. Guidelines for laparoscopic surgery during pregnancy. *Surg Endosc* 2011;25:2479–3492.

7 After appendicitis, acute cholecystitis is the second most common nonobstetrical indication for surgery in pregnant women and the most common cause of maternal hospitalization in the first year after delivery.[121] Pregnancy and the postpartum period appear to predispose women to gallstone formation. This is attributed to increase in sex steroid hormone levels in pregnancy, causing biliary stasis, prolonged intestinal transit, and increased cholesterol saturation of bile. Multiparity and prepregnancy obesity are the two major independent risk factors for cholelithiasis in pregnancy. One study found that gallstones occurred in 7% of nulliparous women, with the rate rising to 19% of women with two or more pregnancies. This risk of gallstones appears to increase during gestation, with sludge or stones found in 5.1% of 3,254 prospectively studied women in the first trimester, 7.9% in the second trimester, and 10.4% by 4 to 6 weeks after delivery.[122] However, among women with sludge or stone, only 1.2% developed any symptoms attributable to the gallbladder during pregnancy.[123] Despite the predilection for stone formation in pregnancy, acute cholecystitis does not occur more frequently during pregnancy. Data suggest that cholecystitis affects only 0.1% of pregnant women.[124] Most patients with symptomatic gallstones present with complaints of biliary colic likely resulting from gallbladder contractions and increased pressure and luminal expansion characteristically exacerbated by a fatty meal. These patients often complain of epigastric or right upper quadrant pain. The onset of pain is typically between 1 and 3 hours postprandially. The discomfort progresses in less than an hour to a steady plateau that ranges from moderate to excruciating and remains constant for more than an hour and then subsides slowly over several hours. Less frequently, the symptoms are those of one of the complications of gallstones, acute cholecystitis, cholangitis, or pancreatitis. Signs and symptoms may include right upper quadrant pain, fever, tachycardia, leukocytosis, anorexia, and vomiting. Sepsis and jaundice may also be seen. Abdominal examination usually demonstrates voluntary and involuntary guarding and frequently a positive Murphy sign. Laboratory studies should be normal in patients with uncomplicated cholelithiasis. However, mild elevations in serum aminotransferases and amylase may occur as a result of the passage of small stones or sludge. Significant elevations in aminotransferases, hyperamylasemia, increased direct bilirubin, and alkaline phosphatase may be signs of complicated gallbladder disease. The differential diagnosis includes appendicitis, pancreatitis, peptic ulcer disease, pyelonephritis, right-sided pneumonia, acute fatty liver of pregnancy, and preeclampsia. Abdominal ultrasound is a reliable diagnostic tool for identifying gallstones, sludge, and acute or chronic cholecystitis with a high sensitivity and specificity.[125] A diagnosis of acute cholecystitis is suspected by findings of gallbladder distention, gallbladder wall thickening, and pericholecystic fluid on ultrasonography.[126] Transabdominal ultrasonography is relatively insensitive for the detection of common bile duct stones, whereas endoscopic ultrasound is highly accurate for that purpose. Magnetic resonance cholangiopancreatography (MRCP) may be used when extrahepatic ductal stones are suspected or in complicated cases when ultrasound is nondiagnostic. Endoscopy of the biliary system by endoscopic

retrograde cholangiopancreatography (ERCP), with its associated radiation exposure, can be performed safely in pregnant patients but should be limited to cases in which treatment of ductal stones is required. The appropriate management for symptomatic cholelithiasis and acute cholecystitis during pregnancy is controversial. Suggested management for a pregnant patient with symptomatic cholelithiasis during the first trimester consists of conservative measures until elective cholecystectomy can be performed safely during the second trimester. Traditional supportive care includes withdrawal of oral food and fluids, pain control, intravenous fluids, and nasogastric aspiration depending upon the clinical presentation. However, nonoperative management of symptomatic cholelithiasis is associated with significant recurrence bouts of symptoms, prolonged total parenteral nutrition, higher rates of preterm delivery, cesarean section, and more technically difficult cholecystectomies compared with laparoscopic cholecystectomy. [127–129] Cholecystectomy can be performed safely and effectively during pregnancy in all trimesters. Either an open or laparoscopic approach may be chosen; however, laparoscopic cholecystectomy is the preferred technique for removal of the gallbladder in pregnant women. Overall, patients have a shorter postoperative stay, resume oral intake earlier, have fewer postoperative hernias, and experience less pain with lower narcotic requirements by avoiding a large open incision.[130–132] Because fetal loss is most likely related to the underlying maternal illness and extent of uterine manipulation during surgery,[133,134] laparoscopic cholecystectomy offers a solution to both problems. Based on the available data, laparoscopic cholecystectomy is safe during pregnancy and is preferable to open cholecystectomy.[135] Removing the diseased gallbladder eliminates the potential for recurrence, and the minimal uterine retraction needed with laparoscopic access to the right upper quadrant should decrease the risk for preterm labor. After an open cholecystectomy, the reported rate of premature labor ranges from 0% to 40%, based on trimester,[136] and a spontaneous abortion or premature birth rate of up to 22% has been reported.[137] The incidence of premature uterine contractions with laparoscopic cholecystectomy has been reported at 0% to 21%, but contractions are usually well controlled by tocolytics. Most series report rates of premature birth or spontaneous abortion ranging from 0% to 7% with the laparoscopic approach.[111,133,134] The second trimester is the optimal time to perform an elective cholecystectomy. Organogenesis is complete and the gravid uterus is not yet large enough to impinge on the operating field.[138] Those patients presenting later in gestation can probably be managed symptomatically until the postpartum period, with cholecystectomy generally performed 6 weeks following delivery to allow the mother to recover and to bond with her infant.

Choledocholithiasis

Indications for evaluation of the common bile duct are no different in the pregnant patient than in the population as a whole – namely, a bilirubin elevated over 1.5 mg/dL, a dilated common bile duct, or gallstone pancreatitis.[111] ERCP can be performed in pregnancy. With proper lead shielding, judicious use of fluoroscopy time, and avoidance of permanent roentgenographic films, ERCP has been performed with no direct exposure of the fetus to radiation. Calculated scatter radiation on the order of 4 mrads during the whole examination presents the only risk from ionizing radiation.[139] Evaluation of the biliary tree, stone retrieval, and sphincterotomy can be performed under these conditions without maternal or fetal complications.[140] Other methods avoid radiation altogether and include imaging of choledocholithiasis with endoscopic ultrasonography,[141] endoscopic papillotomy under ultrasonographic control,[142] and MRCP for choledocholithiasis.[143] Success with all these modalities has been reported but can be limited by operator experience and availability.

INTESTINAL OBSTRUCTION DURING PREGNANCY

8 The incidence of intestinal obstruction during pregnancy rose throughout the 20th century. In the presurgical era, cases were cited as infrequently as 1:68,000 deliveries. Since the 1940s, however, the incidence has increased to 1:2,500 to 3,500 deliveries.[144,145] This change reflects the increased number of pelvic and abdominal surgeries in young women that includes cesarean deliveries.[146–148] Adhesions remain the most common cause of intestinal obstruction in the gravid patient, but intestinal volvulus is a much more common complication than that in the population as a whole. Intussusception, hernia, and carcinoma are responsible for a minority of cases of bowel obstruction (Table 106-5). The incidence of adhesion-related obstruction is highest during the first pregnancy after an operation, when the association between the viscera and adhesions is initially tested. Most cases of intestinal obstruction during pregnancy result from pressure of the growing uterus on intestinal adhesions. According to Davis and Bohon, this likely occurs (1) around midpregnancy, when the uterus becomes an abdominal organ; (2) in the third trimester, when the fetal head descends; or (3) immediately postpartum, when there is an acute change in uterine size.[144,145]

In the general population, incarceration of bowel in groin hernias is the second most common cause of small bowel obstruction, but in the pregnant patient, volvulus becomes the number 2 cause. Sigmoid volvulus, the most common site of volvulus during pregnancy, normally occurs owing to a long and redundant sigmoid colon.[149] Anatomic changes of pregnancy further exacerbate this condition by causing the redundant sigmoid colon to rise out of the pelvis and twist around its point of fixation.[150,151] Cecal volvulus occurs because of failure of lateral peritoneal fixation during development. As the uterus enlarges during pregnancy, it raises the redundant or abnormally mobile cecum out of the pelvis. If a transition point or distal obstruction should occur from uterine pressure or an adhesive band, the colonic distention raises the colon even higher, producing torsion around this fixed point.[152] Volvulus of the small bowel can also result from a congenital abnormality of rotation and fixation. The enlarging uterus potentially predisposes to the presentation of this anomaly during pregnancy by pushing the nonfixed, mobile portions of the small bowel into the upper abdomen, initiating the volvulus.[153,154]

Table 106-5 Causes of Intestinal Obstruction Complicating Pregnancy and the Puerperium in 66 Patients

Adhesions	39 (59%)
Volvulus	15 (23%)
Sigmoid	7
Cecal	3
Midgut	3
Volvulus around vitellointestinal band	2
Intussusception	3 (5%)
Hernia	2 (3%)
Carcinoma	1 (1%)
Appendicitis	1 (1%)
Idiopathic (ileus)	5 (8%)

Reproduced from Perdue PW, Johnson HW, Stafford PW, et al. Intestinal obstruction complicating pregnancy. *Am J Surg* 1992;164:385, with permission.

Presentation and Diagnosis

Perdue[149] reported that 98% of pregnant women had either continuous or colicky abdominal pain, and 80% had nausea and vomiting, symptoms that are similar to those in the nonpregnant patient. Abdominal tenderness was found in 70%, and abnormal bowel sounds noted in only 55%.[149] High small bowel obstruction results in short periods between vomiting episodes with poorly localized, crampy upper abdominal pain. Colonic obstruction can present with less frequent, feculent vomiting and lower abdominal pain. Findings on physical examination such as abdominal distention are often difficult to evaluate because of the gravid uterus. Obstipation, although characteristic of low obstruction such as that of sigmoid volvulus, may not occur with high obstruction. Laboratory studies, although useful to rule out other conditions, are not reliable enough to be considered diagnostic of obstruction. Significant leukocytosis can occur with necrosis and bowel strangulation, but mild elevations are confusing because of the physiologic leukocytosis of pregnancy. Tachycardia and hypotension are also late signs suggesting bowel compromise and shock. The murky clinical picture combined with the tendency to treat the progressive vomiting as a normal part of pregnancy and crampy abdominal pain as early contractions lead to a delay in presentation and diagnosis. The median time from the onset of symptoms to admission in one series was 48 hours, and the median time from admission to a necessary laparotomy was also 48 hours. This delay in diagnosis and treatment contributed to excessive maternal and fetal mortality.[149] Abdominal pain and vomiting in a pregnant patient with an abdominal scar should raise the serious suspicion of small bowel obstruction. If intestinal obstruction is suspected, upright and flat films of the abdomen are the diagnostic studies of choice. Serial films obtained every 4 to 6 hours usually show progressive changes confirming the diagnosis.[144] Small bowel obstruction gives the appearance of a progressive stepladder formation with dilatation and multiple air–fluid levels. Large bowel obstruction can produce a similar picture or reveal a grossly dilated bowel loop suggestive of volvulus. Contrast studies are also useful, and a “bird’s bill” shape of contrast with gradual narrowing after a barium enema can be diagnostic of colonic volvulus, whereas dilute Gastrografin or barium by mouth can usually differentiate partial from complete obstruction. Fetal radiation risks from the plain radiographs are negligible and greatly outweighed by those from the possibility of misdiagnosis. Because plain radiographs are less accurate for diagnosing small bowel obstruction, CT and MRI can be diagnostic.[155,156] Colonoscopy can be both diagnostic and therapeutic for colonic volvulus.[157–160] During pregnancy, mortality rates with obstruction can be excessive because of difficult and thus delayed diagnosis, reluctance to operate during pregnancy, and the need for emergency surgery.[161,162] Perdue and Johnson[149] described a 6% maternal mortality rate and a 26% fetal mortality rate. Two of the four women who died were in late pregnancy, and they had sigmoid or cecal volvulus caused by adhesions.[145]

Treatment

The initial treatment of bowel obstruction in the pregnant patient is no different from that in a nonpregnant patient. Nasogastric tube decompression and fluid resuscitation are the cornerstones of therapy. By the time an obstruction is visible on plain film, the fluid deficit due to vomiting and intraluminal losses is estimated at 1,000 to 1,500 mL. In advanced cases of dehydration presenting with tachycardia and hypotension, fluid losses may be as high as 4 to 6 L.[144] Prompt fluid resuscitation is essential in the pregnant patient because compromise of uterine blood flow leads to fetal compromise and demise. Surgical intervention plays a more prominent and earlier role in the management of the pregnant patient with bowel obstruction. Although adhesion-related small bowel obstruction in the nonpregnant patient usually resolves with nasogastric decompression and fluid administration, numerous series have documented failure of conservative management of small bowel obstruction in the pregnant woman. Eighty-nine percent to 100% of patients eventually require an operation, and 13% to 23% require resection of gangrenous bowel at the time of laparotomy.[151,156] Based on these outcomes, some have stated that once the diagnosis of small bowel obstruction is made in a pregnant patient, the only role of nasogastric decompression and fluid resuscitation is to prepare the patient for an operation.[151] Cecal volvulus is also treated surgically, and although sigmoid volvulus in the nonpregnant patient can be managed with sigmoidoscopic decompression and placement of a rectal tube, the large gravid uterus may act as a mechanical impediment to detorsion. A laparotomy is usually necessary for the treatment.[145,155] A generous midline incision allows for maximum exposure of the abdomen with minimal manipulation of the uterus. During lysis of small bowel adhesions, bowel viability must be carefully assessed. Definitive management of cecal volvulus requires resection of necrotic cecum or detorsion and cecopexy. Sigmoid volvulus should also be treated by resection if necrotic but simple detorsion and placement of a rectal tube can be performed if the sigmoid is viable. Although resection of the redundant sigmoid is the definitive treatment of this disease, it can be delayed until the postpartum period. Aggressive surgical treatment has been credited with reducing the maternal and fetal mortality rates from 20% and 50%, respectively, in the 1930s to 6% and 26% today.[151] Increased awareness of this disease and expeditious management can reduce those rates even further.

COLORECTAL CANCER DURING PREGNANCY

9 Colorectal cancer is the third most frequent malignancy in women of all age groups in the United States,[161] but it rarely complicates pregnancy because it is uncommon before 40 years of age. The mean age at diagnosis of colorectal cancer in pregnancy is 31 years (range 16 to 48 years).[162] The incidence of colon cancer was estimated as 1:50,000 pregnancies based on a 1955 report.[163] More recent reviews estimate the incidence as 1:13,000 deliveries,[164] with the increasing prevalence of colorectal cancer diagnosed during gestation due to the current trend of delaying pregnancy into the later reproductive years.[165] The majority of colorectal carcinoma in pregnant women arise from the rectum. This location is at odds with the pattern seen both in the general population and in nonpregnant patients younger than 40 years in whom, as reported by the American Cancer Society in 1981, 69% of tumors were in the colon and 31% in the rectum.[166] On reviewing more than 200 published cases of colorectal cancer in pregnancy, it was noted that 86% occurred below the peritoneal reflection and were thus rectal tumors.[162] The observed deviation from the usual tumor distribution is likely attributed to detection bias because of the increased frequency of pelvic examinations in the prenatal period or the change in pelvic anatomy and symptoms of rectal compression by the gravid uterus. Pregnant patients present with more advanced cancers than the population as a whole. The advanced stage of disease on presentation most likely results from a delay in the diagnosis and the low clinical suspicion of malignancy in this population. In a study, no patients were Duke stage A, 41% were stage B, 44% stage C, and 15% stage D. In addition, most colorectal cancers are not diagnosed until late in pregnancy ($>$20 weeks) or at the time of delivery.[164] Pregnancy could cause rapid tumor growth and progression of disease. There is a wide variation in the presence and expression of estrogen and progesterone receptors in colorectal tumors and, therefore, their biologic significance is unknown.[167,168] Colonic malignancy during gestation most likely represents pregnancy superimposed on colon cancer rather than a pregnancy-related disease.

Diagnosis

The most frequent symptoms of colorectal cancer are abdominal pain, distention, nausea and vomiting, constipation, and rectal bleeding. The diagnosis may be delayed because many of the symptoms are common in pregnancy. Certainly, when a pregnant patient presents with or without rectal bleeding and persistent signs or symptoms suggestive of colorectal disease, rectal examination, stool tests for occult blood, and flexible sigmoidoscopy or colonoscopy should be done. Complete colonoscopy, as indicated for the nonpregnant patient, is the procedure of choice to obtain a biopsy and confirm the diagnosis of colorectal cancer in pregnancy.[169] However, possible adverse effects of colonoscopy in pregnant women include placental abruption, fetal exposure to potential teratogenic medications, and fetal injury resulting from maternal hypoxia or hypotension.[170] If deemed necessary, both the patient and her family should be fully informed about the potential risks to the mother and the fetus, and informed consent should be obtained. Because most cancers are located below the peritoneal reflection, they can be easily accessed and sampled for biopsy through a limited sigmoidoscopic examination. Endoluminal ultrasonographic staging of rectal cancer is particularly useful during pregnancy because of its ability to evaluate invasion of the uterus or encroachment of the cervix that could prevent vaginal delivery.[171] Serum carcinoembryonic antigen levels are normal or only marginally elevated in a normal pregnancy. Therefore, baseline values should be measured and followed and used in the same way as in the nonpregnant patient.[172,173] Although abdominal CT for staging colon cancer in pregnancy is contraindicated, particularly in the first trimester, it can be performed later in pregnancy in more difficult and advanced cases. Alternatives include ultrasonography and MRI without contrast to assess the extent of the cancer in the abdomen and the pelvis. Ultrasonography has a sensitivity of 75% for detecting hepatic metastases.

Treatment

Treatment of colon cancer in pregnant women involves caring for both the patient and the fetus and requires a multidisciplinary approach, which may include but is not limited to the obstetrician–gynecologist, maternal–fetal medicine specialist, colorectal surgeon, medical oncologist, neonatologist, pharmacist, social worker, and psychological support services. Aside from the difficulty in dealing with a potentially lethal disease in a young person, there is an inherent conflict between the treatment of the mother and the fetus. Treatment of colon cancer puts the two at odds. The necessary treatment must balance oncologic outcomes with the effect on the pregnancy, and decisions regarding the management of pregnancy include termination, iatrogenic prematurity, or intentional delay in treatment. The decision-making process must also account for the wishes of the patient/family, tumor stage, gestational age, and the effects of the specific therapeutic option.[174] In addition, tumor complications such as bowel obstruction, perforation, or bleeding may force surgical intervention.[175] Although there are no universally accepted guidelines for the treatment of colorectal cancer in pregnancy, the general consensus is that if the patient is diagnosed at less than 20 weeks' gestation and there is no evidence of metastatic disease, surgical resection is indicated. Waiting months until adequate fetal maturation for delivery can allow cancer dissemination and disease progression.[171,176] In most cases, a colon resection can be handled without disturbing the pregnancy, and resection of even low-lying tumors can be performed before 20 weeks of gestation.[177] During the first half of pregnancy, hysterectomy is not necessary to perform colon or rectal resection, and thus, therapeutic abortion is not mandated. However, because of the controversial data regarding the risks of such resections to the pregnancy, termination of pregnancy and resection of the tumor should be one of the discussed management options. After 20 weeks, resection may be delayed until after fetal viability.[178] Although abdominal procedures with appropriate fetal and maternal monitoring performed late in pregnancy are not associated with fetal loss, delaying surgery allows fetal maturity of facilitate surgical exposure and dissection. If the colorectal tumor causes obstruction in the first half of pregnancy, primary resection, with or without anastomoses, can be performed. Obstructing tumors discovered in the second half of pregnancy, depending on the size of the uterus, can be treated with primary resection or by proximal diversion, followed by curative resection several weeks after delivery. The surgical management of the patient's ovaries is controversial. However, due to the high incidence of ovarian metastases in pregnant patients with colorectal cancer (25%), compared with a 3% to 8% incidence in the general population, as well as the poor prognosis of metastatic colorectal cancer in the ovaries, the general recommendation is for bilateral salpingo-oophorectomy at the time of primary tumor resection.[179–181] Nesbitt and coworkers[176] recommend performing bilateral ovarian wedge biopsies with frozen section, and the ovaries are removed only when there is metastatic ovarian disease or when hysterectomy is indicated for another reason. Adjuvant chemotherapy or radiation therapy can improve survival of the mother but is generally contraindicated during pregnancy, especially early in gestation. Adjuvant chemotherapy conveys a survival advantage to patients with Dukes

stage C colon cancer. The classic adjuvant chemotherapy includes 5-fluorouracil, an antimetabolite that inhibits DNA synthesis. The safety of this drug during pregnancy is questionable, and evidence of fetal toxicity exists in animal models. Limited data on the human fetal safety of this drug are available, and it is considered a category D drug during pregnancy by the FDA. Chemotherapy during the first trimester is usually contraindicated and should be limited to those patients with Dukes stage C lesions who are willing to accept the risks of fetal teratogenesis or demise. Chemotherapy during the second and third trimesters is less teratogenic because of the completion of organogenesis but still carries some risk for the fetus.[171,182] Adjuvant radiation therapy reduces the local recurrence of rectal cancer. Because the most effective dose to eradicate microscopic disease is on the order of 50 Gy and the fetus cannot be effectively shielded from pelvic exposure, radiation therapy cannot be safely performed during pregnancy. Therapeutic pelvic radiation also results in permanent and irreversible female sterility, so the mother considering this form of therapy must be fully aware of the risks to the current and future pregnancies.[171,183] Vaginal delivery is not contraindicated unless the tumor is obstructing the birth canal or presents a risk of episiotomy entering the tumor bed. However, vaginal birth is usually avoided because lower rectal lesions may cause dystocia, or delivery may cause tumor hemorrhage. If a cesarean section is performed for obstetric reasons or because of tumor impingement on the birth canal, resection can be performed immediately, but the operation may be technically easier if done as a separate procedure and postponed for several days. This is especially important with low rectal lesions, in which decreased pelvic vasculature can facilitate a low anterior or abdominoperineal resection.[176] There is no evidence that pregnancy influences the course of colorectal cancer, and the prognosis appears to be similar than that for identical stages in nonpregnant patients.[184]

References

1. Wilcox AJ, Baird DD, Weinberg CR. Time of implantation of the concepts and loss of pregnancy. *N Engl J Med* 1999;340:1796–1799.
2. Wegienka G, Baird DD. A comparison of recalled date of last menstrual period with prospective recorded dates. *J Womens Health* 2005;14:248–252.
3. Verburg BO, Steegers EA, De Ridder M, et al. New charts for ultrasound dating of pregnancy and assessment of fetal growth: longitudinal data from a population-based cohort study. *Ultrasound Obstet Gynecol* 2008;31:388–396.
4. Robinson HP, Fleming JE. A critical evaluation of "sonar" crown-rump length measurements. *Br J Obstet Gynaecol* 1975;82:702–710.
5. Sladkevicius P, Salvedt S, Almstrom H, et al. Ultrasound dating at 12–14 weeks of gestation: a prospective cross-validation of established dating formulae in in-vitro fertilized pregnancies. *Ultrasound Obstet Gynecol* 2005;26:504–511.
6. Moore KL, Persaud TV. *The **Developing Human***. 8th ed. Philadelphia, PA: WB Saunders; 2008.
7. Stoll BJ, Hansen NI, Bell EF, et al. Neonatal outcomes of extremely preterm infants from the NICDH Neonatal Research Network. *Pediatrics* 2010;26:443–456.
8. Gardner MO, Goldstein RL. The clinical use of antenatal corticosteroids. *Clin Obstet Gynecol* 1995;38:746–754.
9. Carlo WA, McDonald SA, Fanaroff AA, et al. Association of antenatal corticosteroids with mortality and neurodevelopmental outcomes among infants born at 22 to 25 weeks' gestation. *JAMA* 2011;306:2348–2358.
10. Mori R, Kusuda S, Fujimura M; Neonatal Research Network Japan. Antenatal corticosteroids promote survival of extremely preterm infants born at 22 to 23 weeks of gestation. *J Pediatr* 2011;159:110–114.e1.
11. Spong CY. Maternal physiology. In: Cunningham FG, Leveno KJ, Bloom SL, et al., eds. *Williams Obstetrics.* 24th ed. New York, NY: McGraw-Hill Companies; 2014:46–77.
12. Norwitz ER, Mahendroo M, Lye SJ. Biology of parturition. In: Creasy RK, Resnik R, eds. *Maternal–Fetal Medicine.* 7th ed. Philadelphia, PA: WB Saunders; 2014:66–79.
13. Hamilton BE, Martin JA, Ventura SJ. Births: preliminary data for 2009. *Natl Vital Stat Rep* 2010;59(3):1–19.
14. Goldenberg RL, Culhane JF, Iams JD, et al. Epidemiology and causes of preterm birth. *Lancet* 2008;371:75–84.
15. Volpe JJ. Overview: perinatal and neonatal brain injury. *Ment Retard Dev Disabil Res Rev* 1997;3:1–2.
16. Mathews TJ, MacDorman MF. Infant mortality statistics from the 2006 period linked births/infant death data set. *Natl Vital Stat Rep* 2010;58(17):1–31.
17. Institute of Medicine. *Preterm Birth: Causes Consequences, and Prevention.* Washington,

DC: The National Academies Press; 2007.
18. Savitz DA, Blackmore CA, Thorp JM. Epidemiologic characteristics of preterm delivery: etiologic heterogeneity. *Am J Obstet Gynecol* 1991;164:467–471.
19. Berkowitz GS, Blackmore-Prince C, Lapinski RH, et al. Risk factors for preterm birth subtypes. *Epidemiology* 1998;9:279–285.
20. Romero R, Avila C, Brekus CA, et al. The role of systemic and intrauterine infection in preterm parturition. *Ann NY Acad Sci* 1991;622:355–375.
21. Ou CW, Orsino A, Lye S. Expression of connexin-43 and connexin-26 in the rat myometrium during pregnancy and labor is differentially regulated by mechanical and hormonal signals. *Endocrinology* 1997;138:5398–5407.
22. American College of Obstetricians and Gynecologists and Society for Maternal-Fetal Medicine Committee on Obstetric Practice, Society for Maternal-Fetal Medicine. Committee Opinion No. 455. Magnesium sulfate for anticipated preterm birth for neuroprotection. *Obstet Gynecol* 2010;115(3):669–671.
23. King JF, Flenady V, Cole S, et al. Cyclo-oxygenase (COX) inhibitors for treating preterm labour. *Cochrane Database Syst Rev* 2005(2):CD001992.
24. Anotayanonth S, Subhedar NV, Neilson JP, et al. Beta mimetics for inhibiting preterm labour. *Cochrane Database Syst Rev* 2004(4):CD004352.
25. Allen JR, Helling TS, Langefeld M. Intraabdominal surgery during pregnancy. *Am J Surg* 1989;158:567–569.
26. Hunt MG, Martin JN Jr, Martin RW, et al. Perinatal aspects of abdominal surgery for nonobstetric disease. *Am J Perinatol* 1989;6:412–417.
27. Gordon MC, Samuels P. Indomethacin. *Clin Obstet Gynecol* 1995;38:697–705.
28. Gordon MC, Iams JD. Magnesium sulfate. *Clin Obstet Gynecol* 1995;38:706–712.
29. U.S. Food and Drug Administration. *FDA Drug Safety Communication: New Warning Against Use of Terbutaline to Treat Preterm Labor.* Silver Spring, MD: FDA; 2011. http://www.fda.gov/drugs/drugsafety/ucm243539.htm. Accessed March 20, 2012.
30. Witter FR, Zimmerman AW, Reichman JP, et al. In utero beta 2 adrenergic agonist exposure and adverse neurophysiologic and behavioral outcomes. *Am J Obstet Gynecol* 2009;201:553–559.
31. Ray D, Dyson D. Calcium channel blockers. *Clin Obstet Gynecol* 1995; 38:713–721.
32. Hill WC. Risks and complications of tocolysis. *Clin Obstet Gynecol* 1995; 38:725–745.
33. Sood BG, Lulic-Botica M, Holzhausen KA, et al. The risk of necrotizing enterocolitis after indomethacin tocolysis. *Pediatrics* 2011;128:e54–e62.
34. Kort B, Katz VL, Watson WJ. The effects of nonobstetric operation during pregnancy. *Surg Gynecol Obstet* 1993;177:371–376.
35. Han S, Crowther CA, Moore V. Magnesium maintenance therapy for preventing preterm birth after threatened preterm labour. *Cochrane Database Syst Rev* 2010(7):CD000940.

36. Lyell DJ, Pullen KM, Mannan J, et al. Maintenance nifedipine tocolysis compared with placebo: a randomized controlled trial. *Obstet Gynecol* 2008;112:1221–1226.
37. Dodd JM, Crowther CA, Dare MR, et al. Oral beta mimetics for maintenance therapy after threatened preterm labour. *Cochrane Database Syst Rev* 2006(1):CD003927.
38. Hon EH. The fetal heart rate patterns preceding death in utero. *Am J Obstet Gynecol* 1959;78(1):47–56.
39. Paul RH, Suidan AK, Yeh S, et al. Clinical fetal monitoring. VII. The evaluation and significance of intrapartum baseline FHR variability. *Am J Obstet Gynecol* 1975;123:206–210.
40. Alfirevic Z, Devane D, Gyte GM. Continuous cardiotocography (CTG) as a form of electronic fetal monitoring (EFM) for fetal assessment during labour. *Cochrane Database Syst Rev* 2013(5):CD006066.
41. Chen HY, Chauhan SP, Ananth CV, et al. Electronic fetal monitoring and its relationship to neonatal and infant mortality in the United States. *Am J Obstet Gynecol* 2011;204(6):491.e1–10.
42. Resnik R. Electronic fetal monitoring: the debate goes on…and on…and on. *Obstet Gynecol* 2013;121(5):917–918.
43. Martin J, Hamilton BE, Sutton PD, et al. Births: final data for 2002. *Natl Vital Stat Rep* 2003;52:1–113.
44. Macones GA, Hankins GD, Spong CY, et al. The 2008 National Institute of Child Health and Human Development workshop report on electronic fetal monitoring: update on definitions, interpretation, and research guidelines. *Obstet Gynecol* 2008;112(3):661–666.
45. Miller DA, Paul R. Antepartum–intrapartum monitoring. In: Scott JR, DiSaia PJ, Hammond CB, et al., eds. *Danforth's Obstetrics and Gynecology*. 8th ed. Philadelphia, PA: Lippincott Williams & Wilkins; 1999:243–255.
46. Kendrick JM, Neiger R. Intraoperative fetal monitoring during nonobstetric anesthesia. *J Perinatol* 2000;4:276–278.
47. ACOG Committee on Obstetric Practice. Committee Opinion No. 474. Nonobstetric surgery during pregnancy. *Obstet Gynecol* 2011;117(2, pt 1):420–421.
48. Otake M, Schull WJ, Yoshimaru H. A review of forty-five year study of Hiroshima and Nagasaki atomic bomb survivors. Brain damage among the prenatally exposed. *J Radiat Res* 1991;32:249.
49. Wertelecki W. Malformations in a Chernobyl-impacted region. *Pediatrics* 2010;125:e836.
50. Groen RS, Bae JY, Lim KJ. Fear of the unknown: ionizing radiation exposure during pregnancy. *Am J Obstet Gynecol* 2012;206(6):456–462.
51. Harrison JD, Stather JW. The assessment of doses and effects from intakes of radioactive particles. *J Anat* 1996;189(pt 3):521–530.
52. Wagner LK, Lester RG, Saldana LR. *Exposure of the Pregnant Patient to Diagnostic*

Radiation. Madison, WI: Medical Physics Publishing; 1997.

53. Brent RL. Saving lives and changing family histories: appropriate counseling of pregnant women and men and women of reproductive age, concerning the risks of diagnostic radiation exposures during and before pregnancy. *Am J Obstet Gynecol* 2009;200:4–24.
54. Donnely EH, Smith JM, Farfan EB, et al. Prenatal radiation exposure: background material for counseling pregnant patients following exposure to radiation. *Disaster Med Public Health Prep* 2011;5:62–68.
55. Brent RL. Radiation teratogenesis. *Teratology* 1980;21:281–298.
56. Brent RL. The effects of embryonic and fetal exposure to x-ray, microwaves, and ultrasound: counseling the pregnant and non-pregnant patient about these risks. *Semin Oncol* 1989;16:347–368.
57. Brent RL. The effects of embryonic and fetal exposure to x-ray, microwaves, and ultrasound. *Clin Perinatol* 1986;13:615–649.
58. Wood JW, Johnson KG, Omori Y, et al. Mental retardation in children exposed in utero to the atomic bombs in Hiroshima and Nagasaki. *Am J Public Health* 1967;57:1381–1390.
59. Wood JW, Keehan RJ, Kawamoto S, et al. The growth and development of children exposed in utero to the atomic bombs in Hiroshima and Nagasaki. *Am J Public Health* 1967;57:1374–1380.
60. Harvey EB, Boice JD, Honeyman M, et al. Prenatal x-ray exposure and childhood cancer in twins. *N Engl J Med* 1985;312:541–545.
61. Doll R, Wakeford R. Risk of childhood cancer from fetal irradiation. *Br J Radiol* 1997;70:130–139.
62. American College of Obstetrician and Gynecologists. Ultrasonography in pregnancy. ACOG Practice Bulletin no. 101. *Obstet Gynecol* 2009; 113:451–461.
63. Marinac-Dabic D, Krulewitch CJ, Moor RM Jr. The safety of prenatal ultrasound exposure in human studies. *Epidemiology* 2002;13(suppl 3):S19–S22.
64. American Institute of Ultrasound in Medicine. AIUM practice guideline for the performance of obstetric ultrasound examinations. *J Ultrasound Med* 2013;32:1083–1101.
65. Sheiner E, Freeman J, Abramowicz JS. Acoustic output as measured by mechanical and thermal indices during routine obstetric ultrasound examinations. *J Ultrasound Med* 2005;24:1665–1670.
66. Reddy UM, Abuhamad AZ, Levine D, et al.; Fetal Imaging Workshop Invited Participants. Fetal Imaging: Executive Summary of a Joint Eunice Kennedy Shriver national Institute of Child Health and Human Development, Society for Maternal-Fetal Medicine, American Institute of Ultrasound in Medicine, American College of Obstetricians and Gynecologists, American College of Radiology, Society for Pediatric Radiology, and Society of Radiologists in Ultrasound Fetal Imaging

Workshop. *Am J Obstet Gynecol* 2014;210(5):387–397.
67. Lazarus E, Debenedectis C, North D, et al. Utilization imaging in pregnant patients: 10-year review of 5270 examinations in 3285 patients—1997–2006. *Radiology* 2009;251(2):517–524.
68. Leite NP, Pereira JM, Cuhna R, et al. Imaging techniques and diagnostic findings. *AJR Am J Roentgenol* 2007;185:407–417.
69. Lowdermilk C, Gavant ML, Qaisi W, et al. Screening helical CT for evaluation of blunt traumatic injury in the pregnant patient. *Radiographics* 1999;19:S243–S255.
70. Goldman SM, Wagner LK. Radiologic ABCs of maternal and fetal survival after trauma: when minutes may count. *Radiographics* 1999;19:1349–1357.
71. Yousefzadeh D, Ward D, Reft C. Internal barium shielding to minimize fetal irradiation in a spiral chest CT: a phantom simulation experiment. *Radiology* 2006;239:751–758.
72. Dewilde JP, Rivers AW, Price DL. A review of the current use of magnetic resonance imaging in pregnancy and safety implications for the fetus. *Prog Biophys Mol Biol* 2005;87(2–3):335–353.
73. Martin C, Varner MW. Physiologic changes in pregnancy: surgical implications. *Clin Obstet Gynecol* 1994;37:241–255.
74. Bonapace ES, Fisher RS. Constipation and diarrhea in pregnancy. *Gastroenterol Clin North Am* 1998;27:197–211.
75. Gill RC, Bowes KL, Kingma YJ. Effects of progesterone on canine colonic smooth muscle. *Gastroenterology* 1985;88:1941–1947.
76. Katz PO, Castell DO. Gastroesophageal reflux during pregnancy. *Gastroenterol Clin North Am* 1998;27:153–167.
77. Everson GT, McKinley C, Lawson M, et al. Gallbladder function in the human female: effect of the ovulatory cycle, pregnancy, and contraceptive steroids. *Gastroenterology* 1982;82:711–719.
78. Broussard CN, Richter JE. Nausea and vomiting of pregnancy. *Gastroenterol Clin North Am* 1998;27:123–151.
79. Abel TL, Riely CA. Hyperemesis gravidum. *Gastroenterol Clin North Am* 1992;21:835–849.
80. Baker PN, Madeley RJ, Symonds EM. Abdominal pain of unknown aetiology in pregnancy. *Br J Obstet Gynaecol* 1989;96:688–691.
81. Tamir IL, Bongard FS, Klein SR. Acute appendicitis in the pregnant patient. *Am J Surg* 1990;160:571–576.
82. Mazze RI, Kallen B. Appendectomy during pregnancy: a Swedish registry study of 778 cases. *Obstet Gynecol* 1991;77:835–840.
83. Babaknia A, Parsa H, Woodruff JD. Appendicitis during pregnancy. *Obstet Gynecol* 1977;50:40–44.
84. Al-Mulhim AA. Acute appendicitis in pregnancy. A review of 52 cases. *Int Surg*

1996;81:295–297.
85. Masters K, Levine BA, Gaskill HV, et al. Diagnosing appendicitis during pregnancy. *Am J Surg* 1984;148:768–771.
86. Anderson B, Nielsen TF. Appendicitis in pregnancy: diagnosis, management and complications. *Acta Obstet Gynecol Scand* 1999;78:758–762.
87. Hee P, Viktrup L. The diagnosis of appendicitis during pregnancy and maternal and fetal outcome after appendectomy. *Int J Gynaecol Obstet* 1999;65:129–135.
88. Tracey M, Fletcher HS. Appendicitis in pregnancy. *Am Surg* 2000;66:555–559.
89. Hale DA, Molloy M, Pearl RH, et al. Appendectomy: a contemporary appraisal. *Ann Surg* 1997;225:252–261.
90. Weingold AB. Appendicitis in pregnancy. *Clin Obstet Gynecol* 1983;26:801–809.
91. Black WP. Acute appendicitis in pregnancy. *Br Med J* 1960;1:1938–1941.
92. Parker RB. Acute appendicitis in late pregnancy. *Lancet* 1954;266:1252–1257.
93. Wagner JM, McKinney WP, Carpenter JL. Does this patient have appendicitis? *JAMA* 1996;276:1589–1594.
94. Baer JL, Reis RA, Arens RA. Appendicitis in pregnancy. *JAMA* 1932; 98:1359–1364.
95. Schwerk WB, Wichtrup B, Rothmund M, et al. Ultrasonography in the diagnosis of acute appendicitis: a prospective study. *Gastroenterology* 1989;97:630–639.
96. McGory ML, Zingmond DS, Tillou A, et al. Negative appendectomy in pregnant women is associated with a substantial risk of fetal loss. *J Am Coll Surg* 2007;205(4):534–540.
97. Horowitz MD, Gomez GA, Santiesteban R, et al. Acute appendicitis during pregnancy. Diagnosis and management. *Arch Surg* 1985;120:1362–1367.
98. Worrell JA, Drolshagen LF, Kelly TC, et al. Graded compression ultrasound in the diagnosis of appendicitis: a comparison of diagnostic criteria. *J Ultrasound Med* 1990;9:145–150.
99. Freeland M. Diagnosis of appendicitis in pregnancy. *Am J Surg* 2009; 198(6):753–758.
100. Williams R, Shaw J. Ultrasound scanning in the diagnosis of acute appendicitis in pregnancy. *Emerg Med J* 2007;24:359–360.
101. Paulman AA, Huebner DM, Forrest TS. Sonography in the diagnosis of acute appendicitis. *Am Fam Physician* 1991;44:465–468.
102. Abu-Yousef MM, Phillips ME, Franken EA, et al. Sonography of acute appendicitis: a critical review. *Crit Rev Diagn Imaging* 1989;29:381–408.
103. Rao PM, Rhea JT, Novelline RA, et al. Helical CT combined with contrast material administered only through the colon for imaging of suspected appendicitis. *AJR Am J Roentgenol* 1997;169:1275–1280.
104. Katz DS, Klein MA, Ganson G, et al. Imaging of abdominal pain in pregnancy. *Radiol Clin North Am* 2012;50(1):149–171.

105. Rao PM, Rhea JT, Novelline RA, et al. Effect of computed tomography of the appendix on treatment of patients and use of hospital resources. *N Engl J Med* 1998;338:141–146.
106. Rao PM, Rhea JT, Rattner DW, et al. Introduction of appendiceal CT impact on negative appendectomy and appendiceal perforation rates. *Ann Surg* 1999;229:344–349.
107. Raman SS, Osuagwu FC, Kadell B, et al. Effect of CT on false-positive diagnosis of appendicitis and perforation. *N Engl J Med* 2008;358:972–973.
108. Ames CM, Shipp TD, Castro EE, et al. The use of helical computed tomography in pregnancy for the diagnosis of acute appendicitis. *Am J Obstet Gynecol* 2001;184:954–957.
109. Long SS. Imaging strategies for right lower quadrant pain in pregnancy. *AJR Am J Roentgenol* 2011;196(1):4–12.
110. Kanal E, Barcovich AJ, Bell C, et al. ACR guidance document on MR safety practices: 2013. Expert Panel on MR Safety. *J Magn Reson Imaging* 2013;37(3):501–530.
111. Gurbuz AT, Peetz ME. The acute abdomen in the pregnant patient. *Surg Endosc* 1997;11:98–102.
112. SAGES Committee on Standards Practice. Guidelines for laparoscopic surgery during pregnancy. *Surg Endosc* 2011;25:2479–3492.
113. Malangoni MA. Gastrointestinal surgery and pregnancy. *Gastroenterol Clin North Am* 2003;32:181–200.
114. Vissers RJ, Lennarz WB. Pitfalls in appendicitis. *Emerg Med Clin North Am* 2010;28(1):103–118, viii.
115. Saunders P, Milton PJ. Laparotomy during pregnancy: an assessment of diagnostic accuracy and fetal wastage. *Br Med J* 1973;3:165–167.
116. Sadot E, Telem DA, Arora M, et al. Laparoscopy: a safe approach to appendicitis during pregnancy. *Surg Endosc* 2010;24:383–389.
117. Fatum M, Rojansky N. Laparoscopic surgery during pregnancy. *Obstet Gynecol Surv* 2001;56:50–59.
118. Friedman JD, Ramsey PS, Ramin KD, et al. Pneumoamnion and pregnancy loss after second-trimester laparoscopic surgery. *Obstet Gynecol* 2002;99:512–513.
119. Reedy MB, Kallen B, Kuel TJ. Laparoscopy during pregnancy: laparoscopy during pregnancy: a study of five fetal outcome parameters with use of the Swedish Health Registry. *Am J Obstet Gynecol* 1997;177(3):673–679.
120. Wilasrusmee C, Sukrat B, McEvoy M, et al. Systematic review and meta-analysis of safety laparoscopic versus open appendicectomy for suspected appendicitis in pregnancy. *Br J Surg* 2012;99(11):1470–1478.
121. Ko CW. Risk factors for gallstone-related hospitalization during pregnancy and the postpartum. *Am J Gastroenterol* 2006;101(10):2263–2268.
122. Ko CW, Napolitano PG, Lee SP, et al. Physical activity, maternal metabolic measures,

and the incidence of gallbladder sludge or stones during pregnancy: a randomized trial. *Am J Perinatol* 2014;31(1):39–48.

123. Ko CW, Beresford SA, Schulte SJ, et al. Incidence, natural history, and risks factors for biliary sludge and stones during pregnancy. *Hepatology* 2005;41:359–365.
124. Dietrich CS, Hill CC, Hueman M. Surgical diseases presenting in pregnancy. *Surg Clin North Am* 2008;88:408–419.
125. Boregowda G, Shehata HA. Gastrointestinal and liver disease in pregnancy. *Best Pract Res Clin Obstet Gynaecol* 2013;27(6):835–853.
126. Epstein FB. Acute abdominal pain in pregnancy. *Emerg Med Clin North Am* 1994;12:151–165.
127. Lu EJ, Curet MJ, El-Sayet YY, et al. Medical versus surgical management of biliary tract disease in pregnancy. *Am J Surg* 2004;188:755–759.
128. Othman MO, Stone E, Hashimi M. Conservative management of cholelithiasis and its complications in pregnancy is associated with recurrent symptoms and more emergency department visits. *Gastrointest Endosc* 2012;76:564–569.
129. Duphar R, Smaldone GM, Hamad GC. Is there a benefit of delaying cholecystectomy for symptomatic gallbladder disease during pregnancy? *Surg Endosc* 2010;24(1):108–112.
130. Conron RW, Abbruzzi K, Cochrane SO, et al. Laparoscopic procedures in pregnancy. *Am Surg* 1998;65:259–263.
131. Curet MJ, Allen D, Josloff RK, et al. Laparoscopy during pregnancy. *Arch Surg* 1996;131:546–551.
132. Pucci RO, Seed RW. Case report of laparoscopic cholecystectomy in the third trimester of pregnancy. *Am J Obstet Gynecol* 1991;165:401–402.
133. Graham G, Baxi L, Tharakan T. Laparoscopic cholecystectomy during pregnancy: a case series and review of the literature. *Obstet Gynecol Surv* 1998;53:566–574.
134. Elerding SC. Laparoscopic cholecystectomy in pregnancy. *Am J Surg* 1993; 165:625–627.
135. McKellar DP, Anderson CT, Boynton CJ, et al. Cholecystectomy during pregnancy without fetal loss. *Surg Gynecol Obstet* 1992;174:465–468.
136. Steinbrook RA, Brooks DC, Datta S. Laparoscopic cholecystectomy during pregnancy review of anesthetic management: surgical considerations. *Surg Endosc* 1996;10(5):511–515.
137. McLean M, Bisits A, Davies J, et al. A placental clock controlling the length of human pregnancy. *Nat Med* 1995;1:460–463.
138. Printen KJ, Ott RA. Cholecystectomy during pregnancy. *Am Surg* 1978;44:432–434.
139. Baillie J, Cairns SR, Cotton PB. Endoscopic management of choledocholithiasis during pregnancy. *Surgery* 1990;171(1):1–4.
140. Axelrad AM, Fleischer DE, Strack LL, et al. Performance of ERCP for symptomatic choledocholithiasis during pregnancy: techniques to increase safety and improve

patient management. *Am J Gastroenterol* 1994;89:109–112.
141. Amouyal P, Amouyal G, Levy P, et al. Diagnosis of choledocholithiasis by endoscopic ultrasonography. *Gastroenterology* 1994;106:1062–1067.
142. Parada AA, Goncalves MO, Tafner E, et al. Endoscopic papillotomy under ultrasonographic control. *Int Surg* 1991;76(2):75–76.
143. Yu-leung C, Chan AC, Lam WW, et al. Choledocholithiasis: comparison of MR cholangiography and endoscopic retrograde cholangiography. *Radiology* 1996;200:85–89.
144. Davis MR, Bohon CJ. Intestinal obstruction in pregnancy. *Clin Obstet Gynecol* 1983;26(4):832–842.
145. Hill LM, Symmonds RE. Small bowel obstruction in pregnancy: a report and review of four cases. *Obstet Gynecol* 1976;49:170–173.
146. Unal A, Sayherman SE, Ozel L, et al. Acute abdomen in pregnancy requiring surgical management: a 20-case series. *Eur J Obstet Gynecol Reprod Biol* 2011;159(1):87–90.
147. Andolf E, Thorsell M, Kaken K. Cesarean delivery and risk for postoperative adhesions and intestinal obstruction: a nested case-control study of the Swedish Medical Birth Registry. *Am J Obstet Gynecol* 2010;203(4):406. e1–e6.
148. Lyell DJ. Adhesions and postoperative complications of repeat cesarean delivery. *Am J Obstet Gyencol* 2011;205(suppl 6):S11–S18.
149. Perdue PW, Johnson HW Jr, Stafford PW. Intestinal obstruction complicating pregnancy. *Am J Surg* 1992;164(4):384–388.
150. Lord SA, Boswell WC, Hungerpiller JC. Sigmoid volvulus in pregnancy. *Am Surg* 1996;62:380–382.
151. Kantor HM. Midgut volvulus in pregnancy: a case report. *J Reprod Med* 1990;35:577–580.
152. Pratt AT, Donaldson RC, Evertson LR, et al. Cecal volvulus in pregnancy. *Obstet Gynecol* 1981;57:37S–40S.
153. Rothstein RD, Rombeau JL. Intestinal malrotation during pregnancy. *Obstet Gynecol* 1993;81:817–819.
154. Meyerson S, Holtz T, Ehrinpresis M, et al. Small bowel obstruction in pregnancy. *Am J Gastroenterol* 1995;90(2):299–302.
155. Essilfie P, Hussain M, Stokes IM. Small bowel infarction secondary to volvulus during pregnancy. *J Reprod Med* 2007;52(6):553–554.
156. Biswas S, Gray KD, Cotton BA. Intestinal obstruction in pregnancy: a case of small bowel volvulus and review of the literature. *Am Surg* 2006; 72(12):1218–1221.
157. Dray X, Hamzi L, Lo Dico R, et al. Endoscopic reduction of a volvulus of the sigmoid colon in a pregnant woman. *Dig Liver Dis* 2012;44(5):447.
158. Khan MR, Ur Rehman S. Sigmoid volvulus in pregnancy and puerperium: surgical and obstetric catastrophe. Report of the case and review of the growth literature. *World J Emerg Surg* 2012;7(1):10.

159. Firstenberg MS, Malangoni MA. Gastrointestinal surgery during pregnancy. *Gastroenterol Clin North Am* 1998;27(1):73–88.
160. Shiu LH, Rafi J, Corder A, et al. Mid-gut volvulus and mesenteric vessel thrombosis in pregnancy: case report and literature review. *Arch Gynecol Obstet* 2011;183(suppl 1):39–43.
161. American Cancer Society. Cancer facts and figures 2013. http://www.cancer.org/acs/groups/content/@epidemiologysurveillance/documents/031941.pdf. Accessed September 6, 2014.
162. Bernstein MA, Madoff RD, Caushaj PF. Colon and rectal cancer in pregnancy. *Dis Colon Rectum* 1993;36:172–178.
163. McLean DW, Arminski TC, Bradley GT. Management of primary carcinoma of the rectum diagnosed during pregnancy. *Am J Surg* 1955;90:816–825.
164. Woods JB, Martin JN Jr, Ingram FH, et al. Pregnancy complicated by carcinoma of the colon above the rectum. *Am J Perinatol* 1992;9:102–110.
165. Antonelli NM, Dotters DJ, Katz VL, et al. Cancer in pregnancy: a review of the literature, part 1. *Obstet Gynecol Surv* 1996;51:125–142.
166. Silverberg E. *Cancer Statistics.* New York, NY: American Cancer Society; 1981.
167. Meggouh F, Lointier P, Pezet D, et al. Status of sex steroid hormone receptors in large bowel cancer. *Cancer* 1991;67:1964–1970.
168. Francavilla A, Leo D, Polimeno L, et al. Nuclear and cytosolic estrogen receptors in human colon carcinoma and in surrounding noncancerous colonic tissue. *Gastroenterology* 1987;93:1301–1306.
169. Girard RM, Lamarche J, Baillot R. Carcinoma of the colon associated with pregnancy. *Dis Colon Rectum* 1981;24:473–475.
170. Cappell MS. Colon cancer during pregnancy. *Gastroenterol Clin North Am* 2003;32:341–383.
171. Cappell MS. Colon cancer during pregnancy: the gastroenterologist's perspective. *Gastroenterol Clin North Am* 1998;7:225–256.
172. Lamerz R, Ruider H. Significance of CEA determinations in patients with cancer of the colon-rectum, and the mammary gland comparison to physiological states in connection with pregnancy. *Bull Cancer* 1976;63:575–586.
173. McCall JL, Black RB, Rich CA, et al. The value of serum carcinoembryonic antigen in predicting recurrent disease following curative resection of colorectal cancer. *Dis Colon Rectum* 1994;37:875–881.
174. Salani R, Billingsley CC, Crafton SM. Cancer in pregnancy: an overview for obstetricians and gynecologists. *Am J Obstet Gynecol* 2014;211(1):7–14.
175. Minter A, Malik R, Ledbetter L, et al. Colon cancer in pregnancy. *Cancer Control* 2005;12(3):196–202.
176. Nesbitt JC, Moise KJ, Sawyers JL. Colorectal carcinoma in pregnancy. *Arch Surg* 1985;120:636–640.

177. Wobbes T, Beex LV, Koenders AM. Estrogen and progestin receptors in colonic cancer? *Dis Colon Rectum* 1984;27(9):591–592.
178. Walsh C, Fazio VW. Cancer of the colon, rectum, and anus during pregnancy: the surgeon's perspective. *Gastroenterol Clin North Am* 1998;27:257–267.
179. Mason MH III, Kovalcik PJ. Ovarian metastases from colon carcinoma. *J Surg Oncol* 1981;17:33–38.
180. Pitluk H, Poticha SM. Carcinoma of the colon and rectum in patients less than 40 years of age. *Surg Gynecol Obstet* 1983;157:335–337.
181. Gurbuz A, Kir G, Karateke A, et al. Metastatic ovarian carcinoma one year after surgical removal of colon carcinoma during pregnancy: a case report. *Int J Gynecol Cancer* 2006;16(suppl 1):330–333.
182. Zemlickis D, Lishner M, Degendorfer P, et al. Fetal outcome after in utero exposure to cancer chemotherapy. *Arch Intern Med* 1992;152:573–576.
183. Mayr NA, Wen B-C, Saw CB. Radiation therapy during pregnancy. *Obstet Gynecol Clin North Am* 1998;25:301–321.
184. Dahling MT, Xing G, Cress R, et al. Pregnancy-associated colon and rectal cancer: perinatal and cancer outcomes. *J Matern Fetal Neonatal Med* 2009;22(3):204–211.

SECTION O: SKIN AND SOFT TISSUE

Chapter 107

Cutaneous Neoplasms

Michael S. Sabel, Timothy M. Johnson, and Christopher K. Bichakjian

Key Points

1 Cutaneous neoplasms are the most commonly diagnosed malignant tumors in the United States.

2 Risk factors for development of cutaneous melanoma include ultraviolet (UV) light exposure, fair complexion/inability to tan, blue or green eyes, blonde or red hair, freckling, history of actinic keratosis or nonmelanoma skin cancer (NMSC), history of blistering or peeling sunburns, immunosuppression, personal or family history of melanoma, *CDKN2A/p16/MC1R* mutation, xeroderma pigmentosa, atypical (dysplastic) nevus, more than 100 normal nevi, and giant congenital melanocytic nevus.

3 The ABCD rule is used to assess skin lesions for melanoma risk: A is for *a*symmetry; B is *b*order irregularity; C is *c*olor; and D is *difference,* or a change in a lesion.

4 Melanoma prognosis is inversely correlated to tumor thickness; ulceration and increased mitotic rate are independent survival risk factors; and nodal tumor burden (uninvolved vs. microscopic vs. macroscopic disease) has an inverse correlation with survival.

5 For melanoma in situ, excision margins of 0.5 to 1.0 cm are indicated; for invasive melanoma, wide excision of the primary tumor with margins generally ranging from 1 to 2 cm is indicated for local control.

6 Clinically involved lymph nodes should be resected; patients with primary melanomas of 1-mm thickness or greater and clinically negative nodes should be considered for sentinel lymph node biopsy. Patients with primary melanoma 0.75- to 0.99-mm thickness should also be considered for sentinel lymph node biopsy if they have additional risk factors for nodal metastases.

7 Basal cell and squamous cell skin carcinoma account for 96% of new NMSCs.

8 Merkel cell carcinoma (MCC) is an aggressive cutaneous neuroendocrine carcinoma treated by a combination of surgery and radiation, which has a higher mortality than melanoma.

9 Dermatofibrosarcoma protuberans (DFSP) is a rare soft tissue sarcoma (1% of all soft tissue sarcomas) with a propensity for local recurrence rather than systemic metastasis.

1 Cutaneous neoplasms are the most commonly diagnosed malignant tumors in the United States, with an incidence of approximately 1.4 million new cases annually.[1,2] One in five Americans (one in three Caucasians) born today will be diagnosed with skin cancer in their lifetime. More than half of all cancers diagnosed in the United States are skin cancers. The most common skin cancer types are basal cell carcinoma (BCC) and squamous cell carcinoma (SCC). Cutaneous melanoma accounts for $<2\%$ of skin cancer diagnoses but the vast majority of skin cancer deaths, with 9,940 deaths due to melanoma in 2015. One person dies of melanoma every hour. Approximately 73,870 new cases of invasive melanoma (42,670 men and 31,200 women) were diagnosed in the United States in 2015. The incidence of melanoma has dramatically increased, with the lifetime risk of melanoma increasing from 1 in 600 in the 1960s to 1 in 50 in 2015. Of the seven most common cancers in the United States, melanoma is the only one whose incidence is increasing. Invasive melanoma is the fifth most common cancer in men and the seventh most common cancer in women.[1] The early diagnosis and surgical treatment of these skin cancers can be curative.

MELANOMA

Etiology and Risk Factors

2 Numerous environmental and genetic risk factors have been implicated in the development of cutaneous melanoma, many of which center around sun exposure.[3] Risk factors include factors related to exposure to UVA and UVB, such as geography, occupation, a history of blistering or peeling sunburns, and the use of tanning beds/salons, as well as factors related to increased sensitivity to UV light, such as decreased pigmentation, a fair complexion (blue or green eyes, blonde hair, freckling), or xeroderma pigmentosa. Melanoma incidence is subject to large geographic and ethnic variations, mainly because of an inverse correlation with latitude and with degree of skin pigmentation. Populations residing closer to the equator have a higher incidence of melanoma. Many factors that increase risk for melanoma are surrogates for a history of excess sun exposure, such as actinic keratosis, a history of either melanoma or an NMSC, atypical nevi, or multiple normal nevi. Finally, there are inheritable risk factors, such as a family history of melanoma, *CDKN2A/p16* mutation, or *MC1R* mutation.

Adults with more than 100 clinically normal-appearing nevi, children with more than 50 clinically normal-appearing nevi, and any patient with atypical or dysplastic nevi are at risk. A prior history of melanoma places a patient at increased risk, with 5% to 10% of individuals developing a second primary melanoma. This risk of developing a second primary is lifelong and can occur anywhere on the skin. Therefore, long-term surveillance with a thorough total body examination is recommended.

A genetic component has been implicated in the pathogenesis of melanoma. Of patients with melanoma, 10% to 15% report a positive family history. The most common chromosomal mutation associated with melanoma involves *CDKN2A*, also known as *p16*. However, the mutation accounts for only a small percentage of melanoma cases observed, estimated at 0.2%. An *MC1R* gene mutation is clearly a risk factor for cutaneous melanoma.[4] The combination of *MC1R* mutation and red hair is associated with a very high risk of melanoma development. In addition, *MC1R R151 C* modifies the effect of another cutaneous melanoma susceptibility gene, *CDKN2A*.[4] The genetic etiology of melanoma represents an area of future discovery.

The hereditary nature of cutaneous melanoma was also noted in the 1970s.[5] Members afflicted with the "B-K mole syndrome," named after two families, acquired large, irregular, and dysplastic nevi, often in sun-protected regions of the body such as the scalp and trunk. During this time period, Lynch et al.[6] independently reported a familial association of melanoma among individuals with atypical nevi, which he termed *familial atypical multiple mole melanoma syndrome,* or FAMMM syndrome, with an autosomal dominant inheritance pattern. The 10-year melanoma risk in the setting of atypical mole syndrome is reported to be 10.7% compared with 0.62% in control patients. Greene et al.[7] approximated a 56% cumulative risk from the age of 20 to 59 years, with 100% of patients with atypical mole syndrome developing melanoma by the age of 76 years. An atypical nevus is not a premelanoma but represents a genetic marker for increased risk of

development of melanoma, which may occur anywhere on the skin surface including sun-protected sites. In fact, more than 50% to 75% of melanomas develop on clinically normal skin de novo, not in pre-existing melanocytic lesions.

Xeroderma pigmentosa is a rare autosomal recessive disorder associated with a reduced or absent ability to repair DNA damaged by UV light. Consequently, this disorder results in the development of multiple primary cutaneous malignancies, including melanoma as well as BCC and SCC. Individuals are usually diagnosed with their first cancer before the age of 10 years. Unfortunately, the development of skin cancers is relentless.

Congenital melanocytic nevi (CMN) are present at birth or appear within the first 6 months of infancy.[8] An estimated 1% to 6% of children are born with CMN. The nevi are classified by size. Small CMN measure less than 1.5 cm in diameter and account for the majority of lesions. Medium CMN measure between 1.5 and 19.9 cm in diameter. Large CMN, also termed *giant congenital nevi,* measure 20 cm or greater. This large size can lead to significant cosmetic and psychosocial implications. The risk of melanoma development in small- and medium-sized CMN is similar to any other area of skin. Melanoma development in small and medium CMN usually occurs after childhood and arises from the dermoepidermal junction, making early detection feasible. Routine prophylactic removal of small and medium CMN is rarely indicated in the absence of signs or symptoms for malignant progression. Conversely, giant congenital nevi carry an increased risk for melanoma, with an estimated rate of 5% to 20%. Of giant congenital nevi that progress to melanoma, 70% are diagnosed prior to the age of 10 years. Melanoma can originate deep in the epidermis in giant congenital nevi. Consequently, diagnosis within the setting of giant congenital nevi is challenging and may develop deep in the skin with a more advanced primary lesion.

Patients with a giant congenital nevus, especially on the posterior axis, or in conjunction with many satellite lesions are also at risk for neurocutaneous melanocytosis (NCM).[9,10] NCM is characterized by the presence of benign or malignant leptomeningeal tumors. Most patients present in the first 2 years of life with neurologic manifestations of increased intracranial pressure, mass lesions, or malignant transformation to melanoma. Magnetic resonance imaging (MRI) findings of NCM may be present, even in asymptomatic children. NCM is associated with an increased risk of development of central nervous system melanoma. Symptomatic NCM is associated with a poor prognosis, even in the absence of malignancy. Chemotherapy is not effective, but shunt placement to reduce intracranial pressure may be palliative.

Clinical Diagnosis and Classification

3 Melanoma may have a characteristic appearance (Fig. 107-1). Early detection is key. The ABCD rule, which outlines the warning signs of melanoma, was developed decades ago.[11] A stands for *a*symmetry – one-half of the lesion does not match the other half when drawing an imaginary line through the center of the lesion. B is *b*order irregularity – the edges of the lesion are ragged, notched, or fuzzy. C is *c*olor – the pigmentation is not uniform throughout the lesion. Varying shades of tan, dark brown to black, or shades of red, white, and/or blue may be present with a mottled appearance. While historically D has been used for *d*iameter (a width greater than 6 mm, or the size of a pencil eraser), today many use *d*ifference – any change in the lesion. Alternatively, some maintain D as difference and add E for *e*volution. The seven-point checklist used in Europe incorporates several of the ABCD features, including change. Another useful diagnostic aid is the "ugly duckling" sign. A pigmented lesion that is different from the others should be carefully approached with a high index of suspicion.

The goal of any diagnostic aid is early detection and the ability to differentiate between benign and malignant, with 100% sensitivity combined with high specificity. The ABCD (or ABCDE) rule, seven-point checklist, and ugly duckling sign all provide relatively highly sensitivity but none fulfills all of these criteria, especially with respect to specificity, to distinguish melanoma from benign lesions.

The ABCD criteria may fail to detect an important subset of nodular melanoma (NM), which often does not exhibit the ABCDs and is often less than 6 mm in early development. The ABCD rule is also relatively static without the important critical characteristic of change. Studies have documented early signs of a change in size, shape, or color and the early symptom of persistent itching. One of the best tools for diagnosis of early lesions that may fail to exhibit many of the standard melanoma features is the importance of *change,* hence the reason the authors and others have used the D in the ABCD rule to signify "*d*ifference." A difference or change in lesions, especially with respect to size, shape, color, or persistent itching, warrants evaluation. Furthermore, the nevi on the body should globally share a common look or family resemblance. If one of the nevi seems different from the rest, it should be evaluated with a high index of suspicion. In addition, if all of the nevi are atypical or irregular but are morphologically similar to one another and are not changing, there may be no reason for individual lesion concern (atypical or dysplastic nevi). However, the presence of atypical nevi represents a risk factor for melanoma development anywhere on the skin surface with development in clinically normal skin, normal nevi, and dysplastic nevi with relatively equal frequency. Thus, excision of all atypical nevi does little for prevention. Education of the patient for early signs and symptoms, particularly change or difference, is key in this clinical scenario.

It must be emphasized that critical diagnostic decisions concerning skin lesions should still always be based on clinical assessments and the history, with attention to melanoma risk factors. The optimum diagnostic aid that combines 100% sensitivity and specificity currently does not exist. The use of all available means, including the ABCD and seven-

point checklists, ugly duckling sign, difference, photography, dermoscopy, and evolving digital and computer-assisted imaging technologies, enhances the ability to diagnose melanoma at the earliest stage.[11] The result of using these multiple diagnostic aids is earlier detection of melanoma with higher overall survival rates.

Based on histologic patterns and clinical characteristics, melanomas can be classified into multiple categories, with the four major subtypes being lentigo maligna melanoma (LMM), superficial spreading melanoma (SSM), NM, and acral lentiginous melanoma (ALM).[12] In general, these subtypes derive their prognostic biologic behavior and risk of metastasis based on a secondary correlation with Breslow depth and are thus not independent prognostic factors. Invasive LMM constitutes 10% to 15% of cutaneous melanomas and typically occurs on the chronically sun-exposed areas of the head and neck, most often in older individuals. Clinically, the LMM pattern is associated with a significantly higher rate of often extensive and asymmetrical subclinical growth several centimeters beyond the clinical lesion. Failure to completely excise the entire lesion with meticulous margin control results in higher recurrence rates with lethal potential. In addition, amelanotic and desmoplastic melanoma with neurotropism is more frequent in the lentigo maligna (LM) lesion subtype. LM is not a benign disease as once thought. LM represents in situ melanoma and, with time, progresses to invasive LMM. LMM often begins as a flat brown lesion on chronically sun-exposed areas with progression to black and other classic melanoma features over time.


A

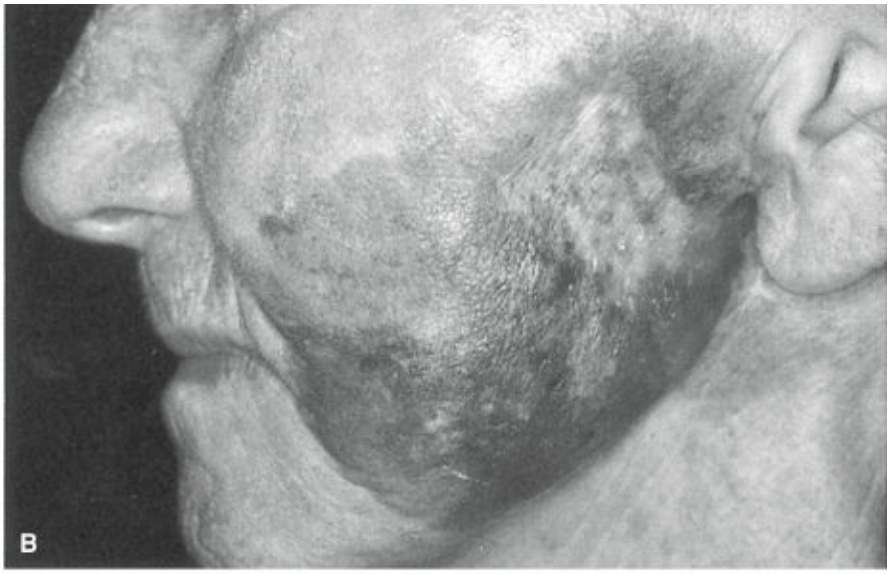
B


C

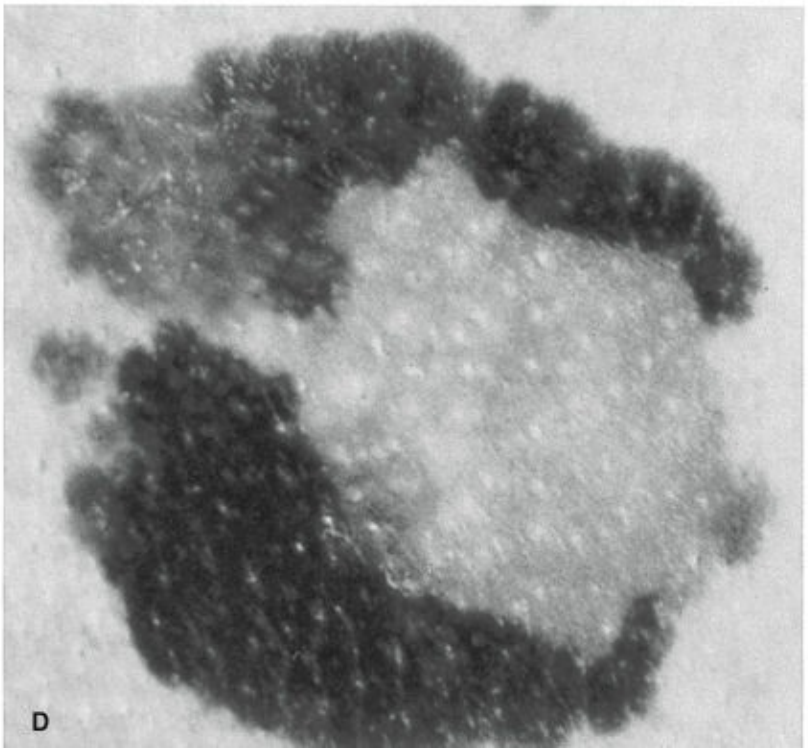
D

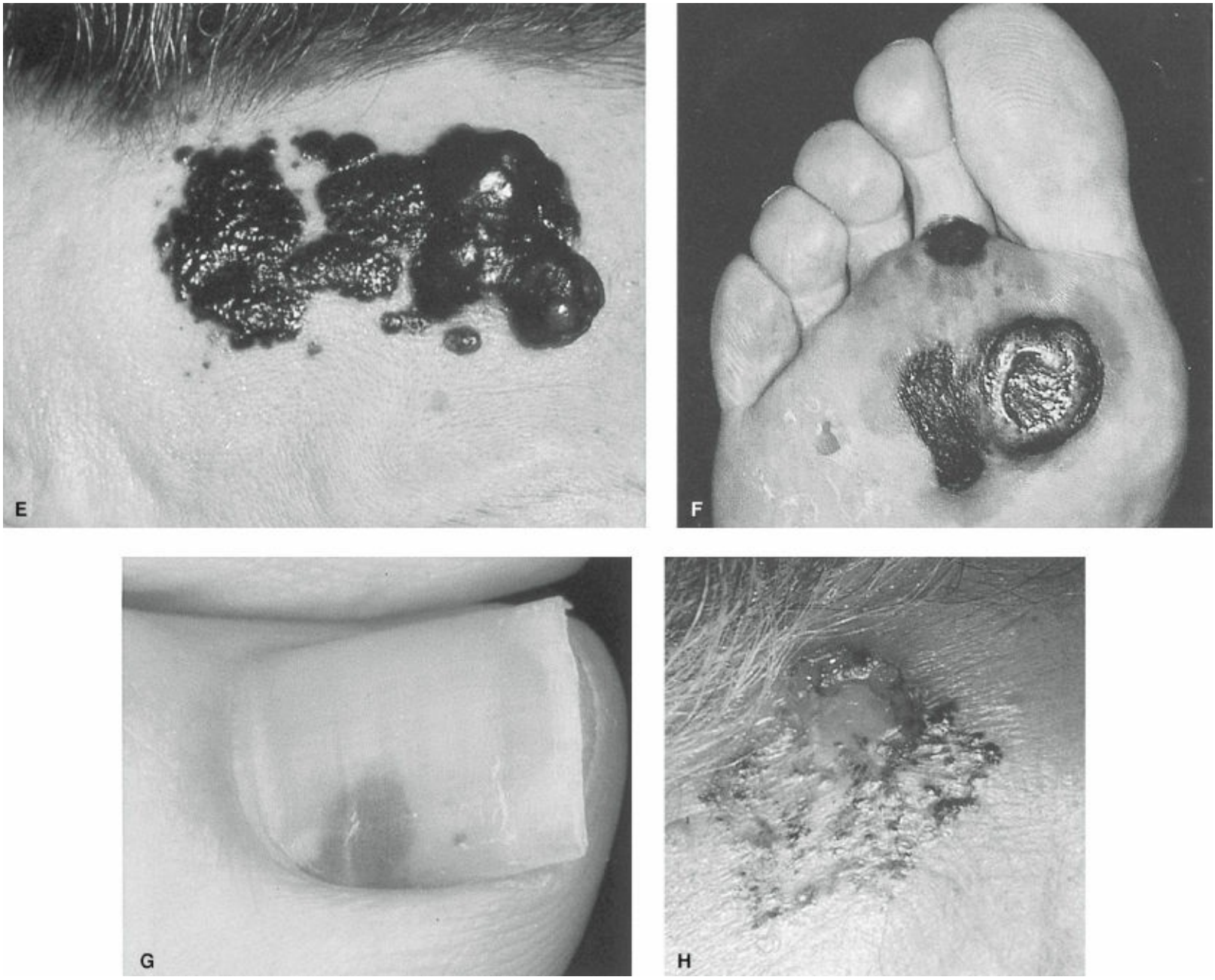

Figure 107-1. Examples of skin lesions. **A:** Giant congenital nevus. **B:** Lentigo maligna (Hutchinson freckle). **C:** Melanoma arising in a lentigo maligna (lentigo maligna melanoma). **D:** Superficial spreading melanoma. **E:** Nodular melanoma. **F:** Acral lentiginous melanoma (ulcerated nodular plantar melanoma with satellite lesions). **G:** Subungual melanoma. **H:** Pigmented basal cell carcinoma.

SSM accounts for approximately 70% of cutaneous melanomas. This pattern is the most common in melanomas arising in a pre-existing nevus. SSM is typically characterized by variation in color, irregular borders, and irregular surface and often exhibits the classic melanoma clinical features.

NM occurs in approximately 15% to 30% of patients with cutaneous melanoma and is often the most aggressive of the four types of melanoma because of later detection and rapid growth. In general, NM may be more uniform in coloration than the other types, have regular borders with size less than 6 mm in early lesions, and lack the classic melanoma features initially. A change in a lesion is important for early detection.

ALM is a distinct clinicopathologic variant of melanoma that most commonly occurs on

the hands, feet, fingers, and toes as well as in subungual locations (Fig. 107-1). ALM represents only 2% to 8% of melanoma in whites but 35% to 60% in people of color. Later detection frequently occurs because of location that is not easily or routinely examined and a low index of suspicion. When corrected for Breslow depth, the overall prognosis for ALM appears similar to the other subtype categories. In subungual locations, ALM can appear as an irregular, tan-brown streak in the nail that originates from the base of the nail bed. More than three fourths of subungual melanomas involve the great toe or thumb, and they can be confused with subungual hematoma.

Other rare melanoma subtypes deserve brief mention. Mucosal, anal, and vulvovaginal melanomas are associated with a poorer prognosis, possibly related to advanced disease at presentation with late detection and high vascularity at the lesion site. Desmoplastic melanoma is associated with a higher rate of neurotropism and lower rate of lymph node metastases.[13–15] Small cell or nevoid melanoma often lacks any of the classic features, is difficult to accurately diagnose without expert dermatopathology interpretation, and thus may be initially more frequently misdiagnosed. And, amelanotic melanoma, occurring in 3% to 4% of cases, is often associated with late detection due to lack of pigment and failure to diagnose early.

Staging and Prognostic Factors

4 A great deal of information is available regarding various factors that correlate with the clinical outcome of patients with melanoma. Some of these prognostic factors, such as microstaging and nodal status, are of sufficient independent significance to be incorporated into staging systems with known survival rates. Other prognostic factors such as tumor ulceration and microscopic versus macroscopic nodal disease have also been found to be significant variables that influence survival and have been incorporated into the staging system.

Microstaging

One of the most important prognostic features of cutaneous melanoma is the stage of development of the primary tumor. The microstaging method that is used routinely was originally described by Breslow.[16] This method classifies the primary tumor according to its thickness in millimeters, as measured with an ocular micrometer, from the top of the granular layer to the base of the tumor. Many investigators have documented an inverse correlation between tumor thickness and survival. The largest series of 17,600 patients reported by Balch et al.[17] is summarized in Table 107-1. The ulceration status and mitotic rate are also independent factors that are used to determine microstaging of the primary lesion.[17,18] Prior to the use of the Breslow microstaging method, melanomas were staged according to the level of invasion into the histologic layer of skin. This was known as the Clark level of invasion and comprised five levels (I, in situ lesions; V, subcutaneous involvement). Several studies have confirmed that Breslow thickness conveys more accurate prognostic information than does the determination of Clark level.[17,19]

The presence of regional lymph node metastases is associated with a worsening prognosis. The tumor burden (microscopic vs. macroscopic disease) of involved lymph nodes has an inverse correlation with long-term survival.[17,19] The 5-year survival rate for patients with involved lymph nodes ranges from 70% to 25%, based primarily on tumor burden and ulceration status of the primary lesion (Table 107-1). The use of sentinel lymph node biopsy (SLNB) has identified a subgroup of patients with micrometastatic nodal disease who have a favorable prognosis compared with patients with macroscopic nodal involvement. This information has been incorporated in the staging system as well.

RESULTS

Table 107-1 Survival Rates for Melanoma TNM and Staging Categories

Stage	TNM	5-Yr Survival (%)	10-Yr Survival (%)
IA	T1aN0M0	97	95
IB	T1bN0M0 T2aN0M0	92	86
IIA	T2bN0M0 T3aN0M0	81	67
IIB	T3bN0M0 T4aN0M0	70	57
IIC	T4bN0M0	53	40
IIIA	T1-4aN1aM0 T1-4aN2aM0	78	68
IIIB	T1-4bN1-2aM0 T1-4aN1-2bM0 T1-4aN2cM0	59	43
IIIC	T1-4bN1-2bM0 T1-4bN2cM0 AnyTN3M0	40	24
IV	AnyTAnyNM1	15	10

From Balch CM, Gershenwald JE, Soong S-J, et al. Final version of 2009 AJCC melanoma staging and classification. *J Clin Oncol* 2009;27: 6199–6206. Reprinted with permission from the American Society of Clinical Oncology.

Clinical and Pathologic Staging

The American Joint Committee on Cancer (AJCC) developed a five-stage system that divides melanomas according to tumor thickness (T), nodal status (N), and metastatic disease (M).[17,19] The current system was updated in 2009 and is summarized in Tables 107-2 and 107-3. There are five stages based on prognosis: stage 0 (in situ melanoma), stage I (local disease), stage II (local disease), stage III (regional nodal, in-transit, or satellite metastases), and stage IV (distant metastases).

Other Prognostic Factors

The major prognostic factors that predict survival in melanoma patients have been accounted for in the AJCC staging system – namely, tumor microstaging, ulceration, nodal status, and distant metastases.[17,19] The presence of ulceration in a melanoma appears to be associated with a poorer prognosis. Men have a higher proportion of ulcerated lesions than women (27% vs. 19%, respectively). Although ulceration appears to correlate with thickness of the melanoma, the presence of ulceration is an independent prognostic factor and has been included in the staging system.[17,19] In addition, a higher mitotic rate of 1.0 mm^2 or greater is an independent prognostic factor of both nodal involvement and survival.[18,20–22] The presence of angiolymphatic invasion is also a poor prognostic sign.

Treatment of Primary Melanoma

Biopsy

For localized melanoma, the tumor thickness (Breslow depth of invasion) is the single variable that most accurately determines therapy and prognosis. The ulceration status and mitotic rate also represent independent prognostic variables. A full-thickness biopsy with 1- to 2-mm margins only, to the adipose tissue, is preferred for any lesion highly suspect for melanoma.[23] If the melanoma is transected with a partial-thickness shave biopsy, the ability to obtain an accurate measurement of tumor thickness is lost. Therefore, a superficial shave biopsy is never recommended for a suspect pigmented lesion. Saucerization, which uses a curved blade to perform a deeper shave biopsy down to the subcutaneous fat, is acceptable.

Excisional biopsy with 1- to 2-mm margins is the preferred method for suspect lesions to provide the pathologist a total specimen for histologic interpretation and accurate microstaging. Performing a wide excision as the first step, especially on the trunk or head and neck, is not recommended, as several benign and malignant lesions can mimic melanoma and because doing so may result in the inability to accurately perform SLNB. Formalin-fixed, paraffin-embedded, permanent sections should be used for biopsy diagnosis of primary cutaneous melanoma to accurately determine tumor thickness and other histopathologic prognostic variables. Frozen sections have no role in the diagnosis or microstaging of primary melanoma. If the lesion is a melanoma, the excisional biopsy represents the first stage of a two-stage procedure. The second stage is reexcision with margins generally ranging from 0.5 to 2.0 cm, with or without SLNB, depending primarily on the tumor thickness. When biopsying a suspected melanoma on the extremities, it is critical that the biopsy be oriented on the long axis of the extremity, parallel to the lymphatics. Performing a biopsy oriented transversely on the extremity may not only compromise the accuracy of lymphatic mapping but may also obligate the patient to a skin graft to close the subsequent wide excision defect.

For suspicious lesions that are too large for complete excision and those that are located where the amount of skin is critical in terms of functional or cosmetic results, an incisional biopsy may be performed with an elliptical incision, deep saucerization shave to adipose or deep dermis in thick skin areas, or a punch biopsy. Incisional biopsies for melanoma do not increase the risk of local recurrence and distant metastasis or affect patient survival. They should generally be performed on the most raised or most pigmented area of the lesion to maximize the obtainable diagnostic and prognostic information. The most raised area usually corresponds to the maximal thickness of the lesion, but not always. Several incisional biopsies can be obtained from different areas for large lesions with multiple morphologic features. In the scenario of incisional biopsy with significant remaining lesion, complete excision for accurate microstaging should be considered prior to definitive treatment, unless the lesion is already 1 mm or greater in Breslow depth.

Metastatic Workup

In an attempt to standardize staging workup for melanoma, the National Comprehensive Cancer Network (NCCN) has published guidelines.[24] There are three basic reasons to perform a metastatic workup following the diagnosis of primary cutaneous melanoma: (*a*) for staging and prognosis, (*b*) to detect an early metastasis with potential survival benefit, and (*c*) to avoid morbidity of an extensive surgical procedure by detection of a distant metastasis.[24] The best test for the staging workup still starts with a history (a focused review concentrating on constitutional, respiratory, neurologic, hepatic, musculoskeletal, gastrointestinal, skin, and lymphatic systems) and physical examination (total body skin examination, palpation of lymph nodes). Routine imaging (chest x-ray, computed tomography [CT] scans, positron emission tomography [PET] scans) and blood studies (complete blood cell count, comprehensive metabolic profile, liver function tests, serum lactate dehydrogenase [LDH] levels) in asymptomatic, clinically node-negative patients are low in both sensitivity and specificity and are not necessary.[25–28] False-positive staging tests are common and lead to more tests and patient distress. SLNB represents the best baseline staging test, with both relatively high sensitivity and specificity in patients at significant risk for metastasis. The ability to detect stage IV disease with routine studies is small if the SLNB is negative. Both ultrasound and PET scanning have been examined as methods of identifying nodal metastases prior to surgery. While they detect disease in a minority of patients, the sizes of most metastases to the regional nodes are below the threshold of ultrasound or PET to detect, so this is not a cost-effective strategy.[29–31] If a thorough history and physical and detailed review of systems reveal no signs or symptoms suspicious for regional or distant disease, then no further staging is necessary. However, a high index of suspicion should be maintained and a thorough symptom-directed workup should be initiated for any worrisome finding on the history and physical.

Table 107-2 American Joint Commission on Cancer Melanoma Staging System, TNM Definitions

Primary Tumor	
TX	Primary tumor cannot be assessed
T0	No evidence of primary tumor
Tis	Melanoma in situ
T1	≤1-mm Breslow thickness a. Without ulceration and mitosis <1 mm^2 b. With ulceration or mitosis ≥1 mm^2
T2	1.01–2.00 mm a. Without ulceration b. With ulceration
T3	2.01–4.00 mm a. Without ulceration b. With ulceration
T4	>4 mm a. Without ulceration b. With ulceration
Regional Lymph Node Involvement	
NX	Nodal status cannot be assessed.
N0	No regional node metastasis
N1	Metastasis in 1 regional node a. Micrometastasis (diagnosed by SLNB or elective lymph node dissection) b. Macrometastasis (clinically palpable or found on imaging studies, confirmed histologically, or gross extracapsular extension)
N2	Metastasis in 2–3 regional nodes a. Micrometastasis b. Macrometastasis c. In-transit or satellite metastasis without metastatic nodes
N3	Metastasis in ≥4 regional nodes, matted nodes, or in-transit or satellite metastasis with positive metastatic nodes
Distant Metastasis	
MX	Cannot be assessed
M0	No distant metastasis
M1a	Distant skin, subcutaneous, or lymph node metastasis with normal LDH
M1b	Lung metastasis with normal LDH
M1c	All other visceral metastases with a normal LDH or any distant metastases with an elevated LDH

LDH, lactate dehydrogenase; SLNB, sentinel lymph node biopsy.

Used with the permission of the American Joint Committee on Cancer (AJCC), Chicago, Illinois. The original source for this material is the AJCC Cancer Staging Manual, Seventh Edition (2010) published by Springer Science and Business Media LLC, www.springer.com

Approximately 5% to 10% of newly diagnosed melanoma patients present with clinically involved lymph nodes. Any clinically suspicious node should be confirmed by fine needle aspiration (FNA) biopsy, as enlarged lymph nodes may be reactive (particularly after a biopsy). Ultrasound-guided FNA biopsy can be useful in cases where the suspicious node is difficult to biopsy by hand. Patients documented to have macroscopic regional disease should undergo complete staging prior to definitive surgery,

as a significant percentage may have more advanced regional or distant disease that may alter surgical therapy.[32,33] Staging should include a serum LDH level; MRI of the head and either CT scan of the chest, abdomen, and pelvis; PET scan; or combined CT/PET scan. For patients with involved groin nodes, CT scan is recommended to visualize the pelvic nodes, as this may help determine the extent of inguinal node dissection.

Table 107-3 Stage Groupings for Cutaneous Melanoma

	Clinical Staging[a]			Pathologic Staging[b]		
	T	N	M	T	N	M
0	Tis	N0	M0	Tis	N0	M0
IA	T1a	N0	M0	T1a	N0	M0
IB	T1b	N0	M0	T1b	N0	M0
	T2a	N0	M0	T2a	N0	M0
IIA	T2b	N0	M0	T2b	N0	M0
	T3a	N0	M0	T3a	M0	M0
IIB	T3b	N0	M0	T3b	N0	M0
	T4a	N0	M0	T4a	N0	M0
IIC	T4b	N0	M0	T4b	N0	M0
III[c]	Any T	N>N0	M0			
IIIA				T1-4a	N1a	M0
				T1-4a	N2a	M0
				T1-4b	N1a	M0
				T1-4b	N2a	M0
IIIB				T1-4a	N1b	M0
				T1-4a	N2b	M0
				T1-a/b	N2c	M0
				T1-4b	N1b	M0
IIIC				T1-4b	N2b	M0
				Any T	N3	M0
IV	Any T	Any N	Any M1	Any T	Any N	Any M1

[a]Clinical staging includes microstaging of the primary melanoma and clinical/radiologic evaluation for metastasis. By convention, it should be used after complete excision of the primary melanoma with clinical assessment for regional and distant metastases.
[b]Pathologic staging includes microstaging of the primary melanoma and pathologic information about the regional lymph nodes after partial or complete lymphadenectomy. Pathologic stage 0 or stage IA patients are the exception; they do not require pathologic evaluation of their lymph nodes.
[c]There are no stage III subgroups for clinical staging.
Used with the permission of the American Joint Committee on Cancer (AJCC), Chicago, Illinois. The original source for this material is the AJCC Cancer Staging Manual, Seventh Edition (2010) published by Springer Science and Business Media LLC, www.springer.com

Surgical Excision of Primary Melanoma

5 The primary purpose of a melanoma excision is to prevent local recurrence due to persistent disease. For melanoma in situ, excision margins of 0.5 to 1.0 cm are indicated. For invasive melanoma, wide excision of the primary tumor, with margins generally ranging from 1 to 2 cm, is indicated for local control. The optimal margin width remains somewhat controversial. The historical approach of excising all primary melanomas with a 3- to 5-cm margin is extinct. At least five randomized controlled trials failed to demonstrate a difference in overall survival or local recurrence with narrow (1- to 2-cm) versus wide (3- to 5-cm) margins (Table 107-4). Of note, one trial demonstrated an increased risk of locoregional recurrence with 1-cm versus 3-cm margins for melanoma more than 2 mm thick.[34] Based on these trials, current consensus guidelines recommend margins of 1 cm for melanomas 1 mm or less thick, 2 cm for melanomas greater than 2 mm thick, and 1 to 2 cm for melanomas 1 to 2 mm thick. For this last group, the size of the margins should be based on the anatomic location of the melanoma and the morbidity of excising 2 cm versus 1 cm, including the need for an advancement flap or skin graft (Table 107-5). For several locations, such as melanomas on the head and neck, the maximum margins attainable are dictated by anatomic limitations. Most subungual invasive melanomas require amputation of the digit. Perianal melanomas should be treated by wide excision, as these achieve similar long-term results compared with more radical surgery.[35,36] Abdominoperineal resection (APR) may be necessary for locally advanced disease or melanoma of the anal mucosa. A complete staging workup should be performed before proceeding with APR, as these patients have a very high rate of regional and distant disease.[37]

RESULTS

Table 107-4 Randomized Controlled Trials: Narrow Versus Wide Excision Margins

Trial[a]	Subjects (No.)	Narrow Resection Margin (cm)	Wide Resection Margin (cm)	Tumor Thickness (mm)	Tumor Site	Median Length Follow-up (years)
French 2003	326	2	5	<2.1	T, E, H&N	10.0
Intergroup 1996	470	2	4	1.0–4.0	T, E	7.6
Swedish 2000	989	2	5	0.8–2.0	T, E	11.0
WHO 1991	612	1	3	<2.0	T, E	7.5
UK 2004	900	1	3	>2.0	T, E	5.0

E, extremity; H&N, head and neck; T, trunk; UK, United Kingdom; WHO, World Health Organization.
[a]There was no difference in any outcomes in the first four trials. UK 2004 showed increased locoregional recurrence but no difference in local or in-transit recurrence.

TREATMENT

Table 107-5 Recommended Surgical Margins for Melanoma Excision

Melanoma Thickness (mm)	Clinical Excision Margin (cm)
In situ	0.5–1.0
≤1.0	1.0
1.1–2.0	1.0–2.0
>2.0	2.0

Margins may need to be modified on the basis of anatomic considerations but still require histologic confirmation of tumorfree margins. For clinically ill-defined lentigo maligna/lentigo maligna melanoma, wider margins may be required for histologic confirmation of tumorfree margins.

For the clinically ill-defined LMM, histologic confirmation of negative margins is important, and it should be emphasized that these margin recommendations may not apply to in situ LM and invasive LMM on the head and neck.[38,39] LM and LMM are often associated with extensive subclinical involvement to as much as several centimeters beyond the clinical component. Careful and complete margin control, including excision of the lesional trailing edge of atypical melanocytic hyperplasia, often beyond the standard margins, may be necessary for complete surgical resection of LM/LMM on the head and neck.

Treatment of Regional Metastatic Melanoma

Lymphadenectomy Results and Indications

6 Surgical excision of metastases to regional lymph nodes is potentially curative therapy. The 5-year survival rate for patients who undergo lymphadenectomy for clinically positive involved nodes (AJCC stage III) ranges from 25% to 70%. In addition, for those patients not cured by lymphadenectomy, resection can avoid potential pain associated with tumor enlargement, skin breakdown, and tumor necrosis (Fig. 107-2). Only 5% to 10% of patients who first present with the diagnosis of melanoma have clinical evidence of nodal metastases, approximately 85% to 90% have localized disease, and the remaining 5% have distant metastases. In less than 3% of patients, a diagnosis of melanoma is made in the absence of a definable primary lesion.[40] When patients present with isolated nodal disease from an unknown primary site (an occult primary melanoma), the results of lymphadenectomy are similar to or better than those for patients with known primary tumors.[41] For patients with melanoma 1 mm thick or greater who present with clinically negative nodes, SLNB should be considered to determine whether therapeutic lymphadenectomy is indicated.[42]



Figure 107-2. A patient with large melanoma axillary involvement with skin ulceration.

Sentinel Lymph Node Biopsy

Morton et al.[43] were the first to develop the concept of "sentinel lymph nodes" in the nodal basins draining cutaneous melanomas. They hypothesized that melanoma involvement of a nodal basin develops in an orderly fashion with metastasis to the sentinel lymph node as the first step in that process. With the intradermal injection of a blue dye, these investigators were able to identify sentinel lymph nodes 90% of the time. If the sentinel node was negative for melanoma, the remaining lymph nodes were also free of involvement in at least 96% of cases. These results have been confirmed by multiple other groups.[44,45]

Two tracers are typically used for identifying the sentinel lymph nodes: a radiolabeled colloid solution, and a blue dye – either methylene blue or 1% isosulfan blue (Lymphazurin). Lymphazurin carries a risk of allergic reaction in 0.5% to 2.0% of patients, which can be life-threatening.[45] Methylene blue dye has an extremely low risk of allergic reaction, although this should be diluted as it can cause skin necrosis if not completely resected. One to 4 hours before surgery, a radiolabeled colloid solution is injected intradermally around the primary tumor site or excision site, taking care to avoid injecting directly into any residual tumor. Lymphoscintigraphy imaging is then performed, which is critical in that it can identify sentinel nodes outside the traditional nodal basin. The blue dye is injected intradermally in the operating room a few minutes before the procedure. Using a handheld gamma detector probe, the surgeon is able to identify the sentinel lymph node location through the skin, thereby limiting the incision necessary to find the node. Blue-stained lymphatics and lymph nodes can be directly visualized (Fig. 107-3). The combined use of the blue dye plus the radiolabeled colloid enables the detection of the sentinel node in 97.3% to 98.6%.[46] The technique of SLNB is most often performed in conjunction with the wide excision of the primary tumor. It can routinely be performed as an outpatient procedure.

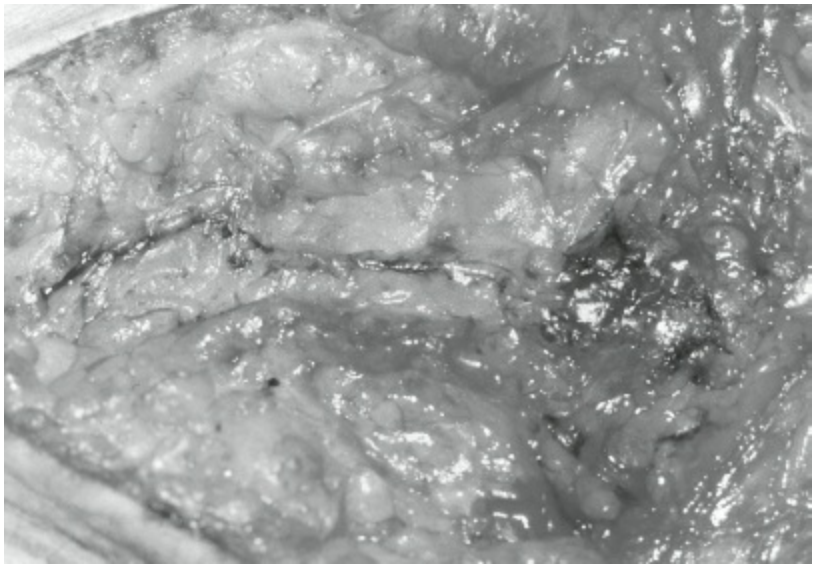

Figure 107-3. Blue dye tracking up a lymphatic vessel to a blue-stained lymph node.

Once the sentinel lymph node is removed, it is processed by the pathologist by step

sectioning the entire node into multiple sections for routine hematoxylin and eosin staining. This is done to examine for micrometastases that could be missed by bivalving the node and performing an examination of only one section. If serial sectioning and staining are negative for metastasis, then immunohistochemical staining for melanoma markers such as S-100, Melan-A, and HMB-45 is performed.[47] These stains can identify microscopic clusters of tumor cells that are hard or impossible to identify by hematoxylin and eosin staining. The thoroughness of assessing the sentinel lymph nodes for metastatic disease has resulted in much more accurate staging of patients. Micrometastases to lymph nodes have been incorporated in the current staging system as described earlier.

If the sentinel lymph node is positive for melanoma, then complete lymph node dissection (CLND) (Fig. 107-4) is indicated on the basis of potential survival and clinical benefit. The final results of the Multicenter Selective Lymphadenectomy Trial I (MSLT-I), which randomized patients to wide local excision (WLE) alone or WLE in combination with SLNB and CLND for a positive SLN, demonstrated that disease-free survival rates were significantly improved in the SLN group, compared with the observation group, for both patients with intermediate-thickness melanoma (71.3 ± 1.8% vs. 64.7 ± 2.3%; HR = 0.76, $P = 0.01$) and thick melanoma (50.7 ± 4.0% vs. 40.5 ± 4.7%; HR = 0.70, $P = 0.03$).[48] Although MSLT-I showed no benefit on overall survival, subset analysis showed that node positive patients discovered on SLN biopsy had a 10-year melanoma-specific survival of 62.1 ± 4.8% compared with 41.5 ± 5.6% for patients who recurred during observation. Even after factoring for false-negative sentinel nodes, this remained significant (HR = 0.67; 95% CI, 0.46 to 0.97; $P = 0.04$). Although this subset analysis has been questioned as being valid,[49,50] latent-subgroup analysis showed a clear, significant benefit of sentinel node biopsy.[48]

An unresolved question is whether every patient with a positive sentinel lymph node requires CLND. Several attempts to retrospectively identify clinical or histologic factors that may predict the absence or presence of disease within the nonsentinel nodes have not identified any absolute way to determine who requires additional surgery, although a combination of the Breslow depth and burden of disease within the sentinel lymph node seems promising.[51–54] In addition, retrospective studies of SLN-positive patients who did not undergo CLND appear to have similar outcomes to those who did.[55–57] The Multicenter Selective Lymphadenectomy Trial-II (MSLT-2), which randomized patients with a positive sentinel lymph node to CLND or serial ultrasonography of the regional basin, has completed accrual and will provide more information regarding the benefit of CLND for sentinel lymph node–positive patients. Until that time, CLND for a positive sentinel lymph node remains the standard of care in the treatment of melanoma.

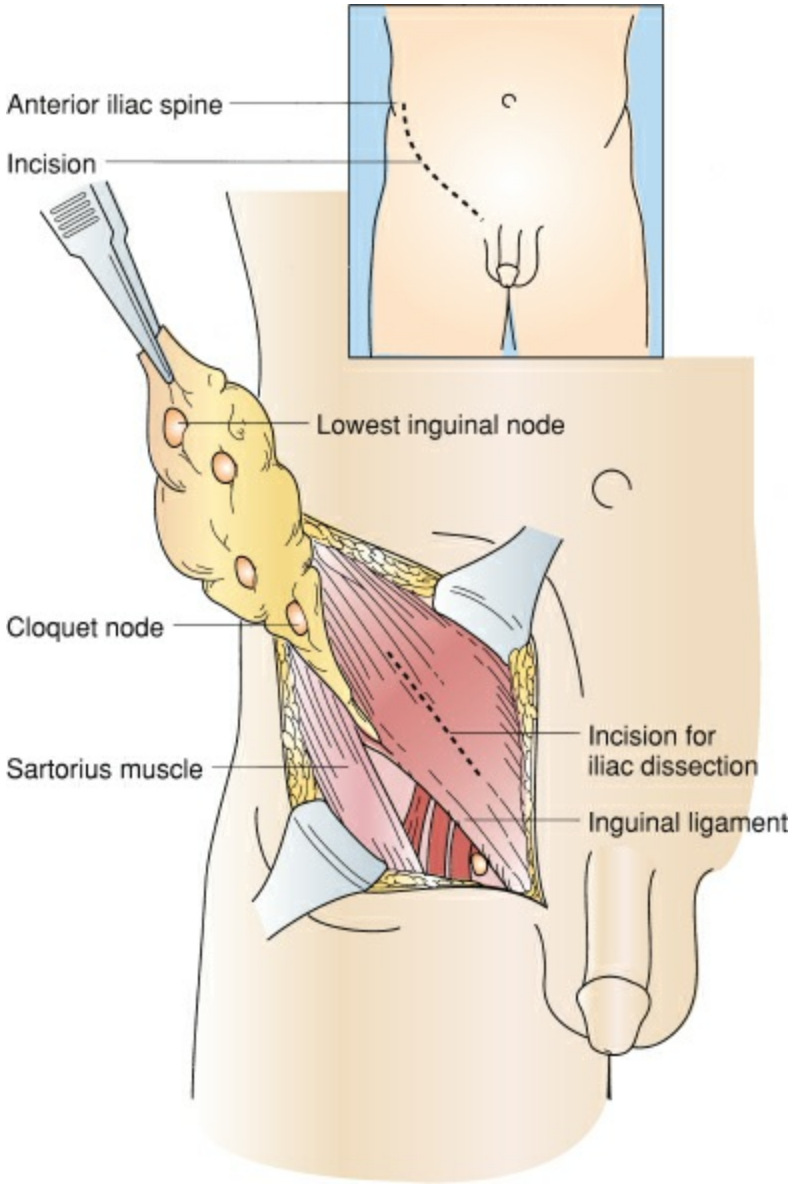

Figure 107-4. Technique of groin dissection.

For patients with primary melanoma equal to or greater than 1-mm thickness with clinically negative nodes, SLN biopsy is recommended.[42] For patients with thin melanoma, SLN should not be performed routinely but can be considered for patients with melanoma Brelsow depth of 0.76 to 0.99, particularly if they have other risk factors for regional micrometastases, including a mitotic rate of 1 mitosis/mm^2 or greater, extensive dermal regression >1 mm, ulceration, angiolymphatic invasion, younger age, or a broadly transected or positive deep margin on shave biopsy.[20,58,59] Reasons not to perform SLNB include significant medical comorbidities or the patient does not desire SLNB after an informed discussion.

Radiation therapy has also been utilized as an adjuvant to the resection of high-risk nodal metastases (extranodal extension, nodes greater than 3 to 4 cm in size, or multiple nodes). Several retrospective studies had suggested improved regional control rates when radiation was combined with surgery, particularly for cervical metastases. A large, prospective randomized trial from the Tasman Radiation Oncology Group randomized patients at high-risk of nodal relapse to adjuvant radiation versus observation. With a median follow-up of 40 months, the risk of relapse in the lymph-node field was reduced

with radiation (HR = 0.56, 95% CI: 0.32 to 0.98; $P = 0.041$) but there was no significant difference in either relapse-free or overall survival.[60] Adjuvant radiation after lymph node dissection will increase the overall morbidity, but this depends on the basin being irradiated, with ilioinguinal Radiation therapy (RT) being more problematic than cervical or axillary RT.[61,62] The decision to consider adjuvant radiation after completion node dissection should be individualized on the basis of the predicted risk of regional recurrence, expected survival, and associated toxicities.

Adjuvant Therapy

Although the prognosis for patients with early-stage cutaneous melanoma is quite good, fewer than 50% of patients with thick primaries (i.e., >4 mm) or regional node involvement are cured by surgery alone. The development of effective adjuvant therapy capable of increasing postsurgical survival in high-risk groups of patients has been a long-standing goal of clinicians. Unfortunately, numerous randomized trials evaluating systemic chemotherapeutic agents (most notably dacarbazine), nonspecific immunotherapy (such as Bacille Calmette–Guérin), and tumor-specific vaccines in the adjuvant setting have failed to demonstrate any impact on survival.[63–67]

Interferon-α2b (IFN-α2b) has a variety of modulatory effects on the immune system that could enhance antitumor reactivity. In 1996, Kirkwood et al.[68] reported the results of the Eastern Cooperative Oncology Group E1684 trial, which studied the effectiveness of high-dose IFN-α2b to improve disease-free and overall survival rates of patients with stage IIb (>4 mm) or III disease after surgery. High-dose IFN-a2b includes a 1-month induction phase (IV 20 MU/m^2 M-F) followed by 11 months of maintenance (SC 10 MU/m^2 3 days/week). In this multi-institutional prospective randomized trial, 287 high-risk patients with deep primary (>4-mm) tumors or positive nodes were randomly assigned after surgery to either postoperative adjuvant treatment with IFN-α2b or observation. IFN-α2b therapy significantly increased median overall survival by 1 year and produced a 24% improvement in the 5-year overall survival rate (46% for IFN-α2b patients vs. 37% for observation patients). On the basis of these results, the Food and Drug Administration (FDA) approved the use of adjuvant IFN-α2b after surgical resection of stage IIb or III melanoma. Two large, prospective randomized trials followed. E1690 compared high-dose interferon with both observation and low-dose interferon. The effect of high-dose interferon on 5-year relapse-free survival was significant (44% vs. 35%, P = 0.03) but neither high-dose nor low-dose interferon had any significant impact on overall survival.[69] Elective node dissection was not mandated in E1690 (nor E1684), and many patients who had regional recurrences on observation subsequently received IFN-α salvage therapy, which may have impacted the overall survival analysis. The third trial, E1694, compared high-dose IFN to the GMK vaccine; the ganglioside GM2 coupled to kehole limpet hemocyanin and combined with the QS-21 adjuvant. The trial was stopped early when an advantage was seen for interferon in both relapse-free (HR = 1.47; P = 0.001) and overall (HR = 1.52; P = 0.009) survival.

Pegylated IFN-α2b (peg-IFN), where the IFN molecule is bound to a polyethylene glycol moiety, allows for sustained absorption and a longer half-life. This regimen has an induction phase of peg-IFN SC 6 μg/kg a week for 8 weeks followed by a maintenance dose of SC 3 μg/kg a week for up to 5 years. In the European Organization for Research and Treatment of Cancer (EORTC) trial 18991 of peg-IFN versus observation in patients with resected stage III melanoma, peg-IFN was associated with an improved RFS (HR = 0.87; 95% CI, 0.76 to 1.00; P = 0.05), with no difference in overall survival.[70] In 2011, the FDA approved peg-IFN as an alternative to high-dose IFN in the adjuvant therapy of melanoma.

Biochemotherapy (BCT) combines chemotherapy and immunotherapy and has been examined in stage IV melanoma for many years.[71,72] It was studied as a potential adjuvant therapy in the Southwest Oncology Group (SWOG) trial S008, which compared a 9-week BCT regimen composed of cisplatin, vinblastine, dacarbazine, interleukin-2 (IL-2), and IFN-α to high-dose interferon.[73] While there was a significant improvement in RFS compared with HDI (4.0 years vs. 1.9 years; $P = 0.029$), there was a higher rate of grade III/IV toxicity and no difference in overall survival (56% 5-year survival in both groups). The use of BCT may be considered for adjuvant therapy in stage IIIA–IIIC melanoma.

Treatment of In-Transit Disease

In-transit disease and satellitosis develop in 5% to 8% of patients with melanomas thicker than 1.5 mm.[74] These are classified as stage III disease but portend not only a poor prognosis but can be a challenge to treat. Treatment involves either local excision or ablation, or regional chemotherapy. Surgical excision is the optimal management when the number of lesions is small and complete excision is possible. Prior to proceeding with surgery, a complete staging workup for metastatic disease is recommended, as these patients often harbor distant disease. When surgery is not feasible, a number of intralesional therapies have been utilized: Bacille Calmette–Guérin, IL-2, granulocyte-macrophage colony stimulating factor (GM-CSF), and rose bengal. A new agent, talimogene laherparepvec (T-VEC), is an oncolytic immunotherapy derived from herpes simplex virus type-1. Injected intralesionally, T-VEC is designed to replicate in tumors and release GM-CSF to enhance systemic antitumor immune responses. In a randomized phase III trial, T-VEC demonstrated an improved durable response rate (16% vs. 2%; $P < 0.0001$) and a trend toward an improved overall survival.[75]

When the in-transit disease is unresectable but limited to an extremity, regional administration of high-dose chemotherapy can be effective in controlling disease. Isolated limb perfusion (ILP) uses an extracorporeal membrane oxygenator (as is used with cardiac surgery) to deliver chemotherapy doses 15 to 25 times higher than can be obtained with systemic delivery. The surgeon isolates the vessels and uses a tourniquet to prevent systemic uptake of the agent(s). Using the bypass machine, the limb is perfused with hyperthermic (38°C to 40°C) chemotherapy solutions, most commonly melphalan. After 60 to 90 minutes of treatment, the drug is flushed from the circulation and systemic circulation is restored. Response rates between 80% and 90% are reported, with complete response rates between 40% and 65%.[74,76–78] In some cases, these can be quite durable. Toxicities can range from mild erythema and edema to epidermolysis, functional impairment, and in extremely rare cases a need for amputation.

Isolated limb infusion (ILI) is a minimally invasive alternative to ILP. Rather than surgical isolation of the vessels, percutaneous catheters are placed radiologically in the artery and vein and connected to an extracorporeal circuit incorporating a heating coil. A tourniquet is placed on the extremity, but because some systemic uptake is anticipated, lower doses of chemotherapeutic agents are used. Some studies have reported response rates equal to ILP, although others report slightly lower response rates.[79–82] However, the role of both ILP and ILI is evolving as new systemic therapeutic options become available.

Treatment of Disseminated Melanoma

Evaluation for Metastatic Disease and Clinical Course

The follow-up evaluation for patients with AJCC stage I, II, or III melanoma who are rendered NED by surgery should include regular histories and physical examinations. The use of extensive and frequent radiographic studies and blood work in asymptomatic, clinically disease-free patients is rarely productive.[24] For AJCC stage IA to IIA, the NCCN recommends that patients should undergo a history and physical examination with emphasis on skin and nodal examinations every 6 to 12 months as clinically indicated. For AJCC stage IIB to IV NED, patients should undergo a history and physical examination every 3 to 6 months for 2 years, then every 3 to 12 months for 3 years, and then annually as clinically indicated. Imaging studies (CXR, CT, or PET/CT) can be considered every 3 to 12 months for the first 3 to 5 years on the basis of the conditional probability of recurrence at any point in time after the initial therapy.[24]

Melanoma can disseminate to any organ. The most common sites of recurrence are skin, subcutaneous tissues, and distant lymph nodes, followed by visceral sites. Common visceral sites of metastasis, in order of decreasing occurrence, are the lung, liver, brain, bone, and gastrointestinal tract. Most patients who die with disseminated disease have multiple organ involvement. Frequently, the cause of death is respiratory failure or brain complications. Cure with any treatment is rare. However, over the past several years, there have been tremendous advances in the systemic therapy of melanoma. Whereas only several years ago there were only two FDA-approved therapies for the treatment of metastatic melanoma (dacarbazine and high-dose IL-2), there are now new targeted therapies and immune checkpoint regulators that have been approved for the treatment of advanced melanoma, with several new therapies and combinations in clinical trial. How to proceed in the management of advanced melanoma should be based on several factors, including the patient's medical condition and comorbidities, the potential for palliation, and the impact of treatment on quality of life.

Chemotherapy

Melanoma is responsive to few chemotherapeutic drugs. The most widely used single chemotherapeutic agents have been dacarbazine and its oral analogue temozolomide, with objective response rates of 5% to 12%.[83] Most responses are transient; only 1% to 2% of patients achieve a durable long-term response.[84] Attempts to improve upon these results using combination chemotherapy, or BCT (where chemotherapy is combined with IFN-α2b ± IL-2), failed to significantly improve upon single-agent therapy alone.[71,83–85]

High-Dose Interleukin-2

IL-2 is a cytokine secreted by antigen-activated helper T cells, initially discovered to be a T-cell growth factor but subsequently found to have many other immunologic effects, including an important role in the enhancement of immune responses. High-dose IL-2 (600,000 IU/kg every 8 hours for up to 14 doses) is associated with an objective response rate of 15% to 20%, with a small percentage of patients (around 5%) experiencing long-term, durable complete responses (Fig. 107-5).[86–88] These results may be improved upon with the addition of vaccines.[89] However, IL-2 treatment requires inpatient intensive care, as toxicity is severe and can include hypotension, pulmonary edema, decreased renal function, respiratory insufficiency, and neurotoxicity.

BRAF and MEK Inhibitors

The MAP kinase pathway is a key pathway in melanoma pathogenesis, with nearly half of melanomas having constitutive activation due to mutations in the *BRAF* gene.[90] Activation of mitogen-activated protein kinase (MAPK) signaling leads to unregulated cell proliferation. Vemurafenib and dabrafenib are targeted therapies that block the constitutively active mutant BRAF. Both have been associated with significant improvements in both progression-free and overall survival compared with dacarbazine.[91,92] Common adverse effects include arthralgia, rash, fatigue, alopecia, and the development of cutaneous keratoacanthomas and SCCs. Patients treated with BRAF inhibition have dramatic responses, but unfortunately the survival benefit is limited because of the eventual development of resistance in most patients.



Figure 107-5. Basal cell carcinoma near the eye.

Trametinib is a small molecule inhibitor of MEK1/2, a downstream regulator of BRAF. As with BRAF inhibition, MEK inhibition with trametinib was associated with an improvement in both progression-free and overall survival compared with chemotherapy.[93] While MEK inhibition had no efficacy in patients who failed BRAF therapy, the combination of BRAF and MEK inhibition was associated with an improvement in objective response, median duration of response, and progression-free survival, compared with BRAF inhibition alone.[94,95] In addition to delaying the development of resistance to MAPK pathway inhibition, combination therapy is also associated with fewer secondary cutaneous malignancies. The FDA granted accelerated approval to the combination of dabrafenib and trametinib for the treatment of patients with advanced melanoma with $BRAF^{V600E/K}$ mutations.

Immune Checkpoint Regulators

For many years, the plethora of immunotherapy research has centered on the generation of an antitumor immune response, primarily through the use of vaccines and assorted adjuvants. However, immune checkpoint regulation, which augments existing, yet clinically insignificant, immune recognition, has rapidly emerged as an alternative and effective form of immunotherapy in melanoma.

Ipilimumab is a human IgG1 mAb that binds to the cytotoxic T-lymphocyte associated antigen-4 (CTLA-4) receptor. This receptor is found on regulatory T-cells and cytotoxic T-cells after they have been activated, with a primary role of inhibiting T-cell responses. Blocking the binding between CTLA-4 and B7 suppresses this inhibitory function (essentially cutting the brakes) and promotes continued T-cell activation. In a phase III trial of ipilimumab alone, ipilimumab with a gp100 vaccine, and the vaccine alone, there was a significant improvement in median overall survival with ipilimumab (10.1 months vs. 6.4 months, HR = 0.66, $P = 0.0026$).[96] In a meta-analysis of pooled data from several clinical trials, the 3-year overall survival rate was 22%, with many of them being durable as the rate of additional deaths between 3 and 10 years was relatively low.[97] Ipilimumab is associated with immune-related toxicities, specifically enterocolitis, hepatitis, endocrinopathies, and dermatitis. While these can be severe, they are reversible if recognized and treated early. Another anti-CTLA-4 antibody, tremelimumab, which has a longer half-life than ipilimumab and thus has a longer interval between doses, is presently being studied.[98]

Activated CD^{4+} and CD^{8+} T cells also express the programmed death 1 (PD-1) receptor, which, once bound to its ligand PD-L1, triggers a decrease in T-cell proliferation, IL-2 release, and T-cell survival. Malignant cells often express PD-L1 that binds to the receptors and blocks T-cell killing. Pembrolizumab and nivolumab are monoclonal antibodies against PD-1 that prevent binding to PD-L1. Both have shown response rates in the 25% to 30% range, primarily in patients who have already progressed on or after treatment with ipilimumab.[99,100] They were both approved by the FDA for second-line treatment, after treatment with ipilimumab. As with anti-CTLA-4, anti-PD-1 can be associated with immune-mediated toxicities, including colitis, endocrinopathies, and pneumonitis. In a phase III randomized trial comparing nivolumab with dacarbazine,[101] in previously untreated patients, nivolumab was associated with a significant improvement in overall survival (72.9%, 95% CI: 65.5 to 78.9 vs. 42.1%, 95% CI: 33.0 to 50.9, HR = 0.42, $P < 0.001$) compared with chemotherapy, leading to a shift toward anti-PD-1 therapy as first-line therapy in advanced melanoma. In addition, early studies of combination therapy with anti-PD-1 and anti-CTLA-4 mAb have demonstrated improved outcomes with increased but manageable toxicity.[102–104]

Surgery

For most cancers, surgery is rarely considered as a curative option in stage IV disease. Historically, melanoma has been an exception to this, with documented long-term survival among patients who undergo resection of metastatic lesions. Several retrospective studies, as well as prospective studies, have suggested that metastasectomy may result in prolonged disease-free survival in select patients.[105–109] The rationale for surgical extirpation of metastatic disease was in part driven by the lack of effective systemic therapies in melanoma. The role of surgery for stage IV disease is rapidly evolving as new, highly effective therapies have emerged. Despite the excitement surrounding these new agents, there may be potential advantages to metastasectomy in select patients, including cost, toxicity, time to palliation, and disease-free survival.[108] Careful patient selection is key, as is a true multidisciplinary approach. Patients being considered for metastasectomy should undergo a thorough search for additional sites of disease, including a detailed history and physical, serum LDH, CT or PET scan, and MRI of the brain. Biopsies should be obtained to document metastases as well as evaluate BRAF, and in some cases c-kit mutation status, as well as PD-L1 expression. Factors to consider when formulating a treatment plan include the age and health of the patient, the number and locations of the metastases as well as the ability to achieve negative margins, the morbidity of the operation, the disease-free interval between the original diagnosis and the development of distant disease, the need for palliation, either now or in the near future, and the available systemic options. For select patients, surgery may be considered as a first-line therapy, potentially delaying the need for systemic therapies, or be used in conjunction with systemic therapies, either after neoadjuvant therapy or for resection of lesions that fail to respond. The successful incorporation of surgery in the management of stage IV disease is dependent upon true multidisciplinary collaboration between surgical, medical, and radiation oncology.

NONMELANOMA SKIN TUMORS

7 BCC and SCC account for 96% of new NMSCs.[1,2] These tumors are derived from epithelial origin. The ratio of BCC to SCC is approximately 4:1. The annual incidence of BCC and SCC in the United States alone exceeds 1 million cases. The public health burden on the US population from NMSC, for which the incidence is rapidly rising, is highly significant. Patients with NMSC have an excellent prognosis, with 90% to 99% curable with appropriate treatment and less than 1% resulting in death. SCCs account for 75% of NMSC deaths, which are estimated at 2,000 to 2,500 per year.[110]

Etiology

Both BCC and SCC are most commonly induced by significant exposure to UV light from the sun or tanning booths.[3] These cancers are the predominant neoplasms of the head, neck, trunk, lower legs, and extensor arms and hands where sun exposure is common. Skin cancer is a significant occupational hazard for people who work outdoors. The phenotype at increased risk is one with fair skin who sunburns and freckles easily, has blue eyes, and has red or blonde hair. Melanin pigment in the skin appears to be the protective factor.

A number of genetic syndromes are associated with an increased risk of developing NMSC, including Gorlin syndrome, xeroderma pigmentosa, and albinism. Gorlin syndrome is an autosomal dominant disorder associated with multiple BCCs, palmoplantar pits, jaw cysts, frontal bossing, and hypertelorism. Albinism is a disorder characterized by a partial or complete deficiency in melanin production and, thus, loss of protective pigment. Another factor associated with NMSC, primarily SCC, is chronic exposure to chemicals such as arsenic and hydrocarbons (found in coal tars, soot, and asphalt). Cigarette smoking has been associated with SCC of the lip and mouth. Human papillomavirus has been associated with cutaneous SCC in the genital and acral/periungual areas. Radiation has been associated with both SCC and BCC.

Basal Cell Carcinoma

BCC is the most common form of skin cancer. These epithelial-derived tumors can be divided into various subtypes according to clinical appearance, histologic pattern, and biologic behavior. Although BCCs rarely metastasize, they are characterized by slow but relentless and destructive local invasion that results in high morbidity without treatment. The subclinical local invasion may be deep, extensive, and asymmetric, with fingerlike extensions several centimeters beyond the clinical borders.

The most common subtype of BCC is the well-circumscribed nodular variety. These tumors often present as pearly papules or nodules with telangiectases. They may be pruritic and bleed occasionally. With time, the center ulcerates to create peripheral "rolled" borders; such ulcerating BCCs are called *rodent ulcers* (Fig. 107-5). Occasionally, the lesions are deeply pigmented and nodular and can be confused with melanoma. This variant has been called *pigmented* BCC (Fig. 107-1H). The histologic features of these tumors demonstrate isolated areas of basaloid tumor islands arising from the epidermis with peripheral palisading of nuclei and stromal retraction. In some cases, the BCC has histologic features of squamous metaplasia with keratinization. These tumors have basosquamous differentiation and can become more aggressive and develop regional lymphatic spread.

The most locally aggressive type of BCC is characterized by a diagnostic histopathologic aggressive growth pattern, known as morpheaform, sclerosing, or fibrosing BCC (Fig. 107-6). Clinically, these tumors may be more subclinical, are flat, and appear to be scarlike. They have a significant incidence of recurrence because of the isolated, fingerlike fronds of basal cell tumor cells that may deeply invade the surrounding structures well beyond the clinical margins of the lesion. These small, fingerlike islands are often missed with standard histologic margin control.

Clinically, superficial BCCs are scaly pink to red lesions. Frequently, they are confused with psoriasis or other eczematous, scaly dermatoses. Although these tumors are usually relatively superficial, extensive superficial subclinical involvement is common. Numerous risk factors are associated with possible extensive subclinical invasion and increased rates of local recurrence for BCC after standard treatment, including surgical excision (Table 107-6).

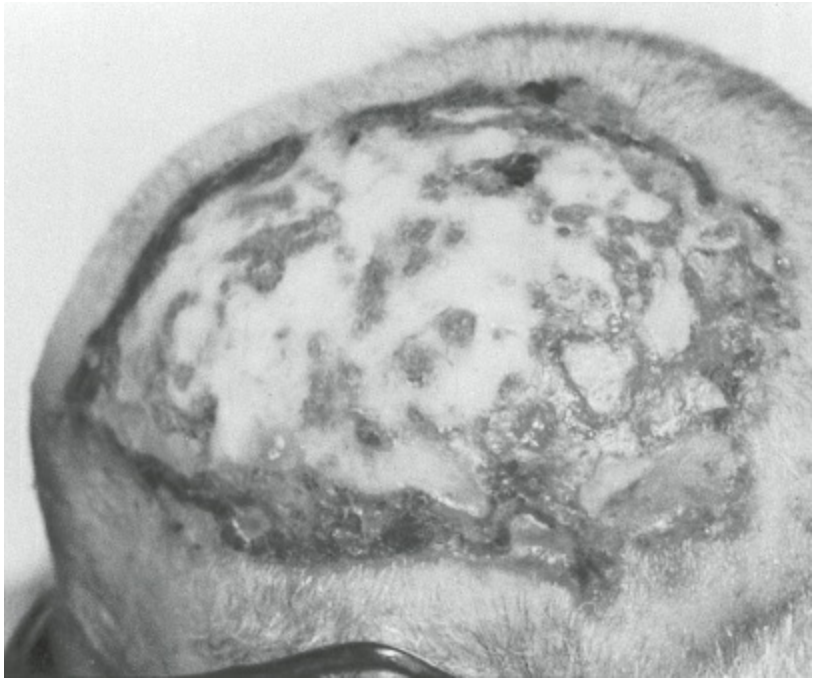

Figure 107-6. Morpheaform basal cell carcinoma of the scalp.

Squamous Cell Carcinoma

SCC is the second most common form of skin cancer and is derived from the epithelial keratinocyte. SCC can deeply invade surrounding structures and metastasizes most commonly to regional lymph nodes. In immunosuppressed transplant individuals, SCC is the most common skin cancer, occurring 65 to 250 times more frequently than in the general population. SCC in these individuals tends to have more aggressive behavior.

Several precursor lesions to invasive SCC exist, most commonly actinic keratoses and Bowen disease (in situ SCC). Erythroplasia of Queyrat, another precursor lesion, represents SCC in situ on the glans penis. Histologically, SCC shows malignant degeneration of epithelial cells with differentiation toward keratin formation. SCC often appears clinically as a nonhealing sore with ulceration and inflammatory pink borders or an erythematous papulonodule with overlying keratotic crust or ulceration (Figs. 107-7 and 107-8). These tumors most often arise in chronically actinically damaged skin or within an actinic keratosis, but they may also develop in burn scars or chronic inflammatory wounds. These lesions may infiltrate widely. Metastasis to regional lymph nodes accounts for approximately 80% to 90% of metastatic cases. Distant sites, such as the lung, liver, brain, bone, and skin, account for the other 10% to 20%. Metastatic SCC portends a poor prognosis with a 10-year survival rate for regional lymph node disease of less than 20% and for distant disease of 10%.

Table 107-6 Basal Cell Carcinoma: Higher-Risk Factors for Subclinical Invasion and Recurrence

■ Recurrent tumor
■ Anatomic location *High risk:* Central face, eyelid, eyebrow, periorbital, nose, lip, chin, mandible, temple, ear, in front or behind the ear, genitalia, hand and foot *Medium risk:* Cheeks, forehead, scalp, and neck *Low risk:* Trunk, extremity (excluding hand/foot)
■ Size Lesions ≥6 mm on high-risk area Lesions ≥10 mm on medium-risk area Lesions ≥20 mm on low-risk area
■ Histologic subtype pattern Aggressive growth (morpheaform, fibrosing, sclerosing, infiltrating) Micronodular
■ Ill-defined clinical borders
■ Perineural invasion
■ Development in sites of prior radiation
■ Immunosuppression

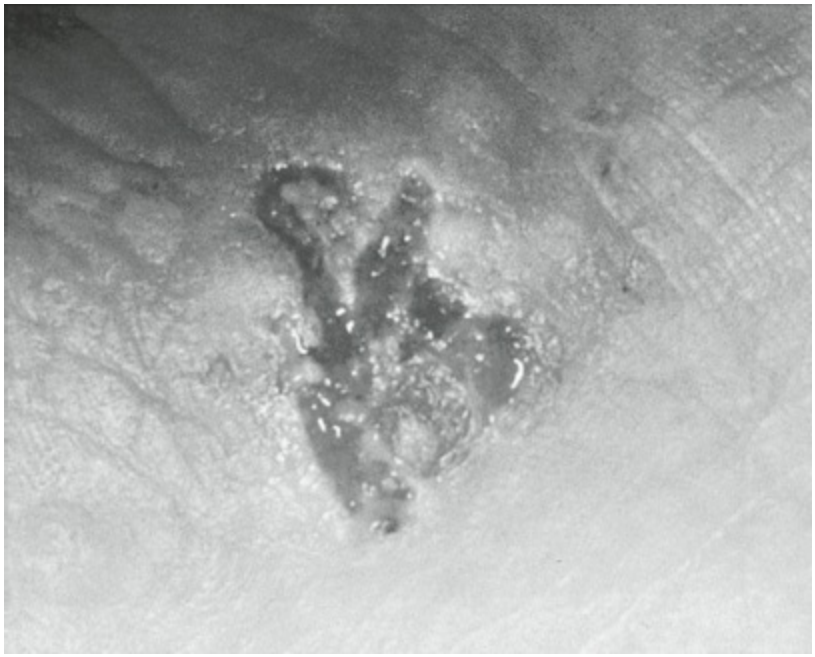

Figure 107-7. Squamous cell carcinoma of the hand secondary to exposure to arsenic in welding flux.



Figure 107-8. Ulcerative squamous cell carcinoma.

Table 107-7 Squamous Cell Carcinoma: Higher-Risk Factors for Subclinical Invasion and Recurrence

- Recurrent tumor
- Anatomic location
  High risk: Central face, eyelid, eyebrow, periorbital, nose, lip, chin, mandible, temple, ear, in front or behind the ear, genitalia, hand, and foot
  Medium risk: Cheeks, forehead, scalp, and neck
  Low risk: Trunk, extremity (excluding hand/foot)
- Size
  Lesions ≥6 mm on high-risk area
  Lesions ≥10 mm on medium-risk area
  Lesions ≥20 mm on low-risk area
- Histology
  Poorly differentiated
- Depth of invasion
  Clark level IV (lesion that involves the reticular dermis), V (lesion that invades into subcutaneous fat), or ≥4 mm
- Perineural invasion
- Rapid growth
- Etiology
  Scar, chronic ulcer or inflammatory process, sinus tract, sites of prior radiation therapy
- Immunosuppression

Accurate assessment of the higher-risk cutaneous SCCs is handicapped because of the lack of large prospective studies using multivariate analysis. Nine variables, however, have been identified as prognostic risk factors by retrospective analysis. Factors that may determine a higher risk for local recurrence, extensive subclinical invasion, and metastasis are noted in Table 107-7.

Surgical Treatment of the Common Nonmelanoma Skin Cancers

A skin biopsy for diagnosis is important before treatment of any skin cancer. Fortunately, most NMSCs are small, low-risk lesions that respond with 90% to 95% cure rates to standard treatment techniques, including curettage and electrodesiccation, cryosurgery, radiation therapy, and surgical resection. Many skin cancers can be removed with elliptical excisions. Margins for low-risk SCC range from 0.5 to 1.0 cm. Margins for low-risk BCC range from 0.3 to 0.5 cm. Mohs surgery should be considered for BCCs and SCCs that exhibit the higher-risk factors in Tables 107-6 and 107-7. If Mohs surgery is not available, excision with careful frozen section control (with permanent section confirmation) is indicated. The fundamental oncologic principle of tumor clearance first and reconstruction second should be followed.

Mohs Surgery

Mohs surgery was developed by Frederick E. Mohs, a general surgeon from the University of Wisconsin, in the 1940s. Initially, a chemical fixative paste was applied to the skin to fix the tissue in situ; hence, the now outdated term *Mohs chemosurgery*. The fresh tissue technique, which omitted the chemical paste, was developed and refined in the 1970s. Mohs micrographic surgery is most useful for the treatment of higher-risk NMSC (Tables 107-6 and 107-7). Mohs surgery is usually performed under local anesthesia in an outpatient Mohs surgical unit. After removal of all gross tumor, the surgeon excises a thin layer of tissue with 2- to 3-mm margins. The tissue is mapped, color-coded for orientation, and sent to the technician for frozen section processing. The specimen is flexible and flattened, with the beveled peripheral skin edge placed in the same horizontal plane with the deep margin. In this plane, both the deep and peripheral margins are examined in one horizontal cut by frozen section analysis with total (theoretically 100%) margin control. Good-quality frozen sections may be achieved only by a skilled and experienced Mohs histotechnician. The Mohs surgeon functions as both a surgeon and pathologist. After histologic interpretation of the frozen section specimens, the precise anatomic location of any residual tumor can be identified and reexcised until all margins are tumor free (Fig. 107-9). The Mohs surgeon's ability microscopically to track subclinical tumor extensions results in the highest cure rate with maximal preservation of normal tissue. Soft tissue reconstruction can then be performed on the same day, after completion of Mohs surgical excision of the tumor (Fig. 107-10). A multidisciplinary approach involving Mohs, plastic, head and neck, and oculoplastic surgeons and radiation oncologists may be needed for extensive tumors. Mastering the Mohs technique is based on a steep learning curve that requires extensive training for optimal competence. Numerous Accreditation Council for Graduate Medical Education (ACGME) postgraduate fellowship training programs are available.

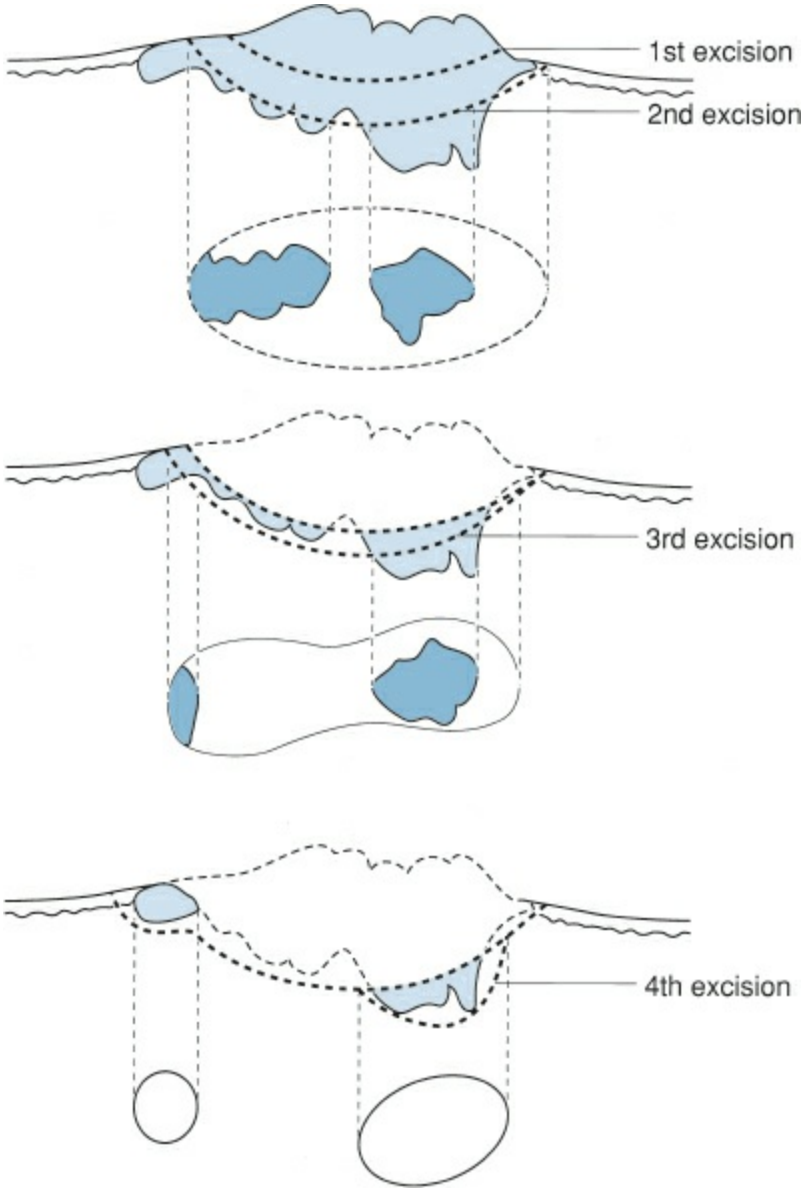

Figure 107-9. Mohs micrographic surgical technique.

Based on a review of all studies from all disciplines since 1950, the 5-year cure rate for treatment of previously untreated primary BCC by Mohs surgery is 99%, versus 90% to 93% for all non-Mohs modalities, including standard surgical excision.[83] For previously treated recurrent BCC, the 5-year cure rates are 94% for Mohs versus 60% to 84% for non-Mohs modalities.[84] In general, Mohs surgery should be considered for NMSCs that are associated with a higher risk of recurrence after standard treatment and for tumors for which conservation of normal tissue is important. Risk factors for recurrence after standard treatment have been mentioned previously. Tumors for which maximal conservation of tissue may be important include tumors in the high-risk locations and tumors in young patients.

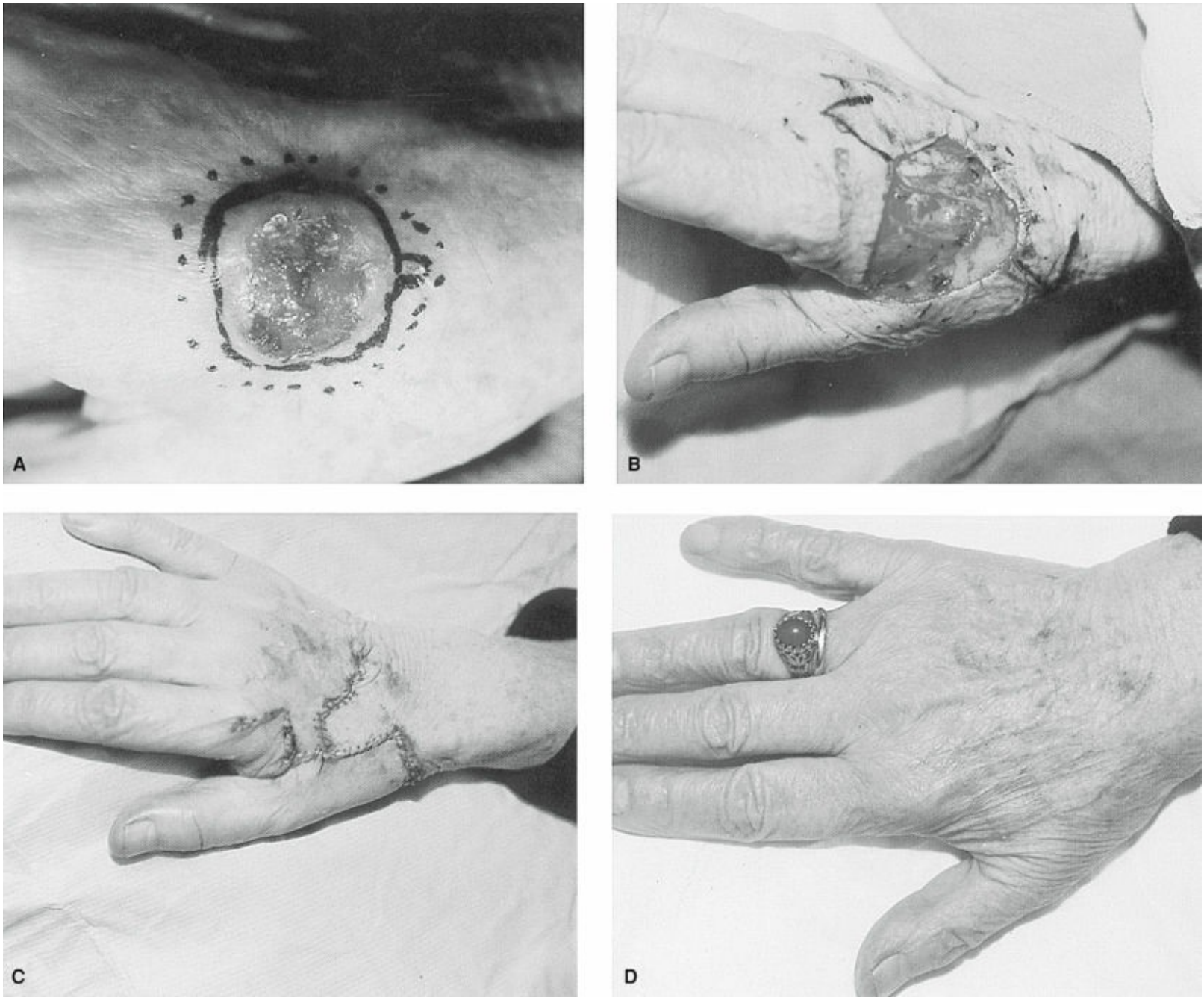

Figure 107-10. **A:** Patient with a 3- × 3-cm basal cell carcinoma on the right dorsal hand with mixed nodular and aggressive growth histologic pattern. **B:** Final Mohs surgery defect measuring 4.0 × 4.8 cm to the underlying tendon with preservation of tendon and nerve structures. Complete excision of the tumor required two Mohs stages (10 frozen sections). **C:** The defect was reconstructed immediately after achievement of clear margins under local anesthesia in the Mohs surgery unit using birhombic flap soft tissue reconstruction. **D:** Result 3 months after surgery.

Adjuvant and Primary Radiation Therapy

Radiation therapy may be useful for primary treatment of low-risk NMSCs. In experienced hands, primary radiation therapy may also be useful for higher-risk tumors with high cure rates. For cutaneous SCC with many high-risk factors and for those with extensive neurotropism, adjuvant prophylactic radiation therapy to the primary site and the primary draining lymph nodes may decrease the risks of local recurrence and regional nodal metastasis. Prophylactic adjuvant radiation therapy should also be considered for highly aggressive, deeply invasive BCCs that exhibit extensive neurotropism.

Locally Advanced and Metastatic BCC

The occurrence of locally advanced and metastatic BCC is uncommon. Uncontrolled Hedgehog (Hh) signaling is associated with the pathogenesis of both hereditary and sporadic BCC. Inactivating mutations on the tumor suppressor patched (PTCH) gene and activating mutations in the proto-oncogene smoothened (SMO) cause some BCC. These mutations result in the unregulated activation of the Hh pathway with an associated growth promotion and cancer development in tumor progenitor cells initially within the epidermis and hair follicle. Vismodegib represents the first hedgehog pathway inhibitor approved by the FDA for the treatment of metastatic and locally advanced BCC, tumors deemed not candidates for surgery or radiation therapy. Initial objective response rates approach 30% for metastatic BCC and 43% for locally advanced BCC. Partial response rates are 30% for metastatic BCC and 22% for locally advanced disease. No complete responses were noted for metastatic BCC, and 20% complete responses for locally advanced BCC. Unfortunately, tumors may recur during or after discontinuation of the drug with a median duration of response about 8 months in both metastatic and locally advanced BCC patients. Adverse events occur in more than 30% of patients, 25% serious, and include most often muscle spasms, taste disturbances, alopecia, weight loss, and fatigue. Data are still immature with future study and long-term results needed for definitive conclusions.

Other Tumors of Interest

Hundreds of cutaneous tumors exist, and their description is beyond the scope of this chapter. Tumors that may be encountered by the surgeon for further management include Merkel cell carcinoma (MCC), sweat gland carcinoma, and dermatofibromasarcoma protuberans (DFSP).

8 MCC, or primary cutaneous neuroendocrine carcinoma, is an aggressive skin cancer with a higher overall mortality than melanoma (approximately 33% vs. 15%, respectively).[111] The incidence of MCC is low compared to other cutaneous malignancies (approximately 1,500 annually in the United States), but the number of cases has at least tripled over the last two decades.[112] While UV radiation and immunosuppression are considered important pathogenetic factors, recent findings suggest a virus (Merkel cell polyomavirus) as a contributing factor in the pathogenesis of MCC.[113] MCC most commonly occurs in older, white individuals, with only 5% diagnosed before the age of 50 years. The majority of tumors (90%) are located on sun-exposed skin, equally distributed between the head and neck and extremities. The remaining 10% are located on the trunk and buttocks. Primary MCC typically presents as a new-onset, growing, red or purple, dome-shaped or subcutaneous nodule, frequently mistaken for a cyst, lipoma, or BCC (Fig. 107-11). The most common location of metastasis is the draining lymph node basin, followed by distant skin, lung, central nervous system, bone, and liver.[114] MCC is a dermal small blue cell tumor with positive immunohistochemical staining for cytokeratin-20 (CK-20) in a characteristic paranuclear dotlike pattern. Small cell lung cancer, another neuroendocrine carcinoma histologically indistinguishable from MCC and occasionally CK-20 positive, expresses thyroid transcription factor-1, which is consistently absent in MCC.[115] Newly established AJCC staging for MCC distinguishes stage I (primary tumor <2 cm without nodal disease), stage II (primary tumor ≥ 2 cm without nodal disease), stage III (microscopic or clinically apparent regional lymph node metastases), and stage IV disease (distant metastasis). Five-year survival rates for stages I, II, and III are 81%, 67%, and 52%, respectively. Stage IV disease carries a dismal 11% 2-year survival rate.[98] The majority (70%) of patients with MCC present with clinically localized disease (stage I or II), 25% have palpable lymphadenopathy (stage IIIB), and 5% present with distant metastases (stage IV).[114] Multidisciplinary management of MCC is encouraged by the NCCN.[116,117] Treatment consists of WLE with 1- to 2-cm margins. Postoperative radiation therapy to the primary tumor bed should be considered and is recommended for stage II disease.[117,118] SLNB with immunostaining using CK-20 is highly recommended for all primary MCC to stage the nodal basin and guide regional nodal therapy.[116,118–120] Regional lymph node metastases can be treated by regional therapeutic lymphadenectomy and/or radiation therapy. Adjuvant radiation therapy to the regional nodal basin should be considered if SLNB is not performed or is thought to be false negative. For nonsurgical candidates, primary treatment of MCC with radiation therapy may also be considered.[121] Chemotherapy has failed to demonstrate a survival benefit in an adjuvant setting in the treatment of localized or regional MCC and should be reserved for distant metastatic (stage IV) disease.[122]

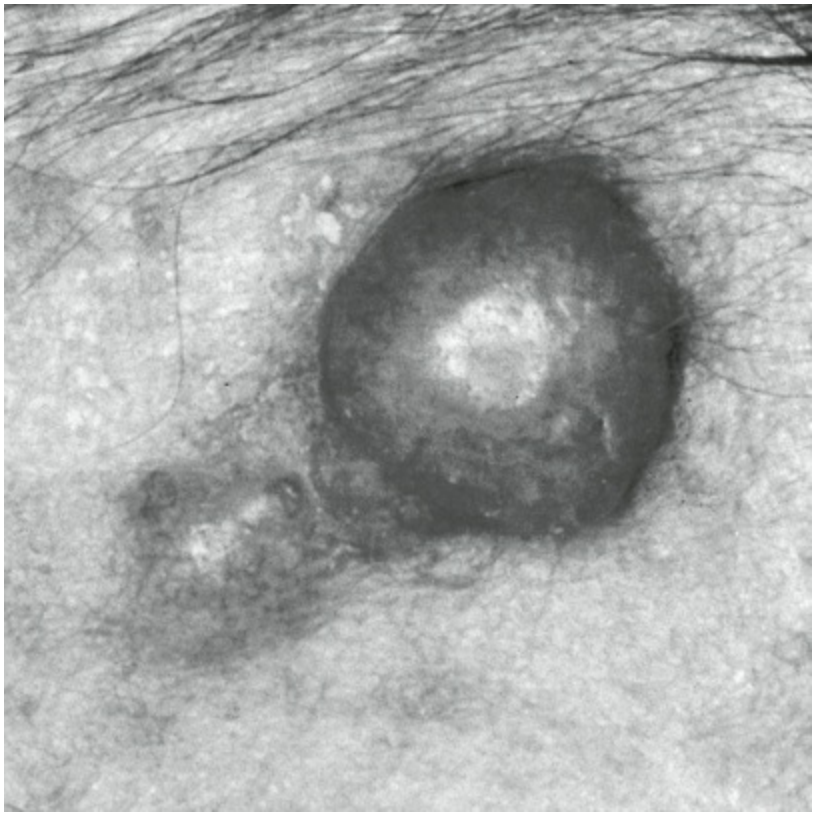

Figure 107-11. Merkel cell carcinoma.

Sweat gland carcinomas represent a broad scope of neoplasms with variable risk for local, regional, or distant metastasis, most commonly of eccrine or apocrine origin.[123] These are rare tumors (0.005% of skin malignancies) that have multiple histologic subtypes, giving rise to a diverse and confusing nomenclature. The aggressive types of sweat gland carcinomas have a propensity for both local recurrence and regional or systemic metastasis. Clinically, these tumors appear as indurated plaques, papules, or nodules commonly on the head and neck or extremities and are red, blue, pink, or skin colored. Histologic subtypes that are associated with a risk of regional lymph node or systemic metastasis include aggressive digital papillary adenocarcinoma, hidradenocarcinoma, and eccrine carcinoma. Recommended treatments have included wide excision of the primary tumor with consideration of SLNB for high-risk lesions commonly based on size, mitotic rate, histologic grade of atypia, or immunosuppression.[123] Postoperative radiation therapy may also be considered as adjuvant treatment.

9 DFSP is a rare soft tissue sarcoma (1% of all soft tissue sarcomas) with a propensity for local recurrence rather than systemic metastasis. It is a spindle cell tumor that characteristically demonstrates immunoreactivity to CD34. Adults in their third to fifth decades are most commonly affected, but DFSP may occur in children or the elderly. These tumors appear as firm flesh-colored to dull red plaques that may be mistaken for keloids or hypertrophic scars. Although DFSPs may appear discrete, they characteristically demonstrate extensive subclinical involvement, which makes this sarcoma difficult to manage. Histologically, these sarcomas are identified by their fingerlike projections of spindle cells that likely account for the increased risk of tumor

recurrence. Standard histologic processing makes it difficult to track these fingerlike projections. Treatment commonly consists of WLE with more comprehensive margin assessment or Mohs surgery, depending on patient and tumor factors. A multidisciplinary approach utilizing the expertise from several fields (surgical subspecialties, pathology, Mohs surgery) may be needed to achieve the goals of complete tumor extirpation, low local recurrence rates, and reconstructive repair.[124,125] Reconstruction involving extensive undermining should be avoided and tissue rearrangement should be delayed until negative histologic margins are confirmed to prevent possible tumor seeding from persistent disease. Radiation therapy is indicated when negative margins cannot be obtained.[123] Imatinib mesylate has shown promising results in the treatment of unresectable or metastatic DFSP.[126,127]

References

1. Siegel RL, Miller KD, Jemal A. Cancer statistics, 2015. *CA Cancer J Clin* 2015;65:5–29.
2. Guy GP, Machlin SR, Ekwueme DU, et al. Prevalence and costs of skin cancer treatment in the U.S., 2002–2006 and 2007–2007. *Am J Prev Med* 2014;104:e69–e74.
3. Diepgen TL, Mahler V. The epidemiology of skin cancer. *Br J Dermatol* 2002;146:1–6.
4. Raimondi S, Sera F, Gandini S, et al. MC1R variants, melanoma and red hair color phenotype: a meta-analysis. *Int J Cancer* 2008;122:2753–2760.
5. Lynch HT, Shaw TG, Lynch JF. Inherited predisposition to cancer: a historical overview. *Am J Med Genet C Semin Med Genet* 2004;129:5–22.
6. Lynch HT, Frichot BC, Lynch JF. Familial atypical multiple mole-melanoma syndrome. *J Med Genet* 1978;15:352–356.
7. Greene MH, Clark WH, Tucker MA, et al. High risk of malignant melanoma in melanoma-prone families with dysplastic nevi. *Ann Intern Med* 1985;102(4):458–465.
8. Marghoob AA, Borrego JP, Halpern AC. Congenital melanocytic nevi: treatment modalities and management options. *Semin Cutan Med Surg* 2003;22:21–32.
9. Di Rocco F, Sabatino G, Koutzoglou M, et al. Neurocutaneous melanosis. *Childs Nerv Syst* 2004;20:23–28.
10. Bittencourt FV, Marghoob AA, Kopf AW, et al. Large congenital melanocytic nevi and the risk for development of malignant melanoma and neurocutaneous melanocytosis. *Pediatrics* 2000;106:736–741.
11. Abbasi NR, Shaw HM, Rigel DS, et al. Early diagnosis of cutaneous melanoma: revisiting the ABCD criteria. *JAMA* 2004;292:2771–2776.
12. Buettner PG, Leiter U, Eigentler TK, et al. Development of prognostic factors and survival in cutaneous melanoma over 25 years: an analysis of the Central Malignant Melanoma Registry of the German Dermatological Society. *Cancer* 2005;103:616–624.
13. Arora A, Lowe L, Su G, et al. Wide excision without radiation for desmoplastic melanoma. *Cancer* 2005;104:1462–1467.
14. Su LD, Fullen DR, Lowe L, et al. Desmoplastic and neurotropic melanoma. Analysis of 33 patients with lymphatic mapping and sentinel node biopsy. *Cancer* 2004;100:598–604.
15. Hawkins WG, Busman KJ, Ben-Porat L, et al. Desmoplastic melanoma: a pathologically and clinically distinct form of cutaneous melanoma. *Ann Surg Oncol* 2005;12:207–213.
16. Breslow A. Thickness, cross-sectional area, and depth of invasion in prognosis of cutaneous melanoma. *Ann Surg* 1970;172:902–908.
17. Balch CM, Gershenwald JE, Seng-jaw S, et al. Final version of 2009 AJCC melanoma staging and classification. *J Clin Oncol* 2009;27:6199–6206.

18. Azzola MF, Shaw HM, Thompson JF, et al. Tumor mitotic rate is a more powerful prognostic indicator than ulceration in patients with primary cutaneous melanoma: an analysis of 3661 patients from a single center. *Cancer* 2003;97:1488–1498.
19. Balch CM, Soong SJ, Gershenwald JE, et al. Prognostic factors analysis of 17,600 melanoma patients: validation of the American Joint Committee on Cancer melanoma staging system. *J Clin Oncol* 2001;19:3622–3634.
20. Paek SC, Griffith KA, Johnson TM, et al. The impact of factors beyond Breslow depth on predicting sentinel lymph node positivity in melanoma. *Cancer* 2007;109:100–108.
21. Sondak VK, Taylor JM, Sabel MS, et al. Mitotic rate and younger age are predictors of sentinel lymph node positivity: lessons learned from the generation of a probabilistic model. *Ann Surg Oncol* 2004;11:247–258.
22. Francken AB, Shaw HM, Thompson JF, et al. The prognostic importance of tumor mitotic rate confirmed in 1317 patients with primary cutaneous melanoma and long follow-up. *Ann Surg Oncol* 2004;11:426–433.
23. Arca MJ, Biermann JS, Johnson TM, et al. Biopsy techniques for skin, soft-tissue, and bone neoplasms. *Surg Oncol Clin N Am* 1995;4:157–174.
24. Coit DG, Thompson JA, Andtbacka R, et al. Melanoma, version 4.2014. *J Natl Compr Canc Netw* 2014;12:621–629.
25. Wang TS, Johnson TM, Cascade PN, et al. Evaluation of staging chest radiographs and serum lactate dehydrogenase for localized melanoma. *J Am Acad Dermatol* 2004;51:399–405.
26. Terhune MH, Swanson N, Johnson TM. Use of chest radiography in the initial evaluation of patients with localized melanoma. *Arch Dermatol* 1998;134:569–572.
27. Hafner J, Schmid MH, Kempf W, et al. Baseline staging in cutaneous malignant melanoma. *Br J Dermatol* 2004;150:677–686.
28. Sabel MS, Wong SL. Review of evidence-based support for pretreatment imaging in melanoma. *J Natl Compr Canc Netw* 2009;7:281–289.
29. Starritt EC, Uren RF, Scolyer RA, et al. Ultrasound examination of sentinel nodes in the initial assessment of patients with primary cutaneous melanoma. *Ann Surg Oncol* 2005;12:18–23.
30. Crippa F, Leutner M, Belli F, et al. Which kinds of lymph node metastases can FDG PET detect? A clinical study in melanoma. *J Nucl Med* 2000; 41:1491–1494.
31. Wagner JD, Schauwecker D, Davidson D, et al. Inefficacy of F-18 flourodeoxy-D-glucose-positron emission tomography scans for initial evaluation in early-stage cutaneous melanoma. *Cancer* 2005;104:570–579.
32. Brady MS, Akhurst T, Spanknebel K, et al. Utility of preoperative [(18)]F fluorodeoxyglucose-positron emission tomography scanning in high-risk melanoma patients. *Ann Surg Oncol* 2006;13:525–532.
33. Tyler DS, Onaitis M, Kherani A, et al. Positron emission tomography scanning in malignant melanoma. Clinical utility in patients with stage III disease. *Cancer*

2000;89:1019–1025.
34. Thomas JM, Newton-Bishop J, A'Hern R, et al. Excision margins in high-risk malignant melanoma. *N Eng J Med* 2004;350:757–766.
35. Nilsson PJ, Ragnarsson-Olding BK. Importance of clear resection margins in anorectal malignant melanoma. *Br J Surg* 2010;97:98–103.
36. Droesch JT, Flum DR, Mann GN. Wide local excision or abdominoperineal resection as the initial treatment for anorectal melanoma? *Am J Surg* 2005;189:446–449.
37. Yeh JJ, Shia J, Hwu WJ, et al. The role of abdominoperineal resection as surgical therapy for anorectal melanoma. *Ann Surg* 2006;244:1012–1017.
38. Anderson KW, Baker SR, Lowe L, et al. Treatment of head and neck melanoma, lentigo maligna subtype: a practical surgical technique. *Arch Facial Plast Surg* 2001;3:202–206.
39. Agarwal-Antal N, Bowen GM, Gerwels JW. Histologic evaluation of lentigo maligna with permanent sections: implications regarding current guidelines. *J Am Acad Dermatol* 2002;47:743–748.
40. Chang AE, Karnell LH, Menck HR. The National Cancer Data Base report on cutaneous and noncutaneous melanoma: a summary of 84,836 cases from the past decade. The American College of Surgeons Commission on Cancer and the American Cancer Society. *Cancer* 1998;83:1664–1678.
41. van der Ploeg AP, Haydu LE, Spillane AJ, et al. Melanoma patients with an unknown primary tumor site have a better outcome than those with a known primary following TLND. *Ann Surg Oncol* 2014;21:3108–3116.
42. Wong SL, Balch CM, Hurley P, et al. Sentinel lymph node biopsy for melanoma: American Society of Clinical Oncology and Society of Surgical Oncology joint clinical practice guideline. *J Clin Oncol* 2012;30:2912–2918.
43. Morton DL, Wen DR, Wong JH, et al. Technical details of intraoperative lymphatic mapping for early stage melanoma. *Arch Surg* 1992;127:392–399.
44. Gershenwald JE, Colome MI, Lee JE, et al. Patterns of recurrence following a negative sentinel lymph node biopsy in 243 patients with stage I or II melanoma. *J Clin Oncol* 1998;16:2253–2260.
45. Balch CM, Morton DL, Gershenwald JE, et al. Sentinel node biopsy and standard of care for melanoma. *J Am Acad Dermatol* 2009;60:872–875.
46. Valscecchi ME, Silbermins D, De Rosa N, et al. Lymphatic mapping and sentinel lymph node biopsy in patients with melanoma: a meta-analysis. *J Clin Oncol* 2011;29:1479–1487.
47. Karimipour DJ, Lowe L, Su L, et al. Standard immunostains for melanoma in sentinel lymph node specimens: which ones are most useful? *J Am Acad Dermotol* 2003;50:759–764.
48. Morton DL, Thompson JF, Cochran AJ, et al. Final trial report of sentine-node biopsy versus nodal observation in melanoma. *N Engl J Med* 2014;370:599–609.

49. Thomas JM. Prognostic false-positivity of the sentinel node in melanoma. *Nat Clin Pract Oncol* 2008;5:18–23.
50. Rosenberg SA. Why perform sentinel-lymph-node biopsy in patients with melanoma? *Nat Clin Pract Oncol* 2008;5:1.
51. Frankel TL, Griffith KA, Lowe L, et al. Do micromorphometric features of metastatic deposits within sentinel nodes predict nonsentinel lymph node involvement in melanoma? *Ann Surg Oncol* 2008;15:2403–2411.
52. Cochran AJ, Wen DR, Huang R-R, et al. Prediction of metastatic melanoma in nonsentinel nodes and clinical outcome based on the primary melanoma and the sentinel node. *Mod Pathol* 2004:1–9.
53. Debarbieux S, Duru G, Dalle S, et al. Sentinel lymph node biopsy in melanoma: a micromorphometric study relating to prognosis and completion lymph node dissection. *Br J Dermatol* 2007;157:58–67.
54. Nagaraja V, Eslick GD. Is complete lymph node dissection after a positive sentinel lymph node biopsy for cutaneous melanoma always necessary? *Eur J Surg Oncol* 2013;39:669–680.
55. Wong SL, Morton DL, Thompson JF, et al. Melanoma patients with positive sentinel nodes who did not undergo completion lymphadenectomy: a multi-institutional study. *Ann Surg Oncol* 2006;13:809–816.
56. Kingham TP, Panageas KS, Ariyan CE, et al. Outcome of patients with a positive sentinel lymph node who do not undergo completion lymphadenectomy. *Ann Surg Oncol* 2010;17:514–520.
57. van der Ploeg IM, Kroon BB, Antonini N, et al. Is completion lymph node dissection needed in case of minimal melanoma metastasis in the sentinel node? *Ann Surg* 2009;249:1003–1007.
58. Kesmodel SB, Karakousis CP, Botbyl JD, et al. Mitotic rate as a predictor of sentinel lymph node positivity in patients with thin melanomas. *Ann Surg Oncol* 2005;12:449–458.
59. Andtbacka RH, Gershenwald JE. Role of sentinel lymph node biopsy in patients with thin melanoma. *J Natl Compr Canc Netw* 2009;7:307–317.
60. Burmeister BH, Henderson MA, Ainslie J, et al. Adjuvant radiotherapy versus observation alone for patients at risk of lymph-node field relapse after therapeutic lymphadenectomy for melanoma: a randomised trial. *Lancet Oncol* 2012;13:589–597.
61. Agrawal S, Kane JM III, Guadagnolo BA, et al. The benefits of adjuvant radiation therapy after therapeutic lymphadenectomy for clinically advanced, high-risk, lymph node-metastatic melanoma. *Cancer* 2009;115:5836–5844.
62. Oxenberg J, Kane JM III. The role of radiation therapy in melanoma. *Surg Clin North Am* 2014;94:1031–1047.
63. Veronesi U, Adamus J, Aubert C, et al. A randomized trial of adjuvant chemotherapy and immunotherapy in cutaneous melanoma. *N Engl J Med* 1982;307:913–916.

64. Lejeune FJ, Macher E, Kleeberg U, et al. An assessment of DTIC versus levamisole or placebo in the treatment of high risk stage I patients after surgical removal of a primary melanoma of the skin: a phase III adjuvant study. EORTC protocol 18761. *Eur J Cancer Clin Oncol* 1988;24:S81–S90.
65. Fisher RI, Terry WD, Hodes RJ, et al. Adjuvant immunotherapy or chemotherapy for malignant melanoma: preliminary report of the National Cancer Institute randomized clinical trial. *Surg Clin North Am* 1981;61:1267–1277.
66. Morton DL, Mozzillo N, Thompson JF, et al. An international, randomized, phase II trial of Bacillus Calmette-Guerin (BCG) plus allogeneic melanoma vaccine (MCV) or placebo after complete resection of melanoma metastatic to regional or distant sites [Abstract]. *J Clin Oncol* 2007;25:Abstract 8508.
67. Eggermont AM, Suclu S, Rutkowski P, et al. Randomized phase III trial comparing postoperative adjuvant ganglioside GM2-KLH/QS-21 vaccination versus observation in stage II melanoma: final results of study EORTC 18961 (abstract). *J Clin Oncol* 2010;28:Abstract 8505.
68. Kirkwood JM, Strawderman MH, Ernstoff MS, et al. Interferon alfa-2b adjuvant therapy of high-risk resected cutaneous melanoma: the Eastern Cooperative Oncology Group Trial EST 1684. *J Clin Oncol* 1996;14:7–17.
69. Kirkwood JM, Ibrahim JG, Sondak VK, et al. High- and low-dose interferon alfa-2b in high-risk melanoma: first analysis of intergroup trial E1690/S9111/C9190. *J Clin Oncol* 2000;18:2444–2458.
70. Eggermont AM, Suciu S, MacKie RM, et al. Adjuvant therapy with pegylated interferon alfa-2b versus observation alone in resected stage III melanoma: final results of EORTC 18911: randomised control trial. *Lancet* 2008;372:117–126.
71. Atkins MB, Hsu J, Lee S, et al. Phase III trial comparing concurrent biochemotherapy with cisplatin, vinblastine, dacarbazine, interleukin-2 and interferon alfa-2b with cisplatin, vinblastine, and dacarbazine alone in patients with metastatic malignant melanoma (E3695): a trial coordinated by the Eastern Cooperative Oncology Group. *J Clin Oncol* 2008;26:5748–5754.
72. Bajetta E, Del Vecchio M, Nova P, et al. Multicenter phase III randomized trial of polychemotherapy (CVD regimen) versus the same chemotherapy (CT) plus subcutaneous interleukin-2 and interferon-alpha2b in metastatic melanoma. *Ann Oncol* 2006;17:571–577.
73. Flaherty KT, Moon J, Atkins MB, et al. Phase III trial of high-dose interferon alpha-2b versus cisplatin, vinblastine, CTIC plus IL-2 and interferon in patients with high-risk melanoma (SWOG S0008): an intergroup study of CALGB, COG, ECOG and SWOG. Paper presented at: *ASCO Annual Meeting Proceedings;* 2012;30:8504.
74. Eggermont AM, van Geel AN, de Wilt JH, et al. The role of isolated limb perfusion for melanoma confined to the extremities. *Surg Clin North Am* 2003;83:371–384.
75. Kaufman HL, Andtbacka RH, Collichio FA, et al. Primary overall survival (OS) from OPTiM, a randomized phase III trial of talimogene laherparepvec (T-VEC) versus

subcutaneous (SC) GM-CSF for the treatment of unresected stage IIIB/C and IV melanoma. *J Clin Oncol* 2014;32:9008a.

76. Sanki A, Kam PC, Thompson JF. Long-term results of hyperthermic, isolated limb perfusion for melanoma: a reflection of tumor biology. *Ann Surg Oncol* 2007;245:591–596.
77. Lens MB, Dawes M. Isolated limb perfusion with melphalan in the treatment of malignant melanoma of the extremities: a systematic review of randomised controlled trials. *Lancet Oncol* 2003;4:359–364.
78. Fraker DL. Management of in-transit melanoma of the extremity with isolated limb perfusion. *Curr Treat Options Oncol* 2004;5:173–184.
79. Thompson JF, Kam PC. Isolated limb infusion for melanoma: a simple but effective alternative to isolated limb perfusion. *J Surg Oncol* 2004; 88:1–3.
80. Thompson JF, Kam PC, Waugh RC, et al. Isolated limb infusion with cytotoxic agents: a simple alternative to isolated limb perfusion. *Semin Surg Oncol* 1998;14:238–247.
81. Beasley GM, Peterson RP, Yoo J, et al. Isolated limb infusion for in-transit malignant melanoma of the extremity: a well-tolerated but less effective alternative to hyperthermic isolated limb perfusion. *Ann Surg Oncol* 2008; 15:706–715.
82. Beasley GM, Caudle A, Petersen RP, et al. A multi-institutional experience of isolated limb infusion: defining response and toxicity in the US. *J Am Coll Surg* 2009;208:706–715.
83. Garbe C, Eigentler TK, Keilholz U, et al. Systematic review of medical treatment in melanoma: current status and future prospects. *Oncologist* 2011;16:5–24.
84. Eigenlter TK, Caroli UM, Radny P, et al. Palliative therapy of disseminated malignant melanoma: a systematic review of 41 randomized clinical trials. *Lancet Oncol* 2003;4:748–759.
85. Ives NJ, Stowe RL, Lorigan P, Wheatley K. Chemotherapy compared with biochemotherapy for the treatment of metastatic melanoma: a meta-analysis of 18 trials involving 2,621 patients. *J Clin Oncol* 2007;25:5426–5434.
86. Rosenberg SA, Lotze MT, Muul LM, et al. A progress report on the treatment of 157 patients with advanced cancer using lymphokine activated killer cells and interleukin-2 or interleukin-2 alone. *N Engl J Med* 1987;316:889–897.
87. Parkinson DR, Abrams JS, Wiernik PH, et al. Interleukin-2 therapy in patients with metastatic malignant melanoma: a phase II study. *J Clin Oncol* 1990;8:1650–1656.
88. Agarwala S. Improving survival in patients with high-risk and metastatic melanoma: immunotherapy leads the way. *Am J Clin Dermatol* 2003;4:333–346.
89. Schwartzentruber DJ, Lawson DH, Richards JM, et al. gp100 peptide vaccine and interleukin-2 in patients with advanced melanoma. *N Engl J Med* 2011;364:2119–2127.
90. Davies H, Bignell GR, Cox C, et al. Mutations of the BRAF gene in human cancer.

Nature 2002;417:949–954.

91. Chapman PB, Hauschild A, Robert C, et al. Improved survival with vemurafenib in melanoma with BRAF V600E mutation. *N Eng J Med* 2011;364:2507–2516.
92. Hauschild A, Grob JJ, Demidov LV, et al. Dabrafenib in BRAF-mutated metastatic melanoma: a multicentre, open-label, phase 3 randomised controlled trial. *Lancet* 2012;380:358–365.
93. Flaherty KT, Robert C, Hersey P, et al. Improved survival with MEK inhibition in BRAF-mutated melanoma. *N Eng J Med* 2012;367:107–114.
94. Flaherty KT, Infante JR, Daud A, et al. Combined BRAF and MEK inhibition in melanoma with BRAF V600 mutations. *N Eng J Med* 2012; 367:1694–1703.
95. Long GV, Stroyakovskiy D, Gogas H, et al. Combined BRAF and MEK inhibition versus BRAF inhibition alone in melanoma. *N Eng J Med* 2014;371:1877–1888.
96. Hodi FS, O'Day SJ, McDermott DF, et al. Improved survival with ipilimumab in patients with metastatic melanoma. *N Engl J Med* 2010;363:711–723.
97. McDermott D, Lebbe C, Hodi FS, et al. Durable benefit and the potential for long-term survival with immunotherapy in advanced melanoma. *Cancer Treat Rev* 2014;40:1056–1064.
98. Ribas A, Kefford R, Marshall MA, et al. Phase III randomized clinical trial comparing tremelimumab with standard-of-care chemotherapy in patients with advanced melanoma. *J Clin Oncol* 2013;31:616–622.
99. Robert C, Ribas A, Wolchok JD, et al. Anti-programmed-death-receptor-1 treatment with pembrolizumab in ipilimumab-refractory advanced melanoma: a randomised dose-comparison cohort of a phase 1 trial. *Lancet* 2014;384:1109–1117.
100. Weber JS, Minor DR, D'Angelo S, et al. A phase 3 randomized, open-label study of nivolumab (anti-PD-1; BMS-936558; ONO-4538) versus investigator's choice chemotherapy (ICC) in patients with advanced melanoma after prior anti-CTLA-4 therapy (abstract). *Ann Oncol* 2014;25:v1–v41.
101. Robert C, Long GV, Brady B, et al. Nivolumab in previously untreated melanoma without BRAF mutation. *N Engl J Med* 2015;372:320–330.
102. Wolchock JD, Kluger HM, Callahan J, et al. Nivolumab plus ipilimumab in advanced melanoma. *N Engl J Med* 2013;369:122–133.
103. Sznol M, Kluger HM, Callahan MK, et al. Survival, response duration and activity by BRAF mutation status of nivolumab and ipilimumab concurrent therapy in advanced melanoma. *J Clin Oncol* 2014;32:LBA9003.
104. Postow MA, Chesney J, Pavlick AC, et al. Nivolumab and ipilimumab versus ipilimumab in untreated melanoma. *N Engl J Med* 2015;372(21):2006–2017.
105. Hameed AM, Ng EE, Johnston E, et al. Hepatic resection for metastatic melanoma: a systematic review. *Melanoma Res* 2014;24:1–10.
106. Howard JH, Thompson JF, Mozzillo N, et al. Metastasectomy for distant metastatic melanoma: analysis of data from the first Multicenter Selective Lymphadenectomy

Trial (MSLT-I). *Ann Surg Oncol* 2012;19:2547–2555.
107. Sosman JA, Moon J, Tuthill RJ, et al. A phase 2 trial of complete resection for stage IV melanoma: results of Southwest Oncology Group Clinical Trial S9430. *Cancer* 2011;117:4740–4806.
108. Leung AM, Hari DM, Morton DL. Surgery for distant melanoma metastasis. *Cancer J* 2012;18:176–184.
109. Wasif N, Bagaria SP, Ray P, et al. Does metastasectomy improve survival in patients with Stage IV melanoma? A cancer registry analysis of outcomes. *J Surg Oncol* 2011;104:111–115.
110. Siegel RL, Miller KD, Jemal A. Cancer Statistics, 2016. *CA Cancer J Clin*. 2016:66(1):7–30.
111. Allen PJ, Bowne WB, Jaques DP, et al. Merkel cell carcinoma: prognosis and treatment of patients from a single institution. *J Clin Oncol* 2005;23:2300–2309.
112. Hodgson NC. Merkel cell carcinoma: changing incidence trends. *J Surg Oncol* 2005;89:1–4.
113. Feng H, Shuda M, Chang Y, et al. Clonal integration of a polyomavirus in human Merkel cell carcinoma. *Science* 2008;319:1096–1100.
114. Medina-Franco H, Urist MM, Fiveash J, et al. Multimodality treatment of Merkel cell carcinoma: case series and literature review of 1024 cases. *Ann Surg Oncol* 2001;8:204–208.
115. Bobos M, Hytiroglou P, Kostopoulos I, et al. Immunohistochemical distinction between Merkel cell carcinoma and small cell carcinoma of the lung. *Am J Dermatopathol* 2006;28:99–104.
116. Schwartz JL, Wong SL, McLean SA, et al. NCCN guidelines implementation in the multidisciplinary Merkel Cell Carcinoma Program at the University of Michigan. *J Natl Compr Canc Netw* 2014;12:434–441.
117. Bichakjian CK, Olencki T, Alam M, et al. Merkel cell carcinoma, version 1.2014. *J Natl Compr Canc Netw* 2014;12:410–424.
118. Bichakjian CK, Lowe L, Lao CD, et al. Merkel cell carcinoma: critical review with guidelines for multidisciplinary management. *Cancer* 2007; 110:1–12.
119. Kachare SD, Wong JH, Vohra NA, et al. Sentinel lymph node biopsy is associated with improved survival in Merkel cell carcinoma. *Ann Surg Oncol* 2014;21:1624–1630.
120. Su LD, Lowe L, Bradford CR, et al. Immunostaining for cytokeratin 20 improves detection of micrometastatic Merkel cell carcinoma in sentinel lymph nodes. *J Am Acad Dermatol* 2002;46:661–666.
121. Pape E, Rezvoy N, Penel N, et al. Radiotherapy alone for Merkel cell carcinoma: a comparative and retrospective study of 25 patients. *J Am Acad Dermatol* 2011;65:983–990.
122. Poulsen MG, Rischin D, Porter I, et al. Does chemotherapy improve survival in high-

risk stage I and II Merkel cell carcinoma of the skin? *Int J Radiat Oncol Biol Phys* 2006;64:114–119.

123. Bogner PN, Fullen DR, Lowe L, et al. Lymphatic mapping and sentinel lymph node biopsy in the detection of early metastases from sweat gland carcinoma. *Cancer* 2003;97:2285–2289.
124. Bichakjian CK, Olencki T, Alam M, et al. Dermatofibrosarcoma protuberans, version 1.2014. *J Natl Compr Canc Netw* 2014;12:863–868.
125. Farma JM, Ammori JB, Zager JS, et al. Dermatofibrosarcoma protuberans: how wide should we resect? *Ann Surg Oncol* 2010;17:2112–2118.
126. McArthur GA, Demetri GD, van Oosterom A, et al. Molecular and clinical analysis of locally advanced dermatofibrosarcoma protuberans treated with imatinib: Imatinib Target Exploration Consortium Study B2225. *J Clin Oncol* 2005;23:866–873.
127. Ugurel S, Mentzel T, Utikal J, et al. Neoadjuvant imatinib in advanced primary or locally recurrent dermatofibrosarcoma protuberans: a multicenter phase II DeCOG trial with long-term follow-up. *Clin Cancer Res* 2014;20:499–510.

Chapter 108

Sarcomas of Soft Tissue and Bone

Sandra L. Wong

Key Points

1 Sarcomas are a rare and heterogeneous group of cancers that arise from mesoderm-derived elements such as muscle, fat, nerve/nerve sheath, cartilage, blood vessels, bone, and other connective tissue. They are histologically distinct from cancers of epithelial origin.

2 Clinical behavior and prognosis are largely defined by anatomic location, tumor grade, size, and ability to achieve complete surgical resection.

3 For extremity sarcomas, radiotherapy is indicated for high-risk tumors to decrease disease relapse and improve survival. Limb-sparing procedures are favored in order to maximize functional outcomes.

4 Surgical resection is the cornerstone of treatment for intra-abdominal or retroperitoneal sarcomas. Complete resection may require en bloc resection of adjacent or involved organs, most commonly of the kidney and colon.

5 The use of imatinib, a selective tyrosine kinase inhibitor, in the management of gastrointestinal stromal tumors (GISTs), is a paradigm for the successful use of targeted molecular therapies.

6 Increasing use of multimodality therapies including surgical resection, chemotherapy, and radiotherapy has dramatically improved outcomes for sarcomas such as osteosarcoma and Ewing sarcoma.

1 Sarcomas are a heterogeneous group of cancers that arise from mesenchymal cells, or mesoderm-derived elements, including muscle, fat, nerve/nerve sheath, cartilage, blood vessels, bone, and other connective tissue. Sarcomas of soft tissue and bone are considered two distinct categories. Though mesoderm-derived elements comprise nearly two-thirds of the body's mass, sarcomas are relatively rare. In 2016, just over an estimated 15,000 new cases of soft tissue and bone sarcoma were expected to be diagnosed in the United States,[1] which account for less than 1% of all new cancers. Sarcomas also represent an extremely heterogeneous group of cancers, but taken together, 5-year overall survival is about 50% to 60%.[2,3] Anatomic location, tumor size, grade, and histopathology, are important determinants of clinical presentation, treatment, and prognosis.

The Greek word “sarkoma,” meaning “fleshy excrescence” is the origin for the term “sarcoma.” As early as AD 130 to 200, these fleshy tumors were regarded as cancerous by Galen.[4] With the evolution of light microscopy and cellular pathology, there was increasing recognition of soft tissue sarcomas. Sarcomas, then called “soft cancers,” were differentiated from carcinomas by neuroanatomist Charles Bell as early as 1816. Vichow refined the definition of sarcoma as “new formations of connective tissue,” and developed classifications according to microscopic features which separated sarcomas from carcinomas of epithelial origin. Modern foundations for the description and histogenic descriptions of sarcoma are attributed to the work of James Ewing, who over the course of his pathology career refined the classification of sarcomas, including the importance of grade in disease outcome.[5]

Multimodality therapies, including surgery, radiation, and chemotherapy, have been combined to improve local and systemic tumor control. Over the past few decades, an evolution of multidisciplinary approach has enabled successful treatment options to evolve from radical amputation to limb-sparing procedures for extremity sarcoma. As refinements in pathologic classification continue, so does progress in the use of treatment modalities. Modern molecular diagnostics are increasingly being translated to clinical practice, and tailored treatment options are being developed as the histologic diversity of soft tissue sarcomas is continually elucidated and better understood. As with many rare tumors, referral to high-volume centers with clinical expertise is indicated when feasible.

EPIDEMIOLOGY

Soft tissue sarcoma can occur in all age groups and are equally distributed between genders. While the median age at diagnosis varies by histopathologic subtype, sarcomas are relatively rare in the adult population. However, sarcomas are among the most common cancers seen in children and young adults, representing approximately 15% of pediatric malignancies and often occurring in children under 5 years of age.[6] There are nearly 75 distinct histopathologic subtypes. Further, sarcomas can occur at any anatomic site, though most arise in the extremities and trunk, and accordingly, anatomic site influences treatment and outcomes (Fig. 108-1).

While the vast majority of sarcomas arise spontaneously, there are some predisposing conditions to consider. Sarcomas are not thought to be the result of malignant degeneration of a long-standing benign lesion such as a lipoma. An injury or other traumatic incident may lead to the initial recognition of a mass, but there are no data to support the notion that antecedent trauma leads to the development of either soft tissue or bony sarcomas. Clinical evaluation and subsequent workup, including biopsy if indicated, should be able to distinguish malignant growths from a variety of benign posttraumatic lesions, such as myositis ossificans, which must be differentiated from an extraosseous osteogenic sarcoma.

Toxic exposures have been related to the development of sarcoma. Largely of historic interest, the industrial use of thorium dioxide (Thorotrast), arsenic, and vinyl chloride led to accumulation of toxins in the liver and were associated with the development of hepatic angiosarcomas. Several other predisposing conditions are known to be associated with the development of sarcoma. The classic Stewart–Treves syndrome was originally described in patients with lymphedema following radical mastectomy and radiation for breast cancer who then developed lymphangiosarcoma of the affected arm.[7] Since then, long-standing extremity edema from other causes has also been linked to the development of lymphangiosarcomas. Kaposi sarcoma was previously an uncommon cutaneous vascular tumor thought limited to elderly men of Mediterranean origin. In the early 1980s it became one of the first described opportunistic disease associated with HIV infection. Though the incidence of HIV-associated Kaposi sarcoma has markedly declined with effective antiretroviral therapy, it remains an important cause of morbidity among HIV-infected patients and other immunosuppressed patients such as renal allograft recipients.[8–10]

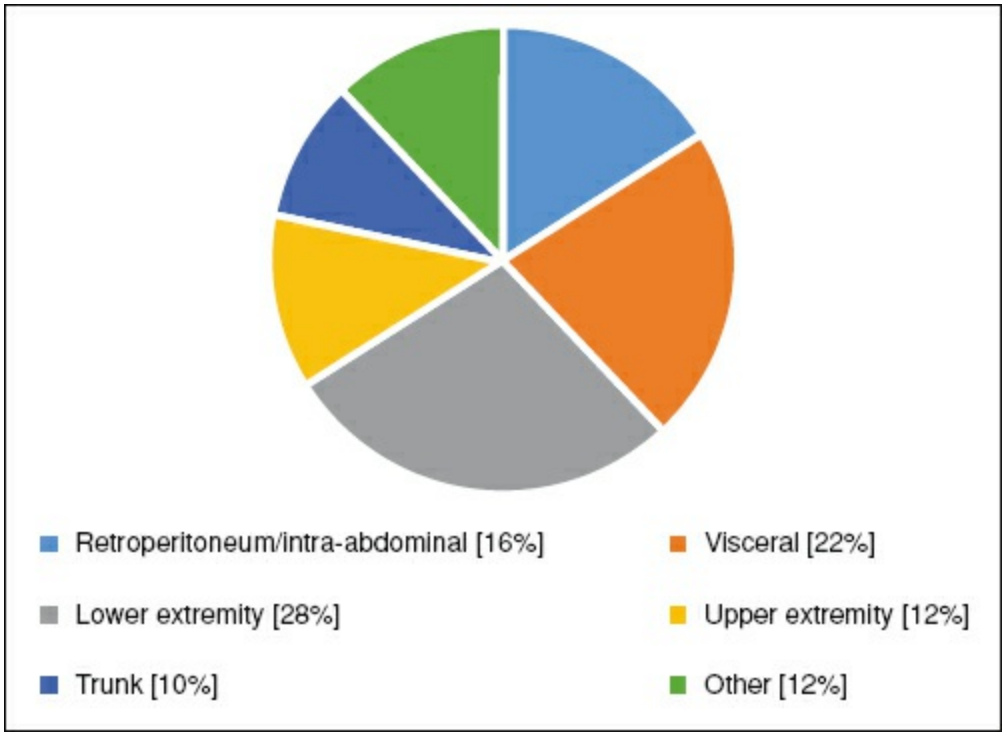

Figure 108-1. Distribution of sarcoma by anatomic location. (Adapted from Brennan MF, Antonescu CR, Moraco N, et al. Lessons learned from the study of 10,000 patients with soft tissue sarcoma. *Ann Surg* 2014;260:416–422.)

Various types of radiation have been implicated in the delayed development of sarcomas. For example, incidental ingestion of luminous paint containing ^{226}radium by factory workers led to the development of osteosarcomas. With the increasing use of external beam radiation in cancer treatment, there has been a noted increase in the modern incidence of secondary sarcoma in patients previously treated with radiation for a variety of malignancies. Following median latent periods of approximately 8 years (range 6 to 20 years), radiation-associated sarcomas are being increasingly diagnosed in previously radiated areas. Common radiation-associated sarcoma subtypes are angiosarcomas, undifferentiated pleomorphic sarcoma, fibrosarcoma, and leiomyosarcoma, and they are commonly, but not uniformly, high grade.[11,12] Notably, with the advent of breast conservation therapy for breast cancer (consisting of partial mastectomy/lumpectomy and adjuvant radiation therapy), there should be an appropriate index of suspicion for breast angiosarcomas with findings of skin changes on the breast (Fig. 108-2).

GENETIC CANCER SYNDROMES

While the vast majority of sarcomas are sporadic, numerous genetic alterations are associated with both bone and soft tissue sarcomas.[13] There are well-described genetic predispositions to sarcoma. Patients with neurofibromatosis type 1 (NF-1, or von Recklinghausen disease) have mutations in the neurofibromin 1 or 2 gene (*NF1* or *NF2,* respectively) which are associated with the development of malignant peripheral nerve sheath tumors (MPNSTs) in an estimated 5% of patients over a lifetime.[14] A genetic predisposition to desmoid tumors or desmoid fibromatosis is associated with familial adenomatous polyposis (FAP), or Gardner syndrome which is the result of germline mutations in the adenomatous polyposis coli (*APC*) gene.[15,16] Intra-abdominal and extremity desmoids are a common extracolonic manifestation of FAP and can be a source of increased morbidity in these patients following proctocolectomy for the prevention or treatment of colon cancer.[17]

While somatic activation of c-KIT and overexpression of KIT protein are well described in the pathogenesis of gastrointestinal stromal tumors (GISTs), there are described germline mutations as well. Familial GIST syndrome has been ascribed to germline mutation in c-KIT as well as in the *SDHB, SDHC,* and *SDHD* succinate dehydrogenase subunits, in association with Carney triad (GIST, pulmonary chondromas, extra-adrenal paragangliomas) or Carney–Stratakis syndrome (GIST, paraganglioma).[18,19]

One well-documented mechanism of sarcoma development is the inactivation of tumor suppressor genes. Retinoblastoma was known to be associated with a mutation in the retinoblastoma gene (RB1), a 13q chromosomal deletion. Investigation of the link between familial retinoblastoma and osteosarcoma led to the discovery that a genetic defect in RB1 also plays a role in the pathogenesis of sarcomas.[20,21]

Another inherited defect of a tumor suppressor gene associated with soft tissue sarcomas is the Li–Fraumeni syndrome, caused by an inherited mutation in the p53 gene, a key growth-regulatory gene.[22] Germline mutations in affected patients are associated with high incidences of childhood rhabdomyosarcomas, breast cancer, brain tumors, lung cancer, and leukemias).[23] p53 abnormalities may be seen in as many as 60% of osteosarcomas and malignant fibrous histiocytomas, as well as approximately 33% of other sarcomas.[24] Several oncogenes that can induce malignant transformation and drive proliferation have also been associated with sarcoma development, including amplifications of N-myc, c-erbB2, and members of the *ras* family.[25]



Figure 108-2. Radiation-associated angiosarcoma. This 79-year-old woman developed skin changes on her breast 7 years after breast conservation therapy (lumpectomy and radiation therapy) for a 2-cm invasive ductal adenocarcinoma. Salvage mastectomy was performed.

Cytogenetic aberrations have been recognized in a number of soft tissue sarcomas.[13] Several histologic subtypes of sarcomas have each been found to have specific genetic alterations – usually simple karyotypes including fusion genes due to reciprocal translocations or specific point mutations (Table 108-1). These chromosomal translocations serve as powerful diagnostic markers and may be important in determining tumor biology and subsequent tumor behavior. For example, identification of the translocation of t(X;18)(p11;q11) can confirm the diagnosis of synovial sarcoma if there is any doubt of its histopathology. There are data to suggest that the SYT-SSX1 fusion transcript carries a worse prognosis than the SYT-SSX2 fusion transcript, with median survivals of 6.1 years and 13.7 years, respectively.[26,27]

A better understanding of the molecular biology of sarcomas has revolutionized diagnosis of specific histopathologic subtypes and has elucidated potential pathways for targeted molecular therapy.

SOFT TISSUE SARCOMAS

Clinical Presentation

The most common presentation of a soft tissue sarcoma is that of an asymptomatic mass. Sarcomas tend to grow in a centrifugal fashion, usually pushing surrounding structures away rather than directly invading them. Encasement of structures can occur, but again, this largely occurs in the absence of direct invasion. Compression generally does not produce pain, swelling, or obstructive symptoms until the tumors become quite large. Because of surrounding anatomic structures, some tumors of the extremities tend to be detected at a relatively smaller size, whereas tumors of the retroperitoneum are infrequently smaller than 10 cm at the time of presentation.[5] Even very large abdominal or retroperitoneal sarcomas present with nonspecific abdominal symptoms such as fullness, early satiety, or minor abdominal discomfort (Fig. 108-3). The differential diagnosis for a soft tissue sarcoma includes many types of benign lesions (e.g., lipomas, leiomyomas, and neuromas) but also other malignant lesions (e.g., primary carcinoma, lymphoma, metastatic disease from melanoma, or testes cancer).

In general, the vast majority of soft tissue masses tend to be benign, but concerning features which should prompt a higher index of suspicion for malignancy include large size (>5 cm), deep location (subfascial, intramuscular, or intra-abdominal), variations in texture on examination, immobile nature or noted fixation to underlying structures, or changes to an existing lesion (increasing size or worsening compressive symptoms). No tumor markers for sarcomas exist, so serum bloodwork is generally not useful in the evaluation of soft tissue masses.

Diagnosis

Diagnostic Imaging

Accurate radiologic imaging is critical in the diagnostic workup of sarcoma to provide information about the precise location and extent of the primary tumor. Computed tomography (CT) scans and magnetic resonance imaging (MRI) are the most important studies for evaluating the resectability of soft tissue sarcomas, providing definition of the primary tumor in relation to bone, muscle, neurovascular structures, and adjacent organs. Plain radiographs of bones and radionuclide bone scans rarely provide useful information regarding invasion of bone by the tumor. Both CT and MRI can provide critical information for treatment planning. While MRI may be preferred for extremity sarcomas, CT is often the modality of choice for abdominal and retroperitoneal tumors. However, there appears to be no difference between high-quality CT and MRI in terms of ability to determine involvement of nearby structures, bone, or neurovascular structures.[28–30]

Table 108-1 Cytogenetic Abnormalities in Soft Tissue Sarcoma Subtypes

Histologic Subtype	Chromosomal Translocation	Fusion Gene
Alveolar rhabdomyosarcoma	t(2;13)(q35;q14) t(1;13)(p36;q14)	PAX3-FKHR PAX7-FKHR
Alveolar soft part sarcoma	t(X;17)(p11;q25)	ASPL-TFE3
Clear cell sarcoma	t(12;22)(q13;q12)	EWS-ATF1
Desmoplastic small round cell tumor	t(11;22)(p13;q12)	EWS-WT1
Dermatofibrosarcoma protuberans	t(17;22)(q21;q13)	COL1A1-PDGFB
Endometrial stromal sarcoma	t(7;17)(p15;q21)	JAZF1-JJAZ1
Ewing sarcoma/PNET	t(11;22)(q24;q12) t(11;22)(q22;q12)	EWS-FLI1 EWS-ERG
Extraskeletal myxoid chondrosarcoma	t(9;22)(p13;q12) t(9;17)(q22;q11) t(9;15)(q22;q11)	EWS-CHN TAF2N-NR4A3 TCF12-NR4A3
Fibrosarcoma	t(12;15)(p13;q26)	ETV6-NTRK3
Inflammatory myofibroblastic tumor	t(1;2)(q22;p23) t(2;19)(p23;p13) t(2;17)(p23;q23) t(2;2)(p23;q13)	TPM3-ALK TPM4-ALK CLTC-ALK RANB2-ALK
Fibromyxoid sarcoma	t(7;16)(q33;p11) t(11;16)(p11;p11)	FUS-CREB3L2 FUS-CREB3L1
Myxoid and round cell liposarcoma	t(12;16)(q13;p11) t(12;16)(q13;p12)	TLS-CHOP
Synovial sarcoma	t(X;18)(p11;q11)	SYT-SSX1 SYT-SSX2

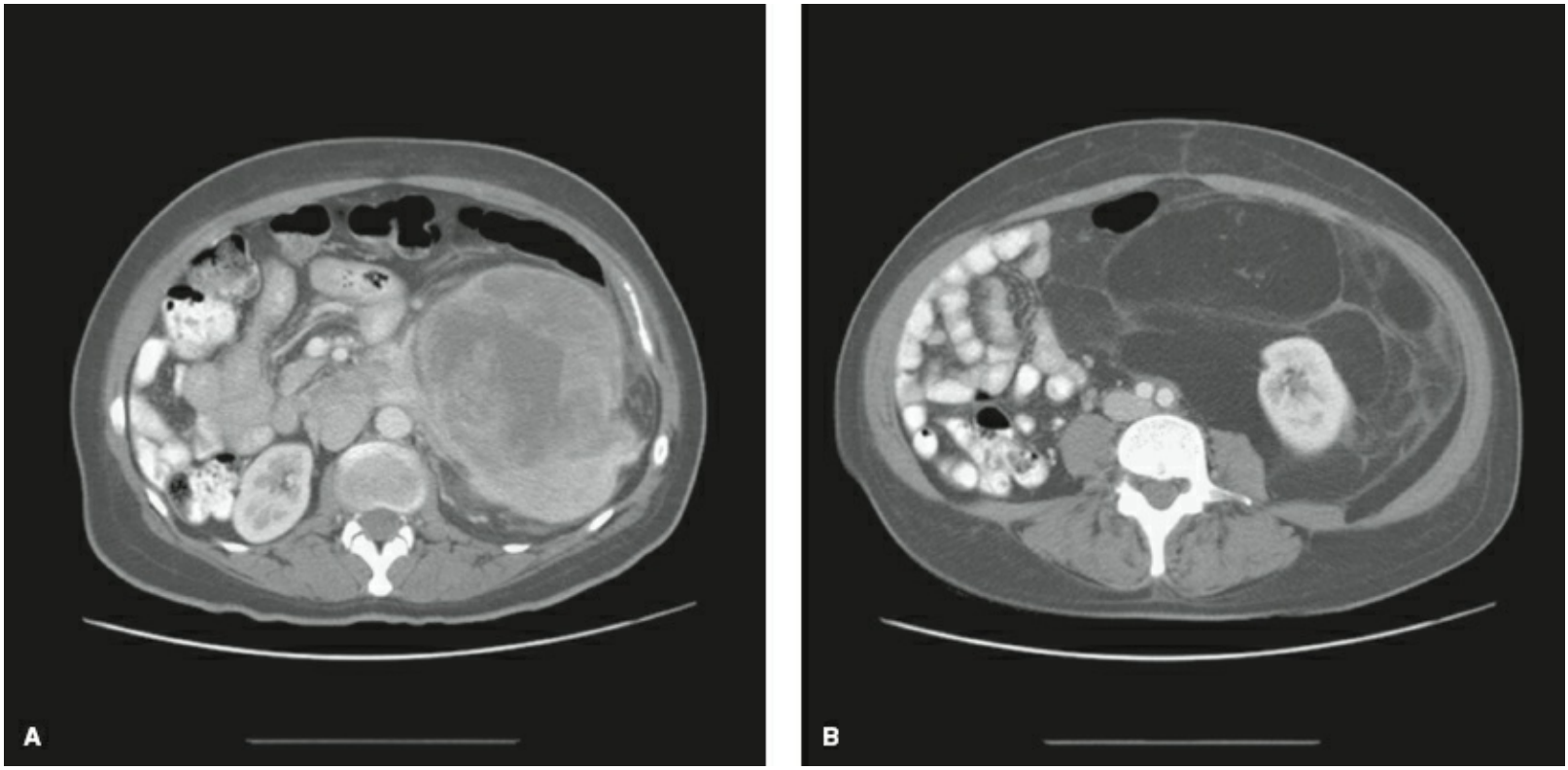

Figure 108-3. Dedifferentiated liposarcoma of the retroperitoneum. This 51-year-old woman presented with only vague symptoms of abdominal fullness from a very large retroperitoneal mass. The CT scan demonstrates a heterogeneous soft tissue mass in the upper abdomen (**A**), which blends into a more fatty component (**B**) which encases the left kidney and displaces abdominal contents. She underwent radical resection en bloc left nephrectomy, distal pancreatectomy, splenectomy, left colectomy, and segmental resection of inferior vena cava.

Imaging is also important as part of the extent of disease workup. Because sarcomas are known to predominantly metastasize to the lungs, directed chest imaging should be performed at time of diagnosis. Chest radiography (CXR) may be used, but CT scans are increasingly being used as the primary screening examination of choice for higher-risk patients, such as those with high-grade lesions or tumors larger than 5 cm.[31] Any abnormal CXR must be followed by a chest CT scan using appropriate nodule protocol, usually involving thinner sections and often not requiring the use of IV contrast, for more detailed evaluation of potential pulmonary metastases (Fig. 108-4). CT of the chest, abdomen, and pelvis should be considered in any patient with a myxoid liposarcoma of an extremity because this subtype often metastasizes to the abdomen or other "fat pads" such as the axilla.[32]

MRI is the most commonly used imaging modality for extremity sarcomas.[28,33] Sequencing routinely involves axial T2-weighted and precontrast/postcontrast T1-weighted images. Contrast enhancement with gadolinium is crucial for detecting and characterizing lesions with coronal, sagittal, and other reconstructions. This imaging modality can accurately delineate between muscle groups and distinguish among tumor and neurovascular structures (Fig. 108-5). Magnetic resonance angiography (MRA) can be performed if more accurate delineation of vascular structures is required for surgical planning.

Positron emission tomography (PET) scanning using fluoro-13-deoxyglucose also offers

the potential for noninvasive analysis of tumor metabolism and has been shown to correlate with both tumor grade and response to treatment for many types of cancers.[34–37] PET maybe helpful in distinguishing between benign and malignant lesions and may be useful for assessing response to treatment.[38] However, its accuracy and potential for false-negative results are still incompletely defined, so its use is not routine, either for staging or for surveillance. Even with a PET scan, formal imaging with contrasted CT or MRI is necessary so costs and extent of imaging should be considered.



Figure 108-4. Pulmonary metastasis. A noncontrasted CT scan of the thorax demonstrates a 1.1-cm noncalcified nodule consistent with pulmonary metastasis in the upper lobe of the right lung.

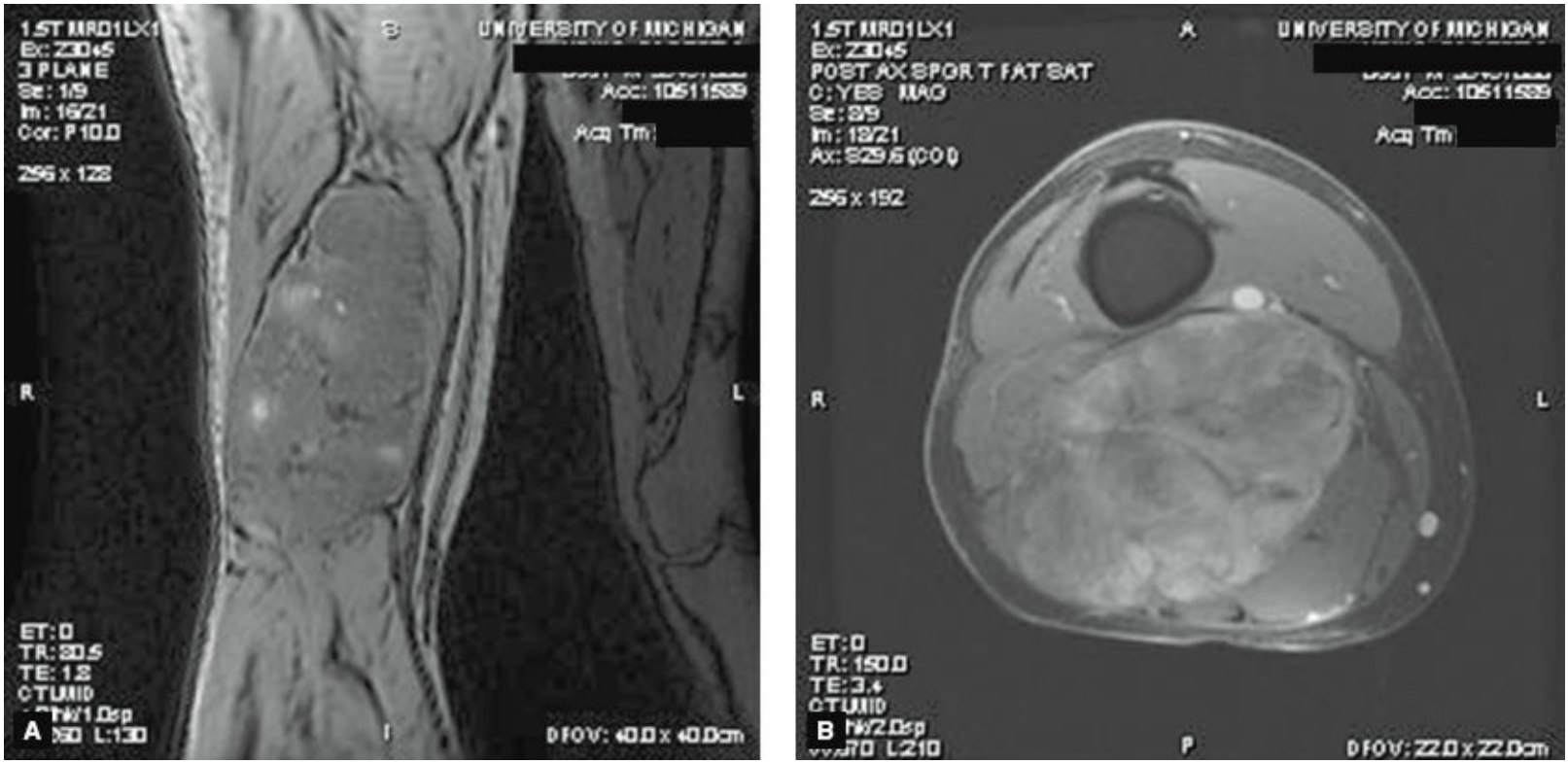

Figure 108-5. Extremity sarcoma. MRI demonstrates a 20-cm low-grade myxoid liposarcoma. **A:** Coronal reconstruction demonstrates location in the distal right thigh. **B:** Axial images show displacement of the popliteal vessels and vastus medialis anteriorly; the common tibioperoneal nerve and biceps femoris laterally; and, the semimembranosus and semitendinosus muscles medially.

Diagnostic Biopsy

Properly performed biopsies are critical in directing a multimodality treatment approach. Image-guided techniques are increasingly being applied so that open biopsy is not mandatory. Fine-needle aspiration (FNA) is frequently used for the evaluation of enlarged lymph nodes, thyroid nodules, or breast masses. However, FNA often does not provide sufficient materials for definitive histopathologic diagnosis, especially for an index presentation. In select cases, FNA may be useful to demonstrate recurrent disease. Core-needle biopsy (CNB) is considered the initial procedure of choice for diagnosis of soft tissue sarcomas.[39] CNB retrieves sufficient material for immunohistochemical staining, and when necessary, for cytogenetic analysis or flow cytometry. Image-guided CNB, either using CT or ultrasound, allows for the biopsy of deep masses that may not be easily palpable and can help target suspicious areas in a heterogeneous field for better diagnostic value. An adequate sample from a viable area of sarcoma is required for definitive diagnosis and accurate grading. CNB is associated with low complication rates (<1%), with major concerns related to bleeding.[40] Concerns about recurrence along the tract are obviated with the use of a sheathed needle device and/or excision of the biopsy tract at the time of definitive resection when possible.

Open surgical biopsy, or incisional biopsy, is uncommonly needed with increasing success of CNB.[41] However, open biopsy should be considered when core-needle specimens yield nondiagnostic findings and if preoperative diagnosis is definitely required for treatment planning. Several important technical factors must be considered when

performing an incisional biopsy. Incisions must be oriented along the long axis of extremities to facilitate complete resection with definitive surgical management. Transverse incisions in the extremity often commits the patient to more extensive procedures than would be otherwise necessary, potentially compromising the ability to obtain clear margins with definitive limb-sparing procedures. Attempts to enucleate the sarcoma within its pseudocapsule is discouraged, though excisional biopsy can be considered as the primary approach for small, superficial lesions.[5] Extensive dissection during a biopsy, including undermining surrounding subcutaneous layers, should be consciously avoided in order to contain the extent of disease and best manage subsequent procedures. Attention to meticulous hemostasis also prevents extensive “seeding” of the area.

PATHOLOGIC CLASSIFICATION

Histopathologic designation of soft tissue sarcomas reflects an extremely heterogeneous group of tumors. Sarcomas are generally classified according to the tissues they mimic rather than the type of tissue from which the tumor arises. Some sarcomas have no recognizable normal tissue counterpart and are characterized by other distinguishing histologic features.[5,42] The various types of benign and malignant soft tissue tumors are noted in Table 108-2. The development of specialized markers for identifying individual types of sarcoma has led to greater precision in their classification. Helpful immunohistochemical stains include the intermediate filaments (i.e., vimentin, keratin) and muscle markers (i.e., desmin, actin). More specific markers can be instrumental in diagnosis, such as myoglobin staining for rhabdomyosarcomas. In a small proportion of tumors (approximately 10% in most series), the tumor cells are so poorly differentiated that no specific histogenesis can be determined, and these may be designated as spindle cell sarcomas or undifferentiated pleomorphic sarcomas.

One of the most critical pieces of pathologic information for clinicians treating sarcoma patients is histologic grade. Histologic grade is assessed based on the expert assessment of degree of cellular atypia, the frequency of mitotic figures, and the presence or absence of spontaneous tumor necrosis. While grading criteria have undergone numerous revisions over the years, in general, low-grade tumors have relatively little cellular atypia, few mitoses, and no tumor necrosis. High-grade tumors show a significant degree of necrosis in addition to atypia and frequent mitotic figures (Fig. 108-6). A consistently applied grading system discriminates between tumors with good prognosis (low grade) and those with relatively poorer prognosis (high grade). In the past, various grading systems have been used (2-tiered systems (low vs. high); 3-tiered systems; and 5-tiered systems). The current American Joint Commission on Cancer (AJCC) staging system recognizes a classification system ranging from grade 1 (G1, well differentiated) to grade 3 (G3, undifferentiated) tumors.[43–45] Evaluation typically takes histology, tumor differentiation, mitotic count, and tumor necrosis into account. There can be disagreement about grading schemas and expert pathology opinion can vary from center to center.[46,47] As such, it is important to take note of tumor classification when interpreting results from clinical trials or retrospective reports.[48] The metastatic potential for low-grade lesions is approximately 5% to 10% compared to up to 50% to 60% for high-grade tumors.[2] For lesions in which disparate areas exist, the highest grade encountered is generally used to categorize the tumor.

Table 108-2 Histologic Classification of Soft Tissue Tumors

Connective Tissue	Benign Soft Tissue Tumor	Malignant Soft Tissue Tumor (Sarcoma)
Adipocyte	Lipoma	Liposarcoma
Fibrous tissue (Fibroblastic)	Fibroma	Fibrosarcoma, Fibromyxoid sarcoma
Skeletal muscle	Rhabdomyoma	Rhabdomyosarcoma
Smooth muscle	Leiomyoma	Leiomyosarcoma
Bone	Osteoma	Osteosarcoma
Cartilage	Chondroma	Chondrosarcoma
Synovium	Synovioma	Synovial sarcoma
Blood vessels	Hemangioma Hemangiopericytoma	Angiosarcoma Epithelioid hemangioendothelioma
Lymphatics	Lymphangioma	Lymphangiosarcoma
Nerve	Neurofibroma	Malignant peripheral nerve sheath tumor, Neurofibrosarcoma
Mesothelium	Benign mesothelioma	Malignant mesothelioma
Histiocytes	Benign fibrous histiocytoma	Undifferentiated pleomorphic sarcoma/ malignant fibrous histiocytoma
Uncertain/other		Ewing sarcoma/primitive neuroectodermal tumor Alveolar soft-part sarcoma Epithelioid sarcoma Clear cell sarcoma of soft tissue Desmoplastic small round cell tumor

STAGING

Because of the prognostic importance of staging, stage classification of the primary tumor is based on both clinical and histologic information. The usual TNM classification used by the AJCC[45] for other solid tumors is modified to a GTNM system (Table 108-3) for soft tissue sarcomas.

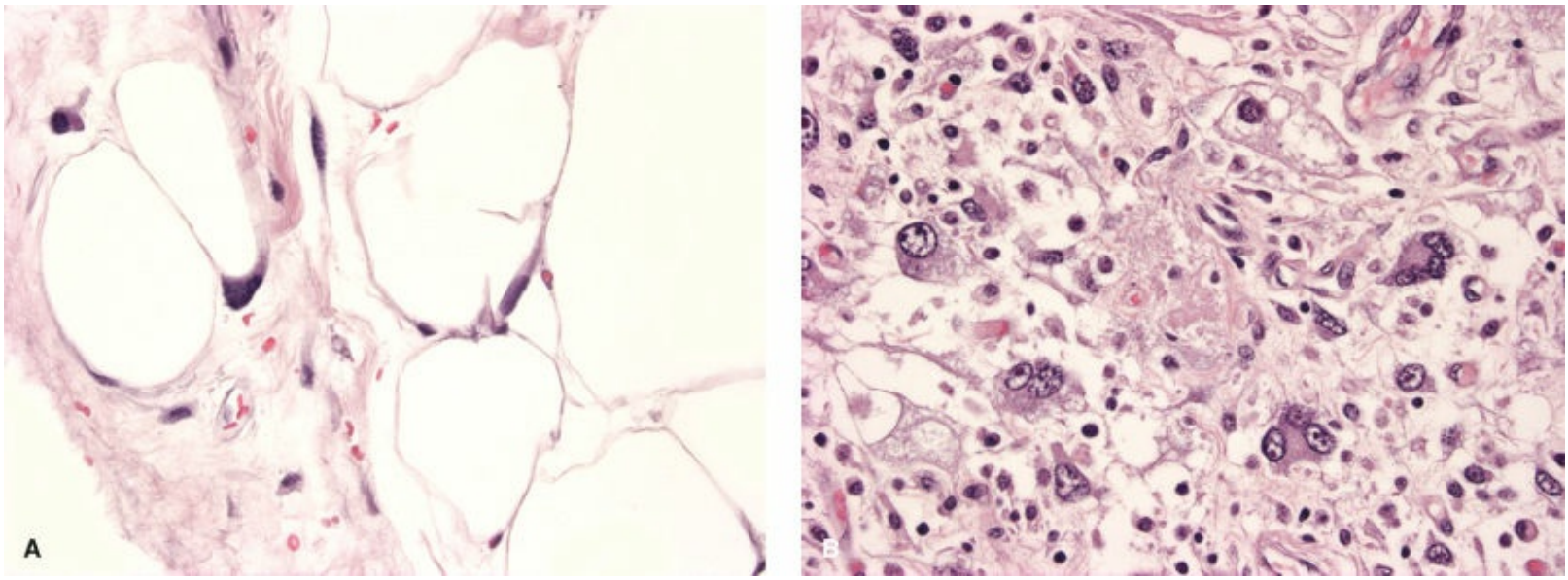

Figure 108-6. Histologic grading of sarcomas. Photomicrographs demonstrate the appearance of different grades within the same histologic subtype. **A:** Well-differentiated liposarcoma (lipoma-like) of the retroperitoneum with noted few atypical lipoblasts. **B:** High-grade, dedifferentiated liposarcoma of the retroperitoneum with highly atypical lipoblasts. (Courtesy of David R. Lucas, MD, University of Michigan, Ann Arbor, MI.)

Table 108-3 American Joint Commission on Cancer (AJCC): GTNM Classification and Stage Grouping of Soft Tissue Sarcomas

Classification	Description
Tumor Grade	
GX	Grade cannot be assessed
G1	Grade 1
G2	Grade 2
G3	Grade 3
Primary Tumor	
TX	Primary tumor cannot be assessed
T0	No evidence of a primary tumor
T1	Tumor <5 cm in greatest diameter
T1a	Superficial tumor
T1b	Deep tumor
T2	Tumor <5 cm in greatest diameter
T2a	Superficial tumor
T2b	Deep tumor
Lymph Node Involvement	
NX	Regional lymph nodes cannot be assessed
N0	No known metastases to lymph nodes
N1	Regional lymph node metastases
Distant Metastasis	
MX	Presence of distant metastasis cannot be assessed
M0	No known distant metastasis
M1	Known distant metastasis
Stage Grouping	
Stage I	G1-2, T1a, N0, M0
	G1-2, T1b, N0, M0
	G1-2, T2a, N0, M0
	G1-2, T2b, N0, M0
Stage II	G3-4, T1a, N0, M0
	G3-4, T1b, N0, M0
	G3-4, T2a, N0, M0
Stage III	G3-4, T2b, N0, M0
Stage IV	Any G, Any T, N1, M0
	Any G, Any T, N0, M1

Not including Gastrointestinal stromal tumors.
Used with the permission of the American Joint Committee on Cancer (AJCC), Chicago, Illinois. The original source for this material is the AJCC Cancer Staging Manual, Seventh Edition (2010) published by Springer Science and Business Media LLC, www.springer.com

In soft tissue sarcoma, the primary tumor is categorized according to size (<5 cm = T1, >5 cm = T2) and depth relative to the fascia (entirely above the fascia, or "superficial" = a; invading or entirely below the fascia, or "deep" = b). Because depth of tumor seemed to add significant prognostic information, this distinction was added to the 1998 edition of the AJCC staging system. One series of 215 patients with superficial extremity sarcomas documented a 10-year survival rate of 85% despite that 53% of

tumors were high grade and 25% of tumors were 5 cm or larger.[49] Though the cutpoint between small and large tumors is 5 cm, tumors larger than 10 cm seem to have an even worse prognosis.[50] When 316 patients with soft tissue sarcoma were grouped into four subgroups (<5 cm, 5 to 10 cm, 10 to 15 cm, and >15 cm), each subgroup had a distinct prognosis (84%, 70%, 50%, and 33%, respectively).[51]

2 For nonmetastatic sarcomas, location is a major determinant of survival (Fig. 108-7). Nodal metastasis of soft tissue sarcomas is rare (far less than 5% of cases), with the exception of a few histologic subtypes for which the incidence of nodal involvement may be between 10% and 20%. These subtypes include angiosarcoma, embryonal rhabdomyosarcoma, epithelioid sarcoma, synovial sarcoma, and clear cell sarcoma.[52] In the past, node involvement in sarcoma received classification as stage IV disease because of the associated poor prognosis. However, evidence suggested that lymph node metastases were associated with significantly better outcomes than systemic disease in the seventh edition of the AJCC staging system, and that survival was equivalent to stage III disease after directed lymphadenectomy.[53,54] Therefore, node involvement (N1) was reclassified as stage III disease in the absence of distant metastasis (M0).

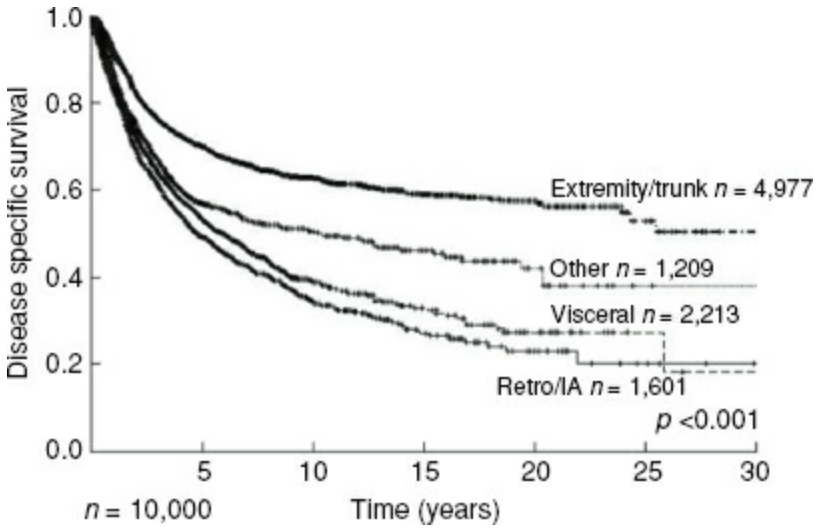

Figure 108-7. Soft tissue sarcoma disease-specific survival by site. *Hash marks* indicate censored patients. (IA = intra-abdominal; Retro = retroperitoneal). (From Brennan MF, Antonescu CR, Moraco N, et al. Lessons learned from the study of 10,000 patients with soft tissue sarcoma. *Ann Surg* 2014;260:416–422.)

By far the most common site of metastasis is the lungs though metastases to other sites do occur. Metastases to the liver should be considered with GIST or leiomyosarcoma.

TREATMENT

Principles of Surgical Resection

Complete surgical resection remains the cornerstone of treatment for soft tissue sarcomas. Performing a wide excision of the tumor with negative margins is the goal of resection with curative intent. Simple enucleation, if even possible, usually results in inadequate resection and should be avoided. Technical aspects of resection must take into consideration the anatomic location and extent of disease. Often, soft tissue sarcomas are surrounded by a zone of compressed reactive tissue that forms a pseudocapsule. Care should be taken to avoid entry into the tumor and pseudocapsule during course of dissection. Enucleation commonly results in microscopically positive margins and reresection can be considered though anatomic location may preclude effective clearance of margins even with a second operation.

Metallic clips placed in the tumor bed following resection can help define the limits of resection and aid in surveillance as well as the planning of future treatment. Suction drainage catheters are routinely used to obviate postoperative seroma formation following resection of extremity or truncal sarcomas. Drains should be placed close to the incision so that the site can be included in a postoperative radiation field and to minimize the extent of proximal involvement if amputation ever becomes necessary. A unique characteristic of sarcoma is the lack of metastasis to regional lymph nodes. If regional lymphadenopathy is discovered in conjunction with a diagnosis of sarcoma, therapeutic lymphadenectomy can be considered since clearance of disease may be associated with improved outcomes.[52,53] For selected histopathologic subtypes, in patients with clinically negative node examination, there may be a role for sentinel lymph node biopsy to identify occult micrometastatic disease.[55]

Taken together, sarcomas of the upper and lower extremities and trunk make up the majority of soft tissue sarcomas. Large truncal tumors may require reconstruction with a myocutaneous flap or prosthetic materials if resultant defects cannot be closed primarily (Fig. 108-8). Largely of historic interest now, radical amputations were once the mainstay of treatment for extremity sarcoma, but modern surgical approaches involve limb-sparing procedures (Fig. 108-9), which maximize functional outcomes. As recently as the 1970s, more than 50% of all soft tissue sarcomas of the extremity were treated with radical amputations. The accepted standard of care changed after the group at the National Cancer Institute, led by Rosenberg,[56] published the results of a randomized trial of limb-sparing resection plus adjuvant radiation therapy compared to amputation, finding no differences in disease-free survival rates (71% vs. 78%, respectively) and the overall survival rates (83% vs. 88%, respectively) at 5 years. This trial demonstrated that amputation was not mandatory and in 1985, a National Institutes of Health consensus statement recommended limb-sparing procedures for most patients with high-grade extremity sarcomas.[57] Radical amputations, such as hemipelvectomy, hip disarticulation, or forequarter amputation, are now reserved for patients who are not suitable candidates for limb-sparing approaches, usually because of extent of disease, bony or joint invasion,

or for otherwise unsalvageable recurrence after previous limb-sparing surgery (Fig. 108-10). There is no improvement in survival with this approach under these circumstances and serious morbidity must be taken into account.[58]

Acceptance of multimodality therapy has led to the ability to perform wide excisions while preserving function when treating extremity or truncal soft tissue sarcomas.[5,59,60] Radiation can be employed in the neoadjuvant or adjuvant setting, and evidence from randomized trials as well as retrospective studies support similar local control and progression-free survival rates with both strategies. A phase III trial in which patients were randomized to preoperative or postoperative radiation showed similar primary outcomes, but found that preoperative radiation was associated with much higher wound complications (35% vs. 17%, respectively) and this was especially true for lower extremity tumors. The interesting tradeoff was a higher rate of late treatment effects in the postoperative radiation group, attributed to relatively higher treatment doses and volumes.[61,62]

Judicious use of radiation has allowed for the sparing of major neurovascular structures, though if necessary, arteries and/or veins can be resected en bloc with the tumor and subsequent reconstruction can be done with autologous or prosthetic graft materials. In cases of neurologic compromise, customized adjuncts from experienced physical medicine departments can help restore reasonable function. For instance, resultant foot drop from peroneal neuropathy can be managed with an ankle–foot orthotic and gait training. In some cases, resection should be planned in conjunction with a plastic surgeon to provide complex soft tissue reconstruction with microvascular free flaps if the size of defect following resection prohibits primary closure.

Adjuvant and Neoadjuvant Therapies

3 The role of external beam radiotherapy is best defined by a trial comparing limb-sparing surgery alone with limb-sparing surgery with adjuvant radiation, showing improved 10-year local recurrence rates with radiation. In high-grade sarcomas, the recurrence rate was 0% versus 22%, respectively, though no significant effect on overall survival was appreciated.[63] Certainly, in the setting of involved surgical margins which could not otherwise be resected, adjuvant radiation therapy is associated with improved local control.[3,64]

There is controversy regarding the optimal use of radiation in the preoperative setting compared to the postoperative setting for extremity and truncal sarcomas. Radiation in the adjuvant setting with either external beam radiation or brachytherapy has long been the standard approach.[3] Typically, the entire surgical bed and drain sites are included in the field, along with wide margins around the sarcoma. Hemaclips marking the site of resection can be placed at the time of resection to help with radiation planning. It is important that an individual approach be taken with each patient since radiation can result in severe complications when used inappropriately (Table 108-4). For example, the entire circumference of the extremity should not be irradiated because massive lymphedema may result. Severe fibrosis, necrosis, fractures, and contractures can also occur with focused treatment and result in impaired function. Wound healing may be compromised in patients undergoing adjuvant radiation and in selected cases, use of rotational flaps for coverage can prevent or minimize chronic wound healing problems.[65] Similarly, radiation must be used judiciously in sensitive areas since nearby visceral structures are exquisitively sensitive to higher doses of radiation. Dose-limiting toxicity must be considered when recommending such therapies.

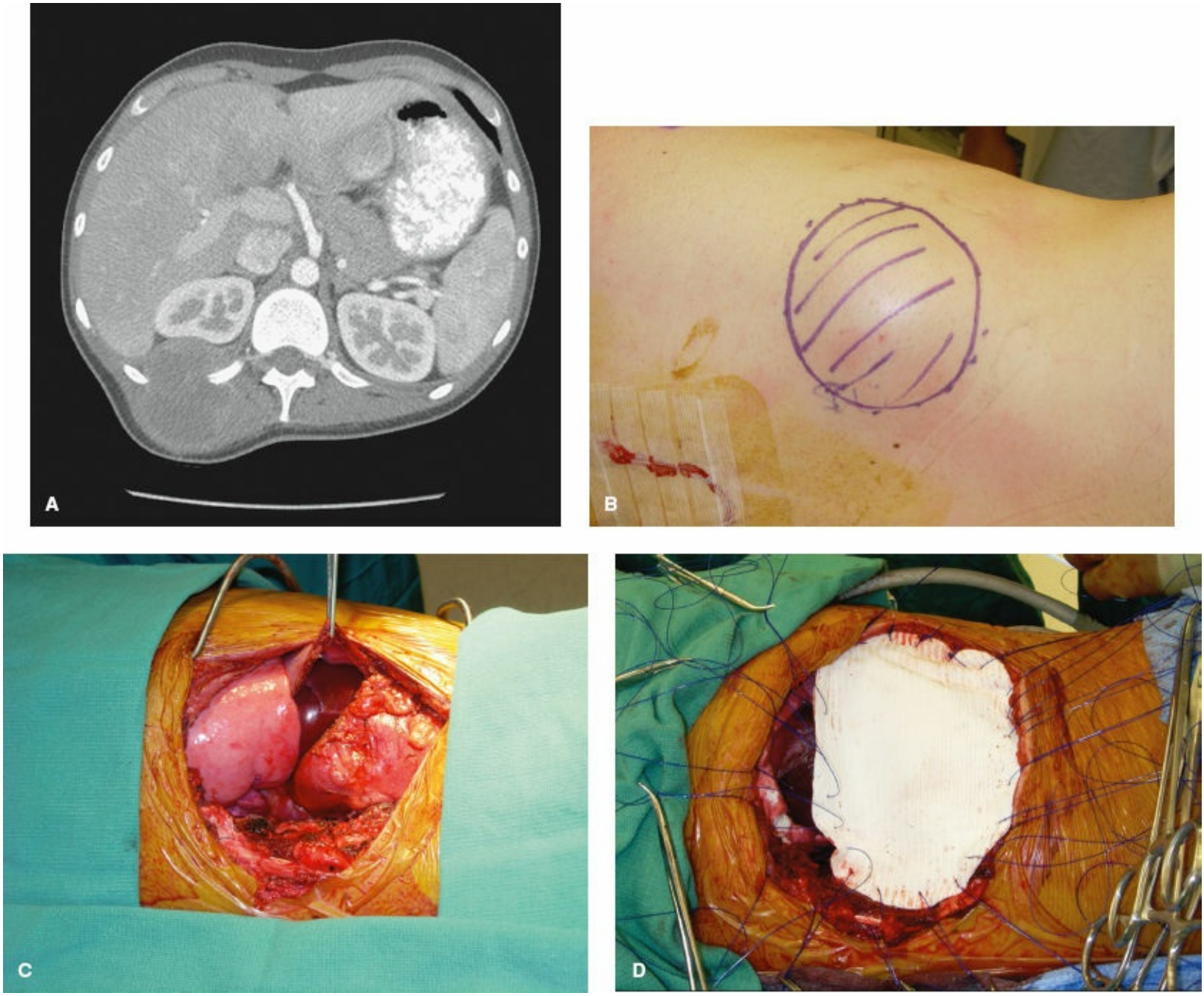

Figure 108-8. Chest wall sarcoma. A 20-year old man with a 7.5-cm right posterior chest wall epithelioid sarcoma involves the 11th and 12th ribs as seen on CT scan (**A**) and on physical examination (**B**). Chest wall resection was performed, including a portion of diaphragm. Resulting chest wall defect (**C**) was repaired using prosthetic mesh (**D**).

An alternate approach to adjuvant radiation is brachytherapy, which involves the placement of multiple catheters or seeds in the tumor resection bed to administer iridium.[192] Unlike the several week course needed to complete external beam radiation, a course of brachytherapy can be completed in a few days' time. In theory, brachytherapy produces less radiation scatter in critical areas, decreasing toxicity while obtaining equivalent functional outcome.[66] However, brachytherapy requires special equipment and can involve technically complex treatment planning by an experienced radiation oncologist. From a therapeutic standpoint, brachytherapy and external beam radiation appear to be equivalent when properly administered. There is increasing interest in the use of intraoperative radiation therapy (IORT), though its effectiveness is unproven. If IORT is employed, it is currently done in conjunction with a planned external beam boost

dose.[67]

Patients with high-risk (large [>10 cm], high-grade) extremity sarcomas should be considered for preoperative treatment with chemotherapy or with chemoradiation since overall local control rates are disappointing with postoperative radiation alone.[59] Local control rates were considerably higher when large tumors were treated before surgery and in some cases, tumors initially considered unresectable without amputation shrank sufficiently to permit limb-sparing resection. There are several benefits of preoperative radiation. With the tumor in situ, there tends to be a smaller overall treatment volume and the theoretical advantages of more effective radiation because it is being delivered to an undisturbed tumor bed. There is also the potential benefit of decreased seeding during the course of resection and improved margin status because the radiation may shrink the tumor's pseudocapsule and render it relatively acellular. However, there is one major disadvantage to preoperative radiation and that is its detrimental effect on wound healing. Some groups have used an intraoperative or postoperative boost dose of radiation to the resection bed if there are concerns that margins are involved.

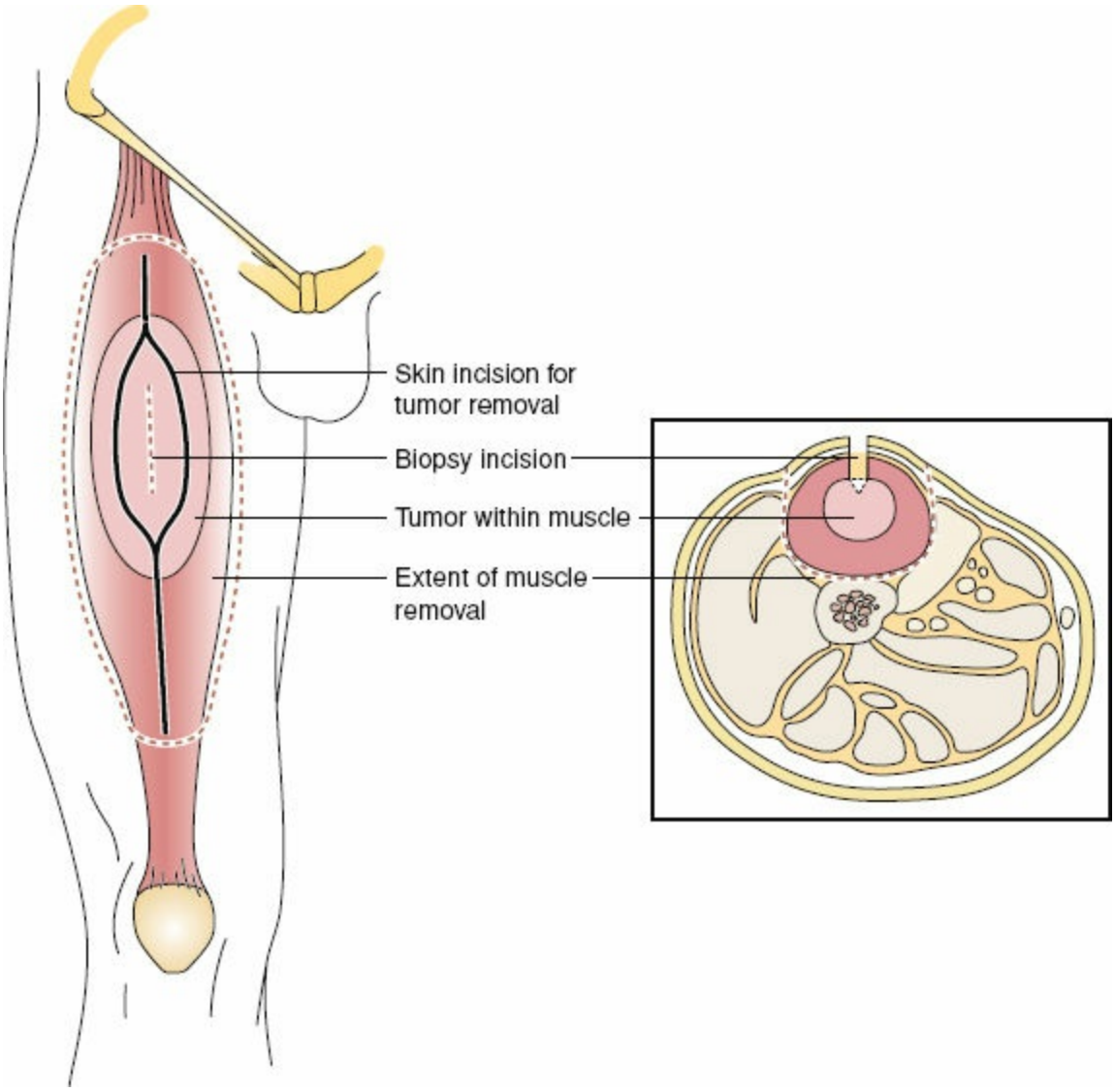

Figure 108-9. Wide excision involves removal of the tumor with a margin of normal tissue. If necessary, major vascular structures or nerves may be resected.



Figure 108-10. **A:** Radical amputations for extremity sarcomas include one joint above the most proximal extent of tumor. Now largely of historic interest, tumors of the proximal thigh or buttock were previously routinely treated with hemipelvectomy. **B:** While limb-sparing procedures are now done whenever possible, amputation may be necessary for certain cases. This 60-year-old woman had high-grade angiosarcoma of the right leg with extensive satellite metastases extending above her knee. She required above-knee amputation.

Table 108-4 Complications of Treatment for Extremity Sarcoma

Treatment Modality	Complication	Comment
Surgical resection	Wound complications Seroma/hematoma Inadvertent damage to neurovascular structures	
Radiation	Fibrosis Edema Pathologic fracture Delayed wound healing/wound complications	Prophylactic intramedullary nailing may be considered Greater incidence with preoperative radiation treatment
Chemotherapy		
Doxorubicin	Myelosuppression Cardiotoxicity (arrhythmia, heart failure)	Baseline echocardiogram and/or MUGA are mandatory Combination therapy may have additive toxicities Alopecia and nausea/vomiting are common side effects of these chemotherapy agents
Ifosfamide	Myelosuppression Neurotoxicity Nephrotoxicity	

Increasing data support the use of resection alone for selected patients; those who have small (<5 cm), low-grade tumors seem to have acceptable local control and excellent long-term survival without radiation if wide margins are obtained at the time of resection.[68,69] Most patients undergoing surgical excision may be candidates for additional radiation therapy because of high risk for recurrence, though its role in lower- or intermediate-risk patients is somewhat undefined, and the so-called therapeutic ratio of risk and benefits to radiation treatment must be carefully considered. Validated prognostic tools may be helpful for individual patients weighing the benefits of available treatment options. Kattan et al.[70] developed a nomogram to help better predict individual risk for 12-year disease-specific mortality in sarcoma patients using multiple prognostic factors simultaneously.

For extremity sarcomas, the importance of pathologically negative margins must be emphasized. While differing widths of margins have been called "optimal," it is generally agreed that 1 to 2 cm are adequate, but that microscopically clear margins may be sufficient. Involved margins, along with age, recurrent presentation, and fibrosarcoma or MPNST subtypes, significantly increases the risk of local recurrence.[3,71] Patients presenting with involved margins following the index operation should be offered reresection in order to obtain surgical clearance of margins. Several studies have shown no compromise in survival if complete resection is achieved with a second operation.[72] Interestingly, it is unclear if local recurrence predisposes to subsequent distant metastasis or if margin status is merely a proxy for aggressive disease.[71,73]

Since the main cause of death in patients with soft tissue sarcoma is distant metastatic disease, continued efforts have been made to develop effective systemic therapies.[5,74] Postoperative adjuvant chemotherapy has been controversial because risk of adverse toxic effects may not be outweighed by the relatively low response rates and lack of durable results. The histologic subtypes of sarcoma vary in their responsiveness to chemotherapy. For example, osteogenic sarcoma, rhabdomyosarcoma, and Ewing sarcoma (the "pediatric" sarcomas) have had high rates of success with multimodality treatments including adjuvant chemotherapy.[59] Unfortunately, most randomized trials are underpowered to detect modest differences in survival and promising response rates reported in smaller nonrandomized clinical trials are not duplicated in subsequent larger randomized trials. In general, adjuvant chemotherapy is not ever indicated for patients with low-grade sarcomas and patients with small sarcomas of higher grades. Initial interest in adjuvant chemotherapy for extremity soft tissue sarcoma was piqued by a randomized trial reported by Rosenberg et al.[75] which demonstrated an improvement in disease-free and overall survival with adjuvant doxorubicin, cyclophosphamide, and high-dose methotrexate. After a longer follow-up period (median follow-up 7.1 years), however, both disease-free and overall survival were not statistically significant.[76]

Over the years, single agents as well as combination chemotherapy regimens have been used in the adjuvant treatment of soft tissue sarcomas. Two of the more active agents include doxorubicin and ifosfamide. However, multiple randomized trials of postoperative chemotherapy have not demonstrated an improvement in disease-free or overall survival with intermediate or long-term follow-up though there was a trend toward chemotherapy

in many studies.[59,77–79] The Sarcoma Meta-analysis Collaboration evaluated the effect of adjuvant doxorubicin-based chemotherapy in 1,568 patients from 14 trials.[80] Although the time to local and distant recurrences, as well as recurrence-free survival, were significantly better in the treatment group, an overall survival advantage was not seen (HR 0.89, $p = 0.12$). Because of the rarity of disease and heterogeneity of tumor characteristics, most studies are too small to provide adequate power for testing responses in specific histologic subtypes. In general, many regimens have combined two of the most active agents, doxorubicin (or other anthracycline) and ifosfamide, and results from a randomized trial did show improved disease-free survival and overall survival; distant relapse rates were not different however.[81] Outside of clinical trials, adriamycin and ifosfamide combination therapy is commonly used for high-risk, primary extremity and truncal sarcomas in the adjuvant setting. Newer regimens with promising results include the combination of gemcitabine and docetaxel which was initially discovered to be active in heavily pretreated uterine leiomyosarcomas and is currently being considered for use in that subtype as well as in high-grade undifferentiated pleomorphic sarcomas and other high-risk subtypes.[82–84] A phase II study comparing adriamycin and ifosfamide to the combination of gemcitabine and docetaxel found that the latter regimen had a slightly lower hospitalization rate and trends toward longer disease-free survival rates.[85]

Even with advances in systemic chemotherapy and targeted agents, data supporting greatly improved overall survival rates are sparse, especially in the adjuvant setting. For advanced tumors, treatments with single agents or combination regimens such as dacarbazine, doxorubicin, epirubicin, ifosfamide, gemcitabine, docetaxel, temozolomide, trabectedin, and eribulin have been trialed extensively. Newer targeted therapies have shown some promise in certain histologic subtypes. For example, tyrosine kinase inhibitor (TKI) agents such as pazopanib, imatinib, sorafenib, and sunitinib have shown efficacy in multiple subtypes after initial success with GISTs. The class of mTOR inhibitors (sirolimus, temsirolimus, and everolimus) has demonstrated promise for perivascular epithelioid cell tumors (PEComas), lymphangioleiomyomatosis, and angiomyolipomas.

One potential advantage of upfront systemic chemotherapy is the ability to assess tumor response in situ. By seeing whether the tumor responds to the chemotherapy, both radiologically and pathologically, it may be possible to spare patients prolonged therapy if they have not shown a response, or to continue therapy postoperatively if there is response. However, data from a trial of preoperative doxorubicin and ifosfamide-based chemotherapy conducted by the European Organisation for Research and Treatment of Cancer (EORTC) and the National Cancer Institute of Canada did not demonstrate any survival benefit compared to surgery alone.[86] Some agents such as gemcitabine may have chemosensitizing properties,[87] making preoperative chemoradiation strategies attractive. Based on current evidence, neoadjuvant chemoradiation, either concurrent or sequential, should only be offered to selected high-risk patients on clinical protocol.[88] It is important to follow patients on neoadjuvant therapy closely since tumor progression is expected to be seen in approximately 30% of patients.[89,90]

Commonly used measures of radiologic response to treatment may not be good

surrogate endpoints for treatment response.[38] The pathologic correlations of treatment-induced necrosis or histologic response to therapy with clinical outcomes have also not been well defined in soft tissue sarcoma.[91] Some patients who have a clinical or pathologic response to chemotherapy may have improved local control and decreased distant disease-free survival, but no overall survival advantage.[92] In other cases, lack of measurable response did not seem to predict significant differences in event-free endpoints.[89] These issues must be carefully considered in the design of future trials.

Alternative approaches to standard systemic therapy have been attempted with limited success. For example, preoperative radiation therapy in combination with intra-arterial doxorubicin chemotherapy initially showed good local control, but results could not be duplicated in subsequent randomized trials and treatments were associated with high morbidity.[93,94] Regional chemotherapy administered via hyperthermic isolated limb perfusion has been attempted for advanced extremity sarcomas. Extracorporeal circulation allows the delivery of drug concentrations 10 to 20 times higher than with systemic delivery and a European study showed a limb-salvage rate of 71% for unresectable extremity sarcomas using melphalan and tumor necrosis factor-α.[95,96] However, this technique is uncommonly used in the United States and usually reserved for highly selected patient populations.

RETROPERITONEAL AND INTRA-ABDOMINAL SARCOMAS

Management of intra-abdominal (visceral) and retroperitoneal sarcomas deserves special consideration since specific anatomic location may dictate workup and subsequent management. The grouping of visceral sarcomas generally includes tumors of the gastrointestinal tract and gynecologic organs, and less commonly, genitourinary organs. Location often precludes early diagnosis, unless the mass is found incidentally. Though some patients have noted increased abdominal girth, an abdominal mass can be appreciated with focused physical examination, but it is uncommonly the presenting complaint. Typically, vague symptoms of mass effect intra-abdominally trigger medical evaluation. Neurovascular symptoms related to compression or invasion can occur and manifest as paresthesia, dysesthesia, weakness, and swelling or varicosities in the lower extremities.

Complete history and physical examination should exclude signs and symptoms of lymphoma (e.g., B-symptoms such as fevers and night sweats) and presence of scrotal masses concerning for testes cancer. Serum laboratory testing can be helpful if lymphoma (e.g., elevated lactate dehydrogenase [LDH]), germ-cell tumors (e.g., elevated beta-human chorionic gonadotropin (B-HCG) or alpha-fetoprotein [AFP]), or adrenal tumors (i.e., cortisol levels or adrenocorticotropic hormone [ACTH]) are in the differential diagnosis. High-quality cross-sectional imaging with CT or MRI is critical for diagnosis and treatment planning. Use of oral and intravenous contrast defines extent of primary disease and the relationship of the tumor to nearby structures. Chest imaging should be obtained to assess for presence of pulmonary metastases. Hepatic involvement is the second most common site of distant spread in intra-abdominal and retroperitoneal sarcomas, so a CT scan that includes the proper contrast phasing for examination of the liver should be done.

4 For large tumors, preoperative image-guided biopsy can almost always be performed by experienced interventional radiologists (Fig. 108-11). However, preoperative biopsy is not mandatory[5,97] if management would not be altered by findings. Use of biopsy is reserved for cases in which a diagnosis of sarcoma is in question or if neoadjuvant approaches are being considered for large, high-grade lesions or lesions which are locally advanced and potentially unresectable. Complete resection is the treatment of choice for intra-abdominal (visceral) and retroperitoneal sarcomas whenever possible. Only complete resection is associated with long-term survival benefit, with retroperitoneal liposarcomas being a possible exception.[98,99] For retroperitoneal sarcomas, median survival for those with an incomplete resection is similar to those who were observed (unresectable)[100] (Fig. 108-12). In general, incomplete resection should only be considered for palliation of intractable symptoms. While successful palliation may be achieved in carefully selected patients, aggressive tumor biology limits the ability to maintain sustained relief of symptoms.[101]

In order to attain complete removal of the sarcoma, en bloc resection of nearby structures should be considered when necessary. Resectability is more a function of location than of size, grade, or histologic subtype. Common reasons for unresectability

include distant metastasis, peritoneal metastasis, extensive multifocality, and prohibitive vascular involvement. Though sarcomas do not uniformly invade other structures, involvement of vascular structures or mesentery (mesocolon) may lead to resection of solid organs or bowel that may not be directly involved. When nephrectomy may be necessary, it is important to assess bilateral renal function with preoperative contrast scanning. Concomitant nephrectomy, when necessary, is associated with comparable outcomes for retroperitoneal sarcomas overall.[102] Commonly resected organs include the following: kidney, colon, adrenal gland, pancreas, and spleen.[103] For tumors located in the pelvis, it may be necessary to perform en bloc resection of the colon/rectum, bladder, and uterus. When vascular structures limit complete resection of tumor, resection with ligation or reconstruction of vessels must be considered if technically feasible (Fig. 108-13).

Even when surgical resection is possible and complete gross resection is achieved, margin status is often compromised by constraints of visceral anatomy. A transperitoneal approach allows for excellent exposure and facilitates en bloc resection of with early control of the vascular supply to the tumor. Analyses of relatively aggressive approaches to resection include complete compartmental resections and liberal use of en bloc visceral resection shows better local control, but high-grade tumors tend to recur systemically. Proper patient selection for so-called “aggressive resection” needs to be weighed against the natural history of sarcoma.[104–106] It is generally agreed that the best chance for curative intent resection is at the time of first operation. Complex multivisceral operations should be referred to higher-volume centers with experienced sarcoma surgeons when possible.

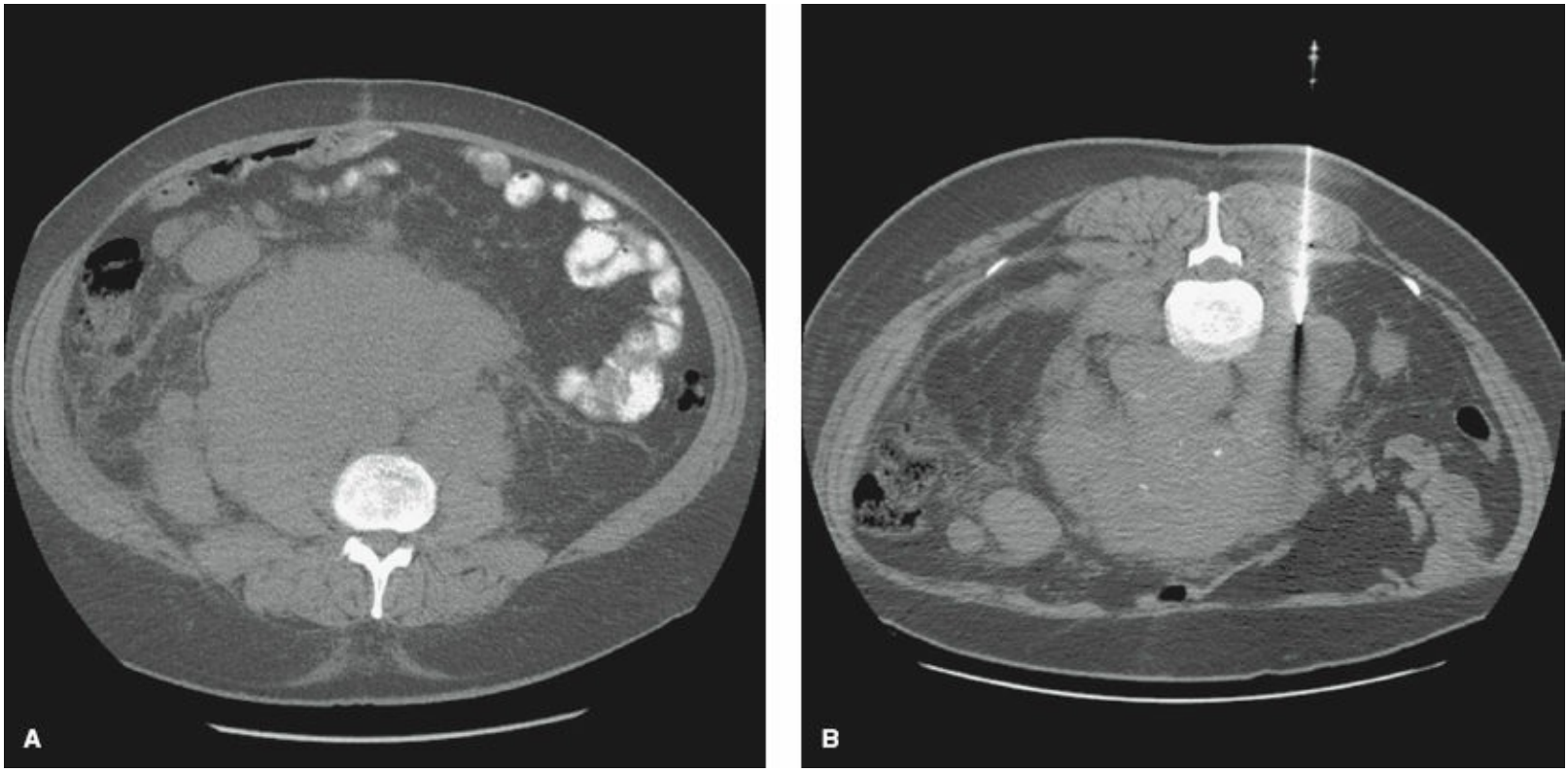

Figure 108-11. Biopsy can be helpful in the workup of retroperitoneal masses. **A:** CT scan shows a retroperitoneal mass encasing the IVC and aorta. **B:** Image-guided biopsy is demonstrated here. Pathology confirmed a diagnosis of large B-cell lymphoma.

Even with aggressive surgical management, local recurrence rates range from 40% to 70% for high-grade tumors.[13,107] Unlike extremity sarcomas, local progression is associated with decreased survival. Difficulty obtaining negative margins and high recurrence rates support a role for carefully selected multimodality treatments. The benefits of radiation for extremity sarcomas have not been similarly appreciated for retroperitoneal sarcomas and no improvement in disease-free intervals have been noted.[108] Large field sizes and the dose-limiting toxicity of abdominal viscera limit the utility of postoperative radiation, and preoperative radiation warrants consideration. The major advantage of preoperative radiation is the displacement of small bowel and other structures by the in situ tumor. Similar to preoperative radiation for extremity tumors, a possible advantage in the abdomen/retroperitoneum is that the radiation may prevent later seeding of tumor cells because radiation is administered to tumor and surrounding peritoneum. With the advent of conformal technology, or intensity-modulated radiation therapy (IMRT), further selective application of radiotherapy may be possible with minimal toxicity.[109,110] The role of chemotherapy, either in the preoperative or postoperative setting, is unproven for intra-abdominal and retroperitoneal sarcomas.[111,112] Several trials of postoperative adjuvant chemotherapy do not show any benefit for patients with retroperitoneal sarcoma, and in one series, treated patients fared worse than those not receiving chemotherapy.[113] In one trial of an aggressive multimodality approach, there was an improvement in locoregional control but no overall survival advantage and significant toxicity from the chemotherapy and radiation therapy.[114] Though some histologic subtypes, such as leiomyosarcoma, pleomorphic

sarcoma, or myxoid/round cell liposarcoma, may be relatively more responsive to systemic treatments, a paucity of data exist to guide appropriate use of therapy. Randomized controlled trials have been notoriously difficult to accrue patients to.

Special consideration is also given to complete resection with functional preservation in head and neck sarcomas and genitourinary sarcomas. As is true of sarcomas in other anatomic locations, histologic grade and size adversely affect prognosis for head and neck sarcomas.[115] Resections with negative margins may not require adjuvant radiotherapy treatments. Similarly, grade, size, location, and histologic subtype similarly predict disease-specific survival for genitourinary sarcomas.[116] Regional relapse is influenced by margin status so radical resections are necessary. Unfortunately, recurrences are not uncommon and may be difficult to control due to anatomic location.

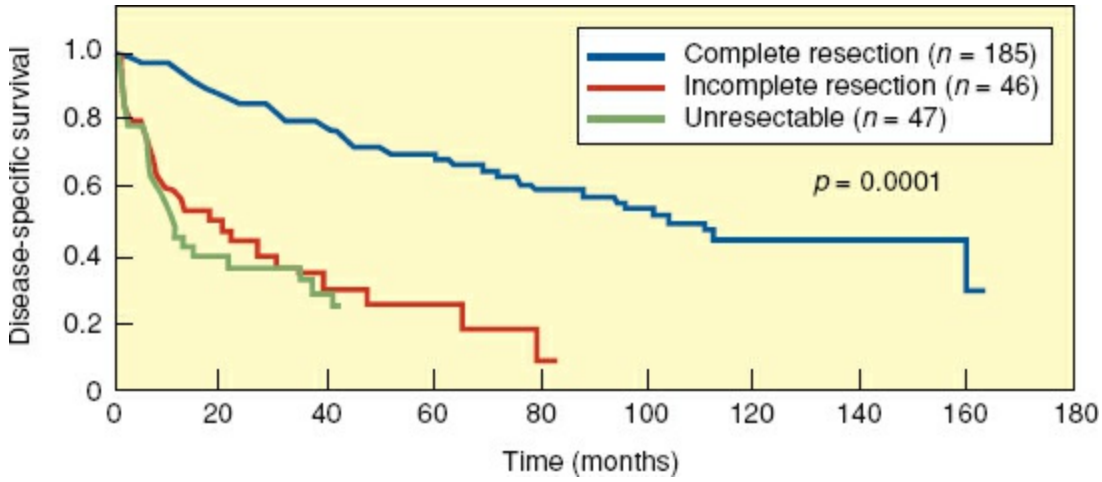

Figure 108-12. Kaplan–Meier plot of disease-specific survival for patients with retroperitoneal sarcomas treated at Memorial Sloan Kettering Cancer Center. Disease-specific survival is 103 months in patients who underwent complete resection of retroperitoneal sarcomas, compared to 18 months in those who had an incomplete resection or just observation. (From Lewis JJ, Leung D, Woodruff JM, et al. Retroperitoneal soft-tissue sarcoma: analysis of 500 patients treated and followed at a single institution. *Ann Surg* 1998;228(3):355–365.)

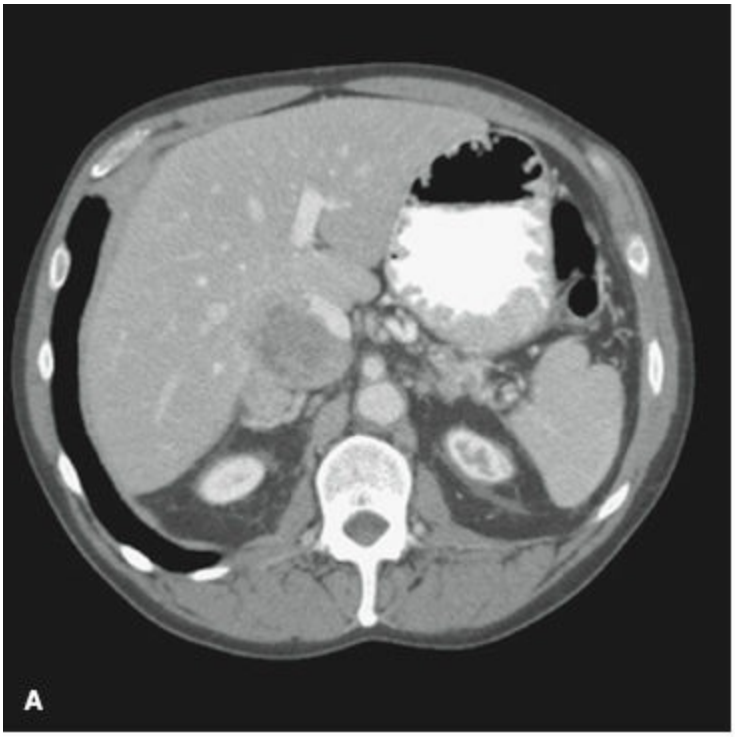



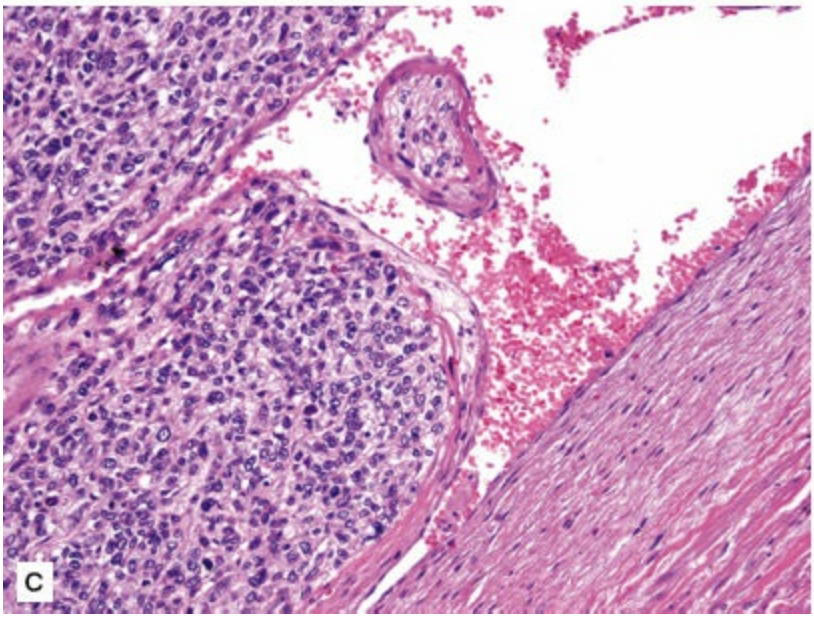

Figure 108-13. Inferior vena cava (IVC) leiomyosarcoma. **A:** CT scan demonstrates a 9.2- × 6.4- × 4.4-cm mass within the lumen of the retrohepatic IVC. **B:** Photograph of the gross specimen. Cross-sectional view from the superior aspect of the specimen demonstrates the extensive filling of the lumen with multilobulated tumor. **C:** Photomicrograph demonstrating intraluminal high-grade leiomyosarcoma with nuclear atypia and pleomorphism. Uninvolved smooth muscle of the IVC is shown (right lower quadrant). (Courtesy of Jason Carvalho, MD and David R. Lucas, MD, University of Michigan, Ann Arbor, MI.)

RECURRENT OR METASTATIC DISEASE

About two-thirds of soft tissue sarcoma recurrences occur in the first 2 years after diagnosis and treatment, though recurrences may be seen at any time.[117] Recurrences may be classified as locoregional or distant. Though no standardized follow-up regimens exist, routine history and physical examination (clinical follow-up) and interval chest imaging are recommended for the first 2 to 3 years. Site-specific imaging guidelines are less clear. Directed cross-sectional imaging studies are helpful if location of tumor precludes early detection of recurrence on clinical evaluation alone. Of course, the choice of imaging study depends on availability, cost, and anatomic site being examined. MRI of the extremity or trunk can help detect locoregional recurrences when they are relatively small. CT scans may be useful for detection of intra-abdominal or retroperitoneal recurrences which would otherwise be undetectable. However, there is no evidence that earlier detection improves survival for retroperitoneal sarcomas,[100] so a less aggressive imaging schedule may be appropriate.

If chest radiography is used, abnormal findings should be followed with a CT scan of the chest. Low-grade lesions infrequently metastasize in the absence of local recurrence, though can recur locally up to 20 years after original resection. For high-grade lesions, surveillance should be directed toward detecting recurrence and metastatic disease. Patients with locally recurrent or even metastatic sarcomas can be considered for surgical resection if tumor biology supports potential cure or effective palliation with removal of known disease. Recurrent disease, especially within the abdomen or retroperitoneum, becomes more difficult to treat with each recurrence.[117]

If a recurrence is suspected, a biopsy should be performed to confirm diagnosis and review histologic subtype as well as tumor grade, with reference to the original tumor if possible. In the absence of distant disease, an aggressive surgical approach is warranted with the goal being the same as with a primary sarcoma – control of the tumor and preservation of as much function as possible. For patients who were initially treated with surgery alone and who failed locally, multimodality treatment with repeat resection, radiation, and sometimes chemotherapy is associated with survival rates close to those of previously untreated patients.[118–120] Independent predictors of survival in patients with locally recurrent extremity soft tissue sarcomas include histologic grade, size of recurrent disease, and recurrence-free interval.[121]

The most common site of distant metastatic disease is the lung, and its presence is not detectable by symptoms. Again, CT is the preferred imaging modality, though its very high sensitivity for detecting pulmonary nodules as small as 2 mm decreases its specificity.[122,123] Occasional patients have liver, bone, or central nervous system metastases though these sites of disease are relatively uncommon. Once diagnosed, metastatic disease is best approached with systemic chemotherapy, either as a single agent or with combination treatments. Pulmonary metastases are the most common form of distant disease, and metastasectomy in carefully selected patients seems to improve outcomes. Taking patient selection into account, resection of pulmonary metastases in combination with radiation and/or chemotherapy, may improve outcomes compared to

resection alone[124,125] (Fig. 108-14).

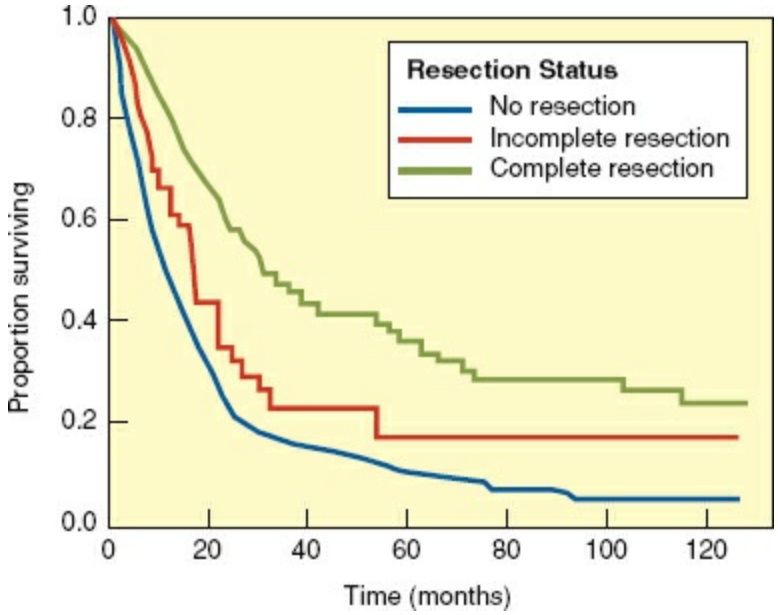

Figure 108-14. Kaplan–Meier plot of disease-specific survival for patients with pulmonary metastases treated at Memorial Sloan Kettering Cancer Center. Patients treated with complete resection had a median survival of 33 months. Patients who underwent incomplete resection or who did not undergo resection had median survival of 16 months and 11 months, respectively. (From Billingsley KG, Burt ME, Jara E, et al. Pulmonary metastases from soft tissue sarcoma: analysis of patterns of diseases and postmetastasis survival. *Ann Surg* 1999;229(5):602–610.)

GASTROINTESTINAL STROMAL TUMORS

Another subtype of sarcoma which deserves separate consideration is GIST. Prior to modern molecular diagnostic techniques, these tumors were likely to have been considered leiomyosarcomas based on histologic features.[13] It is now known that GISTs are differentiated from GI leiomyosarcoma based on lack of well-differentiated smooth muscle cells. GISTs are composed of more primitive mesenchmyal cells and originate from the interstitial cell of Cajal, which functions within the GI autonomic nervous system. Immunohistologic diagnosis is made via expression of KIT (CD 117) cellular markers. KIT overexpression is usually related to mutations in the *KIT* gene, although *PDGFR*-α mutations can also result in KIT overexpression in approximately 3% to 5% of GIST. KIT-negative GISTs have been reported, though tumor genotyping should be done to either *KIT* or *PDGFR*-α mutations even with negative immunohistochemistry for KIT.[126]

The *KIT* proto-oncogene encodes for KIT protein, a transmembrane glycoprotein receptor with an intracellular tyrosine kinase domain. Binding of the KIT ligand induces dimerization and autophosphorylation of KIT, activating a cascade of intracellular signaling which results in cell proliferation and tumorigenesis. A gain of function mutation in KIT occurs in up to 90% of GIST[127] and results in ligand-independent (constitutive) activation of tyrosine kinase function.[128] KIT mutation is found in 90% of GIST and the most frequent sites of mutation are found in exon 11 (70%) or exon 9 (10%), whereas rare mutations are found in exon 13 or exon 17.[129] Mutation status may affect prognosis, and testing has become more routine in the evaluation of GIST.

Swedish epidemiologic data estimates 14.5 cases per million, which translates to an annual US incidence of 4,000 to 5,000 new cases of GIST per year.[130] GISTs are largely sporadic, but they have been seen in association with hereditary syndromes such as von Recklinghausen disease and Carney triad, and familial germline mutations have been identified. Clinical presentation can be indolent – most patients have nonspecific symptoms such as nausea, emesis, or abdominal discomfort. Infrequently, GIST can rupture or bleed, leading to a more emergent presentation. GISTs are most commonly found in the stomach (50% to 60%), with 30% to 40% of tumors in the small bowel, 5% in the colon or rectum, and 5% in the esophagus. Rarely, GISTs develop within the mesentery, omentum, or retroperitoneum. Most GISTs are found in adults over the age of 40, with a median age of 60 years. Tumors found in children or young adults are considered a separate entity since pediatric GISTs have a more epithelioid histology and wild-type KIT or PDGFR-α genotype.[131]

Complete surgical resection is the treatment of choice for GIST, but recurrences are common and 5-year survival following resection of a localized tumor is approximately 50%.[132] Recurrences are common and thought to occur at 18 to 24 months from the time of the index operation. Lymph node dissection is not warranted because GIST very rarely metastasizes to regional nodes. Treatment of GIST was revolutionized with the development of imatinib mesylate (Gleevec), a selective tyrosine kinase inhibitor, representative of the emerging paradigm of molecularly targeted therapies. The proof of concept for this treatment paradigm was demonstrated in 2000 when a patient with

diffuse metastatic disease achieved a near-complete metabolic response[133] on PET and with 75% reduction in tumor size at 8 months and histologic evidence of myxoid degeneration and lack of mitotic activity. Contemporary use of imatinib in patients with metastatic GIST is considered appropriate first-line treatment of metastatic disease (Fig. 108-15).

For patients who present with localized tumors, resection remains the mainstay of treatment. Interestingly, emerging evidence suggests that incidentally discovered, very small GISTs (<2 cm) may be successfully managed expectantly.

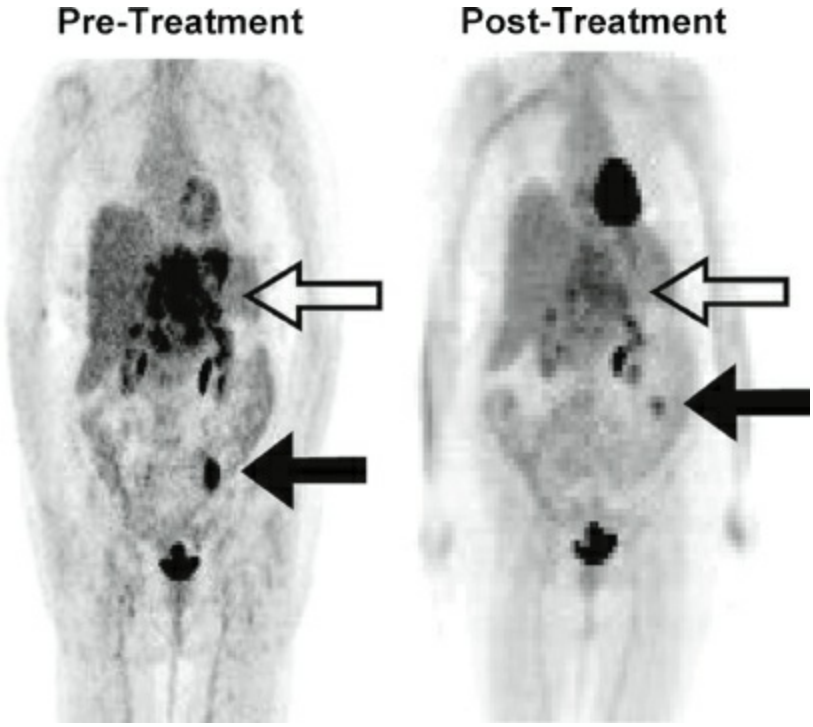

Figure 108-15. ^{18}FDG-PET scan showing response of metastatic GIST to imatinib mesylate. This patient presented with primary disease in the small bowel and synchronous metastatic disease in the liver. The scan at presentation (**left**) compared to the one obtained after 3 weeks of therapy (**right**) shows decrease in size of tumors and decreased ^{18}FDG uptake in both the small bowel and liver tumors consistent with a good response to imatinib. The patient eventually went on to complete surgical resection. (From Gold JS, Dematteo RP. Combined surgical and molecular therapy: the gastrointestinal stromal tumor model. *Ann Surg* 2006; 244(2):176–184.)

5 The use of imatinib in the adjuvant setting has been informed by a number of clinical trials. Mutation status is predictive of treatment success; *KIT* exon 11 mutations are associated with better response rates and survival endpoints than exon 9 mutations and wild-type GISTs. Because of high rates (>50%) of recurrence or metastasis following resection, at least 3 years of imatinib is recommended for high-risk tumors, including tumors which are greater than 5 to 10 cm in size or contain more than 5 mitoses per 50 HPFs. Risk stratification must be approached with care; other factors which need to be considered include location of tumor and mutation status. It is reasonable to consider the use of imatinib for large or borderline resectable lesions prior to surgical resection. Most of these cases require continued treatment after resection given the high risk of recurrence or metastasis. Second- and third-line (and beyond) therapies are available for

drug-resistant disease, but as expected, responses following failure of first-line therapy are highly variable.

DESMOID TUMORS/DESMOID FIBROMATOSIS

Desmoid tumors warrant separate notation in the discussion of soft tissue tumors because of their distinct biologic behavior.[15,134] Desmoid tumors, or aggressive deep-seated fibromatosis, are part of a rare group of fibrous tissue proliferations which have no propensity for metastasis but tend to be locally aggressive. The natural history of desmoid tumors is not well defined and poorly understood. Clinical behavior and therefore, recommended treatments, are often dictated by anatomic site. Location of tumors can limit therapeutic options and result in significant morbidity with or without surgical resection.

Desmoid tumors are uncommon with an estimated incidence rate of 2 to 4 cases per million per year. The median age of diagnosis is 35, range 16 to 79 years. Desmoids are slightly more common in women than men. Desmoid tumors are classically described as an abdominal wall tumor, seen in young women during the postpartum period.[135] However, desmoids can occur at any site in the body and three main anatomic sites are described: (1) trunk or extremity, (2) abdominal wall, and (3) intra-abdominal (bowel and mesentery). Fibromatosis is usually seen sporadically, but can be associated with FAP.

Desmoids are characterized by a monoclonal fibroblastic proliferation arising from muscular or aponeurotic structures. On gross examination, the tumors appear firm and smooth, with a surrounding pseudocapsule. However, microscopically, the tumor characteristically extends beyond this pseudocapsule, with fibrous septae of tumor extending radially. Desmoid tumors had previously been classified as an unchecked reactive process rather than a neoplastic process, but uniform patterns of X-chromosome inactivation seems to confirm tumors of clonal composition.[136] There appears to be an increased estrogen receptor-β, but not estrogen receptor-α, expression in 80% of desmoid specimens.[137] These findings lend some support for the treatment of tumors with adjuvant agents such as tamoxifen.

Tumors tend to be located deep in the muscles or along fascial planes, such as at a point of muscular insertion. Patients will usually present with a greater than 5 cm, localized, firm mass with an indolent pattern of growth, which can be minimally painful. Intra-abdominal presentations can be associated with mass effect, intestinal obstruction, or mucosal ischemia. Desmoid tumors are notoriously infiltrative, and microscopically involved margins are seen in a significant number of patients.

Complete resection is considered the best course of treatment, though resection is sometimes constrained by anatomic boundaries. For intra-abdominal tumors, extensive association with the mesentery limits the extent of resection and could predispose to significant morbidity and ultimately, mortality due to bowel involvement. Resection of large abdominal wall tumors often requires prosthetic reconstruction of the resulting defect. Ability to accomplish complete resection at the first attempt defines likelihood of recurrence, so it is important to have a sufficient preoperative suspicion of fibromatosis and to be circumspect in surgical technique. Positive margins do not inevitably lead to recurrent disease, just as patients with a complete microscopic resection are often found

to have local recurrences.[138] Given the natural history of desmoid fibromatosis, emerging management strategies for selected tumors which are small, asymptomatic, and located such that growth would not change ability to resect or lead to functional limitations are increasingly discussed. Surveillance plans must be adhered to and progression prompts resection or other treatment.

There are no data to support the use of radiation therapy in the adjuvant setting following a complete surgical resection. The utility of radiation in the setting of positive resection margins is thought to be quite minimal given the difficulty in predicting risk of recurrence in these patients. A number of systemic treatment regimens have been used in the past and in present practice with varying results.

BONE SARCOMAS

A variety of primary bone tumors are well described (Table 108-5). The vast majorities (>70%) of bone malignancies represent metastasis from another site or are of hematologic origin (lymphoma or myeloma). Primary bone cancers, however, are an extremely rare type of cancer, with only an estimated 3,300 new cases in 2016.[1] The three main types of bone sarcomas are osteosarcoma (which arises from bone), chondrosarcoma (which arises from cartilage), and Ewing sarcoma (which have an undefined origin). As with soft tissue sarcomas, a GTNM staging system is used by the AJCC[45] (Table 108-6). Modern multimodality treatment approaches have been associated with excellent outcomes, including possibility of cure for many osteosarcoma cases.

Table 108-5 Histologic Classification of Bone Tumors

Tissue Category	Benign Tumor	Malignant Tumor (Bone Sarcoma)
Bone	Osteoid osteoma Osteoblastoma	Osteogenic sarcoma Parosteal osteogenic sarcoma
Cartilage	Osteochondroma Endochondroma Chondroblastoma	Periosteal osteogenic sarcoma Chondrosarcoma Mesenchymal chondrosarcoma
Fibrous lesions	Benign fibrous histiocytoma Giant cell tumor Fibrous dysplasia	Malignant fibrous histiocytoma Adamantinoma Fibrosarcoma
Vascular	Aneurysmal bone cyst	Angiosarcoma
Other	Glomus tumor	Hemangiopericytoma Ewing sarcoma

Table 108-6 American Joint Commission on Cancer (AJCC): GTNM Classification and Stage Grouping of Bone Sarcomas

Classification	Description
Tumor Grade	
GX	Grade cannot be assessed
G1	Well differentiated (low grade)
G2	Moderately well differentiated (low grade)
G3	Poorly differentiated
G4	Undifferentiated
Primary Tumor	
TX	Primary tumor cannot be assessed
T0	No evidence of primary tumor
T1	Tumor ≤8 cm in greatest dimension
T2	Tumor >8 cm in greatest dimension
T3	Discontinuous tumors in the primary bone site
Lymph Node Involvement	
NX	Regional lymph nodes cannot be assessed
N0	No regional lymph node metastasis
N1	Regional lymph node metastasis
Distant Metastasis	
MX	Presence of distant metastasis cannot be assessed
M0	No distant metastasis
M1	Distant metastasis
M1a	Lung
M1b	Other sites
Stage Grouping	
Stage IA	G1-2, T1, N0, M0
Stage IB	G1-2, T2, N0, M0
Stage IIA	G3-4, T1, N0, M0
Stage IIB	G3-4, T2, N0, M0
Stage III	Any G, T3, N0, M0
Stage IVA	Any G, any T, N0, M1a
Stage IVB	Any G, any T, N1, any M
	Any G, any T, any N, M1b

Used with the permission of the American Joint Committee on Cancer (AJCC), Chicago, Illinois. The original source for this material is the AJCC Cancer Staging Manual, Seventh Edition (2010) published by Springer Science and Business Media LLC, www.springer.com

Osteosarcomas are the most common primary bone tumor. Osteosarcomas occur most commonly around the knee, either in the distal femur or proximal tibia, but they can be encountered in any bone (Table 108-7). Osteosarcomas originate in the metaphyseal ends of the involved bone. While there are eleven known variants of osteosarcoma, classic osteosarcoma accounts for nearly 80% of incident cases. They are commonly seen in children and young adults. Other important variants include osteosarcoma associated with Paget disease,[139] which corresponds to a later peak in incidence at 60 years of age. Other well-described etiologies of osteosarcoma include prior radiation or history of

retinoblastoma.[140] Classic osteosarcomas are of intramedullary origin and are high grade. Osteosarcoma patients are at high risk for metastatic disease; metastases to the lung are the most common, though bony metastases are not uncommon. Low-grade variants do exist and these less aggressive tumors are usually parosteal or periosteal in location. Elevated serum alkaline phosphatase and lactate dehydrogenase is associated with reduced disease-free survival and overall survival rates.

Table 108-7 Distribution of Anatomic Locations of Osteosarcoma

Anatomic Site	Percentage (%)
Lower extremity	77.6
Upper extremity	12.9
Pelvis	6.0
Shoulder	2.6
Vertebrae	0.8

Adapted from Eilber FR, Guiliano AE, Huth J, et al. High-grade soft-tissue sarcomas of the extremity: UCLA experience with limb salvage. *Prog Clin Biol Res* 1985;201:59–74.

Chrondrosarcomas are typically classified as either (1) primary or central tumors arising from previously normal-appearing bone, or (2) secondary or peripheral tumors that develop from pre-existing benign cartilage lesions.[141,142] The secondary or peripheral lesions are usually low grade and infrequently metastasize. Chrondrosarcomas are usually seen in middle-aged or elderly people, though can be seen at any age. Ewing sarcomas are broadly considered a family of small round cell neoplasms and include the following subtypes: Ewing sarcoma, primitive neuroectodermal tumor (PNET), and extraosseous Ewing sarcoma. Most Ewing sarcomas occur in adolescents and young adults but can be seen in older individuals. These tumors may arise in soft tissues as well as bone, and are most commonly seen in the femur, pelvic bones, and chest wall (Askin tumor).

CLINICAL PRESENTATION

A painful mass is the most common presenting complaint with an extremity osteosarcoma, though symptoms of chrondrosarcoma may be quite mild. Tumor location in the axial skeleton may also be associated with a more insidious presentation. Limitation of motion is often present when the tumor arises in proximity to a joint. Patients occasionally present with a pathologic fracture of the involved bone. Plain radiographs of the affected area often suggest a diagnosis. High-grade osteosarcomas lead to rapid destruction of bone evidenced by cortical destruction and demonstrate periosteal reaction with new bone formation; an extensive, poorly defined destructive bony lesion, often with an extraosseous component is often seen (Fig. 108-16). Ewing sarcomas have a classic "onion skin" periosteal reaction and underlying bone often appears mottled. Primary or central chrondrosarcomas show cortical destruction and calcification. Further radiologic evaluation with MRI (or CT scan) provides excellent detail of the anatomic extent of tumor and aids operative planning. Chest imaging should be used to determine if there is metastatic disease. Evaluation with radionuclide bone scanning and/or PET scans may also be useful depending on clinical context.

After the radiologic evaluation establishes the extent of the bony lesion, diagnostic biopsy should be performed. Either CNB or open biopsy techniques can be used. Placement of the incision should be carefully planned to avoid jeopardizing subsequent options for a limb-sparing procedure. Consideration should also be given to stabilization techniques if there is risk of pathologic fracture during treatment.

Cytogenic analysis for evaluation of the t(11;22) translocation should be done if Ewing sarcoma is suspected.[13] Presenting features associated with poor prognosis in Ewing sarcoma include elevated serum lactate dehydrogenase levels, fever, anemia, large tumor volume, mutation in p53 or deletion of p16/p14ARF, and pelvic location. Most patients have at least micrometastatic disease at presentation, and bone marrow biopsy can be considered because it is a common site of distant disease.

TREATMENT

6 Standard treatment for Ewing sarcoma involves combination chemotherapy, followed by surgical resection. Regimens have evolved over time and currently involve some combination (or all) of the following agents: ifosfamide, cyclophosphamide, etoposide, doxorubicin, and vincristine.[143] Investigations continue to define the trade-offs between survival benefit and toxicity of high-dose combination chemotherapy.[144] Adjuvant radiation can be considered or used as definitive treatment in some cases. Most patients will receive additional chemotherapy in the postoperative period as well. The aggressive use of multimodality therapy has led to excellent outcomes for patients with localized disease over time. Five-year survival rates have improved from 44% in the 1970s to 68% in the 1990s. Even outcomes with advanced disease at presentation has improved dramatically, increasing from 16% to 39% over the same time period.[145]

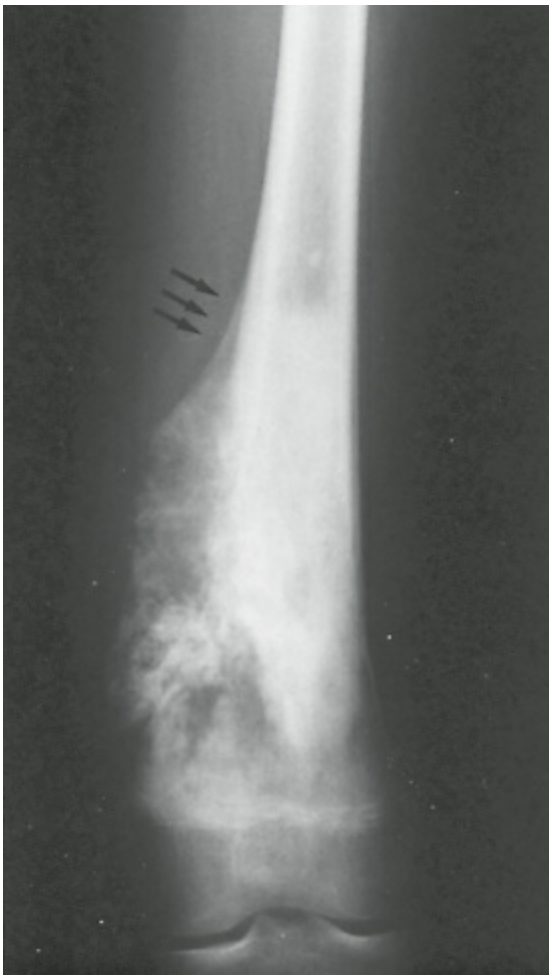

Figure 108-16. Plain radiograph of the femur showing a high-grade osteosarcoma. The tumor is an ill-defined destructive lesion with an extensive soft tissue involvement. Codman triangles (*arrows*) indicate periosteal reaction, which are characteristic, but not pathognomonic, of osteosarcoma.

Surgical resection is the definitive treatment for most chrondrosarcomas (Fig. 108-17). Intracompartmental lesions can be considered for intralesional resection with wide margins. Radiation can be considered as an adjuvant therapy, but chemotherapy is generally not very effective. If lesions are unresectable, radiation may be considered as a

possible definitive treatment modality.

Historically, patients with clinically localized osteosarcoma treated by surgery alone had a 5-year survival rate of approximately 20%. Adjuvant systemic chemotherapy after surgery has greatly improved that figure to 55% to 70% in most randomized trials.[146,147] Several agents have shown to be active and regimens have used differing combinations of those agents – doxorubicin, cisplatin, ifosfamide, and high-dose methotrexate. Disease relapse should be treated with further chemotherapy and repeat resection if possible. Progressive disease carries a poor prognosis.

Extremity osteosarcomas are ideally treated with limb-sparing approaches when possible to maximize functional outcomes. Limb-sparing operations include complete removal of the affected bone and soft tissues. A variety of reconstructive techniques are available after resection of an extremity osteosarcoma. Autografts (such as vascularized or nonvascularized fibular grafts), cadaver allografts, and sophisticated endoprostheses can be used. Because the osteosarcoma population includes many children who continue to grow, modular prostheses that can periodically be expanded are increasingly being used.

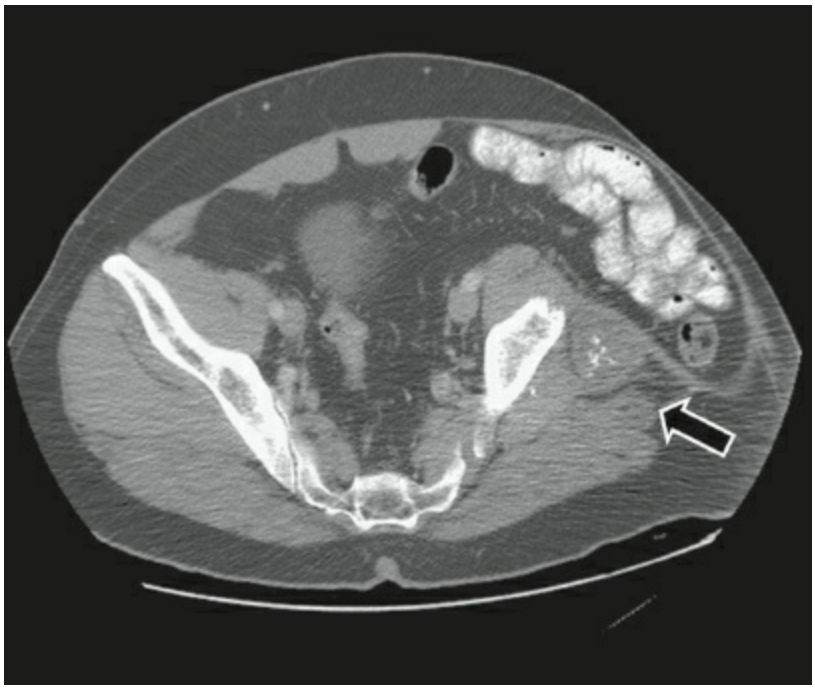

Figure 108-17. Chondrosarcoma recurrence. A 60-year-old man had previously undergone resection of a low-grade chondrosarcoma of the left pelvis, necessitating resection of the left iliac bone. After many local bony recurrences, he was found to have an extraskeletal site of disease. On the CT scan, adjacent to the remaining bone, there is a 4.4- × 3.6-cm soft tissue mass (*arrow*), which contains dystrophic calcifications. Recurrent disease was completely resected.

References

1. Siegel RL, Miller KD, Jemal A. Cancer statistics, 2016. *CA Cancer J Clin* 2016;66(1):7–30.
2. Coindre JM, Terrier P, Bui NB, et al. Prognostic factors in adult patients with locally controlled soft tissue sarcoma. A study of 546 patients from the French Federation of Cancer Centers Sarcoma Group. *J Clin Oncol* 1996;14(3):869–877.
3. Pisters PW, Leung DH, Woodruff J, et al. Analysis of prognostic factors in 1,041 patients with localized soft tissue sarcomas of the extremities. *J Clin Oncol* 1996;14(5):1679–1689.
4. Long ER. *History of Pathology*. Baltimore, MD: Williams & Wilkins; 1928.
5. Brennan MF, Lewis JJ. Diagnosis and management of soft tissue sarcoma. London: Martin Dunitz Ltd, 2002.
6. King T. Epidemiology. In: Pollock R, ed. *Soft Tissue Sarcomas*. London: BC Decker Inc; 2002:1–10.
7. Stewart FW, Treves N. Lymphangiosarcoma in postmastectomy lymphedema; a report of six cases in elephantiasis chirurgica. *Cancer* 1948;1(1):64–81.
8. Safai B, Johnson KG, Myskowski PL, et al. The natural history of Kaposi's sarcoma in the acquired immunodeficiency syndrome. *Ann Intern Med* 1985;103(5):744–750.
9. Dittmer DP, Krown SE. Targeted therapy for Kaposi's sarcoma and Kaposi's sarcoma-associated herpesvirus. *Curr Opin Oncol* 2007;19(5):452–457.
10. Clayton G, Omasta-Martin A, Bower M. The effects of HAART on AIDS-related Kaposi's sarcoma and non-Hodgkin's lymphoma. *J HIV Ther* 2006;11(3):51–53.
11. Cha C, Antonescu CR, Quan ML, et al. Long-term results with resection of radiation-induced soft tissue sarcomas. *Ann Surg* 2004;239(6):903–909; discussion 909–910.
12. Abbott R, Palmieri C. Angiosarcoma of the breast following surgery and radiotherapy for breast cancer. *Nat Clin Pract Oncol* 2008;5(12):727–736.
13. Borden EC, Baker LH, Bell RS, et al. Soft tissue sarcomas of adults: state of the translational science. *Clin Cancer Res* 2003;9(6):1941–1956.
14. Sorensen SA, Mulvihill JJ, Nielsen A. Long-term follow-up of von Recklinghausen neurofibromatosis. Survival and malignant neoplasms. *N Engl J Med* 1986;314(16):1010–1015.
15. Posner MC, Shiu MH, Newsome JL, et al. The desmoid tumor. Not a benign disease. *Arch Surg* 1989;124(2):191–196.
16. Fraumeni JF Jr, Vogel CL, Easton JM. Sarcomas and multiple polyposis in a kindred. A genetic variety of hereditary polyposis? *Arch Intern Med* 1968;121(1):57–61.
17. Latchford AR, Phillips RK. Duodenal adenoma and cancer in FAP. *Gut* 2005;54(1):171.
18. Dwight T, Benn DE, Clarkson A, et al. Loss of SDHA expression identifies SDHA mutations in succinate dehydrogenase-deficient gastrointestinal stromal tumors. *Am J*

Surg Pathol 2013;37:226–233.
19. Janeway KA, Kim SY, Lodish M, et al. Defects in succinate dehydrogenase in gastrointestinal stromal tumors lacking KIT and PDGFRA mutations. *Proc Natl Acad Sci* 2011;108:314–318.
20. Bennicelli JL, Barr FG. Genetics and the biologic basis of sarcomas. *Curr Opin Oncol* 1999;11(4):267–274.
21. Stratton MR, Williams S, Fisher C, et al. Structural alterations of the RB1 gene in human soft tissue tumours. *Br J Cancer* 1989;60(2):202–205.
22. Li FP, Fraumeni JF Jr. Prospective study of a family cancer syndrome. *JAMA* 1982;247(19):2692–2694.
23. Malkin D, Li FP, Strong LC, et al. Germ line p53 mutations in a familial syndrome of breast cancer, sarcomas, and other neoplasms. *Science* 1990; 250(4985):1233–1238.
24. Andreassen A, Oyjord T, Hovig E, et al. p53 abnormalities in different subtypes of human sarcomas. *Cancer Res* 1993;53(3):468–471.
25. Levine EA. Prognostic factors in soft tissue sarcoma. *Semin Surg Oncol* 1999;17(1):23–32.
26. Kawai A, Woodruff J, Healey JH, et al. SYT-SSX gene fusion as a determinant of morphology and prognosis in synovial sarcoma. *N Engl J Med* 1998;338(3):153–160.
27. Ladanyi M, Antonescu CR, Leung DH, et al. Impact of SYT-SSX fusion type on the clinical behavior of synovial sarcoma: a multi-institutional retrospective study of 243 patients. *Cancer Res* 2002;62(1):135–140.
28. Demas BE, Heelan RT, Lane J, et al. Soft-tissue sarcomas of the extremities: comparison of MR and CT in determining the extent of disease. *AJR Am J Roentgenol* 1988;150(3):615–620.
29. Jelinek JS, Kransdorf MJ, Shmookler BM, et al. Liposarcoma of the extremities: MR and CT findings in the histologic subtypes. *Radiology* 1993;186(2):455–459.
30. Panicek DM, Gatsonis C, Rosenthal DI, et al. CT and MR imaging in the local staging of primary malignant musculoskeletal neoplasms: Report of the Radiology Diagnostic Oncology Group. *Radiology* 1997;202(1):237–246.
31. Arca MJ, Sondak VK, Chang AE. Diagnostic procedures and pretreatment evaluation of soft tissue sarcomas. *Semin Surg Oncol* 1994;10(5):323–331.
32. Pearlstone DB, Pisters PW, Bold RJ, et al. Patterns of recurrence in extremity liposarcoma: implications for staging and follow-up. *Cancer* 1999;85(1):85–92.
33. Hanna SL, Fletcher BD. MR imaging of malignant soft-tissue tumors. *Magn Reson Imaging Clin N Am* 1995;3(4):629–650.
34. Jones DN, McCowage GB, Sostman HD, et al. Monitoring of neoadjuvant therapy response of soft-tissue and musculoskeletal sarcoma using fluorine-18-FDG PET. *J Nucl Med* 1996;37(9):1438–1444.
35. Benz MR, Allen-Auerbach MS, Eilber FC, et al. Combined assessment of metabolic and volumetric changes for assessment of tumor response in patients with soft-tissue

sarcomas. *J Nucl Med* 2008;49(10):1579–1584.
36. Kumar R, Chauhan A, Kesav Vellimana A, et al. Role of PET/PET-CT in the management of sarcomas. *Expert Rev Anticancer Ther* 2006;6(8):1241–1250.
37. Heron DE, Andrade RS, Beriwal S, et al. PET-CT in radiation oncology: the impact on diagnosis, treatment planning, and assessment of treatment response. *Am J Clin Oncol* 2008;31(4):352–362.
38. Schuetze SM, Baker LH, Benjamin RS, et al. Selection of response criteria for clinical trials of sarcoma treatment. *Oncologist* 2008;13(suppl 2):32–40.
39. Heslin MJ, Lewis JJ, Woodruff JM, et al. Core needle biopsy for diagnosis of extremity soft tissue sarcoma. *Ann Surg Oncol* 1997;4(5):425–431.
40. Strauss DC, Qureshi YA, Hayes AJ, et al. The role of core needle biopsy in the diagnosis of suspected soft tissue tumors. *J Surg Oncol* 2010;102(5):523–529.
41. Kasraeian S, Allison DC, Ahlmann ER, et al. A comparison of fine-needle aspiration, core biopsy, and surgical biopsy in the diagnosis of extremity soft tissue masses. *Clin Orthop Relat Res* 2010;468(11):2992–3002.
42. Czerniak B, Kram A. Pathology. In: Pollock R, ed. *Soft Tissue Sarcomas.* London: BC Decker Inc; 2002:11–42.
43. Rubin BP, Goldblum JR. Pathology of soft tissue sarcoma. *J Natl Compr Canc Netw* 2007;5(4):411–418.
44. Deyrup AT, Weiss SW. Grading of soft tissue sarcomas: the challenge of providing precise information in an imprecise world. *Histopathology* 2006;48(1):42–50.
45. Edge S, Byrd DR, Compton CC, et al. (eds.). *AJCC Cancer Staging Manual.* New York: Springer-Verlag; 2010.
46. Coindre JM, Trojani M, Contesso G, et al. Reproducibility of a histopathologic grading system for adult soft tissue sarcoma. *Cancer* 1986;58(2):306–309.
47. Guillou L, Coindre JM, Bonichon F, et al. Comparative study of the National Cancer Institute and French Federation of Cancer Centers Sarcoma Group grading systems in a population of 410 adult patients with soft tissue sarcoma. *J Clin Oncol* 1997;15(1):350–362.
48. Tierney JF, Mosseri V, Stewart LA, et al. Adjuvant chemotherapy for soft-tissue sarcoma: review and meta-analysis of the published results of randomised clinical trials. *Br J Cancer* 1995;72(2):469–475.
49. Brooks AD, Heslin MJ, Leung DH, et al. Superficial extremity soft tissue sarcoma: an analysis of prognostic factors. *Ann Surg Oncol* 1998;5(1):41–47.
50. Brennan MF. Staging of soft tissue sarcomas. *Ann Surg Oncol* 1999; 6(1):8–9.
51. Ramanathan RC, A'Hern R, Fisher C, et al. Modified staging system for extremity soft tissue sarcomas. *Ann Surg Oncol* 1999;6(1):57–69.
52. Fong Y, Coit DG, Woodruff JM, et al. Lymph node metastasis from soft tissue sarcoma in adults. Analysis of data from a prospective database of 1772 sarcoma patients. *Ann Surg* 1993;217(1):72–77.

53. Al-Refaie WB, Andtbacka RH, Ensor J, et al. Lymphadenectomy for isolated lymph node metastasis from extremity soft-tissue sarcomas. *Cancer* 2008;112(8):1821–1826.
54. Riad S, Griffin AM, Liberman B, et al. Lymph node metastasis in soft tissue sarcoma in an extremity. *Clin Orthop Relat Res* 2004;426:129–134.
55. Blazer DG 3rd, Sabel MS, Sondak VK. Is there a role for sentinel lymph node biopsy in the management of sarcoma? *Surg Oncol* 2003;12(3):201–206.
56. Rosenberg SA, Tepper J, Glatstein E, et al. The treatment of soft-tissue sarcomas of the extremities: prospective randomized evaluations of (1) limb-sparing surgery plus radiation therapy compared with amputation and (2) the role of adjuvant chemotherapy. *Ann Surg* 1982;196(3):305–315.
57. Limb-Sparing Treatment of Adult Soft-Tissue Sarcomas and Osteosarcomas. NIH Consens Statement. 1984 Dec 3–5;5(6):1–7.
58. Stojadinovic A, Jaques DP, Leung DH, et al. Amputation for recurrent soft tissue sarcoma of the extremity: indications and outcome. *Ann Surg Oncol* 2001;8(6):509–518.
59. Pisters PW, O'Sullivan B, Maki RG. Evidence-based recommendations for local therapy for soft tissue sarcomas. *J Clin Oncol* 2007;25(8):1003–1008.
60. Cormier JN, Ballo MT. Functional outcome after treatment of lower extremity soft tissue sarcoma: what should we tell our patients? *Ann Surg Oncol* 2004;11(5):453–454.
61. O'Sullivan B, Davis AM, Turcotte R, et al. Preoperative versus postoperative radiotherapy in soft-tissue sarcoma of the limbs: a randomised trial. *Lancet* 2002;359(9325):2235–2241.
62. Davis AM, O'Sullivan B, Bell RS, et al. Function and health status outcomes in a randomized trial comparing preoperative and postoperative radiotherapy in extremity soft tissue sarcoma. *J Clin Oncol* 2002;20(22):4472–4477.
63. Yang JC, Chang AE, Baker AR, et al. Randomized prospective study of the benefit of adjuvant radiation therapy in the treatment of soft tissue sarcomas of the extremity. *J Clin Oncol* 1998;16(1):197–203.
64. Alektiar KM, Velasco J, Zelefsky MJ, et al. Adjuvant radiotherapy for margin-positive high-grade soft tissue sarcoma of the extremity. *Int J Radiat Oncol Biol Phys* 2000;48(4):1051–1058.
65. Spierer MM, Alektiar KM, Zelefsky MJ, et al. Tolerance of tissue transfers to adjuvant radiation therapy in primary soft tissue sarcoma of the extremity. *Int J Radiat Oncol Biol Phys* 2003;56(4):1112–1116.
66. Alektiar KM, Leung D, Zelefsky MJ, et al. Adjuvant brachytherapy for primary high-grade soft tissue sarcoma of the extremity. *Ann Surg Oncol* 2002;9(1):48–56.
67. Tran QN, Kim AC, Gottschalk AR, et al. Clinical outcomes of intraoperative radiation therapy for extremity sarcomas. *Sarcoma* 2006;2006(1):91671.
68. Pisters PW, Pollock RE, Lewis VO, et al. Long-term results of prospective trial of

surgery alone with selective use of radiation for patients with T1 extremity and trunk soft tissue sarcomas. *Ann Surg* 2007;246(4):675–681; discussion 681–682.

69. Baldini EH, Goldberg J, Jenner C, et al. Long-term outcomes after function-sparing surgery without radiotherapy for soft tissue sarcoma of the extremities and trunk. *J Clin Oncol* 1999;17(10):3252–3259.
70. Kattan MW, Leung DH, Brennan MF. Postoperative nomogram for 12-year sarcoma-specific death. *J Clin Oncol* 2002;20(3):791–796.
71. Lewis JJ, Leung D, Heslin M, et al. Association of local recurrence with subsequent survival in extremity soft tissue sarcoma. *J Clin Oncol* 1997; 15(2):646–652.
72. Lewis JJ, Leung D, Espat J, et al. Effect of reresection in extremity soft tissue sarcoma. *Ann Surg* 2000;231(5):655–663.
73. Herbert SH, Corn BW, Solin LJ, et al. Limb-preserving treatment for soft tissue sarcomas of the extremities. The significance of surgical margins. *Cancer* 1993;72(4):1230–1238.
74. Huth JF, Eilber FR. Patterns of metastatic spread following resection of extremity soft-tissue sarcomas and strategies for treatment. *Semin Surg Oncol* 1988;4(1):20–26.
75. Rosenberg SA, Tepper J, Glatstein E, et al. Prospective randomized evaluation of adjuvant chemotherapy in adults with soft tissue sarcomas of the extremities. *Cancer* 1983;52(3):424–434.
76. Chang AE, Kinsella T, Glatstein E, et al. Adjuvant chemotherapy for patients with high-grade soft-tissue sarcomas of the extremity. *J Clin Oncol* 1988;6(9):1491–1500.
77. Antman K, Crowley J, Balcerzak SP, et al. An intergroup phase III randomized study of doxorubicin and dacarbazine with or without ifosfamide and mesna in advanced soft tissue and bone sarcomas. *J Clin Oncol* 1993;11(7):1276–1285.
78. Bramwell V, Rouesse J, Steward W, et al. Adjuvant CYVADIC chemotherapy for adult soft tissue sarcoma–reduced local recurrence but no improvement in survival: a study of the European Organization for Research and Treatment of Cancer Soft Tissue and Bone Sarcoma Group. *J Clin Oncol* 1994;12(6):1137–1149.
79. Cormier JN, Huang X, Xing Y, et al. Cohort analysis of patients with localized, high-risk, extremity soft tissue sarcoma treated at two cancer centers: chemotherapy-associated outcomes. *J Clin Oncol* 2004;22(22):4567–4574.
80. Adjuvant chemotherapy for localised resectable soft-tissue sarcoma of adults: meta-analysis of individual data. Sarcoma Meta-analysis Collaboration. *Lancet* 1997;350(9092):1647–1654.
81. Frustaci S, Gherlinzoni F, De Paoli A, et al. Adjuvant chemotherapy for adult soft tissue sarcomas of the extremities and girdles: results of the Italian randomized cooperative trial. *J Clin Oncol* 2001;19(5):1238–1247.
82. Hensley ML, Maki R, Venkatraman E, et al. Gemcitabine and docetaxel in patients with unresectable leiomyosarcoma: results of a phase II trial. *J Clin Oncol* 2002;20(12):2824–2831.

83. Maki RG, Wathen JK, Patel SR, et al. Randomized phase II study of gemcitabine and docetaxel compared with gemcitabine alone in patients with metastatic soft tissue sarcomas: results of sarcoma alliance for research through collaboration study 002 [corrected]. *J Clin Oncol* 2007; 25(19):2755–2763.
84. Leu KM, Ostruszka LJ, Shewach D, et al. Laboratory and clinical evidence of synergistic cytotoxicity of sequential treatment with gemcitabine followed by docetaxel in the treatment of sarcoma. *J Clin Oncol* 2004;22(9):1706–1712.
85. Davis EJ, Chugh R, Zhao L, et al. A randomised, open-label, phase II study of neo/adjuvant doxorubicin and ifosfamide versus gemcitabine and docetaxel in patients with localised, high risk, soft tissue sarcoma. *Eur J Cancer* 2015;51:1794–1802.
86. Gortzak E, Azzarelli A, Buesa J, et al. A randomised phase II study on neo-adjuvant chemotherapy for 'high-risk' adult soft-tissue sarcoma. *Eur J Cancer* 2001;37(9):1096–1103.
87. Murphy JD, Lucas DR, Somnay YR, et al. Gemcitabine-mediated radio sensitization of human soft tissue sarcoma. *Transl Oncol* 2008;1(1):50–56.
88. Grobmyer SR, Maki RG, Demetri GD, et al. Neo-adjuvant chemotherapy for primary high-grade extremity soft tissue sarcoma. *Ann Oncol* 2004; 15(11):1667–1672.
89. Pisters PW, Patel SR, Varma DG, et al. Preoperative chemotherapy for stage IIIB extremity soft tissue sarcoma: long-term results from a single institution. *J Clin Oncol* 1997;15(12):3481–3487.
90. Meric F, Hess KR, Varma DG, et al. Radiographic response to neoadjuvant chemotherapy is a predictor of local control and survival in soft tissue sarcomas. *Cancer* 2002;95(5):1120–1126.
91. Lucas DR, Kshirsagar MP, Biermann JS, et al. Histologic alterations from neoadjuvant chemotherapy in high-grade extremity soft tissue sarcoma: clinicopathological correlation. *Oncologist* 2008;13(4):451–458.
92. Eilber FC, Rosen G, Eckardt J, et al. Treatment-induced pathologic necrosis: a predictor of local recurrence and survival in patients receiving neoadjuvant therapy for high-grade extremity soft tissue sarcomas. *J Clin Oncol* 2001;19(13):3203–3209.
93. Rossi CR, Vecchiato A, Foletto M, et al. Phase II study on neoadjuvant hyperthermic-antiblastic perfusion with doxorubicin in patients with intermediate or high grade limb sarcomas. *Cancer* 1994;73(8):2140–2146.
94. Nijhuis PH, Pras E, Sleijfer DT, et al. Long-term results of preoperative intra-arterial doxorubicin combined with neoadjuvant radiotherapy, followed by extensive surgical resection for locally advanced soft tissue sarcomas of the extremities. *Radiother Oncol* 1999;51(1):15–19.
95. Eggermont AM, Schraffordt Koops H, Lienard D, et al. Isolated limb perfusion with high-dose tumor necrosis factor-alpha in combination with interferon-gamma and melphalan for nonresectable extremity soft tissue sarcomas: a multicenter trial. *J Clin Oncol* 1996;14(10):2653–2665.

96. Hoekstra HJ, van Ginkel RJ. Hyperthermic isolated limb perfusion in the management of extremity sarcoma. *Curr Opin Oncol* 2003;15(4):300–303.
97. Wong S, Brennan MF. [Therapeutic management of intra-abdominal and retroperitoneal soft tissue sarcomas]. *Chirurg* 2004;75(12):1174–1181.
98. Bevilacqua RG, Rogatko A, Hajdu SI, et al. Prognostic factors in primary retroperitoneal soft-tissue sarcomas. *Arch Surg* 1991;126(3):328–334.
99. Bonvalot S, Raut CP, Pollock RE, et al. Technical considerations in surgery for retroperitoneal sarcomas: Position paper from E-Surge, a master class in sarcoma surgery, and EORTC-STBSG. *Ann Surg Oncol* 2012;19(9):2981–2991.
100. Lewis JJ, Leung D, Woodruff JM, et al. Retroperitoneal soft-tissue sarcoma: analysis of 500 patients treated and followed at a single institution. *Ann Surg* 1998;228(3):355–365.
101. Yeh JJ, Singer S, Brennan MF, et al. Effectiveness of palliative procedures for intra-abdominal sarcomas. *Ann Surg Oncol* 2005;12(12):1084–1089.
102. Russo P, Kim Y, Ravindran S, et al. Nephrectomy during operative management of retroperitoneal sarcoma. *Ann Surg Oncol* 1997;4(5):421–424.
103. Jaques DP, Coit DG, Hajdu SI, et al. Management of primary and recurrent soft-tissue sarcoma of the retroperitoneum. *Ann Surg* 1990;212(1):51–59.
104. Gronchi A, LoVullo S, Fiore M, et al. Aggressive surgical policies in a retrospectively reviewed single-institution case series of retroperitoneal soft tissue sarcoma patients. *J Clin Oncol* 2009;27:24–30.
105. Bonvalot S, Riviore M, Castaing M, et al. Primary retroperitoneal sarcomas: a multivariate analysis of surgical factors associated with local control. *J Clin Oncol* 2009;27:31–37.
106. Trans-Atlantic RPS Working Group. Management of primary retroperitoneal sarcoma (PRS) in the adult: a consensus approach from the Trans-Atlantic RPS Working Group. *Ann Surg Oncol* 2015;22:256–263.
107. Henricks WH, Chu YC, Goldblum JR, et al. Dedifferentiated liposarcoma: a clinicopathological analysis of 155 cases with a proposal for an expanded definition of dedifferentiation. *Am J Surg Pathol* 1997;21(3):271–281.
108. Jones JJ, Catton CN, O'Sullivan B, et al. Initial results of a trial of preoperative external-beam radiation therapy and postoperative brachytherapy for retroperitoneal sarcoma. *Ann Surg Oncol* 2002;9(4):346–354.
109. Webb S. Advances in three-dimensional conformal radiation therapy physics with intensity modulation. *Lancet Oncol* 2000;1(1):30–36.
110. Leibel SA, Fuks Z, Zelefsky MJ, et al. Intensity-modulated radiotherapy. *Cancer J* 2002;8(2):164–176.
111. Raut CP, Pisters PW. Retroperitoneal sarcomas: Combined-modality treatment approaches. *J Surg Oncol* 2006;94(1):81–87.
112. Singer S, Corson JM, Demetri GD, et al. Prognostic factors predictive of survival for

truncal and retroperitoneal soft-tissue sarcoma. *Ann Surg* 1995;221(2):185–195.
113. Singer S, Corson JM, Gonin R, et al. Prognostic factors predictive of survival and local recurrence for extremity soft tissue sarcoma. *Ann Surg* 1994;219(2):165–173.
114. Glenn J, Sindelar WF, Kinsella T, et al. Results of multimodality therapy of resectable soft-tissue sarcomas of the retroperitoneum. *Surgery* 1985; 97(3):316–325.
115. Bentz BG, Singh B, Woodruff J, et al. Head and neck soft tissue sarcomas: a multivariate analysis of outcomes. *Ann Surg Oncol* 2004;11(6):619–628.
116. Dotan ZA, Tal R, Golijanin D, et al. Adult genitourinary sarcoma: the 25-year Memorial Sloan-Kettering experience. *J Urol* 2006;176(5):2033–2038; discussion 2038–2039.
117. Stojadinovic A, Leung DH, Allen P, et al. Primary adult soft tissue sarcoma: time-dependent influence of prognostic variables. *J Clin Oncol* 2002;20(21):4344–4352.
118. Midis GP, Pollock RE, Chen NP, et al. Locally recurrent soft tissue sarcoma of the extremities. *Surgery* 1998;123(6):666–671.
119. Karakousis CP, Proimakis C, Rao U, et al. Local recurrence and survival in soft-tissue sarcomas. *Ann Surg Oncol* 1996;3(3):255–260.
120. Giuliano AE, Eilber FR, Morton DL. The management of locally recurrent soft-tissue sarcoma. *Ann Surg* 1982;196(1):87–91.
121. Eilber FC, Brennan MF, Riedel E, et al. Prognostic factors for survival in patients with locally recurrent extremity soft tissue sarcomas. *Ann Surg Oncol* 2005;12(3):228–236.
122. Davis SD. CT evaluation for pulmonary metastases in patients with extrathoracic malignancy. *Radiology* 1991;180(1):1–12.
123. Pfannschmidt J, Bischoff M, Muley T, et al. Diagnosis of pulmonary metastases with helical CT: The effect of imaging techniques. *Thorac Cardiovasc Surg* 2008;56(8):471–475.
124. Billingsley KG, Burt ME, Jara E, et al. Pulmonary metastases from soft tissue sarcoma: analysis of patterns of diseases and postmetastasis survival. *Ann Surg* 1999;229(5):602–610; discussion 610–612.
125. van Geel AN, Pastorino U, Jauch KW, et al. Surgical treatment of lung metastases: The European Organization for Research and Treatment of Cancer-Soft Tissue and Bone Sarcoma Group study of 255 patients. *Cancer* 1996;77(4):675–682.
126. Medeiros F, Corless CL, Duensing A, et al. KIT-negative gastrointestinal stromal tumors: proof of concept and therapeutic implications. *Am J Surg Pathol* 2004;28(7):889–894.
127. Rubin BP, Singer S, Tsao C, et al. KIT activation is a ubiquitous feature of gastrointestinal stromal tumors. *Cancer Res* 2001;61(22):8118–8121.
128. Hirota S, Isozaki K, Moriyama Y, et al. Gain-of-function mutations of c-kit in human gastrointestinal stromal tumors. *Science* 1998;279(5350):577–580.
129. Antonescu CR, Sommer G, Sarran L, et al. Association of KIT exon 9 mutations with

nongastric primary site and aggressive behavior: KIT mutation analysis and clinical correlates of 120 gastrointestinal stromal tumors. *Clin Cancer Res* 2003;9(9):3329–3337.

130. Nilsson B, Bumming P, Meis-Kindblom JM, et al. Gastrointestinal stromal tumors: the incidence, prevalence, clinical course, and prognostication in the preimatinib mesylate era–a population-based study in western Sweden. *Cancer* 2005;103(4):821–829.
131. Prakash S, Sarran L, Socci N, et al. Gastrointestinal stromal tumors in children and young adults: a clinicopathologic, molecular, and genomic study of 15 cases and review of the literature. *J Pediatr Hematol Oncol* 2005;27(4):179–187.
132. DeMatteo RP, Lewis JJ, Leung D, et al. Two hundred gastrointestinal stromal tumors: recurrence patterns and prognostic factors for survival. *Ann Surg* 2000;231(1):51–58.
133. Joensuu H, Roberts PJ, Sarlomo-Rikala M, et al. Effect of the tyrosine kinase inhibitor STI571 in a patient with a metastatic gastrointestinal stromal tumor. *N Engl J Med* 2001;344(14):1052–1056.
134. Wong SL. Diagnosis and management of desmoid tumors and fibrosarcoma. *J Surg Oncol* 2008;97(6):554–558.
135. Gansar GF, Markowitz IP, Cerise EJ. Thirty years of experience with desmoid tumors at Charity Hospital. *Am Surg* 1987;53(6):318–319.
136. Li M, Cordon-Cardo C, Gerald WL, et al. Desmoid fibromatosis is a clonal process. *Hum Pathol* 1996;27(9):939–943.
137. Deyrup AT, Tretiakova M, Montag AG. Estrogen receptor-beta expression in extraabdominal fibromatoses: an analysis of 40 cases. *Cancer* 2006; 106(1):208–213.
138. Crago AM, Denton B, Salas S, et al. A prognostic nomogram for prediction of recurrence in desmoid fibromatosis. *Ann Surg* 2013;258(2):347–353.
139. Shaylor PJ, Peake D, Grimer RJ, et al. Paget's osteosarcoma - no cure in sight. *Sarcoma* 1999;3(3–4):191–192.
140. Tucker MA, D'Angio GJ, Boice JD Jr, et al. Bone sarcomas linked to radiotherapy and chemotherapy in children. *N Engl J Med* 1987;317(10):588–593.
141. Mankin HJ, Cantley KP, Lippiello L, et al. The biology of human chondrosarcoma. I. Description of the cases, grading, and biochemical analyses. *J Bone Joint Surg Am* 1980;62(2):160–176.
142. Mankin HJ, Cantley KP, Schiller AL, et al. The biology of human chondrosarcoma. II. Variation in chemical composition among types and subtypes of benign and malignant cartilage tumors. *J Bone Joint Surg Am* 1980;62(2):176–188.
143. Grier HE, Krailo MD, Tarbell NJ, et al. Addition of ifosfamide and etoposide to standard chemotherapy for Ewing's sarcoma and primitive neuroectodermal tumor of bone. *N Engl J Med* 2003;348(8):694–701.
144. Isakoff MS, Bielack SS, Meltzer P, et al. Osteosarcoma: Current treatment and a

collaborative pathway to success. *J Clin Oncol* 2015;33(27):3029–3035.

145. Esiashvili N, Goodman M, Marcus RB Jr. Changes in incidence and survival of Ewing sarcoma patients over the past 3 decades: Surveillance epidemiology and end results data. *J Pediatr Hematol Oncol* 2008;30(6):425–430.
146. Link MP, Goorin AM, Miser AW, et al. The effect of adjuvant chemotherapy on relapse-free survival in patients with osteosarcoma of the extremity. *N Engl J Med* 1986;314(25):1600–1606.
147. Gaspar N, Hawkins DS, Dirksen U, et al. Ewing Sarcoma: Current management and future approaches through collaboration. *J Clin Oncol* 2015; 33(27):3036–3046.

Chapter 109

Plastic and Reconstructive Surgery

Christian J. Vercler, David L. Brown, Steven R. Buchman, Paul S. Cederna, Kevin C. Chung, Jeffrey H. Kozlow, William M. Kuzon, Jr., Adeyiza O. Momoh, and Edwin G. Wilkins

Key Points

1 A variety of operative procedures have been described for breast reconstruction following mastectomy. These approaches can be categorized as implant-based, autogenous (natural) tissue, and "hybrid" procedures.

2 Currently, the most commonly performed of these procedures are based on the lower abdominal soft tissue.

3 The absolute indications for replantation are (a) thumb amputation, (b) multiple finger amputations, (c) pediatric population amputations, and (d) mid-hand, wrist, or distal forearm amputations.

4 Rigid skeletal fixation, revascularization using vein grafts, and immediate wound coverage are crucial factors in successful limb salvage.

5 Aesthetic surgery requires meticulous attention to detail, careful patient selection, rigorous procedural planning, and precise execution of technically challenging procedures.

6 Patients who smoke are at a significantly increased risk for developing postoperative complications, including skin-flap necrosis, infection, or wound dehiscence; and are consequently instructed to quit prior to undergoing elective aesthetic surgery.

7 A cleft lip deformity can be bilateral or unilateral and is considered complete if it extends into the nose and incomplete if it does not. The cleft lip can extend into the gum partially or completely through the alveolus, creating a bony defect. The cleft lip deformity affects the nose as well as the lip, and therefore both of these structures must be addressed in the reconstruction of the deformity.

8 Craniosynostosis is defined as the premature fusion of one or more of the cranial sutures. The child afflicted with craniosynostosis displays abnormalities in the size and shape of the cranial vault.

Plastic and reconstructive surgery can be defined as a discipline that addresses problem wounds using a diverse array of nonsurgical and, especially, surgical therapies. In this definition, the term *problem wounds* is taken in the broadest sense; plastic surgeons treat traumatic, congenital, developmental, and even psychological wounds. Perhaps it is this

latter aspect of plastic surgery that most fully sets it apart from other surgical specialties:

> We restore and make whole those parts which nature or ill fortune have taken away, not so much to delight the eye but to buoy up the spirit of the afflicted.
>
> —Gaspare Tagliacozzi, 1597

In more concrete terms, plastic surgery is an approach to surgical problems. Plastic surgeons operate "from the top of the head to the tip of the toes," and they envision themselves as surgical innovators. Plastic surgeons have been instrumental in the development of microvascular surgery, craniofacial surgery, head and neck reconstruction, nerve grafting, and even renal transplantation.[1] Although the field of plastic surgery can be arbitrarily divided into "cosmetic" surgery (surgery to improve the appearance of a normal phenotype) and "reconstructive" surgery (repair of damaged anatomy or an abnormal phenotype), in many circumstances, both functional reconstruction and aesthetic improvement are paramount. Plastic surgery is truly "general surgery," with a broad and growing list of subspecialties (Table 109-1).

PRINCIPLES OF MANAGEMENT FOR PROBLEM WOUNDS

Regardless of the etiology or location of a wound, the principles of management are universal and can be embodied by a straightforward algorithm:

1. Evaluate and, if possible, eliminate the factors contributing to the presence of the wound.
2. Control or optimize the wound prior to closure.
3. Close the wound using the simplest method, unless specific factors mitigate a more complex approach.

Although it is the nature of surgeons to focus on the technical details of operative procedures, the first two steps in this algorithm are most critical for the successful reconstruction of problem wounds. This algorithmic approach allows plastic surgeons to treat diabetic foot ulcers, infected sternotomy wounds, major defects after composite resection of the head and neck, pressure ulcers, lower extremity wounds after open tibial fractures, venous stasis ulcers, and other difficult defects with a high degree of success. *This rational approach is the core of plastic surgery*. In plastic surgery there is no one-to-one correlation between a surgical problem and a specific operation. There is no “right” way to reconstruct a given defect, and a spectrum of options must be considered for every reconstructive problem. Selecting the best option for a given patient is the challenge.

Evaluation of Problem Wounds

The evaluation of patients with difficult wounds is best approached using a systematic approach since wounds are rarely secondary to only one isolated cause. Evaluation of both local and systemic (or intrinsic and extrinsic) contributing factors within each portion of the work-up is critical. In the history, local factors of importance include the mechanism that resulted in the wound, symptoms such as pain or loss of function, the time course and progression of the wound, any previous nonsurgical or surgical treatments for the wound, and any history of previous injury, irradiation, malignancy, or other local factors that contributed to the presence of the wound. The history should also uncover systemic factors that impair wound healing, including immunosuppression (e.g., chemotherapy, immune deficiencies), medical conditions known to impair healing (e.g., diabetes, renal failure), medications (e.g., steroids, cyclosporin A), cigarette smoking, and general debility (e.g., nutritional deficiencies, old age).

Table 109-1 The Spectrum of Plastic Surgery

Aesthetic surgery
Burns: acute and reconstructive surgery
Craniofacial surgery
Cutaneous and soft tissue oncology
Hand and upper extremity surgery
Head and neck oncology
Microvascular surgery
Maxillofacial and orthognathic surgery
Peripheral nerve surgery
"General" reconstructive surgery Face (ear, lip, nose, and eyelid) Breast Trunk Lower extremity

The physical examination of patients with problem wounds should be focused on local and systemic signs that affect wound healing. For the wound itself, the location, size, depth, exposure of deep or vital structures, presence of necrotic material, presence of foreign bodies, or signs of any neoplastic processes should be carefully noted. The clinician often needs to consider bacterial colonization and acute/chronic infection as potential addressable causes. All open wounds will have bacterial colonization, but this by itself does not designate a wound as "infected." The diagnosis of infection is contingent on the physical examination findings of local inflammation: erythema, pain, swelling, fluctuance, purulence, and loss of function. Physical examination should be the primary criterion for the diagnosis of local wound infection; surface swabs indicating the presence of pathogenic bacteria do not correlate with clinically significant infection.[2] In addition to

the wound itself, surrounding tissue should be examined for signs of injury (e.g., actinic changes), previous irradiation, arterial or venous insufficiency, lymphedema, loss of sensation, and dermal thinning (e.g., aging, steroid therapy). For all wounds on an arm or leg, a careful neurovascular examination for the entire limb is mandatory. In addition to the local examination, a focused systematic physical examination is mandatory in patients with problem wounds. Systemic signs of infection (e.g., fever, hypotension) are of particular importance. Obesity is a major risk factor that impairs wound healing. The general physical examination should focus on the systemic factors that affect wound healing as noted previously. Table 109-2 lists some of the local and systemic factors that impair wound healing; history and physical examination are the principal modalities for diagnosing these problems.

Laboratory examinations can be invaluable in the management of problem wounds. However, laboratory tests are often misused in wound patients, and a rational, evidence-based approach is necessary to efficiently utilize this expensive resource. Again, the local–systemic paradigm is useful in determining which laboratory examinations are warranted.

For local evaluation, wound swabs can be valuable for surveillance of the flora contaminating a wound but should not be used as a trigger to initiate therapy for wound infection. Wound biopsy and quantitative bacteriology have proved valuable in the management of burns and chronic wounds and can provide both topical and systemic antibiotic sensitivities.[3,4] Bacterial loads in excess of 10^5/g tissue indicate contamination at a level that precludes skin graft take and jeopardizes wound closure of any kind. The use of quantitative cultures, however, is not justified for most acute or uncomplicated chronic wounds. In general, quantitative cultures are reserved for “high stakes” wounds, where a failure of closure on the initial attempt may leave an unreconstructable situation with grave consequences, such as amputation or death. Wound biopsies can be invaluable for diagnosing invasive burn wound infection and are preferred over quantitative culture for this purpose.[5] The presence of bacteria in the deep dermis on biopsy is highly correlated with the risk of systemic sepsis in burn patients. Bone biopsy demonstrating bacteria within the bone is the gold standard test for making the diagnosis of osteomyelitis. Standard radiographs are most useful for diagnosing and delineating acute fractures and are much less useful in the setting of chronic, open wounds. Ultrasound, computed tomography (CT) scan, or magnetic resonance imaging (MRI) may be useful for delineating fluid collections, necrotic tissue, or inflammation in selected circumstances. In contrast, radionuclide bone scans have little role to play in patients with open wounds or fractures. In the face of an open wound or recent fracture, a “hot” bone scan (even a triple-phase bone scan) is not specific for osteomyelitis and has little value. Therefore, obtaining bone scans in patients with suspected sternal osteomyelitis after recent midline sternotomy, in pressure sore patients with exposed bone, or in other patients with open wounds overlying exposed bone is unwarranted. Under these circumstances, bone biopsy is preferred for making a diagnosis of osteomyelitis and for determining the responsible pathogen; MRI is preferred for delineating the extent of bony involvement. Computed tomography angiography (CTA), magnetic resonance angiography (MRA), or standard angiography may be indicated if vascular insufficiency is

suspected or if a free-tissue transfer is planned. The choice of modality depends on both patient and health system-based factors.

Table 109-2 Local and Systemic Factors That Affect Wound Management

Local Factors	Systemic Factors
Infection	Immune deficiencies
Local malignancy	Distant malignancy
Foreign bodies	Diabetes mellitus
Local toxins	Cigarette smoking
Radiation	Chemotherapeutic agents
Ischemia	Hereditary healing disorders
Venous insufficiency	Nutritional deficiency
Lymphatic insufficiency	Old age
Repetitive trauma	Uremia
Reduced sensation	Glucocorticoid therapy, immunosuppressive agents

The use of systemic laboratory investigations should be limited to specific indications; "routine" blood work is not required for patients with acute or chronic wounds. White blood cell differential counts and blood cultures can confirm the diagnosis of systemic infection. Serum prealbumin may be valuable in determining nutritional status. A greatly elevated erythrocyte sedimentation rate and C-reactive protein can help confirm the diagnosis of osteomyelitis or be used to monitor treatment response. Other laboratory tests to confirm the diagnosis and severity of associated medical conditions may be justified for specific indications.

Treatment of the Problem Wound

Once a wound has been fully evaluated, the treatments should be designed to address any modifiable causes for the wound and then to achieve specific targeted goals. In order of greatest priority, these goals are: (a) prevention of complications resulting from the wound, (b) preserving or restoring critical functions, (c) achieving wound closure, and (d) restoration of aesthetics.

Preventive Treatment

The preventive measures that should be taken for patients with open wounds depend on the setting. For an acute laceration, tetanus prophylaxis should be considered. For patients with pressure sores, a strict adherence to pressure-relief protocols, optimization of wheelchair seating/bedding, optimization of social support and wound care, and an assessment of nutritional status take priority. In wounds caused by human or animal bites, prophylactic antibiotics are warranted. In addition, any associated medical conditions that are contributing to the wound must be aggressively optimized including glucose control, vascular disease, and contributing medications. It is the responsibility of the surgeon to ensure that a patient with a wound does not develop a complication from that wound and that the patient does not develop more wounds from the same mechanism. This is of particular importance in bedridden, obtunded, or paralyzed patients, in whom it should be possible to completely prevent pressure sores with proper nursing or family care.

Preservation of Function

Preserving joint motion must always be considered for patients with open wounds of the extremities. Aggressive physiotherapy to maintain or improve joint motion can be instituted in the presence of an open wound. Splinting should be used to minimize joint contractures and any plans for wound closure should include measures to maintain joint function. In the case of facial defects, especially if facial paralysis is present, oral competence and the maintenance of eye protection should weigh heavily into any reconstructive plan. Function takes precedence over form in the reconstructive algorithm.

Nonsurgical Therapy

After careful consideration of preventive measures and the preservation of critical function, a strategy for wound closure can be formulated. The basic tenet is: “débride dirty wounds, close clean wounds.” Therefore, the first step in wound closure is achieving control of the wound by eliminating necrotic debris and controlling any infection present. Nonsurgical therapies are used in conjunction with surgical therapy to achieve a clean wound. The mainstay of local, nonsurgical therapy is the use of wound dressings. It is beyond the scope of this chapter to review the wide range of options available to dress wounds. Recent articles contain a contemporary review of this topic.[6–8] However, the basic principle is to employ débriding dressings for dirty wounds and occlusive dressings for clean wounds. The most commonly employed débriding dressing is the “wet-to-dry” dressing. Gauze made damp with normal saline, weak acetic acid, weak bleach, or various

other solutions is applied to the wound. Over a period of hours, evaporation dries the dressing, which becomes slightly adherent to the wound surface. When the dressing is removed, necrotic debris and biofilm is removed with the dressing, but healthy tissue is left behind. Wet-to-dry dressings work through *mechanical débridement,* and the most important component of their use is how often they are changed. Wet-to-dry dressings must be changed a minimum of twice per day, although more frequent dressings may be necessary in certain wounds. These dressings should not be "soaked" off to reduce patient discomfort because this technique completely defeats their purpose. Enzymatic dressings have also been used to débride wounds, but their use can be limited by patient tolerance to the pain they cause. Débriding dressings are indicated for infected wounds and wounds containing necrotic debris.

If a wound is "clean," meaning that it does not contain necrotic debris and has an acceptable bacterial load, a dressing that maintains a moist wound environment to encourage wound healing should be used.[8] For many simple wounds, allowing a scab to provide the moist healing environment or the application of a nonadherent sterile dressing is all that is required. In the case of more complex wounds, occlusive dressings that maintain a moist environment to maximize wound healing are preferred. Options include hydrocolloid dressings, alginate dressings, and various hydrogels. Again, occlusive dressings must not be used on infected or dirty wounds. For many wounds, judicious application of hydrocolloid dressings may allow closure by secondary intention in a reasonable period of time.

Under some circumstances, it is appropriate to use antibiotic dressings. Multiple combinations of topical antibiotics are available over the counter and generally cover gram-positive bacteria. Mupirocin ointment has the added benefit for treating methicillin-resistant staph aureus (MRSA) colonization. Burn wounds are most commonly dressed with silver sulfadiazine or mafenide acetate due to their high antimicrobial activity. The low toxicity and excellent antibiotic properties of elemental silver have led to the development and widespread use of wound dressings containing nanocrystaline silver including both barrier dressings and in combination with alginates for daily wound care. In general, however, antibiotic dressings are not required for clean wounds, even if they are chronic.

Finally, it should be noted that we are entering a new era of nonsurgical wound management. A rapid advance in our understanding of wound healing has led to the development of growth factor therapy, cellular therapy, and new physical modalities for the treatment of chronic wounds.[6] Although recombinant platelet-derived growth factor appears to be a useful adjunct to the dressing regime for pressure sores and diabetic foot ulcers,[9,10] there is general agreement that exogenously administered growth factors currently play a limited role in the management of acute and chronic wounds.[11] Similarly, laboratory data point to the potential for the use of stem cells as a modality to treat difficult wounds, but cellular therapy for clinical wounds is still largely investigational.[6,12]

There has also been an increase in tissue-engineered dressings and skin substitutes.[13,14] For example, Integra (Integra Life Sciences Corp., Plainsboro, New Jersey), a bilaminar

skin substitute composed of a collagen matrix base with a silicone rubber barrier layer has proven extremely useful in the management of complex wounds and allowing for granulation tissue in compromised wound beds in burns, trauma, and oncologic resections. The development of human, bovine, and ovine acellular dermal matrices are being used in wound care and structural reconstruction of the abdominal wall and breast.[15] The development of new tissue-engineered adjuncts to wound healing remains a very active area of research in plastic surgery.

Negative-pressure wound therapy has become more widespread and can be efficacious and cost effective when applied appropriately for complex wounds.[16–18] Multiple commercial products exist, but all are similar in the use of a sponge-like material connected to a suction device. There is additional variation in sponge material and inclusion of antimicrobial silver that can be used in specific clinical situations. Extensive experimental and clinical data confirm that the negative-pressure wound therapy promotes tissue perfusion, reduces edema, favorably alters wound fluid composition, and stimulates the formation of granulation tissue.[18] Although these systems are easy to use, decrease the frequency of dressing changes, and can manage edema fluid, their use is contraindicated in acutely infected wounds and requires clinical judgment in balancing the tradeoff between negative-pressure therapy and other wound control methods.

Multiple other modalities, such as hyperbaric oxygen treatment, are in use and are being developed on an ongoing basis, underscoring the high prevalence, the significant cost, and the clinical challenge that are posed by complex wounds. Despite these ongoing developments, the basic algorithm for evaluation and nonsurgical management of wounds will not change.

Surgical Therapy

Wound Preparation. For problem wounds, surgical therapy is primarily aimed at wound preparation and wound reconstruction. For dirty wounds with necrotic debris, a judicious but thorough surgical débridement can convert a contaminated, chronic wound into a fresh surgical wound ready for immediate closure. Although débriding dressings can prepare wounds for closure under some circumstances, an operative débridement is preferred to a long course of débriding dressings for most problem wounds. Consequently, most complex wounds require an operative débridement prior to definitive reconstruction. In the case of chronic osteomyelitis, a formal resection of the sequestrum is required before formal wound closure. Prolonged treatment with intravenous or oral antibiotics cannot clear bacteria from a focus of dead bone; chronic osteomyelitis is a surgical disease cured with a saw, rongeur, bur, or bone curette. Therefore, the common practice of placing patients with chronic osteomyelitis on 6 weeks of antibiotic therapy is irrational unless performed in conjunction with a formal sequestrectomy.

Table 109-3 The Reconstructive Ladder

1. Primary wound closure
2. Healing by secondary intention
3. Skin grafting
4. Local flaps
5. Regional flaps
6. Distant flaps

Reconstructive Principles. As stated earlier, there is no "right" way to close any given wound. Plastic surgeons use a straightforward set of principles in delineating the optimum way to close a given wound for a given patient. The predominant principle is that the simplest method to close a wound is usually the best choice. This principle is embodied in the "reconstructive ladder," which is a hierarchy of reconstructive options progressing from simple to complex (Table 109-3). Therefore, when engaging options for wound closure, plastic surgeons "climb" the reconstructive ladder, usually stopping on the lowest rung that will achieve a closed wound. However, other principles of reconstruction sometimes override a slavish adherence to the reconstructive ladder. The choice of a technique for wound closure should take into consideration the need for subsequent procedures and other factors that might mitigate skipping over simpler options for wound closure. An example would be an avulsion injury to the palm of the hand. Although it might be possible to close this wound with a skin graft, the need to restore flexor tendon function is preeminent in the hand, so that the use of a distant flap to provide a suitable bed for tendon grafting may be the preferred choice. In addition to the reconstructive ladder, other examples of guiding reconstructive principles are: function takes precedence over form, single-stage reconstructions are preferred over multistage approaches, and autologous tissue is preferred over alloplastic reconstructions. Other factors to be considered are the durability of the reconstruction over many years, the psychological impact on the patient, and data indicating that some options are sometimes preferred for specific reasons. For any reconstruction, the surgeon must carefully consider the potential secondary consequences of the reconstructive technique and morbidity at the donor site. The increased identification of alternative flap donor sites with less morbidity reconstruction has changed the reconstructive paradigm to sometimes use a "reconstructive elevator" to higher-level reconstructions to better address the secondary reconstructive outcomes. Thus, weighing this complex array of factors to arrive at the optimal reconstruction for a given patient is the true challenge in reconstructive surgery.

Reconstructive Techniques. Regardless of the reconstructive method chosen, plastic surgeons strive for technical virtuosity in the operating room. To maximize healing and minimize scar formation, atraumatic technique includes delicate tissue handling, the use of skin hooks and sharp rakes, bipolar electrocautery, sharp dissection, and loupe magnification. When reconstructing difficult wounds, the margin for error is minimal, and small errors in technical execution can result in failure. It is also critical that secondary plans for reconstruction are considered and preserved during an initial reconstructive attempt. The general surgical methods used by reconstructive surgeons are briefly considered in this chapter.

An important distinction is made between a graft and a flap. A graft consist of tissue that is transferred into a defect in a devascularized state and requires a vascularized environment and subsequent vascular ingrowth in order for incorporation. Skin, fat, muscle, tendon, fascia, cartilage, and bone can all be used as grafts; however, the volume of each that can be successfully incorporated depends on the surrounding wound environment and the physiologic principals of each tissue. In contrast, flaps consist of tissue that is transferred while remaining vascularized. Flaps are much less dependent on the local environment for survival given the inherent blood supply and can be used when immediate coverage is necessary or when the underlying defect will not support a graft. Free tissue transfer (or a "free flap") is the transfer of tissue on a single vascular pedicle which is immediately anastomosed at the recipient site allowing for the transfer of vascularized tissue from a separate area of the body.

Primary Closure. If a laceration or other wound can be closed primarily, consideration is given to a meticulous, layered closure. Emphasis is placed on eversion of skin edges without strangling tissue. Nonabsorbable skin stitches that provoke minimal inflammatory response are preferred, but they must be removed promptly to minimize cross-hatching. Therefore, for most wounds, deep dermal, absorbable stitches are placed to allow early removal of skin stitches while still providing prolonged support to the repair; this may minimize the chances of a dehiscence or scar spread. It is preferable to place a closed suction drain to eliminate dead space rather than suturing fat or other easily devascularized tissue. If a technically perfect repair under physiologic tension cannot be achieved with primary closure, it is preferable to use a more complex surgical option.

Skin Grafting. Skin grafting was one of the foundations on which the specialty of plastic surgery was established. Skin grafts are classified as either split thickness, where epidermis and a portion of the dermis are harvested, or full thickness, where the epidermis and the entire dermis are harvested. Both full-thickness and split-thickness skin grafts can be used to resurface open wounds in cases in which primary closure is not possible. Skin graft take is contingent on the successful revascularization of the graft within a narrow time window (48 to 72 hours). Initially, grafts are nourished by a process of plasmatic imbibition, wherein serum from the wound bed diffuses into the adjacent graft. Revascularization occurs by the process of inosculation and angiogenesis. Vessels from the wound bed grow into the graft, forming functional circulatory connections with the vasculature of the graft. For plasmatic imbibition and inosculation to be successful, two criteria must be met. First, the wound bed must be appropriately vascularized. Therefore, skin grafts cannot be placed on poorly vascularized wound surfaces, including bone denuded of periosteum, tendon denuded of peritenon, or cartilage. Second, a bolster dressing or splint must be used to ensure absolute immobilization of the graft on the bed to prevent shearing of the nascent vascular connections during inosculation. If either of these criteria cannot be met, a more complex reconstructive option must be considered. Split-thickness graft donor sites heal due to

epithelial cell growth from the base of remaining hair follicles and skin appendages. A full-thickness graft donor site must either be closed primarily or reconstructed with a different technique.

Random Skin Flaps. The use of tissue (usually skin) immediately adjacent to the defect as the tissue for reconstruction is referred to as a local flap reconstruction. Skin rearrangement can range in complexity from simple undermining to complex, geometric skin flaps. Which method is appropriate is dependent on multiple factors, including the etiology of the defect, the desired direction of the scar, the fragility or mobility of underlying structures, and the need to avoid distortion to adjacent free margins such as the lip or eyelid. Significant experience is required for the optimal utilization of skin rearrangement. When plastic surgeons think of "classical" skin flaps, they are referring to random skin flaps, without an axial blood supply. These skin flaps rely on a dermal plexus of vessels for their survival, and the perfusion of the distal end of the flap is inadequate to allow tissue survival if the flap design is inappropriate. It was previously thought that survival of the distal part of random skin flaps could be ensured by adhering to length-to-width ratios established for various areas of the body. It is now recognized that these ratios have no basis in circulatory physiology, and the surviving length of a random skin flap does not depend on flap width.[19] In practice, most of the commonly employed skin flaps have been developed empirically. There are three basic types of random skin flaps: rotation, advancement, and transposition, depending on how adjacent skin is shifted into the defect. Each type of flap has specific design criteria and choice of flap design is based on wound location, patient anatomy, and surgeon preferences. Excellent reviews of the use of skin flaps in reconstructive surgery are available.[20,21]

As mentioned, the concern with flap viability limits the utility of random skin flaps. Several strategies have been developed to circumvent this problem. The first of these is the concept of surgical delay. Delay is defined as the partial interruption of blood flow to a defined piece of tissue allowing for preconditioning of the tissue prior to further division or transfer. At present, surgical delay is the only method available to augment the surviving length of random skin flaps (Fig. 109-1). Another strategy is the use of tissue expanders. Tissue expanders are implantable balloons that are inserted in a deflated state and are inflated with sterile saline via percutaneous injection into a self-sealing valve. Except for the scalp, where expanders are placed in the subgaleal plane, tissue expanders are usually placed subcutaneously. In fact, the insertion of the tissue expander into a subcutaneous pocket creates a surgical delay, and the slow expansion has been demonstrated to result in the formation of new skin. However, the most important strategy to circumvent the use of random skin flaps has been to develop axial pattern flaps that do not rely on a random blood supply.



Figure 109-1. Example of surgical delay. Because of associated medical problems, the patient was not a candidate for microvascular tissue transfer. **A:** Lower-third tibial defect secondary to an open ankle fracture. Note exposed bone, which precludes use of a skin graft. **B:** In the first stage, a bipedicle flap was created anterior to the defect. The deep perforators to the skin of the flap were divided by full undermining. The flap is perfused only from the proximal and distal ends. **C:** The incisions were repaired, and the wound was dressed. **D:** After 5 days, the bipedicle flap was again elevated and part of the distal pedicle was divided (*arrow*). The incisions were again closed, and the wound was dressed. This procedure was repeated 10 days after the initial operation to leave only a small skin bridge at the distal end of the flap. **E:** Fourteen days after the initial procedure, the remaining distal skin bridge was divided and the flap transferred. The donor site was skin grafted. This photograph depicts full survival of the flap and complete take of the skin graft.

Flaps with Axial Blood Supply. Regional flaps are defined as the transfer of tissue that

is not immediately adjacent to the defect without the disruption of blood supply to the transferred tissue. For this approach to be practical, an axial blood supply to the transferred tissue must be present.

Axial Skin Flaps. The pioneering work of Bakamjian[22] and McGregor and Jackson[23] identified longitudinal blood vessels of large caliber traversing a defined region of skin. Their descriptions of the deltopectoral and groin flaps, respectively, opened a new era of reconstructive surgery. Surgeons were no longer constrained to the use of random skin flaps; any piece of tissue in the body with an axial blood supply could be transposed on a vascular pedicle with a high degree of assurance that the tissue would survive. Taylor and Palmer's[24] description of the angiosome concept solidified our ability to design flaps based on a sound knowledge of vascular anatomy. An angiosome is defined as a region of tissue supplied by an identifiable, and usually named, artery and its venae comitantes. Because of the ability of choke vessels crossing angiosome boundaries to enlarge, flaps can be designed to encompass an adjacent angiosome. In practice, there are relatively few axial skin flaps, most being better classified as fasciocutaneous flaps.

Fasciocutaneous Flaps. Cormack and Lamberty[25] further expanded our understanding of the blood supply to the skin with their description of fasciocutaneous flaps. They pointed out that the dermal plexus derives its inflow from vertically oriented vessels arising at the level of the deep fascia. The vessels at the deep facial level have horizontal orientation relative to the skin's surface and form a subfacial plexus. This subfacial plexus can form the basis for the design of fasciocutaneous flaps based on several defined anatomical patterns.[25] Several fasciocutaneous flaps have enjoyed widespread use. The radial forearm flap has become a workhorse for hand reconstruction and as a free flap for head and neck reconstruction. The anterolateral thigh (ALT) flap has become a common flap for larger reconstructive needs and is based on septal or muscular perforators from the descending branch of the lateral femoral circumflex artery. The osteoseptocutaneous fibula free flap has been widely used for intraoral reconstruction during reconstruction of oromandibular defects and a primary site for vascularized bone flap harvest.

Muscle and Myocutaneous Flaps. Based on the knowledge that tissue with an axial blood supply can be reliably transferred, muscle and myocutaneous flaps came into widespread use in the 1980s, thanks in large part to the classification system by Mathes and Nahai.[26] Whole muscles can be transferred as a pedicled or free flap if a dominant vascular pedicle is present. Segmental muscle transfers are sometimes possible on minor vascular pedicles. Functional muscle transfer can also occur when innervation is preserved or the motor nerve is coapted to a different motor nerve.

The rediscovery of the musculocutaneous perforator as a predominant vascular supply to the skin in many areas of the body has led to the wide use of musculocutaneous flaps. These flaps derive their inflow from a major muscular artery used to also bring skin along with the underlying muscle. Perforators emanating vertically from the muscle surface supply the skin overlying the muscle. Table 109-4 lists "workhorse" muscle and

myocutaneous flaps. Of particular note is the transverse rectus abdominis myocutaneous (TRAM) flap, based on periumbilical myocutaneous perforators from the rectus abdominis muscle has been widely employed for breast reconstruction.[27] An extension of this concept has led to the increasing use of "perforator" flaps. Perforator flaps are based on fasciocutaneous or myocutaneous perforating vessels. Dissection isolates the skin and subcutaneous tissue to be transferred on one or more perforating vessels; the underlying muscle is left intact, eliminating the functional disturbance that would result if a whole muscle was harvested. Because of their robust vascularity and ability to minimize donor deficit, perforator flaps are often preferred in reconstructions where muscle is not necessary and preservation of the underlying muscle decreases the morbidity at the donor site. An example is highlighted in the section on breast reconstruction where the use of the deep inferior epigastric perforator (DIEP) flap is based on the same donor site anatomy as a TRAM flap, but preserves the rectus abdominis muscle. In reconstructive surgery a large number of perforator flaps have been described and are now used as both pedicled and free flaps.[28]

Table 109-4 Workhorse Muscle, Myocutaneous, and Perforator Flaps

Flap	Myocutaneous	Perforator	Common Uses
Temporalis	No	No	Orbital and intraoral reconstruction, facial reanimation (pedicled flap)
Pectoralis major	Yes	No	Intraoral and neck reconstruction; reconstruction of sternal defects (muscle only)
Latissimus dorsi	Yes	Yes	Breast reconstruction, neck reconstruction, free flap for very large defects
Rectus abdominis	Yes, including TRAM	Yes, including DIEP	Breast reconstruction, sternal reconstruction, reconstruction of groin defects, free flap for medium-sized defects
Gluteus maximus	Yes	Yes, including SGAP	Ischial pressure sores, sacral pressure sores, SGAP used for breast reconstruction
Biceps femoris	Yes	No	Ischial pressure sores
Tensor fascia lata	Yes	No	Trochanteric pressure sores, abdominal wall reconstruction
Gracilis	Yes	Yes	Perineal reconstruction, vaginal reconstruction, facial reanimation (muscle free flap), free flap for small defects
Rectus femoris	Yes	No	Infected hip wounds, abdominal wall reconstruction
Medial gastrocnemius	Rarely	No	Knee defects, proximal third tibial defects
Soleus	No	No	Middle third tibial defects

DIEP, deep inferior epigastric perforator; SGAP, superior gluteal artery perforator; TRAM, transverse rectus abdominis myocutaneous.

Microvascular Tissue Transfer. Historically, pedicled flaps were used to reconstruct distant defects. The distant transfer was accomplished in one of two ways. Flaps could be moved to the defect in a series of pedicled transfers (waltzing or tumbling flaps). Alternatively, flaps could be attached directly to the defect with a temporary pedicle to

the donor site being maintained temporarily. At a second stage the flap was detached from the donor site, after it had developed sufficient blood supply from the recipient bed (e.g., cross leg flaps, pedicled groin flaps). Although the distant transfer of pedicled flaps still has definitive indications (e.g., the median forehead flap for nasal reconstruction), reconstruction using distant tissue is now most commonly performed via microvascular tissue transfer, or "free" flaps. First described clinically by Daniel and Taylor,[29] free flaps have revolutionized reconstructive surgery. Any tissue with an axial blood supply with pedicle vessels 1 mm in diameter or larger can be reliably transferred microsurgically and improved techniques have opened the door to supermicrosurgery and the anastomosis of vessels between 0.3 and 0.8 mm in diameter.[30] Circulation in the transferred tissue is established via microvascular anastomoses between the axial flap vessels and vessels in the recipient site. Microvascular anastomoses are performed with 8-0 or 9-0 suture with the aid of an operating microscope; success rates for free flap transfers exceed 95%.[31] The greatest advantage of free flap reconstruction is that the surgeon is not restricted to the use of available, local tissues; any flap or composite block of tissue that has feeding vessels large enough for microvascular anastomoses can be transferred with this technique. By using composite tissue flaps, massive, complex tissue defects can be reconstructed replacing "like with like" (Fig. 109-2).[32] The transfer of tissue to the site of reconstruction from another area of the body allows the use of tissue which has not been exposed to the damaging effects of radiation or scarring. Bowel, skin, bone, muscle, fascia, and composite tissue can be transferred microsurgically with new flaps continuing to be described clinically. Free flaps are the primary modality for reconstruction of major head and neck defects after composite resection and for the reconstruction of traumatic defects in the distal foreleg. As already mentioned, perforator flaps are increasingly used as microsurgical tissue transfers. The anterior lateral thigh (ALT) perforator flap has become a workhorse for reconstruction of a diverse array of complex defects, especially after extirpative surgery of the head and neck. The deep inferior epigastric artery perforator (DIEP) flap rivals the TRAM as the mainstay for autologous breast reconstruction.[33]

The future of reconstructive techniques continues to evolve. The use of prelaminated and prefabricated flaps can now be used to create complex reconstructions elsewhere on the body and then transfer that reconstruction en bloc to the recipient site.[34] Tissue-engineered reconstructions are emerging with the modification of both biologic and nonbiologic tissues including the modification of stem cells, generation and cellularization of scaffolds, and three-dimensional (3D) printing for reconstructive purposes.[35] In addition, vascularized composite allotransplantation (VCA) has now been successfully performed in multiple areas including both hand and facial transplantation.[36] Continued work on immunosuppression modification should continue to shift the risk–benefit ratio toward standard reconstructive techniques.

RECONSTRUCTIVE AND AESTHETIC SURGERY OF THE BREAST

Plastic surgery of the female breast includes both reconstructive and aesthetic procedures. Breast reconstruction following mastectomy and reduction mammaplasty for macromastia (oversized breasts) are the most common examples of reconstructive breast surgery. By contrast, breast augmentation (enlargement) and mastopexy (breast lift) generally are performed for aesthetic reasons. Although some surgical approaches may be applicable to both categories of breast procedures, the relative benefits, risks, and costs of reconstructive versus aesthetic breast surgery may be quite different, particularly as viewed by patients, providers, and payers.

Before advising women on reconstructive or aesthetic breast procedures, the surgeon should carefully assess the patient's current preferences, concerns, history, and physical findings. Initially, any history of breast disease (as well as familial history of breast pathologies) should be evaluated. On physical examination, careful linear measurements and preoperative photographs should be taken to document existing contour deformities, asymmetries, or other findings. A standard breast examination should be carried out to detect previously undiagnosed masses, nipple discharge, or lymphadenopathy. Finally, it is also advisable that women age 40 years or older undergo mammography unless this study has been performed in the previous 12 months.

Preoperative consultation should include a thorough discussion covering the relative benefits and risks of the various surgical options. The surgeon is well advised to provide comprehensive information in an understandable format. To enhance patient satisfaction with the eventual surgical result, providers should elicit patients' preferences and expectations for surgical outcomes and tailor treatment options accordingly. Because of the prevalence of breast cancer in North American women, the impact of reconstructive or aesthetic procedures on breast cancer monitoring also should be discussed.

Reconstructive Breast Surgery

Postmastectomy Reconstruction

1 A variety of operative procedures have been described for breast reconstruction following mastectomy. These approaches can be categorized as implant-based, autogenous (natural) tissue, and "hybrid" procedures. For purposes of this discussion, the term *hybrid* is applied to procedures combining elements of both implant and autogenous tissue techniques. This overview describes the advantages and disadvantages of the most common techniques. Ultimately, procedure selection is based on a range of patient variables, including size and shape of the desired reconstructed breast; availability of local, regional, and distant donor tissues; coexisting medical problems; and, perhaps most important, patient preferences.

Implant-Based Techniques. As most commonly practiced, implant-based breast reconstruction is either performed as a staged tissue expander–implant reconstruction or as a "single stage" implant reconstruction. The tissue expander–implant approach usually requires two or more operative procedures to reconstruct the female breast. In the first stage, a temporary tissue expander is placed in a soft tissue pocket, usually located deep to the pectoralis major muscle. The tissue expander is a deflated silastic (silicone) envelope with an integrated or remote injection port through which saline solution can be percutaneously injected. Expanders can be completely covered with a combination of flaps including the pectoralis major (superior), serratus anterior (lateral), and rectus fascia (inferior). Alternatively, with the introduction of acellular dermal matrices (ADMs), expanders are now routinely covered with a pectoralis major muscle flap superiorly and ADM sling inferiorly. Following expander placement and meticulous closure of the overlying muscle and skin, saline is periodically injected beginning at 10 to 21 days. As the device enlarges, growth is induced in the overlying skin, recreating soft tissue coverage for the new breast.[37]

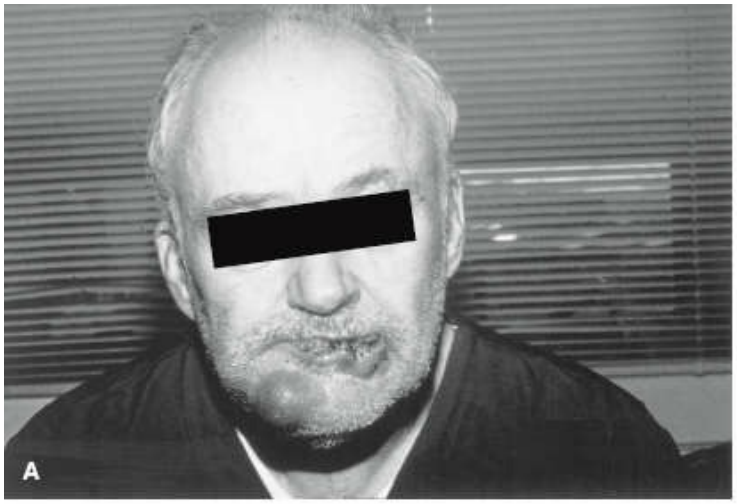
A


B

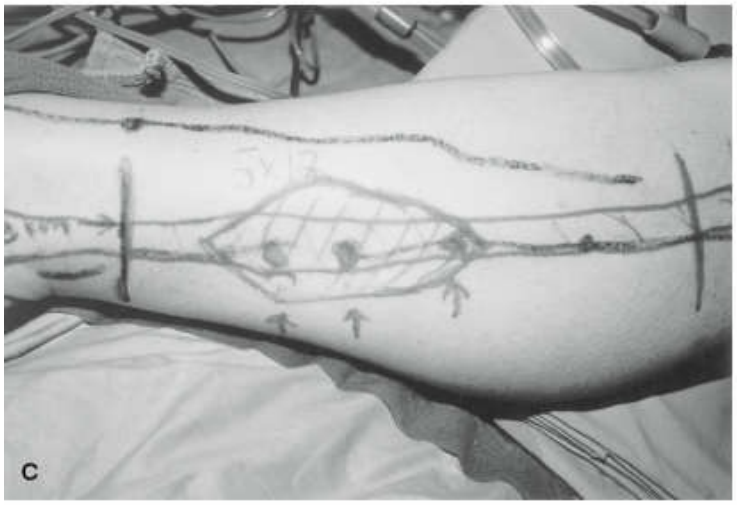
C

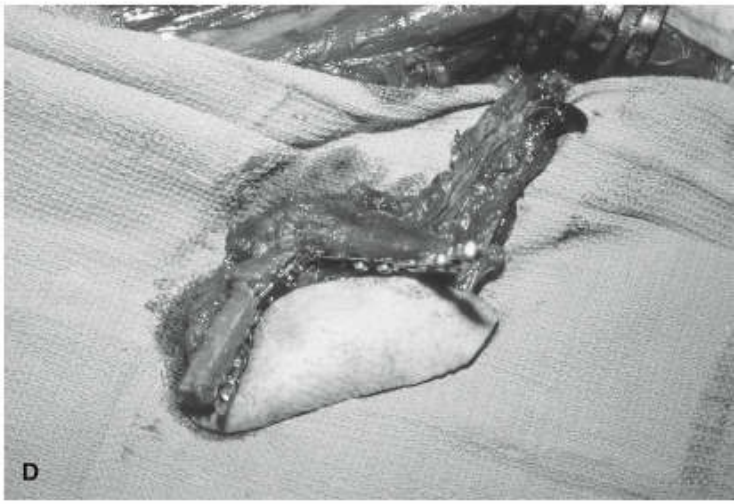
D

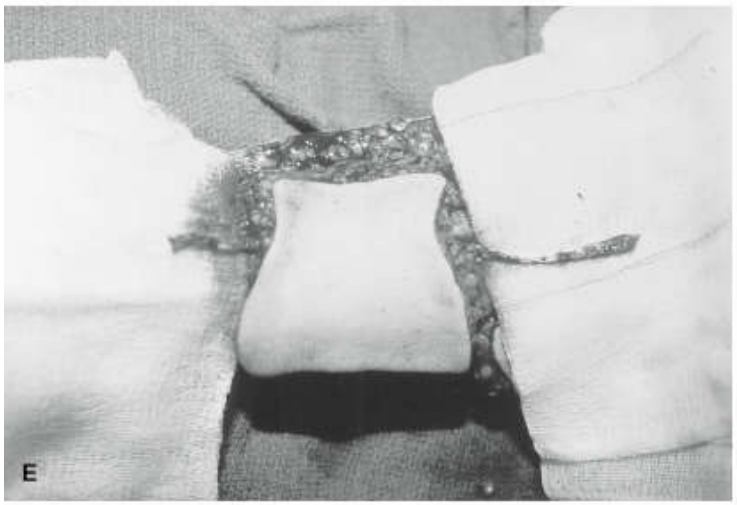
E

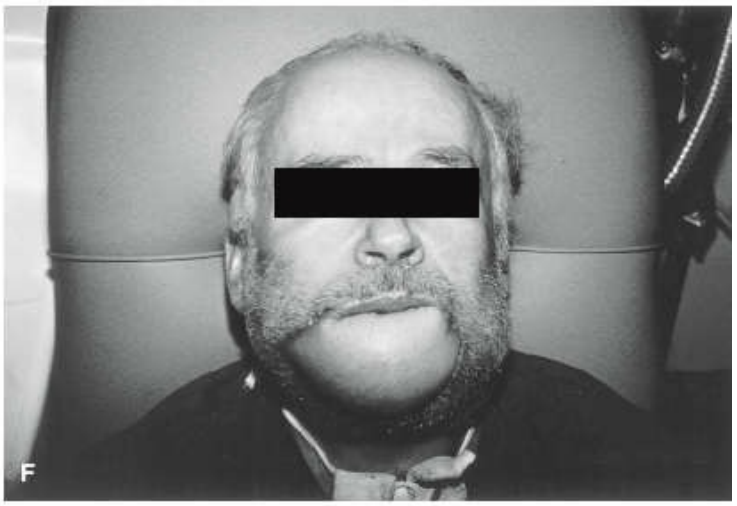
F

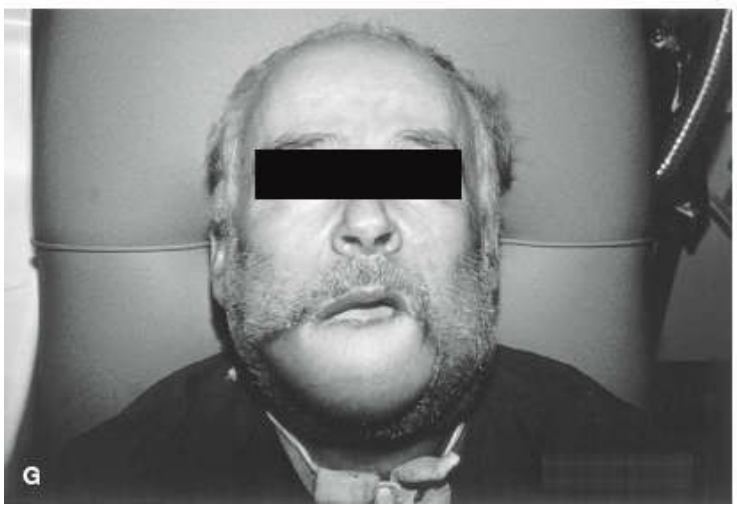
G

Figure 109-2. Double free-flap reconstruction of a massive, complex defect. **A:** Squamous cell carcinoma of lip, chin, mandible, and floor of mouth after resection. Massive tissue defect encompasses skin of the chin, entire lower lip, mandible from midbody to midbody, and floor of the mouth. **B:** Fibula free flap. Skin paddle is centered on fasciocutaneous perforators. **C:** Fibula free flap elevated but still in situ. Osteotomies have been performed to conform to the mandibular contour. The skin paddle will form the floor of the mouth. **D:** Radial forearm free-flap plan. Skin paddle will be harvested along with the palmaris longus tendon. The tendon will be attached to the modiolus on either side of the lower-lip defect, and the skin paddle will reconstruct the skin of the chin and lip. For the lip, the skin paddle will be draped over the tendon like a bed sheet on a clothesline. **E:** Radial forearm flap elevated but in situ. **F:** Postoperative result, mouth closed. **G:** Postoperative result, mouth open. (Reproduced with permission from Kuzon WM Jr, Jejurikar S, Wilkins EG, et al. Double free-flap reconstruction of massive defects involving the lip, chin, and mandible. *Microsurgery* 1998;18:372–378.)

Following completion of expansion, most surgeons delay the second stage of reconstruction for 1 to 4 months to allow for maximal skin growth. At the conclusion of this hiatus, the second procedure is performed, consisting of removal of the expander and placement of the reconstructive implant. Currently available breast implants include a range of options, including variations in shape (round vs. “anatomic” or teardrop configurations), fill material (silicone gel vs. saline), and surface configuration (smooth vs. textured envelopes). The relative advantages and disadvantages of these options are discussed in the Breast Augmentation section later in this chapter. As the most common option for postmastectomy reconstruction in the United States, the expander–implant approach offers several advantages. The lengths of the surgical procedures associated with this approach usually are relatively brief (often 1 hour or less) and are technically straightforward. Particularly when employed in bilateral reconstruction cases, resulting symmetry and aesthetic outcomes are relatively good (Fig. 109-3).

Patients considering implant reconstruction should also be mindful of the disadvantages of these procedures. The expander–implant approach usually requires at least two surgical procedures, multiple visits for expansion, and approximately 6 to 12 months to complete. For patients eager to return to a normal lifestyle following breast cancer treatment, this delay can be particularly frustrating. In addition, tissue expanders and reconstructive implants have been associated with a number of complications. Early in the postoperative period, these devices may be troubled by delays in wound healing, at times resulting in implant exposure and requiring explantation. Implant infections also may necessitate removal of the prosthetic device. Late complications include expander or implant leakage. Also, the development of excessive scar tissue surrounding the implant (termed a *capsular contracture*) can produce a hard, painful, or deformed breast requiring surgical revision.



Figure 109-3. Staged bilateral tissue-expander based breast reconstruction. **A, B:** Pre-operative apperance. **C, D:** After

tissue expansion. **E, F:** Final result after expande/implant exchange and nipple-areolar complex tattoing.

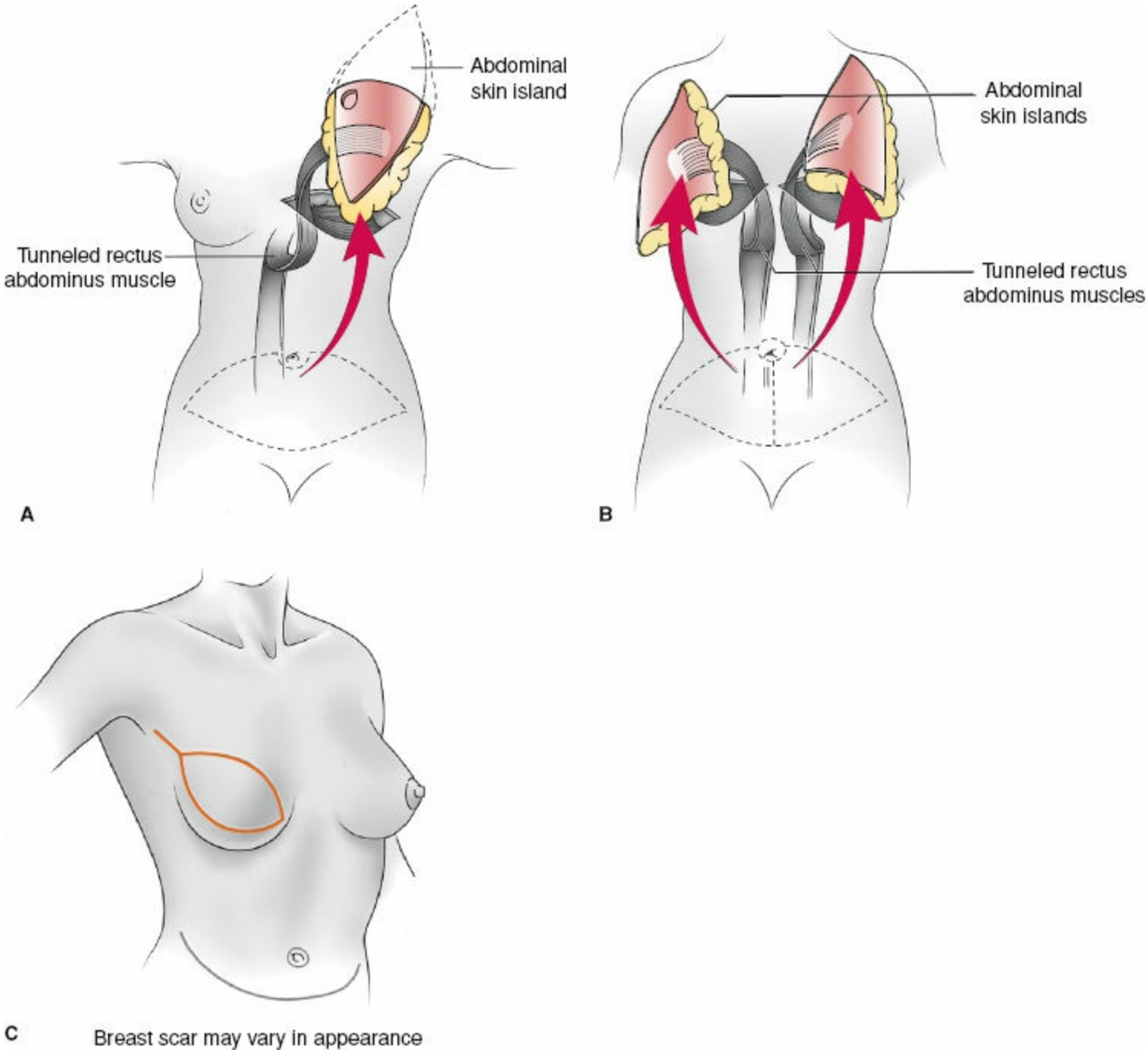

Figure 109-4. Transverse rectus abdominis myocutaneous (TRAM) flap reconstruction.

The "single stage" approach to implant reconstruction bypasses the tissue expander stage, with immediate placement of a full-sized silicone or saline-filled implant.[38] Similar to the tissue expander–implant reconstruction, patients will need revision procedures to achieve a complete reconstruction. The use of ADMs have made this option of reconstruction possible as larger volumes can be placed under an ADM; complete coverage with muscle limits the intraoperative volume placed in an expander at the initial reconstruction. Careful patient selection is necessary when considering this option and patients need to understand the reconstructed breast volume will be about the same size or smaller than their premastectomy volume. Patients who desire to be larger are better served with tissue expansion.

2 Autogenous Tissue Reconstruction. A variety of autogenous (natural) tissue options have been described for postmastectomy breast reconstruction. Currently, the most commonly performed of these procedures are based on the lower abdominal soft tissue. Originally popularized by Hartrampf et al.[30] the TRAM (transverse rectus abdominis myocutaneous) flap was the earliest lower abdominal flap routinely used for breast reconstruction. The flap was commonly performed as a pedicle muscle flap, with transfer of the rectus muscle which is left partially attached to the costal margin, preserving the superior epigastric artery and vein as the flap's blood supply (Fig. 109-4A and B). These tissues are tunneled subcutaneously into the mastectomy defect, where they are sculpted into the desired breast size and shape. Meanwhile, the abdominal donor site is closed by reapproximating the anterior rectus sheath and by advancing the remaining superior skin edge of the donor site as a modified abdominoplasty (Fig. 109-4C). As harvest of the pedicled TRAM flap requires use of an entire rectus muscle and a segment of the abdominal wall fascia, occurrences of postoperative abdominal hernias or (more commonly) abdominal wall laxity are a persistent problem, particularly in patients who undergo bilateral reconstruction using this technique.[39]

Microsurgical techniques for soft tissue transfer have allowed for modifications of the TRAM flap and have also encouraged the development of other alternative flap options. Other lower abdominal flap options requiring microsurgical free-tissue transfer include the free TRAM, muscle sparing TRAM, DIEP (deep inferior epigastric perforator) and SIEA (superficial inferior epigastric artery) flaps. Differences between these flap techniques are based on the amount of rectus muscle and fascia harvested with the flap, with the DIEP and SIEA flaps avoiding muscle or fascia harvest. Allen and Treece took the free TRAM flap a step further with their development of the DIEP flap: by meticulously dissecting vascular perforators from the deep inferior epigastric pedicle into the overlying abdominal fat, avoiding removal of any rectus abdominis muscle or fascia (Fig. 109-5A and B), thereby minimizing disruption of abdominal wall structures.[40] This consequently decreases the occurrence of abdominal bulges or hernias.[39,41,42] The flap is transferred to the chest where the flap vascular pedicle is anastomosed to recipient vessels in the chest with the aid of an operating microscope or high-power surgical loupes. The more common recipients utilized today are the internal mammary vessels (Fig. 109-5C), with the thoracodorsal vessels serving as a second option.

Abdominal soft tissue flap breast reconstruction offers several benefits. Because the flaps usually provide a generous amount of lower abdominal adipose tissue for breast bulk, implants are rarely needed with this approach (Figs. 109-6 and 109-7). The flaps can be inset and sculpted in a virtually infinite number of ways, giving the reconstructive surgeon considerable latitude in the creation of breast shapes and sizes. An additional advantage of abdominal-based flaps is their tendency to gain or lose volume in association with weight changes and body mass, thereby maintaining better symmetry than implant reconstructions over time. Finally, flap reconstructions avoid long-term problems encountered with implants such as implant rupture, which may necessitate additional surgical procedures. Likely based on these benefits, patients tend to be more satisfied with soft tissue flap breast reconstruction than implants in the long term.[43]

Despite these advantages, lower abdominal flaps also are associated with some disadvantages. Compared with implant approaches, flap reconstruction requires an abdominal scar, longer operations, hospitalizations, and recovery times. Furthermore, flap procedures can produce a range of complications, including partial and total flap loss as a result of vascular compromise of the transferred tissue.

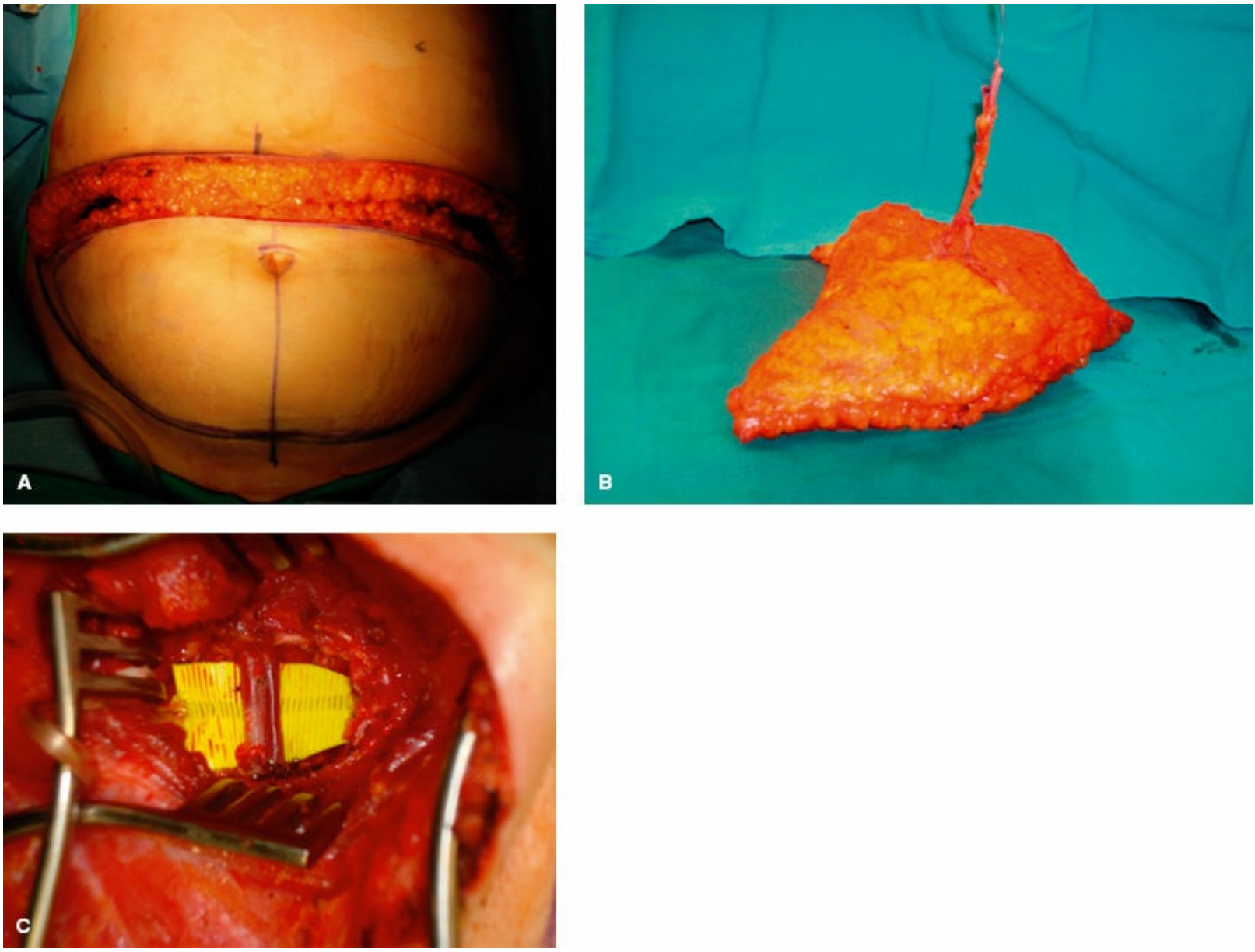

Figure 109-5. Deep inferior epigastric artery perforator (DIEP) flap. **A:** abdominal donor site. **B:** Flap harvested without muscle or fascia. **C:** Microvascular anastomosis to internal mammary vessels.

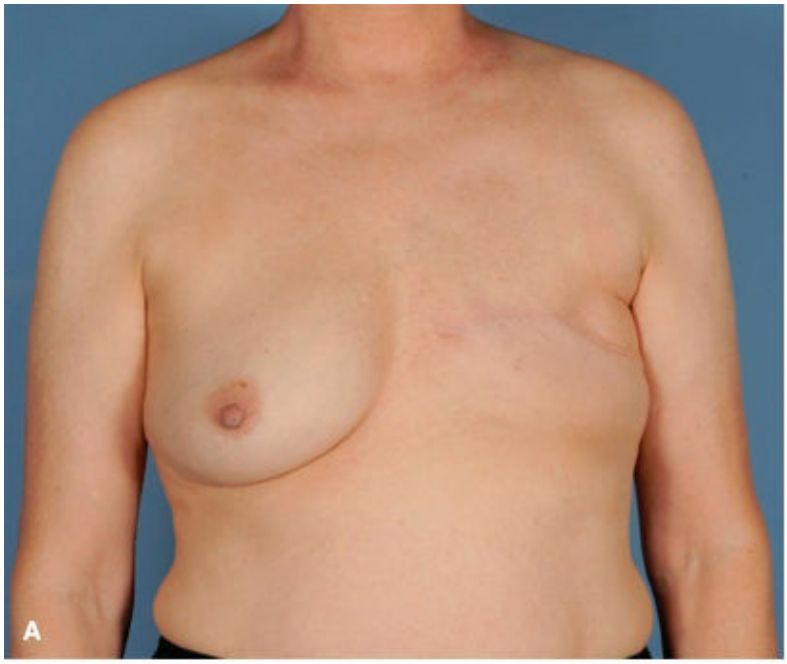
A

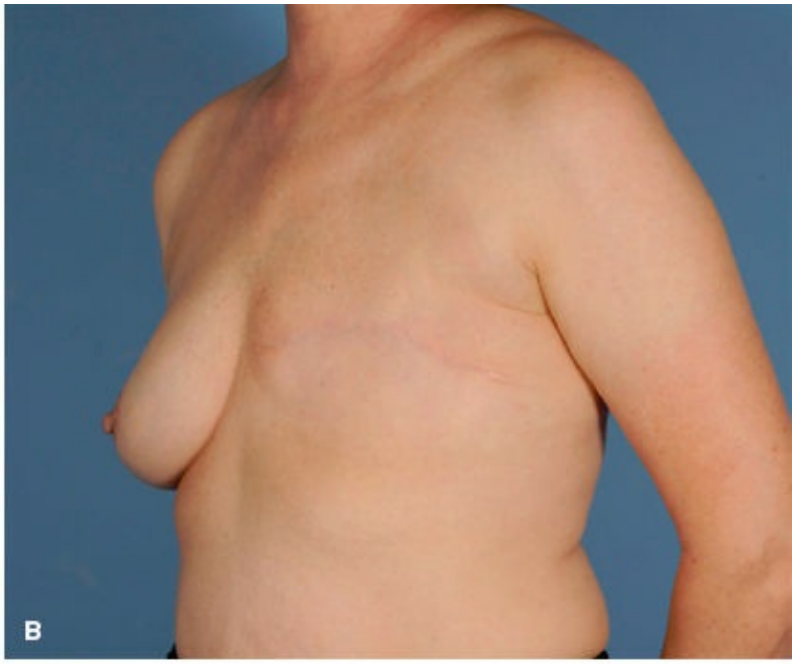
B

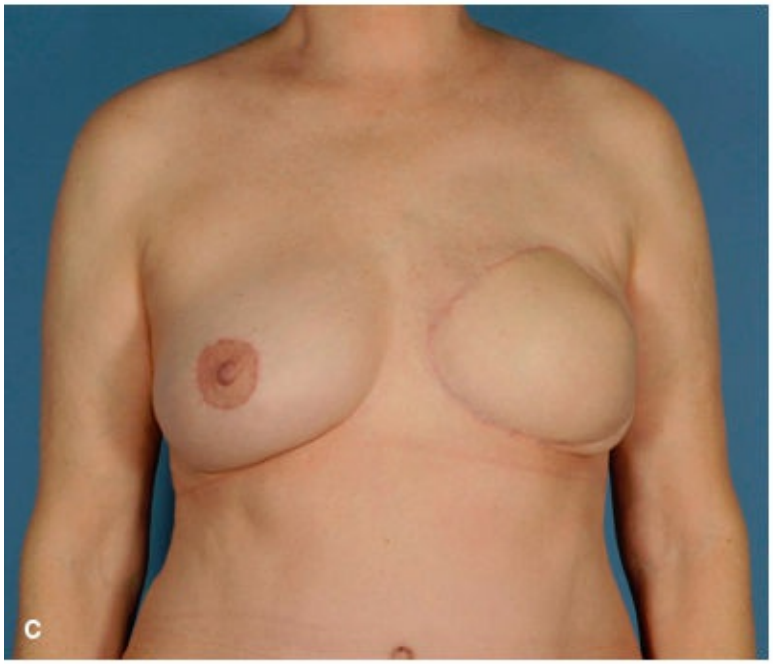
C

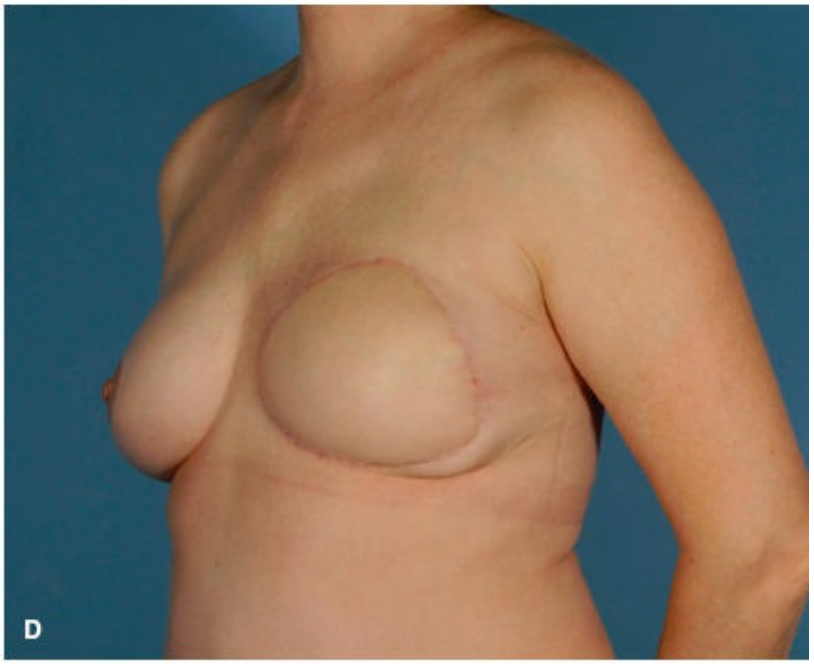
D

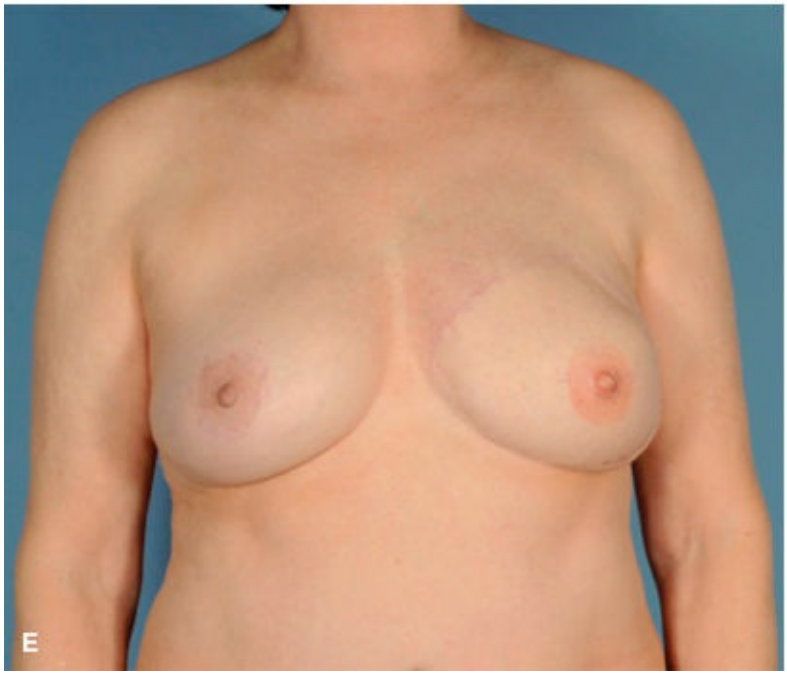
E

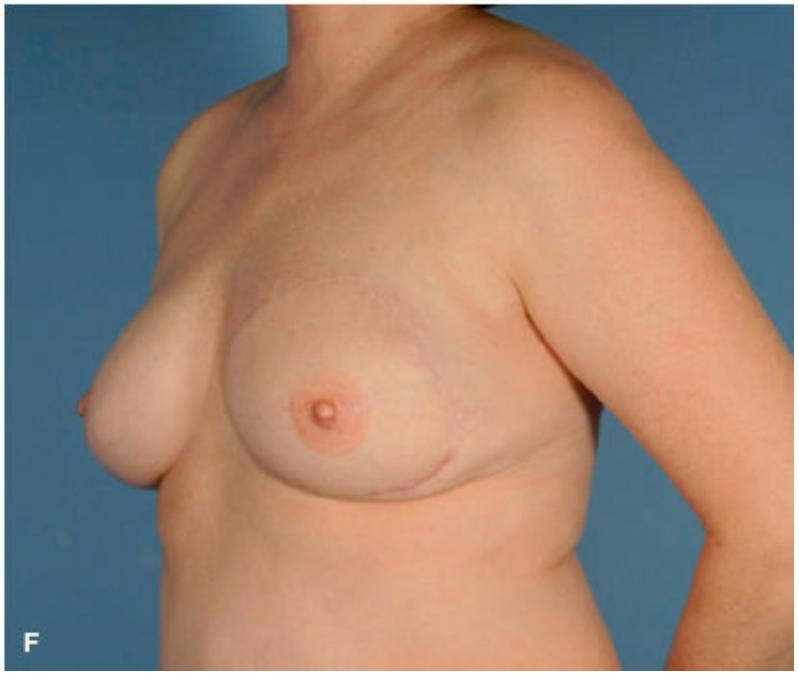
F

Figure 109-6. DIEP breast reconstruction. **A, B:** s/p left mastectomy. **C, D:** After left DIEP flap reconstruction. **E, F:** Final result after tattooing of nipple-areolar complex.

The free flap concept also has been applied to other donor sites for breast reconstruction, most notably the thighs (transverse upper gracilis and profunda artery perforator flaps) and gluteal region (superior and inferior gluteal artery perforator flaps).[44–47] Although perforator flaps appear to avoid the functional deficits associated with muscle flap harvest, they (like all free tissue transfers) entail longer, technically challenging operations requiring special facilities, equipment, and expertise. Also, because the blood supply for the entire flap depends on two or three microsurgical anastomoses (each usually involving vessels no more than 2 to 3 mm in diameter), there is the potential for complete flap loss in the event of anastomotic thrombosis. Flap loss rates are however relatively low at 1% to 2% in high-volume centers.

"Hybrid" Breast Reconstruction Techniques. As an additional alternative for breast reconstruction, flaps can be used in concert with saline or silicone-gel implants. Most commonly, the ipsilateral latissimus dorsi and a segment of overlying skin are harvested as a musculocutaneous pedicle flap and are tunneled anteriorly into the mastectomy defect. Although the latissimus dorsi and its associated skin island constitute an extremely reliable flap when used for wound coverage, this approach usually provides insufficient bulk for breast volume. Tissue expanders or implants are often used to address this volume deficiency. The combination of a latissimus dorsi flap and tissue expansion may be particularly appropriate for cases in which the remaining mastectomy skin is of insufficient quality or quantity to tolerate tissue expansion. Following transfer and expansion of a latissimus dorsi musculocutaneous flap, an appropriately sized breast implant usually can be safely placed in a secondary operation.

Nipple–Areolar Reconstruction. Reconstruction of the nipple–areolar complex (NAC) can be accomplished at the conclusion of breast mound reconstruction or at a later date. Following recreation of the mound, many surgeons prefer to allow several months for tissue healing and settling before proceeding with nipple–areolar reconstruction. To recreate the papule, common options usually rely on local skin flaps or a segment of redundant contralateral papule. For the areola, a full-thickness skin graft or tattooing of the surrounding skin can be used. In recent years 3D tattooing of the NAC has been introduced as an alternative to surgical reconstruction with good aesthetic results (Fig. 109-8).[48]

Breast Reduction (Reduction Mammoplasty)

Because reduction mammoplasty is intended to alleviate functional problems and symptoms of macromastia, this procedure is considered a reconstructive rather than an aesthetic operation. In general, appropriate candidates for reduction mammoplasty are women with macromastia and associated back, neck, or shoulder pain; limitations in daily work or recreational activities; or difficulties obtaining proper fit in bras or other

clothing. Although reduction mammoplasty usually is a covered benefit by most health care payers, patients symptomatic and functional concerns must be carefully assessed and documented before proceeding with surgery. As noted earlier in this section, patients preferences and expectations regarding postoperative breast size, shape, and functional results also should be carefully evaluated.

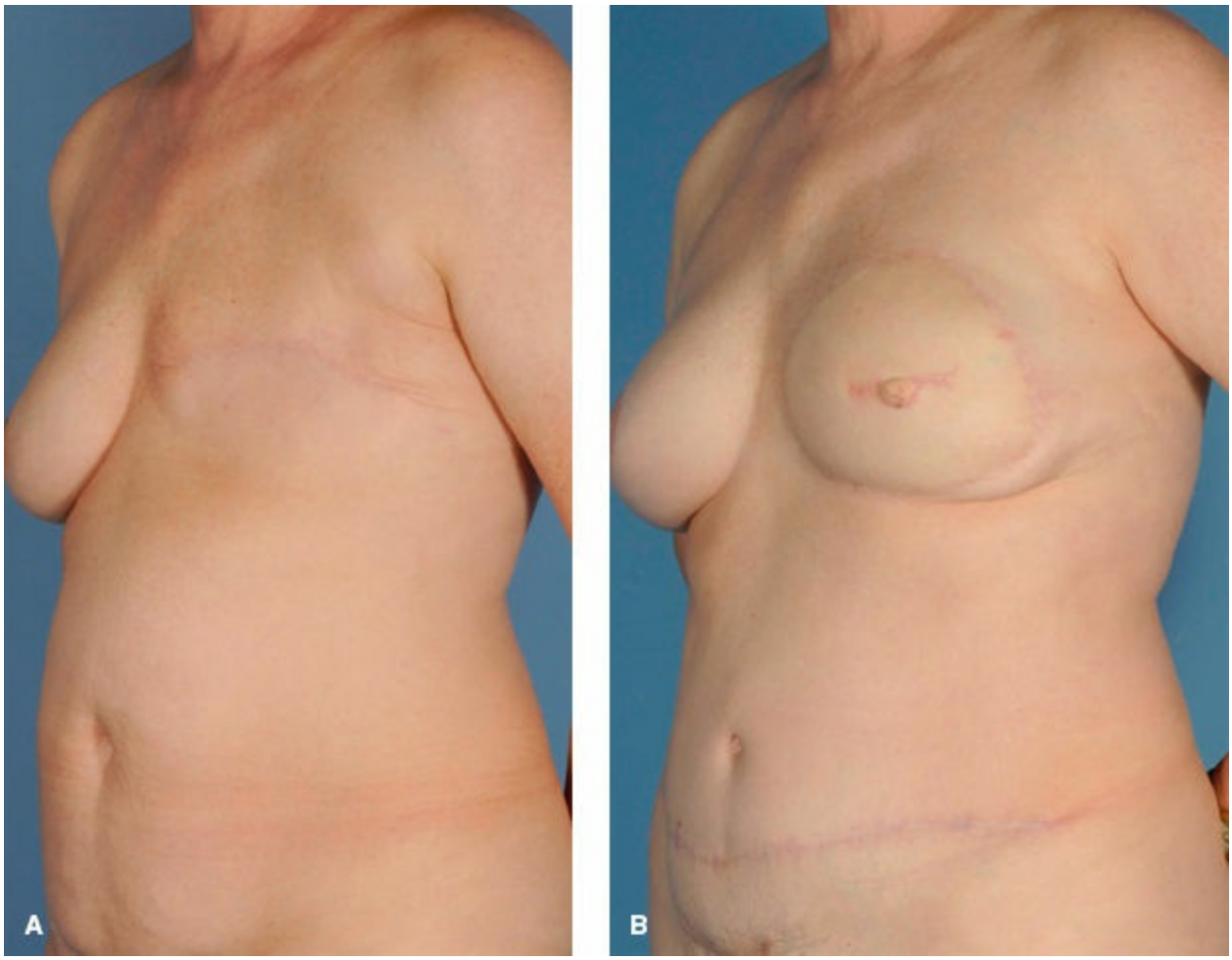

Figure 109-7. DIEP breast reconstruction. **A:** Pre-operative appearance. **B:** Post-operative, showing abdominal donor site scars.

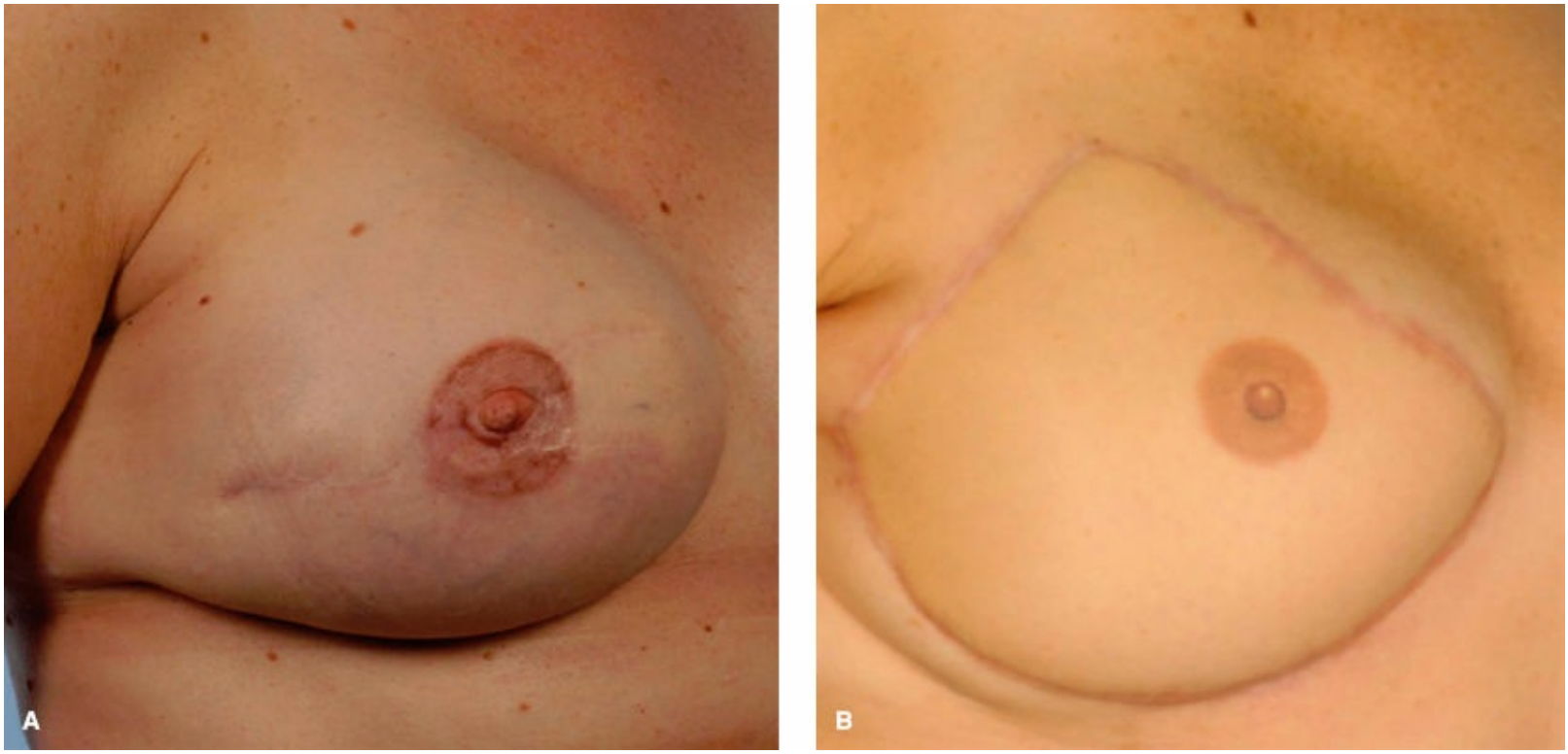

Figure 109-8. **A:** Standard nipple-areolar complex tattooing after nipple reconstruction. **B:** 3D tattooing of nipple-areolar complex without nipple reconstruction.

Although a variety of approaches have been described for breast reduction, common surgical options share a number of characteristics. Most techniques of breast reduction resect both breast parenchyma and redundant skin. Also, reduction procedures generally reposition the NAC to a more superior point on the breast mound. To maintain nipple viability and sensation, the NAC usually is mobilized as part of a pedicle of breast parenchyma or dermis. Following dissection of the nipple pedicle and reduction of the surrounding breast skin and parenchyma, the pedicle is transferred superiorly with its vascular and neural supplies intact, while the remaining breast is reapproximated around the nipple pedicle.

In categorizing reduction mammoplasty techniques, surgical options often are described in terms of the nipple pedicle design. For example, the most common approaches rely on an inferiorly or centrally based dermal–parenchymal pedicle to maintain vascular and nerve supplies to the NAC (Figs. 109-9A to C and 109-10A to C).[49–51] In designing skin incisions, traditional methods of reduction often have incorporated a modification of a pattern originally described by Wise.[52] While allowing considerable flexibility in resection of redundant breast skin, the modified Wise pattern produces an inverted T – shaped scar, the inferior portion of which runs along the inframammary fold (IMF) (Fig. 109-11). In an effort to eliminate the IMF scar, Lejour et al.[53,54] have described a vertical scar reduction mammoplasty.

Prospective outcome analysis of women undergoing reduction mammoplasty indicate that this surgical intervention produces considerable improvements in somatic pain and in functional status.[55,56] However, patients and providers also should be aware of the potential risks associated with reduction. Complications reported with these procedures

include instances of nipple or skin loss, changes in levels of nipple sensation, hypertrophic scarring or keloid formation, contour deformities, and breast asymmetry.

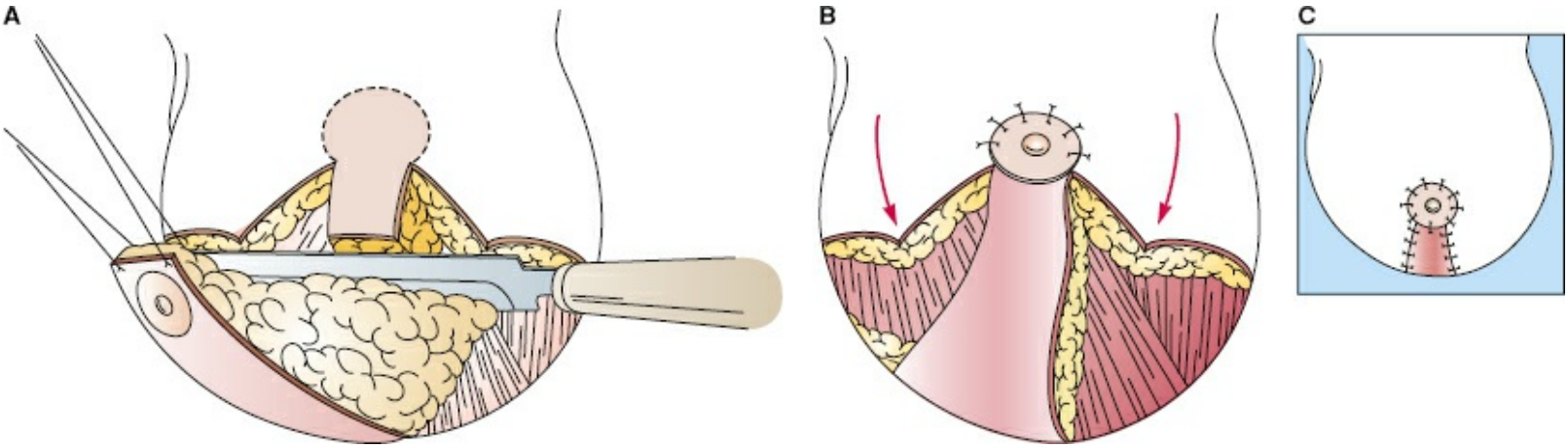

Figure 109-9. Inferior pedicle technique for reduction mammaplasty.

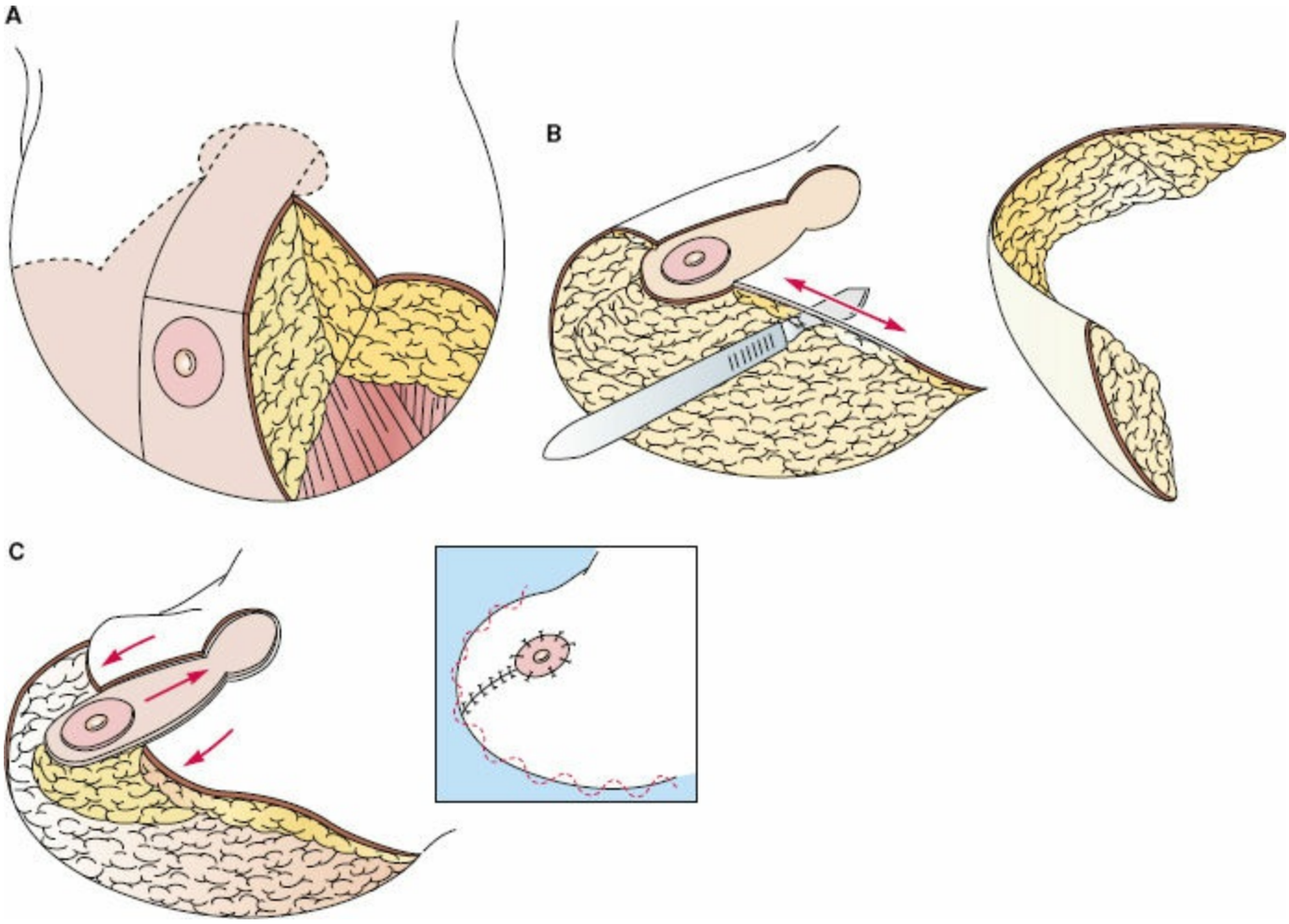

Figure 109-10. Central pedicle technique for reduction mammaplasty.

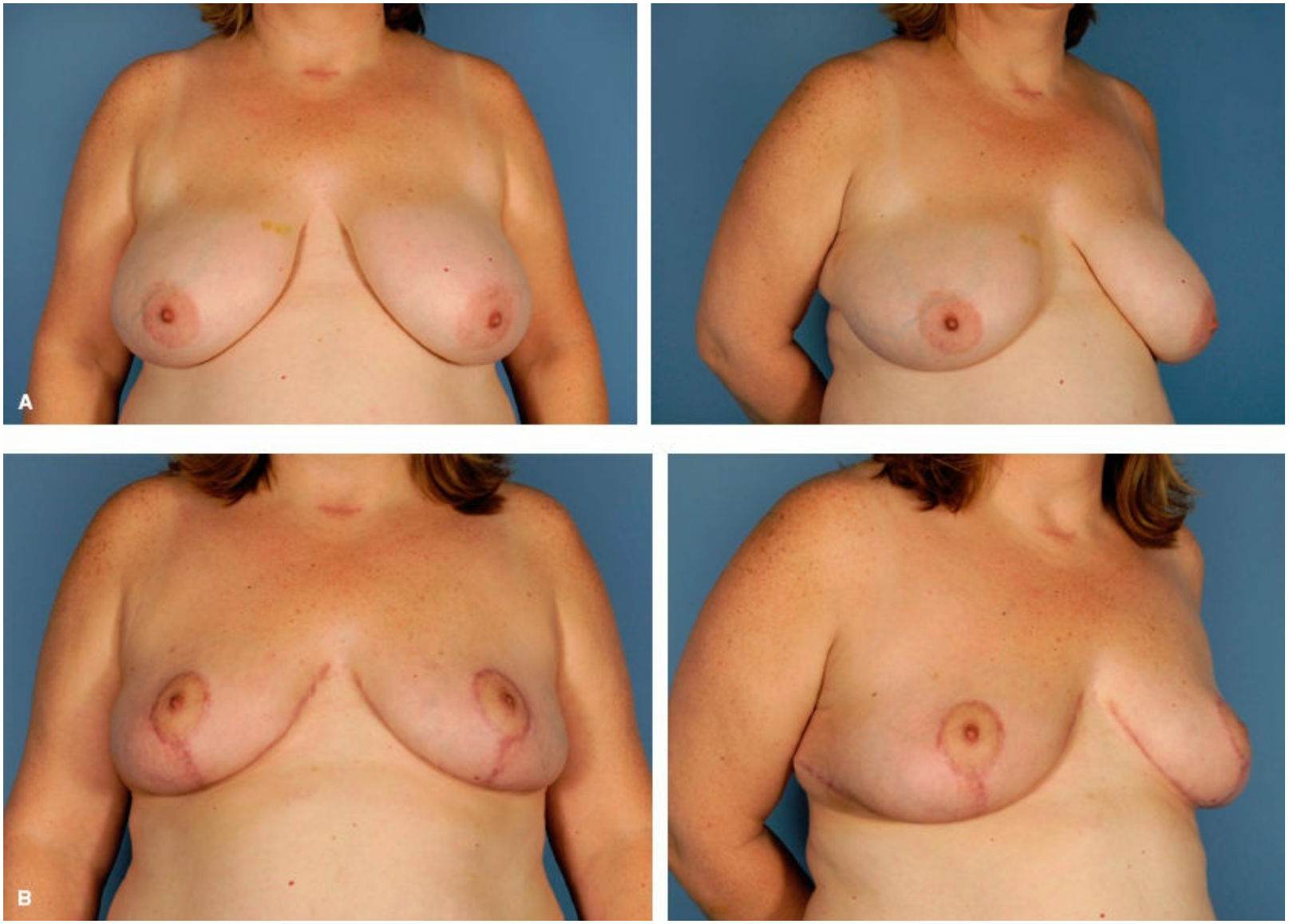

Figure 109-11. Inferior pedicle Wise pattern bilateral breast reduction. **A:** Pre-operative. **B:** Post-operative.

Aesthetic Breast Surgery

Breast Augmentation (Augmentation Mammoplasty)

Augmentation or breast enlargement is one of the most commonly performed aesthetic procedures. Evaluation of patients seeking breast augmentation should follow the guidelines described earlier. Particular attention should be focused on thoroughly assessing several factors, including patient preferences for postoperative breast size and shape, history of breast disease, and physical findings. The preoperative examination should evaluate and document any possible breast masses as well as existing breast size, asymmetries, and contour deficits.

In planning augmentation mammoplasty, a variety of approaches and options are available. Decisions regarding these choices are often best reached in consultation with the patient. Implants can be placed through a variety of incisions including periareolar, IMF, and transaxillary approaches (Fig. 109-12). With the advent of endoscopic techniques in recent years, transaxillary augmentation now can be carried out with direct visualization of the implant pocket. This latter approach commonly produces excellent aesthetic results with minimal visible skin scarring.

Location of the implant pocket is another critical decision in augmentation mammoplasty. Implants can be placed anterior to the pectoralis major muscle ("subglandular" location) or posterior to the muscle ("subpectoral" location). Subglandular placement usually results in less postoperative pain, but a submuscular implant location may produce lower rates of capsular contracture[57] and may pose fewer difficulties in obtaining subsequent mammograms.[58]

Several choices also exist in selection of implant types. Since the mid-1990s, many surgeons have been relying on the use of implants with textured surfaces to reduce capsular contracture rates. Although textured surfaces appear to lessen scar tissue contracture,[59] some patients and surgeons assert that, compared with the smooth-walled envelope, the thicker, less pliable textured envelope gives the augmented breast a less natural appearance and feel. With the reintroduction of silicone gel–filled implants in the United States, patients and providers also have a choice of implant fill materials. Although gel implants may produce aesthetically superior results compared with saline implants in some patients, diagnosis and surgical treatment of implant rupture may be more challenging with gel devices. Further refinements in silicone gel materials have led to the recent introduction of highly cohesive gel implants which have an anatomic shape and a reduced the risk for gel leakage in the event of rupture. Indications for highly cohesive gel implant use and critical aspects of patient selection are currently under investigation.

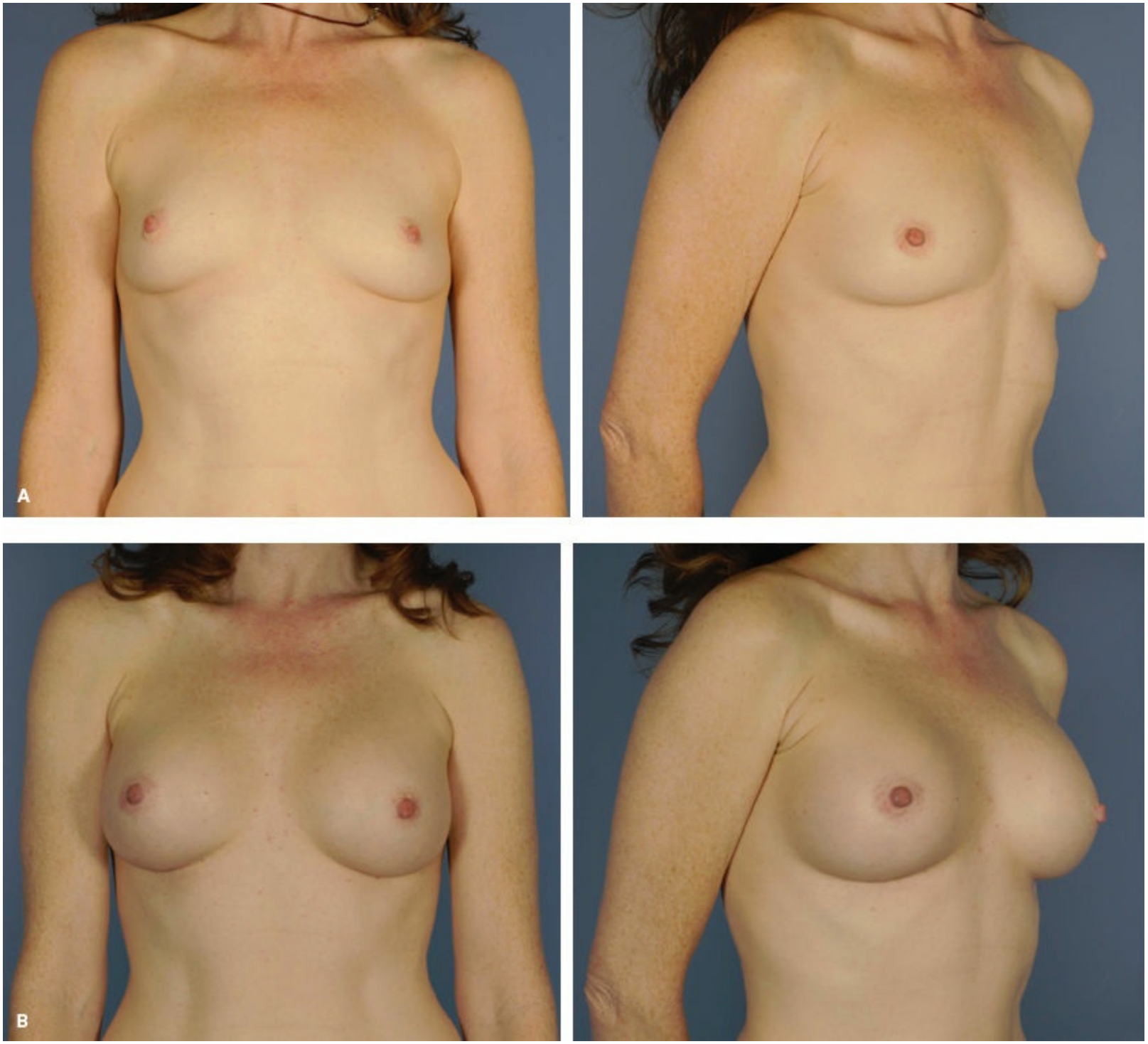

Figure 109-12. Breast augmentation via inferior mammary fold (IMF) incisions. **A:** Pre-operative. **B:** Post-operative.

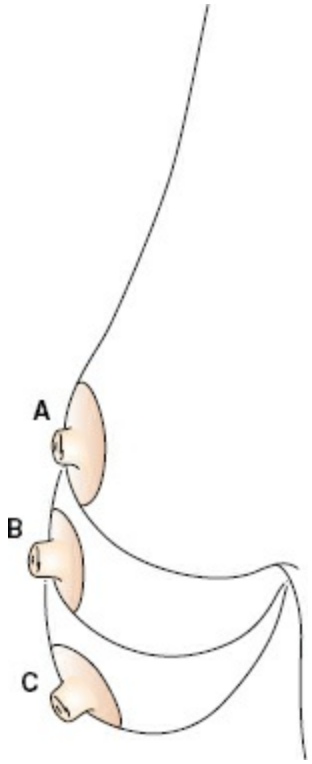

Figure 109-13. **A:** Mild ptosis. **B:** Moderate ptosis. **C:** Severe ptosis.

Whatever options are chosen for breast augmentation, surgeons should clearly communicate with patients about the potential risks of these procedures. The most commonly reported complications include implant rupture, capsular contracture, implant infection, contour deformities, and breast asymmetries.[60] Despite the potential for local complications, there currently is no substantial evidence that silicone gel filler material or implant envelopes are associated with increased risk for systemic disease. To date, concerns voiced in the early 1990s about adverse "health effects" of silicone breast implants appear to be unfounded.[61] However, over the past decade a few cases of anaplastic large cell lymphoma (ALCL) in patients with breast implants have been reported with growing evidence of an association.[62–64] The form of ALCL found in patients with implants tends to be benign, often regressing after implant and capsule removal without systemic therapy.[63,64]

Mastopexy

Mastopexy (or "breast lift") describes a category of surgical procedures designed to address redundancy or laxity of the breast's skin envelope, a condition termed *ptosis of the breast.* Breast ptosis can be classified as mild, moderate, or severe, depending on the location of the NAC relative to the IMF (Fig. 109-13). Ptosis occurs when an imbalance exists between the volume of breast parenchyma and the quantity of overlying skin. Mastopexy procedures usually reduce ptosis by removing redundant breast skin and by relocating the NAC to a more superior position. These goals can be achieved through a variety of skin incisions and excisions, many of which closely resemble techniques described earlier for reduction mammoplasty. Fundamentally, mastopexy differs from breast reduction in that mastopexy removes redundant skin while leaving most or all of the breast parenchyma. Approaches to mastopexy range from minimal periareolar

techniques to more extensive skin resections using more extensive vertical incisions (Fig. 109-14A and B). As always, patients considering this procedure must weigh the potential benefits of mastopexy (most notably, diminished ptosis) with the disadvantages (scars and risks of complications) associated with the operation. Although relatively rare, the potential complications of mastopexy closely parallel those described for reduction mammoplasty.

RECONSTRUCTIVE SURGERY OF THE HAND

Advances in plastic surgery have improved our ability to reconstruct hands that have been mutilated by trauma, destroyed by arthritic diseases, or impaired by congenital conditions. Innovations in microvascular techniques, wound management, and rigid fracture fixation have expanded the capabilities of plastic surgeons by allowing them to borrow tissues from other parts of the body and use them to reconstruct complex defects in the upper extremity in a single procedure. These innovations provide limitless technical possibilities for the restoration of hand function and the eventual return of patients as productive members of society. The following sections highlight the technical aspects of hand reconstruction and discuss indications for and applications of these techniques.

Replantation

3 Since the first successful finger replantation by Komatsu and Tamai[65] in 1968, replantation surgery has flourished throughout the world. Thirty years of experience with replantation surgery has improved our understanding of this procedure and has resulted in the development of indication guidelines to ensure that replanted upper extremity parts not only survive, but have acceptable function as well. The absolute indications for replantation (i.e., situations in which replantation should always be attempted) are (a) thumb amputation, (b) multiple finger amputations, (c) pediatric population amputations, and (d) mid-hand, wrist, or distal forearm amputations. The absolute contraindications for replantation are (a) associated life-threatening injuries, (b) multiple-level injury in the amputated part, causing injuries along the vessels and preventing blood flow into the replanted part, and (c) severe contamination of the part, which carries a high probability of systemic infection if replanted. There are other situations in which the benefit of replantation is debatable because outcome data are not available. For example, single-finger amputation at zone II (a tight fibroosseous tunnel extending from the insertion of the superficialis tendon at the middle phalange to the first annular pulley) is generally not recommended. Tendon adhesion after zone II replantation may result in a stiff finger, which can interfere with the overall performance of the hand. On the other hand, single-finger amputation at zone I (distal to the superficialis insertion) is often recommended (Fig. 109-15). A stiff distal interphalangeal joint generally does not cause much impairment, and nerve regeneration to the replanted part is quite rapid because of the short distance to the terminal sensory organs. Furthermore, the aesthetic appearance of zone I replantation is far superior to that of an amputation stump. In the future, the use of patient-related outcome instruments and an increased body of replantation experience among centers will help to define the utility of various digit replantation procedures.

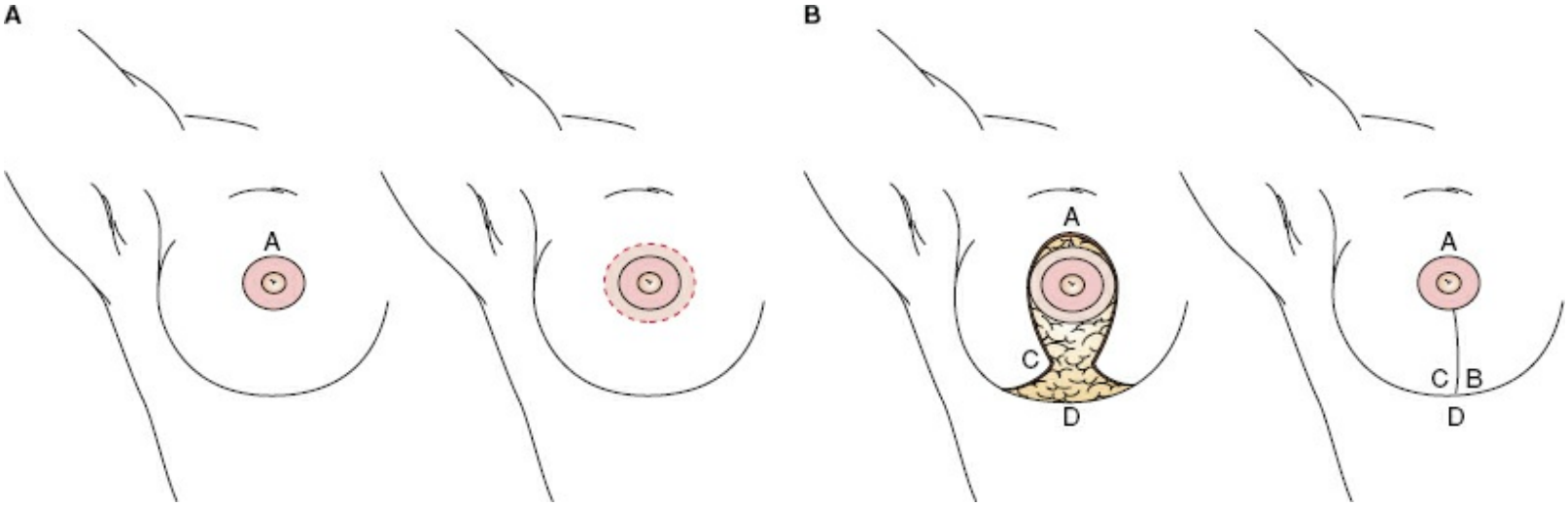

Figure 109-14. Mastopexy procedures. **A:** Circumareolar technique. **B:** Vertical scar technique.

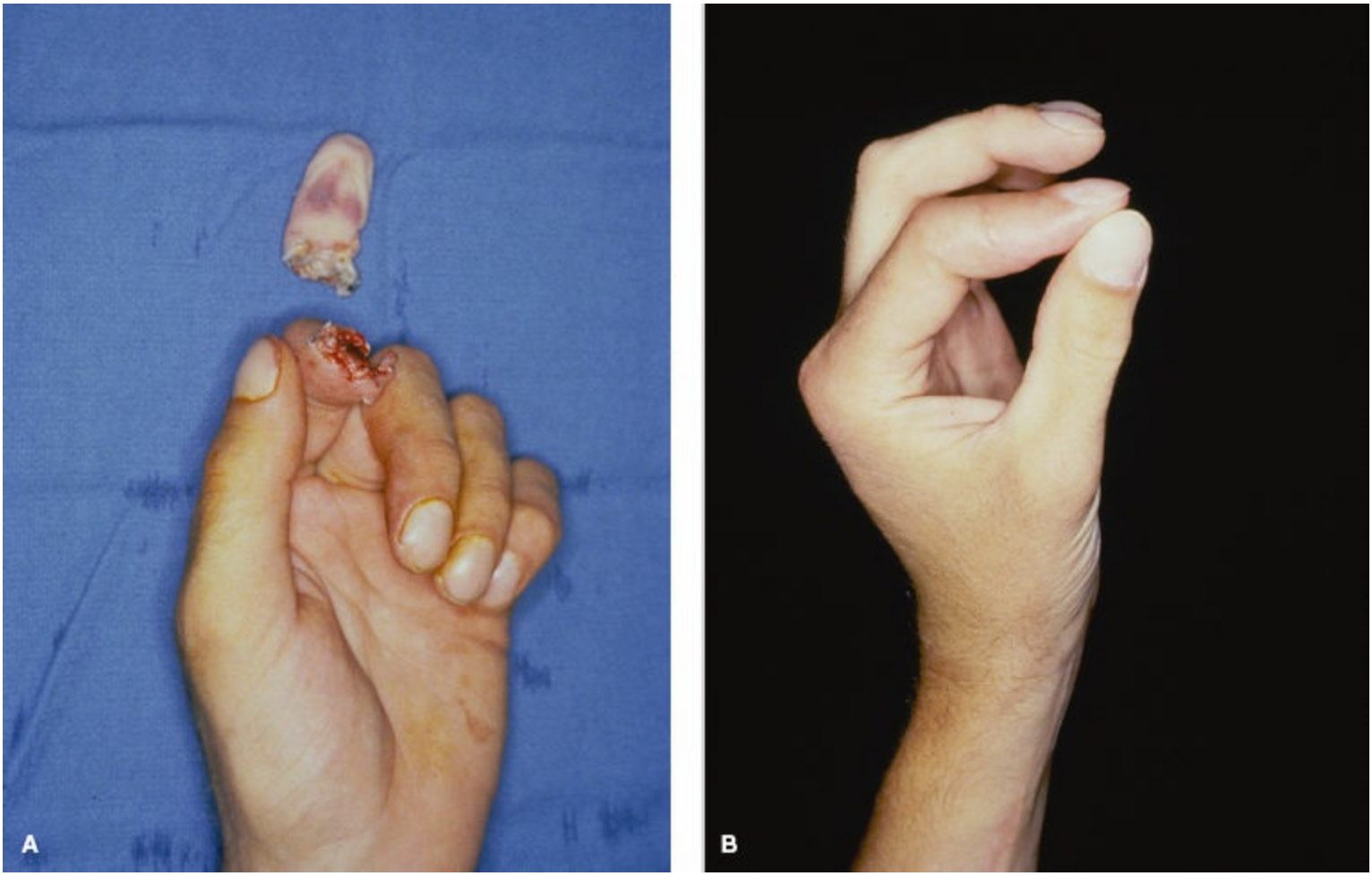

Figure 109-15. **A:** Amputation of the index finger at zone 1 in a mechanic. The patient requested replantation because his work requires fine manipulative tasks. **B:** Successful replantation with good aesthetic outcome and function.

Toe Transfer

When finger replantation is not possible or not successful, patients are left with significant functional loss. Disability is most severe when the thumb has been amputated at or proximal to the metacarpophalangeal joint or when all of the fingers have been amputated in machine injuries. In these cases, toe transfer to the hand is an effective procedure in restoring grasp and pinch function. Although a prosthesis is available to mimic the thumb, lack of sensation is a major drawback and often leads to disuse of the prosthesis. For a patient who has had a thumb amputation at or proximal to the metacarpophalangeal joint, big toe or second toe transfer to the thumb can create a sensate digit that will oppose to the other fingers. Big toe transfer is advantageous because it provides a broad contact surface and closely resembles the shape of the thumb, particularly when the big toe is trimmed and sculptured to match the size of the thumb. However, the disadvantage of the big toe transfer is the conspicuous donor site appearance in the foot and potential gait problems with foot push-off if the head of the first metatarsal is taken along with the big toe. For these reasons, the second toe has become the preferred method of transfer in some centers (Fig. 109-16). The disadvantage of the second toe transfer procedure is the slender appearance of the digit as compared to the original thumb, but the donor site appearance is quite acceptable. A recent outcome study, using objective physical measurements and validated outcome questionnaires, demonstrated that toe-to-thumb transfer is an effective procedure in restoring hand function.[66] In addition, patients did not complain of gait difficulty after either big toe or second toe transfer.

One of the most complex problems in hand surgery is the reconstruction of a hand without digits. To create a new hand capable of tripod pinch, plastic surgeons can transfer multiple toes from both feet to the hand (Fig. 109-17). This type of reconstruction can restore function to an otherwise useless hand and has allowed two farmers who were treated at one center to return to heavy farm labor.

Complex Hand Injuries

Although crush injuries to the hand are common, injuries associated with sufficient force to disrupt the structural integrity of the wrist and to sever the blood supply to the hand are uncommon events (Fig. 109-18). Because multiple structures are traumatized in injuries of this kind, a systematic treatment approach is important in salvaging the hand and in restoring its function. Crucial steps in the management of this injury are: (a) ruling out other injuries, (b) aggressive débridement, (c) skeletal fixation, (d) decompression of fascial compartments in the hand, (e) revascularization, (f) tendon repair, (g) nerve repair, and (h) early soft tissue coverage (within 1 week of injury).

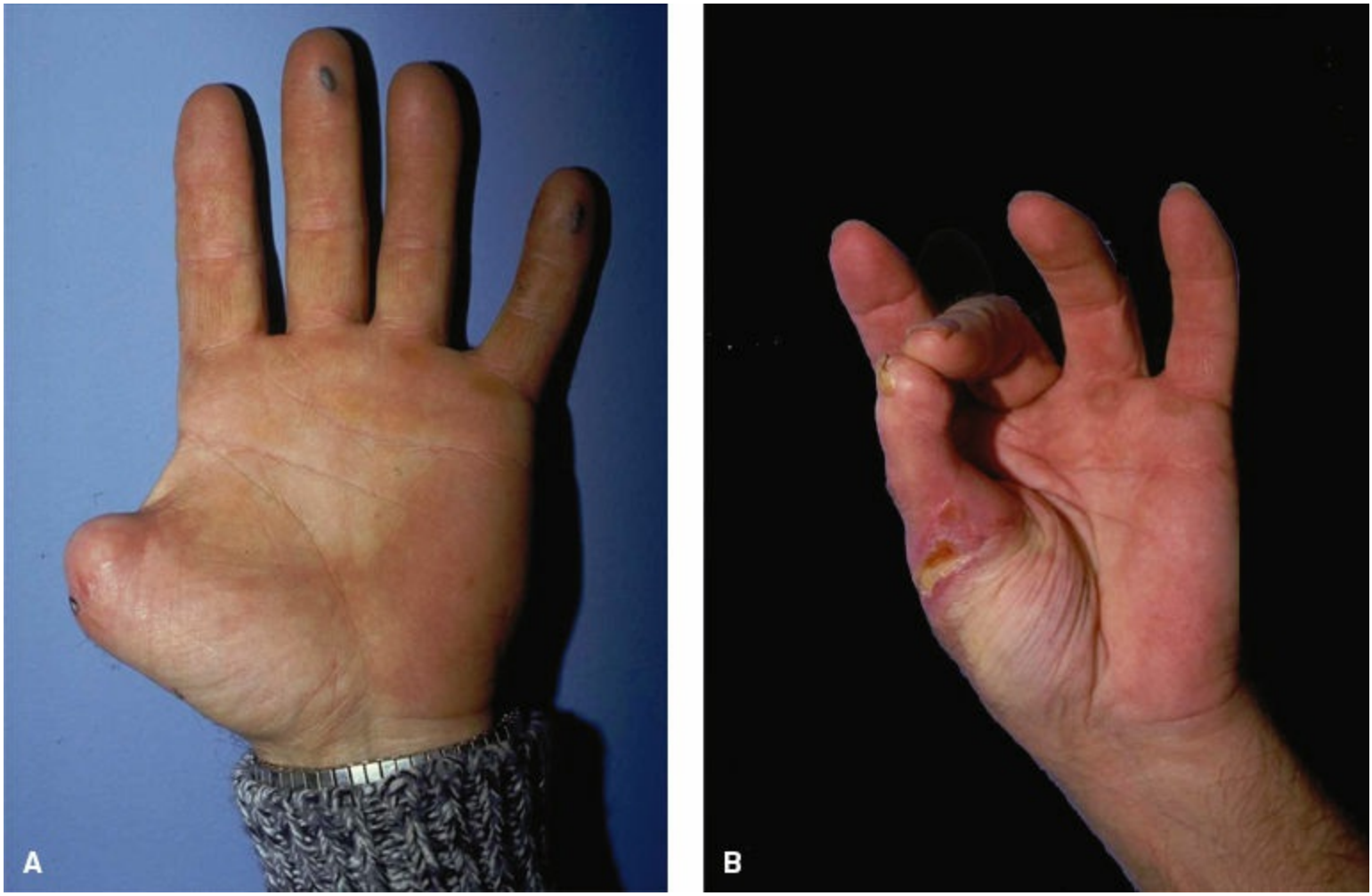

Figure 109-16. **A:** Second-toe transfer for thumb reconstruction in a carpenter. He sustained a thumb amputation at the metacarpophalangeal joint while using a saw at work. **B:** Good function with restoration of fine pinch. The patient returned to work as a carpenter 3 months after the toe reconstruction.



Figure 109-17. **A:** A farmer who lost all his fingers when he was injured by a corn picker. A groin skin flap was used to cover the exposed metacarpal heads. **B:** A second toe was removed from one foot to reconstruct the thumb, and the second and third toes were removed together from the other foot to reconstruct the fingers. Note the good opposition of the thumb and acceptable flexion of the digits. The patient returned to work on his dairy farm after the hand reconstruction.

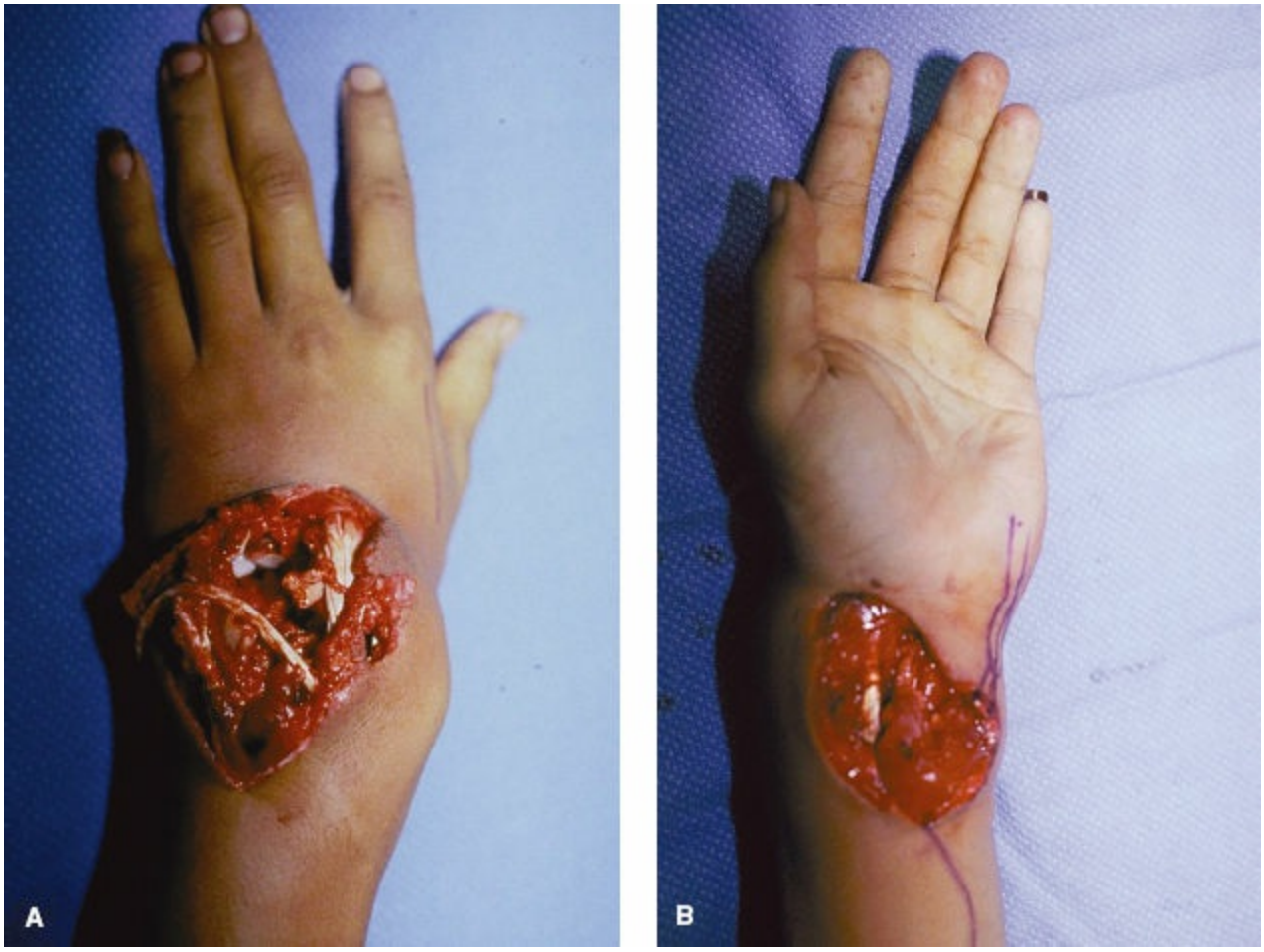

Figure 109-18. **A:** Accidental shotgun blast injury in a 16-year-old boy. Both the radial and ulnar arteries were ruptured, and the hand was ischemic. The wrist was destroyed, and multiple tendons and nerves were severed. **B:** Volar wrist wound. Markings show incision lines for ulnar artery exposure.

Ruling Out Other Injuries

In devastating trauma, attention is often focused on the obvious injury, and injuries to other organ systems may be ignored. In a review of 1,100 patients referred for emergent microsurgery over a 7-year period, investigators found 9 cases (0.8%) of unrecognized life-threatening injuries that required abandonment of the microsurgical procedures.[67] Therefore, systematic trauma evaluation and ruling out other associated injuries should precede treatment of the hand injury.

Débridement

Severe crush and blast injuries are associated with large zones of injury, and the wounds may be contaminated with foreign materials such as grease or paint, as in printing-press injuries. In these cases, aggressive débridement is important in preventing infection. Except for critical structures that include nerves and tendons, all devitalized soft tissues and bone fragments must be excised. The concept of radical débridement has been shown to decrease wound infection and improve success of microvascular reconstruction.[68]

Skeletal Fixation

After débridement, the next priority is to stabilize the wrist and to rigidly fix hand

fractures. A stable wrist provides a platform for repairing other injured structures. If the crush injury is associated with comminuted fractures of multiple carpal bones and rupture of the intercarpal ligaments, wrist fusion may be the best option because it is often impossible to reconstitute the normal anatomy of the distal and proximal carpal rows in face of severe comminution of the carpal bones. To avoid possible bone graft contamination with primary wrist fusion, external fixators are placed for provisional fixation during the initial débridement. Definitive wrist fusion with bone grafting is performed after adequate débridements and during the flap coverage procedure. Two 2.7-mm fixator pins are placed through an incision along the radial index metacarpal, and two proximal 3.5-mm pins are placed into the radius using an incision along the radial border of the distal radius, between the brachioradialis and the extensor carpi radialis longus. The superficial radial nerve, which lies under the brachioradialis, is dissected free and retracted away from the pins. External fixator rods are then secured to the pins with nuts and screws. If the wound is clean during the second-look procedure at 24 or 48 hours, total wrist fusion is then undertaken (Fig. 109-19). Otherwise, the external fixator is left in place until the wound is suitable for fusion using internal plating and cancellous bone grafts. This stable skeletal fixation allows early hand therapy, usually instituted on postinjury day 7 when tissue edema is subsiding.

Revascularization

In a crush injury of the wrist, the zone of injury can be extensive. Use of vein grafts is essential in performing the arterial anastomosis away from the zone of injury. The ulnar artery is chosen for repair because it is the dominant artery in most patients and because it can be exposed readily in the hypothenar area. If the ulnar artery is contused in the palm, distal anastomosis can be performed to the superficial palmar arch. Because soft tissue bridges are often present, venous outflow is not a problem and venous anastomosis is not necessary.

Decompression of Fascial Compartments

Increased edema associated with crush injuries often raises the compartmental pressures in the intrinsic muscle compartments and in the carpal tunnel. Prior reviews have shown a high incidence of ischemia and resultant fibrosis of the intrinsic muscles following crushing trauma to the hand.[69] Consequently, surgeons perform prophylactic carpal tunnel releases and intrinsic muscle decompressions in severe crush injuries of this kind.



Figure 109-19. **A, B:** Note destruction of the wrist joint, in addition to comminuted fractures of the distal ulna and radius. **C:** Total wrist fusion was performed 48 hours after the initial injury.

Soft Tissue Coverage

After aggressive débridement, a soft tissue defect is often present around the wrist. A split-thickness autograft is placed over the vein graft to prevent desiccation. Other open wounds can be covered temporarily with homografts. If wrist fusion is undertaken during the second-look procedure, primary wound closure can be achieved. For residual wound defects, split-thickness autografts are used to cover the exposed muscle bellies. However, if tendons or nerves are exposed, coverage with either fasciocutaneous or muscle free flaps will allow earlier tendon mobilization and prevent tendon adhesions. Definitive early wound coverage is important in protecting vital structures and avoiding wound colonization with bacteria (Fig. 109-20).

Nerve Repair

When nerves are crushed, the delineation between viable and nonviable nerve fascicles is difficult to assess in the acute setting. Therefore, the traditional approach is to delay the nerve grafting procedures until 2 or 3 months after injury. To prevent retraction of the nerve ends, we suture the nerve ends to the surrounding soft tissues. However, secondary nerve grafting is often difficult because of the amount of scar in the wound. One way is to primarily graft the nerve injury at the expense of more aggressive resection of the traumatized nerve ends.



Figure 109-20. **A:** A free rectus muscle was used for immediate coverage of the reconstructed wrist and tendons. **B:** The hand was salvaged, and the patient has acceptable hand function after secondary nerve and tendon reconstruction.

4 In conclusion, rigid skeletal fixation, revascularization using vein grafts, and immediate wound coverage are crucial factors in successful limb salvage.

Syndactyly

Syndactyly is a condition in which the fingers are fused. It can be classified as complete or incomplete. Complete syndactyly is the union of the digits extending to the distal phalanx. Incomplete syndactyly is the union of the digits proximal to the distal phalanx but distal to the normal webbing at the midproximal phalanx. Syndactyly is further categorized as simple or complex. In simple syndactyly, there is no bony union between the digits, whereas complex syndactyly includes bony union.

Typically, syndactyly can be separated when the child is 1 year of age. Surgery should be performed earlier if syndactyly affects the thumb–index finger or ring–little finger web space and causes deviation of the shorter digits during growth. Separating the fingers requires meticulous design of the skin flaps, and the dorsal skin flap is most crucial to creating a web space that is not prone to contracture (Fig. 109-21). Distally, triangular skin flaps are designed to drape the sides of the fingers. A full-thickness skin graft from the groin is often required to cover open areas in the fingers.



Figure 109-21. **A:** A simple, complete syndactyly in a 1-year-old child. Note the design of the dorsal skin flap to reconstruct the web space and the interdigitating distal skin flaps. **B:** Immediate postoperative photograph of the syndactyly release.







Figure 109-22. **A:** Wassel type 3 thumb duplication in a 2-year-old child. **B:** The radial digit was hypoplastic and was removed. **C:** Intraoperative picture shows the aesthetically pleasing reconstructed thumb.

Thumb Duplication

Although thumb duplication does not often cause a functional problem for the child, the presence of this prominent hand malformation can have a significant impact on the child's psychosocial development. Surgery can be undertaken when the child is about 2 years old to prevent progressive deviation of the thumb during growth. Thumb duplication can be classified into seven groups, depending on the level of the duplication. Type I consists of a bifid distal phalanx, whereas type II is a complete duplication of the distal phalanx. Types III and IV involve the proximal phalanx, and types V and VI involve the metacarpal. Type VII is triphalangeal thumb or a thumb with three phalanges. Usually the radial, less developed thumb is removed. Retention of the ulnar thumb has the added advantage of preserving the important stabilizing ulnar collateral ligament. The surgery requires a delicate reconstruction of the bone, ligament, and tendon structures to sculpture the remaining thumb as normally as possible (Fig. 109-22). After the immediate

postsurgical period, these patients are followed once a year to evaluate potential growth abnormality.

Hypoplasia and Aplasia of the Thumb

The thumb contributes about 50% of hand function and is important in pinch and grip. Reconstruction of the underdeveloped thumb is critical in improving hand function for the child. Hypoplasia of the thumb can be classified into five grades, and treatment options are often based on this classification. Grade I consists of minor hypoplasia; all components of the thumb are present, but the thumb is smaller than normal. Grade II consists of adduction contracture of the first web space and laxity of the ulnar collateral ligament at the metacarpophalangeal joint; the thenar musculature is hypoplastic but the skeletal framework of the thumb is normal. Grade III includes severe hypoplasia of the thumb with absent intrinsic muscles and underdeveloped extrinsic tendons; the skeletal framework is hypoplastic and the carpometacarpal joint is vestigial. Grade IV is characterized by a floating, nonfunctional thumb (pouce flottant), with soft tissue attachment of the thumb at the metacarpophalangeal joint of the index finger. Grade V is defined by total absence of the thumb. Grade I hypoplasia does not require treatment and grades III, IV, and V require index pollicization (reconstructing a thumb using the index finger) for optimal function (Fig. 109-23). In grade II, the thumb can be reconstructed by using a combination of tendon, joint, and soft tissue procedures.

Rheumatoid Arthritis

Rheumatoid arthritis (RA) is a crippling disease that severely affects the quality of life for millions of Americans. RA is postulated to be an autoimmune disease mediated by inflammatory cells that attack the synovial tissues in the body. Persistent synovitis in the joints causes erosion of the articular surfaces and disrupts their soft tissue supports.

Because the hand is often damaged by RA, effective surgical treatment of hand deformities can improve patient function and restore independence. The goals of surgery for the rheumatoid hand include: (a) pain control, (b) improvement or restoration of function, (c) prevention of disease progression, and (d) aesthetic improvement. To accomplish these goals, the surgeon must have good rapport with both the rheumatologist and the patient as priorities of treatment are determined. By listening to patients with RA describe their impairments and their goals, the surgeon can gain insight into the surgical plan that will offer the patient the most benefit.

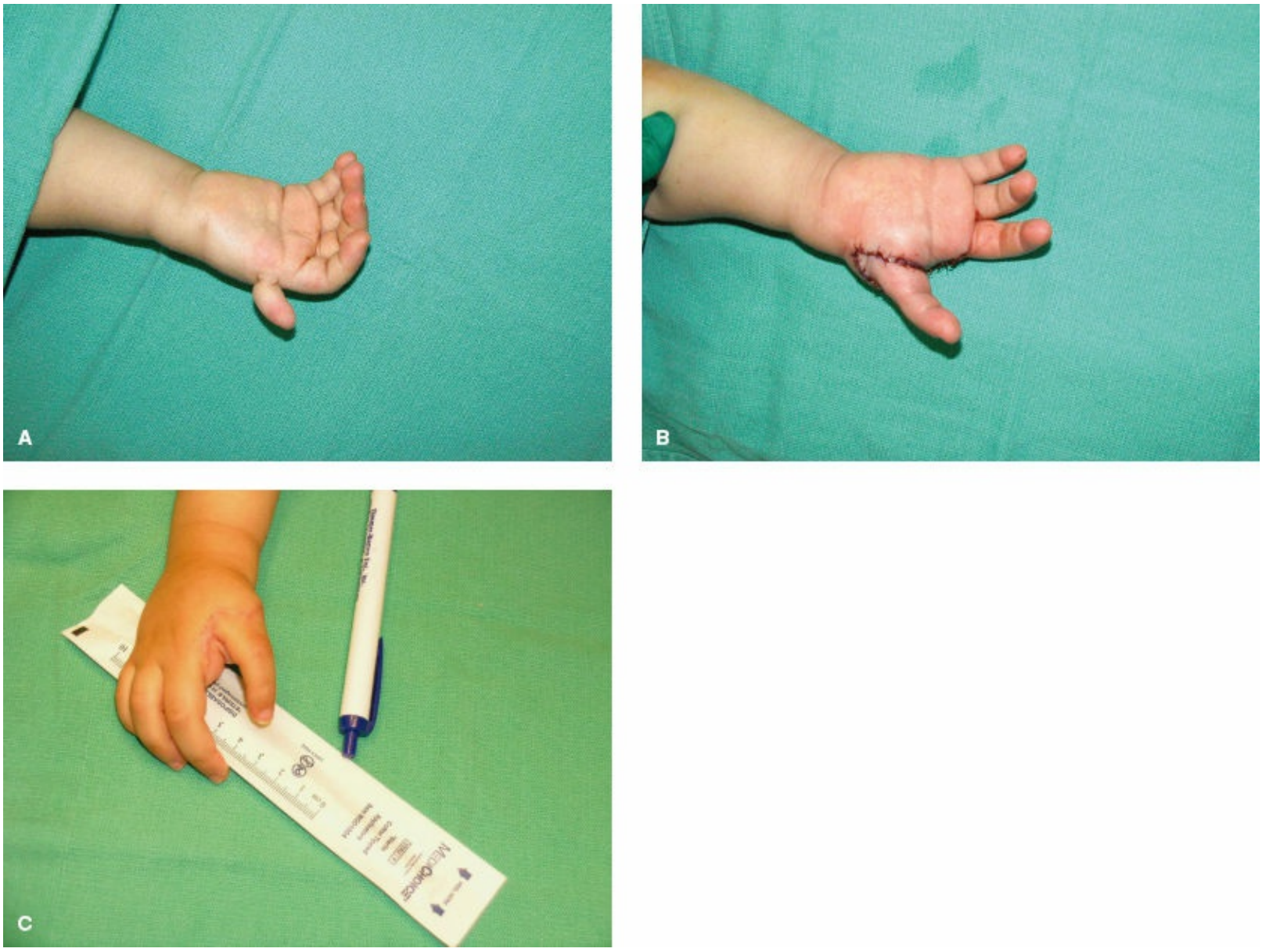

Figure 109-23. **A:** Absence of a thumb in a 2-year-old child. Note the floating thumb attached to the index finger. **B:** Immediate appearance in the operating room after pollicization. **C:** Three months after index pollicization, the child is able to use the new thumb for grasp and fine pinch.

Surgical treatment can be classified as preventive, corrective, or salvage.[70] Preventive procedures include tenosynovectomy to avoid tendon rupture and synovectomy to ameliorate ongoing joint destruction from erosive synovitis in the joints. Corrective procedures include tendon transfers for tendon ruptures and nerve decompression for carpal tunnel syndrome. Salvage procedures consist of joint arthroplasty and joint fusion.

A common hand deformity in RA consists of subluxation and ulnar deviation of the fingers at the level of the metacarpophalangeal joints (MPJs) (Fig. 109-24). Synovitis at the MPJs distends the joints and attenuates the supporting ligaments. Wrist destruction in RA contributes to the radial deviation of the metacarpals, which accentuates the ulnar deviation of the fingers. With progressive MPJ disease, patients have great difficulty opening their hands because of subluxation of the MPJs and difficulty with fine pinch because of the ulnar deviation of the fingers. In addition to pain at the MPJs secondary to their worn articular surfaces, RA patients often complain of the aesthetic appearance of their hands.

The Swanson metacarpophalangeal joint arthroplasty (SMPA) is an effective procedure that will meet all four goals of RA surgery. By replacing the arthritic joints with prosthetic spacers and realigning the soft tissue envelope around the MPJs, surgeons are able to markedly improve function and enhance the aesthetic appearance of RA hands. A recent systematic overview of the world's literature on this procedure showed that SMPA is an effective procedure in improving the health-related quality of life for RA patients.[71]

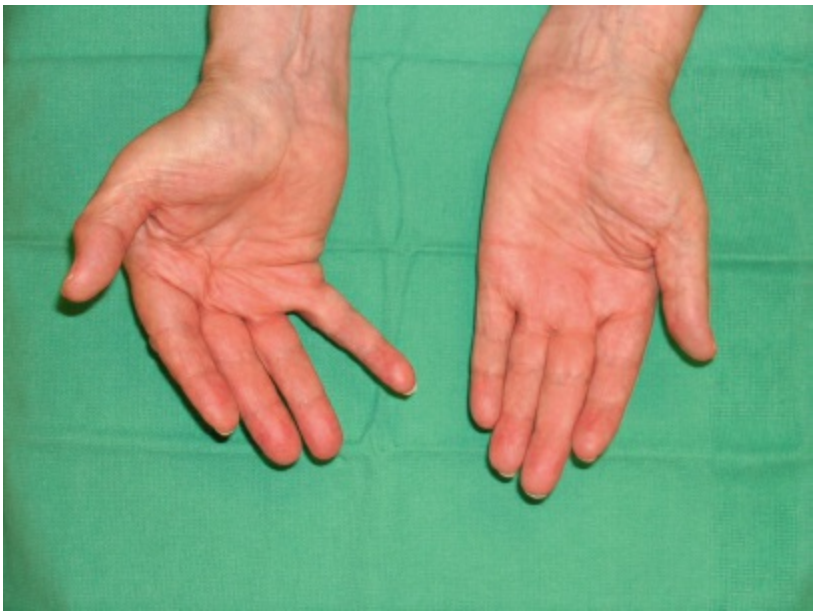

Figure 109-24. Severe destruction of the metacarpophalangeal joints with ulnar deviation of the fingers of the left hand. Note restoration of normal finger alignment of the right hand after Swanson metacarpophalangeal joint arthroplasty.

AESTHETIC SURGERY

Plastic and reconstructive surgery is a discipline that adapts broad surgical principles to a multitude of unique clinical problems by altering form and function. Plastic surgery not only restores physical function, it also enhances a patient's body image and self-esteem. In no other area of surgery is this truer than in aesthetic surgery. A blepharoplasty may not only improve the appearance of baggy, tired eyes, but also may treat visual field defects caused by eyelid ptosis or blepharochalasis. A rhinoplasty can improve the outward appearance of a nose as well as the nasal airflow and breathing.

5 Aesthetic surgery requires meticulous attention to detail, careful patient selection, rigorous procedural planning, and precise execution of technically challenging procedures. If patients are carefully selected and their goals are realistic, then the chances for a successful outcome are good. However, if a patient is poorly selected or they have unrealistic goals, then a technically successful operation with an aesthetically pleasing outcome may be a dismal failure in the eyes of the patient. The aesthetic surgeon must not only diagnose the clinical deformity, but must also carefully evaluate the patient's expectations and motivations for surgery. Through the application of sound surgical principles and technical expertise, the aesthetic surgeon can experience life-long career and personal satisfaction.

Cosmetic Procedures for the Head and Neck

Brow Lift

Brow ptosis is a natural consequence of the biologic process of aging. If left uncorrected, patients can appear angry, tired, or older than their chronologic age. If severe, brow ptosis may cause visual field obstruction on upward gaze; correction of this deformity can produce dramatic functional and aesthetic improvements. Patients frequently present with the complaint of looking tired or angry and request a blepharoplasty. In many cases, the etiology of their complaint is brow ptosis rather than upper eyelid ptosis or blepharochalasis. These patients will require a brow lift alone, or in combination with a blepharoplasty, to correct their functional and aesthetic concerns.

Correction of brow ptosis can be achieved with either an open or endoscopic approach. The traditional open approach requires a transcoronal incision with resection of excess scalp or forehead. Unfortunately, this approach results in a long scar, potential scar alopecia, and anesthesia of the scalp and forehead. In addition, an open brow lift in male patients with a receding hairline requires resection of hair-bearing scalp, which is an undesirable outcome. To reduce these complications, the endoscopic brow lift was developed and has become the primary approach for repair of brow ptosis.[54] The endoscopic brow lift requires only three to five 1-cm incisions behind the hairline to gain access to the forehead and glabellar rhytids, producing less of an aesthetic deformity and limiting the amount of scarring. There is also evidence to suggest that the endoscopic approach produces a more lasting result than the traditional approach.[55] Finally, it has been reported that anesthesia of the forehead and scalp is significantly reduced when an endoscopic approach is utilized for correction of brow ptosis, as compared to an open, transcoronal approach.

Endoscopic and open brow lifts may be performed under local or general anesthesia. Patients are marked preoperatively in the upright position. The desired brow position is at the level of the orbital rim in male patients and 1 cm above the orbital rim in female patients. The position of the brow in relation to the supraorbital rim changes from medial to lateral; the lateral brow should be more elevated than the medial brow. During an open brow lift, a coronal incision is made and the entire forehead is mobilized in a subgaleal or subperiosteal plane down to the orbital rim. The supraorbital and supratrochlear nerves are dissected free of surrounding tissues and preserved. The corrugator and procerus muscles are resected if prominent glabellar rhytids are present. Excessive resection of the corrugator muscles will result in widening of the eyebrows in the midline. The periosteum is released at the level of the supraorbital rim when a subperiosteal plane is utilized for mobilization of the forehead; the dissection is carried down to the level of the supraorbital rim when a subgaleal plane is used for forehead mobilization. The forehead is then elevated and redraped posteriorly, the redundant scalp is resected, and the wound is closed. In an endoscopic brow lift, incisions are made within the hair-bearing scalp at the midpupillary line and over the temporal fossa. The entire forehead flap is elevated under endoscopic guidance, the procerus and corrugator muscles are resected as necessary, and the forehead is retracted posteriorly. The forehead is then

secured into its new position. Various methods of forehead fixation have been described including; absorbable and nonabsorbable plates, screws, mutlipronged anchors, or cortical tunnels.[71,72]

Postoperatively, patients are instructed to avoid vigorous physical exercise for at least 6 weeks. Bruising and swelling are anticipated for the first 2 to 3 weeks following the procedure. The final result is not expected for at least 6 to 8 weeks following the procedure.

Rhytidectomy

The deleterious effects of aging, gravity, sun exposure, and smoking are particularly evident on the face. Ultraviolet radiation and tobacco use produce fine facial wrinkling and skin laxity as a result of the loss of skin elasticity. Aging and gravity result in gradual relaxation of the facial retaining ligaments producing midfacial ptosis, deepened nasolabial folds, "jowling" along the mandibular border, and redundancy of cervical skin.[73] Old family photographs and driver license photographs are constant reminders of a more youthful appearance with high cheekbones, a sharp mandibular border, and smooth skin. However, as the aging process marches on, patients may lose self-confidence and self-esteem in social, political, and business situations, encouraging them to seek facial rejuvenation surgery. If the patients are selected appropriately and the surgery is carefully planned and executed, the results will be gratifying for both patient and surgeon.[74]

During the preoperative evaluation, the patient's expectations and motivations are carefully evaluated and addressed. Surgeons need to be cautious of patients whose concerns about their appearance are out of proportion to their physical deformity. Under these circumstances, a perfectly designed and performed operation may still have a dismal outcome in the eyes of the patient.

6 Patients who smoke are at a significantly increased risk for developing postoperative complications, including skin-flap necrosis, infection, or wound dehiscence, and are consequently instructed to quit prior to undergoing elective aesthetic surgery. Many surgeons will refuse to perform a cervicofacial rhytidectomy in any patient who is actively smoking or utilizing any products containing nicotine. Urine cotinine levels can be determined to confirm whether a patient has been utilizing nicotine in any form. Older patients with coexisting medical illnesses are referred to a general practitioner for optimization of their medical condition preoperatively. If the patient is deemed a moderate or high risk for general anesthesia because of medical comorbidities, then the operation may be postponed until those medical conditions are optimized. Occasionally, if the risk of anesthesia is too high for a patient, then the operation may need to be cancelled.

Younger patients (40 to 50 years old) with good skin quality, mild midfacial ptosis, and early "jowling" may benefit from a minimally invasive facelift. This operation is typically combined with an endoscopic brow lift to provide upper and lower facial rejuvenation with minimal scarring. The operation is performed under local or general anesthesia. Bilateral temporal and superior buccal sulcus incisions are made. The temporal fossa

dissection is carried down to the level of the superficial layer of the deep temporal fascia. Under endoscopic guidance, the superficial layer of the deep temporal fascia is then incised to expose the temporal fat pad. The dissection then proceeds caudally until the zygomatic arch is identified. A subperiosteal plane of dissection provides access to the midface while preserving the integrity of the frontal branch of the facial nerve. The subperiosteal plane of dissection is continued into the midface with care taken to avoid the infraorbital nerves. The masseter is mobilized from its lateral attachments. The superior buccal sulcus incisions are made, and a midface subperiosteal dissection is performed under both direct visualization and endoscopic guidance. Once the dissection is completed, the entire midface is suspended in the desired position with sutures or specialized anchors spanning from the superficial layer of the deep temporal fascia to the midface periosteum. Symmetry of the suspension is then confirmed and the wounds are closed in layers. This technique will nicely correct mild midface ptosis, mild jowling, and early nasolabial fold prominence. However, this technique will not correct deformities from significant skin laxity. Under these circumstances, a traditional cervicofacial rhytidectomy will be required.[71,75]

In patients who require resection of excess skin, a traditional rhytidectomy can be performed under local or general anesthesia. The skin incision is made over the temporal fossa 4 to 5 cm cephalad to the root of the helix and extended caudally toward the apex of the ear. The incision is then extended anterior to the ear, behind the tragus, around the base of the earlobe into the retroauricular sulcus, across the mastoid, and caudally along the anterior hairline of the neck. The skin flap is then elevated just superficial to the superficial musculoaponeurotic system (SMAS) and platysma. This plane of dissection maintains a thin layer of subcutaneous fat on the skin flap to preserve viability, while avoiding injury to the facial nerve branches, greater auricular nerve, parotid gland, and jugular vein. The flaps are elevated medially to the nasolabial fold in the face and to the midline in the neck. Occasionally a platysmal diastasis may exist which creates platysmal banding, an obtuse cervicomental angle, and a prominent neck. Under these circumstances, a platysmal plication may be performed through a 2- to 3-cm submental incision to correct the diastasis and improve the appearance of the neck. At this point, there are many variations in how the remainder of the cervicofacial rhytidectomy is performed with the goal of repositioning all of the tissues which have migrated into dependent positions creating facial aging changes. The surgeon may simply chose to not perform any additional dissection at this point and simply reposition the skin, resect the excess skin, and close the incisions. In other circumstances, the surgeon may choose to do one of the following; SMAS plication, standard SMAS dissection, extended SMAS dissection, or deep-plane dissection. These operations are all designed to improve control of facial and cervical tightening, while reducing the tension on the skin closure. Once the dissection of the facial tissues is completed and all planes are mobilized optimally, the SMAS and platysma are placed under tension and secured to create the desired facial appearance. The skin flaps are then redraped posteriorly, the patient is examined for symmetry, and a skin resection is performed. Hemostasis is obtained through judicious use of bipolar electrocautery. The wounds are closed in layers and a pressure dressing is

applied. Drains are typically used in the face and neck.[76–80]

Postoperatively, the patient is evaluated in the recovery room for any evidence of a hematoma or facial nerve injury. It is crucial to identify a hematoma early to avoid overlying skin necrosis. Facial nerve injuries occur in only 2% to 3% of cases. On the first postoperative day, the pressure dressings and drains are removed and the patient is examined for evidence of a late hematoma, unrecognized facial nerve injury, or compromised skin flap. Patients should expect to have significant swelling and bruising for at least 2 weeks following the procedure. The final postoperative result is not realized until approximately 6 months following the procedure (Fig. 109-25).

Blepharoplasty

Eyelid surgery may be performed to correct functional or aesthetic deformities. Excessive skin and fat of the eyelids can give the patient an angry, aged, or tired look and may cause visual field obstruction. Older patients typically present with redundant skin and fine wrinkling, whereas younger patients commonly complain of persistent bags under their eyes or fine wrinkling ("crow's feet") at the lateral canthus. Treatment of each clinical entity requires a unique approach based on the diagnosis and presentation.[81] All patients being evaluated for blepharoplasty require a complete ophthalmologic examination preoperatively to evaluate visual acuity, upper eyelid ptosis, exophthalmos, lower eyelid laxity, and symptoms of "dry" eye. Meticulous attention to details is critical for the successful outcome of blepharoplasty surgery.[72] If there is lower lid laxity preoperatively, and a standard blepharoplasty is performed, the patient may develop a lower lid ectropion postoperatively. Symptoms of dry eye can also be significantly worsened by a blepharoplasty. As a result it is critically important to perform a comprehensive evaluation of the health of the eye prior to performing any eyelid surgery.

Once a complete evaluation has been performed and a diagnosis has been made an operative plan can be formulated to correct the concerns of the patient. The operation can be performed under local or general anesthesia. Older patients frequently require skin excisions and removal or repositioning of orbital fat. The blepharoplasty incisions are designed preoperatively with the patient in the upright position. Local anesthesia with epinephrine is then infiltrated for pain control and hemostasis. The upper eyelid blepharoplasty then begins with an elliptical excision of upper eyelid skin and orbicularis oculi muscle. The skin excision is designed based on the amount and location of the blepharochalasis. Very rarely will a patient require removal of fat from the upper eyelids. Excessive fat resections will produce a "hollowed-out" appearance. However, occasionally there may be a substantial amount of excess orbital fat in the upper eyelids and conservative fat resection may be helpful to achieve the desired postoperative outcome. If a fat resection is going to be performed, small openings are made in the orbital septum to gain access to the two compartments of periorbital fat. A conservative fat resection is then performed to avoid a postoperative hollowed-out appearance. The skin is then redraped and the wounds are closed in a single layer. If an upper lid blepharoplasty is being performed in conjunction with a brow lift, the brow lift should be performed first, so that the amount of excess upper eyelid skin can be determined after the brow has been

elevated.

The traditional lower eyelid blepharoplasty begins with a subciliary incision. A 4- to 5-mm rim of orbicularis oculi is then preserved along the lower eyelid margin. The dissection is then carried deep to the orbicularis oculi muscle until the orbital septum is identified. The orbital septum is then divided to gain access to the three compartments of periorbital fat in the lower lid. Fat may be resected in cases of prominent herniation, but overresection must be avoided. A trend in blepharoplasty surgery has emphasized periorbital fat repositioning rather than resection. Simply repositioning the herniated periorbital fat over the inferior orbital rim, rather than resecting fat, can dramatically improve the appearance of the lower eyelids.[82] The approach of repositioning the orbital septum medially has proven to be very helpful in eliminating tear–trough deformities. Once the periorbital fat has been resected or repositioned, the skin/muscle flap is redraped superiorly and the redundant tissue is excised. The lower eyelid wounds are closed with interrupted sutures of 6-0 silk. Ancillary procedures may also be necessary to improve the position of the lower eyelid, including a medial canthoplasty, a lateral canthoplasty, lateral canthopexy, or horizontal lid shortening. If a lower lid blepharoplasty is being performed in conjunction with a rhytidectomy, the rhytidectomy should be performed first, so that the amount of excess lower eyelid skin can be determined after the facial soft tissues have been elevated.

In younger patients, the tired appearance of the lower eyelids is commonly a result of excessive or herniated periorbital fat. A lower lid blepharoplasty through a transconjunctival approach allows removal or repositioning of the periorbital fat without an external scar. The conjunctiva is divided transversely 1 mm above the sulcus to gain access to the orbital septum. The septum is divided and the periorbital fat is removed or repositioned from all three compartments. Once again, the emphasis has been to preserve periorbital fat and simply reposition the orbital septum into a more optimal location obviating the need for fat resections. The transconjunctival incision is then allowed to heal by secondary intention, allowing rejuvenation of the lower lids without an external incision.



Figure 109-25. Cervicofacial rhytidectomy with superficial musculoaponeurotic system resection, platysma plication, submental suction-assisted lipectomy, endoscopic browlift, and bilateral subciliary lower eyelid blepharoplasty. **A, B:** Preoperative appearance. **C, D:** Postoperative appearance. Note the dramatic improvement in the appearance of her neck, flattened nasolabial folds, improved definition of the mandibular border, and improved prominence of the malar regions.

Recently, a multiplanar approach for the rejuvenation of the lower eyelids has been employed to reduce the incidence of lower eyelid ectropion postoperatively. These approaches combine both subciliary incisions for removal of excess skin and transconjunctival incision for repositioning or resection of the periorbital fat. Clinical case series from experienced plastic surgeons have demonstrated outstanding outcomes with this approach.

Postoperatively, patients are evaluated in the recovery room for corneal abrasions, changes in visual acuity, or hematomas, which may require emergent intervention. No vigorous physical exercise is permitted during the early postoperative period. Artificial tears are used to maintain appropriate lubrication. Sutures are removed 5 to 7 days postoperatively. Patients are informed that they will be bruised and swollen for approximately 2 weeks and that it will be approximately 6 to 8 weeks before the final result will be seen.

Rhinoplasty

Rhinoplasty is an exacting operation to alter the external appearance and internal anatomy of the nose. The nose may be aesthetically unappealing or functionally impaired as a result of trauma, surgery, or a congenital deformity. Clearly, many familial and ethnic traits result in a multitude of nasal appearances. As a result, it is crucial that the patient and surgeon discuss the goals of the procedure and the likelihood of achieving those goals. The patient must have realistic expectations and be prepared for the operation both physically and mentally.

To successfully achieve the goals of rhinoplasty, a complete nasal history is obtained with particular attention paid to nasal airway obstruction, allergies, trauma, and previous surgery. A photographic analysis is performed to evaluate facial and nasal dimensions. The photographs are examined with the patient, the operative plan is discussed, and the potential structural and functional outcomes are reviewed.[83]

Rhinoplasty may be performed under local or general anesthesia. The patient is prepared for surgery by intranasal injections of vasoconstrictors containing lidocaine and epinephrine. Topical vasoconstrictors are applied to the nasal lining and septum. The operation can be performed in an “open” or “closed” fashion. The open technique requires a transcolumellar incision extended intranasally to allow exposure of the cartilage and bones of the nose. Direct visualization of the structure of the nose allows greater precision in cartilaginous sculpting, grafting, and nasal bone repositioning. The paired lower lateral cartilages create the shape and provide the support for the nasal tip. Any deformity involving the nasal tip requires manipulations of this cartilage, including resections for a bulbous or overprojecting tip, suturing to reposition an asymmetric nasal tip, or cartilage grafting to increase tip projection. The paired upper lateral cartilages and nasal bones define the shape of the nasal dorsum and control nasal airflow. A prominent dorsal hump may require resections of both the upper lateral cartilages and nasal bones. Osteotomies of the nasal bones may be required to narrow nasal width by disconnecting the base of the nasal bones from the maxilla (Fig. 109-26). In contrast, “saddle nose” deformities may require cartilage or bone grafting to provide dorsal augmentation.

Alloplastic materials have been described for use as dorsal grafts, tip grafts, or columellar struts to increase nasal projection. However, many surgeons discourage use of such alloplastic grafts due to problems with infection, extrusion, and migration producing a suboptimal result acutely or chronically. Autogenous cartilage grafts from the nasal septum, ear, or rib may also be used to improve nasal appearance or airflow. These grafts can be harvested and sculpted to create the desired cosmetic appearance of the nasal dorsum and tip. “Spreader grafts” can also be placed between the nasal septum and the upper lateral cartilage to increase the size of the internal nasal valve area, improving nasal airflow.[84] The “closed” rhinoplasty technique allows access to the nasal cartilage and bones through intranasal incisions. Many experienced rhinoplastic surgeons prefer this less invasive approach. Unfortunately, it is difficult to perform many of the complicated cartilage grafting and suturing techniques with this limited exposure.



Figure 109-26. Open tip rhinoplasty with dorsal hump reduction including cartilage and bone, cephalic scroll resection of lower lateral cartilage, nasal septal cartilage spreader grafts, and nasal osteotomies. **A, B:** Preoperative appearance. **C, D:** Postoperative appearance. Note the nice reduction in the dorsal hump, supratip break, and improved dorsal aesthetic lines. The midvault collapse has been dramatically improved.

Postoperatively, the patient is instructed to keep their head elevated and apply ice packs. An external splint is used to maintain the position of the nasal bones and cartilage

for 10 to 14 days. Patients should expect nasal swelling, pain, and bruising for 2 to 3 weeks; if osteotomies are performed, the patient may also experience periorbital ecchymosis. A full year is required for complete resolution of nasal tip swelling, particularly following an open-tip rhinoplasty. Approximately 10% of primary rhinoplasty patients will require an operative revision due to dissatisfaction with the cosmetic or functional outcome; the revision rhinoplasty should not be performed for at least 1 year following the original procedure to ensure that all postoperative swelling and tissue remodeling has stabilized.

Genioplasty

Genioplasties are common plastic surgical procedures to manipulate the position of the chin and thereby improve facial appearance. Based on the design of the mandibular symphysis osteotomy, the vertical height and anterior projection of the chin can be adjusted.[85] Patients with a "weak" chin may undergo an advancement genioplasty to enhance chin projection and improve the cervicomental angle. Chin augmentation may also be accomplished with an alloplastic implant, eliminating the need for an osteotomy. Patients with a very prominent chin can undergo a reduction genioplasty where the vertical height and anterior projection can be reduced. The dental occlusion is not affected by these procedures, but the lip position and neck appearance may be altered.[86]

A complete physical examination, photographic analysis, and radiographic evaluation are performed to evaluate facial harmony and determine the extent of the advancement or reduction. Dental occlusion is carefully examined to ensure that orthognathic surgery is not required to correct chin position.

Operations are typically performed under general anesthesia, but can also be performed under local anesthesia if desired. Local anesthesia containing epinephrine is injected intraorally for hemostasis and postoperative pain control. Access to the mandibular symphysis is achieved through an inferior buccal sulcus incision. The osteotomy is measured and marked based on the preoperative photographs and lateral radiographs; the mental foramen is avoided. The bony segment is mobilized and secured in its new position with plates and screws. If an alloplastic chin augmentation is to be performed, incisions can be performed in the submental region or intraorally for placement of the implant. Postoperatively, swelling and pain persist for approximately 4 to 6 weeks. During this time, the patient should perform meticulous oral hygiene and avoid foods that may traumatize the inferior buccal sulcus incision.

Cosmetic Procedures of the Trunk and Extremities (Body Sculpting)

Abdominoplasty

Abdominoplasties encompass a wide array of surgical procedures used to correct abdominal deformities resulting from excess abdominal skin, fatty tissue, and abdominal wall laxity. Abnormalities in any of these tissue planes may produce an aesthetically unappealing abdomen. Surgical procedures are designed to correct the underlying pathology and include dermatolipectomy, liposuction, and abdominal wall plication. These procedures are often combined and tailored to fit the surgical needs and desires of the patient. It is critical to define the physical anomaly responsible for the abdominal deformity so that the appropriate operative procedure or combination of procedures can be performed.[87,88]

A standard abdominoplasty combines a dermatolipectomy, liposuction, and abdominal wall plication to correct deformity in each of the three previously mentioned abdominal wall layers. The operation is performed under general anesthesia through a bikini-line incision extending from the cephalad margin of the pubic escutcheon to the iliac crests bilaterally. The skin incisions are made and the abdominal flap is elevated off the underlying abdominal wall fascia. A circumferential incision is made around the umbilicus to allow complete elevation of the abdominal flap up to the costal margin. The patient is then placed in a flexed position, the abdominal flap is redraped caudally, and the redundant skin is resected. If any abdominal wall laxity is identified along with the skin redundancy, then a vertical, midline abdominal wall plication is also performed. Occasionally, suction-assisted lipectomy (SAL) is performed at the time of abdominoplasty to help recontour the abdomen and flanks. However, aggressive SAL of the abdominal flap may critically compromise flap vascularity and contribute to flap necrosis. Occasionally it is helpful to perform SAL along the lateral and posterior iliac crests bilaterally to reduce the prominence which may have developed following the anterior dermatolipectomy and caudal repositioning of the skin flap. A small incision is then made in the midline of the abdomen at the level of the iliac crests for delivery of the umbilicus into its new position. Closed-suction drains are placed prior to wound closure (Fig. 109-27).

A “mini-abdominoplasty” is used to treat mild abdominal skin redundancy and abdominal wall laxity. The same approach is used as previously described for a standard abdominoplasty except the skin incision is limited to the central portion of the abdomen. A limited skin resection can be performed through this approach along with an abdominal wall plication. SAL can be used in combination with this procedure if necessary.

Endoscopic abdominoplasty can be used to treat abdominal wall laxity (i.e., postpartum rectus diastasis) and localized collections of fatty tissue. Patients who are candidates for this operation must have good skin quality and only mild to moderate lipodystrophy. The endoscopic abdominoplasty is performed through two incisions, a 3- to 5-cm transverse incision within the pubic hair and a circumferential incision around the umbilicus. These incisions function as the two access ports through which the endoscopic instruments are passed. The entire abdominal wall is then elevated off of the abdominal wall fascia under

endoscopic visualization with electrocautery. The midline of the abdominal wall is plicated from pubis to xiphoid. The abdominal wall is then recontoured with SAL, which is performed through the two access ports.[65]

Liposuction

Liposuction is a surgical procedure designed to resect collections of fat from isolated anatomic regions. It is not a form of weight loss and is not indicated in obese patients. Liposuction is ideally suited to patients who are within 20% to 30% of their ideal body weight and have localized collections of fat that are refractory to dietary modifications and exercise. A complete evaluation of skin elasticity is very important in patients considering liposuction because once fat is surgically removed, the skin must be able to contract down to the contour of the remaining subcutaneous tissue. If the skin quality is poor, then wrinkling, dimpling, or skin ptosis may severely compromise the aesthetic result.[87–90]

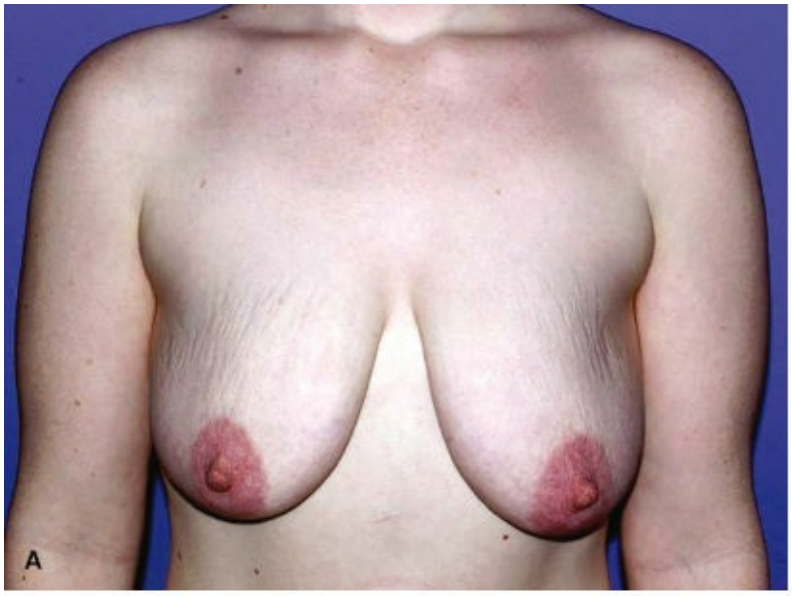
A


B


C


D


E

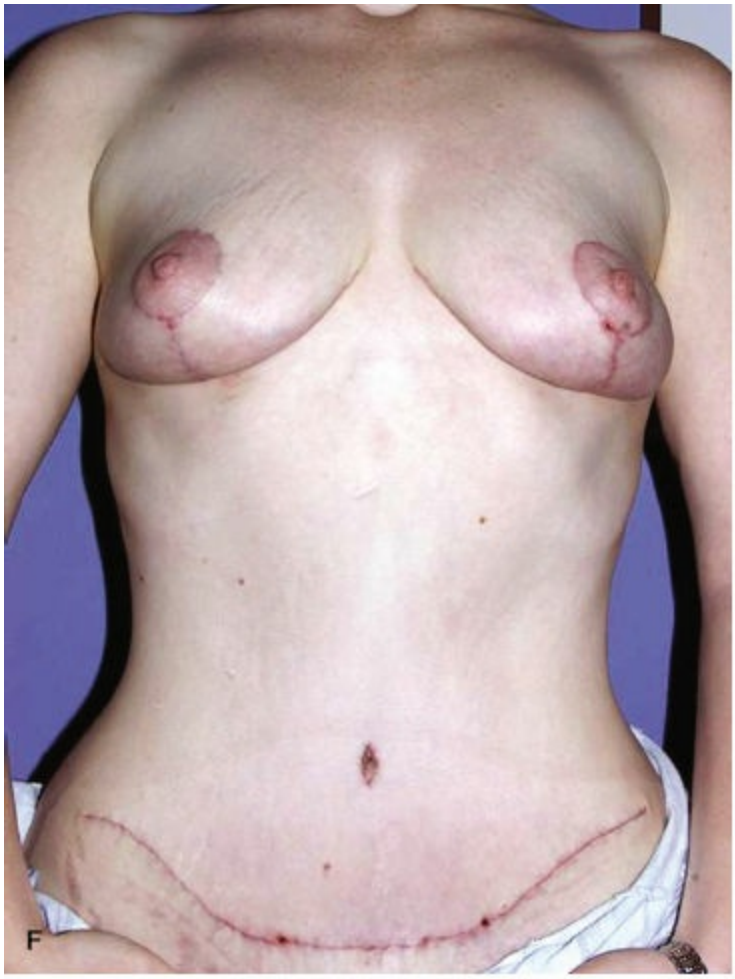

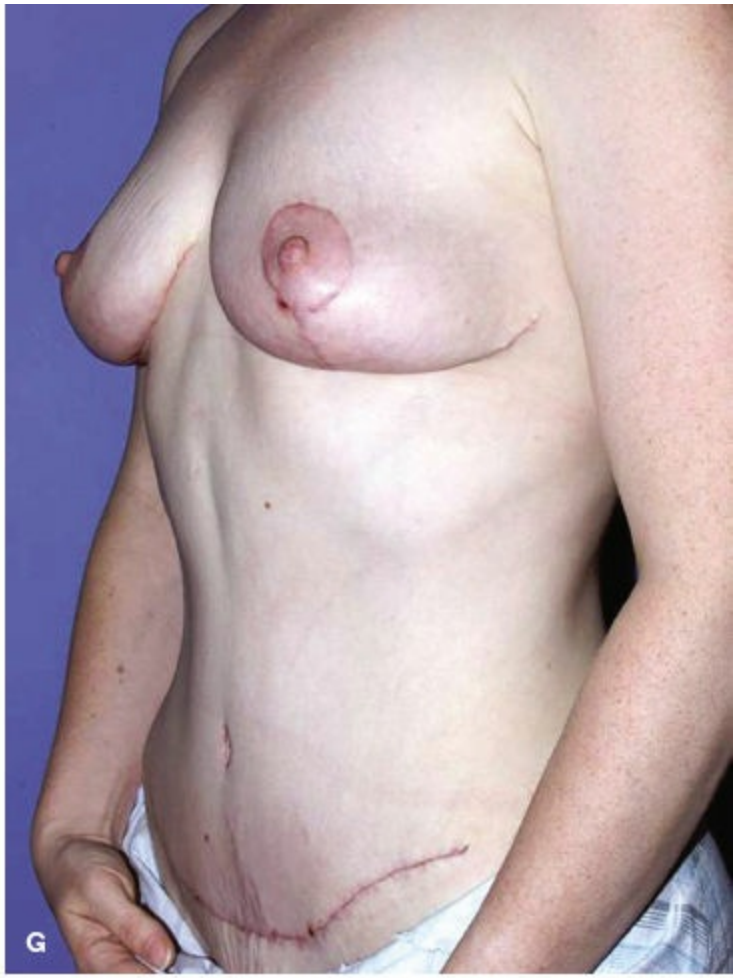

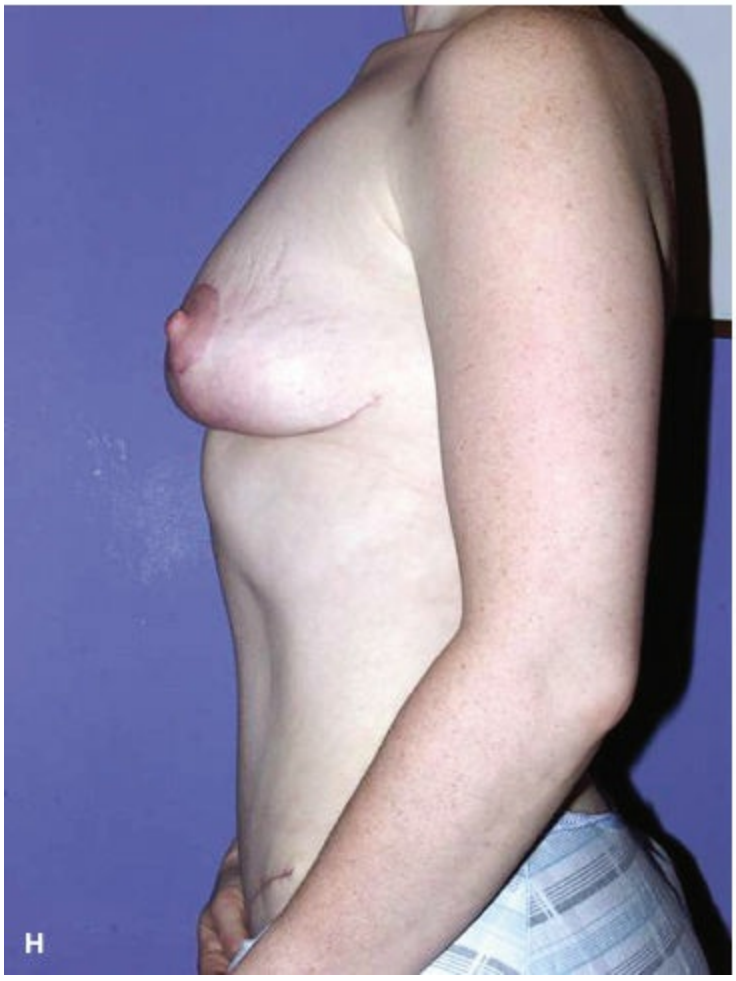

Figure 109-27. Mastopexy, abdominoplasty, and rectus abdominis plication. **A, B:** Preoperative appearance of breasts.

C–E: Preoperative appearance of abdomen. **F–H:** Postoperative appearance. Note the dramatic improvement in the appearance of the breasts and abdomen. The abdomen is flat with a narrowed waistline.

Two forms of liposuction are currently used: SAL and ultrasonic assisted liposuction (UAL). SAL is used in all areas of the body but may not be as effective as UAL in more fibrous anatomic regions such as the flank, upper abdomen, or male breast. Treatment of lipodystrophy in these regions is more effective with UAL alone or UAL in combination with SAL.[87,91] A number of technologic advances have led to new techniques for performance of liposuction or liposculpting (i.e., lipodissolve, endermologie, and Smart-lipo). However, none of these newer devices or techniques has proven to be clinically efficacious in rigorous clinical trials, nor have they been shown to be as effective as Standard SAL or UAL.

As with all aesthetic procedures, careful patient selection is of paramount importance. All patients must undergo a complete evaluation preoperatively to ensure that their goals can be achieved by performance of liposuction. Preoperative photographic documentation is performed on all patients. Markings are then made with the patient in the upright position. Access ports (6 to 8 mm), through which the SAL or UAL is performed, are marked in concealable areas. Patients can undergo these procedures under local or general anesthesia. Tumescent fluid (1,000 mL of LR, 50 mL of 1% lidocaine, and 1 mg of epinephrine) is then infiltrated for pain control and hemostasis.

SAL is performed with metal cannulas connected to an aspirating device that generates a negative pressure of 1 atmosphere. Various cannula configurations are used to perform the resection. Fatty tissue is aspirated into the holes of the cannula and then resected by movement of the cannula tip. The operation is performed through multiple access ports, starting with large (6- to 8-mm diameter) cannulas and progressing to smaller (3- to 4-mm diameter) cannulas with fewer holes to allow more precise body contouring. Overlapping patterns of resection are used to avoid contour irregularities.

UAL is a surgical technique that allows body contouring through the liquefaction and aspiration of fatty tissue. When employed alone or in combination with traditional SAL, UAL is effective for treating lipodystrophy in fibrous anatomic regions such as the flank, upper abdomen, and male breast. The UAL probe tip produces sound waves at an ultrasonic frequency of 20 to 30 kHz. The sound waves cause cavitation which disrupts lipocytes. Low-power suction is then employed to remove the resultant fluid. If UAL is used inappropriately, patients may experience severe complications, including full-thickness skin loss from thermal injury.[91]

All patients are placed in a compressive garment 24 hours per day for 6 weeks postoperatively. Early postoperative compression reduces the chances of hematoma formation. Prolonged compression reduces swelling and the potential for skin wrinkling. All patients experience some degree of ecchymosis, swelling, and decreased sensibility. The end result will not be realized for approximately 2 to 3 months following the procedure.

PEDIATRIC PLASTIC SURGERY

The specialized area of pediatric plastic surgery focuses on the reconstruction of abnormalities in children with congenital malformations and acquired deformities. Utilizing a sound knowledge of embryology as well as the changes inherent during growth and development, pediatric plastic surgeons employ a combination of innovation and technical expertise to restore both form and function to their patients. Although the manifestations of congenital malformations may be diverse, the approach to reconstruction is always based on solid fundamental surgical principles. Similarly, the management of traumatic or other acquired maladies in the pediatric population is founded on essential surgical tenets influenced by the special considerations of maturation and growth. This section concentrates on the most salient aspects of pediatric plastic surgery to give the clinician an accurate grasp of the subspecialty.

Cleft Lip and Palate

Perhaps the area of expertise that best exemplifies the specialty of pediatric plastic surgery is the management of children with cleft lip and palate deformity. The cleft lip and palate pose a variety of structural and functional deficits that must be addressed with respect to growth and development as well as psychosocial concerns of the individual patient and family. The care of these children requires exacting surgical technique in combination with the efforts of a team of allied health professionals to effect a comprehensive level of rehabilitation.

The overall incidence of cleft lip and palate deformity is approximately 1 in 750 children. This incidence is significantly higher in the Asian population, 1 in 300, and significantly lower in the black population, 1 in 2,000.[92–95] The distribution of cleft types is approximately 46% combined cleft lip and palate, 21% isolated cleft lip, and 33% isolated cleft palate.[95] Almost 30% of children with cleft lip and palate deformity have associated birth defects that vary in scope and extent and therefore require vigilance in the physical examination.[96] The chance of having a second child with cleft lip and palate to unaffected parents is approximately 4% as is the chance of one affected parent producing an offspring with a cleft.[97,98] Genetic counseling is usually helpful in both educating the parents and screening for other associated congenital anomalies.

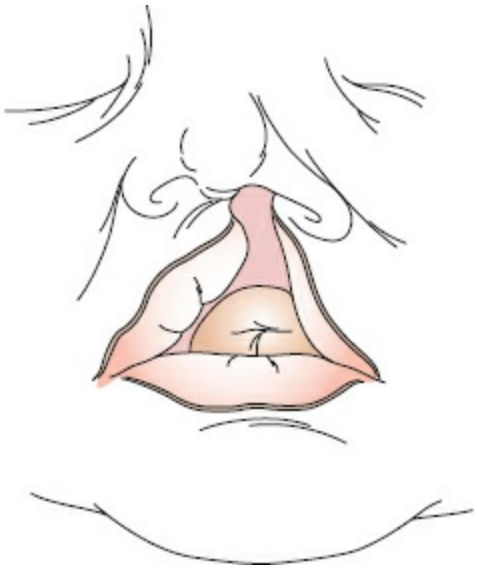

Figure 109-28. Left unilateral complete cleft lip.

7 A cleft lip deformity can be bilateral or unilateral and is considered *complete* if it extends into the nose and *incomplete* if it does not (Fig. 109-28). The cleft lip can extend into the gum partially or completely through the alveolus, creating a bony defect. The cleft lip deformity affects the nose as well as the lip, and therefore both of these structures must be addressed in the reconstruction of the deformity. Although the timing of cleft lip repair is controversial, the repair of the cleft lip is most often addressed in about the third month of life, after the child shows sufficient weight gain. This timing permits a potentially safer anesthetic administration.

There are multitudes of cleft lip repairs, but the goals of the repairs remain the same:

an anatomic reconstruction with minimal scarring and normal function. In general, the skin around the cleft is cut into flaps that are brought together in a way that will give adequate length to the lip and restore the continuity of the orbicularis musculature (Fig. 109-29).[99] Long-term symmetry is the goal of reconstructive procedures to the cleft lip–nasal deformity, and taking into account how the face changes with growth is necessary to execute the appropriate operation in infancy.[96]

The cleft palate can affect the soft palate alone or include the hard palate. Victor Veau classified the degree of clefting I to IV from the least severe (soft palate only) to most severe (through the soft palate, hard palate, and alveolus bilaterally) (Fig. 109-30).[100] In some cases, a cleft palate may have no mucosal separation at all and display only a separation or clefting of the underlying musculature. This special situation is referred to as a submucous cleft palate and may also have functional consequences for the patient. Functionally, the hard palate acts as a structural barrier between the oropharynx and the nose. The soft palate moves superiorly and articulates with the posterior and lateral pharyngeal walls to create a seal between the oropharynx and the nasopharynx during speech and swallowing. The coordinated activity of the soft palate prevents regurgitation of solids and liquids into the nose while eating and prevents hypernasal speech while producing strictly oral sounds. As with cleft lip, there are a multitude of cleft palate repairs but the goals of the repairs remain the same: repositioning the abnormal anatomy and creating normal function. Reconstructive procedures are based on reconstituting the oral and nasal lining of the palate and reapproximating and realigning the palatal musculature. A purely soft palatal cleft may require only the separation of the layers of the palate, reorientation of the muscles, and simple closure. The wider clefts and many of the hard palatal clefts, however, require relaxing incisions and release of the mucosa from the underlying bone. The lateral mucosa from both sides is transposed over the midline cleft and sewn closed. The addition of double-opposing Z-plasties in the velum adds further length to the palate (Fig. 109-31).[100] Flaps derived from the vomer may be required to achieve closure without tension, a chief precept for any repair of the palate. Many children with this deformity exhibit growth restriction of the midface and bony palate, which is thought to be due to the dissection of mucosal tissue off the bone.[101] Delaying palate closure until the maxilla has finished growing allows better facial growth, but leads to poor speech outcomes, whereas early intervention is thought to improve speech. For this reason, the timing of the repair of the cleft palate is controversial; however, the cleft palate repair is most often addressed by the age of 1 year.

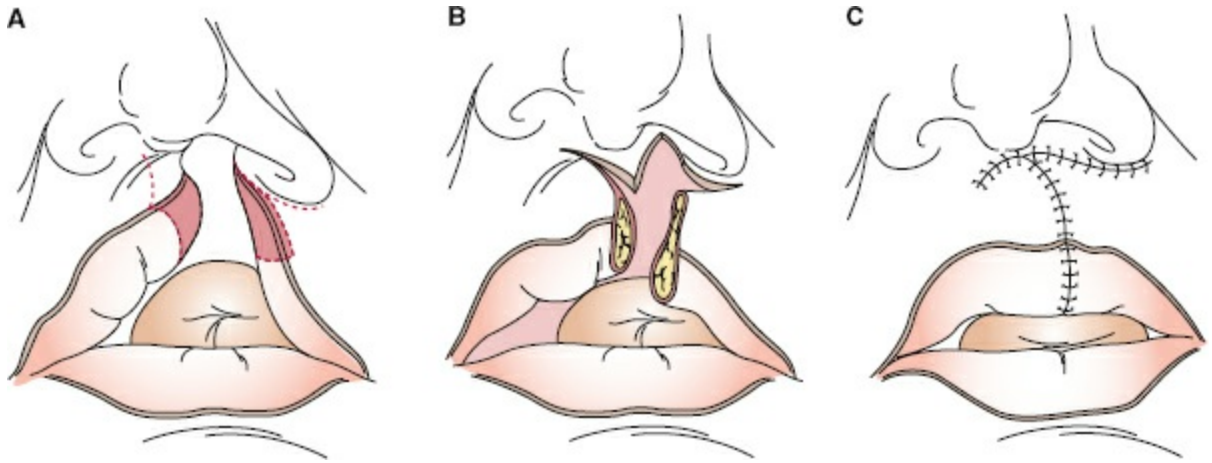

Figure 109-29. **A:** Markings. **B:** Dissection of the orbicularis muscle and rotation of the central (greater segment) and advancement of the lateral (lesser segment). **C:** Appearance of the closure.

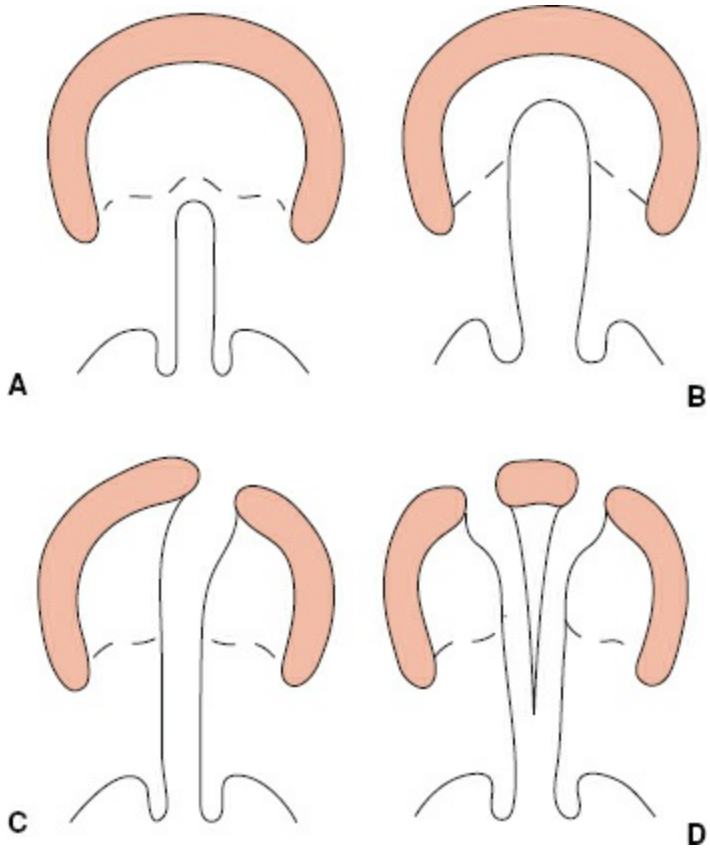

Figure 109-30. Veau classification of cleft palate. **A:** Veau I involves the soft palate only. **B:** Veau II involves the soft palate and hard palate up to the incisive foramen. **C:** Veau III involves the soft and hard palate and is through the alveolar ridge. **D:** Veau IV, the most severe, involves the soft and hard palate and the premaxilla is discontinuous with the alveolar arch.

Speech therapy is almost always required for children with a cleft palate and is instituted as soon as the child develops the necessary language skills. Early intervention programs have arisen for preschoolers, and speech programs are often available through local school systems. Unfortunately, the palate repair alone is successful in normalizing speech in only about 80% of patients.[102] The remainder of patients will require a supplemental operation to decrease residual hypernasality and improve speech. The operations directed at salvaging speech are performed early enough to have the most

beneficial effect on speech development, while giving adequate time to ensure that the patient has been given ample opportunity for speech therapy to maximize the potential of the palate repair. The decision to operate is based on a perceptual analysis of speech and is aided by visualization of palatal function with nasoendoscopy and objective measures of function using nasometry techniques. Techniques vary, but the operative procedures are based on placement of either dynamic or static tissue near the velopharyngeal port to better regulate and impede the abnormal flow of air into the nasopharynx.

Orthodontics is a key portion of the comprehensive restoration of the cleft patient and requires close interaction between the pediatric plastic surgeon and the orthodontist. One of the early interactions involves the repair of any residual clefting of the alveolus. Bone grafting is required for reconstruction of the alveolar cleft to restore the continuity of the upper maxillary dental arch, allow the normal emergence of the canine tooth, close the persistent oral nasal fistula, and provide structural support for the recessed nasal alar base. The orthodontist will monitor tooth eruption and may institute early-phase therapy to align the teeth in preparation for bone grafting. The timing of alveolar bone grafting is also controversial but is mandatory for normal tooth emergence. Bone grafting is often performed at about 7 to 8 years of age and entails the surgical isolation and repair of the oral nasal fistula, the reconstruction of the adjacent nasal floor and palatal roof, the placement of bone graft in the alveolar defect, and coverage anteriorly with gingival flaps. Cancellous bone grafts harvested from the iliac crest is used most commonly. To eliminate the donor site, other bone substitutes have been trialed, with studies using recombinant human bone morphogenic protein (rhBMP2) showing promise[103]; however, iliac bone graft currently remains the standard of care.

Many patients respond favorably to the skilled implementation of a long-term orthodontic plan, but some patients display bony hypoplasia as mentioned earlier and require orthognathic surgery of the maxilla, and possibly the mandible, to assist in establishing normal occlusion. Operations to restore a normal occlusion should await the cessation of growth so that the surgical registration of occlusion will be permanent and not require additional procedures. The most common operation to address midfacial hypoplasia and restore occlusion in the cleft patient is the Le Fort I osteotomy. The orthodontist helps the pediatric plastic surgeon to determine the best postoperative occlusion for the patient based on the orthodontic plan, and an oral surgical splint is fashioned to allow easy registration intraoperatively. The patient undergoes a horizontal osteotomy above the level of the tooth roots and across the nasomaxillary and zygomaticomaxillary buttresses below the level of the zygomatic body (Fig. 109-32). The bones of the midface are separated from the cranial base by performing a pterygomaxillary disjunction, and the floating maxilla is then repositioned into the planned occlusion by registering the teeth in the splint. The bones of the maxilla are then fixed using plates and screws. In severe malocclusion cases, the mandible may also need to be cut and moved into a position that results in an anatomic orthognathic bite.

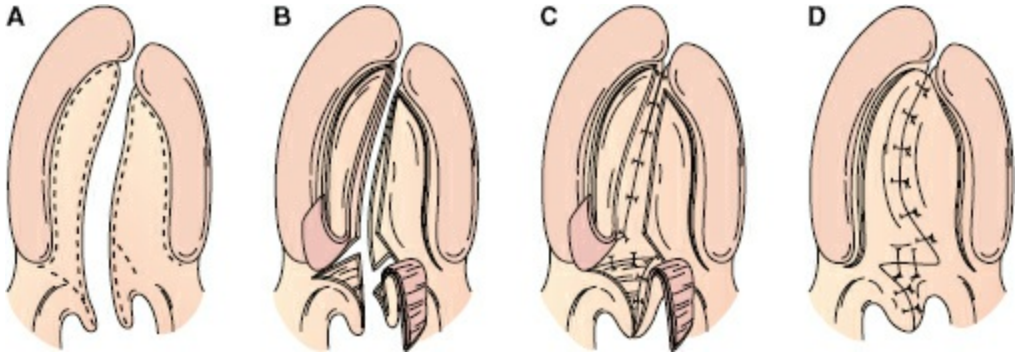

Figure 109-31. Furlow double-reversing Z-plasty cleft palate repair. **A:** Lines of incision. **B:** Dissection of palatopharyngeus muscles and Z-plasty incisions. **C:** Transposition of the musculomucosal flaps. **D:** Final closure.

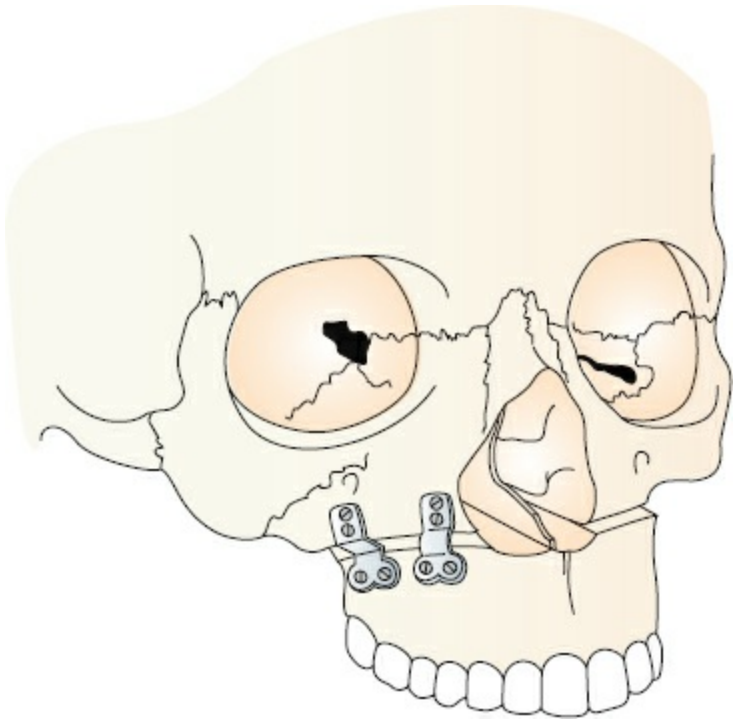

Figure 109-32. Le Fort I osteotomy in an advanced position. One side has been plated into position.

The last operation to be performed on the patient with a cleft lip and nasal deformity is often the formal rhinoplasty. There is almost always septal deviation that must be addressed in these patients and is an important part of the procedure. Each rhinoplasty is necessarily individualized, but the procedure usually entails repositioning and trimming of the nasal tip cartilages, added support to the nasal tip and slumping lower lateral cartilages to achieve projection, straightening of the septum, and finally infracturing of the widened nasal bones.

Although the care of the cleft patient requires interaction with the pediatric plastic surgeon and the cleft team throughout the patient's childhood, it should remain a small and unobtrusive part of life. The number of operations is kept to the minimum needed to attain an adequate reconstruction as deemed necessary by both the patient and the surgeon. Revisional surgery is usually an important part of cleft care but should be guided by the principle that the intervention is done *for* the child and not *to* the child, with an attempt to empower the patient as often as possible.

Craniosynostosis

8 Craniosynostosis is defined as the premature fusion of one or more of the cranial sutures. The child afflicted with craniosynostosis displays abnormalities in the size and shape of the cranial vault. Virchow law states that the growth of the skull will be restricted in the direction perpendicular to a synostosed suture while compensatory growth occurs in a parallel direction.[103] The ensuing skull shape of the patient provides the nomenclature of the deformity and is primarily empiric in nature (Fig. 109-33). Synostosis of the metopic suture most often results in a triangular forehead and is referred to as *trigonocephaly*. Unilateral coronal suture involvement often results in a recessed or slanted supraorbital bar and forehead and is referred to as *plagiocephaly*, whereas bilateral coronal synostosis often results in a shortened and flattened forehead referred to as *brachycephaly*. The sagittal suture is the most commonly fused suture and results in a boat- or keel-shaped head referred to as *scaphocephaly*.

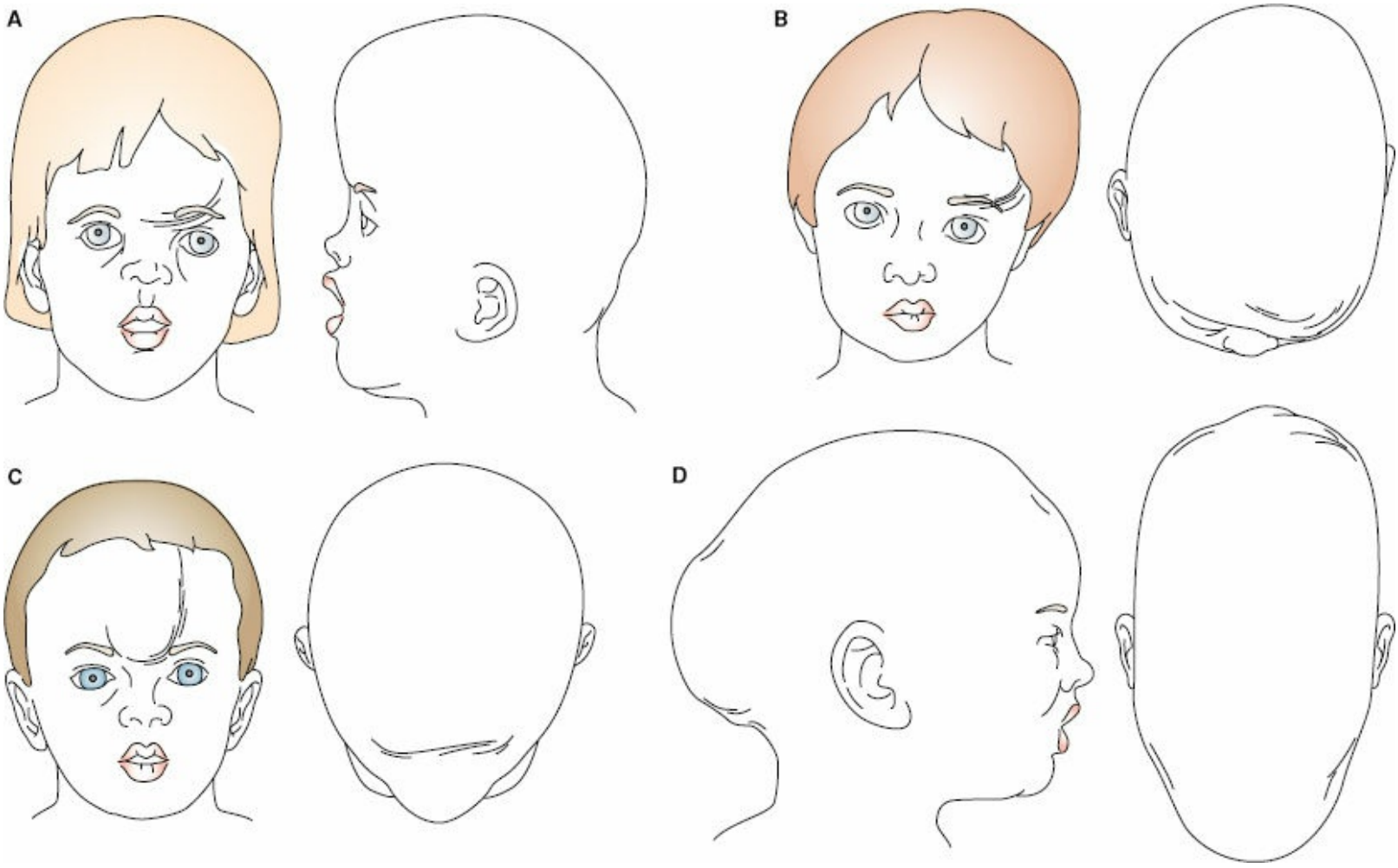

Figure 109-33. **A:** Turribrachycephaly (short, flat head). **B:** Plagiocephaly (slanted head). **C:** Trigonocephaly (triangular head). **D:** Scaphocephaly (keel-shaped head).

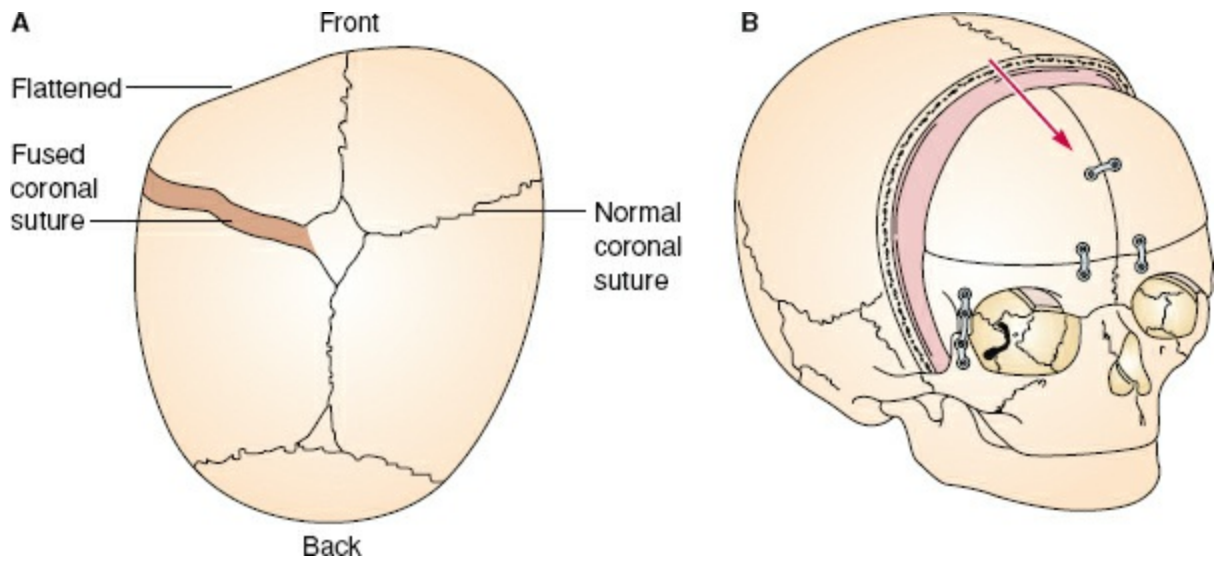

Figure 109-34. **A:** Plagiocephalic head viewed from above. **B:** The surgeon removes the bone of the forehead and advances the forehead to allow the brain to grow and the skull to resume a normal shape.

The abnormal shape of a synostotic cranium can often be severe and progressively worsens as the brain continues to grow and expand in the wrong dimensions. In addition, a small percentage of patients with a single-suture synostosis, and a much larger percentage of children with multiple-suture synostosis, are at risk for the development of increased intracranial pressure.[105,106] The care of these patients, therefore, requires close interaction between a pediatric neurosurgeon and a pediatric craniofacial plastic surgeon. A thorough clinical evaluation is mandatory and an ophthalmologic evaluation to check for papilledema can be beneficial. A CT scan is also useful in these patients to confirm the diagnosis and assess the ventricular system as well as the neuroanatomy for possible associated developmental anomalies of the brain.

Once the functional aspects of craniosynostosis are evaluated and addressed, the operative strategy is then aimed at restoring normal morphology. The operation is tailored to the individual diagnosis and malformation, but the underlying surgical principles remain the same. A sinusoidal coronal incision in the scalp is used to afford access to the cranium and to hide the scar. The pediatric neurosurgeon performs a craniotomy to provide access to the cranial vault. In the case of plagiocephaly and trigonocephaly, the craniofacial pediatric plastic surgeon removes the frontal bar by performing a bilateral osteotomy at the lateral orbital rim, and along the orbital roof meeting in the midline with a cut across the region just above the glabella. The frontal bar is removed, reshaped, and replaced in an advanced position with bone grafts placed to support the reconstruction. The bones of the forehead are similarly cut, bent and reshaped, and placed into a normal anatomic position. The bones are fixed with resorbable plates and screws (Fig. 109-34). A gap is left in the area of the coronal suture to allow growth and expansion of the brain. During infancy the dura is osteogenic and fills the gap in slowly with newly formed bone. In the case of a sagittal synostosis, the frontal bar often need not be removed; the operation entails removing and remodeling the majority of the calvaria, increasing the biparietal distance and decreasing the anteroposterior distance, leaving areas posteriorly open to encourage growth in that

direction. This arrangement encourages subsequent growth to fill out the parietal region and create a more anatomic shape. Another common approach to treating sagittal craniosynostosis is the endoscopic strip craniectomy whereby the synostosed suture and a few centimeter margin of bone on either side are removed. This is followed by approximately 8 to 12 months of helmeting to coax the head into the correct shape. In syndromic craniosynostosis patients, such as those with Apert, Crouzon, or Pfeiffer syndrome, similar reconstructions are required for the cranial vault. Additional operations are often needed to address deformities of the orbits and midface. In contrast to the midfacial hypoplasia exhibited by the cleft patient, the patient with syndromic craniosynostosis has a much more severe and extensive deformity and therefore requires more involved operations. Le Fort III and monobloc advancements move the entire upper and midfacial region forward and can be used to vastly improve the appearance of the patient while establishing a more normal functional anatomy (Fig. 109-35). These operations address the bulging eyes, malar hypoplasia, and recessed and diminutive nasopharyngeal airway of these patients, restoring normal eye position and opening up the breathing passages to relieve obstructions of the airway and symptoms of sleep apnea.[107]

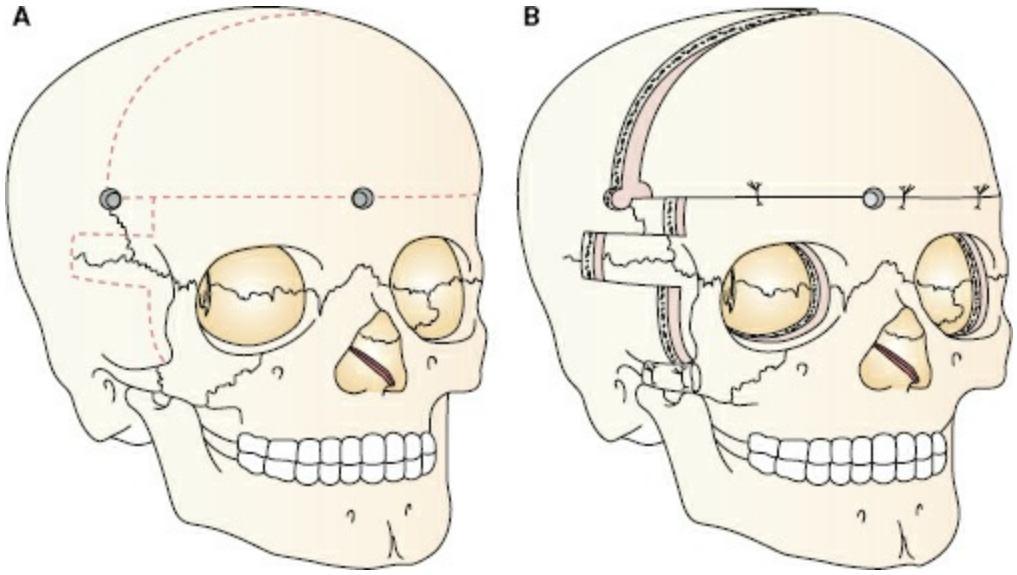

Figure 109-35. **A:** Outline of the osteotomies required. **B:** Appearance after frontofacial advancement and bone grafting.



Figure 109-36. Infantile hemangioma. **A:** Appearance a few weeks after birth. **B:** Proliferative phase. **C:** Involutional phase.

Hemangiomas and Vascular Malformation

The pediatric plastic surgeon is often the primary care giver for children afflicted with cutaneous hemangiomas and vascular malformations. These lesions may present at birth or in the neonatal period and require careful diagnosis and management. Hemangiomas are benign tumors that most often arise just after birth and undergo a spontaneous rapid growth phase followed by a slow involutional stage.[108] In general, acute management of hemangiomas is nonoperative. After the involutional phase is complete some patients will require excision of the fibrofatty residuum, usually before school age (Fig. 109-36). Ulceration or interference with function may prompt intervention. The use of local or systemic steroids can arrest the proliferative phase. Propranolol has recently been shown to effectively halt the growth of these vascular tumors and is replacing steroids in

popularity.[109] Rarely hemangiomas require early excision and in such cases operative strategies should strive to conserve tissue and function, avoiding the creation of significant deformities that would necessitate extensive and delayed reconstruction.

Vascular malformations are comprised of arteries, veins, capillaries, lymphatic vessels, or a combination of each. The malformations are present at birth and grow in proportion to the patient. As opposed to vascular tumors (e.g., hemangiomas) vascular malformations do not grow rapidly nor spontaneously involute. Superficial capillary malformations ("port-wine stains") respond well to pulsed-dye laser therapy. Venous malformations, lymphatic malformations and lymphaticovenous malformations can often be managed with sclerotherapy or intralesional laser treatment. Larger lesions are often infiltrative, and staged partial excisions can be performed if there are functional indications for intervention. Arteriovenous malformations can be the most vexing to treat as no options that ensure eradication exist.

Nevi

Congenital nevi are the most common benign tumor seen by the pediatric plastic surgeon. The small- to moderate-sized nevi are usually of little consequence but need to be monitored closely for any significant changes in size, shape, color, bleeding, or ulceration. The potential for degenerative malignancy into a melanoma for small- to moderate-sized congenital nevi is controversial.[110] Serial examination and even photographs can be helpful to document changes over time, and the gold standard for any doubtful skin lesion is still excisional biopsy.



Figure 109-37. Fully expanded tissue expanders in preparation for excision of a congenital melanocytic nevus.

Giant congenital melanocytic nevi are larger and less common, but they can be devastating to a child and the family. These lesions can affect the entire body or vast areas, including vital structures such as the eyelids, anus, and genitalia. Although the risk of malignancy is higher in these patients, operations have not shown to decrease that risk, hence a reasoned and conservative approach to such difficult cases is mandatory.[111,112]

It is often helpful to enlist the aid of a dermatologist and the patient's pediatrician to

assist in monitoring these lesions. Again, photographic documentation is helpful in serially assessing these lesions. Areas that show significant change warrant incisional biopsy and pathologic evaluation. The aesthetic consequences of these lesions often can be severe, and parents often want them to be excised. The surgical approaches to benign giant congenital melanocytic nevi are varied and range from excision and grafting to serial excision as well as the use of tissue expansion.

The use of extensive skin grafting as a reconstructive option for the reconstruction of giant hairy congenital nevi is usually reserved for malignant or dysplastic lesions. Skin grafts are not a particularly durable long-term cover, and they are often aesthetically displeasing and require subsequent resection and reconstruction. Serial excision can be useful in limited giant hairy congenital nevi, especially in locations near tissues that stretch well. The tissues adjacent to the lesion are undermined and advanced over the nevus to determine the amount that can be resected, and then a portion of the nevus is excised and the tissues are then reapproximated and allowed to heal. After 4 to 6 months the same procedure is performed until the nevus is fully excised. Tissue expansion requires the placement of a tissue expander adjacent to the lesion with slow instillation of saline into the expander over time, allowing stretching and recruitment of new tissue near the nevus to assist in excision and closure (Fig. 109-37). The quality and thickness of the skin, the possibility of exposure and infection, and the cooperation of the young patient at times limit the usefulness of this technique.

Prominent Ears

Prominent ears are a deformity that is mainly in the domain of the pediatric plastic surgeon. Children with prominent ears are prone to ridicule by classmates in school, teasing by siblings, and thoughtless comments by insensitive adults. The deformity does not usually present with an enlarged ear but rather with a lack of an antihelical fold, either with or without conchal hypertrophy. An incision is made on the posterior portion of the ear exposing the cartilage, and sutures are placed in a mattress fashion to reconstruct an antihelical fold. The stiff conchal cartilage can be weakened, and the concha is then secured to the mastoid fascia using permanent suture. A strict postoperative headbanding protocol may be used to avoid trauma to the ear and allow undisturbed healing. Successful otoplasty is one of the most rewarding procedures performed by a pediatric plastic surgeon because the child usually wants the surgery and is rewarded with immense satisfaction.

Myelomeningocele

The interaction between the pediatric neurosurgeon and the pediatric plastic surgeon often extends beyond the realm of craniofacial surgery. A prime example of the symbiotic interaction between the two specialties is in the repair and reconstruction of the myelomeningocele which is a form of spina bifida. The neurosurgeon is often presented with an exposed dural sac and a wide-open skin defect. The neurosurgeon may be faced with a tenuous dural closure and may need to resort to the use of a homograft to achieve an adequate dural repair. The pediatric plastic surgeon can assist by closing the defect over the dural reconstruction with stable, reliable coverage using well-vascularized tissue, protecting the neurosurgeon's repair. The soft tissue coverage may require local paraspinous muscle flaps or various fasciocutaneous flaps, but the goal of a durable reconstruction with a normal contour is paramount so as to avoid persistent long-term complications both at the level of the skin and at the level of the dural repair (Fig. 109-38).

SUMMARY

Although there are a multitude of additional procedures and topics in the specialized domain of the pediatric plastic surgeon, such as pediatric facial trauma, facial reanimation surgery, and various deformities resulting from congenital hypoplasia and hyperplasia, this chapter has focused on some of the major and more common areas of patient management. In fact, the pediatric plastic surgeon is often a chief collaborator with many of the pediatric surgical services when presented with a case of challenging wound care or any case which poses a reconstructive dilemma. Continuing innovation and technical advances combined with an appreciation for sound fundamental surgical principles allow the specialty to continue meeting that challenge.

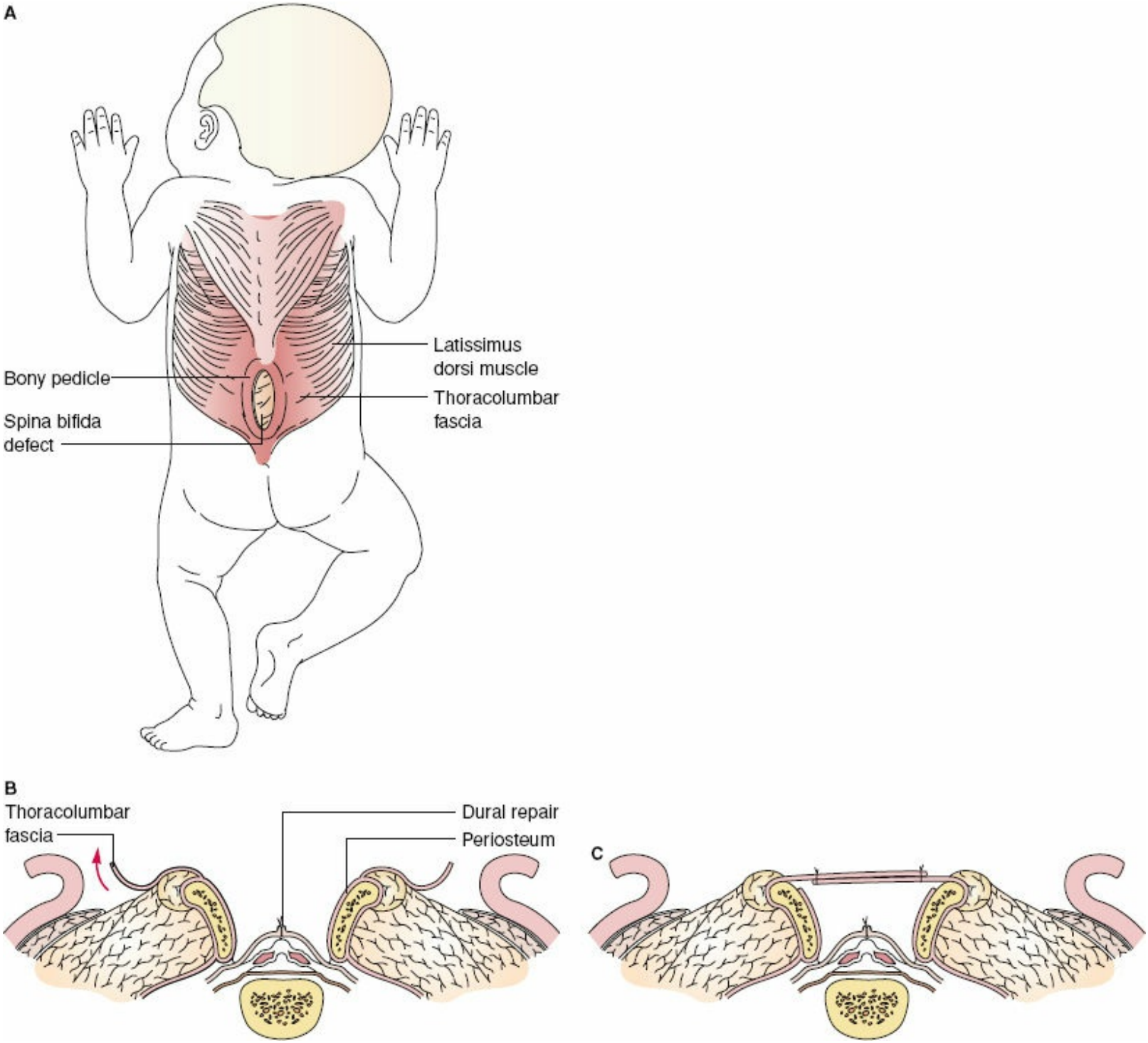

Figure 109-38. **A:** Myelomeningocele defect. **B:** Cross section of local flap coverage of myelomeningocele defect. **C:** Durable closure over defect of muscle, fascia, and skin. This can be mobilized to complete repair.

References

1. Murray JE. Reminiscences for the “50-year retrospective” of transplantation. *Transplant Proc* 1999;34:3101–3102.
2. Brown DL, Smith DJ. Bacterial colonization/infection and the surgical management of pressure ulcers. *Ostomy Wound Manage* 1999;45:109S–118S.
3. Robson M, Heggers J. Delayed wound closure based on bacterial counts. *J Surg Oncol* 1970;2:379–384.
4. Pruitt BA Jr, McManus AT, Kim SH, et al. Burn wound infections: current status. *World J Surg* 1998;22:135–145.
5. McManus AT, Kim SH, McManus WF, et al. Comparison of quantitative microbiology and histopathology in divided burn-wound biopsy specimens. *Arch Surg* 1987;122:74–76.
6. Fan J, Tang J, Escandon J, et al. State of the art in topical wound-healing products. *Plast Reconst Surg* 2011;127:44S–59S.
7. Lazic T, Falanga V. Bioengineered skin constructs and their use in wound healing. *Plast Reconst Surg* 2011;127:75S–90S.
8. Lionelli GT, Lawrence WT. Wound dressings. *Surg Clin North Am* 2003; 83:617–638.
9. Rees RS, Robson MC, Smiell JM, et al. Becaplermin gel in the treatment of pressure ulcers: a phase II randomized, double-blind, placebo-controlled study. *Wound Repair Regen* 1999;7:141–147.
10. Piascik P. Use of regranex gel for diabetic foot ulcers. *J Am Pharm Assoc (Wash).* 1998;38:628–630.
11. Bennett SP. Griffiths GD. Schor AM, et al. Growth factors in the treatment of diabetic foot ulcers. *Br J Surg* 2003;90(2):133–146.
12. Volk SW, Radu A, Zhang L, et al. Stromal progenitor cell therapy corrects the wound-healing defect in the ischemic rabbit ear model of chronic wound repair. *Wound Repair Regen* 2007;15(5):736–747.
13. Pham C. Greenwood J. Cleland H, et al. Bioengineered skin substitutes for the management of burns: a systematic review. *Burns* 2007;33(8):946–957.
14. Jeng JC, Fidler PE, Sokolich JC, et al. Seven years’ experience with Integra as a reconstructive tool. *J Burn Care Res* 2007;28(1):120–126.
15. Novitsky YW, Rosen MJ. The biology of biologics: basic science and clinical concepts. *Plast Reconstr Surg* 2012;130(5S-2):9S–17S.
16. Hunter JE, Teot L, Horch R, et al. Evidence-based medicine: vacuum-assisted closure in wound care management. *Int Wound J* 2007;4(3):256–269.
17. Hess CL, Howard MA, Attinger CE. A review of mechanical adjuncts in wound healing: hydrotherapy, ultrasound, negative pressure therapy, hyperbaric oxygen, and electrostimulation. *Ann Plast Surg* 2003;51:210–218.
18. Orgill DP, Bayer LR. Update on negative-pressure wound therapy. *Plast Reconstr Surg*

2011;127:105S–115S.
19. Milton SH. The effects of “delay” on the survival of experimental pedicled skin flaps. *Br J Plast Surg* 1969;22:244–252.
20. Grabb WC, Myers MB, eds. *Skin flaps.* Philadelphia, PA: Williams and Wilkins, 1975.
21. Jackson IT. *Flaps in head and neck reconstruction.* St. Louis, MO: Harcourt Health Sciences Group;1985.
22. Bakamjian VY. Total reconstruction of pharynx with medially based deltopectoral skin flap. *N Y State J Med* 1968;68:2771–2778.
23. McGregor IA, Jackson IT. The groin flap. *Br J Plast Surg* 1972;25:3–16.
24. Taylor GI, Palmer JH, The vascular territories (angiosomes) of the body: experimental study and clinical applications. *Br J Plast Surg* 1987;40:113–141.
25. Cormack GC, Lamberty BG. A classification of fascio-cutaneous flaps according to their patterns of vascularisation. *Br J Plast Surg* 1984;37:80–87.
26. Mathes SJ, Nahai F. Classification of the vascular anatomy of muscles: experimental and clinical correlation. *Plast Reconstr Surg* 1981;67:177–187.
27. Hartrampf CR, Scheflan M, Black PW. Breast reconstruction with a transverse abdominal island flap. *Plast Reconstr Surg* 1982;69:216–225.
28. Blondeel, P., Morris, S., Hallock, G., Neligan, P. (eds) *Perforator Flaps: Anatomy, Technique, and Clinical Applications.* St. Louis, MO: QMP; 2006.
29. Daniel RK, Taylor GI. Distant transfer of an island flap by microvascular anastomoses. A clinical technique. *Plast Reconstr Surg* 1973;52:111–117.
30. Koshima I, Yamamoto T, Narsuhima M, et al. Perforator flaps and supermicrosurgery. *Clin Plast Surg* 2010;37(4):683-689.
31. Yu P, Chang DW, Miller MJ, et al. Analysis of 49 cases of flap compromise in 1310 free flaps for head and neck reconstruction. *Head Neck* 2009; 31(1):45–51.
32. Kuzon WM Jr, Jejurikar S, Wilkins EG, et al. Double free-flap reconstruction of massive defects involving the lip, chin, and mandible. *Microsurgery* 1998;18:372–378.
33. Granzow JW, Levine JL, Chiu ES, et al. Breast reconstruction with the deep inferior epigastric perforator flap: history and an update on current technique. *J Plast Reconstr Aesthet Surg* 2006;59(6):571–579.
34. Pribaz JJ, Fine NA. Prefabricated and prelaminated flaps for head and neck reconstruction. *Clin Plast Surg* 2001;28(2):261–272
35. Wong VW, Rustad KC, Longaker MT, et al. Tissue engineering in plastic surgery: a review. *Plast Reconst Surg* 2010;126(3):858–868.
36. Chim H, Amer H, Mardini S, et al. Vascularized composite allotransplant in the realm of regenerative plastic surgery. *Mayo Clin Proc* 2014;89(7):1009–1020.
37. Argenta LC. Reconstruction of the breast by tissue expansion. *Clin Plast Surg* 1984;11:257–264.
38. Salzberg C. Focus on technique: one-stage implant-based breast reconstruction. *Plast*

Reconstr Surg 2012;130(5 Suppl 2):95S–103S.
39. Selber JC, Fosnot J, Nelson J, et al. A prospective study comparing the functional impact of SIEA, DIEP, and muscle-sparing free TRAM flaps on the abdominal wall: part II. bilateral reconstruction. *Plast Reconstr Surg* 2010;126(5):1438–1453.
40. Allen RJ, Treece P. Deep inferior epigastric perforator flap for breast reconstruction. *Ann Plast Surg* 1994;32:32–38.
41. Momoh AO, Colakoglu S, Westvik TS, et al. Analysis of complications and patient satisfaction in pedicled transverse rectus abdominis myocutaneous and deep inferior epigastric perforator flap breast reconstruction. *Ann Plast Surg* 2012;69(1):19–23.
42. Selber JC, Nelson J, Fosnot J, et al. A prospective study comparing the functional impact of SIEA, DIEP and muscle-sparing free TRAM flaps on the abdominal wall: part I. unilateral reconstruction. *Plast Reconstr Surg* 2010;126(4):1142–1153.
43. Alderman AK, Kuhn LE, Lowery JC, et al. Does patient satisfaction with breast reconstruction change over time? Two-year results of the Michigan Breast Reconstruction Outcomes Study. *J Am Coll Surg* 2007;204:7–12.
44. Buntic RF, Horton KM, Brooks D, et al. Transverse upper gracilis flap as an alternative to abdominal tissue breast reconstruction. *Plast Reconstr Surg* 2011;128:607e–613e.
45. Allen RJ, Haddock NT, Ahn CY, et al. Breast reconstruction with the profunda artery perforator flap. *Plast Reconstr Surg* 2012;129:16e–23e.
46. Allen RJ, Tucker C Jr. Superior gluteal artery perforator free flap for breast reconstruction. *Plast Reconstr Surg* 1995;95:1207–1212.
47. Guerra A, Metzinger S, Bidros R, et al. Breast reconstruction with gluteal artery perforator (GAP) flaps: a critical analysis of 142 cases. *Ann Plast Surg* 2004;52:118–125.
48. Halvorson EG, Cormican M, West ME, et al. Three-dimensional nipple-areola tattooing: a new technique with superior results. *Plast Reconstr Surg* 2014;133:1073–1075.
49. Mandrekas AD, Zambacos GJ, Anastasopoulos A, et al. Reduction mammaplasty with the inferior pedicle technique: early and late complications in 371 patients. *Br J Plast Surg* 1996;49:442–446.
50. Wallace WH, Thompson WO, Smith RA, et al. Reduction mammaplasty with the inferior pedicle technique. *Ann Plast Surg* 1998;40:235–240.
51. Hester TR Jr, Bostwick J, Miller L, et al. Breast reduction utilizing the maximally vascularized central breast pedicle. *Plast Reconstr Surg* 1985;76:890–900.
52. Wise RJ. Preliminary report on a method of planning the mammaplasty. *Plast Reconstr Surg* 1956;17:367–375.
53. Lejour M. Vertical mammaplasty and liposuction of the breast. *Plast Reconstr Surg* 1994;94:100–114.
54. Hammond DC. Short scar periareolar inferior pedicle (SPAIR) mammaplasty. *Plast*

Reconstr Surg 1999;103:890–901.
55. Mizgala CL, MacKenzie KM. Breast reduction outcome study. *Ann Plast Surg* 2000;44:125–134.
56. Behmand RA, Tang DH, Smith DJ Jr. Outcomes in breast reduction surgery. *Ann Plast Surg* 2000;45:575–580.
57. Gruber RP, Kahn RA, Lash H, et al. Breast reconstruction following mastectomy: a comparison of submuscular and subcutaneous techniques. *Plast Reconstr Surg* 1981;67:312–317.
58. Handel N, Silverstein MJ, Gamagami P, et al. Factors affecting mammographic visualization of the breast after augmentation mammaplasty. *JAMA* 1992;268:1913–1917.
59. Maxwell GP, Falcone PA. Eighty-four consecutive breast reconstructions using a textured silicone tissue expander. *Plast Reconstr Surg* 1992;89:1022–1036.
60. Gutowski KA, Mesna GT, Cunningham BL. Saline-filled breast implants: a plastic surgery educational foundation multicenter outcome study. *Plast Reconstr Surg* 1997;100:1019–1027.
61. Janowsky EC, Kupper LL, Hulka BS. Meta-analysis of the relation between silicone breast implants and the risk of connective-tissue diseases. *N Engl J Med* 2000;342:781–790.
62. Duvic M, Moore D, Menter A, et al. Cutaneous t-cell lymphoma in association with silicone breast implants. *J Am Acad Dermatol* 1995;32:939–942.
63. Kim B, Roth C, Chung KC, et al. Anaplastic large cell lymphoma and breast implants: a systematic review. *Plast Reconstr Surg* 2011;127:2141–2150.
64. Kim B, Roth C, Young VL, et al. Anaplastic large cell lymphoma and breast implants: results from a structured expert consultation process. *Plast Reconstr Surg* 2011;128:629–639.
65. Komatsu A, Tamai S. Successful replantation of a completely cut-off thumb: case report. *Plast Reconstr Surg* 1968;42:374–377.
66. Chung KC, Wei FC. An outcome study of thumb reconstruction using microvascular toe transfer. *J Hand Surg* 2000;25:651–658.
67. Partington MT, Lineaweaver WC, O'Hara M, et al. Unrecognized injuries in patients referred for emergency microsurgery. *J Trauma* 1993;34:238–241.
68. Godina M. Early microsurgical reconstruction of complex trauma of the extremities. *Plast Reconstr Surg* 1986;78:285–292.
69. Weinzweig N, Sharzer LA, Starker I. Replantation and revascularization at the transmetacarpal level: long-term functional results. *J Hand Surg [Am]* 1996;21:877–883.
70. Chung KC, Pushman A. Current concepts in the management of the rheumatoid hand. *J Hand Surg Am* 2011;36:736–747.
71. Chung KC, Kowalski CP, Kim HM, et al. Patient outcomes following Swanson silastic

metacarpophalangeal arthroplasty in the rheumatoid hand: systematic overview. *J Rheumatol* 2000;27:1395–1402.

72. Bostwick J, Eaves F, Nahai F, eds. *Endoscopic plastic surgery.* St. Louis, MO: Quality Medical Publishers; 1995.
73. Romo T 3rd, Sclafani AP, Yung RT. Endoscopic foreheadplasty: temporary vs. permanent fixation. *Aesthetic Plast Surg* 1999;23:388–394.
74. Furnas D. Facial aesthetic surgery: art, anatomy, anthropometrics, and imaging. *Clin Plast Surg* 1987;14:579–788.
75. Antell D, Taczanowski E. How environment and lifestyle choices influence the aging process. *Ann Plast Surg* 1999;43:585–588.
76. Ramirez O, Pozner J. Subperiosteal endoscopic techniques in secondary rhytidectomy. *Aesthetic Surg* 1997;17:22.
77. Barton FE Jr. Rhytidectomy and the nasolabial fold. *Plast Reconstr Surg* 1992;90:601–607.
78. Pitanguy I. Facial cosmetic surgery: a 30 year perspective. *Plast Reconstr Surg* 2000;105:1517–1527.
79. Owsley J. Face lifting: problems, solutions, and an outcome study. *Plast Reconstr Surg* 2000;105:302–315.
80. Rees T. In search of the perfect facelift: a personal odyssey. *Aesthetic Surg* 1997;17:29.
81. Menick F, ed. Aesthetic surgery of the face. *Clin Plast Surg* 1997;24:2.
82. Smith B, ed. *Ophthalmic plastic and reconstructive surgery.* St. Louis, MO: Mosby-Yearbook, 1987.
83. Goldberg R. Transconjunctival orbital fat repositioning: transposition of orbital fat pedicles into a subperiosteal pocket. *Plast Reconstr Surg* 2000;105:743–751.
84. Constantian MB. Four common anatomic variations that predispose to unfavorable rhinoplasty results: a study based on 150 consecutive secondary rhinoplasties. *Plast Reconstr Surg* 2000;105:316–333.
85. Godley FA, Nemeroff RF, Josephson JS. Current trends in rhinoplasty and the nasal airway. *Med Clin North Am* 1993;77:643–656.
86. Zide BM, Pfeifer TM, Longaker MT. Chin surgery: I. Augmentation–the allures and the alerts. *Plast Reconstr Surg* 1999;104:1843–1862.
87. Guyuron B, Kadi JS. Problems following genioplasty: diagnosis and treatment. *Clin Plast Surg* 1997;24:507–514.
88. Pitanguy I. Evaluation of body contouring surgery today: a 30-year perspective. *Plast Reconstr Surg* 2000;105:1499–1516.
89. Wang T, Vasconez LO. Body contour surgery. In: Jurkiewicz, MJ, Krizek TJ, Mathes SJ, et al., eds. *Plastic surgery: principles in practice.* St. Louis, MO: Mosby-Year Book; 1990.

90. Rohrich R, Mathes S. Suction lipectomy. In: Jurkiewicz, MJ, Krizek TJ, Mathes SJ, et al., eds. *Plastic surgery: principles in practice.* St. Louis, MO: Mosby-Year Book; 1990.
91. Zocchi ML. Ultrasonic assisted lipoplasty. Technical refinements and clinical evaluations. *Clin Plast Surg* 1996;23:575–598.
92. Troilius C. Ultrasound-assisted lipoplasty: is it really safe? *Aesthetic Plast Surg* 1999;23:307–311.
93. Fogh-Andersen P. *Inheritance of harelip and cleft palate.* Copenhagen: Arnold Busck; 1942.
94. Millicovsky G, Johnston MC. Maternal hypoxia greatly reduces the incidence of phenytoin-induced cleft lip and palate in A/J mice. *Science* 1981;212:671.
95. Neel JV. A study of major congenital defects in Japanese. *Am J Hum Genet* 1958;10:398–445.
96. Cohen MM Jr: Syndromes with cleft lip and cleft palate. *Cleft Palate J* 1978;15:306.
97. Sando WC, Jurkiewicz MJ. Cleft lip. In: Jurkiewicz, MJ, Krizek TJ, Mathes SJ, et al., eds. *Plastic surgery: principles in practice.* St. Louis, MO: Mosby-Year Book; 1990.
98. Gosman AA. Cleft lip and palate. part 1: embryology, anatomy, epidemiology, and clinical outcomes. *Selected Readings in Plastic Surgery* 2007;10:16.
99. Mulliken JB, LaBrie RA. Fourth-dimensional changes in nasolabial dimensions following rotation-advancement repair of unilateral cleft lip. *Plast Reconstr Surg* 2012;129:491–498.
100. Veau V, Borel S. *Division Palatine: Anatomy, Chirugie, Phonetique.* Paris; Masson; 1931.
101. Randall P, LaRossa D, Solomon M, et al. Experience with the Furlow double-reversing Z-plasty for cleft palate repair. *Plast Reconstr Surg* 1986;77:569–576.
102. Shinbashi T, O'Hata N, Hayashi Y, et al. Changes in bone remodeling after palatal surgery. *Ann Plast Surg* 1985;14:267.
103. Morris HL. Velopharyngeal competence and primary cleft palate surgery 1960–1971: a critical review. *Cleft Palate J* 1973;10:621.
104. Francis CS, Mobin SS, Lypka MA, et al. rhBMP-2 with a demineralized bone matrix scaffold versus autologous iliac crest bone graft for alveolar cleft reconstruction. *Plast Reconstr Surg* 2013;131:1107–1115.
105. Virchow R. Uber den cretinismus nametlich in franken, und uber pathologische schadelforamen. *Ver Phys Med Cesselsch (Wurzburg)* 1891;2:230.
106. Marchac D. Radical forehead remodeling for craniostenosis. *Plast Reconstr Surg* 1978;61:823–835.
107. Renier D, Sainte-Rose C, Marchac D, et al. Intracranial pressure in craniostenosis. *J Neurosurg* 1982;57:370.
108. Buchman SR, Muraszko K. Syndromic Craniosynostosis. In: Thaller SR, Bradley JP, Garri JI, eds. *Craniofacial Surgery.* New York, NY: Informa Healthcare USA, Inc; 2008:103–126.

109. Greene AK. Management of hemangiomas and other vascular tumors. *Clin Plast Surg* 2011; 38:45–63.
110. Bauman NM, McCarter RJ, Guzetta PC, et al. Propranolol vs prednisolone for symptomatic proliferating infantile hemangiomas: a randomized clinical trial. *JAMA Otolarnyg Head Neck Surg* 2014;140: 323–330.
111. Kaplan EN. The risk of malignancy in large congenital nevi. *Plast Reconstr Surg* 1974;53:421–428.
112. Arad E, Zuker RM. The shifting paradigm in the management of giant congenital melanocytic nevi: a review and clinical applications. *Plast Reconstr Surg* 2014;133:367–376.

Index

Note: Page number followed by f and t indicates figure and table respectively.

A

A77 1726 (metabolite of leflunomide), 550
  Abbreviated injury scale (AIS), 323, 403
AbbVie, 948
Abciximab (ReoPro), 1527
Abdomen. *See also* Abdominal aortic aneurysms (AAAs); Abdominal trauma; Abdominal wall; specific organs
  full-thickness graft from, 224, 225f
  pain
    abruptio placentae and, 485
    acute pancreatitis and, 862, 864
    after gastric bypass, 748
    bowel obstruction and, 785, 786
    colorectal cancer and, 1130
    duodenal ulceration and, 728
    intra-abdominal infection and, 129
    small bowel NETs and, 831
  pediatric, 1870–1929
  stab wounds to, 241
  x-ray films
    ileus, 800, 800f
    pancreatitis, 856–857
    for trauma to spleen, 1270, 1270f
    ulcerative colitis, 1084, 1085f
Abdominal aorta, 1563f, 1648, 1661f, 1682
Abdominal aortic aneurysms (AAAs)
  aortoenteric fistula and, 1759
  classifications, 1732, 1733f
  clinical presentation, 1735–1738
  definitions, 1732
  diagnosis, 1735–1738, 1736f, 1737f, 1738f
  dissecting, 1733–1734
  evaluation for, 1605, 1605f
  incidence of, 1732–1733
  infected, 1758–1759
  inflammatory, 1756–1761

intra-abdominal disease and, 1761
isolated iliac artery aneurysms and, 1755–1756
juxtarenal, 1757–1758
management, principles of, 1734–1735
mortality rate, 1735
open/endovascular repair, choice of, 1739–1744
operative repair
endovascular repair, 1749–1754, 1750f–1751f
indications, 1738–1739
open repair, 1744–1749, 1745f
preoperative evaluation, 1744
pathogenesis of, 1733–1734
problem, 1732–1733
renal anomalies and, 1760
renal/visceral artery occlusive disease and, 1760–1761
risk factors, 1733–1734
rupture
endovascular repair, 1755
open repair, 1754–1755
risk, 1734, 1734t
suprarenal, 1757–1758
venous anomalies and, 1759–1760
Abdominal binders, 1247
Abdominal cavity, 441
Abdominal compartment syndrome (ACS), 152, 157, 490–491, 490t, 865
clinical signs, 490
risk factors, 490
Abdominal fistulas, Crohn disease and, 817–818, 818f
Abdominal scintigraphy, in GI bleeding, 1070
Abdominal trauma, 403–421
blunt, 403–405
in children, 467–469 (*see also* Pediatric trauma)
colon injuries, 419–420
diagnosis, 416–417
diaphragmatic injuries, 408–409
duodenum injuries, 418–419
FAST examination for, 405
hepatic injuries, 410
laboratory studies, 406
pancreatic, 415–417
penetrating, 405–406
physical examination, 405
prehospital care, 403

radiographic evaluation, 405
rectal injuries, 420–421
small intestine, 418
splenic injuries, 413–415
stomach injuries, 417–418
Abdominal wall, 1212. *See also* Hernias
anatomic terms, 1212, 1213t
anterior
blood supply, 1218
external abdominal oblique muscle and ligaments, 1214, 1214f, 1215f, 1216f
innervation, 1216, 1218
internal abdominal oblique muscle and aponeurosis, 1214, 1214f, 1215f, 1216f
musculature and ligaments, 1213, 1214f
rectus abdominis, 1215–1216, 1215f, 1216f
rectus sheath, 1216, 1217f
superficial fascia, vessels, and nerves, 1212–1213, 1213f
transversus abdominis muscle and aponeurosis, 1214–1215, 1214f, 1215f, 1217f
defects, pediatric, 1870–1875
hernias, 1212–1259
posterolateral (lumbar), 1218, 1218f
Abdominoperineal excision of rectum (APE), 1144, 1144f
extralevator APE (ELAPE), 1144, 1144f
standard APE (SAPE), 1144
Abdominoperineal resection (APR), 1998
Abdominoplasty, 2059
Above-knee amputation (AKA), 1713
Abruptio placentae, in pregnancy, 485
Abscess, 132, 631–632
amebic, 930–931, 931f
anorectal, 1182–1183, 1182f, 1183f
breast, 1303–1304
lung, 1459, 1462f
peritonsillar, 631
pilonidal, 1187
pyogenic, 930, 931f
spleen, 1283–1284
Acalculous cholecystitis, 938, 1002–1003
diagnosis, 1002–1003
treatment, 1003
Accessory spleens, 1266
Accidental Death and Disability: the Neglected Disease of Modern Society, 456
Accountable Care Organization (ACO), 318
Accreditation, 328

Accreditation Council for Graduate Medical Education (ACGME), 3, 2004
Acellular dermal matrices (ADMs), 2039
Acetaldehyde (ADH), in alcohol-induced liver disease, 946–947
Acetaminophen, 18, 369, 1875
  and acute liver failure, 940
  in idiopathic breast pain, 1302
Acetylcholine, 714, 718
Acetyl coenzyme A (CoA), 8, 12, 15
Acetylcysteine, 1737, 1743
Acid-base
  acid–base disturbances, 208
  acid, definition, 207
  buffer systems, 208
  metabolic acidosis
    anion gap, 208
    bicarbonate, nonrenal loss of, 209
    clinical features of, 209
    diabetic ketoacidosis, 210
    ketoacidosis, 209
    lactic acidosis, 209
    mechanisms of, 208–209
    organic acid production, 209
    renal acidosis, 209
    renal compensation, 210
    respiratory compensation, 210
    treatment of, 210
  metabolic alkalosis, 210–211
    clinical features, 211
    respiratory compensation for, 211
    treatment, 211
  mixed acid–base disorders, 212
  respiratory acidosis
    clinical features, 211
    compensatory mechanisms, 212
    definition, 211
    treatment, 212
  respiratory alkalosis
    clinical features, 211
    compensatory mechanisms, 211
    definition, 211
    treatment, 211
Acidosis, 160, 164
  dilutional, 208

Acid–peptic diseases, 718
Acinar cell carcinomas, pancreatic, 882
Acinar cells, 844, 844f, 846–847, 846f, 860
Acinus, 844–845, 844f
Acquired hypercoagulable states, 76t
Acquired immunodeficiency syndrome (AIDS), 273
  metabolic response to, 31
Acquired renal cystic disease of renal failure (ARCD), 1935
Acral lentiginous melanoma (ALM), 1992
Acromegaly, 1406, 1411, 1411t
  medical therapy, 1412–1413, 1413t
  surgical results for, 1411, 1411t
  treatment algorithm, 1413f
ACS. *See* Abdominal compartment syndrome
ACTH stimulation test, 1398
Acticoat, 223
Activated protein C (APC), 71
Activated protein C resistance (APC-R), 78
Activities of daily living (ADL), 477
Acute bacterial skin and skin structure infections (ABSSSI), definition, 138
Acute cellular rejection (ACR), 523
Acute cholecystitis, 133
  community-acquired, 134t
Acute coronary syndromes (ACS), 1523
Acute dialysis quality initiative (ADQI), 184
Acute fatty liver of pregnancy (AFLP), 940
Acute kidney injury
  defining, 307
  prevention of, 307–308
  risk index classification system, 308t
Acute kidney injury network (AKIN), 184
Acute kidney insufficiency
  acute renal failure, treatment of, 185–186
  etiology, 184–185
Acute life-threatening thoracic injuries, 466t
Acute liver failure (ALF). *See* Liver failure
Acute lung injury (ALI), 175
Acute mesenteric ischemia (AMI), 1648
  biomarker for, 1651
  causes of, 1649
  diagnosis, 1651, 1651f
  laboratory abnormalities, 1650–1651
  management, 1651–1654, 1652f

mortality rates for, 1649
pattern of, 1651f
symptoms, 1650
Acute-phase stress response. *See also* Inflammation
acute-phase protein, 120
mediators of, 121
regulation of acute-phase cytokines/proteins, 121
systemic manifestations, 120–121
Acute Physiology and Chronic Health Evaluation (APACHE), 170, 736
Acute Physiology and Chronic Health Evaluation (APACHE) II score, 863
Acute renal failure, 221–222
diuretics in, 185–186
general care in, 185
Acute respiratory distress syndrome (ARDS), 152, 156, 485
Acute respiratory failure, 175
Acute tubular necrosis (ATN), 156, 185
Acyclovir, 1193
Adalimumab, in Crohn disease, 816t, 817
Additional electrolyte therapy, 200
Adenocarcinoma, 698–699, 754–765
anal canal, 1196
clinical features, 756
curative-intent treatment, 760
diagnosis and staging, 756–758, 758f
endoscopic resection, 760
epidemiology, 754, 755f
gastritis, 755
Helicobacter Pylori, 755–756
hereditary syndromes, 756
neoadjuvant and adjuvant therapies, 763–764
palliative treatment, 764–765
pathology, 759–760
premalignant lesions, 754–755
previous gastric surgery, 756
small bowel, 833–834, 834f, 834t, 835f
staging laparoscopy, 758–759
surgical resection, 760–763, 762f
Adenoid cystic carcinoma (ACC), 635, 1435–1436, 1436f
Adenoma detection rates (ADRs), 1097, 1102
Adenoma Prevention with Celecoxib (APC) trial, 1105
Adenomas. *See also* Colorectal polyps
gallbladder, 1047
hepatic, 981, 982f

mucous gland, 1436
pituitary, 1379, 1403–1404
sessile serrated, 1093, 1096, 1099f, 1106–1107
toxic, 1347
traditional serrated, 1093, 1096
Adenomatous polyposis coli (APC) gene, 2011
Adenomatous polyps, 755. *See also* Colorectal polyps
Adenomyomatosis, of gallbladder, 1047
Adenosine triphosphate (ATP), 21, 92
Adenosquamous carcinoma, pancreatic, 882
Adipocytes, 16
beige, 16, 18, 50
brown, 16, 50
in metabolic disease, 48–50, 50f
white, 16, 50
Adipocyte stem cells, 46
Adipokines, 45, 64
Adipose tissue, 738
Adipose tissue macrophages (ATMs), 48–49
Adipose tissue overflow, systemic effects of, 50–51, 51f
Adipostat set-point, 43
Adjunctive therapies
fluid management, 178
inhaled nitric oxide (iNO) and prostaglandins, 178
positional therapy, 178
sedation and paralysis, 178
steroids, 178
Adjuvant therapy, 2000, 2017–2021
for colon cancer, 1135–1136
for gallbladder cancer, 1038–1039
for non-small cell lung cancer, 1427–1429, 1427t, 1428t
for pancreatic cancer, 893–895, 895t
Adrenal androgens, 1387
Adrenal cortical hormones, 153
Adrenalectomy, 1398–1399. *See also* Adrenal glands
anterior approach, 1399, 1400f
for Cushing syndrome, 1389
laparoscopic, 1399, 1400f
posterior approach, 1399, 1400f, 1401
posterior retroperitoneal laproscopic, 1401
thoracoabdominal approach, 1399, 1400f
Adrenal glands, 1383
anatomy, 1383–1384, 1384f

biochemistry and physiology
adrenal cortex, 1384–1387
adrenal medulla, 1387–1388, 1387f, 1387t
diseases of
adrenal insufficiency, 1398
adrenocortical carcinoma, 1392–1394, 1393f, 1394t
congenital adrenal hyperplasias, 1391–1392, 1392f, 1393t
hyperaldosteronism, 1389–1391
hypercortisolism, 1388–1389, 1389f
incidental adrenal mass, 1396–1398, 1397f, 1397t
pheochromocytomas, 1394–1396
virilizing tumors, 1392
metastasis to, 1396
surgical approaches to, 1398–1401 (*see also* Adrenalectomy)
Adrenal insufficiency, 186, 1398, 1398t
Adrenal vein sampling, 1391
Adrenocortical carcinoma, 1392
diagnosis, 1392–1393, 1393f
signs and symptoms, 1392
treatment, 1393–1394, 1394t
Adrenocorticotropic hormone (ACTH), 153, 1383, 1385
Adrenocorticotropin-producing adenoma, 1403–1404. *See also* Pituitary adenomas
Adriamycin, 66, 2020
Adson maneuver, 1457, 1459f
ADSORB (Acute Uncomplicated Aortic Dissection type B) trial, 1573
Adult cardiac surgery database of society of thoracic surgeons, 321
Adult mechanical intestinal obstructions, 784t
Adult respiratory distress syndrome (ARDS), 175
Adults, burn injury in, 214
Advanced cardiac life support (ACLS), 155, 216, 483
Advanced glycosylation end products (AGE), 609
Advanced life support (ALS), 344, 352
prehospital, 352
Advanced trauma life support (ATLS), 155, 219, 366, 387, 394
classification system, 149
program, 344
Aesthetic Breast Surgery, 2046
Aesthetic surgery, 2055
Age
breast cancer, risk for, 1309
and response to stress, 31–32
surgical complications on, 294–296, 295t
wound healing, effect on, 62–63

Agency for Healthcare Research and Quality (AHRQ), 313, 325, 326f
Aggressive fluid resuscitation, 159
Aggressive venous valve surgery, 1795
Agkistrodon, 499
Agnogenic myeloid metaplasia (AMM), 1267
AIDS-related anal ulcers, 1194
Air-contrast barium enema (ACBE), 1102
Air plethysmography (APG), 1592, 1604
Airway
  assessment, 219
  complications, 601–602
  control, in children, 457
  management, 630–631 (*see also* Head and neck)
  mucosal injury, 221
  obstruction, pediatric patients, 1842–1843
Airway, breathing, and circulation (ABC), 457
Airway diameter, 1811
Airway evaluation for nonanesthesiologist, 248–249
Airway pressure release ventilation (APRV), 177
Airway stents, 1475, 1475t
AKR-505 (thrombopoietin nonpeptide mimetic), 1274
Albumin, 25
  in fluid therapy, 199
  as nutrition biomarker, 25, 25t
  solutions, 159
Albumin levels, 1981
Alcohol
  breast cancer and, 1309
  chronic pancreatitis and, 870
  colorectal cancer and, 1118
  liver disease and, 946–947
  wound healing, effect on, 66
Alcoholic liver disease, 554–555
Alcohol-induced pancreatitis, 861
Aldosterone, 196, 1386, 1386f, 1387t
Aliasing, 1586
Alkali, causing burn, 216
Alkaline reflux gastritis, 735
Alkalosis, 206
All-terrain vehicle laws, 470–471
α-dextrins, 778
Alpha$_1$-antitrypsin deficiency, 1921
Alternating current, injury from, 216

Alvarado/MANTRELS scoring system, acute appendicitis, 1201, 1201t
Alveolar ventilation, 353
Alveolar volume (VA), 256
Alvimopan, 802
  for postoperative ileus, 1059
Amaurosis fugax, 1624
Ambrisentan, 953
Amebic liver abscesses, 930–931, 931f
American Academy of Neurology (AAN), 508
American Academy of Pediatrics, 461
American Association for the Study of Liver Disease (AASLD), 982
American Association for the Surgery of Trauma (AAST), 419, 423, 467
American Association of Clinical Endocrinologists, 751
American Cancer Society (ACS), 1100, 1306
American College of Chest Physicians (ACCP), 297
American College of Gastroenterology (ACG), 1100
American College of Obstetricians and Gynecologists, 485, 1306
American College of Radiology (ACR), 1100
American College of Radiology breast imaging reporting and data system (BI-RADS), 1307, 1308t
American College of Surgeons (ACS), 292, 319
American College of Surgeons-National Surgical Quality Improvement Program (ACS-NSQIP), 315, 321
American College of Surgeons National Trauma Data Bank, 486
American College of Surgeon's Trauma Quality Improvement Program, 369
American Diabetes Association, 745
American Geriatrics Society, 475
American Heart Association, 745
American Joint Committee on Cancer (AJCC), 283, 635, 699, 2016t
  breast cancer, staging system for, 1314, 1315t
  esophageal cancers staging system, 699t
  gallbladder cancer, staging system for, 1034, 1035t
  gastric cancer, 760t
  general AJCC/UICC TNM staging system, 283, 283t
  melanoma staging system, 1996t
  pancreatic cancer, staging for, 885, 885t
  T-staging for parotid malignancies, 635t
American Medical Association (AMA), 475
American Society for Metabolic and Bariatric Surgery (ASMBS), 748
American Society for the Study of Liver Disease (AASLD), 947
American Society of Anesthesiology (ASA), 139
  physical status grading, 292, 294t
American Society of Clinical Oncology (ASCO), 1312

American Urological Association, 423
Amine precursor uptake and decarboxylation (APUD), 772
Amino acids, 14, 14t, 181
  conversion into glucose, 10
  essential, 14, 14t
  metabolism, 23
  synthesis of, 14
Aminosalicylates (5-ASA)
  in Crohn disease, 816, 816t
  in ulcerative colitis, 1085
Amiodarone-induced thyrotoxicosis (AIT), 1348
Ammonia, 14, 15f, 23
Amnesics and anxiolytics, 245, 246t
Amniotic band syndrome, 1834
Amniotic fluid embolism, 485
Amphetamines, 740
Ampicillin, 130
Amputations
  above-knee, 1713
  below-knee, 1709–1710, 1712–1713
  cryoamputation, 1713
  digital, 1707–1708, 1709f
  hip disarticulation, 1713
  lower extremity, 1704
    amputation level, 1705–1706, 1706f, 1706t
    complications, 1714–1715, 1714t
    evaluation, 1705
    indications, 1704–1705, 1705t
    operative technique, 1706–1715
    prosthetic management, 1715
    rehabilitation, 1715
    revascularization, 1705
    wound dressings, 1713–1714
  mortality, 1714t
  ray, 1707–1708
  stump complications, 1714
  Syme, 1709, 1711f
  transmetatarsal, 1708–1709, 1710f
Amrinone and milrinone, 163
Amylase, 846, 848, 848t, 862
Amylin, 741, 845, 850
Amylolytic enzymes, 846
Anal abscess/fistula, in Crohn disease, 821–822, 822f

Anal canal, 1053
Anal continence, 1057
Anal fissure, 1181–1182, 1182f
  clinical manifestations, 1181
  Crohn disease and, 823, 823f
  diagnosis, 1181
  etiology, 1181
  in HIV-positive patient, 1194
  medical management, 1181
  primary, 1181
  secondary, 1181
  surgical management, 1181
    advancement flap, use of, 1181–1182
    lateral internal sphincterotomy, 1181, 1182f
Anal fistula, 1183–1185, 1183f
  classification, 1183, 1183f
  clinical manifestations, 1183–1184
  Crohn disease and, 1185
  definition, 1183
  extrasphincteric fistula, 1184
  Goodsall rule, 1184, 1184f
  incidence, 1183
  intersphincteric fistula, 1183
  management, 1184
    advancement flaps, use of, 1184
    cutting seton, 1184
    fibrin glue and collagen plugs, 1184
    fistulotomy, 1184
    ligation of intersphincteric fistula tract, 1184
  suprasphincteric fistula, 1183
  transsphincteric fistula, 1183
Anal incontinence, 1060–1061
Anal intraepithelial neoplasia (AIN), 1194
Anal skin tags, in Crohn disease, 821, 821f
Anal stenosis/stricture, and Crohn disease, 824, 824f
Anaplastic lymphoma kinase (ALK), 1949
Anaplastic thyroid carcinoma, 1352
Anastomotic pseudoaneurysms
  incidence, 1770
  pathogenesis, 1770
  clinical manifestations, 1771
  diagnosis, 1771, 1771f
  treatment, 1771

Anastrozole (Arimidex), 280t, 1325
Anemia, 159, 296, 308, 1968
Anesthesia, 292
Anesthesiology and pain management
  airway evaluation for nonanesthesiologist, 248–249
  amnesics and anxiolytics, 245, 246t
  anticoagulant therapy, 253
  inhalation agents, 242, 242t
  intravenous sedatives/hypnotics, 242–243
  ketamine, 245
  local anesthetics, 246–247, 246t
  muscle relaxants, 243–244, 243t, 244t
  neuraxial blockade, 247
  opioids (narcotics), 244
  overview, 241–242
  peripheral nerve blockade (PNB), 247–248
  postoperative acute pain management, 261–263
  preoperative evaluation, 253–255, 254t
  problems in postoperative period, 258–261, 259t–261t
  propofol, 245
  recovery protocols, enhanced, 261
  risks associated with anesthesia
    cardiovascular diseases, 249–252
    diabetes mellitus (DM), 252
    obesity, 252
    obstructive sleep apnea (OSA), 253
    pulmonary disease, 252
    renal insufficiency and failure, 252–253
  sedation analgesia, 248, 248t
  surgical patient monitoring
    circulation monitors, 258
    level of consciousness monitors, 258
    oxygenation, monitors of, 255–256
    ventilation monitors, 256–258
Aneurysmosis, 1732
Aneurysms, 1657, 1732
  abdominal aortic, 1732–1761 (*see also* Abdominal aortic aneurysms (AAAs))
  aortic, 1717
  arterial infections and, 1609
  carotid arteries, 1632–1633, 1632f
  celiac artery, 1660
  colic artery, 1660–1661
  dissecting, 1733–1734

gastric artery, 1660
gastroduodenal artery, 1661, 1661f
gastroepiploic artery, 1660–1661
hepatic artery, 1659, 1659f
ileal artery, 1661
inferior mesenteric artery, 1662
isolated iliac artery, 1755–1756
jejunal artery, 1661
juxtarenal abdominal aortic, 1757–1758
mycotic, 1758
pancreaticoduodenal artery, 1661
renal artery, 1667–1668
splanchnic artery, 1656–1662
splenic artery, 1657–1658, 1657f, 1658f
superior mesenteric artery, 1659, 1660f
suprarenal abdominal aortic, 1757–1758
thoracoabdominal aortic, 1717–1729 (*see also* Thoracoabdominal aortic aneurysms (TAAA))
upper extremity arterial disease, 1639, 1641f
Anginal equivalents, 1522
Angina pectoris, 1507
Angiodysplasia
colonic, 1076
stomach and small intestine, 1077
Angiogenesis, 58–59
Angiography, 1624–1625, 1625f
upper extremity arterial disease, 1643, 1643f
Angiojet rheolytic catheter, 1782
Angiosarcoma, cardiac, 1516, 1517f
Angiotensin, 154
Angiotensin-converting enzyme (ACE), 196
Angiotensin-converting enzyme (ACE) inhibitors, 299t
for aortic aneurysms, 1567
in coronary artery disease, 1525
Angiotensin I, 1662, 1663f
Angiotensin II, 1386, 1663f
Angiotensin receptor blockers, for aortic aneurysms, 1567
Angle of Louis, 1446
Anhydrous ammonia, causing burn, 216
Anion gap, 208
Ankle–brachial index (ABI), 436
in aortoiliac occlusive disease, 1676
in peripheral arterial disease, 1686

Ankle–brachial index (ABI), 1593–1594, 1593t, 1615
Annular pancreas, 843–844, 843f, 1879f
Anomalous left coronary artery arising from pulmonary artery (ALCAPA), 1498
Anomalous origin of coronary arteries, 1498, 1519
Anorectal abscess, 1182–1183, 1182f, 1183f
  causes, 1182
  classification, 1183f
  clinical manifestations, 1183
  treatment, 1183
Anorectal cancer, Crohn disease and, 824
Anorectal disorders, 1172–1197
  anal canal tumors
    adenocarcinomas, 1196
    epidermoid/squamous cell carcinoma, 1195–1196, 1196f, 1197t
    melanoma, 1196
  anal margin tumors
    basal cell carcinomas, 1195
    Bowen disease, 1194–1195, 1195f
    Paget disease, 1195, 1195f
    squamous cell carcinoma, 1195, 1195f
  anatomy
    anal canal and sphincters, 1172–1174, 1173f–1177f
    blood supply, 1172, 1175f
    lymphatic drainage, 1172–1173, 1176f
    rectum, 1172, 1173f
    sympathetic and parasympathetic nerve supply, 1173, 1177f
    venous drainage, 1172, 1175f
  benign
    anal fissure, 1181–1182, 1182f
    anal fistula, 1183–1185
    anorectal abscess, 1182–1183, 1182f, 1183f
    fecal incontinence, 1189–1192
    hemorrhoids, 1177–1181
    pilonidal disease, 1186
    rectal prolapse, 1187–1189, 1188f
    rectovaginal fistula, 1185–1187, 1185f, 1185t, 1186f, 1186t
  diagnostic evaluation, 1176–1177
  digital rectal examination, 1178t
  physiology, 1176, 1178f
  sexually transmitted diseases, 1193
    anal intraepithelial neoplasia, 1194
    Chlamydial infections, 1193
    condyloma acuminata, 1193

gonorrhea, 1193
herpes simplex virus, 1193
HIV and AIDS, 1194
lymphogranuloma venereum, 1193
Anorectal injuries, in children, 469
Anorectal malformations
anatomy, 1882–1883, 1882f
anomalies in infants, 1883
classification, 1882–1883, 1883f, 1883t, 1884f
clinical presentation, 1883–1884
complications, 1885
diagnosis, 1884–1885
embryology, 1881–1882, 1881f
outcome, 1885
results, 1885
treatment, 1885
Anorectal manometry, 1899
Anorectal spaces, 1054
Anorectoplasty, 1885
Anoscopy, 1193
Anterior component separation, 1248, 1249f
Anterior lateral thigh (ALT) perforator flap, 2037
Anterior–posterior compression (APC), 445
Anthracyclines, 1325
Anthropometric measurements, for nutritional status assessment, 24
Antiangiogenic therapy, for myelodysplastic syndrome, 1279
Antibiotics
appendectomy and, 130–131
appendicitis, 1202
arterial infections, 1618
breast infections, 1304
complicated intra-abdominal infection (cIAI), 130
Crohn anal fistulas, 1185
Crohn disease, 816, 816t
hepatic encephalopathy, 954
spontaneous bacterial peritonitis, 969
variceal bleeding, 959
Antibody-mediated rejection (AMR), 522, 523–524
Anticholinergic agents, 1059
in irritable bowel syndrome, 1059
Anticoagulant therapy, 253, 299t
Anticoagulation therapy, in TBI, 491–492
Antidiuretic hormone (ADH), 154, 194, 195f, 1662

Antigen-presenting cells (APC), 93, 269, 519
Antihypertensive therapy, 1677
Anti-impulse therapy, for aortic aneurysms, 1567
Antimetabolite drugs, 522
Antimicrobial therapy
  broad-spectrum, 128, 129t, 139
  sepsis guidelines 2012, 129t
Antioxidant therapy
  for chronic pancreatitis, 873
  for liver fibrosis, 945
Antiphospholipid antibody syndrome, 77
Antiplatelet therapy, 300–301, 1677
  in TBI, 491–492
Antireflux surgery, 681
  anatomic failure, 682–683
  complications of, 681
  objective outcomes, 682
  symptomatic outcomes, 681–682
Antithrombin (AT), 71, 71f
  deficiency, 78
Antral glands, 716
AO Foundation (AO), 445
Aortic aneurysm, 1562, 1717
  abdominal (*see* Abdominal aortic aneurysms (AAAs))
  false aneurysms, 1562
  normal anatomic aortic segments, 1563f
  thoracic (*see* Thoracic aortic aneurysm)
  true, 1562
Aortic arch, double, 1497
Aortic dissections, 1562
Aortic endografts, evaluation for, 1606, 1606f
Aortic homografts, 1515
Aortic infections, in stable patient
  anesthetic considerations, 1615
  aortic graft excision, 1615–1616
  aortic ligation and extraanatomic bypass, 1615, 1616
  comparisons of arterial reconstruction methods, 1617, 1618t
  preoperative evaluation, 1615
  in situ reconstruction, 1615
    with autogenous femoral vein, 1616–1617
    with cryopreserved arterial allografts, 1616
    with rifampin-soaked and silver-impregnated grafts, 1616
Aortic injury, 398, 399f

Aortic regurgitation (AR), 1509–1510
diagnosis, 1509–1510
imaging, 1510
natural history, 1510
pathophysiology, 1509
prevalence and etiology, 1509
severity, 1510t
treatment, 1510
Aortic stenosis (AS), 1492–1494, 1493f, 1506–1509
bicuspid, 1507
degenerative calcific, 1507
electrocardiogram and imaging, 1507–1508
natural history, 1508, 1508f
pathophysiology, 1507
prevalence and etiology, 1506–1507
rheumatic, 1507
severity of, 1508, 1508t
subvalvar, 1494
supravalvar, 1494
symptoms and signs, 1507
Aortic stenosis (*continued*)
treatment, 1508–1509
percutaneous AVR, 1508–1509
percutaneous balloon aortic valvotomy (PBAV), 1509
surgical AV replacement (AVR), 1508, 1508f, 1509f
valvar, 1492–1493
Aortic valve (AV), 1505, 1506f
Aortic valve replacement (AVR), 317f
Aortoenteric fistulas (AEF), 1077, 1611–1612, 1759
aortic ligation and extraanatomic bypass for, 1614
diagnosis, 1613
in situ aortic reconstruction for, 1615
Aortofemoral bypass operation, 1682
Aortograms, abdominal, 1678f
Aortoiliac disease
anatomy, 1672, 1673f
antihypertensive therapy for, 1677
antiplatelet therapy for, 1677
balanced diet for, 1677
clinical pathologic types of, 1674–1675
computed tomographic angiography for, 1678–1679, 1678f, 1679f
diagnosis, 1675–1676, 1676f
differential diagnosis, 1676–1677

digital subtraction arteriography for, 1679–1680
endarterectomy for, 1682–1683
endovascular surgical management, 1681–1682, 1682t
evaluation of, 1680
exercise for, 1677
extra-anatomic bypass and, 1683
glycemic control in, 1677
lipid-lowering therapy for, 1677–1678
magnetic resonance angiography for, 1679, 1680f
noninvasive vascular testing for, 1675–1876
open surgical management, 1682–1684
pathophysiology, 1672
presentation, 1672, 1674
revascularization for, 1678–1684
smoking cessation and, 1677
treatment, 1677–1684, 1677f
Aortoiliac occlusive disease (AIOD), 1672, 1673f
aortofemoral bypass operation in, 1682
complications, 1684
diagnosis, 1675–1676, 1676f
differential diagnosis, 1676–1677
evaluation of, 1680
patterns of, 1674–1675
revascularization technique for, 1680–1681
symptomatic, 1677f
Trans-Atlantic Inter-Society Consensus II classification, 1675t
type II disease, 1675
type III disease, 1675
APC gene, 1094
Apixaban, 180, 474, 1781
Apolipoproteins, 11
Aponeurosis, 1213. *See also* Abdominal wall
Aponeurotic arch, 1214, 1217f
Appendages, 1943
Appendectomy, 130, 132
Appendiceal abscess, 1203–1204
Appendiceal adenocarcinoma, 1206–1208, 1207f
Appendiceal cancer, 1206–1208
Appendiceal perforation rates, 1981
Appendiceal phlegmon, 1204
Appendicitis, 1199, 1981–1982
abscess or phlegmon management, 132
Alvarado/MANTRELS scoring system, 1201, 1201t

anatomy of appendix, 1199–1200
antibiotics *vs.* appendectomy, 130–131
diagnosis, 1200
history and physical examination, 1200, 1200t
interval appendectomy, 132
laboratory values, 1200–1201
laparoscopic *vs.* open appendectomy, 131
management, 1202
appendiceal abscess, 1203–1204
appendiceal phlegmon, 1204
complicated appendicitis and, 1203
interval appendectomy, 1204–1205
nonoperative management, 1202–1203
pathophysiology, 1200
perforated, 1203f
with associated abscess, 1204f
preoperative identification, 1201
radiologic imaging, 1201
surgical options
complicated appendicitis, 1206
laparoscopic *versus* open appendectomy, 1205
outpatient appendectomy, 1206
single-incision laparoscopic (SILS) appendectomy, 1205–1206
time to appendectomy/perforation risk, 132
ultrasonographic appearance of, 1982f
Appendectomy, 1983–1984
Appendix, 1052
Apple-peel deformity, 1877
Aprotinin, 579, 1535
Arachidonic acid, 218
Arachnoid cysts, 1404
Arch of Buhler, 1648
Arc of Barkow, 1649
Arc of Riolan, 1054, 1672
Arginine, 63, 182
supplementation, 37
in wound healing, 63
Arginine test, 850
Arginine vasopressin (AVP), 154, 194f
Argon beam coagulator, 1272
Arm claudication, 1638
Aromatase inhibitor (AI), for breast cancer, 1305, 1312
Arterial baroreceptors, 196

Arterial graft infections
classification, 1611
conservative management, 1614
diagnosis, 1611–1613
microbiology, 1610–1611
pathogenesis of, 1610
surgical management, 1614–1617
Arterial infections, secondary, prevention of, 1618–1619
Arterial occlusive disease
amputation after, 1715t
cerebrovascular, 1622–1636
infrainguinal, 1687–1701
Arterial pressure waveform, 172, 172f
Arterial stimulation with venous sampling (ASVS), for pancreatic endocrine neoplasms, 904, 905f
Arterial vasodilation hypothesis, 951
Arterial wave contour analysis, 161–162
Arteria radicularis magna, 1726
Arteriography, for vascular infection, 1613
Arteriomegaly, 1732
Arteriosclerosis
and aortic aneurysm, 1717
renovascular hypertension and, 1664
Artery of Adamkiewicz, 1726
Artery of Drummond, 1054
Articular fractures, 451
Artificial bowel sphincter (ABS), 1192, 1192f
Artificial oxygen carriers, 199
Artificial placenta, 1814
Ascites, 966–969, 1913–1914, 1913t, 1914t
causes of, 966–967
clinical and laboratory features, 967
definition of, 966
development of, in cirrhotic patients, 951
diagnosis, 967
differential diagnosis, 967t
hernias and, 969
paracentesis for, 967
pathophysiology, 967
treatment, 967–969, 968t
Asp caterpillars, 504–505
Asphyxia, in children, 467
Aspirin, 99, 180, 299t, 301

in aortoiliac disease, 1677
in coronary artery disease, 1525, 1526
Assessment of low tidal volume and elevated end-expiratory pressure to obviate lung injury (ALVEOLI), 176
Associating liver partition and portal vein ligation for staged hepatectomy (ALPPS), 989
Asterixis, 953
Atherosclerosis, 1521–1522, 1521f
brachiocephalic disease and, 1634–1635
cerebrovascular occlusive disease, 1622, 1623
diagnostic evaluation, 1622, 1623
upper extremity arterial disease and, 1638
for vertebrobasilar disease, 1634
Atherosclerotic aneurysms, 1769
Athletic pubalgia, 1240–1241
ATMs. *See* Adipose tissue macrophages
Atractaspididae family (snakes), 496
Atrial natriuretic peptides (ANP), 197
Atrial septal defect (ASD), 1481–1483, 1482f, 1819
Atrioventricular septal defect (AVSD), 1485–1486
cardiac anomalies associated with, 1485
operative treatment, 1486
Rastelli classification, 1485t
Atypical adenomas, 1404. *See also* Pituitary adenomas
Atypical ductal hyperplasia (ADH), 1305
Atypical lobular hyperplasia (ALH), 1305
Auerbach plexus, 1056
Autogenous femoral vein, 1616–1617
Autogenous tissue reconstruction, 2041
Autogenous vein bypass, 1696–1698, 1697f, 1698t
Autoimmune hemolytic anemia, 1275
Autoimmune hepatitis (AIH), 940
Autoimmune neutropenia, 1275
Autoimmune pancreatitis, 1030
Automated external defibrillator (AED), 352
Autophagosomes, 860
Autophagy, 118–119
Autophagy-related proteins (ATG), 118
Autosomal dominant polycystic kidney disease (ADPCKD), 1934–1935
Autosomal dominant syndrome, 268
Autosomal recessive polycystic kidney disease (ARPCKD), 1934
Autotransfusion, 160
Auxillary partial orthotopic liver transplantation (APOLT), 568
Avascular necrosis (AVN), 452

Axilla, 1292
Axillary artery, cannulation of, 1567, 1567f
Axillary lymph node dissection (ALND), 1320–1322, 1321f
Axillary lymph nodes, 1292, 1292f
Azathioprine, 522, 575, 1926
  in Crohn disease, 816t, 817
Azurocidin, 89
Azurophil, 89

B

Babcock clamp, 679
Bacitracin, 223
Bacteria, colonic, 1056
Bactericidal/permeability-increasing (BPI) protein, 89
Bag-mask ventilation, 353
Bag-valve devices, 354
Ballooning degeneration, of alcohol-induced liver disease, 947
Balloon tamponade, for variceal bleeding, 959–960, 960f
Balloon valvuloplasty, 1493
Banff classification model, 523
Barbiturate coma and paralysis, 371
Bariatric surgery, 741–742
  abdominal pain management, 749f
  efficacy, 744–745
  internal hernia, 747f
  late morbidity, 747–748
  long-term comorbidity responses, 746t
  long-term weight loss, 745t
  micronutrient deficiencies and, 748, 750t
  modern, 744–752
  nutritional support in, 38
  operative considerations, 749–751
  perioperative and postoperative management, 751
  perioperative mortality and morbidity, 745–747, 746t
  physiologic mechanisms, 751–752
  preoperative preparation, 748–749
Barium-contrast radiographs, 757, 757f
Barium enema, for diverticular disease, 1166–1167, 1167f
Barium esophagram, 388
Barium swallow, 698
Baroreceptor, 196
Barrett esophagus, 646, 654
  dysplasia in, 669, 669f

histologic appearance of, 668f, 669f
Barrett metaplasia, 668
Bartonella henselae, 1841
Basal cell carcinoma (BCC), 1991, 2001f, 1992
of perianal skin, 1195
Basal cell nevus syndrome, 1115
Basal energy expenditure (BEE), 181
Basal metabolic rate (BMR), 181
Bascom procedure, 1187
Basic life support (BLS), 344, 352
Basilar skull fractures, 371
Basiliximab, 520
Basophils, 98
Bassini repair, 1234, 1235f
Batts–Ludwig system, 950
B7/CD28 CTLA4 blockade, 520
BCR-ABL fusion protein, 280
Beck triad, 1578
Beckwith–Wiedemann syndrome, 1871, 1967
Bedside Index for Severity in Acute Pancreatitis (BISAP), 864
Behavioral Risk Factor Surveillance System (BRFSS), 739
Behavioral therapy, for chronic pancreatitis, 873
Behçet disease, and thoracic aneurysms, 1566
Bell-clapper deformity, 1943
Below-knee amputation (BKA), 1709–1710, 1712–1713
Benzodiazepines, 245, 246t, 298
Beta blockers, 297, 299t
for aortic aneurysms, 1567
in coronary artery disease, 1525–1526
for prevention of variceal bleeding, 958–959
Beta-oxidation, 12
Bethesda classification system, for thyroid FNA cytology, 1350–1351, 1350t
Bevacizumab (Avastin), 66, 280t
Bicarbonate
absorption, 777
nonrenal loss of, 209
secretion, 846
Bifidobacterium sp., 1886
Bilateral lung transplant, 597
Bile
composition, 996
function, 996
gallbladder, 996–997, 997t

Bile duct, benign tumors of, 1048, 1048f
clinical findings, 1048
diagnosis, 1048
pathology, 1048
treatment, 1048
Bile duct carcinomas, 1039–1046
adjuvant therapy, 1045–1046
clinical findings and diagnosis, 1041–1043, 1042f
future issues, 1046
incidence, 1039
liver transplantation for hilar CC, 1043–1044
pathology and staging, 1039–1040, 1040t, 1041t
prognosis after resection, 1044, 1044t
recurrence following resection, 1046
surgery, 1043
lymphadenectomy, 1043
pancreaticoduodenectomy, 1043
partial hepatectomy with/without bile duct resection, 1043
staging laparoscopy, role of, 1043
unresectable hilar cholangiocarcinomas, 1044–1045, 1045f
Bile duct strictures, 1015
by cholelithiasis, 1030–1031
chronic pancreatitis and, 1029–1030, 1029f, 1030f
clinical presentation, 1018–1019
due to choledocholithiasis, 1031
endoscopic balloon dilation, 1025–1026, 1027t
5-fluorouracil infusion and, 1031
incidence, 1015
laboratory investigation, 1019
nonoperative management, 1025
and operative management, comparison of, 1026–1028
percutaneous balloon dilation, 1025, 1025t, 1026f
Bile duct strictures (*continued*)
operative management, 1020–1022, 1021f
pathogenesis, 1015–1018
preoperative management, 1020
radiologic examination, 1019
surgical outcome, 1022–1025, 1024f, 1024t
Bile leak test, 991, 991f, 992t
Bile salts, 22
absorption of, 780
Bilevel positive airway pressure (BiPaP), 178
Biliary atresia, 557

anatomy, 1918
clinical presentation, 1919–1920
complications, 1922–1923
diagnosis, 1919–1921
hepatic transplantation, 1923
pathophysiology, 1918–1919, 1919f
portoenterostomy for, 1920f, 1921–1923, 1923f
results, 1922–1923
treatment, 1921–1922
Biliary colic, 1000, 1007
Biliary cystadenoma, 979, 980f
Biliary infections, 132–133
acute cholecystitis, 133
antimicrobials for treatment of, 134t
cholangitis, 133
Biliary leak, 570–571. *See also* Hepatic transplantation
Biliary motility, 997
Biliary neoplasms, 1033
benign bile duct neoplasms, 1048
benign gallbladder neoplasms, 1047–1048
bile duct carcinomas, 1039–1046
gallbladder cancer, 1033–1039
Biliary obstruction, 1968
Biliary reconstruction, technique of, 1022, 1023f
Biliary sludge, 998
Biliary stenting, 854
Biliary surgery, 306
Biliary tract
congenital choledochal cystic disease of, 1923–1925
embryology, 1918
pediatric, 1918–1925
Biliopancreatic diversion, 742, 743f
Bilirubin, 996
Bilirubin-induced neurologic dysfunction (BIND), 1822
Bilirubin IXa, 18
Bilirubin metabolism, 1822–1823
Billroth I, 756
Billroth II, 756
Biochemical analysis of shock, 148
Biofeedback, in fecal incontinence, 1191
Biofilm, effects of, on wound healing, 61, 61f
Biologic agents, in Crohn disease, 816t, 817
Biologic materials, for hernia repair, 1227–1229, 1228t

Biopsy, breast, 1297
core needle biopsy, 1297–1298, 1298t, 1299
excisional biopsy, 1298, 1299f
fine needle aspiration, 1297, 1297f
incisional biopsy, 1298
skin punch biopsy, 1298–1299
Biotin, 780
Biotransformation, 18
Birt–Hogg–Dube syndrome, 1962
Bisphosphonates, 234
Bitemporal hemianopsia, 1402, 1407
Biventricular assist device (BiVAD), 1540. *See also* Mechanical circulatory support (MCS)
B-K mole syndrome, 1992
Black widow spiders, 503
Bladder
anomalies of, 1939
injury, 428–429, 429f
Blalock–Taussig shunt, 1487, 1499, 1819
Blanching, 234
BLEED classification system, GI hemorrhage, 1065
Bleeding disorders. *See also* Hemostasis
coagulation factor deficiency, 80–81
fibrinolysis, abnormalities in, 81
platelet disorders, 81
rare factor deficiencies, 81
Bleomycin (Blenoxane), 280t
Blepharoplasty, 2056
Bloodstream infections (BSI), 325
Blood urea nitrogen (BUN), 195, 302
Blue Cross Blue Shield Association, 319
Blue Distinction Centers, 319
“Blue toe” syndrome, 1674, 1687
Blunt cardiac contusion, 400, 400f
Blunt cerebrovascular injury (BCVI), 387, 389, 440
occurrence of, 389
screening criteria for, 389t
signs and symptoms of, 389t
Blunt trauma, 340, 403–405, 434. *See also* Abdominal trauma
in children, 459
diagnostics, 404–405
resuscitation, 403
B lymphocytes, 94
BMI. *See* Body mass index

B-mode ultrasound, for vascular trauma, 436
Boari flap, 548
Bochdalek hernia, 1861
Body composition
  change in, after trauma/surgery, 20
  factors affecting, 19, 20f
  fluid compartments, 19, 20f
  nonaqueous component, 19, 20f
  and stress response, 31
  total body mass, 19
Body fluid compartments, 192, 193t
Body fluids. *See also* Fluid and electrolyte therapy; Fluid balance
  colloid oncotic pressure, 193
  composition of, 192–193, 193t
  osmoregulation, 194, 195f
  osmotic activity of, 193
  tonicity of, 194–195
  total body water (TBW)/body fluid compartments, 192, 193t
Body mass index (BMI), 20, 24, 252, 296, 588, 738–739
  calculation of, 24
  definition, 738
  and metabolic disease, 738
Body temperature and oxygen uptake, 508
Boerhaave syndrome, 688
Bombesin, 774
Bone healing timeframes, 452t
Bone hunger, 1369
Bone sarcomas
  clinical presentation, 2027
  treatment, 2027–2028
Bone tumors, histologic classification of, 2025t
Bortezomib, 524
Bosentan, 953
Bothrops atrox, 502
Botulinum toxin, in anal fissure treatment, 1181
Bowel obstruction, 790–793
  and bariatric procedure, 792–793
  chronic adhesions, 790–792
  clinical presentation and differential diagnosis, 786
  complications and systemic effects, 785–786
  diagnosis and decisions in, 789t
  local effects of, 784–785
  management of, 789–790

postoperative adhesions, 792, 792f
symptoms and signs of, 784t
Bowel rest, 183
Bowen disease, 1194–1195, 1195f
Brachiocephalic disease
anatomy, 1634
atherosclerosis and, 1634–1635
clinical findings, 1634
diagnostic evaluation, 1635, 1635f
differential diagnosis, 1634–1635
endovascular treatment, 1636, 1636f
open surgical treatment, 1635–1636
repair, indications for, 1635
Brachytherapy, 279
Bradykinin production, 112
BRAF inhibitors, 2001
BRAF therapy, 2001
Brain contusion, 365
Brain death, criteria for, 531t
Brain Trauma Foundation, 362
Branchial cleft remnants, 1837–1838, 1838f
anatomy, 1838–1840, 1838t, 1839f
dermoid cysts, 1840
embryology, 1838–1840, 1838t, 1839f
infection and, 1840–1841
thymic cysts, 1840
thyroglossal duct cysts, 1840, 1840f
treatment, 1840–1841
Bravo system, 658
Braxton Hicks contractions, 1976
Breast
anatomy of, 1291, 1292f
blood supply, 1291
innervation, 1291
lymphatic drainage, 1292, 1292f
surgical anatomy, 1291
benign diseases, 1304–1306, 1304t
biopsy, 1297
core needle biopsy, 1297–1298, 1298t
excisional biopsy, 1298
fine needle aspiration, 1297, 1297f
incisional biopsy, 1298
skin punch biopsy, 1298–1299

clinical breast examination, 1294–1295, 1295f
development, 1292–1293, 1293f
diagnostic mammography, 1295, 1296f
diagnostic MRI, 1297
infections, 1303–1304
lobular carcinoma in situ, 1305–1306, 1306t
masses, 1299–1301, 1299t, 1300f, 1301f
menopause and, 1294
menstrual cycle and, 1293–1294
nipple discharge, 1302–1303
nonproliferative lesions of, 1304, 1304t
pain, 1301–1302, 1302f
in pregnancy and lactation, 1294
problem, clinical evaluation of, 1294–1299, 1294t
proliferative lesions with atypia, 1304t, 1305
proliferative lesions without atypia, 1304–1305, 1304t
ultrasound, 1295–1296
Breast bone, 1446
Breast cancer
adjuvant medical therapy, 1319t, 1326–1327
AJCC TNM staging system, 1314, 1315t
biomarker profile, 1316
BRCA1 and *BRCA2* mutations in, 1309–1310, 1310t
chemotherapy, 1325
clinical risk assessment, 1310–1311, 1311t
diagnostic MRI, 1316–1317
ductal carcinoma in situ, 1312–1313, 1312f, 1313t
in elderly, 1328
endocrine therapy, 1325
familial, 1309
hereditary, 1309
histologic subtype and tumor grade, 1314–1316
inflammatory, 1327–1328
lobular carcinoma in situ and risk for, 1305–1306, 1306t
locally advanced, 1318, 1318f
management, 1311–1312
in men, 1329–1330
molecular subtyping, 1316
Paget disease of breast, 1330–1331, 1331f
phyllodes tumors, 1331–1332, 1331f
during pregnancy, 1328–1329
radiation therapy, 1324
recurrence, 1330

  risk factors, 1308–1309
    age, 1309
    environmental and lifestyle factors, 1309
    estrogen exposure, 1309
    family history, 1309–1310
  sarcomas, 1331
  screening
    breast self-examination, 1306
    clinical breast examination, 1306
    mammography, 1306–1308
    MRI, 1308
  sentinel lymph node biopsy, 1317–1318, 1317t
  sporadic, 1309
  surgical therapy
    axillary lymph node dissection, 1320–1322, 1321f
    breast reconstruction, 1323–1324, 1324f
    partial mastectomy, 1319–1320, 1319f, 1320t
    radical mastectomy, 1324
    simple mastectomy, 1322–1323, 1322f, 1323f
  targeted therapy
    for HER2$^+$ breast cancers, 1325
    for triple negative breast cancers, 1326
  treatment, 1318–1319 (*see also specific treatment*)
Breast conservation therapy (BCT), 1312, 1319–1320, 1319f, 1320t
Breast implants, 1323–1324
Breast pain, 1301
  cyclical, 1301
  noncyclical, 1301–1302
  therapy for, 1302
  workup for, 1302
Breast self-examination (BSE), 1306
Breathing movements (FBM), 1806
Bridge to transplant (BTT), 577
Brief Abuse Screen for the Elderly (BASE), 475
Broad-spectrum antimicrobial therapy, 128, 128t, 139
Bromocriptine
  for breast pain, 1302
  for prolactinomas, 1412, 1412t
Bronchial adenomas, 1852
Bronchial artery embolization (BAE), 1462
Bronchial artery reanastomosis, 587
Bronchial cysts, 1436
Bronchial gland carcinomas, 1435

Bronchiectasis, 1459–1461, 1462f
and lung transplantation, 590
Bronchiolitis obliterans, 602
Bronchiolitis obliterans syndrome (BOS), 594, 667
Bronchogenic carcinoma, 1852
Bronchogenic cysts (BCs), 1467, 1849, 1850f
Bronchoscopy, foreign body removal, 1860, 1860f
Bronchospasm, 252
Broselow Pediatric Emergency Tape, 457, 457f
in ETT estimation, 458
Brown recluse, 503
Brow ptosis, 2055
Brunner glands, 773
Bucket-handle type injury, 404, 404f
Budd–Chiari syndrome (BCS), 557, 558
and cirrhosis, 949
diagnosis, 949, 956
etiologic factors, 950t
management, 949–950
percutaneous portacaval shunting (TIPS) in, 956
and portal hypertension, 955–956
therapy for, 956
Budesonide, in Crohn disease, 816t, 817
Buerger disease, 1638
Buffer systems, 208
Bulbocavernosus muscle, 1187
Buprenorphine, 299t
Bupropion, 741
Burn center referral criteria, 219t
Burns
associated complications
clinical research, 235
heterotopic ossification (HO), 234–235
marjolins ulcer, 235
muscle catabolism and wasting, 233
burn reconstruction
anatomic concerns, 233
hypertrophic scarring, 229–230
need for reconstruction, minimizing, 229
tissue expansion, 231
burn resuscitation flowsheet, 242
burn shock, 217–218
critical care of burn patient

electrolyte abnormalities/acute renal failure, 221–222
hemodynamic monitoring, 221
Burns (*continued*)
metabolic response and nutrition, 222
ventilator strategies, 221
emergency care, 218–219, 219t
airway assessment, 219
fluid resuscitation, 219–220
resuscitation of patients, 220
epidemiology
adults, 214
children, 214
elderly, 214
race and ethnicity, 215
socioeconomic status (SES), 215
etiology
chemical burns, 216
contact burns, 215
electrical burns, 215–216
flame burns, 215
frostbite, 216–217
immunologic response to, 218
infections
pneumonia, 229
vascular catheter–related, 229
wound, 229
metabolic response to, 218
operative interventions
excision and grafting, 223–226
extremity treatment, 227
order of coverage, 226–227
skin alternatives, 227
pain control
acute pain, 228
chronic pain/substance abuse, 228
science/translational science research, 232–233
severity of, 220
wound management, 222–223
Burns, nutritional support in, 39
Buserelin, 1325
14–4 bypass, 741

C

CA 19–9, 886
Cabergoline
  for acromegaly, 1412, 1413t
  in Cushing disease, 1414t
  for prolactinomas, 1412, 1412t
Cachexia, 47
  of cancer and AIDS, 31
Cadaveric vein grafts, 1617
Calcineurin, 521
Calcineurin inhibitor (CNI), 520, 521, 575
Calcitonin, 1344, 1365
Calcitonin gene-related peptide (CGRP), 114
Calcium, 1361–1363
  absorption, 1362
  hypercalcemia, 205, 206t
  hypocalcemia, 206, 207t
  metabolism, regulation of, 1364–1365, 1364t
  reabsorption, 1362–1363
  role of, 1361–1362
  total serum concentration, 1362
Calcium-channel blockers, 299t
  in anal fissure treatment, 1181
Calcium chloride, 164, 207
Calcium gluconate, for hypocalcemia, 1369
Calcium supplementation, for colorectal adenoma recurrence prevention, 1106
Calculated percent reactive antibodies (cPRA), 541
Cameron erosions, 672
Camper fascia, 1213
Canadian Cervical Spine Rules (CCR), 461
Canadian Task Force on Preventive Health Care (CTFPHC), 1306
Canadian Task Force on the Periodic Health Examination, 284
Canal of Nuck hydrocele, 1875
Cancer, 47, 75, 526. *See also specific type*
  biostatistics, 285
  esophagus, 709–710
  immunology, 272–273
  metabolic response to, 31
  obesity and, 52
  screening, 283–284
  staging (traditional/genetic), 282–283
    clinical staging, 282
    neoadjuvant or posttherapy staging, 282
    pathologic stage, 282

restaging, 282
tobacco and, 270, 270t
and wound healing, 66–67
Cancer Genome Atlas Consortium, 1120
Candida albicans, 550
Cantrell pentology, 1847, 1871
Capecitabine (Xeloda), 280t, 1135
Capnography, 256, 356
Caprini risk assessment for VTE, 179t
Capsaicinoids, 741
Capsule endoscopy (CE), for small bowel tumors, 829
Captopril scintigraphy, 1664
Caput medusae, 1245, 1245f
Carbohydrate, 181
digestion and absorption, 778, 779f
as energy fuel, 22
metabolism, 8–11
gluconeogenesis, 10–11, 11f
and glucose, 8–9
glycogenesis and glycogenolysis, 9, 9f
glycolysis, 9–10, 10f
phosphogluconate pathway, 11, 11f
wound healing, effect on, 63
Carbonic anhydrase, 719
Carboplatin, 1325
Carboxypeptidase, 846
Carcinoembryonic antigen (CEA) testing, 285
Carcinoid syndrome, 830–831
Carcinoid tumors
of appendix, 1208
of lungs, 1433–1434, 1433f, 1434f
of rectum, 1109
Cardiac allograft vasculopathy (CAV), 583
Cardiac anomalies, 1883
Cardiac arrest, treatment of, 173–175
Cardiac catheterization, 1525, 1526f
Cardiac cirrhosis, 949
Cardiac function assessment, 172
Cardiac index (CI), 155, 590
Cardiac tamponade
and constrictive pericarditis, 1580t
postoperative, 1579
Cardiac transplantation, 575–585

candidate evaluation, 576
complications, 582–583, 582f, 583f, 584t
contraindications to, 577t
current issues, 584–585
donor selection and management, 576–577
ethics, 584
heart procurement, 578
historical perspective, 575–576
immunosuppression, 581–582, 582t
indications for, 576t
matching donor to recipient, 577
operative recipient management, 578–581, 578f, 579f, 580f
outcomes, 583–584
recipient management, 577–578
stratifying risk and survival results, 576t
survival, 584f
Cardiac troponin, 1524
Cardiac tumors, 1515
benign primary
lipomas, 1516
myxomas, 1515–1516, 1515f
papillary fibroelastomas, 1516
rhabdomyomas, 1516
malignant primary
angiosarcoma, 1516
rhabdomyosarcoma, 1516
metastatic tumors, 1516–1517
Cardiogenic shock, 149–151, 1523
Cardiopulmonary exercise testing (CPET), 1424
Cardiopulmonary resuscitation (CPR), 329, 483
Cardiovascular diseases
congestive heart failure (CHF), 251–252
coronary artery disease, 249–251
hypertension, 249
percutaneous coronary intervention with stenting, 251
Cardiovascular system and geriatric trauma, 473–474
Cardiovascular system, surgery risk
antiplatelet therapy, 300–301
cardiac medication management, 301–302
preexisting cardiac disease, 300
preoperative testing, 300
risk stratification, 299–300, 300t
CardioWest total artificial heart, 1557, 1559f

Carnivore hypothesis, on insulin resistance, 42
Carotid arteries
  aneurysms, 1632–1633, 1632f
  bifurcation, 1623–1624, 1623f
  dissection, 1632
  fibromuscular dysplasia, 1632
  nonatherosclerotic diseases, 1632, 1632f
  stenosis, 1625t
    asymptomatic, 1625–1626
    diagnosis, 1624–1625
    grading, 1625t
    symptomatic, 1625
  trauma, 1633, 1633f
Carotid artery occlusive disease
  diagnostic evaluation, 1624–1625
  epidemiology, 1622
  treatment of, 1625
Carotid artery stenting (CAS), 1622, 1631f
  carotid endarterectomy *vs.,* 1626
  complications, 1630, 1632
  contraindications to, 1626t
  technique, 1629–1630
Carotid bifurcation occlusive disease, 1623, 1623f
Carotid body tumors, 1633, 1633f
Carotid endarterectomy (CEA), 1590, 1591t, 1622
  carotid stenting *vs.,* 1626
  complications, 1629
  cranial nerve injuries associated with, 1629t
  criteria for high-risk, 1626t
  technique, 1626–1627
Carotid patch infection, 1618
Carotid plaque, 1623–1624, 1623f, 1624f
Case fatality rate (CFR), 348
Catecholamines, 218, 483, 1387–1388, 1387f, 1387t
  release, 153
  secretion, 209
  synthetic, 163
Cathartics, in hepatic encephalopathy, 953–954
Catheter associated urinary tract infections (CAUTI), 188
Catheter, balloon-carrying, 347
Catheter-based procedures, 1773
Caustic injury, 693. *See also* Esophagus
Cavitation, 341

Cavitron ultrasonic surgical aspirator, 1969
Cavocavostomy technique, 562–563, 563f. *See also* Hepatic transplantation
C-cell hyperplasia, 1380
CD14, 116
CD91, 117–118
Cecum, 1051–1052
Cefotaxime, in spontaneous bacterial peritonitis, 969
Cefotetan, 130
Celiac artery aneurysms, 1660
Celiac disease, and small bowel tumors, 828
Celiac trunk, 712
Cell adhesion molecules, 72–74
Cell cycle, 272
Cellular components. *See also* Inflammation
  basophils and mast cells, 98
  eosinophils, 97–98
  lymphocytes, 94–97
  mononuclear phagocytes, 93–94
  neutrophils, 87–93
  platelets, 98–99, 99t
Cellular kininogenase activity, 113
Cellular proliferation rate, 1806
Cellulitis, 138, 1303
Centers for Disease Control and Prevention (CDC), 141, 354
Centers for Medicare and Medicaid Services (CMS), 328
Centers of excellence (COE), 319
Centipedes, 504
Central hypogonadism, 1405
Central line associated blood stream infection (CLABSI), 169, 188
Central nervous system (CNS), 335
Central pedicle technique, 2045f
Central pontine myelinolysis, 202
Central venous catheter, 37
Central venous pressure (CVP), 148, 153, 155, 161, 187, 201, 327, 490
Centrifugal pumps, 1556, 1556f
CentriMag VAD, 1553, 1554f
Cerebral blood flow (CBF), 361
Cerebral blood volume (CBV), 361
Cerebral contusion, 365
Cerebral edema, 365
  and osmolar therapy, 369–370
Cerebral microdialysis, 369
Cerebral perfusion, monitoring of, 368–369

Cerebral perfusion pressure (CPP), 361, 448
Cerebral salt wasting (CSW), 202
Cerebral tissue oxygen tension, measurement of, 361
Cerebral vasodilation, 211
Cerebrospinal fluid (CSF), 361
Cerebrovascular accidents (CVA), 1622, 1625–1626
Cerebrovascular occlusive disease, 1622–1636
Ceruloplasmin, 19
Cervical esophageal cancer, 698
Cervical esophageal injuries, 392
Cervical esophagus, 644, 645f
Cervical spine injuries (CSI), 461
Cervical tracheal injuries, 391
Cetuximab (Erbitux), 280t
Chagas disease, 524
Charcot triad, 1012
Chemical burns
  treatment, 216
  types of, 216
Chemokines, 103–104
Chemotherapeutic drugs, effect of, on wound healing, 66
Chemotherapy, 2001
  for adrenocortical carcinoma, 1393
  for breast cancer, 1325
  cancer biostatistics, 285
  in cancer management, 279–282
  clinical trials, 285–286
  for esophageal cancer, 709
  screening, 283–284
  staging (traditional/genetic), 282–283
  surveillance, 284–285, 285t
  therapeutic agents, 280t–282t
Chest. *See also* Chest wall
  injury, 448
  pediatric patients, 1844–1867
  radiograph, 149, 394, 2013
Chest wall
  anatomy, 1446–1447, 1447f–1449f
  benign bony/cartilaginous tumors, 1449t, 1450, 1450f
  benign soft tissue tumors, 1449, 1449t
  congenital abnormalities
    pectus excavatum and pectus carinatum, 1451, 1454–1456, 1454f–1456f
    Poland syndrome, 1457, 1458f

sternal clefts, 1456–1457, 1457f
deformities, 1844–1845
malignant bony/cartilaginous tumors, 1449t, 1450–1451, 1451f
malignant soft tissue tumors, 1449t, 1450
metastatic tumors, 1451
reconstruction, 1451, 1452f–1453f
sarcoma, 2018f
thoracic outlet syndrome, 1457–1459
tumors, 1449, 1449t
in children, 1855
Chicken-wire capillaries, 1961
Chief cells, 722
Chiladiti syndrome, 797
Chilblain, 511
Child abuse, 470
Childhood ascites, 1913–1914, 1914t
Childhood tumors, 1947
classification of childhood, 1947
incidence of, 1947–1948
percentage distribution by age, 1948
Child passenger restraints, 470
Children
burn injury in, 214
fluid management in, 458t
mediastinal tumors in, 1478, 1478t
Child–Turcotte–Pugh (CTP) score, 305t, 957, 957t, 976, 976t
Chimerism, 526–527
Chlamydia trachomatis, 1193
Chlorhexidine, 188
as skin surgical site preparation, 143
Chloride deficiency, 211
Chlorothiazide, 1926
Cholangiocarcinoma, 556, 1028–1029
Cholangiography
for bile duct stricture by chronic pancreatitis, 1030
cholangiocarcinoma, 1041
gallbladder cancer, 1034–1035, 1036f
for primary sclerosing cholangitis, 1028, 1028f
Cholangiohepatitis, 1031, 1031f
Cholangitis, 133, 133t
choledocholithiasis and, 1012, 1012f
Cholecystectomy, 1984
for acute cholecystitis, 1001–1002

indications for, 999t
asymptomatic patients, 999–1000
symptomatic patients, 1000
laparoscopic, 1003
complications, 1004–1005
contraindications to, 1003
technique, 1003–1004, 1004f, 1005f
trocar placement for, 1004f
open, 1004–1005
Cholecystitis
acute, 1000–1002
cholecystectomy, 1001–1002
imaging and diagnosis, 1000–1001, 1001f
medical treatment, 1001
Murphy sign, 1000
percutaneous cholecystostomy, 1002, 1003f
right upper quadrant (RUQ) pain, 1000
treatment, 1001–1002
chronic, 1003
during pregnancy, 1007
Cholecystoenteric fistulae, 1006
Cholecystokinin (CCK), 741, 773, 845, 846, 873, 997
Cholecystosphincter of Oddi reflex allows, 997
Choledochal cyst, 1922f
Choledochal cystic disease
anatomy, 1923–1924
clinical presentation, 1924
complications, 1925
diagnosis, 1924
outcome, 1925
pathophysiology, 1924
treatment, 1925
Choledochoduodenostomy, 1030
Choledocholithiasis, 1007, 1985
and acute cholangitis, 1012, 1012f
classification and etiology, 1007
clinical presentation, 1007, 1007f
diagnostic studies
biochemical liver profile, 1008
cholangiography, 1008–1009, 1009f
computed tomography, 1008, 1009f
magnetic resonance imaging, 1008, 1009f
ultrasonography, 1008, 1009f

intrahepatic stones, 1012–1013
management, 1009–1010, 1010f
endoscopic approach, 1010
laparoscopic approach, 1010–1011
open approach, 1011–1012
percutaneous approach, 1010
predictors of, 1007–1008, 1008t
primary CBD stones, 1007
secondary CBD stones, 1007
Cholelithiasis, 133, 751, 996. *See also* Gallstones
Cholestasis, 948
neonatal, 1919t
Cholestatic jaundice, 1919f
Cholesterol, 996
Cholesterol esterase, 846
Cholesterol gallstones, 998, 998f
cholesterol crystallization, 999
cholesterol supersaturation, 998–999, 998f, 999f
gallbladder absorption/secretion, 999
gallbladder motility, 999
Cholesterol metabolism, 13–14, 13f
Cholesterol polyps (cholesterolosis), 1046
Chondromas, 1450
Chondrosarcomas, 1450–1451
Chordae tendineae, 1506
Chordee, 1940
Christmas tree deformity, 1877
Chromaffin cells, 1383
Chromium
daily requirements of, 24t
deficiency of, 23
Chromogranin A, 850, 902
Chromogranins, 832
Chromosomal instability (CIN), 1120
Chrondrosarcomas, 2027
Chronic cholecystitis, 1000
Chronic granulomatous disease (CGD), 92, 1918
Chronic lymphocytic leukemia (CLL), 1277–1278, 1277f
Chronic mesenteric ischemia (CMI)
management, 1654–1656, 1654f–1655f
symptoms, 1654
Chronic myelogenous leukemia (CML), 280, 1278
Chronic obstructive pulmonary disease (COPD), 473, 666, 1462–1463

and lung transplantation, 589
Chronic venous disease
anatomy, 1784–1785
diagnostic evaluation, 1787–1789
etiology, 1785–1787
pathophysiology, 1785–1787
physiology, 1785
signs and symptoms, 1787
surgical therapy, 1791
Chronic venous insufficiency (CVI), 1779
evaluation of, 1604–1605, 1605f
Chronic venous insufficiency, treatment of, 1791t
Chvostek sign, 207, 1368
Chylomicrons, 11, 779
Chylothorax, 1867
Chymotrypsin, 846
Cigarette smoking, 303. *See also* Smoking
and gastric ulceration, 734
wound healing, effect on, 65–66
Cilostazol, 1678
Circulation monitors, 258
Circumferential resection margin (CRM), 1123
Circumflex coronary artery, 1519
Cirrhosis, 305, 943, 1074
alcoholic, 946–947, 946f
cholestasis and, 948
classification of, 944t, 945–950
complications
hepatic encephalopathy, 953–954, 953t
pulmonary, 952–953
renal, 950–952
definition, 943
diagnosis, 950
end-stage, 946f
etiology, 946–950, 948t
evolution of, 944f
gut microflora in, role of, 945
immune/inflammatory, 948–949
macronodular pattern, 945–946
metabolic disorders and, 949
micronodular pattern, 945
mixed pattern, 946
NASH-related, 947

pathophysiology, 943–945, 945f
physical findings in, 950t
portal hypertension and, 943 (*see also* Portal hypertension)
venous outflow obstruction and, 949–950
viral hepatitis and, 947–948
Wilson disease and, 949
Cisatracurium, 243t
Cisplatin (Platinol), 280t, 735, 1325
Citric acid cycle, 8, 14–16, 16f, 17f
Clamp-and-go technique, 1717
Clark electrode, 361, 369
Claudication
in aortoiliac disease, 1672, 1674
critical limb ischemia and, 1687
Clavien–Dindo classification, 291t
Clear cell sarcoma, 961, 1955
Cleft lip and palate, 2062
Cleveland Clinic Florida Fecal Incontinence Score (CCF-FIS), 1060, 1060t
Clindamycin, 130
Clinical breast examination (CBE), 1294–1295, 1295f, 1306
Clinical Randomization of an Antifibrinolytic in Significant Hemorrhage (CRASH-2) trial, 348
Clinical transplant immunology, 518–527
cell surface receptor blockade, 520
clinical therapeutics, 521–522
immunosuppressive therapy, 524–526, 525f
leukocyte depletion, 521
scientific basis, 518–520
tolerance, 526–527
treating rejection, 522–524, 523f, 524f
Cloaca, 1051
embryology, 1881f
Cloacogenic carcinoma, 1196
Clonorchis sinensis, 1031
Clopidogrel (Plavix), 544, 1527
Cloquet hernia, 1257
Cloquet node, 1221
Closed-loop obstruction, 783, 785–786. *See also* Bowel obstruction
Clostridium difficile, 1056, 1085, 1897
Clostridium difficile infection (CDI), 135
Clostridium septicum, 1611
c-Myc, 1122
Coagulation

definition, 69
factor deficiency, 80–81
homeostasis, 344
Coagulopathy, 158, 199, 307
prevention/Treatment of, 347–348
in TBI, 491
Cobalamin, 780
Coenzyme A reductase inhibitors, 1735
COG hepatoblastoma, 1968
Cold challenge testing, 1598, 1599f
Cold immersion foot, 511
Cold injury, 511–514, 513f, 513t
treatment, 512–514
Cold ischemia time, 537
ColDx, 1125
Colic artery aneurysm, 1660–1661
Colitis cystica profunda, 1109
Collaborative groups, hospital-based, 330
Collagen, 59–60, 63
Collagenolysis, 75
Collateralization, 1648–1649
Collis gastroplasty, 680
Colloid oncotic pressure, 193
Colloids, 159, 199
Colon, 1051
anatomy, 1051–1052, 1052f
arterial blood supply, 1054, 1054f
diagnostics, 419
disorders, 1057–1060
embryology of, 1051
epidemiology, 419
lymphatic drainage, 1055
neural components, 1055–1056
OIS-AAST grading scale, 419t
physiology, 1056
absorption, 1056
colonic flora, 1056–1057
colonic motility, 1057
treatment, 419–420
venous drainage, 1055
Colon cancer. *See also* Colorectal cancer (CRC)
Colonic atresia, congenital, 1877–1878
Colonic diverticulosis, 1075–1076, 1075f

Colonic pseudo-obstruction, 1059–1060, 1060f
diagnosis, 803
etiologic factors, 803
management, 803–804, 803t
risk factors, 803
Colonic pseudopolyps, 811, 811f
Colonoscopy
for colorectal neoplasia, 1101–1102, 1126, 1128
for GI bleeding, 1069, 1078
ColoPrint, 1125
Colorectal cancer (CRC), 1117–1155
colon cancer, treatment of
malignant colonic polyps, 1133, 1133f
postoperative adjuvant therapy, 1135–1136
surgery, 1133–1135, 1134f, 1135t
diagnosis, 1129–1130, 1986–1987
diagnostic evaluation, 1130, 1131f
symptoms and signs, 1130
differential diagnosis, 1130
emergencies related to, 1149–1150
epidemiology, 1117, 1118f, 1119f
histopathology and progression, 1122, 1122t
locally recurrent, treatment of, 1154–1155
metastasis
chemotherapy for, 1152–1154, 1153t
surgical treatment, 1152
molecular characteristics, 1120–1122, 1120f, 1121f
preoperative preparation, 1130–1132
principles of surgical treatment, 1132–1133
prognostic factors, 1125t
rectal cancer, treatment of, 1136–1149 (*see also* Rectal cancer)
risk factors, 1117–1120
screening and prevention, 1125
consequences of screening, 1129
dissemination of information, 1129
risk categories, 1127t–1128t, 1129
screening tests, 1126, 1126t, 1127t–1128t, 1128–1129
stage IV, treatment of, 1150, 1151f, 1152
staging and prognosis, 1122–1125, 1124t
nomogram, 1123, 1125f
TNM staging system, 1123, 1124t
surveillance after curative resection, 1150, 1151t
treatment, 1987

ulcerative colitis and, 1087
Colorectal liver metastases (CLM), 984, 986–987
imaging evaluation, 986
multidisciplinary treatment approach, 986f
surgical indication for, 986
Colorectal polyps, 1093. *See also specific type*
adenomas, management of, 1102–1104
anatomic distribution, 1098
classification, 1093–1094, 1094t
diagnosis, 1099–1102
barium enema, 1102
colonoscopy, 1101–1102
computed tomography colonography, 1102
fecal occult blood tests, 1100–1101, 1101f
sigmoidoscopy, 1101
stool DNA testing, 1102
disease states associated with, 1099
epidemiology, 1097–1098
guidelines for surveillance of adenomas, 1103–1104, 1104t
heredity, role of, 1098
histopathology and malignant potential, 1095–1097, 1096f–1099f
adenomatous polyps, 1095, 1097f
mucosal polyps of colon, 1095, 1096f
sessile serrated adenomas, 1096, 1099f
malignant polyps, management of, 1104–1105, 1105f
natural history, 1098–1099
Colorectal polyps (*continued*)
pathogenesis, 1094–1095, 1095f
primary prevention, 1105–1106
Colorectal surgery and surgical site infections (SSI), 143–144
Colubridae family (snakes), 496
Columnar-lined esophagus (CLE), 654
Columns of Morgagni, 1172
Combitube, 353
Committee on Trauma (COT), 344
Common bile duct (CBD), 997
Common carotid artery (CCA) waveforms, 1587–1588, 1587f
Common femoral artery pseudoaneurysms, infected, 1617–1618
Communicating hydrocele, 1874f, 1875
Community-associated MRSA (CA-MRSA), 139
Compartment syndrome, 439, 449–450
Compensatory anti-inflammatory response syndrome (CARS), 122, 157
Compensatory responses to hypothermia, 157–158

Competitive inhibitors, 243
Complacency, 323
Complete lymph node dissection (CLND), 1999
Complete mesocolic excision (CME), 1133
Complicated intra-abdominal infection (cIAI). *See also* Surgical infections
  antibiotics for, 130
  community-acquired, 129–130
  healthcare-associated, 139
Component separation techniques, 1248, 1250
  anterior, 1248, 1249f
  endoscopic, 1249–1250
  posterior, 1248–1249, 1249f, 1250f
Composite measures, surgical care quality, 315–316
  limitations, 316
  strengths, 316
Comprehensive geriatric assessment (CGA), 475, 477, 1328
Computed tomography (CT), 341, 1980, 1983
  acute cholecystitis, 1000, 1001f, 1002f
  aortic injuries, 398
  appendicitis, 1201, 1202
  blunt trauma, 404
  bowel obstruction, 788, 788f
  CBD stones, 1008, 1009f
  cervical spine injury, 465
  cholangiocarcinoma, 1041, 1042f
  chronic pancreatitis, 872
  colon injuries, 420
  Crohn disease, 812–813, 813f
  diverticular disease, 1166, 1166f
  elderly patient, 475
  esophageal perforation, 689
  gastric lymphoma, 758, 758f
  GI bleeding, 1070–1071
  head injury, 364–366, 364f, 365f
  hepatic neoplasms, 977
  inguinal hernia, 793f
  jugular venous injury, 388
  mandible fractures, 382
  midface injuries, 379
  neck injury, 388
  occult pneumothorax, 396
  pancreatic cancer, 887, 887f
  pancreatic disease, 857

penetrating abdominal trauma, 405
pheochromocytoma, 1395
pituitary tumors, 1407
rectal injuries, 420
renal injury grading, 426f
spleen injury, 413, 413f, 1270, 1271f
stomach injuries, 418
thoracic aortic aneurysm, 1566
thyroid gland, 1346, 1346f
traumatic injuries, 484, 491
vascular infection, 1612, 1612f, 1613f
vascular trauma, 436
Computed tomography angiography (CTA), 388, 1624, 2032
for thoracoabdominal aortic aneurysms, 1719, 1719f
for vascular infection, 1612
for vascular trauma, 436
Computed tomography colonography (CTC)
for colon cancer screening, 1102
for colorectal cancer, 1128–1129
Concurrent chemoradiation, 279
Condyloma acuminata, 1193
Conflict Tactics Scale (CTS), 475
Confocal laser scanning microscopy (CLSM), 232
Congenital adrenal hyperplasias, 1391–1392, 1392f, 1393t
Congenital anomalies, 2052
Congenital colonic atresia, 1877–1878
Congenital cystic adenomatoid malformation (CCAM), 1467, 1467f, 1467t, 1830–1831, 1848, 1849f
Congenital diaphragmatic hernia (CDH), 1810, 1861
diagnosis of, 1862, 1863f
evolving therapies, 1864–1865
magnetic resonance imaging, 1828f
pathology, 1861–1862
pathophysiology, 1861–1862, 1862f
prenatal surgery for, 1832
prognostic factors, 1863
radiograph, 1863f
repair of, 1863–1864, 1864f
surgery, 1863–1864, 1864f
survival rates, 1864
treatment, 1863
Congenital duodenal obstruction
anatomy, 1878–1879, 1880f

annular pancreas and, 1879f
causes of, 1878
clinical presentation, 1879
diagnosis, 1880, 1880f
duodenoduodenostomy in, 1881, 1881f
embryology, 1878–1879, 1879f
results and outcome, 1881
treatment, 1880–1881
Congenital esophageal stenosis, 1859
Congenital heart defects, 1834
Congenital heart disease, 1481–1501, 1818
aortic stenosis, 1492–1494
atrial septal defect, 1481–1483
atrioventricular septal defect, 1485–1486
coarctation of aorta, 1494–1495
coronary artery anomalies, 1498–1499
double-outlet right ventricle, 1487
hypoplastic left-heart syndrome, 1501
patent ductus arteriosus, 1495–1496
tetralogy of Fallot, 1486–1487
transposition of great arteries, 1488–1491
truncus arteriosus, 1491–1492
univentricular heart, 1499–1501
vascular rings, 1496–1498
ventricular septal defect, 1483–1485
Congenital hemolytic jaundice. *See* Hereditary spherocytosis
Congenital high airway obstruction syndrome (CHAOS), 1833
Congenital hypertrophy of retinal pigmented epithelium (CHRPE), 1111
Congenital lobar overinflation (CLO), 1849, 1850f
Congenital lung disease, 1465–1466
bronchogenic cysts, 1467
congenital cystic adenomatoid malformation, 1467, 1467f, 1467t
lobar emphysema, 1467, 1467f
pulmonary sequestration, 1466, 1466f
stages of lung development, 1465–1466, 1466t
Congenital lung lesions, 1810, 1847–1851
Congenital melanocytic nevi (CMN, 992
Congenital nevi, 2066
Congenital pulmonary airway malformations (CPAMs), 1810, 1847–1848, 1849f
Congenital tracheal stenosis, 1860
Congestive heart failure (CHF), 249, 251–252, 1507
Conivaptan, 202
Conn syndrome, 1390

Consensus development, 327–328, 328t
Constipation, 1057–1059
  anal fissure and, 1181
  causes, 1057, 1058t
  laxatives, 1058
  medical therapy, 1058
  Rome criteria, 1057, 1057t
  Sitz marker study, 1058–1059, 1058f
Constrictive pericarditis, 1579–1580, 1580f
  cardiac tamponade and, 1580t
  pericardiectomy for, 1582–1583
  and restrictive cardiomyopathy, 1580, 1581t
Consumer Product Safety Commission, 470
Contact burns, 215
Continence, 1174
Continuing medical education (CME), 4
Continuous arteriovenous rewarming (CAVR), 509
Continuous positive airway pressure (CPAP), 369, 749
Continuous renal replacement therapy (CRRT), 185, 222
Continuous venovenous hemodiafiltration (CVVHDF), 186
Continuous venovenous hemodialysis (CVVHD), 186, 309
Continuous venovenous hemofiltration (CVVH), 186
Contralateral prophylactic mastectomy (CPM), 1323
Contrast angiography, for vascular trauma, 436–437
Contrast enema, 1898, 1898f, 1906f
Controlled resuscitation (CR), 344
Conventional liver resection, 1969
Cooley anemia, 1276
Copper, 19
  daily requirements of, 24t
  deficiency of, 23
  wound healing, role in, 63
Copy number alterations (CNA), 1120
Coral snake, 502
Cords of Billroth, 1266
Core-needle biopsy (CNB), 2014
Cori cycle, 9, 10f
Corona mortis, 1223
Coronary aneurysms, 1499
Coronary angiography, 1525, 1526f
Coronary arteriovenous fistula, 1498
Coronary artery bypass grafting (CABG), 300
  comparative trials, 1537–1538

conduits for, 1529
endoscopic vein harvesting, 1530, 1531f
indications, 1527–1528, 1529f
instrumentation for, 1530f
minimally invasive approach, 1533
off-pump technique, 1532–1534
postoperative care, 1534–1536
results, 1536–1537, 1536f
robotically assisted, 1534
standard technique, 1528–1532, 1530f–1532f
Coronary artery disease, 249–251
Coronary sinus, 1520
Corrugator cutis ani, 1172
Corticosteroids, 164, 1975
in ulcerative colitis, 1085
Corticosteroid therapy of septic shock (CORTICUS) trial, 186
Corticotroph adenomas. *See* Adrenocorticotropin-producing adenoma
Corticotropin-releasing hormone (CRH), 799, 1385
Cortisol, 1385–1386, 1385f, 1385t
excess levels of, 1405–1406, 1406t
COSMOS trial, 947–948
Costal cartilages, 1844, 1846, 1847
Costochondral tumor, 1847
Cottonmouth water moccasin *(Agkistrodon piscivorus),* 500
Coumadin, 80, 474, 475, 579, 1063
Cowden syndrome, 1115
CpG island methylator phenotype (CIMP), 1094
Craniopharyngiomas, 1404, 1407
Craniosynostosis, 2064–2065
Craniotomy, 373, 373f
C-reactive protein (CRP), 815, 864
vascular infections and, 1611
Creatinine height index (CHI), 24
Creatinine phosphokinase (CPK), 185
Cremasteric fascia, 1221
Crescent expanders, 230
Crew resource management, 330
Cricothyroidotomy (CRIC), 353, 387
Critical care, 167–188
acute kidney insufficiency (AKI)
acute renal failure, treatment of, 185–186
etiology, 184–185
acute respiratory failure, 175

adjunctive therapies
fluid management, 178
inhaled nitric oxide (iNO) and prostaglandins, 178
positional therapy, 178
sedation and paralysis, 178
steroids, 178
of burn patient
electrolyte abnormalities/acute renal failure, 221–222
hemodynamic monitoring, 221
metabolic response and nutrition, 222
ventilator strategies, 221
cardiac arrest/dysrhythmias, treatment of, 173–174
ventilator modes and graphics, 174–175
critical care prognostication and scoring, 170
endocrine issues in ICU
glucose control, 186–187
hemodynamic monitoring and treatment
fluid responsiveness, assessment of, 171–173
hemodynamic monitoring, 171
oxygen delivery and consumption, 170–171, 171t
ICU nutrition
enteral nutrition, delivery of early, 182–183
immunitrition, delivery of, 183
supplemental parenteral nutrition, 183
infectious disease issues in ICU
catheter associated urinary tract infections (CAUTI), 188
central line associated blood stream infections (CLABSI), 188
procalcitonin for antibiotic therapy, 187–188
sepsis guidelines, 187
metabolism and nutrition
enteral nutrition, 182
immunonutrition, 182
metabolic requirements and assessment, 181–182
nutrition for specific indications
acute pancreatitis, 183
obesity, 183
stress gastrointestinal bleeding prophylaxis, 183–184
organizational structure of
bundles, 169, 169t, 170t
evidence-based care, 168, 169t
prognostication and scoring, 170
risk factor scoring
transfusion of ICU patient, 180–181

VTE, prevention of, 179–180, 179t
venous thromboembolism (VTE) prophylaxis in ICU, 178–179, 179t
ventilator management
conventional modes, 176–177
liberation from ventilation, 178
ventilator-associated pneumonia (VAP), 177–178
Critical care air transport team (CCATT), 348
Critical illness
energy requirements in, 32
micronutrients during, 37
nutritional support in, 32–33, 37t
Critical limb ischemia (CLI), 1687, 1691
CroFab, 500
antibodies, 500t
and impending compartment syndrome, 501
Crohn disease, 796, 809–824
abdominal fistulas and, 817–818, 818f
and anal fissures, 823, 823f
anal stenosis/stricture and, 824, 824f
anorectal, 811–812, 811f, 820–821
anorectal abscess/fistula in, 821–822, 822f
and anorectal cancer, 824
colonic involvement, 811, 811f
diagnosis, 810–815
differential diagnosis, 815, 815f, 815t
endoscopy, 814, 814f
epidemiology, 809
etiology, 809–810
extra-intestinal disease, 812, 812t
fibrostenotic patterns, 810
gastroduodenal disease and, 819
hemorrhage in, 819
ileo-anal pouch and, 820
imaging studies
computed tomography, 812–813, 813f
Crohn disease (*continued*)
fluoroscopic imaging, 812, 813f
magnetic resonance imaging, 813, 813f
PET scan, 813
video capsule endoscopy, 813–814, 814f
inflammatory, 810
laboratory examination, 815
malignancy with, 819

medical management, 816–817, 816t
obstruction and stricture in, 818–819, 818f
operative management
general principles, 817
indications for surgery, 817
pathologic examination, 814–815, 814f, 815f
penetrating/fistulizing disease, 810
rectovaginal/anovaginal fistula in, 822, 823f
site of disease, 810, 810f
skin tags and hemorrhoids in, 821
small bowel, 811, 811f
and small bowel adenocarcinoma, 828
small bowel disease and, 819–820
toxic colitis and, 820
upper gastrointestinal, 812
Crohn disease endoscopic index of severity (CDEIS), 814
Cronkhite–Canada syndrome, 1115, 1115f
Crural dissection, 678, 678f
Cryoamputation, 1713
Cryopreserved arterial allografts, 1616
Cryopreserved human allograft veins, 1617
Crypts of Lieberkühn, 772
Crystalloids, 158–159, 198–199, 198t, 337
parenteral solutions, 198–199, 198t
Culling, 1267
Culture, 323–324
assessment, 324–326
definition, 323
Curative resection, 274–275
Currant-jelly stool, 1906
Cushing disease, 1388, 1411, 1412t
surgical results for, 1411, 1412t
treatment algorithm, 1415f
Cushing syndrome, 1388–1389
Cutaneous tumors
Cyanosis, 1487
Cyanotic heart diseases, 1819, 1820
Cyclic adenosine monophosphate (cAMP), 163, 720
Cyclin-dependent kinase inhibitor 2A gene *(CDKN2A),* 881
Cyclooxygenase-2 (COX-2), 669, 728
Cyclooxygenase pathway, 110
Cyclosporin A (CsA), 575
Cyclosporine, 524, 552

for ulcerative colitis, 1085
Cyclosporine A, 521
Cystathionine beta synthase, 79
Cystgastrostomy, 869
Cystic duplications, 1911–1912
Cystic fibrosis (CF), 666, 1889–1891
and lung transplantation, 590
Cystic fibrosis transmembrane conductance regulator (CFTR), 846, 1889
Cystic hygromas, 1851
Cystic medial degeneration, 1564
Cystic neck infections, 633–634, 633f, 634f
Cystoduodenostomy, 869
Cystoscopy, for diverticular disease, 1167
Cysts
breast, 1301, 1304
of mediastinum, 1849, 1851
pituitary, 1404, 1407
of spleen, 1283, 1283f
Cytochromes P-454, 18
Cytogenetic aberrations, 2012
Cytokines, 99–101, 100t–101t
chemokines, 103–104
high mobility group box 1 protein (HMGB1), 105–106
interferons (type I), 106
interleukin-1 (IL-1), 102–103
interleukin-6 (IL-6), 105
interleukin-10 (IL-10), 106–107
interleukin-12 (IL-12), 104
interleukin-15 (IL-15), 106
interleukin-18 (IL-18), 106
TNF-a, 101–102, 102f
Cytomegalovirus (CMV), 524, 550, 569, 601, 938
hepatitis related to, 938
infection, 1194
Cytoreductive surgery (CRS), 1153
Cytotoxic T-lymphocyte–associated antigen 4 (CTLA4), 273
Cytotoxic T lymphocytes (CTL), 94
Cytotoxin-associated gene A (CagA), 726

D

Dabigatran, 180, 475, 1780
Dacron, 1627
Dacron grafts, 1562

Damage control approach, 342
Damage control orthopedics (DCO), 447
Damage control resuscitation (DCR), 344, 347, 489
Damage Control Resuscitation protocols, 355
Damus–Kaye–Stanzel operation (DKS), 1487
Danazol, for breast pain, 1302
Danger-associated molecular patterns (DAMP), 115–116
  S100 proteins, 115–116
  uric acid, 115
Danger recognition
  exogenous/endogenous, 115
  receptors for
    CD14, 116
    CD91, 117–118
    Hsp receptors, 118
    RAGE, 117
    toll-like receptors (TLR), 116–117
Dapsone, 573
Dasabuvir, 948
Daunorubicin, 1325
David procedure, 1510
D-dimer test, 80
Dead-space (DS) components, definition, 256
Death
  changing patterns of, 335–339, 336f–339f, 337t
  declaration of, 530–531
Débridement, 2050
Débriding dressings, 2033
Decompressive colonoscopy, 1060
Deep inferior epigastric perforator (DIEP) flap, 1323, 1324, 2037
Deep venous thrombosis (DVT), 74, 179, 483, 1602–1604, 1603f, 1777
  after amputations, 1714
  and pregnancy, 486
Defecation, 1057, 1174, 1176, 1178f
Defecography, 1059
Definitive radiation therapy, 279
Dehydroepiandrostenedione (DHEA), 1385, 1387
Delayed gastric emptying, 33
Delayed graft function (DGF), 532
Delayed neurologic deficits (DND), 1726–1727, 1727f
Delirium tremens (DT), 307
Delta-4-androstenedione, 1387
Demerol®, 508

De Musset sign, 1510
Dendritic cells (DC), 519, 775
Denonvilliers fascia, 1053, 1137, 1172, 1173f
Denver multiple organ failure organ failure scores, 171t
The Denver Protocol, 446, 446f
Denver shunt, 968
Denys–Drash syndrome, 1955
Dermatofibromasarcoma protuberans (DFSP), 2006
Dermoid cysts, 1404, 1840
Des-deoxyargine vasopressin (DDAVP), 579
Desmoid tumors, 1111, 1113, 1450, 2025
Desmoplastic melanoma, 1993
Desmopressin, 185
Desmopressin acetate (DDAVP), 81
Devascularization procedures, for treatment of variceal bleeding, 965–966, 965f, 966f
Dexamethasone suppression test, 1388
Dextran, 199
  in fluid therapy, 199
  for shock, 159
Diabetes, 51–52, 608
  insulin-dependent, 608
  non–insulin-dependent, 608
  and pancreas transplantation effects, 621–622
  and pancreatic cancer, 880
  pathophysiology, 608–609
  and peripheral vascular disease, 65
  secondary complications of, 609–610
  wound healing, effect on, 64, 64f
Diabetes Control and Complications Trial (DCCT), 609
Diabetes insipidus (DI), 1405
Diabetes mellitus (DM), 80, 252. *See also* Diabetes
Diabetes Prevention Program, 740
Diabetes Prevention Trial–Type 1 (DPT-1), 609
Diabetic foot ulcers (DFUs), 64, 64f
Diabetic ketoacidosis, 210, 210f
Diacylglycerol, 719
Diagnostic peritoneal aspiration (DPA), 344, 404
Dialysis Surveillance network (DSN), 141
Diaphoresis, 198
Diaphragm
  anatomy, 408, 1861f
  congenital abnormalities, 1860–1865
  diagnostics, 409, 409f

embryology, 1861
epidemiology, 408–409, 408f, 409f
eventration of, 1865
muscularization, 1861
pacing, 1865
treatment, 409
Diaphragmatic injuries, 398–399
Diastasis recti, 1246
Diazepam, 355
Diet
and diverticular disease, 1163
modification, 739
and pancreatic cancer, 879–880
Dietary risk factors and obesity, 271–272
Diethylenetriamine pentaacetic acid (DTPA), 547
Dieulafoy vascular malformation, 1077
Differentiated thyroid cancer (DTC), 1341
Diffuse axonal injury (DAI), 360
Diffuse brain injury, 372. *See also* Head injuries
Diffuse large B-cell lymphomas (DLBCL), 765
Diffusing capacity of lung for carbon monoxide (DLCO), 1424
Difluoromethylornithine (DFMO), 1105
DiGeorge syndrome, 1369
Digital amputation, 1707–1708, 1709f
Digital hypothermic challenge test, 1598, 1599f
Digital ischemic ulcerations, 1688f
Digital rectal examination, 1178t
Dimethadione test (DMO), 847
DIOS. *See* Distal intestinal obstruction syndrome
Direct-acting antivirals (DAAs), 947
Direct endoscopic necrosectomy (DEN), 137, 866
Disaster triage, 454
Disease-free survival (DFS), 274
Disease recurrence, 276–277
Disease-specific survival (DSS), 285
Disease, trauma after, 335
Disorder of sex development (DSD), 1941
Dissecting aneurysm, 1733–1734
Disseminated intravascular coagulation (DIC), 80, 483, 485
Distal contractile integral (DCI), 657
Distal gastrointestinal tract, 1909
Distal intestinal obstruction syndrome (DIOS), 1889
Distal origin graft, 1694, 1695f

Distal pancreatectomy (DP), 875
Distant recurrence, 276
Distributive shock, 152
Diuretics, 185–186, 211, 299t
Diverticular disease (DD), 1161–1171
  anatomy related to, 1161
  classification, 1161
  contrast enemas, 1166–1167, 1167f
  CT scanning, 1166, 1166f
  cystoscopy, 1167
  diagnosis, 1164–1165
  endoscopy, 1167
  etiology, 1162–1164
    diet, 1163
    motility factors, 1163, 1163f
    other factors, 1163
    structural/anatomic factors, 1162–1163, 1162f
  incidence, 1161–1162
  inflammatory, 1164–1165
  modified Hinchey classification, 1165t
  noninflammatory, 1164
  pathogenesis, 1164
  plain radiographs, 1166
  surgical management, 1168
    elective surgery, 1168–1169
  treatment, 1167–1169
    diverticular hemorrhage, 1167
    diverticulitis, 1167–1168, 1168f
    fistula, 1169
    giant colonic diverticulum, 1169
    obstruction, 1168
    symptomatic diverticulosis, 1167
  ultrasound, 1166
Diverticulitis, 133–134, 1161, 1908. *See also* Diverticular disease (DD)
  imaging and diagnostic studies, 1166–1167
  pathogenesis of, 1164
  symptoms, 1164
  treatment, 1167–1168, 1168f
Diverticulitis-associated colitis, 1164
Diverticulosis, 1161. *See also* Diverticular disease (DD)
  colonic motility patterns in
    disorganized propulsive activity, 1163
    high-pressure waves, 1163

segmentation, 1163, 1163f
slow-wave motility pattern, 1163
etiology, 1162–1164
incidence, 1161–1162, 1162t
treatment, 1167
D-lactic acidosis, 209
DNA mismatch repair (MMR) system, 1095
DNA repair mechanisms, 278
Dobutamine, 163
Docetaxel (taxotere), 280t, 1325
Donate after cardiac death (DCD), 543, 552, 595–596
Donor Risk Index, 615
Donors
deceased, 543, 543f
kidneys, 544
living, 542–543
nephrectomy, 545, 546f
Donor specific antibody (DSA), 523, 619
Dopamine, 162–163
Dopamine agonists (DAs), for prolactinomas, 1412, 1412t
Doppler angle, 1586
Doppler equation, 1586
Doppler-guided transanal hemorrhoid devascularization, 1180
Doppler ultrasound, 1585–1586. *See also* Ultrasonography (US)
Dose-limiting toxicity, 2018
Double-balloon enteroscopy (DBE)
GI bleeding, 1070
small bowel tumors, 829–830
Double-contrast barium enema, for colorectal cancer, 1128
Double-lumen endotracheal tubes, 1461
Double-outlet right ventricle (DORV), 1485, 1487
Downstream arterial blood cultures, 1773
Doxorubicin, 280t, 735, 1325
Doxycycline, 1735
Dreyfus model, for skill development, 4, 5t
levels of skill development, 4
self-regulated learning and, 5
advanced beginner, 6
competent level, 6
expert level, 6
novice learner, 5–6
proficient level, 6
Dried plasma (DP), 347

Driving laws
drunken, 470
junior/safe, 470
Drug-eluting stent (DES), 300
Drug-induced liver injury, 940
Drug poisoning deaths, 340f
Dual antiplatelet therapy, 300
Ductal adenocarcinomas, pancreatic, 881–882, 882f
Ductal carcinoma in situ (DCIS), 1312–1313, 1312f, 1313t, 1314f. *See also* Breast cancer
DCIS Recurrence Score, 1313
diagnosis, 1312
imaging studies, 1312
incidence, 1312
recurrence, 1313
treatment, 1312–1313
Ductal hyperplasia, 1304–1305
Duct of Santorini, 851
Duct of Wirsung, 851, 1878, 1879f, 1926f
Duhamel procedure (Martin modification), 1900–1901, 1900f
Dumping, 735
Dunphy sign, 1200t
Duodenal atresia, 1876
Duodenal injuries, 416. *See also* Abdominal trauma
Duodenal obstruction, congenital
anatomy, 1878–1879, 1880f
annular pancreas and, 1879f
causes of, 1878
clinical presentation, 1879
diagnosis, 1880, 1880f
duodenoduodenostomy in, 1881, 1881f
embryology, 1878–1879, 1879f
results and outcome, 1881
treatment, 1880–1881
Duodenal preserving pancreatic head resection (DPPHR), 875
Duodenal stenosis, 874
Duodenal stenting, 854
Duodenal ulcer, 728, 770
Duodenoduodenostomy, 1881, 1881f
Duodenum, 770–771, 772f
anatomy, 418
arterial blood supply, 771f
epidemiology, 418
obstruction

congenital, 1878–1881, 1879f, 1880f
treatment, 418–419, 418f
Duplex ultrasonography (DUS), 1624
criteria for carotid artery stenosis, 1625t
for vascular infection, 1612
for vascular trauma, 436
Duroziez sign, 1510
Dutch Gastric Cancer Lymphadenectomy, 275
Duvernoy glands, 498
Dysejaculation syndrome, 1243
Dysfibrinogenemia, 79
Dyslipidemia, and coronary artery disease, 1522
Dyspepsia, 755
Dysphagia, 661, 756
Dysphagia lusoria, 1342, 1497
Dysplasia, 755, 1095–1096, 1097f
development of, 669t
Dysplasia-associated mass/lesions (DALM), 1087
Dyspnea, 303
Dysrhythmias, 173–174

E

Eagle–Barrett syndrome, 1945
Early goal-directed therapy (EGDT) study, 187
Eastern Association for the Surgery of Trauma (EAST), 354, 389, 419, 460
guidelines for pregnant female, 484
Eastern Association for Trauma (EAST), 477
Echinococcal cysts, 1283
Echinococcal infection, 931–933, 932f
Echinococcus granulosus, 1283
Echocardiography
for pericardial disease, 1576
for pericardial effusion and tamponade, 1578–1579, 1578f, 1579f
Eck fistula, 962, 962f
Eclampsia, in pregnancy, 485
Ectasia, aortic, 1732
Ectopia cordis, 1871
Ectopic kidney, 1934
Ectopic spleen, 1284
Ectopic ureter, 1936, 1936f
Ectropion, 233
Edoxaban, 1781
Ehlers–Danlos syndrome, 1874, 1875

and thoracic aneurysms, 1565, 1565t
Eicosanoids, 110
Eicosapentaenoic acid (EPA), 1106
EKOS ultrasound accelerated catheter, 1782
Elapidae family (snakes), 496
Elastinolysis, 75
Elder Assessment Instrument (EAI), 475
Elderly abuse, 475. *See also* Geriatric trauma
Elderly, burn injury in, 214–215
Elective surgery, 253
Electrical burns, 215–216
Electrical exposure, 216
Electrocardiogram (ECG), 149, 292, 1524, 1525f
Electrolyte abnormalities, 221–222
Electrolyte exchange, 197–198
Electrolytes, 164. *See also* Fluid and electrolyte therapy
calcium
hypercalcemia, 205, 206t
hypocalcemia, 206, 207t
daily requirements of, 24t
definition, 201
magnesium
hypermagnesemia, 207
hypomagnesemia, 207
potassium
hyperkalemia, 204, 204f
hypokalemia, 204–205, 204t
role of, 23
sodium and water
cerebral salt wasting (CSW), 202
hypernatremia, 203, 203f, 203t
hyponatremia, 202
pseudohyponatremia, 202
syndrome of inappropriate antidiuretic hormone (SiADH), 202
Electrolyte therapy. *See* Fluid and electrolyte therapy
Elephant ear skin tags, Crohn disease, 811, 811f
Elephant trunk technique, 1723, 1724f, 1725, 1728
Elevated procoagulant factors, 80
ELISA test, 77
Eltrombopag, 1274
Embolic protection devices (EPDs), 1630, 1631f
Embolism, 1623
Emergency care, burns, 218–219, 219t

airway assessment, 219
fluid resuscitation, 219–220
resuscitation of patients, 220
Emergency medical services (EMS), 352, 459
Emergency medical technicians (EMT), 352
levels of, 352
and tension pneumothorax patient, 353
Empyemas, 1469–1470, 1470t, 1865–1867, 1866f
Endarterectomy, 1682–1683
End-diastolic velocity (EDV), 1588, 1600, 1624, 1624f
Endobronchial stents, 1463
Endocrine issues in ICU, 186–187
Endografting, as bridge therapy, 1614
Endoleaks, 1742f
definition of, 1741
types of, 1741, 1742f
Endoluminal stent grafts, 1606, 1606f
Endomucosal resection (EMR), of sessile polyp, 1102, 1103f
Endopeptidase, 779, 846
Endoplasmic reticulum (ER) stress response, 48
Endorectal ultrasound, for rectal cancer staging, 1138, 1138f
Endoscopic balloon dilation, of bile duct strictures, 1025–1026, 1027t
Endoscopic component separation, 1249–1250
Endoscopic mucosal resection (EMR), 760
Endoscopic retrograde cholangiopancreatography (ERCP), 135, 469, 557
CBD stones, 1008–1009
chronic pancreatitis, 872, 873, 873t
pancreatic cancer, 887, 887f
pancreatic disease, 857–858
Endoscopic sclerotherapy (ES), for prevention of variceal bleeding, 959
Endoscopic snare polypectomy, 1093f, 1102
Endoscopic submucosal dissection (ESD), 760
Endoscopic ultrasound (EUS), 690
chronic pancreatitis, 872, 873, 873t
pancreatic cancer, 887–888, 888f
pancreatic disease, 857
pancreatic endocrine neoplasms, 904, 904f
Endoscopic variceal ligation (EVL), 959, 960f
Endoscopy
Crohn disease, 814, 814f
for diverticular disease, 1167
ulcerative colitis, 1085
Endostim, 683

Endotension, 1741
Endothelin-1, 945
Endothelins, 197
Endotracheal tubes (ETT), 362, 457
Endovascular stent grafts, 1569
Endovenous thermal ablation, 1792
End-stage heart failure and cardiac transplantation, 576
End-stage renal disease (ESRD), 609
End-tidal carbon dioxide ($EtCO_2$), 367
End-to-end anastomosis (EEA), 707
Energy
  body fuels and, 22–23, 22t
  energy value of various sources, 22, 22t
  measurement of, 21–22
  production of, 21, 21f
  requirements for ambulation, 1706, 1706t
  sources, 181–182
Enhanced Recovery After Surgery (ERAS), 1059, 1132
Entamoeba histolytica, 1918
Enteral nutrition, 32, 33, 182
  acute pancreatitis, 865
  administration routes, 37–38
  benefits of, 34–35
  commonly used formulations, 36t
  complications related to, 35, 35t
  considerations, 34–36
  contraindications to, 35
  early, delivery of, 182–183
  hydrolyzed/monomeric, 35
  intact/polymeric, 35
  modular, 35–36
  timing of initiation of, 35
Entereg™, 802
Enteric duplication, 1911, 1912f
  cysts, 1851, 1851f
Enterochromaffin-like (ECL) cells, 766
Enterocutaneous fistulas, and nutritional support, 39
Entero-enteric-colonic fistula, 817–818, 818f
Enterogenous cysts, 1851, 1851f
Enteroglucagon, 774
Enterohepatic circulation, 997
Enterokinase, 846
Enteroscopy, in GI bleeding, 1069–1070

Envenomation, 496–514. *See also* Environmental injuries
Environmental injuries, 496–514
  asp caterpillars, 504–505
  black widow spiders, 503
  brown recluse, 503
  centipedes and millipedes, 504
  cold injury and frostbite, 511–514
  fire ants, 504
  hymenoptera, 503
  hypothermia, 505–511, 505t, 506f
  insect bites and stings, 502
  killer bees, 503–504
  scorpions, 504
  snakebite, 496–502, 497f, 497t, 498f, 498t, 499f, 501f, 502f
  spiders, 502–503, 503f
  venomous lizards, 502
Environmental interventions and obesity, 740
Environment, role of, in obesity, 43, 43f
Eosinophils
  activation, 97–98
  granules, 98
  recruitment, 97–98
Epidermal growth factor (EGF), 59
Epidermoid cancer, of anal canal, 1195–1196, 1196f
Epidermoid cysts, 1404
Epidural hematomas, 371
  acute, 364
  head injury and, 371
Epidural techniques, 247
Epigastric hernias, 1246
Epigastric pain, 765
Epiglottitis, 1843
Epinephrine, 163, 1387
Epiphora, 378
Epirubicin, 1325
Episcleritis, ulcerative colitis and, 1083
e-aminocaproic acid, 347, 348, 1535
Epstein–Barr virus (EBV), 520, 551, 620, 639, 938–939
Eptifibatide (Integrilin), 1527
Ertapenem, 1131
Erysipelas, 138
Erythema nodosum, ulcerative colitis and, 1084, 1084f
Erythrocytes

glycolysis in, 10
senescent, 1267
Erythrocyte sedimentation rate (ESR), vascular infections and, 1611
Erythromycin, 804
Escherichia coli, 1056, 1085, 1913
Escin, 802
E-selectin, 73
Esophageal atresia, 1855
anatomy, 1856f
associated anomalies, 1856–1857
classification, 1855, 1856f
clinical findings, 1856
complications, 1858–1859
diagnosis, 1856
embryology, 1855
epidemiology, 1855
incidence, 1855
outcomes, 1858–1859
pathophysiology, 1856
preoperative management, 1857
results, 1858–1859
surgical technique, 1857–1858, 1857f, 1858f
tracheoesophageal fistula with, 1858
traction sutures, 1858f
Esophageal body motility, 656–657, 657f
Esophageal duplications, 1859, 1859f
Esophageal intubation, 356
Esophageal symptoms (ES), 654
Esophageal varices, 957–958
and bleeding, 958, 958t
diagnosis, 958
management of bleeding, 959–962
prevention of bleeding, 958–959, 958t
Esophagectomy, 701
Ivor lewis, 701
thoracoabdominal approach, 701, 703
three-field, 701
transhiatal, 701, 702f
Esophagitis, modified Los Angeles classification, 671t
Esophagogastric junction (EGJ), 699, 760
Esophagogastroduodenoscopy (EGD), 695
Crohn disease, 814, 814f
GI bleeding, 1068, 1068t, 1069t

vascular infection, 1613
Esophagus, 687–710, 688f
abdominal, 645, 645f, 646f
acute caustic injury, 694t
anatomy and function, 644–648, 645f
benign neoplasms, 695–697, 696f, 696t, 697f
blood supply, lymphatics, and innervation, 646–648, 647f, 648f, 649f, 650f
cancer, 709–710
diagnostic evaluation, 690
dysmotility, 1859
evaluation of, 653–659
ambulatory pH monitoring, 657–659, 658f, 658t
endoscopic examination, 654, 655f
Esophagus (*continued*)
manometry, 654–657, 655f
radiographic evaluation, 653–654
foreign bodies in, 1909
future prospects of, 683
injury
clinical features, 688
diagnosis, 688–689
management, 689–690, 689f
perforation, 687–688, 688t
malignant neoplasms, 697–701
Meckel diverticulum, 1909
neck injuries and, 391–392
operative management, 701–709, 704f, 707f, 709f
patient selection, 690
physiology, 648–653
poststent management, 691–693, 692f
caustic injury, 693
foreign body, 695
management, 693–695, 694f
operative considerations, 695
stent, 690
placement technique, 690–691
selection, 690
surgical considerations, 701
swallowing mechanism, 648–651, 650f
thoracic, 644–645
tracheomalacia, 1859
wall and mucosa, 646, 646f
Essential amino acids, 181

Essential fatty acids, 1106
Estimated posttransplant survival (EPTS), 543
Estrogen-Plus-Progestin study, 1309
Estrogen–progestin therapy (EPT), 1309
Ethanol, 1072
Ethanolamine oleate, 1072
Ethanol intoxication, 209
Ethnicity, 215
Etomidate, 187, 355
  in Cushing disease, 1414t
Euro-Collins solution, 594
European Association for the Study of the Liver (EASL), 307
European Neuroendocrine Tumor Society (ENETS), 831
European Organisation for Research and Treatment of Cancer (EORTC), 893, 2000, 2021
Evaporation through skin, 198
Everolimus, 522
  insulinoma, 906
Evidence-based critical care, 168, 169t
Evidence base for patient safety, 326–327, 327t
Excess weight lost (EWL), 744
Exchange transfusion, 1823
Excision and grafting, 223–226
Exemestane, 1325
Exenatide (Byetta), 741
Exercise stress testing, 300
Exopeptidases, 846
Expanded criteria donors (ECD), 544
Exstrophy–epispadias complex, 1939, 1939f
Extended FAST (eFAST), 394
External anal sphincter, 1172, 1173–1174, 1173f
External beam radiotherapy, 279
  thyroid cancer, 1356
External carotid artery (ECA), 1590
Extra-anatomic bypass, 1683, 1683f
Extracapsular fractures, 453
Extracardiac obstructive shock, 151
Extracellular fluid (ECF), 19, 20f
Extracellular fluid compartments, 193t
Extracellular matrix (ECM), 58, 59, 59f
Extracorporeal life support (ECLS), 441, 1540, 1549–1551
Extracorporeal membrane oxygenation (ECMO), 177, 329, 400, 538, 577, 589, 592, 1540, 1848
  in CDH, 1863

ex utero intrapartum treatment and, 1833–1834
Extracorporeal shock wave lithotripsy, 1000
Extracorporeal shock wave treatment (ESWT), 232
Extracorporeal ventricular assist device (VAD), 1540
Extrahepatic cholangiocarcioma (ECC). *See* Bile duct carcinomas
Extrapleural pneumonectomy (EPP), 1470
Extremity treatment, 227
Ex utero intrapartum treatment (EXIT), 1827, 1833–1834, 1848
Ex vivo lung perfusion (EVLP), 595

F

Factor V Leiden, 72, 78, 78t, 79
Familial adenomatous polyposis (FAP), 269, 828, 1094, 1109–1113, 1109f, 1121, 1129
APC gene, mutation in, 1110, 1110f
desmoid tumors in, 1111
diagnosis, 1112–1113
extraintestinal manifestations, 1110–1111, 1111f
gastrointestinal features, 1110
genetic basis, 1111–1112, 1112f
management, 1113
Spigelman classification for duodenal adenomas, 1110, 1110t
Familial adenomatous polyposis (FAP) syndrome, 1968
Familial adenomatous polyposis variants, 1113–1115
Familial cancer syndromes, 266, 268t
Familial gastric cancer, 269
Familial hemolytic anemia. *See* Hereditary spherocytosis
Familial hypocalciuric hypercalcemia, 1367
Familial thoracic aortic aneurysms and dissections (FTAAD), 1565
Family involvement, patient and, 330–331
FAMMM syndrome, 1992
Fat, 181
digestion and absorption, 779–780
oxidation, 181
Fatty acids, 181. *See also* Lipids
long-chain, 22–23
medium-chain, 22
metabolism, 11–13, 12f
n-3 to n-6, in critically illness, 37
short-chain, 22
wound healing, effect on, 63
Fecal biomarkers, for intestinal inflammation, 815
Fecal fat test, 847
Fecal immunochemical tests (FITs), for colorectal cancer, 1126

Fecal incontinence, 1189–1192
  evaluation, 1190
  management, 1191–1192
    artificial bowel sphincter, 1192, 1192f
    biofeedback, 1191
    bulking agent, injection of, 1192
    overlapping sphincteroplasty, 1192, 1192f
    radiofrequency treatment, 1192
    sacral nerve stimulation, 1192
Fecal occult blood tests (FOBTs), 1100–1101, 1101f
  for colorectal cancer, 1126
Feeding jejunostomies, 38
Felty syndrome. *See* Autoimmune neutropenia
Femoral aneurysms, 1232
Femoral artery aneurysms
  clinical manifestations, 1769
  degenerative, 1769
    classification, 1769
    incidence, 1769
    types, 1769
  diagnosis, 1769
  history, 1769
  results, 1770
  surgical strategy, 1770
  treatment, 1769–1770
Femoral artery pseudoaneurysms, 1610
Femoral hernias, 1240, 1873. *See also* Groin hernias
Femoral pseudoaneurysms, 1771
  computed tomography scan, 1773f
  diagnosis, 1771
  history, 1771–1772
  incidence, 1771
  management, 1772f
  pathogenesis, 1771
  results, 1772
  treatment, 1772
Femoral trauma, 439
Femoral vein, use of, for in situ reconstruction, 1616–1617
Femur fractures, 448
Fenfluramine, 740, 741
Fentanyl, 865
Ferritin, 18
Fetal circulation, 1808f

Fetal development
anatomy, 1976
appendicitis, 1981
imaging modalities, 1978–1979
intraoperative and postoperative, 1978f
monitoring, 1977
physiology, 1976
premature onset, 1976–1977
tocolysis, 1977
uterus enlargement, 1976f
Fetal heart rate (FHR), 482, 1977–1978
accelerations, 1978
Fetal heart variability, 1978f
Fetal hemoglobin (HbF), 1807
Fetal imaging, 1809
Fetal interventions, 1827
for amniotic band syndrome, 1834
EXIT–ECMO procedure, 1833–1834
imaging, 1827–1828
magnetic resonance imaging, 1828f
maternal–fetal risks, 1829
prenatal diagnoses, 1828
surgery for specific congenital anomalies, 1830–1833
surgical techniques, 1829–1830, 1830f
for twin-reversed arterial perfusion sequence, 1834
Fetal physiology
circulation, 1808f
ECMO II, 1814
fetal cardiac function, 1807–1808
fetal circulation, 1807
iatrogenic injury, 1816
interventions, 1809
lung development, 1806
morphogenesis, 1805
neonatal physiology, 1811
pediatric physiology, 1811
placental gas exchange, 1807
Fetal programming, 42
Fetal thermoneutrality, 1815
^{18}F-fluorodeoxyglucose (FDG), 698, 758
^{18}F-fluorodeoxyglucose positron emission topography (^{18}F-FDG-PET), for liver imaging, 977–978
Fiberoptic endoscopy, 756

Fibrin, 72
Fibrinolysis, 71–72
  abnormalities in, 81
  defective, 79
Fibrinopeptide A (FPA), 69
Fibrinopeptide B (FPB), 69
Fibroadenomas, 1305
Fibroblasts, role of, in wound healing, 58, 59, 59f
Fibrocystic breast disease, 1301
Fibrolipomas, 697, 697f
Fibromuscular dysplasia (FMD), 1632
  renovascular hypertension and, 1664, 1664f, 1667
Fibrosarcoma, 1852t, 1854
Fibrotest (LabCorp), 950
Fibrous dysplasia of rib, 1450, 1450f
Fibrovascular polyps, 697, 697f
Field triage decisions and early priorities, 342–344, 342t
Fight or flight response, 31
Final crossmatch, 542. *See also* Renal transplantation
Fine-needle aspiration (FNA), 1967, 1996, 2014
  thyroid, 1350–1351
Finney strictureplasty, 818
Fire ants, 504
Firearm deaths, 340f
Fistula, diverticular, 1164, 1169
FK506, 521
FKHR genes, 1963
Flail chests, 394
  pathophysiology of, 395f
Flame burns, 214, 215
Flank hernia, 1256
"Flaring" of costal margin, 1847
Flat epithelial atypia (FEA), 1306
Flaviviridae, 271
Flexible bronchoscopy, 1461
Flexible sigmoidoscopy, for colorectal cancer, 1126
Fluconazole, 550
Fluid. *See also* Fluid and electrolyte therapy
  losses, replacement of, 200–201, 201t
    intraoperative fluid therapy, 201
    postoperative fluid therapy and monitoring, 201
  management, 178
  responsiveness, assessment of, 171–173

resuscitation, 159, 219–220
Fluid and catheter treatment trial (FACTT), 178
Fluid and electrolyte therapy. *See also* Electrolytes; Shock
colloids, 159
crystalloids, 158–159
goals of, 199–200
additional electrolyte therapy, 200
maintenance electrolyte therapy, 200
maintenance fluid therapy, 200
parenteral solutions
albumin, 199
artificial oxygen carriers, 199
colloids, 199
crystalloids, 198–199, 198t
dextrans, 199
gelatin, 199
hetastarch, 199
resuscitative strategy, 159
Fluid balance. *See also* Body fluids; Fluid and electrolyte therapy
normal water/electrolyte exchange, 197–198
sodium concentration and water balance, 195
volume control, 195–197
baroreceptor function, 196
baroreceptor modulation of, 196
hormonal mediators of, 196–197
osmoreceptors, 196
Fluorodeoxyglucose positron emitting tomography (FDG-PET), 1837
for vascular infection, 1613
5-fluorouracil (5-FU), 735, 764, 1325
for colon cancer, 1135
in pancreatic cancer, 893–894
Foam sclerotherapy, 1792
Focal nodular hyperplasia (FNH), 980–981, 981f, 1916
Focused assessment with sonography in trauma (FAST), 344, 364, 394, 423
of pediatric trauma, 459
of pregnant women, 482
Fogarty catheter, 387
Folate, 780
Follicular thyroid carcinoma (FTC), 1352
Fondaparinux, 77, 1780
Food and Drug Administration (FDA), 1780, 2000
Food intake, regulation of, and body weight control, 44–45, 44f, 46f
Foramen of Morgagni hernia, 1865

Forced expiratory volume in 1 second (FEV_1), 1424–1425
Forced vital capacity (FVC), 590
Foreign bodies
  airway obstruction, 1843
  ingestion of, 1909
  Meckel diverticulum, 1909
  in pediatric patients, 1843
  tracheobronchial tree, 1860
Fostamatinib disodium, 1274
Fournier gangrene, 1183
Fowler–Stephens orchidopexy, 1942
$Foxp^{3+}$, 526
Fractalkine, 104
Fractionation, 278
Fractures, in elderly patients, 475–476
Frailty, 296–297, 297t
Framingham Heart Study, 739
Frank–Starling curve, 172
Frantz tumor, 884
Frederick Treves, 782
Fresh frozen plasma (FFP), 78, 344, 475
Frontal sinus injuries, 382
Frostbite, 216–217, 511–514, 513f, 513t
  classification of, 511t
  treatment, 512–514
Frostnip, 511
Fructose, 778
Fulminant colitis, ulcerative colitis and, 1087
Fulminant hepatic failure (FHF), 553, 557
Fulminant hepatitis, 939
Fulvestrant, 1325
Functional residual capacity (FRC), 156
Fundoplication
  creation of, 679–680
  fixation of, 680f
Furosemide, in ascites, 967

G

Gabexate mesylate, 865
Gail model, breast cancer risk assessment, 1310, 1311f
Gallbladder
  benign tumors of, 1047–1048
    adenomas, 1047

adenomyomatosis, 1047
clinical findings, 1047
diagnosis, 1047–1048
incidence, 1047
pathology, 1047
polyps and pseudotumors, 1047
treatment, 1048
dysmotility of, 997
filling, 997
function, 997
Gallbladder cancer, 1006, 1006f, 1033–1039
adjuvant therapy, 1038–1039
American Joint Committee on Cancer (AJCC) staging system, 1034, 1035t
clinical findings and diagnosis, 1034–1035, 1036f
follow-up after resection for, 1039
future issues, 1039
and gallstone disease, 1033
incidence, 1033
pathology and staging, 1034
prognosis, 1039
spread of, 1037
surgery, 1035
cholecystectomy with/without partial hepatectomy, 1036–1038
incidentally/laparoscopically discovered, 1038
staging laparoscopy, role of, 1035–1036
Gallstone ileus, 793–795, 795f, 1006
Gallstone pancreatitis, 1003
Gallstones, 997
and acute pancreatitis, 861, 861f
asymptomatic, 999
cholesterol, 998–999, 998f
disease related to, 1000
acalculous cholecystitis, 1002–1003
acute cholecystitis, 1000–1002
chronic cholecystitis, 1003
gallstone pancreatitis, 1003
formation, 997–998
natural history of, 1000t
pigment, 998, 998f, 999
in pregnancy, 1007
Gangrene, 786
Gangrenous cholecystitis, 1000
Gardner syndrome, 1113, 2011

Gastrectomy, bile duct injury during, 1017
Gastroesophageal reflux disease (GERD), 698
Gastric acid secretion, 718–722, 719f, 720f, 721f
Gastric adenocarcinoma, 759
  sporadic, 759
  treatment, 764f
Gastric anatomy and physiology, 712–724
Gastric antral vascular ectasia (GAVE) syndrome, 1077
Gastric artery aneurysm, 1660, 1661f
Gastric aspiration, in GI bleeding, 1068
Gastric band, 744, 744f, 747
Gastric bicarbonate production, 722
Gastric blood flow, 722–723
Gastric bypass, 742, 749
Gastric carcinoids, 766
Gastric function, assessment of, 675–676
Gastric inhibitory polypeptide (GIP), 849
Gastric lymphoma
  AJCC staging system, 760t
  clinical features, 765
  diagnosis, 765
  in Japan and Europe, 757f
  and lymphadenectomy, 762t
  lymph node locations and groupings, 763f
  MALT, 765
  non-MALT lymphoma, 765–766
  survival by stage, 759f
  symptoms and physical findings, 756t
  worldwide geographic variability in, 755f
Gastric metaplasia, 725
Gastric motility, 723–724
Gastric mucosa, 718
Gastric neoplasms, 754–767
  adenocarcinoma, 754–765
  gastric carcinoids, 766
  gastric lymphoma, 765–766
  GIST, 766–767
  surgical options for, 761f
Gastric outlet obstruction, 734, 734f
Gastric peptides, 716–718
Gastric remnant cancer, 756
Gastric silhouette, 757
Gastric smooth muscle, 723

Gastric sympathetic innervation, 715f
Gastric tonometry, 161
Gastric tube, creation of, 704–705, 705f
Gastric tube feeding, 182
Gastric ulcer, 734–735
  benign, 756, 756f
Gastric varices, 966
Gastrin, 716–718, 717f, 721, 773, 997
Gastrin 17, 717
Gastrin cells, 716, 716f
Gastrinoma, 900t, 906–908, 907f, 907t, 908f, 1379
  diagnosis of, 907
  in gastrinoma triangle, 907, 908f
  hypergastrinemia in, 907
  management, 908
  metastatic, 908
  resection, 908
  secretin stimulation test, 907, 907f
  symptoms of, 907, 907t
Gastritis, 755
  atrophic, 755
  chronic, 755
Gastroduodenal artery (GDA) aneurysm, 1661, 1661f
Gastroduodenal disease, Crohn disease and, 819
Gastroduodenal ulceration, 725–737
  diagnosis, 728
  epidemiology, 725
  pathophysiology, 725–728
  proton pump blockers, 728–729
Gastroepiploic artery aneurysm, 1660–1661
Gastroesophageal anastomosis, 707–708, 708f
Gastroesophageal barrier, 652–653, 652f
Gastroesophageal (GE) junction, 406
Gastroesophageal reflux disease (GERD), 666, 744
  anatomic alterations, 662–664, 663f, 664f
  antireflux barrier, 661
  clinical presentation, 660–661, 661f
  complications, 664–669, 664f, 665f
    laryngopharyngeal reflux, 666–667, 667f
    metaplastic and neoplastic complications, 667–668, 668f
    mucosal, 665–666, 665f
    respiratory, 666
  epidemiology, 659–660, 659f

future prospects of, 683
implication, 664
lower esophageal sphincter, 662
pulmonary transplantation and, 602–603
transient relaxation, 661–662
treatment, 670–683, 671t, 673f, 676f, 677f
Gastroesophageal varices, 1074
Gastrogastric fistula, 748
Gastrografin, 787, 1890
Gastrointestinal disorders, 1875–1914
Gastrointestinal (GI) hemorrhage, 1063–1078, 1909–1911, 1910t
causes of, 1063, 1076–1077
angiodysplastic lesions, 1077
aortoenteric fistula, 1077
Dieulafoy vascular malformation, 1077
endoscopic procedures, 1078
gastric antral vascular ectasia, 1077
Meckel diverticulum, 1078
small intestinal diverticulum, 1078
clinical presentation, 1063–1065
diagnostic approach, 1067, 1067f
abdominal scintigraphy, 1070, 1071f
colonoscopy, 1069
CT scanning, 1071
double–balloon enteroscopy, 1070
enteroscopy, 1069–1070
esophagogastroduodenoscopy, 1068, 1068t, 1069t
gastric aspiration, 1068
selective visceral arteriography, 1070, 1070f
wireless capsule endoscopy, 1070
evaluation and resuscitation, 1066–1067
graft infection and, 1611
lower, 1063, 1075–1077
colonic angiodysplasia, 1076
colonic diverticulosis, 1075–1076, 1075f
diagnostic approach, 1075
differential diagnosis, 1065t
ischemic colitis, 1077
patient characteristics, 1063
predictors of risk for, 1065t
prognostic factors, 1065–1066, 1066t
upper, 1063, 1064f
differential diagnosis, 1064t

gastroesophageal varices and, 1074
Mallory–Weiss tears and, 1074–1075
peptic ulcer disease and, 1071–1073
stress gastritis and, 1073–1074
Gastrointestinal stromal tumors (GIST), 696, 766–767, 766f, 835–836, 2024–2025
aggressive behavior in, 767t
diagnosis of, 835
Modified NIH–Fletcher GIST Risk Assessment Criteria, 836t
treatment, 835–836, 837f
Gastrointestinal Symptom Rating Scale, 682
Gastrointestinal tract, 1981
Gastrojejunal anastomotic ulcer, 748
Gastroschisis, 1870, 1871–1872, 1871f, 1872t
Gaucher disease, 1277, 1279–1280
G cells, 773
Gelatin, 199
Gelofusin, 199
Gemcitabine, in pancreatic cancer, 895–897
Gender
abdominal aortic aneurysms and, 1734–1735
and response to stress, 32
wound healing, effect on, 62–63
Genetic Cancer Syndromes, 2011
Genioplasty, 2059
Genitourinary system, pediatric, 1933–1946
Genitourinary trauma, 423–430
AAST organ injury scales, 425t
bladder injury, 428–429, 429f
renal injury in, 423–426
ureteral injury, 425–426, 427f
urethral injury, 429–430, 430f
Genome-wide association studies (GWAS), 42, 266
Geriatric patients
nutritional support for, 39
perioperative evaluation of, 295t
Geriatric syndromes, 477
Geriatric trauma, 473–479
AGS/BGS clinical practice guideline, 476t
assessing frailty, 477
cardiovascular and pulmonary physiology in, 474t
cardiovascular system, 473–474
comorbidity, 473–475
end-of-life care in, 478–479

evaluation and management, 477–478
functional outcomes, 478
gastrointestinal function, 474
hospice, 479
mechanisms and injury, 475–476
and medications, 474–475
mortality outcomes, 478
physiology, 473–475
preinjury anticoagulants, 475t
preinjury medications, 473–475
pulmonary, 474
renal and gastrointestinal, 474
renal function, 474
risk factors and warning signs, 476t
triage criteria for, 476–477
Germ cell tumors, 1404
of mediastinum, 1476, 1477f
Germinomas, 1407
Germline mutations, 756
Gerota fascia, 424, 771
Ghrelin, 45, 741
Ghrelin O-acyltransferase (GOAT), 45
Giant cell arteritis, and thoracic aneurysms, 1566
Giant cell carcinomas, pancreatic, 882
with osteoclast-like giant cells, 882
Giant colonic diverticulum, 1164, 1169
Giant condyloma acuminatum (Buschke–Lowenstein), 1193
Giant macroprolactinomas, 1405
Gibbs–Donnan equilibrium, 193
Gila monster *(Heloderma suspectum),* 502
Glasgow–Blatchford bleeding score (GBS), 1065, 1066t
Glasgow Coma Scale (GCS), 170, 348, 353, 362–363
in children, 459t
components of, 362
triage guide for head injury, 363f
Glidescope, 353
Glomerular filtration rate (GFR), 197, 307, 483, 520, 610, 1662, 1727–1728
Glucagon, 774, 840, 845, 848, 849
blood glucose levels, control of, 849
secretion and action, 849
as stress hormone, 849
Glucagon-like peptide 1 (GLP-1), 741
Glucagonoma, 900t, 909–910, 910f, 910t

Glucocorticoids, 121, 187, 522
  for wound healing, 65
Gluconeogenesis, 8, 10–11, 11f, 36
Glucose, 8, 16. *See also* Carbohydrate
Glucose control, 186–187, 222, 298
Glucose-dependent insulinotropic peptide (GIP), 774
Glucose-6-phosphate (G6P), 9, 9f, 15
Glucose 6-phosphate dehydrogenase (G6PD) deficiency, 1276
Glucuronidase, 999
Glucuronidation, 18
GLUT-1, 1915
Glutamic acid decarboxylase (GAD-65), 620
Glutamine, 36, 63, 182, 183
  supplementation, 36–37
  in wound healing, 63
Glutathione S-transferases, 18
GLUT-2 transporter, 849
Glycine-extended gastrin, 716
Glycogen, 9
Glycogenolysis, 9, 9f
Glycolysis, 9–10, 10f
  aerobic, 9
  anaerobic, 9
Glycoprotein IIb/IIIa inhibitors, 299t
GNRH agonists, for breast pain, 1302
Goblet cells, 772
Goiter, 1348–1349
Golgi apparatus, 779
Golimumab, in ulcerative colitis, 1086
Gonadotroph adenomas, 1404. *See also* Pituitary adenomas
Gonorrhea, anorectal, 1193
Goserelin, 1325
G-protein reaction, 521
Graft dysfunction, 547
Graft-enteric erosions, 1612
Grafting, 223–226
Graft thrombosis, 77
  graft infection and, 1611
Granules
  eosinophils, 98
  platelets, 99
Granulocyte-macrophage colony stimulating factor (GM-CSF), 87
Granulomatous hypophysitis, 1404

Granzymes, 95
Graves disease, 1346–1347
Graves ophthalmopathy, 1346
Grayscale image, in duplex ultrasonography, 1585
Greenstick fractures, 469
Groin dissection, technique of, 1999, 1999f
Groin hernias, 1229–1230, 1230f
  classification, 1230–1231
  clinical diagnosis, 1231–1232
  differential diagnosis, 1232, 1232t
  epidemiology, 1230, 1231f
  European Hernia Society classification, 1231, 1231t
  femoral, 1229
  inguinal, 1229, 1230, 1230f
  Nyhus classification of, 1231t
  in pediatric patients, 1240
  preoperative considerations, 1233
  surgical indications, 1232–1233
  surgical treatment, 1233
    intraperitoneal onlay mesh repair, 1240
    laparoscopic approach, 1237–1238
    open approach, 1233–1237
    preperitoneal approach, 1237
    totally extraperitoneal repair, 1238–1240
    transabdominal preperitoneal repair, 1238, 1239f
Groin pseudoaneurysms, 1606, 1606f
Group A streptococcus (GAS), 140
Growth hormone, excess levels of, 1406
Growth hormone-secreting adenomas, 1403. *See also* Pituitary adenomas
GSV surgery, 1793
Guanine nucleotide-binding proteins (GDP), 97
Guidelines for the Management of Pediatric Brain Injury, 366
Guidelines for the Management of Penetrating Brain Injury, 366
Guidelines for the Management of Severe Brain Injury, 361, 366
Guidelines for the Prehospital Care of Severe Brain Injury, 362
Guidelines for the Prehospital Management of Severe Brain Injury, 366
Guidelines for the Prehospital Management of Traumatic Brain Injury, 366
Guidelines for the Surgical Management of Traumatic Brain Injury, 366
Gunshot wound (GSW), 403
  CT scan of, 365
  and ureteral injuries, 425–426
Gut-associated lymphoid tissue (GALT), 775
Gut microflora, role of, in development of cirrhosis, 945

H

Haemophilus influenzae, 1284, 1287
Hageman factor (HF), 112
Hair removal, 143
Hairy cell leukemia, 1278–1279, 1278f
Haller index, 1454
Hamartoma, 1441
  lung, 1854
  spleen, 1283
Hamoudi tumors, 884
Hand antisepsis, surgical, 143
Hand ischemia, 1639
Harris–Benedict equation, 26, 26t
Hartford Consensus III, 352
Harvoni (ledipasvir and sofosbuvir), 947
Hashimoto thyroiditis, 1347
Hawthorne effect, 321
Head and neck, 629–642
  airway management, 630–631, 631f
  AJCC stage grouping, 639t
  cystic neck infections, 633–634
  differential diagnosis of, 630t
  hypopharynx, 640
  infectious, 631–632, 632f
  larynx, 640–641
  nasopharynx, 639
  neoplasms, 634–635
  oral cavity, 638–639
  oropharynx, 639–640, 640f
  pathology-specific concerns, 635–637
  patient evaluation, 629, 630f
  salivary, 635
  SCC, 638
  sialadenitis, 633
  sinonasal, 637–638
  sinusitis, 632
  subsites of, 630t
  surgery, complications, 642, 642t
  workup, 629–630
Head injuries, 360–373, 448
  ancillary imaging, 366
  biochemical and genomic processes, 361
  cerebral hypoperfusion and hypoxia, 361

in children, 459
clinical assessment, 362–363
computed tomography, 364–366
decompressive craniectomy, 373
epidemiology of, 360
Glasgow Coma Scale, 362–363
intracranial hypertension, 361, 369
management, 366–373
medical intervention, 369–370
neurocritical care in, 369
neuromonitoring, 368–369
pathophysiology of, 360–361
pediatric patients, 1837
airway obstruction, 1842–1843
congenital lesions of, 1837–1841
imaging for, 1837
vascular malformations of, 1841–1842
plain skull radiographs, 364
primary injury, 360–361
radiographic diagnosis, 363–366
secondary injury, 361
surgical intervention, 371–373
Healthcare Cost and Utilization Project (HCUP), 314
Heart, 532–533
procurement, 536–537, 578 (*see also* Cardiac transplantation)
Heart failure, nutritional support in, 38
HeartWare MVAD, 1557, 1558f
Heat-shock proteins (HSP), 92
Heat-shock transcriptional factors (HSF), 120
Hedgehog (Hh), 944
Heineke–Mikulicz method, 818
Heinz bodies, 1267
Helicobacter pylori, 717, 725–726, 1072
and adenocarcinoma, 755–756
infection and gastric cancer, 754
inflammatory responses, 727
virulence factors, 726t
HELLP (Hemolysis, Elevated liver enzymes, Low platelets) syndrome, 940
Hemangioendotheliomas, 1283, 1915–1916, 1915f
Hemangiomas, 1841–1842, 2066
hepatic, 980, 980f
of spleen, 1283
Hematochezia, 1063. *See also* Gastrointestinal (GI) hemorrhage

Hematocrit (HCT), 155, 200
Hematopoiesis, 1267
Hematuria, 423
Heme and porphyrin metabolism, 18, 19f
Heme oxygenase, 115
Hemiparesis, 363
Hemochromatosis of liver, 949
Hemodynamic monitoring, 221
  about, 171
  fluid responsiveness, assessment of, 171–173
  oxygen delivery and consumption, 170–171, 171t
Hemophilia A, 80, 81
Hemophilia B, 80
Hemophilus influenza, 1865
Hemoptysis, 1461–1462, 1463f
Hemorrhage, 1908
  control, 152, 346–347
  in Crohn disease, 819
  gastric bypass and, 747
  pediatric trauma and, 458
Hemorrhagic diverticular disease, 1164, 1167
Hemorrhagic shock, 488
Hemorrhoidectomy, excisional, 1179–1180, 1179f
Hemorrhoids, 1177–1181
  classification, 1178t
  clinical manifestations, 1178–1179
  in Crohn disease, 821, 821f
  external, 1177
  incarcerated, 1180–1181
  internal, 1177
  nonoperative management, 1178–1179, 1179f
  operative management, 1179–1180
    Doppler-guided transanal hemorrhoid devascularization, 1180
    excisional hemorrhoidectomy, 1179–1180, 1179f
    stapled hemorrhoidopexy, 1179, 1179f
  thrombosed external, 1180, 1181f
Hemostasis
  arterial *vs.* venous thrombosis, 75
  basic considerations, 69–71, 70f
  bleeding disorders
    coagulation factor deficiency, 80–81
    fibrinolysis, abnormalities in, 81
    platelet disorders, 81

rare factor deficiencies, 81
endothelium and, 72
fibrinolysis, 71–72
natural anticoagulant mechanisms, 71, 71f
primary, 70f
procoagulant states
acquired, 75–78
inherited, 78–80
thrombosis/inflammation
cell adhesion molecules, 72–74
leukocytes and thrombosis, 74–75
Hemostatic Resuscitation, 344
Hemothorax, 398
causes of, 398
retained, 398
Henderson–Hasselbalch equation, 208
Heparin, 77
Heparin-induced thrombocytopenia (HIT), 77–78, 1545, 1780
Hepatic adenoma (HA), 981, 982f, 1916
Hepatic arterial chemoembolization, 1970
Hepatic artery aneurysms, 1659, 1659f
Hepatic artery thrombosis, 569–570
Hepatic cysts, 978–979, 979f, 1916
Hepatic dysfunction
perioperative management, 306–307
preoperative evaluation, 306
risk stratification, 305–306
surgical considerations, 306
Hepatic encephalopathy, 953–954
ammonia, role of, 953
chronic, 954
clinical features, 953
etiology, 953
overt, 954
TIPS and, 962
treatment, 953–954, 953t
Hepatic fibrosis, 13
Hepatic flexure, 1052
Hepatic glycolysis, 16
Hepatic hydrothorax, 952
Hepatic infections, 1918
Hepatic neoplasms, 975
benign, 978–981

cystic lesions
biliary cystadenoma, 979, 980f
polycystic liver disease, 979, 979f
simple cyst, 978–979, 979f
future liver remnant (FLR), 975
laparoscopic approach for liver resection, 992
and liver transplantation, 975, 992
metastatic tumors
colorectal liver metastases, 984, 986–987
neuroendocrine tumors, 987
preoperative management, 987–989
portal flow modulation, 988–989
vascular anatomy, review of, 987, 987f
volume of FLR, 987–988
primary malignancies
hepatocellular carcinoma, 981–984, 983f, 984f, 985t–986t
intrahepatic cholangiocarcinoma, 984
solid lesions, 979
focal nodular hyperplasia, 980–981, 981f
hemangioma, 980, 980f
hepatic adenoma, 981, 982f
surgical technique
bile leak test, 991, 991f, 992t
bleeding, control of, 990–991, 991f
incision and exposure, 989–990, 989f
parenchymal transection, principles of, 990, 990f
staged surgery, 991–992
treatment selection, assessments for, 975–976
Couinaud segmental anatomy of liver, 977f
imaging studies, 977–978, 977f, 978f
laboratory tests, 976
screening for underlying liver disease, 976
status of hepatic functional reserve, stratification of, 976–977
tumor markers specific to, 976
Hepatic resection, bile duct injury during, 1017
Hepatic steatosis, 51
Hepatic stellate cells (HSCs), 944
Hepatic transplantation, 552–573, 1923
acute rejection, 573
antibody-mediated rejection, 571
cell-mediated rejection, 571–572, 572f
chronic rejection, 572
contraindications to, 553–554

disease-specific indications and outcomes, 554–558, 554f, 555f
immunosuppression induction, 572–573
indications for, 552–553
intracranial hemorrhage and, 554
King's college criteria for, 557t
MELD and PELD score, 553t
surgical procedure
anesthetic management, 558
anhepatic phase and implantation, 561–564, 561f, 562f, 564f, 565f
auxiliary liver transplantation, 568, 569f
complications, 568
hepatic artery thrombosis, 569–570
inferior vena cava stenosis, 570–571
intra-abdominal sepsis, 571
intraoperative management, 558–559
living donor liver transplantation, 566–568, 567f
neurologic complications, 571
portal vein thrombosis, 570
postoperative hemorrhage, 568–569
postrevascularization phase, 565
primary nonfunction, 568
recipient hepatectomy, 559–561, 560f
split liver transplantation, 565, 566f
surgical technique, 559, 559f
urgent listing criteria for, 553t
Hepatic tumors
diagnosis, 1968
epidemiology, 1967–1968
features, 1968
genetic risk, 1967–1968
pathology, 1968
presentation, 1968
staging, 1968
treatment, 1969–1970
Hepatic veins, obstruction of, 949–950
Hepatitis A virus (HAV), 933
clinical features, 933–934, 934f
epidemiology, 933
molecular structure, 933
risk factors for transmission, 933
treatment, 934
Hepatitis B early antigen (HBeAg), 935
Hepatitis B immune globulin, 936

Hepatitis B virus (HBV), 947
clinical features, 935, 935f
epidemiology, 935
molecular structure, 934
risk factors for transmission, 935
treatment, 935–936
Hepatitis B viruses (HBV), 271
Hepatitis C, 555
Hepatitis C virus (HCV), 271, 947–948
clinical features, 936–937, 936f
epidemiology, 936
molecular structure, 936
risk factors for transmission, 936
treatment, 937
Hepatitis D virus (HDV), 948
clinical features, 937, 937f, 938f
epidemiology, 937
molecular structure, 937
risk factors for transmission, 937
treatment and prevention, 937
Hepatitis E virus (HEV), 938, 938f
clinical features, 938
epidemiology, 938
treatment, 938
Hepatobiliary iminodiacetic acid (HIDA), 412
Hepatoblastomas, 556, 1916–1917
Hepatocellular carcinoma (HCC), 271, 552, 943, 981–984, 983f, 984f, 985t–986t, 1916f, 1917, 1970
Barcelona Clinic Liver Cancer (BCLC) staging system, 982, 983f
and hepatic malignancy, 556–557
Milan criteria, 982
screening measures for, 982
and TNM classification, 556t
treatment algorithm, 984f
Hepatolithiasis, 1012–1013
Hepatopulmonary syndrome (HPS), 553, 952
Hepatorenal syndrome (HRS), 554, 950–951
cirrhosis and, 951–952
diagnostic criteria for, 952t
and liver transplantation, 952
management, 952
manifestations, 951
prerenal azotemia and, 951, 951t

Herbal medicines, 298t
Hereditary breast and ovarian syndrome (HBOC), 269
Hereditary diffuse gastric cancer (HDGC), 269, 756
Hereditary elliptocytosis, 1276
Hereditary nonpolyposis colorectal cancer (HNPCC), 266–269, 268t, 269t
  and small bowel tumors, 828
Hereditary nonspherocytic hemolytic anemia, 1276
Hereditary spherocytosis, 1275–1276
Hereditary syndromes, 756. *See also* Adenocarcinoma
HER2 FISH assay, 1316
Hernias, 793, 793f, 794f
  abdominal wall, 1212–1259
  Bochdalek, 1861
  development of, 1224–1225
  epigastric, 1246
  femoral, 1240, 1873
  flank, 1256
  foramen of Morgagni, 1865
  groin, 1229–1240
  hernia accident, 1226
  hiatal, 672
  incarceration, 1226, 1226f
  incisional, 1246–1247
  inguinal, 793, 793f, 1873–1875, 1874f
  interparietal, 1255–1256
  and intestinal obstruction, 1226–1227, 1226f
  Littre, 1256
  lumbar, 1254, 1254t, 1255f
  massive, 1247
  mesocolic, 1894
  obturator, 1254–1255
  paraduodenal, 793, 794f
  parastomal, 1252–1254, 1252t, 1253f
  pediatric patients, 1873–1875
  perineal, 1257
  perivascular, 1257, 1257f
  prosthetic materials for repair of, 1227–1229, 1228t
  reduction of, by taxis, 1226, 1226f
  Richter, 793, 794f, 1227, 1227f
  sciatic, 1255, 1256f
  Spigelian, 1254
  sports, 1240–1241, 1240f
  strangulation of, 1227

supravesical, 1255, 1256f
umbilical and periumbilical, 1245–1246, 1246f, 1873
ventral abdominal wall, 1244–1245
Herniation, 361
clinical signs of, 366–367
transtentorial, 361
Hernia Wound Risk Assessment Tool (HW-RAT), 1258, 1258t
Herniorrhaphy, 1233
complications of, 1257t
Herniotomy, 1233
Herpes, anorectal, 1193
Herpes simplex virus (HSV), 939
Herpesvirus varicella. *See* Varicella zoster virus (VZV)
Hesselbach hernia, 1257
Hetastarch, 199
Heterotopic ossification (HO), 234–235
Heterotopic pancreas, 844
Heterozygous protein C deficiency, 78
Hexitols, 802
Hiatal dissection, 678
HIDA scan (biliary scintigraphy)
acalculous cholecystitis, 1002–1003
acute cholecystitis, 1000, 1001f
Hidradenitis suppurativa, 1184
High-density lipoprotein (HDL), 11, 1522
High-grade dysplasia (HGD), 654
Highly active antiretroviral therapy (HAART), 1194
High mobility group box 1 protein (HMGB1), 105–106
High-resolution impedance, 657
High-resolution manometry (HRM), 654
display, 676f
Hilar cholangiocarcinoma. *See* Bile duct carcinomas
Hinchey classification scheme, 134f
Hip disarticulation, 1713
Hirschsprung's disease
anatomy, 1896–1897
associated conditions, 1897
clinical features, 1897
complications, 1904
diagnosis, 1897–1899, 1898f, 1899f
embryology, 1896
outcome, 1904
pathophysiology, 1897

treatment, 1899–1904
Duhamel procedure (Martin modification), 1900–1901, 1900f
laparoscopically assisted endorectal pull-through, 1902, 1903f
rectal myectomy, 1902
Soave procedure, 1901–1902, 1901f
Swenson procedure, 1902, 1902f
total colonic aganglionosis, 1904
trisomy 21, 1876
Histamine, 718
Histamine-receptor antagonists, 728
Histidine–tryptophan–ketoglutarate (HTK), 615
HIV drugs, 299t
HIV infection and hepatic transplantation, 554
Hobo spiders *(Tegenaria agresis),* 503
Hodgkin lymphoma, 1854
Hollow viscous injury, in children, 469
Homocysteine elevation, 79
Hook effect, 1405
Horizontal Crucifixion, 447
Horseshoe kidneys, 1934
Hospital care, early, 344–345
Hospital Quality Incentive Demonstration (HQID), 321
Howell–Jolly bodies, 1267
Human epidermal growth factor receptor 2 (HER2), 1316, 1325
Human herpes virus 8 (HHV-8), 271
Human immunodeficiency virus (HIV), 524
Human leukocyte antigen (HLA), 541, 542, 577
Human papilloma virus (HPV), 271, 1193
Human solid organ cancers, 270t
Human tumor–associated viruses, 271
Humoral hypercalcemia of malignancy, 1366
Hungry bone syndrome, 206
Hürthle cell carcinoma (HCC), 1352
Hydatid cyst, 1283
Hydatid disease. *See* Echinococcal infection
Hydrocele, 1232, 1875
communicating, 1874f, 1875
of scrotum, 1874f
Hydrocephalus, 1874
Hydrofluoric acid, causing burn, 216
Hydrogen sulfide, 115
Hydronephrosis, 1934
Hydrophidae family (snakes), 496

17-hydroxycorticosteroids, 1385
Hydroxyethyl starch (HES), 159, 199
5-hydroxytryptamine, 802
25-hydroxyvitamin D, 751
Hymenoptera, 503
Hypaque®, 787
Hyperacute rejection, 522–523, 571. *See also* Solid organ transplant
Hyperaldosteronism, 1389–1391
  diagnosis, 1390–1391, 1391f
  primary, 1390
  secondary, 1390
  signs and symptoms, 1390
  treatment, 1391
Hyperamylasemia, 848, 848t
Hyperbaric oxygen (HBO) therapy, 790
Hyperbilirubinemia, 1822
Hypercalcemia, 205, 1365–1368
  causes, 1367t
  causes of, 206t
  clinical manifestations, 1365–1366, 1367t
  differential diagnosis, 206t, 1366
  etiology
    familial hypocalciuric hypercalcemia, 1367
    hyperparathyroidism, 1366
    hyperthyroidism, 1367
    immobilization, 1367
    malignancy, 1366–1367
    milk–alkali syndrome, 1367
    other causes, 1367–1368
    sarcoidosis, 1367
    thiazide diuretics, 1367
    vitamins A and D excess, 1367
  medical treatment, 1368
  signs and symptoms of, 206t
Hypercalcemic crisis, 1377–1378
Hypercoagulability testing, 77
Hypercortisolemia, 1405–1406. *See also* Cushing syndrome
Hypercortisolism, 1388–1389, 1389f
  diagnosis, 1388–1389, 1389f
  signs and symptoms, 1388
  treatment, 1389
Hyperfibrinolysis and traumatic coagulopathy, 489
Hypergastrinemia, 722, 766

Hyperglycemia, 186
in surgical patients, 29, 34
Hyperhomocysteinemia, 79
Hyperkalemia, 204, 204f
Hypermagnesemia, 207
Hypermetabolism, 218
Hypernatremia, 203, 203t, 222
Hyperosmolar states, 195
Hyperparathyroidism, 1370–1378, 1380
asymptomatic, 1374–1375
etiology, 1370
gastrointestinal manifestations, 1372
and hypercalcemia, 1366
hypercalcemic crisis, 1377–1378
imaging techniques, 1373–1374, 1374f
incidence, 1370, 1370t
laboratory findings, 1373
bicarbonate, 1373
calcium, 1373
magnesium, 1373
other tests, 1373
parathyroid hormone, 1373, 1373f
phosphate, 1373
neonatal, 1378
neuromuscular manifestations, 1372
pathology
parathyroid adenoma, 1371, 1371f
parathyroid carcinoma, 1371
parathyroid hyperplasia, 1371, 1371f
persistent, 1377, 1377f
physical findings, 1373
in pregnancy, 1378
primary, 1370
psychological manifestations, 1372
renal manifestations, 1372
secondary, 1370, 1378
skeletal manifestations, 1372, 1372f
systemic effects, 1371–1372
tertiary, 1370
treatment, 1374–1377
extent of resection, 1376
indications for surgery, 1374
limited surgical exploration, 1376

parathyroid autotransplantation, 1377
principles of surgical correction, 1375–1376, 1375f
Hyperplastic polyps (HPs), 755, 1093, 1096, 1106, 1106f
Hyperprolactinemia, 1405, 1405t
Hyperresuscitation, 308
Hypersplenism, 1267, 1268, 1277–1279
causes, 1268t
criteria for, 1268
Hypertension (HTN), 249, 1662–1667. *See also* Renovascular hypertension (RVH)
and heart disease, 1522
in hyperparathyroidism, 1372
pheochromocytoma and, 1394
Hyperthermic intraperitoneal chemotherapy (HIPEC), 1153–1154, 1208
Hyperthyroidism, 1346–1347
and hypercalcemia, 1367
Hypertonic saline solutions (HTS), 198–199
Hypertrophic scarring, 229–230
Hyperventilation, 354
Hypnotics, 242–243
Hypoadrenal shock, 153
Hypocalcemia, 164, 206, 1368–1370
causes, 1368, 1369t
hypomagnesemia, 1369
idiopathic hypoparathyroidism, 1369
other causes, 1369
postoperative hypoparathyroidism, 1368–1369
pseudohypoparathyroidism, 1369
vitamin D deficiency, 1369
causes of, 207t
clinical features, 1368, 1369t
clinical manifestations of, 207t
treatment, 1369–1370, 1370t
Hypocapnia, 483
Hypochlorhydria, acute, 727
Hypochlorous acid (HOCl), 89
Hypoglycemia, 1822, 1928–1929, 1928f
Hypokalemia, 204–205
causes of, 204t
Hypomagnesemia, 207
Hyponatremia, 198, 202, 222, 1405
symptoms of, 203t
Hypoosmolar states, 195
Hypoperfusion, 1623

Hypopharynx, 640
Hypopituitarism, 1405
Hypoplastic aortic syndrome, 1675
Hypoplastic left-heart syndrome (HLHS), 1500f, 1501
Hypoplastic right heart syndrome, 1834
Hypospadias, 1940–1941, 1940f, 1941f
Hyposplenism, 1267–1268, 1268t
  causes, 1267, 1268t
  diagnosis, 1267
  pathophysiologic consequences, 1267–1268, 1268t
  splenectomy and, 1286–1287
Hypotension and head injury, 361
Hypothalamic feeding center (HFC), 43
Hypothalamic–pituitary–adrenal (HPA) axis, 1385, 1976
Hypothenar hammer syndrome, 1639
Hypothermia, 157–158, 258, 505–511, 505t, 506f, 507f. *See also* Environmental injuries
  cardiovascular response and, 506
  cause of, 488
  and physiologic response, 506
  in trauma patients, 488, 508–510
  zones of severity for, 509t
Hypothermic circulatory arrest (HCA), 1562, 1569
Hypothyroidism, 1347
Hypovolemia, physiologic response to, 153, 153f
Hypovolemic shock, 149
Hypoxia, 211
Hypoxia and head injury, 361
Hypoxia-inducible factor (HIF), 59
Hypoxia-inducible factor-1 alpha (HIF-1a), 75
Hypoxic cells, 161

I

Iatrogenic splenectomy, 1269, 1280–1281
Ibuprofen, for wound healing, 65
Icodextrin, 791
Idarucizumab, 475
Idiopathic breast pain. *See* Breast pain
Idiopathic intrauterine growth restriction (IUGR), 1807
Idiopathic pulmonary fibrosis (IPF), 589–590, 666
Ifosfamide, 2020
IGF1 (somatomedin C), 1406
Iiopubic tract, 1220, 1220f
Ileal artery aneurysm, 1661

Ileal pouch-anal anastomosis (IPAA), 1089–1090, 1089f, 1090f
Ileo-anal pouch, in Crohn disease, 820
Ileus, 782
  and bowel obstruction, 782–804
    historical perspective, 782
  diagnosis, 800–801, 800f, 800t
  etiologic factors, 799–800
  management, 801–802, 801t
  prevent prolongation of, 802t
Iliococcygeus muscle, 1053
Iliofemoral venous thrombectomy, 1782
Iliopectineal arch, 1220
Iloprost, 512
IL-2 receptor blockade, 520
Imatinib (Gleevec), 767, 2021, 2025
  gastrointestinal stromal tumor, 836
Immediate Postconcussion Assessment and Cognitive Testing Battery (ImPACT), 461
Immune thrombocytopenic purpura (ITP), 1273–1274
  splenectomy for, 1274, 1274t
Immunitrition, delivery of, 183
Immunity, innate *vs.* adaptive, 87
Immunodeletion, 526
Immunoglobulin E (IgE), 775
Immunologic anergy and exhaustion, 526
Immunomodulators, in Crohn disease, 816t, 817
Immunonutrition, 182
Immunoreceptor tyrosine activation motif (ITAM), 88
Immunosuppressive therapy, 298, 581. *See also* Cardiac transplantation
Impedance plethysmography (IPG), 1602–1603
Impella left ventricular assist device, 1552, 1553f
Imperforate anus
  anatomy, 1882–1883, 1882f
  anomalies in infants, 1883
  classification, 1882–1883, 1883f, 1883t, 1884f
  clinical presentation, 1883–1884
  complications, 1885
  diagnosis, 1884–1885
  embryology, 1881–1882, 1881f
  outcome, 1885
  results, 1885
  treatment, 1885

Imperforate hymen, 1945, 1945f
Implantable cardiac defibrillator (ICD), 1545–1546
Implant-based techniques, 2037
Improvised explosive devices (IED), 346, 355
Incarcerated hemorrhoids, 1180–1181
Incarceration, 1874
Incidental adrenal mass, 1396–1398
  diagnosis, 1396–1398, 1397f, 1397t
  treatment, 1398
Incidental splenectomy, 1269, 1280
Incisional hernias, 1246–1247
  European Hernia Society classification, 1245t
  Ventral Hernia Working Group (VHWG) classification, 1245t
Incretins, 752
Indian Hedgehog (IHh), 944
Indirect calorimetry, 26, 32
Inducible nitric oxide synthetase (iNOS), 799
Induction immunosuppression, 520
Infantile hemangiomas (IH), 1841–1842
Infantile hypertrophic pyloric stenosis
  anatomy, 1904
  clinical presentation, 1904
  diagnosis, 1904–1905, 1904f
  pathophysiology, 1904
  Ramstedt pyloromyotomy for, 1905f
  treatment, 1905
Infantile polycystic kidney disease, 1934
Infected aneurysms, 1609
Infected aortitis, 1609
Infections
  hepatic, 1918
  metabolic changes after, 30–31
  nutritional support in, 38
Inferior lumbar (Petit) triangle, 1218, 1218f
Inferior mesenteric artery (IMA), 1054, 1088
  aneurysm, 1661–1662
Inferior mesenteric vein (IMV), 424, 853, 954, 1055
Inferior pedicle technique, 2044f
Inferior thyroid artery (ITA), 1341
Inferior vena cava (IVC), 158, 433
  filter, 180
  leiomyosarcoma, 2023, 2023f
  stenosis, 570–571

Infiltrating lobular carcinomas (ILCs), 1315–1316. *See also* Breast cancer
Inflammation, 86–122, 799–800
  autophagy, 118–119
  cellular components
    basophils and mast cells, 98
    eosinophils, 97–98
    lymphocytes, 94–97
    mononuclear phagocytes, 93–94
    neutrophils, 87–93
    platelets, 98–99, 99t
  innate *vs.* adaptive immunity, 87
  noncellular components
    complement system, 108–110
    cytokines, 99–101, 100t–101t
    early cytokines/innate immunity, 101–107
    late cytokines/adaptive immunity, 107–108
    lipid mediators, 110–112
  platelet-activating factor (PAF)
    heme oxygenase, 115
    hydrogen sulfide, 115
    kinins, 112–113
    neuropeptides, 113–114
    nitric oxide, 114–115
  recognition and activation processes
    danger-associated molecular patterns (DAMP), 115–116
    exogenous/endogenous danger recognition, 115
    receptors for danger recognition, 116–118
  stress response, 119–120
    acute-phase response, 120–121
    chronic inflammation, 122
    reperfusion injury, 121–122
    systemic inflammatory response syndrome (SIRS), 122
Inflammatory bowel disease (IBD), 76
Inflammatory breast cancer (IBC), 1327–1328
Inflammatory mucosal polyps, 1107, 1107f
Inflammatory pseudotumors, 1854
  in spleen, 1283
Infliximab
  in Crohn anal fistulas, 1185
  in ulcerative colitis, 1086
Infrainguinal arterial occlusive disease
  autogenous vein bypass for, 1696–1698
  complications, 1701

diagnosis, 1689–1690, 1690f
endovascular therapy for, 1692–1694
epidemiology, 1687
graft failure and surveillance, 1700–1701, 1701f
medical treatment, 1690–1701
natural history, 1687, 1689
nonreversed saphenous vein grafts, 1698
operative management, 1694–1696, 1694f, 1695f, 1696f
postreconstruction management, 1700
presentation, 1687, 1689
prosthetic bypass for, 1698–1699
reoperative bypass surgery for, 1699–1700, 1700f
revascularization
approach to, 1691–1692
indications for, 1691
risk factors, 1687
Inguinal hernia
Inguinal hernias, 1229, 1230, 1230f. *See also* Groin hernias
anatomy, 1873–1874
clinical issues, 1874–1875
complications of repair for
bladder injury, 1244
bleeding, 1243
bowel obstruction, 1244
diaphragmatic dysfunction, 1244
gas embolism, 1243–1244
hydrocele, 1243
hypercapnia, 1244
ileus, 1241
infertility, 1242–1243
ischemic orchitis, 1243
postherniorrhaphy groin pain, 1241–1242
prosthetic complications, 1243
recurrence, 1241
seromas, 1243
testicular descent, 1243
urinary retention, 1241
vascular injury, 1243
wound infection, 1243
direct, 1873
embryology, 1873–1874
indirect, 1873
operative considerations, 1874

outcome, 1874
pathophysiology, 1873–1874
risk factors for development of, 1230t
steps for repair of, 1234t
Inguinal interstitial hernias, 1256
Inguinal ligament, 1214, 1216f
Inguinal region, anatomy of, 1218–1223
femoral sheath, canal, and ring, 1220–1221, 1221f
inguinal triangle, 1221, 1221f
lumbar plexus, branches of, 1222–1223, 1222f
spermatic cord, 1221–1222, 1222f
transversalis fascia, 1219, 1220f
transversalis fascia derivatives, 1219–1220, 1219f, 1220f
umbilical peritoneal folds, 1218–1219, 1219f
vasculature, 1223
Inguinal (Hesselbach) triangle, 1221, 1221f
Inhalation agents, 242, 242t
Inhalation injury, 221
Inhaled nitric oxide (iNO) and prostaglandins, 178
Inherited metabolic disorders, 558
Injured patients
advances and controversies
aggressive fluids *vs.* permissive hypotension, 355–356
$ETCO_2$ monitoring, 356
prehospital blood protocols, 356
REBOA, 356–358
RSI *vs.* non-RSI, 355
tourniquet use, 356
prehospital assessments and interventions, 353t
prehospital care
personnel, 352
scoop and run *vs.* stay and play, 352–353
scene assessment and management priorities
airway, 353, 353t
breathing, 353–354
circulation, 354
triage, 354–355
Injury
biomechanics of, 340–342, 341t, 342t
with changing population demographics, 335
patterns of, 341t
Injury severity score (ISS), 410, 508
Innate immunity, 101–107

Innominate artery compression syndrome, 1497
Inotropes and vasopressors
  amrinone and milrinone, 163
  dobutamine, 163
  dopamine, 162–163
  epinephrine, 163
  isoproterenol, 163
  norepinephrine, 163
  pharmacodynamics of, 162t
  phenylephrine, 163
  vasopressin, 163
Insect bites and stings, 502
In situ grafting, 1698, 1699f
Instant blood-mediated inflammatory reaction (IBMIR), 624
Institute of Medicine (IOM), 323, 347
Insulin, 9, 840, 845, 848
  half-life of, 849
  resistance, 849
  secretion and action, 849
  synthesis, 848–849, 849f
  type I diabetes, 849
  type II diabetes, 849
Insulinoma, 850, 900t, 905–906, 905t, 906f, 1379
  blind pancreaticoduodenectomy, 906
  chemotherapy, 906
  distribution, 905
  72-hour monitored fast, 850
  hypoglycemia-induced symptoms, 905
  metastatic, 906
  monitored fast, 905
  surgical exploration, 906, 906f
  Whipple triad, 905
Insulin resistance, 51–52
Insulin therapy, 252, 299t
Integra, 227
Integrated relaxation pressure (IRP), 656
Intensity-modulated radiation therapy (IMRT), 279, 2022
Intensive care unit (ICU), 161
  infectious disease issues in
    catheter associated urinary tract infections (CAUTI), 188
    central line associated blood stream infections (CLABSI), 188
    procalcitonin for antibiotic therapy, 187–188
    sepsis guidelines, 187

nutrition
enteral nutrition, delivery of early, 182–183
immunitrition, delivery of, 183
supplemental parenteral nutrition, 183
scoring systems, comparison, 170t
venous thromboembolism (VTE) prophylaxis in, 178–179, 179t
Intensive care unit (ICU) Outcomes Model (ICOM), 170
Intensive insulin therapy (IIT), 186
Interagency Registry for Mechanically Assisted Circulatory Support (INTERMACS), 1547–1548, 1549t, 1550t
Intercostal space, 1446, 1447f
Interferon-g (IFN-g), 107–108, 520
Interferons (type I), 106
Intergroup pediatric oncology group study, 1970
Intergroup rhabdomyosarcoma study group (IRSG), 1963
Interleukin-1 (IL-1), 102–103
Interleukin-2 (IL-2), 107
Interleukin-4 (IL-4), 107
Interleukin-5 (IL-5), 107
Interleukin-6 (IL-6), 106, 799
Interleukin-10 (IL-10), 106–107
Interleukin-12 (IL-12), 104
Interleukin-13 (IL-13), 107
Interleukin-15 (IL-15), 106
Interleukin-18 (IL-18), 106
Intermittent claudication (IC), 1592
Intermittent hemodialysis (IHD), 186
Intermittent mandatory ventilation (IMV), 175, 1812
Intermittent pneumatic compression (IPC), 1790
Internal anal sphincter (IAS), 1172, 1173
Internal carotid artery (ICA) stenosis
bilateral high-grade, 1591–1592
current criteria for, 1591, 1591t
diagnosis of, 1587
Internal carotid artery (ICA) waveform, 1588–1589, 1589f
Internal jugular vein (IJV), 172
Internal supravesical hernia, 1255, 1256f
International Agency for Research on Cancer (IARC), 270
International Association for Study of the Liver (IASL), 950
International Association of Pancreatology (IAP), 1003
International classification of rhabdomyosarcoma (ICR), 1963
International Diabetes Federation, 745
International Mesothelioma Interest Group (IMIG) staging system, 1470, 1471t

International normalized ratio (INR), 553
International Pancreas Transplant Registry (IPTR), 618
International Registry of Acute Aortic Dissections (IRAD), 1572–1573
International Society for Heart and Lung Transplantation (ISHLT), 582, 591
International system of units, 1979
Interparietal hernia, 1255–1256
Interstitial edematous pancreatitis, 859, 860t
Interval appendectomy, 132, 1204–1205
Intestinal angina, 1654
Intestinal atresia
  anatomy, 1876–1877
  classification, 1877f
  clinical presentation, 1877
  diagnosis, 1877–1878
  embryology, 1876–1877
  outcome, 1878
  results, 1878
  treatment, 1878, 1878f
Intestinal blood flow, 785
Intestinal duplication, 1911, 1912f
Intestinal flora, 784–785
Intestinal fluid, 785
Intestinal gas, 784
Intestinal ischemia, 1649
Intestinal motility, 785
Intestinal obstruction, 1908
  neonatal, 1875–1876, 1876t
Intestinal spillage, control of, 408
Intestinal stenosis, 1876–1878
Intestines
  mechanical obstruction of
    pathophysiology of, 784–786
    radiographs and imaging, 786–790, 787f
    terminology and classification, 782–784, 783f
Intra-abdominal disease, 1761
Intra-abdominal infections
  appendicitis, 130–132
  biliary infections, 132–133
  clostridium difficile infection (CDI), 135
  diverticulitis, 133–134
  pancreatitis, 135–137
Intra-abdominal sarcomas, 2021
Intra-abdominal sepsis, 571

Intra-aortic balloon pump (IABP), 1540, 1549, 1551f
Intracapsular fractures, 453
Intracavitary therapy, 279
Intracavity hemorrhage control, 349
Intracellular fluid (ICF), 19, 20f
Intracellular fluid compartments, 193t
Intracerebral hemorrhage, 365
Intracranial hemorrhage, 360
  and pupillary signs, 363
Intracranial hypertension, 361
  control of, 369
  craniectomy for, 373
  signs of, 367
Intracranial pressure (ICP), 360
  monitoring, 368
Intraductal papillary-mucinous neoplasms (IPMNs), 883–884
  branch-duct, 883
  high-risk stigmata, 884
  main-duct, 883
  management of, 884, 884f
  and mucinous cystic neoplasms, 883, 884t
  surgical therapy for, 884
  worrisome features, 884
Intrahepatic cholangiocarcinoma (ICC), 984. *See* Bile duct carcinomas
Intraocular pressure (IOP), 377
Intraoperative cholangiography (IOC), CBD stones, 1009
Intraoperative fluid therapy, 201
Intraoperative radiation therapy (IORT), 279, 2018
Intraperitoneal metastases, 759
Intraperitoneal onlay mesh (IPOM) repair, 1237, 1240
Intrathoracic kidney, 1934
Intravascular contrast extravasation (ICE), 423
Intravenous analgesics, 244, 245t
Intravenous glucose tolerance test, 850
Intravenous immunoglobulin (IVIG), 97
Intravenous sedatives, 242–243
Intussusception, 795–796
  anatomy, 1905–1906
  anatomy of, 795f
  clinical presentation, 1906
  complications, 1907
  diagnosis, 1906–1907, 1906f
  ileocolic, 1905f

outcome, 1907
pediatric patients, 1905–1907
physiology, 1905–1906
predisposing factors to, 1906t
treatment, 1907
types of, 796f
Intussusceptum, 1906
Intussuscipiens, 1906
Invasive mucinous cystadenocarcinomas, 883
INvestigation of STEnt grafts in Aortic Dissection (INSTEAD) trial, 1573
Iodine, 23
daily requirements of, 24t
deficiency of, 23
Iodine-131 iodohippurate, 547
^{123}Iodine Scintigraphy, 1345
Ionized calcium, 205
Ionizing radiation, 277–279, 1979–1980
fetal effects of, 1979
growth retardation, 1979–1980
lethal effects of, 1979
oncogenic potential of, 1980
physiologic changes of, 1980–1981
teratogenic effects of, 1979
ION-1 trial, 947
Ipilimumab, 1404, 2001
Irisin (protein), 50
Iron, 23
deficiency of, 23
storage of, 18
wound healing, role in, 63
Ischemia, 164
Ischemia-reperfusion injury, 157, 594
Ischemic colitis, 1077
Ischemic heart disease, 1519–1538
atherosclerosis, 1521–1522, 1521f
clinical manifestations, 1522–1523
coronary anatomy and physiology, 1519–1521, 1520f
diagnosis, 1524–1525
medical treatment, 1525–1527
myocardial infarctions, complications of, 1523t
cardiogenic shock, 1523
papillary muscle rupture, 1523–1524
postinfarction ventricular septal defect, 1523

ventricular free wall rupture, 1524
Ischemic injury to liver, 156
Ischemic stroke, 1622
Islets of Langerhans, 840, 845, 848. *See also* Insulin; Pancreas
Islet transplantation, 622
  complications, 624
  donor selection, 623
  future of, 625
  graft failure, 624–625
  history of, 622
  immunosuppression, 624
  metabolic control, 624
  patient selection, 622–623
  perioperative care, 623–624
  transplant techniques, 623, 623f
Isolated iliac artery aneurysms, 1755–1756
Isolated limb perfusion (ILP), 2000
Isoproterenol, 163
Isotonic fluid, 158
Israeli Defense Force, 353
Italian Randomized Controlled Trial (SCORE), 1101

J

Jackson–Pratt drain, 691
JAk2 inhibitors (ruxolitinib), 1279
Janus protein tyrosine kinase (JAK3), 549
Japanese Gastric Cancer Association, 760
Japanese Pancreas Society, 853
Jaundice, 1968
  acute liver failure and, 939, 940
  gallbladder cancer and, 1034
  pancreatic cancer and, 885, 896
  surgical palliation of, 896
Jejunal artery aneurysm, 1661
Jejunoileal bypass, 741, 742f
Jejunostomy tube placement, 706, 706f
Jeune asphyxiating thoracic dystrophy, 1847
Jod-Basedow phenomenon, 1347
Joint Theater Trauma Registry (JTTR), 348, 432
Jugular venous oxygen saturation monitor (JVO_2), 361
Juvenile polyps, 1107, 1115
Juxtarenal abdominal aortic aneurysms, 1757–1758
Juxtarenal aortic occlusion, 1674f

K

Kaplan–Meier plot, 285, 2022f
Kaposi sarcoma, 1194
Kaposi sarcoma-associated herpes virus, 271
Karydakis flap, 1187
Kasabach–Merritt syndrome, 980, 1916
Kawasaki disease, and thoracic aneurysms, 1566
Kehr sign, 413
Kerckring folds, 770
Kerlix gauze, 223
Ketamine, 245, 355
Ketoacidosis, 209
Ketoconazole, in Cushing disease, 1414t
Keyhole technique, 1253
"Keyhole" urethra, 1940
Kidney, 423–426, 532
  anomalies, 1934–1935
  cystic conditions, 1934–1935, 1934t
  rhabdoid tumor of, 1961–1962
  solitary, 1935
Kidney Disease Improving Global Outcomes (KDIGO), 184
Kidney donor profile index (KDPI) score, 543
Kidney procurement, 535–536, 535f
Kidneys, cadaver, 541
Ki-67 index, 899–900, 1316
Killed in action (KIA), 433
Killer bees, 503–504
Killian triangle, 644
King Airway, 353
Kinin
  bradykinin production, 112
  cellular kininogenase activity, 113
  production in tissue, 112–113
Kinks, 1632
Kleihauer–Betke (KB) analysis, 483
Knight and North Classification system, 379
Kocher maneuver, 417, 418, 771, 1022
Konno aortoventriculoplasty, 1494
KRAS mutations, 881
Krebs cycle. *See* Citric acid cycle
Kugel procedure, 1237
Kupffer cells, 157, 944
Kussmaul sign, 1579

L

Labial adhesions, 1944, 1944f
Laboratory Risk Indicator for Necrotizing Fasciitis (LRINEC) score, 139, 140t
Lactate
  conversion of, 9
  serum level, 10
Lactated Ringer solution, 159
Lactic acid, 209
Lactic acidosis, 209
Lactobacillus acidophilus, 790
Lactobacillus sp., 1886
Lactotroph adenomas. *See* Prolactinomas
Lactulose, in hepatic encephalopathy, 954
Lacunar ligament, 1214, 1216f
Ladd bands, 1893
Laennec cirrhosis, 946
Lamivudine, 936
Lanreotide depot, in acromegaly, 1413t
Laparoscopically assisted endorectal pull-through, 1902, 1903f
Laparoscopic antireflux surgery (LARS), 681
Laparoscopic cholecystectomy, and bile duct injury, 1017, 1020
Laparoscopic choledochotomy, 1011
Laparoscopic colectomy, for colorectal cancer, 1134
Laparoscopic common bile duct exploration (LCBDE), 1010–1011
Laparoscopic gastrectomy, 763
Laparoscopic surgery, for chronic pancreatitis, 876
Laparoscopic transcystic CBDE, 1011
Laparoscopic ventral hernia repair, 1251–1252
Laparoscopic *vs.* open appendectomy, 131
Laparotomy. *See also* Abdominal trauma
  damage control, 407–408, 407f, 408f
  trauma, 406–407
Large cell neuroendocrine carcinoma, 1434, 1434f
Laryngeal cancer, 640
  advanced stage, 641
Laryngeal mask, 353
Laryngopharyngeal reflux (LPR), 658, 666–667
Laryngotracheoesophageal clefts, 1859
Larynx, 640–641
Larynx staging, 638t
L-asparaginase, 1926
Lateral aberrant thyroid tissue, concept of, 1341
Lateral canthotomy, 378f

Lateral pancreaticojejunostomy (LPJ), 874
Latissimus dorsi muscle rotation flap, for chest wall reconstruction, 1451, 1453f
Laugier hernia, 1257
Laxatives, 1058, 1058t
Leadership and policy, 324
Leaky gut hypothesis, 947
Leapfrog Group, 314
LEA29Y, 520
Ledipasvir/sofosbuvir, 947
Left anterior descending (LAD) coronary artery, 1519
Left pulmonary artery (LPA), 1497
Left ventricular assist device (LVAD), 1540. *See also* Mechanical circulatory support (MCS)
Left ventricular end-diastolic pressure (LVEDP), 172
Left ventricular end-diastolic volume (LVEDV), 172
Left ventricular stroke area (LVSA), 162
Leiomyoma, 695–697
  esophagogram of, 696f
Leiomyosarcomas, 1852t, 1854, 2017
Lembert sutures, 418
Lentigo maligna melanoma (LMM), 1992
Leptin, 44–45, 44f
Leriche syndrome, 1674
Lethality of war wounds (among US soldiers), 346t
Lethal triad, 488
Letrozole, 1325
Leuconostoc mesenteroides bacteria, 199
Leucovorin, 764
Leukocyte depletion, 521
Leukocytes
  recruitment, 88t
  subsets, 87t
  and thrombosis, 74–75
Leukocyte scintigraphy, for vascular infection, 1613
Leukopenia, 522
Leuprolide, 1325
Levator ani muscle, 1172, 1174f
LeVeen peritoneovenous shunt, 968, 968f
Level of consciousness monitors, 258
Lexipafant, 865
Lichtenstein hernioplasty, 1236–1237, 1237f
Lidocaine, 355
Lifelong learning, 3. *See also* Self-regulated learning

ACGME on, 3
self-regulated learning and, relationship between, 4, 4t
in surgery education, 7
Lifestyle interventions and obesity, 739–740
Li–Fraumeni syndrome, 1310
Ligament of Berry, 1341
Ligament of Treitz, 741, 770
Ligandins, 18
Ligation of intersphincteric fistula tract (LIFT), 1184
Light-emitting diode (LED), 676
Limb abnormalities, 1883
Limb-threatening disease, 1773
Linea alba, 1246
Lipase, 846, 848, 862
deficiency, 847
Lipid-lowering therapy, 1677–1678
Lipid mediators
cyclooxygenase pathway (prostaglandins), 110
eicosanoids, 110
lipoxygenase pathway (leukotrienes and lipoxins), 110–112
Lipids
as fuel for energy, 22–23
storage of, in adipose tissue, 42
transport of, 11
wound healing, effect on, 63
Lipolysis, 218
Lipolytic enzymes, 775, 846
Lipoma, 1107, 1108f
cardiac, 1516
spermatic cord, 1232
Lipopolysaccharide (LPS), 152
Lipopolysaccharide-binding protein (LBP), 864
Lipoproteins, 11, 80
Liposuction, 2059
Lipoteichoic acid (LTA), 116
Lipoxins, 111
Lipoxygenase pathway (leukotrienes and lipoxins), 110–112
Liraglutide (Victoza), 741
Lithium, 299t
Littre hernia, 1256
Liver, 532
abscesses
amebic, 930–931, 931f

pyogenic, 930, 931f
amebic abscess of, 1918
bile production by, 996
biopsy, 1921
biotransformation in, 18
dysfunction, and hyperlactatemia, 9
infections, 1918
macronodular, 945–946
micronodular, 945
pyogenic abscess, 1918
resection, in children, 1917, 1917f
teratomas of, 1916
transplantation, in children, 1923
tumors of childhood, 1914–1918, 1915t
Liver and biliary tract. *See also* Liver
anatomy, 410
diagnostics, 410
epidemiology, 410, 411f
extrahepatic biliary tract injury, 412–413
OIS-AAST grading scale, 410t
treatment, 410–412, 411f, 412f
Liver disease complications, 554t
Liver failure
clinical features, 940
definition, 939
diagnosis, 939–940
etiology, 940
hepatitis B virus infection and, 935
laboratory evaluations, 939t
life support systems, 940–941
liver transplantation, 940
management, 940
nutritional support in, 38
prognosis, 941, 941t
transjugular liver biopsy, 940
Liver fibrosis, 943–945, 944f, 945f, 947. *See also* Cirrhosis
Liver procurement, 533–535
Liver transplantation, 966, 1970
acute liver failure and, 940
hepatic failure and, 936
hepatic malignancies and, 975, 992
for hilar cholangiocarcinoma, 1043–1044
primary sclerosing cholangitis and, 1029

Lloyd–Davis position, 1144
Lobar emphysema, 1467, 1467f
Lobectomy, 1847
Lobular carcinoma in situ (LCIS), 1305–1306
  pleomorphic, 1305
  and risk for breast cancer, 1306, 1306t
Local anesthetics, 246–247, 246t
Localized pancreatic head resection with lateral pancreaticojejunostomy (LR-LPJ), 874–875
Locoregional recurrence, 276
Loeys–Dietz syndrome, and thoracic aneurysms, 1565, 1565t
Look AHEAD study, 740
Lorazepam, 245
Lorcaserin, 740, 741
Lorenz Bar insertion (Nuss procedure), 1846, 1846f
Low anterior resection (LAR), 1143, 1143f
Low anterior resection syndrome (LARS), 1143
Low-density lipoproteins (LDLs), 11, 1522
Lower esophageal sphincter (LES), 651–653, 651f, 652f, 656, 656f, 662
  characteristics of, 651–652
  relaxation, 656
Lower extremity
  amputations, 1704–1715
  graft infections, 1617
Low-molecular-weight heparin (LMWH), 75, 180, 253, 1779
Lumbar hernia, 1254, 1254t, 1255f
Lundh test, 847
Lung, 533
  benign tumors of, 1441, 1441t
  blood flow, 1862
  congenital cystic disease of, 1847–1851
  congenital malformations of, 1465–1466
    bronchogenic cysts, 1467
    congenital cystic adenomatoid malformation (CCAM), 1467, 1467f, 1467t
    lobar emphysema, 1467, 1467f
    pulmonary sequestration, 1466, 1466f
    stages of lung development, 1465–1466, 1466t
  embryology, 1861
  extralobar sequestrations, 1847
  intralobar sequestrations, 1847
  malignant tumors, 1853f, 1854
  measurements, 1812f
  metastatic tumors, 1851

pediatric primary tumors, 1852, 1852t
procurement, 536–537
rhabdomyosarcomas, 1852t, 1854
teratomas, 1854, 1855f
Lung abscesses, 1459, 1462f
Lung allocation score (LAS), 588, 590–591, 590t
critically ill patients, 592
Lung cancer, 1417–1441
epidemiology, 1417–1418
neuroendocrine tumors, 1433–1436
adenoid cystic carcinomas, 1435–1436, 1436f
bronchial gland carcinomas, 1435
carcinoid tumors, 1433–1434, 1433f, 1434f
large cell neuroendocrine carcinoma, 1434, 1434f
mucoepidermoid carcinomas, 1436
mucous gland adenomas, 1436
small cell lung cancer, 1434–1435
non-small cell lung cancer, 1420–1433
pathologic classification, 1418, 1418t
pulmonary metastasis, resection of, 1437–1441
resection, 303
tumor biology, 1418–1420
Lung volume reduction surgery (LVRS), 1462–1463, 1464f
Lupus anticoagulant/antiphospholipid syndrome, 77
Lymphadenectomy, 275–276, 762t
Lymphadenitis, 1840–1841
Lymphadenopathy, 1232
Lymphangiomas of spleen, 1283
Lymphatic malformations (LMs), 1842, 1842f, 1851
Lymph node biopsy, sentinel, 1998–2000
Lymph node sampling, 1967
Lymphocytes
B lymphocytes, 94
T lymphocytes, 95–97
Lymphocytic hypophysitis, 1404
Lymphogranuloma venereum (LGV), 1193
Lymphoid tissue, 775
nonaggregated and aggregated, 775, 776f
Lymphomas, 1854
small bowel, 834–835
Lymphomatous polyposis of colon, 1107, 1108f
Lymphotactin, 104
Lynch syndrome, 1094, 1099, 1129

Lysyl-bradykinin (kallidin), 112
Lysyl oxidase, 60

M

Macroautophagy, 118
Macroglossia, 1842
Macrophages, in wound healing, 58, 59f
Magnesium
  hypermagnesemia, 207
  hypomagnesemia, 207
  role in wound healing, 63
Magnetic resonance angiography (MRA), 1624, 1778, 2013, 2032
  for thoracoabdominal aortic aneurysms, 1719–1720
  for vascular trauma, 436
Magnetic resonance cholangiopancreatography (MRCP), 1984
  CBD stones, 1008, 1009f
  chronic pancreatitis, 872
  hilar cholangiocarcinoma, 1041, 1042f
  pancreatic disease, 857
Magnetic resonance imaging (MRI), 1769, 1948, 1980, 1992
  acute cholecystitis, 1001, 1001f
  bowel obstruction, 789
  breast disease, 1296–1297, 1308
  Crohn disease, 813, 813f
  gallbladder cancer, 1035, 1036f
  hepatic neoplasms, 977
  hilar cholangiocarcinoma, 1041, 1042f
  ligamentous injuries, 484
  pancreatic cancer, 887
  pancreatic endocrine neoplasms, 902–903
  pheochromocytoma, 1395, 1395f
  pituitary tumors, 1407–1408
  rectal cancer staging, 1138–1139, 1139f
  thoracic aortic aneurysm, 1566
  ulcerative colitis, 1084–1085, 1085f
  vascular infection, 1612–1613
  vascular trauma, 436
Magnetic resonance venography (MRV), 1778
Maintenance electrolyte therapy, 200
Maintenance fluid therapy, 200
Major Adverse Cardiac Event (MACE), 299
Major histocompatibility complex (MHC), 94, 519, 541, 775
Marjolins ulcer, 235

Male breast cancer, 1329–1330
Malignant fibrous histiocytomas (MFHs), 1450
Malignant masquerade, 1048
Malignant mesenchymal tumors, 1917
Malignant neoplasms, 697–701, 698f
  diagnosis, 698–699
  neoadjuvant therapy, 699–701
  staging, 699, 699t
Malignant obstruction, 796–797, 797f, 797t
Malignant pleural mesothelioma (MPM), 1470–1472, 1470f, 1471t
Mallampati score, 630
Mallory bodies, alcoholic hepatitis, 946, 946f
Mallory–Weiss tears, 1063, 1074
Malnutrition. *See also* Nutrition
  inflammation and, 27
  and preoperative nutritional support, 32
  starvation and, 27, 27t
  wound healing, impact on, 63
Malrotation, midgut
  anatomy, 1893–1894
  clinical presentation, 1894
  complications, 1895–1896
  correction of, 1896f
  diagnosis, 1894, 1895f
  embryology, 1892–1893, 1892f, 1893f
  incomplete rotation, 1893–1894, 1893f
  nonrotation, 1893, 1893f
  normal fixation, 1893f
  normal rotation, 1892f
  results, 1895–1896
  treatment, 1894–1895
Mammalian target of rapamycin (mTOR), 581
Mammography, 1295
  BI-RADS classification of abnormalities, 1307, 1308t
  microcalcifications, 1295, 1296f
  screening, 1306–1308
  soft tissue masses, 1295, 1296f
Mandible fractures, 382–383, 384f
Mandibular condyle fractures, 383
Mandibular subluxation, 386
Manganese
  daily requirements of, 24t
  deficiency of, 23

MAPK pathway, 1122
MAPK pathway inhibition, 2001
Marcus Gunn pupil, 1407
Marfan syndrome, 1565
  inguinal hernias and, 1874
  pectus excavatum and, 1845
  and thoracic aneurysms, 1565, 1565f, 1565t
Marginal artery of Drummond, 1672
Marlex methylmethacrylate sandwich technique, for chest wall reconstruction, 1451, 1452f
Marshall multiple organ dysfunction syndrome, 171t
Massive hernia, 1247
Massive transfusion protocol (MTP), 344, 345, 345f
Mastalgia. *See* Breast pain
Mast cells, 98
Mastectomy, 1312, 1322–1323, 1322f, 1323f
  nipple-sparing, 1322
  partial, 1319–1320, 1319f, 1320t
  radical, 1324
  skin-sparing, 1322, 1323f
Mastitis, 1303
Mastodynia. *See* Breast pain
Mastopexy, 2047, 2047f
Matrix metalloproteinases (MMPs), 1225, 1564, 1717–1718
Maxillofacial injuries, 376–384
  fractures, 378–384, 380f
  and nasal intubation, 378
  ocular injury, 381
  oral intubation and, 378
  soft tissue injuries, 377–378, 378f, 379f
  treatment of, 376, 377f
Maximum tolerated dose (MTD), 278, 285
Mayer–Rokitansky–Kusterhauser syndrome, 1945
Mayo Severity Index Calculator, ulcerative colitis, 1084t
MC1R gene mutation, 1991
McVay (Cooper ligament) repair, 1234, 1236f
Mean arterial pressure (MAP), 155, 489
Mechanical circulatory support (MCS)
  adverse events, 1546
    bleeding, 1546
    device malfunction and thrombosis, 1547
    infections, 1547
    intracranial bleeding and thromboembolism, 1546–1547

RV failure, 1546
arrhythmias and, 1545–1546
for cardiac failure, 1540–1559
cardiac support devices for, 1540, 1541f–1542f
coagulation parameters and, 1544–1545
contraindications to, 1543
coronary artery disease and, 1545
devices, for long-term MCS, 1553
HeartMate III LVAD, 1557, 1558f
HeartMate II LVAD, 1554–1555, 1555f
HVAD, 1556–1557, 1557f
Jarvik 2000, 1555–1556, 1555f
MVAD, 1557, 1558f
rotary pumps, 1553–1554
rotary pumps with centrifugal flow design, 1556, 1556f
devices, for short-term MCS
extracorporeal life support, 1549–1551
IABP, 1549, 1551f
future directions, 1559
indications for, 1540–1542
bridge to recovery (BTR), 1540
bridge to transplantation (BTT), 1540–1541
destination therapy (DT), 1541
INTERMACS registry, 1547–1548, 1547f–1548f, 1549t, 1550t
and intracardiac shunts, 1546
liver function and, 1544
and nutrition, 1545
patient selection, 1543–1545
percutaneous short-term MCS devices, 1551–1553
CentriMag VAD, 1553, 1554f
Impella left ventricular assist device, 1552, 1553f
Tandem Heart pVAD centrifugal pump, 1551–1552, 1552f
pulmonary function and, 1544
renal function and, 1543–1544
right-sided heart failure and, 1544
timing of implant, 1542
cardiogenic shock and acute heart failure, 1542–1543
chronic heart failure, 1543, 1544f
total artificial hearts
Syncardia total artificial heart, 1557, 1559f
valvular heart disease and, 1545
weaning patients from
long-term MCS, 1549

short-term MCS, 1548
Mechanical ligation, of bleeding vessels, 1072
Mechanical obstruction, definition, 782
Mechanism of injury (MVC), 363
Meckel diverticulum, 1077–1078
anatomy, 1907
clinical presentation, 1908–1909
cystic duplications, 1911–1912
distal gastrointestinal tract, 1909
embryology, 1907
esophagus, 1909
foreign bodies, 1909
gastrointestinal hemorrhage, 1909, 1910t, 1911
as incidental finding, 1908–1909
intestinal duplication, 1911, 1912f
signs and symptoms of, 1908, 1908t
treatment, 1909
tubular duplications, 1912
Meconium ileus, 1889
clinical presentation, 1890
diagnosis, 1890, 1891f
diagnostic evaluation, 1889–1890, 1890f
pathophysiology, 1889, 1889f
postoperative care, 1891
radiograph of, 1891f
results, 1891
treatment
nonoperative, 1890–1891
operative, 1891
Meconium ileus equivalent, 1889
Meconium plug syndrome, 1891–1892
Medialization, for massive abdominal hernias, 1250
Median arcuate ligament syndrome (MALS), 1656, 1656f
Mediastinal tumors, 1854–1855, 1855f
Mediastinitis, 1478
Mediastinum, 1475, 1475f, 1476f
anterior mediastinal masses, 1475–1478, 1475t, 1476t, 1477f
cysts of, 1849, 1851
middle mediastinal masses, 1478, 1478t
pediatric, 1478, 1478t
posterior lesions, 1478
subdivisions, 1475, 1475f
Medical comorbidity

anemia, 296
frailty, 296–297, 297t
obesity/obstructive sleep apnea, 296
preoperative functional status, 296
Medical error, nonpunitive response to, 326
Medical Research Council Adjuvant Gastric Infusional Chemotherapy (MAGIC), 764
Mediterranean anemia, 1276
Mediterranean diets, 739
Medullary thyroid carcinoma (MTC), 1353–1354, 1354t, 1380, 1380f
Medulloblastomas, 1111
Megamitochondria, alcoholic hepatitis, 946
Megaureter, 1937
Meissner plexus, 773, 1051, 1056
MEK inhibitors, 2001
Melanocortin-4 receptor (MC4R), 741
Melanoma
canal, 1196
chemotherapy, 2001
classification, 1992–1994
clinical and pathologic staging, 1995
clinical diagnosis, 1992–1994
etiology, 2002
genetic component, 1991
metastasis to small bowel, 837, 837f
microstaging, 1994–1995
prognostic factors, 1995
risk factors, 1991–1992
stage groupings, 1997t
surgery, 2002
surgical excision, 1997t
surgical margins, 1998t
survival rates, 1995t
treatment, 1995
Melena, 1063. *See also* Gastrointestinal (GI) hemorrhage
Membrane attack complex (MAC), 92
Membrane cofactor protein (MCP), 94
Memory T-cell, 520
Memphis modification, 1249
Meningiomas, 1404, 1407–1408
Menstrual cycle, and mammary gland, 1293
Meperidine, 864
Mercaptopurine (6-MP)
in Crohn disease, 816t, 817

in ulcerative colitis, 1086
MERCURY trial, 1139
Merkel cell carcinoma (MCC), 2006, 2006f
Mesenchymal hamartomas, 1916
Mesenchymal stem cells (MSC), 233, 527
Mesenteric arterial stenosis, detection of, 1600–1601
Mesenteric arteries, evaluation of, 1600–1601
Mesenteric cysts, 1912
Mesenteric vein thrombosis (MVT), 1653
Meshing, 226
Mesocolic hernias, 1894
Mesonephros, 1933
Mesothelioma, 1470–1472, 1470f, 1471t
Metabolic acidosis
acute metabolic acidosis
clinical features of, 209
treatment of, 210
anion gap, 208
bicarbonate, nonrenal loss of, 209
diabetic ketoacidosis, 210, 210f
ketoacidosis, 209
lactic acidosis, 209
mechanisms of, 208–209
organic acid production, 209
renal acidosis, 209
renal compensation, 210
respiratory compensation, 210
Metabolic alkalosis, 210–211
clinical features, 211
respiratory compensation for, 211
treatment, 211
Metabolic bone disease, 1822
Metabolic disease, 738
adipocytes and, 48–50, 50f
cellular stress responses and, 48, 49f
diabetes, 51–52
mediators of, 50–51, 51f
nutrient excess and, 47–48
obesity and, 47–48
pathophysiology of, 47–50
portal overflow and liver disease, 51
visceral adipose tissue (VAT) and, 50
Metabolic energy expenditure, 26, 26t

Metabolic equivalents (MET), 296, 296t
Metabolic rate, and obesity, 45–46
Metabolic requirements
  and assessment, 181–182
  for ICU patients, 181–182
Metabolic thrift, 42
Metabolism, 47
  biotransformation, 18
  carbohydrate, 8–11
  cellular energy generation, 14–18
  cholesterol, 13–14
  fatty acid, 11–13
  heme and porphyrin, 18, 19f
  intermediary, 8
  lipid, 11
  metal, 18–19
  and nutrition
    enteral nutrition, 182
    immunonutrition, 182
    metabolic requirements and assessment, 181–182
  protein, 14
Metabolites, 164
Metalloproteases (MMP), 64
Metal metabolism, 18–19
Metanephros, 1933
MetaPlus study, 183
Metastatic lung tumors, 1851
Metformin, 299t
Methamphetamine, causing burn, 216
Methicillin-resistant *Staphylococcus aureus* (MRSA), 137, 188
Methotrexate, 1325
  in Crohn disease, 816t, 817
  in ulcerative colitis, 1086
Methylenetetrahydrofolate reductase (MTHFR), 79
Methylxanthines, 741
Metoclopramide, 670
Metyrapone, in Cushing disease, 1414t
Mexican beaded lizard *(Heloderma horridum),* 502
Micafungin (FK463), 1618
Microbial arteritis, 1609
Microbiome, 47
Microlithiasis, 861
Micronutrients

administration of, during critical illness, 37
wound healing, role in, 63
Microparticles (MP), 72
Microsatellite instability (MSI), 1094, 1095f, 1120
Microsatellite instability high (MSI-H) phenotype, 756
Microvascular tissue transfer, 2036
Microvilli, 772
Midazolam, 245–246, 355
Midgut
anatomy, 1893–1894
embryology, 1892–1893, 1892f, 1893f
incomplete rotation, 1893–1894, 1893f
malrotation, 1892–1896
nonrotation, 1893, 1893f
normal fixation, 1893f
normal rotation, 1892f
volvulus, 1894–1895
Midodrine, in hepatorenal syndrome, 952
Mifepristone, in Cushing disease, 1414t
Mifflin–St. Jeor equation, 26
Migrating motor complex (MMC), 774
Migrating myoelectric complex (MMC), 997
Mild traumatic brain injury (MTBI), 460
Military Application of Tranexamic Acid in Trauma Emergency Resuscitation (MATTER), 348
Milk–alkali syndrome, 1367
Millipedes, 504
Milrinone, 1863
Minerals, 182
Minimally invasive direct coronary bypass (MIDCAB), 1533
Minimally invasive esophagectomy (MIE), 701, 703
Minimally invasive retroperitoneal pancreatectomy (MIRP), 137
Minnesota tube, 960, 1074
Mirizzi syndrome, 1030
Mitogen-activated protein kinases (MAPK), 97
Mitomycin, 1208
Mitomycin C, 735
Mitophagy, 119
Mitotane, in Cushing disease, 1414t
Mitral annulus, 1505
Mitral regurgitation (MR), 1512–1514
diagnosis, 1512
imaging, 1512

natural history, 1512
pathophysiology, 1512
prevalence and etiology, 1512
severity, 1512t
treatment, 1512–1514, 1513f, 1514f
Mitral stenosis (MS), 1510–1512
diagnosis, 1510–1511
imaging, 1511
natural history, 1511
pathophysiology, 1510
prevalence and etiology, 1510
severity, 1511t
treatment, 1511
MV replacement (MVR), 1512
open mitral commissurotomy, 1511–1512
percutaneous balloon mitral valvuloplasty, 1511
Mitral valve (MV), 1505
Mixed acid-base disorders, 212
Mobile intensive care unit, 352
Model for end-stage liver disease (MELD) score, 305, 305t, 553, 957, 977
Modified radical mastectomy, 1324
Mohs micrographic surgical technique, 2004, 2004f
Mojave rattlesnake *(Crotalus scutulatus),* 500
Molybdenum
daily requirements of, 24t
deficiency of, 23
Mondor disease, 1302, 1302f
Monoamine oxidase inhibitors, 299t
Monocyte chemotactic protein-1 (MCP-1), 75
Monocyte influx, 74
Mononuclear phagocytes, 93–94
activation, 94
antigen presentation, 94
phagocytosis, 94
recruitment, 94
Monosodium urate (MSU), 116
Monospot test, 939
Montgomery glands, 1291
Morgagni hernia, 1865, 1865f
Mortality Probability Model (MPM), 170
MOSAIC trial, 1136
Mosapride, 802
Moschcowitz syndrome. *See* Thrombotic thrombocytopenia purpura (ITP)

Motilin, 774
Motor-evoked potentials (MEPs), 1720
Motor vehicle accident (MVA), 363f
Motor vehicle crash (MVC), 360, 465
Motor vehicle-related injuries, in pregnancy, 481–482
Motor vehicle traffic deaths, 340f
mTOR inhibitors, 521–522
  side effects of, 522
Mucinous appendiceal carcinoma, 1207–1208, 1207f
Mucinous (colloid) carcinoma, 1316
Mucinous cystic neoplasms (MCNs), 883
Mucoceles of appendix, 1206, 1207f
Mucoepidermoid carcinomas, 635, 1436
Mucomyst, 221
Mucosa-associated lymphoid tissue (MALT), 775
  lymphoma, 765
    gastric, 765
    high-grade, 765
    low-grade, 765
    non, 765–766, 765f, 766f
Mucosal atypia, 755
Mucous gland adenomas, 1436
Mucous glycoproteins, gallbladder, 997
Müllerian ducts, 1933
Müller sign, 1510
Multicystic dysplastic kidney (MCDK), 1934
Multidetector CT (MDCT), 1070–1071
  for rectal cancer staging, 1138
Multimodality therapies, 2010
Multiple adenomatous polyps, 755
Multiple biliary papillomatosis, 1048
Multiple blood cultures, 1773
Multiple core needle biopsies, 1966, 1967
Multiple endocrine neoplasia type 1 (MEN1), 766, 1378–1379, 1379f
  pancreatic endocrine neoplasms and, 901, 901t
Multiple endocrine neoplasia type 2 (MEN2), 1379–1381, 1381f
Multiple organ dysfunction syndrome (MODS), 152, 157, 171t
Multiple organ failure (MOF), 171t
Multipolar electrocoagulation (bicap) probes, 1072
Murphy sign, 1000
Muscle catabolism and wasting, 233
Muscle relaxants, 243–244, 243t, 244t
Muscles of pelvic floor, 1172, 1174f

MutYH-associated polyposis (MAP), 1113–1114, 1114t
MYCN amplification, 1950
Mycobacterium avium-intracellulare-scrofulaceum (MAIS), 1841
Mycophenolate, 522
Mycophenolic acid (MPA), 522
Mycotic aneurysms, 1565–1566, 1609, 1758
  clinical manifestations, 1773
  definition, 1772
  diagnosis, 1773
  importance, 1772
  pathogenesis, 1772–1773
  treatment, 1773
Myelodysplastic syndrome (MDS), 1279, 1883
Myelomeningocele (MMC), 1833, 2067
Myeloperoxidase (MPO), 89
Myelosuppression, 522
MYH-associated polyposis, 1129
Myocardial bridging, 1498–1499
Myocardial perfusion, 151
Myopectineal orifice, 1213, 1213f
Myositis, 140
Myxomas, 1515–1516, 1515f
  clinical characteristics, 1516
  diagnosis, 1516
  management, 1516
  morphology, 1515–1516, 1515f

N

N-acetylcysteine, 1890–1891
NAFLD fibrosis score, 950
Naftidrofuryl, 1678
Naloxone, 299t
Naltrexone, 741
Narcotics, 248
Narrow band imaging (NBI), 654
Nasoduodenal tubes, 37
Nasogastric decompression, 790
Nasogastric tubes (NGTs), 37, 1067
Naso-orbital–ethmoid (NOE) fractures, 380–382
Nasopharyngeal carcinoma (NPC), 639
Nasopharynx, 639
Nathensen retractor, 678
National Burn Repository, 214

National Cancer Comprehensive Network, 638
National Center for Injury Prevention and Control, 335
National Comprehensive Cancer Network (NCCN), 1306, 1995
National CT Colonography Trial, 1102
National Emphysema Treatment Trial (NETT), 1463
National Health and Nutrition Examination Survey (NHANES), 739
National Healthcare Safety Network (NHSN), 141, 141t
National Health Interview Survey (NHIS), 739
National Highway Traffic Safety Administration, 470
National Institute of Diabetes and Digestive and Kidney Diseases (NIDDK), 1212
National Institutes of Health, 576
National Nosocomial Infections Surveillance System (NNIS), 141
National Pediatric Trauma Registry, 417
National Polyp Study (NPS), 1099, 1101, 1103
National Quality Forum (NQF), 313, 327, 328t
National Surgical Quality Improvement Program (NSQIP), 76, 131, 291
National Toxicology Program, 522
National Traffic and Motor Vehicle Safety Act, 470
National Trauma Data Bank® (NTDB®), 403, 410, 433, 464–465, 477
National Wilms Tumor Study (NWTS), 1955, 1961
Natural anticoagulant mechanisms, 71, 71f
Natural killer cells, 273
Nausea and vomiting, 259
NCAA Concussion Study, 461
Neck, 386–392
  anatomy, 386–387, 386f
  contractures, 233
  dissection, 641–642, 641f, 641t
  injuries
    blunt trauma, 388–389
    complications, 392, 392t
    exploration of, 388
    initial management, 387, 387f
    management of, 389
    operative exploration, 389–392
    penetrating trauma, 388
    selective *vs.* mandatory exploration, 387–389
    trachea and larynx, 390–391, 391f
    vascular injury, 389–390, 390f
  trauma, 440
Neck injuries
  lymphatic malformations, 1833f
  pediatric patients, 1837

airway obstruction, 1842–1843
congenital lesions of, 1837–1841
imaging for, 1837
vascular malformations of, 1841–1842
Necrolytic migratory erythema, 909
Necrotic collection, pancreas, 860t
Necrotizing enterocolitis (NEC)
clinical presentation, 1886, 1886f
complications, 1888
diagnosis, 1886, 1887f, 1887t
fulminant, 1888f
with gastroschisis, 1873
outcome, 1888–1889
pathophysiology, 1885–1886
results, 1888–1889
treatment
nonoperative, 1886–1887
operative, 1887–1888, 1888f, 1888t
Necrotizing pancreatitis, 859, 860t
Necrotizing soft tissue infections (NSTI), 138, 139–140
diagnostic imaging in, 140
microbiology of, 140
Negative predictive value (NPV), 1777
Negative-pressure wound therapy, 2033
Neisseria gonorrhoeae, 1192
Neisseria meningitides, 1287
Neisserian meningococcus, 1284
Nelson syndrome, 1414
Neoadjuvant therapy, 2017–2021
for pancreatic cancer, 895–896, 895t
Neodymium:yttrium-aluminum-garnet (Nd:YAG) laser fulguration, 709
Neonatal ascites, 1913–1914, 1913t
Neonatal cholestatic syndromes, 1919, 1919t
Neonatal hyperparathyroidism, 1378
Neonatal intestinal obstruction, 1875–1876, 1876t
Neoplastic mucosal polyps, colorectal, 1093–1094, 1094t
Neostigmine, 804, 1060
Nephrocalcinosis, 1372, 1372f
Nerve growth factor (NGF), 1950
Neuraxial blockade, 247
Neuroblastoma, 1854
biologic feature, 1949–146
diagnosis of, 1951–1952

epidemiology, 1948–1949
future directions, 1954
genetic risk, 1948–1949
pathology, 1949–1950
perinatal, 1951
presentation, 1950–1951
primary distribution, 1951f
risk, 1953–1954
staging, 1950–1952, 1952t
treatment of, 1952
Neurocutaneous melanocytosis (NCM), 1992
Neuroendocrine liver metastases, 987
Neuroendocrine tumors (NETs)
of lungs, 1433
adenoid cystic carcinomas, 1435–1436, 1436f
bronchial gland carcinomas, 1435
carcinoid tumors, 1433–1434, 1433f, 1434f
large cell neuroendocrine carcinoma, 1434, 1434f
mucoepidermoid carcinomas, 1436
mucous gland adenomas, 1436
small cell lung cancer, 1434–1435
of small bowel, 830–833, 831t, 832t, 833f
Neurofibromas, 1854
Neurofibromatosis (NF-1), pancreatic endocrine neoplasms and, 901–902, 901t
Neurogenic bladder, 1945–1946, 1946f
Neurogenic shock, 152–153
Neurogenic tumors, 1854
Neurologic imaging, indications for, 364t. *See also* Head trauma/head injury
Neuromuscular blockade (NMB), 178
Neuronal intestinal dysplasia, 1897
Neuron-specific enolase, 902
Neuropeptides, 113–114
Neurotensin, 774
Neutrophil endothelial traps, 74
Neutrophils, 72
neutrophil extracellular traps (NET), 93
neutrophil granules and secretory vesicles, 89, 90t
oxidative burst and oxidant metabolites, *91–93, 91t*
phagocytosis, 88
recruitment, 87–88
regulation of neutrophil activity, 93
New England Journal of Medicine, 662
Nexium, 670

Niacin, 780
Nicotinamide adenine dinucleotide (NADH), 946
Nicotinamide adenine dinucleotide phosphate (NADPH), 89, 91
Nielsen test, 1598, 1599f
Niemann–Pick disease, 558
Nigro Protocol, for squamous cell cancer of anal canal, 1196, 1197t
Nipple-areolar reconstruction, 2043
Nipple discharge, 1302–1303, 1303f
  causes, 1303
  clinical evaluation, 1302
  ductography and ductoscopy, 1303, 1303f
  terminal duct excision, 1303
Nipple-sparing mastectomies, 1322
Nissen fundoplication, 668
  laparoscopic, 677–680, 678t
  transthoracic, 680, 680t
Nitrate, in coronary artery disease, 1526
Nitric oxide, 114–115, 197
  in cirrhosis and portal hypertension, 955
Nitrogen balance
  calculation of, 26
  as nutrition biomarker, 25–26
Nitroglycerin, 164
Nitroglycerin ointment, in anal fissure treatment, 1181
Nitroprusside, 164
Nivolumab, 273
N-nitroso carcinogens, 756
Nonaccidental trauma, in children, 470
Nonalcoholic fatty liver disease (NAFLD), 557, 945, 947
  and cirrhosis, 947
  two-hit model, 947
Nonalcoholic steatohepatitis (NASH), 305, 552, 945, 947
Nonatherosclerotic mesenteric arterial occlusive disease, 1653
Noncommunicating hydrocele, 1875
Noncompressible torso hemorrhage (NCTH), 440–441
Nonerosive disease (NERD), 660
Non-Hodgkin lymphoma, 765, 1278, 1854
Nonimmune fetal hydrops, 1831
Nonocclusive mesenteric ischemia (NOMI), 1652f, 1653–1654
Nonmelanoma skin tumors
  basal cell carcinoma, 2002
  squamous cell carcinoma, 1992
Nonreversed saphenous vein grafts, 1698

Nonrhabdomyosarcoma soft tissue sarcoma
biologic features, 1966
characteristics, 1966t
diagnosis, 1967
epidemiology, 1966
pathology, 1966
presentation, 1967
staging, 1967
treatment, 1967
Non-small cell lung cancer (NSCLC), 1418
adjuvant therapy, 1427–1429, 1427t, 1428t
cervical mediastinoscopy, 1422–1423
chest CT in, 1420, 1422
diagnosis, 1420–1424, 1423f, 1424f
FDG–PET imaging, 1420
IASLC Lung Cancer Staging Project, 1423t
metastatic sites, 1420
Mountain–Dresler lymph node map, 1422t
needle aspiration techniques, 1422
neoadjuvant therapy, 1429–1432, 1431t
pulmonary resection for, 1425–1427, 1426f
postoperative complications after, 1425t
sleeve lobectomy, 1426
sublobar resection, 1426, 1427t
survival after, 1427
recurrence, 1427
risk assessment, 1424–1425, 1425f
stage III disease, treatment of, 1429–1432
superior sulcus tumors, 1432–1433, 1433f
thoracentesis, 1422
TNM classification for staging system of
6th ed., 1419t
7th ed., 1421t
tumor biology, 1418–1420
Nonsteroidal anti-inflammatory drugs (NSAIDs), 99, 298, 299t, 725, 1778
colorectal cancer risk, prevention of, 1105
and peptic ulcer disease, 1071–1072
for pericarditis, 1577
and risk of GI hemorrhage, 1063
and wound healing, 65
Non–ST-segment elevation myocardial infarction (NSTEMI), 1522, 1523
Norepinephrine, 163
in acute liver failure, 940

in hepatorenal syndrome, 952
Normal saline (NS), 366
Normal water exchange/electrolyte exchange, 197–198
Normocapnea, 354
Normoglycemia maintenance during surgery, 143
Normoglycemic in intensive care evaluation survival using glucose algorithm regulation (NICE – SUGAR), 186
Normosol®, 354
Normothermia maintenance during surgery, 143
Norwood procedure for hypoplastic left-heart syndrome, 1500f, 1501
Noxious stimuli, 362
Nuclear factor of activation and transcription (NFAT), 519
Nuclear medicine imaging, thyroid gland, 1345
Nucleic acids, in diet, 23
Nucleic acid testing (NAT), 532
Null cell adenomas, 1404. *See also* Pituitary adenomas
Nuss procedure, 1454, 1846, 1846f
Nutrition. *See also* Enteral nutrition; Nutritional support; Total parenteral nutrition (TPN)
  access routes for, 33–38
  assessment of, 23–26
    anthropometric measurements and nutritional indices, 24–25
    indirect calorimetry, 26
    metabolic energy expenditure, 26
    nitrogen balance, 25–26
    subjective global assessment, 24
  macro- and micronutrient in, selection of, 36–37
  metabolic response and, 222
  metabolism and (*see* Metabolism)
  and postoperative complications, 31
  routes of administration, 37–38
  for specific indications
    acute pancreatitis, 183
    obesity, 183
    stress gastrointestinal bleeding prophylaxis, 183–184
Nutritional indices, 24
Nutritional risk index (NRI), 24
Nutritional support
  bariatric surgery and, 38
  in critical care, 32–33
  in elective surgery, 32
  enterocutaneous fistulas and, 39
  geriatric patients and, 39
  in heart failure, 38

in infectious processes and fever, 38
in liver failure, 38
postoperative ileus and, 39
radiation and chemotherapy enteritis and, 39
in renal failure, 38
in respiratory failure, 38
short bowel syndrome and, 39
thermal injury and, 39
Nyquist limit, 1586

O

Obesity, 20, 42, 183, 252, 296, 738–752
and cancer, 52
definition, 738
diagnosis, 738–739
dietary risk factors and, 271–272
environment, role of, 43, 43f
epidemiology, 739
epigenetic mechanisms and, 42–43
genetics and, 42–43
and liver cancer, 947
liver disease associated with, 51
medical management, 739–741
and metabolic disease, 47–48, 738 (*see also* Metabolic disease)
metabolic thrift and, 42
and multiple diseases, 739
and obesity, 51–52
physiology of
adipocyte physiology, 46–47
adipostat, 43–44
metabolic rate, 45–46
microbiome, 47
satiety and hunger, 44–45, 44f, 46f
and risk of colorectal cancer, 1118
surgical management, 741–752
wound healing, effect on, 63–64
Obesogenic environment, 42
Obstructive sleep apnea (OSA), 253, 296
Obturator hernia, 1254–1255
Obturator sign, 1200t
Octreotide, 774, 865, 1074
in variceal bleeding, 959
Octreotide acetate, in acromegaly, 1413t

Octreotide LAR, in acromegaly, 1413t
^{123}Iodine Scintigraphy, 1345
Office of Naval Research (ONR), 347
Ofloxacin, in spontaneous bacterial peritonitis, 969
Ogilvie syndrome. *See* Colonic pseudo-obstruction
Oil cysts, 1301, 1301f
Oligopeptides, 779
Ombitasvir, 948
Omega-three fatty acids, 181, 183
Omental cysts, 1912, 1913f
Omental flaps, 1451, 1453f
Omeprazole, 729
Omphalocele, 1870–1873, 1871f, 1872f, 1872t
Omphalomesenteric duct, 1907
Oncology
  cancer immunology, 272–273
  cell cycle, 272
  chemotherapy in, 279–282
    cancer biostatistics, 285
    clinical trials, 285–286
    screening, 283–284
    staging (traditional/genetic), 282–283
    surveillance, 284–285, 285t
    therapeutic agents, 280t–282t
  dietary risk factors and obesity, 271–272
  environmental risk factors, 269, 270t
    tobacco and cancer, 270, 270t
  epidemiology, 265, 266t
  genetic risk factors, 265
    familial adenomatous polyposis (FAP), 269
    familial cancer syndromes, 266, 268t
    familial gastric cancer, 269
    hereditary breast and ovarian syndrome (HBOC), 269
    hereditary nonpolyposis colon cancer (HNPCC), 266–269, 268t, 269t
    von Hippel–Lindau Disease (VHL), 269
  radiation therapy
    approaches, 279
    delivery mechanism, 277
    delivery modalities, 279
    radiation therapy delivery, 279
    tissue response to radiation, 277–279
  resection, extent of
    lymphadenectomy, 275–276

of metastatic disease, 276
pathologic margins, 275
surgeon in, 273–274
curative resection, 274–275
diagnosis and staging, 274
palliative surgery, 275
surgical intent, 274
surgical outcomes, cancer-related
disease recurrence, 276–277
progression-free survival, 277
return to intended oncologic treatment (RIOT), 277
viral risk factors, 270–271, 271t
hepatitis B (HBV)/hepatitis C viruses (HCV), 271
human herpes virus 8 (HHV-8), 271
human papilloma virus (HPV), 271
Onco*type* DX Colon Cancer Assay, 1123, 1125
Onlay prosthetic technique, 1250
Open-loop obstruction, 783, 786. *See also* Bowel obstruction
Open mitral commissurotomy (OMC), 1511–1512
Open necrosectomy, 866
Open pneumothorax, 400
Open reduction, internal fixation (ORIF), 469
Operational tolerance, 518
Operation Iraqi Freedom, 354
Operative interventions, burns
excision and grafting, 223–226
extremity treatment, 227
order of coverage, 226–227
skin alternatives, 227
Opioids (narcotics), 244
Oral anticoagulation, 78, 79
Oral cavity, 638–639, 638t
Oral contraceptives, 299t, 1926
Oral glucose tolerance test, 850
Oral hypoglycemic agents, 252
Orbital fractures, 382, 382f
Organ donation, 493, 530–531
deceased donation, 530
living donation, 530, 531f
Organ Donation Breakthrough Collaborative, 552
Organ donor work-up, 532t
Organic acid production, 209
Organic compounds, causing burn, 216

Organ Injury Scale (OIS), 423
Organ preservation, 537–538, 538t
Organ procurement
  operation, 533–537, 533f, 534f, 537f, 538f, 539f
  and preservation, 530–539, 532f
  and transplantation network, 553
Organ procurement organization (OPO), 530, 614
Organ selection, 531–532
  donor history, 532
Oriental cholangiohepatitis, 999
Orlistat (Xenical), 741
Oropharynx, 638t, 639–640, 640f
Orotracheal intubation, 387
Orthopedic Trauma Association (OTA), 445
Orthopedic trauma care, 444
Orthopedic trauma surgery, 448t
  bleeding pelvis, 444–446, 445f, 445t
  complicated pelvic injuries, 446–447
  and complications, 453, 453f
  essential damage control surgery, 447–448, 447f
  hemorrhage, 444
  limit disability, 450–454, 451f
  pelvic packing, 446
  polytrauma situations, 448
  to save life, 444
  to save limbs, 448–450, 448t, 449f
  and vascular injuries, 449
Osmolality of body fluids, 194, 195
Osmoreceptors, 196
Osmoregulation, 194, 195f
Osmo-sodium receptors, 196
Osmotic activity of body fluids, 193
Osteitis fibrosa cystica, 1372
Osteochondromas, of rib, 1450, 1450f
Osteocytic osteolysis, 1364
Osteogenic sarcoma, 1851–1852
Osteomas, 1110–1111
Osteoporosis and elderly patients, 475
Osteosarcoma, 2026t
Osteotomy, 387
Ostium primum, 1481. *See also* Atrial septal defect (ASD)
Ostium secundum, 1481. *See also* Atrial septal defect (ASD)
Outcome feedback, 321

Outcome measures. *See also* Surgical care quality measurement
limitations, 315
strengths, 315
Overfeeding, 26–27
Overweight, 20
Overwhelming postsplenectomy infection (OPSI), 415
Oxaliplatin, in colon cancer, 1135
Oxidative burst and oxidant metabolites, 91–93, 91t
Oxidative phosphorylation, 15–16, 17f
Oxygen
consumption, 160
delivery, 158
delivery and consumption, 170–171, 171t
effect, 278
utilization, 152
Oxygenation, 174, 219
monitors of, 255–256
Oxygenation Index (OI), 1813
Oxygen debt, 490
Oxygen dissociation curve, 180t, 1809f
Oxygen saturation monitoring, 676
Oxyntic glands, 715
Oxyntomodulin, 741

P

PA banding, 1484–1485
Packed red blood cells (PRBC), 345, 345f
Paclitaxel, 1325
Paget disease of breast, 1330–1331, 1331f
Paget–Schroetter syndrome, 1457
Pain, 228
chronic, 228
management
acute pain, 228
chronic pain/substance abuse, 228
postoperative, 261–263
metabolic response to, 31
pancreatic cancer, 885, 896–897
Painless thyroiditis, 1347
Palliative surgery, 275
Pancreas, 532, 840–858
anatomy, 415–416, 415f, 416f, 850, 851f
blood supply, 851–853, 852f

body of pancreas, 851
ductal anatomy, 851
head and uncinate process, 851
innervation, 853, 854f
lymphatic drainage, 853, 853t
pancreatic cancer and, 854–856, 855f, 855t
pancreatic neck, 851
pancreatitis and, 856, 856f
surgical significance, 853–856
tail of pancreas, 851
trauma/pancreatic injury and, 856
venous drainage, 853
annular, 843–844, 843f
autodigestion of, 846–847
congenital anomalies, 842f, 843–844, 843f
cysts, 1927
diagnostics, 416–417, 416f
divisum, 842f, 843, 1926, 1926f, 1927
ductal anatomy, 1926f
embryology, 840–841, 841f, 843, 1925–1926, 1925f
endocrine
function, 848–850
structure, 845
tests, 850
endocrine lesions of, 1927–1929
epidemiology, 416
exocrine
function, 845–847
structure, 844–845, 844f
tests, 847–848
heterotopic, 844
imaging studies, 856
abdominal plain films, 856–857
computed tomography, 857
endoscopic retrograde cholangiopancreatography, 857–858
endoscopic ultrasound, 857
magnetic resonance cholangiopancreatography, 857
ultrasound, 857
upper gastrointestinal series, 857
juvenile adenocarcinoma of, 1927
neoplasms, 1927
OIS-AAST grading scale, 416t
pediatric, 1925–1929

physiology, 845–850
relationship to adjacent structures, 851
treatment, 417, 417f
Pancreas after kidney transplantation (PAK), 610, 611
Pancreas DRI (PDRI), 615
Pancreas procurement, 536
Pancreastatin, 850
Pancreas transplant alone (PTA), 610–612
Pancreas transplantation, 610, 610f, 616t
back-table preparation, 616–617, 616f, 617f
Banff classification, 620t
complications, 618–619
deceased donor pancreas allocation, 614
and diabetes mellitus, 621–622
donor evaluation, 614–615, 615t
evaluation and screening, 612–613
future of, 625
graft failure rates for, 619f
graft survival, 621f
Pancreas transplantation (*continued*)
immunosuppression, 618
living donor kidney-pancreas transplantation, 611, 612f
PAK, 611
patient selection, 611
procurement technique, 615–616
PTA, 611–612
recipient operation, 617–618
recurrent autoimmunity, 620–621
rejection diagnosis and treatment, 619
solitary, 621
SPK, 611
waiting list patients, 613
Pancreatic and biliary injury, in children, 469
Pancreatic cancer, 858, 879
abdominal pain and back pain in, 856
acinar cell carcinomas, 882
adenosquamous carcinoma, 882
adjuvant and neoadjuvant therapy, 893–896, 895t
American Joint Committee on Cancer (AJCC) staging for, 885, 885t
borderline resectable, 855, 855f, 855t
classification, 881, 882t
clinical presentation, 885, 886t
criteria for resectability in, 855t

cystic epithelial tumors, 882–885
ductal adenocarcinomas, 881–882, 882f
epidemiology, 879, 880f
genetic syndromes associated with, 880, 881t
giant cell carcinomas, 882
hereditary, 881t
intraductal papillary-mucinous neoplasms, 883–884
laboratory studies, 886
locally unresectable, 855, 855t
and lymph node dissection, 855–856
metastatic, 855, 855t
molecular genetics, 881, 881t
mucinous cystic neoplasms, 883
non-endocrine, 879–897
occult metastatic disease, 889t
palliation, 896
duodenal obstruction, 896
jaundice, 896
pain, 896–897
pancreatic anatomy and, 854–856
pancreatoblastomas, 882
preoperative staging, 888, 888t, 889f
radiologic imaging, 886–888, 887f, 888f
resectable, 855, 855f, 855t
resection, 889–893
risk factors, 879–880, 880t
serous cystic neoplasms, 883
solid-pseudopapillary tumors, 884–885
staging laparoscopy, use of, 888–889
unresectable, radiation and chemotherapy for, 897
Pancreatic compartment syndrome, 871
Pancreatic divisum, 1926, 1926f
Pancreatic ductal adenocarcinoma (PDAC), 881
Pancreatic endocrine neoplasms (PENs), 899–911
classification, 899, 900t
computed tomography, 902, 903f
diagnosis and management, 902, 903f
endoscopic ultrasound, 904, 904f
familial genetic syndromes associated with, 901–902, 901t
functional, 900, 900t
gastrinoma, 906–908, 907f, 907t, 908f
glucagonoma, 909–910, 910f, 910t
insulinoma, 905–906, 905t, 906f

intraoperative ultrasound, 904
localization and staging, 902–904
magnetic resonance imaging, 902–903
metastatic, 910–911
molecular genetics, 900–902
nonfunctional, 900, 910
origins, 899
pancreatic endocrine microadenomas, 899
poorly differentiated, 900
presentation and evaluation, 902
somatostatinoma, 910, 910t
somatostatin receptor scintigraphy, 903–904, 903f
surgical exploration, 904–905
venous sampling, 904, 904f, 905f
VIPoma, 908–909, 908t, 909f
well-differentiated, 899–900
World Health Organization (WHO) classification, 899, 900t
Pancreatic enzymes, 846–847
Pancreatic fluid, 845–846
Pancreatic head resection, 875, 875t
Pancreatic intraepithelial neoplasia (PanIN), 882
Pancreatic islet cells, 845, 845t
Pancreatic necrosis, 860
Pancreaticoduodenal artery aneurysm, 1661
Pancreaticoduodenectomy (PD), 879, 889–893, 890f, 1030
complications after, 892–893, 893t
minimally invasive, 892, 892t
mortality following, 892
survival after, 893, 894f
Pancreatic polypeptide (PP), 741, 845, 847, 850, 902
Pancreatic pseudocysts, 856, 856f, 1927
Pancreatic secretory trypsin inhibitor (PSTI), 847
Pancreatic stellate cells (PSCs), 870, 871
Pancreatic tumors, 1379, 1379f
Pancreatitis, 135–137, 843, 846
acute, 183, 848, 859–869, 1926–1927
classification, 859, 860t
clinical presentation, 862
complications, 865–869, 865t
CT scanning, 862–863, 862f, 864
definitions, 859
Determinant-Based Classification, 863, 864t
diagnosis, 862–863

etiology, 861–862, 861t
and infected necrosis, 865–867
laboratory tests, 862
management, 864–865
MRI and MRCP, 863
pancreatic cancer and, 885
pathology and pathophysiology, 859–861
plain radiographs, 862
Revised Atlanta Classification, 863, 864t
scoring systems, 863–864
severity assessment, 863, 864t
ultrasonography, 862
autoimmune, 1030
chronic, 870–876
and bile duct strictures, 1029–1030, 1029f, 1030f
clinical presentation, 871
complications of, 871t
epidemiology, 870
ERCP Cambridge classification system, 872, 873t
etiology, 870
medical management, 873
pathophysiology, 871, 871f
radiographic evaluation, 872, 872f, 873t
surgical management, 873–876
gallstone, 1003
hereditary, 870
hypocalcemia and, 206
idiopathic, 862
interstitial edematous, 859, 860t
necrotizing, 859, 860t
pancreatic anatomy and, 856
pediatric, 1926–1927
Pancreatoblastomas, 882, 1927
Pancreatoduodenectomy (PD), 875
Panel of reactive antibodies (PRA), 592
Paneth cells, 772
Panfacial fractures, 384, 384f
Papaverine, 512
Papillary cystadenomas, 1436
Papillary cystic neoplasm, 1927
Papillary fibroelastomas, 1516
Papillary microcarcinoma, 1351
Papillary muscles, 1506

rupture, 1523–1524
Papillary thyroid carcinoma (PTC), 1351
variants of, 1351
Papillitis, 1031
Papillomatosis, 1046
Pap smear, 545
Para–aminobenzoic acid (PABA) test, 847
Paracentesis, in ascites, 967–968
Paradoxical aciduria, 210
Para esophageal hernia (PEH), 651
Paralysis, sedation and, 178
Paralytic ileus, 800
Paramedics, 352
Paramesonephric ducts, 1933
Paraparesis, 363
Paraplegia, 1749
Parastomal hernia, 1252–1254
European Hernia Society (EHS) classification, 1252t
fascial repair, 1252
incidence, 1252
indications for repair of, 1253t
intraperitoneal inlay mesh, 1253
laparoscopic repair, 1253
prosthetic repair, 1253, 1253f
stomal relocation, 1253
Parasympathetic afferent fibers, 714
Parathyroid carcinoma, 1378
Parathyroid glands, 1343, 1361
anatomy, 1361, 1362f, 1363f
calcium and phosphate metabolism, regulation of, 1364, 1364t
calcitonin, 1365
mineral homeostasis, 1365, 1366f
parathyroid hormone, 1364–1365, 1365f
vitamin D, 1365, 1366f
hypercalcemia, 1365–1368
hyperparathyroidism, 1370–1378
hypocalcemia, 1368–1370
multiple endocrine neoplasia, 1378–1381
physiology, 1361, 1364f
calcium, 1361–1363
phosphate, 1363–1364
Parathyroid hormone (PTH), 778, 1361, 1364–1365, 1365f
Parathyroid hormone-related peptide (PTHrp), 206t

Parenchymal lesions, 372
Parenteral nutrition, 182
Parenteral solutions
albumin, 199
artificial oxygen carriers, 199
colloids, 199
crystalloids, 198–199, 198t
dextrans, 199
gelatin, 199
hetastarch, 199
Parietal cell proton pump, 719
Paritaprevir, 948
Parkland formula, 219, 220
Partial thromboplastin time (PTT), 736
Partridge hernia, 1257
Pasireotide, in Cushing disease, 1414t
Passenger leukocytes, 520
Patent ductus arteriosus (PDA), 1495–1496
Patent foramen ovale (PFO), 1482
Patent processus vaginalis, 1873
Pathogen identification, 129
Patient education, 292
Patient safety
consensus development, 327, 328t
consensus, accreditation, and payment, 328, 328t
consensus and accreditation, 327–328
culture, 323–324
culture assessment, 324–326
evidence base for, 326–327, 327t
implementation strategies
collaborative groups of hospitals, developing, 330
crew resource management, 330
pharmacists to rounds, adding, 329
rapid response team (RRT), 329–330, 330t
indicators, 329
leadership and policy, 324
patient and family involvement, 330–331
problem, 323
safety *vs.* quality, definitions, 323
Swiss cheese model, 324
taxonomy for, 331
and World Health Organization, 329
Patient safety indicators (PSI), 329

Pay for performance, 320
Pazopanib, 2021
Peak systolic velocity (PSV), 1624, 1624f
Pectoralis major muscle rotation flap, 1451, 1452f
Pectoralis minor syndrome, 1639, 1641f
Pectus carinatum, 1451, 1454–1456, 1846
Pectus excavatum, 1451, 1454–1456, 1454f–1456f, 1844–1845
  minimally invasive repair/Nuss procedure for, 1846, 1846f
  surgical correction, 1845, 1845f
Pectus index, 1845
Pediatric Emergency Care Applied Research Network (PECARN), 460, 460f
Pediatric End-Stage Liver Disease (PELD), 553
Pediatric oncology group grading system, 1967
Pediatric patients
  abdomen, 1870–1929
  ascites in, 1913–1914, 1913t, 1914t
  chest, 1844–1867
  gastrointestinal disorders, 1875–1914
  genitourinary system, 1933–1946
  head and neck, 1837–1843
  thoracic tumors, 1851–1855
  tumors of liver, 1914–1918, 1915t
Pediatric Plastic Surgery, 2062
Pediatric trauma, 456–471
  abdominal, 467–469
  epidemiology, 456
  initial resuscitation, 457–460, 458f
  injury prevention, 470–471
  management of, 460–470
  pediatric verbal scores, 459t
  pelvic fractures, 469–470
  performance indicators, 457
  prehospital care, 461
  solid organ injury, 467t
  spinal, 461–466
  thoracic, 466–467
Pediatric vital signs, 457t
Pegvisomant, in acromegaly, 1413t
Pelvic congestion syndrome, 1797
Pelvic floor muscles, 1053–1054, 1223–1224, 1224f
Pelvic fractures
  in children, 469
  in pregnancy, 484–485

Pelvic kidney, 1934
Pembrolizumab, 273
Penetrating brain injury (PBI), 366
Penetrating trauma, 340, 342
Penis, anomalies of, 1941–1942
Pentalogy of Cantrell, 1871
Pentamidine, 573
Pentastarch, 159
Pentose phosphate pathway. *See* Phosphogluconate pathway
Pepsin, 722, 778
Pepsinogen, 716
Peptic ulcer disease, 725, 1071–1073
  angiographic embolization, 1073
  clinical presentation, 1071
  endoscopic treatment, 1072
  and GI bleeding, 1071
  and hemorrhage, 731
  medical treatment, 1072
  NSAID use and, 1071–1072
  operative treatment, 1072–1073
  pathogenesis, 726t
Peptic Ulcer Perforation (PULP) score, 733
Peptides, neurohumoral, 799
Percutaneous balloon aortic valvotomy (PBAV), 1509
Percutaneous balloon mitral valvuloplasty (PBMV), 1511
Percutaneous cholecystostomy, for acute cholecystitis, 1002, 1003f
Percutaneous coronary intervention (PCI), 299, 300, 1527, 1528f
Percutaneous endoscopic gastrostomy (PEG), 37–38, 691, 797
Percutaneous renal artery angioplasty, 1666–1667
Percutaneous transhepatic cholangiography (PTC), CBD stones, 1009
Percutaneous transhepatic portal venous sampling (PTPVS), for pancreatic endocrine neoplasms, 904, 904f
Percutaneous transluminal angioplasty (PTA), 1692–1693, 1692f, 1693t
Percutaneous vascular intervention, 1692
Perfadex, 596
Perforation risk, 132
Perforin, 95
Perianal Paget disease, 1195, 1195f
Pericardial biopsy, 1582, 1582f
Pericardial constriction, 1579–1580, 1580f
Pericardial cysts, 1576, 1851
Pericardial effusion, 1578–1579, 1578f, 1579f
Pericardial fluid, 1582

Pericardiectomy, 1582–1583, 1583f
Pericardiocentesis, 1581–1582
  complications, 1582t
Pericarditis
  acute, 1576–1578
  AIDS and, 1577
  causes, 1576t
  connective tissue disease and, 1577
  idiopathic, 1577
  medications and, 1577
  myocardial infarction and, 1577–1578
  and pain, 1577
  purulent, 1577
  radiation-induced, 1578
  tuberculous, 1577
  uremic, 1577
  vasculitis and, 1577
  viral, 1577
Pericardium, 1575–1583
  acute pericarditis (*see* Pericarditis)
  anatomy, 1575, 1576f
  biopsy, 1582, 1582f
  calcification, 1579, 1580f
  congenital abnormalities, 1576
  constriction, 1579–1580, 1580f
  diagnostic studies, 1576
  drainage, 1582, 1582f
  embryology, 1575
  history, 1575
  malignant tumors, 1580–1581
  parietal, 1575
  physiology, 1575, 1576f
  primary tumors, 1580
  reconstruction of, 1582
  visceral, 1575
Periclavicular incision, 386
Perineal body, 1053, 1172
Perineal hernia, 1257
Perioperative radiation therapy, 279
Peripancreatic fluid collection, acute, 860t
Peripheral arterial disease (PAD), 1592, 1672, 1686–1687
  risk factors for, 1687
Peripheral cholangiocarcinoma. *See* Bile duct carcinomas

Peripherally inserted central catheters (PICCs), 37
Peripheral aneurysms
  clinical manifestations, 1769
  definition, 1768
  incidence, 1768
  pathogenesis, 1768
  peripheral aneurysms, 1768
Peripheral nerve blockade (PNB), 247–248
Peripheral parenteral nutrition (PPN), 37
Peripheral vascular disease (PVD), 65
  pathophysiology, 65
  symptoms, 65
Peritoneal Cancer Index (PCI), 1154
Peritoneal Surface Disease Severity Score (PSDSS), 1154
Peritoneovenous shunts, 968, 968f
Perivascular hernia, 1257, 1257f
Periviable birth, 1975
Permanently defective sphincter, 662
Permissive hypotension, 159, 489
  concept of, 355
  vs. aggressive fluids, 355–356
Persistent visceral hypoperfusion, 161
Pertuzumab, for breast cancer, 1325
Peutz–Jeghers syndrome, 1114, 1114t
  and small bowel tumors, 828
Peyer patches, 765, 775
  epithelial anatomy, 776f
Pfannenstiel incision, 545
p53 gene, 881, 1094, 1418
Phagocytosis, 88
  mononuclear phagocytes, 94
Pharmacists, 329
Pharmacotherapy and obesity, 740–741
Pharyngeal arch structures, 1838t
Pharyngeal pH catheter, 676
Pharyngeal tumors, 641
Pharyngitis, 631–632
  acute, 631
Phasix® mesh, 1229
Phenol, causing burn, 216
Phentermine, 741
Phenylephrine, 163
Phenylethanolamine-N-methyltransferase (PNMT), 1387

Phenylpropanolamine, 740
Pheochromocytomas, 1380, 1394–1396
  diagnosis, 1394–1396, 1395f
  extraadrenal, 1394
  familial, 1394
  incidence, 1394
  rule of tens, 1394
  signs and symptoms, 1394
  treatment, 1396
Phlebectomy, 1792
Phlegmon management, 132
Phosphate, 1363–1364, 1364f
  metabolism, regulation of, 1364–1365, 1364t
  normal plasma level, 1363
Phosphatidylcholine, 14
Phosphatidylinositol-4,5-bisphosphate (PIP_2), 719
Phosphogluconate pathway, 8, 11, 11f
Phospholipase A, 846
Phospholipase C, 719
Phospholipids
  formation of, 13
  role of, 13–14
Photocoagulation, for hemorrhoids, 1179
Photodynamic therapy (PDT), for esophageal cancer, 709–710
Photons, 277
Photoplethysmography (PPG), 1597, 1598f, 1604
Phototherapy, 1823
Phrenic nerve palsy, 1244
Phyllodes tumors, 1331–1332, 1331f
Physical activity and obesity, 740
Physician Value-Based Payment Modifier program, 320
Piezoelectric crystals, 1980
Pigeon chest deformity, 1454
Piggyback technique, 562. *See also* Hepatic transplantation
Pigment gallstones, 998, 998f
  black, 999
  brown, 999
PI3K/AKT/MTOR signaling pathway, 1122
Pilonidal disease, 1186
p-Isopropyl acetanilidoiminodiacetic acid (PIPIDA), 1919
Pituitary adenomas, 1379, 1403
  endocrine evaluation, 1405–1406
  imaging

CT scanning, 1407
magnetic resonance imaging, 1407–1408
medical therapy, 1412–1414
molecular pathogenesis, 1404–1405
neurologic evaluation, 1407
pathologic classification, 1403–1404
Pituitary carcinoma, 1404. *See also* Pituitary adenomas
Pituitary cysts, 1404, 1407
Pituitary gland, 1402
anatomy, 1402, 1403f
endocrine evaluation, 1405–1407
hypersecretory syndromes, 1405–1406
hypopituitarism, 1405
pituitary incidentaloma, 1406–1407
imaging, 1407–1408
molecular pathogenesis, 1404–1405
neurologic evaluation, 1407
sellar lesions
differential diagnosis of, 1403t
pathology of, 1403–1404
surgery, 1408
approach, 1408, 1408f
intraoperative MRI (iMRI) imaging, 1409
microscopic and endoscopic approaches, comparison of, 1410t
navigation, 1408
postoperative management, 1409–1410
resection adequacy, determination of, 1409
results and complications, 1410–1411, 1410t, 1411t
socioeconomic considerations, 1414–1415
surgical technique, 1409
visualization, 1408
tumors of, 1403t (*see also* Pituitary adenomas)
Pit vipers, 497
Plain radiographs, for diverticular disease, 1166
Plain skull radiographs, 364. *See also* Head trauma/head injury
Plasma, 19, 20f
Plasmacytoma, of rib, 1451, 1451f
Plasma hyperglycemia, 195
Plasmalyte®, 354
Plasma proteins, 193
Plasmin, 347
primary inhibitors of, 72
Plasminogen, 71

Plasminogen activator inhibitor (PAI), 71
Plastic and reconstructive surgery
  classification, 2036t
  definition, 2031
  nonsurgical therapy, 2033
  reconstructive ladder, 2034t
  spectrum of, 2032t
  treatment, 2033
Platelet
  activation, 217
  aggregation, 69
    abnormal, 80
  disorders, 81
  granules, 99
  recruitment/activation, 98–99, 99t
  wound healing, role in, 55–57, 57f
Platelet-activating factor (PAF), 72
  heme oxygenase, 115
  hydrogen sulfide, 115
  kinins, 112–113
  neuropeptides, 113–114
  nitric oxide, 114–115
Platelet-derived growth factor (PDGF), 57, 98, 944
Platelet-derived growth factor receptor alpha (PDGFRA), 767
Platelet/endothelial cell adhesion molecule 1 (PECAM-1), 88
Platinum agents, 1325
Platysma muscle, 387
Pleomorphic adenoma, 635
Plethysmography, 1584
  air, 1592, 1604
  digital pressures and, 1597, 1598f
  photo, 1597, 1598f
  techniques
    pulse volume recordings, 1592–1593, 1593f
    volume flow, 1592
Pleural diseases, 1467–1468, 1865–1867, 1866f
  empyemas, 1469–1470, 1470t
  mesothelioma, 1470–1472, 1470f, 1471t
  pleural effusions, 1468–1469, 1468t, 1469f
Pleural effusions, 1468–1469, 1468t
  exudative, 1468, 1469
  Light criteria, 1468, 1468t
  management, 1469

transudative, 1468–1469
Pleuropulmonary blastomas, 1852
Plicamycin, for hypercalcemia, 1368
Plug-and-patch repair, 1237
Plummer disease, 1347
Pneumatosis cystoides intestinalis, 1107, 1109
Pneumatosis intestinalis, 1886, 1887f
Pneumocystis carinii, 550, 573
Pneumonia, 229
Pneumothorax, 396, 397f, 1464–1465, 1465f, 1867
diagnosis of, 396
occult, 396
simple, 396
treatment of, 396, 398
types of, 396
Pneumovax, 1284
Poland syndrome, 1457, 1458f, 1846–1847
Polidocanol, 1072
Politano–Leadbetter transvesical ureteroneocystostomy, 547
Polycystic liver disease (PLD), 979, 979f
4-0 polydioxanone, 597
PolyHeme, 199
Polymerase chain reaction (PCR), 188
Polymicrobial infections, 140
Polymorphonuclear leukocytes (PMNs), 155
in wound healing, 57–58, 58f
Polypropylene methylmethacrylate (PPM) sandwich mesh, 1451
Polytetrafluoroethylene (PTFE), 1451, 1610, 1627
Popliteal artery aneurysms
clinical manifestations, 1774
diagnosis, 1774
history, 1774
incidence, 1774
results, 1775–1776
surgical technique, 1775
Popliteal trauma, 439
Porcelain gallbladder, 999, 1033, 1034f
Porphyrias, 18
Portacaval shunts, 962
disadvantages, 962
end-to-side, 962, 962f
side-to-side, 962, 963f
Portal hypertension, 943, 954–969

anatomy related to, 954, 955f
Budd–Chiari syndrome and, 955–956
complications, 957–969
ascites, 966–969
bleeding from varices, 957–966
hepatic encephalopathy, 957
definition, 954
etiology, 955–957, 956t
physiology, 954–955
portal vein thrombosis and, 956–957
splenic vein thrombosis and, 957
Portal hypertensive gastropathy, 966
Portal vein (PV), 853, 954, 955f
Portal vein embolization (PVE), 975, 988–989
Portal vein thrombosis (PVT), 570, 956–957, 1287. *See also* Hepatic transplantation
causes, 956
cirrhosis and, 956
diagnosis, 956
treatment, 956–957
Portoenterostomy, 1921–1923, 1923f
Portopulmonary hypertension, 553, 952–953
Positional therapy, 178
Positive end-expiratory pressure (PEEP), 175, 176, 369, 398, 593
Positron emission tomography (PET), 1995, 2013
Crohn disease, 813
thyroid gland, 1345–1346
Postanesthesia care, 258–261, 259t
Postductal Alveolar-Arterial Oxygen Gradient, 1813
Postembolization syndrome (PES), 1658
Posterior component separation, 1248–1249, 1249f, 1250f
Posterior descending artery (PDA), 1519
Posterior fossa lesions, 372–373. *See also* Head injuries
Posterior urethral valves, 1940, 1940f
Postgastrectomy syndromes, 735. *See also* Gastroduodenal ulceration
Posthepatic mesenchymal plate (PHMP), 1861
Postinfarction ventricular septal defect, 1523
Postinjury management, 488–493
abdominal compartment syndrome, 490–491, 490t
acute traumatic coagulopathy, 488
damage control resuscitation, 489–490, 489t
endpoints of resuscitation, 490
nutritional and metabolic support, 492
organ donation, 493

traumatic brain injury, 491–492, 491t
traumatic coagulopathy, 488
Postintubation stenosis, 1472, 1474f
Postoperative bile duct strictures. *See* Bile duct strictures
Postoperative fluid therapy and monitoring, 201
Postoperative ileus, 1059
Postpartum thyroiditis, 1347–1348
Postpyloric tube feeding, 182
Postthrombotic syndrome (PTS), 1781
Posttransplant lymphoproliferative disorder (PTLD), 551, 620. *See also* Renal transplantation
Potassium, 23, 193
hyperkalemia, 204, 204f
hypokalemia, 204–205, 204t
requirements, 200
Potassium titanyl phosphate (KTP), 1791
Potentially survivable (PS) patients, 339
Potentiation, 721
Potts shunt, 1487
Pouch of Douglas, 1172
Power Doppler, 1586
Practice Guidelines on Urotrauma, 423
Pramlintide (Symlin), 741
Prealbumin, as nutrition biomarker, 25, 25t
Preauricular cysts, 1839–1840
Preauricular pits, 1839–1840
Preauricular sinuses, 1839–1840
Preeclampsia, in pregnancy, 485
Pregnancy
appendicitis, 1981–1982
biliary tract disease, 1984–1985
colorectal cancer, 1986–1987
fetal interventions, 1827–1834
intestinal obstruction, 1985–1986
physiologic changes, 484t
trauma in, 481–486
abruptio placentae, 485
amniotic fluid embolism, 485
cardiovascular system, 483
disseminated intravascular coagulation, 485
DVT and PE, 486
emergent caesarian section, 485–486
epidemiology, 481

evaluation, 482–484
fetal trauma deaths, 482t
fetus monitoring and evaluation, 484
frequency of injury, 484t
gastrointestinal system, 483
genitourinary system, 483
hematologic system, 483–484
patterns of, 481–482
pelvic fractures, 484–485
preeclampsia/eclampsia, 485
pulmonary system, 483
radiographic imaging, 484, 485t
social and ethical considerations, 486
team approach, 486
uterine rupture, 485
Prehospital blood protocols, 356
Prehospital Use of Plasma in Traumatic Hemorrhage (PUPTH trial), 354
Prenatal diagnoses, 1828
Preoperative risk assessment
age, 294–296, 295t
anesthesia, 292
direction of care, 297
disparities, 294
goal of, 289
medical comorbidity
anemia, 296
frailty, 296–297, 297t
obesity/obstructive sleep apnea, 296
preoperative functional status, 296
medication management, 297–298, 298t, 299t
organ system guidelines
cardiovascular, 298–302, 300t
hepatic, 305–307
pulmonary complications, 302–305, 303t
renal dysfunction, 307–309, 308t
risk stratification, 291–292, 291t, 292t
surgical mortality/complications, 289–291, 290t, 291t
surgical procedure, 294
Preperitoneal fascia, 1219
Prepubertal testicular tumors, 1943–1944, 1943f, 1944f
Prepuce, anomalies of, 1941–1942
Preterm birth, 1976
Prevacid, 670

Prevention of Postoperative Adhesion (POPA), 791
Primary arterial infection. *See* Arterial infections, primary
Primary biliary cirrhosis (PBC), 557, 948–949
Primary graft dysfunction (PGD), and pulmonary transplantation, 600
Primary hemostasis, 70f
Primary hyperparathyroidism, 205
Primary lung tumors, 1852, 1852t
Primary megaureters, 1937
Primary peritonitis, 1913
Primary prophylaxis, treatment, 180
Primary sclerosing cholangitis (PSC), 557–558, 949, 1028–1029, 1028f
  causes, 1028
  and cholangiocarcinoma, 1028–1029
  clinical presentation, 1028
  diagnosis, 1028, 1028f
  diseases associated with, 1028t
  and liver transplantation, 1029
  medical therapy, 1029
  surgical approach, 1029
  ulcerative colitis and, 1083
Procalcitonin for antibiotic therapy, 187–188
Procedure for Prolapse and Hemorrhoids (PPH), 1180
Process of care measures. *See also* Surgical care quality measurement
  limitations, 315
  strengths, 315
ProCESS trial, 187
Processus vaginalis, 1873
Procoagulant states. *See also* Hemostasis
  acquired
    antiphospholipid antibody syndrome, 77
    heparin-induced thrombocytopenia (HIT), 77–78
    inflammatory bowel disease (IBD), 76
    malignancy, 75
    trauma, 76–77
  inherited
    disseminated intravascular coagulation (DIC), 80
    dysfibrinogenemia, 79
    elevated procoagulant factors, 80
    fibrinolysis, defective, 79
    high risk for thrombosis, defects with, 78–79, 78t
    lipoprotein, 79–80
    lower risk for thrombosis, defects with, 79
Proctocolectomy, 1087

with Brooke ileostomy, 1088–1089
with ileal pouch-anal anastomosis, 1089–1090, 1089f, 1090f
Progastrin, 716
Prognostic nutritional index (PNI), 24
Progression-free survival (PFS), 277
Progressive preoperative pneumoperitoneum, 1247
Proinsulin syndrome, 849
Prolactin, excess levels of, 1405
Prolactinomas, 1403, 1405, 1411. *See also* Pituitary adenomas
medical therapy, 1412, 1412t
Prolene Hernia System (PHS), 1237
Prolonged POI (PPOI), 800
Pronephros, 1933
Proopiomelanocortin (POMC), 1385
Propagated activity, colonic, 1057
Properdin, 1267
Prophylactic palliation, 276
Propofol, 245
Propylthiouracil (PTU), 187
Prostaglandin E_2, 721
Prostaglandins, 110
Prostaglandin synthetase inhibitors, for hypercalcemia, 1368
Prostate, Lung, Colorectal and Ovarian Cancer Screening Trial (PLCO), 1101
Prosthetic bridging repair, 1250
Prosthetic bypass, 1698–1699
Prosthetic graft infections, 1610
by *Staphylococcus epidermidis,* 1610, 1610f
Protease serine 1 (PRSS1), 847
Protein, 23, 181
deficiency of, 63, 78
metabolism, 14, 14t, 15f
serum levels, in nutritional status assessment, 24–25, 25t
wound healing, effect on, 63
Protein C, 78
Protein digestion and absorption, 778–779
Protein disulfide isomerase (PDI), 69
Protein electrophoresis, 1276
Protein S, 71
deficiency, 78
Proteolysis, 218
Proteolytic enzymes, 775, 846
Prothrombin complex concentrate (PCC), 475, 489
Prothrombin G20210A polymorphism, 79

Prothrombin time, 976
Protocol for frostbite injury, 217f
Proto-fangs, 498
Proton pump inhibitors (PPIs), 184, 728–729
  gastrinoma, 907
  peptic ulcer disease, 1072
Proto-oncogenes, 272, 1094
Proto-oncogene smoothened (SMO), 2005
Proximal femur, 451–453
Prune-belly syndrome (PBS), 1945, 1945f
P-selectin glycoprotein ligand-1 (PSGL-1), 72, 73
Pseudoaneurysms, 1566, 1658, 1768
  carotid artery, 1632
  treatment of, 1606, 1606f
Pseudo-Cushing syndrome, 1388
Pseudocysts, pancreatic, 860t, 868–869, 868f
Pseudodiverticula, 1162
Pseudohernia, 1232
Pseudohyponatremia, 202
Pseudohypoparathyroidism, 1369
Pseudomonas aeruginosa, 221
Pseudomyxoma peritonei (PMP), 1206, 1207
Psoas sign, 1200t
Psychiatric medications, 298
Psychological General Well-Being Index, 682
Pubococcygeus muscle, 1054
Puborectalis muscle, 1053, 1172
Pulmonary artery catheter (PAC), 155, 161, 171, 490
Pulmonary artery hypertension (PAH), and lung transplantation, 590
Pulmonary artery occlusion pressure (PAOP), 171
Pulmonary complications in noncardiac surgery, 302, 303t
  perioperative management, 305
  preoperative evaluation, 303
    prior to lung cancer resection, 303
  risk stratification, 302–303
  surgical considerations, 304
Pulmonary contusion, 398
  in children, 466
Pulmonary disease, 252
Pulmonary embolectomy, 1782
Pulmonary embolism (PE), 483, 1714, 1778
  diagnosis of, 1604
  and pregnancy, 486

Pulmonary hypoplasia, 1862, 1862f
Pulmonary infection, 221
Pulmonary lymphomas, 1436
Pulmonary mechanics, 174
Pulmonary metastasis, resection of, 1437–1441
  clinical presentation and diagnosis, 1437–1439, 1437f, 1438f
  criteria for resection, 1439, 1439t
  histologic subtypes, 1440t
  historical background, 1437, 1437f
  preoperative evaluation, 1439–1440
  results, 1440–1441, 1441t
  surgical technique, 1440
Pulmonary sequestration (PS), 1466, 1466f, 1847, 1848f
Pulmonary system, 1811
Pulmonary transplantation, 587–603
  bilateral, 598–599, 598f
  complications, 599–602, 600t
  contraindications, 588–592, 589t, 591f
  donor management, 593–594, 594f
  donor pool, 595–596, 595f
  donor selection, 593, 593t
  future considerations, 603
  gastroesophageal reflux, 602–603
  immunosuppression, 599
  indications, 588, 588t
  lung preservation, 594–595
  operative technique, 597–599
  outcomes, 599
  primary graft dysfunction, 600
  single, 597–598, 598f
  transplantation operation, 596–597, 596f, 597f
Pulmonary vascular beds, 1810
Pulse contour analysis, 173
Pulsed dye laser (PDL), 230
Pulseless disease, 1638
Pulse oximeter, 255
Pulse volume recordings (PVR), 1592–1593
Pulsus paradoxus, 151, 1578
Pulsus parvus et tardus, 1507
Pupillometry, 363
Purpura fulminans, 78
Purulent pericarditis, 1577
Pyloric stenosis, 1904–1905, 1904f, 1905f

Pyloroplasty, 705–706, 706f
Pylorus preserving pancreatoduodenectomy (PPPD), 875
Pyoderma gangrenosum, peristomal, 812, 812f
Pyoderma gangrenosum, ulcerative colitis and, 1084
Pyogenic liver abscess, 930, 931f, 1918
Pyomyositis, 140
Pyruvate kinase deficiency, 1276

Q

Qsymia, 741
Quadriparesis, 363
Quality, definition, 323
Quality-of-Life (QOL) scale, 682
Quantitative analysis of twin studies, 42
Quincke pulse, 1510

R

Rabbit antithymocyte globulin (rATG), 521
Race, burn injury and, 215
Radiation enteritis, 797
Radiation-induced pericarditis, 1578
Radiation therapy, 1987, 2005, 2006
  in breast cancer, 1324
  in cancer management, 277–279 (*see also* Oncology)
  in ductal carcinoma in situ, 1312, 1313t
  in esophageal cancer, 709
Radiofrequency ablation (RFA), 556, 1792
  for splenic disorders, 1286
RAGE molecule, 117
Raloxifene, 1325
  for breast cancer, 1311
Ramipril, 1677
Ramstedt pyloromyotomy, 1905, 1905f
Randomized Evaluation of Normal *versus* Augmented Level Renal Replacement (RENAL) study, 185
Range-of-motion (ROM), 451
Ranitidine, 670
Ranolazine, 1526
Ranson criteria, acute pancreatitis, 863
Rapamycin, 521, 599
Rapid air evacuation, 348
Rapid response team (RRT), 329–330, 330t
Rapid sequence intubation (RSI), 355

hypotension and, 355
hypoxemia and, 355
vs. non-RSI, 355
Ras proteins, 881
Rathke cysts, 1404
Rattlesnakes, 496, 497
Ravitch procedure, 1454, 1455f–1456f
Ray amputation, 1707–1708
Raynaud disease, 1638
Raynaud phenomenon, 1638
Receptive relaxation, 785
Reconstructive breast surgery, 2037
Recovery protocols, enhanced, 261
Rectal biopsy, 1898–1899, 1899f
Rectal bleeding, anal fissure and, 1181
Rectal cancer, 1136. *See also* Colorectal cancer (CRC)
adjuvant chemoradiation for, 1146–1147
adjuvant chemotherapy for, 1147
clinical staging, 1137–1139, 1138f, 1139f
early-stage, local excision for, 1139–1141, 1140f
minimally invasive surgery for, 1144–1146
open *versus* laparoscopic rectal resections, 1145t
outcomes of treatment in, 1147–1448
rectum, anatomy of, 1136–1137, 1137f
transabdominal resection for, 1141
abdominoperineal excision, 1144, 1144f
sphincter saving procedures, 1142–1144, 1142f, 1143f
total mesorectal excision, 1141–1142, 1142f
treatment selection, 1148–1449
Rectal myectomy, 1902
Rectal prolapse, 1187–1189, 1914, 1915f
evaluation, 1188, 1188f
management, 1188–1189
Delorme plication, 1188, 1190f
perineal rectosigmoidectomy, 1188, 1189f
transabdominal rectopexy, 1188, 1191f
ventral rectopexy, 1189
pathophysiology, 1187–1188
Rectovaginal fistula, 1185–1187, 1185f, 1185t, 1186f, 1186t
causes, 1185, 1185t
classification, 1185, 1185f, 1186t
clinical manifestations, 1185
management, 1186

endorectal advancement of anorectal flap, 1185–1186, 1186f
Rectovaginal fistula, in Crohn disease, 822, 823f
Rectum, 1051. *See also* Anorectal disorders
anatomy, 420, 1052–1053, 1172, 1173f
arterial blood supply, 1054
diagnostics, 420–421, 420f, 421f
embryology of, 1051
epidemiology, 420
Rectus abdominis muscle rotation flap, 1451, 1453f
Rectusial veins, 1223
Recurrent laryngeal nerve (RLN), 1341
injury to, 135
Red blood cell (RBC), 356
Refeeding syndrome, 37
Reflux-induced respiratory symptoms, pathophysiology of, 666
Regulatory T cells, 526
Rehabilitation, 348–349
Reliability adjustment, 317
REMATCH Trial, 1541
Renal acidosis, 209
Renal agenesis, 1934
Renal anomalies, 1883
Renal arteries, 1601–1602, 1601f, 1602f
Renal artery aneurysm (RAA), 1667–1668
Renal artery occlusive disease, 1662–1667
Renal artery stenosis (RAS), 547, 1665t
direct assessment of, 1602, 1602f
indirect assessment of, 1601
Renal artery thrombosis, 547
Renal compensation, 210
Renal dysfunction
acute kidney injury
defining, 307
prevention of, 307–308
perioperative management, 308–309
preoperative evaluation, 307
risk stratification, 307
Renal failure, 1727
with calcineurin inhibitors, 524
hypocalcemia, 206
nutritional support in, 38
Renal hypoperfusion, 156
Renal insufficiency and failure, 252–253

Renal natriuretic peptide, 197
Renal outer medullary potassium (ROMK) channel, 196
Renal prostaglandins, 197
Renal replacement therapy (RRT), 185, 309
Renal : systemic renin index (RSRI), 1664
Renal transplantation, 541–551
  classic acute cell-mediated rejection and, 550
  complications, 547–548, 548f
  deceased donors, 543
  donor kidneys, 544
  future prospects, 551
  and hyperacute rejection, 549
  immunology of, 541–542
  immunosuppression, 549
  immunosuppressive complications, 550–551, 551f
  living donors, 542–543
  procedure, 544–547, 544t, 546f
  rejection, 549–550
Renal tubular acidosis (RTA), 209
Renal vein renin ratio (RVRR), 1663
Renal/visceral artery occlusive disease and, 1760–1761
Renin, 154, 1386
Renin–angiotensin system, 196, 1662f
Renovascular hypertension (RVH)
  arterial reconstructive surgery for, 1665
  arteriosclerosis and, 1664
  endovascular renal revascularization, 1666–1667, 1666f, 1666t
  fibromuscular dysplasia and, 1664–1665, 1664f, 1667
  indications for renal revascularization, 1665t
  medical management of, 1664
  pathophysiology of, 1662
Reoxygenation, 278
Reperfusion injury, 121–122
Repopulation, tumor, 278
Rescue therapies, 176
Resection. *See also* Oncology
  curative, 274–275
  extent of, 275–276
Reserpine, 512
Resistance to APC, 79
Resistive index (RI), 1602
Respiratory acidosis
  clinical features, 211

compensatory mechanisms, 212
definition, 211
treatment, 212
Respiratory alkalosis
clinical features, 211
compensatory mechanisms, 211
definition, 211
treatment, 211
Respiratory compensation, 210
Respiratory failure, nutritional support in, 38
Respiratory papillomatosis, 1855
Respiratory quotient (RQ), 174
Respiratory symptoms (RS), 657
Respiratory system, 1806
embryology, 1855
Response Evaluation Criteria in Solid Tumors (RECIST), 277
Restaged cancer, 282
Rest pain, 1687
Restrictive cardiomyopathy, 1580
Resuscitation
endpoints of, 160–161
of patients, 220
Resuscitation Outcomes Consortium (ROC), 354
Resuscitative endovascular balloon occlusion of aorta (REBOA), 356–358
benefits of, 358
device, 347
performance of, 357f
Resuscitative strategy, 159
Resuscitative thoracotomy (RT), 441
Reteplase, 1527
Retinol-binding protein (RBP), as nutrition biomarker, 25, 25t
Retinopathy of prematurity (ROP), 1817
Retrobulbar hematoma, 377
Retrocolic Roux limbs, 742
Retrograde open mesenteric stenting (ROMS), 1653
Retrograde urethrography (RUG), 429
Retroperitoneal hematomas, 407
Return to intended oncologic treatment (RIOT), 277
Revascularization, 2050
Revised Cardiac Risk Index, 299, 300t
Rex shunt, 957
Reye syndrome, 939
Reynolds pentad, 1012

Rhabdoid tumor, 1956
Rhabdomyolysis, 152
Rhabdomyomas, 1516
Rhabdomyosarcomas, 637, 1516
  alveolar, 1963
  biologic features, 1963
  clinical group assessment, 1964
  diagnosis, 1963–1964
  embryonic, 1963
  epidemiology, 1962–1963
  future directions, 1966
  genetic risk, 1962–1963
  lung, 1852t, 1854
  microscopic image, 1963f
  pathology, 1963
  pleomorphic, 1963
  presentation, 1963–1964
  risk status, 1964
  staging, 1964
  surgical–histopathologic clinical grouping system, 1964t
  tnm pretreatment staging system, 1964t
  treatment, 1965–1966
Rheumatoid arthritis (RA), 2053
Rhinoplasty, 2057–2059
Rhinorockets, 376
Rhinosinusitis, 632
Rib fractures, 394–395, 395f
  treatment of, 395–396, 396f
Ribs, 1446, 1447f
  embryology of, 1844
Richmond Agitation-Sedation Scale (RASS), 178
Richter hernia, 1227, 1227f
Rifampin, in prosthetic graft infections, 1616
Rifaximin, in hepatic encephalopathy, 954
RIFLE (risk, injury, failure, loss, end-stage), 307
Right ventricular assist device (RVAD), 1540. *See also* Mechanical circulatory support (MCS)
Rimonabant (Acomplia), 741
Ringer solution, lactated, 159
Risk stratification
  cardiovascular system, 299–300, 300t
  hepatic dysfunction, 305–306
  renal dysfunction, 307

Ritonavir, 948
Rituximab, 524
  in immune thrombocytopenic purpura, 1274
Rivaroxaban, 180, 474
Rockall risk scoring system, GI hemorrhage, 1065, 1066t
Rocuronium, 243, 355
Rokitansky–Aschoff sinuses, 1046
Romiplostim, 1274
Ross–Konno procedure, 1493
Rotavirus, 1897
Rous sarcoma virus (RSV), 270
Roux-en-Y biliary-enteric anastomosis, 412
Roux-en-Y choledochojejunostomy, 565, 1030, 1031
Roux-en-Y configuration, 617
Roux-en-Y cystojejunostomy, 869
Roux-en-Y gastrojejunal reconstruction, 742, 742f
Roux-en-Y hepaticojejunostomy, 570, 1031
Rovsing sign, 1200t
Royal College of Obstetricians and Gynaecologists, 485
Rubber band ligation, of hemorrhoid, 1179, 1179f

S

Sacral agenesis, 1883
Sacral dysplasia, 1883
Sacral nerve stimulation (SNS), 1061, 1192
Sacrococcygeal teratomas (SCT), 1810, 1831–1832
S-adenosylmethionine (SAMe), 945
Safety attitudes questionnaire (SAQ), 325
Safety rounds, 325, 326f
Salivary tumors, 635, 635t, 636f–637f
Salmon calcitonin, 1368
Salmonella, 1758
Santorini duct, 1925
Saphena varix, 1232
Saphenous vein stripping/ablation, 1792
Sarcomas, 2010
  histologic grading of, 2015
  liver, in children, 1917
  lung, in children, 1854
  osteogenic, 1851–1852
  soft-tissue, in pediatric patients, 1852
Scald burns, 214, 215
Scaphocephaly, 2065

Scarff–Bloom-Richardson scoring system, 1316
Scarpa fascia, 1213
Schistosomiasis, 933, 933f
Schwannomas, 1854
Sciatic hernia, 1255, 1256f
Scientific Registry of Transplant Recipients (SRTR), 321, 553, 591
Sclerosants, 1072
Sclerotherapy, 1791
  for hemorrhoids, 1179
Scorpions, 504
Scottish Intercollegiate Guidelines Network (SIGN), 1072
Scrotum, anomalies of, 1942–1944
Secca™ procedure, 1191
Secondary hyperparathyroidism, 205
Secondary megaureters, 1937
Second-hit phenomenon, 157
Secretin, 773, 845, 846, 997
Secretin test, 847, 847t
Secretory component, 776
Secretory vesicles, neutrophil granules and, 89, 90t
Sedation
  analgesia, 248, 248t
  and paralysis, 178
  scales, 178
Segmental arm pressures, 1597, 1598f
Segmental contractions, colonic, 1057
Selective Digestive Decontamination (SDD), 188
Selective estrogen receptor modulator (SERM), for breast cancer, 1305, 1311, 1312
Selective Oral Decontamination (SOD), 188
Selective relaxant binding agents, 244
Selective serotonin reuptake inhibitors (SSRI), 297, 299t
Selective visceral arteriography, in GI bleeding, 1070, 1070f
Selenium
  daily requirements of, 24t
  deficiency of, 23
  supplementation, 37
Self-expanding metallic stent (SEMS), 797
Self-regulated learning, 3. *See also* Dreyfus model, for skill development
  and lifelong learning, relationship between, 4, 4t
  phases in, 3
    adjustment, 4
    assessment, 4
    learning, 4

planning, 3–4
in surgery education, 7
Semiessential amino acids, 182
Semilunar line, 1216
Sengstaken–Blakemore tube, 960, 960f, 1074
Sentinel lymph node biopsy (SLNB), 1317–1318
Seprafilm, 791
Sepsis
aortic infection and, 1615
guidelines, 187
metabolic adaptations to, 30–31
Septic shock, 152
Septum primum, 1481. *See also* Atrial septal defect (ASD)
Serafini hernia, 1257
Serine protease inhibitor (SERPIN), 78
Serine protease inhibitor, kazal type 1 (SPINK1), 847
Serotonin, 845
Serotonin release assay, 77
Serous cystadenomas, pancreatic, 883
Serrated polyposis syndrome, 1096, 1098f
Serum amyloid A (SAA), 120
Serum analysis, 233
Serum-to-ascitic fluid albumin gradient (SAG), 967
Sessile serrated adenoma (SSA), 1093, 1096, 1099f, 1106–1107
Sheep thyroid extract, 740
Shock
causes of, 150t
compensatory responses to, loss of, 156
compensatory responses to, organ-specific
cardiac and microvascular response, 154
genetic regulation of response, 156
hepatic response, 156
immunoinflammatory response, 155–156
neuroendocrine response, 154–155
pulmonary response, 156
renal response, 156
complications of
abdominal compartment syndrome (ACS), 157
coagulopathy, 158
hypothermia, 157–158
ischemia–reperfusion injury, 157
multiple organ dysfunction syndrome (MODS), 157
second-hit phenomena, 157

evaluation of, 148–149, 148t
hemodynamic patterns in, 151t
monitors
arterial wave contour analysis, 161–162
bedside ultrasound and echocardiography, 162
central venous pressure (CVP), 161
pulmonary artery catheter (PAC), 161
overview, 147–148
pharmaceutical support, 162t
corticosteroids, 164
future therapies, 164
inotropes and vasopressors, 162–163
metabolites and electrolytes, 164
vasodilators, 163–164
treatment
fluid therapy, 158–159
permissive hypotension, 159
resuscitation, endpoints of, 160–161
transfusion, 159–160
types of
cardiogenic shock, 149–151
distributive shock, 152
extracardiac obstructive shock, 151
hypoadrenal shock, 153
hypovolemia, physiologic response to, 153, 153f
hypovolemic shock, 149
neurogenic shock, 152–153
rapid response, 153–154
septic shock, 152
sustained response, 154
traumatic shock, 152
SHOCK-IABP Trial, 1549
Shock resuscitation algorithm, 155
Short bowel syndrome, and nutritional support, 39
Short Form 36 (SF-36) instrument, 682
Short-gut syndrome, 1369
Shouldice repair, 1234, 1235f
Shunts, for variceal bleeding, 962–965
distal splenorenal shunt, 963, 964f
end-to-side portacaval shunts, 962, 962f
interposition mesocaval shunt, 963, 963f
partially diverting shunts, 962–963, 963f, 964f
portacaval Sarfeh shunt, 963, 964f

selective shunts, 963, 964f
side-to-side portacaval shunts, 962, 963f
totally diverting shunts, 962, 963f
Sialadenitis, 633
uncomplicated, 633
Sibutramine, 740
Sickle cell anemia, 1267, 1276–1277
Sick syndrome, 187
Sigmoid colon, 1052
Sigmoidoscopy, 1101
Sigmoid volvulus, 1052
Silvadene (silver sulfadiazine), 222
Silver-impregnated grafts, 1616
Silver nitrate, 222
Simeprevir, 947
Simethicone, 790
Simple Endoscopic Score for Crohn disease (SES-CD), 814
Simplified Acute Physiology Score (SAPS), 170
Simultaneous kidney–pancreas transplants (SPK), 610, 611
Single-balloon enteroscopy, for small bowel tumors, 830
Single-incision approach to laparoscopic cholecystectomy (SILS), 1004
robotic SILS, 1004, 1006f
Single-incision laparoscopic (SILS) appendectomy, 1205–1206
Single-nucleotide polymorphisms (SNPs), 42, 156
Single photon emission tomography (SPECT) scanning, for vascular infection, 1613
Single port laparoscopic surgery (SPLS), for colorectal cancer, 1134–1135
Single-shot techniques, 247
Sinonasal tumors, 637–638, 638f
Sinonasal undifferentiated carcinoma (SNUC), 637
Sinusitis, 632, 633f
complications of, 633t
Sinus venosus defects, 1482. *See also* Atrial septal defect (ASD)
SIOP therapy, 1957
Sirolimus, 521, 624, 1527
Sirolimus–FKBP12 complex, 521
Sistrunk procedure, 1341
Sitz marker study, 1058–1059, 1058f
Skeletal fixation, 2050
Skin alternatives, 227
Skin and soft tissue infections (SSTI), 137–138
broad-spectrum antimicrobial therapy, 139
diagnosis/differentiation, NSTI and nonnecrotizing infections, 138–139
necrotizing soft tissue infections (NSTI), 139–140

pyomyositis, 140
Skin grafting, 2035
Skin integrity, 1816
Skin lesions, 1993f
Skull fracture, 371
closed depressed, 371
depressed, 371t
Sleeve gastrectomy, 744, 744f, 751
Slipping rib syndrome, 1847
Slow continuous ultrafiltration (SCUF), 185
SMAD proteins, 60
Small bowel atresia, 1878f
Small bowel disease, 819–820
Small bowel obstruction (SBO)
management of, 797–799, 798t, 799t
Small bowel tumors, 827–837
benign, 830
capsule endoscopy, 829
clinical presentation, 828, 829t
complications from, 829t
diagnosis, 828–829
epidemiology, 827
exploratory laparoscopy, 830
malignant, 830, 831f
gastrointestinal stromal tumor, 835–836
lymphoma, 834–835
neuroendocrine tumors, 830–833
small bowel adenocarcinomas, 833–834
metastatic tumors, 837, 837f
pathogenesis, 827–828
predisposing risk factors
celiac disease, 828
Crohn disease, 828
dietary and lifestyle factors, 828
familial adenomatous polyposis, 828
hereditary nonpolyposis colorectal cancer, 828
Peutz–Jeghers syndrome, 828
small bowel enteroscopy, 829
double-ballon enteroscopy, 829–830
single-balloon enteroscopy, 830
spiral enteroscopy, 830
Small cell lung cancer, 1434–1435
Small intestine, 770–780

anatomy and embryology, 770
auerbach plexus, 772
digestion and absorption, 776–780, 777f
duodenum, 770–771
immunoglobulin secretion, 775–776
immunology, 774–776
jejunum and ileum, 771
microbiota, 780
microscopic anatomy, 772–774
motility, 774
mucosa, 772
physiology, 773–774, 773f
sodium absorption in, 777f
submucosa, 772–773
villus, 776f
Small intestine submucosa (SIS), 1797
Smoke detectors and carbon monoxide detectors, 470
Smoking, 1677, 1688f
abdominal aortic aneurysms and, 1734–1735
aortic aneurysms and, 1567
and chronic pancreatitis, 870
and colorectal cancer, 1118
and coronary artery disease, 1522
and pancreatic cancer, 879
Smoking cessation, benefits of, 303
Smooth endoplasmic reticulum (SER), 779
Snakebite, 496–502, 497f, 497t, 498f, 498t, 499f, 501f, 502f
Soave procedure, 1901–1902, 1901f
Societe Internationale d'Oncologie Pediatrique (SIOP), 1947
Society of Thoracic Surgeons (STS) Measurement Taskforce, 316
Socioeconomic status (SES) and burns, 215
Sodium, 23, 195
concentration and water balance, 195
content in adult, 192
and water
cerebral salt wasting (CSW), 202
hypernatremia, 203, 203f, 203t
hyponatremia, 202
pseudohyponatremia, 202
syndrome of inappropriate antidiuretic hormone (SiADH), 202
Sodium dependent hexose transporter (SGLUT-1), 778
Sodium morrhuate, 1072
Sodium retention, in cirrhosis, 951

Sofosbuvir, 947
Soft-tissue sarcomas
  clinical presentation, 2012, 2013f
  cytogenetic abnormalities in, 2012t
  diagnosis, 2012
  diagnostic biopsy, 2014
  distribution, 2011f
  epidemiology, 2010
  pathologic classification, 2014–2015
  pediatric, 1852
  radiation-associated, 2011f
  staging, 2015–2017
  treatment, 2017–2021
SOLESTA, 1061
Solid organ injuries, in children, 467–469, 467t, 468f
Solid organ transplant
  antimetabolite drugs in, 522
  immune response to, 518–520, 519f
  immunosuppression induction, 520
  treating rejection in, 522–524
Solid-pseudopapillary tumors (SPTs), 884–885
Solitary kidney, 1935
Solitary rectal ulcer syndrome (SRUS), 1187–1188
Somatosensory-evoked potentials (SSEPs), 1720
Somatostatin, 114, 718, 773, 840, 845, 849–850, 865, 1074
  exogenous administration, 850
  secretion and action, 849–850
  in variceal bleeding, 959
Somatostatin analogs (SSAs), in acromegaly, 1412–1413
Somatostatinoma, 900t, 910, 910t
Somatostatin receptor scintigraphy (SRS)
  in multiple endocrine neoplasia type I, 1379, 1379f
  pancreatic endocrine neoplasms, 903–904, 903f
Somatotroph adenomas. *See* Growth hormone-secreting adenomas
Sonic Hedgehog (SHh), 944
Sorafenib, 2021
Sorbitol, 802
Source control, definition, 129
Sphincter of Oddi, 851, 997
  stenosis of, 1031
Sphingomyelinase D, 503
Sphingomyelins, 14
Spiders, 502–503, 503f

Spigelian hernia, 1254
Spina bifida, 1833
Spinal cord injury
  and cerebrovascular injury, 466
  in children, 461–466
  without radiographic abnormality, 466
Spinal cord stimulation (SCS), 1704
Spinal shock, definition, 153
Spinal trauma, in elderly patient, 476
Spiral enteroscopy (SE), small bowel tumors, 830
Spironolactone, in ascites, 967
Splanchnic artery aneurysms, 1657–1662
Splanchnic ischemia, 157
Splanchnic vascular disease, 1648
  anatomy, 1648–1649, 1649t
  physiology, 1648–1649
Splanchnic vein thrombosis, 1653
Spleen, 1262–1287
  abscess of, 1283–1284
  accessory, 1266
  anatomy, 413
  cysts of, 1283, 1283f
  diagnostics, 413
  embryology and anatomy, 1263–1266
    anatomic relations, 1263, 1263f
    ligaments, 1264–1265, 1265f
    microanatomy, 1265–1266, 1266f
    surface of spleen, 1264f
    vascular anatomy, 1264, 1265f
  epidemiology, 413
  history of surgery for, 1262–1263, 1263f
  metastatic disease to, 1279
  OIS-AAST grading scale, 413t
  pathophysiology
    hypersplenism, 1268, 1268t
    hyposplenism, 1267–1268, 1268t
  physiology, 1266–1267, 1266t
  surgical treatment (*see* Splenectomy)
  trauma, 1270–1273, 1270f–1272f, 1270t
  treatment, 413–415, 414f, 415f
  vascular disorders of, 1282
Splenectomy, 414, 1269
  diagnostic, 1281–1282, 1281t

iatrogenic, 1269, 1280–1281
incidental, 1280
indications for, 1269–1270, 1269t
autoimmune/erythrocyte disorders, 1269, 1273–1277
hypersplenism, 1269, 1277–1280
miscellaneous, 1282–1284
trauma of spleen, 1270–1273, 1270f–1272f
vascular disorders, 1282
infections after, 1286–1287
laparoscopy, 1286
operative technique, 1284–1286, 1284t, 1285f
partial, 1286
sequelae of, 1286–1287
Splenic artery, 1264, 1265f
Splenic artery aneurysms, 1282, 1657–1658, 1657f, 1658f
Splenic rupture, atraumatic, 1273
Splenic sinuses, 1266
Splenic vein, 1264, 1265f
Splenic vein thrombosis, 957, 1282
Splenophrenic ligaments, 1265
Spontaneous bacterial peritonitis, 968–969, 969t
Spontaneous breathing trials (SBT), 178
Sporadic hepatoblastoma, 1968
S100 proteins, 115–116
SpyGlass cholangioscopy, 1029
Squamous cell carcinoma (SCC), 629, 638, 699, 1991
anal canal, 1195–1196, 1197t
oral cavity, oropharynx, larynx, 639t
ulcerative, 2003f
Stab wound (SW), 403
and ureteral injuries, 425–426
Stalk effect, 1405
Stamm gastrostomies, 37
Standard resuscitation (SR), 344
Staphylococcus aureus, 221, 1303, 1348, 1773, 1840, 1865
Staphylococcus epidermidis, 1816
Stapled hemorrhoidopexy, 1180, 1180f
Starvation, 27
metabolic response to, 27, 27t
in surgical patient, 27
State Surgical Care and Outcomes Assessment Program (SCOAP), Washington, 132
Statins, 299t, 301, 1735
in myocardial infarction, 1525

Steatorrhea, pancreatic, 847
and intestinal steatorrhea, 847–848, 848t
Stenosis of sphincter of Oddi, 1031
Stereotactic body radiation therapy (SBRT), 279
Stereotactic core biopsy, 1297–1298
Sternal clefts, 1456–1457, 1457f, 1847
Sternocleidomastoid neck incision, 386
Sternothyroid muscles, 1341
Steroids, 178, 298, 299t, 522
in Crohn disease, 816–817, 816t
side effects of, 522
Stevens–Johnson syndrome, 940
Stewart–Treves syndrome, 276
St. Jude Medical Epic Valve, 1508, 1509f
St. Jude Medical Regent Valve, 1508, 1508f
Stochastic effects, 1979
Stomach, 712, 713f
anatomy, 417
arterial blood supply of, 713f
blunt injury, 417–418
diagnostics, 417–418
lymphatic drainage of, 714f
treatment, 418
vagal innervation of, 714f
Stool tests, for colorectal cancer, 1126
Strength exercise, 234
Streptococcus pneumoniae, 969, 1286, 1469, 1865
Streptococcus pyogenes, 1348
Streptomyces hygroscopicus, 521
Stress
carbohydrate metabolism during, 29
lipid metabolism during, 29
metabolic response to, 27–32
neuroendocrine and cytokine-mediated response to, 27–29, 28f
protein metabolism during, 29
substrate metabolism changes during, 29
wound healing, effect on, 65
Stress gastritis, 735–737, 1073–1074
Stress gastrointestinal bleeding prophylaxis, 183–184
Stress hormones, 154, 181
Stress proteins, 92
Stress response, 119–120
chronic inflammation, 122

reperfusion injury, 121–122
systemic inflammatory response syndrome (SIRS), 122
Stress test, 1524
Strictureplasty, 818–819
Strictures, in Crohn disease, 818–819, 818f
Stroke
and carotid bifurcation occlusive disease, 1623, 1623f
clinical manifestations of, 1624
pathogenesis of, 1623–1624
Stroke volume, reduced, 154
Stroke volume variability (SVV), 201
Stromal cell–derived factor-1 (SDF-1), 104
Structural measures of quality. *See also* Surgical care quality measurement
limitations of, 315
strengths, 314
ST-segment elevation myocardial infarction (STEMI), 1522, 1523
Subacute thyroiditis, 1348
Subarachnoid hemorrhage, CT scan, 365
Subcutaneous emphysema, 396
Subdural hematomas, 372
acute, 365
head injury and, 371–372
Sublay prosthetic repair, 1250–1251, 1251f
Submucosal polyps, 1107–1109, 1108f
Substance abuse, 228
Substance P, 845
Succinate dehydrogenase (SDH), 767
Succinylcholine, 243, 243t, 309, 355
Sucrose disaccharides, 778
Sugar-free chewing gums, 802
Sugiura procedure, 965–966, 966f
Sulbactam, 130
Sulfamethoxazole, 550, 573
Sulfamylon, 222
Sulfotransferases, 18
Sulindac, 1105
Sump syndrome, 1011–1012
Sunitinib, 767, 2021
Superficial spreading melanoma (SSM), 1992
Superficial vein thrombophlebitis (SVT), 1778
Superior laryngeal nerve (SLN), 1342
Superior mesenteric artery (SMA), 275, 616, 771, 851–852, 1648–1649, 1892–1894
aneurysm, 1659–1660, 1660f

Superior mesenteric vein (SMV), 771, 954
Superior vena cava (SVC), 172
Superior vena cava (SVC) syndrome, 1478–1479
Supernumerary kidney, 1934
Supine hypotensive syndrome, 483
Supplemental oxygen, in perioperative period, 143
Supplemental parenteral nutrition, 183
Suprarenal abdominal aortic aneurysms, 1757–1758
Supravesical fossa, 1219
Supravesical hernia, 1255, 1256f
Surgeon in cancer management, 273–274
  curative resection, 274–275
  diagnosis and staging, 274
  palliative surgery, 275
  surgical intent, 274
Surgery
  and accidental injury, differences between, 30, 30t
  nutritional support in, 32 (*see also* Nutritional support)
  physiologic responses to, 29–30
Surgery Education programs, 7
Surgical airways, 1472
Surgical Care Improvement Program (SCIP), 169, 313, 315, 320, 328t
Surgical care quality measurement
  choice of right measure, 316
  composite measures, 315–316
    limitations, 316
    strengths, 316
  current measures, 313–314, 314t
  development of measures, 317–318
  individual quality measures
    outcomes, 315
    process of care, 315
    structure, 314–315
Surgical complications, grading of, 291t
Surgical hand antisepsis, 143
Surgical infections. *See also* Complicated intra-abdominal infection (cIAI); Surgical site infections (SSI)
  broad-spectrum antimicrobial therapy, 128, 129t
  intra-abdominal infections
    classification, 129
    diagnosis, 129
    treatment, 129–130
  pathogen identification, 129

skin and soft tissue infections (SSTI), 137–138
broad-spectrum antimicrobial therapy, 139
classification, 138
diagnosis/differentiation, NSTI and nonnecrotizing infections, 138–139
necrotizing soft tissue infections (NSTI), 139–140
pyomyositis, 140
source control, 129
specific intra-abdominal infections
appendicitis, 130–132
biliary infections, 132–133
clostridium difficile infection (CDI), 135
diverticulitis, 133–134
pancreatitis, 135–137
Surgical Infection Society, 415
and Infectious Disease Society of America, 1201
Surgical mortality, variation in, 290f
Surgical outcomes, cancer-related. *See also* Oncology
disease recurrence, 276–277
progression-free survival, 277
return to intended oncologic treatment (RIOT), 277
Surgical quality improvement
centers of excellence (COE), 319
outcome feedback, 321
pay for performance, 320–321
Surgical readmissions, 291t
Surgical site infections (SSI), 328
challenges in, 144
chlorhexidine as skin surgical site preparation, 143
colorectal surgery and, 143–144, 1130–1131
deep incisional, definition, 141t
definitions, 141, 141f, 141t
epidemiology, 140–141
normoglycemia maintenance, 143
normothermia maintenance, 143
prevention of, 142–143
removal of body hair, 143
risk factors for
basic SSI risk index, 141–142
superficial incisional, definition, 141t
supplemental oxygen, perioperative period, 143
surgical hand antisepsis, 143
treatment of, 144
Surgical wound infection, 307

Surveillance, Epidemiology, and End Results (SEER) program, 1947
Sustained low efficiency dialysis (SLED), 186
Swan–Ganz catheter, 790
Swanson metacarpophalangeal joint arthroplasty (SMPA), 2054
Sweat chloride test, 1889
Sweat gland carcinomas, 2006
Sweating, 198
Swenson procedure, 1902, 1902f
Swinging flashlight test, 1407
Swiss cheese model, 324
Swollen brain, 365
Syme amputation, 1709, 1711f
Synchronized intermittent mandatory ventilation (SIMV), 1812
Syncope, 1507
Syndactyly, 2052
Syndrome of inappropriate antidiuretic hormone (SiADH), 202
SYNERGY trial, 947
Syphilis, 1635
Systemic acidosis, 211
Systemic inflammatory response syndrome (SIRS), 122, 152, 217, 860
Systemic lupus erythematosus (SLE), 77
Systolic blood pressure (SBP), 155, 344
Systolic pressure variation (SPV), 258

T

Tachycardia, 160
Tacrolimus, 521, 624
Tactical Combat Casualty Care Committee, 489
Tactical Field Care (TFC), 347
Taeniae coli, colon, 1051
Takayasu arteritis, 1638, 1640f
  and thoracic aneurysms, 1566
Tamoxifen, 1325
  for breast cancer, 1311
  for breast pain, 1302
Tandem Heart pVAD centrifugal pump, 1551–1552, 1552f
Tangential excision, 223
Tanner stages, of breast development, 1293, 1293f
Tar, causing burn, 216
Taussig–Bing anomaly, 1487
Taxanes, 1325
Taxonomy, 331
T-cell receptors (TCR), 519

^{99m}Tc pertechnetate, 1345
Technetium 99m, 547
Technetium-macroaggregated albumin (MAA) scanning, 952
Temozolomide, 1412
Tendinous arch, 1223
Tendo-achilles lengthening (TAL), 1708
Tenofovir, 936
Tension pneumothorax, 353, 396
  signs and symptoms of, 396
Teratomas
  fetal surgery for, 1831–1832
  of liver, 1916
  lung, 1854, 1855f
  mediastinal, 1855f
  sacrococcyteal, 1831–1832
Terlipressin, in hepatorenal syndrome, 952
Tertiary hyperparathyroidism, 205
Testicles
  anomalies of, 1942–1944
  torsion of, 1943, 1943f
  undescended/cryptorchid, 1942–1943, 1942f
Tetany, 206
Tethered spinal cord syndromes, 1883
Tetracyclines, 1926
Tetralogy of Fallot (TOF), 1486–1487, 1486f
Texas Organ Sharing Alliance, 593
Thalassemia, 1276
The Children's Oncology Group (COG), 1947
Thermal burn injuries, 229
Thienopyridines, 299t, 1527
Thoracic aortic aneurysm (TAAs), 1562, 1563f
  degenerative, 1564–1565
  diagnosis, 1566, 1566t
  etiology and risk factors, 1564–1566, 1564t
  genetically triggered, 1565, 1565f, 1565t
  history, 1562
  infectious and inflammatory, 1565–1566
  management and natural history, 1566
    aortic arch aneurysms, 1568, 1568f
    aortic root and ascending aortic aneurysms, 1567–1568, 1568f
    descending thoracic aortic aneurysms, 1568–1569
    endovascular therapy, 1569, 1570f
    hybrid procedures, 1569–1570

medical management, 1566
open surgical management, 1567
surgical indications, 1566–1567
outcomes and complications, 1570–1571
prevalence and classification, 1564
traumatic pseudoaneurysm, 1566
Thoracic aortic dissection
classification, 1571
Debakey system, 1571, 1571f
Stanford system, 1571
diagnosis, 1572
etiology and risk factors, 1571–1572
history, 1571
management and natural history, 1572
endovascular therapy, 1572, 1573f
type A aortic dissection, 1572, 1572f
outcomes and complications, 1572–1573
prevalence, 1571
Thoracic cavity, 441
Thoracic ectopia cordis, 1847
Thoracic endovascular aneurysm repair (TEVAR), 1569, 1570f
complications, 1570–1571
contraindications to, 1569
planning for, 1569
for type A and B aortic dissections, 1572, 1573f
Thoracic esophageal injury, 401, 401f
Thoracic outlet syndrome (TOS), 1457–1459, 1459f, 1639
Adson maneuver, 1457, 1459f
neurogenic, 1457–1458, 1459f
postoperative complications, 1458
rehabilitation, 1458–1459
surgical approach, 1458, 1460f, 1461f
vascular, 1457
Thoracic trauma, 394–402
ED thoracotomy *vs.* operative thoracotomy, 401–402, 401f
initial imaging, 394
injuries, 394–401
Thoracic tumors, 1851–1855
Thoracoabdominal aortic aneurysms (TAAA), 1717
aortic dissection and, 1728–1729
classification, 1719f
clinical manifestations, 1718–1719, 1718f
complications, 1728, 1728t

delayed neurologic deficits, 1726–1727, 1727f
diagnostic imaging, 1719–1720, 1719f
elephant trunk technique for, 1723, 1724f, 1725
Thoracoabdominal aortic aneurysms (*continued*)
endovascular repair and, 1729
epidemiology, 1717
glomerular filtration rate, 1727–1728
neurologic outcomes, 1725–1727, 1725f–1727f
operative techniques, 1720–1725, 1720f–1724f
pathogenesis, 1717–1718
postoperative management, 1725
preoperative evaluation, 1720
renal failure, 1727
surgical outcomes, 1725–1728
survival rates, 1718f
Thoracotomy, for intralobar sequestration, 1847
Three-hit hypothesis, pancreatitis, 871, 871f
Thrifty gene hypothesis, 42
Thrifty phenotype hypothesis, 42
Thrombectomy, 570
Thrombi, 74
Thrombin, 69
Thrombocytopenia
in cirrhosis, 950
dilutional, 158
Thrombocytosis, 1968
Thrombolytic therapy, 1782
Thrombomodulin (TM), 71
Thrombophlebitis of thoracoepigastric vein, 1302, 1302f
Thromboplastin, 14
Thrombopoietin, 950
Thromboprophylaxis, 75
Thrombosed external hemorrhoids, 1180, 1181f
Thrombosis, 1623
cell adhesion molecules, 72–74
high risk for, 78–79, 78t
leukocytes and thrombosis, 74–75
lower risk for, 79
Thrombotic thrombocytopenia purpura (ITP), 1274–1275
Thumb duplication, 2053
Thymic cysts, 1840, 1851
Thymomas, 1475–1476
Masaoka staging system for, 1476t

resection, 1476, 1477f
Thyroglobulin, 1344
Thyroglobulin autoantibodies (TgAbs), 1344
Thyroglossal duct cysts (TGDCs), 1341, 1840, 1840f
Thyroid abnormalities, 187
Thyroid autoantibodies, 1344
Thyroid cancer, 1351
classification, 1351
external beam radiotherapy, 1356
lymphadenectomy, 1355
metastatic, 1356
molecular markers, 1352
preoperative ultrasound, 1355
radioiodine therapy, 1355–1356
thyroidectomy, 1355
thyroid-stimulating hormone suppression, 1356
Thyroidectomy, 1355, 1356
complications, 1358–1359, 1358t
technique, 1356–1358, 1356f, 1357f
Thyroid gland, 1340–1359
anatomy, 1341
airway relationships, 1341
Cernea classification, 1342f
fascial relationships, 1341
lymphatic relationships, 1342, 1342f
muscular relationships, 1341
neurologic relationships, 1341–1342, 1341f, 1342f
parathyroid relationships, 1342–1343
vascular relationships, 1341
congenital abnormalities, 1340–1341
embryology, 1340
functional disorders
hyperthyroidism, 1346–1347
hypothyroidism, 1347
thyroiditis, 1347–1348
imaging techniques, 1344
computed tomography, 1346, 1346f
cross-sectional imaging, 1346
magnetic resonance imaging, 1346
nuclear medicine, 1345
positron emission tomography, 1345–1346
ultrasonography, 1344–1345, 1345f
laboratory tests, 1344

calcitonin, 1344
free thyroxine and free triiodothyronine, 1344
thyroglobulin, 1344
thyroid autoantibodies, 1344
thyroid-stimulating hormone, 1344
total thyroxine and total triiodothyronine, 1344
lingual, 1340
malignancies, 1351–1356
metastases to, 1355
nodular disease
nontoxic multinodular goiter, 1348–1349
solitary thyroid nodule, 1349–1351
physiology
thyroid hormone, action of, 1344
thyroid hormone, production of, 1343–1344
surgery, 1356–1359 (*see also* Thyroidectomy)
Thyroid hormone, 741
action of, 1344
metabolism, 1343f
production of, 1343–1344
Thyroiditis, 1347–1348
Thyroid lymphomas, 1354–1355
Thyroid nodule, solitary, 1349–1350, 1349f
Thyroid sheath, 1341
Thyroid-stimulating hormone (TSH), 1340, 1344
Thyrotroph adenomas. *See* TSH-secreting adenomas
Thyroxine, 1343–1344
Ticlopidine (Ticlid), 1527
TIGR Matrix Surgical Mesh®, 1229
Time to progression (TTP), 285
Tissue damage, and stress response, 31
Tissue expanders, 1247
Tissue expansion, 231
Tissue factor pathway inhibitor (TFPI), 71
Tissue inhibitors of MMPs (TIMPs), 1225, 1564
Tissue plasminogen activator (tPA), 71, 398, 791
Tissue plasminogen inhibitor, 1527
Tissue typing, 577
T lymphocytes, 95–97
TNF-α, 101–102, 102f
TNM classification, 2015
Tobacco and cancer, 270, 270t
Toe Transfer, 2048, 2049f

Tolazoline, 512
Tolbutamide response test, 850
Toll-interleukin-1 receptor (TIR), 116
Toll-like receptor 4 (TLR4), 947
Toll-like receptors (TLR), 116–117, 1816
Tolvaptan, 202
Tolypocladium inflatum, 521
Tonicity of body fluids, 194–195
Torsion of testicle, 1943, 1943f
Torso vascular injury, 434
Total artificial heart (TAH), 1540, 1557, 1559f. *See also* Mechanical circulatory support (MCS)
Total body surface area (TBSA), 219, 220
Total body water (TBW), 192, 193t
Total colonic aganglionosis, 1904
Totally endoscopic coronary artery bypass (TECAB), 1534
Totally extraperitoneal laparoscopic repair (TEP repair), 1238–1240
Total mesorectal excision (TME), 1133, 1141–1142, 1142f
Total pancreatectomy (TP), for chronic pancreatitis, 871, 875–876
Total parenteral nutrition (TPN), 469, 998
  acute pancreatitis, 865
  administration routes, 37
  complications with use of, 33, 33t, 34
  composition of standard TPN solution, 34, 34t
  considerations, 33–34
  for infants, 1873
  preoperative, 32
  timing of initiation of, 33
Total sympathectomy, 247
Total urinary nitrogen (TUN), 26
Toupet fundoplication, 677, 680
Tourniquet, usage of, 354, 356
Toxic adenoma, 1347
Toxic colitis, in Crohn disease, 820
Toxic exposures, 2010
Toxic megacolon, ulcerative colitis and, 1086–1087
Toxic multinodular goiter (MNG), 1347
Toxic shock syndrome (TSS), 97, 1369
TP53 gene, 881, 1122
TPN. *See* Total parenteral nutrition
TP with islet autotransplantation (TPIAT), 875–876
Trace elements
  daily requirements of, 24t

role of, 23
wound healing, role in, 63
Trachea, 1472
anatomy, 1472, 1472f
benign lesions of, 1472–1474, 1474f
Tracheal intubation, 353
Tracheobronchial foreign body (TFB) aspiration, 1464
Tracheobronchial injury, 400
treatment of, 400–401
Tracheobronchial tree, 1860
Tracheoesophageal displacement index (TEDI), 1832
Tracheoesophageal fistula (TEF), 1855–1859, 1856f
with esophageal atresia, 1858
Tracheoinnominate artery fistula, management of, 1472, 1473f
Tracheomalacia, 1474–1475, 1859
and airway stents, 1475, 1475t
Tracheostomy, 387, 1472
complications, 1472, 1473f, 1474f
Traditional serrated adenoma (TSA), 1093, 1096
Trametinib, 2001
Tranexamic acid (TXA), 347, 1535
Transabdominal preperitoneal repair (TAPP), 1237, 1238, 1239f
Transanal–transabdominal proctectomy, 1146
Transarterial chemoembolization (TACE), 556, 832
Transatlantic Inter-Society Consensus (TASCII) criteria, for critical limb ischemia, 65
Transcapillary refill, 154
Transcranial Doppler (TCD), 1625
Transcutaneous oxygen, measurements of, 1606, 1606f
Transdermal narcotic delivery, 262
Transduodenal sphincteroplasty, 1030
Transesophageal echocardiography (TEE), 258, 1720
thoracic aortic aneurysm, 1566
Transferrin, as nutrition biomarker, 25, 25t
Transforming growth factor alpha (TGFa), 59
Transforming growth factor-b (TGF-b), 57, 108, 791
Transforming growth factor beta 1 (TGF-b1), 944
Transfusion, 159–160, 160t. *See also* Shock
autotransfusion, 160
ICU patient and, 180–181
type O (universal donor) blood, 160
type-specific blood, 160
Transfusion requirements in Critical Care (TRICC) trial, 180
Transhiatal esophagectomy (THE), 703

Transient hypoparathyroidism, 206
Transient ischemic attack (TIA), 1622
Transient relaxations of the lower esophageal sphincter (TLESR), 661–662
Transjugular intrahepatic portosystemic shunt (TIPS), 558, 560, 950
  for ascites, 968
  for variceal bleeding, 960–962, 961f
Transmetatarsal amputation, 1708–1709, 1710f
Transoral laser microsurgery (TLM), 640
Transplantation
  cardiac, 575–585
    candidate evaluation, 576
    complications, 582–583, 582f, 583f, 584t
    contraindications to, 577t
    current issues, 584–585
    donor selection and management, 576–577
    ethics, 584
    heart procurement, 578
    historical perspective, 575–576
    immunosuppression, 581–582, 582t
    indications for, 576t
    matching donor to recipient, 577
    operative recipient management, 578–581, 578f, 579f, 580f
    outcomes, 583–584
    recipient management, 577–578
    stratifying risk and survival results, 576t
    survival, 584f
  hepatic, 552–573, 1923
    acute rejection, 573
    anesthetic management, 558
    anhepatic phase and implantation, 561–564, 561f, 562f, 564f, 565f
    antibody-mediated rejection, 571
    auxiliary liver transplantation, 568, 569f
    cell-mediated rejection, 571–572, 572f
    chronic rejection, 572
    complications, 568
    contraindications to, 553–554
    disease-specific indications and outcomes, 554–558, 554f, 555f
    hepatic artery thrombosis, 569–570
    immunosuppression induction, 572–573
    indications for, 552–553
    inferior vena cava stenosis, 570–571
    intra-abdominal sepsis, 571
    intracranial hemorrhage and, 554

intraoperative management, 558–559
King's college criteria for, 557t
living donor liver transplantation, 566–568, 567f
MELD and PELD score, 553t
neurologic complications, 571
portal vein thrombosis, 570
postoperative hemorrhage, 568–569
postrevascularization phase, 565
recipient hepatectomy, 559–561, 560f
split liver transplantation, 565, 566f
surgical technique, 559, 559f
urgent listing criteria for, 553t
islet, 622
complications, 624
donor selection, 623
future of, 625
graft failure, 624–625
history of, 622
immunosuppression, 624
metabolic control, 624
patient selection, 622–623
perioperative care, 623–624
transplant techniques, 623, 623f
pancreas, 610, 610f, 616t
back-table preparation, 616–617, 616f, 617f
Banff classification, 620t
complications, 618–619
deceased donor pancreas allocation, 614
and diabetes mellitus, 621–622
donor evaluation, 614–615, 615t
evaluation and screening, 612–613
future of, 625
graft failure rates for, 619f
graft survival, 621f
immunosuppression, 618
living donor kidney-pancreas transplantation, 611, 612f
patient selection, 611
procurement technique, 615–616
recipient operation, 617–618
recurrent autoimmunity, 620–621
rejection diagnosis and treatment, 619
solitary, 621
pulmonary, 587–603

bilateral, 598–599, 598f
complications, 599–602, 600t
contraindications, 588–592, 589t, 591f
donor management, 593–594, 594f
donor pool, 595–596, 595f
donor selection, 593, 593t
future considerations, 603
gastroesophageal reflux, 602–603
immunosuppression, 599
indications, 588, 588t
lung preservation, 594–595
operative technique, 597–599
outcomes, 599
primary graft dysfunction, 600
single, 597–598, 598f
transplantation operation, 596–597, 596f, 597f
Transplantation (*continued*)
renal, 541–551
classic acute cell-mediated rejection and, 550
complications, 547–548, 548f
deceased donors, 543
donor kidneys, 544
future prospects, 551
hyperacute rejection, 549
immunology of, 541–542
immunosuppression, 549
immunosuppressive complications, 550–551, 551f
living donors, 542–543
procedure, 544–547, 544t, 546f
rejection, 549–550
Transport, long-distance, 348
Transposition of great arteries (TGA), 1488–1491, 1488f
arterial switch operation, 1489, 1490f
dextro-TGA (d-TGA), 1488
levo-TGA (l-TGA), 1488
Mustard operation, 1489, 1489f
Rastelli procedure, 1489, 1491f
Transpulmonary pressure, 176
Transthoracic echocardiography (TTE), 155
Transversalis fascia, 1219, 1220f
Transverse colon, 1052
Transverse rectus abdominis myocutaneous (TRAM) flap, 1323, 1324, 2040f
Trastuzumab emtansine (T-DM1), for breast cancer, 1325

Trastuzumab, for breast cancer, 1325
Trastuzumab for Gastric Cancer (ToGA), 764
Trauma and trauma care, 76–77, 2047
  biomechanics of injury, 340–342, 341t, 342t
  burden of disease, 335
  death, changing patterns of, 335–339, 337t
  early hospital care and priorities, 344–345
  field triage decisions and early priorities, 342–344, 342t
  injuries, 335
  intracavity hemorrhage control, 349
  wars and, 346–349, 346t
Trauma associated coagulopathy (TAC), 344
Trauma systems, 456–457
  inclusive, 457
Traumatic brain injury (TBI), 337, 346, 354, 360, 456
  causes of, 360
  in children, 460–461, 460f, 462t, 463t
  evaluation and treatment of, 368f
  and geriatric trauma, 475
  management of, 366
  and postinjury management, 491–492, 491t
  prehospital evaluation and treatment of, 367f
Traumatic infected aneurysms, 1609
Traumatic shock, 152
Tregs, 526
Trellis balloon occlusion catheter, 1782
Trench foot, 511
Triad syndrome, 1945
Triage, 354–355
  overtriage, 355
  undertriage, 355
Triangle of Calot, 1003
Tricarboxylic acid cycle. *See* Citric acid cycle
Tricuspic atresia, 1819
Tricuspid valve disease, 1514–1515
Tricyclic antidepressants, in irritable bowel syndrome, 1059
Triiodothyronine, 1343–1344
Trimethoprim, 550, 573
Trimodality therapy, 279
Triolein breath test, 847
Trisomy 21, 1876
TRK receptors, 1950
Trousseau sign, 206, 1368

Truncus arteriosus, 1491–1492, 1491f
Collett and Edwards classification, 1492t
persistent, 1491
Van Praagh and Van Praagh classification, 1492t
Truss, 1232
Trypsin, 779, 846, 860
Trypsinogen, 848
TSH-secreting adenomas, 1404, 1406. *See also* Pituitary adenomas
Tubercle of Zuckerkandl, 1340, 1341–1342, 1342f
Tuberculosis, 1635
Tuberculous pericarditis, 1577
Tuberous sclerosis, 1935
Tube thoracostomy, 353
Tubular duplications, 1912
Tubulovesicles, 720
Tuftsin, 1267
Tumor infiltrating lymphocytes (TIL), 273
Tumor necrosis factor- a (TNF-a), 717
Tumor suppressor genes, 272
Tunica vaginalis, 1873, 1875
Turcot syndrome, 1099
Turkish saddle, 1402
Turner syndrome, and thoracic aneurysms, 1565
Tween-80, 1890
Twin-reversed arterial perfusion (TRAP) sequence, 1834
Twin-to-twin transfusion syndrome (TTTS), 1834
Type 1 diabetes, 608–609
Type 2 diabetes, 608–609
Type O (universal donor) blood, 160
Type-specific blood, 160
Tyrosine kinase inhibitors (TKI), 767, 2021

U

UK Flexible Sigmoidoscopy Screening Trial, 1101
UK Small Aneurysm Trial, 1610
Ulcerative colitis (UC), 1082–1090
clinical features, 1083
cutaneous, 1084, 1084f
hepatobiliary, 1083
musculoskeletal, 1084
ophthalmologic, 1083–1084
and Crohn disease, 1082, 1083t
diagnosis, 1084–1085

differential diagnosis, 1085
endoscopic evaluation, 1085
epidemiology, 1082
etiology and risk factors
environmental factors, 1082–1083, 1083f
genetics, 1082, 1082t
imaging studies, 1084–1085, 1085f
Mayo Severity Index Calculator, 1084t
medical management
aminosalicylic acid compounds, 1085
biologic immunomodulator agents, 1086
corticosteroids, 1085
immunomodulators, 1085
mercaptopurine, 1086
methotrexate, 1086
pathology
macroscopic appearance, 1085, 1086f
microscopic appearance, 1085
surgery, indications for, 1086
carcinoma/dysplasia, 1087
extraintestinal manifestations, 1087
fulminant colitis, 1087
recalcitrance to medical management, 1087
toxic megacolon, 1086–1087
uncontrolled bleeding, 1087
surgical management, 1087
abdominal colectomy with Brooke ileostomy, 1087–1088, 1088f
Brooke ileostomy, 1087, 1087f
proctocolectomy with Brooke ileostomy, 1088–1089
proctocolectomy with ileal pouch-anal anastomosis, 1089–1090, 1089f, 1090f
proctocolectomy with Koch pouch, 1090
Ulcer disease
drug treatment, 728
operative treatment, 729–734, 729f–733f, 732t
Ultrasonic assisted liposuction (UAL), 2060
Ultrasonography (US), 1584, 1975, 1980, 1982
acute cholecystitis, 1000, 1001f
appendicitis, 1201
bilateral high-grade ICA stenosis, 1591–1592
B-mode, 1585
breast, 1295–1296
carotid and vertebral arteries, 1587
carotid stenosis, classification of, 1590–1591, 1591t

CBD stones, 1008, 1009f
CCA and ECA stenosis, 1592
CCA waveforms, 1587–1588, 1587f, 1588f
cholangiocarcinoma, 1041
chronic venous insufficiency, 1604–1605, 1605f
color flow, 1586, 1586f
deep venous thrombosis, 1602–1604, 1603f
for diverticular disease, 1166
Doppler, 1585–1586
duplex, 1584–1585
external carotid artery, 1590
grayscale image, 1585
hepatic neoplasms, 977
ICA waveforms, 1588–1589, 1589f
lower extremity arterial disease, 1592
mesenteric arteries, 1600–1601
pancreatic cancer, 886
pancreatic disease, 857
pneumothorax, 396
prenatal, 1833
sample volume, 1585
scan head, 1585
stented carotid arteries, 1592
techniques
ankle–brachial index, 1593–1594, 1593t
Doppler analog waveform analysis, 1595
exercise testing, 1595
peripheral artery duplex scanning, 1595–1596, 1596f
segmental leg pressures, 1594–1595, 1594f
thyroid gland, 1345, 1345f
transducers, 1585
vascular infection, 1612
vascular trauma, 436
vertebral artery, 1589–1590, 1591f
Ultrasound-based transient elastography, 950
Umbilical anomalies, 1908
Umbilical hernias, 306, 1245–1246
differential diagnosis, 1245, 1245f
laparoscopic approach for, 1246
management, 1245–1246
Mayo repair of, 1246f
predisposing factors, 1245
Uncoupling protein (UCP), 45–46

Undescended/cryptorchid testicle, 1942–1943, 1942f
Unfractionated heparin (UFH), 180
Union for International Cancer Control (UICC), 283
United National Organ Sharing (UNOS), 557
United Network for Organ Sharing (UNOS), 543, 957, 1970
United States Preventive Services Task Force (USPSTF), 284
Univentricular heart, 1499, 1499f, 1501
University of Southern California (USC), 668
  protocol for video esophagram studies, 674t
  Van Nuys Prognostic Index (USC/VNPI), 1313
Upper esophageal sphincter (UES), 644, 657
Upper extremity arterial disease
  aneurysms, 1639, 1641f
  angiography, 1643, 1643f
  atherosclerosis and, 1638
  cause of, 1639
  conditions and risks for, 1640t
  etiology, 1638–1639, 1640f
  history, 1639–1642
  laboratory and noninvasive testing, 1642–1643, 1642f, 1643f
  management, 1643–1646, 1644f–1646f
  manifestations of, 1639f
  physical examination, 1639–1642
  presentation, 1638
Upper extremity duplex scanning, 1599–1600, 1599f, 1600t
Upper extremity segmental pressures, 1597, 1598f
Upper gastrointestinal series, pancreatic disease, 857
Upper respiratory infection (URI), 632
Urachal abnormality, 1939
Urea cycle, 14, 15f
Uremic pericarditis, 1577
Ureter, 425–428, 427f, 428f
  anomalies of, 1935–1939
  ectopic, 1936, 1936f
Ureteral duplication, 1935–1936
Ureterocele, 1936–1937, 1936f, 1937f
Ureterohydronephrosis, graft infection and, 1612
Ureteroneocystostomy, 427
Ureteropelvic junction (UPJ), 423
Ureteropelvic junction obstruction (UPJO), 1934, 1935, 1935f, 1936f
Ureterovesical junction (UVJ), 423
Urethra, anomalies of, 1940–1941
Uric acid, 115

Uridine diphosphate glucuronyl transferase (UDPGT), 1822
Urinary nitrogen, 23
Urinary obstruction, 1833–1834
Urine osmolality, 194
Urine specific gravity, 201
Urine urea nitrogen (UUN), 26
Urodilatin, 197
Urogenital sinus anomalies, 1945
Ursodeoxycholic acid (ursodiol), 948, 999
U.S. Food and Drug Administration, 521
U.S. Multi-Society Task Force on Colorectal Cancer (USMTF), 1100, 1103, 1104t
U.S. Preventative Services Task Force (USPSTF), 1306
  on screening for colorectal cancer, 1100, 1100t
U.S. Special Forces Soldiers, 356
Usual interstitial pneumonia (UIP), 589
Uterine rupture, in pregnancy, 485
Uveitis, ulcerative colitis and, 1083–1084

V

Vaccination, hepatitis A virus, 934
VACTERL association, 1857, 1883
Vacuolating cytotoxin A (VacA), 726
Vagina, anomalies of, 1944–1946
Vagotomy, 722, 756
Vague epigastric, 755
Valacyclovir, 1193
Valproic acid, 1926
Valve prostheses, 1514–1515
  biologic, 1515
  mechanical, 1515
Valve repair, 1796
Valves of Houston, 1172
Valvular heart disease
  aortic regurgitation, 1509–1510
  aortic stenosis, 1506–1509
  mitral regurgitation, 1512–1514
  mitral stenosis, 1510–1512
  tricuspid valve disease, 1514–1515
  valvular anatomy, 1505–1506, 1506f, 1507f
Valvuloplasty technique, 1795
Vanishing bile duct syndrome, 523, 572
Vanishing testicle syndrome, 1942
Van Nuys Prognostic Index (VNPI), 1313

Varicella zoster immune globin, 939
Varicella zoster virus (VZV), 939
Varicocele, 1944
Vascular catheter–related infections, 229
Vascular cellular adhesion molecule 1 (VCAM-1), 88
Vascular ectasias, 1076
Vascular endothelial growth factor (VEGF), 59, 271, 791
Vascular endothelium, 72
Vascular infections, 1609–1619
Vascular lesions, of pediatric liver, 1914–1916
Vascular malformation, 2066
Vascular rings, 1496–1498, 1859–1860
Vascular trauma, 432–442
  background, 432
  civilian population, 433–434
  diagnosis of, 434–437, 435f
  epidemiology of, 432–434
  lower extremity, 439–440
  management, 437–442, 441f, 442f
    extremity trauma, 438–440
  mechanisms, 432–434
  military-specific applications, 433
  operative management, 442
  physical examination, 434–436
  postoperative management, 439
  soft signs of, 434, 437
  surgery, 438t
  and topical hemostatic agents, 438t
Vascular trauma (*continued*)
  treatment of, 438t
  upper extremity, 439
Vasoactive intestinal peptide (VIP), 114, 716, 773, 785, 845, 846, 850
Vasoconstriction, 148, 154
Vasodilators, 163–164. *See also* Shock
  nitroglycerin, 164
  nitroprusside, 164
Vasogenic edema, 369
Vasopressin, 163
  secretion, 155
  in variceal bleeding, 959
Vasopressors, inotropes and. *See* Inotropes and vasopressors
Vecuronium, 243, 355
VEDICO trial, 1793

Veins of Retzius, 954, 955f
Velocity time integral (VTI), 172
Velpeau hernia, 1257
Venom
  composition of, 499t
  duvernoy glands and, 498
Venomous lizards, 502
Veno-occlusive disease, 955
Venous Disease
  Anticoagulants, 1778t
  Categories, 1777
  Diagnosis, 1777–1778
  Incidence, 1777
  Risk Factors, 1777
Venous filling index (VFI), 1604
Venous recovery time (VRT), 1605
Venous thromboembolism (VTE), 69, 75, 78t, 328
  complications, 1780
  pediatric trauma, 469–470
  prevention of
    chemical treatment of, 180
    primary prophylaxis, treatment, 180
    screening – secondary prevention, 179–180
  prophylaxis in ICU, 178–179, 179t
  superficial thrombophlebitis, 1782–1783
  surgical procedures, 1781–1782
  thrombolytic, 1781–1782
  treatment, 1783–1784
Venous thrombosis (VT), 69
Venous ulcer wound care, 1796Û1797
Venous valve repair, 1794
Venous valve transplantation, 1795
Ventilation
  and carbon-di-oxide removal, 174
  liberation from, 178
  monitors, 256–258
Ventilation Index, 1813
Ventilator
  management
    conventional modes, 176–177
    liberation from ventilation, 178
    ventilator-associated pneumonia (VAP), 177–178
  modes and graphics, 174–175

strategies
inhalation injury, treatment for, 221
ventilator-associated pneumonia (VAP), 221
Ventilator-acquired pneumonia (VAP), 327, 328f
Ventilator-associated events (VAE), 177
Ventilator-associated pneumonia (VAP), 177–178, 221
Ventral abdominal wall hernias, 1244–1245
classification, 1244t
complications of hernia repair, 1257, 1257t
bleeding, 1258
ileus, 1257
prosthetic complications, 1258
recurrence, 1257–1258
seromas, 1258
surgical site occurrences, 1258
epigastric hernias, 1246
incisional hernias, 1246–1247
massive hernia, 1247
parastomal hernia, 1252–1254
preoperative preparation, 1247–1248
treatment
component separation, 1248–1250
flaps and grafts, use of, 1251–1252
general principles, 1248, 1248f
nonprosthetic repairs, 1248
prosthetic repairs, 1250–1251, 1250f
umbilical and periumbilical hernias, 1245–1246
Zollinger classification, 1244t
Ventral Hernia Risk Score (VHRS), 1258, 1259f
Ventricular assist device (VAD), 577
Ventricular free wall rupture, 1524
Ventricular septal defects (VSDs), 1483–1485, 1483f, 1819
diagnosis, 1484
inlet defects, 1484
management, 1484–1485
outlet, 1484
perimembranous, 1484
trabecular, 1484
Ventriculostomy, 369
Ventriculostomy catheters, 368
Verner–Morrison syndrome. *See* VIPoma
Vertebral anomalies, 1883
Vertebral arteries, 1589–1590, 1591f

anatomy, 1633
disease, 1633–1634
endovascular management of, 1634
Vertebrobasilar disease
anatomy, 1633
atherosclerosis for, 1634
clinical findings, 1633
diagnostic evaluation, 1634
differential diagnosis, 1634
distribution of, 1634
open surgical treatment, 1634
pathogenesis, 1633
Vertical banded gastroplasty, 743, 743f
Vertical expandable prosthetic titanium rib (VEPTR), 1847
Very late antigen 4 (VLA-4), 88
Very low-density lipoproteins (VLDLs), 11, 51
Vesicoureteral reflux (VUR), 1934, 1937–1939, 1937f, 1938f
Veterans Affairs Total Parenteral Nutrition Cooperative Study Group, 32
Video-assisted airway insertion devices, 353
Video-assisted retroperitoneal débridement (VARD), 137, 866
Video-assisted thoracoscopic surgery (VATS), 1463, 1498, 1866, 1867f
Video capsule endoscopy, Crohn disease, 813–814, 814f
Viekira Pak (AbbVie), 948
Viperidae family (snakes), 496
VIPoma, 900t, 908–909, 908t, 909f
diagnosis, 909
differential diagnosis, 909t
surgical excision, 909
Viral hepatitis, 555–556, 933, 934t, 976
and acute liver failure, 940
and cirrhosis, 947–948
hepatitis A virus, 933–934, 934f
hepatitis B virus, 934–936, 935f
hepatitis C virus, 936–937, 936f
hepatitis D virus, 937, 937f, 938f
hepatitis E virus, 938, 938f
Viral risk factors, cancer, 270–271, 271t
hepatitis B (HBV)/hepatitis C viruses (HCV), 271
human herpes virus 8 (HHV-8), 271
human papilloma virus (HPV), 271
Virchow's Triad, 486
Visceral adipose tissue (VAT), 50
Visceral adiposity, 738

Visceral and parietal collateral networks, 1673f
Visceral arteries, 1600–1601
Visceral pain, 262
Vital signs (VS), 155
Vitamin A deficiency, 63
Vitamin B_1 (thiamine), 780
Vitamin B_2 (riboflavin), 780
Vitamin B_{12} (cobalamin), 780
Vitamin C, 92, 780
  deficiency, 63
Vitamin D, 1365, 1366f
  deficiency, 1369
Vitamin D synthesis, 205f
Vitamin E supplementation, 63
Vitamins, 182
  absorption, 780
  daily requirements of, 24t
  deficiencies, 182t
  fat-soluble, 23
  function of, 23
  water-soluble, 23
  wound healing, role in, 63
Vitelline duct, 1907
Volume abnormalities, correction of
  volume deficits, 200
  volume excess, 200
Volume substitution and insulin therapy in severe sepsis (VISEP) trial, 186
Volumetric diffusive respiration (VDR), 177
Volvulus, 797, 1894–1895
Von Hippel–Lindau (VHL) syndrome, 269, 1935
  pancreatic endocrine neoplasms and, 901, 901t
von Recklinghausen syndrome, 1115
von Willebrand disease (vWD), 80, 81
von Willebrand factor (vWF), 56
VTE. *See* Venous thromboembolism
Vulnerable Elder Survey, 297

W

Wakayama syndrome, 849
Waldeyer fascia, 1053
Walled-off necrosis, 860t, 868–869, 868f
Wandering spleen, 1284

Wangensteen-Rice invertogram, 1884
Warfarin, 77, 180
Wars and trauma, 346–349, 346t. *See also* Trauma and trauma care
  coagulopathy, prevention/treatment of, 347–348
  early hemorrhage control, 346–347
  prevention, 346
  rapid air evacuation/long-distance transport, 348
  rehabilitation, 348–349
Wartime vascular injury, 432–433, 433f. *See also* Vascular trauma
Water retention, in cirrhosis, 951
Waterston shunt, 1487
WDHA syndrome, 908. *See also* VIPoma
Weight loss, 1968
Western Trauma Association, 414
Western Trauma Association Multicenter Study, 405
West-Nile virus, 524
Wharton jelly, 1870
Whipple triad, 905
White phosphorus, causing burn, 216
Wilms tumor
  associated syndromes, 1955t
  bilateral, 1960
  biologic features, 1956
  diagnosis, 1956–1957
  epidemiology, 1954
  future directions, 1960
  genetic risk, 1954
  microscopic examination of, 1956f
  pathology, 1956
  pediatric patients, 1852
  presentation, 1956–1957
  renal vein/inferior vena cava, 1960
  staging, 1955t, 1956–1957
  therapy, 1958t
  treatment, 1957
Wilson disease, 558
  and acute liver failure, 940
  cirrhosis and, 949
Wireless capsule endoscopy, in GI bleeding, 1070
Wisconsin solution, 563
Wiskott–Aldrich syndrome, 1273, 1277
Witzel jejunostomy, 38
WNT signaling pathway, 1120–1121

Wolffian ducts, 1933
World Health Organization (WHO), 329
  definition overweight, 738
  and road traffic injuries, 423
  subclassifies NPC, 639
  surgical safety checklist, 330t
Wound
  healing, 233, 307
  infection, 138, 228, 1796
  management, burns, 222–223
Wound healing, 54
  biofilm on, effects of, 61, 61f
  chronic *vs.* acute wounds, 61, 61t, 62f
  factors affecting, 61, 61t, 62f
    age and gender, 62–63
    alcohol and substance abuse, 66
    chemotherapeutic drugs, 66–67
    diabetes, 64, 64f
    medications and dietary supplements, 65
    nutrition, 63
    obesity, 63–64
    peripheral vascular disease, 65
    radiation, 67
    smoking, 65–66
    stress, 65
  nonhealing wounds, cost of, 54
  normal, 54–60
    hemostasis, 55–57, 57f
    inflammatory phase, 57–58, 58f
    phases of, 54, 55f, 55t, 56f
    proliferative phase, 58–60, 59f
    remodeling phase, 60, 60f
  surgical technique and, 60–61

X

Xase complex, 70
Xeroderma pigmentosa, 1993
Xeroform, 223

Y

Yolk stalk, 1907, 1907f, 1908f
Young-Burgess Classification system, 469

Z

Zenker diverticulum, 644
Zinc, 19
  daily requirements of, 24t
  deficiency of, 23
  wound healing, role in, 63
Ziv-aflibercept (Zaltrap), 280t
Zofran®, 508
Zollinger–Ellison syndrome, 718, 766, 1379, 1927–1928. *See also* Gastrinoma
Zona glomerulosa, 196
Z-plasty, 230, 230f
Zuplenz®, 508
Zygomaticomaxillary complex (ZMC) fractures, 379–380, 380f, 381f
Zymogen granules, 716, 844–845